

Abdelmalik I. Khalafalla  
Mansour F. Hussein



# Infectious Diseases of Dromedary Camels

A Concise Guide



Springer

---

# Infectious Diseases of Dromedary Camels

---

Abdelmalik I. Khalafalla • Mansour F. Hussein

# Infectious Diseases of Dromedary Camels

A Concise Guide



Springer

Abdelmalik I. Khalafalla  
Veterinary Laboratories Division  
Abu Dhabi Agriculture and Food Safety  
Authority  
Abu Dhabi, United Arab Emirates

Mansour F. Hussein  
Dumfries, VA, USA

ISBN 978-3-030-79388-3 ISBN 978-3-030-79389-0 (eBook)  
<https://doi.org/10.1007/978-3-030-79389-0>

© Springer Nature Switzerland AG 2021

This work is subject to copyright. All rights are reserved by the Publisher, whether the whole or part of the material is concerned, specifically the rights of translation, reprinting, reuse of illustrations, recitation, broadcasting, reproduction on microfilms or in any other physical way, and transmission or information storage and retrieval, electronic adaptation, computer software, or by similar or dissimilar methodology now known or hereafter developed.

The use of general descriptive names, registered names, trademarks, service marks, etc. in this publication does not imply, even in the absence of a specific statement, that such names are exempt from the relevant protective laws and regulations and therefore free for general use.

The publisher, the authors, and the editors are safe to assume that the advice and information in this book are believed to be true and accurate at the date of publication. Neither the publisher nor the authors or the editors give a warranty, expressed or implied, with respect to the material contained herein or for any errors or omissions that may have been made. The publisher remains neutral with regard to jurisdictional claims in published maps and institutional affiliations.

Cover illustration: © Photograph by Abdelmalik I. Khalafalla.

This Springer imprint is published by the registered company Springer Nature Switzerland AG.  
The registered company address is: Gewerbestrasse 11, 6330 Cham, Switzerland

---

## Preface

The Food and Agriculture Organization (FAO) of the United Nations estimates the total number of Old-World camelids (*Camelus dromedarius* and *C. bactrianus*) at 35,525,270 heads. Of these, 95% are dromedary camels. Toward the end of the last century, devastating waves of drought struck many traditional camel grazing areas in Africa forcing changes in the distribution and density of these animals. At the same time, cattle breeders in some parts of East Africa have started to adopt camels as part of their livelihood strategy. In this manner, the hardiness of camels in arid regions has made humans more dependent on them as a source of staple protein.

Because of their remarkable adaptability to heat and drought, dromedary camels play a pivotal role in the life and culture of nomadic herdsman and pastoralists in Africa and the Middle East. Besides, the close association between dromedary camels and desert dwellers in the Arabian Peninsula extended over thousands of years and had a profound impact on Arabic, Islamic, and tribal traditions. For more points of interest on these aspects and the evolution and economic importance of the camels, the reader is referred to part one of this book.

In many parts of the world such as Africa, the Middle East, and western and central Asia, camel herders raise their animals under harsh conditions of heat, drought, and transhumance, and they practice non-optimal husbandry, management, and prophylactic methods. It is not surprising, therefore, that around 65% of all mortalities in camels, especially young stock, are caused by infectious diseases. Many of these diseases are picked up by camels from other livestock species and wild animals cohabiting the same areas as the widespread desertification has forced dromedary camels to move side by side with these animals to the higher rainfall areas. Consequently, camels were exposed to diseases that were previously uncommon in their natural habitat such as dermatophilosis, tick paralysis, trypanosomosis, and brucellosis. Besides, the increased demand for camel milk by urban populations in some regions in North Africa, the Middle East, and central Asia, has contributed to the spread of diseases via camel milk vendors and establishment of some dairy camel farms in intensive and semi-intensive systems. These developments have rendered camels more susceptible to diseases such as brucellosis, enterotoxaemia, and paratuberculosis. The increased incidence of colibacillosis and other diarrheal agents has also been reported in camels raised in intensive husbandry systems in some countries.

The migration of camels into new habitats has also been associated with increased incidence and severity of some camel diseases. Besides, close contact of camels with some other domestic species, such as sharing the same premises with equines in some Gulf countries, has led to the emergence of some equine diseases such as glanders, melioidosis, and *Rhodococcus equi* infection in camels.

During the past few decades, concern about human and animal health has increased dramatically because of the so-called perfect microbial storm, which was characterized by extensive and rapid emergence of new diseases and reemergence of others. Nearly half of all human infectious diseases known today are emerging or reemerging diseases, and the vast majority of them are zoonotic. Many factors have contributed to this situation including population explosion, increased urbanization, widespread trade in animals and animal products, increased human and animal movement, closer contacts with wildlife, and microbial adaptation to environmental and ecological changes. One of the interesting examples of an emerging human disease is the Middle East Respiratory Syndrome in humans for which the camel is believed to be the main reservoir host.

Despite a steady increase in camel husbandry worldwide, camel diseases are still relatively under-investigated in comparison to other livestock and companion animals. However, increasing interest in camel products, as well as public health concerns, particularly after the emergence of the Middle East respiratory syndrome coronavirus (MERS-CoV), has led to a marked increase in the number of publications on camel diseases, particularly infectious diseases.

It should be pointed out, however, that despite the accumulation of knowledge of some unique properties of the camel, such as their possession of an efficient hemostatic system and production of single-domain antibodies, it is difficult to identify emerging and reemerging camel diseases by simply looking at the growing list of infections currently reported in these animals. Solid epidemiological data describing the incidence and prevalence of many camel diseases in the field are still lacking and if present cover only limited geographical areas and are not adequately supported by laboratory confirmation to determine whether their incidence is increasing or decreasing. Hence, many of the diagnostic tests currently used to determine the epidemiology of camel diseases are directly transposed from cattle, sheep, or goats without adequate validation for use in camels and may therefore result in unreliable surveillance results. Fortunately, however, this situation is rapidly changing with the establishment of modern and highly specialized camel clinics, research laboratories, and veterinary schools in some countries, particularly the gulf countries.

To address these challenges, this book seeks to update and review current knowledge on bacterial, viral, fungal, and parasitic infectious diseases of camels, specifically the dromedary camels which are the main camels reared in Africa, Asia, and the Middle East. Each section of the book's three parts contains brief information on etiology, clinical signs, epidemiology, pathogenesis, prevention, and treatment written in a concise and digestible manner. To introduce the readers to the subject animal, we included a separate chapter on the evolution, classification, distribution, and uses of the camels, with an emphasis on the dromedary camels.

The book is expected to represent a valuable source of information for a wide spectrum of clinicians, researchers, students, technicians, and the general public.

The information presented in this book reflects not only the extensive experience of its authors on dromedary camel health, but also detailed information from the literature. Only the most important diseases of the dromedary camels have been addressed in this book, while those of minimal clinical significance have been omitted. In total, this book covers 8 viral, 24 bacterial, 4 fungal, 10 parasitic as well as two multifactorial diseases. Although MERS-CoV infection has limited clinical implications on camel health, we included it due to its zoonotic risk and furthermore on the grounds that it is presently considered a notifiable disease by the OIE; therefore, the veterinary authorities need to know about it.

Such a text is expected to serve as an important source of information for a wider range of veterinary clinicians, researchers, students, technicians, and others. The information contained in this book reflects not only the extensive experience of its authors on dromedary camel health, but also much information from the literature. Yet, only the most important dromedary camel diseases are addressed in this book.

Abu Dhabi, United Arab Emirates  
Dumfries, VA, USA

Abdelmalik I. Khalafalla  
Mansour F. Hussein

---

## Acknowledgments

The authors would like to thank all those who have contributed to the preparation and publication of this book. We first wish to express our sincere appreciation to our contributors, Drs Set Bornstein, Ahmed Gameel, and El Awad El Hassan, for their hard work to ensure good quality of the scientific information presented in this book. Special gratitude goes to Dr Silvia Herold, Springer Nature editor, who initially proposed writing this book, for her enthusiasm and valuable advice throughout to make this book a reality. We are also grateful to Mr Bharat Sabnani, Production Coordinator for Springer Nature, for his unlimited help during this process. We highly appreciate the work done by Prof. Babikir Abbas, Prof. Hamid Agab, and Dr Essam Eljalii in reviewing the book manuscript and giving valuable comments. We are grateful to our colleagues Prof. Hamid Agab, Drs Set Bornstein, Mahmoud El-Neweshy, Ahmed El Mamy, Naserldien Hussain, Ahmed Elfadl and Ghada Abdelwahab, Intisar Saeed, Mr Khalifa Sultan, and Mr Abdo Bushara who provided us with nice pictures of camel diseases. At last, we thank our family members for their patience during the epic task of writing and correcting the book.



---

# Contents

<b>1</b>	<b>Evolution, Distribution, and Economic Importance of the Camels</b> . . . . .	<b>1</b>
	Set Bornstein	
1.1	History of the Old-World Camelids (OWC): Starting Point North America . . . . .	3
1.2	A Beast of Burden . . . . .	3
1.3	A True Ship of the Deserts . . . . .	7
1.4	The World Camel Population . . . . .	8
1.5	The Virtues of the Camel . . . . .	10
1.6	The Importance of this Multipurpose Animal: The Camel . . . .	13
1.7	Some Significant Camel Products . . . . .	14
	1.7.1 Milk . . . . .	14
	1.7.2 Meat . . . . .	15
1.8	Hair, Wool, Skin, and Hides . . . . .	15
	1.8.1 Hair Wool (Fiber) . . . . .	16
	1.8.2 Hides . . . . .	16
1.9	Racing Camels . . . . .	17
	References . . . . .	17
 <b>Part I Viral Diseases of Dromedary Camels</b>		
<b>2</b>	<b>Camel Pox</b> . . . . .	<b>23</b>
	Abdelmalik I. Khalafalla	
2.1	Etiology . . . . .	23
2.2	Modes of Transmission . . . . .	25
2.3	Clinical Picture . . . . .	25
2.4	Differential Diagnosis . . . . .	26
2.5	Pathogenesis and Pathology . . . . .	26
2.6	Epidemiology . . . . .	28
2.7	Diagnosis . . . . .	29
	2.7.1 Gel-based PCR . . . . .	29
2.8	Zoonotic Potentiality . . . . .	30

2.9	Treatment . . . . .	30
2.10	Prevention . . . . .	30
2.11	Notification . . . . .	31
	References . . . . .	31
<b>3</b>	<b>Camel Contagious Ecthyma . . . . .</b>	<b>33</b>
	Abdelmalik I. Khalafalla	
3.1	Etiology . . . . .	35
3.2	Modes of Transmission . . . . .	36
3.3	Clinical Picture . . . . .	36
3.4	Differential Diagnosis . . . . .	37
3.5	Pathogenesis and Pathology . . . . .	37
3.6	Epidemiology . . . . .	38
3.7	Diagnosis . . . . .	38
3.8	Zoonotic Potentiality . . . . .	39
3.9	Treatment . . . . .	39
3.10	Prevention . . . . .	40
3.11	Notification . . . . .	40
	References . . . . .	40
<b>4</b>	<b>Camel Papillomatosis . . . . .</b>	<b>43</b>
	Abdelmalik I. Khalafalla	
4.1	Etiology . . . . .	43
4.2	Modes of Transmission . . . . .	45
4.3	Clinical Picture . . . . .	45
4.4	Pathogenesis and Pathology . . . . .	46
4.5	Epidemiology . . . . .	47
4.6	Diagnosis . . . . .	47
4.7	Differential Diagnosis . . . . .	47
4.8	Zoonotic Potentiality . . . . .	47
4.9	Treatment and Control . . . . .	48
4.10	Notification . . . . .	48
	References . . . . .	48
<b>5</b>	<b>Rabies . . . . .</b>	<b>49</b>
	Abdelmalik I. Khalafalla	
5.1	Etiology . . . . .	49
5.2	Modes of Transmission . . . . .	51
5.3	Clinical Picture . . . . .	51
5.4	Differential Diagnosis . . . . .	52
5.5	Epidemiology . . . . .	52
5.6	Diagnosis . . . . .	53
5.7	Zoonotic Potentiality . . . . .	54
5.8	Treatment . . . . .	54
5.9	Control . . . . .	54
5.10	Prevention . . . . .	54

5.11	Notification . . . . .	54
	References . . . . .	55
<b>6</b>	<b>Peste Des Petits Ruminants (PPR)</b> . . . . .	<b>57</b>
	Abdelmalik I. Khalafalla	
6.1	Etiology . . . . .	59
6.2	Modes of Transmission . . . . .	59
6.3	Clinical Picture . . . . .	59
6.4	Differential Diagnosis . . . . .	59
6.5	Pathogenesis and Pathology . . . . .	60
6.6	Epidemiology . . . . .	62
6.7	Diagnosis . . . . .	62
6.8	Zoonotic Potentiality . . . . .	62
6.9	Treatment . . . . .	62
6.10	Prevention . . . . .	62
6.11	Notification . . . . .	63
	References . . . . .	63
<b>7</b>	<b>Rift Valley Fever</b> . . . . .	<b>65</b>
	Abdelmalik I. Khalafalla	
7.1	Etiology . . . . .	66
7.2	Mode of Transmission . . . . .	66
7.3	Clinical Picture . . . . .	66
7.4	Differential Diagnosis . . . . .	66
7.5	Pathogenesis and Pathology . . . . .	67
7.6	Epidemiology . . . . .	67
7.7	Diagnosis . . . . .	67
7.8	Zoonotic Potentiality . . . . .	69
7.9	Treatment . . . . .	69
7.10	Prevention . . . . .	69
7.11	Notification . . . . .	69
	References . . . . .	70
<b>8</b>	<b>MERS-CoV Infection</b> . . . . .	<b>71</b>
	Abdelmalik I. Khalafalla	
8.1	Etiology . . . . .	71
8.2	Modes of Transmission . . . . .	72
8.3	Clinical Picture . . . . .	72
8.4	Differential Diagnosis . . . . .	72
8.5	Pathogenesis and Pathology . . . . .	73
8.6	Diagnosis . . . . .	73
8.7	Zoonotic Potentiality . . . . .	73
8.8	Treatment . . . . .	73
8.9	Prevention . . . . .	74
8.10	Notification . . . . .	74
	References . . . . .	74

<b>9 Camel Prion Disease (CPrD)</b>	75
Abdelmalik I. Khalafalla	
9.1 Etiology	75
9.2 Clinical Picture	76
9.3 Diagnosis	76
9.4 Zoonotic Potentiality	76
References	76

## Part II Bacterial Diseases of Dromedary Camels

<b>10 Anthrax</b>	79
Mansour F. Hussein	
10.1 Modes of Transmission	80
10.2 Clinical Picture	80
10.3 Pathology	81
10.4 Diagnosis	81
10.5 Differential Diagnosis	82
10.6 Treatment	82
10.7 Prevention and Control	82
10.8 Notification	83
References	83
<b>11 Botulism</b>	85
Mansour F. Hussein	
11.1 Etiology	85
11.2 Modes of Transmission	86
11.3 Clinical Picture and Pathology	86
11.4 Diagnosis	86
11.5 Treatment and Prevention	87
11.6 Notification	87
References	87
<b>12 Brucellosis (<i>Brucella abortus</i> and <i>Br. melitensis</i>)</b>	89
Mansour F. Hussein	
12.1 Etiology	89
12.2 Modes of Transmission	89
12.3 Zoonotic Potentiality	90
12.4 Clinical Picture and Pathology	90
12.5 Diagnosis	90
12.6 Treatment and Control	92
References	93
<b>13 Caseous Lymphadenitis (<i>Corynebacterium pseudotuberculosis</i>)</b>	95
Mansour F. Hussein	
13.1 Etiology	95
13.2 Modes of Transmission	96
13.3 Clinical Picture and Pathology	96

13.4	Diagnosis . . . . .	98
13.5	Treatment . . . . .	98
13.6	Prevention and Control . . . . .	99
	References . . . . .	99
<b>14</b>	<b>Chlamydiosis (<i>Chlamydophila abortus</i>) . . . . .</b>	<b>101</b>
	Mansour F. Hussein	
14.1	Etiology . . . . .	101
14.2	Clinical Picture . . . . .	102
14.3	Pathogenesis . . . . .	102
14.4	Diagnosis . . . . .	103
14.5	Zoonotic Potential . . . . .	103
14.6	Treatment and Control . . . . .	103
	References . . . . .	103
<b>15</b>	<b>Clostridial Enterotoxemia . . . . .</b>	<b>105</b>
	Mansour F. Hussein	
15.1	Etiology . . . . .	106
15.2	Clinical Picture . . . . .	106
15.3	Pathology . . . . .	106
15.4	Diagnosis . . . . .	107
15.5	Treatment and Control . . . . .	108
	References . . . . .	109
<b>16</b>	<b>Colibacillosis . . . . .</b>	<b>111</b>
	Mansour F. Hussein	
16.1	Etiology . . . . .	112
16.2	Clinical Picture and Pathology . . . . .	113
16.3	Diagnosis . . . . .	114
16.4	Zoonotic Potentiality . . . . .	114
16.5	Treatment and Control . . . . .	114
	References . . . . .	115
<b>17</b>	<b>Contagious Skin Necrosis (CSN) . . . . .</b>	<b>117</b>
	Mansour F. Hussein	
17.1	Etiology . . . . .	118
17.2	Modes of Transmission . . . . .	118
17.3	Clinical Picture and Pathology . . . . .	119
17.4	Diagnosis . . . . .	120
17.5	Treatment and Prevention . . . . .	120
	References . . . . .	121
<b>18</b>	<b>Coxiellosis (Q-Fever) (<i>Coxiella burnetii</i> Infection) . . . . .</b>	<b>123</b>
	Mansour F. Hussein	
18.1	Etiology . . . . .	124
18.2	Pathogenesis . . . . .	124
18.3	Clinical Picture and Pathology . . . . .	125

18.4	Diagnosis . . . . .	125
18.5	Treatment and Control . . . . .	126
	References . . . . .	127
<b>19</b>	<b>Dermatophilosis (<i>Dermatophilus congolensis</i>) . . . . .</b>	<b>129</b>
	Mansour F. Hussein	
19.1	Etiology . . . . .	129
19.2	Clinical Picture and Pathology . . . . .	130
19.3	Diagnosis . . . . .	131
19.4	Treatment and Control . . . . .	132
19.5	Zoonotic Potentiality . . . . .	132
	References . . . . .	132
<b>20</b>	<b>Endotoxiosis in Camels (Hemorrhagic Disease; Hemorrhagic Diathesis; <i>Bodus cereus</i> Intoxication) . . . . .</b>	<b>135</b>
	Mansour F. Hussein	
20.1	Etiology . . . . .	135
20.2	Clinical Picture . . . . .	136
20.3	Pathology . . . . .	137
20.4	Diagnosis . . . . .	137
20.5	Treatment and Prevention . . . . .	137
	References . . . . .	137
<b>21</b>	<b>Burkholderiosis (Glander's Disease) . . . . .</b>	<b>139</b>
	Mansour F. Hussein	
21.1	Etiology and Zoonotic Potential . . . . .	139
21.2	Clinical Picture . . . . .	139
21.3	Diagnosis . . . . .	140
21.4	Prevention and Control . . . . .	140
21.5	Zoonotic Potentiality . . . . .	141
21.6	Notification . . . . .	141
	References . . . . .	141
<b>22</b>	<b>Leptospirosis (Weil's Disease) . . . . .</b>	<b>143</b>
	Mansour F. Hussein	
22.1	Etiology . . . . .	143
22.2	Modes of Transmission . . . . .	144
22.3	Clinical Picture . . . . .	144
22.4	Diagnosis . . . . .	144
22.5	Treatment and Control . . . . .	145
	References . . . . .	145
<b>23</b>	<b>Listeriosis (Circling Disease) . . . . .</b>	<b>147</b>
	Mansour F. Hussein	
23.1	Etiology . . . . .	147
23.2	Clinical Picture and Pathology . . . . .	148
23.3	Zoonotic Potentiality . . . . .	148

23.4	Listeriosis in New World Camelids . . . . .	149
23.5	Diagnosis . . . . .	149
23.6	Treatment and Control . . . . .	150
	References . . . . .	150
<b>24</b>	<b>Mastitis . . . . .</b>	<b>153</b>
	Mansour F. Hussein	
24.1	Etiology . . . . .	154
24.2	Clinical Picture . . . . .	154
24.3	Diagnosis . . . . .	155
24.4	Treatment and Control . . . . .	156
	References . . . . .	156
<b>25</b>	<b>Melioidosis (Whitmore Disease; <i>Burkholderia pseudomallei</i> Infection) . . . . .</b>	<b>159</b>
	Mansour F. Hussein	
25.1	Etiology . . . . .	159
25.2	Clinical Signs and Pathological Lesions . . . . .	159
25.3	Diagnosis . . . . .	160
25.4	Treatment and Prevention . . . . .	160
	References . . . . .	160
<b>26</b>	<b>Mycoplasmosis . . . . .</b>	<b>163</b>
	Mansour F. Hussein	
26.1	Etiology . . . . .	163
26.2	Clinical Picture and Pathology . . . . .	163
26.3	Diagnosis . . . . .	165
26.4	Treatment . . . . .	165
	References . . . . .	166
<b>27</b>	<b>Paratuberculosis (Johne's Disease) . . . . .</b>	<b>167</b>
	Mansour F. Hussein	
27.1	Etiology . . . . .	167
27.2	Modes of Transmission . . . . .	168
27.3	Clinical Picture . . . . .	168
27.4	Pathogenesis and Pathology . . . . .	168
27.5	Diagnosis . . . . .	170
27.6	Zoonotic Potentiality . . . . .	171
27.7	Treatment and Control . . . . .	171
	References . . . . .	171
<b>28</b>	<b>Pasteurellosis (Hemorrhagic Septicemia) . . . . .</b>	<b>175</b>
	Mansour F. Hussein	
28.1	Etiology . . . . .	176
28.2	Clinical Picture . . . . .	176
28.3	Pathogenesis and Pathology . . . . .	176

28.4	Diagnosis . . . . .	177
28.5	Treatment and Control . . . . .	178
	References . . . . .	179
<b>29</b>	<b>Rickettsial Diseases . . . . .</b>	<b>181</b>
	Mansour F. Hussein	
29.1	Heartwater . . . . .	181
29.1.1	Clinical Picture . . . . .	182
29.1.2	Diagnosis . . . . .	182
29.1.3	Treatment and Control . . . . .	182
29.2	Anaplasmosis . . . . .	183
29.2.1	Clinical Picture and Diagnosis . . . . .	183
29.2.2	Treatment . . . . .	185
	References . . . . .	185
<b>30</b>	<b>Salmonellosis . . . . .</b>	<b>187</b>
	Mansour F. Hussein	
30.1	Etiology . . . . .	187
30.2	Clinical Picture . . . . .	188
30.3	Pathogenesis and Pathology . . . . .	188
30.4	Diagnosis . . . . .	188
30.5	Treatment . . . . .	189
	References . . . . .	189
<b>31</b>	<b>Tetanus (<i>Clostridium tetani</i>) . . . . .</b>	<b>191</b>
	Mansour F. Hussein	
31.1	Etiology . . . . .	191
31.2	Pathogenesis . . . . .	191
31.3	Clinical Picture and Pathology . . . . .	192
31.4	Diagnosis . . . . .	192
31.5	Treatment and Prevention . . . . .	192
	References . . . . .	193
<b>32</b>	<b>Tuberculosis . . . . .</b>	<b>195</b>
	Mansour F. Hussein	
32.1	Etiology . . . . .	195
32.2	Modes of Transmission . . . . .	196
32.3	Clinical Picture and Pathology . . . . .	196
32.4	Diagnosis . . . . .	196
32.5	Zoonotic Potential . . . . .	197
32.6	Treatment and Prevention . . . . .	197
32.7	Notification . . . . .	197
	References . . . . .	198



<b>33</b>	<b><i>Yersinia pestis</i> (Camel Plague)</b>	201
	Mansour F. Hussein	
33.1	Modes of Transmission	201
33.2	Transmission of Plague from Camels to Man	202
33.3	Clinical Picture and Pathology	203
33.4	Diagnosis	203
33.5	Treatment and Control	203
	References	204
 <b>Part III Fungal Diseases of Dromedary Camels</b>		
<b>34</b>	<b>Ringworm (Dermatomycosis)</b>	207
	Mansour F. Hussein	
34.1	Etiology	207
34.2	Modes of Transmission	207
34.3	Clinical Picture and Pathology	208
34.4	Diagnosis	209
34.5	Treatment	209
	References	210
<b>35</b>	<b>Aspergillosis</b>	211
	Mansour F. Hussein	
35.1	Modes of Transmission	211
35.2	Clinical Picture and Pathology	211
35.3	Diagnosis	212
35.4	Treatment and Control	213
	References	213
<b>36</b>	<b>Candidiasis (Moniliasis)</b>	215
	Mansour F. Hussein	
36.1	Etiology	215
36.2	Modes of Transmission	215
36.3	Clinical Picture	215
36.4	Diagnosis	216
36.5	Treatment and Control	216
	References	216
<b>37</b>	<b>Cryptococcosis</b>	219
	Mansour F. Hussein	
37.1	Etiology	219
37.2	Clinical Picture	219
37.3	Diagnosis	219
37.4	Treatment	220
	References	220

## Part IV Ectoparasitic Diseases of Dromedary Camels

<b>38</b>	<b>Mange Mite Infestation (Sarcoptes, Demodex, Psoroptes, and Chorioptes) . . . . .</b>	<b>223</b>
	Ahmed A. Gameel	
38.1	Introduction to Ectoparasites of Dromedary Camels . . . . .	223
38.2	Sarcoptic Mange . . . . .	224
	38.2.1 Etiology . . . . .	224
	38.2.2 Modes of Transmission . . . . .	226
	38.2.3 Sites of Infection . . . . .	226
	38.2.4 Factors Affecting Mange Infection . . . . .	226
	38.2.5 Clinical Picture and Pathology . . . . .	227
38.3	Demodectic Mange . . . . .	228
	38.3.1 Modes of Transmission . . . . .	228
	38.3.2 Clinical Picture . . . . .	229
	38.3.3 Site of Infection . . . . .	229
	38.3.4 Factors Affecting Infection . . . . .	229
38.4	Psoroptic and Choriopic Mange . . . . .	229
38.5	Diagnosis . . . . .	230
	38.5.1 Clinical Diagnosis . . . . .	230
	38.5.2 Laboratory Diagnosis . . . . .	230
38.6	Differential Diagnosis . . . . .	231
38.7	Treatment and Control . . . . .	232
	References . . . . .	232
<b>39</b>	<b>Tick Infestation . . . . .</b>	<b>235</b>
	Ahmed A. Gameel	
39.1	Etiology . . . . .	235
39.2	Site of Infection . . . . .	236
39.3	Tick Collection and Identification . . . . .	236
39.4	Clinical Picture and Pathology . . . . .	236
39.5	Gross Lesions . . . . .	237
39.6	Histopathology . . . . .	237
39.7	Tick Paralysis . . . . .	237
39.8	Health Effects . . . . .	237
	References . . . . .	238
<b>40</b>	<b>Fly Infestation (Myiasis) . . . . .</b>	<b>239</b>
	Ahmed A. Gameel	
40.1	Dipterous Flies Which May Be Associated with Myiasis in the Dromedary Camel . . . . .	239
40.2	Diagnosis . . . . .	240
40.3	Treatment . . . . .	240
	References . . . . .	240

<b>41 Louse and Flea Infestations</b> . . . . .	241
Ahmed A. Gameel	
References . . . . .	242
 <b>Part V Endoparasitic Diseases of Dromedary Camels</b>	
<b>42 Gastrointestinal Helminths (Haemonchosis)</b> . . . . .	245
El Awad Mohamed El Hassan	
42.1 Introduction . . . . .	245
42.2 Mixed Infections . . . . .	247
42.3 Haemonchosis . . . . .	248
42.3.1 Etiology . . . . .	248
42.3.2 Modes of Transmission . . . . .	250
42.3.3 Clinical Picture . . . . .	250
42.3.4 Pathology and Pathogenesis . . . . .	251
42.3.5 Epidemiology . . . . .	251
42.3.6 Diagnosis . . . . .	252
42.3.7 Control . . . . .	253
References . . . . .	254
<b>43 Extraintestinal Helminths</b> . . . . .	257
El Awad Mohamed El Hassan	
43.1 Helminth Infection of the Liver . . . . .	257
43.2 Helminth Infection of the Respiratory Tract . . . . .	257
43.3 Helminth Infection of the Circulatory System . . . . .	258
43.4 Dipetalonemiosis . . . . .	258
43.4.1 Etiology . . . . .	258
43.4.2 Modes of Transmission . . . . .	258
43.4.3 Clinical Picture . . . . .	259
43.4.4 Pathology and Pathogenesis . . . . .	259
43.4.5 Epidemiology . . . . .	259
43.4.6 Diagnosis . . . . .	259
43.4.7 Control . . . . .	260
43.5 Helminth Infection of the Nervous System . . . . .	260
43.6 Helminth Infection of the Eye . . . . .	260
43.7 Helminth Infection of Muscles . . . . .	260
43.8 Helminth Infection of Subcutaneous Connective Tissues . . . . .	260
43.9 Anthelmintic Treatment of Helminth Infection . . . . .	261
References . . . . .	261
<b>44 Gastrointestinal and Tissue Protozoa</b> . . . . .	263
El Awad Mohamed El Hassan	
44.1 Gastrointestinal Protozoa . . . . .	263
44.1.1 <i>Eimeria</i> , <i>Isospora</i> , and <i>Giardia</i> spp. Infections . . . . .	263
44.1.2 <i>Cryptosporidium</i> Infection . . . . .	263
44.2 Tissue Protozoa . . . . .	265
References . . . . .	266

<b>45</b>	<b>Endoparasitic Arthropods</b> . . . . .	269
	El Awad Mohamed El Hassan	
45.1	<i>Linguatula serrata</i> Infection in Camels ( <i>Halzoon; Marara Syndrome</i> ) . . . . .	269
	Reference . . . . .	269
 <b>Part VI Blood Parasites of Dromedary Camels</b>		
<b>46</b>	<b>Trypanosomosis</b> . . . . .	273
	Set Bornstein	
46.1	Etiology . . . . .	274
	46.1.1 Classification of the <i>Trypanosoma</i> . . . . .	275
	46.1.2 Morphology and Structure . . . . .	275
	46.1.3 Origin and Development of Significant Structures . . . . .	276
	46.1.4 <i>Trypanosoma evansi</i> Type A and B . . . . .	277
46.2	Epidemiology . . . . .	277
46.3	Zoonotic Potentiality . . . . .	279
46.4	Modes of Transmission . . . . .	279
46.5	Clinical Picture . . . . .	280
46.6	Pathology . . . . .	282
	46.6.1 Gross Lesions and Histopathological Findings . . . . .	282
46.7	Immunosuppression . . . . .	283
46.8	Diagnosis . . . . .	283
	46.8.1 Methods for the Diagnosis of Trypanosomosis . . . . .	284
46.9	Treatment . . . . .	286
	46.9.1 Trypanocides . . . . .	287
	46.9.2 Aromatic Diamidine Compounds . . . . .	287
	46.9.3 Phenanthridine Compounds . . . . .	287
	46.9.4 Sulfonic Acids (Aminoquinaldine Derivates) . . . . .	288
	46.9.5 Arsenicals . . . . .	288
	46.9.6 Traditional Medicine . . . . .	289
46.10	Control . . . . .	289
	References . . . . .	289
	Further Readings . . . . .	296
<b>47</b>	<b>Tick-Borne Diseases</b> . . . . .	297
	Abdelmalik I. Khalafalla	
47.1	Clinical Picture . . . . .	297
47.2	Diagnosis . . . . .	298
47.3	Treatment . . . . .	298
	References . . . . .	299

**Part VII    Multi-factorial Diseases of Dromedary Camels**

**48    The Respiratory Disease** . . . . . 303  
Abdelmalik I. Khalafalla  
48.1    Clinical Picture . . . . . 304  
48.2    Diagnosis . . . . . 304  
48.3    Treatment . . . . . 305  
References . . . . . 305

**49    Neonatal Diarrhea** . . . . . 307  
Abdelmalik I. Khalafalla  
49.1    Etiology . . . . . 307  
49.2    Clinical Picture . . . . . 308  
49.3    Diagnosis . . . . . 309  
49.4    Treatment . . . . . 309  
References . . . . . 309

---

## Contributors

**Set Bornstein** National Veterinary Institute, Uppsala, Sweden

**Ahmed Abdel Rahim Gameel** Department of Pathology, Faculty of Veterinary Medicine, University of Khartoum, Khartoum, Sudan

**El Awad Mohamed El Hassan** Department of Microbiology, College of Veterinary Medicine, King Faisal University, Al Hofuf, Saudi Arabia

# Evolution, Distribution, and Economic Importance of the Camels

# 1

Set Bornstein

Throughout history the camelids: the dromedary (*Camelus dromedarius*) and the Bactrian (*Camelus bactrianus*), living in the hot, arid lands, from northern Africa and the Middle East to the western and central parts of Asia and in the hot and cold steppes and deserts in Central Asia, respectively, have been of great importance as domestic animals providing people with transport, food, fiber, hides, and dung. They are animals with very special anatomical, physiological, and behavioral features that enable them to cope extremely well in the severe environments of aridness, heat, and cold (Fig. 1.1).

The one-humped camel also called the Arabian or dromedary camel, and the two-humped Bactrian camel are commonly referred to as the “old world camelids” (OWC) or the large camelids belonging to the genus *Camelus* (Table 1.1). The only wild species of OWCs existing today called “the Tartary camel” (*Camelus ferus*) live in a few pockets in the Gobi Desert of Mongolia and China (Hare, 1998). It is an endangered species of between 1000 and 1600 individuals. The Tartary camels are two-humped, with features very like the Bactrian camel and were earlier thought to be a wild Bactrian camel, but have recently been distinguished from the domestic Bactrian camel as a species of its own (Ji et al., 2009).

These three camel species belong to the Camelidae family (Table 1.1) of the order Artiodactyla and the suborder Tylopoda (animals with padded feet) and are different from the true ruminants although the former also “ruminates” (chew the cud). Camelids diverged from ruminants during the evolution between 40–45 million years ago (mya).

The small camelids are the New World camels (NWC) of South America. They are two domestic species (llama and alpaca) and two wild species (guanaco and vicuña).



**Fig. 1.1** A herd of dromedary camels (*Camelus dromedarius*) of the ethnic group Rendille, in Kenya (photo by Dr. Set Bornstein)

**Table 1.1** Classification of camelids

Class	Mammalia
Order	Artiodactyla
Suborder	Suiformes
Suborder	Tylopoda
Family	Camelidae
Tribe	Camelini
Old World	<i>Camelus dromedarius</i> (one-humped), dromedary camel
	<i>Camelus bacterianus</i> (two-humped), Bactrian camel
	<i>Camelus ferus</i> (two-humped) wild camel, <i>the Tartary camel</i>
Tribe	Lamini
New World	<i>Lama glama</i> —(llama)
	<i>Lama guanicoe</i> (guanaco)
	<i>Vicugna pacos</i> —(alpaca)
	<i>Vicugna vicugna</i> (& two subspecies)



## 1.1 History of the Old-World Camelids (OWC): Starting Point North America

The evolutionary history of dromedary and Bactrian camels goes back to the middle Eocene (between 40 and 45 million years ago, mya), when the ancestors of *Camelus* and the ancestors of the New World or South American camels (NWCs or SACs) emerged on the North American continent. After splitting into the tribes; Lamini and Camelini, the latter migrated via the Bering land bridge to the eastern hemisphere (the Old World). The earliest findings of camel-remains, found in Asia, are 5 mya (Kozhamkulova, 1986). The divergence between dromedary and Bactrian camels has been dated to 5 to 8 mya (Wu et al., 2015; Ji et al., 2009).

The closing of the Bering straits enabled the early Camelini to spread into Asia, the Middle East, eastern Europe, and Northern Africa and as far south as to northern Tanzania (Gentry & Gentry, 1969). Wild dromedary camels are thought to have lived in North Africa into the Neolithic period (10,000–4500 BC) and became extinct before 3000 BC (Bulliet, 1975). However, in the Middle East wild dromedaries were present although rarely seen in the southern region of the Arabian Peninsula as late as during Roman times (170–100 BC), (Mason, 1979).

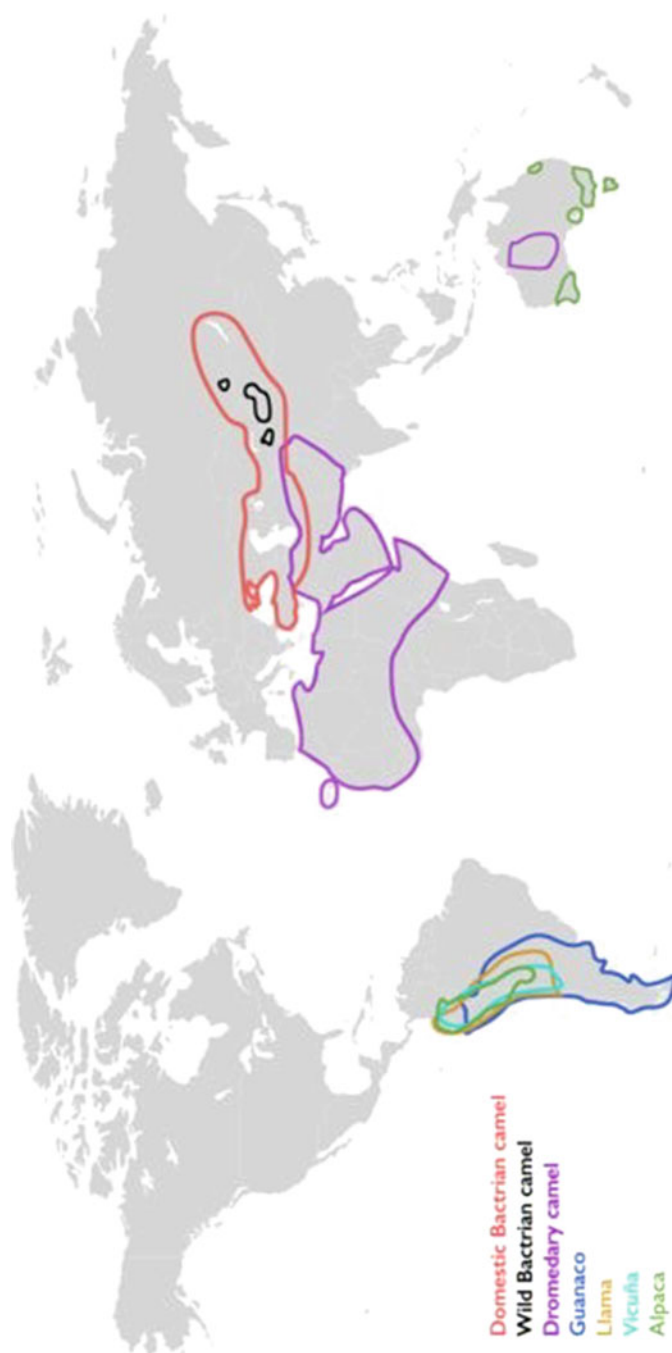The domestication of the dromedary camels is thought to have occurred between 1000 and 2000 BC (Curci et al., 2014; Uerpmann and Uerpmann, 2002). It has not yet been fully elucidated where domestication took place; in the Arabian Peninsula, Palestine, and/or other places in the Middle East and/or Iran. According to Bulliet (1975) it occurred in the region of Hadramut (Hadhramaut, situated on the southern coastline of the Arabian Peninsula; partly in the Yemen Republic and southwest of Oman). Whether the purpose of domestication was first for meat and milk or riding and as pack animals is disputed. In central parts of South Arabia camels are well represented in rock art as game and as riding animals. Bedouin tribes used dromedaries in their occupation of Palestine around 1100 BC (Wilson, 1984) (Fig. 1.2).

---

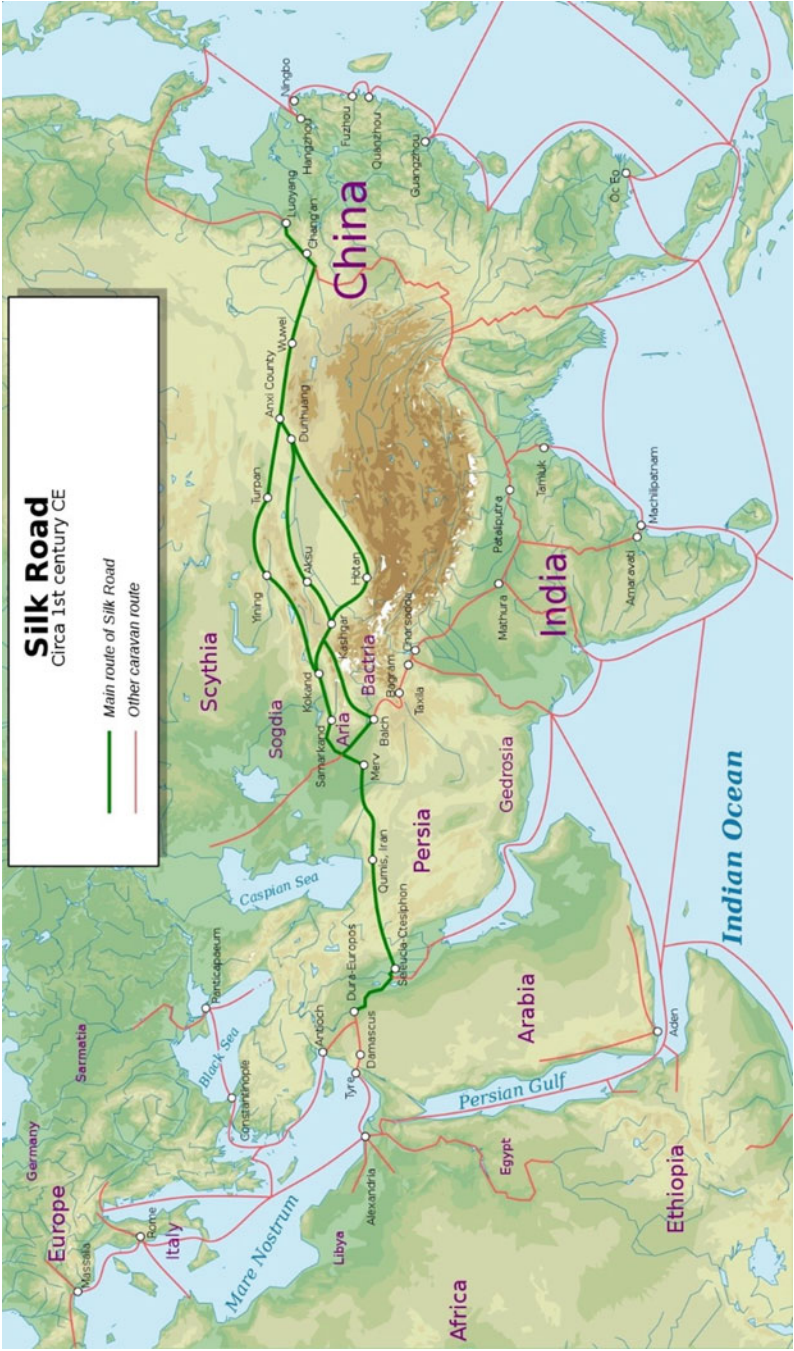## 1.2 A Beast of Burden

The camels being multipurpose beasts were and are not only essential to the subsistent economies of pastoralists and farmers but were and are employed as “beasts of burden.” Camels (both Bactrians and the dromedary camels) were the most common transporters of goods on the famous Old Silk Routes connecting East Asia with South Asia, Persia, the Arabian Peninsula, the Near East, and Southern Europe from the second century BC to the eighteenth century, contributing to the commercial and cultural exchange between the ‘east and west’ (Fig. 1.3).

On the first leg on the Old Silk Roads from China westwards, Bactrian camels were the first to be used as pack animals on the caravans. In Mesopotamia, and in the highlands of Iran and Afghanistan, goods were reloaded on hybrids, between the Bactrians and the dromedary camels, and further west the goods could again be reloaded onto new pack animals, dromedary camels (Mason, 1979).



**Fig. 1.2** Distribution map of the different camelid species (reproduced with permission from Zarrin et al. (2020))



**Fig. 1.3** The Silk Road was a network of trade routes which connected the East and West, and was central to the economic, cultural, political, and religious interactions between these regions from the second century BC to the eighteenth century. Image © Kaidor, published under CC BY-SA 4.0, via Wikimedia Commons

The different species of *Camelus* interbreed readily. All the karyotypes of the camelids have the same number ( $2n = 74$ ), sharing almost identical chromosomes with only slight variations in the amount and distribution patterns of heterochromatin (Balmus et al., 2007). The first-generation hybrid camels are often larger, covered with more fur, and more robust with even greater loading capacity and ability to work in hilly terrains in the wet and cold environment than the parent generations of Bactrian and dromedary camels (Dioli, 2020).

Hybridization between Bactrian and dromedary camels has been carried out since ancient times in various areas of the Middle East and Central Asia. The background for such practice was to get better pack camels for trade caravans and military campaigns. The Ottoman army used hybrid camels extensively because of their exceptional loading capacity: 400–500 kg and their ability to withstand cold and hilly terrains (Leese, 1927).

The OWCs were well known in the Roman world. They were bred as beasts of burden for both military and trade purposes (Pigièrè & Henrotay, 2012; Toynbee, 1973). Camels were also used as riding animals and in agriculture in southern Europe. Some records have been found of camel fighting and racing. Written sources describe the drinking of camel milk and the eating of camel meat. These geographical areas included modern day area of Turkey and Europe.

Today, camel hybridization is practiced in eastern Turkey (Yilmaza & Ertugrul, 2014) and more extensively and more systematically in the former Soviet Republics of Kazakhstan and neighboring Turkmenistan and Uzbekistan (Dioli, 2020; Faye & Konuspayeva, 2012). In Turkey camel crossbreeding between male Bactrian and female dromedary camels is mainly done to acquire larger animals for the annual camel wrestling competitions (Dioli, 2020). In Kazakhstan and neighboring countries, the focus of hybridization is to get camels that produce more milk, wool, and meat and at the same time are more resistant to the harsh climate of Central Asia (Imamura et al., 2017). Hybrids may have a higher milk production than the Turkmen dromedary camels and have a higher live weight than the dromedary and the Bactrian camel parent generations (showing heterosis or hybrid vigor).

Kazakhstan, being the largest country in former Soviet Central Asia with a population of both dromedary and Bactrian camels, has complex camel hybridization practices with well-established crossbreeding strategies developed by Kazakh and Russian scientists.

As early as 1000 BC the “Ships of the desert”<sup>1</sup> were extensively used in the lucrative incense (frankincense and myrrh) trade transporting the valuable goods from Yemen and Oman, “Felix Arabia” (Happy/Fortunate Arabia), crossing the “Empty Quarter,” a large stretch of hostile desert where the dromedaries were irreplaceable as pack animals. These journeys could take the caravans between 50 to 70 days to accomplish.

---

<sup>1</sup> According to Bulliet (1975) the expression “ship of the desert” derives from the seafaring people of southern Arabia.

Arab merchants made fortunes controlling the merchandise carried on dromedaries on the land route from the harbors of the southern shores of the Arabian Peninsula (southern Yemen). There the goods transported from the east on ships were reloaded onto dromedary camels for transport to the northeastern coast of the Mediterranean via ancient trade routes passing through some famous trade centers and market towns of the Nabateans, like the famous Petra.

In North Africa dromedaries carried salt and grain from Maghreb through the Sahara reaching West Africa and when returning carried gold and slaves. Similar dromedary salt caravans are still to be seen between Taoudeni and Timbuktu, in Niger, Mali, and Ethiopia (Kaufmann, 1998).

Since domestication, the dromedary/Arabian camels were most probably used as valuable riding animals as they have been ever since—both for civilian and for military purposes. The fact that camels can go without water for days on end (7–21 days) makes them uniquely suited as multipurpose domestic animals in the arid zones of the world.

The riding camels of the Bedouins in the Middle East, the camels of the Tuaregs of Maghreb, the famous Anafi and Bishari strains of dromedary camels of the nomads of eastern Sudan, and many more are famous for their endurance and speed. Camels were used as cavalry as well as mounted infantry since the Roman age. Napoleon used dromedaries in Egypt 1799–1801, the British army in the Nile campaign 1884–1885, as well as the French in local troops and in their “Foreign Legion” (Wilson, 1984). Camels were used to deliver mail, e.g. in Sudan where post travelled long distances from Khartoum via El Obeid to El Fasher, a distance of 1400 km covered in 9 days.

---

### 1.3 A True Ship of the Deserts

The dromedary camels, also known as the ship of the desert referring to their extremely well adaption to hot and arid environments are mainly found as important domestic species today in northern Africa; the Maghreb including Egypt, Mauretania in the west, right across the Sahel to the Horn of Africa in the east including also parts of Niger, Nigeria, Cameroon, Uganda, and recently Tanzania. They are also common in the Middle East and western and central Asia (Afghanistan, Iran, Pakistan, and India, Turkmenistan, Kazakhstan), reared mainly in nomadic, transhumance, and sedentary production systems.

A large feral population of dromedary camels roams the vast semi-desert regions of inland Australia. They were imported in the nineteenth century. About 10,000–12,000 were introduced between 1860 and 1907 from Afghanistan and India for transport (draught and riding) and construction work. The camels soon became superfluous following the introduction of the more effective motorcars and were released into the bush. Despite their natural relatively slow reproductive rate the camels did extremely well establishing free-ranging herds of feral camels. They are the only dromedaries living freely and exhibiting wild behavior in the world today.

With the aim of reducing the estimated numbers of >1 million (< 1.5 million heads) a big culling program was initiated 2008–2013 because the camels were alleged to cause serious degradation of local environments and cultural sites, *particularly during very dry conditions*. The executors of the culling operation estimated that the culling resulted in 300,000 heads of camels left, but these and earlier estimations are disputed.

The one-humped camel has been introduced to many other regions outside its traditional areas of distribution. Dromedary camels were exported to the Canary Islands in 1405; their populations survive there today, altogether numbering about 2000 that are primarily working in the tourist sector. Between the 17th and 19th centuries attempts were made to introduce the dromedary camel to the Caribbean, Peru, Bolivia, Colombia, and Brazil. They were imported to the western United States in the 1850s but in most of these places dromedaries no longer exist today in any significant numbers (Leese, 1927). Apart from smaller numbers of camels in zoos and private gardens, there has recently been an increase of dromedary dairies in the USA as it is in Australia.

Camels were also imported in four separate entities into southern Africa at the end of the nineteenth and the beginning of the twentieth centuries. The German Colony of south West Africa was the principal country among these southern African countries who imported more than 2000 dromedary camels from different “camel countries.” These animals were used by the military in operations against the local people, in transporting goods for railway construction, for postal deliveries, and by police patrols. Camels were replaced by mechanized transport by the police toward the end of the 1930s. In the early twenty-first century there are probably less than 200 camels in Namibia, and they are mainly used for tourism (Wilson, 2012).

The Bactrians have a heavier fur and are better adapted to a cooler arid environment than the dromedaries. They carry out similar roles as the dromedaries and coexist with dromedaries in Iran, Afghanistan, in Turkmenistan, Uzbekistan, and Kazakhstan. In Mongolia and China in areas where the climate may become searingly hot >45 °C in the summer and can drop to—40 °C in winter, the Bactrians are the sole camelids.

---

## 1.4 The World Camel Population

The (current) official number of camels present in the world is estimated to be about 35.5 million heads (FAOSTAT, 2020, Table 1.2). Of these, 95% are dromedary camels. But among the 46 nations that declare they have camel populations only 50% provided the data to the FAO through their respective national ministries (available FAOSTAT database in 2018), the remainder was based on estimates by the FAO (Faye, 2015). According to Faye (2015) the population of camels globally is probably more than 40 million and could reach 60 million within 25 years if the current trend in population increases continuous. Not recorded are some dromedary camel dairy farms of insignificant numbers found in, e.g., the Netherlands, in Spain, in France, in Germany, in Southern Africa, and in Australia where captured feral



**Table 1.2** Estimated populations of Old-World Camel's distribution worldwide (FAOSTAT, 2020, including a few reports from other sources)

<b>North Africa</b>		<b>Middle East</b>	
Morocco	660,808 <sup>a</sup>	Palestine (West Bank) <sup>c</sup>	1500
Western Sahara	69,000 <sup>b</sup>	Israel	5552
Tunisia	237,516	Lebanon	129
Algeria	416,519	Jordan	12,841
Libya	66,667	Syria	39,725
Egypt	119,885	Turkey	1708
<b>SubTotal</b>	<b>1,501,395</b> (excl West Sahara)	Iraq	91,198
		Kuwait	11,825
<b>North East Africa</b>		Saudi Arabia	492,853
Somalia	7,243,792	Yemen	432,682
Sudan (North)	4,895,000	Oman	273,490
Kenya	4,721,900	UAE	461,788
Ethiopia	1,281,468	Bahrain	1111
Eritrea	388,152	Qatar	115,295
Djibouti	70,894	Iran	137,259
<b>SubTotal</b>	<b>18,601,206</b>	<b>SubTotal</b>	<b>1,975,186</b>
<b>East Africa</b>		<b>Asia</b>	
Tanzania	400 (Wilson, 2011)	Afghanistan	170,368
Uganda	41,000 (Wilson, 2017)	Pakistan	1,090,000
		India	251,956
<b>West Africa</b>		Russia <sup>c</sup>	5863
Mauretania	1,500,973	Azerbaijan	213
Nigeria	289,794	Kyrgyzstan	247
Niger	1,834,943	Tajikistan	61
Senegal	5030	Turkmenistan	127,405
Mali	1,241,093	Kazakhstan	216,358
Chad	8,276,416 <sup>d</sup>	Uzbekistan	19,961
Burkina Faso	20,345		
<b>SubTotal</b>	<b>13,168,594</b>	<b>SubTotal</b>	<b>1,882,438</b>
		Australia	300,000 <sup>f</sup> feral number of domestic camels unknown
<b>Southern Africa</b>			
Botswana	200	<b>Bactrian camels of</b>	
Namibia	93		

(continued)

**Table 1.2** (continued)

<b>Africa SubTotal</b>	<b>31,811,493</b>	Mongolia	472,379
<b>World dromedary (dom)</b>	<b>35,669,117</b>	China	405,300
		<b>Subtotal<sup>g</sup></b>	<b>877,679<sup>g</sup></b>

<sup>a</sup>West Sahara's camel populations are included in Morocco's

<sup>b</sup>The dromedary camels in Western Sahara recorded in FAO database are included in Morocco! In 2019 Western Sahara numbered 110,000 heads (FAOSTAT, 2020) and 6 years earlier 56,000

<sup>c</sup>Volpato and Howard (2014), Ereqat et al. (2020)

<sup>d</sup>In Chad, the population suddenly increased from 1,550,000 heads in 2014 to 6,413,000 in 2015 and into >8 million in 2019 (according to FAOstat). In Nigeria, the ratio between the camel population in 2013 and in 2012 was 14:1 (285,000 vs 20,500). Less important but still surprising, strong spikes occurred in Saudi Arabia (in 2015), in Qatar (in 2011), and in Oman (in 2013). In Chad, this spectacular change was linked to the official census of the national livestock achieved in 2014. Due to this unexpected change in the camel population, FAO has recently modified its former estimations (Faye, 2015)

<sup>e</sup>The camels in Ukraine are found mainly in Crimea, presently part of Russia

<sup>f</sup>The numbers of feral dromedary camels in Australia can be >1 million heads! The estimations are very unreliable

<sup>g</sup>The numbers of Bactrian camels coexisting with dromedary camels are not recorded, i.e. from countries in Turkey, Iran, Afghanistan, and in the former Soviet Union including significant numbers in Kazakhstan

dromedaries during recent years have been re-domesticated and turned into milk producers, in addition to racing animals and for the tourist industry. Smaller herds of Bactrians and dromedaries are found in many countries worldwide in private farms, zoological gardens, in circuses, etc. FAOSTAT does not distinguish between Bactrians and dromedary camels since a few years (Faye, 2015)!


## 1.5 The Virtues of the Camel

Not only do the camels survive and reproduce, utilizing the meager and sparse vegetation and the scarce water resources in dry arid zones, but they also provide milk, meat, wool (fiber), hair, hides, dung, and bone. Additionally, they are versatile working animals (multipurpose), being used for riding, load-carrying, fetching drinking water to homesteads, moving homes and performing several types of traction work in small industry (e.g., operating oil mills) and farming. Relatively recently dromedaries have become very popular and lucrative “racing animals” in the Middle East, particularly in the UAE and also in Australia. Furthermore, they are significant assets in the tourist sector.

The close association between dromedary camels and desert dwellers in the Arabian Peninsula and possibly elsewhere for more than thousands of years has had a profound impact on Arabic, Islamic, and tribal traditions.

An important feature of these animals is that they are mainly browsers (although do well as grazers feeding on grasses and smaller plants as well) and may reach feeding resources to a height of sometimes over 3.5 m in bushes and trees (Fig. 1.4).





**Fig. 1.4** Dromedary camels (*Camelus dromedarius*) doing well in lush bushy ranch- and grass lands in northern Kenya, after the rains (picture to the left). To the right an Arabian camel (*C. dromedarius*) following the dry season with plenty of browse reaching a few meters above the dry overgrazed ground (photos by Dr. Set Bornstein)

Thus, in many environments the camels do not compete with any other ruminant livestock on the range. Their choice of food depends on the availability of vegetation—not so much on availability of water sources because they do not need to be watered as often and regularly as other livestock.

The OWCs developed many very sophisticated adaptation mechanisms to cope with the extreme climatic conditions they live in. Below are listed some significant anatomical, physiological, and behavioral characteristics of dromedaries (*Camelus dromedarius*), that developed through millions of years of adaptations to cope with arid environments and dehydration:

1. A single hump is filled with fat serving as an energy store used in periods of food shortage.
2. The muscles of the nostrils allow the animal to control the inflow of air, thus avoiding inhalation of too much sand during sandstorms.
3. The foot of the camel is excellent for moving on sand, less suitable on stony deserts but the soles harden after becoming accustomed. The camel's feet have two toes (digits) and are well-padded. When hitting the ground, the feet spread out stopping the camel from sinking into the often-hot sand.
4. The camels are tall with relatively long thin legs allowing exposure of the abdomen, to the winds. The fairly large body surface permits the air to cool the body and enhances cooling by increased evaporation. In addition, in the recumbent position the sternum of the camel takes a "plate-like" position also permitting increased air circulation.
5. At the height of the day after feeding for a few hours and without shading trees available all the camels will take their rest facing the sun or turning their back to

it. In this way they avoid the main impact of the scorching heat onto the main part of their body.

6. The red blood cells (RBCs) are small (6.5  $\mu$ ), lack a nucleus, and have an oval shape allowing the RBCs to expand significantly more than those of many other animals, e.g. when rehydrating after two to three weeks of dehydration. Theoretically their oval shape facilitates their flow in the blood vessels in dehydrated camels.
7. The RBCs membrane has a distinctive phospholipid composition that results in a more fluid membrane which enables the RBCs to tolerate high osmotic variations without rupturing even under rapid rehydration.
8. Platelets can resist temperatures of 43–45 °C which would cause marked structural and functional alterations in, e.g., humans.
9. Antibodies in *C dromedarius* consist of dimeric heavy chains without the light chains (Hamers-Casterman et al., 1993).<sup>2</sup>
10. The stomach of the camelids is different from the ruminants who have four compartments compared to the three compartments of the former.
11. Camels like many other land animals fall back on selective brain cooling when it is subjected to heat stress. This protects the heat-sensitive brain tissue from heat stress and at the same time increases the animal's tolerance to high temperatures. This is accomplished by the blood being cooled in the nasal cavity by evaporative heat loss and the blood diverted to the brain sinuses via the nasal and angular veins. In the cavernous sinus, the arterial blood in the carotid rete is cooled by the cooler venous blood before entering the brain (Elkhawad, 1992).
12. The camel's temperature tolerance allows it to store heat during the middle of the day, increasing its body temperature with about 2 °C, which it can dissipate during the cooler parts of the night. This is its normal adaptation to a hot climate when not being dehydrated. This should be borne in mind when recording the body temperature of a diseased camel during the heat of the day. A body

---

<sup>2</sup>Camelids, including both OWCs and NWCs possess an unusual antibody repertoire (De Genst et al., 2006). They possess normal H<sub>2</sub>L<sub>2</sub>-type IgG<sub>1</sub>-like antibodies, as well as IgM, IgD, IgE, and IgA antibodies similar to other mammals. However, another set of antibodies has been identified in addition to conventional antibodies in camelids (Hamers-Casterman et al., 1993). These antibodies lack the light chains as well as one constant domain of the heavy chain (CH1 domain) present in conventional antibodies, thus they are commonly called heavy chain antibodies [HCABs]. The antigen specificity in these HCABs is confined to the variable domain of the heavy chain (VHH, nanobody), and this domain is often referred to as single-domain antibody (sdAb). In HCAB, the VHH is considered as the structural and functional equivalent of the Fv fragment of conventional antibodies, with the main difference that it consists only of one variable fragment composed of a single polypeptide chain. Hence, it has only approximately half the size (about 15 kDa) of the Fv fragment. This monomeric structure of the VHH makes protein engineering, recombinant production as well as heterologous expression in cellular systems considerably easier (Muyldermans, 2001, referring VHHs or sdAb as nanobodies). Overall, the small size, high solubility, specificity, adaptability, and stability make nanobodies a perfect tool for basic research as well as for diagnostic and therapeutic applications. Because of their small size, nanobodies can be synthetically expressed of plasmids in bacteria, and they can target epitopes that are hard for antibodies to get to, like ones that are hidden in the molecular crevices of proteins on the cell surface.

temperature on the thermometer display of 40 might actually be ca. 38 °C, 12 h later.

13. Another supporting mechanism within adaptive heterothermy is the ability of camels to fluctuate their body temperature between 34.6 and 40.6 °C, minimizing perspiration and water loss through evaporation. This means that they may gain around 6 liters of water per day, water that would otherwise be lost through sweating. This only occurs during prolonged periods (>1–3 weeks) of dehydration and heat stress during the hot seasons. Thus, the amplitude of daily body temperature rhythm exceeds 6 °C (Schmidt-Nielsen et al., 1957). Arabian camels use heterothermy to reduce heat surplus. The dehydration induces a decrease in food intake that plays a role in this process (see below paragraph 15).
14. A dehydrated camel with a loss of 25–30% of its body weight can fairly quickly, rehydrate. An adult camel of 600 kg thus can drink within a few minutes nearly 200 l of water. A feat no one else among mammals can copy.
15. A dehydrated lactating camel can continue its lactation but with consequences. Contrary to earlier beliefs recent studies have shown that the milk of dehydrated camels is not diluted. Instead, milk osmolality increased in parallel to osmolality in the blood (Bekele et al., 2011). Being deprived of water the camels maintained the milk volume for a week but started to yield less milk during the second and third week of water deprivation (see above paragraph 13).
16. Kidneys can efficiently excrete highly concentrated urine, consequently tolerating high salt concentrations.
17. Camels can happily drink quite salty water—as salty as the concentration in the oceans.
18. Camels browse preferably on “salty bushes” often found in arid lands. This demonstrates the high requirements the camels have for regular intake of salt, significantly more than other livestock need.
19. The feces of camels are also very dry. This is another way of saving water.

---

## 1.6 The Importance of this Multipurpose Animal: The Camel

The camels are one of the many wonders of evolution with their very special adaptations to arid environments. It is of great importance for people; culturally, socially, economically, particularly in areas of otherwise low productivity. Despite the keeping and utilizing the animals for special purposes; for the production of milk and meat, for transport, racing, etc., few selection programs have been applied yet. A few have been performed “scientifically” in breeding—i.e. selection pressure has been low with few exceptions. This is changing.

## 1.7 Some Significant Camel Products

### 1.7.1 Milk

In many countries milk production is the main aim in rearing dromedary camels. Traditional camel farming systems are extensive and the majority of the world's camels are still husbanded according to old traditions. But these traditions show high variability, exhibiting important productivity increase, particularly in the development of modernized farming systems.

For people breeding dromedaries in arid lands milk is of extraordinary importance:

- (a) The lactations period is often over a year (12–18 months). Thus, there is a supply of milk even during the very dry seasons when other milking livestock are dry. The main part of the daily milk is consumed by the households—thus contributing significantly to the food security in these arid lands.
- (b) There is a growing market for selling the milk locally but also to urbanized populations in many areas and even in cities further away.
- (c) There is an increase of peri-urban camel farming systems integrating into local markets.
- (d) There is also an interest from settled entrepreneurs in developing dairy intensive systems. Such systems exist in Mauretania, Kenya, the Emirates, Saudi Arabia, Kazakhstan, the Netherlands, the USA, and Australia.

In many dromedary cultures the women are the ones who decide and are responsible for the milk, its distribution and economy. In several African countries women are the distributors of the milk from the “farmstead” (boma) to the consumers. Giving priority to their younger children and vulnerable neonatal livestock is paramount—with enough nutritious food better survival and growth is achieved. In addition, the cash from milk sales will undoubtedly go toward paying for necessities including school fees. A similar situation exists in Pakistan where women not only are involved in the rearing of camels but also convert the fresh milk into useful products and market them (Faraz et al., 2013).

At the world level camel milk represents about 0.23% of consumed milk. Faye (2015) estimates the milk production of camels to be 6 million tons a year. The price of camel's milk is significantly higher (up to 30 times higher) than milk from other dairy animals in Africa, the Middle East, Australia, the USA, Europe, and recently in India.

However, there are exceptions to this rule; Pakistan's annual production of camel milk in 2012 was 818,000 tons of camel milk, which amounts to 1.8% of the total milk production in Pakistan (GoP, 2012). However, camel milk is not so appreciated in Pakistan as it is in many other countries with substantial camel populations. This could explain the lower price for camel milk compared to cow's milk. However, camel milk is found on the market in big cities, sold as pure milk or mixed with milk

from cows and buffaloes, especially when the supply of the latter cannot meet the demand of the market (Yaqoob & Nawaz, 2007).

The milk from camels was traditionally seen as a powerful aphrodisiac and has been used in traditional medicine (Galil et al., 2016). These ideas are still present and have influenced the western world for several decades. The momentum for camel dairy products has been slowly gaining popularity across the world, mainly due to the growing interest in the medical properties camel milk is alleged to have. There is a strong belief, widely spread, that the milk of camels has a very significant positive medical impact on a variety of diseases including autism, diabetes, liver disease, jaundice, and even cancer (Mohammadabadi, 2020). Demands are growing and so is the price.

### 1.7.2 Meat

Meat from camels represents 0.13% of the total amount of meat produced in the world and 0.41% of red meat from herbivorous animals (Faye, 2014). Contrary to milk, which is still mainly integrated into local markets, meat from camels is found in international as well as local markets. Guests are usually offered roasted meat from sheep and goats rather than the much more valued (and heavy) camel. Usually live animals, males, and unproductive elderly females are sold. It is often an important “by-product” giving significant incomes. There are export opportunities to large markets in Saudi Arabia, Egypt, Libya, the Gulf, and other Arab nations. About 170,000 camels are slaughtered in various countries during the annual Muslim festival of Eid-al-Adha (Faraz et al., 2013).

The trekking and shipment of camels for slaughter from countries in the Horn of Africa (HA) and Sahel to Egypt, the Kingdom of Saudi Arabia, Qatar, the UAE, Yemen, Libya, and also Bahrain is the largest cross-border camel trade globally. The value is about USD 1000 per adult camel, representing the most valuable livestock export species in the HA. The estimated number of camels exported annually from Somalia and Sudan varies between 250,000 and 300,000 (Younan et al., 2016). In 2012, 304,681 camels were officially exported by Intergovernmental Authority on Development (IGAD) member states, mainly Somalia and Sudan, to the Middle East and to North Africa representing an estimated trade value of 365,000,000 USD (Dr. A. Sebsibe, IGAD/ICPALD Director Livestock, personal communication 2015; Younan et al., 2016).

---

## 1.8 Hair, Wool, Skin, and Hides

“Most countries have resources from livestock that can provide hides and skins for making leather, garments, shoes, handbags, and other leather goods. Hides and skins are most commonly a by-product of meat, milk, or wool production. They become available when an animal is eventually slaughtered and flayed. In developed countries, hides and skins are produced during the course of slaughter in purpose-

built premises (abattoirs), while in developing countries they often emanate from backyard slaughtering or informal slaughter” (Leach and Wilson, 2009).

### 1.8.1 Hair Wool (Fiber)

The fur of dromedary camel differs depending on the environment in which they live. In deserts where night and day temperatures may fluctuate a great deal and can drop significantly during the night, camels have developed a relatively good protection by growing relatively thicker fur as a protection against the cold.

The hair (fibers) from the dromedary is used for making clothes, tents, carpets, ropes, bags, saddle-girths, and blankets. In some countries the growth of the fine fibers growing on the hump of neonates is shorn once and this finer quality of fibers is made into finer products as blankets. Fully grown dromedary camels produce between 1–3 kg of hair per year.

Although wool and hair of the old-world camels are of lesser quality and value than that of the new world camels they still have both a local market as well as a global one which is not yet (fully) exploited.

### 1.8.2 Hides

Camel hides are important products that fulfill many functions. The hides are used to roof traditional houses of pastoral communities. They are also used for making ropes, guards, drums, seats, sandals, praying mats, and water and milk containers.

Among the Turkana community in Kenya, hide and skins are eaten as food, a practice also seen in other communities when food is scarce (famine food). However, the full potential of camel hides as an economical valuable resource has not yet been realized or exploited in many countries having large populations of camels. This may be due to poor quality, attributed to poor curing and flaying methods (AU-IBAR, 2006), and the common branding used in traditional medicine. Studies show that the economic value of camel hides is low as compared to those of cattle hides and sheep/goat skins, as most camel hides are used for domestic purposes (Kagunyu et al., 2013).

Saddles, shoes, and other useful and beautiful articles are made from hides of camels and those of good quality products of well-prepared hides will give better prices. “No hide is too big and no skin too small to provide a source of income and employment in rural areas. Hence it is an activity that many rural dwellers could take on” (Leach and Wilson, 2009) given the right conditions.

## 1.9 Racing Camels

Camel racing refers mostly to the running competition of dromedaries, rather than that of the Bactrian camels. The name dromedary is derived from the Greek verb *dramein*, “to run.” The racing of camels was long a folk sport practiced by the local population at social gatherings and festivals with perhaps a long history from several 1000 years ago—spreading from the Arabian Peninsula, the cradle of the dromedary/Arabian camel. In many countries from Kenya, Sudan, Egypt to India and Australia—but particularly in the Arab countries of the Middle East—the sport has become extremely popular, giving rise to its own training, breeding, and research centers.

Camels are now specially raised for the track, using sophisticated methods of breeding, training, and nutrition. Special artificial insemination and embryo transfer techniques are used for crossbreeding selection of lineages. In the UAE, which is the center of camel racing in the Middle East, sophisticated training methods, such as working animals on treadmills and in swimming pools, are used to prepare racing camels for competition, and the local government encourages breeding programs and provides subsidies to camel owners and breeders. Well-bred racing camels with excellent track records can sell for very high prices as well as give high prize money. In 2017 winning prizes was \$2 million in the UAE and a racing camel bull, e.g., was sold for \$9.5 million. Big money can be won on camel races also elsewhere in the Middle East and even in Australia. The biggest prize money in Australia was in the “The Boulia desert Sands” races in Queensland with a \$500,000 prize purse.

Despite the important role of camels in the livelihood, food security, economy, and cultural identity of many communities these animals have never really been considered major players in international animal production contexts, with few exceptions. Changes associated with climate change may modify this scenario in the near future (Zarrin et al., 2020).

---

## References

- AU-IBAR. (2006). *Kenya livestock sector study: An analysis of pastoralists' livestock products, market value chains and potential external markets for live animals and meat*. African Union Interafrican Bureau for Animal Resources.
- Balmus, G., Trifonov, V. A., Biltueva, L. S., et al. (2007). Cross-species chromosome painting among camel, cattle, pig and human: Further insights into the putative Cetartiodactyla ancestral karyotype. *Chromosome Research*, 15, 499. <https://doi.org/10.1007/s10577-007-1154-x>
- Bekele, T., Lundeheim, N., & Dahlborn, K. (2011). Milk production and feeding behavior in the camel (*Camelus dromedarius*) during 4 watering regimens. *Journal of Dairy Science*, 94(3), 1310–1317. <https://doi.org/10.3168/jds.2010-3654>
- Bulliet, R. W. (1975). *The camel and the wheel*. Harvard University Press.
- Curci, A., Carletti, M., & Tosi, M. (2014). The camel remains from site HD-6 (Ra's al-Hadd, Sultanate of Oman): An opportunity for a critical review of dromedary findings in eastern Arabia. *Anthropozoologica*, 49(2), 207–224. <https://doi.org/10.5252/az2014n2a04>
- De Genst, E., Silence, K., Decanniere, K., Conrath, K., Loris, R., Kinne, J., Muyldermans, S., & Wyns, L. (2006). Molecular basis for the preferential cleft recognition by dromedary heavy-



- chain antibodies. *Proceedings of the National Academy of Sciences of the United States of America*, 103(12), 4586–4591. <https://doi.org/10.1073/pnas.0505379103>
- Dioli, M. (2020). Dromedary (*Camelus dromedarius*) and Bactrian camel (*Camelus bactrianus*) crossbreeding husbandry practices in Turkey and Kazakhstan: An in-depth review. *Pastoralism*, 10(6), 1–20. <https://doi.org/10.1186/s13570-020-0159-3>
- Elkhawad, A. O. (1992). Selective brain cooling in desert animals: the camel (*Camelus dromedarius*). *Comparative Biochemistry and Physiology. Comparative Physiology*, 101(2), 195–201. [https://doi.org/10.1016/0300-9629\(92\)90522-r](https://doi.org/10.1016/0300-9629(92)90522-r)
- Ereqat, S., Nasereddin, A., Al-Jawabreh, A., et al. (2020). Prevalence of *Trypanosoma evansi* in livestock in Palestine. *Parasites Vectors*, 13(21), 1–8. <https://doi.org/10.1186/s13071-020-3894-9>
- FAOSTAT. (2020). Accessed January 2021, from <http://www.fao.org/faostat/en/#data/QA>
- Faraz, A., Mustafa, M. I., Lateef, M., Yaqoob, M., & Younas, M. (2013). Production potential of camel and its prospects in Pakistan. *Punjab University Journal of Zoology*, 28(2), 89–95.
- Faye, B. (2014). The camel today: Assets and potentials. *Anthropozoologica*, 40(2), 15–20. <https://doi.org/10.5252/az2014n2a01>
- Faye, B. (2015). Role, distribution and perspectives of camel breeding in the third millennium economies. *Emirates Journal of Food and Agriculture*, 27(4), 391–449. <https://doi.org/10.9755/ejfa.v27i4.19906>
- Faye, B. (2020). How many large camelids in the world? A synthetic analysis of the world camel demographic changes. *Pastoralism*, 10, 25. <https://doi.org/10.1186/s13570-020-00176-z>
- Faye, B., & Konuspayeva, G. (2012). The sustainability challenge to the dairy sector – The growing importance of non-cattle milk production worldwide. *International Dairy Journal*, 24(2), 50–56. <https://doi.org/10.1016/j.idairyj.2011.12.011>
- Galil, A., Gader, A., & Alhaider, A. A. (2016). The unique medicinal properties of camel products: A review of the scientific evidence. *Journal of Taibah University Medical Sciences*, 11(2), 98–103. <https://doi.org/10.1016/j.jtumed.2015.12.007>
- Gentry, A. W., & Gentry, A. (1969). Fossil camels in Kenya and Tanzania. *Nature*, 222(5196), 898.
- GoP. (2012). *Economic survey of Pakistan 2011–12*. Economic Advisor's Wing. Ministry of Finance, Government of Pakistan.
- Hamers-Casterman, C., Atarhouch, T., Muyldermans, S., Robinson, G., Hamers, C., Songa, E. B., Bendahman, N., & Hamers, R. (1993). Naturally occurring antibodies devoid of light chains. *Nature*, 363(6428), 446–448. <https://doi.org/10.1038/363446a0>
- Hare, J. (1998). *The lost camels of Tartary, A quest into forbidden China*. Little Brown.
- Imamura, K., Salmurzauli, R., Iklasov, V. M. K., Baibayssov, A., Matsui, K., & Nurtazin, S. T. (2017). The Distribution of the two domestic camel species in Kazakhstan caused by the demand of industrial stockbreeding. *Journal of Arid Land Studies*, 26(4), 233–236. [https://doi.org/10.14976/jals.26.4\\_233](https://doi.org/10.14976/jals.26.4_233)
- Ji, R., Cui, P., Ding, F., Geng, J., Gao, H., Zhang, H., Yu, J., Hu, S., & Meng, H. (2009). Monophyletic origin of domestic bactrian camel (*Camelus bactrianus*) and its evolutionary relationship with the extant wild camel (*Camelus bactrianus ferus*). *Animal Genetics*, 40(4), 377–382. <https://doi.org/10.1111/j.1365-2052.2008.01848.x>
- Kagunyu, A. W., Matiri, F., & Ngari, E. (2013). Camel hides: Production, marketing and utilization in pastoral regions of northern Kenya. *Pastoralism*, 3, 25. <https://doi.org/10.1186/2041-7136-3-25>
- Kaufmann, B. (1998). *Analysis of pastoral camel husbandry in Northern Kenya*. Weikersheim.
- Kozhamkulova, B. S. (1986). The Late Cenozoic two-humped (Bactrian) camels of Asia. *Quartärpläontologie (Abh. Ber. Inst. Quartärpläontologie Weimar)*, 6, 93–97.
- Leach, I., & Wilson, T. R. (2009). Value addition through hides and skins. Diversification booklet No 8, pp. 36. FAO.
- Leese, Z. S. (1927). *A treatise on the one-humped camel*. Haynes & Son.
- Mason, I. L. (1979). *Origin, history and distribution of domestic camels* (Camels: Provisional Report No. 6). IFS Symposium Camels. Sudan, pp. 21–34.



- Mohammadabadi, T. (2020). Camel milk as an amazing remedy for health complications: A review. *Basrah Journal of Agricultural Sciences*, 33(2), 125–137.
- Muyldermans, S. (2001). Single domain camel antibodies: Current status. *Journal of Biotechnology*, 74(4), 277–302. [https://doi.org/10.1016/s1389-0352\(01\)00021-6](https://doi.org/10.1016/s1389-0352(01)00021-6)
- Pigière, F., & Henrotay, D. (2012). Camels in the northern provinces of the Roman Empire. *Journal of Archaeological Science*, 39, 1531–1539.
- Schmidt-Nielsen, K., Schmidt-Nielsen, B., Jarnum, S. A., & Houpt, T. R. (1957). Body temperature of the camel and its relation to water economy. *The American Journal of Physiology*, 188, 103–112.
- Toynbee, J. M. C. (1973). *Animals in Roman life and art*. Thames and Hudson.
- Uerpmann, H. P., & Uerpmann, M. (2002). The appearance of the domestic camel in south-east Arabia. *Journal of Oman Studies*, 12, 235–260.
- Volpato, G., & Howard, P. (2014). The material and cultural recovery of camels and camel husbandry among Sahrawi refugees of Western Sahara. *Pastoralism*, 4, 7. <https://doi.org/10.1186/s13570-014-0007-4>
- Wilson, R. T. (1984). *The camel*. Longman.
- Wilson, R. T. (2011). The one-humped camel and the environment in Northern Tanzania. *Journal of Camel Practice and Research*, 18(1), 25–29.
- Wilson, R. T. (2012). The one-humped camel in Southern Africa: Imports to and use in South West Africa/Namibia. *Journal of Camel Practice and Research*, 19, 1–6.
- Wilson, R. T. (2017). The one-humped camel in Uganda. *Journal of Camel Practice and Research*, 24, 1–7.
- Wu, H., Guang, X., Al-Fageeh, M. B., Cao, J., Pan, S., Zhou, H., Zhang, L., Abutarboush, M. H., Xing, Y., Xie, Z., Alshanqeeti, A. S., Zhang, Y., Yao, Q., Al-Shomrani, B. M., Zhang, D., Li, J., Manee, M. M., Yang, Z., Yang, L., . . . Wang, J. (2015). Camelid genomes reveal evolution and adaptation to desert environments. *Journal of Nature Communications*, 28(6), 6107. <https://doi.org/10.1038/ncomms7107>
- Yaqoob, M., & Nawaz, H. (2007). Potential of Pakistani camel for dairy and other uses. *Journal of Animal Science*, 78, 467–475.
- Yilmaza, O., & Ertugrul, M. (2014). Camel wrestling culture in Turkey. *Turkish Journal of Agricultural and Natural Sciences*, 2, 1998–2005.
- Younan, M., Bornstein, S., & Gluecks, I. V. (2016). MERS and the dromedary camel trade between Africa and the Middle East. *Tropical Animal Health and Production*, 48, 1277–1282. <https://doi.org/10.1007/s11250-016-1089-3>
- Zarrin, M., Riveros, J. L., Ahmadpour, A., de Almeida, A. M., Konuspayeva, G., Vargas Bello-Pérez, E., Faye, B., & Hernández-Castellano, L. E. (2020). Camelids: new players in the international animal production context. *Tropical Animal Health and Production*, 52(6), 3931–3932.

---

## **Part I**

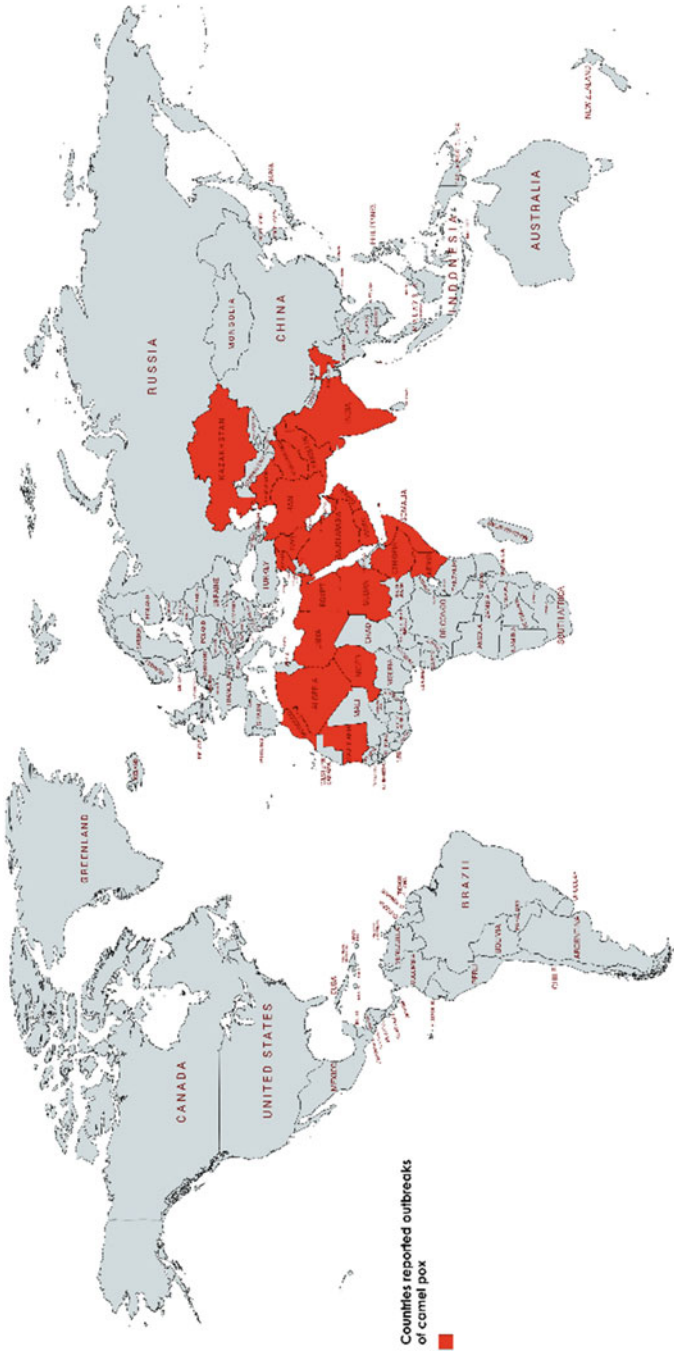
# **Viral Diseases of Dromedary Camels**

Abdelmalik I. Khalafalla

Camel pox is the only species-specific camel disease included in the OIE's list of reportable diseases. Camel pox is a highly contagious skin disease and the most frequent infectious viral disease of the Old-World camelids (Dromedary and Bactrian camels) that occurs in almost every country in which camel husbandry is practiced except Australia (Fig. 2.1). Recently, cases of human infection have been reported in India and Sudan (Bera et al., 2011; Khalafalla & Abdelazim, 2017), but the pathogenicity of the causative virus for humans is still considered to be low. The disease was initially described in Punjab of India in 1909 (Wernery & Kaaden, 2002) and later sporadic or widespread outbreaks have been reported causing economic impact through loss of production and death.

## 2.1 Etiology

Camel pox is caused by the camel pox virus (CMLV) an enveloped DNA virus, which belongs to the genus Orthopoxvirus (OPXV) of the subfamily Poxvirinae in the family Poxviridae (ICTV, 2019). OPXV is morphologically, antigenically, and genetically different from the Parapoxvirus (PPV) genus of the same pox family that causes contagious ecthyma in camels. The virus replicates in the cytoplasm of the host cells and its early genes code for a variety of functions that modify the host cell for optimal virus replication, attenuate the host response to infection, and mediate virus synthetic processes. Phylogenetic analysis of CMLV revealed that CMLV is most closely related to variola virus (VARV), sharing all genes involved in basic replication functions and most genes involved in other host-related functions (Gubser & Smith, 2002). CMLV virions are large, enveloped brick-shaped and range in size from 265 to 295 nm. The virion consists of an envelope, outer membrane covered with irregularly arranged tubular proteins, two lateral bodies, and a core. The virus genome is a double-stranded linear DNA of approximately 205 kb with covalently linked ends.



**Fig. 2.1** Countries reported outbreaks of camel pox (red-color)

In general, pox virions show high environmental stability and can remain infectious over several months especially in crusts, serum, blood, and other excretions. However, CMLV is sensitive to both acidic and alkaline, autoclaving or boiling, and susceptible to various disinfectants including 1% sodium hypochlorite, 1% sodium hydroxide, 1% peracetic acid, formaldehyde, 0.5–1% formalin, and 0.5% quaternary ammonium compounds and readily killed by ultraviolet rays (245 nm wavelength) (Duraffour et al., 2011).

---

## 2.2 Modes of Transmission


The disease spread mainly by direct skin contact or inhalations from sick animals particularly at watering or grazing places. Indirect transmission occurs via a contaminated environment. Pox scabs shed from affected camels contaminate water or pasture that becomes source of infection (Khalafalla & Mohamed, 1996). According to camel herder's, camel pox occurs few days after co-watering with infected herd or the introduction of new animals to a herd through purchase or as a gift. Group watering and introduction of new animals to a susceptible herd are the main risk factors.

---

## 2.3 Clinical Picture

Camel pox is characterized by fever, enlarged lymph nodes, and skin lesions. The incubation period is usually between 1 and 2 weeks and sometimes could be 3 days. Affected animals may develop localized or generalized pox lesions of varying severity depending on age of animal or the strain of the virus as evidence suggest the circulation of both mild and virulent CMLV strains.

After 2–3 days of fever, the classical pox lesion goes through all the stages of pox lesions stages starting from rash or macules to papules, pustules, vesicles, scabs, or crusts and on recovery scars. The course of the disease takes 4–6 weeks before healing. Field observations show that camel pox has three different forms depending on availability and age of susceptible animals, season of the year and virus strain: 1) mild localized form without fever (Alhendi et al., 1994), 2) severe generalized form old with high fever, lymph node enlargement and lesions on internal organs, 3) sporadic cases in adult animals sometimes in a pattern of persistent infection (Yousif & Al-Naeem, 2012). The lesions are commonly seen on the head including the lips, nostrils (Fig. 2.2), ears and eyelids, neck, perineum, and the tail (Figs. 2.3, 2.4, and 2.5). In some cases, the mucus membrane of the oral cavity, limbs, genitalia, mammary glands are involved. Enlarged lymph nodes can be seen by naked eye and some cases are accompanied by lacrimation and pendulous lower lip. In severe form the virus can reach most of the internal organs including the liver, kidney, and lungs resulting in coughing and death of the affected animal. Abortion of pregnant animals is caused by high fever or septicemia caused by secondary bacterial infections.



**Fig. 2.2** Dromedary camel affected with camel pox showing pox lesions on lips and nostrils, Saudi Arabia (Courtesy of Dr. Ahmed Zeialabdeen)

---

## 2.4 Differential Diagnosis

- Camel contagious ecthyma.
- Camel papillomatosis.
- Camel dermatophilosis.
- Reaction to insect bites.

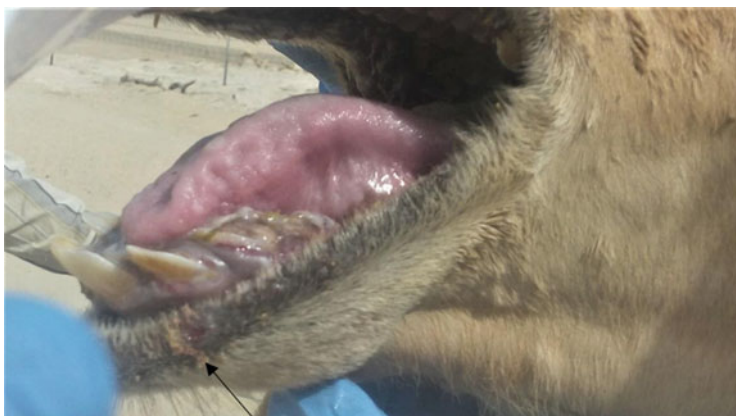
---

## 2.5 Pathogenesis and Pathology

The virus enters commonly through skin. However, the oronasal infection is also reported. Fever and lymph node enlargement proceed the appearance of skin lesion by 1–3 days. Skin lesions start as erythematous macules/nodules that develop into papules/vesicles which rupture to form pustule/ulcers and then scabs. After local replication and development of a primary skin lesion, the virus spreads to local lymph nodes and leads to a leukocyte-associated viremia. Widespread secondary skin lesions appear a few days after the onset of viremia, and new lesions continue to appear for 2–3 days, at that time the viremia subsides.

Histopathology of the skin lesion displays cytoplasmic swelling, vacuolation, and ballooning of the keratinocytes of the outer stratum spinosum, acanthosis, and dermal layer infiltrated with inflammatory cells.

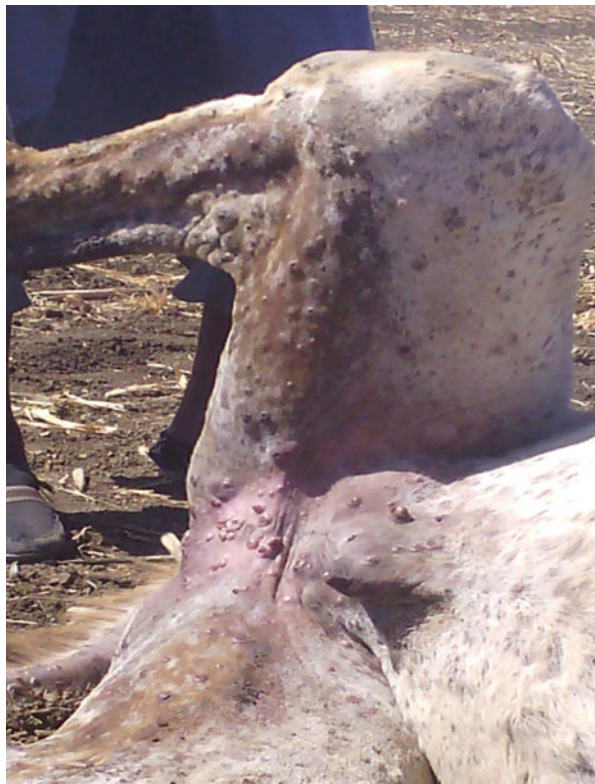**Fig. 2.3** A case of mild form of camel pox showing small nodules on the upper leg, Abu Dhabi 2016



**Fig. 2.4** Ruptured pustule or ulcer (arrow) on lower lip of a camel affected by the mild form of camel pox



**Fig. 2.5** Pox lesion on the perineum of a severely infected 3 years old camel that resulted in its death, Butana, Sudan 2012 (Courtesy of Abdalla Bushara, Camel Research Center, University of Khartoum, Sudan)



## 2.6 Epidemiology

CMLV solely naturally infect old-world camelids and natural infection of new world camelids has never been reported. It is a species-specific disease with rare cases of human infection characterized by localized pox lesions in individuals in contact with affected camels without further human to human spread. Although specific antibody prevalence was demonstrated in sheep and goat, experimental infection has shown that small ruminants and cattle do not succumb to the disease. The disease is endemic in most countries, and a pattern of sporadic or widespread epidemics occurs every 2–4 years depending on availability of susceptible animals with a climb in seasonal incidence usually during the rainy season. It mostly affected young animals of less than 4 years old, and most camels develop camel pox before reaching three years of age. According to some observations pregnant females appear more susceptible to camel pox. Group watering and introduction of new animal to a susceptible herd are the main risk factors (Khalafalla & Ali, 2007). Generally, the morbidity can reach 92% with 0 to 15% mortality rate.



## 2.7 Diagnosis

The presumptive diagnosis of camelpox infection is based on clinical signs (OIE, 2018). However, infections of camels in the early clinical stages and in mild cases can be confused with other skin diseases such as contagious ecthyma, which is caused by a parapox virus (PPV) and papilloma virus infections. Tissue material should be collected from recently infected animals with a forcep and a scalpel blade and placed in a suitable container (e.g., test tube or Petri dish) and stored at +4 °C or ultra low freezing. Various laboratory techniques are available for the diagnosis of camel pox including, in order of sensitivity, simplicity, rapidity, and cost: polymerase chain reaction (PCR), virus isolation on the chorioallantoic membrane (CAM) of embryonated chicken eggs and cell culture (Khalafalla, Mohamed, & Agab, 1998; Khalafalla, Mohamed, & Ali, 1998), transmission electron microscopy (TEM), and immunohistochemistry. Suitable samples include swab of ruptured vesicles, biopsy of skin nodules, skin scabs, blood during the viremic stage, and pox lesions on internal organs upon post-mortem.

### 2.7.1 Gel-based PCR

The PCR is a fast and sensitive method for the detection of CMLV DNA. The PCR assays available to identify CMLV are based on the detection of sequences encoding for the A-type inclusion body protein (ATIP) gene, the hemagglutinin (HA), the ankyrin repeat protein (C18L), and the DNA polymerase (DNA pol) (Duraffour et al., 2011). DNA can be extracted from clinical material using numerous commercial kits. The ATI gene PCR assay allows the detection and differentiation of species of the genus OPXV because of the size differences of the amplicons. Using the primer pair: 5'-AAT-ACA-AGG-AGG-ATC-T-3' and 5'-CTT-AAC-TTT-TTC-TTT-CTC-3', the gene sequence encoding the A-type inclusion protein (ATIP) will be amplified (Meyer et al., 1997). The size of the PCR product, specific for the camel pox virus, is 881 bp. DNA amplification is carried out in a final volume of 50 µl containing 2 µl of each dNTP (10 mM), 5 µl of 10 × PCR buffer, 1.5 µl of MgCl<sub>2</sub> (50 mM), 1 µl of each primer, 2.5 U *Taq* DNA polymerase, 1 µl DNA template, and an appropriate volume of nuclease-free water. Incubate the samples in a thermal cycler: first cycle: 5 min at 94 °C (initial denaturation step), second cycle: 1 min at 94 °C, 1 min at 45 °C, 2.5 min at 72 °C. Repeat the second cycle 29 times. Last cycle: 10 min at 72 °C (final elongation step) and hold at 4 °C until analysis. Mix 10 µl of a sample with loading dye solution and load in 1% agarose gel in TBE (Tris/Borate/EDTA) buffer containing ethidium bromide. Load a parallel lane with a 100 bp DNA-marker ladder. Separate the products at 100 V for 30–40 min and visualize using an UV transilluminator. Confirm the positive reactions according to the size.

## 2.8 Zoonotic Potentiality

The first report of a case of human camelpox was described in Somalia. The case was a 40-year-old camel herder who developed in June 1978 lesions resembled those of smallpox (Jezek et al., 1983). From the 1970s until recently, it has been well accepted that CMLV rarely infects humans. This probably is due to the cross-immunity induced via smallpox vaccination that ended in the late 1970s. The first conclusive evidence of zoonotic CMLV infection in humans, associated with outbreaks in dromedary camels has been recently reported in India (Bera et al., 2011) where three human cases of camel pox have been reported. They were detected in animal handlers during an outbreak of camel pox and the lesions were confined to the hands and fingers of camel handlers and passed through all the stages of pock lesions until the formation of scabs. An additional four cases of camel pox in humans (camel herders) were detected recently in 2015 in Showak area of eastern Sudan (Khalafalla & Abdelazim, 2017).

---

## 2.9 Treatment

Affected animals can be treated with anti-viral medications, however cost is high. The most common medication used to treat camel pox is Cidofovir, a broad-spectrum anti-viral that acts by inhibiting the viral DNA polymerase. Cidofovir has proven to be 100% effective at preventing death in infected camels. Giving systemic antibiotics such as 10 or 20% Oxytetracycline and spraying affected parts with antiseptics such as potassium permanganate or other antibiotics is useful in preventing the ulcers from becoming infected by bacteria. In the field nomads use liquid Tar (ground seed of bitter apple), camel milk, or mixture of sesame and table salt to rub affected areas (Köhler-Rollefson et al., 2001). Additionally, giving antipyretics, antihistamines, and multivitamins are useful in reducing the effects of the infection.

---

## 2.10 Prevention

Programs to control camel pox by the Veterinary Authorities should include sanitary measurements, quarantine of infected areas, restriction of camel movements, management of clean drinking water and avoidance of skin abrasions and vaccination of healthy camels in healthy non-infected herds. At the level of infected herds infected animals should be separated from healthy ones and treated as described above. Vaccination in the face of an outbreak can be considered. Animal can be vaccinated by either live attenuated or inactivated vaccine. The live attenuated vaccine gives long-term protection against camel pox. However, a booster vaccination is recommended for young animals at the age of 8–12 months, 2–3 months after the initial vaccination to avoid interference by maternal antibodies (Khalafalla & El

Dirdiri, 2003). When inactivated vaccine is used, the animals must be vaccinated annually. A good practice is to quarantine newly introduced camels.

---

## 2.11 Notification

Camel pox is a notifiable disease.

---

## References

- Alhendi, A. B., Abuelzein, E. M., Gameel, A. A., & Hassanein, M. M. (1994). A slow-spreading mild form of camel pox infection. *Zentralblatt für Veterinärmedizin. Reihe B*, 41(1), 71–73.
- Bera, B. C., Shanmugasundaram, K., Barua, S., Venkatesan, G., Virmani, N., Riyesh, T., Gulati, B. R., Bhanuprakash, V., Vaid, R. K., Kakker, N. K., Malik, P., Bansal, M., Gadvi, S., Singh, R. V., Yadav, V., Sardarilal, N. G., Balamurugan, V., Hosamani, M., Pathak, K. M., & Singh, R. K. (2011). Zoonotic cases of camelpox infection in India. *Veterinary Microbiology*, 152, 29–38.
- Durafour, S., Meyer, H., Andrei, G., & Snoeck, R. (2011). Camel pox virus. *Antiviral Research*, 92 (2), 167–186.
- Gubser, C., & Smith, G. L. (2002). The sequence of camelpox virus shows it is most closely related to variola virus, the cause of smallpox. *The Journal of General Virology*, 83, 855–872.
- ICTV International Committee on Taxonomy of Viruses. (2019). ICTV. Accessed December, 20, 2020, from [ictvonline.org](http://ictvonline.org)
- Jezek, Z., Kriz, B., & Rothbauer, V. (1983). Camel pox and its risk to the human population. *Journal of Hygiene, Epidemiology, Microbiology, and Immunology*, 27, 29–42.
- Khalafalla, A. I., & Abdelazim, F. (2017). Human and dromedary camel infection with Camelpox virus in eastern Sudan. *Vector Borne and Zoonotic Diseases*, 17, 281–284.
- Khalafalla, A. I., & Ali, Y. H. (2007). Observations on risk factors associated with some camel viral diseases (pp. 101–105). In *Proceedings of the 12th international conference of the Association of Institutions for Tropical Veterinary Medicine (AITVM), Montpellier, France, 20–22 August 2007*
- Khalafalla, A. I., & El Dirdiri, G. A. (2003). Laboratory and field investigation of a live and an inactivated camelpox vaccine. *Journal of Camel Practice and Research*, 10, 191–200.
- Khalafalla, A. I., & Mohamed, M. E. H. (1996). Clinical and epizootiological features of camel pox in eastern Sudan. *Journal of Camel Practice and Research*, 2, 99–102.
- Khalafalla, A. I., Mohamed, M. E. M., & Agab, H. (1998). Serological survey in camels of the Sudan for prevalence of antibodies to camelpox virus using ELISA technique. *Journal of Camel Practice and Research*, 5, 197–200.
- Khalafalla, A. I., Mohamed, M. E. H., & Ali, B. H. (1998). Camel pox in the Sudan: I – Isolation and identification of the causative virus. *Journal of Camel Practice and Research*, 5, 229–233.
- Köhler-Rollefson, I., Mundy, P., & Mathias, E. (2001). *A field manual of camel diseases. Traditional and modern veterinary care for the dromedary*. Intermediate Technology Publications.
- Meyer, H., Ropp, S. L., & Esposito, J. J. (1997). Gene for A-type inclusion body protein is useful for a polymerase chain reaction assay to differentiate orthopoxviruses. *Journal of Virological Methods*, 64, 217–221.
- Wernery, U., & Kaaden, O. R. (2002). Camel pox. In U. Wernery & O.-R. Kaaden (Eds.), *Infectious diseases in camelids* (2nd ed., pp. 176–185). Blackwell Science.
- World Organization for Animal Health (OIE). (2018). *Camel pox. Manual of diagnostic tests and vaccines for terrestrial animals*. Vol. 2. Chapter 3.9.2. Available at [https://www.oie.int/fileadmin/Home/eng/Health\\_standards/tahm/3.09.02\\_CAMELPOX.pdf](https://www.oie.int/fileadmin/Home/eng/Health_standards/tahm/3.09.02_CAMELPOX.pdf)

Yousif, A. A., & Al-Naeem, A. A. (2012). Recovery and molecular characterization of live Camelpox virus from skin 12 months after onset of clinical signs reveals possible mechanism of virus persistence in herds. *Veterinary Microbiology*, 159(3–4), 320–326.

# Camel Contagious Ecthyma

# 3

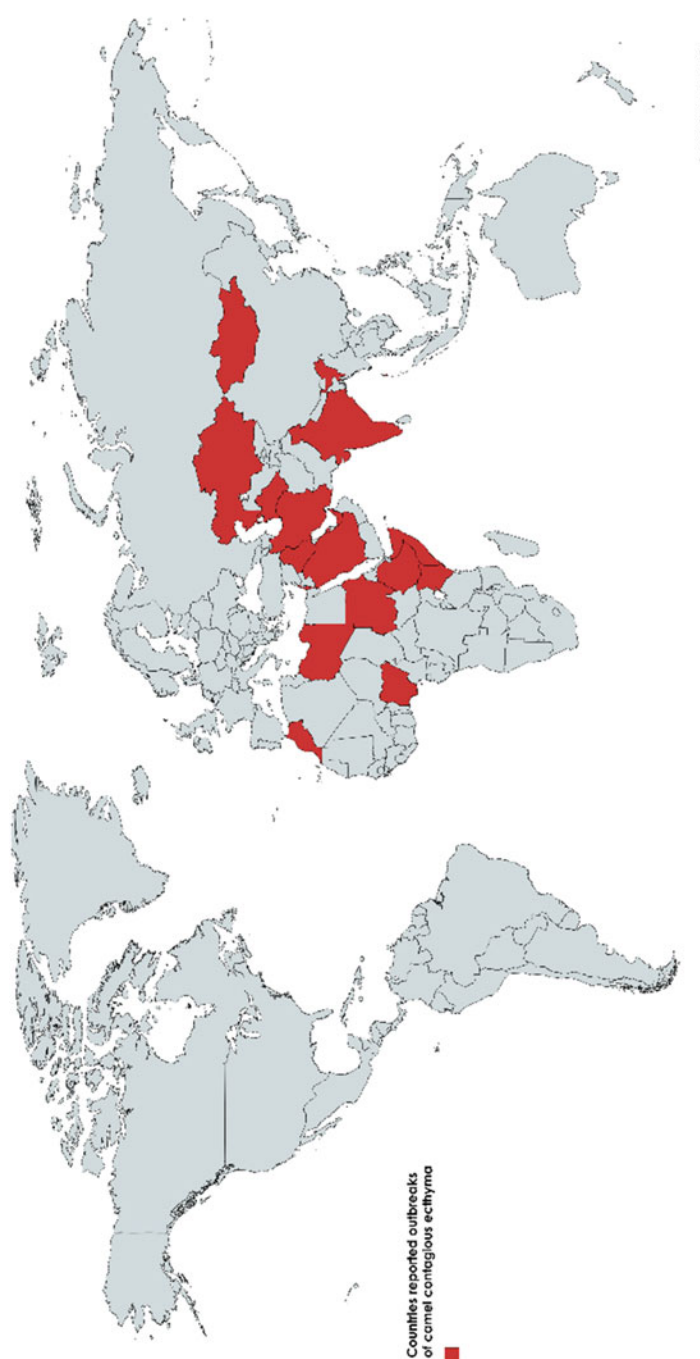
Abdelmalik I. Khalafalla

Camel contagious ecthyma (CCE) is a highly contagious viral disease mostly of young camels that contributes to calf debility and occasionally calf loss. This disease was first described in Kazakhstan in 1968 (Buchnev et al., 1987) and has since been described in many camel rearing countries (Fig. 3.1). It primarily affects young animals exhibiting most regularly localized lesions and frequently generalized changes that resemble camel pox. It was formerly thought to be a form of camel pox since clinical symptoms of both diseases are similar. However, camel herders in many countries regard CCE as a separate disease and give it local names such as *Auzdyk* in Kazakhstan, *Amburur* in Ethiopia, and *Abu Shalambo* and *Al Kolate* in Sudan.

CCE is characterized by proliferative, crusty/scabby epidermal lesions around the mouth, lips, buccal cavity and swelling of heads. Some affected calves showed lacrimation and head swelling. The disease spreads quickly in affected herds; all camel calves born during the same calving season could develop the disease.

The disease is not only a cause of calf mortality, but also affects camel performance with weight loss and severe reduction in milk production since she-camels mostly cease to lactate when their calves die.

The disease is endemic in affected areas with variations in intensity of infection, morbidity and mortality rates and tends to occur annually in the rainy season, as the situation in Sudan and Saudi Arabia, affecting mostly young animals. However, few cases of CCE have been reported in the winter in eastern Sudan. The age group at risk are those less than one year of age including cases reported in month-old camel calves. The marked seasonality associated with the rainy season may be due to the optimum condition for the survival and perpetuation of the virus and skin abrasions caused by browsing thorny trees. In most cases, the disease caused no mortality, but when camel calves are severely affected the ecthyma lesions interferes with the calves' ability to suckle or graze and extends to eyelids leading to blindness, particularly at the Savanah belt in Africa, leading to mortality rates that can reach 9% (Khalafalla, 2000).



**Fig. 3.1** Countries reported outbreaks of camel contagious ecthyma (red-color)

The disease usually passes off without causing death, but a 6.6% herd mortality and 38% case fatality rates have been reported (Khalafalla, 2000).

### 3.1 Etiology

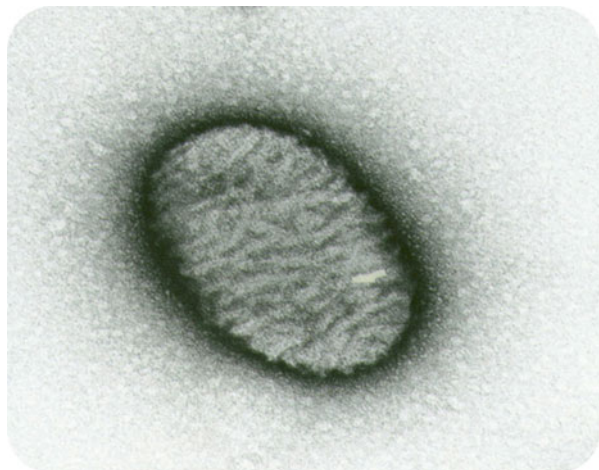Camel contagious ecthyma is caused by a pox virus of the genus *Parapoxvirus* (PPV), subfamily *Chordopoxvirinae* of the family *Poxviridae*. Camel contagious ecthyma is a sparsely studied disease and the causative virus has been only recently genetically characterized based on partial genome sequencing. Several studies showed that CCE viruses are closely related to the pseudocowpox virus (PCPV) species of the PPV genus of the family *poxviridae* (Abubakr et al., 2007; Khalafalla et al., 2015, 2020). The disease was formerly thought to be a form of camel pox since clinical symptoms of both diseases are similar.

The virus virions are ovoid particles that range in size from  $230 \times 131$  to  $360 \times 160$  nm, their axis ratio is about 1:1.56, and their surface shows a regular criss-cross pattern of filaments (ball-of-wool) under electron microscopy (Fig. 3.2).

The virus is genetically and antigenically different from camelpox virus (CMLV) that causes camel pox disease and animals recovered from CCE are susceptible to camel pox. Additionally, there is antigenic diversity between CCE virus, and other related parapox viruses like ORF virus (ORFV) and Bovine papular stomatitis virus (BPSV) and camels were not protected after immunization with a vaccine against sheep and goat contagious ecthyma.

Like Orf virus (ORFV), the CCE virus is heat stable as it survives  $56^{\circ}\text{C}$  for one hour, resistant to pH 3, and remains viable from 8 months to more than a year at room temperature in dried scabs. The virus in scabs from infected animals can be inactivated by carbolic acid (1:100), formalin (1:2000), and mercuric chloride (1:20,000).

**Fig. 3.2** Electron micrograph of camel contagious ecthyma virus (Abdelmalik Khalafalla)



### 3.2 Modes of Transmission

Transmission of CCE occurs through direct and indirect contacts from contaminated environment. In many investigated outbreaks in Eastern Sudan, the infection occurs because of direct contacts between sick and susceptible animals (Khalafalla & Mohamed, 1997). Watering the animals at water boreholes and dug out water reservoirs (Hafeers) provides opportunity for infection transmission as pox scabs shed from affected camels contaminate water that becomes source of infection. Skin abrasion of the lips caused by browsing acacia trees seems to represent the major predisposing factor to CCE. The thorny plants damage the lips allowing virus penetration and multiplication. Movements of camels during the rainy season have a significant role in the spread of CCE, and insects have also been incriminated in the spread of the disease.

The major factors associated with increased likelihood of CCE occurrence are season of the year, camel age, camel movements, and location and their association with thorny acacia trees (Khalafalla & Ali, 2007).

### 3.3 Clinical Picture

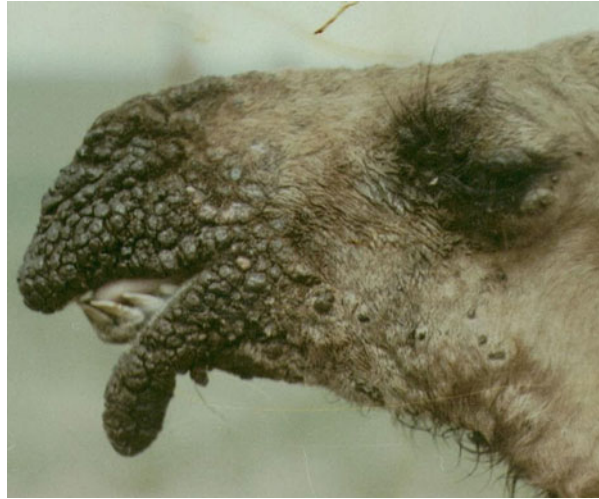The incubation period of CCE is around a week under natural conditions. CCE is characterized by the sudden onset and rapid progression of the lesion and proliferative, crusty/scabby epidermal lesions around the mouth and nostrils usually accompanied with slight fever. Clinically, the pox lesions first appeared on the lips of affected animals as small papules followed in most cases with swelling of the face and sometimes the neck (Fig. 3.3). Papules progressively develop through vesicles

**Fig. 3.3** Early signs of camel contagious ecthyma. Note, ecthyma lesions on lips and swelling of the head (Courtesy of Prof. Hamid Agab, Sudan University of Science and Technology, Sudan)





**Fig. 3.4** Fissured crusts on the lips of young dromedary camel, Sudan (Courtesy of Prof Hamid Agab)



and ulcers into scabs on the lips, muzzle, nostrils, and eyelids culminating into fissured crusts on the lips (Fig. 3.4) that clinically differentiate the disease from camel pox or papillomatosis. The lesion is proliferative and highly vascularized and may extend into gum, palate, and tongue. The pustules develop into fissured crusts that affect lips severely, leading to complete cessation of feeding or suckling (Housawi et al., 2004; Khalafalla & Mohamed, 1997; Munz et al., 1986). This may reduce the body condition of the animal and its natural defense and increase susceptibility to other infectious diseases. Enlargement of superficial lymph nodes particularly the cervical and mandibular has also been reported in field cases.

Affected animals lose appetite, are emaciated, and slightly anemic. At later stages, the scabs become dark brown in color and drop off after six to ten weeks. No lesions are observed on the udders of dams of affected calves.

---

### 3.4 Differential Diagnosis

- Camel pox.
- Camel papillomatosis.
- Mange.
- Reaction to insect bites.

---

### 3.5 Pathogenesis and Pathology

Infection with CCE is confined to the skin (epitheliotropic). The virus rapidly replicates in the skin, including hair follicles and sebaceous glands. These lesions mature into crusty scabs that eventually dry up and fall off around 4–7 weeks after

infection but sometimes the course of the disease extended up to 3 months. The skin surface is largely indistinguishable from that pre-infection. When the scabs are peeled off, they leave an elevated raw bleeding surface that is prone to secondary bacterial infection resulting in local tissue swelling, erythema, pain, and foul smelling.

The pathology includes vacuolar changes of the epithelial layers of the skin accompanied with ulceration, neutrophil infiltration. Hyperkeratosis and acanthosis were also reported. Affected areas were ulcerated, hemorrhagic, and with frequent secondary bacterial superinfection.

---

### 3.6 Epidemiology

The disease affects both dromedary and bactrian camels. In endemic areas, most of the cases occur in calves less than one year old. The disease occurred in young calves born during the same season with higher incidence rates during the wet seasons than dry period. Browsing on thorny trees during the early rainy season may be one of the important predisposing factors as the injuries inflicted while browsing could facilitate the entrance of the causative agent into the body.

The disease has a marked seasonality associated with the rainy season. Field observations point that spread of the disease coincides with the annual movement of nomadic herds of camels toward green pasture in Africa (Khalafalla & Mohamed, 1997). In several tropical zones the disease tends to appear every year to affect young calves in their first season of grazing. The morbidity rate in calves of less than one year can reach 100%, while mortality is more commonly low, although could reach 38% in areas with heavy rains and abandon of thorny trees and in complicated cases. On the other hand, camels in pastures of dry, short grass, and no thorny trees seem to be less affected and usually the infection is mild. Death is probably due to starvation caused by the inability of affected animals to graze or to suckle their dams and the secondary bacterial infection as well.

---

### 3.7 Diagnosis

CCE is easily diagnosed clinically. The lesions are found in most cases to be confined to the head, particularly the lips, nostrils, and eyes without becoming generalized. Their distinctive feature of the appearance of fissured crusts which are different from the lesions of camel pox or camel papillomatosis characterizes the lesions. Epidemiological history related to the seasonality and age group affected may help reaching proper clinical diagnosis. However, in some cases of complicated disease picture laboratory diagnosis is needed.

Currently the most popular, quick, and sensitive diagnostic test is the polymerase chain reaction (PCR). The commonly used protocol is a gel-based PCR amplification of the envelope gene (B2L gene) of the PPV carried out using primer sequences: forward (5'-TTAATTTATTGGCTTGCG AACTCCGAGCGC-3'), reverse

(5'-ATGTGGCCGTTCT CCTCCATC-3') (Inoshima et al., 2001). The thermal profiles are set as initial denaturation at 94 °C for 5 min, followed by 35 cycles of denaturation at 94 °C for 1 min, annealing at 55 °C for 1 min, extension at 72 °C for 1 min, and final extension at 72 °C for 10 min. The PCR-amplified products should be checked by electrophoresis in a 1% agarose gel. Additionally, a multiplex PCR has been used to differentiate CCE from camel pox and papillomatosis (Khalafalla et al., 2005).

Additionally, negative contrast electron microscopy has proven to be an extremely useful procedure for quick diagnosis of CCE. Tissue samples from lesions should be collected with a scalpel blade and placed in a suitable container in test tube or Petri dish. Samples should be collected within 10–14 days from the appearance of lesions (Khalafalla et al., 1994; Munz et al., 1986). Samples can be maintained at room temperature. A 10–20% suspension should be prepared with phosphate buffered saline (PBS, pH 7.2), and centrifuged at 2000 g for 10 min. The supernatants should be stained with phosphotungstic acid, transferred to formvar or pioloform—coated grids and examined under a transmission electron microscope.

Other diagnostic techniques include immunofluorescent and immunoperoxidase (Fig. 3.3).

The disease is associated with increased white blood cell (WBC) and decreased red blood cell (RBC) counts. Besides, serum biochemical tests show significantly decreased total protein, globulin, and glucose values and significantly increased alanine aminotransferase (ALT) values (Narnaware et al., 2015).

---

## 3.8 Zoonotic Potentiality

Though other viruses in the genus PPV such as ORFV and PCPV are known to be zoonotic in various areas of the world, no case of camel contagious ecthyma had been reported in people except a recent human infection in Saudi Arabia, where a 42-year-old man who came into contact with an infected camel developed a typical orf lesion (Alajlan & Alsubeeh, 2020).

---

## 3.9 Treatment

There is no specific treatment for CCE. Nomads in some endemic areas deny the infectious nature of CCE and therefore, the disease is either allowed to take its natural course or traditional treatments are applied. Traditional treatments include cauterization of regional lymph nodes, application of sesame oil and hot milk and sometimes plant tar. Broad-spectrum antibiotics either topic or systemic given for 3–5 days prevent a secondary bacterial infection and reduce the severity of the infection. Additionally, giving antipyretics, antihistamines, and multivitamins is useful in reducing the effects of the infection.

### 3.10 Prevention

There is currently no specific vaccine for CCE. To control CCE, sanitary measures for infectious diseases should be applied. These include quarantine of infected areas, restriction of camel movements, management of drinking water, and avoidance of skin abrasions. These measures are difficult to implement in the open range production system owing to the migratory pattern of camel production and the difficulty to reach camels especially during the rainy season.

At the level of infected herds infected animals should be separated from healthy ones and treated as described above.

### 3.11 Notification

Camel contagious ecthyma is not a notifiable disease.

## References

- Abubakr, M. I., Abu-Elzein, E. M. E., Housawi, F. M., Abdelrahman, A. O., Fadlallah, M. E., Nayel, M. N., Adam, A. S., Moss, S., Forrester, N. L., Coloyan, E., & Gameel, A. (2007). Pseudo cowpox virus: The etiological agent of contagious ecthyma (Auzdyk) in camels (*Camelus dromedarius*) in the Arabian peninsula. *Vector Borne and Zoonotic Diseases*, 7(2), 257–260.
- Alajlan, A. M., & Alsubeeh, N. A. (2020). Orf (Ecthyma Contagiosum) transmitted from a camel to a human: A case report. *American Journal of Case Reports*, 21, e927579. <https://doi.org/10.12659/AJCR.927579>
- Buchnev, K. N., Tulebaev, S. Z., & Sansyzbaev, A. B. (1987). Infectious diseases of camels in the USSR. *Revue Scientifique et Technique (International Office of Epizootics)*, 6(2), 487–495.
- Housawi, F. M., Abu Elzein, E. M. E., Gameel, A., Mustafa, M., Al-Afaleq, A., Gilar, J., et al. (2004). Severe Auzdyk infection in one-month old camel calves (*camelus dromedarius*). *Veterinarski Arkiv*, 74, 467–474.
- Inoshima, Y., Murakami, K., Yokoyama, T., & Sentsui, H. (2001). Genetic heterogeneity among parapoxviruses isolated from sheep, cattle and Japanese serows (*Capricornis crispus*). *The Journal of General Virology*, 2001, 1215–1220.
- Khalafalla, A. I. (2000). Camel contagious ecthyma: Risks in young calve. *Revue d'élevage et de Médecine Vétérinaire des Pays Tropicaux*, 53(2), 173–176.
- Khalafalla, A. I., Agab, H. A. M., & Abbas, B. (1994). An outbreak of contagious ecthyma in camels (*camelus dromedarius*) in eastern Sudan. *Tropical Animal Health and Production*, 26, 253–254.
- Khalafalla, A. I., & Ali, Y. H. (2007). Observations on risk factors associated with some camel viral diseases (pp. 101–105). In *Proceedings of the 12th International Conference of the Association of Institutions for Tropical Veterinary Medicine (AITVM), Montpellier, France, 20–22 August 2007*.
- Khalafalla, A. I., Büttner, M., & Rziha, H.-J. (2005). Polymerase chain reaction (PCR) for rapid diagnosis and differentiation of Para- and orthopox virus infections in camels. In H. P. S. Makkar & G. J. Viljoen (Eds.), *Applications of gene-based technologies for improving animal production and health in developing countries* (pp. 335–342). FAO/IAEA Publications, ISBN: 1-4020-3311-7). Springer.

- Khalafalla, A. I., Elhag, A. E., & Ishag, H. Z. A. (2020). Field investigation and phylogenetic characterization of orf virus (ORFV) circulating in small ruminants and Pseudocowpoxvirus (PCPV) in dromedary camels of eastern Sudan. *Heliyon*, 6, 3e03595.
- Khalafalla, A. I., El-Sabagh, E., Al-Busada, K., Al-Mubarak, A., & Ali, Y. (2015). Phylogenetic analysis of eight Sudanese camel contagious ecthyma viruses based on B2L gene sequence. *Virology Journal*, 12, 124.
- Khalafalla, A. I., & Mohamed, M. E. H. (1997). Epizootiology of camel contagious Ecthyma in eastern Sudan. *Revue d'élevage et de Médecine Vétérinaire des Pays Tropicaux*, 50, 99–103.
- Munz, E., Schillinger, D., Reimann, M., & Mahnel, H. (1986). Electron Microscopical diagnosis of Ecthyma contagiosum in camels (*Camelus dromedarius*) first report of the disease in Kenya. *Journal of Veterinary Medicine, Series B*, 33, 73–77.
- Narnaware, S. D., Nagarajan, G., & Dahiya, S. S. (2015). Hemato-biochemical studies in Indian camel (*Camelus dromedarius*) affected with contagious ecthyma. *Indian Journal of Veterinary Pathology*, 39(2), 168–170.

# Camel Papillomatosis

# 4

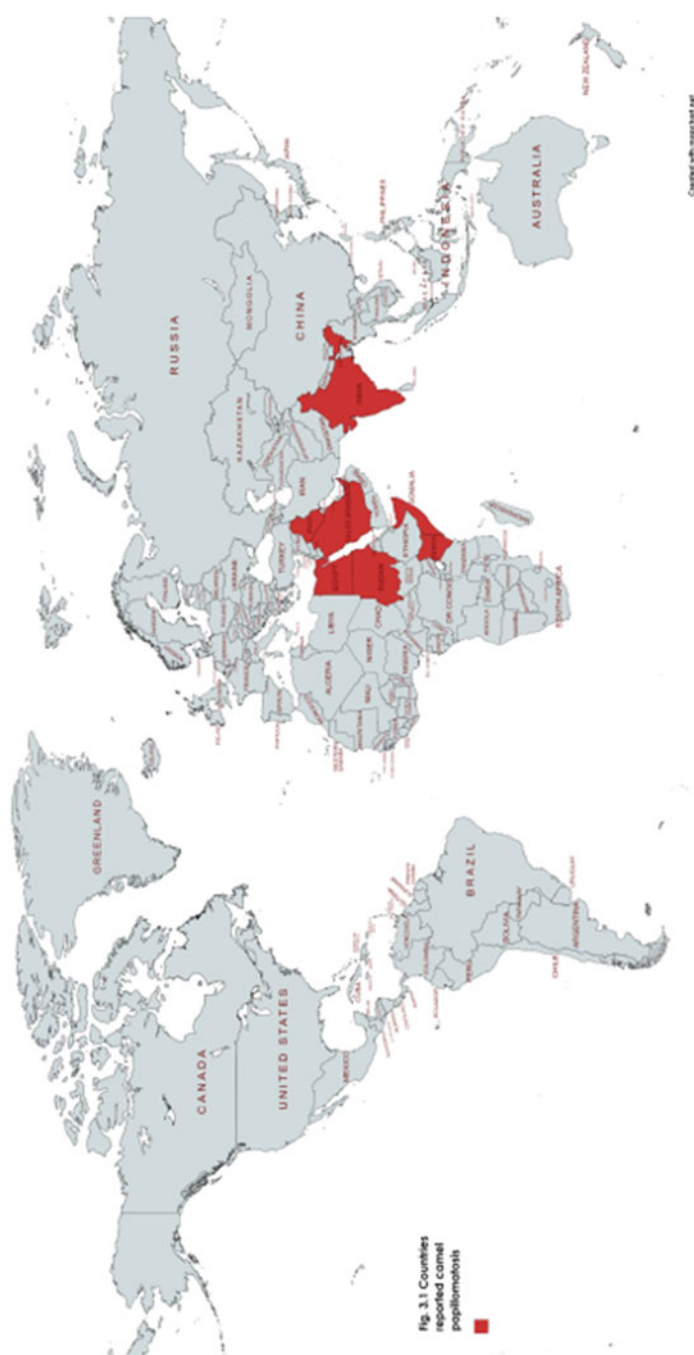Abdelmalik I. Khalafalla

In recent years, papillomaviruses have received consideration because of their association with malignancy development and their wide dissemination. Encompassing >350 distinct papillomavirus types these diverse viruses infect skin, squamous, and mucosal epithelial cells of a broad range of mammalian, avian, and fish hosts in which they cause benign proliferative lesions in the skin (warts) and mucous membranes. Papillomavirus infections may greatly influence animal health and are sometimes linked with great economic losses in farm animals. However, the disease in camels is mild, recovering spontaneously with no significant economic impact (Khalafalla et al., 1998).

The first report of cutaneous papillomatosis in dromedaries was reported in Somalia in 1990 (Munz et al., 1990). After that, cases of papillomatosis in young dromedaries have also been reported from Sudan, United Arab Emirates, Kenya, Somalia, Saudi Arabia, Iraq, India, and Egypt (Fig. 4.1). The disease is fairly well known by herders and given different local names revolving around the meaning benign tumor. The disease is named “*Al Halam*” in many areas of the Sudan, “*Al Nakhla*” or “*Al Anaba*” in Saudi Arabia, and “*Al Thu-olol*” in Iraq.

## 4.1 Etiology

Camel papillomatosis in dromedary camels is caused by *Camelus dromedarius* papilloma virus (CdPV). Papillomavirus (PaV) is a small circular DNA of around 7–8 kb genomes. Currently, the genomes of two *Camelus dromedarius* PV types (type 1, CdPV1, and type 2, CdPV2) detected in field cases of the disease in the Sudan, Saudi Arabia, and Egypt have been completely characterized and both are genetically grouped within the genus *Deltapapillomavirus* of the family Papillomaviridae (Khalafalla et al., 2017, 2018; Sobhy et al., 2020; Ure et al., 2011).



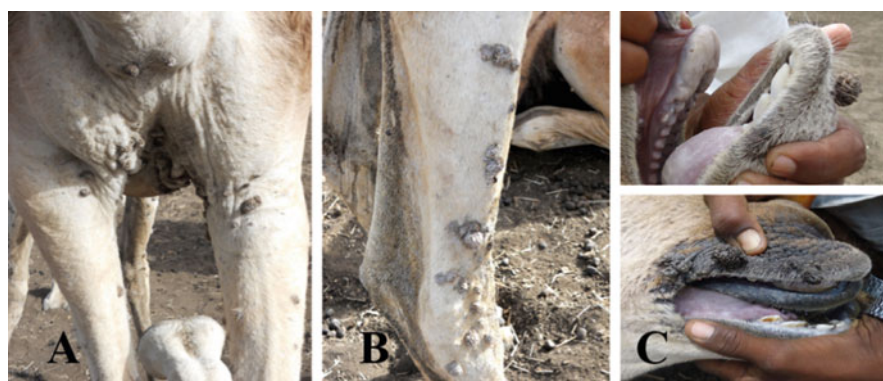**Fig. 4.1** Countries reported cases of camel papillomatosis (highlighted red)

## 4.2 Modes of Transmission

Papillomavirus replication is firmly connected to the differentiation process of the host epithelial cells, and their transmission requires close cutaneous or mucosal contact. Transmission of PVs is usually horizontal and occurs via contact, abrasions, or micro-lesions of the skin and mucosa, but vertical and iatrogenic transmissions have also been reported, as well as mechanical transmission by arthropods. Fomites and handling equipment used on infected animals may also transmit the disease.

## 4.3 Clinical Picture

Camel papillomatosis is characterized by round, cauliflower-like horny masses (warts) on the skin of the lips and rarely legs without impairing the health condition of the affected animals. These wart-like lesions, which range between 0.2 and 2.5 cm in size, are found mainly on the head, particularly the lips, eyelids, nostrils, and mandible. The lesion size in some cases was approximately 5 cm due to coalition of more than one wart. Often, wart-like lesion can be seen on the chest and forearm areas (Fig. 4.2) and their size in some cases can reach 5 cm due to coalescence of more than one wart (Khalafalla et al., 2018). These cauliflower-like papillary pedunculated masses are dark in color with approximate size of 2 cm in diameter. Some animals however showed rounded raised nodules instead (Fig. 4.3). The number of warts per animal can vary from one to 20, with a size ranging from 0.3 to 2.2 cm.



**Fig. 4.2** Papillomatosis in dromedary camels in eastern Sudan. Cauliflower-like single and coalesced nodular warts on the chest (panel A), legs (panel B), and lips (panel C) (Source: Khalafalla et al., 2018)

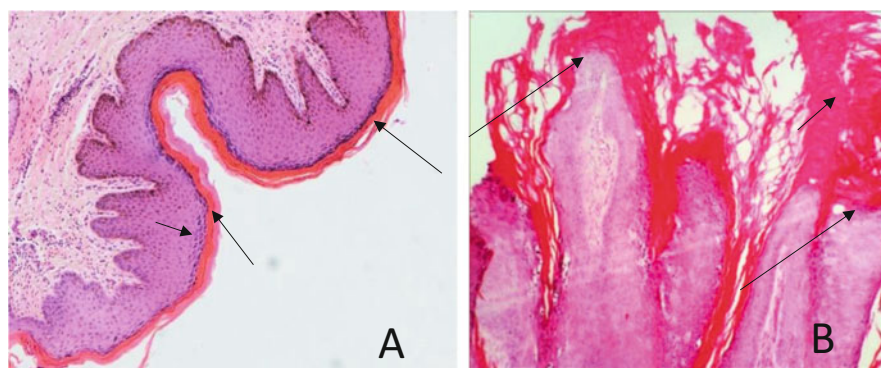




**Fig. 4.3** Papillomatosis in dromedary camels in Khartoum, Sudan (Courtesy of Dr. Ahmed Elfadl, Faculty of Veterinary Medicine, University of Khartoum, Sudan)

#### 4.4 Pathogenesis and Pathology

Histopathological sections show multiple papillary proliferations covered with keratinized epithelium and downgrowth of rete ridges (Fig. 4.4a). Additionally, there is acanthosis with karyopyknosis and cytoplasmic vacuolations in the stratum spinosum cells, and hyperkeratosis in the upper layers as well as subepithelial fibrosis (Fig. 4.4b).



**Fig. 4.4** Histopathology of camel papilloma virus infection. Left panel: skin of camel, showing hyperkeratosis (long arrow), hydropic degeneration of keratinocytes, acanthosis (short arrow), and mild infiltration of inflammatory cells. Right panel: multiple papillary proliferations (long arrows), irregularly thickened epidermis covered by a thick layer of hyperkeratosis (short arrow). Source: Khalafalla et al., 2017)

---

## 4.5 Epidemiology

The majority of the reported cases of papillomatosis in the camel are commonly found in young animals and occur in the late rainy season, matching with episodes of camel contagious ecthyma and camel pox. The disease occurs in animals less than two years old, causing a morbidity rate of 3.3%. Most of the described camel papillomatosis cases are usually seen in young animals and occur in the late rainy season, coinciding with outbreaks of camel contagious ecthyma and camel pox which might act as predisposing factors. Mange, particularly the burrowing mite of the genus *Demodex* could also be a predisposing factor for the PV infection in dromedary camels. Breaks in the integrity of the epidermis caused by poxviruses or mange are likely to facilitate entry of the papillomatosis virus to basal layers of the skin, thereby allowing infection of the epithelial stem cell which results in permanent viral replication in the epidermis.

---

## 4.6 Diagnosis

Camel papillomatosis can be diagnosed clinically. Electron microscopy and histopathology were previously used to confirm the infection by PVs in camels. Additionally, PCR Using degenerate papillomavirus-specific primers FAP59/FAP64<sup>2</sup> and immunohistochemistry using peroxidase anti peroxidase method (PAP) have been utilized in the recent reports of the disease (Forslund et al., 1999). As the differential diagnosis for camel papillomatosis includes camelpox and contagious ecthyma, the DNA sample could be screened using a multiplex gel-based PCR (Khalafalla et al., 2015).

---

## 4.7 Differential Diagnosis

- Camel pox.
- Camel contagious ecthyma.
- Reaction to insect bites.

---

## 4.8 Zoonotic Potentiality

Camel papillomatosis is a species-specific disease and there is no evidence that camels with papillomatosis can spread the condition to people or any other animal species.

## 4.9 Treatment and Control

The camel papilloma lesions are painless and self-limiting being dropped off within 2–5 months without any specific treatment and recovered animals seem to develop long lasting immunity. Depending upon the location, multitude, and thickness of the warts, and if the lesion is causing symptoms, treatment can be done by surgical/laser removal or cauterization. However, there are no documented reports on successful treatment of the camel papillomatosis. Autogenous vaccination, in which warts are removed, homogenized followed by formalin inactivation and injected into the same animal is known as a treatment of choice for papillomatosis in other species of animals such as dogs, cats, and cattle.

## 4.10 Notification

Camel papillomatosis is not a notifiable disease.

## References

- Forslund, O., Antonsson, A., Nordin, P., Stenquist, B., et al. (1999). A broad range of human papillomavirus types detected with a general PCR method suitable for analysis of cutaneous tumours and normal skin. *The Journal of General Virology*, 80, 2437–2443.
- Khalafalla, A. I., Abbas, Z., & Mohamed, M. E. H. (1998). Camel papillomatosis in the Sudan. *Journal of Camel Practice and Research*, 5, 157–159.
- Khalafalla, A. I., Ramadan, R. O., Rector, A., & Barakat, S. (2017). Investigation on papillomavirus infection in dromedary camels in Al-Ahsa, Saudi Arabia. *Open Veterinary Journal*, 7(2), 174–179. <https://doi.org/10.4314/ovj.v7i2.16>. Epub 2017 Jun 24.
- Khalafalla, A. I., Rector, R., & Elfadl, A. K. (2018). Papillomavirus infection in humans and dromedary camels in eastern Sudan. *Vector Borne and Zoonotic Diseases*, 8, 440–444.
- Munz, E., Moallin, A. S., Mahnel, H., & Reimann, M. (1990). Camel papillomatosis in Somalia. *Zentralblatt für Veterinärmedizin. Reihe B*, 37, 191–196.
- Sobhy, N. M., Singh, V., El Damaty, H. M., Mor, S. K., Youssef, C. R. B., & Goyal, S. M. (2020). Molecular characterization of a novel *Camelus dromedarius* papillomavirus. *Comparative Immunology, Microbiology and Infectious Diseases*, 73, 101561.
- Ure, A. E., Elfadl, A. K., Khalafalla, A. I., Gameel, A. A. R., Dillner, J., & Forslund, O. (2011). Characterization of complete genomes of *Camelus dromedarius* papillomavirus 1 and 2. *The Journal of General Virology*, 8, 1769–1777.

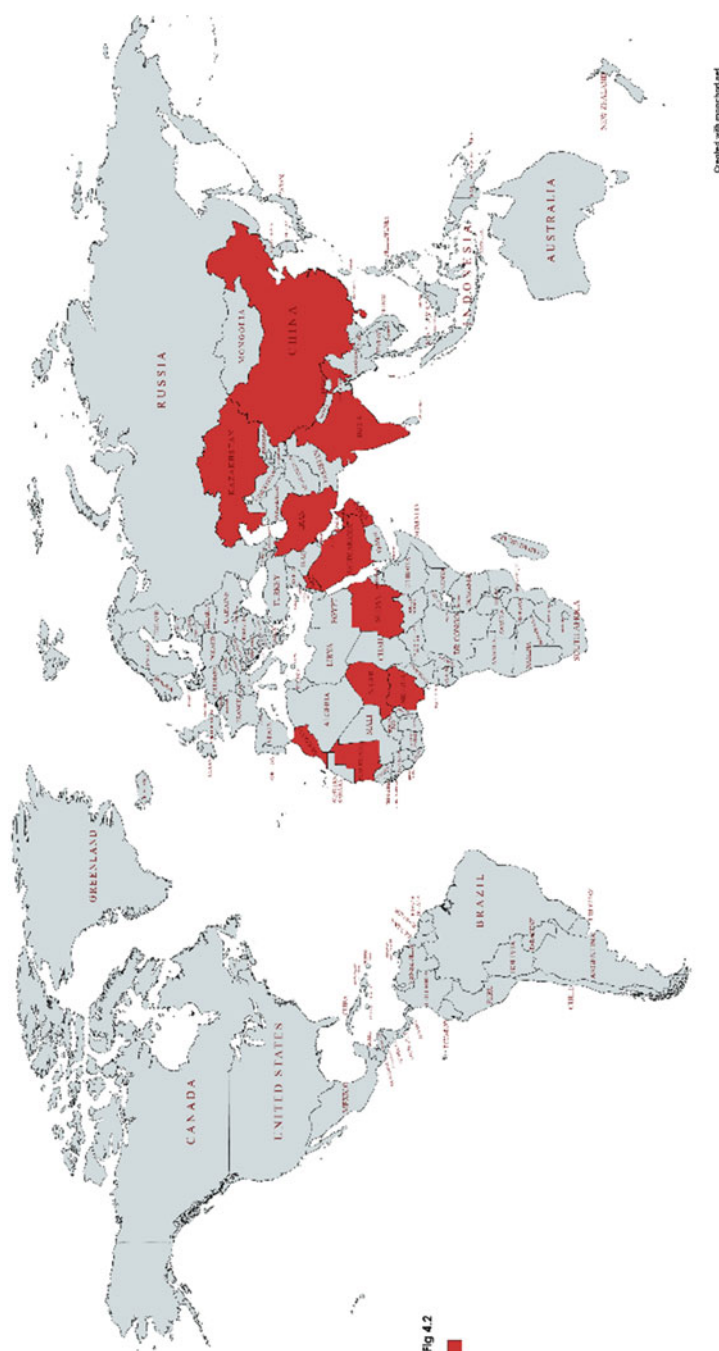
Abdelmalik I. Khalafalla

Rabies is an OIE listed lethal zoonotic encephalomyelitis disease and a major challenge to public and animal health that causes thousands of human deaths yearly worldwide. Developing countries in Asia and Africa bear the heaviest weight and account for 95% of human rabies cases (WHO, 2020). The disease is known by a highly variable incubation period and a high case fatality rate as it is almost fatal upon the appearance of clinical symptoms in both animals and humans when there is no proper postexposure prophylaxis.

Like all warm-blooded animals, camels are susceptible to rabies. Rabies has been accounted for in dromedary camels in all camel raising countries. Growing camel farming stretching into the desert or bushes increases the chance of frequent attacks by wild carnivores. Rabies is believed to be present in every country in which camel husbandry is practiced. However, reported cases of rabies in camels came from UAE, Oman, Qatar, Saudi Arabia, Morocco, Niger, Mauritania, Nigeria, Sudan, India, Kazakhstan, Iran, and China (Fig. 5.1). Transmission of the disease from camels to humans, though unlikely, was reported in Sudan. This poses a potential risk to veterinarians and farmers. Additionally, subclinical rabies virus infections of camels have been suggested which might have serious public health implications.

## 5.1 Etiology

Rabies is a viral disease caused by rabies virus, which is a negative sense, single-stranded RNA virus of the genus *Lyssavirus* in the family *Rhabdoviridae* and order *Mononegavirales*. The rabies virus (RABV) represents the taxonomic prototype species Rabies lyssavirus is enveloped and has a cylindrical morphology (bullet shaped). Lyssaviruses are normally limited to one major reservoir species in each geographic area, although spillover to other species is common. Identification of different virus variants by laboratory techniques such as monoclonal antibody analysis or genetic sequencing has greatly enhanced understanding of rabies epidemiology. Rabies virus has been isolated from nearly all mammals. Herbivores



**Fig. 5.1** Countries reported rabies in camels

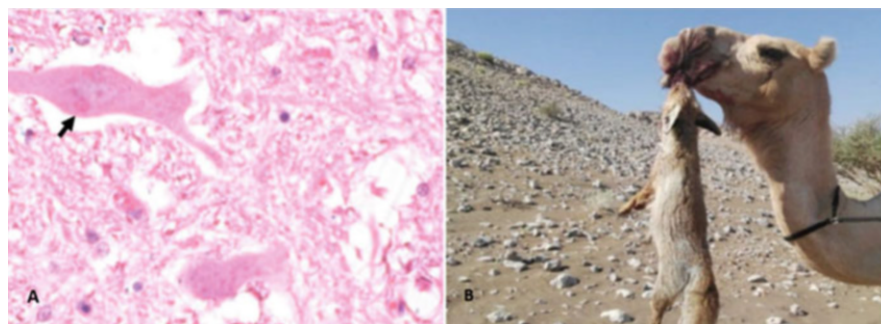
including camels and man are the final hosts, while bats are considered the sources of the virus. Of note, rabies virus has been isolated from both carnivorous and insectivorous bats.

## 5.2 Modes of Transmission

Rabies virus is usually transmitted to the next host by bites through the saliva of a rabid animal, but also via scratch wounds or contaminated mucous. In most cases, the disease is transmitted by bites from rabid wild dogs and less commonly from bites of rabid foxes and cats. However, other animals, such as wolves, jackals, hyenas, monkeys, or mongoose could transmit the disease. Camels are bitten commonly on the fore or hind limbs and in the head of females when they defend their neonates from predator attacks (El Neweshy et al., 2020) (Fig. 5.2b).

## 5.3 Clinical Picture

The disease in camels is mainly of the silent or dumb type. However, the furious form has also been noticed particularly in males in which affected animals become excited, aggressive, attack, and bite any nearby objects as well as self-biting of forelimbs and become self-destructive by pushing into and over obstacles. The early clinical signs of the disease include restlessness, ataxia, posterior paresis, salivation, and rotation of head and neck in all directions (Fig. 5.3). These signs are soon followed by paralysis, recumbency, and death. Other signs that have been observed include bloat, pruritus, muscle tremors, facial paralysis, aimless running, sexual hyperactivity (spontaneous ejaculation), recumbency, convulsions, and coma (Afzal et al., 1993; El Mardi & Ali, 2001; Kuman & Jindal, 1997; Omer et al., 2006).



**Fig. 5.2** (a) Negri bodies (intracytoplasmic oval eosinophilic inclusion; arrows) in pyramidal neuron in the cerebral cortex of a rabid camel; scale bar = 20 $\mu$  and (b) She-camel bitten by an Arabian red fox (Courtesy of Dr. Mahmoud El-Neweshy, Professor of Veterinary Pathology, Alexandria University, Egypt)



**Fig. 5.3** Dromedary camel affected with rabies showing lateral recumbency and excessive salivation

The clinical course can be divided into three general phases: prodromal, acute excitative, and paralytic stage. During the prodromal period, which lasts 1–3 days, animals show only nonspecific signs, which intensify rapidly. The disease progresses rapidly after the onset of paralysis, and death is virtually certain a few days thereafter and some animals may die rapidly without marked clinical signs (Fig. 5.3).

---

## 5.4 Differential Diagnosis

- Meningeal worm and abscess.
- Listeriosis.
- Tick paralysis.
- Copper deficiency.
- Camel Prion disease.
- Normal male sexual behavior (Rutting).
- Cerebral coenurosis.

---

## 5.5 Epidemiology

The incubation period in most animal species varies between 15 and 30 days. All camelids are theoretically susceptible to rabies but most of the available publications described clinical rabies in dromedary camels with few reports in Bactrian camels (*Camelus bactrianus*) (Feng et al., 2020; Liu et al., 2016) and the New World



camelids (Fowler, 2010). Fassi-Fehri (1987), Abbas and Omer (2005) and Ali et al. (2004) reviewed dromedary camel rabies in Sudan, Morocco, Mauritania, Yemen, Saudi Arabia, UAE, Niger, Jordan, India, Pakistan, Israel, and Iran.

According to Kasem et al. (2019) dogs and dromedary camels were the most affected species with rabies in Saudi Arabia during 2010–2017. Mohammadpour et al. (2020) reported that camels are one of the important sources as well as carriers of rabies infection for human, livestock, and wildlife in Iran and worldwide. Al-Rawashdeh et al. (2000) described rabies in eight camels was in Jordan and in India, a report of clinical signs of rabies in she-camel was described (Kuman & Jindal, 1997).

---

## 5.6 Diagnosis

Rabies can easily be confused with other diseases or with normal aggressive behavior of animals. In the past, diagnosis of rabies was performed by detection of Negri bodies in neurons of the hippocampus and other locations in the brain (Fig. 5.2a). Negri bodies are sharply outlined intraneuronal, eosinophilic, cytoplasmic inclusions of 2–10µm diameter found in certain nerve cells that contain rabies virus. However, this test is no longer recommended for diagnosis (OIE, 2019). According to Ahmed et al. (2020), the histopathological examination is a safe and reliable diagnostic tool in rabid dromedary camels when only formalin-fixed and paraffin-embedded material is available, but the negative results should be confirmed by dFAT or RT-PCR. Currently, diagnostic techniques have been standardized internationally that include the direct fluorescent antibody (DFA) test, the direct rapid immunohistochemistry test (dRIT), or pan-lyssavirus polymerase chain reaction (PCR) assays (OIE, 2019). In cases of inconclusive results from these primary diagnostic tests, further confirmatory tests (qRT-PCR, cell culture, or mouse inoculation tests) on the same sample or repeat primary diagnostic tests on other samples are recommended. Wherever possible, virus isolation in cell culture should replace mouse inoculation tests.

According to OIE, laboratory techniques are preferably undertaken on central nervous system (CNS) tissue removed from the cranium (for example, brain stem, Ammon's horn, thalamus, cerebral cortex, cerebellum, and medulla oblongata). A composite of CNS samples should be tested, and the brain stem is the most important component of the sample. Laboratories should follow appropriate biosafety and containment procedures as determined by biorisk analysis. Fresh brain of the camel should carefully be collected into ice and immediately transported to the laboratory.

The direct fluorescent antibody (DFA) test is the most widely used reference method for rabies diagnosis, however, results must be read by experienced skilled analysts already vaccinated against rabies.



## **5.7 Zoonotic Potentiality**

Rabies is a lethal zoonosis.

---

## **5.8 Treatment**

As there is no effective treatment for rabies, any confirmed rabies case must be killed immediately, and its carcass incinerated or burned. In the field, a rabid camel showing clinical signs is usually segregated from the herd and left to die in the desert or destroyed when aggressive. Post-exposure prophylaxis protocol by rabies vaccination should be implemented as soon as possible in a timely manner after exposure. However, there are no reports on the use of vaccination in camels.

---

## **5.9 Control**

Once rabies is diagnosed in a farm the veterinary authorities ought to promptly implement the appropriate control measures that include incineration or burial of all infected animal carcasses, emergency vaccination of dogs in the area, and raising of public awareness. The elimination of stray dogs and other animals by shooting and poisoning is still implemented in certain countries, however, this minimally affects rabies transmission. Certain countries of the Middle East region are confronting expanding problems because of wildlife rabies. The red fox and golden jackal are examples.

---

## **5.10 Prevention**

Measures to protect camels from predators like stray dogs, foxes, and hyenas are fundamental for prevention. The World Organization for Animal Health (OIE) has recommended rabies prophylactic vaccination for companion animals and livestock using inactivated virus; however, rabies vaccination in camels has barely been reported. In a recent study, a single injection of a double dose canine inactivated rabies vaccine was found effective and confer protective immunity in Bactrian camels for at least 1 year (Liu et al., 2016). In any case, successful control and eradication of rabies are accomplished through effective vaccination programs for pet animals and wildlife which is generally difficult to achieve in most developing countries (OIE, 2019).

---

## **5.11 Notification**

Rabies is a notifiable disease.

## References

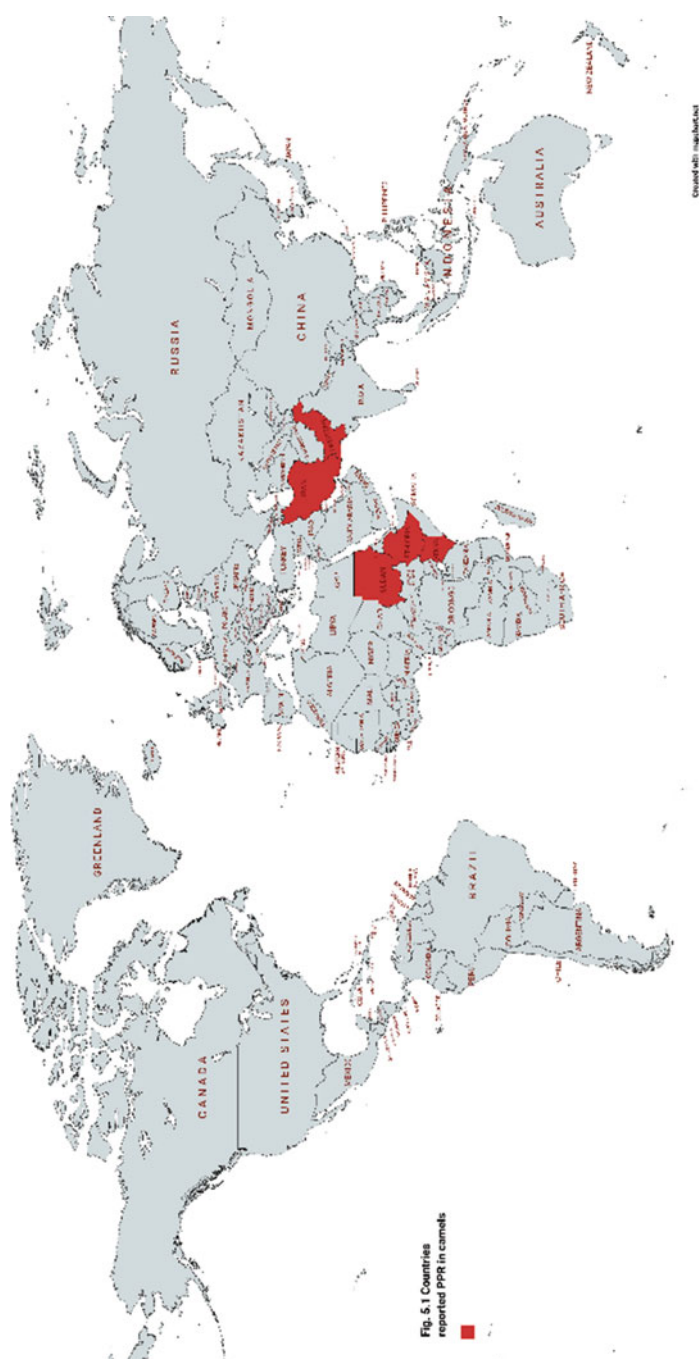
- Abbas, B., & Omer, O. (2005). Review of infectious diseases of the camel. *Veterinary Bulletin*, 75 (8), 1–16.
- Afzal, M., Khan, I. A., & Salman, R. (1993). Symptoms and clinical pathology of rabies in the camel. *The Veterinary Record*, 133(9), 220.
- Ahmed, M. S., Body, M. H., El-Neweshy, M. S., ALrawahi, A. H., Al-Abdawani, M., Eltahir, H. A., & ALmaewaly, M. G. (2020). Molecular characterization and diagnostic investigations of rabiesencephalitis in camels (*Camelus dromedaries*) in Oman: A retrospective study. *Tropical Animal Health and Production*, 52(4), 2163–2168.
- Ali, Y. H., Saeed, I. K., & Zakia, A. (2004). Camel rabies in Sudan. *Sudan Journal of Veterinary Science and Animal Husbandry*, 43(1, 2), 231–234.
- Al-Rawashdeh, O. F., Al-Ani, F., Sharif, L. A., Al-Qudah, K. M., Al-Hami, Y., & Frank, N. (2000). A survey of camel (*Camelus dromedarius*) diseases in Jordan. *Journal of Zoo and Wildlife Medicine*, 31(3), 335–338.
- El Mardi, O. I., & Ali, Y. H. (2001). An outbreak of rabies in camel (*Camelus dromedaries*) in North Kordofan state. *The Sudan Journal of Veterinary Research*, 17, 126–127.
- El-Neweshy, M. S., Al Mayahi, N., Al Mamari, W., Al Rashdi, Z., & Al Mawly, J. H. (2020). Animal rabies situation in Sultanate of Oman (2017–2019). *Tropical Animal Health and Production*, 52(6), 3069–3076.
- Fassi-Fehri, M. (1987). Diseases of camels. *Revue Scientifique Et Technique (International Office of Epizootics)*, 6(2), 337–354.
- Feng, Y., Wang, Y., Xu, W., Tu, Z., Liu, T., Huo, M., Liu, Y., Gong, W., Zeng, Z., Wang, W., Wei, Y., & Tu, C. (2020). Animal rabies surveillance, China, 2004–2018. *Emerging Infectious Diseases*, 12, 2825–2834. <https://doi.org/10.3201/eid2612.200303>
- Fowler, M. E. (2010). *Medicine and surgery of camelids* (3rd ed.). Ames, IA.
- Kasem, S., Hussein, R., Al-Doweriej, A., Qasim, I., Abu-Obeida, A., Almulhim, I., Alfarhan, H., Hodhod, A. A., Abel-latif, M. A., Hashim, O., Al-Mujalli, D., & Al-Sahaf, A. (2019). Rabies among animals in Saudi Arabia. *Journal of Infection and Public Health*, 12, 445–447.
- Kuman, A., & Jindal, N. (1997). Rabies in a camel, a case report. *Tropical Animal Health and Production*, 29(1), 34.
- Liu, Y., Zhang, H.-P., Zhang, S.-F., Wang, J.-X., Zhou, H.-N., Zhang, F., Wang, Y.-M., Ma, L., Li, N., & Hu, R.-L. (2016). Rabies outbreaks and vaccination in domestic camels and cattle in Northwest China. *PLoS Neglected Tropical Diseases*, 10, e0004890.
- Mohammadpour, R., Champour, M., Tuteja, F., & Mostafavi, E. (2020). Zoonotic implications of camel diseases in Iran. *Veterinary Medicine and Science*, 6(3), 59–381.
- OIE. (2019). *Rabies (Infection with rabies virus and other Lyssaviruses)*. Chapter 3.1.17 (file:///E:/New%20Infectious%20Disease%20Book/dataIDC%20book%20data/Rabies/3.01.17\_RABIES.pdf).
- Omer, M. M., Aziz, A. A., & Salih, D. (2006). A note on rabies in a camel (*Camelus dromedarius*) in Kassala State, Eastern Sudan. *The Sudan Journal of Veterinary Research*, 21, 91–92.
- World Health Organization (WHO). (2020). *Rabies*. Accessed from <https://www.who.int/news-room/fact-sheets/detail/rabies>

## Peste Des Petits Ruminants (PPR)

# 6

Abdelmalik I. Khalafalla

Peste des petits ruminants (PPR) is a highly contagious disease of sheep and goats, which has recently re-emerged and is now found widely distributed through large parts of Africa, the Middle East, and Asia. This disease is one of the most economically important transboundary animal diseases as it causes death of small ruminants that are highly depended on by poor people in developing countries. The disease is characterized by severe pyrexia, anorexia, ulcerative necrotic stomatitis, diarrhea, purulent oculo-nasal discharge, and respiratory distress (Radostits et al., 2007). PPR is mainly a disease of small ruminants; however, reports describing the infection in camels are continuously being published from different production zones. The first documented outbreak of PPR in camels reported from Ethiopia in 1996, consisted of a highly contagious respiratory syndrome with elevated morbidity and low mortality rates (Roger et al., 2000). Consecutive outbreaks of a similar disease occurred in eastern Sudan in 2004 and later in Somalia and Kenya (Khalafalla et al., 2010). More recently, PPR outbreaks have been reported in Iran in 2013 (Zakian et al., 2016) and in 2016 in Kenya (Omani et al., 2019). Furthermore, virus antigens were detected in camels of Pakistan (Rahman et al., 2020) (Fig. 6.1). However, experimental infection of camels with PPR virus (PPRV) failed to produce clinical disease except in one single study. This may point to different predisposing factors that govern infection in the field and the biological properties of the circulating PPRV strains. Stress conditions in the field like seasonal movement in search for green pasture coinciding with severe PPR in the comingling sheep flocks could contribute to the appearance of the disease in camels. The most critical elements in the infection of dromedary camels with PPR are virus shedding and the transmissibility to the typical host sheep and goats.



**Fig. 6.1** Countries reported PPR outbreaks or detection of virus (rec color)

---

## 6.1 Etiology

The disease is caused by the peste des petits ruminants virus (PPRV), which belongs to the *morbillivirus* genus of the paramyxovirus family of viruses. PPRV is a non-segmented negative-strand RNA virus closely related to the rinderpest virus of cattle and buffaloes, the measles virus of humans, the distemper virus of dogs and some wild carnivores, and the morbilliviruses of aquatic mammals. The virus exists as a single serotype. However, genetic characterization of virus strains has allowed them to be categorized into four groups (lineages I–IV): three from Africa and one from Asia.

---

## 6.2 Modes of Transmission

The source of infection could be tears, nasal discharge, coughed secretions, and all secretions and excretions of sick and incubating animals. The disease spreads mostly by aerosols or direct contact between animals and fomites may be means of spreading infection.

---

## 6.3 Clinical Picture

The clinical and epidemiological picture of PPR-suspected and confirmed outbreaks in northeast Africa are not consistent. At least two forms can be identified; a peracute disease characterized by sudden death, abortion, and diarrhea with a high mortality rate occurred in the region during 2004–2007, whereas the early outbreaks (1992–1996) showed an acute respiratory disease with low mortality rates (Table 6.1).

In the outbreaks of the disease that occurred in Sudan in 2006 (Fig. 6.2) the disease was characterized by sudden death of apparently healthy animals and yellowish and later bloody diarrhea and abortion. Death has been always sudden and proceeded with colic and difficulty in respiration (Khalafalla et al., 2010).

---

## 6.4 Differential Diagnosis

- Pasteurellosis.
- Contagious ecthyma.
- Mineral poisoning.

**Table 6.1** Features of PPR outbreaks in camels in four countries

	Ethiopia 1995/6	Sudan 2004	Iran 2013	Kenya 2016
Clinical symptoms	Sudden onset, fever, sero-muco-purulent nasal discharge, lachrymation, productive coughing, dyspnea and abdominal breathing, fever, swelling of submandibular area and diarrhea	Sudden death, dyspnea, subcutaneous edema, submandibular swelling, chest pain and coughing, yellowish and later bloody diarrhea, and abortion	Sudden death, fever, oral erosion, and ecthyma like lesions, yellowish diarrhea, pneumonia, and respiratory distress, enlargement of lymph node, severe dehydration, dermatitis, ulcerative keratitis, and conjunctivitis	Sudden death, fever, loss of body condition, general weakness, diarrhea, conjunctivitis oculo-nasal discharges
Morbidity, mortality rates	Morbidity over 90%, mortality: 5–70%	Morbidity—90%, Mortality 0–50% (7.4% total)	Mortality 12/30 = 40%	Morbidity—93%, Mortality ND*
Age group affected/ association with PPR in small ruminants	All age groups Yes	All age groups Yes	All age groups Yes	ND Yes
Laboratory diagnosis	agELISA, RT-PCR, Sequencing, abELISA	PM, AGDT, agELISA, RT-PCR	agELISA, RT-PCR, sequencing	RT-PCR, sequencing
PPRV lineage	II and III	IV	IV	III

ND\* not done

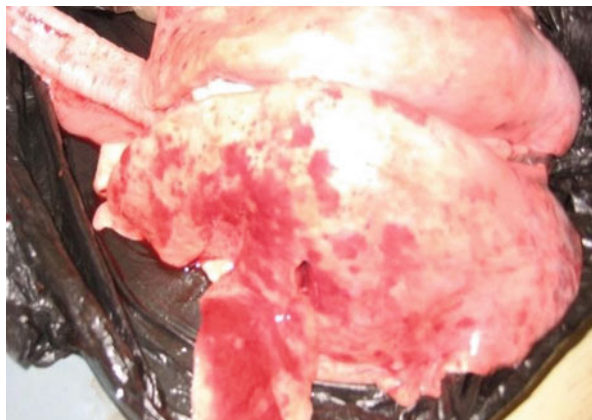
## 6.5 Pathogenesis and Pathology

This virus has an affinity for lymphoid tissues and epithelial tissue of the respiratory and gastrointestinal (GI) tract, where it produces characteristic lesions. At post-mortem, the main findings included lung congestion and consolidation, mostly in apical lobes (Fig. 6.3), paleness, and fragility of liver. Lymph nodes were enlarged and inflamed, and small intestine and stomach showed inflammation and hemorrhage. In one case the lips were swollen, and hemorrhagic ulcers were seen on the tongue. Histopathologically, the bronchioles showed degeneration and denudation of the epithelium and peri-bronchial infiltration of mononuclear cells. The alveolar septa were congested and infiltrated by mononuclear cells and in some areas the lung



**Fig. 6.2** Carcasses of camels died of PPRV infection scattered in northern *Butana*, Sudan in 2004 (Source: Khalafalla et al., 2010)

**Fig. 6.3** Pneumonic lung of a young camel experimentally inoculated with PPRV (Courtesy of Dr. Intisar Saeed, Central Veterinary Research Laboratories, Sudan)



revealed edema and emphysema. The prominent histopathological change was atopic lymphoid follicles.

Disease severity depends on various factors: PPRV strain, host species and breed, and the health status of host animals.

## **6.6 Epidemiology**

The incubation period of PPR is typically 4–6 days but may range from 3 to 10 days. The disease in camels and small ruminants is more frequent during the rainy season or the dry cold season and seasonal periods of increased local movement/trade. Mortality rate ranges between 0 and 50% and varies in accordance with the area. All age, sex, and breed groups are affected. More than 50% of deaths have been reported in adult animals in comparison to calves and young camels. An epidemiological feature of some PPR outbreaks in camels is that a significant number of dead animals were females recently delivered (within a month period) followed by pregnant females (Khalafalla et al., [2010](#)).

---

## **6.7 Diagnosis**

In live animals, nasal swabs and whole blood are collected in EDTA preferably collected in early stages of disease. Upon necropsy, spleen, lung, and lymph nodes should be aseptically collected, chilled on ice, and transported under refrigeration. In previous disease outbreaks, immunocapture ELISA, agar gel diffusion test (AGDT), and RT-PCR were used for detection of PPRV and to differentiate between rinderpest and PPR viruses. Clinical diagnosis of PPR must be confirmed by laboratory diagnostic techniques such as antigen capture ELISA available as a commercial kit, RT-PCR using Pan-morbilli virus primers and PPR specific primers, and virus isolation in cell culture.

---

## **6.8 Zoonotic Potentiality**

PPR is not a zoonotic disease.

---

## **6.9 Treatment**

There is no specific treatment for PPR. However, supportive antibiotic treatment of bacterial co-infections may decrease mortality.

---

## **6.10 Prevention**

In previous outbreaks of PPR in camels in Sudan in 2004 the use of PPR vaccine for sheep and goats gave good results and stopped the spread of the disease. The OIE and the FAO, in their joint strategy for control and eradication of PPR, have set the goal of eradicating the disease by 2030. The role played by the non-typical hosts



such as camels should be considered. Several homologous PPR vaccines are available, being cell culture-attenuated strains of natural PPRV.

---

## 6.11 Notification

PPR is an OIE notifiable disease.

---

## References

- Khalafalla, A. I., Saeed, I. K., Ali, Y. H., Abdurrahman, M. B., Kwiatek, O., Libeau, G., Obeida, A. A., & Abbas, Z. (2010). An outbreak of peste des petits ruminants (PPR) in camels in the Sudan. *Acta Tropica*, 116(2), 161–165.
- Omani, R. N., Gitao, G. C., Gachohi, J., Gathumbi, P. K., Bwihangane, B. A., Abbey, K., & Chemweno, V. J. (2019). Peste des Petits ruminants (PPR) in dromedary camels and small ruminants in Mandera and Wajir counties of Kenya. *Advances in Virology*, 2019, 4028720. <https://doi.org/10.1155/2019/4028720>
- Radostits, O. M., Blood, D. C., Gray, C. C., Hinchcliff, K. W., & Constable, P. D. (2007). *Veterinary medicine: A textbook of the diseases of cattle, horses, sheep, pigs and goats* (Vol. 10e, pp. 1242–1243). Elsevier.
- Rahman, A. U., Dhama, K., Ali, Q., Hussain, I., Oneeb, M., Chaudhary, U., Wensman, J. J., & Shabbir, M. Z. (2020). Peste des petits ruminants in large ruminants, camels, and unusual hosts. *The Veterinary Quarterly*, 40(1), 35–42.
- Roger, F., Yigezu, M., Hurard, C., Libeau, G., Mebratu, G. Y., Diallo, A., & Faye, B. (2000). Investigations on a new pathological condition of camels in Ethiopia. *Journal of Camel Practice and Research*, 7(2), 163–165.
- Zakian, A., Nouri, M., Kahroba, H., Mohammadian, B., & Mokhber-Dezfouli, M. R. (2016). The first report of peste des petits ruminants (PPR) in camels (*Camelus dromedarius*) in Iran. *Tropical Animal Health and Production*, 48(6), 1215–1219.

# Rift Valley Fever

# 7

Abdelmalik I. Khalafalla

Rift Valley fever (RVF), an acute arthropod-borne viral disease, was first reported in Kenya in 1930 and has since made irregular outbreaks in small ruminants and cattle with associated zoonotic spread to humans in sub-Saharan Africa and the Arabian Peninsula. Outbreaks of RVF are rigidly connected with heavy rains and flooding, that increase habitat suitability for arthropod vector populations. Human infections may fluctuate from an asymptomatic-to-mild febrile illness to serious encephalitis, hemorrhagic fever, and death. According to OIE's Terrestrial Manual, camels have been regularly involved in RVF epidemics in East Africa, Egypt, and more recently Mauritania. Camels usually have an inapparent infection with RVF virus (RVFV), but sudden mortality, neonatal mortality and abortion occurs, and abortion rates can be as high as in cattle (OIE, 2018). The camels were added to the list of susceptible animal species, when infection was reported in dromedaries for the first time, during an RVF outbreak in northeastern Kenya in 1962. Clinical disease is usually seldom seen in adult camels, but peracute infection with sudden deaths, abortion, and some early postnatal deaths have been observed (Scott et al., 1963). The disease in camels is secondary to infection of small ruminants with the virus with very few outbreaks in which obvious clinical signs are seen in camels.

Serological evidence of dromedary camel infection with RVF and the demonstration of specific IgG antibodies in camels indicates that these animals are naturally infected. The disease emerged in Egypt in 1977, in Mauritania in 1998, and in the Arabian Peninsula in 2000 and reappeared in Kenya in 2006/2007. In most of these outbreaks, the disease also involved camels beside sheep, goats, and humans, with abortion as the only clinical symptom. In 2010, scientists reported confirmatory evidence for a field camel infection with RVFV in northern Mauritania involving mass abortions in small ruminants and dromedary and at least 63 human clinical cases, including 13 deaths (El Mamy et al., 2011). More recently, Selmi et al. (2020) detected 34% seropositivity and showed that Tunisian one-humped dromedaries succumbed to the disease and may contribute to its dissemination among farmers and other livestock.

---

## 7.1 Etiology

RVF virus (RVFV) is a negative-sense, tri-segmented RNA virus that belongs to the genus *Phlebovirus*, family Phenuiviridae, order of Bunyavirales. There is only one serotype recognized but strains exist of variable virulence. The RVFV is inactivated by lipid solvents like ether, chloroform, sodium deoxycholate, formalin, and by sodium or calcium hypochlorite. Phylogenetic analyses of the genome of isolates from camels in Mauritania in 2010 suggested a shared ancestor between the Mauritania 2010 strain and strains from Zimbabwe, Kenya, South Africa, Uganda, and other strains linked to the 1987 outbreak of RVF in Mauritania.

---

## 7.2 Mode of Transmission

RVF is transmitted by insect vectors or direct contact with organs or fluids of infected animals. RVFV does not cause persistent infection or carrier state and certain *Aedes* species act as reservoirs for RVF virus during inter-epidemic periods.

Several different species of mosquitoes are competent vectors for the RVFV, primarily *Culex* spp. and floodwater-breeding *Aedes* spp. that transmit the virus from infected animals to other animals and to humans.

---

## 7.3 Clinical Picture

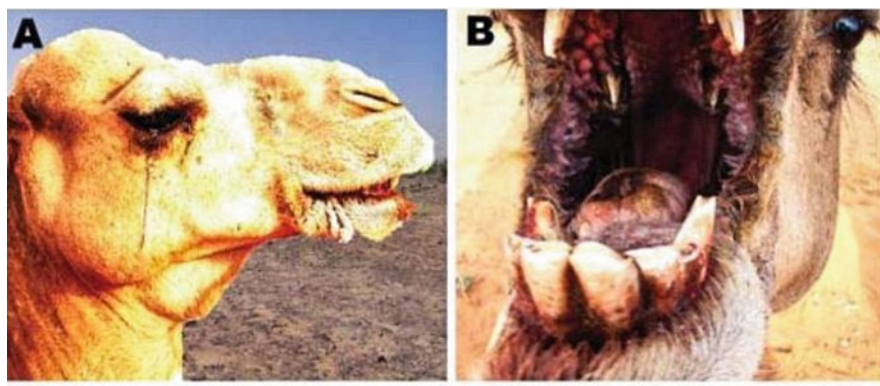
Clinical signs of RVF vary depending on the species, age, the physiological status of animals affected. In camels, clinical signs other than abortions were reported in this species, including hemorrhagic septicemia and severe respiratory distress.

During the outbreak of RVF in Mauritania (El Mamy et al., 2011), two clinical forms were manifested in dromedary camels: a per acute form, with abrupt death in less than 24 h; and an acute form with fever, ataxia, ballooning, edema at the base of the neck, audible expiratory wheeze and ventral positional dyspnea, blood-tinged nasal discharge, icterus, severe conjunctivitis with ocular discharge and blindness, hemorrhages of gums and tongue, foot lesions, nervous symptoms, and abortions (Fig. 7.1).

---

## 7.4 Differential Diagnosis

- Enterotoxaemia.
- Brucellosis.
- Hemorrhagic septicemia.
- Peste des petits ruminants.
- Anthrax.



**Fig. 7.1** Clinical signs of Rift Valley fever in dromedary camels observed in Mauritania. (a) Conjunctivitis, ocular discharge, and submandibular swelling; (b) Stomatitis; hemorrhages of gums and tongue (Courtesy of Dr. Ahmed El Mamy, Mauritania)

---

## 7.5 Pathogenesis and Pathology

Little is known of RVF pathology and pathogenicity in camels.

---

## 7.6 Epidemiology

Generally, the incubation period of RVF varies from 1 to 6 days and could be less than 24 h in newborns. Countries that reported outbreaks of RVF in camels include Mauritania, Egypt, Sudan, and Kenya (Fig. 7.2). Risk factors include above-average rainfalls, floods, and human cases in the same area. Age has been shown to be a significant factor in the animal's susceptibility to disease. Additionally, camels are suspected of playing a major role in the spread of RVF from northern Sudan to southern Egypt in 1977.

---

## 7.7 Diagnosis

RVF may be suspected based on clinical signs characterized by a storm of abortions, insect activity, and concurrent disease in small ruminants, cattle, or humans, but laboratory confirmation must be done by RT-PCR, ELISA, or virus isolation.

Specimens for laboratory diagnosis are hazardous and must be handled with extreme care. These include blood in EDTA, clotted blood, plasma or serum, tissue samples of liver, spleen, kidney, lymph node, heart blood, and brain from dead animals or aborted fetuses.

The most common laboratory procedures include:

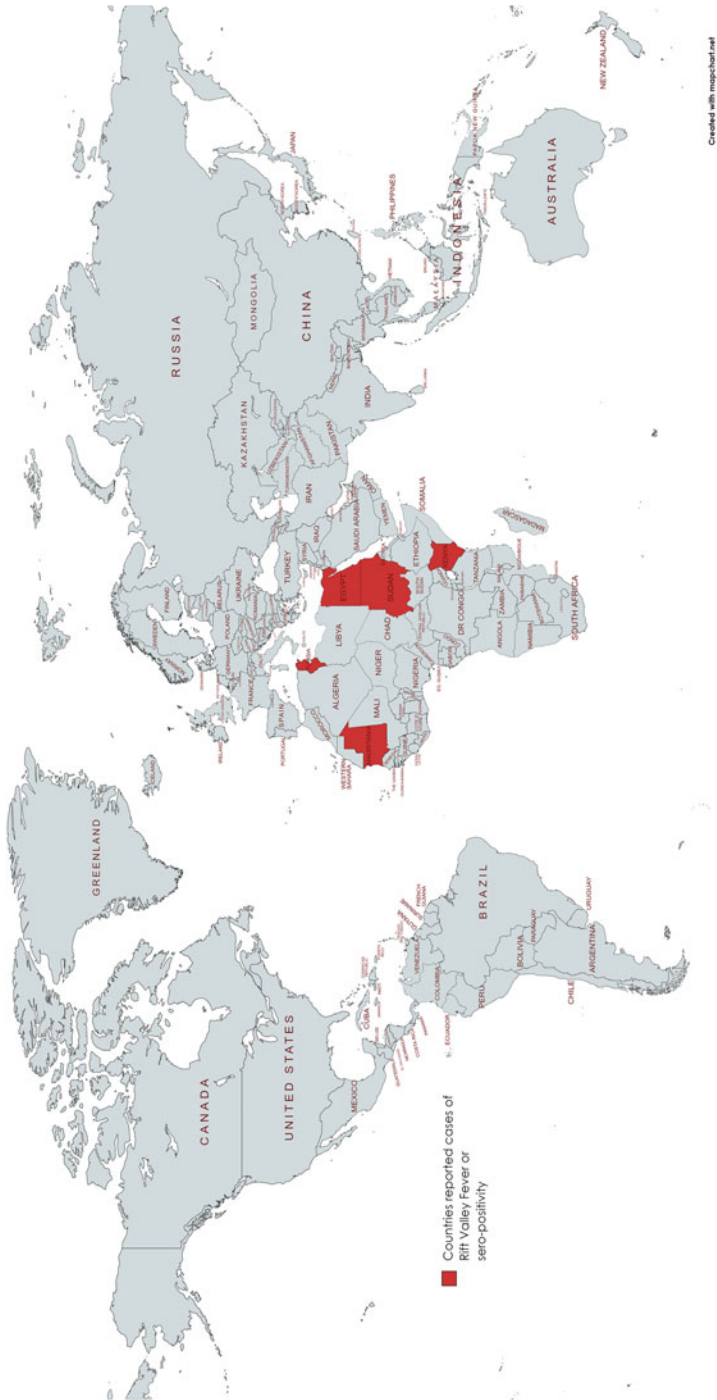


Fig. 7.2 ...

- Reverse transcriptase-polymerase chain reaction (RT-PCR) assay (Selmi et al., 2020).
- IgG and IgM antibody enzyme-linked immunosorbent assay (ELISA).
- Virus isolation by cell culture (require high containment laboratory).

---

## 7.8 Zoonotic Potentiality

Rift Valley fever is a viral zoonosis that primarily affects animals with the capacity to infect humans. In humans, the disease takes different forms ranging from mild-to-severe and fatal forms. The mild form is characterized by a flu-like syndrome, with feverish signs, muscle and joint pain, headache, and loss of appetite. Severe forms include severe hemorrhagic fever, ocular form, and meningoencephalitic form. Virus transmission occurs in humans conducting veterinary procedures and when handling infected animals and meat via wound from an infected knife, contact with broken skin, or inhalation of aerosols produced during the slaughter. Accordingly, people at risk for rift valley fever include herders, veterinarians, and slaughterhouse workers.

---

## 7.9 Treatment

There is no specific treatment for RVF in camels.

---

## 7.10 Prevention

Measures applied in the face of an outbreak include control of animal movements, control at slaughterhouses surveillance within containment and/or protection zone, quarantine, vector surveillance and control, ante- and post-mortem inspections, and vaccination. There are several types of modified live attenuated and inactivated virus vaccines for RVF, but little is known about their use and efficiency in camels.

---

## 7.11 Notification

Rift Valley fever is an OIE enlisted disease and immediate notification of clinical cases upon detection to OIE is mandatory.

## References

- El Mamy, A. B. O., Baba, M. O., Barry, Y., et al. (2011). Unexpected Rift Valley fever outbreak, Northern Mauritania. *Emerging Infectious Diseases*, 17(10), 1894–1896. <https://doi.org/10.3201/eid1710.110397>
- OIE. (2018). *Rift Valley fever (infection with Rift Valley fever virus)*. Chapter 3.1.18. [https://www.oie.int/fileadmin/Home/eng/Health\\_standards/tahm/3.01.18\\_RVF.pdf](https://www.oie.int/fileadmin/Home/eng/Health_standards/tahm/3.01.18_RVF.pdf)
- Scott, G. R., Coackley, W., Roach, R. W., & Cowdy, N. R. (1963). Rift Valley fever in camels. *Journal of Pathology and Bacteriology*, 86(1), 229–231.
- Selmi, R., Mamlouk, A., Ben Said, M., Ben Yahia, H., Abdelaali, H., Ben Chehida, F., Daaloul-Jedidi, M., Gritli, A., & Messadi, L. (2020). First serological evidence of the Rift Valley fever Phlebovirus in Tunisian camels. *Acta Tropica*, 207, 105462.

Abdelmalik I. Khalafalla

Middle East respiratory syndrome coronavirus (MERS-CoV) is an emerging pathogen associated with severe respiratory symptoms and renal failure in infected persons and mild-to-subclinical infection in dromedary camels. Early observations that some MERS-CoV infected people were exposed to camels suggesting a possible role of this animal as an intermediate reservoir host. Serological surveys subsequently conducted in several countries in the Arabian Peninsula and Africa have identified high rates of MERS-CoV-specific antibodies in dromedary camels (Hemida et al., 2013; Perera et al., 2013). Furthermore, researchers have found definitive proof that camels can be infected with MERS-CoV. MERS-CoV infection remains subclinical with only mild upper respiratory tract symptoms (Fig. 8.1) observed in some camels. Accordingly, MERS-CoV causes no well-defined disease in camels and its impact of MERS-CoV on animal health is exceptionally low. However, due to its zoonotic potentiality the OIE recently decided to consider MERS-CoV infection in camels as an enlisted disease, published a case definition to report the disease, and plan to include it in the terrestrial manual. The aims of reporting to the OIE are to mitigate the human health risk of MERS-CoV and to prevent international spread, while ensuring safe international trade of dromedary camels and their products.

## 8.1 Etiology

MERS-CoV is an enveloped, non-segmented, positive-sense, single-stranded RNA virus of the genus *Betacoronavirus* of the family Coronaviridae. The viability of the virus decreases at higher temperatures or higher relative humidity. In aerosol experiments, MERS-CoV retains most of its viability at 20<sup>0</sup> C and 40% relative humidity and is inactivated by common disinfectants such as household bleach (Chlorox), ethanol, paraformaldehyde, and glutaraldehyde.



## 8.2 Modes of Transmission

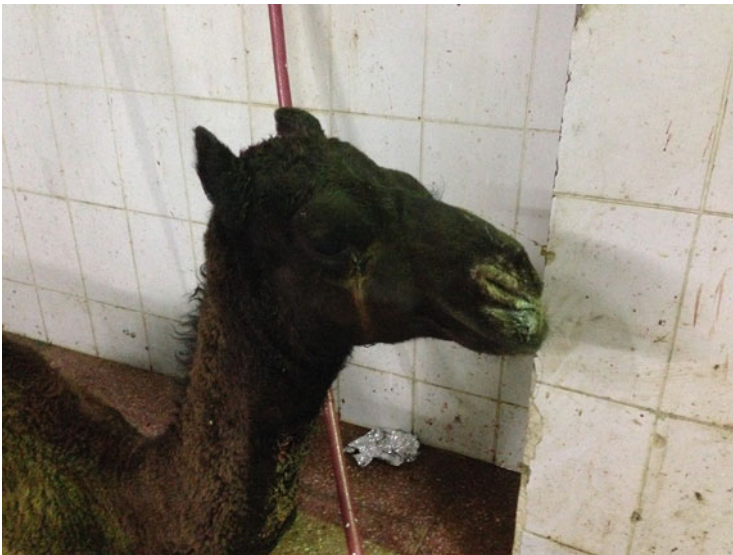The main source of the virus is respiratory secretions of an infected dromedary camel. Infection results in virus shedding for a limited period and reinfection has been shown to occur. MERS-CoV is thought to spread from infected person to others who remain in close contact through respiratory secretions, however, the precise ways the virus spreads are not currently well understood.

## 8.3 Clinical Picture

MERS-CoV is mostly a subclinical infection but can induce clinical signs in some of the affected camels consisting of fever, nasal discharge and lacrimation observed in both field cases (Fig. 8.1, Khalafalla et al., 2015) and experimentally infected camels (Adney et al., 2014).

## 8.4 Differential Diagnosis

Upper and lower respiratory tracts infections.



**Fig. 8.1** Symptoms of MERS-CoV infection in a 10-months-old dromedary camel (source: Khalafalla et al., 2015)

---

## 8.5 Pathogenesis and Pathology

No gross post-mortem lesions have been characterized in camels. Histological changes in experimentally infected adult dromedary camels consisted of degeneration of the pseudostratified epithelium lining the nasal turbinate, trachea, and bronchus.

---

## 8.6 Diagnosis

Laboratories working with MERS-CoV or suspect material must comply with national biocontainment and biosafety regulations and they should also comply with the guidelines for Risk Group 3, as described in Chap. 1.1.3 Biosafety and biosecurity in the veterinary diagnostic microbiology laboratory and animal facilities of the OIE Manual of Diagnostic Tests and Vaccines for Terrestrial Animals (Terrestrial Manual).

Nasal or nasopharyngeal swabs should be collected aseptically in virus transport medium and transported in ice to the laboratory. According to OIE the following defines a laboratory-confirmed case of MERS-CoV infection (with or without clinical signs): MERS-CoV has been isolated from a dromedary camel; OR.

Viral nucleic acid has been identified in a sample from a dromedary camel on:

- (a) At least two specific genomic targets.
- (b) A single positive target with sequencing of a secondary target.
- (c) A single positive target and tested positive to rapid MERS-CoV antigen test.

---

## 8.7 Zoonotic Potentiality

MERS-CoV is a zoonotic virus, transmitted between animals and people. Scientific evidence suggests that people are infected through direct or indirect contact with infected dromedary camels (Alagaili et al., [2014](#)).

---

## 8.8 Treatment

There is no specific treatment for the disease in camels. However, treatment applied to upper and lower respiratory infections is useful.

---

## 8.9 Prevention

No vaccine or specific treatment for MERS is currently available for animals as well as humans; however, supportive treatment is based on the clinical condition of the patient. General hygienic measures should be practiced before visiting farms, barns, or other places where dromedary camels and other animals are present.

---

## 8.10 Notification

OIE Member Countries are obliged to report a confirmed case of MERS-CoV in animals to the OIE, as an “emerging disease” with zoonotic potential in accordance with Article 1.1.4 of the OIE Terrestrial Animal Health Code.

---

## References

- Adney, D. R., van Doremalen, N., Brown, V. R., Bushmaker, T., Scott, D., de Wit, E., Bowen, R. A., & Munster, V. J. (2014). Replication and shedding of MERS-CoV in upper respiratory tract of inoculated dromedary camels. *Emerging Infectious Diseases*, 20, 1999–2005. <https://doi.org/10.3201/eid2012.141280>
- Alagaili, A. N., Brieseman, T., Mishra, N., Kapoor, V., Sameroff, S. C., & de Wit, E. (2014). Middle East respiratory syndrome coronavirus infection in dromedary camels in Saudi Arabia. *MBiol.*, 5, e00884–e00814.
- Hemida, M. G., Perera, R. A., Wang, P., Alhammadi, M. A., Siu, L. Y., & Li, M. (2013). Middle East respiratory syndrome (MERS) coronavirus seroprevalence in domestic livestock in Saudi Arabia, 2010 to 2013. *Euro Surveillance*, 18, 20659.
- Khalafalla, A. I., Lu, X., Al-Mubarak, A. I., Dalab, A. H., Al-Busadah, K. A., & Erdman, D. D. (2015). MERS-CoV in upper respiratory tract and lungs of dromedary camels, Saudi Arabia, 2013–2014. *Emerging Infectious Diseases*, 21, 1153–1158.
- Perera, R. A., Wang, P., Gomaa, M. R., ElShesheny, R., Kandeil, A., & Bagato, O. (2013). Seroepidemiology for MERS coronavirus using microneutralisation and pseudoparticle virus neutralization assays reveal a high prevalence of antibody in dromedary camels in Egypt, June 2013. *Euro Surveillance*, 18, 20574.

# Camel Prion Disease (CPrD)

# 9

Abdelmalik I. Khalafalla

Camel prion disease (CPrD) which is the last disease described in the family of prion diseases was diagnosed in 2018 in three adult camels showing clinical signs at the ante-mortem inspection at an abattoir in the region of Ouargla (Algeria) (Babelhadj et al., 2018). As described in the published report symptoms suggesting prion disease occurred in 3.1% of dromedaries brought for slaughter to the Ouargla abattoir in 2015–2016. More recently, in 2019, the same disease was reported in the region of Tataouine (Tunisia) (OIE, 2019).

## 9.1 Etiology

The term “prions” refers to abnormal, pathogenic agents that are transmissible and are able to induce abnormal folding of specific normal cellular proteins called prion proteins that are found most abundantly in the brain. Change in the conformation of prion protein (PrP<sup>C</sup>) from a mainly  $\alpha$ -helical to a  $\beta$ -sheet rich isoform, PrP-scrapie (PrP<sup>Sc</sup>) is the principal pathogenic event underlying all prion disorders (Singh et al., 2020). Accumulation of PrP<sup>Sc</sup> in the brain parenchyma is the major cause of neuronal degeneration.

Camel prion disease is now a member of the group of animal prion diseases that include scrapie in sheep and goats, chronic wasting disease (CWD) in cervids and Bovine spongiform encephalopathy (BSE) in cattle. As described in the published report the biochemical characterization of the PrP<sup>Sc</sup> that causes the disease in dromedary camels in Algeria showed differences with BSE and scrapie (Babelhadj et al., 2018).

---

## 9.2 Clinical Picture

The clinical manifestations of CPrD cases from Algeria included weight loss, behavioral abnormalities, and neurologic symptoms, such as tremors, aggressiveness, hyperexcitability, abnormal and excessive movement of the neck and head, hesitant and uncertain gait, ataxia of the hind limbs, occasional falls, and difficulty getting up as the disease progresses.

---

## 9.3 Diagnosis

The diagnosis of the camel prion disease depends on histopathology combined with PrP<sup>Sc</sup> detection in the brain. The detection of disease specific PrP<sup>Sc</sup> is obtained by means of Western blot and Immunohistochemistry. Epidemiological criteria to be considered include: (i) reporting in the area of neurological signs in camels for which diagnostic investigations for other diseases causing nervous symptoms were negative or inconclusive and (ii) import of camels from areas where CPrD cases have been reported.

---

## 9.4 Zoonotic Potentiality

To date, no information is available on the risk of CPrD for humans. Therefore, the consumption of central nervous system and lymphoid tissue from CPrD-infected camels should be avoided as precautionary measure.

---

## References

- Babelhadj, B., Di Bari, M. A., Pirisinu, L., Chiappini, B., Gaouar, S. B. S., Riccardi, G., Marcon, S., Agrimi, U., Nonno, R., & Vaccari, G. (2018). Prion disease in dromedary camels, Algeria. *Emerging Infectious Diseases*, 24(6), 1029–1036.
- OIE (2019, December). *OIE bulletin*. [https://oiebulletin.com/wp-content/uploads/2019/12/OIE-News-December-2019-Camel-prion-disease.pdf?utm\\_source=World+Organisation+for+Animal+Health+%E2%80%93+OIE+Bulletin&utm\\_campaign=388d499799-EMAIL\\_CAMPAIGN\\_2019\\_12\\_05\\_09\\_06&utm\\_medium=email&utm\\_term=0\\_7694a173d1-388d499799-54758659](https://oiebulletin.com/wp-content/uploads/2019/12/OIE-News-December-2019-Camel-prion-disease.pdf?utm_source=World+Organisation+for+Animal+Health+%E2%80%93+OIE+Bulletin&utm_campaign=388d499799-EMAIL_CAMPAIGN_2019_12_05_09_06&utm_medium=email&utm_term=0_7694a173d1-388d499799-54758659).
- Singh, N., Chaudhary, S., Ashok, A., & Lindner, E. (2020). Prions and prion diseases: Insights from the eye. *Experimental Eye Research*, 108200. <https://doi.org/10.1016/j.exer.2020.108200>. Online Ahead of Print.

---

## **Part II**

# **Bacterial Diseases of Dromedary Camels**

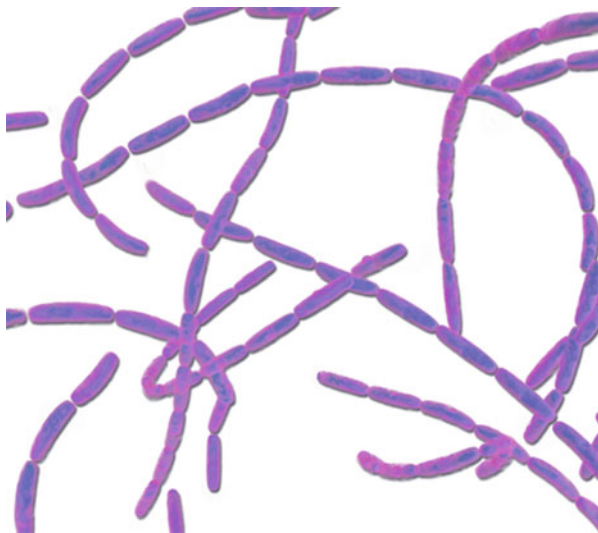Mansour F. Hussein

Anthrax is a serious disease affecting a wide range of domestic and wild animals as well as humans. Its causative agent, *Bacillus anthracis*, is a gram-positive, spore-forming, bacterium (Fig. 10.1) that derives its name from the Greek word “*anthrakis*,” which means coal. It consists of a single uniform antigenic type worldwide, although differences may exist between specific local strains (Wernery & Kaaden, 2002). The disease occurs throughout the world with the possible exception of Antarctica. Within the host, *B. anthracis* develops a capsule; however, upon exposure to oxygen, it forms extremely resistant spores that enable it to survive in the soil for many decades. The anthrax toxin consists of three components acting together: lethal factor, edema factor, and protective antigen.

Anthrax is a zoonotic disease most commonly encountered in herbivorous animals such as cattle, sheep, goats, camels, and wild herbivores. These animals acquire the disease by ingesting anthrax spores from heavily contaminated soil or vegetation while grazing or drinking contaminated stagnant water. They can also be infected via insect vectors. The likelihood of outbreaks among animals increases during heavy rains and floods, and also when animals gather in large numbers at drinking points. Humans may contract the disease as a result of exposure to infected animals or their tissues, or the consumption of undercooked meat from infected animals.

Anthrax is considered to be the most important bacterial disease in the camel (Ashraf et al., 2014). It has been reported from various dromedary camel-rearing areas in Africa, Asia, and the Middle East, including Somalia (Mares, 1954), Chad (Fassi-Fehri, 1987), Sudan (Musa et al., 1993), Tunisia (Burgemeister et al., 1975), Kenya (Bremaud, 1969), Ethiopia (Richard, 1975), Egypt (Barakat et al., 1976), Syria (Tabbaa, 1997), and Pakistan (Ashraf et al., 2014).

**Fig. 10.1** *Bacillus anthracis*  
(From Todar's *Online  
Textbook of Bacteriology*)



---

## 10.1 Modes of Transmission

In common with other herbivores, camels usually acquire anthrax as a result of swallowing anthrax spores while grazing on contaminated soils and pastures or drinking from contaminated water sources. Also inhaling the spores in contaminated dust may occasionally lead to infection. Besides, transmission may occur via biting flies such as *Hippobosca* and *Tabanus* species, and larvae of the camel nasal bot, *Cephalopina titillator* (Curasson, 1947; Leese, 1927). Barakat et al. (1976) incriminated migratory birds as sources of infection during an outbreak of anthrax in camels in the Western Desert of Egypt.

---

## 10.2 Clinical Picture

Anthrax in camels may take a peracute, acute, or apoplectic form (Fazil, 1977). In Pakistani camels in which the overall prevalence of anthrax is around 1.8%, the peracute form of the disease causes sudden death as a result of severe septicemia before appearance of symptoms. However, camels that survive for some time, develop clinical signs, including dark foamy, nonclotting blood oozing from natural orifices, tympany, severe colic, diarrhea, convulsions, apoplexy, and rapid death (Ashraf et al., 2014). During an outbreak involving 100 camels in Syria, Tabbaa (1997) stated that the affected animals exhibited difficulty in breathing, trembling, and large swellings at the throat, neck, and groins and finally collapsed and died, with dark, un-clotted blood oozing from their natural orifices. Other signs reported in camels include excessive salivation, extension of the neck, prostration, bloat, severe



cardiovascular disturbances, and rapid death, often within 24–36 h after the appearance of symptoms (Gatt Rutter & Mack, 1963; Musa et al., 1993; Wernery & Kaaden, 2002). In Somalia, camel herders refer to anthrax as “*gudu*” which means sudden death. However, a protracted form of the disease has also been described in Somali camels, characterized by painful swellings at the throat, base of the neck, chest, and groins (Fassi-Fehri, 1987). Leese (1927) suggested that edematous swellings of the head, throat, neck, and other parts of the body were major signs of camel anthrax and that difficulty in breathing and swallowing might occur due to neck and throat involvement.

---

### 10.3 Pathology

Post-mortem examination should not be performed on camels suspected of anthrax since exposure of the anthrax bacilli to oxygen results in the formation of highly resistant spores that survive and contaminate the environment for many decades. By contrast, if the carcass is left unopen, it decomposes quickly leading to rapid destruction of the vegetative form of the organism within the carcass. In all cases, any camel that dies suddenly should not be necropsied until a blood smear has been examined and proven negative for anthrax. For this purpose, smears are obtained aseptically from a peripheral blood vessel, e. g., from the ear, dried, fixed, and stained with polychrome methylene blue.

The carcass of an animal dying of anthrax is markedly bloated but there is no *rigor mortis*, while tar-like blood that does not clot might ooze from natural orifices such as mouth, nose, and anus.

If the carcass is opened accidentally, lesions of generalized septicemia may be seen, characterized by widespread petechial and ecchymotic hemorrhages throughout the carcass, along with blood-stained effusions in all body cavities, marked enlargement, and blackberry jam consistency of the spleen and pulmonary edema (Boue, 1962; Richard, 1975).

---

### 10.4 Diagnosis

Anthrax may be suspected when a camel is found suddenly dead, bloated, and without rigor mortis, or with only incomplete rigor mortis, while blood oozes from its natural orifices. Initially, a blood smear from an ear vein or another peripheral vein may be checked for anthrax bacilli. The latter are square-ended rods, surrounded by capsules. They can be visualized by polychrome methylene blue staining in which the capsule stains pink and the bacillus cell stains deep blue. This is called the McFadyen’s reaction.

*B. anthracis* can be cultured in blood agar and most nutrient agars from swabs of blood, body fluids, and tissues. Growth is achieved within hours and the bacterial colonies show a characteristic “medusa head” appearance while encapsulated, spore-forming, gram-positive bacilli are found in pairs or short chains in the blood cultures.

The identity of *B. anthracis* may further be confirmed by gamma phage lysis and penicillin susceptibility (Abshire et al., 2005).

Other specific tests used for anthrax diagnosis include polymerase chain reaction (PCR) and fluorescent antibody (FA) staining to demonstrate the organism in blood films or tissues, Western Blot and enzyme-linked immunosorbent assay (ELISA) tests to detect antibodies against the bacterium, and a chromatographic assay for protective antigen in blood. These tests have not yet been developed for camel anthrax tests.

In old, decomposed carcasses and animal products, it may not be possible to demonstrate *B. anthracis* by cultural or direct microscopic methods. In these cases, the Ascoli test may be applied. This is a thermo-precipitin test that detects thermo-stable anthrax antigens in decomposed carcasses and animal products. However, its results should be interpreted with caution since the test is not highly specific for *B. anthracis*. It may also be possible to recover anthrax spores from the turbinate bones of livestock cadavers.

---

## 10.5 Differential Diagnosis

Anthrax should be differentiated from other conditions that might cause sudden death in camels, such as clostridial enterotoxaemia and acute septicemic infections, lightning strikes, snake bites, and poisoning with heavy metals.

---

## 10.6 Treatment

*B. anthracis* is sensitive to penicillin, tetracycline, and many other antimicrobial agents. However, any attempt of treatment is of little value due to the rapid progression of the disease.

---

## 10.7 Prevention and Control

Carcasses of animals that died of anthrax and all their bedding and manure should be properly disposed of, preferably by incineration, or by deep burial and coverage with quick lime. Scavengers should be kept away from the carcass. Contaminated utensils should be disinfected using strong disinfectants such as sodium hydroxide (10%), formaldehyde (5%), hydrogen peroxide (7%), or glutaraldehyde (2%).

Susceptible camels can be vaccinated using the Sterne vaccine bovine dose for dromedary camels. This is a live, avirulent, spore vaccine that has been in use for many years for vaccinating domestic and wild animals, giving them immunity for up to nine months.

The affected premises should remain quarantined until vaccination is completed. Strict sanitary measures should be applied, including the control of rodents and insects.

## 10.8 Notification

Anthrax is a notifiable disease.

---

## References

- Abshire, T. G., Brown, J. E., & Ezzell, J. W. (2005). Production and validation of gamma phage for identification of *Bacillus anthracis*. *Journal of Clinical Microbiology*, 43(9), 4780–4788.
- Ashraf, S., Chaudhry, H. R., Chaudhry, M., Iqbal, Z., Ali, M., Jamil, T., Sial, N., Sharzad, M. I., Basheer, F., Akhtar, S., Hafeez, S., Ur Rahman, S., & Yasin, A. (2014). Prevalence of common diseases in camels of Cholistan Desert, Pakistan. *Pakistan Journal of Infection and Molecular Biology*, 2(4), 49–52.
- Barakat, A. A., Sayour, E., & Fayed, A. A. (1976). Investigation of an outbreak of anthrax in camels in the Western Desert. *Journal of the Egyptian Veterinary Medical Association*, 36(1), 183–186.
- Boue, A. (1962). *l'initiation au dromedaire*. Service biologique et vétérinaire des armées, centre d'instruction du service. Vétérinaire de l'Armée Compiègne, 1957 Remis a jour.
- Bremaud, O. (1969). *Notes on camel production in the northern districts of the Republic of Kenya*. ILCA.
- Burgemeister, R., Leyk, W., & Goessler, R. (1975). Untersuchungen iiber Vorkommen von Parasitosen, bakteriellen und viralen Infektionskrankheiten bei Dromedaren in Siidunesien. *DTW Dtsch Tierarztl Wochenschr*, 82, 352–354.
- Curasson, G. (1947). *Le chameau et ses maladies* (pp. 84–86). Vigot Frères.
- Fassi-Fehri, M. M. (1987). Diseases of camels. *Revue Scientifique et technique (OIE)*, 6(2), 337–354.
- Fazil, M. A. (1977). The camel. *Bulletin of Animal Health and Production in Africa*, 25(4), 454–462.
- Gatt Rutter, T. E., & Mack, R. (1963). Diseases of camels. Part 1: Bacterial and fungal diseases. *Veterinary Bulletin*, 33(3), 119–124.
- Leese, A. S. (1927). *A treatise on the one-humped camel in health and in diseases*. Haynes and Son.
- Mares, R. G. (1954). Animal husbandry, animal industry and animal diseases in the Somaliland Protectorate, Part II. *British Veterinary Journal*, 110, 470–481.
- Musa, M. T., Shomein, A. M., Abd El Razig, Y. M., Meki, N. T., & El Hassan, S. M. (1993). Anthrax in humans and camels in the Sudan, with reference to the disease in the country. *Revue d'élevage et de Médecine Vétérinaire des Pays Tropicaux*, 46(3), 438–439.
- Richard, B. (1975). *Etude de la pathologie du dromedaire, dans la sous- province du Borana (Ethiopie)*. These Doct. Vèt, ENV, Alfort, Creteil, Paris.
- Tabbaa, D. (1997). *Anthrax in camels* (Pamphlet). Syria: Faculty of Veterinary Medicine, Al Baath University.
- Wernery, U., & Kaaden, O. R. (2002). *Infectious diseases in Camelids* (2nd ed.). Blackwell Wissenschafts-Verlag.

Mansour F. Hussein

Botulism is a form of food poisoning, which occurs in man, animals, and birds as a result of ingesting *Clostridium botulinum* toxins in contaminated food, water, mud, animal carcasses, and bones. *C. botulinum* was discovered in 1897 in salted ham that was involved in the death of three people in Belgium (Pal et al., 2014).

## 11.1 Etiology

*Clostridium botulinum* is a gram-positive, motile, catalase-negative, strictly anaerobic, spore-forming, rod-shaped bacterium found in the soil and marine sediments throughout the world. It may contaminate vegetations, and colonize the gastrointestinal tract of fish, birds, and mammals. Furthermore, carrion carcasses and decayed organic matter provide a moist, warm, and low-oxygen environment for botulinum spores to germinate and produce toxins.

*C. botulinum* encompasses a diverse group of bacteria which were initially classified on the basis of their ability to produce botulinum toxin and are currently classified into four distinct phenotypic groups I–IV; these groups, along with some *C. butyricum* and *C. baratii* strains, are capable of producing some types of botulinum toxins (Smith & Sugiyama, 1988).

While *C. botulinum* Group IV has not been shown to cause disease in man or animals, Groups I and II are responsible for most cases of human botulism whereas Group III mainly causes botulism in animals.

*C. botulinum* organisms produce at least eight, serologically distinct, neurotoxins (A–H). These toxins are produced by botulinum endospores under strict anaerobic conditions and are the most powerful toxins known to mankind. Following their ingestion by people or animals, they are absorbed from the intestinal tract and carried by the bloodstream to neuromuscular endings, eventually reaching the axon terminal and blocking excitatory synaptic transmission, thus resulting in severe flaccid paralysis and death (Halpern & Neale, 1995).

Botulism often occurs in areas where the soil, plants, and consequently animals, are deficient in phosphorus. In this situation, animals sometimes tend to consume bones or soil, or even cadavers, in an effort to compensate for the deficiency, thereby increasing their risk of being exposed to botulinum toxins.

Among farm animals, botulism is primarily found in cattle especially in South Africa and South America, although a few cases are sometimes met with in equines and small ruminants as well.

---

## 11.2 Modes of Transmission

Very little information is available on camel botulism. In 1975, Provost et al. (1975), described a devastating outbreak of botulism (Type C) in dromedary camels in Chad, presumably after drinking from a well contaminated with a cadaver, which was the source of toxin. The affected herd consisted of 150 camels of which 45 were dead and 40 were severely ill at the time of reporting.

More recently, Bushara and Musa (2012) reported botulism in livestock, particularly camels, from Northern Darfur State in Western Sudan. They investigated many carcasses from various animal species, as well as water sources, soil, and animal tissue samples from the affected areas. Cultural and biochemical methods were used to isolate and identify *Clostridium botulinum* (Type C) while botulinum neurotoxin was identified by mouse bioassay and typing of the isolates by PCR. These authors stated that inadequate feeding of the animals leads to ingestion of soil and they suggested vaccination and improvement of feeding to reduce the risk of botulism.

---

## 11.3 Clinical Picture and Pathology

Signs of botulism include muscular weakness and flaccid paralysis of the hind legs, which may extend to other parts of the body including muscles of the face, jaw, and tongue resulting in dysphagia and drooling. In the case of camels, Provost et al. (1975) stated that the affected animals exhibited difficulty in standing, hind quarter paresis, collapse, and rapid death apparently due to respiratory or cardiac failure. Also, during botulism outbreaks in Darfur, Sudan, the predominant clinical sign in camels and other livestock was paralysis of the hindquarters (Bushara & Musa, 2012). There are no specific post-mortem lesions in botulism. Sometimes, abnormal material, such as bones or sand, may be found in the animal's digestive system.

---

## 11.4 Diagnosis

Botulism is initially suspected on the basis of clinical signs and differentiation from other conditions causing motor paralysis, e.g., rabies, certain toxic plants, poisoning by organophosphorus compounds, Ca deficiency, etc. Laboratory methods are used to detect bacteria, spores, and toxins. Detection of botulism toxin in suspected

material is the most reliable test method. Samples should be taken from any potential source as soon as botulism is suspected. In peracute cases, the toxin may be detectable in the blood by mouse inoculation tests but usually is not detectable in the average field case in camels and other farm animals. The PCR can be used for typing the toxin. Other detection methods include ELISA, complement fixation test (CFT), and immunodiffusion.

---

## 11.5 Treatment and Prevention

There is no specific treatment for botulism; *C. botulinum* toxoid and Guanidine hydrochloride may be tried but the results are inconsistent.

The source of the toxin should be removed as soon as it is identified, and the carcasses of dead animals should be properly disposed of. Proper nutrition and salt licks should be provided, while P or any other deficiency in the diet should be corrected. Rotten silage and plants should be removed and the contamination of feed and water with bird or rodent carcasses or bird litter should also be prevented.

Vaccines (types C and D) developed for cattle in some countries may be considered for use in camels in endangered areas.

---

## 11.6 Notification

Botulism should be reported to relevant public health authorities as it can sometimes be foodborne.

---

## References

- Bushara, I. A., & Musa, T. M. (2012). *Botulism in livestock in North Darfur State*. Tropentag, September 19–21, 2012, Göttingen – Kassel/Witzenhausen “Resilience of agricultural systems against crises.”
- Halpern, J. L., & Neale, E. A. (1995). Neurospecific binding, internalization, and retrograde axonal transport. *Current Topics in Microbiology and Immunology*, 195, 221–241.
- Pal, M., Mulu, S., Adugna, F., & Slemu, J. (2014). Canned foods and botulism. *Beverage and Food World*, 41(9), 25–27.
- Provost, A., Haas, P., & Dembelle, M. (1975). First cases of animal botulism (type C) in Chad: Intoxication of dromedaries by water from a well. *Revue d'élevage et de méd. Vét. des pays Tropicaux*, 28(1), 9–11.
- Smith, L. D. S., & Sugiyama, H. (1988). *Botulism: The organism, its toxins, the disease* (2nd ed.). Thomas.

# Brucellosis (*Brucella abortus* and *Br. melitensis*)

# 12

Mansour F. Hussein

Brucellosis has been reported in virtually all camel rearing countries with the exception of Australia (reviewed by Sprague et al., 2012) and its incidence in these animals is increasing in some countries as a result of uncontrolled trade in live camels (Wernery, 2014).

## 12.1 Etiology

Brucellosis is a contagious bacterial disease caused by different species of the genus *Brucella*. These are gram-negative, non-motile, nonspore-forming, facultative intracellular organisms that infect a wide range of mammals including all domestic animals and man. It is a true zoonosis in which animals or animal products are the principal sources of human infection (Radostits et al., 2007). To date, at least ten classified *Brucella* species are known, with *Br. abortus* infecting mainly cattle and buffalos, *Br. ovis* infecting mainly sheep and *Br. melitensis* infecting mainly sheep and goats. Other species include *Br. suis* in pigs, *Br. canis* in dogs, *Br. neotomae* in rats, *Br. inopinata* in humans, as well as *Br. maris*, *Br. Pinnipedialis*, and *Br. ceti* in marine mammals such as seals and whales.

## 12.2 Modes of Transmission

Like other farm animals, camels may be infected orally through contaminated pasture, feed, water, or by licking or sniffing at aborted fetuses and placentae. They may also acquire the infection through other mucous membranes and even via the intact skin. While the infection may occur at any age, brucellosis is usually more commonly seen in sexually mature camels. It is also more common in intensively or semi-intensively reared camels compared to free-grazing desert camels (Abbas & Agab, 2002; Ghoneim & Amjad, 1993) and in camels raised in large farms compared to those raised in private homes (Radwan et al., 1992). The

cohabitation of camels with other ruminants or contact with other camels are also important risk factors.

---

### 12.3 Zoonotic Potentiality

The commonest causes of brucellosis in dromedary camels and other camelids, are *Br. abortus* and *Br. melitensis* (reviewed by Gwida et al., 2012). Transmission of these organisms to humans may cause a crippling disease known as undulant fever in the case of *Br. abortus* and Malta fever in the case of *Br. melitensis*. *Br. ovis* which causes epididymitis and orchitis in sheep has not been reported in camels and is not known to infect man.

---

### 12.4 Clinical Picture and Pathology

Following infection, the organism is carried by the bloodstream to the reticuloendothelial system, residing in phagocytic cells in the liver, spleen, lymph nodes, and other hematopoietic tissues (Greenfield et al., 2002; Nielsen & Duncan, 1990). During pregnancy, the organism is attracted to the placenta where it multiplies damaging the placental cotyledons and causing stillbirth or death and abortion of the fetus, or fetal mummification. The infected animals secrete the organism in large numbers in birthing fluid, aborted fetuses, and the placenta thus contaminating the environment (Gul & Khan, 2007). Abortion usually occurs during the second half of pregnancy and in most cases, it occurs only once. Thereafter, the organism moves to the mammary glands where it resides in the supra-mammary lymph nodes.

Brucellosis in female camels may cause no obvious clinical signs apart from abortion or stillbirth; sometimes, however, it may be associated with other disorders such as retention of the placenta, granulomatous endometritis, hydrobursitis, ovario-bursal adhesions, mastitis, and infertility. In male camels, orchitis, epididymitis, accessory sex glands infection and sterility may occur. Visceral abscessation, hygroma (Fig. 12.1), arthritis, and lameness have also been reported in camel brucellosis (Abbas & Agab, 2002; Musa et al., 2008; Musa & Shigidi, 2001; Ramadan et al., 1998).

At the herd level, camel brucellosis can lead to a significant loss in productivity through delay in sexual maturity, longer calving intervals, and low milk yield.

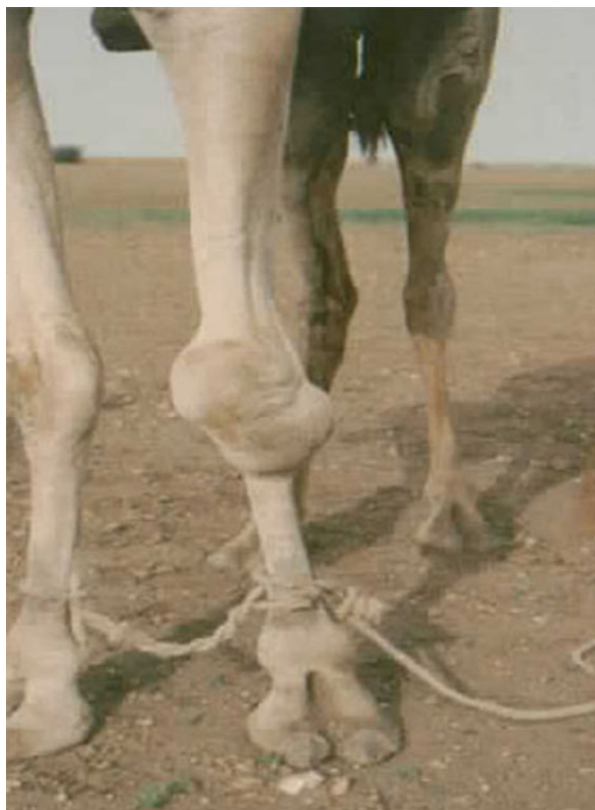---

### 12.5 Diagnosis

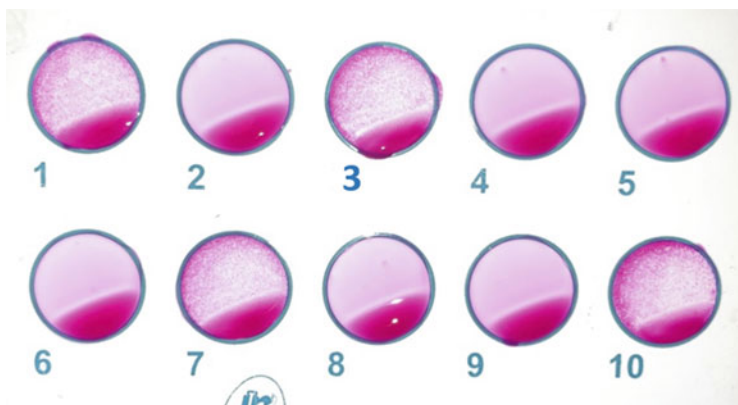
Diagnosis of brucellosis on the basis of clinical symptoms is unreliable and, hence, laboratory confirmation is essential. Direct isolation of *Brucella* spp. from infected animal tissues and secretions including vagina l swabs, aborted fetuses, or fetal membranes is sure evidence of infection; from a practical standpoint, however, it is a hazardous and tedious process. A wide range of indirect tests of varying sensitivity



**Fig. 12.1** Knee hygroma in a *Brucella*-positive dromedary camel, eastern Sudan (Courtesy of Prof. Hamid Agab)



and specificity have been used in the diagnosis and surveillance of brucellosis in animals, e.g., complement fixation test (CFT), Rose Bengal plate test (RBPT) (Fig. 12.2), buffered plate agglutination test (BPAT), standard agglutination test (SAT), tube agglutination test (TAT), fluorescence polarization assay (FPA), and several enzyme-linked immunosorbent assays (ELISA) (Azwai et al., 2001; Dawood, 2008; Gwida et al., 2012; Geresu & Kassa, 2016; Mekonnen, 2016). Some of these tests have been used as the sole methods for the diagnosis of brucellosis in camels in developing countries (Godfroida et al., 2013). It should be pointed out that these different tests were originally developed for brucellosis detection in cattle and small ruminants and have not been adequately validated for use in camels; hence, their results should be interpreted with caution. In a recent study, Kareem et al. (2018) applied and compared three methods, namely Rose Bengal test, standard tube agglutination test, and c-ELISA, for the diagnosis of camel brucellosis, and noted significant differences in seropositivity between these tests. More recently, Khalafalla et al. (2020) investigated the use of a skin test (Brucellergene skin test) for the diagnosis of brucellosis in camels. They stated that the test was highly specific and could be used for the diagnosis of brucellosis in camels.



**Fig. 12.2** Rose Bengal Test (RBT) for the detection of antibodies against camel brucellosis. Note, samples 1, 3, 7, and 19 are positive (Photo by Khalifa Sultan)

DNA detection of brucellosis using conventional or real-time PCR is a reliable technique that has been increasingly used in recent years for the diagnosis and screening of camel brucellosis (Hamdy & Amin, 2002; Alshaikh et al., 2007a, 2007b; Khamesipour et al., 2014; Hanon & Al-Sary, 2019). However, it is expensive and requires special laboratory facilities, which may not always be available in some camel rearing areas (Gwida et al., 2012; Sprague et al., 2012).

Other brucellosis tests such as agar gel immunodiffusion (AGID) test, counter immunoelectrophoresis, fluorescence immune-assay (FIA), radial immunodiffusion (RID) tests, indirect hemolysis test (IHLT), and hemolysis-in-gel test (HIGT) have not been used for the diagnosis of brucellosis in camels.

## 12.6 Treatment and Control

Antibiotic treatment is rarely used for controlling camel brucellosis although Radwan et al. (1995) claimed to have successfully treated the disease in a large herd of seropositive dromedaries using a combination of intramuscular oxytetracycline and streptomycin injections and intramammary oxytetracycline infusion. In camel rearing countries where animal brucellosis is endemic, vaccination offers the most economical method to control brucellosis, particularly in the face of limited financial, technical, and human resources and unfavorable husbandry conditions such as nomadism. There are currently three vaccines against *B. abortus* in cattle, namely, *B. abortus* strain 19 and *B. abortus* RB51, which are live attenuated vaccines, and B45/20 which is an inactivated vaccine. There is also a live attenuated vaccine, Rev. 1, for sheep and goat immunization against *B. melitensis*. Both *Brucella abortus* strain 19 and Rev. 1 vaccines were used in modified doses to vaccinate camels against *B. abortus* and *B. melitensis* (Agab et al., 1994; Benkirane et al., 2014; Radwan et al., 1995).

To prevent the spread of brucellosis, it is also imperative that appropriate management, health, and biosecurity measures be implemented. Regular testing of the animals for brucellosis, elimination of reactors, and vaccination of young and sometimes even adult animals should be undertaken. There is no vaccine for brucellosis in humans and therefore animal vaccination is crucial in controlling the disease both in animals and in humans.

Furthermore, any dam that aborts should be promptly isolated and tested to determine the cause of abortion. Samples from aborted fetuses and fetal membranes should be submitted for laboratory diagnosis, and the rest should be properly disposed of. It is also important for all farmworkers to observe personal hygiene, such as wearing protective clothing and regular hand washing, in order to protect themselves and prevent contamination.

---

## References

- Abbas, B., & Agab, H. (2002). A review of camel brucellosis. *Preventive Veterinary Medicine*, 55 (1), 47–56.
- Agab, H., Abbas, B., El-Jakack, H., & Mamon, I. E. (1994). First report on the isolation of *Brucella abortus* biovar 3 from camel (*Camelus dromedaries*) in Sudan. *Revue d'élevage et de médecine Vétérinaire des pays Tropicaux*, 47, 361–363.
- Alshaikh, M. A. A., Al-Haidary, A. I., Aljumaah, R. S., Al-Korashi, M. M., ElNabi, A. R. G., & Hussein, M. F. (2007a). Camel brucellosis in Riyadh region, Saudi Arabia. *Journal of Camel Practice and Research*, 14, 113–117.
- Alshaikh, M. A. A., Al-Haidary, A. I., Aljumaah, R. S., Mohammed, O. B., Al-Korashi, M. M., Omer, S. A., Gar ElNabi, A. R., & Hussein, M. F. (2007b). First detection of *Brucella abortus* in camel serum in Saudi Arabia using the polymerase chain reaction. *Journal of Applied Animal Research*, 31(2), 149–152.
- Azwai, S. M., Woldehiwet, Z., & Woldehiwet, Z. (2001). Camel brucellosis: Evaluation of field sera by conventional serological tests and ELISA. *Journal of Camel Practice and Research*, 8, 185–193.
- Benkirane, A., El Idrissi, A. H., Doumbia, A., & de Balogh, K. (2014). Innocuity and immune response to *Brucella melitensis* Rev. 1 vaccine in camels (*Camelus dromedarius*). *Open Veterinary Journal*, 4(2), 96–102.
- Dawood, H. A. (2008). Brucellosis in camels (*Camelus dromedarius*) in the south province in Jordan. *American Journal of Agricultural and Biological Sciences*, 3(3), 623–626.
- Geresu, M. A., & Kassa, G. M. (2016). A review on diagnostic methods of brucellosis. *Journal of Veterinary Science and Technology*, 7(3), 1–8.
- Ghoneim, N. A., & Amjad, A. M. (1993, April 10–14). Brucellosis among sheep, goats and camels in Saudi Arabia in Al Jouf region: Incidence and comparison between Rose Bengal test and seroagglutination tube test (pp. 273–281). In *Proc. 21st Arab Medical Veterinary Congress*, Cairo.
- Godfroida, J., Al Dahouk, S., Pappas, G., Roth, F., Matope, G., Muma, J., Marcotty, T., Pfeiffer, D., & Skjerve, E. (2013). A “one health” surveillance and control of brucellosis in developing countries: Moving away from improvisation. *Comparative Immunology, Microbiology and Infectious Diseases*, 36, 241–248.
- Greenfield, R. A., Drevets, D. A., Machado, L. J., Voskuhl, G. W., Cornea, P., & Bronze, M. S. (2002). Bacterial pathogens as biological weapons and agents of bioterrorism. *American Journal of Medical Research*, 323, 299–315.

- Gul, T., & Khan, A. (2007). Epidemiology and epizootiology of brucellosis. *Pakistan Veterinary Journal*, 27(3), 145–151.
- Gwida, M., El-Gohary, A., Melzer, F., Khan, I., Rösler, U., & Neubauer, H. (2012). Brucellosis in camels. *Research in Veterinary Science*, 92(3), 351–355.
- Hamdy, M., & Amin, A. S. (2002). Detection of *Brucella* species in the milk of infected cattle, sheep, goats and camels by PCR. *Veterinary Journal*, 163(3), 299–305.
- Hanon, B. M., & Al-Sary, A. H. K. (2019). Molecular diagnosis of brucellosis in camels by conventional polymerase chain reaction in Wasit Province, Iraq. *Asian Journal of Microbiology, Biotechnology and Environmental Sciences*, 21(February Suppl), S88–S94.
- Kareem, M., Hasanain, A. J., & Al-Gharban, L. F. M. (2018). Application of three diagnostic serologic techniques to detect dromedary camel's brucellosis. *AlQadisiyah Journal of Pure Science*, 23(2), 61–73.
- Khalafalla, A. I., Rashid, J., Khan, R. A., Alamin, K. M., Benkhalil, A., Al Hosani, M. A., & Al Muhairi, S. S. (2020). Preliminary comparative assessment of Brucellergene skin test for diagnosis of brucellosis in dromedary camels (*Camelus dromedarius*). *Vector Borne and Zoonotic Diseases*, 20(6) Published online: 26 May 2020. <https://doi.org/10.1089/vbz.2019.2537>
- Khamesipour, F., Rahimi, E., Shakerian, A., Doosti, A., & Hassan, M. H. (2014). Molecular study of the prevalence of *Brucella abortus* and *Brucella melitensis* in the blood and lymph node samples of slaughtered camels by polymerase chain reaction (PCR) in Iran. *Acta Veterinaria, Beograd*, 64(2), 245–256.
- Mekonnen, K. (2016). Study on camel and human brucellosis in Fentale District, East Shoa Zone, Oromia regional state, Ethiopia. *Journal of Biology, Agriculture and Healthcare*, 6(15), 117–145.
- Musa, M. T., Eisa, M. Z., El Sanousi, M., Abdel Wahab, E. M., & Perrett, L. (2008). Brucellosis in camels (*Camelus dromedarius*) in Darfur, western Sudan. *Journal of Comparative Pathology*, 138, 151–155.
- Musa, M. T., & Shigidi, M. T. A. (2001). Brucellosis in camels in intensive animal breeding areas of Sudan: Implications in abortions and early-life infection. *Revue D'Elevage et de Medecine Vétérinaire des Pays. Tropicaux*, 54, 11–15.
- Nielsen, K., & Duncan, J. R. (1990). *Animal brucellosis* (p. 464). CRC Press.
- Radostits, O. M., Gay, C., Blood, C. D., & Hinchcliff, W. K. (2007). *Veterinary medicine, textbook of the diseases of cattle, sheep, pigs, goats and horses* (10th ed., pp. 963–994). ELBS Bailliere Tindall.
- Radwan, A. I., Bekairi, S. I., Mukayel, A. A., Al-Bokmy, A. M., Prasad, P. V. S., Azar, F. N., & Coloyan, E. R. (1995). Control of *Brucella melitensis* infection in a large camel herd in Saudi Arabia using antibiotherapy and vaccination with Rev. 1 vaccine. *Revue Scientifique et Technique (O.I.E.)*, 14(3), 719–732.
- Radwan, A. I., Bekairi, S. I., & Prasad, P. V. S. (1992). Serological and bacteriological study of brucellosis in camels in Central Saudi Arabia. *Revue Scientifique et Technique (O.I.E.)*, 11(3), 837–844.
- Ramadan, R., Hatem, E. M., & Abdin Bey, R. M. (1998). Isolation of *B. melitensis* from carpal hygroma in camels. *Camel Practice and Research*, 5, 239–241.
- Sprague, L. D., Sascha Al-Dahouk, S., & Neubauer, H. (2012). A review on camel brucellosis: A zoonosis sustained by ignorance and indifference. *Pathogens and Global Health*, 106(3), 144–149.
- Wernery, U. (2014). Camelid brucellosis: A review. *Revue Scientifique et technique (OIE)*, 33(3), 839–857.

# Caseous Lymphadenitis (*Corynebacterium pseudotuberculosis*)

# 13

Mansour F. Hussein

Caseous lymphadenitis (CLA) is a highly contagious bacterial disease caused by *Corynebacterium pseudotuberculosis* (formerly *C. ovis*) and affecting mainly sheep, goats, and camels.

CLA is a common disease of camels in many countries. It has been reported in dromedary camels in Sudan, Egypt, Somalia, Kenya, Ethiopia, Saudi Arabia, United Arab Emirates, Jordan, Iran, India, Kazakhstan, and Australia (Borham et al., 2017; Wernery, 2012; Wernery & Kaaden, 2002; Wernery & Kinne, 2016). Radwan et al. (1989) reported a large outbreak of CLA in a herd of about 2500 adult dromedary camels in Saudi Arabia. Fifteen percent of those animals developed multiple abscesses on the hindquarters, shoulders, base of the neck and tail, under the jaw, and on the joints. *C. pseudotuberculosis* was isolated from the lesions and also from ticks heavily infesting the animals; this suggests that ticks may play a role in the transmission of the disease in camels.

A condition designated caseous lymphadenitis affecting the dorsal and ventral superficial lymph nodes of the left cervicothoracic region of an 11-month-old dromedary was attributed to *C. ulcerans* infection (Tejedor et al., 2000). These authors subsequently reported caseous lymphadenitis caused by *C. pseudotuberculosis* in 13 other dromedaries, comprising 6 adult and 7 juvenile camels of either sex, in the Canary Islands.

## 13.1 Etiology

*C. pseudotuberculosis*, the causative agent of CLA, consists of short, curved, gram-positive, facultative, nonmotile, non-sporulated, and non-capsulated intracellular bacteria that often appear as coccobacilli or filamentous rods. The organism, which is capable of surviving in the environment for several months (Dorella et al., 2006), consists of two biotypes: *biotype ovis* or serotype I, affecting sheep and goats, and *biotype bovis* or serotype II, affecting cattle and equines. Both biotypes have been identified in dromedary camels (Wernery & Kinne, 2016).

## 13.2 Modes of Transmission

*C. pseudotuberculosis* enters the body primarily via skin wounds, such as those caused by shearing or castration, and also via ingestion and inhalation. Wounds and tears caused by thorns in the oral mucosa are also important, especially in camels. The organism survives and multiplies in macrophages which transport it to the regional lymph nodes in which it causes caseous lymphadenitis (CLA). This is a chronic contagious disease of worldwide distribution, characterized by abscessation and drainage of lymph nodes. CLA leads to significant economic losses, especially in wool, meat, and milk in major sheep and goat production areas. Other losses due to CLA include reduced reproductive performance, wasting, and skin and carcass condemnations in abattoirs. The organism also affects horses and cattle causing ulcerative lymphangitis and “pigeon disease” in the former and occasionally skin ulcerations and lymphangitis in the latter (Aleman et al., 1996). Infection with *C. pseudotuberculosis* has also been reported in several other species of animals and rarely in humans (Peel et al., 1997). *C. pseudotuberculosis* attributes its virulence primarily to phospholipase D, an exotoxin produced by all strains of this bacterium.

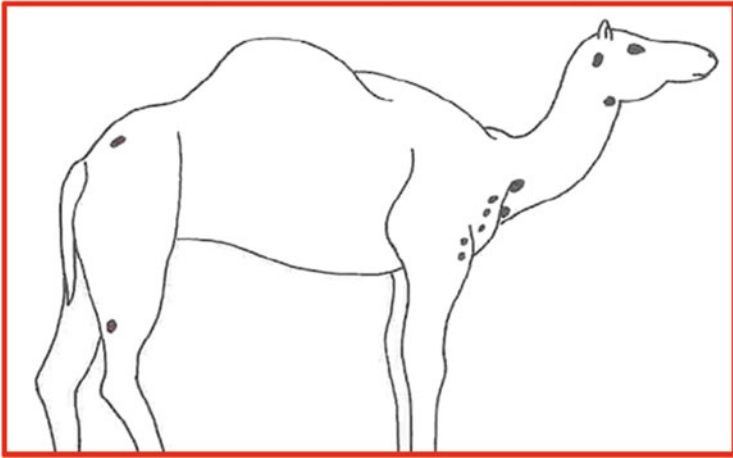
---

## 13.3 Clinical Picture and Pathology

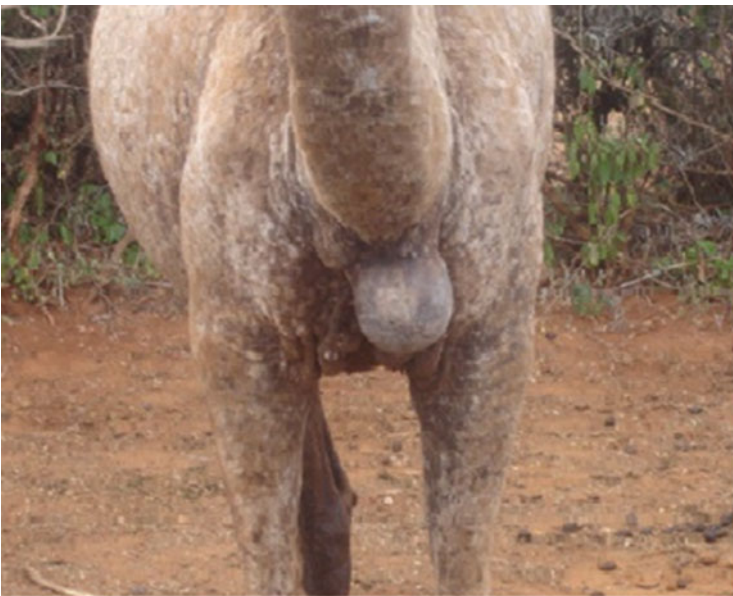
The incubation period of CLA in camels is unknown but it is expected to extend to several months. Both external and internal (visceral) forms of the disease occur in camels. The external disease is more frequently observed and is characterized by abscess formation in peripheral lymph nodes, subcutaneous tissues, and muscles. The most commonly affected nodes in camels are the inferior cervical, prescapular, tuberal, popliteal, mandibular, and pectoral lymph nodes (Fig. 13.1). Other lymph nodes such as the inguinal, axillary, femoral, and mammary lymph nodes (Tejedor et al., 2004) may also be affected (Figs. 13.2 and 13.3). The affected lymph nodes may erode and drain caseous, “cheesy,” yellowish greenish pus. Sometimes, abscesses may develop in the limb joints and the affected animal may have difficulty walking.

Internal abscessation can also develop in visceral organs, such as lungs, kidneys, liver, spleen, and mammary glands, causing various symptoms depending on the site of infection. These symptoms may include diarrhea, pallor of mucosae, depression, and loss of appetite. Pulmonary involvement and abscess formation in the bronchial and mediastinal lymph nodes are common findings during internal CLA; in these cases, fever, polypnea, and pneumonia may be recorded, while focal consolidation, congestion, and edema of the lungs may be observed during post-mortem examination.

Over time, infected animals become progressively emaciated and poorly productive (Borham et al., 2017; Wernery, 2012; Wernery & Kinne, 2016).



**Fig. 13.1** Lymph nodes commonly affected with CLA



**Fig. 13.2** Caseous lymphadenitis abscess (Photo by Prof. Mansour F. Hussain)





**Fig. 13.3** Multiple CLA abscesses at base of the neck (Photo by Prof. Mansour F. Hussain)

---

### 13.4 Diagnosis

Diagnosis is based on clinical signs, lesions, and culturing of the organism. The API coryn system (bioMérieux, France) may also be used. A number of serological tests such as hemagglutination and hemagglutination inhibition (HIT) tests, immunodiffusion tests, and ELISA tests have also been employed for the diagnosis of CLA; however, many of these tests had problems with specificity and/or sensitivity. More recent tests including indirect double antibody sandwich ELISA, Gamma Interferon assay, and Western Blot revealed high specificity and sensitivity at the herd level in goats and sheep. Molecular diagnosis using PCR is currently offering a reliable and reproducible test for the diagnosis and screening of CLA.

---

### 13.5 Treatment

Corynebacterial organisms are susceptible to several antibiotics; however, the use of these agents for CLA treatment is usually futile since the fibrous capsule surrounding the abscess and the pus inside it prevent antimicrobial medications from reaching the bacteria. The abscesses can be surgically lanced, emptied, and repeatedly flushed with iodine or [hydrogen peroxide solutions](#). During treatment, the animal should remain isolated from the rest of the herd.



### 13.6 Prevention and Control

Minimizing environmental contamination, implementing appropriate sanitation and segregating affected camels from healthy camels are essential measures for controlling CLA. All infected camels should be isolated and newly purchased camels should be free from abscesses. The pens and enclosures should be thoroughly disinfected, with regular removal of dung and bedding. Wires and other injurious agents should be removed from the pens, while ticks and other ectoparasites should be controlled. It is also advisable to undertake serological screening of the herd and to isolate or remove reactors.

Some commercial CLA vaccines are currently available for immunization of sheep and goats. These are toxoid vaccines based on inactivated phospholipase D, and most of them are combined with vaccines against other pathogens, particularly clostridial infections. Vaccination has also been used to protect alpacas against CLA (Beghelli et al., 2006). Besides, a live attenuated vaccine (strain 1002) has also been developed for annual vaccination of sheep in some countries. It should be noted, however, that all vaccines currently available for CLA in sheep and goats may not be suitable for camels since any vaccine for use in these animals should include both serotypes I and II of *C. pseudotuberculosis* (Wernery & Kinne, 2016).

**NOTE:** A disease, known as Morel's Disease and grossly indistinguishable from CLA, has been reported in sheep and goats in some countries in Africa, the Middle East, and Europe. It is caused by *Staphylococcus aureus* subspecies *anaerobius*. In countries where CLA and Morel's Disease coexist, the two can only be differentiated by isolating the causative agent or by developing highly specific tests such as PCR. Thus far, Morel's Disease has not been reported in camels.

---

### References

- Aleman, M., Spier, S. J., Wilson, W. D., & Doherr, M. (1996). *Corynebacterium pseudotuberculosis* infection in horses: 538 cases (1982–1993). *Journal of the American Veterinary Association*, 209, 804–809.
- Beghelli, D., Altera, D., Severi, G., Moscati, L., Pezzottaite, G., Foglini, G., Batistes, L., Cagiola, M., & Ayaz Vargas, C. (2006). Evaluation of the immune response to vaccination against *C. pseudotuberculosis* in an alpaca herd in Italy. In M. Gerken & C. Render (Eds.), *Preliminary results, 4th European symposium in South American Camelids/DECAMA European Seminar* (Vol. 1, pp. 133–139). South American Camelid Research.
- Borham, M., Ormesby, A., ElGedawy, A., & Algebras. (2017). Caseous Lymphadenitis in Sudanese and Somalian camels imported for meat consumption in Egypt. *Alexandria Journal of Veterinary Science*, 55(2), 52–59.
- Dorella, F. A., Pacheco, L. G., Oliveira, S. C., Miyoshi, A., & Azevedo, V. (2006). *Corynebacterium pseudotuberculosis*: microbiology, biochemical properties, pathogenesis and molecular studies of virulence. *Veterinary Research*, 37(2), 201–218.
- Peel, M. M., Palmer, G. G., Stacpoole, A. M., & Kerr, T. G. (1997). Human lymphadenitis due to *Corynebacterium pseudotuberculosis*: Report of ten cases from Australia and review. *Clinical Infectious Diseases*, 24, 185–191.

- Radwan, A. I., El-Margaery, S., Hawari, A., Al-Beaker, A., & Rebleza, R. M. (1989). *Corynebacterium pseudotuberculosis* infection in camels (*Camelus dromedarius*) in Saudi Arabia. *Tropical Animal Health and Production*, 21(4), 229–230.
- Tejedor, M. T., Martin, J. L., Lucila, P., & Gutierrez, C. (2000). Caseous lymphadenitis caused by *Corynebacterium ulcerans* in the dromedary camel. *Canadian Veterinary Journal*, 41(2), 126–127.
- Tejedor, M. T., Barrasa, J. L. M., Corbera, J. A., & Gutierrez, C. (2004). Pseudotuberculosis in dromedary camels in the Canary Islands. *Tropical Animal Health and Production*, 36(5), 459–462.
- Wernery, U., & Kaaden, O. R. (2002). *Infectious diseases in Camelids* (2nd ed.). Blackwell Wissenschafts- Verlag.
- Wernery, U. (2012). Caseous lymphadenitis (Pseudotuberculosis) in camelids. *Camel Practice and Research*, 19, 21–27.
- Wernery, U., & Kinne, J. (2016). Caseous lymphadenitis (Pseudotuberculosis) in camelids: a review. *Austin Journal of Veterinary Science and Animal Husbandry*, 3(1), 1–6.

# Chlamydiosis (*Chlamydomphila abortus*)

# 14

Mansour F. Hussein

*Chlamydomphila abortus* is a ubiquitous organism that causes ovine enzootic abortion (OEA), a major form of infectious abortion in sheep and goats, worldwide. In addition to these animals, it causes abortion in other ruminant and less frequently non-ruminant animals. Humans are also susceptible to *C. abortus*. Contracting infection with this organism via contact with aborting animals or abortion products may lead to serious consequences in pregnant women (Aitken & Longbottom, 2007; Aljumaah & Hussein, 2012).

The serological prevalence of *C. abortus* in dromedary camels was estimated to be 7.6% in Tunisia (Burgmeister et al., 1975), 11.1% in Egypt (Schmatz et al., 1978), 12.25% in Libya (Elzlitne & Elhafi, 2016), 19.4% in Saudi Arabia (Hussein et al., 2008), 19.6% in the UAE (Zaher et al., 2017), and 30% in Iraq (Al-Rubaye et al., 2018). It was also noted that the seroprevalence of camel chlamydiosis was generally higher in adult versus young and in female versus male camels (Al Khalifa et al., 2018; Elzlitne & Elhafi, 2016; Hussein et al., 2008; Osman et al., 2016). In Chad, Giraud et al. (cited by Wernery & Kaaden, 2002) reported chlamydiosis in two out of nine camels.

## 14.1 Etiology

*Chlamydomphila abortus* (formerly *Chlamydia psittaci* serotype 1) is an obligate intracellular, non-motile, gram-negative bacterium that causes abortion and fetal death in mammals, including humans. It was previously classified as *Chlamydia psittaci* but has later been recognized as a distinct species on the basis of DNA–DNA hybridization and differences in pathogenicity. In common with other Chlamydiaceae, it possesses a unique biphasic developmental cycle comprising elementary and reticulate bodies. The elementary bodies represent the infectious form of *chlamydia* that binds to host cell receptors and initiates infection while the reticulate bodies are non-infectious intracellular inclusions which comprise

metabolically active replicating forms of *chlamydia* (reviewed by Essig & Longbottom, 2015).

---

## 14.2 Clinical Picture

*C. abortus* infection usually remains silent until the affected animal aborts late in gestation or gives birth to a weak or dead fetus. This applies to camels as it does to other animals. Wernery and Wernery (1990) suggested that although chlamydiosis was a major cause of abortion in sheep, goats, and cows, it does not seem to affect pregnancy in camels since no increase in abortion rate was observed in infected camel herds and no *chlamydia* was found in uterine swabs from these animals. However, Ali et al. (2012) incriminated *C. abortus* as an important cause of ovarian hydrobursitis in female dromedaries which might lead to conception failure, while Osman et al. (2016) directly associated chlamydiosis with abortion and calf mortality in female Maghrabian camels in Egypt; these authors were able to demonstrate chlamydial antibodies in vaginal swabs of camels with history of abortion or stillbirth. In the following year, Zaher et al. (2017) reported that chlamydiosis greatly affected hematobiochemical parameters as well as reproductive performance of dromedary camels in the UAE, resulting in reproductive failure manifested by abortion and/or repeat breeding. Infected camels may also play an important role in the transmission of chlamydiosis to other species of animals (Essig & Longbottom, 2015).

---

## 14.3 Pathogenesis

There is no specific information on the pathogenesis of *C. abortus* in camels. However, studies on sheep and goats indicate that infection is primarily acquired through contact with abortion products, dam's vaginal discharge, and aborted or stillborn fetuses. The same may be true for camels. Following infection in sheep, the organism enters the blood stream and may rarely cause interstitial pneumonia or focal hepatitis. Several weeks or months later, the infection reaches the pregnant uterus, placenta, and fetus. Newly introduced and primigravid ewes are the most vulnerable. The incubation period is about 2–3 months. If the infection occurred during early pregnancy, it may cause late abortion, stillbirth, or birth of weak lambs and retention of fetal membranes. If the infection is acquired during late pregnancy, abortion will occur in the next pregnancy. Abortion is probably the result of multiple factors such as tissue destruction by *C. abortus*, vasculitis, thrombosis, and fetal inflammatory response. An aborted animal will not abort again but may become a carrier of the organism for an extended period of time and may shed the organism in its feces and other discharges.

---

## 14.4 Diagnosis

Chlamydial organisms may be seen in stained smears of the placenta and in vaginal swabs from freshly aborted dams. They can also be isolated from the placenta or fetal organs, products of abortion, uterine discharge, and vaginal fluids. Isolation of the organism is only possible in living cells, such as chicken embryo or tissue culture. Chlamydial DNA can be detected using PCR or microarray methods. The CFT was previously one of the most commonly used serological tests for detecting chlamydiosis antibodies but is now largely replaced by more specific and more sensitive tests. The PCR is currently considered to be the method of choice in many laboratories which have the required facilities. Commonly used serological tests are ELISA and FAT. These include competitive ELISA tests using monoclonal antibody technology (Anderson et al., 1995; Jones et al., 1997) and indirect ELISA tests based on recombinant DNA technology (Sachse et al., 2009; Salti-Montesanto et al., 1997).

Western blot analysis, indirect micro-immunofluorescence and immunohistochemistry have also been used to detect *C. abortus* antigens and to distinguish between *C. abortus* and *C. pecorum* but are too laborious to be used as routine tests.

---

## 14.5 Zoonotic Potential

Transmission of different chlamydial agents from animals and birds to humans is well known. In the case of *C. abortus*, a significant risk of contracting infection is encountered by farm workers, especially women, handling cases of ovine enzootic abortion.

---

## 14.6 Treatment and Control

Several antibiotics are effective against *C. abortus*, the most commonly used of which are oxytetracyclines. Other antibiotics such as chloramphenicol, tylosin, macrolides, and quinolones are also effective. Two live vaccines and one inactivated vaccine were developed for controlling infection in sheep and South American camelids. No information is available on their use in old world camelids. Infected animals should be isolated and farm workers should take necessary measures to protect themselves. Pregnant women should avoid contact with pregnant animals during parturition.

---

## References

- Aitken, I. D., & Longbottom, D. (2007). Chlamydial abortion. In I. D. Aitken (Ed.), *Diseases of sheep* (4th ed., pp. 105–112). Blackwell Science.

- Al Khalifa, I., Alshaikh, M. A., Aljumaah, R. S., Jarelnabi, A., & Hussein, M. F. (2018). Serological prevalence of abortifacient agents in female Mijaheem camels (*Camelus dromedarius*) in Saudi Arabia. *Journal of Animal Research*, 8(3), 335–343.
- Ali, A., Al-Sobayil, F., Hassanein, K., & Al-Hawas, A. (2012). Ovarian hydrobursitis in female camels (*Camelus dromedarius*): The role of *Chlamydophila abortus* and a trial for medical treatment. *Theriogenology*, 77, 1754–1758.
- Aljumaah, R. S., & Hussein, M. F. (2012). Serological prevalence of ovine and caprine chlamydiae in Riyadh region, Saudi Arabia. *African Journal of Microbiology Research*, 6, 2654–2658.
- Al-Rubaye, K. M. I., Khalaf, J. M., & Thamer-mosa, S. (2018). Serological Study on *Chlamydophila abortus* in *Camelus dromedarius* using ELISA. *Advances in Animal and Veterinary Sciences*, 6 (8), 325–327.
- Anderson, I. E., Herring, A. J., Jones, G. E., Low, J. C., & Creig, A. (1995). Development and evaluation of an indirect ELISA to detect antibodies to abortion strains of *Chlamydia psittaci* in sheep sera. *Veterinary Microbiology*, 43(1), 1–12.
- Burgmeister, R., Leyk, W., & Goessler, R. (1975). Untersuchungen über Vorkommen von parasitosis, bakteriellen und viralen Infektions-krankheiten bei Dromedaren in Südtunesien. *Deutsche Medizinische Wochenschrift*, 82, 352–354.
- Elzlitne, R., & Elhafi, G. (2016). Seroprevalence of *Chlamydia abortus* in camel in the western region of Libya. *Journal of Advanced Veterinary and Animal Research*, 3(2), 178–183.
- Essig, A., & Longbottom, D. (2015). *Chlamydia abortus*: New aspects of infectious abortion in sheep and potential risk for pregnant women. *Current Microbiological Reports*, 2, 22–34.
- Hussein, M. F., Alshaikh, M., Gad ElRab, M. O., Aljumaah, R. S., Gar El Nabi, A. R., & Abdel Bagi, A. M. (2008). Serological prevalence of Q fever and chlamydiosis in camels in Saudi Arabia. *Journal of Animal and Veterinary Advances*, 7(6), 685–688.
- Jones, G. E., Low, J. C., Machell, J., & Armstrong, K. (1997). Comparison of five tests for the detection of antibodies against chlamydial (enzootic) abortion of ewes. *Veterinary Record*, 141 (7), 164–168.
- Osman, A. O., El-Metwaly, H. E., Wahba, A. A., & Hefni, S. F. (2016). Studies on causes of abortion in Maghrabian camels. *Egyptian Journal of Agricultural Research*, 4, 955–967.
- Sachse, K., Vretou, E., Livingstone, M., Borel, N., Pospischil, A., & Longbottom, D. (2009). Recent developments in the laboratory diagnosis of chlamydial infections. *Veterinary Microbiology*, 135, 2–21.
- Salti-Montesanto, V., Tsoli, E., Papavassiliou, P., Psarrou, E., Markey, B. K., Jones, G. E., & Vretou, E. (1997). Diagnosis of ovine enzootic abortion, using a competitive ELISA based on monoclonal antibodies against variable segments 1 and 2 of the major outer membrane protein of *Chlamydia psittaci* serotype 1. *American Journal of Veterinary Research*, 58(3), 228–235.
- Schmatz, H., Krauss, H., Viertel, P., Ismail, A., & Hussein, A. (1978). Seroepidemiologische Untersuchungen zum Nachweis von Antikörpern gegen Rickettsien und Chlamydien bei Hauswiederkauern in Ägypten, Somalia und Jordanien. *Acta Tropica* [Internet]. <http://agris.fao.org/agrissearch/search.do?recordID=US201302428565>
- Wernery, U., & Kaaden, O. R. (2002). *Infectious diseases of camelids* (2nd ed., pp. 323–373). Blackwell Science.
- Wernery, U., & Wernery, R. (1990). Seroepidemiological investigations in female camels (*Camelus dromedarius*) for the demonstration of antibodies against brucella, chlamydia, leptospira, BVD/MD-virus, IBR/IPV-virus and enzootic bovine leukosis (EBL)-virus. *Deutsche Tierärztliche Wochenschrift*, 97, 134–135.
- Zaher, H. A., Swelum, A., Alsharif, S., Alkablawy, A., & Ismael, A. (2017). Seroprevalence of chlamydiosis in Abu Dhabi dromedary camels (*Camelus dromedarius*) and its association with hematobiochemical responses towards the infection. *Journal of Advanced Veterinary and Animal Research*, 4(2), 175–180.

Mansour F. Hussein

Enterotoxemia is a serious gastrointestinal condition occurring as a result of the absorption of large quantities of toxins produced by *Clostridium perfringens* (formerly *Cl. welchii*).

Outbreaks of enterotoxemia due to *C. perfringens* type A were reported in dromedary camels in India (Chauhan et al., 1985), the United Arab Emirates (Seifert et al., 1992; Wernery et al., 1991; Wernery & Kaaden, 2002), and the Sudan (Gameel et al., 1986); type D in suckling dromedary camel calves in Saudi Arabia (El-Sanousi & Gameel, 1993); and type B in a two-year-old dromedary calf from Laikipia district in Kenya which died less than 48 hrs after appearance of symptoms (Younan & Glücks, 2007). More recently, different types of *C. perfringens* were isolated from dromedary camel calves in Al Ahsa region in Eastern Saudi Arabia, with type A being the most predominant in those animals (Fayez et al., 2013). It should be noted, however, that establishing a causal relationship between *C. perfringens* type A and disease is difficult due to the ubiquitous nature of that type in the environment, and its ability to multiply in various organs of cadavers. Enterotoxemia caused by *C. perfringens* has also been frequently reported in other species of camelids (Fowler, 2011; Ipatenko, 1974). Other clostridia reported in camels are *C. tetani* and occasionally *C. novyi*, *C. Chauvoei*, and *C. septicum*.

Several predisposing factors have been associated with enterotoxemia in camels and other farm animals. These include insufficient intake of colostrum by neonates, other nutritional errors such as sudden change of food, weaning, over-eating particularly excessive intake of milk or grains, poor sanitation, overcrowding, heavy rainfall, and abrupt weather changes. Trypanosomiasis may also be one of the predisposing factors (Wernery et al., 1991).

## 15.1 Etiology

The organism is a large, gram-positive, anaerobic, spore-forming, and rod-shaped bacterium that occurs singly or in pairs and occasionally as short chains. It is found naturally in decaying vegetations, marine sediment, soil and often in raw meat and poultry. Small numbers of *C. Perfringens* also occur normally in the intestines of man and animals.

*C. perfringens* is composed of six toxinotypes (A, B, C, D, E, and F) based on their production of four major types of toxins: alpha, beta, epsilon, and iota. Other toxins are also produced by *C. perfringens* making a total of at least 16 toxins (Uzal et al., 2010). In humans, it primarily causes food poisoning and wound infection or gas gangrene, whereas in animals, including camelids, different types of *Cl. perfringens* have been associated with enterotoxemia and hemorrhagic enteritis (Fowler, 2011; Ipatenko, 1974).

---

## 15.2 Clinical Picture

Sweating, tremors, ataxia, aggression, hyperexcitability, and convulsions were reported in breeding dromedary camels during an outbreak of enterotoxemia caused by *C. perfringens* type A in the UAE; three out of nine affected camels were treated while the remaining six untreated camels died within only one hour after the onset of clinical signs (Wernery et al., 1991). The latter authors also reported an outbreak of enterotoxemia among racing camels including 20 camels that developed watery diarrhea, and three of them died 4 days later. In Saudi Arabia, El-Sanousi and Gameel (1993) reported an outbreak of enterotoxemia in suckling dromedary calves in which the affected animals exhibited yellowish pasty diarrhea, a staggering gait and weakness, followed by rapid death from exertion. Some of the calves died suddenly in the field before symptoms were noted. Younan and Glücks (2007) described severe bloody-watery diarrhea, recumbency, opisthotonus, and rapid death in a camel calf that died of *C. perfringens* type B infection, while Fayez et al. (2013) reported watery or bloody diarrhea, subnormal rectal temperature, colic, abdominal distention, and recumbency in association with camel enterotoxemia. A wide range of nervous signs including convulsions, prostration, opisthotonos, posterior paralysis, and coma were also recorded.

---

## 15.3 Pathology

During outbreaks of enterotoxemia in camels in the UAE, Wernery et al. (1991) described pathological changes in camels necropsied within 2–4 h after death. The lesions included petechial hemorrhages in the thoracic muscles, cerebellum and brain stem, pharyngeal mucosa, subpleural and subepicardial areas. Other lesions comprised ecchymotic hemorrhages in the omasum, abomasum, and reticulum, hydropericardium with fibrinous exudate, petechial hemorrhages and ecchymosis



in the intestinal tract and dark color of the kidneys with adherence of the renal capsule to the parenchyma. Histopathological examination showed diffuse ulceration and hemorrhagic inflammation in sections from the intestine, omasum, and abomasum, acute congestion in the kidneys, and centrilobular hemorrhages in the liver. *C. perfringens* type A was isolated from the gastrointestinal tract, kidneys, and liver.

Wernery and Kaaden (2002) also mentioned that severe myocardial degeneration and “pulpy kidney” occurred during outbreaks of enterotoxemia in juvenile dromedary camels in the UAE. El-Sanousi and Gameel (1993) reported catarrhal enteritis and myocardial degeneration, calcification, and necrosis in 3–5-weeks-old camel calves that died in large numbers in Al-Kharj region in central Saudi Arabia during an outbreak of enterotoxemia due to *C. perfringens* type D. Other lesions described by these authors included hydrothorax, pulmonary congestion and edema, accumulation of sero-fibrinous fluid in the pericardial sac and peritoneal cavity as well as congestion, mild edema, and patchy mucosal hemorrhages in the abomasum and intestines, particularly in the jejunum and ileum. Histopathological examination showed degenerative changes, necrosis, and calcification of the heart muscles. Hemorrhages, epithelial degeneration, inflammatory cellular infiltration, and goblet cell proliferation were seen in the intestinal mucosa. The abomasum, mesenteric lymph nodes, lungs, kidneys, and liver also showed severe congestion and edema.

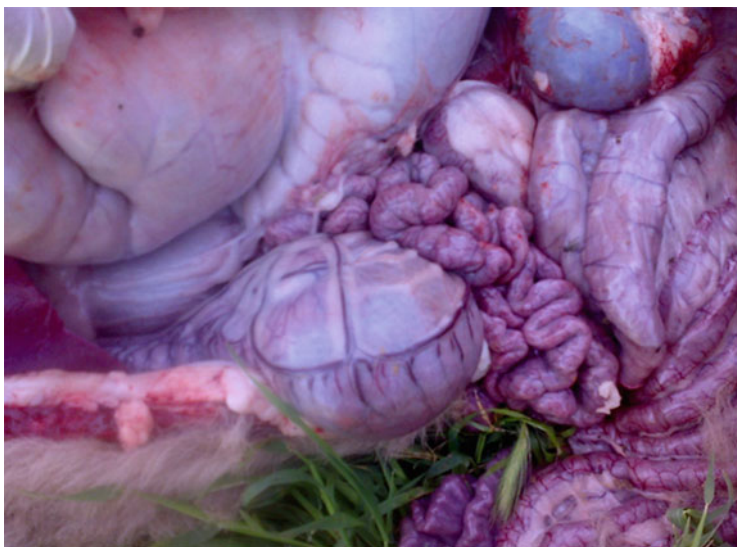Songer (1996) considered the presence of blood-stained intestinal contents and gas distention as the main post-mortem findings in camels affected with enterotoxemia caused by *C. perfringens*. On the other hand, Ahmed (2004) produced experimental enterotoxemia in camel calves following intraduodenal infusion of *Cl. perfringens* type D (strain 97) and type A (strain 95). At necropsy, accumulation of fluid was noted in the pericardial, thoracic, and peritoneal cavities. In addition, widespread hemorrhages, congestion, and vasculitis with disrupted endothelial lining were recorded in various organs including the gastrointestinal tract (Fig. 15.1), brain, heart, lung, liver, kidneys (Fig. 15.2), and other organs. The most striking lesions in the brain were perivascular hemorrhages and edema, microglial proliferation, malacic lesions, and neuronal degeneration particularly in camels inoculated with type D.

---

## 15.4 Diagnosis

History, clinical signs, necropsy findings and detection of numerous, large, square-shaped, gram-positive Clostridia-like rods in smears of the gut contents, fecal samples, and intestinal mucosa are useful in making a presumptive diagnosis of enterotoxemia in animals. Histopathological examination of the brain may also be helpful in the diagnosis of *C. perfringens* type D (Uzal & Songer, 2008).

However, definitive diagnosis is based on the detection of *C. perfringens* toxins in the intestinal contents of freshly dead animals. The organism is isolated in anaerobic cultures using suitable media, and various biochemical reactions and sugar fermentation tests are conducted on the isolates (Carter & Cole, 2012).



**Fig. 15.1** Viscera in a case of enterotoxemia in a 5-week-old dromedary (Courtesy of Dr. Abdelmalik Khalafalla)

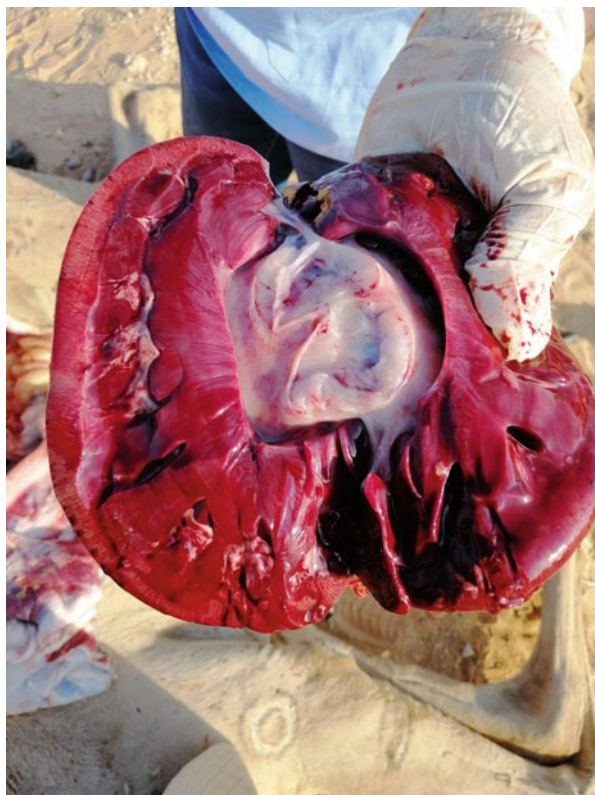Different methods have been used for the detection and characterization of *C. Perfringens* toxins. Of these, the most commonly used methods at present are ELISA tests and PCR (Uzal & Songer, 2008). Different types of ELISA are used to determine the types of toxins in intestinal and fecal samples of animals suspected of enterotoxemia (Layana et al., 2006; Uzal et al., 2003), whereas molecular typing using multiplex PCR is employed to detect toxin genes in *C. perfringens* isolates from fecal samples and intestinal content of the affected animals (Ahsani et al., 2010; Ezatkhah et al., 2016; Fayez et al., 2013; Hamad et al., 2018; Naylor et al., 1987, 1997; Miserez et al., 1998; Mohamed et al., 2010; Piatti et al., 2004).

---

## 15.5 Treatment and Control

Intravenous administration of bovine *C. perfringens* hyperimmune serum has been used successfully for rapid treatment of sick camels. Toxoid vaccines have also been used to protect camels against enterotoxemia; however, since oil-based toxoid vaccines were found to produce allergic reaction in a significant proportion of vaccinated camels, they were replaced by aluminum hydroxide vaccines (Seifert et al., 1992). Identifying the clostridial strains responsible for the outbreak is important to develop a specific vaccine that prevents further cases. Other preventive measures include sanitation, good nutrition, and pursuit of appropriate management practices. Wernery and Kaaden (2002) also suggested adding chlortetracycline to the feed in endangered herds.

**Fig. 15.2** Severe renal congestion in young dromedary camel that died of clostridial enterotoxemia (Photo by Mansour F. Hussain)



---

## References

- Ahmed, Z. A. M. (2004). *The role of Clostridium perfringens in camel calf diarrhea* [PhD thesis]. Khartoum University. Department of Microbiology. <http://pdfs.semanticscholar.org>
- Ahsani, M. R., Mohammedabadi, M. R., & Shamsaddini, M. R. (2010). *Clostridium perfringens* isolate typing by multiplex PCR. *The Journal of Venomous Animals and Toxins including Tropical Diseases*, 6(4), 573–578.
- Carter, G. R., & Cole, J. R. Jr. (2012). *Diagnostic procedures in veterinary bacteriology and mycology* (5th ed.). Academic Press.
- Chauhan, R. S., Kulshreshtha, R. C., & Kaushik, R. K. (1985). A report of enterotoxemia in camels in India. *Indian Veterinary Journal*, 62(10), 825–827.
- El-Sanousi, S. M., & Gameel, A. A. (1993). An outbreak of enterotoxaemia in suckling camels. *Journal of Veterinary Medicine*, A-40, 525–532.
- Ezatkhah, M., Alimolaei, M., Amini, M., & Bafti, M. S. (2016). Typing toxigenic *Clostridium perfringens* strains from the ruminants of Yazd Province by multiplex polymerase chain reaction. *International Journal of Enteric Pathogens*, 4(2), 1–4.
- Fayez, M. M., Suliman, M. B., Al Marzoog, A., & Al Taweel, H. (2013). *Clostridium perfringens* enterotoxaemia in camel (*Camelus dromedarius*) calves. *International Journal of Advanced Research*, 1(5), 239–247.

- Fowler, M. E. (2011). *Medicine and Surgery of Camelids*. Iowa State University Press.
- Gameel, A. A., El Sanousi, S. M., Musa, B., & El Owni, E. E. (1986). *Association of some pathogenic bacteria with hemorrhagic enteritis in camels*. Camel Research Paper, Camel Research Unit, University of Khartoum, Sudan, P. 50-55 (No. SRC 12).
- Hamad, M. A., Habra, N., & Kalb-Allouz, A. (2018). Diagnosis of *Clostridium perfringens* strains isolated from enterotoxemia cases in sheep using polymerase chain reaction (PCR) technique. *Iraqi Journal of Veterinary Science*, 23(1), 229–232.
- Ipatenko, A. G. (1974). Infectious enterotoxaemia of camels. *Veterinary Bulletin*, 44(4), 1481–1484.
- Layana, J. E., Fernandez Miyakawa, M. E., & Uzal, F. A. (2006). Evaluation of different fluids for detection of *Clostridium perfringens* type D epsilon toxin in sheep with experimental enterotoxemia. *Anaerobe*, 12(4), 204–206.
- Miserez, R., Frey, J., Buogo, C., Capaul, S., Tontis, A., Burnens, A., & Nicolet, J. (1998). Detection of alpha- and epsilon-toxigenic *Clostridium perfringens* type D in sheep and goats using a DNA amplification technique (PCR). *Letters in Applied Microbiology*, 26(5), 382–386.
- Mohamed, M., Suelam, I. E., & Saleh, M. E. (2010). The presence of toxin genes of *Clostridium perfringens* isolated from camels and humans in Egypt. *Veterinarski Arhives*, 80(3), 383–392.
- Naylor, R. D., Martin, P. K., & Barker, L. T. (1997). Detection of *Clostridium perfringens*  $\alpha$  toxin by enzyme-linked immunosorbent assay. *Research in Veterinary Science*, 63(1), 101–102.
- Naylor, R. D., Martin, P. K., & Sharp, R. T. (1987). Detection of *Clostridium perfringens* epsilon toxin by ELISA. *Research in Veterinary Science*, 42(2), 255–256.
- Piatti, R. M., Ikuno, A. A., & Baldassi, L. (2004). Detection of bovine *Clostridium perfringens* by polymerase chain reaction. *The Journal of Venomous Animals and Toxins including Tropical Diseases*, 10(2), 154–160.
- Seifert, H. S. H., Boehnel, H., Heitefuss, S., Rengel, J., Schaper, R., Sukop, U., & Wernery, U. (1992). Isolation of *C. perfringens* type A from enterotoxemia in camel and production of a locality-specific vaccine. In A. J. Allen Higgin, I. G. Mayhew, D. H. Snow & J. F. Wade (Eds.), *Proceedings 1st International Camel Conference* (pp. 65–68). R. and W. Publications.
- Songer, I. G. (1996). Clostridial enteric diseases of domestic animals. *Clinical Microbiology Reviews*, 9(2), 216–234.
- Uzal, F. A., Kelly, W. R., Thomas, R., Hornitzky, M., & Galea, F. (2003). Comparison of four techniques for the detection of *Clostridium perfringens* type D epsilon toxin in intestinal contents and other body fluids of sheep and goats. *Journal of Veterinary Diagnostic Investigation*, 15(2), 94–99.
- Uzal, F. A., & Songer, J. G. (2008). Diagnosis of *Clostridium perfringens* intestinal infections in sheep and goats. *Journal of Veterinary Diagnostic Investigation*, 20(3), 253–256.
- Uzal, F. A., Vidal, J. E., McClane, B. A., & Gurjar, A. A. (2010). *Clostridium perfringens* toxins involved in mammalian veterinary diseases. *The Open Toxicology Journal*, 2, 24–42.
- Wernery, U., & Kaaden, O.-R. (2002). *Infectious Diseases in Camelids* (2nd ed.). Blackwell Wissenschafts- Verlag.
- Wernery, U., Seifert, H. S., Billah, A. M., & Ali, M. (1991). Predisposing factors in enterotoxemias of camels (*Camelus dromedarius*) caused by *Clostridium perfringens* type A. *Revue d'élevage et de médecine vétérinaire des pays tropicaux*, 44(2), 147–152.
- Younan, M., & Glücks, I. V. (2007). *Clostridium perfringens* type B enterotoxaemia in a Kenyan camel. *Journal of Camel Practice and Research*, 14(1), 65–67.

Mansour F. Hussein

Considerable economic loss to the camel industry is caused by infection with pathogenic *Escherichia coli* in young dromedary camels. Rombol (1942) described enzootic *E. coli* (*Bacterium coli*) infection and severe diarrhea in newborn dromedaries whereas Chauhan et al. (1986) in India reported colibacillosis in two newborn dromedaries presenting with yellowish diarrhea, fever, discomfort, and anorexia, and isolated *E. coli* serotype 083 from fecal samples of the affected calves. In East Africa, Schwartz and Dioli (1992) reported colibacillosis with a morbidity rate of 30% among neonatal dromedary calves suffering from dysentery, abdominal pain, anorexia, and dehydration; they associated the disease with poor sanitary conditions, contaminated water sources, inadequate intake of colostrum, and inclement weather. The authors also stated that in the absence of immediate veterinary intervention, all of the affected animals could die within few days. Alambédjir et al. (1992) also reported diarrheic episodes associated with colibacillosis in young camels in Niger. Mohamed et al. (1998) isolated pathogenic *E. coli* from 17 (40.5%) out of 42 fecal samples of 1–3 months old dromedary calves in the Sudan. Using colony blot DNA hybridization for pathotyping of eight randomly selected isolates, they identified five isolates as EIEC, two isolates as EPEC, and one isolate as VT2 pathotypes. In studies of bacterial causes of diarrhea in camel calves in the Butana region of the Eastern Sudan, Salih and co-workers (Salih et al., 1997, 1998a, 1998b) isolated enteropathogenic *E. coli* from 69 (66%) out of 106 diarrheic camel calves. They examined some of these isolates for virulence antigens and reported two adhesion factors, K88 and F41, in addition to two heat-stable enterotoxins (StaP and STb), one heat-labile (LT), and one Shiga-like toxin 1 (SLT-1). In Mauritania, *E. coli* was detected as a major pathogen accounting for more than 60% of diarrhea cases in camel calves aged between 1 and 3 months (Dia et al., 2000).

Ibrahim et al. (1998) reported edema disease (bowl edema) and enterotoxemia, with isolation of a hemolytic *E. coli* serotype 0139, from the intestines and abdominal fluid of female dromedary camels in Bahrain. The affected animals exhibited severe swelling and distension of the abdomen, with accumulation of 100–150 L of

fluid in the abdominal cavity; as well as edema of the face, ears, and throat and in some cases neurological manifestations. The disease was slowly progressive and highly fatal, with an overall incidence exceeding 50% and a mortality of about 90%.

Bornstein et al. (2000) described a septicemic form of *E. coli* infection (coli septicemia) in four out of ten camel calves in a breeding herd in northern Kenya. The affected calves showed anorexia, diarrhea, and general weakness before dying. Typical lesions of septicemia were noted during necropsy of the dead animals, and *E. coli* was isolated in pure cultures from lymph nodes, tonsils, spleen, lungs, bone marrow, heart blood, and pericardial fluid. Furthermore, pure growth of *E. coli* was obtained in anaerobic culture of the ileocecal lymph node while cultures of the kidney and intestinal contents produced a clearly predominant growth of *E. coli* intermixed with few clostridial colonies.

Wernery and Kaaden (2002) stated that *E. coli* infection characterized by watery diarrhea, dehydration, and sunken eye appearance occurred regularly in dromedary calves, particularly those aged 2–4 weeks, resulting in severe losses in some camel breeding herds in the UAE. According to these authors, the infection in camel calves might have been associated with initial consumption of solid food and sand, and isolation of hemolytic *E. coli* from the gastrointestinal tract and other parts of the body.

Abubaker et al. (2006) isolated *E. coli* from 52 (27.3%) out of 190 diarrheic calf camels in Saudi Arabia while Agab (2006) stated that camel calf diarrhea was one of the commonest diseases in suckling dromedary calves in that country, leading to a high mortality rate, particularly in intensively reared herds. Similar conclusions were made by Al-Ruwaili et al. (2012) who reported high incidence of diarrhea and deaths in newborn camel calves in northern Saudi Arabia, which was ascribed to different pathogenic bacteria and viruses, including *Salmonella* spp., *Enterococcus* spp., group A rotaviruses, *Cryptosporidia*, and others. In addition, they isolated *E. coli* from 99 (58.2%) out of 170 samples of diarrheic calf camels. The affected animals harbored enterotoxigenic *E. coli* (ET *E. coli*), indicating a strong correlation between camel calf diarrhea and the detection of enterotoxigenic *E. coli*. Al-Harbi (2013) investigated scours in 1200 newborn camel calves, aged 1–14 days, in Taif, Western Saudi Arabia. Out of these, 240 (20%) calves developed scours and more than half of them (54.4%) died, the most predominant isolate from them being *E. coli*. The organism was also incriminated as one of the causes of diarrhea in juvenile camels in Riyadh region of Central Saudi Arabia (El Wathig & Faye, 2016).

---

## 16.1 Etiology

*Escherichia coli* is a facultatively anaerobic, motile, gram-negative bacillus belonging to the family Enterobacteriaceae. Most strains of *E. coli* are harmless commensal of the intestinal flora, especially the lower intestines, of warm-blooded animals. However, some varieties are pathogenic due to the fact that they possess virulence genes which enable them to produce toxins and other virulence factors and hence invade and damage different body tissues.

*E. coli* is excreted in the feces of infected animals and is transmitted between animals primarily via the fecal-oral route. Its pathogenic varieties cause several diseases of considerable economic importance in farm animals, especially in young stock. These diseases include: colibacillosis and coli septicemia in less than 1-week-old bovine and ovine newborns, and 2–4 weeks old camel calves, joint ill in bovine calves and mastitis in dairy cattle, sheep, and camels (Wernery & Kaaden, 2002). They also cause wound infection and retarded wound healing. Colibacillosis in young animals is mostly associated with inadequate colostrum intake and other husbandry errors and is frequently associated with other types of infection.

There are different varieties of pathogenic *E. coli*, all of which possess plasmid-encoded virulence factors, undergo specific interactions with the intestinal mucosa, and produce toxins. These varieties include: Enterotoxigenic *E. coli* (ETEC) which causes most cases of neonatal colibacillosis; Enteropathogenic *E. coli* (EPEC); Entero-invasive *E. coli* (EIEC); Attaching and Effacing *E. coli* (AEEC) and Enterohemorrhagic *E. coli* (EHEC) (Wernery & Kaaden, 2002). *E. coli* varieties possess different antigens which can be used for serotyping.

---

## 16.2 Clinical Picture and Pathology

Colibacillosis in camels is typically characterized by profuse yellowish or whitish diarrhea, abdominal pain, anorexia, weakness, sunken eye appearance, and fever. The affected camels are dehydrated, and their hindquarters and tails are soiled with feces. Death often follows in 2–3 days. At necropsy there is pallor of the carcass and congestion of the small intestine with catarrhal enteritis while the gut contents are gray to yellowish and the mesenteric lymph nodes are edematous (Bornstein et al., 2000; Chauhan et al., 1986; Schwartz & Dioli, 1992; Wernery & Kaaden, 2002).

Coli septicemia often develops in conjunction with enteric colibacillosis but may also occur independently. It is characterized by generalized congestion, petechiation of serous membranes, and edema of the meninges. In addition, necropsy reveals marked pallor of the entire cadaver, inflammation of the intestinal mucosa, and grayish and foul-smelling intestinal contents. In severe cases, a fibrin exudate covers the abdominal organs. A detailed description of post-mortem lesions in Kenyan camel calves that died of coli septicemia was given by Bornstein and co-workers (2000). According to these authors, the lesions included accumulation of fibrinous fluid in the pericardium, petechial hemorrhages in the epicardium, endocardium, and renal pelvis, and generalized swelling and hyperemia of the body lymph nodes. In addition, the liver was pale and hard, the rectum contained pasty whitish feces and the intestinal mucosa, particularly that of the colon, was hyperemic and thickened while the meninges were slightly hyperemic.



### 16.3 Diagnosis

The clinical signs of colibacillosis are not distinguishable from those of other enteric infections in young camels. Therefore, the diagnosis depends on microbiological examinations of fecal samples and specimens from the intestinal tract, lymph nodes, and different organs collected soon after death. Selective media are employed to differentiate *E. coli* from other Enterobacteriaceae while different techniques are used in serotyping of cultured *E. coli* strains isolated from sick camel calves.

---

### 16.4 Zoonotic Potentiality

Few studies have been reported on the possible role of camels as a source of pathogenic *E. coli* infection in humans. Fadlelmula et al. (2016) identified Saudi Arabian dromedary camels as potential reservoirs of extended release  $\beta$ -lactamase producing *E. coli* infecting humans, while Baschera et al. (2019) isolated Shiga-toxin producing *E. coli* (STEC), with virulence markers associated with human disease, from camel fecal samples in Kenya. These authors cautioned that camels could be a potential threat particularly for people in close contact with these animals, as well as consumers of camel-derived foodstuffs such as raw camel milk. On the other hand, Rhuoma et al. (2018) reported that mobilized colistin resistance genes (*mcr*-1 and *mcr*-2) were lacking in *E. coli* isolates from fecal samples of diarrheic and non-diarrheic camels in Tunisia, suggesting that camels do not constitute a major source of *mcr* genes contamination for the local population and tourists.

---

### 16.5 Treatment and Control

Dehydration resulting from severe diarrhea is the most important cause of mortality associated with outbreaks of colibacillosis in camel calves. It is, therefore, essential to administer oral or parenteral electrolytes to the affected animals in order to restore fluid balance. Furthermore, *E. coli* isolates often exhibit multiple antibiotic resistance; therefore, it is important to carry out antibiotic resistance tests on the isolated *E. coli* strain causing the outbreak. Several injectable antimicrobials such as trimethoprim/sulfonamide, neomycin, kanamycin, and colistin have been used in the treatment of coli septicemia (Manefield & Tinson, 1996).

For prevention and control, appropriate husbandry methods, especially housing, nutrition, clean water supply, and protection from extreme weather conditions, should be implemented, in addition to observing good hygienic measures and ensuring adequate intake of colostrum by the newborn. Maternal vaccination is also considered useful for increasing the resistance of newborn calves. A marked reduction in losses among newborn calves was reported by Strauss (1991) as a result of vaccination of all pregnant camels with Colivac at about 8 and then 4 weeks prior to the expected date of parturition.



## References

- Abubaker, M., Nayel, M. N., Fadlalla, M. F., & Abdel Rahman, A. O. (2006, May 10–12). The incidence of bacterial infections in young camels with reference to *E. coli*. The International Scientific Conference on Camels (pp. 479–482). Qassim University–College of Agriculture and Veterinary Medicine.
- Agab, H. (2006). Diseases and causes of mortality in a camel (*Camelus dromedarius*) dairy farm in Saudi Arabia. *Journal of Camel Practice and Research*, 13(2), 57–61.
- Alameddijir, B., Sani, R., Kaboret, Y., Oudar, J., & Akakpo, A. J. (1992). Bacteria associated with diarrheic episodes in young camels in Niger. *Dakar Medical*, 37, 103–108.
- Al-Harbi, M. S. (2013). The prevalence of new-born calf-camel scours with special reflection to epidemiology, bacterial etiology and physiology processing at Taif, KSA. *Assiut Veterinary Medical Journal*, 59(q37), 139–147.
- Al-Ruwaili, M. A., Khalil, O. M., & Selim, S. A. (2012). Viral and bacterial infections associated with camel (*Camelus dromedarius*) calf diarrhea in North Province, Saudi Arabia. *Saudi Journal of Biological Sciences*, 19(1), 35–41.
- Baschera, M., Cernela, N., Stevens, M. J. A., Liljander, A., Jores, J., Corman, V. M., Nueesch-Inderbinnen, M., & Stephan, R. (2019). Shiga toxin-producing *Escherichia coli* (STEC) isolated from fecal samples of African dromedary camels. *One Health*, 7, 100087. <https://doi.org/10.1016/j.onehlt.2019.100087>
- Bornstein, S., Feinstein, R., & Younan, M. (2000). Case of neonatal camel colisepticemia in Kenya. *Revue d'Élevage et de Médecine Vétérinaire Pays tropicaux*, 53(2), 123–124.
- Chauhan, R. S., Caushik, R. K., Gupta, S. C., Satiya, K. C., & Kulshreshta, R. C. (1986). Prevalence of different diseases in camels (*Camelus dromedarius*) in India. *Camel Newsletter*, 3, 10–14.
- Dia, M. L., Diop, A., Ahmed, O. M., Diop, C., & El Hacen, O. T. (2000). Diarrhées du chameleón en Mauritanie: resultants d'enquête. *Revue d'Élevage et de Medecine Veterinaire des Pays Tropicaux*, 53, 149–152.
- El Wathig, M., & Faye, B. (2016). Camel calf diarrhoea in Riyadh region, Saudi Arabia. *Journal of Camel Practice and Research*, 23(2), 283–285.
- Fadlelmula, A., Al Hamam, N. A., & Al Dughaem, A. M. (2016). A potential camel reservoir for extended-spectrum betalactamase-producing *Escherichia coli* causing human infection in Saudi Arabia. *Tropical Animal Health and Production*, 48, 427–433.
- Ibrahim, A. M., Abdelghaffar, A. A., Fadlalla, M. N., Nayel, M. E., Ibrahim, B. A., & Adam, A. S. (1998). Oedema disease in female camels (*Camelus dromedarius*) in Bahrain. *Journal of Camel Practice and Research*, 5(1), 167–169.
- Manefield, G. W., & Tinson, A. H. (1996). *Camels. A Compendium*. The T. G. Hungerford Vade Mecum Series for Domestic Animals.
- Mohamed, M. E. H., Hart, C. A., & Kaaden, O. R. (1998, May 2–3). Agents associated with camel diarrhea in eastern Sudan. In *Proceedings of International Meeting on Camel Production and Future Perspectives* (p. 116). Faculty of Agricultural Science.
- Rhouma, M., Bessalah, S., Salhi, I., Theriault, W., Fairbrother, J. M., & Fravalo, P. (2018). Screening for fecal presence of colistin-resistant *Escherichia coli* and mcr-1 and mcr-2 genes in camel calves in southern Tunisia. *Acta Veterinaria Scandinavica*, 60(1), 35.
- Rombol, B. (1942). Enzootic *bacterium coli* infection in new-born camels. *Nuova Veterinaria*, 20, 85–93.
- Salih, O., Mohamed, H. O., & Shigidi, M. T. (1998a, May 2–3). The epidemiological factors associated with camel-calf diarrhea in eastern Sudan. In *Proceedings of International Meeting on Camel Production and Future Perspectives*. Faculty of Agricultural Sciences.
- Salih O. M., Shigidi H. O., & Mohamed Y. (1998b). The bacterial causes of camel-calf diarrhea in eastern Sudan. In *Proceedings of the Third Annual Meeting for Animal Production* (Vol. 2, pp. 132–137). United Arab Emirates University.

- Salih, O. M., Shigidi, H. O., Mohamed, Y., McDoungh, P., & Chang, Y. F. (1997). Bacteria isolated from camel calves with diarrhea. *Camel Newsletter*, 13(9), 34–43.
- Schwartz, H. J., & Dioli, M. (1992). *The one-humped camel in Eastern Africa: A pictorial guide to diseases, health care and management*. Josef Margraf.
- Strauss, G. (1991). Erkrankungen junger Neuweltkamele im Tierpark Berlin-Friedrichsfelde 11. Arbeitstagung der Zootierärzte im deutschsprachigen Raum. Nov. 1–3 in Stuttgart, Tagungsbericht, pp 80–83.
- Wernery, U., & Kaaden, O.-R. (2002). *Infectious diseases in camelids* (2nd ed.). Blackwell Wissenschafts.

## Contagious Skin Necrosis (CSN)

# 17

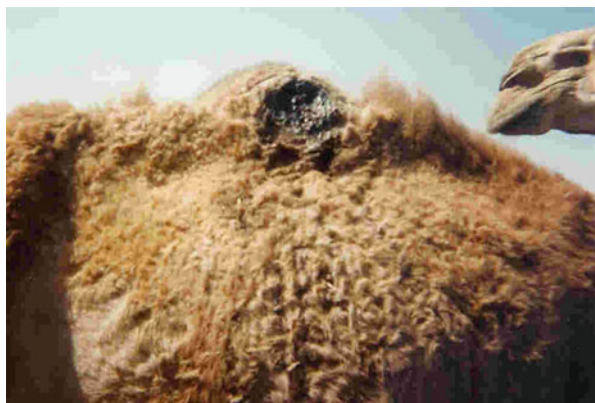Mansour F. Hussein

Contagious skin necrosis (CSN), known among camel herds in the Middle East as *Naeita* or *Alara*, is an important and widespread disease of camels characterized by necrosis, suppuration and sinus formation in the skin, and enlargement of regional lymph nodes. The lesions are predominantly seen on the skin of the back, hump, shoulders, base of the neck, and inguinal region, but may also occur on any other part of the body (Al-Kanzee, 2011; Domenech et al., 1977; Gatt Rutter & Mack, 1963; Mohammed, 2010; Singh et al., 2018)—Figs. 17.1 and 17.2.

CSN primarily affects young camels of both sexes (Osman, 2019) and although adult camels are believed to be relatively resistant, cases of the disease have been reported in adult camels (Mohammed, 2010). According to Zaitoun (2007), the incidence of CSN in dromedary camels in Southern Egypt actually increased with age up to the age of 5.5 years, then gradually decreased with advancing age. It was also noted that CSN was more prevalent in summer months as compared to the winter, and that the susceptibility of camels to the disease did not differ between male and female camels nor between camels in irrigated versus desert areas (Zaitoun, 2007). However, Osman (2019), who examined a large number of affected camels in Qassim region in Saudi Arabia, recorded significantly higher incidence of the disease in male versus female camels.

CSN may occur in an outbreak form. More often, however, it occurs as sporadic cases (Agab & Abbas, 1999). Although it is not a fatal disease, it may lead to considerable economic loss due to reduced working efficiency (Singh et al., 2018). The disease is believed to occur wherever camels are found. It has been reported in dromedary camels in the Sudan (Abdalla & Salim, 2008; Agab & Abbas, 1999; Mohammed, 2010; Yagoub & Mohamed, 1996), Egypt (Abd Ellah, 2012; Ali et al., 2001; Zaitoun, 2007), Somalia (Abdurahman & Bornstein, 1991; Edelstein & Pegram, 1974; Hagi Abdi & Testi, 1993), Kenya (Juma Ngeiywa, 1992), Ethiopia (Domenech et al., 1977; Megersa, 2010), Iraq (Al-Ani, 2004), Saudi Arabia (Al-Kanzee, 2011; Osman, 2019), India (Singh et al., 2018), and Pakistan (Anon, 2017).

**Fig. 17.1** Contagious skin necrosis at the hump of a dromedary camel (Photo by Prof. Mansour F. Hussain)



**Fig. 17.2** Skin necrosis at the neck of a dromedary camel (Courtesy of Dr. Abdelmalik Khalafalla)



---

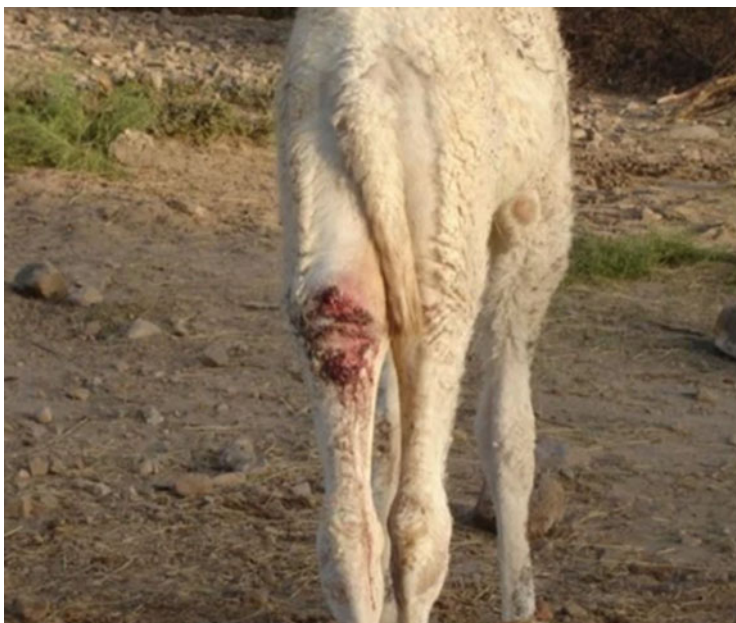
## 17.1 Etiology

Different microbial agents have been isolated from CSN lesions; the most predominant of these organisms is *Staphylococcus aureus*. Other organisms have been isolated including any one or more of the following species: *Streptococcus* species, *Corynebacterium pyogenes*, *Pseudomonas aeruginosa*, *E. coli*, *Bacillus subtilis*, *Erysipelothrix* sp., *Actinomyces* sp., *Streptococci*, *Lactobacilli* as well as a variety of fungal species (Abdalla & Salim, 2008; Al-Kanzee, 2011; Babiker & Salim, 2012; Edelstein & Pegram, 1974; Megersa, 2010; Mohammed, 2010; Suliman & Bakhiet, 1997).

---

## 17.2 Modes of Transmission

According to Abbas and Omer (2005), the mixed bacterial infection that characterizes CSN suggests that camels may pick up the infection from the soil when lying down or sandbathing. It has also been proposed that ticks may be



**Fig. 17.3** Contagious skin necrosis lesion in a dromedary (Photo by Prof. Mansour F. Hussain)

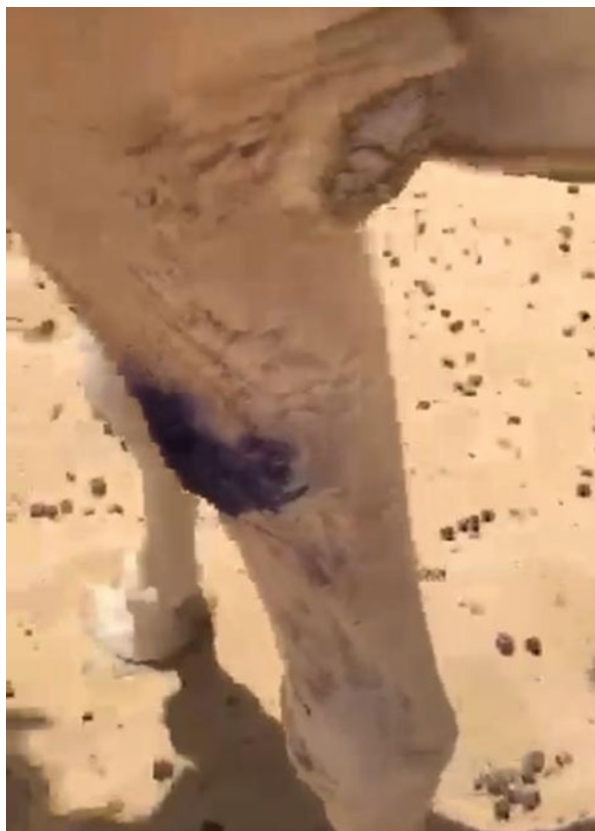involved in transmitting the disease. Furthermore, camel nomads associated CSN with salt deficiency and suggested that the disease was rarely observed in free-grazing camels with access to salty bushes (Peck, 1938; Wilson, 1984). However, this association has not been confirmed by controlled studies. In fact, a high prevalence of CSN was reported in some pastoralist camel herds grazing freely on salty bushes (Agab & Abbas, 1999; Yagoub & Mohamed, 1996).

---

### 17.3 Clinical Picture and Pathology

CSN often starts as a small, hot, and painful swelling on the surface of the skin, especially the skin of the back, limbs, and base of the neck. Gradually, the swelling increases in size and might break open, exuding pus. Hair is lost from the center of the lesion which eventually becomes dry, dark in color and clearly demarcated from the surrounding normal skin. Finally, the center of the lesion sloughs off leaving a purulent ulcer that usually takes a long time to heal, its place being evident as a bald, unpigmented star-shaped scar (Abbas & Omer, 2005; Anon, 2017; Fazil, 1977; Mohammed, 2010; Osman, 2019; Yagoub & Mohamed, 1996)—Figs. 17.3 and 17.4.

**Fig. 17.4** Contagious skin necrosis lesion in dromedary forelimb local treatment with tincture of iodine



---

## 17.4 Diagnosis

Diagnosis of CSN is usually based on clinical signs and distribution of the lesions while the causative agent (s) can be determined using standard microbiological methods.

---

## 17.5 Treatment and Prevention

Isolation of the affected camels and early treatment of the lesions with parenteral antibiotics such as Penicillin and Streptomycin or Amoxycillin and Clavulanic acid, in addition to local application of tincture of iodine or any other suitable antiseptic may aid in quick recovery (Abbas & Omer, 2005). Hygienic measures should also be implemented to reduce the chances of spreading the infection.

## References

- Abbas, B., & Omer, O. H. (2005). Review of infectious diseases of the camel. *Veterinary Bulletin*, 75(8), 1N–16N.
- Abdalla, W. G., & Salim, M. O. (2008). Bacteria associated with contagious skin necrosis in the one-humped camel (*Camelus dromedarius*) in El Showak and El Gadaref areas, El Gadaref State, Sudan. *Sudan Journal of Veterinary Research*, 23, 73–77.
- Abd Ellah, M. R. (2012). Studies on contagious skin necrosis and trypanosomiasis in camels. *Journal of Animal and Veterinary Advances*, 11(2), 284–288.
- Abdurahman, O. S., & Bornstein, S. (1991). Diseases of camels (*Camelus dromedarius*) in Somalia and prospects for better health. Nomadic People (No. 29). Camel Pastoralism in the Horn of Africa; Nomadic People (pp. 104–112).
- Agab, H., & Abbas, B. (1999). Epidemiological studies on camel diseases in eastern Sudan. *World Animal Review*, 92, 42–51.
- Al-Ani, F. K. (Ed.). (2004). *Camel management and diseases* (pp. 197–218). Al-Sharq Printing Press.
- Al-Kanzee, A. G. H. A. (2011). *Clinicopathological study on contagious skin necrosis (CSN) in camels (Camelus dromedarius), in Hail region, Kingdom of Saudi Arabia* [M.Sc. thesis]. Sudan University of Science and Technology, Khartoum North, Sudan.
- Ali, H. S., Murad, I. M., & Thabet, A. E. R. (2001). Clinical and bacteriological investigation of cutaneous abscesses in camels in Assiut Governorate, Egypt. *Assiut Veterinary Medical Journal*, 45(90), 256–263.
- Anon. (2017, January). Contagious necrosis of skin (Jhauling). In *Surveillance and prophylactic measures against camel diseases in Punjab*. Livestock and Dairy Development Department, Government of Punjab, Mid-term Report.
- Babiker, W. A., & Salim, O. M. (2012). Yeast and mold associated with contagious skin necrosis in camels (*Camelus dromedarius*) in Gadarif State, Sudan. 18th International Society for Human and Animal Mycology (Abstract No. P184).
- Domenech, J., Gliidot, G., & Richard, D. (1977). Pyogenic diseases of dromedaries in Ethiopia. *Revue d'Élevage et de Médecine Vétérinaire des Pays Tropicaux*, 30(3), 251–258.
- Edelstein, R. M., & Pegram, R. G. (1974). Contagious skin necrosis of Somali camels associated with *Streptococcus agalactiae*. *Tropical Animal Health and Production*, 6, 255–256.
- Fazil, M. A. (1977). The camel. *Bulletin of Animal Health and Production in Africa*, 25, 435–442.
- Gatt Rutter, T. E., & Mack, R. (1963). Diseases of camels. Bacterial and fungal diseases. *Veterinary Bulletin*, 33(3), 119–124.
- Hagi Abdi, B., & Testi, F. (1993). Contagious skin necrosis of camels (*Camelus dromedarius*) in Somalia. *Obiettivi e Documenti Veterinari* (Italy).
- Juma Ngeiywa, K. J. Z. (1992). *Clinical and pathological investigations on camel skin diseases in some camel rich districts of northern Kenya* [MSc thesis]. College of Agriculture and Veterinary Sciences, University of Nairobi.
- Megersa, B. (2010, September). An epidemiological study of major camel diseases in the Borana lowland, Southern Ethiopia. Drylands Coordination Group Report No. 58 (09). Contagious skin necrosis (pp. 18–19).
- Mohammed, A. M. A. (2010). *Camel abscesses in the Red Sea State of the Sudan* [PhD thesis]. University of Khartoum (pp. 39–42).
- Osman, S. A. (2019). Prevalence and chemotherapy of contagious skin necrosis in dromedary camels at Qassim region, Central Saudi Arabia. *Journal of Camel Health*, 1, 6–10.
- Peck, E. F. (1938). The relationship of salt starvation to contagious necrosis and lameness in camels. *The Veterinary Record*, 14, 409–410.
- Singh, C. P., Mathur, M., Dadhich, H., & Ganguly, S. (2018). Molecular characterization of *Staphylococcus aureus* of camel (*Camelus dromedarius*) skin origin. *International Journal of Current Microbiology and Applied Sciences*, 7(1), 3486–3490.

- Suliman, T. A., & Bakhiet, M. R. (1997). Isolation of *Fusobacterium necrophorum* from a camel. *Revue d'Élevage et de Médecine Vétérinaire des Pays Tropicaux*, 50(1), 10–11.
- Wilson, R. T. (1984). *The Camel*. Longman.
- Yagoub, S. O., & Mohamed, G. E. (1996). Incidence, clinical observations and etiology of contagious skin necrosis in camels (*Camelus dromedarius*) in the Sudan. *Journal of Camel Practice and Research*, 3(2), 95–98.
- Zaitoun, A. M. A. (2007). Contagious skin necrosis of dromedary camels in South Egypt. *Journal of Camel Practice and Research*, 14(2), 125–132.



# Coxiellosis (Q-Fever) (*Coxiella burnetii* Infection)

# 18

Mansour F. Hussein

A high serological prevalence of *C. burnetii* has been reported in dromedary camels in several camel rearing areas in Africa, Asia, and the Middle East. This included a prevalence of 80% in Chad (Schelling et al., 2003), up to 100% in southeastern Ethiopia (Gumi et al., 2013), 71.2% and 85.3% at the individual and herd levels, respectively, in Algeria (Benaissa et al., 2017), 64.5% in the Sudan (Hussein et al., 2017), 62% in Saudi Arabia (Hussein et al., 2008), 44.4% in camels overall and 70% in female camels with previous history of abortion in Tunisia (Selmi et al., 2018), and 40.7% in Egypt (Klemmer et al., 2018). Furthermore, the seroprevalence of *C. burnetii* in camels in Laikipia county in Kenya, which was estimated at 20%, was the highest among other farm animals in the region (Browne et al., 2017). Besides, a relatively high positivity of *C. burnetii* DNA in Iranian camels was reported by Doosti et al. (2014) using the PCR. Molecular studies by these and other authors indicated that *C. burnetii* is not only shed in post-partum discharges but also in the feces, urine, blood, and milk of infected camels (Doosti et al., 2014; Mohammed et al., 2014; Nokhodian et al., 2017).

As in other farm animals, dromedary camels probably contract *C. burnetii* from other infected members of the herd or from contaminated grazing areas through inhalation or ingestion of infective material. Occasionally they might be infected through the bites of infected ticks. In humans, *C. burnetii* is also primarily acquired by direct routes such as inhalation of infected aerosols or exposure to dust in areas contaminated with the organism or by ingestion of raw or unpasteurized milk and milk products of infected animals. It is believed that animals infected with *C. burnetii* carry the organism for life and secrete it in various body secretions and excretions both during abortion and normal birth. Up to ten billion organisms may be shed per gram of placenta during parturition in farm animals (Oliveira et al., 2017). It is therefore not surprising that the vast majority of human infections are acquired from farm animals and are mostly seen among farm workers, veterinarians, and people living in close proximity to animal farms. In recent years, major outbreaks of human Q-fever related to small ruminants were reported in Europe and some parts of the Middle East (Roest et al., 2010; Van den Brom et al., 2015; Van der Hoek et al.,

2012). Of those, an outbreak of the disease which occurred in the Netherlands in 2009 affected 2357 people, of whom 400 were hospitalized, while extensive abortion storms occurred in pregnant dairy goats leading ultimately to the culling of more than 50,000 goats (Roest et al., 2010).

---

## 18.1 Etiology

*Coxiella burnetii*, the causative agent of Q-fever or coxiellosis in man and animals, is a strict intracellular gram-negative bacterium belonging to the phylum proteobacteria (Fig. 18.1). The infection was initially reported by Derrick (1937) as a fever of unknown origin among abattoir workers in Australia, and hence named Q (Query?) fever. The causative organism was discovered by Burnet in 1937 (Burnet & Freeman, 1983). At the same time, an identical organism was isolated by Cox (1938) from Nine Mile Creek in Montana, the USA, and subsequently found to be pathogenic to man. This led to naming the organism *Coxiella burnetii* in honor of both Burnet and Cox.

*C. burnetii* is recognized as one of the most important and widespread anthroponosis, affecting a vast range of hosts including man, domestic and wild mammals, birds, reptiles, amphibians, and invertebrates (Maurin & Raoult, 1999). More than 40 different species of soft and hard ticks act as vectors of *C. burnetii* in the wild (Babudieri, 1959); these ticks shed the organism in their feces for life, pass it trans-ovarially to their offspring (Liebisch, 1983) and circulate it in nature among small wild mammals and birds through tick bites or contact with tick feces (Herenda, 1994). In this way, *C. burnetii* survives almost permanently in the environment. It is also wind-borne over long distances and is so infectious that exposure even to a single organism can initiate disease in man. Infected farm animals constitute the most important source of Q-fever to humans (Anderson et al., 2013; Angelakis & Raoult, 2010; Maurin & Raoult, 1999; Pape et al., 2009; Parker et al., 2006).

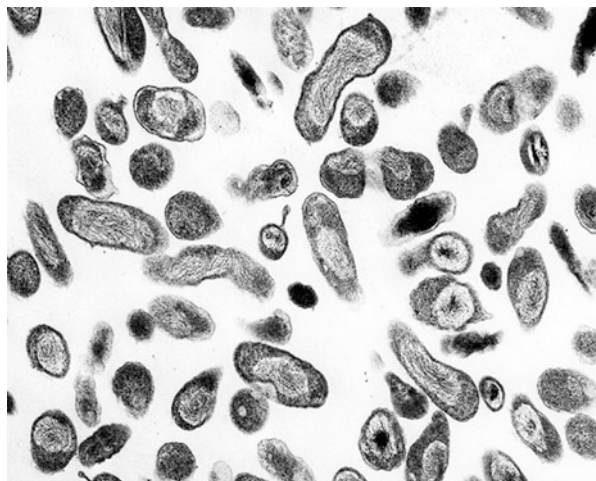
Recent studies incriminated the camel as a major source of Q-fever in humans in some countries like Saudi Arabia, not only because of the remarkably high prevalence of *C. burnetii* infection in camels in those countries but also because of the poor management and sanitary conditions under which camels are reared. This is further complicated by the widespread tradition of consuming raw camel milk and even camel urine (for medicinal purposes) among the inhabitants of the Arabian Peninsula (Hussein et al., 2015).

---

## 18.2 Pathogenesis

*C. burnetii* is a ubiquitous, resilient, and highly infectious agent. Within the mammalian host, it primarily infects monocytes and macrophages in which it survives and multiplies in large vacuoles formed by the fusion of phagolysosomes (Pretat et al., 2009). In pregnant female animals, the organism is attracted to the placenta

**Fig. 18.1** E.M. Image of *Coxiella burnetii* (Obtained from the [NIAID Biodefense Image Library](#), Image credit: Rocky Mountain Laboratories, NIAID, NIH)



where it multiplies and is shed in vast numbers in birthing fluids. There are two distinct morphological forms of *C. burnetii*: a “large cell variant” and a “small cell variant.” The former is the organism’s vegetative form which replicates within infected host cells. The small cell variant is an inactive, spores-like form capable of surviving outside the host’s body; it is resistant to heat and dryness and can survive for long periods of time in the environment (McCaul, [1991](#); Scott & Williams, [1990](#)). Another feature of *C. burnetii* is the occurrence of phase changes in its surface antigens, namely Phase I or “pathogenic phase” and Phase II or “non-pathogenic phase.” In Phase I, the surface antigens are composed mainly of polysaccharides and in Phase II they are composed mainly of proteins.

---

### 18.3 Clinical Picture and Pathology

In dromedary camels, as in other farm animals, *C. burnetii* infection is usually asymptomatic. Some cases of abortion, pneumonia, and mastitis were reported in animals subjected to stress conditions but none of these manifestations has so far been reported in camels (Al Khalifa et al., [2018](#)). Moreover, the infection does not impart obvious changes in infected tissues, milk, or meat; hence, infected animals may continue to carry the organism, contaminate the environment, and pose a significant public health problem for a long period of time without being detected.

---

### 18.4 Diagnosis

If abortion is suspected to be due to *C. burnetii*, a rapid preliminary diagnosis may be made by examining stained placental smears; however, this requires laboratory confirmation. Various immunological and immuno-histochemical (IHC) tests have

been developed for the diagnosis of coxiellosis (Eldin et al., 2017; Fournier et al., 1998). Earlier tests included microagglutination techniques, such as capillary tube agglutination, indirect hemolysis tests, and allergic dermatological tests. Currently, detection of *C. burnetii* and determination of its prevalence in animals is largely based on specific serological tests or the demonstration of *C. burnetii* DNA by the PCR. The commonest serological tests presently used for diagnosing *C. burnetii* in animals are immunofluorescence assays (IFA), enzyme-linked immunosorbent assays (ELISA), and complement fixation test (CFT) (Scola, 2002; Slaba et al., 2005). The CFT has lower sensitivity as a diagnostic test for Q-fever than ELISA and IFA tests. The two latter tests are sensitive and specific to both phase I and phase II antigens and can be carried out using serum or milk samples (Slaba et al., 2005). The IFA assays employ fluorescent markers conjugated to a specific antibody to detect antigen–antibody (Ag: Ab) reaction. There are direct and indirect types of the test, the latter being more commonly used. On the other hand, the most commonly used ELISA assay for screening *C. burnetii* infection in camels and other animals is an indirect test which utilizes a horseradish peroxidase-labelled monoclonal anti-ruminant IgG conjugate that reacts with a wide range of domestic and wild ruminant species (Jarelnabi et al., 2018).

---

## 18.5 Treatment and Control

It is difficult to control *C. burnetii* because of the ubiquitous nature of this organism, its air-borne transmissibility, high infectivity, ability to survive for extended periods in the environment, and extensive host range. This is further complicated by the fact that *C. burnetii* infection in camels and other farm animals is usually asymptomatic. Antibiotic treatment has not been conclusively shown to reduce the shedding of *C. burnetii* in farm animals in general. In some countries like Australia, vaccines have been developed for use in small ruminants. The most effective of these vaccines are those composed of whole, inactivated Phase 1 bacteria. These vaccines are believed to prevent abortion and significantly reduce the shedding of *C. burnetii*, thus reducing the risk of environmental contamination and human infection (Arrkicau-Bouvery & Rodolakis, 2005). In some situations, even people occupationally exposed to infection may be vaccinated. The only vaccine currently available for human use is Q-Vax which consists of formalin-inactivated *C. burnetii* whole cells (Marmion et al., 1990).

At the farm level, every attempt should be made to minimize environmental contamination with *C. burnetii*. Pregnant animals should be isolated to reduce the risk of exposure, while aborted fetuses, stillbirths, and placentae should be removed promptly and deeply buried. Milk and milk products must be pasteurized. All utensils used in the farm should be kept clean and disinfected. Animals should be quarantined and tested before adding to the herd. Animal owners and farm and slaughterhouse workers should be educated about the zoonotic importance of Q-fever and how to protect themselves from infection.

## References

- Al Khalifa, I., Alshaikh, M. A., Aljumaah, R. S., Jarelnabi, A., & Hussein, M. F. (2018). Serological prevalence of abortifacient agents in female Mijaheem camels (*Camelus dromedarius*) in Saudi Arabia. *Journal of Animal Research*, 8(3), 335–343.
- Anderson, A., Bijlmer, A., Fournier, P. E., Graves, S., Harzell, J., Kirch, G., Lemonard, G., Marrie, T. J., Massung, R. F., McQuiston, J. H., Nicholson, W. L., Paddock, C. D., & Sexton, D. J. (2013). Diagnosis and management of Q fever—United States, 2013; recommendations from CDC and the Q fever working group. *Recommendations and Reports*, 62, 1–33.
- Angelakis, E., & Raoult, D. (2010). Q fever. *Veterinary Microbiology*, 240, 297–309.
- Arrikau-Bouvery, N., & Rodolakis, A. (2005). Emerging and re-emerging bacterial zoonoses. *Veterinary Research*, 36(3), 327–349.
- Babudieri, B. (1959). Q fever: A zoonosis. *Advances in Veterinary Science and Comparative Medicine*, 5, 81–182.
- Benaissa, M. H., Ansel, S., Mohamed-Cherif, A., Benfodel, K., Khelef, D., Youngs, C. R., Kaidi, R., & Ait-Oudhia, K. (2017). Seroprevalence and risk factors for *Coxiella burnetii*, the causative agent of Q fever in the dromedary camel (*Camelus dromedarius*) population in Algeria. *Onderstepoort Journal of Veterinary Research*, 84(1), e1–e7. <https://doi.org/10.4102/ojvr.v84i1.1461>
- Browne, A. S., Fèvre, E. M., Kinnaird, M., Muloi, D. M., Wang, C. A., Larsen, P. S., O'Brien, T., & Deem, S. L. (2017). Serosurvey of *Coxiella burnetii* (Q fever) in dromedary camels (*Camelus dromedarius*) in Laikipia county, Kenya. *Zoonoses and Public Health*, 64(7), 543–549.
- Burnet, F. M., & Freeman, M. (1983). Experimental studies on the virus of “Q” fever. *Reviews of Infectious Diseases*, 5, 800–808.
- Cox, H. R. (1938). (1938). A filter-passing infectious agent isolated from ticks. III. Description of organism and cultivation experiments. *Public Health Report*, 53, 2270–2276.
- Doosti, A., Arshi, A., & Sadeghi, M. (2014). Investigation of *Coxiella burnetii* in Iranian camels. *Comparative Clinical Pathology*, 23(1), 43–46.
- Derrick, E. H. (1937). ‘Q’ fever, a new fever entity: Clinical features, diagnosis and laboratory investigation. *Reviews of Infectious Diseases*, 5 (4), 790–800.
- Eldin, C., Mélenotte, C., Mediannikov, O., Ghigo, E., Million, M., Edouard, M. J., Maurin, M., & Raoult, D. (2017). From Q fever to *Coxiella burnetii* infection: A paradigm change. *Clinical Microbiology Reviews*, 30(1), 115–190.
- Fournier, P.-E., Marrie, T. J., & Raoult, D. (1998). Minireview: Diagnosis of Q fever. *Journal of Clinical Microbiology*, 36(7), 1823–1834.
- Gumi, B., Firdessa, R., Yamuah, L., Sori, T., Tolosa, A., Zinsstag, J., & Schelling, E. (2013). Seroprevalence of brucellosis and Q-fever in southeast Ethiopian pastoral livestock. *Journal of Veterinary Science & Medical Diagnosis*, 2(1), 1–5.
- Herenda, D. C. (1994). Manual on meat inspection for developing countries. Food and Agriculture Organization of the United Nations (Rome). FAO Animal Production and Health Paper No. 119.
- Hussein, M. F., Alshaikh, M. A., Aljumaah, R., Garel Nabi, A., Alkhalifa, I., & Mohammed, O. (2015). The Arabian camel (*Camelus dromedarius*) as a major reservoir of Q fever in Saudi Arabia. *Comparative Clinical Pathology*, 24(4), 887–892.
- Hussein, M. F., Alshaikh, M. A., Gad El-Rab, M. O., Aljumaah, R. S., Gar el Nabi, A., & Abdel Bagi, A. (2008). Serological prevalence of Q fever and chlamydiosis in camels in Saudi Arabia. *Journal of Animal and Veterinary Advances*, 7, 685–688.
- Hussein, M. O., Enan, K. A., Alfaki, S. H., Gafar, R. E., Taha, K. M., & El Hussein, A. R. (2017). Seroprevalence of *Coxiella burnetii* in dairy cattle and camel in Sudan. *International Journal of Infection*, 4(3), e42945.
- Jarelnabi, A. A., Alshaikh, M. A., Bakhiet, A. O., Omer, S. A., Aljumaah, R. S., Harkiss, G. D., Mohammed, O. B., & Hussein, M. F. (2018). Seroprevalence of Q fever in farm animals in Saudi Arabia. *Biomedical Research*, 29(5), 895–900.
- Klemmer, J., Njeru, J., Emam, A., El-Sayed, A., Maoad, A. A., Henning, K., Elbeskawy, M. A., Sauter-Louis, C., Straubinger, R. K., Neubauer, H. and El-Diasty, M. M. (2018). Q fever in

- Egypt: Epidemiological survey of *Coxiella burnetii* specific antibodies in cattle, buffaloes, sheep, goats and camels. PLoS One; Published online jyp: [doi.org/10.1371/journal.pone.0192188](https://doi.org/10.1371/journal.pone.0192188).
- Liebisch, A. (1983). Die Rolle einheimischer Zecken (Ixodidae) in der Epidemiologie des Q-Fiebers in Deutschland. *Dtsch Tierärztliche Wochenschrift*, 83, 274–276.
- Marmion, B. P., Ormsbee, R. A., Kyrkou, M., Wright, J., Worswick, D. A., Izzo, A. A., Esterman, A., Feery, B., & Shapiro, A. (1990). Vaccine prophylaxis of abattoir-associated Q fever: 8 years' experience in Australian abattoirs. *Epidemiology and Infection*, 104, 275–287.
- Maurin, M., & Raoult, D. (1999). Q fever. *Clinical Microbiology Reviews*, 12(4), 518–553.
- McCauley, T. F. (1991). The development cycle of *Coxiella burnetii*. In J. C. Williams & H. A. Thompson (Eds.), *Q fever: The biology of Coxiella burnetii* (pp. 223–258). CRC Press, Inc.
- Mohammed, O. B., Jarelnabi, A. A., Aljumaah, R. S., Alshaikh, M. A., Bakhiet, A. O., Omer, S. A., & Hussein, M. F. (2014). *Coxiella burnetii*, the causative agent of Q fever in Saudi Arabia: Molecular detection from camel and other domestic livestock. *Asian Pacific Journal of Tropical Medicine*, 7(9), 715–717.
- Nokhodian, Z., Feizi, A., Ataei, B., Ghaffari, S., Hoseini, S. G., & Mostafavi, E. (2017). Epidemiology of Q fever in Iran: A systematic review and meta-analysis for estimating serological and molecular prevalence. *Journal of Research in Medical Sciences*, 22, 121.
- Oliveira, R. D., Mousel, M. R., Pabilonia, K. L., Highland, M. A., Taylor, J. B., Knowles, D. P., & White, S. N. (2017). Domestic sheep show average *Coxiella burnetii* seropositivity generations after a sheep-associated human Q fever outbreak and lack detectable shedding by placental, vaginal, and fecal routes. *PLoS One*, 12(11), e0188054. Published online 2017 Nov 15. <https://doi.org/10.1371/journal.pone.0188054>
- Pape, M., Mandraveli, K., Arvanitidou-Vagiona, M., Nikolaidis, P., & Alexiou-Daniel, S. (2009). Q fever in northern Greece: Epidemiological and clinical data from 58 acute and chronic cases. *Clinical Microbiology and Infection*, 15(supplement 2), 150–151.
- Parker, N. R., Barralet, J. H., & Bell, A. M. (2006). Q fever. *The Lancet*, 367(9511), 679–688.
- Pretat, L., Toman, R., Vadovic, P., Capo, C., Mege, J. L., & Ghigo, E. (2009). Intracellular trafficking of the *Coxiella burnetii* lipopolysaccharide. *Clinical Microbiology and Infection*, 15(Supplement 2), 185–187.
- Roest, H. I., Tilburg, J. J., van der Hoek, W., Vellema, P., Zijderfeld, F. G., Klaassen, C. H., & Raoult, D. (2010). The Q fever epidemic in the Netherlands: History, onset, response and reflection. *Epidemiology and Infection*, 139, 1–12.
- Schelling, E., Diguimbaye, C., Daoud, S., Nicolet, J., Boerlin, P., Tanner, M., & Zinsstag, J. (2003). Brucellosis and Q-fever seroprevalences of nomadic pastoralists and their livestock in Chad. *Preventive Veterinary Medicine*, 61(4), 279–293.
- Scola, B. L. (2002). Current laboratory diagnosis of Q fever. *Seminars in Pediatric Infectious Diseases*, 13(4), 257–262.
- Scott, G. H., & Williams, J. C. (1990). Susceptibility of *Coxiella burnetii* to chemical disinfectants. *Annals of the New York Academy of Sciences*, 590, 291–296.
- Selmi, R., Mamlouk, A., Yahia, B., Abdelaali, H., Ben Said, M., Sellami, K. D., Jedidi, M., Jemli, M. H., & Messadi, L. (2018). *Coxiella burnetii* in Tunisian dromedary camels (*Camelus dromedarius*): Seroprevalence, associated risk factors and seasonal dynamics. *Acta Tropica*, 188, 234–239.
- Slaba, K., Skultery, L., & Toman, R. (2005). Efficiency of various serological techniques for diagnosing *Coxiella burnetii* infection. *Acta Virologica*, 49(2), 123–127.
- Van den Brom, R., van Engelen, E., Roest, H. I. J., van der Hoek, W., & Vellema, P. (2015). *Coxiella burnetii* infections in sheep or goats: An opinionated review. *Veterinary Microbiology*, 181, 119–129.
- Van den Brom, R., & Vellema, P. (2009). Q fever outbreaks in small ruminants and people in the Netherlands. *Small Ruminant Research*, 86, 74–79.
- Van der Hoek, W., Morroy, G., Renders, N. H., Wever, P. C., Hermans, M. H., Leenders, A. C., & Schneeberger, P. M. (2012). Epidemic Q fever in humans in the Netherlands. *Advances in Experimental Medicine and Biology*, 984, 329–364.

# Dermatophilosis (*Dermatophilus congolensis*)

# 19

Mansour F. Hussein

Dermatophilosis (cutaneous streptothricosis) is an important skin disease caused by the bacterium *Dermatophilus congolensis*. Many species of domestic animals, especially cattle, sheep, goats, equines, and camels, in addition to a wide range of wild animals and occasionally humans may be infected and may develop clinical signs or serve as asymptomatic carriers. Hot weather, high humidity, and prolonged exposure to rain contribute to the spread of dermatophilosis among animals. The disease may occur at any age but is more common in young age.

Dermatophilosis has been reported in both New World and Old-World camelids. Among the latter, it is common in dromedary camels, being reported in many camel rearing areas in Kenya (Gitao, 1992; Gitao et al., 1990; 2014), the Sudan (Gitao et al., 1998a, 1998b, 2014), Ethiopia (Ayalew et al., 2015), Saudi Arabia (Almuzaini et al., 2015; Gitao et al., 1998b), United Arab Emirates (Joseph et al., 1998), Iran (Khodakaram-Tafti et al., 2012), Egypt (Osman, 2014), Jordan (Tarazi & Al-Ani, 2016), and Iraq (Abd, 2018). During an outbreak of dermatophilosis among dromedary camels in a private farm in Qassim region, Central Saudi Arabia, the overall prevalence of the disease was 11.5%. However, the infection rate varied significantly among different age groups, with highest prevalence rate (22.1%) being recorded in camels less than 3 years old.

## 19.1 Etiology

The etiological agent, *Dermatophilus congolensis*, is a gram-positive, facultative anaerobic actinomycete which infects the skin of a wide range of domestic and wild animals and occasionally humans. The disease occurs worldwide, particularly in humid, tropical, and subtropical regions where it is known by various names such as “cutaneous streptothricosis,” “rainscald,” “mud fever,” “lumpy wool disease,” and “strawberry foot rot.” In the camel, it has been associated with rainfall as well as drought and poverty (Moriella, 2019).



*D. congolensis* exists in two forms: filamentous hyphae and motile zoospores. The filamentous hyphae consist of thin branching filaments which eventually become transversely and longitudinally fragmented forming packets of coccoid cells which mature into flagellated ovoid zoospores.

Dermatophilosis may be acute, subacute, or chronic and is characterized by exudation and formation of scabs. Other lesions sometimes occur, including superficial epidermal necrosis, suppuration, and acanthosis. Rainfall, humidity, overcrowding, ectoparasites, skin injuries, concurrent diseases, and stress are important predisposing factors of the disease. Asymptomatic, chronically infected animals or “carriers” serve as primary reservoirs of infection. The addition of infected animals to the herd without prior examination may also lead to the introduction of the disease into a previously clean herd. *D. congolensis* is found on the skin of infected and carrier animals and the infection may spread by direct contact with these animals as well as through contaminated environment, fomites, and biting insects. Dermatophilosis may cause significant economic losses particularly in leather production.

---

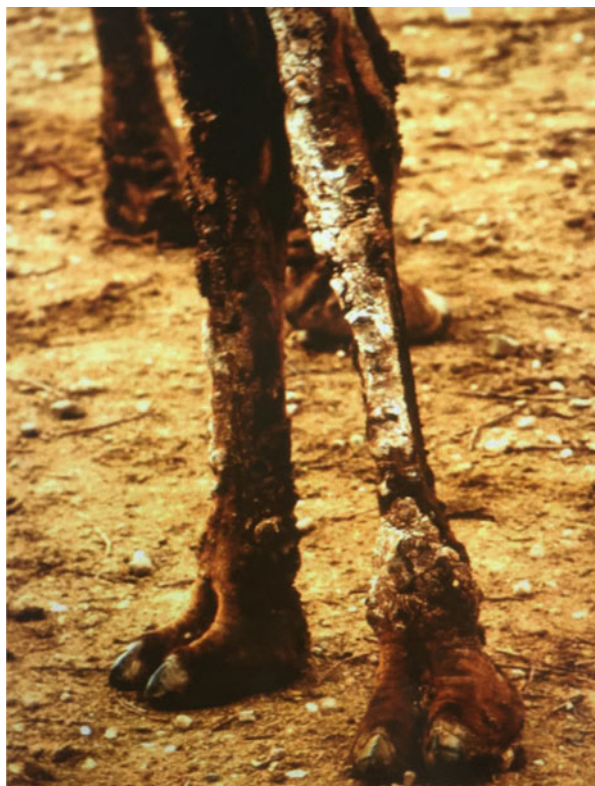## 19.2 Clinical Picture and Pathology

Dermatophilosis often starts in a few camels following days of rain, then spreads to other camels in the herd. Gitao (1992) stated that the clinical signs and lesions of dermatophilosis in camels range from mild to severe. In the latter case, up to 50% of the skin may be involved. The lesions initially appear as matted hair patches and crusts on the rump and other body parts such as the neck, flank, lower abdomen, and limbs. These patches are readily detached exposing hard, hairless, whitish brown crusts (Fig. 19.1). Often, the matted hair patches present a characteristic paint-brush appearance, and when removed, ulcers showing hyperemia and pus exudation are seen underneath. Major epizootics of dermatophilosis have also been reported in camels in the Sudan, with 50–75% infection rate and 10–20% case fatality rate among different herds. The infection was found to be more common and involving a much wider skin area in camel calves (1–3 years old) compared to adults (Gitao et al., 1998a; Tarazi & Al-Ani, 2016). High humidity and wetness of the skin are believed to significantly enhance the maturation and motility of the zoospores.

The lesions of dermatophilosis appear to be restricted to living layers of the epidermis (Moriella, 2019). Histopathological examination of the affected parts shows prominent superficial epidermal thickening, with hyperkeratosis and accumulation of degenerating neutrophils, serous fluid, and bacterial filaments. A mild dermal inflammation with infiltration of mononuclear cells, particularly lymphocytes, around superficial blood vessels is also observed (Khodakaram-Tafti et al., 2012). The pathogenesis of dermatophilosis therefore comprises physical damage to the skin, bacterial multiplication in the epidermis, repeated cycles of invasion by hyphae, infiltration by neutrophils, exudation, regeneration of epidermis and its reinvasion (Ambrose, 1996). In severe cases, the infection leads to gradual loss of condition and decreased overall productivity and reproductive performance



**Fig. 19.1** Dermatophilosis in forelimb of a dromedary camel (From: Maurizio Dioli's Pictorial Guide)



of the affected camels, in addition to significant depreciation of their hides in the case of extensive skin matting.

---

### 19.3 Diagnosis

Diagnosis can be made on the basis of clinical signs and demonstration of *D. congolensis* in smears from scabs or exudate, and by isolating the organism in blood agar media after aerobic incubation in the presence of 5% CO<sub>2</sub> at 37 °C for 48 h. *D. congolensis* appears microscopically as branched filaments dividing both transversely and longitudinally to form packets of coccoid cells. Bacterial cultures, on the other hand, reveal small (1–2 mm in diameter), rough, convex, yellowish colonies with surrounding zone of B-hemolysis, and the diagnosis of the cultured organism is based on various biochemical reactions.

Immunological methods such as immunofluorescence staining of smears from the affected tissues and serological methods such as ELISA may also be used (Gitao, 1993a). Recently, PCR has been applied for the diagnosis of dermatophilosis in camels and other animals (Ayalew et al., 2015).

## 19.4 Treatment and Control

There is no specific treatment for **dermatophilosis**. A variety of topical and parenteral antibiotics and other preparations have been used, with varying degrees of success. Intramuscular injection of long-acting oxytetracycline for about 2 weeks was said to be effective in camels. Another commonly practiced control measure in these animals is regular washing of the animals with 1% potassium aluminum sulfate solution or local application of dilute iodine solution and covering the infected skin lesions with antibiotic ointment. The control of ticks is also considered by some authors to be an important control measure (Ayalew et al., 2015; Osman, 2014). Minimizing the effects of predisposing factors is also helpful in controlling the disease. No vaccine is currently available for the control of dermatophilosis.

## 19.5 Zoonotic Potentiality

*D. congolensis* is a zoonotic bacterium which occasionally infects man. The human disease is relatively mild and short-lived. To avoid infection, animal attendants are advised to protect themselves by wearing protective clothing and gloves when working with infected animals.

## References

- Abd, M. T. (2018). Herd report: Outbreak of mixed dermatophilosis and pox infection in camels (*Camelus dromedarius*) in South Iraq. *Advances in Animal and Veterinary Sciences*, 6(8), 321–324.
- Almuzaini, A. M., Osman, S. S., & Saeed, E. M. A. (2015). An outbreak of dermatophilosis in camel (*Camelus dromedarius*) at Qassim region, central of Saudi Arabia. *Journal of Applied Animal Research*, 44(1), 126–129.
- Ambrose, N. C. (1996). The pathogenesis of dermatophilosis. *Tropical Animal Health and Production*, 28(2 Suppl), 29S–37S.
- Ayalew, Y., Assefa, A., Mekonen, N., Belete, S., & Ayisheshim, A. (2015). A review of camel dermatophilosis. *Advances in Biological Research*, 9(5), 363–372.
- Gitao, C. G. (1992). Dermatophilosis in camels (*Camelus dromedarius* Linnaeus, 1758) in Kenya. 1. *Revue Scientifique et Technique*, 11(4), 1079–1086.
- Gitao, C. G. (1993a). An enzyme-linked immunosorbent assay for the epidemiological survey of *Dermatophilus congolensis* infection in camels (*Camelus dromedarius*). *Revue scientifique et technique (International Office of Epizootics)*, 12(2), 639–645.
- Gitao, C. G. (1993b). The epidemiology and control of camel dermatophilosis. *Revue d'élevage et de Médecine Vétérinaire des Pays Tropicaux*, 46(1–2), 309–311.
- Gitao, C. G., Agab, H., & Khalafalla, A. J. (1998a). Outbreaks of *Dermatophilus congolensis* infection in camels (*Camelus dromedarius*) from the Butana region in Eastern Sudan. *Revue scientifique et technique (International Office of Epizootics)*, 17(3), 743–748.
- Gitao, C. G., Agab, H., & Khalafalla, A. J. (1998b). Camel dermatophilosis in Kenya, Sudan and Saudi Arabia. *Proceedings of the Third Annual Meeting for Animal Production Under Arid Conditions (United Arab Emirates University)*, 2, 93–107.
- Gitao, C. G., Agab, H., & Khalafalla, A. J. (2014). A comparison of camel dermatophilosis in Kenya and Sudan. *Annals of the New York Academy of Sciences*, 849, 457–360.

- Gitao, C. G., Evans, D. J., & Atkins, D. J. (1990). Natural *Dermatophilus congolensis* infection in camels (*Camelus dromedarius*, Linnaeus 1758) from Kenya. *Journal of Comparative Pathology*, 103(3), 307–313.
- Joseph, S., Wernery, U., & Ali, M. (1998). Dermatophilosis caused by a non-hemolytic *Dermatophilus congolensis* strain in dromedary camels in the United Arab Emirates. *Journal of Camel Practice and Research*, 5(2), 247–248.
- Khodakaram-Tafti, A., Khordadmehr, A., & Ardiyan, M. (2012). Prevalence and pathology of dermatophilosis in camels (*Camelus dromedaries*) in Iran. *Tropical Animal Health and Production*, 44(1), 145–148.
- Moriella, K. A. (2019). *Dermatophilosis in animals (dermatophilus infection, lumpy wool, strawberry foot rot)*. *The Merck veterinary manual*. The Merck Whitehouse Station.
- Osman, S. A. (2014). Camel dermatophilosis: Clinical signs and treatment outcomes. *Journal of Camel Practice and Research*, 21(2), 199–204.
- Tarazi, Y. H., & Al-Ani, F. K. (2016). An outbreak of dermatophilosis and caseous lymphadenitis mixed infection in camels (*Camelus dromedaries*) in Jordan. *Journal of Infection in Developing Countries*, 10(5), 506–511.

# Endotoxiosis in Camels (Hemorrhagic Disease; Hemorrhagic Diathesis; *Bodus cereus* Intoxication)

# 20

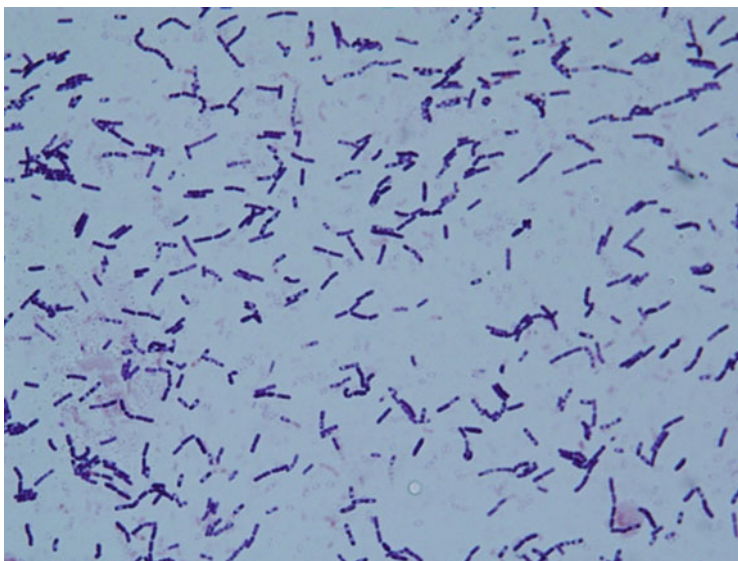
Mansour F. Hussein

Endotoxiosis or hemorrhagic disease (H.D.) was first described as a fatal disease in young racing camels in the United Arab Emirates (UAE), causing the death of many animals, especially in the age group 2–3 years (Al-Juboori et al., 2011). The disease involved individual camels or groups of up to ten or more camels, with highest incidence during the summer. Predisposing factors included environmental stress and other stress-associated conditions such as weaning, heavy exercise, and racing during hot and humid summer months, coupled with sudden change of feed from a poor diet to which camels are usually adapted, to high carbohydrate diets. This causes lactic acidosis, with destruction of rumen flora and release of large amounts of endotoxins and consequently severe manifestations of endotoxiosis.

## 20.1 Etiology

Many species of aerobic bacteria have been involved in the etiology of endotoxiosis or hemorrhagic disease (H.D.) in camels, including *Clostridium perfringens*, *E. coli*, *Pseudomonas aeruginosa*, and *Klebsiella pneumoniae* (Al-Juboori et al., 2011). However, its direct cause in camels in the UAE and other gulf countries is believed to be *Bacillus cereus* and its toxins, which, if present in fresh alfalfa fed to camels, may be responsible for H.D. (Nothelfer & Wernery, 1995; Wernery & Kaaden, 1995; Wernery et al., 1992).

*B. cereus* is a gram-positive, beta-hemolytic, spore-forming, toxin-producing bacterium commonly found in the soil and foods. It is a rod-shaped (Fig. 20.1), motile, and facultatively anaerobic organism capable of multiplying quickly at room temperature. During disease outbreaks among camels, *B. cereus* and its toxin are found in all affected organs as well as in the rumen content and may also be found in the feed. In the UAE, it was suggested that the source of the bacterium could be camel's fodder contaminated with cow's manure which is used as a fertilizer in alpha-alpha fields.



**Fig. 20.1** Gram stain of *B. cereus* isolated from dromedary camel (Courtesy of Dr. Ghada Abdelwahab)

---

## 20.2 Clinical Picture

Initially described in young racing camels of either sex, particularly those aged 2–3 years, in the UAE, endotoxycosis or H.D. has since been reported in all neighboring countries where camel racing is practiced, and the animals are fed on high concentrate diets during the racing season.

The clinical signs of the disease in racing camels (Wernery & Kinne, 2001) include sudden cessation of feeding and rumination, depression, dehydration, abdominal pain, grunting, regurgitation as well as fever and sometimes cough, and marked enlargement of submandibular lymph nodes.

Hematological and blood biochemical analyses reveal a dramatic initial leucopenia, which reverses in 2 days. The affected camels also show a sharp decrease in serum iron and marked increases in BUN and creatinine, AST, ALT, GGT, ALP, CK, and LDH levels. All of the affected animals exhibit ruminal acidosis with pH values of the rumen fluid ranging between five and six.

On the third day after disease onset, affected camels develop melena with passage of fresh or tar-like blood in their feces. They also exhibit nervous signs such as rigorous head shaking, muscle fasciculation, opisthotonus, convulsions, and excessive salivation and lachrymation. The affected animals lie down and die within 48–72 h after the onset of symptoms.

---

## 20.3 Pathology

In the affected camels, endotoxins are produced in large quantity and absorbed from the intestines into the blood stream and hence the liver which fails to detoxify them because of their high quantity. This leads to widespread damage of the vascular endothelium and tissues throughout the body (Wernery & Kinne, 2001). Post-mortem examination shows bleeding, ulcerations, and hemorrhages of varying sizes and severity, particularly in the mucous membranes of the pharynx, trachea, abomasum, intestines, epicardium, and endocardium. Sometimes, the intestines, especially the colon, are filled with fresh or tarry blood. All body lymph nodes are enlarged and hemorrhagic, while ecchymosis, petechiation, and necrotic changes may also be seen in the kidneys. Other changes include disseminated intravascular coagulation, pulmonary congestion, interstitial and subpleural hemorrhages, fatty liver change, hyperemia, meningeal edema of the brain, and destruction of lymphoid tissues (Wernery & Kaaden, 2002).

---

## 20.4 Diagnosis

Diagnosis is based on disease history, clinical signs, and post-mortem findings. Hematology and blood biochemical tests also aid in the diagnosis, particularly the demonstration of marked leukopenia during the initial stage of the disease.

---

## 20.5 Treatment and Prevention

The treatment of endotoxemia should primarily aim at neutralizing rumen acidity by administering antacids such as sodium bicarbonate (500 mg) twice daily. The administration of broad spectrum antibiotics as well as supportive therapy such as anti-inflammatory medications, fluid infusion, and antipyretic drugs is also useful.

Feeding on concentrates or high carbohydrate feeds should be discontinued and the animals allowed access only to dry hay.

---

## References

- Al-Juboori, A., Kurian, J., Ahmad, N., & Iqbal, J. (2011, May 25–28). Studies on hemorrhagic disease in camels (*Camelus dromedarius*) in UAE (United Arab Emirates). International Congress of Mediterranean Federation of Health and Production of Ruminants 19. Belgrade (Serbia). University of Belgrade, Faculty of Veterinary Medicine.
- Nothelfer, H. B., & Wernery, U. (1995). Hemorrhagic disease in dromedary camels (*Camelus dromedarius*)—Etiology and morphology. In *Proceedings of the International Conference on Livestock Production in Hot Climates*, 66, A57.

- Wernery, U., & Kaaden, O.-R. (1995). *Infectious diseases of Camelids*. Blackwell Wissenschafts Verlag.
- Wernery, U., & Kaaden, O. R. (2002). *Infectious diseases of camelids*. Blackwell Wissenschafts-Verlag.
- Wernery, U., & Kinne, J. (2001). Endotoxicosis in racing dromedaries: A review. *Journal of Camel Practice and Research*, 8(1), 65–72.
- Wernery, U., Schimmelpfennig, H. H., Seifert, H. S. H., & Pohlenz, J. (1992, February 2–6). *Bacillus cereus* as a possible cause of hemorrhagic disease in dromedary camels (*Camelus dromedarius*). In W. R. Allen, A. J. Higgins, I. G. Mayhew, D. H. Snow & J. F. Wade (Eds.), *Proceedings of 1st International Camel Conference, Dubai* (pp. 51–58). R. and W. Publications.

# Burkholderiosis (Glander's Disease)

# 21

Mansour F. Hussein

Glanders is an infectious disease caused by *Burkholderia mallei*. Camels are susceptible to the pathogen. This was demonstrated experimentally as early as the 1940s (Curasson, 1947; Samartsev & Arbuzov, 1940). Wernery et al. (2011) reported the first record of naturally occurring infection with *B. mallei* in dromedary camels during an outbreak of glanders in horses in their neighborhood. The affected camels exhibited typical clinical manifestations of glanders.

## 21.1 Etiology and Zoonotic Potential

*Burkholderia mallei* is a gram-negative, non-sporulating, bipolar, aerobic bacterium. It is an obligate mammalian pathogen that primarily causes glanders in horses and other Equidae but may also cause disease in many other mammals including humans.

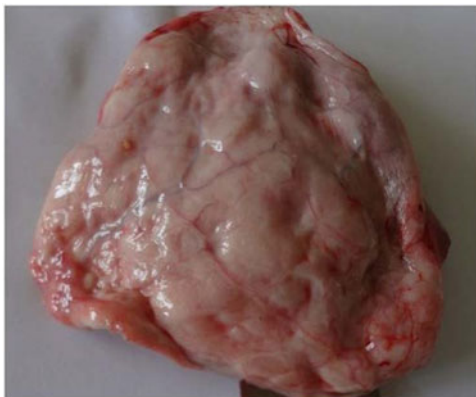*B. mallei* cannot survive naturally outside the host. It must infect a mammalian host in order to survive, being transmitted from one host to another via inhalation, ingestion, or contaminated fomites in animals, and mostly via contact with tissues or body fluids of diseased animals in the case of humans.

## 21.2 Clinical Picture

Typical clinical manifestations of glanders include severe nasal mucopurulent discharge, fever, emaciation, fatigue, and finally death. Upon necropsy of dead camels, glanders lesions can be seen in the lung, choanae, and nasal septae (Fig. 21.1). The lung lesions consist of reddish-gray nodules about the size of golf-balls, with a central gray necrotic zone, while lesions in the choanae and nasal septae consisted of stellate scars, ulcers, and honeycomb necrotic patches covered with yellow pus. No lesions were recorded in other organs (Wernery et al., 2011).



**Fig. 21.1** Large pulmonary abscess in dromedary camel; *Rhodococcus equi* isolated from the lesion (Courtesy Dr. Muna Ahmed, Vet. Research Institute, Soba, Khartoum, Sudan)



---

### 21.3 Diagnosis

Infection with *B. mallei* may initially be suspected on the basis of clinical signs and lesions, and the exclusion of other diseases causing similar symptoms. However, laboratory methods are necessary for definitive diagnosis. These methods, which have been primarily developed for the diagnosis of the disease in equines, include examination of Gram or methylene blue-stained smears from pus or exudates, histopathological sections of fresh lesions, isolation of the organism in culture media and its identification using PCR, in addition to serological tests such as immunoblot assays, ELISA, CFT, and others (Anon., 2018; Sprague et al., 2009; Tomaso et al., 2006; Wernery & Kaaden, 2002).

Biosafety measures should be strictly followed in handling suspected material both in the field and the laboratory.

---

### 21.4 Prevention and Control

Early detection and implementation of strict sanitary measures are essential components of the prevention and control of glanders. The affected premises should be quarantined and thoroughly cleaned and disinfected. Equipment should also be carefully disinfected. *B. mallei* is susceptible to many common disinfectants (such as sodium hypochlorite, glutaraldehyde, iodine, mercuric chloride, and potassium permanganate) and to a lesser extent to phenolic disinfectants. Carcasses of affected animals and all disposable material in the affected premises should be burned or buried.

No vaccine against *B. mallei* is available, and although antibiotic therapy is used for the treatment of glanders in man, and sometimes in horses, no information is currently available on the treatment of the disease in camels.

---

## 21.5 Zoonotic Potentiality

Glanders is a rare zoonotic disease which occurs as a result of the transmission of *B. mallei* from equines to humans. A relatively higher risk of infection might occur among veterinarians, assistants, and students, hoof care workers, and stable workers. Subclinical infections in equines also represent a hidden risk to humans (Van Zandt et al., 2013).

---

## 21.6 Notification

Glanders is a notifiable disease.

---

## References

- Anon. (2018). OIE terrestrial manual, glanders and melioidosis. *OIE Terrestrial Manual*, 3.5.11, 1350–1362.
- Curasson, G. (1947). *Le chameau et ses maladies* (pp. 86–88). Vigot Frères.
- Samartsev, A. A., & Arbuzov, P. N. (1940). The susceptibility of camels to glanders, rinderpest and bovine pleuropneumonia. *Veterinaria (Mosk)*, 4, 59–63.
- Sprague, L. D., Zachariah, R., Neubauer, H., Wernery, R., Joseph, M., Scholz, H. C., & Wernery, U. (2009). Prevalence-dependent use of serological tests for diagnosing glanders in horses. *BMC Veterinary Research*, 5, 32. Published online. <https://doi.org/10.1186/1746-6148-5-32>
- Tomaso, H., Scholz, H. C., Dahouk, A., Eickhoff, M., Treu, T. M., Wernery, R., Wernery, U., & Neubauer, H. (2006). Development of a 5'-nuclease real-time PCR assay targeting fliP for the rapid identification of *Burkholderia mallei* in clinical samples. *Clinical Chemistry*, 52, 307–310.
- Van Zandt, K. E., Greer, M. T., & Gelhaus, C. (2013). Glanders: An overview of infection in humans. *Orphanet Journal of Rare Diseases*, 8, 131. 1–7 published online <http://www.ojrd.com/content/8/1/131>
- Wernery, U., & Kaaden, O.-R. (2002). *Infectious diseases in camelids* (Vol. 2002, 2nd ed., pp. 91–97). Blackwell Science.
- Wernery, U., Wernery, J. M., Al Salloom, F., Johnson, B., Kinne, J., Jose, S., Tappendorf, B., Hornstra, H., & Scholz, H. C. (2011). Natural *Burkholderia mallei* infection in dromedary, Bahrain. *Emerging Infectious Diseases*, 17(7), 1277–1279.

# Leptospirosis (Weil's Disease)

# 22

Mansour F. Hussein

Leptospirosis is probably the most widespread zoonosis known, occurring in both tropical and temperate regions throughout the world (Budihal & Perwez, 2014). It is caused by thin, motile, spiral-shaped bacteria in the genus *Leptospira*. Leptospirosis has been reported in different species of New World camelids (Fowler, 1998; Hodgkin et al., 1984; Ludena & Vargus, 1982) and Bactrian camels (Wernery & Kaaden, 2002). Serological evidence of the disease has also been reported in dromedary camels in several countries including Egypt (Maronpot & Barsoum, 1972), India (Mathur et al., 1986), Ethiopia, Somalia, Tunisia, United Arab Emirates, the former USSR, Mongolia (Wernery & Kaaden, 2002), Saudi Arabia (Hussein & Gar El Nabi, 2009), and Iran (Doosti et al., 2012; Gyimesi et al., 2015).

## 22.1 Etiology

The genus *Leptospira* includes pathogenic leptospires as well as non-pathogenic (saprophytic) species which inhabit water and soil. Based on serological reaction, more than 250 pathogenic and at least 50 saprophytic serovars are recognized, constituting altogether 24 serogroups (Anon, 2013). Prior to 1989, all pathogenic serovars were placed into one species, *L. interrogans*, while all non-pathogenic serovars were placed into another species, *L. biflexa*. The genus *Leptospira* has since then been re-classified by genetic methods into 21 different genomospecies. Although this latter classification is the one used in formal taxonomy, it seems to be unsuitable for clinical purpose because of the frequent exchange of genetic material between *Leptospira* serovars, resulting in poor correlation between serological typing and genetic classification; hence, “the older serovar/serogroup classification is still commonly used in clinical practice” (Anon, 2013).

Clinical cases of leptospirosis occur in numerous species of mammals including farm animals such as cattle, sheep, goats, equines, pigs, South American camelids, and farmed cervids, as well as wildlife and marine mammals. Among pet animals, leptospirosis is most common in dogs but rare in cats.

In general, *Leptospira* serovars are adapted to one or more reservoir host (Anon, 2013), and these animals harbor leptospires in their kidneys and excrete them in their urine. Rats and other rodents, which harbor symptomless infection, constitute, along with dogs, the main reservoirs of pathogenic leptospires.

---

## 22.2 Modes of Transmission

Transmission of leptospirosis to man and animals may occur through ingestion of contaminated food or water or through abrasions and cuts in the skin and mucous membranes. It may also occur through the inhalation of aerosol of infected urine or urine-contaminated fluids. The organisms are then carried by the bloodstream to parenchymatous organs and usually multiply in the distal convoluted tubules of the kidneys where they might persist for long periods of time and are shed in urine.

---

## 22.3 Clinical Picture

In South American camelids, leptospirosis has been associated with various clinical signs including hematuria, icterus, dyspnea, anuria, and constipation (Fowler, 1998). The disease is also considered to be an important cause of abortion (Tibary et al., 2006). By contrast, very little is known about the clinical signs and pathology of leptospirosis in dromedary camels. Higgins (1986) suggested that hematuria in camels might be associated with leptospirosis, while Wernery and Wernery (1990) considered leptospiral infection to be non-pathogenic in these animals (Wernery & Wernery, 1990). However, Gyimesi et al. (2015) recorded a case of acute clinical leptospirosis caused by *Grippotyphosa* serovar in a 9-year-old male dromedary camel. A small watering hole probably contaminated by wildlife was suspected to be the source of infection. The animal presented with lethargy, anorexia, and fever. Hematological and biochemical examination revealed neutrophilia, renal azotemia, and high *Leptospira* antibody titer during the acute stage of the infection. The camel responded well to parenteral treatment with ceftiofur; however, azotemia persisted after treatment indicating chronic renal damage while PCR testing of urine samples from the same animal over a four-months period revealed no evidence of urinary shedding, suggesting that persistent infection was unlikely to have occurred.

---

## 22.4 Diagnosis

Several laboratory tests may be used for the diagnosis of leptospirosis. These include dark field microscopy to visualize *Leptospira* in urine and other fluid samples; they also include different serological tests, the gold standard of which being the Microscopic Agglutination Test (MAT), which detects serovar-specific antibodies, while the most widely used test is the IgM-ELISA. It should be noted, however, that the MAT is labor intensive and complicated, whereas ELISA-IgM and other IgM-based

assays may yield false positives thus requiring confirmation. The PCR can successfully detect leptospiral DNA in urine and serum samples but requires expensive reagents and does not identify the causative serovar.

*Leptospira* organisms can also be isolated from urine, body fluids, and certain organs like the kidney, liver, lung, and brain as well as fetal tissues in the case of abortion. Fletcher's media were used for many years for the cultivation of *Leptospira*. At present, the most widely used culture medium is Ellinghausen–McCullough–Johnson–Harris or EMJH medium. Culturing is not commonly used because it does not allow rapid diagnosis and is a laborious and time-consuming process.

---

## 22.5 Treatment and Control

Leptospirosis in man and animals can be treated effectively with antibiotics such as doxycycline, penicillin, azithromycin, and others, provided that the treatment is started early in the course of the disease. The only record of treatment in the camel is that of Gyimesi et al. (2015) who treated a camel presenting with acute clinical leptospirosis with Ceftiofur crystalline free acid injections.

No vaccination against leptospirosis is available for camels and the development of vaccines for these animals is probably not justified given the rare incidence of clinical cases of camel leptospirosis. Inactivated vaccines against certain strains of *Leptospira* have been used in other animals, particularly dogs. In all cases, however, the use of these vaccines is considered only if there is a high chance of exposure to the disease.

---

## References

- Anon. (2013). *Leptospirosis*. The Center for Food Security and Public Health (cfsph) (pp. 1–10). [www.cfsph.iastate.edu](http://www.cfsph.iastate.edu)
- Budihal, S. V., & Perwez, K. (2014). Laboratory diagnosis: Competency of various laboratory tests. *Journal of Clinical and Diagnostic Research*, 8(1), 199–202.
- Doosti, A., Ahmadi, R., & Arshi, A. (2012). PCR detection of leptospirosis in Iranian camels. *Bulgarian Journal of Veterinary Medicine*, 15(3), 178–183.
- Fowler, M. S. (1998). *Medicine and surgery of South American camelids*. Iowa State University Press.
- Gyimesi, Z. S., Burns, R. B., Erol, R. B., & Bolin, S. R. (2015). Acute clinical leptospirosis (*Grypotyphosa* serovar) in an adult dromedary camel (*Camelus dromedarius*). *Journal of Zoo and Wildlife Medicine*, 46(3), 605–608.
- Higgins, A. J. (1986). *The camel in health and disease*. Baillire Tindall.
- Hodgkin, C., Schillhorn van Veen, T. W., Fayer, R., & Richter, M. (1984). Leptospirosis and coccidial infection in guanaco. *Journal of the American Veterinary Medical Association*, 185, 1442–1444.
- Hussein, M., & Gar El Nabi, A. R. (2009). Serological evidence of leptospirosis in camels in Saudi Arabia. *Journal of Animal and Veterinary Advances*, 8(5), 1010–1012.
- Ludena, J., & Vargus, A. (1982). Leptospirosis in alpacas. *Advances in Veterinary Science and Comparative Medicine*, 2(2), 27–28.

- Maronpot, R. R., & Barsoum, I. S. (1972). Leptospiral agglutinating antibodies in sera of man and domestic animals in Egypt. *American Journal of Tropical Medicine and Hygiene*, 21, 467–272.
- Mathur, K. N., Khanna, V. K., & Purohit, A. K. (1986). Macroscopic plate agglutination results of serological examination of camels, cattle and goats for leptospirosis. *Indian Journal of Public Health*, 20(3), 170–172.
- Tibary, A., Anouassi, A., & Sqhiri, A. (2006). Infectious causes of reproductive loss in camelids. *Theriogenology*, 66(3), 633–647.
- Wernery, U., & Kaaden, O.-R. (2002). *Infectious diseases of Camelids* (pp. 55–58). Blackwell Wissenschafts-Verlag GmbH.
- Wernery, U., & Wernery, R. (1990). Seroepidemiologische Untersuchungen zum Nachweis von Antikörpern gegen Brucellen, Chlamydien, Leptospiren, BVD/MD, IBR/IPV – und Enzootischen Bovinen Leukosevirus (EBL) bei Dromedarstuten (*Camelus dromedarius*). *Dtsch. tierärztl. Wschr.*, 97, 134–135.

# Listeriosis (Circling Disease)

# 23

Mansour F. Hussein

Listeriosis (circling disease or silage sickness) is a serious bacterial disease which occurs sporadically in man and animals throughout the world. It is caused by *Listeria monocytogenes*, and its main sources are cattle, sheep, goats, wild animals, and humans (Heymann, 2015).

Listeriosis is common in sheep, goats, and cattle. A relatively low incidence of clinically severe listeriosis is also known to occur in New World camelids (Fowler, 1998) in which the disease may take the form of sporadic outbreaks or individual cases of septicemia or meningoencephalitis involving both adult and neonatal animals (Butt et al., 1991; Frank et al., 1998; Haenichen & Wiesner, 1995; Hawkins et al., 2017; Lopez-Valladares et al., 2013; Mayer & Gehring, 1975). On the other hand, only one report of the neurological form of listeriosis in the dromedary camel has been published, in which a 6-year-old female dromedary was involved (Al-Swailem et al., 2010). A very low prevalence of *Listeria* mastitis may also occur in camels (Lopez-Valladares et al., 2013; Osman et al., 2014).

## 23.1 Etiology

The causative agent, *Listeria monocytogenes*, is an intracellular, gram-positive, non-spore forming, rod-shaped, facultative anaerobic bacterium. It is catalase-positive, oxidase-negative and produces a beta hemolysin that causes red blood cell lysis. It is also actively motile at room temperature but does not produce flagella at body temperature. Furthermore, the organism is resistant to freezing, dryness, and heat and is found mainly in the soil, water, forage, vegetables, and sewage. It may also be found in genital and nasal secretions of healthy animals and may contaminate raw foods, water, and poor-quality silage; besides, it may grow in refrigerated foods (Al-Swailem et al., 2010; Dehkordi et al., 2013; Farber & Peterkin, 1991; Rahimi et al., 2014; Todar, 2008).

Dehkordi et al. (2013) isolated *L. monocytogenes* from milk, feces, urine, and vaginal secretion of bovine, ovine, caprine, buffalo, and camel species in Iran, while

Safdari and Jahantigh (2014) described contamination of raw camel meat with *Listeria* species in the Sistan region in Iran.

---

## 23.2 Clinical Picture and Pathology

Listeriosis may sometimes be mild but it is often a serious disease associated with high mortality. Its main clinical forms are septicemia, meningitis, meningoencephalitis, and abortion, sometimes it may also cause otitis media, otitis interna, and polyarthrititis (Lopez-Valladares et al., 2013). In the neurological form of the disease, often called circling disease in animals, the organism enters the body through cuts in the oral cavity and is then carried via the trigeminal nerve to the brain (Antal et al., 2005; Dons et al., 2007).

In the only known clinically overt case of listeriosis in the dromedary camel, the clinical signs comprised weakness of the limbs, incoordination of movement, head tremors, and lower lip paralysis. The affected camel, a 6-year-old female, did not respond to treatment with vitamin B<sub>12</sub>, selenium, and dextrose, and its condition deteriorated rapidly, dying in lateral recumbency a few days after showing symptoms (Al-Swailem et al., 2010). At necropsy, congestion and hemorrhages were noted in the brain, meninges, and endocardium, while histopathological examination revealed acute lymphocytic meningoencephalomyelitis with intense lymphocytic perivascular cuffing of blood vessels in the medulla oblongata and the spinal cord. A few micro-abscesses containing intact and degenerate neutrophils were also seen in the medulla oblongata.

---

## 23.3 Zoonotic Potentiality

Few studies have been published on the role of dromedary camel's milk and meat as possible sources of listeriosis in humans. Osman et al. (2014) reported very low incidence of intramammary infection with *L. monocytogenes* in dromedary camels compared to other species of farm animals, while Rahimi et al. (2014) tested 37 raw camel's milk samples collected from camel breeding farms in Iran for listeriosis using cultural and PCR methods and stated that all samples were negative for *Listeria* species. Hence, these and other studies (Jalali & Abedi, 2008; Rahimi et al., 2010) suggested that raw camel's milk may not be an important source of human listeriosis. On the other hand, Safdari and Jahantigh (2014) reported widespread contamination of raw camel meat with *Listeria* species in Sistan and Baluchistan regions of Iran. Furthermore, camel meat samples from Tehran and Isfahan were contaminated with *Listeria* spp. (Mohammadpour et al., 2020) while Ozbey et al. (2006) isolated *L. monocytogenes* from 9% of samples of dromedary camel sausages collected from different retailers in Turkey, thus indicating the need for improved food safety procedures during manufacturing, preservation, and transport.



## 23.4 Listeriosis in New World Camelids

Due to the scarcity of information on leptospirosis in dromedary and Bactrian camels, it may be of interest to briefly outline the manifestations of listeriosis in New World camelids. The most predominant clinical signs in these animals are those of meningoencephalitis, namely circling movement, head tremors, fever, and sometimes unilateral facial nerve paralysis with drooping lips, ears, and eyelids and difficulty in mastication and swallowing due to paralysis of the jaw and pharynx (reviewed by Wernery & Kaaden, 2002). Septicemic (Hawkins et al., 2017) as well as abortive (Butt et al., 1991; Lopez-Valladares et al., 2013) forms of listeriosis have also been reported in these animals in combination with encephalitis. Furthermore, otitis media or otitis interna, polyarthritis, ataxia, weakness, lethargy, and depression were listed among the clinical signs of the disease that are sometimes observed in New World camelids (Frank et al., 1998; Lopez-Valladares et al., 2013). Terminal recumbency and unresponsiveness to stimuli prior to death were also described in these animals while multifocal suppurative encephalitis with perivascular cuffing was recorded during histopathology in the pons and medulla oblongata (Butt et al., 1991). According to Hamir and Moser (1998) the pathological changes in encephalitic listeriosis in the llama included thickening, dark discoloration, and accumulation of thin yellowish exudate on the leptomeninges of the brain and spinal cord, and perivascular mononuclear cell infiltration and micro-abscesses in the medulla oblongata. Hawkins et al. (2017) described pathological changes in two 2-week-old llamas that succumbed to septicemic and meningo-encephalic listeriosis. The brain was markedly congested, the meningeal surfaces were cloudy and mottled yellow, and there was dense perivascular cuffing of the meningeal blood vessels with neutrophils and macrophages. Micro-abscesses were observed in the brain stem.

---

## 23.5 Diagnosis

Listeriosis may be suspected on the basis of clinical signs and histopathology of the brain, spinal cord, and sometimes uterus and other organs, or the detection of the bacteria (small, gram positive, coccoid rods often in short chains) in smears of blood or cerebrospinal fluid. However, a definite diagnosis of listeriosis requires isolation and identification of the causative organism in bacterial cultures from body tissues or fluids such as blood or cerebrospinal fluid. In addition to the isolation of the organism in cultures (including cold culture if necessary), other diagnostic tests are also available, including immunofluorescence, immunohistochemistry, and molecular techniques such as PCR assays (Kuldeep Dhama et al., 2015).

## 23.6 Treatment and Control

*L. monocytogenes* is susceptible to many antibiotics, particularly penicillin and ampicillin (Kuldeep Dhama et al., 2015). However, based on studies carried out on New World camelids, treatment of the disease in camelids is difficult and many animals do not respond to treatment, especially if they have encephalitic listeriosis. On the other hand, during an outbreak of listeriosis in llamas in a German zoo, Mayer and Gehring (1975) used a live *Listeria* vaccine as an emergency vaccine to prevent further spread of the disease.

No specific treatment of listeriosis in Old-World camelids is currently known, and no vaccine development is warranted since only one clinically affected case of listeriosis has been reported so far in these animals.

---

## References

- Al-Swailem, A. A., Al-Dubaib, M. A., Al-Ghamdi, G., Al-Yamani, E., Al-Naeem, A. M., Al-Mejali, A., Shehata, M., Hashad, M. E., Aboelhassan, D. E., & Mahmoud, O. M. (2010). Cerebral listeriosis in a she-camel at Qassim region, Central Saudi Arabia. *Veterinarski arhiv*, 80, 539–547.
- Antal, E. A., Loberg, E. M., Dietrich, E., & Maehlen, J. (2005). Neuropathological findings in 9 cases of *Listeria monocytogenes* in brain stem encephalitis. *Brain Pathology*, 15(3), 187–191.
- Butt, M. T., Weldon, A., Step, D., dela Hunta, A., & Huxtable, C. R. (1991). Encephalitic listeriosis in two adult llamas (*Lama glama*): Clinical presentation, lesions and immunofluorescence of *Listeria monocytogenes* in brain stem lesions. *The Cornell Veterinarian*, 81, 251–258.
- Dehkordi, F. S., Barati, S., Momtaz, H., Ahari, S. N. H., & Dehkordi, S. N. (2013). Comparison of shedding, and antibiotic resistance properties of *Listeria monocytogenes* isolated from milk, feces, urine, and vaginal secretion of bovine, ovine, caprine, buffalo, and camel species in Iran. *Jundishapur Journal of Microbiology*, 6(3), 284–294.
- Dons, L., Jin, Y., Kristensson, K., & Rottenberg, M. E. (2007). Mini review: Axonal transport of *Listeria monocytogenes* and nerve-cell-induced bacterial killing. *Journal of Neuroscience Research*, 85, 2529–2537.
- Farber, J. M., & Peterkin, P. I. (1991). *Listeria monocytogenes*, a food-borne pathogen. *Microbiological Reviews*, 55(3), 476–511.
- Fowler, M. S. (1998). *Medicine and surgery of South American camelids*. Iowa State University Press.
- Frank, N., Couétil, L. L., & Clarke, K. A. (1998). *Listeria monocytogenes* and *Escherichia coli* septicemia and meningoencephalitis in a 7-day-old llama. *Canadian Veterinary Journal*, 39(2), 100–102.
- Haenichen, T., & Wiesner, H. (1995). Erkrankungs- und Todesursachen bei Neuweltkameliden. *Tierärztl. Praxis*, 23, 515–520.
- Hamir, A. N., & Moser, G. (1998). Immuno-histopathological findings in an adult llama with listeriosis. *Veterinary Record*, 143, 477–479.
- Hawkins, I. K., Ilha, M., Anis, E., & Wilkes, R. P. (2017). Septicemia and meningoencephalitis caused by *Listeria monocytogenes* in two neonatal llamas. *Journal of Veterinary Diagnostic Investigation*, 29(5), 700–703.
- Heymann, D. L. (2015). *Control of communicable diseases manual: An official report of the American Public Health Association*. APHA Press.
- Jalali, M., & Abedi, D. (2008). Prevalence of *Listeria* species in food products in Isfahan, Iran. *International Journal of Food Microbiology*, 122, 336–340.

- Kuldeep Dhama, K., Karthik, K., Tiwari, R., Shabbir, M. Z., Barbuddhe, S., Malik, S. V. S., & Singh, R. K. (2015). Listeriosis in animals, its public health significance (food-borne zoonosis) and advances in diagnosis and control: A comprehensive review. *Veterinary Quarterly*, 35(4), 211–235.
- Lopez-Valladares, G., Danielsson-Tham, M.-L., & Than, W. (2013). Listeriosis in South American camelids: A review. *Journal of Camel Practice and Research*, 20, 129–132.
- Mayer, H., & Gehring, H. (1975). Listeriose bei lamas. In *Verhand. Ber. 17th Int. Symp. Erker Zootiere* (Tunis) (Vol. 17, pp. 307–312).
- Mohammadpour, R., Champour, M., Tuteja, F., & Mostafavi, S. (2020). Zoonotic implications of camel diseases in Iran. *Veterinary Medicine and Science*, 1–23. <https://doi.org/10.1002/vms3.239>
- Osman, K. M., Samir, A., Orabi, A., & Zolnikov, T. R. (2014). Confirmed low prevalence of *Listeria* mastitis in she-camel milk delivers a safe, alternative milk for human consumption. *Acta Tropica*, 130(2014), 1–6.
- Ozbey, G., Ertas, H. B., & Kok, F. (2006). Prevalence of *Listeria* species in camel sausages from retail markets in Aydin province in Turkey and RAPD analysis of *Listeria monocytogenes* isolates. *Irish Veterinary Journal*, 59(6), 342–344.
- Rahimi, E., Ameri, M., & Momtaz, H. (2010). Prevalence and antimicrobial resistance of *Listeria* species isolated from milk and dairy products in Iran. *Food Control*, 21, 1448–1452.
- Rahimi, E., Momtaz, H., Behzadina, A., & Baghbadorani, Z. T. (2014). Incidence of *Listeria* species in bovine, ovine, caprine, camel and water buffalo milk using cultural method and the PCR assay. *Asian Pacific Journal of Tropical Disease*, 4(1), 50–53.
- Safdari, A., & Jahantigh, M. (2014). Evaluation of raw meat contamination of *Listeria* species in camel of Sistan region. *Indian Journal of Fundamental and Applied Life Sciences*, 4(3), 537–540.
- Todar, K. (2008). *Listeria monocytogenes*. *Todar's Online Textbook of Bacteriology*.
- Wernery, U., & Kaaden, O.-R. (2002). *Infectious diseases of Camelids* (pp. 157–159). Blackwell Wissenschafts-Verlag GmbH.

Mansour F. Hussein

Mastitis or inflammation of the mammary gland is one of the most important and costly diseases in dairy animals. It is characterized by marked loss of milk production and by physical, chemical, and microbiological changes in the milk and pathological changes in the mammary gland tissue.

Mastitis usually occurs in response to an injurious agent, with the aim of eliminating that agent and paving the way for repairing the damage it did and restoring normal udder function. In the vast majority of cases, the cause of mastitis is one or a mixture of bacterial agents. These organisms enter via the teat canal, multiplying and producing toxins in the glandular tissue and ducts of the mammary gland and consequently leading to reduced milk production, altered milk composition, and sometimes other disease signs.

Normally, the teat canal orifice is surrounded by a sphincter which keeps it closed, thus preventing bacteria from entering and milk from leaking out via the teat. In addition, the mucosal cells lining the teat canal produce keratin which forms a barrier against bacteria, and also has a bacteriostatic effect. During milking and for some time thereafter, the teat canal remains open and bacteria may be able to enter into the teat especially if there is dirt or injury near the canal's orifice. Teat injuries are particularly important since they might cause partial damage to keratin or mucosal lining of the teat rendering it more susceptible to bacterial infection. From the teat canal, the bacteria enter into the glandular tissue of the mammary gland where they multiply and produce toxins, enzymes, and cell-wall components. This process, in turn, stimulates the production of numerous inflammatory mediators and attracts large numbers of inflammatory cells such as neutrophils and phagocytes, setting up an inflammatory response to destroy the invading bacteria. These cells accumulate in large numbers in the mammary gland and pass between secretory cells into the milk alveoli damaging the secretory cells and increasing somatic cell count (SCC) in the milk. Large numbers of somatic cells remain after eliminating the causative bacteria until healing of the mammary gland occurs. Besides, the clots formed by aggregation of dead mammary gland epithelial cells, leukocytes, and blood clotting factors may block small ducts and prevent complete milk removal, while damage to epithelial

cells and blockage of small ducts may result in the formation of scar tissue (Jilo et al., 2017). Otherwise, the inflammation may subside, tissue repair may ensue, and function may be restored.

Mastitis is an important problem in dromedary camels in all countries where these animals are reared. It causes significant economic losses primarily due to the loss of milk production and quality. Some forms of mastitis may also be part of systemic disease-causing deleterious effects on the health of the affected animals or even leading to their death. Furthermore, camel mastitis may pose hazards to human health and to the health and well-being of suckling calves (Abdelgadir, 2013; Jilo et al., 2017).

In general, mastitis is estimated to affect more than 25% of lactating dromedary camels (Abdurahman & Younan, 2004; Abera et al., 2010) and to cause up to 70% loss in milk production in some areas (Al Amin et al., 2013). However, its prevalence varies in different herds depending on geographical location, sanitary standards, general management, and efficiency of milking (Megersa, 2010). Besides, the susceptibility of lactating camels, as in other dairy animals, varies according to the stage of lactation, age, breed, and parity as well as the animal's degree of resistance and nature of the infectious agent.

---

## 24.1 Etiology

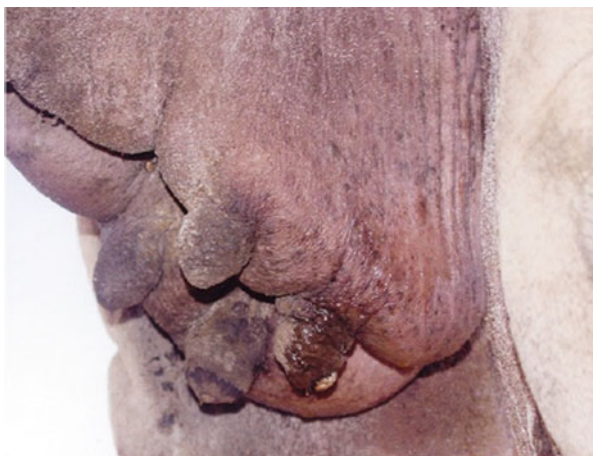Mastitis is predominantly caused by infectious agents, the most important of which are bacteria. The primary sources of infection are the environment and the infected udders. Among the bacteria incriminated in causing camel mastitis are: *Staphylococcus aureus*, *streptococcus agalactiae*, *Staphylococcus epidermidis*, *Micrococcus* spp., *Aerobacter* spp., coagulase-negative *staphylococci*, *Pasteurella haemolytica*, *Escherichia coli*, and *Corynebacterium* spp. (Al-Juboori et al., 2013; Al-Majali et al., 2008; Almaw & Molla, 2000; Gramay & Ftiwi, 2018; Mehamud et al., 2017; Toroitich, 2013). Of these different pathogens, the most important are *Streptococcus agalactiae* and *Staphylococcus aureus* (Hawari & Hassawi, 2008; Mehamud et al., 2017). Predisposing factors include unhygienic milking procedures, heavy tick infestation, udder lesions and teat tying, or the use of teat covers to prevent calves from suckling.

---

## 24.2 Clinical Picture

Both clinical and subclinical mastitis may occur in camels, the subclinical form being much more prevalent than the clinical form. Clinical mastitis is easily detected by palpation and visual examination of the affected quarter, which is usually swollen, red, hot, and painful, as well as changes in the milk which can be seen using a strip-cup and which include changes in the consistency and appearance of milk, such as discoloration, watery consistency, and presence of clots, blood, or pus in the milk. Depending on the severity of disease signs, clinical mastitis can be

**Fig. 24.1** Chronic Mastitis in a female dromedary camel (Courtesy of Prof. Mansour F. Hussain)



classified as acute or subacute. Chronic mastitis is occasionally seen in camels (Fig. 24.1). Gangrenous mastitis is also seen rarely in these animals.

An important feature of mastitis, whether clinical or subclinical, is the presence of a large number of leucocytes (referred to as somatic cells) in the milk.

Little is known about mastitis in Bactrian camels although subclinical mastitis has been reported in these animals on the basis of somatic cell count (SCC), California mastitis tests (CMT), and isolation of *Staphylococcus aureus* and coagulase-negative *staphylococci* from the infected quarters (Abdurahman, 1996). On the other hand, mastitis is considered to be rare and unimportant in New World camelids (Tibary et al. (2006).

---

## 24.3 Diagnosis

Clinical mastitis can be readily diagnosed on the basis of clinical signs such as swelling, redness, pain, and heat of the infected quarters as well as changes in milk consistency, color, and smell, and the presence of clots, blood, or pus in the milk. Physical trauma may or may not be seen in the affected udder. Generalized and systemic signs such as fever, anorexia, and depression may also be observed. On the other hand, subclinical mastitis, which constitutes the vast majority of mastitis in female camels, is not visually detectable; hence several indirect tests are used for its diagnosis and monitoring (reviewed by Jilo et al., 2017). These include CMT, SCC, ATP test, pH test, electrical conductivity, and other tests. According to Guliye et al. (2002), the type of bacteria has a significant effect on SCC; in she-camels with subclinical mastitis, the highest mean SCC is recorded in quarter samples from which coagulase-positive *Staphylococcus aureus* was isolated. Chronic mastitis is characterized by induration and fibrosis of the affected quarter and is relatively uncommon in camels.

Direct diagnosis of mastitis requires bacteriological culture to confirm the diagnosis and determine the causative agent.

---

## 24.4 Treatment and Control

In contrast to cattle, intramammary infusion of antibiotics for the treatment of mastitis is not recommended in camels because of anatomical features of the camel's udder, e.g., each teat may contain 2–3 teat canals which open independently, and the teat canal opening is smaller than that of the cow (Sanaa, 2005). Therefore, treatment of acute mastitis in these animals entails systemic rather than intramammary administration of antibiotics and anti-inflammatory drugs, with regular stripping of the mammary glands (Salah & Faye, 2011). Several antibiotics have been used for the treatment of camel mastitis, e.g. gentamycin, tetracycline, ampicillin, etc. Strict hygienic measures should be observed and trauma to the udder should be avoided. On the other hand, chronic mastitis is difficult to treat and often results in the loss of the affected quarter.

The main principles of mastitis control entail elimination of existing infection, prevention of new infection, and monitoring udder health status in addition to fly and insect control.

---

## References

- Abdelgadir, A. (2013, February 17–20). Mastitis in camels (*Camelus dromedarius*): past and recent research in pastoral production system of both East Africa and the Middle East. In *First International Conference on Sustainability of Camel Population and Production*, College of Agriculture and Food Science, King Faisal University, Al-Hasa, Saudi Arabia.
- Abdurahman, O. A. (1996). The detection of subclinical mastitis in the bactrian camel (*Camelus bactrianus*) by somatic cell count and California mastitis test. *Veterinary Research Communications*, 20(1), 9–14.
- Abdurahman, O. A.-S., & Younan, M. (2004) The udder health. In Farah and Fisher (Ed.), *Milk and meat from the camel handbook on product and processing* (pp. 73–76). vdfhochschulerleg AG and der ETH Zurich.
- Abera, M., Abdi, O., Abunna, F., & Megersa, B. (2010). Udder health problems and major bacterial causes of camel mastitis in Jijiga, Eastern Ethiopia: Implication for impacting food security. *Tropical Animal Health and Production*, 42(3), 341–347.
- Al Amin, M. A., Alqurashi, A. M., Elsheikh, A. S., & Yasin, T. E. (2013). Mastitis incidence and causative bacterial agents isolated from lactating she-camel (*Camelus dromedarius*). *Journal of Agriculture and Veterinary Science*, 2(3), 7–10.
- Al-Juboori, A., Kamal, N., & Sindhu, J. (2013). Prevalence of some mastitis causes in dromedary camels in Abu Dhabi, United Arab Emirates. *Iraqi Journal of Veterinary Science*, 28, 9–14.
- Al-Majali, A. M., Al-Qudah, K. M., Al-Tarazi, Y. H., & Al-Rawashdeh, O. F. (2008). Risk factors associated with camel brucellosis in Jordan. *Tropical Animal Health and Production*, 40, 193–200.
- Almaw, G., & Molla, B. (2000). Prevalence and etiology of mastitis in camels (*Camelus dromedarius*) in Eastern Ethiopia. *Journal of Camel Practice and Research*, 7, 97–100.

- Gramay, S., & Ftiwi, M. (2018). Camel milk production, prevalence and associated risk factors of camel Mastitis Inaysaita Woreda Afar Regional State, North East Ethiopia. *ARC Journal of Animal and Veterinary Sciences*, 4(3), 17–37.
- Guliye, A. Y., Van Creveld, C., & Yagil, R. (2002). Detection of subclinical mastitis in dromedary camels (*Camelus dromedarius*) using somatic cell counts and the N-acetyl-beta-D-glucosaminidase test. *Tropical Animal Health and Production*, 34(2), 95–104.
- Hawari, A. D., & Hassawi, D. S. (2008). Mastitis in one humped she-camels (*Camelus dromedarius*) in Jordan. *Journal of Biological Sciences*, 8, 958–961.
- Jilo, K., Galgalo, W., & Mata, W. (2017). Camel mastitis: A review. *MOJ Ecology & Environmental Science*, 2(5), 00034. <https://doi.org/10.15406/mojes.2017.02.00034>
- Megersa, B. (2010). *Epidemiology of major camel disease in Borana low land, Southern Ethiopia*. Dry Lands Coordination Group Report (pp. 1–2).
- Mehamud, J., Megersa, M., Abebe, M., & Ahmed, N. (2017). Prevalence, risk factors and major bacterial causes of camel mastitis, in Gursum District, eastern Hararghe, Ethiopia. *Global Veterinaria*, 18(3), 203–208.
- Salah, S. K., & Faye, B. (2011). Detection of subclinical mastitis in dromedary camels (*Camelus dromedarius*) using somatic cell counts, California mastitis test and udder pathogen. *Emirates Journal of Food and Agriculture*, 23(1), 48–58.
- Sanaa, O. Y. (2005). Bacterial diseases of the reproductive system of camels (*Camelus dromedarius*) in Eastern Sudan. *Journal of Animal and Veterinary Advances*, 4(7), 642–644.
- Tibary, A., Fite, C., Anouassi, A., & Sghiri, A. (2006). Infectious causes of reproductive loss in camelids. *Theriogenology*, 66(3), 633–647.
- Toroitich, C. K. (2013). *Prevalence of mastitis and associated risk factors in lactating one-humped camels in west Pokot County. Kenya* [MSc thesis]. University of Nairobi, Kenya.



# Melioidosis (Whitmore Disease; *Burkholderia pseudomallei* Infection)

# 25

Mansour F. Hussein

Apart from causing Whitmore Disease in humans, *Burkholderia pseudomallei* (*Pseudomonas pseudomallei*) is also known to affect numerous other host species in humid tropical and subtropical environments worldwide, and particularly in northern parts of Australia and in Thailand. Melioidosis is also endemic in some parts of Africa and the Middle East.

## 25.1 Etiology

*B. pseudomallei* is a gram-negative, bipolar, aerobic, motile, rod-shaped bacterium that lives in the soil and water. It has been isolated from a wide range of domestic and wild mammals, birds, reptiles, and fish. In general, different animals vary in their susceptibility to melioidosis and the disease may be acute or chronic. Sheep, goats, and pigs are particularly susceptible to infection. However, melioidosis has also been reported, though to lesser extent, in other species including cattle, buffalo, bison, equines, camels, alpaca, chickens, emus/ostriches, and wildlife such as kangaroos, wallabies, and koalas (Anon, 2018). The infection may be acquired through wounds exposed to contaminated soil or water, ingestion of contaminated soil or water, or inhalation of contaminated soil, dust, or water droplets during strong winds and heavy rainfall (Anon, 2016).

## 25.2 Clinical Signs and Pathological Lesions

There are very few reports of melioidosis in the camel. Bergin and Torenbeeck (1991) and Forbes-Faulkner et al. (1992) reported fatal cases of the disease in Australian camels, characterized by bronchopneumonia, septicemia, and a range of other clinical signs including pyrexia, dehydration, coughing, nasal discharge, wasting, and weakness of the hind legs with consequent incoordination of movement. *B. pseudomallei* was isolated from the affected camels. It was also reported

that camels moved north, and an alpaca brought to Darwin in northern Australia died of acute melioidosis (Choy et al., 2000). A fatal case of melioidosis was also reported in a 7-year-old female dromedary in the United Arab Emirates (Wernery et al., 1997). In that case, the affected animal became severely emaciated before dying. Necropsy examination revealed widespread greenish areas of caseous necrosis and abscesses in the lungs, liver, kidneys, spleen, nasal mucosa, diaphragm, mediastinal lymph nodes, and pericardium. Similar lesions were also found in the mucosa of the esophagus, uterus, and lymphatic vessels. Histopathological examination of the lesions revealed caseous granulomas with peripheral accumulations of macrophages and some giant cells in the affected organs.

---

### 25.3 Diagnosis

A definitive diagnosis of melioidosis requires isolation and identification of *B. pseudomallei*. The organism can be isolated from lesions and discharges using standard culture media, especially Ashdown's agar, a selective medium that shows distinctive colony morphology and odor of *B. pseudomallei*. Serological tests such as CFT, IHA, ELISA, and more recently DNA probes and PCR tests have also been developed (Lau et al., 2015).

---

### 25.4 Treatment and Prevention

No specific information is available on the treatment and control of melioidosis in camels. However, the disease may be treated in some animals using antibiotics. Often, the treatment is prolonged and expensive, and relapses may occur if the treatment is discontinued. Preventive measures are therefore more practical and less expensive: in this regard, appropriate biosecurity and decontamination procedures should be followed, and the infected animals should be isolated and should not be moved out to other locations. Although transmission of melioidosis from animals to man has not been proven, farm workers and veterinarians handling infected animals should take necessary precautions to protect themselves, e.g. wearing protective clothes and protecting their eyes. Incineration is recommended for disposal of infected animal carcasses while in-contact equipment should be disinfected (Anon, 2016).

---

### References

- Anon. (2016). *Melioidosis*. Center for Food Security and Public Health. [www.cfsph.iastate.edu](http://www.cfsph.iastate.edu)
- Anon. (2018). *Glanders and melioidosis*. OIE Terrestrial Manual; Ch 3.5.11 (pp. 1350–1362).
- Bergin, T. J., & Torenbeeck, L. R. (1991). Melioidosis in camels. *Australian Veterinary Journal*, 68 (9), 309.

- Choy, J. L., Mayo, M., Janmaat, A., & Currie, B. (2000). Animal melioidosis in Australia. *Acta Tropica*, 74(2–3), 153–158.
- Forbes-Faulkner, J. C., Townsend, J. C., & Thomas, A. D. (1992). *Pseudomonas pseudomallei* infection in camels. *Australian Veterinary Journal*, 69(6), 148.
- Lau, S. K. P., Sridhar, S., Ho, C.-C., Chow, W.-N., Lee, K.-C., Lam, C.-W., Yuenm, K. Y., & Woo, P. C. Y. (2015). Laboratory diagnosis of melioidosis: Past, present and future. *Experimental Biology and Medicine (Maywood)*, 260(6), 742–751.
- Wernery, R., Kinne, J., Haydn-Evans, J., & Ul-Haq, A. (1997). Melioidosis in a seven-year-old camel, a new disease in the United Arab Emirates (UAE). *Journal of Camel Practice and Research*, 4, 141–143.

Mansour F. Hussein

Mycoplasmosis refers to a group of saprophytic or pathogenic bacterial agents of the genus *Mycoplasma* and other related genera affecting man and animals, including birds.

Several *Mycoplasma* species were recorded in dromedary camels using different cultural, serological, and/or molecular methods. Both clinically affected camels and pulmonary lesions detected during abattoir surveys were investigated.

---

## 26.1 Etiology

In contrast to other bacteria, mycoplasma organisms are characterized by their lack of a cell wall. This makes them naturally resistant to antibiotics that act against cell-wall synthesis such as penicillin. Different parts of the body including lungs, skin, urinary tract, joints, nasal tract, ears, and other organs may be affected by *Mycoplasma*, depending on the species of mycoplasma causing the infection. There are numerous *Mycoplasma* organisms that are harmless; however, some species are associated with important diseases in animals and birds. These diseases include contagious bovine pleuropneumonia, caused by *M. mycoides* in cattle, contagious caprine pleuropneumonia, caused by *M. mycoides capri*, and *Mycoplasma* F38, in goats, in addition to meningitis, arthritis, and genital conditions in bovines, and chronic respiratory disease and infectious synovitis, caused by *M. gallisepticum* and *M. synoviae*, respectively, in poultry. *M. bovis* is also a major cause of bovine mastitis (Moroni et al., 2018).

---

## 26.2 Clinical Picture and Pathology

In an abattoir study of dromedary camels imported from the Sudan, *Mycoplasma arginini* was isolated from the nasal tracts, lungs, and mediastinal lymph nodes, and *Acholeplasma oculi* and *A. laidlawii* from the nasal tracts, of apparently normal

dromedary camels slaughtered in Egypt (Mederos-Iriarte et al., 2014). The animals were serologically positive for *M. mycoides* subsp. *mycoides* SC type, *M. capricolum* subsp. *capripneumoniae*, and *M. mycoides* subsp. *capri*.

El-Metwally and co-workers (2010) investigated the incidence and histopathological manifestations of mycoplasmosis in tissue samples collected from the lungs, uterus, cervix, vagina, and mammary glands of 100 female camels slaughtered at Kerdasa abattoir in Egypt. *Mycoplasmas* were detected in 6% of the lung samples and 2% of the vaginal swabs, while none was isolated from the uterus, cervix, and mammary gland samples. All mycoplasma isolates were identified as *Mycoplasma arginini*. Microscopic examination of the affected lungs revealed diffuse suppurative bronchopneumonia or diffuse fibrinosuppurative pleuropneumonia and caseous necrosis. Lesions in the uterine tissue samples comprised subepithelial granulomatous lesions consisting of lymphocytes, histiocytes, and multinucleated giant cells. In some cases, the cervix and vagina revealed chronic, granular inflammation, and diffuse or focal infiltration by lymphocytes and plasma cell. Mammary gland lesions ranged from acute diffuse purulent mastitis and chronic mastitis with galactophoritis and extensive alveolar atrophy.

Sokkar et al. (2014) isolated *Mycoplasma* organisms and described their associated histopathological lesions in the lungs of slaughtered dromedary camels in Egypt. Out of 80 lungs examined, four *Mycoplasma* isolates (5%) were recovered, with typical fried egg appearance of *Mycoplasma* colonies being observed on solid media. Histopathological examination of the lesions revealed fibrinopurulent pneumonia, sequestration, marked thickening of interlobular septa, pleuritis, and formation of intravascular fibrinous thrombi. Mycoplasmosis was also associated with reproductive failure in dromedary camels. Using cultural and serological methods, Hassan and Ahmed (1997) identified *Mycoplasma* and *Ureaplasma* from vaginal, cervical, and uterine samples of female camels and from preputial samples of male camels, slaughtered in Cairo and Giza abattoirs in Egypt.

Antibodies against *Mycoplasma capricolum capripneumoniae* (*Mycoplasma* biotype F38), the causative agent of contagious caprine pleuropneumonia, were also detected in a large percentage of asymptomatic camels in Kenya by Paling et al. (1978). However, these authors found no evidence that camels were susceptible to infection with *Mycoplasma mycoides*, the causative agent of contagious bovine pleuropneumonia, or played a role in its epizootiology.

In the Sudan, Elfaki et al. (2001) isolated and characterized *M. arginini* from pneumonic lesions in 100 slaughtered dromedaries. They studied the biochemical profile and serological testing results of the isolated organism and noted that its associated lesions were predominantly those of chronic interstitial pneumonia. Abdelazeem et al. (2020) also investigated the role of *M. arginini* as a cause of slowly developing and mild pneumonia in Sudanese dromedary camels. The study was conducted on 210 pneumonic and 250 apparently healthy lungs. Out of 210 isolates from the pneumonic lungs, 48 (~30%) were identified and confirmed by PCR as *M. arginini* while no *mycoplasma* was isolated from the apparently healthy lungs.

Mohamed et al. (2018) tested 93 nasal and tracheal swabs and lung samples from camels in Al-Taif slaughterhouse in Saudi Arabia. All samples were tested by cultural methods and also by PCR using universal primer of 16S rRNA and species-specific primers for *Mycoplasma arginine*, *M. bovis*, and *M. mycoides subspecies mycoides*. Negative results were obtained by cultural methods whereas 30% of the nasal samples were positive using PCR. In the latter case, however, species-specific primers yielded negative results for *M. arginini*, *M. bovis*, and *M. mycoides subspecies mycoides*, indicating that some unidentified *Mycoplasma* species might have been responsible for the positive PCR results in nasal swabs.

Elghazali et al. (2011) isolated and characterized *Mycoplasma* organisms from tissue samples and swabs collected from 529 camels slaughtered in El-Gezira, Kassala, and Gedarif States in the Sudan. These authors also tested serum samples for antibodies to *Mycoplasma mycoides subsp. Mycoides*. Two *Mycoplasma* isolates were obtained from lung tissues of camels exhibiting pneumonic lesions in El-Gezira State, and two from nasal swabs in both Kassala and El-Gezira States. One isolate was also obtained from nasal swabs of a camel with apparently normal lung. Using conventional bacteriological and biochemical methods, three *Mycoplasma* isolates belonging to several genera and two *Acholeplasma* isolates were recorded.

---

## 26.3 Diagnosis

Diagnosis of mycoplasmosis (*Mycoplasma*, *Ureaplasma*, and *Acholeplasma* species) in farm animals is generally based on the isolation of *mycoplasma* organisms from diseased tissues, coupled with a series of biochemical, serological, and molecular tests to identify the isolate (Mederos-Iriarte et al., 2014). Selective media such as Friis or Hayflick's agar are necessary for *Mycoplasma* culture and should be kept at 10% CO<sub>2</sub>. The detection of serum antibodies and/or antigens in the circulation or tissues of infected animals, in addition to other relevant information, may aid in the diagnosis of some forms of animal mycoplasmosis. ELISA or FAT for antibody detection and real-time PCR tests for antigen detection provide important and sensitive information for early diagnosis and assessment of the status of disease progression and, hence, determination of appropriate treatment and management decisions.

---

## 26.4 Treatment

*Mycoplasma* species are the smallest free-living microorganisms (300 nm diameter) and are unique among bacteria in that they lack a rigid cell wall and are therefore insusceptible to bactericidal antibiotics such as penicillin that act against the synthesis of bacterial cell wall. However, they are susceptible to a variety of bacteriostatic drugs including macrolides like azithromycin and clarithromycin, tetracyclines like doxycycline and tetracycline, and fluoroquinolones like ciprofloxacin and levofloxacin that kill them. It should be noted, however, that *mycoplasma* can

develop resistance to one class of bacteriostatic drugs or the other making it importance to choose an effective alternative.

---

## References

- Abdelazeem, W. M., Zolnikov, T. R., Mohammed, Z. R., Saad, A., & Osman, K. M. (2020). Virulence, antimicrobial resistance and phylogenetic analysis of zoonotic walking pneumonia *Mycoplasma arginini* in the one-humped camel (*Camelus dromedarius*). *Acta Tropica*. <https://doi.org/10.1016/actatropica.2020.105500>
- Elfaki, M. G., Abbas, B., Mahmoud, O. M., & Kleven, S. H. (2001). Isolation and characterization of *Mycoplasma arginini* from camels (*Camelus dromedarius*) with pneumonia. *Comparative Immunology, Microbiology and Infectious Diseases*, 25(1), 49–57.
- Elghazali, F., Hamid, F. M., Ali, A. M. M., & Shallali, A. A. O. (2011). Isolation of mycoplasmas and Sero-surveillance for *Mycoplasma mycoides subsp. mycoides* in the dromedary camel in some areas of the Sudan. *The Sudan Journal of Veterinary Research*, 26, 13–22.
- El-Metwally, A. E., Yassin, M. H., & El-Hallawany, H. A. (2010). Mycoplasmosis in slaughtered she-camels: Pathological studies. *Global Veterinaria*, 4(5), 474–482.
- Hassan, N. I., & Ahmed, T. M. (1997). Mycoplasma and Ureaplasma of the genital tract of camels in Egypt. *Assiut Veterinary Medical Journal*, 38(75), 104–118.
- Mederos-Iriarte, L. E., Poveda, J. B., Poveda, C. G., Vega-Orellana, O. M., Gutierrez, C., Corbera, J. A., & Ramirez, A. S. (2014). Mycoplasma detection and isolation from one-humped camel (*Camelus dromedarius*). *Tropical Animal Health and Production*, 46(7), 1317–1320.
- Mohamed, A. A., Yassin, M. H., Hassan, M. M., Sabry, A. M., & Ibrahim, A. M. (2018). Molecular and bacteriological diagnosis of *Mycoplasma* species infection in camels at Taif Governorate, Saudi Arabia. *Annual Research and Review in Biology*, 23(5), 1–6.
- Moroni, P., Nydam, D. V., Ospina, P. A., Scillieri-Smith, J. C., Virkler, P. D., Watter, R. D., Welcome, F. L., Zurakowski, M. J., Ducharme, N. G., & Yeager, A. E. (2018). Diseases of the teat and udder. In S. F. Peek & T. J. Divers (Eds.), *Rebhun's diseases of dairy cattle* (3rd ed., pp. 389–465). Elsevier.
- Paling, R. W., Macowan, K. J., & Karstad, L. (1978). The prevalence of antibody to contagious caprine pleuropneumonia (*Mycoplasma* strain F38) in some wild herbivores and camels in Kenya. *Journal of Wildlife Diseases*, 14(3), 305–308.
- Sokkar, S. M., Ahmed, K. A., Samir, A., & Sultan, A. A. (2014). Pathological studies on lung mycoplasmosis in camels. *Egyptian Journal of Comparative Pathology and Clinical Pathology*, 27(1), 46–54.

Mansour F. Hussein

Paratuberculosis or Johne's disease is a contagious bacterial disease of worldwide distribution affecting cattle, sheep, goats, buffaloes, farmed deer, camels, and many other species of domestic and wild mammals, particularly ruminants.

Paratuberculosis occurs both in Old and New World camelids and is considered to be one of the most important and widespread diseases in Bactrian camels, especially young camels, in countries where these animals are raised (Bushev et al., 1987; Haghkah et al., 2015; Wernery & Kaaden, 2002). It is also widely reported in dromedary camels in many countries where pastoralists keep dromedaries, often in large numbers, as a major source of food and other products and as a means of transportation. These countries include Kenya (Feldman et al., 1981), Egypt (Salem et al., 2012), Tunisia (Burgmeister et al., 1975), Saudi Arabia (Alharbi et al., 2012; Alhebbabi & Alluwaimi, 2010; Alluwaimi, 2015; El-Sabagh et al., 2017; Radwan et al., 1991; Salem et al., 2019; Zaghawa et al., 2012), UAE (Wernery & Kaaden, 2002), Sultanate of Oman (Hussain et al., 2015), Iran (Haghkah et al., 2015), and India (Chauhan et al., 1987).

---

## 27.1 Etiology

The causative agent of paratuberculosis, *Mycobacterium avium subspecies paratuberculosis* (MAP), is a fastidious, acid-fast, aerobic, non-motile, non-spore forming bacillus. Gene sequencing (Ghosh et al., 2012) indicated that the strain isolated from camels belonged to the sheep lineage (*M. ap-S*) of *M. paratuberculosis*.

Although MAP is 99% genetically related to *Mycobacterium avium*, it differs from it in that it grows slowly, infects mammals, not birds, and requires mycobactin when grown in vitro. MAP can survive for extended periods in the environment, being resistant to heat, cold, and dryness and capable of surviving for more than a year in soil and water.



## 27.2 Modes of Transmission

Infection with MAP is mostly transmitted via the fecal-oral route, with infected animals shedding the organism in their feces and others contracting it through contaminated food, water, or equipment and utensils. The organism may also be shed in milk and passed from an infected dam to her offspring through milk or colostrum. Newborns may also be infected by swallowing infected [manure](#) soiling the [udders](#) of their dams. In utero transmission may also occur. Although newborn animals may be exposed to infection shortly after birth, they do not exhibit clinical signs until later in life due to the long incubation period of the infection. In cattle, males may carry the organism in their accessory reproductive organs and shed it in semen; hence, the possibility exists that the infection may be transmitted to cows through semen from shedder bull or contaminated semen (Abbas et al., 2011; Khol et al., 2010). Whether this applies to camels or not is unknown. Paratuberculosis may also be introduced when replacement animals carrying infection are added to a previously uninfected herd.

---

## 27.3 Clinical Picture

Little is known about the epizootiology of paratuberculosis in camels. Studies on other farm animals, particularly cattle, showed that most infected animals are sub-clinically affected or silent carriers shedding the organism in their feces without showing clinical signs.

However, a portion of the animals exhibit overt clinical signs characterized mainly by incurable [diarrhea](#), inappetence and [wasting](#) (Fig. 27.1). Initial signs of the infection in dromedary camels consist of progressive weight loss, decreased milk production, anorexia, dehydration, intermandibular edema, and roughening of the coat (Alluwaimi, 2015; Gameel et al., 1994; Zaghawa et al., 2012). The diarrhea may be intermittent or persistent depending on the stage of the disease and may or may not contain blood or mucus. Ultrasonographic examination reveals mild to severe thickening and corrugation of the intestinal wall and accumulation of fluid in the abdominal cavity (Tharwat et al., 2012). With advancement of the disease, the infected animals exhibit progressive emaciation and debility, infertility, pallor of mucosae, and intermandibular [edema](#) “bottle jaw” and most of them eventually die as a result of persistent diarrhea, [dehydration](#), and severe [cachexia](#).

---

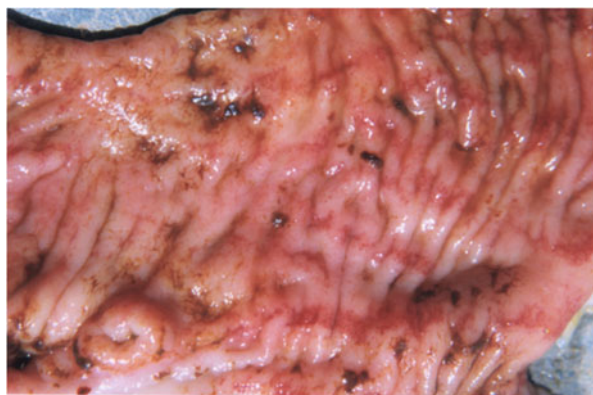## 27.4 Pathogenesis and Pathology

Paratuberculosis is primarily a disease of the small intestine, particularly the ileum, which may eventually extend to other parts of the intestinal tract. The ileum contains numerous Peyer's patches covered by layers of specialized epithelial cells known as M cells which transport antigens like MAP to the underlying lymphoid tissue of Peyer's patches. Macrophages within Peyer's patches engulf the organism but fail to



**Fig. 27.1** A dromedary camel affected with Paratuberculosis, 2014, KSA. Note, the tail is wetted with fecal materials (Courtesy of Dr. Abdelmalik Khalafalla)

**Fig. 27.2** Marked thickening and corrugation of ileal mucosa of camel affected with paratuberculosis (Courtesy Dr. B. Abbas, Bahrain)



destroy it. Hence, it continues to grow in large numbers within the macrophages eventually killing them and spreading to other nearby macrophages. At the same time, several macrophages fuse together forming multinucleated giant cells.

The accumulation of millions of bacteria, macrophages, and giant cells leads to marked thickening and corrugation, and sometimes ulceration, of the affected part of the intestine (Fig. 27.2). This causes failure of nutrient absorption and onset of diarrhea. Mesenteric lymph nodes also show enlargement and granulomatous reaction. In advanced cases, granulomas have also been described in other organs, such

as the liver, spleen, hepatic lymph nodes, and mediastinal lymph nodes, of infected camels (Alharbi et al., 2012; Hereba et al., 2014).

Histopathological changes range from mild or moderate to severe, depending on the clinical stage of the disease. In general, the main histopathological lesions comprise diffuse granulomatous enteritis, with infiltration of macrophages, epithelioid cells, giant cells, lymphocytes, and acid-fast bacilli in the mucosa and submucosa of ileum, and the sinuses of the mesenteric and ileocecal lymph nodes (Almujalli & Al Ghamdi, 2012). Similar infiltrations may be seen in other affected tissues.

Dromedary camels with advanced clinical disease exhibit a wide range of hematological and biochemical changes comprising reduction in total protein (TP), albumen, red blood cell count (RBC), and hemoglobin concentration (Hb), and significant increases in packed cell volume (PCV), neutrophil percentage, creatinine (CRE), blood urea nitrogen (BUN), magnesium (Mg) as well as aspartate aminotransferase (AST), alanine aminotransferase (ALT), and alkaline phosphatase (ALP) activities. Several proinflammatory cytokines, acute phase proteins, oxidative stress mediators, and gamma interferon are also significantly elevated (Almujalli & Al Ghamdi, 2012; El-Deeb et al., 2014; Gameel et al., 1994; Salem et al., 2012; Tharwat et al., 2013).

Little is known about the clinical pathology of paratuberculosis in young camels with subclinical infection. According to Salem et al. (2012), however, early hematological and biochemical changes in 1–3 years old camels at the subclinical stage include reduced mean corpuscular hemoglobin concentration (MCHC), RBC, Hb, and PCV values, moderate reduction in serum TP, and significant increase in total leukocyte count (WBC).

---

## 27.5 Diagnosis

The detection and diagnosis of MAP is difficult due to its long incubation period and variation in host immune response at different stages of the disease. Hence, no single diagnostic test can detect the infection at all stages. This situation constitutes a major obstacle to successful control of the disease. On the other hand, fecal culture, though difficult and time-consuming, can detect infected animals before the development of clinical signs. Hence, Salem et al. (2019) considers it, despite these limitations, to be the gold standard for the diagnosis of MAP.

A combination of methods have been used in the diagnosis of paratuberculosis in animals including clinical and post-mortem findings, examination of Ziehl–Neelsen stained fecal smears and tissue scrapings, fecal culture, and PCR, as well as indirect tests such as gamma interferon assay, ELISA, agar gel immunodiffusion (AGID), CFT, flow cytometry, and other tests.

Apart from necropsy and histopathological examination (Alharbi et al., 2012; Gameel et al., 1994; Tharwat et al., 2013), ELISA tests and PCR have been applied in the diagnosis of paratuberculosis in camels (Alharbi et al., 2012; Alhebab & Alluwaimi, 2010; Alluwaimi, 2008, 2015; Hereba et al., 2014; Hussain et al., 2015; Maroudam et al., 2015; Salem et al., 2019; Wernery et al., 2011). It is worth noting,

however, that ELISA tests have relatively poor sensitivity in detecting *MAP* antibodies in young camels (Alhebabí & Alluwaimi, 2010), whereas PCR amplification of the IS900 gene sequence in fecal and milk sample is more sensitive particularly in sub-clinically infected camels (Haghighi et al., 2015).

---

## 27.6 Zoonotic Potentiality

The clinical and pathological resemblance between paratuberculosis in animals and Crohn's disease in humans has led some investigators to conclude that paratuberculosis was a zoonotic disease (Calderon & Gongora, 2008). However, epidemiological studies have yielded variable results; for instance, in some studies, *MAP* (or an associated immune response) was much more frequently found in patients with Crohn's disease than those unknown to suffer from the latter disease while in other studies the reverse was true.

---

## 27.7 Treatment and Control

There is no known treatment for paratuberculosis; therefore, emphasis should be focused on good management and sanitation. Housawi et al. (2015) suggested that camels (like cattle) may seroconvert at an early stage in their life if exposed to *MAP*. Hence, in order to avoid potential exposure of the newborn to *MAP*, parturition should occur in a clean and manure free area. The newborn should also be kept in a clean area.

Whenever possible, camel herds should be screened to identify and eliminate infected animals. Besides, replacement animals should be quarantined and tested before adding to the herd.

No commercial vaccines are available for the control of paratuberculosis in camels. However, in some countries, vaccines are used against the disease in young cattle, sheep, and goats. While these vaccines are believed to reduce the incidence of the disease, they do not prevent shedding and appearance of new cases.

---

## References

- Abbas, M., Munir, M., Abdul Khaliq, S., Ikram Ul Haq, M. I., Tanveer Khan, M., & Qureshi, Z. A. (2011). Detection of paratuberculosis in breeding bulls at Pakistani semen production units: A continuous source of threat. *International Scholarly Research Notices*, 2011, 4.
- Alharbi, K. B., Al-Swailem, A., Al-Dubaib, M. A., Al-Yamani, E., Al-Naeem, A., Shehata, M., Hashad, M. E., Albusadah, K. A., & Mahmoud, O. M. (2012). Pathology and molecular diagnosis of paratuberculosis of camels. *Tropical Animal Health and Production*, 44, 173–177.
- Alhebabí, A. M., & Alluwaimi, A. M. (2010). Paratuberculosis in camel (*Camelus dromedarius*): The diagnostic efficiency of ELISA and PCR. *The Open Veterinary Scientific Journal*, 4, 41–44.

- Alluwaimi, A. (2008). The efficiency of bovine ELISA in detection of the *Mycobacterium avium* subspecies paratuberculosis (MAP) infection in Camel (*Camelus dromedaries*) at different ages. *Journal of Camel Practice and Research*, 15(2), 163–165.
- Alluwaimi, A. M. (2015). Paratuberculosis infection in camel (*Camelus dromedarius*): Current and prospective overview. *Open Journal of Veterinary Medicine*, 9(07), 153–160.
- Almujalli, A., & Al Ghamdi, G. (2012). Clinicopathological findings of paratuberculosis in camels; possible steps for control strategy. *Research Journal of Biological Sciences*, 7, 128–131.
- Burgmeister, R., Leyk, W., & Goessler, R. (1975). Untersuchungen über Vorkommen von Parasitosen, bakteriellen und viralen Infektions-krankheiten bei Dromedaren in Sudtunesien. *Tierärztliche Wochenschr*, 82, 352–354.
- Bushev, K. N., Tulepbaev, S. Z., & Sansyzbaev, A. R. (1987). Infectious diseases of camels in the USSR. *Revue scientifique et technique (International Office of Epizootics)*, 6(2), 487–495.
- Calderon, J., & Gongora, A. (2008). Clinical and pathological similarities between paratuberculosis and Crohn's disease. A possible zoonotic link? *Revista MVZ Cordoba*, 13(1), 1226–1239.
- Chauhan, R. S., Satija, K. O., Tika Ram, S. M., & Kaushik, R. K. (1987). Diseases of camels and their control. *Indian Farming*, 36, 27–31.
- El-Deeb, W., Fouda, T., & El-Bahr, S. (2014). Clinico-biochemical investigation of paratuberculosis of dromedary camels in Saudi Arabia: Proinflammatory cytokines, acute phase proteins and oxidative stress biomarkers. *Pakistan Veterinary Journal*, 34(4), 484–488.
- El-Sabagh, I. M., Alali, A. M., & Al-Naeem, A. A. (2017). Group A rotavirus and *Mycobacterium avium* subspecies paratuberculosis associated with diarrhea in dromedary camels in eastern province, Saudi Arabia. *Thai Journal of Veterinary Medicine*, 47(3), 383–388.
- Feldman, B. F., Keen, C. L., Kaneko, J., & Barber, T. B. (1981). Husbandry and diseases of camels. *Tierärztliche Praxis*, 9(3), 389–402.
- Gameel, A. A., Ali, A. S., Razig, S. A., Brown, J., Al Hendi, S. A., & El Sanousi, S. A. (1994). A clinicopathological study on spontaneous paratuberculosis in camels (*Camelus dromedarius*) in Saudi Arabia. *Pakistan Veterinary Journal*, 14(1), 15–19.
- Ghosh, P., Hsu, C., Alyamani, E. J., Shehata, M. M., Al-Dubaib, M. A., Al-Naeem, A., Hashad, M., Mahmoud, O. M., Alharbi, K. B. J., Al-Busadah, K., Al-Swailem, A. M., & Talaat, A. M. (2012). Genome-wide analysis of the emerging infection with *Mycobacterium avium* subspecies paratuberculosis in the Arabian camels (*Camelus dromedarius*). *PLoS One*, e31947, 7.
- Haghighi, M., Derakhshandeh, A., Jamshidi, R., Moghiseh, A., Karimaghaei, N., Ayaseh, M., & Mostafaei, M. (2015). Detection of *Mycobacterium avium* subspecies paratuberculosis infection in two different camel species by conventional and molecular techniques. *Veterinary Research Forum*, 6(4), 337–341.
- Hereba, A. E., Hamouda, M. A., & Al-Hizab, F. A. (2014). Johne's disease in dromedary camel: Gross findings, histopathology and PCR. *Journal of Camel Practice and Research*, 21(1), 83–88.
- Housawi, F. M. T., Zaghawa, A. A., & Al-Naeem, A. (2015). Seroprevalence of paratuberculosis among camels in Al-Ahsa and Riyadh regions, Kingdom of Saudi Arabia. *Pakistan Veterinary Journal*, 35(3), 375–378.
- Hussain, M. H., Saqib, M., Al-Maawali, M. G., Al-Makhladi, S., Al-Zadjali, M. S., Al-Sidairi, T., Asubaihi, S., Al-Rawahi, A., & Mansoor, M. K. (2015). Seroprevalence of *Mycobacterium avium* subspecies paratuberculosis (MAP) and evaluation of risk factors in camels of the Sultanate of Oman. *Tropical Animal Health and Production*, 47(2), 383–389.
- Khol, J. L., Kralik, P., Slana, I., Beran, V., Aurich, C., Baumgartner, W., & Pavlik, I. (2010). Consecutive excretion of *Mycobacterium avium* subspecies paratuberculosis in semen of a breeding bull compared to the distribution in feces, tissue and blood by IS900 and F57 quantitative real-time PCR and culture examinations. *The Journal of Veterinary Medical Science*, 72(10), 1283–1288.
- Maroudam, V., Mohana Subramanian, B., Praveen Kumar, P., & Dhinakar Raj, G. (2015). Paratuberculosis: Diagnostic methods and their constraints. *Journal of Veterinary Science and Technology*, 6(5), 259. <https://doi.org/10.4172/2157-7579.1000259>

- Radwan, A. I., El-Magawry, S., Hawari, S. J., Al-Bekairi, S. J., Aziz, S., & Rebleza, R. M. (1991). Paratuberculosis enteritis (Johne's disease) in camels in Saudi Arabia. *Biological Sciences*, 1, 57–66.
- Salem, M., El-Deeb, W. M., Zaghawa, A. A., Housawi, F. M., & Alluwaimi, A. M. (2019). Investigation of mycobacterium paratuberculosis in Arabian dromedary camels (*Camelus dromedarius*). *Veterinary World*, 12(2), 218–223.
- Salem, M., El-Sayed, A., Fayed, A., & Abo El-Hassan, D. G. (2012). Subclinical infection of paratuberculosis among camels in Egypt. *The Journal of American Science*, 8(12), 1141–1147.
- Tharwat, M., Al-Sobayil, F., Ali, A., Hashad, M., & Buczinski, S. (2012). Clinical, ultrasonographic and pathological findings in 70 camels (*Camelus dromedarius*) with Johne's disease. *The Canadian Veterinary Journal*, 53(5), 543–548.
- Tharwat, M., Al-Sobayil, F., & El-Magawry, S. (2013). Clinicobiochemical and postmortem investigations in 60 camels (*Camelus dromedarius*) with Johne's disease. *Journal of Camel Practice and Research*, 20(2), 145–149.
- Wernery, U., Abraham, A., Joseph, S., Thomas, R., Syriac, G., Raghavan, R., & Baker, T. (2011). Evaluation of 5 indirect Elisa for the detection of antibodies to paratuberculosis in dromedaries. *Journal of Camel Practice and Research*, 18, 47–52.
- Wernery, U., & Kaaden, O. R. (2002). *Infectious diseases in camelids* (2nd ed., pp. 83–87). Wiley-Blackwell.
- Zaghawa, A., Housawi, F., Al-Naeem, A., & Hammoda, M. (2012, February 5–10). Clinical investigations on Paratuberculosis in camels in Al-Hasa, KSA. In *11th International Colloquium on Paratuberculosis, International Association for Paratuberculosis*. The University of Sydney.

## Pasteurellosis (Hemorrhagic Septicemia)

# 28

Mansour F. Hussein

Pasteurellosis is a widespread disease caused by infection with bacteria of the genus *Pasteurella*. The most commonly reported species in that genus, *Pasteurella multocida*, occur both as a commensal and as a pathogen, in a wide range of animals, including birds.

Pneumonic pasteurellosis in camels is associated with certain serotypes of *P. multocida* and *P. (mannheimia) haemolytica*. As in other animals, these organisms often occur as commensals of the upper respiratory tract of camels (Abubakar et al., 2008). They become pathogenic following exposure to various factors that lower the animal's resistance, such as severe stress, extreme exhaustion, e.g. transportation over long distances, malnutrition, parasitism, and inclement weather particularly heavy rainfall and high temperature. The addition of new animals to the herd may also contribute to the spread of the disease. Affected camels rarely recover, and death usually occurs within only a few days after the appearance of symptoms.

*P. multocida* is the principal cause of HS or HS-like disease in camels. The disease appears to be less frequently reported in these animals as compared to hemorrhagic septicemia in bovines. However, Abbas and Omer (2005) reported *P. multocida* as the most commonly isolated pathogen from pneumonic camels. It is a highly fatal disease that may spread among dromedaries via direct contact, fomites, or ingestion of contaminated food and water (Chauhan et al., 1986) and has been reported in dromedaries in several countries including Egypt (Awad et al., 1976a, 1976b; Fayed, 1973), Sudan (Hassan & Mustafa, 1985), Ethiopia (Bekele, 1999; Richard, 1979), Kenya (Gluecks et al., 2017), Somalia (Wernery & Kaaden, 2002), Chad (Maurice et al., 1967; Perreau & Maurice, 1968), Tunisia (Burgemeister et al., 1975), Mauritania (Kane, 1987), Algeria (Wernery & Kaaden, 2002), Iraq (unpublished report), Jordan (Al-Rawashdeh et al., 2000), Iran (Tahamtan et al., 2016), Pakistan (Khan, 2011), and India (Chauhan et al., 1986; Momin et al., 1987; Ramachandran et al., 1968).



## 28.1 Etiology

Members of the genus *Pasteurella* are [gram-negative](#), [facultatively anaerobic](#), non-motile, non-spore forming coccobacilli which exhibit bipolar staining with some stains. They have worldwide distribution and are often found as commensals and sometimes symbionts in the nasopharynx and intestines of numerous animal species. Most of them are catalase and oxidase positive and can be grown in blood or serum-enriched media.

Several diseases are associated with *Pasteurella* infection in farm animals. In cattle and water buffaloes, these diseases include “hemorrhagic septicemia (HS),” caused by *Pasteurella multocida* (serotypes B1 and E) and “shipping fever” caused by *P. multocida* (serotype A2) and *P. (mannheimia) haemolytica* (serotypes A1 and A2). In sheep and goats, pasteurellosis is associated with “enzootic pneumonia,” caused by *P. (mannheimia) haemolytica* (serotype A2), while in chickens and waterfowl *P. multocida* causes “fowl cholera.”

---

## 28.2 Clinical Picture

Peracute and acute forms of pasteurellosis, resembling HS in cattle, have been reported during *P. multocida* infection in dromedary camels. According to various authors, the clinical signs of HS in these animals include fever, mucopurulent nasal discharge, lacrimation, labored breathing, tachycardia, mucosal congestion, pneumonia, swellings of the throat, neck, and associated lymph nodes, and sometimes the hindquarters (Hassan & Mustafa, [1985](#); Momin et al., [1987](#); Schwartz & Dioli, [1992](#)). An abdominal form of the disease characterized by hemorrhagic enteritis has also been reported in dromedaries (Higgins, [1986](#)). Besides, abortion or stillbirth may occur in pregnant females infected during late gestation (Richard, [1979](#); Khan, [2011](#)). According to Wernery and Kaaden ([2002](#)), septicemic manifestations of HS in camels and other animals are related to exotoxin production and the disease may sometimes be confused with anthrax. Hassan and Mustafa ([1985](#)) isolated *P. multocida* (serotype B) during an outbreak of HS in Sudanese camels.

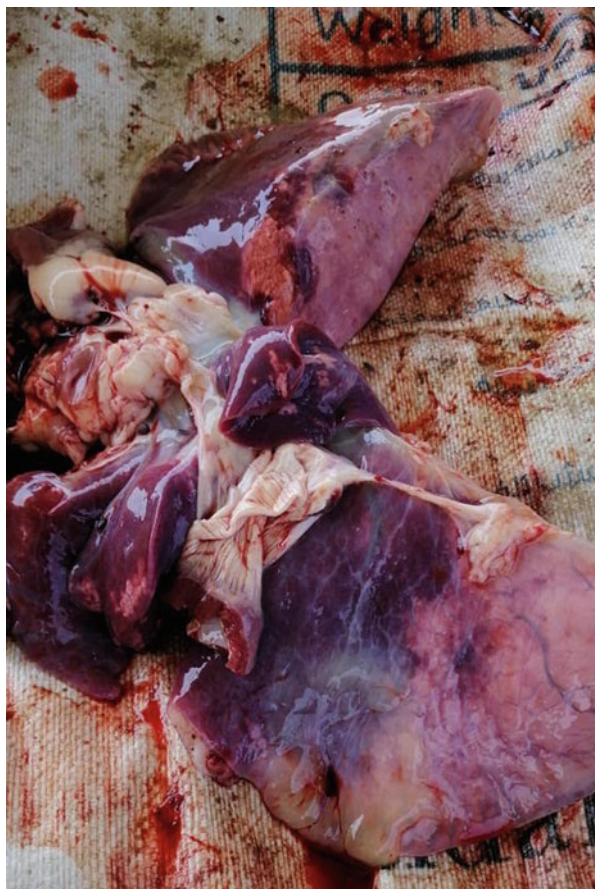---

## 28.3 Pathogenesis and Pathology

The pathological lesions in acute cases (Fig. [28.1](#)) include widespread petechial hemorrhages in serosal surfaces throughout the body, congestion of visceral organs, swelling of the head, neck, chest, and musculature, accumulation of gelatinous fluid in the throat, blood-tinged effusions in the thoracic and abdominal cavities, and pneumonia or bronchopneumonia. The pharyngeal and cervical nodes are often swollen and hemorrhagic. In addition, fibrinous pericarditis and hemorrhagic and necrotic changes may occur in the liver, kidneys, and spleen (Abd El Tawab et al., [2016](#); Khan, [2011](#)).



**Fig. 28.1** Gross pathological lesions in the lungs of a camel that died as a result of peracute pasteurellosis (Photo by Prof. Mansour F. Hussain)

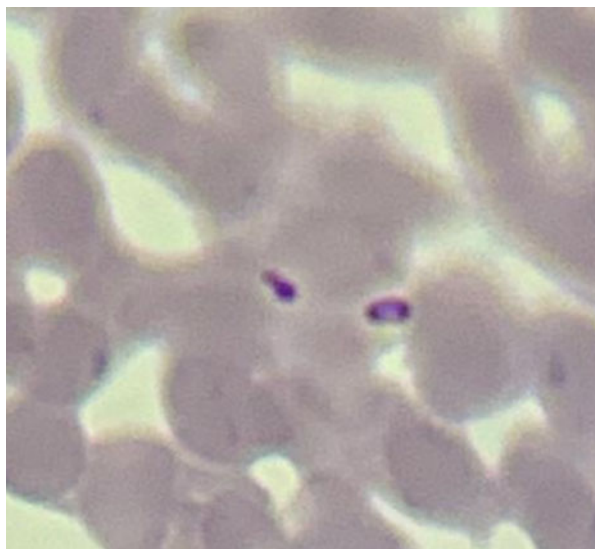


## 28.4 Diagnosis

Pasteurellosis may be suspected based on history, clinical, and pathological findings, and epidemiological considerations. The presence of bipolar-staining coccobacilli in blood smears stained with gram, methylene blue, or Leishman's stain from the affected camels (Fig. 28.2) may also be helpful. However, none of these measures is sufficient for making a conclusive diagnosis, which requires isolation and identification of the causative agent.

*P. multocida* can be isolated from blood, bone marrow, or other tissues and organs of dead animals by cultural and biological methods. The culture media often used are conventional blood agar or casein/sucrose/yeast agar containing 5% blood. Identification of the organism is done using various biochemical, serological, and molecular methods.

**Fig. 28.2** Bipolar organisms in stained blood smear of camel affected with pasteurellosis (Photo by Prof. Mansour F. Hussain)



Serotyping methods include rapid slide agglutination test, indirect hemagglutination test, somatic antigen agglutination tests, agar gel immunodiffusion, counter immunoelectrophoresis, and enzyme-linked immunosorbent assays (ELISA) (Spickler, 2019).

The PCR technology provides a rapid, sensitive, and specific method for the detection of *P. multocida* and *Mannheimia haemolytica*, and if necessary further differentiation may be achieved by PCR fingerprinting (Gluecks et al., 2017).

---

## 28.5 Treatment and Control

Acute pasteurellosis can be treated with various antimicrobial agents such as tetracycline, gentamycin, penicillin, ciprofloxacin, sulfonamides, and others, provided that the treatment is administered early during the course of the disease (Spickler, 2019). It is also important to determine the sensitivity of the causative organism to different antimicrobials.

Sick camels should be isolated and immediately treated, and the carcasses of dead camels should be deeply buried. Mixing of healthy camels with sick, or treated, camels should be avoided.

In some endemic areas, vaccination is used to control HS in camels (Hassan & Mustafa, 1985; Kattan et al., 2016; Momin et al., 1987; Wernery & Kaaden, 2002). For this purpose, vaccines composed of dense bacterin combined with either alum adjuvant or oil adjuvant, and a formalin-inactivated bacterin are used. A vaccine against *M. haemolytica* also has been used to control pneumonic pasteurellosis in camels.

## References

- Abbas, B., & Omer, O. H. (2005). Review of infectious diseases of the camel. *Veterinary Bulletin*, 75(8), 1N–16N.
- Abd El Tawab, A. A., El Hofy, F. I., Al-Jeddawy, A., & Abo Hamda, E. (2016). *Pasteurella multocida* in camels: Incidence, capsular and virulence genes characterization. *Benha Veterinary Medical Journal*, 31(2), 171–175.
- Abubakar, M. S., Fatihu, M. Y., Ibrahim, N. D., Oladele, S. B., & Abubakar, M. B. (2008). Camel pneumonia in Nigeria: Epidemiology and bacterial flora in normal and diseased lung. *African Journal of Microbiology Research*, 4, 2479–2483.
- Al-Rawashdeh, O. F., Al-Ani, F. K., Sharif, L. A., AlQudah, K. M., Al-Hami, Y., & Frank, N. (2000). A survey of camel (*Camelus dromedarius*) diseases in Jordan. *Journal of Zoo and Wildlife Medicine*, 31(3), 335–338.
- Awad, F. I., Salem, A. A., & Fayed, A. A. (1976a). Studies of clinical signs observed on experimentally infected animals with *Pasteurella multocida* type 1. *Egyptian Journal of Veterinary Science*, 13(1), 53–56.
- Awad, F. I., Salem, A. A., & Fayed, A. A. (1976b). Studies on the viability of *Pasteurella multocida* type 1 under simulated environmental conditions in Egypt. *Egypt Journal of Veterinary Science*, 13(1), 57–69.
- Bekele, T. (1999). Studies on the respiratory disease “Sonbole” in camels in eastern lowlands of Ethiopia. *Tropical Animal Health and Production*, 31, 333–345.
- Burgemeister, R., Leyk, W., & Goessler, R. (1975). Untersuchungen iiber Vorkommen von Parasitosen, bakteriellen und viralen Infektions- krankheiten bei Dromedaren in Siidtonesien. *Deutsche Tierärztliche Wochenschrift*, 82, 352–354.
- Chauhan, R. S., Kaushik, R. K., Gupta, S. C., Satiya, K. C., & Kulshreshta, R. C. (1986). Prevalence of different diseases in camels (*Camelus dromedarius*) in India. *Camel Newsletter*, 3, 10–14.
- Fayed, A. A. (1973). *Studies on pasteurellosis in buffaloes in Egypt* [Thesis Vet. Med.]. Faculty of Veterinary Medicine, Cairo University.
- Gluecks, I. V., Bethe, A., Younan, M., & Ewers, C. (2017). Molecular study on *Pasteurella multocida* and *Mannheimia granulomatis* from Kenyan camels (*Camelus dromedarius*). *BMC Veterinary Research*, 13(1), 265.
- Hassan, A. K. M., & Mustafa, A. A. (1985). Isolation of *Pasteurella multocida* type B from an outbreak of haemorrhagic septicemia in camels in Sudan. *Revue d'élevage et de médecine vétérinaire des pays tropicaux*, 38, 31–33.
- Higgins, A. J. (1986). *The camel in health and disease*. Baillire Tindall. ISBN 0-7020-1167-3.
- Kane, M. (1987). La pasteurellose chez dromadaires maliens et mauritaniens. *Bulletin liaison ILCA/ GRPRC*, 9, 21–22.
- Kattan, A., Mahmoud, M., Bakr, H., & Wassif, I. (2016). Immunological and biochemical studies on polyvalent *Pasteurella* vaccine in camels. *Alexandria Journal of Veterinary Sciences*, 61(1), 100–107.
- Khan, M. F. (2011). Field epidemiology of an outbreak of hemorrhagic septicemia in dromedary population of Greater Cholisthan Desert (Pakistan). *Pakistan Veterinary Journal*, 32(1), 31–34.
- Maurice, Y., Bares, J. F., & Baille, M. (1967). Serologic investigation of rickettsiosis in dromedaries in Chad. [Enquete serologique sur le rickettsioses chez le dromedaire du Chad]. *Revue d'Eleavage et de Medicine Veterinaire Pays Tropicaux*, 20(4), 537–542.
- Momin, R. R., Pethkar, D. K., Jiaswal, T. N., & Jhala, V. M. (1987). Haemorrhagic septicaemia: A general review. *The Veterinary Journal*, 64, 896–897.
- Perreau, P., & Maurice. (1968). Épizootologie de la pasteurellose des chameaux au Tchad. Enquête sérologique. *Revue d'Élevage et de Médecine Vétérinaire des Pays Tropicaux*, 21(4), 451–454.
- Ramachandran, P. K., Ramachandran, S., & Joshi, T. B. (1968). An outbreak of hemorrhagic gastroenteritis in camels (*Camelus dromedarius*). *Annales de Parasitologie Humaine et Comparée*, 43(1), 5–14.

- Richard, D. (1979). Study of the pathology of the dromedary in Borana Awraja (IEMUT Maison Alfort, France, Ethiopia). *Agricultural and Research Development*, 25(65-66), 213–214.
- Schwartz, H. J., & Dioli, M. (Eds.). (1992). *The one-humped camel in Eastern Africa. A pictorial guide to diseases, health care and management*. Verl Josef Margraf.
- Spickler, A. R. (2019). *Hemorrhagic septicemia*. <http://www.csfph.iastate.edu/DiseaseInfo/factsheets.php>.
- Tahamtan, O., Amrabad, O., & Shahrayar, R. (2016). Identification of *Pasteurella multocida* and molecular diagnosis of haemorrhagic septicaemia in Iranian camels. *Revue de Médecine Vétérinaire*, 167(5–6), 126–132.
- Wernery, U., & Kaaden, O. R. (2002). *Infectious diseases of camelids*. Blackwell Wissenschafts-Verlag.

Mansour F. Hussein

*Rickettsiae* constitute an important group of intracellular, non-motile, aerobic, gram-negative, pleomorphic bacteria, often appearing as short rods or coccobacilli and are transmitted via insect vectors. Unlike classical bacteria, however, *Rickettsiae* multiply only in living cells and may be cultured in embryonated chicken eggs or tissue cultures. Several Rickettsial genera have been detected in camels or camel ticks. These include:

1. *Ehrlichia ruminantium* (formerly *Cowdria ruminantium*) which causes heartwater in ruminants and wild ungulates and is transmitted by ticks.
2. *Rickettsia prowazekii*: which causes epidemic typhus in man and is transmitted by lice.
3. *R. mooseri*: which causes murine typhus and may be transmitted to other animals and man by fleas.
4. *Anaplasma spp*: which causes gall-bladder disease in animals and is transmitted by ticks.
5. *R. rickettsii*: which causes rocky mountain spotted fever in man and is transmitted by ticks.
6. *R. conorii*: which causes Mediterranean fever in man and is transmitted by ticks.
7. In addition, different *Neorickettsia spp* were reported in camels. Some of these cause salmon poisoning in humans.

Very little is currently known about the clinical significance of rickettsiosis in dromedary camels; however, two of these diseases, namely heartwater and anaplasmosis, deserve special attention.

## 29.1 Heartwater

Heartwater is an infectious but non-contagious disease primarily affecting sheep, goats, cattle, and a wide range of wild ungulates which serve as natural reservoirs. The causative agent, *Ehrlichia* (*Cowdria*) *ruminantium*, is transmitted by

*Amblyomma* ticks of which 12 species are known and the distribution of the disease closely follows that of its tick vectors. *E. ruminantium* does not survive outside its host except for a few hours. It multiplies within vascular endothelial cells and reticulo-endothelial cells of lymph nodes of its animal host, and may cause acute, subacute, chronic, or silent infection.

Heartwater has been known to occur in camels in some parts of the Sudan since the 1970s (reviewed by Abdel Rahman et al., 2003). In December 2013, the World Organization for Animal Health (OIE) reported a significant outbreak of Heartwater in camel herds in south Central Chad where the disease was transmitted by *Amblyomma* ticks (Anon, 2014). In the following year, the OIE reported major outbreaks of heartwater among camels in Kenya in which 31,000 out of 66,000 camels were clinically affected (Anon, 2016). Of these, 257 (0.83%) camels died. The causative agent, *Ehrlichia ruminantium*, was demonstrated in blood smears from affected camels and in *Amblyomma* ticks collected from them. Laboratory confirmation was established using PCR.

### 29.1.1 Clinical Picture

Information on the pathogenesis of heartwater in camels is also very sparse. However, some unpublished reports indicate that the clinical and pathological signs of the disease in these animals resemble those occurring in sheep and goats, namely an incubation period of 2–3 weeks, high fever, excessive salivation, respiratory and digestive disturbances, and nervous manifestations, followed by death. Post-mortem findings include hydropericardium, hydrothorax, enlargement of lymph nodes, splenomegaly, petechial hemorrhages in serous membranes, and congestion of intestines and brain.

### 29.1.2 Diagnosis

In areas where the disease occurs, preliminary diagnosis can be done based on clinical and pathological findings and examination of smears from the endothelium of large blood vessels. The diagnosis can be confirmed by laboratory tests including microscopy, ELISA, FAT, and PCR.

### 29.1.3 Treatment and Control

In addition to the treatment of infected animals with broad-spectrum antibiotics such as oxytetracycline and amoxycillin, vector control measures such as dipping and spraying should be regularly applied along with screening and surveillance of the disease in enzootic areas.

**Note:** Younan et al. (2021) described outbreaks of a heartwater-like disease that killed about 2000 adult dromedary camels in Kenya in 2016. The affected camels

showed excitability, head pressing, rapid breathing, aimless wandering, recumbency, and death within 4 days of the appearance of symptoms. In one herd, the morbidity rate reached 40% while the average mortality rate was around 7.5% in camels receiving antibiotic treatment and up to 100% in untreated camels. Necropsy findings included pulmonary edema, hydrothorax, hydropericardium, pleurisy, ascites, enlargement, and bar-boiled appearance of the liver, nephrosis and hemorrhages in the abomasum and intestines. Using PCR techniques, the authors amplified a sequence close to *Ehrlichia regneryi* and *E. canis* from some sick camels. They also amplified a sequence close to *E. ruminantium* from Amblyomma ticks from sick and healthy camels.

---

## 29.2 Anaplasmosis

Anaplasmosis, also known as gall-bladder disease, is caused by different species of the genus *Anaplasma* including *A. phagocytophilum*, *A. marginale*, *A. centrale*, *A. ovis*, and *A. platys*. These organisms are obligate intraerythrocytic pathogens that infect and destroy the red blood cells of their host causing anemia and jaundice. They are transmitted by ticks and other biting flies and have been reported in many countries in Africa, Asia, and wherever its vectors are found.

*A. marginale* was reported in three (10.7%) out of 28 dromedary camels in Nigeria (Ajayi et al., 1984). More recently, a much higher prevalence of *A. platys* was recorded among Nigerian camels, namely 22 (61%) out of 36 dromedaries, and it was suggested that camels may have a possible role as reservoirs of *A. platys* (Lorusso et al., 2016).

### 29.2.1 Clinical Picture and Diagnosis

Al Saad (2009) described clinical, hematological, and biochemical manifestations of anaplasmosis in dromedary camels in Ninawa province in Iraq. Fifty-two camels naturally infected with *A. marginale* and ten clinically normal control camels were investigated. In addition to tick infestation, the infected animals exhibited pallor of mucosae, diarrhea and/or constipation, emaciation, roughened coat, lacrimation, and cough. They also had fever, tachycardia or tachypnea, and reduced ruminal contractions. Hematological analysis revealed decreased RBC count, Hb, and packed cell volume (PCV), and increased mean corpuscular volume (MCV), erythrocyte sedimentation rate (ESR), and total white blood cell (WBC) count. On the other hand, biochemical analysis showed elevated levels of alanine aminotransferase (ALT), Aspartate aminotransferase (AST), total bilirubin (TB), blood urea nitrogen (BUN), and icteric index in the affected camels.

Similar findings were reported by Ismael and Swelum, (2016) in camels in Saudi Arabia. These authors recorded *A. marginale* in Giemsa-stained blood smears of 72 out of 96 dromedary camels in Riyadh and Makkah regions of the Kingdom. The animals, aged 3–15 year, showed tick infestation and clinical signs suggestive of

anaplasmosis, viz fever, anorexia, diarrhea, pallor of mucosae, lacrimation, abortion, or infertility. They also showed reduced RBC, Hb, HCT, and MCV values, suggestive of hemolytic anemia, while exhibiting increased total WBC count, lymphocyte percentage, mean corpuscular hemoglobin concentration (MCHC) and platelet count, and elevated levels of gamma glutamyl transferase (GGT), AST, ALT, Bilirubin, BUN, and lactate dehydrogenase (LDH) levels. In most cases, these manifestations were relatively mild. In some camels, however, the clinical picture was apparently complicated by the presence of mixed infections with *Theileria*, *Babesia*, and/or gastrointestinal nematodes. Control measures included tick control, treatment of the infected and in-contact camels with long-acting oxytetracycline and anthelmintic treatment of gastrointestinal parasites.

Using competitive ELISA, Al-Gharban and Al-Tae (2016) tested 120 male and female dromedary camels in Al-Najaf and Wasit provinces in Iraq for *A. marginale*. They recorded an overall seroprevalence of 20.83% in camels of both sexes, with a prevalence of 6.67% in those <5 year old and 15% in >5 year old camels.

The first record of camel anaplasmosis in India was that of Sudan et al. (2014) who detected *A. marginale* infection in Giemsa-stained blood smears of a 7-year-old dromedary camel presenting with dullness, progressive loss of condition, depressed hematological indices, constipation, pale yellowish discoloration of conjunctivae, and tick infestation (*Boophilus microplus*). The animal responded to oxytetracycline and supportive treatment and when re-examined 3 weeks later, its hematological indices had returned to normal and erythrocytes were free from infection.

In Tunisia, Belkahia et al. (2015) investigated 226 dromedaries from three different bioclimatic regions for anaplasmosis using quantitative PCR (qPCR) and nested PCR (nPCR) assays. They reported an overall infection rate of 17.7% with *Anaplasma* spp., the prevalence being significantly higher in female than male camels. Molecular studies suggested that dromedary camels in Tunisia were infected with novel *Anaplasma* strains genetically related to *A. platys*.

El Naga and Barghash (2016) recorded *A. marginale* and mixed *A. marginale* and *A. centrale* infection in 51 and 172 dromedaries of either sex, respectively, in three locations in the North Western Coast of Egypt, using Giemsa-stained blood smears and PCR. Statistical analysis showed considerable variation in prevalence with location and age. Other blood pathogens detected in these camels included theileriosis, babesiosis, and Trypanosomiasis.

Lbasha et al. (2017) screened blood samples of 106 randomly selected dromedary camels from six different localities in southern Morocco for infection with Anaplasmataceae strains. Using PCR, a total of 42 (39.62%) samples were found to be positive for species of the family Anaplasmataceae. Nucleotide sequencing indicated that these strains were 100 percent identical to *Candidatus A. camelii*, while genetic characterization revealed their high similarity to *A. platys*, an agent of canine anaplasmosis for which camels might be important reservoir hosts.

Sharifiyazdi et al. (2017) investigated the presence and molecular characteristics of *Anaplasma* infection in dromedary camels in southern Iran. Out of 100 camels investigated, six (6%) were also infected by *Candidatus A. camelii* which exhibited close relationship to *A. platys*. The authors further suggested that the camel tick,



*Hyalomma dromedarii*, might be a potential vector of camel anaplasmosis in the studied region. Subsequently, Bahrami et al. (2018) studied the prevalence of *A. phagocytophilum* in Iranian camels. Using PCR techniques, they detected this organism, which infects a wide range of wild and domestic animals, as a subclinical infection in 71 (34.2%) out of 207 male and female dromedary camels from different regions of Iran. There was a significant effect of age and location, but no significant sex effect, on prevalence. A study of anaplasmosis in Iranian dromedary camels using microscopic and molecular methods was also undertaken by Noaman (2018). In that study, examination of Giemsa-stained blood films of 100 healthy dromedaries showed *Anaplasma*-like structures in the erythrocytes of two animals. The identity of these structures as *Anaplasma* spp. was confirmed by PCR, while nucleotide sequencing and phylogenetic analysis suggested that they might be novel genetic variants associated to *A. ovis*. Further studies remain to be undertaken to elucidate the vector(s), as well as the veterinary and medical significance, of these apparently novel variants in Iranian dromedaries.

According to Abdalla et al. (2017), camel piroplasmosis and anaplasmosis are highly prevalent among camels in Somalia. Based on microscopic examination of stained blood smears of 182 semi-intensive dairy and nomadic camels, the prevalence rate of anaplasmosis in these animals was estimated to be around 13.2%.

In Pakistan, Azmat et al. (2018), using PCR, reported an overall prevalence of 13.33% of anaplasmosis among camels in which the disease was transmitted by ixodid ticks. Molecular sequencing of the causative organism isolated from these animals revealed a high degree of homology with *Anaplasma* isolates from Iran, China, Philippines, and South Africa. The affected camels exhibited neutropenia, lymphocytopenia, and thrombocytopenia.

## 29.2.2 Treatment

Treatment of anaplasmosis and other rickettsial diseases in camels is based on the administration, early during the course of the infection, of broad-spectrum antibiotics such as tetracycline, amoxicillin, deoxycycline, or Rifamycin, while supportive treatment is determined according to symptoms. In addition, the control of these diseases implies controlling animal movement, disease surveillance, spraying of ticks and biting flies, and incineration or deep burial of dead animals.

---

## References

- Abdalla, M. I., Ahmed, A. H. K., & Hamisi, S. N. (2017). Microscopic and molecular detection of camel anaplasmosis and piroplasmosis in Banadir region, Somalia. *Open Access Journal of Veterinary Science and Research*, 2(1), 000127.
- Abdel Rahman, M. B., El Hussein, A. M., Abdel Rahim, A. I., Hamid, H. E., El Gadal, A. A., & Majid, A. A. (2003). Heartwater in the Sudan: Current status. *Sudan Journal of Veterinary Science and Animal Husbandry*, 42(1 and 2), 161–169.

- Ajayi, S. A., Onyali, I. O., Oluigbo, F. O., & Ajayi, S. T. (1984). Serological evidence of exposure to *Anaplasma marginale* in Nigerian one-humped camels. *The Veterinary Record*, 114(19), 478.
- Al-Gharban, H. A. J., & Al-Tae, H. H. R. (2016). Diagnosis of *Anaplasma marginale* bacteria in carrier Arabian one-humped camels. *Basrah Journal of Veterinary Research*, 15(2), 346–359.
- Al Saad, K. M. (2009). Clinical, haematological and biochemical studies of Anaplasmosis in Arabian one-humped camels (*Camelus dromedarius*). *Journal of Animal and Veterinary Advances*, 8(9), 1794–1797.
- Anon. (2014). Heartwater (Cowdriosis). *Emergency Animal Disease Alerts*, 8(2).
- Anon. (2016). *OIE Unpublished report; heartwater*, Kenya.
- Azmat, M., Ijaz, M., Farooqi, S. H., Ghaffar, A., Ali, A., Masud, A., Saleem, S., Rehman, A., Ali, M. M., Mehmood, K., Khan, A., & Zang, H. (2018). Molecular epidemiology associated risk factors, and phylogenetic analysis of anaplasmosis in camel. *Microbiology and Pathology*, 123, 377–384.
- Bahrami, S., Hamidinejat, H., & Tafreshi, A. R. G. (2018). First molecular detection of *Anaplasma phagocytophilum* in dromedaries (*Camelus dromedarius*). *Zoo and Wildlife Medicine*, 49(4), 844–848.
- Belkahia, H., Ben Said, M., Sayahi, I., Alberti, A., & Messadi, L. (2015). Detection of novel strains genetically related to *Anaplasma platys* in Tunisian one-humped camels (*Camelus dromedarius*). *Journal of Infection in Developing Countries*, 9(10), 1117–1125.
- El Naga, T. R. A., & Barghash, S. (2016). Blood parasites in camels (*Camelus dromedarius*) in northern west coast of Egypt. *Journal of Bacteriology and Parasitology*, 7(1), 1–7.
- Ismael, A., & Swelum, A. (2016). First evidence of natural anaplasmosis in *Camelus dromedarius* in Saudi Arabia. *Journal of Camel Practice and Research*, 23(1), 95–101.
- Lbasha, H. A., Zouagui, Z., Alali, S., Rhalem, A., Petit, E., Ducrotoy, M. J., Boulouis, H. J., & Maillard, R. (2017). *Candidatus Anaplasma camelii* in one-humped camels (*Camelus dromedarius*) in Morocco, a novel and emerging *Anaplasma* species. *Infectious Diseases of Poverty*, 6(1), 1–8.
- Lorusso, V., Wijnvld, M., Latrofa, M. S., Fajinmi, A., Majekodunmi, A. O., Dogo, A. G., Igweh, A. C., Orlanto, D., Jongejan, F., Welburn, S. C., & Picozzi, K. (2016). Canine and ovine tick-borne pathogens in camels, Nigeria. *Veterinary Parasitology*, 226, 90–93.
- Noaman, V. (2018). Molecular detection of novel genetic variants associated to *Anaplasma ovis* among dromedary camels in Iran. *Archives of the Razi Institute*, 73(1), 11–18.
- Sharifiyazdi, H., Jafari, S., Ghane, M., Nazifi, S., & Sanati, A. (2017). Molecular investigation of *Anaplasma* and *Ehrlichia* natural infections in the dromedary camel (*Camelus dromedarius*) in Iran. *Comparative Clinical Pathology*, 26, 99–103.
- Sudan, V., Sharma, R. L., & Borah, M. K. (2014). Subclinical anaplasmosis in camel (*Camelus dromedarius*) and its successful therapeutic management. *Journal of Parasitic Diseases*, 38(2), 165–168.
- Younan, M., Ouso, D. O., Bodha, B., Keitany, E. K., Wesonga, H. O., Sitawa, R., Kimutal, J., Kuria, W., Sake, W. S., Svitek, N., Landmann, T., & Villinger, J. (2021). *Ehrlichia* spp. close to *Ehrlichia ruminantium*, *Ehrlichia canis*, and *Candidatus Ehrlichia regneryi* linked to heartwater-like disease in Kenyan camels (*Camelus dromedarius*). *Tropical Animal Health and Production*, 53, 147.

Mansour F. Hussein

Salmonellosis is the most important foodborne disease of man and animals. It occurs worldwide due to ingestion of feed or water contaminated with *Salmonella*, and also as a result of direct contact with the excreta of carriers. The spread of infection is mainly via the fecal-oral route.

A wide range of *Salmonella* serovars has been isolated from apparently healthy dromedary camels or their products as well as from diseased camels. Outbreaks of salmonellosis in these animals have been reported in different countries including Egypt (Osman, 1995; Refai et al., 1992; Selim, 1990; Zaki, 1967), Sudan (Mohamed et al., 1998; Salih et al., 1998), Somalia (Cheyne et al., 1977), Ethiopia (Molla et al., 2004; Pegram & Tareke, 1981), Kenya (Bornstein & Younan, 2013), Nigeria (Raufu et al., 2015), Niger (Faye, 1997), Palestine (Olitzki & Ellenbogen, 1943), Saudi Arabia (Al-Ruwaili et al., 2012), UAE (Moore et al., 2002; Wernery, 1992), Iran (Mohammady & Najafi Mosleh, 2017), Morocco (Bengoumi et al., 1998; Berrada et al., 2000), Moroccan Sahara (Berrada et al., 1998), and India (Ambwani & Jaktar, 1973; Malik et al., 1967).

Microbes of the genus *Salmonella* are also widespread in camel rearing areas where overcrowding, malnutrition, transportation over long distances, weather extremes, contamination of feed and water, filthy surroundings, and incidence of concomitant diseases play an important role in the spread of infection.

---

## 30.1 Etiology

More than 2600 serovars of the genus *Salmonella* are known. They are facultative, gram-negative, non-spore forming, anaerobic bacilli that survive in the environment as a result of fecal shedding. With extremely few exception, all of them are motile. The commonest *Salmonella* serotype is *S. typhimurium* which inhabits the gastrointestinal tract of a very wide range of domestic and wild animals, including birds, reptiles, and amphibians.

## 30.2 Clinical Picture

Salmonellosis in camels and other farm animals is characterized by acute or chronic gastroenteritis and/or septicemia and sometimes abortion. In acute cases, infected animals stop eating and develop a watery greenish or tarry diarrhea, with dehydration, dullness, congestion of mucous membranes, fever, and even shock, especially in young camels. Other manifestations include sunken eye appearance, decreased turgidity of the skin, and excessive passage of mucus in the feces. Untreated animals eventually lie down and die, usually within a week after the onset of symptoms. Pregnant female camels may abort at any stage during pregnancy. On the other hand, chronic infection is characterized by persistent diarrhea, emaciation, pyrexia, and poor response to treatment. The disease progresses slowly in untreated animals with the diarrhea lasting for 1 month or more before death (Wernery & Kaaden, 2002). An unusual case of articular infection caused by non-typhoidal *Salmonella* has been described by Tejedor-Junco et al. (2009) in a dromedary camel.

Salmonellosis is particularly important in suckling camels in which it causes acute gastroenteritis and diarrhea. This occurs sometimes in the form of disease outbreaks with high mortality in newborn camels that did not take sufficient amount of colostrum (Faye, 1997).

---

## 30.3 Pathogenesis and Pathology

Different virulence factors are associated with *Salmonella* infection in camels. The ingested bacteria penetrate the intestinal lamina propria producing toxins leading to enteritis and gut damage. Acute hemorrhagic enteritis may occur in calf camels while chronic enteritis is mainly seen in adult camels. In acute cases, the infection may extend to the blood stream and the affected animal develops acute, hemorrhagic enteritis, swelling of mesenteric lymph nodes, enlargement of Peyer's patches, liver, and spleen, and congestion of serous membranes.

---

## 30.4 Diagnosis

Diagnosis is based on the isolation and identification of the causative *Salmonella* serovar from fecal samples and mesenteric lymph nodes, intestines and other affected organs. Selective media such as tetra-thionate broth may be used and the isolated *Salmonella* colonies can be serotyped on the basis of their somatic (O), flagellar (H), and cell-wall (O) antigens. Serotyping may be used during outbreaks. Analyses of the feed and drinking water is also recommended.

## 30.5 Treatment

Early cases of salmonellosis may be treated with broad spectrum antibiotics such as tetracyclines, ampicillin, chloramphenicol, or gentamycin for septicemic conditions, and sulfonamides and nitrofurantoin compounds for cases of enteritis. In addition, the animals should be injected with electrolyte solutions to compensate for the loss of salts and electrolytes. They may also be given astringents, vitamins, and mineral supplement as supportive treatment. In advanced cases that do not respond to treatment, the affected animals should be slaughtered and incinerated or deeply buried.

Isolation of sick camels and implementation of good management practices and sanitary measure such as cleaning and disinfection are important attributes of disease prevention.

It should also be noted that camels and their products are important sources of salmonellosis in humans and that controlling the infection in camels, even if they are healthy carriers, is important to protect human health. Carrier camels should therefore be identified, isolated, and promptly treated (Werny & Kaaden, 2002).

---

## References

- Al-Ruwaili, M. A., Khalil, O. M., & Selim, S. A. (2012). Viral and bacterial infections associated with camel (*Camelus dromedarius*) calf diarrhea in North Province, Saudi Arabia. *Saudi Journal of Biological Sciences*, 19(1), 35–41.
- Ambwani, V. R., & Jaktar, P. R. (1973). Salmonella infections in camels in Bikaner. *Indian Veterinary Journal*, 50(1), 100–102.
- Bengoumi, M., Barrada, J., Rochdi, M., Hidane, K., De Lafarge, F., & Faye, B. (1998). Physiopathology of diarrhea in the camel calf in Morocco. Clinical signs and metabolic disturbances. *Revue d'élevage et de médecine vétérinaire des pays tropicaux*, 51(4), 277–281.
- Berrada, J., Bengoumi, M., & Hidane, K. (2000). Diarrhées neonatales du chameleón dans les provinces sahariennes du Sud du Maroc: études bactériologique. *Revue d'Élevage et de Médecine Vétérinaire Pays tropicaux*, 53(2), 153–156.
- Berrada, J. M., Gengouni, R., El Mjyad, J., Touti, J., & Fikri, A. (1998, May 2–3). Salmonella infection in newborn dromedaries in Moroccan Sahara. *Proceedings of international meeting on camel production and future perspectives*. Faculty of Agriculture Science.
- Bornstein, S., & Younan, M. (2013). Significant veterinary research on the dromedary camels of Kenya: Past and present. *Journal of Camelid Science*, 2013(6), 1–48.
- Cheyne, I. A., Pegram, R. G., & Cartwright, C. F. (1977). An outbreak of salmonellosis in camels in the north-east of the Somali Democratic Republic. *Tropical Animal Health and Production*, 9, 238–240.
- Faye, B. (1997). *Guide de l'élevage du dromadaire*. Sanofi Sante Nutrition Animale, La Ballastière—BP126, 33501 (pp. 115–1).
- Malik, P. D., Datta, S. K., Singh, L. P., & Kalra, D. S. (1967). *Salmonella* serotypes from camel in India for the years 1960–1963. Résumé in *Veterinary Bulletin*, 38, abstract No. 445.
- Mohamed, M. E. H., Hart, C. A., & Kaaden, O. R. (1998, May 2–3). Agents associated with camel diarrhea in Eastern Sudan. *Proceeding of international meeting on camel production and future perspectives*. Faculty of Agricultural Sciences.
- Mohammady, G. R., & Najafi Mosleh, S. (2017). Salmonellosis outbreak in a herd of camel. *The second national congress of camel in Iran, Hormozgan* (In Persian).

- Molla, B., Mohammed, A., & Salah, W. (2004). *Salmonella* prevalence and distribution of serotypes in apparently healthy slaughtered camels (*Camelus dromedaries*) in eastern Ethiopia. *Animal Health and Production*, 36, 451–458.
- Moore, J. E., McCalmont, M., Xu, J., Nation, G., Tinson, A. H., Crothers, L., & Harron, D. W. (2002). Prevalence of fecal pathogens in calves of racing camels (*Camelus dromedarius*) in the United Arab Emirates. *Tropical Animal Health and Production*, 34(4), 283–287.
- Olitzki, L., & Ellenbogen, V. (1943). A *Salmonella* strain isolated from camels in Palestine. *Journal of Comparative Pathology and Therapeutics*, 57, 47–51.
- Osman, A. R. (1995). *Pathological study on intestinal infections in camels* [Ph.D. thesis]. Faculty of Veterinary Medicine, Cairo University.
- Pegram, R. G., & Tareke, F. (1981). Observation on the health and Afar livestock. *Ethiopian Veterinary Journal*, 5, 11–15.
- Raufu, I. A., Odetokun, I. A., Oladunni, F. S., Adam, M., Kolapo, U. T., Akorede, I. M., Ghali, I. M., Ameh, J. A., & Ambali, A. (2015). Serotypes, antimicrobial profiles and public health significance of *Salmonella* from camels slaughtered in Maiduguri central abattoir, Nigeria. *Veterinary World*, 8(9), 1068–1072.
- Refai, M. (1992). Bacterial and mycotic disease of camels in Egypt. In W. R. Allen, A. J. Higgins, I. G. Mayhew, D. H. Snow & J. F. Wade (Eds.), *Proceedings of the first international camel conference* (pp. 59–64). R&W Publications.
- Salih, O., Mohamed, O., & Shigidi, M. T. (1998, May 2–3). The epidemiological factors associated with camel calf diarrhea in Eastern Sudan. *Proceedings of international meeting on camel production and future perspectives*. Faculty of Agricultural Sciences Al Ain, UAE.
- Selim, A. M. (1990). Salmonellosis in camels in Egypt. In M. F. Wardeh, R. T. Wilson & A. A. Saied (Eds.), *Proceedings international conference on camel production and improvement* (pp. 10–13). Tobruk.
- Tejedor-Junco, M. T., Lupiola, P., Caballero, M. J., Corbera, J. A., & Gutierrez, C. (2009). Multiple abscesses caused by *Salmonella enterica* and *Corynebacterium pseudotuberculosis* in a dromedary camel. *Tropical Animal Health and Production*, 41, 711–714.
- Wernery, U. (1992). The prevalence of *Salmonella* infections in camels (*Camelus dromedarius*) in the UAE. *British Veterinary Journal*, 148, 445–450.
- Wernery U., & Kaaden O. R. (2002). *Infectious diseases in camelids*. Blackwell Science.
- Zaki, H. (1967). Salmonellosis in UAR. *Bulletin de l'Office international des Épizooties*, 68(1), 257–260.

# Tetanus (*Clostridium tetani*)

# 31

Mansour F. Hussein

Tetanus (lockjaw) is a serious bacterial infection caused by *Clostridium tetani* which produces a neurotoxin that affects the brain and nervous system. If a wound is contaminated with *Clostridium tetani* spores, the neurotoxin produced interferes with the nerves that control normal muscle movement thus resulting in marked muscle stiffness, spasms, and convulsions.

Little has been published on the clinical manifestations of tetanus in dromedary camels although individual cases of the disease have been reported in some countries including Egypt, Somalia, Ethiopia, United Arab Emirates, Pakistan, and the former USSR (Abdurahman & Bornstein, 1991; Abbas & Omer, 2005; Fassi-Fehri, 1987; Mares, 1954; McGrane & Higgins, 1985; Morcos, 1965; Rabagliati, 1920; Wernery et al., 2004).

---

## 31.1 Etiology

*Clostridium tetani* is an obligate anaerobic, gram-positive, motile, spore-forming bacillus which causes tetanus in man and animals. It is commonly found in soil and manure. Each bacterial cell can form a spore at one of its ends, giving the cell a characteristic drumstick appearance. These spores are extremely resilient and long-lived spores that resist heat and antiseptics. They occur worldwide in the soil and the intestines and manure of animals including man, especially in hot, damp areas and where the soil is rich in organic matter.

---

## 31.2 Pathogenesis

*C. tetani* spores usually enter the body through cuts and open wounds. In wounds with low oxygen content, the spores may begin to germinate and grow in the wound, releasing two distinct toxins: tetanolysin, which causes local tissue destruction, and tetanospasmin (also known as tetanus toxin), which is a very potent toxin

responsible for tetanus symptoms such as muscle rigidity, convulsions, and spasms of the skeletal muscles, especially upon excitement. This toxin spreads via the lymphatic system and bloodstream, reaching different parts of the nervous system throughout the body where it blocks the release of certain inhibitory neurotransmitters leading to widespread activation of motor neurons and muscle spasms beginning at the top of the body and moving downwards, followed by spasms of the abdominal muscles and limbs.

---

### 31.3 Clinical Picture and Pathology

Wernery et al. (2004) described an acute form of tetanus in a 5-year-old dromedary camel 20 days after its castration. The symptoms started with a stiff gate, extension of the neck, frothy salivation, refusal to feed, and swelling of the preputial sheath and groin. Three days later, the animal developed lockjaw and failure to swallow and by the 26th day after castration it failed to stand up due to hindquarters paralysis and was euthanized. Abbas and Omer (2005) also mentioned lockjaw, opisthotonos, and stiffness of the limbs in affected camels. Other clinical signs include paralysis of the throat muscles and inability to swallow food as well as paralysis and distension of the third eyelid in addition to stiffness of the neck and tail. Acute cases may lead to death of the animal whereas subacute cases may recover.

Schwartz and Dioli (1992) associated tetanus in camels with the condition known as “wry neck;” however, this remains to be proven since several alternative etiologies of wry neck in camels have been proposed.

Successful treatment of an affected camel with 60,000 IU.

---

### 31.4 Diagnosis

The diagnosis of tetanus is based on history of injury (e.g., open castration and deep wounds) followed by the appearance of clinical signs consisting of generalized rigidity, stiffness, and convulsive spasms of the skeletal muscles, and inability to swallow or “lockjaw.” These spasms start at the top of the body and spread down, often terminating fatally. Laboratory tests have little value in the diagnosis of tetanus.

---

### 31.5 Treatment and Prevention

Although *C. tetani* is susceptible to several antibiotics, the usefulness of antibiotics in the treatment of tetanus in camels is unknown. On the other hand, treatment involving the administration of tetanus antitoxin to bind and neutralize the toxin has been reported in camels by Morcos (1965). This author successfully treated a dromedary with 60,000 I.U. of anti-tetanus serum over a period of 3 days. Care of



the wound and supportive treatment using tranquilizers and muscle relaxants may also be helpful.

A tetanus toxoid consisting of formaldehyde-inactivated tetanospasmin is commercially available and is used, often in combination with other vaccines, to protect domestic animals, including new world camelids, against tetanus. No information is currently available on vaccination against tetanus in dromedary and Bactrian camels. However, Wernery et al. (2004) recommended the vaccination of these animals against tetanus prior to castration.

---

## References

- Abbas, B., & Omer, O. H. (2005). Review of infectious diseases of the camel. *The Veterinary Bulletin*, 75(8), 1N–16N.
- Abdurahman, O. S., & Bornstein, S. (1991). Diseases of camels (*Camelus dromedarius*) in Somalia and prospects for better health. *Nomadic People* (No. 29); *Camel Pastoralism in the Horn of Africa*; *Nomadic People*, 104–112.
- Fassi-Fehri, M. M. (1987). Diseases of camels. *Revue scientifique et technique (International Office of Epizootics)*, 6(2), 337–354.
- Mares, R. G. (1954). Animal husbandry, animal industry and animal diseases in the Somaliland protectorate, part II. *British Veterinary Journal*, 110, 470–481.
- McGrane, J. J., & Higgins, A. J. (1985). Infectious diseases of the camel; viruses, bacteria and fungi. *British Veterinary Journal*, 141, 529–547.
- Morcos, M. B. (1965). Treatment of tetanus in the camel. *Veterinary Medical Review*, 2, 132–134.
- Rabagliati, O. B. E. (1920). Tetanus in the camel. *Journal of Comparative Pathology. Theriogenology*, 33, 10–12.
- Schwartz, H. J., & Dioli, M. (1992). *The one-humped camel in eastern Africa. A pictorial guide to diseases, health care and management*. Verlag, Josef and Magraf.
- Wernery, U., Ul-Haq, A., Joseph, M., & Kinne, J. (2004). Tetanus in a camel (*Camelus dromedarius*)—A case report. *Tropical Animal Health and Production*, 36, 217–224.

Mansour F. Hussein

Tuberculosis is a chronic granulomatous disease caused by members of the *Mycobacterium tuberculosis complex* which consists of numerous species of varying pathogenicity and worldwide distribution. The disease is one of the most important and contagious zoonosis affecting man and animals, including farm animals, pets, and wild mammals.

Among dromedary camels, only sporadic cases of tuberculosis are reported in animals raised in dry desert conditions while relatively more cases tend to occur in camels raised in farms and enclosures, especially in humid areas (Gatt Rutter & Mack, 1963).

The disease has been reported in dromedary camels in many countries where these animals are reared, including Ethiopia (Beyi et al., 2014; Dubie et al., 2016; Gumi et al., 2012; Jibril et al., 2019; Kassaye et al., 2013; Mamo et al., 2009, 2011; Zerom et al., 2013), Eritrea (Ghebremariam et al., 2018), Kenya (Lamuka et al., 2018; Paling et al., 1988), Somalia (Abdurahman & Bornstein, 1991; Pellegrini, 1946), Nigeria (Ahmed et al., 2019a, 2019b; Kufi et al., 2012), Egypt (Mustafa, 1987; Yehya & Gobran, 2008), Sudan (Ahmed et al., 2017; Tigani et al., 2007), the United Arab Emirates (Kinne et al., 2006; Wernery & Kinne, 2012), Iran (Mohammadpour et al., 2020; Nourani & Rohani, 2009), India (Narnaware et al., 2015), Pakistan (Zubair et al., 2004), Kazakhstan (Elmossalami et al., 1971), Australia (Manefield & Tinson, 1997), and other countries. While camel tuberculosis is primarily caused by *M. bovis* or *M. tuberculosis*, other mycobacterial species may occasionally cause the disease in these animals (Dubie et al., 2016).

## 32.1 Etiology

The commonest causes of tuberculosis in farm animals are *M. tuberculosis* and *M. bovis*, both of which are also the main causes of tuberculosis in camelids (Elmossalami et al., 1971). They are acid-fast, non-motile, non-sporulating, and highly aerobic bacilli.

## 32.2 Modes of Transmission

The infection spreads between camels by different means such as the introduction of an infected camel into a non-infected camel herd (Bush et al., 1990) or as a result of keeping camels in close contact with infected cattle or wild animals (Gatt Rutter & Mack, 1963; Paling et al., 1988). As in cattle, transmission of tuberculosis in camels is mainly horizontal, with camels suffering from pulmonary tuberculosis infecting healthy camels via aerosols. Oral transmission may also occur following ingestion of contaminated food or water. Congenital and venereal transmission have not been reported in tuberculosis of camelids.

The risks of infection with tuberculosis are higher in camels subjected to hunger or malnutrition, overcrowding, inclement weather conditions, and various other stress factors which lower the animal's resistance.

---

## 32.3 Clinical Picture and Pathology

The clinical signs of tuberculosis in dromedary camels comprise emaciation and general weakness, coupled with dry cough, difficulty in breathing, loss of appetite, grinding of teeth, and mild to moderate fever. Post-mortem examination of the affected camels may reveal tubercles of various sizes and shapes and containing a few acid-fast bacilli in the affected organs and their associated lymph nodes. The lesions may be caseous or calcified and sometimes accompanied by extensive fibrosis (Fig. 32.1). Most lesions involve the lungs, mediastinal, tracheal, and bronchial lymph nodes and the pleura. In some cases, however, tuberculous lesions may also occur in the pericardium, liver, spleen, and kidneys. Often, the tubercles appear as hard, whitish gray, or yellowish nodules with caseous necrotic centers. Miliary tuberculosis may sometimes be seen (Ahmed et al., 2019a, 2019b; Jibril et al., 2019; Mamo et al., 2011; Nourani & Rohani, 2009; Tigani et al., 2007).

Histopathological examination (Wernery & Kinne, 2012) reveals pyogranulomatous lesions with dense centers containing caseous remnants of neutrophils surrounded by epithelioid cells, lymphocytes, plasma cells, neutrophils, and few giant cells. Application of the Ziehl–Neelsen staining technique to these sections often reveals some acid-fast bacilli in the lesions.

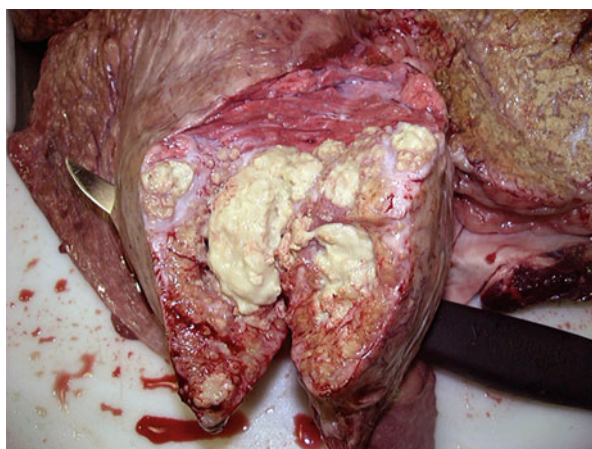
---

## 32.4 Diagnosis

Tuberculosis in camels cannot be diagnosed on the basis of clinical signs. Furthermore, intradermal tuberculin tests are of limited sensitivity in detecting tuberculosis in live camels. This also applies to other antemortem tests, such as lymphocyte transformation and ELISA tests, both of which did not prove to be very reliable. More rapid diagnosis can be made using PCR assays.

Smears can also be made from the lesions and stained with Ziehl–Neelsen (ZN) to see ZN positive rods. The organism can be isolated in special culture media such as

**Fig. 32.1** Tuberculosis and caseation in pulmonary lymph node in dromedary camel (Photo by Prof. Mansour F. Hussain)



Loewenstein–Jensen or Ogawa media. However, mycobacteria are slow growing organisms that may require up to 8 weeks to appear in culture.

Ranjan et al. (2018) developed a lateral flow assay test for the diagnosis of tuberculosis in camels. According to these authors, the test, which is based on immunochromatographic detection of antibodies in serum, plasma, or whole blood, could be useful for rapid antemortem diagnosis of camel tuberculosis.

Molecular characterization of strains causing tuberculosis in camels is recommended by Jibril et al. (2019).

---

## 32.5 Zoonotic Potential

From a zoonotic standpoint, tuberculosis can be transmitted from infected camels to nomadic herdsman living in close contact with these animals as well as those consuming their raw milk.

---

## 32.6 Treatment and Prevention

No program is currently known for the eradication of tuberculosis in camels. There is also no specific treatment for TB in camels. Isoniazid may be tried in the case of highly valued animals. Infected camels should be condemned and incinerated.

---

## 32.7 Notification

Tuberculosis is a notifiable disease.

## References

- Abdurahman, O. S., & Bornstein, S. (1991). Diseases of camels in *Somalia* and prospects for better health. *Nomadic Peoples*, 29(1991), 104–112.
- Ahmad, I., Kudi, C. A., Babashani, M., Chafe, U. M., Yakubu, Y., & Shitto, A. (2019a). Tuberculosis in dromedary camels slaughtered in Nigeria: A documentation of lesions at postmortem. *Tropical Animal Health and Production*, 50, 73–78.
- Ahmad, I., Kudi, C. A., Magaji, A. A., Yakubu, Y., Salisu, M. D., Samuel Shuaibu, S., & Daninna, Z. M. (2019b). Disseminated tuberculosis in a cow and a dromedary bull-camel in Zamfara state in Nigeria. *Veterinary Medicine and Science*, 5, 93–98.
- Ahmed, E.-A., Hassan, A. B., & Abaker, A. (2017). Pathology of tuberculosis in camels (*Camelus dromedaries*) in the Sudan. *Journal of Tuberculosis Research*, 5(1), 77–80.
- Beyi, A. F., Gezahegne, K. Z., Mussa, A., Ameni, G., & Ali, M. S. (2014). Prevalence of bovine tuberculosis in dromedary camels and awareness of pastoralists about its zoonotic importance in eastern Ethiopia. *Journal of Veterinary Medicine and Animal Health*, 6(4), 109–115.
- Bush, M., Montali, R. J., Phillips, L. G., & Holobaugh, P. A. (1990). Bovine tuberculosis in a Bactrian camel herd: Clinical, therapeutic, and pathologic findings. *Journal of Zoo and Wildlife Medicine*, 21(2), 171–179.
- Dubie, L., Sisay, L., Zirul, F., Gerbu, M.-U., & Negash, W. (2016). Preliminary assessment on the epidemiology and public health implication of camel tuberculosis in pastoral area of Ethiopia. *World Journal of Pharmaceutical Research*, 5(1), 95–115.
- Elmossalami, E., Siam, M. A., & El Sergany, M. (1971). Studies on tuberculous-like lesions in slaughtered camels. *Zentralblatt für Veterinärmedizin Reihe B*, 18(4), 253–261.
- Gatt Rutter, T. E., & Mack, R. (1963). Diseases of camels. Part I, bacterial and fungal diseases. *Veterinary Bulletin*, 33, 119–124.
- Ghebremariam, M. K., Michel, A. I., Vernooij, J. C. M., Nielen, M., & Rutten, V. P. M. G. (2018). Prevalence of bovine tuberculosis in cattle, goats, and camels of traditional livestock raising communities in *Eritrea*. *BMC Veterinary Research*, 14(73), 1–13. <https://doi.org/10.1186/s12917-018-1397-0>
- Gumi, B., Schelling, E., Erenso, G., Firdessa, R., Biffa, D., Aseffa, T. R., Yamuah, T. R. Y. D., & Zinsstag, J. (2012). Low prevalence of bovine tuberculosis in *Somali pastoral livestock, Southeast Ethiopia*. *Tropical Animal Health and Production*, 44(7), 1445–1450.
- Jibril, Y., Mamo, G., Ahmed, J., Mulat, G., & Ameni, G. (2019). Abattoir based study on the pathology of tuberculosis in dromedary camels, *Ethiopia*. *Biomedical Journal of Scientific and Technical Research*, 19(2), 14151–14158.
- Kassaye, S., Molla, W., & Ameni, G. (2013). Prevalence of camel tuberculosis at Akaki abattoir in Addis Ababa, *Ethiopia*. *African Journal of Microbiology Research*, 7(20), 2184–2189.
- Kinne, J., Johnson, B., Jahans, K. L., Smith, N. H., Ul-Hag, A., & Wernery, U. (2006). Camel tuberculosis—A case report. *Tropical Animal Health and Production*, 38(3), 207–213.
- Kufi, C., Bello, A., & Ndikum, J. A. (2012). Prevalence of bovine tuberculosis in camels in northern Nigeria. *Journal of Camel Practice and Research*, 19(1), 81–86.
- Lamuka, P. O., Njeruh, F. M., Gitao, G. C., Matofari, J., Bowen, R., & Abey, K. A. (2018). Prevalence of bovine and avian tuberculosis in camel herds and associated public risk factors in Isiolo County, Kenya. *Tropical Animal Health and Production*, 50(5), 937–945.
- Mamo, G., Bayleyegn, G., Tessema, T. S., Legesse, M., Medhin, G., Bjune, G., Abebe, F., & Ameni, G. (2011). Pathology of camel tuberculosis and molecular characterization of its causative agents in pastoral regions of Ethiopia. *PLoS One*, 6(1), e1586. [www.plosone.org](http://www.plosone.org)
- Mamo, G., Kassaye, A., Sanni, M., & Ameni, G. (2009). A cross-sectional study of camel tuberculosis in Ethiopia. *Bulletin of Animal Health and Production in Africa*, 57(1), 13–20.
- Manefield, G. W., & Tinson, A. H. (1997). *Camels*. A Compendium Sydney Post Graduate Foundation Vade Mecum Series C No. 22.
- Mohammadpour, R., Champour, M., & Tuteja, F. M. (2020). Review: Zoonotic implications of camel diseases in *Iran*. *Veterinary Medicine and Science*, 6, 1–23.

- Mustafa, I. E. (1987). Bacterial diseases of dromedary and Bactrian camels. *Scientific and Technical Review of the OIE*, 6, 391–405.
- Narnaware, S. D., Dahiya, S. S., Tuteja, F. C., Nagarajan, G., Nath, K., & Patil, N. V. (2015). Pathology and diagnosis of *Mycobacterium bovis* in naturally infected dromedary camels (*Camelus dromedarius*) in India. *Tropical Animal Health and Production*, 47(8), 1633–1636.
- Nourani, H., & Rohani, F. (2009). Pathological study on lungs of dromedary camels slaughtered in the central part of Iran. *Journal of Camel Practice and Research*, 16(1), 51–54.
- Paling, R. W., Whaghela, S., Macowan, K. J., & Heath, B. R. (1988). The occurrence of infectious diseases in mixed farming of domesticated animals and wild herbivores and livestock in Kenya. II. Bacterial diseases. *Journal of Wildlife Diseases*, 24(2), 308–316.
- Pellegrini, D. (1946). Tuberclosi spontanea del Cammello in Somalia-Ricerche Dianostiche sperimentali. *Veterinary Bulletin*, 16(12), 422.
- Ranjan, R., Narnaware, S. D., Nath, K., Sawal, R. K., & Patil, N. V. (2018). Rapid diagnosis of tuberculosis in dromedary camel (*Camelus dromedarius*) using lateral flow assay-based kit. *Tropical Animal Health and Production*, 50(4), 907–910.
- Tigani, T. A., Hassan, A. B., & Abaker, A. D. (2007). Bacteriological and pathological studies on condemned lungs of one humped camels (*camelus dromedarius*) slaughtered in Tamboul and Nyala abattoirs. *Sudan Journal of Science and Technology*, 8(2), 3–12.
- Wernery, U., & Kinne, J. (2012). Tuberculosis in camelids. *Revue Scientifique et Technique*, 31(3), 899–906.
- Yehya, M., & Gobran, R. A. (2008). Some studies on tuberculosis in camel. *Egyptian Journal of Comparative Pathology and Clinical Pathology*, 21(4), 58–74.
- Zerom, K., Tessema, T. S., Mamo, G., Bayu, Y., & Ameni, G. (2013). Tuberculosis in dromedaries in eastern Ethiopia: Abattoir-based prevalence and molecular typing of its causative agents. *Small Ruminant Research*, 109(1–2), 188–192.
- Zubair, R., Khan, A. M. Z., & Sabri, M. A. (2004). Pathology in camel lungs. *Journal of Camel Science*, 1, 103–106.

## *Yersinia pestis* (Camel Plague)

# 33

Mansour F. Hussein

*Yersinia pestis* is a gram-negative, non-motile, non-spore forming, and facultative anaerobe that causes human plague or Black Death, a dreadful disease transmitted from naturally infected rats to man through the bites of fleas. Other mammals may also be infected with *Y. pestis*, including camels, llama, goats, sheep, gazelles, cats, dogs, and rabbits. During the Middle Ages, overwhelming pandemics of plague resulted in the death of about 200 million people; among these, around 40 million people, comprising one third of Europe's population at the time, died of plague between 1347 and 1353. Today, natural foci of plague still exist in many parts of the world, and although effective treatment is available, thousands of cases of human plague are still reported annually, especially in Africa and Asia, and to a lesser extent Eastern Europe and parts of North and South America.

Dromedary and Bactrian camels as well as new world camelids are susceptible to *Y. pestis*, and plague was recorded in these animals in various camel rearing areas including former USSR countries, viz Mongolia, Russia, Uzbekistan, Kazakhstan, and Turkmenistan (Fedorov, 1960; Sotnikov, 1973; Strogov, 1959), as well as China, India, Iran, Iraq (Sotnikov, 1973), Mauritania (Alonso, 1971), Libya (Christie et al., 1980), Jordan (Arbaji et al., 2005), Saudi Arabia (Bin Saeed et al., 2005), Afghanistan (Leslie et al., 2011) and Egypt, Algeria, Morocco, and southern part of the Western Sahara (Malek et al., 2015; 2016).

### 33.1 Modes of Transmission

Fedorov (1960) listed different ways in which camels could be naturally infected with *Y. pestis*, such as the bites of rodent fleas, mechanical transmission via ticks (*Ixodes* and *Argas* species), consumption of feed contaminated with the excreta of infected rodents, and unknowingly eating dead infected rodents along with the feed. Christie et al. (1980) suggested that in comparison to other farm animals, “the wide-ranging behavior of camels increases their chance of coming in contact with natural foci of plague.”

### 33.2 Transmission of Plague from Camels to Man

In the past, vast numbers of people had apparently captured plague from camels. In fact, ancient Arabs saw the death of many camels as a warning sign of human plague. During the early part of last century, several reports were made from the former USSR on the transmission of *Y. pestis* from plague-infected camels to humans (reviewed by Fedorov, 1960; Malek et al., 2016). In more recent times, similar reports were made from other countries where dromedary camels are reared in large numbers by nomads, primarily as a source of food and transportation.

Malek et al. (2016) stated that the re-emergence of plague in the Western Sahara in 1953 and in Libya in 1976 “was traced to direct contact between nomadic populations and infected goats and camels in natural foci, including the consumption of contaminated meat, thus illustrating this neglected oral route of contamination.” In 1980, an outbreak of plague was reported in 15 villagers in Libya who presented with an acute febrile disease 4 days after slaughtering, skinning, and consuming the meat of a dromedary camel proven to be infected with *Y. pestis*. Five villagers who participated in slaughtering the camel and distributing its meat died. The remaining patients were serologically tested and seven were found to be seropositive for plague using the passive hemagglutination test. Six other villagers contracted plague after slaughtering and consuming the meat of two apparently infected goats; one of the patients died and the remaining five, who received early treatment with antibiotics, survived. Serological testing revealed antibodies against *Y. pestis* in one of the goats (Christie et al., 1980). Eating meat from plague-infected camels was also associated with cases of plague among nomads in Mauritania and other parts of the Arab Maghrib (Alonso, 1971).

An outbreak of pharyngeal plague with cervical lymphadenopathy was also reported in 12 inhabitants of Azraq ad-Druze village in Jordan near the border with Saudi Arabia, 2–4 days after consuming raw (11 patients) or cooked (one patient) meat of an infected dromedary. Using hemagglutination, ELISA, and microagglutination tests, all 12 patients were positive for anti-*Y. pestis* IgM antibodies and all of them were treated with gentamycin. Three dogs randomly shot in the area were also tested and were found to be positive for anti-*Y. pestis* antibodies (Arbaji et al., 2005).

Bin Saeed et al. (2005) reported pharyngeal plague in four patients in Goriat in Saudi Arabia after eating raw liver of a dromedary camel infected with *Y. pestis*, and bubonic plague in a fifth patient who butchered the camel. *Y. pestis* was isolated from the blood of one patient and the spinal fluid of another, and also from meat and bone marrow samples of the camel and from jirds (*Meriones libycus*) and fleas (*Xenopsylla cheopis*) captured at the camel corral. The diagnosis was confirmed by phage lysis, fluorescent antibody staining and passive hemagglutination.

An outbreak of acute gastroenteritis caused by *Y. pestis* was also reported in over 180 people, including 17 deaths, in Nimroz Province in southern Afghanistan (Leslie et al., 2011). The disease was associated with the consumption or handling of plague-infected camel’s meat. Molecular testing of clinical samples from the patients and tissue samples from the camel using PCR/electrospray ionization-mass



spectrometry revealed DNA consistent with *Y. pestis*; the diagnosis was confirmed using real-time PCR and immunological seroconversion tests of one of the patients.

---

### 33.3 Clinical Picture and Pathology

Human plague is known to take one of three forms: bubonic form, pneumonic form, or septicemic form. All of these forms apparently occur in camels, with an incubation period ranging from 1 to 6 days followed, in acutely affected cases, by death in about 20 days (Malek et al., 2016).

However, little has been published about the clinical signs of plague in camels since in most cases they were dead before a diagnosis was made. Besides, individual susceptibility to plague appears to vary widely among camels (Fedorov, 1960). The latter author described typical signs of bubonic plague (enlargement and intense pain in regional lymph nodes) in two camels experimentally infected with *Y. pestis*. The animals also exhibited rise in temperature, depression, loss of appetite, cessation of cud-chewing, and lameness while pus cultures from the bubo showed abundant *Y. pestis* growth. Both camels subsequently tended to improve, and one of them was slaughtered.

---

### 33.4 Diagnosis

Smears from blood, swollen lymph node (bubo), or other affected tissues may reveal small gram-negative and/or bipolar-staining coccobacilli. However, this is not enough to make a diagnosis. Laboratory diagnosis of plague rests mainly on bacteriological results and/or serological evidence such as Passive Hemagglutination (PHA) tests and ELISA, the former being one of the most frequently used tests in the case of human plague. Molecular techniques, such as real-time PCR and DNA hybridization are also used in the diagnosis of the disease. An important, sensitive, and simple test for rapid diagnosis of human plague is the rapid diagnostic test (RDT) based on using monoclonal antibodies to the F1 antigen of *Y. pestis* (Jullien et al., 2019). Such tests are superior to and have largely replaced older methods such as CFT.

---

### 33.5 Treatment and Control

Unless promptly treated, plague can be a very serious and rapidly fatal disease. Fortunately, it is treatable with commonly available antibiotics such as Streptomycin, gentamicin, tetracyclines (specially doxycycline) and ciprofloxacin. For the treatment of plague in camels, a combination of streptomycin and tetracycline can be administered for at least 5 days (Wernery & Kaaden, 2002). Supportive treatment may also be used, as necessary.

The control of plague requires eliminating contact with possible sources of infection, e.g., controlling rodents, cats, and rabbits and their fleas in farms where camels are kept. Spraying of camels with insecticides is also recommended, and if necropsy of a plague-suspected camel is to be carried out, the entire carcass should first be sprayed with insecticides to destroy any ectoparasites. A freeze-dried anti-plague vaccine in a single dose of 30,000 million organisms has been used for immunization of camels, conferring immunity of not less than 4 months (Fedorov, 1960; Sotnikov, 1973). Genetically modified vaccines against bubonic plague have also been recently developed to protect man and animals against plague. However, no information is currently available on the use of these vaccines in camels.

## References

- Arbaji, A., Kharabsheh, S., Al-Azab, S., Al-Kayed, M., Amr, Z. S., Abu Baker, M., & Chu, M. C. (2005). A 12-case outbreak of pharyngeal plague following the consumption of camel meat, in North-Eastern Jordan. *Annals of Tropical Medicine and Parasitology*, 99(8), 789–793.
- Alonso, J. M. (1971). *Contribution à l'étude de la peste en Mauritanie*. Ph.D. thesis. Université de Paris VI, Faculté de Médecine Pitié-Salpêtrière. [in French].
- Bin Saeed, A. A., Al-Hamdan, N. A., & Fontaine, R. E. (2005). Plague from eating raw camel liver. *Emerging Infectious Diseases*, 11(9), 1456–1457. <https://doi.org/10.3201/eid1109.050081>
- Christie, A. B., Chen, T. H., & Elberg, S. S. (1980). Plague in camels and goats: Their role in human epidemics. *Journal of Infectious Diseases*, 141, 724–726.
- Fedorov, V. N. (1960). Plague in camels and its prevention in the USSR. *Bulletin of the World Health Organization*, 23(2–3), 275–281.
- Jullien, S., Dissanayake, H. A., & Chaplin, M. (2019). Rapid diagnostic tests for plague. *The Cochrane Database of Systematic Reviews*, 10, CDO13459. <https://doi.org/10.1002/14651858.CDO13459>
- Leslie, T., Whitehouse, C. A., Yingst, S., Baldwin, C., Kakar, F., Mofleh, J., Hami, A. S., Mustafa, L., Omar, F., Ayazi, E., Rossi, C., Noormal, B., Ziar, N., & Kakar, R. (2011). Outbreak of gastroenteritis caused by *Yersinia pestis* in Afghanistan. *Epidemiology & Infection*, 139, 728–735.
- Malek, M. A., Bitam, I., & Drancourt, M. (2016). Plague in Arab Maghreb, 1940–2015: A review. *Frontiers in Public Health*, 4(112), 1–6. <https://doi.org/10.3389/fpubh.2016.00112>
- Malek, M. A., Hammani, A., Beneldjouzi, A., & Bitam, I. (2015). Enzootic plague foci, Algeria. *New Microbes New Infect*, 4, 13–16.
- Sotnikov, M. I. (1973). Camel plague (in Russian). In E. M. Orlov (Eds.), *Maloizvestnye zarazny bolezni zhivotnykh*, Izdatel'stvo Kolos (pp. 213–222) (Abstract in: Veterinary Bulletin, 44: 937, 1974 [abstract No. 937]).
- Strogov, A. K. (1959). Plague in camels (in Russian). In *Maloizvestnye zaraznye bolezni zhivotnykh*, Sel'khozgiz, Moscow (pp. 262–280). Abstract in Vet. Bull., 30 [abstract No. 2461].
- Wernery, U., & Kaaden, O.-R. (2002). *Infectious diseases of camelids* (pp. 54–55). Blackwell Wissenschafts-Verlag.

---

## **Part III**

# **Fungal Diseases of Dromedary Camels**

Mansour F. Hussein

Ringworm (Dermatomycosis) is a contagious skin disease of mammals affecting humans and all species of farm animals. It is probably the commonest fungal disease in dromedary camels and other camelids, particularly young animals under the age of 3 years. Older camels tend to be less susceptible.

The disease is widespread among dromedary camels and has been reported from almost all countries where these animals are kept, including the Sudan (Fadlelmula et al., 1994), Kenya (Gitao et al., 1998), Ethiopia (Pal, 2016), Somalia (Boever & Rush, 1975; Dalling, 1966), Egypt (El-Kader, 1985), Saudi Arabia (Almuzaini et al., 2016; Salem et al., 2018), Iraq (Al-Ani et al., 1995), Jordan (Rawashdeh et al., 2000) India (Tateja et al., 2013), the United Arab Emirates, and Iran (Mohammadpour et al., 2020).

---

## 34.1 Etiology

The primary cause of ringworm in camels is *Trichophyton verrucosum*. Many other *Trichophyton* and *Microsporum spp* have also been involved in the etiology of dermatomycosis (McGrane & Higgins, 1985).

---

## 34.2 Modes of Transmission

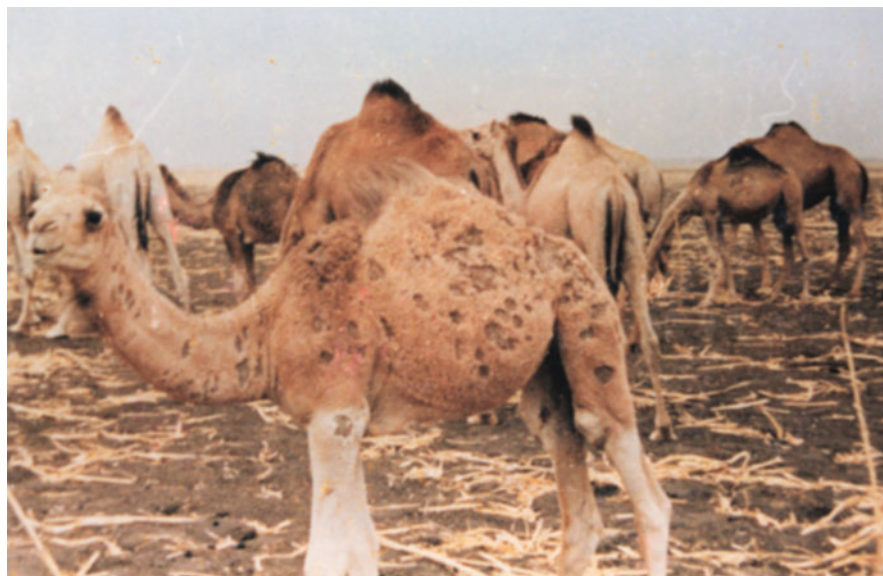The infection is spread among camels through direct contact between sick and healthy animals and also via different other means such as ropes, saddles, brushes, etc. Overcrowding, poor ventilation, high temperature and humidity assist in the spread of the infection between camels. Most cases occur during the summer during which season the disease tends to spread quickly, leading to outbreaks. The prevalence of the disease subsides during the winter.

### 34.3 Clinical Picture and Pathology

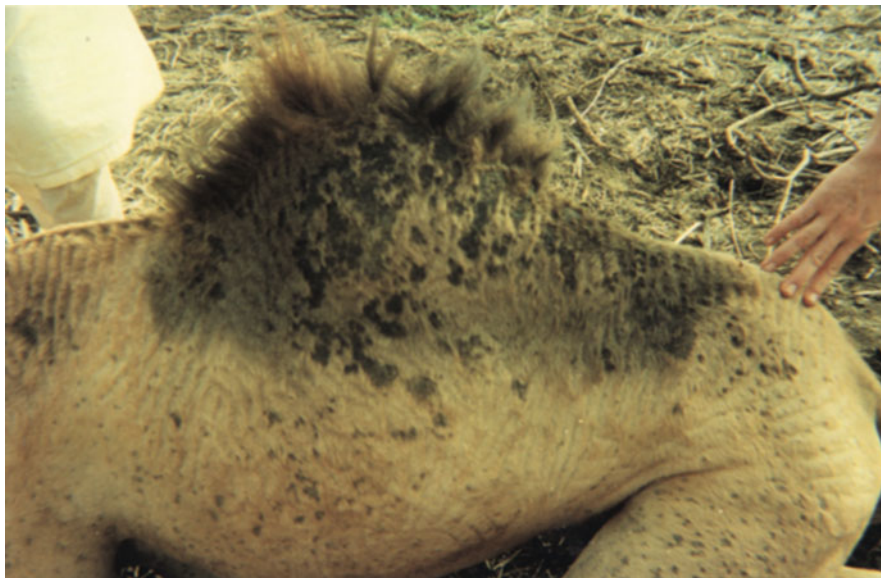Ringworm in camels is characterized by the formation of multiple, circular, grayish-white, alopecic, and often non-pruritic lesions, about 1–2 cm in diameter, on the skin of the head, especially around the eyes, ears, and muzzle, as well as neck and shoulders and often extending to the flanks, limbs and may eventually involve the entire body (Fig. 34.1). Other complications may also occur including pyoderma and emaciation (Al-Ani et al., 1995; Chermette et al., 2008; Fadlelmula et al., 1994; McGrane & Higgins, 1985).

The disease starts with the fungus attacking hair follicles and superficial layers of the skin while lesions might take 1 week to 10 days to appear after exposure to infection. The clinical manifestations begin with loss of hair, necrotic dermatitis, and secretions in the affected parts of the skin. The mixture of these secretions with bits of necrotic skin and dirt leads to the formation of scales which fall off leaving hairless circular areas which enlarge and gradually spread.

Wernery and Kaaden (2002) described two clinical types of ringworm in camels. One type is characterized by grayish-white lesions, which are sometimes coalescent, on the head, neck, and legs of young camels while the other type of lesion is a more generalized type involving the head, neck, limbs, and flanks and may be confused with mange (Fig. 34.2). Camel calves less than 1 year old, and older calves with poor resistance, may develop generalized dermatomycosis. The prevalence of infection varies with the season of the year, with highest prevalence being recorded during the hot and rainy season. On the other hand, Fadlelmula et al. (1994) recorded no difference in prevalence between males and females in Sudanese camels.



**Fig. 34.1** Ringworm infection in a calf camel (Courtesy Dr. B. Abbas, Bahrain)



**Fig. 34.2** Ringworm in a dromedary camel (Courtesy Dr. B. Abbas, Bahrain)

---

### 34.4 Diagnosis

A tentative diagnosis can be made on the basis of history and clinical signs. To confirm diagnosis, scrapings from affected parts of the skin are placed on a clean microscopic slide, dissolved with few drops of 10–25% KOH or NaOH and 5% glycerin mixture, covered with a cover slip and heated gently for 30 min to 1 h, then pressed to collect the oozing fluid which is dried and examined for fungal hyphae and conidia. Special preparations can also be made for fluorescence microscopy if necessary. The fungus may also be isolated in suitable culture media (e.g., Sabouraud dextrose agar with chloramphenicol and acridine) and its cultural characteristics are determined.

---

### 34.5 Treatment

For treatment, the scales and surrounding lesions should be cleaned with water and soap, dried and then rubbed with 2% iodine tincture. The lesions may also be locally treated with thiabendazole ointment or other suitable antifungal cream. However, the use of griseofulvin orally is not recommended since it may cause side effects such as nausea and diarrhea. Intramuscular administration of Vitamin A (400,000 I.U./animal) may assist in rapid recovery (Almuzaini et al., 2016).

For disease prevention, appropriate hygienic measures should be observed, including isolation of infected camels, cleaning, disinfection, and proper ventilation

of the camels' dwellings and avoidance of overcrowding. A vaccine for protecting camels was developed in the former USSR which helped in reducing the incidence of the disease.

## References

- Al-Ani, F. K., Al-Bassam, L. S., & Al-Salahi, K. A. (1995). Epidemiological study of dermatomycosis due to *Trichophyton schoenleinii* in camels in Iraq. *Bulletin of Animal Health and production in Africa*, 43, 87–92.
- Almuzaini, A. M., Osman, S. A., & Saeed, E. M. A. (2016). An outbreak of dermatophytosis in camels (*Camelus dromedarius*) at Qassim region, central of Saudi Arabia. *Journal of Applied Animal Research*, 44(1), 126–129.
- Boever, W. J., & Rush, D. M. (1975). *Microsporum gypseum* infection in a dromedary camel. *Veterinary Medicine and Small Animal Clinician*, 70(10), 1190–1192.
- Chermette, R., Ferreira, L., & Guillot, J. (2008). Dermatophytoses in animals. *Mycopathologia*, 166, 385–405.
- Dalling, T. (1966). Cited by Abdurahman, O. Sh. and Bornstein, S. (1991). Diseases of camels (*Camelus dromedarius*) in Somalia and prospects of better health. Nomadic People, N. 29, Camel Pastoralism in the Horn of Africa (1991) (pp. 104–112).
- El-Kader, A. (1985). *Studies on skin diseases of camels with special reference to mycotic causes and treatment in Assiut province* [M. V. Sc. thesis]. Faculty of Veterinary Medicine, Assiut University.
- Fadlelmula, A., Agab, H., Le Horgne, J. M., Abbas, B., & Abdalla, A. E. (1994). First isolation of *Trichophyton verrucosum* as Etiology of ringworm in the Sudanese camels (*Camelus dromedarius*). *Revue d'Élevage et de Médecine Vétérinaire des Pays Tropicaux*, 42(2), 184–187.
- Gitao, C. G., Agab, H. M. A., & Khalifa, A. J. (1998). Camel dermatomycosis in Kenya, Sudan and Saudi Arabia. In *Proceedings of the 3rd annual meeting for animal production under arid conditions* (Vol. 2, pp. 93–107). © 1998, United Arab Emirates University, UAE.
- McGrane, J. J., & Higgins, A. J. (1985). Infectious diseases of the camel; viruses, bacteria and fungi. *British Veterinary Journal*, 141, 529–547.
- Mohammadpour, R., Champour, M., Tuteja, F., & Mustafavi, E. (2020). Zoonotic implications of camel diseases in Iran. *Veterinary Medicine and Science*, 6, 1–23.
- Pal, M. (2016). First mycological investigation of dermatophytosis in camels due to *Trichophyton verrucosum* in Ethiopia. *Journal of Mycopathological Research*, 54(1), 89–92.
- Rawashdeh, O. F., Al-Ani, F. K., Sharif, L. A., Al-Qudah, K. M., Al-Hami, Y., & Frank, N. (2000). A survey of camel (*Camelus dromedarius*) diseases in Jordan. *Journal of Zoo and Wildlife Medicine*, 31(3), 335–338.
- Salem, M., Al-Bulushi, S., Eljalii, I., Fadlelmula, A., & Housawi, F. (2018). A regional study on dermatophytes infection in Arabian dromedary camels (*Camelus dromedaries*) in Al-Hassa governorate in the eastern province of Saudi Arabia. *Current Journal of Applied Science and Technology*, 27(2), 1–8.
- Tateja, F. C., Patel, N. V., Narnaware, S. D., Nagarajan, G., & Dahiya, S. S. (2013). Camel dermal mycosis caused by dermatophytes. *Journal of Camel Practice and Research*, 20(2), 157–165.
- Wernery, U., & Kaaden, O. R. (2002). *Infectious diseases in camelids*. Blackwell Science.

Aspergillosis is an opportunistic fungal infection of worldwide distribution that affects man, animals, and birds. 90–95% of the cases are caused by *Aspergillus fumigatus*, which primarily affects the lungs, while the remaining cases of aspergillosis have been attributed to various other species such as *A. niger*, *A. flavus*, and *A. terreus*. Camelids including dromedary camels are occasionally infected (Al-Hizab, 2014; Bhatia et al., 1983; el-Khouly et al., 1992).

---

## 35.1 Modes of Transmission

The primary sources of aspergillosis are moldy feeds and litter, and the transmission of infection may occur either via ingestion or inhalation. The disease in camels has been associated with respiratory and alimentary tract lesions, placentitis, mastitis, allergic reactions, rumenitis, and subcutaneous granulomas (Bhatia et al., 1983; el-Khouly et al., 1992; Scaglione et al., 2017). Predisposing factors include stress, malnutrition, metabolic acidosis, and excessive use of antibiotics. Heavy rainfall and bad storage conditions result in moldy hay with high content of different fungal species including *Aspergillus* species.

---

## 35.2 Clinical Picture and Pathology

Bhatia et al. (1983) reported pulmonary aspergillosis in a 9-year-old camel in India. Several nodules were found in the lungs of the affected animal, surrounded by dark colored consolidated pulmonary tissue containing semisolid caseous necrotic material. Numerous abscesses were scattered over the lung parenchyma. A necrotizing suppurative pneumonia was diagnosed, and branching, septate fungal elements resembling *Aspergillus* species were seen. *Corynebacterium pyogenes* was also isolated from the lung.



Respiratory and enteric lesions due to aspergillosis were described by el-Khouly et al. (1992) in racing camels in the UAE. The affected animals showed lethargy, dullness, and loss of appetite coupled with mild, dry cough, lacrimation, and mild fever. Other manifestations included edema of the throat and enlargement of the submandibular lymph nodes. Some camels developed bloody diarrhea during terminal stages of the disease and many of them died. Post-mortem examination revealed marked bleeding in the intestines and other organs. *A. fumigatus* was isolated from different organs, and fungal hyphae and conidia were demonstrable in direct smears from the lesions. The authors, however, were unable to determine whether these lesions were due to a primary or secondary infection by the fungus.

Al-Hizab et al. (2014) also associated *A. fumigatus* with pulmonary and enteric lesions in camels and were able to culture and isolate the fungus from lesions in the lungs, trachea, omasum, and intestines.

Gareis and Wernery (1994) described mycotoxicosis with severe watery diarrhea, hemorrhages, leucopenia, and death in dromedary camels. A high content of *Aspergillus* and other fungal species was found in hay fed to these animals, and extracts of hay samples, body fluids, and intestinal content were shown to be highly toxic.

In 2012, Gabri (cited by Refai et al., 2016) reported fatal, invasive aspergillosis, characterized by high mortality in dromedary camels in Harad region, Central Saudi Arabia. The affected animals showed bloody diarrhea, anorexia, depression, nasal discharge, lacrimation, and swelling of submandibular lymph nodes. Post-mortem examination revealed extensive congestion and hemorrhages in the abomasum, intestines, mesenteric lymph nodes, and other tissues. *A. fumigatus* was isolated from the intestines, lungs, omasum, and trachea.

Aspergillosis granulomas up to 5 cm in diameter were detected in a breeding dromedary camel in the UAE which concurrently suffered from generalized camelpox for several weeks. In addition, Scaglione et al. (2017) described a subcutaneous *Aspergillus* granuloma in the right testes of a 7-year-old neutered dromedary camel held in captivity with other camels in an Italian zoo. The lesion was characterized by formation of a large, firm, granulomatous nodule with necrotic center and surrounding inflammatory cells. Fungal hyphae were found in the lesion.

---

### 35.3 Diagnosis

As with ringworm, scrapings and specimens from affected tissues can be dissolved in KOH, lightly heated, and examined microscopically. Histopathological sections stained with Periodic Acid Schiff (PAS) reagent can also be examined microscopically, while fungal hyphae can be identified in tissue sections using immunofluorescence techniques. The fungus may be isolated in Sabouraud dextrose agar to study its cultural characteristics. Other diagnostic methods include serological tests such as Agar Gel Immunodiffusion and ELISA tests for the detection of antifungal antibodies (Refai et al., 2016). Real-time PCR has also been applied for the detection of *Aspergillus* species in aborted fetuses of camels and other ruminants in Iran (Dehkordi et al., 2012).

## 35.4 Treatment and Control

Treatment of aspergillosis is generally unsatisfactory, and the effect of some anti-fungal drugs such as Flucytosine and Amphotericin B used in treating other species of animals is unknown in camels (Refai et al., 2016; Wernery & Kaaden, 2002). Prevention of the disease entails the application of appropriate hygienic standards and proper storage of feeds to prevent them from becoming moldy. It is also important to protect the animals from overcrowding and stress.

---

## References

- Al-Hizab, F. (2014). *Aspergillus fumigatus* infection among dromedary camels in Saudi Arabia. *Advances in Animal and Veterinary Sciences*, 2(4), 218–221.
- Bhatia, K. C., Kulshreshtha, R. C., & Paul Gupta, R. K. (1983). Pulmonary aspergillosis in camel. *Haryana Veterinary*, XXII, 118–119.
- Dehkordi, F. S., Momtaz, H., & Doosti, A. (2012). Detection of *Aspergillus* species in aborted ruminant fetuses. *Bulgarian Journal of Veterinary Medicine*, 15(1), 30–36.
- El-Khouly, A.-B., Gadir, F. A., Cluer, D. D., & Manefield, G. W. (1992). Aspergillosis in camels affected with a specific respiratory and enteric syndrome. *Australian Veterinary Journal*, 69(8), 182–186.
- Gabri, N. A. (2012). *Fatal invasive aspergillosis in camels in Saudi Arabia*. Cited by Refai et al., 2016.
- Gareis, M., & Wernery, U. (1994). Determination of Gliotoxin in samples associated with cases of intoxication in camels. *Mycotoxin Research*, 10, 2–8.
- Refai, K. R., El-Naggar, A., & Tamam, O. (2016). *Monograph on fungal diseases of camelidae; A guide for postgraduate students*. <http://www.researchgate.net/publication>.
- Scaglione, E. E., Peano, A., Piga, S., Meda, S., Bollo, E., Cannizo, F. T., Pasquetti, M., & Jensen, H. E. (2017). Scrotal granulomatous aspergillosis in a dromedary camel (*Camelus dromedarius*). *BMC Veterinary Research*, 13(1), 1–5.
- Wernery, U., & Kaaden, O. R. (2002). *Infectious diseases in camelids*. Blackwell Science.

Mansour F. Hussein

Candidiasis or Moniliasis is a common fungal disease of man, birds, domestic and wild animals. It may infect any organ or system and may cause generalized infection.

---

## 36.1 Etiology

The disease is distributed worldwide and is most commonly caused by *Candida albicans*, a commensal of the mucous membranes of the nasopharynx and the intestinal and genital tracts. Other species of *Candida* and other yeasts may also be involved.

---

## 36.2 Modes of Transmission

Infection is transmitted via ingestion of contaminated food or water and is more commonly encountered in young animals, especially in the presence of predisposing factors such as malnutrition or prolonged exposure to immunosuppressive and antibacterial treatment.

---

## 36.3 Clinical Picture

Candidiasis has been incriminated as a cause of skin, gastrointestinal tract, genital tract, eye and ear infections, systemic candidiasis, and mastitis in camels. Wernery and Kaaden, (2002) described cutaneous *C. albicans* infection in a 6-week-old camel calf which developed thick crusts on its hump in which *C. albicans* hyphae were shown with PAS staining. According to Tuteja et al. (2010), skin lesions of candidosis in the camel start on the hump region and subsequently enlarge and coalesce, extend to the abdomen, and sometimes spread to the whole body.

The fungus has also been reported to cause alimentary tract infection (Wernery and Kaaden, 2002) and otitis (Pal, 2015) in camels. The latter authors reported candidiasis in 8–48 hours old camel calves which developed a yellowish diarrhea. Upon necropsy, yellow pseudomembranes were found in the small intestines of the animals, and smears from the intestinal mucosa revealed *C. albicans* and *Clostridium perfringens* organisms. Microscopic investigation showed necrosis of the mucous membranes invaded by yeast cells that were limited to the epithelial tissue. The dromedary calves had also developed coli septicemia and some of them developed clostridial enterotoxemia. Ulcers containing large numbers of *C. albicans* organisms were also observed in the abomasum.

*Candida albicans* has been isolated from pneumonic camels and from apparently healthy camel udders and has rarely been associated with mastitis in she-camels in some countries including the Sudan (Mohammed, 1996; Salwa, 1995), Iraq (Abdulkadhim, 2012), and Ethiopia (Pal, 2015). Besides, different *Candida* spp. have been isolated from the nasopharyngeal cavity of apparently healthy camels (Mahmoud et al., 2005; Nawal et al., 1991; Osman et al., 2003), with *C. albicans* being the most abundant and clinically important species.

---

## 36.4 Diagnosis

Diagnosis can be achieved by direct examination of clinical material and isolation of the fungus on specific culture media such as Sabouraud dextrose agar. Different serological tests are also available. Other tests include molecular tests such as PCR, as well as histopathological examination of tissue specimens, animal inoculation, and intradermal tests.

---

## 36.5 Treatment and Control

Different antifungal drugs may be used to treat fungal infection in camels. These include amphotericin B, nystatin, griseofulvin, imidazole, ketoconazole, clotrimazole, fluconazole, itraconazole, and sodium iodide. For external infection, e.g., skin infection, topical therapy may be applied using 2% tincture of iodine solution or 10% iodine ointment daily for 3 weeks or Enilconazole wash or spray with diluted emulsion (2000 ppm) four times at 3–4-day intervals.

Prevention and control of candidosis and other fungal diseases requires isolation of infected animals, minimizing predisposing factors and preventing disease spread by implementing appropriate hygienic measures.

---

## References

- Abdulkadhim, M. A. (2012). Isolation of *Candida* sp. from sub-clinical mastitic she-camels. *Alkoufa Journal of Veterinary Medical Science*, 3(1), 1–9.

- Mahmoud, M. A., Osman, W. A., El-Naggar, A. L., & Balata, A. (2005, April 26–28). Prevalence of respiratory diseases in Shalateen, Halaieb and Abou-Ramad. In *2nd International Scientific Conference*. Guena and Luxor.
- Mohammed, A. M. A. (1996). *Bacteria and fungi isolated from she-camel mastitis in the Red Sea area of the Sudan*. B.V.Sc. University of Khartoum.
- Nawal, G., Ahmed, L. S., Ali, S. M., Elyas, A. H., Nashed, S. M., & Amer, A. A. (1991). Myco and microflora of the nasal cavity of apparently healthy camels. *Assuit Veterinary Medical Journal*, 24, 125–130.
- Osman, W. A., Wafa, A., Mahmoud, M. A., El-Naggar, A. L., & Balata, M. A. (2003). Microbiological studies on nasopharyngeal cavity of apparently healthy camels at Shalateen, Halaieb and Abou-Ramad areas. *Beni-Suef Veterinary Medical Journal*, 13(1), 159–167.
- Pal, M. (2015). First record of camel mastitis due to candida albicans in Ethiopia. *Indian Journal of Comparative Microbiology, Immunology and Infectious Diseases*, 36(1), 32–34.
- Salwa, M. S. (1995). *Studies on camel mastitis, etiology, clinical picture and milk composition* [M. V.Sc. thesis]. University of Khartoum.
- Tuteja, F. C., Pathak, K. M. L., Ghorui, S. K., Chirania, B. L., & Kumar, S. (2010). Skin candidiasis in dromedary camel calves. *Journal of Camel Practice and Research*, 17(1), 59–61.
- Wernery, U., & Kaaden, O. R. (2002). *Infectious diseases in camelids*. Blackwell Science.

Mansour F. Hussein

Cryptococcosis is particularly common in cats but has also been reported in almost all domesticated animals including pets, equines, and farm animals. The infection has been reported several times in South American camelids (Refai et al., 2016) but only once in a dromedary camel in Saudi Arabia (Ramadan et al., 1989).

---

## 37.1 Etiology

Cryptococcosis in camelids is caused by *Cryptococcus neoformans* and *C. gattii*. These are ubiquitous saprophytic fungi inhabiting the soil and are characterized by their large heteropolysaccharide capsule that does not take up common cytologic stains and forms a clear halo in preparations stained with India ink.

---

## 37.2 Clinical Picture

Tissue reactions in *cryptococcus* infection depend on the organ affected and comprise two basic histological patterns: gelatinous and granulomatous. The latter reaction consists of histiocyte, giant cell, and lymphocyte infiltration, modified by secondary bacterial infection.

---

## 37.3 Diagnosis

Initial diagnosis of cryptococcosis is based on direct microscopic examination of India ink-stained preparations, while definitive diagnosis is confirmed by cultural methods of samples of cerebrospinal fluid (CSF) or blood, and sometimes respiratory secretions. Both *C. neoformans* and *C. gattii* grow well at 37 °C. on Sabouraud dextrose agar medium in which the colonies appear as soft, creamy, and opaque

colonies within 3–5 days, then become mucoid and creamy to tan. Other yeasts develop white to creamy colonies.

Several molecular techniques have been used for subtyping *C. neoformans* and *C. gattii* strains. For serological diagnosis, cryptococcal antigen from cerebrospinal fluid constitutes a sensitive test for diagnosis of cryptococcal meningitis. Rapid diagnostic methods to detect cryptococcal antigen include latex agglutination test, lateral flow immunochromatographic assay (LFA), ELISA and enzyme immunoassay (EIA), and Rapid latex agglutination.

---

## 37.4 Treatment

No specific information exists on the treatment of cryptococcosis in dromedary camels. However, various antifungal drugs such as Azoles have been used in treating pets and other animals.

---

## References

- Ramadan, R. O., Fayed, A. A., & El-Hassan, A. A. (1989). Cryptococcosis in a camel (*Camelus dromedarius*). *Agris*, 37(1), 77–82.
- Refai, K. R., El-Naggar, A., & Tamam, O. (2016). *Monograph on fungal diseases of camelidae; A guide for postgraduate students*. <http://www.researchgate.net/publication>.

---

## **Part IV**

# **Ectoparasitic Diseases of Dromedary Camels**



# Mange Mite Infestation (Sarcoptes, Demodex, Psoroptes, and Chorioptes)

# 38

Ahmed A. Gameel

## 38.1 Introduction to Ectoparasites of Dromedary Camels

Many diseases of various etiologies have been reported to affect camels in different regions; among these are parasitic diseases. Ectoparasites may cause severe disease affecting animal health and productivity with negative economic impact, and may also act as vectors for bacterial, parasitic, and viral diseases (Wernery et al., 2014). The host responses depend on the type and species of ectoparasite, site and intensity of infestation, and host immune status. The responses may progress from mild cutaneous reaction, pruritis, and alopecic or ulcerating nodules to hyperkeratotic dermatitis. The lesions may predispose to secondary infections with unwanted systemic reactions.

Determination of the nature and distribution of lesions caused by ectoparasites depends greatly on thorough examination of the skin surface. The areas affected can initially be visualized from a short distance before being closely examined by passing the hand over skin and palpation. Systemic approach of inspection should be adopted starting with the head and neck, trunk and perineum, inguinal region, and udder and then the limbs. By careful examination, abnormalities in the skin could be noted; nature site, number, and size of lesions can be observed, together with self-inflicted damage. All lesions should be well observed. Appropriate samples should be taken for laboratory diagnosis. One important sample is skin scraping which should be taken, preserved, and treated following standard methodology (Soulsby, 1982). Biopsy specimens are useful for diagnosis of skin diseases. Punch or excision biopsies can be properly taken from a representative lesion, attached to a flat surface (pieces of cardboard or thick paper) for maximum 30 sec., to avoid warping. The samples are then fixed in ten times the volume of 10% phosphate buffered formalin. Paraffin sections will be prepared and stained with hematoxylin and eosin for histopathology.

The ectoparasites affecting camels are mites (Acari), ticks, lice, fleas, and flies. Reports are available from different camel raising countries. Mange mite infestation caused by sarcoptes, demodex, psoroptes, and chorioptes mites has been described

in camels from different countries but sarcoptes is by far the most commonly involved. The disease irrespective of the causative mite is locally called “djarab” in many Arab countries. In Tharparkar district, Sindh Province, Pakistan it is called “Khaaji”; in the Netherlands it called “Schurfmijt” and in Germany, the local names Kraetzemilbe; Raeudemilbe; Hundesarcopest” are given. The French term for mange is “la gale” (Pangui, 1994), and in English, it is called “itch” or “scabies”; a term specifically given to Sarcoptes mange.

---

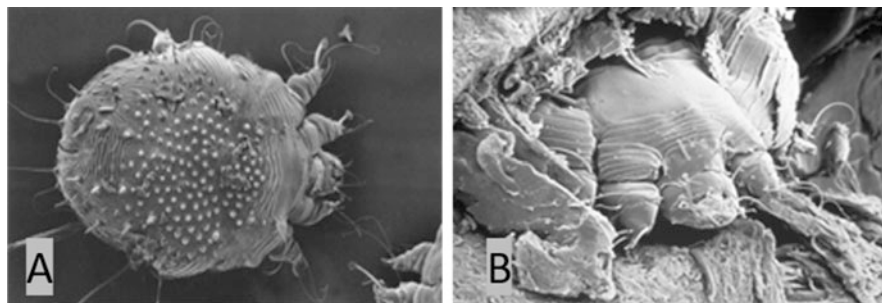
## 38.2 Sarcoptic Mange

*Sarcoptes scabiei var cameli* is the cause of the most common mange infestation in the camels (OIE, 2019; Schillinger, 1987). Varying prevalence has been reported in Africa (e.g., Egypt, Ethiopia, Kenya, Nigeria, Sudan, Morocco), Asia (e.g., Afghanistan, India, Pakistan), and the Middle East (Iraq, Iran, Jordan, Saudi Arabia) (Abdally, 2010; Abu-Samra et al., 1981; Admassu et al., 2005; Ahmed et al., 2020; Al-Rawashdeh et al., 2000; Ashraf et al., 2014; Kamili et al., 2019; Mochabo et al., 2005; Muhammad et al., 2006; Nayel & Abu-Samra, 1986; Sazmand & Joachim, 2017) (Fig. 38.1). The disease is contagious and of zoonotic significance; cases in human have been documented, particularly camel herdsman, attendants, and riders. Direct transmission from camel to man is common, resulting in the condition termed pseudoscabies. Transmission may occur during milking causing lesions mainly in the interdigital spaces of the hands, the flexor surface of the wrists, the forearms, the elbows, and axillary folds. In camel riders, the lesions occur between the thighs (Schillinger, 1987). The mites burrow tunnels in the *stratum corneum* feeding on epithelial cells and serum resulting in skin damage with pruritus (the cardinal symptom). Occurrence is often associated with poor management, crowding, and mingling with stray or newly introduced camels which introduce the parasite to clean herds.

### 38.2.1 Etiology

The causative agent of sarcoptic mange in camels is *Sarcoptes scabiei var. cameli* (Richard, 1987). Fain (1994) stated that “there is one valid but variable species in the genus Sarcoptes. The wide variability of *S. scabiei* suggests that it is not completely adapted to any of the hosts but remains in a continuous process of adaptation.” It is a tiny, rounded parasite (Fig. 38.2), where the dimensions of the female and male are 330–600µm × 250–400µm and 200–240µm × 150–200µm, respectively (Ahmed et al., 2020). Based on morphological characteristic features these mites have circular outline with four pairs of short and stumpy legs. The third and fourth pair of legs do not project beyond the body margins (Nayel & Abu-Samra, 1986).





**Fig. 38.2** Scanning electron microscope (SEM) image of *Sarcoptes scabiei* var. *cameli* x690, Photo by S Bornstein and T Nikkilä (a), and a *Sarcoptes scabiei* looking out from its burrow in hyperkeratotic skin, SEM x1560, (b) (Courtesy of Dr. Set Bornstein)

### 38.2.2 Modes of Transmission

Mange mites can be transmitted by direct contact between animals transmitting larvae, nymphs, or adults or indirectly through fomites (harness, luggage, ropes, blankets) or less likely from the soil. All developmental stages are capable of migration on the skin surface and can penetrate it. The life cycle lasts 4–5 weeks. Fertilized females dig tunnels in the epidermis inciting inflammation and severe itching. The six-legged larvae emerge within 2–4 days and molt after 2–3 days to eight-legged nymphs. Another molt occurs after 3–4 days to produce a male mite or a pubescent female (Higgins, 1985). Incubation period lasts 2–3 weeks, but at reinfection the incubation period is much shorter. The parasite survives off the host for about 2 weeks (Richard, 1987).

### 38.2.3 Sites of Infection

The parasite can infest all parts of the skin starting with that of the head and neck region and extending to areas of thin skin, i.e., flanks, abdomen (Fig. 38.3), prepuce, udder, etc. Generally, dorsal aspects and hump are not involved.

### 38.2.4 Factors Affecting Mange Infection

- Sex: Both male and female camels can be infested but females are reported to be more affected (Awol et al., 2014). Hormonal factors (high prolactin and progesterone levels) and the stress of pregnancy and lactation could render females more susceptible (Awol et al., 2014; Lloyd, 1983). However, some reports mentioned that males were more affected.
- Age: Animals of all ages contract mange but it is repeatedly stated that young and old camels are more prone to infection (Jarso et al., 2018; Richard, 1987).



**Fig. 38.3** Cases of *Sarcoptic* mange in a dromedary camel herd, 2017, UAE (Courtesy of Dr. Abdelmalik Khalafalla)

- Season: Most reports indicate that the prevalence of mange increases in winter and rainy seasons (Higgins, 1985; Jarso et al., 2018; Richard, 1987).
- Poor management and Malnutrition are important factors (See Fassi-Fehri, 1987; Higgins, 1985; Jarso et al., 2018).
- Crowding, particularly in dairy camels, allows contact between animals and favors transmission of the disease.
- Introduction of new camels without quarantine measures.
- Immunodepression associated with malnutrition, concurrent diseases, and stressful conditions.
- Stressful conditions and breeding behavior of males are also considered risk factors.

### 38.2.5 Clinical Picture and Pathology

Burrowing of the parasite and subsequent feeding beneath the skin cause an intense pruritus. Erythema, small papular elevations, and vesicles are felt as evidence of early inflammatory reactions to the mite's invasion and injury to the skin. They may stop grazing and milk production may show a rapid fall. In severe acute sarcoptic mange, most of the body surface may be involved and if untreated the camel rapidly

lose condition. This invasive stage takes about 2 weeks. As irritation increases, the camel rubs, bites, and scratches the affected areas to alleviate the itchiness. The skin becomes excoriated, with hair loss serous exudation and scab formation. Falling scabs may disclose red erosions underneath. This is followed by a hyperkeratotic stage characterized by dry, hard skin with crusts, loss of hair, and thickening of the skin at different infested sites (neck, thigh, and around joints). These changes will predispose to secondary bacterial infections with abscess formation and possibly general debility.

Microscopically, superficial dermatitis with eosinophil, lymphocyte, and mast cell infiltration may be seen together with areas of parakeratosis. In advanced cases, chronic dermatitis may develop with acanthosis hyper-and parakeratosis and inflammatory cell infiltration.

---

### 38.3 Demodectic Mange

This is the second important mange infection in camels caused by *Demodex folliculorum cameli*. The parasites live their entire life cycle in the lumens of hair follicles and sebaceous glands forming nodules stuffed with the mites, hence the name follicular mites. Demodex mites (65 species) can infest domestic animals (*D. canis*, *D. comei*; *D. injai*; *D. gato*; *D. cati*; *D. bovis*) and humans (*D. brevis* and *D. folliculorum*). The mites are specific to their hosts, and so demodicosis cannot be transferred cross species and has no zoonotic potential. Infestation of camels has been reported from some countries like Egypt, Iraq, Iran, Kenya, and Saudi Arabia (Bornstein, 2001; Hussain et al., 2012; Kahn et al., 2005; Khalafalla et al., 2017; Sabra et al., 2012). The Demodex mite is an eight-legged parasite that can reside in hair follicles and sebaceous glands. The adult mites are long and slender (worm shaped) with short legs measuring approximately 0.30 mm long by 0.05 mm wide.

#### 38.3.1 Modes of Transmission

Transmission of the parasite from host to host occurs during close contact from the dam to the offspring mainly during suckling. Skin nodules may enlarge, rupture, and exude the mites, resulting in infestation of the young and other animals in close contact. The mite body is covered with scales for anchoring itself in the hair follicle, and the mite has pin-like mouthparts for eating skin cells and oils which accumulate in the hair follicles. The mites can leave the hair follicles and crawl out onto the epidermal surface of their host. Both male and female Demodex mites have a genital opening, and fertilization is internal. Mating takes place in the follicle opening, and eggs are laid inside the hair follicles or sebaceous glands. The six-legged larvae hatch and develop into adults. The total lifespan of a Demodex mite may take several weeks.



### 38.3.2 Clinical Picture

The disease is characterized by the presence of small, circumscribed skin nodules about 1–2 cm in diameter which may contain large numbers of mites. More advanced lesions have been described: thickened skin, moist dermis, white to gray crusts, and loss of hair. Microscopic changes are not significant but distention of hair follicles with large numbers of mites and peri-folliculitis may be observed. Secondary bacterial infections are associated with neutrophil infiltration.

### 38.3.3 Site of Infection

The parasite affects the shoulders, brisket, legs, thighs, and rarely hump. In some of the affected camels, the eyelids were the main site of infestation. Papules usually appear on the face, neck, auxiliary region, or udder.

### 38.3.4 Factors Affecting Infection

- Poor management and Malnutrition.
- Crowding, particularly in dairy camels and prolonged contact with offspring.
- Introduction of new camels without quarantine measures.
- Immunodepression associated with malnutrition, concurrent diseases, and stressful conditions.
- Age: young suckling animals may be at high risk.

---

## 38.4 Psoroptic and Chorioptic Mange

Both psoroptes and choriopes mites can infest camels but this is rare and non-specific. Available literature (Gabaj et al., 1992) documents one case for psoroptic and two cases for chorioptic mange in the dromedary camel. Reports are also available for one llama and three alpacas (Cremers, 1984). Accordingly, little information can be obtained about both diseases in the dromedary camel.

Psoroptic mites feed superficially at the [stratum corneum](#); cause lesions on the ear, neck, and probably other sites, as reported in llamas and alpacas. The mite lives its entire life under the margins of scabs formed at infested sites inciting an inflammatory reaction with exudation and crust formation. Scabby dermatitis with mild hyperkeratosis may develop. Transmission occurs between animals by direct contact.

Choriopes mite causes chorioptic mange (barn itch) in domestic animals. This mite occurs primarily on the legs and feet and probably other sites like neck tail and udder, where all the developmental stages are likely to exist. The mites can feed on scales and tissue debris at the skin surface without necessarily digging in the intact skin, causing hyperemia and scab formation with pruritis. Chorioptic mange is

relatively mild condition, more localized and less pruritic compared to sarcoptic or psoroptic mange.

---

## **38.5 Diagnosis**

### **38.5.1 Clinical Diagnosis**

Sarcoptic mange can be diagnosed clinically from the concurrence of pruritus, depilation, and encrusted plaques. Only the invasive stage may be difficult to diagnose, but the intense pruritus is a characteristic feature. The hyperkeratotic stage is easy to recognize by marked loss of hair, thickening, and folding of skin.

Demodectic mange species are considered normal mammalian fauna and localized forms may resolve spontaneously. The disease is characterized by the presence of small, circumscribed skin nodules about 1–2 cm in diameter which may contain large numbers of mites. Itching and loss of hair or secondary infections are not usually observed, as in sarcoptes mange.

Chorioptic mange can be recognized clinically by the location of lesions, less invasiveness and damage to the skin, and less intense pruritis. Infestation tends to concentrate on the lower portions of the host, especially the feet and legs.

Psoroptes mites have mild and superficial infestation on skin with varying degrees of pruritis in camels. The mite lives its entire life under the margins of scabs formed at infested sites causing inflammatory reaction mainly on the ear, neck, and, as reported in llamas and alpacas.

### **38.5.2 Laboratory Diagnosis**

Diagnosis of mites can be done on deep skin scrapings from affected animals using scalpel blade (until capillary bleeding is seen). In the lab the scrapings could be placed under a stereo-microscope—heated slightly and after 10–30 minutes checked for living mites. These could be picked up and placed on a slide with some oil under a cover glass and looked at under a microscope for proper morphological diagnosis.

The collected skin scrapings could be transferred to test tubes, mixed with a small amount of 10% potassium hydroxide solution and heated till just boiling or left to stand for 0.5–1 h until the skin particles disintegrate. The tubes are then centrifuged at 3000 revolutions per minute, the supernatant fluid discarded, and a drop of sediment examined under a stereoscopic microscope for the detection of the various stages of sarcoptic mites and their eggs (Ahmed et al., 2020 citing Köhler-Rollefson et al., 2001).

Alternatively, the scrapings could be collected in wide mouthed glass tubes containing 10% KOH to release mites from scabs and crusts. In case of nodular skin lesion suspected to be due to demodectic mange, the nodule content is extruded and smeared for microscopic examination before digestion with KOH. The examination can be done directly or after heating the tubes for 2 minutes at 38 °C. The



parasites detected can then be identified based on morphological characteristics using standard key reference (Soulsby, 1982; Urquhart et al., 1996). Skin scrapings can be preserved in 10% formalin (Feyera et al., 2015) and transported to the laboratory for digestion with 10% KOH.

Skin biopsy may be taken from the margin of lesions, fixed in 10% phosphate buffered formalin for histopathology. Paraffin sections stained by hematoxylin and eosin are useful for establishing diagnosis.

Diagnosis of mange infestation can be achieved by serology (ELISA). Measurable specific antibodies against *Sarcoptes scabiei* and *Psoroptes ovis* infestations in pigs, sheep, dogs, and camels have been detected (Bornstein et al., 1997; Falconi et al., 2002; Lowenstein et al., 2004; Lower et al., 2001). ELISA that detects antibodies to *Sarcoptes* in pigs and dogs is commercially available and has been used for serodiagnosis of scabies in Sweden and Switzerland (Lowenstein et al., 2004). Recombinant antibodies for *S. scabiei* and *P. ovis* are commercially available, and they seem to give more consistent test results than whole mite preparations.

It is also possible to detect mite infestations by molecular techniques. DNA of *Sarcoptes scabiei* has been successfully amplified and detected by PCR from human cutaneous scales (Bezold et al., 2001). This is a promising technique for detecting specific mange mites in skin scrapings. In addition, DNA sequencing for identification of mites' specimens has been approached (Mofiz et al., 2016; World Animal Health Organization (OIE), 2019).

---

## 38.6 Differential Diagnosis

The various types of mite infestation can be differentiated by the clinical symptoms, the gross features and location of the lesions, and identification of the parasite in skin scrapings as mentioned earlier.

Diseases that must be differentiated from mange include pox, Contagious ecthyma, dermatomycosis (ringworm), streptothricosis, contagious skin necrosis, photosensitization, and [parakeratosis](#). Description and diagnosis of these diseases are adequately covered in the relevant parts on camel diseases.

Camel pox can be differentiated from mange by the classical lesions (macules, papules, pustules, vesicles, scabs or crusts, and scars), enlargement of lymph nodes, fever, and lack of pruritis.

Contagious ecthyma is characterized by proliferative, crusty/scabby epidermal lesions around the mouth (lips and nostrils) and eyes. Clinically, it can be diagnosed from the lesions which first appeared as small papules progressing to scabs and crusts which fall off within 4–7 weeks.

Dermatomycosis causes necrotic dermatitis and scale formation on the skin of the head, neck, and shoulders. The lesions differ from that of mange by their circular, grayish-white, alopecic appearance which is often non-pruritic. Fungal hyphae and conidia can be demonstrated in skin scrapings.

Dermatophilosis caused by *Dermatophilus congolensis*. Diagnosis is based on clinical signs, characteristic lesions (matted hair patches with paint-brush

appearance) and crusts on affected body parts, and demonstration of *D. congolensis* in smears from scabs or exudate.

Contagious skin necrosis can be differentiated from mange by the appearance of small painful skin swelling which break open, exuding pus, becomes well demarcated from the surrounding normal skin, in addition to enlargement of regional lymph nodes.

Parakeratosis is dietary problem associated with excessive consumption of calcium and zinc deficiency. It is non-pruritic and can be treated by monitoring blood Ca levels and supplementing zinc salts. Diagnosis is by measuring blood Ca and Zn levels.

Photosensitization causes exudation of serum onto the skin's surface followed by drying, fissuring, and sloughing of necrotic skin and it can be pruritic. Differentiation can be made by the nature and development of lesions and failure to detect mites in skin scraping.

---

## 38.7 Treatment and Control

Control of mange mites on camels can be achieved by application of chemicals, but the disease is not easy to treat as in case of sarcoptic mange, particularly the hyperkeratotic chronic form (Higgins, 1985). In such chronic cases clipping of hair and removal of scabs and crusts prior to treatment greatly enhances cure (Nayel & Abu-Samra, 1986). Topical application of acaricides has not been always successful due to the difficulty in spraying or dipping large numbers of affected camels when the disease is established in a herd. Hexachlorocyclohexane (HCH), deltamethrin, and ivermectin have been reported to be effective for the treatment of mange in camels (Teame, 1997). Treatment can be achieved by (a) application of two doses of 0.1% diazinon as spray 10 days apart, and (b) two doses of Ivomec (ivermectin) given 10 days apart at dose of 0.2 mg/kg body weight injected subcutaneously. Lindane 0.05% has been used by rubbing or as spray and repeated after 8–15 days. A study from in Saudi Arabia showed that the activity of Dectomax (Doramectin) was stronger and last longer than Ivomec as it reduced the number of mites on camels affected by sarcoptic mange 4 weeks after treatment (Abdally, 2010). Oral administration of vitamin and mineral supplements is advocated as supportive treatment (Fassi-Fehri, 1987). Successful treatment should improve the clinical score and clear skin from infection.

Objects in contact with the infested animal and those used during treatment should be eliminated or treated.

---

## References

- Abdally, M. H. (2010). Acaricidal efficacy of Ivomec (ivermectin) and Dectomax (doramectin) on sarcoptic mange mites (*Sarcoptes* spp.) of Arabian camels (*Camelus dromedarius*) in Saudi Arabia. *Journal of Entomology*, 7(2), 95–100. <https://doi.org/10.3923/je.2010.95.100>

- Abu-Samra, M. T., Imbabi, S. E., & Mahgoub, E. S. (1981). Mange in domestic animals in the Sudan. *Annals of Tropical Medicine and Parasitology*, 75, 627–637.
- Admassu, B., Nega, S., Haile, T., Abera, B., Hussein, A., & Catley, A. (2005). Impact assessment of a community-based animal health project in Dollo Ado and Dollo Bay districts, southern Ethiopia. *Tropical Animal Health and Production*, 37(1), 33–48.
- Ahmed, M. A., Elmahallawy, E. K., Gareh, A., Abdelbaset, A. E., El-Gohary, F. A., Elhawary, N. M., Dyab, A. K., Elbaz, E., & MFN, A. (2020). Investigation of sarcoptic mange in camels in Egypt epidemiological and histopathological. *Animals (Basel)*, 10(9), E1485. <https://doi.org/10.3390/ani10091485>
- Al-Rawashdeh, O. F., Al-Ani, F. K., Sharraf, L. A., Al-Qudah, K. M., Al-Hami, Y., & Frank, N. (2000). A survey of camel (*Camelus dromedarius*) diseases in Jordan. *Journal of Zoo and Wildlife Medicine*, 31, 335–338.
- Ashraf, S., Chaudhry, S. H., Chaudhry, M., Iqbal, Z., Ali, M., Jamil, T., Sial, N., Shahzad, M. I., Basheer, F., Akhter, S., Ur Rehman, S. H., & Yasin, A. (2014). Prevalence of common diseases in camels of Cholistan Desert, Pakistan. *Journal of Infection and Molecular Biology*, 2, 49–52. <https://doi.org/10.14737/jimb.2307-5465/2.4.49.52>
- Awol, N., Kiros, S., Tsegaye, Y., Ali, M., & Hadush, B. (2014). Study on mange mite of camel in Raya-Azebo district, northern Ethiopia. *Veterinary Research Forum*, 5(1), 61–64.
- Bezold, G., Lange, M., Schiener, R., Palmedo, G., Sander, C. A., Kersscher, M., & Peter, R. U. (2001). Hidden scabies: Diagnosis by polymerase chain reaction. *The British Journal of Dermatology*, 144, 614–618.
- Bornstein, S. (2001). Skin diseases of camels in: Camel keeping in Kenya. Ed. Evans, J.O., S. Piers Simpkin and D.J. Atkins. *Range Management Handbook of Kenya*, 3(8), 7–13.
- Bornstein, S., Thebo, P., Zakrisson, G., Abu-Samra, M. T., & Muhammed, G. E. (1997). Demonstration of serum antibody to *Sarcoptes scabiei* in naturally infected camels: A pilot study. *Journal of Camel Practice and Research*, 4, 183–185.
- Cremers, H. (1984). The incidence of chorioptes-bovis (acarina, psoroptidae) in domesticated ungulates. *Intropical and geographical medicine*, 36(1), 105–105.
- Falconi, F., Ocho, H., & Deplazer, P. (2002). Serological cross-sectional survey of psoroptic sheep scab in Switzerland. *Veterinary Parasitology*, 109, 119–127.
- Fain, A. (1994). Adaptation, specificity and host-parasite coevolution in mites (ACARI). *International Journal for Parasitology*, 24(8), 1273–1283.
- Fassi-Fehri, M. (1987). Diseases of camels. *Revue scientifique et technique (International Office of Epizootics)*, 6, 337–354.
- Feyera, T., Admasu, P., Abdilahi, Z., & Mummed, B. (2015). Epidemiological and therapeutic studies of camel mange in Fafan zone, Eastern Ethiopia. *Parasites & Vectors*, 1(8), 612. <https://doi.org/10.1186/s13071-015-1228-0>
- Gabaj, M. M., Beesley, W. N., & Awan, M. A. Q. (1992). A survey of mites on farm animals in Libya. *Annals of Tropical Medicine and Parasitology*, 86(5), 537–542.
- Higgins, A. J. (1985). Common ectoparasites of the camel and their control. *The British Veterinary Journal*, 141, 197–216. [https://doi.org/10.1016/0007-1935\(85\)90153-8](https://doi.org/10.1016/0007-1935(85)90153-8)
- Hussain, M. H., Habasha, F. G., & Faraj, M. K. (2012). Demodectic mange in Iraqi camels. *AL-Qadisiya Journal of Veterinary Medicine Sciences*, 11(1), 1–5.
- Jarso, D., Birhanu, S., & Wubishet, Z. (2018). Review on epidemiology of camel mange mites. *Biomedical Journal of Scientific & Technical Research*, 8(1). <https://doi.org/10.26717/BJSTR.2018.08.001605>
- Kahn, C. M., Line, S., Allen, D. G., Anderson, D. P., & Jeffcoth, L. B. (2005). *Acariasis mite infestation*. In *the Merck veterinary manual* (9th ed., pp. 742–749). Merck and Co Inc.
- Kamili, A., Faye, B., Bengoumi, M., & Tligui, N. S. (2019). Camel skin diseases survey in Morocco. *Journal of Camelid Science*, 2019(12), 1–16.
- Khalafalla, A. I., Ramadan, R. O., Rector, A., & Barakat, S. (2017). Investigation on papillomavirus infection in dromedary camels in Al-Ahsa, Saudi Arabia. *Open Veterinary Journal*, 7(2), 174–179. <https://doi.org/10.4314/ovj.v7i2.16>

- Köhler-Rollefson, I., Mundy, P., & Mathias, E. (2001). *A field manual of camel diseases; traditional and modern health care for the dromedary* (p. 272). Practical Action.
- Lloyd, S. (1983). Effect of pregnancy and lactation upon infection. *Veterinary Immunology and Immunopathology*, 4(1–2), 153–176.
- Lowenstein, M., Kahlbacher, H., & Peschke, R. (2004). On the substantial variation in serological responses in pigs to *Sarcoptes scabiei* var. *suis* using different commercially available indirect enzyme-linked immunosorbent assay. *Parasitology Research*, 94(1), 24–30.
- Lower, K. S., Midleau, L. M., Hanilica, K., & Bigler, B. (2001). Evaluation on an enzyme-linked immunosorbent assay (ELISA) for the serological diagnosis of sarcoptic mange in dogs. *Veterinary Dermatology*, 12(6), 315–320.
- Mochabo, K. O., Kitale, P. M., Gathura, P. B., Ogara, W. O., Catley, A., Eregae, E. M., & Kaitho, T. D. (2005). Community perceptions of important camel diseases in Lapur division of Turkana District, Kenya. *Tropical Animal Health and Production*, 37(3), 187–204.
- Mofiz, E., Holt, D. C., Seemann, T., Currie, B. J., Fischer, K., & Papenfuss, A. T. (2016). Genome resources and draft assemblies of the human and porcine varieties of scabies mites, *Sarcoptes scabiei* var. *hominis* and var. *suis*. *Gigascience*, 5(1), 23. <https://doi.org/10.1186/s13742-016-0129-2>
- Muhammad, G., Jabbar, A., Iqbal, Z., Athar, M., & Saqib, M. (2006). A preliminary passive surveillance of clinical diseases of cart pulling camels in Faisalabad metropolis (Pakistan). *Preventive Veterinary Medicine*, 76(3–4), 273–279.
- Nayel, N. M., & Abu-Samra, M. T. (1986). Sarcoptic mange in the one-humped camel (*Camelus dromedarius*): A clinico-pathological and epizootiological study of the disease and its treatment. *Journal of Arid Environments*, 10(3), 199–211.
- Pangui, L. J. (1994). Mange in domestic animals and method of control. Ectoparasite of animals and control method. *OIE Review*, 13, 1227–1247.
- Richard, D. (1987). Camel mange. *Revue scientifique et technique (International Office of Epizootics)*, 6(2), 475–477.
- Sabra, S. M., Al-Harbi, M. S., & AL-Bashan, M. M. (2012). Considering the extend of mange disease in camels through the summer season at Taif region, KSA. *Assiut Veterinary Medical Journal*, 58(135), 60–65.
- Sazmand, A., & Joachim, A. (2017). Parasitic diseases of camels in Iran (1931–2017)—A literature review. *Parasite*, 24, 21.
- Schillinger, D. (1987). Mange in camels—An important zoonosis. *Revue Scientifique et Technique*, 6(2), 479–480.
- Soulsby, E. J. L. (1982). *Helminths, arthropods and protozoa of domestic animals* (7th ed.). Lea and Febiger.
- Teame, G. (1997). An assessment of the efficacy of deltamethrin with HCH for the treatment of sarcoptic mange in camels. *Tropical Animal Health and Production*, 29(1), 33–34. <https://doi.org/10.1007/bf02632345>
- Urquhart, G. M., Amour, J. L., Dunn, A. M., & Jennings, F. W. (1996) *Veterinary parasitology* (2nd ed., pp. 141–205). Blackwell Publishing.
- Wernery, U., Kinne, J., & Schuster, R. K. (2014). *Camelid infectious disorders*. Paris: World Organization for Animal Health (OIE).
- World Animal Health Organization (OIE). (2019). Mange. Chapter 3.9.7 [https://www.oie.int/fileadmin/Home/eng/Health\\_standards/tahm/3.09.07\\_MANGE.pdf](https://www.oie.int/fileadmin/Home/eng/Health_standards/tahm/3.09.07_MANGE.pdf).

Ahmed A. Gameel

Ticks are one of the most important bloodsucking ectoparasites, which infest and transmit serious diseases to animals and humans (Dantas-Torres et al., 2012; Gosh et al., 2007). They serve as vectors to numerous pathogens including protozoans (Trypanosomiasis), rickettsia (ehrlichiosis), viruses (e.g., Foot and mouth disease), bacteria (e.g., *Pasteurella* spp., *Brucella*, *Listeria* spp., and *Staphylococcus*), and spirochetes (Jongejan & Uilenberg, 2004).

Tick infestations in camels have been frequently recognized in many countries and species of several tick genera have been reported, e.g., *Hyalomma*, *Amblyomma*, *Rhipicephalus*, *Dermacentor*, *Ixodes*, *Argas*, *Otobius*, and *Ornithodoros* (Wernery et al., 2014). According to Khelifi-Ouchene et al. (2020), the Algerian camels are significantly more infested with ticks than other skin diseases.

Infestation is reported to be generally high in the rainy season and summer and occurs in animals throughout the year. Female camels may harbor more ticks than males and gray skins may be more attractive to the ticks (Dantas-Torres et al., 2012; Gosh et al., 2007).

---

### 39.1 Etiology

Several species of the genus *Hyalomma* have been identified in camels in various countries; these species include *H. dromedarii*, *H. truncatum*, *H. impressum*, *H. excavatum*, *H. marginatum*, *H. rufipes*, *H. impeltatum*, *H. anatolicum*, *H. detritum*, and *H. scupense*. However, *H. dromedarii* is the predominant tick species infesting the dromedary camel and *H. rufipes* may come next; both species are widely distributed in tropical Africa (Alanazi et al., 2020; Elghali & Hassan, 2009). Generally, the main species infesting camels belong to three genera: *Hyalomma*, *Rhipicephalus*, and *Amblyomma* and the soft tick *Ornithodoros*. In addition, *Boophilus* species are often observed (Lawal et al., 2007). In Algeria, the identification of ticks revealed *Hyalomma dromedarii* (83.98%), *Hyalomma impeltatum*

(10.58%), *Amblyomma variegatum* (5.12%), and *Rhipicephalus sanguineus* (0.32%) (Khelifi-Ouchene et al., 2020).

---

### 39.2 Site of Infection

Except for *Hyalomma dromedarii*, which predominantly attaches in the nostrils of the camel, all other tick species attach themselves at different sites: perineum, inguinal and axillary regions, around eyes, nose, in/on ears, udder, and between the toes (Fig. 39.1). They may be numerous and deeply embedded. Most adult ticks are found attached to the tail, anus, brisket, and udder, and nymphs commonly infest the humps, neck, ears, and sides (Elghali & Hassan, 2009; Isse et al., 2017).

---

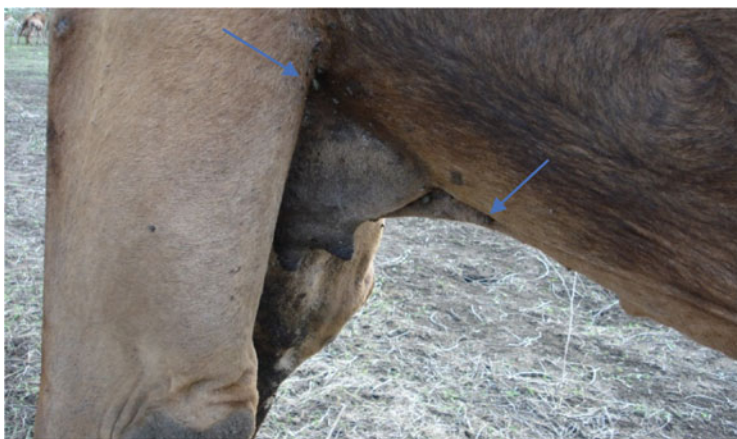### 39.3 Tick Collection and Identification

Ticks should be collected, with intact mouthparts, in vials containing 70% ethanol using forceps, and labeled to indicate animal, site of collection, etc. The ticks should be identified by stereomicroscope following standard taxonomic identification key (Hoogstraal, 1956; Hoogstraal & Kaiser, 1959; Walker et al., 2003).

---

### 39.4 Clinical Picture and Pathology

The embedded ticks cause direct injury at the site of attachment and lyse of the skin predisposing it to secondary bacterial infection and abscess formation. The development of lesions could be partly attributed to secretions in tick saliva, i.e.,



**Fig. 39.1** A female dromedary camel infested with ticks, some engorged (arrows), (Courtesy of Dr. Abdelmalik Khalafalla)

anti-inflammatory, anti-hemostatic, and immunosuppressive factors. Sores may occur in the mucocutaneous junctions of the lips, nose, and vulva and predispose to myiasis. The skin may progressively become thickened with formation of scar tissue.

---

### 39.5 Gross Lesions

The initial changes appear as red papules at the site of the bite. This may be followed by pruritic swellings, vesicles formation, necrosis, ulceration, and crust or nodule formation. Healing is associated with scarring and loss of hair. Most tick bites heal within 3 weeks, but nodules may persist for a longer time causing granulomatous reaction (tick granuloma). This reaction to tick bites results from injected toxins, local irritation, and immunological reactivity. Several factors could influence the severity of the skin reaction to tick feeding, including duration of feeding, size of the mouthparts, type of tick secretions (e.g., saliva or cement), and changes in secretion during feeding, previous exposure, and allergic reactions of the host.

---

### 39.6 Histopathology

The site of tick bite may show congestion/hemorrhage, edema, and keratinocyte damage with infiltration of neutrophils, eosinophils, and lymphocytes. Necrotic changes may extend to the dermis associated with hemorrhage, and infiltration with eosinophils, lymphocytes, and macrophages; fibrosis is also seen. Intradermal cavities containing tick mouthparts may be observed.

---

### 39.7 Tick Paralysis

Ticks may secrete neurotoxins in saliva, and this may cause paralysis in heavily infested animals. Clinical signs include incoordination of movement, unsteady gait, and recumbency ending in death or recovery following tick removal. Larvae of *H. dromedarii* and probably *Rhipicephalus* spp. are often involved.

---

### 39.8 Health Effects

Tick infestation may be associated with pronounced anemia and inappetence with consequent reduction in growth rate and productivity, and higher calf mortality.

## References

- Alanazi, A. D., Nguyen, V. L., Alyousif, M. S., et al. (2020). Ticks and associated pathogens in camels (*Camelus dromedarius*) from Riyadh Province, Saudi Arabia. *Parasites & Vectors*, 13, 110. <https://doi.org/10.1186/s13071-020-3973-y>
- Dantas-Torres, F., Chomel, B. B., & Otranto, D. (2012). Ticks and tickborne diseases in a one health perspective. *Trends in Parasitology*, 28, 437–446.
- Elghali, A., & Hassan, S. M. (2009). Ticks (*Acari: Ixodidae*) infesting camels (*Camelus dromedarius*) in Northern Sudan. *The Onderstepoort Journal of Veterinary Research*, 76, 177–185.
- Gosh, S. G., Bansal, C., Gupta, S. C., Ray, D., Khan, M. Q., Arched, M., Hahiduzzaman, U., & Ahmed, J. S. (2007). Status of tick distribution in Bangladesh, India and Pakistan. *Parasitology Research*, 101, 207–216.
- Hoogstraal, H. (1956). *African ixodoidea* (pp. 200–201). Vol. I. Ticks of the Sudan (with special reference of Equatoria Province and with preliminary reviews of the Genera Boophilus, Margaropus, and Hyalomma).
- Hoogstraal, H., & Kaiser, M. N. (1959). Observations on Egyptian Hyalomma ticks (*Ixodoidea-Ixodidae*). 5. Biological notes and differences in identity of Hyalomma anatolicum and its subspecies anatolicum Koch and excavatum Koch among Russian and other workers. Identity of H. lusitanicum Koch. *Annals of the Entomological Society of America*, 52, 243–261.
- Isse, F., Ahmed, S., & Mahdi, A. (2017). Diversity and Distribution of Ixodid Ticks on Camel in and Around Galkaio District, Somalia. *Acta Parasitologica Globalis*, 8(3), 139–143.
- Jongejan, F., & Uilenberg, G. (2004). The global importance of ticks. *Parasitology*, 129, 1–12.
- Khelifi-Ouchene, N. A., Ouchene, N., Dahmani, A., Kaaboub, E., Ouchetati, I., & Haif, A. (2020). Investigation of internal and external parasites of the camels (*Camelus dromedarius*) in Algeria. *Annals of Parasitology*, 66(3), 331–337.
- Lawal, M. D., Ameh, I. G., & Ahmed, A. (2007). Some Ectoparasites of Camelus dromedarius in Sokoto, Nigeria. *Journal of Entomology*, 4, 143–148.
- Walker, A. R., Bouattour, A., Camicas, J. L., Estrada-Peña, A., Horak, I. G., & Latif, A. A. (2003). *Ticks of domestic animals in Africa. A guide to identification of species*. Bioscience Reports.
- Wernery, U., Kinne, J., & Schuster, R. K. (2014). *Camelid infectious disorders*. World Organization for Animal Health (OIE).



Ahmed A. Gameel

Myiasis is an infestation of living animals with dipteran fly larvae. Fly eggs laid on moist skin or in wounds hatch into larvae that secrete proteolytic enzymes and digest tissue, thus extending the damage; this can involve the eyes, ears, nasal and oral cavities, skin, alimentary tract, and urogenital tract. Myiasis occurs in domestic and wild animals, especially those emaciated.

#### 40.1 Dipterous Flies Which May Be Associated with Myiasis in the Dromedary Camel

***Wohlfahrtia magnifica*:** Is considered the most important of the myiasis-producing flies parasitizing camels. It may also cause severe myiasis of mucosal membranes and wounds in many animal species. It has been observed in the dromedary camel in Iran around the perineal and vaginal region.

***Chrysomya* spp.:** Larvae may cause preputial and vaginal myiasis.

***Calliphoridae* (the blow flies):** Flies lay eggs in decomposing tissue of preexisting wounds and skin lesions upon which larvae feed and secrete enzymes, causing wound enlargement.

***Wohlfahrtia nuba* (Flesh fly):** The fly exists in African and Middle Eastern countries. The larvae infest skin wounds mainly vaginal region.

***Sarcophaga dux*:** The larvae infest decomposing tissue and wounds.

***Hippobosca camelina* (Camel louse fly):** Occurs in camels anywhere infesting the perineal region and between legs to pubic region.

***Cephalopina titillator*:** This fly attacks only camels (Higgins, 1985) and causes camel nasal myiasis and is commonly found in many dromedary camel rearing areas in Africa, the Middle East and Asia. The ova laid around the nostrils hatch and the larvae migrate through the nasal cavity and sinuses, feeding on mucus and debris. The grown larvae migrate back inducing an inflammatory reaction characterized by mucopurulent nasal discharge and congestion. Degenerated larvae may be found embedded between the turbinated bones. Pathological changes in the pharynx

include the formation of lymphoid nodules with central abscesses, degenerative, and reparative processes at the sites of larval attachment (Hussein et al., 1982, 1983). The presence of the larvae, often in large numbers, may cause difficulty in breathing as well as considerable irritation (Higgins, 1985).

---

## 40.2 Diagnosis

Diagnosis is mainly based on direct visualization of larvae on skin and damaged tissue. The presence of flies in the animal's environment can be an additional indicator.

---

## 40.3 Treatment

Treatment can be achieved by (a) correcting underlying conditions, (b) cleaning of wounds and removal of necrotic tissue and fly larvae, (c) treatment of maggots, e.g., by subcutaneous injection of Ivermectin at a dose of 0.2–0.4 mg/kg BW or by other larvicidal antiparasitic drugs, and (d) daily wound management; antibiotics may be used to prevent secondary infections.

---

## References

- Higgins, A. J. (1985). Common ectoparasites of the camel and their control. *British Veterinary Journal*, 141(2), 197–216.
- Hussein, M. F., El Amin, F. M., El-Taib, N. T., & Basmaeil, S. M. (1982). The pathology of nasopharyngeal Myiasis in Saudi Arabian camels (*Camelus dromedarius*). *Veterinary Parasitology*, 9, 253–260.
- Hussein, M. F., Hassan, H. A. R., Bilal, H. K., Basmaeil, S. M., Younis, T. M., Al-Motlaq, A. R., & Al-Shaikh, M. A. (1983). *Cephalopina titillator* in Saudi Arabian camels. *Zentralblatt für Veterinärmedizin Reihe B*, 30, 553–558.

## Louse and Flea Infestations

# 41

Ahmed A. Gameel

Both infestations are occasionally seen in the dromedary camel. Louse infestation may cause pruritus and loss of hair associated with anemia and emaciation.

*Microthoracius cameli* (*Haematopinus cameli*) is the bloodsucking louse of camels and is an obligate parasite, which seems to be species specific (Higgins, 1985). The parasite can be seen around the head, neck, and withers. Heavy infestation causes irritation, scratching, and rubbing, which damage skin and predispose to secondary infections. Besides, the camel may stop feeding and bite, rub or scratch affected areas, and milk production may decline (Higgins, 1985).

*Microthoracius cameli* (*Haematopinus cameli*) is the bloodsucking louse of camels in Africa and Asia. The parasite can be seen anywhere, especially around the head, neck and withers, and spreads by close contact. Laid eggs hatch in 4–14 days and the emerging nymphs feed for two weeks to become adults. Both immature and adult stages suck blood or feed on the skin. The saliva and feces of lice contain substances which may be allergic to skin. Heavy infestation causes irritation, scratching, and rubbing, which damage skin and predispose for secondary infections.

Fleas are insects that live by hematophagy of the blood of their hosts. Infestation with fleas is not uncommon in domestic animals but seems to be rare in camels, especially the dromedary camel. However, *Vermipsylla allacurt* v. *ioffi* and *Ctenocephalides felis felis* may infest other camelids. Fleas have also been implicated in the transmission of *Yersinia pestis* (camel plague) (McGrane & Higgins, 1985).

The commonly used insecticides pyrethrins and organophosphates such as Diazinon will kill lice and fleas. HCH (Gamatox, Wellcome) is an effective control for lice and fleas. In contact animals and other likely fomites must also be treated (Higgins, 1985).

## References

- Higgins, A. J. (1985). Common ectoparasites of the camel and their control. *British Veterinary Journal*, 141(2), 197–216.
- McGrane, J., & Higgins, A. J. (1985). Infectious diseases of the camel: Viruses, bacteria, and fungi. *British Veterinary Journal*, 141(5), 529–547.

---

## **Part V**

# **Endoparasitic Diseases of Dromedary Camels**

# Gastrointestinal Helminths (Haemonchosis) 42

El Awad Mohamed El Hassan

## 42.1 Introduction

Parasitic diseases represent one of the major problems in camel health and production. They lead to economic losses by decreasing meat and milk production and lowering the fertility and calving rate of camels. These diseases may also affect the working power or even lead to death of the animals, in addition to endangering public health through zoonoses.

Most parasitic infections are due to helminthic parasites inhabiting the gastrointestinal tract (GIT) of camels, where up to 50 species have been reported (Tables 42.1 and 42.2) (Banaja & Ghandour, 1994; Dakkak & Ouhelli, 1987; El Bihari, 1985; Kumar et al., 2016; Schuster et al., 2016; Soulsby, 1986). A few species of protozoan parasites (Table 42.2), extraintestinal helminths (Tables 42.3, 42.4, and 42.5) (AlKitani et al., 2020; Dakkak & Ouhelli, 1987; Ebrahimipour et al., 2017; Otranto & Traversa, 2005) and tissue protozoa (Table 42.6) (Dubey et al., 2015; Gebremedhin et al., 2016; Hosseini et al., 2009) have also been reported in camels.

Helminths infecting the gastrointestinal tract of camels belong to three major classes: Nematoda, Cestoda, and Trematoda. The majority of helminths that infect the GIT of camels are nematodes followed by cestodes and only one trematode was reported to inhabit the GIT of camels (Dakkak & Ouhelli, 1987).

Camels usually harbor mixed infections with different species of gastrointestinal helminths. Apart from acute haemonchosis, it is difficult to distinguish the species that caused these helminthoses, since the clinical picture is a combination of symptoms produced by various gastrointestinal species (Dakkak & Ouhelli, 1987).

**Table 42.1** Gastrointestinal nematodes of camels

Abomasum	Small intestine	Large intestine
<i>Haemonchus longistipes</i>	<i>Trichostrongylus vitrinus</i>	<i>Trichuris globulosa</i>
<i>Haemonchus contortus</i>	<i>T. probolurus</i>	<i>Trichuris cameli</i>
<i>Ostertagia ostertagi</i>	<i>T. colubriformis</i>	<i>Trichuris ovis</i>
<i>O. circumcincta</i>	<i>T. calcaratus</i>	<i>Trichuris skrjabini</i>
<i>O. trifurcata</i>	<i>T. affinis</i>	<i>Trichuris affinis</i>
<i>Camelostrongylus mentulatus</i>	<i>Cooperia oncophara</i>	<i>Trichuris raoi</i>
<i>Parabronema skrjabini</i>	<i>C. pectinata</i>	<i>Oesophagostomum columbianum</i>
<i>Marshallagia marshalli</i>	<i>Nematodirus spathiger</i>	<i>O. venulosum</i>
<i>Physocephalus sexalatus</i>	<i>N. mauritanicus</i>	<i>O. vigintimembrum</i>
<i>P. dromedarii</i>	<i>N. abnormalis</i>	<i>Chabertia ovina</i>
–	<i>N. dromedarii</i>	–
–	<i>N. helvetianus</i>	–
–	<i>Nematodirella cameli</i>	–
–	<i>N. dromedarii</i>	–
–	<i>Impalaia tuberculata</i>	–
–	<i>I. nudicollis</i>	–
–	<i>I. aegyptiaca</i>	–
–	<i>I. taurotragi</i>	–
–	<i>Strongyloides papillusus</i>	–
–	<i>Bunostomum trigonocephalum</i>	–

**Table 42.2** Gastrointestinal cestodes, trematodes, and protozoa of camels

Cestodes	Trematodes	Protozoa
<i>Moniezia expansa</i>	<i>Paramphistomum cervi</i>	<i>Eimeria dromedarii</i>
<i>M. benedeni</i>	–	<i>E. cameli</i>
<i>Avitellina centripunctata</i>	–	<i>E. rajasthani</i>
<i>A. woodland</i>	–	<i>E. bactriani</i>
<i>Stilesia globipunctata</i>	–	<i>E. pellerdyi</i>
<i>S. vittata</i>	–	<i>E. leuckarti</i>
<i>S. centripunctata</i>	–	<i>Cystoisospora orlovi</i>
<i>Thysaniezia ovilla</i>	–	<i>Balantidium coli</i>
–	–	<i>Cryptosporidium parvum</i>
–	–	<i>C. andersoni</i>
–	–	<i>C. muris</i>
–	–	<i>C. ubiquitum</i>
–	–	<i>Giardia spp.</i>

**Table 42.3** Extraintestinal nematodes of camels

Respiratory system	Circulatory system	Eye	S/C Tissue and peritoneal cavity
<i>Dictyocaulus filaroa</i>	<i>Dipetalonema evansi</i>	<i>Thelazia leesei</i>	<i>Onchocerca fasciata</i>
<i>D. cameli</i>	<i>Onchocerca armillata</i>	–	<i>O. gutturosa</i>

**Table 42.4** Extraintestinal cestodes of camels

Respiratory system	Liver	Nervous system	Muscles
Hydatid cyst of <i>Echinococcus granulosus</i> , <i>E. ortleppi</i> , and <i>E. canadensis</i>	<i>Stilesia hepatica</i>	<i>Coenurus cerebralis</i> of <i>Taenia multiceps</i>	<i>Cysticercus dromedarii</i> of <i>Taenia hyaena</i>
–	Hydatid cyst of <i>Echinococcus granulosus</i> , <i>E. ortleppi</i> and <i>E. canadensis</i>	–	<i>Cysticercus bovis</i> of <i>Taenia saginata</i>
–	<i>Cysticercus tenuicollis</i> of <i>Taenia hydatigena</i>	–	–

**Table 42.5** Extraintestinal trematodes of camels

Liver	Circulatory system
<i>Fasciola hepatica</i>	<i>Schistosoma bovis</i>
<i>F. gigantica</i>	<i>S. indicum</i>
<i>Dicrocoelium dendriticum</i>	<i>S. mattheei</i>
<i>Eurytrema pancreaticum</i>	<i>Orientobilharzia turkestanicum</i>

**Table 42.6** Tissue protozoa of camels

Muscles and tissues
<i>Sarcocystis cameli</i>
<i>Sarcocystis ippeni</i>
<i>Toxoplasma gondii</i>
<i>Neospora caninum</i>

42.2 Mixed Infections

The clinical manifestations of these mixed infections are usually a combination of symptoms caused by these helminths. In light infection, there is decreased productivity manifested by retarded growth, poor weight gain, and decreased milk production. Heavy infection is characterized by apathy, anorexia, nutrient deficiency progressive wasting manifested by atrophy of the humps, and decreased abdominal volume (unfilled flanks even after watering), diarrhea, constipation, intestinal obstruction, anemia, colic, prostration, and even death after a few weeks or a few



months (Dakkak & Ouhelli, 1987). At postmortem, emaciation is the prominent feature accompanied by peritonitis, subacute or chronic catarrhal gastritis, subacute or chronic catarrhal enteritis, nodule formation in large intestine (*Oesophagostomum* infection), and chronic catarrhal inflammation (*Trichuris* infection) of the large intestine (Dakkak & Ouhelli, 1987; Soulsby, 1986).

Detailed diagnostic procedures will be dealt with under haemonchosis. In brief, clinical symptoms and examination of feces is the routine practice in veterinary clinics. An egg count above 600 eggs per gram (epg) of feces necessitates deworming and an epg above 1000 is considered a severe infection.

---

## 42.3 Haemonchosis

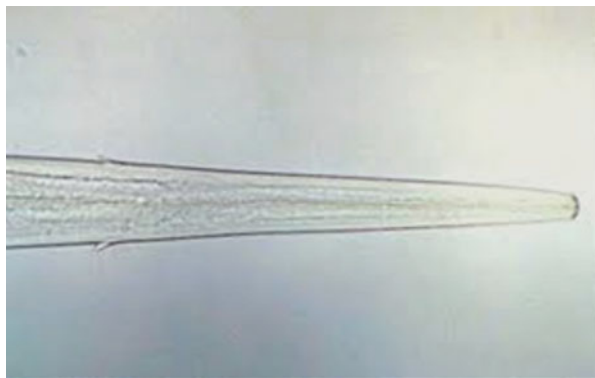
Haemonchosis is the most dangerous gastrointestinal parasitic disease of camels. It represents one of the major constraints to the development of camel production. The disease has an extremely wide geographical range, particularly in tropical and subtropical regions.

It occurs throughout the year, but more commonly during the rainy season and is manifested by anemia and general illness.

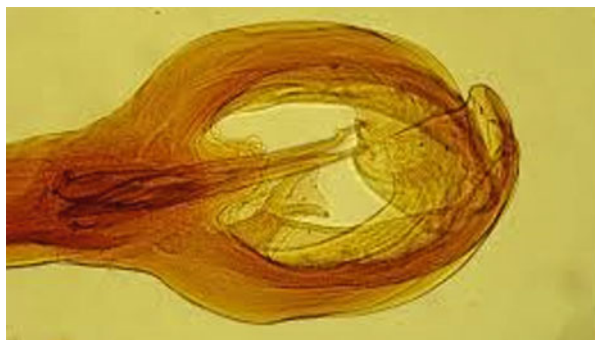### 42.3.1 Etiology

Camel haemonchosis is caused mainly by *Haemonchus longistipes*, a bursate nematode of the family Trichostrongylidae, and to a lesser extent by *H. contortus*. The worm inhabits the abomasum and sucks the blood of its host leading to severe anemia, which may end in death of young animals. Both adults and larval stages possess a piercing lancet enabling them to obtain blood from the blood vessels of their host. Morphologically *Haemonchus longistipes* possesses a buccal capsule containing a dorsal lancet and two cervical papillae in the esophageal region (Fig. 42.1). The male worm possesses a copulatory bursa (Fig. 42.2). The intestine

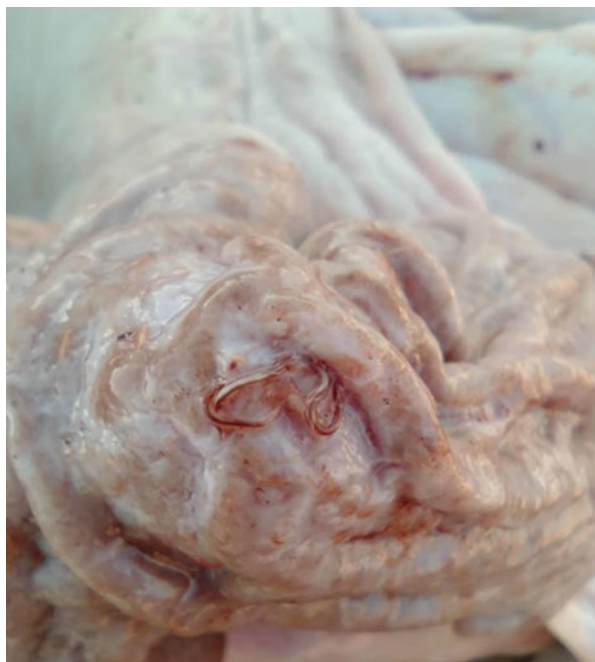**Fig. 42.1** Anterior end of *Haemonchus* spp. showing cervical papillae and buccal lancet. (Source: El Hassan & Al-Jabr, 2014)



**Fig. 42.2** Male copulatory bursa. (Source: El Hassan & Al-Jabr, 2014)

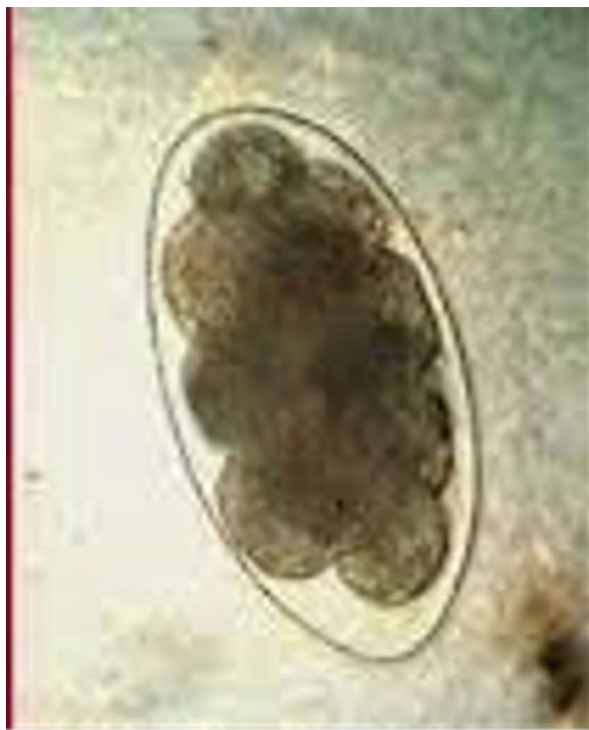

**Fig. 42.3** Female *H. longistipes*, showing barber pole appearance, infesting abomasum of a dromedary (Picture taken for me by Professor E.A. El Amin, Tambool Slaughterhouse, Sudan)



of the female worm that is filled with ingested blood is spirally surrounded by the white ovaries, giving the worm a characteristic barber pole appearance (Fig. 42.3). The tail of the female has a pointed end and the vulva may or may not be covered with a vulvar flap (Soulsby, 1986). The eggs are oval and measure 70–85 $\mu$ m (Fig. 42.4).

**Fig. 42.4** *H. longistipes* eggs (Strongyle eggs). (Source: El Hassan & Al-Jabr, 2014)



### 42.3.2 Modes of Transmission

Infection occurs through ingestion of infective third-stage larvae from pasture. The infective larvae migrate from the feces during favorable conditions such as moisture, rain, and heavy dew to the blades of grass to reach herbage top (Van Dijk & Morgan, 2011) and become available to grazing camels usually during early morning and late afternoon.

### 42.3.3 Clinical Picture

Symptoms include anorexia, weakness, decreased milk production, diarrhea, anemia manifested by pallor of visible mucosa, edema of the hollow above the eye, the lower parts of limbs, the sides of the sternal cushion and between the jaws (bottle jaws), and weight loss (Arzoun et al., 1984; Dakkak & Ouhelli, 1987) (Fig. 42.5). The infected animals ingest large quantities of sand leading to anorexia and progressive loss of weight. Death may occur after several weeks of the disease.



**Fig. 42.5** A dromedary camel infected with *H. longistipes* showing weight loss, diarrhea, and edema of the hollow above the eye (Picture taken for me by Dr. El Aagib Abosum, Gedarif, Sudan)

#### 42.3.4 Pathology and Pathogenesis

Pathological lesions (Dakkak & Ouhelli, 1987) include emaciation, ascites, hydrothorax, and hydropericardium. Usually, there is a lot of sand in the rumen. The abomasum shows hypertrophy of the mucosa, numerous erosions, and petechial hemorrhages.

Hematological disorders include decreased hematocrit, erythrocyte count, hemoglobin content, proteins, albumin, Ca, P, Mg, and Cu levels and increased eosinophils, lymphocytes, neutrophils, urea contents, and globulins (Dakkak & Ouhelli, 1987).

#### 42.3.5 Epidemiology

*H. Longistipes* infestation occurs in camels worldwide particularly in tropical and subtropical areas. It is reported in east, west, north, and central Africa. In Asia, the disease is reported in the Arabian Peninsula, India, Pakistan, and the former USSR. *H. contortus* infests camels sharing grazing areas with sheep in Africa and Asia (Dakkak & Ouhelli, 1987). The favorable environmental temperature for the larvae of these parasites ranges between 22 and 26 °C and relative humidity close to 100%

(Krecek et al., 1992). Desiccation is fatal to *Haemonchus* spp. infective larvae and greatly reduces their number in pasture (Magzoub et al., 1990). Incidence of *H. longistipes* during the rainy season may reach up to 60% (Banaja & Ghandour, 1994). Inhibited development, arrested development, or hypobiosis are important aspects of the biology of gastrointestinal nematodes of ruminants. Ingested larvae do not undergo immediate development to the adult stage. They become, arrested as fourth-stage larvae in the gastric glands (Blitz & Gibbs, 1972). Seasonal change has been, suggested as a major cause of inhibition for *Haemonchus* species and accordingly, this phenomenon is believed to be an adaptation to survive the adverse condition outside the host when the opportunities for larval transmission are restricted. However, some observations suggested that hypobiosis in *H. contortus* is a mandatory genetic strategy for survival rather than an effect of external factors, and the development of arrested larvae is thought to be due to temporary reduction in immunity during lactation (Waller & Thomas, 1975). Following experimental infection of young dromedary camels with infective larvae of *H. longistipes*, Jacquet et al. (1996) found that arrested development took place irrespective of season. They concluded that induction of arrested development of larval stages may be genetically determined in the parasites or host-induced or both.

### 42.3.6 Diagnosis

Clinical diagnosis of haemonchosis, as well as other gastrointestinal helminths, is based on clinical signs and identification of the parasite at different stages of life cycles.

There are many well-established techniques for detection of parasitic components in fecal samples, ranging from recovering eggs or larvae to sophisticated immunoassays designed to detect parasite antigens and molecular techniques for detection of genetic components of the parasite.

Examination of fresh feces is of vital importance for detection of specific parasitic infections particularly when applying traditional parasitological techniques, since development of eggs and larvae in older feces may alter their morphology.

#### 42.3.6.1 Coproscopic Methods

Fecal examination for the diagnosis of helminth infections is probably the most common laboratory procedure performed in veterinary practice. A variety of different methods, such as direct wet mount, flotation technique, egg counting methods (Ljungström et al., 2017), and fecal culture for identification of infective larvae, have been, available for decades (Sumeeta & Shveta, 2017). These methods have different sensitivity and accuracy. Infected animals usually harbor mixed infections with different species that have different pathogenicity and susceptibility to anthelmintic. Therefore, identification of causative species is important. Apart from *Nematodirus* spp., eggs of strongyle nematodes are almost similar, making it difficult to identify these species.

#### 42.3.6.2 Immunological Methods

Several ELISAs-based methods have been, described for serological and immunological diagnosis of different nematode species. Copro-antigen ELISAs and serum ELISAs (Sumeeta & Shveta, 2017) were described for diagnosis of infection with *Haemonchus*. Characterization of proteins suitable for immunodiagnosis of a variety of different gastrointestinal parasites have been described (Kiel et al., 2007). Generally, these serological methods used so far are superior to coproscopic methods in terms of speed, sensitivity, and specificity.

#### 42.3.6.3 Molecular Methods

Molecular diagnostic methods for parasitic infections have been developed in recent years. Strongyle eggs and larvae have been identified using several PCR-based methods (Ljungström et al., 2017; Sumeeta & Shveta, 2017). Limitations of these molecular techniques include unavailability of sufficient quantity of genetic materials in parasite eggs, fecal inhibitors, and problems due to similarities of sequence.

### 42.3.7 Control

Knowledge of the role of internal parasites in livestock health and productivity leads to effective control programs. Animals should be treated according to the level of seasonal infectivity of pastures. Move-and-dose systems, accompanied by other management procedures will decrease the use of drugs and decrease loss from parasitism. The emphasis for these programs is on prevention rather than treatment. The 2-week prepatent period of *Haemonchus*, the development of arrested larvae and the peri-parturient increase in egg count must all be considered in the establishment of effective control program.

For free-range livestock, such as camels, a control program based on treating animals according to the level of seasonal infectivity was implemented in Butana plains of Eastern Sudan (Agab & Abbas, 1999). In this program, all animals were given a therapeutic dose of a broad spectrum anthelmintic at the beginning of the rainy season. Similarly, a second dose of the anthelmintic was administered to the animals at the end of the rainy season. This regimen significantly reduced worm burden and infestation rate throughout the period of study (March 1991–February 1992).

Avoiding grazing during early morning and to some extent late afternoon will reduce the risk of infection, since infective larvae climb the herbage during these periods and tend to avoid direct sunlight during the day by descending down to the bottom of herbage. In addition, alternate grazing of different animal species is also a management technique that can lead to secure pasture and give economic merit when joint with anthelmintics. Reduced egg output and retarded growth of adult worms have been achieved in sheep infected with cameline *H. longisstipes* (Elbihari et al., 1984). However, communal pastoral systems in tropical countries will not allow for organized grazing as means of reducing the burden of infective larvae on pasture.

Increased livestock densities, coupled with drought in some regions, necessitate unregulated animal movement in search of good pasture and water.

## References

- Agab, H., & Abbas, B. (1999). Epidemiological studies on camel diseases in Eastern Sudan. *World Animal Review*, 92(1), 42–51.
- AlKitani, F. A., Baqir, S., Mansoor, M. K., AlRiyami, S., Hussain, M. H., & Roberts, D. (2020). Genetic survey of cystic echinococcosis in farm animals in Oman. *Tropical Animal Health and Production*, 52(1), 331–337.
- Arzoun, I. H., Hussein, H. S., & Hussein, M. F. (1984). The prevalence and pathogenesis of naturally occurring *Haemonchus longistipes* infection in Sudanese camels. *Journal of Comparative Pathology*, 94(2), 169–174.
- Banaja, A. A., & Ghandour, A. M. (1994). A review of parasites of camels (*Camelus dromedarius*) in Saudi Arabia. *Journal of King Abdulaziz University-Science*, 6, 75–86.
- Blitz, N. M., & Gibbs, H. C. (1972). Studies on the arrested development of *Haemonchus contortus* in sheep- I. The induction of arrested development. *International Journal for Parasitology*, 2, 5–12.
- Dakkak, A., & Ouhelli, H. (1987). Helminths and helminthoses of the dromedary. Review of the literature. *Revue Scientifique ET Technique-Office International des Epizooties*, 6(1), 447–461.
- Dubey, J. P., Hilali, M., Van Wilpe, E., Calero-Bernal, R., Verma, S. K., & Abbas, I. E. (2015). A review of sarcocystosis in camels and redescription of *Sarcocystis cameli* and *Sarcocystis ippeni* sarcocysts from the one-humped camel (*Camelus dromedarius*). *Parasitology*, 142(12), 1481–1492.
- Ebrahimipour, M., Sadjjadi, S. M., Yousofi Darani, H., & Najjari, M. (2017). Molecular studies on cystic echinococcosis of camel (*Camelus dromedarius*) and report of *Echinococcus ortleppi* in Iran. *Iran Journal of Parasitology*, 12(3), 323–331.
- El Bihari, S. (1985). Helminths of the camel: A review. *British Veterinary Journal*, 141(3), 315–316.
- El Hassan, E. M., & Al-Jabr, O. A. (2014). *Manual of laboratory diagnosis for tropical gastrointestinal parasites of domesticated animals*. Center of Translation and Authorship and Publication, King Faisal University. ISBN: 978-9960-08-112-0.
- Elbihari, S., Kawasmeh, Z. A., & Elnaiem, A. H. (1984). Experimental infection of sheep by the camel stomach worm *Haemonchus longistipes*. *Veterinary Parasitology*, 15(3–4), 257–261.
- Gebremedhin, E. Z., Dima, N., Beyi, A. F., Dawo, F., Feyissa, N., Jorga, E., Di Marco, V., & Vitale, M. (2016). Toxoplasmosis in camels (*Camelus dromedarius*) of Borana zone, Oromia region, Ethiopia: Seroprevalence and risk factors. *Tropical Animal Health and Production*, 48, 1599–1606.
- Hosseininejad, M., Piral-Kheirabadi, K., & Hosseini, F. (2009). Seroprevalence of *Neospora caninum* infection in camels (*Camelus dromedarius*) in Isfahan Province, Center of Iran. *Iranian Journal of Parasitology*, 4(4), 61–64.
- Jacquet, P., Cabaret, J., Dia, M. L., Cheikh, D., & Thiam, E. (1996). Adaptation to arid environment: *Haemonchus longistipes* in dromedaries of Saharo-Sahelian areas of Mauritania. *Veterinary Parasitology*, 66, 193–204.
- Kiel, M., Josh, P., Jones, A., Windon, R., Hunt, P., & Kongsuwan, K. (2007). Identification of immuno-reactive proteins from a sheep gastrointestinal nematode, *Trichostrongylus colubriformis*, using two-dimensional electrophoresis and mass spectrometry. *International Journal for Parasitology*, 37, 1419–1429.
- Krecek, R. C., Groeneveld, H. T., & Maritz, J. I. (1992). A preliminary study of the effect of microclimate on the third-stage larvae of *Haemonchus contortus* and *Haemonchus placei* on irrigated pasture. *International Journal for Parasitology*, 22, 747–752.

- Kumar, S., Ghorui, S., & Patil, N. V. (2016). *Eimeria leuckarti* from dromedaries camel calves. *Journal of Camel Practice and Research*, 23(1), 91–94.
- Ljungström, S., Melville, L., Skuce, P. J., & Höglund, J. (2017). Comparison of four diagnostic methods for detection and relative quantification of *Haemonchus contortus* eggs in feces samples. *Frontiers in Veterinary Science*, 4, 239. <https://doi.org/10.3389/fvets.2017.00239>
- Magzoub, M., El Hassan, E. M., & Burger, H. J. (1990). Pasture infestation with trichostrongylids of camels in Butana area of eastern Sudan. *Tropical Animal Health and Production*, 22(1), 7–8.
- Otranto, D., & Traversa, D. (2005). Thelazia eyeworm: An original endo-and ecto-parasitic nematode. *Trends in Parasitology*, 21(1), 1–4.
- Schuster, R. K., Sivakumar, S., & Kinne, J. (2016). Life cycle and morphology of development stages of *Physocephalus dromedarii* (Nematoda: Spiroceridae). *Asian Pacific Journal of Tropical Biomedicine*, 6(10), 825–829.
- Soulsby, E. J. L. (1986). *Helminths, arthropods and Protozoa of domesticated animals* (7th ed.). Bailliere Tindall.
- Sumeeta, K., & Shveta, S. (2017). Laboratory diagnosis of soil transmitted helminthiasis. *Tropical Parasitology*, 7(2), 86–91.
- Van Dijk, J., & Morgan, E. R. (2011). The influence of water on the migration of infective trichostrongyloid larvae onto grass. *Parasitology*, 138, 780–788.
- Waller, P. J., & Thomas, R. J. (1975). Field studies on inhibition of *Haemonchus contortus*. *Parasitology*, 71, 285–291.



El Awad Mohamed El Hassan

These include nematodes, cestodes, and trematodes.

## 43.1 Helminth Infection of the Liver

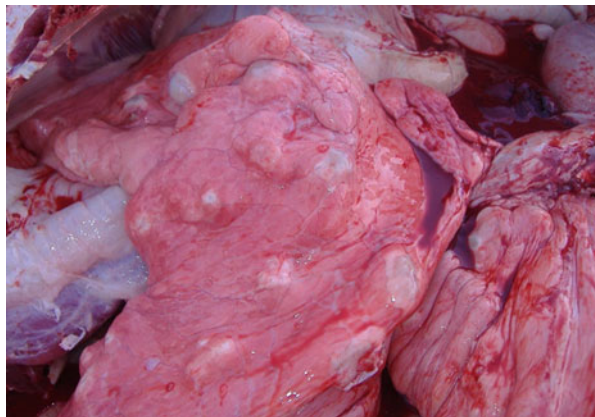
Helminths infesting the liver of camels are mainly the trematodes, *Fasciola hepatica*, *F. gigantica*, *Dicrocoelium dendriticum*, and less often *Eurytrema pancreaticum*. Cestodes infesting camel liver include, *Stilesia hepatica*, Hydatid cyst, and *Cysticercus tenuicollis*. The last two are larval stages of *Echinococcus granulosus* and *Taenia hydatigena*, respectively (Aljameel et al., 2017; Dakkak & Ouhelli, 1987; Soulsby, 1986).

Liver infestations are usually subclinical in camels except for heavy fasciolosis, which is manifested mainly by uncertain digestive symptoms. Pathologically there are hemorrhagic tracts in liver tissues, cirrhosis, chronic cholangitis, catarrhal inflammation, and destruction of bile ducts epithelium, caseated or calcified cysticerci, and protrusions caused by hydatid cysts.

## 43.2 Helminth Infection of the Respiratory Tract

These include *Dictyocaulus filaria*, *D. cameli*, and Hydatid cyst of *Echinococcus granulosus*. Clinically hydatid cyst infection usually passes unnoticed, however, at post-mortem cysts are mainly found in lungs (Fig. 43.1) and also in livers leading to condemnation of carcasses or livers resulting in great economic losses where it reached in certain countries up to hundreds of million USD (Sazmand et al., 2019). The disease is also considered a major zoonotic infection with worldwide distribution (Sazmand et al., 2019). Camels are found to be infected with cysts of *E. granulosus*, *E. ortleppi*, and *E. canadensis*, all of which cause human cystic echinococcosis. *Dictyocaulus* spp. infection causes general illness, cough, polypnea, dyspnea, anorexia, and decreased productivity.

**Fig. 43.1** Camel's lung showing different sizes of hydatid cysts of *Echinococcus granulosus* (Courtesy of Dr. Nasreldein E. Hussain, ADAFSA, UAE)



---

### 43.3 Helminth Infection of the Circulatory System

These include *Schistosoma bovis*, *S. indicum*, *S. mattheei*, *Orientobilharzia turkestanicum*, *Onchocerca armillata*, and *Dipetalonema evansi*. Apart from dipetalonemiasis, infestation of camel circulatory system with other helminthes is well tolerated and often passes unnoticed.

---

### 43.4 Dipetalonemiasis

A filarial disease affecting the circulatory system of camels producing emaciation, apathy, and parasitic orchitis.

#### 43.4.1 Etiology

The disease is caused by *Dipetalonema evansi*, a filarial nematode specific for camels, inhabiting the heart, pulmonary, hepatic, and spermatoc arteries as well as mesenteric lymph nodes and lymphatic vessels (Dakkak & Ouhelli, 1987; Fard et al., 2011). The adult male measures 8–11 cm and females 14.5–18.5 cm in length. The microfilariae are found in the peripheral blood and measure 200–315  $\mu\text{m}$ . The worms possess a small buccal capsule and the mouth opening surrounded by two rudimentary lateral lips (Fard et al., 2011).

#### 43.4.2 Modes of Transmission

The intermediate hosts are mosquitoes of the genus *Aedes* (*A. detritus* and *A. caspius*) transmitting infective larvae during blood meals (Duvallat & Boireau,

2015). Microfilaremia has a biphasic periodicity that peaks around daybreak and early evening.

### 43.4.3 Clinical Picture

Clinical signs in mild infections usually pass unobserved. Acute infections give rise to respiratory symptoms, emaciation, apathy, pale mucous membranes, orchitis, and dilatation of spermatic vessels, arteriosclerosis, heart insufficiency, and nervous symptoms (Dakkak & Ouhelli, 1987; Fard et al., 2011). High burdens of adult worms can lead to pulmonary distress and death of animals.

### 43.4.4 Pathology and Pathogenesis

Lesions in the circulatory system are not specific except aneurysm of the spermatic artery which leads to epididymitis and orchitis. There is hyperplasia of endothelium of these vessels, hypertrophy of smooth muscles in the tunica media, and fibrosis leading to thickening of vascular wall. There is also obstruction of the lumen of arteries by thrombi and degenerative changes of the seminiferous tubules of the testicles as well as pulmonary edema, congestion, mild interstitial pneumonia, and atelectasis (Fard et al., 2011).

### 43.4.5 Epidemiology

The prevalence of the disease is, related to the vector, *Aedes detritus*, which is common in many parts of the world. Dipetalonemiosis has been reported in camel-rearing countries around the world. It was, reported from Egypt, Sudan, North and East Africa, Middle and Far East and eastern parts of the former USSR, India, Iran, and Pakistan (Dakkak & Ouhelli, 1987; Duvallet & Boireau, 2015).

### 43.4.6 Diagnosis

Clinical symptoms depend on the location of adult worms in the animal's body; however, hypertrophic sclerosis and aneurysm are common.

Superficial blood taken during nocturnal activity of microfilariae is recommended for microscopic examination. Techniques include wet mount, thin smear preparation stained with Giemsa and modified Knott Method stained with methylene blue (Karimi et al., 2015).

Immunofluorescence antibody test has been used as a serological method for the diagnosis of infection.

Polymerase chain reaction (PCR) is also used for molecular detection of this parasite (Sazmand et al., 2016).

---

#### 43.4.7 Control

Infection with *Dipetalonema* is directly related to the presence of the vector *Aedes detritus*. The control, therefore, depends on the type of the management system. In farm animals, prevention of the disease can be, made through treatment of infected animals and control of the vector in the farm area, while control of infection of pastoral camels reared in open ranches depends mainly on treatment of animals to reduce circulating microfilariae.

---

### 43.5 Helminth Infection of the Nervous System

*Coenurus cerebralis*, the larval stage of *Taenia multiceps* reported in the brain of camels. It causes behavioral changes, decreased appetite or even anorexia, depression, difficulty or unwillingness to move and the animal may make circling movements (Dakkak & Ouhelli, 1987).

---

### 43.6 Helminth Infection of the Eye

*Thelazia leesei* is a specific spirurid nematode of the eye of camels transmitted by *Musca lucidula* flies (Otranto & Traversa, 2005). It develops within the conjunctival sacs of one or both eyes (Dakkak & Ouhelli, 1987). The infestation was well tolerated by the camel.

---

### 43.7 Helminth Infection of Muscles

Two larval stages of cestodes infest camel muscles, *Cysticercus dromedarii* the larval stage of *Taenia hyaena* and *C. bovis* the larval stage of *T. saginata* (Dakkak & Ouhelli, 1987). Both cysticerci do not show any clinical signs.

---

### 43.8 Helminth Infection of Subcutaneous Connective Tissues

The subcutaneous connective tissue and nuchal ligament of the camel are infested with two filarial nematodes, *Onchocerca fasciata*, a specific parasite of camels, and *O. gutturosa* (Dakkak & Ouhelli, 1987). The camel tolerates these filarial infestations well, although they produce skin nodules ranging from 0.5 to 4 cm in diameter particularly on the neck and head.

### 43.9 Anthelmintic Treatment of Helminth Infection

Most anthelmintic drugs used in cattle and sheep are also used in camels with different therapeutic doses. These include anti-nematodes preparations such as thiabendazole (100–150 mg/Kg oral dose), tetramisole (10 mg/Kg s/c injection or 15mg/Kg oral dose), levamisole (7.5 mg/Kg s/c injection), morantel tartrate (3–7.5 mg/Kg oral dose), pyrantel tartrate (25 mg/Kg orally), parbendazole (20 mmg/Kg orally), thiophanate (100 mg/Kg orally), ivermectin (0.2 mg/Kg s/c injection), and Doramectin (0.2 mg/Kg I.M.). Fouadin (stibophen) at a dose rate of 0.5 mg/Kg I/V injection for treatment and prevention of *Dipetalonema evansi*.

Preparations against mixed infections include albendazole (2.5 mg/Kg against nematodes and at 10 mg/Kg against cestodes and adult *Fasciola*), febantel (7.5 mg/Kg orally against nematodes and larval cestodes), fenbendazole (7 mg/Kg orally against nematodes and at 10–15 mg/Kg against adult cestodes), oxfendazole (5–7 mg/Kg against nematodes and cestodes), nitroxinil (10 mg/Kg s/c injection against *Fasciola*), and rafoxanide (7.5 mg/Kg orally against *Fasciola*).

The dynamics of some of these anthelmintic and development of drug resistance is recently reviewed by Al-Fatlawi et al. (2019).

---

### References

- Al-Fatlawi, M. A. A., Mansoor, K. A., & Neamah, A. A. (2019). Dynamics of some anthelmintic on internal parasites in camels: Review. *Al-Qadisiyah Journal of Veterinary Medicine Sciences*, 18 (1), 33–38.
- Aljameel, M. A., Bakhiet, A. O., & Osman, H. M. (2017). Histopathological characteristics of liver fasciolosis in camels at Nyala Abattoir. In *3rd International Scientific Conference of Camel Research and Production (ISCCRP)*, Khartoum-Sudan, 21st–23rd November 2017.
- Dakkak, A., & Ouhelli, H. (1987). Helminths and helminthoses of the dromedary. Review of the literature. *Revue Scientifique ET Technique-Office International des Epizooties*, 6(1), 447–461.
- Duvallet, G., & Boireau, P. (2015). Other vector-borne parasitic diseases: Animal helminthiases, bovine besnoitiosis and malaria. *Revue Scientifique ET Technique-Office International des Epizooties*, 34(2), 651–658.
- Fard, S. R. N., Kheirandish, R., Fathi, S., & Asl, E. N. (2011). Prevalence of *Dipetalonema evansi* infection in *Camelus dromedarius*. *Online Journal of Veterinary Research*, 15(3), 261–269.
- Karimi, A., Rahbari, S., & Yousefi, A. (2015). Blood parasites of camels from central regions of Iran: comparative evaluation of various detection techniques and serum protein components. *Journal of Advances in Parasitology*, 2(1), 1–4.
- Otranto, D., & Traversa, D. (2005). Thelazia eyeworm: an original endo-and ecto-parasitic nematode. *Trends in Parasitology*, 21(1), 1–4.
- Sazmand, A., Eigner, B., Mirzaei, M., Hekmatimoghaddam, S., Harl, J., Duscher, G. G., Fuchrer, H. P., & Joachim, A. (2016). Molecular identification and phylogenetic analysis of *Dipetalonema evansi* (LEWIS, 1882) in camels (*Camelus dromedarius*) of Iran. *Parasitology Research*, 115, 1605–1610.
- Sazmand, A., Loachim, A., & Otranto, D. (2019). Zoonotic parasites of dromedary camels: So important, so ignored. *Parasites & Vectors*, 12, 610–619.
- Soulsby, E. J. L. (1986). *Helminths, Arthropods and Protozoa of Domesticated Animals* (7th ed.). Bailliere Tindall.

El Awad Mohamed El Hassan

## 44.1 Gastrointestinal Protozoa

### 44.1.1 *Eimeria*, *Isospora*, and *Giardia* spp. Infections

*Eimeria dromedarii* and *E. cameli* are the species of camelid *Eimeria* listed in Table 42.2 that are associated with the disease. They cause hemorrhagic enteritis and bloody diarrhea in young camels. The symptoms also include loss of appetite, dehydration, progressive weight loss, anemia, and mortality rate could reach up to 10% among camel calves less than one year of age. Adult camels are asymptomatic but shed oocysts in their feces (Sazmand, Rasooli, et al., 2012a, Sazmand, Hamidinejat, et al., 2012b; Borji et al., 2009).

*Cystoisospora (Isospora) orlovi* is associated with severe disease in camel calves. Camels as young as nine days old can develop severe diarrhea, sometimes accompanied by blood, abdominal pain, and can die before detection of oocysts in feces. The main lesion is hemorrhagic colitis and confined to the large intestine (Dubey & Schuster, 2018; Gluecks, 2007; Kinne et al., 2002; Kinne & Wernery, 2001).

There is only one report of the presence of *Giardia* cysts and trophozoites in dromedary camels causing diarrhea with soft or watery feces (Al-Jabr et al., 2005).

Diagnostic methods for these parasites include parasitological fecal examination methods, fecal immunoassays, and molecular methods.

Many drugs proved to be effective against these parasites such as fenbendazole, albendazole, metronidazole, sulfonamides, and amprolium.

### 44.1.2 *Cryptosporidium* Infection

Among pathogenic intestinal protozoa causing enteritis in camels due to destruction of intestinal mucosa, *Cryptosporidium* is the most pathogenic causing profuse watery diarrhea leading to death of camel calves.

Cryptosporidiosis is one of the important diseases of camels, particularly neonatal calves. It causes enormous economic losses because of high infection rate, decreased productivity due to emaciation and general malaise in diseased animals, and death of camel calves. It has gained much attention as clinically important zoonotic disease (Sazmand et al., 2019; Sazmand, Hamidinejat, et al., 2012b; Sazmand, Rasooli, et al., 2012a).

#### **44.1.2.1 Etiology**

Among *Cryptosporidium* species infecting camels, *Cryptosporidium parvum* is the most pathogenic. It is an Apicomplexan protozoan, which is highly infectious and highly resistant to inactivation in environment. It is an obligate intracellular protozoan parasite, causing many outbreaks of diarrheal diseases in both man and animals worldwide (Fayer, 2004; Fayer et al., 2000). The only stage outside the host is the oocyst, which contains four sporozoites when fully sporulated and has round to oval shape 1–5µm in diameter.

#### **44.1.2.2 Modes of Transmission**

Cryptosporidial infection has a fecal–oral transmission route (foodborne or waterborne) (Fayer et al., 2000). Extremely low exposure dose of sporulated oocysts can induce infection. In utero transmission has also been suggested since neonates taken immediately to clean rooms start to shed oocysts three days later.

#### **44.1.2.3 Clinical Picture**

The main symptom of the disease in camel calves is voluminous watery diarrhea, accompanied by dehydration, anorexia, weight loss; severe cases may result in death. Adult animals may be asymptomatic (Sazmand & Loachim, 2017).

#### **44.1.2.4 Pathology and Pathogenesis**

There is no available data on the pathogenesis of this disease in camels. However, loss of absorptive epithelium including apoptosis and villus atrophy has been shown to result in reduced absorption of nutrients, and release of inflammatory cell mediators, electrolyte secretions, and diarrhea (Tzipori & Ward, 2002).

#### **44.1.2.5 Epidemiology**

The oocyst is highly resistant to inactivation in the environment particularly during cold weather as low temperature increases oocyst viability. The parasite has been reported with different prevalence rates in many countries from dromedaries and from Bactrian camels (Borji et al., 2009; El Hassan et al., 2020; Nazifi et al., 2010; Razavi et al., 2009). The disease has been reported in Africa, Asia, and Australia.

#### **44.1.2.6 Diagnosis**

Traditional diagnostic methods include detection of the parasite oocysts in fecal samples using concentration methods accompanied with specific staining techniques for appropriate microscopic examination. These methods are based on microscopic modified Ziehl-Neelsen stained fecal smear examinations (Radfar et al., 2013). They

are routinely used in many laboratories but need well-trained personnel since oocysts of different species are virtually identical in size and similarities in oocyst structure can cause confusion for identification of *Cryptosporidium* species, particularly in laboratories of many camel-rearing countries. Immunofluorescence microscopy is a sensitive diagnostic method that is also used. However, it is expensive, laborious, and not available in all laboratories. Enzyme-linked immunosorbent assay (ELISA) for detection of *Cryptosporidium* antigens in fecal samples (Marques et al., 2005) is, also a sensitive, accurate and specific method and is used extensively in survey studies. Serum ELISA and co-agglutination test for antigen in feces and serum (Michel et al., 2000) are also used for diagnosis of this parasite. Molecular methods (Abdel-Wahab & Abdel-Maogood, 2011) for detection of *Cryptosporidium* such as polymerase chain reaction (PCR) and real-time PCR have been used and provide high sensitivity and specificity but require expensive specialized equipment.

#### 44.1.2.7 Control

To minimize contamination of the environment and spread of the disease among animals, good husbandry procedures are required. These include limiting the number of camel calves enclosed in the same facilities as in dairy farms, avoiding overcrowding in parturition area, decreased calving period, in addition to isolation and treatment of diarrheic animals with oral electrolyte solutions accompanied by halofuginone or azithromycin (De Waele et al., 2010).

---

## 44.2 Tissue Protozoa

*Toxoplasma gondii* and *Neospora caninum* (Gebremedhin et al., 2016; Hosseini et al., 2009; Sazmand et al., 2019) can infect a wide range of animal species including camels. The two parasites are closely related and have an indirect life cycle with carnivores as the final hosts. Both protozoan parasites are important causes of abortion in camels.

Sulfonamides and pyrimethamine are used for treatment of infections.

*Sarcocystis* spp. infection in camels (Dubey et al., 2015) induce anorexia, lethargy, pyrexia, and anemia. The cyst can be found in all muscles including the heart muscles. These parasites are prevalent in many countries including Sudan, Egypt, Ethiopia, Somalia, Saudi Arabia, Jordan, Iraq, Iran, India, Afghanistan, Mongolia, and Russia. The economic importance of *Sarcocystis* infection is largely concerned with carcass condemnation, particularly if large infections are found, during meat inspection. Prevention is mainly by breaking the life cycle of the parasite through proper disposal of infected carcasses to avoid their consumption by dogs and cats.

Therapeutic treatment of tissue cysts is ineffective, but amprolium and salinomycin are used as prophylactic drugs.



## References

- Abdel-Wahab, A., & Abdel-Maogood, S. (2011). Identification of *Cryptosporidium* species infecting camels (*Camelus dromedarius*) in Egypt. *Journal of American Science*, 7(2), 609–612.
- Al-Jabr, O. A., Mohammed, G. E., & Al-Hamdan, B. A. (2005). Giardiasis in camels (*Camelus dromedarius*). *Veterinary Record*, 157, 350–352.
- Borji, H., Razmi, G. H., Movassaghi, A. R., Naghibi, A. G., & Maleki, M. (2009). Prevalence of *Cryptosporidium* and *Eimeria* infections in dromedary (*Camelus dromedarius*) in abattoir of Mashhad, Iran. *Journal of Camel Practice and Research*, 16(2), 167–170.
- De Waele, V., Speybroeck, N., Berkvens, D., Mulcahy, G., & Murphy, T. M. (2010). Control of cryptosporidiosis in neonatal calves: Use of halofuginone lactate in different calf rearing systems. *Preventive Veterinary Medicine*, 96, 143–151.
- Dubey, J. P., Hilali, M., Van Wilpe, E., Calero-Bernal, R., Verma, S. K., & Abbas, I. E. (2015). A review of sarcocystosis in camels and redescription of *Sarcocystis cameli* and *Sarcocystis ippeni* sarcocysts from the one-humped camel (*Camelus dromedarius*). *Parasitology*, 142(12), 1481–1492.
- Dubey, J. P., & Schuster, R. C. (2018). A review of coccidiosis in Old World camels. *Veterinary Parasitology*, 15(262), 75–83.
- El Hassan, E. M., Al-Jabr, O. M., & El-Bahr, S. M. (2020). Prevalence of *Cryptosporidium parvum* in diarrheic camel-calves (*Camelus dromedarius*) in Al-Ahsa, Saudi Arabia. *Alexandria Journal of Veterinary Sciences*, 66(1), 60–63.
- Fayer, R. (2004). *Cryptosporidium*: A water-borne zoonotic parasite. *Veterinary Parasitology*, 126, 37–56.
- Fayer, R., Morgan, U., & Upton, S. J. (2000). Epidemiology of *Cryptosporidium*: Transmission, detection and identification. *International Journal for Parasitology*, 30, 1305–1322.
- Gebremedhin, E. Z., Dima, N., Beyi, A. F., Dawo, F., Feyissa, N., Jorga, E., Di Marco, V., & Vitale, M. (2016). Toxoplasmosis in camels (*Camelus dromedarius*) of Borana zone, Oromia region, Ethiopia: Seroprevalence and risk factors. *Tropical Animal Health and Production*, 48, 1599–1606.
- Gluecks, I. V. (2007). *The prevalence of bacterial and protozoal intestinal pathogens in suckling camel calves in Northern Kenya*. PhD thesis. Berlin, Freie Univ., Diss., D188.
- Hosseiniinejad, M., Pirali-Kheirabadi, K., & Hosseini, F. (2009). Seroprevalence of *Neospora caninum* infection in camels (*Camelus dromedarius*) in Isfahan Province, center of Iran. *Iranian Journal of Parasitology*, 4(4), 61–64.
- Kinne, J., & Wernery, U. (2001). Camel coccidiosis caused by *Isospora orlovi* in the United Arab Emirates. *Emirates Journal of Agricultural Science*, 13, 62–65.
- Kinne, J., Ali, M., Wernery, U., & Dubey, J. P. (2002). Clinical large intestinal coccidiosis in camels (*Camelus dromedarius*) in the United Arab Emirates: Description of lesions, endogenous stages, and redescription of *Isospora orlovi*, Tsygankov, 1950 oocysts. *Journal of Parasitology*, 88(3), 448–552.
- Marques, F. R., Cardoso, L. V., Cavasini, C. E., Almeida, M. C., Bassi, N. A., Almeida, M. T. G., Rossit, A. R. B., & Machado, R. L. D. (2005). Performance of an immunoenzymatic assay for *Cryptosporidium* diagnosis of fecal samples. *Brazilian Journal of Infectious Diseases*, 9(1). <https://doi.org/10.1590/S1413-86702005000100002>
- Michel, M. Y., Khalifa, A. M., & Ibrahim, I. R. (2000). Detection of *Cryptosporidium parvum* antigen by co-agglutination test and ELISA. *Eastern Mediterranean Health Journal*, 6(5–6), 898–907.
- Nazifi, S., Behzadi, M. A., Haddadi, S. H., Raayat Jahromi, A., Mehrshad, S., & Amadon, A. (2010). Prevalence of *Cryptosporidium* isolated from dromedary camels (*Camelus dromedarius*) in Qeshm Island, southern Iran. *Comparative Clinical Pathology*, 19(3), 311–314.

- Radfar, M. H., Gowhari, M. A., & Khalili, M. (2013). Comparison of capture ELISA and modified Ziehl-Neelsen for detection of *Cryptosporidium parvum* in feces of camel (*Camelus dromedarius*) in Iran. *Scientia Parasitologica*, 14(3), 147–152.
- Razavi, S. M., Oryan, A., Bahrami, S., Mohammadalipour, A., & Gowhari, M. (2009). Prevalence of *Cryptosporidium* infection in camels (*Camelus dromedarius*) in a slaughterhouse in Iran. *Tropical Biomedicine*, 26, 267–273.
- Sazmand, A., Rasooli, A., Nouri, M., Hamidinejat, H., & Hekmatimoghaddam, S. (2012a). Prevalence of *Cryptosporidium* spp. in camels and involved people in Yazd Province, Iran. *Iranian Journal of Parasitology*, 7(1), 80–84.
- Sazmand, A., Hamidinejat, H., Hekmatimoghaddam, S., Asadollahi, Z., & Mirabdollahi, S. (2012b). *Eimeria* infection in camels (*Camelus dromedarius*) in Yazd province, Central Iran. *Tropical Biomedicine*, 29(1), 77–80.
- Sazmand, A., & Loachim, A. (2017). Parasitic diseases of camels in Iran (1931-2017) – A literature review. *Parasite*, 24(21), 1–15.
- Sazmand, A., Loachim, A., & Otranto, D. (2019). Zoonotic parasites of dromedary camels: So important, so ignored. *Parasites & Vectors*, 12, 610–619.
- Tzipori, S., & Ward, H. (2002). Cryptosporidiosis: Biology, pathogenesis, and disease. *Microbes and Infection*, 4, 1047–1058.

El Awad Mohamed El Hassan

---

**45.1 *Linguatula serrata* Infection in Camels (*Halzoon*; *Marara Syndrome*)**

*Linguatula serrata*, the nasal worm of canids, is a zoonotic pentastome that uses dogs and other carnivores as definitive hosts while its larval stages are found in the mesenteric and mediastinal lymph nodes, liver, and lungs of herbivores, e.g., camels, sheep, goats, and cattle, as well in humans (Sazmand & Joachim, 2017). Human infection with *L. serrata* nymphs causes an intense hypersensitivity reaction in the upper respiratory tract and the buccopharyngeal mucosa. The condition is known as *Halazoun* in Syria, Lebanon, and other parts of the Middle East. In Sudan, it is known as the *Marara syndrome*—*Marrara* is a popular dish in Sudan, consisting of raw liver, lungs, trachea, and rumen of camels, goats, and sheep, which could be infected with larvae of *L. serrata*. *Marara* is typically consumed during festivals.

---

**Reference**

Sazmand, A., & Joachim, A. (2017). Parasitic diseases of camels in Iran (1931–2017) – A literature review. *Parasite*, 24, 1–15.

---

## **Part VI**

# **Blood Parasites of Dromedary Camels**

## Set Bornstein

Trypanosomosis is a common disease in animals and humans in tropical and subtropical regions. It is caused by parasitic trypanosomes (Fig. 46.1) which are mostly heteroxenous, i.e. infesting more than one kind of host and require at least two kinds of hosts to complete its life cycle of which one often acts as a vector. These are primarily insects in which many of the trypanosomes develop and undergo a biological cycle into different morphological forms (cyclical transmitters).

Based on the mode of development in the insect host, the trypanosomes of mammals are divided into two groups (sections): the Stercoraria and the Salivaria. Trypanosomes are further divided into subgenera and species by morphological differences and recently by molecular means (see “classification of the *Trypanosoma*”).

The Stercoraria develops in the posterior part of the gut of the insect which, via the feces transmits the infective development stage of the trypanosome (metacyclic trypomastigotes).

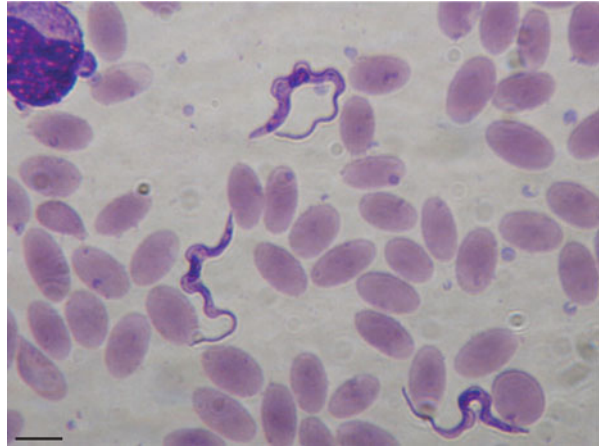
Some of the important trypanosomes of the Salivarian group develop also in the gut but in the anterior part (midgut, proventriculus, and salivary glands) of the vector into several development forms; from trypomastigotes to epimastigotes then back into trypomastigote forms that are the infective forms called metacyclic trypanosomes that migrate to the front in contact with the mouthparts of the vectors.

The transmission is primarily inoculative of the infective metacyclic trypanosomes when the vector injects its saliva when starting to feed.

Transmission of the metacyclic trypanosomes can also be mechanical among the salivarian group via the tsetse flies (*Glossina* spp) and mainly through other hematophagous flies, particularly tabanids (horse flies), *Stomoxys* spp. (stable flies), and the very common camel louse fly (biting ked), *Hippobosca camelina* (Kidambasi et al., 2020).

Particularly the tabanids and stable flies are important vectors of *Trypanosoma evansi*, one of the most important pathogens infecting camels. No cyclical development occurs in these flies transmitting *T. evansi* mechanically. In mechanical

**Fig. 46.1** Giemsa-stained blood smear of a dromedary camel showing *T. evansi* trypanosome (source: Desquesnes et al., 2008)



transmission, the trypanosomes are passively transferred from one mammalian host to another by the interrupted feeding of biting insects.

All the salivarian trypanosomes have their origin in Africa and for a very long time the *Glossina* spp. were thought to be the only ones transmitting them. Many tsetse flies but not all are susceptible to trypanosomes and able to transmit them. However, some of the trypanosomes (*T. evansi* and *T. vivax*) that were previously restricted in their transmission by tsetse flies have developed the ability to transmit mechanically and consequently have successfully spread to other continents worldwide. In Africa, dromedary herders make a point of keeping their animals away from known tsetse areas.

## 46.1 Etiology

Trypanosomosis in camels are primarily caused by *Trypanosoma evansi* (Cross, 1917; Leese, 1927) and called Surra (Hindi name meaning rotten or emaciated).

In Africa within the tsetse belt dromedaries may get occasionally infected by some of the common tsetse transmitted trypanosomes, *T. brucei*, *T. congolense*, *T. vivax* (Bennett, 1933; Masiga & Nyangáo, 2001), and *T. simiae* (Mihok et al., 1994). Also, mixed infections with *T. brucei* and *T. congolense* occur (Masiga & Nyangáo, 2001). These infections may lead to severe disease and may cause mortalities.

*T. vivax* is transmitted cyclically as well as mechanically by *Glossina* spp., tabanids, and stable flies, respectively. The parasite is found in many large ungulates, including cattle and small stock, equids, camels, and wild animals, e.g. antelopes (Hoare, 1972). It is a major pathogen of domestic animals and is the dominant trypanosome species in West Africa (Osório et al., 2008). It is endemic in Latin America. There, its transmission is only mechanical through biting flies (Desquesnes et al., 2013a).

*T. vivax* was recently reported to cause trypanosomosis in dromedaries in Ethiopia and Sudan (Birhanu et al., 2015; Mossaad et al., 2017), in Nigerian dromedaries (Mbaya et al., 2010), and in Kenya was found in “healthy” dromedary camels (Kidambasi et al., 2020).

In the Sudan survey (during 2015–2016), the prevalence was significant; for *T. evansi* (37–59%) and for *T. vivax* (25–31%), depending on tests employed) and in the fairly limited sample of animals tested 18% were of mixed infections (Mossaad et al., 2017).

In the recent study of Kidambasi et al. (2020) in 2017, 249 camels in Laisamis sub-county (Marsabit county), northern Kenya were screened for blood parasites by PCR. Infection rates of *Trypanosoma vivax* were 41% and for *T. evansi* 1.2%, respectively.

These findings during the recent decades may be signs of an emerging pathogen in dromedaries.

### 46.1.1 Classification of the *Trypanosoma*

---

Family Trypanosomatidae

Genus, *Trypanosoma*

Section ***Stercoraria***

Subgenus *Megatrypanum*

Subgenus *Herpetosoma* (ex; *T. rangeli*, *T. lewisi*)

Subgenus *Schizotrypanum* (ex; *T. cruzi*)

Section ***Salivaria***

Subgenus Duttonella

Species; *Trypanosoma vivax*

Species; *T. uniforme*

Subgenus *Nannomonas*

Species; *Trypanosoma congolense*

*Trypanosoma simiae*

*Trypanosoma godfreyi*

Subgenus Trypanozoon

Species; *Trypanosoma brucei*

Subspecies; *Trypanosoma brucei rhodesiense*

Subspecies; *Trypanosoma brucei gambiense*

Subspecies; *Trypanosoma brucei brucei*

Species; *Trypanosoma evansi*

Species; *Trypanosoma equiperdum*

Subgenus *Pycnomonas*

Species; *Trypanosoma suis*

---

### 46.1.2 Morphology and Structure

*Trypanosoma evansi* is found in the blood of the mammalian host and is often indistinguishable from *T. brucei*. *T. evansi* occurs most often as a monomorphic

trypomastigote, long and slender, measuring 15 to 36µm long and 1.5–2.2µm wide. Its cell membrane encloses cell organelles: nucleus, mitochondria, endoplasmic reticulum, Golgi apparatus, ribosomes, and a very special small organelle called the kinetoplast which is placed sub-terminal and connected with the proximal end of the basal body. From the latter arises a single flagellum that runs toward the anterior end along the body surface. The flagellum is attached to the cell membrane forming a clear long undulating membrane.

*T. evansi* as all bloodstream African trypanosomes are coated with dimers of a single type of variant surface glycoprotein (VSG) covering the plasma membrane. These VSGs allow the trypanosome parasites to evade the immune system of the host (Mugnier et al., 2016). This is done by repeatedly replacing its VSG coat from its large genomic VSG repertoire of around 1000 different VSG genes (Pinger et al., 2017). During infection, the host develops potent VSG-specific antibodies that mediate trypanosome clearance, but a minority of parasites evades clearance by switching expression to antigenically distinct VSG. These changed parasite populations then expand within the host until they are removed, after which additional populations expressing distinct VSGs emerge again. This cyclical process results in characteristic waves of parasitemia occurring at ~5–8-day intervals during infection, with parasite suppression synchronized with and mediated by the development of repeated primary, VSG-specific Ab responses (Pinger et al., 2017). VSGs were first isolated from *T. brucei* (Cross, 1975).

### 46.1.3 Origin and Development of Significant Structures

Both *T. equiperdum* and *T. evansi* are derived from the *T. brucei* lineage and have lost part or all of their kinetoplast DNA, called dyskinetoplastidy or akinetoplastidy (Claes et al., 2005; Lai et al., 2008) by adaptation to mechanical transmission by biting flies.

*T. evansi* which genetically is characterized by the loss of its maxicircles of kinetoplastic mitochondrial DNA (a rare exemption was found in a Venezuelan strain, Perrone et al., 2009), required for cyclical development in tsetse flies (Lai et al., 2008), lost their capability of being cyclically transmitted by the tsetse flies. In that process *T. evansi* became close to monomorphic.

As a consequence, *T. evansi* is no longer restricted to Africa or to the *Glossina* spp. as vectors. *T. evansi* is now found worldwide successfully infecting a large range of animals, domestic as well as wild in Africa as in Asia, Latin America, and southwestern Europe.

Lai et al. (2008) are strongly of the opinion that *T. evansi* and *T. equiperdum* should be considered as two subspecies strains of *T. brucei* that relatively recently evolved spontaneously. Phylogenetic analysis has showed that *T. evansi* and *T. equiperdum* evolved from *T. brucei* at least on four independent occasions (Carnes et al., 2015). The finding that *T. evansi* genome sequence shows significant similarity to *T. brucei* supports the contention that *T. evansi* ought to be classified as a subspecies of *T. brucei* (Carnes et al., 2015). However, after decades of debates at



the 10th and 11th international meetings on *Trypanosoma evansi* it was decided to keep the nomenclature as it was; *Trypanosoma* (Trypanozoon) *evansi* (Touratier, 1990, 1992).

#### 46.1.4 *Trypanosoma evansi* Type A and B

*T. evansi* has been found to be divided into two different types, type A and B (Borst et al., 1987; Njiru et al., 2006). Type A is the most prevalent and found in Africa, South America, and Asia. It is characterized by having the gene for the variant surface glycoprotein (VSG) RoTat 1.2, which is expressed early during infections resulting in the detectability of anti-RoTat 1.2 antibodies in animals infected with *T. evansi* type A (Bajyana Songa & Hamers, 1988; Verloo et al., 2001).

However, *T. evansi* type B lacks the RoTat 1.2 gene and has hitherto only been isolated from camels in Kenya (Ngaira et al., 2005), Ethiopia, Chad, Egypt (Aregawi et al., 2019; Birhanu et al., 2015; Birhanu et al., 2016), Sudan (Salim et al., 2011), and Saudi Arabia (Alanazi et al., 2018). The latter findings might have been in camels imported from the Horn of Africa from where Saudi Arabia has a large import of camels (Younan et al., 2016).

Infections with *T. evansi* type B cannot be detected with serological and molecular tests based on RoTat 1.2 VSG, such as the CATT/T *evansi* or RoTat 1.2 PCR (Bajyana Songa & Hamers, 1988; Claes et al., 2004; Ngaira et al., 2005; Njiru et al., 2006).

---

## 46.2 Epidemiology

The most important protozoal and one of the most prevalent camel diseases, if not the most common, is trypanosomosis. Surra in camels is prevalent worldwide, wherever camels thrive and where suitable vectors of *T. evansi* occur, i.e. hematophagous flies, particularly tabanids, *Stomoxys* spp, *Haematobia* spp. and *Hippobosca* spp., and many more (Desquesnes et al., 2013a).

It is considered to be the most important single cause of economic losses, in terms of reduced milk, meat, and work capacity in addition to the loss of animals in camel rearing areas. It causes high morbidity up to 30% and mortality of about 3% (Abdelrahman et al., 2011).

Camels are the most important “host” of *T. evansi* (Desquesnes et al., 2013b; Ouhelle & Dakkak, 1987). It was the first pathogenic trypanosome discovered in the world and was described in 1880 by Griffith Evans, who demonstrated it in blood of equines and dromedaries in Punjab, India (Hoare, 1972; Luckins, 1988).

In Africa *T. evansi* is present in all countries harboring dromedaries. These countries (north of the tsetse belt) are north of a line extending from Senegal on the Atlantic coast (15° north latitude) across to Kenya. These regions include Maghreb, Sahel, and the Horn of Africa and some limited areas in Uganda and Tanzania. Wilson (2013) mentions that surra came to Southern Africa with infected

dromedaries in the nineteenth and early twentieth century. Camels were introduced at that time to the present Namibia, South Africa, and Zambia to replace oxen that died of rinderpest.

It is believed that *T. evansi* spread by camel caravans into North Africa, the Middle East, and then through the Central Asian republics into South Asia (Wernery et al., 2014). Most probably the Silk Road routes played an important role in this.

Dromedaries have been found infected with *T. evansi* and diagnosed with surra in most countries in the Middle East; in Iran (Derakhshanfar et al., 2010), Israel (Berlin et al., 2010), Palestine, Ereqat et al., 2020), Lebanon (Desquesnes et al., 2013b) Jordan (Abo-Shehada et al., 1999), Kuwait (Al-Taqi, 1989), Iraq (Aboed & Faraj, 2017), Oman (Srivastava et al., 1984), Saudi Arabia (Alarabi et al., 2019; Al-Khalifa et al., 2009; Diab et al., 1984), and United Arab Emirates (Wernery et al., 2014).

Surra is a very important disease in India and Pakistan both in camels, buffaloes, equines, and dogs (Ravindran et al., 2008; Shah et al., 2004; Tehseen et al., 2015) as well as in South East Asia affecting particularly horses, dogs, cattle, pigs, and buffaloes as well as deer (Desquesnes et al., 2013b; Holland et al., 2004).

Bactrian camels are also prone to *T. evansi* infections, seen in the Central Asian republics and Mongolia. Here the disease is called Su-Auru, “disease next to the water” (in Kazakh), very appropriate because the vectors are mostly tabanids that need swampy grounds for breeding. It is also present in horses but with lower prevalence. In Kazakhstan and Uzbekistan, also with large populations, surra is more frequent (Desquesnes et al., 2013a).

In China, the disease is present and relatively more prevalent in buffaloes (*Bubalus bubalius*), horses, and mules than in the smaller numbers of Bactrian camels present in the western part of the country.

Thus, surra is found to be a disease in a very broad range of host species not only in domestic animals as camels and equines but also cattle, buffaloes, dogs, cats, and a wide range of wildlife species such as Indian elephants, tigers, foxes, tapirs, and orangutans.

Today, 140 years after the discovery of *T. evansi*, worldwide epidemiological data show that the parasite is found in four continents: Africa, Southern Europe, Asia, and Latin- and South America causing surra.

Surra was recognized on the Canary Islands in a dromedary camel in 1997, the first reported case of *T. evansi* in camels in Europe. It eventually reached France in 2006 following the importation of five camels from the island of Gran Canaria. In 2008 a farm in the province of Alicante in the mainland of Spain was hit by *T. evansi* infecting camels and some equids (Desquesnes et al., 2008; Gutierrez et al., 2010). These local outbreaks were eventually successfully controlled (Desquesnes et al., 2009, 2013b).

### 46.3 Zoonotic Potentiality

Humans are thought to be naturally resistant to some of the pathogenic animal trypanosomes; *T. b. brucei*, *T. evansi*, *T. equiperdum*, *T. congolense*, and *T. vivax* (Radwanska et al., 2018). *T. b. brucei* (the prototype of African trypanosomes) cannot infect humans due to trypanosome lytic factors (TLF-1-2) in human sera which causes lysis to these trypanosomes (particularly by TLF-1) (Pays et al., 2006; Stuart et al., 2008). This applies in general to all the above trypanosomes. *T. b. gambiense* and *T. b. rhodesiense*, that causes human trypanosomosis (sleeping sickness) in Africa, have not TLF-1. However, there are some reports of humans diagnosed with surra (Haridy et al., 2011; Joshi et al., 2005; Powar et al., 2006; Truc et al., 2007). Although *T. evansi* is not today considered to be a zoonosis it is recommended to be cautious. There is a potential risk for humans to get infected considering the many routes of transmission of *T. evansi*; by direct contact (percutaneous infection), per oral, or via blood sucking insects (Desquesnes et al., 2013a).

---

### 46.4 Modes of Transmission

Transmission of *T. evansi* is primarily mechanical by hematophagous insects. The most important are tabanids (horseflies) and *Stomoxys* spp. (Gill, 1977). According to the same author, 29 different *Tabanus* species had been successfully experimentally shown to transmit the parasite. The list of unknown but potential mechanical vectors of *T. evansi* has not yet been explored exhaustively. Sucking flies have also been shown to be able to transmit trypanosomes (Desquesnes et al., 2013a).

Transmission can also be vertical, horizontal, iatrogenic. *T. evansi* can also be transmitted to carnivores through the consumption of infected meat.

The mechanical transmission can take place when a biting fly starts its blood meal on an earlier infected host, begins to feed, and is interrupted and consequently flies off and lands on another, perhaps uninfected camel, to restart its blood meal (Baldacchino et al., 2014; Desquesnes et al., 2009).

Tabanids who are the most common and important vectors of surra in camels, can contain 1–12 nl blood in their mouthparts. *Stomoxys calcitrans* can harbor 0.03 nl blood (Foil et al., 1989). Desquesnes et al. (2009) showed that the probability in cattle of transmission became significant when parasitemia was above  $10^6$  *T. evansi*/ml blood. Parasitemia in camels may vary a great deal, from low to very high  $>10^8$  *T. evansi*/ml. Trypanosomes have a very limited time in the biting flies to implement a transmission successfully. The survival, e.g., for *T. vivax* in tabanids was estimated to 30 min and less than that in *Stomoxys* sp. (Ferenc et al., 1988).

In cattle, the incidence of transmission by Tabanids is directly linked to the parasitemia and the number of biting insects being present around the host (Desquesnes et al., 2009).

## 46.5 Clinical Picture

The clinical signs of Surra show in general similar signs as in any mammal species with trypanosomosis; fever, anemia, loss of appetite, weight loss, loss of condition and productivity, nervous signs, abortion, cachexia, and death (Desquesnes et al., 2013b) (Fig. 46.2). In addition, very important and significant effect of *T. evansi* infections is immunosuppression commonly seen as vaccination failures. However, the clinical signs of surra in camels in particular are multifarious and may be seen as acute, subacute, or chronic and even subclinical, healthy carriers (Desquesnes et al., 2013b).

The course of the disease depends on many environmental and host factors as age, nutritional status, pregnancy, exposure to other diseases and immunosuppression and stress (Röttcher et al., 1987). In addition, the severity of the course of the disease may also depend on whether the animals affected are in a naïve or endemic situation.

The elevation of the body temperature, often a recurrent fever, which according to Luckins (1988) is directly associated with parasitemia, accompanied by progressive anemia and poor general condition are most often seen at the beginning of an acute case or outbreak. Edema and paralysis may soon follow, as well as nervous signs like circling movements, trembling, aggressiveness, running aimlessly, and sudden collapse. Death may follow within a few months.



**Fig. 46.2** Male dromedary camel affected with Trypanosomosis, El Showak, eastern Sudan (Courtesy of Abdalla Bushara, Camel Research Center, University of Khartoum, Sudan)

Experimental infection studies on dromedaries are few. Mbaya et al. (2014a) found the prepatent period being 4 days following a dose of  $1 \times 10^3$  *T. evansi* inoculated intravenously. Clinical symptoms were pyrexia followed by rough fur coat, depression, anorexia, anemic ocular and buccal mucous membranes, edema of the brisket, weight loss, and circling gait. Pulse, respiratory, and heart rates were elevated, and retropharyngeal lymph nodes enlarged. In the same experimental study, the body temperature at pre-infection of  $38.2\text{--}38.3^\circ \text{C} \pm 0.77$  increased within 16 days to  $40.0^\circ \text{C} \pm 0.80$  (Mbaya et al., 2014b) (Note that body temperature can fluctuate considerably in camels depending on the temperature in the environment, time of day, and watering practice (degree of dehydration).

Subacute infections may be seen with fever and edema which may be seen as plaques on the neck and flanks swellings of the muzzle, chest wall, sheath and scrotum, and on the legs reaching up to the knees and hocks. Emaciation is soon followed by high mortalities that may occur a few days or months from outset of clinical signs.

The surra is most often manifested as a chronic wasting disease of several years (2–3 years or more). Intermittent fever ( $<41^\circ \text{C}$ .) of about one week is often seen. The diseased animal seems dull and becomes progressively weaker with rough glossy haircoat, loss of appetite and weight, abortion, seen in all stages of pregnancies (Leese, 1927). If the fetus is born at full time, it may be born alive but weak with parasitemia (Sergeant et al., 1920 cited Röttcher et al., 1987), and death usually ensues within two weeks. Edema (particularly on the ventral parts of the body) is often seen. Surra can be seen in all age groups, including fetuses (Röttcher et al., 1987).

Röttcher et al. (1987) describe what is seen in the “the typical case”; “the dromedary loses weight, develops a drooping hump, is unable to walk long distances, and may or may not develop edema of the feet, brisket, underbelly, and eyelids, the coat becomes rough. In the initial attack of fever there may be lacrimation, shivering, reduced appetite, and mild diarrhea. The infected animal always shows progressive anemia and fluctuating body temperature with initial peaks of fever up to  $41^\circ \text{C}$ . Later, the appetite is relatively unimpaired. The temperature may become normal or slightly increased.” Loss of production, as milk yield and work output are significant signs.

Experienced camel herders may diagnose surra by the foul odor of the urine (Hunter, 1986; Leese, 1927; Stephen, 1986). Most probably due to ketone bodies which have been found to be elevated in trypanosome infected camels (Shillinger unpublished cited Röttcher et al., 1987). Similar traditional diagnostic method referred to as “sand ball test” is practiced by Arabian Bedouins and the Rebaris of southeastern Punjab. Diseased camels are let to urinate on some earth which then is shaped into a ball, dried for a half an hour and then broken and smelled by the expert, the owner of the camel or the herder (Köhler-Rollefson, 1994).

## 46.6 Pathology

There are no pathognomonic lesions observed in surra of camels. Anemia is a major component, and the anoxic condition may lead to dysfunctions in many vital organs of the body in surra generally (Habila et al., 2012).

Owing to the progressive anemia, pale mucous membranes are a common feature and manifested by lowered packed cell volume (PCV)  $\leq 24\%$  even down to 10% (Röttcher et al., 1987).

The anemia is macrocytic and hypochromic (Jatkar & Purohit, 1971), hemolytic and hemophagocytic in the early phase of surra.

Wernery (1995) in a study of race dromedaries chronically infected with *T. evansi*, found that the hemoglobin, hematocrit, and iron were significantly decreased while leucocytes were above normal values. Similar results were seen in dromedaries having subacute surra.

The decrease in erythrocytes is accompanied by an increase in lymphocytes, eosinophils, and monocytes. In addition, there are progressive changes in the protein concentrations of the serum; a decrease in albumin, an increase in  $\gamma$ -globulins and up to a five-fold increase of IgM during the course of infections (Boid et al., 1980).

Above findings of clinico-pathological parameters agree with those reported from one of the few studies found published on experimental infections of dromedaries (Mbaya et al., 2014a); parasitemia increased significantly following infection peaking at day 36 post infection (dpi). The pre-infection PCV values of 38.7% declined to  $12.0 \pm 0.43$  by 36 dpi.

The ability of *T. evansi* to periodically switch its major variant surface glycoprotein (VSG) may enhance the relapse of parasitemia in infected hosts.

### 46.6.1 Gross Lesions and Histopathological Findings

Skeletal muscles and myocardium may be pale. Mbaya et al. (2014b) reported the presence of multifocal areas of myocardial degeneration and mononuclear cellular aggregations histologically. Lymph nodes and spleen are often enlarged. Generalized lymphoid tissue hyperplasia is a common feature of surra in camels (Röttcher et al., 1987). Mbaya et al. (2014b) found that the retropharyngeal lymph nodes were markedly enlarged and congested as well as the spleen. The retropharyngeal lymph nodes in five experimentally infected dromedaries appeared highly reactive with numerous secondary follicles containing large lymphocytes and lymphoblasts, moderately depopulated medulla, and the presence of large numbers of macrophages. All indicate an intense antigenic stimulation commonly encountered in trypanosomosis.

The spleen showed considerable hemosiderosis and the three of the five experimentally infected dromedaries had a rupture in the capsule at the cranial border of the respective spleen (Mbaya et al., 2014b).

Hemorrhages may be present on serous surfaces, in the parenchyma of the liver and kidneys in acute and peracute cases. Mbaya et al. (2014b) found ecchymotic

hemorrhages in the epicardium and endocardium and reported the presence of multifocal areas of myocardial degeneration and mononuclear cellular aggregations histologically.

The kidneys showed widespread glomerulosclerosis and tubular nephrosis. Subcutaneous edema may be present particularly on abdomen and lower extremities. In the three of the five camels experimentally infected Mbaya et al. (2014a) found massive quantity of serosanguineous fluid ( $\leq 15$  l) in the abdomen. Extensive sheaths of blood clots were adherent to the viscera.

In chronic cases, the carcass is anemic and often emaciated. Ascites and hydrothorax are often present and lymph nodes are enlarged.

Small bleedings can be found in the edematous meninges of the cerebellum and brain stem. Edema and mild to moderate non-suppurative meningitis and focal meningoencephalitis can be found in the central nervous system (Acosta et al., 2016, Wernery et al., 2014). In addition, “broad perivascular cuffs” in the grey matter of the brain are commonly found histologically as also eosinophilic PAS-positive corpuscular structures in the meninges.

---

## 46.7 Immunosuppression

One important feature of trypanosomosis is that trypanosome populations evade protective immune responses. Generalized immunosuppression encompassing both humoral antibody and T-cell-mediated immune responses occurs in infected animals. This is a common feature induced by *T. evansi* as well as by other pathogenic trypanosomes. This may aggravate concomitant infections and impede vaccinations.

---

## 46.8 Diagnosis

There are no true pathognomonic signs of trypanosomosis in camels. It can be confused with any chronic wasting disease such as helminthosis or malnutrition. For diagnosis one must rely on laboratory analysis to confirm an infection. The traditional diagnosis was based on the demonstration and identification of the trypanosome in blood samples. However, that was and is difficult due to the often-low parasitemia, particularly in the chronic and subclinical stages. Despite the low sensitivity (50–60%) of the “parasitological” techniques whereby the trypanosomes were both demonstrated and identified are still applied.

Clinical signs like emaciation and anemia (PCV of  $\leq 24\%$ ) are often used as a provisional diagnosis, but proper diagnostic techniques, i.e., confirmation, needs to be done using more modern methods either by microscopy or by molecular tools to demonstrate the pathogen causing the active infection or by serological means to demonstrate specific antibodies (as well as specific antigens) induced by a present or past infection (Büscher, 2001, 2014; Tehseen et al., 2015). There is a long list of



relevant methods to diagnose animal trypanosomosis outlined and recommended by Desquesnes (2017).

### 46.8.1 Methods for the Diagnosis of Trypanosomosis

1. Direct demonstration of trypanosome by direct light microscopy of blood samples preferably taken from peripheral veins rather than the jugular vein and applied to glass slides as wet thin and thick blood films, and aspirates from lymph nodes.
2. Concentration techniques: microhematocrit centrifugation (MHCT), dark field/phase contrast buffy coat technique, and mini-anion exchange centrifugation technique.
3. More elaborate diagnostic methods for diagnosing trypanosomosis at well-equipped laboratories.
4. *Animal inoculation.*
5. *Detection of antigen.*
6. *Analysis of DNA (molecular).*  
*DNA probes.*  
*Polymerase chain reaction (PCR).*
7. *Serological tests.*
8. *Indirect immunofluorescent antibody test (IFAT).*
9. *Enzyme-linked immunosorbent assay (ELISA), testing either for antigen or antibody.*
10. *Card agglutination test for trypanosomosis (CATT) is an antibody test.*
11. *Immuno trypanolysis test (detecting antibody).*

Confirmation of a tentative diagnosis in the field is today still done by relatively insensitive methods as wet, thin, and thick blood films. Half a million trypanosomes per mL of blood is needed to be able to detect them in thin blood smears, i.e. in cases of high parasitemia.

However, concentration techniques improve the chances to find trypanosomes in the blood of animals with lower parasitemia. The most commonly used in the field is the microhematocrit centrifugation technique (MHCT). Another is dark ground/phase contrast buffy coat technique.

In MHCT trypanosomes are found concentrated after centrifugation (at 2500 g) in blood-filled capillary tubes following the centrifugation in a specially designed microhematocrit centrifuge (MHC). The centrifugation separates the blood into three layers; the packed blood cells (PCV), the buffy coat, and the plasma. Motile trypanosomes may be seen in the interface between the buffy coat and the plasma employing a light microscope (Woo, 1969; Woo, 1971).

One may examine the buffy coat as a wet preparation (buffy coat technique, BCT) under a microscope (dark field) by expelling it on a glass slide. Trypanosome species can be identified in such a wet preparation or after Giemsa staining. Spun capillaries can also be examined directly under the microscope.



According to Kelley and Schillinger (1983) via the MHCT one can detect trypanosomes about a week earlier than via wet or thick blood films. This technique is an easy procedure in the field run by a battery-powered MHC that can be driven by a car battery.

Other means to detect very low parasitemia are, e.g., the miniature anion exchange centrifugation technique (MAECT) (Lumsden et al., 1979, 1981a) and the silicone centrifugation technique (Ogbunde & Magaji, 1982). Both techniques can pick up trypanosomes at levels of about 50 parasites per milliliter of blood (Büscher et al., 2009). The latter technique was claimed to be simple and rapid (Nessiem, 1994).

Inoculation of laboratory rodents with blood of camels suspected of trypanosomosis is a sensitive method to detect “patients” with low parasitemia of *T. evansi* (Boid et al., 1985) and *T. brucei* (Godfrey & Killick-Kendrick, 1962). This test should detect two parasites per mL of host blood when 0.5 mL blood is inoculated. The method is time-consuming, expensive, and inappropriate for use in large-scale surveys. In addition, the use of laboratory animals when there are other in vitro methods available is questionable and unethical.

Failure to demonstrate any trypanosomes employing above methods (excluding laboratory rodents) does not exclude infection as most of them have such a poor sensitivity of <50% (Chappuis et al., 2005). If relying only on above “parasitological” techniques, *T. evansi* will be underdiagnosed.

Serological diagnosis of *T. evansi* in camels is currently limited: In the past there were several methods, biochemical tests used to detect increased serum globulins (non-specific antibodies) to confirm surra in camels. Later several different tests have been developed to demonstrate specific humoral antibodies to antigens of trypanosomes; as agglutination tests, complement fixation tests (CFT), immunofluorescent antibody test (IFAT), and the trypanolysis test, the only one presently still in use due to high specificity (OIE, 2018). The others have been replaced by the more easily standardized techniques of ELISA Card agglutination test, CATT/*T. evansi* (Bajyana Songa & Hamers, 1988; Njiru et al., 2004), and latex agglutination test (Gutierrez et al., 2004).

The antibody measuring tests: Indirect fluorescent antibody test (IFAT), enzyme-linked immunosorbent assay (ELISA), and Card agglutination test for trypanosomosis (CATT) have all relatively acceptable sensitivities but they cannot distinguish current from cured or passed infections (Luckins, 1988).

Evaluations of ELISA and CATT have been done in several hosts, including camels (Desquesnes et al., 2009; Verloo et al., 2000). Tests are usually carried out on plasma or serum but for collection of samples for ELISA it can be made easier by using filter paper blood spots for later use and for CATT whole blood (Holland et al., 2002; Hopkins et al., 1998).

A large variety of test procedures exists, e.g., the use of purified native antigens (Verloo et al., 1998) or recombinant antigens (Tran et al., 2009).

For closely related animal species cross-reagents may often be used, e.g. mono-specific anti-IgG conjugates. Protein A conjugate has been validated for use in camels (Desquesnes et al., 2009).

The variable antigen (VAT) RoTat 1.2 cloned from a *T. evansi* strain, isolated in 1982 from a water buffalo in Indonesia, showed that all *T. evansi* strains tested expressed this VAT while *T. brucei* strains did not (Büscher pers. comm via Claes et al., 2003). Later studies have shown that *T. evansi* type B also does not express the VAT RoTat 1.2.

Distinction between *T. evansi* type A and type B can be made with PCRs specific for the type A RoTat 1.2 gene and specific for type B minicircles (Claes et al., 2004; Njiru et al., 2006; Urakawa et al., 2001). This is because *T. evansi* type B lacks the RoTat 1.2 gene thus does not induce anti-RoTat 1.2 antibodies (Ngaira et al., 2005; Njiru et al., 2006).

---

## 46.9 Treatment

Generally, antiprotozoals are used in two ways; therapeutically, to treat existing infections or clinical outbreaks—or prophylactically, when the timing of treatment should be based on knowledge of the epidemiology.

Prophylactic use should preferably be administrated at selected intervals or continuously over a period preventing the reoccurrence of the disease. Thus, trypanocides can be divided into “therapeutic/curative drugs” and “therapeutic/curative-preventive drugs.” The former is used for treatment having a short-term effect that has the objective to kill the parasites. Effective treatment of the acute phase of infection usually leads to recovery. The use of curative drugs is mainly applied when the disease incidence is low and a limited number of animals in a herd is affected in the course of a year.

The use of trypanocides in the chronic phase usually clears the parasitemia but clinical recovery may need a longer time, depending on the severity of symptoms, weight loss, and organ damage. Elimination of parasites is not always 100%.

Preventive drugs are chemoprophylactic drugs that not only kill the parasites but also prevent any new infections or re-circulation of the parasites, sometimes occurring if remnant populations are “hidden,” e.g., in the CNS.

Application of prophylactic treatments may occur shortly before the rains to protect the animals of being infected by the many tabanid species that are particularly abundant during and shortly after the rains.

Treatment may fail due to chemoresistance and underdosing. Estimation of body weight is often done by “eye” which is prone to inaccuracy and often causes errors in drug dosage. Significant underdosing results in ineffective treatment and risking the development of drug resistance. Considerable overdosing may lead to toxic effects. Also, faulty handling and administration of the drugs as well as increased treatment frequency may occur, all leading to treatment failures. In addition, poor quality or counterfeit drugs are widespread in some parts of the world.

Existence of the pathogens in “hidden” sites evading the drugs (e.g., in the CNS), and the toxicity of some of the trypanocides may cause treatment failures (Ali et al., 1985; Jennings et al., 1977; Luckins et al., 1979). Regular monitoring of infections is recommended to prevent too large losses in endemic areas. This has proven

successful in well-managed herds by frequent measurements of PCV. There are camel owners and managers who treat any camel having PCVs of <25% with trypanocides!

### 46.9.1 Trypanocides

Trypanocides are a scarce commodity. Altogether out of the 7 compounds available to treat domestic livestock only four-five can be used for the treatment of surra in camels. The four-five are melarsomine dihydrochloride, quinapyramidine sulfate and quinapyramidine chloride, isometamidium, and suramin (the latter introduced already 1921). Although there are a few more compounds that are effective against *T. evansi* but not suitable or too toxic for dromedaries, e.g. diminazene aceturate (Berenil®), which is nevertheless well tolerated by Bactrian camels with doses up to 5 mg/kg bodyweight (Luckins, 1992). It is therapeutically used on Bactrian camels against *T. evansi* infections in Mongolia and China.

### 46.9.2 Aromatic Diamidine Compounds

Diminazene aceturate (common brand names; Berenil®, Ganaseg®, Veriben®, Trypazen®). The drug was introduced in 1955 against babesia and trypanosome infections in ruminants. It is the most widely used curative trypanocide against surra (note, except for dromedaries) worldwide (Desquesnes et al., 2013a). The recommended dose for treating infections of species in the trypanozoon subgenus is 7 mg/kg body weight (bw) via deep intramuscular (im) injection (Desquesnes et al., 2013a), but subcutaneous (sc) injections are also recommended. It is often found in the field that a dose of 3.5 mg/kg bw is used to control surra. This could be due to the fact that it is the recommended dose for the treatment of *T. congolense* and *T. vivax* infections.

The drug cannot cross the blood–brain barrier, thus cannot reach any pathogens hiding in the CNS. As diminazene aceturate has been used for a long time, trypanosomes have developed chemoresistance in many parts of the world (Desquesnes, 2004; Peregrine & Mamman, 1993).

### 46.9.3 Phenanthridine Compounds

Homidium chloride (Novidium®) and homidium bromide (Ethidium®) are highly toxic due to the fact that they are DNA intercalating agents, thus mutagenic (Macgregor & Johnson, 1977; McCann et al., 1975). Thus, their use in the field is not recommended (Desquesnes et al., 2013a). Although still used against *T. congolense*, *T. vivax*, and partly *T. equiperdum*.

Isometamidium chloride (common brand names; Samorin®, Trypamidium®, Veridium®) is not reported to be carcinogenic, but contains homidium and is thus

potentially also cancerogenic (Wernery et al., 2014). It is used for curative (0.25–0.5 mg/kg bw) and preventive (1 mg/kg bw) treatment for trypanosomosis in ruminants and horses, via intramuscular or subcutaneous injections. However, im injections can cause severe local reactions at the site of the injection and intravenous (iv) injections in camels and horses may avoid local reactions but may cause systemic toxicity as salivation, tachycardia, profuse diarrhea, hindleg weakness, and collapse (Taylor et al., 2013). Isometamidium chloride has only moderate effect against *T. evansi* and has been used in cases of resistance to suramin and quinapyrimine (Wernery et al., 2014). The drug has been used to treat surra in camels, but it is not any longer considered advisable.

Quinapyrimine methyl-sulfate can be used by sc injections at a dose of 5 mg/kg bw as curative. A more effective result is to combine quinapyrimine methyl-sulfate with quinapyrimine chloride (Trypacide Pro-salt<sup>®</sup>, Triquine-S<sup>®</sup>) as curative and preventive drugs against *T. evansi* in camels and horses, administered sc at a dose of 8 mg/kg bw. The chemoprophylactic effect can last up to 4 months. Overdosing can lead to “curare-like” symptoms. Quinapyrimine is generally highly active against *T. congolense*, *T. vivax*, *T. brucei*, and *T. evansi* and reaches therapeutic levels quickly. However, numerous *T. evansi* strains have developed resistance to this drug.

#### 46.9.4 Sulfonic Acids (Aminoquinaldine Derivates)

Suramin (Naganol<sup>®</sup>) was one of the early anti-trypanosomal drugs developed and introduced in 1921. It was used in horses and camels and was effective against *T. evansi*. Some old-timers call it the drug of choice against surra in camels and horses (Taylor et al., 2013). A single dose of 6–10 g of Suramin per camel was described as 100% effective (Bennett, 1930, cited Giordani et al., 2016). However, it is not any longer used due to widespread resistance having been in use nearly a century. However, the drug was shown to be effective against *T. evansi* isolates in Brazil, where it had not been used earlier (Faccio et al., 2013).

#### 46.9.5 Arsenicals

The latest trypanocide on the market, melarsomine dihydrochloride (Cymelarsan<sup>®</sup>, Mel Cy<sup>®</sup>) has been available for use in the control of surra in camels since 1992 (Desquesnes, 2004). It has become the drug of choice and is widely used. Administrated via deep im injection at a dose of 0.25 mg/kg bw which can be increased up to 0.5 mg/kg bw if fully curative or sterilizing treatment is to be achieved. Whether it can cross the blood–brain barrier is yet fully not shown. Cymelarsan<sup>®</sup> is registered only for treating surra in camels. It is used in horses (0.25 mg/kg bw), in cattle (0.5 mg/kg bw), and in buffaloes (0.75 mg/kg bw).

---

### 46.9.6 Traditional Medicine

Traditional medical practices are of course employed since centuries by pastoralist like branding, bleeding, and other common ethnoveterinary practices (Köhler-Rollefson, 1994; McGaw & Ali Abdalla, 2020; Raziq et al., 2010; Wernery et al., 2014). Köhler-Rollefson (1994) refers to the vast accumulated knowledge since centuries which anthropologist and travellers recorded on treatment and prevention of camel diseases by traditional camel breeding people having no written language in Africa, the Middle East, and Asia. She also reminds us that as early as in the twelfth century AD there were “12 general treatises on the camel written.” In those there are detailed inventories of camel diseases and treatment (Froehner, 1933 cited Köhler-Rollefson, 1994).

---

### 46.10 Control

The control of vector-borne diseases can be divided into the control of the pathogens and the vectors. Due to the absence of vaccines against trypanosomosis including surra (due to the repertoire of variable surface antigens in the trypanosomes), control of surra and other trypanosomosis is principally based on treating the infected animals with trypanocides and preventing vectors from transmitting the pathogens.

Efforts to control surra of camels with other methods than treatment by trypanocides have not been effective so far. Control methods for tabanids, stable flies, and other hematophagous flies including trapping, the use of insecticides, repellents, and livestock protection by, e.g., smoke have not yet shown to be a viable option (Baldacchino et al., 2014). Although the latter control methods like using insecticides and smoke as repellents are done but not in any large scale. Application of smoke is still practiced in several ways traditionally (Köhler-Rollefson, 1994). Insecticides including repellents in certain circumstances might be used strategically, i.e. applied to preferred landing and feeding sites of “attacking” flies (Wernery et al., 2014). Macrocyclic lactones have limited systemic efficacy on the hematophagous flies.

There are several applicable traps catching flies including tabanids available but despite the large numbers of such flies caught in the monitoring fly densities and the species identification in the environment of the threatened camels, the successful trapping has no impact on reducing the fly populations in any sustainable way.

---

## References

- Abdelrahman, M. M., Frah, E. A., Katiti, D., Matovu, E., & Elrayah, I. E. (2011). Application of loop-mediated isothermal amplification (LAMP) of the random insertion mobile element (RIME-LAMP) to diagnose camel trypanosomiasis in Sudan. *African Journal of Biotechnology*, 10(21), 4508–4512.
- Aboud, J. T., & Faraj, A. A. (2017). Comparative studies on diagnosis of *Trypanosoma evansi* in camels in Al-Najaf Province, Iraq. *IJSN*, 8, 553–556.

- Abo-Shehada, M. N., Anshassi, H., Mustafa, G., & Amr, Z. (1999). Prevalence of Surra among camels and horses in Jordan. *Preventive Veterinary Medicine*, 38, 289–293. [https://doi.org/10.1016/s0167-5877\(98\)00138-x](https://doi.org/10.1016/s0167-5877(98)00138-x)
- Acosta, H., Rondón-Mercado, R., Avilán, J., & Concepción, L. (2016). Interaction of *Trypanosoma evansi* with the plasminogen-plasmin system. *Veterinary Parasitology*, 226, 189–197.
- Alanazi, A. D., Puschendorf, R., Alyousif, M. S., Al-Khalifa, M. S., Alharbi, S. A., Al Shehri, Z. S., Said, A. E., Alanazi, I. O., & Al-Mohammed, H. I. (2018). Molecular epidemiological studies on *Trypanosoma evansi* type A and type B in camels (*Camelus dromedarius*) from five different regions of Saudi Arabia using the ITS1 rDNA and RoTat 1.2 VSG gene. *Journal of the Egyptian Society of Parasitology*, 48(2), 241–250.
- Alarabi, M. E. M., Mohamed, Y. O., Elshafie, E. J., Alharbi, Y. J. A., & Al-Mekhlafi, H. M. (2019). Molecular detection of *Trypanosoma* in camels in southwestern Saudi Arabia. *Thai Journal of Veterinary Medicine*, 49(1), 93–100.
- Ali, B. H., Hassan, T., & Malik, K. H. (1985). A clinical valuation of samorin in *Trypanosoma evansi* infections in *Camelus dromedarius*. *Journal of Veterinary Pharmacology and Therapeutics*, 8, 208–210.
- Al-Khalifa, M. S., Hussein, H. S., Diab, F. M., & Khalil, G. M. (2009). Blood parasites of livestock in certain regions in Saudi Arabia. *Saudi Journal of Biological Sciences*, 16, 63–67.
- Al-Taqi, M. M. (1989). Characterization of *Trypanosoma (Trypanozoon) evansi* from dromedary camels in Kuwait by isoenzyme electrophoresis. *Veterinary Parasitology*, 32, 247–253.
- Aregawi, W. G., Agga, G. E., Abdi, R. D., & Büscher, P. (2019). Systematic and meta-analysis on the global distribution, host range, and prevalence of *Trypanosoma evansi*. *Parasites & Vectors*, 12, 67. <https://doi.org/10.1186/s13071-019-3311-4>
- Bajjana Songa, E., & Hamers, R. (1988). A card agglutination test (CATT) for veterinary use based on an early VAT RoTat 1.2 of *Trypanosoma evansi*. *Annales de la Société Belge de Médecine Tropicale*, 68, 223–240.
- Baldacchino, F., Desquesnes, M., Mihok, S., Mihok, L., Foil, D., Duvallet, G., & Jittapalaong, S. (2014). Tabanids: Neglected subjects of research, but important vectors of disease agents. *Infection, Genetics and Evolution*, 28, 596–615.
- Bennett, S. C. J. (1930). *Camel trypanosomiasis in the Sudan' in Pan-African agricultural and veterinary conference, Pretoria, 1–17 August 1929* (pp. 10–15). Union of South Africa, Department of Agriculture.
- Bennett, S. C. J. (1933). The control of camel trypanosomiasis. *The Journal of Comparative Pathology and Therapeutics*, 46, 174–185. [https://doi.org/10.1016/S0368-1742\(33\)80024-5](https://doi.org/10.1016/S0368-1742(33)80024-5)
- Berlin, D., Nasereddin, A., Azmi, K., Ereqat, S., Abdeen, Z., & Baneth, G. (2010). Longitudinal study of an outbreak of *Trypanosoma evansi* infection in equids and dromedary camels in Israel. *Veterinary Parasitology*, 174(3–4), 317–322. <https://doi.org/10.1016/j.vetpar.2010.09.002>
- Birhanu, H., Fikru, R., Said, M., Kidane, W., Gebrehiwot, T., Hagos, A., Alemu, T., Dawit, T., Berkvens, D., Goddeeris, B. M., & Büscher, P. (2015). Epidemiology of *Trypanosoma evansi* and *Trypanosoma vivax* in domestic animals from selected districts of Tigray and Afar regions, northern Ethiopia. *Parasites & Vectors*, 8, 212. <https://doi.org/10.1186/s13071-015-0818-1>
- Birhanu, H., Gebrehiwot, T., Goddeeris, B. M., Büscher, P., & Van Reet, N. (2016). New *Trypanosoma evansi* type B isolates from Ethiopian dromedary camels. *PLoS Neglected Tropical Diseases*, 10(4), e0004556. <https://doi.org/10.1371/journal.pntd.0004556>
- Boid, R., Jones, T. W., & Luckins, A. G. (1985). Protozoal diseases of camels. *The British Veterinary Journal*, 111, 87–105. <https://doi.org/10.1016/0007>
- Boid, R., Luckins, A. G., Rae, P. F., Gray, A. R., Mahmoud, M. M., & Malik, K. H. (1980). Serum immunoglobulin levels and electrophoretic patterns of serum proteins in camels infected by *Trypanosoma evansi*. *Veterinary Parasitology*, 6, 333–345.
- Borst, P., Fase-Fowler, F., & Gibson, W. C. (1987). Kinetoplast DNA of *Trypanosoma evansi*. *Molecular and Biochemical Parasitology*, 23(1), 31–38.
- Büscher, P. (2001). Diagnosis of human and animal African trypanosomiasis. In S. J. Black & J. R. Seed (Eds.), *The African trypanosomes* (pp. 51–63). Kluwer Academic Publishers.

- Büscher, P. (2014). Diagnosis of African trypanosomiasis. In S. Magez & M. Radwanska (Eds.), *Trypanosomes and trypanosomiasis* (pp. 189–216). Springer.
- Büscher, P., Mumba Ngoyi, D., Kaboré, J., Lejon, V., Robays, J., Jamonneau, V., et al. (2009). Improved models of Mini anion exchange centrifugation technique (mAECT) and modified single centrifugation (MSC) for sleeping sickness diagnosis and staging. *PLoS Neglected Tropical Diseases*, 3(11), e471. <https://doi.org/10.1371/journal.pntd.0000471>
- Carnes, J., Anupama, A., Balmer, O., Jackson, A., Lewis, M., et al. (2015). Genome and phylogenetic analysis of *Trypanosoma evansi* reveal extensive similarity to *T. brucei* and multiple independent origins for dyskinetoplasty. *PLOS Neglected Tropical Diseases*, 9, 1. <https://doi.org/10.1371/journal.pntd.0003404>
- Chappuis, F., Loutan, L., Simarro, P., Lejon, V., & Büscher, P. (2005). Options for field diagnosis of human African trypanosomiasis. *Clinical Microbiology Reviews*, 18(1), 133–146.
- Claes, F., Büscher, P., Touratier, L., & Goddeeris, B. (2005). *Trypanosoma equiperdum*: Master of disguise or historical mistake? *Trends in Parasitology*, 21, 316–321.
- Claes, F., de Waal, T., Majiwa, P. A., Balz, T., Goodeeris, B., & Büscher, P. (2003). The expression of RoTat 1.2 variable surface glycoprotein (VSG) in *Trypanosoma evansi* and *T. equiperdum*. *Veterinary Parasitology*, 116, 209–216. [https://doi.org/10.1016/S0304-4017\(02\)00359-X](https://doi.org/10.1016/S0304-4017(02)00359-X)
- Claes, F., Radwanska, M., Urakawa, T., Majiwa, P. A. O., Goddeeris, B., & Büscher, P. (2004). Variable surface glycoprotein RoTat 1.2 PCR as a specific diagnostic tool for the detection of *Trypanosoma evansi* infections. *Kinetoplastid Biology and Disease*, 3(3), 1–6. <https://doi.org/10.1186/1475-9292-2-3>
- Cross, H. E. (1917). *The camel and its diseases; being notes for veterinary surgeons and commandants of camel corps* (p. 151). Baillie're, Tindall and Cox.
- Cross, G. A. (1975). Identification, purification and properties of clone specific glycoprotein antigens constituting the surface coat of *Trypanosoma brucei*. *Parasitology*, 71(3), 393–417. <https://doi.org/10.1071/s003118200004717x>
- Derakhshanfar, A., Mozaffari, A. A., & Mohaghegh Zadeh, A. (2010). An outbreak of trypanosomiasis (Surra) in camels in the southern Fars Province of Iran: Clinical, hematological and pathological findings. *Research Journal of Parasitology*, 5, 23–26. <https://doi.org/10.3923/jp.2010.23.26>
- Desquesnes, M. (2004). *Livestock Trypanosomoses and their vectors in Latin America*. Paris: CIRAD-EMVT Publications, OIE. <http://www.oie.int/doc/ged/D9818.PDF>
- Desquesnes, M. (2017). Compendium of standard diagnostic protocols for animal Trypanosomosis of African origin. In *OIE reference Laboratory for Animal Trypanosomosis of African origin 2017*. OIE/CIRAD/CIRNES.
- Desquesnes, M., Biteau-Coroller, F., Bouyer, J., Dia, M. L., & Foil, L. (2009). Development of a mathematical model for mechanical transmission of trypanosomes and other pathogens of cattle transmitted by tabanids. *International Journal for Parasitology*, 39(3), 333–346.
- Desquesnes, M., Bossard, G., Patrel, D., Herder, S., Patout, O., Cuny, G., et al. (2008). First outbreak of *Trypanosoma evansi* in camels in metropolitan France. *The Veterinary Record*, 162(23), 750–752. <https://doi.org/10.1136/vr.162.23.750>
- Desquesnes, M., Dargantes, A., Lai, D. H., Lun, Z. R., Holzmüller, P., & Jittapalapong, S. (2013a). *Trypanosoma evansi* and Surra: A review and perspectives on transmission, epidemiology and control, impact, and zoonotic aspects. *BioMed Research International*, 2013, Article ID 321237, 20. <https://doi.org/10.1155/2013/321237>
- Desquesnes, M., Holzmüller, P., Lai, D. H., Dargantes, A., Lun, Z. R., & Jittapalapong, S. (2013b). *Trypanosoma evansi* and Surra: A review and perspectives on origin, history, distribution, taxonomy, morphology, hosts and pathogenic effects. *BioMed Research International*, Article ID 194176, 22. <https://doi.org/10.1155/2013/194176>
- Diab, F. M., Al-Asgah N. A., Al Khalifa, M. S., Hussein, H. S. (1984). Ticks and blood parasites from indigenous domesticated animals in Saudi Arabia. In: *7th Symposium on the Biological Aspects of Saudi Arabia, Qassim*, p. 79.



- Ereqat, S., Nasereddin, A., Al-Jawabreh, A., Al-Jawabreh, H., Al-Laham, N., & Abdeen, Z. (2020). Prevalence of *Trypanosoma evansi* in livestock in Palestine. *Parasites & Vectors*, 15, 21. <https://doi.org/10.1186/s13071-020-3894-9>
- Faccio, L., Da Silva, A. S., Gressler, L., Tonin, A., Lazzarote, C. R., Miletti, L. C., & Monteiro, S. (2013). Susceptibility of Brazilian isolates of *Trypanosoma evansi* to suramin sodium: Test in experimentally infected mice. *Experimental Parasitology*, 134, 309–312. <https://doi.org/10.1016/j.exppara.2013.03.027>
- Ferenc, S. A., Raymond, H. L., Lancelot, R. (1988). Essai de transmission mecanique de *Trypanosoma vivax* (Ziemann) (Kinetoplastida, Trypanosomatidae) par le taon neotropical *Cryptolys unicolor* (Wiedermann) (Diptera, Tabanidae). In Proc of the 17th International Congress of Entomology, Vancouver, Canada. 295pp.
- Foil, L. D. (1989). Tabanids as vectors of disease agents. *Parasitology Today*, 5, 88–96.
- Gill, B. S. (1977). *Trypanosomes and trypanosomiasis of Indian livestock* (1st ed., 137p). Indian Council of Agricultural Research (ICAR).
- Giordani, F., Liam, J., Morrison, T. I. M., Rowan, G., DE Koning, H. P., & Barrett, M. P. (2016). The animal trypanosomiasis and their chemotherapy: A review. *Parasitology*, 143, 1862–1889. <https://doi.org/10.1017/S0031182016001268>
- Godfrey, D. G., & Killick-Kendrick, R. (1962). *Trypanosoma evansi* of camels in Nigeria: A high incidence demonstrated by the inoculation of blood into rats. *Annals of Tropical Medicine and Parasitology*, 56, 14–19. <https://doi.org/10.1080/00034983.1962.11686084>
- Gutierrez, C., Corbera, J. A., Morales, M., & Buscher, P. (2004). Performance of serological tests for *Trypanosoma evansi* in experimentally inoculated goats. *Annals of the New York Academy of Sciences*, 1026, 152–153.
- Gutierrez, C., Desquesnes, M., Touratier, L., & Büscher, P. (2010). *Trypanosoma evansi*: Recent outbreaks in Europe. *Veterinary Parasitology*, 174(1–2), 26–29.
- Habila, N., Inuwa, M. H., Aimola, I. A., Udeh, M. U., & Haruna, E. (2012). Pathogenic mechanisms of *Trypanosoma evansi* infections. *Research in Veterinary Science*, 93, 13–17.
- Haridy, F. M., El-Metwally, M. T., Khalil, H. H. M., & Morsy, T. A. (2011). *Trypanosoma evansi* in dromedary camel: With a case report of zoonosis in greater Cairo, Egypt. *Journal of the Egyptian Society of Parasitology*, 41, 65–76.
- Hoare, C. A. (1972). *The trypanosomes of mammals. A zoological monograph* (p. 750). Blackwell.
- Holland, W. G., Than, N. G., My, L. N., Do, T. T., Goddeeris, B. M., & Vercruysse, J. (2004). Prevalence of *Trypanosoma evansi* in water buffaloes in remote area in northern Vietnam using PCR and serological methods. *Tropical Animal Health and Production*, 36, 45–48.
- Holland, W. G., Thanh, N. G., My, L. N., Magnus, E., Verloo, D., Buscher, P., Goddeeris, B., & Vercruysse, J. (2002). Evaluation of plain and blotted blood in serological tests for *Trypanosoma evansi* in experimentally infected water buffaloes. *Acta Tropica*, 81, 159–165.
- Hopkins, J. S., Chitambo, H., Machilac, N., Luckins, A. G., Rae, P. F., van den Bossche, P., & Eisler, M. C. (1998). Adaptation and validation of antibody-ELISA using dried blood spots on filter paper for epidemiological surveys of tsetse-transmitted trypanosomosis in cattle. *Preventive Veterinary Medicine*, 37(1–4), 91–99. [https://doi.org/10.1016/s0167-5877\(98\)00101-9](https://doi.org/10.1016/s0167-5877(98)00101-9)
- Hunter, A. G. (1986). Urine odour in a camel suffering from Surra (*Trypanosoma evansi* infection). *Tropical Animal Health and Production*, 18, 146–148. <https://doi.org/10.1007/BF02359524>
- Jatkar, P. R., & Purohit, M. S. (1971). Pathogenesis: Anaemia in *Trypanosoma evansi* infection. 1. Haematolog. *Indian Veterinary Journal*, 48(3), 239–244.
- Jennings, F. W., Whitelaw, D. D., & Urquhart, G. M. (1977). The relationship between duration of infection with *Trypanosoma brucei* in mice and the efficacy of chemotherapy. *Parasitology*, 75 (2), 143–153. <https://doi.org/10.1017/S0031182000062284>
- Joshi, P. P., Shegokar, V. R., Powar, R. M., Herder, S., Katti, R., Salkar, H. R., Dani, V. S., Bhargava, A., Jannin, A., & Truc, P. (2005). Human trypanosomiasis caused by *Trypanosoma evansi* in India: The first case report. *The American Journal of Tropical Medicine and Hygiene*, 73(3), 491–495.



- Kelley, S., & Schillinger, D. (1983). Improved field diagnostic technique for trypanosomiasis by use of a minicentrifuge. *The Veterinary Record*, 113, 219. <https://doi.org/10.1136/vr.113.10.219>
- Kidambasi, K. O., Masiga, D. K., Villinger, J., Carrington, M., & Bargul, J. L. (2020). Detection of blood pathogens in camels and their associated ectoparasitic camel biting keds, *Hippobosca camelina*: The potential application of keds in xenodiagnosis of camel haemopathogens (version 2; peer review: 2 approved). *AAS Open Research*, 2, 164.
- Köhler-Rollefson, I. (1994). Ethnoveterinary practices of camel pastoralists in northern Africa and India. *Journal of Camel Practice and Research*, 1(2), 75–82.
- Lai, D.-H., Hashimi, H., Lun, Z.-R., Ayala, F. J., & Lukes, J. (2008). Adaptations of *Trypanosoma brucei* to gradual loss of kinetoplast DNA: *Trypanosoma equiperdum* and *Trypanosoma evansi* are petite mutants of *T. brucei*. *Proceedings of the National Academy of Sciences of the United States of America*, 105, 1999–2004.
- Leese, A. S. (1927). *A treatise on the one humped camel, in health and disease* (382pp). Haynes & Son.
- Luckins, A. G. (1988). *Trypanosoma evansi* in Asia. *Parasitology Today*, 4(5), 137–142.
- Luckins, A. (1992). Protozoal diseases of camels. In W. R. Allen, A. J. Higgins, I. G. Mayhew, & D. H. Snow (Eds.), *Proceedings of the 1st Int camel Conf* (pp. 23–27). R and W Publications.
- Luckins, A. G., Boid, R., Rae, P. F., Mahmoud, M. M., El-Malik, K. H., & Gray, A. R. (1979). Serodiagnosis of infection with *Trypanosoma evansi* in camels in Sudan. *Tropical Animal Health and Production*, 11, 1–12.
- Lumsden, C. D., Kimber, C. D., Dukes, P., Haller, L., Stanghellini, A., & Duvallet, G. (1981). Field diagnosis of sleeping sickness in the Ivory Coast. I. Comparison of the miniature anion-exchange/centrifugation technique with other protozoological methods. *Transactions of the Royal Society of Tropical Medicine and Hygiene*, 75(2), 242–250. [https://doi.org/10.1016/0035-9203\(81\)90326-6](https://doi.org/10.1016/0035-9203(81)90326-6)
- Lumsden, W. H., Kimber, C. D., Evans, D. A., & Doig, S. J. (1979). *Trypanosoma brucei*: Miniature anion-exchange centrifugation technique for detection of low parasitaemias: Adaptation for field use. *Transactions of the Royal Society of Tropical Medicine and Hygiene*, 73(3), 312–317. [https://doi.org/10.1016/0035-9203\(79\)90092-0](https://doi.org/10.1016/0035-9203(79)90092-0)
- Macgregor, J. T., & Johnson, I. J. (1977). In vitro metabolic activation of ethidium bromide and other phenanthridinium compounds: Mutagenic activity in *Salmonella typhimurium*. *Mutation Research*, 48(1), 103–107. [https://doi.org/10.1016/0027-5107\(77\)90194-4](https://doi.org/10.1016/0027-5107(77)90194-4)
- Masiga, R. C., & Nyangao, J. M. N. (2001). Identification of trypanosome species from camel using polymerase chain reaction and procyclic transformation test. *Journal of Camel Practice and Research*, 8(1), 17–22.
- Mbaya, A. W., Ibrahim, U. I., & Apagu, S. T. (2010). Trypanosomosis of the dromedary camel (*Camelus dromedarius*) and its vectors in the tsetse-free arid zone of north eastern, Nigeria. *Nigerian Veterinary Journal*, 31(3), 195–200. <https://doi.org/10.4314/nvj.v31i3.68975>
- Mbaya, A. W., Kumshe, H. A., & Dilli, H. K. (2014a). Serum biochemical changes in dromedaries experimentally infected with *Trypanosoma evansi* and treated with melarsenoxyde cysteamine hydrochloride. *Veterinarski Arhiv*, 84(4), 377–385.
- Mbaya, A. W., Kumshe, H. A., Samfor, N., Abba, Y., & Ogwiji, M. (2014b). The effect of melarsenoxyde cysteamine hydrochloride (Cymelarsan®) on the clinico-pathology of an experimental *Trypanosoma evansi* infection in dromedary camels (*Camelus dromedarius*). *Journal of Camelid Science*, 7, 15–34.
- McCann, J., Choi, E., Yamasaki, E., & Ames, B. N. (1975). Detection of carcinogens as mutagens in the Salmonella/microsome test: Assay of 300 chemicals. *PNAS*, 72(12), 5135–5139.
- McGaw, L. J., & Ali Abdalla, M. (Eds.). (2020). *Ethnoveterinary medicine, present and future concept* (435pp). Springer.
- Mihok, S., Zweggarth, E., Munyoki, E. N., Wambua, J., & Kock, R. (1994). *Trypanosoma simiae* in the white rhinoceros (*Ceratotherium simum*) and the dromedary camel (*Camelus dromedarius*). *Veterinary Parasitology*, 53(3–4), 191–196. [https://doi.org/10.1016/0304-4017\(94\)90182-1](https://doi.org/10.1016/0304-4017(94)90182-1)

- Mossaad, E., Bashir, S., Suganuma, K., Musinguzi, P., Hassan, M. A., Elamin, E. A., Mohammed, G. E., Bakhiet, A. O., Xuan, X., Satti, R. A., & Inoue, N. (2017). *Trypanosoma vivax* is the second leading cause of camel trypanosomosis in Sudan after *Trypanosoma evansi*. *Parasites & Vectors*, 10(1), 176. <https://doi.org/10.1186/s13071-017-2117-5>
- Mugnier, M. R., Stebbins, C. E., & Papavasiliou, F. N. (2016). Masters of disguise: Antigenic variation and the VSG coat in *Trypanosoma brucei*. *PLoS Pathogens*, 12(9), e1005784. <https://doi.org/10.1371/journal.ppat.1005784>
- Nessiém, M. G. (1994). Evaluation of the silicon centrifugation technique in the detection of *Trypanosoma evansi* infections in camels and experimental animals. *Tropical Animal Health and Production*, 26(4), 227–229. <https://doi.org/10.1007/bf02240387>
- Ngaira, J. M., Olembó, N. K., Njagi, E. N., & Ngeranwa, J. J. (2005). The detection of non-RoTat 1.2 *Trypanosoma evansi*. *Experimental Parasitology*, 110(1), 30–38. <https://doi.org/10.1016/j.exppara.2005.01.001>
- Njiru, Z. K., Constantine, C. C., Masiga, D. K., Reid, S. A., Thompson, R. C., & Gibson, W. C. (2006). Characterization of *Trypanosoma evansi* type B. *Infection, Genetics and Evolution*, 6(4), 292–300. <https://doi.org/10.1016/j.meegid.2005.08.002>
- Njiru, Z. K., Ndungu, K., Matete, G., Ndungu, J. M., & Gibson, W. C. (2004). Detection of *Trypanosoma brucei rhodesiense* in animals from sleeping sickness foci in East Africa using the serum resistance associated (SRA) gene. *Acta Tropica*, 90, 249–254.
- Ogbunde, P. O. J., & Magaji, Y. (1982). A silicone centrifugation technique for the detection of low parasitaemias of salivarian trypanosomes. *Transactions of the Royal Society of Tropical Medicine and Hygiene*, 76, 137–318.
- OIE. (2018). Terrestrial manual. *Trypanosoma evansi* infection (surra), Chapter 3.1.21, pp. 660–674.
- Osório, A. L., Madruga, C. R., Desquesnes, M., Soares, C. O., Ribeiro, L. R., & Costa, S. C. (2008). *Trypanosoma* (Duttonella) *vivax*: Its biology, epidemiology, pathogenesis, and introduction in the New World – A review. *Memórias do Instituto Oswaldo Cruz*, 103(1), 1–13.
- Ouhelle, H., & Dakkak, A. (1987). Protozoal diseases of dromedaries. In diseases of camels. *Revue Scientifique et Technique - Office International Des Épizooties*, 6(2), 417–422.
- Pays, E., Vanhollebeke, B., Vanhamme, L., Puturiaux-Hancocq, F., Nolan, D. P., & Perez-Morga, D. (2006). The trypanolytic factor of human serum. *Nature Reviews. Microbiology*, 4, 477–486. <https://doi.org/10.1038/nrmicro1428>
- Peregrine, A. S., & Mamman, M. (1993). Pharmacology of diminazene: A review. *Acta Tropica*, 54, 185–203.
- Perrone, T. M., Gonzatti, M. I., Villamizar, G., Escalante, A., & Aso, P. M. (2009). Molecular profiles of Venezuelan isolates of *Trypanosoma* sp. by random amplified polymorphic DNA method. *Veterinary Parasitology*, 161, 194–200. <https://doi.org/10.1016/j.vetpar.2009.01.034>
- Pinger, J., Chowdhury, S., & Papavasiliou, F. (2017). Variant surface glycoprotein density defines an immune evasion threshold for African trypanosomes undergoing antigenic variation. *Nature Communications*, 8, 828. <https://doi.org/10.1038/s41467-017-00959-w>
- Powar, R. M., Shegokar, V. R., Joshi, P. P., Dani, V. S., Tankhiwale, N. S., Truc, P., Jannin, J., & Bhargava, A. (2006). A rare case of human trypanosomiasis caused by *Trypanosoma evansi*. *Indian Journal of Medical Microbiology*, 24, 72–74.
- Radwanska, M., Verecke, N., Deleeuw, V., Pinto, J., & Magez, S. (2018). Salivarian Trypanosomosis: A review of parasites involved, their global distribution and their interaction with the innate and adaptive mammalian host immune system. *Frontiers in Immunology*, 9, 2253. <https://doi.org/10.3389/fimmu.2018.02253>
- Ravindran, R., Rao, J. R., Mishra, A. K., Pathak, K. M. L., Babu, N., Satheesh, C. C., & Rahul, S. (2008). *Trypanosoma evansi* in camels, donkeys and dogs in India: Comparison of PCR and light microscopy for detection. *Veterinarski Arhiv*, 78, 89–94.
- Raziq, A., de Verdier, K., & Younas, M. (2010). Ethnoveterinary treatments by dromedary camel herders in the Suleiman mountainous region in Pakistan: An observation and questionnaire

- study. *Journal of Ethnobiology and Ethnomedicine*, 6, 6. <https://doi.org/10.1186/1746-4269-6-16>
- Röttcher, D., Schillinger, D., & Zweygarth, E. (1987). Trypanosomiasis in the camel (*Camelus dromedarius*). *Revue Scientifique et Technique - Office International Des Épizooties*, 6(2), 463–470.
- Salim, B., Bakheit, M. A., Kamau, J., Kamau, J., Nakamura, J., & Sugimoto, J. (2011). Molecular epidemiology of camel trypanosomiasis based on ITS1 rDNA and RoTat 1.2 VSG gene in the Sudan. *Parasites & Vectors*, 4, 31. <https://doi.org/10.1186/1756-3305-4-31>
- Shah, R., Phulan, M. S., Memon, M. A., Rind, R., & Bhatti, W. M. (2004). Trypanosomes infection in camels. *Pakistan Veterinary Journal*, 24(4), 209.
- Srivastava, V. K., Obeid, H. M., & El Bosaidi, S. M. (1984). Trypanosomiasis in camels in the sultanate of Oman. *Tropical Animal Health and Production*, 16, 148. <https://doi.org/10.1007/BF02252780>
- Stephen, L. E. (1986). *Trypanosomiasis: A veterinary perspective* (551pp). Pergamon Press.
- Stuart, K., Brun, R., Croft, S., Fairlamb, A., Gurtler, R. E., McKerrow, J., Reed, S., & Tarleton, R. (2008). Kinetoplastids: Related protozoan pathogens, different diseases. *The Journal of Clinical Investigation*, 118(4), 1301–1310. <https://doi.org/10.1172/JCI33945>
- Taylor, M. A., Coop, R. L., & Wall, R. L. (2013). *Veterinary parasitology* (3rd ed., p. 600). Wiley-Blackwell.
- Tehseen, S., Jahan, N., Qamar, M. F., Desquesnes, M., Shahzad, M. I., Deborggraeve, S., & Büscher, P. (2015). Parasitological, serological and molecular survey of *Trypanosoma evansi* infection in dromedary camels from Cholistan Desert, Pakistan. *Parasites & Vectors*, 8, 415. <https://doi.org/10.1186/s13071-015-1002-3>
- Touratier, L. (1990). Dixième réunion internationale sur *Trypanosoma evansi*: Rapport du groupe de travail. *Revue Scientifique et Technique - Office International des épizooties*, 9(4), 1197–1207.
- Touratier, L. (1992). Onzième réunion internationale sur *Trypanosoma evansi*: Rapport du groupe de travail. *Revue Scientifique et Technique - Office International Des Épizooties*, 11, 285–294.
- Tran, T., Claes, F., Verloo, D., De Greve, H., & Büscher, P. (2009). *Clinical and Vaccine Immunology*, 16, 999–1002. <https://doi.org/10.1128/CVI.00096-09>
- Truc, P., Gibson, W., & Herder, S. (2007). Genetic characterization of *Trypanosoma evansi* isolated from a patient in India. *Infection, Genetics and Evolution*, 7(2), 305–307. <https://doi.org/10.1016/j.meegid.2006.07.004>
- Urakawa, T., Verloo, D., Moens, L., Büscher, P., & Majiwa, P. A. O. (2001). *Trypanosoma evansi*: Cloning and expression in *Spodoptera frugiperda* insect cells of the diagnostic antigen RoTat 1.2. *Experimental Parasitology*, 99(4), 181–189.
- Verloo, D., Holland, W., My, L. N., Thanh, N. G., Tame, P. T., Goddeeris, B., Vercruyse, J., & Büscher, P. (2000). Comparison of serological tests for *Trypanosoma evansi* natural infections in water buffaloes from North Vietnam. *Veterinary Parasitology*, 92(2), 87–96. [https://doi.org/10.1016/s0304-4017\(00\)00284-3](https://doi.org/10.1016/s0304-4017(00)00284-3)
- Verloo, D., Magnus, E., & Büscher, P. (2001). General expression of RoTat 1.2 variable antigen type in *Trypanosoma evansi* isolates from different origin. *Veterinary Parasitology*, 97(3), 183–189. [https://doi.org/10.1016/s0304-4017\(01\)00412-5](https://doi.org/10.1016/s0304-4017(01)00412-5)
- Verloo, D., Tibayrenc, R., Magnus, E., Büscher, P., & Van Meirvenne, N. (1998). Performance of serological tests for *Trypanosoma evansi* infections in camels from Niger. *Journal of Protozoology Research*, 8(3), 190–193.
- Wernery, U. (1995). Blutparameter und Enzymwerte von gesunden und kranken Rennkamelen (*Camelus dromedarius*). *Tierärztliche Praxis*, 23, 187–191.
- Wernery, U., Kinne, J., & Schuster, R. K. (2014). *Camelid infectious disorders*. World Organisation for Animal Health (OIE). <https://doi.org/10.1155/2013/194176>

- Wilson, R. T. (2013). The one-humped camel in southern Africa: Unusual and new records for seven countries in southern African development community. *African Journal of Agricultural Research*, 8, 3716–3723. <https://doi.org/10.5897/AJAR12.2165>
- Woo, P. T. K. (1969). The haematocrit centrifugation technique for the detection of trypanosomes in blood. *Canadian Journal of Zoology*, 47, 921–923.
- Woo, P. T. K. (1971). Evaluation of the haematocrit centrifuge and other techniques for the field diagnosis of human trypanosomiasis and filariasis. *Acta Tropica*, 28, 298–303.
- Younan, M., Bornstein, S., & Gluecks, I. V. (2016). MERS and the dromedary camel trade between Africa and the Middle East. *Tropical Animal Health and Production*, 48, 1277–1282. <https://doi.org/10.1007/s11250-016-1089-3>

## Further Readings

- OIE. (2017). *Trypanosoma evansi* infections. Chapter 2.1.17; Manual of diagnostic tests and vaccines for terrestrial animals, Paris.

Abdelmalik I. Khalafalla

Tick-Borne Diseases (TBD) continue to pose threat to domestic and wild ruminants. Protozoan *Theileria* and *Babesia* parasites are transmitted by tick vectors to some animals worldwide and cause considerable economic damage (Li et al., 2014). Theileriosis is one of the most fatal TBD of animals caused by different *Theileria* spp. The parasite induces lymphohematopathies resulting in fever, anorexia, immunosuppression, body depletion, hemorrhagic anemia and, in some rare cases, hemolytic anemia with hematuria. *Theileria* spp. are known to be intracellular parasites capable to infect both leukocytes and erythrocytes. On the other hand, *Babesia* spp. which is a single-celled parasite infects only erythrocytes. *Theileria* and *Babesia* are detected in *Camelus dromedarius* and *Camelus bactrianus* in some countries, such as Iran, Mongolia, Jordan, Ethiopia, Saudi Arabia, and Egypt (Hamed et al., 2011; Ismael et al., 2014; Li et al., 2014; Qablan et al., 2012; Sazmand et al., 2016; Youssef et al., 2015). *Theileria equi*, *Theileria mutans*, *Theileria annulata* and *Theileria ovis* have been detected in dromedary camels. *Babesia caballi* and *Babesia behnkei* have been detected in dromedary camels (Bahrami et al., 2017).

In most of the above-mentioned references *Theileria* and *Babesia* spp. were detected from apparently healthy camels or in samples collected at abattoirs. Despite the detection of these blood parasites, it is still not clear whether these findings result from proliferation of *Theileria* in camels or transmission of blood parasites at the time of a tick bite (Sazmand & Joachim, 2017). Therefore, in the absence of experimental infection experiments these blood parasites are regarded as benign or moderately pathogenic to camels.

---

## 47.1 Clinical Picture

According to Sazmand and Joachim (2017) clinical examination of naturally infected camels showed fever, superficial lymph node swelling, loss of appetite, emaciation, and lacrimation. The morbidity rate was high with no lethal cases. According to Ismael et al. (2014), 67 out of 173 dromedary camels suffered

clinically from fever, anorexia, swelling of the superficial lymph nodes, a rapid loss of condition, lacrimation, abortion, and/or infertility were reported in dromedaries in Saudi Arabia. In a recent study, Abdelwahab et al. (2019) noticed a completely homogenized hematuria in two dromedary camels infected with *Theileria* piroplasms.

Biochemical analysis revealed pathological profile marked by lymphopenia, anemia, hypoproteinemia, increased GGT, AST, ALT, Total bilirubin, blood urea nitrogen, LDH, and cytokines IL-4 and IL-10 blood level were also found (El-Fayoumy et al., 2005; Hamed et al., 2011; Ismael et al., 2014).

---

## 47.2 Diagnosis

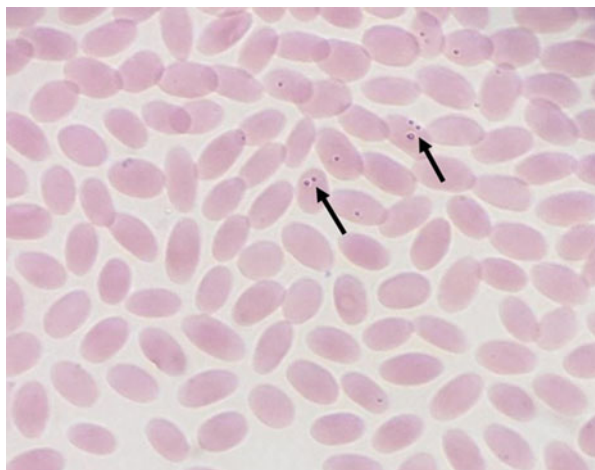
Like other blood parasites, parasitological examination of Giemsa-stained blood films is used to demonstrate the pleomorphic intraerythrocytic *theileria* piroplasms (Fig. 47.1). Gel-based and quantitative Polymerase chain reaction (qPCR) have been used for the diagnosis of these parasites in camels. PCR and sequencing method targeting 18S rRNA gene of *Babesia* and *Theileria* parasites was also used to screen camel blood samples for the presence of piroplasmid infection (Bahrami et al., 2017).

---

## 47.3 Treatment

A successful treatment with buparvaquone in camels affected by *Theileria* piroplasms and showing typical signs like cattle *T. annulata* infection confirmed by detection of the parasite in blood smears followed by the disappearance of the

**Fig. 47.1** Blood film from infected dromedary camel shows intraerythrocytic pleomorphic *Theileria* piroplasms (arrows), Giemsa stain, 100X (Abdelwahab et al., 2019)



parasite from the blood was reported (Hamidinejat et al., 2008; Sazmand & Joachim, 2017).

---

## References

- Abdelwahab, G. E., El Tigani-Asil, E., Yusof, M. F., Zayed Saud Abdullah, Z. S., Rifat, J. F., Al Hosani, M. A., Almuhairei, S. S., & Khalafalla, A. I. (2019). *Salmonella enterica* and *Theileria* co-infection in dromedary camels (*Camelus dromedarius*) in UAE. *Open Veterinary Journal*, 9 (3), 263–268.
- Bahrami, S., Tabandeh, M. R., Nikbin, A., Albrozi, A. R., & Ghadrzan, A. R. (2017). Prevalence and phylogenetic analysis of *Theileria equi* in Iranian dromedaries. *Archives of Razi Institute*, 71 (3), 169–175.
- El-Fayoumy, M. M., Abou Elnga, T. R., Abd El-Baky, S. M. M., & Abdou, T. A. (2005). Prevalence of camel theileriosis and its vector tick in north coast of Egypt. *Journal of the Egyptian Veterinary Medical Association*, 65, 291–302.
- Hamed, M. I., Zaitoun, A. M. A., El-Allawy, T. A. A., & Mourad, M. I. (2011). Investigation of *Theileria camelensis* in camels infested by *Hyalomma dromedarii* tick in upper Egypt. *Journal of Advanced Veterinary Research*, 1, 4–7.
- Hamidinejat, H., Razi Jalali, M. H., & Nouri, M. (2008). Report of clinical theileriosis in one-humped camel (*Camelus dromedarius*) in Khuzestan Province, Iran. In 15th Iran Veterinary Congress. Tehran, Iran, [in Persian].
- Ismael, A. B., Swelum, A. A., Khalaf, A. F., & Abouheif, M. A. (2014). Clinical, hematological and biochemical alterations associated with an outbreak of theileriosis in dromedaries (*Camelus dromedarius*) in Saudi Arabia. *Pakistan Veterinary Journal*, 34(2), 209–213.
- Li, Y., Chen, Z., Liu, Z., Liu, J., Yang, J., Li, Q., Li, Y., Cen, S., Guan, G., Ren, Q., Luo, J., & Yin, H. (2014). Molecular identification of *Theileria* parasites of northwestern Chinese Cervidae. *Parasites & Vectors*, 7, 225.
- Qablan, M. A., Sloboda, M., Jirků, M., Oborník, M., Dwairi, S., Amr, Z. S., et al. (2012). Quest for the piroplasms in camels: Identification of *Theileria equi* and *Babesia caballi* in Jordanian dromedaries by PCR. *Veterinary Parasitology*, 186(3–4), 456–460.
- Sazmand, A., Eigner, B., Mirzaei, M., Hekmatimoghaddam, S., Harl, J., Duscher, G. G., Fuehrer, H.-P., & Joachim, A. (2016). Molecular identification of hemoprotozoan parasites in camels (*Camelus dromedarius*) of Iran. *Iranian Journal of Parasitology*, 11(4), 568–573.
- Sazmand, A., & Joachim, A. (2017). Parasitic diseases of camels in Iran (1931–2017) – a literature review. *Parasite*, 2017(24), 21.
- Youssef, S. Y., Yasien, S., Mousa, W. M. A., Nasr, S. M., El-Kelesh, E. A. M., Mahran, K. M., et al. (2015). Vector identification and clinical, hematological, biochemical, and parasitological characteristics of camel (*Camelus dromedarius*) theileriosis in Egypt. *Tropical Animal Health and Production*, 47(4), 649–656.

---

## **Part VII**

# **Multi-factorial Diseases of Dromedary Camels**



Abdelmalik I. Khalafalla

Three local terms are used for the respiratory diseases in Sudan and probably other Arab countries: *Al Nihaz* for pneumonia (coughing), *Al Reeh* for bronchopneumonia (gurgling and rales), and *Um Nikhairat* for rhinitis/sinusitis (inflammation of nostrils and sinuses) (Agab & Abas, 1998). As in other livestock, the respiratory disease complex has a multifactorial etiology and develops because of complex interactions between environmental factors, host factors, and pathogens. According to Schwartz and Dioli (1992), the most important predisposing factors are sudden climatic changes, poor management practices, exposure to various diseases, over traveling, and low-grade nutrition.

Two respiratory viruses namely influenza A and MERS-CoV have been detected in camels with obvious clinical signs in Bactrian and dromedary camels. Outbreaks of severe respiratory disease caused by H1N1 influenza A virus were recorded in Mongolia in Bactrian camels between 1978 and 1988. The disease was accompanied by a few mortalities and severe respiratory symptoms including mucous ocular and nasal discharge, dry cough, bronchitis, pneumonia, and fever. MERS-CoV causes acute infection, mostly subclinical, but can induce clinical signs of purulent nasal and lachrymal discharge in some of the naturally affected camels and most of the experimentally infected camels confirmed by virus detection.

Besides these two virus infections, several viruses have been detected in apparently healthy camels (Table 48.1). However, the exact role played by these viruses in causing clinical respiratory signs in camels remains uncertain. However, it is not known whether detected respiratory viruses were transmitted from cattle or small ruminants or they are circulating in the camel populations and have been adapted to the camel host.

A natural infection of dromedaries with glanders associated with cases in horses was reported in Bahrain in 2011. Analysis of a *Burkholderia mallei* strain isolated from a diseased dromedary revealed close genetic proximity to a strain that caused glanders in horses (Wernery et al., 2011).

Secondary bacterial respiratory infections are primarily initiated by viral infection, as viral respiratory infections impair respiratory defense mechanisms. The most

**Table 48.1** The list of viruses detected in the respiratory system of the dromedary camels

Virus	Method of detection	References
Parainfluenza-3 virus (PI-3)	Ag-ELISA, RT-PCR	Intisar et al. (2009), Kebede and Gelaye (2010), Saeed et al. (2015)
Bovine herpes virus-1 (BHV-1)	Ag-ELISA	Intisar et al. (2009), Saeed et al. (2015)
Adenovirus	Ag-ELISA	Intisar et al. (2009)
Pesti virus	RT-PCR	Intisar et al. (2010)
Peste des Petits ruminants (PPR)		Khalafalla et al. (2010), Saeed et al. (2015)
Middle East respiratory syndrome corona virus (MERS-CoV)	RT-PCR	Haagmans et al. (2014), Alagaili et al. (2014), Hemida et al. (2014), Chu et al. (2014), Khalafalla et al. (2015)
Respiratory syncytial virus (RSV)	Ag-ELISA, RT-PCR	Saeed et al. (2015)
Influenza C and D	Hemagglutination inhibition (HI) and microneutralization (MN) assays	Salem et al. (2017)
Bovine viral diarrhea virus (BVD)	Ag-ELISA, RT-PCR	Intisar et al. (2010), Gao et al. (2013), Saeed et al. (2015), Saidi et al. (2018)

widely recognized organisms associated with pneumonia in camels are opportunistic bacteria originating from the surrounding environment including *Manhaemiya hemolytica*, *Pasteurella multocida*, *Staphylococcus aureus*, *Streptococcus equi*, *Streptococcus pyogenes*, *Escherichia coli*, *Proteus species*, *Klebsiella pneumoniae*, *Pneumococcus spp.*, *Enterobacteria spp.*, *Micrococcus spp.*, *Haemophilus spp.*, *Actinomyces spp.*, *Pseudomonas spp.*, *Corynebacterium spp.*, *Arcanobacterium pyogenes*, and *Mycoplasma arginine*.

## 48.1 Clinical Picture

Clinical signs include pyrexia, cough, serous nasal (Fig. 48.1) and lacrimal discharge, increased respiratory rate, and increased breath sounds. The clinical manifestations of the upper and lower respiratory tract infections are similar and include rhinitis or nasal discharge, serous and purulent nasal discharge, cough, and to a lesser extend submandibular lymphadenopathy or anorexia.

## 48.2 Diagnosis

When bacterial pneumonia is suspected, bacterial culture of nasal swabs or tracheal wash, and sensitivity testing are recommended. Bacterial culture and sensitivity testing is required and may include anaerobe and mycoplasma culture, especially in refractory cases.



**Fig. 48.1** Dromedary camel showing purulent nasal discharge, Syria, 2011 (photo by Abdelmalik Khalafalla)

PCR is a useful and rapid method commonly used to detect virus infection. Antigen-ELISA for bovine respiratory viruses including PI-3, RSV, BHV-1, PPRV, and BVDV have been successfully used to detect these viruses in nasal swabs and lung tissues.

---

### 48.3 Treatment

As there is no specific treatment for viral respiratory infections in animals, treatment should focus on the antimicrobial therapy directed toward bacterial pneumonia. Antibiotics are used if there is a positive culture or if the animal has fever and systemic signs. Antihistamines and/or corticosteroids may be of benefit, but most animals will recover in several days without treatment.

---

### References

- Agab, H., & Abas, B. (1998). Epidemiological studies on camel disease in eastern Sudan. *Camels Newsletter*, 14, 53–57.
- Alagaili, A. N., Briese, T., Mishra, N., Kapoor, V., Sameroff, S. C., & de Wit, E. (2014). Middle East respiratory syndrome coronavirus infection in dromedary camels in Saudi Arabia. *MBiol*, 5, e00884–e00814.
- Chu, D. K. W., Poon, L. L. M., Gomaa, M. M., Shehata, M. M., Perera, R. A. P. M., & Zeid, D. A. (2014). MERS coronaviruses in dromedary camels, Egypt. *Emerging Infectious Diseases*, 20, 1049–1053.

- Gao, S., Luo, J., Du, J., Lang, Y., Cong, G., Shao, J., Lin, T., Zhao, F., Belák, S., Liu, L., Chang, H., & Yin, H. (2013). Serological and molecular evidence for natural infection of Bactrian camels with multiple subgenotypes of bovine viral diarrhea virus in Western China. *Veterinary Microbiology*, 163(1–2), 172–176. <https://doi.org/10.1016/j.vetmic.2012.12.015>. Epub 2012 Dec 22.
- Haagmans, B. L., Al Dhahiry, S. H., Reusken, C. B., Raj, V. S., Galiano, M., & Myers, R. (2014). Middle East respiratory syndrome coronavirus in dromedary camels: An outbreak investigation. *The Lancet Infectious Diseases*, 14, 140–145.
- Hemida, M. G., Chu, D. K. W., Poon, L. L. M., Perera, R. A. P. M., Alhammadi, M. A., & Ng, H.-Y. (2014). MERS coronavirus in dromedary camel herd, Saudi Arabia. *Emerging Infectious Diseases*, 20, 1231–1234.
- Intisar, K. S., Ali, Y. H., Khalafalla, A. I., Mahasin, E. A., & Amin, A. S. (2009). Natural exposure of dromedary camels in Sudan to infectious bovine rhinotracheitis virus (bovine herpes virus-1). *Acta Tropica*, 111(3), 243–246.
- Intisar, K. S., Ali, Y. H., Khalafalla, A. I., Mahasin, E. A., & Amin, A. S. (2010). Respiratory syncytial virus infection of camels (*Camelus dromedaries*). *Acta Tropica*, 113(2), 129–133.
- Intisar, K. S., Ali, Y. H., Khalafalla, A. I., Rahman-Mahasin, E. A., & Amin, A. S. (2009). Respiratory infection of camels associated with parainfluenza virus 3 in Sudan. *Journal of Virological Methods*, 163(1), 82–86.
- Kebede, F., & Gelaye, E. (2010). Studies on major respiratory diseases of camel (*Camelus dromedarius*) in northeastern Ethiopia. *African Journal of Microbiology Research*, 4(14), 1560–1564.
- Khalafalla, A. I., Lu, X., Al-Mubarak, A. I. A., Dalab, A. H. S., Al-Busadah, K. A. S., & Erdman, D. D. (2015). MERS-CoV in upper respiratory tract and lungs of dromedary camels, Saudi Arabia, 2013–2014. *Emerging Infectious Diseases*, 21(7), 1153–1158. <https://doi.org/10.3201/eid2107.150070>
- Khalafalla, A. I., Saeed, I. K., Ali, Y. H., Abdurrahman, M. B., Kwiatek, O., Libeau, G., Obeida, A. A., & Abbas, Z. (2010). An outbreak of peste des petits ruminants (PPR) in camels in the Sudan. *Acta Tropica*, 116(2), 161–165.
- Saeed, I. K., Ali, Y. H., Abdul Rahman, M. B., Mohammed, Z. A., Osman, H. M., Taha, K. M., Musa, M. Z., & Khalafalla, A. I. (2015). Mixed infection of peste des petits ruminants virus (PPRV) and other respiratory viruses in dromedary camels in Sudan, an abattoir study. *Tropical Animal Health and Production*, 47(5), 995–998. <https://doi.org/10.1007/s11250-015-0798-3>. Epub 2015 Apr 24.
- Saidi, R., Bessas, A., Bitam, I., Ergün, Y., & Ataseven, V. S. (2018). Bovine herpesvirus-1 (BHV-1), bovine leukemia virus (BLV) and bovine viral diarrhea virus (BVDV) infections in Algerian dromedary camels (*Camelus dromedarius*). *Tropical Animal Health and Production*, 50(3), 561–564. <https://doi.org/10.1007/s11250-017-1469-3>. Epub 2017 Nov 13. PMID: 29134541.
- Salem, E., Cook, E. A., Lbacha, H. A., Oliva, J., Awoume, F., Aplogan, G., Hymann, E. C., Muloi, D., Deem, S. L., Alali, S., et al. (2017). Serologic evidence for influenza C and D virus among ruminants and camelids, Africa, 1991–2015. *Emerging Infectious Diseases*, 23, 1556–1559. <https://doi.org/10.3201/eid2309.170342>
- Schwartz, H. J., & Dioli, M. (1992). *The one-humped camel in eastern Africa. A pictorial guide to diseases, health care and management* (p. 282). Josef Margraf.
- Wernery, U., Wernery, R., Joseph, M., Al-Salloom, F., Johnson, B., Kinne, J., Jose, S., Jose, S., Tappendorf, B., Hornstra, H., & Scholz, H. C. (2011). Natural *Burkholderia mallei* infection in dromedary, Bahrain. *Emerging Infectious Diseases*, 17(7), 1277–1279.

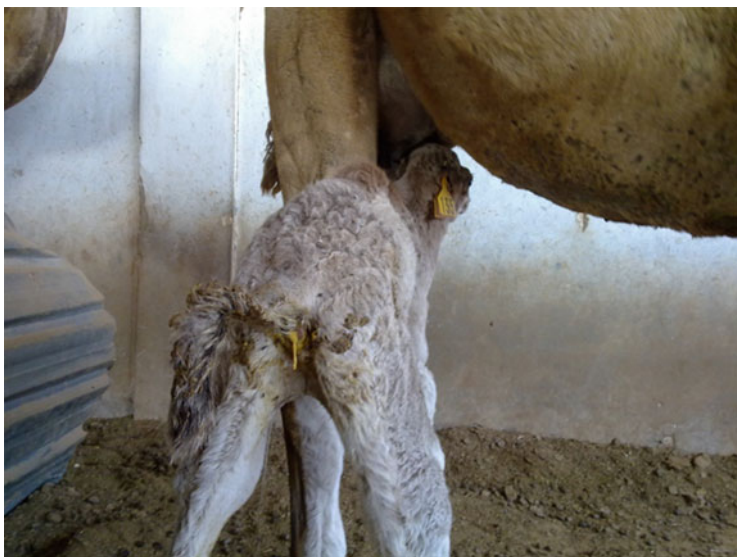
Abdelmalik I. Khalafalla

Newborn camel calves are highly susceptible to neonatal diarrhea or calf scours during their first 12 weeks of life and is considered a major cause of economic loss. Multiple enteric pathogens such as viruses, bacteria, and protozoa are involved in the development of this disease and coinfection is frequently observed in diarrheic camel calves these pathogens attack the lining of the calf's intestine giving rise to diarrhea that in turn decreases the absorption of essential nutrients from milk and leads to weight loss and dehydration (Fig. 49.1). However, there are many other noninfectious contributing factors that allow the development of the disease including inadequate quantity and/or quality of colostrum, overconsumption of milk, poor sanitation, or cold weather.

According to Schwartz and Dioli (1992), the morbidity and mortality rates due to camel calf diarrhea could reach up to 30% and 100%, respectively. Abbas et al. (1992) reported that camel calf diarrhea affects about 33% of the neonates causing 23% mortality in Sudan.

### 49.1 Etiology

The main virus that causes camel calf diarrhea is *Rotavirus A* species of the genus *Rotavirus* in the family Reoviridae. The G10 group of rotavirus was detected in dromedary camels in Egypt (Abo Hatab et al., 2008) and VP4 and VP7 genotypes of group A rotaviruses were detected in Sudanese camel calves in 2000 and 2002 (Ali et al., 2005, 2008). Phylogenetic analysis of the camel Rotavirus revealed that its genome is closely related to those of human–animal reassortant strains and shared common ancestry with some bovine rotaviruses-like strains, whereas segment 2 was closely related to a guanaco rotavirus strain suggesting that this strain potentially emerged through multiple reassortment events between several mammalian rotaviruses (Jere et al., 2014). Of note, up to date no Coronavirus was reported to be involved in outbreaks of camel neonatal diarrhea including field investigations carried out in Sudan (Ali et al., 2005, 2008) and Saudi Arabia (Al-Ruwaili et al.,



**Fig. 49.1** Newborn camel affected with calf diarrhea, note yellow color of the feces (photo by Abdelmalik Khalafalla)

2012), except for a single case of enteric coronavirus infection in a 6-week-old dromedary calf in the USA (Wünschmann et al., 2002).

A study on the role of pathogenic bacteria and viruses in the causation of camel calf diarrhea in six different towns of North Province in Saudi Arabia revealed group A rotavirus (14.7%), *Salmonella* spp. (12%), *Brucella abortus* (8.9%), *Enterococcus* spp. (8.8%), and enterotoxogenic *E. coli* (7%).

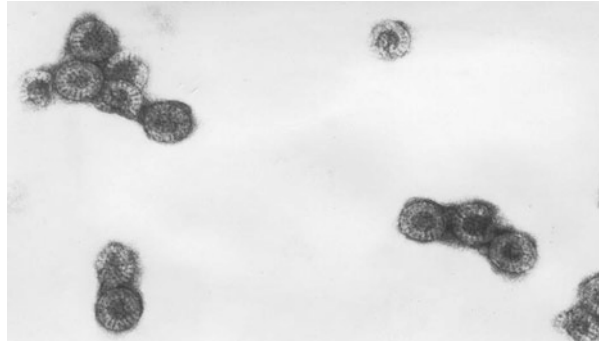
Camel calf diarrheic disease results from complex infectious agents. In the present study, 33 calves presenting diarrhea were sampled for *Cryptosporidium*, *E. coli*, Coronavirus, and Rotavirus. The prevalence rates were 15.1%, 9%, 6%, and 6%, respectively. The prevalence of diarrhea was found to be 8.1% in calves' less than 3 months. This is the first report of *Cryptosporidium* and Coronavirus of Saudi camels (Mohamed & Faye, 2016).

---

## 49.2 Clinical Picture

Clinically, neonatal calf diarrhea can range from mild diarrhea without overt systemic involvement to profuse watery, acute diarrhea associated with extreme disturbance of acid-base and electrolyte balance, weight loss and dehydration (Fig. 49.1), and sometimes death.

**Fig. 49.2** Electron micrograph showing the camel rotavirus particles. Note, the characteristic wheel-like structure of the virus particles (source: Abdelmalik Khalafalla)



---

### 49.3 Diagnosis

Diagnosis can be made on clinical signs and epidemiology, but additional examinations are often needed. Fecal samples are examined by microscopy for *C. parvum* and Coccidia, bacterial culturing for *Salmonella* spp., *E. coli*, and *C. perfringens*, and PCR and antigen-capturing enzyme-linked immunosorbent assay (Ag-ELISA) for rotavirus. Electron microscopy is also useful particularly in detecting Rotavirus based on morphological characteristics (Fig. 49.2).

---

### 49.4 Treatment

Successful treatment of calf scours depends upon rapidly rehydrating scouring calves.

Oral rehydration products help restore fluid balance, lost electrolytes, and essential nutrients.

In bacterial scours cases, oral or injectable antibiotic therapy may be advised.

---

### References

- Abbas, B., Mohamed, G. E., Agab, H., Yagoub, S. O., & Mustafa, K. (1992). Clinical observations on field cases of some clinical diseases with emphasis on diarrhoea in camel calves. In *Proc. 5th Conf. General Federation of Arab Veterinarians*. Sudan Veterinary Association.
- Abo Hatab, E. M., Hussein, H. A., El-Sabagh, I. M., & Saber, M. S. (2008). Isolation and antigenic and molecular characterization of G10 of Group A rotavirus in camel. *Egyptian Journal of Virology*, 5, 220–238.
- Ali, Y. H., Khalafalla, A. I., Gaffar, M. E., Peenze, I., & Steele, A. D. (2005). Rota virus associated camel calf diarrhea in Sudan. *JAVA*, 4, 401–406.
- Ali, Y. H., Khalafalla, A. I., Gaffar, M. E., Peenze, I., & Steele, A. D. (2008). Detection and isolation of group A rotavirus from camel calves in Sudan. *Veterinarski Arhiv*, 78, 477–485.

- Al-Ruwaili, M. A., Khalil, O. M., & Selim, S. A. (2012). Viral and bacterial infections associated with camel (*Camelus dromedarius*) calf diarrhea in North Province, Saudi Arabia. *Saudi Journal of Biological Sciences*, 1, 35–41.
- Jere, K. C., Esona, M. D., Ali, Y. H., Peenze, I., Roy, S., Bowen, M. D., Saeed, I. K., Khalafalla, A. I., Nyaga, M. M., Mphahlele, J., Steele, D., & Seheri, M. L. (2014). Novel NSP1 genotype characterized in an African camel G8P[11] rotavirus strain. *Infection, Genetics and Evolution*, 21, 58–66.
- Mohamed, E., & Faye, B. (2016). Camel calf diarrhea in Riyadh region, Saudi Arabia. *Journal of Camel Practice and Research*, 23(2), 283–285.
- Schwartz, H. J., & Dioli, M. (1992). *The one-humped camel in eastern Africa. A pictorial guide to diseases, health care and management* (p. 282). Josef Margraf.
- Wünschmann, A., Frank, R., Pomeroy, K., & Kapil, S. (2002). Enteric coronavirus infection in a juvenile dromedary (*Camelus dromedarius*). *Journal of Veterinary Diagnostic Investigation*, 14 (5), 441–444.