

Fourth Edition

Hendrix  
Robinson

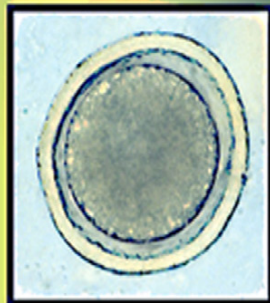
# DIAGNOSTIC PARASITOLOGY

*for* **Veterinary  
Technicians**

**DIAGNOSTIC PARASITOLOGY**  
*for* **Veterinary Technicians**

**4**

ELSEVIER



ELSEVIER  
MOSBY

**Charles M. Hendrix  
Ed Robinson**

<http://evolve.elsevier.com>

# DIAGNOSTIC PARASITOLOGY

*for* **Veterinary  
Technicians**



This page intentionally left blank

Fourth Edition

# DIAGNOSTIC PARASITOLOGY

*for* **Veterinary  
Technicians**

**Charles M. Hendrix, DVM, PhD**

Professor  
Department of Pathobiology  
College of Veterinary Medicine  
Auburn University  
Alabama

**Ed Robinson, VT**

Shakespeare Veterinary Hospital  
Veterinary Technology Program Instructor  
PennFoster Career Schools  
Fairfield, Connecticut

**ELSEVIER**

**ELSEVIER**  
MOSBY

3251 Riverport Lane  
St. Louis, Missouri 63043

DIAGNOSTIC PARASITOLOGY FOR VETERINARY TECHNICIANS  
Copyright © 2012, 2006, 1998 by Mosby, Inc., an affiliate of Elsevier Inc.

ISBN: 978-0-323-07761-3

No part of this publication may be reproduced or transmitted in any form or by any means, electronic or mechanical, including photocopying, recording, or any information storage and retrieval system, without permission in writing from the publisher. Details on how to seek permission, further information about the Publisher's permissions policies and our arrangements with organizations such as the Copyright Clearance Center and the Copyright Licensing Agency, can be found at our website: [www.elsevier.com/permissions](http://www.elsevier.com/permissions).

This book and the individual contributions contained in it are protected under copyright by the Publisher (other than as may be noted herein).

#### Notices

Knowledge and best practice in this field are constantly changing. As new research and experience broaden our understanding, changes in research methods, professional practices, or medical treatment may become necessary.

Practitioners and researchers must always rely on their own experience and knowledge in evaluating and using any information, methods, compounds, or experiments described herein. In using such information or methods they should be mindful of their own safety and the safety of others, including parties for whom they have a professional responsibility.

With respect to any drug or pharmaceutical products identified, readers are advised to check the most current information provided (i) on procedures featured or (ii) by the manufacturer of each product to be administered, to verify the recommended dose or formula, the method and duration of administration, and contraindications. It is the responsibility of practitioners, relying on their own experience and knowledge of their patients, to make diagnoses, to determine dosages and the best treatment for each individual patient, and to take all appropriate safety precautions.

To the fullest extent of the law, neither the Publisher nor the authors, contributors, or editors, assume any liability for any injury and/or damage to persons or property as a matter of products liability, negligence or otherwise, or from any use or operation of any methods, products, instructions, or ideas contained in the material herein

ISBN: 978-0-323-07761-3

*Vice President and Publisher:* Linda Duncan  
*Publisher:* Penny Rudolph  
*Managing Editor:* Teri Merchant  
*Publishing Services Manager:* Julie Eddy  
*Project Manager:* Kelly Milford  
*Design Direction:* Ashley Eberts

Printed in United States of America

Last digit is the print number: 9 8 7 6 5 4 3 2 1

Working together to grow  
libraries in developing countries

[www.elsevier.com](http://www.elsevier.com) | [www.bookaid.org](http://www.bookaid.org) | [www.sabre.org](http://www.sabre.org)

ELSEVIER BOOK AID International Sabre Foundation

*To John Schlotthauer, who taught me that the most important part  
of any veterinary curriculum is the individual student*

**CMH**

*To Margi Sirois, who taught me the greatest thing about veterinary  
technology is helping others learn about the profession*

**ER**



This page intentionally left blank

# PREFACE

**V**eterinary clinical parasitology is one of the most important disciplines in any veterinary curriculum, be it a curriculum training veterinary students or one that trains veterinary technicians.

## ORGANIZATION

This new edition was prepared to follow the educational structure used in parasitology classes in veterinary technology education. Our textbook is intended to inform the reader of the most commonly encountered internal and external parasites of both domesticated and laboratory animals. The text begins with a chapter detailing the language of parasitology, the many terms that describe the intricate host-parasite relationships of veterinary parasitology. These terms are the “framework” of the discipline, the means of communication among veterinarians, veterinary technicians, and their clients. Every veterinary practitioner, veterinarian, veterinary technician, or student, must learn to effectively communicate in this language. Each succeeding chapter describes a different parasite group: protozoans (one-cell organisms), trematodes (flukes), cestodes (tapeworms), nematodes (roundworms), acanthocephalans (thorny-headed worms), arthropods (insects, mites, and ticks), hirudineans (leeches), and pentastomes (tongue worms). As with the last edition, each of these parasite groups is described in detail, with special emphasis placed on morphology, uniqueness of the life cycle, and important parasites within the group.

## NEW TO THIS EDITION

The text begins with a new parasite table arranged by host species that provides key information on each parasite with page numbers for cross-reference throughout the book.

Information on the parasites has been updated and new parasite information has been added to better prepare the technician for the parasites currently seen in the veterinary practice. A brief synopsis of each parasite is given before the in depth discussion. This synopsis includes the parasite genus, species, host (including other hosts the parasite may affect), location of adult in host, distribution (where available), derivation of genus (many provided by Bowman: Georgis’ *Parasitology for Veterinarians*), transmission route and common name (where applicable). Treatments and preventive measures have been added to the sections on the major parasites seen in veterinary medicine. A new chapter with a quick reference to the most common parasites has been added, containing pictures of the most common parasite ova seen in diagnostic tests. We have also made a major improvement with this edition with the replacement of black and white photographs with color photographs. We have endeavored to use as many color photographs as possible to assist in the demonstration of key morphologic and diagnostic features needed for proper identification of all classes of parasites. A glossary that defines the terms used in the text and an appendix that provides a quick reference to each parasite in the book, referenced by species, have been added.

This latest edition of *Diagnostic Veterinary Parasitology* was prepared with the veterinary technician in mind. Parasitology is a large part of the technician’s job in any veterinary clinic. Veterinary technicians are responsible for collecting, preparing, and examining fecal tests. In addition, the veterinary technician is responsible for client education in general and parasite education in particular. The information contained within this text will help veterinary technicians become familiar with the parasites seen in veterinary medicine.

---

**EVOLVE RESOURCES—ELECTRONIC  
FLASH CARDS**

Each card contains 10 categories, including scientific name, common name, derivation of name, audio pronunciation, type of parasite, adult morphology, immature stage morphology, location, clinical signs, infection route, diagnostic test, zoonosis, human disease, and a unique fact.

The flash cards will help the student of parasitology learn the important facts about each parasite in fun and interactive ways. They are an exciting new addition to this text, which will help make learning and teaching parasitology fun.

***Charles M. Hendrix***  
***Ed Robinson***

# CONTENTS

## 1 THE LANGUAGE OF VETERINARY PARASITOLOGY, 1

Symbiosis, 2  
Parasitism, 3  
Life Cycle, 6  
The Linnaean Classification Scheme, 8

## 2 PARASITES THAT INFECT AND INFEST DOMESTIC ANIMALS, 11

Monogenetic Trematodes (Monogenetic Flukes), 11  
Digenetic Trematodes (Digenetic Flukes), 12  
Eucestodes (True Tapeworms), 12  
Cotyloda (Pseudotapeworms), 12  
Nematodes (Roundworms), 12  
Acanthocephalans (Thorny-Headed Worms), 13  
Hirudineans (Leeches), 13  
Arthropods, 13  
Protista (Protozoa), 14

## 3 INTRODUCTION TO THE NEMATODES, 15

Nematodes of Importance in Veterinary Medicine, 16  
Key Morphologic Features, 16  
External Morphologic Features, 17  
Internal Morphologic Features, 18  
Life Cycle of the Nematode, 20

## 4 NEMATODES THAT INFECT DOMESTIC ANIMALS, 25

Nematodes of Dogs and Cats, 26  
Gastrointestinal Tract, 26  
Circulatory System, 36  
Respiratory System, 43  
Urinary Tract, 44

Skin, 46

Eye and Adnexa, 49

### Nematodes of Ruminants, 49

Gastrointestinal Tract, 49

Circulatory System, 52

Respiratory System, 53

Skin, 53

Eye and Adnexa, 56

Abdominal Cavity, 56

### Nematodes of Equids, 57

Gastrointestinal Tract, 57

Respiratory System, 64

Skin, 64

Eye and Adnexa, 66

Abdominal Cavity, 66

### Nematodes of Swine, 66

Gastrointestinal Tract, 66

Respiratory Tract, 70

Urinary Tract, 70

Musculoskeletal System, 71

### Nematodes of Mice, 72

Gastrointestinal Tract, 72

### Nematodes of Rats, 74

Gastrointestinal System, 74

### Nematodes of Hamsters, 75

Gastrointestinal Tract, 75

### Nematodes of Gerbils, 75

Gastrointestinal Tract, 75

### Nematodes of Guinea Pigs, 76

Gastrointestinal Tract, 76

### Nematodes of Rabbits, 77

Gastrointestinal Tract, 77

### Nematodes of Pet and Aviary Birds, 79

Gastrointestinal Tract, 79

## 5 THE PHYLUM PLATYHELMINTHES, CLASS CESTODA, 83

### Eucestoda (True Tapeworms), 84

Key Morphologic Features, 84

Life Cycle of the True Tapeworm, 87



**Cotyloda (Pseudotapeworms)**, 89  
*Key Morphologic Features*, 89  
*Life Cycle of the Pseudotapeworm*, 90

## 6 **TAPEWORMS THAT PARASITIZE DOMESTIC ANIMALS AND HUMANS**, 93

**Eucestoda (True Tapeworms)**, 94  
*Mice, Rats, Gerbils, and Hamsters*, 94  
 Intestinal Tract, 94  
*Ruminants*, 95  
 Intestinal Tract, 95  
*Metacestode (Larval) Stages Found in Musculature of Food Animals*, 99  
*Metacestode (Larval) Stages Found in Abdominal Cavity of Food Animals*, 100  
*Horses*, 101  
 Intestinal Tract, 101  
*True Tapeworms of Dogs and Cats*, 103  
*Dipylidium caninum*, 103  
*Taenia pisiformis*, *T. hydatigena*, and *T. ovis*, 106  
*Taenia taeniaeformis (Hydatigera taeniaeformis)*, 108  
*Multiceps multiceps* and *multiceps serialis*, 110  
*Echinococcus granulosus* and *Echinococcus multilocularis*, 112  
*Mesocostoides Species*, 114  
**Cotyloda (Pseudotapeworms)**, 116  
*Spirometra Species*, 117  
*Diphyllobothrium Species*, 117

## 7 **THE PHYLUM PLATYHELMINTHES, CLASS TREMATODA**, 123

**Subclass Monogenea**, 124  
**Subclass Digenea**, 124  
*Key Morphologic Features*, 124  
*Life Cycle of the Fluke*, 125

## 8 **TREMATODES (FLUKES) OF ANIMALS AND HUMANS**, 131

**Flukes of Ruminants (Cattle, Sheep, and Goats)**, 131  
**Flukes of Small Animals (Dogs and Cats)**, 135

## 9 **THE PHYLUM ACANTHOCEPHALA**, 143

**Common Acanthocephalans**, 143  
*Key Morphologic Features*, 144  
*Life Cycle of the Thorny-Headed Worm*, 144  
*Acanthocephalans of Importance in Veterinary Parasitology*, 145  
*Macracanthorhynchus hirudinaceus*, 145  
*Oncicola canis*, 147

## 10 **THE PROTOZOANS**, 149

**Characteristics of the Protozoans**, 149  
**Mastigophora (Flagellates)**, 150  
**Sarcodina (Amoebae)**, 150  
**Ciliophora (Ciliates)**, 151  
**Apicomplexa (Apicomplexans)**, 152

## 11 **COMMON PROTOZOANS THAT INFECT DOMESTIC ANIMALS**, 155

**Dogs and Cats**, 156  
*Gastrointestinal Tract*, 156  
 Flagellates, 156  
 Amoebae, 158  
 Ciliates, 159  
 Apicomplexans, 159  
*Circulatory System and Blood*, 164  
 Flagellates, 164  
 Apicomplexans, 165  
**Ruminants (Cattle and Sheep)**, 166  
*Gastrointestinal Tract*, 166  
 Ciliates, 167

Apicomplexans, 167  
*Circulatory System and Blood*, 168  
 Flagellates, 168  
 Apicomplexans, 168  
*Urogenital System*, 168  
**Horses**, 169  
*Gastrointestinal Tract*, 169  
 Flagellates, 169  
 Ciliates, 169  
 Apicomplexans, 170  
*Circulatory System and Blood*, 170  
 Apicomplexans, 170  
*Urogenital System*, 171  
 Apicomplexans, 171  
*Nervous System*, 171  
 Apicomplexans, 171  
**Swine**, 172  
*Gastrointestinal Tract*, 172  
 Ciliates, 172  
 Apicomplexans, 172  
**Pet and Aviary Birds and Other Domestic Fowl**, 173  
*Gastrointestinal Tract*, 173  
 Flagellates, 173  
 Apicomplexans, 175  
*Circulatory System and Blood*, 175  
 Flagellates, 175  
 Apicomplexans, 175  
*Respiratory System*, 177  
 Apicomplexans, 177  
**Rabbits**, 177  
*Gastrointestinal Tract*, 177  
 Apicomplexans, 178  
**Mice**, 179  
*Gastrointestinal Tract*, 179  
 Flagellates, 179  
 Apicomplexans, 180  
*Urogenital System*, 181  
 Apicomplexans, 181  
**Rats**, 181  
*Gastrointestinal Tract*, 181  
 Flagellates, 181  
 Apicomplexans, 181  
**Hamsters**, 182  
*Gastrointestinal Tract*, 182  
 Flagellates, 182  
**Guinea Pigs**, 182

*Gastrointestinal Tract*, 182  
 Flagellates, 182  
 Amoebae, 183  
 Apicomplexans, 183  
**Fish**, 184  
*Skin*, 184  
 Ciliates, 184

## 12 INTRODUCTION TO THE ARTHROPODS, 187

**Arthropoda**, 187  
*Key Morphologic Features*, 188  
**Divisions of the Phylum Arthropoda**, 188  
**Crustacea (Aquatic Arthropods)**, 188  
**Myriopoda (Centipedes and Millipedes)**, 188  
**Insecta (Insects)**, 189  
*Key Morphologic Features*, 189  
*Orders of Insecta*, 190  
**Acarina (Mites and Ticks)**, 190

## 13 ARTHROPODS THAT INFECT AND INFEST DOMESTIC ANIMALS, 193

**Crustaceans**, 194  
**Myriopodans**, 195  
**Insects**, 196  
*Dictyoptera (Cockroaches)*, 196  
*Coleoptera (Beetles)*, 196  
*Lepidoptera (Butterflies and Moths)*, 197  
*Hymenoptera (Ants, Bees, and Wasps)*, 197  
*Hemiptera (True Bugs)*, 198  
*Mallophaga (Chewing or Biting Lice) and Anoplura (Sucking Lice)*, 199  
 Lice of Mice, Rats, Gerbils, and Hamsters, 202  
 Lice of Guinea Pigs, 205  
 Lice of Rabbits, 206  
*Diptera (Two-Winged Flies)*, 206  
 Periodic Parasites of Which Only Adult Females Feed on Vertebrate Blood, 207  
 Periodic Parasites of Which Both Adult Males and Females Feed on Vertebrate Blood, 211

Periodic Parasites That Feed on  
Mucus, Tears, and Saliva, 216

Myiasis-Producing Flies, 219

*Siphonaptera* (Fleas), 226

#### **Mites and Ticks, 231**

*Mites of Veterinary Importance*, 231

Family Sarcoptidae (Mites), 231

Psoroptidae, 237

Nonsarcoptiform Mites, 241

Fur Mites, 247

*Ticks of Veterinary Importance*, 252

Argasid (Soft) Ticks, 254

Ixodid (Hard) Ticks, 256

## **14 INTRODUCTION TO THE PHYLUM ARTHROPODA, SUBPHYLUM PENTASTOMIDA, 267**

### **Pentastomes (Parasites of Reptiles), 267**

*Morphology*, 268

*Life Cycle*, 268

*Diagnosis*, 270

Definitive Host, 270

Incidental Host, 270

### **Adult Pentastome That Infects Nasal**

**Passages and Turbinates of a**

**Mammalian Host, 271**

*Diagnosis*, 271

Definitive Host, 270

Intermediate Host, 272

## **15 THE PHYLUM ANNELIDA, 273**

### **Hirudinea (Leeches), 273**

*Morphology*, 274

*Life Cycle of the Leech*, 274

## **16 PARASITES OF PUBLIC HEALTH IMPORTANCE IN VETERINARY PARASITOLOGY, 279**

### **Protozoans of Public Health**

**Importance**, 281

*Toxoplasma gondii* (*Toxoplasmosis*), 281

Human Infection with

*Toxoplasmosis*, 281

Symptoms and Diagnosis, 281

Treatment, 282

Prevention of Transmission to  
Humans, 282

*Cryptosporidium parvum*

(*Cryptosporidiosis*), 282

Human Infection with

*Cryptosporidiosis*, 282

Symptoms and Diagnosis, 283

Treatment, 283

Prevention of Transmission to

Humans, 283

### **Trematodes of Public Health**

**Importance**, 283

*Schistosomes of Wild Migratory Birds*

(*Schistosome Cercarial Dermatitis*,

*Swimmer's Itch*), 283

Human Infection with Swimmer's

Itch, 284

Symptoms and Diagnosis, 284

Treatment, 284

Prevention of Transmission to

Humans, 284

### **Cestodes of Public Health**

**Importance**, 285

*Taenia saginata* (*Beef Tapeworm*), 285

Human Infection with Beef

Tapeworm, 285

Symptoms and Diagnosis, 285

Treatment, 285

Prevention of Transmission to

Humans, 285

*Taenia solium* (*Pork Tapeworm*), 286

Human Infection with Pork

Tapeworm, 286

Symptoms and Diagnosis, 286

Treatment, 287

Prevention of Transmission to

Humans, 287

*Echinococcus granulosus* and

*Echinococcus multilocularis*

(*Unilocular and Multilocular Hydatid  
Disease*), 287

Human Infection with Hydatid

Disease, 287

Symptoms and Diagnosis, 288

Treatment, 288

Prevention of Transmission to

Humans, 288

- Dipylidium caninum* (Human Dipylidiasis), 288  
 Human Infection with *Dipylidium*, 288  
 Symptoms and Diagnosis, 288  
 Treatment, 289  
 Prevention of Transmission to Humans, 289
- Spirometra Mansonoides* (Benign Plerocercoidosis/Malignant Sparganosis), 289  
 Human Infection with *Spirometra* Species, 289  
 Symptoms and Diagnosis, 289  
 Treatment, 290  
 Prevention of Transmission to Humans, 290
- Hymenolepis nana* (Hymenolepiasis), 290  
 Human Infection with *Hymenolepis*, 290  
 Symptoms and Diagnosis, 290  
 Treatment, 290  
 Prevention of Transmission to Humans, 290
- Diphyllobothrium latum* (Diphyllobothriasis), 291  
 Human Infection with *Diphyllobothrium latum*, 291  
 Symptoms and Diagnosis, 291  
 Treatment, 291  
 Prevention of Transmission to Humans, 291
- Nematodes of Public Health Importance, 292**
- Toxocara canis* and *Toxocara cati* (Toxocaral Larva Migrants, Visceral Larva Migrants, Ocular Larva Migrants), 292  
 Human Infection with Toxocaral Larva Migrants, 292  
 Symptoms and Diagnosis, 292  
 Treatment, 292  
 Prevention of Transmission to Humans, 292
- Baylisascaris procyonis* (Neural Larva Migrants, Cerebrospinal Nematodiasis), 293  
 Human Infection with Larvae of *Baylisascaris procyonis*, 293  
 Symptoms and Diagnosis, 293  
 Treatment, 294  
 Prevention of Transmission to Humans, 294
- Ancylostoma caninum*, *Ancylostoma braziliense*, *Ancylostoma tubaeforme*, and *Uncinaria stenocephala* (Cutaneous Larva Migrants, Creeping Eruption, Plumber's Itch), 294  
 Human Infection with Cutaneous Larva Migrants, 295  
 Symptoms and Diagnosis, 295  
 Treatment, 296  
 Prevention of Transmission of Humans, 296
- Ancylostoma caninum* (Enteric Hookworm Disease), 296  
 Human Infection with Enteric Hookworm Disease, 297  
 Symptoms and Diagnosis, 297  
 Treatment, 297  
 Prevention of Transmission to Humans, 297
- Strongyloides stercoralis* (Strongyloidiasis), 298  
 Human Infection with *Strongyloides stercoralis*, 298  
 Symptoms and Diagnosis, 298  
 Treatment, 298  
 Prevention of Transmission to Humans, 299
- Trichinella spiralis* (Trichinosis, Trichinellosis), 299  
 Human Infection with Trichinosis, 299  
 Symptoms and Diagnosis, 299  
 Treatment, 300  
 Prevention of Transmission to Humans, 300
- Dirofilaria immitis* (Pulmonary Dirofilariasis), 300



Human Infection with  
 Dirofilaria, 300  
 Symptoms and Diagnosis, 301  
 Treatment, 301  
 Prevention of Transmission to  
 Humans, 301

### **Arthropods of Public Health**

#### **Importance, 302**

*Sarcoptes scabiei varietal canis* (Canine  
 Scabies), 302

Human Infection with Canine  
 Scabies, 302

Symptoms and Diagnosis, 302

Treatment, 302

Prevention of Transmission to  
 Humans, 302

### **Pentastomes of Public Health**

#### **Importance, 303**

*Reptilian Pentastomiasis*, 303

Human Infection with  
 Pentastomes, 303

Symptoms and Diagnosis, 303

Treatment, 303

Prevention of Transmission to  
 Humans, 304

### **Conclusion, 304**

## **17 COMMON LABORATORY PROCEDURES FOR DIAGNOSING PARASITISM, 307**

### **Diagnosis of Parasites of the Digestive Tract, 308**

*Collection of the Fecal Sample*, 309

Small Animal Samples, 309

Large Animal Samples, 309

*Examination of the Fecal Sample*, 310

Gross Examination of Feces, 311

Microscopic Examination of  
 Feces, 313

Direct Smear, 315

*Concentration Methods for Fecal  
 Examination*, 316

Fecal Flotation, 316

Fecal Sedimentation, 319

*Quantitative Fecal Examination*, 319

*Examination of Feces for Protozoa*, 321

*Fecal Culture*, 323

Nematode (Roundworm) Eggs, 323

Coccidial Oocysts, 323

*Sample Collection at Necropsy*, 324

*Shipping Parasitologic Specimens*, 326

*Miscellaneous Procedures for Detection of  
 Digestive Tract Parasites*, 326

Cellophane Tape Preparation, 326

Baermann Technique, 327

*Blood in the Feces*, 328

*Gross Examination of Vomitus*, 328

*Microscopic Examination of Vomitus*, 328

### **Diagnosis of Parasites of the Blood and Vascular System, 328**

*Collection of Blood Samples*, 329

*Examination of Blood*, 329

Direct Microscopic Examination, 329

Thin Blood Smear, 329

Thick Blood Smear, 329

Buffy Coat Method, 329

Modified Knott's Technique, 331

Commercial Filter Technique, 333

Immunologic Heartworm Tests, 334

Miscellaneous Methods for

Microfilarial Identification, 334

### **Diagnosis of Parasitism of the Respiratory System, 335**

*Fecal Examination for Respiratory  
 Parasites*, 335

*Examination of Sputum and Tracheal  
 Washes*, 335

### **Diagnosis of Parasitism of the Urinary System, 336**

*Collection of the Urine Sample*, 336

*Urine Examination for Parasites*, 336

### **Diagnosis of Parasitism of the Skin, 336**

*Skin Scrapings*, 336

*Cellophane Tape Preparation*, 337

*Gross Specimens*, 338

### **Diagnosis of Parasitism of Miscellaneous Body Systems, 338**

*Parasites of the Eye*, 338

*Parasites of the Ear*, 338

*Parasites of the Genital Tract*, 339

## 18 REFERENCE TO COMMON PARASITE OVA AND FORMS SEEN IN VETERINARY MEDICINE, 343

Common Parasites of Dogs and Cats, 344

Common Parasites of Horses, 348

Common Parasites of Ruminants, 350

Common Parasites of Swine, 352

Common Parasites of Exotic Pets  
and Birds, 353

Pseudoparasites, 360

## APPENDIX. PARASITE REFERENCE LIST BY SPECIES AND PARASITE TYPE, 363

### Parasites of Dogs and Cats, 363

*Nematodes*, 363

*Cestodes*, 363

*Trematodes*, 363

*Acanthocephalans*, 363

*Protozoans*, 363

*Arthropods*, 364

*Pentastomes*, 364

*Annelids*, 364

### Parasites of Ruminants, 364

*Nematodes*, 364

*Cestodes*, 364

*Trematodes*, 365

*Protozoans*, 365

*Arthropods*, 365

*Annelids*, 365

### Parasites of Horses, 365

*Nematodes*, 365

*Cestodes*, 365

*Protozoans*, 366

*Arthropods*, 366

*Annelids*, 366

### Parasites of Swine, 366

*Nematodes*, 366

*Cestodes*, 366

*Acanthocephalans*, 366

*Protozoans*, 366

*Arthropods*, 366

*Annelids*, 366

### Parasites of Birds, 367

*Nematodes*, 367

*Trematodes*, 367

*Protozoans*, 367

*Arthropods*, 367

*Annelids*, 367

### Parasites of Rabbits, 367

*Nematodes*, 367

*Protozoans*, 367

*Arthropods*, 367

### Parasites of Guinea Pigs, 367

*Nematodes*, 367

*Protozoans*, 367

*Arthropods*, 368

### Parasites of Rats, 368

*Nematodes*, 368

*Cestodes*, 368

*Protozoans*, 368

*Arthropods*, 368

### Parasites of Mice, 368

*Nematodes*, 368

*Cestodes*, 368

*Protozoans*, 368

*Arthropods*, 368

### Parasites of Hamsters, 369

*Nematodes*, 369

*Cestodes*, 369

*Protozoans*, 369

*Arthropods*, 369

### Parasites of Gerbils, 369

*Nematodes*, 369

*Cestodes*, 369

*Arthropods*, 369

### Parasites of Fish, 369

*Protozoans*, 369

### Parasites of Reptiles, 369

*Pentastomes*, 369

## Glossary, 371

This page intentionally left blank

## Parasites by Host Species

Parasite	Host	Location of Adult	Distribution	Common Name	Page
<b>CANINES AND FELINES</b>					
<i>Nematodes</i>					
<b>Gastrointestinal Tract</b>					
<i>Spirocerca lupi</i>	Dogs and cats	Esophageal wall	Tropical and sub-tropical regions	Esophageal worm of dogs and cats	26
<i>Physaloptera</i> sp.	Dogs and cats	Lumen of stomach and small intestine	Worldwide	Stomach worm of dogs and cats	27
<i>Aonchotheca putorii</i>	Cats	Small intestine		Gastric capillariid of cats	28
<i>Ollulanus tricuspis</i>	Cats	Stomach		Feline trichostrongyle	28
<i>Toxocara canis</i>	Dogs	Small intestine	Worldwide	Canine roundworm	28
<i>Toxocara cati</i>	Cats	Small intestine	Worldwide	Feline roundworm	28
<i>Toxascaris leonine</i>	Dogs and cats	Small intestine	Worldwide	Roundworm of dogs and cats	28
<i>Baylisascaris procyonis</i>	Raccoons, dogs, cats, and other species	Small intestine	North America	Roundworm of raccoons	30
<i>Ancylostoma caninum</i>	Dogs	Small intestine	Worldwide	Canine hookworm	31
<i>Ancylostoma tubaeforme</i>	Cats	Small intestine	Worldwide	Feline hookworm	31
<i>Ancylostoma braziliense</i>	Dogs and cats	Small intestine	Worldwide	Hookworm of dogs and cats	31
<i>Uncinaria stenocephala</i>	Dogs	Small intestine	Northern regions of North America	Canine hookworm	31
<i>Strongyloides stercoralis</i>	Dogs, cats, and humans	Small intestine	Worldwide	Canine intestinal threadworm	34
<i>Strongyloides tumefaciens</i>	Dogs and cats	Small intestine	Worldwide	Canine intestinal threadworm	34
<i>Trichuris vulpis</i>	Dogs	Cecum and colon	Worldwide	Canine whipworm	35
<i>Trichuris campanula</i>	Cats	Cecum and colon	Worldwide but rare in North America	Feline whipworm	35
<i>Trichuris serrata</i>	Cats	Cecum and colon	Worldwide but rare in North America	Feline whipworm	35

Continued



## Parasites by Host Species—cont'd

Parasite	Host	Location of Adult	Distribution	Common Name	Page
<b>Circulatory System</b>					
<i>Dirofilaria immitis</i>	Dogs, cats, and humans	Right ventricle and pulmonary artery	Warm to temperate climates	Heartworm	36
<b>Respiratory System</b>					
<i>Aelurostrongylus abstrusus</i>	Cats	Bronchioles and alveolar ducts	Worldwide	Feline lungworm	43
<i>Filaroides osleri</i>	Dogs	Trachea	North America, Europe, and Japan	Canine lungworm	43
<i>Filaroides hirthi</i>	Dogs	Lung parenchyma	North America, Europe, and Japan	Canine lungworm	43
<i>Filaroides milksi</i>	Dogs	Bronchioles	North America, Europe, and Japan	Canine lungworm	43
<i>Eucoleus aerophilus</i>	Dogs and Cats	Bronchi and trachea		Capillariid lungworm of dogs and cats	44
<i>Eucoleus böehmi</i>	Dogs	Nasal cavity and frontal sinuses		Capillariid respiratory worm of dogs	44
<b>Urinary Tract</b>					
<i>Diectophyma renale</i>	Dogs	Right kidney	North America and Europe	Giant kidney worm of dogs	44
<i>Capillaria plica</i>	Dogs	Urinary bladder		Bladder worm of dogs	45
<i>Capillaria feliscati</i>	Cats	Urinary bladder		Bladder worm of cats	45
<b>Skin</b>					
<i>Rhabditis strongyloides</i>	Dogs	Superficial layers of the skin			46
<i>Acanthocheiloneema reconditum</i>	Dogs	Subcutaneous tissues	Tropical and subtropical regions	Canine subcutaneous filarial worm	47
<i>Dracunculus insignis</i>	Dogs	Subcutaneous tissues		Guinea worm	48
<b>Eye and Adnexa</b>					
<i>Thelazia californiensis</i>	Dogs and cats	Conjunctival sac and lacrimal duct	North America	Eyeworm of dogs and cats	49

## Parasites by Host Species—cont'd

Parasite	Host	Location of Adult	Distribution	Common Name	Page
<i>Cestodes</i>					
<b>Gastrointestinal Tract</b>					
<i>Dipylidium caninum</i>	Dogs and cats	Small intestine	Worldwide	Cucumber seed tapeworm or double-pored tapeworm	103
<i>Taenia pisiformis</i>	Dogs	Small intestine		Canine taeniid	106
<i>Taenia hydatigena</i>	Dogs	Small intestine		Canine taeniid	106
<i>Taenia ovis</i>	Dogs	Small intestine		Mutton tapeworm of dogs	106
<i>Taenia taeniaeformis</i>	Cats	Small intestine		Feline taeniid	108
<i>Multiceps multiceps</i>	Dogs	Small intestine	Worldwide	Coenurus-producing tapeworm	110
<i>Multiceps serialis</i>	Dogs	Small intestine		Coenurus-producing tapeworm	110
<i>Echinococcus granulosus</i>	Dogs	Small intestine	Worldwide	Unilocular hydatid tapeworm	112
<i>Echinococcus multilocularis</i>	Cats	Small intestine	Countries in Northern Hemisphere	Multilocular hydatid tapeworm	112
<i>Mesocestoides</i> sp.	Dogs, cats, and carnivores	Small intestine	North America, Asia, Europe, and Africa	Tetrathyridium tapeworm	114
<i>Spirometra</i> sp.	Dogs and cats	Small intestine	North America, South America, Far East, and Australia	Zipper tapeworm	117
<i>Diphyllbothrium latum</i>	Dogs, cats, and humans	Small intestine	North America, Scandinavian and Ukrainian countries	Broad fish tapeworm	118
<i>Trematodes</i>					
<i>Platynosomum fastosum</i>	Cats	Bile ducts	South America, Southern United States, West Africa, Pacific Islands, Malaysia, and the Caribbean	"Lizard poisoning fluke" of cats	135

Continued

### Parasites by Host Species—cont'd

Parasite	Host	Location of Adult	Distribution	Common Name	Page
Nanophyetus salmincola	Dogs	Small intestine	Pacific and North-western North America	"Salmon poisoning fluke" of dogs	136
Alaria sp.	Dogs and Cats	Small intestine	Northern United States and Canada	Intestinal fluke of dogs and cats	
Paragonimus kellicoti	Dogs and Cats	Lung parenchyma	North America	Lung fluke of dogs and cats	137
Heterobilharzia americana	Dogs	Mesenteric veins of small and large intestines and portal veins	North America	Schistosome of dogs	138

#### Protozoans

#### Gastrointestinal Tract

##### Flagellates

Giardia sp.	Dogs, cats, horses, humans, exotic species	Intestinal mucosa	Worldwide	Giardia	156
-------------	--------------------------------------------	-------------------	-----------	---------	-----

##### Amoeba

Entamoeba histolytica	Dogs, cats, primates, and humans	Large intestine	Worldwide	Entamoeba	158
-----------------------	----------------------------------	-----------------	-----------	-----------	-----

##### Ciliates

Balantidium coli	Dogs and pigs	Cecum and colon	Worldwide	Balantidium	159
------------------	---------------	-----------------	-----------	-------------	-----

##### Apicomplexans

Cystoisospora sp.	Dogs, cats, and pigs	Small intestines		Coccidia	159
Toxoplasma gondii	Cats	Intestines	Worldwide	Toxoplasma	160
Cryptosporidium sp.	Dogs, cats, cattle, pigs, birds, guinea pigs, snakes, and mice	Small intestines		Cryptosporidia	161
Sarcocystis sp.	Dogs and cats	Small intestines	Worldwide	Sarcocystis	161

## Parasites by Host Species—cont'd

Parasite	Host	Location of Adult	Distribution	Common Name	Page
<b>Circulatory System</b>					
<i>Flagellates</i>					
Trypanosoma cruzi	Dogs and humans	Peripheral blood	Central and South America and Southern United States	Trypanosomes	164
Leishmania sp.	Dogs	Reticuloendothelial cells of capillaries, spleen, and WBCs	Worldwide	Leishmania	164
<i>Apicomplexans</i>					
Babesia canis	Dogs	Within RBCs	Europe, Africa, Asia, North and South America	Babesia	165
Cytauxzoon felis	Cats	Within RBCs	Africa and United States		165
Hepatozoon canis	Dogs	Gamonts in WBCs; schizonts in spleen, bone marrow, and liver	United States, Africa, Asia, and Southern Europe		166
<i>Pentostomes</i>					
Linguatula serrata	Dogs	Nasal passages and sinuses		Canine pentastome	271
<i>Arthropods</i>					
<b>True Bugs</b>					
Reduviid bugs	Dogs and humans	Periodic skin parasite		Kissing bugs	198
Rhodnius sp.	Dogs, humans, cats, guinea pigs, armadillos, rats, raccoons, and monkeys	Periodic skin of mouth and lips	South and Central America, Southern and Western United States	Kissing bugs	199
Panstrongylus sp.	Dogs, humans, cats, guinea pigs, armadillos, rats, raccoons, and monkeys	Periodic skin of mouth and lips	South and Central America, Southern and Western United States	Kissing bugs	199

Continued

### Parasites by Host Species—cont'd

Parasite	Host	Location of Adult	Distribution	Common Name	Page
<i>Triatoma</i> sp.	Dogs, humans, cats, guinea pigs, armadillos, rats, raccoons, and monkeys	Periodic skin of mouth and lips	South and Central America, Southern and Western United States	Kissing bugs	199
<b>Lice</b>					
Mallophagan sp.	Mammals and birds	Among hairs of host		Chewing lice	199
Anopluran sp.	Mammals and birds	Among hairs of host		Sucking lice	200
<b>Dipterans</b>					
<i>Simulium</i> sp.	Domesticated animals, poultry, and humans	Skin surface when feeding	Worldwide	Black flies or buffalo gnats	207
<i>Lutzomyia</i> sp.	Mammals, reptiles, avians, and humans	Skin surface when feeding	Worldwide	New World sand flies	208
<i>Phlebotomus</i> sp.	Mammals, reptiles, avians, and humans	Skin surface when feeding	Subtropical and Mediterranean regions	Sand flies	208
<i>Culicoides</i> sp.	Domestic animals and humans	Skin surface when feeding	Worldwide	No-see-ums, punkies, or sand flies	208
<i>Anopheles quadrimaculatus</i>	Mammals, reptiles, avians, and humans	Skin surface when feeding	Worldwide	Malaria mosquito	209
<i>Aedes aegypti</i>	Mammals, reptiles, avians, and humans	Skin surface when feeding	Worldwide	Yellow fever mosquito	209
<i>Culex</i> sp.	Mammals, Reptiles, avians, and humans	Skin surface when feeding	Worldwide	Mosquito	209

### Parasites by Host Species—cont'd

Parasite	Host	Location of Adult	Distribution	Common Name	Page
Chrysops sp.	Large mammals, humans, and occasionally small mammals and birds	Skin surface when feeding	Worldwide	Deerflies	210
Tabanus sp.	Large mammals, humans, and occasionally small mammals and birds	Skin surface when feeding	Worldwide	Horseflies	210
Glossina sp.	Mammals, reptiles, birds, and humans	Skin surface when feeding	Africa	Tsetse fly	211
Musca domestica	Variety of animals and humans	Within the house	Worldwide	House fly	216
Calliphora sp.	Domestic animals, wild animals, and humans	Free living in environment		Bottle flies or blow flies	217
Lucilia sp.	Domestic animals, wild animals, and humans	Free living in environment		Bottle flies or blow flies	217
Phormia sp.	Domestic animals, wild animals, and humans	Free living in environment		Bottle flies or blow flies	217
Phaenicia sp.	Domestic Animals, Wild Animals and Humans	Free living in environment		Bottle flies or blow flies	217
Sarcophaga sp.	Domestic animals, wild animals, and humans	Free living in environment		Flesh fly	218
Hippelates sp.	Dogs and cattle	Mucocutaneous junction of eyes, lips, and penis		Dog penis gnats	219
Cochliomyia hominivorax	Domestic animals	Fresh, uncontaminated wounds	North America	Screw fly	221

Continued

### Parasites by Host Species—cont'd

Parasite	Host	Location of Adult	Distribution	Common Name	Page
Cuterebra sp.	Rabbits, squirrels, mice, rats, chipmunks, dogs, and cats	Larva around the head and neck		Warbles or wolves	222
<i>Siphonaptera</i>					
Ctenocephalides felis	Dogs and cats	Skin surface		Cat flea	226
Ctenocephalides canis	Dogs	Skin surface		Dog flea	226
<i>Mites</i>					
Sarcoptes scabiei variety canis	Dogs	Superficial layers of epidermis	Worldwide	"Scabies" mite of dogs	232
Sarcoptes scabiei variety felis	Cats	Superficial layers of epidermis	Worldwide	"Scabies" mite of cats	232
Notoedres cati	Cats and rabbits	Superficial layers of epidermis	Worldwide	Notoedric mange mite	233
Otodectes cynotis	Dogs, cats, and ferrets	External ear canal	Worldwide	Ear mites	240
Demodex canis	Dogs	Hair follicles and sebaceous glands	Worldwide	Demodectic mange mite of dogs	241
Demodex cati	Cats	Hair follicles and sebaceous glands	Worldwide	Demodectic mange mite of cats	241
Trombicula sp.	Domestic animals, wild animals, and humans	Larval stage on skin surface		Chiggers	244
Pneumonyssus caninum	Dogs	Nasal turbinates and nasal sinuses	Worldwide	Nasal mites	245
Cheyletiella parasitivorax	Dogs, cats, and rabbits	Surface of skin and hair coat	Worldwide	Walking dandruff	247
Lynxacarus radovskyi	Cats	Hair shafts on back, neck, thorax, and hind limbs	Tropical and warm regions of United States, Puerto Rico, Australia, and Fiji	Feline fur mite	248
<i>Ticks</i>					
Otobius megnini	Dogs, horses, cattle, sheep, and goats	Larval and nymphal stages in the external ear canal	Arid and semi-arid regions in Southwestern United States	Spinose ear tick	254

### Parasites by Host Species—cont'd

Parasite	Host	Location of Adult	Distribution	Common Name	Page
<i>Ixodes scapularis</i>	Adult on dogs, horses, deer, and humans	Attached to skin when feeding	Eastern United States	Deer tick	256
<i>Rhipicephalus sanguineus</i>	Small mammals, dogs, and humans	Below hair coat attached to skin, especially ear canal and between toes	North America	Brown dog tick	257
<i>Dermacentor variabilis</i>	Small mammals, dogs, and humans	Attached to skin when feeding	Eastern two-thirds of United States	Wood tick or American dog tick	258
<i>Dermacentor andersoni</i>	Adult on dogs, horses, cattle, goats, sheep, and humans	Attached to skin when feeding	Rocky Mountain regions	Rocky Mountain wood tick	258
<i>Dermacentor occidentalis</i>	Adult on large Mammals	Attached to skin when feeding	Sierra Nevada Mountains	Pacific coast dog tick	259
<i>Amblyomma americanum</i>	Adult on wide range of mammals and humans	Attached to skin when feeding	Southern United States, Midwestern and Atlantic coast of United States	Lone Star tick	259
<i>Amblyomma maculatum</i>	Adults on cattle, sheep, horses, dogs, and Humans	Attached to skin when feeding	Atlantic and Gulf Coast of United States	Gulf Coast tick	260
<i>Haemaphysalis leporispalustris</i>	Larval and nymphal stages on rabbits, birds, dogs, cats, and humans	Attached to skin when feeding	United States	Continental rabbit tick	261

## RUMINANTS

### Nematodes

#### Gastrointestinal Tract

<i>Gongylonema pulchrum</i>	Sheep, goats, cattle, and occasionally pigs	Submucosa and mucosa of esophagus		Esophageal worm of ruminants	49
<i>Bunostomum</i> sp.	Cattle, sheep, and goats	Abomasum, small and large intestines	Worldwide	Trichostrongyle of ruminants	50

Continued



### Parasites by Host Species—cont'd

Parasite	Host	Location of Adult	Distribution	Common Name	Page
Chabertia sp.	Cattle, sheep, and goats	Abomasum, small and large intestines	Worldwide	Trichostrongyle of ruminants	50
Cooperia sp.	Cattle, sheep, and goats	Abomasum, small and large intestines	Worldwide	Trichostrongyle of ruminants	50
Haemonchus sp.	Cattle, sheep, and goats	Abomasum, small and large intestines	Worldwide	Trichostrongyle of ruminants	50
Oesophagostomum sp.	Cattle, sheep, and goats	Abomasum, small and large intestines	Worldwide	Trichostrongyle of ruminants	50
Ostertagia sp.	Cattle, sheep, and goats	Abomasum, small and large intestines	Worldwide	Trichostrongyle of ruminants	50
Trichostrongylus sp.	Cattle, sheep, and goats	Abomasum, small and large intestines	Worldwide	Trichostrongyle of ruminants	50
Nematodirus sp.	Cattle, goats, and sheep	Abomasum, small and large intestines	Worldwide	Trichostrongyle of ruminants	51
Marshallagia sp.	Cattle, sheep, and goats	Abomasum, small and large intestines	Tropical and subtropical regions	Trichostrongyle of ruminants	51
Strongyloides papillosus	Cattle	Small intestine	Worldwide	Bovine intestinal threadworm	52
Trichuris ovis	Cattle, sheep, and goats	Cecum and colon	Worldwide	Whipworms	52

### Circulatory System

Elaeophora schneideri	Sheep	Common carotid artery	Western and Southwestern United States	Arterial worm of sheep	52
-----------------------	-------	-----------------------	----------------------------------------	------------------------	----

### Respiratory System

Dictyocaulus sp.	Cattle, sheep, and goats	Bronchi	Worldwide	Lungworms of ruminants	53
Muellerius capillaris	Sheep and goats	Bronchioles	Worldwide	Hair lungworm of sheep and goats	54
Protostrongylus sp.	Sheep and goats	Small bronchioles	Worldwide		55

### Skin

Stephanofilaria stilesi	Cattle, goats, buffalo, and wild ruminants	Ventral midline		Skin worm of ruminants	55
-------------------------	--------------------------------------------	-----------------	--	------------------------	----

### Eye and Adnexa

Thelazia rhodesii	Cattle, sheep, and goats	Conjunctival sac and lacrimal duct	Worldwide	Eyeworm of cattle, sheep, and goats	56
-------------------	--------------------------	------------------------------------	-----------	-------------------------------------	----

## Parasites by Host Species—cont'd

Parasite	Host	Location of Adult	Distribution	Common Name	Page
<i>Thelazia gulosa</i>	Cattle, sheep, and goats	Conjunctival sac and lacrimal duct	Worldwide	Eyeworm of cattle, sheep, and goats	56

### Abdominal Cavity

<i>Setaria cervi</i>	Cattle	Free within peritoneal cavity	Worldwide	Abdominal worm of cattle	56
----------------------	--------	-------------------------------	-----------	--------------------------	----

### Cestodes

#### Gastrointestinal Tract

<i>Monezia benedini</i>	Cattle	Small intestine	Worldwide	Bovine tapeworm	97
<i>Monezia expansa</i>	Cattle, sheep, and goats	Small intestine	Worldwide	Ruminant tapeworm	
<i>Thysanosoma actinoides</i>	Cattle, sheep, and goats	Lumen of bile duct, pancreatic duct and small intestine	North and South America	Fringed tapeworm of sheep and goats	98

### Larval Stages in Musculature

<i>Taenia saginata</i>	Cattle	Muscle	Worldwide	Beef tapeworm of humans	99
------------------------	--------	--------	-----------	-------------------------	----

### Larval stages in Abdominal Cavity

<i>Taenia hydatigena</i>	Cattle, sheep, and goats	Abdominal cavity	Worldwide	Canine taeniid	100
--------------------------	--------------------------	------------------	-----------	----------------	-----

### Trematodes

<i>Dicrocoelium dendriticum</i>	Cattle, sheep, and goats	Bile ducts	Worldwide	Lancet fluke	131
<i>Paramphistomum</i> sp.	Cattle, sheep, and goats	Rumen and reticulum	Worldwide	Rumen flukes	132
<i>Cotylophoron</i> sp.	Cattle, sheep, and goats	Rumen and reticulum		Rumen flukes	132
<i>Fasciola hepatica</i>	Cattle, sheep	Bile duct	Worldwide	Liver fluke	133
<i>Fascioloides magna</i>	White-tailed deer	Liver parenchyma	North America, Central and South-western Europe	Liver fluke of wild ruminants	134

### Protozoans

#### Gastrointestinal Tract

#### Apicomplexans

<i>Eimeria</i> sp.	Ruminants	Cecum and colon	Worldwide	Coccidia of ruminants	167
<i>Eimeria bovis</i>	Ruminants	Cecum and colon	Worldwide	Coccidia of ruminants	167

Continued

### Parasites by Host Species—cont'd

Parasite	Host	Location of Adult	Distribution	Common Name	Page
<i>Eimeria zuernii</i>	Ruminants	Cecum and colon	Worldwide	Coccidia of ruminants	167
<i>Cryptosporidium</i> sp.	Dogs, cats, cattle, pigs, birds, guinea pigs, snakes, and mice	Small intestines		Cryptosporidia	167

### Circulatory System

#### Flagellates

<i>Trypanosoma</i> sp.	Ruminants	Peripheral blood	Central and South America	Trypanosomes	168
------------------------	-----------	------------------	---------------------------	--------------	-----

#### Apicomplexans

<i>Babesia bigemina</i>	Cattle	Within RBCs	Europe, Africa, Asia, South America and North America	Babesia	168
-------------------------	--------	-------------	-------------------------------------------------------	---------	-----

### Urogenital System

<i>Tritrichomonas foetus</i>	Cattle	Prepuce in bull; cervix, uterus, and vagina in cow	Worldwide	Trichomonas	168
------------------------------	--------	----------------------------------------------------	-----------	-------------	-----

### Arthropods

#### Lice

Mallophagan sp.	Mammals and birds	Among hairs of host		Chewing lice	199
Anopluran sp.	Mammals and birds	Among hairs of host		Sucking lice	200

#### Dipterans

<i>Simulium</i> sp.	Domesticated animals, poultry, and humans	Skin surface when feeding	Worldwide	Black flies or buffalo gnats	207
<i>Lutzomyia</i> sp.	Mammals, reptiles, avians, and humans	Skin surface when feeding	Worldwide	New World sand flies	208
<i>Phlebotomus</i> sp.	Mammals, reptiles, avians, and humans	Skin surface when feeding	Subtropical and Mediterranean regions	Sand flies	208

### Parasites by Host Species—cont'd

Parasite	Host	Location of Adult	Distribution	Common Name	Page
Culicoides sp.	Domestic animals and humans	Skin surface when feeding	Worldwide	No-see-ums, punkies, or sand flies	208
Anopheles quadrimaculatus	Mammals, reptiles, avians, and humans	Skin surface when feeding	Worldwide	Malaria mosquito	209
Aedes aegypti	Mammals, reptiles, avians, and humans	Skin surface when feeding	Worldwide	Yellow fever mosquito	209
Culex sp.	Mammals, reptiles, avians, and humans	Skin surface when feeding	Worldwide	Mosquito	209
Chrysops sp.	Large mammals, humans, and occasionally small mammals and birds	Skin surface when feeding	Worldwide	Deerflies	210
Tabanus sp.	Large mammals, humans, and occasionally small mammals and birds	Skin surface when feeding	Worldwide	Horseflies	210
Glossina sp.	Mammals, reptiles, birds, and humans	Skin surface when feeding	Africa	Tsetse fly	211
Stomoxys calcitrans	Variety of animals and humans	Around large amounts of decaying vegetation	Worldwide	Stable fly	212
Haematobia irritans	Cattle and buffalo	Around horns, shoulders, back, side, and ventral abdomen	North America, Europe, and Australia	Horn fly	213
Melophagus ovinus	Sheep and goats	Deep within wool or fleece	Worldwide	Sheep ked	214
Musca domestica	Variety of animals and humans	Within the house	Worldwide	House fly	216

*Continued*

### Parasites by Host Species—cont'd

Parasite	Host	Location of Adult	Distribution	Common Name	Page
<i>Musca autumnalis</i>	Predominantly cattle but also other large animals	Feeds around medial canthus of eyes	Worldwide	Face fly	217
<i>Calliphora</i> sp.	Domestic animals, wild animals, and humans	Free living in environment		Bottle flies or blow flies	217
<i>Lucilia</i> sp.	Domestic animals, wild animals, and humans	Free living in environment		Bottle flies or blow flies	217
<i>Phormia</i> sp.	Domestic animals, wild Animals, and humans	Free living in environment		Bottle flies or blow flies	217
<i>Phaenicia</i> sp.	Domestic animals, wild animals, and humans	Free living in environment		Bottle flies or blow flies	217
<i>Sarcophaga</i> sp.	Domestic animals, wild animals, and humans	Free living in environment		Flesh fly	218
<i>Hippelatus</i> sp.	Dogs and cattle	Mucocutaneous junction of eyes, lips and penis		Dog Penis Gnats	219
<i>Cochliomyia hominivorax</i>	Domestic animals	Fresh, uncontaminated wounds	North America	Screw fly	221
<i>Hypoderma</i> sp.	Cattle, rarely in horses, sheep, and humans	Larva in large boil-like cyst on back	Northern and Southern United States and Canada	Gadflies or cattle grubs	223
<i>Oestrus ovīs</i>	Sheep and goats	Nasal passages	Worldwide	Nasal bot fly or grub	225
<b>Mites</b>					
<i>Sarcoptes scabiei</i> variety <i>bovis</i>	Cattle	Superficial layers of epidermis	Worldwide	"Scabies" of cattle	232
<i>Sarcoptes scabiei</i> variety <i>ovīs</i>	Sheep and Goats	Superficial layers of epidermis	Worldwide	"Scabies" of sheep and goats	232
<i>Psoroptes cuniculi</i>	Rabbits, Horses, Goats and Sheep	External ear canal	Worldwide	Rabbit ear mite	237

### Parasites by Host Species—cont'd

Parasite	Host	Location of Adult	Distribution	Common Name	Page
Psoroptes ovis	Sheep	Skin surface of body	Worldwide	"Scabies" of sheep	238
Psoroptes bovis	Cattle	Skin surface of withers, neck, and rump	Worldwide	"Scabies" of cattle	238
Chorioptes bovis	Cattle	Skin surface of lower hind legs, flanks, and shoulders	Worldwide	Foot and tail mite or itchy leg mite	239
Chorioptes caprae	Goats	Skin surface of lower hind legs, flanks, and shoulders	Worldwide	Foot and tail mite or itchy leg mite	239
Chorioptes ovis	Sheep	Skin surface of lower hind legs, flanks, and shoulders	Worldwide	Foot and tail mite or itchy leg mite	239
Demodex bovis	Cattle	Hair follicles and sebaceous glands	Worldwide	Demodectic mange mite of cattle	241
Demodex caprae	Goats	Hair follicles and sebaceous glands	Worldwide	Demodectic mange mite of goats	241
Trombicula sp.	Domestic animals, wild animals, and humans	Larval stage on skin surface		Chiggers	244
<b>Ticks</b>					
Otobius megnini	Dogs, horses, cattle, sheep, and goats	Larval and nymphal stages in the external ear canal	Arid and semi-arid regions in Southwestern United States	Spinose ear tick	254
Ixodes scapularis	Adult on dogs, horses, deer, and humans	Attached to skin when feeding	Eastern United States	Deer tick	256
Dermacentor andersoni	Adult on dogs, horses, cattle, goats, sheep, and humans	Attached to skin when feeding	Rocky Mountain Regions	Rocky Mountain wood tick	258
Dermacentor occidentalis	Adult on large mammals	Attached to skin when feeding	Sierra Nevada Mountains	Pacific coast dog tick	259

Continued

### Parasites by Host Species—cont'd

Parasite	Host	Location of Adult	Distribution	Common Name	Page
<i>Amblyomma americanum</i>	Adult on wide range of mammals and humans	Attached to skin when feeding	Southern United States, Midwest, and Atlantic coast of United States	Lone Star tick	259
<i>Amblyomma maculatum</i>	Adults on cattle, sheep, horses, dogs, and Humans	Attached to skin when feeding	Atlantic and Gulf Coast of United States	Gulf Coast tick	260
<i>Boophilus annulatus</i>	Cattle	Attached to skin when feeding	Mexico and enzootic areas of United States	Texas cattle fever tick or North American tick	260

### EQUINES

#### Nematodes

#### Gastrointestinal Tract

<i>Habronema microstoma</i>	Horses	Stomach mucosa	Worldwide	Stomach worm of horses	57
<i>Habronema muscae</i>	Horses	Stomach mucosa	Worldwide	Stomach worm of horses	57
<i>Draschia megastoma</i>	Horses	Stomach mucosa	Worldwide	Stomach worm of horses	57
<i>Trichostrongylus axei</i>	Horses, cattle, sheep, and pigs	Stomach	Worldwide	Stomach worm of horses and pigs	58
<i>Parascaris equorum</i>	Horses	Small intestine	Worldwide	Equine roundworm	58
<i>Strongylus vulgaris</i>	Horses	Large intestine	Worldwide	Strongyle of horses	60
<i>Strongylus edentatus</i>	Horses	Large intestine	Worldwide	Strongyle of horses	60
<i>Strongylus equinus</i>	Horses	Large intestine	Worldwide	Strongyle of horses	60
<i>Strongyloides westeri</i>	Horses	Small intestine	Worldwide	Intestinal threadworm of horses	61
<i>Oxyuris equi</i>	Horses	Cecum, colon, and rectum	Worldwide	Pinworm of horses	62

#### Respiratory System

<i>Dictyocaulus arnfieldi</i>	Horses, mules, and donkeys	Bronchi and bronchioles	Worldwide	Equine lungworm	64
-------------------------------	----------------------------	-------------------------	-----------	-----------------	----

### Parasites by Host Species—cont'd

Parasite	Host	Location of Adult	Distribution	Common Name	Page
<b>Skin</b>					
<i>Habronema microstoma</i>	Horses	Larvae in skin	Worldwide	Stomach worm of horses	64
<i>Habronema muscae</i>	Horses	Larvae in skin	Worldwide	Stomach worm of horses	64
<i>Draschia megastoma</i>	Horses	Larvae in skin	Worldwide	Stomach worm of horses	64
<i>Onchocerca cervicalis</i>	Horses	Adult in ligamentum nuchae; larvae in dermis	Worldwide	Equine filarial worm	64
<b>Eye and Adnexa</b>					
<i>Thelazia lacrymalis</i>	Horses	Conjunctival sac and lacrimal duct	Worldwide	Eyeworm of the horse	64
<b>Abdominal Cavity</b>					
<i>Setaria equina</i>	Horses	Free within peritoneal cavity	Europe and North America	Abdominal worm of horses	66
<b>Cestodes</b>					
<b>Gastrointestinal Tract</b>					
<i>Anoplocephala perfoliata</i>	Horses	Small and large intestine and cecum	Worldwide	Lappeted equine tapeworm	101
<i>Anoplocephala magna</i>	Horses	Stomach and small intestine	Worldwide	Equine tapeworm with large scolex	101
<i>Paranoplocephala mamillana</i>	Horses	Stomach and small intestine	Worldwide	Equine tapeworm	101
<b>Protozoans</b>					
<b>Gastrointestinal Tract</b>					
<b>Flagellates</b>					
<i>Giardia assemblage E</i>	Horses, cattle, sheep, goats, and pigs	Small intestine	Worldwide	Giardia	169
<b>Ciliates</b>					
<i>Eimeria leuckarti</i>	Horses	Small intestine	Worldwide	Coccidia	170

Continued



## Parasites by Host Species—cont'd

Parasite	Host	Location of Adult	Distribution	Common Name	Page
----------	------	-------------------	--------------	-------------	------

### Circulatory System

#### Apicomplexans

Babesia equi	Horses	Within RBCs	Europe, Africa, Asia, North and South America	Equine piroplasm	170
Babesia caballi	Horses	Within RBCs	Europe, Africa, Asia, North and South America	Equine piroplasm	170

### Urogenital System

#### Apicomplexans

Klossiella equi	Horses	Kidneys			171
-----------------	--------	---------	--	--	-----

### Nervous System

#### Apicomplexans

Sarcocystis neurona	Horses	Asexual stage in nervous system			171
---------------------	--------	---------------------------------	--	--	-----

### Arthropods

#### Lice

Mallophagan sp.	Mammals and birds	Among hairs of host		Chewing lice	199
Anopluran sp.	Mammals and birds	Among hairs of host		Sucking lice	200

#### Dipterans

Simulium sp.	Domesticated animals, poultry, and humans	Skin surface when feeding	Worldwide	Black flies or buffalo gnats	207
Lutzomyia sp.	Mammals, reptiles, avians, and humans	Skin surface when feeding	Worldwide	New World sand flies	208
Phlebotomus sp.	Mammals, reptiles, avians, and humans	Skin surface when feeding	Subtropical and Mediterranean regions	Sand flies	208
Culicoides sp.	Domestic Animals and Humans	Skin surface when feeding	Worldwide	No-see-ums, punkies, or sand flies	208

## Parasites by Host Species—cont'd

Parasite	Host	Location of Adult	Distribution	Common Name	Page
Anopheles quadrimaculatus	Mammals, reptiles, avians, and humans	Skin surface when feeding	Worldwide	Malaria mosquito	209
Aedes aegypti	Mammals, reptiles, avians, and humans	Skin surface when feeding	Worldwide	Yellow fever mosquito	209
Culex sp.	Mammals, reptiles, avians, and humans	Skin surface when feeding	Worldwide	Mosquito	209
Chrysops sp.	Large mammals, humans, and occasionally small mammals and birds	Skin surface when feeding	Worldwide	Deerflies	210
Tabanus sp.	Large mammals, humans, and occasionally small mammals and birds	Skin surface when feeding	Worldwide	Horseflies	210
Glossina sp.	Mammals, reptiles, birds, and humans	Skin surface when feeding	Africa	Tsetse fly	211
Stomoxys calcitrans	Variety of animals and humans	Around large amounts of decaying vegetation	Worldwide	Stable fly	212
Musca domestica	Variety of animals and humans	Within the house	Worldwide	House fly	216
Musca autumnalis	Predominantly cattle but also other large animals	Feeds around medial canthus of eyes	Worldwide	Face fly	217
Calliphora sp.	Domestic animals, wild animals, and humans	Free living in environment		Bottle flies or blow flies	217
Lucilia sp.	Domestic animals, wild animals, and humans	Free living in environment		Bottle flies or blow flies	217

Continued

### Parasites by Host Species—cont'd

Parasite	Host	Location of Adult	Distribution	Common Name	Page
Phormia sp.	Domestic animals, wild animals, and humans	Free living in environment		Bottle flies or blow flies	217
Phaenicia sp.	Domestic animals, wild animals, and humans	Free living in environment		Bottle flies or blow flies	217
Sarcophaga sp.	Domestic animals, wild animals, and humans	Free living in environment		Flesh fly	218
Cochliomyia hominivorax	Domestic animals	Fresh, uncontaminated wounds	North America	Screw fly	221
Hypoderma sp.	Cattle, rarely in horses, sheep, and humans	Larva in large boil-like cyst on back	Northern and Southern United States and Canada	Gadflies or cattle grubs	223
Gasterophilus sp.	Horses	Attached to gastric mucosa	Worldwide	Bot flies or horse bots	224
<b>Mites</b>					
Sarcoptes scabiei variety equi	Horses	Superficial layers of epidermis	Worldwide	"Scabies" of horses	232
Psoroptes cuniculi					
Psoroptes cuniculi	Rabbits, horses, goats, and sheep	External ear canal	Worldwide	Rabbit ear mite	237
Psoroptes equi	Horses	Skin surface of mane and tail	Worldwide	Scabies of horses	238
Chorioptes equi	Horses	Skin surface of lower hind limbs, flanks, and shoulders	Worldwide	Foot and tail mite or itchy leg mite	239
Demodex equi	Horses	Skin of face and eyes	Worldwide	Demodectic mange mite of horses	241
Trombicula sp.	Domestic animals, wild animals, and Humans	Larval stage on skin surface		Chiggers	244

### Parasites by Host Species—cont'd

Parasite	Host	Location of Adult	Distribution	Common Name	Page
<b>Ticks</b>					
<i>Otobius megnini</i>	Dogs, horses, cattle, sheep, and goats	Larval and nymphal stages in the external ear canal	Arid and semi-arid regions in Southwestern United States	Spinose ear tick	254
<i>Ixodes scapularis</i>	Adult on dogs, horses, deer, and Humans	Attached to skin when feeding	Eastern United States	Deer tick	256
<i>Dermacentor andersoni</i>	Adult on dogs, horses, cattle, goats, sheep, and humans	Attached to skin when feeding	Rocky Mountain regions	Rocky Mountain wood tick	258
<i>Dermacentor occidentalis</i>	Adult on large mammals	Attached to skin when feeding	Sierra Nevada Mountains	Pacific coast dog tick	259
<i>Amblyomma americanum</i>	Adult on wide range of mammals and humans	Attached to skin when feeding	Southern United States, Midwest and Atlantic coast of United States	Lone Star tick	259
<i>Amblyomma maculatum</i>	Adults on cattle, sheep, horses, dogs, and humans	Attached to skin when feeding	Atlantic and Gulf Coast of United States	Gulf Coast tick	260

### SWINE

#### Nematodes

#### Gastrointestinal Tract

<i>Ascarops strongylina</i>	Pigs	Stomach		Stomach worm of pigs	66
<i>Physocephalus sexalatus</i>	Pigs	Stomach		Stomach worm of pigs	66
<i>Hyostrongylus rubidus</i>	Pigs	Stomach	Worldwide	Red stomach worm of pigs	67
<i>Trichostrongylus axei</i>	Horses, sheep, cattle, and pigs	Stomach	Worldwide	Stomach worm of pigs	67
<i>Ascaris suum</i>	Pigs	Small intestine	Worldwide	Large intestinal roundworm of pigs	67
<i>Strongyloides ransomi</i>	Pigs	Small intestine	Worldwide	Intestinal threadworm of pigs	68
<i>Oesophagostomum dentatum</i>	Pigs	Large intestine	Worldwide	Nodular worm of pigs	68

Continued

### Parasites by Host Species—cont'd

Parasite	Host	Location of Adult	Distribution	Common Name	Page
<i>Trichuris suis</i>	Pigs	Cecum and colon	Worldwide	Whipworm	69
<i>Trichinella spiralis</i>	Pigs, definitive hosts	Small intestine	Worldwide except Denmark or Australia	Trichina worm	69

#### Respiratory System

<i>Metastrongylus elongates</i>	Pigs	Bronchi and bronchioles	Worldwide	Swine lungworm	70
---------------------------------	------	-------------------------	-----------	----------------	----

#### Urinary Tract

<i>Stephanurus dentatus</i>	Pigs	Cystic spaces around kidneys, ureters, and perirenal tissue		Swine kidney worm	70
-----------------------------	------	-------------------------------------------------------------	--	-------------------	----

#### Musculoskeletal System

<i>Trichinella spiralis</i>	Pigs	Small intestine, larvae in muscle	Worldwide except Denmark and Australia	Trichina worm	71
-----------------------------	------	-----------------------------------	----------------------------------------	---------------	----

#### Cestodes

##### Larvae in Muscle

<i>Taenia solium</i>	Pigs, intermediate host	Larvae in muscle tissue	Underdeveloped countries	Pork tapeworm of humans	99
----------------------	-------------------------	-------------------------	--------------------------	-------------------------	----

#### Protozoans

##### Gastrointestinal Tract

##### Ciliates

<i>Balantidium coli</i>	Pigs and dogs	Large intestine	Worldwide	Balantidium	159
-------------------------	---------------	-----------------	-----------	-------------	-----

##### Apicomplexans

<i>Cystoisospora suis</i>	Pigs	Small intestines		Coccidia	159
<i>Cryptosporidium</i> sp.	Canines, felines, bovines, swine, avians, guinea pigs, snakes, and mice	Small intestines		Cryptosporidium	172

## Parasites by Host Species—cont'd

Parasite	Host	Location of Adult	Distribution	Common Name	Page
<b>Arthropods</b>					
<i>Lice</i>					
Mallophagan sp.	Mammals and birds	Among hairs of host		Chewing lice	199
Anopluran sp.	Mammals and birds	Among hairs of host		Sucking lice	200
<i>Dipterans</i>					
Simulium sp.	Domesticated animals, poultry, and humans	Skin surface when feeding	Worldwide	Black flies or buffalo gnats	207
Lutzomyia sp.	Mammals, reptiles, avians, and humans	Skin surface when feeding	Worldwide	New World sand flies	208
Phlebotomus sp.	Mammals, reptiles, avians, and humans	Skin surface when feeding	Subtropical and Mediterranean regions	Sand flies	208
Culicoides sp.	Domestic animals and humans	Skin surface when feeding	Worldwide	No-see-ums, punkies, or sand flies	208
Anopheles quadrimaculatus	Mammals, reptiles, avians, and humans	Skin surface when feeding	Worldwide	Malaria mosquito	209
Aedes aegypti	Mammals, reptiles, avians, and humans	Skin surface when feeding	Worldwide	Yellow fever mosquito	209
Culex sp.	Mammals, reptiles, avians, and humans	Skin surface when feeding	Worldwide	Mosquito	209
Chrysops sp.	Large mammals, humans, and occasionally small mammals and birds	Skin surface when feeding	Worldwide	Deerflies	210

Continued

### Parasites by Host Species—cont'd

Parasite	Host	Location of Adult	Distribution	Common Name	Page
Tabanus sp.	Large mammals, humans, and occasionally small mammals and birds	Skin surface when feeding	Worldwide	Horseflies	210
Glossina sp.	Mammals, reptiles, birds, and Humans	Skin surface when feeding	Africa	Tsetse fly	211
Stomoxys calcitrans	Variety of animals and humans	Around large amounts of decaying vegetation	Worldwide	Stable fly	212
Musca domestica	Variety of animals and humans	Within the house	Worldwide	House fly	216
Calliphora sp.	Domestic animals, wild animals, and humans	Free living in environment		Bottle flies or blow flies	217
Lucilia sp.	Domestic animals, wild animals, and humans	Free living in environment		Bottle flies or blow flies	217
Phormia sp.	Domestic animals, wild animals, and humans	Free living in environment		Bottle flies or blow flies	217
Phaenicia sp.	Domestic animals, wild animals, and humans	Free living in environment		Bottle flies or blow flies	217
Sarcophaga sp.	Domestic animals, wild animals, and humans	Free living in environment		Flesh fly	218
Cochliomyia hominivorax	Domestic animals	Fresh, uncontaminated wounds	North America	Screw fly	221
<b>Mites</b>					
Sarcoptes scabiei variety suis	Pigs	Superficial layers of epidermis	Worldwide	"Scabies" of pigs	232
Demodex phylloides	Pigs	Hair follicles and sebaceous glands	Worldwide	Demodectic mange mite	242

### Parasites by Host Species—cont'd

Parasite	Host	Location of Adult	Distribution	Common Name	Page
<i>Trombicula</i> sp.	Domestic animals, wild animals, and humans	Larval stage on skin surface		Chiggers	244

#### Ticks

<i>Amblyomma americanum</i>	Adult on wide range of mammals and humans	Attached to skin when feeding	Southern United States, Midwest, and Atlantic coast of United States	Lone Star tick	259
-----------------------------	-------------------------------------------	-------------------------------	----------------------------------------------------------------------	----------------	-----

### EXOTIC ANIMALS AND BIRDS

#### Nematodes

#### Gastrointestinal Tract

<i>Syphacia obvelata</i>	Mice, rats, hamsters, and gerbils	Cecum and rectum		Pinworms of rodents	72
<i>Aspicularis tetraptera</i>	Mice	Cecum and rectum		Pinworms of mice	72
<i>Syphacia muris</i>	Mice, rats, hamsters, and gerbils	Cecum and rectum		Pinworms of rodents	72
<i>Dentostomella translucida</i>	Gerbils	Stomach and proximal third of small intestine		Pinworm of gerbils	75
<i>Paraspidodera uncinata</i>	Guinea pig	Cecum and colon		Ascarid of guinea pigs	76
<i>Passalurus ambiguus</i>	Rabbits	Cecum and colon		Pinworm of rabbits	77
<i>Obeliscoides cuniculi</i>	Rabbits	Stomach		Trichostrongyle of rabbits	78
<i>Trichostrongylus calcaratus</i>	Rabbits	Small intestine		Trichostrongyle of rabbits	78
<i>Ascaridia</i> sp.	Birds	Small intestines	Worldwide	Ascarid of birds	79
<i>Spiroptera inesta</i>	Australian finches	Ventriculus		Spirurid of birds	79
<i>Dyspharynx nasuta</i>	Finches	Ventriculus	Tropical and sub-tropical regions	Spirurid of birds	79
<i>Tetrameres</i> sp.	Pigeons	Proventriculus		Spirurid of birds	79
<i>Capillaria</i> sp.	Pheasants, peafowl, and poultry	Crop and upper alimentary tract	Worldwide	Capillaria	80

Continued



### Parasites by Host Species—cont'd

Parasite	Host	Location of Adult	Distribution	Common Name	Page
<b>Urinary Tract</b>					
Trichosomoides crassicauda	Rats	Urinary bladder		Bladder worm of rats	74
<i>Cestodes</i>					
<b>Gastrointestinal Tract</b>					
Hymenolepis nana	Mice, rats, Gerbils, hamsters, dogs, and Humans	Small intestine		Tapeworm of rodents	94
Hymenolepis diminuta	Mice, rats, gerbils, hamsters, dogs, and humans	Small intestine		Tapeworm of rodents	94
<i>Trematodes</i>					
<b>Circulatory System</b>					
Schistosoma sp.	Birds	Blood vasculature	North America	Avian schistosomes	140
<i>Protozoans</i>					
<b>Gastrointestinal Tract</b>					
<b>Flagellates</b>					
Giardia psittaci	Birds	Intestinal mucosa		Giardia	173
Histomonas meleagridis	Turkeys, peafowl, chickens, and pheasants	Liver	Worldwide	"Blackhead"	174
Trichomonas gallinae	Pigeons, doves, poultry, and raptors	Crop		Trichomonas	174
Tetratrichomonas microti	Mice	Small intestine		Flagellate of mice	179
Tritrichomonas muris	Mice	Cecum and Colon		Flagellate of mice	179
Giardia assemblage G	Rodents	Proximal small intestine		Giardia	179
Spironucleus muris	Mice	Proximal small intestine		Flagellate of mice	179
Tritrichomonas caviae	Guinea pigs	Cecum		Flagellate of guinea pigs	182

### Parasites by Host Species—cont'd

Parasite	Host	Location of Adult	Distribution	Common Name	Page
<b>Apicomplexans</b>					
<i>Eimeria irresidua</i>	Rabbits	Small intestine		Coccidia of rabbits	178
<i>Eimeria magna</i>	Rabbits	Small intestine		Coccidia of rabbits	178
<i>Eimeria media</i>	Rabbits	Small intestine and large intestine		Coccidia of rabbits	178
<i>Eimeria perforans</i>	Rabbits	Small intestine		Coccidia of rabbits	178
<i>Eimeria stiedai</i>	Rabbits	Bile ducts		Coccidia of rabbits	179
<i>Eimeria falciformis</i>	Mice	Small intestine		Coccidia of mice	180
<i>Eimeria ferrisi</i>	Mice	Cecum		Coccidia of mice	180
<i>Eimeria hansonorum</i>	Mice	Small intestine		Coccidia of mice	180
<i>Eimeria nieschultzi</i>	Rats	Intestines		Coccidia of rats	181
<i>Eimeria caviae</i>	Guinea pigs	Large intestine		Coccidia of guinea pigs	183
<i>Cryptosporidium wrairi</i>	Guinea pigs	Tips of intestinal villi of the ileum			184
<b>Amoeba</b>					
<i>Entamoeba caviae</i>	Guinea pigs	Cecum		Amoeba of guinea pigs	183
<b>Circulatory System</b>					
<b>Flagellates</b>					
<i>Trypanosoma</i> sp.	Cockatoos	Peripheral blood	Worldwide	Trypanosomes of birds	168
<b>Apicomplexans</b>					
<i>Haemoproteus</i> sp.	Cockatoos, macaws, and conures	Within RBCs	Worldwide		175
<i>Plasmodium</i> sp.	Birds	Within RBCs	Worldwide		176
<i>Leucocytozoon</i> sp.	Raptors	Within RBCs	Worldwide		176
<i>Aegyptianella</i> sp.	Pet birds	Within RBCs			177
<b>Respiratory System</b>					
<b>Apicomplexans</b>					
<i>Cystoisospora serini</i>	Canaries and finches	Lung, liver, and spleen		Coccidia of birds or Atoxoplasmosis	177

Continued

## Parasites by Host Species—cont'd

Parasite	Host	Location of Adult	Distribution	Common Name	Page
<b>Urogenital System</b>					
<b><i>Apicomplexans</i></b>					
<i>Klossiella muris</i>	Mice	Kidneys			181
<b>Skin</b>					
<b><i>Ciliates</i></b>					
<i>Ichthyophthirius multifiliis</i>	Freshwater and ornamental fish	Skin, gills, fins, and eyes		Ciliate of fish	184
<b>Arthropods</b>					
<b><i>True Bugs</i></b>					
<i>Cimex lectularius</i>	Humans, rabbits, poultry, and pigeons			Bed bugs	198
<i>Rhodnius</i> sp.	Dogs, humans, cats, guinea pigs, armadillos, rats, raccoons, and monkeys	Periodic skin of mouth and lips	South and Central America and Southern and Western United States	Kissing bugs	199
<i>Panstrongylus</i> sp.	Dogs, humans, cats, guinea pigs, armadillos, rats, raccoons, and monkeys	Periodic skin of mouth and lips	South and Central America and Southern and Western United States	Kissing bugs	199
<i>Triatoma</i> sp.	Dogs, humans, cats, guinea pigs, armadillos, rats, raccoons, and monkeys	Periodic skin of mouth and lips	South and Central America and Southern and Western United States	Kissing bugs	199
<b>Lice</b>					
<i>Polyplox serrata</i>	Mice	Within haircoat		Mouse louse	202
<i>Polyplox spinulosa</i>	Rat	Within haircoat		Rat louse	204
<i>Hoplopleura merionidis</i>	Gerbil	Within haircoat		Gerbil louse	204

### Parasites by Host Species—cont'd

Parasite	Host	Location of Adult	Distribution	Common Name	Page
<i>Gliricola porcelli</i>	Guinea pig	Within haircoat		Guinea pig louse	205
<i>Gyropus ovalis</i>	Guinea pig	Within haircoat		Guinea pig louse	205
<i>Hemodipsus ventricosus</i>	Rabbit	Within haircoat		Rabbit louse	206
<i>Dipterans</i>					
<i>Simulium</i> sp.	Domesticated animals, poultry, and humans	Skin surface when feeding	Worldwide	Black flies or buffalo gnats	207
<i>Lutzomyia</i> sp.	Mammals, reptiles, avians, and humans	Skin surface when feeding	Worldwide	New World sand flies	208
<i>Phlebotomus</i> sp.	Mammals, reptiles, avians, and humans	Skin surface when feeding	Subtropical and Mediterranean regions	Sand flies	208
<i>Anopheles quadrimaculatus</i>	Mammals, reptiles, avians, and humans	Skin surface when feeding	Worldwide	Malaria mosquito	209
<i>Aedes aegypti</i>	Mammals, Reptiles, Avians and Humans	Skin surface when feeding	Worldwide	Yellow fever mosquito	209
<i>Culex</i> sp.	Mammals, reptiles, avians, and humans	Skin surface when feeding	Worldwide	Mosquito	209
<i>Chrysops</i> sp.	Large mammals, humans, and occasionally small mammals and birds	Skin surface when feeding	Worldwide	Deerflies	210
<i>Tabanus</i> sp.	Large mammals, humans, and occasionally small mammals and birds	Skin surface when feeding	Worldwide	Horseflies	210
<i>Glossina</i> sp.	Mammals, reptiles, birds, and humans	Skin surface when feeding	Africa	Tsetse fly	211

Continued

### Parasites by Host Species—cont'd

Parasite	Host	Location of Adult	Distribution	Common Name	Page
<i>Lynchia</i> sp.	Wild birds	Deep within feathers		Bird keds	215
<i>Pseudolynchia</i> sp.	Wild birds	Deep within feathers		Bird keds	215
<i>Cuterebra</i> sp.	Rabbits, squirrels, mice, rats, chipmunks, dogs, and cats	Larva around the head and neck		Warbles or Wolves	222
<i>Siphoneptera</i>					
<i>Cediopsylla simplex</i>	Rabbits	On skin		Common eastern rabbit flea	226
<i>Odontopsylla multispinosus</i>	Rabbits	On skin		Giant eastern rabbit flea	226
<i>Echidnophaga gallinacea</i>	Poultry	On skin		Poultry flea	226
<i>Mites</i>					
<i>Notoedres cati</i>	Cats and rabbits	Superficial layers of epidermis	Worldwide	Notoedric mange mite	233
<i>Notoedres muris</i>	Rats	Superficial layers of epidermis		Scabies mite of rats	234
<i>Cnemidocoptes pilae</i>	Budgerigars and parakeets	Superficial epidermis of feet, cere and beak	Worldwide	Scaly leg mite of parakeets	236
<i>Cnemidocoptes mutans</i>	Poultry	Superficial epidermis of feet	Worldwide	Scaly leg mite of chickens	236
<i>Trixacarus caviae</i>	Guinea pigs	Superficial layers of epidermis		Burrowing mite of guinea pigs	237
<i>Psoroptes cuniculi</i>	Rabbits, horses, goats, and sheep	External ear canal	Worldwide	Rabbit ear mite	237
<i>Otodectes cynotis</i>	Dogs, cats, and ferrets	External ear canal	Worldwide	Ear mites	240
<i>Demodex aurati</i>	Hamsters and gerbils	Hair follicles and sebaceous glands	Worldwide	Demodectic mange mite of hamsters and gerbils	241
<i>Demodex criceti</i>	Hamsters and gerbils	Hair follicles and sebaceous glands	Worldwide	Demodectic mange mite of hamsters and gerbils	242
<i>Ornithonyssus sylviarum</i>	Poultry	On skin	Worldwide in temperate zones	Northern fowl mite	245

### Parasites by Host Species—cont'd

Parasite	Host	Location of Adult	Distribution	Common Name	Page
Dermanyssus gallinae	Poultry	In environment	Worldwide	Red fowl mite	245
Ornithonyssus bacoti	Rat, mice, hamsters, and guinea pigs	On skin when feeding	Tropical and sub-tropical regions	Tropical rat mite	246
Cheyletiella parasitivorax	Dogs, cats, and rabbits	Surface of skin and hair coat	Worldwide	Walking dandruff	247
Myobia musculi	Mice	Hair shafts		Mouse fur mite	248
Mycoptes musculus	Mice	Hair shafts		Mouse fur mite	248
Radfordia affinis	Mice	Hair shafts		Mouse fur mite	248
Radfordia ensifera	Rats	Hair shafts		Rat fur mite	251
Chirodiscoides caviae	Guinea pigs	Within pelt		Guinea pig fur mite	251
Listrophorus gibbus	Rabbits	Hair shafts		Rabbit fur mite	252
<b>Ticks</b>					
Argas persicus	Chicken, turkeys, and wild birds	Attached to skin when feeding		Fowl tick	256
Ixodes scapularis	Adult on dogs, horses, deer, and humans	Attached to skin when feeding	Eastern United States	Deer tick	256
Dermacentor andersoni	Adult on dogs, horses, cattle, goats, sheep, and humans	Attached to skin when feeding	Rocky Mountain regions	Rocky Mountain wood tick	258
Dermacentor occidentalis	Adult on large mammals	Attached to skin when feeding	Sierra Nevada Mountains	Pacific coast dog tick	259
Amblyomma americanum	Adult on wide range of mammals and Humans	Attached to skin when feeding	Southern United States, Midwest and Atlantic coast of United States	Lone Star tick	259
Amblyomma maculatum	Adults on cattle, sheep, horses, Dogs, and Humans	Attached to skin when feeding	Atlantic and Gulf Coast of United States	Gulf Coast tick	260

Continued

Parasites by Host Species—cont'd					
Parasite	Host	Location of Adult	Distribution	Common Name	Page
Haemaphysalis leporispalustris	Larval and nymphal stages on rabbits, birds, dogs, cats, and humans; adult stage on rabbits	Attached to skin when feeding	United States	Continental rabbit tick	261

# The Language of Veterinary Parasitology

1

## KEY TERMS

Aberrant parasite  
Acaricides  
Animalia  
Anthelmintics  
Antiprotozoals  
Classification scheme  
Commensalism  
Common name  
Definitive host  
Ectoparasite  
Ectoparasitism  
Endoparasitism  
Erratic parasite  
Euryxenous parasite  
Facultative parasite  
Fungi  
Genus name  
Homoxenous parasite  
Host  
Incidental parasite  
Infection  
Infestation  
Insecticides  
Intermediate host  
Life cycle  
Monera  
Monoxenous parasite  
Mutualism  
Obligatory parasite  
Parasite  
Parasitiasis  
Parasiticides  
Parasitism  
Parasitology  
Paratenic host  
Periodic parasite  
Phoresis  
Planta  
Predator

## OUTLINE

Symbiosis  
Parasitism

Life Cycle  
The Linnaean Classification Scheme

## LEARNING OBJECTIVES

After studying this chapter, the reader should be able to do the following:

- Briefly discuss the importance of veterinarians in public health.
- Briefly discuss the importance of veterinary parasitology.
- Describe the important types of symbiotic relationships.
- Become fluent in the language of veterinary parasitology.
- Utilize the Linnaean classification scheme within the discipline of veterinary parasitology.
- Define and describe terms associated with veterinary parasitology and give examples of parasites that exemplify these terms.

Veterinary medicine continues to be one of the most rapidly evolving health care professions of the twenty-first century. Veterinarians are responsible for many aspects of human health promotion and disease prevention, especially in the areas of food safety, environmental health, prevention and control of zoonotic diseases, and the human-animal bond. To accomplish these important missions, successful veterinarians, along with their professional associates, must learn to communicate effectively with a variety of individuals, ranging from health care professionals in other disciplines, to print and electronic journalists, to the day-to-day clients who walk off the street into the veterinary practice.



**TECHNICIAN'S NOTE** Veterinarians and technicians are responsible for many aspects of human health promotion and disease prevention.



Predator-prey  
relationship  
Prey  
Protista  
Pseudoparasite  
Reservoir host  
Scientific name  
Specific epithet  
Stenoxenous parasite  
Symbiont  
Symbiosis  
Transport host  
Veterinary parasitology  
Zoonosis

One of the most important lines of communication, however, exists between the veterinary practitioner and the members of his or her own veterinary health care team. Veterinary technicians serve as vital members of these health care teams. As such, these technicians must be able to understand and correctly use the nomenclature and terminology for almost every specialty discipline within veterinary medicine. This is especially true for the discipline of **veterinary parasitology**, the study of parasitic relationships affecting domesticated, wild, exotic, and laboratory animals, and, to some extent, those parasites that have the potential to be transmitted directly from animals to humans. If animal parasites are to be effectively treated and controlled, the veterinary technician must become “fluent” in the language of parasitology and be able to communicate effectively, using the specialized terminology associated with these parasites and with the complex interactions between parasites and their animal hosts. This chapter assists the veterinary technician in acquiring fluency with regard to veterinary parasitology.


## SYMBIOSIS

Planet Earth is home to millions of species of diverse, living organisms that include plants, animals, fungi, algae, and unicellular organisms. Inevitably, there are millions of complex relationships taking place between and among these differing species. Many organisms live together in varied, intricate relationships. The term **symbiosis** (*sym* meaning “together” and *biosis* meaning “living,” thus “living together”) describes any association, either temporary or permanent, between at least two living organisms of different species. Each member of this association is called a **symbiont**. For example, lichen growing on the side of a tree (Figure 1-1) is actually a very complex symbiotic relationship between a fungus and an alga. Even the act of a human owning a dog and living with that dog is a type of symbiotic relationship. Two different living species cohabitate; the human “owner” and the “pet” dog are members of a very ancient symbiotic relationship.

**TECHNICIAN'S NOTE** Symbiosis means living together between two different species or organisms. Some of these relationships can be beneficial, some are indifferent, and others are detrimental to one or more of the organisms.

There are five types of symbiotic relationships: predator-prey, phoresis, mutualism, commensalism, and parasitism. In a **predator-prey relationship**, there is an extremely short-term relationship in which one symbiont benefits at the expense of the other. For example, the lion (the **predator**) will kill the zebra (the **prey**). The prey pays with its life and serves as a food source for the predator.

In **phoresis** (*phore* meaning “to carry”), the smaller member of the symbiotic relationship is mechanically carried about by the larger member. The bacterium *Moraxella bovis*, the etiologic agent of infectious bovine keratoconjunctivitis, or “pinkeye” of cattle, is mechanically carried



**FIGURE 1-1:** Lichen growing on side of tree is symbiotic relationship between fungus and alga.

from the eyes of one cow to those of another on the sticky foot pads of the face fly, *Musca autumnalis* (Figure 1-2).

The term **mutualism** describes an association in which both organisms in the symbiotic relationship benefit. For example, within the liquid rumen environment of a cow are millions of microscopic, swimming, unicellular, ciliated protozoans. The cow provides these tiny creatures with a warm, liquid environment in which to live. In return, the rumen ciliates break down cellulose for the cow and aid in its digestion processes.

**TECHNICIAN'S NOTE** In mutualistic symbiosis, both organisms benefit from the relationship.

The term **commensalism** describes an association in which one symbiont benefits and the other is neither benefited nor harmed. An example is the relationship between the shark and the remora, its “hitchhiker.” The remora attaches to the underside of the shark and hitches a ride. The remora also eats the food scraps, or leftovers, after the shark’s meal. The remora benefits from this relationship, whereas the shark is neither benefited nor harmed.

In **parasitism**, an association exists between two organisms of different species, in which one

member (the **parasite**) lives on or within the other member (the **host**), and may cause harm. The parasite becomes metabolically dependent on the host.

This book discusses the host-parasite relationships between domesticated and wild animals and their parasites. **Parasitology** is the study of such parasitic relationships.

## PARASITISM

Parasitism can occur in differing degrees. In **parasitiasis** the parasite is present on or within the host and is potentially pathogenic (harmful); however, the animal does not exhibit outward clinical signs of disease. For example, healthy cattle on pasture may harbor bovine trichostrongyles (roundworms) in their gastrointestinal tracts, but the cattle do not exhibit outward clinical signs of parasitism (Figure 1-3). Parasitiasis describes this type of parasitic relationship.

In **parasitosis**, the parasite is present on or within the host and does produce obvious injury or harm to the host animal. The host exhibits obvious outward signs of clinical parasitism (Figure 1-4). For example, an emaciated cow on pasture certainly harbors bovine trichostrongyles (roundworms) in its gastrointestinal tract. Parasitosis describes this type of parasitic relationship.



**FIGURE 1-2:** *Moraxella bovis*, etiologic agent of infectious bovine keratoconjunctivitis (“pinkeye”), is mechanically carried from eyes of one cow to those of another on sticky foot pads of the face fly *Musca autumnalis*.



**FIGURE 1-3:** Healthy cattle on pasture may harbor bovine trichostrongyles (roundworms) in their gastrointestinal tracts but not exhibit outward clinical signs of parasitism. This condition is known as **parasitiasis**.

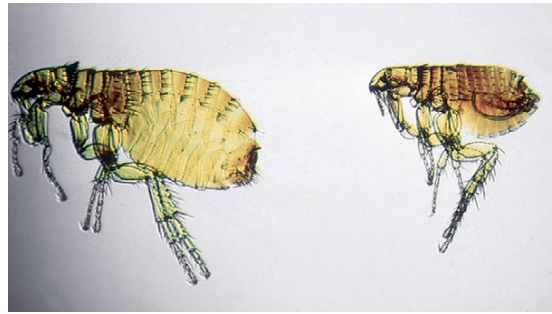

**FIGURE 1-4:** This emaciated cow probably harbors millions of bovine trichostrongyles (roundworms) in its gastrointestinal tract. As a result of this parasitism, the cow exhibits obvious outward clinical signs. This condition is referred to as **parasitosis**.

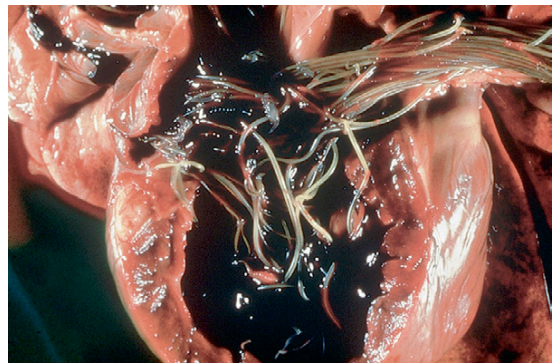
**TECHNICIAN'S NOTE** A parasite can cause parasitiasis in some animals with a low parasite burden or number; however, it may also cause parasitosis with a high parasite burden.

In any parasitic relationship, the parasite may live on or within the body of the host. If the parasite lives *on* the body of the host, it is called an **ectoparasite**. Cat fleas (*Ctenocephalides felis*) on a dog are ectoparasites (Figure 1-5). If the parasite lives *within* the body of the host, it is called an **endoparasite**. The dog heartworm (*Dirofilaria immitis*) is an endoparasite (Figure 1-6). **Ectoparasitism** is parasitism by an external parasite. **Endoparasitism** is parasitism by an internal parasite. Similarly, an ectoparasite will produce an **infestation** on the host, and an endoparasite will produce an **infection** within that host.

**TECHNICIAN'S NOTE** It is important to understand that an infection is a condition caused inside the host's body while an infestation is a condition being caused on the outside of the host's body.



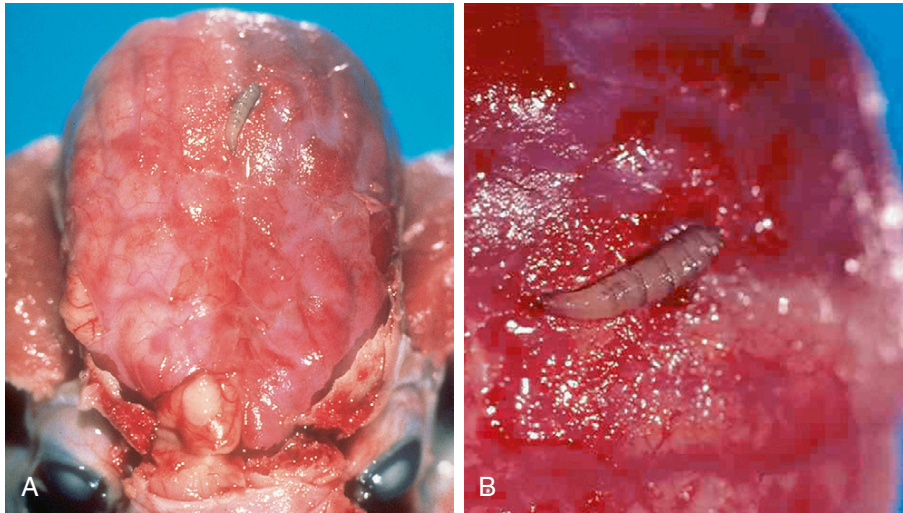
**FIGURE 1-5:** These cat fleas (*Ctenocephalides felis*) live within a dog's hair coat. They are ectoparasites and produce **ectoparasitism**. Similarly, these fleas produce infestation in the host's hair coat.



**FIGURE 1-6:** These heartworms (*Dirofilaria immitis*) lived in a dog's heart. They are endoparasites and produce **endoparasitism**. Heartworms produce infection within the host's heart. The dog is a definitive host for canine heartworm and harbors adult, sexual, or mature stages of the parasite.

Both endoparasitism and ectoparasitism in domestic animals can be treated by administering **parasiticides**, chemical compounds (both simple and complex) used to treat specific internal and external parasites. The different types of parasiticides include **anthelmintics** (or anthelmintics, compounds developed to kill roundworms, tapeworms, flukes, and thorny-headed worms), **acaricides** (compounds developed to kill mites and ticks), **insecticides** (compounds developed to kill insects), and **antiprotozoals** (compounds developed to kill protozoan organisms).



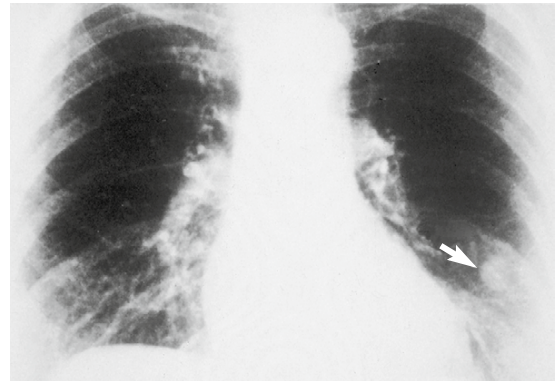


**FIGURE 1-7:** **A**, *Cuterebra* species (“warbles,” “wolves”) in the skin of dogs or cats may migrate into cranial vault; *Cuterebra* is then an erratic (aberrant) parasite. This parasite has become “lost” on its migration path. **B**, Enlargement of parasite in cranial vault.

Sometimes a parasite will wander from its usual site of infection into an organ or location in which it does not ordinarily live. When this happens, the parasite is called an **erratic parasite**, or **aberrant parasite**. For example, *Cuterebra* species, called “warbles” or “wolves,” found in the skin of dogs or cats may accidentally “wander” or migrate into the cranial vault. When this happens, *Cuterebra* becomes an erratic (aberrant) parasite (Figure 1-7).

A parasite can occur in a host in which it does not usually live. When this occurs, the parasite is called an **incidental parasite**. For example, humans can become infected with larval stages of *D. immitis*, the canine heartworm (Figure 1-8). Because humans are not the usual host for the heartworm, the canine heartworm is an incidental parasite in humans.

Organisms that are “free-living” (nonparasitic) can become parasitic in certain hosts. These organisms are called **facultative parasites**. An example is *Pelodera strongyloides*, a free-living soil nematode (roundworm). This free-living roundworm usually lives in the superficial layers of the soil as a “non-parasite.” However, this roundworm is capable of penetrating the skin of many domesticated animals, particularly dogs lying in moist dirt and “downer



**FIGURE 1-8:** Humans can become infected with larval stages of *Dirofilaria immitis*, the canine heartworm. Humans are not the usual host for heartworm, so canine heartworm is an incidental parasite in humans. (Courtesy Ronald E. Bowers, MD.)

cattle,” and establishing a parasitic skin infection. *P. strongyloides* is therefore a facultative parasite.

An **obligatory parasite**, however, is a parasite that must lead a parasitic existence. These are not capable of leading a free-living existence. *D. immitis*, the canine heartworm, is an obligatory parasite; most of the parasites that affect domesticated and wild animals are obligatory parasites.



**TECHNICIAN'S NOTE** Some parasites can have obligatory stages in their development where they need a host and some life stages can be nonparasitic. In addition, with some parasites, only the female adult is parasitic while the free-living males and females are nonparasitic.

A parasite does not necessarily have to live on or within a host. It can make frequent short visits to its host to obtain nourishment or other benefits. Such a parasite is called a **periodic parasite**. The best example of a periodic parasite is the female mosquito, which sucks blood from the vertebrate host; the host's blood is required for her egg development. Without a blood meal, the female mosquito will not have sufficient protein to lay her eggs.

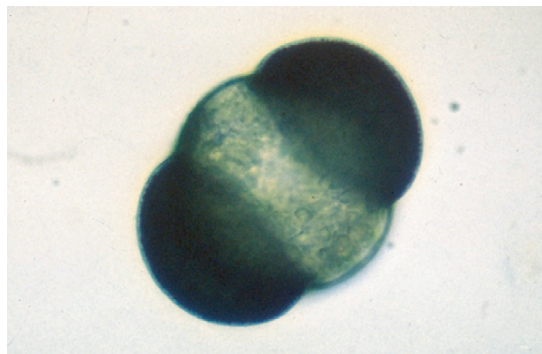
Living creatures or objects that are not parasitic may be mistaken for or erroneously identified as parasites. These are referred to as **pseudoparasites**. Sometimes, fecal flotation procedures will reveal pollen grains from trees, such as pine pollen (Figure 1-9), or from flowering plants. A novice veterinary student or veterinary technician may view these pollen grains on fecal flotation and erroneously identify them as parasites; they are pseudoparasites.



**TECHNICIAN'S NOTE** Novice veterinary students and veterinary technicians might mistake air bubbles on a fecal flotation slide for a parasite egg as well.

## LIFE CYCLE

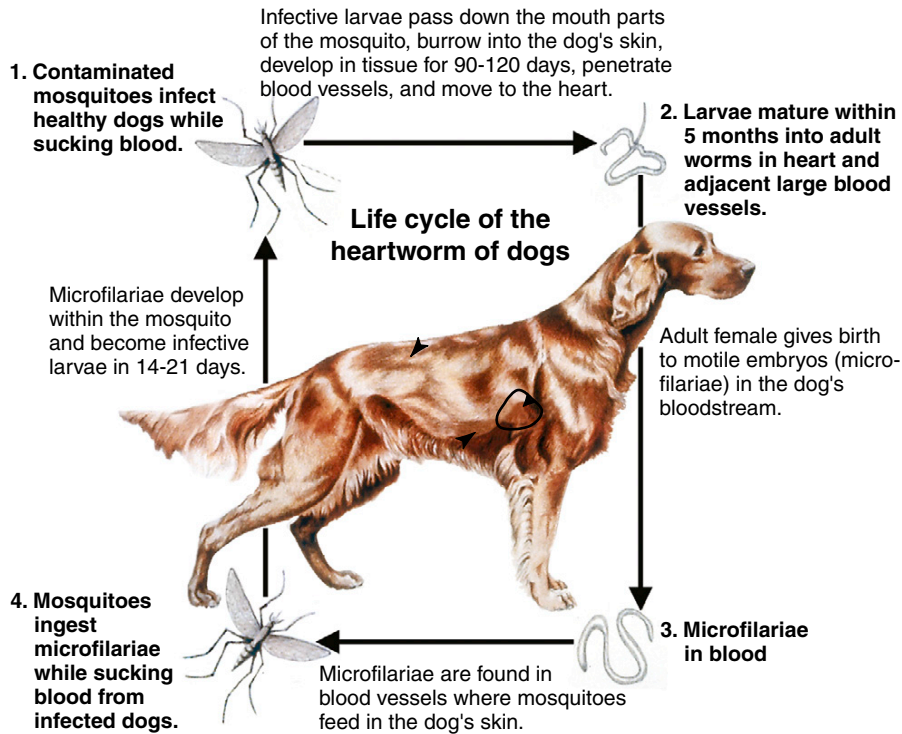
Each parasite has its own **life cycle** (Figure 1-10). The life cycle is the development of a parasite through its various life stages. Every parasite has at least one definitive host and may have one or more intermediate hosts. The **definitive host** is the host that harbors the adult, sexual, or mature stages of the parasite. For example, the dog is



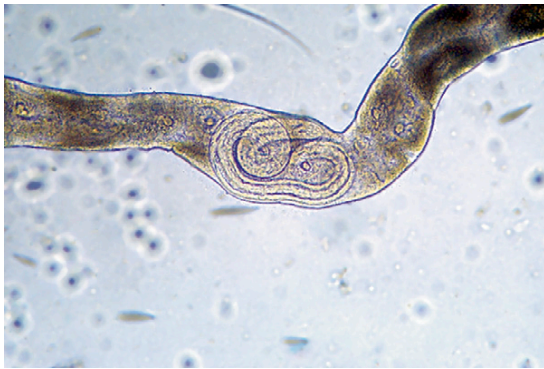**FIGURE 1-9:** Pollen grain from pine tree revealed on fecal flotation. A beginning veterinary student or technician may view this pollen on fecal flotation and erroneously assume the grains are parasites, when they are actually pseudoparasites.

the definitive host for *D. immitis*; mature male and female heartworms (the sexual stages of the parasite) are found in the right ventricle and pulmonary arteries of the dog's heart (see Figure 1-6). The **intermediate host** is the host that harbors the larval, juvenile, immature, or asexual stages of the parasite. The female mosquito is the intermediate host for *D. immitis*; larval or immature heartworms (the developing stages of the parasite) are found in the Malpighian tubules and proboscis of the mosquito (Figures 1-11 and 1-12). The intermediate host transfers the parasite from one definitive host to another. A parasite may have more than one intermediate host. In the life cycle of *Platynosomum concinnum*, the lizard-poisoning fluke of cats, a land snail is the first intermediate host and a lizard is the second intermediate host for the parasite. This liver fluke requires two intermediate hosts to infect the cat.

In a special type of intermediate host, a parasite does not undergo any development, but instead remains arrested, or **encysted** ("in suspended animation") within the host's tissues. This host is called the **transport host**, or **paratenic host**. The larvae remain in this suspended state until the definitive host eats the transport host. Once within the definitive host, the larvae "wake up," establish an infection, migrate to their predilection site, and grow to adult parasites within the definitive host.



**FIGURE 1-10:** Life cycle of *Dirofilaria immitis*. In this life cycle the dog is definitive host and the mosquito is intermediate host. Mature male and female heartworms (sexual stages of parasite) are found in right ventricle and pulmonary arteries of dog's heart.



**FIGURE 1-11:** The mosquito is intermediate host for *Dirofilaria immitis*; larval or immature heartworms (developing stages of parasite) are found in the mosquito's malpighian tubules.

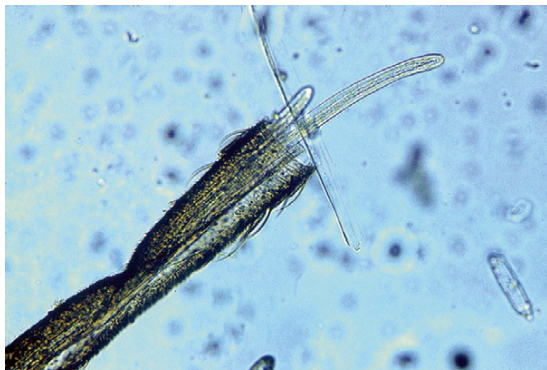A **reservoir host** is a vertebrate host in which a parasite or disease occurs in nature and is a source of infection for humans and domesticated animals. Heartworms may develop in the right ventricle and pulmonary artery of wild wolves

and coyotes. Wolves and coyotes may be reservoir hosts for heartworm; the infection may be spread from the wolf or coyote to the family pet by the mosquito intermediate host.

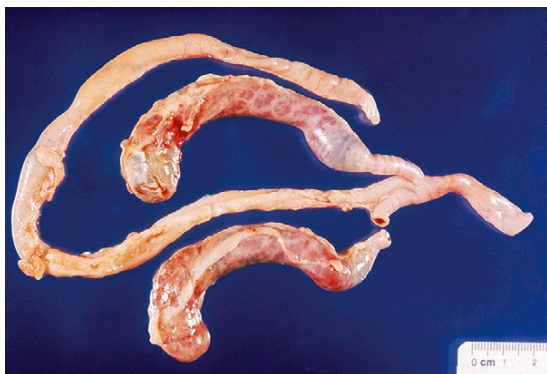**TECHNICIAN'S NOTE** Some parasites can serve as intermediate hosts for other parasites as well as being parasites themselves. For example, the mosquito feeds off animals and is thus a parasite but also acts as an intermediate host to the parasite that causes heartworm disease.

A **homoxenous** or **monoxenous** parasite is a parasite that will infect only one type of host. For example, *Eimeria tenella*, a coccidian, will only infect chickens. Similarly, a **stenoxenous** parasite is a parasite with a narrow host range. Because *E. tenella* will only infect chickens, it is





**FIGURE 1-12:** Larval or immature heartworms (developing stages of parasite) may also be found in the mosquito's proboscis. The mosquito intermediate host transmits heartworm infection from one dog to another.



**FIGURE 1-13:** *Eimeria tenella* will only infect ceca of chickens; therefore it is a homoxenous or monoxenous parasite.

a **stenoxenous** parasite. This protozoan parasite only infects the ceca of chickens (Figure 1-13). A **euryxenous** parasite is a parasite with a very broad host range. For example, *Toxoplasma gondii* infects more than 300 species of warm-blooded vertebrates; therefore it is a euryxenous parasite.



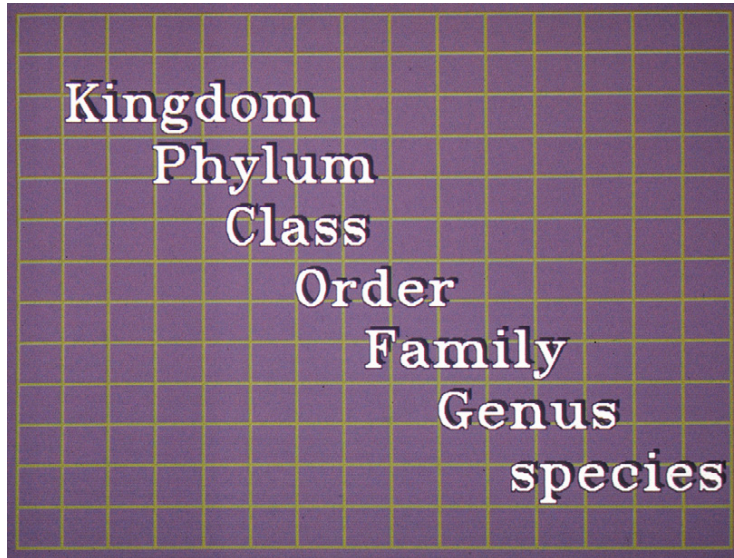
**TECHNICIAN'S NOTE** It should be noted that *Toxoplasma gondii* infects more than 300 species of warm-blooded vertebrates; its sexual stages only occur in the feline.

A **zoonosis** is any disease or parasite that is transmissible from animals to humans. Examples of parasites that are zoonotic are *T. gondii*, *Trichinella spiralis*, *Ancylostoma caninum*, and *Toxocara canis*. Zoonotic parasites are discussed in later chapters.

## THE LINNAEAN CLASSIFICATION SCHEME

In beginning biology, students must learn the classification scheme perfected by Linnaeus, an early Swedish biologist. Every organism can be classified using the following **classification scheme**: kingdom, phylum, class, order, family, genus, and species (Figure 1-14). Students often remember this classification scheme with the simple mnemonic device, “King Philip came over for good spaghetti,” in which the first letter of each word in the sentence corresponds to the first letter in the Linnaean classification scheme.

The Linnaean classification scheme works in the following manner. Several million species of animals, plants, fungi, protozoa, and algae live on the earth. These creatures may have different **common names** in different regions of the world. A common name may refer to different organisms in different places. The solution to this problem was to give each organism a **scientific name** composed of two Latin words, which is commonly written in italics. The first word is capitalized and is the **genus name**. The genus indicates the group to which a particular type of animal or plant belongs. The second word is not capitalized; it is the **specific epithet** and indicates the type of animal itself. Examples of common names of animals and their corresponding scientific names are the dog, *Canis familiaris*; the cat, *Felis catus*; the housefly, *Musca domestica*; and a bacterium normally found in the gut, *Escherichia coli*. Similar species are grouped together into the same genus. Similar genera (plural form of genus) are grouped together in the same family. Similar families are grouped together in the same order. Similar orders are grouped together in the same class. Similar classes are grouped together in the same phylum. Similar phyla are grouped



**FIGURE 1-14:** All organisms can be classified using the Linnaean classification scheme.

together in the same kingdom. Therefore the classification scheme for the dog is as follows:

**TECHNICIAN'S NOTE** For ease of finding particular parasites, this book is organized by the Phylum/Class of the parasites. Tables are provided to view parasites by the hosts they affect with pages they correspond to.

Kingdom: Animalia  
 Phylum: Chordata  
 Subphylum: Vertebrata  
 Class: Mammalia  
 Order: Carnivora  
 Family: Canidae  
 Genus: *Canis*  
 Species: *familiaris*

Every living creature has its own unique classification scheme. This text discusses many parasites that affect domesticated animals. It is important to learn the scientific names, the common names, the hosts, and the key identifying features for all these parasites.

The classification scheme contains the following five kingdoms: **Planta** (plants), **Animalia** (animals), **Protista** (unicellular organisms), **Monera** (algae), and **Fungi** (fungi). Veterinary

parasitology is concerned with only two of these kingdoms as true parasites of domesticated animals. The first is the kingdom **Animalia**, which contains platyhelminths (flatworms—trematodes [flukes] and cestodes [tapeworms]), nematodes (roundworms), acanthocephalans (thorny-headed worms), annelids (leeches), and arthropods (insects, mites, ticks, spiders, pentastomes, and other creatures with jointed appendages). The second is the kingdom **Protista**, which contains protozoans (unicellular organisms). The following chapters present parasites from each of these groups and relate their significance in veterinary parasitology.

**TECHNICIAN'S NOTE** Most parasites of domestic animals belong to the kingdom **Animalia**.

Any student of veterinary parasitology must use the terms presented in this chapter and their definitions as the “framework” on which to build a greater proficiency in this discipline. As with the veterinarians with whom they work, veterinary technicians must be encouraged to embrace the continual improvement of professional knowledge and competence.



## CHAPTER ONE TEST

---

MATCHING—Match the term with the correct phrase or term.

- |                                   |                                                                           |
|-----------------------------------|---------------------------------------------------------------------------|
| A. Phoresis                       | 1. Parasite that wanders into an organ in which it does not normally live |
| B. Parasitology                   | 2. A parasite in a host in which it does not usually live                 |
| C. Ectoparasite                   | 3. The study of parasitic relationships                                   |
| D. Endoparasite                   | 4. A creature or object that is mistaken for a parasite                   |
| E. Erratic/aberrant parasite      | 5. A parasite that makes frequent visits to a host to obtain nourishment. |
| F. Pseudoparasite                 | 6. Kingdom, Phylum, Class, Order, Family, Genus, Species                  |
| G. Incidental parasite            | 7. The face fly carries the pinkeye bacterium from one cow to another     |
| H. Periodic parasite              | 8. Disease or parasite that is transmissible from animals to humans       |
| I. Zoonosis                       | 9. Parasitism by an internal parasite                                     |
| J. Linnaean classification scheme | 10. Parasitism by an external parasite                                    |

## QUESTIONS FOR THOUGHT AND DISCUSSION

---

- |                                                                                                                                                                                                                                                                                                                                                                                                                                                                                                                                                                   |                                                                                                                                       |
|-------------------------------------------------------------------------------------------------------------------------------------------------------------------------------------------------------------------------------------------------------------------------------------------------------------------------------------------------------------------------------------------------------------------------------------------------------------------------------------------------------------------------------------------------------------------|---------------------------------------------------------------------------------------------------------------------------------------|
| 1. Why is it important for a veterinary technician to know and understand the terminology associated with veterinary parasitology?                                                                                                                                                                                                                                                                                                                                                                                                                                | 3. Define three types of symbiotic relationships and give one example for each type of relationship.                                  |
| 2. Compare and contrast the following terms. Why is it important to understand the difference between each pair of terms? <ul style="list-style-type: none"><li>• Intermediate host <i>versus</i> definitive host</li><li>• Parasitosis <i>versus</i> parasitiasis</li><li>• Infestation <i>versus</i> infection</li><li>• Common name <i>versus</i> scientific name</li><li>• Anthelmintic <i>versus</i> insecticide</li><li>• Obligatory parasite <i>versus</i> facultative parasite</li><li>• Stenoxenous parasite <i>versus</i> euryxenous parasite</li></ul> | 4. Briefly discuss the importance of the Linnaean classification scheme.                                                              |
|                                                                                                                                                                                                                                                                                                                                                                                                                                                                                                                                                                   | 5. What are the five kingdoms within the Linnaean classification scheme? Which two are the most important in veterinary parasitology? |

# Parasites That Infect and Infest Domestic Animals

## 2

### KEY TERMS

Parasitism  
Monogenetic flukes  
Digenetic flukes  
True tapeworms  
Alimentary canal  
Tegument  
Pseudotapeworms  
Roundworms  
Acanthocephalans  
Leeches  
Causal agents  
Intermediate hosts  
Vectors  
Toxins  
Venomous substances

### OUTLINE

Monogenetic Trematodes (Monogenetic Flukes)	Nematodes (Roundworms)
Digenetic Trematodes (Digenetic Flukes)	Acanthocephalans (Thorny-Headed Worms)
Eucestodes (True Tapeworms)	Hirudineans (Leeches)
Cotyloda (Pseudotapeworms)	Arthropods
	Protista (Protozoa)

### LEARNING OBJECTIVES

After studying this chapter, the reader should be able to do the following:

- Understand that many types of living “creatures” are capable of parasitizing domesticated, wild, exotic, and laboratory animals.
- Understand that the Linnaean classification scheme is an important tool for studying veterinary parasitology.

Chapter 1 describes **parasitism** as an association between two organisms of different species in which one member (the parasite) lives on or within the other member (the host) and may cause harm. The parasite is metabolically dependent on the host.

In parasitology, the study of parasitic relationships, parasitic groups are classified according to the Linnaean classification system. This chapter presents the parasites that infect and infest domesticated animals, indicating their important characteristics and their place in the Linnaean system.

### MONOGENETIC TREMATODES (MONOGENETIC FLUKES)

Kingdom: Animalia (animals)

Phylum: Platyhelminthes (flatworms)

Class: Trematoda (flukes)

Subclass: Monogenea (monogenetic flukes)

**Monogenetic flukes** are ectoparasites of fish, amphibians, and reptiles. They are rarely parasites of mammals. These flukes are seen most often as ectoparasites of the gills, skin, fins, and mouth of fishes and are rarely

observed in a veterinary clinical situation. They might be seen by a veterinarian who specializes in diseases of aquarium fish. Also, some veterinarians may specialize in fish farming or some aspect of aquaculture. Under these conditions, monogenetic flukes may be frequently observed.



**TECHNICIAN'S NOTE** Monogenetic flukes are ectoparasites that parasitize fish, amphibians, and reptiles. They are rarely seen in a veterinary clinic setting.

### DIGENETIC TREMATODES (DIGENETIC FLUKES)

Kingdom: Animalia (animals)  
 Phylum: Platyhelminthes (flatworms)  
 Class: Trematoda (flukes)  
 Subclass: Digenea (digenetic flukes)

**Digenetic flukes** are important parasites of both large and small animals. These flattened, leaf-shaped flukes are primarily endoparasites of the gastrointestinal tract; however, digenetic flukes can also infect the lungs and blood vasculature. Regardless of the site of infection, the operculated eggs of these flukes can be identified in the feces of domestic animals.



**TECHNICIAN'S NOTE** Digenetic flukes infect both large and small animals and are seen in the veterinary clinic setting.

### EUCESTODES (TRUE TAPEWORMS)

Kingdom: Animalia (animals)  
 Phylum: Platyhelminthes (flatworms)  
 Class: Eucestoda (true tapeworms)

Adult **true tapeworms** are ribbonlike flatworms found in the gastrointestinal tract of their definitive hosts. True tapeworms lack a “gut” or **alimentary canal**; they absorb nutrients through their **tegument** (skin). The eggs of these tapeworms are frequently observed on fecal flotation.

The larval stages of these true tapeworms may be found in a variety of extraintestinal tissue sites in domestic animals; the animals harboring the larval stages serve as the intermediate hosts. In these extraintestinal sites, the larval stages of these tapeworms may cause more pathology to the intermediate hosts than the adult tapeworm does to the definitive host in its intestinal sites.



**TECHNICIAN'S NOTE** True tapeworms absorb nutrients from the host through their skin.

### COTYLODA (PSEUDOTAPEWORMS)

Kingdom: Animalia (animals)  
 Phylum: Platyhelminthes (flatworms)  
 Class: Cotyloda (pseudotapeworms)

Similar to true tapeworms, adult **pseudotapeworms** are flattened and ribbonlike. They resemble true tapeworms and also are found in the gastrointestinal tract of their definitive hosts. Their egg stages may be diagnosed on fecal flotation; they produce operculated eggs. The larval stages of pseudotapeworms are found in microscopic aquatic crustaceans and in the musculature of fish and reptiles. These larval stages seldom produce pathology in domestic animals.



**TECHNICIAN'S NOTE** Pseudotapeworms use microscopic aquatic crustaceans and the musculature of fish and reptiles as intermediate hosts for part of their life cycle.

### NEMATODES (ROUNDWORMS)

Kingdom: Animalia (animals)  
 Phylum: Nematoda (roundworms)

Nematodes, or **roundworms**, are elongated, unsegmented, cylindric worms. They are called “roundworms” because they are round when observed in cross section on histopathologic examination. Nematodes are the most numerous,

complex, and variable among the helminth parasites of domesticated animals. They come in all sizes and shapes and can infect a variety of organs and organ systems. They can produce significant pathology in domesticated animals. On planet Earth, nematodes are second only to arthropods with regard to their numbers and complexity of life cycles. The eggs and larvae of nematodes are most often diagnosed on fecal flotation, so it is important that veterinary technicians become proficient in their identification. Both adult and larval stages of nematodes can produce significant pathology in domesticated animals.



**TECHNICIAN'S NOTE** The nematodes are the largest group of helminths that parasitize domesticated animals.

## ACANTHOCEPHALANS (THORNY-HEADED WORMS)

Kingdom: Animalia (animals)

Phylum: Acanthocephala (thorny-headed worms)

**Acanthocephalans**, or thorny-headed worms, are elongated, unsegmented, cylindric worms. They are different, however, from nematodes in that they possess a spiny proboscis on their anterior ends. This spiny proboscis is used as an organ of attachment. Because of this anterior proboscis, acanthocephalans are often referred to as “thorny-headed worms.” As with the cestodes (tapeworms), thorny-headed worms lack a gut or alimentary tract; they also absorb nutrients through their tegument (skin). Adult acanthocephalans are very uncommon parasites and are most often found in the gastrointestinal tract. The eggs of these unusual parasites are diagnosed on fecal flotation.



**TECHNICIAN'S NOTE** Acanthocephalans are referred to as “thorny-headed worms” because of the spiny proboscis on the anterior end, which is used as an organ of attachment.

## HIRUDINEANS (LEECHES)

Kingdom: Animalia (animals)

Phylum: Annelida (segmented worms)

Class: Hirudinea (leeches)

**Leeches** are blood-feeding ectoparasites of both wild and domesticated animals. These annulated (ringed) worms are typically found in fresh water, although there may be marine and terrestrial varieties. Leeches may produce significant pathology in both wild and domesticated animals, or they may be beneficial when used after reconstructive surgical procedures in both animals and humans.



**TECHNICIAN'S NOTE** Some species of leeches are used for medicinal purposes in reconstructive surgical procedures in humans and animals.

## ARTHROPODS

Kingdom: Animalia (animals)

Phylum: Arthropoda (animals with jointed legs)

The phylum **Arthropoda** is the largest phylum in the animal kingdom. This phylum is quite complex, containing pentastomes, crustaceans, centipedes, millipedes, insects, mites, ticks, scorpions, and spiders.

Arthropods are important in veterinary medicine for the following four reasons:

1. Arthropods may serve as **causal agents** themselves.
2. They may serve as **intermediate hosts** for certain helminths and protozoans.
3. They may serve as **vectors** for bacteria, viruses, spirochetes, and chlamydial agents.
4. They may produce **toxins** or **venomous substances**.

Arthropods may parasitize the host as adult or juvenile stages.



**TECHNICIAN'S NOTE** Arthropoda is the largest phylum in the animal kingdom and includes most of the ectoparasites seen in the veterinary profession.

## PROTISTA (PROTOZOA)

Kingdom: Protista (protozoans—unicellular, or single-cell, organisms)

Trematodes, tapeworms, pseudotapeworms, roundworms, thorny-headed worms, leeches, and arthropods are all members of the animal kingdom. All the parasites described here are metazoan, or multicellular, organisms. The remaining parasites belong to the kingdom Protista, which is made up of all of the unicellular organisms. The majority of protozoans on planet Earth are free-living; however, those that are parasitic can cause significant pathology in domesticated animals. Within this kingdom are several phyla, which include flagellates, amoebae,

apicomplexans, and ciliates. These protozoans are the primary protozoans that cause significant pathology in domesticated animals. Despite their tiny size, protozoans have complex life cycles and may cause significant pathologic changes in the tissues and organs of domesticated animals.



**TECHNICIAN'S NOTE** The protozoans are single-celled endoparasites that include such organisms as *Giardia* species and the organisms that cause coccidia.

Each of these groups of parasites and its significance to veterinary parasitology is discussed in detail in the upcoming chapters.

## CHAPTER TWO TEST

**MATCHING**—Match the term with the correct phrase or term.

- |                     |                                         |
|---------------------|-----------------------------------------|
| A. Platyhelminthes  | 1. Thorny-headed worms                  |
| B. Protists         | 2. Pseudotapeworms                      |
| C. Eucestodes       | 3. Leeches                              |
| D. Cotyloda         | 4. True tapeworms                       |
| E. Nematodes        | 5. Roundworms                           |
| F. Acanthocephalans | 6. Animals with jointed appendages      |
| G. Metazoans        | 7. Flukes                               |
| H. Hirudineans      | 8. Unicellular or single cell organisms |
| I. Arthropods       | 9. Flatworms                            |
| J. Trematodes       | 10. Multicellular organisms             |

## QUESTIONS FOR THOUGHT AND DISCUSSION

1. Why is the Linnaean classification system so important in the study of veterinary parasitology? Can you think of a more efficient way to study, learn, and remember the various groups of parasites of domesticated, wild, exotic, and laboratory animals?

# Introduction to the Nematodes

# 3

## KEY TERMS

Cervical alae  
Copulatory bursa  
Bursal rays  
Spicules  
Dioecious  
Ascaroid- or ascarid-  
type egg  
Trichostrongyle,  
strongyle-type egg  
Spiruroid-type egg  
Trichinelloid-  
trichuroid-type egg  
Oviparous nematode  
Ovoviviparous  
nematode  
Larviparous nematode  
Molt  
Infective third-stage  
larva  
Direct life cycle  
Indirect life cycle

## OUTLINE

Nematodes of Importance in  
Veterinary Medicine  
Key Morphologic Features  
*External Morphologic Features*  
*Internal Morphologic Features*  
Life Cycle of the Nematode

## LEARNING OBJECTIVES

After studying this chapter, the reader should be able to do the following:

- Briefly discuss the importance of nematodes in veterinary practice.
- Describe the important external morphologic features for identifying nematodes.
- Name the important parts of the male nematode's reproductive system.
- Name the important parts of the female nematode's reproductive system.
- Determine which reproductive system (male or female) is more important in veterinary parasitology (diagnostically speaking).
- Describe the four types of nematode eggs.
- Determine the difference among these reproductive terms: oviparous, ovoviviparous, and larviparous.
- Describe the "typical life cycle" of a representative nematode.
- Explain the difference between a direct life cycle and an indirect life cycle.
- Be able to integrate these terms with the nematode parasites covered in Chapter 4.

Members of the phylum Nematoda, the nematodes, or roundworms, are the most numerous and most diverse group of animals on Earth. Approximately 10,000 species thrive in very diverse habitats. There are three basic types of nematodes: (1) the free-living nematodes residing in marine water, freshwater, and soil environments; (2) the nematodes that parasitize plants; and (3) the nematodes that parasitize domesticated and wild animals and humans. This chapter discusses the third category, nematodes that parasitize domesticated and wild animals and, to some extent, humans.

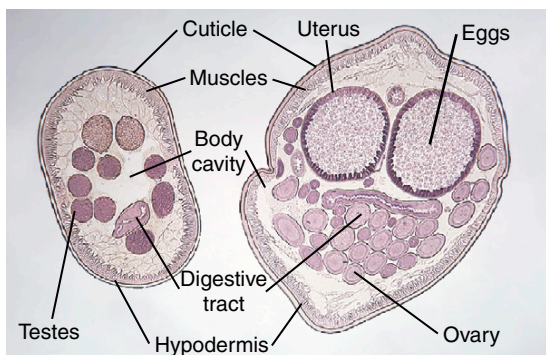
**TECHNICIAN'S NOTE** Nematodes are collectively referred to as roundworms and are the most numerous and diverse group of animals on Earth.

## NEMATODES OF IMPORTANCE IN VETERINARY MEDICINE

Nematodes in domesticated farm animals in the United States alone cause losses of billions of dollars in animal agriculture resulting from veterinary bills and death. Plant nematodes cause approximately 10% of cultivated crops to be lost each year. It is impossible to determine similar monetary losses in the pet or companion animal “industry.”

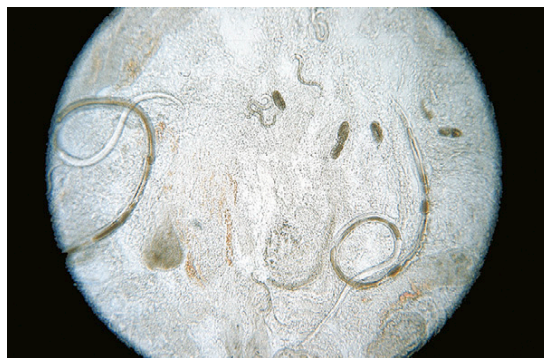### Key Morphologic Features

Protozoans, discussed in Chapters 10 and 11, are unicellular organisms; nematodes, however, are multicellular organisms. Whereas trematodes (leaflike in form) and cestodes (chainlike or boxcarlike in form) are dorsoventrally flattened in cross section, nematodes are unsegmented, elongate, rounded on both ends, circular in cross section, and bilaterally symmetric (Figure 3-1); thus they are often referred to as *roundworms*.

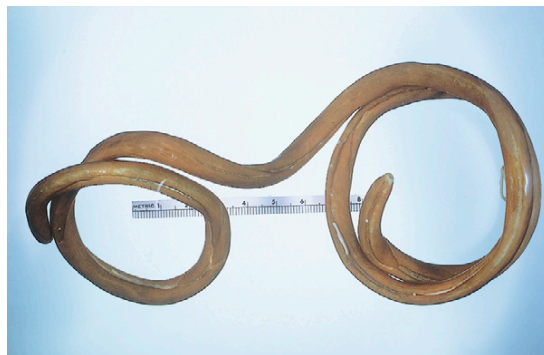

**FIGURE 3-1:** Cross section of male (left) and female (right) *Ascaris suum*, the pig roundworm. Whereas flukes and tapeworms are dorsoventrally flattened, roundworms are usually round in cross section.

Nematodes come in a variety of sizes, from *Strongyloides stercoralis*, a tiny parasitic female worm only 2 mm in length and about 35  $\mu\text{m}$  wide (Figure 3-2), to *Diectophyma renale*, “the giant kidney worm,” measuring 100 cm (1 m) in length and 1.2 cm wide (Figure 3-3). As mentioned previously, most nematodes are cylindric and rounded on both ends; however, nematodes come in a wide variety of shapes, from spherical (definitely not cylindric), such as *Tetrameres* species, parasites of the gizzard of domesticated and wild birds (Figure 3-4), to the whiplike *Trichuris*



**FIGURE 3-2:** Numerous parasitic female *Strongyloides stercoralis* (approximately 2 mm in length and about 35  $\mu\text{m}$  wide) recovered from mucosal scraping from canine small intestine. Also note presence of eggs and first-stage larvae. This is an unusual nematode in that parasitic males do not exist.



**FIGURE 3-3:** Largest nematode known to parasitize domesticated animals, *Diectophyma renale*, the “giant kidney worm” of dogs. This largest of parasites measures 100 cm (1 m) in length and is approximately 1.2 cm wide.



species, which parasitize every domesticated animal except the horse (Figure 3-5).



**TECHNICIAN'S NOTE** Nematodes are referred to as roundworms because they are circular in cross section, rounded at both ends, unsegmented, elongate, and bilaterally symmetric.

### External Morphologic Features

Nematodes are covered by a thin cuticle (see Figure 3-1). This cuticle covers the exterior body surface of the nematode and extends into all its body openings, that is, the mouth, esophagus, and rectal and



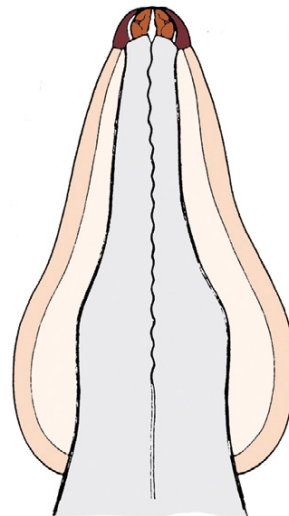
**FIGURE 3-4:** Nematodes come in a variety of shapes. Some are spherical, such as *Tetrameres* species, which parasitize the gizzard of domesticated and wild birds.



**FIGURE 3-5:** Whiplike *Trichuris* species parasitize every domesticated animal except the horse.

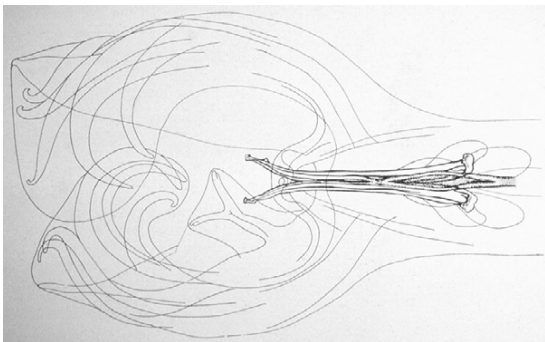
genital openings. On the external surface the cuticle has a variety of modifications. There may be lateral flattened expansions of the cuticle in the region of the anterior end; these expansions are called **cervical alae** (Figure 3-6). There also may be lateral flattened expansions of the cuticle in the region of the posterior end of some male nematodes; this posterior lateral expansion is called the **copulatory bursa** and serves to hold onto or to grasp the female nematode during the mating process (Figure 3-7). The copulatory bursa is composed of fingerlike projections called **bursal rays**. Between each adjacent bursal ray are thin membranes. The male's highly chitinous and pigmented **spicules** (see Figure 3-7) (the intromittent organs, or “penis”) are associated with the copulatory bursa. The cervical alae and the copulatory bursa are only two of the many modifications of the external cuticle of nematodes. The nematode's cuticle is secreted, or formed, by the thin layer directly beneath it, the **hypodermis** (see Figure 3-1).

Just beneath the hypodermis lies the **somatic muscular layer**, the layer of muscles that enables the nematode to move about (see Figure 3-1, *muscles*). These muscle fibers are spindle-shaped and lie along the edge of the hypodermis.



**FIGURE 3-6:** Diagrammatic representation of lateral flattened expansion of cuticle on anterior end of *Toxocara cati*, the feline ascarid. These expansions are called cervical alae.





**FIGURE 3-7:** Diagrammatic representation of lateral flattened expansion of cuticle on posterior end of male *Haemonchus contortus*, the “barberpole worm” of ruminants. This expansion is called the copulatory bursa and serves to hold onto or grasp the female nematode during the mating process. The copulatory bursa is composed of fingerlike projections called bursal rays. Between each adjacent bursal ray are thin membranes. Male spicules (or intromittent organs) are associated with the copulatory bursa.

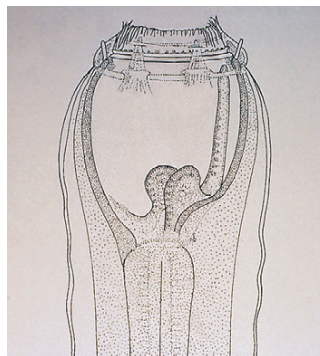
Nematodes also possess specialized muscles that aid in feeding and reproductive activities. The muscles line the nematode’s **body cavity** (see Figure 3-1). Unlike trematodes (flukes) and cestodes (tapeworms), which lack a body cavity, nematodes (roundworms) do have a body cavity. The body cavity of a typical nematode is not considered a true coelom; it is a **pseudocoelom**, lined by a **pseudocoelomic membrane**.

**TECHNICIAN’S NOTE** The nematode has a pseudocoelom (that lies between the middle and inner layers of the three body-tissue layers) rather than a true coelom (or true body cavity).

### Internal Morphologic Features

The most important of the nematode’s organ systems are the digestive and the reproductive systems.

The digestive tract of the typical nematode is a long, straight tube that extends from the mouth to the anus. On cross section the digestive tract resembles a tube within a tube (see Figure 3-1, *digestive tract*).



**FIGURE 3-8:** Fingerlike projections, or bumps, called papillae on the anterior end of *Strongylus vulgaris*. Collectively, these papillae may number as many as 40 and are referred to as the “leaf crown.” The mouth connects to a buccal cavity, which connects to the esophagus, which eventually connects to the long, winding intestine.

The mouth may be surrounded by lips, numbering two up to eight. In some nematodes the lips are replaced by fingerlike projections, or bumps, called **papillae**. Collectively, these papillae may number as many as 40 and are referred to as the **leaf crown** (Figure 3-8). The mouth connects to a buccal cavity, which connects to the esophagus, which connects to a long, winding intestine. The intestine ends with an opening to the outside. Female nematodes have a **rectum**, and male nematodes have a **cloaca**. Remember that the cloaca and the rectum are lined by cuticle and open to the outside through an anus. The part of the nematode’s body posterior to the anus is the tail.

**TECHNICIAN’S NOTE** The most important organ systems of the nematode are the reproductive system and the digestive system.

Whereas trematodes (flukes) and cestodes (tapeworms) are hermaphroditic (or monoecious), nematodes are **dioecious**; that is, they have separate sexes. There are both male nematodes and female nematodes.

The male reproductive organs consist of one or two **tubular testes** (see Figure 3-1). Usually, a **vas deferens** leads from the testes to the cloaca.

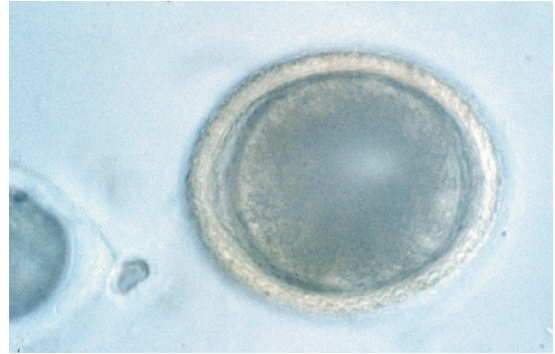There may be a **spicule pouch**, which contains two spicules. Remember that the male nematode's spicules (or intromittent organs) are associated with the copulatory bursa and serve to open the female nematode's vulva during copulation to allow sperm to enter the vagina.

The female reproductive organs consist of one or two **tubular ovaries** (see Figure 3-1, *ovary*). Usually, an **oviduct** leads from the ovary to the uterus. A **seminal receptacle** for sperm storage may be present. The uterus leads to the vagina, which opens to the outside through the vulva. The uterus may contain thousands of eggs or larvae (see Figure 3-1, *uterus* and *eggs*). Parasitic nematodes are very prolific; a single female nematode may produce several thousand eggs (or larvae) each day. The reproductive system is important because it allows for the production of eggs (and eventually offspring). A veterinary diagnostician confronted with an unrecognized type of nematode can dissect it, and if the nematode is a female, characteristic eggs (or larvae) may be released. When examined microscopically, these eggs or larvae provide a valuable clue as to the type (or species) of nematode.

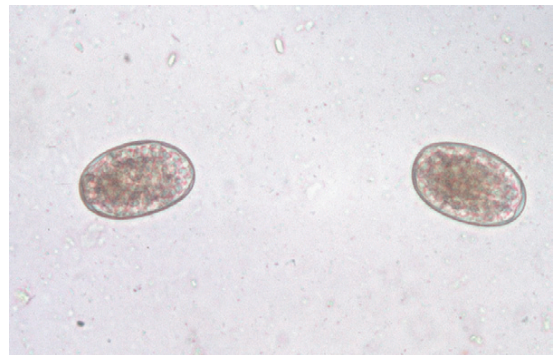


**TECHNICIAN'S NOTE** A female nematode can produce thousands of eggs or larvae each day; however, whipworms tend to produce fewer eggs and only release them every third day.

Female nematodes produce several egg types: (1) the **ascaroid**, or ascarid, type (e.g., *Toxocara canis*) (Figure 3-9); (2) the **trichostrongyle** or strongyle, or hookworm, type (e.g., *Haemonchus contortus* of ruminants, *Strongylus vulgaris* of horses, *Ancylostoma caninum* of dogs) (Figure 3-10); (3) the **spiruroid**, or spirurid, type (e.g., *Spirocera lupi* of dogs, *Physaloptera* spp. of dogs and cats) (Figure 3-11); and (4) the **trichineloid** or **trichuroid** type (e.g., *Trichuris vulpis*, the whipworm of dogs, *Capillaria* spp.) (Figure 3-12). In addition, some adult female

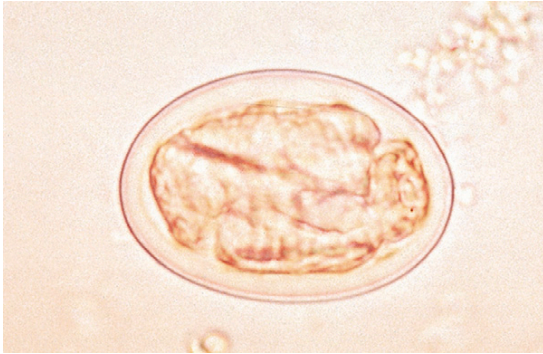


**FIGURE 3-9:** Ascaroid, or ascarid, type of nematode egg is best represented by that of *Toxocara canis*, the canine roundworm. Adult female nematode producing this egg type is oviparous. This nematode egg contains a single-cell stage within the eggshell.

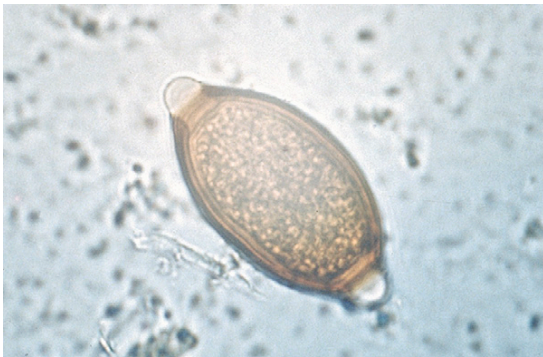

**FIGURE 3-10:** Trichostrongyle or strongyle, or hookworm, type of nematode egg is best represented by that of *Ancylostoma caninum*, the hookworm of dogs. Adult female nematode producing this egg type is oviparous. This nematode egg contains a morula stage within the eggshell.

nematodes produce characteristic larval stages: (1) the microfilariae, or prelarval, stage (e.g., *Dirofilaria immitis* of dogs) (Figure 3-13); (2) the lungworm, or kinked-tail, larvae (e.g., *Aelurostrongylus abstrusus* of cats, *Filaroides osleri* of dogs) (Figure 3-14); and (3) the dracunculoid, or long-tailed, larvae (e.g., *Dracunculus insignis* of dogs) (Figure 3-15). Nematode eggs (and larvae) vary greatly in size and composition. This fact is very important when attempting to render a diagnosis.



**FIGURE 3-11:** Spiruroid, or spirurid, type of nematode egg is best represented by that of *Spirocerca lupi*, the esophageal worm of dogs. Adult female nematode producing this egg type is ovoviviparous. This nematode egg contains a first-stage larva within the eggshell.



**FIGURE 3-12:** Trichinelloid type of nematode egg is best represented by that of *Trichuris vulpis*, the whipworm of dogs. Adult female nematode producing this egg type is oviparous. This nematode egg contains a single-cell stage within the eggshell.

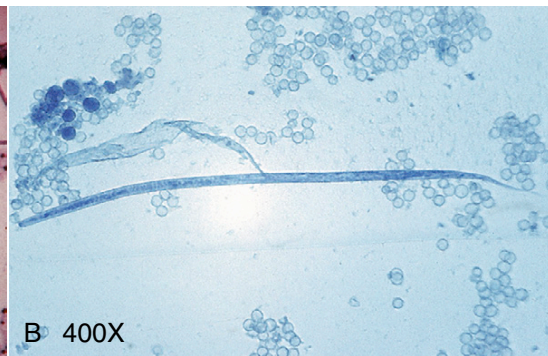
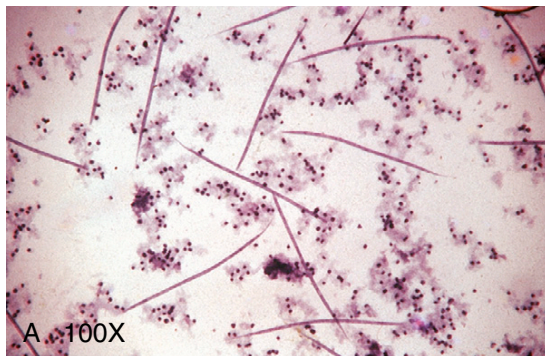


**TECHNICIAN'S NOTE** Nematodes produce one of four types of characteristic eggs and can produce one of three types of characteristic larvae; however, the size and composition will vary greatly.

Some female nematodes are **oviparous**; that is, the eggs produced by these nematodes contain a single-cell stage (see Figures 3-9 and 3-12) or a **morula stage** within the eggshell (see Figure 3-10). Some female nematodes are **ovoviviparous**; that is, the eggs produced by these nematodes contain a first-stage larva within the eggshell (see Figure 3-11). Finally, some female nematodes are **larviparous**; that is, they retain their eggs within the uterus and incubate them, then give birth to live larvae (see Figures 3-13, 3-14, and 3-15).

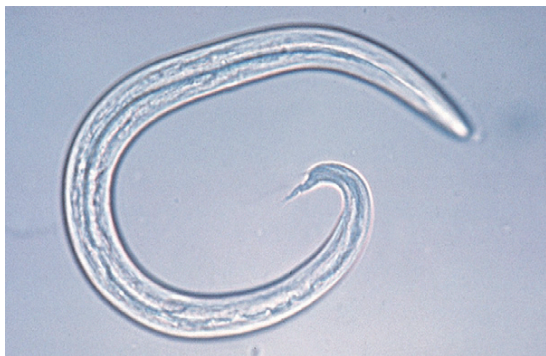### LIFE CYCLE OF THE NEMATODE

When compared with the complex life cycles of trematodes (flukes) and cestodes (tapeworms), the typical nematode life cycle is quite simple (Figure 3-16). The adult female nematode produces an egg, which is a single-cell stage within the eggshell. The original cell divides into two cells, two cells divide into four, four cells divide into eight, and so on. The original single-cell

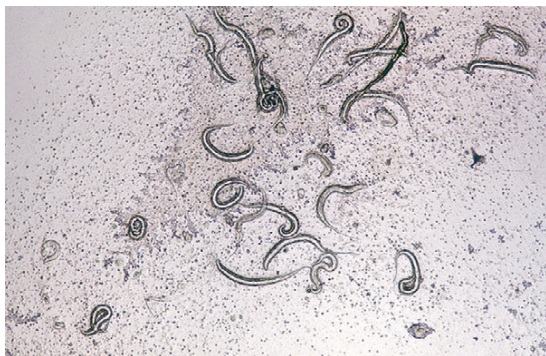

**FIGURE 3-13:** Some adult female nematodes produce characteristic larval stages. Microfilariae, or prelarval, stages of *Dirofilaria immitis*, the heartworm of dogs and cats, are characteristic of filarial parasites. Adult female nematode producing this larval type is larviparous. She produces live offspring.





**FIGURE 3-14:** The first-stage, kinked-tail larvae of *Aelurostrongylus abstrusus*, the lungworm of cats, are characteristic of lungworm larvae. Adult female nematode producing this larval type is larviparous. She produces live offspring.



**FIGURE 3-15:** Long-tailed larvae of *Dracunculus insignis*, the guinea worm of dogs, are also characteristic larvae. Adult female nematode producing this larval type is larviparous. She produces live offspring.

stage eventually develops into a morula stage, which in turn develops into a tadpole stage. The tadpole stage develops into a fully formed first-stage larva within the eggshell. This first-stage larva is ready to hatch. The larva emerges from the eggshell, **molts** (sheds its external cuticle), and develops into a second-stage larva. The second-stage larva eventually molts into the third-stage larva. This stage is often referred to as the **infective third-stage larva** because it is infective for the definitive host.

The first three larval stages can develop in the external environment or within the intermediate host. The intermediate host serves as the means

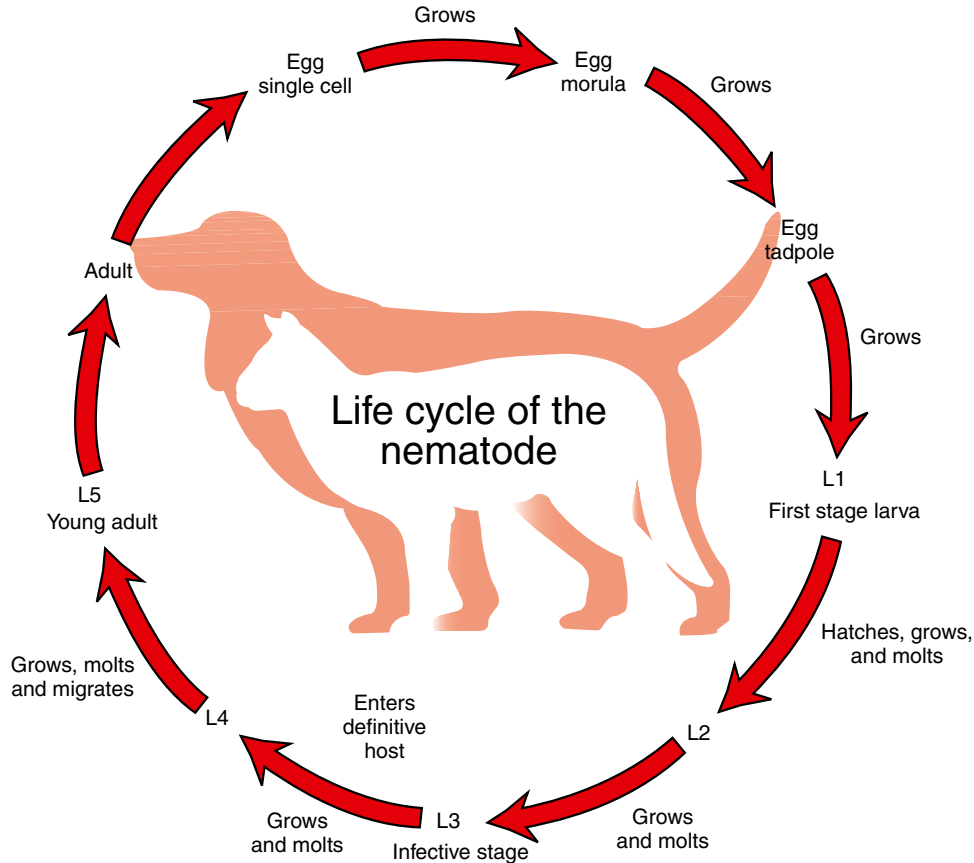
of transmission to the definitive host. Once the infective third larval stage has been reached, it must return to the definitive host to survive. It infects the host either by direct penetration or by intervention of the intermediate host. The intermediate host serves as a means of transmission to the definitive host. Once within the definitive host, the third larval stage molts to the fourth larval stage, which subsequently molts to the fifth larval stage. The fifth larval stage is actually the immature, or preadult, nematode. This stage eventually migrates to its organ or system predilection site and develops into the sexually mature adult stage. The male and female nematodes breed, and the cycle begins again.



**TECHNICIAN'S NOTE** The general nematode life cycle is a simple life cycle compared to the trematode and cestode life cycles.

Nematodes may or may not use an intermediate host. If there is no intermediate host, the life cycle is said to be a **direct life cycle**. For example, canine hookworms (*Ancylostoma* spp.) develop to the infective third stage in the external environment. They penetrate the dog's skin and migrate to the small intestine, where they mature to adults. The canine hookworm's life cycle is said to be "direct."

If the nematode uses an intermediate host, the life cycle is said to be an **indirect life cycle**. For example, a female mosquito ingests microfilariae of the canine heartworm, *D. immitis*, along with her blood meal. The mosquito incubates the microfilariae, and they eventually develop into infective third-stage larvae within the proboscis (mouthparts) of the mosquito. When the mosquito takes a blood meal from an uninfected dog, the infective third-stage larvae emerge from the mouthparts and migrate into the puncture wound made by the mosquito. Within the dog, the third-stage larvae molt to fourth-stage larvae and then molt again to fifth-stage larvae (immature, or preadult, heartworms). These larvae migrate to the dog's right ventricle and



**FIGURE 3-16:** Life cycle of the nematode.

pulmonary artery, where they mature to adults. The adults breed and the females produce microfilariae. The life cycle begins again. (See Figure 1-10.) The canine heartworm's life cycle is said to be "indirect."



#### TECHNICIAN'S NOTE

The nematode can develop by a direct life cycle with no intermediate host or it can develop through an indirect life cycle where an intermediate host is necessary to complete the life cycle.

A few nematodes produce eggs that do not hatch in the external environment. Within this egg the larva develops to the second stage but does not hatch from the egg. It remains within the egg; the infective stage for these nematodes is the egg containing the second-stage larva.

It is important to remember that there are many variations for this typical nematode life cycle. For every nematode, there is a distinct life cycle; however, the life cycles of most of the nematodes discussed in this book fit those described here.

## CHAPTER THREE TEST

---

MATCHING—Match the term with the correct phrase or term.

- |                        |                                                                 |
|------------------------|-----------------------------------------------------------------|
| A. Direct life cycle   | 1. Fingerlike projections of a copulatory bursa                 |
| B. Indirect life cycle | 2. The infective stage for many nematodes                       |
| C. Spicules            | 3. The “penis” of a male nematode                               |
| D. Cervical alae       | 4. The nematode does not utilize an intermediate host           |
| E. Copulatory bursa    | 5. Female nematode gives “birth” to live larvae                 |
| F. Bursal rays         | 6. Having separate sexes—both male and female nematodes         |
| G. Larviparous         | 7. The shedding of the cuticle (“skin”) of a nematode           |
| H. Third-stage larva   | 8. Morphologic feature on the anterior end of an adult nematode |
| I. Molt                | 9. Morphologic feature on the posterior end of a male nematode  |
| J. Dioecious           | 10. The nematode does utilize an intermediate host              |

## QUESTIONS FOR THOUGHT AND DISCUSSION

---

1. Diagnostically speaking, which reproductive system (male or female) is more important in veterinary practice? Would you rather use a male nematode for diagnosis or a female nematode for diagnosis of a parasite problem? Why?
2. Compare and contrast the following types of nematode eggs. You may use drawings with labels to illustrate differences. Give examples of nematodes that typify these egg types (see Chapter 4 for examples).
  - Ascaroid- or ascarid-type egg
  - Trichostrongyle or strongyle-type egg
  - Spiruroid-type egg
  - Trichinelloid- or trichuroid-type egg
3. Compare and contrast the terms direct life cycle versus indirect life cycle. For each type, give an example of a genus of nematodes that utilizes this type of life cycle.
4. What are some external morphologic features that are used to identify intact adult nematodes?
5. Describe the “typical nematode life cycle.”
6. Define the following terms that are commonly used in a veterinary practice:
  - Direct life cycle
  - Indirect life cycle
  - Infective third-stage larva
  - Trichinelloid- or trichuroid-type egg
  - Oviparous nematode

This page intentionally left blank

# Nematodes That Infect Domestic Animals

## KEY TERMS

Prepatent period  
Vermifuge  
Vermicide  
L2 larvae  
Parthenogenesis  
Microfilaria  
Adulticide  
Rhabditiform  
  esophagus  
Benzimidazoles  
Probenzimidazoles  
Strongyles  
Cutaneous  
  habronemiasis  
Cutaneous draschiasis  
Summer sores  
Cutaneous  
  onchocerciasis  
Thumps  
Asymptomatic  
Oxyurids  
Neotenic

## OUTLINE

Nematodes of Dogs and Cats	Nematodes of Swine
<i>Gastrointestinal Tract</i>	<i>Gastrointestinal Tract</i>
<i>Circulatory System</i>	<i>Respiratory Tract</i>
<i>Respiratory System</i>	<i>Urinary Tract</i>
<i>Urinary Tract</i>	<i>Musculoskeletal System</i>
<i>Skin</i>	Nematodes of Mice
<i>Eye and Adnexa</i>	<i>Gastrointestinal Tract</i>
Nematodes of Ruminants	Nematodes of Rats
<i>Gastrointestinal Tract</i>	<i>Gastrointestinal Tract</i>
<i>Circulatory System</i>	Nematodes of Hamsters
<i>Respiratory System</i>	<i>Gastrointestinal Tract</i>
<i>Skin</i>	Nematodes of Gerbils
<i>Eye and Adnexa</i>	<i>Gastrointestinal Tract</i>
<i>Abdominal Cavity</i>	Nematodes of Guinea Pigs
Nematodes of Equids	<i>Gastrointestinal Tract</i>
<i>Gastrointestinal Tract</i>	Nematodes of Rabbits
<i>Respiratory System</i>	<i>Gastrointestinal Tract</i>
<i>Skin</i>	Nematodes of Pet and Aviary
<i>Eye and Adnexa</i>	Birds
<i>Abdominal Cavity</i>	<i>Gastrointestinal Tract</i>

## LEARNING OBJECTIVES

*After studying this chapter, the reader should be able to do the following:*

- Remember scientific names and corresponding common names for major parasites affecting domestic and laboratory animals.
- Recognize pathology produced by nematodes of domesticated and laboratory animals.
- Recognize ova and distinctive larval stages of major parasites affecting domestic and laboratory animals.
- Understand life cycles of:
  - Canine roundworm (*Toxocara canis*)
  - Canine hookworm (*Ancylostoma caninum*)
  - Canine whipworm (*Trichuris vulpis*)
  - Canine heartworm (*Dirofilaria immitis*)



- Feline heartworm (*Dirofilaria immitis*)
- Ruminant lungworm (*Dictyocaulus viviparus*)
- Equine roundworm (*Parascaris equorum*)
- Equine large and small strongyles (*Strongylus vulgaris*)

This chapter includes brief descriptions of many of the common nematode parasites of domesticated (and wild) animals in the United States. The discussions include information on the tissue, organ, or organ system parasitized in the host. Where appropriate, information is also provided on the **prepatent period** (time from the point of infection until a specific diagnostic stage can be recovered), the diagnostic stage (life cycle stage) most often identified, a morphologic description of this diagnostic stage (e.g., eggs, larvae, or adult), and treatment for the most common parasites.

## NEMATODES OF DOGS AND CATS

### Gastrointestinal Tract

**Parasite:** *Spirocerca lupi*

**Host:** Canines and felines

**Location of Adult:** Esophageal wall

**Distribution:** Tropical and subtropical regions

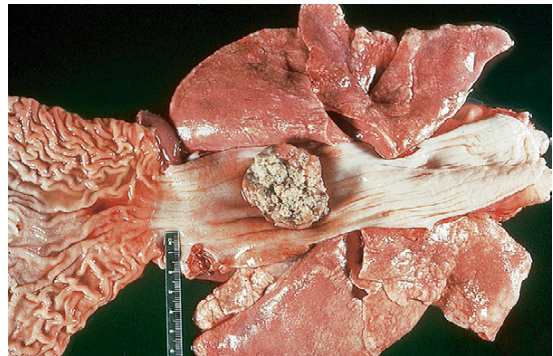
**Derivation of Genus:** Coiled tail

**Transmission Route:** Ingestion of egg

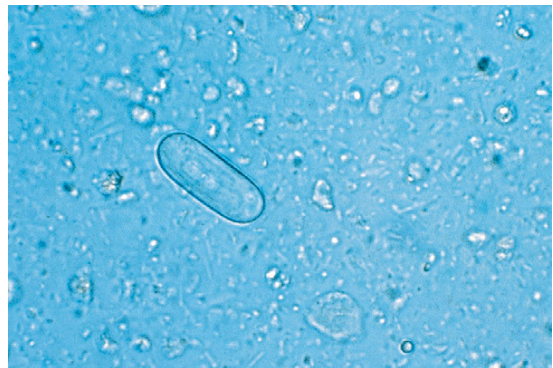**Common Name:** Esophageal worm

*Spirocerca lupi*, the esophageal worm, is a nematode usually associated with the formation of nodules in the esophageal wall of dogs and cats. Occasionally, this roundworm may be found in granulomas or nodules in the stomach wall of both dogs and cats (Figure 4-1). Adult worms reside in tunnels deep within these nodules and expel their eggs through the fistulous (tract-like) openings in the nodules. These nodules can cause obstruction of the gastrointestinal tract, esophagus, or stomach. Eggs are passed down the esophagus and out in the feces. The thick-shelled eggs of *S. lupi* are 30 to 37  $\mu\text{m} \times 11$  to

15  $\mu\text{m}$  and contain a larva when laid. These eggs have a unique “paper clip” shape (Figure 4-2). An animal is infected by ingesting the eggs of this parasite. Eggs usually can be observed on fecal flotation but may also be recovered from vomitus that has been subjected to standard fecal flotation procedures. Radiographic or endoscopic examination may reveal a characteristic nodule



**FIGURE 4-1:** *Spirocerca lupi*, the esophageal worm, is a nematode usually associated with formation of nodules in the esophageal wall of dogs and cats.



**FIGURE 4-2:** Characteristic thick-shelled eggs of *Spirocerca lupi*, with unique “paper clip” shape.

or granuloma within the esophagus or stomach. The prepatent period for this roundworm is 6 months.

**TECHNICIAN'S NOTE** Adult *Spriocerca lupi* reside inside nodules, which can cause esophageal obstruction.

**Parasite:** *Physaloptera* species

**Host:** Canines and felines

**Location of Adult:** Lumen of the stomach or small intestine, more commonly attached to the stomach mucosa

**Distribution:** Worldwide

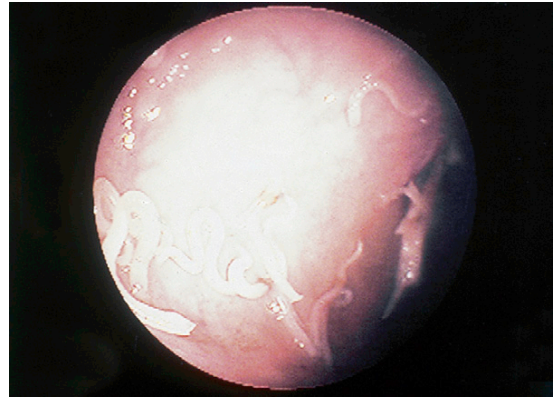
**Derivation of Genus:** Bladder wing

**Transmission Route:** Ingestion of eggs

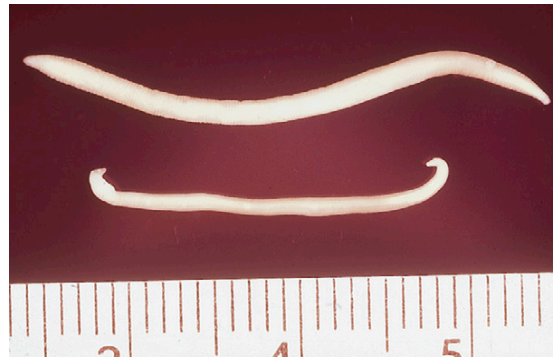
**Common Name:** Canine and feline stomach worms

*Physaloptera* species are stomach worms of both the dog and the cat. Although occasionally found in the lumen of the stomach or small intestine, *Physaloptera* species are usually firmly attached to the mucosal surface of the stomach, where they suck blood. With the use of an endoscope, these nematodes can be observed in their attachment sites (Figure 4-3). Their diet consists of blood and tissue derived from the host's gastric mucosa. The feeding habits of these worms may expose their attachment sites, which often continue to bleed after the parasite has detached. Vomiting, anorexia, and dark, tarry stools are often observed in infected animals. The adults are creamy white, sometimes tightly coiled, and 1.3 to 4.8 cm long (Figure 4-4). They may also be recovered in the pet's vomitus; when this happens, *Physaloptera* can easily be confused with ascarids. A quick way to differentiate the two parasites is to break open an adult specimen and (if the specimen is female) examine the eggs microscopically.

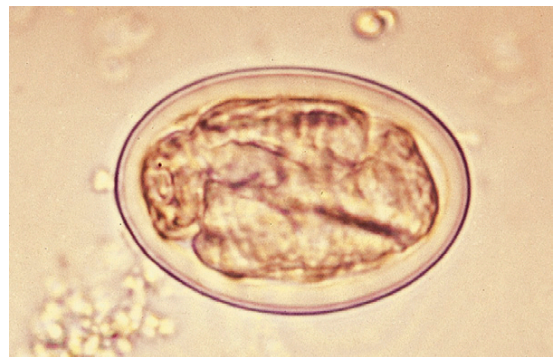The eggs of *Physaloptera* species are small, smooth, thick-shelled, and embryonated (larvated) when passed in feces. These eggs are quite similar in appearance to the eggs of *S. lupi*. They are 30 to 34  $\mu\text{m}$   $\times$  49 to 59  $\mu\text{m}$  and contain a larva when laid. (See Figure 4-5 for the characteristic egg of *Physaloptera* species.) This parasite infects



**FIGURE 4-3:** Endoscopic view of *Physaloptera* species firmly attached to mucosal surface of stomach.



**FIGURE 4-4:** Adult of *Physaloptera* is creamy white, sometimes tightly coiled, and 1.3 to 4.8 cm long.



**FIGURE 4-5:** Characteristic smooth, thick-shelled, embryonated (larvated) eggs of *Physaloptera* species. Eggs usually can be recovered on standard fecal flotation, using solutions with a specific gravity above 1.25.

animals that ingest the larvated eggs. Eggs can usually be recovered on standard fecal flotation of either feces or vomitus, using solutions with a specific gravity greater than 1.25. The prepatent period for this nematode is 56 to 83 days.



**TECHNICIAN'S NOTE** The eggs of *Physaloptera* species can be confused with ascarids.

**Parasite:** *Aonchotheca putorii*

**Host:** Felines and minks

**Location of Adult:** Small intestine

**Distribution:** Tropic and temperate countries, worldwide.

**Derivation of Genus:** Sheath diminished in bulk

**Transmission Route:** Ingestion of egg

**Common Name:** Gastric capillarid of cats

*Aonchotheca putorii* is commonly referred to as the “gastric capillarid of cats.” This nematode was once known by another scientific name, *Capillaria putorii*. This capillarid frequently parasitizes mink but has also been reported in cats. *A. putorii* is rarely reported in North America. The adult parasites can be found in the small intestine where they suck blood. The eggs of *A. putorii* are easily confused with other trichuroid nematodes. (See the following section on identification of feline whipworms.) The eggs of *A. putorii* are 53 to 70  $\mu\text{m}$   $\times$  20 to 30  $\mu\text{m}$  and exhibit a netlike surface similar to the eggs of *Eucoleus aerophilus*, another capillarid found in the upper respiratory system. The eggs of *A. putorii* are dense and less delicate than those of *E. aerophilus*; they have flattened sides and contain a one- or two-cell embryo that fills the egg. This parasite is passed to new hosts by ingestion of the embryonated egg. The eggs can be detected on fecal flotation.

**Parasite:** *Ollulanus tricuspis*

**Host:** Felines

**Location of Adult:** Stomach

**Distribution:** Worldwide

**Derivation of Genus:** Small feline hair

**Transmission Route:** Ingestion of larvae from vomitus

**Common Name:** Feline trichostrongyle

*Ollulanus tricuspis* is the feline trichostrongyle. As a group, the trichostrongyles are considered to be parasites of the gastrointestinal tract of ruminants, such as cattle, sheep, and goats; it is quite unusual for the cat to serve as a host for a trichostrongyle. *O. tricuspis* is often diagnosed in cats that exhibit chronic vomiting. These nematodes are usually identified by examining the cat's vomitus under a dissecting or compound microscope. Feline vomitus can also be examined with a standard fecal flotation procedure. The best flotation solution for identification is a modified Sheather's flotation solution. Adult female *O. tricuspis* are tiny, only 0.8 to 1 mm long, and possess three major tail cusps, or toothlike processes, on the tip of the tail (thus the specific epithet *tricuspis*). Adult male nematodes are 0.7 to 0.8 mm long and possess a copulatory bursa. The female worms are larviparous and release infective third-stage larvae (500  $\times$  22  $\mu\text{m}$ ), which mature to adults in the cat's stomach. This feline trichostrongyle also is unusual in that these third-stage larvae are immediately infective for any cat that may ingest vomitus containing them. Free-living stages in the external environment are not required for completion of the life cycle.



**TECHNICIAN'S NOTE** *Ollulanus tricuspis* females release third-stage infective larvae that are immediately infective to cats.

**Parasites:** *Toxocara canis*, *Toxocara cati*, and *Toxascaris leonina*

**Host:** Canines and felines

**Location of Adults:** Small intestine

**Distribution:** Worldwide

**Derivation of Genus:** *Toxocara* – arrowhead, *Toxascaris* – arrow ascaris

**Transmission Route:** Ingestion of egg with infective larva

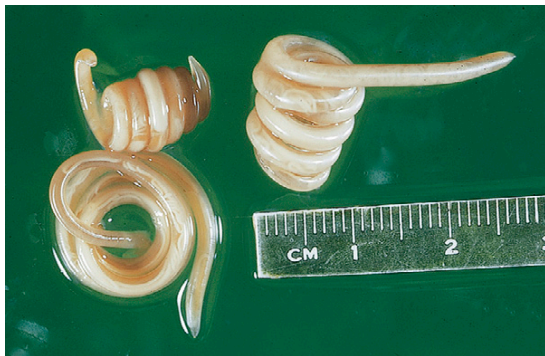**Common Name:** Canine and feline roundworms

*Toxocara canis*, *Toxocara cati*, and *Toxascaris leonina* are the **ascarids**, or large roundworms, of dogs and cats. These roundworms may be found in the small intestine of dogs and cats in



most areas of the world. All young puppies and kittens presenting to a veterinary clinic should be examined for the presence of these large, robust nematodes. Adult ascarids may vary in length from 3 to 18 cm and, when passed in the feces, are usually tightly coiled, similar to a coiled bedspring (Figure 4-6). Ascarids in young puppies and kittens may produce vomiting, diarrhea, constipation, and other nonspecific clinical signs. The adult worm does not attach to the host but rather uses an undulating motion to remain in the small intestine. Therefore, adult worms may “swim” into the stomach and cause vomiting. The worm may then be present in the vomitus. Because of the presence of the adult worm in the vomitus, the owner may describe the vomitus as having “spaghetti” in it. An accumulation of adults can cause gastrointestinal obstruction.

The eggs of *Toxocara* species are unembryonated, spherical, and have a deeply pigmented center and rough, pitted outer shell. Eggs of *Toxocara canis* are  $75 \times 90 \mu\text{m}$  in diameter (Figure 4-7), whereas those of *Toxocara cati* are smaller, 65 to  $75 \mu\text{m}$  in diameter (Figure 4-8). The eggs of *Toxascaris leonina* are spherical to ovoid, with dimensions of  $75 \times 85 \mu\text{m}$ . In contrast to the eggs of *Toxocara* species, the eggs of *T. leonina* have a smooth outer shell and a hyaline, or “ground glass,” central portion (Figure 4-9). The prepatent period for *T. canis* is 21 to 35 days, whereas that of *T. leonina* is 74 days.

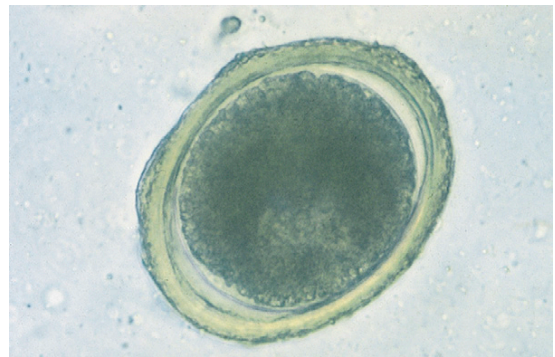


**FIGURE 4-6:** Adult ascarids may vary in length from 3 to 18 cm and when passed in feces are usually tightly coiled.

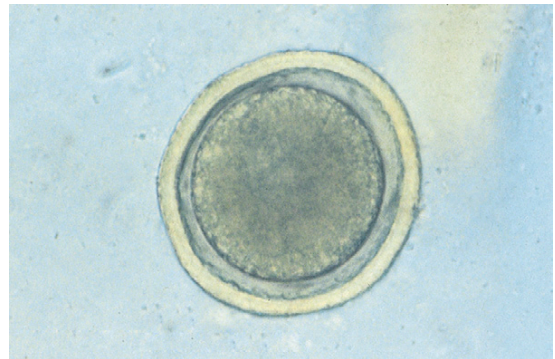
Ascarids are among the most frequently diagnosed nematodes in young puppies and kittens.

**TECHNICIAN'S NOTE** Adult ascarids are commonly seen in vomitus and may be described by pet owners as “spaghetti-like” worms.

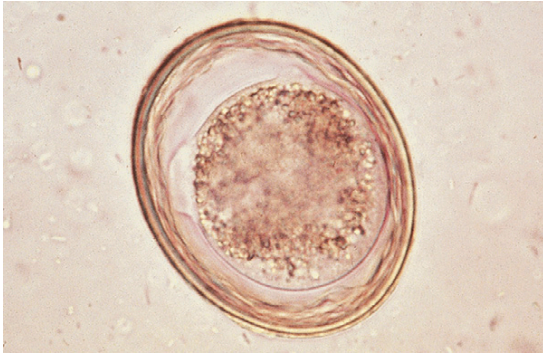
Adult roundworms are present in the small intestine, where they mate. The female produces unembryonated eggs that are passed in the host's feces. The eggs embryonate on the ground, to the point that they contain **L2 larvae**. They are ingested by a host and the L2 larvae are



**FIGURE 4-7:** Egg of *Toxocara canis* with unembryonated, spherical form with deeply pigmented center and rough, pitted outer shell.



**FIGURE 4-8:** Characteristic egg of *Toxocara cati* is similar in structure to that of *T. canis* but smaller in diameter.



**FIGURE 4-9:** Eggs of *Toxascaris leonina* are spherical to ovoid, with dimensions of  $75 \times 85 \mu\text{m}$ . In contrast to eggs of *Toxocara* species, these eggs have a smooth outer shell and hyaline, or “ground glass,” central portion.

released from the eggs. The L2 larvae may go into dormancy in an adult host, but they grow and migrate to various tissues in the young host. Finally, the L2 larvae migrate to the young host’s lungs, where they are coughed up and swallowed by the host. They grow to adulthood in the host’s small intestine and begin a new life cycle (Figure 4-10).

In the adult female host, the infective larvae remain dormant until the female host mates and produces hormones during pregnancy. At this time the larvae become active once more and migrate through the female host’s body. The larvae (with the exception of *T. cati*) can cross the placental barrier to infect the host’s offspring. The most common symptoms of a roundworm infection are diarrhea, vomiting, and a potbellied appearance.

The most common way of identifying an infection by *T. canis*, *T. cati*, or *T. leonina* is through the fecal flotation technique. Usually the pregnant female will have feces tested for these parasites to determine the chances of her puppies or kittens becoming infected. Puppies and kittens are routinely dewormed during their first few visits to the veterinary office.

Several types of anthelmintics can be used to treat a roundworm infection. A **vermifuge** (anthelmintic that paralyzes the parasite so it passes out in the feces) such as piperazine or

pyrantel is often used to treat this type of parasite. A **vermicide** (anthelmintic that kills the parasite and allows the parasite to be broken down by the body) such as thiabendazole or mebendazole can also be used to treat a roundworm infection.



**TECHNICIAN’S NOTE** The best way to identify a roundworm infection is through the fecal flotation technique.

*T. canis*, although primarily a parasite of the dog, can also infect humans (*visceral larva migrans*), as discussed in Chapter 17. The best way to prevent infection to humans and other animals is cleaning up feces in the yard daily. Also, prevent children from playing in the yard and placing their contaminated hands to their mouths.

**Parasite:** *Baylisascaris procyonis*

**Host:** Raccoon, but also seen in many species

**Location of Adult:** Small intestine

**Distribution:** North America (Mississippi-Ohio River basin)

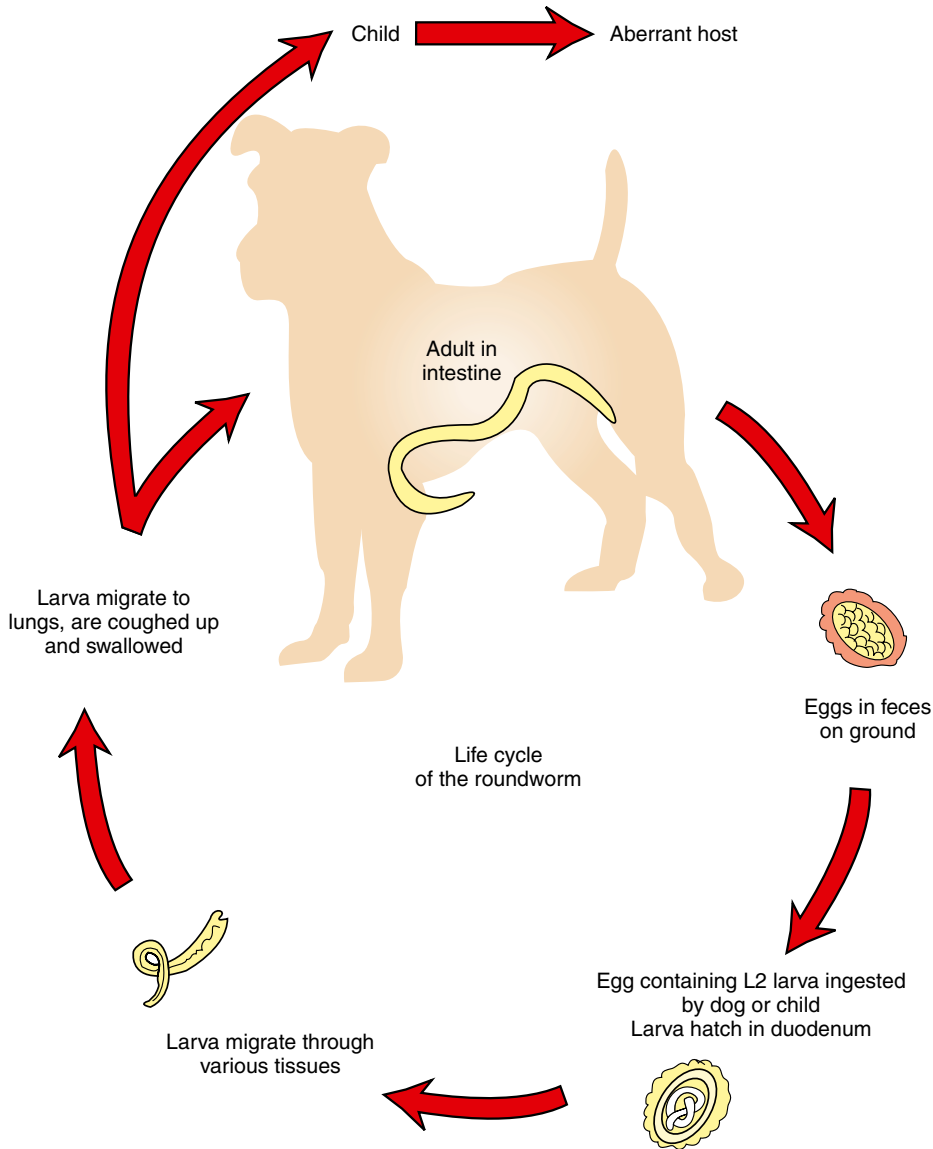
**Derivation of Genus:** Named after a famous parasitologist, Dr. Baylis

**Transmission Route:** Ingestion of eggs

**Common Name:** Raccoon roundworm

*Baylisascaris procyonis* is the roundworm of the raccoon. *Baylisascaris procyonis* is common in North America and is a zoonotic parasite. The adult resides in the small intestine of the raccoon. The ova are found in the feces. The ova are unembryonated and spherical with a deeply pigmented center and a rough/pitted outer shell. It is slightly smaller than the ova of *Toxocara canis* (Figure 4-11). Accumulation of the adults in the small intestine can cause a gastrointestinal obstruction in the natural host.

*B. procyonis* is diagnosed by finding the ova on fecal flotation. The ova can be found anywhere that raccoons defecate and in naturally infected canines. While the raccoon is the natural host, it can cause zoonotic disease in many species. Since the larvae migrate to the central nervous system, this is a very pathogenic parasite in the incidental



**FIGURE 4-10:** Life cycle of the roundworm.

host (Bowman, 2009), producing a zoonotic condition known as *neurologic larva migrans*.

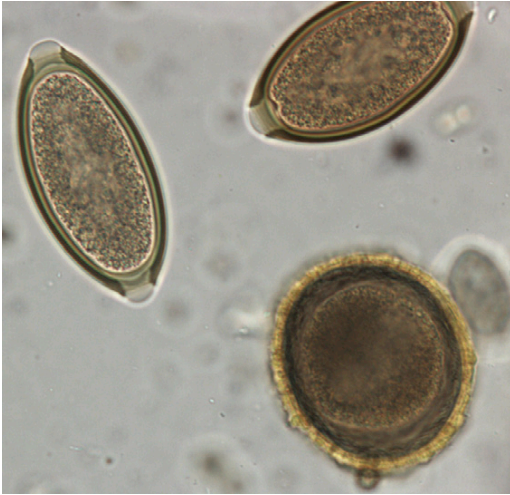

**TECHNICIAN'S NOTE** *Baylisascaris procyonis* is a very pathogenic zoonotic parasite that can infect humans.

**Parasites:** *Ancylostoma caninum*, *Ancylostoma tubaeforme*, *Ancylostoma braziliense*, and *Uncinaria stenocephala*

**Host:** *A. caninum* (canine), *A. tubaeforme* (feline), *A. braziliense* (canine and feline), and *U. stenocephala* (canine)

**Location of Adult:** Small intestine



**FIGURE 4-11:** Egg of *Baylisascaris procyonis* and two eggs of *Trichuris vulpis*. (From Bowman: Georgis' Parasitology for Veterinarians, ed 9, 2008, Elsevier.)

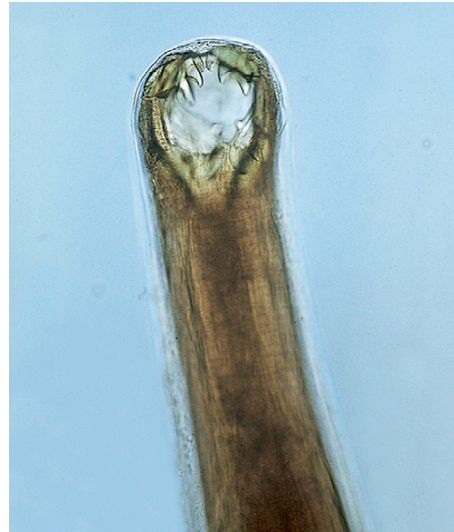**Distribution:** *Ancylostoma* species (worldwide), *Uncinaria stenocephala* (northern regions of North America)

**Derivation of Genus:** *Ancylostoma*-curved mouth and straight trumpet shape, *Uncinaria*-hooked nose and narrow head

**Transmission Route:** Ingestion of eggs, through the skin, across placenta, and through mammary milk

**Common Name:** Canine and feline hookworm

*Ancylostoma caninum*, the canine hookworm; *Ancylostoma tubaeforme*, the feline hookworm; *Ancylostoma braziliense*, the canine and feline hookworm; and *Uncinaria stenocephala*, the northern canine hookworm, are nematodes that infect the small intestine. Hookworms are found throughout the world but are most often found in tropical and subtropical areas of North America. Hookworms attach to the small intestinal mucosa. *A. caninum* demonstrates a frightful buccal cavity—it has three pairs of ventral teeth with which it attaches to the mucosa of the small intestine (Figure 4-12). These parasites may change feeding sites and reattach elsewhere in the small intestine. Because this hookworm feeds on blood, it secretes an anticoagulant from its mouth, which causes the former attachment

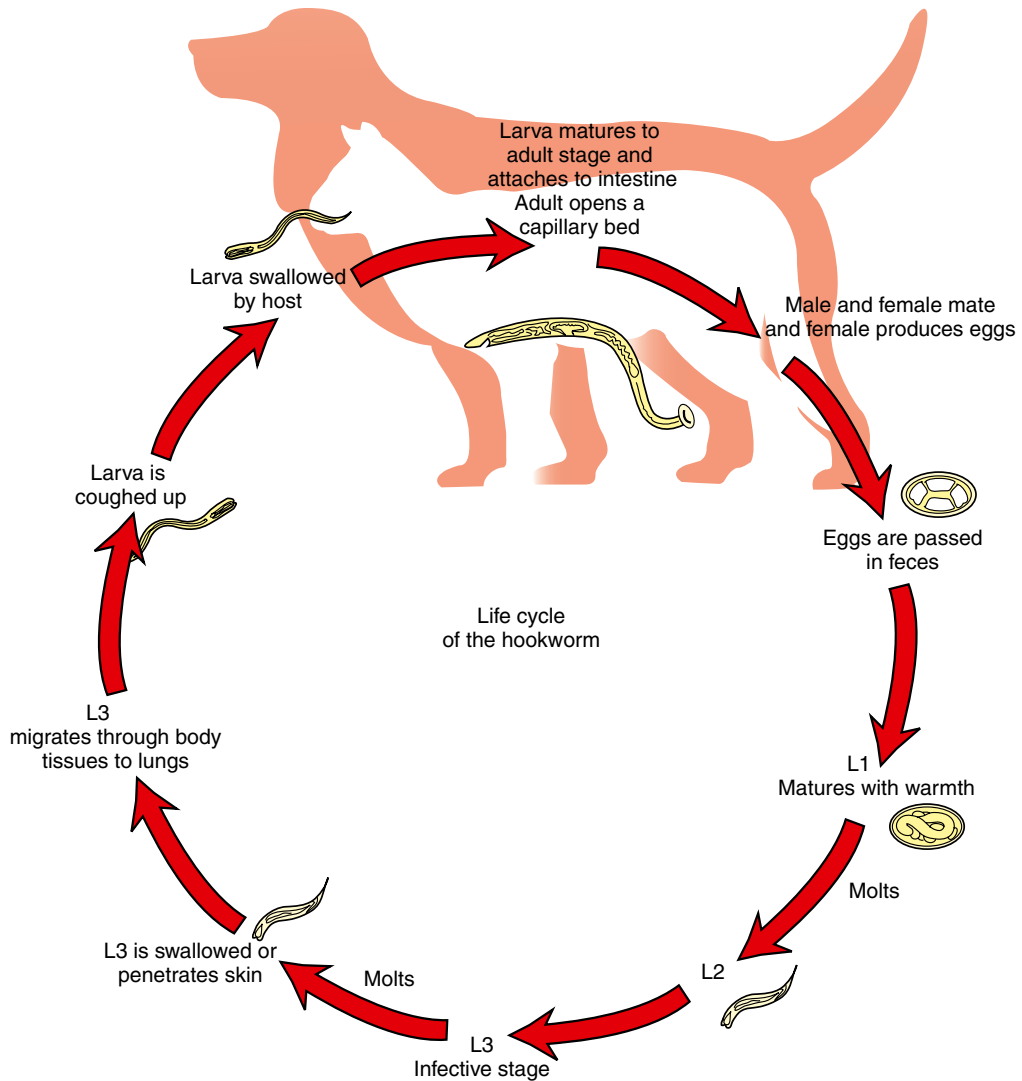


**FIGURE 4-12:** *Ancylostoma caninum* demonstrates a frightful buccal cavity, with three pairs of ventral teeth with which it attaches to mucosa of the small intestine of dogs.

sites to continue to bleed. Thus the hookworm's voracious feeding activity and the secondary hemorrhage produced can cause significant anemia. Because this bleeding occurs within the small intestine, the blood is often digested by the host and often appears as a black, tarry stool. The resulting anemia can be quite severe in young kittens and puppies. Hookworms often produce serious problems in kennels and catteries. The prepatent period depends on the species of hookworm. Animals are usually infected through percutaneous, prenatal, and transmammary routes.

The male and female worms attach to adjacent villi of the intestinal wall. The male and female mate continuously, and therefore the female continually produces eggs that are laid in the feces. The egg contains the morula stage as it is passed out of the host's body in the feces. These eggs embryonate into L1 larvae in the external environment. The L1 larvae hatch, feed, grow, and molt to L2 larvae. The L2 larvae feed, grow, and molt to L3 larvae, but do not release the cuticle of the L2 larvae. They are ensheathed L3 larvae that do not feed. They are the infective stage larvae. The L3 larvae can be ingested, or they can penetrate





**FIGURE 4-13:** Life cycle of the hookworm.

the host's intact skin and migrate through the tissues of the body until they reach the lungs. Once in the lungs, the larvae are coughed up and swallowed by the host (Figure 4-13).



**TECHNICIAN'S NOTE** Hookworms can cause a black, tarry stool in the host due to the attachment and reattachment of the parasite and digestion of free blood in the intestinal tract.

The larvae of this parasite are able to cross the placenta and also can be passed from mother to offspring through the colostrum. Therefore the pregnant host should be checked several times during pregnancy for the presence of these parasites. Since these parasites can penetrate intact skin, they can also enter the skin of humans (*cutaneous larval migrans*), as discussed in Chapter 17.

Eggs of all hookworm species are oval or ellipsoidal, thin-walled, and contain an 8- to 16-cell



morula when passed in feces. Because these eggs embryonate, or larvate, rapidly in the external environment (as early as 48 hours), fresh feces are needed for diagnosing hookworm infections. Eggs of *A. caninum* are 56 to 75  $\mu\text{m} \times 34$  to 47  $\mu\text{m}$ ; those of *A. tubaeforme*, 55 to 75  $\mu\text{m} \times 34.4$  to 44.7  $\mu\text{m}$ ; those of *A. braziliense*, 75  $\times$  45  $\mu\text{m}$ ; and those of *U. stenocephala*, 65 to 80  $\mu\text{m} \times 40$  to 50  $\mu\text{m}$ . These eggs can be easily recovered on standard fecal flotation (Figure 4-14).



**TECHNICIAN'S NOTE** Hookworms are easily recovered and identified in a standard fecal flotation technique.

Treatment for the hookworm species can take two forms. The first is prevention with the use of once-a-month heartworm preventive agents; Interceptor™ and Heartgard Plus™ are the most common brands although there are other brands of heartworm preventatives that also work against hookworms. Many of these preventive medications are also labeled for the prevention of hookworms. If the parasite eggs are found on fecal flotation or other techniques, the veterinarian may choose a vermicide such as mebendazole or fenbendazole.

The best way to prevent hookworm species from infecting animals or humans is removing the feces after defecation by the host. Removal during warm weather should take place immediately after defecation, whereas removal during cold months may take place every other day.



**TECHNICIAN'S NOTE** The best way to prevent hookworm infections is to remove feces from the yard on a daily basis before the larvae hatch from the ova.

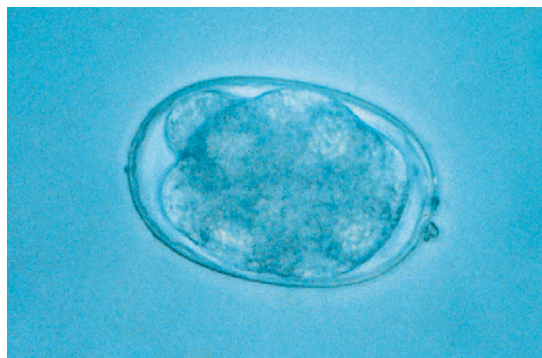
**Parasites:** *Strongyloides stercoralis* and *Strongyloides tumiefaciens*

**Host:** Dogs, cats, and humans

**Location of Adult:** Small intestines

**Distribution:** Worldwide

**Derivation of Genus:** Round-like shape



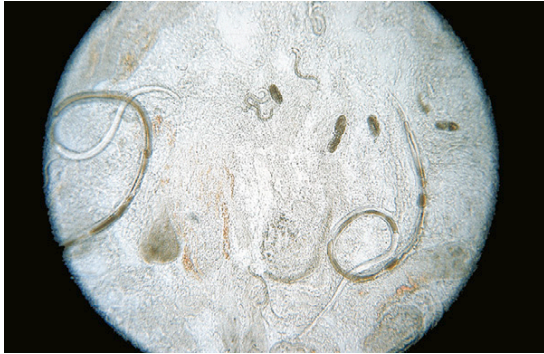**FIGURE 4-14:** Eggs of all hookworm species are oval or ellipsoidal, thin-walled, and contain an 8- to 16-cell morula when passed in feces. These eggs may represent one of several genera that parasitize dogs and cats: *Ancylostoma caninum*, *A. tubaeforme*, *A. braziliense*, and *Uncinaria stenocephala*.

**Transmission Route:** Through the skin and in mammary milk

**Common Name:** Intestinal threadworms

Because parasitic males do not exist, the female worms are capable of producing viable ova without fertilization from a male worm. This process is called **parthenogenesis**.

*Strongyloides stercoralis* and *S. tumiefaciens* are often referred to as intestinal threadworms. These nematodes are unique in that only a parthenogenetic female is parasitic in the host and resides in the small intestines. The female has an approximately cylindric esophagus that is one-quarter the length of the parasite's body. These females produce embryonated or larvated eggs, but in dogs, the eggs hatch in the intestine, releasing first-stage larvae that may be observed in fresh feces. (Figure 4-15 shows the parasitic adult females, eggs, and first-stage larvae of *Strongyloides* species.) The larval *Strongyloides* species are 280 to 310  $\mu\text{m}$  long and possess a rhabditiform esophagus with a club-shaped anterior corpus, a narrow median isthmus, and caudal bulb. The larvae go through a free-living stage in the environment before becoming infective third-stage larvae that can penetrate the skin and cause migratory damage in the host. In the dog, the major method of transmission is from mother to pups through the mammary



**FIGURE 4-15:** Parasitic adult females, eggs, and first-stage larvae of *Strongyloides stercoralis*, intestinal threadworms.

glands. The prepatent period is 8 to 14 days. These nematodes are frequently associated with a moderate-to-severe diarrhea in young puppies, particularly in kennel environments during the summer months. Since humans can also be infected with *S. stercoralis* there is the potential of zoonosis called Strongyloidiasis.

**TECHNICIAN'S NOTE** In dog feces, you will commonly find the larvae (rather than ova) of *Strongyloides* species.

**Parasites:** *Trichuris vulpis*, *Trichuris campanula*, and *Trichuris serrata*

**Host:** *T. vulpis* (canine), *T. campanula*, and *T. serrata* (feline)

**Location of Adult:** Cecum and colon

**Distribution:** Worldwide but *T. campanula* and *T. serrata* are rare in North America

**Derivation of Genus:** Hair tail

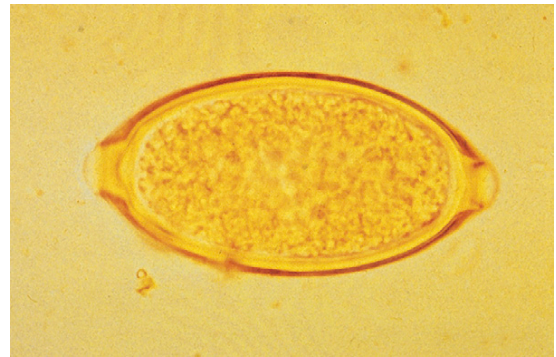**Transmission Route:** Ingestion of eggs

**Common Name:** Whipworm

*Trichuris vulpis*, the canine whipworm, and *Trichuris campanula* and *Trichuris serrata*, the feline whipworms, reside in the cecum and colon of their respective definitive hosts. Whipworms are a common clinical occurrence in dogs; however, it is important to remember that feline whipworms are quite rare in North America and have been diagnosed only sporadically



**FIGURE 4-16:** *Trichuris vulpis*, the canine whipworm, derives its common name from the fact that adults possess a thin, filamentous anterior end ("lash" of the whip) and thick posterior end ("handle" of the whip).



**FIGURE 4-17:** Characteristic egg of *Trichuris vulpis* is described as *trichinelloid* or *trichuroid*; it has a thick, yellow-brown, symmetric shell with polar plugs at both ends. Eggs are unembryonated (not larvated) when laid.

throughout the world. Whipworms derive their name from the fact that the adults have a thin, filamentous anterior end (the "lash" of the whip) and a thick posterior end (the "handle" of the whip (Figure 4-16). The thin end of the whipworm was once thought to be the tail of the parasite. The egg of the whipworm is described as *trichuroid* or *trichinelloid*; it has a thick, yellow-brown, symmetric shell with prominent polar plugs at both ends. The eggs are unembryonated (not larvated) when laid. Eggs of *T. vulpis* are 70 to 89  $\mu\text{m} \times 37$  to 40  $\mu\text{m}$ . (Figure 4-17 shows the characteristic egg of *T. vulpis*.) The prepatent period for *T. vulpis* is 70 to 90 days.

The adult *Trichuris* species are attached to the wall of the cecum or colon where they suck blood and produce eggs. The eggs are passed out in the feces of the host every third day. Once in the environment, the eggs will go through a period of development to become an L2 (infective) larva within the egg. Unlike the hookworm species, the whipworm species must be ingested by the host. The L2 larva will hatch from the egg once in the host's small intestine. The larva will molt several times in the small and large intestine before becoming an adult. The new adult will migrate back through the colon to the cecum and attach to the intestinal wall (Figure 4-18). The most common symptoms seen in infected animals are diarrhea, anemia, and mucus-coated stool.

**TECHNICIAN'S NOTE** The eggs of *Trichuris* species are only passed in the stool every third day rather than every day like most nematodes.

The eggs of *T. campanula* and *T. serrata*, the feline whipworms, may be easily confused with *Aonchotheca putorii*, *Eucoleus aerophilus*, and *Personema feliscati*, parasites of the feline stomach, respiratory tract, and urinary system, respectively. The eggs of *T. campanula* average 63 to 85  $\mu\text{m} \times 34$  to 39  $\mu\text{m}$  (Figure 4-19). When examining a cat's feces for trichurids, it is important that the diagnostician remember that pseudoparasites, that is, the eggs of trichurids or capillarids, may parasitize nonfeline hosts, such as mice, rabbits, or birds (an outdoor cat's prey). The eggs of trichurids or capillarids from a cat's prey may pass undigested and unaltered through the cat's gastrointestinal system, remaining intact and unembryonated.

Fecal flotation is the most common way of identifying the eggs of this parasite; however, whipworm eggs do not float well in most common fecal flotation media. Therefore, it is imperative that the eggs be allowed to float for a minimum of 15 minutes before viewing under the microscope. Once identified, the veterinarian

will most often use the vermicides mebendazole or fenbendazole for treatment of these worms. Prevention involves daily feces removal to remove the uninformative eggs from the host's environment.

**Parasite:** *Enterobius vermicularis*

**Host:** Humans

**Distribution:** Worldwide

**Derivation of Genus:** Intestinal life

**Transmission Route:** Ingestion of eggs

**Common Name:** Human pinworm

Dogs and cats may often be blamed for serving as hosts for certain parasites of humans. *Enterobius vermicularis* is the pinworm found in humans and is often found in young children. This pinworm *does not* parasitize dogs or cats. Nevertheless, the family pet is often falsely incriminated by physicians, family practitioners, and pediatricians as a source of pinworm infection in young children. The veterinary diagnostician should remember this rule: Pinworms are parasites of omnivores (mice, rats, monkeys, and humans) and herbivores (rabbits and horses) but *never* carnivores (dogs and cats).

**TECHNICIAN'S NOTE** Because whipworm ova are heavy and hard to float, they require at least 15 minutes with a standard fecal flotation technique before viewing under a microscope. Ideally, centrifugal flotation should be used to better float the whipworm ova.

## Circulatory System

**Parasite:** *Dirofilaria immitis*

**Host:** Canine, feline, and ferret. Has been observed in humans as an incidental parasite.

**Intermediate Host:** Female mosquito

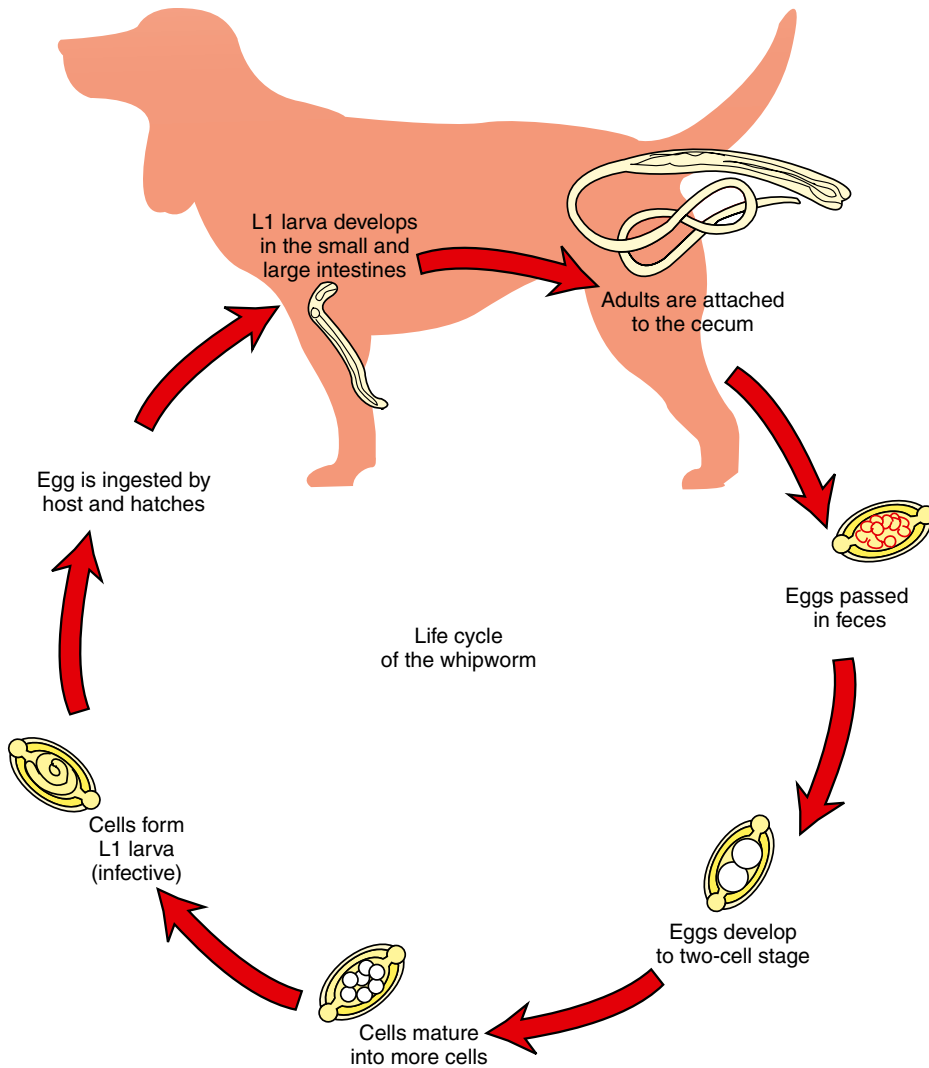
**Location of Adult:** Right ventricle and pulmonary arteries

**Distribution:** Warm-temperate climates around the world

**Derivation of Name:** Dread thread and inexorable

**Transmission Route:** Bite of infective mosquito

**Common Name:** Heartworm



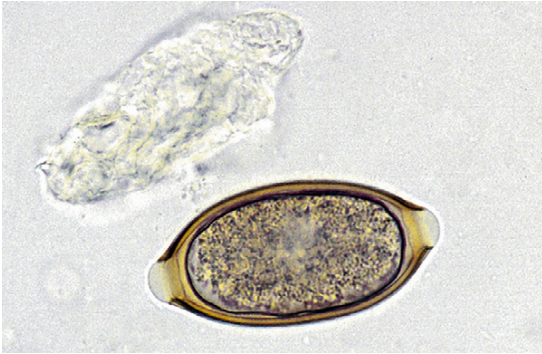
**FIGURE 4-18:** Life cycle of the whipworm.

*Dirofilaria immitis* is often referred to as the canine heartworm (Figure 4-20); however, this nematode has been known to parasitize cats and ferrets as well (Figure 4-21). The definitive host for *D. immitis* is the canine. Although cats and ferrets have been parasitized by this parasite, they rarely serve as a source for transmission. Heartworms are long, slender parasites (Figure 4-22). As adults, these parasites are found within the right ventricle and the pulmonary artery and

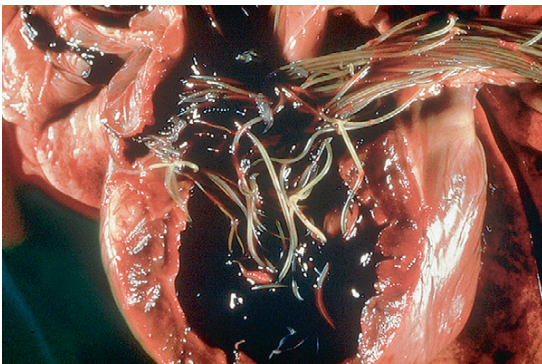
its fine branches. The offspring of filarial worms such as *D. immitis* are known as **microfilariae**.

Among the nematodes of small animals, *D. immitis* is perhaps the one nematode that may be found in sites other than its normal predilection sites. This parasite is often recovered in a variety of aberrant sites, such as the brain, anterior chamber of the eye (Figure 4-23), and subcutaneous sites. The prepatent period in dogs is approximately 6 months.

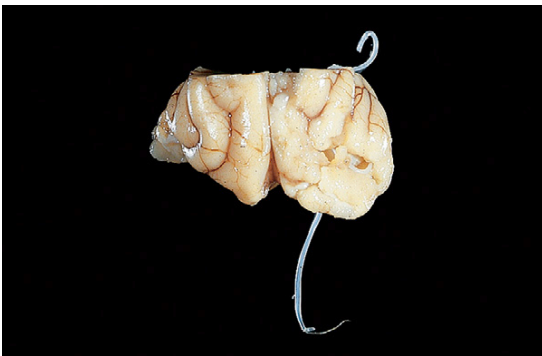



**FIGURE 4-19:** Egg of *Trichuris campanula* (pictured) and *T. serrata*, the feline whipworms, may be easily confused with *Aonchotheca putorii*, *Eucoleus aerophilus*, and *Personema feliscati*, parasites of the feline stomach, respiratory tract, and urinary system, respectively. Eggs of *T. campanula* average 63 to 85  $\mu\text{m}$   $\times$  34 to 39  $\mu\text{m}$ .




**FIGURE 4-20:** Adults of *Dirofilaria immitis*, the canine heartworm, are found within right ventricle and pulmonary artery and its fine branches.



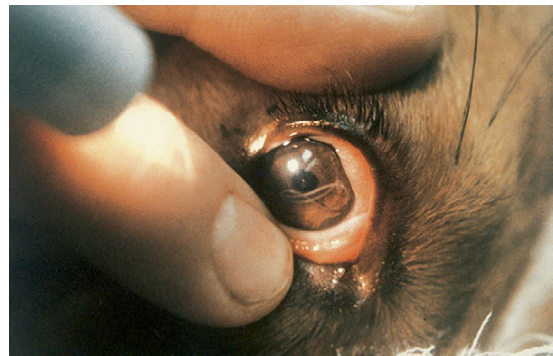
**FIGURE 4-21:** Canine heartworms may be found in sites other than the heart and in hosts other than the dog. These heartworms have been recovered from the brain of a ferret.

**TECHNICIAN'S NOTE** *Dirofilaria immitis* is the parasite that causes heartworm disease in dogs and cats. It has a prepatent period of 6 months before it can be diagnosed in the dog.

The life cycle of *D. immitis* requires the mosquito intermediate host to be transmitted from animal to animal. The adults live in the right ventricle and pulmonary artery where they can obstruct the blood vasculature. The male and female adults mate, and the female produces microfilariae. The microfilariae are released into the host's bloodstream, where they are ingested by feeding female mosquitoes. The microfilariae grow and molt in the mosquito until they reach



**FIGURE 4-22:** Heartworms are long, slender parasites, evolved for fitting into the fine branches of pulmonary arteries.



**FIGURE 4-23:** *Dirofilaria immitis*, the canine heartworm, may also be recovered from a variety of aberrant sites, such as the anterior chamber of the eye.

the infective stage. Once they become infective, they enter a new host the next time the mosquito feeds (Figure 4-24). Once in the new host, the larvae migrate and molt through various body tissues on their way to the heart. It is at this time that the larvae may grow and molt to become adults in sites other than the heart.



**TECHNICIAN'S NOTE** *Dirofilaria immitis* larvae must develop to an infective stage within a mosquito before they can be transferred to a new host.

In microfilaremic dogs, diagnosis is made by observing microfilariae in blood samples, using one of several concentration techniques, such as the modified Knott's test (Figures 4-25 and 4-26) or commercially available filter techniques (Figure 4-27). For dogs (amicrofilaremic or microfilaremic), infection can also be diagnosed using one of the commercially available enzyme-linked immunosorbent assay (ELISA) tests (Figure 4-28). It is important to remember that a subcutaneous filariid of dogs, *Acanthocheilonema* (formerly known as *Dipetalonema*) *reconditum*, also produces microfilariae in the peripheral blood (Figures 4-29 and 4-30). The microfilariae of this non-pathogenic nematode must be differentiated from those of *D. immitis* (see Figures 4-25 and 4-26).

The damage that *D. immitis* causes to the heart will cause the hallmark symptoms of heartworm disease in dogs. The symptoms are a decrease in exercise tolerance, right-sided heart enlargement, and abdominal ascites (fluid accumulation in the abdomen). These symptoms are caused by the parasite's location in the heart and pulmonary arteries, which reduces blood flow on the right side of the heart and causes inflammation to the lining of the blood vessels.



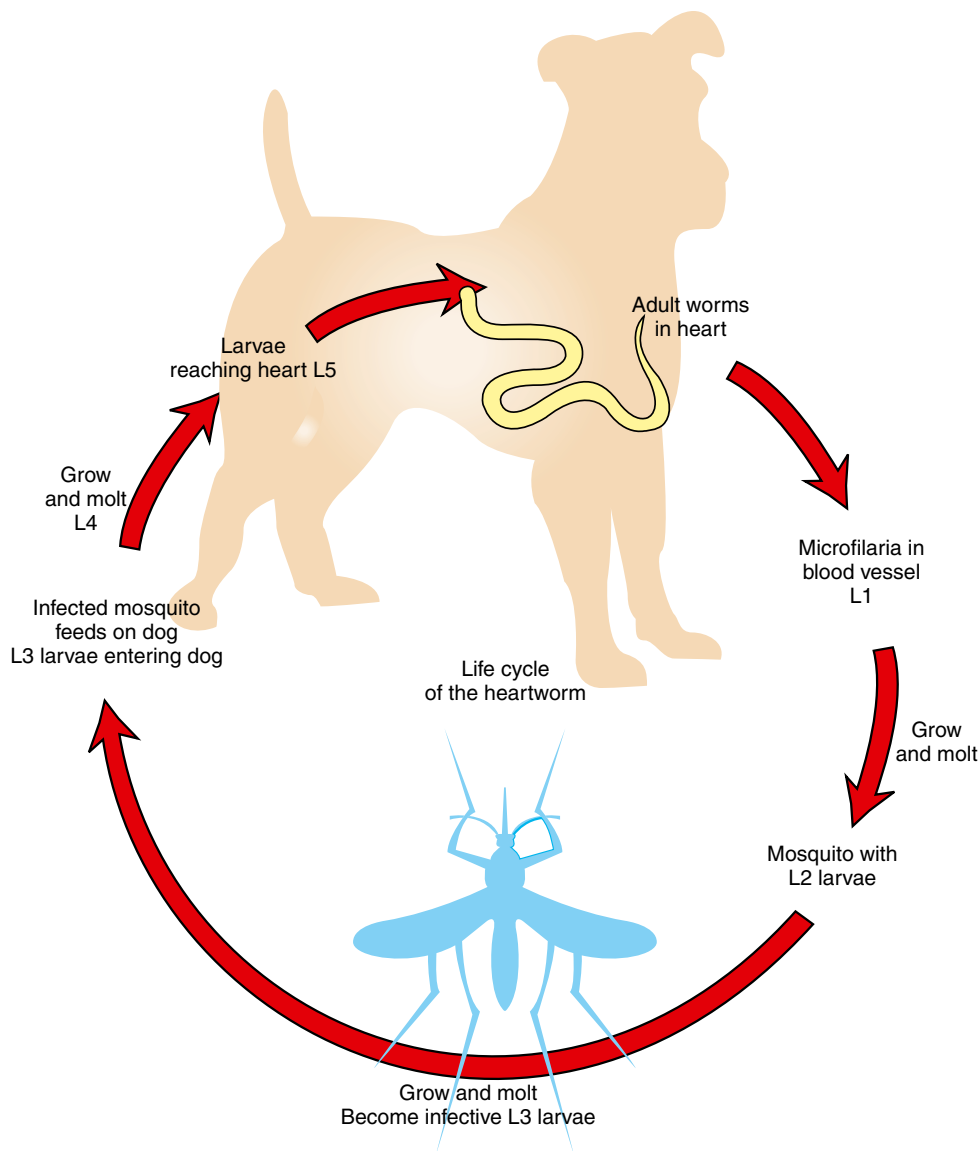
**TECHNICIAN'S NOTE** The classic symptoms of heartworm disease are exercise intolerance, right-sided heart enlargement, and abdominal ascites caused by reduced blood flow on the right side of the heart.

The treatment for heartworm disease involves pretreatment testing, treatment, and posttreatment rest. The first step in treatment involves determining the canine's ability to withstand the treatment by performing blood work; this determines the status of the internal organs. Radiographs are taken to determine the status of the heart and the stage of the disease. After testing, the canine is treated for the adult heartworms. **Adulticides** (drugs that will kill the adult stages of the parasite) such as Immiticide™ (Merial Limited, [www.merial.com](http://www.merial.com)) are used to kill the adult heartworms. As the adults die, they will move with the flow of blood toward the lungs. This could cause problems for the canine if it is allowed to exercise after the adulticide treatment. The canine must be kept quiet for several weeks after treatment while the body resorbs the dead adults. Once the adults have been treated and resorbed by the body, the canine is treated with a **microfilaricide** (usually ivermectin) to clear the blood of any microfilariae. The final part of the treatment is the heartworm testing. This usually involves a microfilariae test and an ELISA test to confirm the microfilariae and adults have been cleared from the canine's body.

The treatment for canine heartworm disease can be very stressful on the dog's body. Therefore, prevention is recommended so that the dog does not contract the parasite. The various preventive regimens include daily preventive medications, monthly medications, and an injection every 6 months.

Feline hosts for *Dirofilaria immitis* occur in the same areas that canines are infected. Cats are susceptible to the parasite but tend to be very resistant to infection. Therefore, it takes a greater exposure to the microfilariae from the mosquito to infect a cat than it does a dog. Whereas *D. immitis* causes enough damage to produce hallmark symptoms in dogs, cats do not show specific symptoms of the infection. Cats tend to show signs similar to those seen with respiratory disease.

The life cycle of *D. immitis* in cats begins as it does in dogs. The adults live in the right ventricle and pulmonary arteries of the dog. The adults mate, and the female produces microfilariae, which are present in the vessels of the dog.

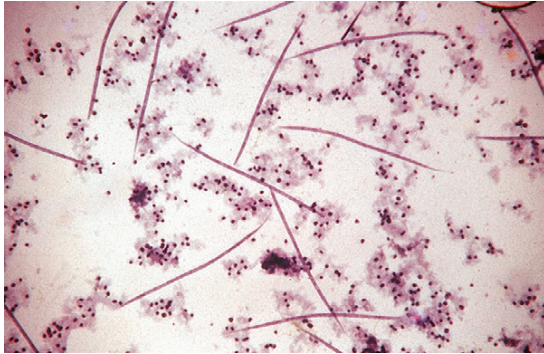


**FIGURE 4-24:** Life cycle of the canine *Dirofilaria immitis*.

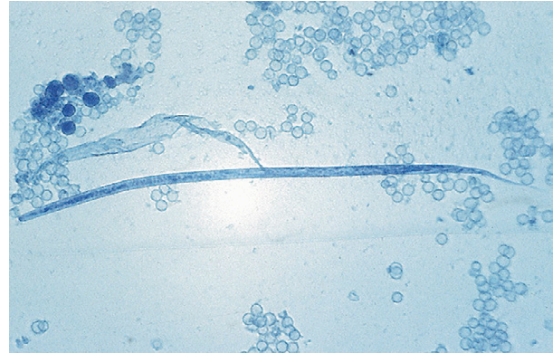
Mosquitoes feed on the infected canine and ingest the microfilariae. The microfilariae grow and molt to the infective L3 larvae. Once infective, the mosquito feeds on a cat, and the larvae are transferred to the cat. The larvae grow, molt, and migrate in the cat on their way to the heart (Figure 4-31).

**TECHNICIAN'S NOTE** Feline heartworm diseases do not produce the hallmark symptoms observed in canine heartworm disease. The symptoms are similar to those seen with respiratory disease.

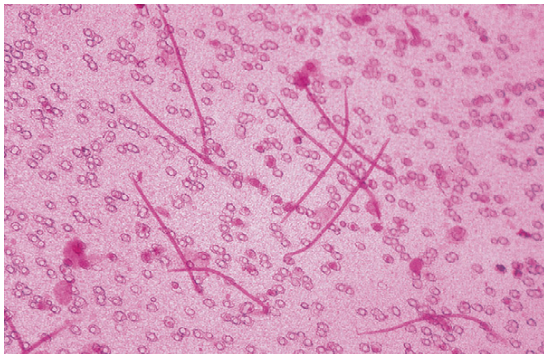




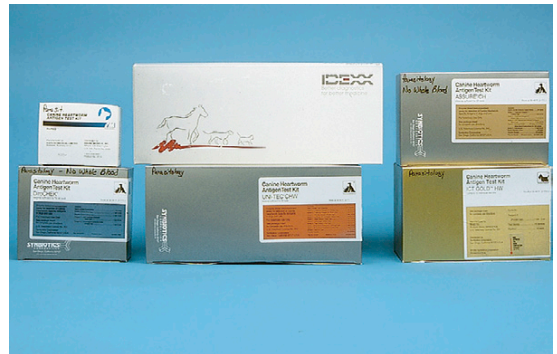**FIGURE 4-25:** Microfilariae of *Dirofilaria immitis* subjected to modified Knott's test. Microfilariae of this pathogenic nematode must be differentiated from those of *A. reconditum*.



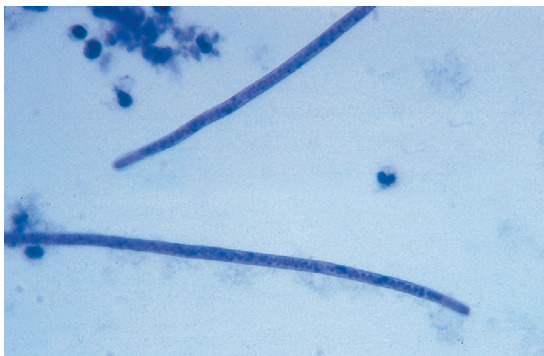
**FIGURE 4-26:** Microfilaria of *Dirofilaria immitis* subjected to modified Knott's test. Note tapering anterior end and straight tail. This microfilaria measures approximately 310  $\mu\text{m}$  in length.



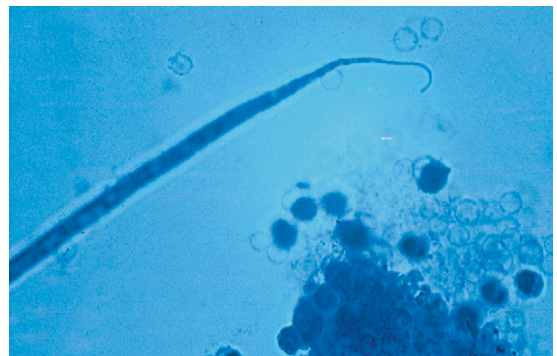
**FIGURE 4-27:** Microfilariae of *Dirofilaria immitis* subjected to commercially available filter technique.



**FIGURE 4-28:** Heartworm infection can also be diagnosed using commercially available enzyme-linked immunosorbent assay (ELISA) tests.

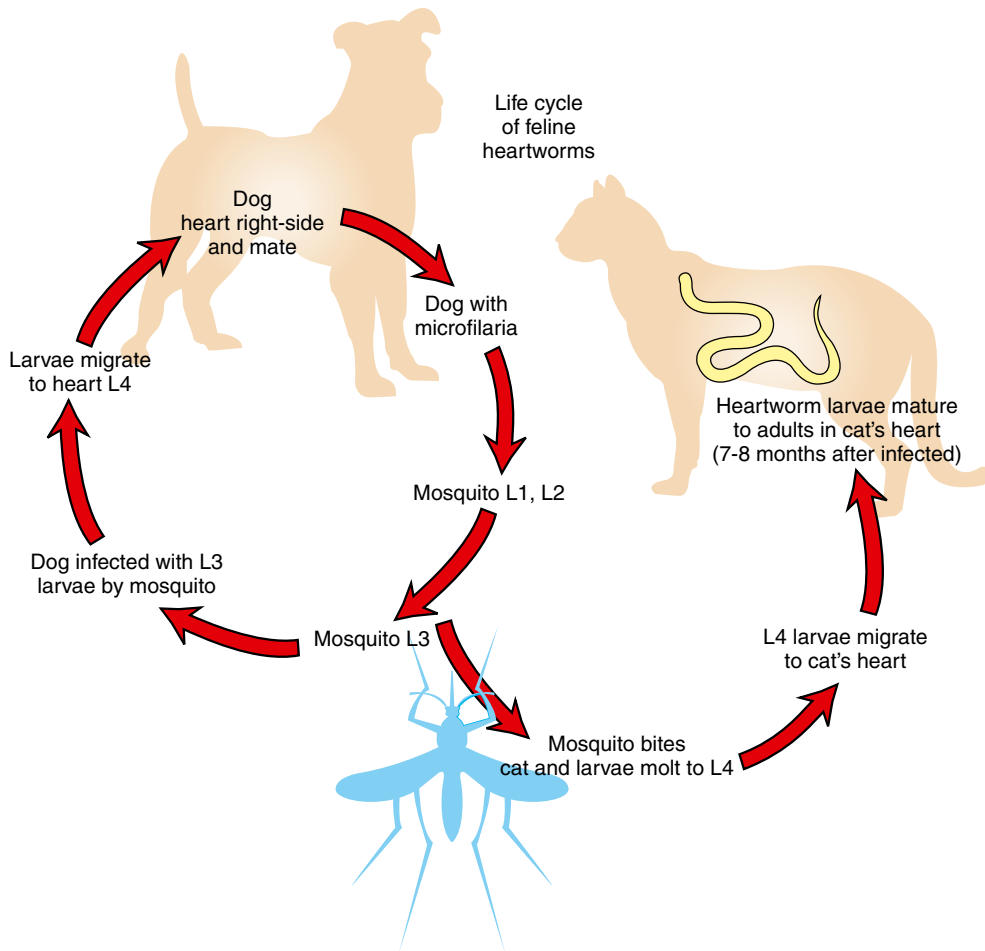


**FIGURE 4-29:** Microfilariae of *Acanthocheilonema reconditum* subjected to modified Knott's test. Note "broom handle" anterior end. This microfilaria measures approximately 280  $\mu\text{m}$  in length. Microfilariae of this nonpathogenic nematode must be differentiated from those of *Dirofilaria immitis*.



**FIGURE 4-30:** Microfilaria of *Acanthocheilonema reconditum* subjected to modified Knott's test. Note "buttonhook" posterior end, which is an artifact of formalin fixation used in modified Knott's procedure.





**FIGURE 4-31:** Life cycle of the feline *Dirofilaria immitis*.

Identification of the parasite in the cat is difficult. The adults do not produce many microfilariae in the cat, so the microfilarial tests will produce negative results in most cases. Tests developed for dogs are not sensitive enough for the infection in cats, so ELISA tests have been developed for detection of *D. immitis* in cats. Two types of tests are available for in-clinic use: antigen tests and antibody tests. The antigen test is the definitive test, although a negative result does not rule out a heartworm infection. The antibody test can detect a reaction by the cat's body to the microfilariae, but the

microfilariae may die before becoming adults. Therefore the positive antibody test does not positively detect an active infection. A positive antigen or antibody test in the presence of clinical respiratory symptoms indicates an active infection ([www.heartwormsociety.org/felineheartworminfo](http://www.heartwormsociety.org/felineheartworminfo)).

At this time there are no approved treatments for feline heartworm disease. Therefore the best treatment is prevention. Preventive options available for cats include once-a-month pills or a single topical monthly application for the prevention of feline heartworm disease.



**TECHNICIAN'S NOTE** The best way to test for feline heartworm disease is to use both an antigen test and an antibody test made for feline heartworm disease since those made for canines alone are not sensitive enough for feline heartworm disease.

## Respiratory System

**Parasite:** *Aelurostrongylus abstrusus*

**Host:** Feline

**Location of Adult:** Respiratory bronchioles and alveolar ducts

**Distribution:** Worldwide

**Derivation of Genus:** Cat strongyle

**Transmission Route:** Ingestion of larvae

**Common Name:** Feline lungworm

*Aelurostrongylus abstrusus* is the feline lungworm. The adults live in the terminal respiratory bronchioles and alveolar ducts, where they form small egg nests or nodules where they can obstruct the bronchioles. Initially, this parasite lays embryonated (larvated) eggs. The eggs of this parasite are forced into the lung tissue, where they hatch to form characteristic first-stage larvae, approximately 360  $\mu\text{m}$  long. These larvae are quite distinct; each has a tail with a unique, S-shaped bend with a dorsal spine (Figure 4-32). These larvae are coughed up by the cat, swallowed, and passed out in the feces. Diagnosis is made by finding these characteristic larvae on fecal flotation or by the Baermann technique (see Chapter 17). It is also possible to recover the larvae using a tracheal wash (Figure 4-33). The prepatent period for the feline lungworm is approximately 30 days.

**Parasite:** *Filaroides osleri*, *Filaroides hirathi*, and *Filaroides milksi*

**Host:** Canine

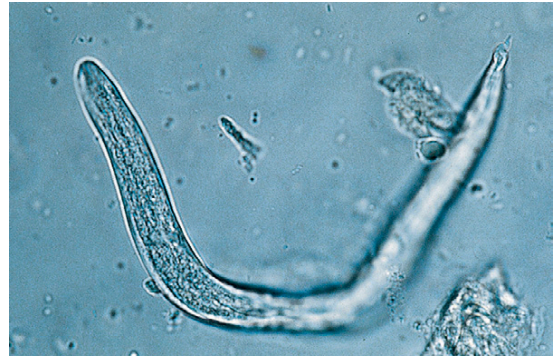**Location of Adult:** Trachea, lung parenchyma, and bronchioles, respectively

**Distribution:** North America, Europe, and Japan

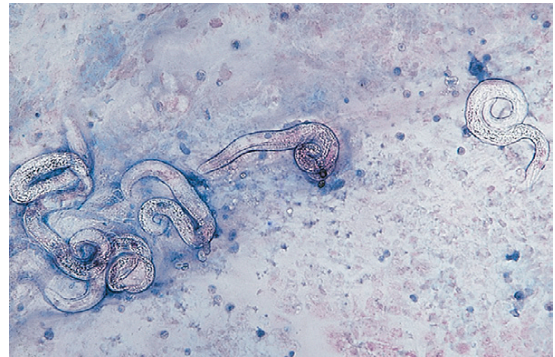
**Derivation of Genus:** Thread-like shape

**Transmission Route:** Ingestion of infected L1 larvae

**Common Name:** Canine lungworm

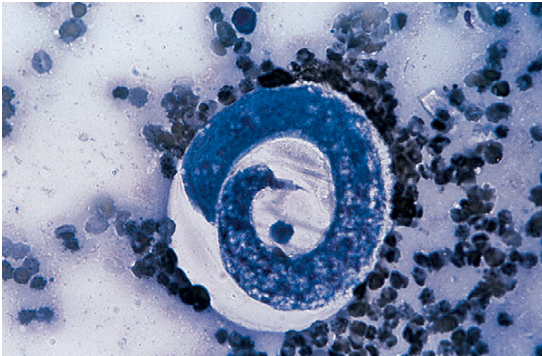


**FIGURE 4-32:** First-stage larva of *Aelurostrongylus abstrusus*, the feline lungworm. Each larva has a tail with an S-shaped bend and dorsal spine. Diagnosis is by finding these characteristic larvae on fecal flotation or by the Baermann technique.



**FIGURE 4-33:** First-stage larvae of *Aelurostrongylus abstrusus* recovered on tracheal wash.

*Filaroides osleri*, *F. hirathi*, and *F. milksi*, the canine lungworms, are found in the trachea, lung parenchyma, and bronchioles, respectively. The larva is 232 to 266  $\mu\text{m}$  in length and has a tail with a short, S-shaped appendage. *Filaroides* species are unique among nematodes in that their first-stage larvae are immediately infective for the canine definitive host. No period of development is required outside the host. These parasites are transmitted from the dam to her offspring as she licks and cleans her puppies. Diagnosis is by finding these characteristic larvae on fecal flotation or by the Baermann technique. (Figure 4-34 shows the unique infective larvae of *F. osleri*.) Nodules of *F. osleri* are usually found at the bifurcation of the trachea, where they can cause



**FIGURE 4-34:** Tracheal wash revealing characteristic first-stage larva of *Filaroides osleri*, the canine lungworm, which has a tail with a short, S-shaped appendage. *Filaroides* species are unique among nematodes in that their first-stage larvae are immediately infective for the canine definitive host. No period of development is required outside the host.

obstruction of the airway and be easily observed at necropsy (Figure 4-35). The prepatent period for *F. osleri* is approximately 10 weeks.

**Parasite:** *Eucoleus aerophilus* and *Eucoleus böehmi*

**Host:** Canines/felines and canines, respectively

**Location of Adult:** Bronchi and trachea, nasal cavity and frontal sinuses, respectively

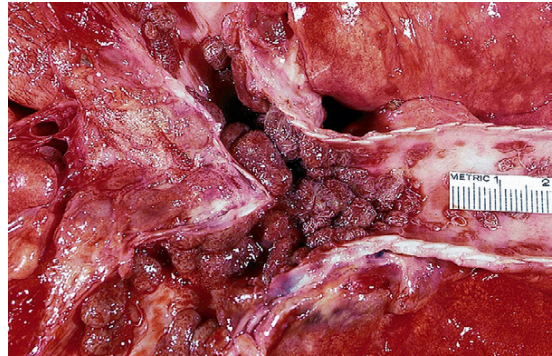
**Distribution:** North America, South America + Europe

**Derivation of Genus:** Good sheath

**Transmission Route:** Ingestion of ova from feces or mucoid discharge

**Common Name:** Respiratory capillarid

*Eucoleus aerophilus* (*Capillaria aerophila*) is a capillarid nematode found in the trachea and bronchi of both dogs and cats where they can cause an inflammatory response by the host. The prepatent period is approximately 40 days. The ova are passed through the feces or mucoid discharge from coughing them up in sputum. The ova are ingested by the host. During standard fecal flotation, eggs of *Eucoleus* species are often confused with those of *Trichuris* species (whipworms). Eggs of *E. aerophilus* are smaller than whipworm eggs (59 to 80  $\mu\text{m} \times 30$  to 40  $\mu\text{m}$ ), more broadly barrel-shaped, and lighter in color. The egg has a rough outer surface with a netted appearance (Figure 4-36). *Eucoleus böehmi* is



**FIGURE 4-35:** Nodules of *Filaroides osleri* are usually found at the bifurcation of the trachea, where they can be easily observed at necropsy.

found in the nasal cavity and frontal sinuses of dogs where it can cause obstruction of the nasal cavity and sinuses. Its eggs are smaller and have a smoother outer surface than those of *E. aerophilus*. Its shell has a pitted appearance. *E. böehmi* can be diagnosed by standard fecal flotation.

**TECHNICIAN'S NOTE** *Eucoleus aerophilus* and *Eucoleus böehmi* ova are easily confused with *Trichuris* ova on fecal flotation.

## Urinary Tract

**Parasite:** *Diectophyma renale*

**Host:** Canine

**Location of Adult:** Right kidney

**Distribution:** North America (primarily Canada) and Europe (but not Britain)

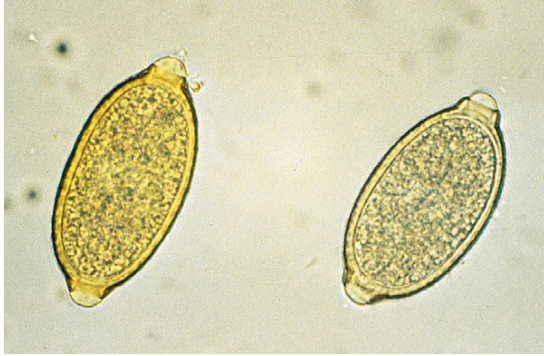**Derivation of Genus:** Distended growth

**Transmission Route:** Ingestion of infected larvae within annelid

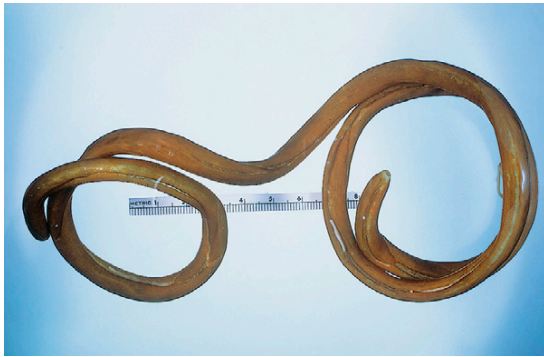**Common Name:** Canine giant kidney worm

*Diectophyma renale* is the giant kidney worm of dogs. This largest of the parasitic nematodes that affect domestic animals (Figure 4-37) frequently infects the right kidney of dogs and ingests the parenchyma, leaving only the capsule of the kidney (Figure 4-38). The eggs from the canine urine will be ingested by an annelid worm and mature into an infective larva. Ingestion of the annelid



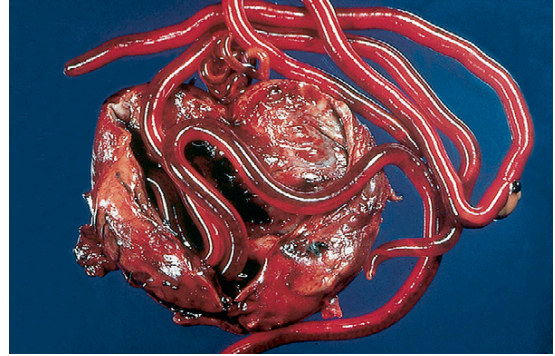


**FIGURE 4-36:** Egg of *Eucoleus aerophilus* (*Capillaria aerophila*), a capillariid nematode found in trachea and bronchi of dogs and cats. Eggs are smaller than whipworm eggs and more broadly barrel-shaped and lighter in color. Eggs have rough outer surface with netted appearance.

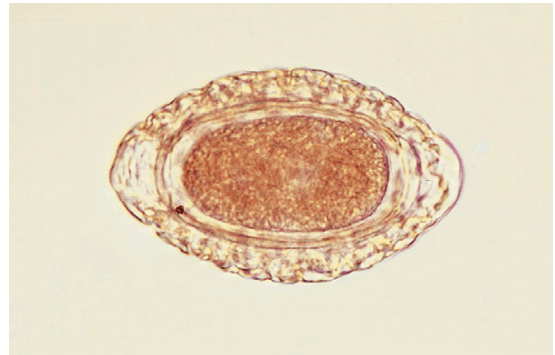


**FIGURE 4-37:** *Dioctophyma renale*, the giant kidney worm of dogs, is the largest of parasitic nematodes that affect domestic animals.

worm with an infective larva will spread the parasite to a new canine host. Eggs may be recovered by centrifugation and examination of the urine sediment. They are characteristically barrel-shaped, bipolar, and yellow-brown. The shell has a pitted appearance. Eggs measure 71 to 84  $\mu\text{m} \times$  46 to 52  $\mu\text{m}$ . (Figure 4-39 shows the characteristic egg of *D. renale*.) *D. renale* is also known for its wandering activity; it often “gets off course” during its migration to the kidney. This nematode also may occur freely within the peritoneal cavity. When the kidney worm is in an aberrant site, its eggs cannot be passed to the external environment. The prepatent period for this largest of nematodes is approximately 18 weeks.



**FIGURE 4-38:** *Dioctophyma renale* frequently infects the right kidney of dogs and ingests the entire parenchyma, leaving only the capsule of the kidney.



**FIGURE 4-39:** Egg of *Dioctophyma renale* with its characteristic barrel-shaped, bipolar, yellow-brown appearance. Shell has a pitted appearance.

**TECHNICIAN'S NOTE** *Dioctophyma renale* is the largest parasitic nematode of domestic animals and can ingest the parenchyma of the right kidney.

**Parasite:** *Pearsonema plica* and *Pearsonema feliscati*

**Host:** Canines and felines, respectively

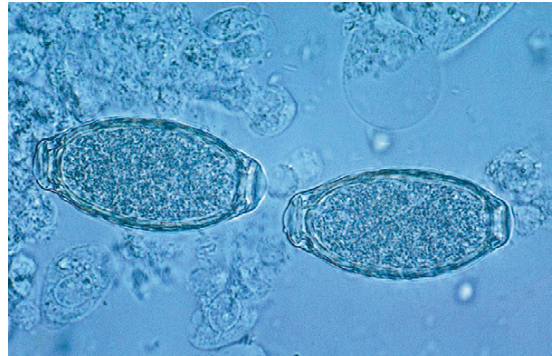
**Location of Adult:** Urinary bladder

**Distribution:** Southeastern US

**Transmission Route:** Ingestion of infective intermediate host, earthworm; ingestion of earthworm containing infected L3 larvae

**Common Name:** Bladder worm of canines and felines, respectively

*Pearsonema plica* and *Pearsonema feliscati* (formerly *capillaria*) are nematodes of the urinary bladder of dogs and cats, respectively. Their eggs may be found in urine or in feces contaminated with urine. Eggs are clear to yellow, measure 63 to 68  $\mu\text{m}$   $\times$  24 to 27  $\mu\text{m}$ , and have flattened, bipolar end plugs. The outer surface of the shell is roughened (Figure 4-40). These eggs may be confused with eggs of the respiratory and gastric capillarids and eggs of the whipworms. The eggs are ingested by an earthworm where they mature to infective larvae. If the earthworm is ingested by a new host, the larvae will migrate to the urinary bladder.



**FIGURE 4-40:** Egg of *Capillaria plica*, the urinary capillarid. Eggs are clear to yellow and have flattened bipolar end plugs and a rough outer surface. Eggs may be confused with those of respiratory and gastric capillarids and whipworms.

**TECHNICIAN'S NOTE** *Pearsonema* species can be found in urine sediment or in fecal samples contaminated with urine but the eggs can be easily confused with other capillarid ova of the respiratory and intestinal tract as well as with *Trichuris* species ova.

## Skin

**Parasite:** *Rhabditis strongyloides*

**Host:** Canine

**Location of Adult:** Superficial layers of the skin

**Distribution:** Worldwide

**Derivation of Genus:** Rod-shaped

**Transmission Route:** First-stage larvae enter directly through the skin (percutaneous)

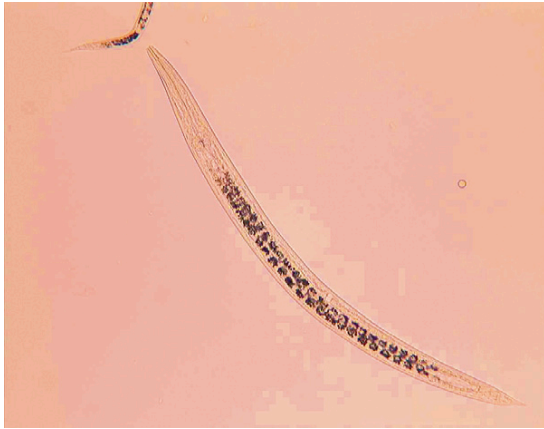**Common Name:** Free living soil nematodes

*Rhabditis strongyloides* (formerly *Pelodera*) are free-living saprophytic nematodes that normally live in moist soil. These roundworms are **facultative parasites**; that is, they are normally free-living, but under certain circumstances invade mammalian skin and develop to a parasitic mode of existence. Male and female adult *R. strongyloides* are found in soil mixed with moist organic debris, such as straw or hay. The females produce eggs that hatch into first-stage larvae. These larvae invade the superficial layers of damaged or scarified skin, producing a mild dermatitis. The skin may become reddened, denuded, and covered with a crusty material. Occasionally, a pustular

dermatitis develops. Because dogs acquire the infection by lying on contaminated bedding or soil, these lesions are usually observed on the ventral, or inner, surface of the limbs. Larvae of *R. strongyloides* also can be recovered from the skin of almost any domesticated animal, particularly downer cattle when these cows come in direct contact with soil containing larval *R. strongyloides*.

Larval (and adult) stages can be identified following superficial skin scrapings of the affected areas on the ventral, or inner, surface of the thighs where the larvae have a distinctive esophagus (Figure 4-41). Larvae of *P. strongyloides* are 596 to 600  $\mu\text{m}$  long. These larvae must be differentiated from the microfilariae of the canine heartworm, *D. immitis* (Figures 4-25 and 4-26), the microfilariae of *A. reconditum* (Figures 4-29 and 4-30), and the first-stage larvae of *Dracunculus insignis* (Figure 4-42).

As discussed earlier, *D. immitis*, the canine heartworm, normally resides in the right ventricle and pulmonary arteries of the canine definitive host. This parasite tends to wander aberrantly and may be found in a variety of extravascular sites, including cystic spaces in subcutaneous sites. Figure 4-43 shows an aberrant adult *D. immitis* in a subcutaneous interdigital cyst. When heartworms are found aberrantly, they are usually single, immature, isolated worms that have become “lost” en route to the heart. If the worm within the cyst is female, she will not have been fertilized



**FIGURE 4-41:** Larval and adult stages of *Rhabditis strongyloides* can be identified following superficial skin scrapings of affected areas that have come in contact with infected soil.

by a male heartworm. Therefore she will not be gravid and will not produce microfilariae.

**TECHNICIAN'S NOTE** Although *Rhabditis strongyloides* can cause inflammation of the skin in animals, it is usually a free-living organism.

However, other adult male and female heartworms may be in their predilection sites, the right ventricles and pulmonary arteries. It is possible for these adult females to produce microfilariae. These microfilariae occasionally may be recovered in deep skin scrapings that draw blood.

Aberrant *D. immitis* within cystic spaces in the skin can be removed surgically. When subjected to the modified Knott's procedure, the microfilariae of *D. immitis* are 310 to 320  $\mu\text{m}$  long, with straight tails and tapering anterior ends. They must be differentiated from microfilariae of *A. reconditum* (Figures 4-29 and 4-30), the first-stage larvae of *R. strongyloides* (Figure 4-41), and first-stage larvae of *D. insignis* (Figure 4-42).

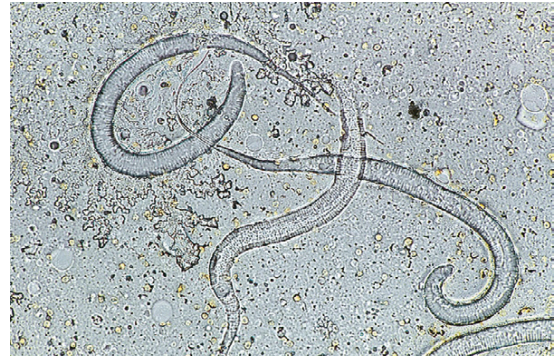**Parasite:** *Acanthocheilonema reconditum*

**Host:** Canine

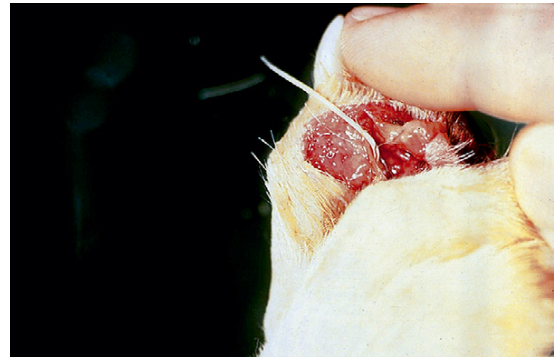**Location of Adult:** Subcutaneous tissues

**Distribution:** Tropical and subtropical regions

**Derivation of Genus:** Thorny-lipped worm



**FIGURE 4-42:** Unique first-stage larva of *Dracunculus insignis* with characteristic long, pointed tail.




**FIGURE 4-43:** Aberrant adult *Dirofilaria immitis* in subcutaneous interdigital cyst. Heartworms found aberrantly are usually single, immature, isolated worms "lost" en route to the heart.

**Transmission Route:** Bite from infected flea

**Common Name:** Canine subcutaneous filarial worm

Adult *Acanthocheilonema reconditum*, the subcutaneous filarial worm, is a nonpathogenic nematode residing in the subcutaneous tissues of the dog. The adult filarial parasites are seldom found (Figure 4-44). (See Figures 4-29 and 4-30 for the frequently seen microfilariae.) These parasites may also be found within the body cavity. Occasionally, subcutaneous abscesses and ulcerated areas have been associated with *A. reconditum*. The intermediate host for this parasite is the cat flea, *Ctenocephalides felis*. Because this parasite is found in enzootic areas where *D. immitis* is present, it is necessary to differentiate the microfilariae of these two filarial parasites.





**FIGURE 4-44:** Adults of *Acanthocheilonema reconditum*, the subcutaneous filarial worm, are nonpathogenic. They reside in subcutaneous tissues of the dog and are seldom recovered at necropsy.

**TECHNICIAN'S NOTE** *Acanthocheilonema reconditum* is transmitted to the dog by ingestion of the cat flea, *Ctenocephalides felis*.

Adult *A. reconditum* are rarely recovered from subcutaneous sites. More often, their microfilariae are recovered in peripheral blood samples. These microfilariae may be rarely recovered in deep skin scrapings that draw blood. On examination of microfilaremic peripheral blood subjected to the modified Knott's procedure, the microfilariae of *A. reconditum* average about 285  $\mu\text{m}$  in length and have "buttonhook" tails and blunt (broom handle–shaped) anterior ends (Figures 4-29 and 4-30). It is important to differentiate these microfilariae from the microfilariae of *D. immitis* (Figures 4-25 and 4-26), the first-stage larvae of *R. strongyloides* (Figure 4-41), and first-stage larvae of *D. insignis* (Figure 4-42).

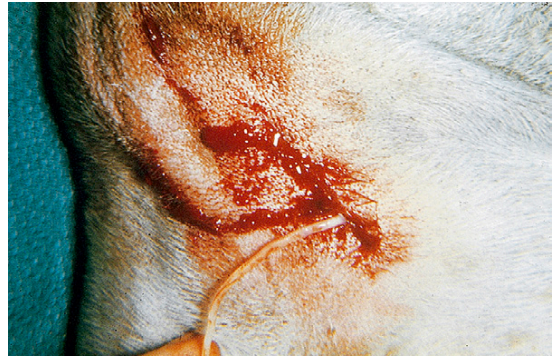**TECHNICIAN'S NOTE** *Acanthocheilonema reconditum* larvae are often confused with *Dirofilaria immitis* in a Knott's test or heartworm filter test.

**Parasite:** *Dracunculus insignis*

**Host:** Canine

**Location of Adult:** Subcutaneous tissues

**Distribution:** North America



**FIGURE 4-45:** Adult female *Dracunculus insignis*, the guinea worm, is often found in subcutaneous tissues of the dog. She causes a draining, ulcerous lesion in the skin, usually on the limb.

**Derivation of Genus:** Small dragon

**Transmission Route:** Ingestion of intermediate host, small aquatic crustaceans

**Common Name:** Guinea worm

*Dracunculus insignis*, the guinea worm, is a nematode found in the subcutaneous tissues of the dog. The adult female nematode may be extremely long, up to 120 cm in length. In comparison, the male is quite short, only 2 to 3 cm in length; however, it is rarely seen. The female resides subcutaneously and produces a draining, ulcerous lesion in the skin, usually on the dog's limb (Figure 4-45). The anterior end of the female worm extends from this ulcer. If the female worm within the lesion comes in contact with water, her uterus will prolapse through her anterior end and rupture, releasing a mass of first-stage larvae into the water. These larvae are 500 to 750  $\mu\text{m}$  in length and have long tails that are quite distinct. (See Figure 4-42 for the first-stage larvae of *D. insignis*.) Larvae are ingested by tiny crustaceans in the water; within the crustaceans, the larvae develop to the infective third stage. Dogs become infected with *D. insignis* by drinking water containing these infected crustaceans.

If *D. insignis* is observed in the ulcerous lesion, the ulcer with its associated worm should be dipped in cool water. The cool water is a stimulus for the female worm to expel her larvae. The water containing expelled larvae should be collected and centrifuged; the sediment must then

be examined for the presence of the characteristic first-stage larvae. Larvae of *D. insignis* must be differentiated from the microfilariae of *D. immitis* (Figures 4-25 and 4-26), the microfilariae of *A. reconditum* (Figures 4-29 and 4-30), and the first-stage larvae of *R. strongyloides* (Figure 4-41). Once diagnosed, the adult female worm must be surgically removed.

**TECHNICIAN'S NOTE** *Dracunculus insignis* larvae can be found on a deep skin scraping and therefore, must be differentiated from larvae of *Dirofilaria immitis* and *Acanthocheilonema reconditum*.

## Eye and Adnexa

**Parasite:** *Thelazia californiensis*

**Host:** Canine and feline

**Location of Adults:** Conjunctival sac and lacrimal duct of the eye

**Distribution:** North America

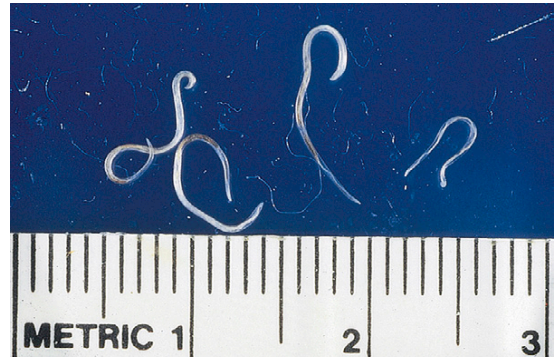
**Derivation of Genus:** Nipple saliva

**Transmission Route:** Infection by infective larvae from intermediate host, *Musca autumnalis*

**Common Name:** Eyeworm of canines and felines

*Thelazia californiensis* is the eyeworm of dogs and cats. Adult parasites can be recovered from the conjunctival sac and lacrimal duct (Figure 4-46). Examination of the lacrimal secretions may also reveal eggs or first-stage larvae. The cat or dog is infected with *T. californiensis* by larvae passed to the animal by the face fly, *Musca autumnalis*.

As mentioned previously, *D. immitis* can be recovered from a variety of aberrant sites, including the anterior chamber of the eye (Figure 4-43). As with aberrant parasites that occur in the skin, those found in the eye are usually single, immature, isolated worms that have become lost en route to the heart. If the worm within the anterior chamber is female, she will not have been fertilized by a male heartworm. Therefore she will not be gravid and will not produce microfilariae. This nematode can be surgically removed from the eye.



**FIGURE 4-46:** *Thelazia californiensis* is the eyeworm of dogs and cats. Adult parasites can be recovered from the conjunctival sac and lacrimal duct. Examination of lacrimal secretions may also reveal eggs or first-stage larvae.

**TECHNICIAN'S NOTE** *Thelazia californiensis* adults are seen in the conjunctival sac and lacrimal ducts of the dog or cat, while ova can be recovered in lacrimal secretions.

## NEMATODES OF RUMINANTS

### Gastrointestinal Tract

**Parasite:** *Gongylonema pulchrum*

**Host:** Sheep, goats, cattle, and occasionally pigs

**Location of Adult:** Submucosa and mucosa of the esophagus

**Distribution:** Worldwide

**Intermediate Host:** Dung beetle or cockroach


**Derivation of Genus:** Worms with bumps

**Transmission Route:** Ingestion of infective intermediate host, dung beetle, or cockroach

**Common Name:** Esophageal worm of ruminants

*Gongylonema pulchrum* inhabits the esophagus of sheep, goats, cattle, and occasionally pigs and horses. This parasite lies embedded within the submucosa or mucosa of the esophagus; it has a unique appearance in that it lies in a zig-zag fashion within the tissues (Figure 4-47). Its eggs are 50 to 70  $\mu\text{m}$   $\times$  25 to 37  $\mu\text{m}$ . *G. pulchrum* requires an intermediate host in which to develop before it can be transmitted to the ruminant





**FIGURE 4-47:** *Gongylonema pulchrum* inhabits the esophagus of sheep, goats, cattle, and occasionally pigs and horses. Parasite lies embedded within submucosa or mucosa of esophagus; it has a unique appearance in that it lies in a zigzag fashion.

host. A dung beetle or cockroach is required as an intermediate host. The ova can be identified by standard fecal flotation.

**Parasite:** *Bunostomum* species, *Chabertia* species, *Cooperia* species, *Haemonchus* species, *Oesophagostomum* species, *Ostertagia* species, and *Trichostrongylus* species

**Host:** Cattle, sheep, and goats

**Location of Adult:** Abomasum, small and large intestines

**Distribution:** Worldwide

**Derivation of Genus:** Mound mouth (*Bunostomum*), blood spear (*Haemonchus*), esophagus mouth (*Oesophagostomum*), and hair round (*Trichostrongylus*)

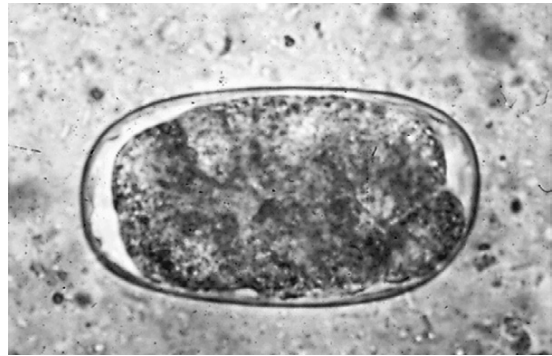
**Transmission Route:** Ingestion of infective ova

**Common Name:** Trichostrongyles of cattle and sheep



**TECHNICIAN'S NOTE** Trichostrongyle ova of any genera are too similar in appearance to accurately identify them to specific genus and species.

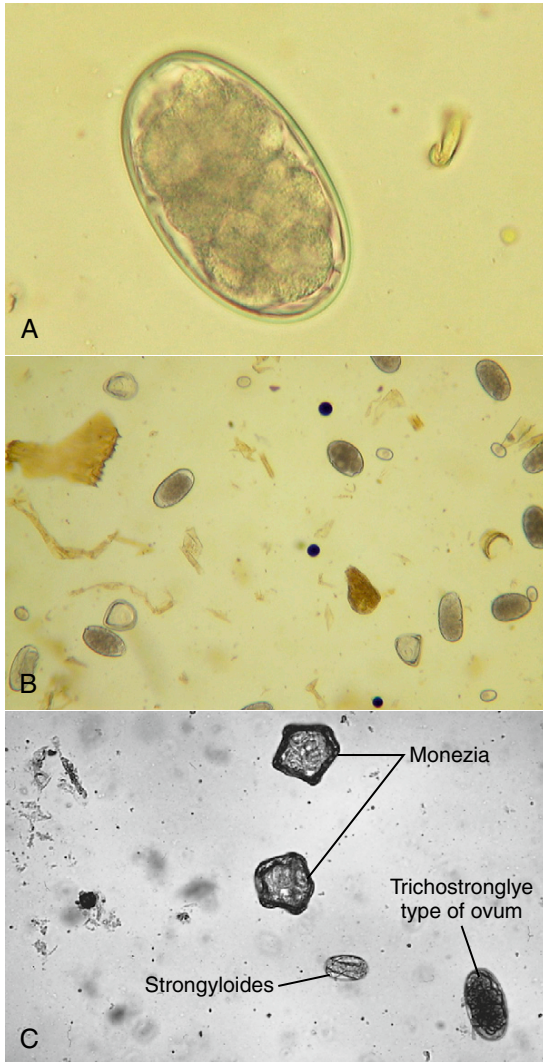
The bovine trichostrongyles comprise several genera of nematodes within the abomasum and the small and large intestines of cattle and other ruminants. The genera that can be classified as producing the trichostrongyle type



**FIGURE 4-48:** Oval, thin-shelled eggs that typify eggs of ruminant trichostrongyles. Eggs contain a morula with four or more cells. Some eggs can be identified to their respective genera; however, identification is usually difficult because mixed infections are common. Identification of these should be recorded as “trichostrongyle types of eggs,” and no attempt should be made to identify them to individual genus names.

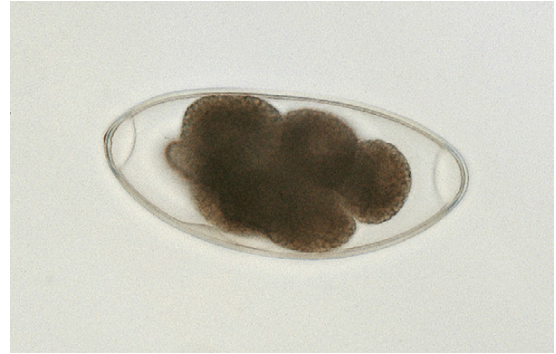
of eggs are *Bunostomum*, *Chabertia*, *Cooperia*, *Haemonchus*, *Oesophagostomum*, *Ostertagia*, and *Trichostrongylus* species. These seven genera (there are many others) produce oval, thin-shelled eggs. The bovine trichostrongyles have a similar life cycle. The adults live in the abomasum and intestines where they feed on blood from the host. The female passes eggs in the feces. The eggs have a morula that contains four or more cells and are 70 to 120  $\mu\text{m}$  in length (Figure 4-48). Some of these eggs can be identified to their respective genera; however, identification is usually difficult because mixed infections are quite common. On identification of the characteristic eggs, the veterinary diagnostician should record the identification as “trichostrongyle type of egg” and should not attempt to identify them to the individual genus names. Identification to genus and species is usually performed by fecal culture and larval identification. (Figure 4-49 shows representative examples of trichostrongyle type of eggs.) The trichostrongyles are perhaps the most common nematodes diagnosed on fecal flotation of ruminants.

The most common dewormers used for the trichostrongyles are fenbendazole, levamisole, and ivermectin.



**FIGURE 4-49:** Representative examples of trichostrongyle type of eggs. Trichostrongyles are perhaps the most common nematodes diagnosed on fecal flotation of ruminants. **A**, 400 × close-up of trichostrongyle type of egg. **B**, 100 × normal magnification. **C**, Trichostrongyle type egg with other species of parasite eggs.

**TECHNICIAN'S NOTE** The most common dewormers used for trichostrongyles are fenbendazole, levamisole, and ivermectin.



**FIGURE 4-50:** Large eggs of *Nematodirus* species. Eggs are largest of the ruminant trichostrongyle eggs and have tapering ends and a morula with four to eight cells.

**Parasite:** *Nematodirus* species and *Marshallagia* species

**Host:** Cattle, goats, and sheep

**Location of Adult:** Abomasum, small and large intestines

**Distribution:** Worldwide (*Nematodirus*) and tropical/subtropical regions (*Marshallagia*)

**Derivation of Genus:** Terrible nematode (*Nematodirus*), parasite studied by Dr. Marshall

**Transmission Route:** Ingestion of infective ova

**Common Name:** Trichostrongyles with very large eggs

*Nematodirus* species and *Marshallagia* species are also ruminant trichostrongyles; however, the eggs of these nematodes are much larger than those of the genera just mentioned and are the largest in the trichostrongyle family. Figure 4-50 shows the eggs of *Nematodirus* species. In standard fecal flotation, the eggs of *Nematodirus* species are large, 150 to 230  $\mu\text{m}$   $\times$  80 to 100  $\mu\text{m}$ , and have tapering ends and a four- to eight-cell morula. The eggs of *Marshallagia* species are also large, 160 to 200  $\mu\text{m}$   $\times$  75 to 100  $\mu\text{m}$ , and have parallel sides, a rounded end, and contain a 16- to 32-cell morula.

**TECHNICIAN'S NOTE** *Nematodirus* species and *Marshallagia* species have ova similar to the other trichostrongyle species except the eggs are the largest of the trichostrongyles.

**Parasite:** *Strongyloides papillosus*

**Host:** Cattle

**Location of Adult:** Small intestine

**Distribution:** Worldwide

**Derivation of Genus:** Round-like shape

**Transmission Route:** Ingestion of infective larvae or penetration of skin by infective larvae

**Common Name:** Bovine intestinal threadworm

*Strongyloides papillosus* is the intestinal threadworm of cattle. These nematodes are unique in that only a parthenogenetic female is parasitic in the bovine host. Parasitic male *Strongyloides* do not exist. The female worms produce larvated eggs with a **rhabditiform esophagus** measuring 40 to 60  $\mu\text{m} \times 20$  to 25  $\mu\text{m}$ . Eggs are usually recovered in flotation of fresh feces. (See Figure 4-15 for the parasitic adult females, eggs, and first-stage larvae of *Strongyloides* species.) The eggs grow and molt as they pass through the feces to the environment. Once the eggs hatch, the larvae become free-living adults or infective-stage female larvae. The infective-stage larvae can enter the host by penetration of the skin (usually between the hooves) or by ingestion. The larval *Strongyloides* species are 280 to 310  $\mu\text{m}$  long and possess a rhabditiform esophagus, with a club-shaped anterior corpus, narrow median isthmus, and caudal bulb. The larvae migrate to the lungs through the circulatory system, are coughed up, and swallowed. Once in the intestines, they mature to adults and feed on the host's blood. The larvae can be passed to the ruminant neonate through the colostrum. The prepatent period is 5 to 7 days. Light infections may be asymptomatic, but heavy infections will produce diarrhea, anorexia, blood and mucus in the feces, and weight loss.

The most common anthelmintics for *S. papillosus* are the **benzimidazoles** (e.g., fenbendazole, oxfendazole, albendazole), the **probenzimidazoles** (e.g., thiophanate, febantel, netobimin), and ivermectin. Since most ruminants spend part or all of their lives in pasture, the animals are subject to constant reinfection. Treatment with dewormers is only part of the treatment for ruminant parasites. Prevention plays a major role in the treatment procedure. Pasture rotation with nonruminant animals, such as horses,

mules, and donkeys, will reduce the infective larvae in the pasture.



**TECHNICIAN'S NOTE** Only the parthenogenetic female *Strongyloides papillosus* is parasitic to the bovine host. Parasitic males do not exist. The female worm is commonly treated with benzimidazoles, probenzimidazoles, and ivermectin.

**Parasite:** *Trichuris ovis*

**Host:** Cattle, sheep, and goats

**Location of Adult:** Cecum and colon

**Distribution:** Worldwide

**Derivation of Genus:** Hair tail

**Transmission Route:** Ingestion of infective ova

**Common Name:** Whipworms

*Trichuris ovis* parasites are commonly called whipworms and infect the cecum and colon of ruminants. (See discussion of nematode parasites of gastrointestinal tract of dogs and cats for details of gross morphology of adult whipworms.) The egg of the whipworm is described as trichinelloid or trichuroid; it has a thick, yellow-brown, symmetric shell with polar plugs at both ends. The eggs are unembryonated (not larvated) when laid. Eggs of bovine whipworms measure 50 to 60  $\mu\text{m} \times 21$  to 25  $\mu\text{m}$ . (See Figure 4-17 for the characteristic egg.) Symptoms are usually not apparent with *Trichuris ovis* but can include dark feces, anorexia, and anemia. As with whipworms of dogs and cats, ruminant whipworms are diagnosed with the standard fecal flotation technique. The most common anthelmintics are the benzimidazoles, probenzimidazoles, and ivermectin.



**TECHNICIAN'S NOTE** Trichurids of ruminants pass ova intermittently. Whipworm ova may be hard to find, so daily collection is recommended.

## Circulatory System

**Parasite:** *Elaeophora schneideri*

**Host:** Sheep

**Location of Adult:** Common carotid artery

**Distribution:** Western and southwestern United States

**Derivation of Genus:** Bearing oil

**Transmission Route:** Bite of an infective horse fly, *Tabanus* species

**Common Name:** Arterial worms of sheep

*Elaeophora schneideri*, the arterial worm, is found in the common carotid arteries of sheep in the western and southwestern United States. Although the adults are found in these predilection sites where they can cause obstruction of the arteries, their microfilariae are restricted to the skin. Microfilariae are 270  $\mu\text{m}$  in length  $\times$  17  $\mu\text{m}$  in thickness, bluntly rounded anteriorly, and tapering posteriorly. In the skin the microfilariae usually reside in the capillaries of the forehead and face. In sheep, filarial dermatitis is seen on the face, poll region, and feet.

Diagnosis of *E. schneideri* is by observation of characteristic lesions and identification of microfilariae in the skin. The most satisfactory means of diagnosis is to macerate a piece of skin in warm saline and examine the fluid for microfilariae after about 2 hours. In sheep, microfilariae are rare and may not be found in the skin of affected animals. Postmortem examination may be necessary to confirm the diagnosis of adult parasites within the common carotid arteries. The prepatent period for *E. schneideri* is 4½ months or longer.

**TECHNICIAN'S NOTE** Filarial dermatitis caused by *E. schneideri* is found on the face, poll region, and feet of sheep.

## Respiratory System

**Parasite:** *Dictyocaulus* species

**Host:** Cattle, sheep, and goats

**Location of Adult:** Bronchi

**Distribution:** Worldwide

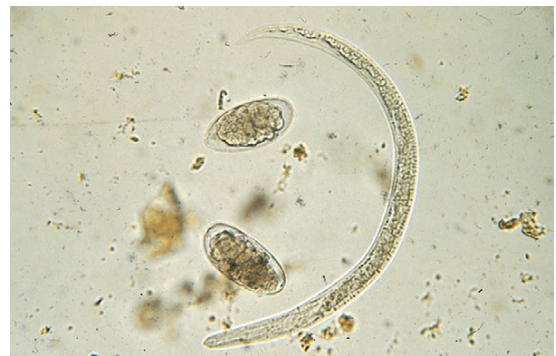**Derivation of Genus:** Net-like stalk

**Transmission Route:** Ingestion of infective larvae

**Common Name:** Lungworms of ruminants

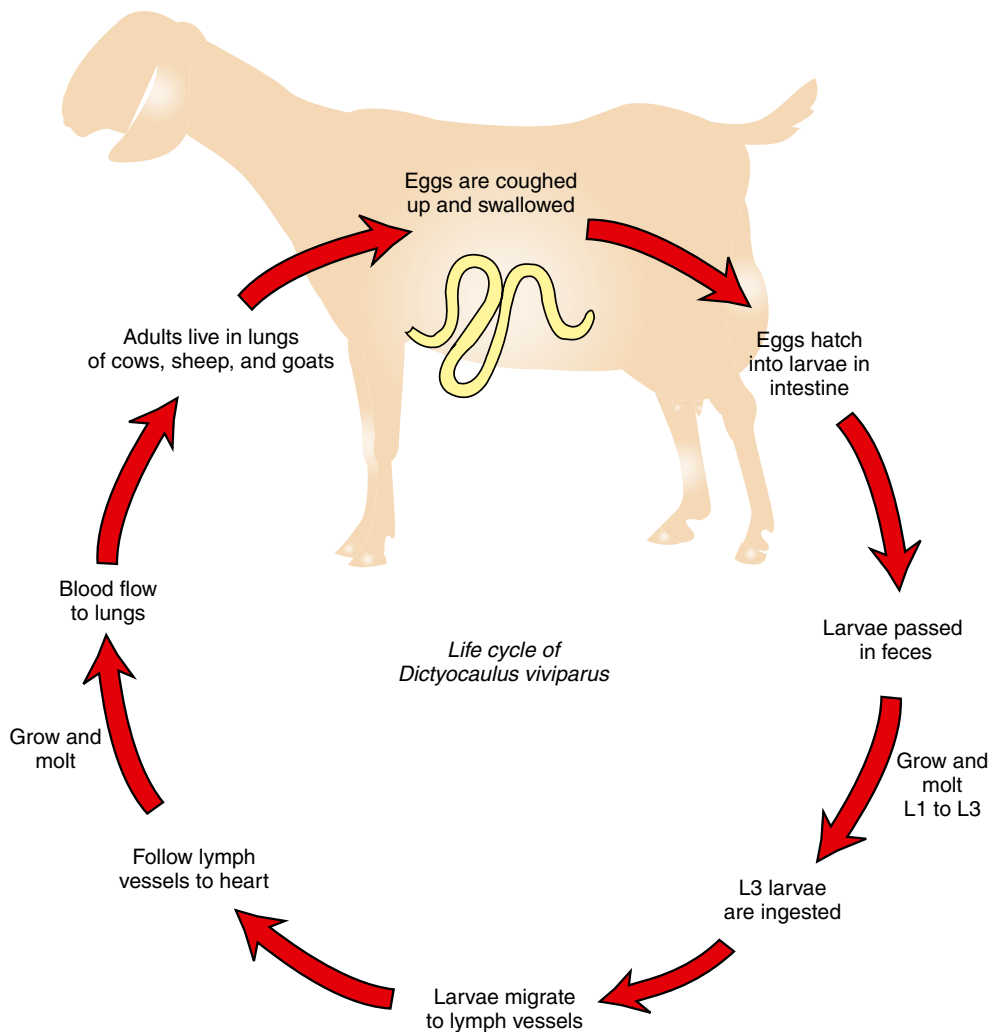
*Dictyocaulus* species are the lungworms of cattle (*D. viviparus*), sheep, and goats (*D. filaria*).

Adult parasites are found in the bronchi of infected hosts. The prepatent period varies between the species but is approximately 28 days. The female worm lays her eggs in the lungs. The eggs are usually coughed up, swallowed, and hatch in the intestine, producing larvae that may be recovered in the feces. Larvae of *D. filaria* have brown food granules in their intestinal cells, a blunt tail, and an anterior cuticular knob. These larvae are from 550 to 580  $\mu\text{m}$  in length. Larvae of *D. viviparus* also have brown food granules in their intestinal cells, but they have a straight tail. They are from 300 to 360  $\mu\text{m}$  in length but lack the anterior cuticular knob. (Figure 4-51 shows representative examples of eggs and larvae of *D. viviparus*.) The larvae pass out of the host through the feces to grow and molt from L2 to L3 larvae in the environment. The L3 infective larvae are ingested by the host and migrate through the tissues to the lymph vessels. The larvae grow and molt to L4 larvae and follow the lymph vessels to the heart. From the heart, the larvae follow the circulatory system to the lungs, where they mature into adults (Figure 4-52). The adult worms are white with a small buccal cavity and short, dark, and granular spicules with the vulva in the center of the body. The most common symptom is coughing. The eggs can be found in mucous discharge or coughed-up sputum.



**FIGURE 4-51:** Representative examples of eggs and larvae of *Dictyocaulus viviparus* species, the lungworms of cattle. Eggs are usually coughed up, swallowed, and hatch in the intestine, producing larvae that may be recovered in feces. Larvae of *D. viviparus* have brown food granules in their intestinal cells, a straight tail, and an anterior cuticular knob.





**FIGURE 4-52:** Life cycle of *Dictyocaulus viviparus*.

Benzimidazoles, probenzimidazoles, and ivermectin are the most common anthelmintics used in ruminants.



**TECHNICIAN'S NOTE** The ova of *Dictyocaulus* species hatch in the host's intestines and the larvae are present in the feces. Therefore, diagnosis is made by finding the larvae on standard fecal flotation or flotation of the sputum-mucus discharge, or by use of the Baermann technique.

**Parasite:** *Muellerius capillaris*

**Host:** Sheep and goats

**Location of Adult:** Bronchioles

**Distribution:** Worldwide

**Derivation of Genus:** a parasite named for Dr. Mueller

**Transmission Route:** Ingestion of infective larvae

**Common Name:** Hair lungworm of sheep and goats

*Muellerius capillaris* is often called the hair lungworm of sheep and goats. Adults are found

within the bronchioles, mostly in nodules in the lung parenchyma where they can obstruct the bronchioles. The eggs develop in the lungs of the definitive host, and first-stage larvae are coughed up, swallowed, and passed out with the feces. The larvae are from 230 to 300  $\mu\text{m}$  long. The larval tail has an undulating tip and a dorsal spine. Figure 4-53 shows representative examples of eggs and larvae of *M. capillaris*.

**TECHNICIAN'S NOTE** *Muellerius capillaris* is best diagnosed by finding the first-stage larvae in the feces on a standard fecal flotation.

**Parasite:** *Protostrongylus* species

**Host:** Sheep and goats

**Location of Adult:** Small bronchioles

**Distribution:** Worldwide

**Derivation of Genus:** First round

**Transmission Route:** Ingestion of infective larvae

Adult *Protostrongylus* species occur in the small bronchioles of sheep and goats where the adults can cause obstruction of the bronchioles. The eggs develop in the lungs of the definitive host. First-stage larvae are coughed up, swallowed, and passed out with the feces. These larvae are 250 to 320  $\mu\text{m}$  long. This nematode's larval tail has an undulating tip but lacks the dorsal spine.

The Baermann technique is used to diagnose lungworm infection in ruminants (see Chapter 17).

**TECHNICIAN'S NOTE** The ova of *Protostrongylus* species develop in the lungs of the host and larvae are passed in the feces where they can be found by using the Baermann technique.

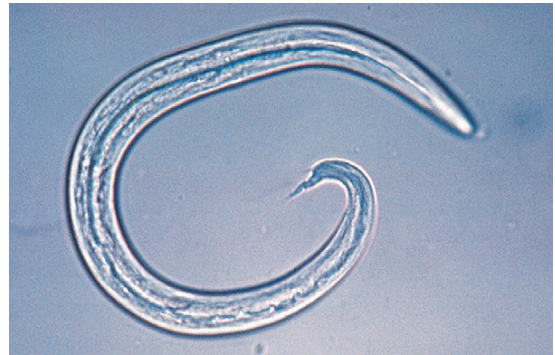## Skin

**Parasite:** *Stephanofilaria stilesi*

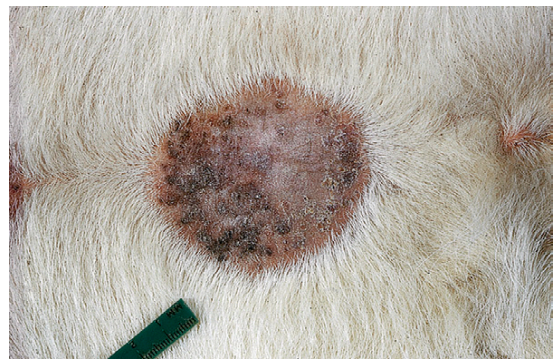**Host:** Cattle, goats, buffalo and wild ruminants

**Location of Adult:** Ventral midline skin

**Distribution:** United States



**FIGURE 4-53:** Representative examples of eggs and larvae of *Muellerius capillaris*, the hair lungworm of sheep and goats. Eggs develop in lungs of definitive host, and first-stage larvae are coughed up, swallowed, and passed out with feces. Larval tail has undulating tip and dorsal spine.



**FIGURE 4-54:** *Stephanofilaria stilesi* are small nematodes found in skin of cattle, goats, buffalo, and other wild ruminants. They typically produce dermatitis—a plague-like lesion—along ventral midline of cattle in the United States.

**Derivation of Genus:** Crown thread

**Transmission Route:** Bite by an infective horn fly, *Haematobia irritans*

**Common Name:** Skin worm of ruminants

*Stephanofilaria stilesi* parasites are small nematodes found in the skin of cattle, goats, buffalo, and other wild ruminants. In the United States they typically produce a dermatitis along the ventral midline of cattle (Figure 4-54). The infective larvae are transmitted by the bite of the horn fly, *Haematobia irritans*. The skin lesions are thought to be caused by both adult and microfilarial stages of this parasite.

The lesions caused by *S. stilesi* are located at or near the umbilicus and consist initially of small, red papules. Later, the lesions develop into large pruritic areas (up to 25 cm) of alopecia, with thick, moist crusts. Both the adults (6 mm) and microfilariae may be found in deep skin scrapings after the crusts have been removed from the lesions.

**TECHNICIAN'S NOTE** *Stephanofilaria stilesi* adults and microfilariae cause skin lesions in the host that can be found on deep skin scraping. Remember that other parasite larvae can also be recovered from the skin of many animals.

Although *Elaeophora schneideri*, the arterial worm, is found in the common carotid arteries of sheep in the western and southwestern United States, the microfilariae are restricted to the skin (see earlier discussion under circulatory system).

It is important that the veterinary diagnostician remember that larvae of *Rhabditis strongyloides* also can be recovered from the skin of almost any domesticated animal, particularly downer cattle that come in contact with moist soil containing larvae of the genus *Rhabditis*. The larvae actively penetrate the skin and can produce a severe dermatitis (Figure 4-41).

## Eye and Adnexa

**Parasite:** *Thelazia rhodesii* and *Thelazia gulosa*

**Host:** Cattle, sheep and goats

**Location of Adult:** Conjunctival sac and lacrimal duct

**Intermediate Host:** *Musca autumnalis*

**Distribution:** Worldwide

**Derivation of Genus:** Nipple saliva

**Transmission Route:** Infective larvae in face fly (*Musca autumnalis*) feces around eyes

**Common Name:** Eyeworms of cattle, sheep and goats

*Thelazia rhodesii* and *Thelazia gulosa* are the eyeworms of cattle, sheep, and goats. Adult parasites can be recovered from the conjunctival sac and lacrimal duct. Examination of lacrimal secretions

may reveal eggs or first-stage larvae. The larvae require an intermediate host, *Musca autumnalis*, the face fly, to develop into an infected larva. The infected larvae are deposited by the face fly when it feeds around the eyes of the definitive host. The larvae and adults can cause inflammation of the conjunctival sacs and lacrimal ducts. Microscopic evaluation of lacrimal secretions is used for diagnosis by finding ova or first-stage larvae.

**TECHNICIAN'S NOTE** *Thelazia rhodesii* and *Thelazia gulosa* are diagnosed by finding the ova or first-stage larvae in lacrimal secretions.

## Abdominal Cavity

**Parasite:** *Setaria cervi*

**Host:** Cattle

**Location of Adult:** Free within the peritoneal cavity

**Intermediate Host:** Female mosquito

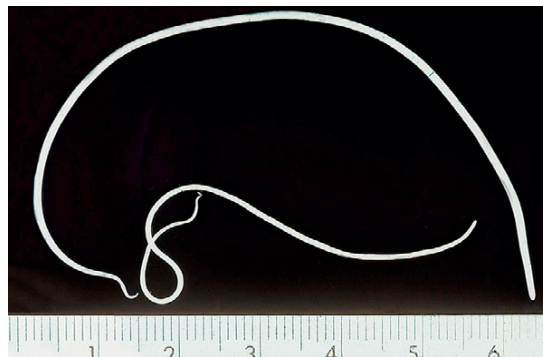
**Distribution:** Worldwide

**Derivation of Genus:** Bristles

**Transmission Route:** Bite by an infective mosquito

**Common Name:** Abdominal worm of cattle

*Setaria cervi* is the abdominal worm of cattle. Large white adults are usually observed on postmortem examination and are found free within the peritoneal cavity (Figure 4-55). The sheathed microfilariae are approximately  $250 \times 7 \mu\text{m}$ . Antemortem diagnosis is by demonstration



**FIGURE 4-55:** *Setaria cervi* is the abdominal worm of cattle. Adults are usually observed on postmortem examination and found free within the peritoneal cavity.



of microfilariae in peripheral blood smears. Damage to the cow may occur due to the migration of the microfilariae to the peritoneal cavity through the tissues.

**TECHNICIAN'S NOTE** *Setaria cervi* may be found free in the abdomen when performing abdominal surgery. During routine abdominal surgery, adult *S. cervi* may be found free within the abdominal cavity.

## NEMATODES OF EQUIDS

### Gastrointestinal Tract

**Parasite:** *Habronema microstoma*, *Habronema muscae*, and *Draschia megastoma*

**Host:** Horses

**Location of Adult:** Stomach mucosa

**Intermediate Host:** Muscidae fly

**Distribution:** Worldwide

**Derivation of Genus:** Delicate thread (*Habronema*); worm named for Dr. Drasch

**Transmission Route:** Ingestion of infective *Muscidae* fly

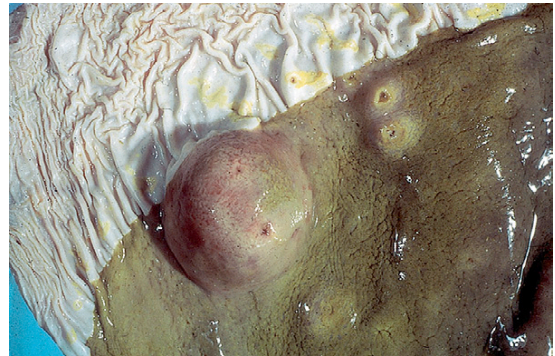
**Common Name:** Stomach worms of horses

*Habronema microstoma*, *Habronema muscae*, and *Draschia megastoma* are nematodes found in the stomach of horses. *H. microstoma* and *H. muscae* reside on the mucosa of the stomach, just beneath a thick layer of mucus. *D. megastoma* is often associated with the formation of large, thickened fibrous nodules within the stomach mucosa (Figure 4-56). Larvae of both *Habronema* and *Draschia* species may also parasitize skin lesions, causing a skin condition of horses known as “summer sores” (see Figure 4-66 and later discussion under skin), or cutaneous habronemiasis/draschiasis.

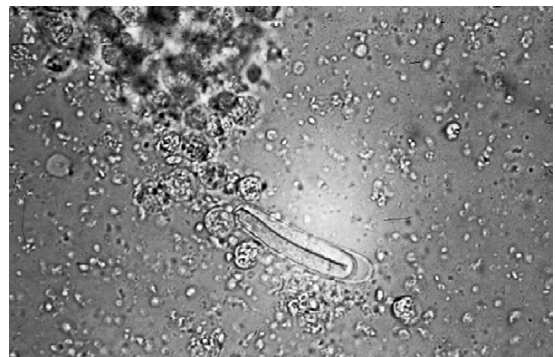
Larvated eggs or larvae may be recovered on standard fecal flotation. The eggs of both genera are elongate, thin-walled, and measure 40 to 50  $\mu\text{m}$   $\times$  10 to 12  $\mu\text{m}$  (Figure 4-57). These eggs (or hatched larvae) pass to the outside environment and are ingested by flies belonging to the family Muscidae. The larvae develop to the

infective third stage within the fly, and if a horse accidentally ingests the fly, the larvae develop to the adult stage within the stomach of the horse. The prepatent period is approximately 60 days. Antemortem diagnosis of gastric habronemiasis is based on observation of eggs or larvae on fecal flotation. Symptoms for *H. microstoma*, *H. muscae*, and *D. megastoma* occur with heavy infections and include gastritis, colic, and diarrhea caused by inflammation of the stomach tissues.

**TECHNICIAN'S NOTE** Larval infections of *Habronema* and *Draschia* cause “summer sores” in horses when the larvae parasitize skin lesions.



**FIGURE 4-56:** *Draschia megastoma* is often associated with formation of large, thickened fibrous nodules within stomach mucosa of horses.



**FIGURE 4-57:** Larvated eggs or larvae of *Habronema* and *Draschia* species may be recovered on standard fecal flotation. Eggs of both genera are elongate, thin-walled, and often contain first-stage larvae.

Benzimidazoles and ivermectin are the most common anthelmintics used for these species in horses. As with ruminants, equines are pasture animals, so pasture management plays an important role in treatment and prevention. In addition, a good fly control program will help reduce the infected flies in the horse's environment.

**Parasite:** *Trichostrongylus axei*

**Host:** Horses, cattle, sheep, and pigs

**Location of Adult:** Stomach

**Distribution:** Worldwide

**Derivation of Genus:** Hair round

**Transmission Route:** Ingestion of infective larvae

**Common Name:** Stomach worms of horses and pigs

*Trichostrongylus axei* is another species of nematode that may reside in the stomach of horses where they suck the host's blood. These unusual nematodes can cross species lines and can also infect cattle, sheep, and swine by ingesting the infective third-stage larvae. The egg of *T. axei* is classified as a strongyle or trichostrongyle type of egg and measures  $79$  to  $92\ \mu\text{m} \times 31$  to  $41\ \mu\text{m}$  (see following discussion on strongyles) when seen on standard fecal flotation.

**TECHNICIAN'S NOTE** *Trichostrongylus axei* can cross species lines and infect cattle, sheep, and pigs.

**Parasite:** *Parascaris equorum*

**Host:** Horses

**Location of Adult:** Small intestine

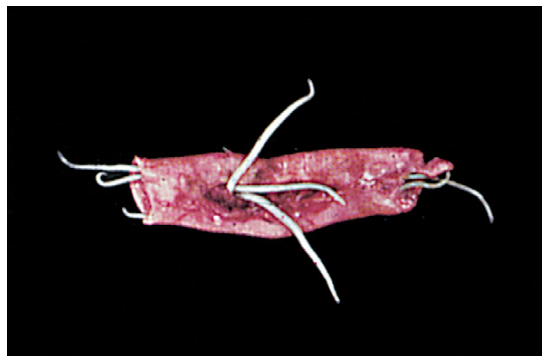**Distribution:** Worldwide

**Derivation of Genus:** Bearing worms

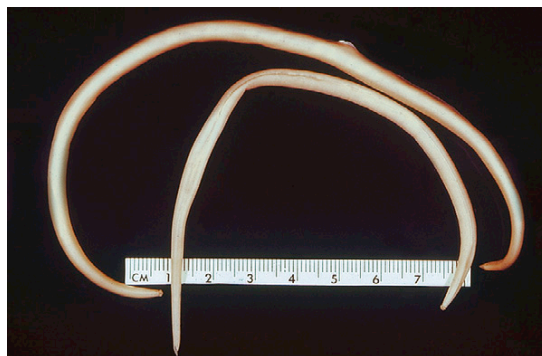
**Transmission Route:** Ingestion of ova

**Common Name:** Equine roundworm or equine ascarid

*Parascaris equorum* is often called the equine ascarid or equine roundworm. These nematodes are found in the small intestine of young foals (Figure 4-58). These large, robust nematodes are the largest of the equine nematodes. Sometimes, young foals will pass these nematodes in their feces (Figure 4-59). The eggs are passed in the

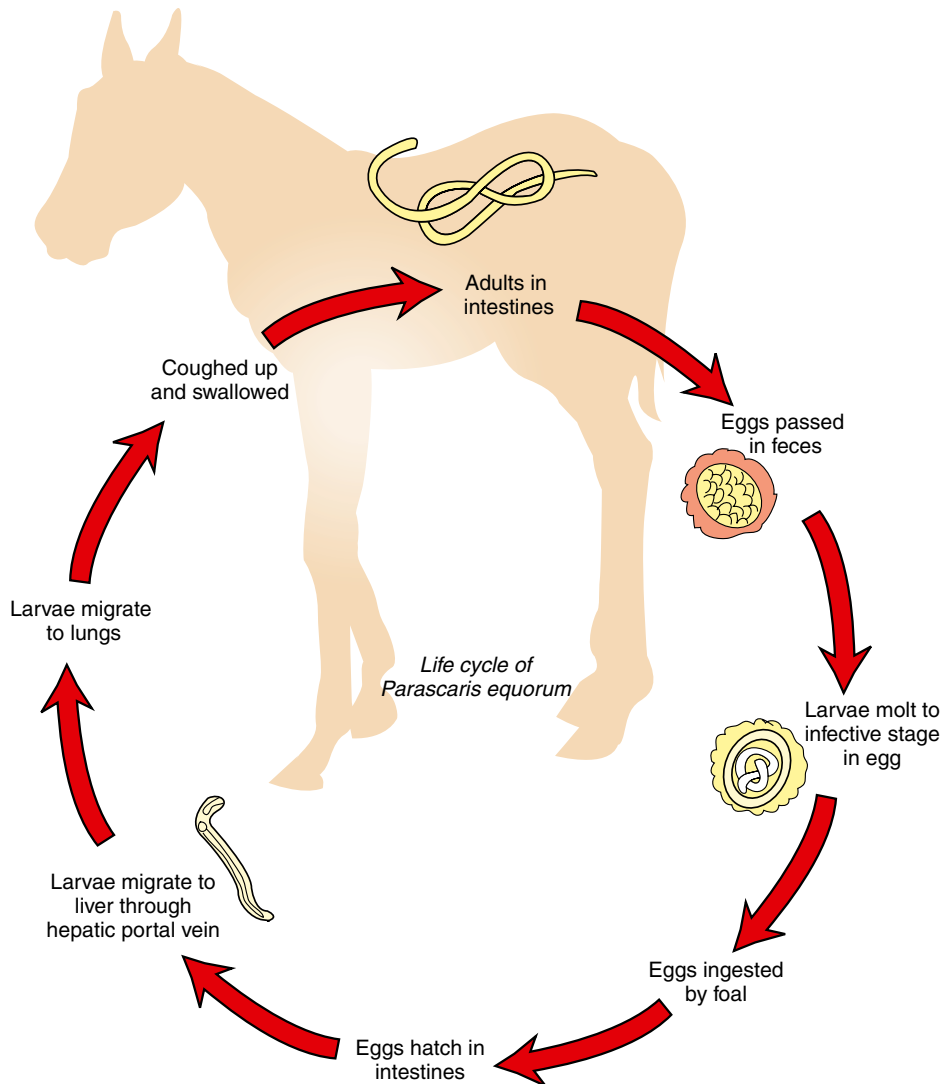


**FIGURE 4-58:** *Parascaris equorum* nematodes are often called "equine ascarids" or "equine roundworms." These nematodes are found in the small intestine of young foals.



**FIGURE 4-59:** *Parascaris equorum* is the largest of the equine nematodes. Young foals may pass these large parasites in feces.

feces, which tends to be sticky, and the larvae grow and molt within the egg. The egg containing an L2 larva is ingested by the young foal and hatches in the intestines. The larvae migrate to the liver through the hepatic portal vein, where they grow and molt to the next stage of larvae. The larvae are carried to the lungs through the circulatory system, where they are coughed up and swallowed. Once back in the intestines, the larvae mature into adults (Figure 4-60) where they suck on blood. The adult worms have large distinctive lips (Figure 4-61). The prepatent period for these ascarids is 75 to 80 days. The eggs are recovered from the feces of young horses and are round to oval and deeply pigmented.



**FIGURE 4-60:** Life cycle of *Parascaris equorum*.

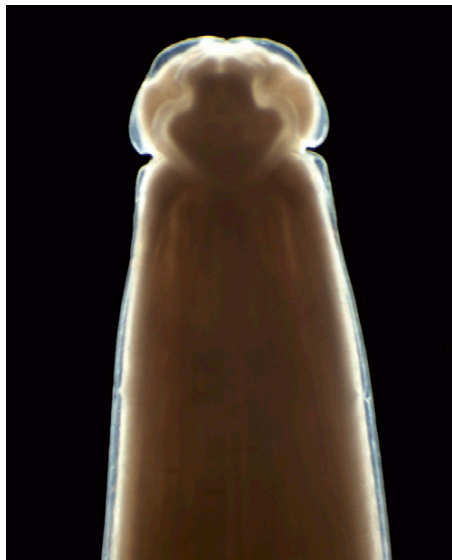The shell is thickened, with a finely granular surface. These eggs measure 90 to 100  $\mu\text{m}$  in diameter. The center of the egg contains one or two cells (Figure 4-62). Eggs can be easily recovered on standard fecal flotation.

The adult worms of *P. equorum* also may be passed in the feces of the young foal. This is one of the largest nematodes to infect horses and may grow to a length of 50 cm; however, such large specimens are the exception rather than the rule.

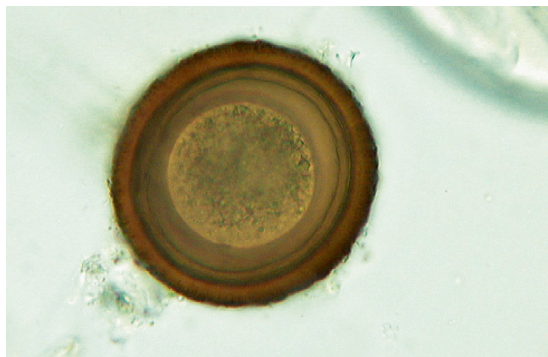


**TECHNICIAN'S NOTE** *Parascaris equorum* is the largest of the equine nematodes.

Mild infections of *P. equorum* are usually asymptomatic, but heavy infections can cause unthriftiness, depression, a pot-bellied appearance, anorexia, colic, and a cough with nasal discharge. Treatment involves pasture management to reduce chances of reinfection and a sound



**FIGURE 4-61:** Distinctive lips of the adult *Parascaris equorum*. (From Bowman: 'Georgis' Parasitology for Veterinarians, ed 9, 2008, Elsevier.)



**FIGURE 4-62:** Egg of *Parascaris equorum*. Eggs are recovered from feces of young horses and are round to oval and deeply pigmented. Shell is thickened, with a finely granular surface.

deworming program with benzimidazoles, ivermectin, piperazine, moxidectin, or pyrantel. Prevention includes thoroughly washing the feeders and waterers to remove the contaminating eggs. In addition, pasture management involves rotating the pastures where the weanlings and foals graze.

**Parasite:** *Strongylus vulgaris*, *Strongylus edentatus*, and *Strongylus equinus*

**Host:** Horses

**Location of Adult:** Large intestines

**Distribution:** Worldwide

**Derivation of Genus:** Round and common

**Transmission Route:** Ingestion of infective larvae

**Common Name:** Strongyles of horses

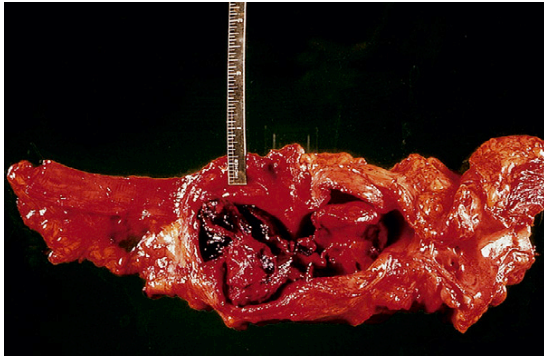
**Strongyles** are nematodes that parasitize the large intestine of horses and are typically divided into two types, large strongyles and small strongyles. The small strongyles comprise several genera that vary in pathogenicity. The large strongyles are the most pathogenic of the strongyles. *Strongylus vulgaris* is often associated with thrombi within the anterior mesenteric artery of horses (Figure 4-63). *S. vulgaris*, *S. edentatus*, and *S. equinus* are the large strongyles (Figure 4-64).



**TECHNICIAN'S NOTE** While horses are infected with large and small strongyles, it is the large strongyles that are most pathogenic of the two types.

Regardless of whether these endoparasites are a small strongyle or a large strongyle, their eggs are virtually identical. Identification to the species level is accomplished by fecal culture and identification of larvae. Strongyle eggs are most often observed during standard fecal flotation of horse feces. The eggs contain an 8- to 16-cell morula and measure approximately 70 to 90  $\mu\text{m}$   $\times$  40 to 50  $\mu\text{m}$ . In addition, the life cycles of the strongyles are very similar. The eggs are passed in the feces and hatch in the environment. The infective-stage larvae migrate up and down blades of grass until the equine host ingests the larvae. The larvae are swallowed and migrate through the intestines to the mesenteric arteries and the liver, where they grow and molt to the next larval stage. The larvae migrate back toward the large intestine and grow and molt on their way. Once in the large intestine, the larvae enter the mucosa of the large intestine and mature to adults (Figure 4-65, large strongyles and Figure 4-66, small strongyles). When these characteristic eggs are found on fecal flotation,





**FIGURE 4-63:** *Strongylus vulgaris* is often associated with thrombi in anterior mesenteric artery of horses.

the veterinary diagnostician should record their presence as a “strongyle type of egg,” rather than trying to identify a particular species of large or small strongyles.

Clinical signs of a strongyle infection include colic, weight loss, lethargy, fever, and poor appetite. Most of the signs are related to the migration of the larvae through the mesenteric arteries and liver. The most common anthelmintics include fenbendazole, oxfendazole, thiabendazole, and ivermectin. Preventive measures include pasture management, a good deworming program, and routine fecal examinations.

**TECHNICIAN'S NOTE** Most of the damage associated with strongyle infections is caused by the migration of larvae through the mesenteric arteries and liver.

**Parasite:** *Strongyloides westeri*

**Host:** Horses

**Location of Adult:** Small intestine

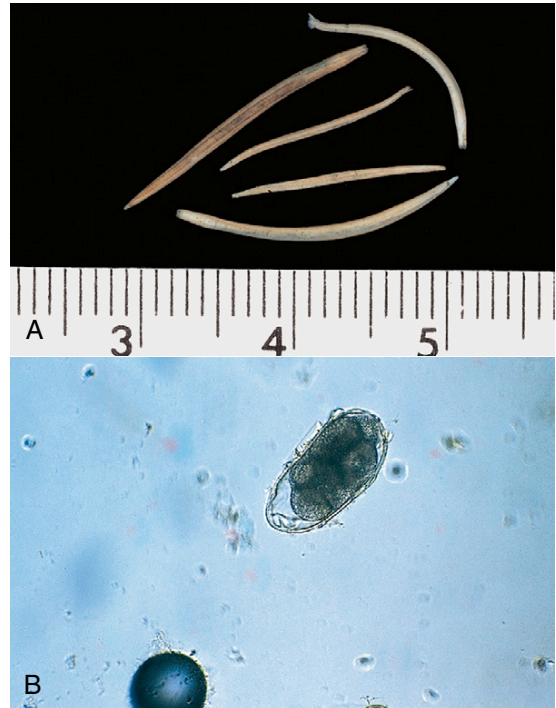
**Distribution:** Worldwide

**Derivation of Genus:** Round-like shape

**Transmission Route:** Transmammary through colostrums and larval penetration through the skin

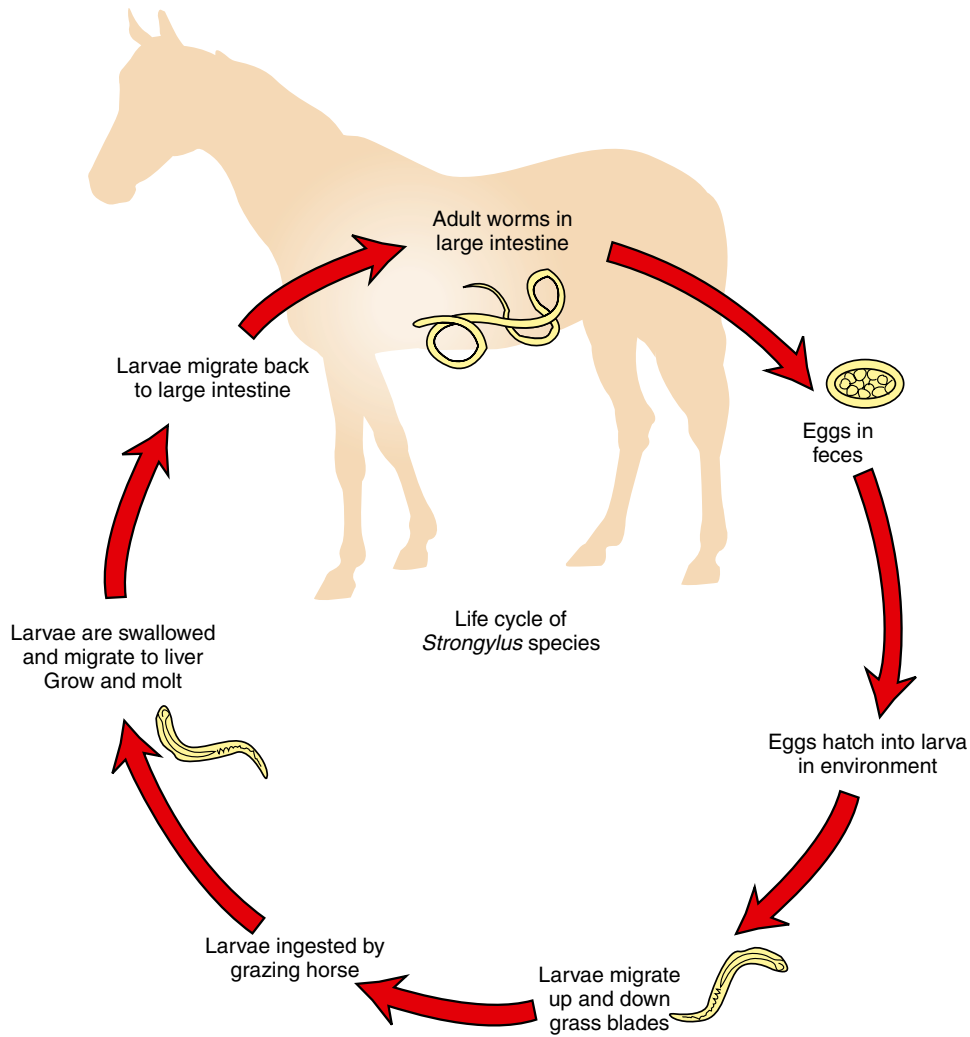
**Common Name:** Intestinal threadworm of horses

*Strongyloides westeri* is the intestinal threadworm of horses residing in the small intestine.



**FIGURE 4-64:** Strongyles are nematodes that parasitize the large intestine of horses and are typically divided into two types, large strongyles and small strongyles. **A**, Small strongyles comprise several genera that vary in pathogenicity. **B**, Large strongyles are the most pathogenic strongyles. Both large and small strongyles produce the typical strongyle type of egg.

These nematodes are unique in that only a parthenogenetic female is parasitic in the host. Parasitic males do not exist. The female parasitic worm has a near cylindric esophagus that is one-quarter the length of the body (Figure 4-15). *S. westeri* produces larvated eggs measuring  $40$  to  $52\ \mu\text{m} \times 32$  to  $40\ \mu\text{m}$ . The mare can transmit the parasite to the foal through the colostrum. Larvae are able to enter the host through the skin or percutaneously. Eggs are usually recovered on flotation of fresh feces. The prepatent period is 5 to 7 days (Figure 4-15). The clinical symptoms include diarrhea, weight loss, anemia, and poor appetite due to the adult feeding on the host's blood. A good deworming program for the mare and foal with oxbendazole, thiabendazole, or ivermectin will help control the parasite.



**FIGURE 4-65:** Life cycle of the large strongyle species.

**TECHNICIAN'S NOTE** The parthenogenetic female is the only parasitic form of *Strongyloides westeri*. There are no parasitic males.

**Parasite:** *Oxyuris equi*

**Host:** Horses

**Location of Adult:** Cecum, colon, and rectum

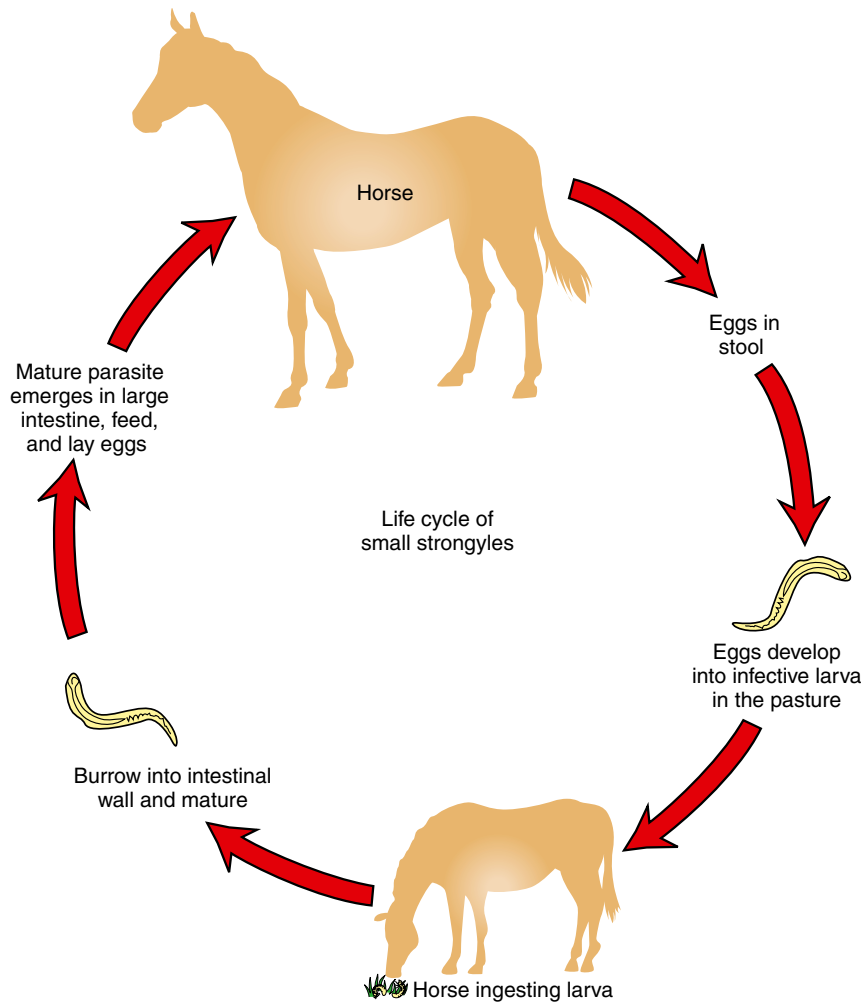
**Distribution:** Worldwide

**Derivation of Genus:** Sharp tail

**Transmission Route:** Ingestion of infective ova

**Common Name:** Pinworm of horses

*Oxyuris equi* is a pinworm of horses. The adult worms are found in the cecum, colon, and rectum. Adult worms are often observed protruding from the anus. Adult female worms attach their eggs to the exterior of the anus with a gelatinous, sticky material that produces inflammation and anal pruritus in infected horses. The eggs can be rubbed off the anus onto waterers, feeders, and fences, where the eggs can be ingested by the



**FIGURE 4-66:** Life cycle of the small strongyle species.

same host or a new host. Pinworm eggs can also be recovered from the feces; eggs are  $90 \times 40 \mu\text{m}$  and have a smooth, thick shell. They are operculate and slightly flattened on one side. Pinworm eggs may be larvated (Figure 4-67). The prepatent period is approximately 4 to 5 months.

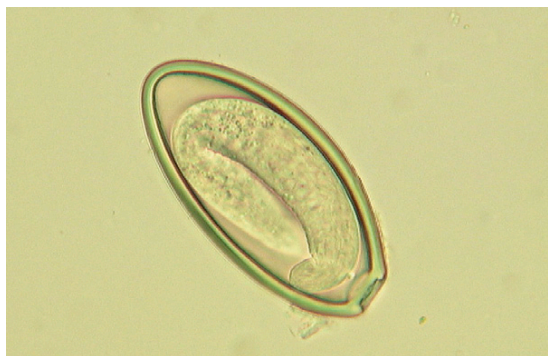Diagnosis of pinworms in horses is made by finding the characteristic eggs on microscopic examination of cellophane tape impressions or by scraping the surface of the anus. The pruritus produced will often cause the horse to rub its rump against solid objects to relieve the itching.

As a result, hairs in the region of the tail head are often broken. A good deworming program with oxbendazole, thiabendazole, or ivermectin and thoroughly washing the anus of infected horses will help control the spread of *Oxyuris equi*.



**TECHNICIAN'S NOTE** The female *Oxyuris equi* attaches her eggs to the anus of the horse rather than laying them in the intestinal contents; thus it is rare to find ova on a fecal flotation test.





**FIGURE 4-67:** Egg of *Oxyuris equi*, the equine pinworm. Eggs are operculate and slightly flattened on one side. Pinworm eggs may be larvated.

## Respiratory System

**Parasite:** *Dictyocaulus arnfieldi*

**Host:** Horses, mules, and donkeys

**Location of Adult:** Bronchi and bronchioles

**Distribution:** Worldwide

**Derivation of Genus:** Net-like stalk

**Transmission Route:** Ingestion of larvae

**Common Name:** Equine lungworm

*Dictyocaulus arnfieldi*, the equine lungworm, is found in the bronchi and bronchioles of horses, mules, and donkeys. The adults can cause obstruction of the bronchi and bronchioles. Its eggs are ellipsoidal, embryonated, and measure approximately  $80$  to  $100\ \mu\text{m} \times 50$  to  $60\ \mu\text{m}$ . Eggs can be recovered on fecal flotation of fresh feces ( $<24$  hours old). Larvae hatch from the eggs within a few hours after feces are passed to the outside. The lungworm larvae become infective in the external environment; horses become infected by ingesting the larvae. The larvae migrate to the bronchi through lymphatic vessels. The prepatent period for the equine lungworm is 42 to 56 days. The ova or larvae can be found on standard fecal flotation. The common anthelmintics (thiabendazole, fenbendazole, ivermectin) used in a good deworming program will also treat *D. arnfieldi*.



**TECHNICIAN'S NOTE** The larvae of *Dictyocaulus arnfieldi* hatch from the ova within hours of being defecated.

## Skin

**Parasite:** *Habronema microstoma*, *Habronema muscae*, and *Draschia megastoma*

**Host:** Horses

**Location of Adult:** Stomach mucosa

**Distribution:** Worldwide

**Intermediate Host:** Muscid flies

**Derivation of Genus:** Delicate thread (*Habronema*), worm named for Dr. Drasch

**Transmission Route:** Deposition of infected larvae into skin wounds by Muscid flies

**Common Name:** Cutaneous habronemiasis, cutaneous draschiasis, “summer sores”

Adult *Habronema* species that occur in horses are gastrointestinal nematodes (see earlier discussion). The adults never parasitize the skin; however, the larval stages can be deposited by flies (*Musca domestica*) onto the skin wounds of horses. Here the larvae are aberrant, or “off course,” and produce a condition known as **cutaneous habronemiasis**, **cutaneous draschiasis**, or **summer sores**. The lesions vary in size and have an uneven surface that consists of a soft, reddish-brown material and covers a mass of firmer granulation tissue. These lesions are seen on the parts of the body likely to be injured, such as the legs, withers, male genitalia, and medial canthus of the eye (Figure 4-68). These wounds tend to increase in size and do not respond to usual treatment until the following winter, when they spontaneously heal.

Diagnosis of cutaneous habronemiasis is based on clinical signs and skin biopsies, which may reveal cross sections or longitudinal sections of these aberrant larvae.

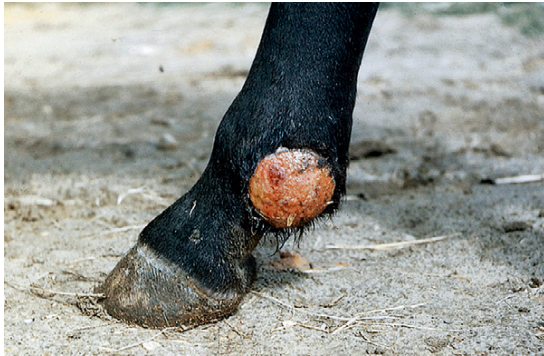

**TECHNICIAN'S NOTE** Summer sores are caused by *Habronema* species and *Draschia* species becoming aberrant when the larvae are deposited in skin wounds by flies that carry the larval stage of the parasites.

**Parasite:** *Onchocerca cervicalis*

**Host:** Horses

**Location of Adult:** Ligamentum nuchae, microfilariae are found in the dermis



**FIGURE 4-68:** Lesions of cutaneous habronemiasis (cutaneous draschiasis, or summer sores) vary in size and have uneven surface that consists of soft, reddish-brown material and covers a mass of firmer granulation tissue. Lesions are seen on body parts that are likely to be injured, such as legs, withers, male genitalia, and medial canthus of the eye.

**Intermediate Host:** Biting midges of the *Culicoides* species

**Distribution:** Worldwide

**Derivation of Genus:** Tumor tail

**Transmission Route:** Bite by infective *Culicoides* species, no-see-ums

**Common Name:** Equine filarial worm

The microfilariae of *Onchocerca cervicalis*, the equine filarial parasite, produce recurrent dermatitis and periodic ophthalmia in horses. The adults live in the ligamentum nuchae of horses. The female worms produce microfilariae that migrate to the dermis through connective tissue. This parasite is spread by the biting midges of *Culicoides* species. The flies feed on host blood and ingest the microfilariae, which develop to the infective third stage within the fly. When the fly bites another horse, larvae are injected into the connective tissue and develop to adults during migration to the ligamentum nuchae.

The microfilariae produce the characteristic lesions of **cutaneous onchocerciasis** due to the inflammation the microfilariae cause: patchy alopecia and scaling on the head, neck, shoulders, and ventral midline that may be accompanied by intense pruritus.

Many infected horses are asymptomatic. Microfilariae of *Onchocerca* concentrate in certain areas, most often along the ventral midline.

Because more than 90% of normal hosts are probably infected with *O. cervicalis*, detection of microfilariae in the skin of the ventral midline is not diagnostic for cutaneous onchocerciasis. However, the presence of microfilariae in diseased skin is highly indicative of, although not diagnostic of, cutaneous onchocerciasis.



**TECHNICIAN'S NOTE** Cutaneous onchocerciasis is caused by the inflammation of the microfilariae within the skin. The inflammation causes patchy alopecia, scaling on the head, neck, shoulders, and ventral midline, which may be accompanied by intense pruritus.

*Onchocerca* microfilariae may be demonstrated by the following procedure. After clipping and a surgical scrub, a 6-mm punch biopsy is obtained (see Chapter 17). With a single-edged razor blade or scalpel blade, half the tissue is minced in a small amount of preservative-free physiologic saline on a glass slide and allowed to stand for 5 to 10 minutes. Drying of the specimen is prevented by placing the slide in a covered chamber with a small amount of saline. The slide is then examined under a low-power (10×) objective on the microscope. Because the translucent microfilariae are difficult to observe, low-intensity light and high contrast (achieved by lowering the condenser) are essential. Live microfilariae are identified by the vigorous swimming activity at the edge of the tissue. *O. cervicalis* microfilariae are slender and 207 to 240 μm long. The other half of the biopsy should be submitted for routine histopathologic examination.

The unsheathed microfilariae of *Onchocerca cervicalis* have been incriminated as causing periodic ophthalmia and blindness in the eyes of horses. These may be detected by ophthalmic examination.



**TECHNICIAN'S NOTE** *Onchocerca cervicalis* can be diagnosed by taking a biopsy of the infected skin lesion, mincing the biopsy tissue, and placing ½ of the sample in physiologic saline on a glass slide to identify the microfilariae.

## Eye and Adnexa

**Parasite:** *Thelazia lacrymalis*

**Host:** Horse

**Location of Adult:** Conjunctival sac and lacrimal duct

**Distribution:** Worldwide

**Intermediate Host:** *Musca autumnalis*

**Derivation of Genus:** Nipple saliva

**Transmission Route:** Infective larvae deposited near eyes when intermediate host, *Musca autumnalis*, defecated after feeding on tears.

**Common Name:** Eyeworm of the horse

*Thelazia lacrymalis* is the eyeworm of horses throughout the world. Adult parasites can be recovered from the conjunctival sac and lacrimal duct where they can cause obstruction of the lacrimal ducts. Examination of the lacrimal secretions may reveal eggs or first-stage larvae.

## Abdominal Cavity

**Parasite:** *Setaria equina*

**Host:** Horses

**Location of Adult:** Free within the peritoneal cavity

**Distribution:** Europe and North America

**Intermediate Host:** Mosquito

**Derivation of Genus:** Bristle

**Transmission Route:** Bite by infective mosquito

**Common Name:** Abdominal worm of horses

*Setaria equina* is the abdominal worm of horses. Adults are large white worms and found free within the peritoneal cavity. The sheathed microfilariae are 240 to 256  $\mu\text{m}$  long. Antemortem diagnosis is by demonstration of microfilariae in peripheral blood smears. Adults may be observed freely within the peritoneal cavity during postmortem examination. The primary cause of pathology is migration of the larvae from the insertion point to the abdominal cavity.



**TECHNICIAN'S NOTE** Adults of *Setaria equina* may be found free within the peritoneal cavity during abdominal surgery.

## NEMATODES OF SWINE

### Gastrointestinal Tract

**Parasite:** *Ascarops strongylina* and *Physocephalus sexalatus*

**Host:** Pigs

**Location of Adult:** Stomach

**Distribution:** Worldwide

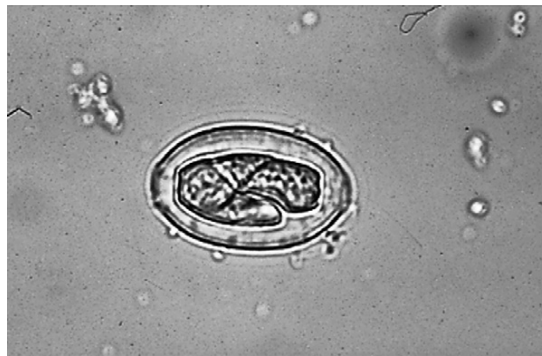**Intermediate Host:** Beetle

**Derivation of Genus:** Ascarops: Late worm; *Physocephalus*: Air head

**Transmission Route:** Ingestion of infective beetle

**Common Name:** Stomach worms of pigs

*Ascarops strongylina* and *Physocephalus sexalatus* are the thick stomach worms of the porcine stomach where the adults suck the host's blood. Both these nematodes produce thick-walled, larvated eggs that can be recovered on fecal flotation. The eggs of both species are similar in appearance. The egg of *A. strongylina* is 34 to 39  $\mu\text{m} \times 20 \mu\text{m}$  and has a thick shell surrounded by a thin membrane, producing an irregular outline (Figure 4-69). The egg of *P. sexalatus* is 34 to 39  $\mu\text{m} \times 15$  to 17  $\mu\text{m}$ . The larvated egg is ingested by a beetle and develops into an infective larva. The beetle is then ingested by the pig. The prepatent period for both species is approximately 42 days. Diagnosis is by observation of typical eggs on routine fecal flotation. Clinical signs include anemia, diarrhea, and weight loss. Anthelmintics used for treating



**FIGURE 4-69:** Egg of *Ascarops strongylina* is 34 to 39  $\mu\text{m} \times 20 \mu\text{m}$  and has a thick shell surrounded by a thin membrane that produces an irregular outline.

*A. strongylina* and *P. sexalatus* are ivermectin, fenbendazole, thiabendazole, and oxfendazole.

**TECHNICIAN'S NOTE** The stomach worms of the pig require a beetle intermediate host to harbor the infective larval stage.

**Parasite:** *Hyostrongylus rubidus*

**Host:** Pigs

**Location of Adult:** Stomach

**Distribution:** Worldwide

**Derivation of Genus:** U-shaped and round

**Transmission Route:** Ingestion of infective ova

**Common Name:** Red stomach worm of pigs

*Hyostrongylus rubidus* is the red stomach worm of swine. The egg is a trichostrongyle type of egg, that is oval and thin-shelled. It contains a morula with four or more cells and measures 71 to 78  $\mu\text{m}$   $\times$  35 to 42  $\mu\text{m}$ . These eggs can be recovered on fecal flotation. As with the bovine trichostrongyles, definitive diagnosis can only be made by fecal culture and larval identification. The prepatent period is approximately 20 days. Clinical signs include dehydration, weight loss, diarrhea, and anemia due to the fact the adult sucks the host's blood. Deworming with benzimidazoles (fenbendazole, thiabendazole, oxfendazole) and ivermectin will control the parasite.

**TECHNICIAN'S NOTE** *Hyostrongylus rubidus* or the red stomach worm of pigs, produces a trichostrongyle type of egg that contains a morula with four or more cells. It can be found on fecal flotation but only a fecal culture and larval identification can provide a definitive diagnosis of specific genus and species.

**Parasite:** *Trichostrongylus axei*

**Host:** Horses, sheep, cattle, and pigs

**Location of Adult:** Stomach

**Distribution:** Worldwide

**Derivation of Genus:** Hair round

**Transmission Route:** Ingestion of ova

**Common Name:** Stomach worm of horses, cattle, sheep, and pigs

*Trichostrongylus axei* is another species of nematode that may reside in the stomach of pigs and suck blood. It is important to remember that *T. axei* can cross species lines and also parasitize cattle, sheep, and horses. The eggs of *T. axei* are classified as the trichostrongyle type and measure 79 to 92  $\mu\text{m}$   $\times$  31 to 41  $\mu\text{m}$ . As with bovine trichostrongyles, definitive diagnosis can be made only by fecal culture and larval identification. Benzimidazoles are the anthelmintics of choice. Diagnosis of trichostrongyle ova can be made with a standard fecal flotation technique.

**Parasite:** *Ascaris suum*

**Host:** Pigs

**Location of Adult:** Small intestine

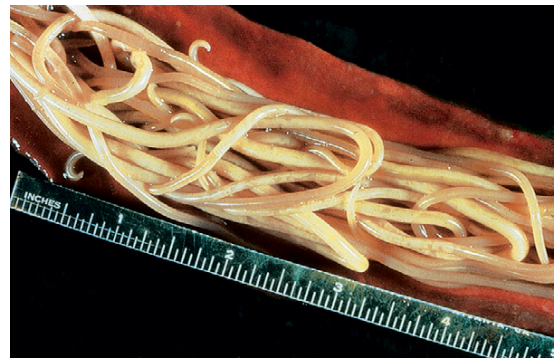**Distribution:** Worldwide

**Derivation of Genus:** Worm

**Transmission Route:** Ingestion of infective ova

**Common Name:** Swine ascarid or large intestinal roundworm of pigs

*Ascaris suum*, the swine ascarid, or large intestinal roundworm, is the largest nematode found in the small intestine of pigs (Figure 4-70). It may attain a length of up to 41 cm and can be as wide as 5 mm. Large numbers of these worms can cause intestinal obstruction. These large, robust nematodes may also be passed in feces. They produce eggs that are passed in the feces and hatch in the environment. The larvae grow to infective larvae within the eggs, which are ingested by the pig. The larvae hatch and migrate to the liver,



**FIGURE 4-70:** *Ascaris suum*, the swine ascarid or large intestinal roundworm, is largest nematode found within small intestine of pigs.



where they grow to the next larval stage. The larvae migrate through the circulatory system to the lungs and the bronchial tree, where they are swallowed. Once in the intestines, the larvae mature into adults.

**TECHNICIAN'S NOTE** This is the largest nematode found in the pig; the ova can be found on standard fecal flotation.

Eggs of *A. suum* can be recovered on standard fecal flotation. They are oval and golden brown with a thick, albuminous shell bearing prominent projections that give a lumpy, bumpy appearance. The eggs measure 70 to 89  $\mu\text{m}$   $\times$  37 to 40  $\mu\text{m}$  (Figure 4-71). *A. suum* can cause a reduced growth rate, weight loss, unthriftiness, respiratory symptoms (coughing, abdominal breathing, or **thumps**). Benzimidazoles, levamisole, ivermectin, pyrantel, piperazine, and hydromycin (a feed-additive dewormer) are the anthelmintics of choice.

**Parasite:** *Strongyloides ransomi*

**Host:** Pigs

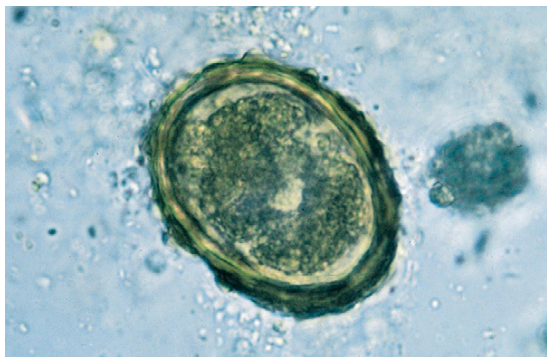
**Location of Adult:** Small intestine

**Distribution:** Worldwide

**Derivation of Genus:** Roundlike

**Transmission Route:** Transmammary (through the colostrum), percutaneous

**Common Name:** Intestinal threadworm of pigs



**FIGURE 4-71:** Eggs of *Ascaris suum* can be recovered on standard fecal flotation. Eggs are oval and golden brown with a thick, albuminous shell bearing prominent projections that give a lumpy, bumpy appearance.

*Strongyloides ransomi*, the intestinal threadworm of pigs, is unique in that only a parthenogenetic female is parasitic in the host. Parasitic males do not exist. These females produce larvated eggs measuring 45 to 55  $\mu\text{m}$   $\times$  26 to 35  $\mu\text{m}$ . Eggs are usually recovered in flotation of fresh feces. The life cycle of *S. ransomi* closely resembles that of *Strongyloides papillosus*. Transmission can occur through the colostrum. The prepatent period is 3 to 7 days (Figure 4-15). *S. ransomi* can produce diarrhea, anemia, and weight loss in the host as the parasite sucks its blood. Anthelmintics of choice are the benzimidazoles and ivermectin.

**TECHNICIAN'S NOTE** *Strongyloides ransomi* is the intestinal threadworm of pigs where only the female is parasitic and the larvae can enter a host through the skin or in the colostrum.

**Parasite:** *Oesophagostomum dentatum*

**Host:** Pigs

**Location of Adult:** Large intestine

**Distribution:** Worldwide

**Derivation of Genus:** Esophagus mouth; carry food mouth

**Transmission Route:** Ingestion of infective larvae

**Common Name:** Nodular worm of pigs

*Oesophagostomum dentatum*, the nodular worm of swine, is found in the large intestine of swine (Figure 4-72). It is called the nodular worm because its larval stages induce the formation of large nodules within the wall of the large intestine, which can cause intestinal disturbance and obstruction (Figure 4-73). The prepatent period is 50 days. The eggs of *O. dentatum* are of the trichostrongyle type, that is, oval, thin-shelled eggs. They contain 4 to 16 cells and measure 40  $\times$  70  $\mu\text{m}$ . These eggs can be recovered on standard fecal flotation. As with the bovine trichostrongyles, definitive diagnosis can be made only by fecal culture and larval identification. The parasite can cause anorexia, diarrhea, weight loss, and gastrointestinal disturbances in

the host. Benzimidazoles, ivermectin, levamisole, piperazine, and pyrantel are the anthelmintics of choice.

**TECHNICIAN'S NOTE** The nodules formed by the third-stage larvae in the large intestine cause intestinal disturbances and can cause a mechanical obstruction of the intestinal tract.

**Parasite:** *Trichuris suis*

**Host:** Pigs

**Location of Adult:** Cecum and colon

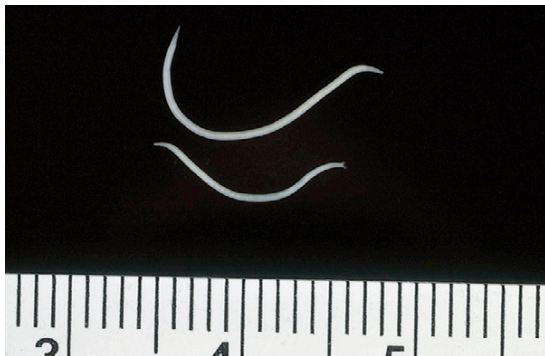**Distribution:** Worldwide

**Derivation of Genus:** Hair tail

**Transmission Route:** Ingestion of infective ova

**Common Name:** Whipworm of pigs

*Trichuris suis*, commonly called whipworms, infect the cecum and colon of swine. (See previous discussion of nematodes of dogs and cats for gross morphology of adult worms and life cycle.) The egg of the whipworm is trichuroid or trichinelloid and has a thick, brown, barrel-shaped shell with polar plugs at both ends (Figure 4-17). The eggs are unembryonated (not larvated) when laid. Eggs of porcine whipworms measure  $50$  to  $60\ \mu\text{m} \times 21$  to  $25\ \mu\text{m}$ . The prepatent period is 42 to 49 days. Common symptoms seen in the host are anemia, bloody diarrhea, anorexia, and stunted growth due to the fact that the adult attaches to the intestinal wall and sucks the host's blood.



**FIGURE 4-72:** *Oesophagostomum dentatum*, the nodular worm of swine, is found in large intestine of swine.

Levamisole, dichlorvos, and fenbendazole are the anthelmintics of choice.

**TECHNICIAN'S NOTE** The whipworm of the pig is similar in life cycle and appearance to dog and cat whipworms. The thin end of the adult was once thought to be the tail of the worm rather than the head.

**Parasite:** *Trichinella spiralis*

**Host:** Pigs can serve as both definitive and intermediate hosts.

**Location of Adult:** Small intestine

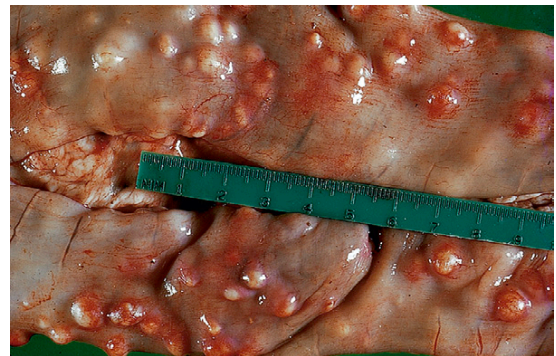**Distribution:** Worldwide but does not occur in Australia or Denmark

**Derivation of Name:** Small hair

**Transmission Route:** Ingestion of contaminated raw and undercooked meat, usually pork

**Common Name:** Trichina worm

The adult *Trichinella spiralis*, the “trichina worm,” is found in the small intestine of the porcine definitive host. The adult worm is very fine and slender. The female is very tiny, only 4 mm in length; the male is even smaller. This stage is seldom recovered by the veterinarian. The egg is larvated and measures  $30 \times 40\ \mu\text{m}$ . (See discussion under musculoskeletal system for larval stage in porcine intermediate host.) *T. spiralis* is a very unusual parasite because the definitive host and the intermediate host may be the same



**FIGURE 4-73:** *Oesophagostomum dentatum* is called the “nodular worm” of swine because its larval stages induce formation of large nodules within the wall of the large intestine.



animal. *T. spiralis* can be passed to humans in undercooked pork (see Chapter 16). Most animal hosts are **asymptomatic** (showing no symptoms); however, since larvae encyst in muscle tissue, the larvae can cause damage to the muscle by its encysted presence.

**TECHNICIAN'S NOTE** While *Trichinella spiralis* does not typically cause symptoms in the definitive host, it does cause problems in human muscles. The only test that can be used for diagnosis in the intermediate host is a biopsy of the muscle tissue for encysted larvae.

## Respiratory Tract

**Parasite:** *Metastrongylus elongatus*

**Host:** Pigs

**Location of Adult:** Bronchi and bronchioles

**Intermediate Host:** Earthworm

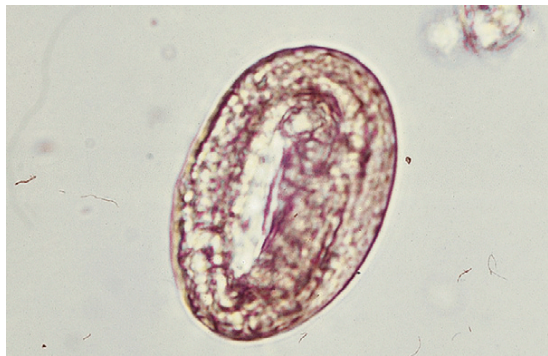**Distribution:** Worldwide

**Derivation of Genus:** After round

**Transmission Route:** Ingestion of infective earthworm

**Common Name:** Swine lungworm

*Metastrongylus elongatus*, the swine lungworm, is found within the bronchi and bronchioles of pigs. The oval, thick-walled eggs measure  $60 \times 40 \mu\text{m}$  and contain larvae (Figure 4-74). Eggs can be recovered on fecal flotation using flotation medium with a specific gravity greater than 1.25



**FIGURE 4-74:** *Metastrongylus elongatus* (april), the swine lungworm, is found in bronchi and bronchioles of pigs. Oval, thick-walled eggs measure  $60 \times 40 \mu\text{m}$  and contain larvae.

or by using the fecal sedimentation technique. The prepatent period is approximately 24 days. *M. elongatus* uses the earthworm as an intermediate host. Therefore, control of earthworms in the pigs' environment will help eliminate this parasite. Control may include keeping pigs on concrete rather than pasture or dirt. Infected pigs may have a persistent cough, reduced growth rate, and unthriftiness due to partial obstructions in the airways. Infected pigs can be treated with fenbendazole, ivermectin, or levamisole.

**TECHNICIAN'S NOTE** Fecal flotation with a solution having a specific gravity greater than 1.25 or fecal sedimentation technique are the best ways to diagnose the swine lungworm using feces.

## Urinary Tract

**Parasite:** *Stephanurus dentatus*

**Host:** Pigs

**Location of Adult:** Cystic spaces connected to the kidneys, ureters, and perirenal tissue

**Intermediate Host:** Earthworm

**Distribution:** Tropical and sub-tropical regions

**Derivation of Genus:** Encircling the urinary system

**Transmission Route:** Ingestion of infective intermediate host, earthworm, or percutaneous

**Common Name:** Swine kidney worm

*Stephanurus dentatus*, the swine kidney worm, is found in cystic spaces that connect to the kidney, ureters, and perirenal tissues of pigs (Figure 4-75). The eggs are the oval, thin-shelled strongyle type of eggs, containing 4 to 16 cells and measuring  $90$  to  $120 \mu\text{m} \times 43$  to  $70 \mu\text{m}$ . Eggs can be recovered from the urine using sedimentation (Figure 4-76). The prepatent period is extremely long, approximately 9 to 24 months. *Stephanurus dentatus* can use the earthworm as an intermediate host or the infective larvae can enter the pig directly through the skin. Infected pigs may show signs of anorexia, decreased growth rate, and weight loss. Much of the damage caused by the parasite comes from the migration of larvae to the cystic spaces

around the kidneys, ureters, and perirenal tissues. Anthelmintics of choice include fenbendazole, levamisole, and ivermectin.

**TECHNICIAN'S NOTE** *Stephanurus dentatus* can have a direct life cycle by entering the host through the skin or can have an indirect life cycle by using an intermediate host, the earthworm.

### Musculoskeletal System

**Parasite:** *Trichinella spiralis*

**Host:** Pigs are the definitive host.

**Location of Adult:** Small intestine

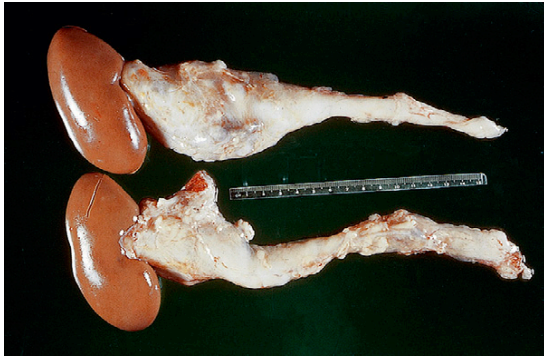
**Distribution:** Worldwide but does not occur in Australia or Denmark

**Derivation of Name:** Small hairs

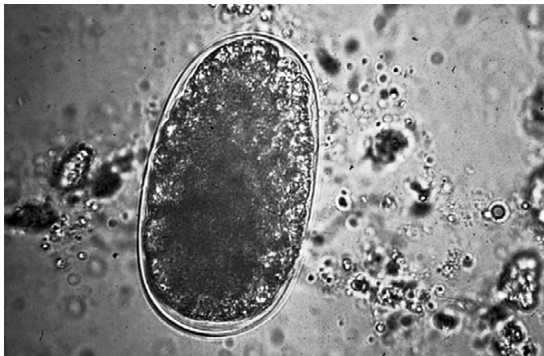**Transmission Route:** Ingestion of contaminated raw and undercooked meat

**Common Name:** Trichina worm

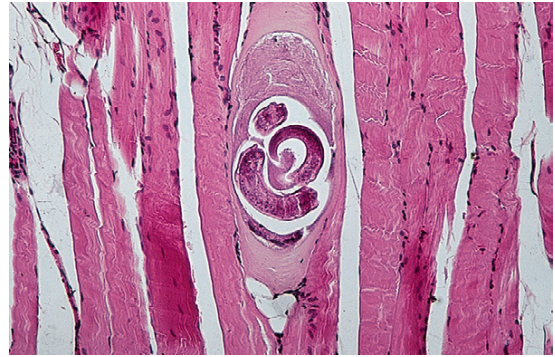The larval form of *Trichinella spiralis*, the trichina worm, is found in the musculature of the porcine intermediate host. The adult worm is very fine and slender and is found within the small intestine. The larval *T. spiralis* is found in striated muscle fibers. It measures approximately 1 mm in length and is found in cystic spaces within the musculature (Figures 4-77 and 4-78). The cyst measures 0.4 to 0.6 mm  $\times$  0.25 mm.



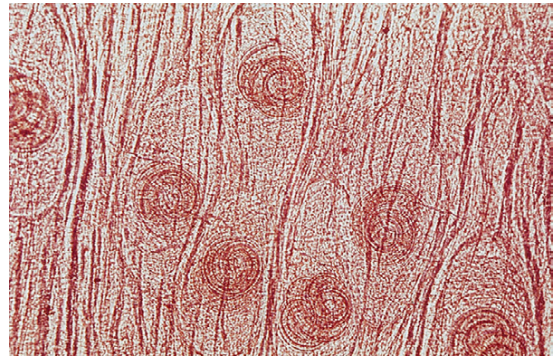
**FIGURE 4-75:** *Stephanurus dentatus*, the swine kidney worm, is found in cystic spaces that connect to kidney, ureters, and perirenal tissues of pigs.



**FIGURE 4-76:** Eggs of *Stephanurus dentatus* are of the strongyle type, that is, oval, thin-shelled eggs. They contain 4 to 16 cells and measure 90 to 120  $\mu\text{m}$   $\times$  43 to 70  $\mu\text{m}$ . Eggs can be recovered from urine using sedimentation.



**FIGURE 4-77:** Muscle biopsy revealing larval form of *Trichinella spiralis*, the trichina worm, found in musculature of porcine intermediate host. Larvae measure approximately 1 mm in length and are found in cystic spaces in musculature.



**FIGURE 4-78:** Histopathologic section revealing larval form of *Trichinella spiralis*, the trichina worm, found in musculature of porcine intermediate host.

In chronic cases the cyst may become calcified. (See discussion under Gastrointestinal Tract for adult stage of this parasite in the definitive host.) Humans may become infected with *T. spiralis*.

Diagnosis of the larval stage of *T. spiralis* is made by performing a biopsy of muscle tissue and demonstrating encysted larvae within skeletal musculature. As a result of the zoonotic potential for this parasite, pork should *always* be cooked thoroughly.

**TECHNICIAN'S NOTE** *Trichinella spiralis* uses the pig as both the intermediate host and the definitive host. It can be passed to other hosts by the eating of raw or undercooked pork, thus using the pig as an intermediate host. However, it also uses the pig as the definitive host, where it reproduces within the pig to continue its life cycle.

## NEMATODES OF MICE

### Gastrointestinal Tract

**Parasite:** *Syphacia obvelata*, *Aspiculuris tetraptera*, and *Syphacia muris*

**Host:** Mice (*Aspiculuris tetraptera*), mice, rats, hamsters, and gerbils (*Syphacia* species)

**Location of Adult:** Cecum and rectum

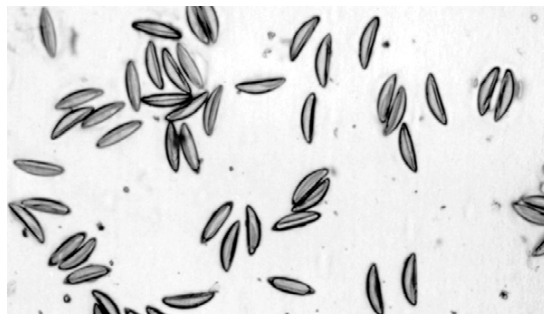
**Distribution:** Worldwide

**Derivation of Genus:** *Syphacia*, love together; *Aspiculuris*, toward a small tail

**Transmission Route:** Ingestion of infective ova and retrograde infection

**Common Name:** Pinworms

**Oxyurids**, or pinworms, of mice include *Syphacia obvelata*, *Aspiculuris tetraptera*, and to a lesser extent, *Syphacia muris*, the common pinworm of rats. Patent *Syphacia* infections can be detected both antemortem and postmortem with the perianal cellophane test. The adults of *Syphacia* reside in the cecum of the mouse until the gravid female migrates the length of the colon to deposit a large batch of eggs in the perianal region, at which time the female dies.



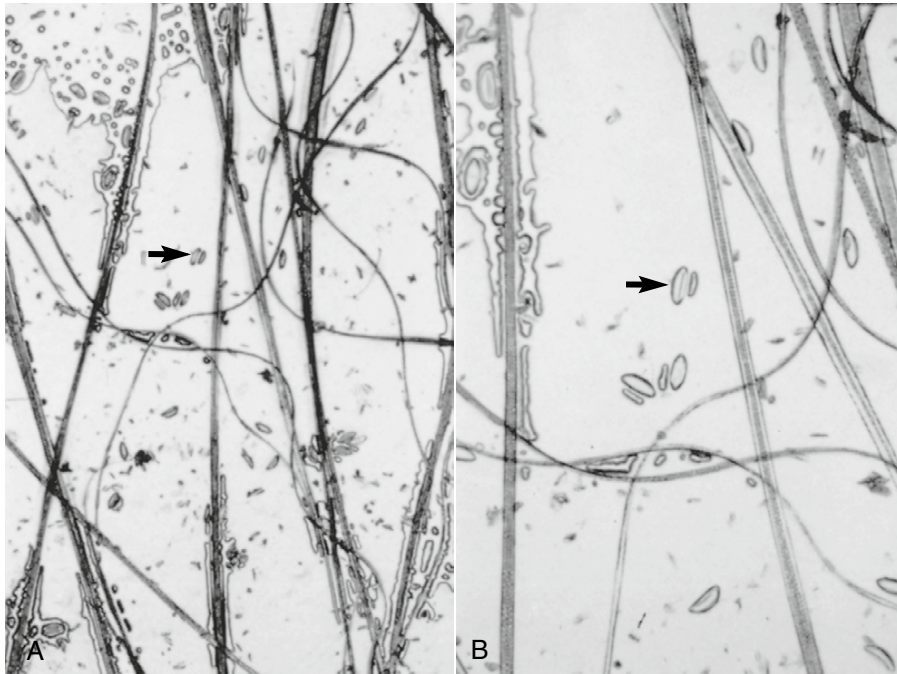
**FIGURE 4-79:** Eggs of *Syphacia obvelata*, the mouse cecal pinworm, as they appear on cellophane tape presentation.

Eggs of *A. tetraptera* cannot be detected with the perianal cellophane tape test. *A. tetraptera* adults reside mainly in the proximal loop of the colon of the mouse and do not migrate to deposit eggs on the perianal area, as do *Syphacia* species. Eggs of *A. tetraptera* can be detected antemortem by fecal flotation and occasionally by direct smear examination of feces.

The banana-shaped eggs of *S. obvelata* are elongated with pointed ends (Figure 4-79). They are flat on one side and convex on the other, measuring 118 to 153  $\mu\text{m} \times 33$  to 55  $\mu\text{m}$ . *S. muris* is found less frequently and in smaller numbers in mice than *S. obvelata*. The more symmetric, football-shaped eggs of *S. muris* are smaller than those of *S. obvelata*, measuring only 72 to 82  $\mu\text{m} \times 25$  to 36  $\mu\text{m}$ , and are blunted or rounded on the ends (Figure 4-80). When observed on fecal flotation, the eggs of *A. tetraptera* are seen to have a thinner shell than the eggs of the *Syphacia* species and do not have a flattened side. *A. tetraptera* eggs are 89 to 93  $\mu\text{m} \times 33$  to 42  $\mu\text{m}$ , symmetrically ellipsoid, and midway in size between eggs of the two *Syphacia* species.

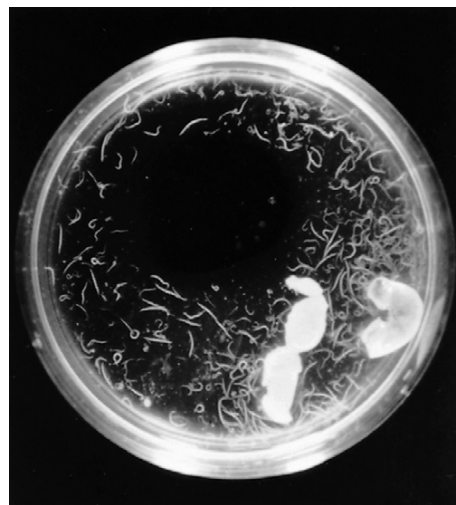**TECHNICIAN'S NOTE** *Aspiculuris tetraptera* females do not deposit ova on the perianal area as other pinworms do. Therefore, the cellophane tape method cannot be used for diagnosis. Instead, standard fecal flotation or direct fecal smear is used to diagnose this species of pinworm.



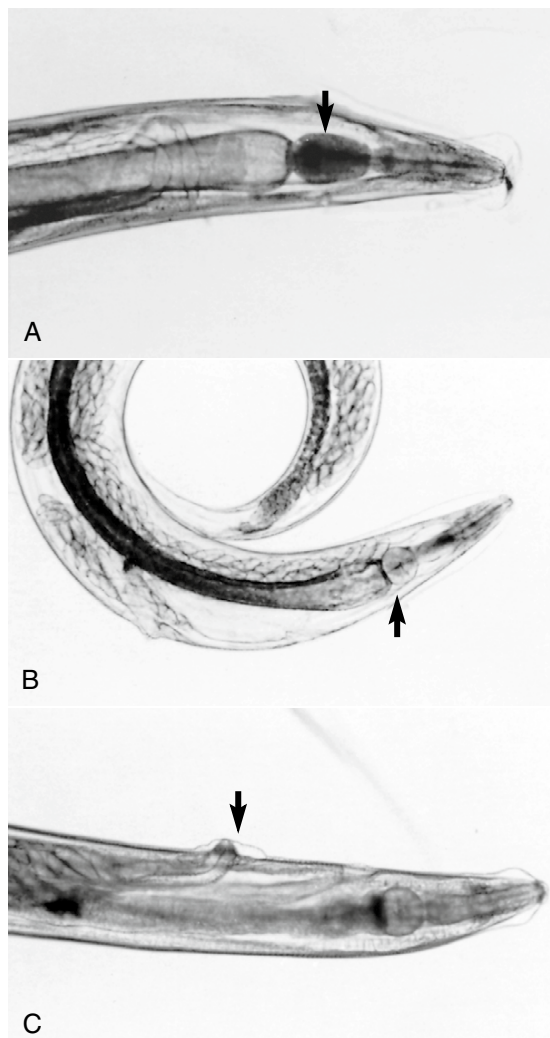


**FIGURE 4-80:** Cellophane tape presentation of *Syphacia muris* eggs viewed at **A**, low, and **B**, medium, magnification. Arrow points to same egg at each magnification. Smaller object right of egg is an artifact.

On postmortem examination, pinworms of mice may be detected by placing a small piece of the cecum and proximal loop of the colon in a Petri dish with a small amount of normal saline. Within a few minutes, pinworms may be observed in the saline grossly or with the aid of a hand-held magnifying lens or a dissecting microscope (Figure 4-81). The adult pinworms can be collected with a bulb and pipette, applied to a glass slide with a coverslip, and examined microscopically at low magnification (4× objective). *A. tetraaptera* is usually recovered from the proximal colon and is easily distinguished from *Syphacia* species by its oval esophageal bulb and prominent cervical ala (Figure 4-82, A). *S. obvelata* and *S. muris* are usually recovered from the cecum. *Syphacia* species have a rounded esophageal bulb and a small cervical ala (Figure 4-82, B). Additionally, the vulva is in the cranial one sixth of the body of *S. obvelata* females (Figure 4-82, C), whereas the vulva of *S. muris* is in the cranial one fourth



**FIGURE 4-81:** Two-inch Petri dish containing saline and proximal loops of colon from three mice. White, hairlike objects are *Aspiculuris tetraaptera* roundworms that have moved into saline from colon sections.



**FIGURE 4-82:** A, Cranial end of *Aspiculuris tetraptera* female, showing oval esophageal bulb (arrow). B, *Syphacia muris*, showing round esophageal bulb (arrow). C, Cranial end of *Syphacia obvelata* female (arrow indicates vulva).

of the body (Figure 4-82, B). Adult males of the two *Syphacia* species can be differentiated by the position of the three ventral mamelons. In males of *S. obvelata*, the middle mamelon is located centrally on the length of the body (Figure 4-86, A). The first mamelon is at the center of the male in *S. muris* (Figure 4-86, B). Although differentiation of the adults of the two *Syphacia* species may be difficult and

time-consuming for veterinary technicians, experienced diagnosticians can easily differentiate the eggs on the cellophane tape preparations by size and shape (Figures 4-79 and 4-80).

In general, mice carry light-to-medium loads of pinworms without demonstrating clinical signs of infection. However, large numbers of pinworms may lead to rectal prolapse, enteritis, sticky stools, and pruritus, which results in biting at the base of the tail. Symptoms are caused by inflammation due to the female and eggs at the perianal region of the animal.

Pinworms are transmitted by the ingestion of the eggs. The eggs are hardy, resistant to environmental extremes, and light enough to aerosolize, making control difficult. Retrograde infection is also possible with *Syphacia* species. The multi-species owner should be instructed that *Syphacia* species can be easily transmitted among mice, rats, hamsters, and gerbils. *A. tetraptera* has also been diagnosed in rats. Rodent pinworms are not of zoonotic significance.



**TECHNICIAN'S NOTE** While pinworms are species specific, *Syphacia* species are able to survive and replicate in mice, rats, hamsters, and gerbils due to the fact that they are all rodent species and closely related.

## NEMATODES OF RATS

### Gastrointestinal Tract

The three oxyurids, or pinworms, discussed in the previous section, *Syphacia muris*, *S. obvelata*, and *Aspiculuris tetraptera*, may also infect rats. *S. muris* is by far the most common pinworm and is often referred to as the “rat pinworm.”

**Parasite:** *Trichosomoides crassicauda*

**Host:** Rats

**Location of Adult:** Urinary bladder


**Distribution:** Worldwide

**Derivation of Genus:** body shaped like a hair

**Transmission Route:** Ingestion of ova from urine (urinary-oral)

**Common Name:** Bladder worm of the rat

*Trichosomoides crassicauda* is a nematode found in the urinary bladder of rats. The adult female *T. crassicauda* is approximately 10 mm long; it is a thin worm and is grossly visible in the wall of the urinary bladder. This parasite is unique in that the male is **neotenic**. This means that he is very small and resides in the vagina of the immature female and the uterus of the mature female, *T. crassicauda*. The eggs are double operculate, approximately  $65 \times 33 \mu\text{m}$ , and resemble whipworm eggs, especially those of *Trichuris* species. The main difference between the eggs is that the eggs of *T. crassicauda* are lighter in color, slightly smaller, and contain a single larva. This parasite has been associated with bladder tumors in rats; however, few clinical signs are associated with infection by *T. crassicauda*, most damage coming from the presence of the parasite in the bladder wall. Transmission is by the urinary-oral route. This parasite can be a significant problem in rat colonies but can be eliminated by cesarean delivery of neonates. This is a species-specific nematode and is not of zoonotic significance.

 **TECHNICIAN'S NOTE** The male urinary bladder worm of rats resides inside the vagina of the immature female or the uterus of the mature female.

Infections with *T. crassicauda* may be diagnosed in three ways: antemortem or postmortem observation of eggs in the urine, gross observation at postmortem of adult worms in the wall or lumen of the urinary bladder, and microscopic observation of the adult worms in histopathologic sections of the urinary bladder, ureters, or renal pelvis.

## NEMATODES OF HAMSTERS

### Gastrointestinal Tract

Hamsters are susceptible to infection with the mouse and rat pinworm, *Syphacia obvelata* and *S. muris*, although it is unlikely that hamsters will develop clinically apparent infections (see previous discussion of nematodes of mice).

## NEMATODES OF GERBILS

### Gastrointestinal Tract

**Parasite:** *Dentostomella translucida*

**Host:** Gerbil


**Location of Adult:** Stomach and proximal  $\frac{1}{3}$  of the small intestine

**Distribution:** Worldwide

**Derivation of Genus:** little tooth in mouth

**Transmission Route:** Ingestion of infective ova

**Common Name:** Pinworm of gerbils

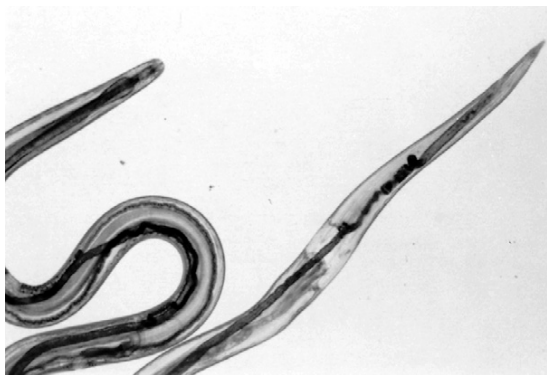 **TECHNICIAN'S NOTE** Pinworms are not reported as commonly in gerbils as they are in other rodent species.

*Dentostomella translucida*, the gerbil pinworm, is not reported as frequently as other rodent pinworms (*Syphacia* species and *Aspiculuris tetraptera*). This may be the result of the lack of information on its life cycle. Adult male and female nematodes have a short, muscular esophagus. The vulva of the female is located just cranial to the midbody (Figure 4-83). Males are distinguished by a cuticular inflation just cranial to the cloaca (Figure 4-84). Adults are 6 to 31 mm long, with the female generally larger than the male, as is true of other rodent pinworms. Eggs of *D. translucida* are asymmetric and oval, measuring  $120$  to  $140 \mu\text{m} \times 30$  to  $60 \mu\text{m}$  (Figure 4-85). They resemble those of *A. tetraptera*, which are smaller, measuring  $89$  to  $93 \mu\text{m} \times 36$  to  $42 \mu\text{m}$ .

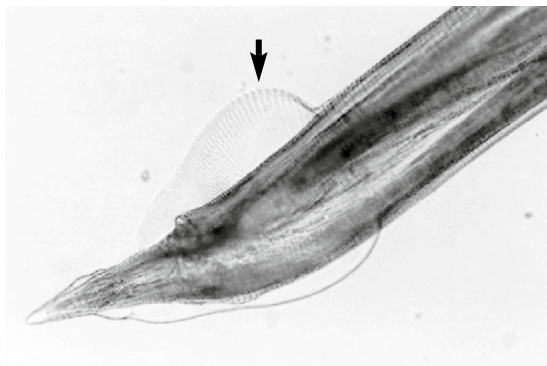
Fecal flotation may be used to detect eggs of *D. translucida*, but this method is unreliable because of the poorly understood life cycle (intermittent shedding of eggs). On postmortem examination, *D. translucida* may be found in the stomach and the proximal one third of the small intestine.

*D. translucida* has a direct life cycle and is transmitted by ingestion of infective eggs from feces of infected animals. The parasite has been found in the golden hamster, as well as the gerbil. This parasite has no zoonotic significance.

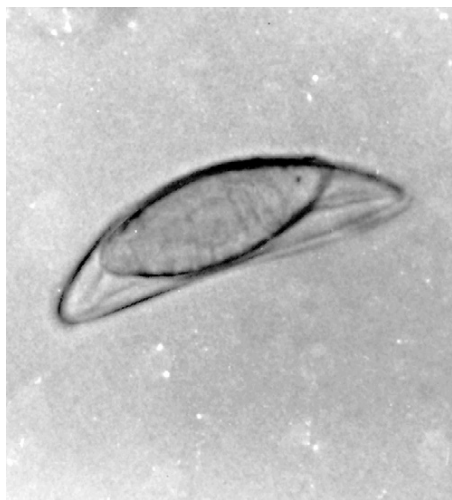



**FIGURE 4-83:** Adult female *Dentostomella translucida*.



**FIGURE 4-84:** Cuticular inflation (arrow) on tail of male *Dentostomella translucida*.



**FIGURE 4-85:** Egg of *Dentostomella translucida* in fecal flotation.

As with hamsters, gerbils are susceptible to infection with the mouse and rat pinworm, *S. obvelata* and *S. muris* (Figure 4-86; also Figures 4-79, 4-80, and 4-81, and previous discussion of nematodes of mice).



**TECHNICIAN'S NOTE** As with other pinworm species, the damage done by pinworms is most commonly caused by inflammation and irritation.

## NEMATODES OF GUINEA PIGS

### Gastrointestinal Tract

**Parasite:** *Paraspidodera uncinata*

**Host:** Guinea pig

**Location of Adult:** Cecum and colon

**Distribution:** Worldwide

**Derivation of Genus:** bears a peculiar neck

**Transmission Route:** Ingestion of infective ova

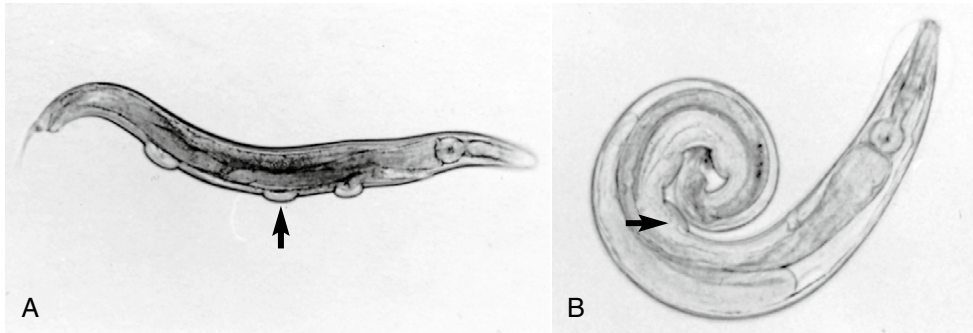
**Common Name:** Ascarid of guinea pigs

*Paraspidodera uncinata* is generally a non-pathogenic nematode of guinea pigs that can be found in cecal contents or in the mucosa of the cecum and colon. Adult worms are 11 to 28 mm × 0.3 to 0.4 mm. The male of *P. uncinata* has a sucker and two spicules of equal length immediately cranial to the anus. The eggs are oval and have a characteristic thick ascarid shell (Figure 4-87). Eggs are 40 to 50 μm × 30 to 40 μm. Antemortem, eggs may be detected by fecal flotation or direct fecal smear. Occasionally, extremely heavy infections may cause diarrhea and weight loss.

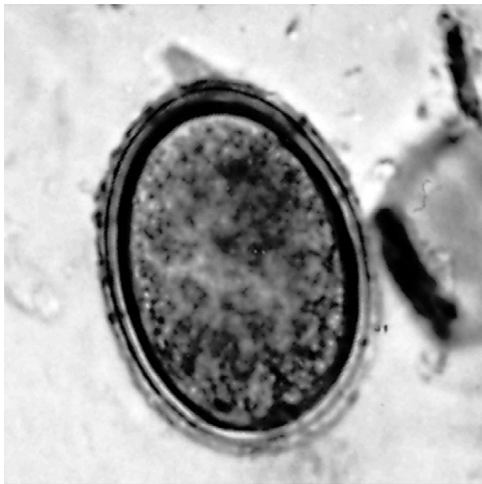
The life cycle of *P. uncinata* is direct, and transmission occurs through feed and water contaminated with infective eggs. *P. uncinata* has not been found in other species of animals and is not considered a public health hazard.



**TECHNICIAN'S NOTE** The ascarid of guinea pigs is nonpathogenic but will cause symptoms from intestinal disturbance with extremely heavy infections.



**FIGURE 4-86:** A, *Syphacia obvelata* male, showing middle mamelon (arrow) at center of body. B, *S. muris* male, showing first mamelon at midbody (arrow).



**FIGURE 4-87:** Egg of *Paraspisodera uncinata*, the cecal pinworm of guinea pigs.

## NEMATODES OF RABBITS

### Gastrointestinal Tract

**Parasite:** *Passalurus ambiguus*

**Host:** Rabbits

**Location of Adult:** Cecum and colon

**Distribution:** Worldwide

**Derivation of Genus:** Tailed worm named for a researcher named Passal

**Transmission Route:** Ingestion of infective ova

**Common Name:** Pinworm of rabbits

*Passalurus ambiguus* is a nonpathogenic pinworm found in the cecum and colon of

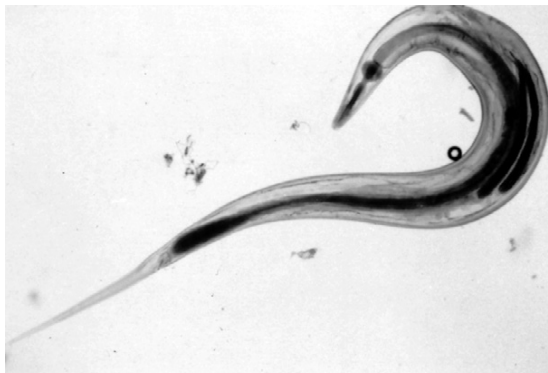domestic and cottontail rabbits and hares. It is a pinworm that has an obvious round esophageal bulb. Adult females are approximately 10 mm long (Figure 4-88), and males are 4 to 5 mm long (Figure 4-89). Females have a long, finely pointed tail. Eggs are oval and slightly flattened on one side, measuring approximately  $43 \times 103 \mu\text{m}$  (Figure 4-90). Eggs are deposited in the feces and resemble the morulated hookworm eggs of dogs.

Infection with *P. ambiguus* can be detected antemortem by observing typical eggs in fecal flotation preparations. On postmortem examination, the white, hairlike adult worms can be found in the cecum and proximal colon. Rabbits can tolerate heavy infections with no apparent clinical signs. It is believed that these pinworms feed on bacteria in the intestinal contents without disturbing the mucosal lining of the cecum.

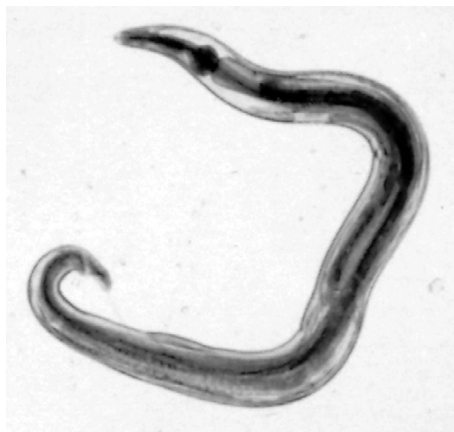Eggs passed in the feces are immediately infective, so control of this parasite is quite difficult. Transmission is by ingestion of infective eggs. Clients should be advised to use feeders elevated off the floor of the rabbit hutch and to prevent wild hares and cottontail rabbits from having access to pet rabbits and their feed and bedding. *P. ambiguus* is species specific and has no zoonotic potential.



**TECHNICIAN'S NOTE** The pinworm of rabbits is nonpathogenic and believed to feed on the bacteria of the intestinal contents, thus not disturbing the intestinal mucosa.



**FIGURE 4-88:** Adult female *Passalurus ambiguus*. Note the long, slender tail.



**FIGURE 4-89:** Adult male *Passalurus ambiguus*.

**Parasite:** *Obeliscoides cuniculi* and *Trichostrongylus colcaratus*

**Host:** Rabbits

**Location of Adult:** Stomach (*O. cuniculi*) and small intestine (*T. calcaratus*)

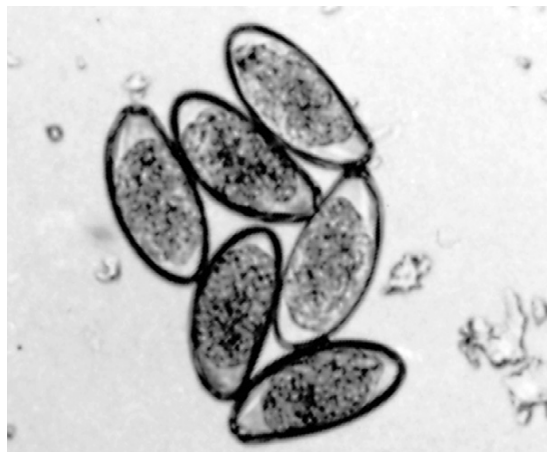**Distribution:** Worldwide

**Derivation of Genus:** Round hair (*T. calcaratus*); *Obeliscoides*, shaped like a pointed pillar

**Transmission Route:** Ingestion of infective larvae

**Common Name:** Trichostrongyles of rabbits

Trichostrongyles are primarily parasites of ruminants and other large animals. However, these nematodes are also common in wild rabbits, and uncommon in domestic rabbits. Diagnosticians must be aware of the possibility of infection with one or more rabbit trichostrongyles. Adult



**FIGURE 4-90:** Ova of *Passalurus ambiguus* in fecal flotation.

*Obeliscoides cuniculi* are found in the stomach of rabbits, and adult *Trichostrongylus colcaratus* are found in the small intestine where they feed on the host's blood. The males of these species are distinguished by the copulatory bursa on the posterior end. *O. cuniculi* females are 16 mm long and 0.5 mm wide, and males are 12 × 0.2 mm. Male and female adults may be found in the stomach on postmortem examination. Eggs are 80 × 45 μm and are thin-shelled and oval. They may be easily observed on fecal flotation procedures. This nematode can produce a hemorrhagic gastritis. Transmission is by ingestion of the larval form after eggs are passed in the feces.



**TECHNICIAN'S NOTE** The trichostrongyles of rabbits use a direct life cycle where a new host is infected by ingestion of infective larvae rather than using an intermediate host. The ova can be found on fecal flotation.

Adults of *T. calcaratus* are found in the small intestine and generally are smaller than those of *O. cuniculi*. Females of *T. calcaratus* are 6.4 mm × 100 μm, and males are 5.7 mm × 115 μm. The thin-shelled eggs are 65 × 33 μm and may be observed on fecal flotation. Rabbits infected with *T. calcaratus* may develop anemia. The life cycle of this trichostrongyle is direct, and transmission

is by ingestion of infective larvae. As with other parasites that infect wild rabbits, prevention and control depend on keeping feed and bedding inaccessible to wild hares and cottontail rabbits.

**TECHNICIAN'S NOTE** Rabbit trichostrongyles are typically found in wild rabbits rather than domestic rabbits.

## NEMATODES OF PET AND AVIARY BIRDS

### Gastrointestinal Tract

**Parasite:** *Ascaridia* species

**Host:** Love birds, cockatiels, macaws, parakeets, poultry, and waterfowl

**Location of Adult:** Small intestine

**Distribution:** Worldwide

**Derivation of Genus:** Intestinal worm

**Transmission Route:** Ingestion of infective ova

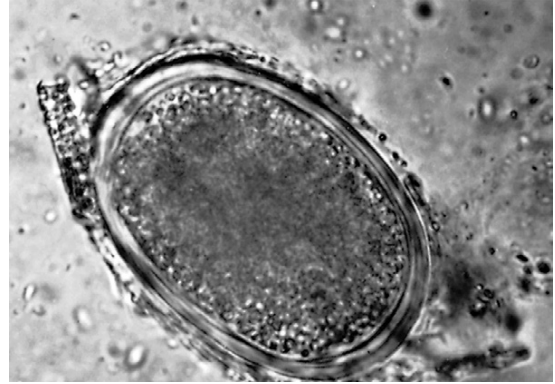**Common Name:** Ascarids of birds

Nematodes occur infrequently in pet and aviary birds. *Ascaridia* is occasionally seen in lovebirds, cockatiels, and macaws (Figures 4-91 and 4-92). Ascarids are very common in grass parakeets and can be demonstrated on both direct smear examination and fecal flotation. The eggs are thick-shelled roundworm type eggs (Figure 4-91). These roundworms are also common in backyard poultry and in waterfowl and can cause intestinal obstruction with large infections. In turkeys and peafowl, *Heterakis gallinarum* serves as an intermediate host for *Histomonas meleagridis*, the protozoan that produces infectious enterohepatitis.

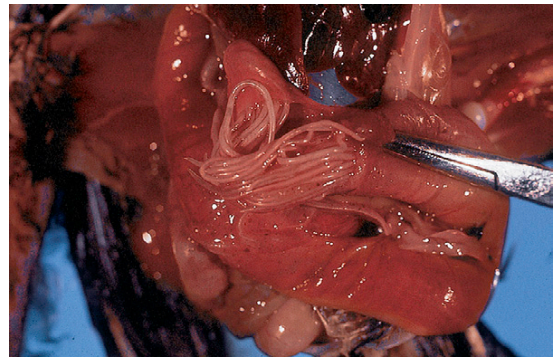
**TECHNICIAN'S NOTE** While the ascarid of birds infects different bird species, it is most commonly seen in backyard poultry and waterfowl.

**Parasite:** *Spiroptera incesta*, *Dyspharynx nasuta*, and *Tetrameres* species

**Host:** Australian finches (*S. incesta*), finches (*D. nasuta*), and pigeons (*Tetrameres* species)



**FIGURE 4-91:** A roundworm (*Ascaridia*) egg in a fecal smear from a cockatiel.



**FIGURE 4-92:** Nematodes occur infrequently in pet and aviary birds. *Ascaridia* is occasionally seen in small intestine of lovebirds, cockatiels, and macaws.

**Location of Adult:** Ventriculus, ventriculus, and proventriculus, respectively

**Intermediate Host:** Insect, insect, sow bug; respectively.

**Distribution:** Tropical and subtropical regions (*D. nasuta*)

**Derivation of Genus:** Spiroptera: coiled wing; Dyspharynx: abnormal throat; Tetrameres: made up of four parts

**Transmission Route:** Ingestion of infective insect, ingestion of infective insect, and ingestion of infective sow bug, respectively.

**Common Name:** Spirurids of birds



Spirurids can infect a variety of avian species but are generally uncommon in pet birds. *Spiroptera inesta* can infect Australian finches; *Dyspharynx nasuta* infects other finches. Infection by spirurids can be difficult to detect in finches. When spirurids are suspected, histologic examination of the ventriculus is recommended. The eggs of the spirurids are characterized by a thick wall and the presence of an embryonating larva within each egg. *Tetrameres*, a globose (spherical) spirurid, is typically found in the wall of the proventriculus of pigeons (Figure 4-4). Adults typically produce damage by living within the host.

 **TECHNICIAN'S NOTE** The spirurids of birds are not commonly found in pet birds.

**Parasite:** *Capillaria* species

**Host:** Pheasants, peafowl and other poultry

**Location of Adult:** Crop and upper alimentary tract


**Distribution:** Worldwide

**Derivation of Genus:** hair-like

**Transmission Route:** Ingestion of infective ova or paratenic host, earthworm

**Common Name:** poultry capillariid

*Capillaria* species may be found in the crop and upper alimentary tract of pheasants, peafowl, and other poultry. These hairlike nematodes have been reported in a variety of imported psittacine birds. The tiny adult worms can often be recovered from the wall of the esophagus or the crop where they can cause inflammation and other disturbances. A direct smear of a sample from this area or a fecal flotation often reveals the characteristic thick-walled bipolar eggs, which are similar to whipworms, the *Trichuris* species. The eggs are shed in the feces and develop into infective ova. These infective ova can be ingested directly by a new host or by an earthworm as a paratenic host. The earthworm can then be ingested and the parasite will continue its life cycle in the bird.

 **TECHNICIAN'S NOTE** *Capillaria* species use a direct life cycle or a paratenic host, earthworm, as a means of transmission from one host to another. The parasite does not undergo any life cycle stages in the earthworm. It is merely used to transport the parasite from one host to another.

## CHAPTER FOUR TEST

**MATCHING**—Match the scientific name of each parasite with its common name, phrase, or term.

- |                                                  |                                   |
|--------------------------------------------------|-----------------------------------|
| A. <i>Spirocerca lupi</i>                        | 1. Hookworms of dogs and cats     |
| B. <i>Ollulanus tricuspis</i>                    | 2. Bovine trichostrongyles        |
| C. <i>Toxocara</i> , <i>Toxascaris</i> species   | 3. Canine heartworm               |
| D. <i>Ancylostoma</i> , <i>Uncinaria</i> species | 4. Intestinal threadworm of swine |
| E. <i>Trichuris vulpis</i>                       | 5. Swine kidney worm              |
| F. <i>Dirofilaria immitis</i>                    | 6. Esophageal worm of dogs        |
| G. <i>Diectophyma renale</i>                     | 7. Rabbit pinworm                 |
| H. <i>Aelurostrongylus abstrusus</i>             | 8. Equine ascarid                 |



- |                                                                                                        |                                                         |
|--------------------------------------------------------------------------------------------------------|---------------------------------------------------------|
| I. <i>Haemonchus</i> , <i>Ostertagia</i> ,<br><i>Trichostrongylus</i> , and <i>Cooperia</i><br>species | 9. Feline lungworm                                      |
| J. <i>Thelazia rhodesii</i>                                                                            | 10. Equine pinworm                                      |
| K. <i>Setaria cervi</i>                                                                                | 11. Proventriculus worm of pigeons                      |
| L. <i>Parascaris equorum</i>                                                                           | 12. Ascarids of dogs and cats                           |
| M. <i>Strongylus vulgaris</i> , <i>S. edentatus</i> ,<br>and <i>S. equinus</i>                         | 13. Abdominal worm of cattle                            |
| N. <i>Oxyuris equi</i>                                                                                 | 14. Feline trichostrongyle                              |
| O. <i>Strongyloides ransomi</i>                                                                        | 15. Mouse pinworm                                       |
| P. <i>Oesophagostomum dentatum</i>                                                                     | 16. Free-living soil nematodes or facultative parasites |
| Q. <i>Ascaris suum</i>                                                                                 | 17. Large strongyles of horses                          |
| R. <i>Stephanurus dentatus</i>                                                                         | 18. Whipworm of dogs                                    |
| S. <i>Trichinella spiralis</i>                                                                         | 19. Swine ascarid                                       |
| T. <i>Syphacia obvelata</i>                                                                            | 20. Guinea worm of dogs                                 |
| U. <i>Passalurus ambiguus</i>                                                                          | 21. Eyeworm of ruminants                                |
| V. <i>Tetrameres</i> species                                                                           | 22. Giant kidney worm                                   |
| W. <i>Enterobius vermicularis</i>                                                                      | 23. Human pinworm (pseudoparasite of dogs and cats)     |
| X. <i>Pelodera strongyloides</i>                                                                       | 24. Stomach worm of dogs and cats                       |
| Y. <i>Physaloptera</i> species                                                                         | 25. Trichina worm                                       |
| Z. <i>Dracunculus insignis</i>                                                                         | 26. Nodular worm of swine                               |

MATCHING—Match the parasite with the correct diagnostic technique or term.

- |                                    |                                                                                                            |
|------------------------------------|------------------------------------------------------------------------------------------------------------|
| A. <i>Spirocerca lupi</i>          | 1. Observing of microfilariae using modified Knott's test in conjunction with commercially available ELISA |
| B. <i>Diectophyma renale</i>       | 2. Observing bipolar, football-shaped eggs in fecal flotation                                              |
| C. <i>Trichuris vulpis</i>         | 3. Necropsy revealing large nodules within the wall of the large intestine                                 |
| D. <i>Filaroides osleri</i>        | 4. Observing "paper clip-shaped eggs" on fecal flotation                                                   |
| E. <i>Dirofilaria immitis</i>      | 5. Observing infective first-stage larvae with S-shaped appendage on the tail                              |
| F. <i>Stephanurus dentatus</i>     | 6. Observing large, rough, bipolar, barrel-shaped eggs on urine sedimentation                              |
| G. <i>Oesophagostomum dentatum</i> | 7. Flotation of feline vomitus revealing infective third-stage larvae                                      |

- |                                |                                                                                        |
|--------------------------------|----------------------------------------------------------------------------------------|
| H. <i>Oxyuris equi</i>         | 8. Microscopic examination of muscle biopsy revealing encysted larvae in muscle tissue |
| I. <i>Ollulanus tricuspis</i>  | 9. Cellophane tape impressions of anus revealing larvated eggs                         |
| J. <i>Trichinella spiralis</i> | 10. Observation of strongyle-type eggs in pig urine                                    |

MATCHING—Match the parasite with the pathology it produces.

- |                                |                                                                                                   |
|--------------------------------|---------------------------------------------------------------------------------------------------|
| A. <i>Physaloptera</i> species | 1. Adult nematodes firmly attached to the mucosa of small intestine; voracious blood suckers      |
| B. <i>Toxocara canis</i>       | 2. Blood suckers; tiny stylet in the tip of the whiplike anterior end cannulates blood vessels    |
| C. <i>Trichuris vulpis</i>     | 3. Ingestion of solid tissue; renal parenchyma                                                    |
| D. <i>Filaroides osleri</i>    | 4. Physical blockage of the lumen of the small intestine                                          |
| E. <i>Gongylonema pulchrum</i> | 5. Parasite lies embedded in esophageal submucosa in a zigzag fashion                             |
| F. <i>Setaria equina</i>       | 6. Adult nematodes firmly attached to the stomach mucosa; blood suckers                           |
| G. <i>Ancylostoma caninum</i>  | 7. Formation of nodules in the esophagus                                                          |
| H. <i>Oxyuris equi</i>         | 8. Formation of nodules at the bifurcation of the trachea                                         |
| I. <i>Spirocerca lupi</i>      | 9. Pruritus in the anal region; hairs at base of tail broken off from attempts at scratching anus |
| J. <i>Dioctophyma renale</i>   | 10. Nonpathogenic; solitary worms are found free within the abdominal cavity                      |

## QUESTIONS FOR THOUGHT AND DISCUSSION

1. Why is it important to learn the life cycles of the nematode parasites of domesticated animals?
2. Why is it important to learn the scientific names, hosts, and locations of the nematode parasites of domesticated animals?

# The Phylum Platyhelminthes, Class Cestoda

5

## KEY TERMS

Cestode  
True tapeworm  
Pseudotapeworm  
Proglottid  
Scolex  
Acetabula, suckers  
Tegument  
Rostellum  
Armed tapeworm  
Unarmed tapeworm  
Neck  
Immature proglottid  
Mature proglottid  
Gravid proglottid  
Hermaphroditic  
Hexacanth embryo  
Metacestode stage  
Cysticercoid  
Cysticercus  
Coenurus  
Hydatid cyst  
Tetrathyridium  
Bothria  
Coracidium  
Copepod  
Proceroid  
Plerocercoid

## OUTLINE

Eucestoda (True Tapeworms)  
*Key Morphologic Features*  
*Life Cycle of the True Tapeworm*

Cotyloda (Pseudotapeworms)  
*Key Morphologic Features*  
*Life Cycle of the Pseudotapeworm*

## LEARNING OBJECTIVES

*After studying this chapter, the reader should be able to do the following:*

- Briefly discuss the external morphology of cestodes.
- Describe the important external morphologic features for differentiating both true tapeworms and pseudotapeworms.
- Describe the four types of cestode eggs.
- Compare the life cycle of a typical true tapeworm with that of a typical pseudotapeworm.
- Be able to integrate vocabulary terms with the cestode parasites covered in Chapter 6.

The phylum Platyhelminthes, the flatworms, includes the **trematodes** (or flukes) discussed in Chapters 7 and 8, and the **cestodes** (or tapeworms) detailed in this chapter and Chapter 6. Remember that the morphologic feature shared by these two classes is that they are both dorsoventrally flattened. However, whereas the flukes are flattened and leaf-shaped, the tapeworms are ribbonlike and segmented into identical compartments called **proglottids** (Figure 5-1).



**TECHNICIAN'S NOTE** Cestodes are dorsoventrally flattened, ribbonlike, and segmented into identical compartments called proglottids.

Members of the phylum Platyhelminthes, class Cestoda, are often referred to as cestodes or “tapeworms.” Their bodies are usually long, segmented, and flattened, almost ribbonlike in appearance. Within the class Cestoda are two subclasses, the subclass Eucestoda (true tapeworms)

and the subclass Cotyloda (pseudotapeworms). Members of both of these classes are important parasites of domesticated and wild animals and of humans.

### EUCESTODA (TRUE TAPEWORMS)

Phylum: Platyhelminthes

Class: Cestoda

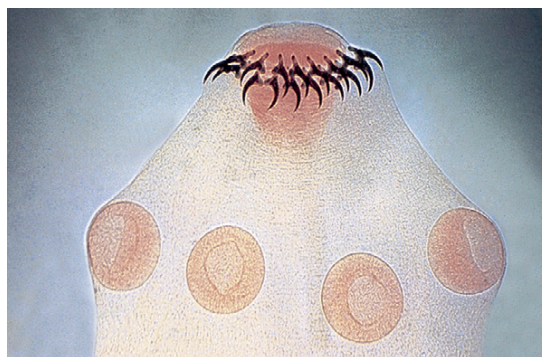
### Key Morphologic Features

As mentioned, tapeworms are long, segmented, flattened, almost ribbonlike parasites. On the extreme anterior end of the typical true tapeworm is the holdfast organelle, the **scolex**, or head (Figure 5-2). The scolex of the adult true tapeworm has four suckers called **acetabula**, with which the tapeworm holds on to the lining of the small intestine, the predilection site, or “home,” of most adult tapeworms. Unlike the oral sucker of the digenetic trematode, the suckers of the true tapeworm are *not* associated with intake of food but rather serve as organs of attachment. True tapeworms do not have a mouth; instead, they absorb the nutrients acquired from the host’s intestine through their **tegument**, or body wall. In addition to the suckers, some true tapeworms may possess an anchorlike organelle called the **rostellum** (Figure 5-3). The rostellum

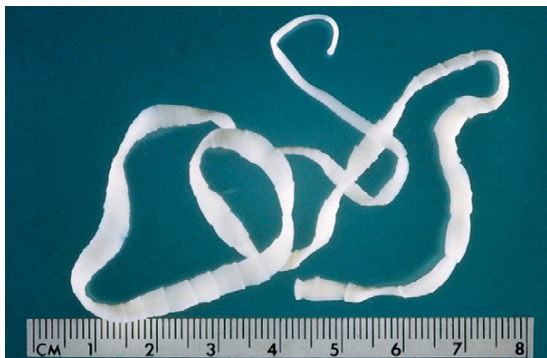usually has backward-facing hooks. With these hooks, the tapeworm further anchors itself in the mucosa of the small intestine. If the tapeworm has a rostellum, it is said to be an **armed tapeworm**; if the tapeworm lacks the rostellum, it is said to be an **unarmed tapeworm**.



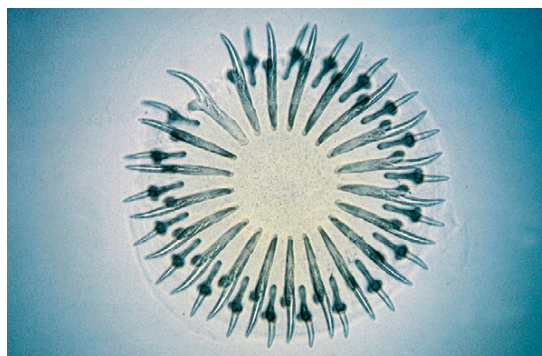
**TECHNICIAN'S NOTE** The suckers on the cestode are not associated with food intake; instead, the cestode absorbs nutrients from the host through its tegument.



**FIGURE 5-2:** Located on the anterior end of the true tapeworm is the holdfast organelle, the scolex, or head. The scolex of the adult true tapeworm has four suckers called acetabula, with which the tapeworm holds on to the lining of the small intestine, the predilection site of most adult tapeworms.



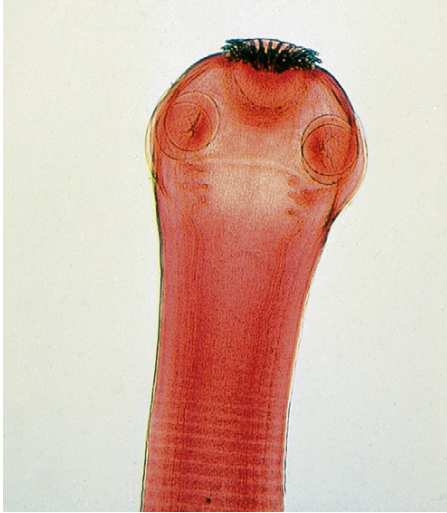
**FIGURE 5-1:** Example of typical tapeworm with dorsoventrally flattened, ribbonlike appearance. Every tapeworm is segmented into identical compartments called proglottids.



**FIGURE 5-3:** Anchorlike organelle, the rostellum, on anterior end of tapeworm. The rostellum usually has backward-facing hooks used to anchor the tapeworm further in the mucosa of the small intestine. If the tapeworm has a rostellum, it is said to be an “armed” tapeworm; if the tapeworm lacks the rostellum, it is said to be an “unarmed” tapeworm.



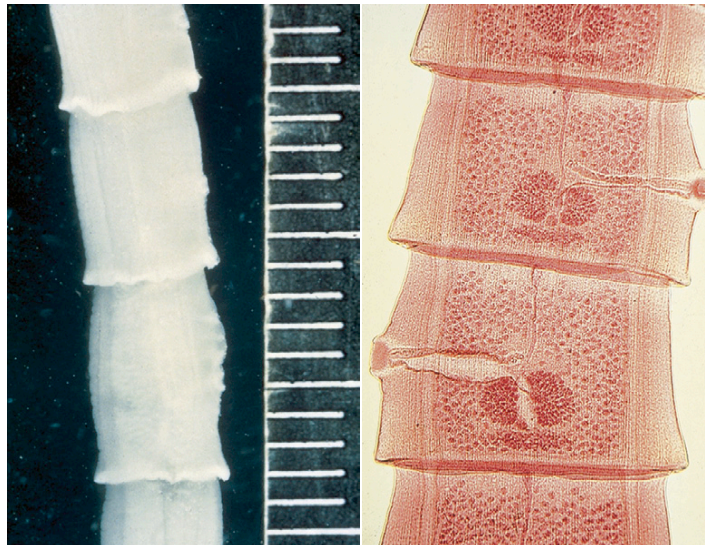
Just posterior to the scolex of the true tapeworm is a germinal, or growth, region called the **neck**. It is from the neck that the rest of the true tapeworm's body, the **strobila**, arises. The strobila is composed of individual proglottids that



**FIGURE 5-4:** Proglottids closest to scolex and neck of the true tapeworm are immature, or “youngest,” proglottids. Immature proglottids contain immature, nonfunctional male and female reproductive organs.

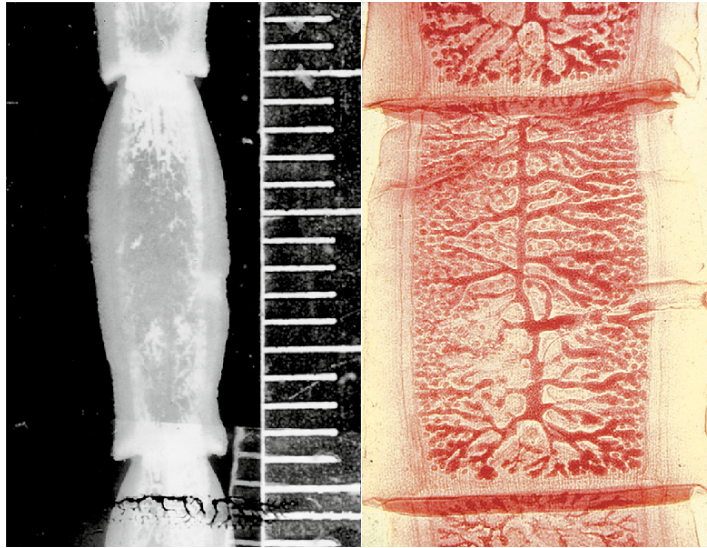
are arranged similar to the boxcars in a railroad train. The proglottids closest to the scolex and the neck of the true tapeworm are the **immature**, or youngest, proglottids (Figure 5-4); those that are intermediate in distance from the scolex and the neck are the **mature** proglottids (Figure 5-5); and those farthest from the scolex and the neck are the **gravid**, or oldest, proglottids (Figure 5-6).

As with the hermaphroditic digenetic trematodes, each proglottid of a true tapeworm contains complete sets of both male and female reproductive organs. As with the flukes, tapeworms are hermaphroditic. The sex organs of these tapeworms are usually located along the lateral aspects of the proglottid. Cross-fertilization and self-fertilization take place between and among individual proglottids. Immature proglottids contain male and female reproductive organs that are sexually immature; these are “prepuberty” proglottids. Mature proglottids contain male and female reproductive organs that are sexually mature and completely functional, or capable of reproduction. Gravid proglottids contain male and female reproductive organs that have grown old or are “spent,” having degenerated to the point that the only portion remaining is the uterus filled with



**FIGURE 5-5:** Tapeworm proglottids intermediate in distance to scolex and neck of the true tapeworm are mature, or “adolescent,” proglottids. Mature proglottids contain mature, functional male and female reproductive organs.





**FIGURE 5-6:** Tapeworm proglottids farthest from the scolex and the neck of the true tapeworm are gravid, or “aged,” proglottids. Gravid proglottids contain male and female reproductive organs that have grown old and degenerated so that only the uterus filled with eggs remains.

tapeworm eggs. Tapeworm proglottids can usually be observed with the naked eye in the feces of the definitive host (Figure 5-7). Other organ systems (nervous, excretory) are represented; however, they are not as important as the reproductive system. As with the digenetic trematodes, or flukes, tapeworms are “designed” to reproduce and produce offspring.

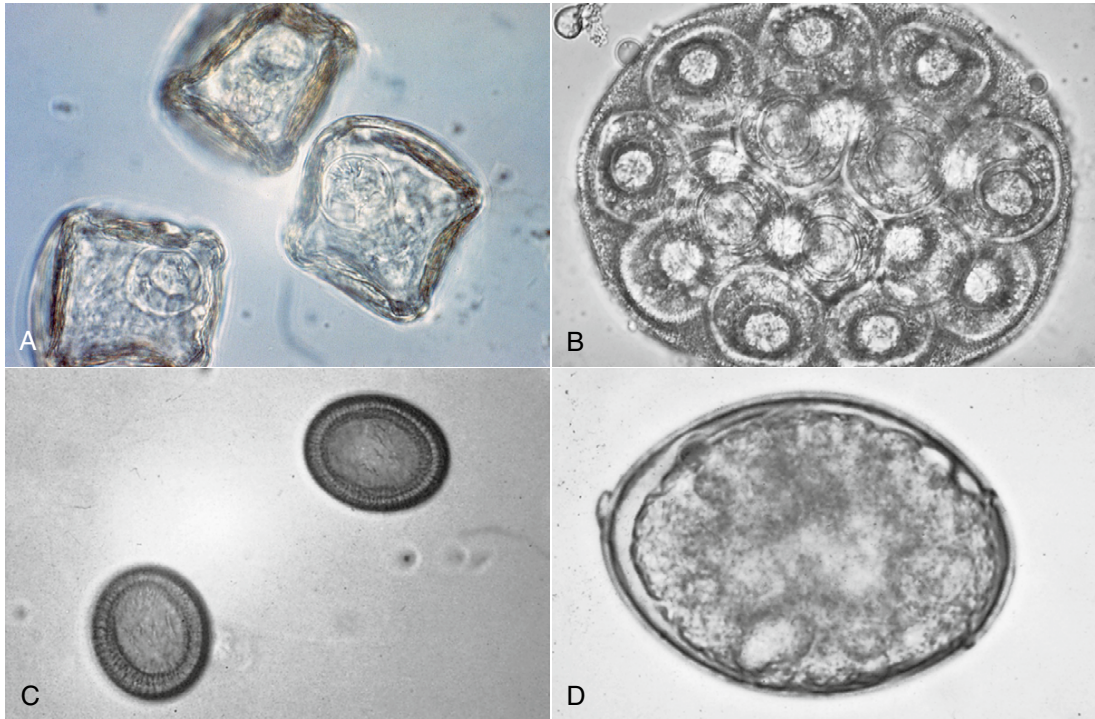
**TECHNICIAN'S NOTE** Each segment of the tapeworm contains male and female reproductive organs. Mature proglottids can self-fertilize or can cross-fertilize with other segments. The gravid proglottids contain the eggs of the tapeworm.

The eggs found in the gravid proglottids contain the larval stage, or **hexacanth**, with six hooks. The hexacanths can be contained within one of four egg types: “**pyriform apparatus type**,” *Dipylidium* type, *Taenia* type, and pseudophyllidean type. The pyriform apparatus type (Figure 5-8, A) is an egg with three coverings, the



**FIGURE 5-7:** Tapeworm proglottids (*Dipylidium caninum*) observed in feces of definitive host.

innermost of which is pear-shaped and is called the pyriform apparatus. The *Dipylidium* egg packet contains multiple hexacanths within one egg (Figure 5-8, B). The *Taenia* egg has a wide outer shell with a thicker outer covering and a six-hooked hexacanth within the egg (Figure 5-8, C). The **pseudophyllidian egg** resembles the *Ancylostoma* egg; however, it has an operculum (Figure 5-8, D). It has an oval shape with the operculum at one end. Each hexacanth contains six hooks.



**FIGURE 5-8:** Tapeworm eggs can be seen in four basic types. **A**, Pyriform apparatus type egg. **B**, Dipylidium eggs, as seen in *Dipylidium caninum*. **C**, Taenia egg, as seen in *Taenia pisiformis*. **D**, Pseudophyllidia egg, as seen in *Diphylobothrium latum*.

**TECHNICIAN'S NOTE** Tapeworms can produce one of four types of eggs: Pseudophyllidium egg type, Dipylidium egg type, and Taenia egg type, and Pyriform apparatus type.

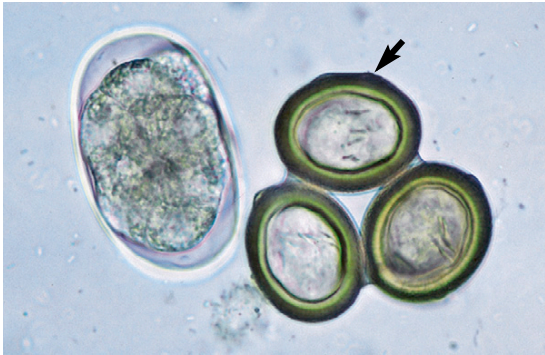### Life Cycle of the True Tapeworm

The life cycle of a typical true tapeworm is more complicated than that of a digenetic trematode. In most cases the gravid proglottids of the true tapeworm pass to the outside environment, sometimes singly and sometimes in chains, one behind the other. These proglottids rupture in the external environment and release thousands of **hexacanth embryos**, or eggs, to the outside environment (Figure 5-9). To continue the life cycle, the egg must be ingested by a suitable intermediate host, either an invertebrate or a vertebrate. Within this host, the egg develops into a **metacestode**, or larval tapeworm. The

metacestode may take one of several forms: **cysticercoid**, **cysticercus**, **coenurus**, **hydatid cyst**, or **tetrathyridium**. These larval stages differ in their choice of host, their structure, their predilection site, and their pathogenicity to the intermediate host. Sometimes the metacestode, or larval stage of the tapeworm is more pathogenic to the intermediate host than the adult or mature tapeworm is to the definitive host. The definitive host becomes infected by ingesting the intermediate host containing the metacestode stage. The “juvenile,” or developing, tapeworm emerges from the metacestode stage, attaches to the lining of the small intestine, and begins to produce the strobila, which is composed of proglottids.

Tapeworm proglottids have muscles that enable them to move about. Owners of infected animals often observe these tapeworms as “little white worms” crawling on the animal’s feces, hair coat, or bedding. Tapeworm proglottids





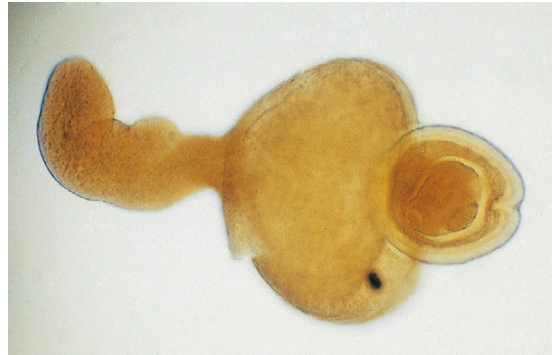**FIGURE 5-9:** Tapeworm egg, or hexacanth embryo. Tapeworm eggs are released to outside environment. Each tapeworm egg is infective for the intermediate host and produces one metacestode stage.

often contain eggs when they are passed into the feces. These hexacanth embryos are eggs with embryos that have an internal structure and six hooks (Figure 5-9). The hexacanth embryos are ingested by the intermediate host in which the tapeworm develops.

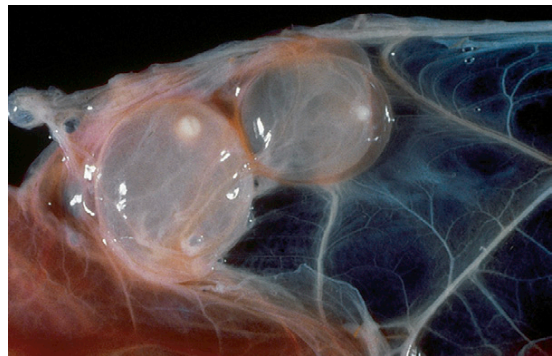**TECHNICIAN'S NOTE** The owner of an animal infected with tapeworms will often see “little white worms” crawling in the animal’s feces when the animal defecates. When the segment dries out, they will often see “rice” in the stool.

The intermediate host may be an arthropod, such as a flea or a grain mite. In this host the hexacanth embryo develops into a microscopic larval stage known as a **cysticercoid** (Figure 5-10). The cysticercoid is tiny and contains a small, fluid-filled space. The definitive host becomes infected by ingesting the intermediate host containing the cysticercoid larval stage. Examples of tapeworms that develop into a cysticercoid stage in an intermediate host are the fringed tapeworms of cattle (*Thysanosoma actinoides*) and the double-pored tapeworm of dogs and cats (*Dipylidium caninum*).

Sometimes the intermediate host is a mammalian host, such as a rabbit, in which the



**FIGURE 5-10:** Microscopic larval (metacestode) stage known as a **cysticercoid**. The cysticercoid is tiny (microscopic) and contains a small, fluid-filled space; the cysticercoid develops within the intermediate host. Definitive host becomes infected by ingesting the intermediate host containing cysticercoid larval stage. Examples of tapeworms that develop into cysticercoid stage in the intermediate host are *Thysanosoma actinoides* of cattle, *Anoplocephala* species of horses, and *Dipylidium caninum* of dogs and cats.



**FIGURE 5-11:** Hexacanth embryo of some tapeworms develops into a **cysticercus**, or “bladder worm,” stage. Bladder worm is a fluid-filled larval stage within tissues of vertebrate intermediate host. Definitive host becomes infected by ingesting the intermediate host containing bladder worm larval stage. Examples of tapeworms that develop into cysticercus stage in an intermediate host are *Taenia* species.

hexacanth embryo develops into a **cysticercus**, or “bladder worm,” stage (Figure 5-11). The bladder worm is a fluid-filled larval stage within the tissues of the vertebrate intermediate host. The definitive host becomes infected by ingesting the intermediate host containing the bladder worm larval stage (Figure 5-12). Examples

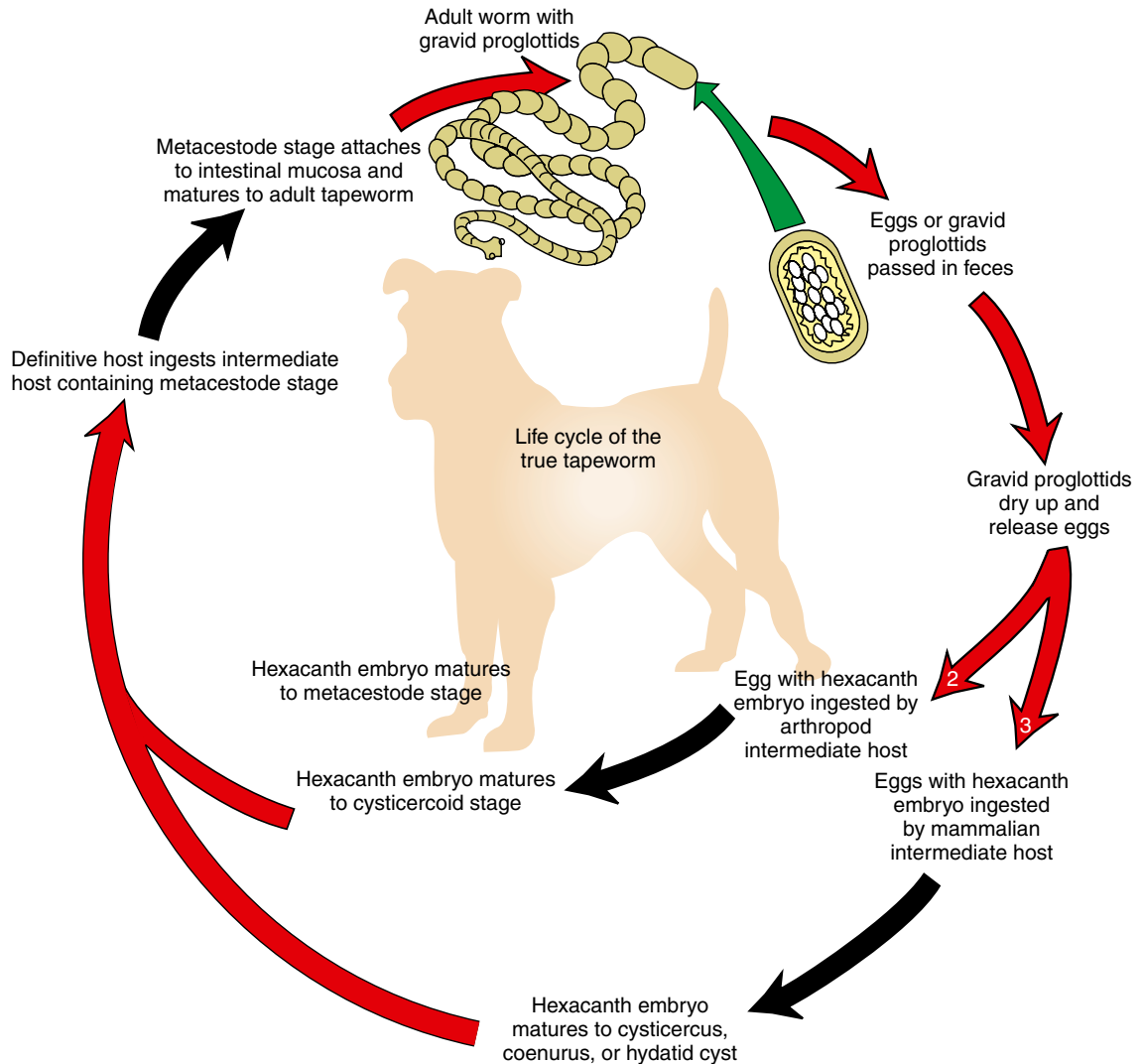


FIGURE 5-12: Life cycle of the true tapeworm.

of tapeworms that have a bladder worm stage (or a variation of the bladder worm stage) in an intermediate host are the canine Taeniid tapeworm (*Taenia pisiformis*) and the *Coenurus* tapeworm (*Multiceps multiceps*). Other tapeworms that use a variation of the bladder worm stage are *Echinococcus granulosus* and *E. multilocularis*, the hydatid cyst tapeworms. Chapter 6 covers these tapeworms and their larval stages in greater detail.

### COTYLODA (PSEUDOTAPEWORMS)

Phylum: Platyhelminthes  
Class: Cestoda

#### Key Morphologic Features

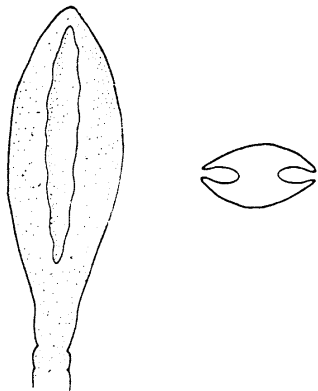
Members of the subclass Cotyloda, the pseudotapeworms, are tapeworms; they are long, segmented, flattened, almost ribbonlike parasites.

These tapeworms resemble true tapeworms in that on the extreme anterior end of the typical pseudotapeworm is the holdfast organelle, the scolex, or head. Instead of possessing four holdfast suckers, or acetabula, the typical pseudotapeworm has two slitlike organelles called **bothria** (Figure 5-13). Bothria are longitudinal grooves along the length of the scolex. The pseudotapeworm attaches to the lining of the small intestine by means of the bothria. As with true tapeworms, pseudotapeworms do not have a mouth; instead, they absorb the nutrients acquired from the host's intestine through their tegument, or body wall.



**TECHNICIAN'S NOTE** Instead of using a scolex with suckers to attach to the host, the pseudotapeworm uses two slitlike organelles called bothria to attach to the host's intestines.

The strobila of the pseudotapeworm is similar to that of the true tapeworm. The neck, or growth region, is just posterior to the scolex, and the pseudotapeworm's body arises from this. The strobila of the pseudotapeworm also is composed of immature, mature, and gravid proglottids. As with true tapeworms, pseudotapeworms are hermaphroditic, and each proglottid of a pseudotapeworm contains complete



**FIGURE 5-13:** Slitlike bothria on anterior end of typical pseudotapeworm.

sets of both male and female reproductive organs. The sex organs of these tapeworms are usually located along the central region of each proglottid. There is a centrally located uterine pore through which eggs are voided to the external environment. The eggs of the pseudotapeworm do not resemble those of the true tapeworm. Oddly, they resemble the eggs of a digenetic trematode—they are operculated. In most cases the spent proglottids of the pseudotapeworm pass to the outside environment in long chains.



**TECHNICIAN'S NOTE** The body of the pseudotapeworm is composed of immature, mature, and gravid proglottids with male and female reproductive organs in each segment.

### Life Cycle of the Pseudotapeworm

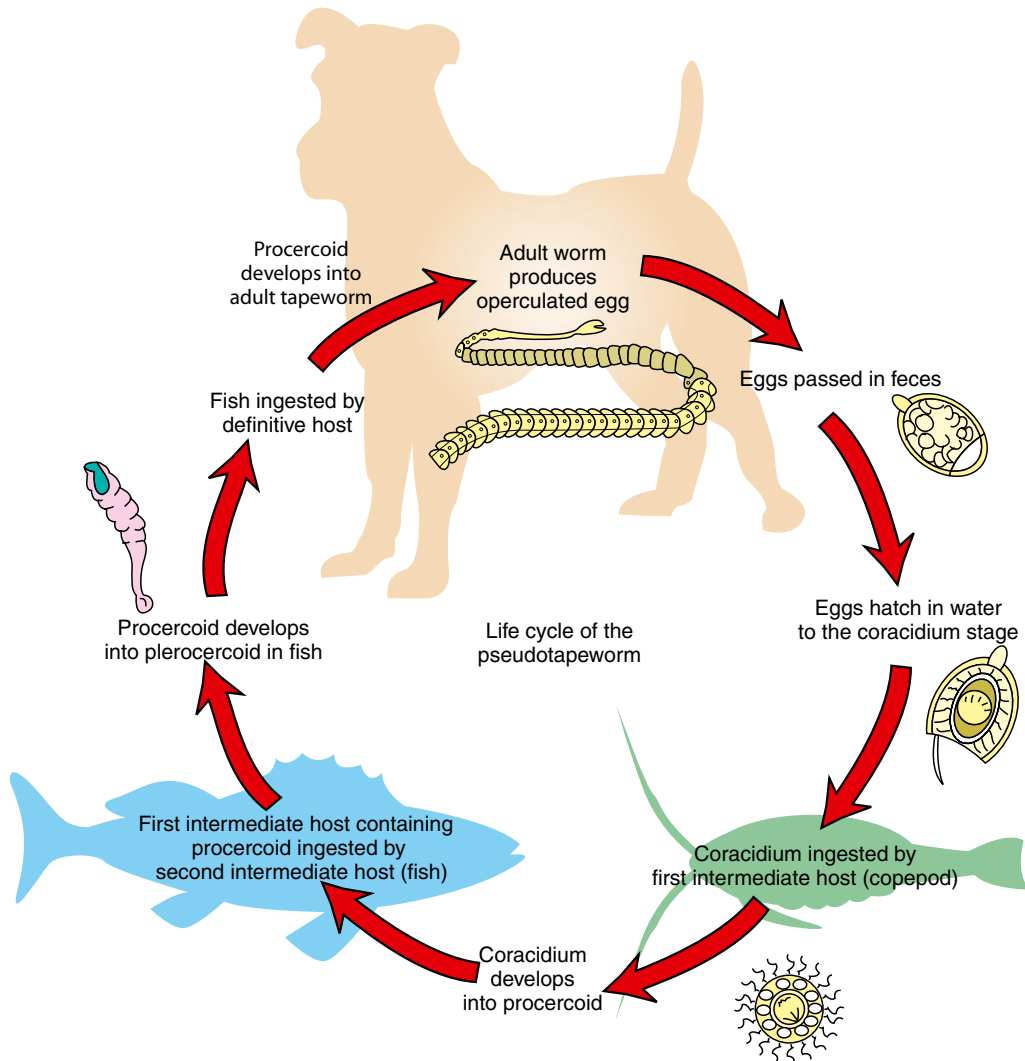
The life cycle of the pseudotapeworm is slightly more complicated than that of a true tapeworm. The operculated eggs are passed singly to the external environment. If these eggs make contact with water, they hatch, releasing a ciliated hexacanth embryo out of the operculum. This ciliated hexacanth embryo is called a **coracidium**. The coracidium must be ingested by a suitable first intermediate host, an aquatic crustacean called a **copepod**. Within the copepod, the coracidium develops to a stage called a **proceroid**. If the copepod containing the proceroid is ingested by the second intermediate host, usually a fish of some type, the proceroid develops into the second stage, which is infective for the definitive host. This stage is called the **plerocercoid** stage. The definitive host becomes infected by ingesting the second intermediate host containing the plerocercoid stage. This plerocercoid stage is the “juvenile,” or developing, tapeworm; it possesses slitlike bothria. When the plerocercoid stage is ingested by the definitive host, it emerges from the metacystode stage, attaches to the lining of the small intestine, and begins to produce the strobila (Figure 5-14).



**TECHNICIAN'S NOTE** The life cycle of the pseudotapeworm is more complex than the true tapeworm using two intermediate hosts, the second of which is infective to the definitive host.

There are two important species of pseudotapeworms: *Diphyllbothrium latum*, the “broad fish tapeworm,” and *Spirometra mansonoides*, the “zipper tapeworm.”

Chapter 6 details the major true tapeworms and pseudotapeworms that infect domesticated animals.



**FIGURE 5-14:** Life cycle of the pseudotapeworm.

**CHAPTER FIVE TEST**

MATCHING—Match the term with the correct phrase or term.

- |                     |                                                                                |
|---------------------|--------------------------------------------------------------------------------|
| A. Eucestode        | 1. Slitlike structures on scolex of pseudotapeworm                             |
| B. Armed scolex     | 2. Possessing both male and female reproductive organs                         |
| C. Tegument         | 3. Lacking a rostellum                                                         |
| D. Hexacanth embryo | 4. True tapeworm                                                               |
| E. Coracidium       | 5. Larval tapeworm                                                             |
| F. Hermaphroditic   | 6. Ciliated stage emerging from an operculated pseudotapeworm egg              |
| G. Bothria          | 7. All of the connected proglottids (immature, mature, and gravid proglottids) |
| H. Metacestode      | 8. A tapeworm egg containing six hooks                                         |
| I. Strobila         | 9. Tapeworm's body wall                                                        |
| J. Unarmed scolex   | 10. Possessing a rostellum                                                     |

**QUESTIONS FOR THOUGHT AND DISCUSSION**

1. How can a gravid proglottid be used in making a definitive diagnosis of cestodiasis in any definitive host?
2. Compare and contrast the following types of cestode eggs. You may use drawings with labels to illustrate differences. Give examples of cestodes that typify these egg types (see Chapter 6 for examples).
  - Egg packet
  - Egg with a pyriform apparatus
  - Hexacanth embryo
  - Pseudotapeworm egg
3. Compare and contrast the “typical cestode life cycle” of a true tapeworm versus the life cycle of a pseudotapeworm.
4. What are some external morphologic features that are used to identify intact adult cestodes, both true tapeworms and pseudotapeworms?
5. Define the following terms that are commonly used in a veterinary practice.
  - Gravid proglottid
  - Scolex
  - Hexacanth embryo
  - Egg packet
  - Cysticeroid

# Tapeworms That Parasitize Domestic Animals and Humans

## KEY TERMS

True tapeworm  
Pseudotapeworm  
Metacestode  
Cysticeroid  
Lappets  
Egg packets  
Oribatid grain mite  
Cysticercus or  
bladderworm  
Hexacanthr six  
toothed embryo  
Coenurus  
Unilocular hydatid cyst  
Multilocular or alveolar  
hydatid cyst  
Strobilocercus  
Tetrathyridium  
Operculated ovum  
Proceroid  
Plerocercoid  
Sparganum  
Hyatid cysts

## OUTLINE

Eucestoda (True Tapeworms)

*Mice, Rats, Gerbils, and Hamsters*

*Ruminants*

*Metacestode (Larval) Stages Found  
in Musculature of Food Animals*

*Metacestode (Larval) Stages Found  
in Abdominal Cavity of Food  
Animals*

*Horses*

*True Tapeworms of Dogs and Cats*

Cotyloda (Pseudotapeworms)

*Spirometra* species

*Diphylobothrium* species

## LEARNING OBJECTIVES

*After studying this chapter, the reader should be able to do the following:*

- Identify the tapeworm parasites (both adult and larval forms) of the following domesticated animals: dog, cat, cattle, sheep, horse, and selected laboratory animals.
- Understand that many cestode parasites are associated with two scientific names, one scientific name for the adult form of the parasite and one scientific name for the larval (metacestode) stage of the parasite.
- Understand the correlation and integration between vertebrate or invertebrate hosts that serve as intermediate hosts for larval (metacestode) stages of cestodes and the vertebrate hosts that serve as definitive hosts for the adult stages of their corresponding cestode parasites.
- Understand the concepts behind the following metacestode stages, regarding their role in the life cycles of both true and pseudotapeworms.

## EUCESTODA (TRUE TAPEWORMS)

Phylum: Platyhelminthes (flatworms)

Class: Cestoda (tapeworms)

Subclass: Eucestoda (true tapeworms)

### Mice, Rats, Gerbils, and Hamsters Intestinal Tract

**Parasite:** *Hymenolepis nana* and *Hymenolepis diminuta*

**Host:** Mice, rats, gerbils, hamsters, dogs, and humans

**Location of Adult:** Small intestine

**Distribution:** Worldwide

**Derivation of Genus:** Membrane covering

**Intermediate Host:** None necessary (*H. nana*); fleas, flour beetles and other arthropods (*H. diminuta*)

**Transmission Route:** Ingestion of infective fleas, grain beetle, or cockroach (*H. diminuta*); ingestion of infective egg or autoinfection (*H. nana*)

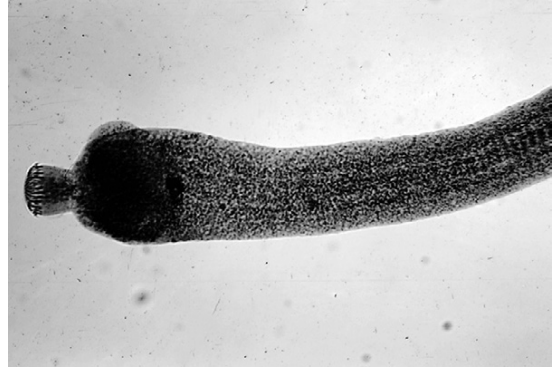**Common Name:** Rodent tapeworm



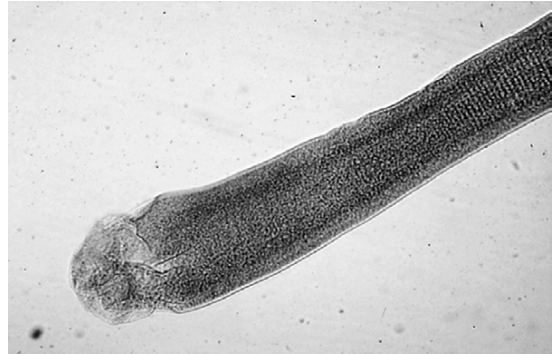**TECHNICIAN'S NOTE** While *Hymenolepis nana* and *Hymenolepis diminuta* are mainly parasites of mice, rats, gerbils, and hamsters, they have been found in dogs and humans.

*Hymenolepis nana* and *Hymenolepis diminuta* parasitize mice, rats, gerbils, and hamsters. These tapeworms are small and slender. Adults of *H. nana* are 1 mm wide and 25 to 40 mm in length, and adults of *H. diminuta* are 3 to 4 mm wide and 20 to 60 mm in length. These true tapeworms reside in the small intestine of the rodent definitive host and are usually detected on postmortem examination of the small intestine. The scolex of *H. nana* has a ring of hooks on its anterior end; it has an armed rostellum (Figure 6-1). The scolex of *H. diminuta* has no hooks; it is unarmed (Figure 6-2).

The life cycle of *H. nana* is a direct life cycle, whereas *H. diminuta* requires an intermediate host for infection. The eggs of *H. nana* are passed in the feces and are swallowed by a host. The



**FIGURE 6-1:** Scolex of *Hymenolepis nana*, showing armed rostellum on scolex.



**FIGURE 6-2:** Scolex of *Hymenolepis diminuta*, showing unarmed scolex.

hexacanth enters the villus of the small intestine and matures into a nontailed cysticercoid. The cysticercoid returns to the lumen of the small intestine, attaches to the lining, and matures to adulthood. *H. diminuta* also passes its eggs in the feces, which are ingested by an intermediate arthropod host. The **hexacanth embryo** (embryo containing three pairs of hooks) matures into a tailed cysticercoid. The arthropod is ingested by a definitive host, and the cysticercoid attaches to the lining of the small intestine and matures into an adult.



**TECHNICIAN'S NOTE** *Hymenolepis nana* is unique in that it is the only tapeworm that does not need an intermediate host for any developmental stage in its life cycle.

The eggs of *Hymenolepis* species may be detected on fecal flotation. Veterinary technicians should be aware that the eggs of this tapeworm are shed intermittently in the feces. Sometimes, individual proglottids may also be recovered, but these do not float. Figure 6-3 shows stained proglottids of *H. diminuta*. The oval egg of *H. nana* measures  $44$  to  $62\ \mu\text{m} \times 30$  to  $55\ \mu\text{m}$  (Figure 6-4). The egg of *H. diminuta* is more spherical and measures  $62$  to  $88\ \mu\text{m} \times 30$  to  $55\ \mu\text{m}$ . The embryo within the egg of both species measures  $24$  to  $30\ \mu\text{m} \times 16$  to  $25\ \mu\text{m}$  and contains three pairs of hooks (hexacanth embryo). Infected animals may be treated with niclosamide or praziquantel.

Both of these tapeworms have zoonotic potential. *H. nana* is unique in that it does not require an intermediate host; therefore it is directly infective to other rodents and to humans. Autoinfection by *H. nana* can occur when its eggs hatch in the small intestine of the host and subsequently infect that host. *H. diminuta* uses an insect (flea, grain beetle, or cockroach) as an intermediate host to complete its life cycle. The cysticercoid develops within the insect intermediate host (Figure 6-5).



**TECHNICIAN'S NOTE** Both *Hymenolepis nana* and *Hymenolepis diminuta* can infect humans.

## Ruminants

### Intestinal Tract

*Moniezia* species and *Thysanosoma actinoides* are true tapeworms that infect the intestinal tract of ruminants.

**Parasite:** *Moniezia benedini* and *Moniezia expansa*

**Host:** Cattle (*M. benedini*); cattle, sheep, and goats (*M. expansa*)

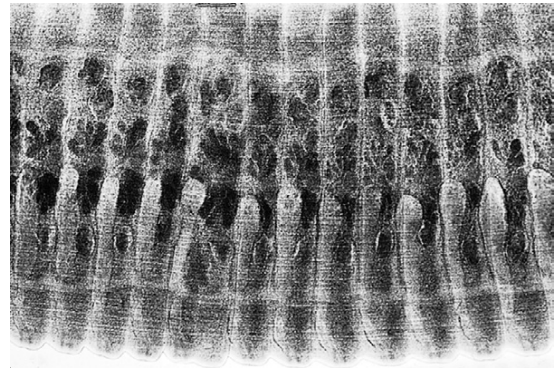
**Location of Adult:** Small intestine

**Intermediate Host:** Grain mites

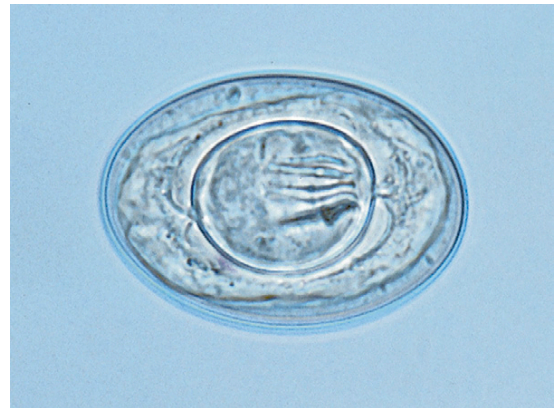**Distribution:** Worldwide

**Derivation of Genus:** *Moniezia*-to be single

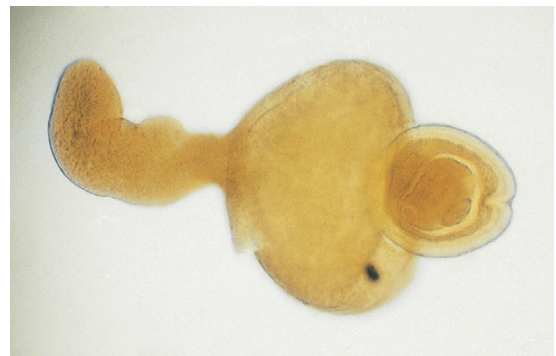
**Transmission Route:** Ingestion of infective grain mite



**FIGURE 6-3:** Stained proglottids of *Hymenolepis diminuta*.



**FIGURE 6-4:** Oval egg of *Hymenolepis nana* measures  $44$  to  $62\ \mu\text{m} \times 30$  to  $55\ \mu\text{m}$ .

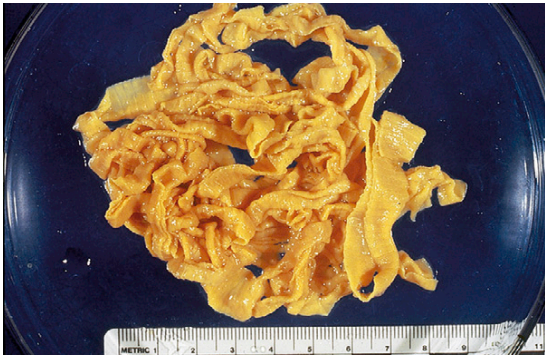


**FIGURE 6-5:** Cysticercoid (larval) stage has been dissected from insect intermediate host.

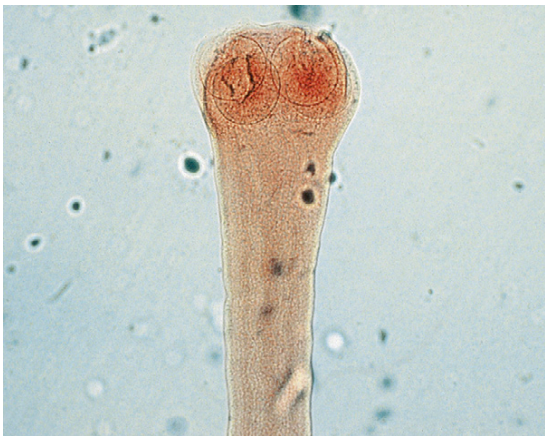

**Common Name:** Ruminant tapeworms

**Moniezia species.** *Moniezia* species are long (up to 6 m) tapeworms found in the small intestine of cattle, sheep, and goats. *Moniezia* species are large tapeworms and can be up to 1.6 cm at the widest margins (Figure 6-6). The scolex of *Moniezia* is unarmed; it lacks an armed rostellum (Figure 6-7). Individual proglottids are very short and wide—“squatty.” Each proglottid contains two sets of laterally located genital organs and associated pores (Figure 6-8). These tapeworms produce eggs with a characteristic square or triangular shape. The eggs of both species possess a **pyriform** (pear-shaped) **apparatus**. Two species are common among ruminants: *Moniezia*

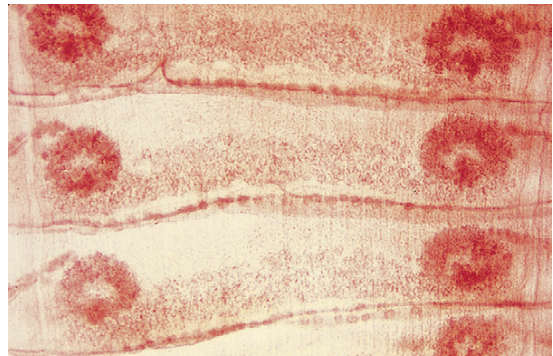


**FIGURE 6-6:** *Moniezia* species are large tapeworms. They can grow to 6 m long and up to 1.6 cm at the widest margins.

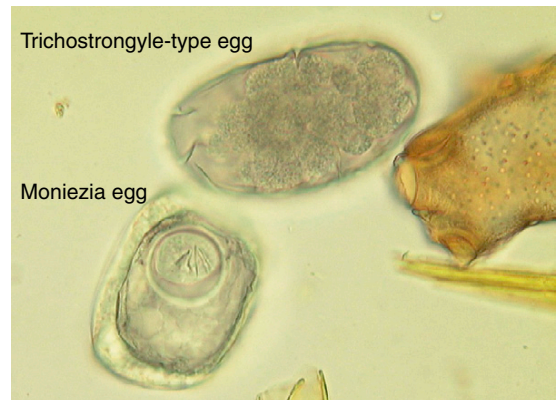

**FIGURE 6-7:** Scolex of *Moniezia* is unarmed; it lacks an armed rostellum.

*benedini* in cattle and *Moniezia expansa* in cattle, sheep, and goats. The eggs of both species can be easily differentiated using standard fecal flotation procedures. The eggs of *M. expansa* are triangular or pyramidal in shape and 56 to 67  $\mu\text{m}$  in diameter. The eggs of *M. benedini* are square or cuboidal in shape and approximately 75  $\mu\text{m}$  in diameter (Figure 6-9). The prepatent period for these tapeworms is approximately 40 days.



**FIGURE 6-8:** Each proglottid of adult *Moniezia* species contains two sets of laterally located genital organs and genital pores.

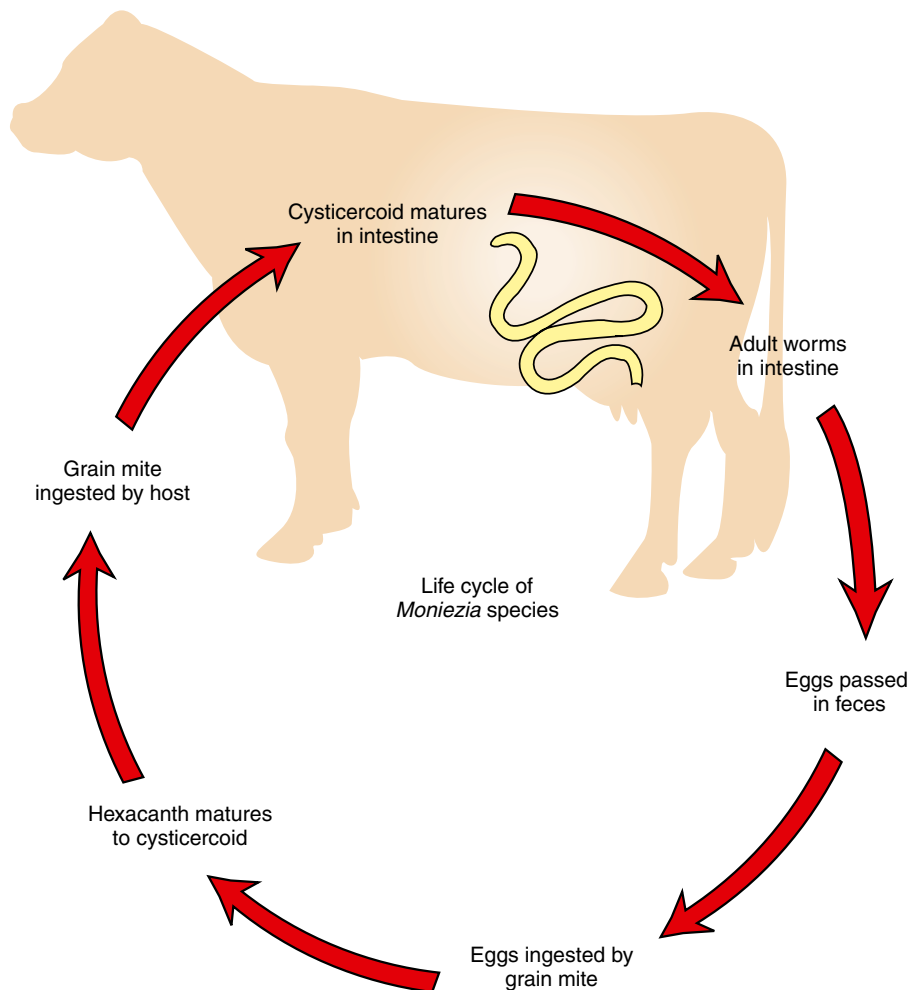


**FIGURE 6-9:** *Moniezia* species produce eggs with a characteristic square or triangular shape. Two species are common among ruminants, *M. benedini* in cattle and *M. expansa* in cattle, sheep, and goats. Eggs of both species can be easily differentiated using standard fecal flotation procedures. Eggs of *M. expansa* are triangular or pyramidal and 56 to 67  $\mu\text{m}$  in diameter. The eggs of *M. benedini* are square or cuboidal and approximately 75  $\mu\text{m}$  in diameter. Both eggs contain a pyriform apparatus.

**TECHNICIAN'S NOTE** *Moniezia* species can be found with standard fecal flotation techniques. *Moniezia benedini* eggs have a square or cuboidal shape while *Moniezia expansa* eggs are triangular or pyramidal.

The **metacestode**, or larval, stage of *Moniezia* is the cysticeroid stage, which may be found within the intermediate hosts, **oribatid** grain mites. Intact proglottids and eggs are found in the feces of the ruminant definitive host. Mites become infected by ingesting the hexacanth

embryo, which develops into the cysticeroid stage within the body of the grain mite. Ruminants become infected by ingesting cysticeroid-infected mites that infest the grain. The cysticeroid is a tiny, microscopic stage and probably will not be observed by the veterinarian (Figure 6-5). For every cysticeroid that is ingested by the ruminant, one adult tapeworm will develop in the small intestine of that ruminant (Figure 6-10). Large numbers of adults can cause rupture of the gut or obstruct the lumen of the intestines, especially in young animals. It is important that the veterinarian recognize the



**FIGURE 6-10:** Life cycle of *Moniezia* species.

oribatid mite as the source of this tapeworm and understand the importance of effective tapeworm therapeutics (morantel, niclosamide, albendazole, fenbendazole, or oxfendazole) in cattle. Pasture rotation in addition to therapeutics is essential in greatly reducing the transmission of this parasite.

**TECHNICIAN'S NOTE** Pasture rotation is essential in reducing the transmission of ruminant tapeworms.

**Parasite:** *Thysanosoma actinoides*

**Host:** Sheep, goats, and cattle

**Location of Adult:** Lumen of the bile duct, pancreatic ducts, and small intestines

**Intermediate Host:** Unknown, proposed host is psocids insects

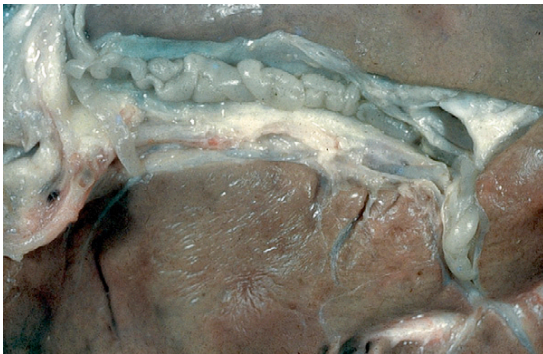**Distribution:** North and South America

**Derivation of Genus:** Fringed body

**Transmission Route:** Ingestion of unknown intermediate host

**Common Name:** Fringed tapeworm of sheep and goats

**Thysanosoma actinoides.** *Thysanosoma actinoides* is the fringed tapeworm found in the bile ducts (can cause bile duct obstruction), pancreatic ducts (can cause obstruction of pancreatic duct), and small intestine of ruminants (Figure 6-11). The adult tapeworm measures



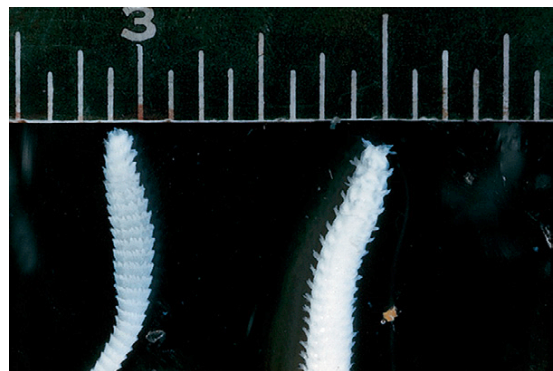**FIGURE 6-11:** *Thysanosoma actinoides*, the fringed tapeworm, is unusual in that it is not found in the intestine (as are most adult tapeworms). Instead, it resides in the bile duct of sheep.

8 mm × 15 to 30 cm and possess an unarmed scolex. As with *Moniezia* species, the proglottids are very short; however, these proglottids possess a unique feature: a very prominent fringe located on the posterior aspect of each proglottid. (Figure 6-12 shows the fringed adult *T. actinoides*.)

Eggs of this tapeworm occur in packets of 6 to 12 eggs, with individual eggs measuring 19 × 27 μm. These eggs do not possess a pyriform apparatus. The eggs can be found on standard fecal flotation procedures. Adults can be identified at necropsy.

**TECHNICIAN'S NOTE** These fringed tapeworms are unique among the adult tapeworms in that they possess a very prominent fringe along the posterior margin of each and every proglottid. The adults are also found in an unusual location for tapeworms, the lumen of the bile duct.

The metacestode (larval) stage of *T. actinoides* is the cysticercoid stage, which may be found within the proposed intermediate hosts, psocids. **Psocids** are primitive insects often associated with vegetation. These insects become infected



**FIGURE 6-12:** Adult *Thysanosoma actinoides* measures 8 mm × 15 to 30 cm. Note that proglottids are very short. They demonstrate a unique morphologic feature, a conspicuous fringe located on posterior aspect of each proglottid, thus the common name, "fringed tapeworm."



by ingesting the hexacanth embryo, which develops into the cysticercoid stage within the body of the psocid. Ruminants may become infected by accidentally ingesting cysticercoid-infected psocids that infest vegetation. The cysticercoid is a microscopic stage and probably will not be observed by the veterinarian. For every cysticercoid that is ingested by the ruminant, one adult tapeworm will develop in the small intestine of that ruminant. It is important that the veterinarian recognize psocids as the source of this tapeworm and understand the importance of effective tapeworm therapeutics (niclosamide or praziquantel, as well as pasture rotation) in cattle.

### Metacestode (Larval) Stages Found in Musculature of Food Animals

**Parasite:** *Taenia saginata* (Adult tapeworm)/*Cysticercus bovis* (metacestode [larval] stage)

**Host:** Humans

**Location of Adult:** Small intestine

**Intermediate Host:** Cattle

**Distribution:** Worldwide

**Derivation of Genus:** Flat band, bandage, or tape/bladder tail

**Transmission Route:** Ingestion of raw or undercooked infective beef

**Common Name:** Beef tapeworm of humans/beef measles, measly beef of cattle

Cattle may serve as intermediate hosts for a tapeworm of humans, *Taenia saginata*. The adult tapeworm is unusual among the *Taenia* species in that it does not have an armed rostellum like the rest of the species. Adults possess 14 to 32 lateral branches of the uterus within the gravid proglottid. The eggs are typical taeniid type ova with a striated embryophore (shell) surrounding an oncosphere with six hooklets inside. The adults can cause obstruction of the intestinal tract if present in sufficient numbers.



**TECHNICIAN'S NOTE** *Taenia saginata* is unusual in that it has an unarmed rostellum while all other *Taenia* species possess an armed rostellum.

The larval stage for this tapeworm is a cysticercus, or bladder worm, called *Cysticercus bovis*. A cysticercus is a single invaginated scolex in a large, fluid-filled cyst, cavity, or vesicle. This condition in cattle is often referred to as “beef measles” or “measly beef.” These infective metacestodes are found in the musculature (skeletal and cardiac muscles) of cattle. If enough cysticerci are present in the muscle tissue, they can interfere with muscle function, produce pain, and myositis. Humans become infected with this zoonotic tapeworm by ingesting poorly cooked beef. (Figure 6-13 shows the cysticercus of *C. bovis* within beef muscle.)

**Parasite:** *Taenia solium* (adult tapeworm)/*Cysticercus cellulosae* (metacestode [larval] stage)

**Host:** Human

**Location of Adult:** Small intestine

**Intermediate Host:** Pigs

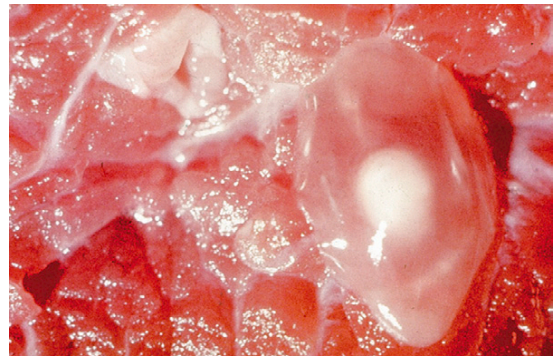**Distribution:** Underdeveloped countries including Latin America, India, Africa, and the Far East

**Derivation of Genus:** Flat band, bandage or tape/bladder tail

**Transmission Route:** Ingestion of infective undercooked or raw pork

**Common Name:** Pork tapeworm of humans, measly pork, pork measles of swine

Pigs may serve as the intermediate host for a similar tapeworm of humans, *Taenia solium*. The adult possesses an armed rostellum with a double row of hooks. It is best identified by its 7 to 16

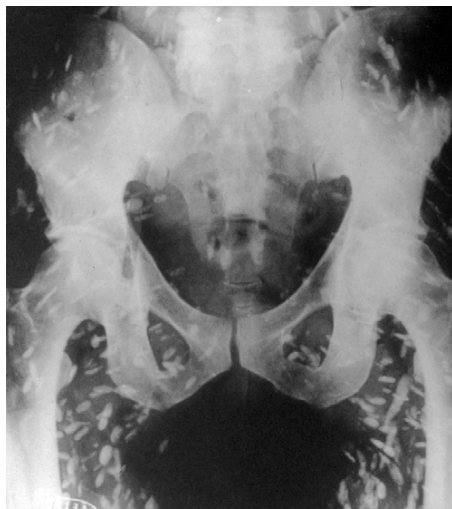


**FIGURE 6-13:** Gross view of cysticercus of larval form of beef tapeworm, *Taenia saginata* (*Cysticercus bovis*) within muscle of a beef cow.

lateral branches of the uterus within each gravid proglottid. The eggs are typical taeniid type ova with a striated embryophore surrounding an oncosphere with six hooklets inside. In large numbers, the adult worms can cause intestinal obstruction. The ova can be found on standard fecal flotation. The adults can be identified by their characteristic lateral branches of the uterus.

**TECHNICIAN'S NOTE** The adult pork tapeworm of humans can cause intestinal obstruction in the human host if present in sufficient numbers.

The larval stage for this tapeworm is a cysticercus, or bladder worm, known as *Cysticercus cellulosae*. This metacestode stage in pigs is often referred to as “pork measles” or “measly pork.” These metacestodes are found in the musculature (skeletal and cardiac muscles) of pigs. Humans become infected with this zoonotic tapeworm by ingesting poorly cooked pork. It is also important to note that if humans ingest the eggs of *T. solium*, the cysticercus can develop within their muscles (Figure 6-14) and within nervous tissue such as the brain, eye, and spinal cord.



**FIGURE 6-14:** Radiographic view of cysticerci of larval form of pork tapeworm, *Taenia solium* (*Cysticercus cellulosae*) within human muscle.

The adult stages of the metacestode stages (*C. bovis* and *C. cellulosae*) are found in the small intestine of humans. Because humans may become infected by ingesting poorly cooked beef or pork, these are important zoonotic tapeworms.

**TECHNICIAN'S NOTE** Prevention of *Taenia saginata* and *Taenia solium* can be accomplished by thoroughly cooking the beef or pork to destroy the cysticercus within the meat, thus stopping the life cycle. Also, wash hands after handling raw beef or pork.

### Metacestode (Larval) Stages Found in Abdominal Cavity of Food Animals

**Parasite:** *Taenia hydatigena* (adult tapeworm)/*Cysticercus tenuicollis* (metacestode [larval] stage)

**Host:** Dogs

**Location of Adult:** Small intestine

**Intermediate Host:** Cattle, sheep, goats

**Distribution:** Worldwide

**Derivation of Genus:** Flat band, bandage, or tape/bladder tail

**Transmission Route:** Ingestion of infective abdominal omentum of ruminants

**Common Name:** Canine taeniid/bovine bladderworm

For *Taenia hydatigena*, an adult tapeworm found in the small intestine of dogs, the larval stage is a ping-pong-ball-sized, fluid-filled bladder called *Cysticercus tenuicollis*, which is usually attached to the greater omentum or other abdominal organs of the ruminant intermediate host (Figure 6-15) and is considered nonpathogenic to the intermediate host. The adult worm has an armed rostellum. The proglottids have a single, lateral genital pore. The eggs are typical taeniid-type ova with a striated embryophore surrounding an oncosphere with six hooklets inside. In large numbers, the adults can cause obstruction of the intestinal tract. To acquire this tapeworm, dogs become infected by ingesting the abdominal viscera of cysticercus-infected ruminants. For every



cysticercus that is ingested by the dog, one adult tapeworm will develop in the small intestine of that dog. Diagnosis is made by finding the taeniid ova on standard fecal flotation. It is important that the veterinarian recognize the ruminant as the source of this tapeworm and understand the importance of preventing predation or ingestion of ruminant offal by the dog. Necropsy of the intermediate host will reveal the cysticercus stage in the abdominal cavity of the ruminant intermediate host.

**TECHNICIAN'S NOTE** Taeniid eggs can be found on standard fecal flotation.

## Horses

### Intestinal Tract

**Parasite:** *Anoplocephala perfoliata*, *Anoplocephala magna*, and *Paranoplocephala mamillana*

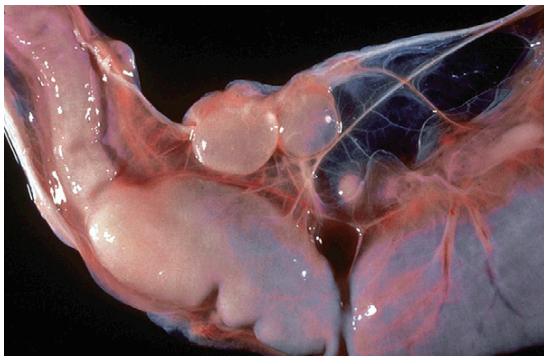**Host:** Horses

**Location of Adult:** Small intestine, large intestine, and cecum (*A. perfoliata*); small intestine and occasionally stomach (*A. magna* and *P. mamillana*)

**Intermediate Host:** Grain mites

**Distribution:** Worldwide

**Derivation of Genus:** Unarmed head/Bearing an unarmed head




**FIGURE 6-15:** Larval stage for *Taenia hydatigena* is a ping-pong-ball-sized, fluid-filled bladder (*Cysticercus tenuicollis*) that is usually attached to greater omentum or other abdominal organs of ruminant intermediate host.

**Transmission Route:** Ingestion of infective grain mites

**Common Name:** Lappeted equine tapeworm (*A. perfoliata*) and equine tapeworm with large scolex (*A. magna*); Dwarf tapeworm (*P. mamillana*) collectively, equine tapeworms

**TECHNICIAN'S NOTE** *Anoplocephala perfoliata* adults are easily identified by their morphologic features (lappets just posterior to the scolex) and the characteristic ovum with its pyriform apparatus.


*Anoplocephala perfoliata*, *Anoplocephala magna*, and *Paranoplocephala mamillana* are the equine tapeworms. *A. perfoliata* is found in the small and large intestine and cecum; *A. magna* and *P. mamillana* are found in the small intestine and occasionally the stomach. *A. perfoliata* can measure from 5 to 8 cm in length and up to 1.2 cm in width. The scolex is oblong, 2 to 3 mm in diameter, unarmed, with very prominent **lappets** (two round protubences) behind each of the four suckers. The proglottids are wider than long, and each proglottid has only one set of male and female reproductive organs (Figure 6-16). *A. magna* can measure up to 80 cm in length and 2.5 cm in width. The scolex is large and oblong, 4 to 6 mm in diameter, unarmed



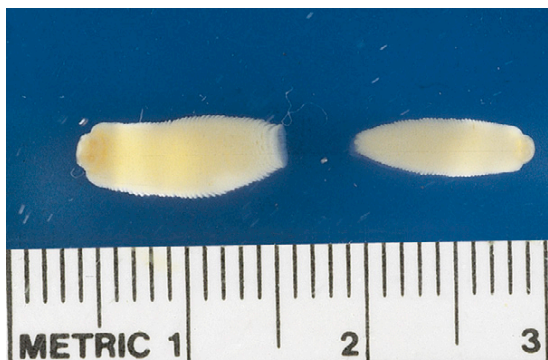
**FIGURE 6-16:** Adult specimen of *Anoplocephala perfoliata*, an equine tapeworm. Scolex is oblong, 2 to 3 mm in diameter, and has very prominent lappets behind each of four suckers. Proglottids are wider than long, and each has only one set of male and female reproductive organs.

but lacking the lappets of *A. perfoliata* (Figure 6-17). *P. mamillana*, also known as the dwarf tapeworm, is only 6 to 50 mm in length and 4 to 6 mm in width (Figure 6-18). The scolex is quite narrow. The adults of all three species can cause granulation tissue at the site of attachment in the intestinal wall.

The eggs of *A. perfoliata* are thick-walled, with one or more flattened sides measuring 65 to 80  $\mu\text{m}$  in diameter; those of *A. magna* are similar but slightly smaller, measuring 50 to 60  $\mu\text{m}$ . The eggs of *P. mamillana* are oval and thin-walled, measuring  $51 \times 37 \mu\text{m}$ . Eggs of all three species have a three-layered eggshell; the innermost lining is a pyriform apparatus. The hexacanth embryo can be visualized just inside the pyriform



**FIGURE 6-17:** Adult specimen of *Anoplocephala magna*, an equine tapeworm. Scolex is quite large, 4 to 6 mm in diameter, and lacks prominent lappets.



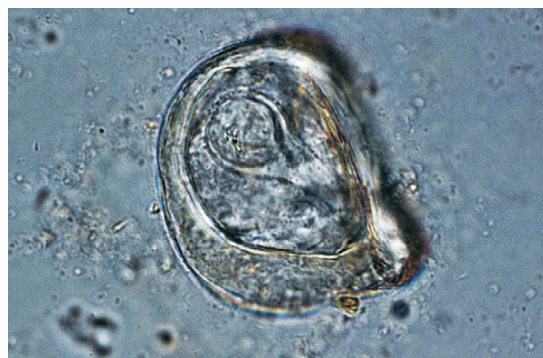**FIGURE 6-18:** Adult specimens of *Paranoplocephala mamillana*, the dwarf equine tapeworm. Scolex is quite narrow and lacks prominent lappets. Note: These specimens are entire specimens and not individual proglottids.

apparatus (Figure 6-19). Eggs of all equine tapeworms can be recovered using standard fecal flotation. The prepatent period for all three species ranges from 28 to 42 days.



**TECHNICIAN'S NOTE** All three species of equine tapeworms can be identified on standard fecal floatation by observing their triangular, three-layered-shell ova with the pyriform apparatus.

As in *Moniezia* species in ruminants, the metacystode (larval) stage of equine tapeworms is the cysticeroid stage, which may be found within the intermediate hosts, oribatid grain mites. Intact proglottids and eggs are found in the feces of the equine definitive host. Mites become infected by ingesting the hexacanth embryo, which develops into the cysticeroid stage within the body of the grain mites. Horses become infected by ingesting cysticeroid-infected mites infesting the grain. The cysticeroid is a microscopic stage and probably will not be observed by the veterinarian. For every cysticeroid that is ingested by the ruminant, one adult tapeworm will develop in the small intestine of that ruminant (Figure 6-10). It is important that the veterinarian recognize the oribatid mite as the source of this tapeworm and



**FIGURE 6-19:** Fecal flotation revealing egg of *Anoplocephala perfoliata*. Egg is thick-walled, with one or more flattened sides measuring 65 to 80  $\mu\text{m}$  in diameter; those of *A. magna* are similar but slightly smaller, measuring 50 to 60  $\mu\text{m}$ . Eggs have an innermost lining called the pyriform (pear-shaped) apparatus.

understand the importance of pasture rotation and effective tapeworm therapeusis (pyrantel pamoate and pyrantel tartrate; praziquantel has been used with success but is not FDA approved) in horses.

**TECHNICIAN'S NOTE** Pasture rotation and deworming protocols are effective in reducing these equine tapeworms in horses.

## True Tapeworms of Dogs and Cats

Tapeworms that infect dogs and cats are *Dipylidium caninum*, *Taenia pisiformis*, *T. hydatigena*, *T. ovis*, *T. taeniaeformis*, *Multiceps multiceps*, *M. serialis*, *Echinococcus granulosus*, *E. multilocularis*, and *Mesocestoides* species.

### Dipylidium caninum

**Parasite:** *Dipylidium caninum*

**Host:** Dogs and cats

**Location of Adult:** Small intestine

**Intermediate Host:** Adult fleas

**Distribution:** Worldwide

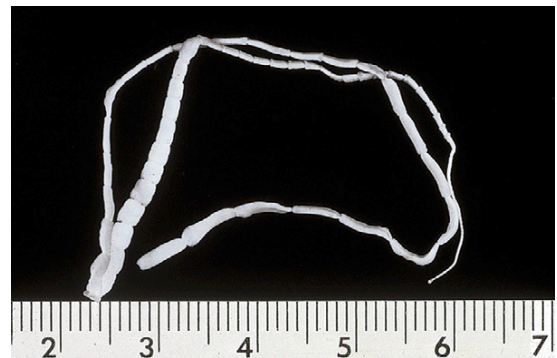
**Derivation of Genus:** Having two entrances

**Transmission Route:** Ingestion of infective adult flea

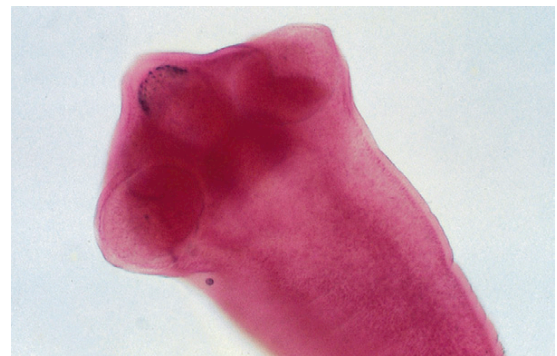**Common Name:** Double-pored tapeworm or cucumber seed tapeworm

*Dipylidium caninum* is often called the “double-pored” or “cucumber seed” tapeworm. This tapeworm is the most common tapeworm found in the small intestine of the dog and cat, because the dog or cat becomes infected by ingesting the flea intermediate host. Fleas often contain this parasite’s infective cysticercoid stage. The adult tapeworm can grow to a length of 50 cm (Figure 6-20). The scolex of this tapeworm is armed and consists of a prominent proboscis covered with rearward-facing rose-thorn-like hooks (Figure 6-21). This tapeworm usually demonstrates its presence by the release of and the appearance of its motile, terminal, gravid proglottids, which are usually found on the feces (Figure 6-22). They may also be found on the pet’s hair coat or in

the bedding of the host. In the fresh state, these proglottids resemble cucumber seeds (“cucumber seed” tapeworm). These proglottids have a lateral pore located along the midpoint of each of their long edges (“double-pored” tapeworm) (Figure 6-23). Gravid proglottids contain thousands of unique egg packets, each containing 20 to 30 hexacanth embryos (Figure 6-24). (Figure 6-25 shows individual egg packet of *D. caninum* containing hexacanth embryos.) The proglottids of *D. caninum* often dry out in the



**FIGURE 6-20:** Adult specimen of *Dipylidium caninum*, the “double-pored” or “cucumber seed” tapeworm of dogs and cats. Adult tapeworm can grow to 50 cm long. This tapeworm usually demonstrates its presence by release of and appearance of motile, terminal, gravid proglottids, which are usually found on feces, hair coat, or bedding. In fresh state, proglottids resemble cucumber seeds, thus the common name, “cucumber seed” tapeworm.



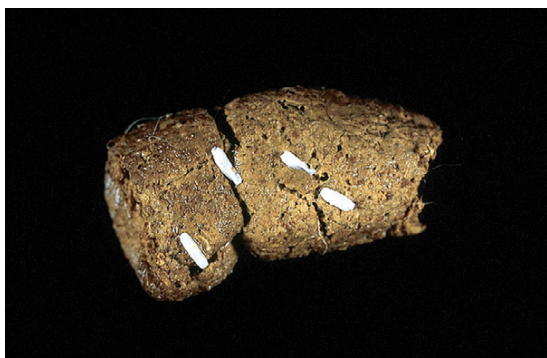**FIGURE 6-21:** Scolex of *Dipylidium caninum* is armed and consists of prominent proboscis covered with rearward-facing rose-thorn-like hooks.



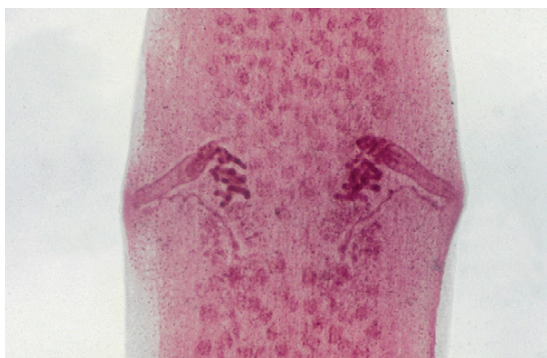
external environment. As they lose moisture, they shrivel up, resembling uncooked grains of rice (Figure 6-26). If reconstituted with water, the dried proglottids usually assume their former cucumber seed appearance. The prepatent period for *D. caninum* is 14 to 21 days.

**TECHNICIAN'S NOTE** In sufficient numbers, adult *Dipylidium caninum* tapeworms can cause intestinal obstruction in the host.

The metacestode (larval) stage of this tapeworm is the cysticercoid stage, which may be found within the flea intermediate host. Larval fleas become infected by ingesting the hexacanth

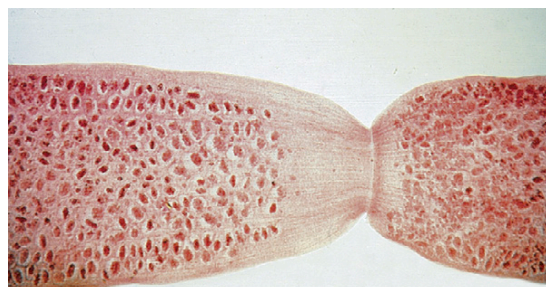

**FIGURE 6-22:** *Dipylidium caninum* usually demonstrates its presence by release of and appearance of motile, terminal, gravid proglottids, which are usually found on feces.

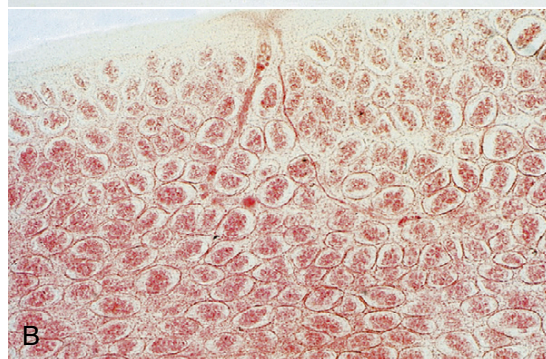


**FIGURE 6-23:** These proglottids of *Dipylidium caninum* have a lateral pore along midpoint of each long edge, thus the second common name, "double-pored" tapeworm.

embryo, which develops into the cysticercoid stage within the body of the adult flea. Dogs and cats become infected by ingesting cysticercoid-infected adult fleas (Figure 6-27). The cysticercoid is a microscopic stage and probably will not be observed by the veterinarian. For every

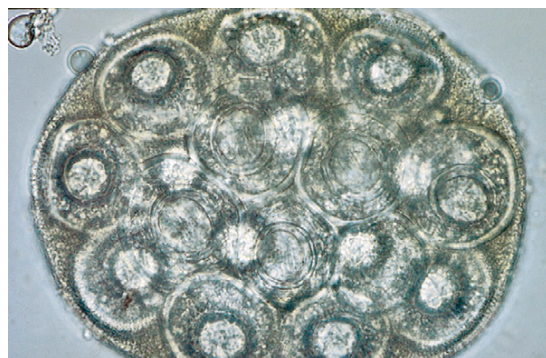


A

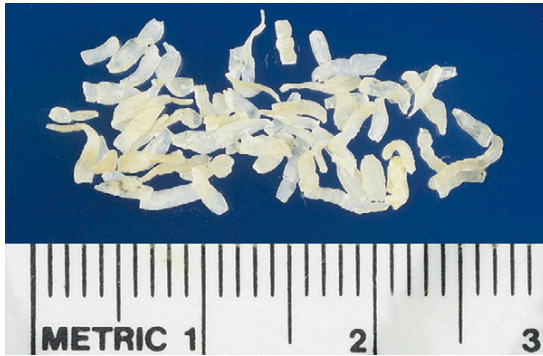

B

**FIGURE 6-24:** Gravid proglottids of *Dipylidium caninum* are filled with thousands of egg packets. **A**, Gravid proglottid showing egg packets. **B**, Closeup of gravid proglottid showing egg packets containing hexacanthembryo.



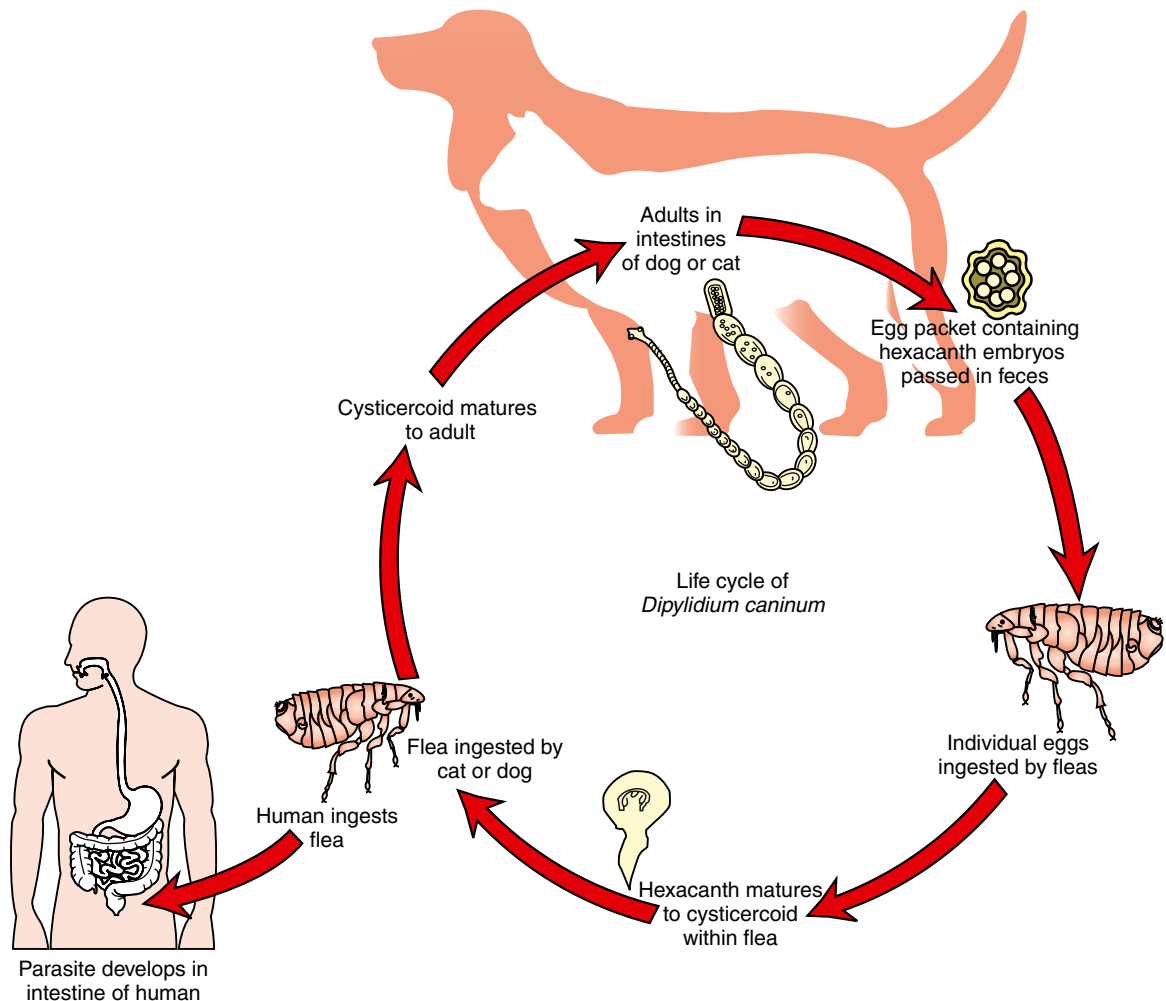
**FIGURE 6-25:** If fresh proglottids of *Dipylidium caninum* are teased or broken open, they may reveal thousands of egg packets, each containing 20 to 30 hexacanth embryos.



**FIGURE 6-26:** Dried proglottids of *Dipylidium caninum* resemble uncooked grains of rice. When water is added, they assume their natural state.

cysticercoid that is ingested by the dog or cat, one adult tapeworm will develop in the small intestine of that dog or cat. If a human (e.g., child) ingests a flea containing the cysticercoid stage, this tapeworm will develop to the adult stage within the small intestine. It is a zoonotic parasite.

This tapeworm is typically diagnosed in one of two ways. The egg packets can be found on fecal flotation (Figure 6-24) if the gravid proglottids dry up and release the egg packets. The gravid proglottids may also be seen by the client in the feces, on bedding, or in the hair coat. It is important that the veterinarian recognize the



**FIGURE 6-27:** Life cycle of *Dipylidium caninum*.



flea as the source of this tapeworm and understand the importance of flea control in effective tapeworm therapeusis. *D. caninum* is typically treated with a single dose of praziquantel or epsiprantel. All pets in the household must be treated for both fleas and tapeworms.

**TECHNICIAN'S NOTE** *Dipylidium caninum* can be diagnosed by finding the characteristic egg packets on standard fecal flotation (this tends to be rare) or by observing the gravid proglottids in the feces.

***Taenia pisiformis*, *T. hydatigena*, and *T. ovis*/Cysticercus pisiformis, Cysticercus tenuicollis, and Cysticercus ovis (Metacestode [larval] tapeworm)**

**Parasite:** *Taenia pisiformis*, *Taenia hydatigena*, and *Taenia ovis*

**Host:** Dogs

**Location of Adult:** Small intestine

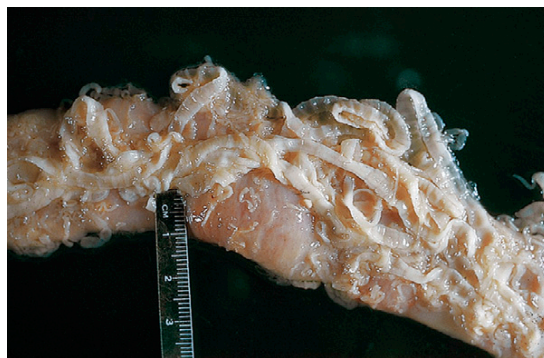**Intermediate Host:** Rabbits and hares (*T. pisiformis*); Ruminants (*T. hydatigena*); Sheep (*T. ovis*)

**Distribution:** Worldwide

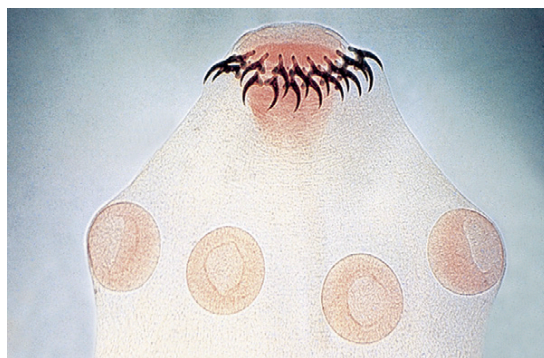**Derivation of Genus:** Flat band, bandage, or tape  
**Transmission Route:** Ingestion of infective intermediate host

**Common Name:** Canine taeniid (*T. pisiformis* and *T. hydatigena*); mutton tapeworm of dogs (*T. ovis*)

*Taenia pisiformis*, *T. hydatigena*, and *T. ovis* are the canine taeniids. The canine taeniids measure from 1 to 2 cm (*T. ovis*), to 200 cm (*T. pisiformis*), and up to 75 to 500 cm (*T. hydatigena*) in length. These adult taeniids are found within the small intestine of the canine definitive host (Figure 6-28) where in sufficient numbers they can cause intestinal obstruction. The scolex of all these tapeworms is armed, consisting of two rows of rostellar hooks (Figure 6-29). As with *D. caninum*, the *Taenia* species manifest by the appearance of motile, terminal, gravid proglottids on the feces, on the pet's hair coat, or in the bedding of the host. In the fresh



**FIGURE 6-28:** Adult canine taeniids are found in small intestine of canine definitive host.

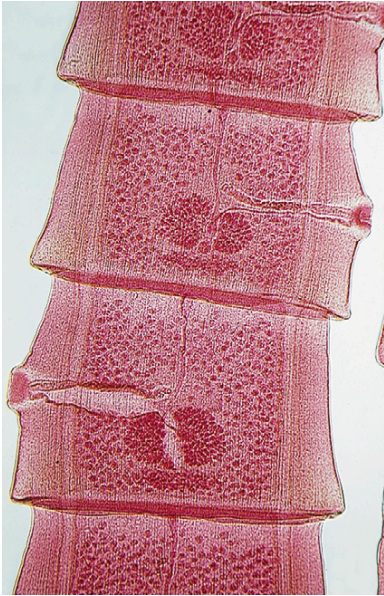


**FIGURE 6-29:** Details of scolex of canine taeniid. Note four suckers and armed rostellum.

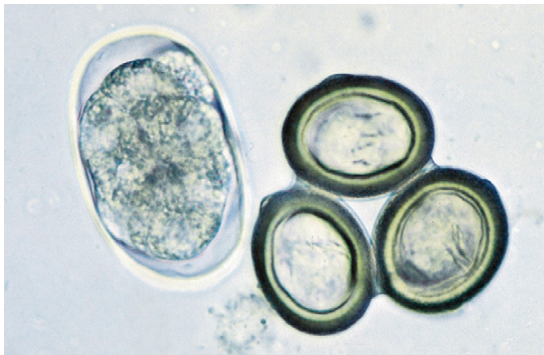
state, these proglottids have a single lateral pore located along the midpoint of either of their long edges (unlike the double-pored tapeworm) (Figure 6-30).

**TECHNICIAN'S NOTE** Gravid proglottids found in the feces can be teased open and the ova identified as *Dipylidium* or taeniid type ova to speciate the genus of the tapeworm represented by the gravid proglottids.

As with *D. caninum*, if the fresh proglottids are teased or broken open, they may reveal typical hexacanth embryos (Figure 6-31). These hexacanth embryos have a striated eggshell (called the **embryophore**) and contain six hooks (or



**FIGURE 6-30:** Mature proglottids of *Taenia* species demonstrating single lateral pore located along midpoint of long edges (as opposed to the double-pored tapeworm).



**FIGURE 6-31:** Typical taeniid egg with striated shell and six inner hooks. Because of the hooks, this egg is referred to as a **hexacanth** or **six-toothed** embryo. Egg is characteristic for tapeworms of genera *Taenia*, *Multiceps*, and *Echinococcus*.

teeth) within the interior of the egg. This egg is referred to as a **typical taeniid type of egg**. The proglottids of *Taenia* species also dry out in the external environment and resemble uncooked grains of rice. If reconstituted with water, they usually assume their former single-pored appearance. If gravid proglottids of *Taenia* species are recovered from a dog's or cat's feces, the

proglottid should be torn open or macerated in a drop of saline solution on a glass slide to reveal the characteristic eggs under the compound microscope.

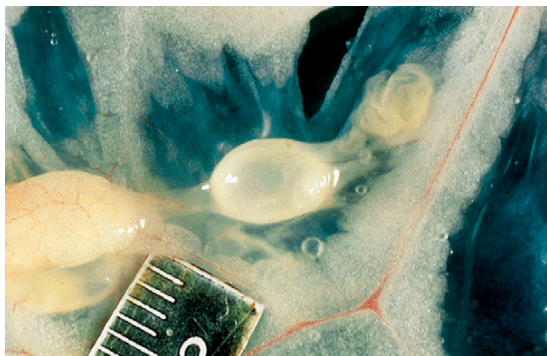
The eggs of the taeniid tapeworms are slightly oval and are 43 to 53  $\mu\text{m}$   $\times$  43 to 49  $\mu\text{m}$  in diameter (*T. pisiformis*), 36 to 39  $\mu\text{m}$   $\times$  31 to 35  $\mu\text{m}$  in diameter (*T. hydatigena*), and 19 to 31  $\mu\text{m}$   $\times$  24 to 26  $\mu\text{m}$  (*T. ovis*). Eggs of *Taenia* species contain a single **oncosphere** with three pairs of hooks. The oncosphere is often called a “hexacanth embryo.” The eggs of the taeniids are very similar to those of *Echinococcus* and *Multiceps* species.

The metacestode (larval) stage for *T. pisiformis*, *T. hydatigena*, and *T. ovis* is the cysticercus, or bladder worm stage, which may be found within the respective rabbit, ruminant, or ovine intermediate hosts.



**TECHNICIAN'S NOTE** The intermediate hosts of the canine taeniid tapeworms ingest the ova from the feces of the canine host. The ova then develop into a cysticercus stage in the intermediate host.

For *T. pisiformis* and *T. hydatigena*, the rabbit and the ruminant become infected by ingesting the taeniid eggs or hexacanth embryos, often found close to canine feces. These embryos hatch and develop into the cysticercus stage within the peritoneal cavity of the intermediate hosts. For *T. pisiformis*, the larval stage is a pea-sized, fluid-filled bladder (called *Cysticercus pisiformis*), usually attached to the greater omentum or other abdominal organs of the rabbit (Figure 6-32). Dogs become infected by killing and ingesting cysticercus-infected rabbits. For every cysticercus that is ingested by the dog, one adult tapeworm will develop in the small intestine of that dog (Figure 6-33). It is important that the veterinarian recognize the rabbit as the source of this tapeworm and understand the importance of preventing predation or the ingestion of rabbit carrion by the dog. *T. pisiformis* can be treated with praziquantel or epsiprantel.



**FIGURE 6-32:** Larval stage for *Taenia pisiformis* is pear-sized, fluid-filled bladder (*Cysticercus pisiformis*). Larval stage is usually attached to greater omentum or other abdominal organs of rabbit intermediate host.

For *T. hydatigena*, the tenuicollis stage is a ping-pong-ball-sized, fluid-filled bladder (called *Cysticercus tenuicollis*), usually attached to the greater omentum or other abdominal organs of the ruminant intermediate host (Figure 6-34; see also Figure 6-15). To acquire this tapeworm, dogs become infected by ingesting the abdominal viscera of cysticercus-infected ruminants (Figure 6-33). For every cysticercus that is ingested by the dog, one adult tapeworm will develop in the small intestine of that dog. It is important that the veterinarian recognize the ruminant as the source of this tapeworm and understand the importance of preventing predation or ingestion of ruminant offal by the dog.

For *T. ovis*, the larval stage is a fluid-filled bladder (called *Cysticercus ovis*) found within the musculature of the ovine intermediate host (very similar to the cysticerci of *Cysticercus bovis* and *C. cellulosae* described earlier) (see Figure 6-13). To acquire this tapeworm, dogs become infected by ingesting the musculature of cysticercus-infected sheep (Figure 6-33). For every cysticercus that is ingested by the dog, one adult tapeworm will develop in the small intestine of that dog. It is important that the veterinarian recognize sheep muscle (uncooked mutton) as the source of this tapeworm and understand the importance of preventing predation and ingestion of sheep muscle by dogs.



**TECHNICIAN'S NOTE** The dog is infected with the canine taeniid by eating the intermediate host containing the cysticercus stage of the tapeworm. Preventing predation of the intermediate host will stop the life cycle of the tapeworm.

### *Taenia taeniaeformis* (*Hydatigera taeniaeformis*)

**Parasite:** *Taenia taeniaeformis*/*Cysticercus fasciolaris* (Metacestode [larval] stage)

**Host:** Cats

**Location of Adult:** Small intestines

**Intermediate Host:** Rats and mice

**Distribution:** Worldwide

**Derivation of Genus:** Flat band, bandage, or tape

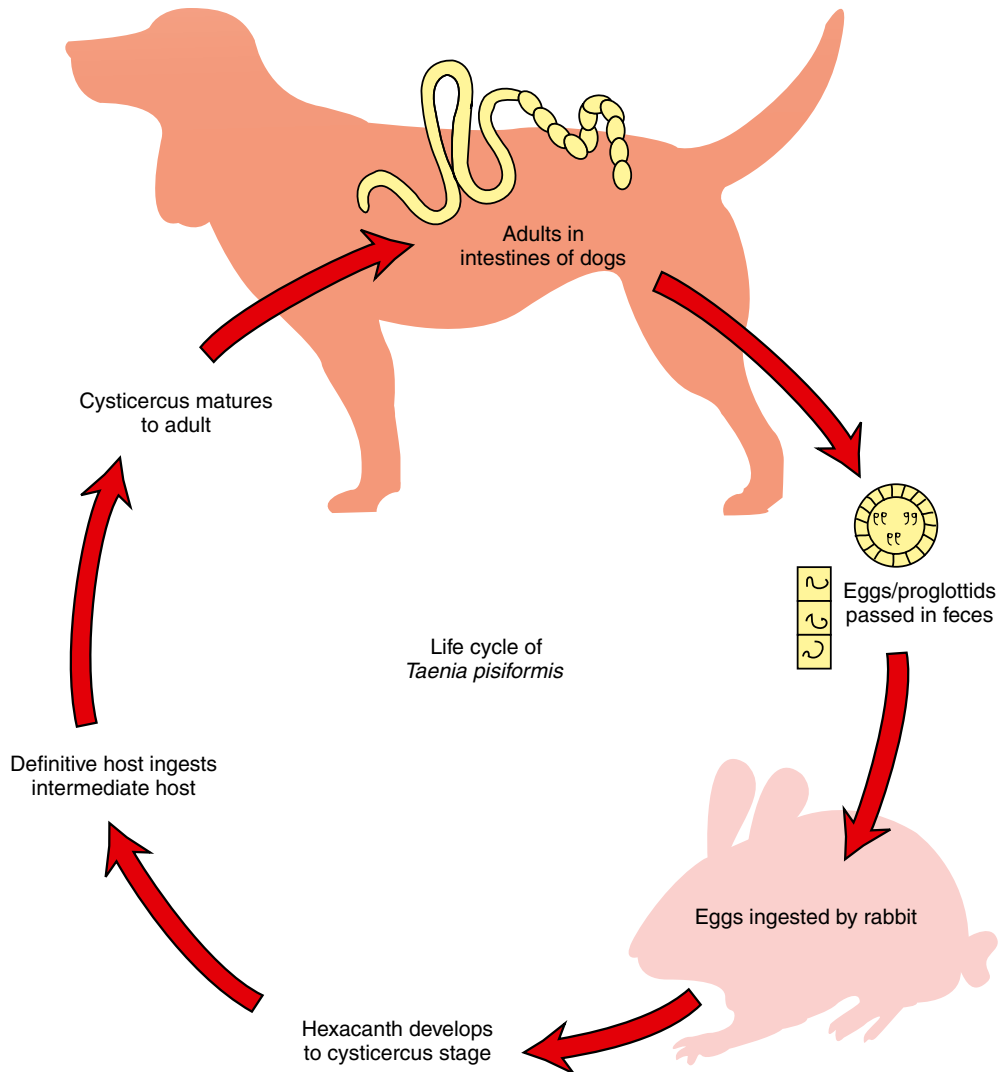
**Transmission Route:** Ingestion of infective rats or mice

**Common Name:** Feline taeniid or feline tapeworm

*Taenia taeniaeformis*, or *Hydatigera taeniaeformis*, is called the **feline tapeworm** or the **feline taeniid**. This tapeworm, which may be up to 60 cm in length, is observed infrequently in cats allowed to roam and prey on rabbits and rodents. The armed scolex is similar to that of the canine taeniids, as are the proglottids; however, in the fresh or intact state the terminal proglottids of *T. taeniaeformis* are said to be bell-shaped. The egg of this tapeworm is 31 to 36  $\mu\text{m}$  in diameter and contains a single oncosphere with three pairs of hooks. For this reason, the oncosphere is often called a “hexacanth” (or “six-toothed”) embryo. As with the eggs of the canine taeniids, the egg is very similar to that of *Echinococcus* species. (See Figure 6-31 for unique features of this taeniid type of tapeworm egg.)



**TECHNICIAN'S NOTE** *Taenia taeniaeformis* produces a taeniid-type ovum and appears similar to that of the canine taeniids except the terminal proglottids are bell-shaped.

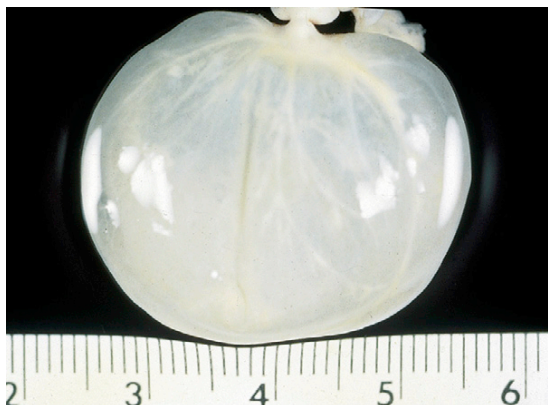

**FIGURE 6-33:** Life cycle of *Taenia pisiformis*.

The metacestode (larval) stage for *T. taeniaeformis* is the **strobilocercus**, a morphologic variation of the cysticercus (bladder worm) stage. For *T. taeniaeformis* to develop, the rodent intermediate host becomes infected by ingesting the taeniid eggs, or hexacanth embryos, often found in proximity to feline feces. These embryos hatch and develop into the cysticercus stage within the liver of the intermediate host. For the first 42 days in this location, it develops

as a cysticercus. On day 42, however, the cysticercus changes its form into that of a strobilocercus. For *T. taeniaeformis*, the strobilocercus is a scolex attached to a long neck, which connects to a bladder; this stage has a scientific name, *Cysticercus fasciolaris* (Figures 6-35, 6-36, and 6-37). The cat becomes infected by killing the rat and ingesting the strobilocercus from the liver. The neck and its connected bladder are digested, the scolex attaches, and the tapeworm begins





**FIGURE 6-34:** Larval stage for *Taenia hydatigena* is a ping-pong-ball-sized, fluid-filled bladder (*Cysticercus tenuicollis*), usually attached to greater omentum or other abdominal organs of ruminant intermediate host.

to grow in the cat's intestine (Figure 6-33). For every strobilocercus that is ingested by the cat, one adult tapeworm will develop in the small intestine of that cat. It is important that the veterinarian recognize the rat as the source of this tapeworm and understand the importance of preventing predation or the ingestion of rat or mouse carrion by the cat. The cat can be treated with praziquantel.

**TECHNICIAN'S NOTE** *Taenia taeniaeformis* uses a strobilocercus as its metacestode stage. The strobilocercus is a fluid-filled bladder that connects to a long strobila that connects to a scolex. This life cycle is unique as it is like no other taeniid tapeworm life cycle.

### ***Multiceps multiceps* and *Multiceps serialis***

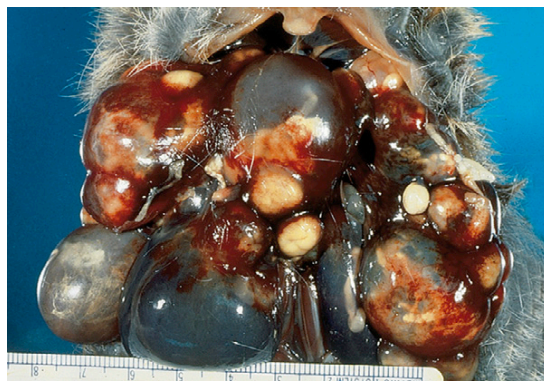**Parasite:** *Multiceps multiceps* and *Multiceps serialis*/*Coenurus cerebralis*, *Coenurus serialis* (Metacestode [larval] tapeworm)

**Host:** Dogs

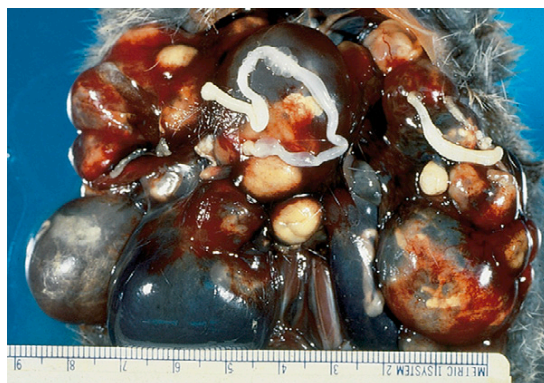**Location of Adult:** Small intestines

**Intermediate Host:** Sheep (*M. multiceps*) and rabbits (*M. serialis*)

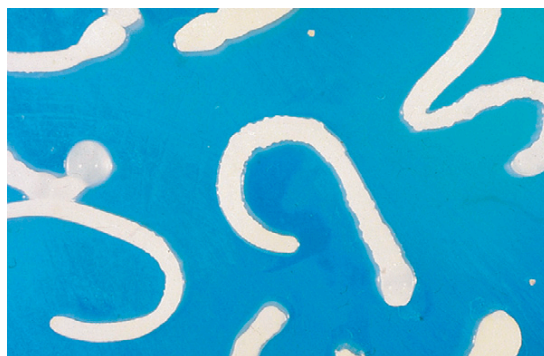**Distribution:** Worldwide (*M. multiceps*)



**FIGURE 6-35:** Larval stage for *Taenia taeniaeformis* is a strobilocercus (*Cysticercus fasciolaris*). The strobilocercus is a scolex attached to a long neck, which connects to a bladder.



**FIGURE 6-36:** The strobilocercus is found in the liver of a rodent intermediate host.



**FIGURE 6-37:** Detail of individual strobilocercus, *Cysticercus fasciolaris*.




**Derivation of Genus:** Many heads

**Transmission Route:** Ingestion of infected intermediate host

**Common Name:** Coenurus-producing tapeworm

*Multiceps multiceps* and *M. serialis* are also taeniid tapeworms of the small intestine of canids. The adults of *M. multiceps* are 40 to 100 cm in length; those of *M. serialis* can grow up to 72 cm. Both possess a scolex with a double row of rostellar hooks. In sufficient numbers, the adult tapeworms can obstruct the intestinal tract.


The eggs of *M. multiceps* are 29 to 37  $\mu\text{m}$  in diameter, and those of *M. serialis* are elliptic and measure 31 to 34  $\mu\text{m}$   $\times$  29 to 30  $\mu\text{m}$ . Both contain a single oncosphere with three pairs of hooks. As with the eggs of the canine and feline taeniids, the eggs of *Multiceps* species are very similar to those of *Taenia* and *Echinococcus* species. (See Figure 6-31 for unique features of this taeniid type of tapeworm.)

 **TECHNICIAN'S NOTE** The taeniid type ova of *Multiceps* species can be found on standard fecal flotation.

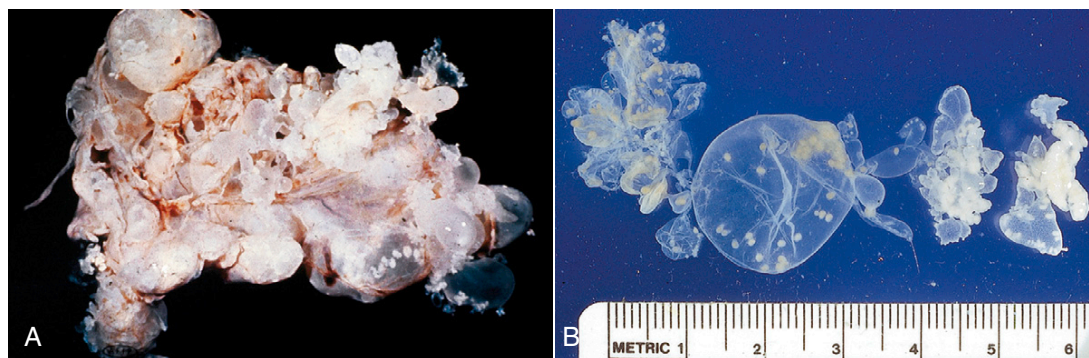
The metacystode (larval) stage for *M. multiceps* and *M. serialis* is the **coenurus** stage, which may be found within the respective ovine or rabbit intermediate host. This coenurus also has a scientific name: *Coenurus cerebralis* for *M. multiceps* and *Coenurus serialis* for *M. serialis*. It is essentially a single, large bladder with several invaginated scolices attached to its inner wall. The coenurus is found within the tissues of the respective intermediate host. For each coenurus that is ingested by the dog, several adult tapeworms will develop, one for each invaginated scolex ingested.

For *M. multiceps*, the sheep intermediate host becomes infected by ingesting taeniid eggs, or hexacanth embryos, which are often found close to canine feces. These embryos hatch and migrate to neurologic tissue (either brain or spinal cord tissue), where they develop into the coenurus stage within the tissue hosts. Naturally, the presence of these large, space-occupying

lesions within the brain and spinal cord can produce neurologic signs in the infected sheep. The larval stage of *M. multiceps* may be up to 5 cm in diameter and is a fluid-filled bladder (called *C. cerebralis*) with many individual scolices lining the walls of the bladder. Dogs become infected either by killing the sheep and ingesting coenurus-infected neural tissue or by being fed such tissues by their sheepherder owners. For every coenurus that is ingested by the dog, many adult tapeworms will develop in the small intestine of that dog. It is important that the veterinarian recognize the sheep as the source of this tapeworm and understand the importance of preventing predation or the ingestion of sheep carrion or offal by the dog.

 **TECHNICIAN'S NOTE** *Multiceps multiceps* is associated with the formation of a coenurus in the brain or nervous tissue of the ovine intermediate host.

For *M. serialis*, the rabbit intermediate host becomes infected by ingesting the taeniid eggs or hexacanth embryos often found in proximity to canine feces. These embryos hatch and migrate to the rabbit's subcutaneous tissues, where they develop into the coenurus stage. The presence of these large, bladderlike cysts within the subcutaneous tissues of the rabbit can interfere with movement and speed, making the rabbit easy prey. For *M. serialis*, the larval stage may be up to 4 cm in diameter and is a fluid-filled bladder called *C. serialis* (Figure 6-38) with many individual invaginated scolices lining the walls of the bladder. Dogs become infected either by killing the slow-moving rabbit and ingesting coenurus-infected subcutaneous tissues or by being fed such tissues by their rabbit-hunting owners. For every coenurus that is ingested by the dog, many adult tapeworms will develop in the small intestine of that dog. It is important that the veterinarian recognize the rabbit as the source of this tapeworm and understand the importance of preventing predation or the ingestion of rabbit carrion or offal by the dog.



**FIGURE 6-38:** A, *Coenurus serialis* from subcutaneous connective tissues of a rabbit. B, Note individual invaginated scolices lining walls of bladder.

**TECHNICIAN'S NOTE** *Multiceps serialis* is associated with the formation of a coenurus in the subcutaneous or intermuscular connective tissue of the rabbit intermediate host.

### ***Echinococcus granulosus* and *Echinococcus multilocularis***

**Parasite:** *Echinococcus granulosus* and *Echinococcus multilocularis*

**Host:** Dogs (*E. granulosus*); cats (*E. multilocularis*)

**Location of Adult:** Small intestine

**Intermediate Host:** Sheep, cattle, and other herbivores (*E. granulosus*); rats, mice, and voles (*E. multilocularis*); humans (both)

**Distribution:** Worldwide (*E. granulosus*); countries in the Northern Hemisphere (*E. multilocularis*)

**Derivation of Genus:** Spiny berry

**Transmission Route:** Ingestion of infective intermediate host

**Common Name:** Unilocular hydatid tapeworm (*E. granulosus*); multilocular hydatid tapeworm (*E. multilocularis*)

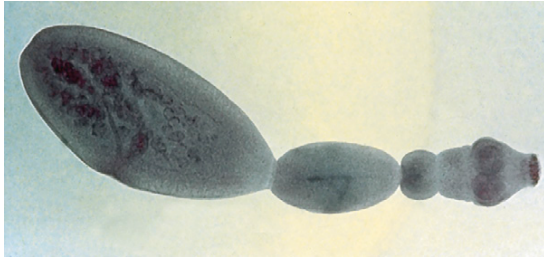*Echinococcus granulosus* and *E. multilocularis* are the hydatid disease tapeworms associated with unilocular and multilocular hydatid disease. *E. granulosus* is the hydatid cyst tapeworm of dogs, and *E. multilocularis* is the hydatid cyst tapeworm of cats. These are important parasites because of their extreme zoonotic potential.

The adult *Echinococcus* is a tiny tapeworm, only 1.2 to 7 mm in length. The entire tapeworm has a

scolex followed by only three proglottids: immature, mature, and gravid (Figure 6-39). When passed, the tiny gravid proglottids likely will be overlooked by the client, the veterinary technician, and the veterinarian. Definitive diagnosis of *Echinococcus* species infection is best achieved by identifying adult tapeworms taken from the host's intestinal tract. In the rare instances in which *Echinococcus* species infection is suspected, antemortem diagnosis is accomplished by purging the dog or cat using arecoline hydrobromide, 3.5 mg/kg body weight, and collecting its feces.

**TECHNICIAN'S NOTE** The adult *Echinococcus* tapeworms cannot accumulate in sufficient numbers to cause intestinal blockage. Their pathogenicity lies in the fact that their eggs can develop into unilocular or multilocular (depending on species) hydatid cysts in the liver, lungs, or brain of the intermediate hosts.

Purging the infected dog or cat is usually only performed when infection is strongly suspected. Entire worms or their proglottids may be collected from the final clear mucus. Because of serious zoonotic potential, all evacuated material should be handled with caution. After the feces have been examined, the evacuate should be incinerated. Rubber gloves should be worn when handling suspect feces.



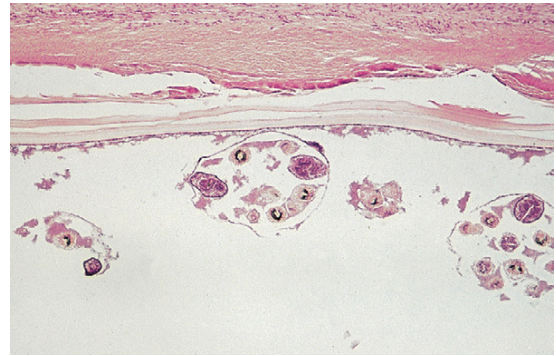
**FIGURE 6-39:** Adult *Echinococcus* species is a tiny tapeworm, only 1.2 to 7 mm in length. Entire tapeworm has only three proglottids: immature, mature, and gravid.

Diagnosis of *Echinococcus* species in either definitive or intermediate hosts warrants reporting to state and federal authorities.

The egg of *E. granulosus* is ovoid,  $32$  to  $36\ \mu\text{m} \times 25$  to  $30\ \mu\text{m}$ , and contains a single oncosphere with three pairs of hooks. The egg of *E. multilocularis* is ovoid,  $30$  to  $40\ \mu\text{m}$ , and contains a single oncosphere with three pairs of hooks. Because of serious zoonotic potential (see Chapter 16), any “suspect” eggs of *Echinococcus* species should be handled with extreme caution. These eggs are very similar in appearance to those of *Taenia* and *Multiceps* species. (See Figure 6-31 for unique features of this taeniid type of tapeworm.)

The metacestode (larval) stage for *E. granulosus* and *E. multilocularis* is the **hydatid cyst** stage, which may be found within the respective ruminant or rodent intermediate host. The hydatid cyst for *E. granulosus* is a unilocular hydatid cyst found within the liver, lung, and other organs of the ruminant intermediate host. The hydatid cyst for *E. multilocularis* is a multilocular hydatid cyst found within the liver or lungs of the rodent intermediate host. Humans may also serve as an intermediate host for both these tapeworms. Humans become infected by ingesting eggs of these tapeworm species.

The unilocular (single-compartment) hydatid cyst of *E. granulosus* has a thick cyst wall with a thin germinal membrane located just inside it. Brood capsules containing protoscolices “bud” from this germinal membrane. When a dog ingests the hydatid cyst containing the brood capsules and protoscolices, each protoscolex develops into an adult tapeworm (Figure 6-40).



**FIGURE 6-40:** Photomicrograph of a unilocular hydatid cyst of *Echinococcus granulosus* has a thick, multilayered wall and a thin, granular germinal membrane. Spherical brood capsules containing protoscolices arise from the germinal membrane.

**TECHNICIAN'S NOTE** Humans can serve as intermediate host for both species of *Echinococcus* tapeworms.

The multilocular (multicompartment) hydatid cyst of *E. multilocularis* lacks the thick cyst wall of the unilocular hydatid cyst. It is often described as being “alveolar” or similar to a “bunch of grapes.” Lacking the thick cyst wall of the unilocular cyst, the multilocular cyst is very invasive, often replacing normal tissue, similar to a malignant cancer. It also possesses a thin germinal membrane. Brood capsules containing protoscolices bud from the germinal membrane. When a cat ingests the hydatid cyst containing the brood capsules and protoscolices, each protoscolex develops into an adult tapeworm in the intestine of the cat.

Praziquantel can be used to treat adult *Echinococcus* worms but will not affect the hydatid cyst stage. The best treatment for the hydatid cyst stage of the parasites is preventing ingestion of the eggs.

**TECHNICIAN'S NOTE** *Echinococcus* species are the tiniest tapeworm of veterinary parasitology, but “dynamite comes in little packages.” As zoonotic diseases go, these tapeworms pack a BIG PUNCH! If diagnosed, this parasite must be reported to the state and federal authorities.



### *Mesocestoides* species

**Parasite:** *Mesocestoides* species

**Host:** Dogs, cats and other carnivores

**Location of Adult:** Small intestine

**Intermediate Host:** First intermediate host – oribatid mite; second intermediate host – rats and mice

**Distribution:** North America, Asia, Europe, and Africa

**Derivation of Genus:** The form of a middle girdle

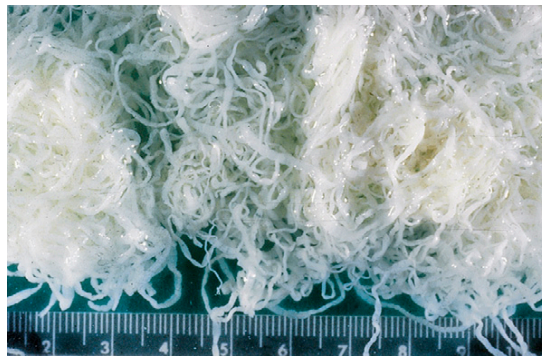**Transmission Route:** Ingestion of infective intermediate host

**Common Name:** Tetrathyridium tapeworm

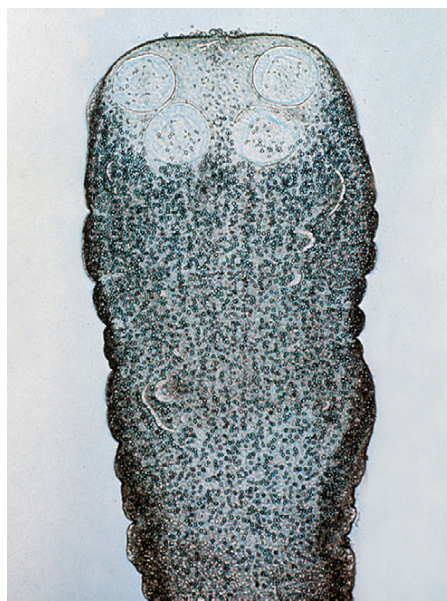
*Mesocestoides* species may parasitize the small intestine of carnivores, including the dog and the cat. These are small- to medium-sized true tapeworms, ranging from 12 cm to more than 2 m in length (Figure 6-41). The scolex of this tapeworm is oblong, with four suckers, is unarmed (Figure 6-42) and has a centrally located uterine pore. In sufficient numbers, the adult tapeworms can cause intestinal obstruction. Gravid proglottids of *Mesocestoides* have a unique appearance (Figure 6-43). The eggs of *Mesocestoides* species contain a single oncosphere (hexacanth embryo) with three pairs of hooks. (See Figure 6-44 for features of this egg.) The striated embryophore (shell) is lacking.

**TECHNICIAN'S NOTE** *Mesocestoides* species of tapeworms are unusual true tapeworms in that they use two intermediate hosts instead of one intermediate host.

*Mesocestoides* is an unusual genus among the true tapeworms in that it is the only one that uses two intermediate hosts. (The pseudotapeworms described in the next section use two intermediate hosts.) The egg is a hexacanth embryo. If it is ingested by an oribatid mite, it develops into a cysticercoid within that mite (much like the cysticercoid of *Dipylidium*, *Moniezia*, *Thysanosoma*, and *Anoplocephala* species). If this cysticercoid-containing mite is ingested by a mouse or reptile, the cysticercoid develops into a **tetrathyridium**, a solid-bodied metacestode stage with a deeply



**FIGURE 6-41:** Adult *Mesocestoides* species are medium-sized tapeworms, ranging from 12 cm to over 2 m long.

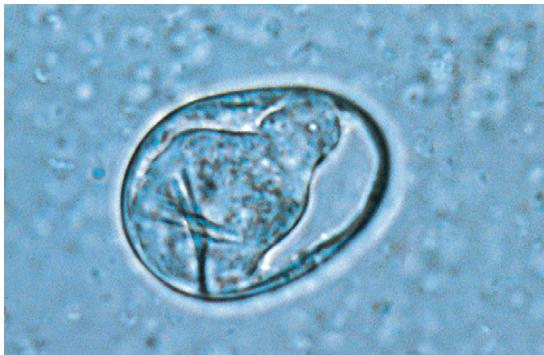

**FIGURE 6-42:** Scolex of *Mesocestoides* species is oblong, has four suckers, and is unarmed.

invaginated, acetabular scolex (Figure 6-45). This tetrathyridium is approximately 1 cm in diameter and is capable of multiplying exponentially; that is, one tetrathyridium becomes two, two become four, four become eight, and so on (Figures 6-46 and 6-47). This type of asexual reproduction produces large numbers of tetrathyridia that are infective to the canine or feline definitive host. The tetrathyridia multiply in the body of the second intermediate host and are often confined to the

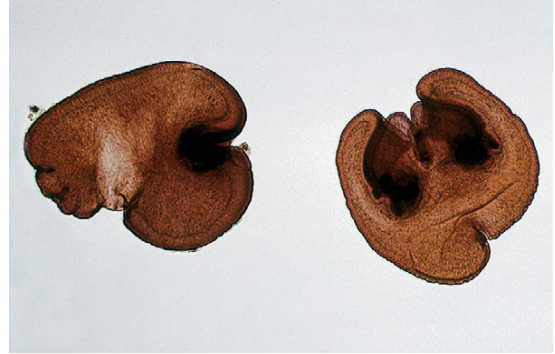

**FIGURE 6-43:** Gravid proglottids of *Mesocostoides* have a unique appearance.

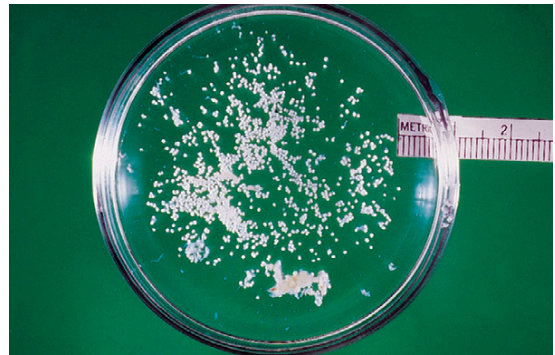

**FIGURE 6-44:** Eggs of *Mesocostoides* species contain a single oncosphere with three pairs of hooks. The oncosphere is often called a "hexacanth embryo."


serous cavities, particularly the peritoneal cavity (Figure 6-48), and other internal organs, such as the liver (Figures 6-49 and 6-50). Tetrathyridia often multiply so much within the abdominal cavity that they greatly expand the girth of the intermediate host. When ingested by the definitive host, each tetrathyridium becomes an adult tapeworm within the intestine of that definitive host.



**FIGURE 6-45:** Metacestode stage for *Mesocostoides* species is a tetrathyridium, a solid-bodied metacestode stage with a deeply invaginated, acetabular scolex.



**FIGURE 6-46:** Tetrathyridium is about 1 cm in diameter and is capable of multiplying exponentially (i.e., one tetrathyridium becomes two, two become four, four become eight).



**FIGURE 6-47:** This type of asexual reproduction produces large numbers of tetrathyridia that are infective to canine or feline definitive host.





**TECHNICIAN'S NOTE** The ova of the tetrathyridium tapeworms can be found with standard fecal flotation procedures.

## COTYLODA (PSEUDOTAPEWORMS)


Phylum: Platyhelminthes

Class: Cestoda

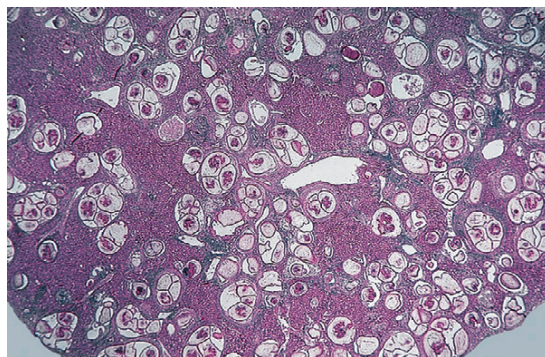
Subclass: Cotyloda

Members of the subclass Cotyloda, or pseudotapeworms, grossly resemble the members of the subclass Eucestoda. These flatworms are ribbonlike and divided into a long chain of proglottids. These are hermaphroditic tapeworms, but instead of possessing laterally located

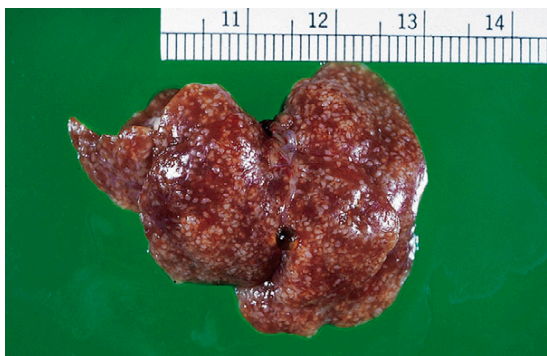reproductive organs and genital pores, they have centrally located reproductive organs and genital pores (Figure 6-51). The egg for members of this subclass is operculated (Figure 6-52) and almost identical to the egg of the digenetic trematodes. Most pseudotapeworms release their operculated eggs directly from the uterus; the eggs then pass out to the external environment in the feces of the definitive host. The adult tapeworms occasionally release chains of gravid proglottids when these terminal proglottids have become aged or spent. Instead of possessing four suckers and (possibly) a rostellum, the pseudotapeworm has two slitlike organs of attachment (known as **bothria**) on the lateral aspects of the scolex. Figure 6-53 shows the scolex of *Diphylllobothrium latum*.



**FIGURE 6-48:** Tetrathyridia multiply in body of second intermediate host and are often confined to serous cavities, particularly peritoneal cavity.



**FIGURE 6-50:** Histopathology of liver of rat infected with tetrathyridia.



**FIGURE 6-49:** Tetrathyridia multiply in internal organs, such as the liver.



**FIGURE 6-51:** Representative pseudotapeworm (*Diphylllobothrium latum*), with centrally located reproductive organs and genital pores.

During its life cycle, the pseudotapeworm uses two intermediate hosts. The pseudophyllidian-type operculated egg makes contact with water and releases a ciliated, hexacanth embryo. This stage is called a **coracidium**. The coracidium is ingested by a microscopic aquatic crustacean and, within that crustacean, develops into a stage called a **proceroid**. The crustacean, with the proceroid, is later ingested by a fish or an amphibian and, within the musculature of that host, develops into a solid-bodied metacystode stage called a **plerocercoid**, or **sparganum**. The definitive host becomes infected by ingesting the second intermediate host with this plerocercoid (sparganum) stage. The scolex attaches in the small intestine and begins to “grow” a new tapeworm.

The important pseudotapeworms of animals are *Spirometra* species and *Diphyllobothrium* species.



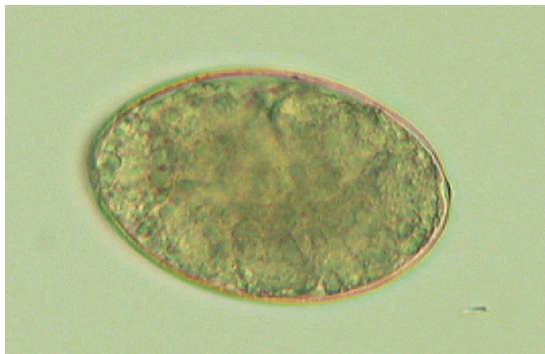
**TECHNICIAN'S NOTE** The pseudotapeworms use two intermediate hosts in their life cycle.

### *Spirometra* species

**Parasite:** *Spirometra* species

**Host:** Dogs and cats

**Location of Adult:** Small intestine



**FIGURE 6-52:** Operculated egg of pseudotapeworm is almost identical to egg of digenetic trematodes. Most pseudotapeworms release eggs directly from the uterus; eggs then pass out to external environment in feces of definitive host.

**Intermediate Hosts:** First intermediate host – aquatic crustacean; second intermediate host – fish or frogs

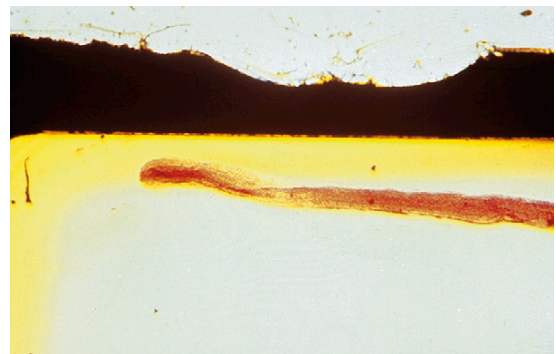
**Distribution:** North and South America, Far East, and Australia

**Derivation of Genus:** Coiled or spiral uterus

**Transmission Route:** Ingestion of infective fish or frog

**Common Name:** Zipper tapeworm or sparganosis tapeworm

*Spirometra* species are often referred to as “zipper” or “sparganosis” tapeworms. These medium-sized tapeworms are often found in the small intestine of both the dog and the cat and are often found in pets residing in Florida and along the Gulf Coast of North America. The adult pseudotapeworm possesses four suckers on its anterior end. This pseudotapeworm has two slit-like holdfast organs called bothria. In sufficient numbers, the adults can cause intestinal obstruction. This tapeworm is a clinical oddity because it produces an operculated egg. Each proglottid of *Spirometra* species possesses a centrally located, spiraled uterus and an associated uterine pore through which eggs are released. These tapeworms characteristically release eggs until they exhaust their uterine contents. Gravid segments are usually not discharged into the pet’s feces. The tapeworm is unique because while it is attached to the host’s jejunum, the mature proglottids often separate along the longitudinal axis for a short distance. The tapeworm appears to “unzip,”



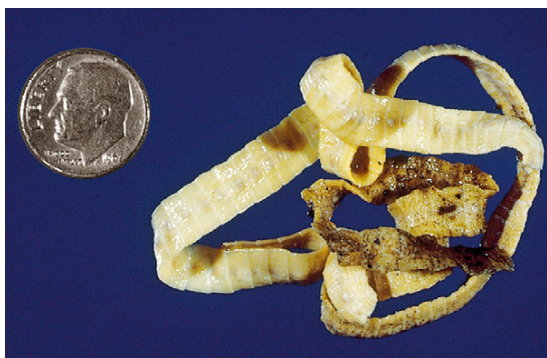**FIGURE 6-53:** Anterior end (scolex) of *Diphyllobothrium latum*.

thus its common name, the “zipper tapeworm.” Spent “zipped” and “unzipped” proglottids often appear in the feces of the pet. (See Figure 6-54 for unique features of this pseudotapeworm.)

**TECHNICIAN'S NOTE** Dogs and humans are capable of serving as second intermediate hosts—becoming infected by ingesting copepods with procercoid stage larvae.

The egg of *Spirometra* species resembles that of a fluke (digenetic trematode). The egg has a distinct operculum at one end of the pole of the shell. The eggs are oval and yellowish brown. They average  $60 \times 36 \mu\text{m}$ , have an asymmetric appearance, and tend to be rather pointed at one end (Figure 6-55). When the eggs rupture, a distinct operculum is visible. The eggs are unembryonated when passed in the feces.

The metacystode (larval) stage for *Spirometra* species is the sparganum, a solid-bodied stage with slitlike mouthparts. This stage is found in the musculature of its intermediate hosts, fish and amphibians such as frogs. Dogs and cats can become infected with both the tetrathyridial and adult stages of the parasites, by ingesting the fish and amphibian intermediate hosts.



**FIGURE 6-54:** Adult *Spirometra* species with centrally located, spiraled uterus and uterine pore through which eggs are released. Gravid segments usually are not discharged into feces. This tapeworm is unique because while attached to host's jejunum, mature proglottids often separate along longitudinal axis for a short distance. Tapeworm appears to “unzip,” thus its common name, “zipper tapeworm.”

It is important that the veterinarian recognize the fish and the amphibian as the sources of this tapeworm and understand the importance of preventing predation or the ingestion of carrion or offal by the dog and cat.

**TECHNICIAN'S NOTE** The eggs of the zipper tapeworm can be found with standard fecal flotation procedures.

### *Diphyllobothrium* species

**Parasite:** *Diphyllobothrium latum*

**Host:** Dogs, cats, and humans

**Location of Adult:** Small intestine

**Intermediate Hosts:** First intermediate host – aquatic crustacean; second intermediate host – fish

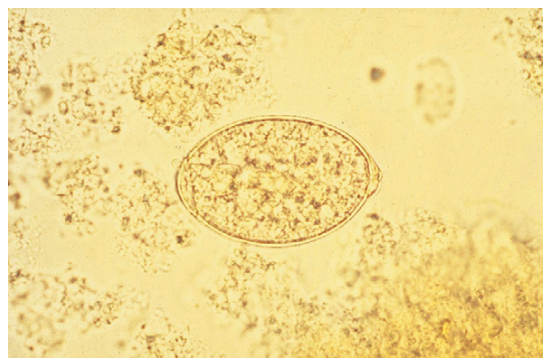
**Distribution:** Scandinavian countries, the Ukraine, and North America

**Derivation of Genus:** Double leaf

**Transmission Route:** Ingestion of infective fish

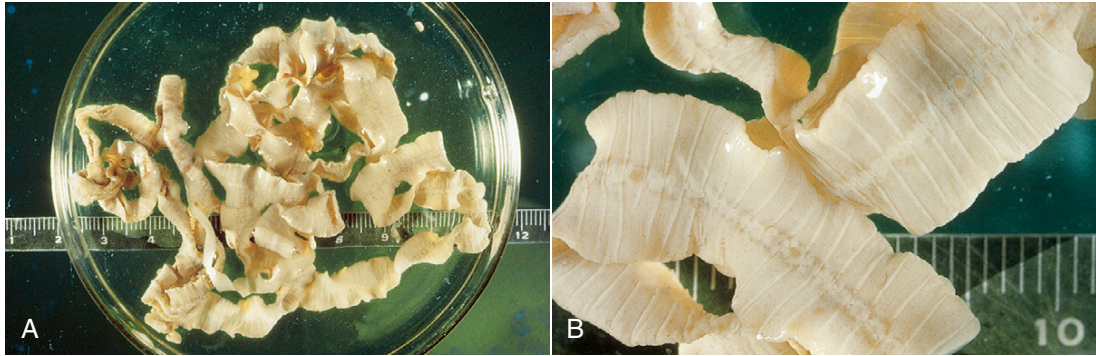
**Common Name:** Broad fish tapeworm

*Diphyllobothrium* species are often referred to as “broad fish tapeworms.” This tapeworm can be 2 to 12 m in length; however, it probably does not attain this maximum length in dogs and cats. Instead of possessing four suckers on its anterior end, this pseudotapeworm has two slitlike holdfast organs called bothria. The adults absorb vitamin B<sub>12</sub> to the point that the tapeworm can

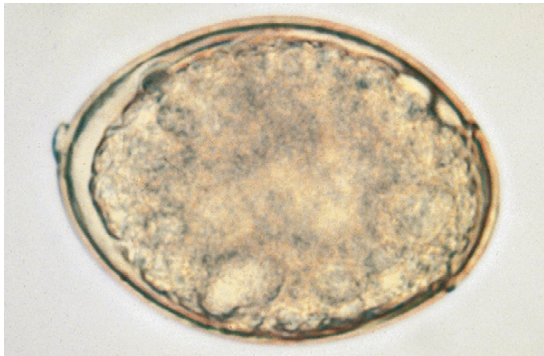


**FIGURE 6-55:** Egg of *Spirometra mansonoides* is operculated, resembling egg of a fluke (digenetic trematode).





**FIGURE 6-56:** A, Adult *Diphyllobothrium* species can measure 2 to 12 m long, although this tapeworm probably does not attain maximum length in dogs and cats. B, Each proglottid has a centrally located, rosette-shaped uterus and an associated uterine pore through which eggs are released.



**FIGURE 6-57:** Egg of *Diphyllobothrium* species also resembles that of a fluke (digenetic trematode). Egg is oval, with distinct operculum at opposite end of pole of shell. Eggs are light brown and average 67 to 71  $\mu\text{m}$   $\times$  40 to 51  $\mu\text{m}$ . Eggs tend to be rounded on one end, with operculum on opposite end. Eggs are unembryonated when passed in feces.

produce pernicious anemia in the host as well as causing intestinal obstruction. Each proglottid of this tapeworm has a centrally located, rosette-shaped uterus and an associated uterine pore through which the eggs are released (Figure 6-56). These tapeworms continually release eggs until they exhaust their uterine contents. The terminal proglottids become senile rather than gravid and detach in chains rather than

individually. The egg of *Diphyllobothrium* species also resembles that of a fluke (digenetic trematode). The egg is oval and possesses a distinct operculum at one end of the pole of the shell. The eggs are light brown, averaging 67 to 71  $\mu\text{m}$   $\times$  40 to 51  $\mu\text{m}$ , and tend to be rounded on one end (Figure 6-57). The operculum is present on the end opposite the rounded pole. The eggs are unembryonated when passed in the feces.



**TECHNICIAN'S NOTE** The eggs are unembryonated with an operculum opposite the rounded pole. The eggs can be found with standard fecal flotation procedures.

The metacystode (larval) stage for *Diphyllobothrium* species is the plerocercoid, a solid-bodied stage with slitlike mouthparts. This stage is found in the musculature of the fish intermediate host. Dogs and cats become infected by ingesting the fish intermediate host. It is important that the veterinarian recognize the fish as the source of this tapeworm and understand the importance of preventing predation or the ingestion of raw fish by the dog and cat.

## CHAPTER SIX TEST

MATCHING—Match the term with the correct phrase or term.

- |                                       |                                                                                         |
|---------------------------------------|-----------------------------------------------------------------------------------------|
| A. <i>Coenurus cerebralis</i>         | 1. Noninvaginated scolex in a small cavity or vesicle or bladder found in invertebrates |
| B. <i>Cysticercus fasciolaris</i>     | 2. Zipper tapeworm                                                                      |
| C. <i>Echinococcus granulosus</i>     | 3. Double-pored tapeworm or the cucumber seed tapeworm                                  |
| D. <i>Anoplocephala perfoliata</i>    | 4. Ruminant tapeworm                                                                    |
| E. <i>Dipylidium caninum</i>          | 5. Neurologic signs in infected sheep                                                   |
| F. <i>Paranoplocephala mamillana</i>  | 6. Embryo containing three pairs of hooks                                               |
| G. <i>Cysticercus bovis</i>           | 7. Sparganum                                                                            |
| H. <i>Cysticercus cellulosae</i>      | 8. Lappets behind scolex                                                                |
| I. Typical taeniid-type ova           | 9. Strobilocercus in rats                                                               |
| J. <i>Moniezia</i> species            | 10. Rat tapeworm                                                                        |
| K. Egg packet                         | 11. Broad fish tapeworm                                                                 |
| L. Hexacanth embryo                   | 12. <i>Dipylidium caninum</i>                                                           |
| M. Pyriform apparatus                 | 13. <i>Taenia saginata</i>                                                              |
| N. <i>Hymenolepis nana</i>            | 14. <i>Taenia</i> or <i>Multiceps</i> or <i>Echinococcus</i> species                    |
| O. Cysticeroid                        | 15. Found in <i>Cyclops</i> species – aquatic crustacean                                |
| P. <i>Taenia hydatigena</i>           | 16. Fringed tapeworm                                                                    |
| Q. <i>Thysanosoma actinoides</i>      | 17. Larval tapeworm                                                                     |
| R. <i>Mesocestoides</i> species       | 18. Innermost lining of eggs of <i>Moniezia</i> species, <i>Anoplocephala</i> species   |
| S. <i>Spirometra mansonoides</i>      | 19. Dwarf equine tapeworm                                                               |
| T. Ovum of pseudotapeworm             | 20. Unilocular hydatid cyst                                                             |
| U. <i>Diphyllbothrium latum</i>       | 21. <i>Cysticercus tenuicollis</i> in bovine omentum                                    |
| V. Plerocercoid                       | 22. “Measly pork,” “pork measles”                                                       |
| W. Proceroid                          | 23. Effective cestocide – kills tapeworms                                               |
| X. <i>Echinococcus multilocularis</i> | 24. Tetrathyridium                                                                      |
| Y. Praziquantel                       | 25. Alveolar hydatid disease in rodents                                                 |
| Z. Metacestode stage                  | 26. Operculated on one end                                                              |



## QUESTIONS FOR THOUGHT AND DISCUSSION

---

1. How might *Coenurus cerebralis* and *Coenurus serialis* affect the behavior of the intermediate host, thus facilitating transmission to the definitive host?
2. Compare and contrast the following types of metacestode stages. You may use drawings with labels to illustrate differences. Give examples of cestodes that typify these egg types (see Chapter 6 for examples).
  - Cysticercoid and cysticercus
  - Cysticercus and coenurus
  - Unilocular and multilocular hydatid cysts
3. Why is a single gravid proglottid of *Dipylidium caninum* so important in facilitating the transmission of the parasite to the flea intermediate host?
4. What feature makes the tetrathyridia of *Mesocystoides* species so pathogenic to the second intermediate host?
5. Three genera of Taeniid tapeworms (*Taenia*, *Multiceps*, or *Echinococcus* species) produce similar ova (typical taeniid-type ova) in a canine fecal flotation. Why is it important to wear disposable gloves when performing fecal examinations? HINT: The ovum of one of these three genera is capable of infecting humans, that is, one is a very serious zoonotic parasite. What might happen if a human ingested this pathology-producing ovum?
6. Why are the following terms or phrases so important in a veterinary clinical practice, either small animal or large animal?
  - Identifying the gravid proglottid of *Dipylidium caninum*
  - *Cysticercus bovis* and *Cysticercus cellulosae*
  - Unilocular and multilocular hydatid cysts

This page intentionally left blank

# The Phylum Platyhelminthes, Class Trematoda

7

## KEY TERMS

Monogenetic fluke  
Digenetic fluke  
Oral sucker  
Ventral sucker  
(acetabulum)  
Hermaphroditism  
Operculated egg  
Miracidium  
Sporocyst  
Redia  
Cercaria  
Metacercaria  
Adult fluke

## OUTLINE

Subclass Monogenea  
Subclass Digenea  
*Key Morphologic Features*  
*Life Cycle of the Fluke*

## LEARNING OBJECTIVES

After studying this chapter, the reader should be able to do the following:

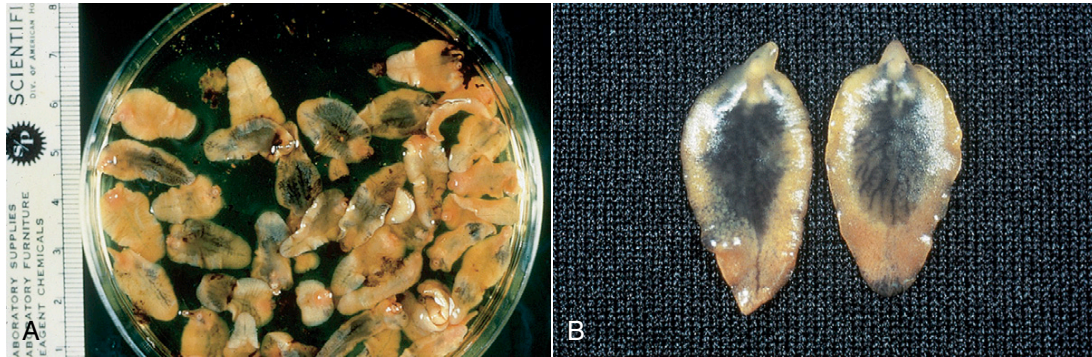
- Identify the external and internal morphologic features of the digenetic fluke.
- Identify the developmental stages in the life cycle of a typical digenetic fluke.
- Compare and contrast monogenetic trematodes and digenetic trematodes.

The phylum Platyhelminthes, the flatworms, includes two of the strangest classes in the animal kingdom, the **trematodes** (or flukes) and the **cestodes** (or tapeworms). The morphologic feature common to these two classes is that the worms are dorsoventrally flattened.

Members of the phylum Platyhelminthes, class Trematoda, are often referred to as trematodes or “flukes.” Their bodies are often flattened, unsegmented, and leaflike. An example of a typical fluke is *Fasciola hepatica* (Figure 7-1). Within this class are two subclasses, the subclass Monogenea (the monogenetic trematodes) and the class Digenea (the digenetic trematodes). Monogenetic trematodes usually parasitize fish, amphibians, and reptiles, whereas digenetic trematodes are usually associated with wild and domestic animals and humans.



**TECHNICIAN'S NOTE** Trematodes are dorsoventrally flattened, unsegmented, and leaflike.



**FIGURE 7-1:** A Representative flukes B (*Fasciola hepatica*) with flattened, unsegmented, leaflike bodies.

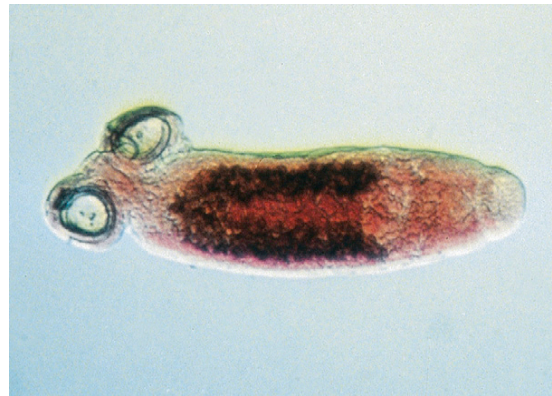### SUBCLASS MONOGENEA

Phylum: Platyhelminthes

Class: Trematoda

Subclass: Monogenea

Monogenetic trematodes are usually ectoparasites of fish, amphibians, and reptiles. They attach to the exterior surfaces, such as gills, skin, fins, and the mouth. These trematodes attach to the host with a posterior adhesive organ that may have suckers, hooks, or clamps (Figure 7-2). These parasites are usually diagnosed in veterinary practices that specialize in treating saltwater or freshwater aquarium fish or in aquacultural environments (e.g., fish farming). Because monogenetic trematodes are diagnosed so infrequently in veterinary practice, the emphasis in this chapter (and the text) is on the digenetic trematodes.



**FIGURE 7-2:** Representative monogenetic fluke with posterior adhesive organ that may have suckers, hooks, or clamps.

**TECHNICIAN'S NOTE** Monogenetic trematodes are seen in aquatic fish, amphibians, and reptiles.

### SUBCLASS DIGENEA

Phylum: Platyhelminthes

Class: Trematoda

Subclass: Digena


Digenetic trematodes, or flukes, are usually endoparasites of both domestic and wild animals and occasionally humans. Digenetic flukes

are generally broad, leaf-shaped, and flattened, although a few, such as *Fascioloides magna*, are thick and fleshy (Figure 7-3). One group of trematodes (the schistosomes) are long, thin, and wormlike, resembling the nematodes or roundworms.

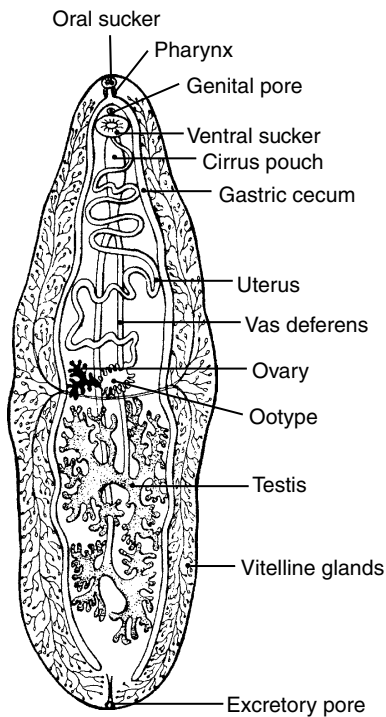
**TECHNICIAN'S NOTE** Digenetic trematodes are seen in domestic animals, wild animals, and occasionally, in humans.

### Key Morphologic Features

Figure 7-4 details the internal morphology of a representative digenetic fluke. On or near the anterior end is the fluke's mouth, which



**FIGURE 7-3:** Digenetic flukes are usually broad, leaf-shaped, and flattened (Figure 7-1), although a few are thick and fleshy.



**FIGURE 7-4:** Internal morphology of representative digenetic fluke. Note that digenetic flukes are hermaphroditic; that is, they contain both male and female reproductive organs.

is surrounded by a muscular oral sucker. This mouth connects to a muscular pharynx, which in turn leads to an esophagus, which bifurcates into two blind ceca. Flukes do not possess an anus; to release digested food, they regurgitate their cecal

contents back into the tissues or organs they infect. These contents are often observed in the tissues on histopathologic section and are colloquially referred to as “fluke puke.” Flukes also possess a muscular organ of attachment called an **acetabulum**, or ventral sucker. This organ is used as a “holdfast organ” and is not associated with feeding.



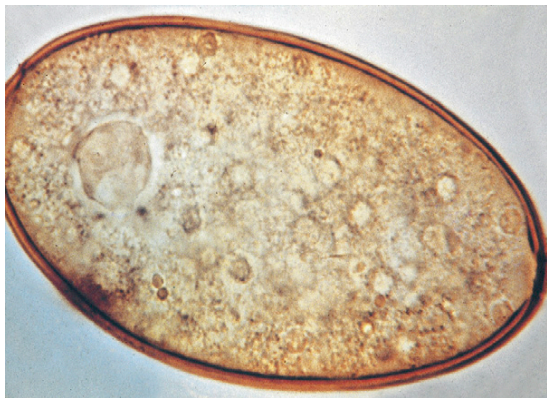**TECHNICIAN'S NOTE** Flukes or digenetic trematodes do not possess an anus. They regurgitate their cecal contents back into the tissues or organs of the host.

With the exception of the schistosomes, or blood flukes, all flukes are hermaphroditic; that is, each fluke possesses complete sets of both male and female reproductive organs. The male reproductive organs consist of two testes, the vas efferens, the vas deferens, the seminal vesicle, and the cirrus (the fluke's version of a penis). The female reproductive organs consist of an ovary, an oviduct, a seminal receptacle, the yolk glands, the ootype, Mehlis' gland, vitelline glands, and the uterus. Self-fertilization usually takes place; however, cross-fertilization between two adult flukes also occurs.

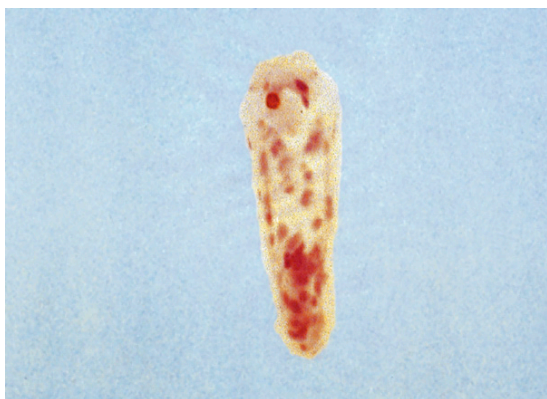### Life Cycle of the Fluke

The female portion of the fluke's reproductive tract produces operculated eggs that have been stored in the uterus (Figure 7-5). Eggs pass out of the uterus through the genital pore and are usually passed out to the external environment within the host's feces. The operculated eggs embryonate in the external environment. If the egg makes contact with water, it will hatch and produce a motile stage called a **miracidium** (Figure 7-6). The miracidium is covered with tiny hairs called **cilia**. The movement of the cilia allows the miracidium to swim in the water. The miracidium seeks out an aquatic snail (Figure 7-7), the first intermediate host, then penetrates the skin of the snail, and develops to





**FIGURE 7-5:** Fertilized operculated egg released by female portion of reproductive system of the hermaphroditic fluke. The operculum is a tiny “trapdoor” through which the miracidium emerges.



**FIGURE 7-6:** The miracidium is the motile, ciliated stage that emerges through the operculum and eventually penetrates the snail, the first intermediate host.

the next stage, the **sporocyst**. The sporocyst is merely a sack in which the next stage, the **redia**, develops. Many rediae develop within the sporocyst. Within each redia, many cercariae develop (Figure 7-8). The cercarial stage often has a tail and will emerge from the snail and swim in the water (Figure 7-9). Depending on the species of fluke, at this point the cercaria will take one of the following three paths:

1. The cercaria may directly penetrate the skin of the definitive host.



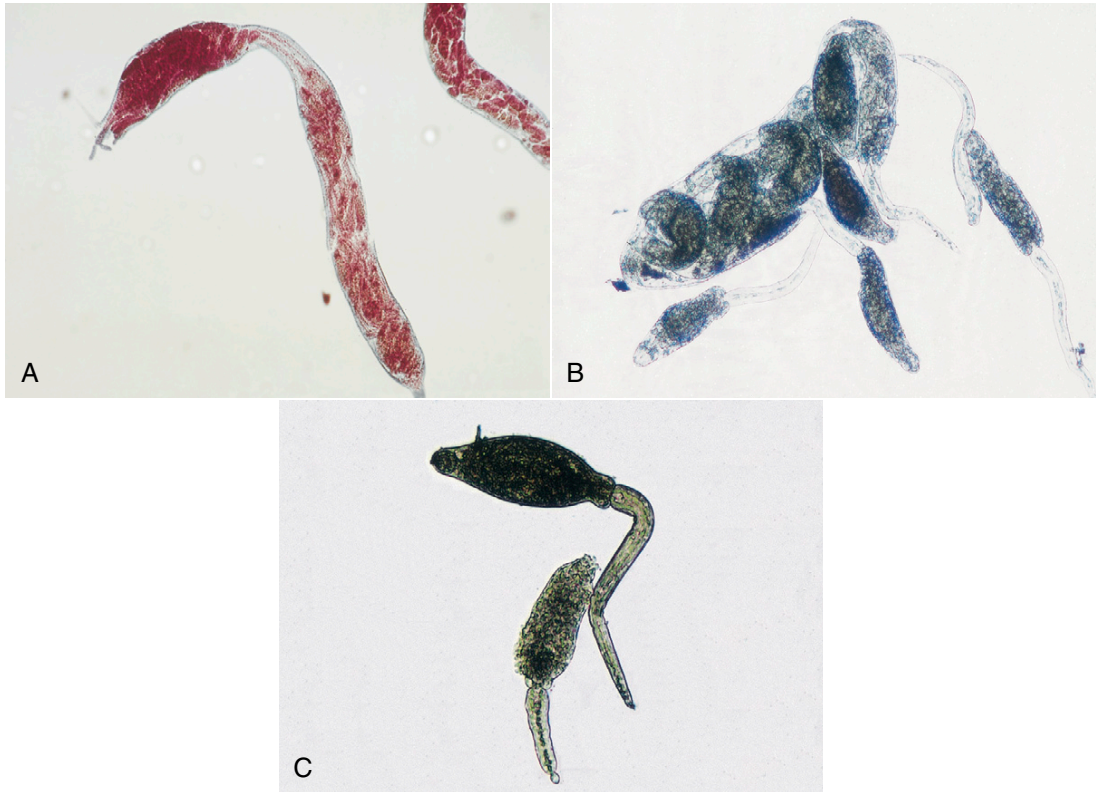
**FIGURE 7-7:** For most digenetic flukes, a snail is the first intermediate host.

2. The cercaria may attach to vegetation, lose its tail, secrete a thick cyst wall around itself, and thus develop into a metacercaria (Figure 7-10). The vegetation with the attached, encysted metacercaria will be ingested by the definitive host.
3. The cercaria may lose its tail, penetrate the second intermediate host, secrete a thick cyst wall around itself, and develop into a metacercaria within the second intermediate host. The second intermediate host with the encysted metacercaria will be ingested by the definitive host.

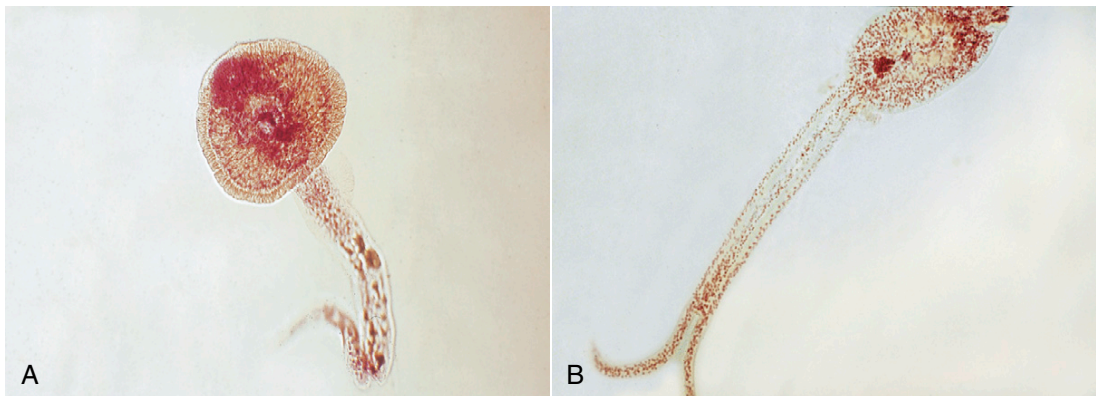


**TECHNICIAN'S NOTE** The cercarial stage of the trematode life cycle can take one of three ways to enter a definitive host: penetrate the skin directly, attach to vegetation and await ingestion, or penetrate the skin of a second intermediate host and await ingestion.

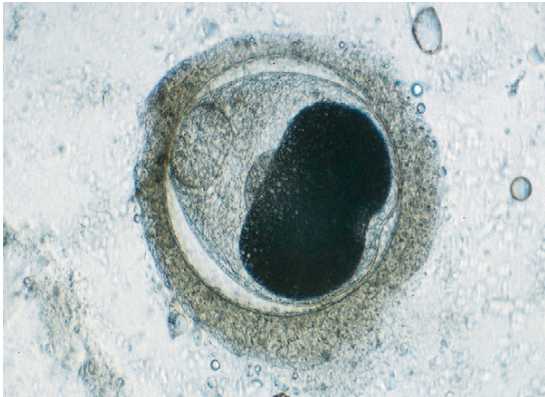
If the fluke takes the first option, the cercaria will migrate to its predilection site (the site of infection) and develop into the adult fluke. If the fluke takes the second option, the thick cyst wall will be digested by the host and the juvenile fluke released. The juvenile fluke then migrates to the predilection site and develops into an



**FIGURE 7-8:** After penetration of the snail intermediate host, the next developmental stage, **A**, the sporocyst, is formed by the miracidium. **B**, The sporocyst stage forms many internal redial stages. **C**, Each redial stage forms many internal cercarial stages.



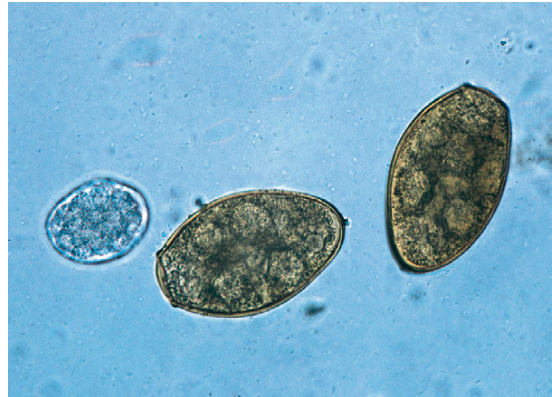**FIGURE 7-9:** Cercarial stage is released from redial stage. This stage often has a tail and emerges from snail to swim in water. Rarely, cercarial stage penetrates skin of the definitive host.



**FIGURE 7-10:** Metacercarial stage dissected from muscles of salmonid fish. Cercarial stage may swim to vegetation, drop its tail, secrete thick cyst wall, and develop into metacercarial stage; or cercarial stage may drop its tail, penetrate or be eaten by second intermediate host, secrete thick cyst wall around itself, and develop to metacercaria within the second intermediate host.

adult fluke. If the fluke takes the third option, the second intermediate host and the thick cyst wall are digested and the juvenile fluke released. The juvenile fluke then migrates to the predilection site and develops into an adult fluke. Most of the predilection sites of the flukes are associated with the digestive system. The exceptions are *Paragonimus kellicotti*, the lung fluke of dogs and cats, and the schistosomes, or blood flukes, which are flukes that reside in the blood vessels. Once the adult stage of the fluke is reached, self-fertilization and cross-fertilization occur, and the life cycle begins again, with operculated eggs being released to the outside environment.

**TECHNICIAN'S NOTE** With two exceptions, the flukes may be found within the digestive system.



**FIGURE 7-11:** Digenetic flukes have characteristic ovum, the operculated egg, which is almost unique to this subclass. Most of these flukes possess this oval egg with a distinct operculum, or door, on one end of the egg. The egg of *Paragonimus kellicotti* has an operculum that is easily observed.

Chapter 8 details some of the important flukes of domestic animals (and, in some cases, wild animals) in North America. As individual species, adult flukes can be quite distinctive in appearance. Flukes tend to be found in certain predilection tissue or organ sites within the host's body. Although some may "wander" off course in the developmental life cycle, adult flukes are usually associated with certain tissue or organ sites. It is important for the diagnostician to associate certain flukes with their predilection sites.

Finally, digenetic flukes have a characteristic ovum that is almost unique to this subclass, the operculated egg (Figure 7-11). Most of these flukes possess an oval egg with a distinct **operculum**, or door, on one pole (either end) of the egg. There are a few exceptions, and these are noted as these flukes are discussed.

**TECHNICIAN'S NOTE** Digenetic trematodes have a characteristic operculated egg.



## CHAPTER SEVEN TEST

---

MATCHING—Match the term with the correct phrase or term.

- |                           |                                                                                                                     |
|---------------------------|---------------------------------------------------------------------------------------------------------------------|
| A. Monogenetic trematodes | 1. Developmental stage following penetration of the miracidium into snail (first intermediate host)                 |
| B. Acetabulum             | 2. “Door” or cap at one end or pole of the trematode egg                                                            |
| C. Miracidium             | 3. Ectoparasites of fish, amphibians, and reptiles                                                                  |
| D. Sporocyst              | 4. Encysted stage in the life cycle of the trematode usually found on vegetation or within second intermediate host |
| E. Redia                  | 5. Endoparasitic flukes of both domestic and wild animals                                                           |
| F. Cercaria               | 6. Stage that follows the redia; stage that emerges from the second intermediate host                               |
| G. Operculum              | 7. Motile stage emerging from operculated fluke egg                                                                 |
| H. Hermaphroditic         | 8. Ventral sucker that is used as a “holdfast” organ of attachment for digenetic flukes                             |
| I. Metacercaria           | 9. Simultaneously possessing both male and female reproductive organs                                               |
| J. Digenetic trematodes   | 10. Stage that develops on the inside of the sporocyst                                                              |

## QUESTIONS FOR THOUGHT AND DISCUSSION

---

- How are monogenetic trematodes different from digenetic trematodes?
- Describe the developmental stages in the life cycle of a typical digenetic fluke.

This page intentionally left blank



# Trematodes (Flukes) of Animals and Humans

## 8

### KEY TERMS

Operculum  
Amphistome  
Schistosome  
Schistosome cercarial dermatitis  
Black spot

### OUTLINE

Flukes of Ruminants (Cattle, Sheep, and Goats)  
Flukes of Small Animals (Dogs and Cats)

### LEARNING OBJECTIVES

After studying this chapter, the reader should be able to do the following:

- Identify digenetic flukes to *genus* and/or *species* when given a trematode specimen, and the host and location where the specimen was found within that host.

The following organisms are flukes that may parasitize domesticated and wild animals. A few species are known to parasitize humans.

### FLUKES OF RUMINANTS (CATTLE, SHEEP, AND GOATS)

**Parasite:** *Dicrocoelium dendriticum*

**Host:** Sheep, goats, and cattle

**Location of Adult:** Bile duct

**Intermediate Hosts:** First intermediate host – *Cionella lubrica*, land snail; second intermediate host – *Formica fusca*, ant

**Distribution:** Worldwide

**Derivation of Genus:** Forked bowel

**Transmission Route:** Ingestion of infected ants

**Common Name:** Lancet fluke



**TECHNICIAN'S NOTE** The lancet fluke is an unusual trematode in that it uses intermediate hosts from dry habitats rather than a first intermediate host from an aquatic habitat.

*Dicrocoelium dendriticum* is commonly referred to as the “lancet fluke” of sheep, goats, and cattle. This tiny, flattened, leaflike fluke is only 6 to 10 mm long and 1.5 to 2.5 mm wide (Figure 8-1) and has an oral sucker, a ventral sucker, tandem testes, and a lateral **vitellaria** (an accessory genital gland that secretes the yolk and shell for the fertilized ovum). These flukes are found in the fine branches of the bile duct and can produce hyperplasia of the bile duct’s glandular epithelial lining resulting in bile duct obstruction. This fluke produces brown, embryonated eggs that are 36 to 46  $\mu\text{m} \times 10$  to 20  $\mu\text{m}$ . The egg possesses an **operculum** (similar to a hinged hatch) on one pole (end) of the egg. This operculum is said to be indistinct. The first intermediate host is the land snail, *Cionella lubrica*, while the second intermediate host is the ant, *Formica fusca*. The eggs can be found on standard fecal flotation or fecal sedimentation procedures.

**TECHNICIAN’S NOTE** *Dicrocoelium dendriticum* alters the behavior pattern of both the land snail and the ant.

**Parasite:** *Paramphistomum* species and *Cotylophoron* species

**Host:** Cattle, sheep, goats, and other ruminants

**Location of Adult:** Rumen and reticulum

**Intermediate Hosts:** First intermediate host—aquatic snail; second intermediate host—none, cercariae encyst upon aquatic vegetation


**Distribution:** Worldwide (*Paramphistomum* sp.)

**Derivation of Genus:** Beyond a mouth on both sides (*Paramphistomum* sp.); ridge cup (*Cotylophoron* sp.), bears a cup shape

**Transmission Route:** Ingestion of aquatic vegetation with metacercariae

**Common Name:** Rumen flukes

Rumen flukes comprise two genera of veterinary importance, *Paramphistomum* and *Cotylophoron* (Figure 8-2). Rumen flukes belong to a group of flukes called **amphistomes** (*amphi* means “on both sides” or “double,” and *stome* means “mouth”); these flukes appear to possess a “mouth” at both ends of their bodies. Amphistomes have an oral sucker (the feeding organelle, or “true mouth”) on the anterior end and a large ventral sucker (an organ of attachment) on the posterior end. The adult flukes closely resemble Kellogg’s Rice Krispies™. In the fresh state, amphistomes are light-colored to bright red and pear-shaped, approximately 5 to 13 mm  $\times$  2 to 5 mm. They attach with the oral sucker to the lining of the rumen and reticulum of cattle, sheep, goats, and many other ruminants and expose the ventral suckers (Figure 8-3). The adult flukes are nonpathogenic; the pathogenicity of these flukes lies in the migration of the juvenile forms in the small intestine. These juvenile forms are known for the ability to ingest large plugs of intestinal lining. The eggs of *Paramphistomum* species measure 114 to 176  $\mu\text{m} \times 73$  to 100  $\mu\text{m}$ ; the eggs of *Cotylophoron* species measure 125 to



**FIGURE 8-1:** Adult *Dicrocoelium dendriticum*, commonly referred to as the “lancet fluke” of sheep, goats, and cattle. This tiny, flattened, leaflike fluke (6 to 10 mm long and 1.5 to 2.5 mm wide) is found in fine branches of bile duct.

135  $\mu\text{m}$  by  $61 \times 68 \mu\text{m}$ . The prepatent period for *Paramphistomum* species is 80 to 95 days.

**TECHNICIAN'S NOTE** The oral sucker of the rumen flukes is on one end of the fluke and the ventral sucker is on the other end.

**Parasite:** *Fasciola hepatica*

**Host:** Cattle, sheep, and other ruminants

**Location of Adult:** Bile duct

**Intermediate Hosts:** First intermediate host – aquatic snail; second intermediate host – none, cercariae encyst on aquatic vegetation

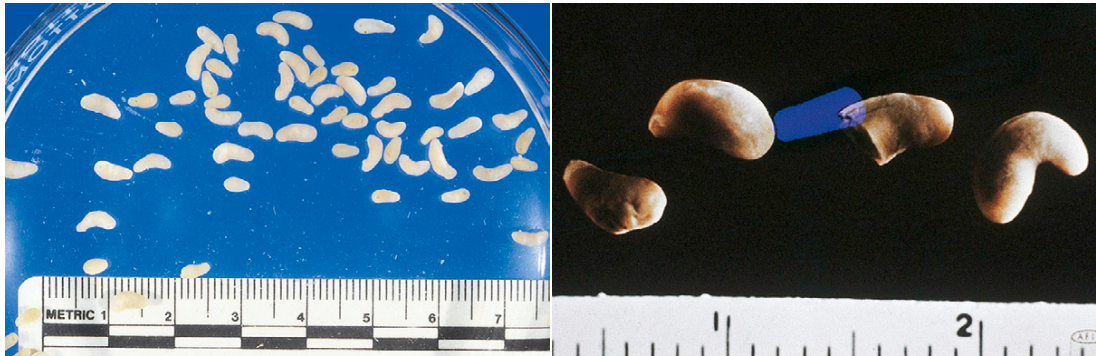**Distribution:** Worldwide

**Derivation of Genus:** Small band

**Transmission Route:** Ingestion of aquatic vegetation with metacercariae

**Common Name:** Liver fluke

*Fasciola hepatica* is the liver fluke of cattle, sheep, and other ruminants. It is perhaps the most economically important fluke in veterinary medicine because it causes “liver rot,” clay pipe stem fibrosis or liver condemnation, at slaughter due to obstruction of the bile ducts. This fluke is the best-known fluke among those parasitizing food animals; parasitologists have studied *F. hepatica* more than any other fluke. Adult flukes are found in the bile ducts of the liver and possess a unique appearance. They are flattened and leaf-like, measuring  $30 \times 13 \text{ mm}$  (Figure 8-4). These liver flukes are broader in the anterior region than in the posterior region and possess an anterior



**FIGURE 8-2:** Rumen flukes, or amphistomes (*Paramphistomum* and *Cotylophoron* species), have an oral sucker (feeding organelle) on the anterior end and a large ventral sucker (organ of attachment) on the posterior end.



**FIGURE 8-3:** Rumen flukes among rumen papillae.

cone-shaped projection that is followed by a pair of prominent, laterally directed shoulders. The internal morphology is not easily discernible due to the superimposition of a high branched ceca over highly branched testes, ova, and vitellaria. These flukes are tan to reddish brown in the fresh state; preserved specimen take on a grayish appearance. Their eggs are oval, yellow-brown, and measure 130 to 150  $\mu\text{m}$   $\times$  60 to 90  $\mu\text{m}$ . Each egg will possess a distinct operculum (Figure 8-5). The eggs can be found on fecal sedimentation.

**TECHNICIAN'S NOTE** *Fasciola hepatica* is the most studied fluke affecting domestic livestock and it is a very important fluke in terms of economical effects on the hosts.

**Parasite:** *Fascioloides magna*

**Host:** White-tailed deer

**Location of Adult:** Liver parenchyma

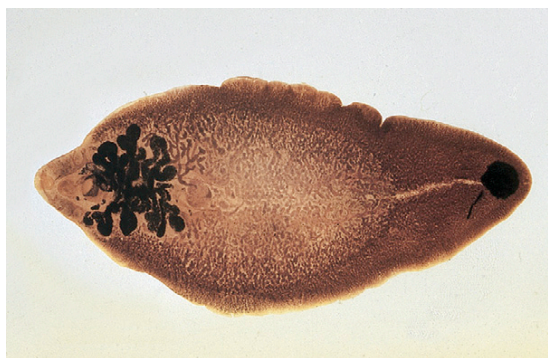**Intermediate Host:** Aquatic snail, the cercariae encysts on aquatic vegetation.

**Distribution:** North America, Central and Southwestern Europe

**Derivation of Genus:** Band shape

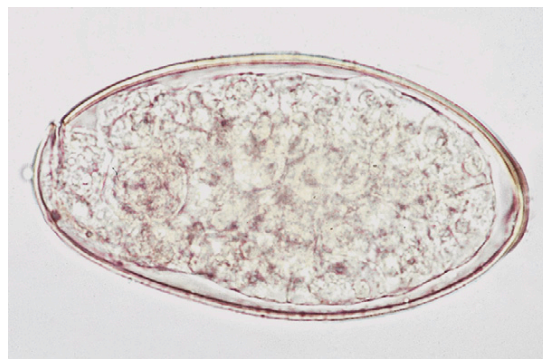
**Transmission Route:** Ingestion of vegetation with metacercariae

**Common Name:** Liver fluke of wild ruminants (deer)

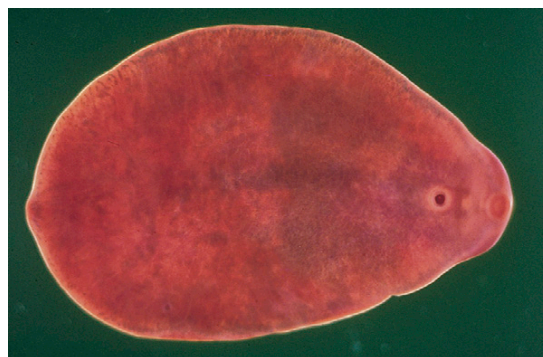

**FIGURE 8-4:** Adult liver flukes (*Fasciola hepatica*) are broader in the anterior region and have a prominent, anterior cone-shaped projection followed by prominent shoulders. In the fresh state, these flukes are grayish brown and measure 30  $\times$  13 mm.

*Fascioloides magna* is also a liver fluke; however, this fluke has the white-tailed deer as its true definitive host. It may also use cattle, sheep, and pigs as incidental hosts. The adult flukes are found in the liver parenchyma and possess a unique appearance. They are large, flattened, flesh-colored, oval flukes, measuring up to 10 cm in length, 2.5 cm in width, and 4.5 mm in thickness, approximately the size of a US gold dollar (Figure 8-6). These flukes lack the anterior conelike projection of *F. hepatica*. The egg is operculated, up to 170  $\mu\text{m}$  in length and 100  $\mu\text{m}$  in width. *F. magna* flukes produce open cysts in the liver parenchyma of white-tailed deer. These cysts communicate with the bile ducts, allowing



**FIGURE 8-5:** Egg of *Fasciola hepatica*. Eggs are oval, operculated, and yellow-brown and measure 130 to 150  $\mu\text{m}$   $\times$  60 to 90  $\mu\text{m}$ .



**FIGURE 8-6:** Adult *Fascioloides magna* are large, flattened, flesh-colored, oval flukes measuring up to 10 cm in length, 2.5 cm in width, and 4.5 mm in thickness. These flukes lack the anterior conelike projection of adult *Fasciola hepatica*.



eggs to be passed to the external environment. Thus, eggs are often found on fecal sedimentation procedures of these infected hosts. In incidental hosts such as cattle and sheep, however, these flukes produce closed cysts in the liver parenchyma. These cysts do not communicate with the bile ducts, so the egg of *F. magna* cannot pass to the external environment. Incidental hosts act as “dead end” hosts; that is, they are not capable of transmitting this parasite to other animals.

Eggs of the flukes just mentioned may be recovered from feces using either the fecal sedimentation procedure or a commercially available fluke egg recovery test.



**TECHNICIAN'S NOTE** The eggs can be found on fecal sedimentation technique from feces of the white-tailed deer. Necropsy is necessary to find the adult flukes in the incidental hosts.

### FLUKES OF SMALL ANIMALS (DOGS AND CATS)

**Parasite:** *Platynosomum fastosum*

**Host:** Cats

**Location of Adult:** Bile ducts

**Intermediate Host:** First intermediate host – land snail; second intermediate host – lizard

**Distribution:** South America, Southern United States, West Africa, Pacific Islands, Malaysia, and the Caribbean

**Derivation of Genus:** Flat disease-causing

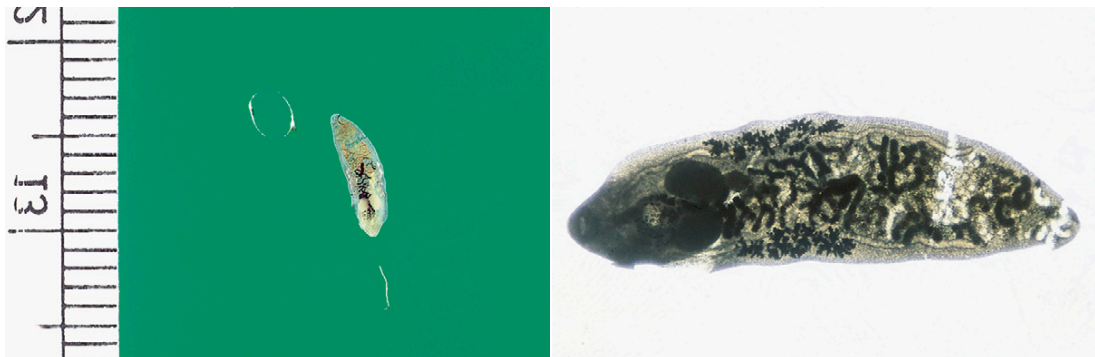
**Transmission Route:** Ingestion of infected lizards

**Common Name:** “Lizard poisoning fluke” of cats

*Platynosomum fastosum* is the “lizard poisoning fluke” of cats. This fluke received this common name because cats became infected by ingesting the lizard second intermediate host that contains the infective metacercarial stages of the fluke. These adult flukes are found in the liver, gallbladder, bile ducts, and less often the small intestine of cats, producing signs such as diarrhea, vomiting, icterus, and even death from the obstruction of the bile duct. *P. fastosum* is a tiny, flattened, leaf-like fluke, only 4 to 8 mm long and 1.5 to 2.5 mm wide, with an oral sucker, ventral sucker, parallel (side by side) testes, and lateral vitellaria, found in the fine branches of the bile duct of cats; it can produce desquamation (stripping) of the bile duct’s glandular epithelial lining (Figure 8-7). The fluke’s brownish, operculated eggs are oval, measuring 34 to 50  $\mu\text{m}$   $\times$  20 to 35  $\mu\text{m}$  (Figure 8-8). The eggs can be found on standard fecal flotation. Adults can be found in the bile ducts on necropsy.

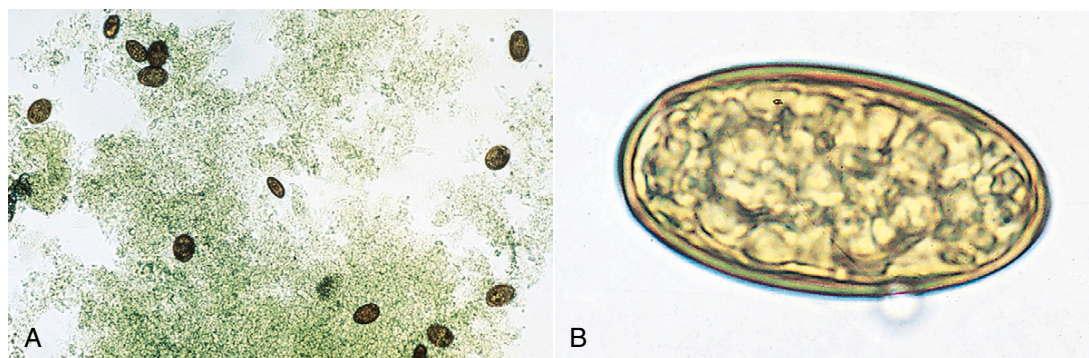


**TECHNICIAN'S NOTE** *Platynosomum fastosum* is associated with “lizard poisoning” in cats.



**FIGURE 8-7:** Adult *Platynosomum fastosum*, the “lizard-poisoning fluke” of cats, is a tiny, flattened, leaflike fluke (only 4 to 8 mm long and 1.5 to 1.2 mm wide) found in fine branches of bile duct of cats.





**FIGURE 8-8:** A, Eggs of *Platynosomum fastosum*. B, These oval, brown, operculated eggs measure 34 to 50  $\mu\text{m}$  by 20 to 35  $\mu\text{m}$ .

**Parasite:** *Nanophyetus salmincola*

**Host:** Dogs

**Location of Adult:** Small intestine

**Intermediate Host:** First intermediate host – freshwater snail; second intermediate host – salmon

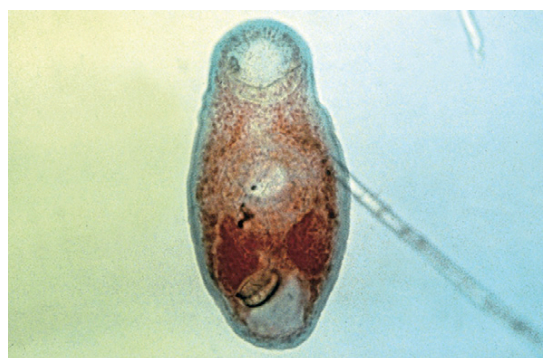**Distribution:** Pacific Northwest region of North America

**Derivation of Genus:** Dwarf form

**Transmission Route:** Ingestion of infected salmon

**Common Name:** Salmon poisoning fluke of dogs

*Nanophyetus salmincola* is the “salmon-poisoning fluke” of dogs in the Pacific Northwest region of North America. This fluke received its common name because dogs became infected by ingesting the salmon (fish) second intermediate host that contains the infective metacercarial stage of this fluke. The adult fluke inhabits the small intestine and serves as a vector for rickettsial agents that produce “salmon poisoning” and “Elokomín fluke fever” in dogs. Whereas *F. magna* is the largest fluke of our domesticated animals, *N. salmincola* is the smallest, measuring only 0.5 to 1.1 mm in length (Figure 8-9). The color of adult flukes is white to cream. The eggs are yellowish brown, with an indistinct operculum and a small, blunt point at the end opposite to the operculum. Eggs are 52 to 82  $\mu\text{m}$   $\times$  32 to 56  $\mu\text{m}$  (Figure 8-10).



**FIGURE 8-9:** Adult *Nanophyetus salmincola*, the “salmon-poisoning fluke” of the Pacific Northwest. This fluke measures only 0.5 to 1.1 mm in length. Color of adult flukes is white to cream.



**TECHNICIAN'S NOTE** The salmon poisoning fluke causes pathology to the host by harboring the rickettsial agents that produce salmon poisoning and Elokomín fluke fever.

**Parasite:** *Alaria* species

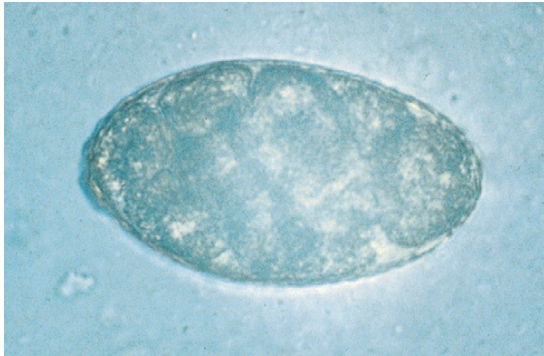**Host:** Dogs and cats

**Location of Adult:** Small intestine

**Intermediate Host:** First intermediate host – snail; second intermediate host – frog, snake, or mouse

**Distribution:** Northern United States and Canada

**Derivation of Genus:** Winged



**FIGURE 8-10:** Egg of *Nanophyetus salmincola* is yellowish brown, with indistinct operculum and small, blunt point at end opposite operculum. Eggs are 52 to 82  $\mu\text{m}$   $\times$  32 to 56  $\mu\text{m}$ .



**FIGURE 8-11:** Egg of *Alaria* species is large, golden brown, and operculated, measuring 98 to 134  $\mu\text{m}$   $\times$  62 to 68  $\mu\text{m}$ .

**Transmission Route:** Ingestion of infected frog, snake, or mouse

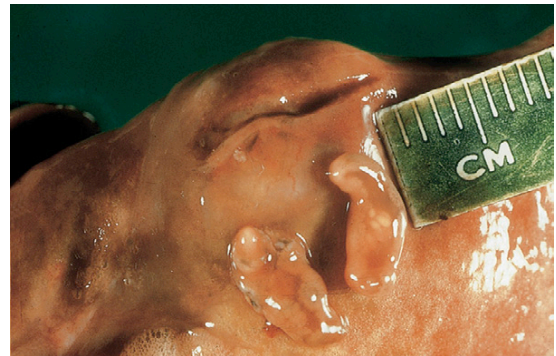
**Common Name:** Intestinal flukes of dogs and cats

*Alaria* species are intestinal flukes of dogs and cats and are found throughout the northern half of the North American continent. This fluke is 2 to 6 mm in length. It has a unique appearance among the flukes in that its anterior half is flattened and expanded and its posterior half is rounded and globose. The eggs are large, golden brown, and operculated. They measure 98 to 134  $\mu\text{m}$   $\times$  62 to 68  $\mu\text{m}$  (Figure 8-11).



**TECHNICIAN'S NOTE** The adult *Alaria* does not seem to cause any apparent effect on the host. It is the migration of the larvae that seem to cause pathology in the host.

All the flukes covered in this chapter so far (in both ruminants and small animals) are parasites of portions of the digestive system, either the intestine or the ducts within the liver. The following flukes, however, are found in sites other than those associated with the digestive system. *Paragonimus kellicotti* is the lung fluke of dogs and cats found in cystic spaces in the lung parenchyma. *Heterobilharzia americanum*, the canine schistosome, is a blood fluke that parasitizes the mesenteric veins of the small and large intestines and the portal veins of the dog.



**FIGURE 8-12:** Adult *Paragonimus kellicotti* flukes are unusual in that they are found in the lung parenchyma, not the gastrointestinal tract.

**Parasite:** *Paragonimus kellicotti*

**Host:** Dogs and cats

**Location of Adult:** Lung parenchyma

**Intermediate Host:** First intermediate host – operculated snail; second intermediate host – crayfish

**Distribution:** North America

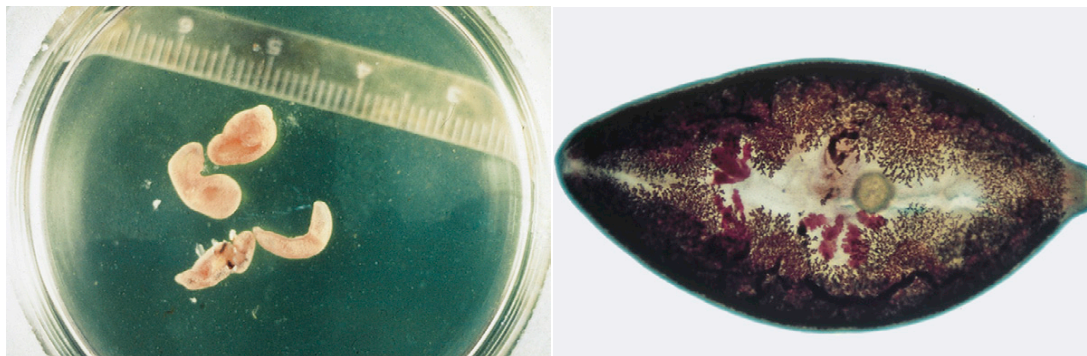
**Derivation of Genus:** Alongside gonads

**Transmission Route:** Ingestion of infective crayfish

**Common Name:** Lung fluke of dogs and cats

Adult *Paragonimus kellicotti* flukes are found in cystic spaces within the lung parenchyma of both dogs and cats (Figure 8-12). These cystic spaces connect to the terminal bronchioles. The eggs are found in sputum or feces. Adults are thick,





**FIGURE 8-13:** Adult *Paragonimus kellicotti* are thick, brownish-red flukes measuring up to 16 mm long  $\times$  8 mm wide. Adult flukes are found within lung parenchyma.

brownish-red flukes measuring up to 16 mm long  $\times$  8 mm wide (Figure 8-13). Eggs are yellowish brown, with a rather distinct operculum. The eggs are 75 to 118  $\mu\text{m}$   $\times$  42 to 67  $\mu\text{m}$ ; the shell at the pole opposite the operculum is somewhat thickened (Figure 8-14). These fluke eggs can be recovered using fecal sedimentation techniques; however, the eggs of *P. kellicotti* are usually recovered using standard fecal flotation solutions. These eggs can also be recovered in the sputum by tracheal washing. The adult flukes within the cystic spaces in the lung parenchyma can be observed with thoracic radiography.

**TECHNICIAN'S NOTE** Eggs of the lung fluke can be found on fecal sedimentation of feces or sputum. The adults may be seen in cystic spaces in the lung parenchyma on thoracic radiographs.

**Parasite:** *Heterobilharzia americana*

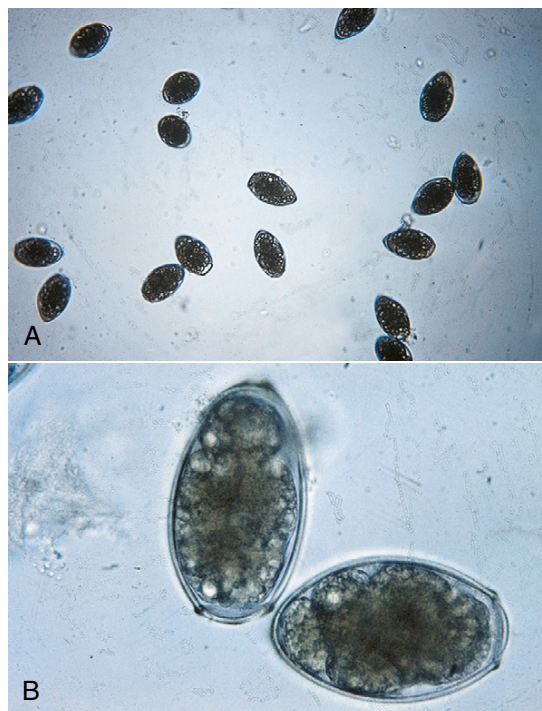
**Host:** Dogs

**Location of Adult:** Mesenteric veins of the small and large intestines and the portal veins

**Intermediate Host:** Freshwater snail

**Distribution:** North America, particularly the Gulf States of the United States

**Derivation:** Another fluke-named after Theodor Bilharz, German physician

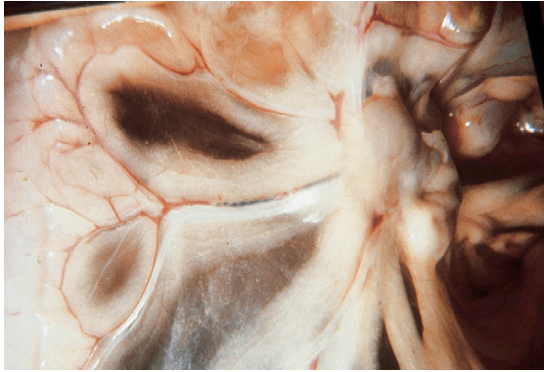


**FIGURE 8-14:** The distinctly operculated eggs of *Paragonimus kellicotti* are yellowish brown and 75 to 118  $\mu\text{m}$   $\times$  42 to 67  $\mu\text{m}$ . The shell at the pole opposite the operculum is somewhat thickened.

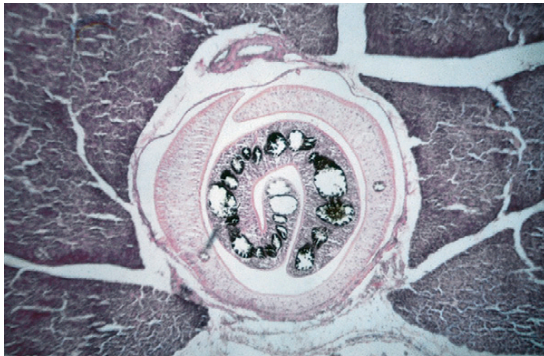
**Transmission Route:** Metacercariae enters through the skin of the dog

**Common Name:** Schistosome of the dog

*Heterobilharzia americana*, the canine schistosome, is a blood fluke that parasitizes the

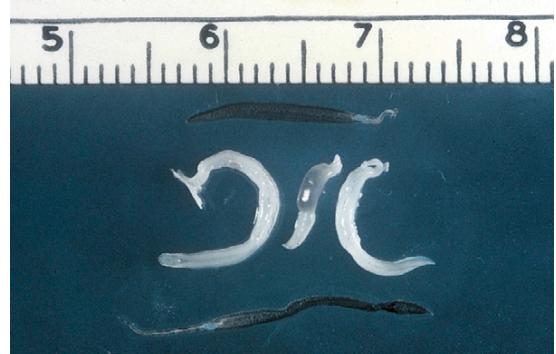

**FIGURE 8-15:** Gross necropsy revealing adult *Heterobilharzia americanum* in mesenteric veins of dog.

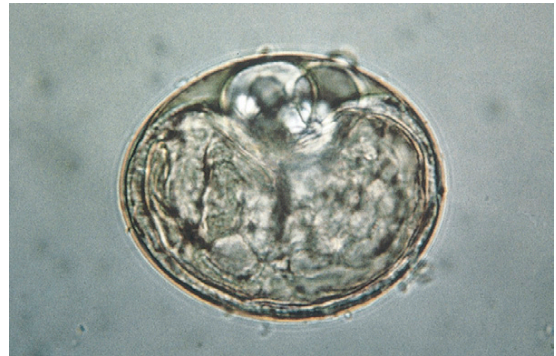

**FIGURE 8-16:** Histopathology of adult *Heterobilharzia americanum* in mesenteric veins of dog.

mesenteric veins of the small and large intestines and the portal veins of the dog (Figures 8-15 and 8-16). Schistosome means “split body.” The blood flukes, or **schistosomes**, are unique flukes in that they are not hermaphroditic. Separate sexes exist, so there are male schistosomes and female schistosomes. Because these flukes reside in the fine branches of the mesenteric veins where they can obstruct the veins, they are long and slender. Females may be as long as 9 mm, and males are about 6.5 mm in length (Figure 8-17). This fluke is enzootic in the mudflats of the Mississippi delta and the coastal swampland of Louisiana. Although *H. americana* inhabits the blood vasculature, it manifests its presence by a bloody diarrhea. Infected dogs also exhibit



**FIGURE 8-17:** Adult male and female *Heterobilharzia americanum* recovered from mesenteric veins of dog.



**FIGURE 8-18:** Thin-shelled egg of *Heterobilharzia americanum*, approximately  $80 \times 50 \mu\text{m}$ . Miracidium sometimes may be observed within egg.

emaciation and anorexia. Diagnosis is by identification of the thin-shelled egg, about  $80 \times 50 \mu\text{m}$ , which contains a miracidium on fecal sedimentation. (See Figure 8-18 for morphologic features of the egg of *H. americana*.)



**TECHNICIAN'S NOTE** The canine schistosome does not use a second intermediate host. Instead, the cercariae leave the freshwater snail and enter the dog by penetration of the skin.

## BOX 8-1 A Few Words About Flukes of Humans

**Parasite:** *Schistosoma* (Bilharzia) species

**Host:** Humans

**Location of Adult:** Mesenteric veins of the small and large intestines and the urinary bladder

**Intermediate Host:** Freshwater snails

**Distribution:** Africa; Middle East the Caribbean

**Derivation of Genus:** Split body

**Transmission Route:** Cercariae enter through skin penetration

**Common Name:** Blood flukes of humans

Humans serve as definitive hosts for an important group of flukes called the schistosomes or the “blood flukes.” These flukes are similar to *Heterobilharzia americanum* and inhabit the blood vasculature of the mesenteric veins and the blood vasculature associated with major organs (large and small intestine and urinary bladder) of the abdominal cavity of humans. These flukes are members of the genus *Schistosoma* (also known as Bilharzia) and are important parasites of humans in Africa, the Middle East, the Caribbean, and other areas of the world. These parasites are important in human medicine; however, other than this mention, they are beyond the scope of this textbook. The cercarial stage of this important fluke infects the definitive host by direct penetration of the skin of humans as they are wading or bathing in water. Some members of the genus *Schistosoma* infect the blood vasculature of the mesenteric and portal veins of cattle; however, these schistosomes occur in Africa, the Mediterranean, and the Middle East and are not usually associated with domesticated animals in North America. Schistosomes are species specific; that is, human schistosomes infect humans, and bovine schistosomes infect cattle. Schistosomes of domestic animals are not zoonotic. The veterinary technician who has interest in the schistosomes of humans should consult a textbook on the parasitology of humans.

## BOX 8-2 A Few Words About Flukes of Wild Birds

**Parasite:** *Schistosoma* species

**Host:** Birds

**Location of Adult:** Blood vasculature

**Intermediate Host:** Freshwater snails

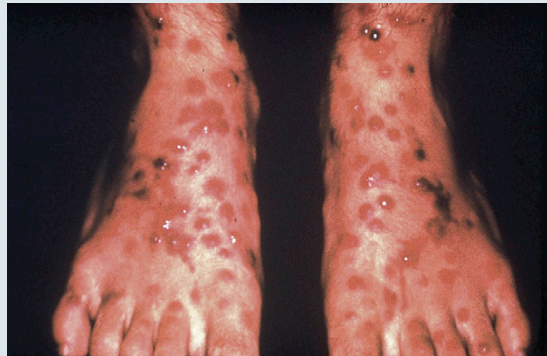**Distribution:** North America

**Derivation of Genus:** Split body

**Transmission Route:** Cercariae enter through skin penetration

**Common Name:** Avian schistosomes

Avian schistosomes occur in the blood vasculature of many wild birds (particularly aquatic birds) that migrate across the North American continent along seasonal “flyways.” Migrating aquatic birds frequently rest in rivers and lakes of North America along their seasonal journeys. These birds are frequently infected with avian schistosomes in their blood vessels. The schistosomes produce eggs that pass to the external environment in the birds’ feces. The eggs often make contact with water, hatch, and release the miracidia, the stage infective for the snail intermediate host. The miracidia penetrate aquatic snails and, within the snails, develop into the cercarial stage. The cercariae emerge from the snail, and to complete the life cycle, usually penetrate the skin of the appropriate avian definitive host. However, if the cercariae penetrate the skin of a human (swimming or playing in the lake, river, or ocean), with repeated exposure, the cercariae can produce a severe papular or pustular dermatitis called **swimmer’s itch** or **schistosome cercarial dermatitis** (Figure 8-19). This pruritic dermatitis is the only zoonotic parasite found among the digenetic trematodes. The dermatitis is quite pruritic and can ruin a vacation at the lake or the seashore.



**FIGURE 8-19:** Severe papular or pustular dermatitis (swimmer’s itch, or schistosome cercarial dermatitis) in human. This pruritic dermatitis is the only zoonotic digenetic trematode. (Courtesy Paul Honig, MD.)



**BOX 8-3 A Few Words About Flukes of Game Fish**

Birds near a lake or seashore may have flukes that reside in the gastrointestinal tract. As with the avian schistosomes described in Box 8-2, these flukes produce eggs that pass to the external environment and often make contact with water. The eggs hatch, releasing the miracidia. The miracidia penetrate aquatic snails and, within the snails, develop into the cercarial stage. The cercariae emerge from the snails and normally penetrate the skin of fish. When the cercariae penetrate the skin of fish, they produce a metacercarial stage. The metacercaria is actually a juvenile fluke. Fish often react to the presence of metacercaria by depositing melanin (black) pigment around the organism, producing a condition called **black spot** (Figure 8-20). Aquatic birds become infected with the fluke by ingesting the fish containing the metacercarial stage. Sometimes, fishermen catch these fish and during the cleaning process may notice these conspicuous black metacercarial stages in the skin or in the muscles of the fish. If the fish is properly cooked, it is safe for human consumption. Humans are not harmed when they ingest these stages; humans cannot become infected with this avian fluke. Therefore, this is not a zoonotic condition; however, it may not be aesthetically pleasing! The unsightly appearance of these metacercarial spots in the fish's tissues may prevail over the hungry fisherman's appetite.



**FIGURE 8-20:** Fish exhibiting “black spot,” deposition of melanin pigment in response to presence of metacercaria.

**CHAPTER EIGHT TEST**

**MATCHING**—Match the term with the correct phrase or term.

- |                                                  |                                                                    |
|--------------------------------------------------|--------------------------------------------------------------------|
| A. <i>Dicrocoelium dendriticum</i>               | 1. Salmon-poisoning fluke of dogs                                  |
| B. <i>Paramphistomum</i> and <i>Cotylophoron</i> | 2. Canine schistosomes (blood flukes)                              |
| C. <i>Fasciola hepatica</i>                      | 3. Liver fluke of cattle                                           |
| D. <i>Fascioloides magna</i>                     | 4. The lancet fluke of ruminants                                   |
| E. <i>Platynosomum fastosum</i>                  | 5. Rumen flukes                                                    |
| F. <i>Nanophyetus salmincola</i>                 | 6. Melanin deposition in response to the presence of metacercariae |
| G. <i>Paragonimus kellicotti</i>                 | 7. Schistosome cercarial dermatitis                                |
| H. <i>Heterobilharzia americanum</i>             | 8. Liver fluke of white-tailed deer                                |
| I. Swimmer's itch                                | 9. Lizard-poisoning fluke of cats                                  |
| J. Black spot                                    | 10. Lung fluke of dogs and cats                                    |

**QUESTIONS FOR THOUGHT AND DISCUSSION**

---

1. Discuss the zoonotic potential for the digenetic trematodes. In what way are trematodes zoonotic?
2. Trematodes are usually associated with the gastrointestinal tract or with some duct associated with the gastrointestinal tract. Which digenetic trematode is the exception to this rule?
3. Explain how schistosomes are different from the other digenetic flukes.

# The Phylum Acanthocephala

9

## KEY TERMS

Acanthocephalan  
Spiny proboscis  
Tegument  
Acanthor  
Acanthella  
Cystacanth

## OUTLINE

Common Acanthocephalans  
*Key Morphologic Features*  
*Life Cycle of the Thorny-Headed Worm*  
*Acanthocephalans of Importance in Veterinary Parasitology*

## LEARNING OBJECTIVES

After studying this chapter, the reader should be able to do the following:

- Identify acanthocephalans relative to their morphology and egg type.
- Correctly spell *Macracanthorhynchus hirudinaceus*, the swine acanthocephalan. This parasite has the longest scientific name among all of the parasites of wild and domesticated animals.

The phylum Acanthocephala consists of the “thorny-headed worms,” or “spiny-headed worms.” With regard to number of acanthocephalan parasites that infect domesticated animals, the phylum Acanthocephala is very small.

## COMMON ACANTHOCEPHALANS


Most acanthocephalans are parasites of marine and freshwater fish and aquatic birds; their predilection site is within the small intestine of the definitive host. Only two species, *Macracanthorhynchus hirudinaceus*, the thorny-headed worm of swine, and *Oncicola canis*, the canine acanthocephalan, are important to veterinary medicine.



**TECHNICIAN'S NOTE** Only two species of acanthocephalans are important to veterinary medicine. Most species parasitize marine fish, freshwater fish, and aquatic birds.

## Key Morphologic Features

Members of the phylum Acanthocephala are important parasites of domesticated and wild animals. Adult acanthocephalans are internal parasites, living in the small intestine of their vertebrate hosts. Acanthocephalans are typically elongate, cylindric worms, tapering on both ends. One acanthocephalan (*M. hirudinaceus*) can measure up to 70 cm in length. Acanthocephalans are dioecious; that is, they have separate sexes. Female acanthocephalans are typically larger than their male counterparts. The colloquial names “thorny-headed worm” and “spiny-headed worm” are derived from the fact that acanthocephalans possess a retractable proboscis, or “nose,” on the anterior end (Figure 9-1). This proboscis is covered with tiny, backward-facing spines and serves as an organ of attachment (Figure 9-2). The proboscis embeds in the small intestinal mucosa and allows the acanthocephalan parasite to attach to the host, similar to the scolex of the true tapeworm. It is in this enteric site that acanthocephalans feed; however, these are



**FIGURE 9-1:** Anterior end of *Macracanthorhynchus hirudinaceus*, the thorny-headed worm of swine. This colloquial name is derived from acanthocephalans possessing a retractable proboscis, or “nose,” on the anterior end.

unusual parasites in that they lack a mouth. Instead, these strange-looking helminths have a trait that is similar to the tapeworms: they do not possess an alimentary tract (a gut or intestinal tract). As a result, acanthocephalans must absorb nutrients through their body surface, or **tegument**.

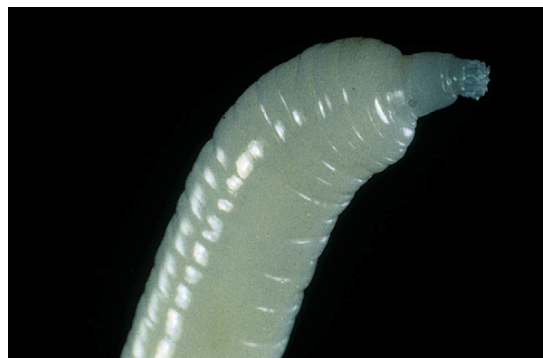

**TECHNICIAN'S NOTE** Acanthocephalans attach or imbed in the small intestine of their host with a proboscis covered with tiny, backward-facing spines. They absorb their nutrients through their body walls.

Another important organ system in the acanthocephalan is the reproductive tract. As with all helminths, acanthocephalans have a tremendous reproductive potential—one adult female worm can produce in excess of a quarter of a million eggs per day! These eggs pass out of the definitive host within its feces and embryonate in the external environment.

## Life Cycle of the Thorny-Headed Worm

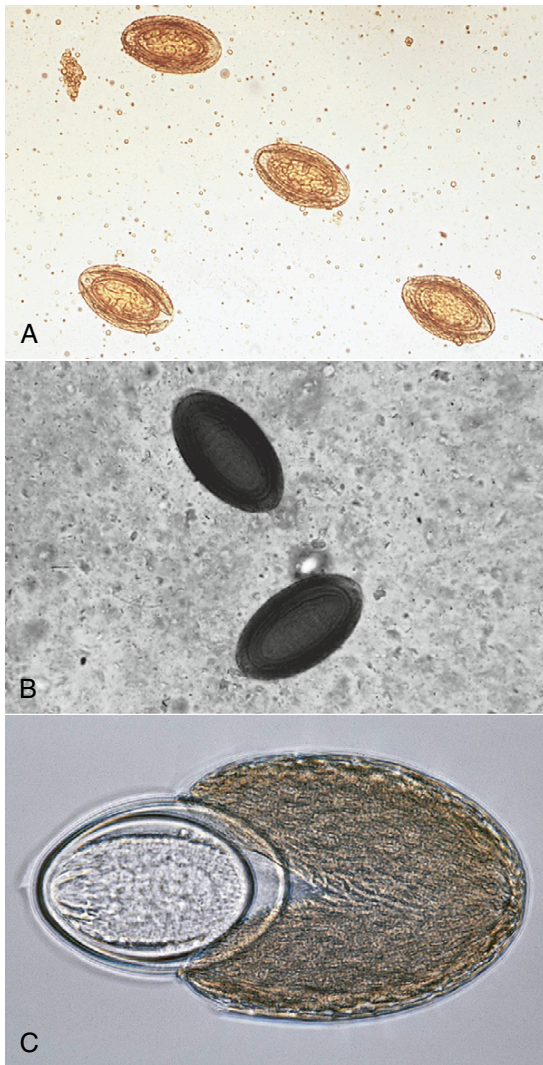
The typical acanthocephalan has a unique life cycle. Because adult acanthocephalans are found attached to the small intestinal mucosa, the eggs



**FIGURE 9-2:** Proboscis of *Macracanthorhynchus hirudinaceus* is covered with tiny, backward-facing spines and serves as an organ of attachment.

are voided in the feces of the definitive host. The egg is spindle-shaped and has a shell of three layers (Figure 9-3). This egg contains the larval acanthocephalan, or **acanthor**. The intermediate host, usually some type of arthropod (e.g., dung beetle), ingests the egg, and the acanthor larva hatches in that intermediate host. Within the intermediate host, the larva develops to the next stage, the **acanthella**. The acanthella develops

into the **cystacanth** stage, which has an inverted proboscis. The definitive host ingests the arthropod intermediate host. Within the intestine of the definitive host, the acanthella everts its proboscis and attaches to the wall of the small intestine. This juvenile acanthocephalan grows to the adult stage, and the life cycle begins again (Figure 9-4).



**FIGURE 9-3:** Egg of *Macracanthorhynchus hirudinaceus* is spindle-shaped and has a shell of three layers. Egg contains the larval acanthocephalan, or acanthor.

**TECHNICIAN'S NOTE** The adult female can produce 250,000 eggs per day. The eggs are ingested by an arthropod and develop into an acanthor larva, then an acanthella to a cystacanth stage. The arthropod is ingested by the new host and the acanthella everts its proboscis to imbed in the intestinal mucosa.

### Acanthocephalans of Importance in Veterinary Parasitology

*M. hirudinaceus* and *O. canis* are the acanthocephalans of importance in veterinary medicine.

#### *Macracanthorhynchus hirudinaceus*

**Parasite:** *Macracanthorhynchus hirudinaceus*

**Host:** Pigs

**Location of Adult:** Small intestinal mucosa

**Intermediate Host:** Dung beetle

**Distribution:** Worldwide

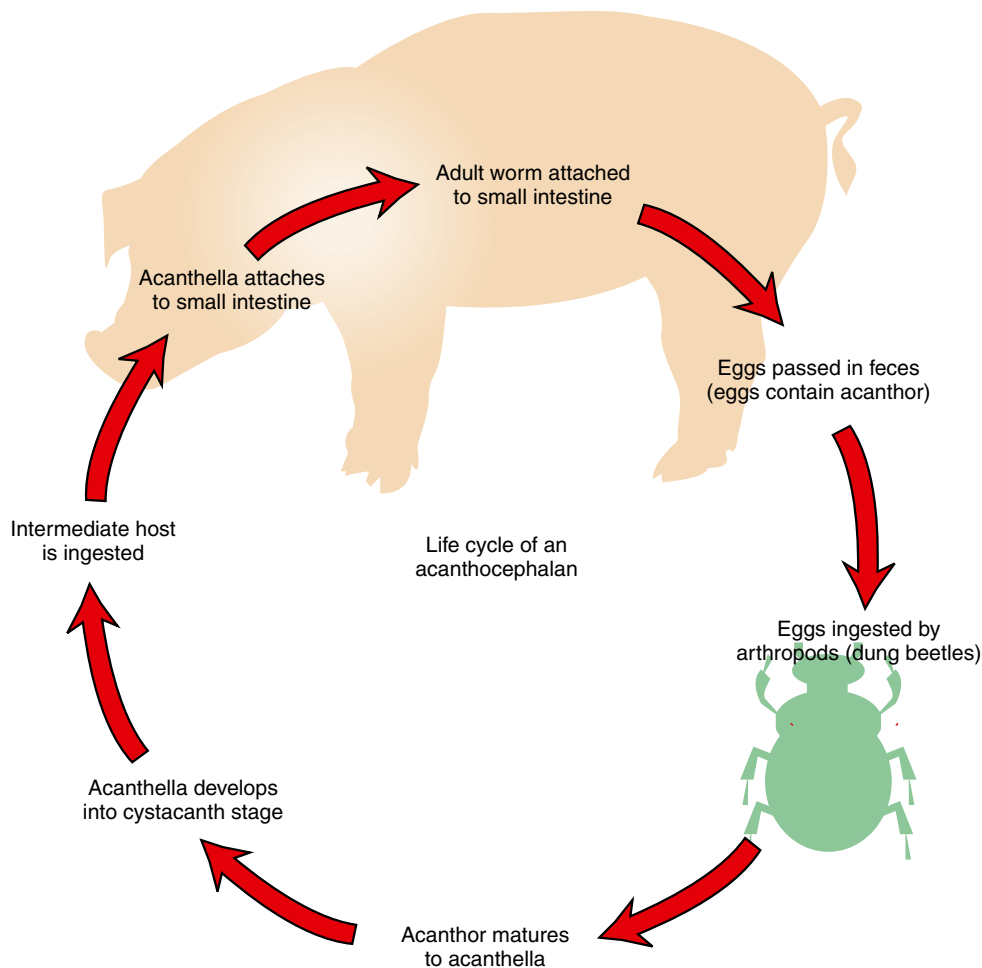
**Derivation of Genus:** Large thorny nose

**Transmission Route:** Ingestion of infective dung beetle

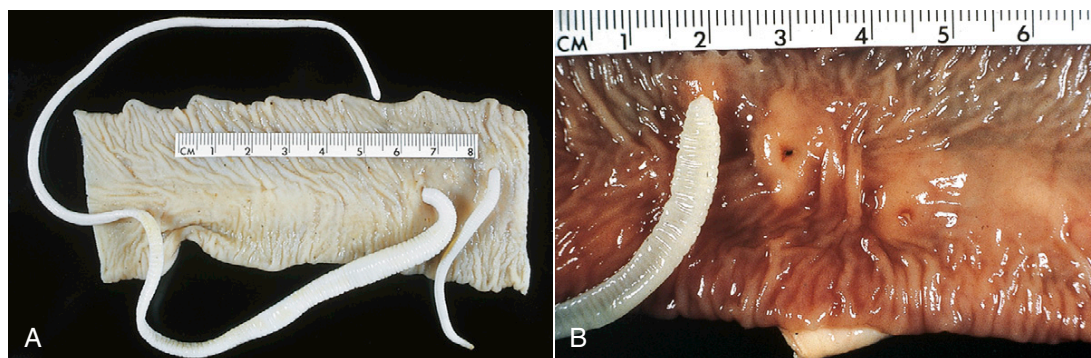
**Common Name:** Thorny-headed worm of swine

*Macracanthorhynchus hirudinaceus*, the thorny-headed worm of swine, is the acanthocephalan found attached to the lining of the small intestine of pigs (Figure 9-5). Due to the attachment to the intestinal mucosa, the parasite has the potential to perforate the intestine, thus causing peritonitis and possible death. This parasite has the dubious distinction of having the longest scientific name among all the parasites of wild and domesticated animals. During postmortem examination, the prosecutor (pathologist) might, at first glance, make





**FIGURE 9-4:** Life cycle of the acanthocephalan.



**FIGURE 9-5:** *Macracanthorhynchus hirudinaceus*, the thorny-headed worm of swine, is found attached to lining of small intestine of pigs.

a diagnosis of the swine roundworm, *Ascaris suum* (see Chapter 4). On closer examination, however, it is apparent that the parasite is firmly attached to the mucosa of the small intestine rather than free within the lumen. *A. suum* does not attach to the mucosa but remains within the lumen of the small intestine. *M. hirudinaceus* can grow up to 70 cm in length, although the males average up to 10 cm in length and the females up to 35 cm, and these worms are 4 to 10 mm thick. The proboscis is tiny and is covered with six rows of six hooks each. These backward-facing hooks are used to anchor the adult parasite to the mucosa. The eggs of *M. hirudinaceus* are 40 to 65  $\mu\text{m}$   $\times$  67 to 110  $\mu\text{m}$  and have a three-layered shell; the second shell is brown and pitted (Figure 9-3) and can be found on standard fecal flotation procedures. Because humans seldom intentionally eat dung beetles (the intermediate host of *M. hirudinaceus*), this acanthocephalan is seldom identified as a zoonotic parasite.



**POSTMORTEM EXAMINATION** On postmortem examination, one may confuse *M. hirudinaceus* with *Ascaris suum*. On closer examination, the worm will be found to be firmly attached to the mucosal lining rather than being free within the lumen of the intestine.

### **Oncicola canis**

**Parasite:** *Oncicola canis*

**Host:** Dogs

**Location of Host:** Small intestinal mucosa

**Intermediate Host:** Dung beetle

**Distribution:** North & South America

**Derivation of Genus:** Strain mass

**Transmission Route:** Ingestion of infective dung beetle

**Common Name:** Thorny-headed worm of dogs

*Oncicola canis*, the thorny-headed worm of dogs, is the acanthocephalan found attached to the lining of the small intestine of dogs. This is a tiny acanthocephalan, only 14 mm in length. The body is tapered posteriorly, and on the anterior end is the characteristic proboscis armed with hooks. As with *M. hirudinaceus*, these are backward-facing hooks used to anchor the adult parasite to the mucosa of the small intestine. With their proboscides embedded within the small intestinal wall, they often penetrate through to the peritoneum. Perforation of the intestinal wall leading to peritonitis and death is possible. The eggs of *O. canis* are brown and oval, approximately 65  $\times$  45  $\mu\text{m}$  and can be found on standard fecal flotation procedures.



**TECHNICIAN'S NOTE** This parasite is an acanthocephalan but it is very rare to find this parasite, *Oncicola canis*, in the dog.

Although with regard to domesticated animals the phylum Acanthocephala is extremely small, veterinarians should understand its importance, especially with regard to the swine industry.

## CHAPTER NINE TEST

---

MATCHING—Match the term with the correct phrase or term.

- |                                            |                                                                   |
|--------------------------------------------|-------------------------------------------------------------------|
| A. Acanthocephalans                        | 1. Larval acanthocephalan stages within intermediate host         |
| B. Spiny proboscis                         | 2. Three-layered shell                                            |
| C. Tegument                                | 3. “Feeding organelle”—absorbs nutrients through the body surface |
| D. Dung beetle                             | 4. Organ of attachment; holdfast organelle                        |
| E. Acanthocephalan egg                     | 5. Larval acanthocephalan stage within egg                        |
| F. Acanthor                                | 6. Thorny-headed worm of dogs                                     |
| G. Acanthella and cystacanth               | 7. Thorny-headed worm of swine                                    |
| H. <i>Macracanthorhynchus hirudinaceus</i> | 8. “Thorny-headed” or “spiny-headed” worms                        |
| I. <i>Oncicola canis</i>                   | 9. Usual intermediate host for an acanthocephalan                 |
| J. Acanthocephalan pathology               | 10. Attachment to small intestine wall                            |

## QUESTIONS FOR THOUGHT AND DISCUSSION

---

1. *Macracanthorhynchus hirudinaceus*, the swine acanthocephalan, is often confused with *Ascaris suum*, the swine ascarid. Compare and contrast these two important swine parasites relative to their size, location within the host, pathology produced, description of the eggs (ova), and life cycle.
2. What two features or qualities do acanthocephalans have in common with true tapeworms?

# The Protozoans

# 10

## KEY TERMS

Protozoans  
Sarcomastigophorans  
Flagellates  
Amoebae  
Ciliophorans  
Apicomplexans  
Flagellum  
Cilia  
Pseudopodia  
Pathogenicity  
Trophozoite

## OUTLINE

Characteristics of the Protozoans	Ciliophora (Ciliates)
Mastigophora (Flagellates)	Apicomplexa (Apicomplexans)
Sarcodina (Amoebae)	

## LEARNING OBJECTIVES

After studying this chapter, the reader should be able to do the following:

- Identify the four basic types of protozoans.
- Describe how the four different groups of protozoans move.

Only two kingdoms of living creatures have members that are true parasites of domesticated animals. These parasites belong to the kingdom Animalia and the kingdom Protista. Most of the parasites of domesticated animals belong to the Animal kingdom (flukes, tapeworms, roundworms, thorny-headed worms, arthropods, and leeches). The rest of animal parasites belong to the kingdom Protista. This kingdom contains the unicellular, or one-cell, organisms (better known as the **protozoans**).

Most protozoans are free-living organisms; however, those protozoans that are parasitic may produce significant pathology in domesticated animals and humans. Within the kingdom Protista are several phyla, which contain (1) flagellated protozoans, (2) ameboid protozoans, (3) apicomplexans, and (4) ciliated protozoans. These phyla contain the primary protozoans that may cause significant pathology in domesticated animals and humans.



**TECHNICIAN'S NOTE** The parasitic protozoans are categorized in several phyla: flagellated, ameboid, apicomplexan, and ciliated protozoans.

## CHARACTERISTICS OF THE PROTOZOANS

Protozoans are unicellular organisms; that is, they are one-cell organisms. Protozoans vary greatly in size, form, and structure; most are microscopic, and a very few are macroscopic, that is, visible to the naked eye.

The kingdom Protista is divided into several phyla. These phyla differ in the manner in which the protozoans move within their tiny microenvironments. In veterinary parasitology, the most important phyla are Sarcomastigophora (containing the flagellates and amoebae), Ciliophora (containing the ciliates), and Apicomplexa (containing the coccidia, malarial organisms, and piroplasms).

**TECHNICIAN'S NOTE** Protozoans are single-celled organisms or parasites.

## MASTIGOPHORA (FLAGELLATES)

Kingdom: Protista

Phylum: Sarcomastigophora

Subphylum: Mastigophora (flagellates)


The flagellates are those protozoans that possess at least one **flagellum** (a long, whiplike or lashlike appendage) in their **trophozoite**, or moving, form. This flagellum allows the protozoan to move about in a fluid medium. As a result of this activity, parasitic flagellates live in the liquid world of the host's blood, lymphatic fluid, or cerebrospinal fluid. Flagellates are often pear-shaped or bullet-shaped and are able to swim in their host's body fluids, meeting very little resistance. These flagellates vary greatly in **pathogenicity** (disease-causing potential). Some flagellates are highly pathogenic, whereas others appear to cause little or no harm to the host. Some important genera of parasitic flagellates of domestic animals are *Leishmania*, *Trypanosoma*, *Trichomonas*, *Histomonas*, and *Giardia* species. Figure 10-1 is a diagram of a representative flagellate, *Tritrichomonas foetus*, a flagellated protozoan of the reproductive tract of cattle.

## SARCODINA (AMOEBAE)

Kingdom: Protista

Phylum: Sarcomastigophora

Superclass: Sarcodina (amoebae)

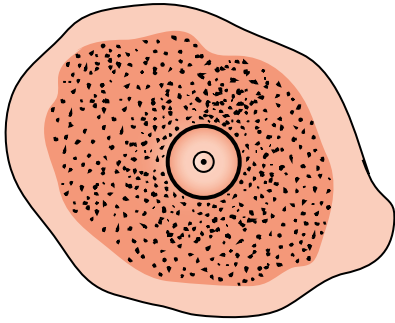


**FIGURE 10-1:** Diagram of representative flagellate, *Tritrichomonas foetus*, a flagellated protozoan of the reproductive tract of cattle. Note three anterior flagella, undulating membrane, and trailing posterior flagellum.


The amoebae are protozoans that move via **pseudopodia** ("false feet"). Amoebae have two forms: the motile **trophozoite** form and the resistant **cyst** form. In their motile trophozoite form, amoebae glide or flow along a solid surface, usually the surface at the bottom of the liquid medium. Amoebae are amorphous (poorly defined, or bloblike, in shape). As with the flagellates, the amoebae vary greatly in their pathogenicity. Some amoebae are highly pathogenic, whereas others appear to cause little or no harm to the host. Amoebae demonstrate a resistant cyst form that allows them to survive in adverse conditions in the external environment.

The most important parasitic amoeba of humans is *Entamoeba histolytica*. *Entamoeba coli*, a nonpathogenic amoeba, may also be found in humans and pigs. Figure 10-2 is a diagram of the motile trophozoite stage of a representative amoeba, *E. histolytica*, an amoebid protozoan. Figure 10-3 is a diagram of the resistant cyst stage of *E. histolytica*.





**FIGURE 10-2:** Diagram of motile trophozoite stage of a representative amoeba, *Entamoeba histolytica*, an ameboid protozoan, with characteristic nucleus and “bull’s-eye” nucleolus.



**FIGURE 10-3:** Diagram of resistant cyst stage of representative amoeba, *Entamoeba histolytica*, with thick cyst wall, four nuclei, and dark chromatoid bodies.



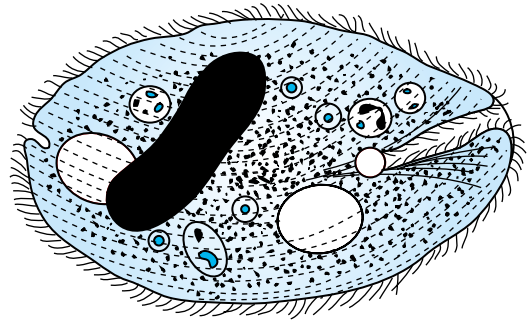
**TECHNICIAN'S NOTE** *Entamoeba histolytica* is the most important amebic protozoan in humans.

## CILIOPHORA (CILIATES)

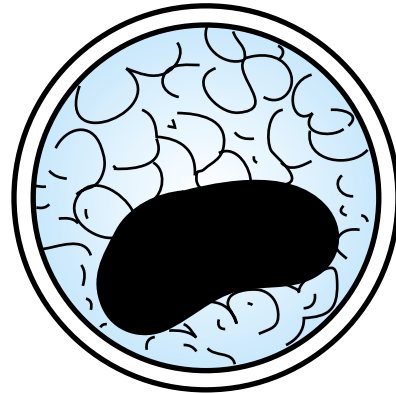
Kingdom: Protista

Phylum: Ciliophora (ciliates)

Ciliates are protozoans that are covered with tiny, short hairs over most of their body surface. These tiny hairs are called **cilia**, thus the name **ciliates**. Ciliates move with these beating, undulating hairs. As with amoebae, ciliates demonstrate two forms: the motile trophozoite form and the resistant cyst form. In their trophozoite, or moving, form, ciliates dart and twirl speedily in liquid media. Ciliates come in



**FIGURE 10-4:** Diagram of motile trophozoite form of representative ciliate, *Balantidium coli*, a ciliated protozoan of the intestinal tract of pigs.



**FIGURE 10-5:** Diagram of resistant cyst stage of *Balantidium coli*, with thick cyst wall and large, dark nucleus.

a variety of sizes and shapes, but all are covered with these tiny hairs. Figure 10-4 is a diagram of the motile trophozoite form of a representative ciliate, *Balantidium coli*, a ciliated protozoan of the intestinal tract of pigs. Some amoebae, such as *B. coli* and *Ichthyophthirius multifiliis*, are highly pathogenic to their hosts, whereas other ciliates, such as those in the rumen of the cow or sheep or the cecum of the horse, have beneficial roles. As with amoebae, ciliates demonstrate a resistant cyst form that allows them to survive in adverse conditions in the external environment. Figure 10-5 is a diagram of the resistant cyst stage of *B. coli*. The ciliates are unique among the protozoans in that they possess two types of nuclei: a macronucleus and a micronucleus.

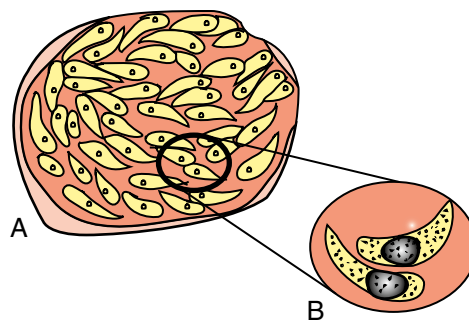
**TECHNICIAN'S NOTE** Some ciliate protozoan parasites can have beneficial roles for their hosts.

## APICOMPLEXA (APICOMPLEXANS)

Kingdom: Protista

Phylum: Apicomplexa (apicomplexans)

Of the protozoans, the apicomplexans are the most diverse and the most complicated. The apicomplexans are parasites of almost every animal phylum. In domesticated animals, they are found primarily in the epithelium of the intestine, within blood cells, and within cells of the reticuloendothelial system. The life cycles of these protozoans vary among the genera that affect domesticated animals; however, they do have a common trait in that their life cycles are complex and intimately integrated into the physiology of the host's body. The locomotory organelles of the flagellates, amoebae, and ciliates (i.e., flagella, pseudopodia, and cilia, respectively) are discernible. In contrast, the locomotory organelles of the apicomplexans are not visible to the naked eye; their locomotory organelles are internal. The apicomplexans are often banana-, comma-, or boomerang-shaped (Figure 10-6) and move via undulations. Some of the most important genera of parasitic apicomplexans of domestic



**FIGURE 10-6:** A, Diagram of cyst containing banana-, comma-, or boomerang-shaped sporozoites typical of apicomplexans of domestic animals, for example, *Eimeria*, *Isospora*, *Toxoplasma*, *Sarcocystis*, *Cryptosporidium*, *Plasmodium*, *Haemoproteus*, *Leukocytozoon*, *Babesia*, and *Theileria* species. B, Note enlarged banana-, comma-, or boomerang-shaped sporozoites.

animals are *Eimeria*, *Cystoisospora*, *Toxoplasma*, *Sarcocystis*, *Cryptosporidium*, *Plasmodium*, *Haemoproteus*, *Leukocytozoon*, *Babesia*, *Theileria*, *Cytauxzoon*, and *Hepatozoon*. These protozoans are perhaps the most diverse, complicated members of the regulan Protista kingdom.

**TECHNICIAN'S NOTE** The apicomplexan parasites do not have visible locomotory organelles but move via undulations. Some of the most commonly seen apicomplexans are *Eimeria* and *Cystoisospora*.

## CHAPTER TEN TEST

**MATCHING**—Match the term with the correct phrase or term.

- |                        |                                                                    |
|------------------------|--------------------------------------------------------------------|
| A. Protozoans          | 1. Tiny, short, moving hairs over most of the body surface         |
| B. Sarcomastigophorans | 2. Disease-causing potential                                       |
| C. Ciliophorans        | 3. Organelles of internal movement, not visible to the naked eye   |
| D. Apicomplexans       | 4. A long, whiplike or lashlike appendage                          |
| E. Flagellum           | 5. <i>Balantidium coli</i> and <i>Ichthyophthirius multifiliis</i> |

- F. Trophozoite
- G. Pathogenicity
- H. Pseudopodia
- I. Cilia
- J. Locomotory organelles of apicomplexans and piroplasms
- 6. Unicellular or one-cell organisms
- 7. Flagellates and amoebae
- 8. “False feet” of amoebae
- 9. Moving or motile form
- 10. Coccidia, malarial organisms

### QUESTIONS FOR THOUGHT AND DISCUSSION

---

1. Discuss the different ways by which protozoans move.
2. Most of the parasites affecting domestic and wild animals are in the kingdom Animalia. Why do you think that protozoans are included in a separate kingdom, Protista?

This page intentionally left blank

# Common Protozoans That Infect Domestic Animals

11

## KEY TERMS

Flagellates  
Amoebae  
Ciliates  
Apicomplexans  
Trophozoite  
Cyst  
Endosome  
Hemoprotozoan  
Phlebotomine  
sand flies  
Canine piroplasm  
Ring form  
Gamonts  
Commensals or  
commensalism  
Equine protozoan  
myeloencephalitis  
(EPM)  
Infectious  
enterohepatitis or  
blackhead  
Ichthyophthiriosis

## OUTLINE

Dogs and Cats	Rabbits
<i>Gastrointestinal Tract</i>	<i>Gastrointestinal Tract</i>
<i>Circulatory System and Blood</i>	Mice
Ruminants (Cattle and Sheep)	<i>Gastrointestinal Tract</i>
<i>Gastrointestinal Tract</i>	<i>Urogenital System</i>
<i>Circulatory System and Blood</i>	Rats
<i>Urogenital System</i>	<i>Gastrointestinal Tract</i>
Horses	Hamsters
<i>Gastrointestinal Tract</i>	<i>Gastrointestinal Tract</i>
<i>Circulatory System and Blood</i>	Guinea Pigs
<i>Urogenital System</i>	<i>Gastrointestinal Tract</i>
<i>Nervous System</i>	Fish
Swine	<i>Skin</i>
<i>Gastrointestinal Tract</i>	
Pet and Aviary Birds and Other	
Domestic Fowl	
<i>Gastrointestinal Tract</i>	
<i>Circulatory System and Blood</i>	
<i>Respiratory System</i>	

## LEARNING OBJECTIVES

After studying this chapter, the reader should be able to do the following:

- Remember the scientific names and the corresponding common names for the major protozoan parasites affecting domestic animals, laboratory animals, and fish.
- Recognize cyst and trophozoite forms of protozoans infecting the gastrointestinal tract when presented with a definitive host.
- Recognize intra- and extra-erythrocytic forms of the hemoprotozoans when presented with a definitive host.
- Recognize the significance of protozoans that are zoonotic parasites.



This chapter is a continuation of Chapter 10 in that it details the common protozoans that infect domestic animals. The parasitic protozoans are discussed in the same order as in Chapter 10: flagellates, amoebae, ciliates, and apicomplexans. These parasites are discussed in the same system-by-system manner, that is, those infecting the gastrointestinal tract, the circulatory system and peripheral blood, and the urogenital system. These parasites are discussed in the following species of domesticated animals: dogs and cats, ruminants (i.e., cattle and sheep), horses, pigs, pet and aviary birds, domestic fowl, rabbits, mice, rats, hamsters, guinea pigs, and fish.

## DOGS AND CATS

### Gastrointestinal Tract

Protozoans that infect the gastrointestinal tract of dogs and cats are flagellates, amoebae, ciliates, and apicomplexans.

### Flagellates

**Parasite:** *Giardia* species

**Host:** Dogs, cats, horses, ruminants, and exotic species

**Location:** Intestinal mucosa

**Distribution:** Worldwide

**Derivation of Genus:** Named after a famous protozoologist, Giard

**Transmission Route:** Ingestion of oocysts

**Common Name:** Giardia

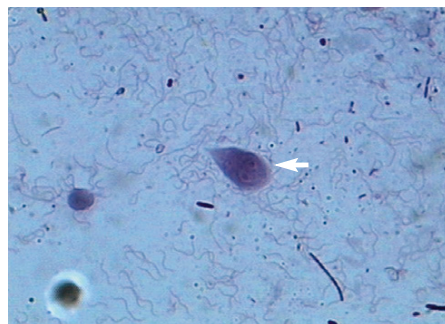
*Giardia* species are flagellated protozoans often recovered from the feces of dogs and cats with diarrhea. They may also be recovered from animals with normal stools. These parasites occur in two morphologic forms: a rarely observed, motile feeding stage (the trophozoite) and a frequently observed, resistant cyst stage.

The motile trophozoite stage is pear-shaped and dorsoventrally flattened and possesses four pairs of flagella. This stage is  $9$  to  $21\ \mu\text{m} \times 5$  to  $15\ \mu\text{m}$ . Two nuclei and a prominent adhesive disc are present on the anterior portion of the trophozoite, suggesting to the observer that a pair

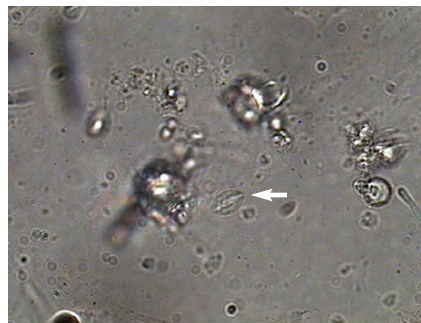
of eyes is “staring back.” Figure 11-1 presents the motile trophozoite form of *Giardia* species.

The mature cysts of *Giardia* species are oval and are  $8$  to  $10\ \mu\text{m} \times 7$  to  $10\ \mu\text{m}$ . They have a refractile wall and four nuclei. Immature cysts, which represent recently encysted motile forms, contain only two nuclei. Figure 11-2 presents a cyst of *Giardia* species. In dogs, diarrhea may begin as early as 5 days after exposure to *Giardia*, with cysts first appearing in the feces at 1 week.

**TECHNICIAN'S NOTE** The trophozoites of *Giardia* species are typically seen in animals with diarrhea rather than formed stool.



**FIGURE 11-1:** Motile trophozoite of *Giardia* species is pear-shaped and dorsoventrally flattened and possesses four pairs of flagella. Two nuclei and prominent adhesive disc are present on anterior portion of the trophozoite, suggesting a pair of eyes staring back.

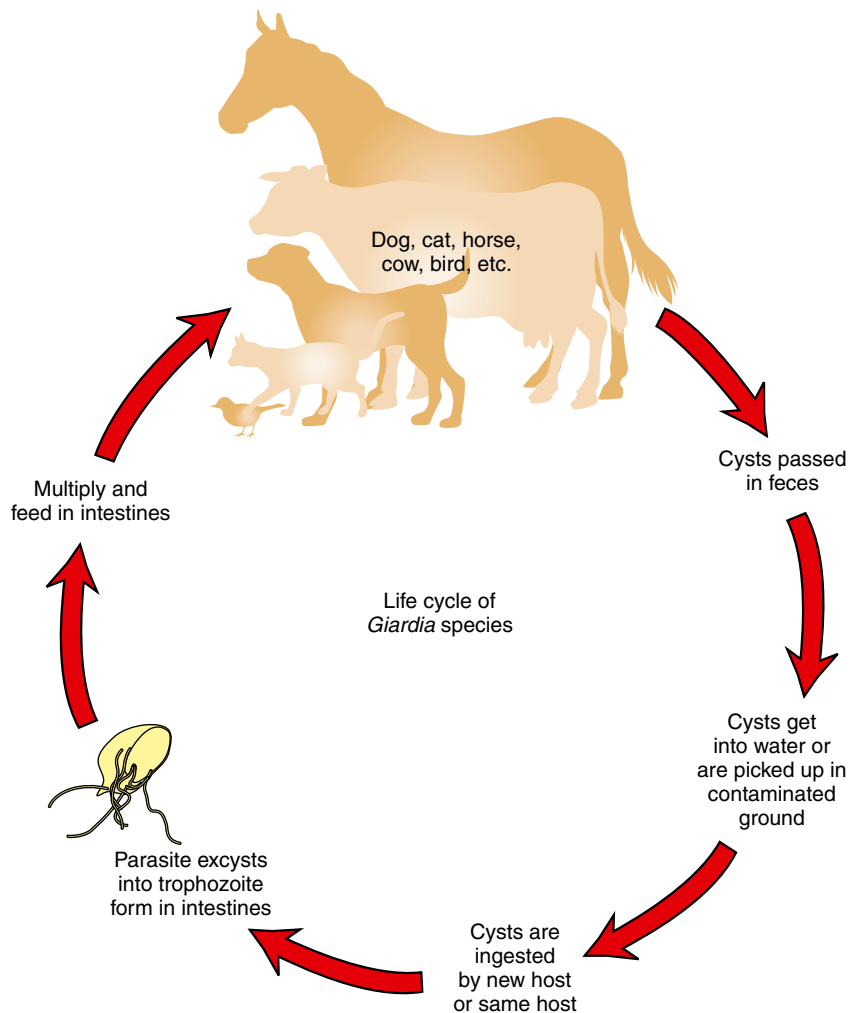


**FIGURE 11-2:** Mature cysts of *Giardia* species are oval and possess a refractile wall and four nuclei. Immature cysts, which represent recently encysted motile forms, contain only two nuclei.

Recent advances in molecular biology have changed the way *Giardia* species are named. Currently, *Giardia* is referred to in terms of assemblages rather than species. Assemblages A and B are associated with human beings while assemblages C and D constitute the organisms found in dogs. Those organisms associated with cows, sheep, goats, horses, pigs, etc., are grouped in assemblage E. Assemblage F encompasses the forms found in cats while assemblage G includes the organisms found in rodents. While *Giardia* seems to be more species specific than once thought, assemblage A (that affecting humans)

has been found in dogs and cats. This means there can still be a source of zoonotic infection from animals. However, it is more common that people are infected with *Giardia* by other people. Figure 11-3 shows the life cycle of *Giardia* species (Bowman, 2009).

Diagnosis of *Giardia* species is by standard fecal flotation. Zinc sulfate (specific gravity, 1.18) and Sheather's sugar solution are considered the best flotation media for recovering cysts. Cysts are often distorted, with a semilunar appearance. The motile trophozoite occasionally can be found on direct smear of fresh feces



**FIGURE 11-3:** Life cycle of *Giardia* species.

using isotonic saline. Lugol's iodine stain may be used to visualize the internal structures of both cysts and trophozoites. Fecal immunodiagnostic tests are also frequently used. Using immunodiagnostic tests in conjunction with fecal flotation tests will provide the best diagnostic protocol for diagnosing *Giardia* infection.

**TECHNICIAN'S NOTE** The cysts are hard to find in diarrheic samples, thus immunodiagnostic tests may be helpful with a definitive diagnosis.

## Amoebae

**Parasite:** *Entamoeba histolytica*

**Host:** Canines, felines, primates, and humans

**Location:** Large intestines

**Distribution:** Worldwide but rare in the United States

**Derivation of Genus:** Internal amoeba

**Transmission Route:** Ingestion of cysts

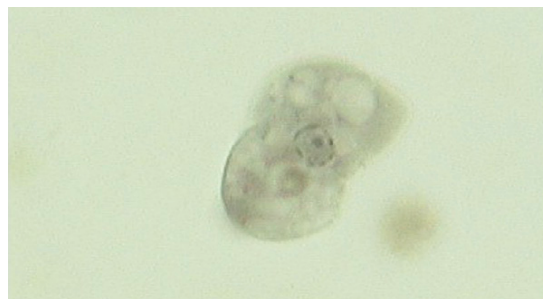**Common name:** Entamoeba

*Entamoeba histolytica*, the etiologic agent that produces amebic dysentery (an extremely severe dysentery) in humans may also produce sporadic infections in dogs. These cases usually have been acquired by association with infected humans. Although *E. histolytica* may produce acute or chronic diarrhea in dogs, it usually produces no pathology. Cats are rarely infected; most infections have been experimental.

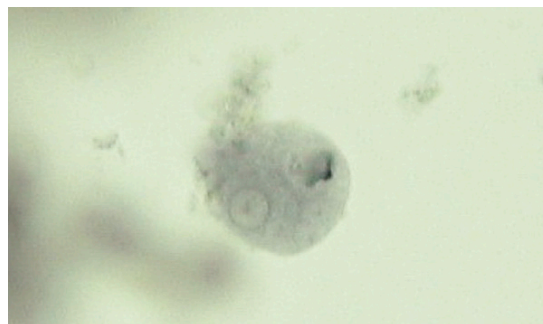*E. histolytica* occurs in two morphologic forms: a motile feeding stage (the trophozoite) and an environmentally resistant cyst stage. The motile trophozoite of *E. histolytica* ranges in size from 10 to 60  $\mu\text{m}$  and has a single spherical nucleus that is 4 to 7  $\mu\text{m}$  with a tiny pinpoint center, a structure called an **endosome** (Figure 11-4). The mature cysts are round and are 5 to 20  $\mu\text{m}$ . They have a thin refractile wall and may demonstrate as many as four nuclei, each with its own endosome. Immature cysts, which represent recently encysted motile forms, contain only one nucleus (Figure 11-5).

**TECHNICIAN'S NOTE** *Entamoeba histolytica* is the parasite that causes amebic dysentery in humans.

Diagnosis of *E. histolytica* is by standard fecal flotation, which may be used to demonstrate both cyst and trophozoite forms. In a formed stool, usually the cyst form will be found; however, in diarrheic stool, both the cyst and the trophozoite forms may be observed. The direct smear technique may be used to observe motile forms in warm, freshly passed diarrheic stools. Lugol's iodine stain may be used to visualize the internal structures of both cysts and trophozoites. Zinc sulfate may be used to concentrate cysts. If infection with *E. histolytica* is suspected in a



**FIGURE 11-4:** Motile feeding stage of *Entamoeba histolytica*, the trophozoite stage. Note single spherical nucleus with tiny pinpoint center, or endosome.



**FIGURE 11-5:** Cyst of *Entamoeba histolytica*. Cyst may demonstrate as many as four nuclei. Immature cysts, which represent recently encysted motile forms, contain only one nucleus.

human, a human pathology laboratory should be consulted for assistance with diagnosis. Because *E. histolytica* is primarily a human pathogen, great care should be taken with suspect feces.

*E. histolytica* also can be a significant problem in primates, such as monkeys and chimpanzees. Great care should be taken when handling suspect feces. Infection in monkeys has great public health significance.



**TECHNICIAN'S NOTE** *E. histolytica* is primarily a human parasite.

## Ciliates

**Parasite:** *Balantidium coli*

**Host:** Canines and swine

**Location:** Cecum and colon of canines and large intestines of swine

**Distribution:** Worldwide

**Derivation of Genus:** Small bag

**Transmission Route:** Ingestion of cysts

**Common Name:** Balantidium

*Balantidium coli* is the ciliated protozoan found occasionally in the cecum and colon of dogs. This parasite has been associated with diarrhea in dogs. *B. coli* is more intimately associated with pigs (see the section on swine protozoan parasites).

## Apicomplexans

**Parasite:** *Cystoisospora* species (formerly *Isospora* species)

**Host:** Canines, felines, and swine

**Location:** Small intestines

**Distribution:** Worldwide

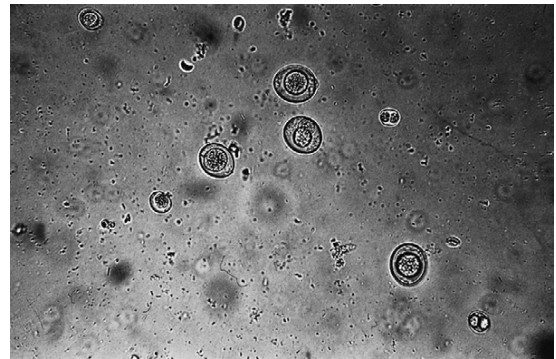
**Derivation of Genus:** Equal seeds; sac same spore

**Transmission Route:** Ingestion of oocysts

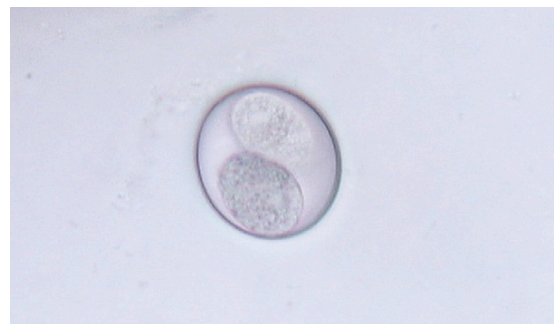**Common Name:** Coccidia

*Cystoisospora* species (coccidians) are protozoan parasites of the small intestine of dogs and cats. They produce a clinical syndrome known as **coccidiosis**, caused by inflammation of the intestine, one of the most commonly diagnosed protozoan diseases in puppies and kittens.

It produces loose stool to a watery diarrhea. Coccidiosis is rarely a problem in mature animals. The oocyst is the diagnostic stage observed in a fecal flotation of fresh feces; it is unsporulated in fresh feces and varies in size and shape among the common *Cystoisospora* species. Figure 11-6 shows an unsporulated oocyst, and Figure 11-7 shows a sporulated oocyst. The canine coccidians and their measurements are *Cystoisospora canis*, 34 to 40  $\mu\text{m}$   $\times$  28 to 32  $\mu\text{m}$ ; *C. ohioensis*, 20 to 27  $\mu\text{m}$   $\times$  15 to 24  $\mu\text{m}$ ; and *C. burrowsi*, 10 to 14  $\mu\text{m}$   $\times$  7.5 to 9  $\mu\text{m}$ . The feline coccidians and their measurements are *Cystoisospora felis*, 38 to 51  $\mu\text{m}$   $\times$  27 to 29  $\mu\text{m}$ , and *C. rivolta*, 21 to 28  $\mu\text{m}$   $\times$  18 to 23  $\mu\text{m}$ . Figure 11-8 shows the life cycle of *Cystoisospora* species. The prepatent period varies among species, but it is usually 7 to 14 days.



**FIGURE 11-6:** Unsporulated oocysts of *Cystoisospora* species. *C. canis* (large oocysts) and *C. burrowsi* (small oocysts) are present.



**FIGURE 11-7:** Sporulated oocyst of *Cystoisospora rivolta* from older feces.

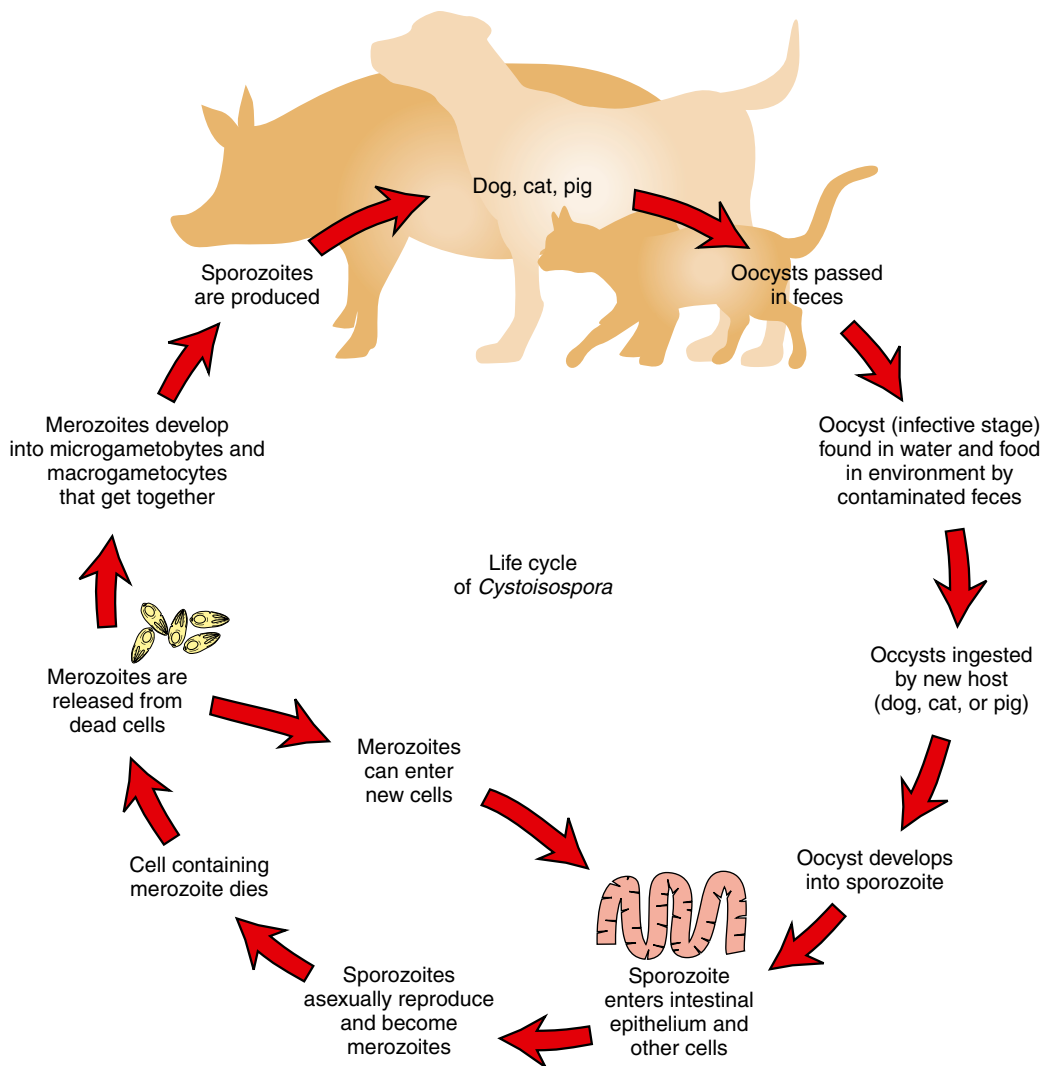


FIGURE 11-8: Life cycle of *Cystoisospora* species.

**TECHNICIAN'S NOTE** *Cystoisospora* spp. are some of the most commonly diagnosed of the most commonly diagnosed parasites in puppies and kittens.

**Parasite:** *Toxoplasma gondii*

**Host:** Definitive host is the feline. Can also occur in other animals and humans as incidental parasite.

**Location:** Intestines

**Distribution:** Worldwide

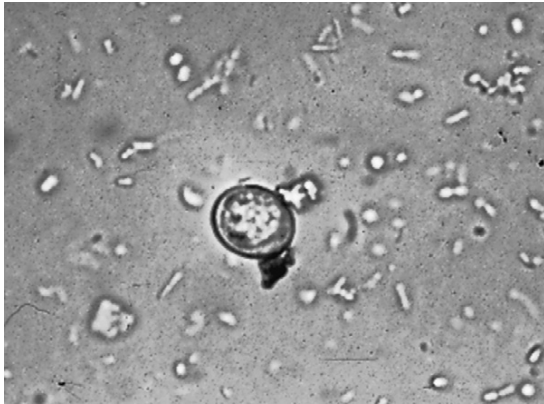**Derivation of Genus:** Bow body

**Transmission Route:** Ingestion of sporulated oocysts

**Common Name:** Toxoplasma

*Toxoplasma gondii* is an intestinal coccidian of cats. Its oocysts are usually diagnosed using a standard fecal flotation solution. Oocysts of *T. gondii* are unsporulated in fresh feces and measure  $10 \times 12 \mu\text{m}$  (Figure 11-9). Several immunodiagnostic tests using whole blood or serum are available for diagnosis of *T. gondii*. The





**FIGURE 11-9:** Unsporulated oocyst of *Toxoplasma gondii*, an intestinal coccidian of cats, from fresh feline feces. Its oocysts measure  $10 \times 12 \mu\text{m}$ .

prepatent period is highly variable, ranging from 5 to 24 days, and depends on the infection route. Figure 11-10A shows the life cycle of *Toxoplasma gondii* in the feline host and Figure 11-10B shows the life cycle in the nonfeline host. Because this parasite can use humans (and many other warm-blooded vertebrates) as intermediate hosts, *T. gondii* is a very important zoonotic parasite.

*T. gondii* can be a significant pathogen in humans (particularly the pregnant woman and her developing fetus). It is important to discuss this parasite with clients. Great care should be taken when handling suspect feces. Infection in cats has great public health significance.

**TECHNICIAN'S NOTE** The feline only sheds *Toxoplasma gondii* oocysts for up to 2 weeks of its life.

**Parasite:** *Cryptosporidium* species

**Host:** Canines, felines, ovines, swine, avians, guinea pigs, snakes, and mice

**Location:** Small intestine

**Distribution:** Worldwide

**Derivation of Genus:** Hidden small seeds

**Transmission Route:** Ingestion of oocysts

**Common Name:** Cryptosporidium, “Crypto”

*Cryptosporidium* species is another coccidian-like parasite that parasitizes the mucosal cells of the small intestine of a variety of animals and causes inflammation of those cells. These animals include cows, pigs, dogs, cats, birds, and guinea pigs. *Cryptosporidium* species in snakes, mice, and some species in cows parasitize the stomach and abomasum (cows). There is also a species of *Cryptosporidium* that parasitizes humans. In most cases of infection, diarrhea is the major clinical sign. The sporulated oocysts in the feces are oval to spherical and measure only 4 to 6  $\mu\text{m}$ . Diagnosis is by standard fecal flotation. The oocysts are extremely small and may be observed just under the coverslip, not in the same plane of focus as other oocysts and parasite eggs (Figure 11-11). Examination of fresh fecal smears using special stains (modified acid-fast stain) is also helpful. ELISA tests are also being used to diagnose this parasite.

Because humans may become infected with *Cryptosporidium* species, feces suspected of harboring this protozoan should be handled with great care. *Cryptosporidium* is a zoonotic parasite. *Cryptosporidium parvum* is the most common zoonotic species. However, *C. canis*, *C. felis*, *C. meleagridis* (birds), *C. muris* (mice), and *C. suis* (pigs) have been seen in humans.

**TECHNICIAN'S NOTE** Feces suspected of containing *Cryptosporidium* oocysts should be handled with great care.

**Parasite:** *Sarcocystis* species

**Host:** Canines and felines

**Location:** Small intestine

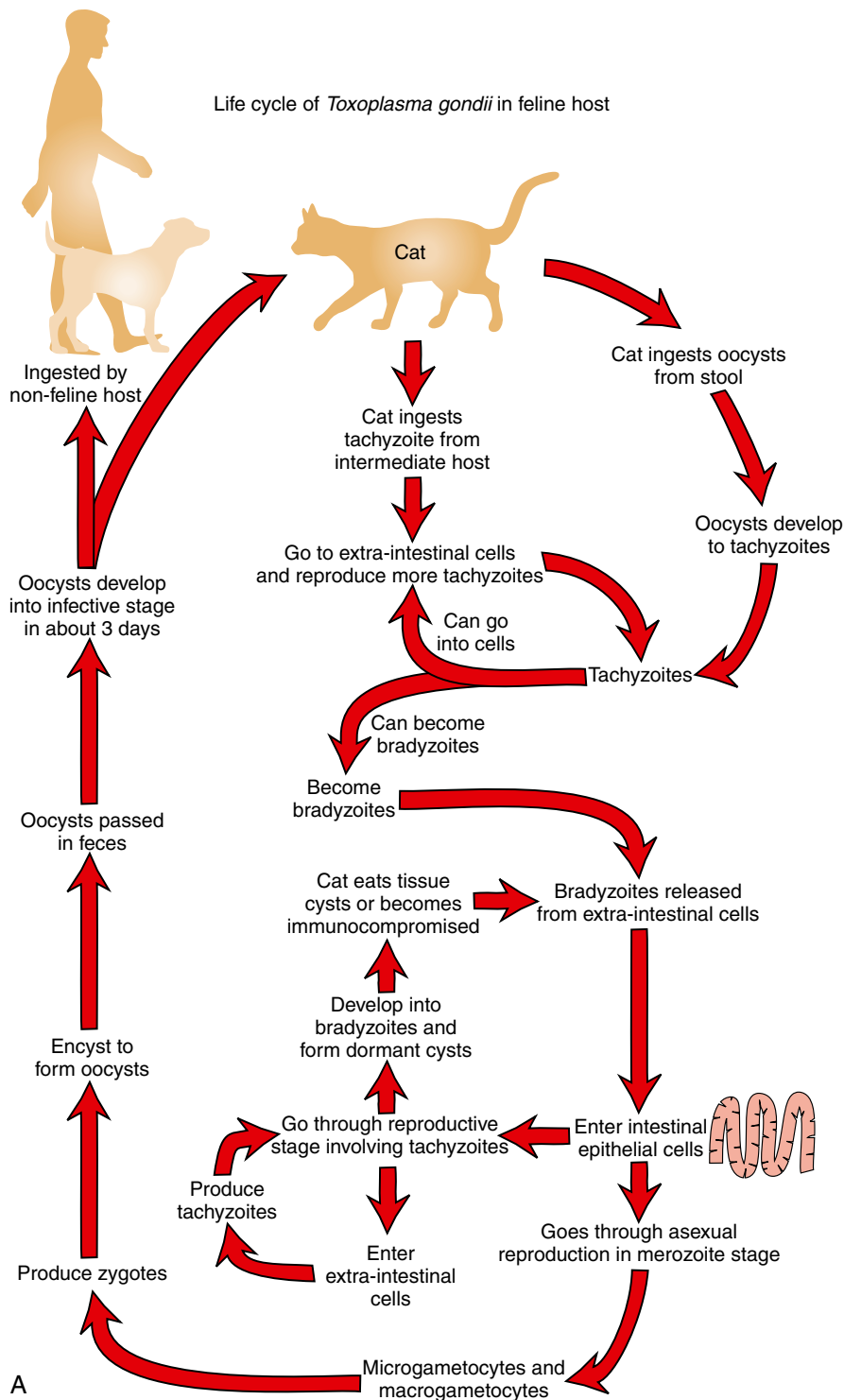
**Distribution:** Worldwide

**Derivation of Genus:** Flesh cyst

**Transmission Route:** Ingestion of muscle of horses, pigs, and ruminants

**Common Name:** Sarcocystis

*Sarcocystis* species are the final coccidian parasites cited here that are found in the small intestine. Several species infect dogs and cats, and identification of an individual species can be quite difficult. The oocysts of *Sarcocystis* species



**FIGURE 11-10:** A, Life cycle of *Toxoplasma gondii* for feline hosts. B, Life cycle of *Toxoplasma gondii* for nonfeline hosts.

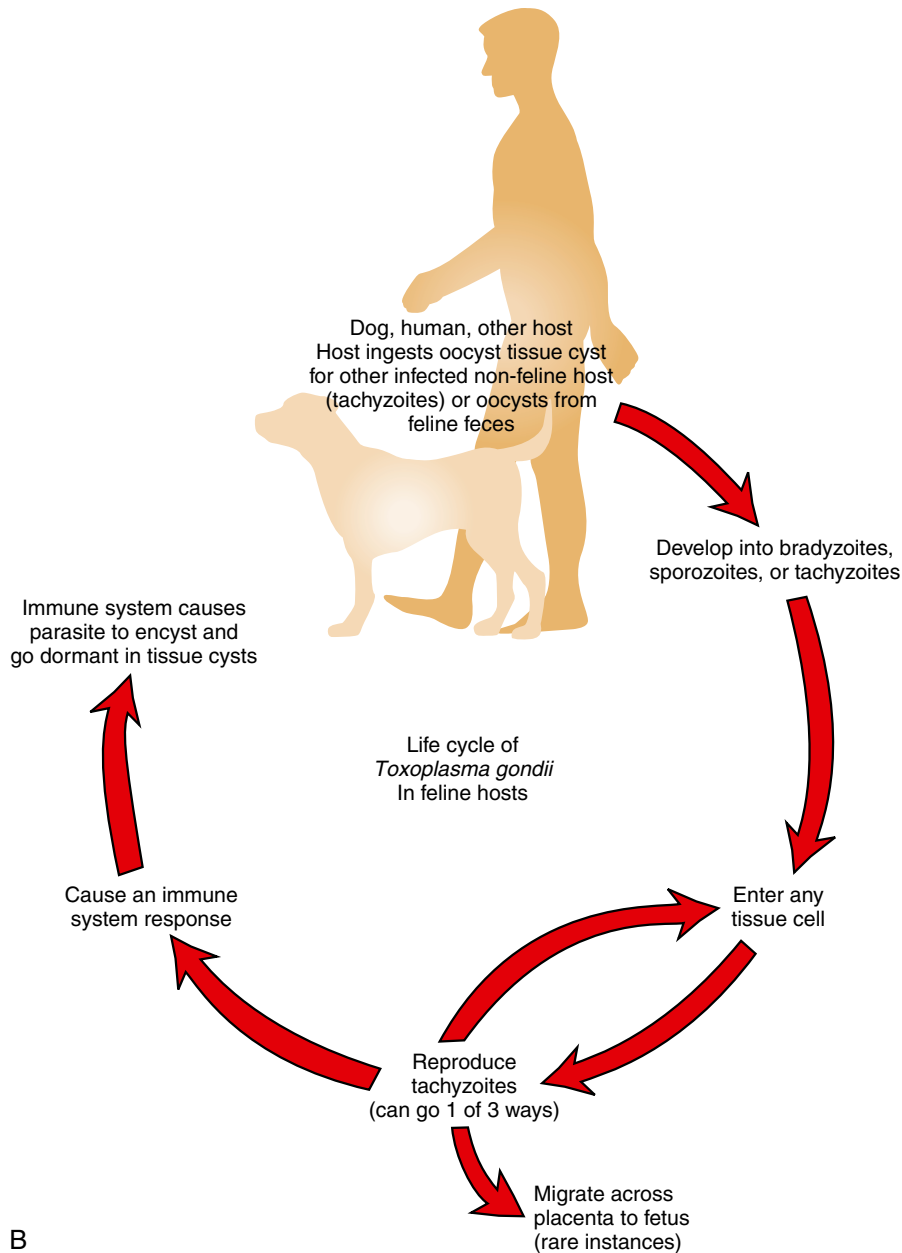
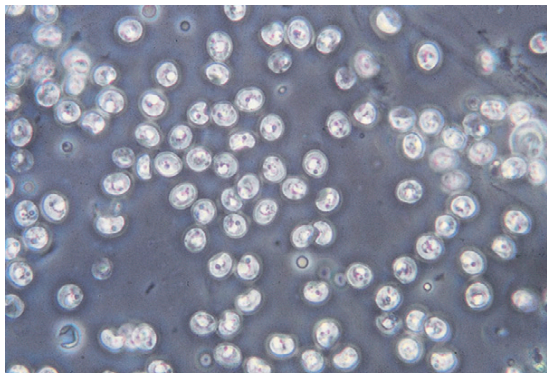


FIGURE 11-10, Cont'd

are sporulated when passed in the feces. Each oocyst contains two sporocysts, each with four sporozoites. These individual oocysts measure 12 to 15  $\mu\text{m} \times 8$  to 12  $\mu\text{m}$  and may be recovered in a standard fecal flotation of fresh feces. The

oocysts are ingested by a ruminant, horse, or pig depending on the specific species of *Sarcocystis*. The oocysts will excyst and go through multiple asexual reproductive stages before encysting in the muscles of the intermediate host. The muscle



**FIGURE 11-11:** Numerous oocysts of *Cryptosporidium*, a coccidian parasite that parasitizes the small intestine of dogs and cats. Sporulated oocysts in feces are oval to spherical and measure 3 to 5  $\mu\text{m}$ . Diagnosis is by standard fecal flotation. Oocysts are extremely small and may be observed just under coverslip, not in same plane of focus as other oocysts and parasite ova. Examination of fresh fecal smears using special stains (modified acid-fast stain) is also helpful.

tissue of the intermediate host must be ingested to complete the maturation to the oocyte stage in the final host species, canine or feline.

**TECHNICIAN'S NOTE** There are seven species of *Sarcocystis* that infect dogs and five species that infect cats. Each of the species has a different intermediate host.

## Circulatory System and Blood

Protozoans that infect the circulatory system and blood of dogs and cats are flagellates and apicomplexans.

### Flagellates

**Parasite:** *Trypanosoma cruzi*

**Host:** Humans and occasionally canines

**Location:** Peripheral blood

**Distribution:** Primarily in Central and South America but occasionally in the southern United States

**Derivation of Genus:** Borer body

**Transmission Route:** Ingestion of intermediate host, reduviid bug, or feces of reduviid bug left on mucous membranes of final host

**Common Name:** Trypanosome

*Trypanosoma cruzi* is a **hemoprotozoan** (a protozoan found circulating in the peripheral blood). It is primarily found in Central and South America; however, it is occasionally reported in dogs in the southern half of the United States. This trypanosome is extracellular; it is not found within the red blood cell (RBC) itself. It “swims” within the blood. This swimming stage is called a **trypomastigote** and is 16 to 20  $\mu\text{m}$  in length, approximately 3 to 10 times as long as an RBC is wide. It is banana-shaped and possesses a lateral, undulating membrane and a thin, whiplike tail (the flagellum) that is used for swimming. These parasites are also transmitted by blood-feeding arthropods called **reduviid bugs**, or “kissing bugs” (see Chapter 13). *T. cruzi* also has a resting cyst stage (the **amastigote** stage) that may be found encysted within cardiac muscle and other tissues such as the esophagus. The encysted amastigote stage lacks the undulating flagellum of the swimming trypomastigote stage.

The trypomastigote stage of *T. cruzi* may be found swimming within the peripheral blood and may be demonstrated in direct blood smears. The amastigote stage must be confirmed using histopathologic sectioning. Suspect tissues should be submitted to a histopathology laboratory for diagnosis by a veterinary pathologist or parasitologist.

**TECHNICIAN'S NOTE** The trypomastigote stage of *Trypanosoma cruzi* can be found in a peripheral blood smear.

**Parasite:** *Leishmania* species

**Host:** Canines

**Location:** Reticuloendothelial cells of capillaries and spleen as well as other internal organs and white blood cells

**Distribution:** Worldwide but rarely seen in North America

**Derivation of Genus:** Named after a famous physician, William Leishman

**Transmission Route:** Bite by an infective intermediate host, phlebotomine sand flies

**Common Name:** Leishmania

*Leishmania* species is another hemoprotozoan (blood protozoan). The parasite is primarily found in areas other than North America; however, it is occasionally reported in dogs that have traveled or been born overseas. It is rarely diagnosed in dogs that have never left the United States. This flagellate is intracellular and found within reticuloendothelial cells of the capillaries, spleen, and other internal organs and in monocytes, polymorphonuclear leukocytes, and macrophages. Instead of having a flagellum and being called the trypomastigote stage, as with *T. cruzi*, this parasite lacks the flagellum and is called the amastigote stage. *Leishmania* is transmitted by blood-feeding arthropods called **phlebotomine sand flies** (see Chapter 13).

The amastigote stage of *Leishmania* must be confirmed using histopathologic sectioning of infected organs. Suspect tissues should be submitted to a histopathology laboratory for diagnosis by a veterinary pathologist or parasitologist.

**TECHNICIAN'S NOTE** *Leishmania* species are rarely seen in dogs in North America.

## Apicomplexans

**Parasite:** *Babesia canis*

**Host:** Canine

**Location:** Within red blood cells

**Distribution:** Europe, Africa, Asia, North and South America

**Derivation of Genus:** Named after a famous bacteriologist, Victor Babès

**Transmission Route:** Bite of an infective intermediate host, ticks

**Common Name:** *Babesia* or canine piroplasm

*Babesia canis* is an intracellular parasite found within the RBCs of dogs. It has been referred to as the **canine piroplasm**. The parasite demonstrates pear-shaped organisms within canine RBCs. This protozoan parasite is spread by the bite of infected ticks. Diagnosis is by observing

basophilic, pear-shaped organisms within RBCs in stained blood smears (Figure 11-12). This parasite causes damage by residing within the red blood cells. Common symptoms include pale mucus membranes, icterus, hemoglobinuria, depression, hemoglobinemia, weakness, splenomegaly, fever, and anorexia.

**TECHNICIAN'S NOTE** *Babesia canis* can be broken down into three subspecies that denote in which country the species is found. *B. canis canis* is found in Europe, *B. canis vogeli* is found in Northern Africa and North America, and *B. canis rossi* is found in Southern Africa (Bowman, 2009).

**Parasite:** *Cytauxzoon felis*

**Host:** Feline

**Location:** Within red blood cells

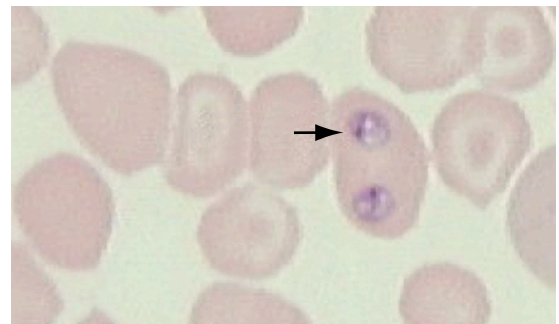
**Distribution:** Africa and United States

**Derivation of Genus:** Hollow vessel-increasing animal

**Transmission Route:** Bite from an infective intermediate host, tick

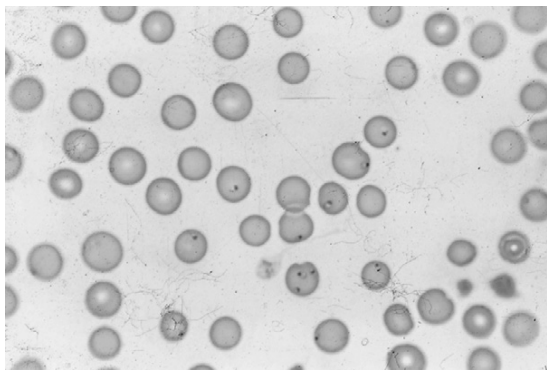
**Common Name:** Cytauxzoon

*Cytauxzoon felis* is another intracellular parasite that has been reported in the RBCs of cats in sporadic sites (Missouri, Arkansas, Georgia, and Texas) throughout the United States and Africa. It also produces piroplasms; however, these bodies have been described as being in the shape of a “bejeweled ring” and are



**FIGURE 11-12:** Trophozoites of *Babesia canis* within canine red blood cells.





**FIGURE 11-13:** Ring form of *Cytauxzoon felis* in stained feline red blood cells.

referred to as the **ring form** in stained blood smears (Figure 11-13). This disease is spread by ticks, and its prognosis is poor. Diagnosis is made by observing the bejeweled-ring piroplasms within the RBCs in stained blood smears. Common symptoms include fever, icterus, anemia, dehydration, and death. As with *Babesia canis*, *Cytauxzoon felis* causes damage by inflammation within the red blood cells.

**TECHNICIAN'S NOTE** *Cytauxzoon felis* is diagnosed by finding the bejeweled ring form in the RBCs in stained blood smears.

**Parasite:** *Hepatozoon canis* and *Hepatozoon americanum*

**Host:** Canines

**Location:** Gamonts are within white blood cells while schizonts are found in the endothelial cells of the spleen, bone marrow, and liver.

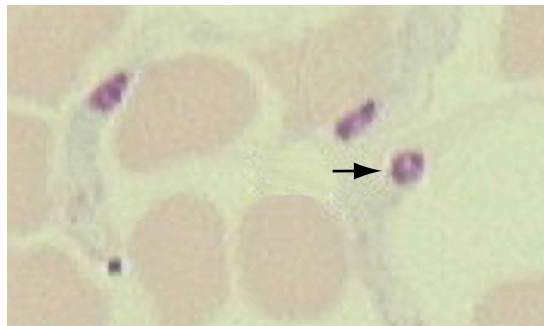
**Distribution:** United States, Africa, Asia, and Southern Europe

**Derivation of Genus:** Liver animal

**Transmission Route:** Ingestion of infective intermediate host, *Rhipicephalus sanguineus* tick for *H. canis* and *Amblyomma maculatum* tick for *H. americanum*

**Common Name:** Hepatozoon

*Hepatozoon canis* and *Hepatozoon americanum* are intracellular, malaria-like parasites affecting dogs. The blood forms (the **gamonts**) of these protozoan parasites are found in the leukocytes.



**FIGURE 11-14:** The "onion skin" tissue cysts of *Hepatozoon americanum* are found in skeletal muscle of dogs.

(Leukocytes containing gamonts of *H. canis* are common in peripheral blood smears, whereas those of *H. americanum* are rare.) Schizonts are found in the endothelial cells of the spleen, bone marrow, and liver. The gamonts are surrounded by a delicate capsule and stain pale blue with a dark, reddish purple nucleus. Numerous pink granules are found in the cytoplasm of the leukocyte. The "onion skin" tissue cysts of *H. americanum* are found in skeletal muscle of dogs (Figure 11-14). This is an unusual parasite in that the dog becomes infected by ingestion of an infected tick, *Amblyomma americanum*. *H. canis* is well adapted to its canine host and varies from being subclinical to producing mild disease. *H. americanum* produces a violent and frequently fatal course of disease; it is theorized to have crossed the species barrier from a wild animal host to the domestic dog.

**TECHNICIAN'S NOTE** Almost all intracellular malaria-like parasites are transmitted by the bite of an arthropod (a mosquito or a mite), but *Hepatozoon* species is spread by the ingestion of an arthropod.

## RUMINANTS (CATTLE AND SHEEP)

### Gastrointestinal Tract

Protozoans that infect the gastrointestinal tract of ruminants are ciliates and apicomplexans.

## Ciliates

Nonpathogenic ciliates live in the rumen of all ruminants, including cattle and sheep. These are **mutualists**; in this type of symbiotic relationship, both individuals benefit from the association. The cow provides a warm, moist, particulate medium in which the ciliates live; the ciliates, in exchange, aid in digestion by breaking down cellulose. Sometimes, ciliates may be observed in the diarrheic feces of cattle and sheep. These ciliates may be recovered on fecal flotation. Similar ciliates occur in the cecum of the horse and are often recovered from diarrheic feces.

## Apicomplexans

**Parasite:** *Eimeria* species, *Eimeria bovis*, and *Eimeria zuernii*

**Host:** Ruminants

**Location:** Cecum and colon

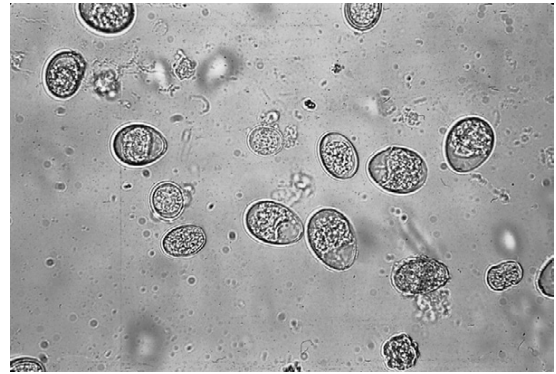
**Distribution:** Worldwide

**Derivation of Genus:** Named after a famous zoologist, Gustav Eimer

**Transmission Route:** Ingestion of oocysts

**Common Name:** Coccidia

Ruminants serve as host to many species of the coccidian parasite *Eimeria*. It is often difficult to identify the individual species of *Eimeria* because their oocysts are similar in size and shape. The life cycle is similar to that of *Cystoisospora* species (see Figure 11-8) and causes damage by inflammation of the intestinal cells. The two most common species of coccidia in cattle are *Eimeria bovis* and *Eimeria zuernii*; they can be differentiated on a standard fecal flotation. Oocysts of *E. bovis* are oval, have a micropyle (opening), and measure  $20 \times 28 \mu\text{m}$ ; the oocysts of *E. zuernii* are spherical, lack the micropyle, and measure  $15 \text{ to } 22 \mu\text{m} \times 13 \text{ to } 18 \mu\text{m}$ . When oocysts are recovered on fecal flotation, the observation is usually noted as **coccidia**. The coccidian oocysts of ruminants can be partially differentiated by size and appearance and cause diarrhea and possibly neurologic signs, such as muscle tremors, convulsions, and blindness (Figure 11-15).



**FIGURE 11-15:** Unsporulated oocysts of *Eimeria* species recovered from fresh goat feces.

**Parasite:** *Cryptosporidium* species (discussed in greater detail in canine and feline section)

**Host:** Canines, felines, bovines, swine, avians, guinea pigs, snakes, and mice

**Location:** Small intestine

**Distribution:** Worldwide

**Derivation of Genus:** Hidden small seeds

**Transmission Route:** Ingestion of sporulated oocysts

**Common Name:** *Cryptosporidium*; “crypto”

*Cryptosporidium* species is another coccidian that parasitizes the small intestine of a variety of animals, including cattle, sheep, and goats. The sporulated oocysts in the feces are colorless and transparent and measure only 3 to 5  $\mu\text{m}$ . Diagnosis is by standard fecal flotation and stained fecal smears. Because humans may become infected with *Cryptosporidium* species, feces suspected of harboring this protozoan should be handled with great care. These oocysts are often recovered using Sheather’s sugar solution. (See Figure 11-11 for features of the oocysts of *Cryptosporidium* species.)



**TECHNICIAN’S NOTE** Individual species of *Eimeria* can be partially differentiated by oocyst size and appearance.



**TECHNICIAN’S NOTE** Feces suspected of being infected with *Cryptosporidium* should be handled with great care due to the potential for zoonosis.

## Circulatory System and Blood

Protozoans that infect the circulatory system and blood are flagellates and apicomplexans.

### Flagellates

**Parasite:** *Trypanosoma* species (general discussion in canine and feline section)

**Host:** Ruminants

**Location:** Peripheral blood

**Distribution:** Primarily in Central and South America but occasionally in the southern United States

**Derivation of Name:** Borer body

**Transmission Route:** Bite of infective fly

**Common Name:** Trypanosome

*Trypanosoma* species are hemoprotozoans found in the peripheral blood of many ruminants. This trypanosome has a long narrow body, a dark nucleus, anterior flagellum, and a sail-like undulating membrane (Figure 11-16). These protozoans may be observed among the RBCs in a thin blood smear. *Trypanosoma* species are not pathogenic and are very common but are seldom seen in a routine smear.

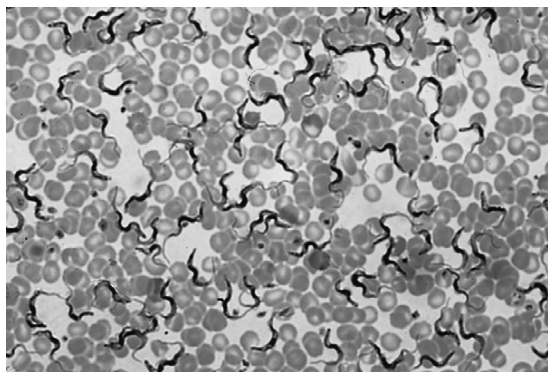


**TECHNICIAN'S NOTE** These parasites are very common in ruminants but rarely seen on a routine blood smear.

### Apicomplexans

**Parasite:** *Babesia bigemina*

**Host:** Bovines



**FIGURE 11-16:** *Trypanosoma* species in bovine blood smear.

**Location:** Within red blood cells

**Distribution:** Europe, Africa, Asia, North and South America

**Derivation of Genus:** Named after a famous bacteriologist, Victor Babès

**Transmission Route:** Bite of an infective *Boophilus annulatus* tick

**Common Name:** Babesia

*Babesia bigemina* is an intracellular parasite found within the RBCs of cattle. This parasite is a large piroplasm, which causes damage by residing within the red blood cell, 4 to 5  $\mu\text{m}$  in length  $\times$  about 2  $\mu\text{m}$  wide, and can be observed in a stained blood smear. These piroplasms are characteristically pear-shaped and lie in pairs, forming an acute angle within the erythrocyte (Figure 11-17). The intermediate host for this protozoan parasite is the tick *Boophilus annulatus* (see Chapter 13). Common symptoms include fever, depression, icterus, anorexia, hemoglobinuria, pale mucus membranes, weakness, and splenomegaly.



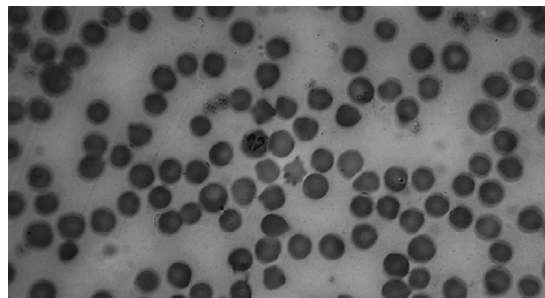
**TECHNICIAN'S NOTE** If diagnosed, both the protozoan and its tick intermediate host should be reported to state and federal authorities.

## Urogenital System

**Parasite:** *Tritrichomonas foetus*

**Host:** Bovine

**Location:** Prepuce of bulls and vagina, cervix, and uterus of cows



**FIGURE 11-17:** Trophozoites of *Babesia bigemina* within bovine red blood cells. Piroplasms are characteristically pear-shaped and lie in pairs, forming an acute angle within the erythrocyte.

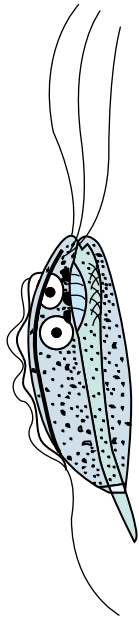
**Distribution:** Worldwide but becoming rare where artificial insemination is used

**Derivation of Genus:** Three hair unit

**Transmission Route:** Sexual transmission

**Common Name:** Trichomonas

*Tritrichomonas foetus* is a protozoan parasite residing in the reproductive tract of cattle. These protozoans reside in the prepuce of infected bulls and in the vagina, cervix, and uterus of infected cows. In the cow, the parasite causes physiologic disturbance leading to abortion. *T. foetus* is pear-shaped and approximately 10 to 25  $\mu\text{m}$  long, with a sail-like undulating membrane and three rapidly moving, anterior whiplike flagella (Figure 11-18). In fresh specimens they move actively with a jerky movement. Diagnosis is by finding these protozoans in fluid freshly collected from the stomach of an aborted fetus, from uterine discharges, or from washings of the vagina and prepuce. Fluid material should be centrifuged at 2000 rpm for 5 minutes. The supernatant is then removed and a drop of sediment transferred



**FIGURE 11-18:** Diagram of *Tritrichomonas foetus*. This flagellated protozoan is pear-shaped and approximately 10 to 25  $\mu\text{m}$  long, with sail-like undulating membrane, trailing posterior flagellum, and three rapidly moving, anterior whiplike flagella.

to a glass slide for microscopic examination for the moving organisms. Several slides should be examined. For more accurate diagnosis, fluid material from the sources just mentioned can be cultured in special media. A specialized parasitology laboratory should be consulted for information on these techniques.



**TECHNICIAN'S NOTE** *Tritrichomonas foetus* is typically spread through a herd by the bull.

## HORSES

### Gastrointestinal Tract

Protozoan parasites that infect horses are flagellates, ciliates, and apicomplexans.

#### Flagellates

**Parasite:** *Giardia* assemblage E (*Giardia* is discussed in canine and feline section)

**Host:** Horses, cows, sheep, goats, and pigs

**Location:** Small intestine

**Distribution:** Worldwide

**Derivation of Name:** Named after a famous biologist, Alfred Giard

**Transmission Route:** Ingestion of oocysts

**Common Name:** *Giardia*

*Giardia* assemblage E is a flagellated protozoan of low incidence in horses. The trophozoites and cysts of this parasite are morphologically similar to those of the species found in dogs and cats (see Figure 11-1). *Giardia* invades the small intestine and causes chronic diarrhea. Normal flotation techniques rarely detect *Giardia*, but zinc sulfate and Sheather's sugar solution will float the cysts.

#### Ciliates

As with the rumen ciliates of cattle and sheep, non-pathogenic ciliates live in the cecum of the horse. These mutualists live in the warm, moist, particulate-rich medium of the cecum. Sometimes, ciliates may be observed in the diarrhetic feces of horses and are often recovered on fecal flotation.



## Apicomplexans

**Parasite:** *Eimeria leuckarti*

**Host:** Equine

**Location:** Small intestine

**Distribution:** Worldwide

**Derivation of Genus:** named after German zoologist, Gustav Eimer

**Transmission Route:** Ingestion of oocysts

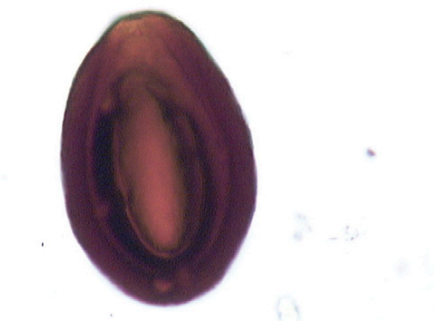
**Common Name:** Coccidia

*Eimeria leuckarti* is the coccidian found in the small intestine of horses, particularly young ones, in the United States. Infections are usually asymptomatic and self-limiting but can cause inflammation of the intestinal cells. Horses rapidly become immune to further infection. This protozoan demonstrates unique oocysts that are quite large, 80 to 87  $\mu\text{m}$   $\times$  55 to 60  $\mu\text{m}$ , and dark brown, with a thick wall and a distinct micropyle at the narrow end (Figure 11-19). These oocysts can be recovered on fecal flotation using saturated sodium nitrate (1:360) and saturated sugar solution (1:320); however, they also may be easily recovered using fecal sedimentation. The oocysts of *E. leuckarti* are the largest coccidian oocysts. They are frequently described in histopathologic examination.

**TECHNICIAN'S NOTE** *Eimeria leuckarti* infections are typically asymptomatic and self-limiting.

## Circulatory System and Blood

Apicomplexans are the protozoans that infect the circulatory system and blood of horses.



**FIGURE 11-19:** Unsporulated oocyst of *Eimeria leuckarti*. (350 $\times$ .)

## Apicomplexans

**Parasite:** *Babesia equi* and *Babesia caballi*

**Host:** Equine

**Location:** Within red blood cells

**Distribution:** Europe, Africa, Asia, North and South America

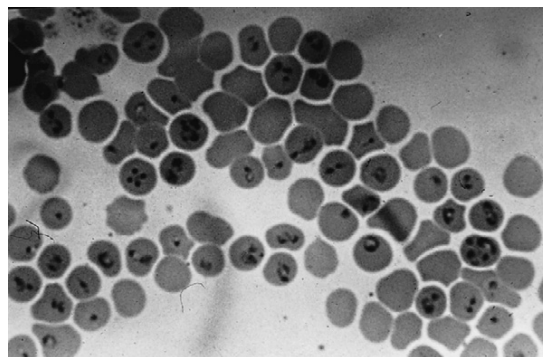
**Derivation of Genus:** Named after a famous bacteriologist, Victor Babès

**Transmission Route:** Bite by infective tick

**Common Name:** Equine piroplasm

*Babesia equi* and *Babesia caballi* are intracellular parasites found within the erythrocytes of horses. They are also referred to as the “equine piroplasms.” The parasites cause damage by residing in the red blood cells. These parasites are spread by the bite of infected ticks. Diagnosis is by observing basophilic, pear-shaped trophozoites in RBCs in stained blood smears. Trophozoites of *B. equi* may be round, ameboid, or pyriform (pear-shaped). Four organisms may be joined, giving the effect of a Maltese cross (Figure 11-20). Individual organisms are 2 to 3  $\mu\text{m}$  long. Trophozoites of *B. caballi* are pyriform, round, or oval and 2 to 4  $\mu\text{m}$  long. They occur characteristically in pairs at acute angles to each other (Figure 11-21). Common symptoms include fever, depression, icterus, anorexia, hemoglobinuria, pale mucus membranes, weakness, and splenomegaly.

**TECHNICIAN'S NOTE** Each species of *Babesia* uses a different tick intermediate host.



**FIGURE 11-20:** Basophilic, pear-shaped trophozoites of *Babesia equi* in red blood cells in stained equine blood smear. Trophozoites of *B. equi* may be round, ameboid, or pyriform (pear-shaped). Four organisms may be joined, giving the effect of a Maltese cross. Individual organisms are 2 to 3  $\mu\text{m}$  long.



## Urogenital System

The protozoans that infect the urogenital system of horses are apicomplexans.

### Apicomplexans

**Parasite:** *Klossiella equi*

**Host:** Equine

**Location of Adult:** Kidneys

**Distribution:** World wide

**Derivation of Genus:** Little organism. Named after parasitologist, Kloss

**Transmission Route:** Ingestion of oocysts in urine

**Common Name:** *Klossiella*

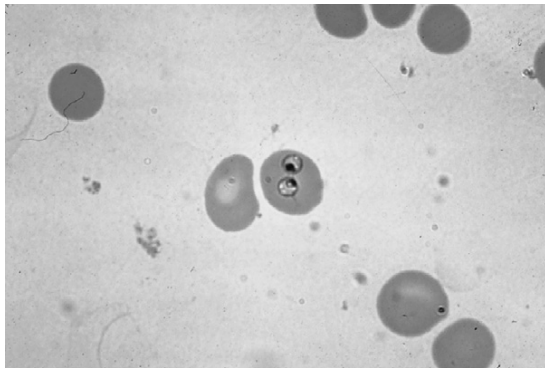
*Klossiella equi* is a nonpathogenic coccidian infecting the kidney of horses. Oocysts can occasionally be found during histopathologic examination of the kidney and in urine sediment. There is no marked inflammatory response to infection with *Klossiella* in the horse.



**TECHNICIAN'S NOTE** Pathologic effects due to inflammation have only been reported in immune-compromised horses.

## Nervous System

Apicomplexans are the protozoans that infect the nervous system of horses.



**FIGURE 11-21:** Trophozoites of *Babesia caballi* in red blood cells in stained equine blood smear. These piroplasms are pyriform, round, or oval and 2 to 4  $\mu\text{m}$  long. They occur characteristically in pairs at acute angles to each other.

## Apicomplexans

**Parasite:** *Sarcocystis neurona*

**Host:** Equine

**Location:** Schizogonous or asexual stage found in nervous system

**Distribution:** North, Central & South America

**Derivation of Genus:** Flesh cyst

**Transmission Route:** Ingestion of oocysts from opossum feces

**Common name:** (*Sarcocystis*)

*Sarcocystis neurona* is sporadically found in the asexual, or schizogonous, stage of development in the nervous system, particularly the spinal cord, of horses. This stage can invade the central nervous system, producing a condition called **equine protozoal myeloencephalitis** (EPM). This disease most often affects standardbreds and thoroughbreds. Clinical signs are caused mainly by destruction of neurons. Clinical signs are ataxia, weakness, stumbling, muscle wasting, and disorientation. *Sarcocystis neurona* oocysts are ingested from food or water that has been contaminated with opossum feces. EPM can resemble many other equine neurologic diseases, including wobbler syndrome, the neurologic form of herpesvirus infection, rabies, West Nile virus infection, and other equine viral encephalitis diseases (e.g., eastern and western equine encephalitis). These developmental stages cannot be seen antemortem. Diagnosis of this parasite is by histopathologic examination. Tissues suspected of harboring developmental stages of *S. neurona* should be submitted to a histopathology laboratory for diagnosis by a veterinary pathologist or parasitologist.

*Sarcocystis neurona* causes encephalomyelitis in many species of mammals and is the most important cause of neurologic disease in horses. Its complete life cycle is unknown, particularly its development and localization in the opossum intermediate host or the equine aberrant host.



**TECHNICIAN'S NOTE** *Sarcocystis neurona* can invade the central nervous system of the horse and cause equine protozoal myeloencephalitis.

## SWINE

### Gastrointestinal Tract

Protozoans that infect the gastrointestinal tract of swine are ciliates and apicomplexans.

#### Ciliates

**Parasite:** *Balantidium coli* (also see discussion in canine section)

**Host:** Swine and occasionally canines

**Location:** Large intestine

**Distribution:** Worldwide

**Derivation of Name:** Small bag

**Transmission Route:** Ingestion of oocysts

**Common Name:** *Balantidium*

*Balantidium coli* is the ciliated protozoan found in the large intestine of swine. Although it is often observed during microscopic examination of fresh diarrhetic feces, it is generally considered to be nonpathogenic. Two morphologic stages can be found in feces: the cyst stage and the trophozoite stage. Both stages may vary in size. This is a very large protozoan parasite. The trophozoites may be  $150 \times 120 \mu\text{m}$ , with a sausage-to-kidney-shaped macronucleus. *B. coli* is covered with numerous rows of cilia and moves about the field with lively motility. The cyst is spherical to ovoid, 40 to 60  $\mu\text{m}$  in diameter, and has a slight greenish yellow color. Both these stages may be easily recognized by microscopic examination of the intestinal contents of fresh, diarrhetic feces by fecal flotation and fecal direct smear. Figure 11-22 demonstrates the trophozoite stage of *B. coli* recovered on fecal flotation, and Figures 11-23 and 11-24 demonstrate *B. coli* in histopathologic section.

#### Apicomplexans

**Parasite:** *Cystoisospora suis* (see also discussion of *Cystoisospora* sp. in canine and feline section)

**Host:** Swine

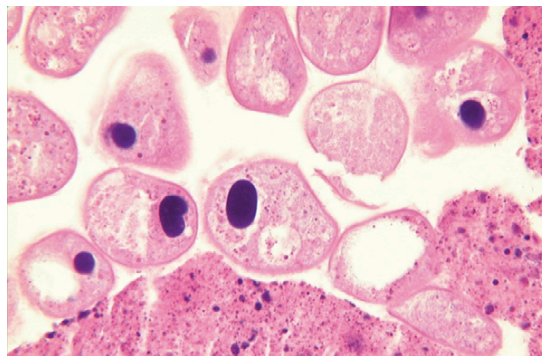
**Location:** Small intestine

**Distribution:** Worldwide

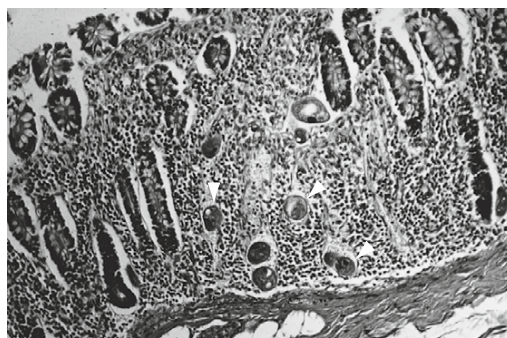
**Derivation of Genus:** Bladder same spore

**Transmission Route:** Ingestion of oocysts

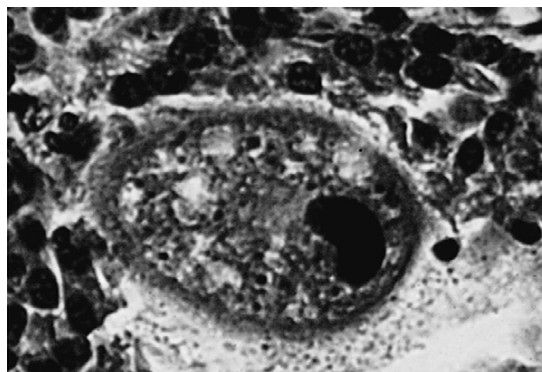
**Common Name:** Coccidia



**FIGURE 11-22:** Motile trophozoite stage of *Balantidium coli*, ciliated protozoan found in the large intestine of swine, is often observed during microscopic examination of fresh diarrhetic feces. It is covered with numerous rows of cilia and moves about the field of view with lively motility.



**FIGURE 11-23:** *Balantidium coli* of swine in histopathologic section. This photomicrograph was taken at low magnification. Note that *B. coli* is quite large and easily visible (arrows).



**FIGURE 11-24:** *Balantidium coli* of swine in histopathologic section. This photomicrograph was taken at higher magnification than Figure 11-23.

*Cystoisospora suis* is the coccidian that parasitizes the small intestine of swine, especially young piglets. The merozoite stage causes inflammation in the small intestine. Oocysts are usually found on flotation of fresh feces. They are subspherical, lack the micropyle, and measure 18 to 21  $\mu\text{m}$ . Common symptoms include diarrhea, dehydration and weight loss. Postmortem diagnosis in piglets exhibiting clinical signs but not shedding oocysts can be achieved by direct smear of the jejunum stained with Diff-Quik. Diagnosis is by observation of the banana-shaped merozoites. The prepatent period is 4 to 8 days. (Figure 11-25 shows features of the oocyst of *C. suis*.)

**TECHNICIAN'S NOTE** The prepatent period for *Cystoisospora suis* is a short 4 to 8 days.

**Parasite:** *Cryptosporidium* species (also see discussion in canine and feline section)

**Host:** Canines, felines, bovines, swine, avians, guinea pigs, snakes, and mice

**Location:** Small intestine

**Distribution:** Worldwide

**Derivation of Genus:** Hidden small seeds

**Transmission Route:** Ingestion of oocysts

**Common Name:** Cryptosporidium, “Crypto”

*Cryptosporidium* species is another coccidian that parasitizes the small intestine of a variety of

animals, including swine. The sporulated oocysts in the feces are colorless and transparent and measure only 3 to 5  $\mu\text{m}$ . Diagnosis is by standard fecal flotation and stained fecal smears. Because humans may become infected with *Cryptosporidium* species, feces suspected of harboring this protozoan should be handled with great care. (See Figure 11-11 for features of the oocysts of *Cryptosporidium* species.)

**TECHNICIAN'S NOTE** *Cryptosporidium* species are transferred from host to host by ingestion of oocysts. Since humans are hosts, feces suspected of containing the oocysts should be handled with great care.

## PET AND AVIARY BIRDS AND OTHER DOMESTIC FOWL

### Gastrointestinal Tract

Protozoans that infect the gastrointestinal tract of birds are flagellates and apicomplexans.

#### Flagellates

**Parasite:** *Giardia psittaci* (see also discussion at beginning of chapter)

**Host:** Avians

**Location of Adults:** Intestinal mucosa

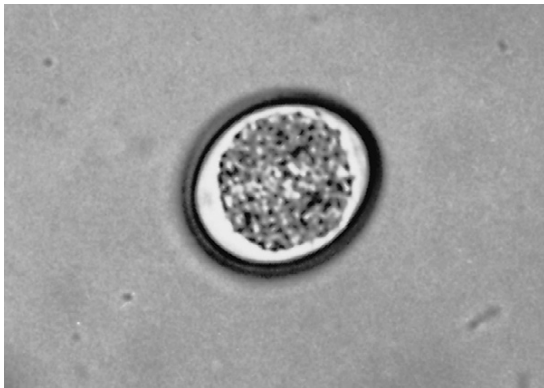
**Distribution:** Worldwide

**Derivation of Genus:** Named after a famous protozoologist, Giard

**Transmission Route:** Ingestion of oocysts

**Common Name:** Giardia

*Giardia psittaci* is the most common protozoan seen in pet bird practices. This flagellated parasite is most often found in cockatiels, budgerigars, and lovebirds. The feces of affected birds often become voluminous and chunky, with a pea-soup consistency. Fresh saline mounts can demonstrate the motile trophozoites, with the characteristic “falling leaf” motility. Allergic skin conditions may be associated with giardiasis in cockatiels. It may be difficult to demonstrate *Giardia* in some of these cases.



**FIGURE 11-25:** Unsporulated oocyst of swine coccidian, *Cystoisospora suis*, recovered from swine feces. (560 $\times$ .)

The fecal trichrome stain can enhance visualization of *Giardia* species (Figure 11-26). Other stains used to enhance visualization of this flagellate include Lugol's iodine, Gram's iodine, and Wright's stain. Other stains, such as acid-fast stain or Gram's stain, may incidentally demonstrate trophozoites (Figure 11-27).

**Parasite:** *Histomonas meleagridis*

**Host:** Turkeys, peafowl, chickens, and pheasants

**Location:** Liver

**Distribution:** Worldwide

**Derivation of Genus:** Tissue unit

**Transmission Route:** Ingestion of intermediate host ova, *Heterakis gallinarum* or direct ingestion of ova.

**Common Name:** "Blackhead"

*Histomonas meleagridis* infects turkeys, chickens, pheasants, and peafowl, causing a fatal liver disease called **infectious enterohepatitis**, or "blackhead." The oocysts are ingested directly from infective feces or within the intermediate host ova, *Heterakis gallinarum*. *H. gallinarum* ova can survive for extended periods of up to years in the environment. Within several days of being ingested, the oocysts are released by the intermediate host ova, reproduce in the cecum, and migrate to the liver where they cause inflammation and necrosis of liver cells. Diagnosis is usually by necropsy and histopathologic examination of the liver. Suspect tissues should be submitted to a histopathology laboratory for

diagnosis by a veterinary pathologist or parasitologist. Suspicion of infection is increased by finding the eggs of the cecal worm, *Heterakis gallinarum* on fecal flotation, which serves as the intermediate host for this parasite.



**TECHNICIAN'S NOTE** If *Heterakis gallinarum* ova are found on fecal flotation, *Histomonas meleagridis* should also be suspected.

**Parasite:** *Trichomonas gallinae*

**Host:** Pigeons, doves, poultry, and raptors that feed on pigeons

**Location of Adult:** Crop

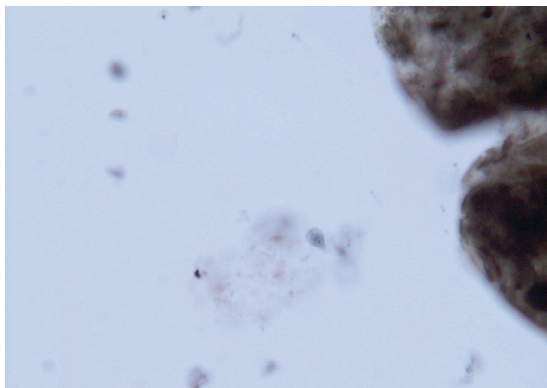
**Distribution:** North America & (countries with doves and pigeons)

**Derivation of Genus:** Hair unit

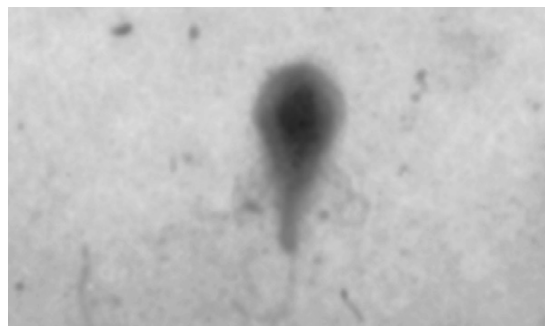
**Transmission Route:** Direct contact with contaminated water or infected bird

**Common Name:** Trichomonas

*Trichomonas gallinae* is frequently found in crop washes and crop swabs of pigeons, doves, and poultry. Occasionally, this parasite is associated with mortality in finches. In North America, trichomoniasis appears to be rare in psittacine birds but has been reported in budgerigars. *T. gallinae* does not produce oocysts so only direct contact with contaminated water from an infected bird or direct contact with an infected bird from fighting or feeding will result



**FIGURE 11-26:** *Giardia* trophozoites (trichrome stain) from feces of cockatiel.



**FIGURE 11-27:** *Giardia* trophozoite, showing flagellar detail, in Gram-stained fecal smear. This was an incidental finding, because Gram's stain is not the stain of choice for flagellates.



in a transfer of the parasite. *T. gallinae* produces nodules in the crop that can cause cell death and obstructions. The parasite is best demonstrated by a direct saline smear of crop contents and is characterized by four anterior flagella. An air-dried smear can be stained with Wright's stain. The parasite assumes an oval shape, staining blue with a red axostyle (Figure 11-28).

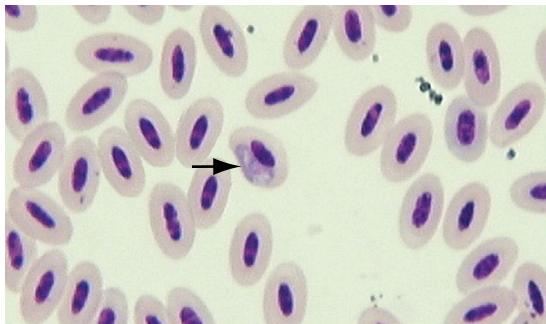
**TECHNICIAN'S NOTE** A severe infection of *Trichomonas gallinae* can result in the parasite spreading to the esophagus and even to the liver.

### Apicomplexans

Coccidial infections are rare in pet birds, although *Cystoisospora* and *Eimeria* have been reported. Coccidia are often observed in poultry and pigeons. A common error made by inexperienced veterinary technicians is to mistake normal urate crystals for coccidia. *Cryptosporidium* species has been reported in cockatiels. This tiny apicomplexan parasite is difficult to visualize in fecal samples and is usually diagnosed by histopathologic examination of the small intestine. Suspect tissues should be submitted to a histopathology laboratory for diagnosis by a veterinary pathologist or parasitologist.

### Circulatory System and Blood

Protozoans that infect the circulatory system and blood of birds are flagellates and apicomplexans.



**FIGURE 11-28:** *Trichomonas gallinae* in crop wash from dove.

### Flagellates

**Parasite:** *Trypanosoma* species (see discussion in canine and feline section)

**Host:** Cockatoos

**Location of Adult:** Peripheral blood

**Distribution:** Worldwide

**Derivation of Genus:** Borer body

**Transmission Route:** No definitive intermediate hosts have been identified for birds

**Common Name:** Trypanosome

*Trypanosoma* species is occasionally found in cockatoos and rarely produces clinical disease. As with the trypanosomes of mammals, this swimming, flagellated protozoan does not infect the RBCs. It has a very distinctive appearance, with posterior flagellum and an undulating membrane (Figure 11-29).

**TECHNICIAN'S NOTE** *Trypanosoma* species are not a major concern in cockatoos as they rarely produce clinical disease.

### Apicomplexans

**Parasite:** *Haemoproteus* species

**Host:** Cockatoos, green-winged macaws, and some species of conures

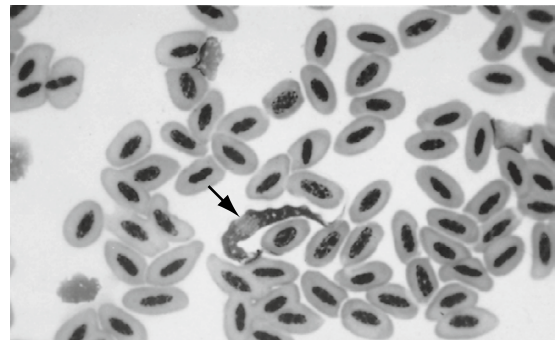
**Location:** Within red blood cells

**Distribution:** Worldwide

**Derivation of Genus:** Many forms in the blood

**Transmission Route:** Bite by an infected *Culicoides* species or *Chrysops* species of fly

**Common Name:** *Haemoproteus*



**FIGURE 11-29:** *Trypanosoma* species in blood of cockatoo.



*Haemoproteus* species is often found within the RBCs of the white species of cockatoos, green-winged macaws, and some species of conures. This blood parasite is rarely associated with clinical disease such as anemia but can destroy red cells if anemia is associated with the clinical disease. *Haemoproteus* is characterized by a bluish, sausage-shaped body in the cytoplasm of the RBC; sometimes the body is overlain with blue dots (Figure 11-30). It infects a variety of wild waterfowl and can cause death in these birds.

**TECHNICIAN'S NOTE** Some species of *Haemoproteus* infect turtles and lizards.

**Parasite:** *Plasmodium* species

**Host:** Avians

**Location:** Within red blood cells

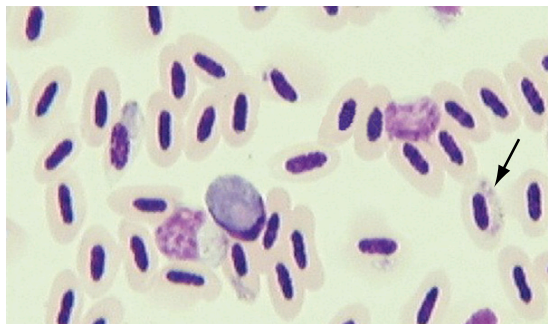
**Distribution:** Worldwide

**Derivation of Genus:** Any thing formed

**Transmission Route:** Bite of infected mosquito

**Common Name:** Avian malaria

*Plasmodium* species is the etiologic agent of avian malaria. It can cause mortality in canaries in some parts of the United States. This may be the result of the transmission of a local passerine strain by the mosquito intermediate host to susceptible canaries. The organism may not be observable in the peripheral blood cells; many of the developmental stages of *Plasmodium* species occur in internal organs, such as the



**FIGURE 11-30:** *Haemoproteus* is normally seen as “sausage-shaped body” within cytoplasm of avian red blood cell.

liver and spleen and can cause inflammation in these organs. A “signet ring” form, in which the body of the organism displaces the nucleus of the RBC, is the most frequently observed form (Figure 11-31), which can cause cell destruction leading to anemia. Diagnosis of infections with *Plasmodium* species is also by organ impression smears and histopathologic examination of the liver and the spleen. Tissues suspected of harboring developmental stages of *Plasmodium* should be submitted to a histopathology laboratory for confirmation by a veterinary pathologist or parasitologist. Polymerase chain reaction (PCR) tests have also been developed for testing of *Plasmodium* species.

**Parasite:** *Leucocytozoon* species

**Host:** Raptors

**Location:** Within white blood cells

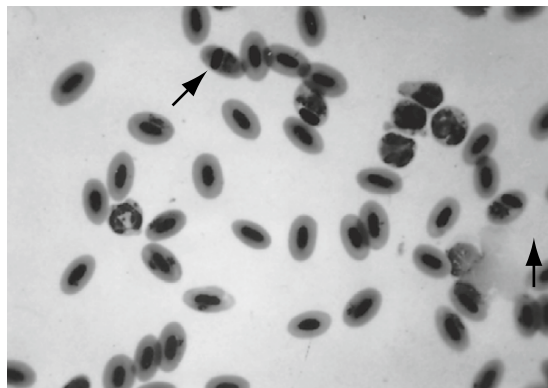
**Distribution:** Worldwide

**Derivation of Genus:** White cell organism

**Transmission Route:** Bite of infected black flies, *Simulium* species

**Common Name:** *Leucocytozoon*

*Leucocytozoon* species infects the white blood cells of raptors—birds of prey such as owls, hawks, and falcons. The presence of this large protozoan organism greatly distorts the shape and appearance of the white blood cell (WBC). A variety of forms can be present and can be associated with occasional leukocytosis and disease. The most common morphology of this



**FIGURE 11-31:** *Plasmodium* displacing nucleus of erythrocyte in blood of canary.

protozoan is the fusiform, or spindle, shape (Figure 11-32). Most infections are subclinical but deaths have been reported.

**TECHNICIAN'S NOTE** The *Leucocytozoon* parasite distorts the WBC to the point that it may not be recognized as such.

**Parasite:** *Aegyptianella* species

**Host:** Pet birds

**Location of Adult:** Within red blood cells

**Distribution:** Primarily in the Mediterranean areas

**Derivation of Genus:** Little organism from Egypt

**Transmission Route:** Bite of an *Argasid* tick

**Common Name:** *Aegyptianella*

*Aegyptianella* species is occasionally found in pet birds, such as the African gray parrot. This protozoan causes little clinical problem. The organism infects the RBCs, appearing as a margined dot on the cells.

## Respiratory System

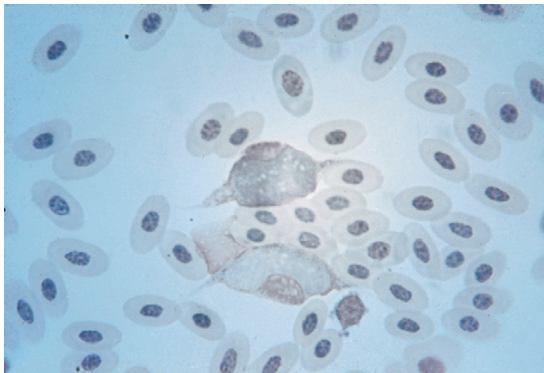
The protozoans that infect the respiratory system of birds are apicomplexans.

### Apicomplexans

**Parasite:** *Cystoisospora serini*

**Host:** Canaries and finches

**Location:** Lung, liver, and spleen



**FIGURE 11-32:** *Leucocytozoon* species in avian peripheral blood smear.

**Distribution:** Worldwide

**Derivation of Genus:** Same bladder organism

**Transmission Route:** Ingestion of oocysts during sexual stage

**Common Name:** Coccidia or Atoxoplasmosis

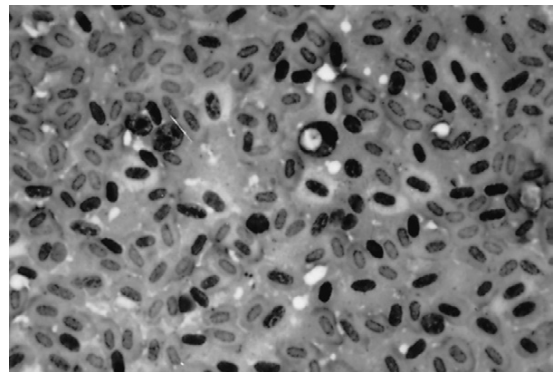
*Cystoisospora* (formerly *Atoxoplasma*) *serini* is a protozoan coccidial parasite of canaries and finches (Figure 11-33). *Cystoisospora serini* can affect several organs, causing respiratory signs due to inflammation of those organs. The parasite goes through a sexual cycle in the intestinal mucosa at which time oocysts can be passed in the feces. However, few oocysts are typically seen after the sexual cycle has passed. An asexual cycle occurs in the liver, lungs, and spleen causing inflammation to these organs. This parasite is best visualized on organ impression smears of the lung, liver, and spleen.

**TECHNICIAN'S NOTE** *Cystoisospora serini* causes *Atoxoplasmosis* in canaries and finches.

## RABBITS

### Gastrointestinal Tract

The protozoans that infect the gastrointestinal tract of rabbits are apicomplexans.



**FIGURE 11-33:** *Cystoisospora* (formerly *Atoxoplasma*) *serini* in mononuclear cell on lung impression smear from canary (Wright's stain).

## Apicomplexans

**Parasite:** *Eimeria irresidua*, *Eimeria magna*, *Eimeria media*, and *Eimeria perforans*

**Host:** Lagomorph (rabbit)

**Location:** Small intestine, *E. media* also affects the large intestine

**Distribution:** Worldwide

**Derivation of Genus:** Organism named after German zoologist, Gustav Eimer

**Transmission Route:** Ingestion of oocysts

**Common Name:** Coccidia of rabbits

Numerous species of *Eimeria* can infect rabbits. Most infect the intestine, causing intestinal coccidiosis, and one species, *Eimeria stiedai*, affects the bile ducts within the liver. The more pathogenic varieties of *Eimeria* species that affect the intestine are discussed in this section, and *E. stiedai* is considered separately. The intestinal coccidia of rabbits include *Eimeria irresidua*, *E. magna*, *E. media*, and *E. perforans*. All species of *Eimeria* infect the small intestine; *E. media* may also affect the large intestine.

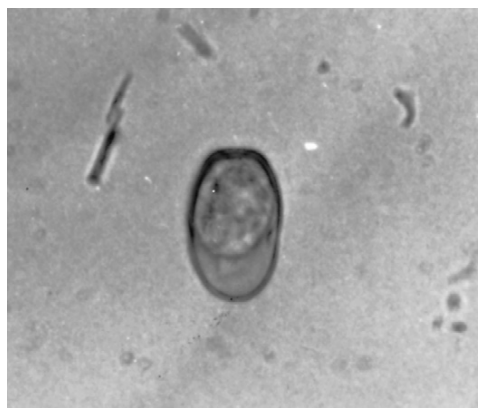The oocysts of *E. irresidua* are  $38 \times 26 \mu\text{m}$  and ovoid. The wall of the oocyst is smooth and light yellow. There is a wide micropyle, with no polar granules or residuum. Sporocysts within the oocyst are also ovoid, with both a body and residuum. Antemortem diagnosis depends on recognition of the mature oocyst, along with clinical signs, which may include severe hemorrhagic diarrhea, excessive thirst, and dehydration caused by inflammation of the intestines. Postmortem indications include inflammation of the intestines and sloughing of the lining of the intestine.

**TECHNICIAN'S NOTE** *E. irresidua*, *E. magna*, *E. media*, and *E. perforans* all infect the small intestine, while *E. stiedai* infects the bile ducts.

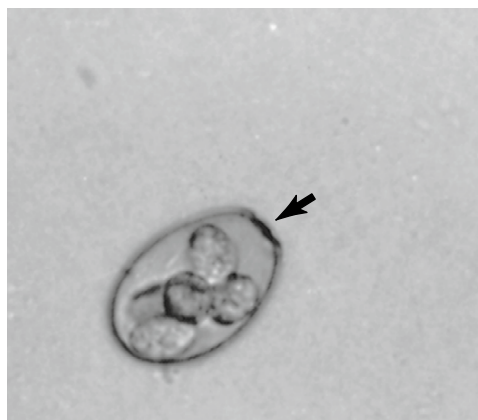The mature oocyst of *E. magna* is  $35 \times 24 \mu\text{m}$  and ovoid, with a distinctive dark, yellow-brown wall (Figure 11-34). A wide micropyle appears built up around the rim, with no micropyle cap. Oocysts and sporocysts contain a residuum (Figure 11-35). The sporocysts are ovoid and

have a body. *E. magna*, like *E. irresidua*, is highly pathogenic. Clinical signs include weight loss, anorexia, and mucoid diarrhea. Necropsy signs include inflammation and sloughing of the lining of the intestine.

*E. media* oocysts are ovoid and  $31 \times 18 \mu\text{m}$ , with a smooth wall and a light-pink color. There is a micropyle and a residuum. Sporocysts within the mature oocyst are ovoid, with a body and a residuum. *E. media* is moderately pathogenic and may cause enteritis and diarrhea caused by inflammation of the intestines. At necropsy, the intestinal wall may be edematous and contain gray foci of necrosis.



**FIGURE 11-34:** Unsporulated oocyst of rabbit intestinal coccidian, *Eimeria magna*.



**FIGURE 11-35:** Oocyst of *Eimeria magna* after sporulation. Arrow indicates micropyle. Round darkened body in center of oocyst is residuum. Four oval lighter bodies are sporocysts.

**Parasite:** *Eimeria stiedai*

**Host:** Rabbit (lagomorph)

**Location:** Bile ducts

**Distribution:** Worldwide

**Derivation of genus:** Organism Named after German Zoologist, Gustav Eimer

**Transmission Route:** Ingestion of oocysts

**Common Name:** Coccidia of rabbits

*E. stiedai* is a highly pathogenic coccidian that affects the bile ducts of rabbits. It causes variable mortality, which is highest in young rabbits. Oocysts of *E. stiedai* are  $35 \times 20 \mu\text{m}$  and ovoid, with a flattened pole at the micropyle end. The wall is smooth and yellow. There is no polar granule or residuum. Sporocysts are ovoid, with a body and a residuum.

Light infections with *E. stiedai* usually produce no clinical signs. Heavier infections may cause blockage of the bile ducts and impaired liver function, resulting in icterus and a distended abdomen caused by liver enlargement. Diarrhea or constipation and anorexia may be noted. At necropsy, white, dilated nodules are likely to be seen in the liver. Hyperplastic bile ducts contain a yellow-green creamy material, in which oocysts may be seen in impression smears when examined microscopically. Transmission of *E. stiedai* is by ingestion of sporulated oocysts passed in the feces. The prepatent period is 15 to 18 days. As in all *Eimeria* species, there is no cross-species contamination or public health significance.



**TECHNICIAN'S NOTE** *Eimeria stiedai* is a highly pathogenic coccidian of rabbits.

## MICE

### Gastrointestinal Tract

Protozoans that infect the gastrointestinal tract of mice are flagellates and apicomplexans.

#### Flagellates

A few flagellates may be found by direct smear or fecal flotation from the mouse. They include *Giardia* assemblage G, *Spironucleus muris*, *Tetratrichomonas microti*, and *Tritrichomonas muris*.

**Parasite:** *Tetratrichomonas microti* and *Tritrichomonas muris*

**Host:** Mouse

**Location:** Small intestine, cecum, and colon

**Distribution:** Worldwide

**Derivation of Genus:** Four hair unit, three hair unit

**Transmission Route:** Ingestion of oocysts

**Common Name:** Flagellates of mice

*Tetratrichomonas microti* and *Tritrichomonas muris* are generally considered nonpathogenic in the mouse. Tritrichomonads and tetratrichomonads have three and four anterior flagella, respectively. Both genera have a trailing caudal flagellum. These trichomonads are frequently found in the small intestine, cecum, and colon of the mouse. Mice with diarrhea, regardless of the etiology, often have numerous tritrichomonads and tetratrichomonads on fecal smear and flotation because the diarrheic fluid medium secondarily provides an optimal habitat for the multiplication of these intestinal protozoa. Transmission of these trichomonads is by ingestion of organisms passed in the feces. *T. microti* is approximately  $22 \times 10 \mu\text{m}$ , and *T. muris* is approximately  $7 \times 5 \mu\text{m}$ .



**TECHNICIAN'S NOTE** *Tetratrichomonas microti* and *Tritrichomonas muris* are commonly found in diarrhea because diarrhea supplies an optimal habitat for multiplication.

**Parasite:** *Giardia* assemblage G and *Spironucleus muris*

**Host:** Rodents (*Giardia* assemblage G), mice

**Location:** Proximal small intestine

**Distribution:** Worldwide

**Derivation of Genus:** Named after a famous biologist, Alfred Giard (*Giardia*)

**Transmission Route:** Ingestion of oocysts

**Common Name:** *Giardia* (*Giardia* sp.), flagellates of mice (*Spironucleus muris*)


*Giardia* and *S. muris* are the most common mouse flagellates and demonstrate the greatest potential for pathogenicity. Both *S. muris* and *Giardia* occur in the proximal small intestine



and can produce enteritis due to inflammation, particularly in young weanling mice. The location of these flagellates in the intestines is proportional to the severity of the enteritis produced; the more severe the enteritis, the farther back (more distally) in the intestinal tract they are found. *Giardia* assemblage G appears similar to other *Giardia* species. The trophozoite is pyriform (pear-shaped), with two nuclei at the anterior end. Eight flagella emerge in symmetric pairs from different locations cranial to caudal in the organism. *Giardia* species may be suspected when motile forms are observed on a direct smear at 100× (high dry) magnification. *Giardia* species are identified by staining the direct fecal smear with Lugol's iodine, which will enhance the detail of the cranial nuclei and flagella.

Transmission of *Giardia* is by ingestion of cysts that have been passed in the feces. *Giardia* has also been found in the rat and hamster; therefore the owner of multiple species should be made aware of the possibility of cross-contamination. Although other species of *Giardia* are pathogenic to humans, the *Giardia* species found in rodents and rabbits have no known zoonotic potential.

*Spironucleus muris* appears somewhat similar to *Giardia* species except that the trophozoite of *S. muris* is uniformly slender, unlike the widened anterior end of *Giardia* species. *S. muris* has two anterior nuclei. There are three pairs of anterior flagella and one pair of trailing caudal flagella.

 **TECHNICIAN'S NOTE** *Spironucleus muris* appears similar to *Giardia* assemblage G on fecal flotation, but the trophozoite is uniformly slender compared to the widened anterior end of *Giardia* species on direct smear.

## Apicomplexans

**Parasite:** *Eimeria falciformis*, *Eimeria ferrisi*, and *Eimeria hansonorum*

**Host:** Mice

**Location:** *E. falciformis* and *E. hansonorum* (small intestines), *E. ferrisi* (cecum)

**Distribution:** Worldwide

**Derivation of Genus:** Named after German biologist, Gustav Eimer


**Transmission Route:** Ingestion of oocysts

**Common Name:** Coccidia of mice

Several species of *Eimeria* infect mice, including *E. falciformis*, *E. ferrisi*, and *E. hansonorum*. *E. falciformis* and *E. hansonorum* infect the small intestine, whereas *E. ferrisi* is found in the cecum. Although mixed infections can occur, little is known concerning the pathogenicity of *E. ferrisi* and *E. hansonorum*.

*E. falciformis* is common in wild mouse populations. Oocysts are 14 to 26  $\mu\text{m}$   $\times$  11 to 24  $\mu\text{m}$ , round to oval, smooth, and colorless. There is no micropyle or residuum. Sporocysts are oval and have a residuum and a small body. There are two sporozoites per sporocyst and four sporocysts per sporulated oocyst. Oocysts of *E. ferrisi* and *E. hansonorum* appear similar to those of *E. falciformis*, except they are small, 16 to 18  $\mu\text{m}$ , and more spherical. *E. ferrisi* has a small body on the sporocysts, whereas *E. hansonorum* has a broad body.

Oocysts of *Eimeria* species can be detected by fecal flotation. As in coccidial infections in other species, finding oocysts on fecal flotation does not necessarily mean that *Eimeria* species is a primary cause of the disease. Diagnosis is made by considering clinical signs usually caused by inflammation, enteric lesions, and identification of the coccidia in histopathologic section. Again, tissues suspected of harboring developmental stages of murine coccidiosis should be submitted to a histopathology laboratory for confirmation by a veterinary pathologist or parasitologist.

 **TECHNICIAN'S NOTE** Finding *Eimeria* sp. oocysts does not mean that this organism is the primary cause of disease.

Clinical signs, if seen, are usually in younger animals that have developed little to no immunity and may include diarrhea, catarrhal enteritis, anorexia, hemorrhage, and epithelial sloughing.



As with other species of *Eimeria*, transmission is by ingestion of sporulated oocysts that have been passed in the feces. Oocysts passed in the feces sporulate in about 3 days. *Eimeria* species are host specific and thus are not considered zoonotic parasites.

## Urogenital System

The protozoans that infect the urogenital system of mice are apicomplexans.

### Apicomplexans

**Parasite:** *Klossiella muris*

**Host:** Mice

**Location:** Kidneys

**Distribution:** Worldwide

**Derivation of Genus:** Little organism found by a researcher named Kloss.

**Transmission Route:** Ingestion of oocysts

**Common Name:** Klossiella

*Klossiella muris* is a relatively nonpathogenic coccidian that occurs mainly in the kidneys of both wild and laboratory mice. This parasite has also been found in different stages of its life cycle in the adrenal and thyroid glands and in the brain, lung, and spleen. The oocyst of *K. muris* matures in the endothelial cells that line the arterioles and capillaries associated with the glomeruli of the kidney. At maturity, the oocyst is 40  $\mu\text{m}$  in diameter. The oocyst grows and divides to form sporoblasts, which eventually rupture the host endothelial cell and pass through the urine as sporocysts. Other mice are then infected by ingestion of sporulated oocysts.

*K. muris* cannot be detected antemortem. On postmortem examination, the kidneys may appear enlarged and have small, gray necrotic areas on the surface. Histopathologic examination reveals that most of the necrotic areas are at the corticomedullary junction. Infection with *K. muris* is usually diagnosed from gross and microscopic lesions, including finding the organism in renal tissue. Tissues suspected of harboring developmental stages of renal coccidiosis should be submitted to a histopathology laboratory for confirmation by a veterinary pathologist or parasitologist.

Transmission of *K. muris* is by ingestion of the sporulated sporocysts passed in the urine. Because wild mice can carry this parasite, strict sanitation and prevention of wild mouse access to the pet population are necessary to control this parasite. *K. muris* is species specific and is not a zoonotic parasite.



**TECHNICIAN'S NOTE** *Klossiella muris* cannot be detected antemortem.

## RATS

### Gastrointestinal Tract

The protozoans that infect the gastrointestinal tract of rats are flagellates and apicomplexans.

### Flagellates

Although somewhat less susceptible than mice, rats may be infected with the flagellates discussed previously in the mouse section: *Giardia assemblage G*, *Spironucleus muris*, *Tetratrichomonas microti*, and *Tritrichomonas muris*. Identification, detection, clinical signs, and transmission in rats are similar to those discussed for the mouse.

### Apicomplexans

**Parasite:** *Eimeria nieschultzi*

**Host:** Rats

**Location:** Intestines

**Distribution:** Worldwide


**Derivation of Genus:** Named after zoologist Gustav Eimer

**Transmission Route:** Ingestion of oocysts

**Common Name:** Coccidia of rats

*Eimeria nieschultzi* is an intestinal coccidian uncommon in laboratory rats but common in wild rats. The sporulated oocyst of *E. nieschultzi* is oval, 16 to 26  $\mu\text{m}$   $\times$  13 to 21  $\mu\text{m}$ , with no residuum. It has a smooth or colorless wall, with no micropyle. The sporulated oocyst contains four oval sporocysts, each with a small Stieda body and a residuum.

Antemortem, *E. nieschultzi* may be detected by finding the oocysts in fecal flotations or direct fecal smears. However, diagnosis is usually based on identification of the organism histopathologically in sections of the intestinal epithelium. Clinical signs of *E. nieschultzi* infections are usually seen in young rats less than several months of age. Signs include diarrhea, weakness, emaciation, and possibly death due to inflammation of the intestines. Rats become infected with *E. nieschultzi* by ingestion of sporulated oocysts in the feces. *E. nieschultzi* is species specific and therefore is not considered a potential cross-contaminant or zoonotic problem.

 **TECHNICIAN'S NOTE** *E. nieschultzi* is uncommon in pet rats but is common in wild rats.

## HAMSTERS

### Gastrointestinal Tract

The protozoans that infect the gastrointestinal tract of hamsters are flagellates.

#### Flagellates

Hamsters typically carry numerous intestinal flagellates without showing clinical signs. These parasites can be observed in fecal flotations or direct smear preparations. These flagellates include *Giardia* species, *Spironucleus muris*, *Tetranucleus microti*, and *Tritrichomonas muris (criceti)*. Infected hamsters may serve as a source of infection for more susceptible rodents, such as in the transmission of *S. muris* to mice.

Identification, detection, clinical signs, transmission, and public health significance of this parasite in hamsters are similar to those discussed for the mouse.

 **TECHNICIAN'S NOTE** Hamsters carry numerous intestinal flagellates but don't tend to show clinical signs of these protozoans.

## GUINEA PIGS

### Gastrointestinal Tract

The protozoans that infect the gastrointestinal tract of guinea pigs are flagellates, amoebae, and apicomplexans.

#### Flagellates

**Parasite:** *Giardia* assemblage G

**Host:** Rodents

**Location of Adult:** Proximal small intestine

**Distribution:** Worldwide


**Derivation of Genus:** Named after a famous zoologist, Alfred Giard

**Common Name:** Giardia

Trophozoites of *Giardia* assemblage G are similar to those previously described. The body is pyriform, or pear-shaped. Two nuclei lie at the anterior end, and four pairs of flagella emerge at various points of the body. Trophozoites are 8 to 15  $\mu\text{m}$   $\times$  6.5  $\mu\text{m}$ . Cysts are about the same size as the trophozoites and contain two to four nuclei.

Cysts or trophozoites of *Giardia* may be detected in a direct fecal smear or possibly in a fecal flotation preparation. If fecal flotation is used, zinc sulfate solution is preferred because sugar and salt solutions may distort the cysts. Diarrheic animals should be examined by direct smear for the presence of motile trophozoites; cyst forms will not be present.

There are no specific clinical signs in infected guinea pigs; however, mucoid diarrhea has been reported in other infected rodents. *Giardia* assemblage G is not considered a public health problem.

 **TECHNICIAN'S NOTE** *Giardia* assemblage G is not considered a public health hazard.

**Parasite:** *Tritrichomonas caviae*

**Host:** Guinea pig

**Location:** Cecum

**Distribution:** Worldwide

**Derivation of Genus:** Three hair unit

**Transmission Route:** Ingestion of oocysts

**Common Name:** Flagellate of guinea pigs

*Tritrichomonas caviae* is of little or no pathologic significance in the guinea pig. As with *T. muris*, *T. caviae* has three anterior flagella and a trailing posterior flagellum. *T. caviae* measures 10 to 22  $\mu\text{m} \times 6$  to 11  $\mu\text{m}$  and is larger than *G. caviae*. It has an undulating membrane that extends the length of its body. These trichomonads are usually found in the cecum of the guinea pig. The veterinary technician should be aware that in cases of protracted diarrhea produced by another pathogen, *T. caviae* protozoans proliferate secondarily because of the fluid medium produced by the diarrhea. *T. caviae* therefore may be observed on direct fecal smear, particularly in animals exhibiting clinical signs of diarrhea.

*T. caviae* is transmitted between guinea pigs by ingestion of the trophozoites passed in the feces of carrier animals. *T. caviae* is not seen in other species of animals and is not considered a public health hazard.

**TECHNICIAN'S NOTE** *Tritrichomonas caviae* typically proliferate (as a secondary infection) in the presence of another pathogen causing diarrhea due to the fluid medium produced by the diarrhea.

## Amoebae

**Parasite:** *Entamoeba caviae*

**Host:** Guinea pigs

**Location:** Cecum

**Distribution:** Worldwide

**Derivation of Genus:** Internal amoeba

**Transmission Route:** Ingestion of oocysts

**Common Name:** Amoeba of guinea pigs

*Entamoeba caviae* is a relatively common nonpathogenic cecal organism in guinea pigs; it is mentioned in this chapter to make the veterinary technician aware that it should be disregarded as a pathogenic organism. The most frequently observed form of this protozoan is the motile trophozoite. Cysts are infrequently observed on concentration with zinc sulfate

flotation medium. Mature cysts are 11 to 27  $\mu\text{m}$  and have eight nuclei. The trophozoites are most often found in a direct fecal smear and measure 10.5 to 20  $\mu\text{m}$  in diameter. The appearance of these trophozoite stages can be enhanced by staining the direct fecal smear with Lugol's iodine.

*E. caviae* is transmitted by ingestion of infective cyst forms that have been passed in the feces of chronic carrier guinea pigs. *Entamoeba caviae* is species specific and is not considered to be of zoonotic significance.

**TECHNICIAN'S NOTE** *Entamoeba caviae* is nonpathogenic and can be found on fecal flotation and direct fecal smears.

## Apicomplexans

**Parasite:** *Eimeria caviae*

**Host:** Guinea pigs

**Location:** Large intestine

**Distribution:** Worldwide

**Derivation of Genus:** named after zoologist, Gustav Eimer

**Transmission Route:** Ingestion of oocysts

**Common Name:** Coccidia of guinea pigs

*Eimeria caviae* is a typical coccidian, with an oval to slightly subspherical oocyst that is 13 to 26  $\mu\text{m} \times 12$  to 23  $\mu\text{m}$ . Oocyst walls are brown and have no micropyle or polar granule. However, oocysts contain a residuum, as do sporocysts. *E. caviae* is commonly found in the guinea pig's large intestine, particularly the ascending or proximal colon.

*E. caviae* can be detected by fecal flotation. Repeated flotation should be done 4 to 5 days apart for 2 to 3 weeks. Diagnosis is made more consistently postmortem, at which time intestinal scrapings placed in saline may be examined microscopically for both intracellular intestinal stages and oocysts of *E. caviae*.

*E. caviae* is generally nonpathogenic, but young animals stressed by poor nutrition and husbandry may show clinical signs. Clinical signs are limited to diarrhea seen 11 to 13 days after exposure due to inflammation of the intestine.

The diarrhea ceases after a few days if the animal is not reinfected. Diarrhea may continue if reinfection occurs. As with the other protozoans of guinea pigs, *Eimeria caviae* is species specific and is not considered of zoonotic significance.



**TECHNICIAN'S NOTE** *Entamoeba caviae* is essentially nonpathogenic but can cause symptoms in young stressed animals with poor nutrition and husbandry.

**Parasite:** *Cryptosporidium wrairi*

**Host:** Guinea pigs

**Location of Adult:** Tips of the intestinal villi of the ileum

**Distribution:** Worldwide

**Derivation of Genus:** Hidden small seeds

**Transmission Route:** Ingestion of oocysts

**Common Name:** *Cryptosporidium* or “Crypto”

*Cryptosporidium wrairi* of guinea pigs is similar to *C. parvum* and *C. muris* of mice. However, *C. wrairi* is considered a distinct species. *C. wrairi* is most often seen lining the tips of the intestinal villi in the ileum of young guinea pigs. Examination of fresh mucosal scrapings by phase-contrast microscopy may provide the best results in the detection and identification of *C. wrairi*. Examination of paraffin-embedded materials is least satisfactory, especially when formalin is used as a fixative. The organisms appear to be extracellular but actually are within the microvilli of the intestinal epithelial cells. The only clinical sign of *C. wrairi* infection is weight loss. Younger guinea pigs at 250 to 300 g are most likely to carry the parasite. Older animals seem to be resistant or to have developed immunity to *C. wrairi*. *C. wrairi* is not found in other species of animals and is not considered a public health problem.



**TECHNICIAN'S NOTE** Examination of fresh mucosal scrapings of the intestinal villi is the preferred diagnostic test for *Cryptosporidium wrairi*.

## FISH

### Skin

Protozoans that infect the skin of fish are ciliates.

### Ciliates

**Parasite:** *Ichthyophthirius multifiliis*

**Host:** Freshwater and ornamental fish

**Location:** Skin, gills, fins, and eyes

**Distribution:** Worldwide

**Derivation of Genus:** Fish louse with many children

**Transmission Route:** Contact with infective stage of life cycle

**Common Name:** Ciliate of fish

*Ichthyophthirius multifiliis* is a ciliate that infects the skin, gills, fins, and eyes of many freshwater tropical and ornamental fish in home aquaria and in hatcheries. This ciliated protozoan causes a skin disease called **ichthyophthiriosis**, or, more commonly, “ich.” Ich is characterized by the formation of tiny white spots (the thin-walled trophozoite stage just beneath the epidermis) over many of the exposed surfaces of the fish. These parasites may be from 100 to 1000  $\mu\text{m}$  in diameter, so they are grossly visible to the observer. Diagnosis is by observation of typical lesions; however, it is possible to perform skin scrapings on infected fish to reveal characteristic ciliates. A similar parasite, *Cryptocaryon irritans*, affects warm water marine (saltwater) fish. Other ciliates infecting fish include *Chilodonella*, *Tetrahymena*, and *Piscinoodinium*. As with *I. multifiliis*, there are marine counterparts for these genera. For details of these and other protozoan parasites of both freshwater and marine fish, a fish disease textbook should be consulted.



**TECHNICIAN'S NOTE** *Ichthyophthirius multifiliis* is diagnosed by observation of typical lesions and skin scrapings.

## CHAPTER ELEVEN TEST

MATCHING—Match the scientific name of each parasite with its correct common name, phrase, or term.

- |                                                  |                                                                                                                             |
|--------------------------------------------------|-----------------------------------------------------------------------------------------------------------------------------|
| A. <i>Giardia</i> species                        | 1. Protozoan parasite residing in reproductive tract of cattle                                                              |
| B. <i>Entamoeba histolytica</i>                  | 2. Equine piroplasm – pear-shaped organisms that may join, giving the effect of a Maltese cross                             |
| C. <i>Balantidium coli</i>                       | 3. “Onion skin” tissue cysts found in skeletal muscle of dogs transmitted by ingestion of tick, <i>Amblyomma americanum</i> |
| D. <i>Cystoisospora</i> species in dogs and cats | 4. Intestinal protozoan of cats (only definitive host) – zoonotic parasite.                                                 |
| E. <i>Toxoplasma gondii</i>                      | 5. Coccidiosis in cattle                                                                                                    |
| F. <i>Trypanosoma cruzi</i>                      | 6. Infectious enterohepatitis – “blackhead” in turkeys – intermediate host is <i>Heterakis gallinarum</i>                   |
| G. <i>Babesia canis</i>                          | 7. Greatly distorts the shape of the avian WBC                                                                              |
| H. <i>Cytauxzoon felis</i>                       | 8. Canine piroplasm – basophilic, pear-shaped organism within canine RBCs                                                   |
| I. <i>Hepatozoon americanum</i>                  | 9. Amebic dysentery in humans                                                                                               |
| J. Rumen ciliates                                | 10. Unique oocysts that are the largest of the coccidians                                                                   |
| K. <i>Eimeria bovis</i> , <i>Eimeria zuernii</i> | 11. Very large ciliated protozoan found in the large intestine of swine                                                     |
| L. <i>Cryptosporidium</i> species                | 12. Colorless sporulated oocysts – 3 to 5 $\mu\text{m}$ in diameter on fecal flotation (zoonotic parasite).                 |
| M. <i>Babesia bigemina</i>                       | 13. Bluish, sausage-shaped body within the cytoplasm of the avian RBC                                                       |
| N. <i>Tritrichomonas foetus</i>                  | 14. Cecal ciliate of guinea pig – usually non-pathogenic, but may be observed in diarrheic conditions                       |
| O. Cecal ciliates of horses                      | 15. Equine protozoal myeloencephalitis (EPM)                                                                                |
| P. <i>Eimeria leuckarti</i>                      | 16. Most commonly diagnosed clinical condition in puppies and kittens (coccidiosis).                                        |



- |                                         |                                                                                                                                                                           |
|-----------------------------------------|---------------------------------------------------------------------------------------------------------------------------------------------------------------------------|
| Q. <i>Babesia equi</i>                  | 17. Oval cysts with a refractile wall and two to four nuclei – may be distorted to semilunar appearance on standard fecal flotation                                       |
| R. <i>Klossiella equi</i>               | 18. Coccidian that parasitizes the small intestine of swine, especially young piglets                                                                                     |
| S. <i>Sarcocystis neurona</i>           | 19. Coccidiosis within the bile ducts of the liver of rabbits                                                                                                             |
| T. <i>Klossiella muris</i>              | 20. Intracellular flagellate (amastigote) found within reticuloendothelial cells of capillaries, spleen, etc. – transmitted by phlebotomine sand flies – oonotic parasite |
| U. <i>Cystoisospora suis</i>            | 21. “Mutuals” of horses                                                                                                                                                   |
| V. <i>Histomonas meleagridis</i>        | 22. Piroplasm of cattle transmitted by tick, <i>Boophilus annulatus</i>                                                                                                   |
| W. <i>Trichomonas gallinae</i>          | 23. Feline piroplasm – “bejeweled ring” within stained RBCs of cats                                                                                                       |
| X. <i>Haemoproteus</i> species          | 24. Nonpathogenic coccidian found in kidneys of wild and laboratory rats                                                                                                  |
| Y. <i>Plasmodium</i> species of birds   | 25. Ciliate infecting the skin, gills, fins, and eyes of freshwater tropical and ornamental fish in home aquaria                                                          |
| Z. <i>Leukocytozoon</i> species         | 26. “Mutuals” of cattle                                                                                                                                                   |
| AA. <i>Eimeria stiedai</i>              | 27. Oocysts found on histopathologic examination of the horse kidney and in urine sediment                                                                                |
| BB. <i>Tritrichomonas caviae</i>        | 28. Found within crop washes and crop swabs of pigeons, doves, and poultry                                                                                                |
| CC. <i>Ichthyophthirius multifiliis</i> | 29. Hemoprotozoan of Central and South America with two forms: trypomastigote and amastigote (zoonotic parasite)                                                          |
| DD. <i>Leishmania</i> species           | 30. Avian malaria                                                                                                                                                         |

## QUESTIONS FOR THOUGHT AND DISCUSSION

- Which protozoan parasites have life cycles that involve arthropods that serve as intermediate hosts? What is the significance of these relationships?
- What are the four kinds of protozoans that affect domesticated animals? Give three examples of parasites for each of these groups.

# Introduction to the Arthropods 12

## KEY TERMS

Arthropod  
Chitin  
Hemolymph  
Mandibulata  
Chelicerata  
Crustaceans  
Myriopodans  
Insects  
Head  
Thorax  
Abdomen  
Simple  
Metamorphosis  
Egg  
Nymph  
Adult  
Complex  
Metamorphosis  
Pupa  
Dictyopterans  
Coleopterans  
Lepidopterans  
Hemipterans  
Hymenopterans  
Anoplurans  
Mallophagans  
Dipterans  
Siphonapterans  
Chelicerates  
Acarines  
Acariasis  
Capitulum  
Idiosoma

## OUTLINE

Arthropoda	Insecta (Insects)
<i>Key Morphologic Features</i>	<i>Key Morphologic Features</i>
Divisions of the Phylum	<i>Orders of Insecta</i>
Arthropoda	Acarina (Mites and Ticks)
Crustacea (Aquatic Arthropods)	
Myriopoda (Centipedes and Millipedes)	

## LEARNING OBJECTIVES

*After studying this chapter, the reader should be able to do the following:*

- Describe the key morphologic features for all arthropods.
- Identify four reasons arthropods are important.
- Detail the importance of crustaceans in veterinary parasitology.
- Detail the importance of insects in veterinary parasitology.
- Describe the key morphologic features of insects.
- Compare complex metamorphosis *versus* simple metamorphosis of insects.
- Identify the members of different orders of insects.
- Describe the key morphologic features of mites and ticks.

## ARTHROPODA


The phylum Arthropoda is one of the largest phyla. There are more than a million species of arthropods, including the extinct trilobites, spiders, mites, ticks, crabs, crayfish, lobsters, water fleas, copepods, millipedes, centipedes, and other insects. The insects include the cockroaches, beetles, bedbugs, fleas, bees, ants, wasps, mosquitoes, butterflies, moths, grasshoppers, lice, silverfish, and dragonflies. With more than 900,000 species, insects are by far the largest class within the phylum Arthropoda.



**TECHNICIAN'S NOTE** The insects are the largest class in the phylum Arthropoda with more than 900,000 species.

## Key Morphologic Features

The name **arthropod** means “jointed foot” (*arthro* means “joint,” and *pod* means “foot”). All adult arthropods have jointed appendages. All arthropods are covered with a chitinous exoskeleton that is composed of segments. **Chitin** is a hard (yet elastic) body covering that envelops the entire body of all arthropods. Whenever you step on a cockroach, the chitin makes the “crunch” sound. Arthropods have a **hemocoel**, a body cavity filled with hemolymph. **Hemolymph** is a bloodlike fluid that bathes the internal organs of an arthropod. When a flying insect hits the windshield of a speeding car and “splats,” hemolymph is the fluid that creates the “splat.” Arthropods have a very simple circulatory system composed of a heartlike dorsal tube. This dorsal tube is actually a primitive heart that pumps the hemolymph to the arthropod’s head. The digestive system of arthropods begins with a **ventral mouth** and ends with a **terminal anus**. Arthropods possess a variety of respiratory systems; they may use gills, book lungs, or tracheal tubes as respiratory organs. Arthropods have complex nervous and excretory systems. However, the most important organ system of the arthropods is the reproductive system. Arthropods have separate sexes; they are **dioecious**. Reproduction is by means of eggs. Arthropods have a tremendous reproductive capacity.


 **TECHNICIAN'S NOTE** Arthropods are dioecious and use eggs for reproduction. They have a tremendous capacity for reproduction.

## DIVISIONS OF THE PHYLUM ARTHROPODA

The phylum Arthropoda is made up of the following subphyla: Trilobitomorpha (the extinct trilobites), Onychophora (onychophorans, or “living fossils”), Tardigrada (water bears), Pycnogonida (sea spiders), Chelicerata (mites, ticks, spiders, scorpions, and others), and Mandibulata (crustaceans, centipedes and millipedes, and insects).

Most of the arthropods important to veterinary parasitology are members of **Chelicerata** and **Mandibulata**.

Members of the phylum Arthropoda are important because (1) they may serve as causal agents themselves, (2) they may produce venoms or toxic substances, (3) they may serve as intermediate hosts for protozoan and helminth parasites, and (4) they may serve as vectors for bacteria, viruses, spirochetes, rickettsiae, chlamydial agents, and other pathogens.

 **TECHNICIAN'S NOTE** Arthropods are extremely important ectoparasites as they can act as parasites themselves, serve as intermediate hosts for other parasites, produce toxins or venoms, or serve as vectors for bacteria, viruses, spirochetes, rickettsiae, and other pathogens.

## CRUSTACEA (AQUATIC ARTHROPODS)

Phylum: Arthropoda

Subphylum: Mandibulata

Class: Crustacea (aquatic arthropods)

Members of the class Crustacea are always aquatic. Crustaceans are important because they serve as intermediate hosts for many helminth parasites, including flukes (e.g., *Paragonimus kellicotti*), tapeworms (e.g., *Spirometra mansonioides*), and roundworms (e.g., *Dracunculus insignis*). Crustaceans also serve as causal agents because they are ectoparasites of many fish, amphibians, and exotic reptiles.

## MYRIOPODA (CENTIPEDES AND MILLIPEDES)

Phylum: Arthropoda

Subphylum: Mandibulata

Class: Myriopoda (centipedes and millipedes)

Members of the class Myriopoda are represented by centipedes and millipedes.

Myriopodans are important because they produce venoms and toxic substances. Centipedes and millipedes are usually slow-moving arthropods. As defense mechanisms, they are capable of producing venoms and toxic substances that can sting, blind, paralyze, burn, or even kill.

## INSECTA (INSECTS)

Phylum: Arthropoda


Subphylum: Mandibulata

Class: Insecta (insects)


As mentioned earlier, the class Insecta has the largest number of members (>900,000 species) in the phylum Arthropoda. This is also the most diverse group. Members of the class Insecta are important because (1) they may serve as causal agents themselves, (2) they may produce venoms or toxic substances, (3) they may serve as intermediate hosts for protozoan and helminth parasites, and (4) they may serve as vectors for bacteria, viruses, spirochetes, rickettsiae, chlamydial agents, and other pathogens. Examples of all of these important pathogenic mechanisms are covered in Chapter 13.

### Key Morphologic Features

As members of the phylum Arthropoda, insects share the following morphologic characteristics: a segmented body with three pairs of segmented legs, bilateral symmetry, a chitinous exoskeleton, a dorsal heart, a ventral nerve cord, a digestive system from mouth to anus, an excretory system, and a reproductive system. As with all other arthropods, insects are dioecious (they, too, have separate sexes) and demonstrate a tremendous reproductive capacity.

 **TECHNICIAN'S NOTE** All insects have the same morphologic characteristics: segmented body with three pairs of segmented legs, bilateral symmetry, chitinous exoskeleton, dorsal heart, ventral nerve cord, digestive system from mouth to anus, excretory system, and reproductive system.

The body of all adult insects is divided into three basic body sections: the head, thorax, and abdomen. The **head** is on the anterior, or front end, of the insect; the head contains the insect's brain, its antennae, the ventrally directed mouthparts, and the eyes (if eyes are present; some insects are eyeless). The **thorax** is the middle body section. The thorax of the adult insect always has three pairs of legs and may have either one or two pairs of wings; however, many insects, such as lice and fleas, are wingless. The **abdomen** is the posterior, or the hind section, of the insect. It often contains the reproductive organs but has no ventral, segmented appendages (e.g., mouthparts of the head, legs of the thorax).

 **TECHNICIAN'S NOTE** The insect body is divided into the head, thorax, and abdomen.

To achieve the size and development of the adult insect, the young insect must undergo changes in size, form, and structure. This series of changes is called **metamorphosis**. For purposes of this text, there are two types of metamorphosis: simple metamorphosis and complex metamorphosis. **Simple metamorphosis** consists of three developmental stages: the egg stage, the nymphal stage, and the adult stage. In this form of metamorphosis, the nymphal stage resembles the adult stage in form, except that it is smaller and is not sexually mature (and therefore cannot reproduce). In winged insects the wings may be absent in the nymphal stage. An example of an insect that undergoes simple metamorphosis is the cockroach.

**Complex metamorphosis** consists of four developmental stages: the egg stage, the larval stage, the pupal stage, and the adult stage. None of these developmental stages bears a resemblance to any of the others. The egg stage does not resemble the larval stage, which in turn does not resemble the pupal stage, which in turn does not resemble the adult stage. The larval stage is described as "wormlike." To reach the adult stage, the insect must develop through

the pupal stage, which is a resting stage. The adult stage emerges from the pupal stage and eventually becomes sexually mature and reproduces, producing large numbers of offspring.



**TECHNICIAN'S NOTE** The insect goes through a simple or complex metamorphosis as it progresses through its life cycle. The metamorphosis depends on the species of the insect.

## Orders of Insecta

With regard to veterinary parasitology, the class Insecta is further divided into nine orders. The orders of greatest significance in parasitology are Dictyoptera (cockroaches and grasshoppers), Coleoptera (beetles), Lepidoptera (moths and butterflies), Hemiptera (true bugs), Hymenoptera (ants, bees, wasps, yellow jackets, and other stinging insects), Anoplura (sucking lice), Mallophaga (chewing lice), Diptera (two-winged flies), and Siphonaptera (fleas). Each of the orders within the class Insecta and its relative importance in veterinary medicine is discussed in detail in chapter 13.

## ACARINA (MITES AND TICKS)

Phylum: Arthropoda

Subphylum: Chelicerata

Class: Acarina (mites and ticks)

The subphylum Mandibulata comprises crustaceans, centipedes and millipedes, and insects. The members of the subphylum Chelicerata include mites, ticks, spiders, and scorpions. Within this subphylum are members of the class Arachnida, order Acarina, the mites and the ticks. Mites and ticks are often referred to as **acarines**, and infestation with mites or ticks is referred to as **acarasis**.



**TECHNICIAN'S NOTE** Ectoparasites cause infestations rather than infections. Infestation with mites and ticks is called acarasis.

Mites and ticks are *not* insects; they are acarines. They are morphologically different from insects. First, the body segmentation of mites and ticks is different from that of insects. Insects are divided into head, thorax, and abdomen; mites and ticks, however, have lost all the external signs of body segmentation and are divided into two body components, the **capitulum** (the “mouthparts,” or a fusion of the head and thorax), and the **idiosoma** (the abdomen). Discussions in this text refer to the two basic body parts of mites and ticks as the “mouthparts” and the “abdomen.” Whereas insects may have antennae, wings, and compound eyes, acarines lack these structures. The mouthparts of the mites and ticks have two basic functions: sucking blood or tissue fluids or attaching or holding onto the host. The following organ systems are represented in mites and ticks: digestive, excretory, respiratory, nervous, and reproductive systems. As with insects, mites and ticks are dioecious (have separate sexes) and possess a tremendous reproductive capacity.

In contrast to insects, mites and ticks do not undergo metamorphosis. There are four developmental stages in the life cycle of acarines: the egg stage, the larval stage, the nymphal stage, and the adult stage. The major difference among these life stages is that the larval acarine has three pairs of legs (or six legs), whereas both nymphal and adult acarines have four pairs of legs (or eight legs). Only the adult stage is capable of sexual reproduction.



**TECHNICIAN'S NOTE** Mites and ticks do not go through a metamorphosis as insects do. Instead, their four life stages resemble each other with the exception of the number of pairs of legs possessed at each stage of development. Only the adult is capable of sexual reproduction.

Mites and ticks are significant in veterinary medicine and are discussed in detail in chapter 13.



**CHAPTER TWELVE TEST**

---

MATCHING—Match the term with the correct phrase or term.

- |                                          |                                                                       |
|------------------------------------------|-----------------------------------------------------------------------|
| A. Arthropods                            | 1. Beetles                                                            |
| B. Chitin                                | 2. Ants, bees, wasps, yellow jackets, and other stinging insects      |
| C. Dioecious                             | 3. Centipedes and millipedes                                          |
| D. Mandibulata                           | 4. Jointed appendages                                                 |
| E. Chelicerata                           | 5. Two-winged flies                                                   |
| F. Myriopoda                             | 6. Egg, larva, pupa, and adult                                        |
| G. Body sections of insects              | 7. Fleas                                                              |
| H. Simple metamorphosis                  | 8. Having separate sexes – both male and female                       |
| I. Complex metamorphosis                 | 9. Crustaceans, centipedes, millipedes, and insects                   |
| J. Dictyopterans                         | 10. True bugs                                                         |
| K. Coleopterans                          | 11. Causal agents, venom producers, intermediate hosts, vectors       |
| L. Lepidopterans                         | 12. The “blood” of most arthropods                                    |
| M. Hemipterans                           | 13. Mites and ticks collectively                                      |
| N. Hymenopterans                         | 14. Sucking lice                                                      |
| O. Anoplurans                            | 15. Hard, elastic covering that envelops the bodies of all arthropods |
| P. Mallophagans                          | 16. Mites, ticks, spiders, scorpions, etc.                            |
| Q. Dipterans                             | 17. Head, thorax, and abdomen                                         |
| R. Siphonapterans                        | 18. TREMENDOUS!                                                       |
| S. Capitulum                             | 19. Developmental stages in the life cycle of a mite or tick          |
| T. Idiosoma                              | 20. Mouthparts of a mite or tick                                      |
| U. Acarines                              | 21. Infestation with either mites or ticks                            |
| V. Acariasis                             | 22. Moths and butterflies                                             |
| W. Egg, larva, nymph, adult              | 23. Cockroaches and grasshoppers                                      |
| X. Importance of arthropods              | 24. Egg, nymph, and adult                                             |
| Y. Reproductive potential for arthropods | 25. Chewing lice                                                      |
| Z. Hemolymph                             | 26. Abdomen of a mite or tick                                         |

**QUESTIONS FOR THOUGHT AND DISCUSSION**

---

1. Compare and contrast “insects” and “acarines.” How are they similar? How are they different?
2. There are many diverse orders within the class Insecta. How does each of these orders integrate into the ways in which arthropods are important? These facts will become evident after studying the following chapter.

# Arthropods That Infect and Infest Domestic Animals

13

## KEY TERMS

Arthropodology  
Mandibulata  
Chelicerata  
Crustaceans  
Myriopodans  
Insects  
Dictyopterans  
Coleopterans  
Lepidopterans  
Hymenopterans  
Mallophaga  
Egg stage  
Nit  
Nymph  
Adult stage  
Pediculosis  
Diptera  
Periodic parasite  
Buffalo gnat  
New World sand flies  
No-see-ums, punkies, sand flies  
Queensland itch, sweat itch, sweet itch, summer dermatitis  
Biting house fly or stable fly  
Horn fly  
Sheep ked  
Hippoboscid fly  
Face fly  
Myiasis  
Facultative myiasis  
Obligatory myiasis  
Spiracular plate  
Screwworm fly  
Reportable parasite

## OUTLINE

Crustaceans	<i>Hemiptera (True Bugs)</i>
Myriopodans	<i>Mallophaga (Chewing or Biting Lice) and Anoplura (Sucking Lice)</i>
Insects	<i>Diptera (Two-Winged Flies)</i>
<i>Dictyoptera (Cockroaches)</i>	<i>Siphonaptera (Fleas)</i>
<i>Coleoptera (Beetles)</i>	Mites and Ticks
<i>Lepidoptera (Butterflies and Moths)</i>	<i>Mites of Veterinary Importance</i>
<i>Hymenoptera (Ants, Bees, and Wasps)</i>	<i>Ticks of Veterinary Importance</i>

## LEARNING OBJECTIVES

After studying this chapter, the reader should be able to do the following:

- Describe the subclass Mandibulata and the subclass Chelicerata.
- Identify the three types of arthropodan parasites that are reportable to the USDA.
- Identify and give examples of arthropods that serve as causal agents themselves.
- Identify and give examples of arthropods that serve as producers of venoms or toxic substances.
- Identify and give examples of arthropods that serve as intermediate hosts for tapeworms, flukes, and especially nematodes.
- Identify and give examples of arthropods that serve as vectors of diseases.
- Compare and contrast the following disease entities in domestic animals: pediculosis, myiasis, siphonapterosis, and acariasis.
- Compare and contrast facultative myiasis and obligatory myiasis.
- Compare and contrast localized and generalized demodicosis.
- Compare and contrast insects and acarines.
- Identify the major arthropodan parasites of domestic animals (when given the host and the location within that host).

Reportable parasites  
(this is NOT a repeat)  
Wolves, warbles  
Ox warbles, cattle grubs  
Gadding  
Horse bots or stomach  
bots  
Nasal bots or nasal bot  
flies  
Siphonapterans  
Siphonapterosis  
Flea dirt or flea frass  
Acariasis  
Pedicels or stalks  
Suckers on pedicels  
Sarcoptidae family  
Psoroptidae family  
Scabies  
Scaly leg  
Foot and tail mites  
Demodicosis  
Localized demodicosis  
Generalized  
demodicosis  
Northern poultry mites  
Red mites of poultry  
Tropical rat mite  
Walking dandruff  
Empodia  
Palps  
Chelicerae  
Hypostome  
Pedipalps  
Scutum  
Inornate tick  
Ornate tick  
Borreliosis  
Tick paralysis  
Argasid or soft tick  
Ixodid or hard ticks  
Seed ticks  
Spinose ear tick  
Fowl tick  
Brown dog tick  
American dog tick or  
wood tick

The study of arthropods is referred to as **arthropodology**. Arthropods, members of the phylum Arthropoda, are important in veterinary parasitology for several reasons. Arthropods (1) serve as causal agents themselves by producing pathology or disease in domesticated or wild animals (or in humans); (2) serve as intermediate hosts for **helminths** (flukes, tapeworms, and roundworms) and **protozoans** (single-cell organisms) that infect domesticated or wild animals (or humans); (3) serve as vectors for bacteria, viruses, spirochetes, chlamydial agents, and other pathogens that produce disease in domesticated or wild animals (or humans); and (4) produce venoms and other substances that may be toxic to domesticated or wild animals (or humans). From one to four of these important criteria are true for each group of arthropods.



**TECHNICIAN'S NOTE** Arthropods can serve as agents of disease, intermediate hosts for other parasites, vectors for bacterial, viral, spirochete, chlamydial, and other pathogenic diseases and can produce venoms or other substances that may be toxic to animals and humans.

The phylum Arthropoda is broken down into several subphyla, two of which are important in veterinary parasitology. These two subphyla are the **Mandibulata** (crustaceans, myriopodans, and insects) and the **Chelicerata** (mites, ticks, spiders, and scorpions).

## CRUSTACEANS

Kingdom: Animalia

Phylum: Arthropoda (arthropods)

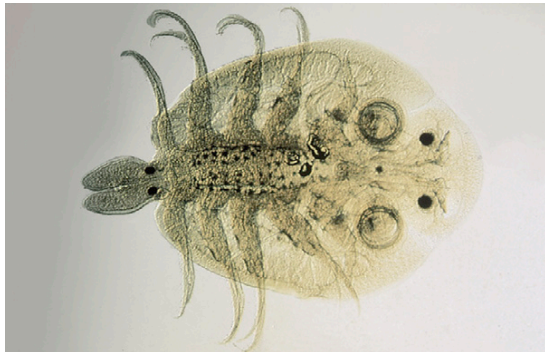
Subphylum: Mandibulata (possess mandibulate mouthparts)

Class: Crustacea (aquatic crustaceans)

Crustaceans are important in veterinary medicine for several reasons. First, crustaceans may be causal agents themselves when they serve as ectoparasites of fishes and amphibians. Tiny, microscopic crustaceans, such as *Argulus* species (Figure 13-1), parasitize the skin and gills of aquatic animals and can produce significant pathology. Crustaceans such as crabs can also be important as causal agents when they are swallowed by dogs that frequent beaches; in this scenario, crustaceans act as foreign bodies within the stomach or other portions of the gastrointestinal tract. Crustaceans may also serve as intermediate hosts for certain helminth parasites of domesticated animals. For example, the crayfish serves as the intermediate host for *Paragonimus kellicotti*, the lung fluke of dogs and cats. Certain aquatic copepods serve as first intermediate hosts for *Diphylllobothrium latum* and *Spirometra mansonoides*, pseudotapeworms of dogs and cats. Finally, certain freshwater crustaceans serve as the intermediate host for *Dracunculus insignis*, the guinea worm, a subcutaneous parasite of dogs.

Lone star tick  
 Gulf coast tick  
 Texas cattle fever tick  
 or North  
 American tick  
 Continental rabbit tick

**TECHNICIAN'S NOTE** *Argulus* species of crustaceans parasitize the gills and skin of aquatic animals while other crustacean species act as intermediate hosts to several types of parasites.



**FIGURE 13-1:** Tiny, microscopic *Argulus* species parasitizes skin and gills of fish.

## MYRIPODANS

Kingdom: Animalia

Phylum: Arthropoda (arthropods)

Subphylum: Mandibulata (possess mandibulate mouthparts)

Class: Myriopoda (centipedes and millipedes)

The class Myriopoda comprises the centipedes and the millipedes. This strange class of arthropods is important because its members produce venoms or toxic substances.

**Parasite:** Centipedes

**Host:** None

**Location:** Free in environment

**Distribution:** Truly poisonous centipedes in jungles and dense vegetation worldwide with exception of North America

**Derivation of Name:** Hundred-legged

**Common Name:** Centipede

**Transmission Route:** Not transmitted

**Centipedes** are usually small, terrestrial arthropods, predatory on creatures smaller than

themselves. Centipedes have one pair of legs for every body segment. On the anterior end, they possess poison claws that connect to large poison glands. Centipedes often subdue their prey with these poison claws. It is important to note, however, that most of the truly poisonous centipedes are restricted to the jungles and areas of dense vegetation throughout the world and *not* to the continent of North America. Some pet stores sell exotic varieties of centipedes, and veterinarians are infrequently asked to “treat” these exotic arthropods; however, a medical arthropodologist (or entomologist) might be consulted. Great care should be taken when handling all centipedes because they can bite. The bite of some of the larger centipede varieties has been likened to the sting of a hornet.

**TECHNICIAN'S NOTE** Centipedes have one pair of legs for every body segment while millipedes have two pairs of legs for every body segment.

**Parasite:** Millipedes

**Host:** None

**Location:** Free in environment

**Derivation of common Name:** Thousand legged

**Distribution:** Truly poisonous centipedes in jungles and dense vegetation worldwide with exception of North America

**Transmission Route:** Not transmitted

**Common Name:** Millipede

**Millipedes** are also small, terrestrial arthropods. Whereas centipedes are predatory on smaller creatures, millipedes are vegetarians. Millipedes have two pairs of legs for every body segment; remember that centipedes have only one pair. Beneath



each pair of legs are repugnatorial glands that contain caustic substances capable of burning the skin. Millipedes are able to “squirt” these caustic, irritating substances onto the skin of any creature that might threaten them. As with the centipedes, most of the truly poisonous millipedes are restricted to the jungles and areas of dense vegetation throughout the world and *not* to the continent of North America. Some tribal people in these jungle areas grind up caustic millipedes and dip their arrow tips into the “juice” to make poisonous arrows. Although centipedes are sold as exotic pets in some pet stores, millipedes do not make good family pets.

## INSECTS

Kingdom: Animalia

Phylum: Arthropoda (arthropods)

Subphylum: Mandibulata (possess mandibulate mouthparts)

Class: Insecta (insects)

A major portion of this chapter discusses the orders of the class Insecta and their place in veterinary parasitology. The following orders are discussed:

Class: Insecta

Order: Dictyoptera (cockroaches)

Order: Coleoptera (beetles)

Order: Lepidoptera (butterflies and moths)

Order: Hymenoptera (ants, bees, and wasps)

Order: Hemiptera (true bugs)

Order: Mallophaga (chewing or biting lice)

Order: Anoplura (sucking lice)

Order: Diptera (two-winged flies)

Order: Siphonaptera (fleas)

### Dictyoptera (Cockroaches)

Cockroaches are members of the order Dictyoptera. These disgusting creatures are perhaps the most commonly occurring insects that may actively “infest” a veterinary clinic. Because of their voracious feeding habits and their close association with stored food products (e.g., dried dog and cat food), cockroaches are often associated with the nocturnal environment of

the veterinary clinic. Cockroaches habitually disgorge portions of their partly digested food and also defecate wherever they roam and feed. Under the proper circumstances, cockroaches may be incriminated in the natural transmission of pathogenic organisms, such as *Salmonella* species, to both humans and domesticated animals.

### Coleoptera (Beetles)

Members of the order Coleoptera, or beetles, are important because they may serve as intermediate hosts for certain parasites of domesticated animals. Dung beetles serve as intermediate host for *Spirocerca lupi*, the roundworm that produces esophageal nodules in dogs, and for *Gongylonema* species, a roundworm found in the tissues of the oral cavity and esophagus of goats and swine. Beetles can also serve as the intermediate host for the swine acanthocephalan, *Macracanthorhynchus hirudinaceus*.



**TECHNICIAN'S NOTE** Dung beetles are intermediate hosts to several parasites including *Spirocerca lupi* in dogs and *Gongylonema* species in goats and swine.

**Parasite:** Blister beetles

**Host:** None

**Location:** Free in environment

**Distribution:** Continental United States and Canada

**Derivation of Genus:** Based on individual type of Beetle

**Transmission Route:** Usually ingested

**Common Name:** Blister beetles

Certain types of beetles, commonly called **blister beetles**, produce within their tissues a toxic substance called **cantharidin** (Figure 13-2). If these beetles are ingested by a mammalian host, they can produce a blistering of the skin, the oral mucosa, and the epithelium lining the alimentary tract. These beetles often infest the earth immediately below alfalfa hay, and when the hay is harvested, the beetles may be collected and



**FIGURE 13-2:** Blister beetles often infest alfalfa hay. They contain cantharidin, a toxic substance that produces colic in horses.

subsequently fed to horses. When horses ingest these beetles, a fatal colic often results. Blister beetles have been referred to as “Spanish fly,” a type of aphrodisiac or “love potion”; however, blister beetles are caustic and will burn living tissues and should not be used as an aphrodisiac.



**TECHNICIAN'S NOTE** Blister beetles produce a toxic substance that is caustic and will burn living tissue and are often found below alfalfa hay.

### Lepidoptera (Butterflies and Moths)

Members of the order Lepidoptera have two life cycle stages—the adult stage and the larval, or caterpillar, stage—that may be pathogenic to domestic animals. Some moths and butterflies in certain parts of Southeast Asia feed on the lachrymal (lacrimal) secretions (tears) of domestic and wild animals. These are exotic creatures, not native to North America. Some moths and butterflies from these exotic regions also have been known to suck blood.

Several species of larval moths and butterflies found in North America are covered with tiny, urticating, or stinging, hairs. Because caterpillars are often slow moving, these hairs serve as defense mechanisms against their predators.

These stinging hairs cause significant stings in humans and domestic animals.

### Hymenoptera (Ants, Bees, and Wasps)

The veterinarian should remember three basic facts about ants, bees, wasps, and hornets (members of the order Hymenoptera). First, “fire ants” are indigenous to the southeastern United States and can bite and sting almost any domesticated animal. “Downer cows” and newborn animals (weak, young lambs and calves and hatchling chicks) are particularly at risk to the perils of fire ants. Fire ants can attack any animal with which they come in contact. Second, bees, wasps, and hornets can sting domestic animals, particularly curious dogs and cats. These are minor envenomizations, seldom resulting in the death of an animal. Third, after being released in Brazil, Africanized honeybees, or “killer bees,” have spread throughout South America and have crossed the border separating Texas and Mexico. Each year, these bees invade farther into the united states. Almost any domestic animal (and humans) can be at risk of inadvertently disturbing a ground hive containing these bees and arousing its inhabitants. Death will often result from thousands of stings from these killer bees. Bees and wasps can cause anaphylactic reactions in allergic animals and humans. If not treated, these reactions can be severe enough to cause death.

If the veterinary diagnostician suspects that ants, bees, wasps, or hornets may be causing problems, the intact Hymenopteran should be collected in a sealed container containing 10% formalin or ethyl alcohol and submitted to an entomologist for identification.



**TECHNICIAN'S NOTE** The Hymenopterans can bite and/or sting domesticated animals causing from mild envenomization to death depending on the species and number of bites or stings and the reaction by the animal's or human's body.

## Hemiptera (True Bugs)

**Parasite:** Reduviid bugs

**Host:** Dogs and humans

**Location:** On host lips & skin of mouth when feeding

**Distribution:** Species can be found worldwide

**Derivation of Genus:** None found

**Transmission Route:** Periodic parasite

**Common Name:** Kissing bugs

The veterinary diagnostician should remember the following basic facts about true bugs (members of the order Hemiptera). There are two groups of hemipterans that are of veterinary importance: reduviid bugs (“kissing bugs”) and bedbugs. **Reduviid bugs** are **periodic parasites**; that is, they make frequent visits to the host to obtain a blood meal. Kissing bugs serve as intermediate hosts for *Trypanosoma cruzi*, a protozoan parasite that can produce a rare disease called **Chagas disease** in humans and dogs. This disease is also called **South American trypanosomiasis** and is rarely diagnosed in the United States. *T. cruzi* infects a variety of internal organs; its infective stages swim in the blood of an infected host. Kissing bugs take blood meals from infected hosts and incubate the parasite in their intestinal tracts. The parasites are then transmitted to uninfected mammals as the bugs defecate. After taking a blood meal from a host, a kissing bug turns around and defecates on the feeding site. This inoculates the infective trypanosomes into the uninfected host. Kissing bugs play a key role in the transmission of Chagas disease.

**TECHNICIAN'S NOTE** Reduviid bugs are an intermediate host to *Trypanosoma cruzi*.

**Parasite:** *Cimex lectularius*

**Host:** Humans, rabbits, poultry, and pigeons

**Location:** On host when feeding

**Distribution:** North America, Europe and Central Asia

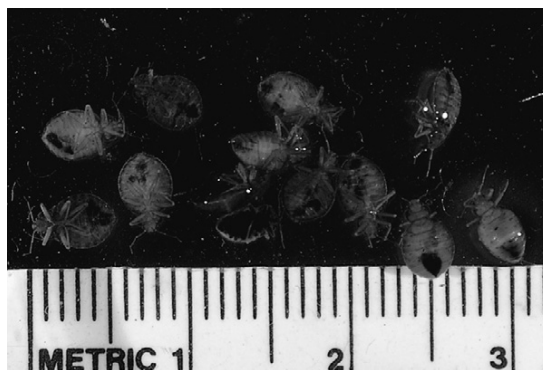**Derivation of Genus:** Latin for bug

**Transmission Route:** Periodic parasite

**Common Name:** Bed bug

**Bedbugs**, *Cimex lectularius*, are the second type of hemipteran important in veterinary parasitology. Bedbugs are dorsoventrally flattened, wingless hemipterans with a three-segmented proboscis tucked under the thorax and ventral “stink glands” producing a characteristic “bed-bug odor,” that often infest human dwellings. They have operculated ova that are deposited on mattresses, in wall cracks and crevices, and under peeling wall paper. They are periodic parasites, making frequent visits to the host to obtain a blood meal. Bedbugs are nocturnal feeders. They are diagnosed by the identification of wingless adult hemipterans, characteristic bed bug odor, and identification of operculated ova in the host environment. Although bedbugs are most often incriminated as human parasites, they may also be found in rabbit colonies, poultry houses, and pigeon colonies, preying on domesticated animals (Figure 13-3). Unlike kissing bugs, bedbugs do not serve as intermediate hosts for pathogenic agents that infect humans or domestic animals.

**TECHNICIAN'S NOTE** After feeding, the bedbug turns around and defecates onto the former feeding site. This act should set up a scenario for transmission of human pathogens, but the bedbug does not serve as a vector or intermediate host.



**FIGURE 13-3:** Bedbugs are periodic parasites of rabbit colonies, poultry houses, and pigeon colonies.

If the veterinary diagnostician suspects that reduviid bugs or bedbugs may be causing problems, the intact hemipteran should be collected and stored in 10% formalin or ethyl alcohol and submitted to an entomologist for identification.



**TECHNICIAN'S NOTE** The bedbug is making a comeback as a significant periodic parasite of humans. It has been found in many “high price” hotels, condominiums, and apartments in New York City.

**Parasite:** *Rhodnius* species, *Panstrongylus* species, and *Triatoma* species

**Host:** Dogs, humans, opossums, cats, guinea pigs, armadillos, rats, raccoons, and monkeys

**Location of Adult:** Lips and skin of the mouth when feeding (periodic parasites)

**Distribution:** South America, Central America, and parts of southwest and western United States (i.e., Texas, Arizona, California, New Mexico, etc.)

**Derivation of Genus:** *Rhodnius* – rose, *Panstrongylus* – all round, *Triatoma* – cut into three

**Transmission Route:** Fly or move from host to host

**Common Name:** Kissing bugs

*Rhodnius*, *Panstrongylus*, and *Triatoma* species are known as the “kissing bugs” because they like to feed on **muco cutaneous** junctions like those between the lips and the skin of the mouth. They appear to be “kissing” the host. The adults have three body portions: head, thorax, and abdomen. These species are winged hemipterans capable of flying. They have a three-segment proboscis reflexed back (tucked) under the thorax. The ova can be found in the environment of the host but are not usually observed. “Kissing bugs” are periodic parasites and voracious blood-feeders. They do not reside upon the host but frequent the host to obtain a blood meal. The kissing bugs serve as intermediate hosts for *Trypanosoma cruzi*, a protozoan parasite. These parasites reside in the host’s environment and travel to the host to obtain their blood meal. They transmit

*T. cruzi* to dogs and humans but may feed on other mammalian hosts. These other hosts may serve as reservoirs for *T. cruzi*. Humans infected with *T. cruzi* develop the disease called Chagas disease. Diagnosis is made by identifying the kissing bug within the host’s environment, such as within the thatched roof of a hut and in cracks and crevices of mud walls.



**TECHNICIAN'S NOTE** After feeding on the host’s blood, the kissing bug turns around and defecates onto its former feeding site. This act sets up transmission of infective forms of *Trypanosoma cruzi* to uninfected hosts.

### Mallophaga (Chewing or Biting Lice) and Anoplura (Sucking Lice)

Lice are some of the most prolific ectoparasites of domesticated and wild animals. There are two orders of lice: **Mallophaga**, the chewing or biting lice, and **Anoplura**, the sucking lice. Lice are dorsoventrally flattened, wingless insects. As insects, lice have bodies divided into three divisions: (1) the head, with mouthparts and antennae; (2) the thorax, with three pairs of legs and noticeable lack of wings; and (3) the abdomen, the portion that bears the reproductive organs. These body divisions and their relationship to each other are important in diagnostic veterinary parasitology.



**TECHNICIAN'S NOTE** Lice are dorsoventrally flattened and wingless insects with three distinctive body parts: head, thorax, and abdomen.

**Parasite:** Mallophagan species

**Host:** Mammals and birds

**Location of Parasite:** In and among the hairs and feathers of the respective hosts.

**Distribution:** Worldwide

**Derivation of Genus:** Wool eaters

**Transmission Route:** Animal-to-animal contact

**Common Name:** Chewing lice

Members of the order Mallophaga (chewing or biting lice) are usually smaller than members of the order Anoplura (sucking lice). Mallophagans are usually yellow and have a large, rounded head. The mouthparts are mandibulate and are adapted for chewing or biting. Characteristically, the head of every chewing louse is wider than the widest portion of the thorax. On the thorax are the three pairs of legs, which may be adapted for clasping or for moving rapidly among feathers or hairs. Chewing (biting) lice may parasitize birds, dogs, cats, cattle, sheep, goats, and horses. Chewing lice of cattle and fowl include *Damalinea bovis* (Figure 13-4), *Goniocotes gallinae* (Figure 13-5), and *Menacanthus stramineus* (Figure 13-6).

**TECHNICIAN'S NOTE** Chewing lice are found on both birds and mammals but they are species specific and there is no crossover between species of animals.

**Parasite:** Anopluran species

**Host:** Domestic animals except cats and birds

**Location of Parasite:** Clinging to the host's hair

**Distribution:** Worldwide

**Derivation of Genus:** Unarmed tail

**Transmission Route:** Animal-to-animal contact

**Common Name:** Sucking lice

Members of the order Anoplura (sucking lice) are larger than chewing lice. These lice range from red to gray; the color usually depends on

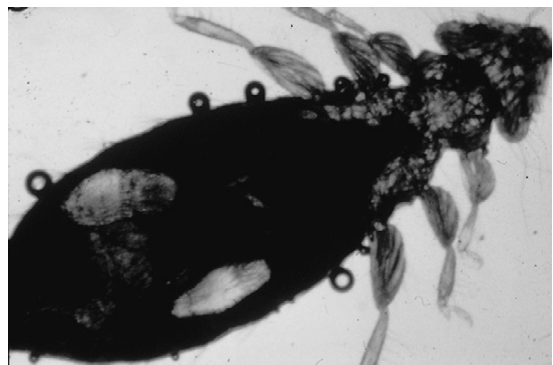
the amount of blood that has been ingested from the host. Anoplurans have three body portions: the head, thorax, and abdomen. The adult anoplurans are wingless. In contrast to the large-headed mallophagans, anoplurans have a head that is narrower than the widest part of the thorax. Their mouthparts are of the piercing type and are adapted for sucking. Their pincer-like claws are adapted for clinging to the host's hairs. Interestingly, although they are found on many species of domestic animals, sucking lice do not parasitize birds or cats. Sucking lice of sheep, swine, monkeys, and dogs include, respectively, *Solenopotes capillatus* (Figure 13-7), *Haematopinus suis* (Figure 13-8), *Pedicinus obtusus* (Figure 13-9), and *Linognathus setosus* (Figure 13-10) and are species specific.



**FIGURE 13-5:** *Goniocotes gallinae*, the fluff louse of poultry.




**FIGURE 13-4:** *Damalinea bovis*, the bovine-biting, chewing louse.



**FIGURE 13-6:** *Menacanthus stramineus*, the avian body louse.



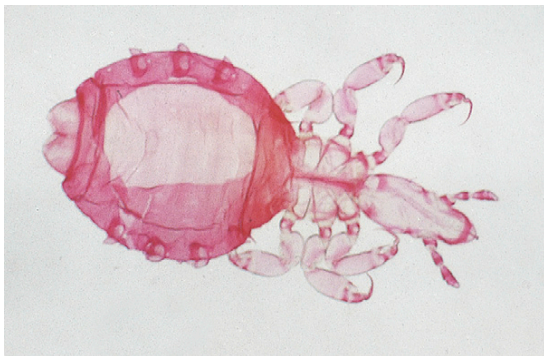
**TECHNICIAN'S NOTE** Sucking lice are species specific and do not parasitize birds or cats. However, they can attach to other species to carry them from one host to another.



**FIGURE 13-7:** Sucking louse *Solenopotes capillatus* of sheep.

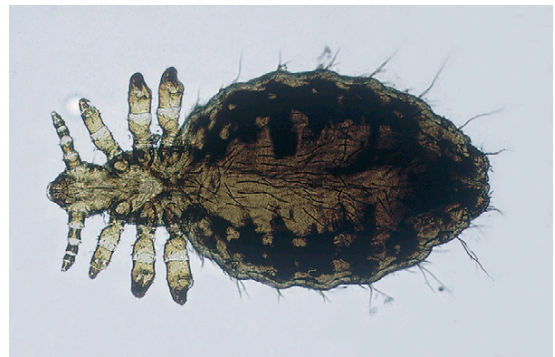

**FIGURE 13-8:** Sucking louse *Haematopinus suis* of swine.




**FIGURE 13-9:** Sucking louse *Pedicinus obtusus* of monkeys.

Anoplurans and mallophagans have a life cycle consisting of three developmental stages. The **egg stage**, which is also called a **nit**, is tiny, approximately 0.5 to 1 mm in length. Nits are oval and white and are usually found cemented to the hair or feather shaft. Figure 13-11 shows *Linognathus setosus*, a gravid female sucking louse and an associated nit collected from a dog. Nits hatch about 5 to 14 days after being laid by the adult female louse. Thousands of nits can be “cemented” by female lice to the hair coat of domesticated animals (Figure 13-12). The **nymphal stage** is similar in appearance to the adult louse. However, the **nymph** is smaller and lacks functioning reproductive organs and genital openings. There are three nymphal stages, each progressively larger than its predecessor. The nymphal stage



**FIGURE 13-10:** Sucking louse *Linognathus setosus* of dogs.



**FIGURE 13-11:** *Linognathus setosus*; gravid female sucking louse and associated nit on hair shaft collected from a dog. Nits are oval, white, and usually found cemented to hair or feather shaft of definitive host.

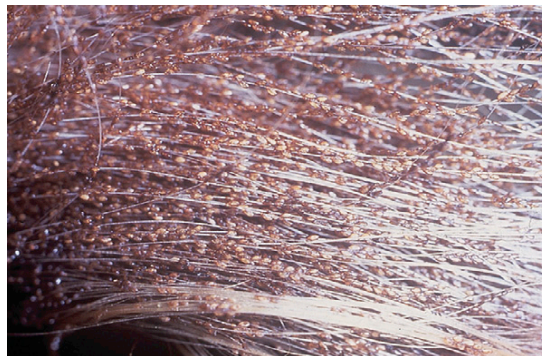
lasts from 2 to 3 weeks. The **adult stage** is similar in appearance to the nymphal stage, except that it is larger and has functional reproductive organs (Figure 13-13). The male and female lice copulate, the female louse lays eggs, and the life cycle begins again, taking 3 to 4 weeks to complete. Nymphal and adult stages may live no longer than 7 days if removed from the host. Eggs hatch within 2 to 3 weeks during warm weather, but seldom hatch off of the host.

Lice usually are transmitted by direct contact, but all life stages may be transmitted by **fomites**, inanimate objects such as blankets, brushes, and other grooming equipment. Lice are easily transmitted among young, old, and malnourished animals. Veterinarians often cannot determine why certain animals in a flock or herd are heavily infested, whereas others have only a few lice.

**TECHNICIAN'S NOTE** Sucking and chewing lice have three body portions: head, thorax, and abdomen. Chewing lice have a head that is wider than the thorax while sucking lice have a head that is narrower than the thorax.

Infestation by lice (either mallophagan or anopluran) is referred to as **pediculosis** (Figure 13-14). Sucking lice can ingest blood to such a degree that they produce severe anemia in the parasitized host; fatalities can occur, especially in young animals. The packed cell volume can decrease as much as 10% to 20%. As many as a million lice may be found on a severely infested animal. Infested animals become more susceptible to other diseases and parasites and may succumb to stresses not ordinarily pathologic to uninfested animals. When animals are poorly fed and kept in overcrowded conditions, they often become severely infested with lice and quickly become anemic and unthrifty.

Careful examination of the hair coat or feathers of infested animals easily reveals the presence of adult lice and their accompanying nits. Hair clippings also serve as a good source for collecting lice. For those animals with a thick hair coat, pediculosis may be overlooked. A hand-held magnifying lens



**FIGURE 13-12:** Thousands of nits can be cemented by female lice to hair coat of domesticated animals. This calf's tail contains thousands of nits.

or a binocular headband magnifier (e.g., Optivisor) may assist in isolation of adult or nymphal lice crawling through or clinging to hair or feathers or tiny nits cemented to individual hairs.

When lice or nits are isolated, they may be collected with tiny thumb forceps and placed within a drop of mineral oil on a glass microscope slide. A coverslip should be placed over the specimen and the slide examined using the 4× or 10× objective of the microscope (Figure 13-15).

Identification of louse to genus and specific epithet is quite difficult. It is better to identify the specimen as being anopluran (sucking) versus mallophagan (chewing or biting). The veterinary diagnostician should remember that the head of every chewing louse is wider than the widest portion of its thorax. The typical sucking louse has a head that is narrower than the widest part of the thorax.

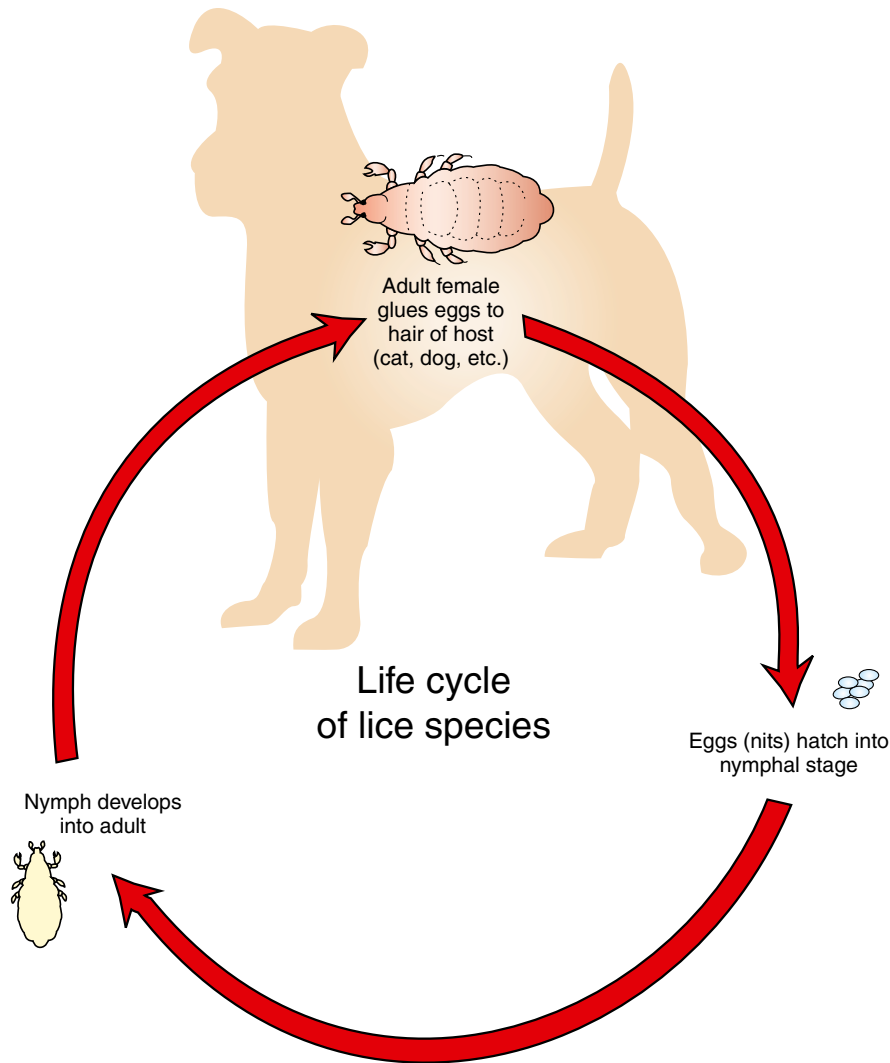
**TECHNICIAN'S NOTE** Identification of lice to specific species is very difficult and should, therefore, be made as to identifying the louse as an anopluran or a mallophagan.

### Lice of Mice, Rats, Gerbils, and Hamsters

**Parasite:** *Polyplax serrata*

**Host:** Mouse

**Location of Parasite:** Within hair coat



**FIGURE 13-13:** Life cycle of the lice species.

**Distribution:** Worldwide

**Derivation of Genus:** Many plates

**Transmission Route:** Direct contact between mice

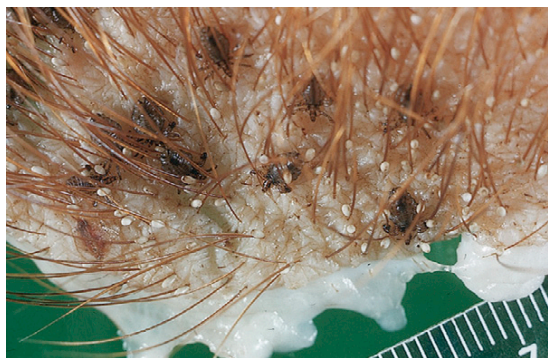**Common Name:** Mouse louse

*Polyplax serrata* is the house mouse louse. This louse is an anopluran (sucking louse), with mouthparts morphologically adapted for sucking blood from its host. Anoplurans are generally more debilitating than mallophagans (chewing lice). *P. serrata* is 0.6 to 1.5 mm long. It is a

slender, yellow-brown to white louse with a head that is narrower than the widest part of the thorax. As with most lice, *P. serrata* is large enough to be detected by careful visual inspection of the hair coat or by microscopic examination of pulled hairs. The adult stage of *P. serrata* is most likely found on the forebody of the mouse. Oval nits may be seen attached near the base of the hair shafts.

Clinical signs associated with infestation by *P. serrata* include restlessness, pruritus, anemia,





**FIGURE 13-14:** Pediculosis can be defined as infestation by either chewing or sucking lice; in this case, *Haematopinus suis* infestation in a pig.

unthrifty appearance, and death. The diagnostician should not attribute dermal signs to pediculosis unless a louse or a nit is detected. The dermal signs may be the result of other causes, such as concurrent infestation with mites. Therefore, it is wise to examine an animal or hair sample thoroughly, rather than ceasing when a single parasite has been identified.

**TECHNICIAN'S NOTE** Clinical signs of *Polyplax serrata* include restlessness, pruritus, anemia, unthrifty appearance and even death; however, dermal signs should not be attributed to pediculosis unless lice or nits are found.

*P. serrata* is transmitted by direct contact between mice. Because lice are species specific, cross-contamination of other species housed in the same area and transmission to humans are not considerations. However, *P. serrata* may serve as a vector for several rickettsial organisms and should therefore be handled with caution.

**Parasite:** *Polyplax spinulosa*

**Host:** Rat

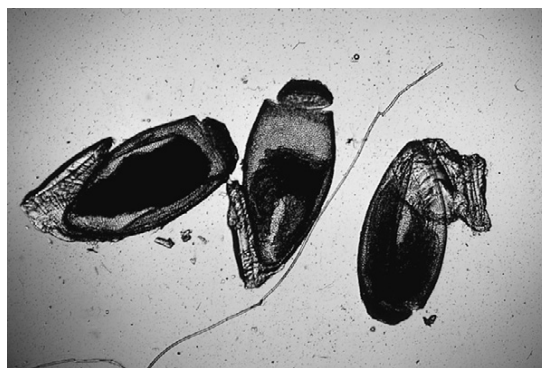**Location of Adult:** Within the hair coat

**Distribution:** Worldwide

**Derivation of Genus:** Many plates

**Transmission Route:** Direct animal-to-animal contact

**Common Name:** Rat louse



**FIGURE 13-15:** Appearance of operculated nits viewed with compound microscope.

As with *P. serrata* in the mouse, the rat louse, *Polyplax spinulosa*, is an anopluran louse (sucking louse). *P. spinulosa* is similar to *P. serrata*, also having a narrow head compared with the thorax. Similarly, its mouthparts are adapted for sucking blood from the rat.

*P. spinulosa* may be detected by gross visual examination of the midbody and shoulders of the rat. Hair may be pulled from these areas and examined for nits, nymphs, and adults. Nits are often found attached to the base of the hair shafts. Nymphs resemble small, pale adult lice. Clinical signs include restlessness, pruritus, anemia, debilitation, and, potentially, death. Transmission of the rat louse is by direct contact. Ivermectin has been used successfully to treat lice in rodents. Because lice are species specific, transmission to other animals or humans is not a concern. *P. spinulosa* is a vector responsible for spread of *Haemobartonella muris* and *Rickettsia typhi* between rats. *R. typhi* also can be transmitted from infected rats to humans by rat fleas.

**TECHNICIAN'S NOTE** *Polyplax spinulosa* is the vector of transmission for *Haemobartonella muris* and *Rickettsia typhi* in rats.

**Parasite:** *Hoplopleura meridionidis*

**Host:** Gerbil

**Location of Adult:** Within the hair coat

**Distribution:** Not Found

**Derivation of Genus:** Unknown

**Transmission Route:** Direct animal-to-animal contact

**Common Name:** Gerbil louse

The louse found on the common pet store gerbil is *Hoplopleura meridionidis*. It is interesting that there are no records of lice reported from either the common pet store hamster, *Cricetus cricetus*, or the common laboratory hamster, *Mesocricetus auratus*.



**TECHNICIAN'S NOTE** *Hoplopleura meridionidis* of gerbils is similar to the lice of rats and mice. There have been no reports of lice from the pet store hamster or the laboratory hamster.

## Lice of Guinea Pigs

**Parasite:** *Gliricola porcelli* and *Gyropus ovalis*

**Host:** Guinea pig

**Location of Adult:** Within the hair coat

**Distribution:** Predominantly South & North America

**Derivation of Genus:** Unknown

**Transmission Route:** Direct animal-to-animal contact

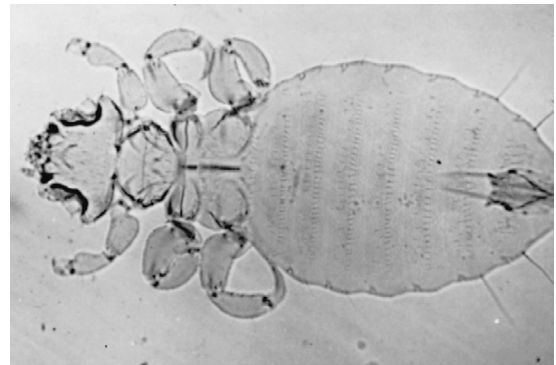
**Common Name:** Guinea pig lice

*Gliricola porcelli* and *Gyropus ovalis* are the lice of guinea pigs. Both species belong to the order Mallophaga (chewing lice). These lice differ from those of the order Anoplura (sucking lice) by their wide, triangular heads. Chewing lice have a strong pair of mandibles, which are used to abrade skin and obtain cutaneous fluids. *G. porcelli* and *G. ovalis* belong to the family Gyropidae, distinguished by having one or no claws on the second and third pairs of legs.

*Gliricola porcelli*, the slender guinea pig louse, is 1 to 1.5 mm × 0.3 to 0.44 mm (Figure 13-16). *Gyropus ovalis*, as its name implies, is more oval than *G. porcelli* and measures 1 to 1.2 mm × 0.5 mm (Figure 13-17). The head of *G. ovalis* is much broader than that of *G. porcelli*. Of these two lice, *G. porcelli* is the more common.



**FIGURE 13-16:** *Gliricola porcelli*, the slender, commonly found guinea pig louse.



**FIGURE 13-17:** *Gyropus ovalis* is more oval than *Gliricola porcelli*, and its head is much broader.

Guinea pig lice can be detected antemortem by careful inspection of the hair coat, either grossly or with a hand-held magnifying lens. Postmortem, a method similar to that used to detect lice in other species of animals may be useful. That is, a piece of the pelt from the dead animal may be placed in a covered Petri dish and placed under a mild heat source, such as a small reading lamp. In a short time, as the pelt cools, the lice migrate toward the warmth of the lamp, to the tips of the hairs. The lice can be easily observed grossly or with a hand-held magnifying lens.

Light infestations of *G. porcelli* and *G. ovalis* usually cause no clinical signs. In heavy infestations, however, alopecia and scablike areas may develop, especially in the areas caudal to



the ears of the guinea pig. Excessive scratching may be noticed. Ivermectin can be used to treat *G. porcelli* and *G. ovalis* in guinea pigs.

**TECHNICIAN'S NOTE** Diagnosis of guinea pig lice is made by finding the living parasites on the animal with a magnifying glass.

Transmission of *G. porcelli* and *G. ovalis* is by direct contact with another host guinea pig or bedding or other fomites from infested guinea pigs. As with other lice, lice of guinea pigs are species specific and do not cross-infest other species, including humans.

### Lice of Rabbits

**Parasite:** *Hemodipsus ventricosus*

**Host:** Rabbit

**Location of Adult:** Within the hair coat

**Distribution:** Not found

**Derivation of Genus:** Unknown

**Transmission Route:** Direct animal-to-animal contact

**Common Name:** Rabbit louse

*Hemodipsus ventricosus* is not typically found on domestic rabbits; however, when infestation does occur, it is especially debilitating. *H. ventricosus* is an anopluran louse, with a head narrower than the widest part of the thorax. Its mouthparts are specially designed for sucking blood from the host. It has a small thorax and a large, rounded abdomen covered with numerous long hairs. Adult *H. ventricosus* are 1.2 to 2.5 mm long and can be observed antemortem by careful visual examination of the hair coat, especially on the dorsal and lateral aspects of the rabbit. On postmortem examination, hairs may be pulled and placed in a Petri dish under a warm lamp and examined with a dissecting microscope or magnifying glass. Adult lice are drawn by the warmth of the lamp to the tips of the hairs. The oval nits of *H. ventricosus* are 0.5 to 0.7 mm in length and may be found attached to the base of the hair shafts by pulling the fur and examining it microscopically.

**TECHNICIAN'S NOTE** *Hemodipsus ventricosus* is not commonly found on pet rabbits but can be debilitating if it is found to infest the pet rabbit.

Clinical signs of *H. ventricosus* include alopecia and ruffled fur. Rabbit lice are avid bloodsuckers, so anemia may occur in severe infestations.

*H. ventricosus* is transmitted from rabbit to rabbit by prolonged direct contact. This mostly occurs between a doe and her litter. Although *H. ventricosus* is not considered zoonotic, it is a vector of *Francisella tularensis*, the etiologic agent that causes tularemia.

### Diptera (Two-Winged Flies)

The order Diptera is a very large, complex order of insects. As adults, all members have one pair of wings (two wings), thus the ordinal name **Diptera**; *di* means “two,” and *ptera* means “wing.” The members vary greatly in size, food source preference, and developmental stage or stages that parasitize animals or produce pathology. With regard to their role as ectoparasites, dipterans produce two contrasting pathologic scenarios. As adults, they may feed intermittently on vertebrate blood, saliva, tears, and mucus; as larvae, they may develop in the subcutaneous tissues or internal organs of the host. When adult dipterans make frequent visits to the vertebrate host and intermittently feed on that vertebrate host's blood, they are referred to as **periodic parasites**. When dipteran larvae develop in the tissue or organs of vertebrate hosts, they produce a condition known as **myiasis**.

**TECHNICIAN'S NOTE** Dipteran larvae can cause a condition known as myiasis (maggot infestation) if they develop in the tissues or organs of vertebrate hosts.

As periodic parasites, blood-feeding dipterans can be classified in several ways based on the way in which the adult male and female dipterans feed

on vertebrate blood and on their food preference. There are certain dipteran groups in which only the females feed on vertebrate blood; these female flies require vertebrate blood for laying their eggs. Included in this group are biting gnats (*Simulium*, *Lutzomyia*, and *Culicoides* spp.), the mosquitoes (*Anopheles*, *Aedes*, and *Culex* spp.), the horseflies (*Tabanus* spp.), and the deerflies (*Chrysops* spp.).

In the second group of blood-feeding dipterans, both male and female adult flies require a vertebrate blood meal. These species include *Stomoxys calcitrans*, the stable fly; *Haematobia irritans*, the horn fly; and *Melophagus ovinus*, the sheep ked.

Another dipteran fly, *Musca autumnalis*, feeds on mucus, tears, and saliva of large animals, particularly cattle.

**TECHNICIAN'S NOTE** In some types of dipterans, the female is the only periodic parasite that feeds on vertebrate blood while in other species of dipterans, both males and females feed on vertebrate blood.

### Periodic Parasites of Which Only Adult Females Feed on Vertebrate Blood

In the first dipteran group of periodic parasites, only the female dipterans feed on vertebrate blood. The tiniest members of this group are the biting gnats of *Simulium*, *Lutzomyia*, and *Culicoides* species.

**Parasite:** *Simulium* species

**Host:** Domesticated animals, poultry, and humans

**Location of Adults:** Surface of skin when feeding; otherwise, in the vicinity of swiftly flowing streams

**Distribution:** Worldwide, but not in Hawaii or New Zealand

**Derivation of Genus:** At the same time


**Transmission Route:** Fly from host to host

**Common Name:** Black flies or buffalo gnats

***Simulium* Species (Black Flies).** Members of the genus *Simulium* are commonly called

**black flies**, although they may vary from gray to yellow, or **buffalo gnats**, because their thorax humps over their head, giving the appearance of a buffalo's hump (Figure 13-18). These are tiny flies, ranging from 1 to 6 mm in length. The adults have broad, unspotted wings that have prominent veins along the anterior margins. They have serrated, scissorlike mouthparts, and thus their bites are very painful. Because the females lay eggs in well-aerated water, these flies are often found in the vicinity of swiftly flowing streams. They move in great swarms, inflicting painful bites and sucking the host's blood. These flies are voracious feeders (periodic parasites) but only the female flies feed on vertebrate blood. The males feed on nectar and pollen. The females fly great distances to find vertebrate blood. The female needs a vertebrate blood meal to lay her eggs. These flies may keep cattle from grazing or cause them to stampede. The ears, neck, head, and abdomen are favorite feeding sites. Black flies also feed on poultry and can serve as an intermediate host for a protozoan parasite known as *Leucocytozoon* species.

**TECHNICIAN'S NOTE** The common name, "black Fly" is a misnomer; not all black flies are black. They can come in a variety of colors from yellow to grey to black.



**FIGURE 13-18:** Members of the genus *Simulium* are commonly called black flies (but may be gray to yellow) or buffalo gnats (thorax humped over head gives appearance of buffalo's hump). Note small size compared with straight pin that is sticking them.

Black flies prefer the daylight hours and tend to be active in open air. Repellents may offer some relief from these flies. The best method of preventing infestation with black flies is by keeping the equine or bovine hosts in the barn during daylight hours.

Black flies are most often collected in the field (usually in the vicinity of their breeding sites, swiftly flowing streams) and not found on animals presenting to a veterinary clinic. They are diagnosed by their small size, humped back, and strong venation in the anterior region of the wings. Identification of black flies to the level of genus is probably best left to an entomologist.

**TECHNICIAN'S NOTE** Black flies are typically found in the field rather than on the animals presenting to a veterinary clinic.

**Parasite:** *Lutzomyia* species and *Phlebotomus* species

**Host:** Mammals of many species, reptiles, avians, and humans (*Lutzomyia* species); mammals, reptiles, avians, and humans (*Phlebotomus* species)

**Location of Adult:** On skin surface when feeding, otherwise, in dark, moist, and organic environments

**Distribution:** Worldwide (*Lutzomyia* species); tropics, subtropics, and Mediterranean regions (*Phlebotomus* species)

**Derivation of Genus:** *Phlebotomus* – vein cutting, *Lutzomyia* – Lutz was a renowned entomologist and *myia* means “fly”

**Transmission Route:** Fly from host to host

**Common Name:** New World sand flies (*Lutzomyia* species); sand flies (*Phlebotomus* species)

**Lutzomyia Species (New World Sand Flies) and Phlebotomus Species.** Members of the genus *Lutzomyia* are commonly referred to as **New World sand flies**. *Phlebotomus* species are commonly referred to as “sand flies.” These two genera represent the group of flies called the phlebotomine sand flies. They are tiny, moth-like flies, rarely more than 5 mm in length. A key feature for identification is that the body (head,

thorax, and abdomen) is **hirsute** (covered with fine hairs). *Lutzomyia* and *Phlebotomus* species tend to be active only at night and are weak fliers. These tiny flies transmit a zoonotic protozoan parasite known as *Leishmania* species and the rodents that reside in the burrows in which the flies live serve as reservoirs for *Leishmania* species.

**TECHNICIAN'S NOTE** The sand flies and New World sand flies are only active at night and do not fly far to get to a host.

As with black flies, sand flies most often can be collected in the field and are not found on animals presenting to a veterinary clinic. The adult flies are weak fliers and are often collected in rodent burrows, where they breed in moist organic debris. Phlebotomine sand flies can be diagnosed by their small size and hairy wings and bodies. Identification of sand flies is probably best left to an entomologist.

**TECHNICIAN'S NOTE** Sand flies are diagnosed by their small size and hairy wings on their bodies.

**Parasite:** *Culicoides* species

**Host:** Domestic animals and humans

**Location of Adult:** On the skin surface when feeding; otherwise, in their aquatic or semi-aquatic breeding grounds

**Distribution:** Worldwide

**Derivation of Genus:** Mosquito-like

**Transmission Route:** Fly from host to host

**Common Name:** No-see-ums, punkies, or sand flies (not to be confused with the phlebotomine sand flies: *Lutzomyia* and *Phlebotomus* species)

**Culicoides Species (No-See-Ums).** *Culicoides* gnats are also commonly known as **no-see-ums**, **punkies**, or **sand flies**. They are tiny gnats (1 to 3 mm in length) and similar to black flies in that they inflict painful bites and suck the blood of their hosts. The adults have a short proboscis and mottled or spotted wings with hairs on the wing

margins. They are active at dusk and at dawn, especially during summer months. The adults tend to be found around their aquatic or semiaquatic breeding grounds when not feeding. The developmental stages are primarily aquatic and are seldom observed in a veterinary clinic setting. These female gnats tend to feed on the dorsal or ventral areas of the host during dusk and evening hours; the feeding site preference depends on the species of biting gnat. Horses often become allergic to the bites of *Culicoides* species, scratching and rubbing these areas, causing alopecia, excoriations, and thickening of the skin. This condition has several names, including **Queensland itch**, **sweat itch**, and **sweet itch**. Because this condition is often seen during the warmer months of the year, it is also referred to as **summer dermatitis**. The best prevention for these flies is stabling animals during the hours between dusk and dawn. Repellents may offer some protection against *Culicoides* species. These flies also serve as the intermediate host for *Onchocerca cervicalis*, a nematode whose microfilariae are found in the skin of horses. These flies also transmit the blue-tongue virus of sheep.

**TECHNICIAN'S NOTE** Several of the *Culicoides* species are intermediate hosts for protozoan and helminth parasites and can also transmit viral diseases. They are associated with the transmission of the blue-tongue virus.

In contrast to the clear, heavily veined wings of black flies, the wings of *Culicoides* species are mottled. Identification of *Culicoides* species is probably best left to an entomologist.

**Parasite:** *Anopheles quadrimaculatus*, *Aedes aegypti*, and *Culex* species

**Host:** Mammals, reptiles, avians, and humans

**Location of Adult:** Skin surface when feeding

**Distribution:** Worldwide

**Derivation of Genus:** *Anopheles* – hurtful, *Aedes* – unpleasant, *Culex* – gnat


**Transmission Route:** Fly from host to host

**Common Name:** Malaria mosquito (*A. quadrimaculatus*), yellow fever mosquito (*A. aegypti*), and mosquito (*Culex* species)

***Anopheles quadrimaculatus*, *Aedes aegypti*, and *Culex* species (Mosquitoes).** Although they are tiny, fragile dipterans, mosquitoes are some of the most voracious blood-feeders (Figure 13-19) and strong fliers. Mosquitoes plague livestock, and as with black flies, swarms of mosquitoes have been known to keep cattle from grazing or cause them to stampede. The feeding of large swarms of mosquitoes can cause significant anemias in domestic animals. Because of their aquatic breeding environments, large numbers of mosquitoes can be produced from eggs laid in relatively small bodies of water.

*Anopheles quadrimaculatus* females lay their eggs on the surface of still water. Each egg possesses two lateral corrugated areas called “floats.” These “floats” allow the eggs of *Anopheles quadrimaculatus* to float on the water’s still surface. At the tip of the *Anopheles* larval abdomen is a breath pore that lacks a **siphon**. The larva floats parallel to the surface of the water and wriggles in the water if disturbed. The pupa floats right at the surface of the water and if disturbed, will tumble down to a lower level within the water and slowly float back to the surface.

**TECHNICIAN'S NOTE** The female mosquito requires a vertebrate blood meal in order to lay her eggs.



**FIGURE 13-19:** Female *Culex* species, one genus among several pathogenic genera of mosquitoes. Although mosquitoes are tiny, fragile dipterans, they are some of the most voracious blood-feeders known.

*Aedes aegypti* females lie on dry surfaces where water will accumulate. These eggs lack the “floats” of *A. quadrimaculatus*. The larval *A. aegypti* has three portions: head, thorax, and abdomen. On the tip of the abdomen is a breathing pore at the tip of the siphon. This mosquito larva floats parallel to the surface of the water and wriggles in the water if disturbed. As with *A. quadrimaculatus*, the *A. aegypti* pupa floats right at the surface of the water and if disturbed will tumble down to a lower level within the water and slowly float back to the surface.



**TECHNICIAN'S NOTE** Mosquito eggs, larvae, and pupae are associated with still water since this is where they carry out these life stages of the mosquito.

*Culex* species females lay their eggs perpendicular to the surface of water to form a floating “egg raft.” The larval mosquito has three portions: head, thorax, and abdomen. In the tip of the abdomen is a breathing pore at the tip of the siphon. This mosquito larva floats parallel to the surface of the water and wriggles in the water if disturbed. The pupa floats right at the surface of the water and if disturbed will tumble down to a lower level within the water and slowly float back to the surface.

Although they are known for spreading malaria (*Plasmodium* spp.), yellow fever, and elephantiasis in humans, mosquitoes are probably best known in veterinary medicine as intermediate hosts for the canine heartworm, *Dirofilaria immitis*.

Many of the repellents on the market are effective against mosquitoes. The repellents must be applied to the entire body at labeled frequencies to provide protection to the animal. In addition, preventing the buildup of small bodies of water on the premises (e.g., water in old tires, small puddles after rains, cleaning water troughs frequently) will help reduce the breeding grounds available to mosquitoes.

The adult and larval body of the mosquito has three portions: head, thorax, and abdomen.

Adult mosquitoes have wings and body parts (head, thorax, and abdomen) covered by tiny, leaf-shaped scales. The adult female of the *Anopheles* species has a proboscis with long palps. The adult female of the *Aedes* species and *Culex* species have a proboscis with short palps. **Palps** are appendages found near the mouth in invertebrate organisms used for sensation, locomotion, and feeding. All females have a pilose (covered with fine hairs) antenna. Identification of both adult and larval *Anopheles*, *Aedes*, and *Culex* species is probably best left to an entomologist.



**TECHNICIAN'S NOTE** Mosquitoes are capable of transmitting bacteria, viruses, spirochetes, *Chlamydia*, protozoans (e.g., *Plasmodium* species [malaria]), and helminths (e.g., *Dirofilaria immitis* [heartworm]). Some of these may be zoonotic agents.

**Parasite:** *Chrysops* species and *Tabanus* species

**Host:** Large mammals and humans but small animals and avians can be attacked

**Location of Adult:** Skin surface when feeding, otherwise, around lakes and ponds

**Distribution:** Worldwide

**Derivation of Genus:** *Chrysops* – golden eye, *Tabanus* – gadfly

**Transmission Route:** Fly from host to host

**Common Name:** Deerflies (*Chrysops* species) and horseflies (*Tabanus* species)

***Chrysops* species (Deerflies) and *Tabanus* species (Horseflies).** *Tabanus* species (horseflies) are **very large** flies (up to 3.5 cm in length) while *Chrysops* species are smaller with banded wings. They both are heavy-bodied, robust, swift dipterans with powerful wings. These flies also have very large eyes. Horseflies and deerflies are the largest flies in this dipteran group in which only the females feed on vertebrate blood (Figure 13-20). Horseflies are much larger than deerflies. Deerflies have a dark band passing from the anterior to the posterior margin of the wings.





**FIGURE 13-20:** *Tabanus* species (horseflies) are large (up to 3.5 cm in length), heavy-bodied, robust dipterans with powerful wings. Horseflies are swift, speedy dipterans. These flies have very large eyes. Horseflies are much larger than deerflies.

**TECHNICIAN'S NOTE** Deerflies and horseflies are the largest flies in the dipteran group and are voracious blood feeders that can consume large amounts of blood.

Adult flies lay eggs in the vicinity of open water such as lakes and ponds. Larval stages of horseflies and deerflies are found in aquatic to semiaquatic environments, often buried deep in mud at the bottom of lakes and ponds. Adults are seen in summer and prefer sunlight. The female flies feed in the vicinity of open water and have reciprocating, scissorlike mouthparts, which they use to lacerate the tissues of vertebrates and lap up the oozing blood. These flies feed primarily on large animals, such as cattle and horses. Site preferences include the underside of the abdomen around the navel, the legs, and the neck and withers. Horseflies and deerflies feed several times in multiple sites before becoming filled with blood. When disturbed by the animal's swatting tail or by the panniculus reflex, the flies leave the host, although blood often continues to ooze from the open wound. The bites of these flies are very painful. Cattle and horses become restless in their presence. Stabling cattle and horses during the day will help reduce the annoyance of these parasites. The newer varieties of insect repellents offer a degree of relief to those

animals turned out during the day. These flies may act as mechanical transmitters of anthrax, anaplasmosis, and the virus of equine infectious anemia.

The veterinary diagnostician can probably best identify these flies by their large, scissorlike mouthparts. Species identification of intact adult horseflies and deerflies is probably best left to an entomologist.

**TECHNICIAN'S NOTE** Identification is best made by observation of the large scissorlike mouthparts while species identification is best left to an entomologist.

### Periodic Parasites of Which Both Adult Males and Females Feed on Vertebrate Blood

In the second group of blood-feeding dipterans, both male and female adult flies require a vertebrate blood meal. These species include *Glossina* species (Tsetse fly); *Stomoxys calcitrans*, the stable fly; *Haematobia irritans*, the horn fly; and *Melophagus ovinus*, the wingless sheep ked.

**Parasite:** *Glossina* species

**Host:** Mammals, reptiles, avians, and humans

**Location of Adult:** Skin surface when feeding

**Distribution:** Continent of Africa

**Derivation of Genus:** Little tongue

**Transmission Route:** Fly from host to host

**Common Name:** Tsetse fly (*tsetse* means “fly destructive to cattle” in Setswana, the language of Botswana and South Africa)

***Glossina* Species (Tsetse Fly).** The tsetse fly, *Glossina* species, is a dipteran biting fly. The adult tsetse fly resembles a wasp or a large honeybee. This biting fly has a bayonet-like proboscis that is designed for piercing the skin and sucking blood. Both male and female flies are avid blood-feeders. There is an onion-shaped bulb at the base of the proboscis. Adult dipterans are identified by their unique wing pattern (**venations**). The tsetse fly has a cleaver or hatchet cell in the middle of each wing.

These flies are unique in that they only breed once during their life cycle. The female will retain

the larva within her abdomen until she is ready to deposit a single larva at a time. She will produce only four to six eggs during her lifetime. The female deposits individual larvae in loose, sandy soil. The larva develops into a pupa in a short period of time. Following pupation, the adults emerge from the pupal case and are on the wing. They copulate only once and the life cycle begins again.



**TECHNICIAN'S NOTE** The tsetse flies only breed once in their lifetime and the female only produces one larva at time.

These flies are found in fly belts (tropical) throughout the continent of Africa. They are periodic parasites; however, they serve as the intermediate host for *Trypanosoma* species, a protozoan parasite that produces both human and animal trypanosomiasis. These flies are not zoonotic as they only transmit animal trypanosomiasis between animals and human trypanosomiasis (African sleeping sickness) between humans. Animal trypanosomiasis is not transmitted to humans. Diagnosis is made by identifying the adult fly.



**TECHNICIAN'S NOTE** Since tsetse flies only breed once during their lifetime, the flies can be controlled by using the sterile male release technique. Sterile males are released into the wild to compete with the intact males. The sterile male will mate with a female without producing an offspring.

**Parasite:** *Stomoxys calcitrans*

**Host:** A variety of animals and humans

**Location of Adult:** Around large animals, especially areas with large amounts of decaying vegetation

**Distribution:** Worldwide

**Derivation of Genus:** Mouth sharp

**Transmission Route:** Fly from host to host

**Common Name:** Stable fly, biting house fly, or legsticker

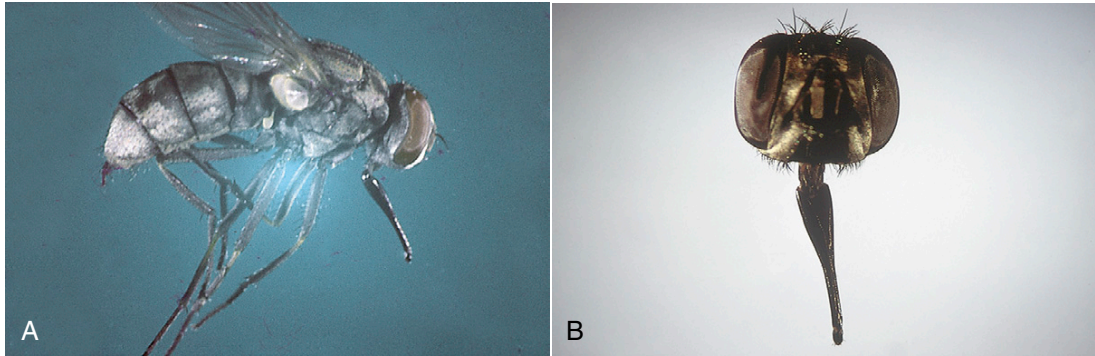
**Stomoxys Calcitrans (Stable Fly).** The stable fly, *Stomoxys calcitrans*, is often called the **biting house fly**. It is approximately the size and coloration of the house fly, *Musca domestica*, but instead of having a sponging type of mouthpart, the stable fly has a bayonet-like proboscis that protrudes forward from its head (Figure 13-21). These flies are found worldwide. In the United States, they are found in the central and southeastern states, areas known for raising cattle. As mentioned previously, both male and female flies are avid blood-feeders, preying on most domestic animals. They usually attack the legs and ventral abdomen but also may bite the ears. These flies tend to feed on the tips of the ears of dogs with pointed or raised ears (commonly called “fly strike”), such as German shepherds. This problem can be resolved by applying topical repellents to the ear tips.



**TECHNICIAN'S NOTE** These flies prefer to feed on the ear tips of dogs with erect ears such as German shepherds.

*S. calcitrans* also feeds on horses and cattle, with horses being the preferred host. The fly usually lands on the host with its head pointed upward. It is a sedentary fly, not moving on the host. The flies inflict painful bites that puncture the skin and bleed freely. Stable flies stay on the host for short periods, during which they obtain their blood meals. This is an outdoor fly; however, in late fall and during rainy weather, it may enter barns or other enclosed areas. Topical insect repellents made for large animals work well against *S. calcitrans*. The repellents should be applied as recommended on the label for adequate protection.

Stable flies are mechanical vectors of anthrax in cattle and equine infectious anemia. This fly is the intermediate host for *Habronema muscae*, a nematode found in the stomach of horses and *Stephanofilaria stilesi*, a nematode found in the skin of cattle, goats, and buffalo. When large numbers of stable flies attack dairy cattle, a decrease in milk production can result. Beef cattle



**FIGURE 13-21:** *Stomoxys calcitrans*, the stable fly or biting house fly, is approximately the size of the house fly, *Musca domestica*. It has a bayonetlike proboscis that protrudes forward from its head.

may refuse to graze in the daytime when attacked by large numbers of flies; as a result, these cattle do not gain the usual amount of weight.

Stable flies use decaying organic material for laying eggs. Removing piles of leaves, grass clippings, soiled bedding, and other decaying matter from the premises will reduce the stable fly breeding areas and reduce the *S. calcitrans* population. Eggs hatch and produce larvae. Each larva develops into a pupa in a short period of time. Following pupation, the adult emerges from the pupal case and is on the wing.

**TECHNICIAN'S NOTE** Control of the stable fly can be accomplished by removing piles of leaves, grass clippings, soiled bedding, and other decaying material from the premises to reduce the breeding areas.

The veterinary diagnostician can easily identify the stable fly by its size (approximately the same size as a house fly) and the bayonet-like proboscis that protrudes forward from the head.

**Parasite:** *Haematobia irritans*

**Host:** Cattle and buffalo

**Location of Adult:** Clustered around the horns but can be around the shoulders, back, sides, and ventral abdomen

**Distribution:** North America, Europe, and Australia

**Derivation of Genus:** Bloody life

**Transmission Route:** Fly from host

**Common Name:** Horn fly

**Haematobia irritans (Horn Fly).** *Haematobia irritans* is often called the **horn fly**. It is a dark-colored fly, approximately 3 to 6 mm in length, half the size of *Stomoxys calcitrans*, the biting house fly. As with the stable fly, the horn fly has a bayonet-like proboscis that protrudes forward from the head (Figure 13-22). These flies are found almost exclusively on cattle throughout North America.

When the air temperature is below 70° F, horn flies cluster around the base of the horns, thus the common name “horn fly.” In warmer climates, horn flies often cluster in large numbers on the host’s shoulders, back, and sides; these are the areas least disturbed by tail swishing. On hot sunny days, horn flies often accumulate on the host’s ventral abdomen. Use of insecticides effective against *H. irritans* will help reduce the horn fly population on the individual cow. This may be accomplished with a fly spray or pour-on solution. A walk-through horn fly trap will cut the individual population in half by mechanically removing the flies from the animal.

Adult horn flies spend most of their life on cattle; females leave the host to deposit their eggs in fresh cow manure. Within the “cow pie,” the eggs hatch into larvae. Each larva develops into a pupa in a short period of time. At the end of the larval development, the larvae will crawl from the cow feces and pupate in loose soil.



**FIGURE 13-22:** *Haematobia irritans* is approximately half the size of the stable fly, *Stomoxys calcitrans*. It also possesses a bayonet-like proboscis that protrudes forward from its head.

Following pupation, the adult flies emerge from the pupal case and are on the wing. The egg, larval, and pupal morphology are significant in a veterinary clinic setting for the case of control purposes. Disruption of the life cycle can be accomplished by spreading the cow feces so it can dry out.

**TECHNICIAN'S NOTE** While these flies can be loosely classified as periodic parasites, they spend most of their adult lives on the animal until they are disrupted. Once disrupted, they fly off the host and either fly back to the same host or fly to a new host.

Using their tiny, bayonet-like mouthparts, horn flies feed frequently, sucking blood and other fluids, and cause considerable irritation. Female flies are more aggressive than males. The energy lost in disturbing the feeding flies coupled with the loss of blood often result in reduced weight gain and milk production. Horn flies probably cause greater losses in cattle in the United States than any other blood-feeding fly. Adult horn flies also cause focal midline dermatitis on the ventral abdomen of horses. These flies serve as the intermediate hosts for *Stephanofilaria stilesi*, a filarial parasite that produces ventral plaquelike lesions on the underside of the abdomen of cattle.

The veterinary diagnostician can easily identify *H. irritans* by its dark color and size (approximately half the size of a stable fly). As with the stable fly, the horn fly's bayonet-like proboscis protrudes forward from the head.

**TECHNICIAN'S NOTE** Although the horn fly is loosely classified as a periodic parasite, they are typically found on the backs of cattle in the pasture in numbers as large as 20,000.

**Parasite:** *Melophagus ovinus*

**Host:** Sheep and goats

**Location of Adult:** Deep within the sheep's wool or goat's fleece

**Distribution:** Worldwide

**Derivation of Genus:** Sheep eater

**Transmission Route:** Direct contact with infested animals

**Common Name:** Sheep ked

**Melophagus ovinus (Sheep Ked).** *Melophagus ovinus* is often referred to as the **sheep ked**. As mentioned earlier, members of the order Diptera usually possess one pair of wings; sheep keds are exceptions to that rule: they are wingless dipterans. Sheep keds have an unusual appearance; they are hairy and appear leathery and measure approximately 4 to 7 mm in length (Figure 13-23). The head of this dipteran is short and broad and contains piercing (bloodsucking) mouthparts. The thorax is brown, and the abdomen broad and grayish brown. The legs are strong and armed with stout claws (Figure 13-24). Keds are often described as having a "louselike" appearance, but they definitely are not lice.

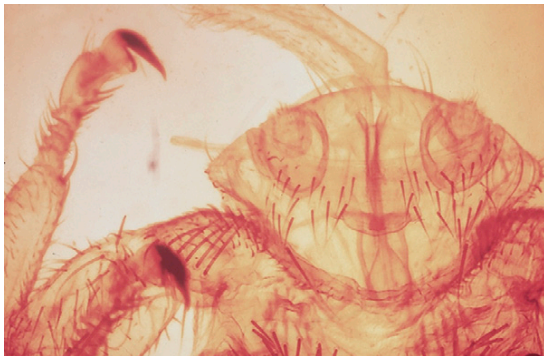
**TECHNICIAN'S NOTE** The sheep ked, while placed in the order Diptera, is a wingless dipteran that has an unusual hairy and leathery appearance.

The female sheep ked does not lay eggs but will retain one larva within her abdomen until she





**FIGURE 13-23:** *Melophagus ovinus*, the sheep ked, is a wingless dipteran that is hairy, leathery, and approximately 4 to 7 mm in length.



**FIGURE 13-24:** The head of *Melophagus ovinus* is short and broad. The legs are strong and armed with stout claws. Some say keds have a louselike appearance.

is ready to deposit that one larva in the sheep's wool or goat's fleece. The larvae develop into pupae quickly; the pupae are dark brown and are also found in the wool or fleece. Following pupation, the adults emerge from the pupal case and can be found within the wool. The life cycle then begins again with the male and female sheep ked breeding. The entire life cycle of this dipteran takes place on the host.

Keds are permanent ectoparasites of sheep and goats. Their pupal stages are often found attached to the wool or fleece of the host. Keds are avid blood-feeders. Heavy infestation can reduce the condition of the host considerably and even cause significant anemia. The bites of *M. ovinus* cause pruritus over much of the host's

body; the infested sheep will often bite, scratch, and rub itself, thus damaging the wool. Ked feces is dark brown, stains the wool, and does not wash out readily. Keds are most numerous in cold temperatures during fall and winter. Their numbers decline as temperatures rise in spring and summer. Close inspection of the wool and underlying skin reveals infestation by these wingless dipterans. Infested wool often has a dark-brown appearance because of discoloration by ked feces. Control of *M. ovinus* may be accomplished by applying an effective insecticide to the sheep after shearing.



**TECHNICIAN'S NOTE** There are other species of keds found on other hosts; *Lipoptena cervi* is the deer ked found on deer.

Sheep keds are closely related to the **hippoboscids**, winged dipterans that parasitize wild birds. These flattened, swiftly flying, blood-feeding dipterans are often found among the feathers of wild birds. Two important hippoboscids are *Lynchia* and *Pseudolynchia* species (Figure 13-25). They can serve as intermediate hosts for *Haemoproteus* species, a malaria-like parasite of wild birds.

**Parasite:** *Lynchia* species and *Pseudolynchia* species

**Host:** Wild birds

**Location of Adult:** Deep within the feathers

**Distribution:** Tropical and Subtropical regions

**Derivation of Genus:** Unknown

**Transmission Route:** Direct contact with infested bird

**Common Name:** Bird keds

***Lynchia* Species and *Pseudolynchia* Species (Bird Keds).** The bird keds are winged dipterans in that they possess one pair of wings and are strong and swift fliers. The adults have piercing (bloodsucking) mouthparts. Both males and females are avid blood-feeders. The adults can be found deep within the feathers of the bird. At the end of each of the adult fly's legs is a fierce-looking claw designed to grip the feathers.





**FIGURE 13-25:** Louse flies, *Lynchia* or *Pseudolynchia* species, often parasitize wild birds.

The female bird ked does not lay eggs but will retain a single larva within her abdomen until she is ready to deposit the single larva. The larvae develop into pupae very quickly. The pupae are dark brown. Following pupation, adults emerge from the pupal case and can be found among the feathers. The life cycle begins again with the male and female breeding. The entire life cycle usually takes place on the host. While transmission is usually from infested bird to uninfested bird by direct contact, the adults are strong fliers so they can fly from host to host; thus, they should be considered periodic parasites.

**TECHNICIAN'S NOTE** If one is handling birds infested with bird keds, the flies may fly off the avian host and try to get in the hair of the veterinarian, technician, or presenting client.

### Periodic Parasites That Feed on Mucus, Tears, and Saliva

The final periodic parasites among the dipteran flies discussed here are ones that are not blood-feeders but instead feed on the mucus, tears, saliva, or feces of animals. These flies are known as *Musca domestica* (house fly), *Musca autumnalis* (face fly), *Calliphora* species, *Lucilia* species, *Phormia* species, *Phaenicia* species, *Sarcophaga* species, and *Hippelates* species.

**Parasite:** *Musca domestica*

**Host:** A variety of animals

**Location of Adult:** Within the house

**Distribution:** Worldwide

**Derivation of Genus:** Fly

**Transmission Route:** Fly from host to host

**Common Name:** House fly

***Musca domestica* (House Fly).** *Musca domestica*, or the house fly, are medium-sized, mouse-grey flies that have sponging mouthparts. These mouthparts cannot be used for lacerating flesh but are designed for lapping up liquid food, including secretions from animals. These flies are “vomit drop feeders.” The adults disgorge their stomach contents, which contain digestive enzymes that liquefy their food. They have a freely movable head and are covered with tiny hair-like bristles called **setae**. Their legs have sticky foot pads. These flies are “designed” for spreading pathogens.

Egg and pupal morphologies of *M. domestica* are not of great veterinary significance but larval morphology is very important in the clinic setting. The larval stage is called “facultative myiasis.” In facultative myiasis, the larval stages may be found in tissues or organs of domestic or wild animals and sometimes in humans. This is discussed more in “Facultative Myiasis-Producing Flies.”

**TECHNICIAN'S NOTE** The larval stage of the house fly life cycle is of great veterinary significance that produces a facultative myiasis.

*M. domestica* are **synanthropic** (“living with humans”), meaning they are house-invading flies. House flies fly freely from feces to food and can transmit a variety of pathogens to animals and humans. The identification of the adult flies is best left to a trained entomologist.

**TECHNICIAN'S NOTE** House flies are efficiently designed for spreading pathogens.

**Parasite:** *Musca autumnalis*

**Host:** Cattle, predominately

**Location of Adult:** Feeding around the medial canthus of the eye

**Distribution:** Worldwide

**Derivation of Genus:** Fly

**Transmission Route:** Fly from host to host

**Common Name:** Face fly

**Musca autumnalis (Face Fly).** Face flies, *Musca autumnalis*, are so named because they gather around the eyes and muzzle of livestock, particularly cattle. They may also be found on the withers, neck, brisket, and sides. Face flies feed mostly on saliva, tears, and mucus. They usually are not considered blood-feeders because their mouthparts are not piercing or bayonet-like. Instead, their mouthparts are adapted for sponging up saliva, tears, and mucus (Figure 13-26). These flies often follow flies that feed on blood, disturb them during their feeding process, then lap up the blood and body fluids that ooze and accumulate on the host's skin. Face flies are found on animals that are outdoors; they usually will not follow animals into barns or other enclosures.

Face flies produce considerable pathology because of their annoyance of the host. The irritation around the host's eyes stimulates the flow of tears, which attracts more flies. The flies' activity produces annoyance, which ultimately interferes with the host's productivity. Face flies may be vectors in the transmission of *Moraxella bovis*, a bacterium that causes infectious keratoconjunctivitis, or pinkeye, in cattle. Face flies may be controlled with the application of an insecticide to the animal's body to offer a degree of relief. Spraying potential breeding sites with insecticide will help reduce fly populations. The eggs are laid in fresh cow feces, while the larval and pupal stages can be found in the soil surrounding dried cow feces.



**TECHNICIAN'S NOTE** The face fly is a great annoyance to the host and is a vector for transmitting the etiologic agent for infectious bovine keratoconjunctivitis, *Moraxella bovis*.

Grossly, the face fly is morphologically similar to the house fly, *Musca domestica*. These two species in the genus *Musca* can be differentiated only through minor differences in eye position and color of the abdomen. The veterinary diagnostician should probably not attempt to speciate this fly; speciation requires the skills of a trained entomologist. Rather, the veterinary diagnostician should remember this rule of thumb: if a fly with sponging mouthparts is found around the face of a cow or horse, it is most probably a face fly.



**TECHNICIAN'S NOTE** A symbiotic relationship between two organisms of different species in which a smaller organism (*Moraxella bovis*) is carried about by a larger organism (*Musca autumnalis*) is called phoresis. The relationship between *Musca autumnalis* and *Moraxella bovis* is an excellent example of phoresis.

**Parasite:** *Calliphora* species, *Lucilia* species, *Phormia* species and *Phaenicia* species

**Host:** Domestic animals, wild animals, and humans

**Location of Adult:** Free-living with humans

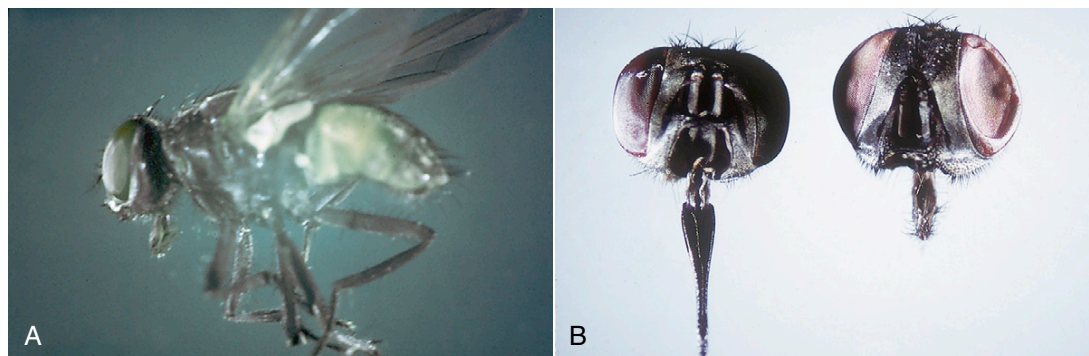
**Distribution:** Australia, England And North America (*Calliphora*); Worldwide (*Lucilia*, *Phormia* and *Phaenicia* species)

**Derivation of Genus:** *Calliphora* – beauty-bearing, *Lucilia* – light

**Transmission Route:** Fly from feces to food

**Common Name:** Bottle flies or blow flies

**Calliphora Species, Lucilia Species, Phormia Species, and Phaenicia species.** These dipteran species are collectively known as the bottle flies or blow flies. These flies are medium size, shiny, and iridescent (blue, black, and green resembling the color of glass bottles, hence the name bottle flies) with sponging mouthparts. The mouthparts cannot be used for lacerating flesh but are designed for lapping up liquid food. These flies are “vomit drop feeders.” The adult flies disgorge their stomach contents, which contain digestive enzymes that liquefy their food. They have



**FIGURE 13-26:** A, *Musca autumnalis*, the face fly. These flies gather around the eyes and muzzle of livestock, particularly cattle. Their mouthparts are adapted for sponging up saliva, tears, and mucus. B, Left, *Stomoxys calcitrans*; right, *Musca autumnalis*.

a freely movable head and are covered with tiny hair-like bristles called setae. Their legs have sticky foot pads. These flies are “designed” for spreading pathogens.

The egg and pupal stages of the life cycle are not of great veterinary significance. However, the morphology of the larval stage is very important in the clinical scenario called “facultative myiasis.” In facultative myiasis, the larval stages of these flies may be found in tissues or organs of domestic or wild animals and, sometimes, human beings. This is discussed further under the topic “*Calliphora*, *Lucilia*, *Phormia*, and *Phaenicia* species – larval stages.”

**TECHNICIAN'S NOTE** Bottle or blow flies are important in veterinary parasitology as facultative myiasis-producing flies.

Like the house flies, the bottle or blow flies are synanthropic (“living with humans”), meaning they are house-invading flies. The bottle or blow flies fly freely from feces to food, transmitting a variety of pathogens. These pathogens are spread by the host eating the infected food on which the flies have disgorged their stomach contents. Thus, they can spread a variety of zoonotic pathogens.

**TECHNICIAN'S NOTE** Some of the larvae of some species of bottle or blow flies are classified as surgical maggots because their larvae have been purposefully introduced into infected wounds of both animals and humans to facilitate the healing process.

**Parasite:** *Sarcophaga* species

**Host:** Domestic animals, wild animals, and humans

**Location of Adult:** Free-flying in the environment

**Distribution:** North America and Hawaii

**Derivation:** Flesh eater

**Transmission Route:** Fly from feces to food

**Common Name:** Flesh fly

***Sarcophaga* species (Flesh Fly).** *Sarcophaga* species are known as the flesh flies. They are medium- to large-size flies possessing a striped thorax and a checkerboard abdomen. They possess sponging mouthparts that cannot be used for lacerating flesh but instead are designed for lapping up liquid food. These flies are “vomit drop feeders.” The adult flies disgorge their stomach contents, which contain digestive enzymes that liquefy their food. They have a freely movable head and are covered with setae. Their legs have sticky foot pads. These flies are “designed” for spreading pathogens.

The female fly retains her eggs within her abdomen. These flies do not lay eggs but instead deposit first-stage larvae in either feces, carrion, or contaminated wounds. The pupal stage is not of great veterinary significance; however, the larval stage is very important in the clinical scenario called “facultative myiasis.” In facultative myiasis, the larval stages of these flies may be found in tissues or organs of domestic and wild animals and sometimes in humans. This is discussed more under the topic “*Sarcophaga* species – larval stage.”

Adult flesh flies fly freely from feces to food and (like house flies and bottle and blow flies) are efficiently designed for transmitting a variety of pathogens some of which are zoonotic.

**TECHNICIAN'S NOTE** Speciation of flesh flies should be left to an entomologist.

**Parasite:** *Lihippelates* species (formerly *Hippelates*)

**Host:** Bovines and canines

**Location of Adult:** On or about mucocutaneous junctions of the eyes, lips, and teats of cattle and the penis of the dog

**Distribution:** North and South America

**Derivation of Genus:** Unknown

**Transmission Route:** Fly from host to host

**Common Name:** Dog Penis Gnats (DPG.s)

**Hippelates species.** *Lihippelates* species of dipterans are known as dog penis gnats due to their proximity to the glans penis of the male dog. These are tiny, nonbiting gnats (not to be confused with the biting gnats *Simulium*, *Phlebotomus*, *Lutzomyia*, or *Culicoides* species). Instead of the lacerating mouthparts possessed by the biting gnats, these nonbiting gnats have sponging mouthparts very similar to those of the house fly, *Musca domestica*. These flies are found in locations on or about the mucocutaneous junctions around the eyes, lips, and teats of cattle and around the penis of the male dog. These flies are irritating to the host. They feed on moisture associated with the mucocutaneous junctions.

**TECHNICIAN'S NOTE** The dog penis gnats are often found in the proximity of the glans penis of the male dog, hence the common name, dog penis gnats.

## Myiasis-Producing Flies

With regard to their roles as ectoparasites, larval dipterans may develop in the subcutaneous tissues of the skin of many domestic animals. When dipteran larvae develop in the tissues or organs of vertebrate hosts, these larvae produce a condition known as myiasis. Based on degree of host dependence, there are two types of myiasis: (1) facultative myiasis, in which the fly larvae are usually **free-living**, and (2) obligatory myiasis. In **facultative myiasis**, the normally free-living larvae adapt themselves to a parasitic dependence on a host. In **obligatory myiasis**, the fly larvae are completely parasitic; that is, they are dependent on the host during development through the life cycle. In other words, without the host, the obligatory parasites will die.

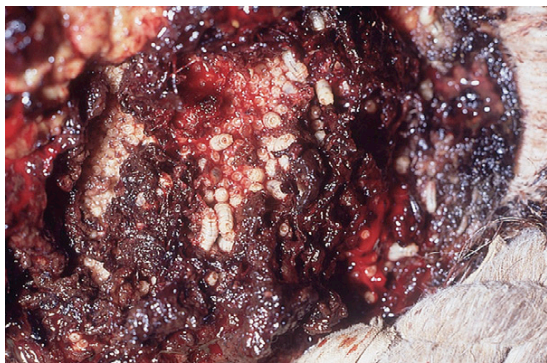
**TECHNICIAN'S NOTE** Free-living fly larvae can become adapted to being parasitic and being dependent on a host to survive to the next stage of their life cycle.

## Dipteran Fly Larvae That Infest The Skin

**Facultative Myiasis-Producing Flies.** The dipteran larvae capable of producing facultative myiasis in the skin are *Musca domestica*, the house fly; *Calliphora*, *Phaenicia*, *Lucilia*, and *Phormia* species, the blow flies, or bottle flies; and *Sarcophaga* species, the flesh flies. Larval stages of these flies are usually associated with skin wounds contaminated with bacteria or with a matted hair coat contaminated with feces.

Under normal conditions, adult flies of these genera lay their eggs in decaying animal carcasses or in feces. In facultative myiasis the adult flies are attracted to an animal's moist wound, skin lesion, or soiled hair coat. These sites provide the adult fly with moist media on which

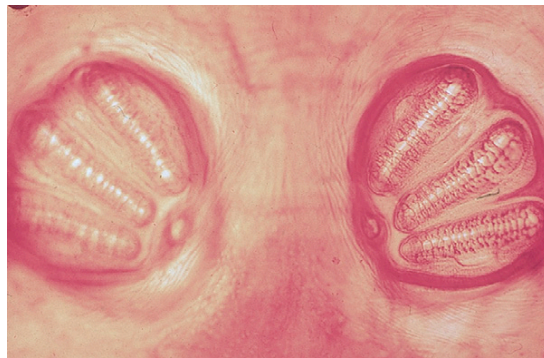



**FIGURE 13-27:** Fly strike in a Hereford cow. The fly larvae (maggots) move independently about the wound surface, ingesting dead cells, exudate, secretions, and debris, but not live tissue. This condition is known as fly strike, or strike.

to feed. As adult female flies feed in these sites, they lay eggs. The eggs hatch, producing larvae (maggots), which move independently about the wound surface, ingesting dead cells, exudate, secretions, and debris, but not live tissue. This condition is known as **fly strike**, or **strike**. These larvae irritate, injure, and kill successive layers of skin and produce exudates. Maggots can tunnel through the thinned epidermis into the subcutis. This process produces tissue cavities in the skin that measure up to several centimeters in diameter (Figure 13-27). Unless the process is halted by appropriate therapy, the infested animal may die from shock, intoxication, histolysis, or infection. A peculiar, distinct, pungent odor permeates the infested tissue and the affected animal. Advanced lesions may contain thousands of maggots. It is important to remember that as adults, these flies can be pestiferous in a veterinary clinical setting. These flies are “vomit drop” feeders and fly from feces to food, spreading bacteria on their feet and within their disgorged stomach contents.

**TECHNICIAN'S NOTE** Facultative myiasis fly eggs can be laid in a moist wound, skin lesion, or soiled hair coat of an animal or human. These eggs then hatch and produce a maggot infestation in that area.



**FIGURE 13-28:** Diagnostic spiracular plates on the posterior end of fly maggot. This plate can be used for positive identification of the fly maggot.

A tentative diagnosis of maggot infestation in any domestic animal can easily be made by a veterinary diagnostician, because maggots can be observed in an existing wound or among the soiled, matted hair coat. A specific diagnosis can be made by examining the **spiracular plate** on the posterior end of the fly maggot. Each species of fly maggot has its own distinctive spiracular plate, much like a fingerprint (Figure 13-28). Dichotomous keys are available for identifying the specific spiracular plate of each species. As soon as a diagnosis of facultative myiasis has been made, the veterinary diagnostician must rule out the possibility of obligatory myiasis caused by *Cochliomyia hominivorax*.

**TECHNICIAN'S NOTE** Maggot infestation is easily made by a veterinarian since the maggots can be observed in an existing wound or around the soiled and matted hair coat.

*Calliphora*, *Lucilia*, *Phormia*, *Phaenicia*, and *Sarcophaga* species larval stages are very recognizable by the owner or the veterinarian. The typical larva is fusiform (bullet-shaped). On its anterior end is a pair of hooks that are used to assist the larva in crawling about the contaminated wound surface. *Sarcophaga* species deposits larvae rather than eggs into contaminated wounds (particularly



skin wounds) of warm-blooded animals so the larvae may live a “parasitic existence,” thus they are considered “facultative parasites.” Wounds are not absolutely necessary for the laying of eggs as flies can lay their eggs in the pelage (haircoat) that is contaminated with urine or feces. Bottle or blow fly larvae can be differentiated from *Cochliomyia hominivorax* by the absence of the two deeply pigmented (black), parallel tracheal tubes on the dorsal-posterior third of the third-stage larva of *Cochliomyia hominivorax*.



**TECHNICIAN'S NOTE** There are some species of bottle or blow flies that produce larvae that *only* ingest unhealthy tissues (tissues contaminated with pathogenic species of bacteria). These species are referred to as “surgical maggots.”

**Obligatory Myiasis-Producing Flies.** The dipteran larvae capable of producing obligatory myiasis in the skin are *Cochliomyia hominivorax*, *Cuterebra* species, and *Hypoderma* species. In obligatory myiasis the dipteran larvae lead a parasitic existence.

**Parasite:** *Cochliomyia hominivorax*

**Host:** Domestic animals

**Location of Larva:** Fresh, uncontaminated wounds of warm-blooded animals

**Distribution:** North America

**Derivation of Genus:** Screw fly

**Transmission Route:** Fly from host to host

**Common Name:** Screwworm, primary screwworm, or New World screwworm

***Cochliomyia hominivorax*.** Only one fly in North America, *Cochliomyia hominivorax*, is a primary invader of fresh, uncontaminated skin wounds of domestic animals. These larvae must not be confused with the larvae of the facultative myiasis-producing flies just described. *C. hominivorax* is often referred to as the **screwworm fly**. In economic terms, it is the most important of the flies that attack livestock in the southwestern and southern United States. These are nonbiting muscoid flies. Adult female flies are attracted to fresh skin wounds (such as recent surgical sites

or recent lacerations, etc.) on warm-blooded animals, where they lay batches of 15 to 500 eggs in a shinglelike pattern at the edge of wounds. The female fly lays several thousand eggs during her lifetime. The cream-colored, elongated eggs hatch within 24 hours. Larvae enter the wound, where they feed for 4 to 7 days before they become third-stage (fully grown) larvae. The veterinarian *must* be able to identify the third-stage larvae of this obligatory myiasis-producing fly. The third-stage larvae are segmented with each segment being emphasized by the presence of rows of tiny, backward-facing black spines along each segment, giving the larvae the appearance of a spiraling wood screw. These larvae can be as long as 1.5 cm; at this stage they resemble a wood screw, thus the name “screwworm.” The third larval stage is *unique* in its appearance. It possesses two deeply pigmented (black) and parallel tracheal tubes on the dorsal-posterior third of the third-stage larva (Figure 13-29). When fully grown, the larvae drop to the ground, after which the adult flies emerge. The adult male and female fly breed only once during their lifetime, a key fact that is used to control these flies biologically. Adult screwworm flies are shiny, greenish blue with a reddish orange head and eyes, and 8 to 15 mm long.

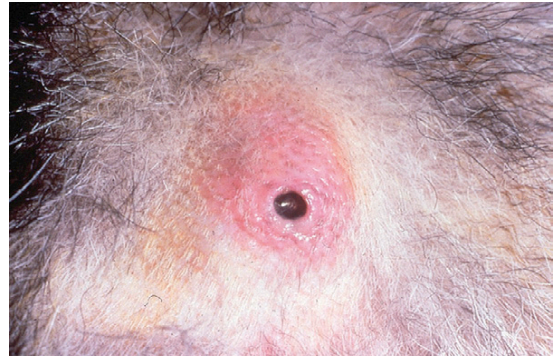

**TECHNICIAN'S NOTE** Identification of the distinct third-stage larva is used to diagnose this stage of *Cochliomyia hominivorax*. Unique features include the characteristic wood-screw shape and the presence of two deeply pigmented and parallel tracheal tubes at the dorsal-posterior third of the larva.

Because of the obligatory nature of the screwworm with regard to breeding in the fresh wounds of warm-blooded animals, the veterinary diagnostician must report the parasite to both state and federal authorities. *C. hominivorax* has been eradicated from the United States but occasionally enters the country surreptitiously in imported animals. While *C. hominivorax* is not a true zoonotic parasite, it can develop in any warm-blooded animal, including humans.



**FIGURE 13-29:** Larvae of *Cochliomyia hominivorax* can be identified by wood-screw shape and two deeply pigmented tracheal tubes on dorsal aspect of caudal ends of third larval stage.



**FIGURE 13-30:** Larval *Cuterebra* species are usually found in swollen, cystlike subcutaneous sites, with a fistula (pore, or hole) communicating to outside environment. The larva breathes through the pore.

**TECHNICIAN'S NOTE** *C. hominivorax* was once present in most of the United States and Canada; however, they have been eradicated from these portions of North America. Since these flies breed only once in their lifetime, they can be controlled using the Sterile Male Release Control Technique.

**Parasite:** *Cuterebra* species

**Host:** Rabbits, squirrels, mice, rats, chipmunks, occasionally dogs and cats

**Location of Larva:** Areas around the head and neck

**Distribution:** North America

**Derivation of Genus:** Skin borer

**Transmission Route:** Direct contact with first-stage larvae

**Common Name:** Warbles or wolves

*Cuterebra* species (*wolves*, *warbles*). Larvae of the genus *Cuterebra* (commonly called **wolves** or **warbles**) infest the skin of rabbits, squirrels, mice, rats, chipmunks, and occasionally dogs and cats. The adult flies look almost exactly like bumblebees. Ova are never observed on the animal. A large discrepancy exists concerning the morphologic descriptions of larval *Cuterebra*. Most of the specimens recovered in a clinical setting are of the second-stage or third-stage larvae. Second-stage

larvae are grublike, 5 to 10 mm long, and cream to grayish white; this stage is often sparsely covered with tiny, black, toothlike spines. Third-stage larvae are large, robust, and coal black, with a heavily spined appearance; they are up to 3 cm in length. Larval stages are usually found in swollen, cystlike subcutaneous sites, with a fistula (pore or hole) communicating to the outside environment (Figure 13-30). It is through this pore that the larval *Cuterebra* breathes.

Adult flies lay eggs near the entrance to rodent burrows. Pets usually contract this parasite while investigating or seeking out rodent prey. As a result, the most frequently affected cutaneous sites in dogs and cats are the subcutaneous tissues of the neck and head. Most cases occur during the late summer and early fall. Among the myiasis-producing flies, this dipteran larva is known for its aberrant or erratic migrations, having been found in a variety of extracutaneous sites, such as the cranial vault, the anterior chamber of the eye, the nose, and the pharyngeal regions. Clinical signs will vary with the site of infection or infestation. Larval *Cuterebra* species are often discovered in cutaneous sites during physical examination. They are usually removed surgically by enlarging the breathing pore and removing the larva with thumb forceps. Great care must be taken not to crush the larva during the extraction process because anaphylaxis might result.



**FIGURE 13-31:** Different developmental stages of *Cuterebra* species. Larval *Cuterebra* are either sparsely or thickly covered with tiny black spines.

**Cuterebrosis** is diagnosed by observing the characteristic swollen, cystlike subcutaneous lesion with its fistula or central pore that communicates to the outside environment. Second-stage or third-stage larvae are usually removed from these cutaneous lesions. These larvae are usually covered with tiny black spines (Figure 13-31).

**TECHNICIAN'S NOTE** *Cuterebra* species should be removed carefully; great care must be taken not to crush the larva during extraction to avoid possible anaphylactic reaction in the host.

**Parasite:** *Hypoderma* species

**Host:** Cattle, and in rare instances horses, sheep, and humans

**Location of Larva:** In large boil-like cysts in the back of the cow

**Distribution:** Northern and southern United States and Canada

**Derivation of Genus:** Under the skin

**Transmission Route:** Adult female flies from host to host

**Common Name:** Gad flies (adults) and cattle grubs (larvae)

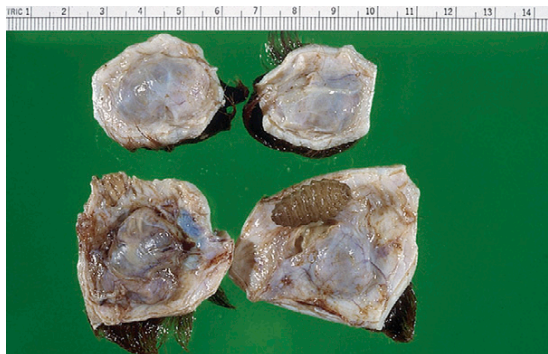
*Hypoderma* species (ox warbles). Two larval species of *Hypoderma* flies (**ox warbles** or **cattle grubs**) infect cattle: *Hypoderma lineatum* and

*H. bovis*. *H. lineatum* is found in the southern United States, and both species are found in the northern United States and Canada. The adult flies are heavy and resemble honeybees; they are often called **heel flies**. These adult flies have very primitive mouthparts so they are not capable of biting the cow; however, they do produce much annoyance to the cow.

The entire life cycle is almost a year long. Adult flies are bothersome to cattle as they approach to lay eggs. Animals often become apprehensive and disturbed and attempt to escape this pesky fly by running away, an action called **gadding**. At the end of the adult female's abdomen there is an ovipositor, which she uses to deposit her eggs on the hairs of the cow's leg. The eggs are about 1 mm long, white, and are attached to hairs on the legs of cattle. *H. lineatum* deposits a row of six or more eggs on an individual hair shaft; *H. bovis* lays its eggs singly on the hair shaft. The larvae hatch in about 4 days and crawl down the hair shaft to the skin, which they penetrate. The larvae wander through the subcutaneous connective tissues in the leg, migrating through the esophagus (*H. lineatum*) or the region of the spinal canal and epidural fat (*H. bovis*), until they reach the subcutaneous tissues of the back. Here the larvae create breathing holes in the skin of the dorsum; it is through these pores that they later exit and fall to the ground to pupate. The adult flies emerge from the pupae.

**TECHNICIAN'S NOTE** *Hypoderma* species produces pathology both as an adult (in the form of annoyance and *gadding*) and as a larval stage (within boil-like cysts in the skin of the back of the cow). If systemic insecticides are used while the larvae are migrating through the spinal cord or esophagus, limb paralysis or bloat may result.

Adult *Hypoderma* species are beelike and are covered with yellow-to-orange hairs. Mature larvae are 25 to 30 mm long, cream to dark brown, and covered with small spines. Lesions consist of large, cystlike swellings on the back, with a



**FIGURE 13-32:** Mature larvae of *Hypoderma* species are 25 to 30 mm long, cream to dark brown, and covered with small spines. Lesions consist of large, cystlike swellings on back, with central breathing pore.

central breathing pore (Figure 13-32). As with *Cuterebra* species, great care must be taken not to crush the *Hypoderma* larva during the extraction process because anaphylaxis may result.

#### **Dipteran Fly Larvae That Infect the Gastrointestinal Tract.**

**Parasite:** *Gasterophilus* species

**Host:** Horses and donkeys

**Location of Larva:** Attached to horse's gastric mucosa


**Distribution:** Worldwide

**Derivation of Genus:** Stomach loving

**Transmission Route:** Adult female lays eggs on horse's leg, horse grooms itself, larvae hatch and penetrate the mucosa

**Common Name:** Bot flies (adults), horse bots (larvae)


*Gasterophilus* species (**horse bots** or **stomach bots**) have three developmental stages that may be associated with pathology in the horse. Just as adult *Hypoderma* species are annoying to the host, adult *Gasterophilus* species are similarly annoying. These adult flies resemble honeybees. The adult flies have very primitive mouthparts; thus, they are not able to bite the horse. During late summer and early fall, adult females fly around the fetlocks of the forelegs and the chin and shoulders of the horse to oviposit eggs on the hairs in these regions (Figure 13-33). This fly's activity and the accompanying oviposition cause



**FIGURE 13-33:** Numerous eggs cemented to forelimb of a horse.

extreme annoyance to the host. Some horses will panic because of the egg-laying activity of these flies. The bot fly eggs are small and white. The female fly “glues” each egg individually to single hairs on the leg of the horse (or appropriate location). Within each egg is a tiny fly larva (first-stage larva), which is ringed by several rows of backward-facing spines. Once the eggs have been laid on the hairs, the horses lick themselves. The abrasive tongue and accompanying saliva are a stimulus for the larvae to hatch from the eggs (Figure 13-34). The larvae penetrate the mucosa of the lips, tongue, and buccal cavity and migrate through the oral mucosa. They eventually emerge and migrate to the cardiac portion of the stomach, where they remain attached for 10 to 12 months. The larvae measure up to 20 mm in length, are red to brown, and possess dense spines on the anterior border of each body segment. There is a pair of indistinct mouth hooks (organs of attachment) on the anterior end of the first body segment and a spiracular plate on the posterior end. These larvae usually pass out of the host in the spring (Figure 13-35) and pupate on the ground for 3 to 5 weeks. The adult flies emerge from the pupal case and live during the latter half of the summer. The larval stage of the *Gasterophilus* species can be treated with dichlorvos, trichlorfon, or ivermectin dewormers in the fall and spring seasons. A bot knife may be used on the legs of the animal to remove the eggs before they are able to infect the animal.





**FIGURE 13-34:** Individual egg of *Gasterophilus* species cemented by adult female fly to hairs on a horse's leg. Friction and moisture of horse's licking causes the egg to hatch. Note emergence of larval bot.



**FIGURE 13-35:** Final larval stage of *Gasterophilus* species is often found within feces of equine host. Note presence of anterior hooks, with larva attached to gastric mucosa.

**TECHNICIAN'S NOTE** *Gasterophilus* species produces pathology as both an adult (annoyance) and as a larva (attachment to gastric mucosa).

The veterinary diagnostician should be able to identify the annoying adult female flies seen around the horse in the fall. The telltale egg stages contain tiny larvae, and the dark-brown bots pass out with the feces. It is through the feces that the third larval stage exits the gastrointestinal tract; therefore this parasitic stage may be recovered in horse feces.

### Dipteran Fly Larvae that Infect the Respiratory Tract.

**Parasite:** *Oestrus ovis*

**Host:** Sheep and goats

**Location of Larva:** Nasal passages

**Distribution:** Worldwide

**Derivation of Genus:** Gadfly

**Transmission Route:** Adult female flies from host to host and lays larvae in the nares

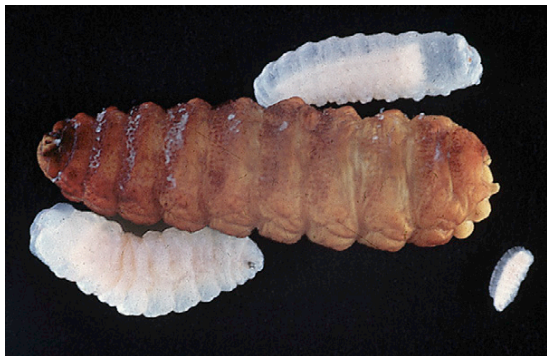
**Common Name:** Nasal bot fly (adult), grub (larvae)

**TECHNICIAN'S NOTE** How does a bot fly get a name that sounds like a portion of a female's reproductive cycle? It was once believed that when women were undergoing the estrus phase of their menstrual cycle, they would "act irrationally" or become "hysterical." When sheep are plagued by the adult nasal bot fly, they will run about madly, hence the name, *Oestrus ovis*.

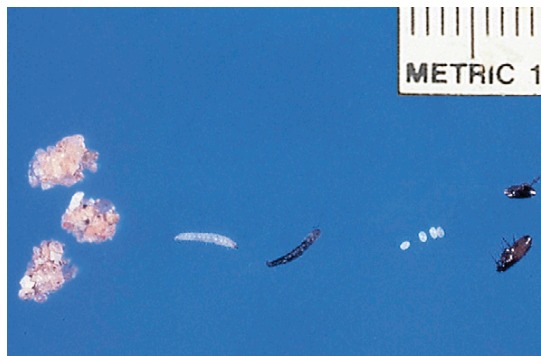**Oestrus ovis (Nasal Bots).** *Oestrus ovis* (nasal bots or nasal bot flies) produce a respiratory myiasis in sheep. The adults are beelike flies and, like both *Hypoderma* and *Gasterophilus* species, are quite annoying to the sheep or goat. The adult female fly flies into the area of the nostrils, where she deposits a tiny, first-stage larva. This causes a great deal of annoyance, resulting in the sheep or goat keeping its nostrils very close to the ground as an avoidance mechanism. This tiny, white-to-yellow larva crawls upward into the nostrils and sinuses of the sheep or goat, often producing a purulent rhinitis or sinusitis. The larvae grow rapidly into 3-cm, dark-brown larvae with large, black oral hooks (Figure 13-36). When fully developed, the larvae drop out of the nostrils and pupate in the ground; the adults then emerge from the pupa. Ivermectin has been shown to be very effective against *O. ovis*.

The veterinary diagnostician should be able to identify the large, dark-brown bots as they pass out of the nostrils.





**FIGURE 13-36:** Several larval stages of *Oestrus ovis* extracted from nasal passages of sheep.



**FIGURE 13-37:** Life stages of *Ctenocephalides felis*, the cat flea: adult males and females, eggs, larvae, and pupae.

**TECHNICIAN'S NOTE** Occasionally, the larvae of *Oestrus ovis* wander aberrantly and get into the host's cranial vault, producing neurologic abnormalities. This neurologic condition is referred to as "false gid."

### Siphonaptera (Fleas)

Of all the orders of arthropods discussed thus far, members of the order Siphonaptera, or fleas, are perhaps the most important insect with respect to veterinary economics. Treating for fleas can be a veterinary practice builder. Because of the extreme popularity of dogs and cats and the prolific nature of the flea (and thus its ability to return after populations are exterminated on the animal and within the animal's environment), the veterinarian should pay special attention to diagnosing the various life cycle stages of fleas both on the pet and in the pet's environment (Figure 13-37).

**Parasite:** *Ctenocephalides felis*, *Ctenocephalides canis*, *Cediopsylla simplex*, *Odontopsylla multispinosus* and *Echidnophaga gallinacea*

**Host:** Cats and dogs (*C. felis*), dogs (*C. canis*), rabbits (*C. simplex*), rabbits (*O. multispinosus*), and poultry but will feed on dogs and cats (*E. gallinacea*)

**Location of Adult:** On the skin

**Distribution:** Worldwide

**Derivation of Genus:** Cockle or comblike head (*Ctenocephalides*), monster eater (*Echidnophaga*)

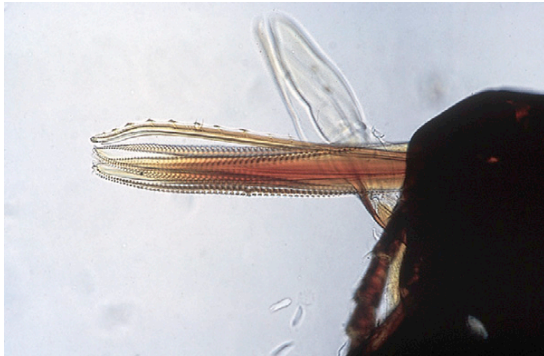**Transmission Route:** Host-to-host contact and contact with infested environment

**Common Name:** Cat flea and dog flea, common eastern rabbit flea, giant eastern rabbit flea, and poultry flea, respectively

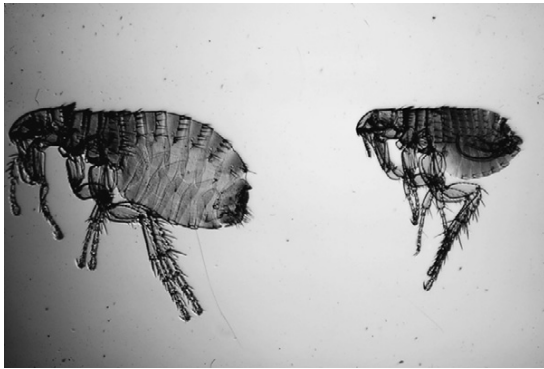
Fleas, or **siphonapterans**, are small (4 to 9 mm in length), laterally compressed, wingless insects with powerful hind legs that are used for jumping onto hosts. Their "flatness" allows them to run through the pelage (haircoat). Adult fleas have piercing and sucking (siphonlike) mouthparts that are used to suck the blood of their hosts (Figure 13-38). Adult female fleas are usually larger than male fleas. The adult flea has three body components: the head, the thorax, and the abdomen. They also have three pairs of legs with the posterior pair being larger than the first two pairs. It is this posterior pair of legs that allows fleas to jump great distances. More than 2000 species of fleas have been identified throughout the world. Adult fleas are always parasitic, feeding on both mammals and birds (Figure 13-39). Dogs and cats are host to comparatively few species of fleas.

**TECHNICIAN'S NOTE** Adult fleas are able to jump great distances with their very powerful rear legs.

The flea life cycle consists of four stages: (1) adult stage, (2) egg stage, (3) larval stage, and (4)



**FIGURE 13-38:** Mouthparts of *Echidnophaga gallinacea*, the sticktight flea of poultry. Adult fleas are placed in the order Siphonaptera because they possess piercing-sucking (siphon-like) mouthparts used to suck host's blood.



**FIGURE 13-39:** Morphologic details of adult male (left) and female *Ctenocephalides felis* (right), cat fleas. Note penis rods of male and spermatheca of female.

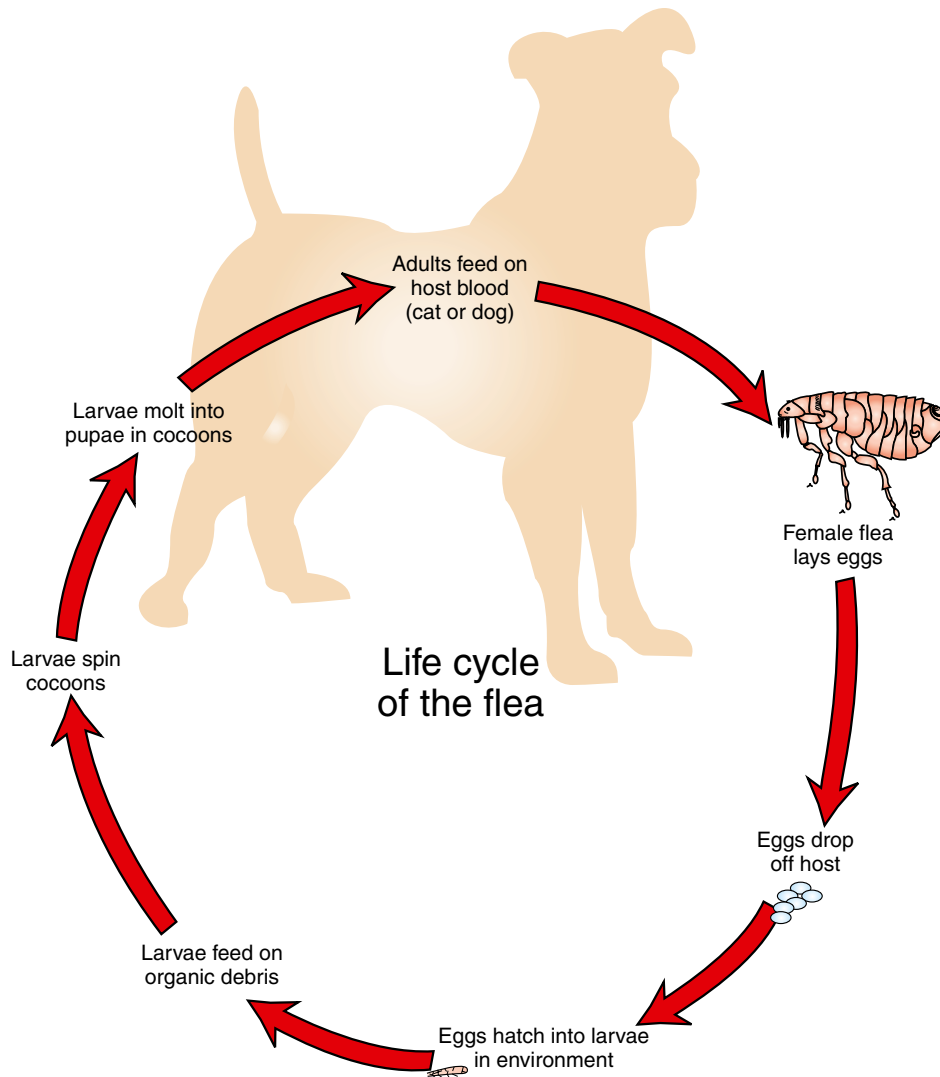
pupal stage. The female flea can lay up to several thousand eggs in her lifetime. The eggs may be laid on the infested animal or in the environment. Eggs laid on the animal will drop to the ground or bedding. The eggs are very tiny and resemble tiny pearls. Typical flea eggs are smooth, white, and oval. They are not sticky so they will fall off the host and be found in the host's environment. The eggs will hatch into larvae within 2 weeks. Flea larvae are maggotlike in appearance and sparsely covered in hairs. The larvae eat organic debris (e.g., dead skin, dead hair, flea feces) from the environment. The larva will begin to form a cocoon as it passes into the pupal stage. The pupal stage is carried out entirely within the cocoon

and can last for months. The cocoon keeps the pupa from desiccating over long periods (Figure 13-40). The flea pupae are seldom observed by the client or veterinarian. The flea pupa has a loosely spun cocoon that is very sticky—so sticky that environmental debris like sand and dust will adhere to the pupa. Flea eggs, larvae, and pupae are found in the host's environment—from the pet's bedding to the owner's bed—any site to which the infested pet has access. The flea will only emerge from the pupal stage if environmental signs (air pressure, vibrations, warmth) indicate a host is present. The adult flea can survive only up to 1 week without a blood meal. Once emerged, the adult flea will find a host, take a blood meal, and begin the life cycle again.

*Ctenocephalides felis*, the cat flea, is the most common flea found on dogs and cats. The dog flea, *Ctenocephalides canis*, is uncommon and occurs much less frequently on dogs than does the cat flea.

When flea infestation is suspected in domestic rabbits, a complete physical examination of the rabbit hair coat should be performed, because different species of fleas prefer different areas of the body surface. *Cediopsylla simplex*, the **common eastern rabbit flea**, is often found around the face and neck of domestic rabbits. *Odontopsylla multispinosus*, the **giant eastern rabbit flea**, is often found over the "tail-head" region at the base of the tail of domestic rabbits (when they curl in sleep with head close to tail).

*Echidnophaga gallinacea* is also known as the **sticktight flea of poultry** (Figure 13-41; see also Figure 13-38). A common flea of chickens and guinea fowl, *E. gallinacea* also feeds on dogs and cats. This flea has unique feeding habits. The female flea inserts her mouthparts into the skin of the host and remains attached at that site. On first observation, these specimens resemble attached ticks; however, they are indeed fleas. *E. gallinacea* prefer to attach and feed around the eyes and ears of dogs and cats. Since these fleas are usually associated with farm environments, the egg, larval, and pupal stages are rarely observed. However, these stages would be exactly the same as those corresponding to the same stages of *Ctenocephalides felis*.



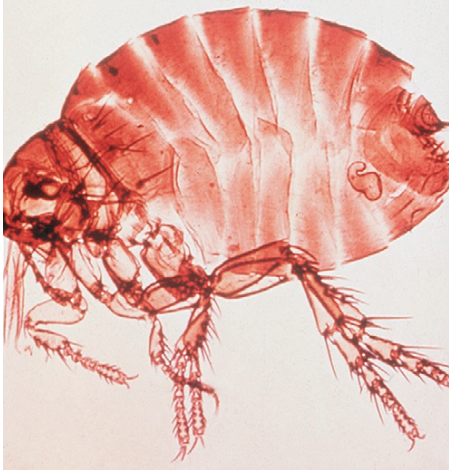
**FIGURE 13-40:** Life cycle of the flea.

Fleas are not typically found on either horses or ruminants. In barns where “barn cats” abound and excessive straw is present, large numbers of fleas have been found on calves. Under these conditions, fleas can produce significant anemias in young calves. *Pulex irritans*, the flea of humans, has been recovered from dogs and cats, especially in the southeastern United States.

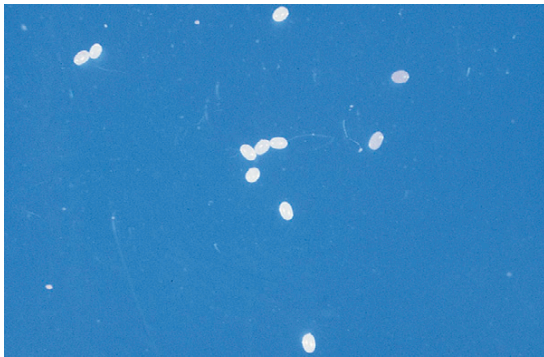


**TECHNICIAN'S NOTE** Cat and dog fleas will get on human hosts and bite them. Certain species of fleas are also capable of transmitting zoonotic disease (e.g., *Yersinia pestis*, the bacterium that causes bubonic plague is transmitted from rats to humans by fleas).





**FIGURE 13-41:** Adult *Echidnophaga gallinacea*, the stick-tight flea of poultry. Note angular profile. A common flea of chickens and guinea fowl, it also feeds on dogs and cats.

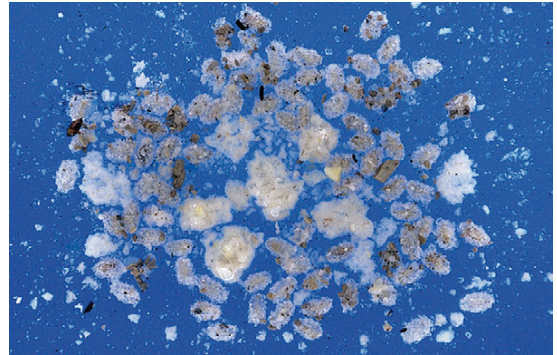


**FIGURE 13-42:** Eggs of *Ctenocephalides felis*, the cat flea. Flea eggs resemble tiny pearls; they are nonsticky, 0.5 mm long, white, oval, and rounded at both ends.

Although the adult flea is the life cycle stage most often encountered, the veterinary diagnostician may also be presented with flea eggs or with larval fleas from the pet's environment. Flea eggs and larvae are frequently found in the owner's bedclothes, the pet's bedding, travel carriers, doghouses, and clinic cages. Flea eggs resemble tiny pearls; they are nonsticky, 0.5 mm long, white, oval, and rounded at both ends (Figure 13-42). Flea larvae resemble tiny fly maggots; they are 2 to 5 mm long, white (after feeding they become brown), and sparsely covered with hairs (Figures 13-43 and 13-44).



**FIGURE 13-43:** Larva of *Ctenocephalides felis*, the cat flea. Flea larvae resemble tiny fly maggots; they are 2 to 5 mm long, white (after feeding they become brown), and sparsely covered with hairs.

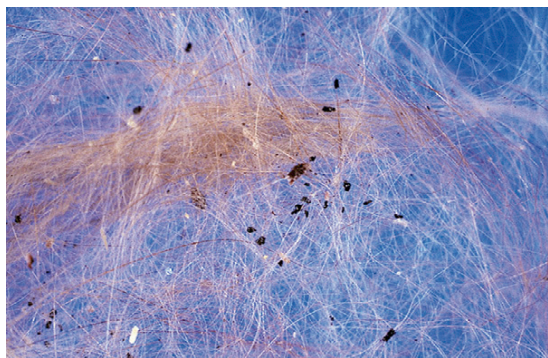


**FIGURE 13-44:** Sand-covered pupae of *Ctenocephalides felis*, the cat flea.

Adult fleas are usually encountered on the animal but may also be collected in the pet's environment. Observed on recovery from the pet, the larger fleas with an orange-to-light-brown abdomen are females; the smaller, darker specimens are males.

Because adult fleas spend most of their time on the host, diagnosis of flea infestation is usually obvious. However, in animals with flea-allergy dermatitis, fleas may be so few on the pet that the diagnosis of flea infestation is quite difficult.

Definitive diagnosis of flea infestation requires demonstration of the adult fleas and/or their droppings (flea dirt, flea feces, or flea frass) (Figure 13-45). Flea dirt can be used to diagnose current or recent infestations of fleas. Fleas can be easily collected by spraying the pet with an



**FIGURE 13-45:** Flea dirt (flea feces or flea frass) of *Ctenocephalides felis*, the cat flea. Flea dirt can be used to diagnose current or recent infestations by fleas. If water is slowly dropped onto flea dirt on a gauze sponge, the flea dirt will reconstitute to host's blood.

insecticide. After a few minutes, dead fleas drop off the animal. Alternatively, fleas may be collected using a fine-toothed flea comb, available from any veterinary supply company or pet store.

**TECHNICIAN'S NOTE** Flea infestation on a dog with flea-allergy dermatitis can be difficult to diagnose since there may be only a few fleas on this type of allergic dog.

Adult fleas defecate large quantities of partially digested blood, commonly called **flea dirt** or **flea frass**. These feces are reddish black and can appear as fine pepperlike specks, comma-shaped columns, or long coils. To collect a sample of flea dirt, the diagnostician must comb the pet with a flea comb and place the collected debris on a piece of white paper towel moistened with water. Rubbing the flea dirt with a fingertip causes the flea dirt to dissolve, producing a characteristic blood-red or rust-red color.

Flea control is important because fleas not only cause discomfort and irritation to the pet but also serve as intermediate hosts to certain helminth parasites. Fleas serve as intermediate host for *Dipylidium caninum*, the double-pored tapeworm of dogs and cats, and

for *Acanthocheilonema reconditum*, the filarial parasite that resides in the subcutaneous tissues of dogs. Some types of fleas can also transmit diseases, such as bubonic plague and endemic typhus, to humans.


**TECHNICIAN'S NOTE** The sale of flea control products for dogs and cats can be a practice builder in a veterinary clinic; however, many of these products are being sold over-the-counter in pet stores.

Flea control makes up a large part of pet care costs in the United States. There are many different types and styles of flea prevention products on the market. Flea prevention should encompass three different areas to ensure proper control: (1) the yard, (2) the house, and (3) the animal. The yard is the major source of initial flea infestation. A good-quality yard spray approved for fleas will reduce the flea population in the outside environment, thus reducing the chances of the pet bringing new adult fleas into the home. The house is a major source of animal reinfestation. Once the adult fleas breed and the female lays eggs, the eggs are present in the house. The pupae that result from the life cycle of the flea remain in the house and hatch as adults to reinfest the pet. Several types of products are available for use in the house, including foggers, sprays, and powders. Each of these products may incorporate an **adulticide** to kill the adult fleas and an **insect growth regulator** (IGR) to prevent the other life stages from developing to maturity. Although many products can be used to treat the yard and home, great improvements have been made in the products for animal application. There are daily or weekly sprays and powders available. However, the greatest advancements have been made to include once-a-month applications. Topical products such as Frontline TopSpot,\* Advantage<sup>†</sup>, Advantix<sup>†</sup>, and Advantage Multi<sup>†</sup>

\*Merial, 1-888-637-4251.



can be applied once a month, are resistant to water, and contain adulticide or adulticide and IGR. Other products, such as Program‡ and Sentinel‡ (also contains heartworm prevention), contain IGR and are given monthly in pill form for dogs. Program‡ can also be given as a 6-month injection to cats. Capstar‡ can be given to dogs and cats orally for the treatment of adult fleas over a 24-hour period; however, there is no residual activity after 36 hours. Regardless of the product used, all three forms of flea prevention (yard, house, animal) should be used for proper control of the flea population.

 **TECHNICIAN'S NOTE** Once-a-month flea preventatives have made great advances and make client compliance with flea preventative use much higher than it was in the past.

## MITES AND TICKS

Kingdom: Animalia

Phylum: Arthropoda (arthropods)

Subphylum: Chelicerata (possess chelicerate mouthparts)

Class: Acarina (mites and ticks)

Because mites and ticks belong to the class Acarina, any infestation of domestic animals by either mites or ticks is referred to as **acariasis**. The four developmental stages in the typical life cycle of the mite or tick are (1) the egg stage, (2) the six-legged larval stage, (3) the eight-legged nymphal stage, and (4) the eight-legged adult stage.


### Mites of Veterinary Importance

The first group of parasitic mites can be classified as **sarcoptiform mites**. As sarcoptiform mites, they have the following key features in common:


1. These mites can produce severe dermatologic problems in a variety of domestic animals.

This dermatitis is usually accompanied by a severe pruritus, or itching.

2. Typically, sarcoptiform mites are tiny mites barely visible to the naked eye, approximately the size of a grain of salt.
3. In silhouette, the bodies of sarcoptiform mites have a round-to-oval shape.
4. Sarcoptiform mites have legs that have **pedicels**, or stalks, at the tips. The pedicels may be long or short. If the pedicel is long, it may be straight (unjointed) or jointed. At the tip of each pedicel, there may be a tiny sucker. Veterinary diagnosticians should use the description of the pedicel (long or short, jointed or unjointed) to identify sarcoptiform mites.

 **TECHNICIAN'S NOTE** Sarcoptiform mites can cause severe dermatologic problems in a variety of domestic animals and even humans.

Sarcoptiform mites can be broken down into two basic families: the **Sarcoptidae** family, sarcoptiform mites that burrow or tunnel within the epidermis, and the **Psoroptidae** family, sarcoptiform mites that reside on the surface of the skin or within the external ear canal. Sarcoptidae includes *Sarcoptes*, *Notoedres*, *Cnemidocoptes*, and *Trixacarus* species. Psoroptidae includes *Psoroptes*, *Chorioptes*, and *Otodectes* species.

 **TECHNICIAN'S NOTE** Sarcoptiform mites are broken down into two families: Sarcoptidae mites that burrow or tunnel within the epidermis and Psoroptidae mites that reside on the surface of the skin or within the external ear canal.

### Family Sarcoptidae (Mites)

Members of the family Sarcoptidae burrow or tunnel within the epidermis of the infested definitive host. The entire four-stage life cycle is spent on the host. Male and female mites breed on the skin surface. The female mite penetrates

‡Novartis Animal Health, Greensboro, NC.

the keratinized layers of the skin and burrows or tunnels through the epidermis. Over a 10- to 15-day period, she deposits 40 to 50 eggs within the tunnel. After egg deposition, the female dies. Six-legged larvae emerge from the eggs in 3 to 10 days and exit the tunnel to wander on the skin surface. These larvae molt to the eight-legged nymphal stage within tiny pockets in the epidermis. Nymphs become sexually active adults in 12 to 17 days, and the life cycle begins again.

**Sarcoptes scabiei (Scabies Mite).** The disease caused by *Sarcoptes scabiei* is called **scabies**, or **sarcoptic acariasis**. Sarcoptic acariasis is extremely pruritic. *Sarcoptes* species exhibit host specificity. For example, *Sarcoptes scabiei* variety *canis* affects only dogs, and *Sarcoptes scabiei* variety *suis* affects only pigs. Almost every domestic animal has its own distinct variety of this mite, which does not infest other hosts.

**TECHNICIAN'S NOTE** *Sarcoptes scabiei* species are species specific but *S. scabiei* variety *canis* can cause a self-limiting infestation in humans so it is considered zoonotic. *Sarcoptes scabiei* variety *hominis* is the human sarcoptic mite that causes scabies in humans.

**Parasite:** *Sarcoptes scabiei* variety *canis*

**Host:** Canines

**Location of Adult:** Tunneling in the superficial layers of the epidermis for the majority of their life cycle. For a short period of their life cycle, they can be found on the skin surface.

**Distribution:** Worldwide

**Derivation of Genus:** Flesh cutters

**Transmission Route:** Direct contact from host to host

**Common Name:** Scabies mite of the dog

Canine scabies is caused by *Sarcoptes scabiei* variety *canis*, which produces lesions consisting of an erythematous, papular rash. Scaling, crusting, and excoriations are common. The ears, lateral elbows, and ventral abdomen are sites that are likely to harbor mites. The animal's entire

body, however, may be infested. The eight-legged adult mite has a unique silhouette—an oval shape. Each leg will possess a sucker (much like the “cup” of a plumber's plunger) on the ends of some of its legs. If present, the sucker is connected to the legs by a pedicel. The condition of the pedicel (long or short pedicels; jointed or unjointed) will assist in speciating or identifying the Sarcoptiform mites. *S. scabiei* has long, unjointed pedicels. The anus of the adult *Sarcoptes scabiei* is terminal not dorsal. These mites are spread by direct contact or by combs and brushes containing mites and/or their eggs and can affect all dogs in the household. For only a short period of their life cycle, these mites are found on the skin surface. For most of their life cycle, however, they may be found tunneling in the superficial layers of the epidermis. *Sarcoptes scabiei* variety *canis* is extremely contagious. The dog owner can become infested with this mite, but the disease is self-limiting. The mites burrow into the skin of humans, producing a papule-like lesion; however, the mites will not establish a full-blown infestation in humans. Therefore, *Sarcoptes scabiei* variety *canis* is considered to be a zoonosis. Some dogs may be asymptomatic carriers of *Sarcoptes scabiei* variety *canis*.

**TECHNICIAN'S NOTE** *Sarcoptes scabiei* variety *canis* is extremely contagious and dogs can be asymptomatic carriers of the mite.

Superficial skin scrapings (to the extent that a bit of capillary blood is drawn) are used to diagnose this mite. Impression smears onto glass slides can also be used. The skin scrapings or impression smears are viewed microscopically for developmental stages of mites (egg, larva, nymph, adult).

**Parasite:** *Sarcoptes scabiei* variety *felis*, *suis*, *bovis*, *equi*, and *ovis*

**Host:** Feline (*felis*), pigs (*suis*), cattle (*bovis*), horses (*equi*), and sheep and goats (*ovis*)

**Location of Adult:** For most of its life cycle it is found tunneling in the superficial layers of the

epidermis. For a short period of its life cycle, it is found on the surface of the skin.

**Distribution:** Worldwide

**Derivation of Genus:** Flesh cutters

**Transmission Route:** Direct contact from host to host

**Common Name:** Scabies mite of cats, scabies mite of pigs, scabies mite of cattle, scabies mite of horses, scabies mite of sheep and goats, respectively

Cats also are parasitized by a variety of this mite, *Sarcoptes scabiei* variety *felis*. Feline scabies caused by this variety is an extremely rare condition.

Among large animals, pigs are most often affected by scabies. Lesions caused by *Sarcoptes scabiei* variety *suis* include small red papules, alopecia, and crusts, most frequently on the trunk and ears. Scabies in cattle (*Sarcoptes scabiei* variety *bovis*) is rare. The main areas of infestation are the head, neck, and shoulders. Scabies in horses (*Sarcoptes scabiei* variety *equi*) is an even rarer entity. The main area of infestation is the neck. *Sarcoptes scabiei* variety *ovis* affects the face of sheep and goats, rather than the fleece.

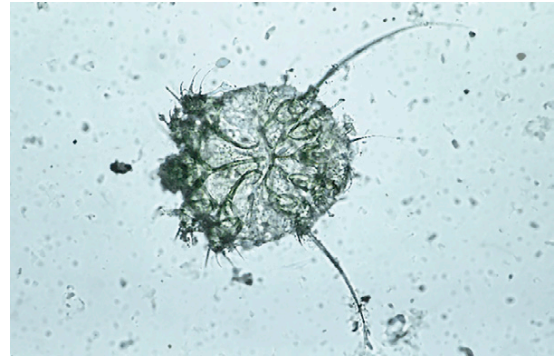
Areas with an erythematous, papular rash and crust should be scraped, especially the areas most associated with sarcoptic infestation in dogs, that is, the ears, lateral elbows, and ventral abdomen. Adult sarcoptic mites are oval and approximately 200 to 400  $\mu\text{m}$  in diameter, with eight legs. The key morphologic feature used to identify this species is the long, unjointed pedicel with a sucker on the end of some of the legs. The anus is located on the caudal end of the body (Figure 13-46). The eggs of *Sarcoptes* mites are oval (Figure 13-47).

*Sarcoptes scabiei* can be treated with ivermectin, lime-sulfur dips, or amitraz (not used for horses).


**Parasite:** *Notoedres cati*

**Host:** Felines and occasionally rabbits

**Location of Adult:** Most of its life cycle, the adult is found tunneling in the superficial layers of the epidermis but for a short period of its life cycle, it can be found on the surface of the skin around the ear pinna, face, neck, and feet of the cat.



**FIGURE 13-46:** Adult *Sarcoptes scabiei* mite. Anus is located on caudal end of body.



**FIGURE 13-47:** Oval eggs of *Sarcoptes scabiei*; note emergence of six-legged larval mite.

**Distribution:** Worldwide

**Derivation of Genus:** Back (referring to the dorsal anus)

**Transmission Route:** Direct contact from host to host

**Common Name:** Notoedric mange mite of cats or feline scabies mite

**Notoedres cati (Feline Scabies Mite) and Notoedres muris.** Although cats may be parasitized by *Sarcoptes scabiei* variety *felis*, the mite most often associated with feline scabies is *Notoedres cati*. This mite infests mainly cats but occasionally parasitizes rabbits. This sarcoptiform mite is found chiefly on the ears, back of the neck, face, and feet; in extreme cases, however, the entire body may be affected. This mite is almost identical to the mite of *Sarcoptes scabiei*, except for the position of the anus. The anus in

*S. scabiei* is terminal while the anus in *Notoedres cati* is dorsal. Like *S. scabiei*, *Notoedres cati* has long, unjointed pedicels. The life cycle is similar to that of *Sarcoptes scabiei*, with the mite burrowing or tunneling in the superficial layers of the epidermis, with only a short period of the life cycle being spent on the surface of the skin. The characteristic lesion of notoedric acariasis is a yellowing crust in the region of the ears, face, or neck.



**TECHNICIAN'S NOTE** *Notoedres cati* parasitize the cat but can occasionally infest the rabbit. It is found mainly around the ear pinna, back of the neck, face, and feet but can affect the entire body in extreme cases.

Superficial skin scrapings (with a bit of capillary blood being drawn) and impression smears can be used to microscopically diagnose this mite of the cat. Diagnosis is made by identifying the developmental stages of the mite life cycle (egg, larva, nymph, and adult). Notoedric mites are easier to demonstrate in cats than are sarcoptic mites in dogs. Again, likely infestation sites should be scraped. As with *Sarcoptes* species, *Notoedres* mites have a long, unjointed pedicel with a sucker on the end of some of the legs. Adult notoedric mites are similar to sarcoptic mites but are smaller, with a dorsal subterminal anus. The eggs of notoedric mites are oval. *N. cati* can be transmitted to humans where it causes pruritic papules. Therefore, it is a zoonotic parasite.

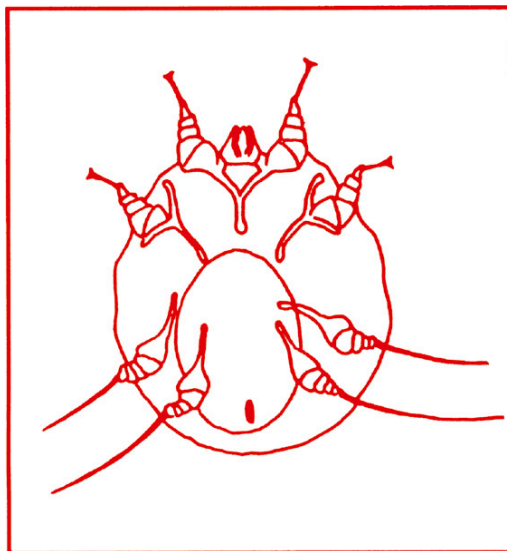
*Notoedres cati* mites are treated with ivermectin. The best prevention is avoiding contact between infected cats and uninfected cats.



**TECHNICIAN'S NOTE** *Notoedres cati* is easier to demonstrate on cats with a skin scraping or impression smears than *Sarcoptes scabiei* is in the dog.

**Parasite:** *Notoedres muris*

**Host:** Rats



**FIGURE 13-48:** Drawing of female *Notoedres muris*, showing dorsal subterminal anal opening.

**Location of Adult:** Most of their life cycle is spent tunneling in the superficial epidermis with only a short period being spent on the skin surface

**Distribution:** Worldwide

**Derivation of Genus:** Back (referring to the dorsal anus)

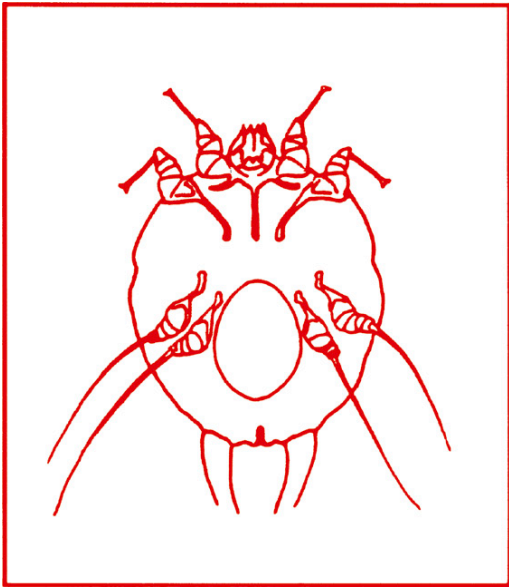
**Transmission Route:** Direct contact from host to host

**Common Name:** Scabies mite of rats

A related species, *Notoedres muris*, produces otic acariasis in rats (Figure 13-48). This mite resembles *Sarcoptes scabiei*, with a rounded body and suckers on the first two pairs of legs of female mites and on the first, second, and fourth pairs of legs of male mites. Female *N. muris* can be distinguished from female *S. scabiei* by the dorsal subterminal anal opening of *N. muris*. The anal opening of *S. scabiei* is terminal (Figure 13-49).

The burrowing mite, *N. muris*, usually can be detected and diagnosed before and after death by collecting deep skin scrapings from the edges of suspected lesions. Lesions are usually on the unfurred parts of the body, such as the ear pinnae, tail, nose, and extremities. Lesions appear as crusted areas with reddened vesicles. *N. muris* is



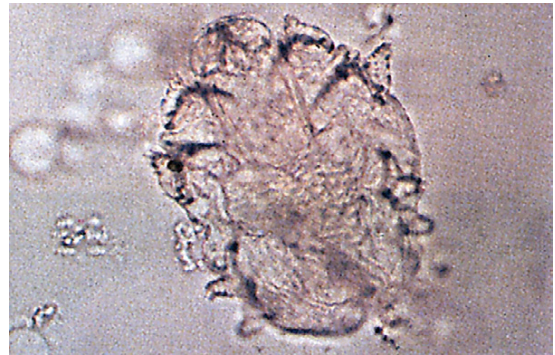


**FIGURE 13-49:** Drawing of female *Sarcoptes scabiei*, showing terminal anal opening.

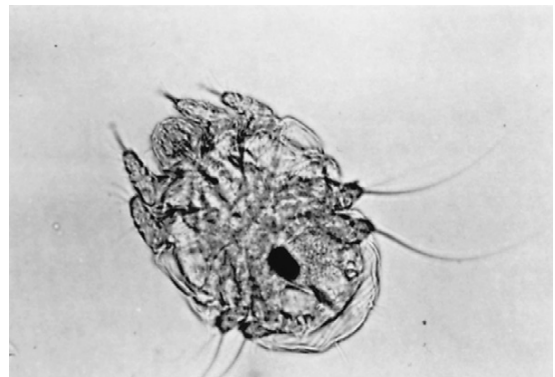
quite common in wild rodents. Transmission is by direct contact, so owners should be cautioned to keep pet rats safely away from wild rodent contact. This mite is also known to infest guinea pigs, but it does not infest humans.

Rabbits can be infested by notoedric and sarcoptic acarines. These mites cause similar lesions, usually on the head, neck, and legs. Lesions may also appear on the pinnae, making it necessary to distinguish *Notoedres cati* and *Sarcoptes scabiei* (see Figure 13-49) from the guinea pig mite *Trixacarus caviae* (Figure 13-50) and the rabbit ear mite *Psoroptes cuniculi* (Figure 13-51).

In general, notoedric mites are smaller than sarcoptic mites, and *P. cuniculi* is larger than both. Except for size, the major distinguishing characteristic of *N. cati* and *S. scabiei* is the location of the mite's anus. The anus is dorsal and subterminal in *N. cati* and terminal in *S. scabiei*. In both *N. cati* and *S. scabiei*, suckers are found at the end of long, unjointed stalks on the first two pairs of legs in adult females and on the first, second, and fourth pairs of legs in adult males. Psoroptic mites are distinguished by suckers at the end of long, jointed stalks on the first, second,



**FIGURE 13-50:** *Trixacarus caviae*, typical sarcoptiform mite of guinea pigs.



**FIGURE 13-51:** Adults of *Psoroptes cuniculi*, occurring most often in external ear canal of rabbits but also collected from horses, goats, and sheep. Mites exhibit characteristic long, jointed pedicels with suckers on ends of some legs.

and fourth pairs of legs in adult females and on the first, second, and third pairs of legs in adult males.

Diagnosis of infestation by *N. cati* and *S. scabiei* is by identification of larval, nymphal, or adult mites or the eggs from deep skin scrapings. Deep skin scrapings from the edges of lesions are necessary to detect the burrowing mites. Lesions normally begin near the nose or lips, spread over the face, and may eventually involve the external or lateral pinnae, extremities, and genital region. Both *N. cati* and *S. scabiei* cause intense pruritus that may result in self-mutilation. A crust or scale may develop over infested areas, and the skin may become thick and wrinkled. Secondary bacterial infection may occur.



**TECHNICIAN'S NOTE** *Notoedres muris* can be diagnosed with deep skin scrapings at the edges of suspected lesions, usually found at the ear pinnae, tail, nose, and extremities.

Transmission of notoedric and sarcoptic mites is by direct contact. *Sarcoptes scabiei* is extremely contagious from rabbit to rabbit and from rabbit to human. The pet owner can become infested with this mite, but the disease is self-limiting. The mites burrow into the skin of humans, producing a papulelike lesion; however, the mites will not establish a full-blown infestation. Both *Notoedres cati* and *Sarcoptes scabiei* are considered to be zoonotic.

**TECHNICIAN'S NOTE** *Sarcoptes scabiei* and *Notoedres cati* cause an intense pruritus that can result in self-mutilation of the host. Lesions are characterized by crusting and scaling while the skin may become thick and wrinkled.

**Parasite:** *Cnemidocoptes pilae* and *Cnemidocoptes mutans*

**Host:** Budgerigars and parakeets (*C. pilae*) and poultry (*C. mutans*)

**Location of Adult:** *C. pilae* spends most of its life cycle tunneling under the superficial epidermis of the feet, cere, and beak while *C. mutans* tunnels under the superficial epidermis of the feet. They both spend a short period on the surface of the skin.

**Distribution:** Worldwide

**Derivation of Genus:** *Koptein* means “to cut” in Greek

**Transmission Route:** Direct contact from host to host

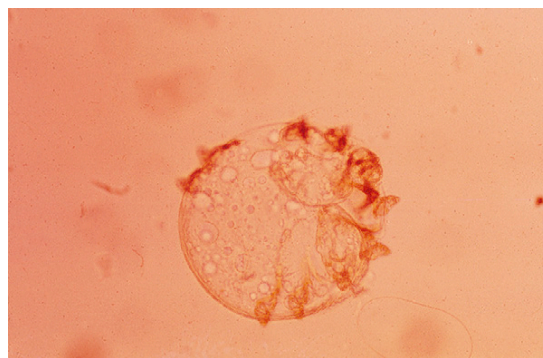
**Common Name:** Scaly leg mite of parakeets, scaly leg mite of chickens, respectively

***Cnemidocoptes pilae* (Scaly Leg Mite of Budgerigars).** *Cnemidocoptes pilae* is the sarcopitiform mite that causes scaly leg or scaly face in budgerigars or parakeets. This mite tunnels in the superficial layers of the epidermis, affecting

the pads and shanks of the feet; in severe cases, it may also affect the beak and the cere, the junction of the feathers and the beak. The mite characteristically produces a yellow-to-gray-white mass resembling a honeycomb. This condition can be quite disfiguring to the parakeet. The parasites pierce the skin underneath the scales, causing an inflammation with exudate that hardens on the surface and displaces the scales upward. This process causes the thickened scaly nature of the skin. In canaries, *Cnemidocoptes* species produces a syndrome called **tasselfoot**, a proliferation of the toes and feet. A related species, *C. mutans*, produces a condition called **scaly leg** in chickens, turkeys, and wild birds. These mites are extremely pruritic producing a severe disfigurement of the beak, cere, and feet of parakeets and the legs of chicken.

**TECHNICIAN'S NOTE** *Cnemidocoptes pilae* cause an extreme pruritus on the feet of parakeets but can also affect the beak and cere (the junction of the feathers and the beak).

Infestation sites should be scraped. Great care should be taken in handling the infested birds



**FIGURE 13-52:** Adult *Cnemidocoptes pilae*, sarcopitiform mite that causes scaly leg or scaly face in budgerigars or parakeets. Adults are eight-legged, round to oval in silhouette, and about 500  $\mu\text{m}$  in diameter. Adult females have very short legs and lack suckers. Adult male has longer legs and long, unjointed pedicel with sucker on the end of some legs.

because parakeets and canaries are fragile creatures. The adult mites are eight-legged, round to oval in silhouette, and about 500  $\mu\text{m}$  in diameter (Figure 13-52). The adult female mites have very short legs and lack suckers. The adult male has longer legs and possesses the long, unjointed pedicel with sucker on the end of some of the legs.

*Cnemidocoptes pilae* is treated with ivermectin.



**TECHNICIAN'S NOTE** *Cnemidocoptes* species have very short stubby legs, very similar in appearance to the legs of a tortoise.

**Parasite:** *Trixacarus caviae*

**Host:** Guinea pigs

**Location of Adult:** Most of its life cycle, the adult can be found tunneling into the superficial epidermis while a short period is spent on the surface of the skin

**Distribution:** Europe and North America

**Derivation of Genus:** Unknown

**Transmission Route:** Direct contact from host to host

**Common Name:** Burrowing mite of guinea pigs

**Trixacarus Caviae.** A burrowing or tunneling mite that infests guinea pigs is *Trixacarus caviae* (see Figure 13-50). *T. caviae* is a typical sarcopitiform mite with a rounded body and suckers on long, unjointed stalks on the first two pairs of legs of females and on the first, second, and fourth pairs of legs of males.

Deep skin scrapings from the edge of suspected lesions around the back, neck, and shoulders is necessary to detect this mite both antemortem and postmortem. Lesions include dry, scaly skin, with pruritus, alopecia, and dermatitis.



**TECHNICIAN'S NOTE** *Trixacarus caviae* mites cause lesions with dry, scaly skin, pruritus, alopecia and dermatitis.

Other burrowing mites that may infest guinea pigs are *Sarcoptes scabiei* (see Figure 13-49) and *Notoedres muris* (see Figure 13-48). *S. scabiei* can

be transmitted from rabbits to guinea pigs, in which they produce scabby lesions on the nose and lips. Young guinea pigs are particularly susceptible and may become anorectic to the point of death if not treated. (See previous discussion on identification, detection, and transmission of *S. scabiei* in rabbits.) *N. muris* is generally associated with rats but has also been reported in guinea pigs. This mite produces red, crusty lesions on the face of guinea pigs. (See previous discussion on identification, detection, and transmission of *N. muris* in rats.)

## Psoroptidae

Members of the family Psoroptidae reside on the surface of the skin or within the external ear canal. The entire five-stage life cycle (egg, larva, protonymph, deutonymph or pubescent female, and adult ovigerous female) is spent on the host. Adult male and female mites breed on the skin surface. The female produces 14 to 24 elliptic, opaque, shiny white eggs that hatch within 1 to 3 days. The six-legged mites are small, oval, soft, and grayish brown. Eight-legged nymphs are slightly larger than larvae. Larval and nymphal stages may last 7 to 10 days. The life cycle is completed in about 10 to 18 days. Under favorable conditions, mites can live off the host for 2 to 3 weeks or longer. Under optimum conditions, mite eggs may remain viable for 2 to 4 weeks.

**Parasite:** *Psoroptes cuniculi*

**Host:** Rabbits (most common), horses, goats, and sheep

**Location of Adult:** External ear canal

**Distribution:** Worldwide

**Derivation of Genus:** Scabby

**Transmission Route:** Direct contact from host to host

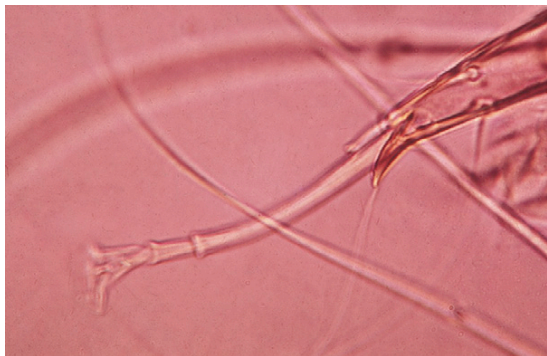
**Common Name:** Rabbit ear mite or rabbit ear canker mite



**TECHNICIAN'S NOTE** *Psoroptes cuniculi* mites are commonly seen in the ears of rabbits but have also been reported in horses, goats, and sheep.

**Psoroptes cuniculi (Ear Canker Mite of Rabbits).** *Psoroptes cuniculi* occurs most often in the external ear canal of rabbits but has also been collected from horses, goats, and sheep. These nonburrowing mites reside on the surface of the skin and feed on the rabbit host by puncturing the epidermis to obtain tissue fluids. Within the external ear canal of the infested host are the characteristic dried crusts of coagulated serum. (In chronic cases, the rabbit's ears appear to be packed with dried cornflakes cereal). Affected animals shake their head and scratch their ears. Although usually associated with otitis media produced by secondary infection with *Pasteurella multocida*, the ear mites themselves are not responsible for this condition. Lesions sometimes occur on the head and legs. *Psoroptes cuniculi* are extremely pruritic and severely infested animals may become debilitated. Loss of equilibrium may occur with torticollis abnormal contraction of neck muscles.

Diagnosis can be made by superficial skin scrapings or the removal of the scablike lesions. The samples are viewed microscopically for the developmental stages of the mite (egg, larva, nymph, and adult). The *Psoroptes cuniculi* mites within the cornflakelike crusty debris inside the ear can be easily isolated. The brownish-white female mite is large, 409 to 749  $\mu\text{m} \times 351$  to 499  $\mu\text{m}$ ; males are 431 to 547  $\mu\text{m} \times 322$  to 462  $\mu\text{m}$  (see Figure 13-51). The mites exhibit characteristic long, jointed pedicels with suckers on the ends of some of the legs



**FIGURE 13-53:** Detail of long, jointed pedicel on leg of *Psoroptes cuniculi*.

(Figure 13-53). The anus is in a terminal slit. In addition, mites can be observed with the unaided eye or with a hand-held magnifying glass.

Transmission of *P. cuniculi* is by direct contact. This parasite has no zoonotic potential. Treatment may be accomplished with the use of ivermectin otic (not approved for rabbits), milbemycin otic, or thiabendazole-dexamethasone-neomycin sulfate solution.



**TECHNICIAN'S NOTE** *Psoroptes cuniculi* mites are easily diagnosed with an ear cytology viewed under the microscope for the eggs, larva, nymph, and adult stages of the parasite. Adult mites can also be seen with the aid of a magnifying glass or with an otoscope.

**Parasite:** *Psoroptes ovis*, *Psoroptes bovis*, and *Psoroptes equi*

**Host:** Sheep, cattle, and horses, respectively

**Location of Adult:** Skin surface on the body (*P. ovis*), withers, neck, and rump (*P. bovis*), and mane and tail (*P. equi*)

**Distribution:** Worldwide

**Derivation of Genus:** Scabby

**Transmission Route:** Direct contact from host to host

**Common Name:** Scabies mites of sheep, cattle, and horses, respectively

**Psoroptes of Large Animals.** *Psoroptes ovis*, *P. bovis*, and *P. equi* are the scab mites of large animals, residing on sheep, cattle, and horses, respectively. These mites are host specific and reside within the thick-haired or long-wooled areas of the animal. The adults are eight-legged with an oval shape. Each leg will possess a sucker on the ends of some of its legs. If present, the sucker is connected to the legs by a pedicel. They are surface dwellers and feed by puncturing the host's epidermis to feed on lymphatic fluid. Serum exudes through the puncture site; after the serum coagulates and forms a crust, wool is lost. The feeding site is extremely pruritic, and the animal excoriates itself, producing further wool loss. Mites migrate to undamaged

skin. As *Psoroptes* mites proliferate, tags of wool are pulled out, and the fleece becomes matted. Finally, patches of skin are exposed, and the skin becomes parchmentlike, thickened, and cracked and may bleed easily. Infested sheep constantly rub against fences, posts, farm equipment, and any object that might serve as a scratching post. The disease is spread by direct contact or infested premises.

**TECHNICIAN'S NOTE** *Psoroptes* species of large animals are extremely pruritic and cause the host to rub the affected area against fences, posts, equipment, or any object it can use as a scratching post. This can lead to areas of alopecia (hair loss) and excoriations.

*Psoroptes bovis* produces lesions on the withers, neck, and rump that consist of papules, crusts, and wrinkled, thickened skin. *Psoroptes equi* in horses is rare and affects the base of the mane and tail.

Because of the intense pruritus and the highly contagious nature of this infestation, the occurrence of *Psoroptes* species in large animals should be reported to both state and federal authorities. This disease is reportable to the United States Department of Agriculture.

Mites of *Psoroptes* species that infest large micrometer animals are host specific. Adults are up to 600  $\mu\text{m}$  in length. The mites exhibit characteristic long, jointed pedicels with suckers on the ends of some of the legs.

Large-animal *Psoroptes* species can be treated with lime-sulfur dips or ivermectin.

**TECHNICIAN'S NOTE** The species of *Psoroptes* that are found on large animals produce a highly pruritic, highly transmissible dermatologic condition known as *scabies*. These species of *Psoroptes* mites in large animals are reportable to both state and federal authorities while *Psoroptes cuniculi* is not a reportable parasite.

**Parasite:** *Chorioptes equi*, *Chorioptes bovis*, *Chorioptes caprae*, and *Chorioptes ovis*

**Host:** Horses, cattle, goats, and sheep, respectively

**Location of Adult:** Surface of skin, particularly lower hind legs, flanks and shoulders, and on dairy cattle in the region of the escutcheon

**Distribution:** Worldwide

**Derivation of Genus:** Membrane visible

**Transmission Route:** Direct contact from host to host

**Common Name:** Foot and tail mites or itchy leg mite

**Chorioptes Species (Foot and Tail Mite, Itchy Leg Mite).** *Chorioptes equi*, *C. bovis*, *C. caprae*, and *C. ovis* are the **foot and tail mites** of large animals, residing on horses, cattle, goats, and sheep, respectively. As with *Psoroptes*, these mites are found on the skin surface. Their predilection sites are on the lower part of the hind legs, but they may spread to flank and shoulder areas. On cattle, they are frequently found in the tail region, especially in the area of the escutcheon. These mites do not spread rapidly or extensively. They puncture the skin, causing serum to exude. Thin crusts of coagulated serum form on the skin surface. The skin eventually wrinkles and thickens, although pruritus is not severe. The presence of these mites on the lower limbs may cause intense pruritus, although the pruritus is not normally severe, with much scratching and licking of the area.

Infested horses stamp, bite, and kick, especially at night. Mites typically infest the pasterns, especially those of the hind legs.

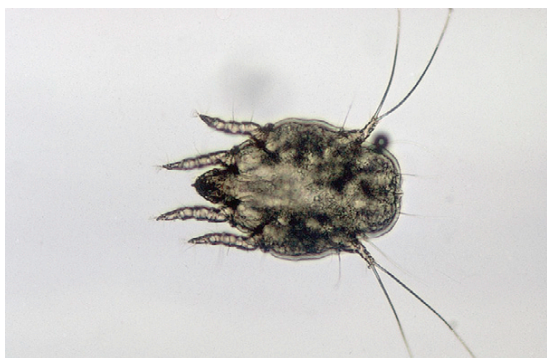Characteristic mites of the genus *Chorioptes* can be identified from skin scrapings of infested areas. The mites have characteristic short, unjointed pedicels with suckers on the ends of some of the legs. The female mites are about 400  $\mu\text{m}$  long (Figure 13-54). Due to the fact that these mites can be licked by the infected animal, developmental stages of these mites may be found on fecal flotation.

Ivermectin and lime-sulfur dips are used to treat *Chorioptes equi*, *C. bovis*, *C. caprae*, and *C. ovis*.





**FIGURE 13-54:** Female and male *Chorioptes* species. Note short, unjointed pedicels.



**FIGURE 13-55:** Adult male ear mite, *Otodectes cynotis*.

**TECHNICIAN'S NOTE** On superficial inspection, *Chorioptes* species have been found to have the same configuration of pedicels as *Otodectes cynotis*. The “pedicel formula” (position of suckers and pedicels on the mite’s limbs) may be similar but the mite location of the host of the two different mites will vary greatly in the site of infestation.

**Parasite:** *Otodectes cynotis*

**Host:** Canines, felines, and ferrets

**Location of Adult:** External ear canal

**Distribution:** Worldwide

**Derivation of Genus:** Ear biter or ear receiver

**Transmission Route:** Direct contact from host to host

**Common Name:** Ear mites

***Otodectes cynotis* (Ear Mites).** Ear mites, *Otodectes cynotis*, are a common cause of otitis externa in dogs, cats, and ferrets. Although they occur primarily in the external ear canal, ear mites may be found on any area of the body. A common infestation site is the tail–head region, because as dogs and cats curl up to sleep, their heads (and ears) are often close to the base of the tail. These mites are spread by direct contact and are highly transmissible both among and between dogs, cats, and ferrets.

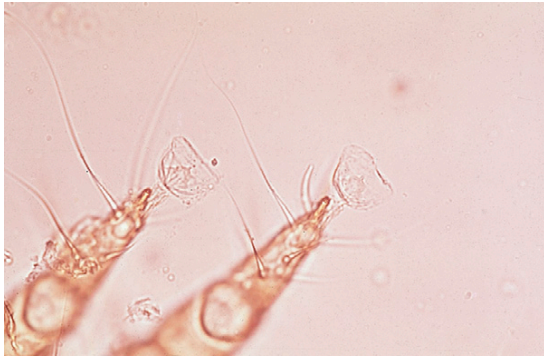**TECHNICIAN'S NOTE** *Otodectes cynotis* mites are highly transmissible from host to host and can be found at the tail–head region due to the way dogs, cats, and ferrets tend to sleep when curled up.

Mites are found within the external ear canal, where they feed on epidermal debris and produce intense irritation. Infestation is usually in both ears. The host responds to the mite infestation by shaking its head and scratching its ears. In cases of infestation with these mites, the “massaging” or petting of the external ear canal will elicit a scratching response by the animal called the *pedal–pinnal response* (“foot–ear response”). In severe infestations, otitis media, with head tilt, circling, and convulsions, may occur. Auricular hematomas may develop.

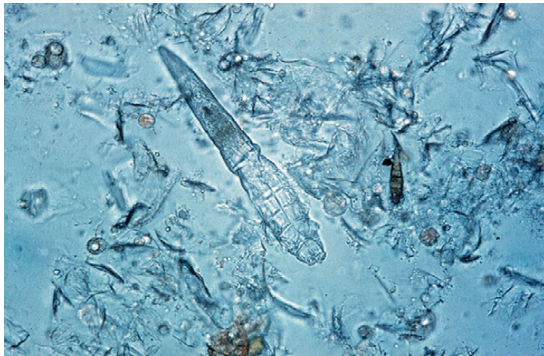Ear mites are usually identified with an otoscope, through which the mites appear as white, motile objects. Exudate collected by swabbing the ear may be placed in mineral oil on a glass slide and the mites observed under a compound microscope using the 10× objective. These mites are fairly large, approximately 400  $\mu\text{m}$  (Figure 13-55); they can also be easily seen with the unaided eye. The mites exhibit characteristic short, unjointed pedicels with suckers on the ends of some of the legs (Figure 13-56). The anus of *O. cynotis* is terminal.

Ivermectin otic, milbemycin otic, and thiabendazole-dexamethasone–neomycin sulfate solution are used to treat *Otodectes cynotis*. In addition to medication, the ears should be cleaned to remove the debris and mites from the ears.





**FIGURE 13-56:** Detail of leg of *Otodectes cynotis* with short, unjointed pedicel.



**FIGURE 13-57:** Adult *Demodex canis*. *Demodex* mites resemble eight-legged alligators; they are elongated, with very short, stubby legs. Adult and nymphal stages have eight legs; larvae have six legs.

**TECHNICIAN'S NOTE** If *Otodectes cynotis* is found in one pet of the household, all pets (hosts) in the household should be treated.

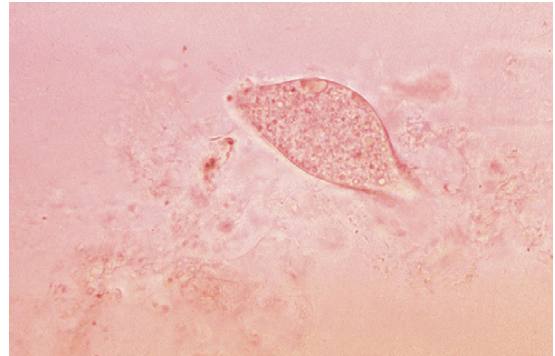
### Nonsarcoptiform Mites

The following group of parasitic mites are discussed together because they are not sarcoptiform mites. They can, however, produce severe dermatologic problems in a variety of domestic animals. These mites lack the pedicels or stalks on their legs that are so important in diagnosing the sarcoptiform mites.

**Parasite:** *Demodex* species

**Host:** Domestic animals and humans (host specific)

**Location of Adult:** Hair follicles and sebaceous glands of the skin



**FIGURE 13-58:** Egg of *Demodex canis* is either spindle-shaped or tapered at each end.

**Distribution:** Worldwide

**Derivation of Genus:** Fat worm or tallow receiver

**Transmission Route:** Direct contact especially intimate contact between dam and neonates

**Common Name:** Red mange mite, follicular mite, canine follicular mite, or demodectic mange mite

**Demodex Species.** Mites of the genus *Demodex* reside in the hair follicles and sebaceous glands of humans and of most domesticated animals. In many species, mites of the genus *Demodex* are considered normal, nonpathogenic fauna of the skin. These mites are host specific and are not transmissible from one species of host to another. The clinical disease caused by many of these mites is called **demodicosis**.

*Demodex* mites resemble eight-legged alligators or cigars and some even say they have a carrot shape—elongated with very short, stubby legs. No other mite looks like this mite. Adult and nymphal stages have eight legs, and larvae have six. Adult *Demodex* mites are approximately 250  $\mu\text{m}$  long (Figure 13-57). The eggs are spindle-shaped or tapered at each end (Figure 13-58).

**TECHNICIAN'S NOTE** The *Demodex* mites has a characteristic carrot-, cigar- or alligator-shaped body with very short and stubby legs. The nymphal and adult stages have eight legs while the larval stage has six legs.

Of all the domestic animals infested with *Demodex* species, the dog is the most often and the most seriously infested. These mites are considered to be part of the normal skin flora of all dogs; in some dogs with immunodeficiencies, however, they proliferate to the point that they produce pathology. The clinical syndromes relative to the form of demodicosis present in dogs are localized demodicosis and generalized demodicosis.

The predominant clinical sign of the **localized form of demodicosis** is a patchy alopecia, especially of the muzzle, face, and forelimbs. It is thought that *Demodex* mites are acquired during the close, intimate contact that develops as the dam nurses the puppy. As a result of that contact, localized demodicosis often develops in the region of the face or forelimbs.

**Generalized demodicosis** is characterized by diffuse alopecia, erythema, and secondary bacterial contamination over the entire body surface of the dog. An inherited defect in the dog's immune system is thought to be an important factor in the development and the pathogenesis of generalized demodicosis. Generalized demodicosis can affect the entire skin surface, and on occasion, demodectic mites have been known to infect internal organs.

**TECHNICIAN'S NOTE** *Demodex* mites can produce three syndromes in animals—the asymptomatic carrier, localized demodicosis, and generalized demodicosis.

Cats are infested by two species of demodectic mites, *Demodex cati* and an unnamed species of *Demodex*. *Demodex cati* is an elongated mite similar to *D. canis*. The unnamed species has a broad, blunted abdomen, unlike the elongated abdomen of *D. cati*. The presence of either species in the skin of cats is rare. In localized feline demodicosis, patchy areas of alopecia, erythema, and occasionally crusting occur on the head (especially around the eyes), ears, and neck. In generalized feline demodicosis, the alopecia, erythema, and crusting usually involve the entire

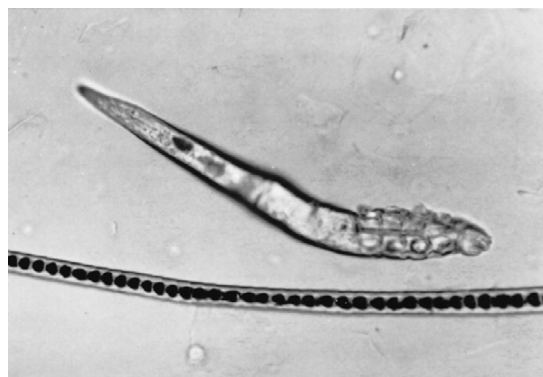
body. Demodicosis also has been associated with ceruminous otitis externa.

Demodectic mites reside in the hair follicles of other species of domestic animals but rarely produce clinical disease. Cattle and goats are those most often infested, and then only rarely.

**TECHNICIAN'S NOTE** *Demodex* mites live within the hair follicles and sebaceous glands of the skin, but dogs are the hosts most commonly seen with clinical signs of infestation.

In cattle, *Demodex bovis* causes large nodules or abscesses on the shoulders, trunk, and lateral aspects of the neck. In goats, *Demodex caprae* occurs in small, papular, or nodular lesions on the shoulders, trunk, and lateral aspects of the neck. Rarely, in sheep, *Demodex ovis* causes pustules and crusting around the coronet, nose, ear tips, and periorbital areas. Rarely, in pigs, *Demodex phylloides* produces pustules and nodules on the face, abdomen, and ventral neck. In horses, *Demodex equi* occurs around the face and eyes and rarely produces clinical disease.

*Demodex aurati* (Figure 13-59) and *Demodex criceti* (Figure 13-60) infest hamsters. As with other *Demodex* species, they live in hair follicles and adjacent sebaceous glands. Deep skin scrapings at the edges of the lesions are necessary to detect the mites. Lesions are most often seen on the dorsum of the hamster near the rump.



**FIGURE 13-59:** *Demodex aurati*, burrowing mite of hamsters.

Clinical signs that may indicate demodicosis in the hamster include alopecia and dry scaly skin or scabby dermatitis, particularly over the rump and on the back of the hamster. Demodicosis is most often observed in aged or otherwise stressed hamsters. The mite population in hamsters is usually greater in males than in females. As with *D. canis* in dogs, *D. aurati* and *D. criceti* may be present without producing clinical signs.

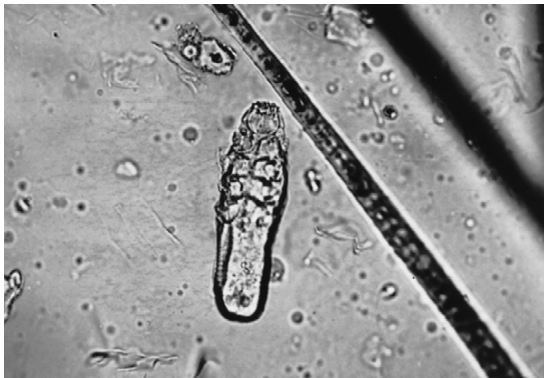Gerbils have been reported to carry two species of *Demodex*, *D. aurati* and *D. criceti* (see Figures 13-59 and 13-60). These mites are similar in size and shape to the demodectic mites of hamsters. Demodectic mites also have been recovered from gerbils with facial dermatitis. As in other species with demodectic acariasis, infested gerbils have

other concomitant disease. Lesions are similar to those described in the hamster.

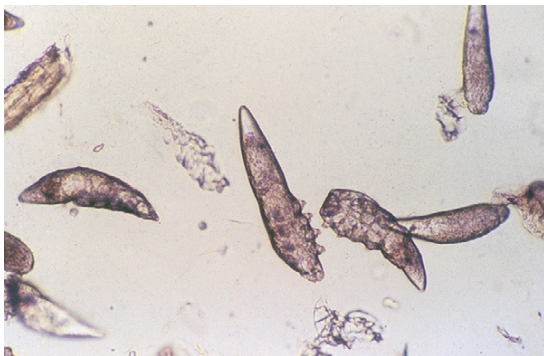Demodicosis may be detected on postmortem examination by histopathologic examination of skin sections. Transmission is by direct contact, with the primary route thought to be from mother to suckling young. *Demodex* species of hamsters are considered to be species specific, with the possible exception of the gerbil, and thus are not likely to cross-contaminate other species or pose a zoonotic problem to humans.



**TECHNICIAN'S NOTE** *Demodex* infestation in animals showing clinical symptoms is diagnosed by deep skin scrapings to find the developmental stages of the mite (egg, larva, nymph, and adult).



**FIGURE 13-60:** *Demodex criceti*, a hamster mite, is distinguishable from *Demodex aurati* by its blunt body shape.



**FIGURE 13-61:** Results of thorough, deep skin scraping, revealing numerous mites of *Demodex canis*.

Skin with altered pigmentation, obstructed hair follicles, erythema, or alopecia should always be scraped with a deep skin scraping to the extent of drawing capillary blood. In localized demodicosis, the areas most often affected are the forelegs, the perioral region, and the peri-orbital regions. In generalized demodicosis of dogs, the entire body may be affected; however, the face and feet usually are the most severely involved. In dogs, normal skin should also be scraped to determine if the disease is generalized. The areas should be clipped and a fold of skin gently squeezed to express any mites from the hair follicles. Scraping should be continued until capillary blood is observed oozing, because these mites live deep in the hair follicles and sebaceous glands (Figure 13-61).

Nodular lesions in large animals should be incised with a scalpel and the caseous material within smeared on a microscope slide with mineral oil, covered with a coverslip, and examined for mites.

The veterinary diagnostician should count the mites on the glass slide and determine the live:dead ratio. The presence of larval or nymphal stages or eggs should be noted. Treatment for demodicosis involves dipping the affected animal



in an amitraz (not used on horses) or trichlorfon dip. During therapy for *Demodex* species, a decrease in the number of eggs and the number of live or moving mites is a good prognostic indicator.

**TECHNICIAN'S NOTE** The veterinarian or technician should count the live versus dead mites for a live:dead ratio to determine the prognosis of treating the infection during therapy.

**Parasite:** *Trombicula* species

**Host:** Domestic animals, wild animals, and humans

**Location of Larva:** Larval stage is the only stage that parasitizes animals and humans. It is found attached to the skin of the host.

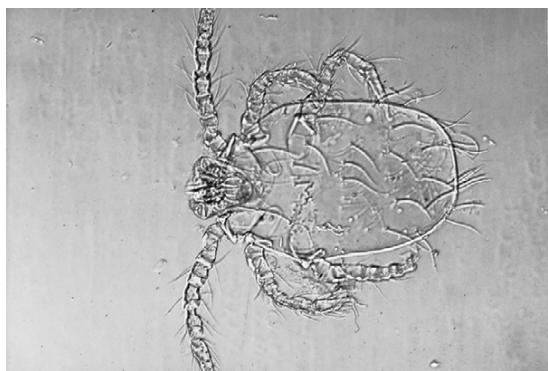**Distribution:** Worldwide

**Derivation of Genus:** Unknown

**Transmission Route:** Direct contact of host and larval mites within forest environments with underbrush

**Common Name:** Chiggers or red bugs

***Trombicula* Species (Chiggers).** The **chigger**, *Trombicula* species, is yellow to red, has six legs, and ranges in size from 200 to 400  $\mu\text{m}$  in diameter (Figure 13-62). The larval stage is the only developmental stage that parasitizes



**FIGURE 13-62:** The chigger, *Trombicula* species, is yellow to red, has six legs, and ranges in size from 200 to 400  $\mu\text{m}$  in diameter.

humans, domestic animals, and wild animals. The larvae are most common during the late summer and early fall and are transmitted by direct contact of the host with the ground or by brushing against foliage in fields or heavy underbrush. The nymphal and adult stages of chiggers are nonparasitic and are free-living in nature.

Larval chiggers do *not* burrow into the skin, as commonly believed, nor do they feed primarily on host blood. Their food consists of the serous components of tissues. Chiggers attach firmly to the host and inject a digestive fluid that produces liquefaction of host cells. The host's skin becomes hardened, and a tube called a **stylostome** forms at the chigger's attachment site. Chiggers suck up liquefied host tissues. When the mite has finished feeding, it loosens its grip and falls to the ground. The injected digestive fluid causes the attachment site to itch intensely. In animals, cutaneous lesions tend to be restricted to areas of the body that come in contact with the ground or underbrush, that is, the head, ears, limbs, interdigital areas, and ventrum.

The most common chigger mite affecting animals and humans is *Trombicula alfreddugesi*, the **North American chigger**. Lesions caused by *T. alfreddugesi* consist of an erythematous, often pruritic, papular rash on the ventrum, face, feet, and legs.

The diagnosis of chiggers is based on the presence of an orange crusting dermatosis, a history of exposure (roaming outdoors), and identification of the typical six-legged larval stage on skin scraping or on collection from the host. The larval chigger remains attached to the skin only for several hours. Consequently, **trombiculosis** may be difficult to diagnose, because the pruritus persists after the larva has dropped off the host.

**TECHNICIAN'S NOTE** Diagnosis of chiggers is made by finding the six-legged larval stage of the parasite on the affected skin of the host on skin scraping.

**Parasite:** *Pneumonyssus* (*Pneumonyssoides*) *caninum*

**Host:** Canines

**Location of Adult:** Nasal turbinates and nasal sinuses

**Distribution:** Worldwide

**Derivation:** Lung piercer

**Transmission Route:** Direct contact from host to host

**Common Name:** Nasal mites

**Pneumonyssus (formerly, Pneumonyssoides) caninum (Nasal Mites of Dogs).** *Pneumonyssus* (*Pneumonyssoides*) *caninum* is a rare species of mite that lives in the nasal turbinates and associated paranasal sinuses of dogs. Generally, nasal mites are considered to be nonpathogenic; however, reddening of the nasal mucosa, sneezing, shaking of the head, and rubbing of the nose often accompany infestation. Fainting, labored breathing, asthmalike attacks, and orbital disease have been associated with this mite. Sinusitis caused by these mites may lead to disorders of the central nervous system. Owners will observe these mites exiting the nostrils.

The life cycle of *P. caninum* is unknown, but it apparently takes place entirely within the host. Adult males, females, and larvae have been identified, but no nymphal stages have been observed. Transmission probably occurs through direct contact with an infested animal.

**TECHNICIAN'S NOTE** Diagnosis of *Pneumonyssoides caninum* infestation can be made from the owner's observation of mites exiting the dog's nostrils.

Nasal mites are oval and pale yellow. They are 1 to 1.5 mm × 0.6 to 0.9 mm and possess a smooth cuticle with very few hairs. The abdomen lacks setae (fine hairs). Larvae have six legs, and adults have eight legs. All legs are located on the anterior half of the body (Figure 13-63). Diagnosis is usually made at necropsy on asymptomatic animals by finding the characteristic adult mites.

**TECHNICIAN'S NOTE** When dogs infested with *Pneumonyssoides caninum* lie down in front of a fireplace with a roaring fire, the mites may be seen temporarily exiting the nares of the dog as they are attracted to the warmth of the fire.

**Parasite:** *Ornithonyssus sylviarum* and *Dermanyssus gallinae*

**Host:** Poultry

**Location of Adult:** On the skin of poultry (*O. sylviarum*), in the environment of poultry (*D. gallinae*)

**Distribution:** Worldwide in temperate zones (*O. sylviarum*), worldwide (*D. gallinae*)

**Derivation of Genus:** Bird piercer (*Ornithonyssus*), skin piercer (*Dermanyssus*)

**Transmission Route:** Direct contact from host to host (*O. sylviarum*), direct contact with infested environment (*D. gallinae*)

**Common Name:** Northern fowl mite (*O. sylviarum*), red fowl mite (*D. gallinae*)

**Ornithonyssus sylviarum (Northern Mite of Poultry) and Dermanyssus gallinae (Red Mite of Poultry).** *Ornithonyssus sylviarum* and *Dermanyssus gallinae* both parasitize poultry but differ in the sites where they are collected. *O. sylviarum* is a 1-mm, elongate-to-oval mite with eight legs usually found on birds; it also may



**FIGURE 13-63:** (*Pneumonyssus*) *Pneumonyssoides caninum*, a rare mite that lives in nasal passages and associated paranasal sinuses of dogs.



be found on nests or within poultry houses. The adults are sparsely covered with setae. In specimens that have been cleared in lactophenol, on the ventral surface of the mite there is an anal plate. The anus of this mite is on the posterior half of that anal plate. This species, the **northern mite of poultry**, feeds intermittently on birds, producing irritation, weight loss, decreased egg production, anemia, and even death. These mites have been known to bite humans. The adult is the only life stage that feeds on the host. The larval and nymphal stages do not feed on the host.

*D. gallinae* is similar in appearance to *O. sylviarum* except the anus is on the anterior surface of the anal plate and is approximately 1 mm in length; elongate to oval; whitish, grayish, or black; and feeds on birds. This mite has a distinct red color when it has recently fed on its host's blood, thus its common name, the **red mite of poultry**. *D. gallinae* lays its eggs in the cracks in the walls of poultry houses. Both the nymphal stage and the adults are periodic parasites, hiding in cracks and crevices of poultry houses and making frequent visits to the host to feed. Because of their blood-feeding activity, these mites may produce significant anemia and much irritation to the host. Birds are listless, and egg production may decrease. Loss of blood may result in death. These mites also occur in bird nests in the eaves of houses or in air conditioners. They migrate into homes and attack humans. *D. gallinae* can be treated with pyrethrin sprays or ivermectin. If a flock is infected with *D. gallinae*, dichlorvos strips may be used to treat the flock.

Because of their similar morphology, these mites are difficult to differentiate. *O. sylviarum* is usually found on the avian host, whereas *D. gallinae* is a periodic parasite, usually found in the host's environment. If specimens are recovered, they should be cleared in lactophenol and the ventral anal plates examined under a compound microscope. The anus of *O. sylviarum* is on the anterior half of the ventral anal plate, whereas that of *D. gallinae* is on the posterior half of the ventral anal plate.



**TECHNICIAN'S NOTE** Since *Ornithonyssus sylviarum* and *D. gallinae* are similar in appearance, it is important to determine the location of the anus on the anal plate for identification of these mites.

**Parasite:** *Ornithonyssus bacoti*

**Host:** Rat and mice, can infect hamsters and guinea pigs

**Location of Adult:** In host environment most of life cycle, on skin surface when feeding

**Distribution:** Tropical and subtropical climates

**Derivation of Genus:** Bird piercer

**Transmission Route:** Direct contact with contaminated environment

**Common Name:** Tropical rat mite

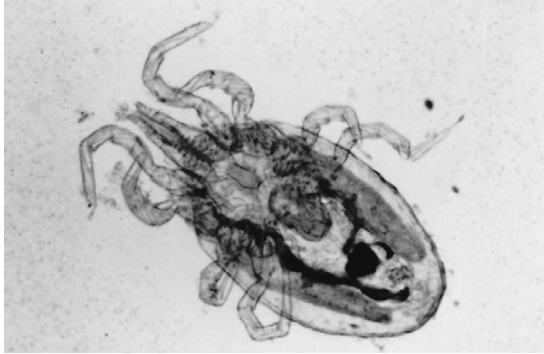**Ornithonyssus (Liponyssus) bacoti.** *Ornithonyssus (Liponyssus) bacoti* is commonly called the **tropical rat mite**. This bloodsucking mite can cause severe problems in rats and mice and can also infect hamsters and guinea pigs. It is especially common in tropical and subtropical climates. *O. bacoti* has a wide host range beyond rodents and can also infect hamsters and guinea pigs.

Oddly, even though *O. bacoti* is a bloodsucking mite, it is more closely related to ticks than mites. This mite is unusual in that it spends most of its life cycle off the host animal, in the host's environment. Both male and female mites are bloodsuckers. The females are larger than the males. These mites may be filled with blood, which produces a reddish-brown color, or, if they have not fed, they may be white. The mites can measure up to 750  $\mu\text{m}$  in length (Figure 13-64).



**TECHNICIAN'S NOTE** The tropical rat mite can cause anemia in rats and mice; however, they can also infect hamsters and guinea pigs. They are bloodsucking mites that are only found on the host when they feed.

*O. bacoti* mites intermittently feed on rodent blood, dropping into nests or surrounding cracks



**FIGURE 13-64:** *Ornithonyssus* (*Liponyssus*) *bacoti*, the tropical rat mite.

and crevices between feedings. These mites can gain access to other pet animals by dropping from wild or feral animals; days later, when the original host is no longer in the area, they may attack a pet animal for a blood meal.

Infestation with *O. bacoti* is usually diagnosed by observing the blood-filled mites in the bedding, nests, or cracks and crevices near the cages of pet animals. Animals in an environment infested with *O. bacoti* may be anemic and may exhibit a marked reproductive decline. The mite can transmit rickettsial organisms and cause allergic dermatitis in humans. In the absence of a suitable rodent host, *O. bacoti* will readily attack humans for a blood meal.

*O. bacoti* has a wide host range beyond rodents and is especially common in tropical and subtropical climates.



**TECHNICIAN'S NOTE** *Ornithonyssus bacoti* can carry rickettsial organisms that can be transmitted to humans as well as cause allergic dermatitis in humans.

## Fur Mites

**Parasite:** *Cheyletiella parasitivorax*

**Host:** Dogs, cats, and rabbits

**Location of Adult:** Surface of the skin and hair coat

**Distribution:** Worldwide



**FIGURE 13-65:** Adult mite, *Cheyletiella parasitivorax*. *Cheyletiella* species have hooklike accessory mouthparts (palpi) on the anterior end and comblike structures at the tip of legs. These mites have a characteristic body shape variously described as a shield, bell pepper, acorn, or western horse saddle, when viewed from above.

**Derivation of Genus:** Small lip

**Transmission Route:** Direct contact from host to host

**Common Name:** Walking dandruff

***Cheyletiella* species (Walking Dandruff).**

Mites of the genus *Cheyletiella* are surface-dwelling (nonburrowing) mites that reside in the keratin layer of the skin and in the hair coat of various definitive hosts, which may be dogs, cats, or rabbits. These mites ingest keratin debris and tissue fluids and are often referred to as **walking dandruff**, because the motile mites resemble large, moving flakes of dandruff. Cheyletid mites have unique morphologic features. They are large mites ( $386 \times 266 \mu\text{m}$ ), visible to the naked eye. The compound microscope allows easy visualization of this mite's most characteristic morphologic feature, enormous hooklike accessory mouthparts (**palpi**) on the anterior end. These palpi assist the mite in attaching to the host as it feeds on tissue fluids. The mite also has comblike structures at the tip of each of its legs. Members of the genus are also known for their characteristic body shape, a silhouette that has been reported as resembling a shield, a bell pepper, the acorn of an oak tree, or a western horse saddle when viewed from above (Figure 13-65). Eggs are  $235$  to  $245 \mu\text{m}$  long  $\times$   $115$  to  $135 \mu\text{m}$  wide (smaller than

louse nits) and supported by cocoonlike structures bound to the hair shaft by strands of fibers. Two or three eggs may be bound together on one hair shaft or found in keratin debris of pet dander.

**TECHNICIAN'S NOTE** Walking dandruff has been reported to look like a bell pepper from the lateral view or an acorn from an oak tree.

The key feature of active infestation by *Cheyletiella parasitivorax* is often the moving, white, dandrufflike flakes along the dorsal midline and head of the host. A hand-held magnifying lens or a binocular headband magnifier (e.g., Optivisor) may be used to view questionable dandruff flakes or hairs; these are perhaps the quickest methods of diagnosing **cheyletiellosis**. A fine-toothed flea comb may be used to collect mites; combing dandrufflike debris onto black paper often facilitates visualization of these highly motile mites. Using clear cellophane tape to entrap mites collected from the hair coat often simplifies localization and viewing under the compound microscope.

*Cheyletiella parasitivorax* can be treated with ivermectin (not approved for rabbits) and malathion dips.

**TECHNICIAN'S NOTE** Superficial combing with a flea comb onto black paper, examination of the dorsal midline and head of the host and the cellophane tape technique are used to diagnose *Cheyletiella parasitivorax*.

**Parasite:** *Lynxacarus radovskyi*

**Host:** Cats

**Location of Adult:** Hair shafts on the back, neck, thorax, and hind limbs

**Distribution:** Tropical or warm regions of the United States and Puerto Rico, Australia, and Fiji

**Derivation of Genus:** Lynx mite

**Transmission Route:** Direct contact from host to host

**Common Name:** Feline fur mite



**FIGURE 13-66:** *Lynxacarus radovskyi*, the feline fur mite, attaches to hair shafts on back, neck, thorax, and hind limbs of cats.

***Lynxacarus radovskyi* (Feline Fur Mite).** *Lynxacarus radovskyi*, the feline fur mite, is found attached to the shafts of individual hairs on the back, neck, thorax, and hind limbs of cats residing in tropical or warm areas of the United States, such as Florida, Puerto Rico, and Hawaii. These fur mites are laterally compressed. The adults are approximately 500  $\mu\text{m}$  long (Figure 13-66). Pruritus is not always associated with infestations of *L. radovskyi* in cats. These mites are diagnosed by observing the mites attached to hair shafts and examining the dander and other debris after combing. This mite may also affect humans who handle infested cats, producing a papular dermatitis.

**TECHNICIAN'S NOTE** The feline fur mite can be diagnosed by seeing the adult mites attached to the hair shafts and examining the dander and debris after combing.

**Parasite:** *Myobia musculi*, *Myocoptes musculus*, and *Radfordia affinis*

**Host:** Mice

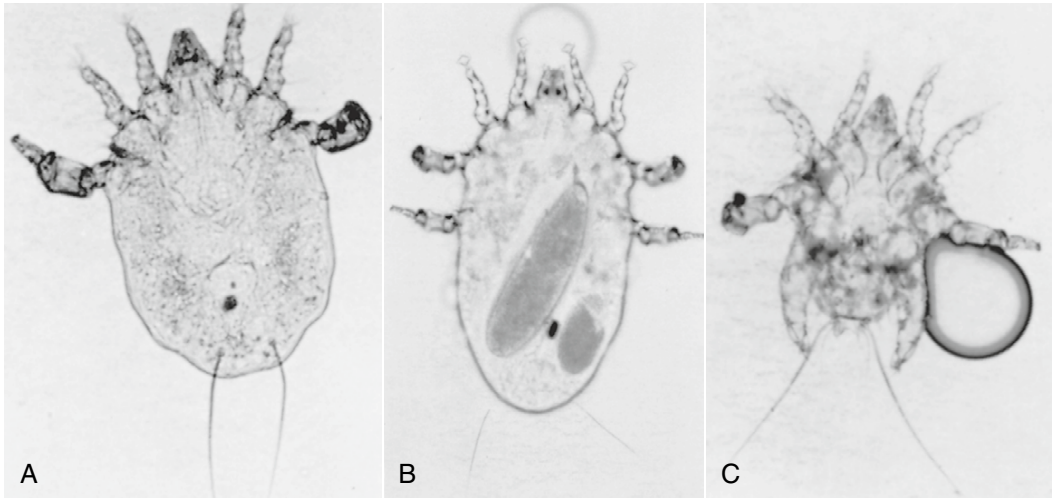
**Location of Adult:** Hair shafts

**Distribution:** Worldwide

**Derivation of Genus:** Unknown

**Transmission Route:** Direct contact from host to host

**Common Name:** Mouse fur mites



**FIGURE 13-67:** *Myocoptes musculus*, fur mite of mice. **A**, Nymphal female. Note absence of adult's hind legs. **B**, Adult female. Oval shape within is an egg. **C**, Adult male with air bubble artifact.

**Myobia musculi, Myocoptes musculus, and Radfordia affinis (Mouse Fur Mites).** The three most common fur mites of the mouse are *Myobia musculi*, *Myocoptes musculus*, and *Radfordia affinis*. Mice housed in close association with rats may become infested with *Radfordia ensifera*, a fur mite of rats (see next discussion). Rodent mites have life cycles similar to those of mites of other animal species, with larval and nymphal stages. Larval mites have only six legs, whereas nymphal stages (Figure 13-67, A) and adult specimens have eight legs (Figure 13-67, B).

The first pair of legs of *M. musculi*, *R. affinis* and *M. musculus* are distinctly short and adapted for clasping the hair of the host, with the first two pairs of legs being somewhat clublike at the ends (Figure 13-67, C).

The second pair of legs of *M. musculi* and *R. affinis* end with clawlike features referred to as **empodia**. The empodia of *M. musculi* and *M. musculus* are long and single (Figure 13-68, A), whereas *R. affinis* has a shorter pair of empodia of unequal length on the second set of legs (Figure 13-68, B). This feature distinguishes *R. affinis* from both *M. musculi* and *M. musculus*.

Adult females of *M. musculi* are about 400 to 500  $\mu\text{m}$  long and 200  $\mu\text{m}$  wide. Males are similarly shaped but proportionately smaller.

*R. affinis* is similar in size and shape to *M. musculi*. Adult females of *M. musculus* are smaller than other fur mites of mice, measuring  $300 \times 130 \mu\text{m}$ . The male is  $190 \times 135 \mu\text{m}$ .

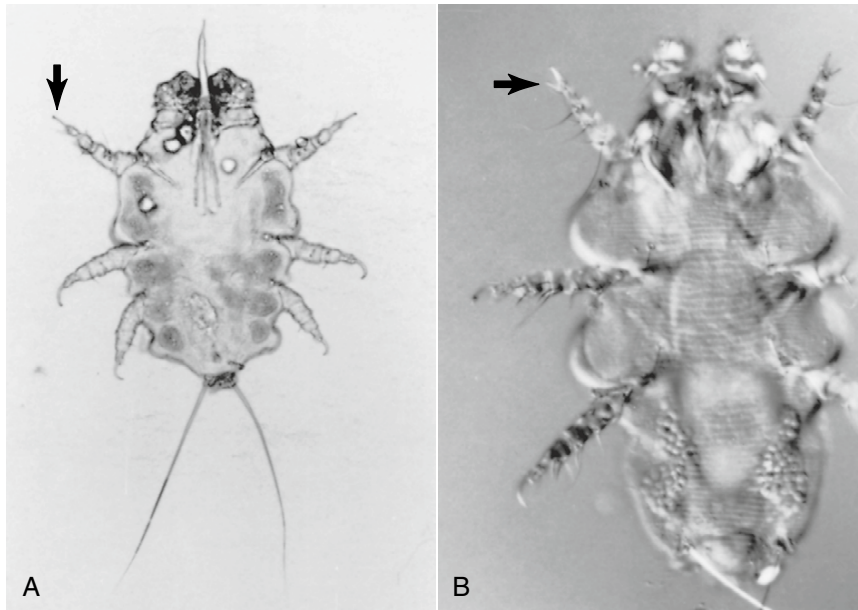
**TECHNICIAN'S NOTE** The second pair of legs end with clawlike features referred to as empodia. Empodia of *M. musculi* and *M. musculus* are longer than those of *R. affinis*.

Fur mite eggs can be found attached near the base of the host's hairs. The eggs are oval and about 200  $\mu\text{m}$  long (Figure 13-69).

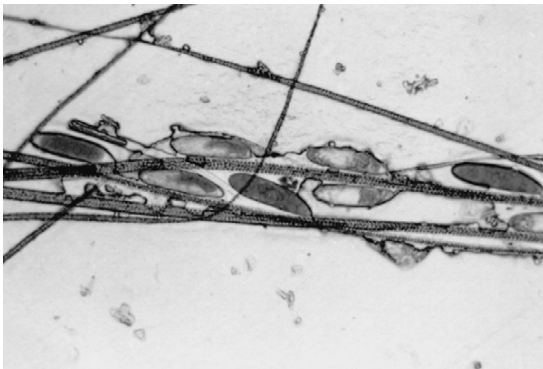
To detect fur mites on a live mouse, fur can be obtained by plucking with forceps or by pressing the adhesive side of cellophane tape on the pelt of the mouse. The plucked fur can be placed in a drop of mineral oil on a glass slide and examined microscopically for mites or eggs. The cellophane tape can be placed adhesive side down on a drop of mineral oil on a glass slide and similarly examined. Fur samples should be taken from the neck or shoulder area, because that is where the mites most often reside and produce lesions.

Postmortem detection of fur-inhabiting mites of mice may be approached as in the antemortem method, or the dead mouse may be placed under





**FIGURE 13-68:** **A**, Eight-legged nymphal form of *Myobia musculi*, showing single long empodial claw on second pair of legs (arrow). Extended mouthpart is typical of nymphal form. **B**, *Radfordia affinis*, showing paired empodial claws on second leg pair (arrows).



**FIGURE 13-69:** Nits of *Myocoptes musculus* attached to hair shafts of mouse.

a warm lamp for a few minutes. The heat attracts the mites in the pelt, causing them to migrate to the tips of the hairs. A hand-held magnifying glass, a head loupe, or a dissecting microscope aids in the detection of the mites. The mites may be collected on the tip of a metal probe or similar instrument that has been dipped in mineral oil, then placed in a drop of mineral oil on a glass slide and under a coverslip, and examined microscopically.

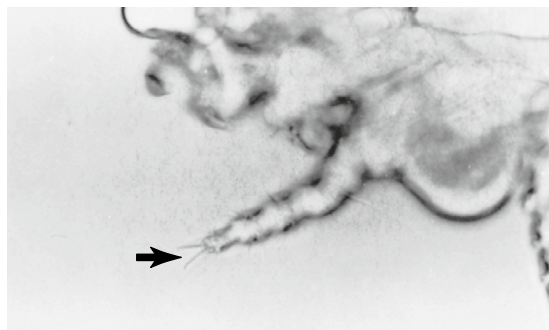
**TECHNICIAN'S NOTE** Diagnosis of the mouse fur mites can be made by plucking the fur or using the cellophane tape technique to find the mites under a microscope. Samples should be taken from the neck or shoulder areas.

The pathogenicity of mouse fur mites varies greatly with the host and the degree of infestation, similar to demodectic acariasis in dogs. Clinical signs may be absent or may include alopecia, pruritus, and ulceration. More severe lesions may be the result of host sensitivity to the mites, in which case few if any mites are observed.

Transmission of mouse fur mites is by direct contact. Although mites are generally host specific, the owner of multiple species of rodents should be advised that *M. musculi* and *R. affinis* may infest rats and guinea pigs housed in the same area with mice infested with *M. musculi* and *R. affinis*. The three species of mouse fur mites are not known to infest humans.

*M. musculi* and *M. musculus* are treated with ivermectin.





**FIGURE 13-70:** Second leg of *Radfordia ensifera*, showing equal length of empodial claws (arrow).

**Parasite:** *Radfordia ensifera*

**Host:** Rats

**Location of Adult:** Hair shafts

**Distribution:** Worldwide

**Derivation of Genus:** Unknown

**Transmission Route:** Direct contact from host to host

**Common Name:** Rat fur mite

***Radfordia ensifera* (Rat Fur Mite).** *Radfordia ensifera*, a fur mite of rats, is similar to *Myobia musculi* and *Radfordia affinis* (see Figure 13-68). *R. ensifera* is distinguished from *M. musculi* and *R. affinis* by the empodial claws of the second pair of legs. *M. musculi* has a single, long empodial claw (see Figure 13-68, A), whereas *R. ensifera* and *R. affinis* both have a pair of short claws. The two empodial claws of *R. ensifera* are of equal length (Figure 13-70), whereas those of *R. affinis* are of unequal length (see Figure 13-68, B).

Antemortem or postmortem, *R. ensifera* is detected using methods described for mouse fur mites. Light infestation of *R. ensifera* usually causes no clinical signs; however, self-inflicted trauma may be seen in heavy infestations. Transmission is by direct contact. *R. ensifera* is not known to infest humans.



**TECHNICIAN'S NOTE** The rat fur mite can be diagnosed by plucking fur or use of the cellophane tape method to identify adult mites under the microscope.



**FIGURE 13-71:** Male *Chirodiscoides caviae*, fur mite of guinea pig.

**Parasite:** *Chirodiscoides caviae*

**Host:** Guinea pig

**Location of Adult:** Within the pelt

**Distribution:** Worldwide

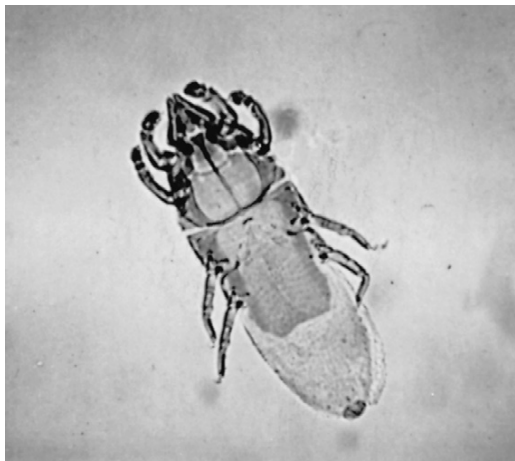
**Derivation of Genus:** Disc-likehand

**Transmission Route:** Direct contact from host to host

**Common Name:** Guinea pig fur mite

***Chirodiscoides caviae* (Guinea Pig Fur Mite).** The fur mite that typically infests guinea pigs is *Chirodiscoides caviae*. *C. caviae* is an elongated mite, with a triangular cranial portion that appears similar to the head of the mite. All eight legs are adapted for grasping onto the hair. There are no empodial claws on the first two pairs of legs. The male is about  $363 \times 138 \mu\text{m}$  (Figure 13-71), and the female is  $515 \times 164 \mu\text{m}$  (Figure 13-72).

*C. caviae* is somewhat difficult to observe antemortem with the unaided eye. It may be detected by pulling hairs, either with forceps or by the cellophane tape method, then examining the specimen microscopically. *C. caviae* is found in the pelt and occurs in the greatest numbers in the area over the rump. Postmortem, a piece of the pelt from the rump of the dead animal may be placed in a Petri dish to cool and then examined with a hand-held magnifying glass or dissecting microscope for mites at the tip of the hairs.



**FIGURE 13-72:** Female *Chirodiscoides caviae*, fur mite of guinea pig.

**TECHNICIAN'S NOTE** Diagnosis of the guinea pig fur mite can be made by plucking hairs or using the cellophane tape technique and observing the adult mites under the microscope.

Usually there are no clinical signs unless infestation is severe, when alopecia and pruritus may be seen. Although *C. caviae* is not considered transmissible to humans, transient infestation causing a pruritic, papular urticarial skin condition has been reported.

*Myocoptes musculinus* and *Radfordia affinis* are also transmissible to guinea pigs (see previous discussion).

**Parasite:** *Listrophorus gibbus*

**Host:** Rabbits

**Location of Adult:** Hair shafts

**Distribution:** Worldwide

**Derivation of Genus:** Not found

**Transmission Route:** Direct contact from host to host

**Common Name:** Rabbit fur mite

**Listrophorus gibbus (Rabbit Fur Mite).** Similar to *Cheyletiella parasitivorax* (see Figure 13-65), *Listrophorus gibbus* is a small, nonburrowing fur mite of rabbits. *L. gibbus* females are about 435  $\mu\text{m}$  and males 340  $\mu\text{m}$  long. Both species

have a dorsal hoodlike projection covering the mouthparts. Males are further characterized by the clasping organs at their caudal end.

In the same manner as for *C. parasitivorax*, *L. gibbus* may be detected by pulling fur with forceps or cellophane tape and then examining the hairs under a dissecting microscope. Combing or brushing the fur may also be used to obtain mites for identification. *L. gibbus* mites are most likely located on the back and abdomen of rabbits. This mite appears to produce no clinical signs, even in heavy infestations.

*L. gibbus* is transmitted by direct contact. Infestation with *L. gibbus* is treated with malathion dips or ivermectin (not approved for rabbits). This mite is more often associated with wild rabbits than with domestic species, so owners should be aware that control of this parasite depends on controlling the rabbit's environment. *L. gibbus* is not a known vector of disease and has no zoonotic significance in humans.

**TECHNICIAN'S NOTE** The rabbit fur mite is more commonly associated with wild rabbits than it is with pet rabbits.

## Ticks of Veterinary Importance

Ticks are small to medium-sized acarines with dorsoventrally flattened, leathery bodies. The tick's head, the capitulum, has two cutting, or lacerating, organs called **chelicerae**; a penetrating, anchorlike sucking organ, the **hypostome**; and two leglike accessory appendages, the **pedipalps**, that act as sensors or supports when the tick fastens to the host's body. The tick's body may be partially or entirely covered by a hard, chitinous plate, the **scutum**. Mouthparts may be concealed under the tick's body or may extend from the anterior border of the body. Most ticks are **inornate**, meaning solid-colored (reddish or mahogany) and unpatterned.

Some species are **ornate**; that is, they demonstrate distinctive white patterns on the dark reddish or mahogany background of the scutum. Larval ticks have six legs, and nymphal and

adult ticks have eight legs with strong claws on the ends.



**TECHNICIAN'S NOTE** The tick's body has a capitulum (head) with chelicerae (two cutting or lacerating organs); a hypostome (penetrating and anchorlike sucking organ); and pedipalps (two leglike accessory appendages) that act as sensors or supports when the tick fastens to the host's body.

Ticks are important parasites because of their voracious blood-feeding activity. They are also important because they are capable of transmitting many parasitic, bacterial, viral, rickettsial, and other pathogenic diseases, such as **borreliosis** (Lyme disease), among animals and from animals to humans. These pathogenic organisms may be transmitted passively, or the tick may serve as an obligatory intermediate host for certain protozoan parasites.

Ticks are also important because the salivary secretions of some female ticks are toxic and can produce a syndrome known as **tick paralysis** in humans and domestic and wild animals. Tick species associated with tick paralysis are *Dermacentor andersoni*, the Rocky Mountain spotted fever tick; *Dermacentor occidentalis*, the Pacific coast tick; *Ixodes holocyclus*, the paralysis tick of Australia; and *Dermacentor variabilis*, the wood tick.



**TECHNICIAN'S NOTE** Ticks are important veterinary parasites because they are voracious blood-feeders and act as vectors for transmitting various parasitic, bacterial, viral, rickettsial, and other pathogenic diseases as well as causing tick paralysis.

The ticks of veterinary importance can be divided into two families, the **argasid**, or soft, ticks and the **ixodid**, or hard, ticks. Argasid ticks lack a scutum, the hard, chitinous plate that covers the body of the tick. The mouthparts of the adult soft tick cannot be seen when viewed from the dorsal aspect. Ixodid ticks,

on the other hand, have a hard, chitinous scutum that covers all the male tick's dorsum and about a third or less of the female tick's dorsum, depending on the degree of engorgement. As a rule of thumb, male ticks are much smaller than female ticks.

Among the argasid ticks, two species are important: *Otobius megnini*, the spinose ear tick, and *Argas persicus*, the fowl tick. In the ixodid tick family, there are 13 economically important tick species. These include *Rhipicephalus sanguineus*, *Ixodes scapularis*, *Dermacentor* species, and *Amblyomma* species. Of these species, *R. sanguineus* infests buildings such as dwellings and kennels; the other ticks attack their hosts in outdoor environments.



**TECHNICIAN'S NOTE** There are two families of ticks: the argasid ticks (ticks with soft bodies) and the ixodid ticks (ticks with hard bodies).

Specific identification of ticks is difficult and should be performed by a veterinary parasitologist or trained acarologist or arthropodologist. Ticks are usually identified by the shape and length of the capitulum or mouthparts, the shape and color of the body, and the shape and markings on the scutum. Male and unengorged female ticks are easier to identify than engorged female ticks. It is most difficult to speciate larval or nymphal ticks. The common species can be identified by their size, shape, color, body markings, host, and location on the host.

There are four major stages in the life cycle of ticks: egg, larva, nymph, and adult. Following their engorgement on the host, female ticks drop off the host and seek protected places, such as cracks and crevices or under leaves and branches, to lay their eggs (Figure 13-73). The six-legged larvae, or **seed ticks**, hatch from the eggs and feed on the host (Figure 13-74). The larva molts to the eight-legged nymphal stage, which resembles the adult stage but lacks the functioning reproductive organs of adult ticks. After one or two blood



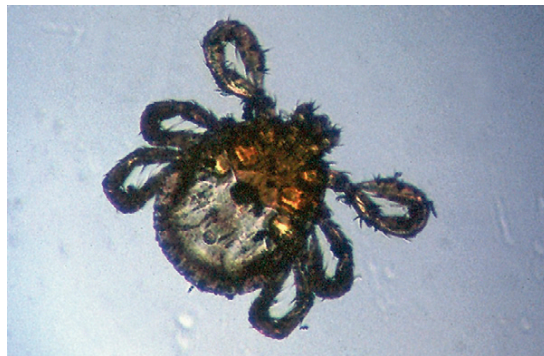**FIGURE 13-73:** Adult female *Dermacentor variabilis* laying hundreds of eggs.

meals, the nymph becomes mature and molts to the adult stage. During the larval, nymphal, and adult stages, ticks may infest one, two, three, or even many different host species (Figure 13-75). This ability to feed on several hosts during the life cycle plays an important role in the transmission of disease pathogens among hosts. It is important to remember that any infestation of domestic animals by either mites or ticks is referred to as acariasis.

**TECHNICIAN'S NOTE** There are four stages to the tick life cycle: egg, larval, nymphal, and adult. In addition, ticks can be one-, two-, three-, or many-host ticks: meaning the tick uses one host for its entire life cycle, one host for a particular life stage, and another host for the other life stages, etc. A three-host tick uses a different host for each life stage.

Most ticks do not tolerate direct sunlight, dryness, or excessive rainfall. They can survive as long as 2 to 3 years without a blood meal, but female ticks require a blood meal before fertilization and subsequent egg deposition. Tick activity is restricted during the cold winter months but increases dramatically during the spring, summer, and fall seasons.

Tick prevention is the best way to avoid acariasis by ticks. Prevention includes inspecting the



**FIGURE 13-74:** Six-legged larva, or seed tick, of *Rhipicephalus sanguineus* hatches from egg and feeds on host.

animal for ticks each time the animal is outside and removing the ticks as soon as possible. Tick products, such as Frontline\* or Frontline Plus\* and Advantix,† will kill some species of ticks and are applied once a month. Amitraz is an effective dip for ticks, although there is no long-term residual benefit. Amitraz may also be purchased as a tick collar and is effective against ticks. New monthly preventatives and collars are being developed constantly.

### Argasid (Soft) Ticks

**Parasite:** *Otobius megnini*

**Host:** Horses, cattle, sheep, goats, and dogs

**Location of Adult:** Environment of animal, only larval and nymphal stages feed on external ear canal of animal

**Distribution:** Associated with arid and semi-arid regions of the southwestern United States but can be found throughout North America

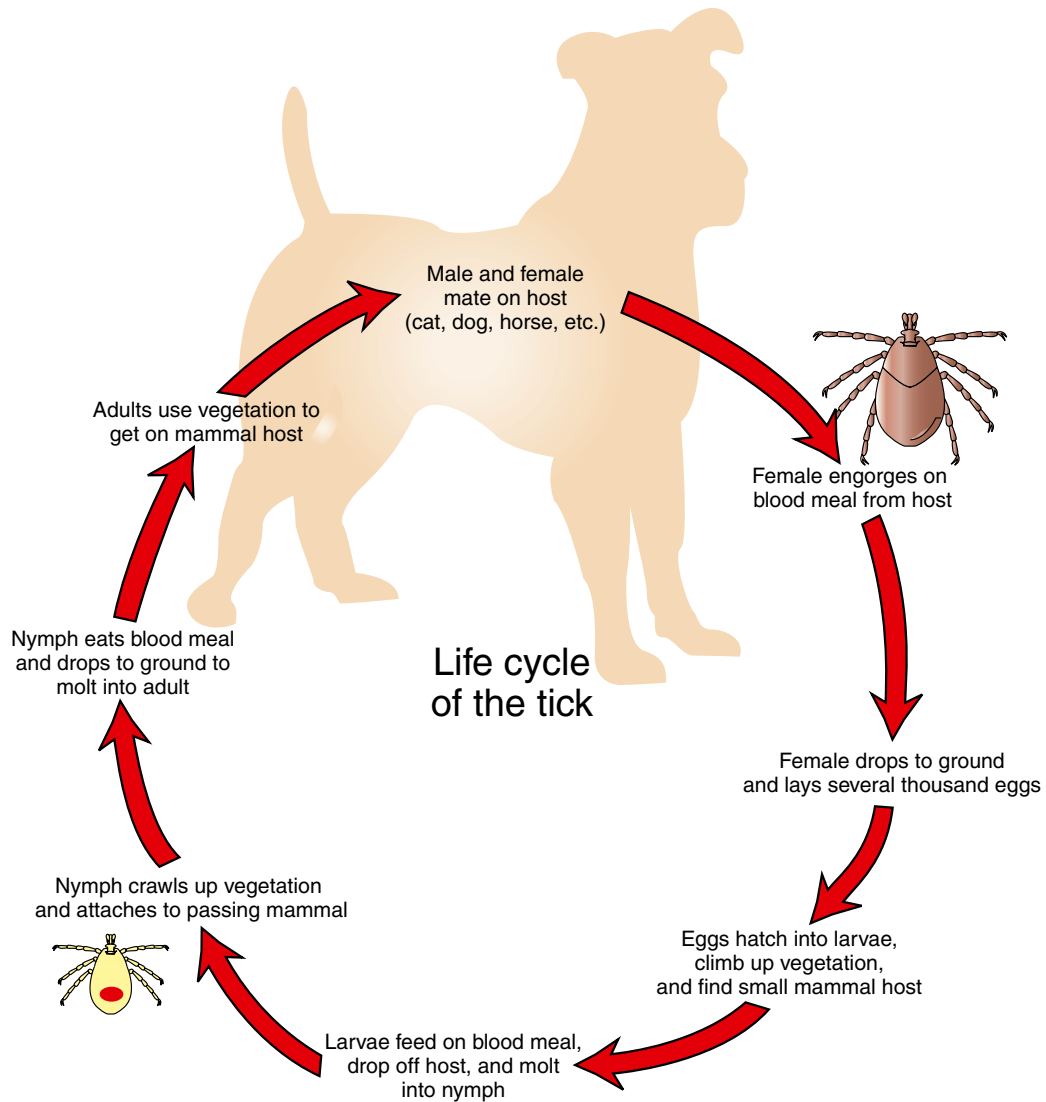
**Derivation of Genus:** Ear way of life

**Transmission Route:** Direct contact with infested environment

**Common Name:** Spinose ear tick

**TECHNICIAN'S NOTE** *Otobius megnini* can attach to humans and cause tick paralysis. (NOTE: Every tick has the potential to cause tick paralysis.)

†Bayer Animal Health Corporation, Bedford, NH.

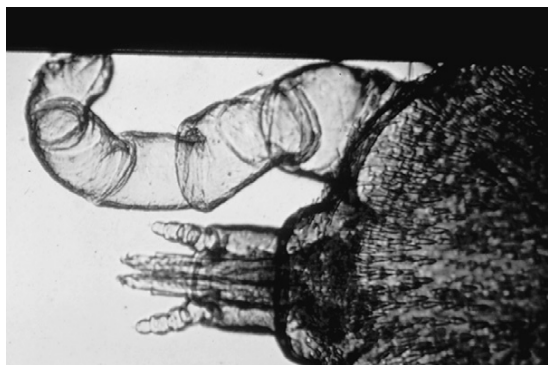


**FIGURE 13-75:** Life cycle of the tick.

**Otobius megnini (Spinose Ear Tick).** *Otobius megnini*, the **spinose ear tick**, is an unusual soft tick in that only the larval and nymphal stages are parasitic. The eight-legged adult stages are not parasitic, but instead are free-living and are found in the environment of the definitive host, usually in dry protected places, in cracks and crevices, and under logs and fence posts. The larval and nymphal stages feed on horses, cattle, sheep, goats, and dogs. These ticks are associated with

the semiarid or arid areas of the southwestern United States; with widespread interstate transportation of animals, however, this soft tick may occur throughout North America. As with most soft ticks, the mouthparts may not be visible when viewed from the dorsal aspect (Figure 13-76). The nymphal stage of *O. megnini* is widest in the middle and is almost violin shaped. It is covered with tiny, backward-projecting spines, thus the name **spinose**. The larval and nymphal forms





**FIGURE 13-76:** Only larval and nymphal stages of *Otiobius megnini*, the spinose ear tick, are parasitic. Mouthparts of this soft tick may not be visible when viewed from dorsal aspect.

are usually found within the ears of the definitive host, thus the name **ear tick**. The body of the larval stage is covered with stout, tiny spines while the nymphal stage resembles the adult tick on a smaller scale.

**TECHNICIAN'S NOTE** Only the larval and nymphal stages feed on the animal host where they can consume large amounts of blood without engorging or swelling.

Spinose ear ticks are extremely irritating to the definitive host. They often occur in large numbers deep within the external ear canal. These ticks imbibe large amounts of host blood; however, because they are soft ticks, they do not engorge or swell. Large numbers of these ticks may produce ulceration deep within the external ear. The ears become highly sensitive, and the animals may shake their heads. The pinnae may become excoriated by the constant shaking and rubbing of the animal's head.

The ticks may be visualized in situ with an otoscope. Any waxy exudate should be examined for the presence of larval (six-legged) and nymphal (eight-legged) stages of the spinose ear tick.

**Parasite:** *Argas persicus*

**Host:** Chickens, turkeys, and wild birds

**Location of Adult:** Attached to the skin of the bird when feeding and in the bird's environment when not actively feeding

**Distribution:** Worldwide

**Derivation of Genus:** Named for the 100-eyed monster that Hermes in Greek mythology

**Transmission Route:** Direct contact with infested environment

**Common Name:** Fowl tick

***Argas persicus* (Fowl Tick).** *Argas persicus*, the **fowl tick**, is a soft tick of chickens, turkeys, and wild birds. These ticks are periodic parasites, hiding in cracks and crevices during the day and becoming active during the evening hours, when they feed intermittently on the avian host. The adults are 7 mm long and 5 mm wide. In the unengorged state, they are reddish brown, but after engorgement, they take on a slate-blue color. These ticks are flat and leathery, and the tegument is covered with tiny bumps. Because they are soft ticks, they lack a scutum. The mouthparts are not visible when the adult tick is viewed from the dorsal aspect.

Birds heavily infested with *A. persicus* may develop significant anemias. These ticks are worrisome to birds, particularly during the evening hours. The feeding activity of these ticks may cause the birds' egg laying to decrease or even cease.

All stages of *A. persicus* may be collected from infested birds but it is most often found in cracks, crevices, and contaminated bedding in poultry houses.

**TECHNICIAN'S NOTE** *Argas persicus* adults are reddish brown before feeding but after feeding, they turn slate-blue.

## Ixodid (Hard) Ticks

**Parasite:** *Ixodes scapularis*

**Host:** Larval and nymphal stages – mice and voles; adult stage – horses, dogs, deer, and humans

**Location of Adult:** Attached to host for feeding, environment when not feeding and can be found on tips of vegetation waiting for a host

**Distribution:** United States east of the Ohio River Valley

**Derivation of Genus:** Sticky, like bird-lime

**Transmission Route:** Direct contact with life stage on tip of vegetation

**Common Name:** Deer tick

***Ixodes scapularis* (Deer Tick).** *Ixodes scapularis*, the deer tick, is a hard-bodied three-host tick. The deer tick is found in regions east of the Ohio River valley in the eastern United States. The adult ticks have eight legs that lack **festoons** (indentation or folds along the margin of an external body part such as the scutum, posterior edge of the body or the legs). The palps (mouth-parts) are long and the anal groove surrounds the anus anteriorly. The adult females have a small scutum while the males have a large scutum. Adult females will engorge or swell up when they take a blood meal. The eggs laid by the female are tiny and round. The larvae have six legs while the nymphs have eight legs like the adult tick.

**TECHNICIAN'S NOTE** Deer ticks can be found from the Atlantic Ocean to the Ohio River valley and can be vectors in transmitting several bacteria and parasites.

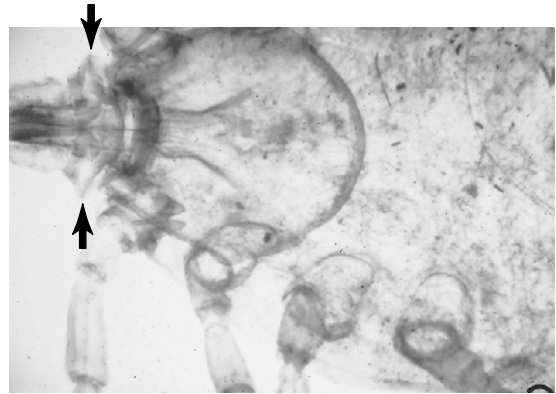
*Ixodes scapularis* is a blood sucking tick that requires a blood meal prior to developing to the next life stage or laying eggs. These ticks are vectors for bacterial diseases such as tularemia, *Babesia microti*, *Borrelia burgdorferi* (Lyme disease) and granulocytic ehrlichiosis (in humans). All developmental stages can be collected from the tips of vegetation where they await the opportunity for a host to pass by so they can attach themselves to the host. The adults can attach to humans and transmit Lyme disease, tularemia, and babesiosis to the human host. The tick does not cause disease itself, although it can cause tick paralysis, but serves as a vector and intermediate host for the bacteria and parasites that do cause disease.

**TECHNICIAN'S NOTE** *Ixodes scapularis* is the vector for spreading Lyme disease to dogs, horses, and humans.

**Parasite:** *Rhipicephalus sanguineus*

**Host:** Dogs

**Location of Adult:** Attached below the haircoat on the body but especially the external ear canal and between the toes



**FIGURE 13-77:** Lateral expansion of basis capitulum of *Rhipicephalus sanguineus*, the brown dog tick. This key morphologic feature is used to identify this tick, which can breed in host's environment.

**Distribution:** North America

**Derivation of Genus:** Fan head

**Transmission Route:** Direct contact with infested environment

**Common Name:** Brown dog tick

***Rhipicephalus Sanguineus* (Brown Dog Tick).** *Rhipicephalus sanguineus*, the brown dog tick, is an unusual hard tick in that it invades both kennel and household environments. This tick is widely distributed throughout North America. It has an inornate, uniformly reddish brown scutum and feeds almost exclusively on dogs, thus the common name **brown dog tick**. The adult can be found in the haircoat all over the dog's body, but is especially fond of the external ear canal and the area between the toes. *R. sanguineus* also has a distinguishing key morphologic feature: its basis capitulum (or head) has prominent lateral extensions that give the structure a decidedly hexagonal appearance (Figure 13-77). The engorged female is often slate gray. In southern climates the tick is found outdoors, but in northern climates it becomes a serious household pest, breeding indoors in both home and kennel environments.

The bites of this tick can be very irritating to the dog. In severe infestations, heavy blood loss may occur. This tick is also an intermediate host for *Babesia canis*, the etiologic agent that causes canine piroplasmosis.

**TECHNICIAN'S NOTE** *Rhipicephalus sanguineus* ticks do not transmit any zoonotic diseases but can cause tick paralysis in humans.

*R. sanguineus* can be identified (with dichotomous keys) by its inornate brown color and characteristic lateral projections of the basis capitulum. These ticks are unique in that they can be found in indoor or kennel environments. Treatment can be accomplished by foggers that will kill ticks or a house spray labeled for use against ticks. This treatment will kill ticks indoors or in the kennel.

**Parasite:** *Dermacentor variabilis*

**Host:** Small mammals, dogs, and humans

**Location of Adult:** Attached to skin when feeding

**Distribution:** Primarily, the eastern two-thirds of the United States but can be found throughout the United States

**Derivation of Genus:** Skin stabber or skin puncturer

**Transmission Route:** Direct contact with life stage at tip of infested vegetation

**Common Name:** American dog tick or wood tick

***Dermacentor variabilis* (American Dog Tick, Wood Tick).** *Dermacentor variabilis*, the **American dog tick** or **wood tick**, is found primarily in the eastern two-thirds of the United States; however, with the increased mobility of American households, the tick may become distributed throughout the country. Unlike *R. sanguineus*, the *D. variabilis* tick only inhabits grassy, scrub-brush areas, especially roadsides and pathways. This three-host tick initially feeds on small mammals, such as field mice and other rodents. However, dogs and humans can serve as preferred hosts for this ubiquitous tick. *D. variabilis* can serve as a vector of Rocky Mountain spotted fever, tularemia, and other microbes. It has also been associated with tick paralysis in domestic and wild animals and in humans. This tick has an ornate scutum that is dark brown with white striping. The adults have eight festooned legs and the hypostome and palps are somewhat shortened. Unfed adult ticks are approximately 6 mm long; the adult engorged female is about



**FIGURE 13-78:** Engorged, adult female *Dermacentor variabilis*. Unfed adults are approximately 6 mm long; engorged adult females are about 12 mm long and blue-gray.

12 mm and is blue-gray (Figure 13-78). *D. variabilis* is a seasonal annoyance to humans and domestic animals.

**TECHNICIAN'S NOTE** The American dog tick is commonly found on dogs in the United States. *Dermacentor variabilis* can transmit Rocky Mountain spotted fever, tularemia, and other microbes. It is a source for tick paralysis.

*D. variabilis* can be diagnosed by its key morphologic features (with a dichotomous key) and the rectangular base of the capitulum and characteristic white markings on the dorsal shield.

**Parasite:** *Dermacentor andersoni*

**Host:** Larval and nymphal stages – small rodents; adult stage – dogs, horses, cattle, goats, sheep, and humans

**Location of Adult:** Attached to the skin surface

**Distribution:** Rocky Mountain regions but can travel on host to other parts of the United States and North America


**Derivation of Genus:** Skin sticker or skin puncturer

**Transmission Route:** Direct contact with infested vegetation

**Common Name:** Rocky Mountain wood tick


***Dermacentor andersoni* (Rocky Mountain Wood Tick).** *Dermacentor andersoni* or the

**Rocky Mountain wood tick** is typically seen in the Rocky Mountain regions but with the ease of travel, the host is able to carry it to other regions in the United States and North America. This is an ornate tick and the adult has eight festooned legs. The hypostome and palps are short with the female having a small scutum while the male has a large scutum. The eggs tend to be tiny and round. The female tick can lay as many as 4000 eggs in her lifetime. The larval stage has six legs while the nymph has eight legs.

 **TECHNICIAN'S NOTE** *Dermacentor andersoni* is the Rocky Mountain wood tick that is considered the primary vector for the spread of Rocky Mountain spotted fever.

The larval (“seed ticks”) and nymphal stages are found on many small mammals, especially rodents. The adult stages are found on large mammals that include horses, dogs, cattle, sheep, goats, and humans. The male and female ticks are blood-feeders that can serve as vectors for a variety of animal and human pathogens. All life stages can be collected from the tips of vegetation where they await a host to pass by.

These ticks can be identified by matching their short palps and hypostome, festooned legs, and ornate scutum with a dichotomous key. These ticks are capable of transmitting Rocky Mountain spotted fever (RMSF) to animals and humans and is considered the primary vector for the transmission of RMSF.

 **TECHNICIAN'S NOTE** *Dermacentor andersoni*, being a three-host tick, is an excellent vector for spreading diseases of animals and humans.

**Parasite:** *Dermacentor occidentalis*

**Host:** Larval and nymphal stages – small mammals; adult stage – large mammals such as dogs, deer, cattle, horses, sheep, rabbits, and humans

**Location of Adult:** Attached to skin of host when feeding

**Distribution:** Sierra Nevada Mountains to the Pacific Ocean

**Derivation of Genus:** Skin stabber or skin puncturer


**Transmission Route:** Direct contact with infested vegetation

**Common Name:** Pacific coast dog tick

**Dermacentor Occidentalis (Pacific Coast Dog Tick).** *Dermacentor occidentalis* or the Pacific coast dog tick is a brown tick with eight festooned legs. The adult has short palps and hypostome. The female has a small scutum while the male possesses a large scutum. This tick is found in the United States between the Sierra Nevada Mountains and the Pacific Ocean from Oregon to Southern California.

The eggs are tiny and round while the larvae have six legs. The nymphal stage resembles a smaller version of the adult tick with eight legs. The larval and nymphal stages can be found feeding on small mammals, especially rodents. The adults are typically found feeding on large mammals including horses, deer, cattle, donkeys, rabbits, sheep, and humans. All developmental stages can be collected from the tips of infested vegetation where they await a host to pass by so they can attach to the host.

All developmental stages are blood-feeders and can act as vectors or intermediate hosts for a variety of animal and human pathogens including tularemia. In addition, the tick can serve as a cause for tick paralysis in animals and humans.

 **TECHNICIAN'S NOTE** *Dermacentor occidentalis* or the Pacific coast dog tick is typically found between the Sierra Nevada Mountains and the Pacific Ocean. However, with the ease of travel, the host can carry it to other regions of the United States and North America.

**Parasite:** *Amblyomma americanum*

**Host:** Larval and nymphal stages – small mammals, adult stage – wide range of mammal hosts including humans



**Location of Adult:** Attached to the skin of the host, particularly the ear

**Distribution:** Southern United States, Midwest, and Atlantic coast of the U.S.

**Derivation of Genus:** Dull eye

**Transmission Route:** Direct contact with infested vegetation

**Common Name:** Lone star tick

**Amblyomma Americanum (Lone Star Tick).**

*Amblyomma americanum* demonstrates a characteristic white spot on the apex of its scutum, thus its common name, the **lone star tick**. The spot is more conspicuous on male than female ticks. This tick is distributed throughout the southern United States but is also found in the Midwest and on the Atlantic coast. All developmental stages can be collected from infested vegetation where they await a host to pass by to which to attach.

This three-host tick is found most often in spring and summer, parasitizing the head, belly, and flanks (the ear is the favored site) of wild and domestic animal hosts. It also will feed on humans and is said to have a painful bite. It can produce anemia and has been incriminated as a vector of tularemia and Rocky Mountain spotted fever.

*Amblyomma americanum* is easily diagnosed by the white spot on its scutum.

**TECHNICIAN'S NOTE** *Amblyomma americanum* is a vector for the transmission of tularemia and Rocky Mountain spotted fever in animals and humans. It can be identified by a single white spot on its scutum.

**Parasite:** *Amblyomma maculatum*

**Host:** Larval and nymphal stages – ground birds; adult stage – cattle, horses, sheep, dogs, and humans

**Location of Adult:** Attached to the skin of the host when feeding

**Distribution:** Regions of high humidity such as the Atlantic coast and Gulf Coast of the United States

**Derivation of Genus:** Dull eye

**Transmission Route:** Direct contact with infested vegetation

**Common Name:** Gulf Coast tick

**Amblyomma Maculatum (Gulf Coast Tick).**

*Amblyomma maculatum*, the **Gulf Coast tick**, is a three-host tick found in the ears of cattle, horses, sheep, dogs, and humans. It occurs in areas of high humidity on the Atlantic and Gulf Coast seaboards. It produces severe bites and painful swellings and is associated with tick paralysis. This tick has silvery markings on its scutum. Larval and nymphal stages occur on ground birds throughout the year. The numbers of adult ticks on cattle decreases during winter and spring and increases in summer and fall. When the ear canals of cattle and horses are infested, the pinnae may droop and become deformed.

*Amblyomma maculatum* is easily diagnosed by the silvery markings on its ornate scutum (Figure 13-79).

**TECHNICIAN'S NOTE** While *Amblyomma maculatum* is not associated with the transmission of any diseases in humans, it can cause tick paralysis.

**Parasite:** *Boophilus annulatus*

**Host:** Cattle

**Location of Adult:** Attached to the skin of host while feeding



**FIGURE 13-79:** Ornate adult male, *Amblyomma maculatum*. *A. maculatum* is easily diagnosed by silvery markings on its scutum.



**Distribution:** Mexico or enzootic areas of the United States

**Derivation of Genus:** Cattle lover

**Transmission Route:** Direct contact from host to host, all stages are found on the host

**Common Name:** Texas cattle fever tick or North American tick

**Boophilus Annulatus (Texas Cattle Fever Tick).** *Boophilus annulatus*, the **Texas cattle fever tick** or **North American tick**, uses only one host. This tick has historical significance in that it was the first arthropod shown to serve as an intermediate host for a protozoan parasite, *Babesia bigemina*, of cattle. This tick therefore marks a milestone in veterinary parasitology. *B. annulatus* has been completely eradicated from the United States; however, if it is ever diagnosed by a veterinary diagnostician, that fact *must* be reported to the proper regulatory agencies. The tick should be identified by a specialist and the appropriate control methods applied. *B. annulatus* frequently enters the United States from Mexico.

The engorged *B. annulatus* female is 10 to 12 mm in length, and the male is 3 to 4 mm. The mouthparts are very short, and there are no festoons on the posterior aspect of the abdomen. It is an inornate tick.



**TECHNICIAN'S NOTE** In 1892, Theobald Smith and the veterinarian F.L. Kilbourne found that *Boophilus annulatus* was the first arthropod to be shown to serve as an intermediate host for a protozoan parasite (*Babesia bigemina*).

Because this is a one-host tick, larvae, nymphs, and adult ticks may be found on cattle. They do not leave the host to complete the life cycle. Animals with heavy infestations are restless and irritated. To rid themselves of ticks, they rub, lick, bite, and scratch. Irritated areas may become raw and secondarily infested. If ticks are numerous, anemia may occur.

The veterinary diagnostician must use a key to identify adults of *B. annulatus*. Again, ticks identified as such must be reported to both state and

federal authorities. Determining the origin of suspect ticks is of paramount importance. Most often these ticks may be collected from within an enzootic area in the United States or from animals originating from Mexico.

**Parasite:** *Haemaphysalis leporispalustris*

**Host:** Larval and nymphal stages – rabbits, birds, and occasionally dogs, cats, and humans; adult stage – rabbits

**Location of Adult:** Attached to skin of host when feeding

**Distribution:** Worldwide

**Derivation of Genus:** Blood bladder or blood bubble

**Transmission Route:** Direct contact with infested vegetation

**Common Name:** Continental rabbit tick

**Haemaphysalis leporispalustris (Continental Rabbit Tick).** Although numerous kinds of ticks may infest rabbits, most have a limited geographic distribution and are generally recognized by veterinarians in each geographic area. This discussion centers on *Haemaphysalis leporispalustris*, the **continental rabbit tick**. This tick has the widest geographic distribution of rabbit ticks in the Western Hemisphere. *H. leporispalustris* is a three-host tick, meaning that each developmental stage (larva, nymph, and adult) requires a separate host for a blood meal. Although rabbits may serve as the host for each stage, they seem to be the definitive host for only the adult stage. Larval and nymphal stages also feed on birds, occasionally on dogs and cats, and rarely on humans. Feeding on birds is thought to account for much of the wide geographic distribution of *H. leporispalustris*, because these birds are often migratory.



**TECHNICIAN'S NOTE** *Haemaphysalis leporispalustris* is a three-host tick that may use the rabbit in all developmental stages but is the definitive host for the adult stage of the tick.

*H. leporispalustris* is a small, eyeless tick and is distinguished in all stages of the life cycle by the laterally pointed angles formed at the base of

the mouthparts, the basis capitulum. The basis capitulum causes the mouthparts to resemble a triangular head. Males are 2.2 mm long and females 2.6 to 10 mm long, depending on whether they are engorged with blood. The ticks may be found in the external ear canal and on the pinnae but are more frequently seen on the head and neck.

In extreme cases, large numbers of these ticks may produce emaciation and death. These rabbit ticks may spread diseases such as Rocky Mountain spotted fever, Q fever, and tularemia.

In general, *H. leporispalustris* occurs more frequently on wild than domestic rabbits, so owners should be warned of the disease potential for domestic rabbits that are not kept safely away from wild rabbits and birds.



**TECHNICIAN'S NOTE** The continental rabbit tick is known to harbor and spread Q fever, Rocky Mountain spotted fever, and tularemia to humans and can also cause tick paralysis.

## CHAPTER THIRTEEN TEST

MATCHING—Match the term with the correct phrase or term.

- |                                    |                                                                          |
|------------------------------------|--------------------------------------------------------------------------|
| A. Arthropodology                  | 1. Bedbug                                                                |
| B. Crustaceans                     | 2. Infestation or infection with dipteran larvae or "maggots"            |
| C. Centipedes and millipedes       | 3. Infestation with lice – either Mallophagan or Anopluran               |
| D. Blister beetles ("Spanish fly") | 4. No-see-ums                                                            |
| E. Caterpillars                    | 5. Sheep ked                                                             |
| F. Kissing bugs                    | 6. Blowflies or bottle flies                                             |
| G. <i>Cimex lectularius</i>        | 7. Stable fly or biting house fly                                        |
| H. Mallophagans ("chewing lice")   | 8. "Wolves" or "warbles" in the skin of dogs and cats                    |
| I. Anoplurans ("sucking lice")     | 9. Urticating or "stinging" hairs                                        |
| J. Dictyopterans                   | 10. Produce venomous substances                                          |
| K. Nit                             | 11. Horn flies                                                           |
| L. Pediculosis                     | 12. Morphologic feature used to identify or speciate dipteran fly larvae |
| M. <i>Simulium</i> species         | 13. Heel flies or ox warbles                                             |
| N. <i>Lutzomyia</i> species        | 14. Face fly                                                             |
| O. <i>Culicoides</i> species       | 15. Completely parasitic dipteran fly larvae                             |

- |                                                                                       |                                                                                                                                                                               |
|---------------------------------------------------------------------------------------|-------------------------------------------------------------------------------------------------------------------------------------------------------------------------------|
| P. <i>Chrysops</i> species, <i>Tabanus</i> species                                    | 16. The study of arthropods, creatures with jointed appendages                                                                                                                |
| Q. <i>Stomoxys calcitrans</i>                                                         | 17. Colloquial term used to describe cattle running or evading adult heel flies                                                                                               |
| R. <i>Haematobia irritans</i>                                                         | 18. Head more narrow than widest part of thorax                                                                                                                               |
| S. <i>Melophagus ovinus</i>                                                           | 19. Black flies                                                                                                                                                               |
| T. <i>Musca autumnalis</i>                                                            | 20. Importance – first intermediate hosts for <i>Paragonimus kellicotti</i> , <i>Diphyllbothrium latum</i> , <i>Spirometra mansonioides</i> , and <i>Dracunculus insignis</i> |
| U. Myiasis                                                                            | 21. Sand flies capable of transmitting <i>Leishmania</i> species                                                                                                              |
| V. Facultative myiasis                                                                | 22. Intermediate hosts for <i>Trypanosoma cruzi</i> (Chagas disease)                                                                                                          |
| W. Obligatory myiasis                                                                 | 23. Free-living dipteran fly larvae developing a parasitic dependence                                                                                                         |
| X. <i>Calliphora</i> , <i>Phaenicia</i> , <i>Lucilia</i> , and <i>Phormia</i> species | 24. Cantharidin                                                                                                                                                               |
| Y. <i>Musca domestica</i>                                                             | 25. Horse bots                                                                                                                                                                |
| Z. Strike or fly strike                                                               | 26. Dipteran fly larvae or maggots within contaminated wounds                                                                                                                 |
| AA. Posterior spiracular plate                                                        | 27. Head wider than widest part of thorax                                                                                                                                     |
| BB. <i>Cochliomyia hominivorax</i>                                                    | 28. Deerflies, horseflies                                                                                                                                                     |
| CC. <i>Cuterebra</i> species                                                          | 29. Reddish-black, pepper-like specks found with dog or cat's haircoat – actually, dried flea feces                                                                           |
| DD. <i>Hypoderma</i> species                                                          | 30. Feline scabies mite                                                                                                                                                       |
| EE. “Gadding”                                                                         | 31. Cockroaches and grasshoppers                                                                                                                                              |
| FF. <i>Gasterophilus</i> species                                                      | 32. House fly                                                                                                                                                                 |
| GG. <i>Oestrus ovis</i>                                                               | 33. Canine and feline ear mite                                                                                                                                                |
| HH. <i>Ctenocephalides felis</i>                                                      | 34. Hard ticks                                                                                                                                                                |
| II. <i>Echidnophaga gallinacea</i>                                                    | 35. Egg of either an Anopluran or Mallophagan                                                                                                                                 |
| JJ. Larval Siphonapterans                                                             | 36. Ear canker mite of rabbits                                                                                                                                                |
| KK. Flea eggs                                                                         | 37. Primary screwworm – dipteran larvae reportable to USDA                                                                                                                    |
| LL. Flea frass                                                                        | 38. Cat flea                                                                                                                                                                  |
| MM. Pedicel                                                                           | 39. Feline fur mite                                                                                                                                                           |

NN. Acariasis	40. Stalk at the tip of a sarcoptiform mite's leg; they can be long or short, jointed or unjointed
OO. Scabies	41. Nasal bot fly of sheep and goats
PP. <i>Notoedres cati</i>	42. Chiggers
QQ. <i>Cnemidocoptes pilae</i>	43. Scaly leg mite of budgerigars (parakeets)
RR. <i>Trixacarus caviae</i>	44. Resemble tiny fly maggots, sparsely covered with tiny hairs
SS. <i>Psoroptes cuniculi</i>	45. Infestation with <i>Sarcoptes scabiei</i>
TT. <i>Psoroptes</i> species of large animals	46. Tropical rat mite
UU. <i>Chorioptes</i> species	47. Fowl tick
VV. <i>Otodectes cynotis</i>	48. American dog tick
WW. <i>Demodex canis</i>	49. Resemble tiny pearls – nonsticky, 0.5 mm long, white, oval, and rounded at both ends
XX. <i>Trombicula</i> species	50. Sticktight flea of poultry
YY. <i>Pneumonyssoides caninum</i>	51. Infestation with either mites or ticks
ZZ. <i>Ornithonyssus bacoti</i>	52. Soft ticks
AAA. <i>Cheyletiella</i> species	53. Rabbit tick
BBB. <i>Lynxacarus radovskyi</i>	54. Hard ticks with a dark-colored scutum
CCC. Argasid ticks	55. Brown dog tick
DDD. Ixodid ticks	56. Guinea pig mite
EEE. <i>Otobius megnini</i>	57. Nasal mite of dogs
FFF. <i>Argas persicus</i>	58. Mite reportable to USDA
GGG. <i>Rhipicephalus sanguineus</i>	59. Hard ticks with scutum with a pattern of white on a dark background
HHH. <i>Dermacentor variabilis</i>	60. Follicular mite of dogs
III. <i>Amblyomma americanum</i>	61. Foot and tail mite; itchy leg mite
JJJ. <i>Boophilus annulatus</i>	62. “Walking dandruff” of dogs, cats, and rabbits
KKK. <i>Haemaphysalis leporispalustris</i>	63. Tick reportable to USDA – Texas cattle fever tick
LLL. Ornate ticks	64. Spinose ear tick
MMM. Inornate ticks	65. Lone star tick

## QUESTIONS FOR THOUGHT AND DISCUSSION

---

1. Of all of the arthropods in this chapter, which do you think is the best practice builder in a small animal veterinary clinic?
2. Of all of the arthropods in this chapter, which do you think is the most important parasite to be able to successfully identify with respect to your reputation or standing with your state veterinarian or with the United States Department of Agriculture?
3. One of the major ways in which arthropods are important is that they are capable of serving as intermediate hosts for both protozoan and helminth parasites. List 10 arthropods and link them to the protozoan or parasites with which they are associated.
4. What morphologic features or characteristics can be used to identify the following:
  - Adult dipteran flies
  - Larval dipterans (maggots)
  - Sarcoptiform mites
  - Ticks



This page intentionally left blank

# Introduction to the Phylum Arthropoda, Subphylum Pentastomida

14

## KEY TERMS

Pleomorphic  
Larval stage of  
pentastome  
Nymphal pentastome  
Tongue worms  
Linguatulids  
Pentastomiasis  
Linguatulosis  
Linguatuliasis

## OUTLINE

Pentastomes (Parasites of Reptiles)

*Morphology*

*Life Cycle*

*Diagnosis*

Adult Pentastome That Infects

Nasal Passages and Turbinates of  
a Mammalian Host

*Diagnosis*

## LEARNING OBJECTIVES

*After studying this chapter, the reader should be able to do the following:*

- Describe the life cycle of the pentastomes.
- Understand the zoonotic potential for reptilian pentastomes and the importance of thorough hand washing after contact with snake feces.

## PENTASTOMES (PARASITES OF REPTILES)

Reptiles have served as hosts to protozoan and metazoan parasites for eons. One of the oldest continuing host-parasite relationships is that between snakes and pentastomes. Pentastomes are almost exclusively parasites of the reptilian respiratory system. According to theory, the pentastomes' ancestors were once land animals that invaded the respiratory passages of reptiles. These rare parasites hold serious zoonotic consequences for humans, who can unwittingly serve as incidental hosts.

Pentastomes have lost most of their morphologic similarity to other major phyla; they are a taxonomist's dilemma. During their life cycle, pentastomes are **pleomorphic** (demonstrating a variety of morphologic forms). They resemble **acarines** (mites) during their larval stage, but look like **annelids** (earthworms) during their nymphal and adult stages. It is difficult to assign them to either phylum, which probably means that they possess a common ancestor with annelids and arthropods. Therefore these creatures have been assigned to the subphylum Pentastomida.

**TECHNICIAN'S NOTE** Pentastomes resemble mites during their larval stage and annelids during their nymphal and adult stages; therefore, they have been assigned to the subphylum Pentastomida.

## Morphology

The name **pentastome** (*penta* meaning “five” and *stome* meaning “mouth,” thus five mouths) was chosen because these parasites, as adults, have a mouth on the anterior end that is surrounded by four hooked claws. Early investigators erroneously believed these claws to be four additional mouths; “one mouth” plus “four mouths” equals “five mouths.” Pentastomes have also been called **tongue worms** and **linguatulids** because of their distinct tongue-shaped appearance, being wider anteriorly than posteriorly (Figure 14-1). Infection with pentastomes is referred to as **pentastomiasis**, **linguatuliasis**, **linguatulosis**, or rarely, **porocephalosis** or **porocephaliasis** (after *Porocephalida*, one of two orders composing the subphylum Pentastomida).

Grossly, pentastomes resemble helminths; however, they are often grouped with the phylum Arthropoda because of the mitelike larval stage that appears during their life cycle.



**FIGURE 14-1:** Distinctive tongue-shaped appearance of a pentastome. Because these strange parasites are flattened and wider anteriorly than posteriorly, they are often referred to as “tongue worms.” The canine pentastome, *Linguatula serrata*, has transversely striated cuticle. The female is 8 to 13 cm long, and the male is 1.8 × 2 cm.

Pentastomes are almost always parasites of reptiles; the exceptions to this rule are species of *Linguatula serrata* (which parasitize carnivores) and *Reighardia sterna* (a parasite of seagulls and terns). Within the phylum are nine genera that parasitize snakes, three that parasitize lizards, four that parasitize crocodiles, and two that favor turtles. Among snakes, the most common genera are *Armillifer* species that parasitize pythons and vipers, *Kiricephalus* that parasitize cobras, and *Porocephalus* that parasitize boas and rattlesnakes (Figure 14-2).

**TECHNICIAN'S NOTE** With the exception of two species of pentastomes, almost all pentastomes parasitize reptiles.

## Life Cycle

Adult reptilian pentastomes are **dioecious** parasites; they have separate sexes, and there are both male and female pentastomes. Pentastomes are parasites that occur almost exclusively within the lungs, trachea, and nasal passages of the reptilian definitive host, feeding on tissue fluids and blood cells. Female pentastomes produce several million fully embryonated eggs, each containing a single larva with two or three pairs of rudimentary clawed legs. Eggs are “coughed up,” swallowed, and passed to the outside environment

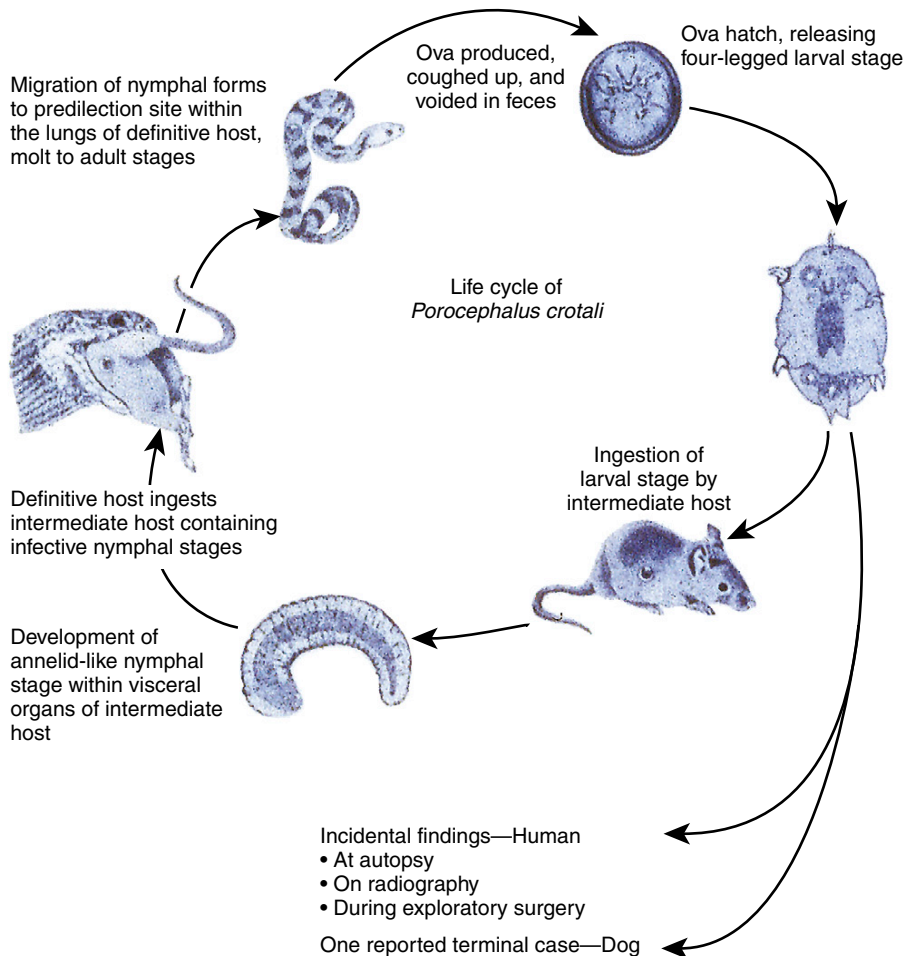


**FIGURE 14-2:** Assorted adult reptilian pentastomes from the respiratory tract of snakes. Left to right, Mature *Kiricephalus* species, immature *Kiricephalus* species, and mature *Armillifer* species.

within the host feces. Oval, tailed larvae with four to six stumpy legs, each with one or two retractable, pincerlike claws, hatch from the eggs and are infective for the intermediate host. Figure 14-3 shows the life cycle of a reptilian pentastome.

Intermediate hosts include rodents, herbivores, carnivores, nonhuman primates, and humans. The larva bores through the intestinal wall of the intermediate host and passes with the blood to the mesenteric lymph nodes, the liver, the lungs, the omentum, or other internal organ, where it becomes encysted. The larva becomes “quiescent” and changes into the annelid (worm-like) nymphal stage, which can pass through as

many as five molts. The reptilian definitive host becomes infected by ingesting the intermediate host with its encysted nymphal pentastomes. The infective nymphs penetrate the host’s intestine and bore into the lungs, where they become sexually mature, adult parasites. The life cycle of the typical pentastome is an oddity in that the organism serving as the intermediate host (e.g., a mammal) is *higher* in the phylogenetic classification scheme than the definitive host (the reptile); this situation is uncommon among the life cycles of parasites. With most parasites, the organism serving as the intermediate host is *lower* in the phylogenetic classification scheme than the host that serves as definitive host.



**FIGURE 14-3:** Life cycle of *Porocephalus crotali*, a pentastome of rattlesnakes.



**TECHNICIAN'S NOTE** The intermediate hosts for reptilian pentastomes include rodents, herbivores, carnivores, nonhuman primates, and humans.

## Diagnosis

### Definitive Host

Clinical signs of reptilian pentastomiasis include lethargy, anorexia, dyspnea, and production of blood-tinged sputum or mucus within the pharynx or the trachea. The sputum can contain eggs that microscopically appear to contain four-legged to six-legged larvae with retractable claws. These pentastome eggs also can be found in the feces of the definitive host. Hematologic studies might demonstrate leukocytosis and eosinophilia. Radiographic examination might reveal adult worms or remnants of calcified cysts.

Adult reptilian pentastomes are not confined to the lungs. Adult and juvenile pentastomes might attempt to exit the host through the reptile's nostrils or the mouth or through the body wall and skin whenever the reptile is stressed. Reptilian pentastomiasis also can be diagnosed by biopsy of infected tissues or recovery of the parasite at necropsy.



**TECHNICIAN'S NOTE** Pentastome eggs can be found on standard fecal flotation procedures on the feces of the definitive host.

### Incidental Host

In contrast to pentastomid infections in natural intermediate hosts, infections in incidental hosts are striking. An incidental host is usually asymptomatic to nymphal invasion; nymphs are often found during radiographic examination, during surgery, or at necropsy. Nymphs can affect vital structures and produce pathology that leads to demonstration of related clinical signs. Death can result.

A case of incidental nymphal pentastomiasis has been reported in dogs. Eosinophilic inflammatory responses were noted in thoracic and abdominal cavities. These responses were

presumably caused by the extensive migratory paths of the pentastomes. During exploratory surgery, it was noted that all peritoneal and visceral surfaces were covered with 3- to 5-mm, C-shaped, cystic structures, each of which contained an elongated, coiled nymph. The nymphs were identified as those of *Porocephalus crotali*, a pentastome of rattlesnakes.

Humans also are incidental mammalian hosts of pentastomids. The fact that humans can serve as intermediate hosts for reptilian pentastomes is sufficient need for veterinarians to recognize the zoonotic potential of these parasites. Human infections with reptilian pentastomes have been reported from all continents but are most common in Africa and Malaysia. Almost all recorded infections in humans have been incidental findings during radiographic examination (pentastomes often die in tissue locations and become calcified), exploratory surgery, or autopsy. Those pentastomes recovered during autopsy are usually not related to the cause of death; however, under certain circumstances, nymphs may cause significant pathology because of the organ location, the large number of nymphs involved, or their extensive tissue migrations.



**TECHNICIAN'S NOTE** With the exception of humans, incidental infection with pentastomes can cause death to the incidental host due to the migration of larval and nymphal stages and the damage to organs that these migrations produce.

On histopathologic examination of tissue, the characteristic C shape of the nymph can be seen. Pentastomid nymphs have a pseudosegmented body with a prominent body cavity, striated musculature, a digestive tract with numerous villi, and acidophilic glands surrounding the intestine. The nymphal pentastome's cuticle may be spiny, smooth, or annulated and may possess numerous acidophilic skin glands that communicate with the cuticle through sclerotized openings. Most of these morphologic features can be identified by either a trained pathologist or a parasitologist.



Antemortem diagnosis of pentastomiasis in the intermediate host can be accomplished by radiographic examination. In these hosts, pentastomes may die in their tissue sites and become calcified; these calcified pentastomes may be visible on radiography.

**TECHNICIAN'S NOTE** Diagnosis of pentastomiasis in the intermediate host can be made by radiographic examination for calcified pentastomes.

### ADULT PENTASTOME THAT INFECTS NASAL PASSAGES AND TURBINATES OF A MAMMALIAN HOST

**Parasite:** *Linguatula serrata*

**Host:** Dogs

**Location of Adult:** Nasal passages and sinuses

**Distribution:** Worldwide

**Intermediate Host:** Cats, rats, porcupines, guinea pigs, rabbits, hedgehogs, pigs, and ruminants

**Derivation of Genus:** Small tongue

**Transmission Route:** Ingestion of infective intermediate host

**Common Name:** Canine pentastome

*Linguatula serrata*, the canine pentastome, is found in the nasal passages and sinuses of dogs and other canids. Intermediate hosts are cats, rats, porcupines, guinea pigs, rabbits, hedgehogs, pigs, and wild and domestic ruminants. In North America, rabbits are the most common intermediate hosts. Both adult and nymphal stages of this parasite may infect humans. Humans harbor nymphal stages after ingesting eggs from contaminated feces. Nymphs may be found in a variety of organs—the spleen, liver, and mesenteric lymph nodes. Humans become definitive hosts by eating raw or undercooked meat or meat byproducts that contain the nymphal stages.

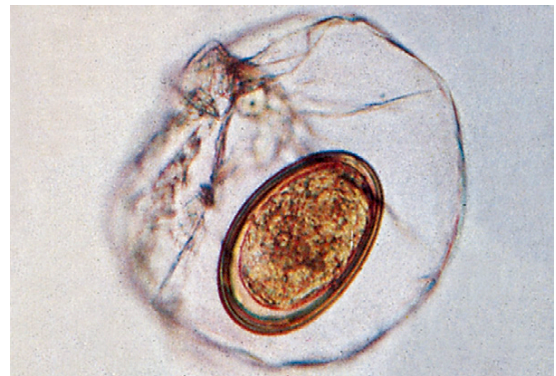**TECHNICIAN'S NOTE** In North America, the rabbit is the common intermediate host; humans can harbor nymphal stages after ingesting eggs from contaminated feces.

## Diagnosis

### Definitive Host

Usually there are no signs of infection; however, dogs may exhibit catarrhal or suppurative rhinitis and bleeding of the nose usually due to inflammatory damage. Restlessness, sneezing, difficulty breathing, and a reduced sense of smell have been observed. The adult parasite may be observed in its predilection site or may be sneezed out or coughed up. The adult parasite resembles a helminth (worm), but as with all pentastomes, it is an arthropod. The parasite is tongue-shaped and flattened and has a transversely striated cuticle. The female is 8 to 13 cm long, and the male is  $1.8 \times 2$  cm in size (see Figure 14-1).

Eggs may be observed on fecal flotation or nasal swabs. Eggs are yellow-brown, oval,  $70 \times 90$   $\mu\text{m}$ , and have a thick chitinous shell. An embryo with two pairs of irregularly arranged, chitinous claws may be observed on the inside of the egg. Each egg is initially enclosed in a thin, bladderlike envelope containing a clear fluid. This envelope is usually removed during passage through the gastrointestinal tract (Figure 14-4).



**FIGURE 14-4:** Eggs of *Linguatula serrata* are yellow-brown, oval,  $70 \times 90$   $\mu\text{m}$ , and have a thick chitinous shell. An embryo with two pairs of irregularly arranged chitinous claws may be observed on inside of egg. Each egg is initially enclosed in a thin, bladderlike envelope containing clear fluid. This envelope is usually removed during passage through the gastrointestinal tract.

### Intermediate Host

Nymphs of *L. serrata* in the intermediate host are detected by biopsy, exploratory laparotomy, postmortem examination, and subsequent histopathology.

The veterinarian must remember that pentastomes are rare, unusual parasites of snakes and dogs. It is important to note that the hands should *always* be washed after handling snake

feces. Humans can serve as an intermediate host for this strange parasite.



**TECHNICIAN'S NOTE** While pentastome infections are rare, hands should always be washed after handling snake feces as a precautionary measure.

## CHAPTER FOURTEEN TEST

MATCHING—Match the term with the correct phrase or term.

- |                                        |                                                                        |
|----------------------------------------|------------------------------------------------------------------------|
| A. Pentastomes                         | 1. Derivation of the term “pentastome”                                 |
| B. Pentastome’s larval stage           | 2. Thorough hand washing following handling of snakes or snake feces   |
| C. Pentastome’s nymphal or adult stage | 3. Tongue worms or linguatulids                                        |
| D. Reptiles                            | 4. Rattlesnake pentastome                                              |
| E. <i>Porocephalus crotali</i>         | 5. Very similar to an annelid – they are very wormlike in appearance   |
| F. <i>Linguatula serrata</i>           | 6. Site of infection for canine pentastomes                            |
| G. Prevention of human pentastomiasis  | 7. Characteristic trait of pentastome nymph in histopathologic section |
| H. Acidophilic glands around intestine | 8. Very similar to a mite – it has jointed appendages                  |
| I. Nasal passages and sinuses          | 9. Principal definitive hosts for pentastomes                          |
| J. “Five mouths”                       | 10. Canine pentastome                                                  |

## QUESTIONS FOR THOUGHT AND DISCUSSION

1. Snakes are becoming increasingly popular with the public at large. From a public health view, how might one counsel a client with regard to maintaining a snake in the home?
2. What should a veterinarian tell the owner of a dog infected with adult *Linguatula serrata*?

# The Phylum Annelida

# 15

## KEY TERMS

Annelids  
Hirudineans  
Pseudosucker  
Swimming leech  
Stepping leech  
Hirudin  
Hirudiniasis  
*Hirudo medicinalis*  
Beneficial use of leeches

## OUTLINE

Hirudinea (Leeches)  
*Morphology*  
*Life Cycle of the Leech*

## LEARNING OBJECTIVES

After studying this chapter, the reader should be able to do the following:

- Describe the morphology of leeches.
- Describe the pathology associated with hirudiniasis.
- Describe the beneficial use of leeches in both human and veterinary medicine.

Kingdom: Animalia  
Phylum: Annelida  
Class: Hirudinea

Leeches and earthworms are **annelids**. Leeches are not considered to be true helminths but are often described as **parasitic worms**. As external parasites of humans and domesticated and wild animals, leeches are members of the phylum Annelida and the class Hirudinea.



**TECHNICIAN'S NOTE** While leeches are considered ectoparasites, one species is used for medicinal purposes.

## HIRUDINEA (LEECHES)

Leeches can be predatory or scavenging. Most often they are parasitic on a wide variety of vertebrates and invertebrates. The ectoparasitic leeches feed on blood from fish, crustaceans, frogs, turtles, mollusks, birds, and land animals such as cattle, horses, assorted primates, and humans. These ectoparasites range in size from tiny species that are 5 mm long to varieties such as *Haemopsis sanguisuga*, the horse leech, which has been reported to be as long as 45 cm when extended and swimming.

## Morphology

Leeches have slender, leaf-shaped bodies that lack bristles. The typical leech has two suckers, a large, adhesive posterior sucker and a smaller anterior sucker. The anterior sucker is actually a **pseudosucker** and surrounds the mouth. As a member of the phylum Annelida, the leech is segmented and lacks a hard exoskeleton; in its place the leech has a thin, flexible cuticle. Because of this thin cuticle, leeches dry out quickly and must always be closely associated with water. A few leeches are found in saltwater; a few terrestrial (land) leeches are found in moist, damp locations. For the most part, leeches should be considered aquatic animals.



**TECHNICIAN'S NOTE** The leech has a segmented body that lacks a hard exoskeleton. Instead, it has a thin, flexible cuticle.

As a result of these different habitats, leeches have developed two widely different locomotory habits, swimming and stepping. **Swimming** is the method of locomotion used when the leech is in water. The leech's body becomes flattened dorsoventrally as waves of muscular contraction pass down its length. The result is an undulating motion that propels the leech forward.

**Stepping** is the method of locomotion used when the leech is on solid ground. While in this mode, the leech moves in an “inchworm-like” manner, using its cranial and caudal suckers as organs of attachment to move along the substrate (surface). The layer of circular muscle just beneath the epidermis contracts, and the leech becomes long and thin. The cranial sucker then attaches to the substrate, the caudal sucker releases, and the longitudinal muscle layer beneath the circular muscle brings the caudal sucker up to the vicinity of the cranial sucker, where it attaches. The overall effect is “stepping.”



**TECHNICIAN'S NOTE** When on land, the leech moves using an inchworm-like motion called stepping. It alternates using its cranial and caudal suckers to attach to and move along surfaces.

While the leech is attached to the host with its caudal sucker, it uses the cranial sucker to explore the host's skin to locate a suitable feeding site and to attach tightly. Three rows of jaws with approximately 100 teeth are found in the cranial sucker. These teeth operate similar to a circular saw, penetrating through the skin to a depth of 1.5 mm. The wound produced by the leech bite is a characteristic Y-shaped skin incision. When the incision is made, the host feels very little pain.

In the past, analgesia was thought to be caused by the release of an anesthetic in the leech saliva, but it is now believed that leech saliva does *not* contain an anesthetic. The ability of a leech to feed is made easier by the secretion of powerful anticoagulants into the site of attachment. A histamine-like substance is added to the wound to prevent the collapse of adjacent capillaries. As blood passes through the mouth, the anticoagulant hirudin is added to it. **Hirudin** is a 64-amino acid peptide whose function is similar to anti-thrombokinase. It has been described as the most powerful anticoagulant known. Active agents in the saliva of various species of leeches include a hyaluronidase, a collagenase, and two fibrinases.



**TECHNICIAN'S NOTE** Hirudin, one of the most powerful anticoagulants known, is secreted into the bite wound of the leech to keep the host bleeding as the leech feeds.

When engorged with blood, the leech is dark and bloated; some leeches can ingest blood meals that are 900% of their body weight. True blood-sucking leeches require a blood meal only occasionally; consumed blood is used very slowly, so slowly that some leeches have been kept in

captivity for more than 2 years without being fed. The mouth leads to a pharynx with salivary glands that secrete hirudin, a crop where ingested blood is stored, a stomach, an intestine, a rectum, and an anal pore near the caudal sucker.

### Life Cycle of the Leech

As with the flatworms (flukes and tapeworms), leeches are hermaphroditic. Because male and female organs are located on adjacent body segments, self-fertilization is impossible, and cross-fertilization must take place. After copulation, both partners are fertilized. Eggs are laid in cocoons. The cocoon of each species of leech has a characteristic shape and design. **Hirudo medicinalis**, the medicinal leech, produces from one to seven cocoons, each of which may contain 5 to 15 eggs. Depending on the species of leech, cocoons may be attached to the parent's body or adhere to solid surfaces within the aquatic environment. Young leeches hatch from the eggs, feed for a few days on the yolk, and develop to the adult bloodsucking mode. Adult leeches can live for as long as 18 to 27 years.

The term **hirudiniasis** is derived from the classic Linnaean nomenclature and can be defined as invasion of the nose, mouth, pharynx, or larynx by leeches or the attachment of leeches to the skin. The terrestrial, or land, varieties of leeches are primarily found in the tropical regions of the world, particularly Southeast Asia, the Pacific islands, the Indian subcontinent, and South America. Land leeches are found on the surface of trees and grasses and under stones in damp places. One terrestrial leech, *Haemopsis terrestris*, has been plowed up in fields in the midwestern United States.



**TECHNICIAN'S NOTE** Land leeches are found on the surface of trees and grasses or under stones in damp places. They mostly occur in tropical regions of the world.

Punctures made in the skin by land leeches are painless, remain open, and continue to bleed

long after the leech has detached. Land leeches in Southeast Asia and India congregate in such large numbers on the legs of cattle, horses, and other native animals that they interfere with the ambulation of the host. Because leeches can ingest so much blood, further complications for the host include anemia and even death from blood loss.

Terrestrial leeches that attach to the skin should never be pulled off but instead must be induced to detach. If pulled off, these leeches may leave their jaws embedded in the skin; such remnants can induce ulceration and serve as a site of infection. Drops of concentrated salt solution, alcohol, or strong vinegar applied around the mouth of the leech or heat with a lighted match or cigarette applied to the leech's body will cause land leeches to release their hold. The open wound should be treated with a styptic and an antiseptic.



**TECHNICIAN'S NOTE** Never pull an attached leech off of a host; instead, the leech must be induced to detach on its own. Pulling the leech off can result in leaving mouthparts in the skin resulting in ulceration of the site and possibly infection.

Aquatic leeches can be external or internal parasites. Two genera of aquatic leeches (*Limnatis* and *Dinobdella*) have veterinary significance because they parasitize monkeys and domestic animals. *Theromyzon tessulatum* parasitizes wild and domestic aquatic birds. These genera reside in freshwater, where they come in contact with the vertebrate host.

Leeches entering the mouth or nostrils of the host can pass to the nasopharynx, epiglottis, esophagus, trachea, and bronchi. After attaching itself to the mucous membranes, the leech secretes its anticoagulant and engorges. Depending on the site of attachment, leeches may cause the host to exhibit nosebleeds, cough up blood, or vomit blood. A leech attached in the laryngeal region may produce a cough with a bloody discharge, difficulty in breathing, pain, and even suffocation. A leech localized in the



region of the epiglottis may cause difficulty in swallowing. In severe breathing disturbances, the host's neck may be extended, and the animal may exhibit open-mouthed breathing.



**TECHNICIAN'S NOTE** Aquatic leeches can attach to the nasopharynx, epiglottis, esophagus, trachea, and bronchi causing nosebleeds and the coughing and vomiting of blood.

**Parasite:** *Hirudo medicinalis*

**Host:** Humans

**Location of Adult:** On the skin

**Distribution:** Worldwide for medicinal use but native to Europe, Asia, and South America

**Derivation of Genus:** Leech

**Transmission Route:** Intentional placement for medicinal purposes

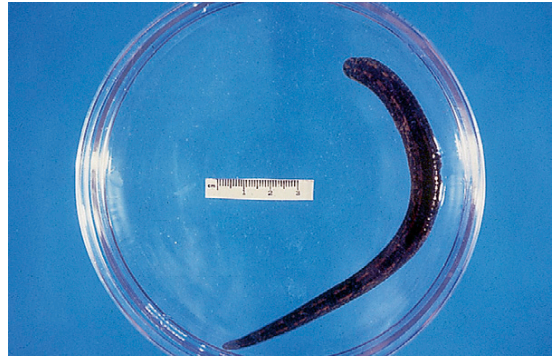**Common Name:** Medicinal leech

Several species of leeches have proved to be beneficial to humans. Perhaps the best-known leech used for bloodletting is *Hirudo medicinalis*, the European medicinal leech. This leech is a native of Europe, parts of Asia, and (after its introduction) South America. It possesses a distinct green pattern of pigmentation with brown stripes and ranges in size from less than 1 cm to more than 20 cm in length (Figures 15-1 and 15-2). On its anterior end is a muscular sucker that contains three sharp chitinous jaws armed with saw-shaped teeth; its caudal end has a characteristic suckerlike disk. This species can ingest an amount of blood up to five times its own weight. When the leech has taken a blood meal from the host, it may take as long as 200 days for digestion. This leech is reported to have gone without food for as long as 18 months.

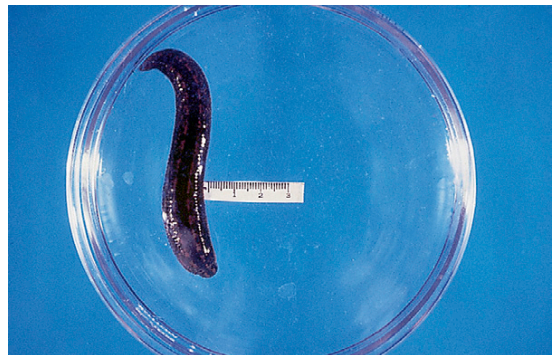

**TECHNICIAN'S NOTE** Medicinal leeches can consume blood up to five times their own weight.

*H. medicinalis* has been the leech used most often for bloodletting purposes throughout history. Its present use in reconstructive and



**FIGURE 15-1:** Extended *Hirudo medicinalis* in Petri dish. Note that narrow end is cranial end and has an oral sucker. Wide end is caudal end with sucker.



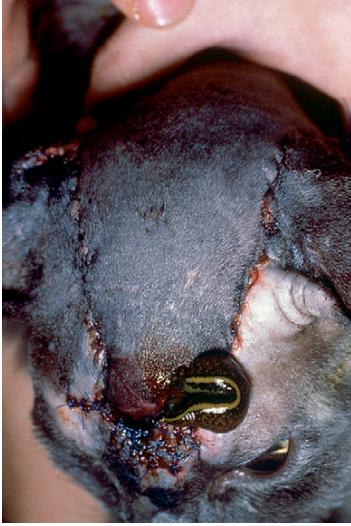**FIGURE 15-2:** Contracted *Hirudo medicinalis* in Petri dish. Note external segmentation on body.

microvascular surgery in humans is gaining impetus. Medicinal leeches have also been used in applications in both veterinary surgery and medicine. Recently there has been revived interest in these unique ectoparasites.



**TECHNICIAN'S NOTE** Medicinal leeches are most often thought of in conjunction with bloodletting throughout history.

*H. medicinalis* serves as an important medical tool because it can produce a small, bleeding wound that mimics venous outflow in tissues with impaired venous circulation (Figure 15-3). Leeches are indicated only for tissues with such impairment. The leech's main benefit is not the



**FIGURE 15-3:** *Hirudo medicinalis* feeding on full-thickness skin graft in a cat 24 hours after surgery. Surgical techniques used were a single-pedicle advancement flap and full-thickness mesh with graft bed. Note congested area in rostral portion of pedicle flap.

average 5 mL of blood removed during attachment but rather the volume of blood (reportedly as much as 50 mL) that continues to ooze for 24 to 48 hours after the leech has detached. This local bleeding is related to pharmacologically active anticoagulants and vasodilator substances introduced by the leech bite. Each bite can be encouraged to bleed further by gently removing clots that form. Research has demonstrated that new vessels begin to grow around the flap margins after approximately 72 to 120 hours.

Thus the leeches can demonstrate both pathogenic and beneficial effects on humans and wild and domesticated animals.



**TECHNICIAN'S NOTE** The benefit of the medicinal leech is not in the blood it ingests but in the bleeding that occurs after it releases. This blood seems to help mimic the venous flow of blood to impaired tissues.

## CHAPTER FIFTEEN TEST

**MATCHING**—Match the term with the correct phrase or term.

A. Class Hirudinea

B. *Haemopsis sanguisuga*

C. Swimming

D. Stepping

E. Leech bite

F. Hirudin

G. Hirudiniasis

H. *Hirudo medicinalis*

1. 64-amino acid peptide whose function is similar to antithrombokinase; it is the most powerful anticoagulant known.
2. Method of locomotion when leech is in water
3. The European medicinal leech
4. Reconstructive and microvascular surgery in both humans and animals
5. Y-shaped skin incision
6. Leeches
7. Method of locomotion when leech is in on land
8. The horse leech

- I. Beneficial use of leeches
- J. Incentive for leech to release
- 9. Concentrated salt solution, strong vinegar, or touch with a lighted match or cigarette
- 10. Invasion of the nose, mouth, pharynx, or larynx by leeches or attachment of leeches to the skin

### QUESTIONS FOR THOUGHT AND DISCUSSION

---

- 1. Compare pediculosis, myiasis, siphonapterosis, acariasis, and linguatulosus to hirudiniasis. Why do you think these terms are important?
- 2. What was once old is new! What were leeches used for during the eighteenth and nineteenth centuries? Discuss the potential for their use in the twenty-first century.
- 3. Compare and contrast leeches with trematodes.

# Parasites of Public Health Importance in Veterinary Parasitology

16

## KEY TERMS

Zoonosis  
Toxoplasmosis  
Congenital  
toxoplasmosis  
Tachyzoites  
Acquired  
toxoplasmosis  
Bradyzoites  
Cryptosporidiosis  
Coccidiostats  
Swimmer's itch  
Schistosome cercarial  
dermatitis  
Measly beef/beef  
measles  
Measly pork/pork  
measles  
Neurocysticercosis  
Hydatid disease  
Unilocular hydatid  
disease  
Multilocular hydatid  
disease  
Oncosphere  
Dipylidiasis  
Hymenolepiasis  
Dwarf tapeworm  
Rat tapeworm  
Sparganum  
Pernicious anemia  
Toxocaral larva  
migrans  
Visceral larva migrans  
(VLM)  
Ocular larva migrans  
(OLM)

## OUTLINE

### Protozoans of Public Health

#### Importance

*Toxoplasma gondii*  
(*Toxoplasmosis*)

*Cryptosporidium parvum*  
(*Cryptosporidiosis*)

### Trematodes of Public Health

#### Importance

*Schistosomes of Wild Migratory  
Birds (Schistosome Cercarial  
Dermatitis, Swimmer's Itch)*

### Cestodes of Public Health

#### Importance

*Taenia saginata (Beef Tapeworm)*

*Taenia solium (Pork Tapeworm)*

*Echinococcus granulosus and  
Echinococcus multilocularis*  
(*Unilocular and Multilocular  
Hydatid Disease*)

*Dipylidium caninum*  
(*Human Dipylidiasis*)

*Spirometra mansonoides*  
(*Benign Plerocercoidosis/  
Malignant Sparganosis*)

*Hymenolepis nana*  
(*Hymenolepiasis*)

*Diphyllobothrium latum*  
(*Diphyllobothriasis*)

### Nematodes of Public Health

#### Importance

*Toxocara canis and Toxocara  
cati (Toxocaral Larva Migrans,  
Visceral Larva Migrans, Ocular  
Larva Migrans)*

*Baylisascaris procyonis (Neural  
Larva Migrans, Cerebrospinal  
Nematodiasis)*

*Ancylostoma caninum,  
Ancylostoma braziliense,  
Ancylostoma tubaeforme,  
and Uncinaria stenocephala*  
(*Cutaneous Larva Migrans,  
Creeping Eruption, Plumber's  
Itch*)

*Ancylostoma caninum (Enteric  
Hookworm Disease)*

*Strongyloides stercoralis*  
(*Strongyloidiasis*)

*Trichinella spiralis (Trichinosis  
Trichinellosis)*

*Dirofilaria immitis (Pulmonary  
Dirofilariasis)*

### Arthropods of Public Health

#### Importance

*Sarcoptes scabiei Variety canis*  
(*Canine Scabies*)

### Pentastomes of Public Health

#### Importance

*Reptilian Pentastomiasis*

### Conclusion

Neural larva migrans (NLM)  
Paratenic host  
Cutaneous larva migrans (CLM)  
Creeping eruption  
Dermal larva migrans  
Ground itch  
Plumber's itch  
Sandworms  
Trichinosis/  
trichinellosis  
Pulmonary  
dirofilariasis  
Deet  
Canine scabies  
Papules  
Vesicles  
Incidental nymphal  
pentastomiasis

## LEARNING OBJECTIVES

After studying this chapter, the reader should be able to do the following:

- Detail the types of zoonotic diseases that might be encountered in a veterinary clinical practice.
- Communicate symptoms, diagnostic procedures, and prevention of major zoonotic diseases that might be encountered in a veterinary clinical practice.
- Understand that veterinarians and veterinary technicians should never provide direct treatment for a human patient infected with a zoonotic disease.
- Understand that veterinarians and veterinary technicians should only act in an advisory capacity regarding zoonotic diseases.

Chapter 1 defines **zoonosis** as any disease or parasite that is transmissible from animals to humans. In veterinary clinical practice, it is important for veterinarians to inform their clients concerning zoonotic diseases or parasites that may be transmitted from their domestic animals. Such zoonotic parasites include *Toxoplasma gondii*, *Trichinella spiralis*, *Ancylostoma caninum*, and *Toxocara canis*. This chapter discusses the major parasitic diseases that are of public health importance in veterinary clinical practice.

It is often the veterinarian's role (and also the role of the veterinary diagnostician) to diagnose a parasite in a domestic animal. The veterinary diagnostician must also communicate to the public and often to medical personnel, such as physicians, laboratory personnel, and other public health workers, the significance of many of the zoonotic parasites. It is important for veterinary personnel to understand that in suspected cases of zoonotic parasites or conditions, the client should *always* be referred to a physician, family practitioner, obstetrician, or public health worker, as appropriate, for diagnosis or treatment. In no instance should a veterinarian or veterinary technician attempt to diagnose or treat any of these zoonotic parasites in humans. The veterinarian's role is to inform, not to treat. Attempting to diagnose or treat a human is a violation of state veterinary practice acts across the United States. Treatments are included in this chapter for veterinarians strictly for the purpose of advising human health care workers and not for the purpose of treating human patients.



**TECHNICIAN'S NOTE** It is the role of the veterinarian or technician to educate the client or owner about zoonotic parasites and diseases, *not* to treat the client or owner for zoonoses.

For each zoonotic parasite discussed here, the following areas are addressed:

- The symptoms of parasitic infection in humans and the ways in which infection is diagnosed.
- Treatment of the parasitic condition in humans.
- Prevention of the transmission of zoonotic parasites, conditions, or syndromes from animals to humans.

Just as parasites are broken down in previous chapters into major groups, the important zoonotic parasites are divided into zoonotic protozoans, zoonotic trematodes, zoonotic cestodes, zoonotic nematodes, zoonotic arthropods, and zoonotic pentastomes. The acanthocephalans and the leeches have no zoonotic significance.



## PROTOZOANS OF PUBLIC HEALTH IMPORTANCE

### *Toxoplasma gondii* (Toxoplasmosis)

**Toxoplasmosis** in humans is an extremely rare protozoan disease with which humans (particularly a pregnant woman and her developing fetus) can become infected. It is an important zoonotic parasite because a very popular domestic pet, the cat, is the only definitive host for this parasite. The cat can serve as a source of infection for the pregnant woman and her unborn child. Toxoplasmosis can infect the fetus in the womb and produce serious birth defects. This parasite can also wreak havoc in individuals with acquired immunodeficiency syndrome (AIDS).



**TECHNICIAN'S NOTE** The cat is the only definitive host for *Toxoplasma gondii* and can serve as a source of infection in humans, especially pregnant women and their unborn children.

Although this is a very rare parasite, several precautions must be taken to prevent infection. To sell papers, the “sensational press” often exploits this parasite in its headlines, alarming the general public. As a result, the veterinary clinical practice may receive phone calls regarding this parasite. Also, uninformed clients may request that veterinarians find a new home for (or even euthanize) the family cat. It is important for the veterinarian to alleviate the client's concerns and to work in conjunction with the obstetrician-gynecologist to answer questions, thwart this parasite, and prevent toxoplasmosis. It is important to note that almost every warm-blooded animal can become infected with *Toxoplasma gondii*.



**TECHNICIAN'S NOTE** The news media exploits toxoplasmosis to sell papers; it is the job of the veterinary professional in conjunction with physicians to prevent and thwart this disease with proper client education.

### Human Infection with Toxoplasmosis

Humans become infected with toxoplasmosis in one of two ways: congenitally (in the case of unborn babies) or through acquisition. **Congenital toxoplasmosis** occurs when a woman becomes infected during her pregnancy; the woman ingests sporulated oocysts of *T. gondii* found in the feces of the cat. The domestic house cat with access to the outdoors (and predation) serves as the definitive host for *T. gondii* and will shed unsporulated oocysts in its feces. These unsporulated oocysts will sporulate (or become infective) in 1 to 5 days. If a pregnant woman accidentally ingests the sporulated oocyst, the parasite's **tachyzoites** (rapidly multiplying stages) can infect the developing fetus.

**Acquired toxoplasmosis** occurs when a human ingests the sporulated oocyst containing tachyzoites or ingests infected meat or tissue stages containing bradyzoites. Many domesticated animals (e.g., cattle, pigs, sheep) serve as intermediate hosts for *T. gondii*. Within their muscle, these intermediate hosts harbor **bradyzoites** (slowly multiplying stages) that can infect various tissue sites, including lymph nodes, meninges, eyes, and the heart, of humans. The infected human ingests the bradyzoites, which then infect a variety of tissue sites.



**TECHNICIAN'S NOTE** Unborn babies can be infected with toxoplasmosis if their mothers become infected by ingesting tachyzoites and the infection spreads to the fetus (congenital toxoplasmosis). Acquired toxoplasmosis occurs when humans ingest tachyzoites (in cat feces) or bradyzoites (in meat or muscle).


### Symptoms and Diagnosis

If congenital infection occurs early in the pregnancy, abortion is common. If this infection occurs late in the pregnancy, the central nervous system may become infected, and a variety of neurologic abnormalities may result. These include cerebral calcification, chorioretinitis, hydrocephaly, microcephaly, and psychomotor

irregularities. The child may be born dead or alive. If alive, the child may be mentally retarded.

Infected humans with acquired toxoplasmosis exhibit lymphadenopathy, malaise, fever, lymphocytosis, and myocarditis. Most cases, however, are characterized by mild fever and slight enlargement of the lymph nodes.

Diagnosis of clinical toxoplasmosis in humans is quite difficult. Diagnosis relies on the demonstration of organisms or antibodies against it. The best diagnostic test is the inoculation of suspected material into mice and demonstration of the organism multiplying in the mice. Serologic tests are also available. The veterinary diagnostician must remember that these tests need to be delegated to a more sophisticated diagnostic laboratory.

 **TECHNICIAN'S NOTE** The diagnosis of toxoplasmosis in humans is difficult and involves testing for the presence of multiplying organisms or antibodies against the organisms in inoculated mice. Serologic tests are also used.


### Treatment

There is no completely satisfactory treatment for toxoplasmosis in humans, although pyrimethamine has been found effective. This drug, in conjunction with triple sulfa drugs, has given good results in ocular toxoplasmosis. Remember that suspected cases of toxoplasmosis in humans should *always* be referred to a neonatologist, pediatrician, gynecologist, obstetrician, or family practitioner. The Centers for Disease Control and Prevention (CDC) has many specialists who are qualified to answer the most complex issues of toxoplasmosis in humans.

### Prevention of Transmission to Humans

Transmission of *T. gondii* to pregnant women is prevented by having someone else empty the cat's litter box for the duration of her pregnancy. This step eliminates the woman's potential exposure to the sporulated oocysts of *T. gondii*. A person should always wash his or her hands

after handling a cat and before eating. Litter boxes should never be placed in the kitchen or dining area. Gloves should be worn while gardening because feral cats often defecate in flower beds. If children's sandboxes are present in the backyard, they should remain covered when not in use. After gardening, hands should be thoroughly washed. Cats should never be allowed to roam freely and hunt. Likewise, uncooked meat should never be fed to cats. Rodent prey or uncooked meat may contain the tissue stages of *T. gondii*, which will set the life cycle in motion in the cat. Likewise, to avoid acquired infection with *T. gondii* (and a variety of pathogenic bacteria), humans should be wary of undercooked infected meat.

 **TECHNICIAN'S NOTE** Prevention of toxoplasmosis involves reducing exposure to pregnant women by having someone else clean the litter box, washing hands after cleaning the litter box or handling raw meat, covering sandboxes, wearing gloves when gardening, and not eating undercooked meat.

### *Cryptosporidium parvum* (Cryptosporidiosis)

**Cryptosporidiosis** is a rare protozoan disease that produces a prolific, painful, watery diarrhea in humans. This protozoan parasite has been reported in the news because it has contaminated the drinking water supplies of several major metropolitan areas throughout North America and the world. As with toxoplasmosis, cryptosporidiosis is especially harmful in individuals with AIDS. For this reason, it is also an important parasite. Cryptosporidiosis was first reported in farmworkers and individuals who worked around very young calves. This organism is spread by ingestion of infective oocysts in calf feces.

### Human Infection with Cryptosporidiosis


Humans become infected with cryptosporidiosis by ingestion of oocysts from feces of young calves or from contaminated supplies of drinking water.

## Symptoms and Diagnosis

Cryptosporidiosis produces a transient, painful, watery diarrhea in humans, and all ages are susceptible. The duration of clinical signs in affected individuals varies considerably. Acute cases last from 3 to 7 days, and chronic wasting syndromes can persist for weeks to a few months. The development of natural immunity against the parasite determines the duration of clinical signs. Most humans infected with *Cryptosporidium* species develop immunity and recover from the infection.

Infections with *Cryptosporidium* species may persist indefinitely in people with immunodeficiencies, particularly AIDS. The prognosis for immunologically compromised individuals with cryptosporidiosis is poor.

Fecal flotation and concentrating solutions, such as zinc sulfate and Sheather's sugar solution, may be used to identify oocysts of *Cryptosporidium* species. These parasites are extremely tiny, less than 5  $\mu\text{m}$  in diameter, and thus may be easily overlooked. Acid-fast stains such as Ziehl-Neelsen or Kinyoun can be used, as well as auramine-rhodamine, Giemsa, and methylene blue. All these stains may be used to improve the identification of the parasite in fecal flotation.

 **TECHNICIAN'S NOTE** Cryptosporidiosis is diagnosed in humans with fecal flotation techniques using zinc sulfate or Sheather's solution to identify oocysts.


There are several commercially available enzyme-linked immunosorbent assay (ELISA) tests. These tests have a higher degree of sensitivity and specificity in diagnosing infections with *Cryptosporidium* species than can be obtained from stained fecal flotation smears. A commercially available indirect fluorescent antibody (IFA) test has been shown to be quite effective in diagnosing infection with *Cryptosporidium* species.

## Treatment

Although cryptosporidiosis is caused by a protozoan parasite with a life cycle similar to that of coccidia, **coccidiostats** have shown minimal to


no efficacy when used to treat infected cattle. An effective chemotherapeutic means of eliminating the parasite is not available.

Human cryptosporidiosis is treated symptomatically. Individuals who become dehydrated should be given appropriate fluids either intravenously or orally. Clinical improvement has been demonstrated in patients treated with dialyzable leukocyte extract from calves immunized with *Cryptosporidium* species.

 **TECHNICIAN'S NOTE** Cryptosporidiosis in humans is treated symptomatically.

## Prevention of Transmission to Humans

Infection with *Cryptosporidium* species can be prevented by good sanitation and hygiene practices when handling young animals, particularly calves. Infants, young children, or immunologically compromised individuals should not handle animals with diarrhea. Immunocompromised individuals should be advised to wash their hands after handling pets, especially before eating, and should avoid contact with their pet's feces. Many of the agents and processes used to sanitize public drinking water have little effect on *Cryptosporidium* species.

 **TECHNICIAN'S NOTE** Prevention of cryptosporidiosis is best accomplished with good hygiene habits and sanitation.

## TREMATODES OF PUBLIC HEALTH IMPORTANCE

### Schistosomes of Wild Migratory Birds (Schistosome Cercarial Dermatitis, Swimmer's Itch)

**Swimmer's itch** is a highly pruritic skin condition in humans caused by repeated penetration of the cercariae of the schistosomes (blood flukes) of wild migratory aquatic birds and small mammals native to the water's edge. On first exposure

of the cercariae, there is mild redness and edema in the skin; with repeated exposure, however, there is severe pruritus (itching) and a papular or pustular dermatitis (a pus-filled pimple). This dermatitis may persist for several days or even weeks and can become secondarily infected.

### Human Infection with Swimmer's Itch

Migratory waterfowl frequently harbor schistosomes (blood flukes) in their blood vasculature. These schistosomes produce eggs that pass in the bird's feces to the watery environment. The eggs hatch, producing miracidia, which in turn penetrate aquatic snails. Within the snail, the miracidia undergo asexual reproduction and produce thousands of cercariae. These cercariae exit the snail to penetrate the definitive host, the migratory waterfowl.

Humans serve as incidental hosts for these avian schistosomes. During summer, people swim or wade in the lakes, ponds, rivers, and even ocean waters frequented by wild birds. These waters are home to aquatic snails. The cercariae produced within the snails penetrate the skin of humans instead of the skin of migratory birds. The cercariae cannot complete the migration in the human host, and the host's immune system kills the cercariae. At the same time, the cercariae release allergenic substances that cause severe dermatitis. Repeated exposure produces the highly pruritic, papular or pustular dermatitis, or **schistosome cercarial dermatitis** ("swimmer's itch"). This condition may have many other regional or colloquial descriptive names.



**TECHNICIAN'S NOTE** Schistosomiasis in humans tends to be self-limiting but can cause severe dermatitis when the cercariae that cause the dermatitis release allergenic substances.

### Symptoms and Diagnosis

After the cercaria penetrates the skin, a reddened spot appears at the point of entry. The diameter of this spot increases, and the itching commences. If

the area becomes raised, it is called a **papule** and will reach its maximum size in about 24 hours. In severe cases the affected individual may develop a fever, become nauseated, and spend several sleepless nights. The papule itches for several days before subsiding, but in a week or so the symptoms disappear.

Swimmer's itch can be diagnosed by the observation of typical lesions in skin that has come in contact with pond, lake, stream, or ocean water containing infective cercariae from the snail intermediate host. A history of swimming in infested waters also aids in diagnosis. Laboratory findings usually have no role in establishing a diagnosis of swimmer's itch.


### Treatment

Suspected cases of swimmer's itch in humans should *always* be referred to a dermatologist or family practitioner. Antihistamines are prescribed to relieve the itch and topical steroid creams to reduce the swelling. Remember that these are prescription drugs and must be prescribed by a physician or dermatologist.

### Prevention of Transmission to Humans

During the seasonal occurrence of swimmer's itch, many public health agencies post warnings about swimmer's itch on beaches adjacent to ponds, lakes, streams, or the ocean. The public should heed these warnings and comply with the ban on swimming in infested waters. Swimming in water away from the shore will reduce the chance of contact with the cercariae; cercariae tend to congregate close to the shoreline. If contact is suspected, the swimmer should towel off immediately after leaving the water.

For those who must work in such waters, protective waterproof clothing is available. Repellents, such as benzyl benzoate and dibutylphthalate, are available. **Molluscicides** (snail-killing compounds) are available; however, they may have adverse effects on plants and other animals in the environment.

 **TECHNICIAN'S NOTE** The best prevention for swimmer's itch is to avoid water contaminated with schistosomes.


## CESTODES OF PUBLIC HEALTH IMPORTANCE

### *Taenia saginata* (Beef Tapeworm)

*Taenia saginata*, the beef tapeworm, parasitizes the small intestine of humans. Its larval or metacystode stage, *Cysticercus bovis*, is found in the musculature of beef cattle, the intermediate host.

#### Human Infection with Beef Tapeworm


Humans become infected with the beef tapeworm by ingesting the musculature of beef cattle that contains the cysticercus, or bladder worm, the larval (metacystode) stage for this tapeworm. This cysticercus stage has a scientific name, *Cysticercus bovis*, and may be found in a variety of sites in the bovine musculature: skeletal and heart muscle, masseters, diaphragm, and tongue. Humans are infected by ingesting raw or undercooked, cysticercus-infected beef. This meat is often referred to as **measly beef** or **beef measles**. The covering of the cysticercus is digested away, and the young tapeworm is released and attaches to the wall of the small intestine. This young tapeworm begins to grow its proglottids. The gravid proglottids are released to the outside environment. Each gravid proglottid contains about 80,000 eggs. In the outside environment the gravid proglottids rupture, and the released eggs may be ingested by a beef cow. The eggs hatch, the embryos penetrate the intestinal mucosa and enter into general circulation; they are then distributed throughout the musculature of the beef cow.

 **TECHNICIAN'S NOTE** Humans become infected with *Taenia saginata* by ingesting undercooked beef muscle that contains the cysticercus stage of the tapeworm.

### Symptoms and Diagnosis

Adult *Taenia saginata* in the small intestine of humans may cause a variety of nonspecific abdominal signs, such as diarrhea, constipation, and cramps. About 10 gravid proglottids are passed in the feces each day; this fact is quite evident to the infected individual. These proglottids are quite motile and will migrate a few centimeters over the human host's body, clothes, or bedding.

The gravid proglottids from human feces are unusual in appearance. Each proglottid has a prominent uterus with 14 to 32 lateral branches. The uterus contains approximately 80,000 eggs. Perianal swabs may be used to detect these eggs. Diagnosis of cysticerci in cattle is usually made by meat inspection procedures.

 **TECHNICIAN'S NOTE** A human infected with *Taenia saginata* will be very evident when the gravid proglottids are seen in the stool specimen upon defecation.

### Treatment

Suspected cases of the beef tapeworm in humans should *always* be referred to a family practitioner or internist. The treatment of choice is praziquantel or niclosamide.

### Prevention of Transmission to Humans

All infected humans should be treated by a physician. Feedlot employees should be educated concerning transmission of bovine cysticercosis and personal hygiene practices. Adequate and accessible toilet facilities must be provided for all workers. Meat inspection should be thorough. Infected carcasses may be condemned for human consumption or treated by freezing for 10 days to 2 weeks at  $-10^{\circ}\text{C}$  or by cooking at  $50^{\circ}$  to  $60^{\circ}\text{C}$ . Likewise, humans should be wary of undercooked meat, to avoid acquired infection with *T. saginata* (and a variety of pathogenic bacteria).



**TECHNICIAN'S NOTE** Proper sanitation, personal hygiene, and thorough meat inspection will help prevent infection with the beef tapeworm.

### *Taenia solium* (Pork Tapeworm)

*Taenia solium*, the pork tapeworm, parasitizes the small intestine of humans. The larval, or metacestode, stage of this tapeworm, *Cysticercus cellulosae*, is found in the musculature of pigs, the intermediate host. This is an unusual parasite in that humans can also harbor the larval stage, which may occur not only in the musculature, but also within the eye and brain. Therefore, humans can serve as both the definitive and the intermediate host for this parasite.

#### Human Infection with Pork Tapeworm

Humans become infected with the pork tapeworm by ingesting the musculature of pigs that contains the cysticercus, or bladder worm, the larval (metacestode) stage. This cysticercus stage has a scientific name, *Cysticercus cellulosae*, and may be found in a variety of muscle sites: skeletal and heart muscle, masseters, diaphragm, and tongue. Humans are infected by ingesting raw or undercooked, cysticercus-infected pork. This meat is often referred to as **measly pork** or **pork measles**. The covering of the cysticercus is digested away, and the young tapeworm is released and attaches to the wall of the small intestine. This young tapeworm begins to grow proglottids. The gravid (terminal) proglottids are released to the outside environment. Each gravid proglottid contains about 40,000 eggs. In the outside environment the gravid proglottid ruptures; the released eggs must be ingested by a pig. The eggs hatch, and the embryos penetrate the intestinal mucosa and reach general circulation, to be distributed throughout the musculature of the pig.

**TECHNICIAN'S NOTE** Pork tapeworm can infect humans if humans ingest undercooked pork meat that contains the cysticercus stage of the tapeworm.

If a human ingests one of the eggs, the egg hatches in the intestine. This embryo penetrates the intestinal mucosa and reaches general circulation, to be distributed not only throughout the musculature of the human, but also in subcutaneous sites and within the brain and the eye. In such sites, tremendous damage can result.

When the metacestode stage develops in the brain, the condition is known as **neurocysticercosis**. The parasite usually develops in the ventricles and is proliferative.

**TECHNICIAN'S NOTE** If humans ingest pork tapeworm eggs, the eggs can hatch in the intestine and the resulting embryo can reach general circulation, ending up in the brain, eye, and subcutaneous sites, as well as the musculature.

#### Symptoms and Diagnosis

Adult *Taenia solium* in the small intestine of humans may cause a variety of nonspecific abdominal signs, such as diarrhea, constipation, and cramps. Chains of gravid proglottids do not leave the host spontaneously but are passed in the feces each day; this fact is quite evident to the infected individual. These proglottids are quite motile and will migrate a few centimeters over the human host's body, clothes, or bedding.

Neurologic symptoms vary with the site of the offending cysticercus in the nervous tissue. Pain, paralysis, and epileptic seizures have been associated with neurocysticercosis. Ocular lesions may result in blindness.

The gravid proglottids from human feces are unusual in appearance. Each proglottid has a prominent uterus with fewer than 16 lateral branches. The uterus contains approximately

40,000 eggs. Diagnosis of cysticerci in pigs is usually made by meat inspection procedures.

Sophisticated radiographic imaging techniques, such as computed tomography (CT) and magnetic resonance imaging (MRI), may reveal the presence of cysticerci within the brain and other sites in the central nervous system (CNS).

**TECHNICIAN'S NOTE** The symptoms of pork tapeworm infection in humans vary by where the cysticercus ends up in the human in the case of ingesting the eggs. Intestinal infection can produce nonspecific abdominal symptoms such as diarrhea, cramps, and constipation.

### Treatment

Suspected cases of pork tapeworm in humans should *always* be referred to a family practitioner, neurologist, surgeon, or internist. The treatment of choice is praziquantel. Because of the infectivity of the eggs for humans and the resulting CNS involvement, these cases must be handled with great care. Treatment of human cysticercosis is by surgical removal of the offending lesion.

### Prevention of Transmission to Humans

All infected humans should be treated by a physician. Feedlot employees should be educated concerning transmission of porcine cysticercosis and personal hygiene practices. Household workers such as maids and cooks should be educated regarding proper hygiene, such as hand-washing before preparing a meal. Adequate and convenient toilet facilities must be provided for all workers. Meat inspection should be thorough. Infected carcasses may be condemned for human consumption or treated by freezing for 10 days to 2 weeks at  $-10^{\circ}\text{C}$  or by cooking at  $50^{\circ}$  to  $60^{\circ}\text{C}$ . Likewise, humans should be wary of undercooked meat to avoid acquired infection with *T. solium* (and a variety of pathogenic bacteria).

**TECHNICIAN'S NOTE** Pork tapeworm infection can be prevented by proper sanitation, personal hygiene, and thorough meat inspection as well as not eating undercooked pork.

### *Echinococcus granulosus* and *Echinococcus multilocularis* (Unilocular and Multilocular Hydatid Disease)

**Hydatid disease** is a syndrome characterized by the development of the larval, or metacestode, stage of a genus of tapeworm, *Echinococcus* species, found in the small intestine of dogs and cats, the definitive hosts. Hydatid disease is characterized by the formation of large, fluid-filled cysts in the internal organs of the intermediate host. There are two species of importance in veterinary parasitology: *E. granulosus*, a tapeworm that produces a **unilocular** (large, singular, thick-walled, fluid-filled) hydatid cyst, and *E. multilocularis*, a tapeworm that produces a **multilocular** (multiple, extremely invasive, thin-walled, fluid-filled) hydatid cyst. These hydatid cysts may occur in a variety of internal organs in the human intermediate host: the liver, lungs, kidney, spleen, bone, and brain.

**TECHNICIAN'S NOTE** The hydatid cysts produced by *Echinococcus* species can develop in a variety of organs in the human intermediate host.

### Human Infection with Hydatid Disease

Humans become infected with hydatid disease by ingesting the egg of *Echinococcus* species. Once ingested, the egg hatches in the intestine of the human intermediate host. The released **oncosphere** ("growth ball") penetrates an intestinal venule or lymphatic lacteal and reaches the liver, lungs, or other internal organs. Once in these extraintestinal sites, the oncosphere develops into the hydatid cyst. *E. granulosus* produces

a unilocular hydatid cyst. This cyst has a thick, multilayered cyst wall that keeps the developing cyst restricted to a single compartment. The hydatid cyst may grow up to 50 cm in diameter; however, it will not invade the surrounding tissues of the parasitized organ. *E. multilocularis* produces a multilocular hydatid cyst. In contrast to the unilocular hydatid cyst of *E. granulosus*, this hydatid cyst lacks the thick, multilayered cyst wall. Without this cyst wall, the developing cyst is capable of “budding off,” or producing additional compartments, which in turn, bud off other compartments. As a result, this type of hydatid cyst readily invades the surrounding tissues. This multilocular hydatid cyst takes on a “malignant,” invasive role.

### Symptoms and Diagnosis

The symptoms of infection with hydatid disease depend on the site where the organism develops; these sites include the liver, lungs, kidney, spleen, bone, and brain. Neurologic symptoms vary with the site of the offending cysticercus in the nervous tissue. Pain, paralysis, and epileptic seizures have also been associated with **echinococcosis**.

In humans, examination of histopathologic sections of unilocular hydatid cysts reveals the unique structure of the germinal membrane supported by a thicker, acellular, laminated membrane. Protoscolices are contained in the saclike brood capsules. When viewed macroscopically, these brood capsules look like sand. Humans with *E. multilocularis* develop tumorlike masses, or nodules, in their livers. When sectioned, these masses reveal the alveolar-like microvesicles containing protoscolices.

Sophisticated radiographic imaging techniques, such as CT and MRI, may reveal the presence of hydatid cysts within the brain and other organ sites throughout the body.



**TECHNICIAN'S NOTE** Diagnosis of echinococcosis in humans can be made by histopathologic sectioning, or CT or MRI scans.

### Treatment

Suspected cases of echinococcosis in humans should always be referred to a surgeon, internist, or neurologist. Surgical intervention is recommended for the disease syndromes caused by *E. granulosus* and *E. multilocularis*. For patients in whom the hydatid cyst cannot be removed or those for whom surgery is not an option, there may be new therapeutic alternatives. Treatment with mebendazole has shown varied success, although albendazole has been more promising.

State public health officials should be notified when canine or feline echinococcosis is diagnosed. Additionally, the CDC should be notified. The CDC has many specialists who are qualified to answer the most complex questions regarding both unilocular and multilocular hydatid disease in humans.



**TECHNICIAN'S NOTE** The state public health officials and CDC should be notified if canine or feline echinococcosis is diagnosed.

### Prevention of Transmission to Humans

Handwashing, particularly for children, should be emphasized. It is important to prevent exposure to eggs of *Echinococcus* species. Dogs should never be fed raw livestock viscera or allowed to roam freely to feed on wild rodents.

### *Dipylidium caninum* (Human Dipylidiasis)


#### Human Infection with *Dipylidium*

Children become infected with the common **tapeworm** of dogs and cats, *Dipylidium caninum*, by ingesting dog or cat fleas containing cysticercoids of this common canine and feline tapeworm.

### Symptoms and Diagnosis

As in the canine or feline host, proglottids are passed in the feces or are found around the anus (if the child is an infant and is still wearing diapers). Most infections occur in children under 8 years of age. Most patients are asymptomatic, but diarrhea,

abdominal pain, and anal pruritus may occur. The child may have moderate eosinophilia.

 **TECHNICIAN'S NOTE** Humans, especially children, can be infected with *Dipylidium caninum* by ingesting an infective flea.

### Treatment

Suspected cases of *D. caninum* in humans should *always* be referred to a family practitioner or internist. This human disease occurs rarely; humans appear to be highly resistant to the infection, given the high frequency of flea infestation on dogs and cats. Suspected cases of **dipylidiasis** in children should always be referred to a pediatrician or general practitioner. The drugs of choice for human dipylidiasis are praziquantel and niclosamide. For treating *D. caninum*, the adult dose of praziquantel is 10 to 20 mg/kg given once; the pediatric dose is the same. The adult dose of niclosamide is 2 g given once. For children weighing 11 to 34 kg, the dose is 1 g given once; for children weighing more than 34 kg, the one-time dose is 1.5 g. Since the method of transmission is by ingestion of dog or cat fleas containing the infected cysticercoids, the child probably is the only family member infected with this canine parasite. It would not be necessary to treat other family members for infection with this canine and feline cestode. All household pets should be treated with anthelmintics; a rigorous flea control program should be instituted for all dogs and cats.

### Prevention of Transmission to Humans

Infection in humans or animals by *D. caninum* requires ingestion of the intermediate host, the dog or cat flea containing the larva (cysticercoids) of the tapeworm. Many cases in humans are asymptomatic. Dipylidiasis affects mainly infants and young children, who may swallow a flea that hops up while the infant is crawling on the floor or cuddling the family pet. Again, humans appear to be highly resistant to the infection, given the high frequency of flea infestation on dogs and cats and the relative rarity of human disease.

### *Spirometra Mansonoides* (Benign Plerocercoidosis/Malignant Sparganosis)

#### Human Infection with *Spirometra* Species

While human infection with *Diphylllobothrium latum* is an intestinal infection, human infection with *Spirometra* spp. is usually associated with a variety of extraintestinal tissue sites. Humans may become infected with the plerocercoid stage or sparganum of *Spirometra* spp. within the tissues. The human is actually serving as the second intermediate host. Infection with the plerocercoid stage of the pseudotapeworm is referred to as sparganosis.

There are two forms of infection with *Spirometra* spp. that may occur in the second intermediate host: the nonproliferative form and the proliferative form. Most infections are of the nonproliferative form (benign plerocercoidosis) and are associated with the presence of a single larva of *Spirometra mansonoides*. Proliferative sparganosis (malignant sparganosis) is caused by the presence of and asexual replication of larvae within host tissues and the subsequent migration of these larvae to new tissue sites, where they grow and repeat the process *ad infinitum*.

### Symptoms and Diagnosis

For benign plerocercoidosis, the human will ultimately act as a dead-end host. Symptoms will depend on the site(s) of infection.

Proliferative sparganosis in humans may occur in sites from subcutaneous tissue sites to deep visceral forms, involving a variety of internal organs: ocular, central nervous system, auricular, pulmonary, intraosseous, and intraperitoneal sites. Again, symptoms will depend upon the severity and site of infection. Once infected with the malignant form, the human may ultimately die. Infections of both benign plerocercoidosis and proliferative sparganosis have been reported primarily in Asia and South America; however, two cases were reported in the United States in the early twentieth century.

## Treatment

It would be prudent for a physician to report any occurrence of human sparganosis, especially the malignant form, to the Centers for Disease Control and Prevention in Atlanta, Georgia.

Depending on the tissue sites where benign plerocercoidosis is occurring in the infected human, surgical intervention may be possible.

In humans infected with proliferative sparganosis, treatment with praziquantel and mebendazole has proven ineffective. Adverse side effects to these anthelmintics include severe nausea, vomiting, gastritis, sinus tachycardia, muscle tenderness, and a burning sensation at the injection site. Nitazoxanide is an antiprotozoal drug approved for use in humans that has been shown in preclinical trials to be effective against cestodes.

## Prevention of Transmission to Humans

Since sparganosis is zoonotic, precautions must be undertaken to prevent infection through consumption of infected water containing the first intermediate host, a *Cyclops* spp., an aquatic crustacean containing the procercoid stage. Humans may also become infected by ingesting poorly cooked fish containing the plerocercoid (sparganum) stage. Finally, humans may become infected during the application of medicinal poultices to open wounds; such poultices might contain the plerocercoid stage, which might infiltrate and ultimately infect the open wound.

Although this parasite is not a reportable parasite, it would be wise to report the occurrence of human sparganosis to the local public health authorities, owing to the severity of infection, particularly with malignant sparganosis that may develop in humans.

## *Hymenolepis nana* (Hymenolepiasis) Human Infection with *Hymenolepis*

*Hymenolepis nana*, the **dwarf tapeworm**, is usually found in rodents, primates, and humans. It is common in children under 3 years of age throughout the world and can be passed from human to

human. The tapeworms are usually regarded as hand-to-mouth parasites. *Hymenolepis diminuta*, the **rat tapeworm**, is primarily a parasite of rodents and humans. Children become infected with *Hymenolepis* species by ingesting insects (e.g., rat fleas, mealworms, cockroaches) containing cysticercoids of these tapeworms.



**TECHNICIAN'S NOTE** The dwarf tapeworm and rat tapeworm are regarded as hand-to-mouth parasites.

## Symptoms and Diagnosis

Large numbers of tapeworms can cause necrosis and desquamation of the intestinal epithelial cells. Light infections cause no significant damage to the mucosa and are either asymptomatic or cause vague abdominal complaints. Young children frequently have loose bowel movements or frank diarrhea with mucus. Bloody diarrhea is rare; diffuse, persistent abdominal pain is the more common complaint. A pruritic anus is another common complaint among infected individuals. Many children also have headaches, dizziness, and sleep and behavioral disturbances, which resolve after therapy. Serious neurologic disturbances have been reported. A moderate eosinophilia (5% to 10%) may be associated with **hymenolepiasis**.

Diagnosis is by finding the characteristic eggs in fecal flotation. Proglottids are usually not found because they degenerate before passage in the stool.

## Treatment

In suspected cases of *H. diminuta*, humans should *always* be referred to a family practitioner or internist. Praziquantel is the drug of choice. For treating *H. diminuta*, the dose of praziquantel (for both adults and children) is 25 mg/kg given once.

## Prevention of Transmission to Humans

Control depends on improved personal and environmental hygiene. Within institutions, all children should be treated.



**TECHNICIAN'S NOTE** Prevention of the dwarf and rat tapeworm depends on improved personal and environmental hygiene.

## ***Diphyllobothrium latum*** **(Diphyllobothriasis)**

### **Human Infection with *Diphyllobothrium***

The **broad fish tapeworm**, or *Diphyllobothrium latum*, is often found in many areas of the world where raw, insufficiently cooked, or lightly pickled freshwater fish are consumed. Infected fish contain the plerocercoid, or **sparganum**, stage; this is the stage eaten by the human. These parasites are often found in northern temperate and subarctic regions. The adult tapeworms are found within the small intestine of the host; humans may also become infected with the plerocercoid (sparganum) stage. When a homeopathic doctor uses an infected piece of fish as a poultice, the sparganum moves into the wound and sets up an infection in the subcutis, the connective tissue of the muscles, or in other sites within the body.

### **Symptoms and Diagnosis**

Intestinal infections in humans are often asymptomatic. Often the diagnosis is made during routine fecal examination when eggs or chains of proglottids are observed in the feces. Infection in humans may also cause nonspecific abdominal symptoms. Some individuals may complain of abdominal pain, bloating, allergic reactions, hunger pains, loss of appetite, or increased appetite. On rare occasions, mechanical intestinal obstruction may result from tapeworms becoming entangled; intussusception may result. Diarrhea may occur, and infected individuals may pass long sections of spent proglottids in the stool.

**TECHNICIAN'S NOTE** Intestinal infections in humans with the broad fish tapeworm are often asymptomatic or exhibit nonspecific abdominal symptoms.

Adult tapeworms in the small intestine may successfully absorb vitamin B<sub>12</sub> from the gut; this loss of vitamin B<sub>12</sub> produces **megaloblastic anemia** or **pernicious anemia**. This condition manifests itself as a macrocytic, hypochromic anemia.

Infection with the sparganum, or **sparganosis**, produces a severe inflammatory reaction and fibrosis of infected tissues. Clinical signs include urticaria, painful edema, and irregular nodules containing the plerocercoids. If spargana infect the eye, the infection may lead to exophthalmos, swelling of the eyelids, lagophthalmos, and corneal ulcers.

### **Treatment**

Suspected cases of the intestinal form of the broad fish tapeworm in humans should *always* be referred to a family practitioner or internist. Praziquantel and niclosamide are the drugs of choice. For treating *Diphyllobothrium latum*, the adult dose of praziquantel is 10 to 20 mg/kg given once; the pediatric dose is the same. The adult dose of niclosamide is 2 g given once. For children weighing 11 to 34 kg, the dose is 1 g given once; for children weighing more than 34 kg, the one-time dose is 1.5 g.

Suspected cases of the sparganum (plerocercoid) form of the broad fish tapeworm in humans should *always* be referred to a surgeon. Spargana within tissue sites in humans must be surgically removed.

**TECHNICIAN'S NOTE** As with all human zoonotic parasite infections, a physician should be seen for treatment. The broad fish tapeworm can be treated with praziquantel or niclosamide; however, sparganum infection should be referred to a surgeon.

### **Prevention of Transmission to Humans**

Proper cooking of freshwater fish eliminates all possibility of human infection. Likewise, domestic animals such as dogs, cats, and pigs should not be fed raw fish. Freezing at  $-10^{\circ}\text{C}$  will kill the infective plerocercoid (sparganum)

stage. In the United States, smoked salmon is brined before hot smoking; this process eliminates salmon as a source of infection. Food handlers should never taste raw fish while preparing it for cooking. Practitioners of natural medicine should be discouraged from applying poultices made of fish to openings in the skin or to the eye.

## NEMATODES OF PUBLIC HEALTH IMPORTANCE

### *Toxocara canis* and *Toxocara cati* (Toxocaral Larva Migrants, Visceral Larva Migrants, Ocular Larva Migrants)

**Toxocaral larva migrants** is a disease of humans caused by the migration of certain parasitic larvae in the organs and tissues. The most incriminated nematodes are the common ascarids of dogs and cats, *Toxocara canis* and *Toxocara cati*, respectively. *Baylisascaris procyonis*, an ascarid of raccoons, causes a similar syndrome.

### Human Infection with Toxocaral Larva Migrants

Humans become infected with toxocaral larva migrants when they ingest eggs of *Toxocara* species from the soil or on contaminated hands or other objects. Eggs of *Toxocara* species require 2 or more weeks before infective larvae develop within the eggs. Persons should also take precautions when handling young puppies still being nursed by their dams. The entire litter area (and their hair coats) may often become extremely contaminated with their aged feces, which may contain infective eggs.



**TECHNICIAN'S NOTE** Humans become infected with toxocaral larva migrants by ingesting eggs of *Toxocara* species of canine and feline roundworms.

## Symptoms and Diagnosis

Infection by a few larvae is usually asymptomatic. Two distinct syndromes are produced by *Toxocara* species: **visceral larva migrants** (VLM) and **ocular larva migrants** (OLM). VLM results from the migration of larvae through the human's somatic tissues and organs, including the liver, lungs, heart, and brain. VLM is characterized by fever, leukocytosis, persistent eosinophilia, hypergammaglobulinemia, and hepatomegaly. Pulmonary involvement, with symptoms that include bronchiolitis, asthma, or pneumonitis, may be common. Fatalities may result when the myocardium or CNS becomes involved.

OLM results when larval *Toxocara* species invade the eye. Ocular disease may be seen in the absence of VLM and is often seen in young children. Faulty vision may result; blindness may also occur.

VLM may be diagnosed based on the demonstration of lesions and the larvae in biopsy material. Serum samples may be sent to the CDC for serodiagnostic confirmation of toxocariasis. With OLM, the larvae may be observed during an ophthalmic examination.



**TECHNICIAN'S NOTE** Visceral larva migrants or ocular larva migrants can be seen in humans infected with toxocariasis.


## Treatment

Suspected cases of toxocaral larva migrants in humans, particularly young children, should always be referred to a family practitioner, pediatrician, internist, or ophthalmologist. No proven treatment is available. Suggested drugs of choice include mebendazole and diethylcarbamazine. Prednisone helps to control symptoms.

## Prevention of Transmission to Humans

Three major methods are used to prevent transmission of *Toxocara* species from dogs and cats to humans. First, it is important to prevent the fouling of backyard and public places, especially playgrounds, with dog and cat feces. All

fecal material should be disposed of properly. Second, pet owners should be educated regarding the potential health hazards of roundworms in cats and dogs. Pet owners should be informed of the methods of transmission and of the special risks associated with puppies and their nursing mothers. After handling any young puppy, hands should be thoroughly washed in soap and warm water. Third, it is important that all cats and dogs be routinely tested for intestinal parasites, such as ascarids. If infected, pets should be treated with an appropriate anthelmintic.

 **TECHNICIAN'S NOTE** Prevention of toxocariasis uses three methods: prevent fouling of the backyard and public places with dog and cat feces (use proper disposal of fecal material); client education; and routine examination of feces in dogs and cats.


### **Baylisascaris procyonis** (Neural Larva Migrans, Cerebrospinal Nematodiasis)

**Neural larva migrans**, a variation of visceral larva migrans, is the prolonged migration and persistence of parasite larvae of *Baylisascaris procyonis* (an ascarid that normally resides in the small intestine of the raccoon) in the brain and spinal cord of humans and animals. In this case, the human or other animal is serving as a **paratenic host**. This syndrome is similar to that of VLM and OLM of *Toxocara* species of both dogs and cats.

### **Human Infection with Larvae of Baylisascaris procyonis**

Humans become infected with the larvae of *B. procyonis* by accidentally ingesting eggs that contain its infective second-stage larvae. The eggs are ingested from the environment, from raccoon feces, or from contaminated soil, water, fomites, or hands. The source of these ascarid eggs is the raccoon, a feral animal that should *never* be maintained in any interior or exterior household environment. These eggs are extremely resistant and can remain viable in the environment for several months to years. This resistance increases

the likelihood of transmission from animals to humans.

 **TECHNICIAN'S NOTE** Humans contract neural larva migrans by accidental ingestion of infective second-stage larvae from raccoon feces in the environment.

### **Symptoms and Diagnosis**

As mentioned, *B. procyonis* can produce visceral and ocular larva migrans in humans, similar to that produced by *Toxocara* species of both dogs and cats. However, these larvae tend to be more pathogenic because they can migrate through the CNS. Typically, the extent of the infection depends on the number of infective larvae ingested and their locations and behavior in the body. When only a few larvae are ingested, individuals probably are asymptomatic; visceral damage is minor, and most larvae become encapsulated (walled off) in noncritical sites such as skeletal muscle or connective tissue. If larger numbers of larvae are ingested, however, the host may exhibit nonspecific clinical signs or more classic signs attributable to those of classic VLM: fever, leukocytosis, persistent eosinophilia, hepatomegaly, and pneumonitis. These larvae also have an affinity for migration in neurologic tissues, and depending on the location and extent of migration, neurologic signs vary. If enough larvae are ingested, progressive CNS disease can develop rapidly, producing signs such as sudden lethargy, loss of muscle coordination, decreased head control, torticollis, ataxia, and nystagmus. These signs progress to stupor, extensor rigidity, or hypotonia, coma, and finally, death. Clinical signs of OLM include unilateral loss of vision and photophobia.

Because neither eggs nor larvae of *B. procyonis* are found on fecal flotation or in blood samples from humans, diagnosis of *B. procyonis* in humans must be made based on history, clinical findings, and serologic testing. A history of exposure to raccoons or their feces is important. Clinical findings of VLM include leukocytosis, persistent eosinophilia, hypergammaglobulinemia, hepatomegaly, and pneumonitis. CNS disease may present

suddenly and develop progressively. Eosinophilia may be present in both the peripheral blood and the cerebrospinal fluid. OLM may be diagnosed by ophthalmologic examination that reveals inflammatory tracks in the retina and inflammation of the vitreum and choroid. A specific diagnosis may be made by identification of characteristic morphologic features of larval *B. procyonis* in histopathologic section. Serologic tests, such as indirect immunofluorescence, protein immunoblotting, and ELISA, are being evaluated.

**TECHNICIAN'S NOTE** Diagnosis of neural larva migrans in humans is based on history, clinical findings, and serologic tests.

### Treatment

Any person who has contact with raccoons or raccoon feces and develops visual or CNS disturbances should be examined by a physician, who should be alerted to the possibility of infection with *B. procyonis*. Suspected cases of **cerebrospinal nematodiasis** in humans should *always* be referred to a neurologist, ophthalmologist, internist, or family practitioner. It is unfortunate that effective anthelmintic treatments do not exist for visceral or ocular larva migrans or for cerebrospinal nematodiasis. Patients with the ocular form of this syndrome can be treated with a laser, if the larvae can be localized and visualized with the eye.

### Prevention of Transmission to Humans

*B. procyonis* is more prevalent in raccoons from northern states than in raccoons from southern states, especially those states in the deep South. Nevertheless, precautions should be taken around raccoons in all areas of the United States.

First in regard to prevention, raccoons are *not* suitable pets. Wild raccoons should not be encouraged to visit or frequent urban, suburban, or rural dwellings or environments.

For those who rehabilitate raccoons and return them to nature, it is important to prevent shedding of the eggs and to limit the exposure of humans and other animals to contaminated

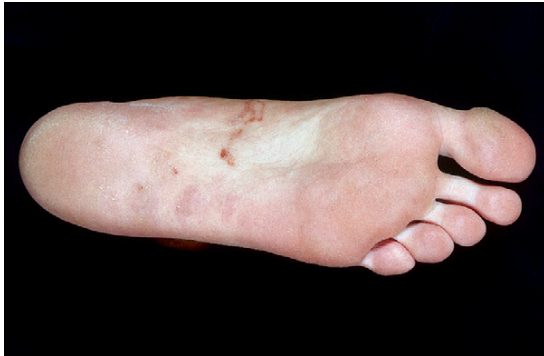areas. Raccoons should be quarantined away from other animals, in cages or enclosures that could be decontaminated if needed. All raccoons should be on a strict anthelmintic program to eliminate adult *B. procyonis* from the small intestine.

**TECHNICIAN'S NOTE** Raccoons should never be kept as pets and should not be encouraged to visit or frequent human environments.

Access by humans, especially children, to known or potentially contaminated areas should be restricted. Raccoon feces should be removed and disposed of daily, in a manner that prevents contact with humans and animals. The feces should be destroyed. Contaminated areas, cages, or traps that have held infected raccoons should be decontaminated. Gloves and rubber boots should be worn by individuals who clean these cages, and hot, soapy water should be used. Protective coveralls should be worn, and these should be washed in near-boiling water and bleach.

### *Ancylostoma caninum*, *Ancylostoma braziliense*, *Ancylostoma tubaeforme*, and *Uncinaria stenocephala* (Cutaneous Larva Migrans, Creeping Eruption, Plumber's Itch)

**Cutaneous larva migrans (CLM)** is a skin condition caused by the migration of hookworm larvae in the skin of humans (Figure 16-1). It is also known as **creeping eruption, dermal larva migrans, ground itch, plumber's itch, sandworms**, and many other regional or colloquial names. It is a serpentine, reddened, elevated pruritic skin lesion usually caused by the larvae of *Ancylostoma braziliense*, a hookworm of both dogs and cats. Other nematode parasites of domestic and wild animals have been implicated in causing similar lesions in humans. These nematodes include *Ancylostoma caninum*, the canine hookworm; *Uncinaria stenocephala*, the northern hookworm of dogs; *Bunostomum phlebotomum*,



**FIGURE 16-1:** Cutaneous larva migrans in sole of man's foot. This skin condition is caused by migration of hookworm larvae in skin of humans. It is also known as creeping eruption, dermal larva migrans, ground itch, plumber's itch, and sandworms.

the cattle hookworm; *Gnathostoma spinigerum* (a genus of Nematode); *Dirofilaria* species (such as aberrant *Dirofilaria immitis*, the heartworm); *Strongyloides procyonis*, a parasite of raccoons; and *Strongyloides westeri*, an equine parasite. Even the larvae of some of the myiasis-inducing flies (*Gasterophilus* and *Hypoderma* spp.) have been associated with the condition. However, hookworm larvae (*Ancylostoma* spp., particularly *A. braziliense*) are the pathogens most often incriminated.

**TECHNICIAN'S NOTE** Cutaneous larva migrans is caused by skin penetration of larvae of *Ancylostoma* species and *Uncinaria stenocephala*.

### Human Infection with Cutaneous Larva Migrans

Humans become infected with larvae of canine and feline hookworms when these larvae penetrate unprotected skin. This usually happens when human skin (usually of the bare feet) contacts moist, sandy soil contaminated with larval hookworms. Larval hookworms penetrate and migrate within the skin; in most cases they do not complete their life cycle or mature to adults in the small intestine.

Three scenarios have been developed regarding cutaneous hookworm infections in humans. The first scenario involves young children and

adults who go barefoot in areas frequented by hookworm-infected pets. Children may also become exposed to contaminated sand or soil for extended periods (e.g., by playing in sandboxes or dirt containing larvae).

**TECHNICIAN'S NOTE** No matter which scenario of contact is involved, cutaneous larva migrans results from the hookworm larvae penetrating the skin of the affected individual.

The second scenario involves travelers returning from exotic vacation sites around the world who may have walked barefoot or been nude in the sand for an extended time. Third-stage hookworm larvae developing from eggs passed from parasitized dogs and cats can penetrate the naked skin and cause cutaneous larva migrans. This dermatitis usually occurs in individuals who frequent beaches; therefore the persons infected are said to be parasitized with "sandworms."

The third scenario concerns plumbers, electricians, masons, and technicians working in the crawl space beneath houses and horticulturists tending flower beds and vegetable gardens. If hookworm-infected dogs or cats have been allowed access to these moist sites and have defecated there, infective larvae may penetrate the laborer's skin. These workers are most often infected on their knees, elbows, buttocks, and shoulders. Cutaneous larva migrans acquired in this manner is also known as "plumber's itch."


### Symptoms and Diagnosis

The skin-penetrating larval hookworms migrate in the dermis of humans and cause distinct symptoms. The human is an abnormal, or incidental, host. The severity of skin lesions is directly related to the degree of exposure to infective larvae. Symptoms are characterized by red, tunnel-like migration tracks, with severe pruritus; therefore the common name for the condition is "creeping eruption." After




skin penetration, the larvae reside in the superficial layers of the skin, actively producing and secreting hyaluronidase, an enzyme that aids their tunneling activity. Hookworm dermatitis is characterized by blisters, red bumps, and red tracts within a few days of initial penetration. The reddened site is usually 3 to 4 cm away from the penetration site, with the larva itself 1 to 2 cm ahead of the lesion. Within weeks to months after the initial infection, the larva dies and is resorbed by the host.

The skin condition is diagnosed by the observation of typical lesions in skin that has come in contact with moist soil containing infective hookworm larvae. A history of contact with the soil also aids in diagnosis. Laboratory findings usually have no role in the establishment of a diagnosis of cutaneous larva migrans.

 **TECHNICIAN'S NOTE** Cutaneous larva migrans is a self-limiting disease as the larvae cannot survive in the human incidental host for more than a few weeks to months.

## Treatment

Suspected cases of cutaneous larva migrans in humans should *always* be referred to a dermatologist or family practitioner. Patients often receive both oral and topical treatment with thiabendazole. Pruritus often ceases rapidly for all patients after treatment with this anthelmintic. Surgical treatment to extract migrating larvae is often unsuccessful. Because the larva is situated 1 to 2 cm ahead of the visible track, it cannot be localized and removed surgically. The application of liquid nitrogen has been advocated; however, the larvae may continue to migrate. Hookworm larvae are capable of surviving temperatures as low as  $-21^{\circ}\text{C}$  for more than 5 minutes.

 **TECHNICIAN'S NOTE** Cutaneous larva migrans has been successfully treated with topical and oral thiabendazole.


## Prevention of Transmission to Humans

Pets should be routinely examined for the presence of parasites and treated appropriately with anthelmintics. Pet owners should not allow their pet's feces to accumulate in the lawn or garden environment. Children's sandboxes should remain covered when not in use.

The seaside resort, with its moist, sandy environment, is an excellent locale for propagating larval hookworms. Pet owners should not allow dogs or cats infected with intestinal parasites to frequent beaches, either at home or abroad. Infected pets residing in seaside communities are most likely to transmit cutaneous larva migrans to humans. Seaside communities should also have leash laws, and well-trained animal control officers should regularly patrol beaches and remove free-roaming dogs and cats.

If an infected pet on a leash defecates in a public area, the feces should be promptly removed from the area, preferably by use of a disposable plastic bag. Burial of feces on the beach is not sufficient because tides and shifting sands are capable of exposing feces at a later time.

Travelers to exotic (or even local) beaches without enforced leash laws are at increased risk of contracting infective hookworm larvae if sandals or appropriate attire are not worn. Likewise, a person should never sit directly in the sand on beaches where infected animals have been allowed to roam and defecate freely.

 **TECHNICIAN'S NOTE** Prevention of CLM can be accomplished by cleaning the yard of feces on a daily basis before infective larvae are hatched, covering sandboxes when not in use, not allowing infected cats or dogs to walk on beaches, and wearing footwear when traveling, especially in suspected areas of infection.

## *Ancylostoma caninum* (Enteric Hookworm Disease)

Infective larvae of the canine and feline hookworms that penetrate the skin usually produce a cutaneous manifestation. Recently, *Ancylostoma*

*caninum* has been found to grow to the adult stage within the intestine of humans. Human enteric infections with *A. caninum* have been reported in Australia and, more recently, in the United States. Pulmonary involvement and corneal opacities also have been reported in humans infected with *A. caninum*, and an *Ancylostoma* larva has been recovered from the muscle fiber of a patient with cutaneous larva migrans.

**TECHNICIAN'S NOTE** While hookworms produce cutaneous larva migrans in humans, *Ancylostoma caninum* has been found to be able to grow to the adult stage in the human intestines.

### Human Infection with Enteric Hookworm Disease

Humans become infected with hookworm when the larval hookworms penetrate unprotected skin. This usually happens when skin (usually of the bare feet) contacts moist, sandy soil contaminated with larval hookworms. Larval hookworms penetrate and migrate within the skin; in most cases they do not complete their life cycle or mature to adults in the small intestine. In the case of enteric hookworm disease, however, they do complete the life cycle and mature to adults in the small intestine.

### Symptoms and Diagnosis

It is interesting that *A. caninum* has caused enteric infections in humans residing in developed, urban communities in northeastern Australia. Although the infections may be subclinical, the chief symptom is abdominal pain, which is frequently severe with sudden onset. After biopsy the chief pathologic finding is focal or diffuse eosinophilic inflammation resulting from a type 1 hypersensitivity response to secreted antigens. Additionally, two cases of eosinophilic enterocolitis attributable to canine hookworms have been reported in the United States. Canine hookworms adapt poorly in the human host; the infection is scant, and the worms do not produce eggs. Therefore, fecal flotation will not reveal the presence of hookworm eggs.

**TECHNICIAN'S NOTE** The common symptom of human hookworm infection is abdominal pain.

*A. caninum* also has been reported to occur sporadically in the human intestine in several locales throughout the world, such as the Philippines, South America, and Israel. In these instances, *A. caninum* did not produce clinically evident disease, was not fully developed, or was not capable of producing eggs. Three cases of infection with a single adult *A. caninum* were reported in eastern Australia, with results confirmed by ELISA and Western blot testing. Not all recent cases of canine hookworm infection in humans have been restricted to Australia, however. Cases of eosinophilic enterocolitis in two female children were reported in the United States in Louisiana.

**TECHNICIAN'S NOTE** Enteric hookworm infection has been reported in two female children in the United States.


### Treatment

Suspected cases of enteric hookworm infection in humans should *always* be referred to a family practitioner or gastroenterologist. In the Australian study, canine hookworms were extracted using biopsy forceps, during either laparotomy or colonoscopy. After removal of the worms, all patients recovered and remained well. Both patients in the United States were treated with mebendazole (100 mg twice a day for 3 days), with repeat treatment in 2 to 6 weeks.

### Prevention of Transmission to Humans

Human exposure to infective third-stage larvae of hookworms is directly related to the prevalence of the parasite in the local canine population. The same precautions as listed for cutaneous larva migrans should be observed. Because most of the world's population shares the environment with dogs infected with *A. caninum*, hookworms could be encountered widely

as a human enteric pathogen. As more physicians and human pathologists become aware of this condition, enteric infections with hookworms acquired from pets will become recognized as a major zoonosis. This zoonosis also stresses the need for awareness among public health workers, veterinarians, and pet owners.

 **TECHNICIAN'S NOTE** Prevention of enteric hookworm infection can be accomplished by cleaning the yard of feces on a daily basis before infective larvae are hatched, covering sandboxes when not in use, not allowing infected cats or dogs to walk on beaches, and wearing footwear when traveling, especially in suspected areas of infection.

### ***Strongyloides stercoralis* (Strongyloidiasis)**


Strongyloidiasis is a disease in humans caused by *Strongyloides stercoralis*, the threadworm. Humans can be infected with this parasitic nematode by dogs, cats, and other carnivores that have the parasite.

### **Human Infection with *Strongyloides stercoralis***

The female parasite will lay eggs in the intestines of the host where the eggs will hatch into larvae. The larvae are typically passed in the feces. The larvae develop into third-stage infective larvae, which can then penetrate the skin of a human host and migrate to the intestines. There will often be inflammation at the site of skin penetration. The larvae can migrate through the lungs on their way to the intestine. Once in the intestine, the larvae will mature to an adult worm. The adult worms then produce eggs that will hatch in the human intestinal tract. In immune-compromised patients, the larvae can remain in the patient, repenetrates the intestinal mucosa, and develop into adult worms (autoinfection). This autoinfection increases the number of adult worms in the intestines thus making the disease and symptoms worse.

### **Symptoms and Diagnosis**


The larvae can migrate through the lungs on their way to the intestines causing respiratory symptoms such as coughing as well as other symptoms associated with respiratory disease. These symptoms can include mild to severe pneumonia. Once in the intestines, the larvae can cause inflammation of the intestinal mucosa as well as diarrhea. The diarrhea can lead to exhaustion and emaciation in the human host. The human patient can be asymptomatic or the worms can cause a mild to severe infection even causing death. Most fatal infections have been linked to autoinfection increasing the worm burden and causing the symptoms to become more severe.

 **TECHNICIAN'S NOTE** Symptoms of strongyloidiasis can include death to the host, most often occurring from autoinfection causing a significant increase in the worm burden on the host.

Diagnosis in humans is essentially the same as seen in animals. A direct fecal smear can be used to identify the larvae in the feces. Fecal flotation or the Baermann technique can also be used for identification of the larval stage of the parasite.

### **Treatment**

All suspected infections of *Strongyloides stercoralis* in humans should be referred to the individual's family physician or gastroenterologist. Ivermectin at 200 mcg/kg/day given orally for 1 to 2 days has been successful in many human patients. Thiabendazole at 50 mg/kg/day given every 12 hours for 2 days has also been successful in human patients. However, thiabendazole may need to be given for 7 to 10 days with hyperinfection caused by autoinfection.

 **TECHNICIAN'S NOTE** Humans can be given ivermectin subcutaneously if oral administration does not build up enough serum levels.

## Prevention of Transmission to Humans


Human exposure to infective third-stage larvae of threadworms is directly related to prevalence of the parasite in the local canine or feline population. The same precautions as listed for cutaneous larva migrans should be observed. Because most of the world's population shares the environment with dogs infected with *S. stercoralis*, threadworms could be encountered widely as a human enteric pathogen. This zoonosis also stresses the need for awareness among public health workers, veterinarians, and pet owners.\*

## *Trichinella spiralis* (Trichinosis or Trichinellosis)

**Trichinosis** (also known as **trichinellosis**) is a disease caused by parasitic nematodes of the genus *Trichinella*. The most common cause of clinical trichinosis in humans is *Trichinella spiralis*, a parasite acquired from domestic pigs.


## Human Infection with Trichinosis

Humans become infected with trichinosis by eating pork products containing infective larvae of *T. spiralis*. Pork products have been found to be the cause of approximately two-thirds of the reported cases and disease episodes of trichinosis. These products usually are obtained through commercial outlets. Humans become infected by eating lightly processed, partially cooked or raw pork sausage or spiced pork. Home-raised or locally purchased swine also serve as an important source for human infection. Another important source of infection in humans is the consumption of wild game, particularly bear and boar.

 **TECHNICIAN'S NOTE** Human trichinosis infection is caused primarily from eating lightly processed, undercooked, or raw pork sausage or spiced pork.

## Symptoms and Diagnosis

The severity and clinical outcome of the disease are related to the number of larvae ingested, the species of *Trichinella*, and a variety of host factors, such as age, gender, ethnic group, and immune status. Most cases of trichinosis in humans are subclinical, related to the low infection level. Mild, moderate, and severe cases also occur. These clinical manifestations increase in severity and may be life-threatening. The clinical manifestation can be classified into two types: the early abdominal syndrome, and the later general trichinosis syndrome. In the **early abdominal syndrome**, clinical signs may commence 2 to 7 days after infection and may last for many weeks. This syndrome is typified by an enteritis, caused by the development and maturity of the worms parasitizing the small intestine and by the penetration of the newborn larvae into the intestinal wall. Infected humans may exhibit malaise, nausea, vomiting, anorexia, mild fever, abdominal pain, or diarrhea. Diarrhea may become persistent.

 **TECHNICIAN'S NOTE** The severity of symptoms is directly linked to the number of larvae ingested by the human host, the species of *Trichinella*, and the signalment of the host.

The **later general trichinosis syndrome** may appear weeks to months after the abdominal syndrome. On penetration of the intestine, the larvae have migrated throughout the body via the circulatory system. Although these larvae invade various tissues, the encysts are found only in striated skeletal muscle cells. Infected individuals develop an allergic vasculitis. This appears as vascular leakage and hemorrhage and may be observed as periorbital edema and fingernail-bed and conjunctival hemorrhages. Myalgia (muscle pain) and muscle weakness are common signs, related to invasion of the skeletal muscle, inflammation, and related damage. In severe cases, patients may also develop immune-mediated myocarditis, pneumonitis, encephalitis, and other, even more serious complications.

\*[www.emedicine.com](http://www.emedicine.com), [www.peteducation.com](http://www.peteducation.com), [www.diagnosis-me.com](http://www.diagnosis-me.com).


Human trichinosis is usually diagnosed during the muscle phase of the disease. Cases of trichinosis may be diagnosed by blood hemograms and serum chemistries. Persistent eosinophilia is a characteristic sign of trichinosis in humans. Patients may also exhibit a leukocytosis. Serum chemistries may reveal increased immunoglobulin E (IgE), creatine kinase (CK), and lactate dehydrogenase (LDH) values.

### Treatment

Suspected cases of trichinosis in swine should *always* be reported by the veterinarian to both state and federal authorities. Humans infected with trichinosis should *always* be referred to a physician. The benzimidazole anthelmintics, particularly mebendazole, flubendazole, and cambendazole, are highly effective against the muscle larvae. The CDC has many specialists who are qualified to answer the most complex issues regarding trichinosis in humans.

### Prevention of Transmission to Humans

Trichinosis can be contracted only by eating infected meat containing live *Trichinella*. People must assume that pork and wild game may be infected and should prepare the meat accordingly. Pork should be cooked at a uniform temperature of 140° F (60° C) throughout for at least 1 minute. Consumers at home are encouraged to cook pork at a temperature of 160° F (71° C), which ensures that all larval *Trichinella* are killed. Because microwave cooking often may produce “cold spots” in meat, it is considered least effective for killing larvae. People must take care to ensure uniform heating of pork products in microwave ovens.


 **TECHNICIAN'S NOTE** Since trichinosis can only be contracted by eating infected meat, pork and wild game should be fully cooked and hands should be washed after handling raw meat.

Larval *Trichinella* also may be killed by freezing. Meat less than 15.25 cm (6 inches) thick

should be frozen to 5° F (–15° C) for 20 days, –10° F (–23° C) for 10 days, and –22° F (–30° C) for 6 days. Gamma irradiation of pork by the packing industry may also safeguard consumers from infection with this parasite.

### *Dirofilaria immitis* (Pulmonary Dirofilariasis)

Only *Dirofilaria immitis*, the **canine heartworm**, causes pulmonary dirofilariasis in humans. **Pulmonary dirofilariasis** has been reported in more than 20 instances outside the United States and more than 90 times within the borders of the United States. Because humans are an incidental host for this parasite, most of the cases of pulmonary dirofilariasis result in the formation of a single, isolated nodule containing one necrotic (rotting) heartworm at its center.

 **TECHNICIAN'S NOTE** Pulmonary dirofilariasis is only caused by *Dirofilaria immitis* in humans.

### Human Infection with Dirofilariasis

Mosquitoes are the intermediate host for *D. immitis*, the canine heartworm. Infected mosquitoes must readily attack both the canine definitive host and the human incidental host. The infective third-stage larvae emerge from the proboscis of the mosquito and are contained in a small drop of the mosquito's body fluid. These moist larvae must be close to the puncture wound made by the mosquito; the larvae enter this wound. After passage through the puncture wound made by the mosquito, the larva continues to develop in the subcutaneous tissues. It begins its wandering migration. Rather than residing in the right ventricle and pulmonary arteries, the larva finds its way to the lungs. In the lungs, the single larval *D. immitis* produces an infarction that results in a solitary pulmonary nodule. This infarction is caused by the occlusion (blockage) of an arteriole when a thrombus (blood clot) forms around



an impacted worm. The nodule assumes a spherical shape from the secondary granuloma and the fibrotic reaction that occurs when the antigen from the degenerating worm diffuses into the surrounding pulmonary tissues. These nodules have been reported to occur in every lobe of the lung.

### Symptoms and Diagnosis

Most cases of pulmonary dirofilariasis in humans are asymptomatic. Infected patients usually are found by radiographic detection of a density or an opacity in the lung field after routine radiography of the chest. The patient is scheduled for exploratory thoracic surgery, and the nodule is excised. Histopathology usually reveals the presence of a single, necrotic worm at the center of the fibrotic nodule. Special stains are available for identification of necrotic worm fragments. Tissue samples from suspected cases should be sent to a pathologist who is familiar with the appearance of these parasites in histopathologic section.



**TECHNICIAN'S NOTE** Radiographs of the thorax will reveal a nodule or density in the lung field. Surgical histopathology will usually reveal the presence of a single, necrotic worm at the center of the nodule.

Eosinophil counts vary considerably among humans with pulmonary dirofilariasis and consequently are of little value. Both IgM and IgG ELISA for *D. immitis* antibodies have been used in studies of human populations. An ELISA has also been used to detect *D. immitis*-specific IgE in human sera.

### Treatment

Suspected cases of pulmonary dirofilariasis in humans should *always* be referred to a thoracic surgeon or human histopathologist. Additionally, the CDC has many specialists who are qualified to answer the most complex issues of pulmonary dirofilariasis in humans.

### Prevention of Transmission to Humans

The transmission cycle of dirofilariasis can be interrupted in several different ways. Veterinarians play an important role in the prevention of dirofilariasis in humans by encouraging pet owners to provide their dogs with preventive medicine. The daily or monthly administration of larvicidal drugs is an effective means of controlling the disease in dogs and preventing “spillover” infection in humans. These drugs are safe and effective. Because the weather in many southern states in the United States is mild, preventive medication should be given throughout the year. Control of stray and feral dogs also is an important consideration for the control of dirofilariasis. These animals represent a major reservoir for this disease.




**TECHNICIAN'S NOTE** Human infection with canine heartworm can be prevented by the use of heartworm preventative to control the spread of the disease in dogs, mosquito-control methods, and using mosquito repellent.

Control of mosquitoes can reduce the exposure of humans and dogs and cats to these parasites. The removal of mosquito breeding sites and proper drainage of low-lying areas can be helpful. Mosquito larvicides may be used in some cases; however, resistance to these compounds can occur, and such compounds also disrupt the normal ecologic balance in the area. Recently, the biologic control of mosquitoes has been attempted in some areas, and the use of various species of fish to reduce larval populations has been successful.

A final line of defense is the prevention of mosquito bites in both humans and animals. People can prevent mosquito bites by the application of repellents and by wearing protective clothing. All effective mosquito repellents contain **deet** (diethyltoluamide). Walking dogs in the early evening hours when mosquitoes are most abundant should be avoided to reduce exposure in both humans and animals. Mosquitoes are not

attracted to light, so electrocution devices are not helpful for their control; use of these devices may actually be detrimental because they destroy insects that may feed on adult mosquitoes.

 **TECHNICIAN'S NOTE** Avoid walking dogs in the early evening hours when mosquitoes are most abundant.


## ARTHROPODS OF PUBLIC HEALTH IMPORTANCE

### *Sarcoptes scabiei* Variety *Canis* (Canine Scabies)

**Canine scabies** is a zoonotic skin condition caused by an ectoparasitic, tunneling sarcoptiform mite, *Sarcoptes scabiei*. Both human and canine varieties of this mite are found; these varieties are classified as *Sarcoptes scabiei* variety *hominis* and *Sarcoptes scabiei* variety *canis*, respectively. Although these varieties are morphologically identical, they are different in their primary definitive host and in the characteristic lesions they produce.

### Human Infection with Canine Scabies


Humans become infected with canine scabies by coming into direct contact with infested dogs. During most of their life cycle, these mites tunnel in the cornified layer of the epidermis (the outermost layer of the skin). During a short period, however, they reside on the surface of the skin and are capable of transferring from one host to another. Infested dogs can pass mites to uninfested dogs or humans through direct contact. It is important to remember that this mite is transitory and does not establish itself in the skin of humans.

 **TECHNICIAN'S NOTE** *Sarcoptes scabiei* variety *canis* can be passed to humans but does not establish itself in the skin of the human incidental host.

### Symptoms and Diagnosis

Canine scabies in humans, particularly children, is characterized by the presence of characteristic lesions on the trunk, arms, abdomen, and rarely the face and genitalia. These lesions have been described as **papules** (red bumps) or **vesicles** (tiny blisters). Although these mites tunnel in the canine definitive host, they do not tunnel in human skin. The lesions caused by these mites are extremely pruritic; the onset of the pruritus commences with the appearance of the lesions.

Skin scrapings of the infested human's papular or vesicular lesions are rarely positive. The skin condition is diagnosed by the observation of typical lesions in skin that has come in contact with infested dogs. A history of contact with such dogs also aids in the diagnosis. Laboratory findings usually have no role in the establishment of a diagnosis of canine scabies.

 **TECHNICIAN'S NOTE** Typically, laboratory findings do not play a role in diagnosing human scabies infections caused by canine scabies mites.

### Treatment

Suspected cases of canine scabies in humans should *always* be referred to a dermatologist or family practitioner. Antihistamines are prescribed to relieve the itch and topical steroid creams to reduce the papules and vesicles. Antibiotics may be administered to prevent secondary bacterial infection. Remember that these are prescription drugs and must be prescribed by a dermatologist or physician.

### Prevention of Transmission to Humans

Transmission of this mite to humans can be prevented by avoiding contact with infested dogs harboring *S. scabiei* variety *canis*. Naturally, when one dog is diagnosed with this parasitic mite, all dogs in the household must be treated to kill the offending ectoparasite.

## PENTASTOMES OF PUBLIC HEALTH IMPORTANCE

### Reptilian Pentastomiasis

Reptilian pentastomiasis is the presence of encysted, wormlike nymphal stages of snake pentastomes within the mesenteric lymph nodes, liver, lungs, omentum, and other visceral organs of humans. One mammalian pentastome, *Linguatula serrata*, the tongue worm of dogs, behaves similarly and should be handled with precautionary measures as thorough as those for the reptilian pentastomes.

### Human Infection with Reptilian Pentastomes



**TECHNICIAN'S NOTE** Humans can act as intermediate hosts for reptilian pentastomes when the infective larvae are ingested.

Adult reptilian pentastomes occur within the lungs, trachea, and nasal passages of the reptilian definitive host, feeding on tissue fluids and blood cells. Female pentastomes can produce several million fully embryonated eggs, each containing a single larval stage with two or three pairs of rudimentary, jointed legs that are clawed. These eggs are “coughed” up by the host, swallowed, and passed to the outside environment in snake feces. An oval-tailed larva with four (or six) stumpy legs, each of which has two retractable pincerlike claws, hatches from the egg and is infective for the intermediate host. Intermediate hosts include rodents, herbivores, carnivores, nonhuman primates, and in this case, humans. The larva bores into the intestinal wall of the intermediate host and passes with the blood to the mesenteric lymph nodes, liver, lungs, omentum, or other visceral organ, where it becomes encysted. The larva becomes quiescent and metamorphoses into a wormlike, nymphal stage. The reptilian definitive host is infected by ingesting the intermediate host with its encysted nymphal pentastomes. The infective nymphs penetrate the snake’s intestine, bore to the lungs,

and become sexually mature adult parasites. It is important to note that humans serve as incidental intermediate hosts.

### Symptoms and Diagnosis

Most cases of nymphal pentastomiasis in humans are asymptomatic; the patient is unaware of the infection. **Incidental nymphal pentastomiasis** in humans is diagnosed during exploratory surgery, on radiographic examination, and by histopathologic examination of autopsy specimens. The nymphal pentastome may assume a characteristic C shape during its development in the intermediate host. On histopathologic examination, certain morphologic features of the nymphal pentastome can be used for definitive diagnosis.

Antemortem diagnosis of pentastomiasis in humans can be accomplished by radiographic examination. Nymphal pentastomes often die in the human incidental intermediate host. In response, the human host will calcify the dead parasite. These dead, calcified parasites may be visible on radiographic examination. There are no satisfactory laboratory tests for antemortem diagnosis of nymphal pentastomiasis in humans.



**TECHNICIAN'S NOTE** Pentastomiasis in humans is diagnosed by radiographic examination finding calcified, dead nymphal stage.

### Treatment

Persons having contact with snakes or snake feces and who suspect that they may be serving as an incidental host for reptilian pentastomes should be examined by an internist, who should be alerted to the possibility of pentastomiasis. In cases of limited infection in humans, free or encysted nymphs can be surgically removed. If tissues are removed for biopsy or autopsy purposes, a histopathologist should be alerted to the suspicion. Additionally, the CDC has many specialists who are qualified to answer the most complex issues of nymphal pentastomiasis in humans.

## Prevention of Transmission to Humans

It is now “trendy” or “fashionable” to keep snakes and other reptiles as pets. Many individuals believe erroneously that reptiles are easier to maintain than either cats or dogs; reptiles do not require daily feeding. Many drawbacks await the unsuspecting owner, including the zoonotic potential of reptilian pentastomes.

In the United States, snakes and other reptiles can be easily obtained in pet stores in almost any mall or shopping center. The initial sources of these snakes often are unknown to the proprietor and owner. Snakes and other reptiles can originate from across town, across the continent, or from the other side of the globe. The public is largely unaware of the potential risks involved in caring for snakes. It is the veterinarian’s duty to educate the client regarding the severity of incidental nymphal pentastomiasis and to instruct the owner in the proper care and husbandry of captive snakes and other reptiles.



**TECHNICIAN’S NOTE** The most important part of preventing pentastomiasis infection in humans is proper education of reptile owners.

A newly acquired reptile, whether purchased or collected from the wild, should be presented to the veterinarian for physical examination. This visit should include a routine fecal flotation. If this initial fecal examination is negative, examinations should be performed on at least two successive fecal specimens to reduce the possibility

of false-negative results. If pentastome eggs are present in the feces, the client should be warned of the zoonotic potential of these parasites and advised to select another reptile. Anthelmintic drugs are probably ineffective against pentastomes because of the location of the adult parasites within the lungs of snakes. Clients who insist on maintaining poisonous reptiles as pets should be referred to zoos or herpetaria for instruction regarding proper hygienic procedures and good husbandry techniques. Owners and veterinarians should wash their hands after handling snakes, snake feces, or cage and aquarium items. Water bowls and cages must be cleaned regularly.

Snake owners should be instructed about the intricate life cycle of the pentastomes. Because rodent intermediate hosts cannot be identified antemortem, the one practical preventive measure is to feed only clean, laboratory-reared rodents to captive snakes, lizards, crocodilians, and tuataras. Feeding wild, potentially pentastome-infected rodents to reptiles should be avoided.

## CONCLUSION

Because of the public health significance of the parasites discussed in this chapter, it is the veterinarian’s responsibility to inform and protect the general public in regard to pathogenic zoonoses.



**TECHNICIAN’S NOTE** It is up to the veterinary professional to properly educate clients on the zoonotic potential of parasites that their pets may have.

**CHAPTER SIXTEEN TEST**

MATCHING—Match the term with the correct phrase or term.

- |                                           |                                                                                         |
|-------------------------------------------|-----------------------------------------------------------------------------------------|
| A. Diagnosing or treating humans          | 1. Ingesting pork products containing infective larvae in muscle cyst                   |
| B. Cat                                    | 2. Ingesting fish containing plerocercoid or sparganum within fish muscle               |
| C. Tachyzoites                            | 3. Tiny blisters in the skin                                                            |
| D. Bradyzoites                            | 4. Schistosome cercarial dermatitis from penetration of cercariae of bird flukes        |
| E. Methods of acquiring cryptosporidiosis | 5. Violation of state practice act                                                      |
| F. Swimmer's itch                         | 6. Rapidly multiplying stages of <i>Toxoplasma gondii</i>                               |
| G. Acquiring <i>Taenia saginata</i>       | 7. Cerebrospinal nematodiasis                                                           |
| H. Acquiring <i>Taenia solium</i>         | 8. Definitive host for both <i>Taenia saginata</i> and <i>Taenia solium</i>             |
| I. Neurocysticercosis                     | 9. Red bumps in the skin                                                                |
| J. <i>Echinococcus granulosus</i>         | 10. Communication with human health care workers                                        |
| K. Acquiring <i>Dipylidium caninum</i>    | 11. Ophthalmic examination                                                              |
| L. Acquiring <i>Diphyllbothrium latum</i> | 12. <i>Cysticercus cellulosae</i> in brain of human (serving as an "intermediate host") |
| M. Pernicious anemia                      | 13. Vitamin B <sub>12</sub> deficiency due to <i>Diphyllbothrium latum</i>              |
| N. <i>Baylisascaris procyonis</i>         | 14. Only definitive hosts for <i>Toxoplasma gondii</i>                                  |
| O. <i>Ancylostoma braziliense</i>         | 15. Tongue worm of dogs                                                                 |
| P. <i>Trichinella spiralis</i>            | 16. Cooking pork at a temperature of 160° F (71° C)                                     |
| Q. Papules                                | 17. Ingesting cysticercoids within flea intermediate host                               |
| R. Vesicles                               | 18. Slowly multiplying stages of <i>Toxoplasma gondii</i>                               |
| S. <i>Linguatula serrata</i>              | 19. Mosquito repellent                                                                  |
| T. Prevention of trichinosis              | 20. Ingesting measly pork                                                               |



- |                                |                                                                                          |
|--------------------------------|------------------------------------------------------------------------------------------|
| U. Human                       | 21. <i>Cutaneous larva migrans</i>                                                       |
| V. Raccoons                    | 22. Ingesting oocysts from the feces of young calves or from contaminated drinking water |
| W. Paratenic host              | 23. Ingesting measly beef                                                                |
| X. Diagnosis of OLM in a child | 24. Human infected with VLM or OLM                                                       |
| Y. Diethyltoluamide (deet)     | 25. Unilocular hydatid cyst in human intermediate host                                   |
| Z. Advisory capacity           | 26. Definitive host for <i>Baylisascaris procyonis</i>                                   |

### QUESTIONS FOR THOUGHT AND DISCUSSION

---

1. There are eighteen zoonotic parasites that have been discussed in this chapter. Of these parasites, which three do you think would be most important in a small animal veterinary practice?
2. Of these parasites, which three do you think would be most important in a large animal veterinary practice?
3. Veterinarians and veterinary technicians should always be concerned about the zoonotic potential of parasites. Who do you think knows more about zoonotic diseases, veterinarians or other health care workers?

# Common Laboratory Procedures for Diagnosing Parasitism

17

## KEY TERMS

Correct fecal sample submission  
Accession number  
“Pooled fecal samples” from herds  
Central record book  
Gross examination of feces  
Calcareous bodies/calcareous corpuscles  
Field  
Pattern of movement  
Calibration of the compound microscope  
Stage micrometer  
Ocular micrometer  
Direct fecal smear  
Concentration methods  
Fecal flotation  
Specific gravity  
Flotation media  
Sheather’s solution  
Sodium nitrate solution  
Zinc sulfate solution  
Magnesium sulfate solution  
Saturated sodium chloride solution  
Simple flotation  
Centrifugal flotation  
Fecal sedimentation  
Qualitative fecal procedures  
Quantitative fecal procedures

## OUTLINE

Diagnosis of Parasites of the Digestive Tract  
*Collection of the Fecal Sample*  
*Examination of the Fecal Sample*  
*Concentration Methods for Fecal Examination*  
*Quantitative Fecal Examination*  
*Examination of Feces for Protozoa*  
*Fecal Culture*  
*Sample Collection at Necropsy*  
*Shipping Parasitologic Specimens*  
*Miscellaneous Procedures for Detection of Digestive Tract Parasites*  
*Blood in the Feces*  
*Gross Examination of Vomitus*  
*Microscopic Examination of Vomitus*  
Diagnosis of Parasites of the Blood and Blood Vascular System  
*Collection of Blood Samples*  
*Examination of Blood*

Diagnosis of Parasitism of the Respiratory System  
*Fecal Examination for Respiratory Parasites*  
*Examination of Sputum and Tracheal Washes*  
Diagnosis of Parasitism of the Urinary System  
*Collection of the Urine Sample*  
*Urine Examination for Parasites*  
Diagnosis of Parasitism of the Skin  
*Skin Scrapings*  
*Cellophane Tape Preparation*  
*Gross Specimens*  
Diagnosis of Parasitism of Miscellaneous Body Systems  
*Parasites of the Eye*  
*Parasites of the Ear*  
*Parasites of the Genital Tract*

## LEARNING OBJECTIVES

*After studying this chapter, the reader should be able to do the following:*

- Recognize the various types of diagnostic procedures that are used in a parasitology laboratory.
- Detail the types of parasites the various diagnostic procedures can be used to identify.
- Understand the importance of maintaining a well-managed, well-equipped diagnostic facility.
- Understand the importance of good parasitology practices in a diagnostic laboratory.

Modified Wisconsin technique  
McMaster technique  
Modified D'Antoni's iodine  
Fecal culture  
Sporulation  
Cellophane tape preparation  
Baermann technique  
Occult blood  
Direct smear  
Feathered edge thin blood smear  
Buffy coat preparation  
Modified Knott's technique  
Tracheal washes  
Urine sedimentation  
Skin scrapings  
Ear smear procedure  
Preputial washes

The term **parasite** represents many different types of organisms that live within or on animals, feeding on tissues or body fluids or competing directly for the animal's food. These parasites demonstrate an amazing variety in size and appearance. Although none of the bacteria or viruses is visible to the naked eye, parasites include organisms that range in size from those that must be observed with the most powerful microscopes up to organisms that measure more than a meter in length. Parasites also show great variety in the locations in which they live in animals and the ways in which they are transmitted from one animal to another. Because of the wide variations in sizes and life cycles, there is no one particular diagnostic procedure to identify all parasites.

This chapter describes many of the procedures that a veterinary diagnostician may perform to diagnose both internal and external parasites. Generally, these procedures are used to detect the presence of parasites or their offspring, their eggs or larval stages, on the skin or in the animal's excretions or blood. Additionally, serologic tests are being used more frequently in veterinary clinical practice. Many of the diagnostic procedures described in this chapter, however, are not in common use in most veterinary practices but are mentioned because they may be useful to technicians employed in diagnostic or research laboratories.



**TECHNICIAN'S NOTE** There are many procedures used to diagnose internal and external parasites. Some of these tests will not be seen in the clinic but will be of value to a technician working in a research lab or reference lab.

It is important to note that these tests are not by themselves totally reliable. Sometimes an animal may be infected with parasites, but because the infection is slight, no detectable stages can be observed. If the wrong test is used, no parasite will be detected. For this reason, veterinary practitioners use not only these tests but also the animal's history, clinical signs, and other laboratory tests, such as blood values, to arrive at a specific diagnosis of internal parasites.



**TECHNICIAN'S NOTE** The tests described may not identify parasites if the parasite burden is low, the female is not actively producing eggs, or there are no detectable stages that can be observed. Therefore, these tests should not be the only tests relied upon to make a diagnosis of parasites if the tests are negative.

## DIAGNOSIS OF PARASITES OF THE DIGESTIVE TRACT

The following procedures can be used as aids in diagnosis of parasitism of the esophagus, stomach, liver, bile ducts, and large and small intestines. They can also be used for diagnosis of parasitic infections in other parts of the body, when the eggs or the larval stages are passed by

way of the digestive tract (e.g., “coughed up and swallowed” eggs of lung parasites).

### Collection of the Fecal Sample

Veterinary diagnosticians usually do not have the opportunity to collect fecal samples and must rely on samples brought in by clients or samples collected during farm calls. Regardless of how the samples are obtained, it is important to have fresh feces for testing; this fact must be emphasized to clients. Feces collected from the yard, pen, or litter box may be old, and as a result, parasite eggs may have embryonated or larvated, oocysts may have sporulated, or pseudoparasites may be present. Some protozoans are recognized by their distinctive movements, and in old feces, these parasites may have died. The need for fresh feces stems from the rapid development and changes that occur in some common parasites’ eggs or larvae once they are passed from the animal. If fresh feces cannot be promptly submitted, clients should be advised to refrigerate the sample for no more than 24 hours.



**TECHNICIAN'S NOTE** Fecal samples should be fresh when used for parasite diagnosis. The feces should not be older than 24 hours and should be collected as fresh as possible and, if necessary, refrigerated to prevent eggs from larvating, oocysts from sporulating, or larva from changing.

Feces should be submitted in a sealed glass or plastic container, clearly marked with the time and date of collection, species of animal, animal's name, owner's name, and any other information relevant to the case. The condition of the stool should be noted for color, consistency, and presence of parasites. Adult nematodes or tapeworm segments observed by the client may be overlooked by the veterinary practitioner.

Clients are often confused about the amount of feces needed to perform a fecal examination. An excellent rule of thumb is that the amount of feces submitted should be approximately the size of an adult man's thumb.

### Small Animal Samples

For small animal samples, it is best that the client actually witness the animal defecating to be sure of the source of the sample and to note any straining, blood in the feces, or other problems. Again, all samples should be properly identified. In laboratories that process a large number of fecal samples, it is sometimes convenient to assign each sample an “accession number” to ensure that samples are processed in the order in which they are received and to aid in thorough recordkeeping.



**TECHNICIAN'S NOTE** The owner should be instructed to collect a fecal sample from an animal that he or she actually sees defecate to be sure of the source of the sample.


### Large Animal Samples

Large animal fecal samples should be collected directly from the animal's rectum, if possible. While wearing a disposable plastic glove, the veterinarian performing the rectal examination of cattle or horses can grasp a handful of feces and retrieve it from the rectum. These feces can then be placed in a sealed container and the container appropriately marked with the owner's name, animal's name or number, and date and time of collection.

The practice of turning the disposable palpation glove inside out while removing it and tying the open end with a knot, thus containing the feces, should be discouraged. These makeshift containers are difficult to label, and the process of removing collected feces from such a flexible container can be difficult and distasteful.

Samples from pigs, feedlot cattle, or other grouped animals are often “pooled” samples; that is, several fecal samples are collected from a pen without the specific animal of origin being known. Again, these samples should be as fresh as possible, and each sample should represent only one group of animals in direct contact with one another. Disposable, zipper-locking plastic bags make good containers for pooled, large animal fecal samples. These samples should be labeled with the owner's name, specific location


of the pen, number of animals, and date and time of collection. The basic rule of thumb is to always have clean containers that can be tightly sealed to prevent spillage or loss of samples. Any fecal sample that cannot be examined within an hour after collection should be refrigerated to slow down or stop the parasite's development and reduce unpleasant odors.

 **TECHNICIAN'S NOTE** Large animal samples should be taken fresh when the veterinarian is doing a rectal exam. In the case of group-housed animals, one "pooled" sample per group is used. All samples should be properly labeled to avoid confusing samples later.

### Examination of the Fecal Sample

Several procedures commonly used to examine feces for internal parasites are described in this section. Before attempting to apply these procedures, the following rules should be remembered:

- *Always handle fecal samples carefully.* Some parasites, bacteria, and viruses in animal feces are a threat to human health. When examining the samples, the diagnostician should always wear appropriate outer clothing (e.g., clean laboratory coat) and rubber or plastic gloves. If gloves are not available, hands should be washed thoroughly with a disinfectant soap when the diagnostic tests have been completed. Under no circumstances should food or drink be consumed or tobacco products used in the area where these tests are performed. Likewise, makeup or contact lenses should never be applied in the diagnostic laboratory.


 **TECHNICIAN'S NOTE** The technician should always wear latex or plastic gloves and proper outerwear when handling feces as some parasites are zoonotic and can even enter through the skin.

- *Always clean up immediately after the tests have been performed.* Leaving spilled fecal material

or dirty glassware or equipment lying about creates a source of contamination and could lead to serious infections in both animals and humans. The surface top of the area should be thoroughly cleaned with Roccal-D, Nolvasan solution<sup>1</sup> or other parasiticide cleaning solution.

- *Always keep good records.* A central record book should be kept in the laboratory area, and every sample should be listed by date, owner's name, and animal's name or number. Any observations about the appearance of the fecal sample, as well as any parasites found, should be written down immediately. If no parasites are recovered, that fact should be reported; otherwise it will appear that a particular diagnostic test has not been performed. In recording negative results, the phrase "No Parasites Observed" should be written in the results column. It is always important to transfer the results from the central record book to the animal's permanent veterinary medical record and to the clinic's central computer file.

The record book serves as a backup for veterinary medical records and provides a catalogue of parasites that are prevalent in the pet and livestock population of that geographic area. An accurate diagnosis of parasitism is based primarily on the diagnostician's awareness of parasites prevalent within the geographic region. Because twenty-first century humans are extremely mobile, however, the movement of pets and livestock to and from other geographic regions should also be considered when parasitism is suspected.

 **TECHNICIAN'S NOTE** Laboratory results should be recorded in a central laboratory result book and also recorded in the patient's medical record. The central result book is used as a backup to make sure tests are run. If results are not recorded in the central book or in the record, they did not happen.

<sup>1</sup>Roccal-D Manufactured by Pharmacia & Upjohn Company, Kalamazoo, MI; Nolvasan solution manufactured by Wyeth, Madison, NJ.



## Gross Examination of Feces

The following characteristics of feces should be recorded and relayed to the attending veterinarians:

- **Consistency.** The condition of the feces, that is, soft, watery (diarrheic), or very hard (constipation), should be noted. This description will vary with the animal species. For example, cattle feces are normally softer than those of horses or sheep.
- **Color.** Unusual fecal colors should always be reported. For example, light-gray feces may indicate excessive fat in the feces, a sign of poor intestinal absorption.
- **Blood.** In fresh feces, blood may appear dark brown to black and tarlike (a melanous stool) or demonstrate the red color associated with fresh blood. Blood may indicate severe parasitism, as well as other intestinal disease. It is important to record the presence of blood because this will assist the veterinary practitioner in identifying certain diseases.
- **Mucus.** Mucus on the surface of fresh feces may be associated with intestinal parasitism or some other metabolic disease.
- **Age of the feces.** If the feces appear old and dry, this should be noted. In aged samples, as noted earlier, parasite eggs may have embryonated or larvated, oocysts may have sporulated, or pseudoparasites may be present. Some protozoan parasites are recognized by their distinctive movements. In old feces, these parasites may have died.
- **Gross parasites.** Some parasites, portions of parasites, or larvae are large enough to observe with the naked eye. Probably the most common are the proglottids of tapeworms, entire roundworms, or even larval arthropods (horse bot fly larvae).




**TECHNICIAN'S NOTE** The physical appearance of the feces should be recorded in the central laboratory record book as well as on the animal's medical record (e.g., color, consistency, presence of blood, gross parasites seen, and presence of mucus).

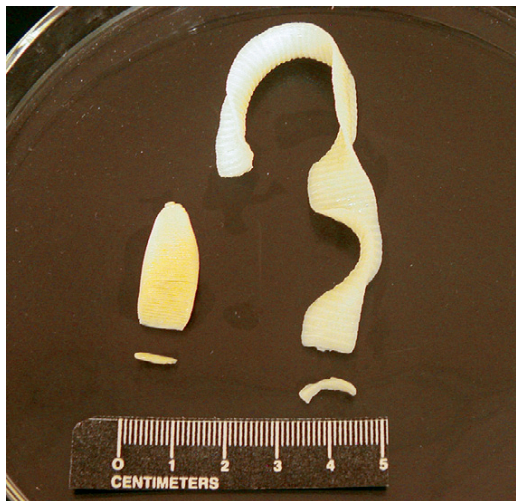Figure 17-1 shows tapeworm segments (**proglottids**) in fresh feces. These should be gently removed from the feces with thumb forceps and examined with a hand-held lens or dissecting microscope. Figure 17-2 shows segments of two common tapeworms (*Dipylidium caninum* and *Taenia pisiformis*) found in the feces of dogs and cats; their morphology, shape, size, and movement may aid in identification. Short segments of ruminant and equine tapeworms may also be recovered from feces (Figure 17-3). Of interest, swine in the United States do not demonstrate adult tapeworm segments in their feces.



**FIGURE 17-1:** Fresh dog feces containing tapeworm proglottids (segments). Proglottids may be motile and will exit from feces into surrounding environment.



**FIGURE 17-2:** Segments of two common tapeworms (*Dipylidium caninum* and *Taenia pisiformis*) found in feces of dogs and cats. Morphology, shape, size, and movement of these common small animal tapeworms may aid in identification.



**FIGURE 17-3:** Chains and individual mature proglottids of tapeworms of ruminants, *Moniezia* species (left), and horses, *Anoplocephala* species (right).

Occasionally, clients will bring in dried tapeworm segments that they have found in their pet's bedding or hair coat. For identification, these segments must be rehydrated by soaking for 1 to 4 hours in a Petri dish or small container of water or physiologic saline. These segments will resume their natural state and can then be identified by their morphologic features. Alternatively, they may be "teased" open in a small amount of water on a glass microscope slide. If they are **gravid** (egg-containing) proglottids, they may release their eggs and be easily identified.

The diagnostician should always attempt to identify the parasite in terms of genus and species so that the veterinarian can use this information in the control and treatment of the tapeworm infection. The morphology of the segment can assist in the identification of the tapeworms. For example, with *D. caninum*, the tapeworm of dogs and cats that is transmitted by fleas, the diagnostician can observe with a hand-held magnifying lens the "double-pored effect," the presence of a genital pore on both sides of every segment. Segments of tapeworms of the genus *Taenia*, which uses rodents and mammals as intermediate hosts, have a single pore on each segment.

These pores are irregularly alternating. Again, tapeworm segments can also be definitively identified by teasing them open and demonstrating the characteristic eggs they contain.

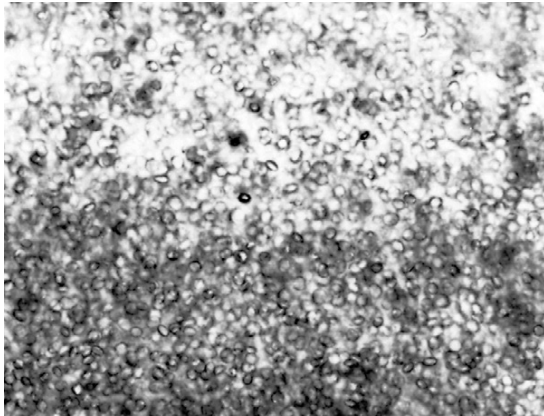


**TECHNICIAN'S NOTE** Parasites should be identified by genus and species when possible (as some medications will work for some types of parasites and not others, some types of parasites [tapeworms] have different intermediate hosts, etc.) so the veterinarian can use proper control and treatment measures.

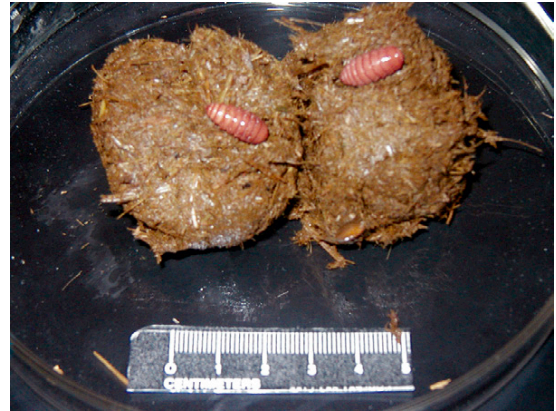Segments of some uncommon tapeworm species may be "spent" proglottids; that is, the proglottids have dispelled their eggs and the uteri are empty. If the diagnostician is confused as to whether these are tapeworms, the suspect material can be macerated between two microscope slides and examined microscopically to determine if the tissue has small mineral deposits (called **calcareous bodies**, or **calcareous corpuscles**) that are unique to tapeworms (Figure 17-4).

Other types of parasites are large enough to be observed in animal feces. These include adult worms expelled from their host by drug treatments or overcrowding by fellow parasites (Figure 17-5). Horse feces may contain **bots**, which are the larvae of a certain type of fly, *Gasterophilus* species. The larval flies are parasitic in the stomach of horses and are passed in the feces to complete their life cycle outside the body of the equine host (Figure 17-6).

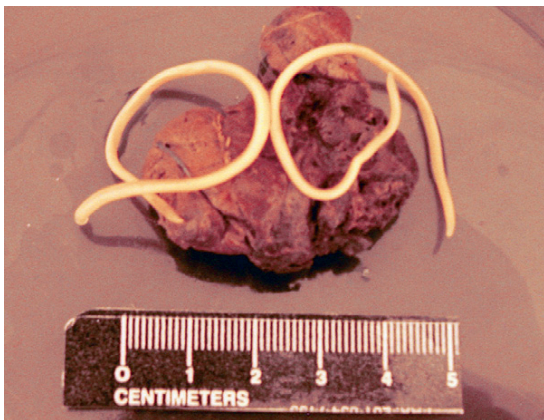
Aged feces may also contain nonparasitic fly larvae called **maggots** (Figure 17-7). The maggots do not live within the animal's intestines but instead develop from eggs laid by free-living adult flies after the feces have been passed. Flesh flies of the genus *Sarcophaga* deposit larvae (rather than eggs) on the feces of many domestic animals. Usually, fly maggots seen in feces voided more than 12 hours previously should not be mistaken for internal parasites; they should be considered **pseudoparasites**. There is



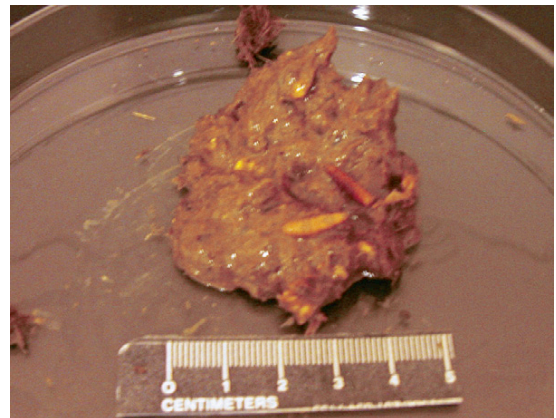
**FIGURE 17-4:** Microscopic calcium deposits (calcareous bodies, or calcareous corpuscles) are unique to tapeworm tissue. (140x magnification.)



**FIGURE 17-6:** Two larvae (bots) of bot flies (*Gasterophilus* spp.) in equine feces.



**FIGURE 17-5:** Two roundworms (*Toxocara canis*) in canine feces after treatment with a nematocide.



**FIGURE 17-7:** Free-living fly larvae (maggots) in 2-day-old bovine feces.

one exception to this rule: *Gasterophilus* species, or horse bot fly larvae, may be found in fresh horse feces.

**TECHNICIAN'S NOTE** Aged feces may contain pseudoparasites picked up from the environment or nonparasitic larvae from flies that have grown after defecation occurred.

In general, when the veterinary diagnostician cannot identify parasite-like material (whether parasite or pseudoparasite) found within feces,

the unidentified specimen should be sent to a diagnostic facility (a university or state diagnostic laboratory) for proper identification. These specimens should be preserved in 70% alcohol or 10% formalin and shipped as described later in this chapter. An up-to-date history should accompany each specimen.

### Microscopic Examination of Feces

Compound microscopes used in a veterinary diagnostic setting vary widely in features and in the magnifications they provide. For parasitologic diagnostic examinations, objective lenses with magnification powers of 4x, 10x, and 40x

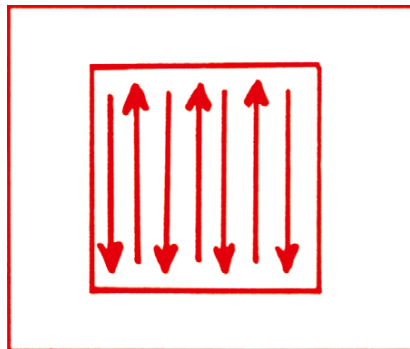


are most often used. Oil-immersion objectives (e.g., 100 $\times$  magnification) are occasionally used in veterinary practice, particularly in blood smear preparations. A mechanical stage is preferable and convenient for parasitologic work because it allows for smooth, uniform movement in a thorough search of the microscope slide. Regardless of how the slide is moved, the area under the coverslip must be thoroughly and uniformly searched (Figure 17-8).

**TECHNICIAN'S NOTE** Compound microscopes with 4 $\times$ , 10 $\times$ , and 40 $\times$  objectives are usually sufficient for proper identification of parasite larvae, eggs, and oocysts.

To search the slide thoroughly, the diagnostician must begin using an objective lens that magnifies at least 10 $\times$  and, with experience, should be able to scan the slides more rapidly at 4 $\times$ . The edge of the coverslip can be used for adjusting the coarse focus and any debris under the coverslip used for fine focus adjustment. Each circular area of the slide seen through the coverslip is called a **field**. The slide should be moved so that the field follows either of the patterns of arrows shown in Figure 17-8. Each time the edge of the coverslip is reached, a piece of debris or other object at the edge of the field (in the direction of the search) should be identified. The slide is then moved until the piece of debris or other object is at the edge of the field. In this manner, every field scanned slightly overlaps the previous field, and every area beneath the coverslip is examined. When the slide is being scanned in this manner, it is important to move the fine focus knob continually back and forth slightly to aid in visualization of parasite eggs or cysts not in a single plane of focus. When a parasite egg or cyst is observed at low magnification, higher-power objectives (10 $\times$  or 40 $\times$ ) may be used to more closely examine it.

**Calibrating the Microscope.** The size of various stages of many parasites is often important for correct identification. Some examples are eggs of *Trichuris vulpis* versus eggs of *Capillaria*



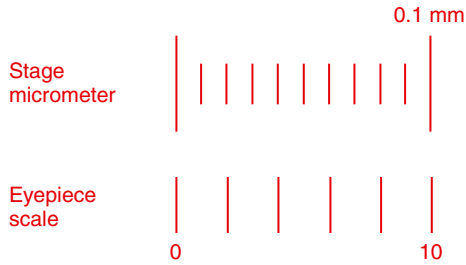
**FIGURE 17-8:** Pattern of movement of microscopic field for thorough examination of area under coverslip.

species and microfilariae of *Acanthocheilonema reconditum* versus microfilariae of *Dirofilaria immitis*. Accurate measurements are easily obtained by using a calibrated eyepiece on the microscope. Calibration must be performed on every microscope to be used in the laboratory. Each objective lens (4 $\times$ , 10 $\times$ , 40 $\times$ ) of the microscope must be individually calibrated.

**TECHNICIAN'S NOTE** Microscopes with calibrated eyepieces should be calibrated for each objective for accurately measuring parasite larvae, ova, or oocysts.

**Instruments.** The stage micrometer is a microscope slide etched with a 2-mm line marked in 0.01-mm (10- $\mu$ m) divisions (Figure 17-9). Note that 1 micron (micrometer,  $\mu$ m) equals 0.001 mm. Also note that the stage micrometer is used only once to calibrate the objectives of the microscope. Once the ocular micrometer within the compound microscope has been calibrated at 4 $\times$ , 10 $\times$ , and 40 $\times$ , it is calibrated for the service life of the microscope; the stage micrometer will never be used again. Therefore it is a good idea not to purchase a stage micrometer, but instead borrow one from a university or some other diagnostic laboratory and return it following calibration.<sup>2</sup>

<sup>2</sup>Item number 59-1430; Carolina Biological Supply Company, Burlington, NC.



**FIGURE 17-9:** Stage micrometer (upper scale) and eyepiece scale (lower scale) used to calibrate microscope.

The eyepiece scale (or ocular micrometer) is a glass disc that fits into and remains in one of the microscope eyepieces. The disc is etched with 30 hatch marks spaced at equal intervals (see Figure 17-9). The number of hatch marks on the disc may vary, but the calibration procedure does not change.<sup>3</sup>

The stage micrometer is used to determine the distance in microns between the hatch marks on the ocular micrometer for each objective lens of the microscope being calibrated. This information is recorded and firmly affixed to the base of the microscope for future reference.

**TECHNICIAN'S NOTE** The calibration is used to measure the hatch marks on the ocular micrometer in the eyepiece. This is done at each objective power, recorded and affixed to the microscope for future reference.

**Procedure.** Start at low power (10×) and focus on the 2-mm line of the stage micrometer. Note that 2 mm equals 2000 μm. Rotate the ocular micrometer within the eyepiece so that its hatch-mark scale is horizontal and parallel to the stage micrometer (see Figure 17-9). Align the 0 points on both scales.

Determine the point on the stage micrometer aligned with the 10 hatch mark on the ocular micrometer. In Figure 17-9, this point is at 0.1 mm on the stage micrometer.

Multiply this number by 100. In this example,  $0.1 \times 100 = 10 \mu\text{m}$ . This means that at this power (10×), the distance between each hatch mark on the ocular micrometer is 10 μm. Any object may be measured with the ocular micrometer scale, and that distance is measured by multiplying the number of ocular units by a factor of 10. For example, if an object is 10 ocular units long, its true length is 100 μm (10 ocular units  $\times$  10 μm = 100 μm).

This procedure should be repeated at each magnification (4× and 40×). For each magnification, this information is recorded and labeled on the base of the microscope for future reference.

#### **Objective Distance between Hatch Marks (Microns)**

- 4×—25 μm
- 10×—10 μm
- 40×—2.5 μm

#### **Direct Smear**

**TECHNICIAN'S NOTE** The simplest method of microscopic fecal examination for parasites is the direct smear.

The simplest method of microscopic fecal examination for parasites is the direct smear, which consists of a small amount of feces placed directly on the microscope slide (Box 17-1). The advantages of the direct smear are the short procedure time and minimal equipment needed. Some veterinary practitioners make direct smears with only the amount of feces that clings to a rectal thermometer after the animal's temperature has been recorded. The direct smear allows the diagnostician to observe eggs and larvae undistorted by the procedures discussed later.

**TECHNICIAN'S NOTE** The direct smear is a good diagnostic test for viewing the motile forms of protozoans that might be destroyed by other methods.

<sup>3</sup>Item number 59-1423 or 59-1425; Carolina Biological Supply Company, Burlington, NC.

A disadvantage to the direct smear technique is that the small amount of fecal material required



for this procedure is not a good representative sample size; this procedure can be inaccurate. Such a small quantity of feces may not contain the larvae or eggs of the adult parasite the animal is harboring. The animal may be incorrectly assumed to be free of parasites. This procedure also leaves much fecal debris on the slide that may be confusing to the veterinary diagnostician.

### Concentration Methods for Fecal Examination

The greatest disadvantage to the direct smear procedure is the small amount of feces used, which greatly reduces the chance of finding parasite eggs or larvae or protozoan cysts. To overcome this problem, methods have been developed to concentrate parasitic material from a larger fecal sample into a smaller volume, which may be examined microscopically. Two primary types of concentration methods are used in veterinary practice: fecal flotation and fecal sedimentation.



**TECHNICIAN'S NOTE** Fecal concentration methods are preferred for identifying parasite ova, larvae, and oocysts in the feces because larger volumes of feces are used making it more likely the developmental stages will be seen if present in the feces.

### Fecal Flotation

Fecal flotation procedures are based on differences in specific gravity of parasite eggs, cysts, and larvae and that of fecal debris. **Specific gravity** refers to the weight of an object (e.g., the parasite egg) compared with the weight of an equal volume of pure water. Most parasite eggs have a specific gravity between 1.1 and 1.2 (g/mL), whereas tap water is only slightly higher than 1 g/mL. Therefore, parasite eggs are too heavy to float in tap water. To make the eggs float, a liquid with a higher specific gravity than that of the eggs must be used. Such liquids are called **flotation solutions** and consist of concentrated sugar or various salts added to water to increase its specific

### BOX 17-1 Direct Fecal Smear Procedure

1. Place several drops of saline or fecal flotation solution on a slide with an equal amount of feces.
2. Mix the solution and feces together with a wooden applicator until the solution is homogenous.
3. Smear the solution over the slide into a thin film. The film should be thin enough to read print through.
4. Remove any large pieces of feces.
5. Place a coverslip over the smear.
6. Examine the area of the slide under the coverslip with the compound microscope (see text), and record any protozoan cysts, eggs, larvae, or gross parasites seen.

gravity. Flotation solutions usually have specific gravities between 1.2 and 1.25. In this range, fecal material, much of which has a specific gravity of 1.3 or greater, does not float (Figure 17-10). The result of using flotation solutions is that parasite eggs float to the surface of the liquid and large particles of fecal material sink to the bottom, making eggs easier to observe (Box 17-2).




**TECHNICIAN'S NOTE** Fecal flotation solutions with a specific gravity of 1.2 to 1.25 are used to "float" parasite ova, cysts, and larvae while the fecal material sinks to the bottom of the container.

If the specific gravity is below the desired range (1.2 to 1.25), add more reagent until the hydrometer indicates this range. If the specific gravity is above 1.25, add water until the proper reading is obtained.

Sugar (Sheather's solution), saturated sodium chloride (table salt), magnesium sulfate (Epsom salt), zinc sulfate, and sodium nitrate solutions are the flotation solutions most often used in veterinary practices. Veterinarians may select from among these solutions based on personal preference, availability of reagents, and target parasites.

**Sheather's solution** is less efficient than sodium nitrate solution because it floats fewer eggs and is messy to work with (it is quite sticky). Sugar, however, is readily available and inexpensive, does not distort roundworm eggs, and floats an adequate percentage of the eggs. **Sodium nitrate solution** is the most efficient flotation solution, but it forms crystals and distorts the eggs after a time. Sodium nitrate may be difficult to acquire, but it can be purchased through chemical supply houses. Sodium nitrate solution is used in commercial fecal diagnostic kits and may be purchased already prepared in the form of refill bottles for these kits. Sodium nitrate solution is more expensive than sugar solution.



**FIGURE 17-10:** Measuring specific gravity of flotation solution with hydrometer.

## BOX 17-2 Preparation of Flotation Solutions

### Sugar Flotation Solution (Sheather's Solution)

Determine the amount of sugar solution required, and use about half that amount of water. Use an appropriate-size pot (e.g., cooking pot). Heat the water, but be careful not to let it boil. Add granulated pure cane sugar (table sugar) to the water while stirring. About 454 g (1lb) are required for every 355 mL (12 oz) of water. Add 6 mL of 40% formaldehyde solution or 1 g of crystalline phenol for every 100 mL of solution; these chemicals serve as preservatives and prevent mold from growing in this sugar solution. The solution's specific gravity should always be checked with a hydrometer (see Figure 17-10), an instrument available from scientific supply houses.\*

### Sodium Nitrate Flotation Solution

Add about 315 g of sodium nitrate for every liter of water, while stirring. Heating is not necessary but hastens the dissolution process. Adjust the solution to a specific gravity of 1.2 to 1.25, as discussed for the sugar solution.

### Zinc Sulfate Flotation Solution

Add 386 g of zinc sulfate for every liter of water, while stirring. Heating the water is not necessary but hastens the dissolution process. Using a hydrometer, adjust the solution to a specific gravity of 1.2 to 1.25, as discussed for the sugar solution.

### Magnesium Sulfate Flotation Solution

Add about 350 g of magnesium sulfate (Epsom salt) for every liter of water, while stirring. Heating the water hastens the dissolution process. Using a hydrometer, adjust the solution to a specific gravity of 1.3, as discussed for the sugar solution.

### Saturated Sodium Chloride Flotation Solution

Add sodium chloride (table salt) to boiling water until the salt no longer dissolves and settles to the bottom of the pot. There is no need to adjust the specific gravity because it cannot go above 1.2 with this solution.

\*Scientific Products, McGraw Park, IL.

**Saturated sodium chloride solution** is the least desirable flotation solution. Its main disadvantages are that it corrodes expensive laboratory equipment, such as compound microscopes and centrifuges; forms crystals on the microscope slide; and severely distorts the eggs. Because it reaches a specific gravity of 1.2, some heavier eggs may not float in this solution. However, sodium chloride is inexpensive, easily prepared, and readily available.




**TECHNICIAN'S NOTE** The fecal solutions of choice are Sheather's sugar solution, sodium nitrate solution, and zinc sulfate solution; however, it will depend on the specific gravity of the solution as to how many different types of eggs, larvae, and cysts are able to be floated.

**Zinc sulfate solution** is similar in efficiency to sugar solution and can be purchased through chemical supply houses or from veterinary suppliers in ready-to-mix gallon containers. Cystic stages of intestinal protozoans such as *Giardia* are best concentrated with zinc sulfate solution. **Magnesium sulfate solution** (Epsom salt) also forms crystals on the microscope slide. It is an inexpensive solution and is easily prepared and readily available.

**Simple Flotation.** The simple flotation method is probably the second most common parasitologic test performed in veterinary practices, after the direct smear (Box 17-3). A specimen of 2 to 5 g of feces is placed in a suitable container, such as a paper cup. Flotation solution is added directly to the feces, mixed thoroughly with a tongue depressor, and strained through a metal tea strainer (or cheesecloth) into a second paper cup. The contents of the second paper cup are poured into a test tube, and the flotation medium is added until a meniscus is formed (Figure 17-11). A glass coverslip is placed over the meniscus and allowed to remain for 10 to 15 minutes (depending on the flotation medium used), after which the coverslip is removed and placed on a glass microscope slide. The parasite eggs are lighter than the solution

### BOX 17-3 Simple Flotation Procedure

1. Place about 2 g ( $\frac{1}{2}$  tsp) of the fecal sample in a 90- to 150-ml waxed paper cup. Add approximately 30 mL of flotation medium. Using a tongue depressor, make an emulsion by thoroughly mixing the solution with the feces until a fecal slurry has been made.
2. Bend the side of the wax paper cup into a spout, and cover the spout with a piece of cheesecloth. Pour the emulsion through the cheesecloth into a straight-sided shell vial. A tea strainer may be used rather than cheesecloth, pouring the contents of the cup through the strainer into a second wax paper cup, and the contents of that cup into the shell vial. Wash the tea strainer thoroughly in hot, soapy water before using it again.
3. Fill the shell vial to the top and slightly overfill it so that a meniscus forms above the lip of the vial (see Figure 17-11). If there is not enough fluid in the cup to fill the shell vial, a small amount of fresh flotation medium may be added. Place a glass coverslip gently on top of the fluid, and allow it to settle on the meniscus.
4. Allow the coverslip to remain undisturbed on top of the vial for 10 to 20 minutes (sugar solution requires longer than sodium nitrate). If removed before this time, all the eggs may not have had time to float to the top. If left for more than 1 hour, some eggs may become waterlogged and begin to sink or become distorted.
5. Remove the coverslip carefully, picking it straight up, and immediately place it on the microscope slide. When placing the coverslip on the slide, be sure to hold the coverslip with one edge tilted slightly up, and allow it to gradually settle level on the slide. This reduces the number of air bubbles beneath the coverslip.
6. Examine the area of the slide under the coverslip with the compound microscope (see text), and record any protozoan cysts, eggs, larvae, or gross parasites seen.



**FIGURE 17-11:** Shell vial filled with flotation medium, showing meniscus (arrow).

and float to the top of the tube (or vial) of flotation solution. The coverslip is removed from the liquid and examined with a microscope. This method is less efficient than the centrifugal flotations described next, but it does not require a centrifuge.

Some veterinary diagnostics companies have packaged simple flotation kits consisting of prepared flotation solution, disposable plastic vials, and strainers; examples include the Ovassay, Fecalyzer, and Ovatector (Figure 17-12).<sup>4</sup> Instructions for use are included with these kits. The main disadvantages to these kits are the expense and the environmental contamination by the disposal of plastics.

**Centrifugal Flotation.** The centrifugal flotation procedure more efficiently recovers parasite eggs and cysts and requires less time than the simple flotation procedure (Box 17-4 and Figure 17-13). However, it does require a centrifuge capable of holding 15-mL test tubes and producing a centrifugal force of 400× to 650× g. Most tabletop centrifuges are capable of producing this force. Centrifuges with a fixed-angle head piece are not suitable for such centrifugal flotation procedures.

<sup>4</sup>Ovassay manufactured by Synbiotics Corp., San Diego, CA; Fecalyzer manufactured by EVSCO Pharmaceuticals, Buena, NJ; Ovatector manufactured by BGS Medical Products, Inc., Venice, FL.

**TECHNICIAN'S NOTE** Fecal centrifugation is the method of choice for fecal flotation testing as it has been shown, in multiple studies, to float a higher concentration of ova, cysts, and larvae than simple fecal flotation.

### Fecal Sedimentation

Sedimentation procedures concentrate both feces and eggs at the bottom of a liquid medium, usually water (Box 17-5). Sedimentation detects most parasite eggs but is not as good as flotation for providing a clear sample for microscopic examination. Sedimentation is primarily used to detect eggs or cysts that have too high a specific gravity to float or that would be severely distorted by flotation solution.

Sedimentation can be used for roundworm and tapeworm eggs, but there is usually too much fecal debris hiding the eggs to make it worthwhile. Therefore, this procedure is not used routinely and has its greatest use in suspected trematode (flake) infections. Flake eggs are somewhat denser and sometimes larger than roundworm eggs. Some fluke eggs float in flotation solutions, and others do not. Some laboratories increase the specific gravity of their flotation solutions to 1.3 to ensure recovery of fluke eggs by the flotation technique. The problem with use of flotation methods for recovery of fluke eggs is that the eggs may be damaged by the high concentration of the solution and may become difficult to identify.

**TECHNICIAN'S NOTE** Fecal sedimentation is rarely used for routine fecal analysis. It is more commonly used to test for trematode eggs, which are heavier than other parasite eggs and thus do not float as well.

### Quantitative Fecal Examination

All the procedures previously described are **qualitative**, which means they reveal the presence or absence of parasite ova or cysts. **Quantitative**





**FIGURE 17-12:** Three commercially available fecal flotation kits: Fecalyzer (*left*), Ovassay (*center*), and Ovatector (*right*). These kits are based on the principles of the simple flotation procedure.

### BOX 17-4 Centrifugal Flotation Procedure

1. Using a paper cup and tongue depressor, mix approximately 1 tsp of feces with enough water to make a semisolid suspension.
2. Place a wire tea strainer (or piece of cheesecloth) over a second paper cup and empty the fecal suspension into it. Use the tongue depressor to press out most of the liquid; return the solid waste to the first cup and discard. Wash the strainer in hot running water; soak it in water containing dishwashing solution.
3. Pinch the rim of the second paper cup to form a pouring spout, and transfer the contents into a 15-mL centrifuge tube (a test tube). Place the tube into the centrifuge, remembering to counterbalance the tube with an identical tube filled to the same level with water. Be sure that all tubes are marked so they can be identified after centrifugation.
4. Centrifuge for 3 minutes at 400x to 650x g. For many centrifuges, this is about 1500 revolutions per minute (rpm). Decant the supernatant, which contains fats and dissolved pigments that interfere with the identification of parasite eggs, larvae, or cysts.
5. Add concentrated flotation solution to within  $\frac{1}{2}$  to  $\frac{3}{4}$  inch of the top of the tube, and resuspend the sediment using a stirring action with a wooden applicator stick. Insert a rubber stopper and mix by four or more inversions so that the solution is thoroughly mixed with the sediment.

#### Variation A


Return the tube to the centrifuge, remembering to counterbalance the tube with an identical tube filled to the same level with the same flotation solution. Centrifuge for 5 minutes. Without removing the tube from the centrifuge, pick up the surface film containing eggs, larvae, or cysts by touching the surface gently with a wire loop (bent at a 90-degree angle) (see Figure 17-13) or a glass rod. Transfer the surface film to a glass microscope slide and add a coverslip. Examine under the compound microscope using the 10x objective (see text).

#### Variation B

Return the tube to the centrifuge and fill the centrifuge tube with the flotation solution until a meniscus is formed. Apply a coverslip to the top of the tube. Remember to counterbalance the tube with an identical tube filled to the same level with the same flotation solution and covered with a coverslip. Centrifuge for 5 minutes. After centrifugation, lift the coverslip straight up and place it on the glass slide. This modification will work only if a variable-angle (not a fixed-angle) centrifuge is used. Examine under the compound microscope, using the 10x objective (see text).



procedures indicate the number of eggs or cysts present in each gram (g) of feces. The results of these procedures are a rough, or approximate, indication of the number of adult parasites present within the host (the severity of the infection).



**FIGURE 17-13:** Use of bacteriologic loop to transfer drop from top of fecal flotation emulsion after centrifugation procedure. Note that loop is bent at 90-degree angle to wire handle.

These procedures are not completely accurate, because different species of parasites produce different numbers of eggs. Also, the most severe signs of disease are produced by parasites that have not yet started to produce eggs or larvae.



**TECHNICIAN'S NOTE** Qualitative procedures will tell you whether parasite ova or cysts are present in the fecal sample while quantitative procedures will provide the number of ova or cysts in one gram of feces.

Several procedures are used to estimate the numbers of parasite eggs or cysts per gram of feces, including the Stoll egg-counting technique, the modified Wisconsin sugar flotation method, and the McMaster technique. These techniques are used most often in research laboratories and are not usually performed in veterinary clinical practice. Of these tests, the modified Wisconsin sugar flotation method is used most often (Box 17-6).

### BOX 17-5 Sedimentation Procedure

1. Using a tongue depressor, mix about 2 g of feces with tap water in a cup or beaker. Strain the mixture through cheesecloth or a tea strainer into a centrifuge tube, as described for centrifugal flotation.
2. Balance the centrifuge tubes and centrifuge the sample at about 400x g (about 1500 rpm). If a centrifuge is unavailable, allow the mixture to sit undisturbed for 20 to 30 minutes.
3. Pour off the liquid in the top of the tube without disturbing the sediment at the bottom.
4. Using the pipette and bulb, transfer a small amount of the top layer of sediment to a microscope slide. If the drop is too thick, dilute it with a drop of water. Lugol's iodine solution (diluted 1:5 in water) may be used for dilution instead of water to aid in identification of protozoan cysts. Apply a coverslip to the drop. Repeat the procedure using a drop from the bottom layer of the sediment.
5. Examine both slides microscopically (see text).



**TECHNICIAN'S NOTE** Quantitative procedures are used more often in research facilities than in the veterinary clinic.

### Examination of Feces for Protozoa

All the procedures for microscopic fecal examination are useful for detection of cysts of intestinal protozoa. However, some protozoa do not form cysts and will be passed in the feces as **trophozoites** (motile forms). Cyst-forming protozoa may also pass trophozoites in the feces in large numbers when the host has diarrhea. Trophozoites lack the rigid wall of cysts, and they collapse and become difficult to recognize in flotation solutions.

To observe live trophozoites, a fecal smear should be prepared as previously described, but physiologic saline must be used to dilute the feces. Trophozoites are recognized by their movement, which varies among the different

### BOX 17-6 Modified Wisconsin Sugar Flotation Method

1. Fill a 20-mm × 150-mm test tube with Sheather's solution 1 inch below the top of the tube.
2. Using scales, weigh exactly 3 g of the fecal sample into a paper cup.
3. Pour the Sheather's solution from the test tube into the paper cup containing the feces and mix well.
4. Place a tea strainer in a second paper cup and pour the Sheather's solution and feces mixture through the strainer. Using a tongue depressor, press all the liquid out of the fecal pat and through the tea strainer.
5. Return the Sheather's solution and strained feces mixture to the test tube originally containing the Sheather's solution and place in a test tube rack.
6. Add Sheather's solution to the test tube until a small meniscus forms. Carefully place a glass coverslip on top of the meniscus.
7. Allow the test tube with its coverslip to stand undisturbed for 4 hours.
8. Remove the coverslip, place it on a glass microscope slide, and examine the entire coverslip on low power (10×), counting parasite eggs, cysts, or oocysts. This count represents the number of eggs, cysts, or oocysts per 3 g of feces.

groups of protozoa. *Balantidium coli*, a parasite of humans, pigs, and dogs, moves in a slow, tumbling manner. *Giardia* species, which are found in several species of animals, swim in a jerky motion. Trichomonads, also found in several different types of hosts, appear to wobble and have a sail-like, undulating membrane that ripples as they swim. Amoebae, found in humans and dogs, move by extending part of their cell body (the pseudopod) and moving the rest of the body after it.



**TECHNICIAN'S NOTE** *Giardia* trophozoites swim in a jerky motion in a fecal smear.

### BOX 17-7 Preparation of Modified D'Antoni's Iodine Solution

1. Before preparing this solution, the technician should remove all jewelry because this iodine solution can permanently stain precious metals.  
Distilled water, 100 mL  
Potassium iodide (KI), 1 g  
Powdered iodine crystals, 1.5 g
2. The potassium iodide solution should be saturated with iodine, with some excess remaining in the bottle. It should be stored in brown, glass-stoppered bottles and kept in the dark. The solution is ready for use immediately and should be decanted into a brown, glass dropping bottle. When the solution lightens, it should be discarded and replaced with fresh stock. The stock solution is good as long as an excess of iodine remains in the bottom of the bottle.
3. When using this solution in the laboratory around the compound microscope, the technician should take great care not to spill the solution onto the metal parts of the microscope because it is extremely corrosive.

Many methods have been used to stain and preserve intestinal protozoa. The simplest method to stain cysts is a direct smear stained with an iodine solution (as described under the direct smear procedure). This method does not preserve the sample but highlights any protozoa in the smear, facilitating identification. Several iodine solutions are available for staining. Modified D'Antoni's iodine or Lugol's iodine is often used in diagnostic laboratories to stain protozoan cysts (Box 17-7).



**TECHNICIAN'S NOTE** Modified D'Antoni's iodine or Lugol's iodine can be used to stain protozoan cysts on a direct smear.

Fecal smears containing protozoal trophozoites may be allowed to dry and then are stained

with Giemsa, Wright's, or Diff-Quik stain.<sup>5</sup> Once stained in this manner, the slides may be sent to a diagnostic laboratory for identification of the organism.

Other procedures for the concentration, staining, and preservation of intestinal protozoa include merthiolate-iodine-formaldehyde (MIF) solution, polyvinyl alcohol, and iron hematoxylin. These staining procedures are generally too complex and time-consuming for use in veterinary practice.

### Fecal Culture

Fecal culture is used in diagnostic parasitology to differentiate parasites whose eggs and cysts cannot be distinguished by examination of a fresh fecal sample. For example, the eggs of large strongyles in horses are very similar to those of small strongyles. To distinguish between them, feces containing strongyle eggs are allowed to incubate at room temperature for several days while the larvae hatch from the eggs. The newly hatched larvae can then be identified.

### Nematode (Roundworm) Eggs

The procedure for culture of nematode (roundworm) eggs in feces is simple; however, identifying the larvae once they are recovered is much more tedious (Box 17-8). Diagnosticians required to culture and identify nematode larvae are referred to state or private diagnostic laboratories.



**TECHNICIAN'S NOTE** Culture and identification of nematode larvae is often referred to state or private diagnostic laboratories.

### Coccidial Oocysts

Another type of fecal culture that has some use in veterinary practices is sporulation of coccidial oocysts (Box 17-9). **Sporulation** is a process of development that takes place within the oocyst. In fresh feces, oocysts of various species

### BOX 17-8 Fecal Culture of Roundworm Eggs

1. Place 20 to 30 g of fresh fecal sample in a jar. Break up the feces with a tongue depressor and moisten slightly with tap water. The mixture should not be so wet as to appear soupy.
2. Place the jar on a shelf, away from direct sunlight, and allow it to incubate at room temperature for 7 days. There should be enough moisture so that droplets of condensed water can be seen on the sides of the glass jar. If moisture does not form, add a few drops of water.
3. Some species of nematode larvae can migrate up the walls of the jar. These may be recovered by removing condensation drops from the glass with an artist's paintbrush and transferring them to a drop of water on a microscope slide. Other species must be recovered with the Baermann technique (see p. 333).
4. Apply a coverslip to the slide (a drop of modified D'Antoni's iodine may be added) and pass it over the open flame of a Bunsen burner once or twice to kill the larvae while they are in an extended position. Place the slide on the microscope slide stage and identify the larvae.

### BOX 17-9 Fecal Culture of Coccidial Oocysts

1. When coccidial oocysts are found in a fresh fecal sample, place 10 to 20 g of the sample in a beaker or a paper cup and cover with about 60 mL of 2.5% potassium dichromate solution. Mix this solution thoroughly with a tongue depressor.
2. Pour into a Petri dish and let incubate at room temperature for 3 to 5 days. Open the plate daily and swirl the contents gently to allow air to reach the developing oocysts.
3. After incubation, centrifuge the plate's contents as described under the sedimentation procedure (see p. 327).
4. Process the fecal sediment by the centrifugal flotation procedure to recover the oocysts, then examine microscopically.

<sup>5</sup>Diff-Quik, product number B4132-1; Baxter Diagnostics, Scientific Products Division, McGaw Park, IL.

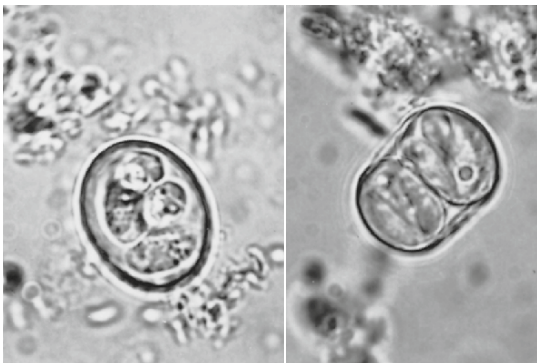
of coccidia may appear similar to one another; however, once sporulation occurs, coccidia of the genus *Eimeria* can be easily distinguished from those of the genus *Cystoisospora*. A fully sporulated oocyst of the genus *Eimeria* contains four sporocysts, whereas a fully sporulated oocyst of the genus *Cystoisospora* has two sporocysts (Figure 17-14).

**TECHNICIAN'S NOTE** *Cystoisospora* species have two sporocysts when sporulated while *Eimeria* species have four sporocysts.

### Sample Collection at Necropsy

**Necropsy**, or postmortem examination, is an important method for diagnosing parasitism of the digestive tract. Lesions of internal organs are often fairly indicative of the type of parasites that produce them. The veterinary technician is responsible for assisting during necropsy procedures and, in particular, helping with the preservation and processing of the samples collected. During necropsy and the processing of samples, all workers should wear gloves.

**TECHNICIAN'S NOTE** Technicians are usually responsible for assisting with necropsy examinations and all participants should wear gloves.



**FIGURE 17-14:** Fully sporulated oocysts of *Eimeria* species (left) and *Cystoisospora* species (right). (1400x.)

The contents of the digestive system may contain many types of parasites, some of which may be nematodes (roundworms). Trematodes (flukes) and cestodes (tapeworms) are easily seen and can be individually isolated. The two preferred methods for recovering roundworms are the decanting method (Box 17-10) and the sieving method (Box 17-11). With either method, the contents of the different parts of the digestive tract should be separated into individual containers.

It is not always necessary to examine all sediment or sievings. An estimate of the number of worms may be obtained by counting an **aliquot**

#### BOX 17-10 Decanting Method for Sample Collection at Necropsy

1. Using wrapping twine, tie off each portion of the digestive tract, that is, stomach, duodenum, small intestine, large intestine, and so on. Open each individual organ and pour its contents into a bucket marked with the animal's identification and the organ being examined. Scrape the interior lining of the organ with a spatula or blunt edge of a pair of scissors, and add the scraping into the bucket.
2. Add an equal volume of water to the contents in each labeled bucket and mix thoroughly with a stirring spoon or paddle.
3. Allow the heavier part of the contents to settle to the bottom of the bucket. This usually takes about 45 minutes. Carefully pour off the liquid on top, leaving the sediment.
4. Add an equal volume of water to the sediment and stir again. Allow this to resettle. Repeat this process until the water over the sediment becomes clear.
5. Pour off the clear water over the sediment, then transfer the sediment to the dissection pan.
6. Using the dissecting microscope, examine a small amount of the sediment at a time. Any parasite found should be gently removed from the sediment with thumb forceps and preserved (see text). Each parasite should be identified using a compound microscope.

(a known percentage of the total volume) of the sediment.

When parasites are recovered from the digestive tract or other parts of the body, it may be necessary to preserve them for identification later. **Nematodes** (roundworms) should be briefly washed in water to remove any attached debris and then placed in hot 70% ethyl alcohol (ethanol). Isopropyl alcohol may be used but is not preferred. The alcohol is allowed to cool, after which the worms are examined. The worms may be stored in the alcohol after adding glycerine to make a 5% concentration. **Cestodes** (tapeworms), including the scolices (heads), should be placed in water at about 37° C (98.6° F) for about 1 hour and then stored in a mixture of 5% glycerine or 70% alcohol or 5 to 10% formalin. **Trematodes** (flukes) may be preserved in

the same manner as tapeworms. If tapeworms and flukes are to be stained later, they should be “relaxed” in alternate changes of ice water and tap water for about 3 hours and then lightly pressed between sheets of glass immersed in 10% formalin.



**TECHNICIAN'S NOTE** Parasites may be preserved and stored for future analysis.

The preservation technique will depend on the type of parasite. Nematodes are preserved differently than cestodes or trematodes.

### BOX 17-11 Sieving Method for Sample Collection at Necropsy

1. Using wrapping twine, tie off each portion of the digestive tract, that is, stomach, duodenum, small intestine, large intestine, and so on. Open each individual organ and pour its contents into a bucket marked with the animal's identification and the organ being examined. Scrape the interior lining of the organ with a spatula or blunt edge of a pair of scissors, and add the scraping into the bucket.
2. Add an equal volume of water to the contents in each labeled bucket and mix thoroughly with a stirring spoon or paddle.
3. Pour the mixture through a 1-mm mesh (no. 18) sieve and then through a 0.354-mm mesh (no. 45) sieve. \* Reverse wash the sieves' contents with water.
4. Using the dissecting microscope, examine a small amount of the sieve contents at a time. Any parasite found should be gently removed from the contents with thumb forceps and preserved (see text). Each parasite should be identified using a compound microscope.

\*Sieves available from Fisher Scientific, Pittsburgh, PA.

Sometimes during necropsy of domestic animals, **cysticerci**, or bladder worms, may be seen in the abdomen, muscles, or other internal organs. These are the larval stages of certain species of tapeworms and appear as fluid-filled, balloonlike structures that vary from the size of a pea to the size of a basketball, depending on the species of tapeworm. Caution should be used in handling these parasites because the fluid inside could produce allergic reactions.

Also during necropsy of large animals, long filarial parasites of the genus *Setaria* may be observed in the abdominal cavity. These should be recorded and saved as part of the tissues collected and parasites recovered from the animal.

Government or private diagnostic laboratories are useful in assisting with identification when questions arise, but they must be supplied with well-preserved specimens and adequate histories from the animals on which the necropsies were performed.

Many diagnostic laboratories have the capability of identifying both protozoan and metazoan parasites in histopathologic section. Again, the laboratories must be provided with well-preserved tissue samples and adequate histories from the animals. These procedures are beyond the scope of this textbook; however, the diagnostician must remember that even tiny cross sections or longitudinal sections of parasites in histopathologic section may be used to diagnose both infections and infestations of all types of parasites.



## Shipping Parasitologic Specimens

Any parasitologic specimen shipped to a diagnostic laboratory by the United States Postal Service or other private carrier should be in a preservative, such as 70% ethyl alcohol or 10% formalin, to render it noninfectious. Specimen jars must be sealed well so that they do not leak, and a suitable packing material, such as Styrofoam “peanuts,” added to cushion the contents from any rigorous handling during the shipping process. During the summer months or during any hot spell, cool packs should accompany any specimen.

**TECHNICIAN'S NOTE** Parasitologic samples sent through the US Postal Service or other private carriers should be preserved in 70% ethyl alcohol or 10% formalin and properly packaged so the contents do not leak.

Fecal materials should be mixed with 10% formalin at a ratio of 1 volume of feces to 3 volumes of formalin and placed in a screw-cap vial of 20- to 30-mL capacity. The vials should be sealed with tape and labeled with the practitioner's name, the client's name, and the species of animal and its name or number, gender, and age. The relevant clinical history or diagnostic questions should also accompany the specimen. It is always wise to place any pertinent papers detailing the case history in a separate plastic bag in case leakage occurs during the shipping process. Parasite specimens preserved in alcohol or formalin should be shipped in similar vials. The vials should be wrapped in absorbent material, such as soft tissue or paper towels, and placed in a Styrofoam mailing container or heavy cardboard mailing tubes. To ensure the greatest care during shipping, specimens should be checked in at a postal window in a post office with instructions on the package requesting that postal workers “hand cancel” and “handle with care.” For either private or postal carriers, it is important to consult with them regarding proper rules and regulations.

**TECHNICIAN'S NOTE** All fecal samples or parasite samples being sent to reference laboratories should be labeled with practitioner's name, client's name, animal name or number, gender, age, and species with as much history as possible for accurate analysis.

## Miscellaneous Procedures for Detection of Digestive Tract Parasites

### Cellophane Tape Preparation

The cellophane tape preparation is used to detect the eggs of **pinworms** (Box 17-12). Female pinworms are nematodes (roundworms) that protrude from the anus and deposit their eggs on the skin around the anus. Pinworm eggs usually are not seen in routine fecal examinations. Of the major domesticated species, only horses are infected by pinworms (*Oxyuris equi*). Of animals used in laboratory research, primates, rodents, and rabbits serve as hosts for pinworms. It is important to remember that dogs and cats are never hosts for pinworms. Pinworms are parasites of herbivores (horses and rabbits) and omnivores (rodents,

### BOX 17-12 Cellophane Tape Presentation for Detection of Pinworms in the Horse

1. Place transparent cellophane tape in a loop, adhesive (sticky) side out, on one end of a tongue depressor.
2. Stand to the side of the horse's hindquarters and raise the tail with one hand while using the other hand to press the tape on the tongue depressor firmly against the skin immediately around the anus.
3. Place a small drop of water on the slide, allowing the water to spread out under the tape.
4. Using a compound microscope, examine the tape for the presence of asymmetric pinworm eggs.

primates, and humans) but never parasites of carnivores (dogs and cats).



**TECHNICIAN'S NOTE** The cellophane tape preparation is used to detect the eggs of pinworms and a number of ectoparasites. Remember that pinworms are parasites of herbivores but never carnivores.

### Baermann Technique

The Baermann technique is used to recover the larvae of roundworms from feces, soil, or animal tissues (Box 17-13). This method takes advantage of the fact that warm water stimulates nematode larvae in a sample to move about. Once the larvae move out of the sample, they relax in the water and sink to the bottom of the container. A Baermann apparatus may be easily constructed to perform this function (Figure 17-15). The Baermann apparatus consists of a ring stand and a ring supporting a large glass funnel. The funnel's stem is connected by a piece of rubber tubing to a tapered tube (a cut of Pasteur pipette). The rubber tubing is clamped shut with a pinch clamp.

#### BOX 17-13 Baermann Technique


1. Spread a piece of cheesecloth or a gauze square out on the support screen in the Baermann apparatus. Place 5 to 15 g of the fecal, soil, or tissue sample on the cheesecloth. Fold any excess cheesecloth over the top of the sample. Be sure that the sample is covered by the warm water or physiologic saline; add more if necessary.
2. Allow the apparatus to remain undisturbed overnight.
3. Hold a glass microscope slide under the cut-off pipette, and open the pinch clamp long enough to allow a large drop of fluid to fall on the slide. Apply a coverslip to the slide and examine it microscopically for the presence of larvae. Repeat by examining several slides before deciding that the sample is negative.

A piece of metal screen is placed in the funnel to serve as a support for the sample. The funnel is then filled with water or physiologic saline at about 30° C (86° F) to a level 1 to 3 cm above the sample. Innovative alternative designs of this apparatus can be devised from similar materials, provided the same features are preserved.



**TECHNICIAN'S NOTE** If a Baermann apparatus is needed in the clinic but the proper materials are not immediately available, a 60 cc syringe, gauze, short length of IV tubing and a 3-way stopcock can be used as a substitute when necessary; however, the proper apparatus is recommended for routine use of the Baermann technique.

Larvae recovered from fresh ruminant and equine feces are almost always lungworms. Larvae of *Strongyloides stercoralis*, the intestinal



**FIGURE 17-15:** Baermann apparatus is used to recover larvae of roundworms from feces, soil, or animal tissues. This apparatus is most useful in recovering larvae of lungworms.

threadworm, also may be recovered from canine feces. Larvae of *Aelurostrongylus abstrusus* may be found in feline feces. Both larvae and adults of *Ollulanus tricuspis* may be found in feline vomitus.

### Blood in the Feces

Some parasitic infections of the digestive tract cause extensive damage to the intestinal lining, resulting in bleeding. This blood may be visible in the fecal sample or may be present in such small quantities that it is only detectable by means of a chemical test. Blood present in such small amounts is termed **occult blood**. Numerous tests are available for the detection of blood in the feces. The simpler tests are based on detection of enzymelike activity of the red blood cell component, hemoglobin.<sup>6</sup>

These tests are easily performed by following the directions provided by the manufacturer. Blood is detected through an obvious color change. False-positive results may be obtained in fecal samples from animals on a meat diet, so dogs or cats to be tested should be maintained on a meat-free diet for 24 to 48 hours before testing. The presence of fecal blood may be the result of a condition other than parasitic infection, such as gastrointestinal ulcers, other infectious agents, or neoplasms.



**TECHNICIAN'S NOTE** When testing dogs or cats for occult blood in the stool, the patient should be fed a meat-free diet for 24 to 48 hours prior to collection of the stool sample.

### Gross Examination of Vomitus

Vomitus (the product of vomiting) may be grossly examined for adult parasites. These parasites are usually roundworms, which may be particularly common in the vomitus of puppies or kittens. In these young animals, infections with *Toxocara* species or *Toxascaris leonina* may be

extensive. Some of the adult worms are expelled by vomiting.

### Microscopic Examination of Vomitus

The microscopic examination of vomitus may reveal the presence of parasites of the stomach of dogs and cats. Parasites of the stomach may cause an inflammation of the stomach lining, producing a condition known as **gastritis**. One of the signs of this inflammation is chronic vomiting. *Physaloptera* species, a nematode that attaches to the lining of the stomach of both dogs and cats, is a voracious blood-feeder. A standard flotation procedure performed on the vomitus (as with feces) may reveal the presence of oval, thick-walled, larvated eggs. *Ollulanus tricuspis*, a tiny nematode found in the stomach of cats, produces chronic vomiting. Likewise, a standard flotation procedure performed on the cat's vomitus (as with feces) may reveal the presence of adult parasites and third-stage larvae of *O. tricuspis*. When confronted with chronic vomiting in a dog or cat, practitioners often overlook this important diagnostic procedure.

## DIAGNOSIS OF PARASITES OF THE BLOOD AND BLOOD VASCULAR SYSTEM

*Dirofilaria immitis*, the canine heartworm, is the most important parasite of the vascular system of domestic animals in North America. For this reason, most of the blood examinations for parasites in veterinary practices are aimed specifically at heartworm identification, although other blood parasites occasionally may be diagnosed in the United States. This section describes general tests that may be used to detect some blood parasites, as well as some specific tests for *D. immitis*.



**TECHNICIAN'S NOTE** *Dirofilaria immitis* is the most important blood parasite in North America although other blood parasites may occasionally be diagnosed in the United States.


<sup>6</sup>Hematest reagent tablets, Ames Division, Miles Laboratories, Elkhart, IN.

## Collection of Blood Samples

Any collection of blood from an animal should be performed **aseptically**. This includes swabbing the skin over the vein with isopropyl alcohol and using a sterile needle.

Blood may be drawn with a standard needle and syringe or a vacuum collection tube (e.g., Vacutainer, Becton Dickinson, Rutherford, NJ). No anticoagulant is required if the blood is to be used immediately for tests, such as the direct smear or filter test, or if it is to be allowed to clot so that serum may be obtained. If the tests cannot be performed immediately or if some of the blood must be reserved for further testing, clotting must be prevented by addition of an anticoagulant.

Vacuum blood collection tubes are sold containing several different anticoagulants, with color-coded stoppers indicating the particular anticoagulant in each tube. Of these, ethylenediaminetetraacetic acid (EDTA), in tubes with lavender stoppers is among the best for collecting blood for parasite examination, because the amount of distortion it produces is minimal. If the blood is allowed to clot to obtain the clear serum, as for immunologic tests for canine heartworm, vacuum tubes with red stoppers, which contain no anticoagulant, should be used.

 **TECHNICIAN'S NOTE** When using an anticoagulant sample tube like EDTA, you should make sure that you collect at least a 1 mL sample of whole blood for proper mixture of the anticoagulant to prevent unexpected cell distortions that can occur with too much anticoagulant and not enough blood sample.

Blood samples should always be labeled with the client's name, the animal's name or number, and the date of collection.


The microfilariae of *D. immitis* are more common in canine blood at certain times of the day than at other times. These microfilariae are found in greater numbers during the evening hours than during the daylight hours.

## Examination of Blood

General observations of blood samples should always be recorded. For example, if the blood appears watery, the animal may be anemic. Clinical pathology tests, such as packed cell volume and white blood cell counts, may aid in the diagnosis of parasitism.

### Direct Microscopic Examination

The simplest blood parasite detection procedure is by direct microscopic examination of whole blood, known as the **direct smear** technique. This procedure is aimed primarily at detecting movement of parasites that live outside the red blood cells. In the United States and Canada, direct smear usually is used to demonstrate the microfilariae of the canine heartworm, *Dirofilaria immitis*; trypanosome protozoans also may be observed. The direct smear is quick and easy to perform, but only a small amount of blood is examined; that is, the sample size is very small. This is a major disadvantage to using this technique; unless the parasites are present in very large numbers, they may be easily overlooked.

 **TECHNICIAN'S NOTE** The direct blood smear is a good and quick scanning technique but should not be relied upon if the sample does not reveal parasites since only a very small sample is being used.

**Trypanosomes** are found primarily in the tropical regions of the world; occasionally, however, they may be reported in the United States. Trypanosomes are more easily identified as such on stained blood smears than by direct examination of whole blood.

The microfilariae of primary interest in North America are those found in dogs, *D. immitis* and *Acanthocheilonema reconditum*. It is important that veterinary diagnosticians differentiate between these two filarial parasites, because the treatment for *D. immitis* can be stressful and expensive for the pet owner, whereas treatment for *A. reconditum* is not necessary.

Direct microscopic examination of whole blood is an unsatisfactory method for differentiating microfilariae. There are better methods for diagnosing these parasites. Nevertheless, the microfilariae of *D. immitis* are more numerous than those of *A. reconditum*. It is possible to observe low levels of microfilariae in the peripheral blood. There are also subtle differences in the behavior of these microfilariae in the blood smear. Microfilariae of *D. immitis* tend to remain in one spot on the slide and coil and gyrate in place. If they do move, the movement is sluggish. Microfilariae of *A. reconditum* (on rare occasions) will move rapidly across the microscopic field with a snakelike movement.



**TECHNICIAN'S NOTE** While the direct blood smear will reveal microfilariae, it is hard to differentiate the genus and species of the microfilariae from the blood smear.

### Thin Blood Smear

A thin blood smear is prepared in the same manner as a blood smear prepared for a white blood cell differential count (Box 17-14 and Figure 17-16).

The area of the smear farthest from the original drop of blood should be the thinnest part of the smear. This region is known as the **feathered edge** of the smear. Because of the large relative size of microfilariae, they are not carried into the feathered edge. The entire slide is fixed and stained with Diff-Quik.

A thin blood smear cannot be used for accurate differentiation of the microfilariae of *D. immitis* from those of *A. reconditum*. Trypanosomes can be seen between the red blood cells in the smear. Protozoans such as *Babesia* and *Theileria* species can be seen within the red blood cells. Rickettsiae such as *Anaplasma* species may be seen on the surface of the red blood cells.



**TECHNICIAN'S NOTE** A thin blood smear will reveal such blood parasites as *Babesia* and *Theileria* within the red blood cells but cannot be used for accurate differentiation of *Dirofilaria immitis* and *Acanthocheilonema reconditum*.

### BOX 17-14 Thin Blood Smear

1. Place a glass microscope slide (the "surface slide") flat on the bench surface, then place a small drop of the whole-blood sample near the short end of the slide.
2. Place the short end of a second slide (the "spreader slide") near the middle of the bench surface slide and hold it at a 35- to 45-degree angle. Holding the spreader slide at that angle, slide the short side of that slide backward across the surface slide until it just contacts the drop of blood (see Figure 17-16). When the drop is contacted, it rapidly spreads along the juncture between the two slides.
3. The spreader slide is then smoothly and rapidly slid forward the length of the surface slide, producing a smear with a feathered edge.
4. Allow the surface slide to air-dry, then stain it. Examine the slide with the 10× objective for microfilariae or trypanosomes; the 100× (or oil-immersion) objective may be used for the intracellular parasites.

This blood examination technique uses minute amounts of whole blood. As with the direct smear, the thin blood smear uses only a small amount of blood. Again, the sample size is very small. This is a major disadvantage to using this technique; unless the parasites are present in very large numbers, they may be easily overlooked. To ensure that mild infections are not missed, several blood concentration techniques using larger volumes of blood have been developed.

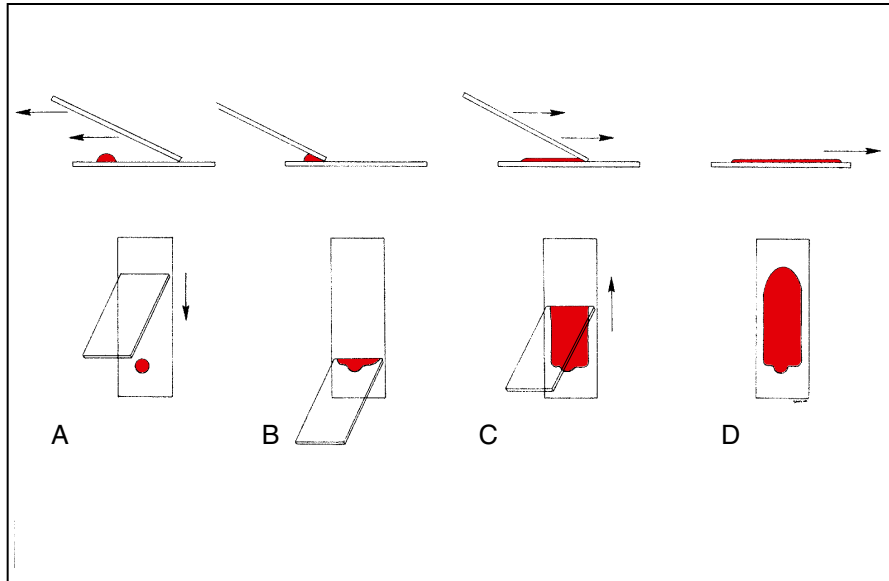
### Thick Blood Smear

A thick blood smear allows examination of a slightly larger amount of blood than a thin blood smear (Box 17-15). Microfilariae, protozoa, and rickettsiae may be seen using this method.

### Buffy Coat Method

The buffy coat method is a concentration technique for detection of microfilariae in blood samples (Box 17-16). The buffy coat is the layer





**FIGURE 17-16:** Demonstration of correct angle and direction of movement of thin blood smear.

### BOX 17-15 Thick Blood Smear

1. Place 3 drops of the blood sample together on a glass slide, and with a wooden applicator stick, spread them out to an area about 2 cm in diameter.
2. Allow the smear to air-dry.
3. Place the glass slide in a slanted position, smear side down, in a glass beaker containing distilled water. Allow the slide to remain in the beaker until the smear loses its red color.
4. Remove and air-dry the slide, then immerse it for 10 minutes in methyl alcohol. Stain with Giemsa stain for 30 minutes. Wash excess stain with tap water.

of white blood cells located between the red blood cells and the clear plasma formed by the centrifugation of whole blood. The specific gravity of microfilariae causes them to gravitate to the upper surface of the buffy coat layer (Figures 17-17 and 17-18). This test is quick and can be performed in conjunction with a packed cell volume determination. It is not possible, however, to determine the species of microfilariae.

### Modified Knott's Technique

The modified Knott's technique is a fairly rapid method that detects microfilariae and allows for differentiation between the microfilariae of *Dirofilaria immitis* and *Acanthocheilonema reconditum* (Box 17-17). This technique concentrates the microfilariae from 1 mL of blood and hemolyzes the red blood cells so that the microfilariae may be observed more clearly.



**TECHNICIAN'S NOTE** The buffy coat technique and modified Knott's technique can be used to properly differentiate between *Dirofilaria immitis* and *Acanthocheilonema reconditum*.


Using the modified Knott's technique, the characteristics in Table 17-1 can be used to distinguish the microfilariae of *D. immitis* from those of *A. reconditum*. Some of these characteristics are unique to the modified Knott's procedure and may not be indicative of other tests that depend on observation of morphologic features of the microfilariae. The most accurate features are the total length of the microfilaria, the

**BOX 17-16 Buffy Coat Method**

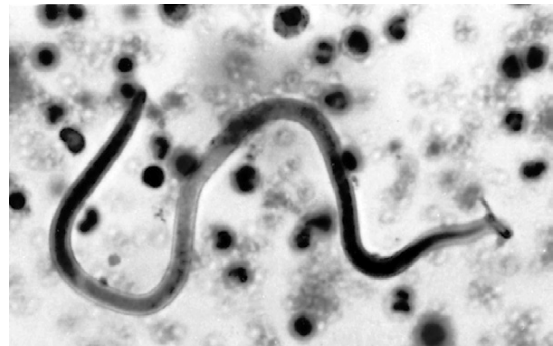1. Fill a hematocrit tube with the whole-blood sample and seal one end with hematocrit clay.
2. In the hematocrit centrifuge, centrifuge the hematocrit tube for 5 minutes.
3. If desired, read the packed cell volume to determine if the animal is anemic. Observe the location of the buffy coat layer between the red cell layer and the plasma (Figure 17-17).
4. Place the hematocrit tube on the stage of the compound microscope. Using the 4× objective, examine the zone between the buffy coat layer and the plasma for the presence of microfilarial activity. Use the iris diaphragm to decrease the light, because low light intensity and high contrast increase visualization of the motile microfilariae.

or

Using a small file or glass cutter, deeply scratch the hematocrit tube at the level of the buffy coat. Snap the hematocrit tube by applying thumb pressure opposite the scratch. Immediately take the part of the buffy coat and plasma and tap the buffy coat onto the center of a microscope slide, including some plasma with it. Add a drop of physiologic saline and a drop of methylene blue stain, and cover with a coverslip. Using the 10× objective, examine the slide for the presence of microfilariae.



**FIGURE 17-17:** Buffy coat in hematocrit tube.



**FIGURE 17-18:** Microfilariae in buffy coat smear of canine blood. (560×.)

midbody width, and the shape of the cranial end. Body length and width should be measured using an ocular micrometer (see p. 321). The body length of the microfilaria of *Acanthocheilonema immitis* ranges from 295 to 325  $\mu\text{m}$  (average, 310  $\mu\text{m}$ ), whereas the body length of the microfilaria of *A. reconditum* ranges from 250 to 288  $\mu\text{m}$  (average, 280  $\mu\text{m}$ ). The midbody width of the microfilaria of *D. immitis* ranges from 5 to 7.5  $\mu\text{m}$ , whereas the midbody width of the microfilaria of *A. reconditum* ranges from 4.5 to 5.5  $\mu\text{m}$ . It is important for the differentiation between the morphologic parameters of the parasites on the modified Knott's procedure that veterinary clinics own and calibrate an ocular micrometer within at least one compound microscope. The anterior end of the microfilaria of *D. immitis*

tapers gradually from its midbody, whereas the microfilaria of *A. reconditum* has a blunt anterior end, much like the end of a wooden broom handle. Likewise, the posterior end of the microfilaria of *D. immitis* is said to be straight, whereas the microfilaria of *A. reconditum* may have a curved or “buttonhook” or “shepherd’s crook” tail. It is important to remember that the bending, or hooking, of the tail of the microfilaria of *A. reconditum* is an artifact of 2% formalin fixation and may not be observed as a consistent diagnostic feature. Likewise, other microfilarial tests (e.g., commercial filter tests) will not produce this “hooking” characteristic. Veterinary diagnosticians should remember to measure several microfilariae to confirm that the microfilariaemia is not a concomitant infection (i.e., both

**BOX 17-17** Modified Knott's Technique

1. In a centrifuge tube with a conical end, mix 1 mL of the whole-blood sample and 9 mL of 2% formalin (2 mL of 40% formaldehyde per 98 mL of distilled water). Stopper the tube and rock it back and forth for 1 to 2 minutes until the mixture becomes a clear, red-wine color.
2. Centrifuge the tube at 1500 rpm for 5 minutes.
3. Pour off the liquid supernatant. It is permissible to let the tube stand with open end down for 45 minutes to 1 hour, if time permits. The purpose of this step is to remove as much fluid as possible, leaving sediment only.
4. Add 1 drop of methylene blue stain to the sediment at the bottom of the tube. Transfer a drop of the mixture to a glass slide and apply a coverslip.
5. Examine the slide for the presence of microfilariae using the 10× objective. When microfilariae are found, use a higher-power objective (40×) to observe the fine differences between them (see Table 17-1).
6. The diagnostician may stop this procedure at one of two stopping points: (a) the diagnostician has identified microfilariae as those of *Dirofilaria immitis* or *Acanthocheilonema reconditum*, or (b) the diagnostician runs out of the sediment/stain mixture.

parasites may be present). In some areas of North America (those with high indigenous populations of both mosquitoes and fleas), infection with both filarial parasites is quite possible.

**TECHNICIAN'S NOTE** The morphological features of *Dirofilaria immitis* and *Acanthocheilonema reconditum* are used for differentiation.

**Commercial Filter Technique**

A commercial filter technique, such as the DIFIL-Test, is another means of concentrating microfilariae within blood samples. The materials required are available in a diagnostic kit.<sup>7</sup>

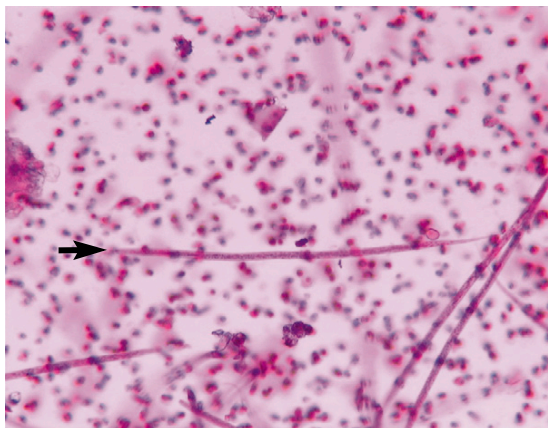
<sup>7</sup>DIFIL-Test, EVSCO Pharmaceuticals, Buena, NJ.

**TABLE 17-1** Morphologic Characteristics for Differentiation of *Dirofilaria immitis* and *Acanthocheilonema reconditum*

Characteristic	<i>Dirofilaria immitis</i>	<i>Acanthocheilonema reconditum</i>
Body shape	Usually straight	Usually curved
Body length	295 to 325 $\mu\text{m}$ (average, 310 $\mu\text{m}$ )	250 to 288 $\mu\text{m}$ (average, 280 $\mu\text{m}$ )
Anterior end	Tapered	Blunt ("broom handle")
Posterior end	Straight	Curved or hooked (artifact of formalin fixation)

This kit contains complete directions for use. One mL of the blood sample (no anticoagulant is required if the test is performed immediately) is mixed with 9 mL of a red blood cell lysing solution in a 10- or 12-mL syringe. A new, disposable porous filter (a sieve with tiny holes) is placed in a filter holder. The fluid in the syringe is injected into the filter holder and is then flushed with 10 mL of water. Unlysed cells and microfilariae are retained on the surface of the filter. The filter is then gently transferred with thumb forceps to a glass microscope slide and stained with 2 drops of the stain provided in the commercial kit. The filter is covered with a coverslip and examined with a 10× objective for the presence of microfilariae (Figure 17-19).

The filter technique uses an amount of blood equal to that used in the modified Knott's procedure and can be rapidly performed. This test is best used as an indicator of microfilaremia, the presence of microfilariae in the peripheral blood. It is important to remember that microfilarial species often cannot be identified using a commercial filter technique. If microfilariae are found, additional tests, such as the modified



**FIGURE 17-19:** Microfilariae of *Dirofilaria immitis* using the DIFIL-Test.

Knott's technique, should be performed to determine if the infection is that of *D. immitis* or *A. reconditum*.

**TECHNICIAN'S NOTE** The commercial filter test is a good technique for detecting microfilariae in the blood but not reliable for differentiation of microfilaria species.

### Immunologic Heartworm Tests

About 25% of dogs with adult heartworm infection in the heart and pulmonary vasculature do not have circulating microfilariae in the peripheral blood. These infections may consist of (1) heartworms that are too young to produce microfilariae, (2) a “unisex” or “single sex” infection, (3) an infection in which circulating microfilariae are produced by the adult female heartworms but for some reason are removed by the host, or (4) an infection in which the circulating microfilariae have been killed by a drug, but the adults have not been affected. This type of infection is referred to as an **occult infection**. The hosts are said to be **amicrofilaremic**, without microfilariae. It is important to remember that cats also can be infected with canine heartworms. Because the heartworms are in cats rather than in their natural host (the dog), the adult heartworms

produce either low numbers of microfilariae or none at all.

**TECHNICIAN'S NOTE** With the monthly heartworm preventatives being used, the animals are amicrofilaremic since the preventatives kill the microfilariae.

To detect infections, tests have been developed in which antibodies against antigens of adult *D. immitis* react with chemicals to produce a color change when those antigens are in a blood sample. These tests are available commercially and are easy to perform and fairly rapid (15 to 20 minutes) if the directions are carefully followed and samples are correctly labeled. Older styles of kits detected only canine antibodies in response to heartworm and were unsuitable for use in cats.

**TECHNICIAN'S NOTE** Many heartworm immunologic test kits now are sensitive enough to detect antibodies in cats. However, it is recommended that an antibody test and an antigen test be used for cats since the worm burden is so low.

Other tests for parasites such as *Toxoplasma gondii* can be performed by diagnostic laboratories. The laboratory will provide information on the nature and amount of specimens they require. Box 17-18 provides a method for collecting serum for these immunologic tests.

### Miscellaneous Methods for Microfilarial Identification

Other heartworm diagnostic procedures used in detection and differentiation of microfilariae include staining with brilliant cresyl blue and acid phosphatase. These procedures are often too cumbersome and time-consuming to be used in a veterinary practice. Many of the reagents used in the processing of these specimens are not found in the practice setting. Diagnostic referral laboratories usually are able to perform both procedures.

**BOX 17-18 Serum Collection**

1. Using a needle and syringe, dispense 10 mL of blood into a blood collection vacuum tube lacking anticoagulant (tube with red stopper). Slowly dispense the blood from the syringe into the tube to avoid lysis of the red blood cells. Lysis of red blood cells often interferes with the functions of many tests.
2. Keep the blood at room temperature (25° C) for 2 to 3 hours to allow a solid clot to form.
3. Remove the formed blood clot with a wooden applicator stick by gently “rimming” the clot and then sliding it up the side of the tube with the applicator stick. Discard the clot. (Some laboratories request that the clear serum then be transferred to a new tube.)
4. Correctly label each tube of serum with the client’s name, animal’s name or number, and practitioner’s name. Refrigerate the sample until it can be shipped.
5. Ship samples to the laboratory packed in an insulated container with ice or a cool pack. Use the fastest shipper possible, for next-day delivery.

**DIAGNOSIS OF PARASITISM OF THE RESPIRATORY SYSTEM****Fecal Examination for Respiratory Parasites**

The life cycles of helminth (nematode and trematode) parasites of the lungs are completed through the passage of their eggs or larvae up the airways to the pharyngeal region, from which they are swallowed and passed to the outside environment in the feces. Because of this dependence on fecal transmission, parasitism of the lungs and airways is often diagnosed by microscopic examination of the feces, as described previously. The Baermann technique can be used to recover the larvae of lungworms from feces. Again, this method takes advantage of the fact that warm water stimulates the larvae in a sample to move about. Once the larvae move out of the sample, they relax in the water and sink to the

bottom of the container. The Baermann apparatus should be employed when parasitism with lungworms is suspected (see p. 333).



**TECHNICIAN'S NOTE** Because lungworms use the digestive system to pass their eggs or larvae after the animal coughs them up and swallows them, routine fecal flotation techniques and the Baermann technique can be used to find most of these parasite infections.

**Examination of Sputum and Tracheal Washes**

The larvae and eggs of respiratory parasites have the same characteristics as those found in the feces. An exception is *Dictyocaulus* species, lungworms of cattle and sheep, which are usually seen in the sputum as eggs containing larvae rather than as free larvae in the feces.

A drop of sputum or nasal discharge on a microscope slide is easily examined. Several slides should be examined. When the sputum is especially viscous, a drop of the material should be placed between two microscope slides and both slides examined microscopically. Larger quantities of fluid obtained from the respiratory tract should be concentrated by centrifugation at 1500 rpm for 5 minutes. A drop of the sediment can then be placed on a slide and examined microscopically.



**TECHNICIAN'S NOTE** Some endoparasites do not use the digestive tract to complete their life cycle but instead use sputum. Therefore, the sputum can be examined for eggs or larvae by either a direct smear or centrifugation performed like a fecal sample.

Dogs may occasionally become infested with the nasal mite, *Pneumonyssoides caninum*, or *Linguatula serrata*, the tongue worm. A cotton swab dipped in mineral oil may be inserted into the nose of a suspect dog and rubbed against the nasal membranes. *Pneumonyssoides* mites have eight



legs and are white and hairless and 1 to 1.5 mm long. The eggs of *L. serrata* measure  $90 \times 70 \mu\text{m}$  and contain a mitelike larval stage. Tiny hooked feet may be observable in the interior of the egg.

### DIAGNOSIS OF PARASITISM OF THE URINARY SYSTEM

Roundworms are common parasites of the kidney and urinary bladder. They complete their life cycle by passing eggs out of the host's body in the urine. These nematodes include *Pearsonema* (Formerly *Capillaria*) species, which inhabit the walls of portions of the urinary system of both dogs and cats, *Diectophyma renale*, the giant kidney worm of dogs, and *Stephanurus dentatus*, the swine kidney worm.



**TECHNICIAN'S NOTE** Some endoparasite eggs can be found in the urine of the animal.

### Collection of the Urine Sample

Urine for parasitologic examination may be collected during normal urination. Catheterization and cystocentesis are usually not necessary unless part of the sample is to be used for bacteriologic or cytologic examination. A waxed paper cup (3-5 mL) with a lid or other clean container may be used for collection. The cup is held in the urine stream and filled. Unless the sample is to be used for other tests, it is not necessary to collect the sample at a certain time during urination. Clients can be instructed to collect a sample at home. Urine samples should be properly labeled with the client's name and the animal's identification and refrigerated until the examination can be conducted.

### Urine Examination for Parasites

The primary method of examining urine for parasites is by microscopic examination of the sediment (Box 17-19). Just as with microscopic

### BOX 17-19 Urine Sedimentation

1. Thoroughly mix the urine sample, and put 5 to 10 mL into a centrifuge tube with a conical tip.
2. Centrifuge the sample for 5 minutes at 1500 rpm.
3. Pipette all but about 0.5 mL of the fluid from the centrifuge tube, leaving the sediment at the bottom undisturbed.
4. Mix the remaining fluid and sediment together with the pipette; transfer a drop of the mixture to a microscope slide and apply a coverslip.
5. Thoroughly examine the drop of sediment microscopically, using the 10 $\times$  objective.

examination of feces using the compound microscope, uniform movement and a thorough search of the microscope slide must be performed. Regardless of how the slide is moved, the area under the coverslip must be thoroughly and uniformly searched (see Figure 17-8). When a parasite egg is observed at low magnification, higher-power objectives may be used to examine it more closely.




**TECHNICIAN'S NOTE** Urine sedimentation is used to find parasite eggs in the urine of an animal.

### DIAGNOSIS OF PARASITISM OF THE SKIN

#### Skin Scrapings

Skin scraping is one of the most common diagnostic tools used in evaluating animals with dermatologic problems. Equipment required includes an electric clipper with a no. 40 blade, a scalpel or spatula, mineral oil in a small dropper bottle, microscope slide, coverslip, and a compound microscope. Typical lesions or sites likely to harbor the particular parasite should be scraped (e.g., margins of ear for *Sarcoptes scabiei*).



**FIGURE 17-20:** Safe method of holding scalpel blade with thumb and second finger for skin scrapings.

The scraping is performed with a no. 10 scalpel blade, used with or without a handle. A stainless steel spatula is preferred by some clinicians. The scalpel blade should be held between the thumb and the second finger, with the first finger used to help prevent cutting the animal (Figure 17-20). Before the skin is scraped, the blade is dipped in a drop of mineral oil on the slide, or a drop of mineral oil may be placed on the skin.

During the scraping process, the blade must be held perpendicular to the skin. Holding it at another angle may result in the animal being incised. The average area scraped should be 6 to 8 cm<sup>2</sup>.

**TECHNICIAN'S NOTE** Skin scraping is performed with a no. 10 scalpel blade held perpendicular to the skin so the blade will not incise the animal.

The depth of the scraping varies with the typical location of the parasite in question. When scraping for mites that live in tunnels (e.g., *Sarcoptes* spp.) or hair follicles and sebaceous glands (e.g., *Demodex* spp.), the skin should be scraped until a small amount of capillary blood oozes from the area. Clipping the area with a no. 40 blade before scraping enables better visualization of the lesion and removes excess hair that impedes proper scraping and interferes with collection of epidermal debris.

For surface-dwelling mites (e.g., *Chorioptes* spp., *Cheyletiella* spp.), the skin is scraped superficially to collect loose scales and crusts. Clipping before scraping is not always necessary when infestation with surface-dwelling mites is suspected.

**TECHNICIAN'S NOTE** The depth of the skin scrape will depend on the type of ectoparasite suspected of causing the skin problem.

All the scraped debris on the forward surface of the blade is then spread in a drop of mineral oil on a glass microscope slide. A glass coverslip is placed on the material, and the slide is ready for microscopic examination using the 4× (scanning) objective. The slide should be examined systematically in rows so that the entire area under the coverslip is evaluated (see Figure 17-8). Low light intensity and high contrast increase visualization of mites and eggs. If necessary, the slide may be evaluated using the 10× (low-power) objective.

Demonstration of a characteristic mite or egg is frequently diagnostic for most diseases. In certain circumstances, however, more than identification of the parasite is necessary. For example, determining live:dead ratios and observing immature stages of demodectic mites are important in evaluating a patient with demodectic mites. A decrease in the number of live mites and eggs during therapy is a good prognostic sign.

### Cellophane Tape Preparation

When attempting to demonstrate the presence of lice or mites that live primarily on the surface of the skin (e.g., *Cheyletiella* spp.), use a cellophane tape preparation instead of a skin scraping. Clear cellophane tape is applied to the skin to pick up epidermal debris. A ribbon of mineral oil is placed on a glass slide, and the adhesive surface of the tape is placed on a glass slide and then placed on the mineral oil. Additional mineral oil and a coverslip may be placed on the tape to prevent the tape from wrinkling, but this is not necessary. The slide is then examined systematically in rows.

## Gross Specimens

Unknown, large **ectoparasites** such as fleas, ticks, chigger mites, biting flies, and myiasis-producing maggots are often collected from the surface of the animal's skin. It is important that these arthropods be placed in a sealed container in either 10% formalin or 95% ethyl alcohol for shipment to a diagnostic laboratory. As many intact specimens as possible should be collected and shipped to a diagnostic laboratory capable of **speciating** these important ectoparasites. Again, containers should be properly labeled with the client's name and the animal's identification.



**TECHNICIAN'S NOTE** Large, unknown ectoparasites being sent to a diagnostic lab should be preserved in either 10% formalin or 95% ethyl alcohol for shipment.

## DIAGNOSIS OF PARASITISM OF MISCELLANEOUS BODY SYSTEMS

### Parasites of the Eye

*Thelazia* species are nematodes that live within the conjunctival sac and on the surface of the eye of several species of domestic animals, including cattle, sheep, goats, horses, dogs, and cats. The adult parasites are milky white, 7 to 17 mm long, and reside in the conjunctival sac, just under the eyelids, particularly the third eyelid. Diagnosis is made by anesthetizing the eye with a local ophthalmologic anesthetic and directly examining the eye for parasites. If observed, these nematodes should be removed while the eye is anesthetized.



**TECHNICIAN'S NOTE** Parasites found in the eye should be removed by the veterinarian while the eye is anesthetized for examination.

Another nematode parasite often associated with the eye is *Dirofilaria immitis*, the canine heartworm. This parasite is often associated with aberrant locations throughout the body of both dogs and cats. A site that may become infected is the anterior chamber of the eye; this is usually noted with alarm by the pet owner. Treatment is by surgical extraction of the wandering ("lost") parasite by a veterinary ophthalmologist.

### Parasites of the Ear

*Otodectes cynotis*, the ear mite, is a common cause of external ear irritation in both dogs and cats. These white mites are frequently observed during otoscopic examination. *O. cynotis* are approximately the size of a grain of salt; they may be seen on a cotton swab after it has been moistened with mineral oil and used to clean the dark, waxy debris from the ears of infested animals. This material may be transferred to a drop of mineral oil on a microscope slide and spread out with the swab. A coverslip is applied to the debris, and the slide is examined microscopically in a systematic manner. This mite has suckers on short stalks at the tips of some of its legs (Box 17-20).



**TECHNICIAN'S NOTE** The ear smear is used to diagnose parasites of the ear.

### BOX 17-20 Ear Smear Procedure

1. Obtain a sample of debris from the affected ear.
2. Place 2 or 3 drops of mineral oil on the slide and an equal amount of ear debris.
3. Mix the ear debris and mineral oil with a wooden applicator to form a homogenous solution.
4. Remove large pieces of debris.
5. Place a coverslip over the smear.
6. Examine under the compound microscope and record any parasites or parasite eggs found.

## Parasites of the Genital Tract

*Tritrichomonas foetus* is a protozoan parasite of the reproductive tract of cattle. These parasites reside in the prepuce of infected bulls and in the vagina, cervix, and uterus of infected cows. It may also be found within the stomach contents of aborted fetuses. *T. foetus* is pear-shaped and 10 to 25  $\mu\text{m}$  long, with a sail-like, undulating membrane and three rapidly moving, whip-like anterior flagella. In fresh specimens, these protozoans move actively with a jerky motion. Diagnosis is by finding the organisms in washings from its predilection sites or from the stomach of the aborted fetus. Fluid material should

be centrifuged at 2000 rpm for 5 minutes. The supernatant is then removed and a drop of sediment transferred to a slide for microscopic examination for the organisms. Several slides should be examined. For more accurate diagnosis, fluid material from the predilection sites can be cultured in a special medium. Laboratories specializing in diagnostic parasitology should be consulted for information on these techniques.



**TECHNICIAN'S NOTE** Fluid samples from the genital parasite's predilection site should be centrifuged to concentrate the parasites and the sediment examined for organisms.

## CHAPTER SEVENTEEN TEST

**MATCHING**—Match the term with the correct phrase or term.

- |                                         |                                                                                                                                                                     |
|-----------------------------------------|---------------------------------------------------------------------------------------------------------------------------------------------------------------------|
| A. Mineral deposits unique to tapeworms | 1. Eyepiece scale                                                                                                                                                   |
| B. Stage micrometer                     | 2. Does not require the use of a centrifuge                                                                                                                         |
| C. Ocular micrometer                    | 3. A process of development that takes place within a coccidian oocyst                                                                                              |
| D. Specific gravity                     | 4. Cystic stages of <i>Giardia</i> are best concentrated with this flotation medium                                                                                 |
| E. Flotation solutions                  | 5. Used primarily in suspected trematode (fluke) infections                                                                                                         |
| F. Sheather's solution                  | 6. Calcareous bodies or calcareous corpuscles                                                                                                                       |
| G. Sodium nitrate solution              | 7. Concentrated sugar or various salts added to water to increase its specific gravity and thus make parasite eggs float because they are lighter than the solution |
| H. Saturated sodium chloride            | 8. Weight of an object compared with the weight of an equal volume of pure water                                                                                    |
| I. Zinc sulfate solution                | 9. Two sporocysts, each with four sporozoites                                                                                                                       |
| J. Simple flotation technique           | 10. An apparatus used to collect larval nematodes from fresh feces. A funnel is an essential part of this apparatus                                                 |

- |                                              |                                                                                                                         |
|----------------------------------------------|-------------------------------------------------------------------------------------------------------------------------|
| K. Fecal sedimentation technique             | 11. Used to stain protozoan cysts such as <i>Giardia</i>                                                                |
| L. Quantitative procedures                   | 12. Four sporocysts, each with two sporozoites                                                                          |
| M. Modified D'Antoni's iodine                | 13. Messy to work with because it is quite sticky; it is a sugar solution.                                              |
| N. Sporulation                               | 14. Instrument used to calibrate a compound microscope                                                                  |
| O. Sporulated oocyst of <i>Eimeria</i>       | 15. Many of these "color change" test kits use antibodies against adult <i>D. immitis</i> antigen                       |
| P. Sporulated oocyst of <i>Cystoisospora</i> | 16. A term meaning "without microfilariae"                                                                              |
| Q. Cellophane tape preparation               | 17. Collection of eggs of pinworms such as <i>Oxyuris equi</i>                                                          |
| R. Baermann apparatus                        | 18. Most efficient flotation solution, but it forms crystals and distorts eggs                                          |
| S. Modified Knott's procedure                | 19. Indicate the number of eggs or cysts present in each gram of feces                                                  |
| T. Immunologic heartworm tests               | 20. Least desirable flotation solution—it can corrode the microscope                                                    |
| U. Occult heartworm infection                | 21. Diagnosed using ear smear procedure                                                                                 |
| V. Amicrofilaremic                           | 22. Used to differentiate microfilariae of <i>Dirofilaria immitis</i> from those of <i>Acanthocheilonema reconditum</i> |
| W. Microscopic exam of urine sediment        | 23. Finding organisms in preputial washings of infected bulls                                                           |
| X. Skin scraping                             | 24. Dog has adult heartworms but does not demonstrate circulating microfilariae.                                        |
| Y. <i>Tritrichomonas foetus</i>              | 25. Performed using a number 10 scalpel blade                                                                           |
| Z. <i>Otodectes cynotis</i>                  | 26. Detection of ova of <i>Diocetophyma renale</i> or <i>Stephanurus dentatus</i>                                       |

## QUESTIONS FOR THOUGHT AND DISCUSSION

- For the parasites listed below, which procedure is the *best* procedure for diagnosing?
  - Giardia* species
  - Aelurostrongylus abstrusus* larvae (feline lungworms)
  - Fasciola hepatica*
  - Dirofilaria immitis*
  - Stephanurus dentatus*
  - Sarcoptes scabiei* variety *canis*
  - Acanthocheilonema reconditum*
  - Tritrichomonas foetus*
  - Dipylidium caninum*



2. Discuss the importance of accurate diagnoses of the following parasites in a veterinary clinical situation.
  - *Giardia* species
  - *Aelurostrongylus abstrusus* larvae (feline lungworms)
  - *Fasciola hepatica*
  - *Dirofilaria immitis*
  - *Stephanurus dentatus*
  - *Sarcoptes scabiei* variety *canis*
  - *Acanthocheilonema reconditum*
  - *Tritrichomonas foetus*
  - *Dipylidium caninum*

This page intentionally left blank

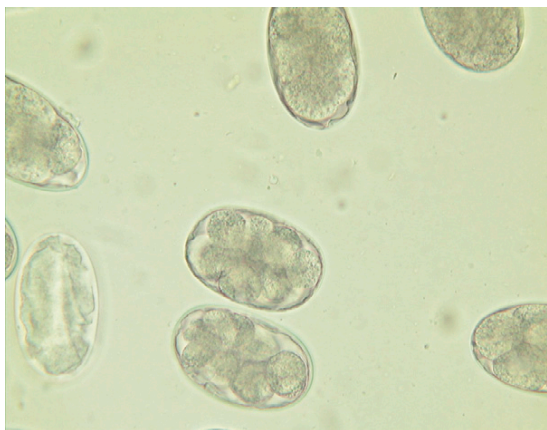
# Reference to Common Parasite Ova and Forms Seen in Veterinary Medicine

## OUTLINE

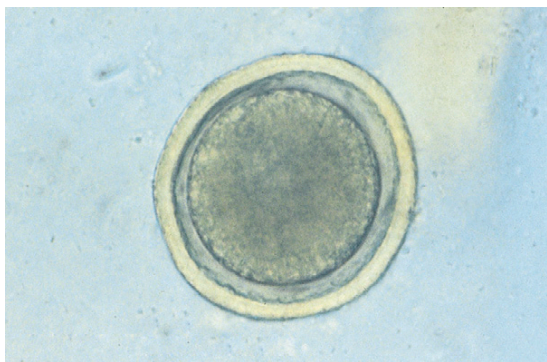
---

Common Parasites of Dogs and Cats	Common Parasites of Swine
Common Parasites of Horses	Common Parasites of Exotic Pets and Birds
Common Parasites of Ruminants	Pseudoparasites

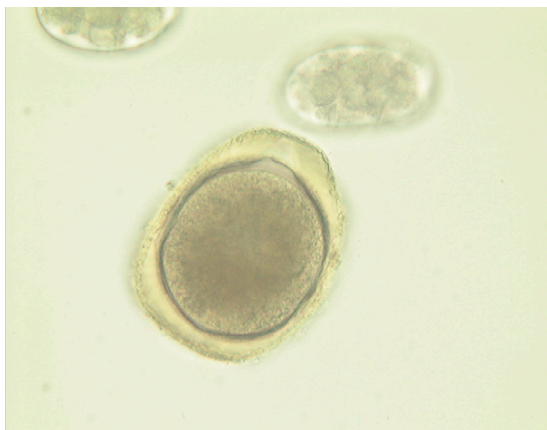
A major part of the veterinary technician’s job is identifying parasites in feces, blood, skin scrapings, and cellophane tape techniques. This chapter is a quick reference guide for identifying those parasites often seen in feces, blood, and on the skin of dogs, cats, horses, ruminants, swine, and exotic animals.

**COMMON PARASITES OF DOGS AND CATS**

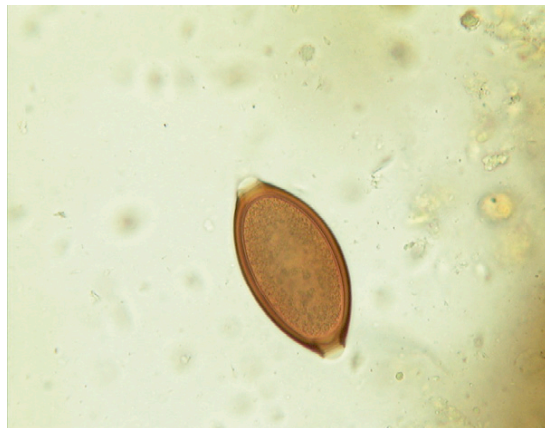**FIGURE 18-1:** *Ancylostoma caninum* ("hookworm").



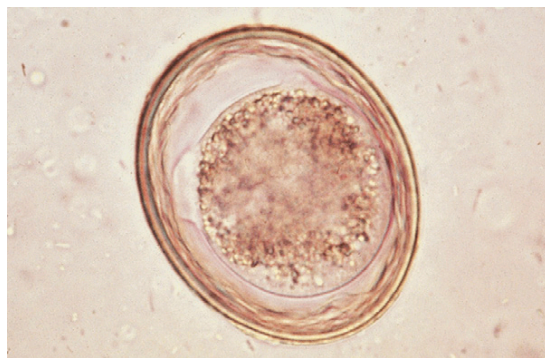
**FIGURE 18-2:** *Toxocara canis* ("roundworm").



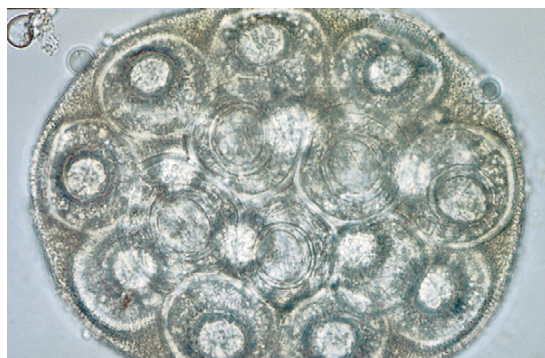
**FIGURE 18-3:** *Toxocara cati* ("roundworm").



**FIGURE 18-4:** *Trichuris vulpis* ("whipworm").



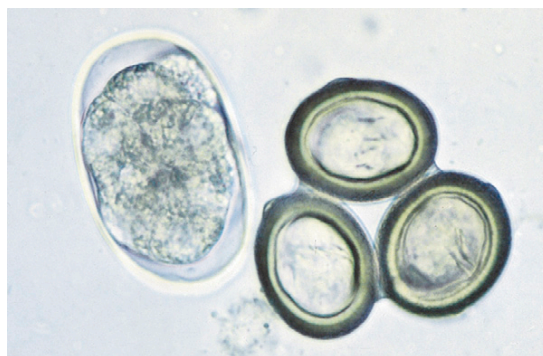**FIGURE 18-5:** *Toxascaris leonina* ("roundworm").



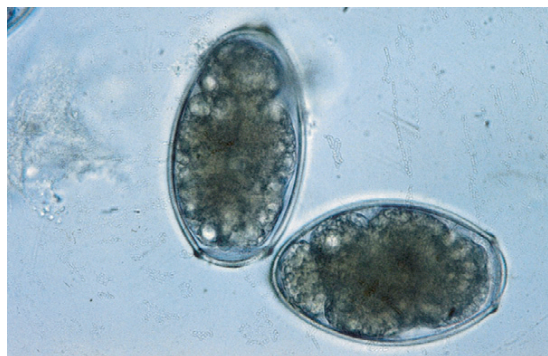
**FIGURE 18-6:** *Dipylidium caninum* ("tapeworm").



**FIGURE 18-7:** *Dipylidium caninum* segments in stool ("cucumber seed tapeworm").



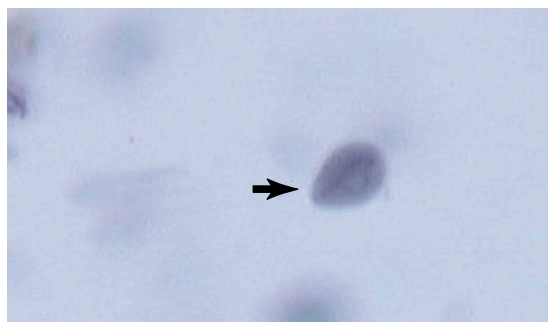
**FIGURE 18-8:** *Taenia pisiformis* ("tapeworm").



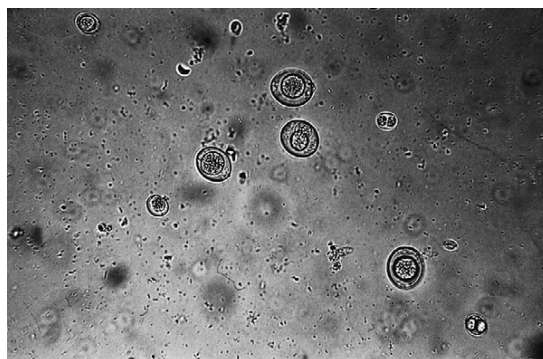
**FIGURE 18-9:** *Paragonimus kellicotti* ("lung fluke").



**FIGURE 18-10:** *Giardia* species trophozoite.

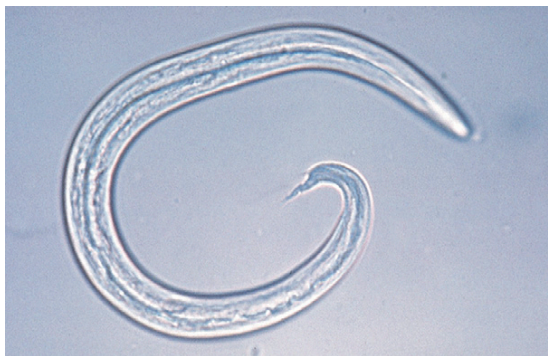

**FIGURE 18-11:** *Giardia* species oocyst.

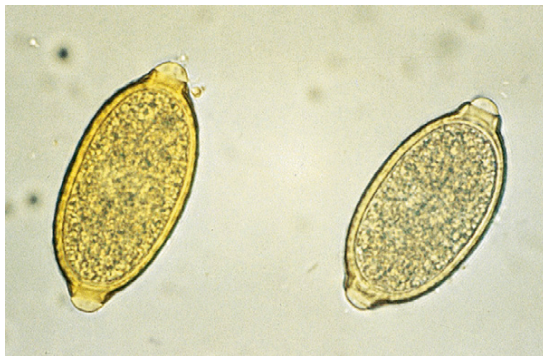


**FIGURE 18-12:** *Cystoisospora canis*, large oocysts ("coccidia").

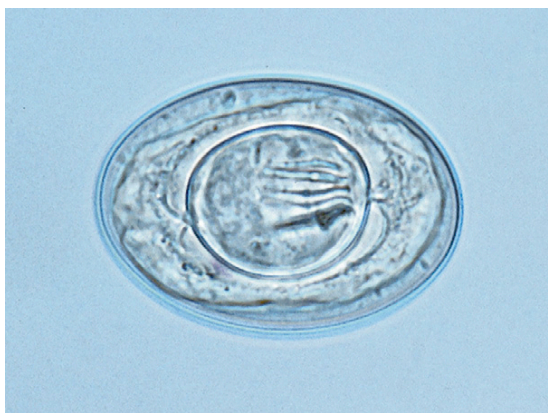



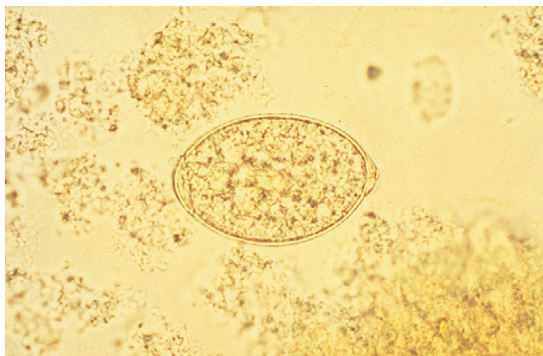
**FIGURE 18-13:** *Aelurostrongylus abstrusus* ("feline lungworm").



**FIGURE 18-14:** Left, *Trichuris vultis* (whipworm). Right, *Eucoleus aerophilus* (lungworm).



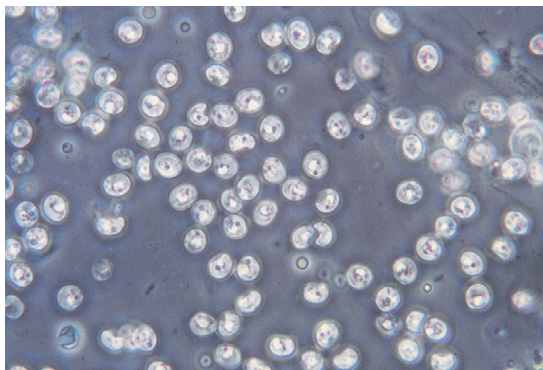
**FIGURE 18-15:** *Hymenolepis nana*.



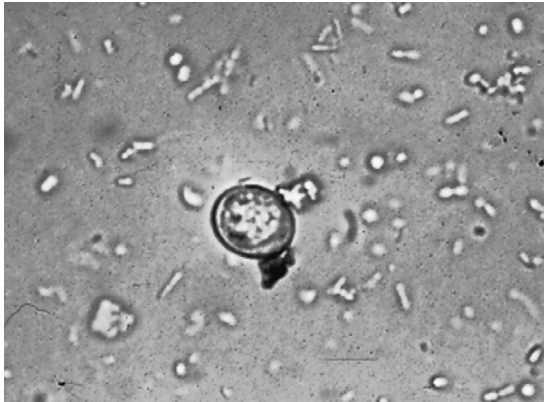**FIGURE 18-16:** *Spirometra mansonioides* ("zipper tapeworm").



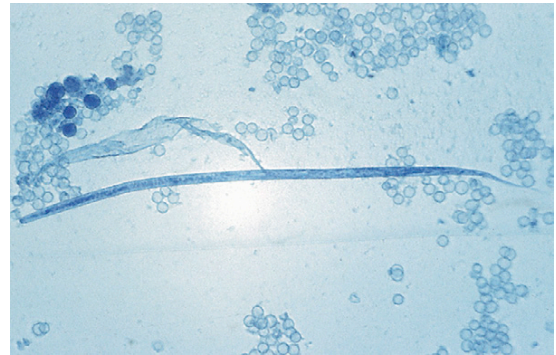
**FIGURE 18-17:** *Alaria* species ("intestinal fluke of dogs and cats").



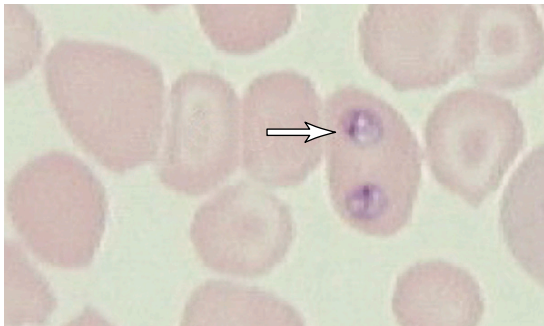
**FIGURE 18-18:** *Cryptosporidium* species ("cryptosporidium" or "cryptosporidiosis").



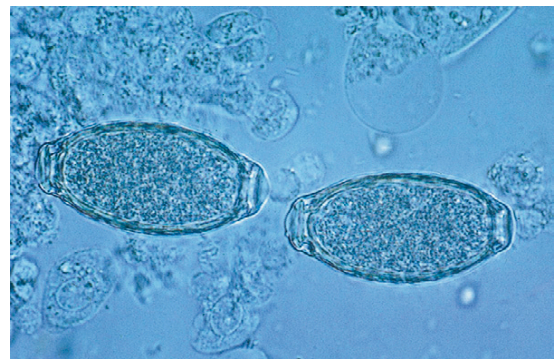**FIGURE 18-19:** *Toxoplasma gondii* ("toxoplasma or toxoplasmosis").



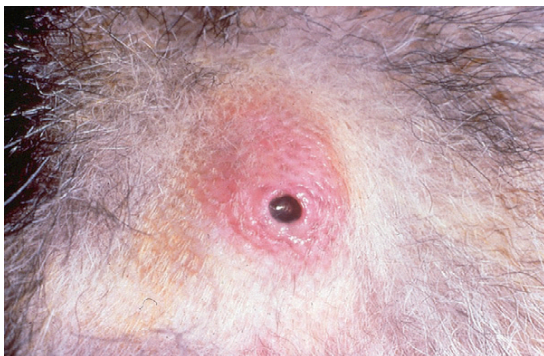**FIGURE 18-20:** *Dirofilaria immitis* microfilariae ("heartworm").



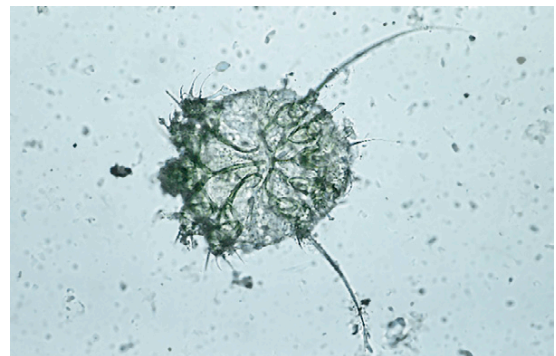**FIGURE 18-21:** *Babesia canis* ("babesia").



**FIGURE 18-22:** *Capillaria plica* ("bladder worm").

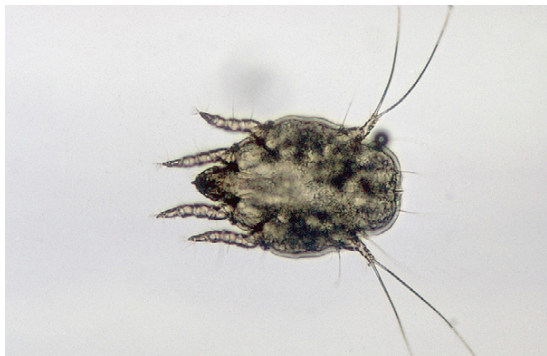

**FIGURE 18-23:** *Cuterebra* species ("warbles or wolves").




**FIGURE 18-24:** *Sarcoptes scabiei* variety *canis* ("scabies").

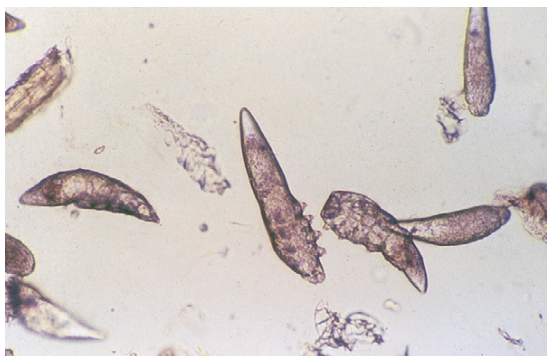



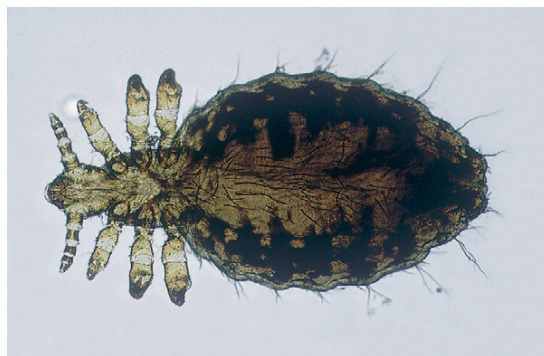**FIGURE 18-25:** *Otodectes cynotis* ("ear mites").




**FIGURE 18-28:** Adult fleas (male and female).



**FIGURE 18-26:** *Demodex canis* ("demodectic mange mite").

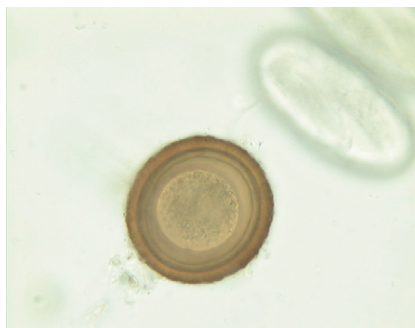

**FIGURE 18-29:** *Linognathus setosus* ("sucking louse of dogs").

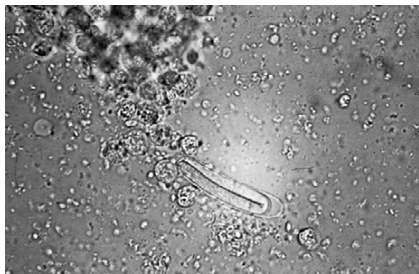


**FIGURE 18-27:** Flea life cycle stages (adults, eggs, larvae and pupae).

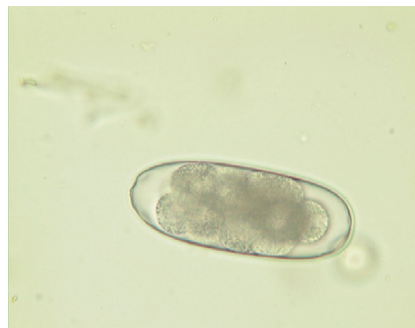## COMMON PARASITES OF HORSES



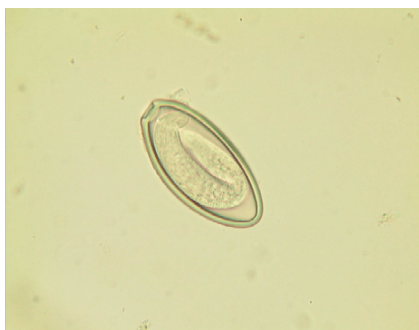**FIGURE 18-30:** *Parascaris equorum* ("equine roundworm").



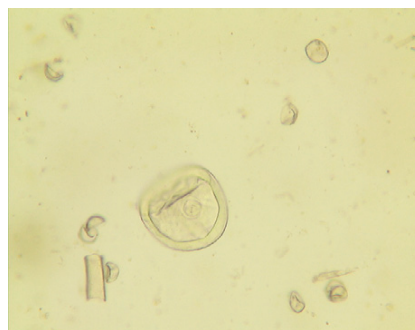
**FIGURE 18-31:** *Habronema* species ("equine stomach worm").



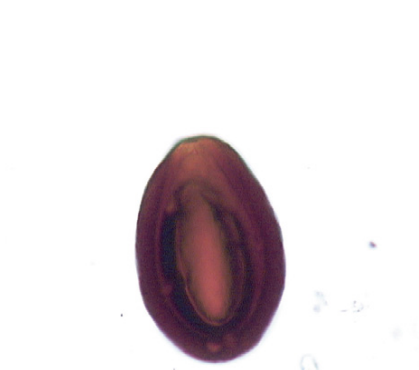**FIGURE 18-32:** *Strongylus vulgaris* ("equine hookworm").



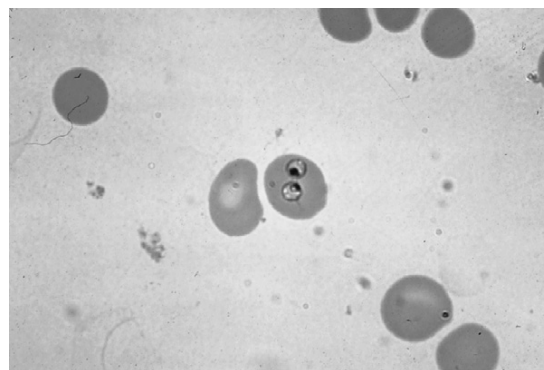
**FIGURE 18-33:** *Oxyuris equi* ("equine pinworm").




**FIGURE 18-34:** *Anoplocephala perfoliata* ("equine tapeworm").



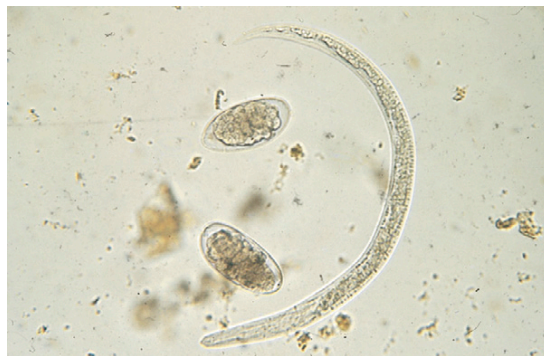**FIGURE 18-35:** *Eimeria leuckarti* ("equine coccidia").



**FIGURE 18-36:** *Babesia caballi* ("equine piroplasm").



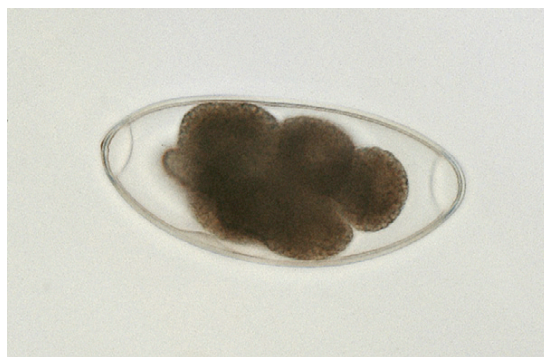
**FIGURE 18-37:** *Gastrophilus* species eggs ("horse bot fly eggs").



**FIGURE 18-40:** *Dictyocaulus viviparus* ("bovine lungworm").

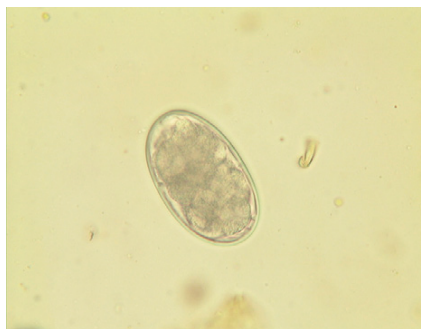


**FIGURE 18-38:** *Gastrophilus* species larvae ("horse bot fly larvae").

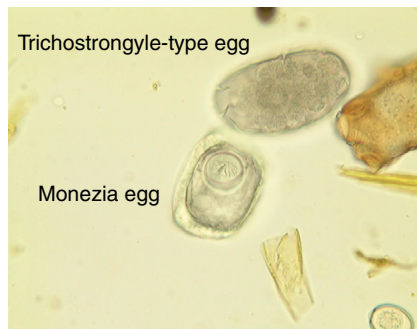

**FIGURE 18-41:** *Nematodirus* species ("ruminant trichostrongyle").

## COMMON PARASITES OF RUMINANTS

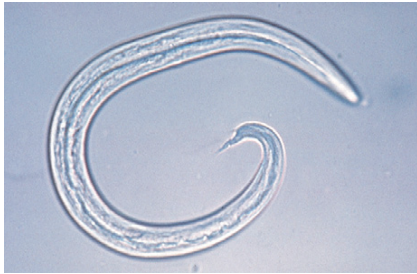

**FIGURE 18-39:** *Trichostrongylus* species ("ruminant hookworm").

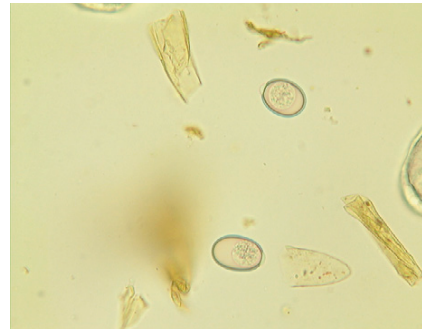


**FIGURE 18-42:** *Monezia* species, square ("ruminant tapeworm").

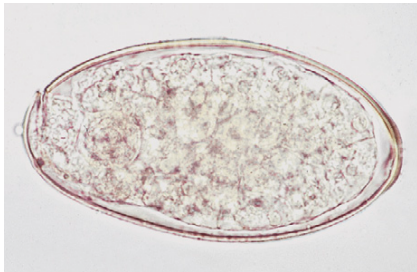




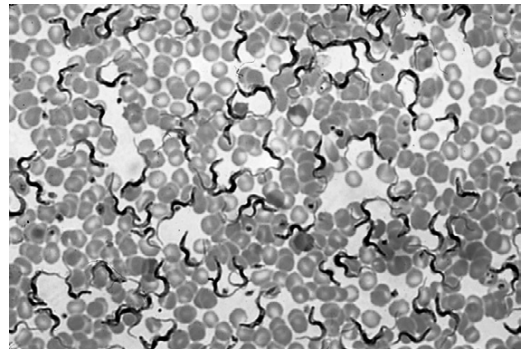
**FIGURE 18-43:** *Muellerius capillaris* ("lungworm of sheep and goats").



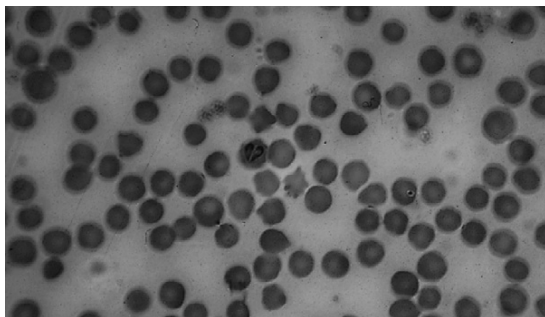
**FIGURE 18-44:** *Eimeria* species ("ruminant coccidia").



**FIGURE 18-45:** *Fasciola hepatica* ("ruminant liver fluke").



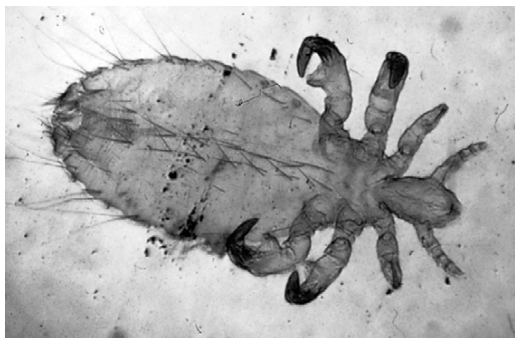**FIGURE 18-46:** *Trypanosoma* species in bovine blood ("trypanosome").



**FIGURE 18-47:** *Babesia bigemina* in bovine red blood cells ("babesia").



**FIGURE 18-48:** *Damalinia bovis* ("biting/chewing louse of cattle").

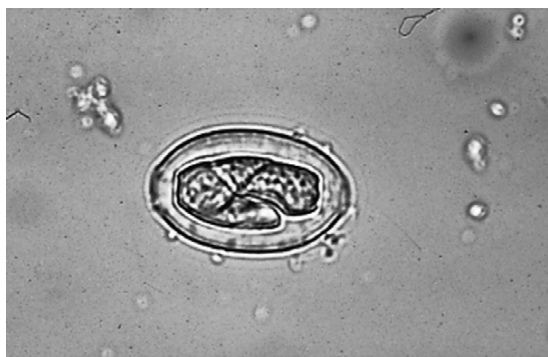

**FIGURE 18-49:** *Solenopotes capillatus* ("sucking louse of sheep").

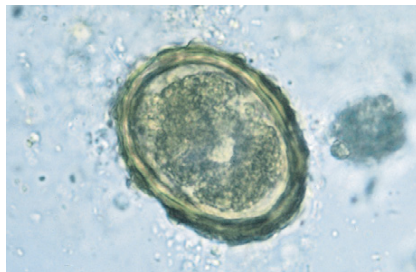


**FIGURE 18-50:** *Melophagus ovinus* ("sheep ked").

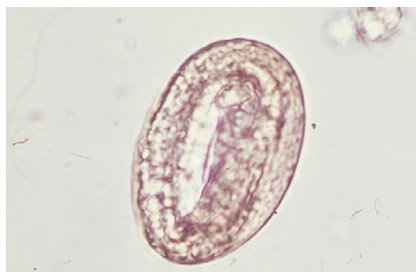### COMMON PARASITES OF SWINE



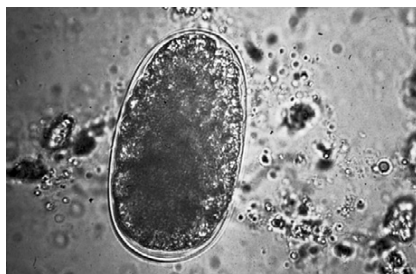**FIGURE 18-51:** *Ascarops strongylina* ("swine stomach worm").



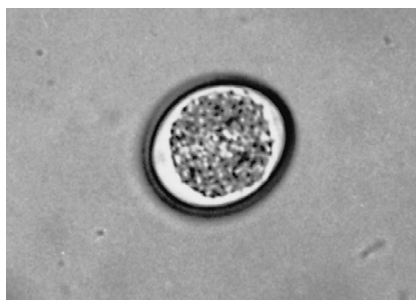
**FIGURE 18-52:** *Ascaris suum* ("swine roundworm").



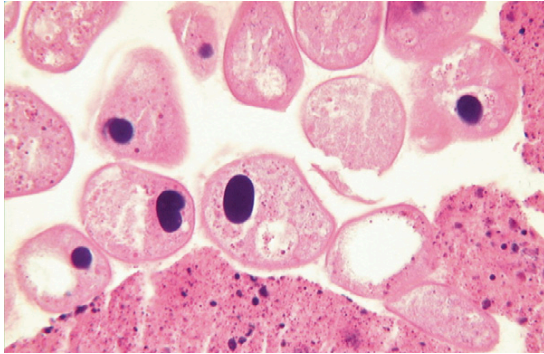
**FIGURE 18-53:** *Metastrongylus apri* ("swine lungworm").



**FIGURE 18-54:** *Stephanurus dentatus* ("swine kidneyworm").



**FIGURE 18-55:** *Cystoisospora suis* ("swine coccidia").

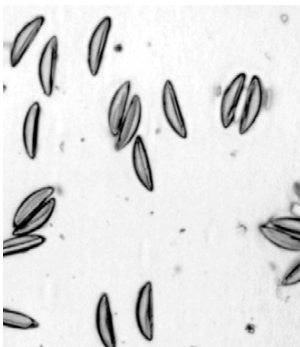


**FIGURE 18-56:** *Balantidium coli* ("balantidium").

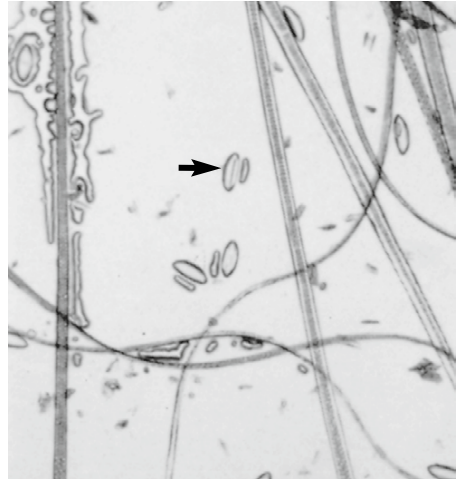

**FIGURE 18-57:** *Haematopinus suis* adult ("sucking lice of pigs").

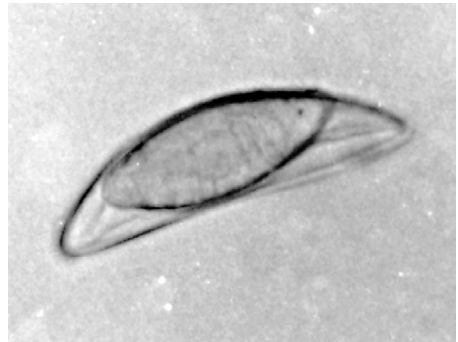## COMMON PARASITES OF EXOTIC PETS AND BIRDS



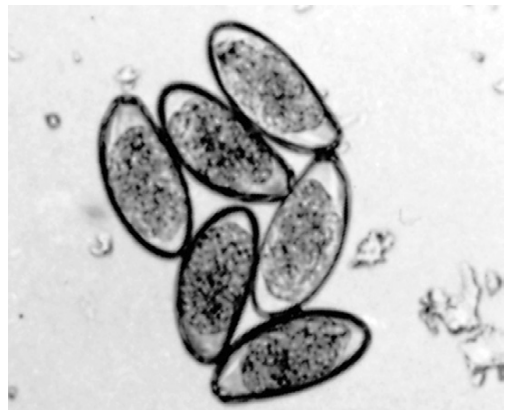
**FIGURE 18-58:** *Syphacia obvelata* ("pinworm of mice").



**FIGURE 18-59:** *Syphacia muris* ("pinworm of mice and rats"—cellophane tape technique).

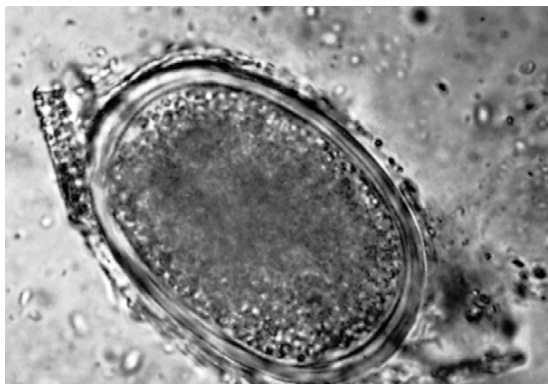

**FIGURE 18-60:** *Dentostomella translucida* ("pinworm of gerbils").

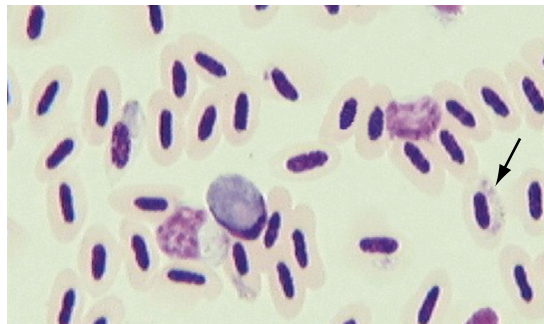


**FIGURE 18-61:** *Passalurus ambiguus* ("pinworm of rabbits").

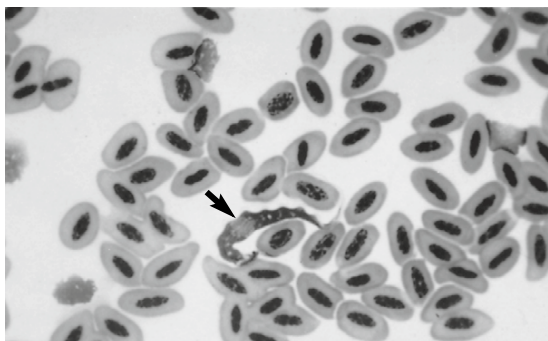




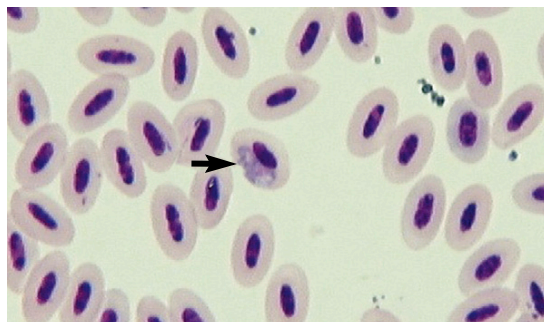
**FIGURE 18-62:** *Ascaridia* species ("roundworm of birds").



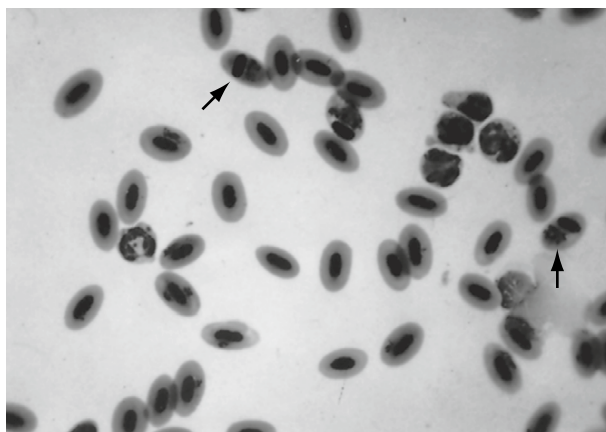
**FIGURE 18-63:** *Trichomonas gallinae* ("trichomona of birds").



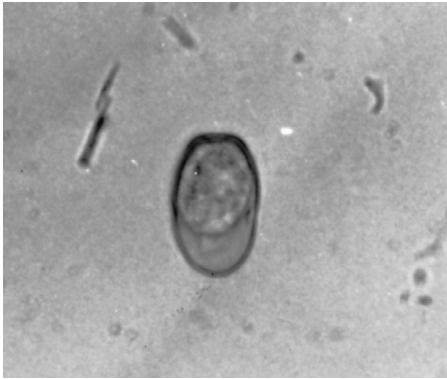**FIGURE 18-64:** *Trypanosoma* species ("trypanosomes of birds").



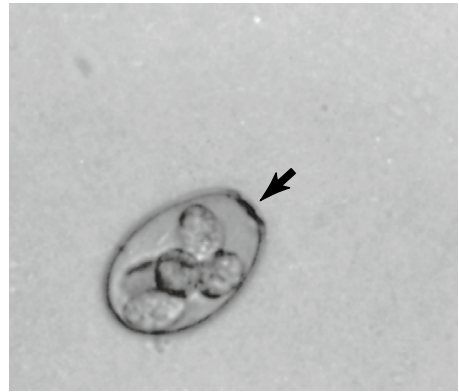**FIGURE 18-65:** *Haemoproteus* species ("haemoproteus of birds").



**FIGURE 18-66:** *Plasmodium* species ("avian malaria").



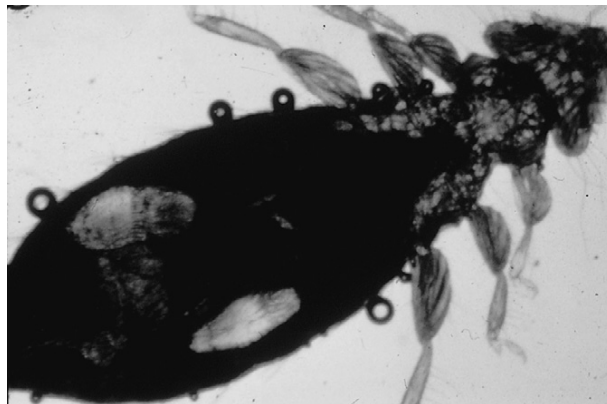
**FIGURE 18-67:** Unsporulated *Eimeria magna* ("coccidia of rabbits").



**FIGURE 18-68:** Sporulated *Eimeria magna* ("coccidia of rabbits").



**FIGURE 18-69:** *Goniocotes gallinae* ("fluff louse of poultry").

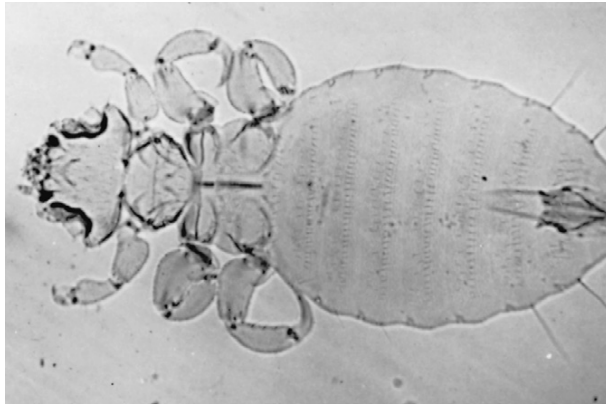


**FIGURE 18-70:** *Menacanthus stramineus* ("avian body louse").

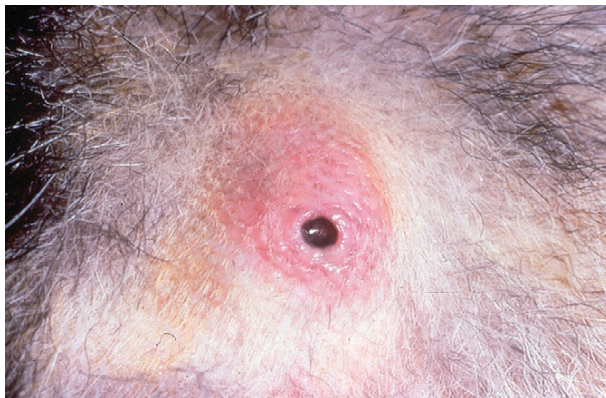



**FIGURE 18-71:** *Gliricola porcelli* ("guinea pig chewing louse").



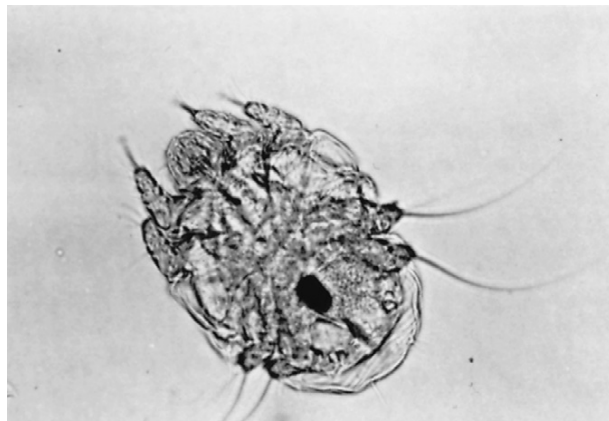
**FIGURE 18-72:** *Gyropus ovalis* ("guinea pig chewing louse").



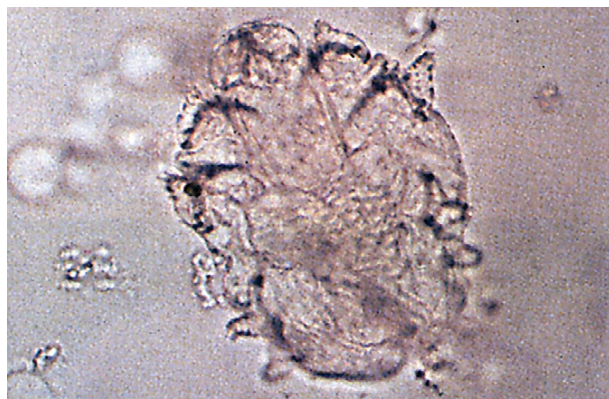**FIGURE 18-73:** *Cuterebra* species under skin ("wolves or warbles of rabbits").



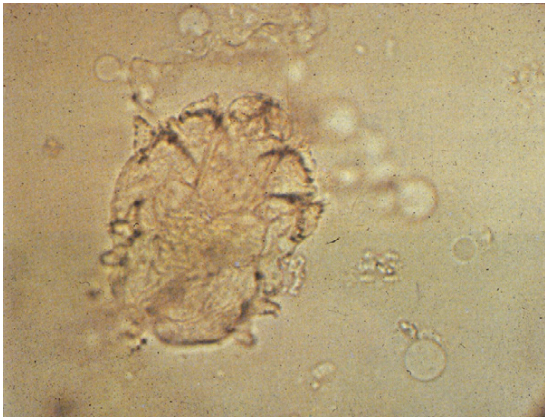
**FIGURE 18-74:** *Cuterebra* species larval stages ("wolves or warbles of rabbits").



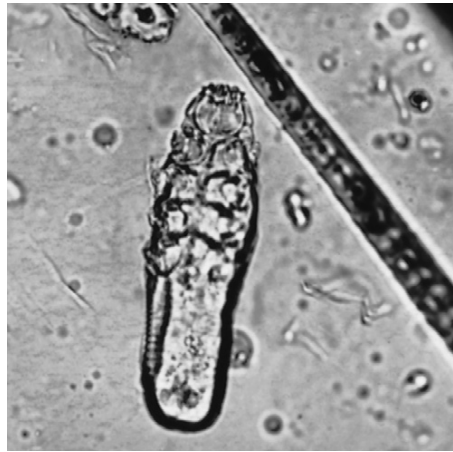**FIGURE 18-75:** *Psoroptes cuniculi* ("ear canker mite of rabbits").



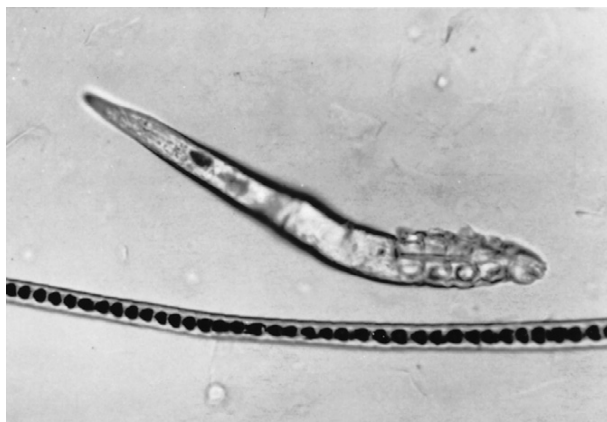**FIGURE 18-76:** *Trixacarus caviae* ("sarcoptic mite of guinea pigs").



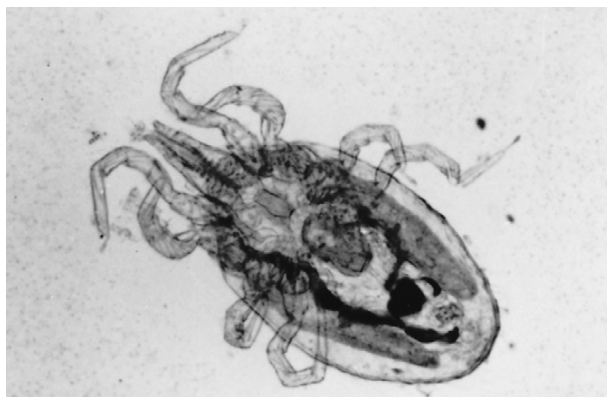**FIGURE 18-77:** *Cnemidocoptes pilae* ("sarcoptic mite of birds").



**FIGURE 18-78:** *Demodex criceti* ("demodectic mite of hamsters").

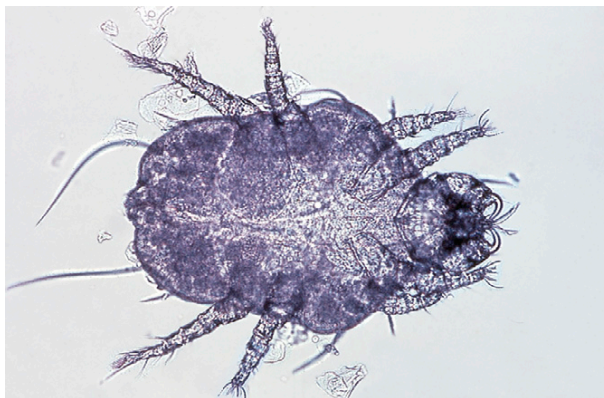

**FIGURE 18-79:** *Demodex aurati* ("demodectic mite of hamsters").

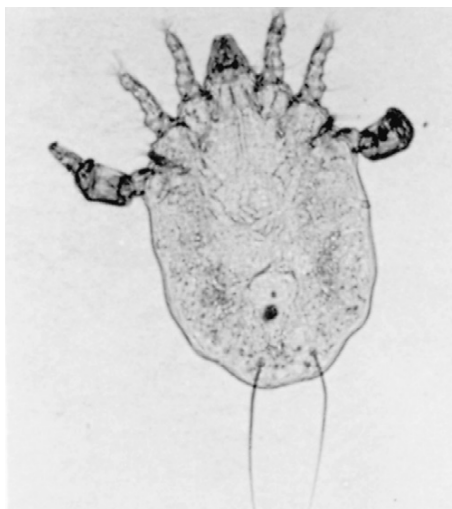


**FIGURE 18-80:** *Ornithonyssus bacoti* ("tropical mite of rats").

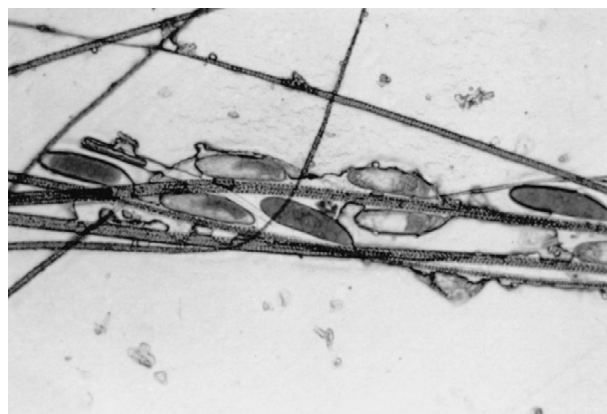




**FIGURE 18-81:** *Cheyletiella parasitivorax* ("fur mite of rabbits, dogs, and cats").




**FIGURE 18-82:** *Myocoptes musculus* ("fur mite of mice").



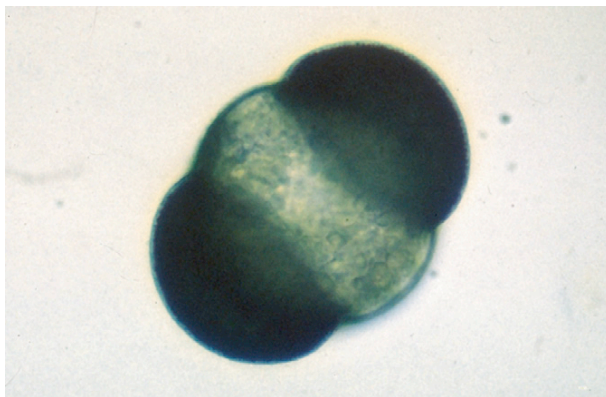
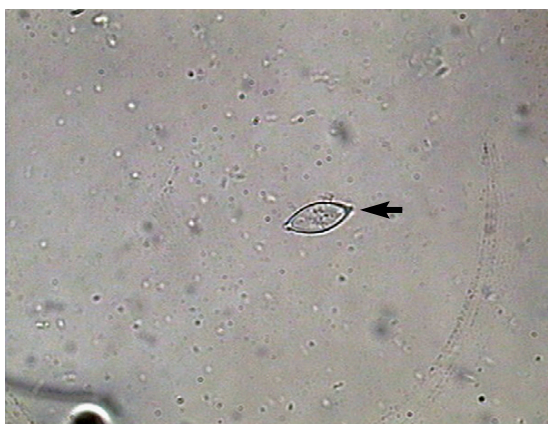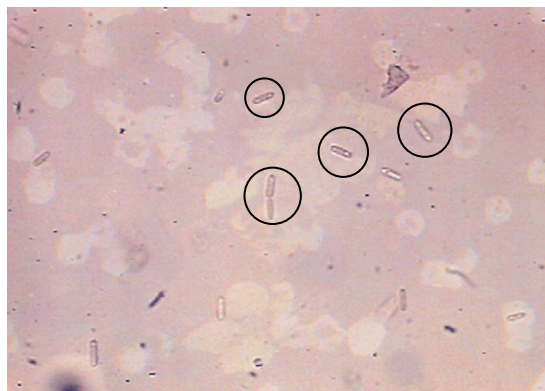
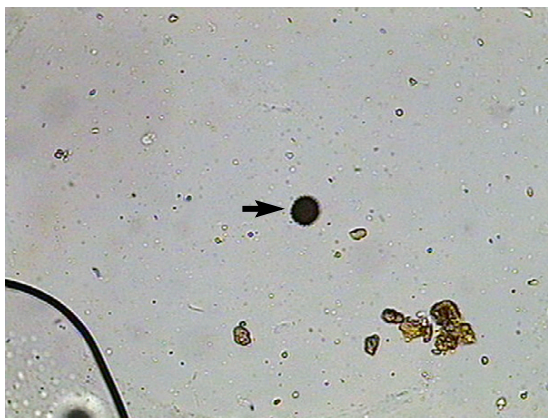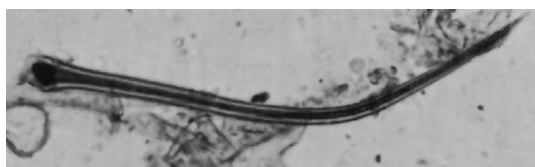**FIGURE 18-83:** *Myocoptes musculus* nits ("fur mite of mice" nits).



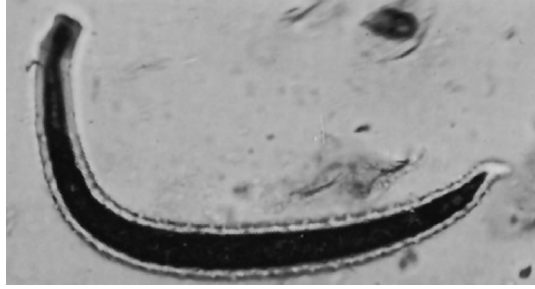
**FIGURE 18-84:** *Chirodiscoides caviae* ("fur mite of guinea pigs").



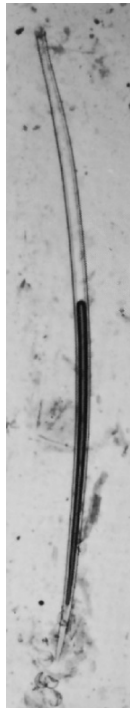
**FIGURE 18-85:** *Chirodiscoides caviae* (female "fur mite of guinea pigs").

**PSEUDOPARASITES****FIGURE 18-86:** Pine pollen.**FIGURE 18-87:** *Monocystis* (sporulated) parasite of the earthworm.**FIGURE 18-89:** *Saccharomycopsis guttulatus*, a yeast of the rabbit alimentary tract.**FIGURE 18-88:** Pollen.**FIGURE 18-90:** Plant hair. (From Bowman: *Georgis' parasitology for veterinarians*, ed 9, 2008, Elsevier.)





**FIGURE 18-91:** Plant hair. (From Bowman: Georgis' parasitology for veterinarians, ed 9, 2008, Elsevier.)



**FIGURE 18-92:** Plant hair. (From Bowman: Georgis' parasitology for veterinarians, ed 9, 2008, Elsevier.)

This page intentionally left blank

# APPENDIX

## Parasite Reference List by Species and Parasite Type

### PARASITES OF DOGS AND CATS

#### Nematodes

*Aelurostrongylus abstrusus*, pp.75  
*Acanthocheilonema reconditum*, pp.236  
*Ancylostoma braziliense*, pp.35, 36, 294  
*Ancylostoma caninum*, pp.8, 19, 25, 31, 32, 279, 280, 294, 296, 297, 344  
*Ancylostoma tubaeforme*, pp.31, 32  
*Aonchotheca putorii* or *Capillaria putorii*, p.28, 36  
*Pearsonema (Capillaria) feliscati*, p.45, 336  
*Pearsonema (Capillaria) plica*, pp.45, 336  
*Diectophyma renale*, pp.16, 44, 336  
*Dirofilaria immitis*, pp.4, 19, 37-9, 49, 210, 295, 300, 314, 328-31, 333-4, 338, 347  
*Dracunculus insignis*, p.19, 21, 46-9, 188, 194  
*Enterobius vermicularis*, p.36  
*Eucoleus aerophilus* or *Capillaria aerophila*, pp.28, 36, 38, 44-5, 346  
*Eucoleus böehmi*, p.44  
*Filaroides hirthi*, p.43  
*Filaroides milksi*, p.43  
*Filaroides osleri*, p.19, 43  
*Ollulanus tricuspis*, pp.28, 328  
*Pelodera strongyloides*, pp.5  
*Physaloptera* species, pp.19, 27-8, 328  
*Spirocerca lupi*, p.19, 20, 26, 196  
*Strongyloides stercoralis*, pp.16, 34-5, 298, 327  
*Strongyloides tumefaciens*, p.34  
*Thelazia californiensis*, pp.49  
*Toxascaris leonina*, pp.28-9, 30, 328, 344  
*Toxocara canis*, pp.28  
*Toxocara cati*, pp.28  
*Trichuris campanula*, p.35, 38

*Trichuris serrata*, p.16-7, 35, 46, 52  
*Trichuris vulpis*, pp.16, 19, 20, 32, 35, 46, 52  
*Uncinaria stenocephala*, pp.31-2, 34, 294-5

#### Cestodes

*Diphyllbothrium* species, pp.117-9  
*Dipylidium caninum*, pp.86-8, 103-6, 288-9, 311, 344-5  
*Echinococcus granulosus*, pp.89, 103, 112-3, 287  
*Echinococcus multilocularis*, pp.112  
*Mesocestoides* species, p.103, 114-5  
*Multiceps multiceps*, pp.89, 103, 110-1  
*Multiceps serialis*, pp.110, 112  
*Spirometra* species, pp.117-8, 289  
*Taenia hydatigena*, p.100-1, 106, 110  
*Taenia ovis*, p.106  
*Taenia pisiformis*, pp.87, 89, 103, 106, 108-9, 311, 345  
*Taenia taeniaeformis* or *Hydatigera taeniaeformis*, p.108, 110

#### Trematodes

*Alaria* species, p.136-7, 346  
*Heterobilharzia americanum*, pp.137, 139, 140  
*Nanophyetus salmincola*, p.136-7, 141  
*Paragonimus kellicotti*, pp.128, 137-8, 141, 345  
*Platynosomum fastosum*, p.135-6, 141

#### Acanthocephalans

*Oncicola canis*, pp.143, 147-8

## Protozoans

*Babesia canis*, pp.165-6, 347  
*Balantidium coli*, pp.151-2, 159, 172, 322, 353  
*Cryptosporidium* species, pp.161, 167, 173, 175, 283, 346  
*Cytauxzoon felis*, p.165-6  
*Entamoeba histolytica*, p.150-1, 158  
*Giardia* species, pp.150, 156-7, 174, 180, 182, 322, 345  
*Hepatozoon americanum*, p.166  
*Hepatozoon canis*, p.166  
*Isospora canis*, pp.159, 160, 167, 172-3, 175, 177, 324, 345, 352  
*Isospora felis*, pp.159, 160, 167, 172-3, 175, 177, 324, 345, 352  
*Isospora ohioensis*, pp.159, 160, 167, 172-3, 175, 177, 324, 345, 352  
*Isospora rivolta*, pp.159, 160, 167, 172-3, 175, 177, 324, 345, 352  
*Isospora wallacei*, pp.159, 160, 167, 172-3, 175, 177, 324, 345, 352  
*Leishmania* species, p.164-5  
*Sarcocystis* species, p.161  
*Toxoplasma gondii*, pp.160-3, 280-1, 334, 347  
*Trypanosoma cruzi*, pp.164

## Arthropods

*Amblyomma americanum*, p.259, 260, 264  
*Amblyomma maculatum*, p.260  
*Calliphora* species, p.216-7  
*Cheyletiella* species, pp.247  
*Cochliomyia hominivorax*, p.220-2  
*Ctenocephalides felis*, pp.226-7, 229, 230  
*Culex* species, p.209, 210  
*Cuterebra* species, p.221-4, 347, 356-7  
*Demodex canis*, pp.241, 243, 348  
*Demodex cati*, pp.242  
*Dermacentor andersoni*, p.253, 258-9  
*Dermacentor occidentalis*, p.253, 259  
*Dermacentor variabilis*, p.253-4, 258  
*Glossina* species, p.211  
*Hippelates* species, p.216, 219  
*Ixodes scapularis*, p.253, 256-7  
*Linognathus setosus*, p.200-1, 348  
*Lucilia* species, p.216-7

*Lynxacarus radovskyi*, p.248  
*Musca autumnalis*, p.207, 216-8  
*Musca domestica*, p.212-3, 216-7, 219  
*Notoedres cati*, p.233-6  
*Otobius megnini*, p.253-6  
*Otodectes cynotis*, pp.240-1, 338, 348  
*Panstrongylus* species, p.199  
*Phaenicia* species, p. 216-8  
*Phormia* species, p.216-7, 219  
*Pneumonyssoides caninum*, pp.245, 335  
*Pulex irritans*, p.228  
*Rhipicephalus sanguineus*, p.253-4, 257-8  
*Rhodnius* species, p.199  
*Sarcophaga* species, p.216, 218-20  
*Sarcoptes scabiei*, pp.232-6, 302, 347  
*Triatoma* species, p.199  
*Trombicula* species, p.244

## Pentastomes

*Linguatula serrata*, pp.268, 271, 303, 335

## Annelids

*Hirudo medicinalis*, pp.275-7

## PARASITES OF RUMINANTS

### Nematodes

*Bunostomum* species, p.50  
*Chabertia* species, p.50  
*Cooperia* species, p.50  
*Dictyocaulus viviparus*, pp.53-4, 350  
*Elaeophora schneideri*, pp.52-3, 56  
*Gongylonema pulchrum*, p.49, 50  
*Haemonchus* species, p.50  
*Marshallagia* species, p.51  
*Muellerius capillaris*, pp.54-5, 351  
*Nematodirus* species, p.51, 350  
*Oesophagostomum* species, p.50  
*Ostertagia* species, p.50  
*Protostrongylus* species, p.55  
*Setaria cervi*, pp.56-7  
*Stephanofilaria stilesi*, p.55-6  
*Strongyloides papillosus*, p.52, 68

*Thelazia gulosa*, pp.56  
*Thelazia rhodesii*, pp.56  
*Trichostrongylus* species, pp.50, 350  
*Trichuris ovis*, p.52

### Cestodes

*Cysticercus bovis*, p.99, 108, 285  
*Cysticercus cellulosae*, p.99, 100  
*Cysticercus tenuicollis*, p.100-1, 108  
*Moniezia benedini*, pp.100-1, 108  
*Moniezia expansa*, pp.95-7  
*Taenia hydatigena*, p.100-1, 106  
*Taenia saginata* or *Taeniarhynchus saginata*,  
 pp.99, 100, 285  
*Thysanosoma actinoides*, pp.88, 95, 98

### Trematodes

*Cotylophoron* species, p.132-3  
*Dicrocoelium dendriticum*, p.131-2  
*Fasciola hepatica*, pp.123-4, 133-4, 351  
*Fascioloides magna*, pp.124, 134  
*Paramphistomum* species, p.132-3

### Protozoans

*Babesia bigemina*, pp.168, 351  
*Cryptosporidium* species, pp.161,167, 173, 175,  
 283, 346  
*Eimeria bovis*, pp.167, 351  
*Eimeria zuernii*, pp.167  
*Trichostrongylus foetus*, pp.150, 168-9, 339  
*Trypanosoma* species, pp.168, 175, 351

### Arthropods

*Aedes* species, p.210  
*Amblyomma americanum*, p.259, 260  
*Amblyomma maculatum*, p.260  
*Anopheles* species, p.210  
*Boophilus annulatus*, p.260-1  
*Calliphora* species, p.216-7  
*Chorioptes bovis*, pp.239  
*Chorioptes caprae*, pp.239  
*Chorioptes ovis*, pp.210  
*Chrysops* species, p.220-2

*Cochliomyia hominivorax*, p.209-10  
*Culex* species, p.207-9, 219  
*Culicoides* species, p.207-9, 219  
*Damalinia bovis*, p.200, 351  
*Demodex* species, pp.241-3  
*Dermacentor andersoni*, p.253, 258-9  
*Dermacentor occidentalis*, p.253, 9  
*Glossina* species, p.211  
*Haematobia irritans*, p.207, 211, 213-4  
*Hippelates* species, p.216, 219  
*Hypoderma lineatum*, p.223  
*Lucilia* species, pp.216-7  
*Lutzomyia* species, p.208  
*Melophagus ovinus*, p.207, 211, 214, 215, 356  
*Musca autumnalis*, p.207, 216-8  
*Musca domestica*, p.212-3, 216-7  
*Oestrus ovis*, p.225-6  
*Otobius megnini*, p.253-6  
*Phaenicia* species, p.216-8  
*Phormia* species, p.216-7, 219  
*Psoroptes bovis*, p.238-9  
*Psoroptes ovis*, p.238  
*Sarcophaga* species, p.216, 218-9, 220  
*Sarcoptes scabiei*, pp.232-7, 302, 305  
*Simulium* species, p.207  
*Solenopotes capillatus*, p.200, 201, 352  
*Stomoxys calcitrans*, p.207, 211-4, 218  
*Tabanus* species, p.210, 211  
*Trombicula* species, p.244

### Annelids

*Haemopsis terrestris*, p. 275

## PARASITES OF HORSES

### Nematodes

*Dictyocaulus arnfieldi*, p.64  
*Draschia megastoma*, p. 57, 64  
*Habronema microstoma*, pp.57, 64  
*Habronema muscae*, pp.57, 64  
*Onchocerca cervicalis*, p.64-5  
*Oxyuris equi*, pp.62-4, 326, 349  
*Parascaris equorum*, pp.58-9, 60, 348  
*Setaria equina*, pp.66



*Strongyloides westeri*, p.61-2, 295  
*Strongylus edentatus*, p.60  
*Strongylus equinus*, p.60  
*Strongylus vulgaris*, pp.18-9, 60-1, 349  
*Thelazia lacrymalis*, p.66  
*Trichostrongylus axei*, p.67

## Cestodes

*Anoplocephala magna*, p.101-2  
*Anoplocephala perfoliata*, pp.101-2  
*Paranoplocephala mamillana*, p.101-2

## Protozoans

*Babesia caballi*, pp.170-1, 349  
*Babesia equi*, pp.170  
*Eimeria leuckarti*, pp.170, 349  
*Giardia equi*, pp.150, 169  
*Klossiella equi*, p.171  
*Sarcocystis neurona*, p.171, 180

## Arthropods

*Aedes* species, p.210  
*Amblyomma americanum*, p.166 , 260 , 260b  
*Amblyomma maculatum*, p.260-1  
*Anopheles* species, p.101-3  
*Calliphora* species, p.217-8, 220-1  
*Chorioptes equi*, pp.239-0  
*Chrysops* species, p.210-1  
*Cochliomyia hominivorax*, p.220-2  
*Culex* species, p.209-10  
*Culicoides* species, p.208-9  
*Demodex equi*, pp.241-4  
*Dermacentor andersoni*, p.258-9  
*Dermacentor occidentalis*, p.259-60  
*Gastrophilus* species, pp.224-5, 312  
*Glossina* species, p.211-2  
*Haematobia irritans*, p.55, 213-4  
*Ixodes scapularis*, p.257  
*Lucilia* species, p.217-218, 220-1  
*Lutzomyia* species, p.207 , 208  
*Musca autumnalis*, p.2-3, 56, 217  
*Musca domestica*, p.216-7  
*Otobius megnini*, p.255-6

*Phaenicia* species, p.217-8, 220-1  
*Phormia* species, p.217-8, 220-1  
*Psoroptes equi*, p.238-9  
*Sarcophaga* species, p.218-221, 312-3  
*Sarcoptes scabiei*, pp.232-3, 302  
*Simulium* species, p.207-8  
*Stomoxys calcitrans*, p.212-3  
*Tabanus* species, p.210-1  
*Trombicula* species, p.244-5

## Annelids

*Dinobdella* species, p.275  
*Limnatis* species, p.275

## PARASITES OF SWINE

### Nematodes

*Ascaris suum*, pp.67-8, 145-7  
*Ascarops strongylina*, pp.66-7  
*Hyostrongylus rubidus*, p.67  
*Metastrongylus elongatus*, pp.70  
*Oesophagostomum dentatum*, p.68-9  
*Physocephalus sexalatus*, p.66-7  
*Stephanurus dentatus*, pp.70-1  
*Strongyloides ransomi*, p.68  
*Trichinella spiralis*, pp.69-72, 299-300  
*Trichostrongylus axei*, p.67  
*Trichuris suis*, p.69

### Cestodes

*Taenia solium*, pp.99-100, 286-7

### Acanthocephalans

*Macracanthorhynchus hirudinaceus*, pp.145-7, 196

### Protozoans

*Balantidium coli*, pp.151, 159, 172  
*Cryptosporidium* species, pp.159, 172-3, 323-4

**Arthropods**

*Cochliomyia hominivorax*, p.220-2  
*Demodex phylloides*, pp.221-4  
*Glossina species*, p.211-2  
*Haematopinus suis*, p.200  
*Musca autumnalis*, p.217  
*Musca domestica*, p.2-3, 56, 217  
*Sarcoptes scabiei*, pp.232-3, 302  
*Simulium species*, p.207-8  
*Trombicula species*, p.244-5

**Annelids**

*Dinobdella species*, p.275  
*Limnatis species*, p.275

**PARASITES OF BIRDS****Nematodes**

*Ascaridia species*, p.79-80  
*Capillaria species*, p.80  
*Dyspharynx nasuta*, p.79-80  
*Heterakis gallinarum*, p.174  
*Spiraptera inesta*, p.79-80  
*Tetrameres species*, p.16-17, 79-80

**Trematodes**

*Schistosoma species*, pp.140

**Protozoans**

*Aegyptianella species*, p.177  
*Atoxoplasma serini*, p.177  
*Cryptosporidium species*, pp.161, 167, 173  
*Eimeria species*, pp.167, 178-179  
*Giardia species*, pp.173-4  
*Haemoproteus species*, p.175-6, 215  
*Histomonas meleagridis*, pp.174  
*Isospora species*, pp.159, 172-3, 323-4  
*Leucocytozoon species*, p.176-7, 207  
*Plasmodium species*, p.176, 210  
*Trichomonas gallinae*, p.174-5  
*Trypanosoma species*, pp.168, 175, 212, 329

**Arthropods**

*Argas persicus*, p.256  
*Cnemidocoptes pilae*, p.236-7  
*Cnemidocoptes mutans*, p.236-7  
*Dermanyisus gallinae*, p.245-6  
*Echidnophaga gallinacea*, p.226-231  
*Glossina species*, p.211-2  
*Goniocotes gallinae*, p.200  
*Haemaphysalis leporispalustris*, p.261-2  
*Lynchia species*, p.215-6  
*Menacanthus stramineus*, p.200  
*Ornithonyssus sylviarum*, p.245-6  
*Pseudolynchia species*, p.215-6

**Annelids**

*Theromyzon tessulatum*, p.275

**PARASITES OF RABBITS****Nematodes**

*Obeliscoides cuniculi*, p.78-9  
*Passalurus ambiguus*, p.77  
*Trichostrongylus calcaratus*, p.78-9

**Protozoans**

*Eimeria irresidua*, pp.167  
*Eimeria magna*, pp.167  
*Eimeria media*, pp.167  
*Eimeria perforans*, pp.167  
*Eimeria stiedai*, pp.167

**Arthropods**

*Cediopsylla simplex*, p.226-231  
*Cheyletiella parasitivorax*, pp.247-8  
*Cuterebra species*, p.222-3  
*Dermacentor occidentalis*, p.259-260  
*Dermacentor variabilis*, p.258  
*Haemaphysalis leporispalustris*, p.261-2  
*Hemodipsus ventricosus*, p.206  
*Listrophorus gibbus*, p.252  
*Odontopsylla multispinosus*, p.226-231

*Psoroptes cuniculi*, pp.235, 238  
*Sarcoptes scabiei*, pp.232-3, 302

## PARASITES OF GUINEA PIGS

### Nematodes

*Paraspidodera uncinata*, p.76

### Protozoans

*Cryptosporidium wrairi*, pp.184  
*Eimeria caviae*, pp.183-4  
*Entamoeba caviae*, p.183  
*Giardia caviae*, pp.179-180  
*Giardia muris*, pp.179-180  
*Tritrichomonas caviae*, p.182-3

### Arthropods

*Chirodiscoides caviae*, p.251-2  
*Dermacentor andersoni*, p.258-9  
*Dermacentor occidentalis*, p.259-260  
*Dermacentor variabilis*, p.258  
*Gliricola porcelli*, p.205-6  
*Gyropus ovalis*, p.205-6  
*Notoedres muris*, p.234  
*Ornithonyssus bacoti*, p.246-7  
*Panstrongylus species*, p.199  
*Rhodnius species*, p.199  
*Sarcoptes scabiei*, pp.232-3, 302  
*Triatoma species*, p.199  
*Trixacarus caviae*, pp.235, 237

## PARASITES OF RATS

### Nematodes

*Aspicularis tetraptera*, p.72-4  
*Syphacia muris*, pp.72-4  
*Syphacia obvelata*, p.72-4  
*Trichosomoides crassicauda*, p.74-5

### Cestodes

*Hymenolepis diminuta*, p.94-95, 290-1  
*Hymenolepis nana*, pp.94-95, 290-1

### Protozoans

*Eimeria nieschultzi*, pp.181-2  
*Giardia muris*, pp.179-180  
*Spironucleus muris*, p.179-180  
*Tetratrichomonas microti*, p.179  
*Tritrichomonas muris*, p.179

### Arthropods

*Cuterebra species*, p.222-223  
*Dermacentor andersoni*, p.258-9  
*Dermacentor occidentalis*, p.259-260  
*Dermacentor variabilis*, p.258  
*Notoedres muris*, p.234  
*Ornithonyssus bacoti*, p.246-7  
*Panstrongylus species*, p.199  
*Polyplax spinulosa*, p.204  
*Radfordia ensifera*, p.251  
*Rhodnius species*, p.251  
*Triatoma species*, p.199

## PARASITES OF MICE

### Nematodes

*Aspicularis tetraptera*, p.72-4  
*Syphacia muris*, p.72-4  
*Syphacia obvelata*, p.72-4

### Cestodes

*Hymenolepis diminuta*, p.94-95, 290-1  
*Hymenolepis nana*, pp.94-95, 290-1

### Protozoans

*Eimeria falciformis*, pp.168, 178-9, 323-4  
*Eimeria ferrisi*, pp.168, 178-9, 323-4  
*Eimeria hansonorum*, pp.168, 178-9, 323-4  
*Eimeria hansomium*, pp.168, 178-9, 323-4

*Giardia muris*, pp.179-180  
*Klossiella muris*, p.181  
*Spironucleus muris*, p.179-180  
*Tetratrichomonas microti*, p.179  
*Tritrichomonas muris*, p.179

### Arthropods

*Cuterebra* species, p.5, 222-3  
*Dermacentor andersoni*, p.258-9  
*Dermacentor occidentalis*, p.259-260  
*Dermacentor variabilis*, p.258  
*Ixodes scapularis*, p.257  
*Myobia musculi*, p.249-251  
*Myocoptes musculinus*, p.249-251  
*Polyplax serrata*, p.202-4  
*Ornithonyssus bacoti*, p.246-7  
*Radfordia affinis*, p.249-251  
*Radfordia ensifera*, p.251

## PARASITES OF HAMSTERS

### Nematodes

*Syphacia muris*, p.72-4  
*Syphacia obvelata*, p.72-4

### Cestodes

*Hymenolepis diminuta*, p.94-5, 290-1  
*Hymenolepis nana*, pp.94-5, 290-1

### Protozoans

*Giardia* species, pp.182  
*Spironucleus muris*, p.179-180  
*Tritrichomonas muris (criceti)*, p.179

### Arthropods

*Demodex aurati*, p.241-4  
*Demodex criceti*, p.242  
*Ornithonyssus bacoti*, p.241-4

## PARASITES OF GERBILS

### Nematodes

*Dentostomella translucida*, p.75-6, 353

### Cestodes

*Hymenolepis diminuta*, p.94-5, 290  
*Hymenolepis nana*, pp.290, 346

### Arthropods

*Demodex aurati*, pp.242-3, 358  
*Demodex criceti*, pp.242-3, 358  
*Hoplopleura meridionidis*, p.204-5

## PARASITES OF FISH

### Protozoans

*Cryptocaryon irritans*, p.184  
*Ichthyophthirius multifiliis*, p.151, 184

## PARASITES OF REPTILES

### Pentastomes

*Armillifer* species, pp.268  
*Porocephalus crotali*, pp.268-272  
*Porocephalus* species, pp.268-272  
*Kiricephalus* species, pp.268

### Arthropods

*Glossina* species, p.211-2

This page intentionally left blank



# GLOSSARY

**Aberrant parasite** Parasite that has wandered from its usual site of infection into an organ or location in which it does not ordinarily live; also called *erratic parasite*.

**Acanthella** Larval acanthocephalan within the intermediate host, where the acanthella will develop into a juvenile acanthocephalan, the *cystacanth*.

**Acanthocephalan** A thorny-headed worm.

**Acanthor** Larval acanthocephalan parasite within an egg.

**Acariasis** Any infestation or infection by either mites or ticks.

**Acaricides** Chemical compounds developed to kill mites and ticks.

**Acarines** Mites

**Acetabulum** One of four suckers on anterior end of a true tapeworm (*eucestode*).

**Acquired toxoplasmosis** Infection with *Toxoplasma gondii* by ingestion of sporulated oocysts or ingestion of bradyzoites from infected meat.

**Aliquot** Percentage of a solution or sample.

**Alopecia** Hair loss

**Amastigote** Resting cyst stage of some protozoans.

**Amicrofilaremic** Referring to the absence of immature filarial parasites.

**Amphistome** Type of digenetic fluke with an oral sucker on one end and a ventral sucker on the other end.

**Annelids** Earthworms

**Anthelmintics** Chemical compounds developed to kill roundworms, tapeworms, flukes, and thorny-headed worms; also *anthelminthics*.

**Antiprotozoals** Chemical compounds developed to kill protozoan organisms.

**Apicomplexan** Banana-, comma-, or boomerang-shaped protozoan found in epithelial cells of intestine, in blood cells, and in cells of reticuloendothelial and nervous systems. Apicomplexans have complex life cycles that are intimately integrated into physiology of host's body. Their locomotory (movement) organelles are internal and are not grossly visible as with other types of protozoans.

**Aragasid** A family of ticks with soft bodies

**Armed tapeworm** True tapeworm that possesses a rostellum on its anterior end.

**Arthropodology** The study of arthropods.

**Arthropods** The creatures possessing a chitinous exoskeleton and jointed legs.

**Ascariasis** Infection with ascarids, either larval or adult.

**Ascaroid** One of 4 egg types produced by nematodes (see figure 3-9 for characteristic look).

**Aseptically** Referring to the use of sterile technique.

**Axostyle** A filamentous or hyaline rod-like structure passing through the center of some flagellate protozoans that has a skeletal function.

**Baermann technique** Type of diagnostic technique in which nematode larvae are collected using gravity (sedimentation).

**Benzimidazoles** A family of anthelmintics that include fenbendazole, oxfendazole and albendazole.

**Body Cavity** Hollow area of the body that contains the major organs of an organism.

**Borreliosis** Lyme disease

**Bothria** Two slitlike holdfast organs on anterior end of a pseudotapeworm.

**Bradyzoites** Slowly multiplying stages of toxoplasmosis within the muscle of an intermediate host.

**Buccal cavity** Large opening that connects to the mouth of a nematode; connects the mouth to the esophagus.

**Bursal rays** Fingerlike projections that make up the copulatory bursa of a male nematode.

**Calcareous corpuscles** Microscopic calcium deposits unique to the tissues of cestodes (tapeworms); also called *calcareous bodies*.

**Cantharidin** Toxic or blistering compound found in a certain group of beetles; often referred to as "Spanish fly" but has no aphrodisiac effect.

**Capitulum** Mouthparts of an acarine (mite or tick).

**Catarrhal** Inflammation of the mucous membranes

**Cercaria** Asexual stage within the life cycle of a digenetic trematode. The cercarial stage emerges from the snail, the first intermediate host. Each cercarial stage will produce one metacercarial stage, found in the second intermediate host or on vegetation. Sometimes the cercaria can penetrate the definitive host directly.

**Cervical alae** Lateral expansion of the cuticle in anterior end of nematodes.

**Cestodes** Tapeworms.

**Chelicerae** Two cutting or lacerating organs of the capitulum.

**Chelicerata** Subphylum of the Arthropods that include the mites, ticks, spiders and scorpions that possess chelicerae mouth parts.

**Chitin** Hard but elastic body covering that envelops the entire body of an arthropod.

- Cilia** Tiny hairs that cover the body surface of one type of protozoans, the ciliates, which move by these beating hairs.
- Ciliates** Protozoans that possess cilia.
- Cloaca** Opening of the intestine of the male nematode to the outside.
- Coelom** The true body cavity
- Coenurus** Type of metacestode (larval tapeworm) stage characterized by a large, fluid-filled bladder with a number of invaginated (inside-out) scolices attached to the wall of the bladder.
- Commensalism** Type of symbiotic relationship in which one symbiont benefits while other neither benefits nor is harmed.
- Common name** Name for a living organism in different regions of the world; may refer to different organisms in different places.
- Complex metamorphosis** One of two types of metamorphosis by insects; four developmental stages are egg, larva (maggot), pupa, and adult. Each stage is morphologically and structurally different from the other stages.
- Copepod** An aquatic Crustacean
- Congenital toxoplasmosis** Infection of *Toxoplasma gondii* acquired by the fetus during pregnancy.
- Copulatory bursa** Flattened, lateral expansion of a nematode's cuticle in posterior region of certain male nematodes; serves to hold onto or grasp the female nematode during the mating process; composed of fingerlike projections called *bursal rays*.
- Coracidium** Ciliated hexacanth embryo unique to the pseudotapeworms (cotylodans); when ingested by the first intermediate host (an aquatic crustacean), forms a procercoid within the intermediate host.
- Cotylodan** Pseudotapeworm, or "false" tapeworm.
- Cutaneous larva migrans** Migration of larval stages of a nematode through the skin of humans, most often seen with *Ancylostoma braziliense*.
- Cyst stage** Nonmotile, resistant stage of a protozoan parasite.
- Cystacanth** Juvenile acanthocephalan that possesses an inverted proboscis.
- Cysticercoid** Type of metacestode (larval tapeworm) stage characterized by a small, fluid-filled bladder containing a single, noninvaginated scolex; usually microscopic.
- Cysticercus** Type of metacestode (larval tapeworm) stage characterized by a large, fluid-filled bladder containing a single invaginated (inside-out) scolex.
- Definitive host** Host that harbors the adult, sexual, or mature stages of the parasite.
- Demodicosis** Infection with demodectic (*Demodex*) species of mites.
- Dermatitis** Inflammation of the skin.
- Dioecious** Having separate sexes, both male and female; the nematodes and the arthropods are dioecious.
- Diptera** Two winged flies
- Dipterans** Referring to two winged flies
- Dipylidium egg** Tapeworm egg type containing a packet of multiple hexacanth within one egg.
- Direct life cycle** Life cycle that does not involve an intermediate host.
- Ectoparasite** Parasite that lives *on* the body of the host.
- Ectoparasitism** Parasitism by an external parasite; an ectoparasite will produce an *infestation* on the host.
- ELISA test** Enzyme-linked immunosorbent assay, an immunodiagnostic technique that detects the presence of antigen.
- Embryophore** Tapeworm hexacanth embryo with striated eggshell.
- Empodia** Clawlike features on the end of the second pair of legs of *Myobia musculi* and *Radfordia affinis*.
- Encysted** Encapsulated in suspended animation
- Endoparasite** Parasite that lives *within* the body of the host; an endoparasite will produce an *infection* within that host.
- Endoparasitism** Parasitism by an internal parasite.
- Endosome** A tiny pinpoint center within the nucleus of the amoebas.
- Entomologist** One who specializes in the study of insects.
- Erratic parasite** See Aberrant parasite.
- Eucestode** True tapeworm.
- Euryxenosus parasite** Parasite with a very broad host range.
- Excoriation** Self-induced skin trauma.
- Facultative myiasis** Condition resulting from fly larvae, normally free-living, that become parasitic and use a host for their development.
- Facultative parasite** Organism that is usually free-living (nonparasitic) in nature that develops a parasitic existence in certain hosts.
- Feathered edge** Thinnest part of a blood smear at the edges.
- Festoons** Indentations or folds along the margin of an external body part.
- Fistula** Pore or hole within tissue.
- Flagellum** Long, whiplike or lashlike appendage that is used by group of protozoans (the flagellates) as a means of moving about in a fluid medium.
- Flea dirt** Partially digested blood defecated by fleas; also called *flea feces* and *flea frass*.
- Flotation solutions** Liquids used to float parasite ova, cysts, and larvae for identification.
- Fly strike** Lesion(s) produced in the tissues of vertebrate hosts by maggots or fly larvae.
- Free-living** Life cycle stage that does not require a host to survive.
- Gadding** Action of a vertebrate host marked by running away from irritating flies.

**Gastritis** Inflammation of the stomach.

**Genus name** The group a particular type of animal, parasite or plant belongs too.

**Gravid proglottids** Oldest segments of a tapeworm or pseudotapeworm farthest from the scolex or bothria that contain spent or degenerated reproductive organs and viable eggs.

**Helminths** Parasitic worms

**Hemocoel** A body cavity filled with a blood-like fluid.

**Hemolymph** Blood-like fluid that bathes the internal organs of arthropods.

**Hermaphroditic** Having complete sets of both male and female reproductive organs; the tapeworms and the flukes (except for the schistosomes) are hermaphroditic.

**Hexacanth embryos** Type of tapeworm egg containing a six-toothed embryo (an embryo that contains six hooklets).

**Hippoboscid flies** Winged dipterans that parasitize wild birds.

**Hirsute** Very hairy

**Hirudin** Anticoagulant produced in the oral cavity of leeches.

**Hirudiniasis** Infestation with leeches.

**Holdfast organelle** Scolex or head of the pseudotapeworm.

**Homoxenous parasite** Parasite that will infect only one type of host; also called *monoxenous parasite*.

**Host** In a parasitic relationship, the member in which or on which the parasite lives.

**Hydatid cyst** Large, fluid filled bladder that contains brood capsules, which bud from the internal germinal membrane; each brood capsule contains several protoscolices.

**Hydrometer** Tool used for measuring specific gravity of solutions.

**Hypodermis** Thin layer beneath the cuticle that secretes the cuticle layer of the nematode.

**Hypostome** Penetrating, anchorlike sucking organ of the tick.

**Idiosoma** Abdomen of a mite or a tick.

**Immature proglottids** Youngest segments closest to the scolex or bothria of the tapeworm or pseudotapeworm and contains sexually immature reproductive organs.

**Incidental parasite** Parasite that is found in a host in which it does not usually live.

**Indirect life cycle** Life cycle of a parasite that requires an intermediate host.

**Infection** A condition caused by an endoparasite, within the host's body.

**Infective third-stage larva** Stage in the life cycle that is able to infect the definitive host.

**Infestation** A condition caused by an ectoparasite, outside or on the host's body.

**Inornate** Species of ticks with a reddish or mahogany color.

**Insecticides** Chemical compounds developed to kill insects.

**Intermediate host** Host that harbors the larval, juvenile, immature, or asexual stages of the parasite. A parasite may have more than one intermediate host.

**Invaginated scolices** Tapeworm heads turned inside out within the bladder worm life stage.

**Ixodid** Tick family with hard bodies.

**Lappets** Round protuberances behind the suckers of the scolex in *Anoplocephala perfoliata*.

**Larviparous** Type of female nematode that retains her eggs within the uterus and produces live first-stage larvae.

**Leaf Crown** The collection of papillae of nematodes.

**Leeches** Bloodsucking annelids.

**Life cycle** Development of a parasite through its various life stages. Every parasite has its own distinct, individual life cycle with at least one *definitive host* and may have one or more *intermediate hosts*.

**Linguatuliiasis** See pentastomiasis

**Linguatulosis** See pentastomiasis

**Linnaean classification scheme** Classification for all living organisms (animals, plants, fungi, protozoa, and algae) perfected by Linnaeus, an early Swedish biologist. Every living organism can be classified using the following scheme: kingdom, phylum, class, order, family, genus, and species.

**Maggots** Fly larvae.

**Mandibulata** Subphylum of Arthropods that possess mandibulate mouth parts

**Mature proglottids** The segments in the middle of the tapeworm or pseudotapeworm body that contain sexually mature reproductive organs.

**Measly meat** Meat that is infected with the cysticerci (larval stages) of certain human and canine tapeworms; includes measly beef (*Cysticercus bovis*), measly pork (*Cysticercus cellulosae*), and measly mutton (*Cysticercus ovis*).

**Megablastic anemia** Anemia caused by the loss of vitamin B12.

**Metacercaria** Asexual stage within life cycle of a digenetic trematode. The cercarial stage emerges from the snail (first intermediate host) and produces one metacercarial stage. If the cercaria is ingested by the second intermediate host, it will encyst within its tissues. The metacercarial stage may be found encysted on vegetation.

**Metacestode** Larval tapeworm found within the intermediate host; types of metacestodes include cysticercoid, cysticercus, coenurus, hydatid, tetrathyridium, proceroid, plerocercoid, and sparganum

- Metamorphosis** To achieve the adult stage, an insect must undergo a series of developmental changes in size, form, or structure called metamorphosis; two types are simple metamorphosis and complex metamorphosis.
- Metazoan parasites** Multicellular or complex organisms that include trematodes, tape-worms, pseudotape-worms, roundworms, thorny-headed worms, leeches, and arthropods.
- Microfilaria** Immature stage of filarial parasites.
- Microfilaricide** Dewormer that kills the immature filarial worm.
- Micropyle** A small pore at one end of some protozoan oocysts.
- Miracidium** Developmental stage in the life cycle of a digenetic trematode. This stage emerges from the operculated egg and penetrates the first intermediate host, usually a snail.
- Molt** Shedding of the outside cuticle.
- Monocercous** Hermaphroditic; having both sexes in a single organism.
- Monoxenous parasite** A parasite that will only infect one type of host.
- Morula** Type of nematode egg that contains an undeveloped grapelike cluster of cells within the eggshell.
- Mucocutaneous** Pertaining to the mucous membrane and the skin.
- Mutualism** Type of symbiotic relationship in which both organisms in the symbiotic relationship derive some benefit.
- Myiasis** Infection or infestation of the tissues or organs of humans or domesticated or wild animals by larval members (maggots) of the Order Diptera (two-winged flies).
- Myositis** Inflammation of the muscle tissue.
- Neck** Germinal or growth region of a tapeworm that lies just posterior to the scolex.
- Necropsy** Postmortem examination or autopsy on an animal.
- Nematodes** Roundworms.
- Neotenic** A type of parasite where the small male lives inside the vagina of the immature female or the uterus of the mature female parasite.
- Neurocysticercosis** Human infection with the pork tapeworm that develops in the brain of the human.
- Nit** Egg of a sucking or chewing louse.
- Obligatory myiasis** Lesions caused by fly larvae that require a vertebrate host for their development.
- Obligatory parasite** Parasite that must lead a parasitic existence; most parasites of domestic animals are obligatory parasites.
- Occult blood** Blood present in small amounts so as not to be visible to the unaided eye.
- Occult infection** Parasitic filarial infection without the presence of microfilaria.
- Onchosphere** Growth ball released by the ingested egg of *Echinococcus* species.
- Operculum** Tiny “door” at either end (pole) of an egg.
- Ornate** Species of ticks with distinctive white patterns on the dark reddish or mahogany background of the scutum.
- Oviduct** Female nematode reproductive organ that connects the tubular ovaries to the uterus.
- Oviparous** Type of nematode egg that contains either a single cell or a morula, a grapelike cluster of cells.
- Ovoviviparous** Type of nematode egg that contains a first-stage larva.
- Palpi** Mouth parts
- Palps** Appendages found near the mouth in invertebrate organisms used for sensation, locomotion and/or feeding.
- Papillae** Fingerlike or bumplike projections on the cuticle of a nematode.
- Papules** Red bumps
- Parasite** In a parasitic relationship, the member that lives on or within the host.
- Parasitiasis** Type of parasitic relationship in which the parasite is present on or within the host and is potentially pathogenic (harmful); however, the animal does not exhibit outward clinical signs of disease.
- Parasiticides** Chemical compounds (either very simple or very complex) used to treat specific internal and external parasites (endoparasites and ectoparasites); different types include anthelmintics, acaricides, insecticides, and antiprotozoals.
- Parasitism** Type of symbiotic relationship between two organisms of different species in which one member (the *parasite*) lives on or within the other member (the *host*) and may cause harm; parasite is metabolically dependent on host for its survival.
- Parasitology** The study of parasitic relationships.
- Parasitosis** Type of parasitic relationship in which the parasite is present on or within the host and causes obvious injury or harm to the host animal; host exhibits obvious outward signs of clinical parasitism.
- Paratenic host** A host used for transport of a parasite. The parasite does not go through any developmental stages.
- Parthenogenesis** Modified form of sexual reproduction characterized by the development of offspring by a female nematode from eggs that have not been fertilized by a male nematode; genus best known for parthenogenesis is *Strongyloides*.
- Pathogenecity** Disease causing potential.
- Pedicels** Stalks at the tip of sarcopitiform mite legs.
- Pediculosis** Infestation by either chewing or sucking lice.
- Pedipalps** Two leglike accessory appendages attached to the capitulum that act as sensory support.
- Pelage** Haircoat

- Pentastome** Tongue worms, or linguatulids. These annelid-like arthropods have a mitelike larval stage; nymphal stages are found in the visceral organs of many mammalian intermediate hosts; adults usually parasitize snakes and other reptiles. The one pentastome found in domestic animals is *Linguatula serrata*.
- Pentastomiasis** Infection with pentastomes
- Percutaneous** Through the skin.
- Periodic parasite** Parasite that makes frequent short visits to its host to obtain nourishment or other benefits.
- Pernicious anemia** See megaloblastic anemia
- Phoresis** Type of symbiotic relationship in which the smaller member in the relationship is mechanically carried by the larger member.
- Pilose Antennae** Antennae covered with fine hairs
- Piroplasmosis** Disease caused by *Babesia canis*.
- Pleomorphic** Demonstrating a variety of morphologic forms or body forms.
- Plerocercoid** Type of metacystode stage unique to the pseudotapeworms (cotylodans); this solid-bodied metacystode stage with slitlike mouthparts is found within the second intermediate host, usually a fish or an amphibian; also called a *sparganum*.
- Predator-prey** Extremely short-term symbiotic relationship in which one symbiont benefits at the expense of the other; for example, a lion (the *predator*) will kill a zebra (the *prey*). The prey ultimately pays with its life and serves as a food source for the predator.
- Prepatent period** Time from the point of infection by a nematode until a specific diagnostic stage can be recovered.
- Probenzimidazoles** Family of anthelmintics that include thiopantate, febantel and metobimin.
- Proboscis** Retractable “nose” on anterior end of an acanthocephalan covered with tiny, backward-facing spines and serving to anchor the acanthocephalan to the mucosa of the intestine.
- Procercoid** Type of metacystode stage unique to the pseudotapeworms (cotylodans). This metacystode stage is found within the first intermediate host, usually a tiny aquatic crustacean.
- Proglottid** Individual boxlike components of the tapeworm strobila; three types are immature, mature, and gravid proglottids.
- Protoscolices** Multiple tapeworm heads in a hydatid cyst that will develop into adult tapeworms when ingested by a definitive host.
- Protozoan parasites** Unicellular, or single-cell, organisms that may be flagellates, amoebae, sporozoans, apicomplexans, or ciliates.
- Pruritus** Itchy or itchiness
- Pseudocoelom** Cavity between the middle layer and inner layer of the 3 body tissue layers of the nematode
- Pseudocoelomic Membrane** The tissue that surrounds and lines the pseudocoelom.
- Pseudoparasites** Living creatures or inanimate objects that are not parasitic but may be mistaken for, or erroneously identified as, parasites.
- Pseudophyllidium egg** Tapeworm egg type with an operculum at one end and an oval shape.
- Pseudosucker** A false sucker surrounding the mouth of a leech.
- Psocids** Primitive insects associated with vegetation.
- Pseudopodia** “False feet”
- Psoroptidae** Family of sarcoptiform mites that reside on the surface of the skin or within the external ear canal.
- Pyriform apparatus** The innermost lining (third lining) of the covering of certain types of tapeworm eggs; pear shaped.
- Rectum** Opening of the intestine of the female nematode to the outside.
- Qualitative** Indicates the presence or absence of parasite ova, cysts or larvae.
- Quantitative** Indicates the number of eggs or cysts present in one gram of feces.
- Redia** Asexual stage in life cycle of a digenetic trematode. This stage is preceded by the sporocyst stage, which will produce many rediae; each redia will form many cercariae.
- Reportable parasites** Parasites that must be reported to both state and federal authorities (e.g., *Cochliomyia hominivorax*, *Psoroptes* species in large animals, *Boophilus annulatus*).
- Repugnatorial glands** Areas beneath the legs of millipedes that produce caustic substances.
- Reservoir host** Vertebrate host in which a parasite or disease occurs in nature and is a source of infection for humans or other domesticated animals.
- Rhabditiform esophagus** Type of nematode esophagus that has a corpus, isthmus, and posterior bulb.
- Rostellum** Holdfast organ on anterior end of an armed true tapeworm; has backward-facing hooks used to anchor the tapeworm to wall of the host’s gut.
- Sarcoptic acariasis** Infection caused by *Sarcoptes* mites.
- Sarcoptidae** Family of sarcoptiform mites that burrow or tunnel within the epidermis.
- Sarcoptiform mites** A classification of mites that can cause severe dermatologic problems in the host.
- Scabies** see Sarcoptic acariasis
- Schistosome cercarial dermatitis** Swimmer’s itch; highly pruritic papular or pustular dermatitis in humans caused by cercarial stages of bird schistosomes.
- Scientific name** Name for a living organism that is composed of two Latin words, usually written in italics. The *genus name* (capitalized; e.g., *Felis*) indicates the group to which a particular type of animal or plant



- belongs; the *specific epithet* (lowercase; e.g., *catus*) indicates the type of animal itself.
- Scolex** The “head” of a tapeworm.
- Scutum** Hard, chitinous plate that covers the body of some ticks.
- Seed ticks** Six-legged larval stage of tick life cycle.
- Seminal receptacle** A female nematode reproductive organ used to store sperm.
- Setae** Tiny hair-like bristles found on *Musca domestica* and other arthropods.
- Simple metamorphosis** One of two types of metamorphosis by insects; three developmental stages are egg, nymph, and adult. The nymphal and adult stages are similar in morphology and structure; nymphal stage is smaller than the adult and is not sexually mature.
- Siphon** A structure used by larvae to breath oxygen from the air.
- Siphonapterosis** Infestation with fleas.
- Somatic muscular layer** The layer of muscles below the hypodermis used by nematodes to move.
- Sparganosis** Infection with the plerocercoid stage within the tissues of the second intermediate host.
- Sparganum** See Plerocercoid.
- Specific epithet** The type of animal in a genus.
- Specific gravity** The weight of an object compared with the weight of an equal volume of pure water.
- Spicule pouch** Pocket that contains the male reproductive organs used to open the female nematode’s vulva.
- Spicules** Male nematode intromittent organs (“penis”) associated with the copulatory bursa.
- Spiracular plate** Opening used for breathing on the posterior end of some arthropod larvae.
- Spiruroid** One of 4 egg types produced by nematodes (see figure 3-11 for characteristic look).
- Sporocyst** Asexual stage in life cycle of a digenetic trematode. This miracidium penetrates the snail (first intermediate host) and forms the sporocyst stage.
- Stenoxenous parasite** Parasite with a narrow host range.
- Stepping** Inchworm-like manner of movement used by leeches when moving on land.
- Strike** See fly strike
- Strobila** Body of the tapeworm composed of individual proglottids (immature, mature, and gravid).
- Strobilocercus** Type of metacystode stage found in the liver of rats; has a scolex that attaches to a long neck, which connects to a fluid-filled bladder.
- Stylostome** Tube that forms in the host at the attachment site of chiggers.
- Symbiont** Each living organism in a symbiotic association.
- Symbiosis** Any association (temporary or permanent) between at least two living organisms of different species.
- Synanthropic** Living with humans
- Taenia egg** Tapeworm egg type with a wide outer shell and a thicker outer covering and a single six-hooked hexacanth within.
- Tachyzoites** Rapidly multiplying stages of toxoplasmosis in sporulated oocysts.
- Tegument** Body wall of a helminth.
- Tetrathyridium** Solid-bodied metacystode stage with a deeply invaginated acetabular scolex. This stage is capable of asexual reproduction and divides by splitting into two stages; two then become four, four become eight, and so on.
- Tick paralysis** Paralysis seen in animals and humans caused by the toxic saliva in some ticks.
- Transport host** Special type of intermediate host in which the parasite does not undergo any development, but instead remains arrested, or encysted (“in suspended animation”), within the host’s tissues; also called *paratenic host*.
- Trematodes** The flukes.
- Trichinelloid** One of 4 egg types produced by nematodes (see figure 3-12 for characteristic look).
- Trichoroid** See trichinelloid
- Trichostrongyle type** One of 4 egg types produced by nematodes (see figure 3-10 for characteristic look).
- Trypomastigote** Swimming life stage of Trypanosomes.
- Trophozoite stage** Motile or moving form of a protozoan.
- Tubular ovaries** Female nematode reproductive organs.
- Tubular testes** Male nematode reproductive organs.
- Unarmed tapeworm** True tapeworm that lacks a rostellum on its anterior end.
- Urticating** The act of stinging.
- Vas deferens** Male nematode reproductive organ connecting the tubular testes to the cloaca.
- Venations** Possessing veins in a part of the body.
- Vermicide** Dewormer that kills the parasite so that it can be broken down by the host’s body.
- Vermifuge** Dewormer that paralyzes (but does not kill) the adult parasite so that it passes in the feces.
- Vesicles** Tiny blisters
- Veterinary parasitology** The study of parasitic relationships affecting domesticated, wild, exotic and laboratory animals.
- Visceral larva migrans** Migration of larval stages of a nematode through the organs or tissues of humans (e.g., lungs, liver, eye); most often seen with *Toxocara canis*.
- Vitellaria** Accessory genital gland that secretes the yolk and shell for the fertilized ovum.
- Warbles** Larvae of dipteran flies found in the skin of domestic or wild animals, producing cutaneous myiasis.
- Wolves** See Warbles.
- Zoonosis** Any disease or parasite that is transmissible from animals to humans.

## A

- Abdominal worm. *See* *Setaria* spp.
- Aberrant (erratic) parasitism, 5, 5f
- Acanthocephalans (thorny-headed worms)
  - in dogs, 147
  - key morphologic features of, 144
  - life cycle of, 144–145, 146f
  - overview of, 13, 13b, 143–147, 143b
  - in pigs, 145–147
- Acanthocheilonema reconditum*
  - diagnosis of, 329–333, 331b, 333t
  - intermediate hosts of, 230
  - overview of, 39, 41f, 47–48, 48f, 48b
- Acanthor, 144–145
- Acaricides, overview of, 4
- Acarina. *See* Mites; Ticks
- Acetabula, 84, 124–125
- Acquired toxoplasmosis, 281
- Adnexa. *See* Eye and Adnexa
- Aedes aegypti*, 209–210
- Aegyptianella* spp., 177
- Aelurostrongylus abstrusus*, 19, 21f, 43, 43f, 346f
- Alaria* spp., 136–137, 137b, 346f
- Amblyomma americanum*, 166, 260, 260b
- Amblyomma maculatum*, 260–261, 260f, 260b
- American dog tick. *See* *Dermacentor variabilis*
- Amicrofilaremic hosts, 334, 334b
- Amoebae (Sarcodina)
  - in cats and dogs, 158–159
  - in guinea pigs, 183
  - overview of, 150–151, 151f, 151b
- Amphistomes, 132–133
- Ancylostoma* spp. *See* Hookworm
- Animalia kingdom, overview of, 9, 9b
- Annelids. *See* Leeches
- Anopheles quadrimaculatus*, 209–210
- Anoplocephala* spp., 101–103, 101f–102f, 102b, 349f
- Anoplura and Mallophaga (lice)
  - of guinea pigs, 205–206
  - life cycle of, 201–202, 203f
  - of mice, rats, gerbils, hamsters, 202–205
  - overview of, 199–206
  - of rabbits, 206
- Anthelmintics, overview of, 4
- Anticoagulants, 274, 274b, 329b
- Antiprotozoals, overview of, 4
- Ants. *See* Hymenoptera
- Aonchotheca putorii*, 28
- Apicomplexans
  - in birds, 175–177
  - in cats and dogs, 159–166
  - in guinea pigs, 183–184
  - in horses, 170–172
  - in mice, 180–181
  - overview of, 152, 152f, 152b
  - in rabbits, 178–179
  - in rats, 181–182
  - in ruminants, 167–168
  - in swine, 172–173
- Argas persicus*, 256, 256b
- Argasid (soft) ticks, 253–256, 253b
- Argulus* spp., 194, 195f, 195b
- Armed tapeworms, 84, 84f
- Armillifer* spp., 268, 268f
- Arterial worm. *See* *Elaeophora schneideri*
- Arthropodology, 194
- Arthropods
  - Acarina (mites and ticks)
    - of fur, 247–252
    - nonsarcoptiform, 241–247
    - overview of, 190, 190b, 231–252
    - sarcoptiform, 231–252
  - crustaceans, 188, 194–195
  - divisions of phylum Arthropoda, 188, 188b
  - insects
    - Coleoptera (beetles), 196–197, 197f, 197b
    - Dictyoptera (cockroaches), 196
    - Diptera (two-winged flies), 206–226
    - Hemiptera (true bugs), 198–199
    - Hymenoptera (ants, bees, wasps), 197–198, 197b
    - Lepidoptera (butterflies and moths), 197
    - Mallophaga and Anoplura (lice), 199–206
    - overview of, 189–190, 189b
    - Siphonaptera (fleas), 226–231
    - key morphologic features of, 188

Arthropods (*Continued*)

- myriopoda (centipedes and millipedes), 188–189, 195–196, 195b
- overview of, 13–14, 13b, 187–188, 187b, 194, 194b
- zoonotic, 302
- Ascarid nematodes, 19, 19f, 28–29, 76, 76b, 77f
- Ascaridia* spp., 79–80, 79f, 79b, 354f
- Ascaris suum*, 16f, 67–68, 67f–68f, 68b, 145–147, 147b, 352f
- Ascarops strongylina*, 66–67, 66f, 67b, 352f
- Aspiculuris tetraptera*, 72–74, 72b, 73f–74f
- Atoxoplasma serini*. *See* *Cystoisospora serini*
- Atoxoplasmosis, 177, 177b
- Avian malaria, 176
- Avian schistosomes. *See* *Schistosoma* spp.

**B**

- Babesia bigemina*, 168, 168f, 168b, 261b, 351f
- Babesia caballi*, 170, 170b, 171f, 349f
- Babesia canis*, 165, 165f, 165b, 257, 347f
- Babesia equi*, 170, 170f, 170b
- Babesia leuckharti*. *See* *Eimeria leuckharti*
- Babesia microti*, 257
- Baermann technique, 327–328, 327f, 327b, 335
- Balantidium coli*, 151, 151f, 159, 172, 172f, 353f
- Barberpole worm. *See* *Haemonchus contortus*
- Baylisascaris procyonis*, 30–31, 31b, 32f, 292–294
- Bed bugs, 198–199, 198f, 198b–199b
- Beef tapeworm of humans. *See* *Taenia saginata*
- Bees. *See* Hymenoptera
- Beetles. *See* Coleoptera
- Birds
  - pet, aviary, and domestic
    - mites of, 236–237, 236f, 236b, 245–246, 246b
    - nematodes infecting, 79–80
    - protozoans of, 173–177
    - ticks of, 256, 256b
  - reference to common parasites of, 353–360
  - wild
    - flukes of, 140f, 140b
    - ticks of, 256, 256b
    - zoonoses of, 283–285
- Biting house fly. *See* *Stomoxys calcitrans*
- Black flies. *See* *Simulium* spp.
- Black spot in fish, 141f, 141b
- Blackhead. *See* *Histomonas meleagridis*
- Bladder worm, 28, 45–46, 46f, 46b, 74–75, 75b, 80, 80b, 325, 347f
- Blister beetles, 196–197, 197f, 197b
- Blood. *See* Circulatory system and blood

## Blood sample analyses

- buffy coat method, 330–331
  - commercial filter technique, 333–334
  - immunologic heartworm tests, 334
  - microscopic examination, 329–330
  - modified Knott's technique, 331–333
  - sample collection in, 329
  - thick smear, 330
  - thin smear, 330
  - Blow flies, 217–218, 218b, 221b
  - Blue tongue virus, 208–209, 209b
  - Boophilus annulatus*, 168, 168b, 261, 261b
  - Borrelia burgdorferi*, 257, 257b
  - Bothria, 89–90, 90f, 90b
  - Bots
    - nasal, 225–226, 225b–226b, 226f
    - stomach, 224–225, 312, 313f, 350f
  - Bottle flies, 217–218, 218b, 221b
  - Bradyzoites, 281, 281b
  - Broad fish tapeworm. *See* *Diphyllbothrium latum*
  - Brown dog tick. *See* *Rhipicephalus sanguineus*
  - Buffalo gnats. *See* *Simulium* spp.
  - Buffy coat concentration method, 330–331, 331b–332b, 332f
  - Bunostomum* spp., 50, 50b–51b
  - Bursal rays, 17, 18f
  - Butterflies, 197
- C**
- Calcareous bodies/corpuscles, 312, 313f
  - Calibration, 314, 314b–315b, 315f
  - Calliphora* spp., 217–218, 218b, 220–221, 221b
  - Canine taeniid. *See* *Taenia hydatigena*;  
*Taenia pisiformis*
  - Cantharidin, 196–197, 197f
  - Capitulum*, 190
  - Cats
    - fleas infesting, 4, 4f, 226–231, 227f, 229f–230f
    - flukes of, 135–139
    - mites of
      - demodectic, 241–244
      - ear mites, 240–241, 240f, 241b
      - fur mites, 247–248, 247f–248f, 248b
      - scabies, 232–236, 233f, 234b
    - nematodes infecting
      - circulatory system of, 36–43
      - eye and adnexa of, 49
      - gastrointestinal tract of, 26–36
      - respiratory system of, 43–44
      - skin of, 46–49
      - urinary tract of, 44–46

- Cats (*Continued*)  
 protozoans of  
   circulatory system, 164–166  
   gastrointestinal tract, 156–164  
 reference to common parasites of, 344–348  
 true tapeworms infecting, 103–116  
 zoonotic parasites of, 281–282, 288–289, 292–302
- Cattle grubs. *See* *Hypoderma* spp.
- Cediopsylla simplex*, 226–231
- Cellophane tape preparation, 326–327, 326b–327b, 337
- Centipedes, 195, 195b
- Centrifugal flotation, 319, 319b–320b
- Cercariae, 125–128, 126b, 127f
- Cerebrospinal nematodiasis, 294
- Cervical alae, 17, 17f
- Cestodes. *See* Tapeworm
- Chabertia* spp., 50, 50b–51b
- Chagas disease, 198–199
- Chelicerae, 188, 252, 253b
- Cheyletiella* spp., 247–248, 247f, 248b, 359f
- Chiggers. *See* *Trombicula* spp.
- Chirodiscoides caviae*, 251–252, 251f–252f, 252b, 359f
- Chitin, 188
- Chorioptes* spp., 239–240, 240f, 240b
- Chrysops* spp., 210–211, 211b
- Ciliates  
   in cats and dogs, 159  
   in fish, 184  
   in horses, 169  
   overview of, 151–152, 151f, 152b  
   in ruminants, 167  
   in swine, 172
- Cimex lectularius*, 198–199, 198f, 198b–199b
- Circulatory system and blood  
   of birds, 175–177  
   canine/feline, 36–43, 164–166  
   of horse, 170–171  
   laboratory procedures for, 329–334  
   of ruminant, 52–53, 168
- Classification, Linnaean, 8–9, 9f, 9b
- CLM. *See* Cutaneous larval migrans
- Cnemidocoptes* spp., 236–237, 236f, 236b–237b, 357f
- Coccidians  
   in birds, 175, 177, 177f, 177b  
   in dogs and cats, 7–8, 8b, 160–161, 161f–163f, 161b, 164b, 281–282, 347f  
   in fecal samples, 323–324, 323b  
   in guinea pigs, 183–184, 184b  
   in horses, 170, 170f, 170b, 349f  
   in humans, 281–282  
   in mice, 180–181, 180b
- Coccidians (*Continued*)  
   in rabbits, 167, 167f, 167b, 178–181, 178f, 178b–180b, 323–324, 324f, 324b, 351f, 355f  
   in rats, 181–182, 182b  
   in ruminants, 159, 159f–160f, 160b, 167, 167f, 167b, 172–173, 173f, 173b, 178–181, 178f, 178b–180b, 323–324, 324f, 324b, 345f, 351f–352f, 355f
- Coccidiostats, 283
- Cochliomyia hominivorax*, 220
- Cochliomyia hominivorax*, 220–222, 221b–222b, 222f
- Cockroaches. *See* Dictyoptera
- Coenurus cerebralis*, 110–111
- Coenurus serialis*, 110–111, 112f
- Coenurus-producing tapeworm. *See* *Multiceps* spp.
- Coleoptera (beetles), 196–197, 197f, 197b
- Commensalism, overview of, 3
- Common names, 8–9
- Complex metamorphosis, 189–190, 190b
- Congenital toxoplasmosis, 281, 281b
- Continental rabbit tick. *See* *Haemaphysalis leporispalustris*
- Cooperia* spp., 50, 50b–51b
- Copepods, 90, 91f, 194
- Copulatory bursa, 17, 18f
- Coracidium, 90, 91f, 117
- Cotyloda. *See* Pseudotapeworms
- Cotylophoron* spp., 132–133, 133f, 133b
- Creeping eruption. *See* Cutaneous larval migrans
- Crustaceans, overview of, 188, 194–195
- Cryptocaryon irritans*, 184
- Cryptosporidium parvum*, 282–283
- Cryptosporidium* spp., 161, 161b, 164f, 167, 167b, 173, 173b, 346f
- Cryptosporidium wrairi*, 184, 184b
- Ctenocephalides felis*, 4, 4f, 227f, 229f–230f
- Ctenocephalides* spp., 226–231
- Cucumber seed tapeworm. *See* *Dipylidium caninum*
- Culex* spp., 209–210, 209f
- Culicoides* spp., 208–209, 209b
- Culture and identification methods, 323–324, 323b
- Cutaneous habronemiasis, 57, 57b, 63f, 64, 64b, 65f
- Cutaneous larval migrans (CLM), 33, 294–296
- Cuterebra* spp.  
   as erratic parasites, 5, 5f  
   overview of, 222–223, 223, 222f–223f, 223b  
   reference images of, 347f, 356f–357f
- Cuticle, of nematode, 16f–17f, 17
- Cystacanth stage, 144–145
- Cysticeroid stage, 88, 88f
- Cysticercus bovis*, 99–100, 285
- Cysticercus cellulosae*, 99–100, 286

*Cysticercus fasciolaris*, 108–110, 110f  
*Cysticercus hydatigena*, 106, 108  
*Cysticercus ovis*, 106, 108  
*Cysticercus pisiformis*, 106–107  
*Cysticercus tenuicollis*, 100–101, 110f  
*Cystoisospora serini*, 177, 177f, 177b  
*Cystoisospora* spp., 159, 159f–160f, 160b, 172–173, 173f, 173b, 323–324, 324f, 324b, 345f, 352f  
*Cytauxzoon felis*, 165–166, 166f, 166b

## D

*Damalinia bovis*, 200, 200f, 351f  
D'Antonis iodine solution, 322, 322b  
Decanting method of necropsy sample collection, 324b  
Deer, liver fluke of, 134–135  
Deer ked. *See* *Lipopteni cervi*  
Deer tick. *See* *Ixodes scapularis*  
Deerflies. *See* *Chrysops* spp.  
Definitive hosts, overview of, 6, 7f  
*Demodex* spp., 241–244, 241f, 241b, 348f, 358f  
Demodicosis, 241–242  
*Dentostomella translucida*, 75–76, 75b–76b, 76f, 353f  
*Dermacentor andersoni*, 258–259, 259b  
*Dermacentor occidentalis*, 259–260, 259b  
*Dermacentor variabilis*, 254f, 258, 258f, 258b  
Dermal larva migrans, 33, 294–296  
*Dermanyssus gallinae*, 245–246, 246b  
Diagnosis. *See* Laboratory procedures  
*Dicrocoelium dendriticum*, 131–132, 131b–132b, 132f  
*Dictyocaulus arnfieldi*, 64, 64b  
*Dictyocaulus* spp., 53, 53–54, 53f–54f, 54b, 350f  
Dictyoptera (cockroaches), 196  
DIFIL-Test, 333–334, 334f  
Digenetic flukes (trematodes). *See* Flukes  
Digestive tract  
  of food animals, 100–101  
  laboratory procedures for, 309–328  
  of nematode, 16f, 18, 18b  
*Dinobdella* spp., 275  
*Diectophyma renale*, 16–17, 16f, 44, 45f, 45b  
*Dipetalonema reconditum*. *See* *Acanthocheilonema reconditum*  
*Diphyllbothrium latum*, 87f, 91, 116f–117f, 118–119, 119f, 119b, 194, 291–292  
Diptera (two-winged flies)  
  feeding on mucus, tears, and saliva, 207, 216–219  
  females only feed on blood, 206–211, 207b  
  males and females feed on blood, 207, 207b, 211–216  
  myiasis-producing, 219–226  
  overview of, 206–226

*Dipylidium caninum*  
  cysticercoid stage of, 88, 88f  
  egg of, 87f  
  in humans, 288–289  
  intermediate hosts of, 230  
  overview of, 103–106, 103f–105f, 104b, 106b  
  proglottids of, 86f  
  reference images of, 344f–345f  
Dipylidium type eggs, 86, 87f, 87b  
Direct life cycle, 21  
Direct smears  
  blood, 329, 329b–330b  
  fecal, 315–316, 315b–316b  
*Dirofilaria immitis* (heartworm)  
  aberrant, 46–47, 47f  
  canine, 37–39, 38f, 39b, 46–47  
  diagnosis of, 328–334, 328b, 330b–331b, 333t, 338  
  as endoparasite, 4, 4f  
  feline, 39–40, 40b, 42, 42f, 43b  
  in humans, 5, 5f, 300–302  
  indirect life cycle of, 20f, 21–22  
  life cycle of, 6, 7f–8f, 20f, 21–22, 39–40, 40f, 42f  
  mosquitoes and, 210, 210b  
  as obligatory parasite, 5  
  overview of, 36, 38f, 38b–39b, 41f  
  reference images of, 347f  
  reservoir hosts for, 7  
Dirt. *See* Flea dirt  
Dog penis gnats. *See* *Hippelates* spp.  
Dog ticks. *See* *Dermacentor occidentalis*; *Rhipicephalus sanguineus*  
Dogs  
  fleas infesting, 226–231  
  flukes of, 135–139  
  mites of  
    demodectic, 241–244, 241f  
    ear mites, 240–241, 240f, 241b  
    fur mites, 247–248, 247f, 248b  
    nasal, 245, 245f, 245b  
    scabies, 232–233, 232b  
  nematodes of  
    circulatory system, 36–43  
    eye and adnexa, 49  
    gastrointestinal tract, 26–36  
    respiratory system, 43–44  
    skin, 46–49  
    urinary tract, 44–46  
  pentastomids of, 270–272  
  protozoans of, 156–166  
  reference to common parasites of, 344–348  
  thorny-headed worms in, 147



Dogs (*Continued*)

- ticks of, 196, 257f–258f, 258–260, 258b–259b
- true tapeworms of, 100–101, 103–116
- zoonotic parasites of, 288–289, 292–302
- Double-pored tapeworm. *See* *Dipylidium caninum*
- Downer cows, fire ants and, 197
- DPG. *See* *Hippelates* spp.
- Dracunculoid larvae, 19, 21f
- Dracunculus insignis*, 19, 21f, 47f–48f, 48–49, 194
- Draschia megastoma*, 57–58, 57f, 57b, 64, 64b
- Draschiasis, cutaneous. *See* Summer sores
- Dung beetles, 196, 196b
- Dysentery, 158, 158b
- Dyspharynx nasuta*, 31b, 79–80

## E

- Ear mites. *See* *Otodectes cynotis*; *Psoroptes* spp.
- Ear parasites, laboratory procedures for, 338–339
- Earthworms, *Capillaria* spp. and, 80b
- Echidnophaga gallinacia*, 226–231, 227f, 229f
- Echinococcus granulosus*, 112–114, 112b–113b, 113f, 287–288
- Echinococcus multilocularis*, 112–114, 112b–113b, 113f, 287–288
- Ectoparasitism, 4, 4f, 338, 338b
- Eggs
  - of fleas, 229, 229f
  - of nematodes, 19–20, 19f–20f, 20b, 22
  - of tapeworm, 86, 87f–89f, 87b
- Eimeria caviae*, 183–184, 184b
- Eimeria leuckharti*, 170, 170f, 170b, 349f
- Eimeria nieschultzi*, 181–182, 182b
- Eimeria* spp.
  - diagnosis of, 323–324, 324f, 324b
  - in mice, 180–181, 180b
  - overview of, 167, 167f, 167b, 178–179, 178f, 178b–179b
  - reference images of, 351f, 355f
- Eimeria tenella*, 7–8, 8f
- Elaeophora schneideri*, 52–53, 53b, 56
- Elkomin fluke fever, 136
- Empodia, 249
- Encephalomyelitis, 171b
- Encysted parasites, 6
- Endoparasitism, 4, 4f
- Endosomes, 158, 158f
- Entamoeba caviae*, 183, 183b
- Entamoeba coli*, 150
- Entamoeba histolytica*, 150, 151f, 158–159, 158f, 158b–159b
- Enteric hookworm disease, 296–298

- Enterobius vermicularis*, 36
- Equids. *See* Horses
- Equine protozoal myeloencephalitis, 171b
- Erratic (aberrant) parasitism, 5, 5f
- Esophageal worm. *See* *Gongylonema pulchrum*; *Spirocerca lupi*
- Eucoleus* spp., 44, 44b, 45f, 346f
- Euryxenous parasitism, 7–8
- Eye and adnexa
  - canine/feline, nematodes infecting, 49
  - of horse, nematodes infecting, 65–66
  - laboratory procedures for, 338
  - ruminant, nematodes infecting, 56
- Eyeworm. *See* *Thelazia* spp.

## F

- Face fly. *See* *Musca autumnalis*
- Facultative myiasis, 216, 219–221, 220b
- Facultative parasitism, 5, 220–221
- False gid, 226b
- Fasciola hepatica*, 123, 124f, 133, 134f, 134b, 351f
- Fascioloides magna*, 124, 134–135, 134f, 135b
- Fecal flotation
  - modified Wisconsin, 321
  - overview of, 316–319, 316b–318b, 317f, 320f
  - pseudoparasites and, 6, 6f, 6b
- Fecal samples
  - blood in, 328
  - collection of, 309–310
  - culture of, 323–324
  - direct smear method and, 315–316
  - examination of, 310–316
  - in necropsy, 324–325
  - protozoa in, 321–323
  - quantitative examination of, 319–321
  - sedimentation of, 319, 319b, 321f, 321b
- Fecalalyzer, 320f
- Feline ascariid. *See* *Toxocara cati*
- Filarial worm. *See* *Onchocerca cervicalis*
- Filaroides* spp., 43–44, 44f
- Filter techniques, 333–334, 334f, 334b
- Fire ants, 197
- Fish, 141b, 184, 291–292
- Flagellates (Mastigophora)
  - in birds, 173–175
  - in cats and dogs, 156–158, 164–165
  - in guinea pigs, 182–183
  - in hamsters, 182
  - in horses, 169
  - in mice, 179–180
  - overview of, 150, 150f

Flagellates (*Continued*)

in rats, 181

in ruminants, 168

Flea dirt/frass, 230, 230f

## Fleas

of cat, 4, 4f, 226–231, 227f, 229f–230f

of dog, 226–231

overview of, 226–231, 228f, 348f

Flesh fly. *See* *Sarcophaga* spp

Fluke puke, 124–125

## Flukes (trematodes)

in autopsy samples, 325, 325b

digenetic, 12, 12b, 124–128, 124b, 125f, 128f, 128b

of dogs and cats, 135–139

of fish, 141f, 141b

of humans, 140b

intermediate hosts of, 6

key morphologic features of, 124–125, 125f, 125b

life cycle of, 125–128, 126b, 128b

monogenetic, 11–12, 12b, 124, 124f, 124b

overview of, 123, 123b

proglottids of, 83

of ruminants, 131–135

of wild birds, 140f, 140b

zoonotic, 283–285

Fly strike, 219–220, 220f

Follicular mite. *See* *Demodex* spp.

Fomites, 202

Foot and tail mites. *See* *Chorioptes* spp.Fowl tick. *See* *Argas persicus**Francisella tularensis*, 206Frass. *See* Flea dirt

Fur mites, 247–252

## G

Gad flies. *See* *Hypoderma* spp.

Gadding, 223, 223b

Gamonts, 166

Gastric capillariid of cats. *See* *Aonchotheca putorii*

## Gastrointestinal tract parasites

of birds, 79–80, 173–175

canine/feline, 26–36, 156–164

of gerbils, 75–76, 94–95

of guinea pigs, 76–77, 182–184

of hamsters, 75, 94–95, 182

of horse, 57–64, 101–103, 169–170, 224–225

of mice, 72–74, 94–95, 179–181

of rabbits, 77–79, 177–179

of rats, 74–75, 94–95, 181–182

Gastrointestinal tract parasites (*Continued*)

of ruminants, 49–52, 95–99, 166–168

of swine, 66–70, 172–173

*Gastrophilus* spp., 224–225, 312, 313f, 350f

Generalized demodicosis, 242

Genus names, 8–9

## Gerbils

lice of, 202–205

mites of, 243

nematodes infecting, 75–76

reference to common parasites of, 353–360

true tapeworms infecting, 94–95

Giant kidney worm. *See* *Diectophyma renale**Giardia* spp.

in birds, 173–174, 174f

in dogs and cats, 156–158, 156f–157f, 156b

in fecal samples, 321–323, 322b

in guinea pigs, 182, 182b

in horses, 169

image of, 345f

in mice, 179–180

*Gliricola porcelli*, 205–206, 205f, 206b, 356f*Glossina* spp., 211–212, 212b*Gongylonema pulchrum*, 49–50, 50f*Goniocotes gallinae*, 200, 200f, 355f

Ground itch, 33, 294–296

## Guinea pigs

lice of, 205–206

mites of, 235, 235f, 237, 237b, 251–252, 251f–252f, 252b

nematodes of, 76–77

protozoans of, 182–184

reference to common parasites of, 353–360

Guinea worm. *See* *Dracunculus insignis*Gulf Coast tick. *See* *Amblyomma maculatum**Gyropus ovalis*, 205–206, 205f, 206b, 356f

## H

*Habronema* spp.

intermediate hosts of, 212–213

overview of, 57–58, 57f, 57b, 349f

skin sores and, 64, 64b, 65f

Habronemiasis, cutaneous. *See* Summer sores*Haemaphysalis leporispalustris*, 261–262, 262b*Haematobia irritans*, 55, 213–214, 214f, 214b*Haematopinus suis*, 200, 201f, 353f*Haemobartonella muris*, 204, 204b*Haemonchus contortus*, 18f, 19*Haemonchus* spp., 50, 50b–51b*Haemopsis sanguisuga*, 273*Haemopsis terrestris*, 275, 275b*Haemoproteus* spp., 175–176, 176f, 176b, 215, 354f

## Hamsters

- lice of, 202–205
- mites of, 242, 242f–243f
- nematodes infecting, 75
- protozoans of, 182
- true tapeworms infecting, 94–95

Hard (ixodid) ticks, 253, 253b, 256–262

Heartworm. *See* *Dirofilaria immitis*

Hemiptera (true bugs), 198–199

Hemocoel, 188

*Hemodipsus ventricosus*, 206, 206b

Hemolymph, 188

*Hepatozoon* spp., 166, 166f, 166b

*Heterakis gallinarum*, 174, 174b

*Heterobilharzia americana*, 137–139, 139f, 139b

Hexacanth stage (tapeworm), 86, 87f–89f, 87b, 94

*Hippelates* spp., 219, 219b

Hippoboscids flies, 215

Hirudin, 274, 274b

Hirudinea. *See* Leeches

Hirudiniasis, 275

*Hirudo medicinalis*, 275–277, 276f–277f, 276b

*Histomonas meleagridis*, 174, 174b

Homoxenous (monoxenous) parasitism, 7–8, 8f

Hookworm (*Ancylostoma* spp.)

- canine/feline, 31–34, 32f–34f, 33b–34b, 344–348
- direct life cycle of, 21
- egg of, 19f
- in humans, 294–298
- life cycle of, 33f

*Hoplopleura meridionidis*, 204–205, 205b

Horn fly. *See* *Haematobia irritans*

Horse bot. *See* *Gastrophilus* spp.

Horsefly. *See* *Tabanus* spp.

## Horses

- dipteran fly larvae of, 224–225, 224f–225f, 225b
- ear mites of, 238–239, 239b
- nematodes of
  - abdominal cavity, 66
  - eye and adnexa, 65–66
  - gastrointestinal tract, 57–64
  - respiratory system, 64
  - skin, 64–65
- protozoans of
  - circulatory system and blood, 170–171
  - gastrointestinal tract, 169–170
  - nervous system, 171–172
  - urogenital system, 171
- reference to common parasites of, 348–350
- scabies mites of, 232–233, 233f
- true tapeworms of, 101–103

House fly. *See* *Musca domestica*

Hydatid disease, 287–288. *See also* *Echinococcus granulosus*; *Echinococcus multilocularis*

Hymenolepiasis, 290–291

*Hymenolepis* spp., 94–95, 94f–95f, 94b–95b, 290–291, 346f

Hymenoptera (ants, bees, wasps), 197–198, 197b

*Hyostrogylus rubidus*, 67, 67b

*Hypoderma* spp., 223–224, 223b, 224f

Hypodermis, 16f, 17

## I

*Ichthyophthirius multifiliis*, 151, 184, 184b

Idiosoma, 190

Immunologic heartworm tests, 334, 334b–335b

Incidental hosts, 5f

Incidental nymphal pentastomiasis, 303

Indirect life cycle, 21–22

Infectious bovine keratoconjunctivitis, 217

Infectious enterohepatitis, 174, 174b

Infective third-stage larva, 20–21, 22f

Infestation, infection vs., 190b

Insecticides, overview of, 4

## Insects

- ants, bees, wasps (Hymenoptera), 197–198, 197b
- beetles (Coleoptera), 196–197, 197f, 197b
- butterflies and moths (Lepidoptera), 197
- cockroaches (Dictyoptera), 196
- fleas (Siphonaptera)
  - of cat, 4, 4f, 226–231, 227f, 229f–230f
  - of dog, 226–231
  - overview of, 226–231, 228f, 348f
- lice (Mallophaga and Anoplura), 199–206
- mosquitoes
  - heartworm life cycle and, 6, 7f–8f, 7b
  - malaria, 209–210
  - overview of, 209–210, 209f, 209b–210b
  - as periodic parasites, 6
  - yellow fever, 209–210
- overview of, 189–190, 189b
- true bugs (Hemiptera), 198–199
- two-winged flies (Diptera)
  - feeding on mucus, tears, and saliva, 216–219
  - females only feed on blood, 207–211
  - males and females feed on blood, 211–216
  - myiasis-producing, 219–226
  - overview of, 206–226
- Intermediate hosts
  - nematodes and, 21–22
  - overview of, 6, 7f–8f, 7b
  - of pentastomids, 268–269, 271–272, 271b

Intestinal threadworm. *See* Threadworm

Intestines. *See* Gastrointestinal tract

*Isoospora* spp. *See* *Cystoisospora* spp.

Itchy leg mites. *See* *Chorioptes* spp.

*Ixodes scapularis*, 257, 257b

Ixodid (hard) ticks, 253, 253b, 256–262

## K

### Keds

bird, 215–216, 216f, 216b

deer, 215b

sheep, 214–215, 214b, 215f, 352f

Kidney worm. *See* *Stephanurus dentatus*

Killer bees, 197

Kingdoms, overview of, 9, 9b

*Kiricephalus* spp., 268f

Kissing bugs. *See* *Panstrongylus* spp.; *Reduviid* bugs;

*Rhodnius* spp.; *Triatoma* spp.

*Klossiella equi*, 171, 171b

*Klossiella muris*, 181, 181b

## L

### Laboratory procedures

for blood/blood vascular system parasites

buffy coat method, 330–331

commercial filter technique, 333–334

immunologic heartworm tests, 334

microscopic sample examination, 329–330

modified Knott's technique, 331–333

sample collection, 329

thick blood smear, 330

thin blood smear, 330

for digestive tract parasites

Baermann technique, 327–328

blood in feces, 328

cellophane tape preparation, 326–327,

326b–327b, 337

direct smear, 315–316

examination of feces for protozoa,  
321–323

fecal culture, 323–324

fecal flotation, 316–319

fecal sample collection, 309–310

fecal sample examination, 310–316

fecal sedimentation, 319

gross examination of feces, 311–313

microscopic examination of feces, 313–315

necropsy sample collection, 324–325

quantitative fecal examination, 319–321

vomitus gross examination, 328

vomitus microscopic examination, 328

### Laboratory procedures (*Continued*)

for ear parasites, 338–339

for eye parasites, 338

for genital tract parasites, 339

overview of, 308, 308b

for respiratory system parasites, 335–336

for skin parasites, 336–338

specimen shipping and, 326

for urinary system parasites, 336

Lancet fluke. *See* *Dicrocoelium dendriticum*

Land leeches. *See* *Haemopsis terrestris*

Lappets, 101–102

Larviparous nematodes, 20f–21f

Leaf crown, 18, 18f

Leeches (Hirudinea)

life cycle of, 275–277

morphology of, 274–275, 274b

overview of, 13, 13b, 273–277

Legstickler. *See* *Stomoxys calcitrans*

*Leishmania* spp., 164–165, 165b

Lepidoptera (butterflies and moths), 197

*Leucocytozoon* spp., 176–177, 177f, 177b, 207

### Lice

of guinea pigs, 205–206

life cycle of, 201–202, 203f

of mice, rats, gerbils, hamsters, 202–205

overview of, 199–206

of rabbits, 206

Lichens, 2, 2f

### Life cycles

of acanthocephalans, 144–145, 146f

of *Cystoisospora* spp., 160b

of equine roundworm/ascaris, 59f

of flea, 226–227, 228f

of fluke, 125–128

of *Giardia* spp., 157f, 158b

of heartworm, 40f, 42f

of hookworm, 33f

of large strongyle species, 62f

of leech, 275–277

of lice, 201–202, 203f

of lungworm, 54f

of *Moniezia* sp., 97f

of nematode, 20–22, 21b–22b, 22f, 31f

overview of, 6–8, 7f

of penastomes, 268–269, 269f

of pseudotapeworm, 90–91, 91f, 91b

of ticks, 253–254, 254b, 255f

of true tapeworm, 87–89, 89f, 97f, 105f, 109f

of whipworm, 37f

*Limnatis* spp., 275

*Linguatula serrata*, 268, 268f, 271–272, 271f, 303–304, 335–336  
 Linguatulids. *See* Pentastomes  
 Linnaean classification scheme, 8–9, 9f, 9b  
*Linognathus setosus*, 200, 201f, 348f  
*Lipopteni cervi* (deer ked), 215b  
*Listrophorus gibbus*, 252, 252b  
 Liver fluke. *See* *Fasciola hepatica*; *Fascioloides magna*  
 Lizard poisoning fluke. *See* *Platynosomum fastosum*  
 Localized demodicosis, 242  
 Lone star tick. *See* *Amblyomma americanum*  
 Long-tailed larvae. *See* *Dracunculoid larvae*  
*Lucilia* spp., 217–218, 218b, 220–221, 221b  
 Lung fluke. *See* *Paragonimus kellicotti*  
 Lungworm  
   canine, 43–44, 44f  
   equine, 64, 64b  
   feline, 19, 21f, 43, 43f, 346f  
   larvae of, 19, 21f  
   life cycle of, 54f  
   ruminant, 28, 53–54, 53f–54f, 54b, 350f  
   swine, 70, 70f, 70b, 352f  
*Lutzomyia* spp., 207, 208, 208b  
 Lyme disease. *See* *Borrelia burgdorferi*  
*Lynchia* spp., 215–216, 216f, 216b  
*Lynxacarus radovskyi*, 248, 248f, 248b

## M

*Macracanthorhynchus hirudinaceus*, 144f–146f, 145–147, 147b, 196  
 Maggots, 312–313, 313f  
 Magnesium sulfate flotation solution, 316, 317b, 318  
 Malaria, avian, 176  
 Malaria mosquito. *See* *Anopheles*  
 Malignant sparganosis, 289–290  
 Mallophaga and Anoplura (lice)  
   of guinea pigs, 205–206  
   life cycle of, 201–202, 203f  
   of mice, rats, gerbils, hamsters, 202–205  
   overview of, 199–206  
   of rabbits, 206  
 Mandibulata, 188  
*Marshallagia* spp., 51, 51b  
 Mastigophora (flagellates). *See* Flagellates  
 Measly beef, 99, 285  
 Measly pork, 100, 286  
 Medicinal leech. *See* *Hirudo medicinalis*  
 Megaloblastic anemia, 291  
*Melophagus ovinus*, 214–215, 214b, 215f, 352f  
*Menacanthus stramineus*, 200, 200f, 355f  
*Mesocetoides* spp., 114–116, 114f–115f, 114b

*Metacercaria*, 125–126, 128f  
 Metacestodes, 87, 88f–89f, 99–101  
 Metamorphosis, 189–190, 190b  
*Metastrongylus* spp., 70, 70f, 70b, 352f  
 Mice  
   lice of, 202–205  
   mites of, 249–251, 249f–250f, 250b  
   nematodes of, 72–74  
   protozoans of, 179–181  
   reference to common parasites of, 353–360  
   true tapeworms of, 94–95  
 Microfilariae larvae, 19, 20f  
 Microfilaricides, 39  
 Microscopy  
   of blood samples, 329–330  
   of fecal samples, 313–315, 314f, 314b–315b  
 Millipedes, 195–196  
 Miracidium, 125–126, 126f  
 Mites (Acarina)  
   of fur, 247–252  
   nonsarcoptiform, 241–247  
   overview of, 190, 190b, 231–252  
   sarcoptiform, 231–252  
 Modified D'Antonis iodine solution, 322, 322b  
 Modified Knott's technique, 331–333, 331b, 332f  
 Modified Wisconsin sugar flotation method, 321  
 Molluscicides, 284  
 Molting, nematode life cycle and, 20–21, 22f  
*Moniezia* spp., 95–98, 96f–97f, 97b–98b, 350f  
 Monogenetic flukes (trematodes). *See* Flukes  
 Monoxenous (homoxenous) parasitism, 7–8, 8f  
*Moraxella bovis*, 2–3, 3f, 217, 217b  
 Morula stage, 19f–20f  
 Mosquitoes  
   heartworm life cycle and, 6, 7f–8f, 7b  
   overview of, 209–210, 209f, 209b–210b  
   as periodic parasites, 6  
   yellow fever, 209–210  
 Moths, 197  
 Mucus, diptera of, 216–219  
*Muellerius capillaris*, 54–55, 55f, 55b, 351f  
*Multiceps* spp., 88–89, 110–112, 111b–112b  
 Multilocular hydatid tapeworm. *See* *Echinococcus multilocularis*  
*Musca autumnalis*  
   overview of, 217, 217b, 218f  
   phoresis and, 2–3, 3f  
   ruminant eyeworm and, 56  
*Musca domestica*, 216–217, 216b  
 Musculoskeletal system, 71–72, 99–100  
 Mutton tapeworm of dogs. *See* *Taenia ovis*



Mutualism, overview of, 3, 3b  
 Myeloencephalitis, equine protozoal, 171b  
 Myiasis, 206–226, 206b  
*Myobia musculi*, 249–251  
*Myocoptes musculus*, 249–251, 249f–250f, 249b, 359f  
 Myriopoda (centipedes and millipedes), overview of, 188–189, 195–196, 195b

## N

N verte, 5  
*Nanophyetus salmincola*, 136, 136f–137f, 136b  
 Nasal bots. *See Oestrus ovis*  
 Nasal mites. *See Pneumonyssus caninum*  
 Necropsy, 324–325, 324b–325b  
 Nematodes  
   in autopsy samples, 325, 325b  
   in birds, 79–80  
   in cats and dogs  
     circulatory system, 36–43  
     eye and adnexa, 49  
     gastrointestinal tract, 26–36  
     respiratory system, 43–44  
     skin, 46–49  
     urinary tract, 44–46  
   external morphologic features of, 16f–18f, 17–18  
   as facultative parasite, 5  
   in fecal samples, 323, 323b, 327–328, 327f, 327b, 335, 335b  
   in gerbils, 75–76  
   in guinea pigs, 76–77  
   in hamsters, 75  
   in horses  
     abdominal cavity, 66  
     eye and adnexa, 65–66  
     gastrointestinal tract, 57–64  
     respiratory system, 64  
     skin, 64–65  
   internal morphologic features of, 18–20, 18f–21f, 18b–19b  
   key morphologic features of, 16–20, 16f–17f, 17b  
   life cycle of, 20–22, 21b–22b, 22f, 31f  
   in mice, 72–74  
   overview of, 12–13, 13b, 16b  
   in rabbits, 77–79  
   in rats, 74–75  
   in ruminants  
     abdominal cavity, 56–57  
     circulatory system, 52–53  
     eye and adnexa, 56  
     gastrointestinal tract, 49–52

Nematodes (*Continued*)  
   respiratory system, 53–55  
   skin, 55–56  
   in swine  
     gastrointestinal tract, 66–70  
     musculoskeletal system, 71–72  
     respiratory system, 70  
     urinary tract, 70–71  
   in urine samples, 336, 336b  
   zoonotic, 292–302  
*Nematodirus* spp., 51, 51f, 51b, 350f  
 Neotenic parasites, 75  
 Nervous system, protozoans in, 171–172  
 Neural larva migrans, 293–294  
 Neurocysticercosis, 286  
 New World sand flies. *See Lutzomyia* spp.  
 New World screwworm. *See Cochliomyia hominivorax*  
 Nits, 201–202, 202f–204f  
 Nodular worm. *See Oesophagostomum dentatum*  
 Nonsarcoptiform mites, 241–247  
 North American tick. *See Boophilus annulatus*  
 Northern mite. *See Ornithonyssus sylviarum*  
 No-seeums. *See Culicoides* spp.  
*Notoedres cati*, 233–236, 234b  
*Notoedris muris*, 234, 234f, 236b

## O

*Obeliscoides cuniculi*, 78–79, 78b–79b  
 Obligatory myiasis, 219–224  
 Obligatory parasitism, 5, 6b  
 Occult blood, 328, 328b  
 Occult infection, 334  
 Ocular larva migrans, 292–302  
*Odontopsylla multispinosus*, 226–231  
*Oesophagostomum dentatum*, 68–69, 69f, 69b  
*Oesophagostomum* spp., 50, 50b–51b  
*Oestrus ovis*, 225–226, 225b–226b, 226f  
*Ollulanus tricuspis*, 28, 28b, 328  
*Onchocerca cervicalis*, 64–65, 65, 65b, 208–209  
*Oncicola canis*, 147, 147b  
*Oncospheres*, 287–288  
 Opercula, 128, 128b, 132  
*Ornithonyssus bacoti*, 246–247, 246b–247b, 247f, 358f  
*Ornithonyssus sylviarum*, 245–246, 246b  
*Ostertagia* spp., 50, 50b–51b  
*Otobius megnini*, 255–256, 256f  
*Otodectes cynotis*, 240–241, 240f, 241b, 338–339, 338b, 348f  
 Ovaries, of nematode, 19

Ovassay, 320f  
 Ovatector, 320f  
 Oviduct, of nematode, 19  
 Oviparous nematodes, 20  
 Ox warbles. *See* *Hypoderma* spp.  
*Oxyuris equi*, 62–63, 63b, 64f, 349f

## P

Pacific coast dog tick. *See* *Dermacentor occidentalis*  
 Palps, 210  
*Panstrongylus* spp., 199, 199b  
 Papillae, 18, 18f  
*Paragonimus kellicotti*, 126–128, 128f, 137–138, 137f–138f, 138b, 194, 345f  
*Paramphistomum* spp., 132–133, 133f, 133b  
*Paranoplocephala mamillana*, 101–103, 102f, 102b  
*Parascaris equorum*, 58–60, 58f–60f, 59b, 348f  
 Parasitiasis, 3, 3f, 4b  
 Parasitocides, 4  
 Parasitism  
   ectoparasitism, 4, 4f  
   endoparasitism, 4, 4f  
   erratic/aberrant, 5, 5f  
   euryxenous, 7–8  
   facultative, 5  
   homoxenous/monoxenous, 7–8, 8f  
   incidental, 5, 5f  
   obligatory, 5, 6b  
   overview of, 3  
   parasitiasis, 3, 3f, 4b  
   parasitosis, 3, 4f, 4b  
   periodic, 6  
   pseudoparasitism vs., 6, 6f, 6b  
   stenoxenous, 7–8  
 Parasitosis, 3, 4f, 4b  
*Paraspidodera uncinata*, 76, 76b, 77f  
 Paratenic (transport) hosts, 6, 293  
*Passalurus ambiguus*, 77, 77b, 78f, 353f  
 Pedal-pinnal response, 240  
 Pedicels, 231  
*Pedicinus obtusus*, 200, 201f  
*Pediculosis*, 202, 204f  
 Pedipalps, 252, 253b  
*Pelodera strongyloides*, 5  
 Pentastomes  
   definitive hosts of, 270–272  
   incidental hosts of, 270–271  
   intermediate hosts of, 268–269, 271b, 272  
   life cycle of, 268–269, 269f  
   morphology of, 268  
   of nasal passages of mammalian hosts, 271–272

Pentastomes (*Continued*)  
   overview of, 267–271, 268f  
   zoonotic, 303–304  
 Periodic parasitism, 6  
 Pernicious anemia, 291  
*Phaenicia* spp., 217–218, 218b, 220–221, 221b  
 Phlebotomine sandflies, 165  
*Phlebotomus* spp., 208, 208b  
 Phoresis, overview of, 2–3, 3f  
*Phormia* spp., 217–218, 218b, 220–221, 221b  
*Physaloptera* spp., 27–28, 27f, 28b, 328  
*Physocephalus sexalatus*, 66–67, 67b  
 Pigs. *See* Swine  
 Pinkeye, 217  
 Pinworm  
   cellophane tape preparation for, 326–327, 326b–327b  
   in gerbils, 75–76, 75b–76b, 76f, 353f  
   in horses, 62–63, 63b, 64f, 349f  
   in humans, 36  
   in mice, 72–74, 72f–74f, 72b, 74b, 77f, 353f  
   in rabbits, 77, 77b, 78f, 353f  
 Piroplasm  
   in dogs, 165, 165f, 165b, 257, 347f  
   in horses, 170, 170f–171f, 170b, 349f  
   in ruminants, 168, 168f, 168b, 261b, 351f  
 Plant hairs, 360f–361f  
*Plasmodium* spp., 176, 176f, 210, 210b, 354f  
 Platyhelminthes. *See* Flukes  
*Platynosomum concinnum*, 6  
*Platynosomum fastosum*, 135, 135f–136f, 135b  
 Pleomorphism, 267  
 Plerocercoids, 90, 91f, 117–119, 289–290  
 Plumber's itch, 33, 294–296  
*Pneumonyssus caninum*, 245, 245f, 245b, 335–336  
*Polyplax serrata*, 202–204, 204b  
*Polyplax spinulosa*, 204, 204b  
 Pork tapeworm. *See* *Taenia solium*  
 Porocephalosis. *See* Pentastomes  
*Porocephalus crotali*, 269f, 270  
 Predator-prey relationships, 2  
 Prepatent period, defined, 26  
 Primary screwworm. *See* *Cochliomyia hominivorax*  
 Proceroids, 90, 91f, 117  
 Proglottids  
   of flukes vs. tapeworms, 83, 84f  
   of pseudotapeworm, 90, 90b  
   of tapeworm, 85–88, 85f–86f, 86b, 89f  
 Proliferative sparganosis, 289–290  
 Protista, overview of, 9, 13b, 14  
*Protostrongylus* spp., 55, 55b

## Protozoans

- amoebae (sarcodina), 150–151, 151f, 151b
- apicomplexans, 152, 152f, 152b
- characteristics of, 149–150, 150b
- Protozoans (*Continued*)
- ciliates (ciliophora), 151–152, 151f, 152b
- of dogs and cats, 156–166
- in fecal samples, 321–323
- of fish, 184
- flagellates (Mastigophora), 150, 150f
- of guinea pigs, 182–184
- of hamsters, 182
- of horses
  - circulatory system and blood, 170–171
  - gastrointestinal tract, 169–170
  - nervous system, 171–172
  - urogenital system, 171
- of mice, 179–181
- overview of, 149, 149b
- of rabbits, 177–179
- of rats, 181–182
- of ruminants
  - circulatory system and blood, 168
  - gastrointestinal tract, 166–168
  - urogenital system, 168–169
- of swine, gastrointestinal tract, 172–173
- zoonotic, 281–283
- Pseudocoelom, 17–18, 18b
- Pseudolynchia* spp., 215–216, 216f, 216b
- Pseudoparasitism, 6, 6f, 6b, 312–313, 313b, 360
- Pseudophyllidean type eggs, 86, 87f, 87b
- Pseudopodia, 150
- Pseudosuckers, 274
- Pseudotapeworms
  - of domestic animals and humans, 116–119
  - in humans, 289–290
  - key morphologic features of, 89–90
  - life cycle of, 90–91, 91f, 91b
  - overview of, 12, 13b
- Psoroptes* spp.
  - of rabbits, 235, 235f, 238, 238f, 238b, 357f
  - of sheep, cattle, and horses, 238–239, 239b
- Public health importance, parasites of See Zoonoses
- Pulex irritans*, 228
- Pulmonary dirofilariasis, 300–302
- Punkies. See *Culicoides* spp.
- Pyriform apparatus type eggs, 86, 87f

## Q

- Q fever, 262b
- Quantitative fecal examination, 319–321, 321b
- Queensland itch, 208–209

## R

## Rabbits

- fleas of, 226–231
- lice of, 206
- mites of, 235, 235f, 238, 238f, 238b, 247–248, 247f, 248b, 252, 252b
- nematodes of, 77–79
- protozoans of, 177–179
- reference to common parasites of, 353–360

Raccoon roundworm. See *Baylisascaris procyonis*

*Radfordia affinis*, 249–251, 249b, 250f

*Radfordia ensifera*, 251, 251f, 251b

## Rats

- lice of, 202–205
- mites of, 246–247, 246b–247b, 247f, 251, 251f, 251b
- nematodes of, 74–75
- protozoans of, 181–182
- reference to common parasites of, 353–360
- scabies mites of, 234, 234f, 236b
- true tapeworms of, 94–95

Rectum, of nematode, 18

Red mange mite. See *Demodex* spp.

Red mite. See *Dermanyssus gallinae*

Red stomach worm. See *Hyostrongylus rubidus*

Reduviid bugs (kissing bugs), 164, 198

*Reighardia sterna*, 268

## Reproductive system

- laboratory procedures for, 339
- of nematode, 15, 18–21, 18b

Reptiles, parasites of. See Pentastomes

Reservoir hosts, overview of, 7

Respiratory capillarid. See *Eucoleus* spp.

## Respiratory system

- of birds, 177
- canine/feline, 43–44
- of horse, 64
- laboratory procedures for, 335–336
- of ruminants, 53–55, 225–226
- of swine, 70

Rhabditiform esophagus, 52

*Rhabditis strongyloides*, 46–47, 47b, 56

*Rhipicephalus sanguineus*, 196, 254f, 257f, 258b

*Rhodnius* spp., 199, 199b

*Rickettsia typhi*, 204, 204b

Rocky Mountain spotted fever, 259, 262b

Rocky Mountain wood tick. See *Dermacentor andersoni*

Rostellum, 84, 84f

Roundworms. See Nematodes

Rumen fluke. See *Cotylophoron* spp; *Paramphistomum* spp.

## Ruminants

- beef tapeworm of, 99, 99f, 99b–100b, 285–286
- dipteran fly larvae infecting, 225–226
- flukes of, 131–135
- mites of
  - demodectic, 242
  - ear mites, 238–239, 239b
- nematodes of
  - abdominal cavity, 56–57
  - circulatory system, 52–53
  - eye and adnexa, 56
  - gastrointestinal tract, 49–52
  - respiratory system, 53–55
  - skin, 55–56
- protozoans of
  - circulatory system and blood, 168
  - gastrointestinal tract, 166–168
  - urogenital system, 168–169
- reference to common parasites of, 350–352
- scabies mites of, 232–233, 233f
- true tapeworms of, 95–101
- zoonotic parasites of, 282–283, 285–286

## S

- Saccharomycopsis guttulatus*, 360f
- Salenopotes capillatus*, 352f
- Saliva, diptera of, 216–219
- Salmon poisoning fluke. *See* *Nanophyetus salmincola*
- Sand flies. *See* *Culicoides* spp.; *Lutzomyia* spp.; *Phlebotomus* spp.
- Sandworms. *See* Cutaneous larval migrans
- Sarcocystis neurona*, 171–172, 171b
- Sarcocystis* spp., 161, 164b
- Sarcodina. *See* Amoeboae
- Sarcophaga* spp., 218–221, 219b, 312–313
- Sarcoptes scabiei*, 232–233, 232b, 233f, 235f, 302, 347f
- Sarcoptiform mites, 231–252
- Saturated sodium chloride flotation solution, 316, 317b, 318
- Scabies, 233, 239b
- Scaly leg, 236–237
- Schistosoma* spp., 140f, 140b
- Schistosome cercarial dermatitis, 140f, 140b, 283–285
- Schistosomes, 124, 140b, 283–285. *See also* *Heterobilharzia americana*
- Schizonts, 166
- Scientific names, 8–9
- Scolex, 84, 84f, 90
- Screwworm. *See* *Cochliomyia hominivorax*
- Scutum, 252, 253b
- Sedimentation
  - fecal, 319, 319b, 321f, 321b
  - of urine, 336b
- Seed ticks, 253–254, 254f
- Serum collection, 335b
- Setaria cervi*, 56, 56f, 57b
- Setaria equina*, 66, 66b
- Sheather's solution, 316–317, 317b–318b
- Sheep ked. *See* *Melophagus ovinus*
- Shipment of parasitologic specimens, 326, 326b
- Sieving method for necropsy sample collection, 324, 325b
- Simple flotation method, 318–319, 318b
- Simple metamorphosis, 189, 190b
- Simulium* spp., 207, 207–208, 207f, 208b
- Siphonaptera. *See* Fleas
- Skin
  - canine/feline, 46–49
  - of fish, 184
  - of horse, 64–65
  - laboratory procedures for, 336–338
  - of ruminants, 55–56
- Skin scrapings, 336–337, 337f, 337b
- Smears
  - blood, 329–330, 329b–331b, 331f
  - ear, 338b
  - fecal, 315–316, 315b–316b
- Snails, 125–126, 126f
- Snakes, parasites of. *See* Pentastomes
- Sodium chloride flotation solution, 316, 317b, 318
- Sodium nitrate flotation solution, 316–317, 317b–318b
- Soft (argasid) ticks, 253–256, 253b
- Solenopotes capillatus*, 200, 201f
- Somatic muscular layer, 16f, 17–18
- South American trypanosomiasis, 198
- Spanish fly. *See* Blister beetles
- Sparganosis, malignant, 289–290
- Sparganosis tapeworms. *See* *Spirometra* spp.
- Sparganum. *See* Plerocercoids
- Species epithets, 8–9
- Specific gravity, 316
- Specimen shipping, overview of, 326
- Spicule pouch, 18–19
- Spicules, 17–19, 18f
- Spinose ear tick. *See* *Otobius megnini*
- Spiny-headed worm. *See* Acanthocephalans
- Spirocercia lupi*, 20f, 26–27, 26f, 27b, 196
- Spirometra* spp., 91, 117–118, 118f, 118b, 194, 289–290, 346f
- Spironucleus muris*, 179–180, 180b
- Spiroptera incesta*, 31b, 79–80
- Spiruroid nematodes, 19, 20f

Spiuracular plates, 220, 220f  
 Sporocysts, 125–126, 127f  
 Sporulation, 323–324  
 Sputum examination, 335–336  
 Stable fly. *See Stomoxys calcitrans*  
 Stenoxenous parasitism, 7–8  
*Stephanofilaria stilesi*, 55, 55–56, 55f, 212–214  
*Stephanurus dentatus*, 70–71, 71f, 71b, 352f  
 Stepping, 274, 274b  
 Sticktight flea of poultry. *See Echidnophaga gallinacia*  
 Stomach bots. *See Gastrophilus* spp.  
 Stomach worm  
   in dogs and cats, 27–28, 27f, 28b, 328  
   in horses, 57–58, 57f, 57b–58b, 64, 64b, 65f, 212–213, 349f  
   in swine, 66–67, 66f, 67b, 352f  
*Stomoxys calcitrans*, 212–213, 212b–213b, 213f  
 Strike. *See Fly strike*  
 Strobila, 85, 90  
 Strobilocercus, 109–110, 110f, 110b  
*Strongyloides papillosus*, 52, 52b  
*Strongyloides ransomi*, 68, 68b  
*Strongyloides stercoralis*, 16–17, 16f, 298–299  
*Strongyloides westerei*, 61, 62f, 62b  
*Strongylus* spp., 18f, 19, 60–61, 60b–61b, 61f, 349f  
 Stylosomes, 244, 244b  
 Sugar flotation solutions, 316–317, 317b, 317b–318b  
 Summer dermatitis, 208–209  
 Summer sores, 57, 57b, 63f, 64, 64b, 65f  
 Sweat (sweet) itch, 208–209  
 Swimmer's itch, 140f, 140b, 283–285  
 Swine  
   mites of, 242  
   nematodes of, 66–72  
   pork tapeworm of, 99–100, 100f, 100b, 286–287  
   protozoans of, 172–173  
   reference to common parasites of, 352–353  
   scabies mites of, 232–233, 233f  
   tapeworm in musculature of, 99–100  
   thorny-headed worms of, 145–147, 146f  
   zoonotic parasites of, 286–287, 299–300  
 Symbionts, defined, 2  
 Symbiotic relationships. *See also Parasitism*  
   commensalism, 3  
   mutualism, 3, 3b  
   overview of, 2, 2f, 2b  
   phoresis, 2–3, 3f  
*Syphacia* spp., 72–74, 72f–74f, 74b, 77f, 353f

## T

*Tabanus* spp., 210–211, 211f, 211b  
 Tachyzoites, 281, 281b  
*Taenia hydatigena*, 100–101, 106–108, 106f  
*Taenia ovis*, 106–108, 106b  
*Taenia pisiformis*, 87f, 88–89, 106–108, 108f–109f, 345f  
*Taenia saginata*, 99, 99f, 99b–100b, 285–286  
*Taenia solium*, 99–100, 100f, 100b, 286–287  
*Taenia taeniaeformis*, 108–110, 108b, 110b  
 Taenia type eggs, 86, 87f, 87b  
 Tapeworm (cestodes). *See also Pseudotapeworms*  
   in autopsy samples, 325, 325b  
   of dogs and cats, 100–101, 103–116  
   in fecal samples, 311–312, 311f–312f  
   of horses, 101–103  
   in humans, 288–289  
   key morphologic features of, 84–87, 84f–87f, 84b, 86b–87b  
   life cycle of, 87–89, 89f  
   metacystode (larval) stages in musculature, 99–100  
   overview of, 12, 12b, 83–84, 83b, 84f  
   of rodents, 94–95  
   of ruminants, 95–101  
   zipper, 91, 117–118, 118f, 118b, 194, 289–290, 346f  
   zoonotic, 285–292  
 Tasselfoot, 236–237  
 Tears, diptera of, 216–219  
 Tegument, 84, 84b  
 Testes, of nematode, 18–19  
*Tetrameres* spp., 16–17, 17f, 31b, 79–80  
 Tetrathyridia, 114–115, 115f–116f, 116b  
*Tetratrichomonas microti*, 179, 179b  
 Texas cattle fever tick. *See Boophilus annulatus*  
 Thelazia spp.  
   in cats and dogs, 49, 49f, 49b, 53  
   diagnosis of, 308  
   in horses, 66  
   in ruminants, 53, 56, 56b  
*Theromyzon tessulatum*, 275  
 Thick blood smears, 330, 331b  
 Thin blood smears, 330, 330b, 331f  
 Thorax, 189, 189b  
 Thorny-headed worms. *See Acanthocephalans*  
 Threadworm (*Strongyloides* spp.)  
   of cats and dogs, 34–35, 35f, 35b  
   of horses, 61, 62f, 62b  
   in humans, 298–299



- Threadworm (*Continued*)  
 of pigs, 68, 68b  
 of ruminants, 52, 52b  
*Thysanosoma actinoides*, 88, 88f, 98–99, 98f, 98b  
 Tick paralysis, 253, 258f, 258b, 262b  
 Ticks  
 hard (ixodid), 253, 253b, 256–262  
 life cycle of, 254b, 255f  
 overview of, 190, 190b, 252–262  
 soft (argasid), 253–256, 253b  
 Tongue worms. *See* Pentastomes  
*Toxascaris leonina*, 28–30, 29f–30f, 29b–30b, 344f  
*Toxocara canis*, 19, 19f, 28–30, 29f, 29b–30b, 292–293, 344f  
*Toxocara cati*, 17f, 28–30, 29f, 29b–30b, 292–293, 344f  
 Toxocaral larval migrans, 292–293  
*Toxoplasma gondii*  
 as euryxenous parasite, 7–8, 8b  
 in humans, 281–282  
 overview of, 160–161, 161f–163f, 161b, 281–282, 347f  
 Tracheal washes, 335–336  
 Transport (paratenic) hosts, 6, 293  
 Trematodes. *See* Flukes  
*Triatoma* spp., 199, 199b  
*Trichinella spiralis*, 69–72, 70b, 71f, 299–300  
 Trichineloid nematodes, 19, 20f  
 Trichinosis, 299–300  
*Trichomonas gallinae*, 174–175, 175f, 175b, 354f  
*Trichosomoides crassicauda*, 74–75, 75b  
 Trichostrongyle nematodes  
 bovine, 50  
 overview of, 19, 19f, 28  
 in rabbits, 78–79, 78b–79b  
 in ruminants, 50–51, 50f–51f, 50b–51b  
*Trichostrongylus axei*  
 in horses, 58, 58b  
 in swine, 67  
*Trichostrongylus* spp.  
 in rabbits, 78–79, 78b–79b  
 in ruminants, 50, 50b–51b, 350f  
*Trichuris ovis*, 52, 52b  
*Trichuris* spp., 16–17  
*Trichuris suis*, 69, 69b  
*Trichuris vulpis*, 20f, 344f  
*Tritrichomonas caviae*, 182–183, 183b  
*Tritrichomonas foetus*, 150, 150f, 168–169, 169f, 169b, 339  
*Tritrichomonas muris*, 179, 179b  
*Trixacarus caviae*, 235, 235f, 237, 237b, 357f  
*Trombicula* spp., 244–245, 244f  
 Trophozoites, 321–322  
 Tropical rat mite. *See* *Ornithonyssus bacoti*  
 True bugs. *See* Hemiptera  
*Trypanosoma cruzi*, 164, 164b, 198–199  
*Trypanosoma* spp., 168, 168f, 168b, 175, 175f, 175b, 212, 329, 351f, 354f  
 Trypomastigote, 164  
 Tsetse fly. *See* *Glossina* spp.  
 Tularemia, 262b  
 Two-winged flies. *See* Diptera
- U**
- Unarmed tapeworms, 84, 84f  
*Uncinaria stenocephala*, 294–296  
 Unilocular hydatid tapeworm. *See* *Echinococcus granulosus*  
 Urine samples, 336, 336b  
 Urogenital system  
 canine/feline, 44–46  
 of horse, 171  
 laboratory procedures for, 336  
 of mice, 181  
 of ruminant, 168–169  
 of swine, 70–71
- V**
- Vas deferens, 18–19  
 Venations, 211  
 Vermicides, 30  
 Vermifuges, 30  
 Visceral larva migrans, 292–302  
 Vitellaria, 132  
 Vomitus, 328
- W**
- Walking dandruff. *See* *Cheyletiella* spp.  
 Warbles. *See* *Cuterebra* spp.  
 Wasps. *See* Hymenoptera  
 Whipworm (*Trichuris* spp.)  
 of cats and dogs, 35–36, 35f, 36b, 37f–38f  
 of ruminants, 52, 52b  
 of swine, 69, 69b  
 Wisconsin sugar flotation method, 321  
 Wolves. *See* *Cuterebra* spp.  
 Wood ticks. *See* *Dermacentor andersoni*; *Dermacentor variabilis*
- Y**
- Yellow fever mosquito. *See* *Aedes aegypti*

**Z**

Zinc sulfate flotation solution, 316, 317b–318b, 318

Zipper tapeworm. *See* *Spirometra* spp.

Zoonotic parasites

arthropods, 302

cestodes, 285–292

Zoonotic parasites (*Continued*)

defined, 8

nematodes, 292–302

overview of, 280, 280b

pentastomes, 303–304

protozoans, 281–283

trematodes, 283–285