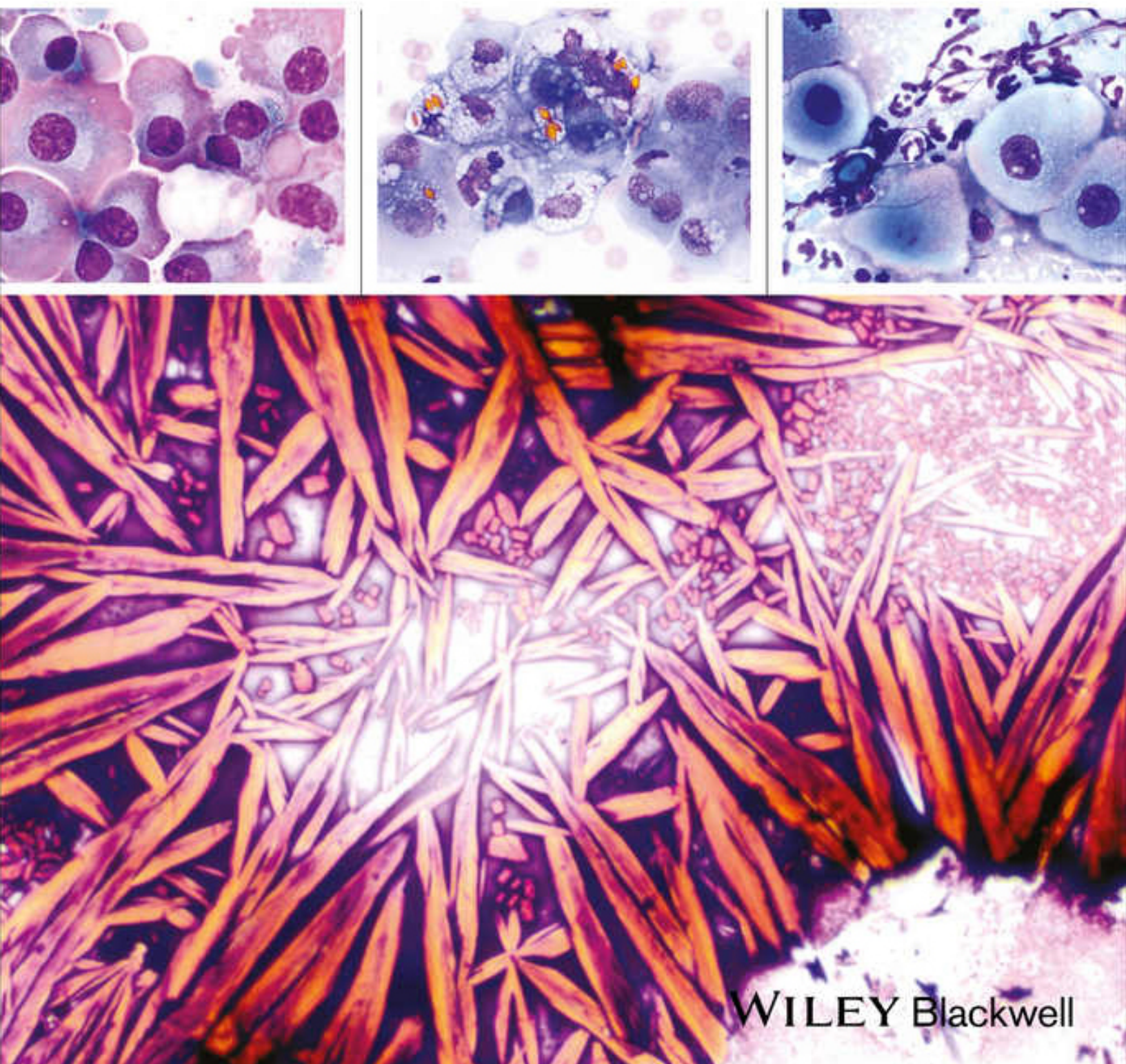


Clinical Atlas of Small Animal Cytology

Andrew G. Burton



WILEY Blackwell

Clinical Atlas of Small Animal Cytology

Clinical Atlas of Small Animal Cytology

Andrew G. Burton, BVSc, DACVP
Clinical Pathologist
IDEXX Laboratories, Inc.
North Grafton, Massachusetts, USA

WILEY Blackwell

This edition first published 2018
© 2018 John Wiley & Sons, Inc.

All rights reserved. No part of this publication may be reproduced, stored in a retrieval system, or transmitted, in any form or by any means, electronic, mechanical, photocopying, recording or otherwise, except as permitted by law. Advice on how to obtain permission to reuse material from this title is available at <http://www.wiley.com/go/permissions>.

The right of Andrew G. Burton to be identified as the author of this work has been asserted in accordance with law.

Registered Office

John Wiley & Sons, Inc., 111 River Street, Hoboken, NJ 07030, USA

Editorial Office

111 River Street, Hoboken, NJ 07030, USA

For details of our global editorial offices, customer services, and more information about Wiley products visit us at www.wiley.com.

Wiley also publishes its books in a variety of electronic formats and by print-on-demand. Some content that appears in standard print versions of this book may not be available in other formats.

Limit of Liability/Disclaimer of Warranty

The contents of this work are intended to further general scientific research, understanding, and discussion only and are not intended and should not be relied upon as recommending or promoting scientific method, diagnosis, or treatment by physicians for any particular patient. In view of ongoing research, equipment modifications, changes in governmental regulations, and the constant flow of information relating to the use of medicines, equipment, and devices, the reader is urged to review and evaluate the information provided in the package insert or instructions for each medicine, equipment, or device for, among other things, any changes in the instructions or indication of usage and for added warnings and precautions. While the publisher and authors have used their best efforts in preparing this work, they make no representations or warranties with respect to the accuracy or completeness of the contents of this work and specifically disclaim all warranties, including without limitation any implied warranties of merchantability or fitness for a particular purpose. No warranty may be created or extended by sales representatives, written sales materials or promotional statements for this work. The fact that an organization, website, or product is referred to in this work as a citation and/or potential source of further information does not mean that the publisher and authors endorse the information or services the organization, website, or product may provide or recommendations it may make. This work is sold with the understanding that the publisher is not engaged in rendering professional services. The advice and strategies contained herein may not be suitable for your situation. You should consult with a specialist where appropriate. Further, readers should be aware that websites listed in this work may have changed or disappeared between when this work was written and when it is read. Neither the publisher nor authors shall be liable for any loss of profit or any other commercial damages, including but not limited to special, incidental, consequential, or other damages.

Library of Congress Cataloging-in-Publication Data

Names: Burton, Andrew G., 1985– author.

Title: Clinical atlas of small animal cytology/by Andrew G. Burton.

Description: Hoboken, NJ : Wiley, 2017. | Includes bibliographical references and index. |

Identifiers: LCCN 2017016287 (print) | LCCN 2017018763 (ebook) | ISBN 9781119215134 (pdf) | ISBN 9781119215141 (epub) |

ISBN 9781119215127 (cloth)

Subjects: | MESH: Cytological Techniques–veterinary | Pets | Atlases

Classification: LCC SF757.25 (ebook) | LCC SF757.25 (print) | NLM SF 757.25 | DDC 636.089/1–dc23

LC record available at <https://lccn.loc.gov/2017016287>

Cover Design: Wiley

Cover Image: Courtesy of Andrew G. Burton

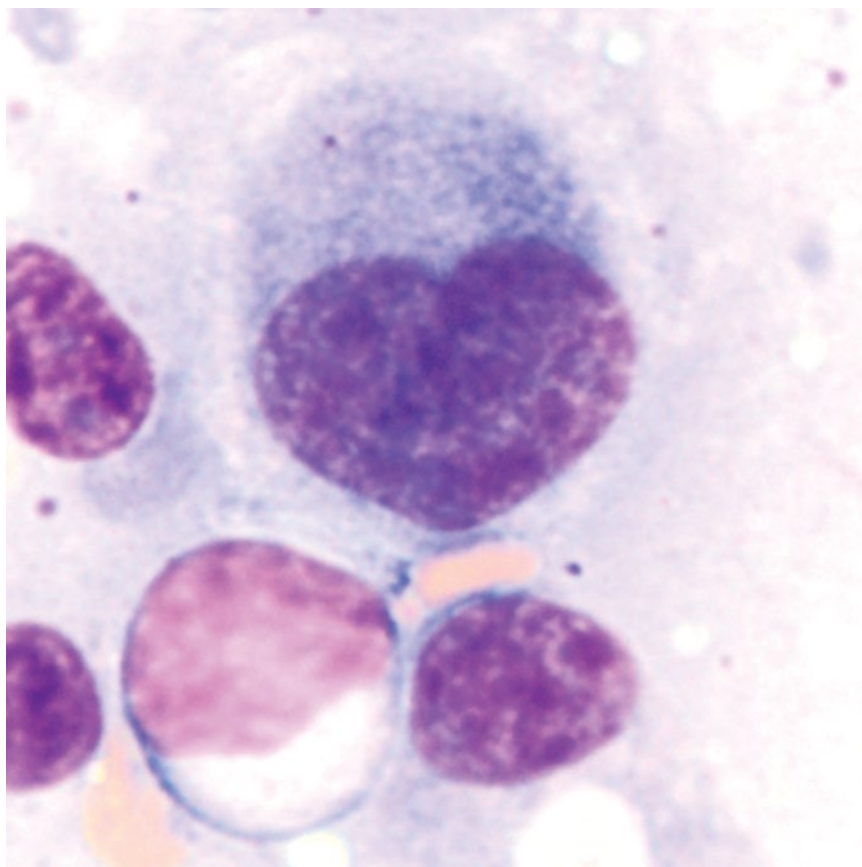
Set in 10/12pt Warnock by SPi Global, Pondicherry, India

Dedication

To my parents: for inspiring the dream.

To my mentors: for making it possible.

To my fiancé: for making it all worthwhile.



Contents

Preface *xi*

Acknowledgment *xiii*

1 Cytologic Analysis of Cells 1

- 1.1 Approach to Cytology Samples 1
- 1.2 Sample Quality and Background 1
- 1.3 Cell Types 4
- 1.4 Cell Shape, Distribution, and Features 17
- 1.5 Benign Versus Malignant 21
- References 31

2 Infectious Agents 33

- 2.1 Fungi 33
- 2.2 Oomycetes 40
- 2.3 Algae 40
- 2.4 Mesomycetozoea 42
- 2.5 Protozoa 43
- 2.6 Helminths 48
- 2.7 Bacteria 51
- 2.8 Ectoparasites 57
- References 59

3 Integument 63

- 3.1 Cutaneous and Subcutaneous Lesions 63
- References 102

4 Hemolymphatic 107

- 4.1 Lymph Nodes 107
- 4.2 Spleen 118
- 4.3 Thymus 131
- 4.4 Bone Marrow 133
- References 151

5 Body Cavity Fluids 155

- 5.1 General Classification 155
- 5.2 Specific Effusions 157
- References 167

6 Musculoskeletal 169

- 6.1 Bone 169
- 6.2 Joints 175

6.3	Muscle	183
	References	186
7	Hepatobiliary	189
7.1	Liver	189
7.2	Biliary Tract	202
	References	205
8	Digestive System	207
8.1	Salivary Glands	207
8.2	Stomach/Intestines	210
8.3	Feces	217
8.4	Pancreas	222
	References	229
9	Urinary	233
9.1	Kidney	233
9.2	Bladder	237
9.3	Urine	240
9.4	Urinary Crystals	245
9.5	Urinary Casts	248
	References	253
10	Respiratory	255
10.1	Nasal Cavity	255
10.2	Lung	259
10.3	Bronchoalveolar Lavage (BAL)/Transtracheal Wash (TTW)	263
	References	270
11	Endocrine	273
11.1	Thyroid	273
11.2	Parathyroid	276
11.3	Chemoreceptor Tumors	277
11.4	Adrenal Gland	279
11.5	Pituitary Gland	281
	References	283
12	Reproductive	285
	Male	285
12.1	Testes	285
12.2	Semen Analysis	289
12.3	Prostate	290
12.4	Penis	298
	Female	298
12.5	Ovary	298
12.6	Mammary Glands	301
12.7	Vaginal Cytology	304
	References	313
13	Neurologic	317
13.1	Brain	317
13.2	Cerebrospinal Fluid (CSF)	325

13.3	Spinal Cord	337
	References	338

14 Ocular and Special Senses 341

14.1	Eyes: Cornea	341
14.2	Eyes: Conjunctiva	344
14.3	Ears	346
	References	350

Index 353

Preface

The *Clinical Atlas of Small Animal Cytology* is written for all enthusiasts of cytology. It aims to be the most clinically friendly cytology resource, through the use of superior quality images and thorough, yet succinct, clinical summaries for common diseases encountered in small animal practice.

Chapter 1 provides a template for a routine approach to examining cytology samples. Normal, incidental, and artifactual findings are discussed to help establish confidence in the interpretation of true pathologic changes. Different cell types, features, and criteria of malignancy are reviewed, and all sections are accompanied by exceptional, representative images. Cells do not always mimic the textbooks— even atlases dedicated to their splendor — and this introductory section will empower clinicians with a strong foundation to extrapolate their findings to the many exciting variations on samples they will encounter in clinical practice.

The *Clinical Atlas of Small Animal Cytology* provides the highest quality images that are large and clear, with lighting and color that mimic the appearance of samples under the microscope. Multiple images of common lesions are available to account for variations in clinical presentation or appearance. Additionally, this atlas

contains only photographs of diseases where the diagnosis was confirmed by pathognomonic cytologic features, histopathology, special stains, microbial culture, or other confirmatory tests. All slides are stained with Romanowsky stains unless otherwise stated.

Photographs are accompanied by full cytologic descriptions to guide readers through the diagnostic process and to ensure that all features of each image are highlighted to aid in making confident diagnoses. The characteristic features of each disease are discussed, and distinguishing features from similar appearing lesions are emphasized. This is achieved through written descriptions and side-by-side placement of photos of differential diagnoses for easy and rapid visual comparison.

Clinical information is provided for each disease, based on the most current, relevant, and scientifically sound literature available. The bulleted format of this section allows a comprehensive review for each diagnosis to be condensed into a succinct summary, promoting rapid and efficient access to the most clinically important information to assist in medical decision making.

Above all, it is hoped this book will improve the accessibility, utility and quality of cytology in small animal practice to positively impact patient outcomes.

Acknowledgments

To Wiley Publishers and the many individuals who took this atlas from concept to reality – I thank you for your vision, tireless work and dedication.

I am exceptionally grateful to the many veterinarianary professionals who have shared with me their passion, knowledge, and skills. I am particularly indebted to those who had a fundamental impact on inspiring and shaping my journey: Dr Simon Turner, Dr Danny Jedwab,

Dr Elizabeth Tudor, Dr Phil Thomas, Dr Karl Jandrey, and Dr Bill Vernau.

I would like to acknowledge the support of my incredible colleagues, particularly Dr Reema Patel, for their encouragement and contributions.

I am also filled with gratitude for the love and support of my family.

1

Cytologic Analysis of Cells

1.1 Approach to Cytology Samples

Adopting a routine approach to evaluating cytology samples makes cytopathology easier to approach, more efficient, and increases the chance of making a diagnosis. Four major components of every sample should be evaluated:

- 1) Sample quality and background
- 2) Cell types
- 3) Cell shape, distribution, and features
- 4) Benign versus malignant

1.2 Sample Quality and Background

The background of the sample is the first component to be evaluated, as it can provide important clues about underlying pathology. Some common background changes include:

- *Cystic material*: Cystic lesions often have a thick blue, purple or pink background that may be scalloped. Cholesterol crystals are a hallmark of cell degeneration that occurs commonly in cystic lesions. These appear cytologically as rectangular, flat, non-staining crystals, often with a notched corner (Figure 1.1).
- *Necrosis*: Necrotic debris is seen as amorphous, globular, blue/purple/gray material (Figure 1.2). This material may predominate, and obscure cellular detail.
- *Hemorrhage*: Blood often is present in the background of samples as a consequence of sampling, which may be supported if platelets are present. Prior hemorrhage within the lesion is confirmed when macrophages are erythrophagocytic, and/or contain heme breakdown pigment such as hemosiderin or hematoidin (Figure 1.3).
- *Extracellular matrix*: Extracellular matrix is mostly bright pink and may be smooth, fibrillar or stippled

Figure 1.1 Cholesterol crystals, 20× objective.



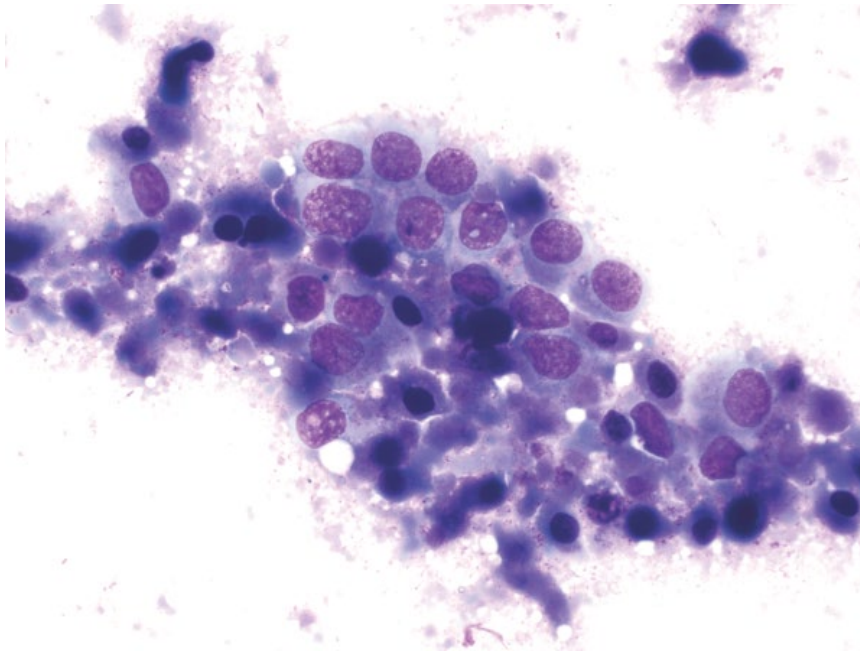


Figure 1.2 Necrotic material, 50× objective. Prostatic carcinoma cells are surrounded by globular, blue/purple necrotic material.

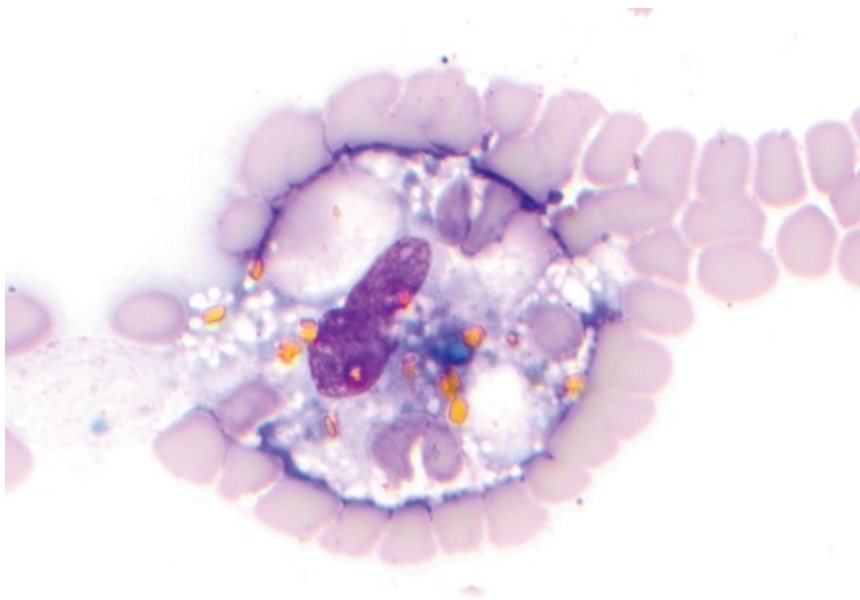


Figure 1.3 Hemorrhage, 100× objective. A macrophage is seen with a central purple nucleus. Red blood cells, blue/green hemosiderin, and golden hematoidin crystals are present within the cytoplasm.

(Figure 1.4). It is most common with mesenchymal proliferation, but basement membrane of epithelium can appear similarly.

- **Cytoplasmic fragments:** Fragments of cytoplasm (Figure 1.5) may be seen with any cell type; however, they are most commonly associated with lymphocytes (and have previously been called 'lymphoglandular bodies') [1].
- **Mineralization:** Mineralized debris is seen as clear, irregular/gritty, refractile aggregates, and often is seen

outside the plane of focus of cells in the sample (Figure 1.6). It may be seen in chronic, cystic, or necrotic lesions.

1.2.1 Artifacts and Incidental Findings

It is also important to recognize artifacts or incidental findings in samples. Glove powder starch crystals are round with a characteristic cross in the middle (Figure 1.7), and should be distinguished from mineralized debris.

Figure 1.4 Extracellular matrix, 50× objective. Note the bright pink, smooth, streaming matrix material intimately associated with spindle cells (synovial cell sarcoma).

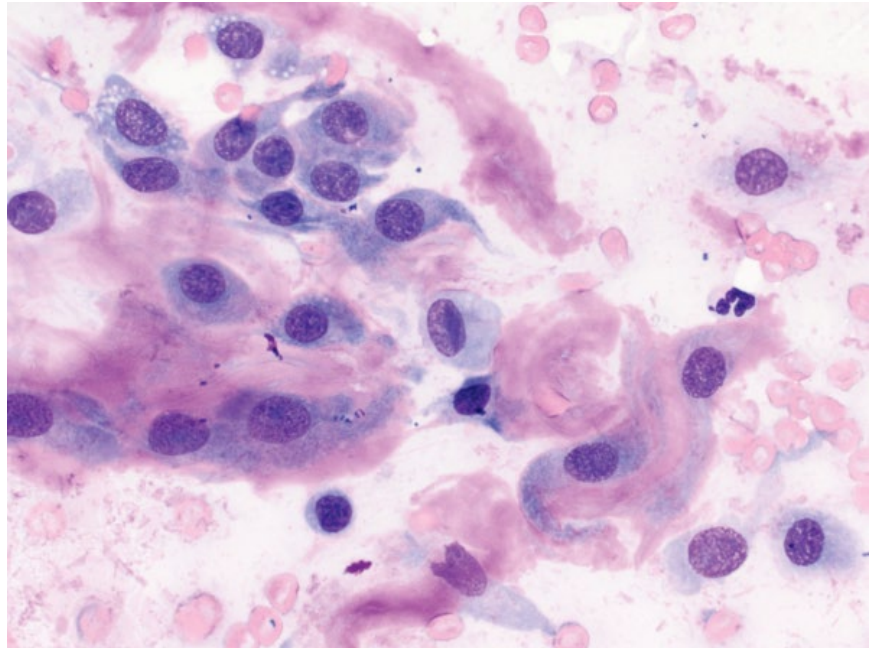
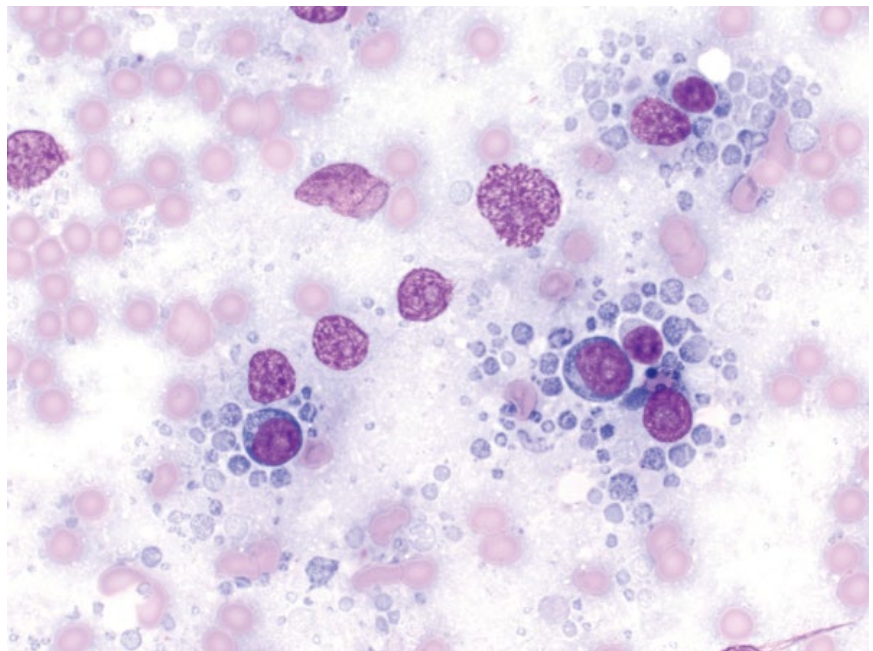


Figure 1.5 Cytoplasmic fragments, 50× objective. Note the small round fragments of pale blue cytoplasm surrounding lymphocytes in a case of canine lymphoma.



Precipitation of stain appears as variably coarse, granular pink/purple material (Figure 1.8). It may be seen in the background, but can cover cells, and care should be taken to distinguish it from cytoplasmic granules, or even intracellular bacteria. Crystals may form incidentally in the background of thick samples, making geometric patterns (Figure 1.9). Other common artifacts/incidental findings include lubricant/ultrasound gel (Figure 1.10), nuclear material or bare nuclei from lysed cells (Figures 1.11 and 1.12), apoptotic cells (Figure 1.13), and hemoglobin crystal formation (Figures 1.14 and 1.15), the latter forming

if samples are exposed to humidity. Formalin artifact results in a pale, homogeneous blue appearance to cells, and cellular detail is obscured (Figure 1.16). Cytologic samples should be transported separately from samples in formalin, or should be in separate, airtight containers.

Some normal tissue components are commonly seen as incidental findings in fine-needle aspirate samples, including capillaries (Figures 1.17 and 1.18), adipose/lipid (Figures 1.19 and 1.20), skin surface keratin debris (Figure 1.21), skeletal muscle (Figure 1.22), and normal mesothelium (Figure 1.23).

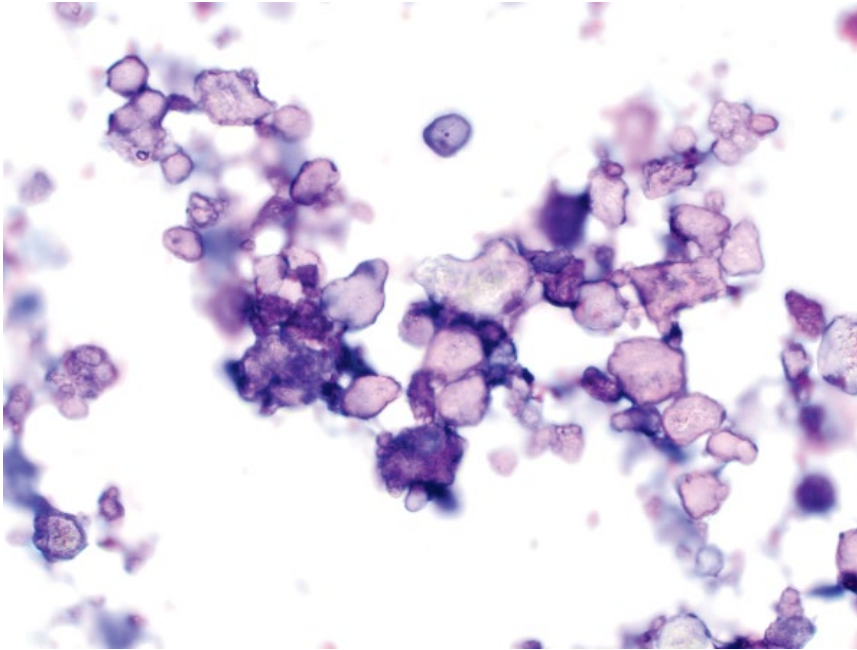


Figure 1.6 Mineralized debris, 50x objective. The material is seen in different planes of focus.

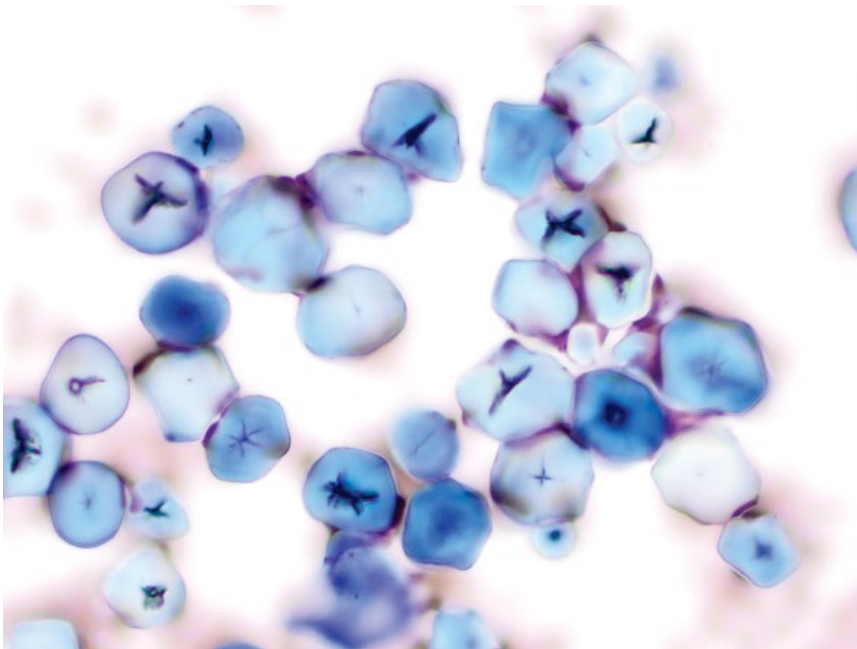


Figure 1.7 Glove powder starch crystals, 50x objective. Note the characteristic cross in the center of the crystals.

1.3 Cell Types

If nucleated cells are seen, it is important to determine if the cell types present are of inflammatory or tissue origin, or if both are present.

1.3.1 Inflammatory Cells

Inflammatory cells in tissues often appear similar to their counterparts in blood (Figure 1.24). The types

of inflammatory cell present may give clues as to the underlying cause:

- Neutrophils = Bacteria, immune-mediated disease, tissue injury.
- Eosinophils = Fungal agents, protozoa, allergy/hypersensitivity, some neoplasms (e.g., mast cell tumors and T-cell lymphoma) [2].
- Macrophages = Fungi, *Mycobacteria*, tissue injury/necrosis, cystic lesions.

Figure 1.8 Stain precipitate, 50x objective. Stain precipitate is granular and may be pink, purple or deeply basophilic and varies from fine (center/right) to coarse (lower left).

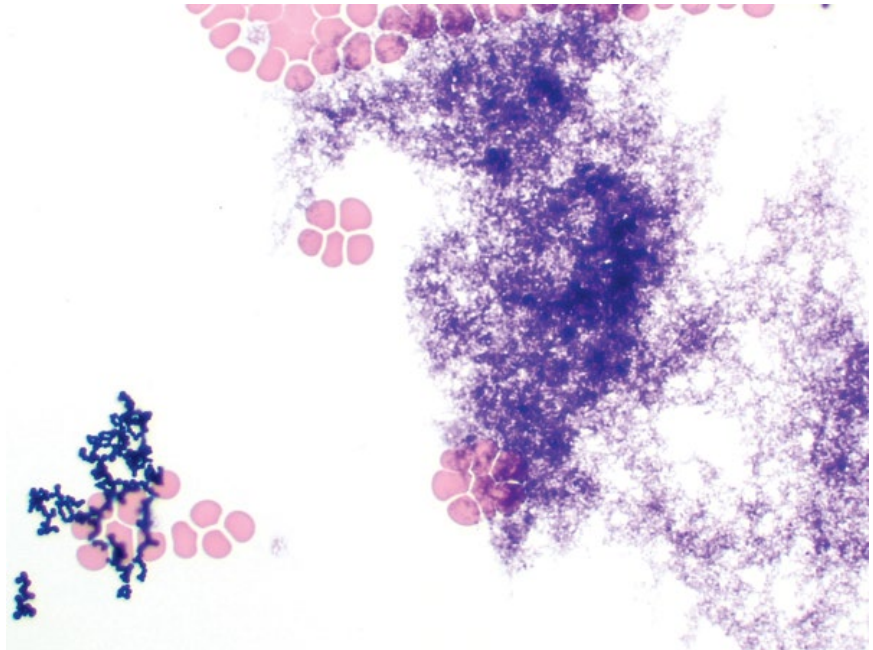
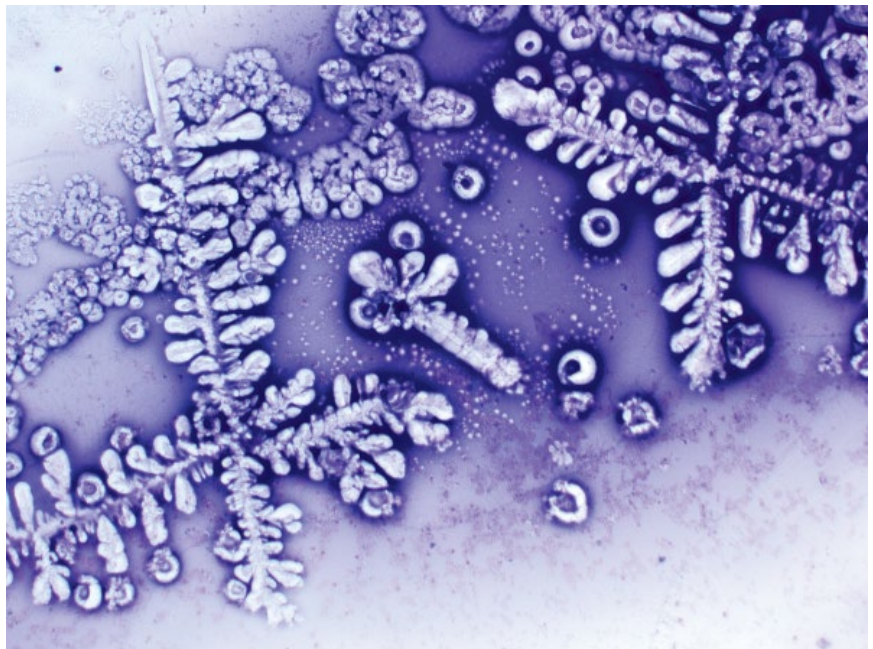


Figure 1.9 Background crystals, 20x objective. Geometric crystals may form incidentally in the background of thick samples.



- Lymphocytes = Chronic disease, immune-mediated disease.
- Plasma cells = Chronic disease, immune-mediated disease. Plasma cells are terminally differentiated B lymphocytes, and may accumulate immunoglobulins in their cytoplasm seen as blue (or rarely pink) smooth globular inclusions (Mott cells) [3], or bright pink peripheral cytoplasmic coloration (flame cells).

The morphology of inflammatory cells is also important. Neutrophils are more likely to be degenerative with an infectious etiology. Degenerative changes include swelling of the nuclei, loss of lobulation, and karyorrhexis/karyolysis (Figure 1.25). Degenerative changes are not to be confused with toxic changes. Degenerative changes affect the *nuclei*, occur in tissues, and may help raise suspicion for an infectious etiology.

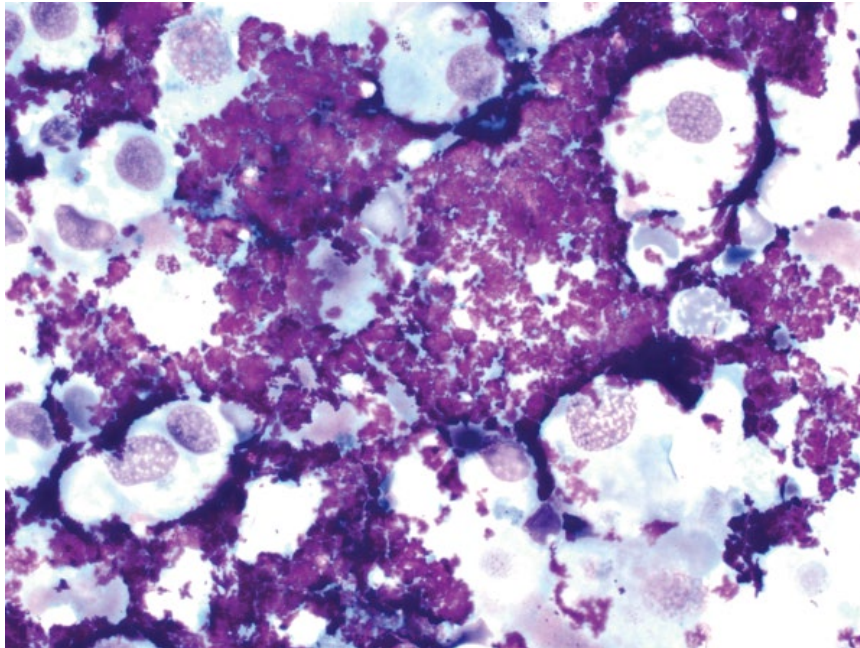


Figure 1.10 Ultrasound/lubricant gel, 50× objective. Bright purple granular material (ultrasound gel) surrounds transitional epithelial cells in a catheter urine sample from a dog.

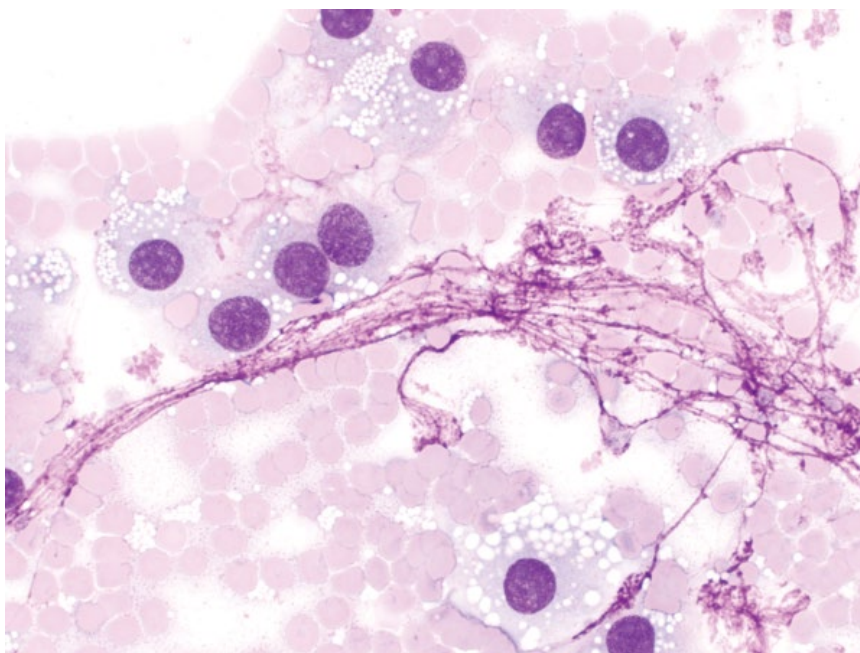


Figure 1.11 Nuclear material, 50× objective. Note the streaming pink nuclear material from lysed cells in an ovarian granulosa cell tumor.

Toxic changes mostly affect the *cytoplasm* of neutrophils (Döhle bodies, increased basophilia, vacuolation; Figure 1.26), and are only assessed on peripheral blood smears [4, 5]. Neutrophils are more likely to be apoptotic or pyknotic (Figure 1.27) in sterile inflammatory lesions.

1.3.2 Tissue Cells

If cells present are not recognizably inflammatory, they likely represent aspiration of tissue cells. These cells are further investigated based on their shape, distribution/interactions with each other, and criteria of malignancy.

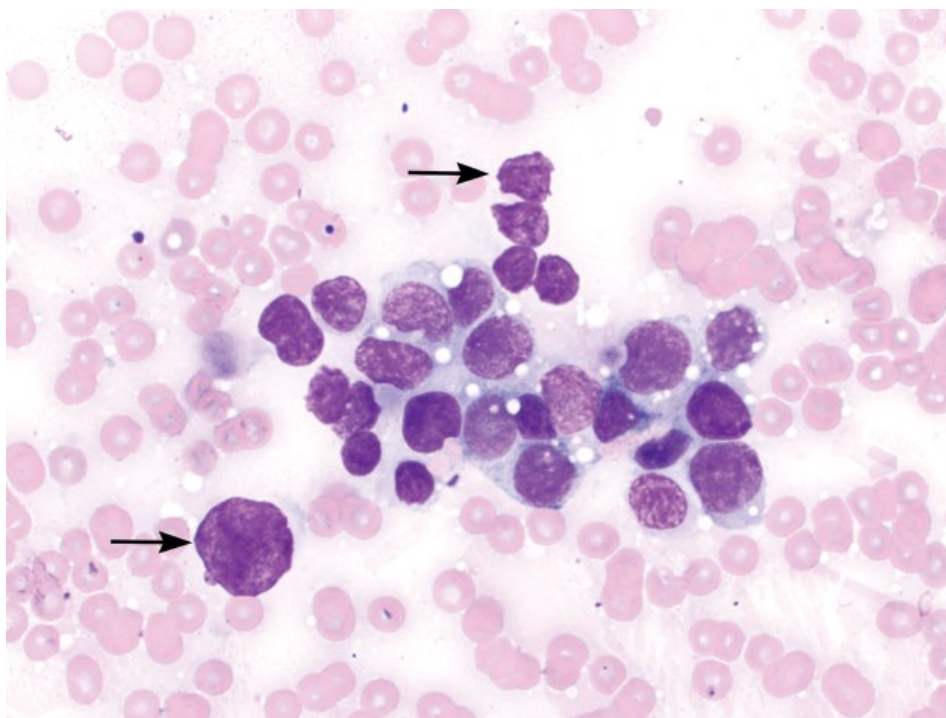


Figure 1.12 Bare nuclei, 50× objective. Nuclei from lysed cells (arrows) appear puffy and lack surrounding cytoplasm.

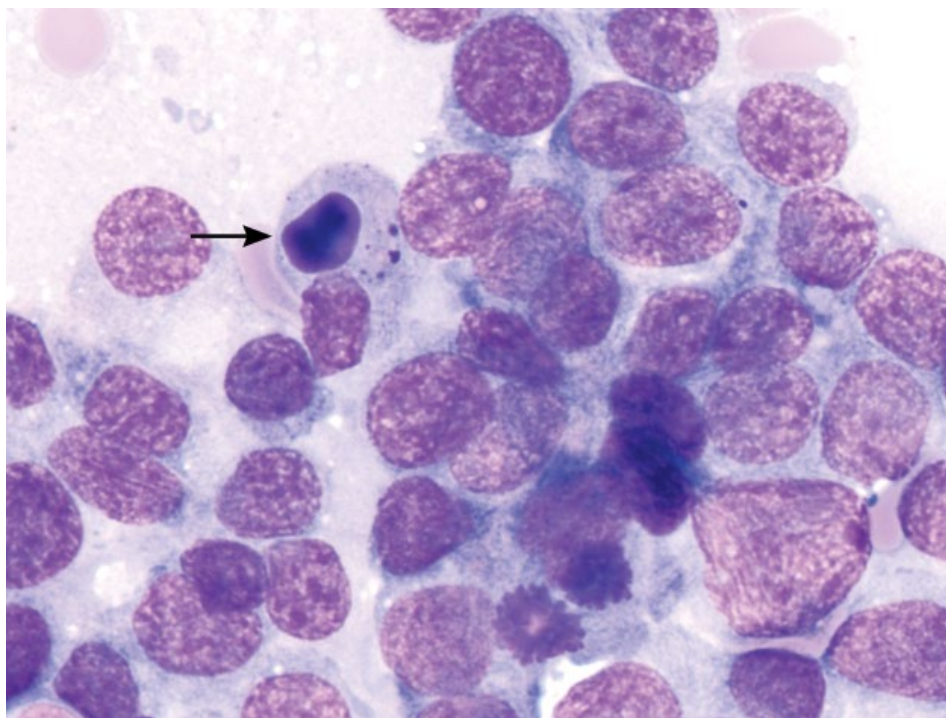


Figure 1.13 Apoptotic cells, 100× objective. Apoptotic cells have pyknotic nuclei with deeply basophilic, dense chromatin (arrow).

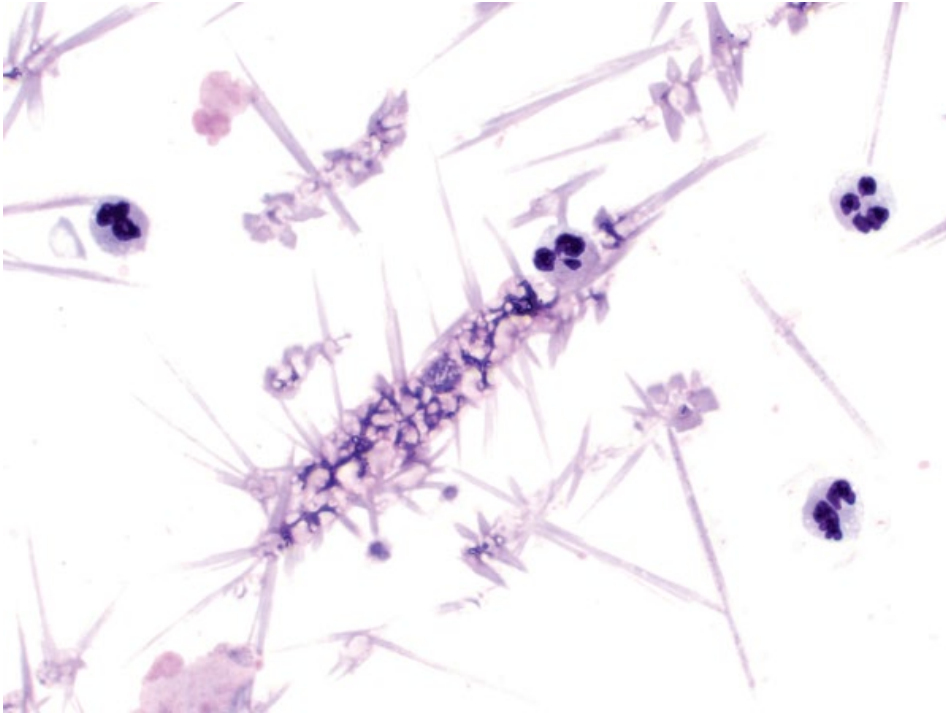


Figure 1.14 Hemoglobin crystals, 50x objective. These crystals are needle-shaped and the color of red blood cells. Note the blood-associated neutrophils.

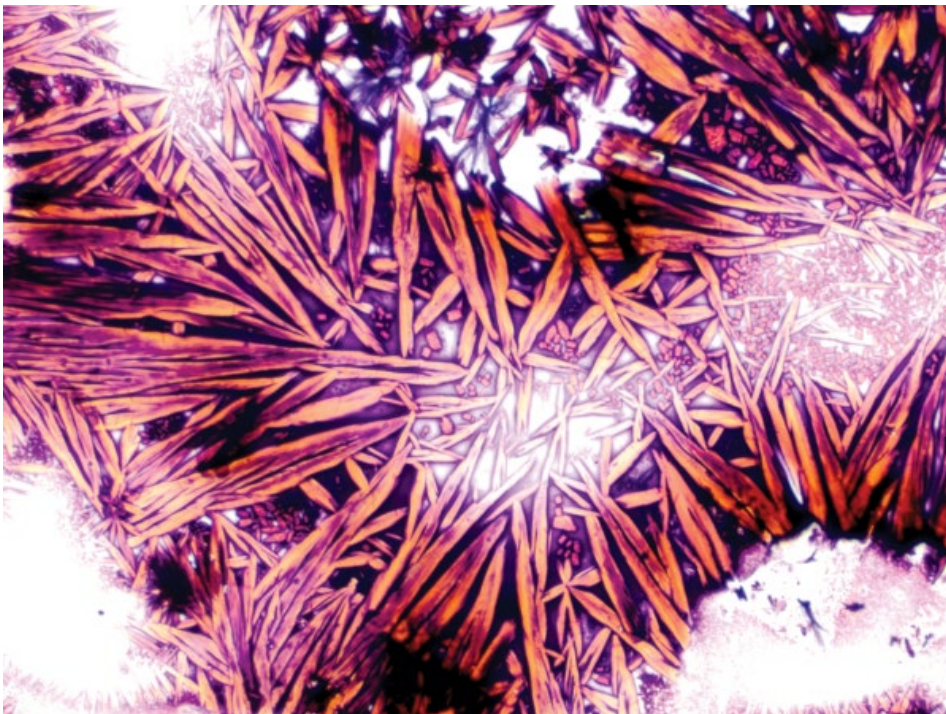


Figure 1.15 Hemoglobin crystals, 50x objective. These crystals are similar in shape to those in Figure 1.14, but are variably sized, and pink/orange.

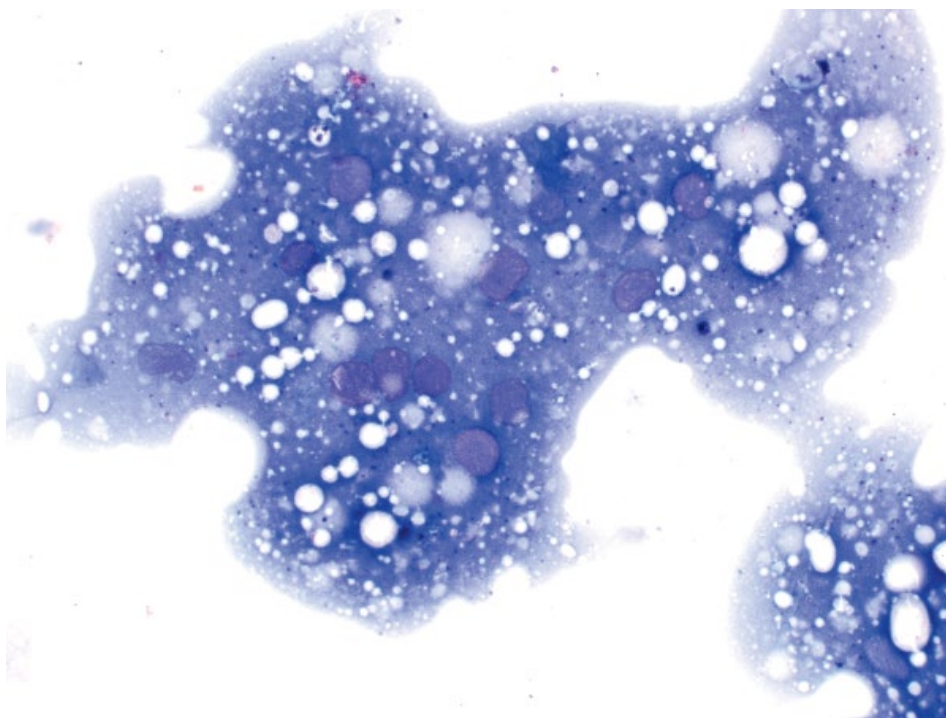

Figure 1.16 Formalin artifact, lymph node, dog, 50× objective. Note the pale blue homogeneous material and poor cellular detail.

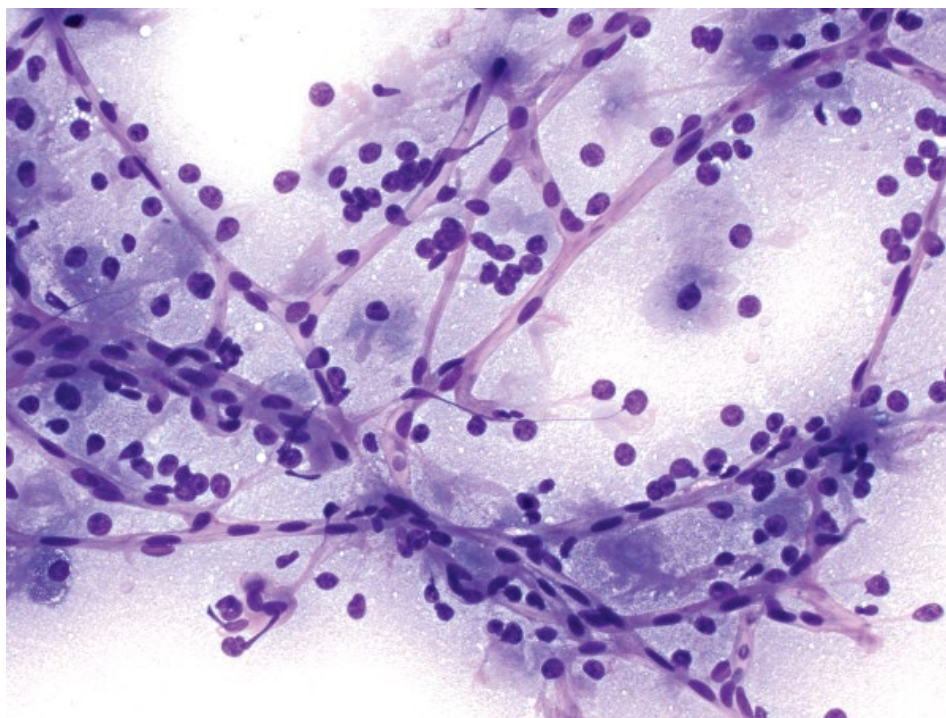


Figure 1.17 Capillaries, 20× objective. Linear pink capillaries course across the sample.

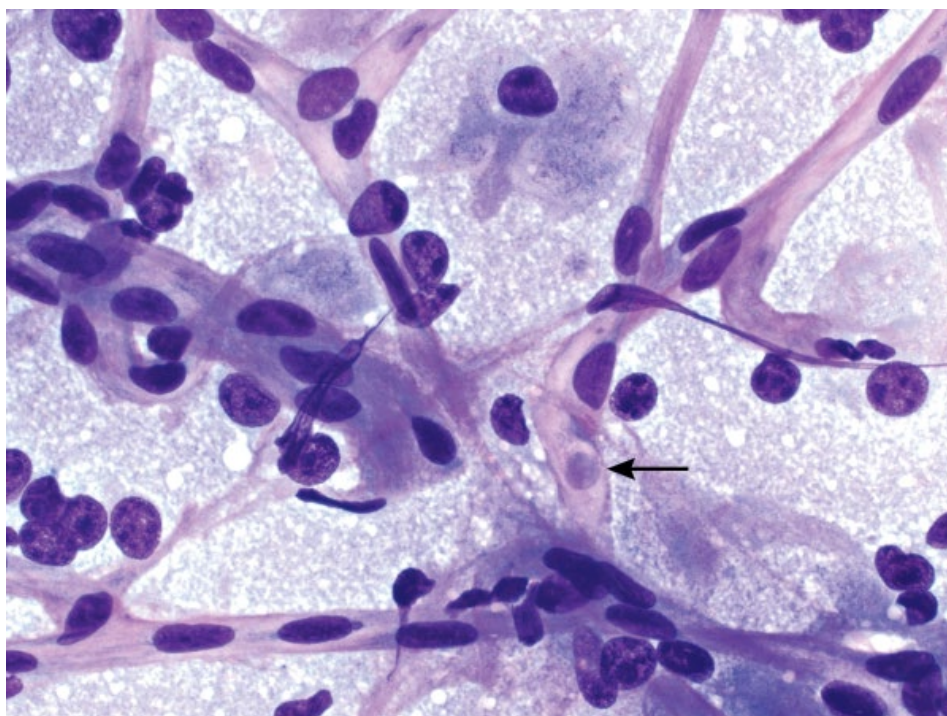


Figure 1.18 Capillaries, 50× objective. Pink, linear capillaries with elongated basophilic nuclei seen in rows. Note the red blood cell travelling within the capillary (arrow).

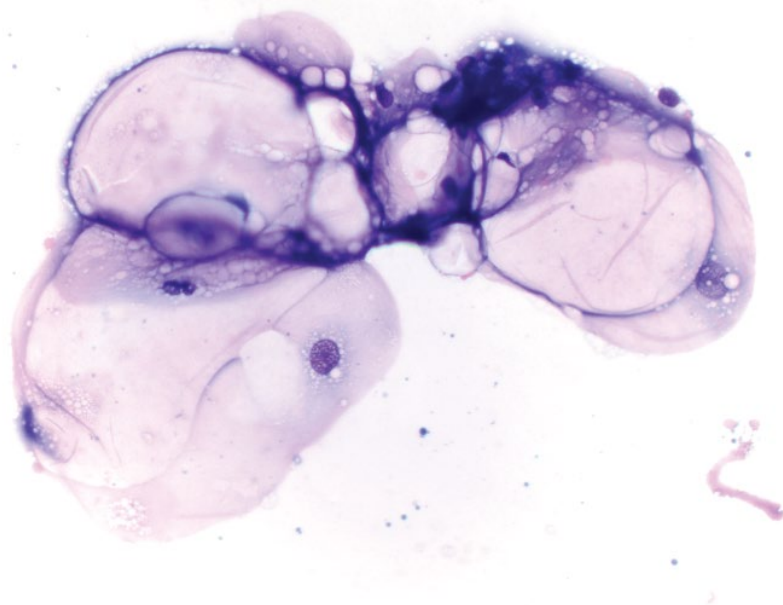


Figure 1.19 Adipose tissue, 20× objective.

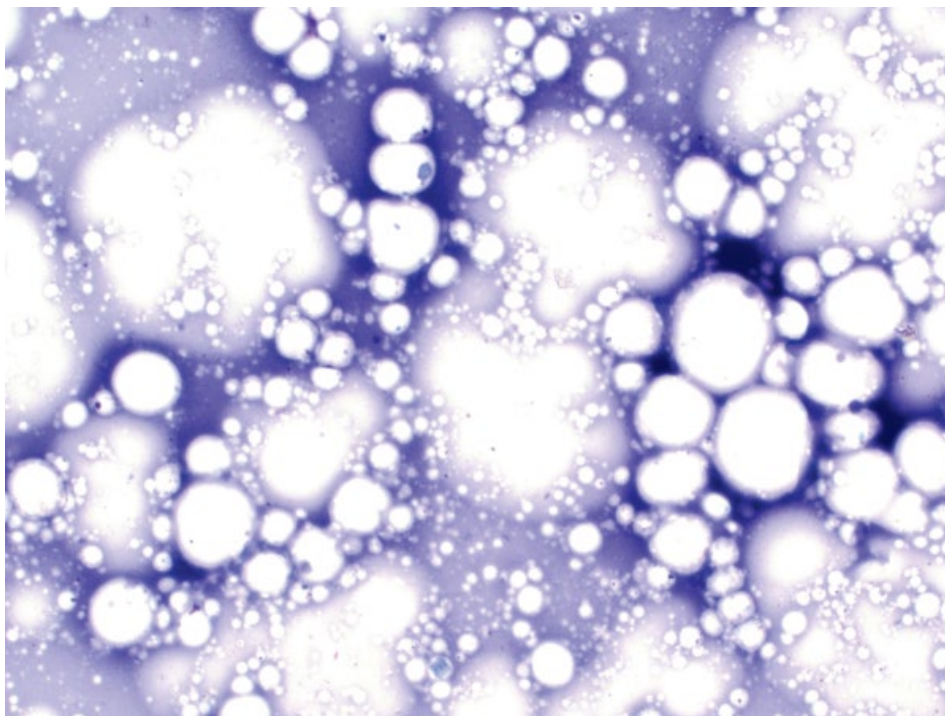


Figure 1.20 Lipid vacuoles, 50x objective.

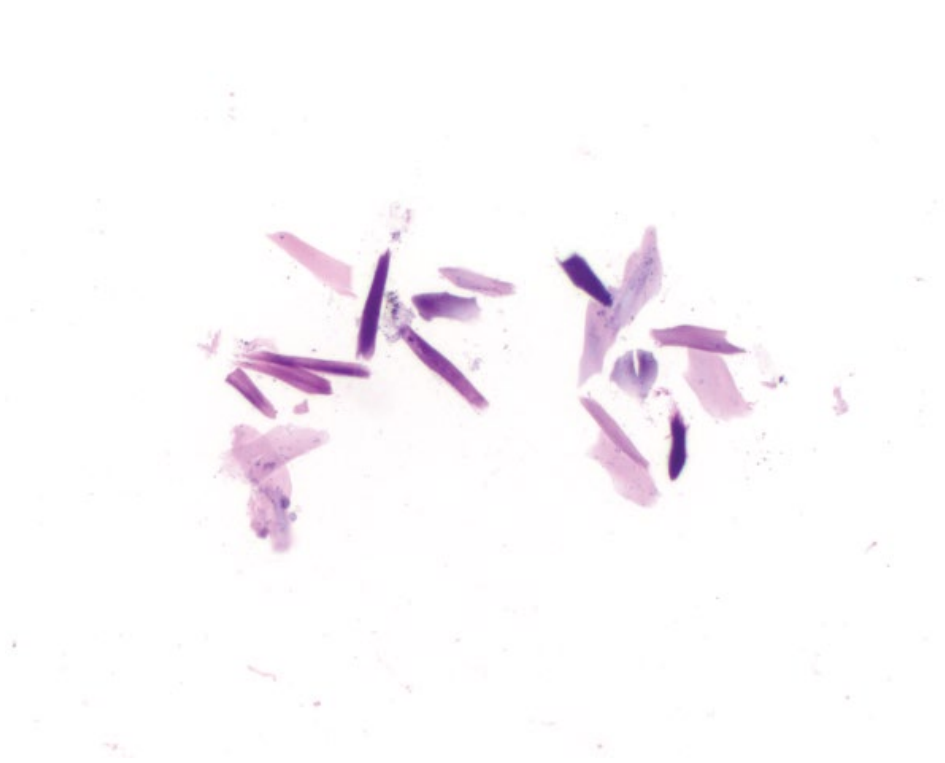


Figure 1.21 Keratin debris, 20x objective.

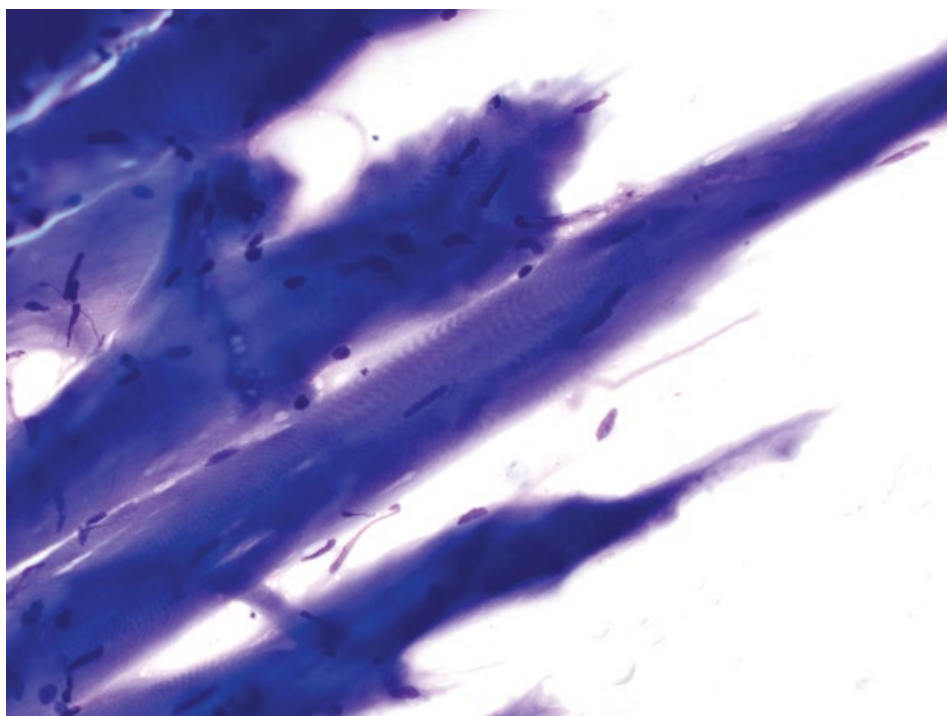


Figure 1.22 Skeletal muscle, 50x objective. Skeletal muscle is deep blue and has subtle parallel cross-striations.

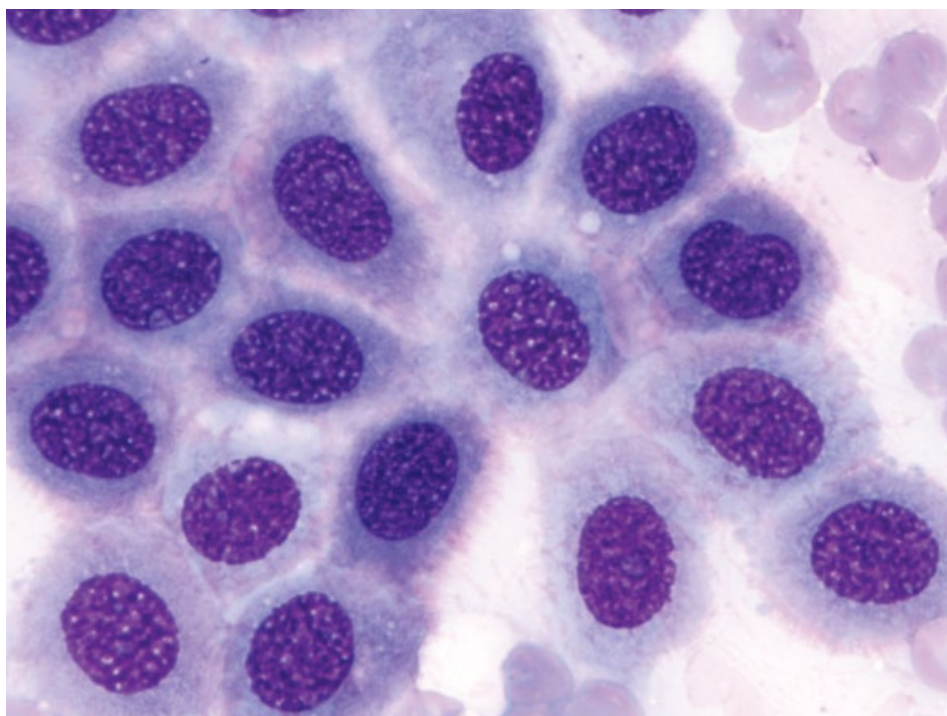
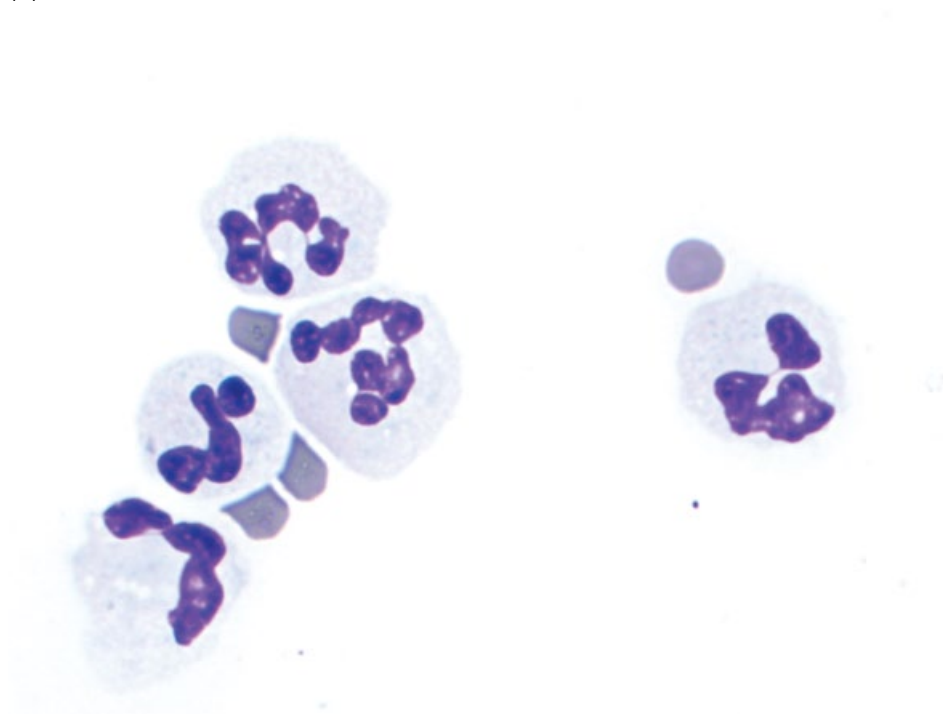


Figure 1.23 Normal mesothelium, 100x objective. Note the pink fringe border.

(A)



(B)

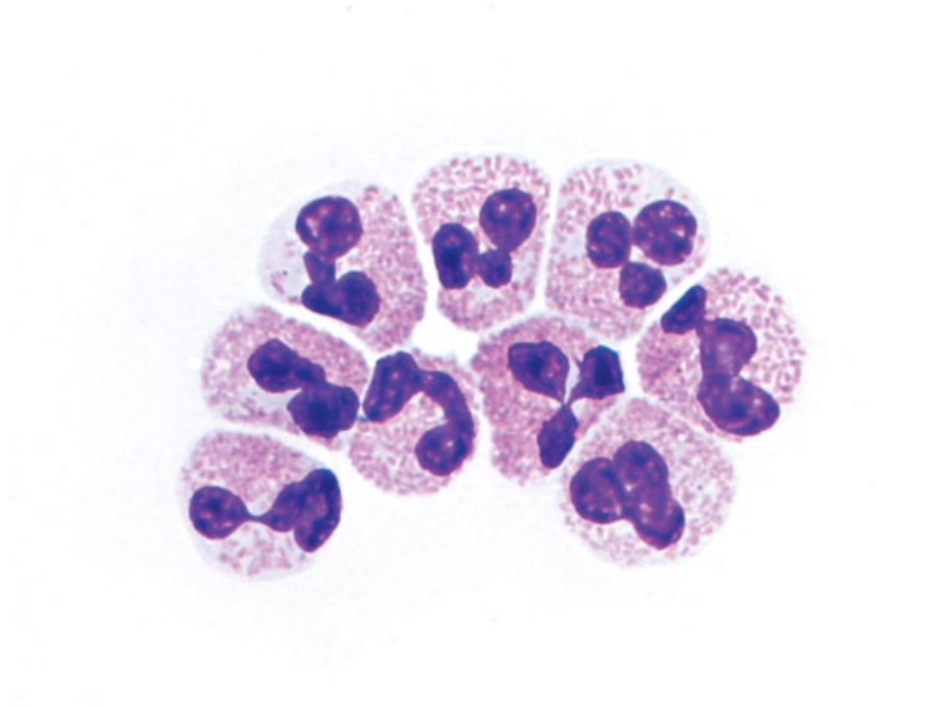
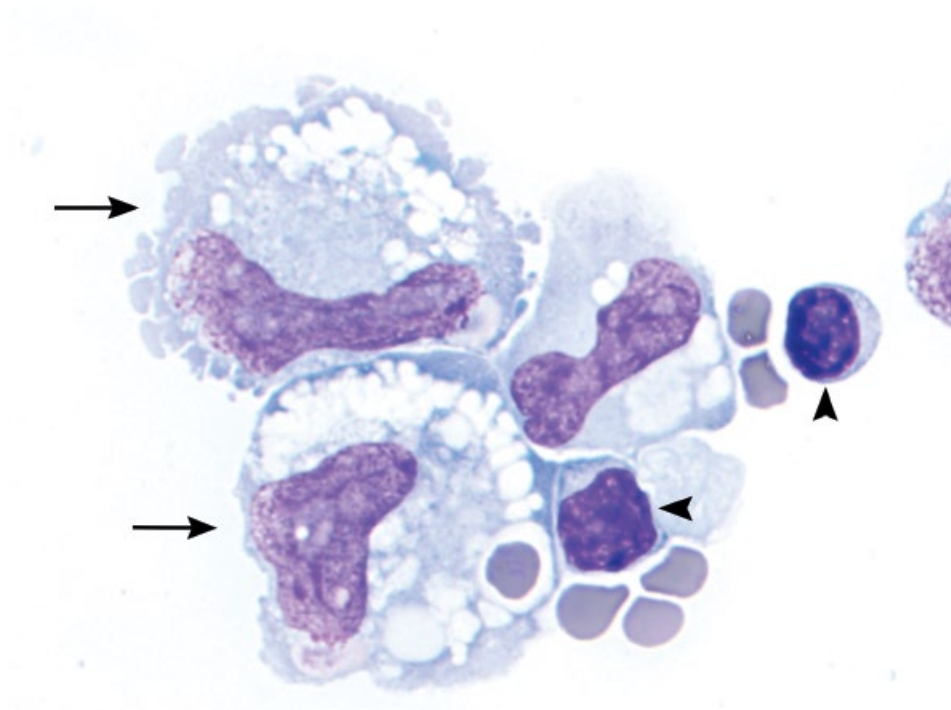


Figure 1.24 Inflammatory cells, all 100× objective. (A) Neutrophils. (B) Eosinophils.

(C)



(D)

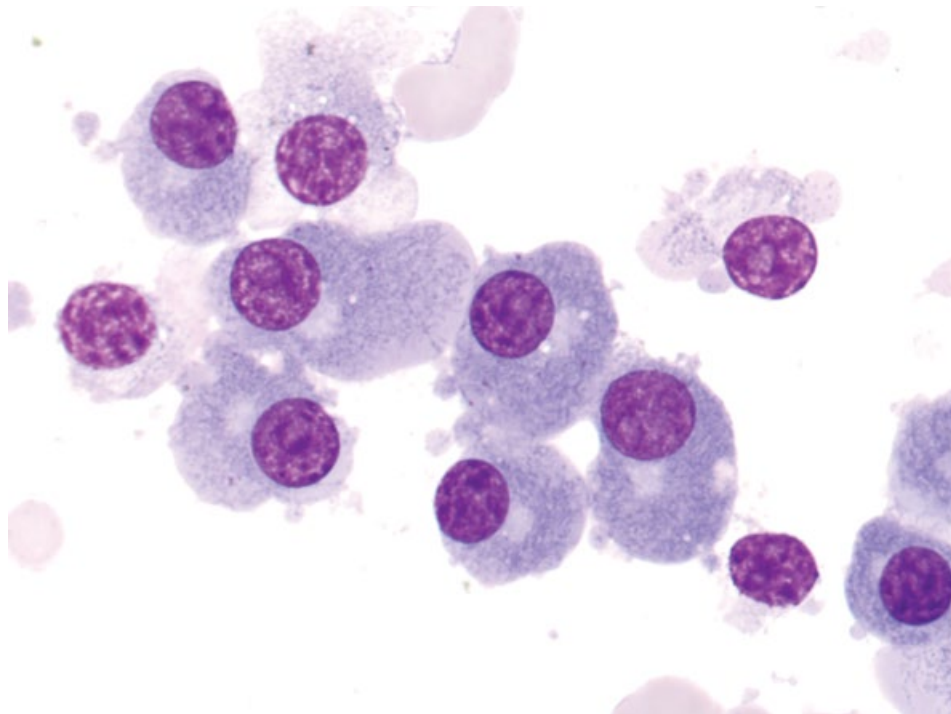
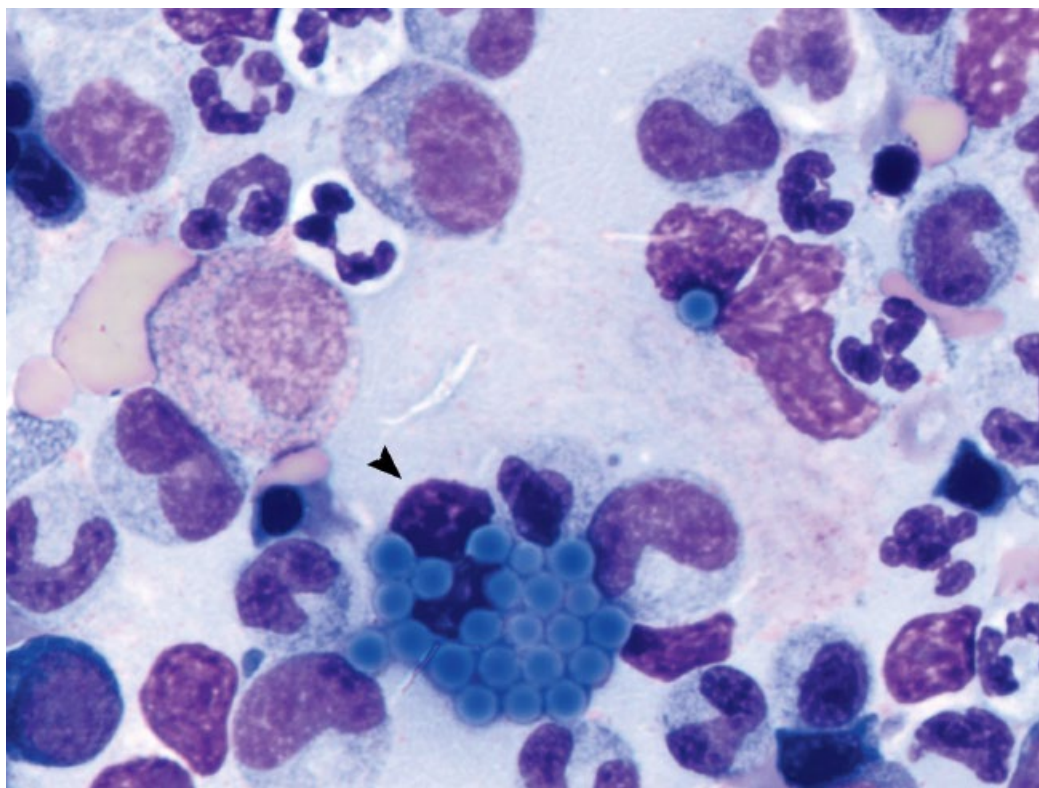


Figure 1.24 (Continued) (C) Macrophages (arrows) and lymphocytes (arrowheads). Note erythrophagia within a macrophage (lower left). (D) Plasma cells. Note the prominent perinuclear clearing (Golgi zone).

(E)



(F)

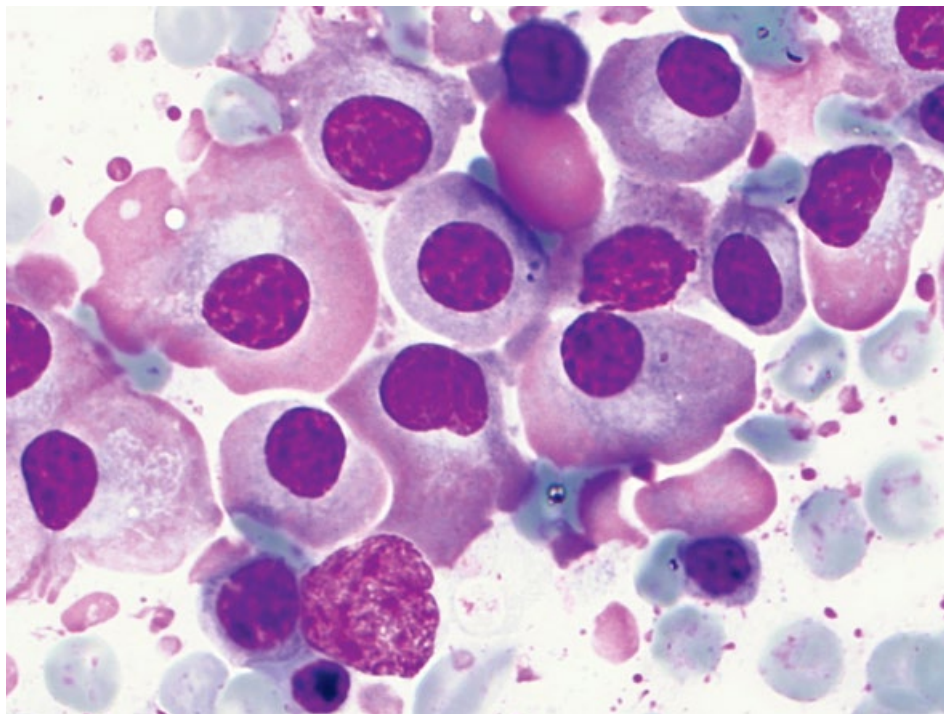


Figure 1.24 (Continued) (E) Mott cells. A Mott cell (arrowhead) contains numerous bright blue aggregates of immunoglobulin. (F) Flame cells.

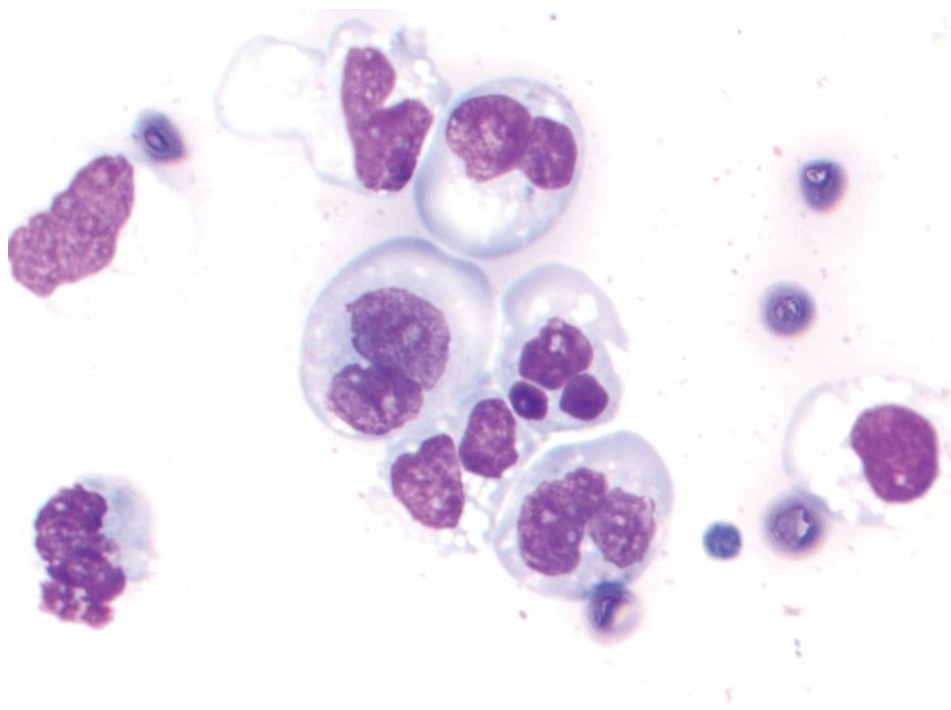


Figure 1.25 Degenerative neutrophils, 100× objective.

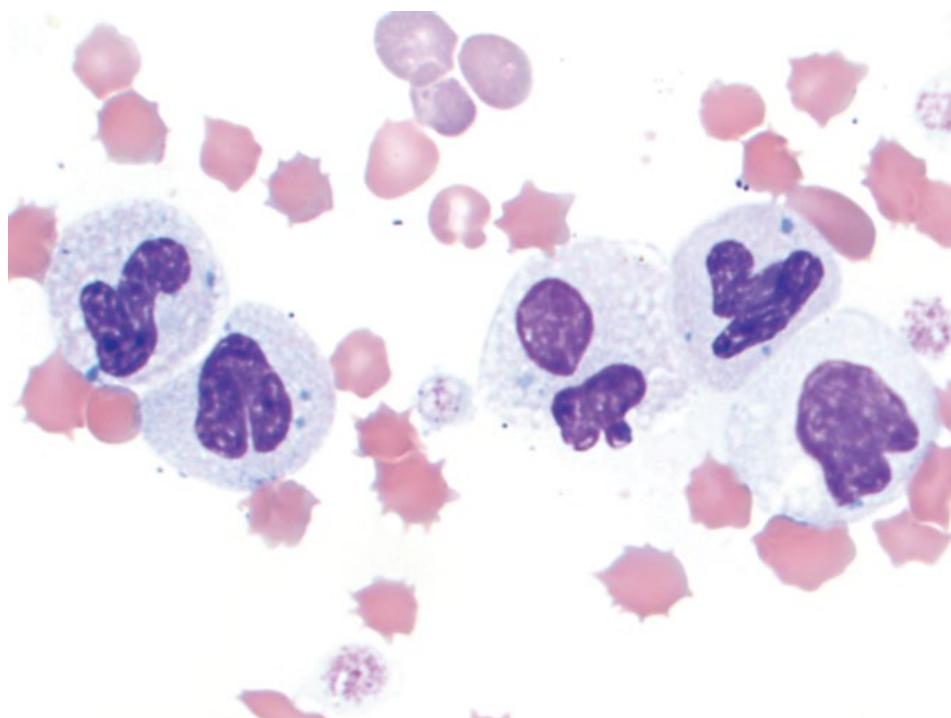
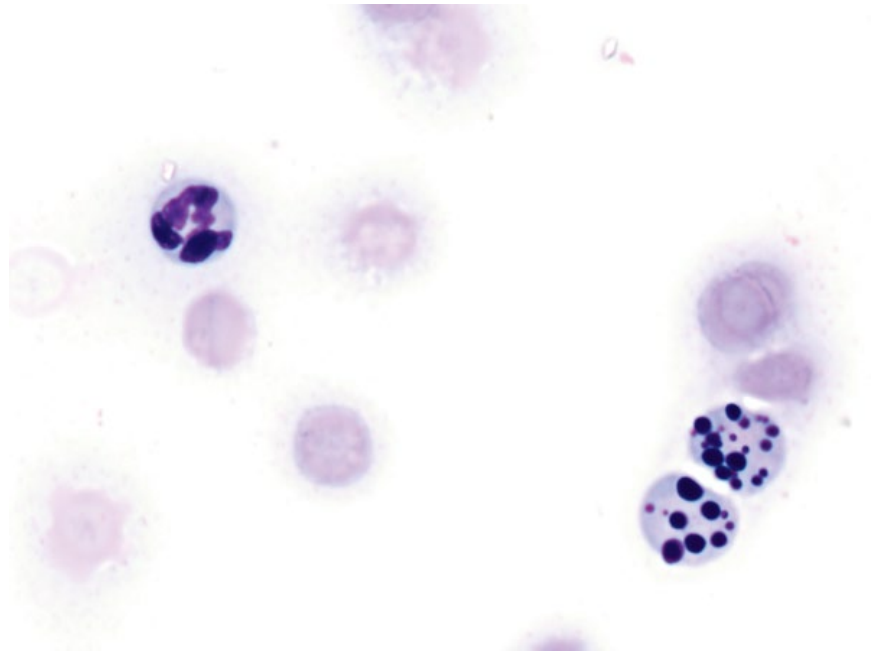


Figure 1.26 Toxic neutrophils, peripheral blood, cat, 100× objective.

Figure 1.27 Apoptotic/pyknotic nuclei, 100× objective. Two apoptotic neutrophils (lower right) with multiple variably sized, deeply basophilic, pyknotic nuclear fragments.



1.4 Cell Shape, Distribution, and Features

The shape of cells and the way they interact with each other can give valuable information regarding the origin of the cells. In cytopathology, cells often are grouped into one of three clinically useful categories: round cells; epithelial cells; and mesenchymal cells [6].

1.4.1 Epithelial Cells

Cells of epithelial origin often exfoliate in large numbers, and are seen mostly in cohesive sheets whereby cells share prominent intercellular borders with each other, like bricks and mortar (Figure 1.28).

1.4.2 Mesenchymal Cells

Mesenchymal cells exfoliate variably well. They generally are fusiform or spindloid with tapering ends (Figure 1.29). Some cells of mesenchymal origin are round (e.g., osteosarcoma; see Figure 1.30 and Chapter 6). Mesenchymal tumors also are most likely to be associated with extracellular matrix production (see Figure 1.4).

1.4.3 Round Cells

Round cell tumors technically are mesenchymal in origin (derived embryologically from mesoderm) [7]. However, it is clinically useful to consider common round cell neoplasms separately, including mast cell tumors, lymphoma, plasma cell tumors, histiocytic neoplasia, and transmissible venereal tumor (see Chapter 3 for details). Cells from these neoplasms often exfoliate in large numbers, and mostly are individualized or discrete (Figure 1.31).

It is important to note, that cytology is not always able to accurately assign cells into one of these categories. While such generalizations are useful, they do not replace histopathologic assessment of tissue architecture for accurate assessment of cell type and origin. Some common exceptions to the above rules include:

- Round cell tumors may be so cellular that cells are pushed together and appear cohesive (Figure 1.32).
- Anaplastic carcinomas often lose the ability to form cell junctions, and may appear as individualized or round cells (Figure 1.33).
- Melanoma cells may be round or spindloid, seen individually, in aggregates or sheets and may be associated with extracellular matrix (Figure 1.34; see Chapter 3 for details).
- Cells of some mesenchymal tumors are round (e.g., osteosarcoma, chondrosarcoma, rhabdomyosarcoma) (Figure 1.30; see Chapter 6 for details).

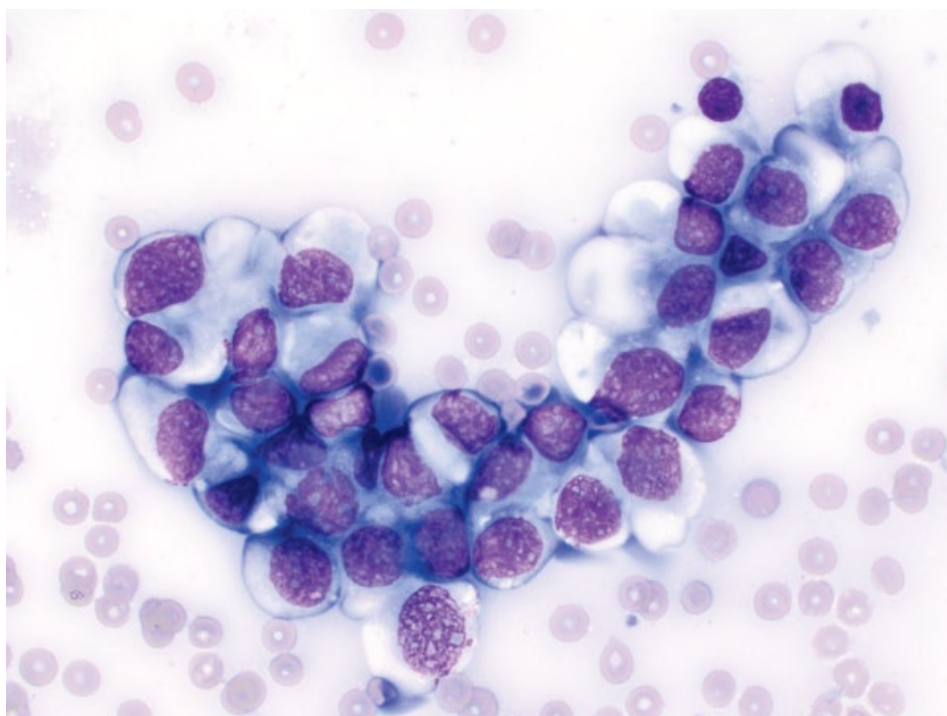


Figure 1.28 Epithelial cells, prostatic carcinoma, dog, 50× objective. Cells are cohesive and 'sticky' with prominent intercellular borders.

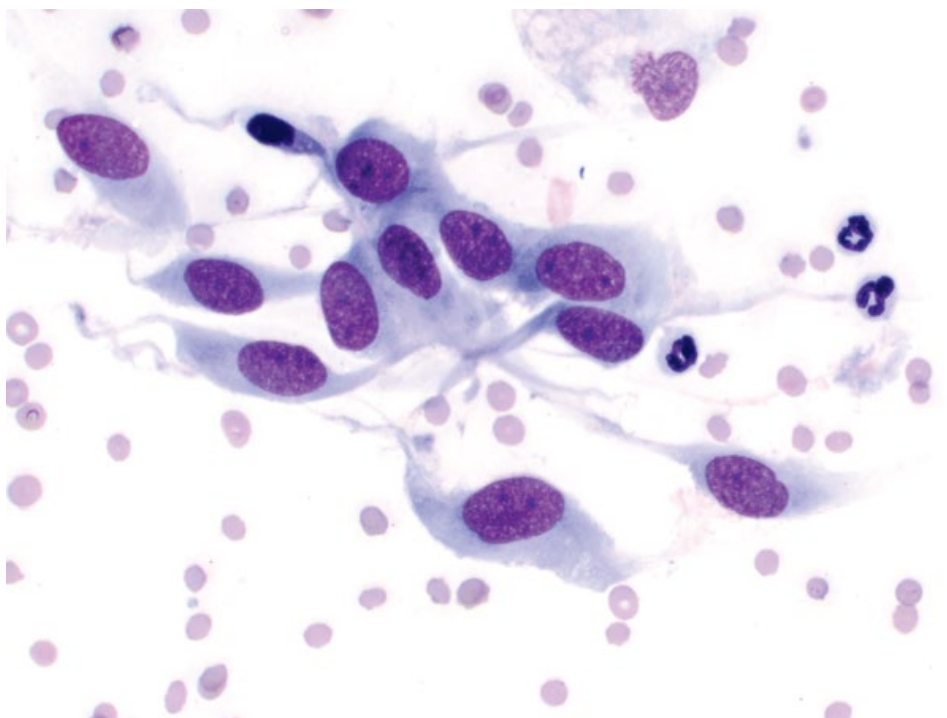


Figure 1.29 Mesenchymal cells, leiomyosarcoma, cat, 50× objective.

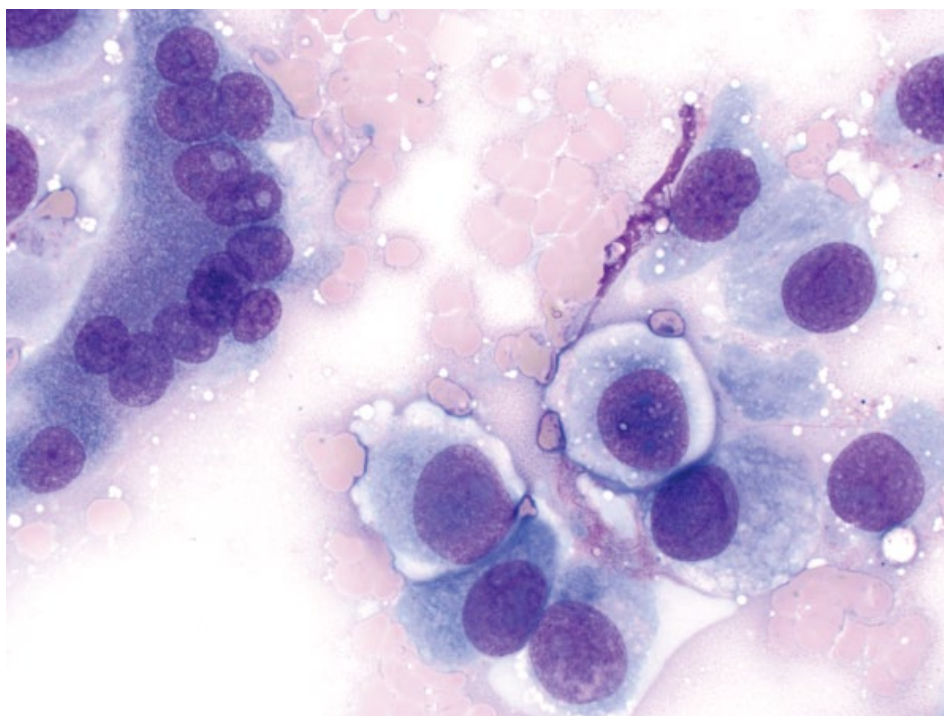


Figure 1.30 Mesenchymal cells, osteosarcoma, dog, 50x objective. The neoplastic mesenchymal cells are round. Note the normal, multinucleated osteoclast (upper left).

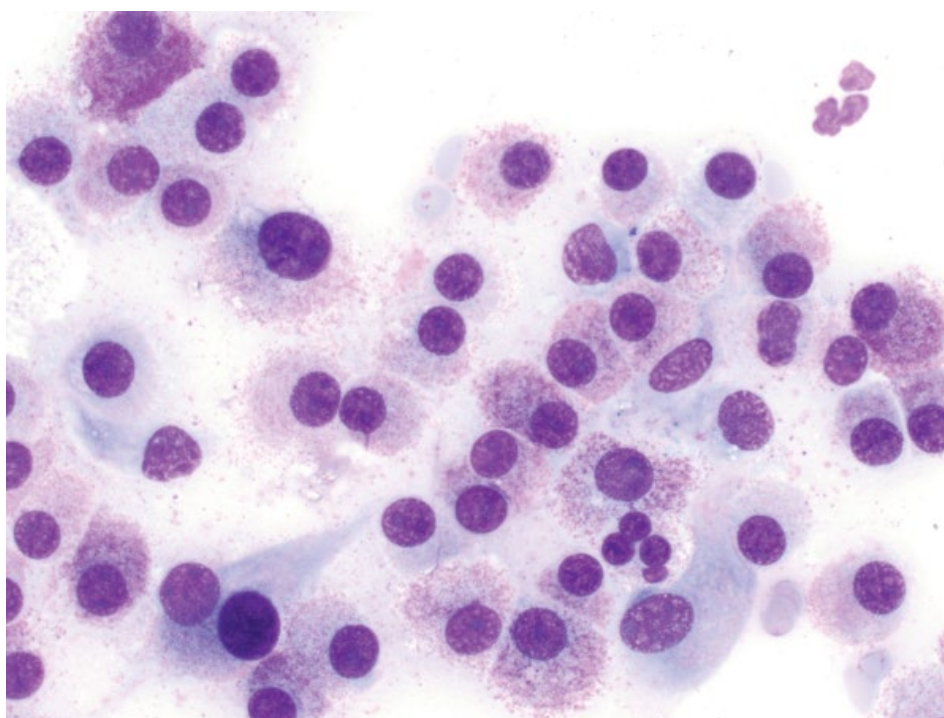


Figure 1.31 Round cell tumor, mast cell tumor, dog, 50x objective.

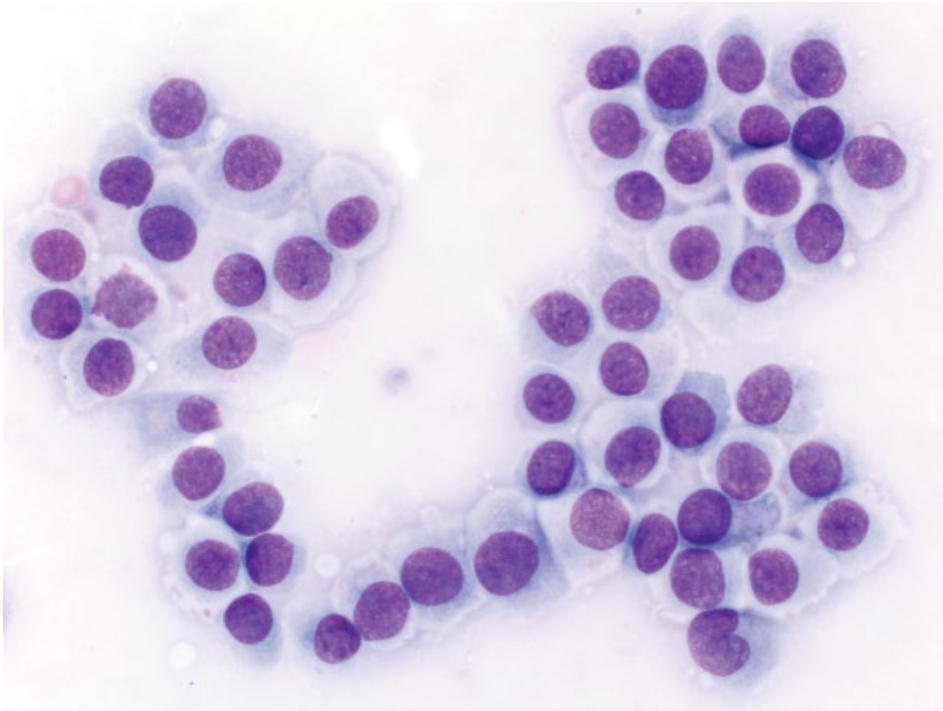


Figure 1.32 Round cell tumor, histiocytoma, dog, 50× objective. Note that the cells are pushed into sheets, but still appear discrete, without prominent intercellular borders.

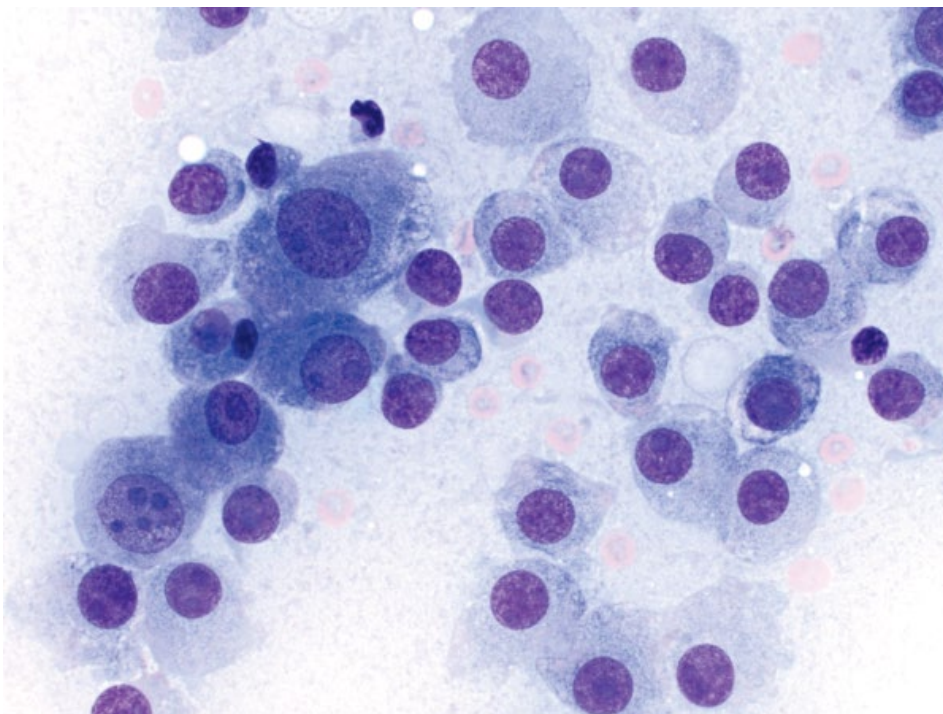
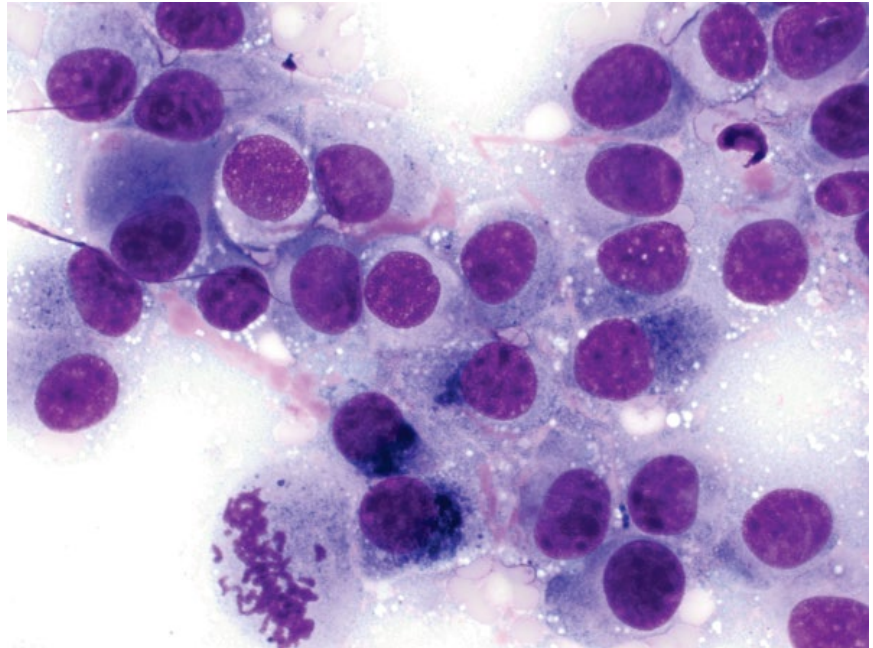


Figure 1.33 Poorly cohesive carcinoma (hepatocellular carcinoma), dog, 50× objective.

Figure 1.34 Melanoma, dog, 50× objective. The cells are vaguely cohesive, round to spindloid, and associated with pink extracellular matrix. Note the green/black pigment in some cells, and the mitotic figure (lower left).



1.5 Benign Versus Malignant

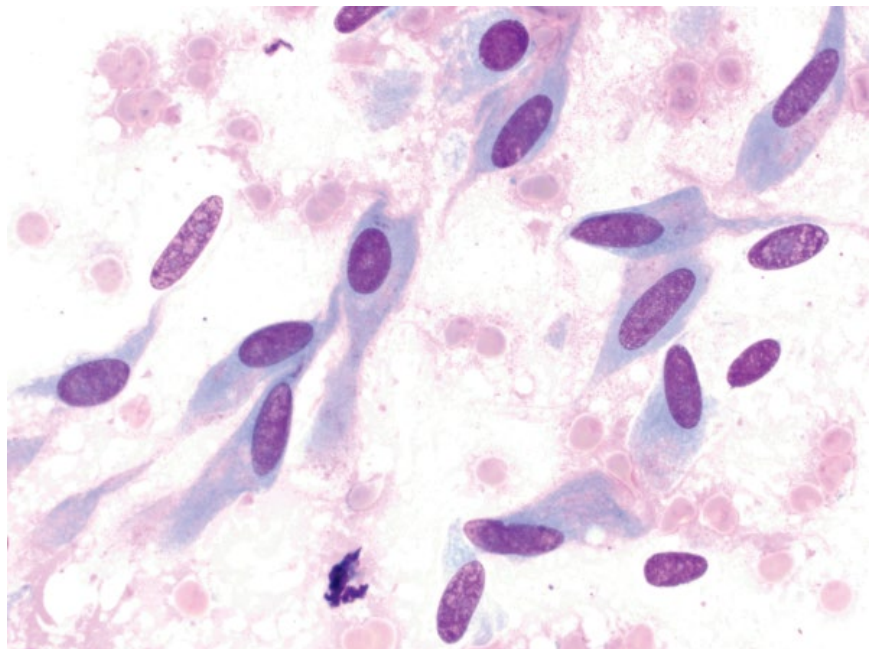
Benign lesions typically are composed of well-differentiated, uniform populations of cells (Figures 1.35 and 1.36). Variation in cellular features between cells is more suggestive of malignancy. Criteria of malignancy are listed below, according to the cell features affected:

- **Cellular:** **Anisocytosis** (variation in cell size) (Figure 1.37); cell piling (Figure 1.38); **cell cannibalism**

(Figure 1.39); poor cohesion in epithelial tumors; poor differentiation.

- **Cytoplasmic:** **High nuclear to cytoplasmic (N/C) ratios** (decreased volume of cytoplasm) (Figure 1.40); increased cytoplasmic basophilia.
- **Nuclear:** **Anisokaryosis** (variation in nuclear size) (Figure 1.41); **mitotic figures**; **multinucleation** (Figure 1.42); **satellite nuclei** (Figure 1.43); **nuclear**

Figure 1.35 Benign mesenchymal neoplasia, fibroma, dog, 50× objective.



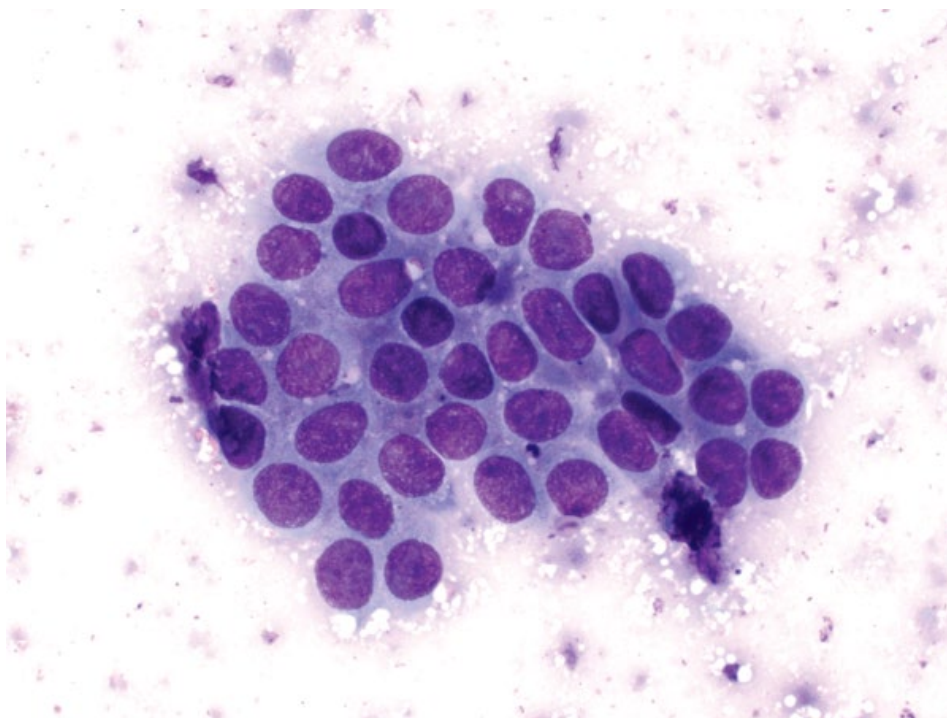


Figure 1.36 Benign epithelial neoplasia, mammary adenoma, dog, 50× objective.

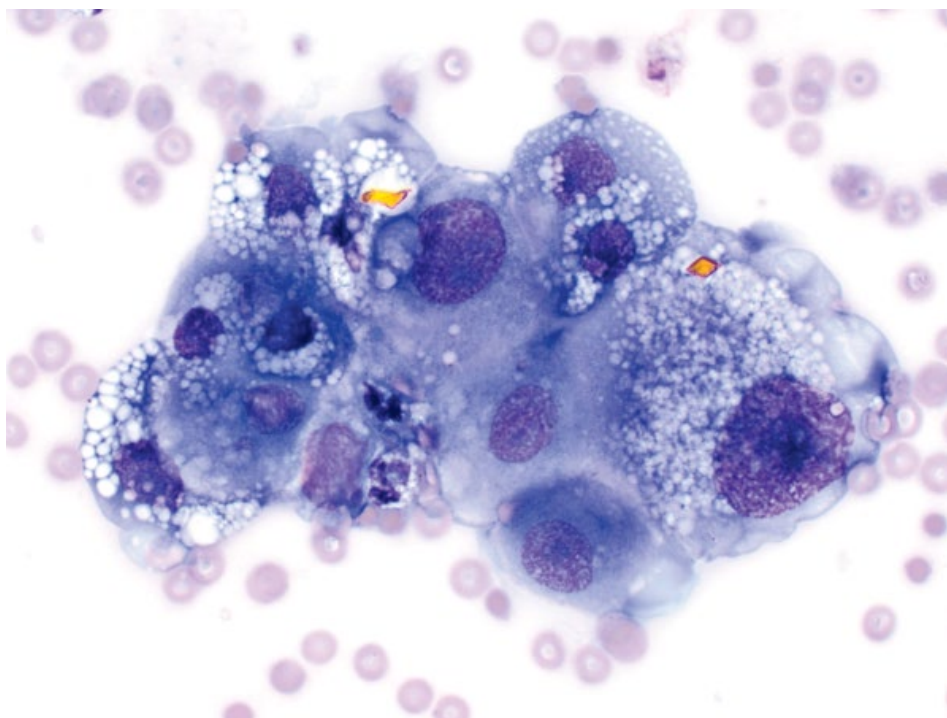


Figure 1.37 Anisocytosis, mesothelioma, dog, 50× objective. Note the variation in size between cells.

Figure 1.38 Cell piling, perianal gland carcinoma, dog, 50× objective. The cells are overlapping, crowded, and disorganized.

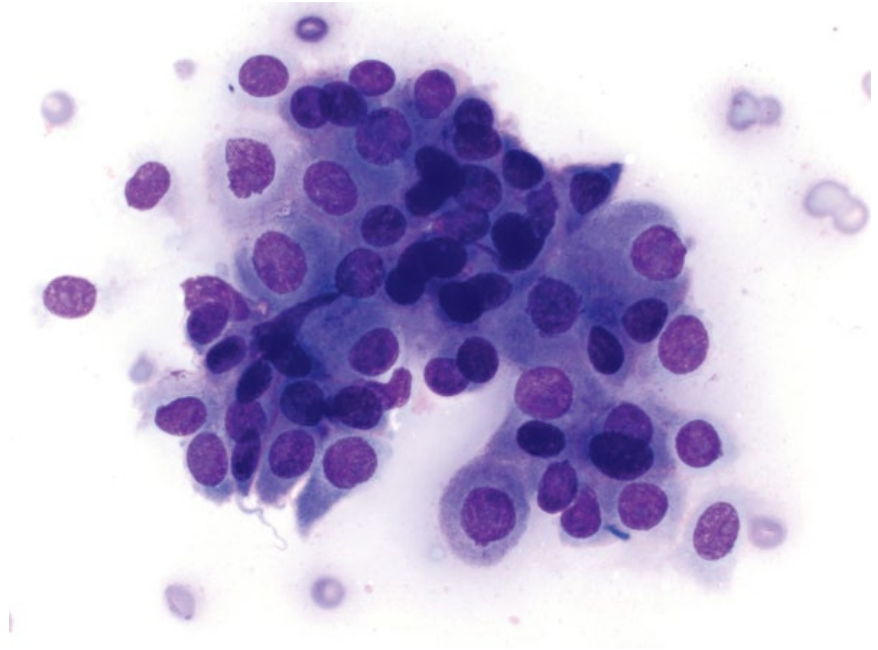
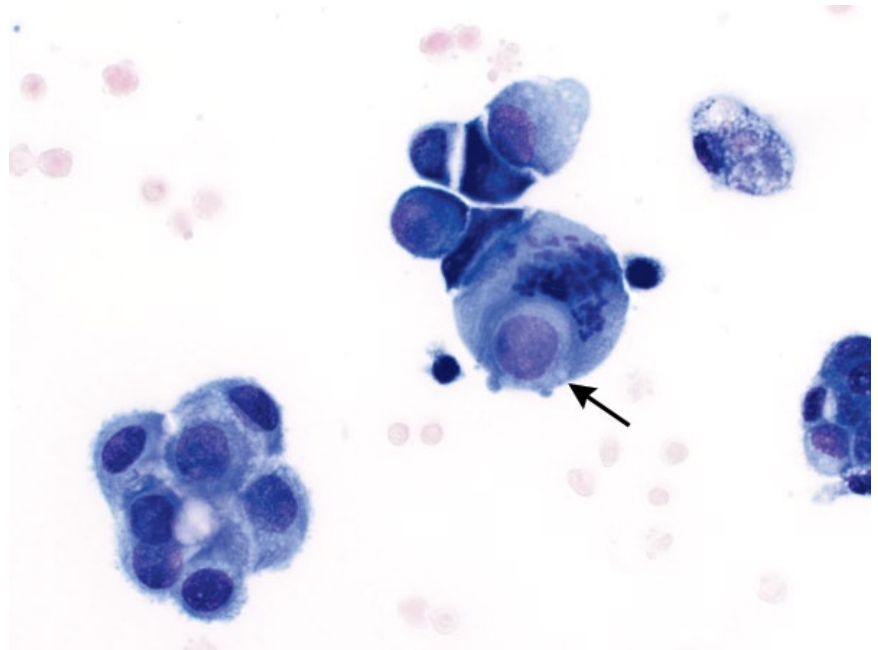


Figure 1.39 Cell cannibalism, mesothelioma, dog, 50× objective. A mitotic neoplastic cell has phagocytosed another neoplastic cell (arrow).



fragmentation (Figure 1.44); **hyperchromasia** (Figure 1.45); nuclear crowding/molding.

- **Nucleolar:** **Prominent nucleoli** (Figure 1.46); **multiple nucleoli** (Figure 1.47); anisonucleosis (variation in nucleolar size); abnormal nucleolar shape.

Criteria of malignancy that are most common and/or reliable are shown in bold type. Most of these affect the nucleus, and careful examination of nuclei in suspected neoplastic lesions is recommended.

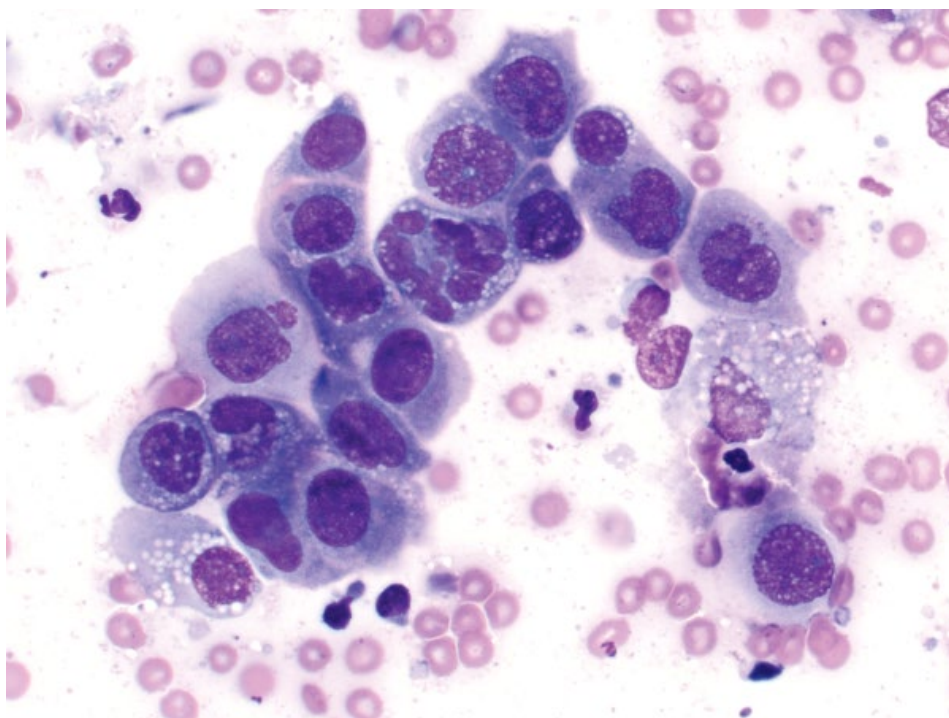


Figure 1.40 High N/C ratios, mammary carcinoma, dog, 50× objective.

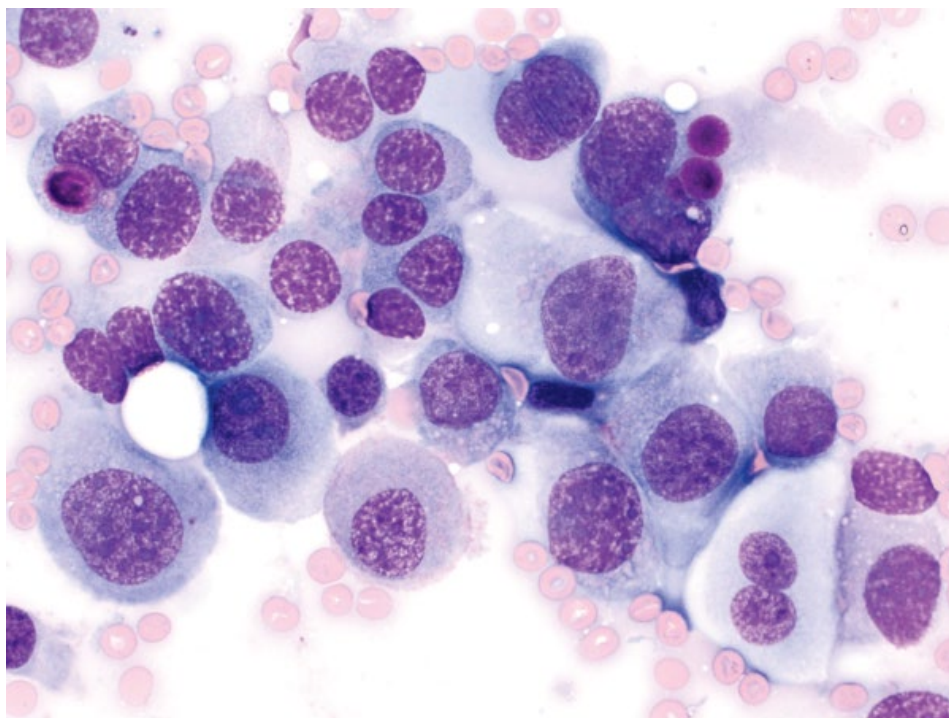


Figure 1.41 Anisokaryosis, transitional cell carcinoma, dog, 50× objective.

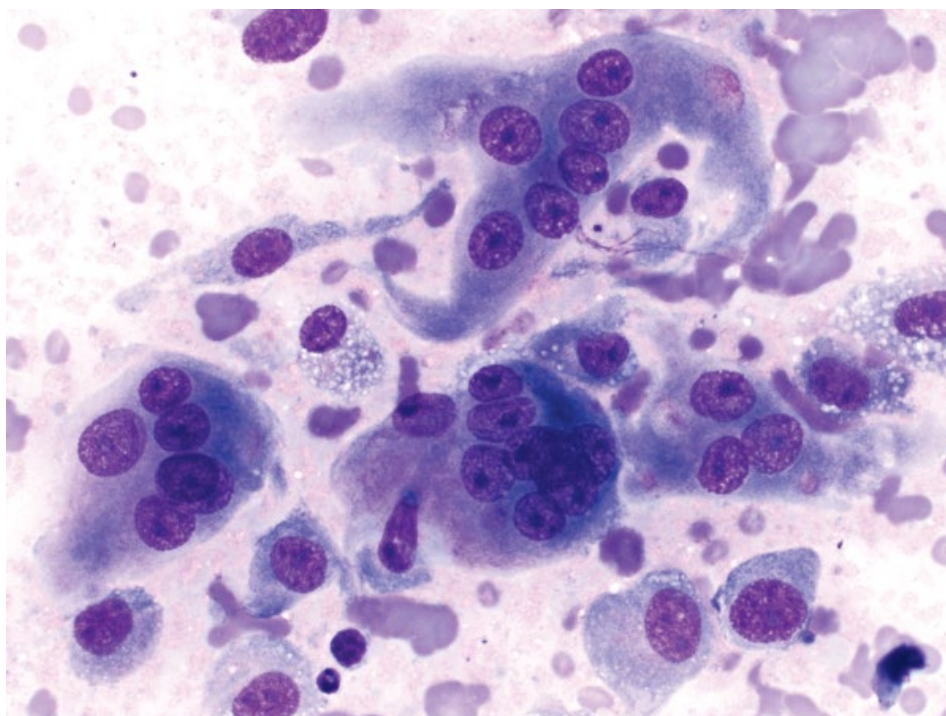


Figure 1.42 Multinucleation, anaplastic sarcoma with giant cells, cat, 50× objective.

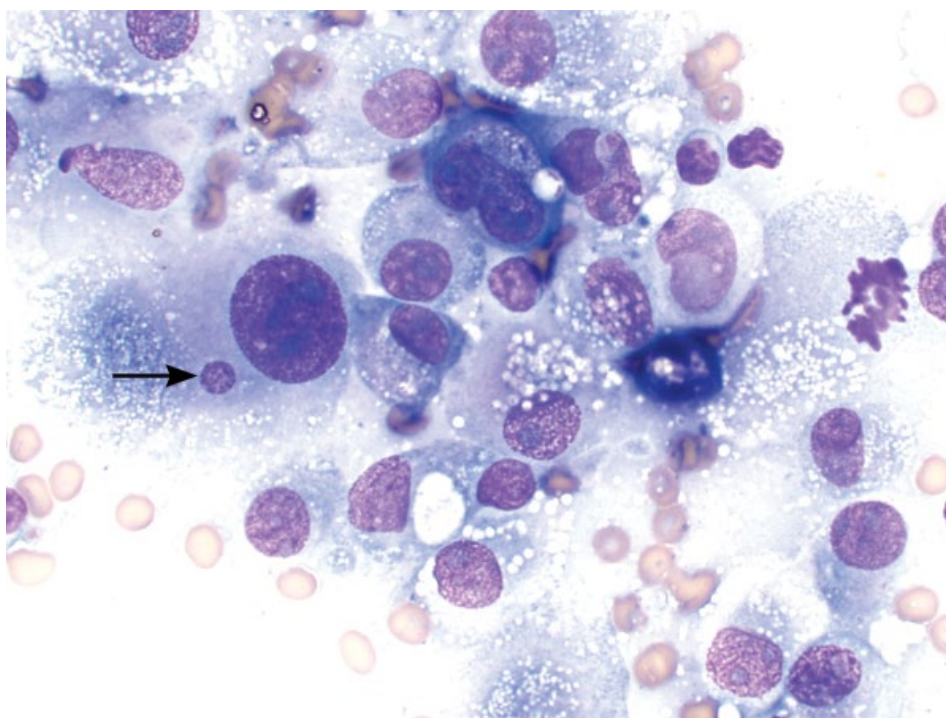


Figure 1.43 Satellite nuclei, histiocytic sarcoma, dog, 50× objective. Note the small satellite nucleus next to the larger nucleus (arrow).

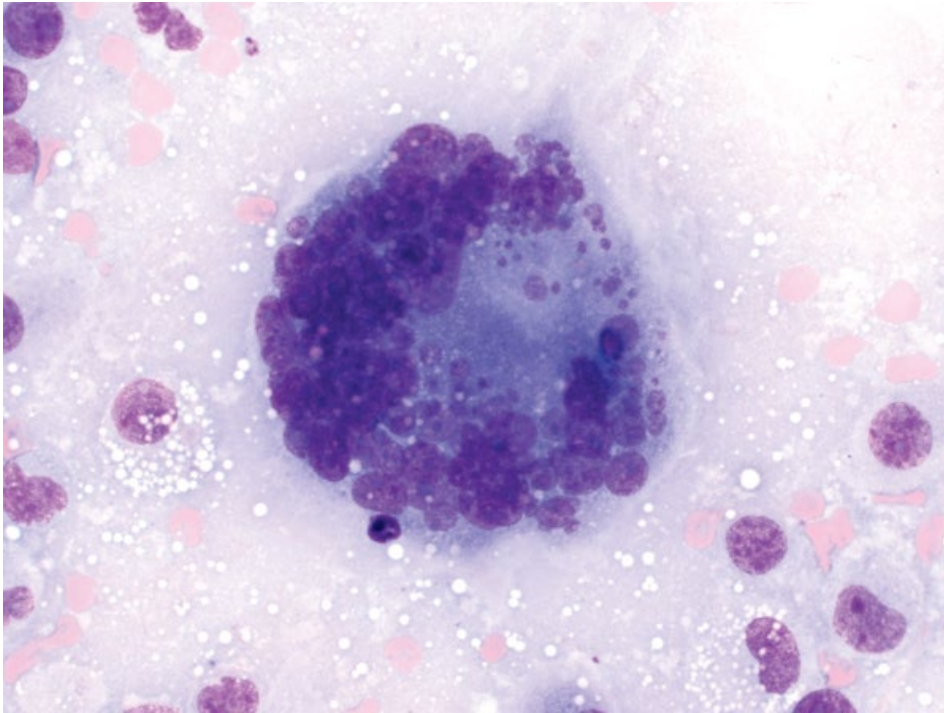


Figure 1.44 Nuclear fragmentation, histiocytic sarcoma, dog, 50× objective.

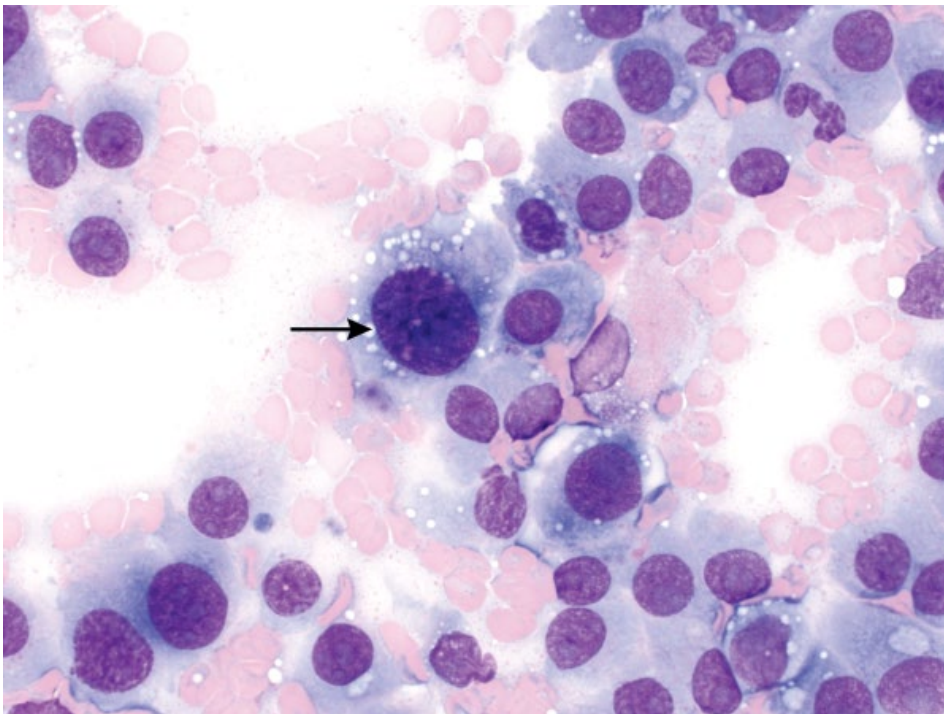


Figure 1.45 Hyperchromasia, osteosarcoma, dog, 50× objective. Note how dark the chromatin is (arrow) relative to other cells.

Figure 1.46 Prominent nucleoli, histiocytic sarcoma, dog, 50× objective.

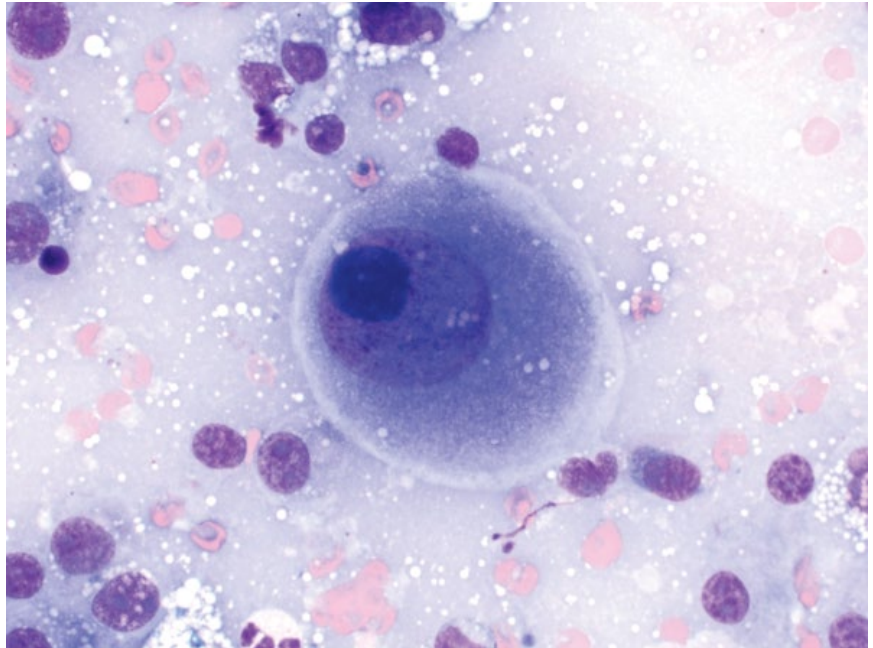
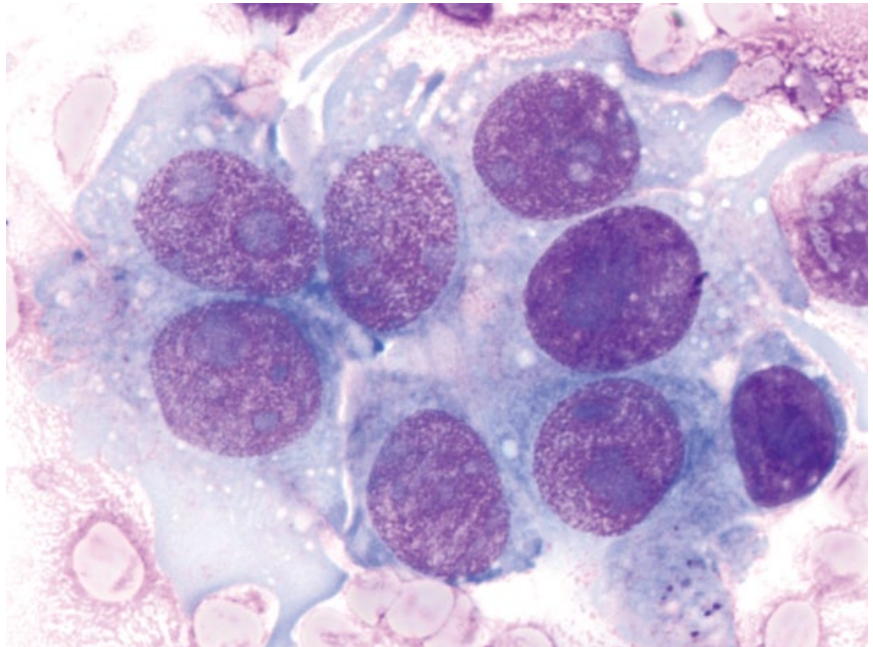


Figure 1.47 Multiple nucleoli, osteosarcoma, dog, 100× objective. Note the varying sizes, shapes, and numbers of nucleoli in each nucleus.

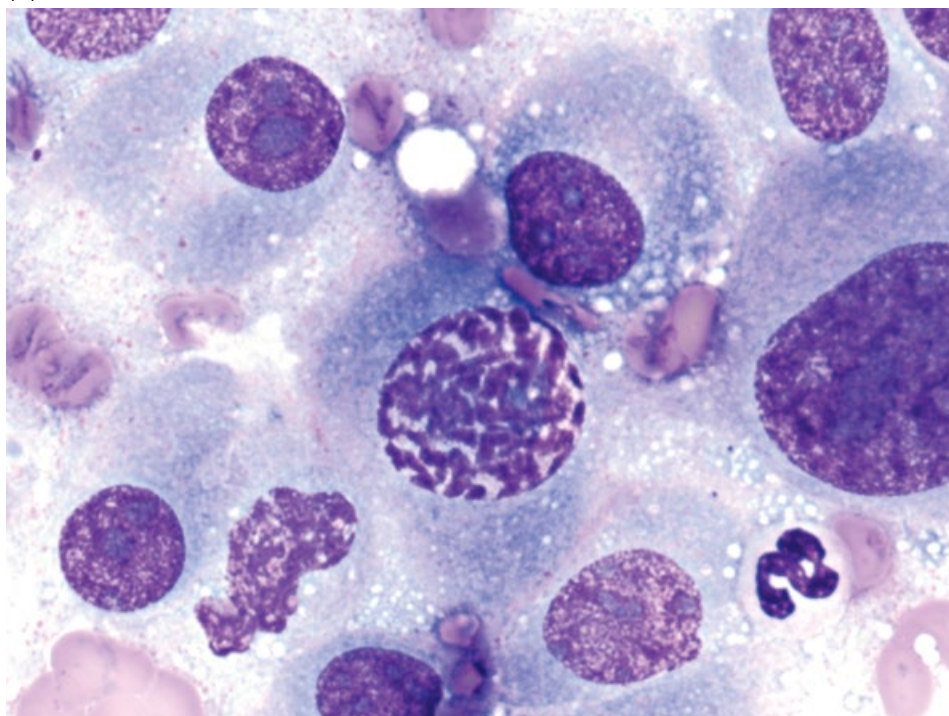


1.5.1 Mitotic Figures

Increased numbers of mitotic figures indicate increased proliferation in tissues. Normal stages of mitosis include prophase, metaphase, anaphase, and telophase (Figure 1.48A–E) [8]. These may be seen in normal tissues with high turnover rates of cells, such as bone

marrow, gastrointestinal tract, and even in hyperplastic lymph nodes. Mitoses frequently are seen in increased numbers in neoplastic lesions, and are an important criterion of malignancy. Additionally, atypical or bizarre mitotic figures that do not resemble normal stages of mitosis are highly suggestive of neoplasia (Figure 1.48F).

(A)



(B)

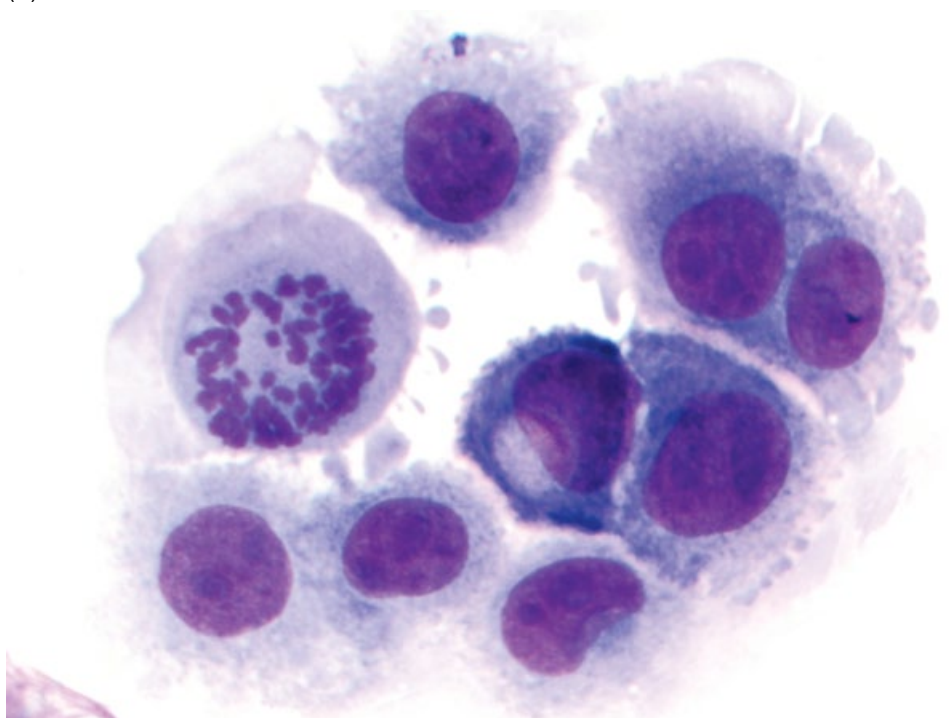
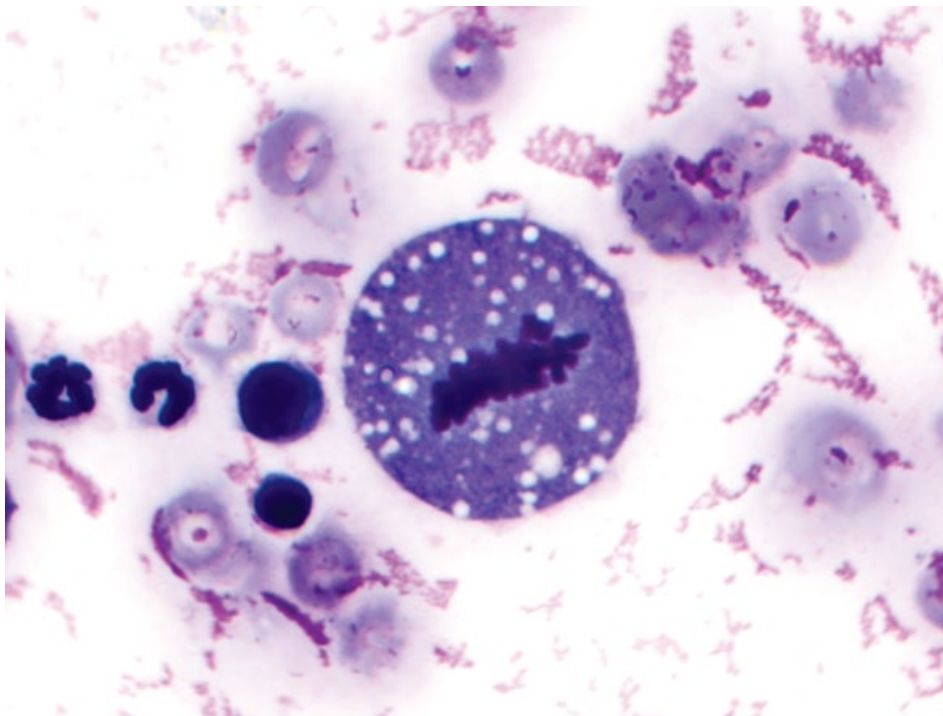


Figure 1.48 Mitotic figures. (A) Prophase. (B) Metaphase (end-on).

(C)



(D)

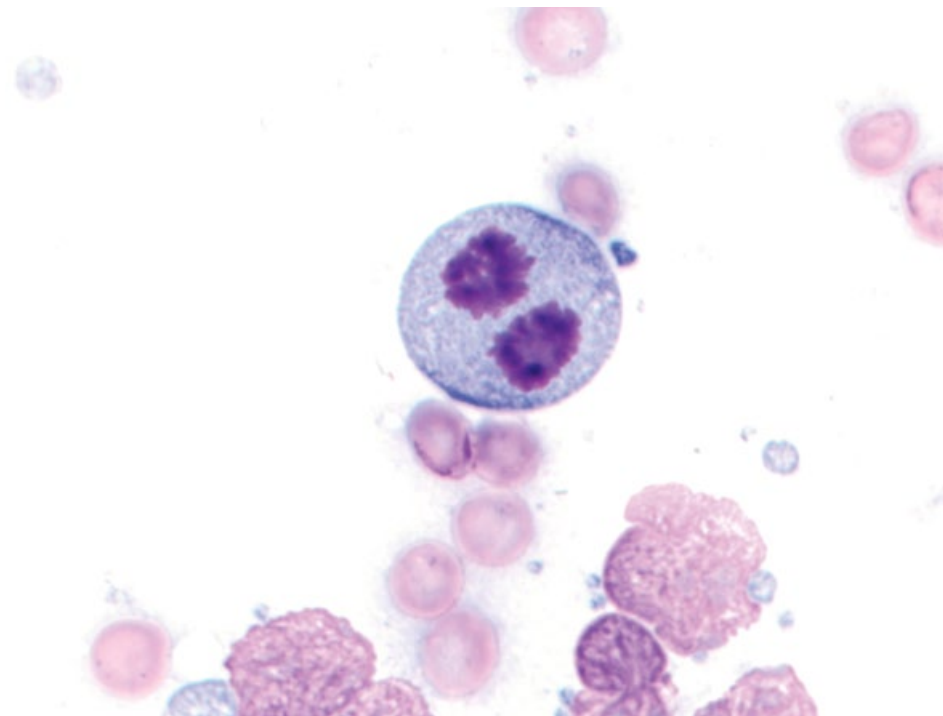
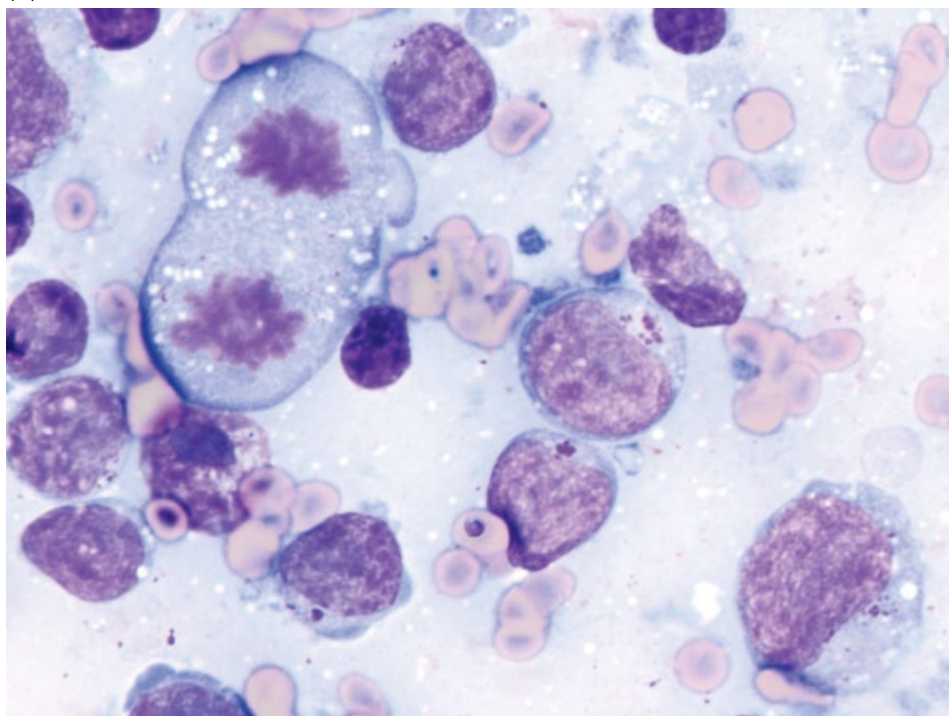


Figure 1.48 (Continued) (C) Metaphase (side-on). (D) Anaphase.

(E)



(F)

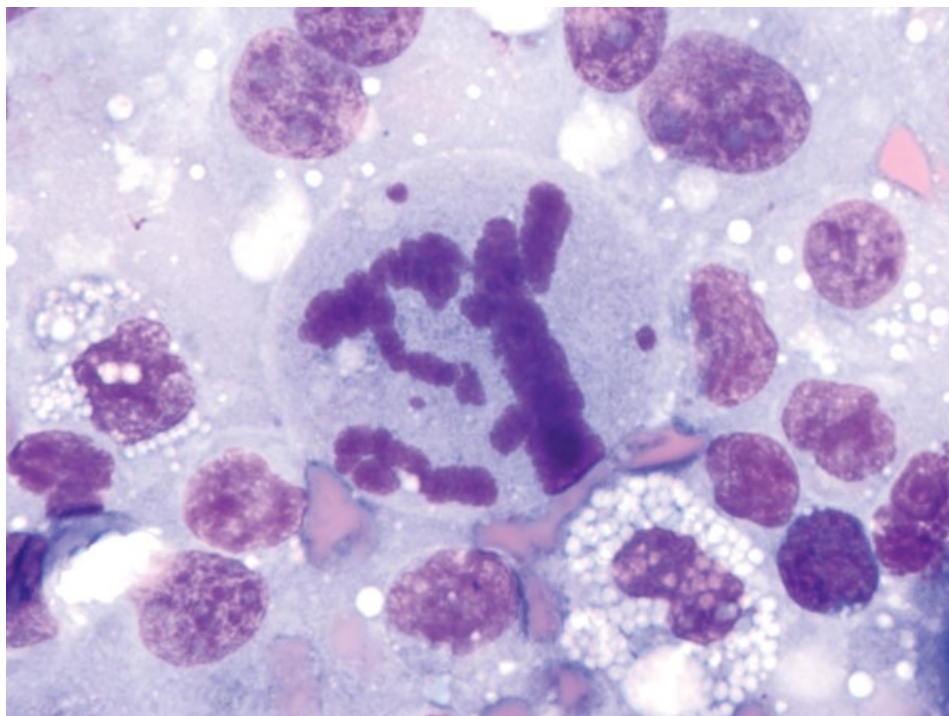


Figure 1.48 (Continued) (E) Telophase. (F) Bizarre mitosis.

References

- 1 Francis, I.M., Das, D.K., al-Rubah, N.A., *et al.* (1994) Lymphoglandular bodies in lymphoid lesions and non-lymphoid round cell tumours: a quantitative assessment. *Diagn. Cytopathol.*, **11** (1), 23–27.
- 2 Bray, K.Y., Muñana, K.R., Meichner, K., *et al.* (2016) Eosinophilic meningomyelitis associated with T-cell lymphoma in a cat. *Vet. Clin. Pathol.*, **45** (4), 698–702.
- 3 Cazzini, P., Watson, V.E., Brown, H.M. (2013) The many faces of Mott cells. *Vet. Clin. Pathol.*, **42** (2), 125–126.
- 4 Aroch, I., Klement, E., Segev, G. (2005) Clinical, biochemical, and hematological characteristics, disease prevalence, and prognosis of dogs presenting with neutrophil cytoplasmic toxicity. *J. Vet. Intern. Med.*, **19** (1), 64–73.
- 5 Segev, G., Klement, E., Aroch, I. (2006) Toxic neutrophils in cats: clinical and clinicopathologic features, and disease prevalence and outcome – a retrospective case control study. *J. Vet. Intern. Med.*, **20** (1), 20–31.
- 6 Meinkoth, J.H., Cowell, R.L. (2002) Recognition of basic cell types and criteria of malignancy. *Vet. Clin. North Am. Small Anim. Pract.*, **32** (6), 1209–1235.
- 7 Andrew, A., Rawdon, B.B. (1987) The embryonic origin of connective tissue mast cells. *J. Anat.*, **150**, 219–227.
- 8 Tvedten, H. (2009) Atypical mitoses: morphology and classification. *Vet. Clin. Pathol.*, **38** (4), 418–420.

2

Infectious Agents

2.1 Fungi

2.1.1 *Cryptococcus*

2.1.1.1 Cytologic Features

Small and large forms exist. Organisms are round, ranging from ~5 to 20 μm in diameter. They have basophilic cytoplasm with a thick capsule and a prominent non-staining encircling halo (Figure 2.1). The organisms divide via narrow-based budding, which is a helpful distinguishing feature from *Blastomyces*, which divide via broad-based budding. Variation in size is common with cryptococcal organisms compared to uniform *Histoplasma*. Infection is mostly associated with granulomatous inflammation (Figure 2.2).

2.1.1.2 Clinical Considerations

- Cats > dogs.
- *Cryptococcus neoformans* and *Cryptococcus gattii*.
- Most common in nasal cavity or skin. May be disseminated.

2.1.1.3 Prognosis

Cats = Generally good with appropriate therapy, though relapse can occur, even after long periods of remission [1]. CNS involvement carries a poor prognosis [2, 3].

Dogs = Guarded to poor [1, 3, 4].

2.1.2 *Histoplasma Capsulatum*

2.1.2.1 Cytologic Features

Small, uniform, round yeast organisms ~2 to 5 μm in diameter, with deep purple cytoplasm that frequently forms an eccentric purple crescent. A small, clear halo encircles the cells (Figure 2.3). Narrow based budding

rarely is seen. The organisms usually are seen within macrophages.

2.1.2.2 Clinical Considerations

- Dogs and cats.
- Mostly affect respiratory tract. Often disseminated in cats [5].

2.1.2.3 Prognosis

Dogs with respiratory histoplasmosis have a good prognosis with appropriate therapy. Disseminated disease in cats and dogs carries a guarded to poor prognosis [6].

2.1.3 *Sporothrix Schenckii*

2.1.3.1 Cytologic Appearance

Mostly ovoid to cigar-shaped (Figure 2.4), ~4–10 μm in length, and 1–3 μm wide. The elongated shape helps distinguish *Sporothrix* from perfectly round *Histoplasma*. The organisms have pale blue cytoplasm, with prominent pink to purple nuclei that often are eccentrically placed. They have a thin clear capsule. Organisms divide via narrow-based budding. Mostly accompanied by pyogranulomatous inflammation.

2.1.3.2 Clinical Considerations

- Cats > dogs.
- Cutaneous lesions around the face most common. Pulmonary and generalized disease possible.
- Zoonotic potential.

2.1.3.3 Prognosis

Cure rates are good in cats with prolonged therapy, but relapse can occur [7]. Cats with respiratory signs have a

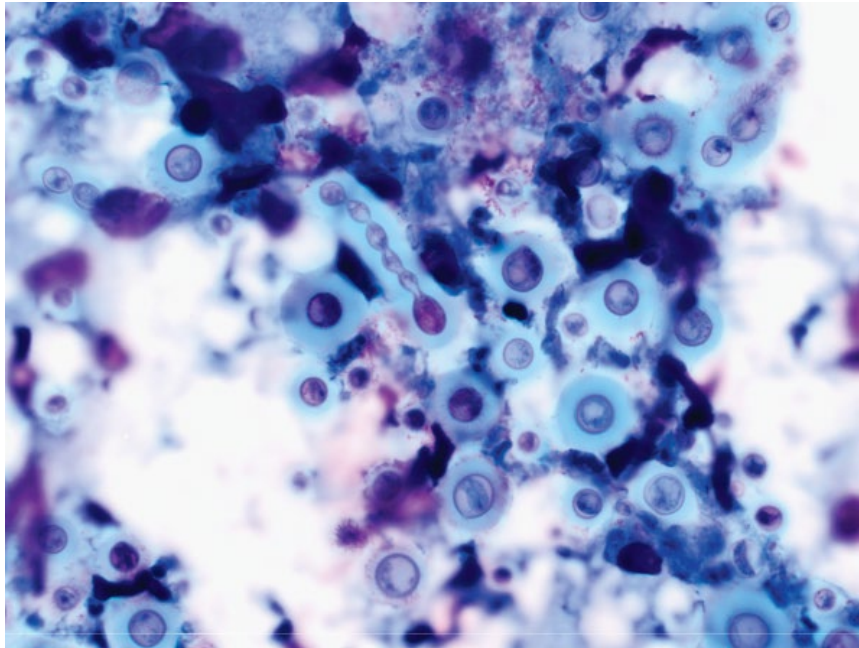


Figure 2.1 *Cryptococcus neoformans*, cat, 50× objective. Note the narrow-based budding forming a chain of organisms.

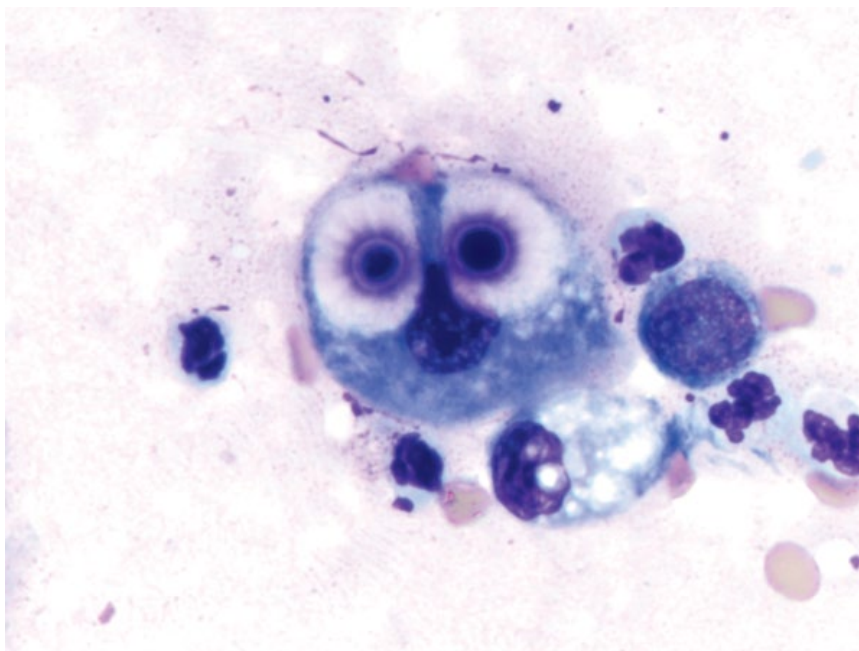


Figure 2.2 *Cryptococcus neoformans*, cat, 100× objective. Two organisms are phagocytosed by a macrophage.

poorer prognosis [8]. Spontaneous regression may occur in a small number of dogs [9].

2.1.4 Dermatophytes

2.1.4.1 Cytologic Appearance

Fungal arthrospores often are associated with hair shafts and are ovoid, 2–4 μm in diameter, and stain deeply basophilic, with a thin clear capsule (Figure 2.5).

They may be associated with an inflammatory response in kerions, characterized by macrophages, neutrophils, and eosinophils.

2.1.4.2 Clinical Considerations

- Cats > dogs
- Caused by *Microsporum* and *Trichophyton* spp.
- Mainly seen in young or immunocompromised patients.

Figure 2.3 *Histoplasma capsulatum*, cat, 100× objective. Organisms are seen within a macrophage and in the background.

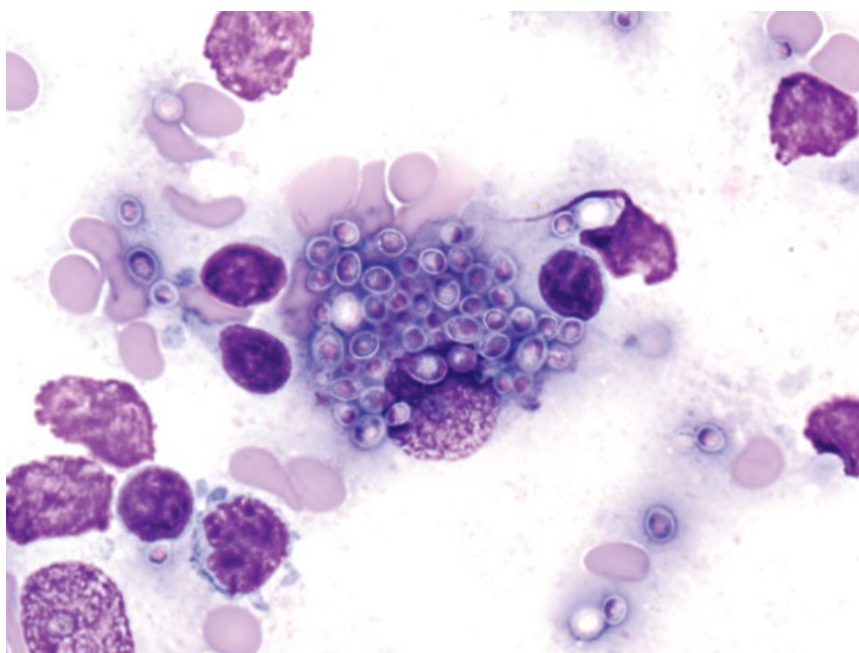
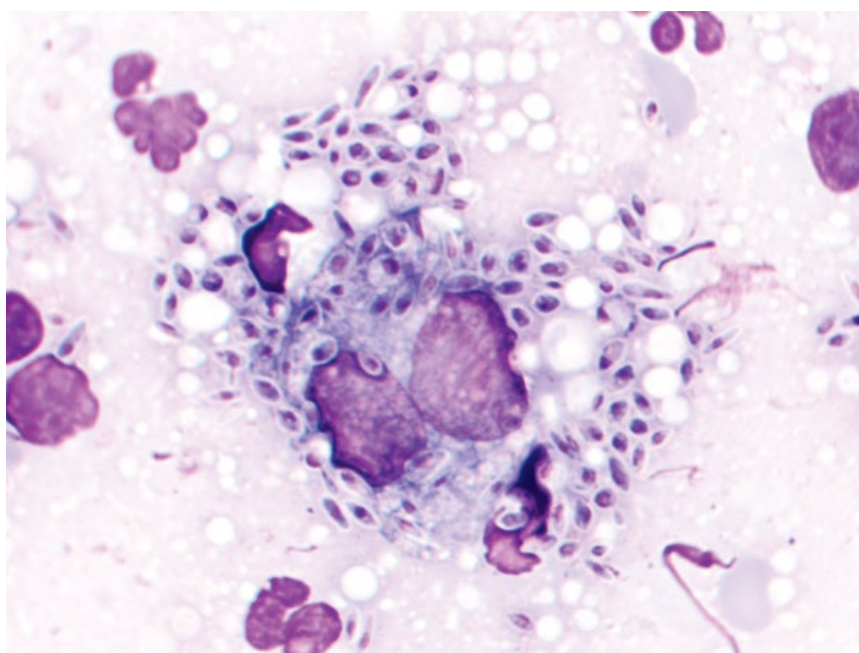


Figure 2.4 *Sporothrix schenckii*, cat, 100× objective. Organisms seen within and around a macrophage. Note their elongated shape.



- Classically present as circular regions of alopecia, often around the face and limbs. Raised nodules (kerions) may also be seen [10].
- Zoonotic potential.

2.1.4.3 Prognosis

Good. Healthy animals clear infection within 3 months. Prognosis may be worse in persistently immunocompromised patients.

2.1.5 *Blastomyces Dermatitis*

2.1.5.1 Cytologic Appearance

Organisms exfoliate variably well, ranging from single organisms, to abundant. They are ~10–20 µm in diameter, and round with a thick, refractile, deep-blue cell wall, but lack a capsule (compared to *Cryptococcus*) and divide via broad-based budding (Figure 2.6). Typically associated with a mixed inflammatory response, with extracellular organisms (rarely phagocytosed by macrophages).

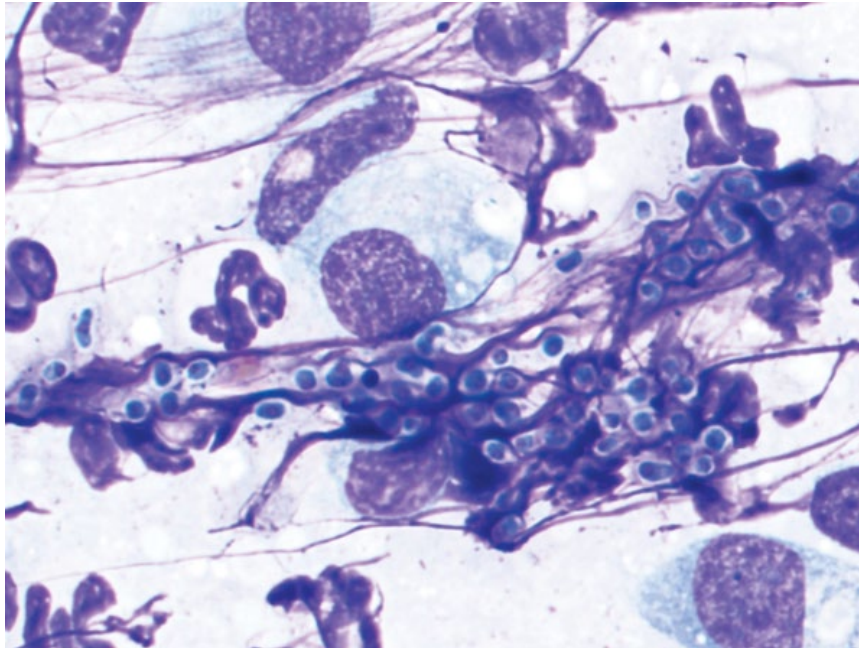


Figure 2.5 Dermatophytes, cat, 100× objective. Note the small basophilic organisms with a clear halo.

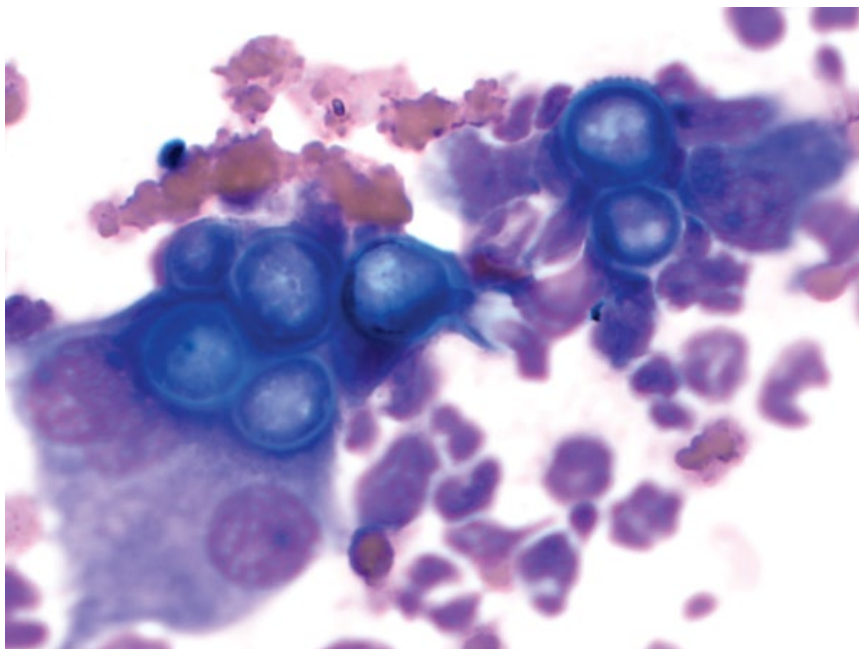


Figure 2.6 *Blastomyces dermatitidis*, dog, 100× objective.

2.1.5.2 Clinical Considerations

- Dogs (typically large breed) > cats.
- Pulmonary disease most prevalent. Common extrapulmonary sites include skin, bone, and lymph nodes [11].

2.1.5.3 Prognosis

Variable. Cure rates range from 50–75%, and recurrence may occur [12, 13]. Central nervous system (CNS)

involvement and severe pulmonary pathology are poor prognostic factors [12].

2.1.6 *Coccidioides*

2.1.6.1 Cytologic Appearance

Coccidioides spherules generally are very large but range from 10 to 200 μm in diameter. The spherules have a thick, double-contoured wall that may fold on itself (Figure 2.7). Some spherules will contain numerous

Figure 2.7 *Coccidioides immitis* spherule, dog, 50× objective. Note the large size relative to red blood cells, and the folded capsule.

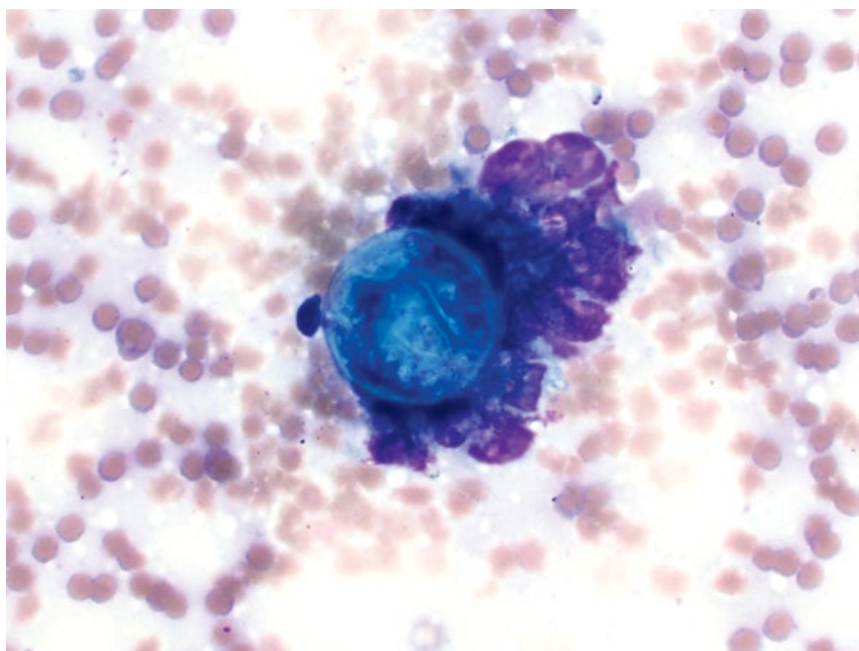
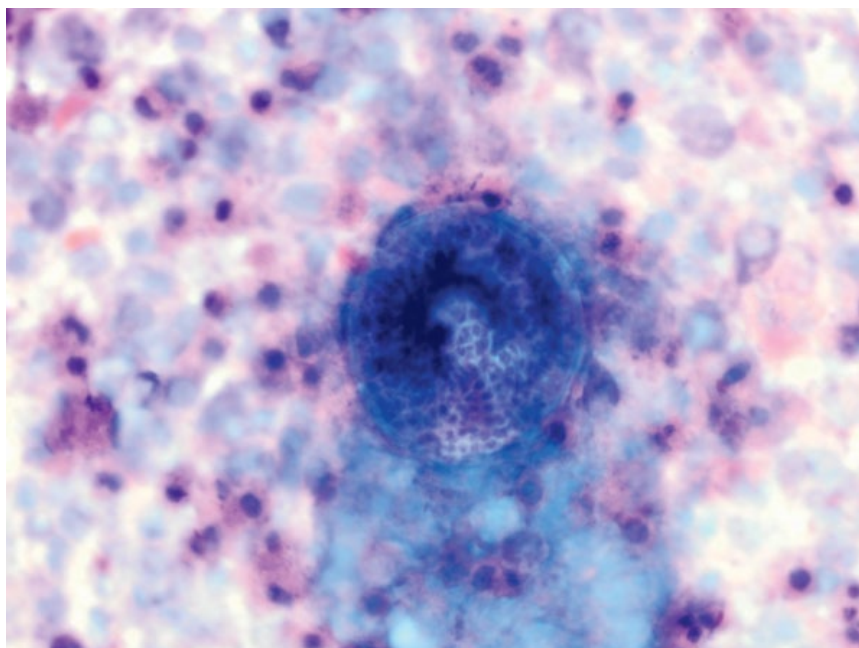


Figure 2.8 *Coccidioides immitis*, dog, 50× objective. A spherule contains numerous small endospores.



small, spherical endospores (2–5 μm) (Figure 2.8). The size and presence of endospores make distinguishing *Coccidioides* spp. from other fungal agents generally straightforward. They often are seen in low numbers, and incite a marked pyogranulomatous response.

2.1.6.2 Clinical Considerations

- Dogs > cats.
- *Coccidioides immitis* and *C. posadasii* spp.
- Primarily pulmonary disease \pm bone, skin, or disseminated disease.

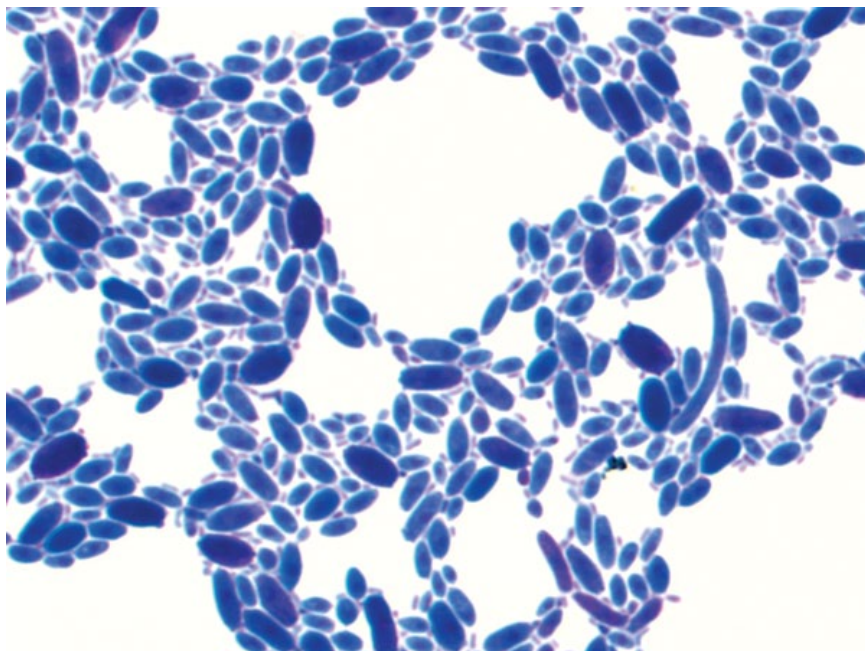


Figure 2.9 *Candida albicans*, dog, 100× objective.

2.1.6.3 Prognosis

Guarded. Response to therapy is variable based on extent of disease.

2.1.7 *Candida*

2.1.7.1 Cytologic Appearance

Candida spp. are budding yeast that can form long pseudohyphae (chains of yeast organisms), germ tubes, or true non-constricted hyphae, giving them a highly variable appearance (Figure 2.9). Neutrophils play a key role in defense against *Candida* spp. and usually predominate [14].

2.1.7.2 Clinical Considerations

- Dogs and cats.
- Common commensal in the gastrointestinal tract, urogenital tract, and skin.
- Disease may be localized or generalized and often is associated with predisposing disease [15].

2.1.7.3 Prognosis

Generally good for localized infection and if underlying predisposing factors can be controlled. Guarded prognosis for disseminated disease.

2.1.8 *Pneumocystis*

2.1.8.1 Cytologic Appearance

Cysts and trophozoites may be present in pulmonary secretions. Cysts are round, ~5 µm in diameter, and have

clear cytoplasm with 1–2 µm round, purple inclusions, often arranged in a ring formation (Figure 2.10). Trophozoites are more variable in shape, and range from 2 to 5 µm, often seen extracellularly. Often accompanied by granulomatous or eosinophilic inflammation.

2.1.8.2 Clinical Considerations

- Clinical disease in dogs. Subclinical disease reported rarely in cats.
- Dachshunds and Cavalier King Charles Spaniels over-represented [16, 17].
- Mostly seen in young or immunocompromised patients [17].
- Clinical signs = exercise intolerance, cough and severe weight loss.

2.1.8.3 Prognosis

Good with appropriate therapy.

2.1.9 *Malassezia*

2.1.9.1 Cytologic Appearance

Malassezia yeast stain intensely basophilic, and are ovoid but divide via broad-based budding, frequently giving them a bilobed 'peanut' or 'snowman' appearance (Figure 2.11).

2.1.9.2 Clinical Considerations

- Dogs > cats.
- Commensal organisms of skin found in low numbers in healthy animals.

Figure 2.10 *Pneumocystis* spp., dog, 100× objective. Note the small size relative to the red blood cell, and the small purple inclusions.

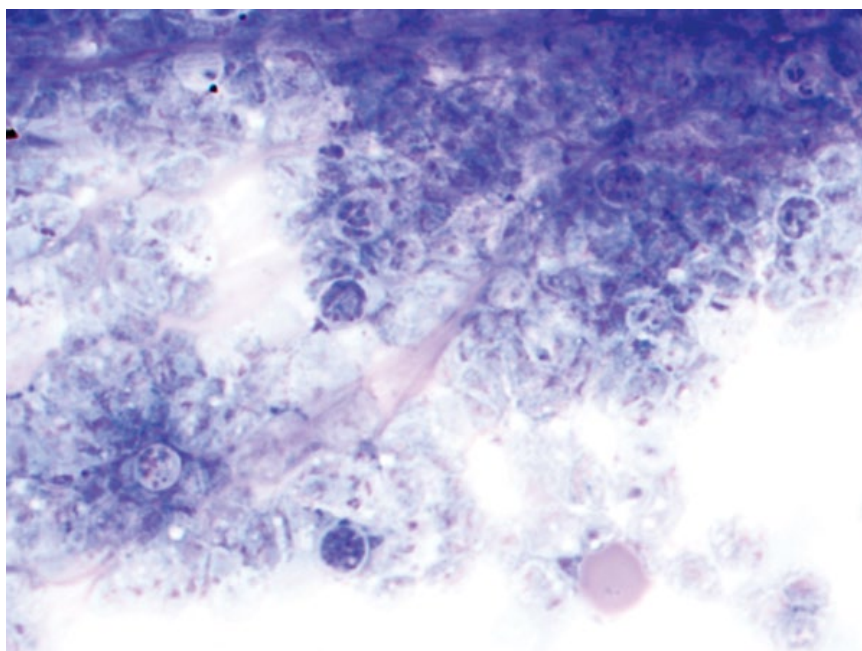
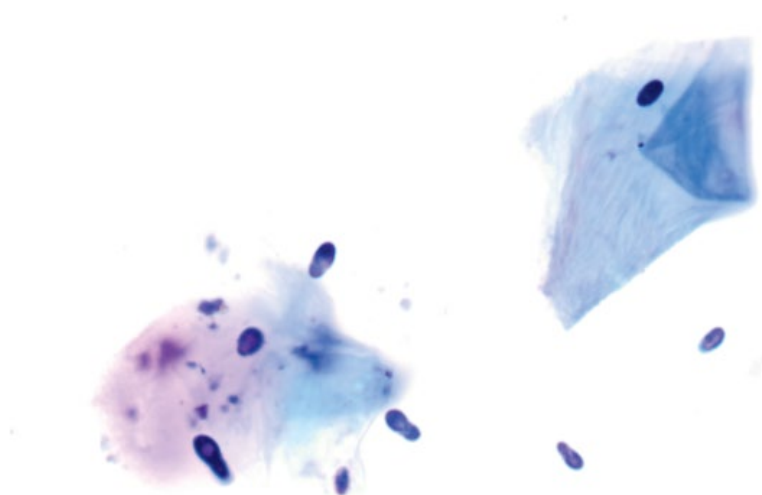


Figure 2.11 *Malassezia*, dog, 100× objective.



- Disease manifests mostly on the skin (periocular, perioral, inguinal region, interdigital), and in the ears (otitis externa; see Chapter 14).

2.1.9.3 Prognosis

Generally good with appropriate therapy and treatment of any predisposing disorders.

2.1.10 *Cyniclomyces*

2.1.10.1 Cytologic Appearance

Cyniclomyces guttulatus are large (10–20 μm long, and 5 μm wide), cylindrical yeast found individually or in forking chains (Figure 2.12). They have a clear cell wall and a centrally placed basophilic band.

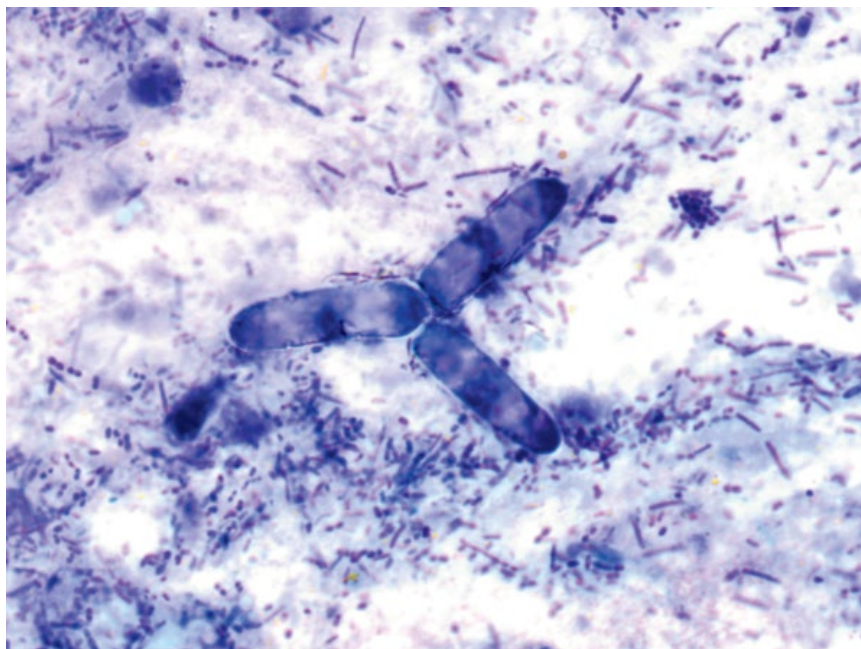


Figure 2.12 *Cyniclomyces guttulatus*, dog, 100× objective. Three organisms in a characteristic forking arrangement. Note the large size relative to bacteria in the background.

2.1.10.2 Clinical Considerations

- Mostly an incidental finding in feces, resulting from coprophagia.
- Rare cases of chronic diarrhea linked to overgrowth of *Cyniclomyces*, though the organisms likely are opportunists rather than primary agents [18].

2.1.10.3 Prognosis

Excellent.

2.1.11 *Aspergillus*

2.1.11.1 Cytologic Appearance

Hyphae from *Aspergillus* spp. have parallel sides, are septated and branching, with branches mostly emanating at 45° angles (Figure 2.13). Fungal hyphae appear similar to other fungal diseases, and culture is required for definitive diagnosis.

2.1.11.2 Clinical Considerations

- Dogs and cats.
- Most common in the nasal cavity, but may affect any organ system (e.g., keratitis, otitis, or disseminated).
- Nasal aspergillosis most common in dolichocephalic dog breeds.

2.1.11.3 Prognosis

Highly variable based on location and extent of disease, but often guarded. Prognosis for disseminated disease is poor [19].

2.2 Oomycetes

2.2.1 *Pythium Insidiosum*

2.2.1.1 Cytologic Appearance

Hyphae are broad (~5 μm wide) with parallel walls, and stain poorly with routine stains (compared to *Aspergillus* spp.). They are branching and infrequently septated with rounded tapering ends (Figure 2.14). Infection frequently is associated with a marked pyogranulomatous inflammatory response that may include eosinophils.

2.2.1.2 Clinical Considerations

- Dogs >> cats.
- Gastrointestinal and cutaneous forms.
- DDX = Lagendiosis and Zygomycosis. Culture is required for definitive diagnosis.

2.2.1.3 Prognosis

Guarded based on location and stage of disease. Surgical excision of lesions with wide margins may be curative. Non-resectable lesions carry a poor prognosis [20].

2.3 Algae

2.3.1 *Prototheca*

2.3.1.1 Cytologic Appearance

Prototheca are round to ovoid (width and length vary from 5 to 15 μm), with thick, clear cell walls and granular

Figure 2.13 *Aspergillus* spp. hyphae, dog, 20x objective.

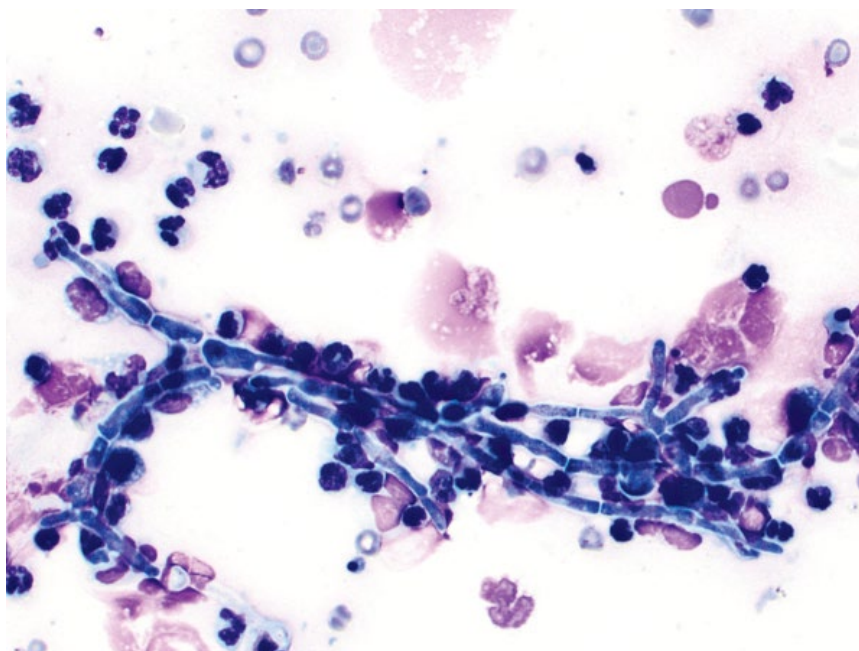
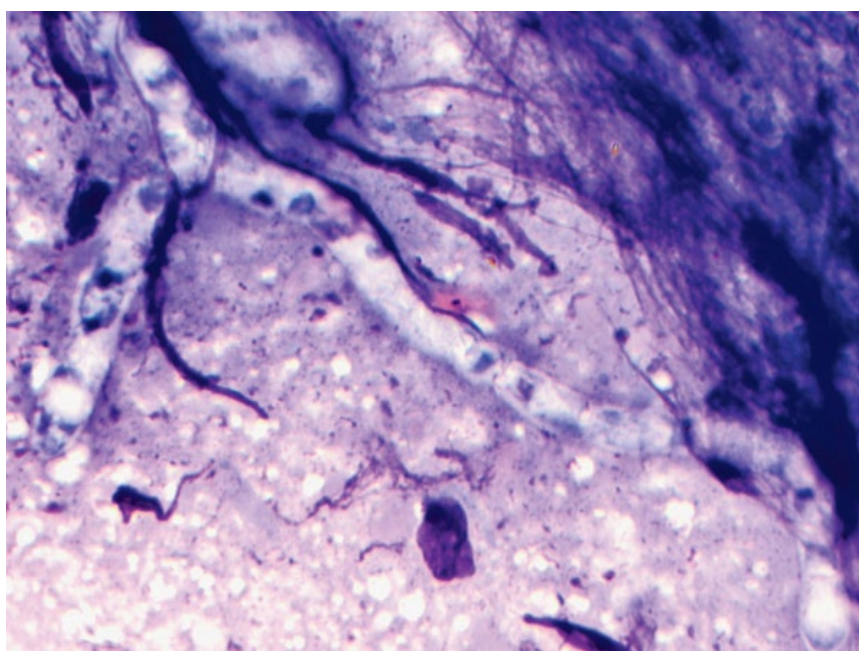


Figure 2.14 *Pythium insidiosum* hyphae, dog, 100x objective.



basophilic cytoplasm. Organisms may undergo endosporulation, forming multiple endospores within the cell wall (Figure 2.15). A granulomatous or mixed inflammatory response frequently is present.

2.3.1.2 Clinical Considerations

- Dogs > cats.
- Often associated with immunosuppression.

- Disease manifests in the skin (dogs and cats) or systemically (dogs, not reported in cats), primarily affecting the gastrointestinal tract, CNS, and eyes.

2.3.1.3 Prognosis

Surgical excision of cutaneous disease can be curative. Prognosis for disseminated disease in dogs is poor [21].

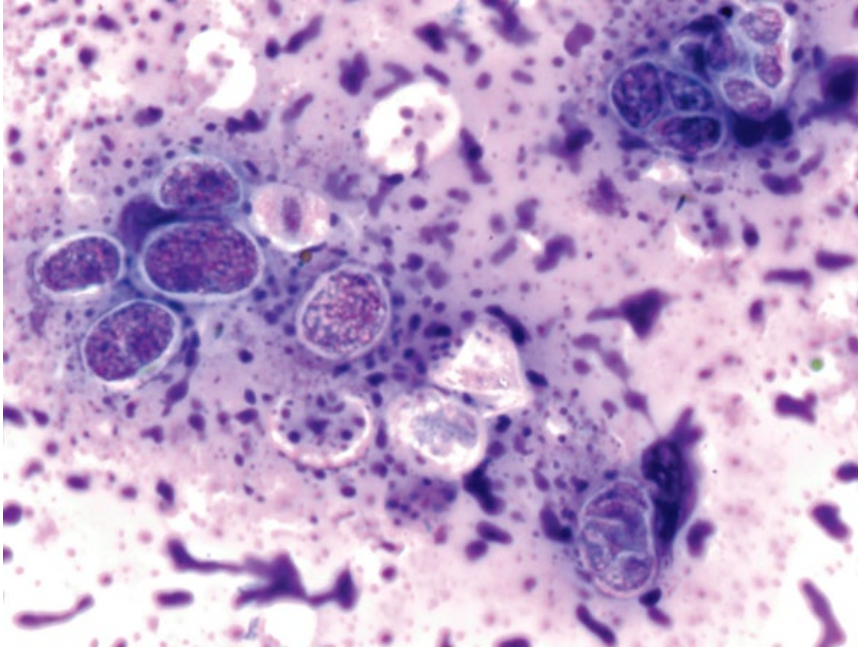


Figure 2.15 *Prototheca*, dog, 100× objective. Slide courtesy of Dr Ty McSherry.

2.4 Mesomycetozoea

2.4.1 *Rhinosporidium Seeberi*

2.4.1.1 Cytologic Appearance

Mature endospores are most commonly seen, which are round, 10–15 μm in diameter, with a thick cell wall and an intensely purple cytoplasm (Figure 2.16). Immature endospores are 2–4 μm in diameter, and stain pale pink

with purple areas thought to represent nuclear material. Large, round sporangia may be present that contain numerous endospores. Mixed inflammation is common.

2.4.1.2 Clinical Considerations

- Dogs >> cats.
- Presents as a tumor-like mass in the nasal cavity, usually in the rostral third [22, 23].
- Difficult to culture.

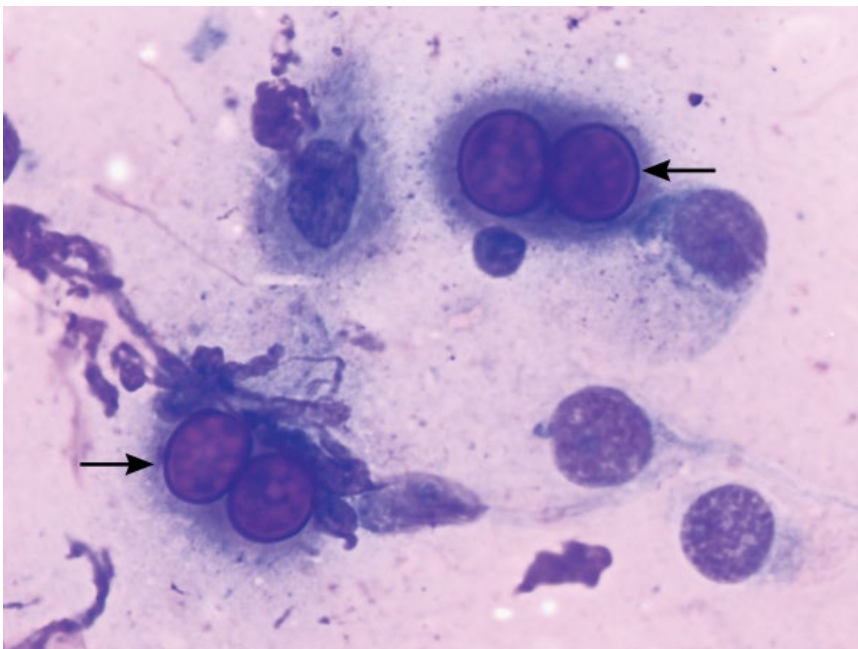
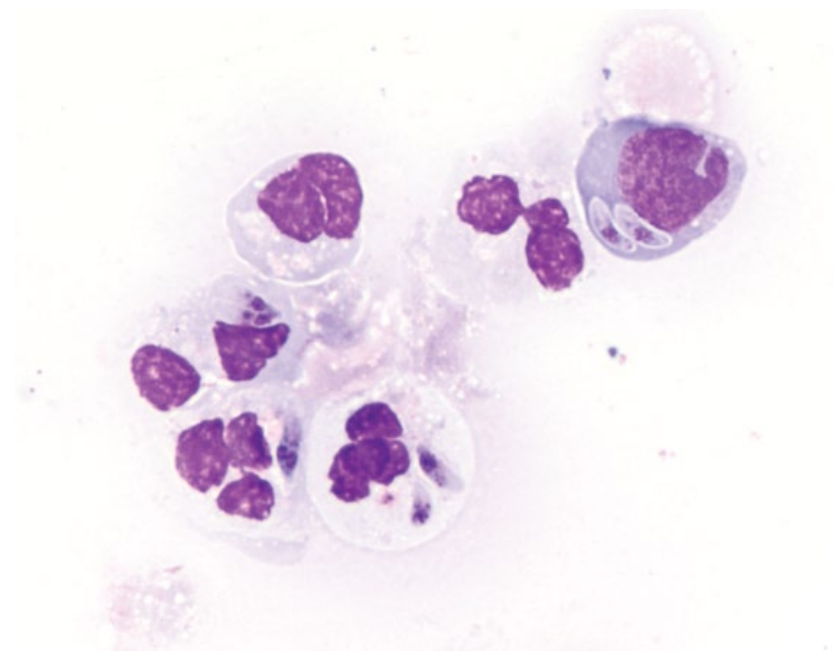


Figure 2.16 *Rhinosporidium seeberi* endospores (arrows), dog, 100× objective.

Figure 2.17 *Neospora caninum*, dog, 100× objective.



2.4.1.3 Prognosis

Good with surgical removal of polyps [23].

2.5 Protozoa

2.5.1 *Neospora Caninum*

2.5.1.1 Cytologic Appearance

Tachyzoites of *Neospora caninum* are crescent or 'banana' shaped, ~5µm long, and ~1µm wide. They have pale purple cytoplasm and round pink/purple nuclei that may be centrally or eccentrically placed (Figure 2.17). They are cytologically indistinguishable from *Toxoplasma gondii*.

2.5.1.2 Clinical Considerations

- Dogs > cats. Dogs are definitive host.
- Neuromuscular signs most common (ataxia, tetraparesis, head tilt, muscle atrophy). Cardiac, pulmonary, and cutaneous disease may be seen.
- PCR most reliable test to distinguish from *T. gondii*.

2.5.1.3 Prognosis

Variable based on severity and stage of disease.

2.5.2 *Toxoplasma Gondii*

2.5.2.1 Cytologic Appearance

Tachyzoites are cytologically similar to *Neospora caninum*, and cannot be distinguished cytologically (compare Figures 2.18 and 2.17).

2.5.2.2 Clinical Considerations

- Cats > dogs. Cats are definitive host.
- Clinical signs = fever, retinitis, seizures, ataxia, and respiratory distress.
- Clinical disease may be seen in immunosuppressed patients (e.g., FIV+) [24].
- Zoonotic potential.

2.5.2.3 Prognosis

Variable, but mostly good. Most disease is subclinical. Appropriate therapy is successful in most patients. CNS involvement, especially in immunocompromised patients, carries a poor prognosis [25].

2.5.3 *Leishmania*

2.5.3.1 Cytologic Appearance

Leishmania amastigotes are small (~2–4µm long, 1–2µm wide), ovoid, and have pale cytoplasm with prominent, pink, round nuclei. A characteristic feature is a deep purple kinetoplast (a single large mitochondrion) that forms a right-angle with the nucleus, often forming a 'T' shape (Figure 2.19). This is an important feature used to distinguish *Leishmania* spp. from other small infectious organisms. They induce mostly granulomatous inflammation.

2.5.3.2 Clinical Considerations

- Dogs > cats.
- Mostly affect skin, spleen and bone marrow.
- Clinical signs = lymphadenomegaly, cutaneous lesions, ocular lesions, and onychodystrophy.

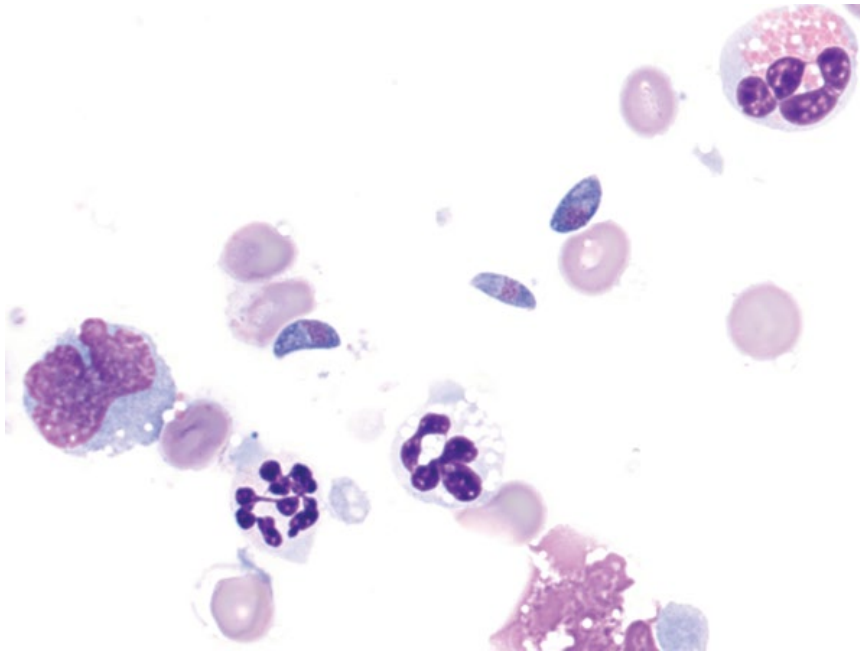


Figure 2.18 *Toxoplasma gondii*, dog, 100× objective. Three crescent-shaped organisms are accompanied by mixed inflammatory cells.

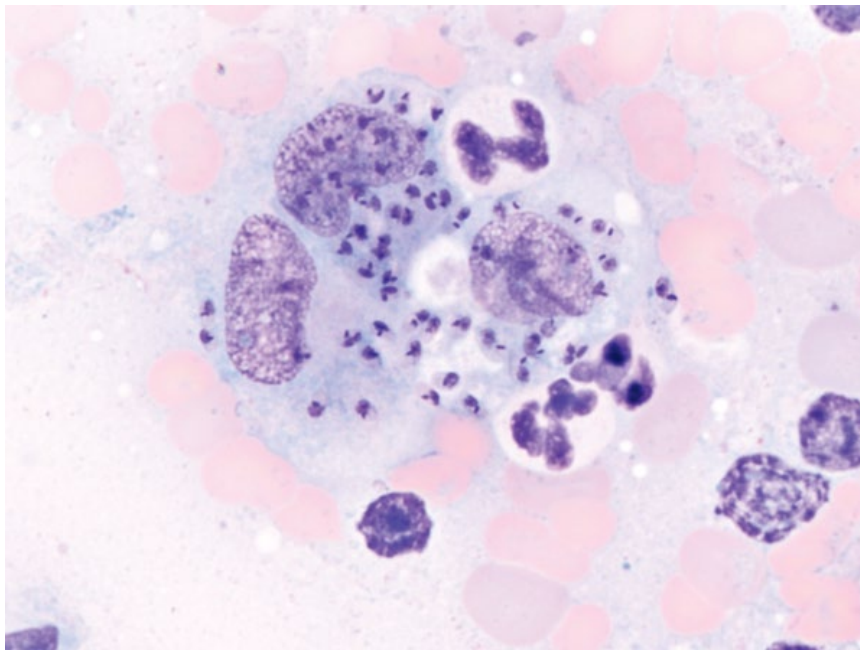


Figure 2.19 *Leishmania* spp., dog, 100× objective. Note the characteristic 'T' shape of the organisms.

2.5.3.3 Prognosis

Variable. High rates of full or partial remission and long survival times are possible with appropriate therapy [26]. Concurrent kidney disease and advanced stage of disease are poor prognostic markers [27].

2.5.4 *Cytosuxoon Felis*

2.5.4.1 Cytologic Appearance

Tissue macrophages are distended by schizonts, which contain numerous small purple granular developing merozoites (Figures 2.20 and 2.21). Macrophages have a

Figure 2.20 *Cytauxzoon felis* schizont, cat, 50x objective. A macrophage contains numerous merozoites. Note the small merozoites free in the background and the macrophage nucleus with its prominent nucleolus. Slide courtesy of Dr Maggie McCourt.

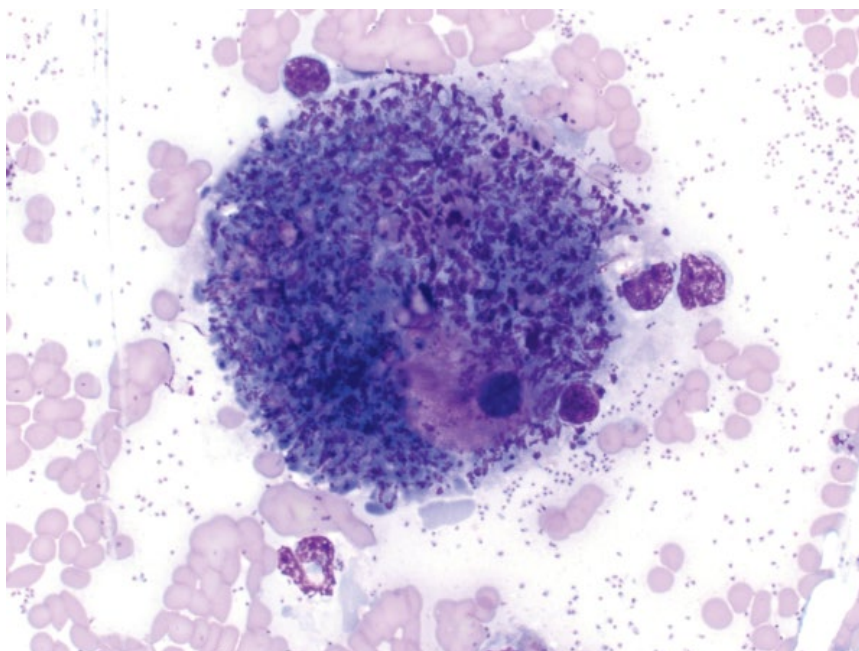
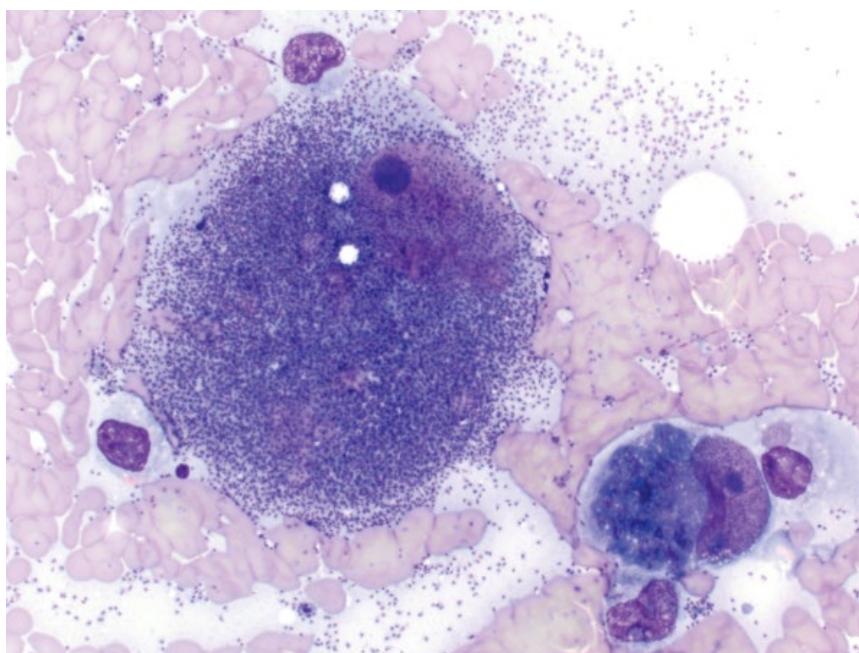


Figure 2.21 *Cytauxzoon felis* schizont, cat, 50x objective. A large macrophage contains numerous mature merozoites, and an early schizont (lower right). Slide courtesy of Dr Maggie McCourt.



characteristic prominent nucleolus. Merozoites will then enter the circulation and infect red blood cells as characteristic ring-formed 'piroplasms' (Figure 2.22).

2.5.4.2 Clinical Considerations

- Cats only.
- Schizonts most common in liver, spleen, lungs, lymph nodes, and blood.
- Clinical signs = fever, jaundice, anemia, thrombocytopenia.

2.5.4.3 Prognosis

Guarded to poor, and mortality rates are high. Some cats may be infected without clinical illness, and others may survive with aggressive therapy [28].

2.5.5 Giardia

2.5.5.1 Cytologic Appearance

Giardia spp. may be seen as either trophozoites or cysts in feces. Trophozoites are round to pear-shaped,

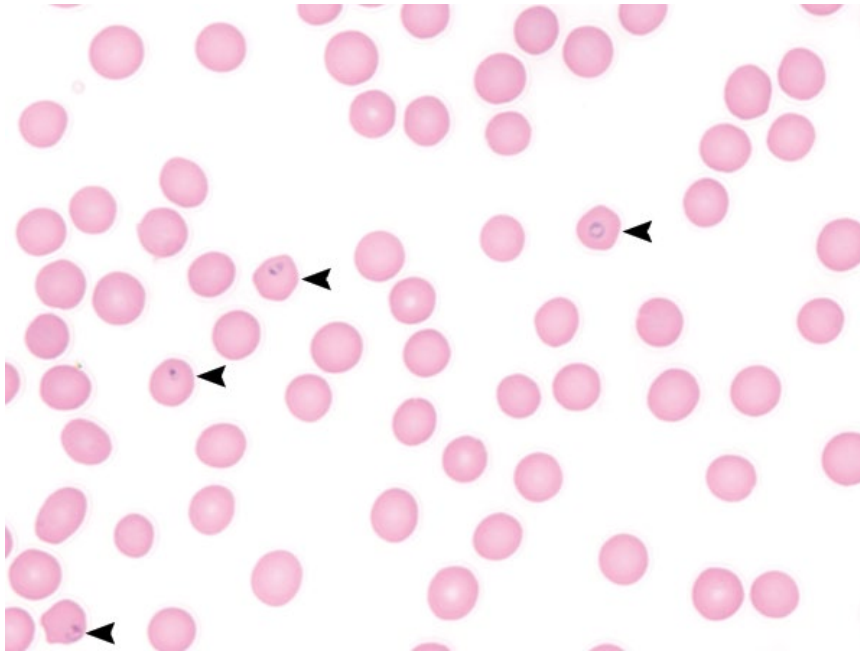


Figure 2.22 *Cytauxzoon felis*, cat, peripheral blood, 100× objective. Note the round piroplasms within the red blood cells (arrowheads).

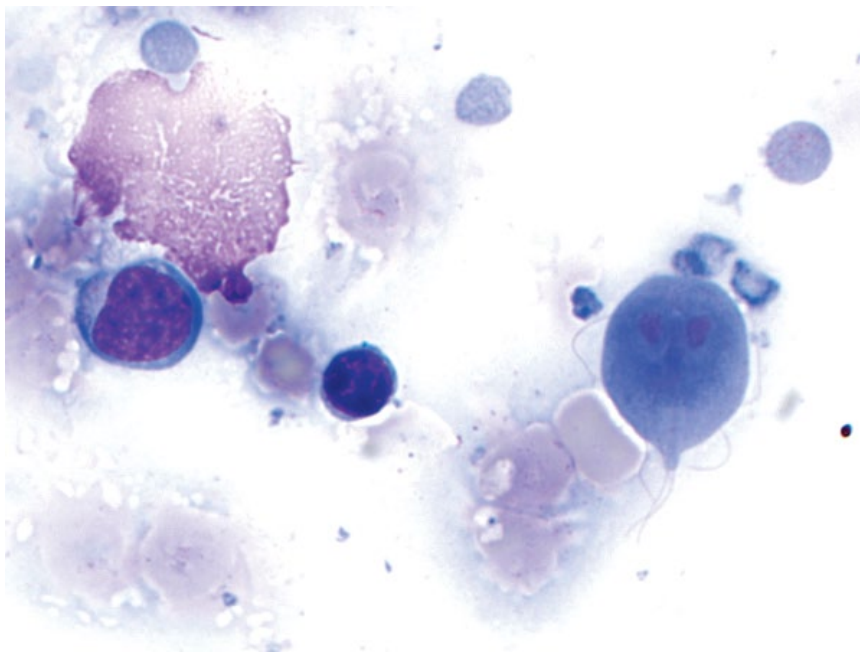


Figure 2.23 *Giardia lamblia* trophozoite, dog, 100× objective. Slide courtesy of Dr Heather Wamsley.

~10µm in length, and have four pairs of flagella, making them highly motile. They have two nuclei, separated by a longitudinal axoneme (Figure 2.23). Cysts are ovoid, ~12µm long and ~7µm wide, and often have a folded or concave surface (Figure 2.24). When viewed in fresh fecal samples, *Giardia* spp. have a smooth, deliberate movement across the slide (compared to Trichomonads).

2.5.5.2 Clinical Considerations

- Common parasite in dogs and cats [29].
- Clinical signs = diarrhea (mucoid, pale, soft ± steatorrhea), and weight loss. Some infected patients may be asymptomatic.

2.5.5.3 Prognosis

Good with appropriate therapy.

Figure 2.24 *Giardia lamblia* cysts, dog, 100× objective.

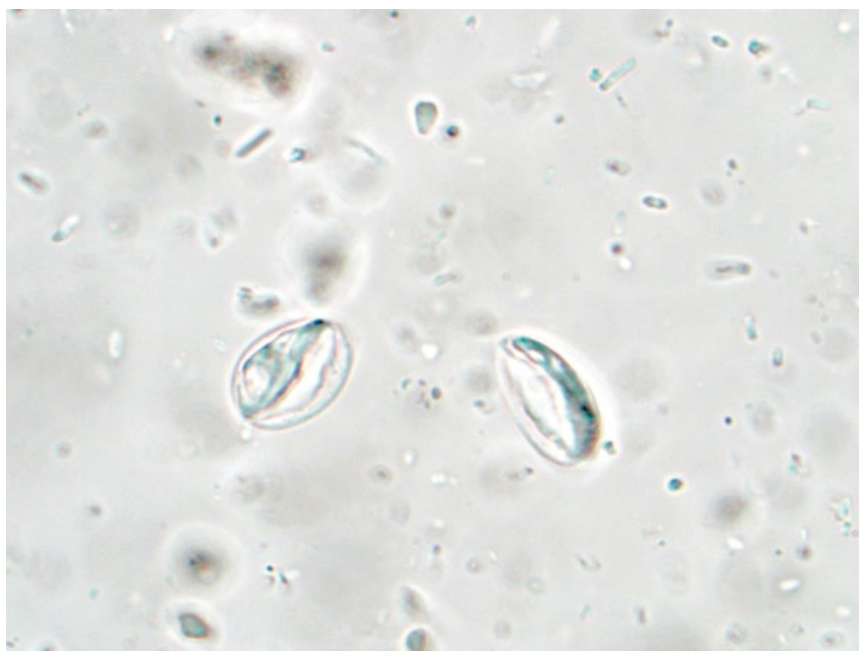
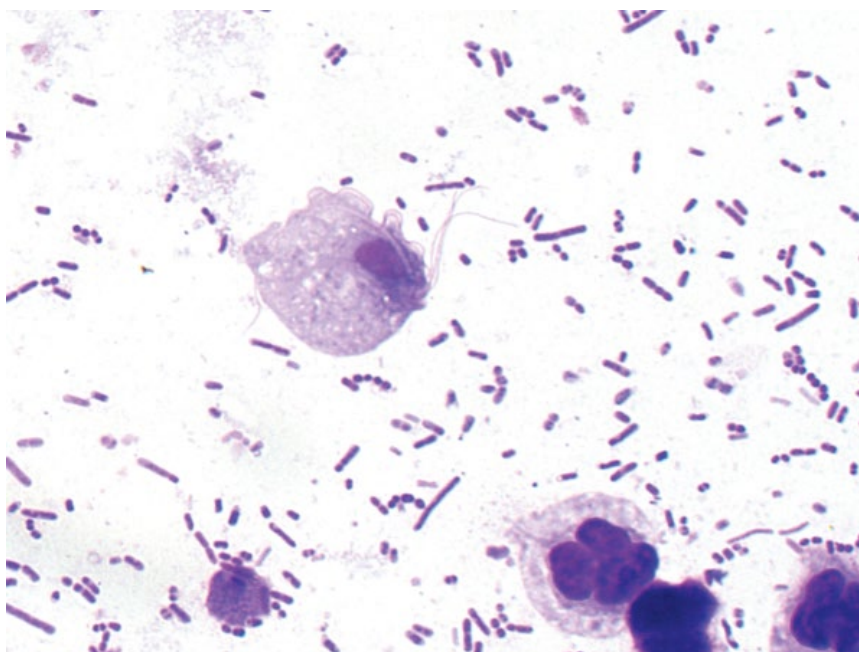


Figure 2.25 *Tritrichomonas fetus*, cat, 100× objective. Note the flagella and undulating membrane. Slide courtesy of Dr Emily Walters.



2.5.6 Trichomoniasis

2.5.6.1 Cytologic Appearance

Trichomonads are fusiform to pear-shaped organisms, and have undulating membranes and flagella that make them highly motile (Figure 2.25). When fresh fecal samples are inspected, the movement of Trichomonads is

more ‘jerking’ and random than that of *Giardia* spp., which is smooth and deliberate.

2.5.6.2 Clinical Considerations

- *Tritrichomonas foetus* (cats > dogs) and *Pentatrichomonas hominis* (dogs > cats).

- Many animals are asymptomatic carriers. Disease mostly seen in young animals.
- Clinical signs = chronic diarrhea.
- PCR used for differentiation.

2.5.6.3 Prognosis

Excellent. Spontaneous resolution of disease secondary to *T. foetus* occurs in many cats, but may take months [30].

2.5.7 *Cryptosporidium*

2.5.7.1 Cytologic Features

Cryptosporidium oocysts can be difficult to identify in feces, as they are colorless and small (~5 µm in diameter). Stained samples (with Romanowsky stains or Kinyoun acid-fast) highlight oocysts, which often appear 'crinkled' (Figure 2.26).

2.5.7.2 Clinical Considerations

- *Cryptosporidium canis* (dogs) and *Cryptosporidium felis* (cats).
- Mostly subclinical infections. Clinical signs = watery diarrhea.
- Immunocompromised patients (e.g., FeLV+ cats) predisposed [31].
- Zoonotic potential (mainly in immunocompromised people).

2.5.7.3 Prognosis

Mostly excellent. Investigation for underlying disease in clinical patients is recommended.

2.5.8 *Hepatozoon* spp.

2.5.8.1 Cytologic Appearance

Gamonts most frequently are seen in blood, but also rarely in cytologic samples from tissues. These are ovoid, ~8–11 µm long and ~4 µm wide, mostly seen phagocytosed by leukocytes (Figure 2.27). They stain pale blue or may be negatively staining. Nuclei are variably visible. *H. canis* gamonts are slightly larger than those of *H. americanum*, but cannot be reliably distinguished by cytology [32].

2.5.8.2 Clinical Considerations

- *H. canis* and *H. americanum* species infect dogs. Hepatozoonosis in cats is rare.
- Affected tissues include skeletal muscle and bone (*H. americanum*); spleen, bone marrow, lymph nodes ± bone (*H. canis*) [33, 34].

2.5.8.3 Prognosis

Short- and long-term control can be achieved with appropriate therapy [35]. Relapse may occur with *H. americanum*, and persistent infections may carry a more guarded prognosis [36].

2.6 Helminths

2.6.1 *Mesocestoides*

2.6.1.1 Cytologic Appearance

Parasites mostly detected in peritoneal fluid, which has a characteristic flocculent gross appearance with

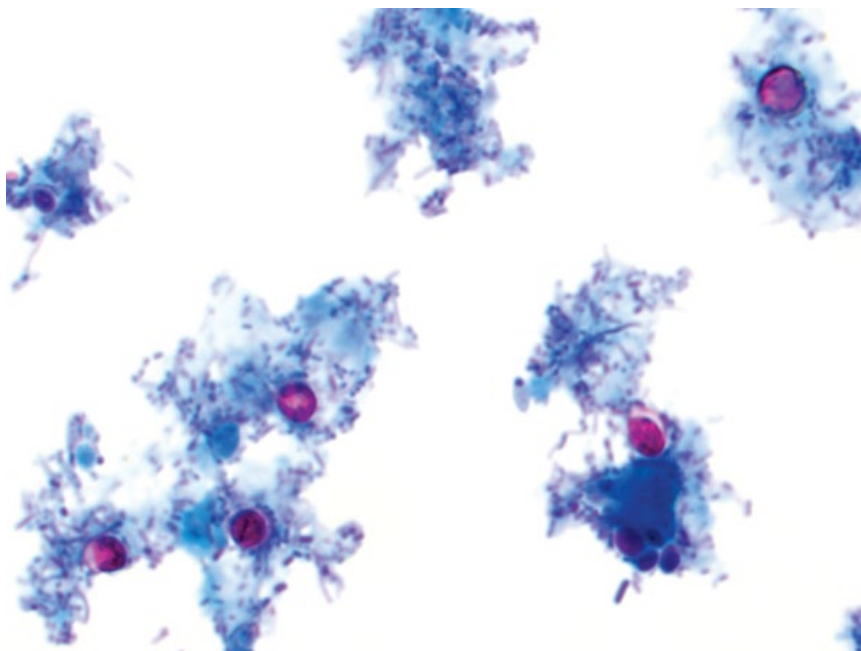


Figure 2.26 *Cryptosporidium canis* oocysts, dog, 100× objective, Kinyoun acid-fast stain.

Figure 2.27 *Hepatozoon americanum*, dog, peripheral blood, 100x objective.

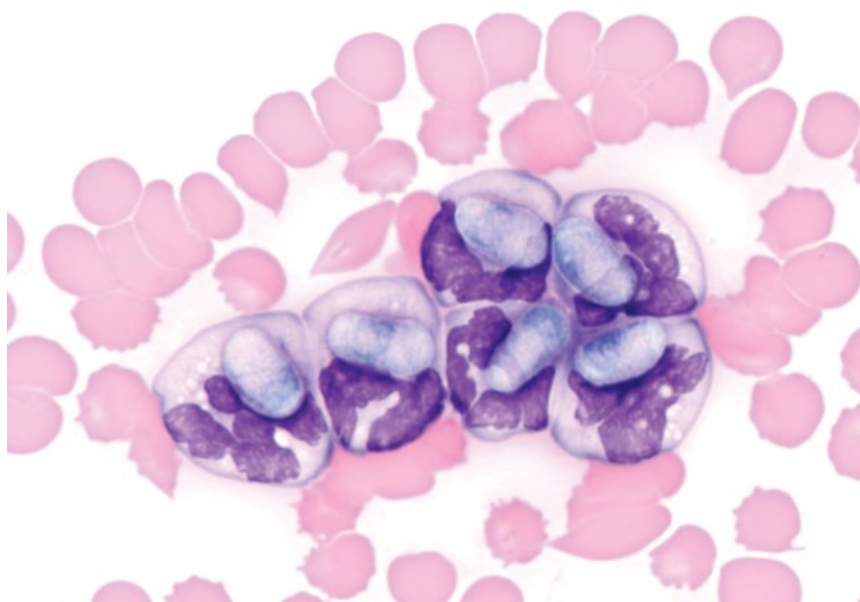
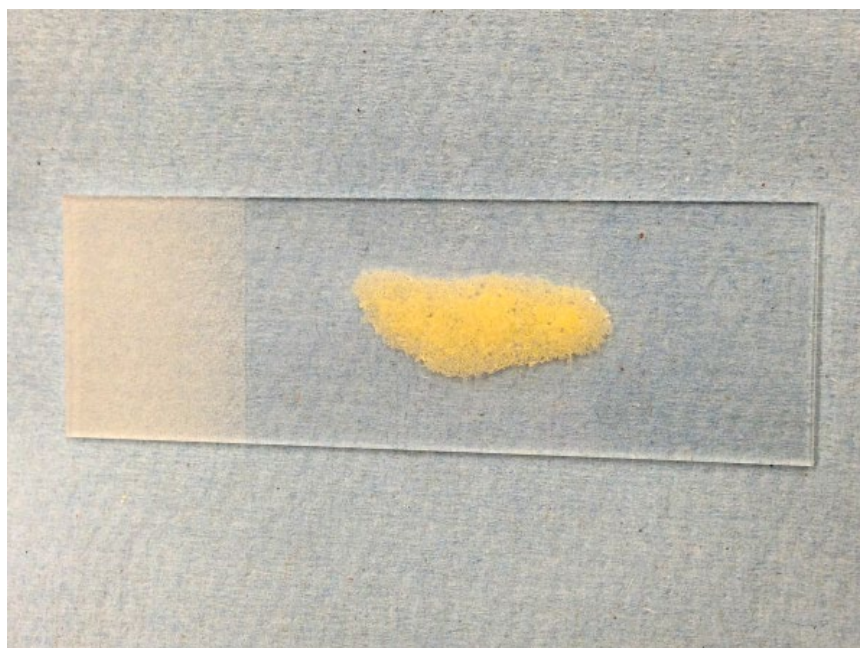


Figure 2.28 *Mesocestoides*, abdominal fluid gross appearance, dog. Note the granular texture of the fluid.



yellow particulate matter (Figure 2.28). Larvae and their fragments are large (200–2000 μm), tubular/verminous with deep blue cytoplasm and often clear/tan refractile structures ($\sim 10 \mu\text{m}$) that are calcareous

corpuscles (calcium deposits unique to cestodes) (Figure 2.29). Rarely, tetrathyridia – the asexual reproductive form which have round parasitic suckers – may be present.

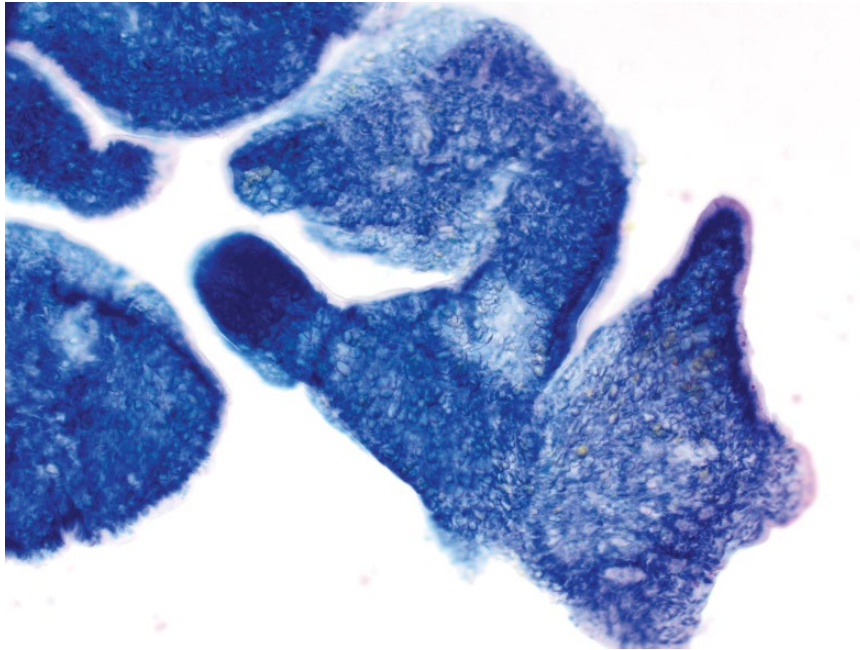


Figure 2.29 *Mesocestoides* larval fragments, abdominal fluid, dog, 20× objective. Note the refractile, clear-to-tan calcareous corpuscles.

2.6.1.2 Clinical Considerations

- Dogs >> cats.
- Usually cause peritonitis, but can be found in organs (liver and lymph node) [37].
- Clinical signs = ascites, anorexia/weight loss, and vomiting [38].

2.6.1.3 Prognosis

Guarded. Aggressive therapy is required for a positive outcome [38].

2.6.2 *Filaroides Hirthi*

2.6.2.1 Cytologic Appearance

Larvae are large (~250–300 μm in length, ~15 μm wide), verminous, and tightly coiled. They stain pale blue, with basophilic internal organs. Concurrent inflammation is usually neutrophilic or eosinophilic (Figure 2.30).

2.6.2.2 Clinical Considerations

- Dogs.
- Immunosuppressed patients at increased risk [39].

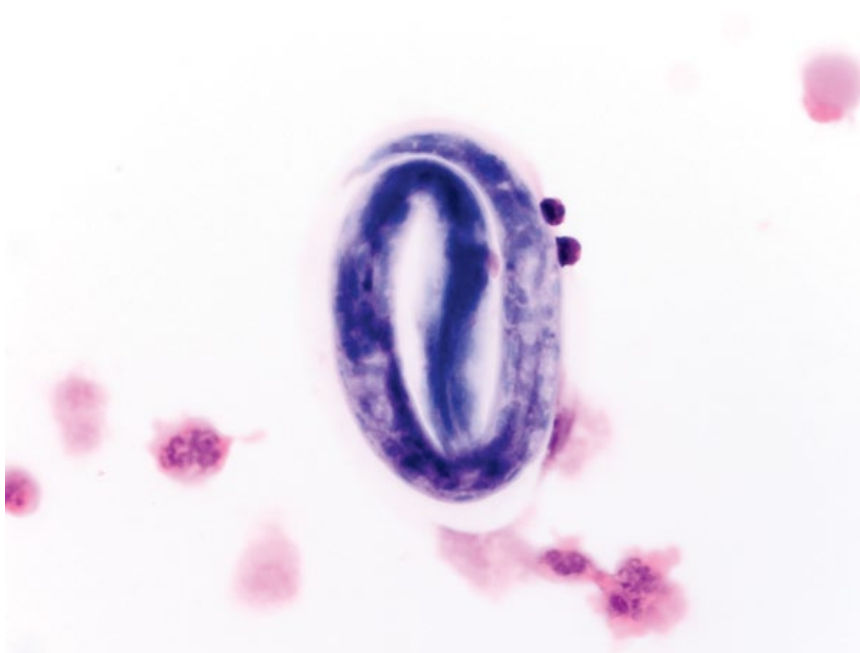
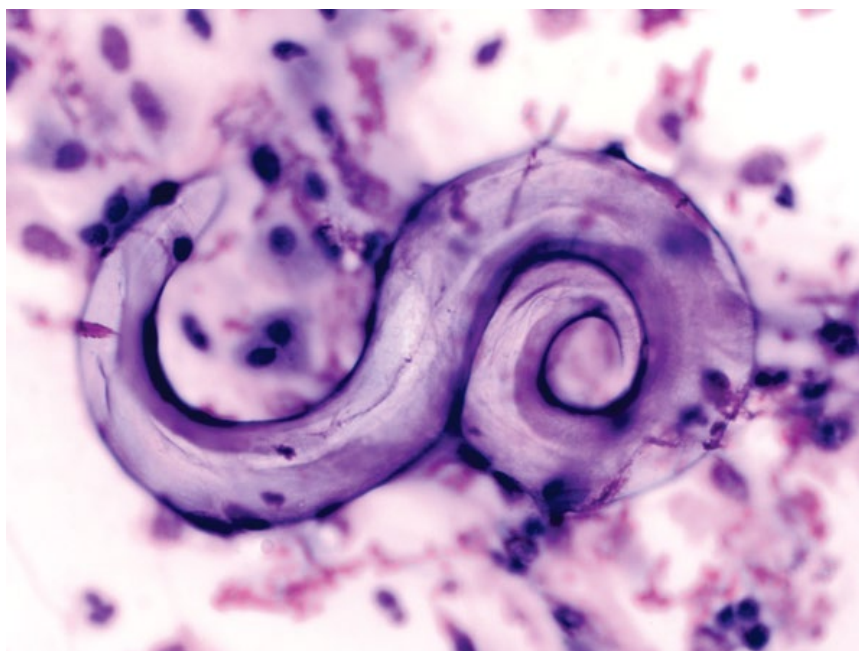


Figure 2.30 *Filaroides hirthi*, dog, 50× objective.

Figure 2.31 *Aelurostrongylus abstrusus*, cat, 50× objective. Note the prominent dorsal spine down the center.



- Clinical signs = cough and dyspnea.
- Peripheral eosinophilia inconsistently reported [39].
- DDx = *Oslerus osleri*, which appear similar, but have a kinked distal tail.

2.6.2.3 Prognosis

Generally good to excellent.

2.6.3 *Aelurostrongylus Abstrusus*

2.6.3.1 Cytologic Appearance

Larvae are large (~400 µm long, ~20 µm wide), vermiform, pale purple to unstained, and often tightly coiled on themselves. Characteristic features include a dorsal spine, and a short, kinked tail (Figure 2.31).

2.6.3.2 Clinical Considerations

- Cats.
- Animals may be asymptomatic. Clinical signs = cough, nasal discharge, and dyspnea.
- Disease more pronounced in young or immunosuppressed patients [40].

2.6.3.3 Prognosis

Generally good to excellent.

2.6.4 *Dracunculus*

2.6.4.1 Cytologic Appearance

Larvae are ~500 µm in length and ~25 µm wide, and have a characteristic whip-like tail (Figure 2.32). Often accompanied by a marked neutrophilic/eosinophilic inflammatory response.

2.6.4.2 Clinical Considerations

- Dogs.
- Associated with subcutaneous nodules that may be pruritic and form fistulae [41].

2.6.4.3 Prognosis

Excellent.

2.6.5 *Paragonimus*

2.6.5.1 Cytologic Appearance

Paragonimus ova are most frequently encountered in either lung aspirates or feces. They are ovoid, ~100 µm in length and ~50 µm wide, tan-colored, and often have thick ridges (Figure 2.33). A unipolar operculum may be observed.

2.6.5.2 Clinical Considerations

- Cats > dogs.
- *Paragonimus kellicotti* most common.
- Infection may be asymptomatic, but may cause respiratory signs of cough, dyspnea, nasal discharge, or rarely pneumothorax [42, 43].

2.6.5.3 Prognosis

Good with appropriate therapy.

2.7 Bacteria

2.7.1 *Mycobacteria*

2.7.1.1 Cytologic Appearance

Mycobacterium spp. do not stain with routine stains, and appear as clear to refractile, rod-shaped organisms that

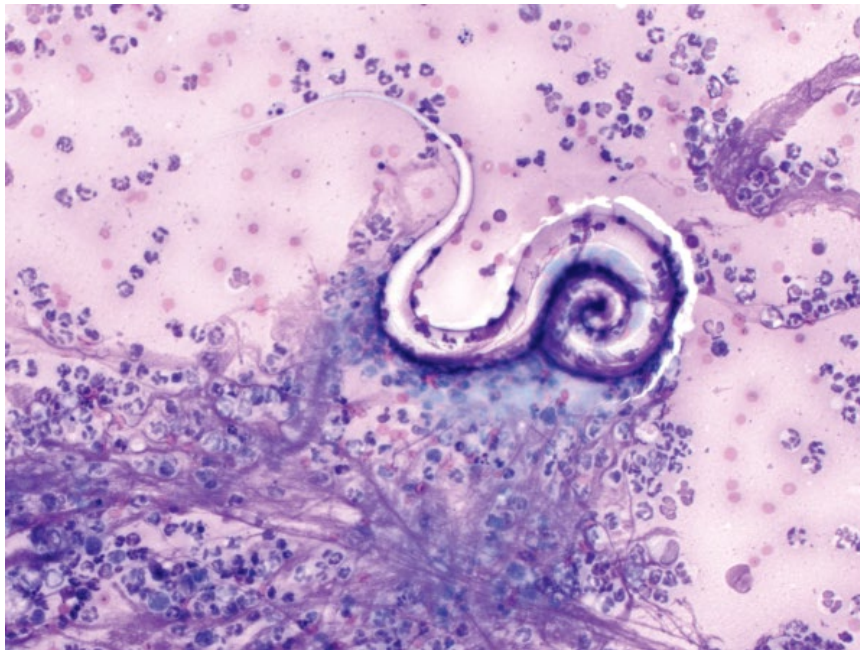


Figure 2.32 *Dracunculus*, dog, 20× objective.

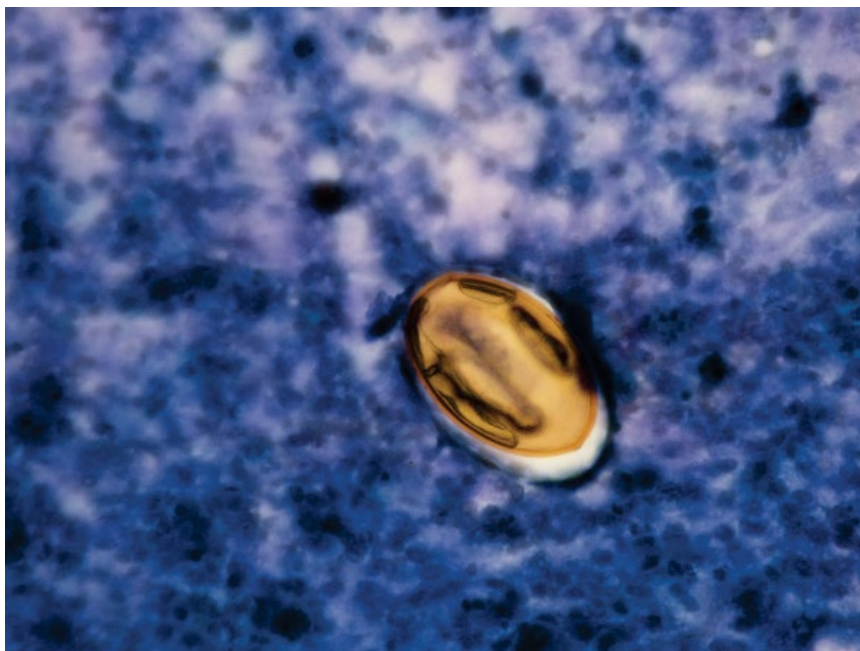


Figure 2.33 *Paragonimus kellicotti* ovum, cat, 40× objective. Photo courtesy of Drs Michelle Plier and Lon Rich.

may be found within macrophages, or scattered across the background of the sample (Figure 2.34). They induce a mostly granulomatous inflammatory response.

2.7.1.2 Clinical Considerations

- Dogs and cats.
- Aerobic, Gram-positive, acid-fast bacilli.
- Numerous *Mycobacterium* spp. exist that cause different diseases. Infections may affect skin, respiratory tract, bone, or be disseminated.

2.7.1.3 Prognosis

Variable based on organ involvement and severity of disease. Disseminated disease is associated with a poor prognosis.

2.7.2 *Actinomyces/Nocardia*

2.7.2.1 Cytologic Appearance

Actinomyces and *Nocardia* spp. are cytologically similar, appearing as slender, filamentous bacteria with

Figure 2.34 *Mycobacterium* spp., cat, 100× objective. A macrophage contains numerous clear, rod-shaped bacteria.

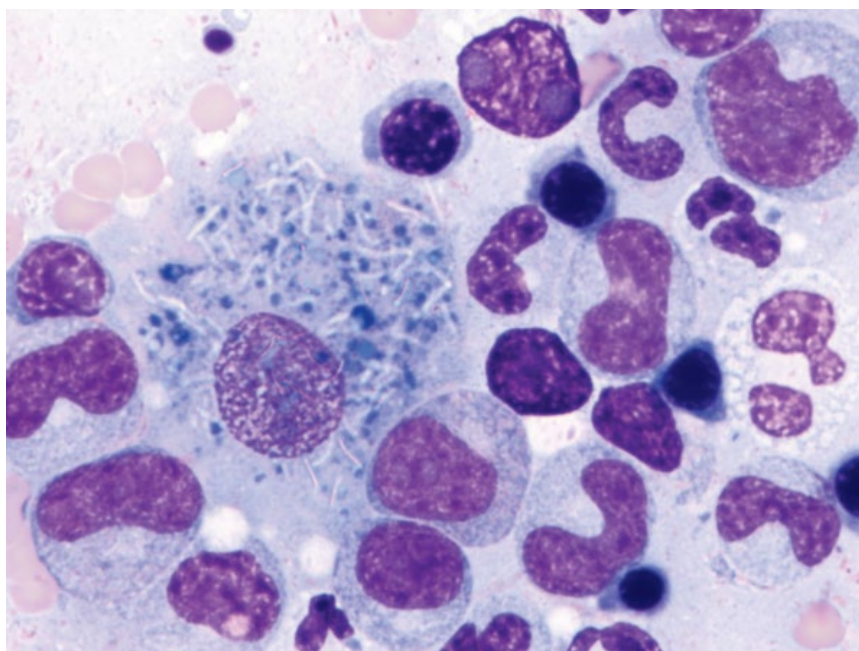
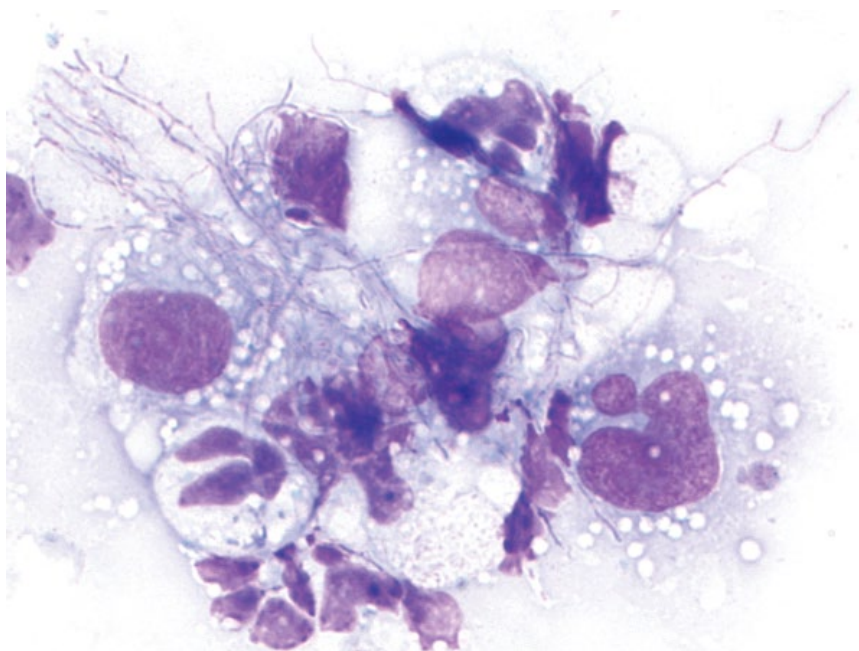


Figure 2.35 *Actinomyces* spp., cat, 100× objective. Note the long, fine, branching filamentous bacteria.



characteristic branching (Figure 2.35). They are lightly basophilic and have red, beaded areas. They may be seen in macrophages or extracellularly, and occasionally in large bacterial mats. They are mostly accompanied by a granulomatous or pyogranulomatous inflammatory response.

2.7.2.2 Clinical Considerations

- Dogs and cats. Actinomycosis more common than Nocardiosis.

- Both Gram-positive. *Nocardia* spp. are variably acid-fast positive.
- Subcutaneous masses with draining lesions and pulmonary disease most common. Disseminated disease may occur.

2.7.2.3 Prognosis

Actinomycosis has a good prognosis with appropriate therapy [44, 45]. Nocardiosis is more commonly associated

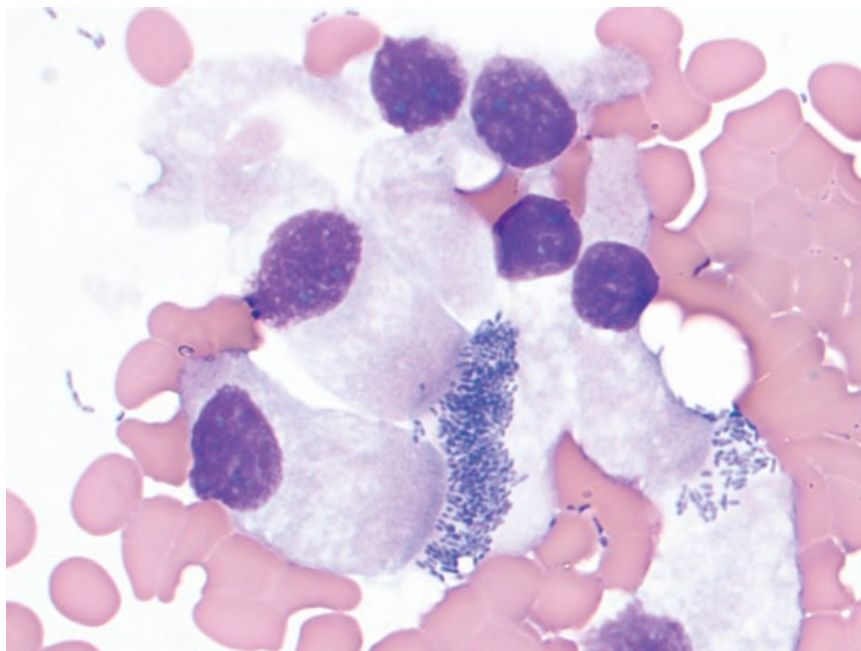


Figure 2.36 *Bordetella bronchiseptica*, bronchoalveolar lavage, dog, 100× objective. Note the basophilic coccobacilli adhered to the cilia of the columnar respiratory epithelial cells.

with underlying immunosuppression, and overall carries a poorer prognosis [46, 47].

2.7.3 *Bordetella Bronchiseptica*

2.7.3.1 Cytologic Appearance

Bordetella bronchiseptica may be seen as coccobacilli adhered to cilia and interciliary spaces of respiratory epithelial cells (Figure 2.36). They mostly induce a neutrophilic response, but mononuclear inflammation may predominate [48].

2.7.3.2 Clinical Considerations

- Dogs and cats. More prevalent in young and group-housed animals [49].
- Clinical signs = productive hacking cough, lethargy, fever ± serous or seromucous nasal discharge.
- Cytologic identification of bacteria more likely to diagnose infection than microbial culture, but quantitative PCR is the best diagnostic test [48].
- Zoonotic potential, but rare [50].

2.7.3.3 Prognosis

Good to excellent with appropriate therapy. Mild/uncomplicated cases may be self-limiting.

2.7.4 Rickettsial Bacteria

2.7.4.1 Cytologic Appearance

Rickettsial bacteria form morulae (round aggregates of bacteria) within phagosomes of leukocytes (Figure 2.37). They most commonly are seen in circulating leukocytes,

but may also be seen in fluids or organs (see Chapter 6). *Ehrlichia canis* infects monocytes and lymphocytes, while *E. ewingii* and *Anaplasma phagocytophilum* infect granulocytes [51]. *Neorickettsia helminthoeca* is the causative agent of salmon poisoning disease, and is seen in lymph node aspirates of affected dogs (see Figure 2.38 and Chapter 4).

2.7.4.2 Clinical Considerations

- Gram-negative, intracellular bacteria.
- Dogs >> cats. *Neorickettsia helminthoeca* infects dogs only.
- Clinical signs = lethargy, fever, lymphadenopathy, thrombocytopenia, neurologic signs, and polyarthropathy [51].

2.7.4.3 Prognosis

Generally good with appropriate therapy. Severe acute cases of *E. canis* and *N. helminthoeca* have a guarded prognosis.

2.7.5 *Clostridium* spp.

2.7.5.1 Cytologic Appearance

Clostridium spp. (*C. perfringens* and *C. difficile*) are rod-shaped bacteria that often have a characteristic 'safety pin' appearance due to the presence of endospores (Figure 2.39). The presence of even large numbers of these bacteria in fecal samples does not correlate with disease or toxin production, and while they may raise

Figure 2.37 *Anaplasma phagocytophilum*, peripheral blood, dog, 100× objective. A basophilic morula of organisms is seen within a neutrophil.

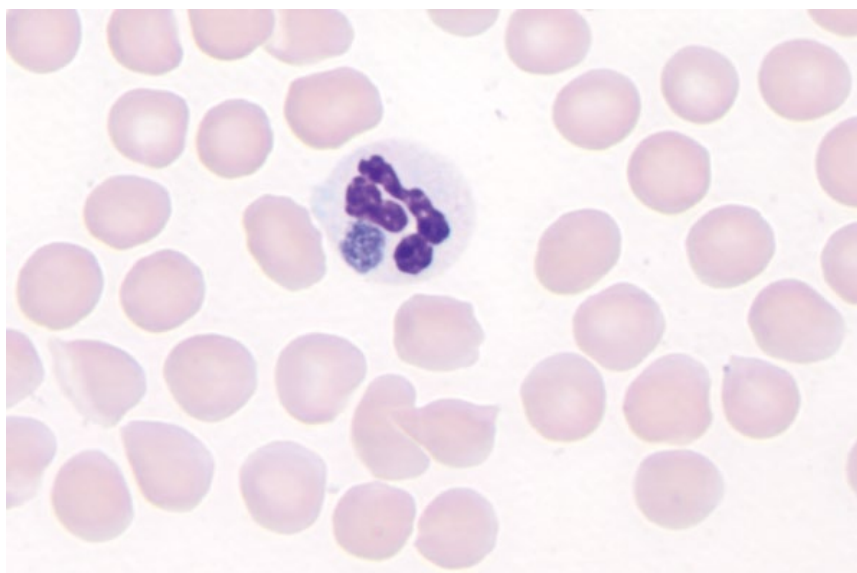
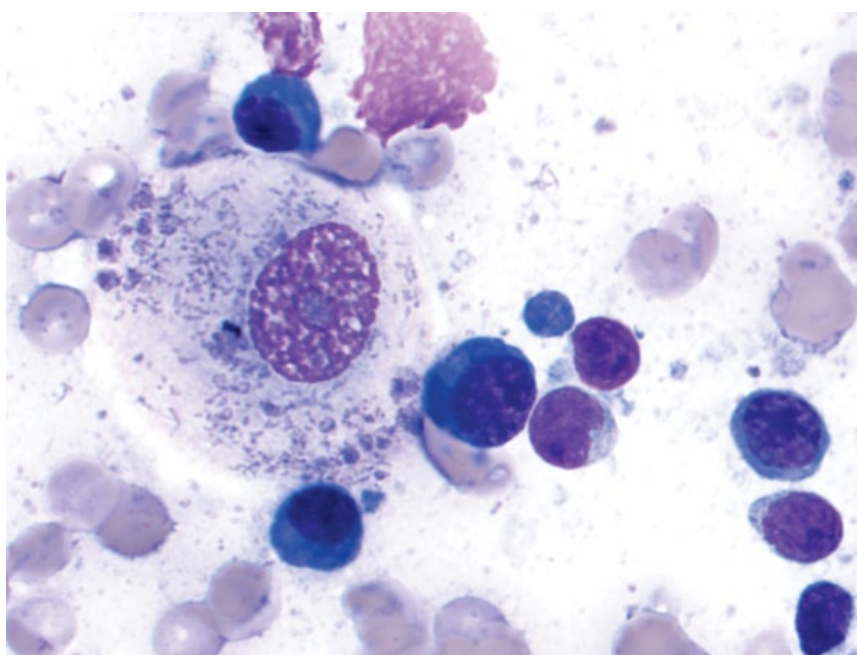


Figure 2.38 *Neorickettsia helminthoeca* (salmon poisoning disease), lymph node, dog, 100× objective. A macrophage contains many small blue/gray organisms that also are seen in the background.



suspicion of *Clostridium* spp. diarrhea, further testing is recommended [52].

2.7.5.2 Clinical Considerations

- Gram-positive, spore-forming, anaerobic rods.
- Commensal bacteria in gastrointestinal tract of dogs and cats. Overgrowth and toxin production associated with disease.
- Clinical signs = diarrhea, lethargy, anorexia, ± vomiting.

2.7.5.3 Prognosis

Generally good, but severe disease can be life-threatening.

2.7.6 *Campylobacter* spp.

2.7.6.1 Cytologic Appearance

Campylobacter spp. are thin, curved to spiral bacteria that often have a characteristic 'gull-wing' shape when seen in fecal samples (Figure 2.40). The presence of such bacteria is suggestive of campylobacteriosis; however,

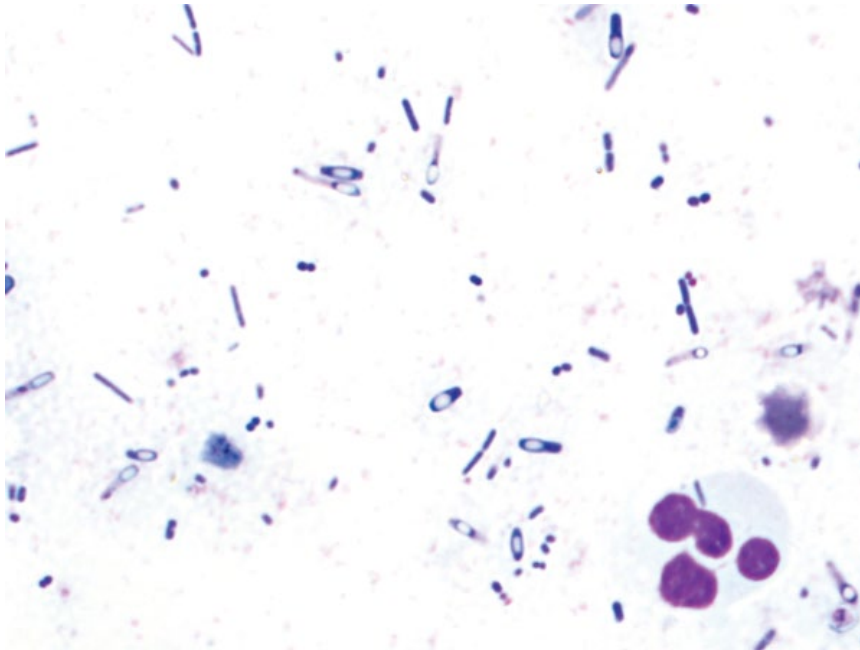


Figure 2.39 *Clostridium perfringens*, dog, 100× objective. Note the characteristic clear spores in the bacteria giving them a 'safety-pin' appearance.

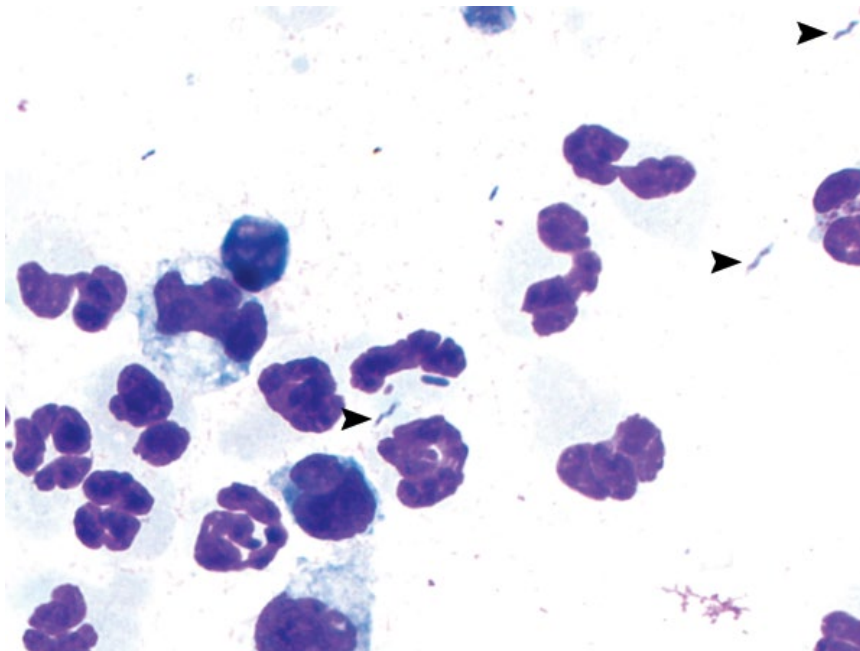


Figure 2.40 *Campylobacter* spp., dog, 100× objective. Note the small, 'gull-wing' or 'M'-shaped bacteria (arrowheads) accompanied by neutrophilic inflammation.

further diagnostics are warranted as non-pathologic spiral bacteria may appear similar.

2.7.6.2 Clinical Considerations

- Dogs and cats, mostly affects young patients.
- Isolated from feces of normal and diseased animals [52].
- Clinical signs = diarrhea, lethargy, anorexia ± vomiting.
- Zoonotic potential.

2.7.6.3 Prognosis

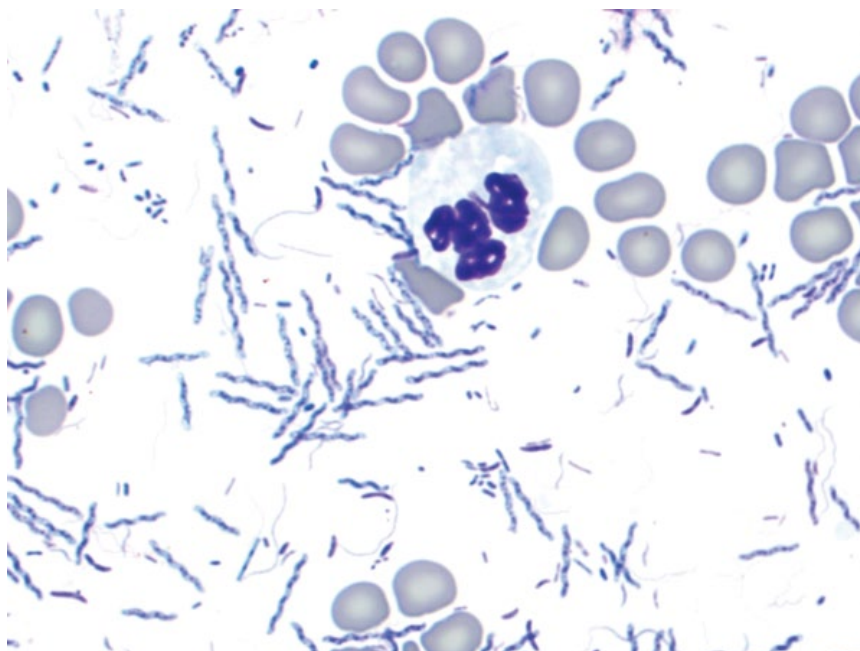
Good to excellent with appropriate therapy. Mild/uncomplicated cases generally are self-limiting.

2.7.7 *Helicobacter* spp.

2.7.7.1 Cytologic Appearance

Helicobacter-like organisms are long (5–10 μm), tightly spiral-shaped bacteria that mostly are thicker than other

Figure 2.41 *Helicobacter* spp., dog, 100× objective. Note the large-size and tight spirals.



spiral-shaped bacteria, and have a textured basophilic appearance. Infection may be accompanied by inflammatory cells (Figure 2.41).

2.7.7.2 Clinical Considerations

- Gram-negative, microaerophilic, spiral-shaped bacteria.
- *H. pylori* (an important gastric pathogen in humans) is extremely rare in cats and not reported in dogs [53]. Other *Helicobacter* spp. are common in dogs and cats [54].
- Clinical signs = chronic intermittent vomiting, inappetence, pica, and weight loss [55]. Note that the majority of dogs and cats with infection are asymptomatic, and strong evidence for *Helicobacter* spp. as a primary pathogen is lacking.

2.7.7.3 Prognosis

Good with appropriate therapy, but recurrence of infection can be high [56].

2.7.8 *Simonsiella* spp.

2.7.8.1 Cytologic Appearance

Simonsiella spp. are large, rod-shaped bacteria that align in rows after division, and have a characteristic, stacked appearance (Figure 2.42).

2.7.8.2 Clinical Considerations

- Rod-shaped, Gram-negative commensals of the oropharynx.
- Incidental finding.

- Their presence is a hallmark of oropharyngeal contamination of airway samples (see Chapter 10).

2.7.8.3 Prognosis

Excellent.

2.8 Ectoparasites

2.8.1 *Demodex* spp.

2.8.1.1 Cytologic Appearance

Demodex spp. are elongated ('cigar-shaped'), with four pairs of short legs grouped in the podosoma region (Figure 2.43). Adults typically are 150–250 µm in length, while nymphs are shorter. Deep skin scrapes or hair plucks usually are required to find mites.

2.8.1.2 Clinical Considerations

- Dogs > cats.
- Local or generalized disease may be seen. Generalized disease in adults is mostly associated with immunosuppression [57].
- Predilection sites = face, ventrum, and limbs.
- Skin is crusted, alopecic (often symmetrical), thickened, or hyperpigmented.

2.8.1.3 Prognosis

Good to excellent with appropriate therapy. Investigation for concurrent disease is warranted for generalized disease in dogs aged >18 months [57].

Figure 2.42 *Simonsiella* spp., dog, 100× objective.

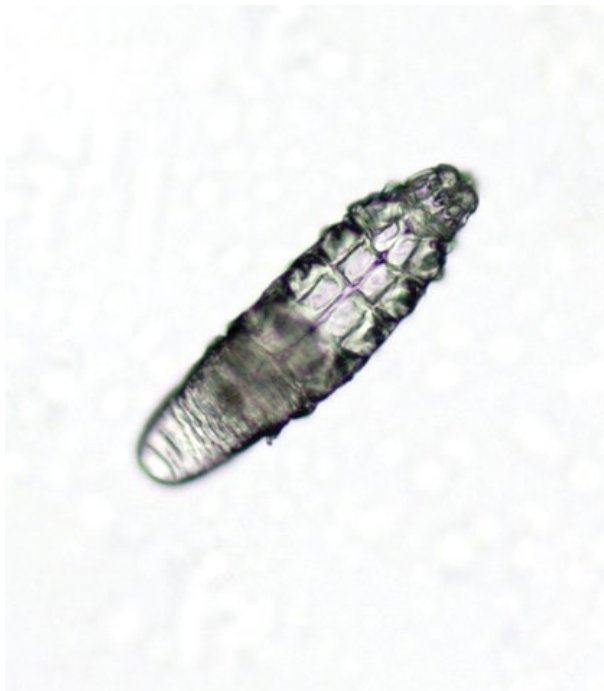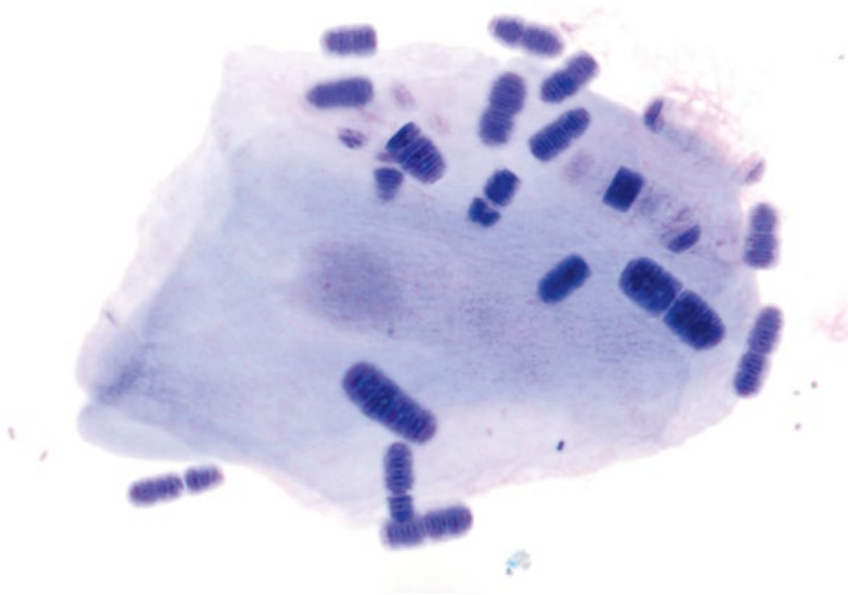


Figure 2.43 *Demodex canis* nymph, dog, 50× objective.

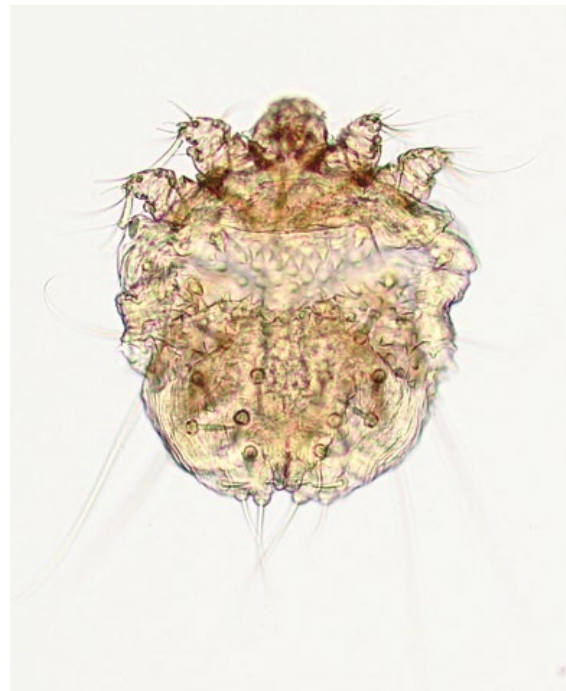


Figure 2.44 *Sarcoptes scabiei*, dog, 20× objective.

2.8.2 *Sarcoptes Scabiei*

2.8.2.1 Cytologic Appearance

These mites are circular (200–600 μm in diameter, with females twice as large as males), and have two pairs of legs at their anterior portion, and two pairs at the posterior portion that do not extend beyond the body margin (Figure 2.44).

2.8.2.2 Clinical Considerations

- Dogs > cats.
- Young dogs most susceptible [57].
- Predilection sites = limbs (especially elbow and hock), pinnae, and ventral abdomen.
- Lesions are intensely pruritic and vary from papules to thick crusts with poor hair condition.

Figure 2.45 *Otodectes cynotis*, dog, 20× objective.



2.8.2.3 Prognosis

Excellent.

2.8.3 Otodectes Cynotis

2.8.3.1 Cytologic Appearance

Adult mites range from 250–450 µm in length (females are larger than males). They have two anterior and two posterior pairs of legs (Figure 2.45). Eggs often are also present, that are ovoid and ~200 µm long.

2.8.3.2 Clinical Considerations

- Common in cats and dogs.
- Clinical signs = head shaking, ear scratching, ear droop.
- May be accompanied by neutrophilic inflammation and ceruminous discharge.

2.8.3.3 Prognosis

Excellent.

References

- 1 O'Brien, C.R., Krockenberger, M.B., Martin, P., *et al.* (2006) Long-term outcome of therapy for 59 cats and 11 dogs with cryptococcosis. *Aust. Vet. J.*, **84** (11), 384–392.
- 2 Duncan, C., Stephen, C., Campbell, J. (2006) Clinical characteristics and predictors of mortality for *Cryptococcus gattii* infection in dogs and cats of southwestern British Columbia. *Can. Vet. J.*, **47** (10), 993–998.
- 3 Sykes, J.E., Sturges, B.K., Cannon, M.S., *et al.* (2010) Clinical signs, imaging features, neuropathology, and outcome in cats and dogs with central nervous system cryptococcosis from California. *J. Vet. Intern. Med.*, **24** (6), 1427–1438.
- 4 McGill, S., Malik, R., Saul, N., *et al.* (2009) Cryptococcosis in domestic animals in Western Australia: a retrospective study from 1995–2006. *Med. Mycol.*, **47** (6), 625–639.
- 5 Davies, C., Troy, G.C. (1996) Deep mycotic infections in cats. *J. Am. Anim. Hosp. Assoc.*, **32** (5), 380–391.
- 6 Brömel, C., Sykes, J.E. (2005) Histoplasmosis in dogs and cats. *Clin. Tech. Small Anim. Pract.*, **20** (4), 227–232.
- 7 Crothers, S.L., White, S.D., Ihrke, P.J., *et al.* (2009) Sporotrichosis: a retrospective evaluation of 23 cases seen in northern California (1987–2007). *Vet. Dermatol.*, **20** (4), 249–259.
- 8 Pereira, S.A., Passos, S.R., Silva, J.N., *et al.* (2010) Response to azolic antifungal agents for treating feline sporotrichosis. *Vet. Rec.*, **166** (10), 290–294.
- 9 Schubach, T.M., Schubach, A., Okamoto, T., *et al.* (2006) Canine sporotrichosis in Rio de Janeiro, Brazil: clinical presentation, laboratory diagnosis and therapeutic response in 44 cases (1998–2003). *Med. Mycol.*, **44** (1), 87–92.
- 10 Logan, M.R., Raskin, R.E., Thompson, S. (2006) 'Carry-on' dermal baggage: a nodule from a dog.

- Pyogranulomatous inflammation with intralesional fungal agents. *Vet. Clin. Pathol.*, **35** (3), 329–331.
- 11 Rudmann, D.G., Coolman, B.R., Perez, C.M., *et al.* (1992) Evaluation of risk factors for blastomycosis in dogs: 857 cases (1980–1990). *J. Am. Vet. Med. Assoc.*, **201** (11), 1754–1759.
 - 12 Legendre, A.M., Rohrbach, B.W., Toal, R.L., *et al.* (1996) Treatment of blastomycosis with itraconazole in 112 dogs. *J. Vet. Intern. Med.*, **10** (6), 365–371.
 - 13 Legendre, A.M., Selcer, B.A., Edwards, D.F., *et al.* (1984) Treatment of canine blastomycosis with amphotericin B and ketoconazole. *J. Am. Vet. Med. Assoc.*, **184** (10), 1249–1254.
 - 14 Cheng, S.C., Joosten, L.A., Kullberg, B.J., *et al.* (2012) Interplay between *Candida albicans* and the mammalian innate host defense. *Infect. Immun.*, **80** (4), 1304–1313.
 - 15 Pressler, B.M., Vaden, S.L., Lane, I.F., *et al.* (2003) *Candida* spp. urinary tract infections in 13 dogs and seven cats: predisposing factors, treatment, and outcome. *J. Am. Anim. Hosp. Assoc.*, **39** (3), 263–270.
 - 16 Lobetti, R.G., Leisewitz, A.L., Spencer, J.A. (1996) *Pneumocystis carinii* in the miniature dachshund: case report and literature review. *J. Small Anim. Pract.*, **37** (6), 280–285.
 - 17 Watson, P.J., Wotton, P., Eastwood, J., *et al.* (2006) Immunoglobulin deficiency in Cavalier King Charles Spaniels with *Pneumocystis pneumonia*. *J. Vet. Intern. Med.*, **20** (3), 523–527.
 - 18 Mandigers, P.J., Duijvestijn, M.B., Ankringa, N., *et al.* (2014) The clinical significance of *Cynicomyces guttulatus* in dogs with chronic diarrhoea, a survey and a prospective treatment study. *Vet. Microbiol.*, **172** (1–2), 241–247.
 - 19 Schultz, R.M., Johnson, E.G., Wisner, E.R., *et al.* (2008) Clinicopathologic and diagnostic imaging characteristics of systemic aspergillosis in 30 dogs. *J. Vet. Intern. Med.*, **22** (4), 851–859.
 - 20 Berryessa, N.A., Marks, S.L., Pesavento, P.A., *et al.* (2008) Gastrointestinal pythiosis in 10 dogs from California. *J. Vet. Intern. Med.*, **22** (4), 1065–1069.
 - 21 Stenner, V.J., Mackay, B., King, T., *et al.* (2007) Protothecosis in 17 Australian dogs and a review of the canine literature. *Med. Mycol.*, **45** (3), 249–266.
 - 22 Hill, S.A., Sharkey, L.C., Hardy, R.M., *et al.* (2010) Nasal rhinosporidiosis in two dogs native to the upper Mississippi river valley region. *J. Am. Anim. Hosp. Assoc.*, **46** (2), 127–131.
 - 23 Caniatti, M., Roccabianca, P., Scanziani, E., *et al.* (1998) Nasal rhinosporidiosis in dogs: four cases from Europe and a review of the literature. *Vet. Rec.*, **142** (13), 334–338.
 - 24 Davidson, M.G., Rottman, J.B., English, R.V., *et al.* (1993) Feline immunodeficiency virus predisposes cats to acute generalized toxoplasmosis. *Am. J. Pathol.*, **143** (5), 1486–1497.
 - 25 Singh, M., Foster, D.J., Child, G., *et al.* (2005) Inflammatory cerebrospinal fluid analysis in cats: clinical diagnosis and outcome. *J. Feline Med. Surg.*, **7** (2), 77–93.
 - 26 Torres, M., Bardagi, M., Roura, X., *et al.* (2011) Long term follow-up of dogs diagnosed with leishmaniasis (clinical stage II) and treated with meglumine antimoniate and allopurinol. *Vet. J.*, **188** (3), 346–351.
 - 27 Roura, X., Fondati, A., Lubas, G., *et al.* (2013) Prognosis and monitoring of leishmaniasis in dogs: a working group report. *Vet. J.*, **198** (1), 43–47.
 - 28 Cohn, L.A., Birkenheuer, A.J., Brunner, J.D., *et al.* (2011) Efficacy of atovaquone and azithromycin or imidocarb dipropionate in cats with acute cytauxzoonosis. *J. Vet. Intern. Med.*, **25** (1), 55–60.
 - 29 Bouzid, M., Halai, K., Jeffreys, D., *et al.* (2015) The prevalence of *Giardia* infection in dogs and cats, a systematic review and meta-analysis of prevalence studies from stool samples. *Vet. Parasitol.*, **207** (3–4), 181–202.
 - 30 Foster, D.M., Gookin, J.L., Poore, M.F., *et al.* (2004) Outcome of cats with diarrhea and *Tritrichomonas foetus* infection. *J. Am. Vet. Med. Assoc.*, **225** (6), 888–892.
 - 31 Monticello, T.M., Levy, M.G., Bunch, S.E., *et al.* (1987) Cryptosporidiosis in a feline leukemia virus-positive cat. *J. Am. Vet. Med. Assoc.*, **191** (6), 705–706.
 - 32 Vincent-Johnson, N.A., Macintire, D.K., Lindsay, D.S., *et al.* (1997) A new Hepatozoon species from dogs: description of the causative agent of canine hepatozoonosis in North America. *J. Parasitol.*, **83** (6), 1165–1172.
 - 33 Baneth, G. (2011) Perspectives on canine and feline hepatozoonosis. *Vet. Parasitol.*, **181** (1), 3–11.
 - 34 Marchetti, V., Lubas, G., Baneth, G., *et al.* (2009) Hepatozoonosis in a dog with skeletal involvement and meningoencephalomyelitis. *Vet. Clin. Pathol.*, **38** (1), 121–125.
 - 35 Macintire, D.K., Vincent-Johnson, N.A., Kane, C.W., *et al.* (2001) Treatment of dogs infected with *Hepatozoon americanum*: 53 cases (1989–1998). *J. Am. Vet. Med. Assoc.*, **218** (1), 77–82.
 - 36 Macintire, D.K., Vincent-Johnson, N.A., Dillon, A.R., *et al.* (1997) Hepatozoonosis in dogs: 22 cases (1989–1994). *J. Am. Vet. Med. Assoc.*, **210** (7), 916–922.
 - 37 Patten, P.K., Rich, L.J., Zaks, K., *et al.* (2013) Cestode infection in 2 dogs: cytologic findings in liver and a mesenteric lymph node. *Vet. Clin. Pathol.*, **42** (1), 103–108.
 - 38 Boyce, W., Shender, L., Schultz, L., *et al.* (2011) Survival analysis of dogs diagnosed with canine peritoneal larval cestodiasis (*Mesocestoides* spp.). *Vet. Parasitol.*, **180** (3–4), 256–261.

- 39 Genta, R.M., Schad, G.A. (1984) *Filaroides hirthi*: hyperinfective lungworm infection in immunosuppressed dogs. *Vet. Pathol.*, **21** (3), 349–354.
- 40 Traversa, D., Di Cesare, A. (2016) Diagnosis and management of lungworm infections in cats: Cornerstones, dilemmas and new avenues. *J. Feline Med. Surg.*, **18** (1), 7–20.
- 41 Langlais, L. (2003) Dracunculosis in a German shepherd dog. *Can. Vet. J.*, **44** (8), 682.
- 42 Saini, N., Ranjan, R., Singla, L.D., *et al.* (2012) Successful treatment of pulmonary paragonimiasis in a German shepherd dog with fenbendazole. *J. Parasit. Dis.*, **36** (2), 171–174.
- 43 Pechman, R.D., Jr (1980) Pulmonary paragonimiasis in dogs and cats: a review. *J. Small Anim. Pract.*, **21** (2), 87–95.
- 44 Hardie, E.M., Barsanti, J.A. (1982) Treatment of canine actinomycosis. *J. Am. Vet. Med. Assoc.*, **180** (5), 537–541.
- 45 Kirpensteijn, J., Fingland, R.B. (1992) Cutaneous actinomycosis and nocardiosis in dogs: 48 cases (1980–1990). *J. Am. Vet. Med. Assoc.*, **201** (6), 917–920.
- 46 Malik, R., Krockenberger, M.B., O'Brien, C.R., *et al.* (2006) *Nocardia* infections in cats: a retrospective multi-institutional study of 17 cases. *Aust. Vet. J.*, **84** (7), 235–245.
- 47 Marino, D.J., Jaggy, A. (1993) Nocardiosis. A literature review with selected case reports in two dogs. *J. Vet. Intern. Med.*, **7** (1), 4–11.
- 48 Canonne, A.M., Billen, F., Tual, C., *et al.* (2016) Quantitative PCR and cytology of bronchoalveolar lavage fluid in dogs with *Bordetella bronchiseptica* infection. *J. Vet. Intern. Med.*, **30** (4), 1204–1209.
- 49 Binns, S.H., Dawson, S., Speakman, A.J., *et al.* (1999) Prevalence and risk factors for feline *Bordetella bronchiseptica* infection. *Vet. Rec.*, **144** (21), 575–580.
- 50 Egberink, H., Addie, D., Belák, S., *et al.* (2009) *Bordetella bronchiseptica* infection in cats. ABCD guidelines on prevention and management. *J. Feline Med. Surg.*, **11** (7), 610–614.
- 51 Allison, R.W., Little, S.E. (2013) Diagnosis of rickettsial diseases in dogs and cats. *Vet. Clin. Pathol.*, **42** (2), 127–144.
- 52 Marks, S.L., Rankin, S.C., Byrne, B.A., *et al.* (2011) Enteropathogenic bacteria in dogs and cats: diagnosis, epidemiology, treatment, and control. *J. Vet. Intern. Med.*, **25** (6), 1195–1208.
- 53 Handt, L.K., Fox, J.G., Dewhirst, F.E., *et al.* (1994) *Helicobacter pylori* isolated from the domestic cat: public health implications. *Infect. Immun.*, **62** (6), 2367–2374.
- 54 Van den Bulck, K., Decostere, A., Baele, M., *et al.* (2005) Identification of non-*Helicobacter pylori* spiral organisms in gastric samples from humans, dogs, and cats. *J. Clin. Microbiol.*, **43** (5), 2256–2260.
- 55 Lecoindre, P., Chevallier, M., Peyrol, S., *et al.* (2000) Gastric helicobacters in cats. *J. Feline Med. Surg.*, **2** (1), 19–27.
- 56 Anacleto, T.P., Lopes, L.R., Andreollo, N.A., *et al.* (2011) Studies of distribution and recurrence of *Helicobacter* spp. gastric mucosa of dogs after triple therapy. *Acta Cir. Bras.*, **26** (2), 82–87.
- 57 Sood, N.K., Mekhib, B., Singla, L.D., *et al.* (2012) Cytopathology of parasitic dermatitis in dogs. *J. Parasit. Dis.*, **36** (1), 73–77.

3

Integument

3.1 Cutaneous and Subcutaneous Lesions

3.1.1 Mast Cell Tumor: Dog

3.1.1.1 Cytologic Features

Mast cell tumors are characterized by individualized cells that usually contain abundant purple/metachromatic granules. They frequently are accompanied by ribbons of collagen (Figure 3.1), fibroplasia (Figure 3.2), and eosinophilic inflammation (Figure 3.3). Cytologic criteria associated with a high tumor grade include poorly granulated/agranular cells, mitotic figures, multinucleation, anisokaryosis, and nuclear pleomorphism [1] (Figures 3.3 and 3.4). Note that granules stain variably well with aqueous Romanowsky stains (e.g., Diff-Quik®) (Figure 3.5) [2]. Agranular or poorly staining mast cell tumors can be difficult to differentiate from histiocytomas or transmissible venereal tumors (compare to Figures 3.9 and 3.17).

3.1.1.2 Clinical Considerations

- Most are solitary, dermal or subcutaneous, and occur on the trunk, perineum or limbs.
- Primarily seen in older dogs (8–10 years), but can be present in young dogs [3].
- Seen in a diverse range of breeds. Some predisposed breeds include dogs of Bulldog descent (including Boxers and Pugs), Golden Retrievers, and Weimaraners.

3.1.1.3 Prognosis

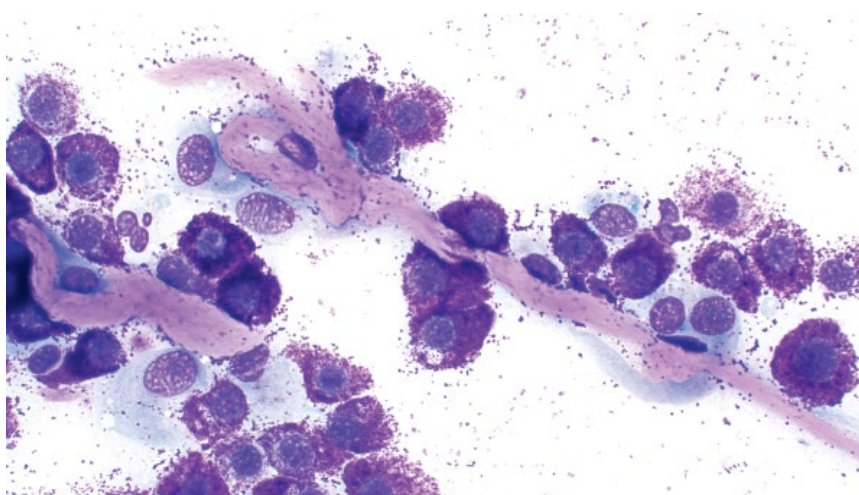
Highly variable based on numerous factors such as histologic tumor grade (considered most important), clinical stage, location, and cell proliferation rate [4, 5]. Surgical excision with wide margins can be curative.

3.1.2 Mast Cell Tumor: Cat

3.1.2.1 Cytologic Features

Mast cell tumors from cats comprise individualized cells, though they frequently exfoliate in crowded sheets.

Figure 3.1 Mast cell tumor, dog, 40× objective. Note the linear ribbons of bright pink collagen.



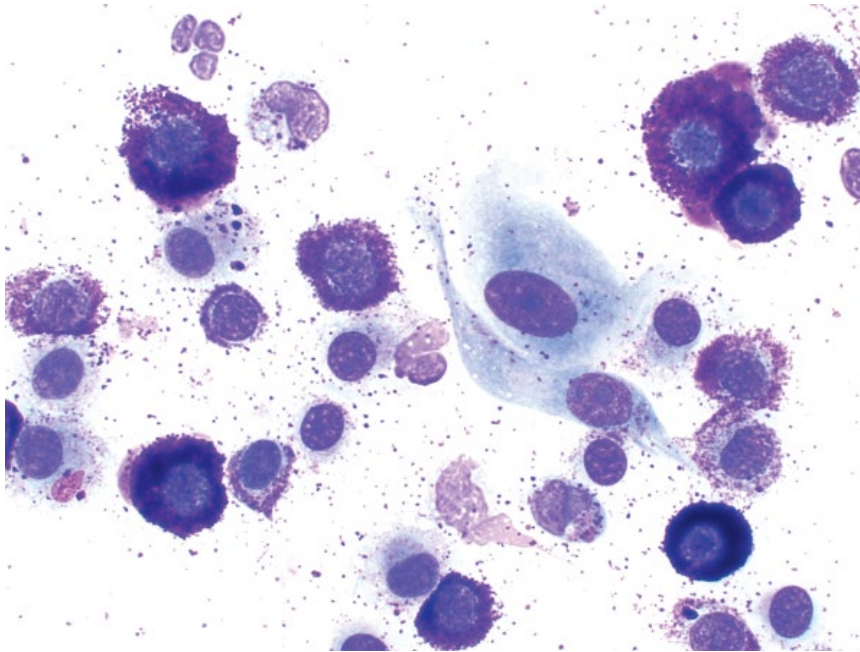


Figure 3.2 Mast cell tumor, dog, 50× objective. Two reactive fibroblasts (center/right) are present.

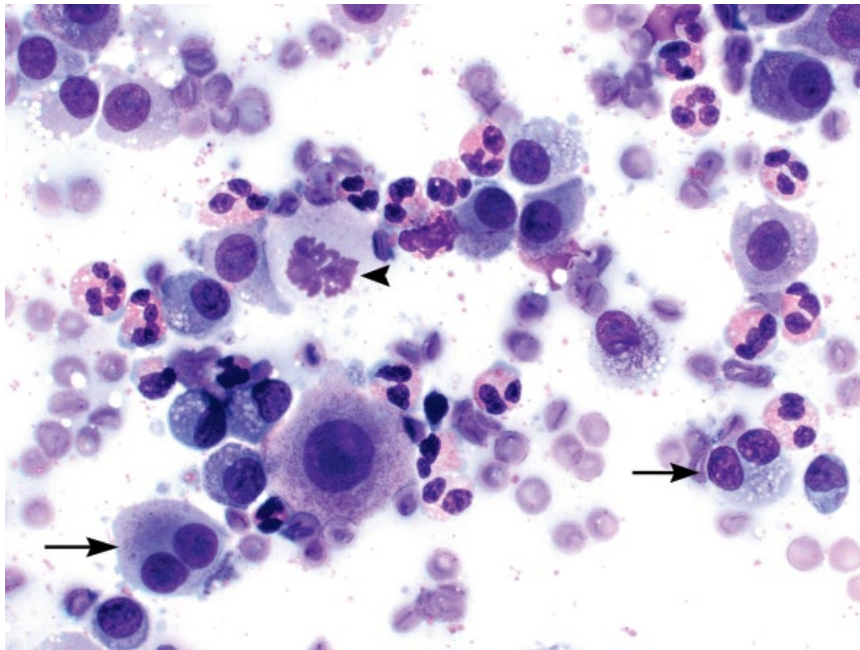


Figure 3.3 Mast cell tumor (grade III, high grade), dog, 50× objective. Note the many eosinophils in the background, binucleation (arrows) and mitotic figure (arrowhead).

They are variably granular, often more subtly so than canine mast cell tumors (Figure 3.6). The cells tend to be uniform in appearance. Similar to dog mast cell tumors, the granules stain variably well with aqueous Romanowsky stains (e.g., Diff Quik®) (Figure 3.7). Skin tumors may rarely represent part of an aggressive, malignant process, and in such cases typically are poorly

granulated, and have high N/C ratios, mitotic figures and increased anisocytosis/anisokaryosis (Figure 3.8).

3.1.2.2 Clinical Considerations

- Mostly single, though may be multiple, raised, hairless dermal nodules, common around the head and neck.
- Solitary tumors typically are benign.

Figure 3.4 Mast cell tumor, dog, 50× objective. Note the variable granulation of the cells and occasional binucleation.

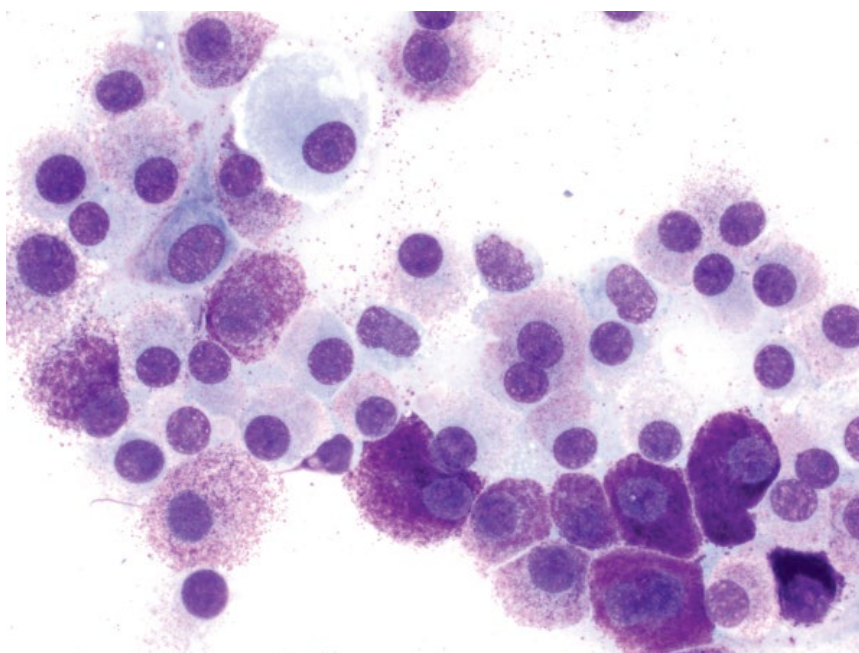
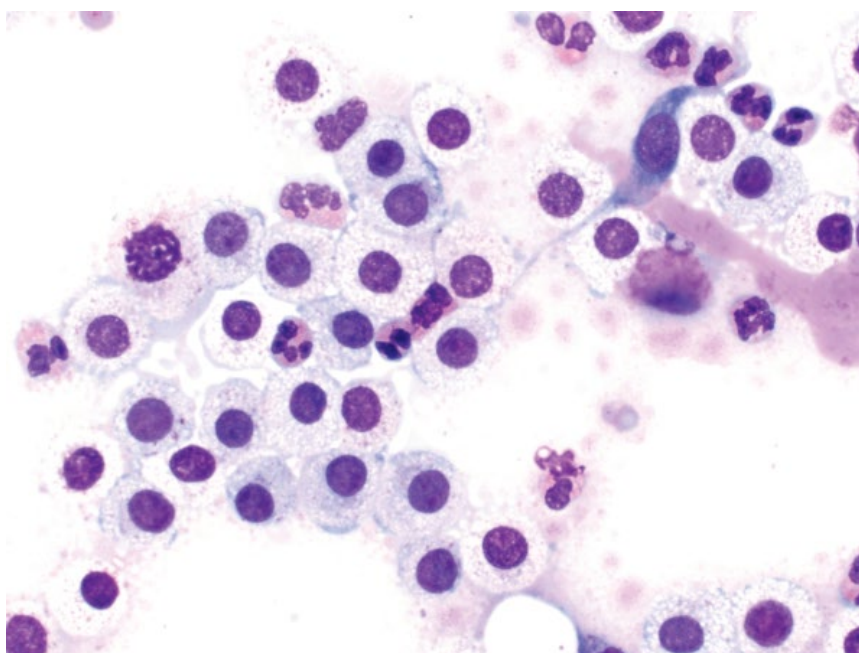


Figure 3.5 Mast cell tumor, dog, 50× objective, Diff Quik® stain. Although granules stain poorly, the cells are uniform and minimally pleomorphic.



- Multiple nodules may be associated with visceral mast cell disease, and evaluation of the spleen/gastrointestinal tract may be warranted [6].

3.1.2.3 Prognosis

The prognosis for solitary lesions with no evidence of metastasis is excellent, with surgical excision generally curative, and low rates of recurrence [7]. Histologic

tumor grading systems used in dogs have no effect on prognosis, though an increased mitotic index may [8].

3.1.3 Histiocytoma

3.1.3.1 Cytologic Features

Histiocytomas are characterized by a uniform population of individualized cells that may be pushed together into aggregates. The cells have a moderate volume of

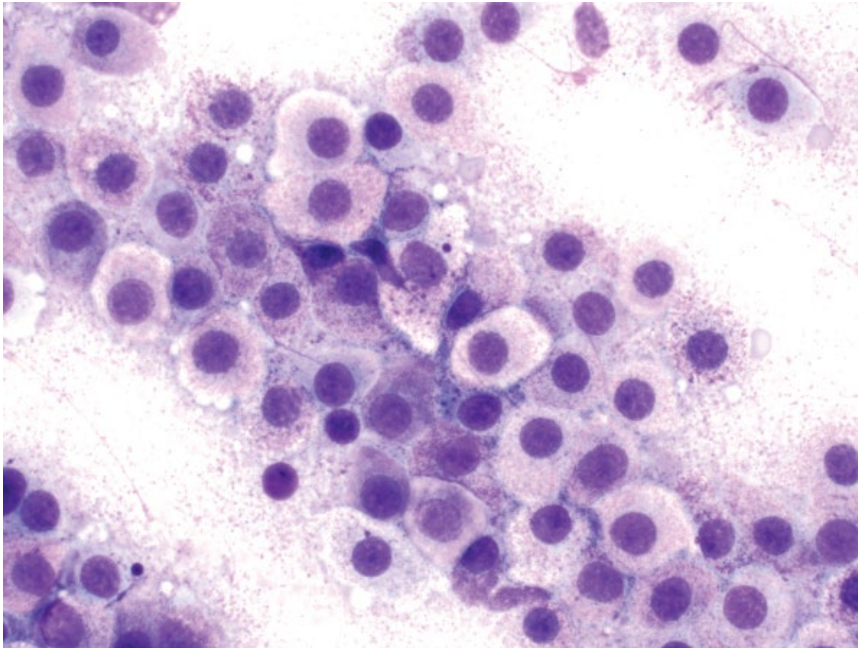


Figure 3.6 Mast cell tumor, cat, 50x objective.

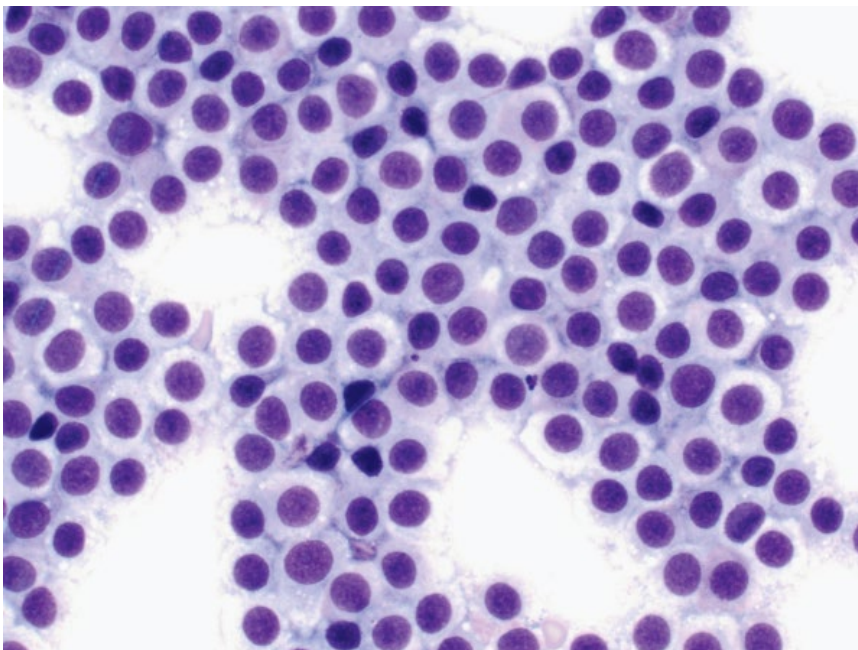


Figure 3.7 Mast cell tumor, cat, 50x objective, Diff Quik® stain. Granules stain poorly.

watery-blue cytoplasm. Nuclei are round and have finely granular chromatin with multiple small nucleoli (Figure 3.9). Small mature lymphocytes and plasma cells are seen in regressing histiocytomas, and may be the predominant cell types (Figure 3.10).

3.1.3.2 Clinical Considerations

- Occur at any age, but most dogs are aged <3 years (reported from 2 months to 12 years in one study) [9].
- Usually solitary lesions around the head (particularly pinnae) and limbs.

Figure 3.8 Mast cell tumor, cat, 50× objective. Samples from this aggressive tumor contain cells that are poorly granular and have high N/C ratios. Note the mitotic figure.

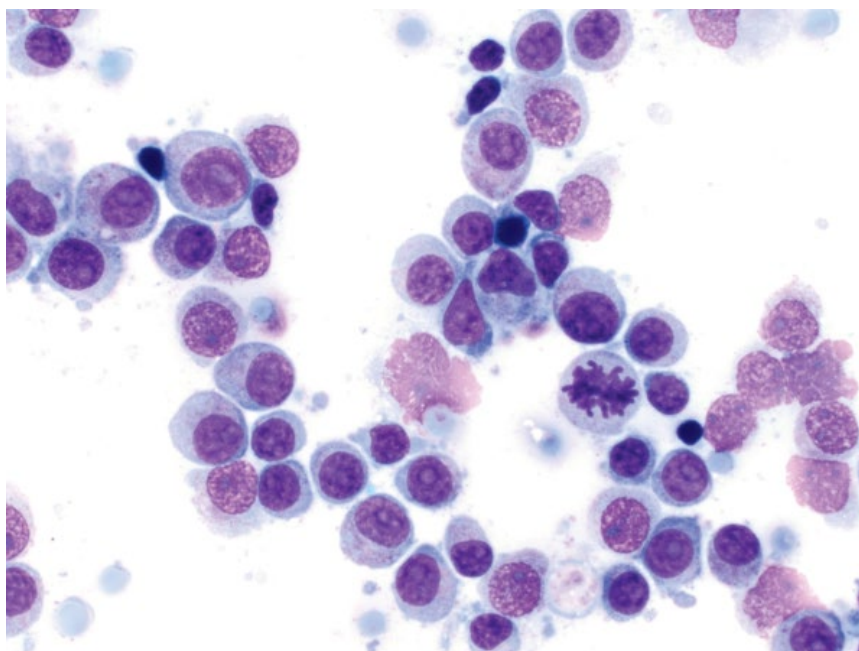
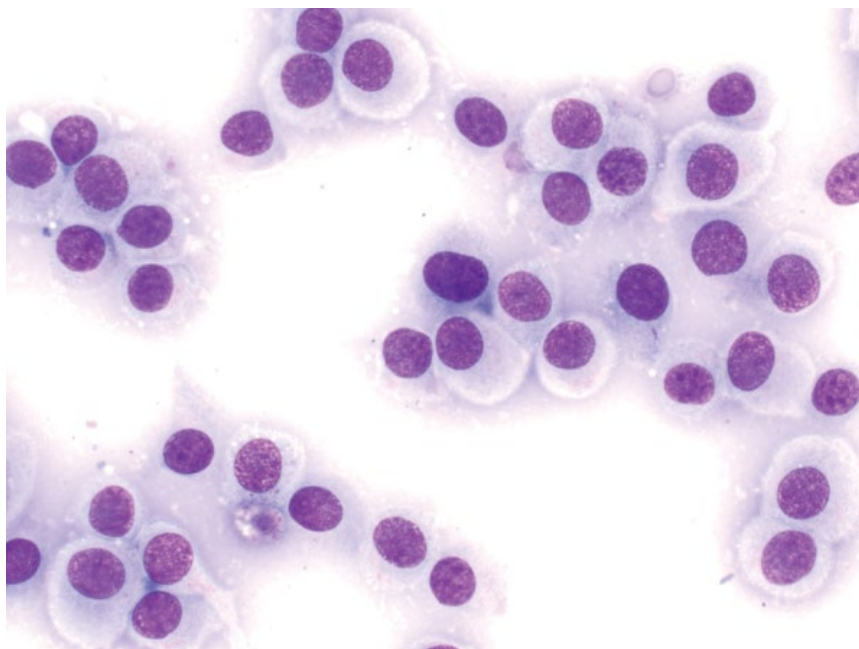


Figure 3.9 Histiocytoma, dog, 50× objective. Note the abundant watery blue cytoplasm.



- Most spontaneously regress within 1–2 months. Ulceration is common.
- Surgical excision generally curative.

3.1.3.3 Prognosis

Excellent.

3.1.4 Histiocytic Sarcoma

3.1.4.1 Cytologic Features

Histiocytic sarcoma (HS) is characterized by individualized cells with many criteria of malignancy, including marked anisocytosis and anisokaryosis, with karyomegaly a common finding. Multinucleation, nuclear fragmentation

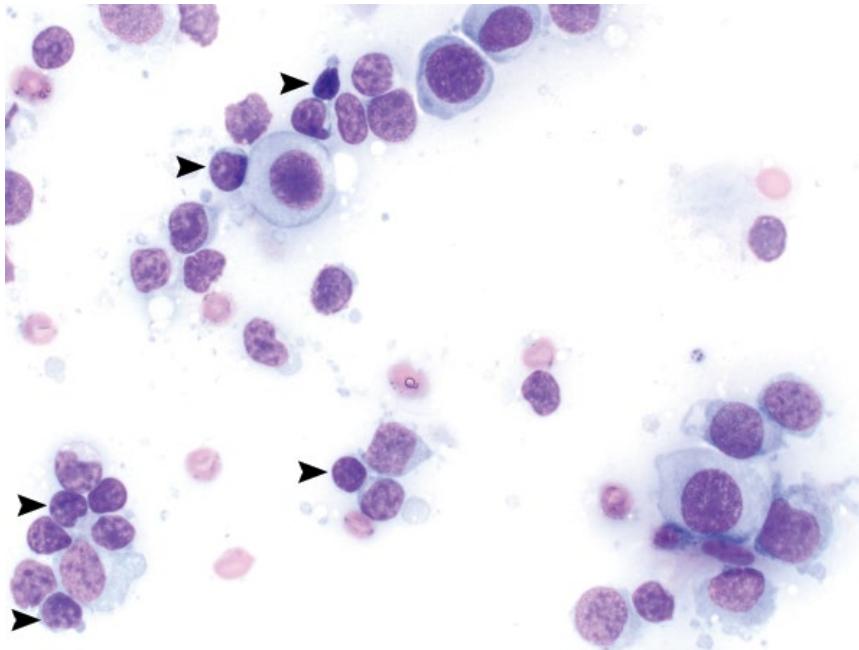


Figure 3.10 Regressing histiocytoma, dog, 50× objective. Note the many small mature lymphocytes (arrowheads).

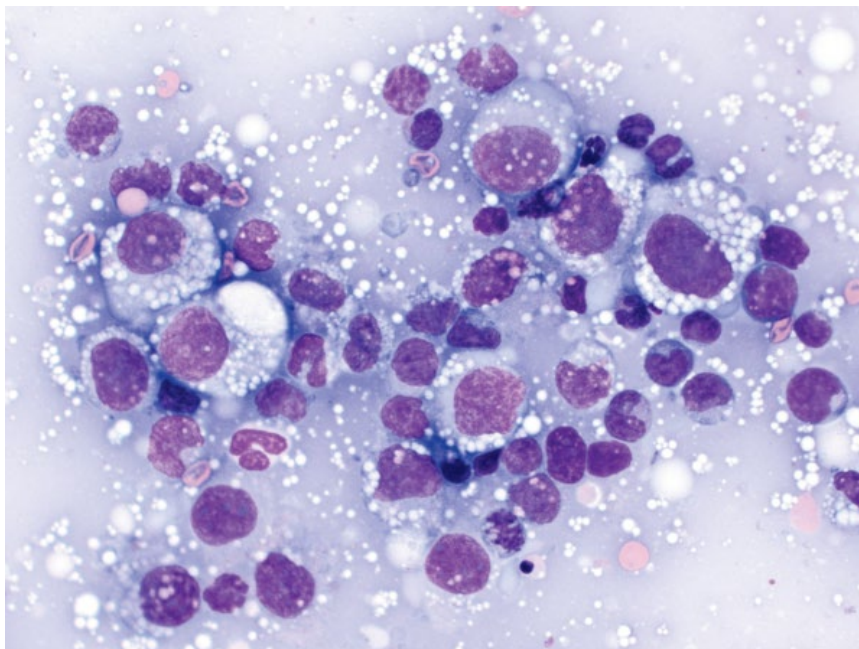


Figure 3.11 Histiocytic sarcoma, dog, 50× objective.

and hyperchromasia also are common (Figure 3.11). The cytoplasm usually is vacuolated.

3.1.4.2 Clinical Considerations

- Dogs >> cats
- Disease may be localized to a single organ, or generalized.
- Reported in many dog breeds, but Bernese Mountain Dogs, Rottweilers, Golden Retrievers,

Labrador Retrievers and Flat-Coated Retrievers predisposed [10].

- Organs commonly affected by disseminated HS = spleen, liver, lung, bone marrow, lymph nodes.

3.1.4.3 Prognosis

Dependent on whether localized or generalized. Prognosis for disseminated HS is grave. Localized HS

Figure 3.12 Cutaneous lymphoma, dog, 50x objective. Note the high N/C ratios and monomorphism of the population. A mitotic figure is seen (center).

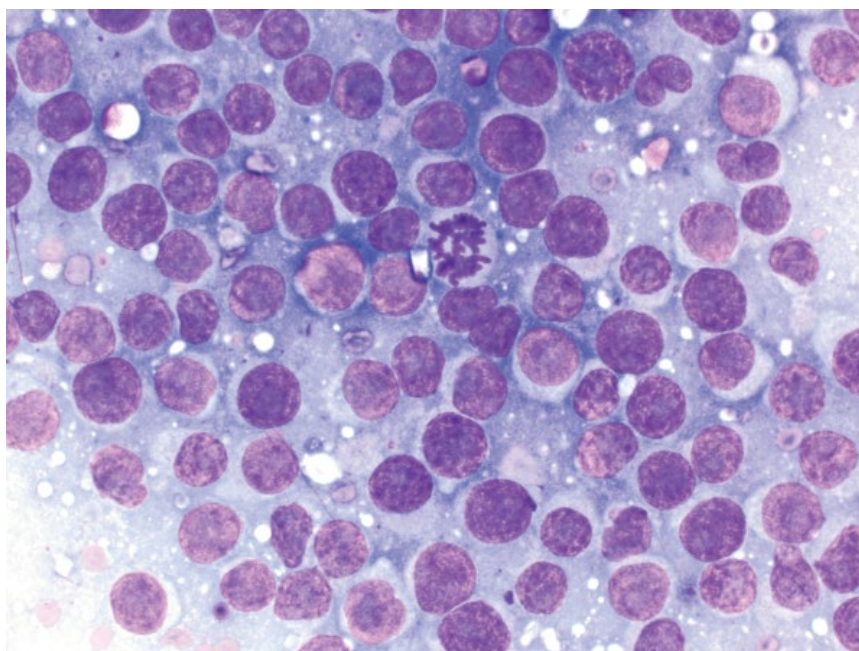
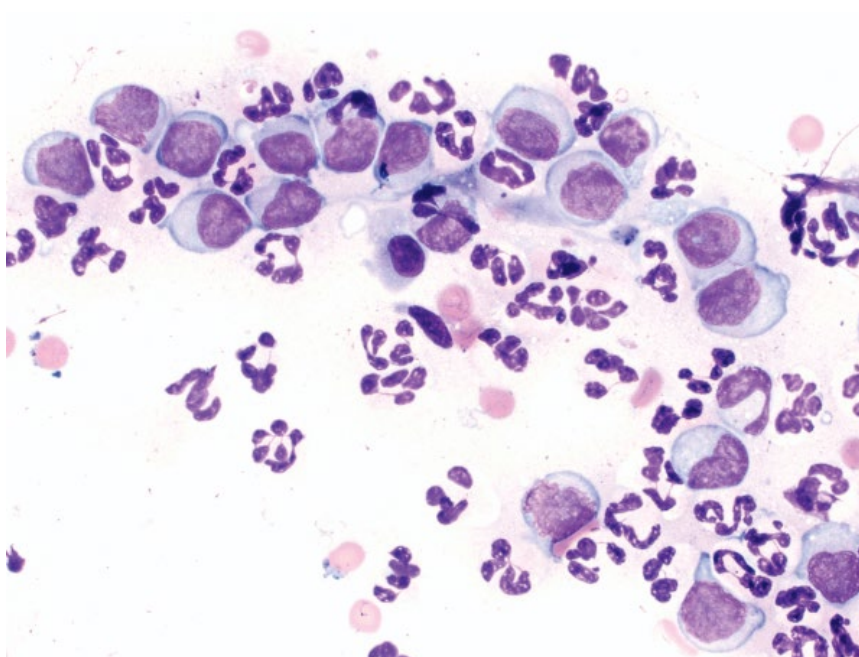


Figure 3.13 Cutaneous lymphoma, dog, 50x objective. Large, neoplastic lymphocytes are accompanied by many neutrophils.



and periarticular location (see Chapter 6) are associated with a better prognosis [11].

3.1.5 Cutaneous Lymphoma

3.1.5.1 Cytologic Features

Lymphocytes in these cases are monomorphic and large, with round nuclei that have finely stippled, immature chromatin and variably prominent nucleoli (Figure 3.12). The cells have a small to moderate volume of pale-blue cytoplasm that may contain a perinuclear packet of pink

granules, compared to diffuse granules in mast cells. Cutaneous lymphomas frequently are associated with concurrent inflammation, which may predominate and obscure the neoplastic cells (Figure 3.13).

3.1.5.2 Clinical Considerations

- Generally middle-aged to older dogs and cats.
- Epitheliotropic and non-epitheliotropic forms exist and most have a T-cell phenotype.
- May be solitary or generalized. The non-epitheliotropic form usually presents as solitary or multiple nodules,

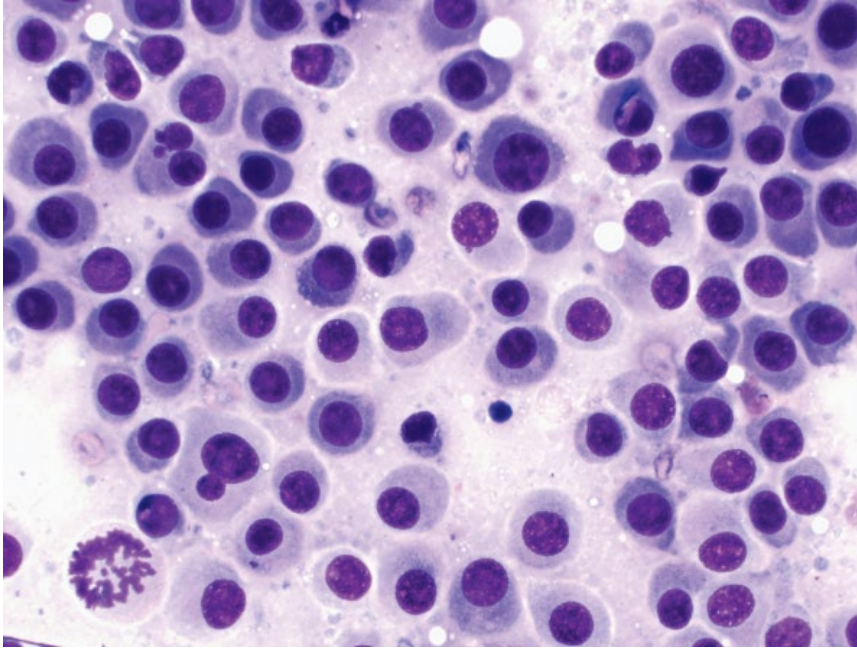


Figure 3.14 Plasmacytoma, dog, 50× objective. Note the perinuclear clearing, nuclear pleomorphism and mitotic figure (lower left).

while the epitheliotropic form progresses from alopecia or erythema in the early stages, to plaques or masses in later stages.

- Feline cutaneous lymphoma is not associated with FeLV or FIV status [12].

3.1.5.3 Prognosis

Dogs = poor to grave for diffuse cutaneous forms. Indolent, T-cell cutaneous lymphomas are rare, but carry a better prognosis [13].

Cats = more variable than in dogs, with some indolent forms that are slowly progressive [12].

3.1.6 Plasmacytoma

3.1.6.1 Cytologic Features

Plasmacytomas contain discrete cells with distinct cell borders, though they may be pushed together into aggregates. The cytologic appearance of plasmacytomas can vary greatly. Cells mostly have a small to moderate volume of mid-blue cytoplasm that frequently has a pale, perinuclear clearing (Golgi zone) (Figure 3.14). The cells may have a bright pink, peripheralized border due to the production of immunoglobulins (flame cells) (Figure 3.15). Nuclei are eccentrically placed, with regularly clumped chromatin. Binucleation and multinucleation are common (Figure 3.16). Anisocytosis and anisokaryosis mostly are mild to moderate, but can be marked, and are not associated with biologic behavior.

3.1.6.2 Clinical Considerations

- Middle-aged to older dogs. Rare in cats.
- Most are solitary, raised, pink/red, smooth nodules, commonly seen on the limbs (especially digits) and head (especially margins of the lips and ears) [14].

3.1.6.3 Prognosis

Solitary cutaneous plasmacytomas mostly are benign neoplasms and have an excellent prognosis, with surgical excision generally curative, and low rates of recurrence. Metastatic spread or a manifestation of multiple myeloma is rare [14].

3.1.7 Transmissible Venereal Tumor (TVT)

3.1.7.1 Cytologic Features

TVT is characterized by a monomorphic population of large, round cells that have a moderate volume of pale-blue cytoplasm. The cytoplasm of many cells contains characteristic, coarse, clear vacuoles (Figure 3.17). Nuclei are round, with reticulated/ropey chromatin and prominent, mostly single, basophilic nucleoli. Mitotic figures are common. TVT can appear similar to lymphoma or histiocytomas; however, the cytoplasmic vacuoles, chromatin pattern and prominent nucleoli of TVT cells are helpful to differentiate these lesions.

3.1.7.2 Clinical Considerations

- Thought to be of histiocytic origin [15].
- Lesions are nodular to multilobulated with an erythemic, ulcerated surface.
- External genitalia most commonly affected, but lesions may be found around the nose, oral cavity, and eyes.
- Usually localized, but can spread to local lymph nodes (see Chapter 4) and other locations.

3.1.7.3 Prognosis

Excellent. TVT may spontaneously regress in some dogs over a period of 3–6 months. Those that require treatment still carry an excellent prognosis.

Figure 3.15 Plasmacytoma, dog, 50× objective. Note the peripheralized pink coloration of the cytoplasm.

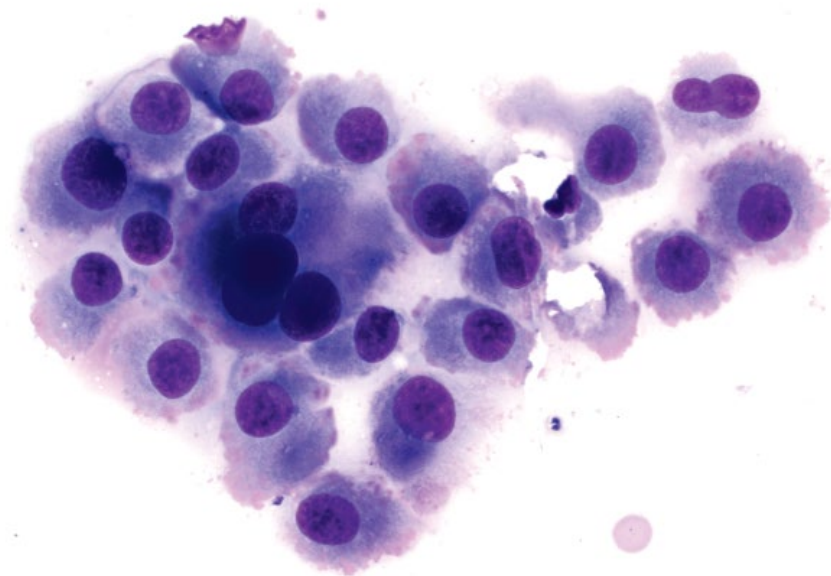
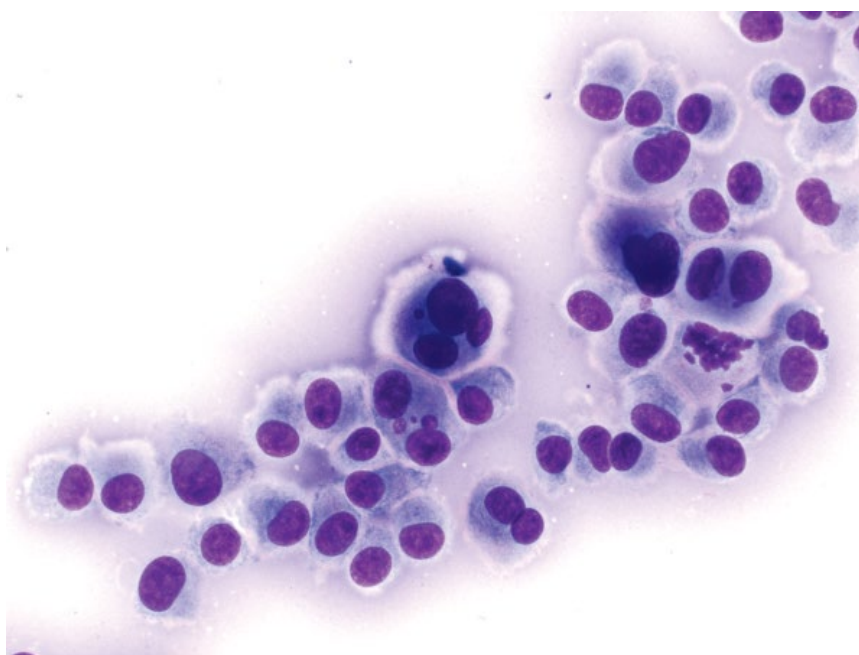


Figure 3.16 Plasmacytoma, dog, 50× objective. Note the binucleation and multinucleation.



3.1.8 Melanomas

The cytologic appearance and biologic behavior of melanomas are highly variable. The anatomic site, stage, and certain histologic findings may all affect outcome [16]. The following sections describe benign (melanocytomas) and malignant melanomas separately (as defined by the World Health Organization nomenclature) [17] as the two distinct, and usually distinguishable, ends of a continuous spectrum. It is imperative however to

correlate findings with clinical staging and histopathologic evaluation.

3.1.9 Benign Melanoma (Melanocytoma)

3.1.9.1 Cytologic Features

Melanocytomas often are highly cellular and comprise aggregates of round to spindloid melanocytes. They have a moderate volume of cytoplasm containing a variable amount (often abundant) of green/black melanin pigment

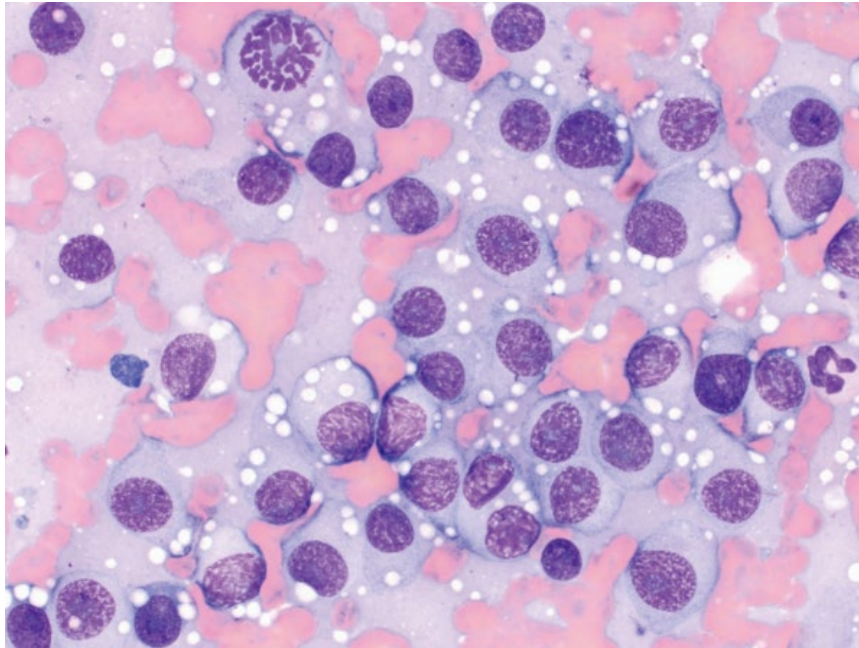


Figure 3.17 Transmissible venereal tumor, dog, 50× objective. Note the prominent clear vacuoles in the cytoplasm, and the mitotic figure (top left).

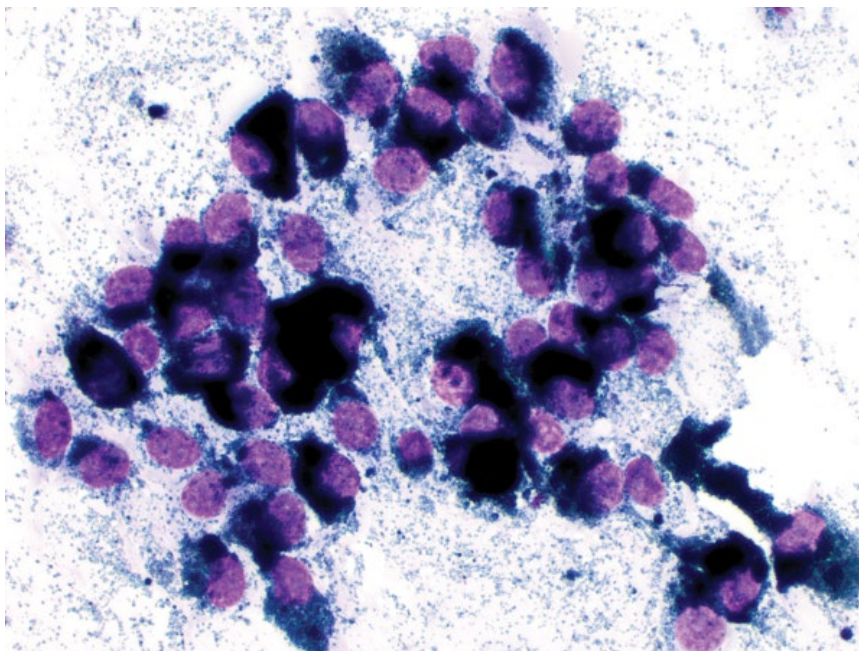


Figure 3.18 Melanocytoma, dog, 50× objective. Note the abundant green/black pigment in cells and in the background.

granules (Figure 3.18). Nuclei are ovoid with stippled chromatin and small basophilic nucleoli. Anisocytosis/anisokaryosis are mild, and N/C ratios are low.

3.1.9.2 Clinical Considerations

- Benign tumors in older dogs and cats.
- Usually cutaneous, well-circumscribed, pigmented/black, alopecic nodules found in haired skin around

the head, neck or trunk, and not in proximity to mucosal margins.

- Note: tumors of adnexal origin can be pigmented, and may be confused with melanocytomas/melanomas.

3.1.9.3 Prognosis

Mostly excellent, with surgical excision often curative. Cutaneous tumors generally have a good prognosis;

Figure 3.19 Malignant melanoma, dog, 50x objective. Cells are variably pigmented (see cells on left), and have prominent nucleoli and high N/C ratios. Note the mitotic figure (middle).

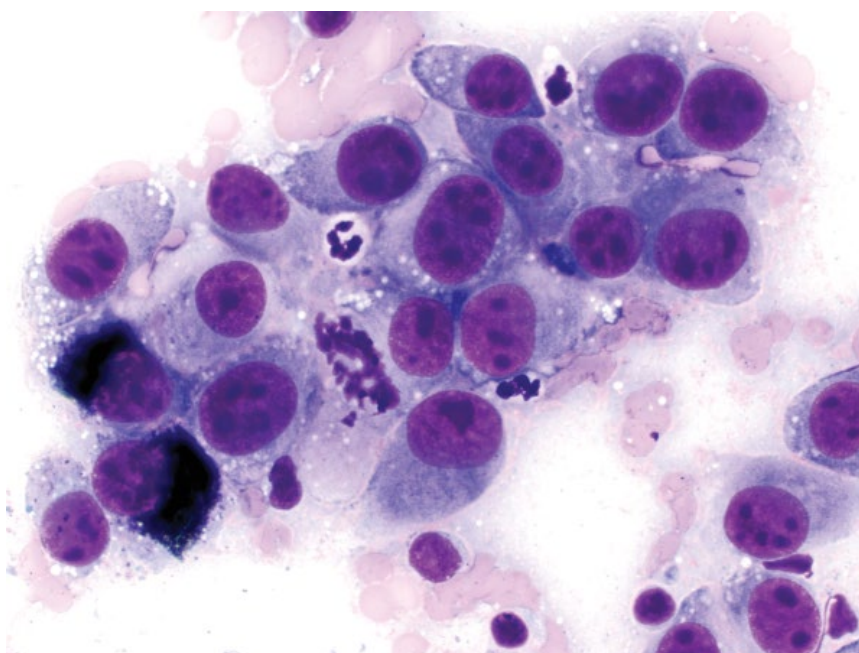
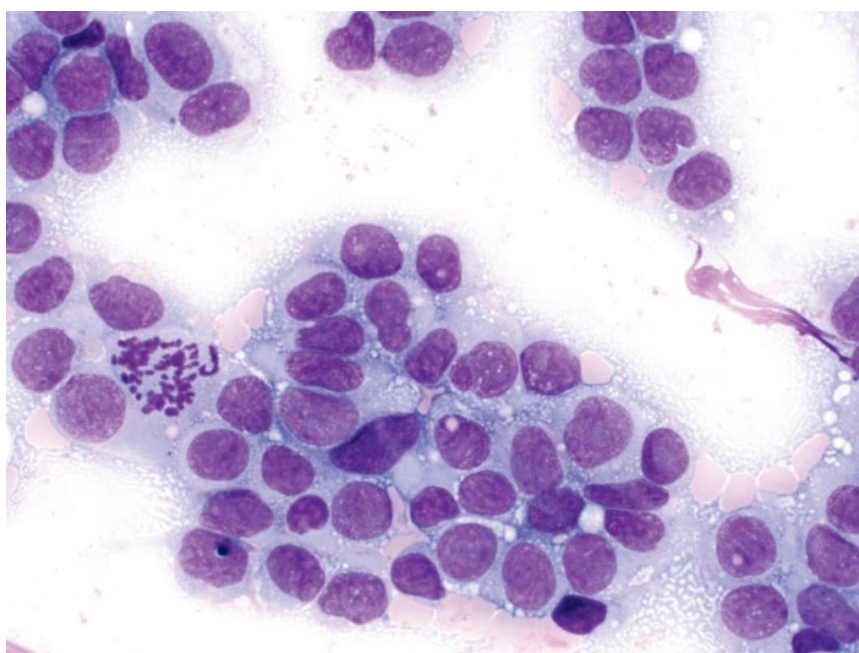


Figure 3.20 Malignant melanoma (poorly melanotic), dog, 50x objective. Note the bizarre mitotic figure on the left.



however, tumors on the lip or digit have a worse prognosis [16]. Highly pigmented tumors carry a favorable prognosis.

3.1.10 Malignant Melanoma

3.1.10.1 Cytologic Features

Malignant melanomas comprise a highly heterogeneous category, and can be difficult to diagnose via cytology, and

even histopathology, without specific stains. Many tumors will contain green/black melanin pigment granules (Figure 3.19), but some may lack melanin pigment (poorly melanotic melanoma; Figure 3.20). Cells may be round or spindloid, and arranged individually, in sheets or aggregates. In general, malignant melanomas have many criteria of malignancy, including marked anisocytosis/anisokaryosis, prominent basophilic nucleoli, and mitotic figures.

3.1.10.2 Clinical Considerations

- Seen mostly in older dogs and cats.
- Frequently larger than melanocytomas, and variably pigmented.
- Often found in and around the mouth, as well as the nail bed and feet [18].
- Evaluation of lymph nodes is strongly recommended, as metastatic disease may be present even in the absence of lymphadenomegaly [19].

3.1.10.3 Prognosis

Malignant melanomas often have a poor to grave prognosis, especially if distant metastatic disease is present [16]. Poorly pigmented tumors also confer a worse prognosis. Many histopathologic parameters (e.g., invasion, Ki67 index) may offer important prognostic information.

3.1.11 Infundibular/Epidermal Cysts**3.1.11.1 Cytologic Features**

Samples vary greatly in appearance but almost all contain many anucleated squamous epithelial cells and aggregates of keratinized debris (Figure 3.21). Cholesterol crystals are a frequent finding (see Figure 1.1). Other common cytologic features include mineralization (Figure 3.22), hair shaft fragments (Figure 3.23), and melanin pigment granules. If the cysts rupture and keratin leaks into the dermis, a pyogranulomatous inflammatory response may ensue (Figure 3.24).

3.1.11.2 Clinical Considerations

- Dogs and cats. Most common in middle-aged to older dogs.
- Grossly = variably firm, well-circumscribed, smooth masses, found mostly on the dorsum and extremities.
- Waxy or gritty, gray/tan material may express from lesions.
- Often solitary, but multiple masses may be present.
- Note: Similar cystic material may exfoliate from tumors of adnexal/hair follicular origin (see section 3.1.12).

3.1.11.3 Prognosis

Excellent. Surgical excision may be required to treat persistent inflammation from ruptured cysts and generally is curative.

3.1.12 Cutaneous Basilar Epithelial Neoplasia**3.1.12.1 Cytologic Features**

Samples are variably cellular, with tight sheets of uniform cuboidal epithelial cells, distributed in papillary arrangements. They may be associated with bright pink, smooth extracellular matrix (basement membrane) (Figure 3.25). The cells have a scant volume of medium-blue cytoplasm. Some tumors may contain melanin pigment. Nuclei are round and centrally located with small or inapparent nucleoli. Anisocytosis/anisokaryosis are mild and N/C ratios are high. Cystic material may predominate (see Infundibular/epidermal cysts).

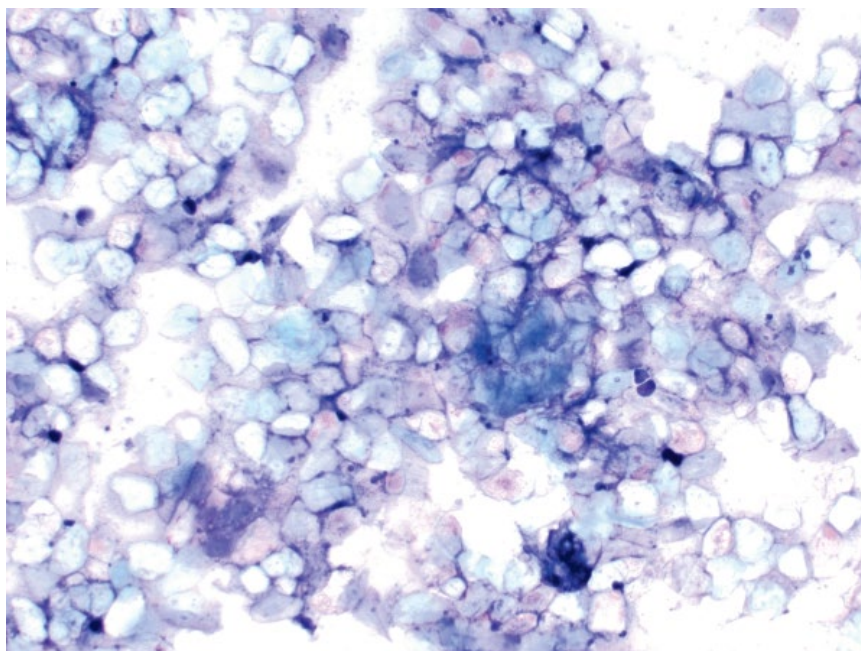
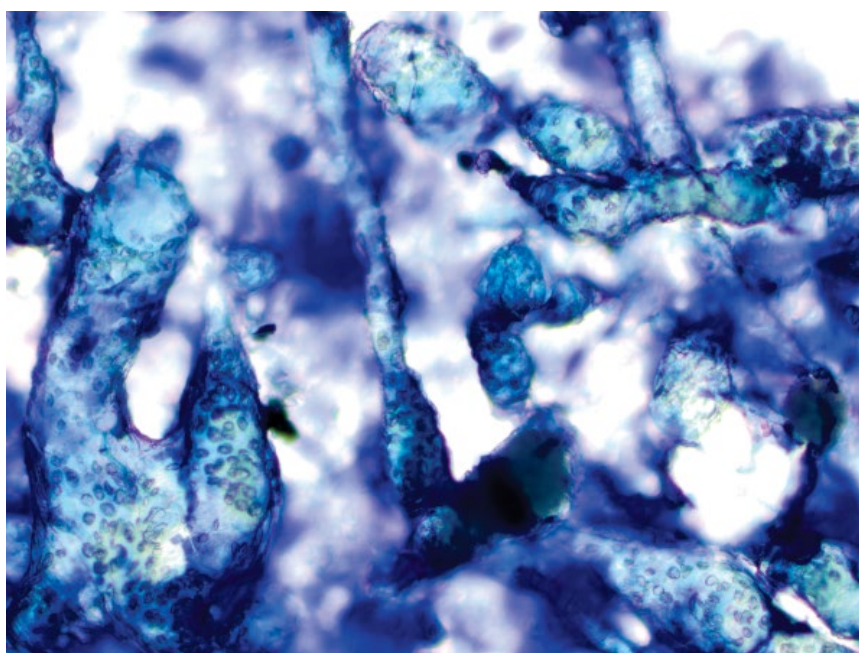


Figure 3.21 Infundibular/epidermal cyst, dog, 10× objective. Many anucleated squamous epithelial cells are seen.

Figure 3.22 Infundibular/epidermal cyst, dog, 20× objective. Keratinized debris is studded with aggregates of refractile, mineralized debris.

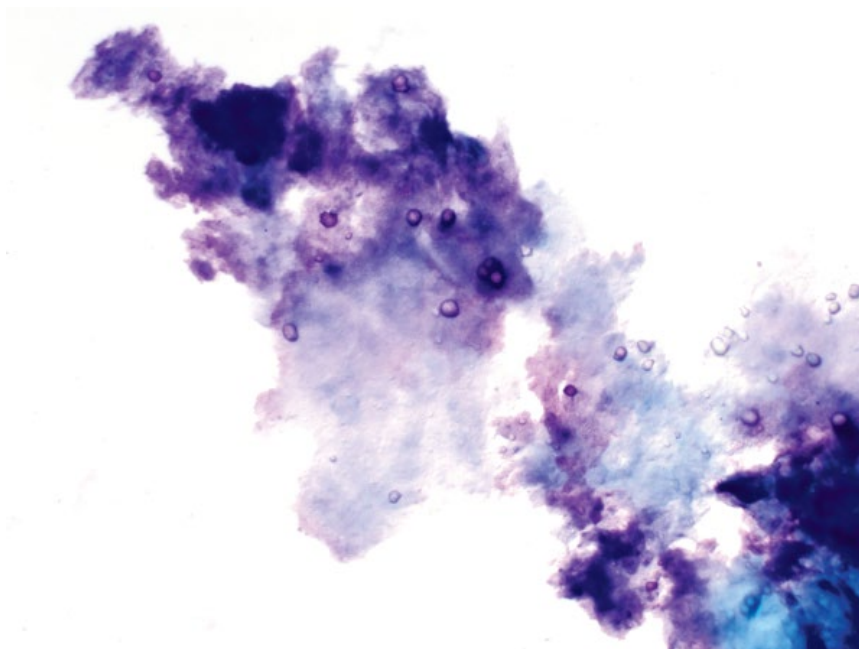

Figure 3.23 Pigmented hair shafts, dog, 20× objective. Note the different plane of focus from other material.



3.1.12.2 Clinical Considerations

- Large category of tumors arising from basal epithelial cells that differentiate toward epidermal, trichofollicular, or adnexal structures. These include trichoblastomas (most common), trichoepitheliomas, pilomatricomas, and many others. Histopathology is required for differentiation.

- Common around the head and neck in older dogs and cats [20].
- Usually solitary, firm, well-demarcated, hairless, variably pigmented masses.

3.1.12.3 Prognosis

Excellent. Malignant variants are rare.

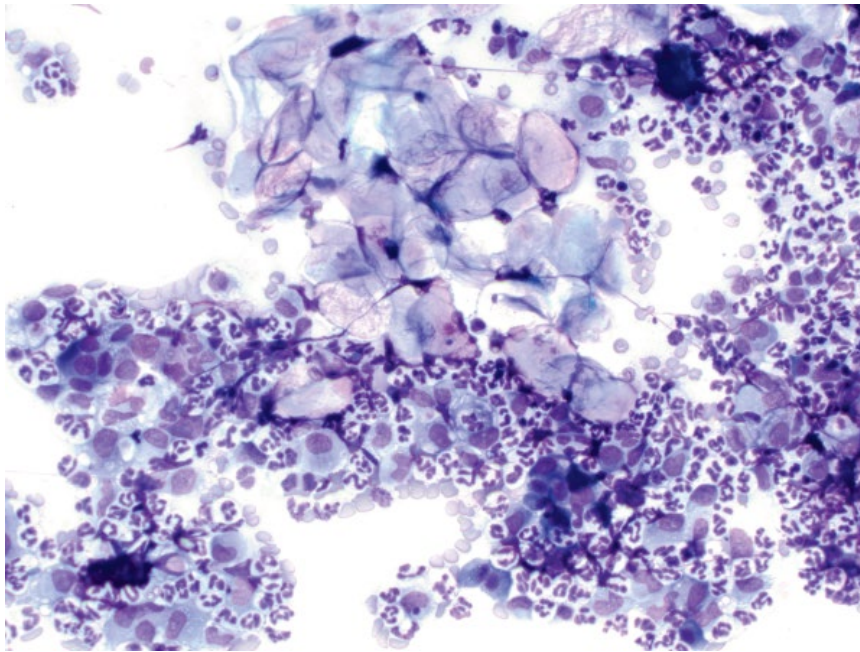


Figure 3.24 Infundibular/epidermal cyst, dog, 20× objective. Aggregates of anucleated squamous epithelial cells with marked mixed inflammation.

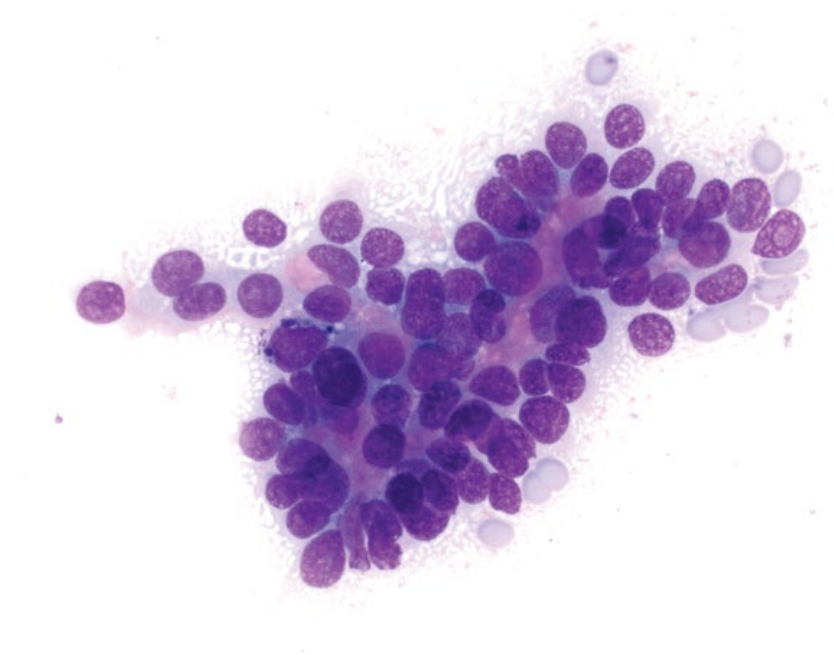


Figure 3.25 Cutaneous basilar epithelial neoplasm (trichoblastoma), dog, 50× objective. Note the bright pink basement membrane material.

3.1.13 Basal Cell Carcinoma

3.1.13.1 Cytologic Features

These are similar to those seen in cutaneous basilar epithelial neoplasms, with sheets of cuboidal epithelial cells noted. However, greater criteria of malignancy are seen, including cellular piling and crowding, anisokaryosis, and prominent basophilic nucleoli (Figure 3.26).

3.1.13.2 Clinical Considerations

- Rare tumors in dogs and cats.
- Grossly = variably pigmented and haired, raised plaques or nodules.
- Pleomorphism can be seen in benign cutaneous basilar epithelial neoplasms (usually <30% of cells), and histopathology is required for definitive diagnosis [20].

Figure 3.26 Basal cell carcinoma, cat, 50× objective. Note the cell piling and prominent nucleoli compared to Figure 3.25.

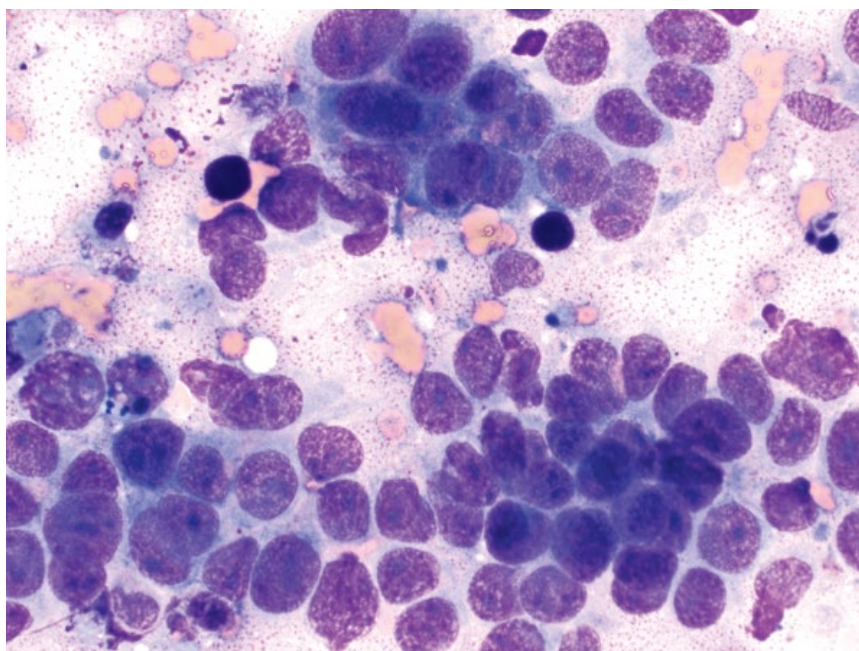
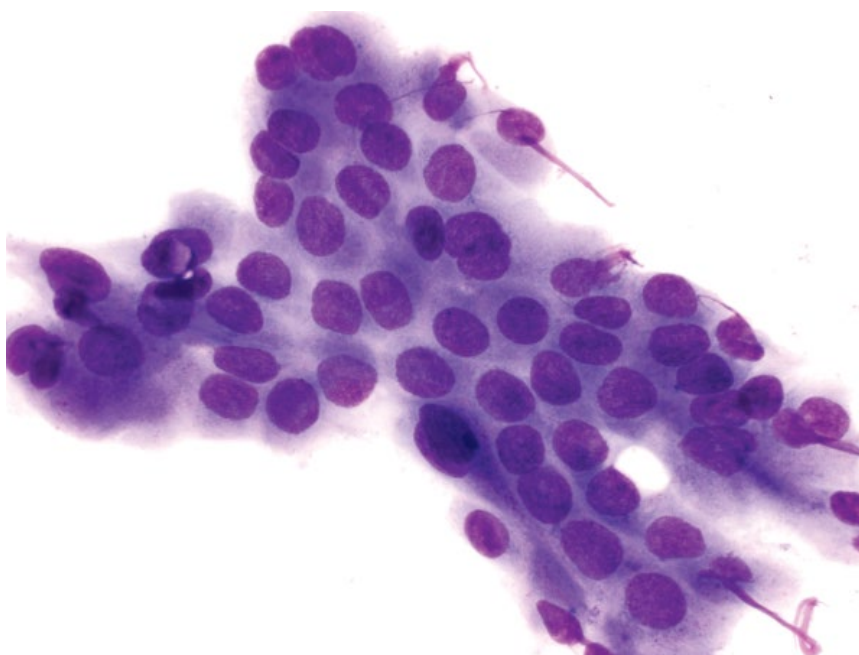


Figure 3.27 Sweat gland adenoma, dog, 50× objective.



3.1.13.3 Prognosis

Good. Basal cell carcinomas are considered low-grade malignancies in both dogs and cats. Surgical excision appears to provide good long-term control. Local recurrence and metastatic disease are rare [21].

3.1.14 Sweat Gland Adenomas

3.1.14.1 Cytologic Features

Sweat gland adenomas are characterized by sheets of cuboidal to short columnar epithelial cells with round,

eccentrically placed nuclei that have condensed chromatin. Inter cellular borders often are poorly defined. Anisocytosis/anisokaryosis are mild (Figure 3.27). These tumors can appear similar to cutaneous basilar epithelial tumors (compare to Figure 3.25), and can become cystic.

3.1.14.2 Clinical Considerations

- Single lesions mostly around the head and limbs [22].
- Adenomas more common than adenocarcinomas [23].
- Multiple histological subtypes.

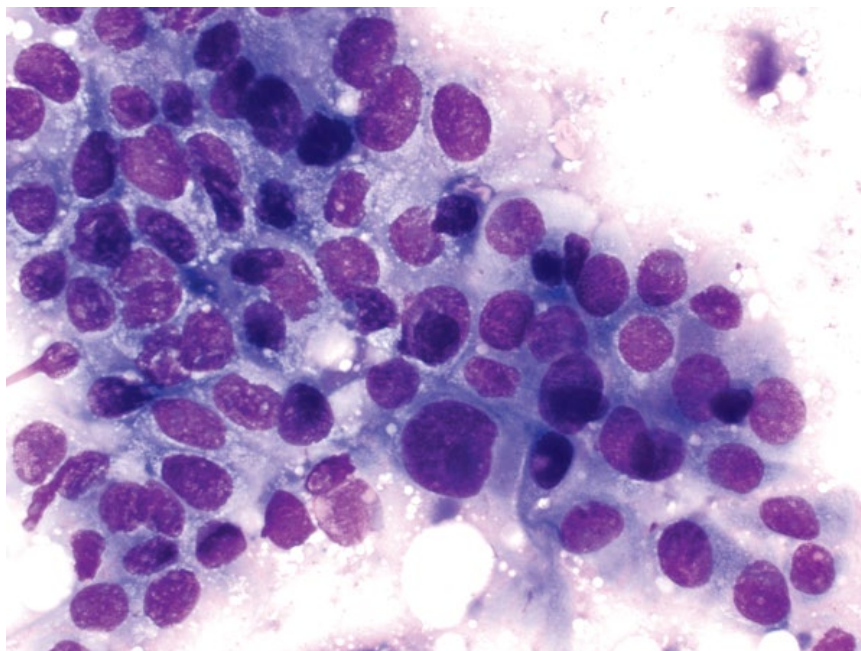


Figure 3.28 Sweat gland adenocarcinoma, dog, 50× objective.

3.1.14.3 Prognosis

Excellent.

3.1.15 Sweat Gland Adenocarcinomas

3.1.15.1 Cytologic Features

Sweat gland adenocarcinomas are seen as cohesive sheets and nests of cells. Cells are round, with a small to moderate volume of pale-blue cytoplasm, and often eccentrically placed nuclei. Anisocytosis/anisokaryosis are moderate to marked, and N/C ratios are moderate to high (Figure 3.28).

3.1.15.2 Clinical Considerations

- Occur mostly on the legs, thorax, and head in dogs and cats [24, 25].
- Well circumscribed. Majority are solitary, but multiple masses may be seen.
- Multiple histological subtypes.

3.1.15.3 Prognosis

Generally good with surgical excision. Tumors may be locally invasive, and distant metastases occur rarely in dogs, and confer a poor prognosis [24].

3.1.16 Sebaceous Adenoma

3.1.16.1 Cytologic Features

Sebaceous adenomas exfoliate variably well as uniform sheets of tightly cohesive cells with abundant clear, foamy cytoplasm (Figure 3.29). Nuclei are centrally located with condensed chromatin and small or inapparent nucleoli. Nodular sebaceous hyperplasia appears cytologically similar.

3.1.16.2 Clinical Considerations

- Dogs > cats. Typically older patients.
- Common in many dog breeds, but Miniature Schnauzers, Poodles and Cocker Spaniels are over-represented [26].
- Grossly = single, raised, hairless, smooth to wart-like, red lesions.
- Predilection sites = limbs, trunk, eyelids (dogs) and head, back (cats).

3.1.16.3 Prognosis

Excellent. Surgical excision (if required) is curative.

3.1.17 Sebaceous Epithelioma

3.1.17.1 Cytologic Features

Sebaceous epitheliomas exfoliate well, and comprise well-differentiated basal epithelial cells, intimately associated with nests of mature sebaceous epithelial cells (Figure 3.30). Basilar epithelial cells often predominate; however, the ratio of the two populations varies, with no effect on biologic behavior [27].

3.1.17.2 Clinical Considerations

- Common in dogs, uncommon in cats.
- Similar gross appearance to sebaceous adenomas.

3.1.17.3 Prognosis

Generally good with wide surgical excision. Sebaceous epitheliomas may behave as low-grade malignancies, recurring at sites of excision or invading local lymphatics, and rarely are metastatic [28].

Figure 3.29 Sebaceous adenoma, dog, 50× objective.

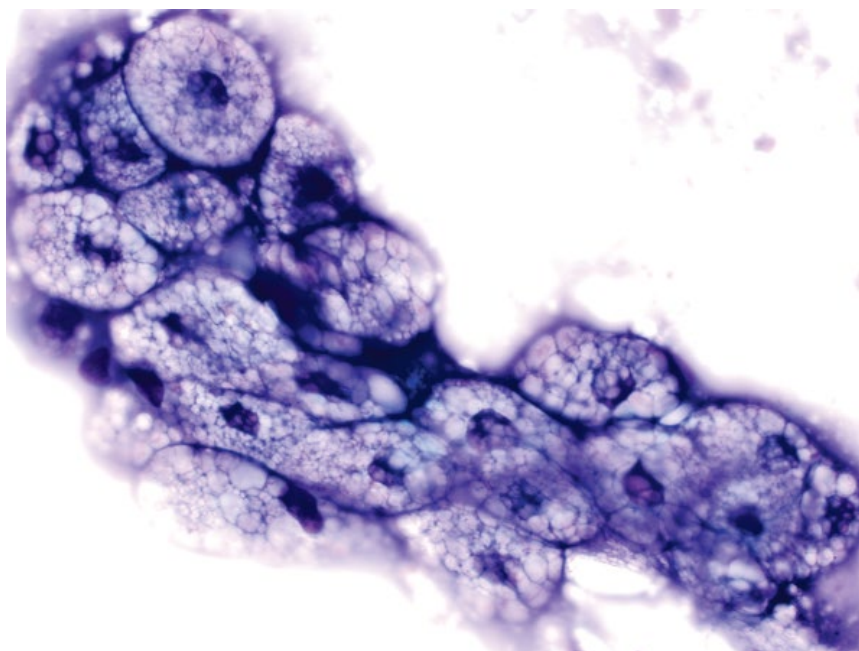
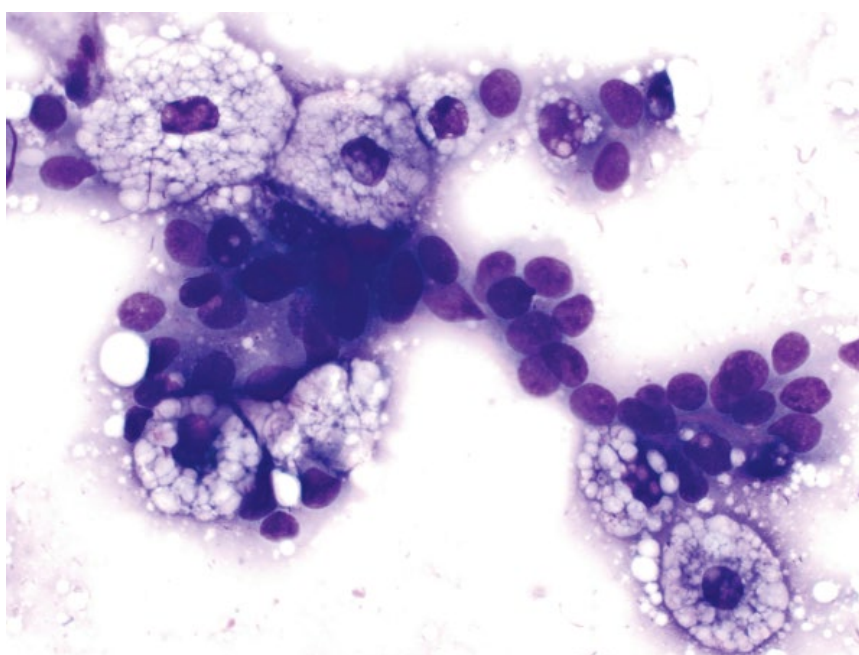


Figure 3.30 Sebaceous epithelioma, dog, 50× objective.



3.1.18 Sebaceous Carcinoma

3.1.18.1 Cytologic Features

Often highly cellular, with large cohesive sheets of epithelial cells that have prominent intercellular borders. The cells have clear to medium blue cytoplasm with numerous fine clear vacuoles and round, central nuclei with stippled chromatin and prominent nucleoli

(Figure 3.31). Anisocytosis/anisokaryosis are moderate to marked, and N/C ratios are high.

3.1.18.2 Clinical Considerations

- Uncommon tumors in older dogs and cats [26, 29].
- Grossly = pink, exophytic, wart-like lesions. Ulceration is common.

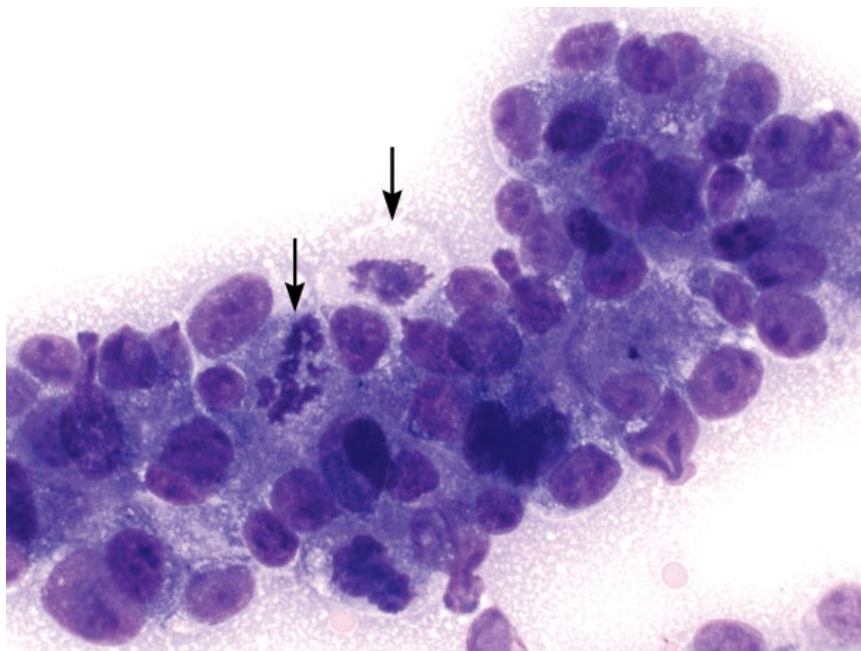


Figure 3.31 Sebaceous carcinoma, dog, 50× objective. Note the fine clear vacuoles, prominent nucleoli and mitotic figures (arrows).

- Predilection sites = head/neck (dogs), and head, thorax, and perineum (cats).
- Predisposed dog breeds = Cocker Spaniels, West Highland White Terriers, Scottish Terriers and Siberian Huskies.

3.1.18.3 Prognosis

Fair to good. Sebaceous carcinomas are considered low-grade malignancies, and are locally invasive. Wide surgical excision can be curative, but recurrence is common. Metastatic disease is rare, usually to local lymph nodes.

3.1.19 Cutaneous Metastatic Carcinoma

3.1.19.1 Cytologic Features

Carcinomas may metastasize to the skin. These mostly appear as cohesive sheets of cells with prominent intercellular borders; however, anaplastic variants may lose cohesion. Criteria of malignancy often are marked, including anisocytosis/anisokaryosis, high N/C ratios and increased mitotic activity (Figure 3.32).

3.1.19.2 Clinical Considerations

- Mammary, urinary, and pulmonary tumors reported [30–32].
- Pulmonary carcinomas in cats have a propensity for cutaneous metastasis, often to digits, but also the abdominal wall [32, 33].

3.1.19.3 Prognosis

Poor.

3.1.20 Squamous Papilloma

3.1.20.1 Cytologic Features

Squamous papillomas are characterized by polygonal squamous cells that have abundant cytoplasm containing bright-pink keratohyaline granules. Nuclei are large, round, and pyknotic with condensed chromatin. Squamous papillomas frequently are inflamed (see Figure 3.33).

3.1.20.2 Clinical Considerations

- Often caused by infection with canine papilloma viruses.
- Grossly = wart-like or cauliflower-like lesions.
- Common locations = head, eyes, mouth, and feet.
- Mostly seen in young, stressed or immunocompromised patients.

3.1.20.3 Prognosis

Excellent. Most spontaneously regress over a period of 2–6 months, but may persist for up to a year [34]. Surgical excision, if required, is curative.

3.2.21 Squamous Cell Carcinoma (SCC)

3.1.21.1 Cytologic Features

Variably cohesive sheets of cells that range from polygonal to round. They often have prominent criteria of malignancy, with marked anisocytosis and anisokaryosis. The cells frequently have keratinized cytoplasm, which appears as bright sky-blue and

Figure 3.32 Cutaneous metastatic carcinoma (pulmonary carcinoma), cat, 50× objective.

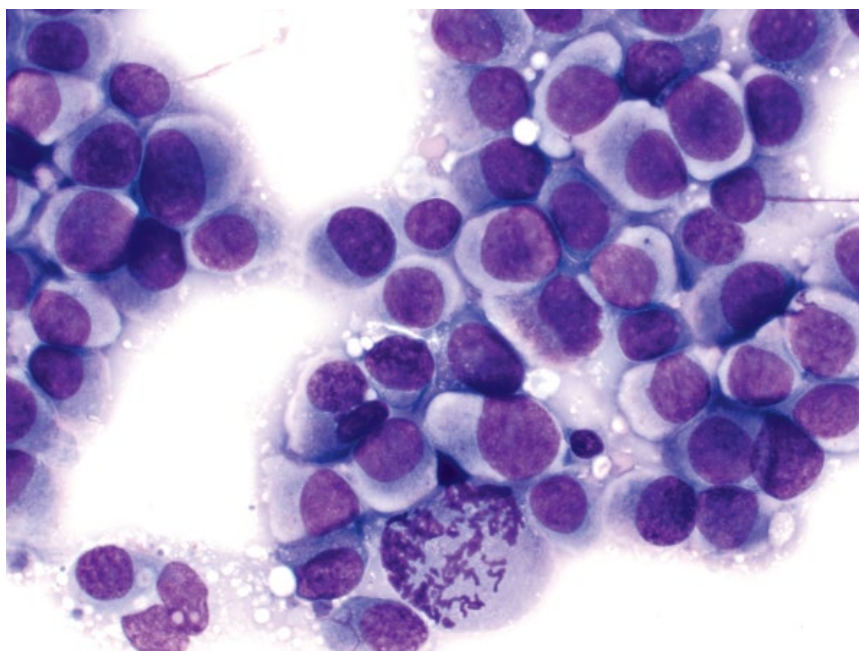
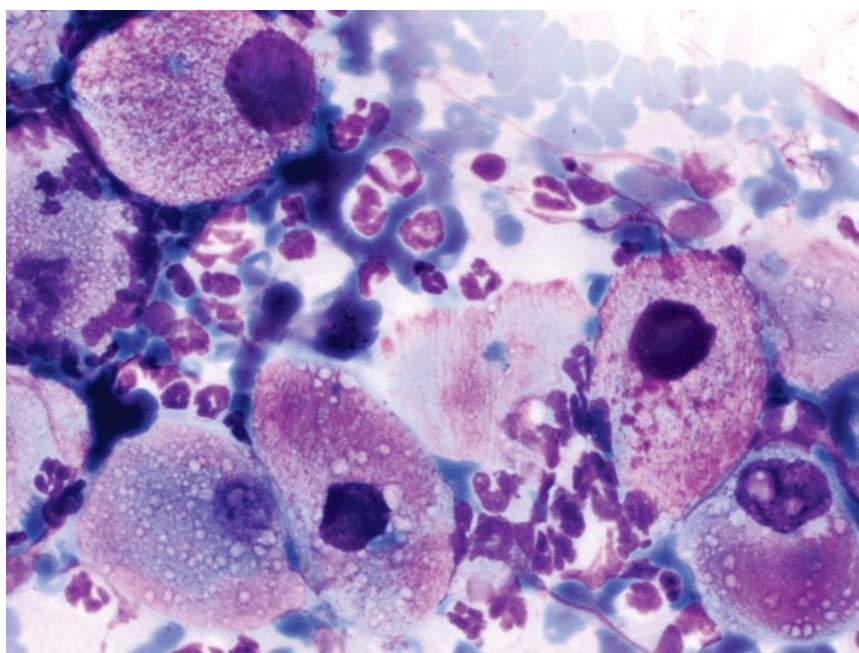


Figure 3.33 Squamous papilloma, dog, 50× objective.



hyalinized (Figure 3.34). Keratinized squamous cells should have small, pyknotic nuclei with dense chromatin. The finding of large, immature nuclei in keratinized cells suggests nuclear to cytoplasmic dissociation, and can be seen with both neoplasia and dysplasia. Perinuclear vacuolation is a common finding in SCC.

3.1.21.2 Clinical Considerations

- Common sites = nasal planum, pinnae, eyelids (cats) and flank, abdomen, and nail bed (dogs).

3.1.21.3 Prognosis

Variable based on location and presence of metastatic disease. SCC of the digit in dogs has a greater metastatic potential than those elsewhere in the body, with metastasis of cutaneous SCC uncommon [35].

3.1.22 Perianal Gland Adenoma

3.1.22.1 Cytologic Features

Perianal gland adenomas exfoliate as cohesive sheets of ovoid cells with abundant, medium blue/purple

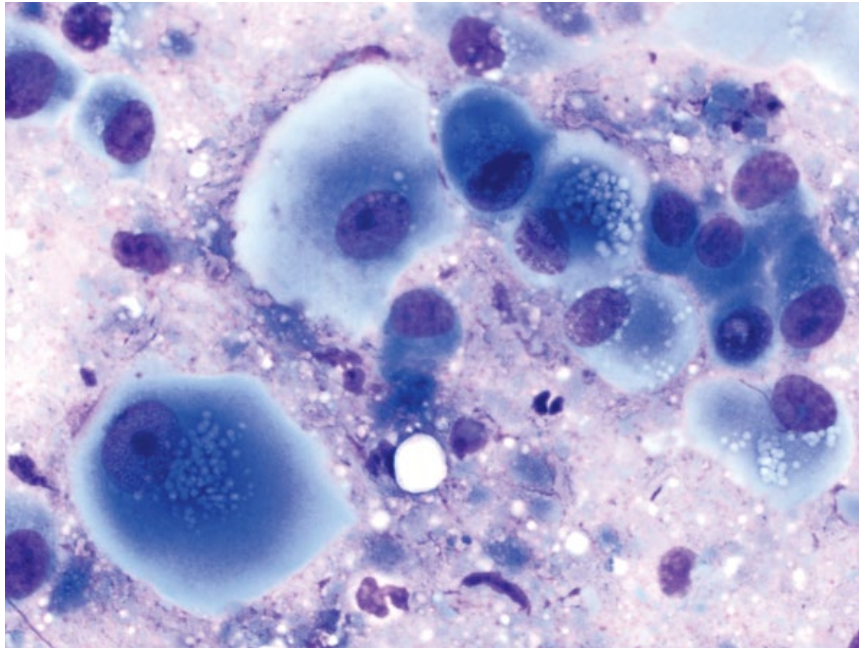


Figure 3.34 Squamous cell carcinoma, cat, 50x objective. Note the sky-blue cytoplasm, immature nuclei, and perinuclear vacuolation.

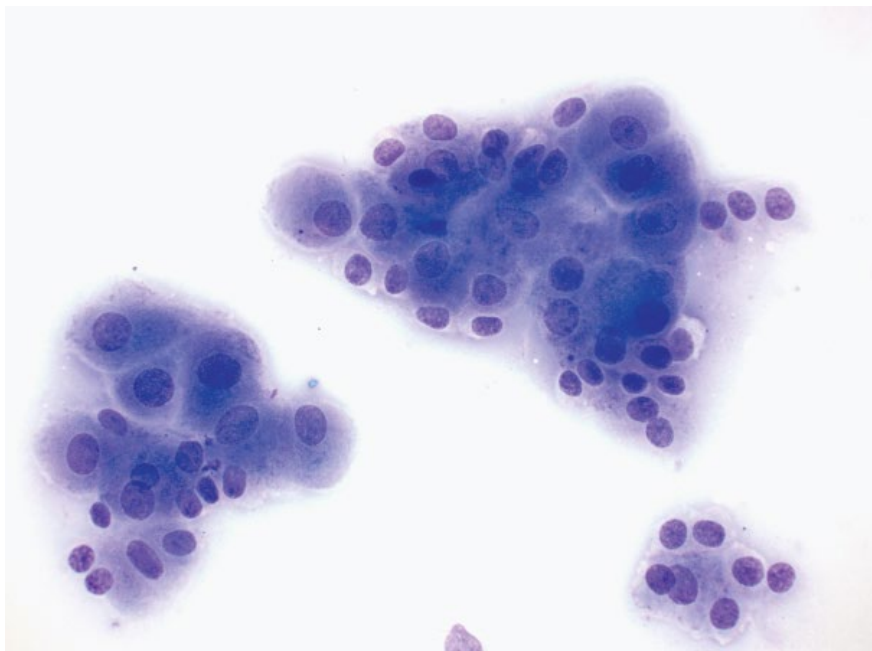


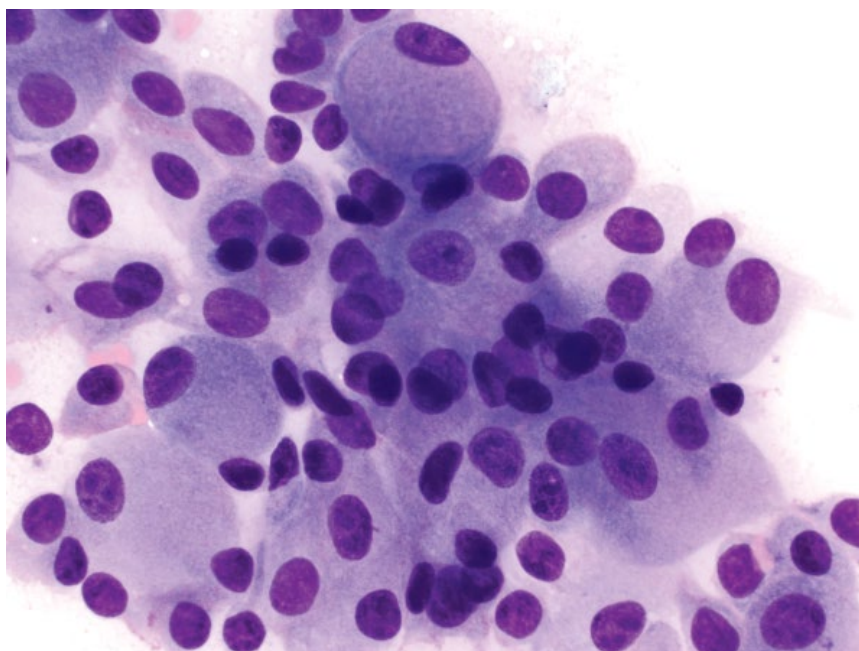
Figure 3.35 Perianal gland adenoma, dog, 20x objective.

cytoplasm, and round, centrally located nuclei with prominent, single, basophilic nucleoli (Figure 3.35). This appearance gives them a 'hepatoid' look (compare to normal hepatocytes in Figure 7.1). Small, cuboidal cells with higher N/C ratios (basilar reserve cells) are intimately associated with the hepatoid cells. They often are highly vascular tumors, and abundant blood may be present in the background.

3.1.22.2 Clinical Considerations

- Mostly seen in hairless areas around the anus, but may be seen in haired skin around the tail base or perineum.
- Multiple masses may be present.
- Older, intact males are at increased risk due to androgen-mediated growth, but tumors are seen in both sexes (neutered or intact) [36].
- Tumors have a tendency to ulcerate.

Figure 3.36 Perianal gland adenocarcinoma, dog, 50× objective. Note the higher N/C ratios and cellular crowding relative to perianal gland adenomas.



3.1.22.3 Prognosis

Excellent. Tumors may regress with castration alone for intact dogs. Surgical excision generally is curative.

3.1.23 Perianal Gland Adenocarcinoma

3.1.23.1 Cytologic Features

Perianal gland adenocarcinomas can look very similar to adenomas, and accurate differentiation requires evaluation of tissue architecture via histopathology. In general, adenocarcinomas have a tendency toward higher N/C ratios, and crowding of cells (compare Figures 3.36 and 3.35). Increased numbers of reserve cells also are associated with dysplasia or malignancy.

3.1.23.2 Clinical Considerations

- Less common than adenomas [37].
- Often adherent to underlying tissues and tendency to ulcerate.
- No sex predilection.

3.1.23.3 Prognosis

Fair to good based on stage and size of tumor. Tumors <5 cm carry a better prognosis, and metastatic disease confers a poor prognosis [38].

3.1.24 Anal Sac Apocrine Gland Adenocarcinoma

3.1.24.1 Cytologic Features

These tumors are characterized by sheets of cells that frequently lack defined intercellular borders (compared to perianal gland tumors), and are arranged in

palisading rows and acinar arrangements (Figure 3.37). Nuclei are round with granular chromatin and multiple small nucleoli. Despite an aggressive biologic behavior, anisokaryosis often is mild, and mitotic figures are rare.

3.1.24.2 Clinical Considerations

- Dogs >> cats.
- No sex predisposition [39].
- Hypercalcemia seen in ~25% of cases [40].
- High metastatic rate to sublumbar lymph nodes, less commonly to lungs, liver and spleen.

3.1.24.3 Prognosis

Fair to poor based on stage of disease and treatment. Hypercalcemia confers a poor prognosis [40].

3.1.25 Clear Cell Adnexal Carcinoma

3.1.25.1 Cytologic Features

Although of epithelial origin, these tumors contain cells that mostly are individualized, and are round to spindle-shaped, which can make differentiating these from a mesenchymal tumor difficult (Figure 3.38). Cells may contain abundant clear secretory material or cytoplasmic clearing, and pink inclusions may be present. Criteria of malignancy are marked, including anisokaryosis, prominent basophilic nucleoli, and multinucleation. These tumors frequently have a pale gray, streaming background with small clear vacuoles from ruptured cells, as well as bare nuclei.

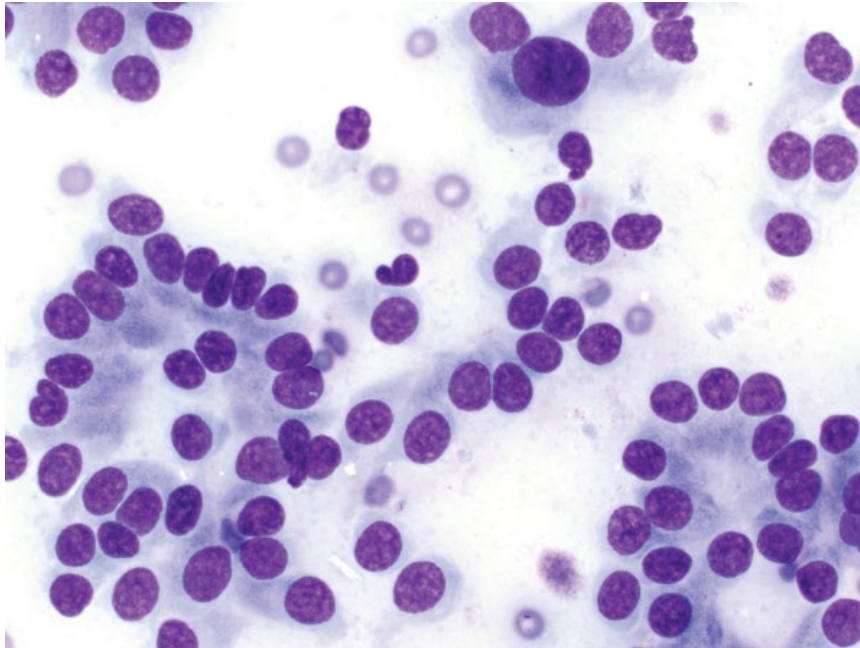


Figure 3.37 Anal sac apocrine gland adenocarcinoma, dog, 50× objective.

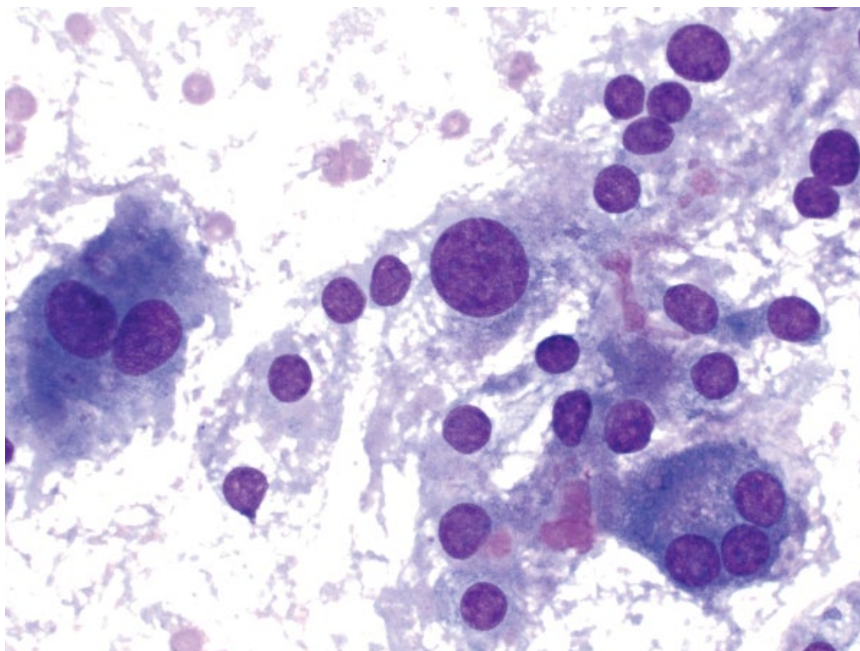


Figure 3.38 Clear cell adnexal carcinoma, dog, 50× objective.

3.1.25.2 Clinical Considerations

- Rare tumors, only reported in dogs [41].
- Likely originate from epithelial stem cells, with no definitive apocrine, sebaceous or follicular differentiation.

3.1.25.3 Prognosis

Mostly good. Complete surgical excision is curative in the majority of cases, with a low recurrence rate, and metastasis is rare [42].

3.1.26 Reactive Fibroplasia

3.1.26.1 Cytologic Features

Reactive fibroplasia is characterized by variable numbers of spindle cells. These cells often have a maturational gradient, ranging from mature cells with a scant volume of cytoplasm and elongated nuclei, to plump spindle cells with abundant deep-blue cytoplasm and ovoid nuclei with stippled chromatin. The reactive response can be florid, and differentiating reactive fibroplasia

Figure 3.39 Reactive fibroplasia, dog, 50× objective. Note the accompanying inflammation.

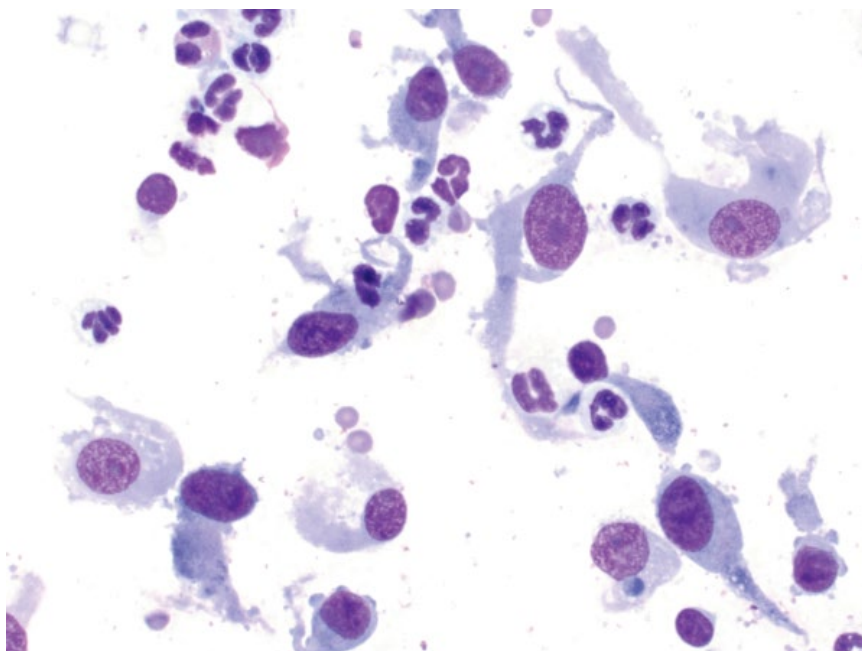
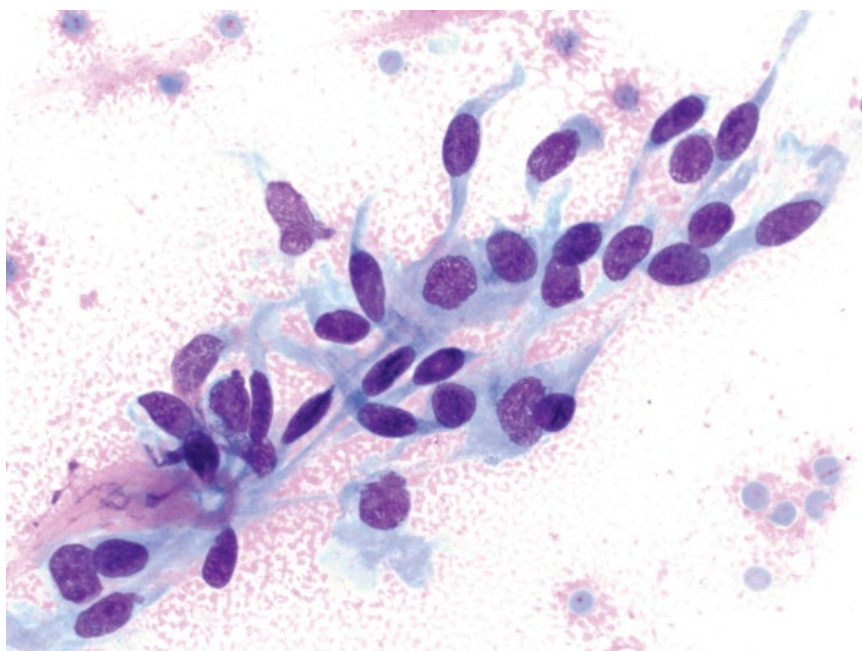


Figure 3.40 Fibroma, dog, 50× objective.



from spindle cell neoplasms is not always possible with cytology (compare Figures 3.39 and 3.40).

3.1.26.2 Clinical Considerations

- May present as firm nodules or diffuse thickening.
- Commonly associated with trauma or chronic inflammation.
- Often self-limiting, but may take many months to resolve.

3.1.26.3 Prognosis
Excellent.

3.1.27 Fibroma

3.1.27.1 Cytologic Features

Fibromas often exfoliate poorly. When present, cells are spindloid, and seen individually or in small aggregates, that may be accompanied by pink extracellular matrix.

The cells have a scant volume of pale cytoplasm that forms delicate bipolar tendrils and wisps. Nuclei are elongated, with granular chromatin and small basophilic nucleoli. Anisocytosis/anisokaryosis are mild, and N/C ratios are high. These often are cytologically indistinguishable from reactive fibroplasia (compare Figures 3.40 and 3.39).

3.1.27.2 Clinical Considerations

- Uncommon tumors in older dogs and cats [43, 44].
- Grossly = firm, well-circumscribed, solitary lesions, most commonly found on the extremities (especially in cats), flank or head [43].

3.1.27.3 Prognosis

Excellent with surgical removal. Recurrence is rare but may occur if excision is incomplete.

3.1.28 Fibrosarcoma

3.1.28.1 Cytologic Features

Fibrosarcomas exfoliate variably well, either individually or in aggregates. The background often contains bright-pink extracellular matrix (Figure 3.41). The cells have a variable volume of cytoplasm forming tendrils and wisps, and may contain fine pink granules or clear vacuoles. Nuclei are ovoid to elongated, with finely granular chromatin and prominent nucleoli. Anisocytosis/anisokaryosis often are marked, and multinucleation and mitotic figures may be present.

3.1.28.2 Clinical Considerations

- Generally firm and adherent to surrounding tissue.
- Locally aggressive/invasive.

3.1.28.3 Prognosis

Good with wide surgical excision, which can result in prolonged survival times. Metastatic rates generally are low to moderate, ranging from 8% to 17%, but recurrence of tumors is high [45, 46]. Histologic tumor grade is an important prognostic determinant for metastatic potential (up to 44% of grade III tumors metastasize) [47].

3.1.29 Keloidal Fibroma/Fibrosarcoma

3.1.29.1 Cytologic Features

Keloidal fibromas and fibrosarcomas contain aggregates of spindle cells often centered around characteristic, polygonal to rounded aggregates of bright-pink, smooth collagen (Figure 3.42). Differentiating keloidal fibromas from keloidal fibrosarcomas cytologically is difficult; however, anisokaryosis often is greater in fibrosarcomas.

3.1.29.2 Clinical Considerations

- Dogs only.
- Males (neutered and intact) predisposed [48].
- Fibromas are more common, but may undergo malignant transformation to fibrosarcomas.

3.1.29.3 Prognosis

Excellent for keloidal fibromas, with surgical excision generally curative [48]. Wide excision is warranted due to potential for malignant transformation.

3.1.30 Soft-tissue Sarcoma

3.1.30.1 Cytologic Features

Frequently highly exfoliative with aggregates of spindle cells often centered around capillaries (Figure 3.43). Cells

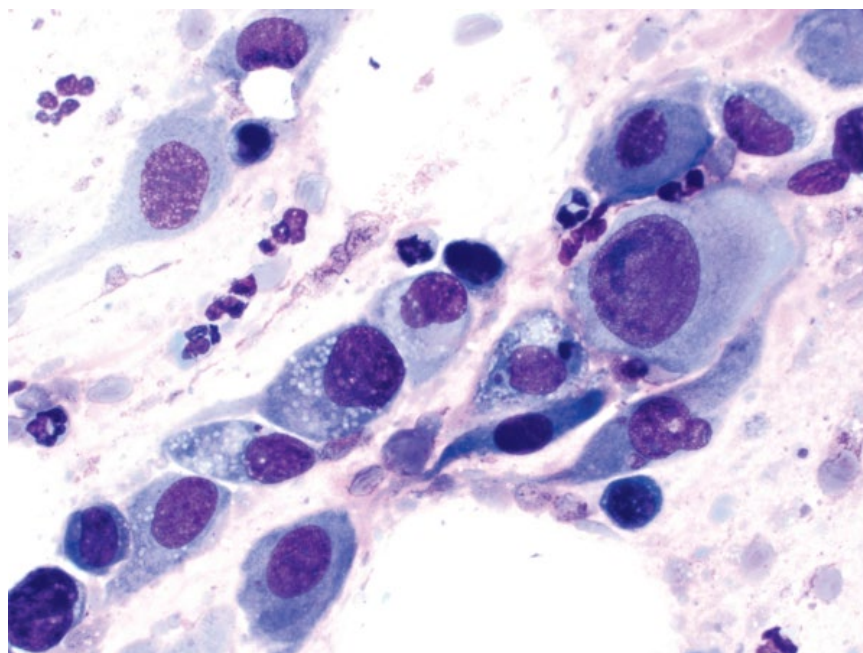


Figure 3.41 Fibrosarcoma, dog, 50× objective.

Figure 3.42 Keloidal fibroma, dog, 20× objective. Note the characteristic large, smooth, bright pink aggregates of collagen.

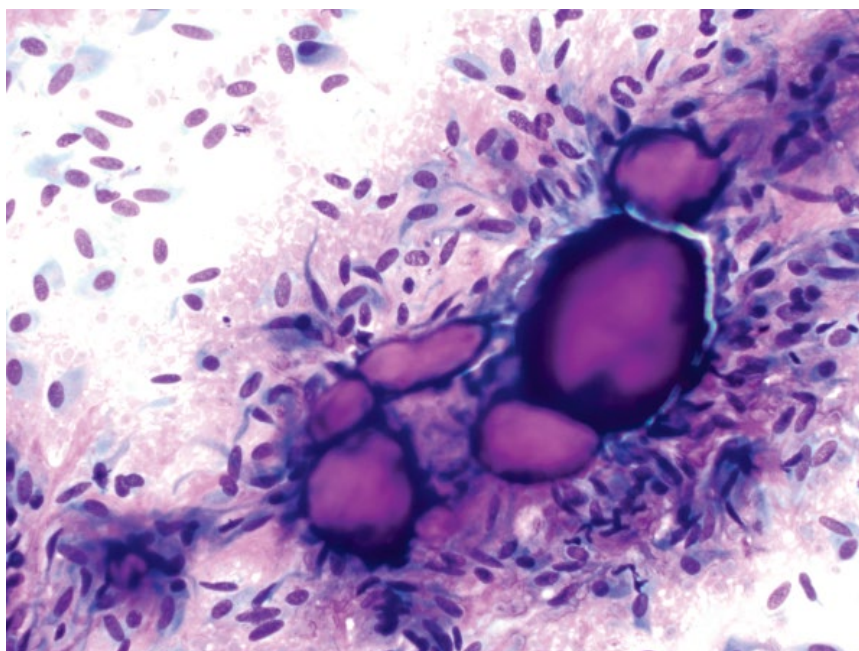
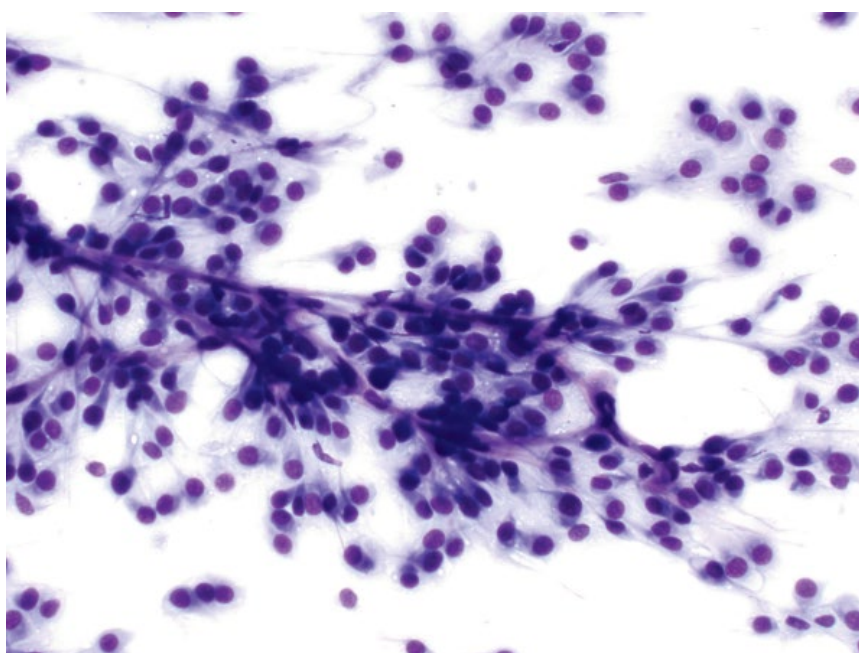


Figure 3.43 Soft-tissue sarcoma (hemangiopericytoma), dog, 20× objective. Note the cells emanating from linear, streaming capillaries.



have pale-blue cytoplasm forming delicate wisps and tendrils, which may contain fine, clear vacuoles. Nuclei are ovoid with granular chromatin and small nucleoli (Figure 3.44). Anisocytosis/anisokaryosis are mild, and N/C ratios are moderate to high. Multinucleated cells with peripheralized nuclei forming a ring ('crown cells') may be seen and are suggestive of perivascular wall tumors [49] (Figure 3.45).

3.1.30.2 Clinical Considerations

- A diverse category of tumors that appear similar cytologically, and may even be difficult to differentiate with histopathology [50]. Notably, this category includes peripheral nerve sheath tumors and perivascular wall tumors (e.g., hemangiopericytomas). Other soft-tissue sarcomas (e.g., fibrosarcomas, liposarcomas, hemangiosarcomas) are described separately in

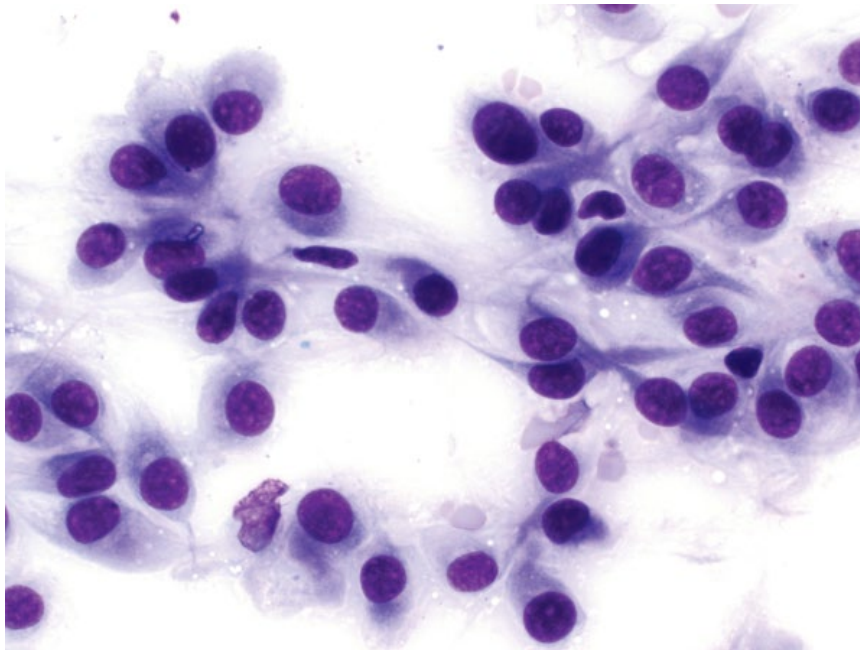


Figure 3.44 Soft-tissue sarcoma (hemangiopericytoma), dog, 50× objective.

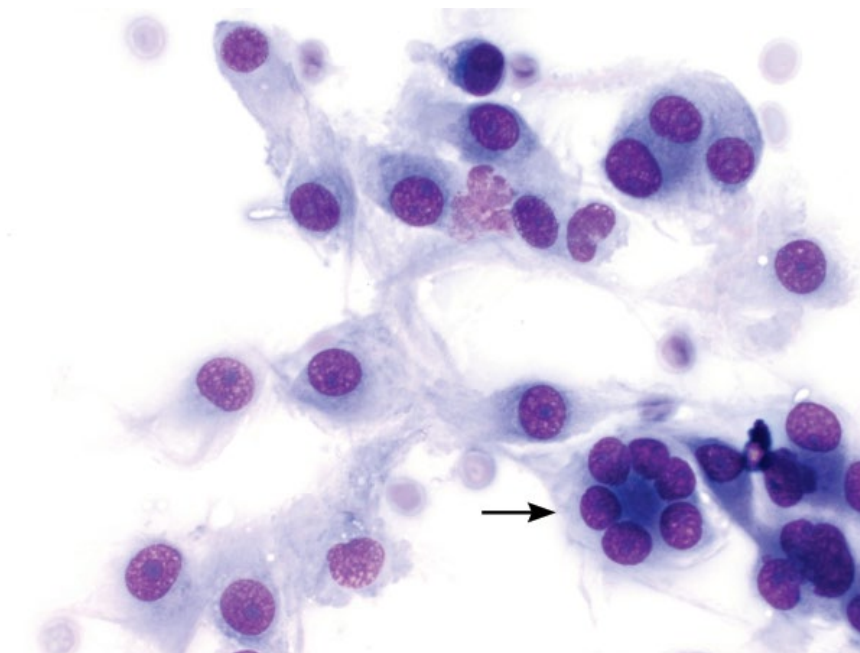


Figure 3.45 Soft-tissue sarcoma (hemangiopericytoma), dog, 50× objective. Note the characteristic 'crown cell' (arrow).

this text due to often having distinct morphologic features and clinical considerations.

- Common in middle-aged to older dogs > cats.
- Mostly solitary, haired, soft to firm tumors, common on extremities.

3.1.30.3 Prognosis

Complete, wide excision generally is curative, but recurrence is common with conservative surgical excision. The propensity for recurrence increases with histologic

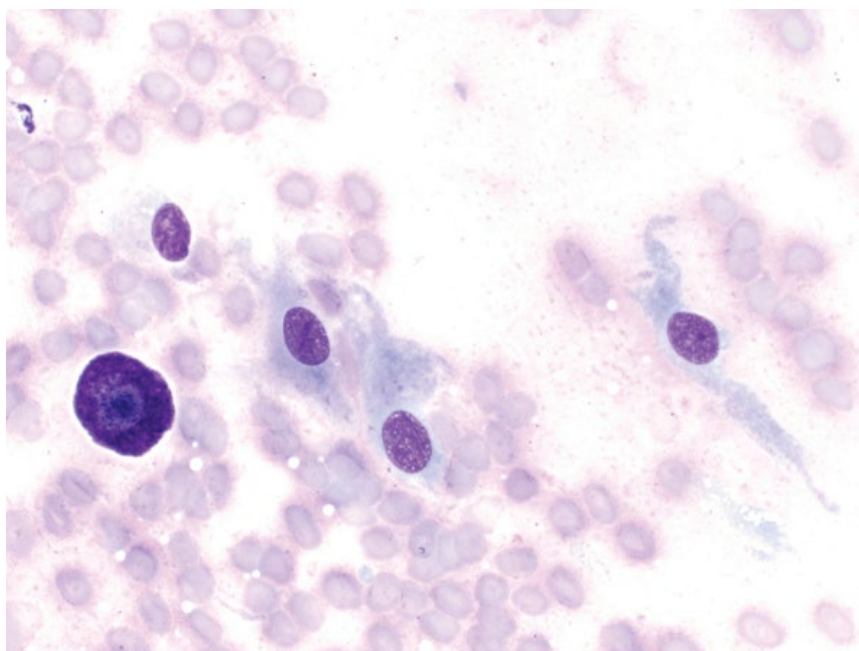
tumor grade [50]. Metastatic potential generally is low, but also increases with histologic tumor grade.

3.1.31 Hemangioma

3.1.31.1 Cytologic Features

Hemangiomas frequently have a densely bloody background, and may only yield a small number of cells. When cells are present, they mostly are individualized spindle cells, with a scant volume of pale-blue cytoplasm that forms delicate bipolar tendrils and wisps

Figure 3.46 Hemangioma, dog, 50× objective. Note the bloody background, spindle cells with fine tendrils and the mast cell (left).



(Figure 3.46). Nuclei are ovoid to elongated, with finely granular chromatin and small, single basophilic nucleoli. Anisocytosis/anisokaryosis are mild, while N/C ratios are high. Low numbers of well-granulated mast cells may be present. Macrophages may be present, with evidence of chronic hemorrhage (erythrophagia or hemosiderin pigment) (see Figure 1.3).

3.1.31.2 Clinical Considerations

- Grossly = hairless, smooth, red/purple dermal nodules.
- Solitary or multiple, often found on the head, limbs or trunk.
- May be induced by ultraviolet exposure in poorly pigmented skin.
- Boxers are predisposed [51].

3.1.31.3 Prognosis

Excellent. Complete surgical excision is curative.

3.1.32 Hemangiosarcoma (Cutaneous)

3.1.32.1 Cytologic Features

Frequently have a densely bloody background, and are variably exfoliative. Cells are spindloid, with a moderate volume of medium-blue cytoplasm. Erythrophagia may be seen in neoplastic cells. Nuclei are ovoid with granular chromatin and prominent basophilic nucleoli. Anisocytosis/anisokaryosis are marked, and N/C ratios are high (Figure 3.47). These tumors are difficult to differentiate definitively from other sarcomas cytologically.

3.1.32.2 Clinical Considerations

- Variably well-circumscribed; stage II and III tumors often have a bruised appearance [52].
- Predilection for poorly haired skin of the ventral abdomen and preputial region (stage I tumors in dogs) and skin of the pinna, head and ventral abdomen (cats) [52, 53].

3.1.32.3 Prognosis

Dogs = Variable based on tumor stage. Stage I tumors may be treated with surgery alone and are associated with a prolonged survival time. Stage II and III tumors carry a poor prognosis.

Cats = Wide surgical excision is associated with prolonged survival; however, if untreated the prognosis is poor [52, 53].

3.1.33 Myxoma

3.1.33.1 Cytologic Features

Myxomas have a thick, pink-stippled background of extracellular matrix, often distributing the cells in a streaming pattern (Figure 3.48). Cells are spindloid, with a scant volume of pale-blue cytoplasm forming delicate wisps. Nuclei are elongated with finely granular chromatin and small basophilic nucleoli. Anisocytosis/anisokaryosis are mild and N/C ratios are high.

3.1.33.2 Clinical Considerations

- Most common in large breed, middle-aged to older dogs (Doberman Pinschers are over-represented), but rare overall in both dogs and cats [54].

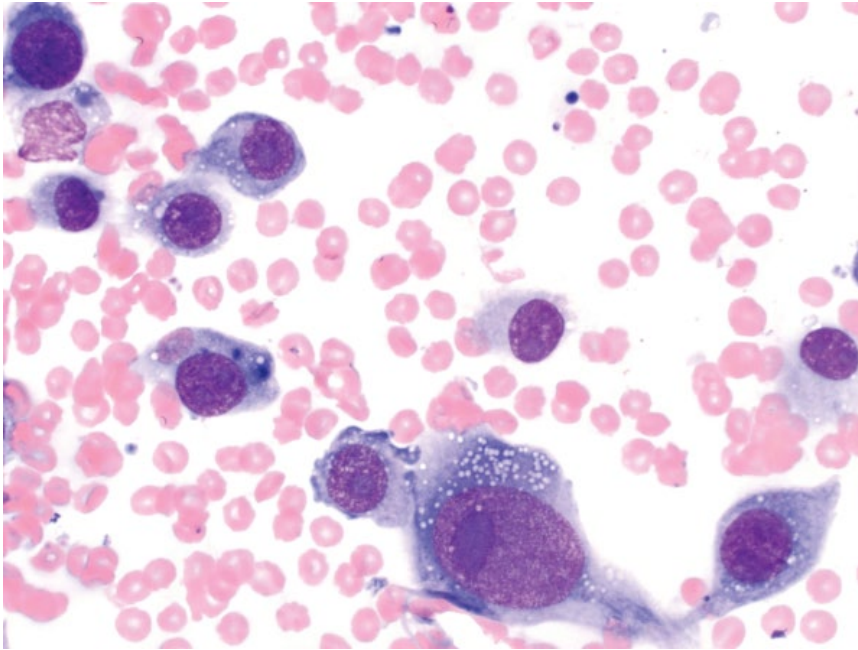


Figure 3.47 Hemangiosarcoma (cutaneous), dog, 50× objective. Note the prominent nucleoli.

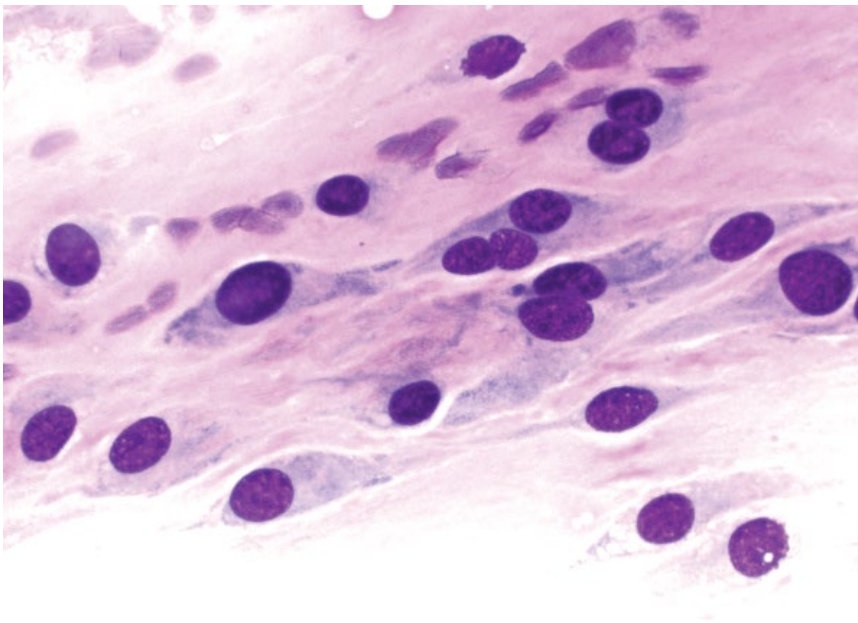


Figure 3.48 Myxoma, dog, 50× objective. Note the dense pink, streaming mucinous background.

- Predilection sites = joints (especially digits and stifle) > heart and skin [54, 55].
- May be locally invasive.

3.1.33.3 Prognosis

Excellent. Prolonged survival times are reported, even in cases with incomplete excision [54].

3.1.34 Myxosarcoma

3.1.34.1 Cytologic Features

Myxosarcomas have a similar thick, pink-stippled myxoid background as myxomas. The cells have more prominent criteria of malignancy, particularly anisokaryosis and larger basophilic nucleoli (Figure 3.49).

Figure 3.49 Myxosarcoma, dog, 50× objective. Note the dense pink stippled, mucinous background and prominent anisokaryosis.

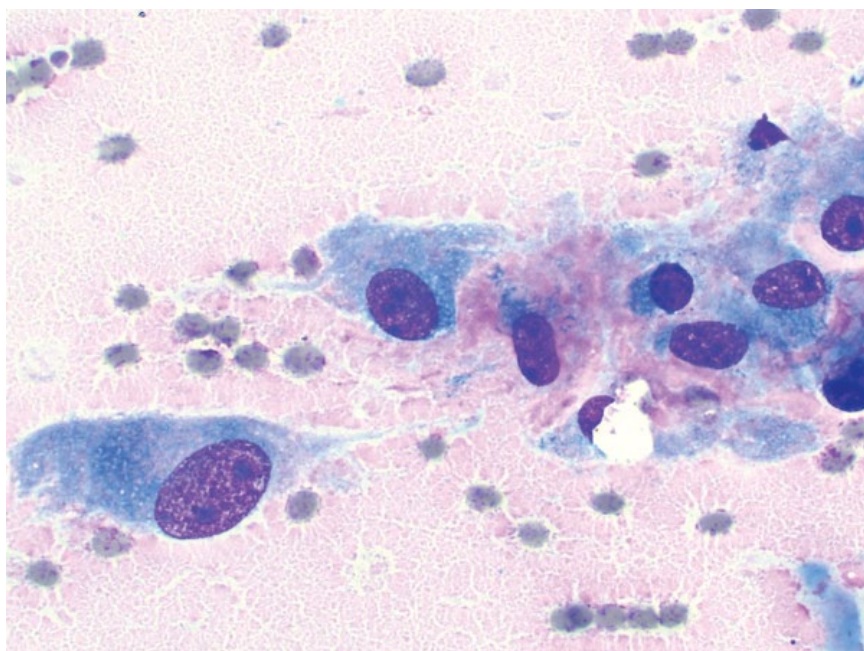
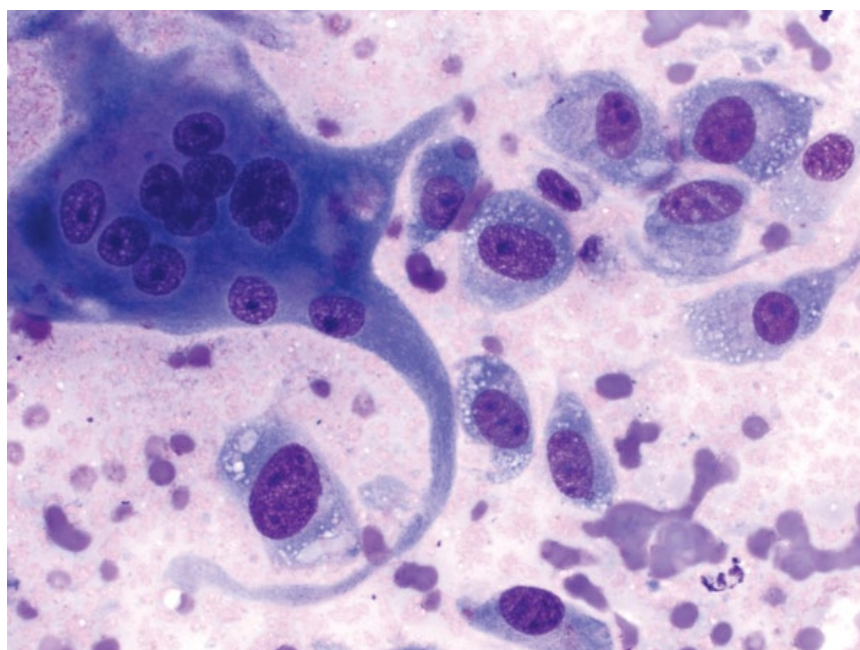


Figure 3.50 Anaplastic sarcoma with giant cells, cat, 50× objective.



3.1.34.2 Clinical Considerations

- Rare tumors in older dogs and cats.
- Predilection sites = trunk and limbs > joints, heart, and eye.
- Locally infiltrative with ill-defined margins.

3.1.34.3 Prognosis

Guarded. Recurrence is common after surgical removal, and metastasis may occur [56, 57].

3.1.35 Anaplastic Sarcoma with Giant Cells

3.1.35.1 Cytologic Features

Cells generally are spindloid with tapering ends, and have ovoid to elongated nuclei with granular chromatin and prominent nucleoli. Multinucleated giant cells may be round or spindloid with tendrils and wisps (Figure 3.50). These cells often have nuclei of varying size and shape, relative to osteoclasts (see Figure 1.30) or

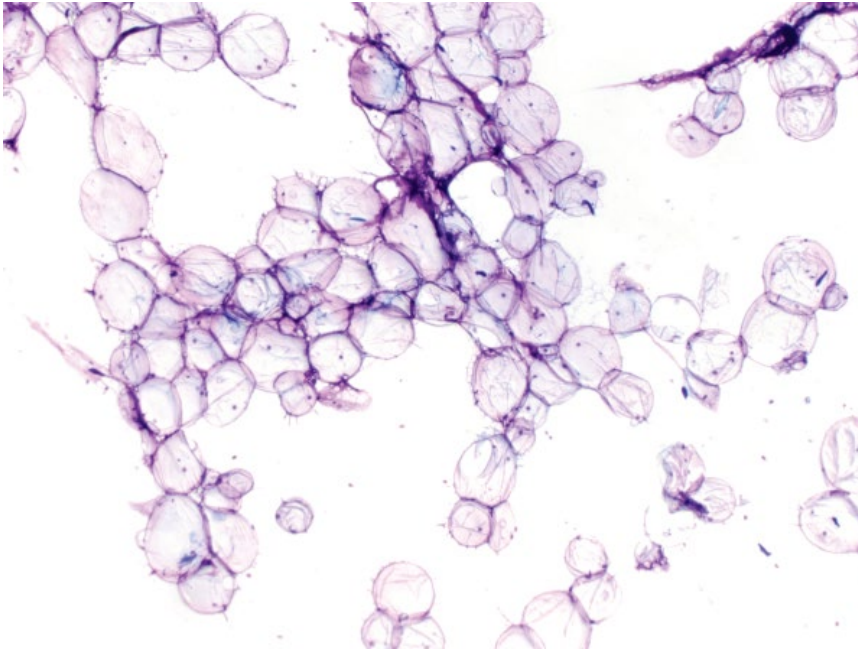


Figure 3.51 Lipoma, dog, 4× objective.

multinucleated macrophages (see Figure 3.59), which have multiple, regular nuclei.

3.1.35.2 Clinical Considerations

- Rare in dogs and cats.
- Previously known as malignant fibrous histiocytomas or giant cell tumor of soft tissues.
- Likely poorly differentiated sarcomas of multiple tumor types including fibrosarcoma, leiomyosarcoma, rhabdomyosarcoma [58].
- Solitary, firm, poorly circumscribed lesions around the legs and shoulders.

3.1.35.3 Prognosis

Variable based on grade and underlying origin.

3.1.36 Lipoma

3.1.36.1 Cytologic Features

Lipomas contain large aggregates of mature adipocytes that balloon with abundant clear cytoplasm (Figure 3.51). Nuclei are small and condensed, with inapparent nucleoli, and frequently are pushed to the periphery of the cells. Capillaries frequently course through clusters of adipocytes (Figure 3.52), and occasional supporting stromal cells (e.g., fibroblasts) may be present. Free lipid often is present in the background of the slide.

3.1.36.2 Clinical Considerations

- Common subcutaneous tumors in middle-aged to older dogs > cats.
- Fat can dissolve with alcohol-based fixatives, and slides may be acellular.

- Aspiration of normal adipose tissue may look similar, and interpretation should be correlated with clinical impressions.
- Infiltrative lipomas have a similar cytologic appearance. They do not metastasize, but can be locally invasive/aggressive.

3.1.36.3 Prognosis

Excellent, with surgical excision curative. Infiltrative lipomas may require more aggressive therapy to obtain local control, and have high recurrence rates [59].

3.1.37 Liposarcoma

3.1.37.1 Cytologic Features

There are numerous histologic subtypes of liposarcomas, resulting in a wide array of cytologic appearances. Well-differentiated liposarcomas (Figure 3.53) contain neoplastic cells that vaguely resemble adipocytes, but are characterized by basophilic cytoplasm, and immature nuclei, with prominent nucleoli and moderate anisokaryosis. Poorly, or dedifferentiated liposarcomas (Figure 3.54) appear somewhat cohesive, and contain coarse, clear lipid vacuoles in their cytoplasm. Such a finding should raise suspicion for a liposarcoma, regardless of cell shape or arrangement. Anisocytosis and anisokaryosis are moderate to marked, and N/C ratios are high.

3.1.37.2 Clinical Considerations

- Most common in appendicular or axial locations.
- Locally invasive tumors with low metastatic potential, though metastatic disease is reported [60].
- No evidence for malignant transformation from lipomas.

Figure 3.52 Lipoma, dog, 20× objective. Note the streaming, linear capillaries.

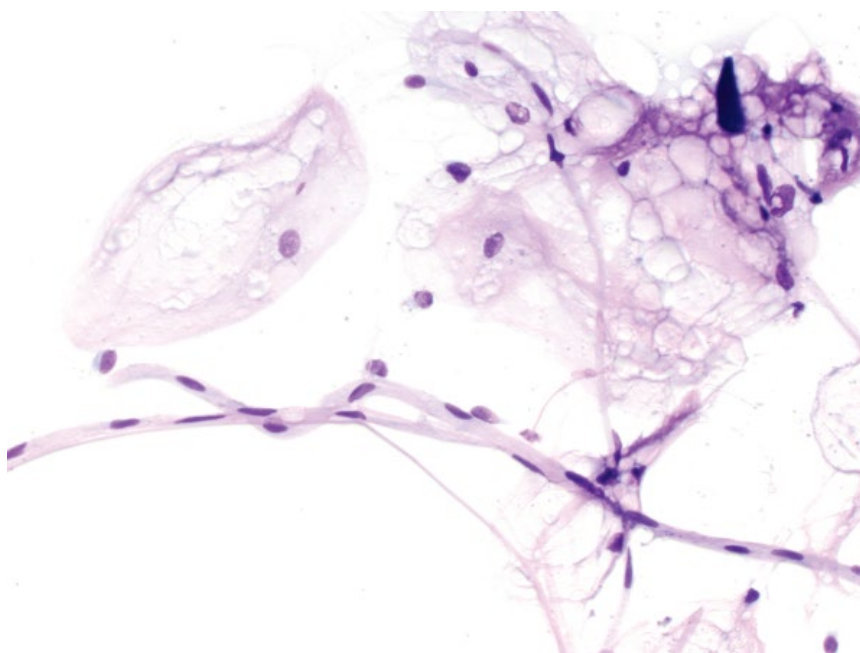
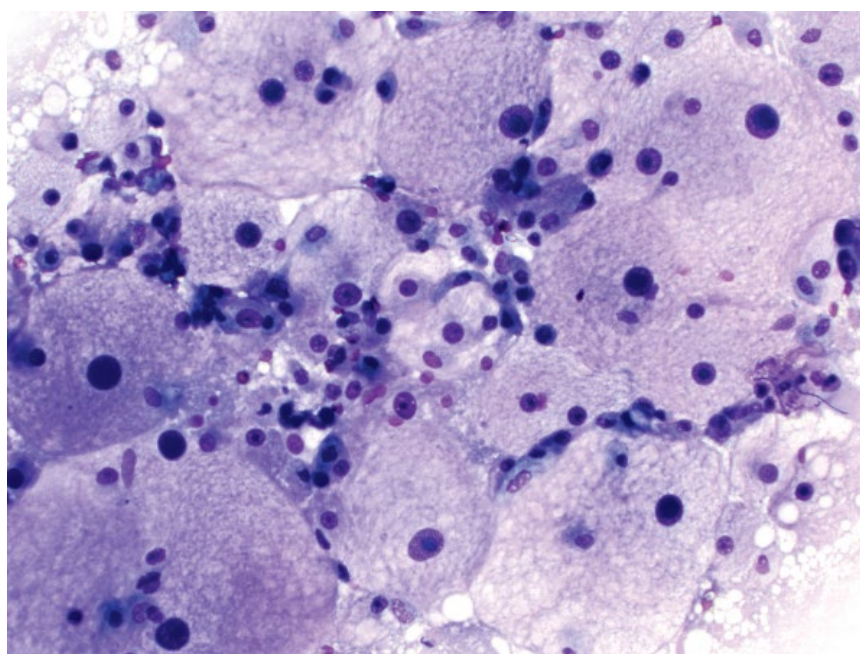


Figure 3.53 Liposarcoma (well differentiated), dog, 10× objective.



3.1.37.3 Prognosis

Good with wide surgical margins. Tumors with marginal excision are associated with lower median survival times. Factors not associated with survival time in one study included tumor size, location, and histological subtype [60].

3.1.38 Xanthoma

3.1.38.1 Cytologic Features

Xanthomas exfoliate well as individualized cells that have abundant cytoplasm containing variably sized, coarse, clear vacuoles (Figure 3.55). Nuclei are round, eccentrically placed, and have finely stippled

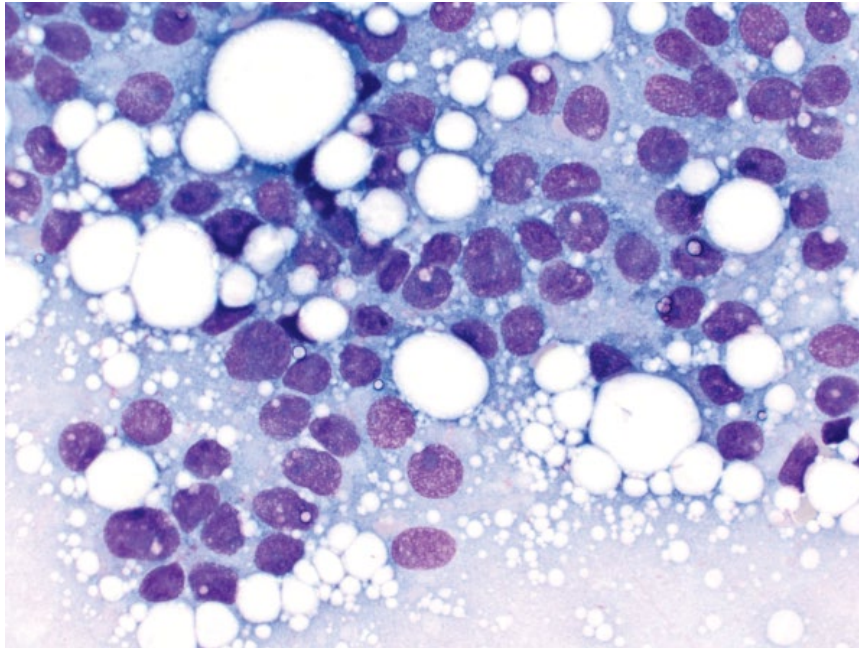


Figure 3.54 Liposarcoma (poorly differentiated), dog, 50× objective. The cells appear almost cohesive and contain coarse, clear lipid vacuoles. Note also the small size relative to Figure 3.53.

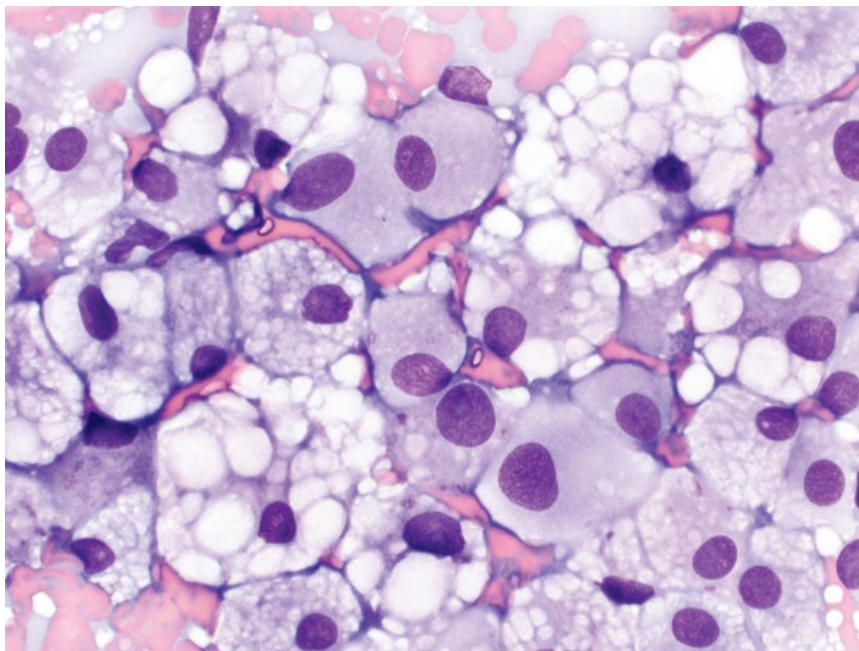


Figure 3.55 Xanthoma, dog, 50× objective. Macrophages are monomorphic and frequently contain coarse, clear vacuoles.

chromatin with small nucleoli. Anisocytosis is moderate, and anisokaryosis is mild. Varying degrees of inflammation are seen. Cytologically, xanthomas can be difficult to differentiate from liposarcomas and reactive fibrohistiocytic nodules (compare to Figures 3.54 and 3.56).

3.1.38.2 Clinical Considerations

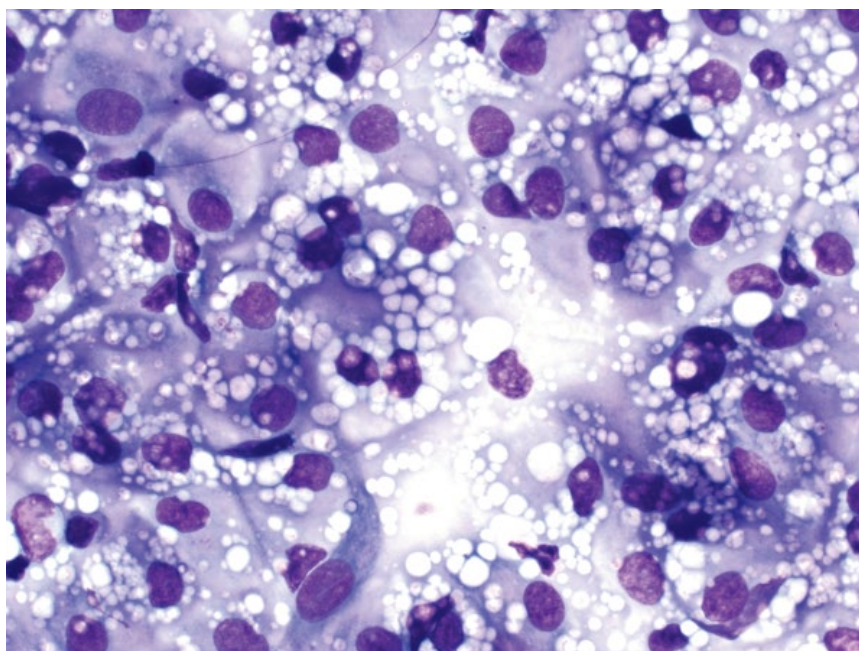
- Cats > dogs.
- Benign inflammatory lesions of macrophages laden with cholesterol and lipid.

- Usually multiple (rarely solitary) raised, hairless, white/yellow, plaques or nodules.
- Most common around the face and periorbital regions. Rarely disseminated [61].
- May be idiopathic [62], or manifest secondary to diseases of lipid metabolism (e.g., hyperlipidemia from diabetes mellitus or glucocorticoid therapy).

3.1.38.3 Prognosis

Excellent with surgical resection and treatment of any underlying predisposing cause.

Figure 3.56 Reactive fibrohistiocytic nodule, dog, 50× objective. Note the reactive, vacuolated macrophages and the spindle cell (lower left).



3.1.39 Reactive Fibrohistiocytic Nodule

3.1.39.1 Cytologic Features

Reactive fibrohistiocytic nodules contain reactive macrophages seen individually and in sheets. The cells have a moderate volume of pale- to medium-blue cytoplasm that contains fine, coarse, clear vacuoles. Nuclei are round with stippled chromatin and small or inconspicuous nucleoli (Figure 3.56). Anisocytosis/anisokaryosis are mild (compared to liposarcomas). These lesions can appear similar to cutaneous xanthomas (compare to Figure 3.55), but generally have more fine vacuoles. Additionally, cutaneous xanthomas usually are multiple, while reactive fibrohistiocytic nodules are solitary.

3.1.39.2 Clinical Considerations

- Rare lesions. Seen in young dogs (aged <3 years).
- Usually single, <1 cm, haired or partially alopecic nodules [63].
- Most common on face and legs.

3.1.39.3 Prognosis

Excellent with surgical excision.

3.1.40 Canine Sterile Nodular Panniculitis

3.1.40.1 Cytologic Features

These lesions are characterized by a population of reactive macrophages that have abundant, vacuolated cytoplasm, and numerous clear vacuoles in the background (Figure 3.57). Variable numbers of other inflammatory cells are present.

3.1.40.2 Clinical Considerations

- Usually multiple nodules on the trunk and neck ± ulceration or draining tracts.
- Predisposed breeds = Australian Shepherd, Brittany Spaniel, Dalmatian, Pomeranian, Chihuahua [64].
- May be associated with other inflammatory diseases, especially immune-mediated polyarthritis [64, 65].
- Rule out other causes of panniculitis (see section 3.1.41) and histopathology required for definitive diagnosis.

3.1.40.3 Prognosis

Good. High rate of remission with appropriate therapy. Investigation for underlying systemic disease may be recommended [64, 65].

3.1.41 Panniculitis/Steatitis

3.1.41.1 Cytologic Features

These lesions are characterized by an inflammatory population of cells, intimately associated with abundant adipose tissue (Figure 3.58). The inflammatory population ranges from neutrophilic to mononuclear, and the process may be sterile or septic.

3.1.41.2 Clinical Considerations

- May present with nodules or diffuse subcutaneous thickening.
- Infectious agents are a common cause (see Chapter 2).
- Non-infectious causes = blunt or penetrating trauma, foreign body reactions, drug reactions, pancreatic

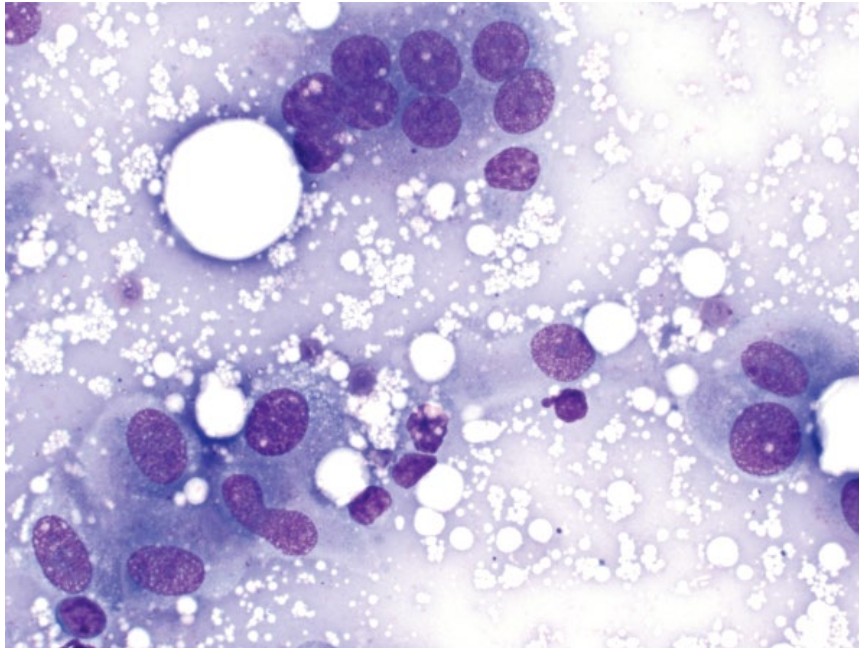


Figure 3.57 Sterile nodular panniculitis, dog, 50× objective. Note the abundant free lipid vacuoles, and the multinucleated macrophage (top).

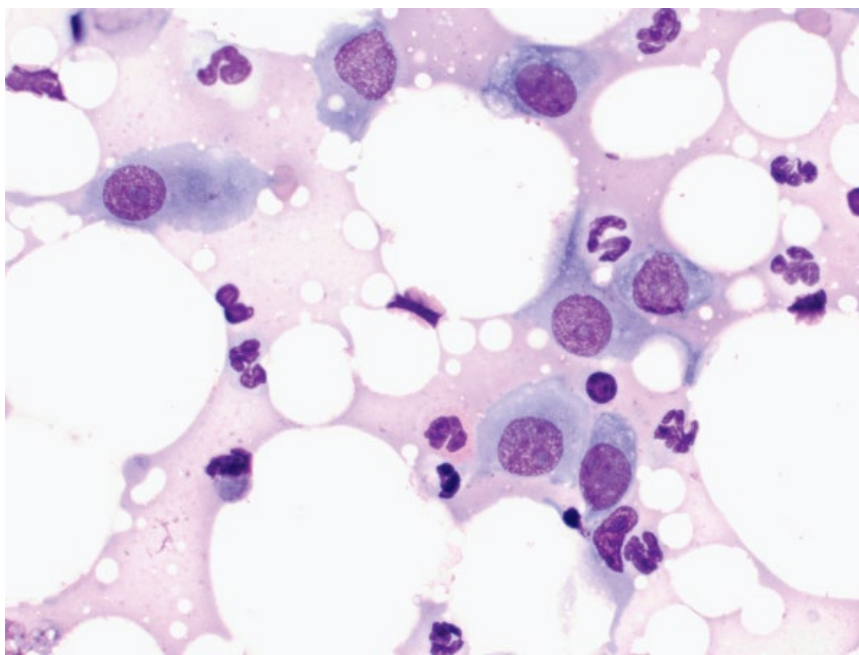


Figure 3.58 Steatitis, dog, 50× objective. Mixed inflammation is centered around numerous clear lipid vacuoles.

disease and immune-mediated causes (see canine sterile nodular panniculitis).

- Rule out inflamed/traumatized lipomas.

3.1.41.3 Prognosis

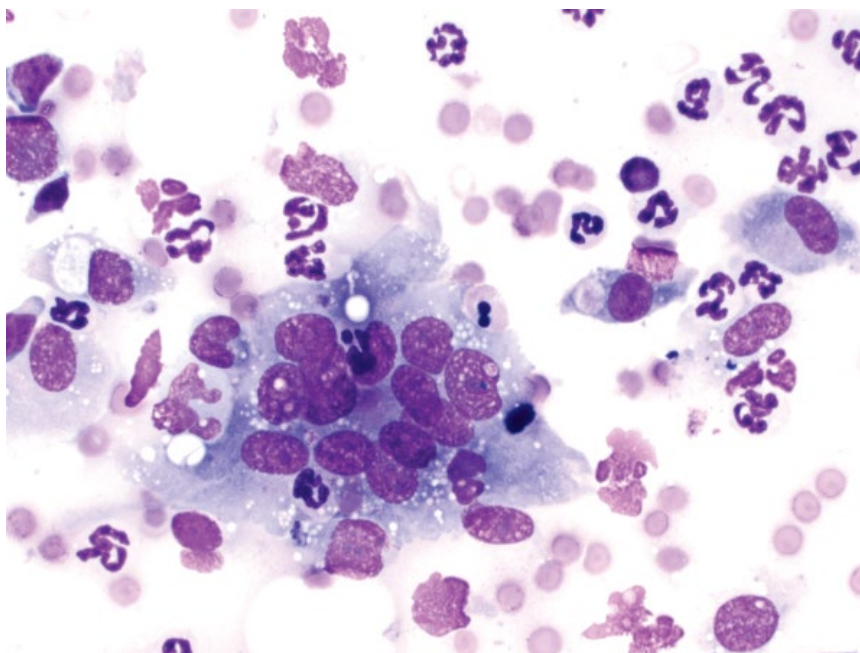
Generally good based on underlying cause and treatment.

3.1.42 Granulomatous/Pyogranulomatous Inflammation

3.1.42.1 Cytologic Features

Granulomatous lesions are characterized by a predominance of reactive macrophages, which may be seen individually or in crowded aggregates (epithelioid macrophages). Multinucleated macrophages frequently

Figure 3.59 Pyogranulomatous inflammation, dog, 50× objective. Note the large, multinucleated macrophage, accompanied by neutrophils.



are seen (Figure 3.59). Other inflammatory cells often are present, and may include neutrophils (pyogranulomatous inflammation) or small mature lymphocytes.

3.1.42.2 Clinical Considerations

- DDx = acral lick granulomas, furunculosis, foreign body reactions, injection site reactions, infectious agents (especially fungi and atypical bacteria such as *Mycobacterium spp.* or *Actinomyces*; see Chapter 2) or secondary to rupture of epidermal cysts.

3.1.42.3 Prognosis

Mostly good depending on treatment of the underlying cause. Some lesions are self-limiting.

3.1.43 Vaccination Reaction

3.1.43.1 Cytologic Features

Vaccination reactions mostly are characterized by a granulomatous or pyogranulomatous inflammatory response, with infiltration of lymphocytes and plasma cells in chronic lesions. Vaccine adjuvant is often (but not always) present in the background or phagocytosed by macrophages and appears as globular magenta to blue material (Figure 3.60). Reactive fibroblasts may be present.

3.1.43.2 Clinical Considerations

- Firm, single, subcutaneous nodules in area of injection/vaccine.
- Often delayed onset after vaccination (weeks).
- May take weeks, or even months to resolve.

3.1.43.3 Prognosis

Excellent.

3.1.44 Abscess

3.1.44.1 Cytologic Features

Abscesses generally are characterized by large numbers of degenerative neutrophils (see Chapter 1). When these changes are seen, close evaluation for infectious organisms is warranted. Intracellular organisms confirm a septic etiology (Figure 3.61). Many different infectious organisms can cause cutaneous abscesses (see Chapter 2). Sterile abscessation is less common.

3.1.44.2 Clinical Considerations

- Lesions variably fluctuant, warm, and painful. Draining tracts may be present.
- Purulent material often aspirated.
- Microbial culture and susceptibility testing recommended.

3.1.44.3 Prognosis

Generally excellent with appropriate therapy, but variable based on the underlying cause/etiologic agent.

3.1.45 Seroma/Hygroma

3.1.45.1 Cytologic Features

Seromas typically have a variably thick, blue/purple proteinaceous background, with low numbers of inflammatory cells scattered individually (Figure 3.62). The type of

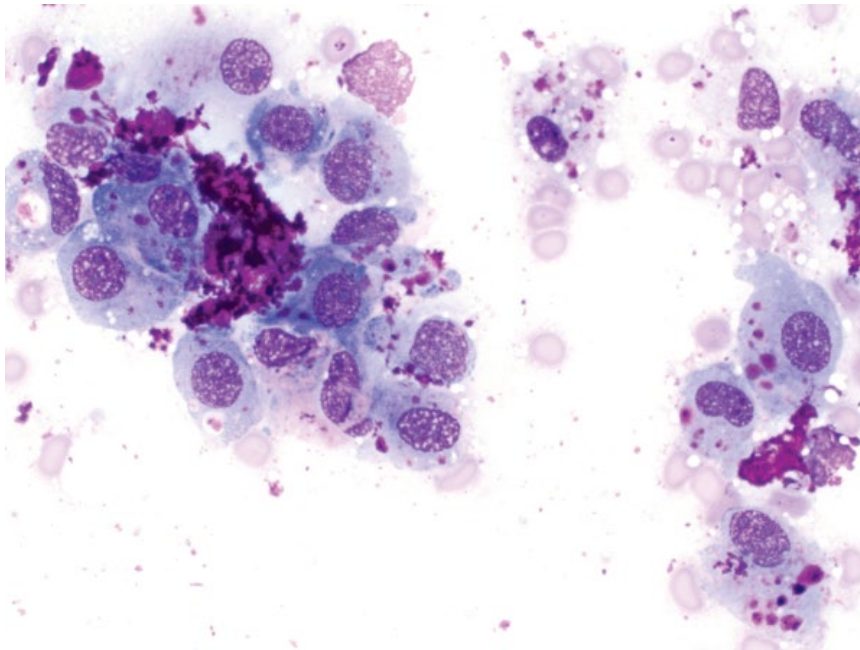


Figure 3.60 Vaccine reaction (rabies vaccine), dog, 50× objective. Note the abundant purple granular material in the background and phagocytosed by macrophages.

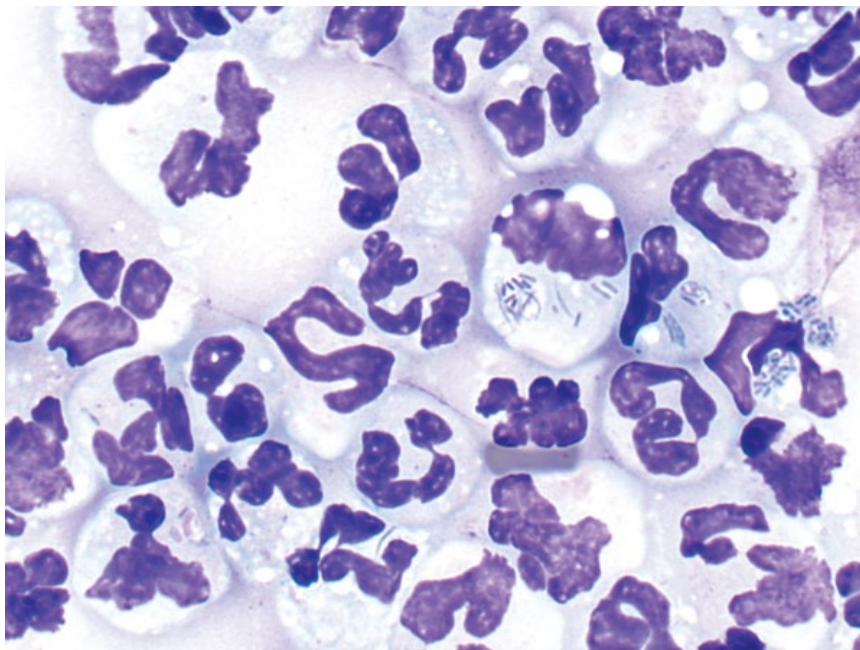


Figure 3.61 Abscess, cat, 100× objective. Neutrophils are degenerative and contain intracellular bacteria.

inflammatory cells often reflects the time course of the lesion, dominated by non-degenerative neutrophils acutely, and macrophages in the chronic stages. There may be evidence of hemorrhage (see Chapter 1).

3.1.45.2 Clinical Considerations

- Soft, fluctuant, fluid-filled lesions.
- Associated with trauma or surgery.
- Hygromas form over bony prominences secondary to chronic trauma and appear similar to seromas.

3.1.45.3 Prognosis

Excellent. Spontaneous resolution is common, but drainage may be required.

3.1.46 Calcinosis Circumscripta

3.1.46.1 Cytologic Features

Samples have a thick purple background with abundant aggregates of refractile, crystalline material (Figure 3.63). Nucleated cells usually are present in low numbers, mostly

Figure 3.62 Seroma, dog, 50× objective. Macrophages contain phagocytosed proteinaceous material.

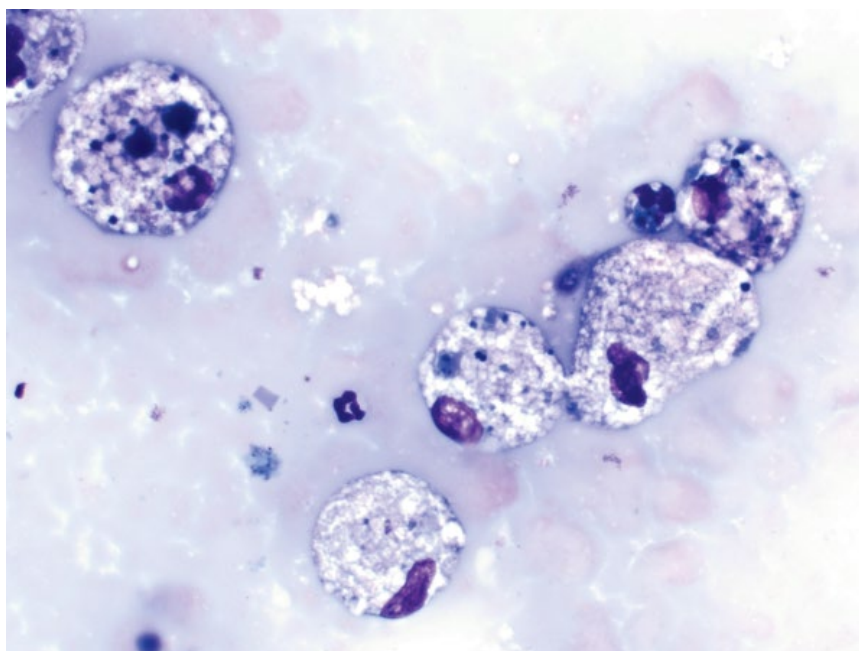
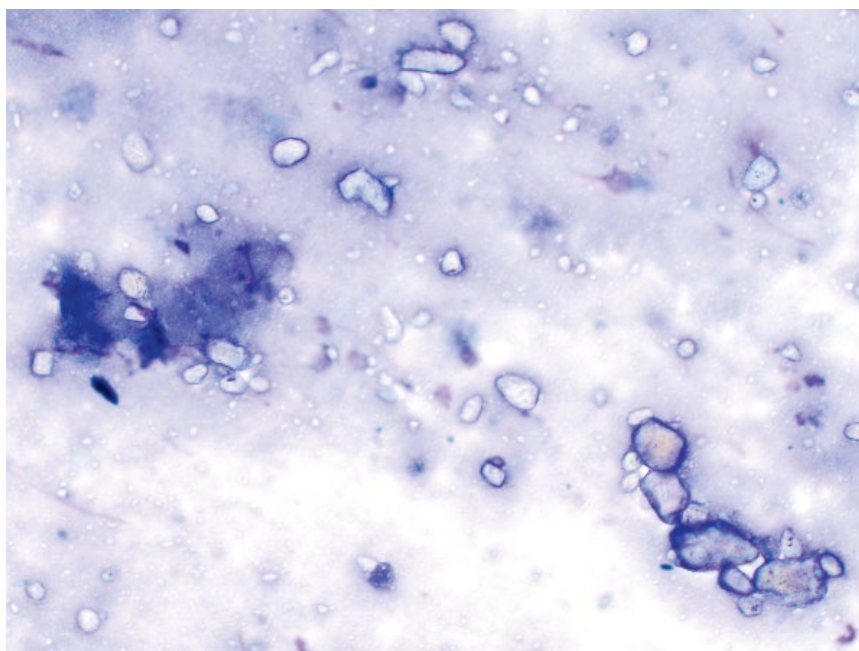


Figure 3.63 Calcinosis circumscripta, dog, 20× objective. Note the thick background and aggregates of refractile mineralized debris.



reactive macrophages, which may contain phagocytosed mineralized debris. Grossly, stained sides have a characteristic chalky appearance (Figure 3.64).

3.1.46.2 Clinical Considerations

- Dogs > cats. German Shepherds are predisposed.
- Young animals over-represented (88% of dogs <4 years of age in one study) [66].

- Mostly firm, gritty, solitary lesions between 0.5 and 3 cm around the joints, and bony prominences of limbs. Other sites include tongue and paw pads.
- Pathogenesis is unknown, but dystrophic mineralization secondary to trauma has been proposed.

3.1.46.3 Prognosis

Excellent. Spontaneous regression may occur, and surgical excision generally is curative.




Figure 3.64 Calcosinosis circumscripta (gross appearance), dog. The samples have a characteristic, thick chalky appearance.

3.1.47 Calcosinosis Cutis

3.1.47.1 Cytologic Features

Samples have a similar appearance to those of calcosinosis circumscripta, but usually are more cellular with greater numbers of inflammatory cells (Figure 3.65).

3.1.47.2 Clinical Considerations

- Erythematous papules or gritty plaques commonly found on the dorsal trunk and head, as well as the inguinal region and extremities.

- DDx = glucocorticoid exposure, hyperadrenocorticism (dogs), calcium/phosphorus imbalance, tissue trauma.
- Idiopathic calcosinosis cutis occurs in young dogs (usually aged <1 year) and spontaneously resolves [67].

3.1.47.3 Prognosis

Good to excellent with spontaneous resolution after treatment of the underlying cause.

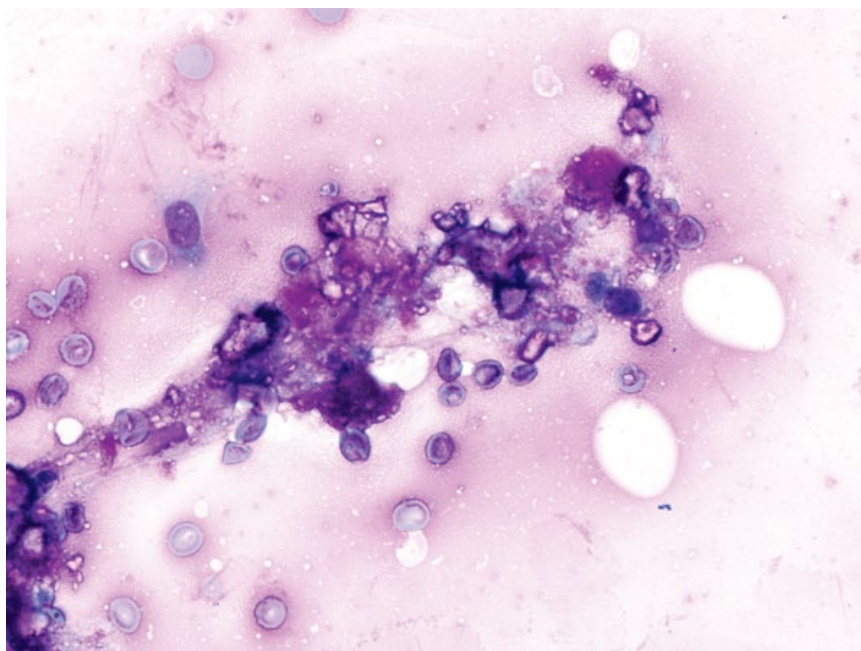
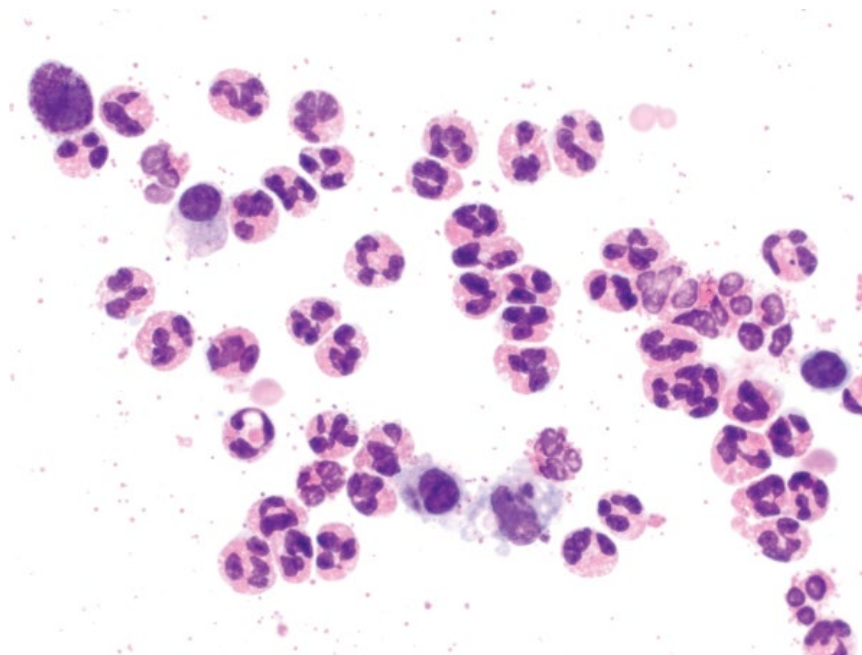


Figure 3.65 Calcosinosis cutis, dog, 50x objective.

Figure 3.66 Hypersensitivity reaction, dog, 50× objective. Note the mast cell (top left).



3.1.48 Hypersensitivity Reaction

3.1.48.1 Cytologic Features

Hypersensitivity reactions frequently are dominated by eosinophils, with lesser numbers of mast cells and other inflammatory cells (Figure 3.66). Differential diagnoses may include eosinophilic granuloma or mast cell tumor. Useful findings to help differentiate from mast cell tumors include individualized cells (compared to aggregates of mast cells in neoplastic lesions), and well-differentiated mast cells with many granules (compare to mast cell tumors; sections 3.1.1 and 3.1.2).

3.1.48.2 Clinical Considerations

- Acute onset of single or multiple, haired nodules.
- May be associated with arthropod bites or contact allergens.

3.1.48.3 Prognosis

Excellent. Lesions mostly spontaneously resolve, but those requiring therapy also have a good prognosis.

3.1.49 Eosinophilic Granuloma/Inflammatory Disease

3.1.49.1 Cytologic Features

Eosinophils predominate and frequently are found in aggregates. Many free eosinophil granules may be seen in the background (Figure 3.67). A variable number of other inflammatory cells may be present, with macrophages generally present in eosinophilic granulomas.

3.1.49.2 Clinical Considerations

- Eosinophilic granulomas occur in cats and dogs. Lesions are erythematous to yellow, raised nodules or linear bands most common on the inner thigh/posterior hind limbs > head and mouth.
- Eosinophilic ulcers and plaques also are common lesions in cats around the oral cavity and ventral abdomen [68].
- Rule out allergic/hypersensitivity disease, infectious agents and immune-mediated/idiopathic.
- Concurrent sepsis is common [69].

3.1.49.3 Prognosis

Good with appropriate therapy.

3.1.50 Pemphigus Foliaceus

3.1.50.1 Cytologic Features

Pemphigus lesions are characterized by acantholytic keratinocytes. These cells are round, with intensely staining magenta, granular cytoplasm and large, round, central nuclei (Figure 3.68). Neutrophils and other inflammatory cells are frequent findings. Although acantholytic cells are not pathognomonic for pemphigus (and can be seen in other chronic or immune-mediated conditions), they are most common in this disease, and were present in 77% of cases in one study [70].

3.1.50.2 Clinical Considerations

- Most common autoimmune disease of skin in dogs and cats.
- May occur spontaneously or secondary to drug administration or neoplasia.

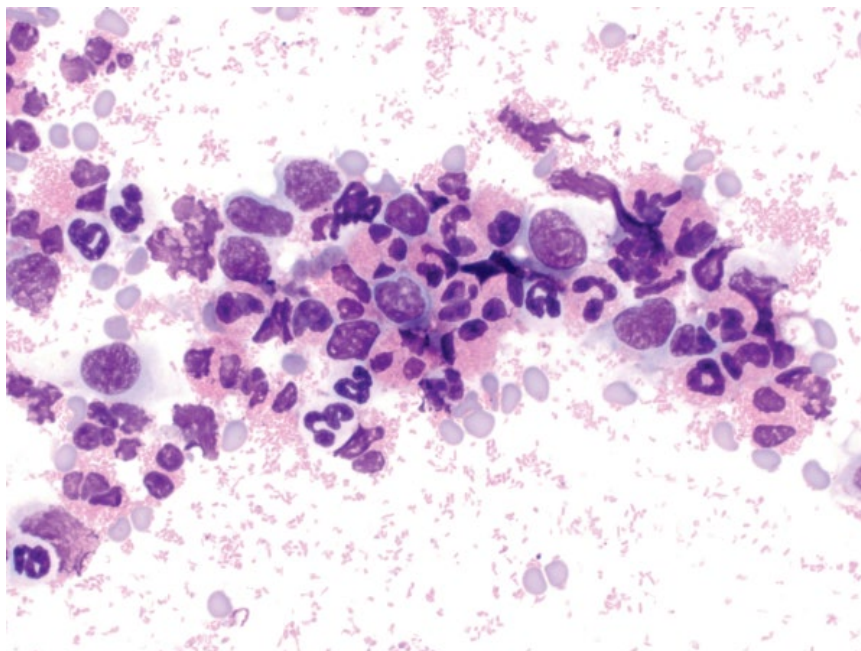


Figure 3.67 Eosinophilic granuloma, cat, 50× objective. Note the abundant eosinophil granules in the background.

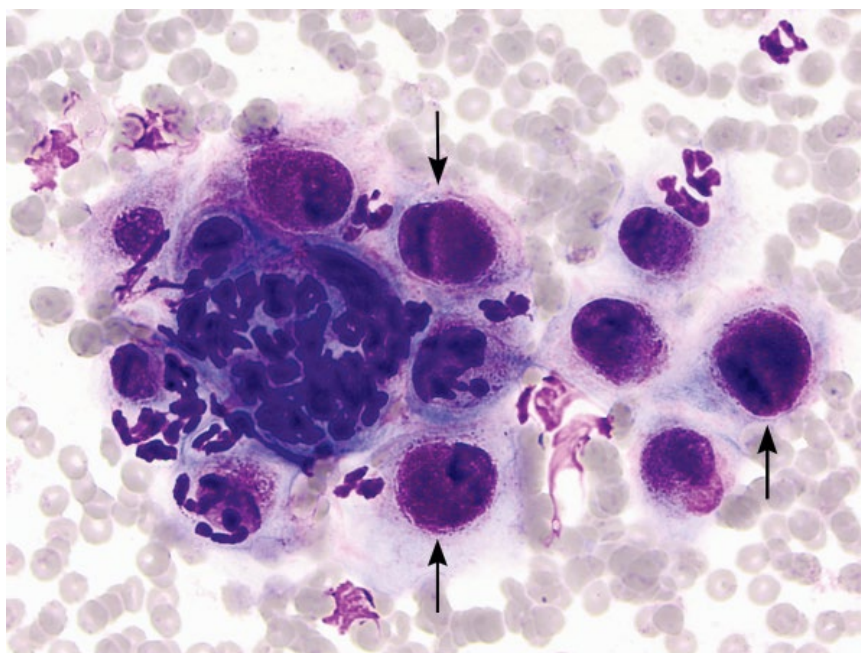


Figure 3.68 Pemphigus foliaceus, dog, 50× objective. Numerous acantholytic cells (arrows) accompanied by neutrophilic inflammation.

- Grossly = crusts, papules, and alopecia.
- Predilection sites in order of frequency = trunk, inner pinna, face, and footpads [70].

3.1.50.3 Prognosis

Variable. High mortality can be seen in early stages of disease, but long-term survival is possible with response to therapy [70, 71].

References

- 1 Camus, M.S., Priest, H.L., Koehler, J.W., *et al.* (2016) Cytologic criteria for mast cell tumor grading in dogs with evaluation of clinical outcome. *Vet. Pathol.*, **53** (6), 1117–1123.
- 2 Allison, R.W., Velguth, K.E. (2010) Appearance of granulated cells in blood films stained by automated aqueous versus methanolic Romanowsky methods. *Vet. Clin. Pathol.*, **39** (1), 99–104.

- 3 Shoop, S.J., Marlow, S., Church, D.B., *et al.* (2015) Prevalence and risk factors for mast cell tumours in dogs in England. *Canine Genet. Epidemiol.* 2015;2:1. doi: 10.1186/2052-6687-2-1. eCollection. Last accessed May 1 2017.
- 4 Kiupel, M., Webster, J.D., Bailey, K.L., *et al.* (2011) Proposal of a 2-tier histologic grading system for canine cutaneous mast cell tumors to more accurately predict biological behavior. *Vet. Pathol.*, **48** (1), 147–155.
- 5 Mullins, M.N., Dernell, W.S., Withrow, S.J., *et al.* (2006) Evaluation of prognostic factors associated with outcome in dogs with multiple cutaneous mast cell tumors treated with surgery with and without adjuvant treatment: 54 cases (1998–2004). *J. Am. Vet. Med. Assoc.*, **228** (1), 91–95.
- 6 Litster, A.L., Sorenmo, K.U. (2006) Characterisation of the signalment, clinical and survival characteristics of 41 cats with mast cell neoplasia. *J. Feline Med. Surg.*, **8** (3), 177–183.
- 7 Molander-McCrary, H., Henry, C.J., Potter, K., *et al.* (1998) Cutaneous mast cell tumors in cats: 32 cases (1991–1994). *J. Am. Anim. Hosp. Assoc.*, **34** (4), 281–284.
- 8 Melville, K., Smith, K.C., Dobromylskyj, M.J. (2015) Feline cutaneous mast cell tumours: a UK-based study comparing signalment and histological features with long-term outcomes. *J. Feline Med. Surg.*, **17** (6), 486–493.
- 9 Moore, P.F., Schrenzel, M.D., Affolter, V.K., *et al.* (1996) Canine cutaneous histiocytoma is an epidermotropic Langerhans cell histiocytosis that expresses CD1 and specific beta 2-integrin molecules. *Am. J. Pathol.*, **148** (5), 1699–1708.
- 10 Affolter, V.K., Moore, P.F. (2002) Localized and disseminated histiocytic sarcoma of dendritic cell origin in dogs. *Vet. Pathol.*, **39** (1), 74–83.
- 11 Klahn, S.L., Kitchell, B.E., Dervisis, N.G. (2011) Evaluation and comparison of outcomes in dogs with periarticular and nonperiarticular histiocytic sarcoma. *J. Am. Vet. Med. Assoc.*, **239** (1), 90–96.
- 12 Fontaine, J., Heimann, M., Day, M.J. (2011) Cutaneous epitheliotropic T-cell lymphoma in the cat: a review of the literature and five new cases. *Vet. Dermatol.*, **22** (5), 454–461.
- 13 Affolter, V.K., Gross, T.L., Moore, P.F. (2009) Indolent cutaneous T-cell lymphoma presenting as cutaneous lymphocytosis in dogs. *Vet. Dermatol.*, **20** (5-6), 577–585.
- 14 Baer, K.E., Patnaik, A.K., Gilbertson, S.R., *et al.* (1989) Cutaneous plasmacytomas in dogs: a morphologic and immunohistochemical study. *Vet. Pathol.*, **26** (3), 216–221.
- 15 Mukaratirwa, S., Gruys, E. (2003) Canine transmissible venereal tumour: cytogenetic origin, immunophenotype, and immunobiology. A review. *Vet. Q.*, **25** (3), 101–111.
- 16 Smedley, R.C., Spangler, W.L., Esplin, D.G., *et al.* (2011) Prognostic markers for canine melanocytic neoplasms: a comparative review of the literature and goals for future investigation. *Vet. Pathol.*, **48** (1), 54–72.
- 17 Goldschmidt, M.H., Dunstan, R.W., Stannard, A.A., *et al.* (1998) Histological classification of epithelial and melanocytic neoplasms of the skin of domestic animals. In: *World Health Organization International Histological Classification of Neoplasms of Domestic Animals*, 2nd series, Vol. III. Armed Forces Institute of Pathology, Washington DC, pp. 38–40.
- 18 Spangler, W.L., Kass, P.H. (2006) The histologic and epidemiologic bases for prognostic considerations in canine melanocytic neoplasia. *Vet. Pathol.*, **43** (2), 136–149.
- 19 Williams, L.E., Packer, R.A. (2003) Association between lymph node size and metastasis in dogs with oral malignant melanoma: 100 cases (1987–2001). *J. Am. Vet. Med. Assoc.*, **222** (9), 1234–1236.
- 20 Bohn, A.A., Wills, T., Caplazi, P. (2006) Basal cell tumor or cutaneous basilar epithelial neoplasm? Rethinking the cytologic diagnosis of basal cell tumors. *Vet. Clin. Pathol.*, **35** (4), 449–453.
- 21 Simeonov, R., Simeonova, G. (2008) Nucleomorphometric analysis of feline basal cell carcinomas. *Res. Vet. Sci.*, **84** (3), 440–443.
- 22 Nibe, K., Uchida, K., Itoh, T., *et al.* (2005) A case of canine apocrine sweat gland adenoma, clear cell variant. *Vet. Pathol.*, **42** (2), 215–218.
- 23 Kalaher, K.M., Anderson, W.I., Scott, D.W. (1990) Neoplasms of the apocrine sweat glands in 44 dogs and 10 cats. *Vet. Rec.*, **127** (16), 400–403.
- 24 Simko, E., Wilcock, B.P., Yager, J.A. (2003) A retrospective study of 44 canine apocrine sweat gland adenocarcinomas. *Can. Vet. J.*, **44** (1), 38–42.
- 25 Hazirolu, R., Haligur, M., Keles, H. (2014) Histopathological and immunohistochemical studies of apocrine sweat gland adenocarcinomas in cats. *Vet. Comp. Oncol.*, **12** (1), 85–90.
- 26 Scott, D.W., Anderson, W.I. (1990) Canine sebaceous gland tumors: a retrospective analysis of 172 cases. *Canine Pract.*, **15** (1), 19–21, 24–27.
- 27 Sabattini, S., Bassi, P., Bettini, G. (2015) Histopathological findings and proliferative activity of canine sebaceous gland tumours with a predominant reserve cell population. *J. Comp. Pathol.*, **152** (2-3), 145–152.
- 28 Bettini, G., Morini, M., Mandrioli, L., *et al.* (2009) CNS and lung metastasis of sebaceous epithelioma in a dog. *Vet. Dermatol.*, **20** (4), 289–294.
- 29 Scott, D.W., Anderson, W.I. (1991) Feline sebaceous gland tumors: a retrospective analysis of 9 cases. *Feline Pract.*, **19**, 16–18, 20–21.
- 30 White, S.D., Rappaport, J., Carpenter, J.L., *et al.* (1985) Cutaneous metastases of a mammary adenocarcinoma

- resembling eosinophilic plaques in a cat. *Feline Pract.*, **15** (3), 27–29.
- 31 Reed, L.T., Knapp, D.W., Miller, M.A. (2013) Cutaneous metastasis of transitional cell carcinoma in 12 dogs. *Vet. Pathol.*, **50** (4), 676–681.
 - 32 Favrot, C., Degorce-Rubiales, F. (2005) Cutaneous metastases of a bronchial adenocarcinoma in a cat. *Vet. Dermatol.*, **16** (3), 183–186.
 - 33 Petterino, C., Guazzi, P., Ferro, S., *et al.* (2005) Bronchogenic adenocarcinoma in a cat: an unusual case of metastasis to the skin. *Vet. Clin. Pathol.*, **34** (4), 401–404.
 - 34 DeBey, B.M., Bagladi-Swanson, M., Kapil, S., *et al.* (2001) Digital papillomatosis in a confined beagle. *J. Vet. Diagn. Invest.*, **13** (4), 346–348.
 - 35 Wobeser, B.K., Kidney, B.A., Powers, B.E., *et al.* (2007) Diagnoses and clinical outcomes associated with surgically amputated canine digits submitted to multiple veterinary diagnostic laboratories. *Vet. Pathol.*, **44** (3), 355–361.
 - 36 Pisani, G., Millanta, F., Lorenzi, D., *et al.* (2006) Androgen receptor expression in normal, hyperplastic and neoplastic hepatoid glands in the dog. *Res. Vet. Sci.*, **81** (2), 231–236.
 - 37 Berrocal, A., Vos, J.H., van den Ingh, T.S., *et al.* (1989) Canine perineal tumours. *J. Vet. Med. Ser. A*, **36** (1-10), 739–749.
 - 38 Vail, D.M., Withrow, S.J., Schwarz, P.D., *et al.* (1990) Perianal adenocarcinoma in the canine male: a retrospective study of 41 cases. *J. Am. Anim. Hosp. Assoc.*, **26** (3), 329–334.
 - 39 Bennett, P.F., DeNicola, D.B., Bonney, P., *et al.* (2002) Canine anal sac adenocarcinomas: clinical presentation and response to therapy. *J. Vet. Intern. Med.*, **16** (1), 100–104.
 - 40 Williams, L.E., Gliatto, J.M., Dodge, R.K., *et al.* (2003) Carcinoma of the apocrine glands of the anal sac in dogs: 113 cases (1985–1995). *J. Am. Vet. Med. Assoc.*, **223** (6), 825–831.
 - 41 Piviani, M., Sánchez, M.D., Patel, R.T. (2012) Cytologic features of clear cell adnexal carcinoma in 3 dogs. *Vet. Clin. Pathol.*, **41** (3), 405–411.
 - 42 Schulman, F.Y., Lipscomb, T.P., Atkin, T.J. (2005) Canine cutaneous clear cell adnexal carcinoma: histopathology, immunohistochemistry, and biologic behavior of 26 cases. *J. Vet. Diagn. Invest.*, **17** (5), 403–411.
 - 43 Miller, M.A., Nelson, S.L., Turk, J.R., *et al.* (1991) Cutaneous neoplasia in 340 cats. *Vet. Pathol.*, **28** (5), 389–395.
 - 44 Pakhrin, B., Kang, M.S., Bae, I.H., *et al.* (2007) Retrospective study of canine cutaneous tumors in Korea. *J. Vet. Sci.*, **8** (3), 229–236.
 - 45 Kuntz, C.A., Dernell, W.S., Powers, B.E., *et al.* (1997) Prognostic factors for surgical treatment of soft-tissue sarcomas in dogs: 75 cases (1986–1996). *J. Am. Vet. Med. Assoc.*, **211** (9), 1147–1151.
 - 46 McKnight, J.A., Mauldin, G.N., McEntee, M.C., *et al.* (2000) Radiation treatment for incompletely resected soft-tissue sarcomas in dogs. *J. Am. Vet. Med. Assoc.*, **217** (2), 205–210.
 - 47 Selting, K.A., Powers, B.E., Thompson, L.J., *et al.* (2005) Outcome of dogs with high-grade soft tissue sarcomas treated with and without adjuvant doxorubicin chemotherapy: 39 cases (1996–2004). *J. Am. Vet. Med. Assoc.*, **227** (9), 1442–1448.
 - 48 Mikaelian, I., Gross, T.L. (2002) Keloidal fibromas and fibrosarcomas in the dog. *Vet. Pathol.*, **39** (1), 149–153.
 - 49 Avallone, G., Helmbold, P., Caniatti, M., *et al.* (2007) The spectrum of canine cutaneous perivascular wall tumors: morphologic, phenotypic and clinical characterization. *Vet. Pathol.*, **44** (5), 607–620.
 - 50 Dennis, M.M., McSporran, K.D., Bacon, N.J., *et al.* (2011) Prognostic factors for cutaneous and subcutaneous soft tissue sarcomas in dogs. *Vet. Pathol.*, **48** (1), 73–84.
 - 51 Trappier, M.C., Popovitch, C.A., Goldschmidt, M.H., *et al.* (2014) Scrotal tumors in dogs: a retrospective study of 676 cases (1986–2010). *Can. Vet. J.*, **55** (1), 1229–1233.
 - 52 Ward, H., Fox, L.E., Calderwood-Mays, M.B., *et al.* (1994) Cutaneous hemangiosarcoma in 25 dogs: a retrospective study. *J. Vet. Intern. Med.*, **8** (5), 345–348.
 - 53 McAbee, K.P., Ludwig, L.L., Bergman, P.J., *et al.* (2005) Feline cutaneous hemangiosarcoma: a retrospective study of 18 cases (1998–2003). *J. Am. Anim. Hosp. Assoc.*, **41** (2), 110–116.
 - 54 Craig, L.E., Krimer, P.M., Cooley, A.J. (2010) Canine synovial myxoma: 39 cases. *Vet. Pathol.*, **47** (5), 931–936.
 - 55 Machida, N., Hoshi, K., Kobayashi, M., *et al.* (2003) Cardiac myxoma of the tricuspid valve in a dog. *J. Comp. Pathol.*, **129** (4), 320–324.
 - 56 Bostock, D.E., Dye, M.T. (1980) Prognosis after surgical excision of canine fibrous connective tissue sarcomas. *Vet. Pathol.*, **17** (5), 581–588.
 - 57 Headley, S.A., Faria Dos Reis, A.C., Bracarense, A.P. (2011) Cutaneous myxosarcoma with pulmonary metastases in a dog. *J. Comp. Pathol.*, **145** (1), 31–34.
 - 58 Schneider, P., Busch, U., Meister, H., *et al.* (1999) Malignant fibrous histiocytoma (MFH). A comparison of MFH in man and animals. A critical review. *Histol. Histopathol.*, **14** (3), 845–860.
 - 59 Bergman, P.J., Withrow, S.J., Straw, R.C., *et al.* (1994) Infiltrative lipoma in dogs: 16 cases (1981–1992). *J. Am. Vet. Med. Assoc.*, **205** (2), 322–324.

- 60 Baez, J.L., Hendrick, M.J., Shofer, F.S., *et al.* (2004) Liposarcomas in dogs: 56 cases (1989–2000). *J. Am. Vet. Med. Assoc.*, **224** (6), 887–891.
- 61 Chanut, F., Colle, M.A., Deschamps, J.Y., *et al.* (2005) Systemic xanthomatosis associated with hyperchylomicronaemia in a cat. *J. Vet. Med. A. Physiol. Pathol. Clin. Med.*, **52** (6), 272–274.
- 62 Banajee, K.H., Orandle, M.S., Ratterree, W., *et al.* (2011) Idiopathic solitary cutaneous xanthoma in a dog. *Vet. Clin. Pathol.*, **40** (1), 95–98.
- 63 Gross, T.L., Ihrke, P.J., Walder, E.J., *et al.* (2005) Histiocytic tumors. In: *Skin Diseases of the Dog and Cat: Clinical and Histopathological Diagnosis*, 2nd edn, Blackwell Science, Oxford, UK, pp. 837–840.
- 64 Contreary, C.L., Outerbridge, C.A., Affolter, V.K., *et al.* (2015) Canine sterile nodular panniculitis: a retrospective study of 39 dogs. *Vet. Dermatol.*, **26** (6), 451–458.
- 65 O’Kell, A.L., Inteeworn, N., Diaz, S.F., *et al.* (2010) Canine sterile nodular panniculitis: a retrospective study of 14 cases. *J. Vet. Intern. Med.*, **24** (2), 278–284.
- 66 Tafti, A.K., Hanna, P., Bourque, A.C. (2005) Calcinosis circumscripta in the dog: a retrospective pathological study. *J. Vet. Med. A. Physiol. Pathol. Clin. Med.*, **52** (1), 13–17.
- 67 Doerr, K.A., Outerbridge, C.A., White, S.D., *et al.* (2013) Calcinosis cutis in dogs: histopathological and clinical analysis of 46 cases. *Vet. Dermatol.*, **24** (3), 355–361.
- 68 Buckley, L., Nuttall, T. (2012) Feline eosinophilic granuloma complex(ities): some clinical clarification. *J. Feline Med. Surg.*, **14** (7), 471–481.
- 69 Wildermuth, B.E., Griffin, C.E., Rosenkrantz, W.S. (2012) Response of feline eosinophilic plaques and lip ulcers to amoxicillin trihydrate-clavulanate potassium therapy: a randomized, double-blind placebo-controlled prospective study. *Vet. Dermatol.*, **23** (2), 110–118.
- 70 Mueller, R.S., Krebs, I., Power, H.T., *et al.* (2006) Pemphigus foliaceus in 91 dogs. *J. Am. Anim. Hosp. Assoc.*, **42** (3), 189–196.
- 71 Gomez, S.M., Morris, D.O., Rosenbaum, M.R., *et al.* (2004) Outcome and complications associated with treatment of pemphigus foliaceus in dogs: 43 cases (1994–2000). *J. Am. Vet. Med. Assoc.*, **224** (8), 1312–1316.

4

Hemolymphatic

4.1 Lymph Nodes

4.1.1 Normal

4.1.1.1 Cytologic Appearance

Small mature lymphocytes predominate (~80+%) in normal lymph nodes. These cells have nuclei with diameters approximately equal to that of a red blood cell, and mature, clumped chromatin with inapparent nucleoli. A scant amount of cytoplasm is present. Low numbers of intermediate-sized lymphocytes, and rare plasma cells and larger lymphocytes may be seen (Figures 4.1 and 4.2).

4.1.2 Reactive Lymphoid Hyperplasia

4.1.2.1 Cytologic Appearance

Reactive lymphoid hyperplasia is characterized by a heterogeneous population of lymphocytes (Figures 4.3–4.5).

Small mature cells typically predominate, but are admixed with variably increased numbers of plasma cells, intermediate and large reactive lymphocytes. Mitotic figures can be seen in reactive lymph nodes (Figure 4.5). Some plasma cells may accumulate immunoglobulin, seen as bright-blue or pink inclusions (Mott cells) or diffuse pink coloration (Flame cells) (see Figure 1.24E and F).

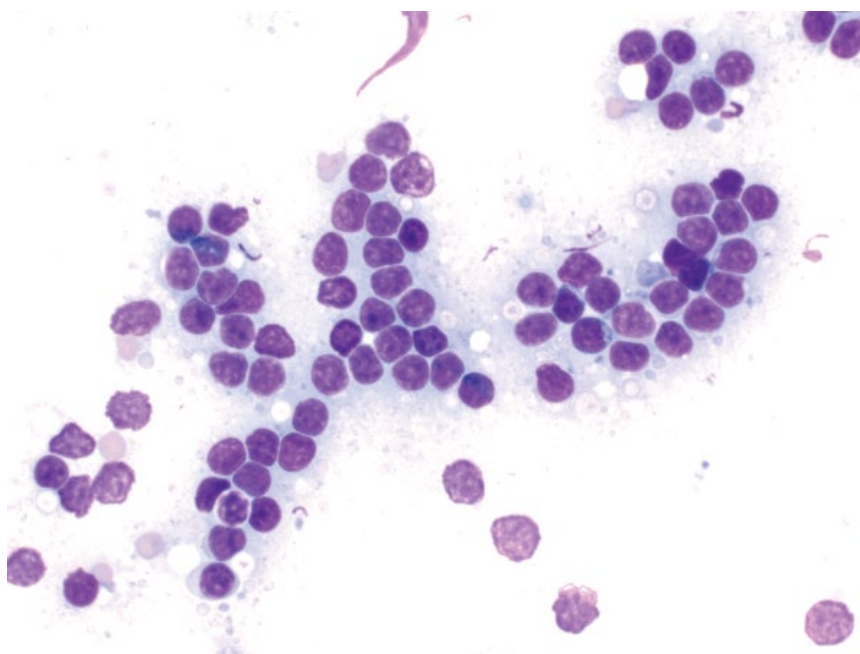
4.1.2.2 Clinical Considerations

- Associated with enlargement of single or multiple lymph nodes.
- Secondary to antigenic stimulation, which may be local or generalized.

4.1.2.3 Prognosis

Mostly good, but variable, based on underlying cause.

Figure 4.1 Lymph node (normal), cat, 50× objective. Small lymphocytes constitute >80% of cells, and have nuclei about one red blood cell in diameter, with clumped chromatin.



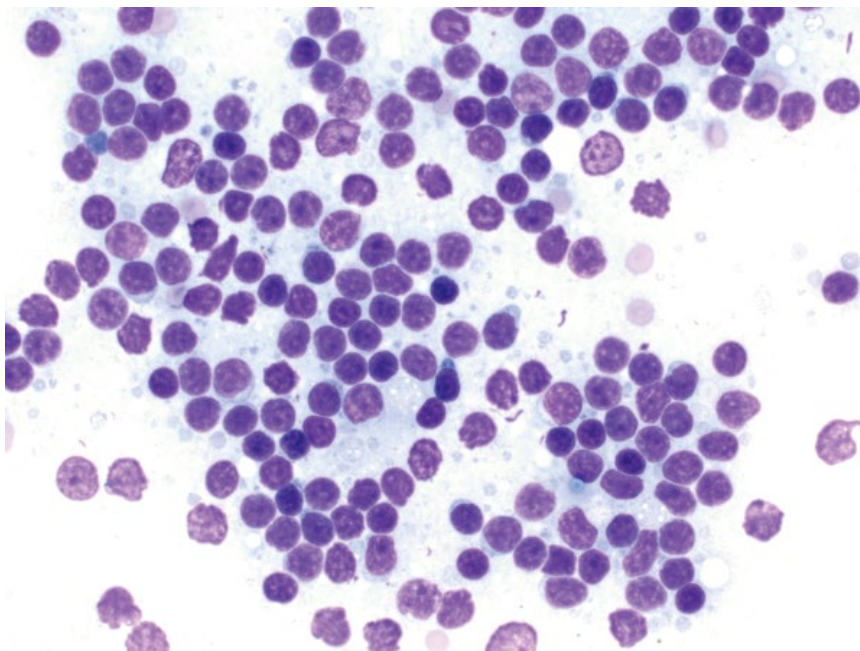


Figure 4.2 Lymph node (normal), cat, 50x objective.

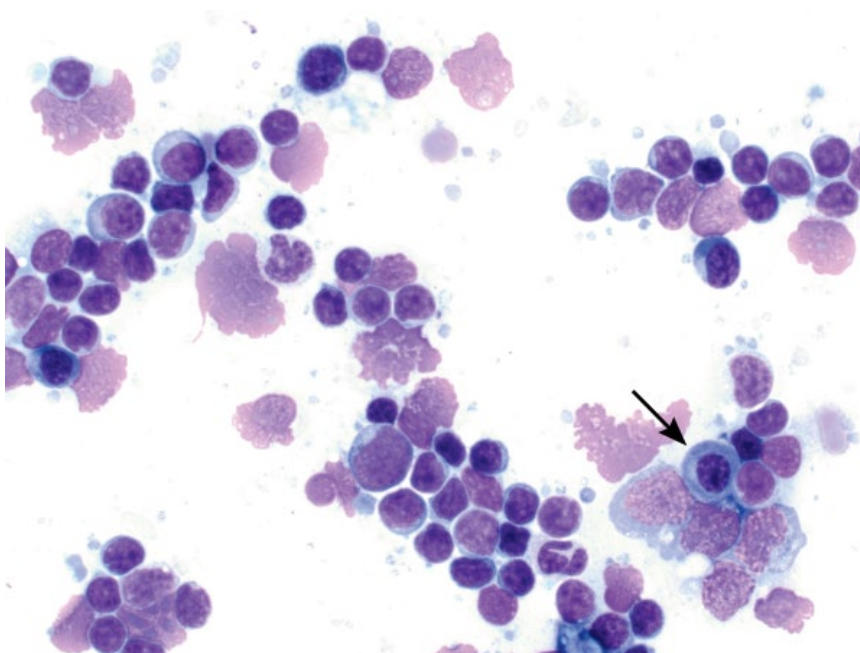


Figure 4.3 Lymph node (reactive), dog, 50x objective. Note the variation in lymphocyte size, amount and color of cytoplasm and plasma cells (arrow).

4.1.3 Neutrophilic Lymphadenitis

4.1.3.1 Cytologic Appearance

Neutrophils should be seen in very low numbers in lymph nodes, especially in the absence of any blood. Increased numbers may indicate a sterile inflammatory process (Figure 4.6) or septic process (Figure 4.7).

4.1.3.2 Clinical Considerations

- May be primary (lymphadenitis) or secondary (inflammation draining to the node).
- Sterile inflammatory responses may include juvenile cellulitis [1], other pyoderma, paraneoplastic, or immune-mediated disease.
- Sepsis (typically bacterial) may accompany neutrophilic lymphadenitis.

Figure 4.4 Lymph node (reactive), dog, 50x objective.

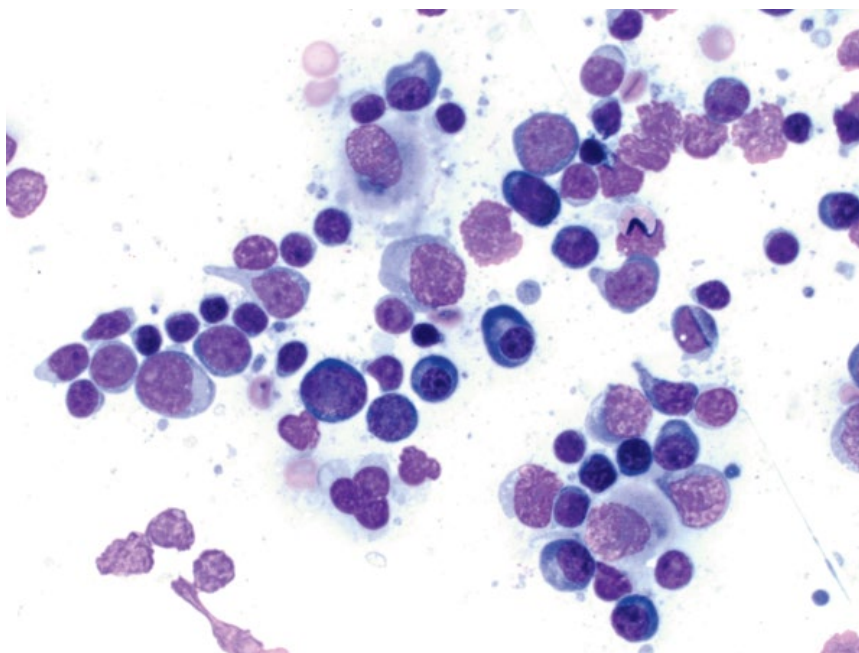
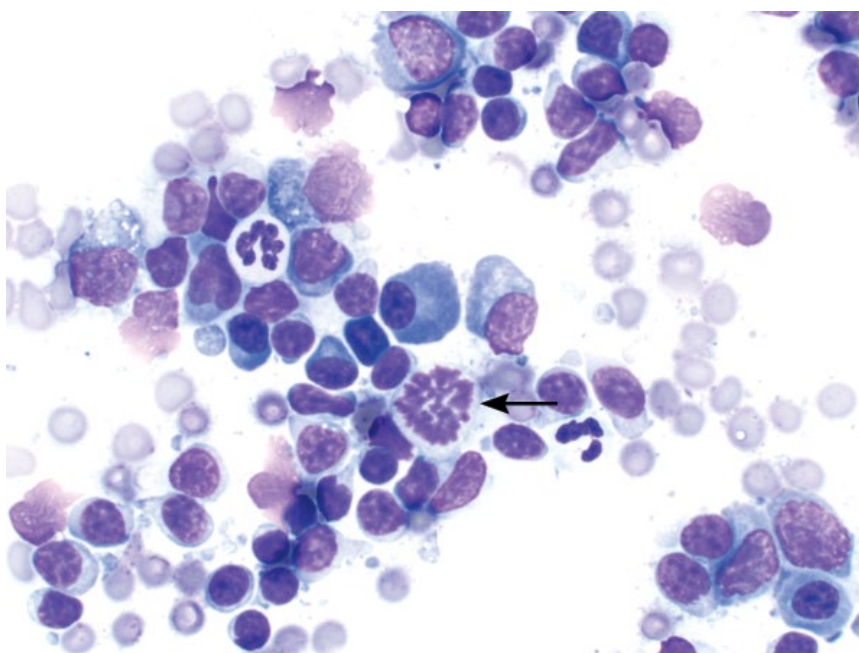


Figure 4.5 Lymph node (reactive), dog, 50x objective. Note that mitotic figures may be present in hyperplastic nodes (arrow).



4.1.3.3 Prognosis

Mostly good, but variable with underlying diagnosis and appropriate therapy.

4.1.4 Eosinophilic Lymphadenitis

4.1.4.1 Cytologic Appearance

Eosinophils are rare in normal lymph nodes. Increased numbers may be distributed individually or in aggregates. Evidence of chronic hemorrhage (hemosiderin

in the background and within macrophages) may also be seen, and is common in cases of chronic skin disease (Figure 4.8).

4.1.4.2 Clinical Considerations

- DDx = inflammation (e.g., chronic skin disease, allergic/hypersensitivity disease), paraneoplastic (e.g., mast cell neoplasia, T-cell lymphoma) or infectious (especially fungal or protozoal).

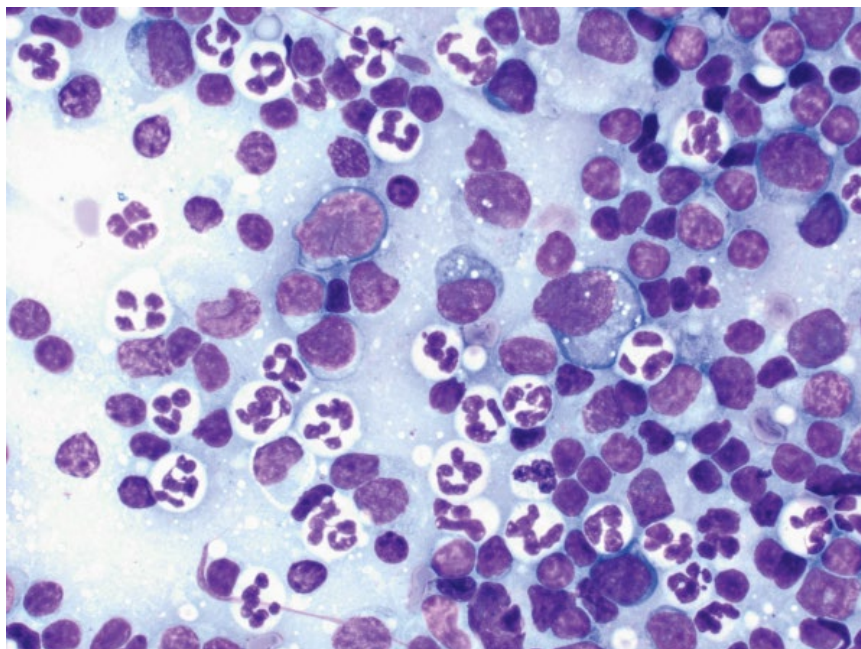


Figure 4.6 Lymph node, neutrophilic lymphadenitis from puppy with juvenile cellulitis, 50× objective.

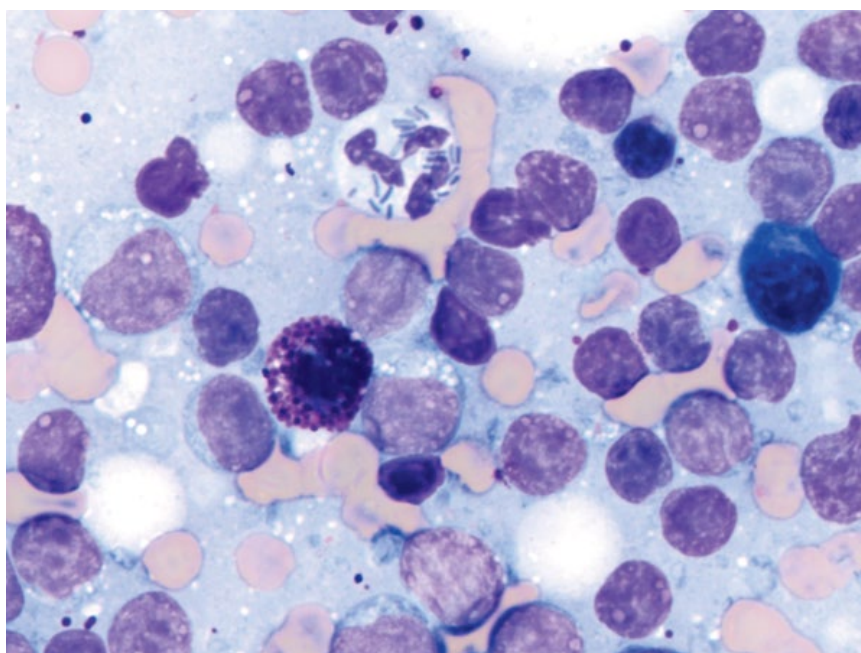


Figure 4.7 Lymph node, septic neutrophilic lymphadenitis, 100× objective.

4.1.4.3 Prognosis

Mostly good, but variable based on underlying diagnosis (e.g., inflammatory versus paraneoplastic).

4.1.5 Infectious Organisms

Many infectious organisms may be found in lymph nodes (see Chapter 2 for detailed descriptions of common organisms). Lymph node involvement is an important manifestation of salmon poisoning disease, which is described in detail in the next section.

4.1.6 Salmon Poisoning Disease

4.1.6.1 Cytologic Appearance

Salmon poisoning disease is characterized by a granulomatous infiltrate, with macrophages containing numerous intracellular organisms ~1–2 μm in length. Organisms appear as curvilinear structures distributed individually and clumped throughout the cytoplasm (Figure 4.9). An expanded population of intermediate to large reactive lymphocytes is seen, as well as many plasma cells.

Figure 4.8 Lymph node, eosinophilic lymphadenitis, dog, 50x objective. Note the blue/green hemosiderin pigment granules in the background.

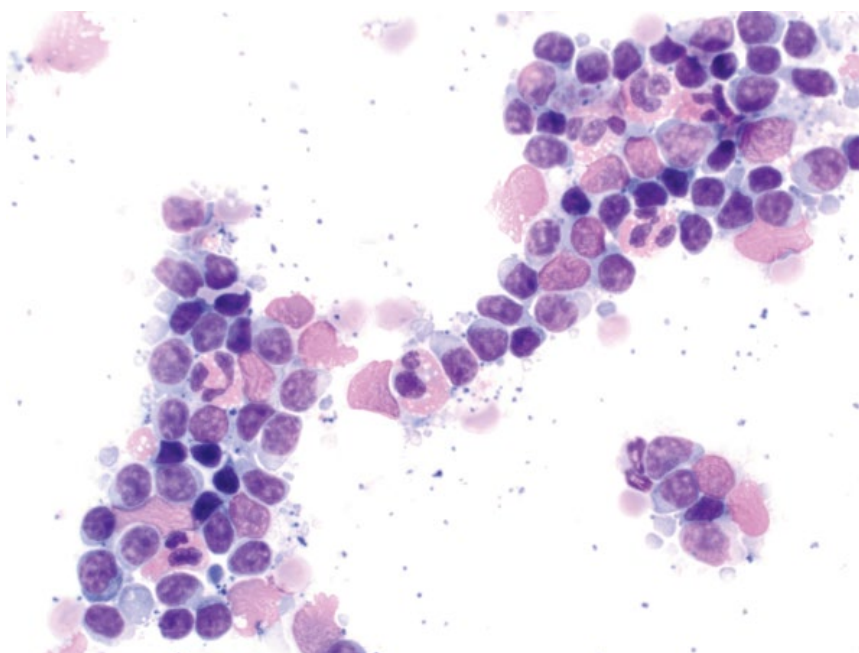
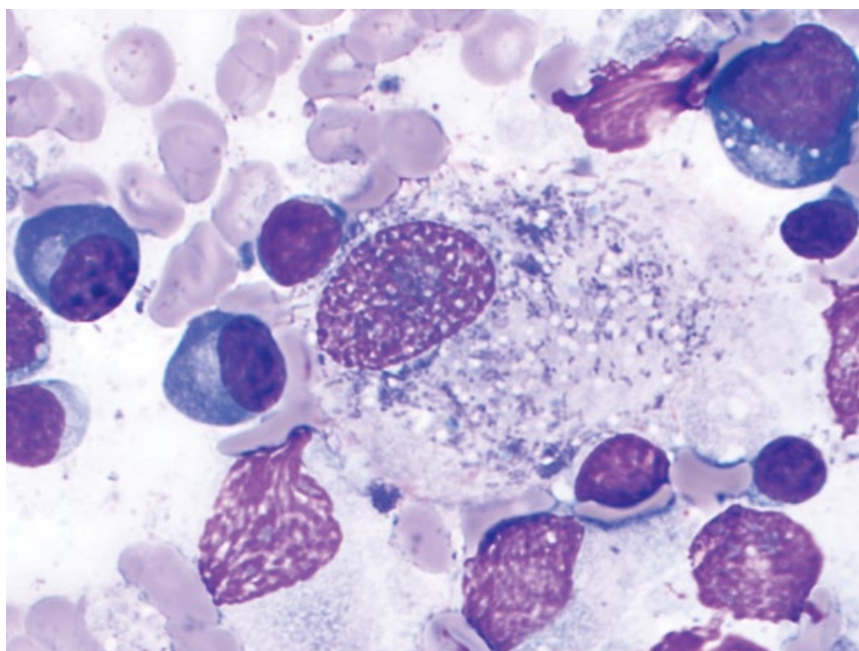


Figure 4.9 Lymph node, *Neorickettsia helminthoeca* (salmon poisoning disease), dog, 100x objective. Note the curvilinear organisms within the macrophage and in the background.



4.1.6.2 Clinical Considerations

- Dogs only. Caused by *Neorickettsia helminthoeca*.
- Seen in the pacific North West of the United States, and in Brazil [2, 3].
- Clinical signs = lethargy, vomiting, diarrhea, peripheral lymphadenopathy, and fever [2].

4.1.6.3 Prognosis

Good with appropriate therapy, but mortality can be up to 90% without treatment [4].

4.1.7 Lymphoma (Large-cell)

4.1.7.1 Cytologic Appearance

Large-cell lymphomas exfoliate well, with cells distributed individually and in sheets. The cells have nuclei with diameters about twofold to more than threefold that of red blood cells, and have finely stippled chromatin. The nucleoli vary in prominence and number. Mitotic figures frequently are seen, but vary in number. The cells mostly have a small to moderate volume of encircling deep-blue cytoplasm (see Figures 4.10–4.13).

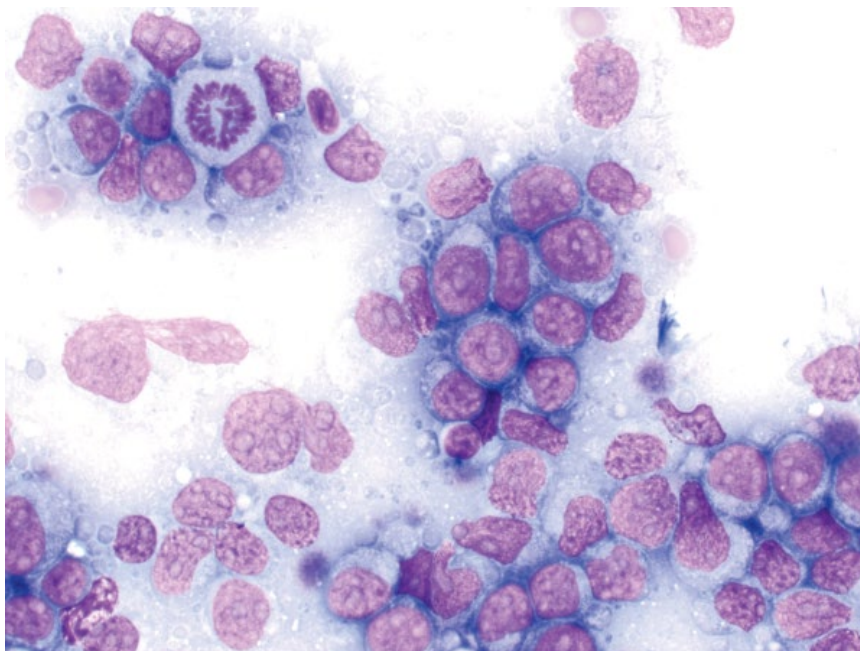


Figure 4.10 Lymph node, large-cell lymphoma, dog, 50× objective. Note the large nuclei (2–3 red blood cells in diameter), prominent nucleoli, and mitotic figure (upper left).

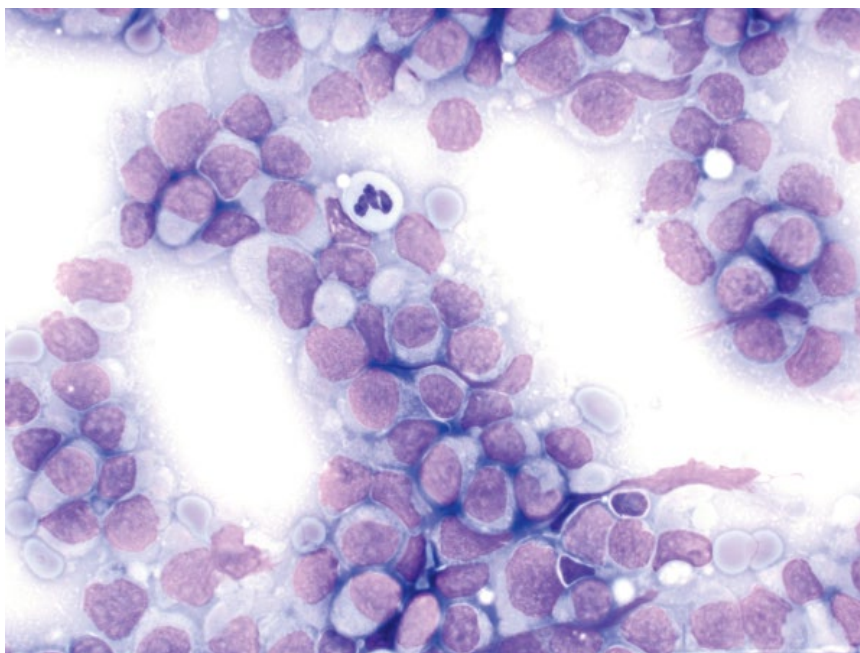


Figure 4.11 Lymph node, large-cell lymphoma, cat, 50× objective. The cells are large, monomorphic, and have finely stippled chromatin.

Large neoplastic cells frequently efface the lymph node, making diagnosis straightforward. As a guide, the large, neoplastic cells should constitute 30–50% of the lymphoid population for a diagnosis of lymphoma. However, emerging or early disease may result in lesser numbers, and re-sampling of a node in 1–2 weeks, or histopathology, may be required for definitive diagnosis.

4.1.7.2 Clinical Considerations

Dogs

- Multicentric lymphoma (affecting peripheral lymph nodes) is the most common form of lymphoma.
- Generally seen in middle-aged to older dogs (median age 7–9 years), but dogs <1 year of age have been reported [5, 6].

Figure 4.12 Lymph node, large-cell lymphoma, dog, 50× objective. Note the smooth pink nuclear material in the background from lysed cells.

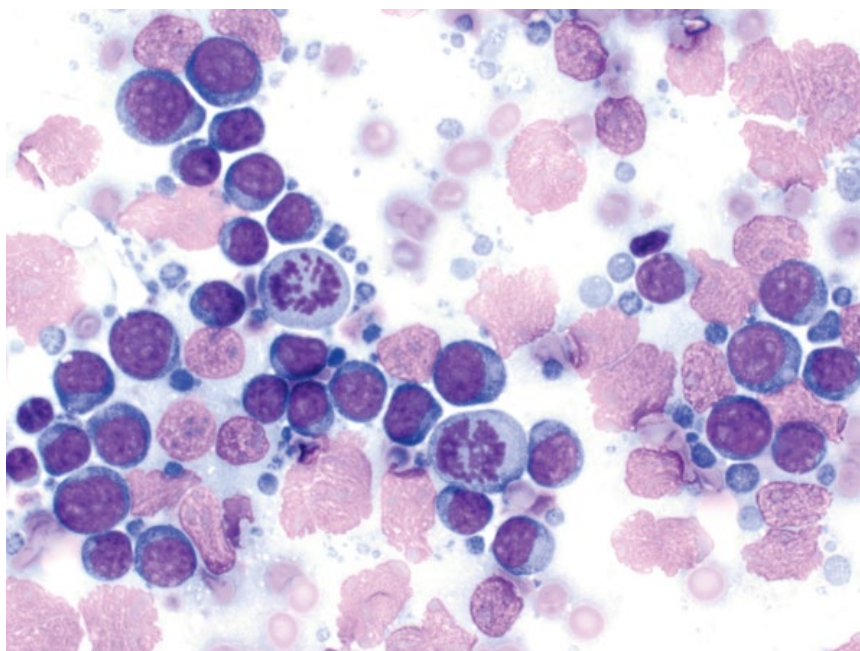
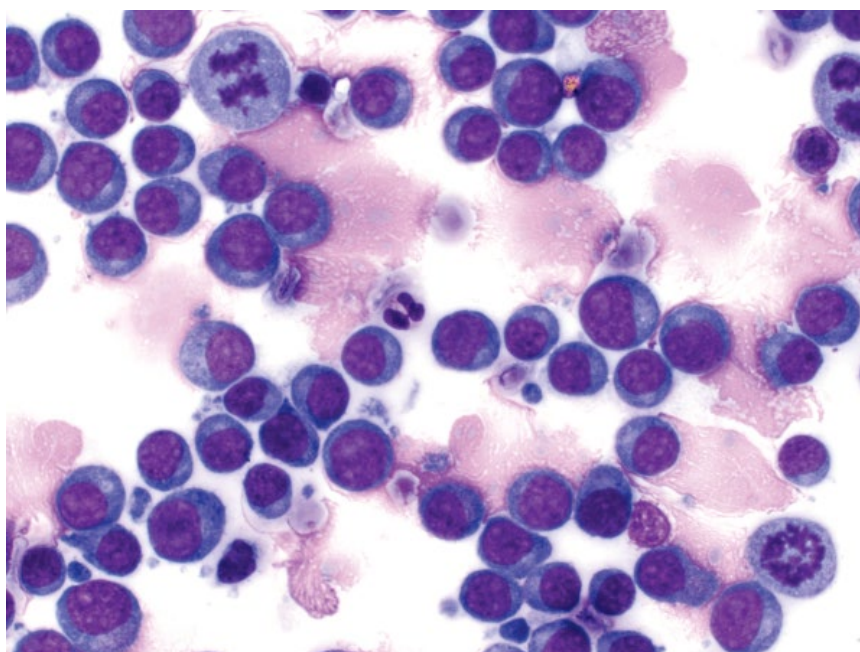


Figure 4.13 Lymph node, large-cell lymphoma, dog, 50× objective. Diff-Quik® stain.



- Many dog breeds affected. Over-represented breeds include Boxers, Bull Mastiffs, Bulldogs, Bassett Hounds, and Golden Retrievers [7, 8].
- B-cell phenotype is the most common form of multicentric lymphoma involving lymph nodes (60–80% of cases). Involvement of abdominal nodes or viscera is seen in 15–20% of cases [5, 9].
- T-cell phenotype is associated with shorter remission and survival times, and is more commonly associated with hypercalcemia [10, 11].

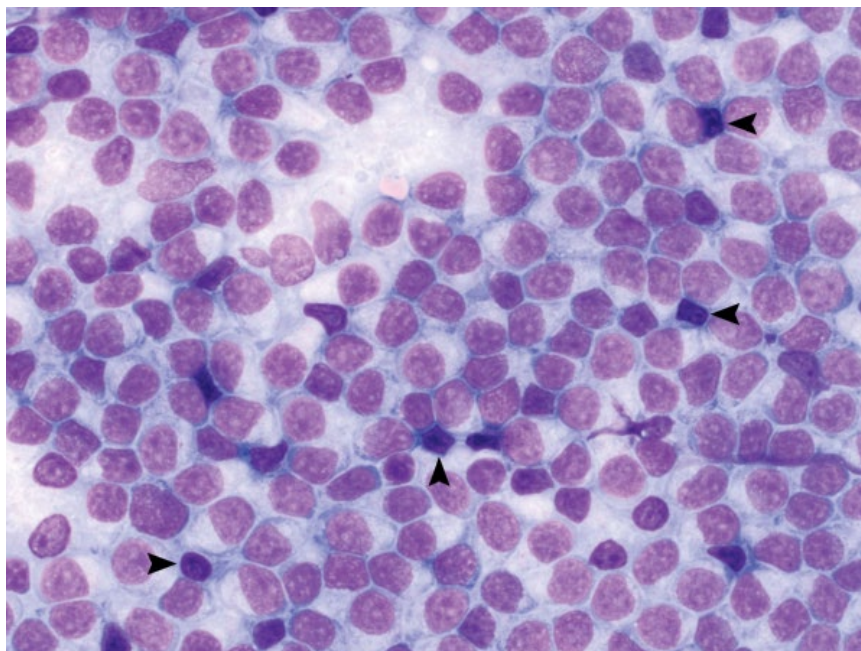


Figure 4.14 Lymph node, small-cell lymphoma, dog, 50× objective. Note the expansion of small cells (nuclei ~1.25 red blood cells in diameter) with prominent nucleoli. These cells outnumber small mature lymphocytes with clumped chromatin (arrowheads).

Cats

- Lymphoma limited to peripheral lymph nodes is uncommon in cats (5–19% of cases) [12, 13]; however, many other anatomic forms will involve lymph nodes.
- Nodal lymphoma is the most common form in cats <1 year old [14].
- T-cell phenotype is more common in cats [5].
- FeLV and FIV increase the risk of lymphoma.

4.1.7.3 Prognosis

Highly variable, based on treatment and many prognostic factors. Without treatment, most dogs with large-cell lymphoma will die within 4–6 weeks of diagnosis [15]. Combination chemotherapeutic protocols may result in long-term clinical remission that is longer in dogs than cats. Some factors contributing to poorer prognosis include T-cell phenotype, World Health Organization (WHO) clinical stage (stage V = poor outcome) and sub-stage b (clinically ill patients).

4.1.8 Lymphoma (Small-cell)

4.1.8.1 Cytologic Appearance

Nodal small-cell lymphomas comprise monomorphic sheets of small lymphocytes. When compared to normal small mature lymphocytes, these cells have slightly larger nuclei (diameter ~1.25-fold the size of a red blood cell), and more open, less-clumped chromatin, often with prominent nucleoli (Figures 4.14 and 4.15). The cells typically have an increased volume of pale-blue cytoplasm forming a unipolar cap.

4.1.8.2 Clinical Considerations

- Dogs > cats.
- T-cell phenotype more common [9, 16].
- Single or multiple nodes affected.
- May be associated with a lymphocytosis with small mature cells.

4.1.8.3 Prognosis

Good. Typically indolent and associated with prolonged survival times (years), even in the absence of systemic therapy [16]. See Chapter 8 for considerations of small-cell lymphoma affecting the gastrointestinal tract.

4.1.9 Specific Lymphoma Types

Specific types of lymphoma can be suspected based on characteristic cytologic features; three such types are described in the following sections.

4.1.10 Lymphoma (Lymphoblastic)

4.1.10.1 Cytologic Appearance

Cells are intermediate in size, with nuclei ~1.5 red blood cells in diameter. Nuclei frequently have subtle nuclear membrane irregularity, and finely stippled chromatin with mostly inapparent nucleoli (Figure 4.16). Many mitotic figures typically are seen. The cells have a small volume of pale-blue cytoplasm, forming a unipolar cap.

4.1.10.2 Clinical Considerations

- T-cell phenotype.
- Common in Boxers [17].

Figure 4.15 Lymph node, small-cell lymphoma, dog, 100× objective. The more open chromatin pattern and nucleoli of neoplastic cells can be contrasted to the clumped, dark chromatin of small mature cells.

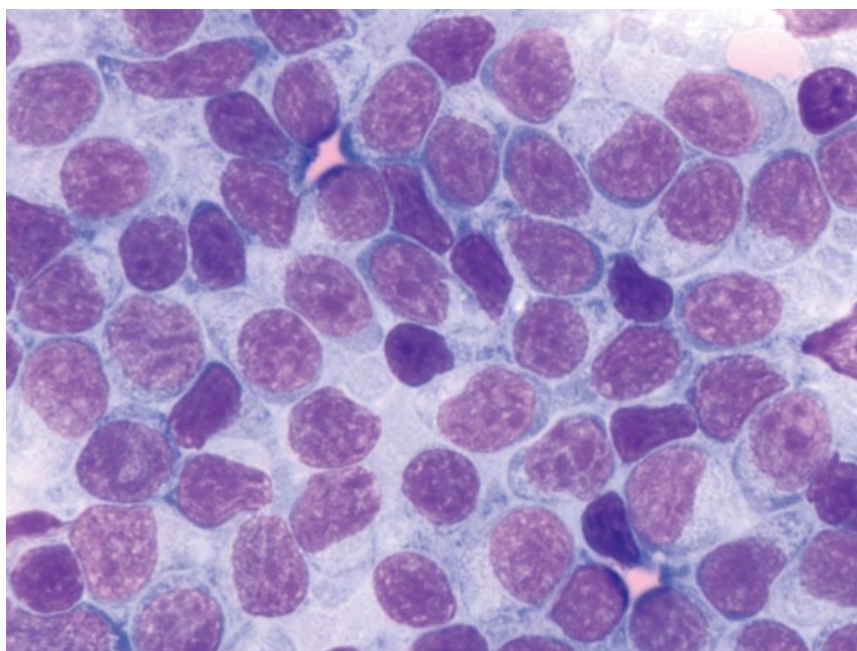
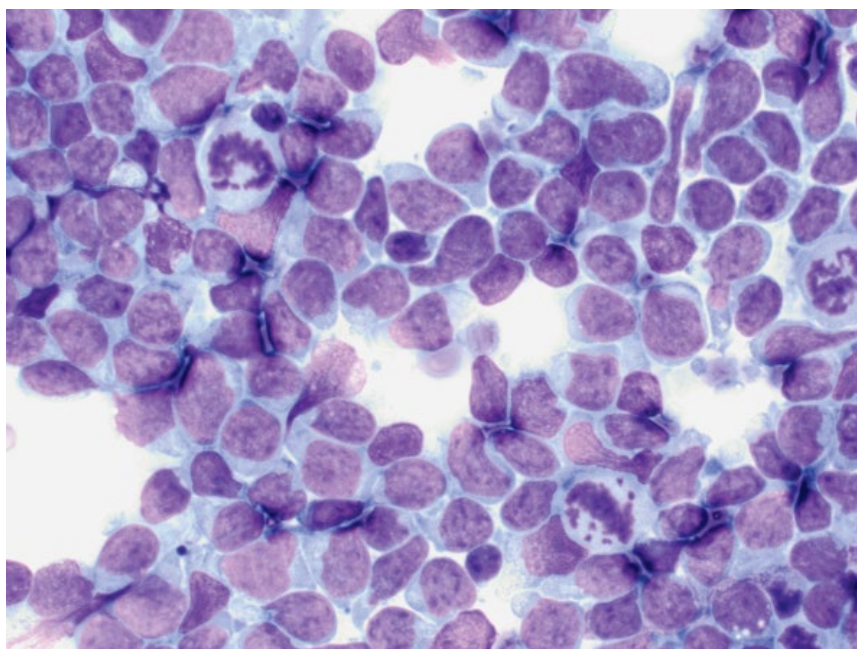


Figure 4.16 Lymph node, lymphoblastic lymphoma, dog, 50× objective. Note the irregular nuclear membranes and many mitotic figures.



- Aggressive biologic behavior despite intermediate cell size.
- Often associated with hypercalcemia [17].
- Histopathology required for definitive diagnosis.

4.1.10.3 Prognosis
Poor.

4.1.11 Lymphoma (Mott Cell Differentiation)

4.1.11.1 Cytologic Appearance

Lymphoma with Mott cell differentiation is characterized by neoplastic lymphocytes that contain bright-blue (rarely pink), smooth cytoplasmic inclusions that are highly variable in size and shape (Figure 4.17) (relative to

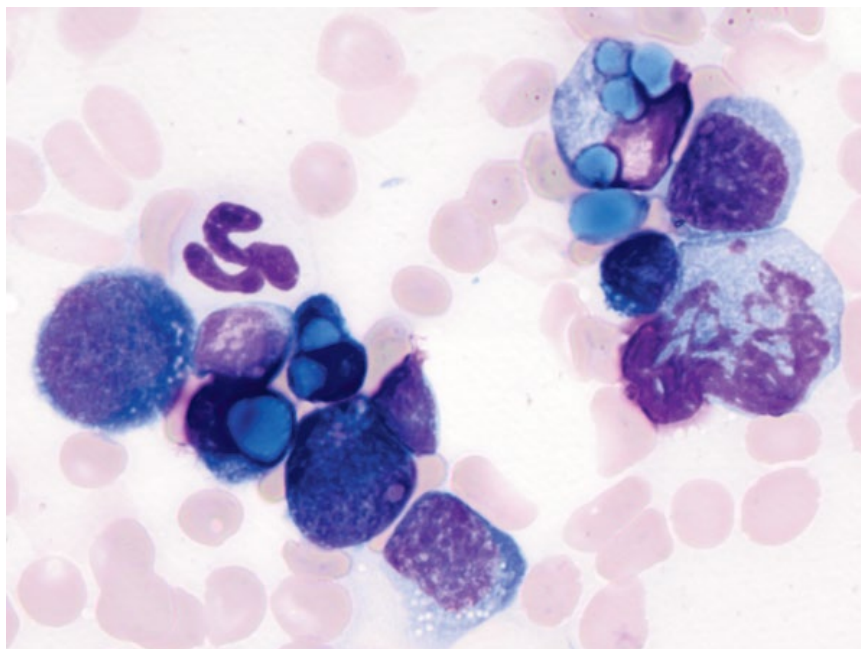


Figure 4.17 Lymph node, lymphoma with Mott cell differentiation, dog, 100× objective. Note the large, irregular bright blue Russell bodies within the cytoplasm.

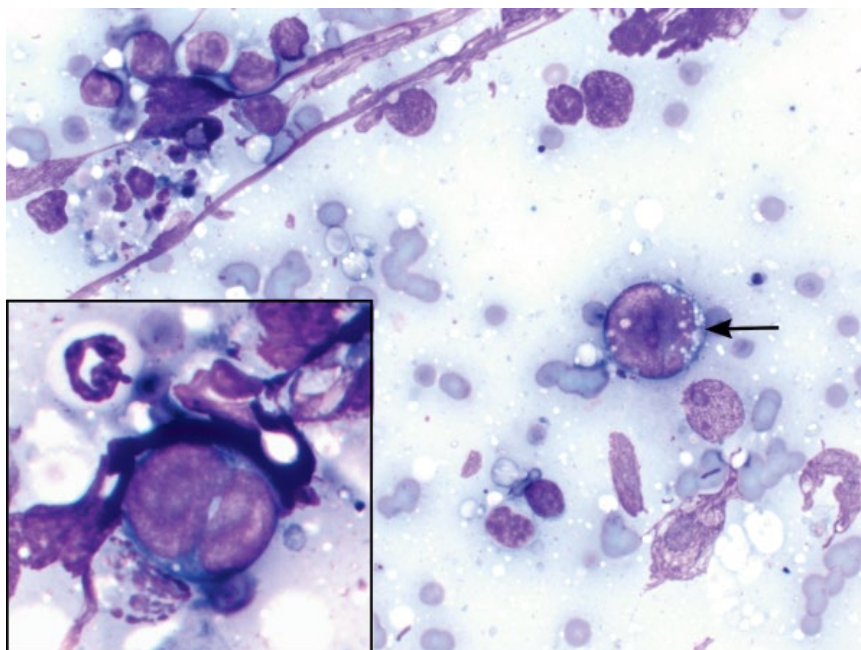


Figure 4.18 Lymph node, Hodgkin's-like lymphoma, cat, 50× objective. Most lymphocytes are small and mature (upper left), with low numbers of large, Reed–Sternberg cells (arrow and inset).

uniform inclusions in normal Mott cells; see Figure 1.24E). The cells typically have large nuclei (>2 red blood cells in diameter) with finely stippled, immature chromatin.

4.1.11.2 Clinical Considerations

- Rare in dogs, not reported in cats.
- High grade, B cell lymphoma.
- Most commonly affects peripheral or abdominal lymph nodes/gastrointestinal tract [18, 19].

4.1.11.3 Prognosis

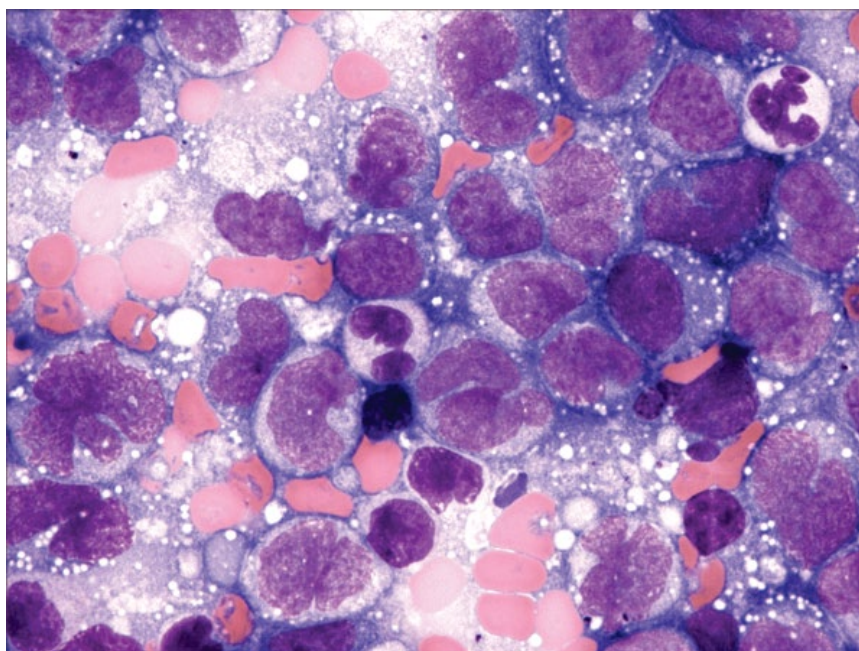
Poor. Response to chemotherapy is mixed [18–20].

4.1.12 Lymphoma (Hodgkin's-like)

4.1.12.1 Cytologic Appearance

Cases of Hodgkin's-like lymphoma are characterized by a mixed lymphoid population, and the presence of large, binucleated (Reed–Sternberg) cells (Figure 4.18), seen in low numbers.

Figure 4.19 Lymph node, acute leukemia infiltration, dog, 60× objective. Acute myeloid (myelomonocytic) leukemia (AML-M4). Photo courtesy of Dr Bill Vernau.



4.1.12.2 Clinical Considerations

- Uncommon in cats, rare in dogs.
- Most cats >6 years old.
- Most present in a single node around the neck/mandibular region [21, 22].
- Due to the mixed nature of the lymphoid population, Hodgkin's-like lymphomas often mimic reactive lymphoid hyperplasia, necessitating histopathology for definitive diagnosis.

4.1.12.3 Prognosis

Fair to good. Hodgkin's-like lymphoma is a less aggressive neoplasm and long survival times are possible, even in the absence of treatment [21].

4.1.13 Leukemia

4.1.13.1 Cytologic Appearance

Acute leukemias can infiltrate lymph nodes. The neoplastic cells are large, with nuclei having diameters about twofold to fourfold those of red blood cells, with finely stippled, immature chromatin, often with prominent nucleoli. Cytoplasm varies from scant and deep-blue (lymphoid leukemia) to moderate with fine pink granules (myeloid leukemia) (Figure 4.19). Mitotic figures often are seen in increased numbers. These can be difficult to distinguish from large-cell lymphomas – correlate with CBC findings ± bone marrow evaluation.

4.1.13.2 Clinical Considerations

- Commonly associated with a neoplastic leukocytosis, as well as thrombocytopenia, neutropenia, or anemia.

- Neoplastic cells usually CD34+ on immunocytochemistry.

4.1.13.3 Prognosis

Grave.

4.1.14 Metastatic Disease

4.1.14.1 Cytologic Appearance

Metastatic neoplasia within lymph nodes is characterized by a population of cells not normally present in lymphoid tissue. Neoplasms that commonly metastasize to lymph nodes include carcinomas (e.g., squamous cell carcinoma; Figure 4.20), round cell neoplasms such as mast cell tumors (Figure 4.21), transmissible venereal tumors (Figure 4.22), and melanomas (Figure 4.23). Sarcomas metastasize less frequently to lymph nodes; however, spindloid cells are readily identified when present (Figure 4.24).

4.1.14.2 Clinical Considerations

- Metastatic disease may be focal or multifocal in the node, and the whole slide should be examined on low power (e.g., 10× objective) to avoid missing any foci of disease.
- Mast cells can be seen in low numbers within normal or hyperplastic lymph nodes [23], and aggregates of cells or increased pleomorphism are required to confirm metastatic disease.
- Lymph nodes with metastatic disease are not always grossly enlarged.

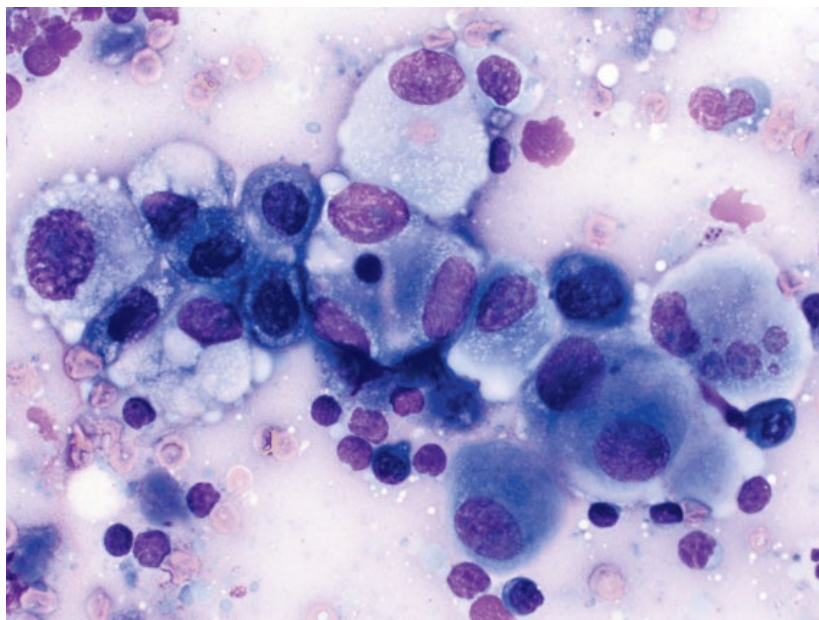


Figure 4.20 Lymph node, metastatic squamous cell carcinoma, dog, 50× objective. Small mature lymphocytes surround a sheet of neoplastic cells with marked criteria of malignancy.

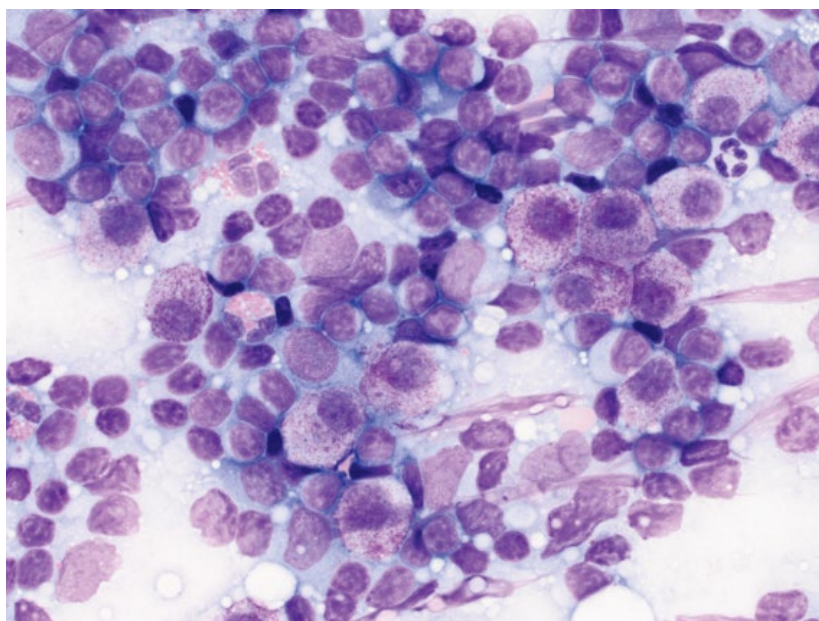


Figure 4.21 Lymph node, metastatic mast cell tumor, dog, 50× objective.

4.1.14.3 Prognosis

Guarded to poor. Metastasis to lymph nodes generally is associated with advanced disease and a poor prognosis. Correlate with specific neoplasm.

4.2 Spleen

4.2.1 Normal

4.2.1.1 Cytologic Appearance

Aspirates from normal spleen typically have a densely bloody background. Small aggregates of splenic red pulp/

stroma are useful to confirm aspiration of splenic parenchyma (Figure 4.25). Nucleated cells are predominated by small mature lymphocytes, with low numbers of plasma cells or intermediate-sized lymphocytes. Low numbers of hematopoietic cells may be seen.

4.2.2 Hyperplasia

4.2.2.1 Cytologic Appearance

Nodular hyperplastic lesions are characterized by increased numbers of stromal aggregates of splenic red pulp (Figure 4.26), and a mixed population of lymphocytes, with

Figure 4.22 Lymph node, metastatic transmissible venereal tumor, dog, 50× objective. The neoplastic cells appear similar to lymphocytes, but have an increased volume of pale-blue cytoplasm that contains fine clear vacuoles (arrows).

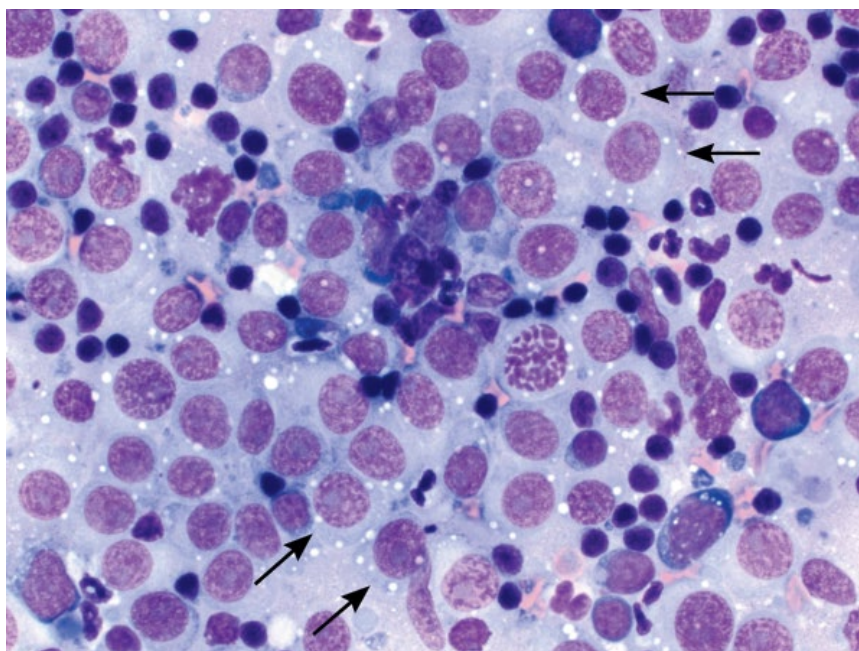
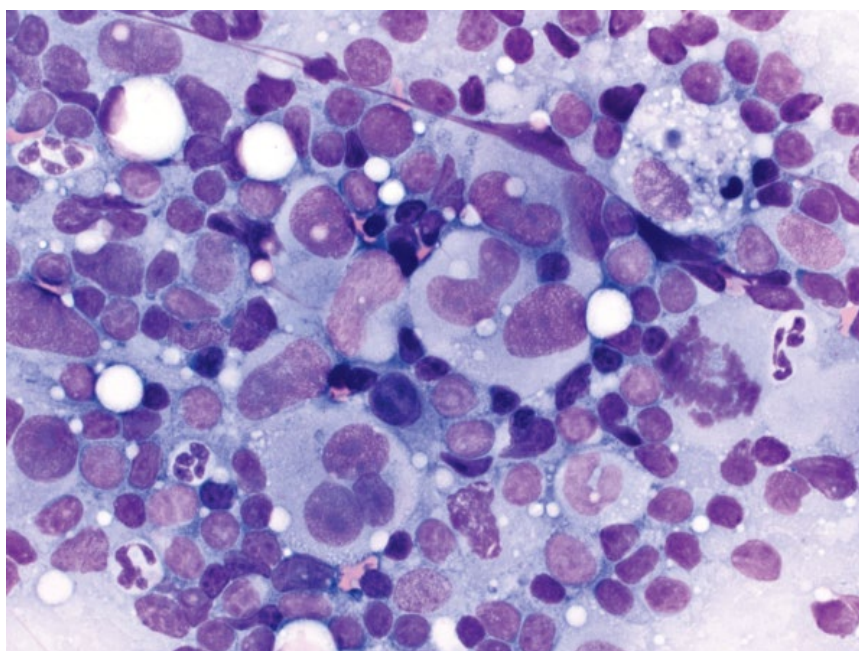


Figure 4.23 Lymph node, metastatic poorly melanotic melanoma, dog, 50× objective.



variably increased numbers of hematopoietic precursors (Figure 4.27).

4.2.2.2 Clinical Considerations

- Spleen mostly contains single or multiple nodules. Diffuse splenic enlargement possible.
- Common incidental finding in older dogs.
- Lymphoid hyperplasia may reflect antigenic stimulation.

4.2.2.3 Prognosis
Generally good.

4.2.3 Extramedullary Hematopoiesis

4.2.3.1 Cytologic Appearance

Erythroid precursors tend to predominate, with lesser numbers of granulocytic and megakaryocytic precursors (Figure 4.28), though ratios may differ based on peripheral demand.

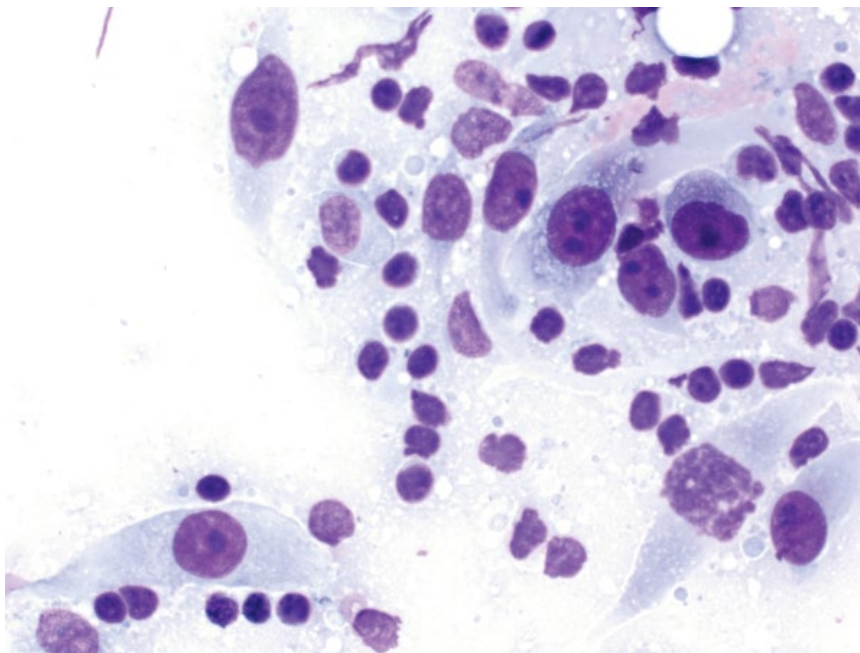


Figure 4.24 Lymph node, metastatic fibrosarcoma, dog, 50x objective.

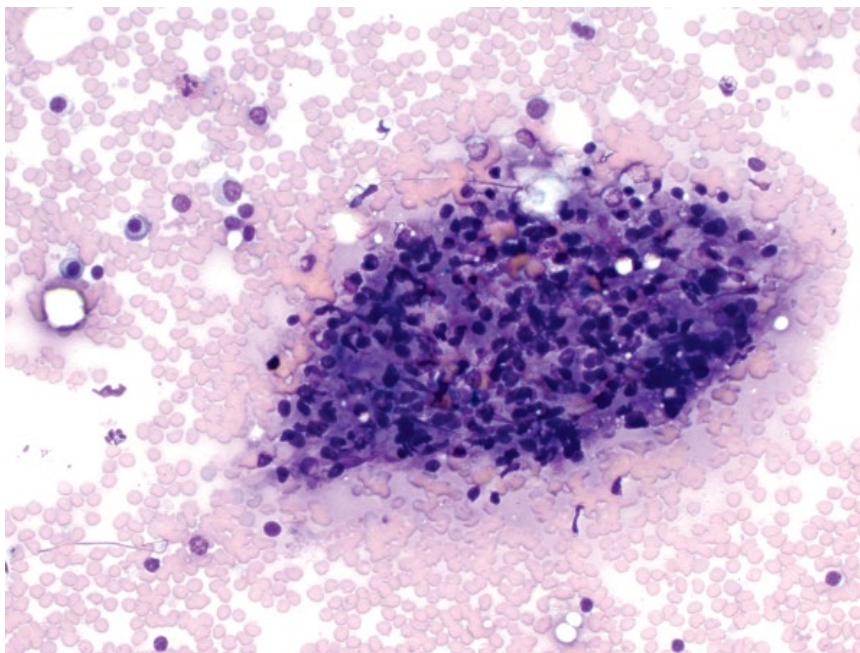


Figure 4.25 Spleen (normal), dog, 20x objective. Note the stromal aggregate (red pulp) center image.

4.2.3.2 Clinical Considerations

- Seen in low numbers in normal spleen.
- Increased amounts may be seen in times of increased demand.
- May be diffuse or nodular [24].

4.2.3.3 Prognosis

Variable based on any underlying cause/disease.

4.2.4 Myelolipoma

4.2.4.1 Cytologic Appearance

Myelolipomas contain hematopoietic precursors, similar to cases of extramedullary hematopoiesis, but can be differentiated due to concurrent presence of abundant variably sized clear lipid vacuoles (Figures 4.29 and 4.30).

Figure 4.26 Spleen, benign nodular hyperplasia, dog, 20× objective. An aggregate of red pulp is present (lower right), with many lymphoid and hematopoietic cells.

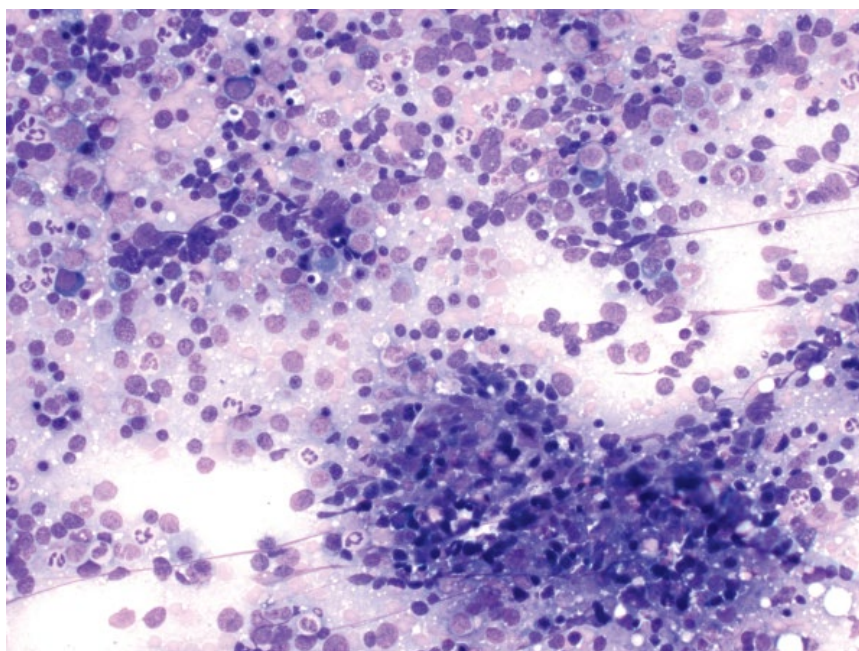
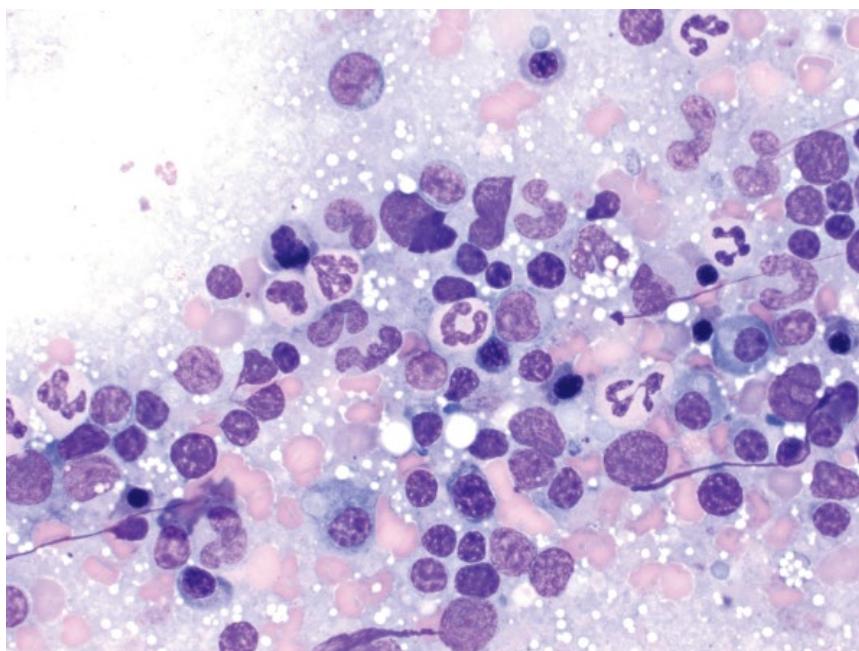


Figure 4.27 Spleen, benign nodular hyperplasia, dog, 50× objective. The mixed lymphocytes/plasma cells and hematopoietic precursors can be seen.



4.2.4.2 Clinical Considerations

- Reported in cats (spleen and liver) and dogs (spleen).
- Benign tumors.
- Usually small (1–2 cm) masses, but can be >5 cm. Hyperechoic and not cavitated on ultrasound [25].

4.2.4.3 Prognosis

Excellent.

4.2.5 Hemangiosarcoma

4.2.5.1 Cytologic Appearance

Hemangiosarcomas (HSA) exfoliate variably well as pleomorphic spindle cells seen individually or in aggregates/sheets that may form cords (Figure 4.31). The spindle cells are plump, with a moderate volume of medium-blue cytoplasm that forms tapering ends, and occasionally long tendrils (Figure 4.32). Erythrophagia by neoplastic

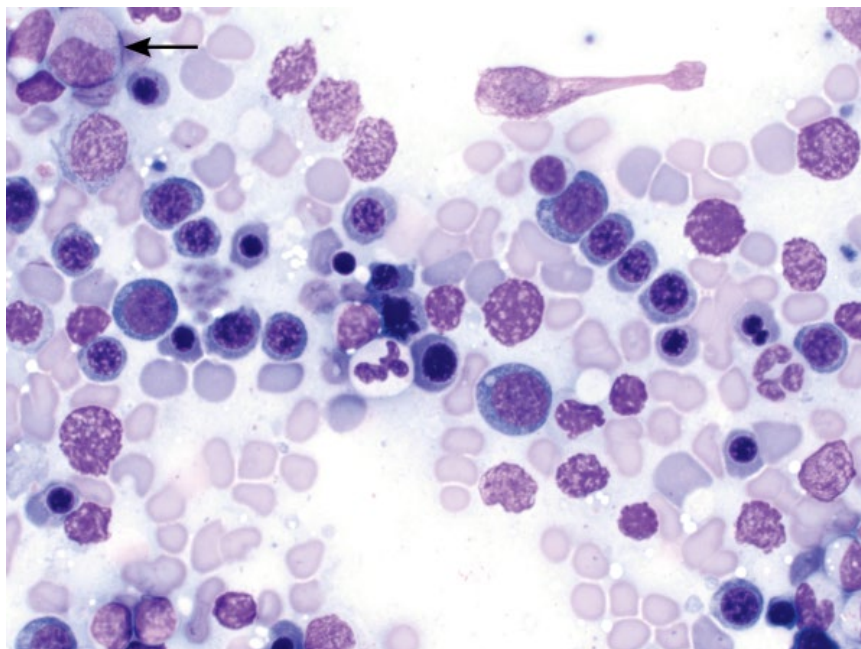


Figure 4.28 Spleen, extramedullary hematopoiesis, dog, 50× objective. Erythroid precursors predominate, with rare granulocyte precursors (arrow).

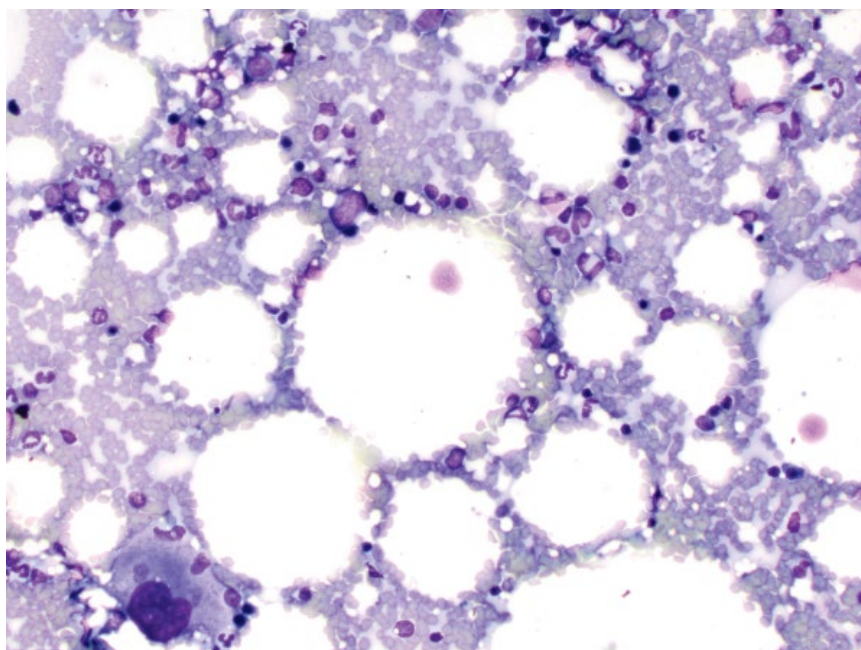


Figure 4.29 Spleen, myelolipoma, cat, 20× objective. Note the abundant lipid and the megakaryocyte (lower left).

cells is reported, but not specific to HSA [26]. Nuclei are ovoid, with finely stippled chromatin, and multiple prominent basophilic nucleoli. Multinucleation and mitotic figures are common. Anisocytosis/anisokaryosis are marked.

4.2.5.2 Clinical Considerations

- Most common malignant neoplasm in the spleen of dogs. Rare in cats.

- Often rupture, causing hemoabdomen.
- Metastatic disease is common at diagnosis, mostly to the liver, omentum, and lungs [27, 28].

4.2.5.3 Prognosis

Poor to grave. Survival times overall are short, although clinical stage is the most important prognostic factor. Distant metastatic disease (stage III) is associated with a grave prognosis [27].

Figure 4.30 Spleen, myelolipoma, dog, 50× objective. Lipid vacuoles are seen, with many erythroid precursors.

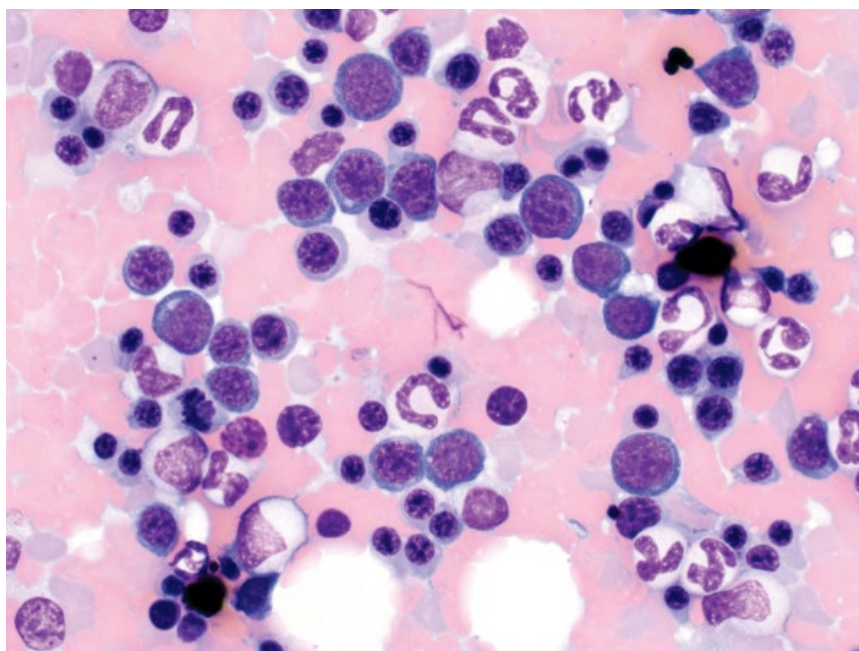
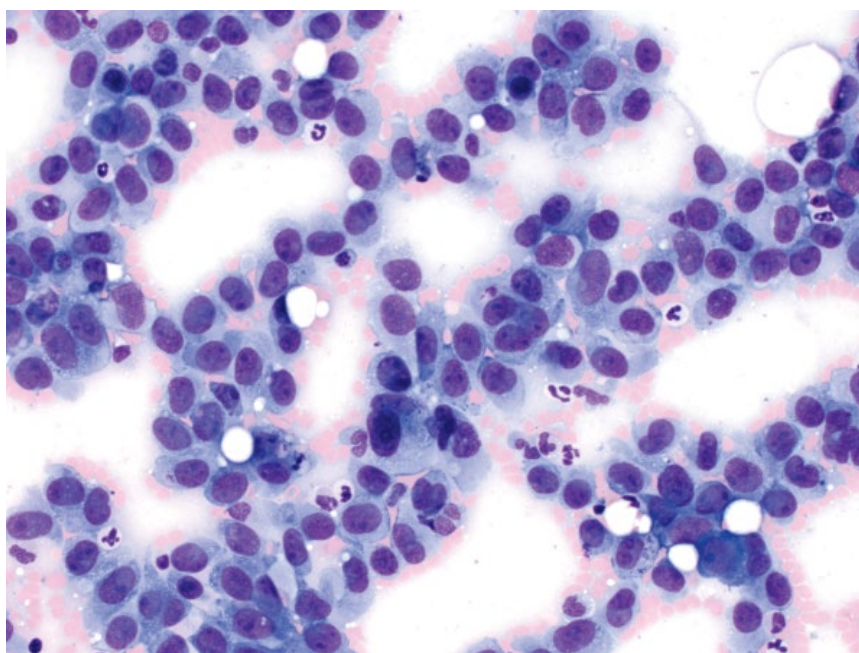


Figure 4.31 Spleen, hemangiosarcoma, dog, 20× objective. Note the spindle cells forming cords.



4.2.6 Lymphoma (Large-cell)

4.2.6.1 Cytologic Appearance

Large-cell lymphoma appears similarly to other organs, characterized by an expanded population of large, immature lymphocytes with nuclei having diameters about twofold to threefold that of red blood cells, and with finely stippled chromatin (Figure 4.33). These cells should ideally be seen in large numbers in the spleen to help differentiate from a hyperplastic germinal center, or florid lymphoid hyperplasia.

4.2.6.2 Clinical Considerations

- Normally part of multicentric disease.
- May present with diffuse splenic enlargement or nodules.

4.2.6.3 Prognosis

Similar to nodal large-cell lymphoma (see section 4.1.7). Hemoabdomen and clinical signs of lethargy, anorexia and abdominal distension are associated with a poor prognosis [29].

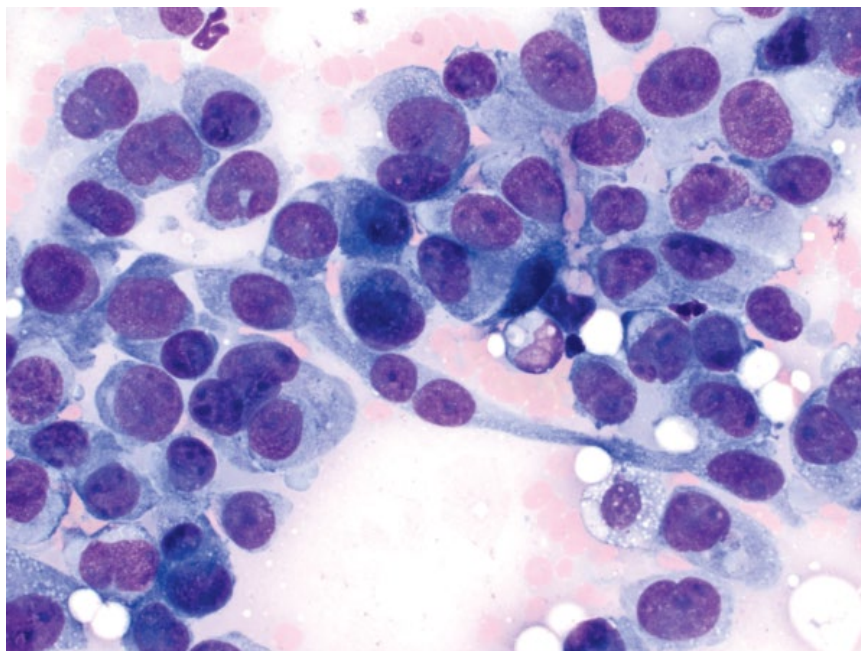


Figure 4.32 Spleen, hemangiosarcoma, dog, 40x objective.

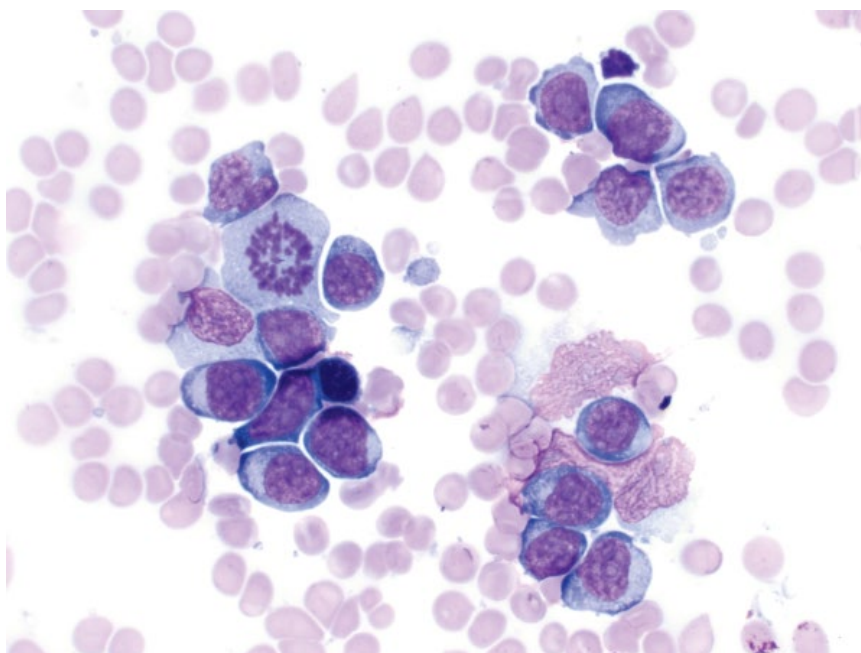


Figure 4.33 Spleen, large cell lymphoma, dog, 50x objective.

4.2.7 Lymphoma (Marginal Zone)

4.2.7.1 Cytologic Appearance

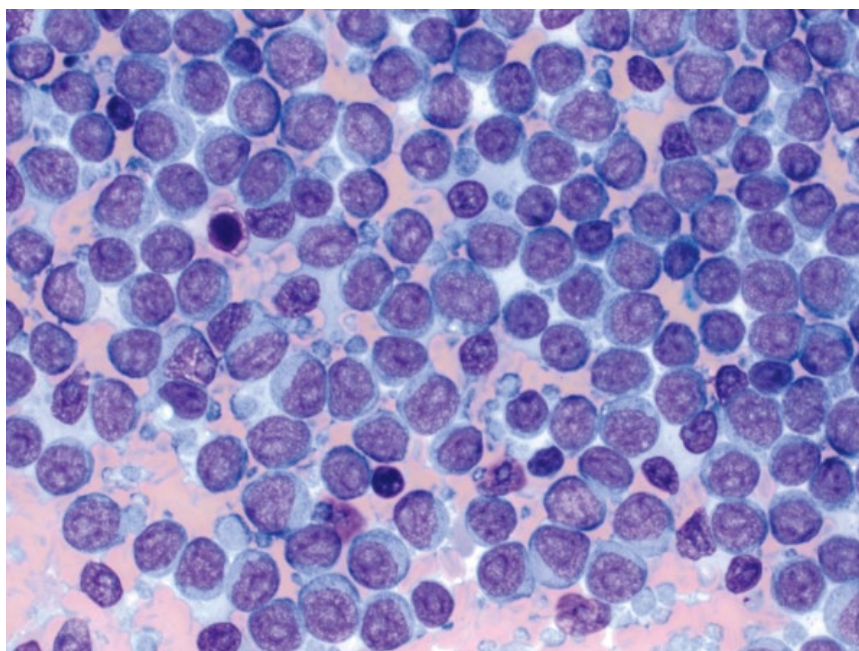
Marginal zone lymphoma (MZL) of the spleen is characterized by sheets of large lymphocytes with round nuclei approximately two red blood cells in diameter, and a characteristic single, centrally located, prominent nucleolus (Figure 4.34). A moderate volume of pale-blue cytoplasm encircles the cells. *Note:* Large sheets of such cells

should be present to raise any suspicion of neoplasia, as marginal zone hyperplasia is common in reactive lymphoid follicles secondary to antigenic stimulation.

4.2.7.2 Clinical Considerations

- Indolent form of B-cell lymphoma, often an incidental finding.
- Usually a single splenic nodule [30].

Figure 4.34 Spleen, marginal zone lymphoma, dog, 50× objective. Note the large sheet of lymphocytes with prominent, single, centrally located nucleoli.



- Masses may rupture causing hemoabdomen.
- Although cytologic findings may be suggestive of MZL, a definitive diagnosis requires histopathologic assessment of the splenic architecture [30].

4.2.7.3 Prognosis

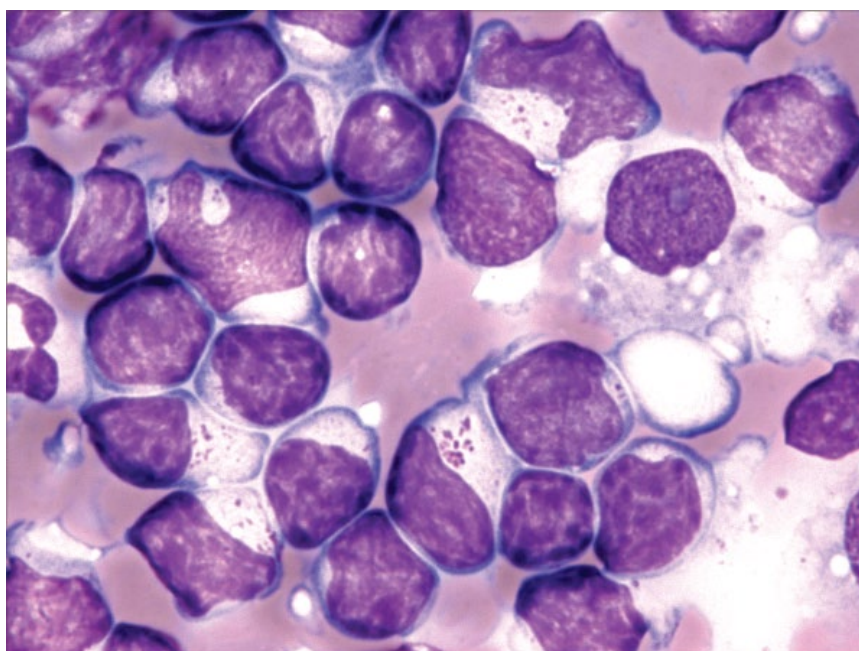
Fair to excellent. Splenectomy alone in asymptomatic dogs is associated with prolonged survival. Prognosis is less favorable in dogs with clinical signs of disease (e.g., hemoabdomen, vomiting). Disseminated disease is rare [30].

4.2.8 Lymphoma (Hepatosplenic)

4.2.8.1 Cytologic Appearance

Neoplastic lymphocytes have nuclei approximately two to three red blood cells in diameter, that frequently have irregular membrane boundaries and finely stippled, immature chromatin. They have a small volume of medium-blue cytoplasm that frequently contains a perinuclear packet of faint azurophilic granules (Figure 4.35). Neoplastic cells may be erythrophagocytic. Extramedullary hematopoiesis and reactive histiocytes

Figure 4.35 Spleen, hepatosplenic lymphoma, dog, 100× objective. Note the perinuclear, azurophilic cytoplasmic granules. Photo courtesy of Dr Bill Vernau.



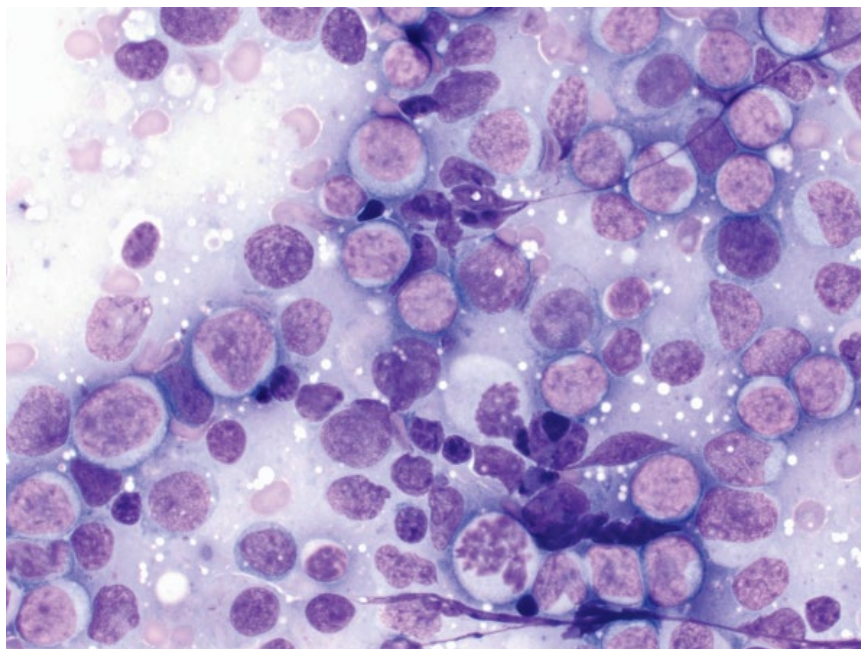


Figure 4.36 Spleen, acute granulocytic leukemia, dog, 50× objective.

(often erythrophagocytic) typically are present in abundance.

4.2.8.2 Clinical Considerations

- Distinct clinical entity, separate from other lymphomas affecting spleen, liver, and bone marrow.
- Granular, T-cell phenotype.
- Often associated with regenerative anemia and thrombocytopenia [31, 32].
- Histopathology is required for definitive diagnosis.

4.2.8.3 Prognosis

Grave. Aggressive form of lymphoma associated with very short survival times [31, 32].

4.2.9 Acute Leukemias

4.2.9.1 Cytologic Appearance

Acute leukemias are characterized by large numbers of neoplastic cells, with nuclei about twofold to threefold the size of a red blood cell, that have finely stippled, immature chromatin and mostly prominent nucleoli. Mitotic rates generally are high. The cells have a variable volume of cytoplasm, which may contain pink granules if the cells are of granulocytic origin (Figure 4.36) or be deep-blue in erythroid leukemias (Figure 4.37).

4.2.9.2 Clinical Considerations

- Neoplastic leukemia cells infiltrate the red pulp of the spleen [24].
- Normally associated with circulating neoplastic cells and cytopenias.

4.2.9.3 Prognosis

Grave.

4.2.10 Lymphoma (Small-cell)/Chronic Lymphocytic Leukemia

4.2.10.1 Cytologic Appearance

Small-cell lymphoma and chronic lymphocytic leukemia are cytologically similar, characterized by sheets of a monomorphic population of small lymphocytes. When compared to normal small mature lymphocytes, these cells have slightly larger nuclei (diameter ~1.25-fold the size of a red blood cell), and more open, less-clumped chromatin, often with prominent nucleoli (Figure 4.38).

4.2.10.2 Clinical Considerations

- Affects middle-aged to older patients.
- Usually diffuse splenic enlargement [33].
- Accompanied by lymphocytosis (range in dogs = 15 000 to 1 600 000 cells μl^{-1} ; median value in cats = 34 200 cells μl^{-1}) [33, 34].

4.2.10.3 Prognosis

Good.

4.2.11 Multiple Myeloma

4.2.11.1 Cytologic Features

Multiple myeloma is characterized by large sheets and aggregates of well-differentiated plasma cells. The cells have a moderate volume of pale-blue cytoplasm, and often have a characteristic, perinuclear clear zone

Figure 4.37 Spleen, acute erythroid leukemia, cat, 50× objective. Note the deep-blue cytoplasm of the cells.

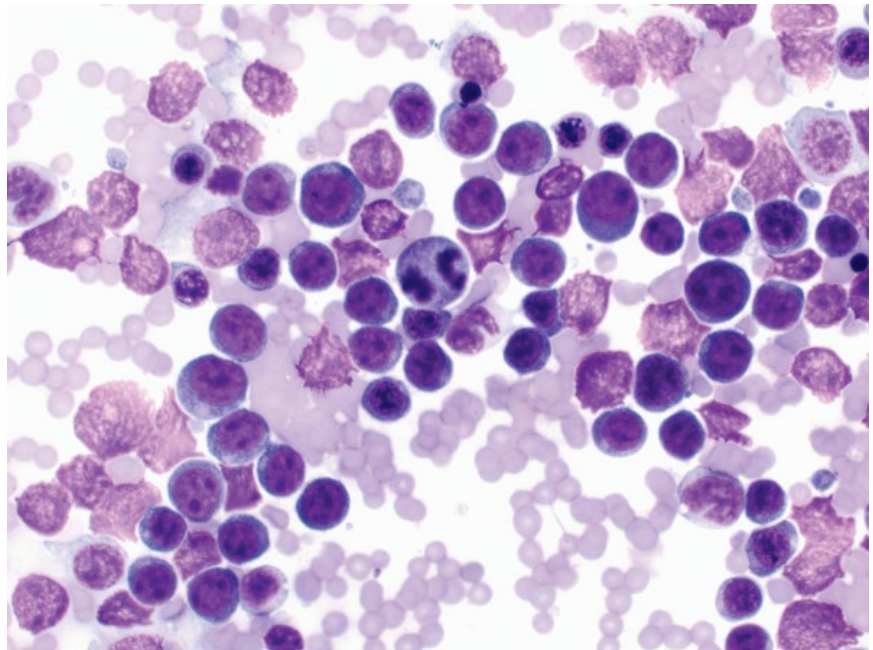
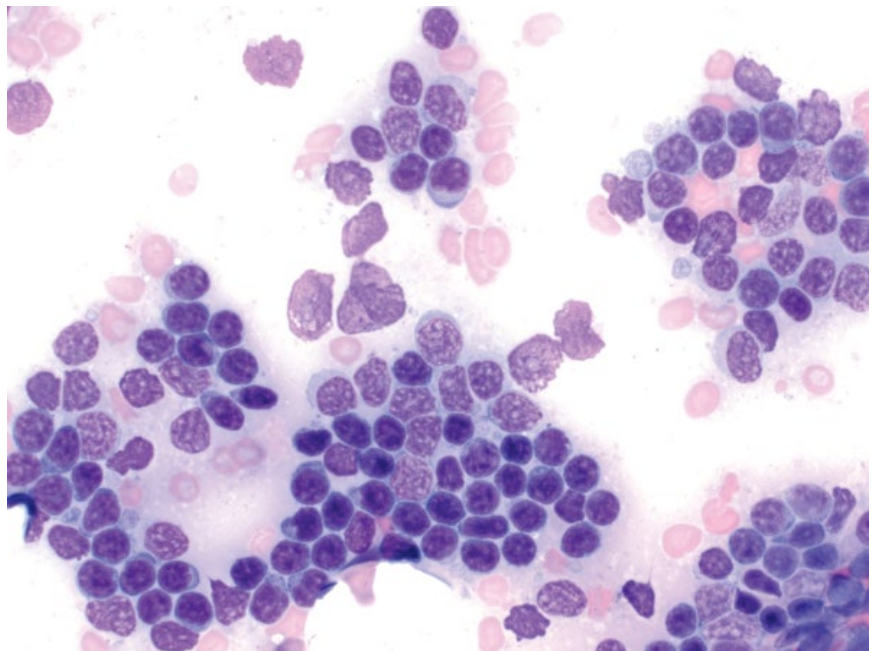


Figure 4.38 Spleen, chronic lymphocytic leukemia (CLL), dog, 50× objective.



(Golgi zone) (Figure 4.39). The nuclei are round, eccentrically placed, and have clumped chromatin.

4.2.11.2 Clinical Considerations

- Dogs > cats.
- Other clinical features = monoclonal gammopathy, lytic bone lesions, anemia, bleeding diatheses, Bence–Jones proteinuria [35, 36].

4.2.11.3 Prognosis

Dogs = Good short-term prognosis with treatment, and long-term control is possible. Negative prognostic factors include extensive bone lysis/involvement as well as hypercalcemia and Bence–Jones proteinuria [35].

Cats = Guarded prognosis, with generally short survival times [36, 37].

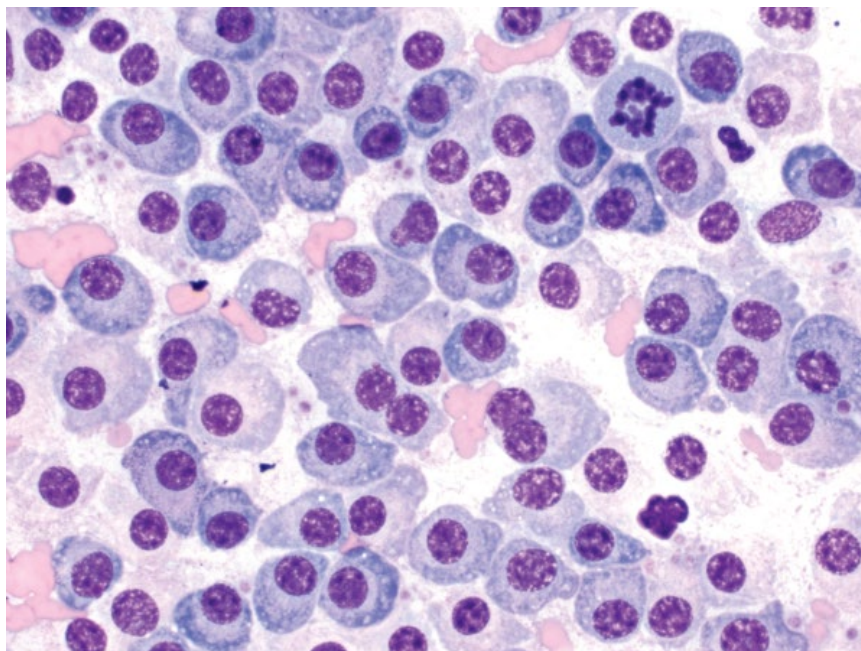


Figure 4.39 Spleen, multiple myeloma, cat, 50x objective.

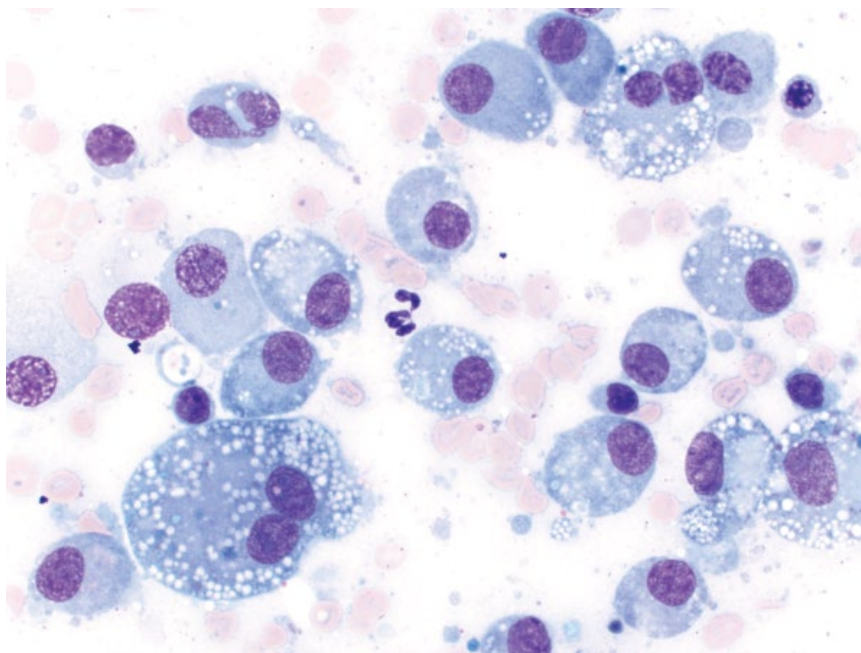


Figure 4.40 Spleen, histiocytic sarcoma, dog, 50x objective.

4.2.12 Histiocytic Sarcoma

4.2.12.1 Cytologic Features

Histiocytic sarcoma is characterized by individualized cells with many criteria of malignancy, including marked anisocytosis and anisokaryosis, with karyomegaly a common finding. Multinucleation, nuclear fragmentation and hyperchromasia also are common (Figure 4.40). The cytoplasm usually is vacuolated.

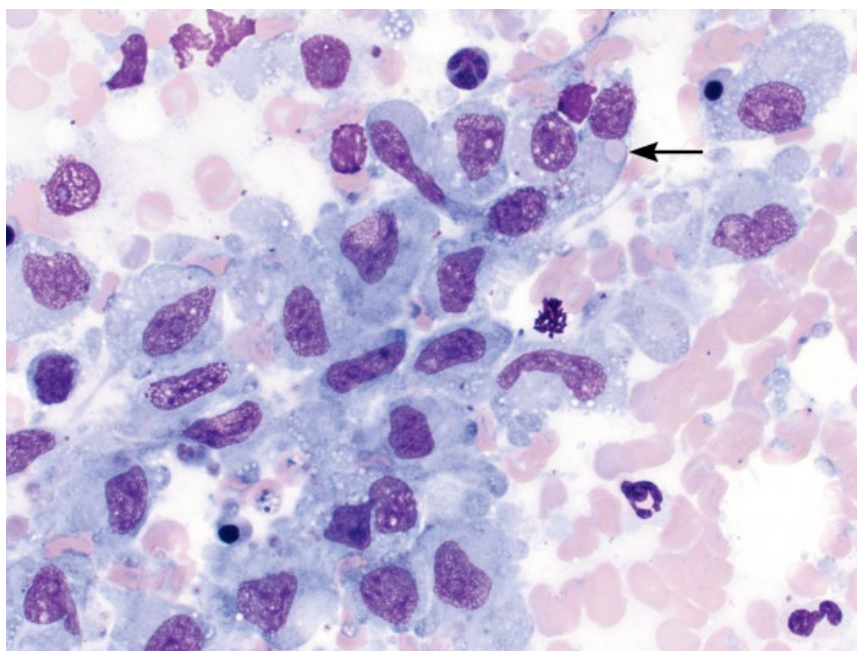
4.2.12.2 Clinical Considerations

- Dogs >> cats
- Reported in many dog breeds, but Bernese Mountain Dogs, Rottweilers, Golden Retrievers, Labrador Retrievers and Flat-Coated Retrievers are predisposed [38].
- Seen as part of disseminated disease.

4.2.12.3 Prognosis

Grave.

Figure 4.41 Spleen, hemophagocytic histiocytic sarcoma, dog, 50× objective. Note the erythrophagia (arrow).



4.2.13 Hemophagocytic Histiocytic Sarcoma (HHS)

4.2.13.1 Cytologic Appearance

HHS is characterized by well-differentiated histiocytes/macrophages, seen mostly in aggregates but also individually. They have a moderate to abundant volume of medium-blue cytoplasm that may contain clear vacuoles, and cells often are erythrophagocytic (Figure 4.41). Anisocytosis/anisokaryosis are mild to moderate. Note: it is important to rule out causes of reactive histiocytosis.

4.2.13.2 Clinical Considerations

- Rare in dogs. Not reported in cats.
- Predisposed breeds = Bernese Mountain Dog, Golden Retriever, Labrador Retriever.
- Arises in spleen and bone marrow. May metastasize to liver and lungs.
- Common concurrent hematologic findings (% of cases): Coomb's negative regenerative anemia (94%), hypoalbuminemia (94%), thrombocytopenia (88%), hypocholesterolemia (69%) [39].
- Ultrasound = diffuse splenomegaly with ill-defined masses.

4.2.13.3 Prognosis

Grave. HHS is an aggressive malignancy associated with short survival times (median survival time of four weeks post diagnosis), even with therapy [39].

4.2.14 Feline Visceral Mast Cell Neoplasia

4.2.14.1 Cytologic Appearance

Visceral mast cell neoplasia is characterized by large sheets of mast cells (Figure 4.42). These cells have a moderate volume of cytoplasm that contains a variable number of metachromatic granules. Nuclei are centrally located and have granular chromatin with prominent nucleoli.

4.2.14.2 Clinical Considerations

- Most common cause of splenic disease in cats [40].
- Spleen may be diffusely enlarged or nodular.
- Often associated with mastocytemia [41].
- Common metastatic sites = liver, internal lymph nodes, bone marrow, and skin.

4.2.14.3 Prognosis

Prolonged survival seen if disease confined to the spleen [42]. Variable survival times for disseminated disease [43, 44].

4.2.15 Metastatic Disease

4.2.15.1 Cytologic Appearance

Many neoplasms metastasize to the spleen. Epithelial neoplasms are particularly apparent, as epithelial cells are not normally seen in splenic aspirates (Figure 4.43). Metastatic mesenchymal tumors (Figure 4.44) may be difficult to differentiate from primary sarcomas of the spleen (e.g., hemangiosarcoma). Round-cell neoplasms frequently metastasize to the spleen, including mast cell

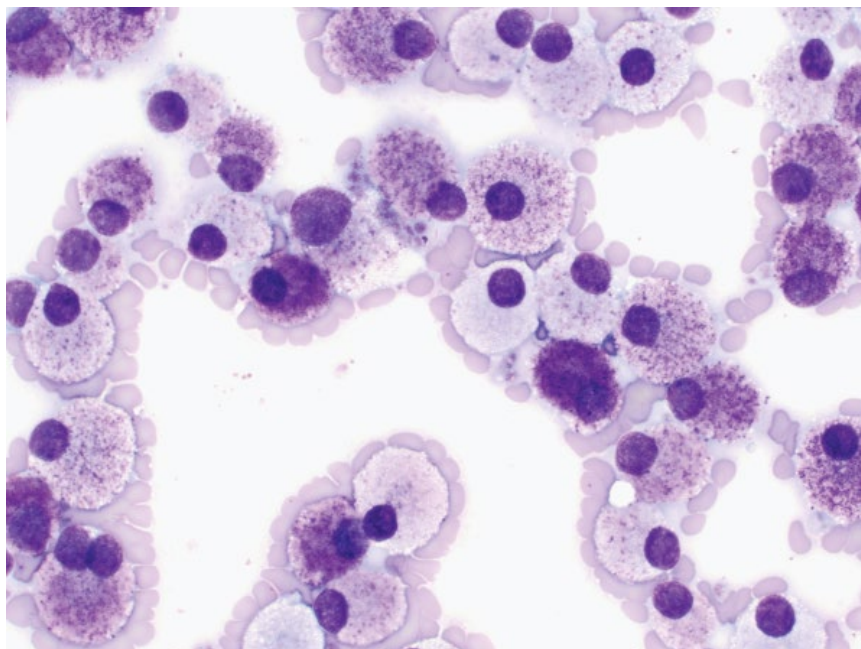


Figure 4.42 Spleen, visceral mast cell neoplasia, cat, 50× objective.

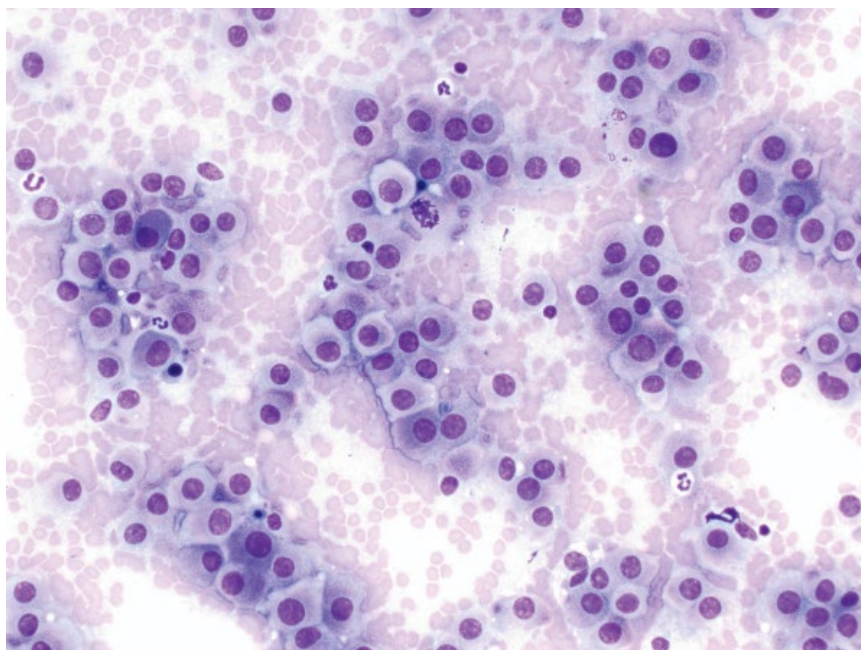


Figure 4.43 Spleen, metastatic hepatocellular carcinoma, dog, 20× objective.

neoplasia (Figure 4.45), histiocytic sarcoma (see section 4.2.12), and lymphoma (see section 4.2.6).

4.2.15.2 Clinical Considerations

- The spleen is a common site for metastatic disease [45].

4.2.15.3 Prognosis

Poor. Dogs with metastatic cutaneous mast cell neoplasia involving the spleen have shorter survival times [46].

4.2.16 Amyloid

4.2.16.1 Cytologic Appearance

Amyloid is seen as smooth to fibrillar, magenta extracellular material, mostly associated with stromal aggregates of red pulp (Figure 4.46).

4.2.16.2 Clinical Considerations

- Amyloid deposition may be localized or systemic (involving kidney, liver, etc.) [47].

Figure 4.44 Spleen, metastatic fibrosarcoma, dog, 50× objective.

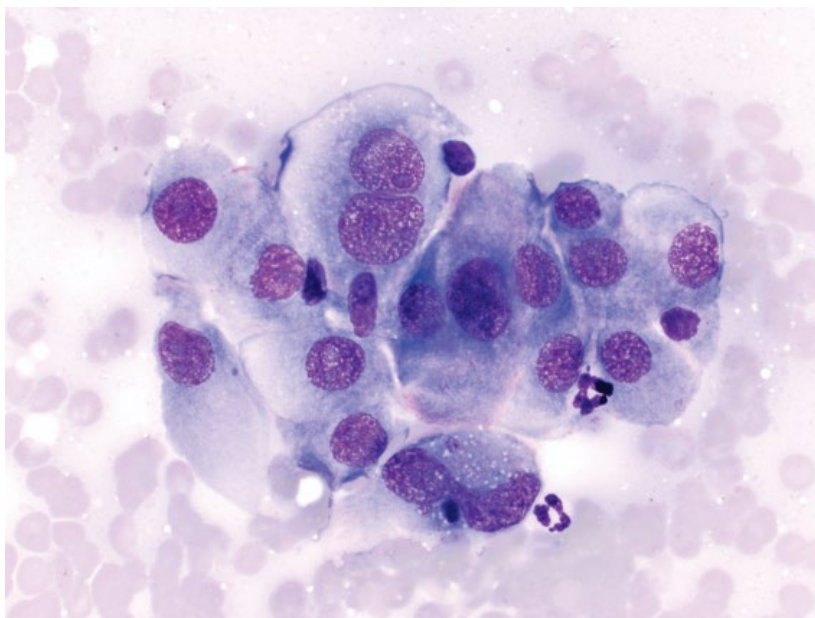
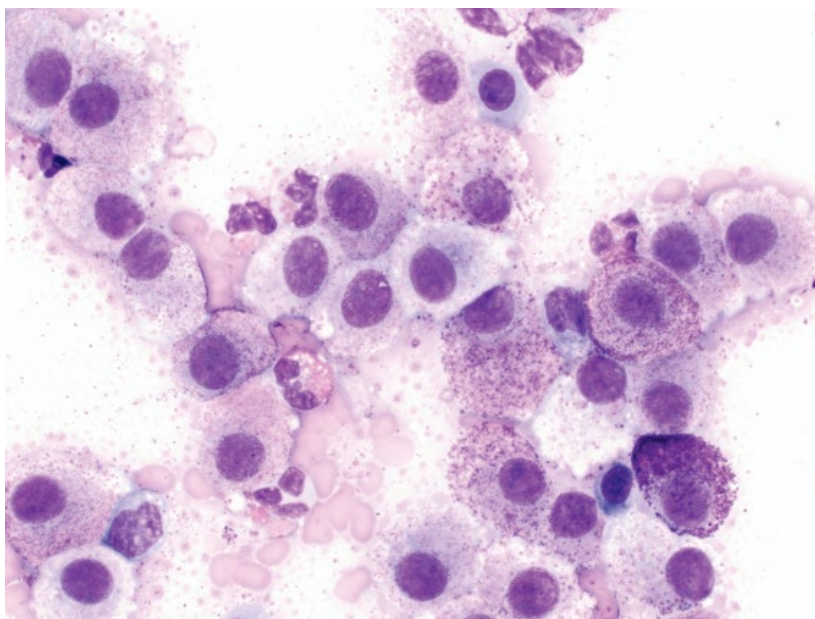


Figure 4.45 Spleen, metastatic mast cell neoplasia, dog, 50× objective.



- Amyloid may accumulate due to a primary familial predisposition, or secondary to chronic systemic inflammation.
- Predisposed breeds = Shar Pei dogs and Abyssinian cats.

4.2.16.3 Prognosis

Variable based on primary or secondary, organs involved, and ability to treat any underlying disease.

4.2.17 Infectious Organisms

Many infectious organisms may affect the spleen, and details of such organisms are available in Chapter 2.

4.3 Thymus

4.3.1 Thymoma

4.3.1.1 Cytologic Appearance

Cytologic samples from thymomas usually comprise mostly of resident thymic small mature lymphocytes, admixed with lesser numbers of intermediate or large lymphocytes. The neoplastic cells exfoliate as sheets of polygonal cells with moderate to abundant pale-blue cytoplasm and ovoid nuclei with reticular chromatin and variably prominent nucleoli (Figure 4.47). Anisocytosis/anisokaryosis are mild, and N/C ratios are low. The

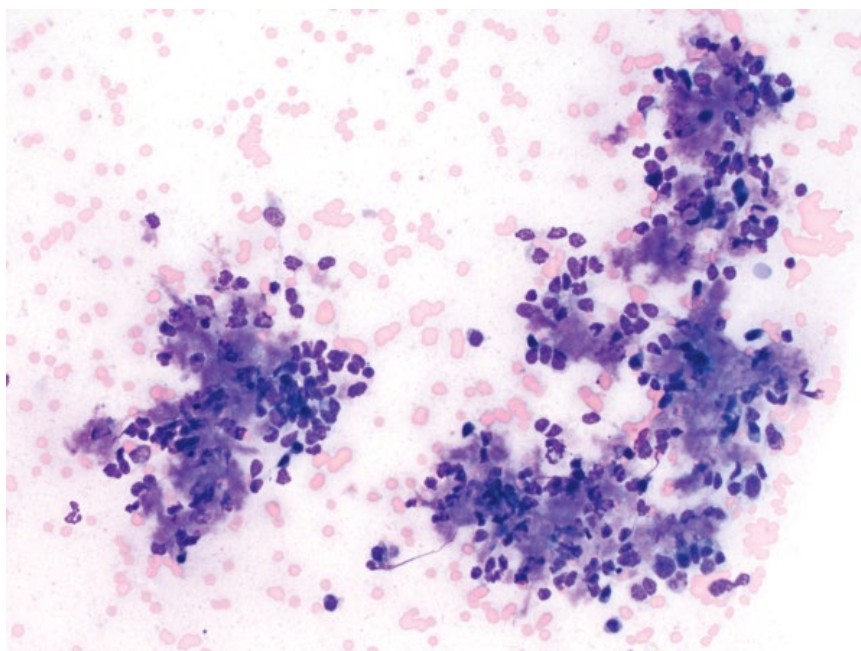


Figure 4.46 Spleen, amyloid, cat, 20x objective. Note the bright purple fibrillar material between cells.

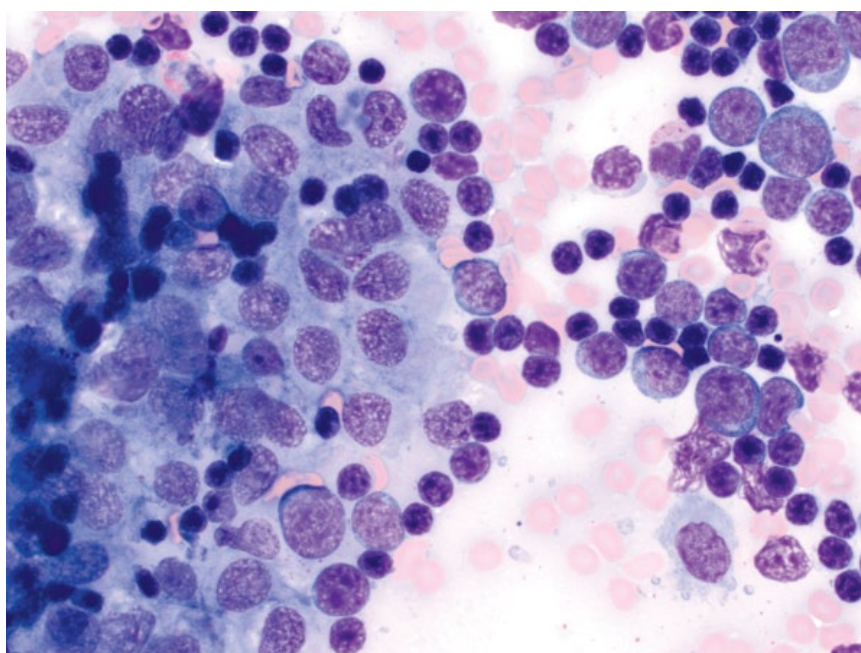


Figure 4.47 Thymus, thymoma, dog, 50x objective. A cohesive sheet of thymic epithelial cells (left) is accompanied by a mixed population of lymphocytes.

neoplastic epithelial cells do not always exfoliate, which can make cytologic diagnosis of thymoma difficult. Mast cells may be scattered individually across samples.

4.3.1.2 Clinical Considerations

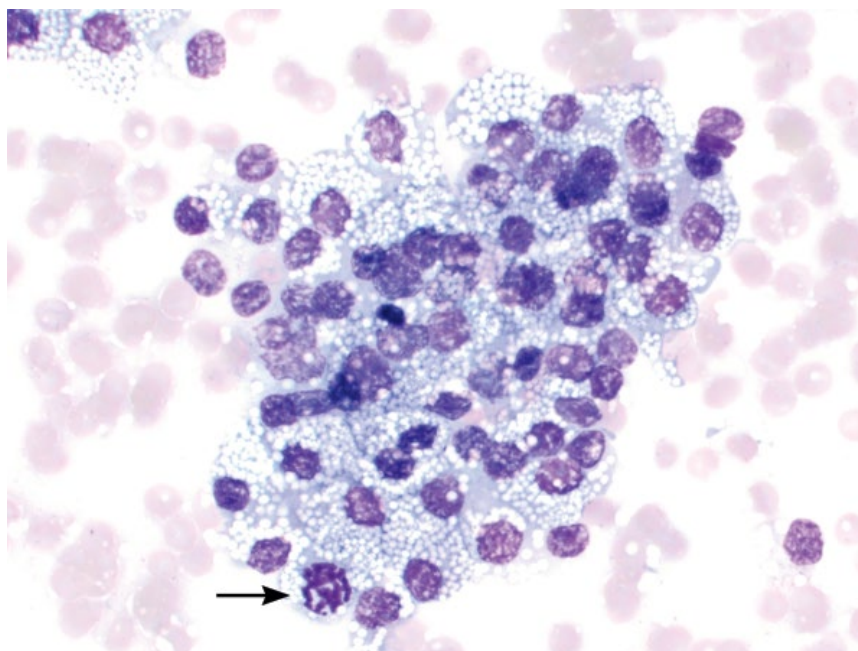
- Mostly older dogs and cats.
- Commonly located in the cranial mediastinum. Ectopic tumors rare [48].
- Paraneoplastic syndromes include hypercalcemia (reported in up to 34% of dogs), and myasthenia

gravis [49]. Thymomas may be associated with a reactive lymphocytosis that resolves with surgical excision of the tumor [50].

4.3.1.3 Prognosis

Good with surgical excision, even in patients with paraneoplastic syndromes. Recurrence rate is low [49, 51]. Improved survival seen in dogs and cats with lymphocyte-rich tumors [51]. Untreated patients have short survival times [49].

Figure 4.48 Thymus, thymic carcinoma, dog, 50× objective. The cells have a decreased volume of vacuolated cytoplasm. Note the mitotic figure (arrow).



4.3.2 Thymic Carcinoma

4.3.2.1 Cytologic Appearance

Thymic carcinoma cells are cohesive, and have a moderate volume of cytoplasm, which may contain fine clear vacuoles. Nuclei are ovoid with finely granular chromatin, and increased numbers of mitotic figures often are seen (Figure 4.48).

4.3.2.2 Clinical Considerations

- Reported rarely in dogs.
- Myaesthesia gravis seen as a paraneoplastic syndrome [52].

4.3.2.3 Prognosis

Metastasis is uncommon but tends to be seen in the lung and liver [53]. Median survival times generally are short, even with therapy [52].

4.3.3 Thymic (Mediastinal) Lymphoma

4.3.3.1 Cytologic Appearance

Lymphoma of the thymus and mediastinal lymph nodes is a high-grade disease, characterized by cells with nuclei 1.5–3 red blood cells in diameter. Nuclei often have irregular membrane boundaries, and mitotic figures are common (Figure 4.49). The cells have a small volume of pale-blue cytoplasm. Lesser numbers of residual small mature lymphocytes may be present.

4.3.3.2 Clinical Considerations

Mediastinal lymphoma involves the mediastinal lymph nodes, thymus or both.

Dogs

- Patients may present with respiratory distress or pre-caval syndrome.
- T-cell phenotype (and lymphoblastic type) most common [54].
- Hypercalcemia is common (up to 43% of patients) [55].

Cats

- Most common in young, FeLV-positive cats [13, 14].
- Hypercalcemia is rare.

4.3.3.3 Prognosis

Guarded to poor. The T-cell phenotype provides a poorer prognosis in dogs. FeLV-positive cats with lymphoma have a grave prognosis.

4.4 Bone Marrow

4.4.1 Normal

4.4.1.1 Cytologic Appearance

Normal bone marrow contains a mixture of granulocytic and erythroid cells. Both lineages should have orderly maturation, with low numbers of blasts (<5%) leading to progressively greater numbers of mature cells. Stages of maturation are shown in Figures 4.50 to 4.52. Megakaryocytes should mostly be mature, and about three to four should be seen per unit particle.

4.4.1.2 Clinical Considerations

- Cellularity decreases with age: juveniles ~75%, adults ~50% and geriatrics ~30% cellular relative to marrow lipid.

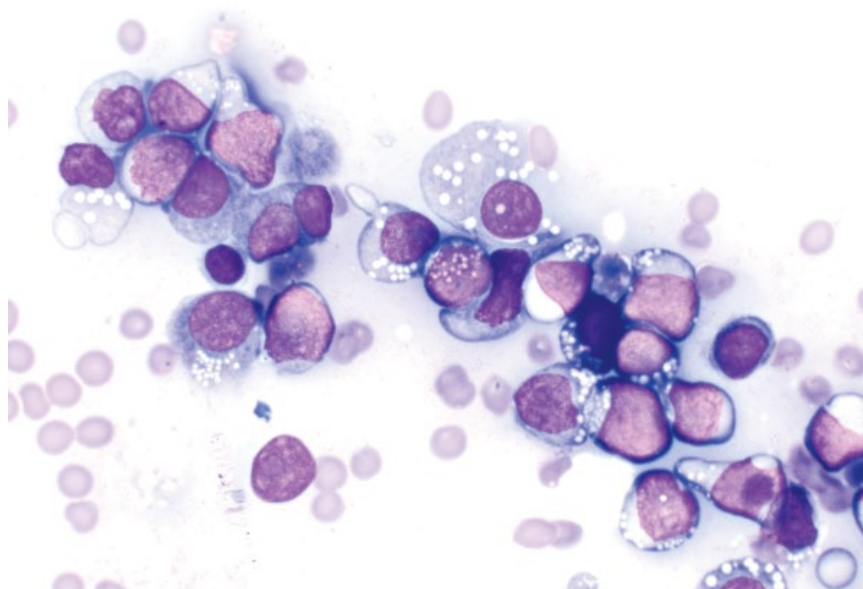


Figure 4.49 Thymus, lymphoma, dog, 50× objective. Note the irregular nuclear membrane boundaries.

- The granulocytic to erythroid (G/E) ratio typically is between 1.0 and 2.0 in dogs and cats (range 0.45 to 2.87) [56].
- Lymphocytes are seen in low numbers (<5% dogs and <10–15% cats), as are plasma cells (<2% both species) [56, 57].

4.4.2 Acute Myeloid Leukemia

Acute myeloid leukemias (AMLs) may have a granulocytic, monocytic, erythroid, or megakaryocytic origin. Acute leukemias should be considered when the percentage of blasts exceeds 30% of nucleated cells (excluding lymphoid cells and macrophages) [58]. These can often be distinguished based on cytomorphology (see below), but definitive diagnosis may require special stains. Spleen, liver, and lymph nodes may be involved, and peripheral cytopenias (anemia, leukopenia, thrombocytopenia) often are seen.

4.4.3 Acute Granulocytic/Monocytic Leukemia

4.4.3.1 Cytologic Appearance

Cells of granulocytic origin have a moderate volume of pale- to medium-blue cytoplasm, and often have diffuse pink granules in their cytoplasm (Figures 4.53 and 4.54). Monocytic leukemias frequently have lobulated nuclei (Figure 4.55).

4.4.3.2 Clinical Considerations

- Multiple subtypes: AML-M1 (myeloblastic leukemia without maturation); AML-M2 (myeloblastic leukemia

with differentiation); AML-M3 (promyelocytic leukemia – not reported in veterinary species); AML-M4 (myelomonocytic leukemia); and AML-M5 (monocytic leukemia).

- Eosinophilic and basophilic variants reported [58, 59].

4.4.3.3 Prognosis

Grave [60].

4.4.4 Acute Erythroid Leukemia

4.4.4.1 Cytologic Appearance

Erythroblasts have a small volume of deep-blue cytoplasm, and nuclei often have irregularly condensed chromatin (Figure 4.56).

4.4.4.2 Clinical Considerations

- AML-M6/M6Er subtype.
- Cats > dogs [61].
- Associated with Feline Leukemia Virus in cats [62].

4.4.4.3 Prognosis

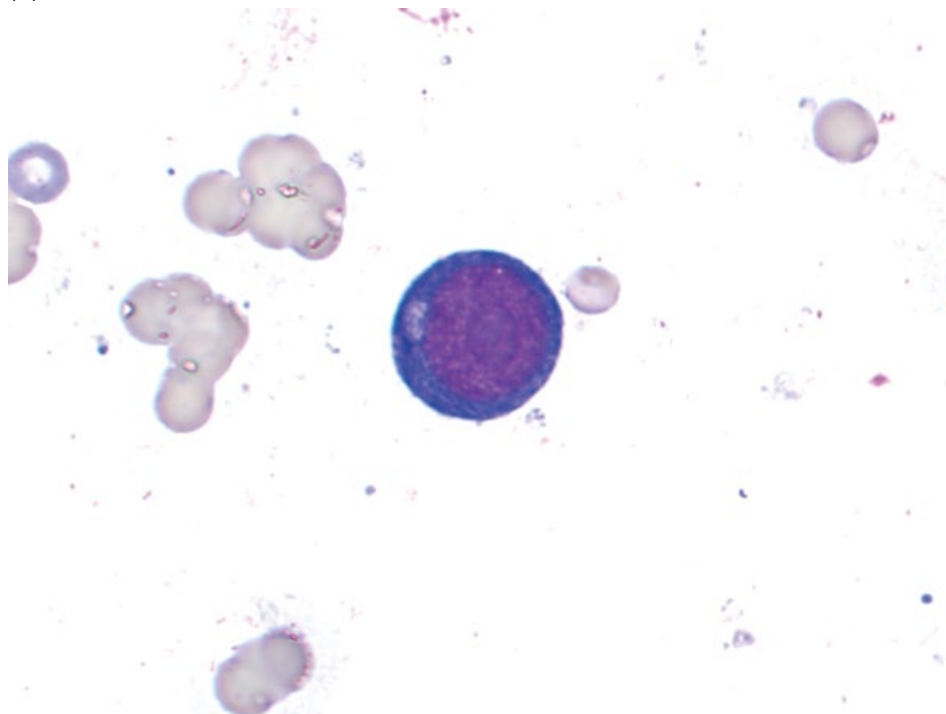
Grave [61].

4.4.5 Acute Megakaryoblastic Leukemia

4.4.5.1 Cytologic Appearance

Blast cells of megakaryocytic origin have a moderate volume of medium to deep-blue cytoplasm, which can appear similar to erythroid leukemias. Nuclei however often are bilobed or multilobulated, and have finely stippled chromatin with prominent basophilic nucleoli.

(A)



(B)

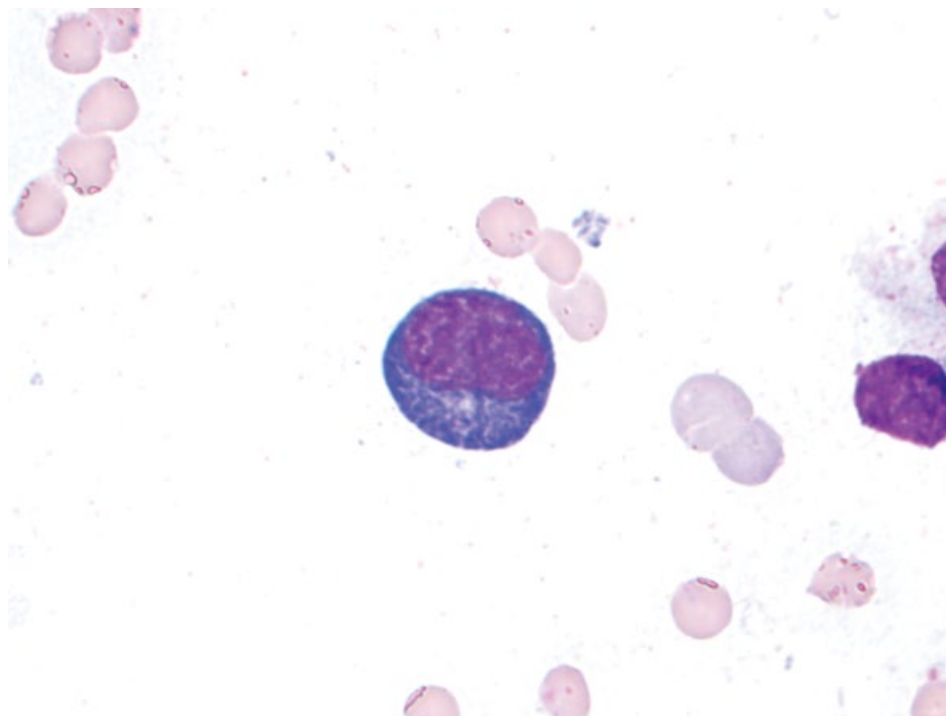
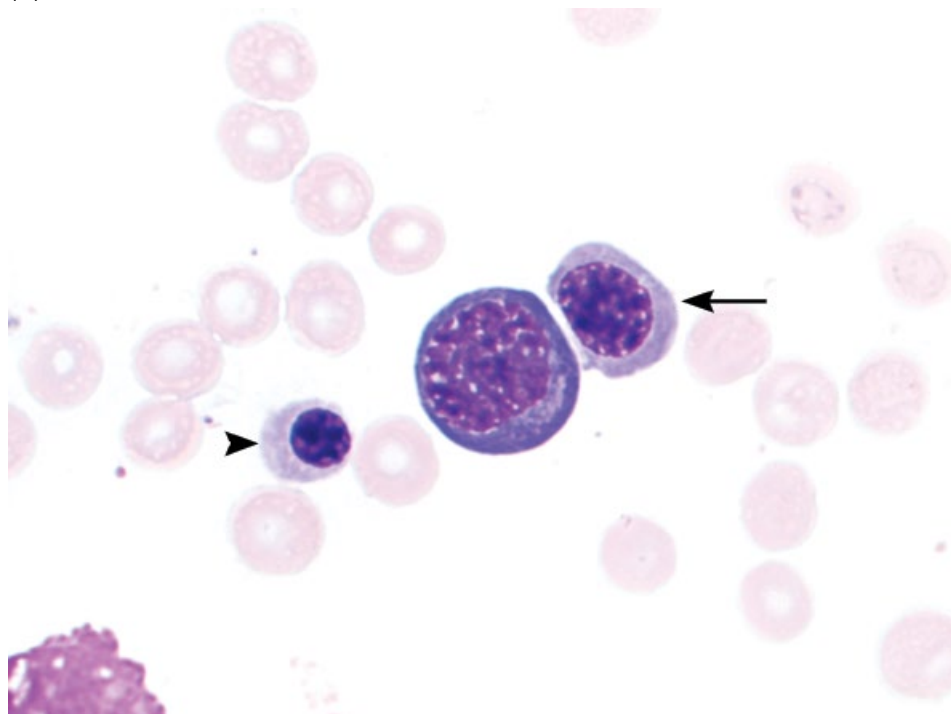


Figure 4.50 Erythroid precursor cells from most immature to mature. (A) Rubriblast. (B) Prorubricyte.

(C)



(D)

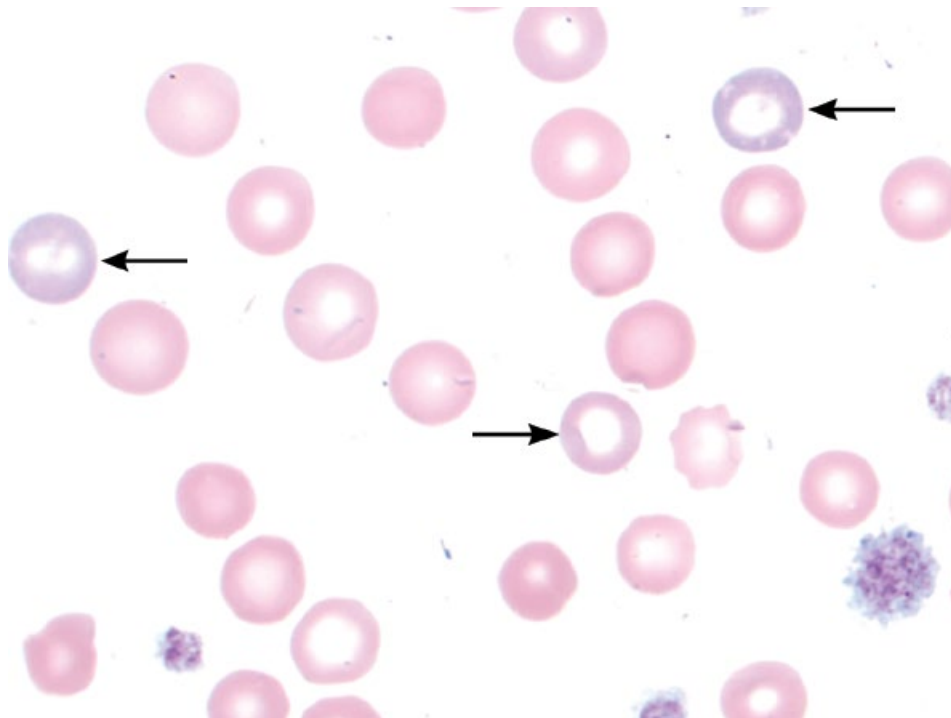
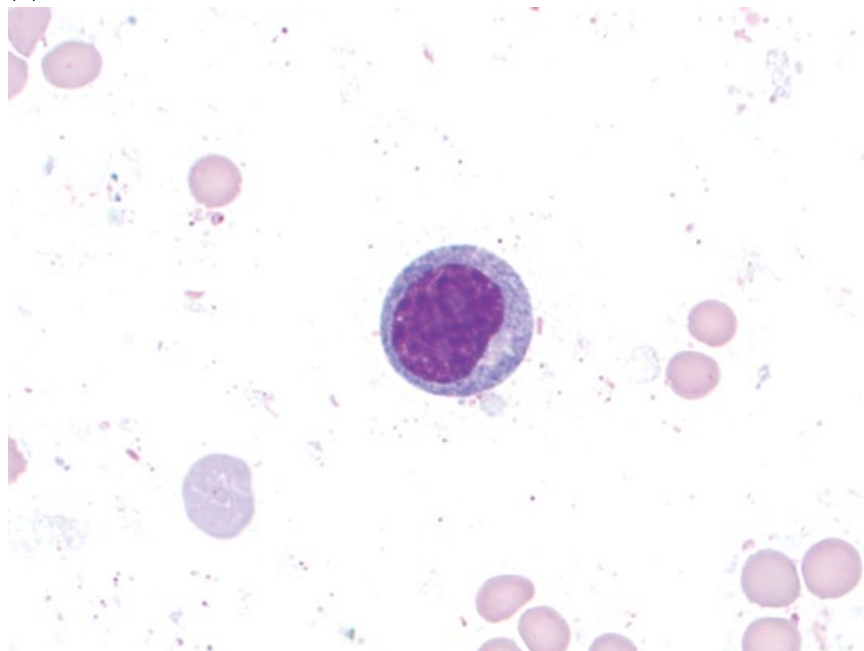


Figure 4.50 (Continued) (C) Basophilic rubricyte, polychromatophilic rubricyte (arrow) and metarubricyte (arrowhead). (D) Polychromatophils (arrows) and mature erythrocytes.

(A)



(B)

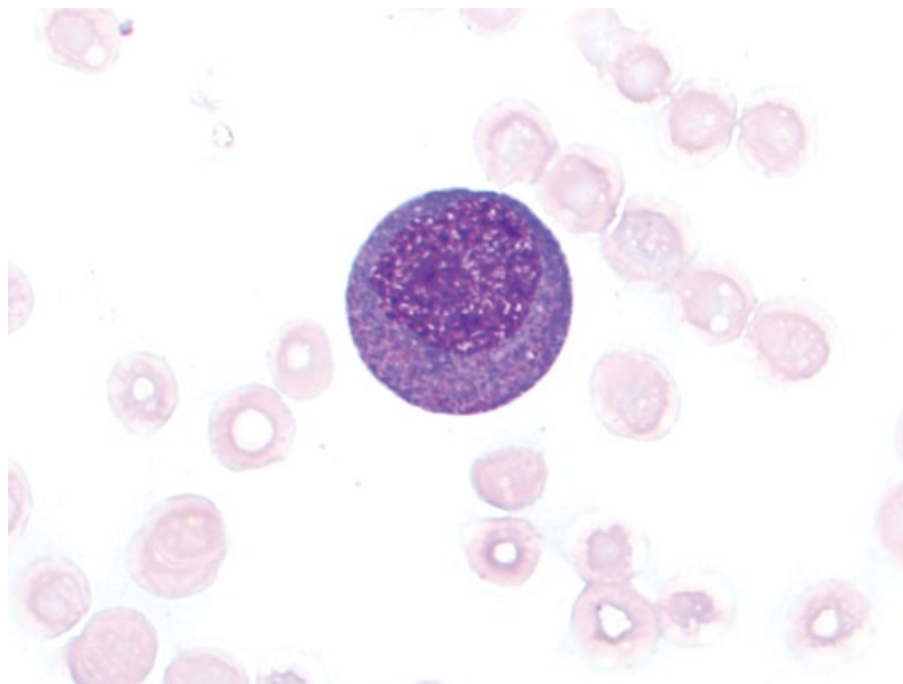
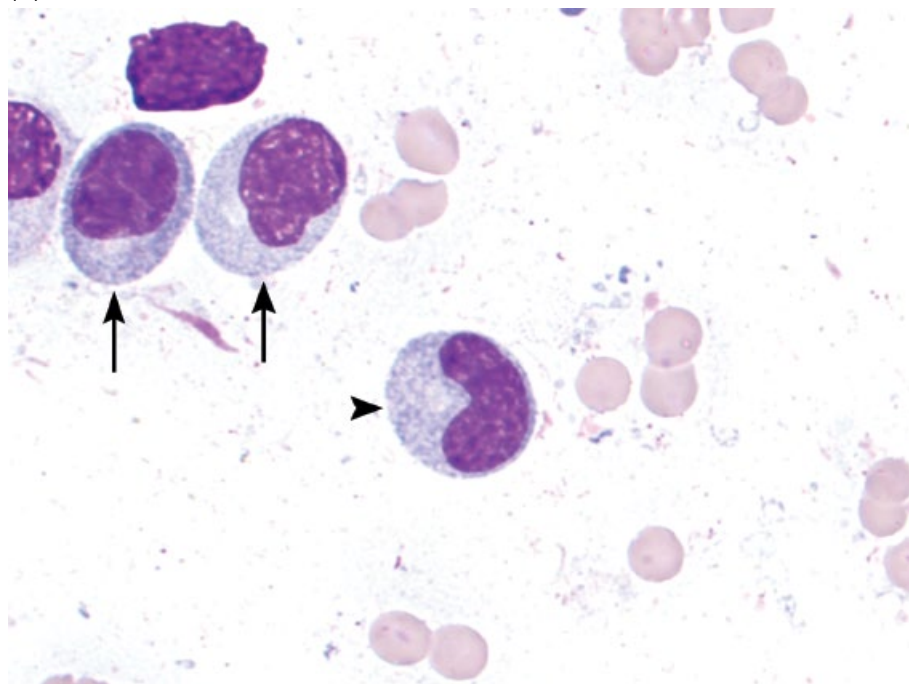


Figure 4.51 Granulocytic precursor cells from most immature to mature. (A) Myeloblast. (B) Promyelocyte (note abundant pink cytoplasmic granules).

(C)



(D)

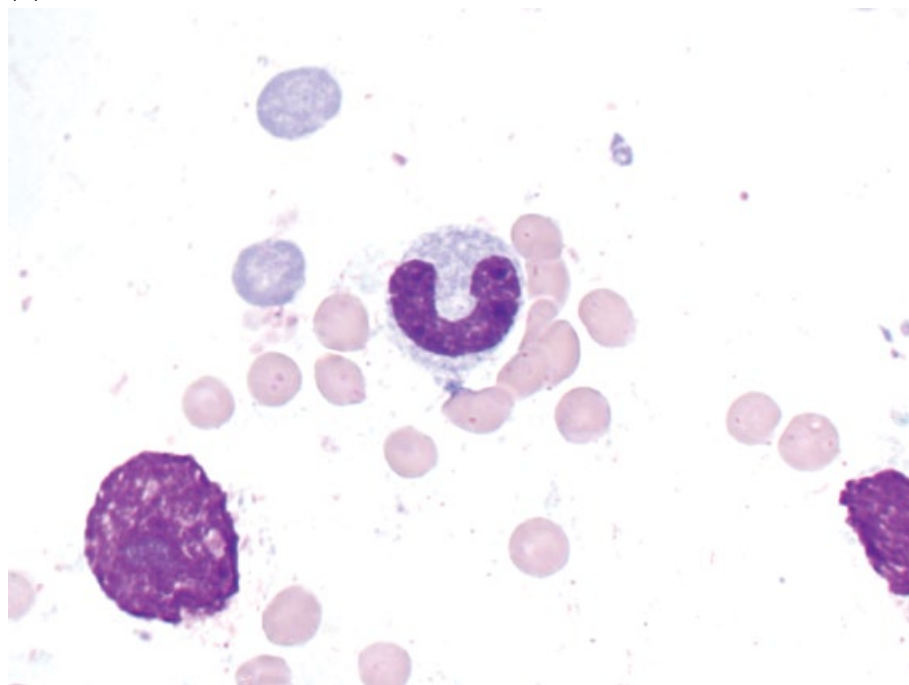

Figure 4.51 (Continued) (C) Myelocytes (arrows) and metamyelocyte (arrowhead). (D) Band neutrophil.

(E)

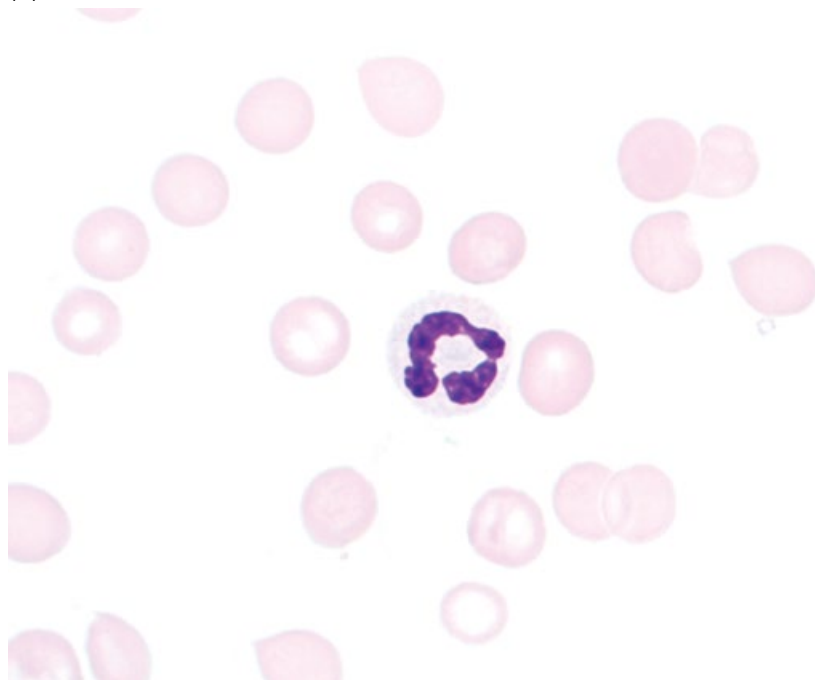

Figure 4.51 (Continued) (E) Mature neutrophil.

Unique features include cytoplasmic projections and multiple discrete cytoplasmic vacuoles (Figure 4.57) [63].

4.4.5.2 Clinical Considerations

- AML-M7 subtype.
- Dogs > cats.
- May be associated with platelet dysfunction [64].
- Thrombocytopenia common, but thrombocytosis reported [65].

4.4.5.3 Prognosis

Grave.

4.4.6 Acute Lymphoid Leukemia (ALL)

4.4.6.1 Cytologic Appearance

ALL is characterized by an expanded population of lymphocytes with large nuclei, finely stippled, immature chromatin and variably prominent nucleoli. Nuclei often have irregular nuclear margins (Figure 4.58). The cells mostly have high N/C ratios with a small volume of medium-blue cytoplasm. Differentiation from metastatic large-cell lymphoma is difficult (compare to Figure 4.59) and although number of cells may be helpful, other clinical information (concurrent cytopenias, enlarged lymph nodes, etc.) is essential.

4.4.6.2 Clinical Considerations

- Dogs and cats.
- May affect bone marrow and spleen.
- Associated with Feline Leukemia Virus infection in cats [66].

4.4.6.3 Prognosis

Grave [67].

4.4.7 Lymphoma (Large-cell)

4.4.7.1 Cytologic Appearance

Large-cell lymphoma may metastasize to the bone marrow and appear similar to ALL or other acute leukemias (Figure 4.59).

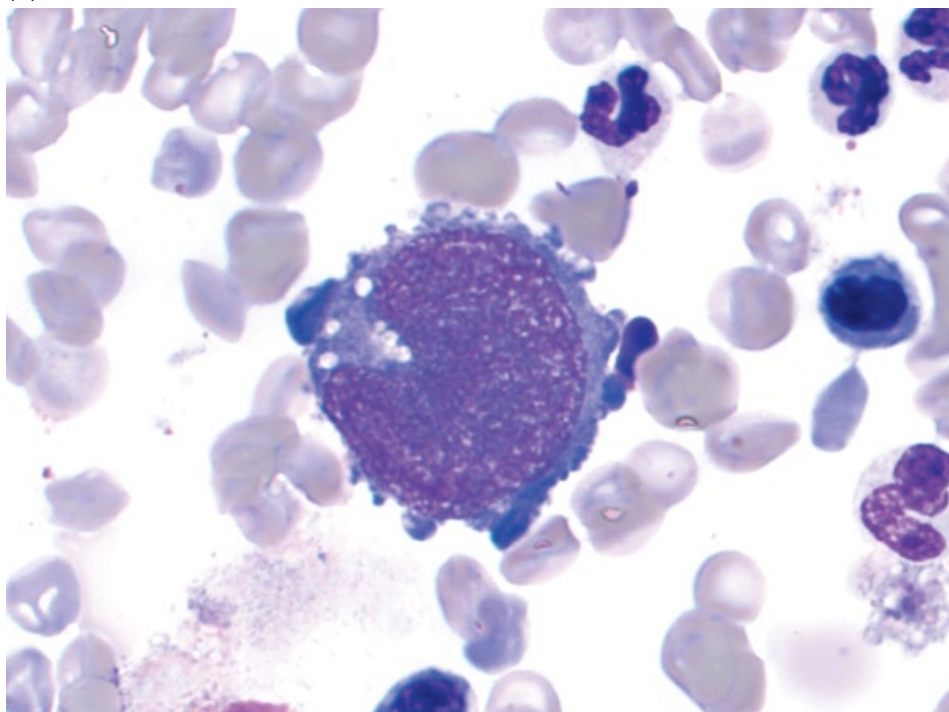
4.4.7.2 Clinical Considerations

- Associated with enlarged lymph nodes/lymphoid organs.
- Marrow involvement often associated with circulating neoplastic cells and thrombocytopenia [68].

4.4.7.3 Prognosis

Poor. >3% bone marrow infiltration associated with short survival times and poor prognosis [69].

(A)



(B)

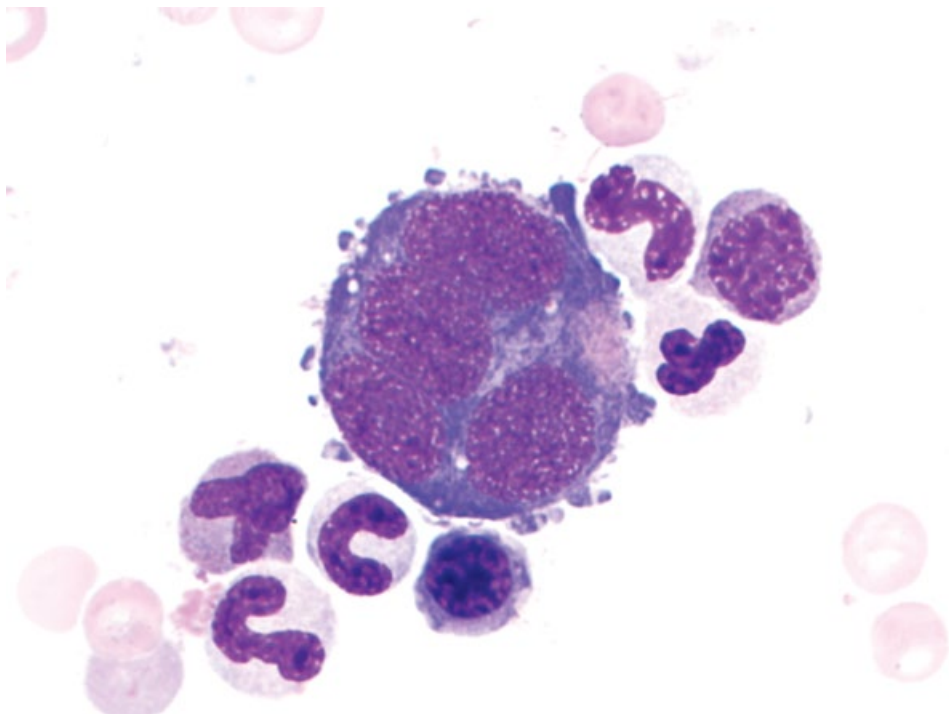


Figure 4.52 Megakaryocytic precursor cells from most immature to mature. (A) Megakaryoblast. (B) Promegakaryocyte.

(C)

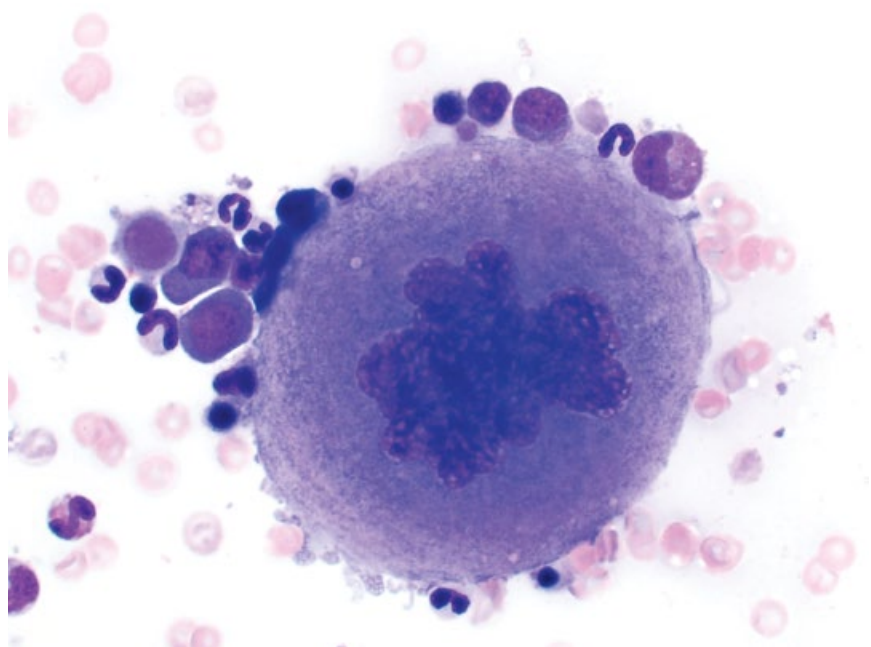
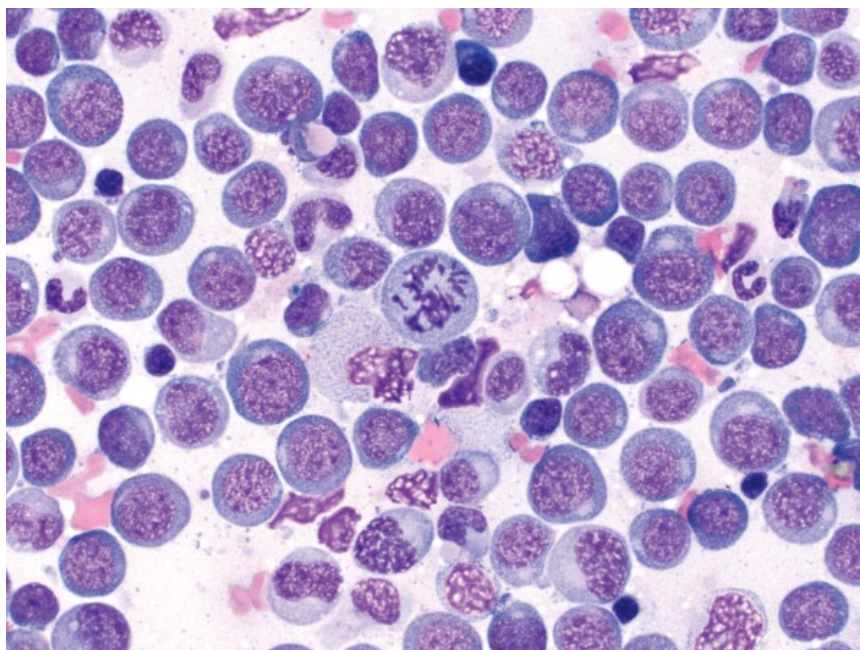


Figure 4.52 (Continued) (C) Mature megakaryocyte.

Figure 4.53 Bone marrow, acute granulocytic leukemia (AML-M2), dog, 50× objective.



4.4.8 Granulocytic Hyperplasia

4.4.8.1 Cytologic Appearance

Granulocytic hyperplasia is characterized by an overall orderly increase in the granulocytic series, with increased numbers of immature cells including bands, metamyelo-

cytes, promyelocytes, and myeloblasts. Increased numbers of mitotic figures may be seen (Figure 4.60).

4.4.8.2 Clinical Considerations

- Myeloblasts are increased, but comprise <20–30% of nucleated cells.

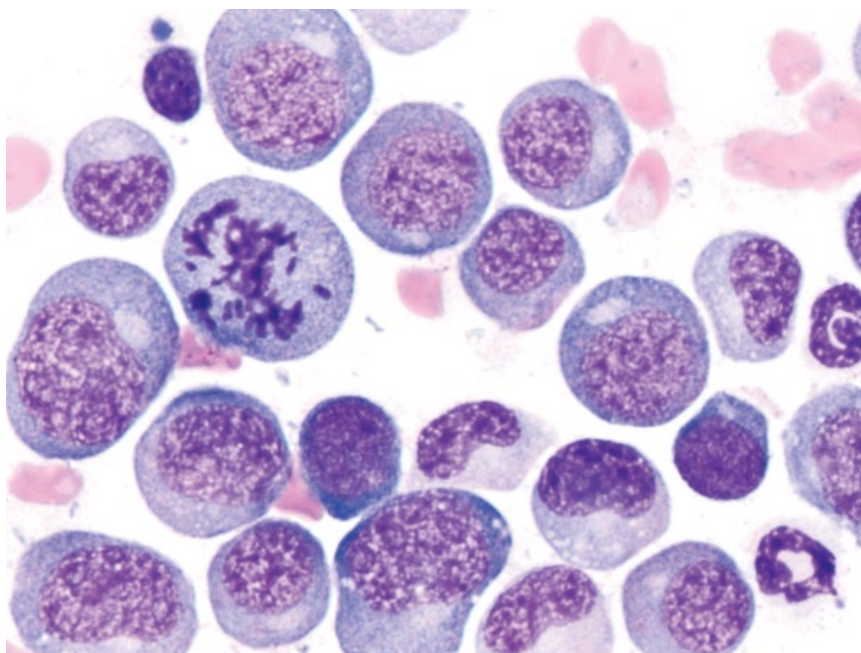


Figure 4.54 Bone marrow, acute granulocytic leukemia (AML-M2; same case as Figure 4.53), dog, 100× objective. Note the subtle diffuse, pink cytoplasmic granules.

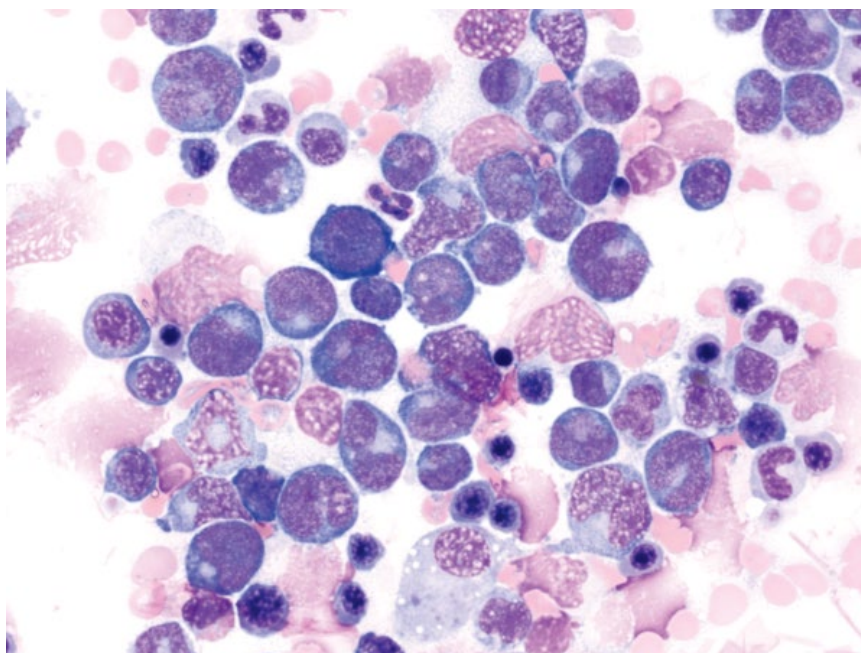


Figure 4.55 Bone marrow, acute myelomonocytic leukemia (AML-M4), dog, 50× objective. Note the indented and vaguely lobulated nuclei.

- Mature neutrophil production takes ~3–4 days [70].
- Appropriate response to increased peripheral demand or previous bone marrow insults.

4.4.8.3 Prognosis

Excellent if regenerative response is effective.

4.4.9 Erythroid Hyperplasia

4.4.9.1 Cytologic Appearance

Erythroid hyperplasia is characterized by an overall orderly increase in the erythroid series, with increased numbers of immature cells including basophilic rubricytes, prorubricytes, and rubriblasts (Figure 4.61).

Figure 4.56 Bone marrow, acute erythroid leukemia (AML-M6Er), cat, 100× objective. Note the deep-blue cytoplasm.

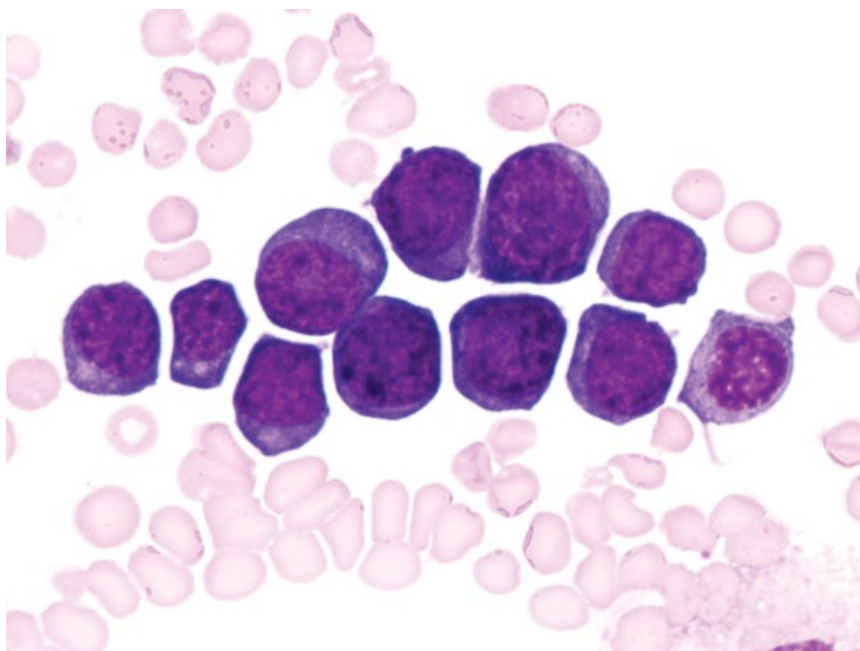
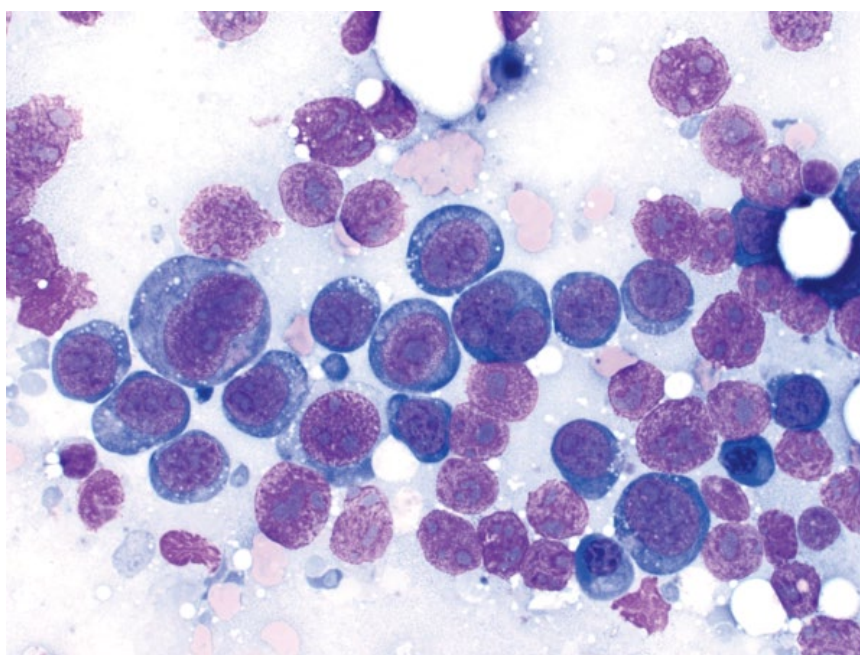


Figure 4.57 Bone marrow, acute megakaryoblastic leukemia (AML-M7), dog, 50× objective. Characteristic features include indented nuclei, binucleation, and deep-blue cytoplasm with fine clear vacuoles.



4.4.9.2 Clinical Considerations

- Rubriblasts are increased, but comprise <20–30% of nucleated cells.
- Erythrocyte regeneration takes ~4 days [71].
- Appropriate response to hemolysis/hemorrhage or previous bone marrow insults.
- Ineffective erythroid hyperplasia may result from iron deficiency, myeloproliferative/dysplastic diseases and immune-mediated disease [72].

4.4.9.3 Prognosis

Guarded to excellent, based on underlying cause.

4.4.10 Hemophagocytosis

4.4.10.1 Cytologic Appearance

Hemophagocytosis in the bone marrow is characterized by increased numbers of well-differentiated macrophages containing phagocytosed red blood cells. Earlier erythroid

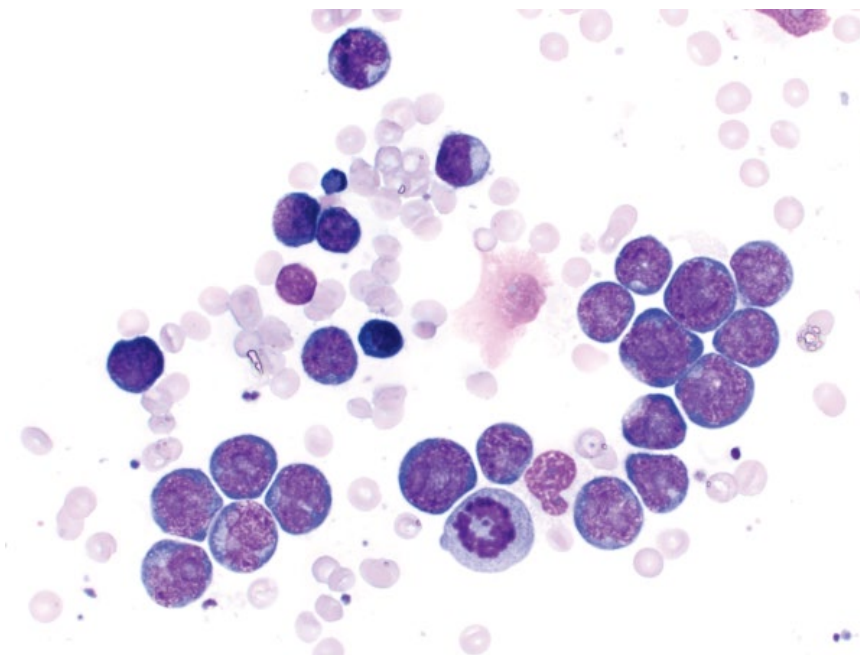


Figure 4.58 Bone marrow, acute lymphoid leukemia, dog, 50× objective.

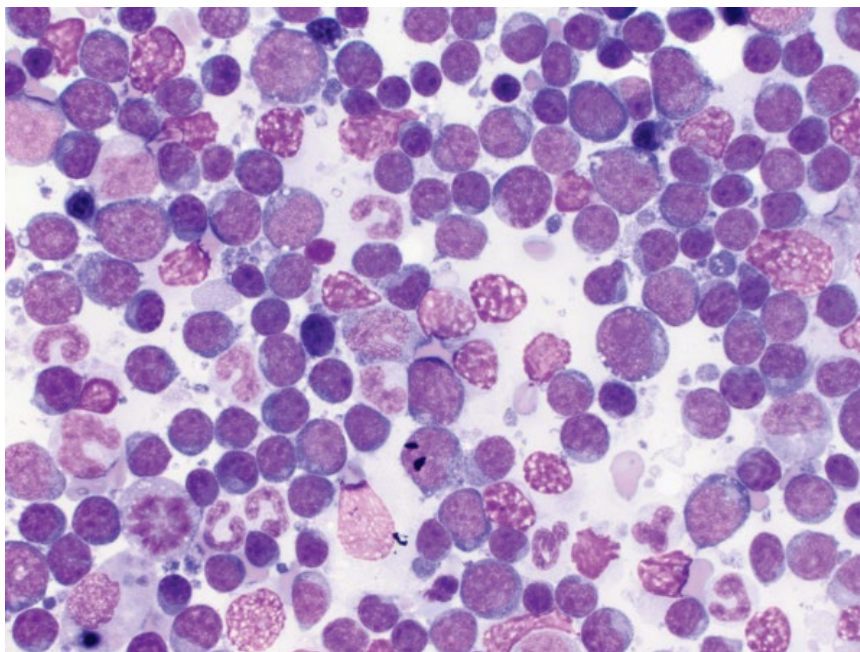


Figure 4.59 Bone marrow, metastatic large-cell lymphoma, dog, 50× objective.

precursors may even be ingested, especially in cases of immune-mediated hemolytic anemia at the level of the bone marrow (Figure 4.62). Macrophages generally are seen individually and in lesser numbers than in cases of hemophagocytic histiocytic sarcoma (compare to Figure 4.63).

4.4.10.2 Clinical Considerations

- Seen secondary to immune-mediated destruction of red blood cells. Arrest at the level of destruction usually is apparent.
- May also be secondary to infectious, neoplastic or metabolic diseases [73].

Figure 4.60 Bone marrow, granulocytic hyperplasia, cat, 50× objective. The series is left-shifted, with increased numbers of bands and metamyelocytes, but low numbers of promyelocytes and rare myeloblasts.

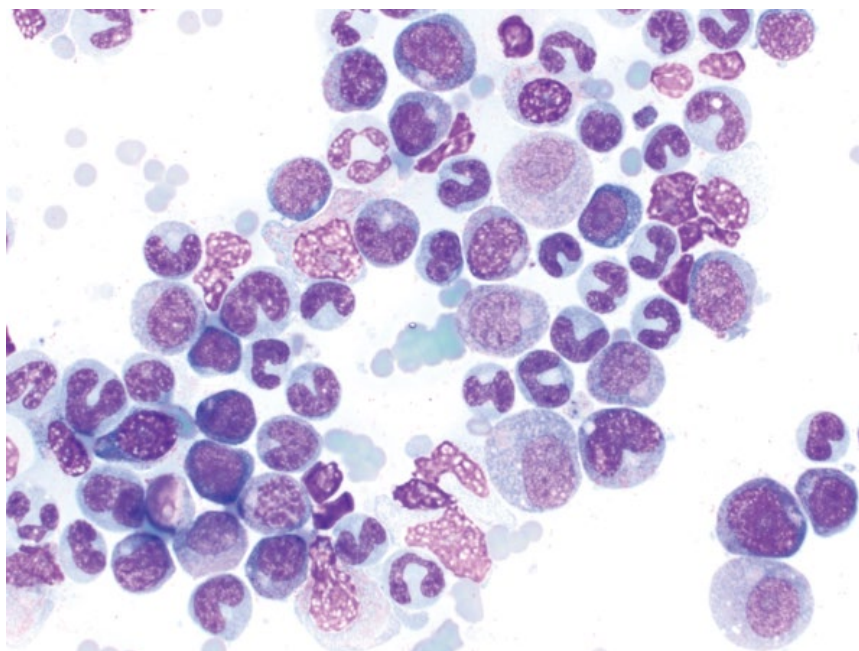
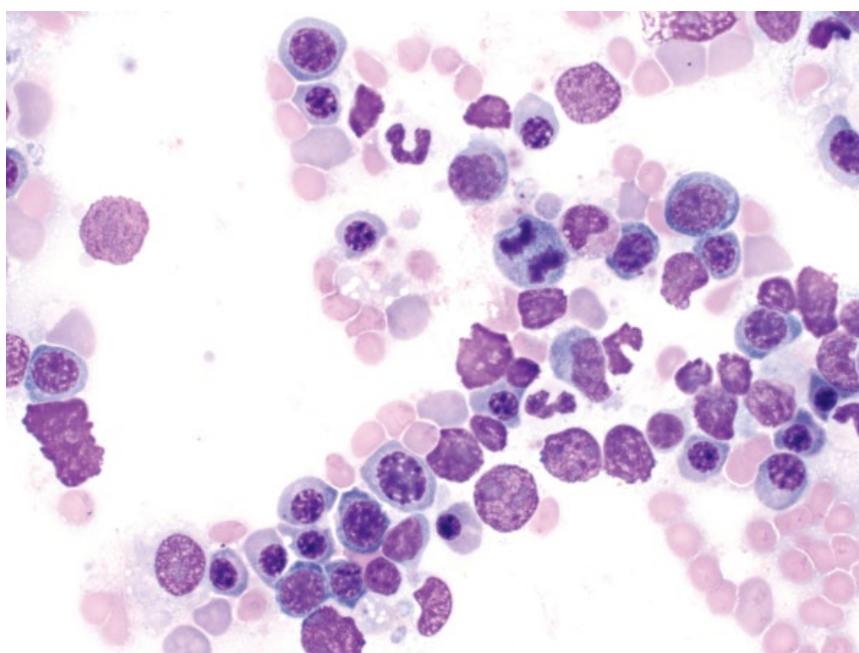


Figure 4.61 Bone marrow, erythroid hyperplasia, dog, 50× objective. Increased numbers of erythroid precursors are seen. Note the mitotic figure.



4.4.10.3 Prognosis

Variable, based on underlying cause.

4.4.11 Hemophagocytic Histiocytic Sarcoma (HHS)

4.4.11.1 Cytologic Appearance

Similar to that described in the spleen, HHS is characterized by well-differentiated histiocytes/macrophages, seen mostly in aggregates (Figure 4.63). Anisocytosis/

anisokaryosis are mild to moderate. *Note:* It is important to rule out causes of reactive histiocytosis and erythrophagocytosis (see section 4.4.10).

4.4.11.2 Clinical Considerations

- Rare in dogs. Not reported in cats.
- Predisposed breeds = Bernese Mountain Dog, Golden Retriever, Labrador Retriever.
- Arises in bone marrow and spleen. May metastasize to liver and lungs.

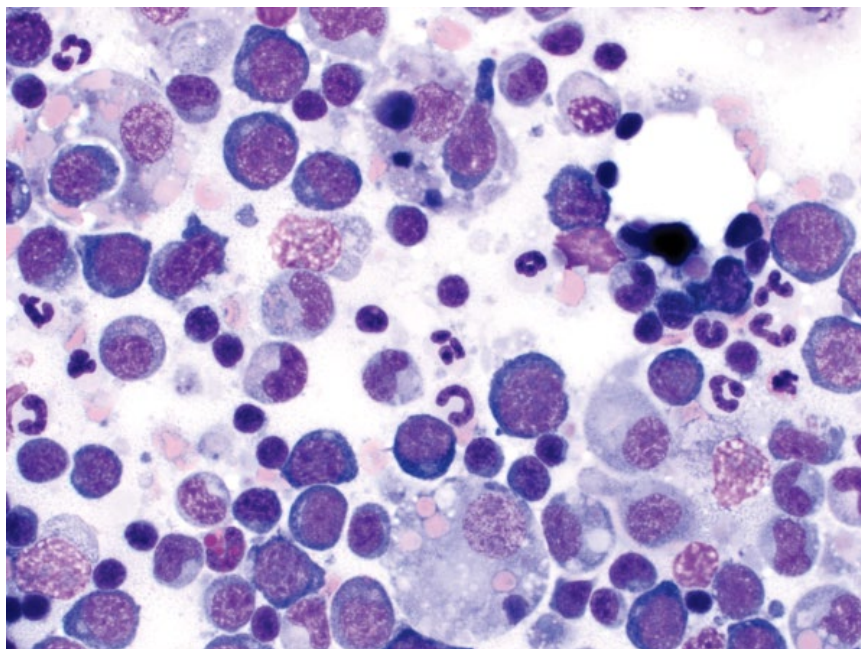


Figure 4.62 Bone marrow, hemophagocytosis, dog, 50× objective. Case of immune-mediated hemolytic anemia at the level of the bone marrow, with maturational arrest at the level of basophilic rubricytes.

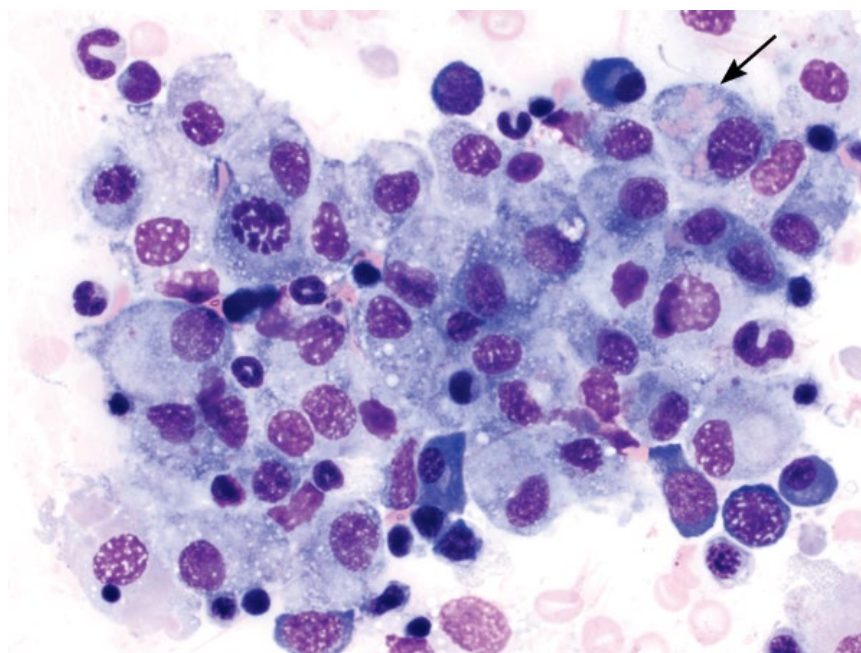


Figure 4.63 Bone marrow, hemophagocytic histiocytic sarcoma, dog, 50× objective. Note sheets of well differentiated macrophages that are erythrophagocytic (arrow).

- Common concurrent hematologic findings (% of cases): Coomb's negative regenerative anemia (94%); hypoalbuminemia (94%); thrombocytopenia (88%); hypocholesterolemia (69%) [39].

4.4.11.3 Prognosis

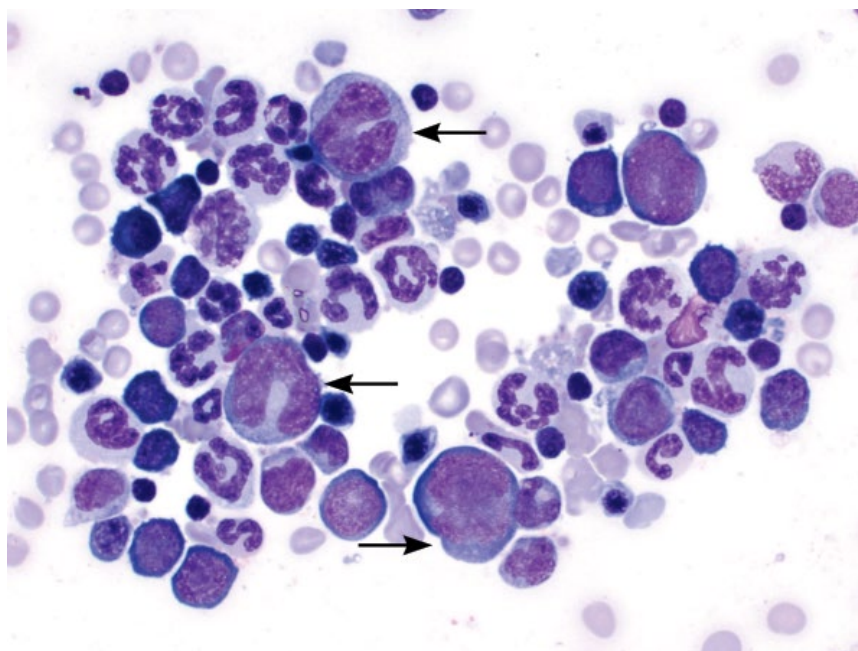
Grave. HHS is an aggressive malignancy associated with short survival times (median survival time of 4 weeks post diagnosis), even with therapy [39].

4.4.12 Histiocytic Sarcoma

4.4.12.1 Cytologic Features

Histiocytic sarcoma (HS) is characterized by individualized cells with many criteria of malignancy including marked anisocytosis and anisokaryosis, and with karyomegaly a common finding. Multinucleation, nuclear fragmentation and hyperchromasia also are common (Figure 4.64). The cytoplasm is variably vacuolated.

Figure 4.64 Bone marrow, histiocytic sarcoma, dog, 50× objective. Note the large, bizarre, neoplastic cells (arrows).



4.4.12.2 Clinical Considerations

- Dogs >> cats
- Reported in many dog breeds, but Bernese Mountain Dogs, Rottweilers, Golden Retrievers, Labrador Retrievers and Flat-Coated Retrievers are predisposed [38].
- Other organs commonly affected by disseminated HS = spleen, liver, lung, lymph nodes.

4.4.12.3 Prognosis

Grave.

4.4.13 Inflammation/Infection

4.4.13.1 Cytologic Appearance

Inflammation can be difficult to diagnose in bone marrow samples due to the normal presence of neutrophils and monocytes. Plasma cells and lymphocytes should be seen in low numbers normally (see section 4.4.1), and increased numbers may be indicative of inflammation/antigenic stimulation (Figure 4.65). The presence of infectious organisms confirms inflammation/infection (Figure 4.66). Many infectious organisms may affect the bone marrow (see Chapter 2 for details).

4.4.13.2 Clinical Considerations

- Reactive lymphocytosis associated with immune-mediated and inflammatory diseases [57].
- Reactive lymphocytes seen in aggregates and smaller than those of chronic lymphocytic leukemia (CLL) [57].

4.4.13.3 Prognosis

Variable, based on underlying cause.

4.4.14 Chronic Lymphocytic Leukemia (CLL)

4.4.14.1 Cytologic Appearance

CLL is considered present when small mature lymphocytes exceed 15–30% of nucleated cells in the bone marrow [33, 74]. The cells have nuclei that are about one red blood cell in diameter, and mature, clumped chromatin with inapparent nucleoli (Figure 4.67). Hematopoietic cells may be present in normal or decreased numbers, depending on the stage of disease.

4.4.14.2 Clinical Considerations

- Dogs > cats.
- Affects middle-aged to older patients.
- Accompanied by lymphocytosis (range in dogs = 15 000 to 1 600 000 cells μl^{-1} ; median value in cats = 34 200 cells μl^{-1}) [33, 34].

4.4.14.3 Prognosis

Generally good, with long survival times reported. Young age and presence of anemia may confer a poorer prognosis in dogs [75].

4.4.15 Multiple Myeloma

4.4.15.1 Cytologic Features

Multiple myeloma is characterized by a neoplastic expansion of well-differentiated plasma cells that are seen in large sheets and aggregates. The cells have a moderate volume of pale-blue cytoplasm, and often have a characteristic, perinuclear clear zone (Golgi zone) (Figure 4.68). The nuclei are round, eccentrically placed, and have clumped chromatin. Normal bone marrow elements may be replaced by neoplastic cells.

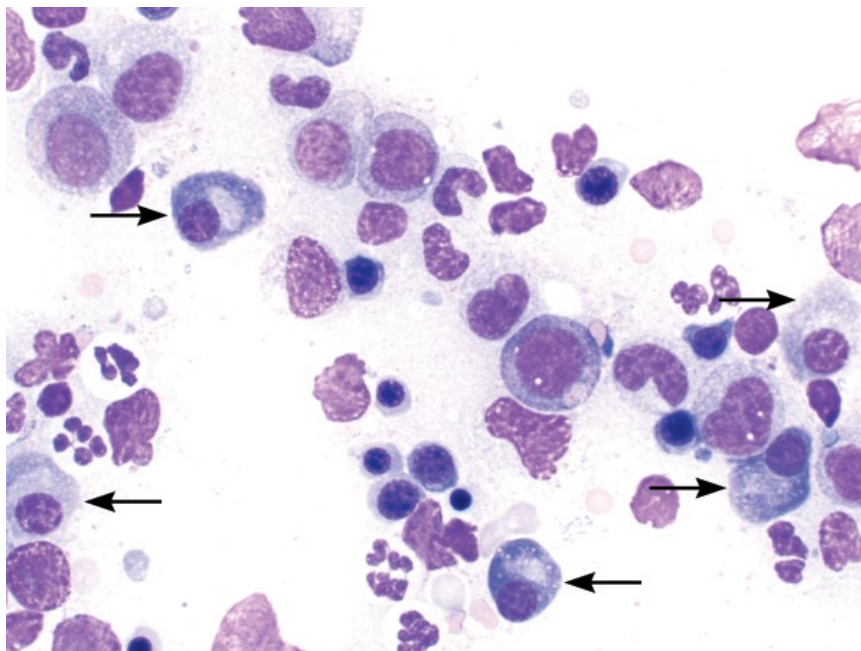


Figure 4.65 Bone marrow, plasmacytosis, dog, 50× objective. Increased numbers of plasma cells are seen (arrows).

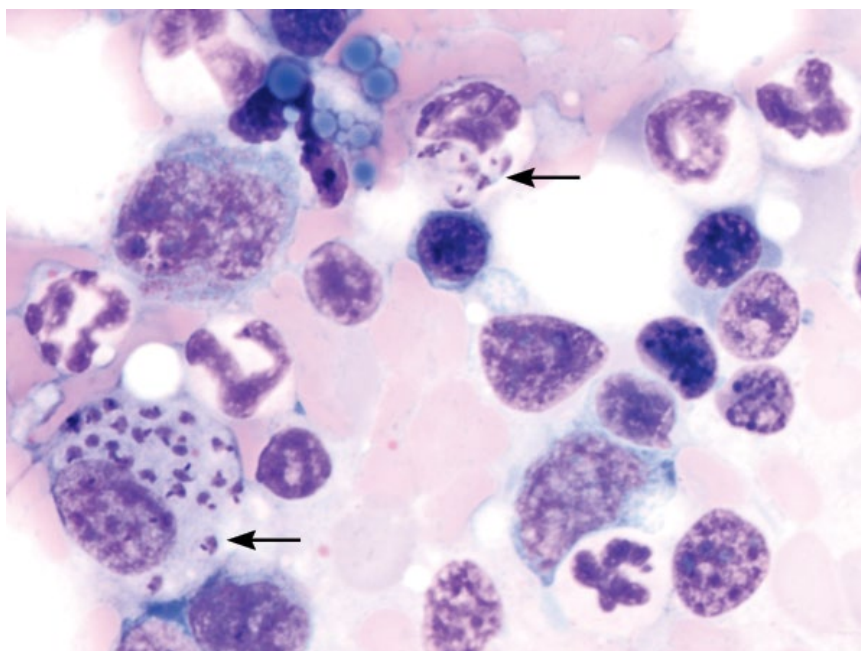


Figure 4.66 Bone marrow, Leishmaniasis, dog, 100× objective. Note the *Leishmania* organisms within macrophages (arrows).

4.4.15.2 Clinical Considerations

- Dogs > cats.
- Other clinical features = monoclonal gammopathy, lytic bone lesions, anemia, bleeding diatheses, Bence–Jones proteinuria [35, 36].

4.4.15.3 Prognosis

Dogs = Good short-term prognosis with treatment, and long-term control is possible. Negative prognostic

factors include extensive bone lysis/involvement as well as hypercalcemia and Bence–Jones proteinuria [35].

Cats = Guarded prognosis, with generally short survival times [36, 37].

4.4.16 Metastatic Disease

4.4.16.1 Cytologic Appearance

Metastatic disease is characterized by a population of cells not normally present within the bone marrow. Carcinoma

Figure 4.67 Bone marrow, chronic lymphocytic leukemia (CLL), dog, 50× objective.

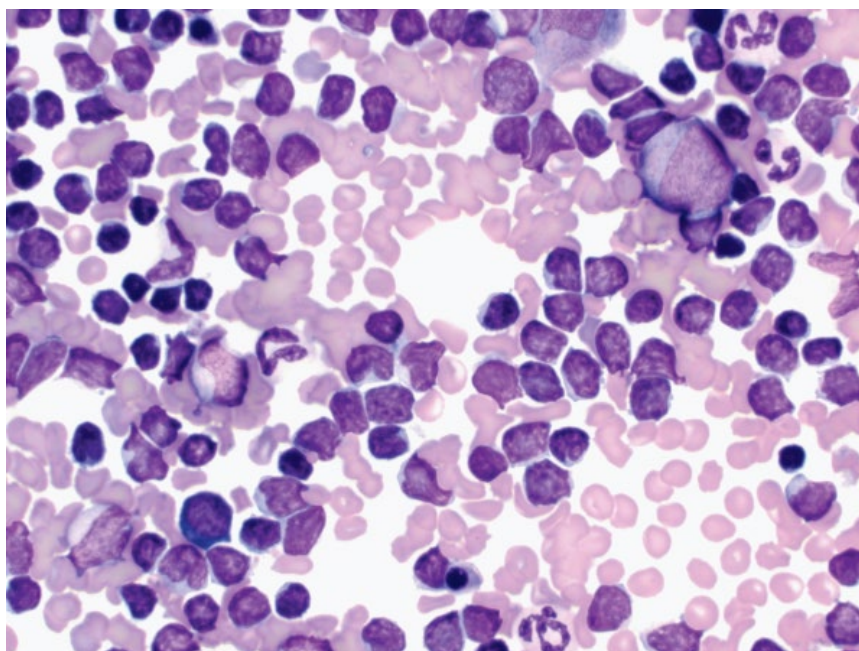
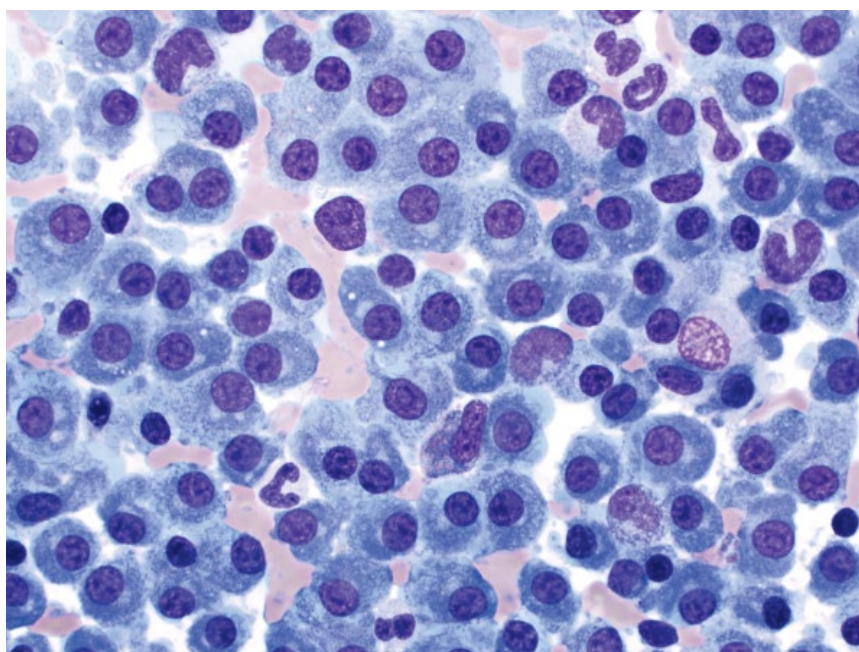


Figure 4.68 Bone marrow, multiple myeloma, dog, 50× objective.



cells (Figures 4.69 and 4.70) and round cell neoplasms such as mast cell neoplasia (Figure 4.71) may be seen.

4.4.16.2 Clinical Considerations

- Rare in dogs and cats, though true incidence unknown [76].

- Epithelial tumors most common [77].
- Mast cells are seen in extremely low numbers in normal bone marrow [23].

4.4.16.3 Prognosis

Poor to grave.

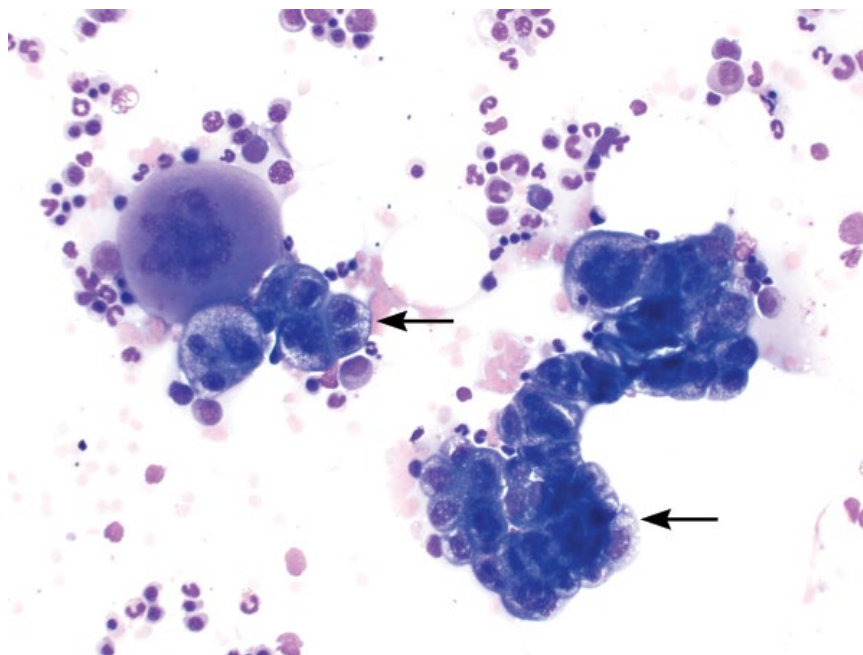


Figure 4.69 Bone marrow, metastatic carcinoma (prostatic), dog, 20× objective. Note the sheets of cohesive neoplastic cells (arrows).

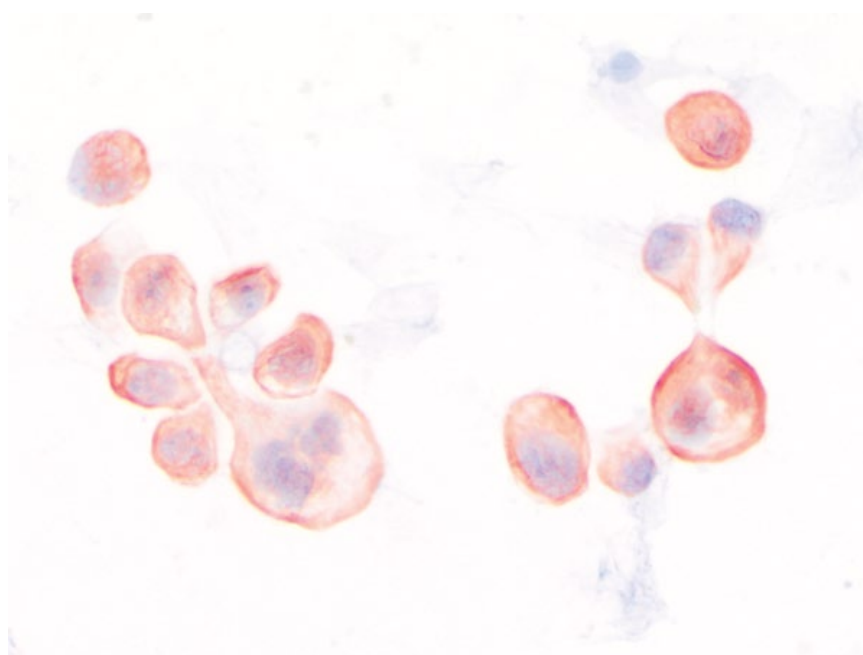


Figure 4.70 Bone marrow, metastatic carcinoma (prostatic), dog, 50× objective. Same case as Figure 4.69 stained with immunocytochemical stain PanCK.

4.4.17 Marrow Hypoplasia/Aplasia

4.4.17.1 Cytologic Appearance

Hypocellular bone marrow is characterized by unit particles with >75% lipid in adults (Figure 4.72). Hypoplasia may be due to one or more cell lines being decreased. Aplasia is seen when all cell lines are decreased.

4.4.17.2 Clinical Considerations

- DDx = drug/toxin exposure (e.g., estrogen, phenylbutazone), infectious agents (e.g., parvovirus, FeLV), myelofibrosis [78].

4.4.17.3 Prognosis

Variable, based on underlying cause and ability for reversal.

Figure 4.71 Bone marrow, metastatic mast cell neoplasia, dog, 50× objective.

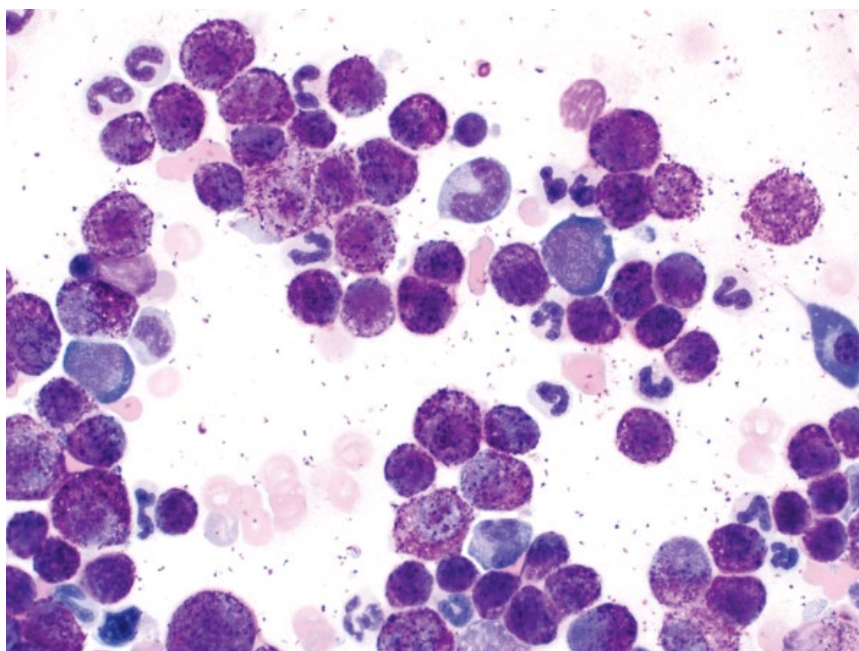
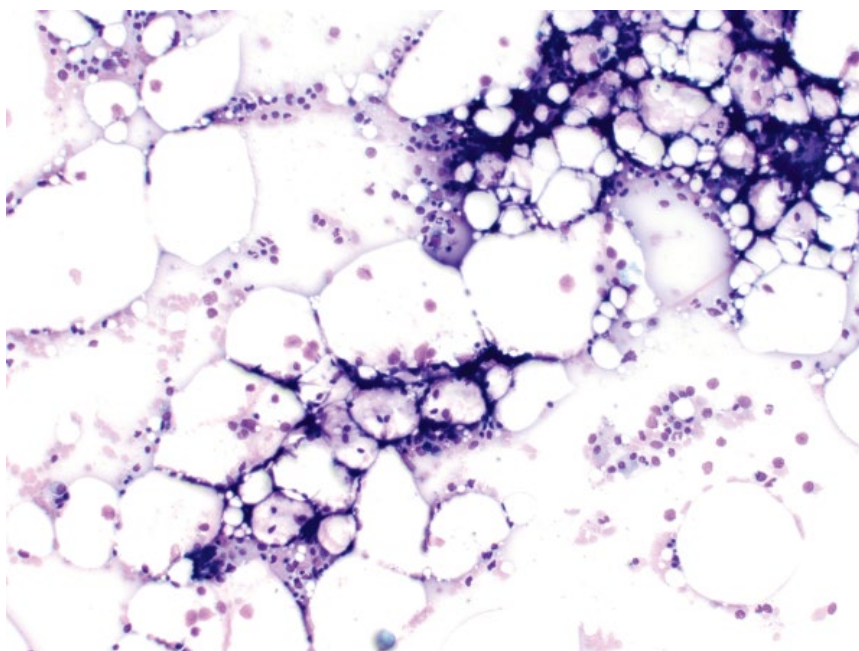


Figure 4.72 Bone marrow, hypoplasia, dog, 10× objective.



References

- 1 White, S.D., Rosychuk, R.A., Stewart, L.J., *et al.* (1989) Juvenile cellulitis in dogs: 15 cases (1979–1988). *J. Am. Vet. Med. Assoc.*, **195** (11), 1609–1611.
- 2 Sykes, J.E., Marks, S.L., Mapes, S., *et al.* (2010) Salmon poisoning disease in dogs: 29 cases. *J. Vet. Intern. Med.*, **24** (3), 504–513.
- 3 Headley, S.A., Kano, F.S., Scorpio, D.G., *et al.* (2009) *Neorickettsia helminthoeca* in Brazilian dogs: a cytopathological, histopathological and immunohistochemical study. *Clin. Microbiol. Infect.*, **15**, 21–23.
- 4 Johns, J.L. (2011) Salmon poisoning in dogs: a satisfying diagnosis. *Vet. J.*, **187** (2), 149–150.

- 5 Vezzali, E., Parodi, A.L., Marcato, P.S., *et al.* (2010) Histopathologic classification of 171 cases of canine and feline non-Hodgkin lymphoma according to the WHO. *Vet. Comp. Oncol.*, **8** (1), 38–49.
- 6 Merlo, D.F., Rossi, L., Pellegrino, C., *et al.* (2008) Cancer incidence in pet dogs: findings of the Animal Tumor Registry of Genoa, Italy. *J. Vet. Intern. Med.*, **22** (4), 976–984.
- 7 Edwards, D.S., Henley, W.E., Harding, E.F., *et al.* (2003) Breed incidence of lymphoma in a UK population of insured dogs. *Vet. Comp. Oncol.*, **1** (4), 200–206.
- 8 Dobson, J.M. (2013) Breed-predispositions to cancer in pedigree dogs. *ISRN Vet. Sci.*, **2013**, 941275. doi: 10.1155/2013/941275. Last accessed 2 January 2017.
- 9 Valli, V.E., San Myint, M., Barthel, A., *et al.* (2011) Classification of canine malignant lymphomas according to the World Health Organization criteria. *Vet. Pathol.*, **48** (1), 198–211.
- 10 Valli, V.E., Kass, P.H., San Myint, M., *et al.* (2013) Canine lymphomas: association of classification type, disease stage, tumor subtype, mitotic rate, and treatment with survival. *Vet. Pathol.*, **50** (5), 738–748.
- 11 Kiupel, M., Teske, E., Bostock, D. (1999) Prognostic factors for treated canine malignant lymphoma. *Vet. Pathol.*, **36** (4), 292–300.
- 12 Vail, D.M., Moore, A.S., Ogilvie, G.K., *et al.* (1998) Feline lymphoma (145 cases): proliferation indices, cluster of differentiation 3 immunoreactivity, and their association with prognosis in 90 cats. *J. Vet. Intern. Med.*, **12** (5), 349–354.
- 13 Louwerens, M., London, C.A., Pedersen, N.C., *et al.* (2005) Feline lymphoma in the post-feline leukemia virus era. *J. Vet. Intern. Med.*, **19** (3), 329–335.
- 14 Schmidt, J.M., North, S.M., Freeman, K.P., *et al.* (2010) Feline paediatric oncology: retrospective assessment of 233 tumours from cats up to one year (1993 to 2008). *J. Small Anim. Pract.*, **51** (6), 306–311.
- 15 MacEwen, E.G., Patnaik, A.K., Wilkins, R.J. (1977) Diagnosis and treatment of canine hematopoietic neoplasms. *Vet. Clin. North Am.*, **7** (1), 105–118.
- 16 Flood-Knapik, K.E., Durham, A.C., Gregor, T.P., *et al.* (2013) Clinical, histopathological and immunohistochemical characterization of canine indolent lymphoma. *Vet. Comp. Oncol.*, **11** (4), 272–286.
- 17 Lurie, D.M., Milner, R.J., Suter, S.E., *et al.* (2008) Immunophenotypic and cytomorphologic subclassification of T-cell lymphoma in the boxer breed. *Vet. Immunol. Immunopathol.*, **125** (1–2), 102–110.
- 18 Kol, A., Christopher, M.M., Skorupski, K.A., *et al.* (2013) B-cell lymphoma with plasmacytoid differentiation, atypical cytoplasmic inclusions, and secondary leukemia in a dog. *Vet. Clin. Pathol.*, **42** (1), 40–46.
- 19 Stacy, N.I., Nabity, M.B., Hackendahl, N., *et al.* (2009) B-cell lymphoma with Mott cell differentiation in two young adult dogs. *Vet. Clin. Pathol.*, **38** (1), 113–120.
- 20 Seelig, D.M., Perry, J.A., Zaks, K., *et al.* (2011) Monoclonal immunoglobulin protein production in two dogs with secretory B-cell lymphoma with Mott cell differentiation. *J. Am. Vet. Med. Assoc.*, **239** (11), 1477–1482.
- 21 Walton, R.M., Hendrick, M.J. (2001) Feline Hodgkin's-like lymphoma: 20 cases (1992–1999). *Vet. Pathol.*, **38** (5), 504–511.
- 22 Steinberg, J.D., Keating, J.H. (2008) What is your diagnosis? Cervical mass in a cat. *Vet. Clin. Pathol.*, **37** (3), 323–327.
- 23 Bookbinder, P.F., Butt, M.T., Harvey, H.J. (1992) Determination of the number of mast cells in lymph node, bone marrow, and buffy coat cytologic specimens from dogs. *J. Am. Vet. Med. Assoc.*, **200** (11), 1648–1650.
- 24 Christopher, M.M. (2003) Cytology of the spleen. *Vet. Clin. North Am. Small Anim. Pract.*, **33** (1), 135–152.
- 25 Schwarz, L.A., Penninck, D.G., Gliatto, J. (2001) Canine splenic myelolipomas. *Vet. Radiol. Ultrasound*, **42** (4), 347–348.
- 26 Barger, A.M., Skowronski, M.C., MacNeill, A.L. (2012) Cytologic identification of erythrophagocytic neoplasms in dogs. *Vet. Clin. Pathol.*, **41** (4), 587–589.
- 27 Wendelburg, K.M., Price, L.L., Burgess, K.E., *et al.* (2015) Survival time of dogs with splenic hemangiosarcoma treated by splenectomy with or without adjuvant chemotherapy: 208 cases (2001–2012). *J. Am. Vet. Med. Assoc.*, **247** (4), 393–403.
- 28 Clifford, C.A., Mackin, A.J., Henry, C.J. (2000) Treatment of canine hemangiosarcoma: 2000 and beyond. *J. Vet. Intern. Med.*, **14** (5), 479–485.
- 29 van Stee, L.L., Boston, S.E., Singh, A., *et al.* (2015) Outcome and prognostic factors for canine splenic lymphoma treated by splenectomy (1995–2011). *Vet. Surg.*, **44** (8), 976–982.
- 30 O'Brien, D., Moore, P.F., Vernau, W., *et al.* (2013) Clinical characteristics and outcome in dogs with splenic marginal zone lymphoma. *J. Vet. Intern. Med.*, **27** (4), 949–954.
- 31 Fry, M.M., Vernau, W., Pesavento, P.A., *et al.* (2003) Hepatosplenic lymphoma in a dog. *Vet. Pathol.*, **40** (5), 556–562.
- 32 Keller, S.M., Vernau, W., Hodges, J., *et al.* (2013) Hepatosplenic and hepatocytotropic T-cell lymphoma: two distinct types of T-cell lymphoma in dogs. *Vet. Pathol.*, **50** (2), 281–290.

- 33 Campbell, M.W., Hess, P.R., Williams, L.E. (2013) Chronic lymphocytic leukaemia in the cat: 18 cases (2000–2010). *Vet. Comp. Oncol.*, **11** (4), 256–264.
- 34 Vernau, W., Moore, P.F. (1999) An immunophenotypic study of canine leukemias and preliminary assessment of clonality by polymerase chain reaction. *Vet. Immunol. Immunopathol.*, **69** (2–4), 145–164.
- 35 Matus, R.E., Leifer, C.E., MacEwen, E.G., *et al.* (1986) Prognostic factors for multiple myeloma in the dog. *J. Am. Vet. Med. Assoc.*, **188** (11), 1288–1292.
- 36 Patel, R.T., Caceres, A., French, A.F., *et al.* (2005) Multiple myeloma in 16 cats: a retrospective study. *Vet. Clin. Pathol.*, **34** (4), 341–352.
- 37 Hanna, F. (2005) Multiple myelomas in cats. *J. Feline Med. Surg.*, **7** (5), 275–287.
- 38 Affolter, V.K., Moore, P.F. (2002) Localized and disseminated histiocytic sarcoma of dendritic cell origin in dogs. *Vet. Pathol.*, **39** (1), 74–83.
- 39 Moore, P.F., Affolter, V.K., Vernau, W. (2006) Canine hemophagocytic histiocytic sarcoma: a proliferative disorder of CD11d+ macrophages. *Vet. Pathol.*, **43** (5), 632–645.
- 40 Spangler, W.L., Culbertson, M.R. (1992) Prevalence and type of splenic diseases in cats: 455 cases (1985–1991). *J. Am. Vet. Med. Assoc.*, **201** (5), 773–776.
- 41 Piviani, M., Walton, R.M., Patel, R.T. (2013) Significance of mastocytosis in cats. *Vet. Clin. Pathol.*, **42** (1), 4–10.
- 42 Sabattini, S., Barzon, G., Giantin, M., *et al.* (2016) Kit receptor tyrosine kinase dysregulations in feline splenic mast cell tumours. *Vet. Comp. Oncol.* 2016; doi: 10.1111/vco.12246. Epub ahead of print. Last accessed May 1 2017.
- 43 Gordon, S.S., McClaran, J.K., Bergman, P.J., *et al.* (2010) Outcome following splenectomy in cats. *J. Feline Med. Surg.*, **12** (4), 256–261.
- 44 Liska, W.D., MacEwen, E.G., Zaki, F.A., *et al.* (1979) Feline systemic mastocytosis: a review and results of splenectomy in 7 cases. *J. Am. Anim. Hosp. Assoc.*, **15** (5), 589–597.
- 45 Rossi, F., Aresu, L., Vignoli, M., *et al.* (2015) Metastatic cancer of unknown primary in 21 dogs. *Vet. Comp. Oncol.*, **13** (1), 11–19.
- 46 Stefanello, D., Valenti, P., Faverzani, S., *et al.* (2009) Ultrasound-guided cytology of spleen and liver: a prognostic tool in canine cutaneous mast cell tumor. *J. Vet. Intern. Med.*, **23** (5), 1051–1057.
- 47 Flatland, B., Moore, R.R., Wolf, C.M., *et al.* (2007) Liver aspirate from a Shar Pei dog. *Vet. Clin. Pathol.*, **36** (1), 105–108.
- 48 Lara-Garcia, A., Wellman, M., Burkhard, M.J., *et al.* (2008) Cervical thymoma originating in ectopic thymic tissue in a cat. *Vet. Clin. Pathol.*, **37** (4), 397–402.
- 49 Robat, C.S., Cesario, L., Gaeta, R., *et al.* (2013) Clinical features, treatment options, and outcome in dogs with thymoma: 116 cases (1999–2010). *J. Am. Vet. Med. Assoc.*, **243** (10), 1448–1454.
- 50 Burton, A.G., Borjesson, D.L., Vernau, W. (2014) Thymoma-associated lymphocytosis in a dog. *Vet. Clin. Pathol.*, **43** (4), 584–588.
- 51 Zitz, J.C., Birchard, S.J., Couto, G.C., *et al.* (2008) Results of excision of thymoma in cats and dogs: 20 cases (1984–2005). *J. Am. Vet. Med. Assoc.*, **232** (8), 1186–1192.
- 52 Burgess, K.E., DeRegis, C.J., Brown, F.S., *et al.* (2016) Histologic and immunohistochemical characterization of thymic epithelial tumours in the dog. *Vet. Comp. Oncol.*, **14** (2), 113–121.
- 53 Bellah, J.R., Stiff, M.E., Russell, R.G. (1983) Thymoma in the dog: two case reports and review of 20 additional cases. *J. Am. Vet. Med. Assoc.*, **183** (3), 306–311.
- 54 Ruslander, D.A., Gebhard, D.H., Tompkins, M.B., *et al.* (1997) Immunophenotypic characterization of canine lymphoproliferative disorders. *In Vivo*, **11** (2), 169–172.
- 55 Rosenberg, M.P., Matus, R.E., Patnaik, A.K. (1991) Prognostic factors in dogs with lymphoma and associated hypercalcemia. *J. Vet. Intern. Med.*, **5** (5), 268–271.
- 56 Mischke, R., Busse, L. (2002) Reference values for the bone marrow aspirates in adult dogs. *J. Vet. Med. A. Physiol. Pathol. Clin. Med.*, **49** (10), 499–502.
- 57 Weiss, D.J. (2005) Differentiating benign and malignant causes of lymphocytosis in feline bone marrow. *J. Vet. Intern. Med.*, **19** (6), 855–859.
- 58 Jain, N.C., Blue, J.T., Grindem, C.B., *et al.* (1991) Proposed criteria for classification of acute myeloid leukemia in dogs and cats. *Vet. Clin. Pathol.*, **20** (3), 63–82.
- 59 Bounous, D.I., Latimer, K.S., Campagnoli, R.P., *et al.* (1994) Acute myeloid leukemia with basophilic differentiation (AML, M-2B) in a cat. *Vet. Clin. Pathol.*, **23** (1), 15–18.
- 60 Juopperi, T.A., Bienzle, D., Bernreuter, D.C., *et al.* (2011) Prognostic markers for myeloid neoplasms: a comparative review of the literature and goals for future investigation. *Vet. Pathol.*, **48** (1), 182–197.
- 61 Tomiyasu, H., Fujino, Y., Takahashi, M., *et al.* (2011) Spontaneous acute erythroblastic leukaemia (AML-M6Er) in a dog. *J. Small Anim. Pract.*, **52** (8), 445–447.
- 62 Comazzi, S., Paltrinieri, S., Caniatti, M., *et al.* (2000) Erythremic myelosis (AML6er) in a cat. *J. Feline Med. Surg.*, **2** (4), 213–215.
- 63 Bolon, B., Buerge, C.D., Harvey, J.W., *et al.* (1989) Megakaryoblastic leukemia in a dog. *Vet. Clin. Pathol.*, **18** (3), 69–74.
- 64 Cain, G.R., Feldman, B.F., Kawakami, T.G., *et al.* (1986) Platelet dysplasia associated with megakaryoblastic

- leukemia in a dog. *J. Am. Vet. Med. Assoc.*, **188** (5), 529–530.
- 65 Comazzi, S., Gelain, M.E., Bonfanti, U., *et al.* (2010) Acute megakaryoblastic leukemia in dogs: a report of three cases and review of the literature. *J. Am. Anim. Hosp. Assoc.*, **46** (5), 327–335.
 - 66 Essex, M.E. (1982) Feline leukemia: a naturally occurring cancer of infectious origin. *Epidemiol. Rev.*, **4**, 189–203.
 - 67 Matus, R.E., Leifer, C.E., MacEwen, E.G. (1983) Acute lymphoblastic leukemia in the dog: a review of 30 cases. *J. Am. Vet. Med. Assoc.*, **183** (8), 859–862.
 - 68 Graff, E.C., Spangler, E.A., Smith, A., *et al.* (2014) Hematologic findings predictive of bone marrow disease in dogs with multicentric large-cell lymphoma. *Vet. Clin. Pathol.*, **43** (4), 505–512.
 - 69 Marconato, L., Martini, V., Aresu, L., *et al.* (2013) Assessment of bone marrow infiltration diagnosed by flow cytometry in canine large B cell lymphoma: prognostic significance and proposal of a cut-off value. *Vet. J.*, **197** (3), 776–781.
 - 70 Deubelbeiss, K.A., Dancey, J.T., Harker, L.A., *et al.* (1975) Neutrophil kinetics in the dog. *J. Clin. Invest.*, **55** (4), 833–839.
 - 71 Smith, J.E., Agar, N.S. (1975) The effect of phlebotomy on canine erythrocyte metabolism. *Res. Vet. Sci.*, **18** (3), 231–236.
 - 72 Grimes, C.N., Fry, M.M. (2015) Nonregenerative anemia: mechanisms of decreased or ineffective erythropoiesis. *Vet. Pathol.*, **52** (2), 298–311.
 - 73 Walton, R.M., Modiano, J.F., Thrall, M.A., *et al.* (1996) Bone marrow cytological findings in 4 dogs and a cat with hemophagocytic syndrome. *J. Vet. Intern. Med.*, **10** (1), 7–14.
 - 74 Leifer, C.E., Matus, R.E. (1986) Chronic lymphocytic leukemia in the dog: 22 cases (1974–1984). *J. Am. Vet. Med. Assoc.*, **189** (2), 214–217.
 - 75 Comazzi, S., Gelain, M.E., Martini, V., *et al.* (2011) Immunophenotype predicts survival time in dogs with chronic lymphocytic leukemia. *J. Vet. Intern. Med.*, **25** (1), 100–106.
 - 76 Turinelli, V., Gavazza, A., Stock, G., *et al.* (2015) Canine bone marrow cytological examination, classification and reference values: A retrospective study of 295 cases. *Res. Vet. Sci.*, **103**, 224–230.
 - 77 Taylor, B.E., Leibman, N.F., Luong, R., *et al.* (2013) Detection of carcinoma micrometastases in bone marrow of dogs and cats using conventional and cell block cytology. *Vet. Clin. Pathol.*, **42** (1), 85–91.
 - 78 Withers, S.S., Lawson, C.M., Burton, A.G., *et al.* (2016) Management of an invasive and metastatic Sertoli cell tumor with associated myelotoxicosis in a dog. *Can. Vet. J.*, **57** (3), 299–304.

5

Body Cavity Fluids

5.1 General Classification

Body cavity fluids often are classified broadly as transudates, modified transudates and exudates based on cell concentration and protein concentration. While these categories can be clinically helpful, they do not always accurately reflect the underlying pathophysiology of the effusion, and should be considered as guidelines only, and interpreted with other clinical and diagnostic findings.

5.1.1 Transudate

5.1.1.1 Cytologic Appearance

Transudates have a clear background, and should contain rare erythrocytes. Nucleated cells are seen in very low numbers and comprise mostly variably reactive macrophages (Figure 5.1). Low numbers of small mature lymphocytes and non-degenerative neutrophils \pm reactive mesothelial cells may be seen.

5.1.1.2 Clinical Considerations

- Cell concentration typically <1500 cells μL^{-1} ; protein concentration <2.5 g dL^{-1} .
- Classically associated with hypoalbuminemia (<1.5 g dL^{-1}).
- DDx = decreased production of albumin (liver failure), loss of protein (e.g., protein-losing nephropathy/enteropathy, exudation) or decreased protein intake.
- Uroabdomen may appear similar, and further testing may be required for differentiation (see section 5.2.4).

5.1.1.3 Prognosis

Variable, based on underlying cause.

5.1.2 Modified Transudate

5.1.2.1 Cytologic Appearance

Modified transudates may have a pale-blue background due to the increased concentration of protein. Red blood cells usually are present in low numbers. Cells also are seen in low to moderate numbers, and typically comprise

a mixture of non-degenerative neutrophils and variably reactive macrophages. Reactive mesothelial cells may be seen in low numbers.

5.1.2.2 Clinical Considerations

- Cell concentration typically between 1500 and 5000 cells μL^{-1} ; protein concentration typically between 2.5 and 3.5 g dL^{-1} .
- Classically associated with increased intravascular hydrostatic pressure.
- DDx = cardiac disease, liver disease, space-occupying lesions (non-exfoliating neoplasia, granuloma, organ enlargement, etc.), or early inflammatory disease.

5.1.2.3 Prognosis

Variable, based on underlying cause.

5.1.3 Exudate: Septic

5.1.3.1 Cytologic Appearance

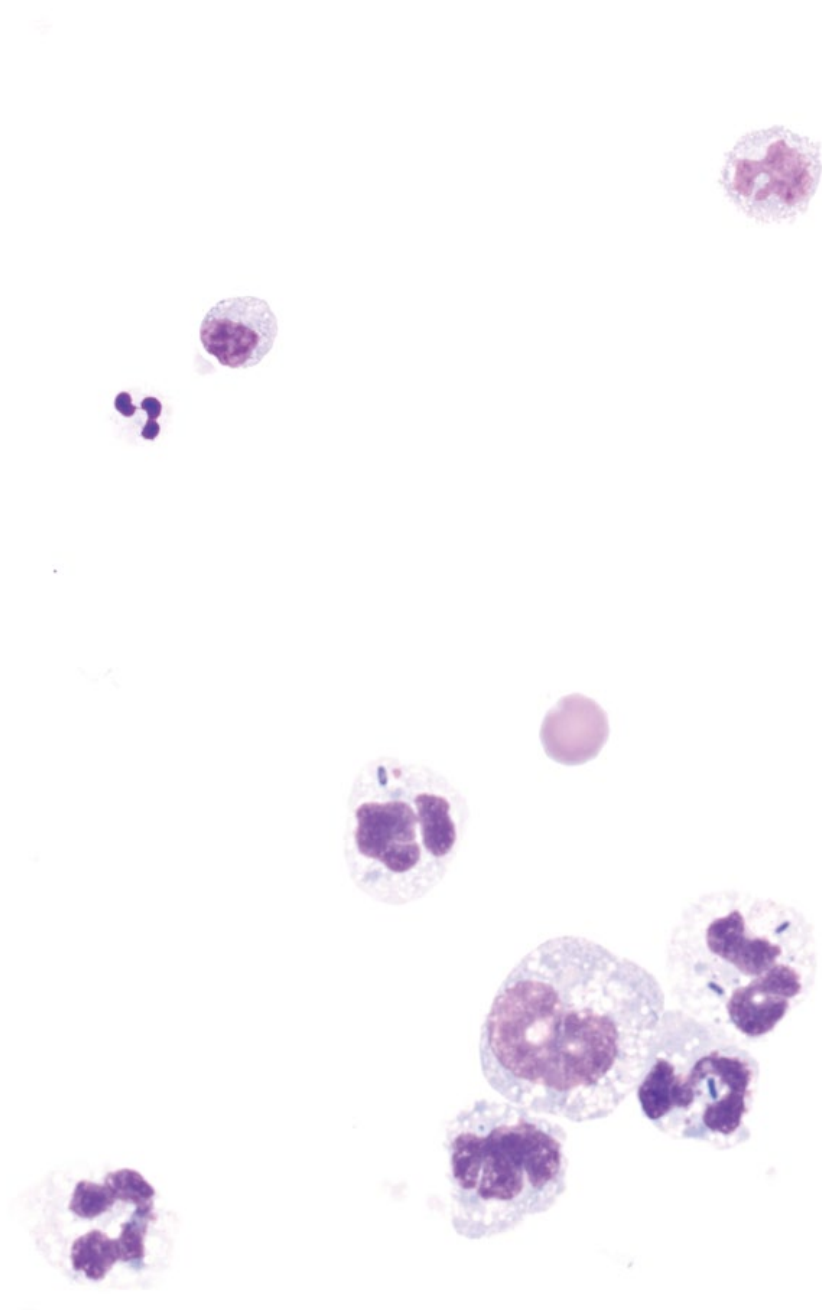
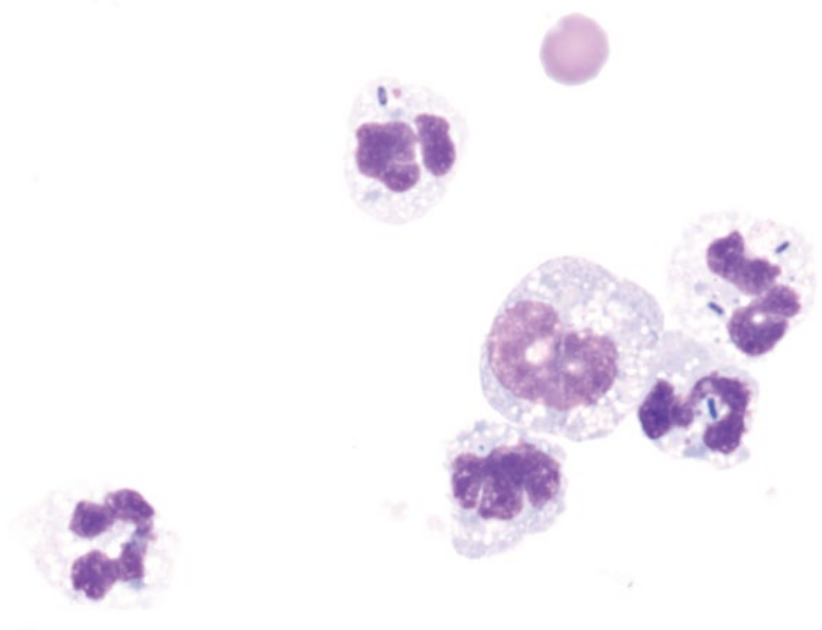
Septic effusions often are highly cellular (>5000 cells μL^{-1}), and have an elevated total protein (>3.5 g dL^{-1}). They most commonly are associated with degenerative neutrophils (see Chapter 1). The presence of intracellular/phagocytosed organisms confirms sepsis, though some organisms may be present extracellularly. Bacteria are most common (Figure 5.2), but many fungal, protozoal, and parasitic agents (especially *Mesocostoides*) have been reported (see Chapter 2).

5.1.3.2 Clinical Considerations

- Reported in the abdomen (septic peritonitis), thorax (pyothorax), and pericardial sac (septic pericarditis).
- Septic peritonitis most commonly associated with gastrointestinal pathology/rupture in dogs and cats [1, 2].
- Pyothorax commonly associated with penetrating wounds.

5.1.3.3 Confirmation

- Intracellular organisms confirm sepsis. Microbial culture and susceptibility testing, or fungal culture and identification are recommended.

Figure 5.1 Transudate, dog, 50× objective.**Figure 5.2** Septic exudate (bacterial septic peritonitis), dog, 100× objective. Note the degenerative neutrophils and intracellular bacterial rods.

- When organisms are not seen, but there is suspicion of bacterial sepsis, a blood-to-fluid glucose difference $>20 \text{ mg dl}^{-1}$ was 100% specific for septic peritoneal effusion in dogs and cats, and 100% and 86% sensitive in dogs and cats, respectively [3].

5.1.3.4 Prognosis

Guarded. Septic effusions can be associated with high mortality rates [2] and are an independent risk factor for

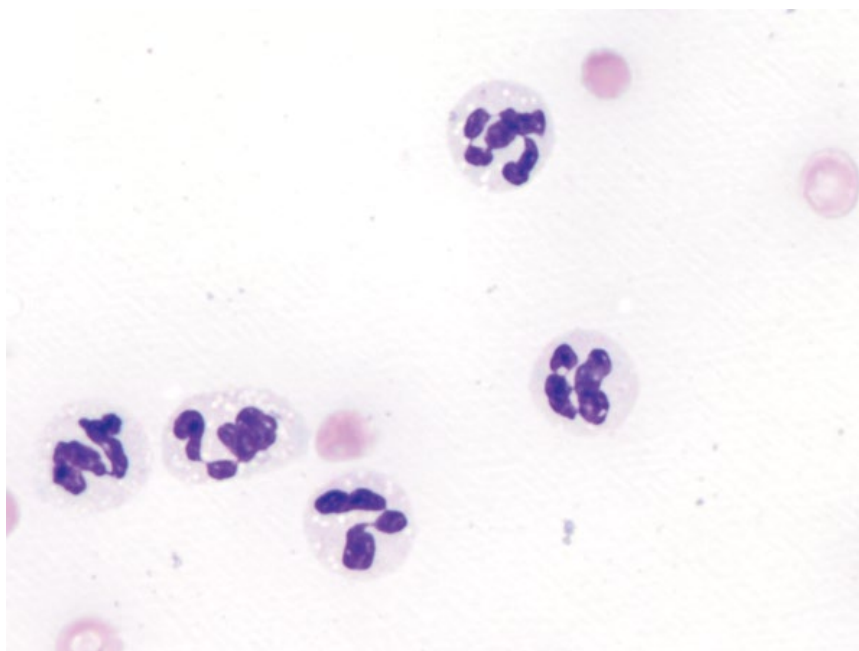
mortality in hospitalized dogs [4]. Cats tend to have a better prognosis for pyothorax than dogs [5, 6].

5.1.4 Exudate: Sterile (Neutrophilic)

5.1.4.1 Cytologic Appearance

Neutrophilic exudates may be caused by non-infectious etiologies. Neutrophils typically are non-degenerative or even pyknotic/apoptotic (see Chapter 1). Variable numbers of other inflammatory cells may be present,

Figure 5.3 Sterile neutrophilic exudate from a dog with pancreatitis, 100× objective. Note the clear lipid vacuoles within the cytoplasm.



particularly if the inflammatory process is chronic (e.g., increased small mature lymphocytes).

5.1.4.2 Clinical Considerations

- Pancreatitis is a common cause of neutrophilic exudates in the abdomen of dogs and cats. Neutrophils may contain coarse clear vacuoles of lipid in their cytoplasm (Figure 5.3).
- Other differentials include inflammation of other viscera, vasculitis or non-exfoliating neoplasia (inflammation or paraneoplastic).
- Microbial culture and susceptibility testing may be warranted to rule out incipient infectious disease.

5.1.4.3 Prognosis

Variable, based on the underlying cause.

5.1.5 Exudate: Sterile (Eosinophilic)

5.1.5.1 Cytologic Appearance

Eosinophilic exudates comprise a marked increase in the percentage of eosinophils (Figure 5.4). Other inflammatory cells are seen to varying degrees, and neoplastic cells or infectious agents may be present, depending on the underlying etiology.

5.1.5.2 Clinical Considerations

- Neoplasia is the most common cause (e.g., mast cell neoplasia or lymphoma) [7].
- Other rule-outs include infectious organisms (parasitic disease, fungal disease), allergic/hypersensitivity disease, and primary eosinophilic inflammatory disease.

5.1.5.3 Prognosis

Variable, based on underlying cause.

5.1.6 Exudate: High Protein

5.1.6.1 Cytologic Appearance

Exudates with high protein concentrations ($>5\text{ g dl}^{-1}$) often have a thick blue/purple, scalloped proteinaceous background (Figure 5.5). The cell concentrations and differentials in these fluids are variable.

5.1.6.2 Clinical Considerations

- Feline infectious peritonitis (FIP) is a common cause of high protein exudates, typically in young cats (aged <2 years) [8].
- In one study, 90% of cats with FIP had protein $>5.0\text{ g dl}^{-1}$ (range $3.0\text{--}7.8\text{ g dl}^{-1}$) [8].
- Other rule-outs may include fulminant inflammation of viscera (e.g., pancreatitis), other causes of vasculitis (immune-mediated, neoplasia), and incipient infectious disease.

5.1.6.3 Prognosis

Variable, based on underlying cause. Prognosis for FIP is poor.

5.2 Specific Effusions

Many body cavity fluids have characteristic diagnostic and cytologic features, allowing a more specific diagnosis to be made.

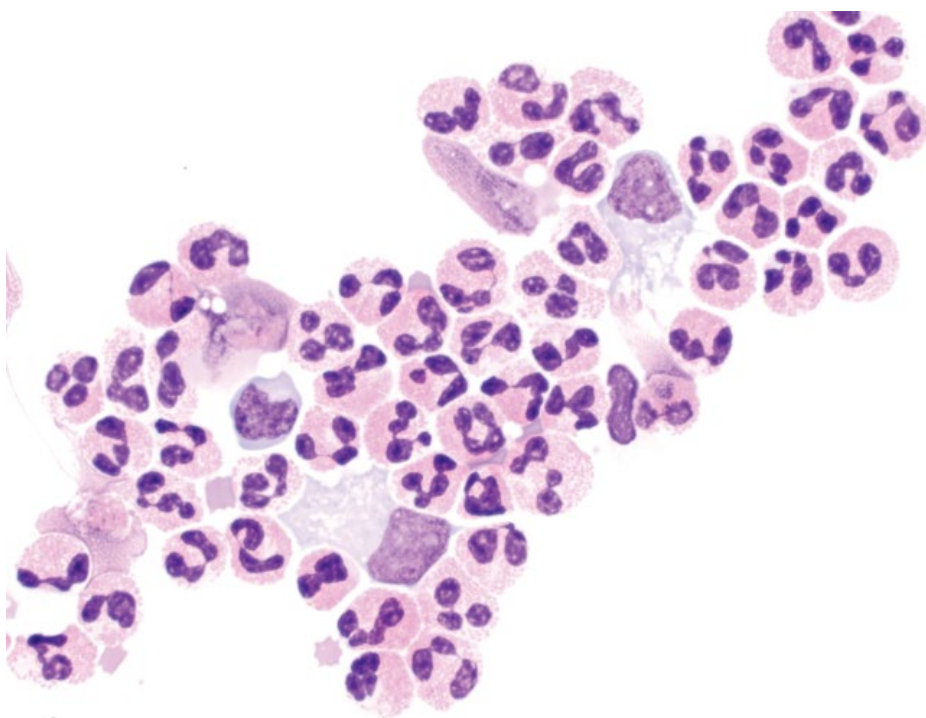


Figure 5.4 Eosinophilic exudate, cat, 50× objective.

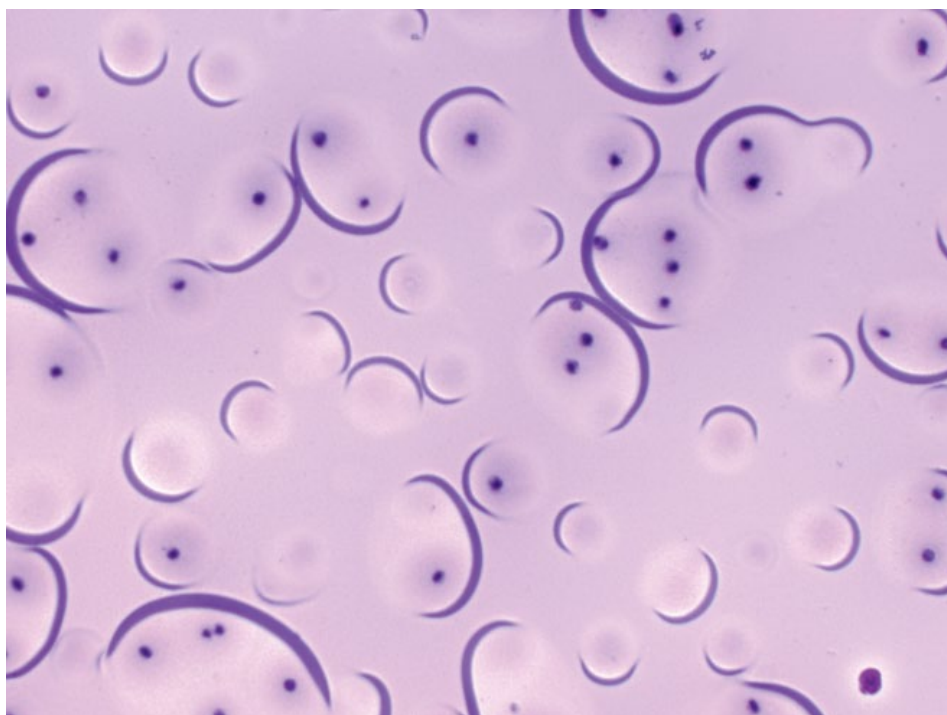
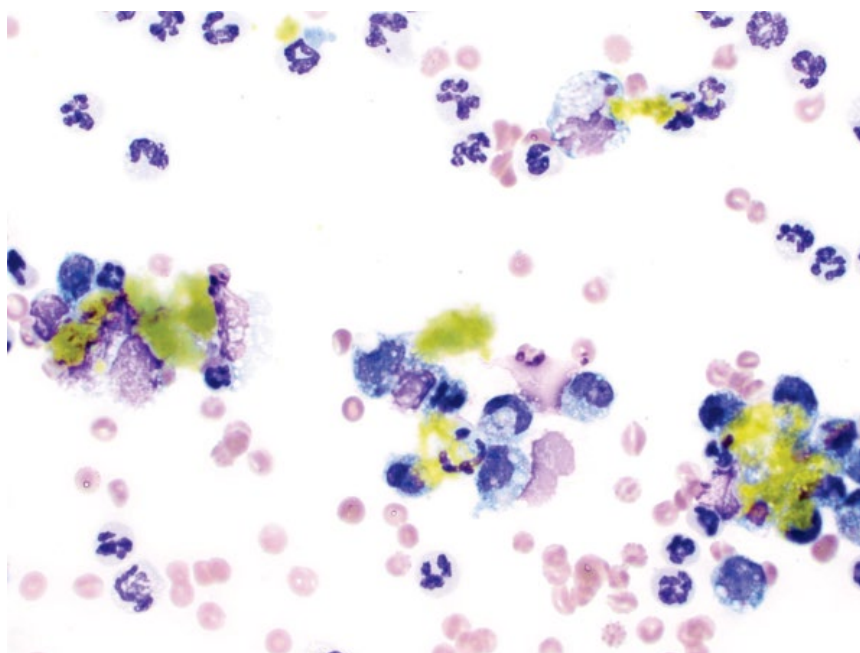


Figure 5.5 High-protein exudate, cat, 10× objective. Note the thick, proteinaceous and scalloped background with low numbers of red blood cells.

Figure 5.6 Bile peritonitis, dog, 50× objective. Note the aggregates of green/yellow bile.



5.2.1 Bile Peritonitis

5.2.1.1 Cytologic Features

Bile peritonitis is characterized by aggregates of yellow/green bile pigment that are seen both extracellularly and phagocytosed by macrophages or neutrophils (Figure 5.6). Bile peritonitis is frequently accompanied by a marked inflammatory response.

5.2.1.2 Clinical Considerations

- Dogs > cats.
- Mostly associated with trauma to the biliary tract, or necrotizing cholecystitis.
- May be septic or sterile.

5.2.1.3 Confirmation

- Compare the concentration of bilirubin in serum and fluid collected at the same time: a bilirubin concentration twofold or more that of serum is consistent with bile peritonitis [9].

5.2.1.4 Prognosis

Bile peritonitis is a surgical emergency. Prognosis is excellent for sterile effusions, but poorer for septic bile peritonitis [9].

5.2.2 White Bile Peritonitis

5.2.2.1 Cytologic Features

White bile appears as amorphous pools of smooth, pale-blue material, and can readily be differentiated from the yellow/green aggregates of classic bile peritonitis (compare Figures 5.7 and 5.6). The amount of white bile

present is variable, and close examination of inflammatory effusions is warranted.

5.2.2.2 Clinical Considerations

- Only reported in dogs.
- White bile comprises mucinous material from the gallbladder [10].

5.2.2.3 Prognosis

White bile peritonitis represents a variant on classic bile peritonitis, and prognosis is similar.

5.2.3 Chylous Effusion

5.2.3.1 Cytologic Features

Chylous effusions are characterized by variably sized clear lipid vacuoles in the background of the sample (Figure 5.8). Small mature lymphocytes usually predominate. Increased neutrophils are seen in chronic effusions. Evidence of chronic hemorrhage may be present.

5.2.3.2 Clinical Considerations

- Gross appearance is milky or opaque.
- DDx = right-sided heart failure, mediastinal masses (neoplasia, granuloma, enlarged lymph nodes), trauma to the thoracic duct, thrombi in the vena cava, diaphragmatic hernia, idiopathic [11].

5.2.3.3 Confirmation

- Measure concentrations of triglycerides and cholesterol in the fluid. A triglyceride concentration $>100\text{mgdl}^{-1}$ is supportive of chylous effusion [12].

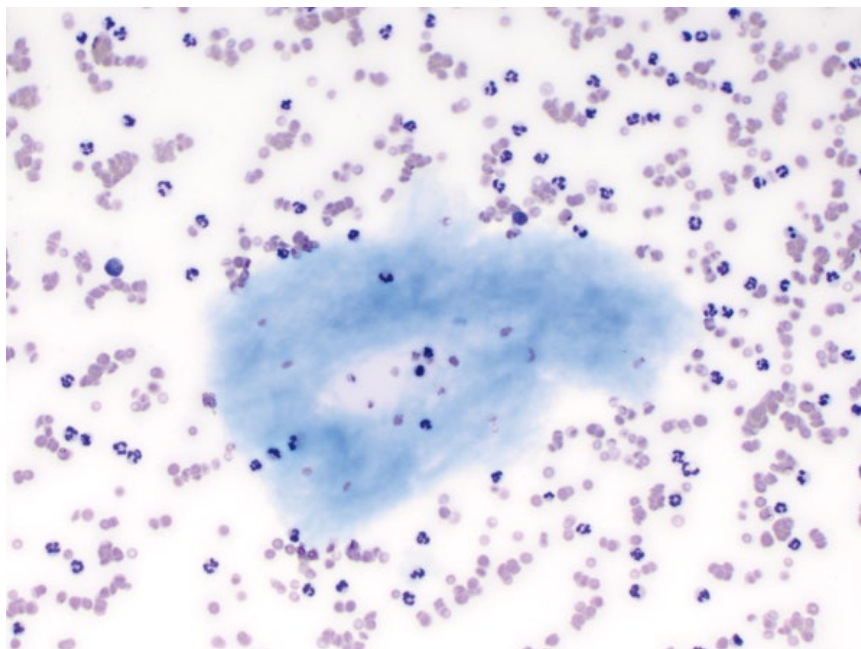


Figure 5.7 White bile peritonitis, dog, 20× objective. Note the large aggregates of smooth, pale-blue mucinous material.

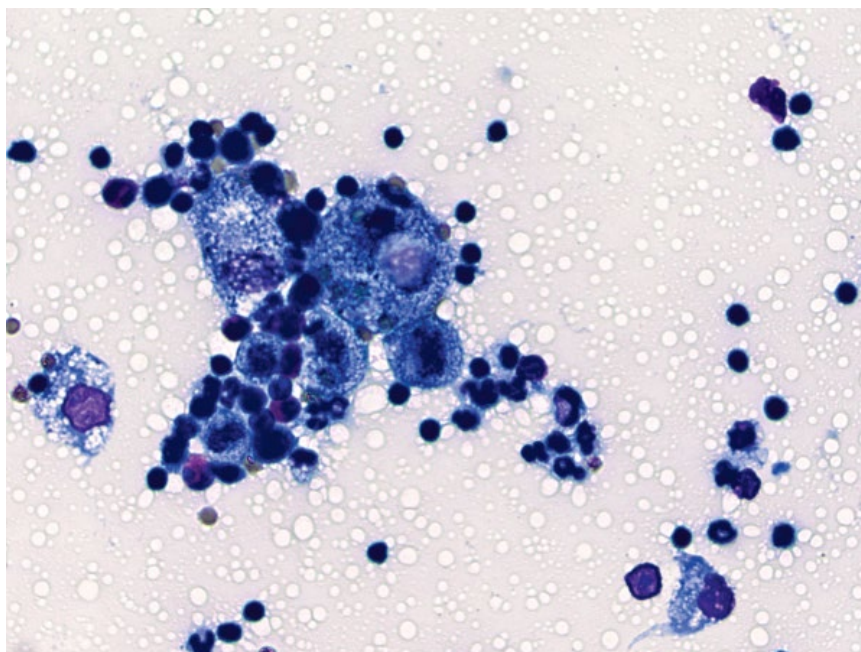


Figure 5.8 Chylous effusion, cat, 50× objective. Note the abundant, variably sized clear lipid vacuoles and predominance of small mature lymphocytes.

The cholesterol-to-triglyceride ratio (Chol: TG) is <1 in chylous effusions, and usually >1 in non-chylous effusions.

5.2.3.4 Prognosis

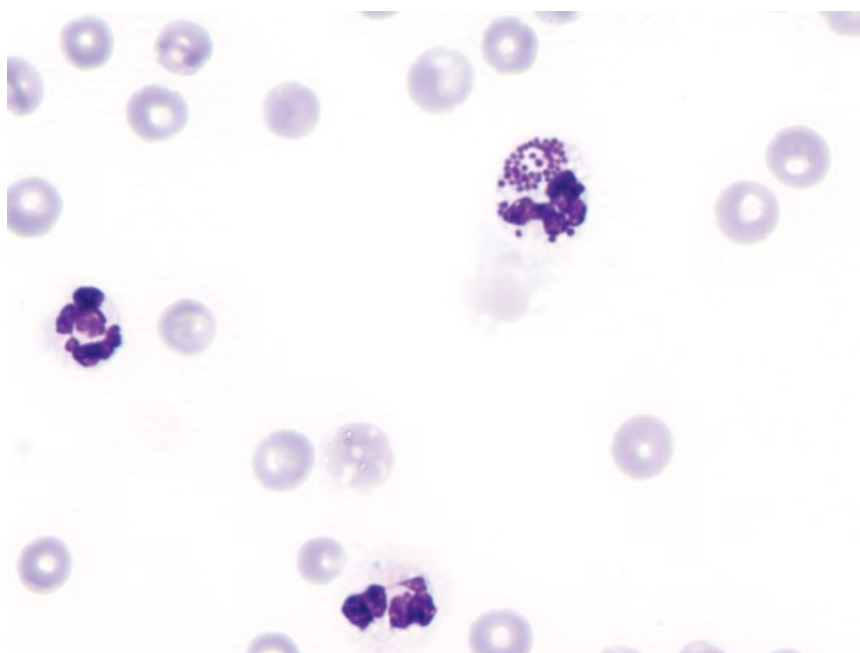
Variable, based on the underlying cause.

5.2.4 Uroabdomen

5.2.4.1 Cytologic Appearance

Fluid from cases of uroabdomen can vary from a transudate to exudate with components of hemorrhage or sepsis (Figure 5.9) based on the original composition of urine, as well as the duration of fluid accumulation [13].

Figure 5.9 Uroabdomen, septic, dog, 100× objective.



Urine is a chemical irritant, and inflammation develops over time.

5.2.4.2 Clinical Considerations

- Fluid may smell like ammonia.
- DDx = trauma, urethral obstruction, bladder neoplasia [14].

5.2.4.3 Confirmation

- A fluid-to-serum potassium ratio >1.4 to 1 has 100% sensitivity and specificity for uroabdomen [15]. A fluid-to-serum creatinine ratio >2 to 1 has a 100% specificity, and 86% sensitivity [15].

5.2.4.4 Prognosis

Variable, based on the underlying cause and therapy.

5.2.5 Hemorrhagic Effusion

5.2.5.1 Cytologic Appearance

Hemorrhagic effusions are characterized by a dense background of erythrocytes. Platelets may be present if acute hemorrhage has occurred, and may also indicate iatrogenic hemorrhage at the time of sampling. Chronic hemorrhage is confirmed by the presence of reactive macrophages that are erythrophagocytic, or contain heme-breakdown pigments such as hemosiderin or hematoidin crystals (Figure 5.10).

5.2.5.2 Clinical Considerations

- PCV of peripheral blood and the effusion often are similar [16].

- DDx = coagulopathies, trauma, rupture of neoplasia/hematomas/gastrointestinal ulcers, and idiopathic (pericardial).
- Common finding in pericardial effusions, often accompanied by mesothelial hyperplasia (see section 5.2.6).

5.2.5.3 Prognosis

Variable, based on the underlying cause and site. Rodenticide toxicity generally carries a favorable prognosis with appropriate therapy. Hemoperitoneum secondary to rupture of hemangiosarcoma confers a poor prognosis [17]. Cats with hemoperitoneum have a poor prognosis [16].

5.2.6 Reactive Mesothelial Hyperplasia

5.2.6.1 Cytologic Appearance

Reactive/hyperplastic mesothelial cells vary in appearance from readily to poorly recognizable. They may be seen individually, or in variably sized cohesive sheets. Classic features of mesothelium include a pink fringe border, and peripheralized blebbing of the cytoplasm (Figure 5.11). They occasionally have a perinuclear ring of small clear vacuoles. Highly reactive cells may lose these features, and assume many criteria of malignancy, including moderate to marked anisocytosis/anisokaryosis and prominent nucleoli (Figures 5.12 and 5.13).

5.2.6.2 Clinical Considerations

- Common finding in effusions, particularly chronic effusions.
- More common, greater numbers and more pleomorphism in dogs than cats.

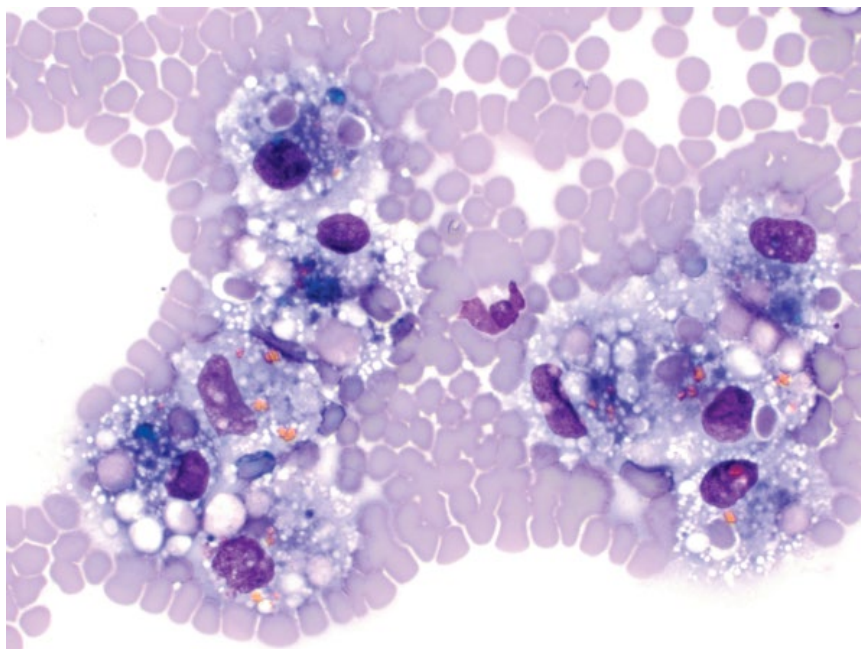


Figure 5.10 Hemorrhagic effusion, dog, 50× objective. Reactive macrophages contain phagocytosed red blood cells and heme-breakdown pigment including hemosiderin (green/blue) and hematoidin (golden/orange).

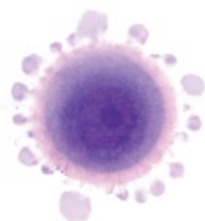

Figure 5.11 Reactive mesothelial cell, dog, 50× objective. Classic features of cytoplasmic blebbing and a pink fringe border are seen.

- Marked mesothelial hyperplasia may be difficult to distinguish from neoplastic effusions (see sections 5.2.7 and 5.2.8).

5.2.7 Neoplastic Effusion: Mesothelioma

5.2.7.1 Cytologic Appearance

Mesothelioma exfoliates in large sheets, which frequently have a papillary arrangement. Marked criteria of malignancy are present, including anisokaryosis and karyomegaly, multinucleation, and even cell cannibalism

(Figure 5.14). Cannibalism is also reported in other malignancies [18]. Neoplastic mesothelial cells may be erythrophagocytic or contain heme-breakdown pigments (hematoidin crystals seen in Figure 5.15). Differentiation of mesothelioma from carcinoma or even florid mesothelial hyperplasia is difficult with cytology alone (compare to Figures 5.13 and 5.17). Useful cytomorphic criteria in human mesothelioma cases include the presence of microvesicles in the cytoplasm, dense cytoplasm, and angulated cell shape [19] (Figure 5.16).

Figure 5.12 Reactive mesothelial hyperplasia, dog, 50× objective.

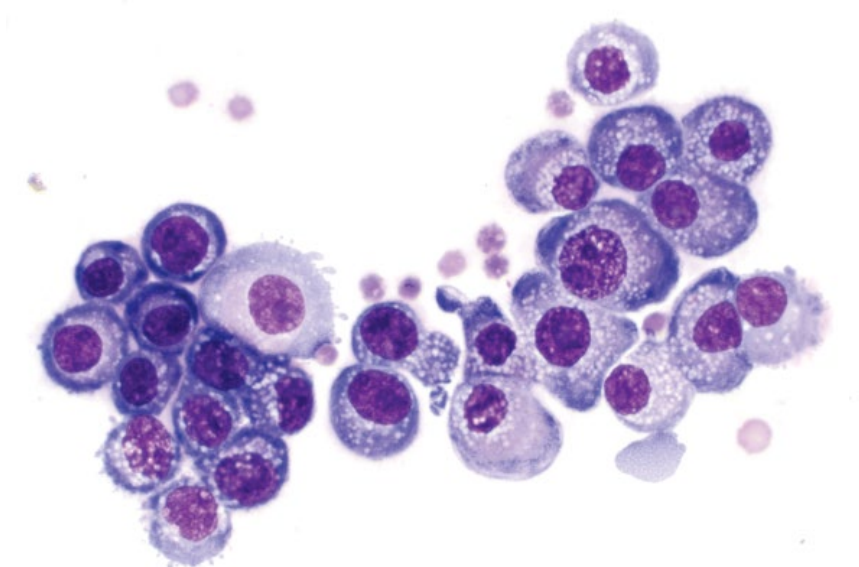
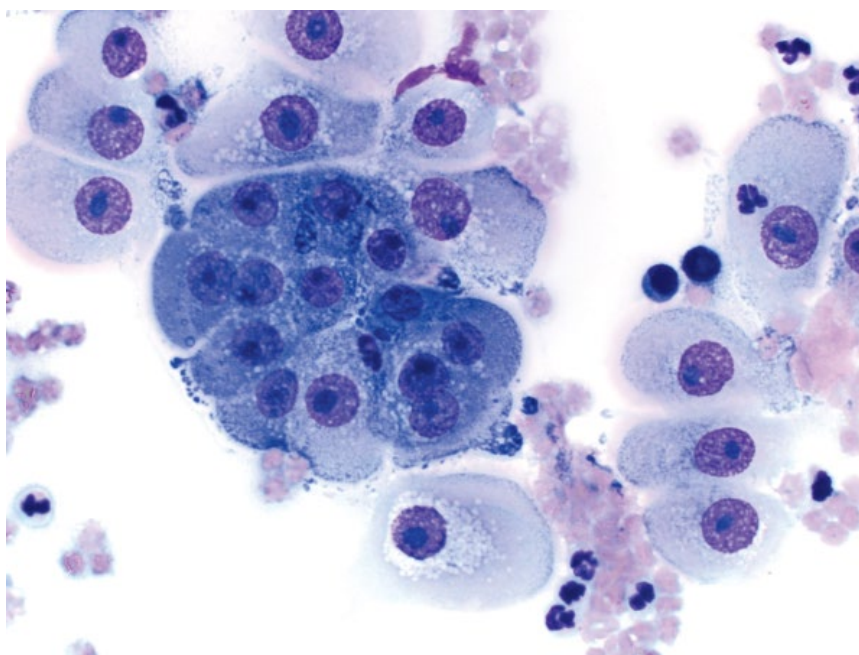


Figure 5.13 Reactive mesothelial hyperplasia, dog, 50× objective.



5.2.7.2 Clinical Considerations

- Rare in dogs and cats.
- Can arise from pleura (most common), pericardium, peritoneum or tunica vaginalis [20, 21].
- Usually multinodular and disseminated throughout the affected cavity.
- Often highly effusive, with a large amount of fluid present that returns quickly after drainage.

5.2.7.3 Prognosis

Grave.

5.2.8 Neoplastic Effusion: Carcinoma

5.2.8.1 Cytologic Appearance

Carcinoma cells frequently exfoliate in large numbers, often in a papillary or acinar arrangement. Cells are mostly round, with a variable volume of cytoplasm that may balloon with abundant secretory material (Figure 5.17). Nuclei often have the greatest pleomorphism, and common criteria of malignancy include multinucleation, anisokaryosis (both within and between cells), mitotic figures, and multiple, large basophilic nucleoli

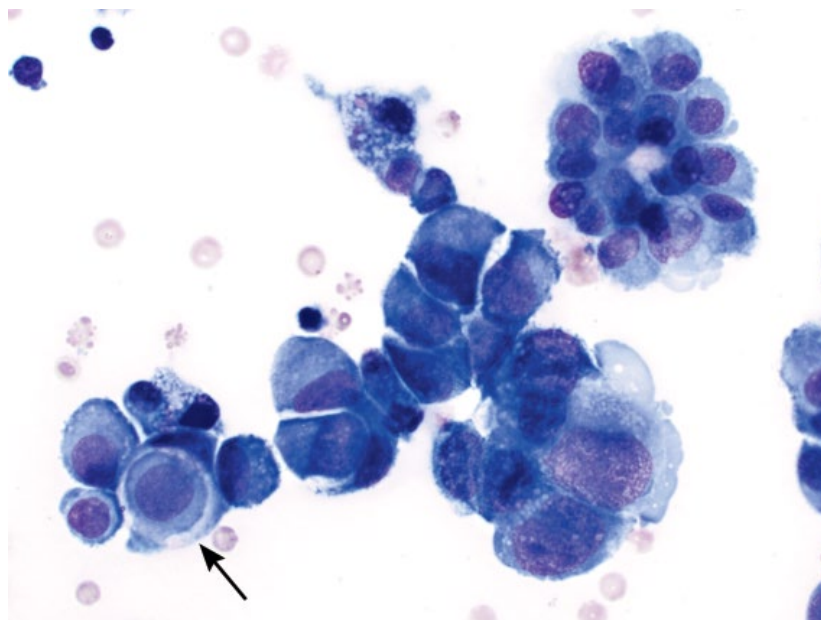


Figure 5.14 Mesothelioma, dog, 50x objective. Note the neoplastic cell that has been phagocytosed by another neoplastic cell (cell cannibalism, arrow).

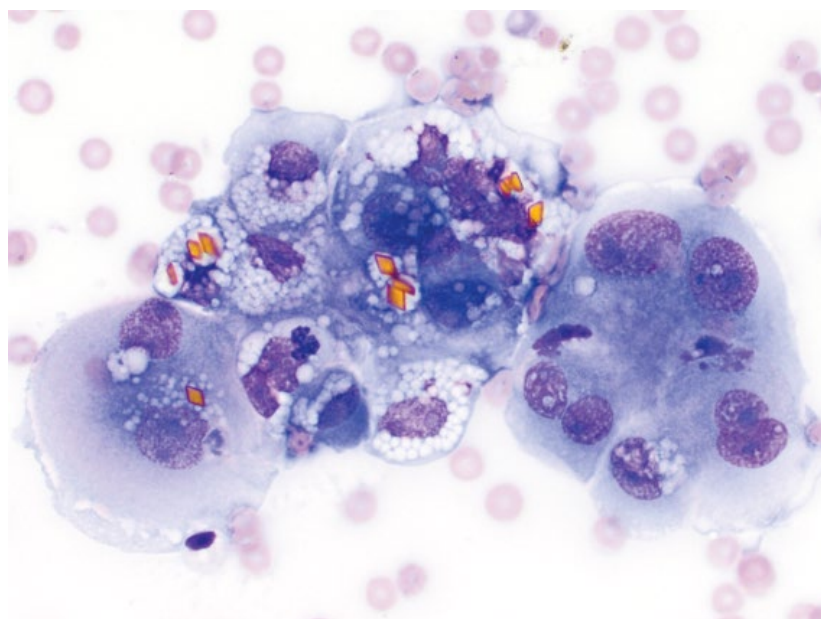


Figure 5.15 Mesothelioma, dog, 50x objective. Neoplastic cells contain golden hematoidin crystals.

(Figures 5.18 and 5.19). Carcinomas can be difficult to differentiate from reactive mesothelial hyperplasia or mesothelioma – correlate with imaging and clinical findings.

5.2.8.2 Clinical Considerations

- May arise from tumors within the cavity or be metastatic.
- Inflammatory cells may be present (concurrent inflammation or paraneoplastic).

5.2.8.3 Prognosis

Poor.

5.2.9 Neoplastic Effusion: Lymphoma

5.2.9.1 Cytologic Appearance

Effusions secondary to lymphoma are associated with large-cell, high-grade disease. The neoplastic cells are large, with nuclear diameter more than two red blood cells, and finely stippled or reticulated chromatin. Nucleoli are variably prominent. The cells have a small to moderate volume of deep-blue cytoplasm that may contain fine clear vacuoles (Figure 5.20). Lymphoma may appear similar to histiocytic sarcoma (compare to Figure 5.21).

Figure 5.16 Mesothelioma, dog, 50× objective. Note the angular cell shape and microvesicles within the cytoplasm.

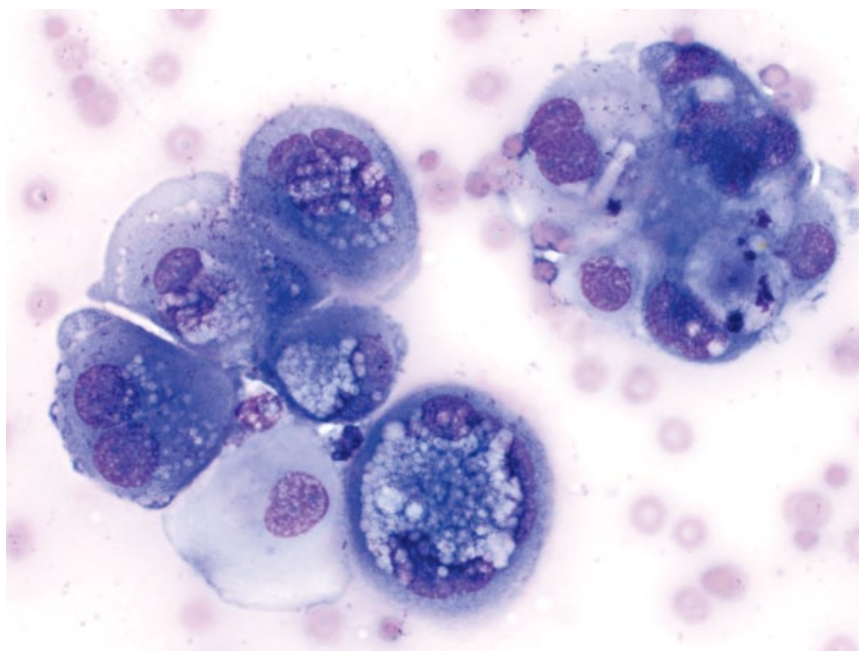
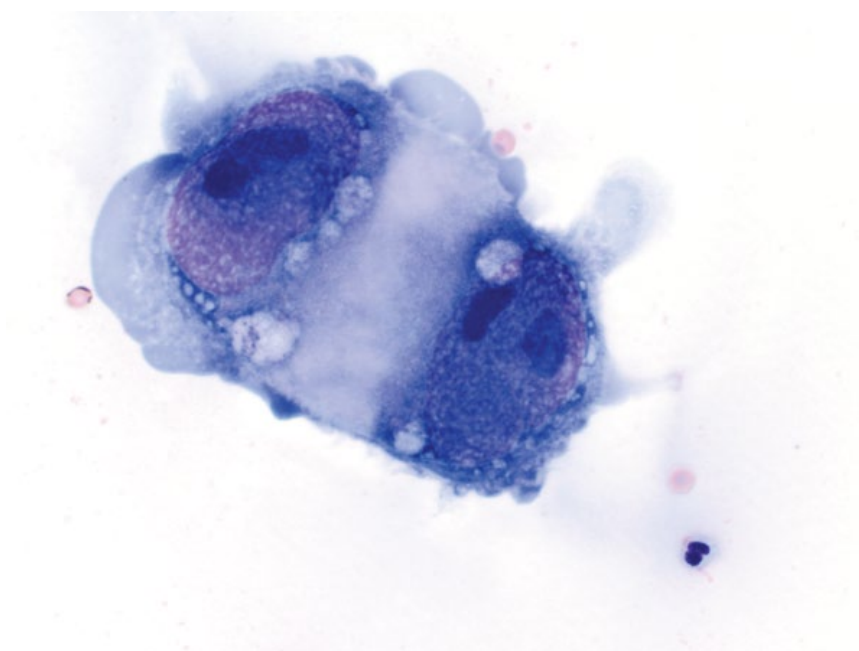


Figure 5.17 Carcinoma, abdominal fluid, cat, 50× objective. Note the enormous size of the neoplastic cells relative to the neutrophil and red blood cells.



5.2.9.2 Clinical Considerations

- Dogs and cats
- Reported in pleural, abdominal and pericardial effusions [22, 23].

5.2.9.3 Prognosis

Lymphoma within effusions confirms stage V disease, and prognosis is guarded to poor.

5.2.10 Neoplastic Effusion: Histiocytic Sarcoma

5.2.10.1 Cytologic Appearance

Histiocytic sarcoma may exfoliate into body cavities, and appears as round, individualized cells. Nuclei are ovoid to amoeboid, and frequently have irregular or festooning borders. Binucleation or multinucleation may be seen, and mitotic figures are common (Figure 5.21).

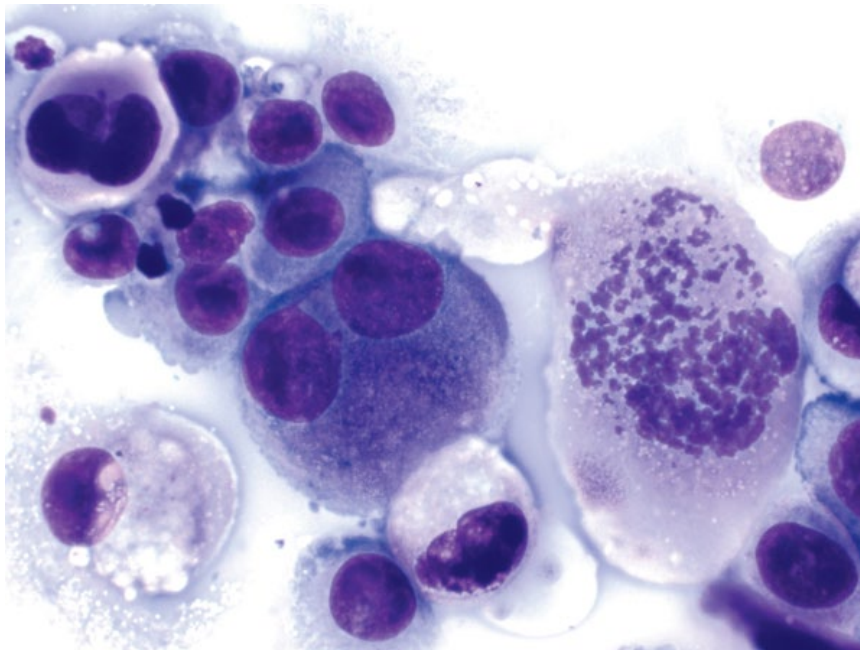


Figure 5.18 Carcinoma, pleural fluid, cat, 50× objective. There is a bizarre mitotic figure and marked anisocytosis/anisokaryosis.

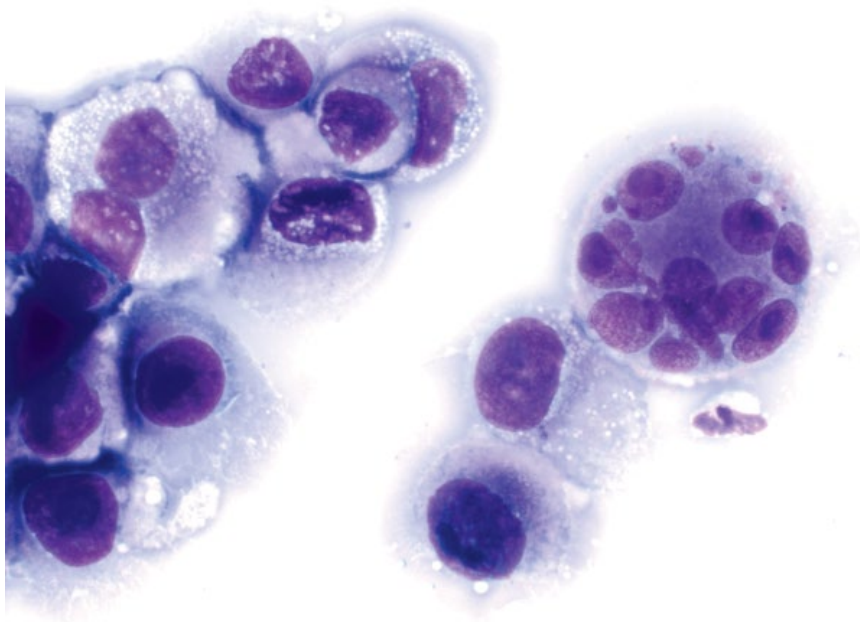


Figure 5.19 Carcinoma, pleural fluid, cat, 50× objective. Note the multinucleated cells with anisokaryosis and nuclear fragmentation.

Cells have a variable volume of medium-blue cytoplasm that often contains clear vacuoles.

5.2.10.2 Clinical Considerations

- Reported rarely in pleural and pericardial fluid in dogs [22, 24].

- May appear similar to other round-cell neoplasms (e.g., lymphoma; compare to Figure 5.20), and further diagnostics may be required.

5.2.10.3 Prognosis

Grave.

Figure 5.20 Lymphoma, pleural effusion, dog, 50× objective.

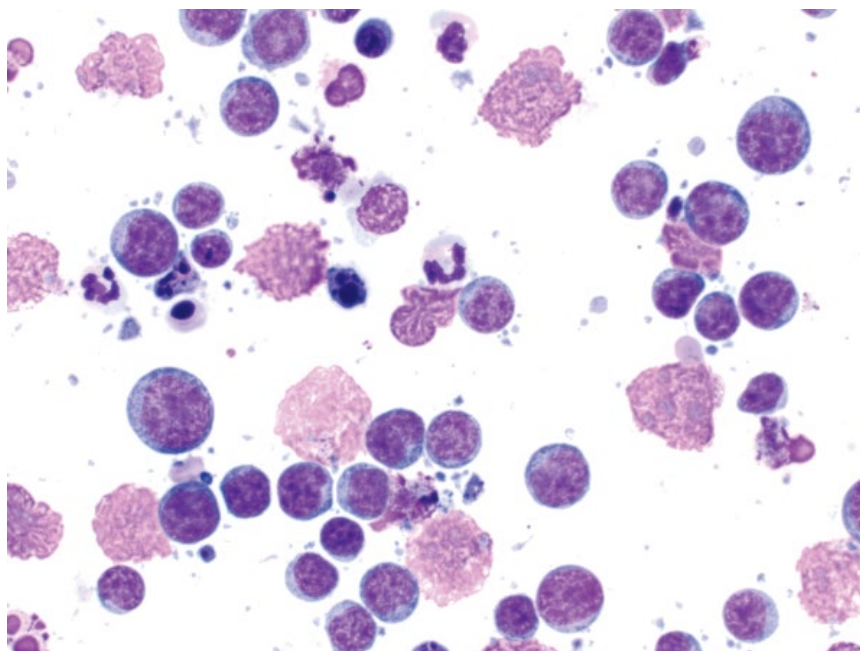
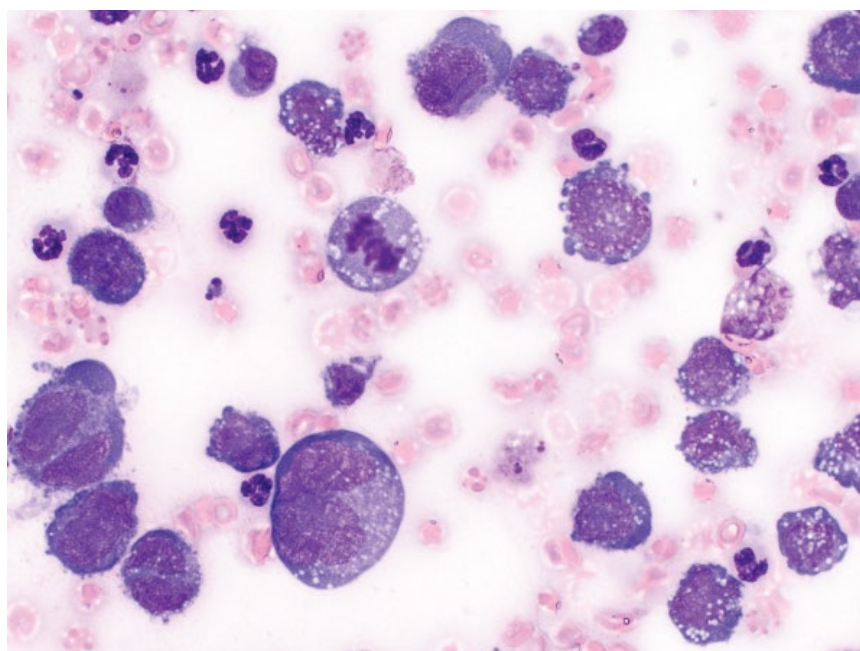


Figure 5.21 Histiocytic sarcoma, pericardial effusion, dog, 50× objective.



References

- 1 Costello, M.F., Drobatz, K.J., Aronson, L.R., *et al.* (2004) Underlying cause, pathophysiologic abnormalities, and response to treatment in cats with septic peritonitis: 51 cases (1990–2001). *J. Am. Vet. Med. Assoc.*, **225** (6), 897–902.
- 2 Bentley, A.M., Otto, C.M., Shofer, F.S. (2007) Comparison of dogs with septic peritonitis: 1988–1993 versus 1999–2003. *J. Vet. Emerg. Crit. Care*, **17** (4), 391–398.
- 3 Bonczynski, J.J., Ludwig, L.L., Barton, L.J., *et al.* (2003) Comparison of peritoneal fluid and peripheral blood pH, bicarbonate, glucose and lactate concentration as a diagnostic tool for septic peritonitis in dogs and cats. *Vet. Surg.*, **32** (2), 161–166.

- 4 Burton, A.G., Harris, L.A., Owens, S.D., *et al.* (2013) The prognostic utility of degenerative left shifts in dogs. *J. Vet. Intern. Med.*, **27** (6), 1517–1522.
- 5 Demetriou, J.L., Foale, R.D., Ladlow, J., *et al.* (2002) Canine and feline pyothorax: a retrospective study of 50 cases in the UK and Ireland. *J. Small Anim. Pract.*, **43** (9), 388–394.
- 6 Boothe, H.W., Howe, L.M., Boothe, D.M., *et al.* (2010) Evaluation of outcomes in dogs treated for pyothorax: 46 cases (1983–2001). *J. Am. Vet. Med. Assoc.*, **236** (6), 657–663.
- 7 Fossum, T.W., Wellman, M., Relford, R.L., *et al.* (1993) Eosinophilic pleural or peritoneal effusions in dogs and cats: 14 cases (1986–1992). *J. Am. Vet. Med. Assoc.*, **202** (11), 1873–1876.
- 8 Norris, J.M., Bosward, K.L., White, J.D., *et al.* (2005) Clinicopathological findings associated with feline infectious peritonitis in Sydney, Australia: 42 cases (1990–2002). *Aust. Vet. J.*, **83** (11), 666–673.
- 9 Ludwig, L.L., McLoughlin, M.A., Graves, T.K., *et al.* (1997) Surgical treatment of bile peritonitis in 24 dogs and 2 cats: a retrospective study (1987–1994). *Vet. Surg.*, **26** (2), 90–98.
- 10 Owens, S.D., Gossett, R., McElhaney, M.R., *et al.* (2003) Three cases of canine bile peritonitis with mucinous material in abdominal fluid as the prominent cytologic finding. *Vet. Clin. Pathol.*, **32** (3), 114–120.
- 11 Fossum, T.W., Forrester, S.D., Swenson, C.L., *et al.* (1991) Chylothorax in cats: 37 cases (1969–1989). *J. Am. Vet. Med. Assoc.*, **198** (4), 672–678.
- 12 Waddle, J.R., Giger, U. (1990) Lipoprotein electrophoresis differentiation of chylous and nonchylous pleural effusions in dogs and cats and its correlation with pleural effusion triglyceride concentration. *Vet. Clin. Pathol.*, **19** (3), 80–85.
- 13 Connally, H.E. (2003) Cytology and fluid analysis of the acute abdomen. *Clin. Tech. Small Anim. Pract.*, **18** (1), 39–44.
- 14 Aumann, M., Worth, L.T., Drobatz, K.J. (1998) Uroperitoneum in cats: 26 cases (1986–1995). *J. Am. Anim. Hosp. Assoc.*, **34** (4), 315–324.
- 15 Schmiedt, C., Tobias, K.M., Otto, C.M. (2001) Evaluation of abdominal fluid: peripheral blood creatinine and potassium ratios for diagnosis of uroperitoneum in dogs. *J. Vet. Emerg. Crit. Care*, **11** (4), 275–280.
- 16 Culp, W.T., Weisse, C., Kellogg, M.E., *et al.* (2010) Spontaneous hemoperitoneum in cats: 65 cases (1994–2006). *J. Am. Vet. Med. Assoc.*, **236** (9), 978–982.
- 17 Aronsohn, M.G., Dubiel, B., Roberts, B., *et al.* (2009) Prognosis for acute nontraumatic hemoperitoneum in the dog: a retrospective analysis of 60 cases (2003–2006). *J. Am. Anim. Hosp. Assoc.*, **45** (2), 72–77.
- 18 Ferreira, F.C., Soares, M.J., Carvalho, S., *et al.* (2015) Four cases of cell cannibalism in highly malignant feline and canine tumors. *Diagn. Pathol.*, **10**, 199.
- 19 Paintal, A., Raparia, K., Nayar, R. (2016) Cytomorphologic findings of malignant mesothelioma in FNA biopsies and touch preps of core biopsies. *Diagn. Cytopathol.*, **44** (1), 14–19.
- 20 Espino, L., Vazquez, S., Faílde, D., *et al.* (2010) Localized pleural mesothelioma causing cranial vena cava syndrome in a dog. *J. Vet. Diagn. Invest.*, **22** (2), 309–312.
- 21 Vascellari, M., Carminato, A., Camali, G., *et al.* (2011) Malignant mesothelioma of the tunica vaginalis testis in a dog: histological and immunohistochemical characterization. *J. Vet. Diagn. Invest.*, **23** (1), 135–139.
- 22 Cagle, L.A., Epstein, S.E., Owens, S.D., *et al.* (2014) Diagnostic yield of cytologic analysis of pericardial effusion in dogs. *J. Vet. Intern. Med.*, **28** (1), 66–71.
- 23 Bauer, N., Moritz, A. (2005) Flow cytometric analysis of effusions in dogs and cats with the automated haematology analyser ADVIA 120. *Vet. Rec.*, **156** (21), 674–678.
- 24 Tsai, S., Sutherland-Smith, J., Burgess, K., *et al.* (2012) Imaging characteristics of intrathoracic histiocytic sarcoma in dogs. *Vet. Radiol. Ultrasound*, **53** (1), 21–27.

6

Musculoskeletal

6.1 Bone

6.1.1 Osteosarcoma

6.1.1.1 Cytologic Features

Osteosarcomas frequently are highly cellular and associated with bright pink, fibrillar extracellular matrix (osteoid) (Figure 6.1). Cells are distributed individually and in aggregates, and range from ovoid to fusiform. Their cytoplasm may contain fine clear vacuoles, or fine pink granules. Nuclei are round to ovoid and often eccentrically placed, with the appearance of 'falling out' of the cell (Figure 6.2). They have finely granular chromatin with multiple basophilic nucleoli, and hyperchromasia is common. Marked criteria of malignancy often are present, including multinucleated giant cells. *Note:* subtypes of osteosarcoma exist, including chondroblastic and fibroblastic, which can make differentiation from chondrosarcomas and fibrosarcomas difficult.

6.1.1.2 Clinical Considerations

- Most common primary bone tumor in dogs. Rare in cats.
- Large breed dogs predisposed. Bimodal age distribution: mostly middle-aged to older dogs, but a small peak in frequency for dogs 18-24 months [1].
- Seen most frequently in the metaphyseal region of the appendicular skeleton, with tumors twice as likely in the front limbs [2].
- Primary osteosarcomas are seen rarely in extraskeletal sites, and can metastasize to extraskeletal sites.
- Metallic implants may increase the risk of osteosarcoma, which are significantly more likely to involve the diaphysis [3].
- Early metastasis to the lungs is common (but is often subclinical at the time of diagnosis). Metastatic disease to lymph nodes is rare, and is associated with a poor prognosis [4].

6.1.1.3 Prognosis

Osteosarcomas are highly aggressive malignancies, and prognosis is guarded to poor. Factors contributing to a poor outcome include tumor size and histologic grade.

Elevated serum ALP and proximal humeral location have been reported as negative prognosticators in a meta-analysis [5]. Metastatic disease also confers a poor prognosis, with median survival times of 2 months compared to 12 months for dogs without evidence of metastases [6]. Tumors affecting flat bones may have a better prognosis.

6.1.2 Chondrosarcoma

6.1.2.1 Cytologic Features

Chondrosarcomas are characterized by dense, metachromatic extracellular chondroid (Figure 6.3) in which cells may be embedded, forming lacunae. Cells mostly are round but can be spindle, and have pale-blue cytoplasm that often contains diffuse, fine pink granules. Unlike osteosarcomas, nuclei are more often centrally placed within the cell, but also have finely stippled chromatin and multiple basophilic nucleoli.

6.1.2.2 Clinical Considerations

- Second most common bone tumor in dogs. Rare in cats.
- Predilection sites = nasal cavity > ribs, scapula and other flat bones.
- Occurs in extraosseous sites, including mammary gland tissue.
- Metastatic disease is not a feature of nasal chondrosarcomas, and extra-nasal tumors are generally slow to metastasize.

6.1.2.3 Prognosis

Variable. Nasal chondrosarcomas carry a poor prognosis. Wide surgical excision of extra-nasal chondrosarcomas in dogs significantly improves survival time, and can be associated with long-term survival [7].

6.1.3 Multilobular Osteochondrosarcoma (MLO)

6.1.3.1 Cytologic Features

Cytologic samples from MLO are highly variable, as tumors are composed of cartilaginous, osseous and spindle cells (the latter predominate in Figure 6.4). Multiple

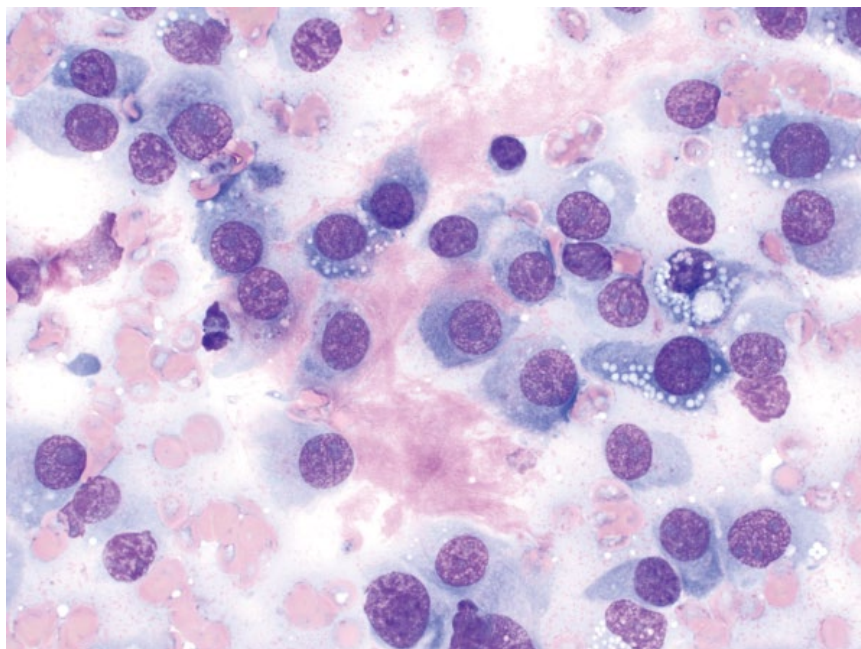


Figure 6.1 Bone, osteosarcoma, dog, 50× objective. Note the smooth to fibrillar pink osteoid between cells.

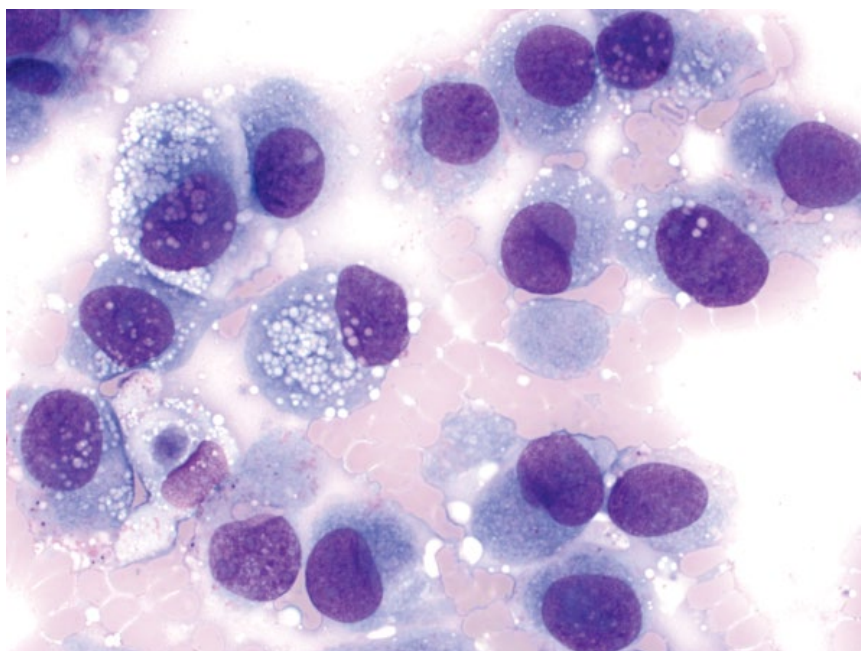


Figure 6.2 Bone, osteosarcoma, dog, 50× objective. Note the round cells with fine pink granules in their cytoplasm. Nuclei are eccentrically placed.

such components, together with clinical considerations (see below), should raise suspicion of these tumors.

6.1.3.2 Clinical Considerations

- Synonyms = Multilobular tumor of bone, chondroma rodens, multilobular osteoma.
- Dogs >> cats.
- Affects flat bones, particularly of the skull > ribs, pelvis, os penis.
- Moderately metastatic, generally to lungs [8].

6.1.3.3 Prognosis

Long-term survival is expected with complete resection. Incomplete resection dramatically decreases survival times [8]. Recurrence and metastatic rates are linked to histologic grade [8].

6.1.4 Hemangiosarcoma

6.1.4.1 Cytologic Features

Hemangiosarcomas of bone may exfoliate poorly, and samples may be very bloody. When present, cells are

Figure 6.3 Bone, chondrosarcoma, dog, 50x objective. Neoplastic cells are embedded within thick chondroid.

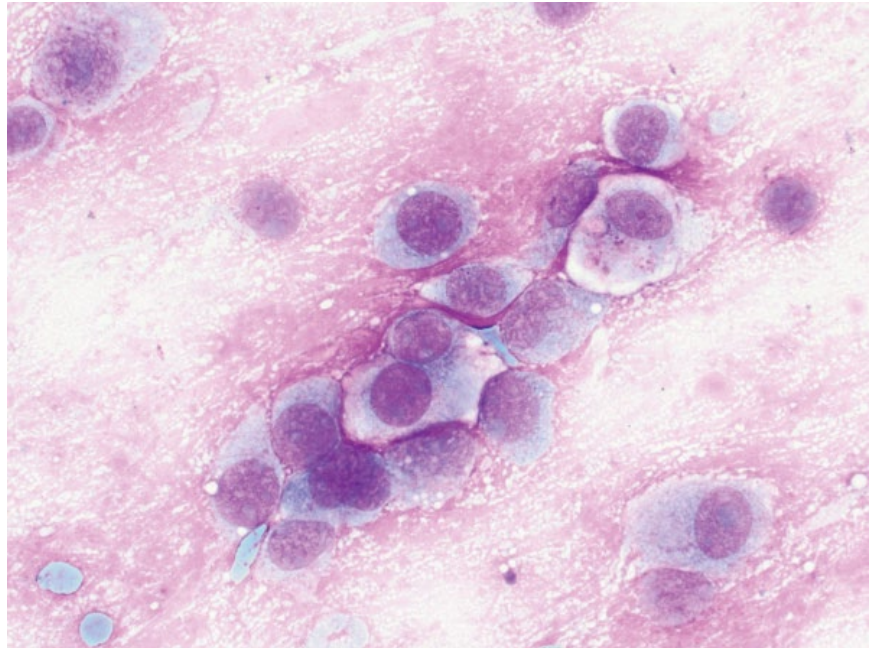
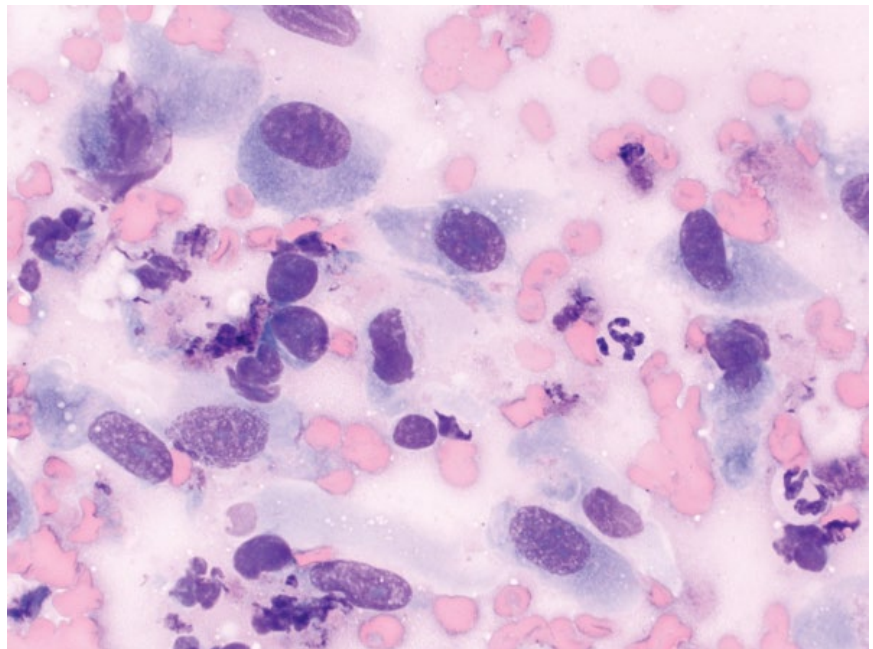


Figure 6.4 Bone, multilobular osteochondrosarcoma dog, 50x objective.



ovoid to spindloid and may be seen in aggregates/epithelioid sheets. The cells have a small to moderate volume of medium-blue cytoplasm that may form streaming cytoplasmic wisps. Nuclei are ovoid to occasionally amoeboid, and have finely granular chromatin with prominent, often large, basophilic nucleoli. Mitotic figures and hyperchromasia of nuclei are common

(Figure 6.5). Anisocytosis/anisokaryosis are marked, and N/C ratios mostly are high.

6.1.4.2 Clinical Considerations

- Rare primary tumors of bone [9].
- May be primary or metastatic.

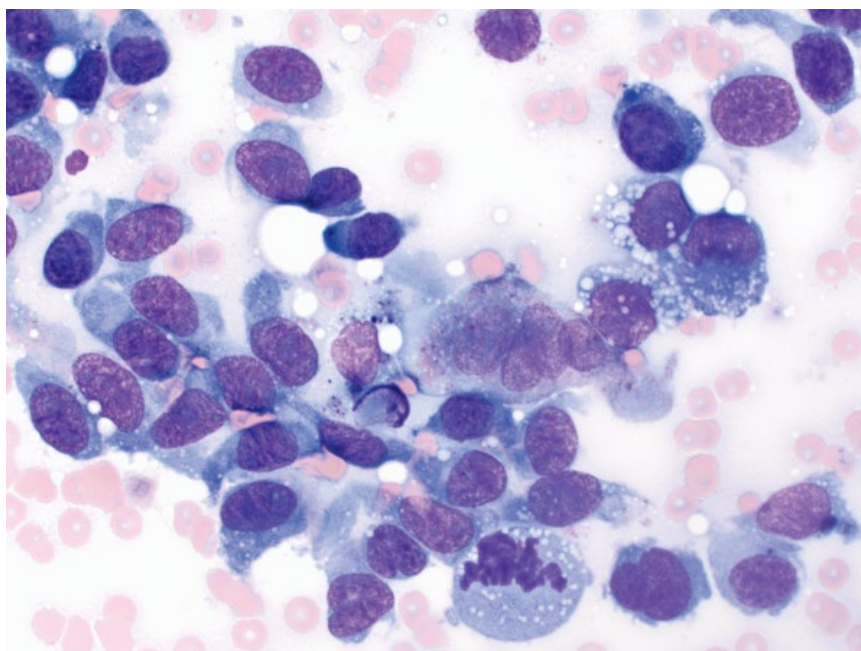


Figure 6.5 Bone, hemangiosarcoma, dog, 50x objective.

- Radiography=marked lysis (often accompanied by pathologic fracture) and minimal or no periosteal new bone formation [10].

6.1.4.3 Prognosis

Poor to grave, even if confined to a single bony lesion at time of diagnosis [10].

6.1.5 Fibrosarcoma

6.1.5.1 Cytologic Features

Fibrosarcomas in bone are characterized by a population of spindloid cells with a small to moderate volume of pale-blue cytoplasm forming bipolar tapering ends. Nuclei are round to ovoid, with finely granular chromatin and multiple prominent nucleoli. Anisocytosis/anisokaryosis are moderate to marked (Figure 6.6). Care should be taken to differentiate these from reactive fibroplasia, and histopathology is required to differentiate from the fibroblastic variant of osteosarcoma and multilobular osteochondrosarcoma (compare to Figure 6.4).

6.1.5.2 Clinical Considerations

- Rare primary tumors of bone [9].
- Most commonly affects the skull > appendicular bones.
- May be primary or metastatic [11].

6.1.5.3 Prognosis

Variable, based on location and presence of metastatic disease. Complete surgical excision of a single tumor may be curative [3, 12].

6.1.6 Histiocytic Sarcoma

6.1.6.1 Cytologic Features

Histiocytic sarcoma cells are round and discrete, which can make them difficult to distinguish from osteosarcoma (compare to Figure 6.2). Distinguishing features may include vacuolation of the cytoplasm, and lack of pink granules. Differentiation from osteosarcoma is more straightforward when criteria of malignancy are marked, as karyomegaly and prominent nucleoli are more common in histiocytic sarcoma (Figure 6.7).

6.1.6.2 Clinical Considerations

- May be localized to bone or part of disseminated disease.
- Sites of predilection = periarticular bones, vertebrae, proximal humerus [13].
- Predisposed breeds = Rottweilers and Golden Retrievers [13, 14].

6.1.6.3 Prognosis

Poor to grave.

6.1.7 Multiple Myeloma

6.1.7.1 Cytologic Features

Multiple myeloma is characterized by a neoplastic expansion of mostly well-differentiated plasma cells seen in large sheets. The cells have a moderate volume of pale-blue cytoplasm, and often have a characteristic, perinuclear clear zone (Golgi zone). Some cells may contain

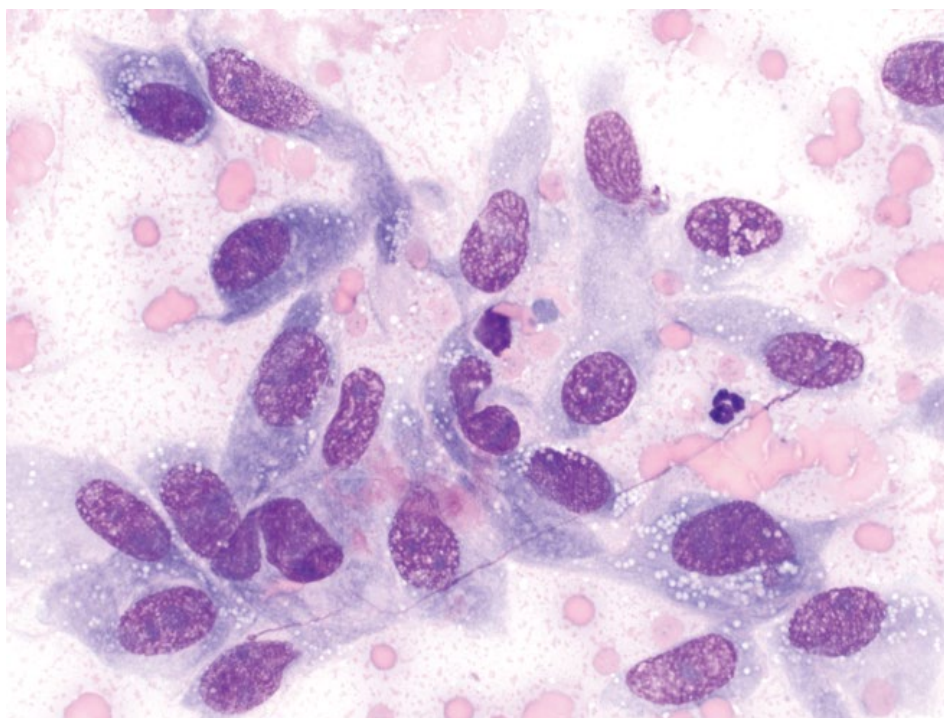


Figure 6.6 Bone, fibrosarcoma, dog, 50× objective.

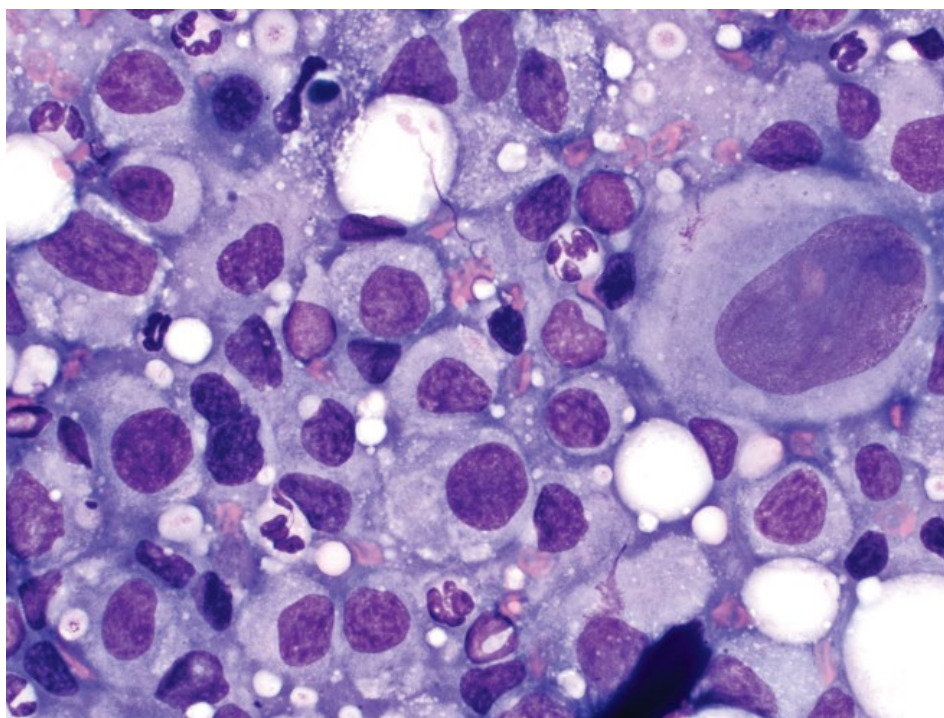


Figure 6.7 Bone, histiocytic sarcoma, dog, 50× objective.

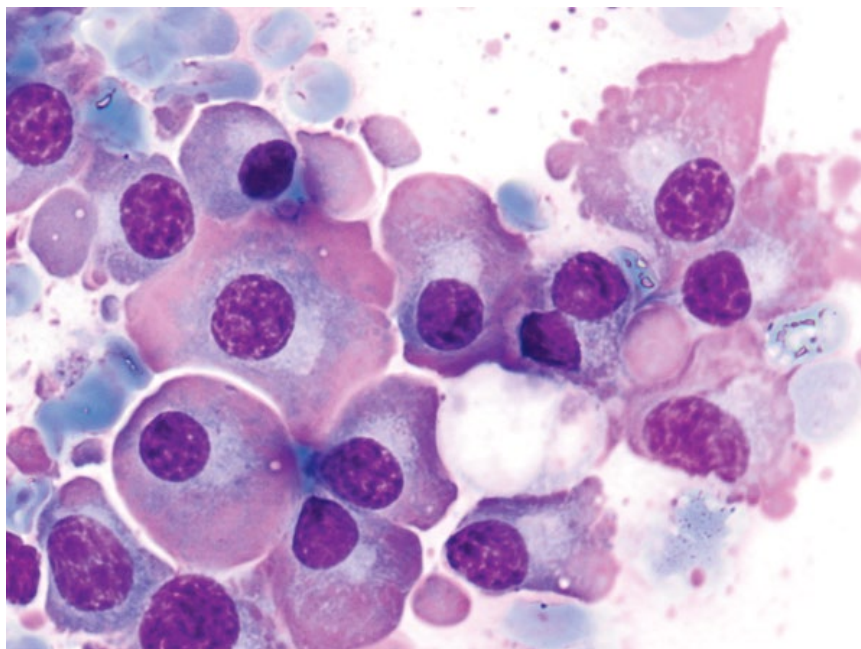


Figure 6.8 Bone, multiple myeloma, dog, 100× objective. Lytic lesion in spinal process. Note the bright-pink immunoglobulin accumulation within the cytoplasm ('flame cells').

bright-pink material within the periphery of the cytoplasm, representing the production of immunoglobulins ('flame cells') (Figure 6.8). Nuclei are round, eccentrically placed, and have clumped chromatin.

6.1.7.2 Clinical Considerations

- Dogs > cats.
- Other clinical findings = monoclonal gammopathy, bone marrow plasmacytosis, anemia, bleeding diatheses, Bence–Jones proteinuria [15, 16].

6.1.7.3 Prognosis

Dogs = Good short-term prognosis with treatment, and long-term control is possible. Negative prognostic factors include extensive bone lysis/involvement, hypercalcemia and Bence–Jones proteinuria [15].

Cats = Guarded prognosis, with generally short survival times [16, 17].

6.1.8 Metastatic Neoplasia to Bone

6.1.8.1 Cytologic Features

Metastatic bone tumors will appear cytologically similar to the primary tumor, often with marked criteria of malignancy. Mildly pleomorphic, reactive osteoblasts or osteoclasts may accompany neoplastic cells (Figure 6.9).

6.1.8.2 Clinical Considerations

- Most common in the axial skeleton (particularly vertebrae) and proximal appendicular bones (particularly the humerus) [11, 18].
- Often affect multiple bones.

- Carcinomas are most common, and mammary gland is most common origin [11].

6.1.8.3 Prognosis

Grave.

6.1.9 Osteomyelitis

6.1.9.1 Cytologic Features

Osteomyelitis is characterized by an infiltration of inflammatory cells, the type of which will vary with the underlying infectious agent. Granulomatous inflammation generally accompanies fungal agents, while neutrophils are seen with bacterial osteomyelitis. Osteoblasts or osteoclasts may be seen, confirming involvement of bone (Figure 6.10).

6.1.9.2 Clinical Considerations

- May be associated with puncture wounds/trauma, hematogenous spread or orthopedic procedures [19, 20].
- Aerobic bacteria most common with bacterial osteomyelitis. Anaerobes seen secondary to bite/puncture wounds or tooth root abscess [19, 21].
- Common fungal agents = *Blastomyces*, *Coccidioides*, *Histoplasma*, *Cryptococcus*, *Aspergillus* (see Chapter 2 for details).

6.1.9.3 Prognosis

Bacterial osteomyelitis generally carries a favorable prognosis with appropriate therapy. Fungal osteomyelitis is more guarded, based on extent of disease.

Figure 6.9 Bone, metastatic mammary carcinoma, dog, 50× objective. Note the cytologically normal osteoblast (arrow).

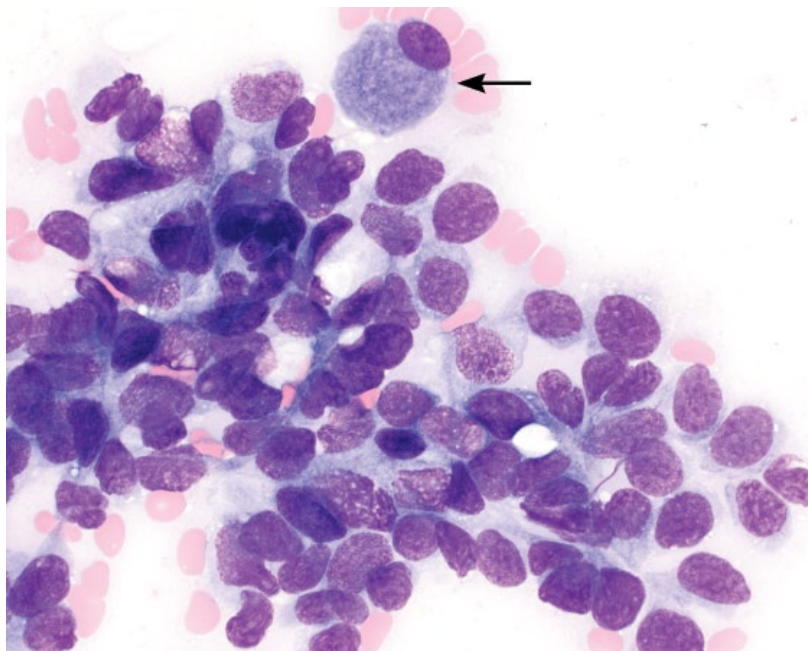
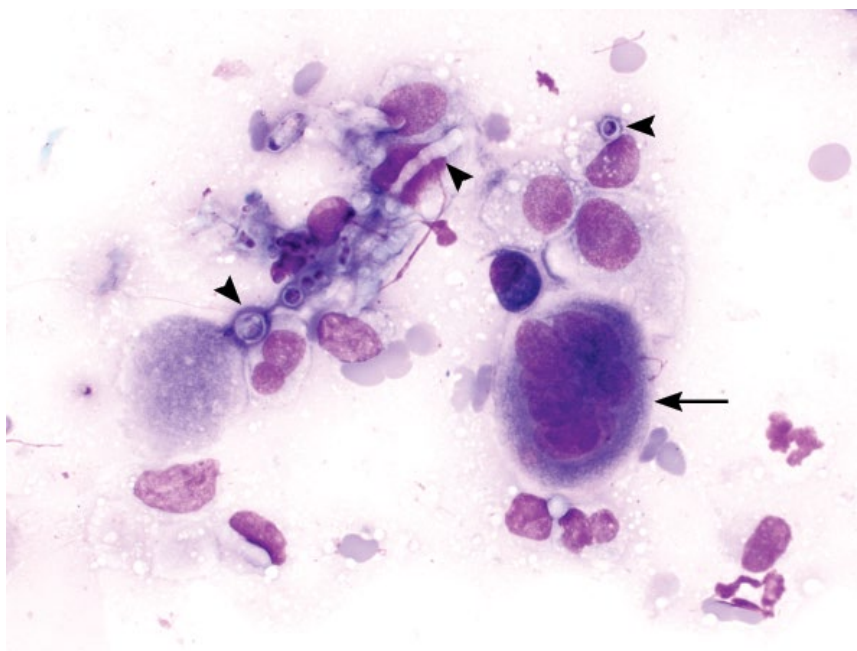


Figure 6.10 Bone, osteomyelitis, dog, 50× objective. Fungal organisms are seen budding and forming hyphae (arrowheads), and an osteoclast is present (arrow).



6.2 Joints

6.2.1 Normal Synovial Fluid

6.2.1.1 Cytologic Features

Synovial fluid from normal joints has a variably thick, pink stippled, mucinous background (Figure 6.11). Erythrocytes should be absent or seen in very low numbers. Nucleated cells are seen individually in low numbers,

and should comprise almost exclusively quiescent large mononuclear cells (macrophages or synoviocytes that look cytologically similar). Rare small mature lymphocytes may be seen. Neutrophils should be absent.

6.2.1.2 Clinical Considerations

- Grossly, fluid should be clear and viscous.
- Cell count: Generally <1500 cells μl^{-1} . Stifle joints often have higher cell counts, up to 3000 cells μl^{-1} .

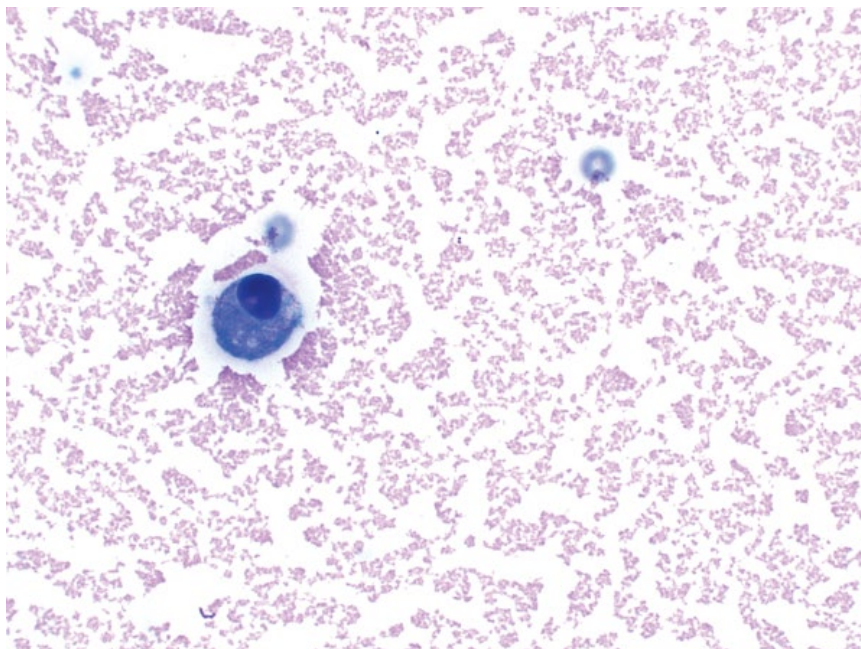


Figure 6.11 Synovial fluid (normal), dog, 50× objective. There is a medium-pink stippled background, rare erythrocytes, and a single, quiescent macrophage/synoviocyte.

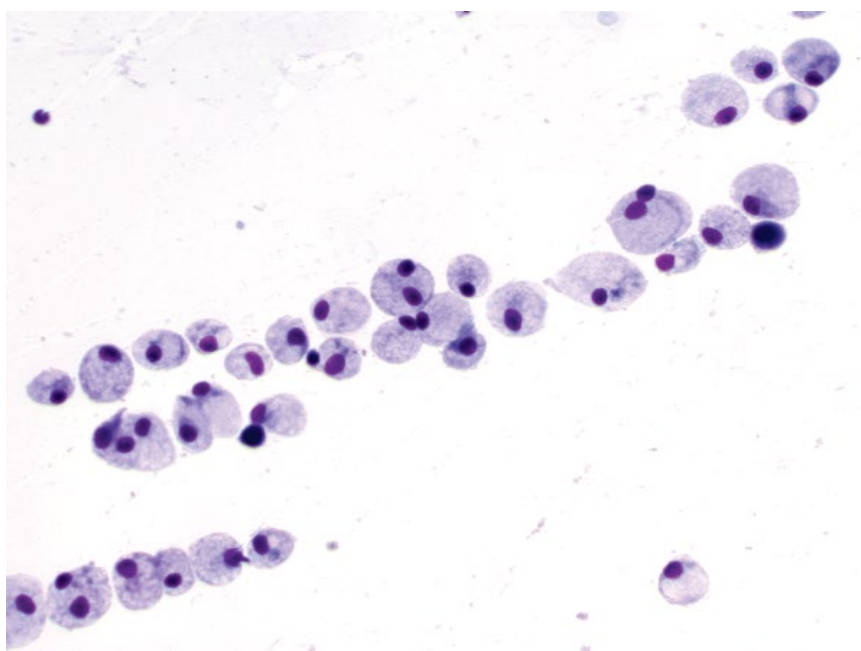


Figure 6.12 Synovial fluid, mononuclear inflammation and reactive changes, dog, 20× objective.

6.2.2 Mononuclear Reactivity/Inflammation

6.2.2.1 Cytologic Features

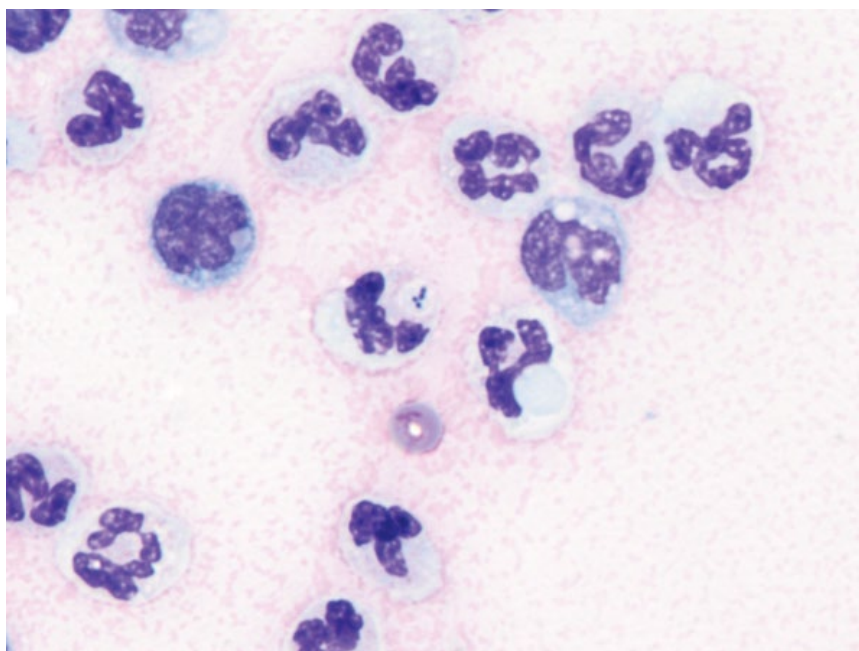
Mononuclear reactive changes may be seen with either a normal or elevated cell count. Relative to quiescent macrophages/synoviocytes, the cells are larger, and have a greater volume of cytoplasm that frequently becomes vacuolated (compare Figures 6.12 and 6.11). These

mononuclear cells may form sheets or dense aggregates, suggestive of synovial hyperplasia.

6.2.2.2 Clinical Considerations

- Classically seen with degenerative diseases of the joint.
- DDx = osteoarthritis, ligament/meniscal disease, chronic irritation/trauma to the joint, chronic orthopedic disease (e.g., osteochondritis dissecans).

Figure 6.13 Synovial fluid, septic arthritis, dog, 100× objective. Note bacterial cocci within a phagolysosome in the neutrophil.



- Cytologic abnormalities may precede radiographic changes [22].

6.2.2.3 Prognosis

Disease is seldom reversible, but progression is variable with underlying cause.

6.2.3 Neutrophilic Inflammation (Bacterial Sepsis)

6.2.3.1 Cytologic Features

Bacterial septic arthritis is associated with a markedly elevated cell count, predominated by neutrophils. Neutrophils frequently are non-degenerative. Bacteria may be seen in neutrophil phagolysosomes (Figure 6.13), but are not always seen in cases of septic arthritis. Care should be taken to differentiate bacteria from phagocytosed immunoglobulin, which can be seen in immune-mediated disease (compare to Figure 6.16).

6.2.3.2 Clinical Considerations

- Bacteria may not be seen cytologically, and microbial culture is recommended, though also may not yield growth [23].
- Stifle and elbow joints most commonly affected [24].
- May be secondary to surgical procedures, hematogenous spread or penetrating wounds [24, 25].

6.2.3.3 Prognosis

Generally good with appropriate therapy. Full joint function may not be restored [24, 25].

6.2.4 Neutrophilic Inflammation (Rickettsial Sepsis)

6.2.4.1 Cytologic Appearance

Neutrophilic arthritis is seen with Rickettsial infections (see Chapter 2 for details). Organisms may be visible within neutrophils in synovial fluid, often in low numbers, and careful examination of many neutrophils is recommended. The bacteria form round aggregates known as morulae (Figure 6.14).

6.2.4.2 Clinical Considerations

- Polyarthropathy is most commonly due to infection with *Ehrlichia ewingii* or *Anaplasma phagocytophilum* [26].
- Absence of organisms does not rule out underlying Rickettsial disease [27].

6.2.4.3 Prognosis

Good with appropriate therapy.

6.2.5 Neutrophilic Inflammation (Non-infectious)

6.2.5.1 Cytologic Features

Non-infectious neutrophilic inflammation is characterized by variably increased numbers of neutrophils that are non-degenerative (Figure 6.15). In cases of immune-mediated polyarthritis (IMPA), neutrophils may rarely contain numerous, variably sized cytoplasmic inclusions that are pink to purple, and irregularly shaped (Figure 6.16). These represent phagocytosed immune complexes or

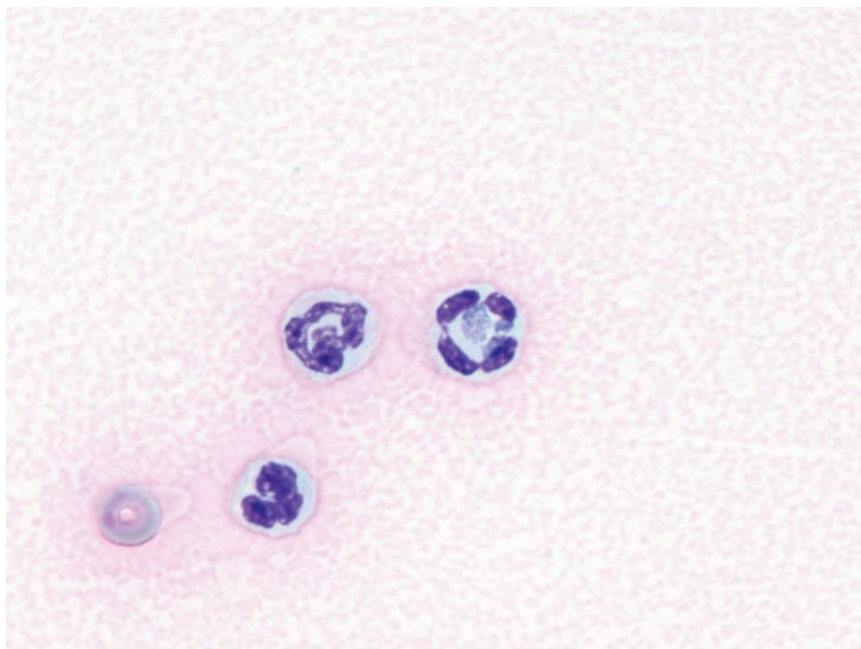


Figure 6.14 Synovial fluid, Rickettsial infection, dog, 100× objective. Note the morula of *Anaplasma phagocytophilum* in the neutrophil on the right.

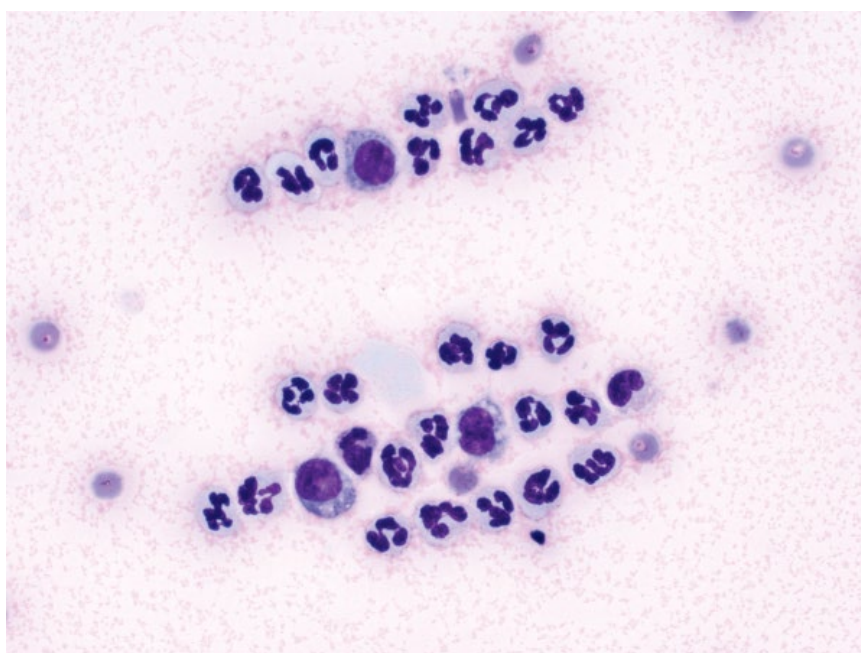


Figure 6.15 Synovial fluid, sterile neutrophilic inflammation, immune-mediated polyarthritis (IMPA), dog, 50× objective.

nuclear remnants. These cells are called 'ragocytes' when unstained. These inclusions can be distinguished from ingested bacteria, the latter being uniform in size, staining and shape (compare to Figure 6.13).

6.2.5.2 Clinical Considerations

- Clinical signs = shifting limb lameness, fever, joint pain [28].

- May be primary autoimmune, or secondary to other pathology (e.g., neoplasia or infectious organisms such as Rickettsial agents).

6.2.5.3 Prognosis

Primary immune-mediated polyarthritis has a good prognosis with appropriate therapy. Prognosis variable for secondary cases based on underlying disease.

Figure 6.16 Synovial fluid, immune-mediated polyarthritis (IMPA), with ragocytes, dog, 100× objective. Note the amorphous, pink/purple inclusions within the cytoplasm of some neutrophils.

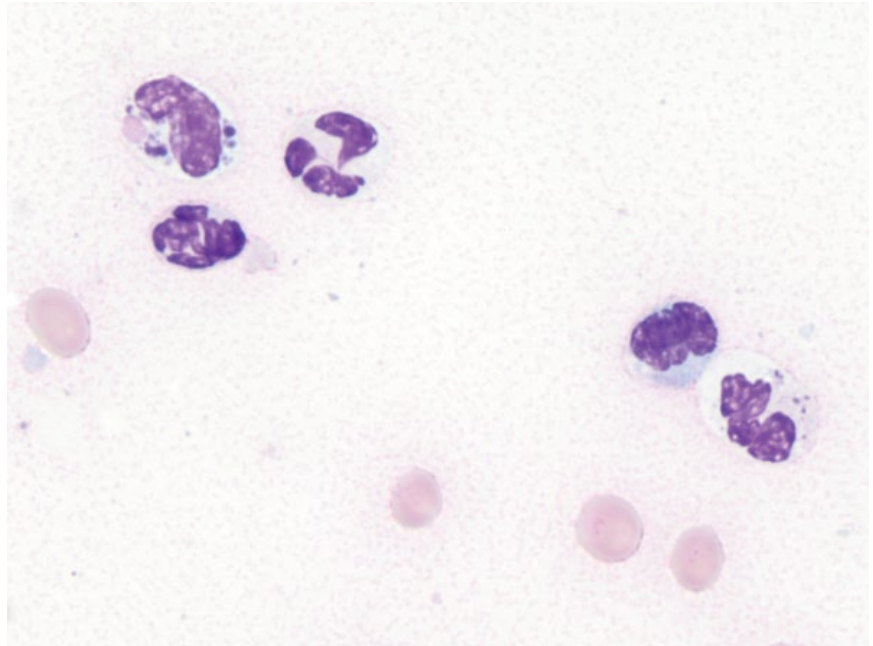
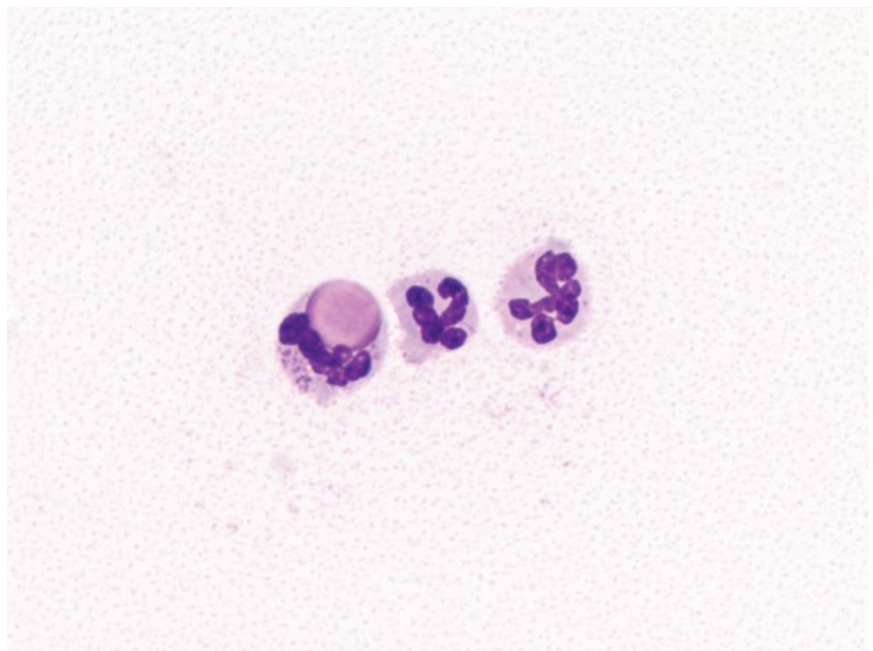


Figure 6.17 Synovial fluid, dog with systemic lupus erythematosus, 100× objective. Note the bright-pink, spherical inclusion within the neutrophil or lupus erythematosus (LE) cell.



6.2.6 Systemic Lupus Erythematosus (SLE)

6.2.6.1 Cytologic Features

Patients with SLE often have polyarthritis, characterized by large numbers of non-degenerative neutrophils. In addition, a (rare) characteristic finding is the presence of lupus erythematosus (LE) cells. LE cells are neutrophils that have large, round, homogeneous pink inclusions

with a smooth border, representing phagocytosis of nuclear material (Figure 6.17).

6.2.6.2 Clinical Considerations

- LE cells are rare but, when present, strongly support a diagnosis of SLE.
- Rare disease in dogs and cats.

- Further confirmation of SLE should include the presence of other signs including: a positive antinuclear antibody test (ANA); dermatopathy; glomerulonephritis; hemolytic anemia, etc [29].

6.2.6.3 Prognosis

Variable, based on disease severity and organ systems involved.

6.2.7 Metastatic Neoplasia

6.2.7.1 Cytologic Features

Rarely, neoplastic cells may be seen in synovial fluid, and their appearance will reflect the tumor of origin. They often display marked criteria of malignancy (see Chapter 1 for details), such as anisokaryosis and prominent nucleoli. Cells may be present in low numbers, and examination of sedimented or cytocentrifuged samples may be necessary.

6.2.7.2 Clinical Considerations

- Neoplasia may invade from around the joint (e.g., histiocytic sarcoma; Figure 6.18), or metastasize to the joint [30] (e.g., bronchogenic carcinoma; Figure 6.19).

6.2.7.3 Prognosis

Poor.

6.2.8 Hemarthrosis

6.2.8.1 Cytologic Features

Erythrocytes within synovial fluid can pose a diagnostic challenge to distinguish between iatrogenic hemorrhage

from sampling, and true hemorrhage (hemarthrosis). Prior hemorrhage is confirmed by visualizing erythrophagia or heme-breakdown pigments within mononuclear cells (Figure 6.20).

6.2.8.2 Clinical Considerations

- DDx = trauma, coagulopathy, neoplasia.
- Clearance of erythrocytes occurs quickly after onset of hemorrhage [31].

6.2.8.3 Prognosis

Generally excellent.

6.2.9 Synovial Cyst

6.2.9.1 Cytologic Features

Synovial cysts frequently have a similar pink stippled, mucinous background to normal synovial fluid; however, a clear background may be present. Cellularity generally is low, and comprises reactive macrophages/synoviocytes. Cholesterol crystals may also be seen (Figure 6.21).

6.2.9.2 Clinical Considerations

- Fluid-filled, variably fluctuant lesions around joints.
- Often have acute onset and may be associated with trauma.
- Chronic lesions may be associated with underlying degenerative joint disease.

6.2.9.3 Prognosis

Excellent.

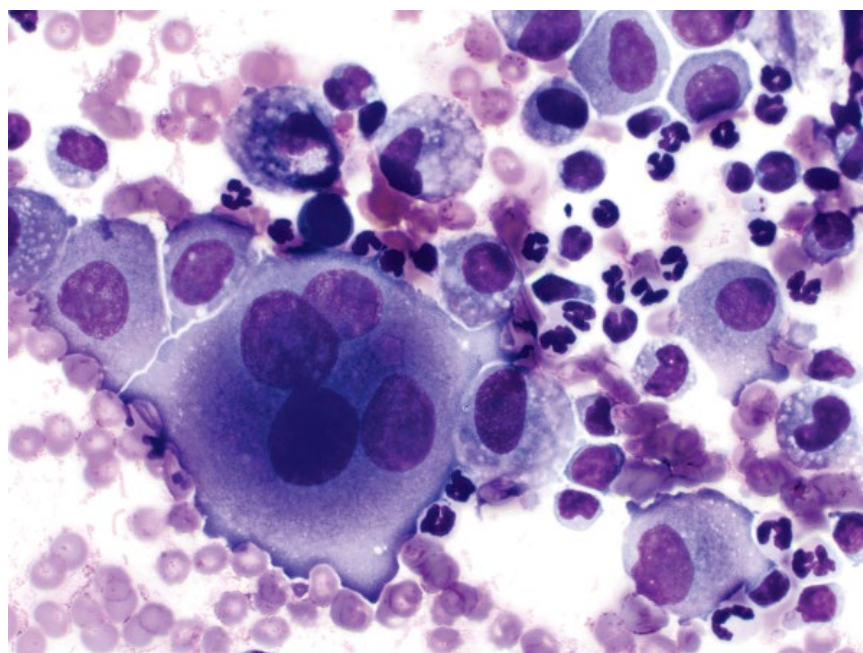


Figure 6.18 Synovial fluid, metastatic histiocytic sarcoma, dog, 50× objective.

Figure 6.19 Synovial fluid, metastatic bronchogenic carcinoma, dog, 50× objective.

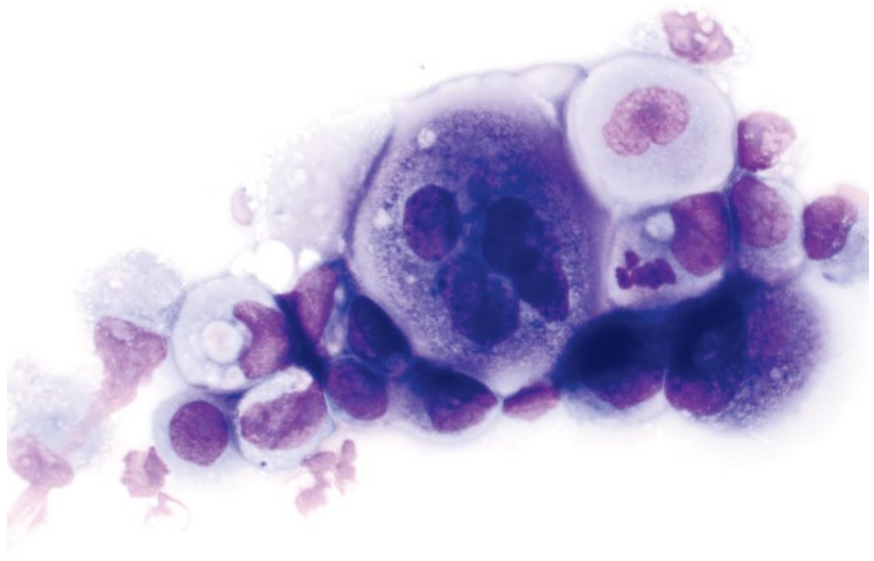
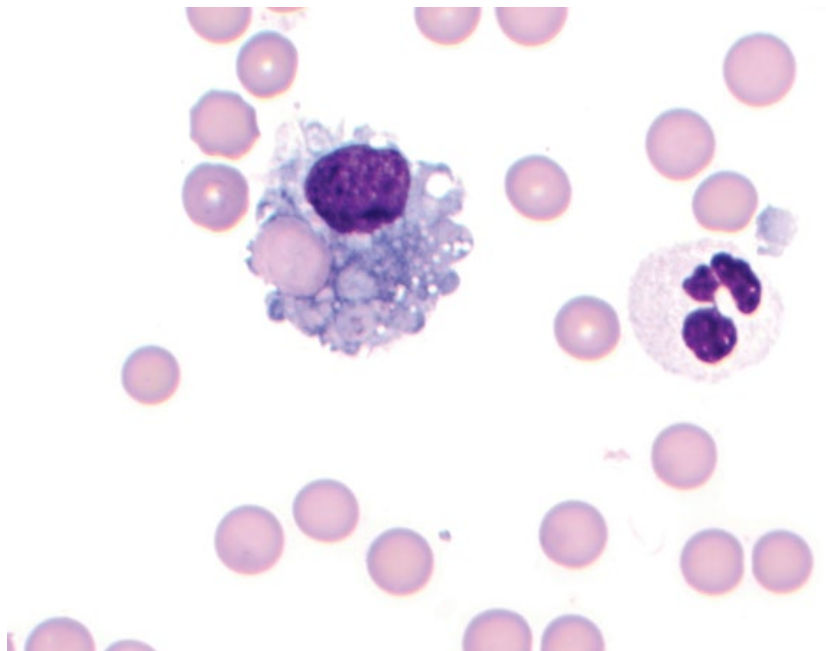


Figure 6.20 Synovial fluid, hemarthrosis, 100× objective. Note the red blood cell phagocytosed by the macrophage and blood in the background.



6.2.10 Synovial Cell Sarcoma

6.2.10.1 Cytologic Features

Synovial cell sarcomas frequently are associated with a thick, pink stippled background, and cells may be seen in a streaming or windrowing distribution. This can make differentiation from myxosarcomas difficult (compare to Figure 3.49). Cells are spindloid and have a moderate volume of medium-blue cytoplasm that forms bipolar tendrils and wisps, and may contain fine pink granules

or fine clear vacuoles. Nuclei are ovoid with coarsely granular chromatin and multiple, prominent, basophilic nucleoli (Figure 6.22). Anisocytosis/anisokaryosis are moderate, and N/C ratios are high.

6.2.10.2 Clinical Considerations

- Dogs >> cats
- More common in larger joints (particularly stifle) in middle-aged to older, large breed dogs [14].

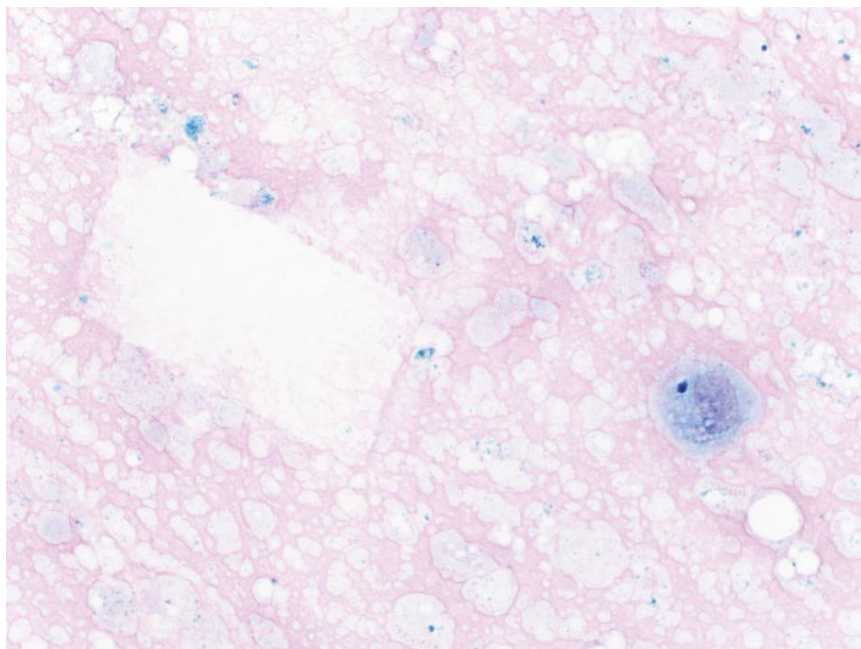


Figure 6.21 Synovial cyst, dog, 50× objective. Note the thick pink mucinous background, cholesterol crystal (left) and macrophage/synoviocyte (right).

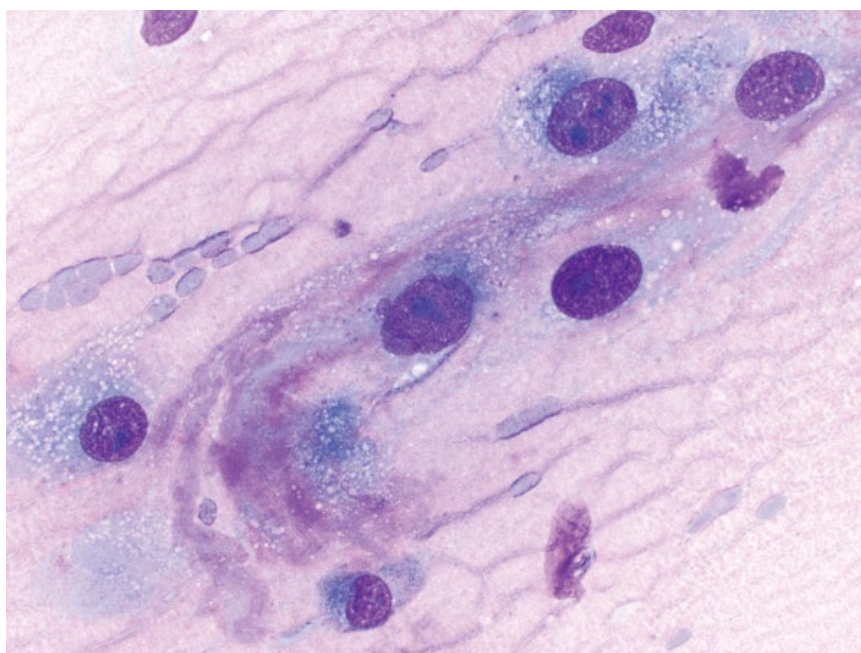


Figure 6.22 Synovial sarcoma, dog, 50× objective.

- Locally aggressive and moderate metastatic potential (linked to tumor grade) with metastatic disease detected in ~25% of dogs at the time of diagnosis [14, 32].
- Bone involvement common in dogs, rare in cats [32, 33].

6.2.10.3 Prognosis

Variable, based on clinical stage and histologic grade. Complete surgical removal of tumors without metastatic

disease can carry a good long-term prognosis [14, 32]. Metastatic disease at the time of diagnosis confers a poor prognosis.

6.2.11 Histiocytic Sarcoma (Periarticular)

6.2.11.1 Cytologic Features

Periarticular histiocytic sarcomas contain discrete cells with marked criteria of malignancy including anisokaryosis, karyomegaly, multinucleation, and high mitotic rates (Figure 6.23). Cells usually are vacuolated.

Figure 6.23 Periarticular histiocytic sarcoma, dog, 50× objective.

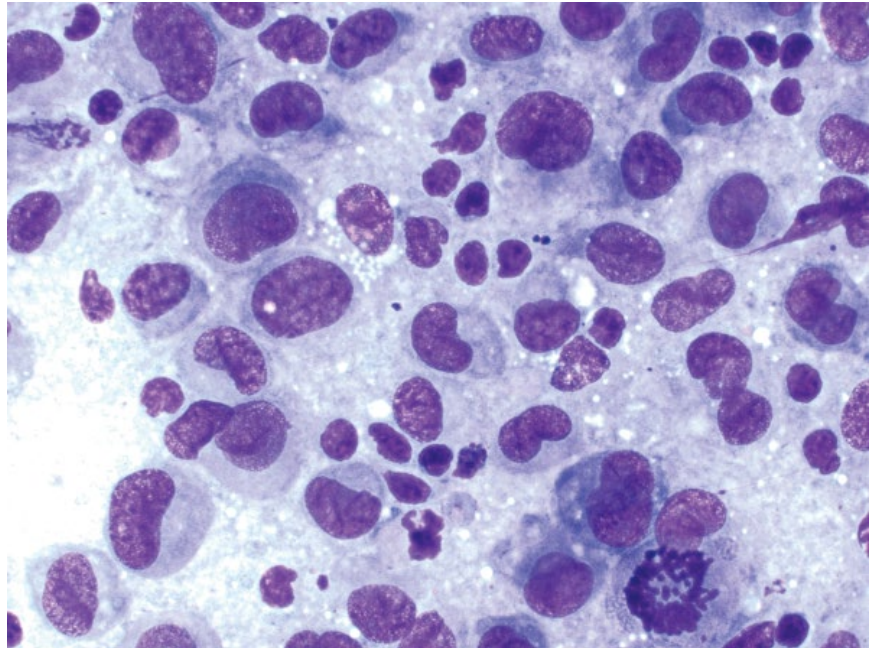
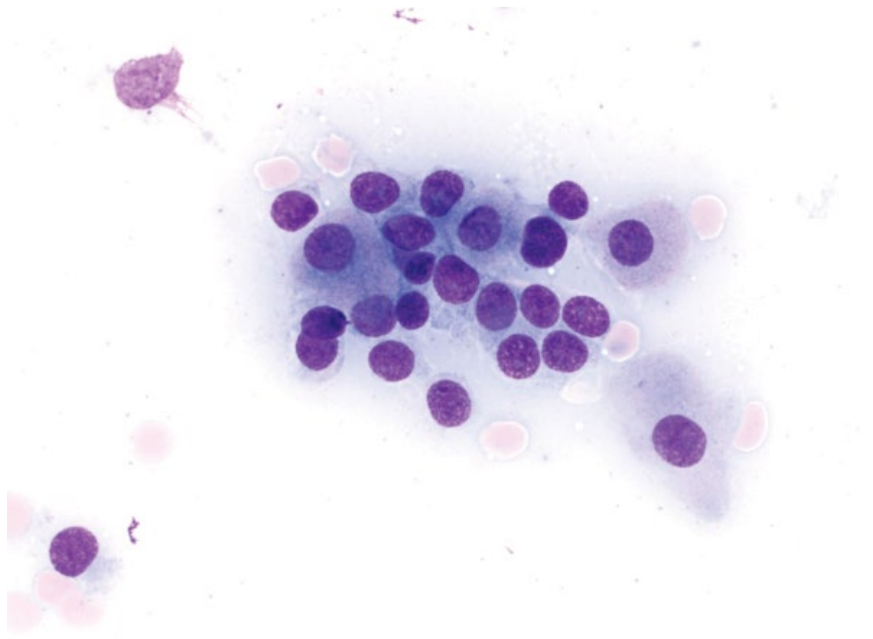


Figure 6.24 Rhabdomyoma, dog larynx, 50× objective. Note the faint pink granular appearance of the cytoplasm of some cells.



6.2.11.2 Clinical Considerations

- Most common synovial tumor in dogs [14].
- Rottweilers appear to be predisposed.
- There is a relation between previous traumatic injury to joints (especially cranial cruciate ligament rupture) and the development of periarticular histiocytic sarcoma [14, 34].

6.2.11.3 Prognosis

While prognosis is still poor, periarticular histiocytic sarcoma appears to carry a better prognosis than non-periarticular sites, even in the presence of metastatic disease [35].

6.3 Muscle

6.3.1 Rhabdomyoma

6.3.1.1 Cytologic Features

Rhabdomyomas contain round to polygonal cells seen individually and in loose aggregates. They have abundant pale-blue cytoplasm that often has a faint pink granular appearance (due to abundant mitochondria) (Figure 6.24) [36]. Nuclei are round, centrally located, and have coarsely granular chromatin with small, single

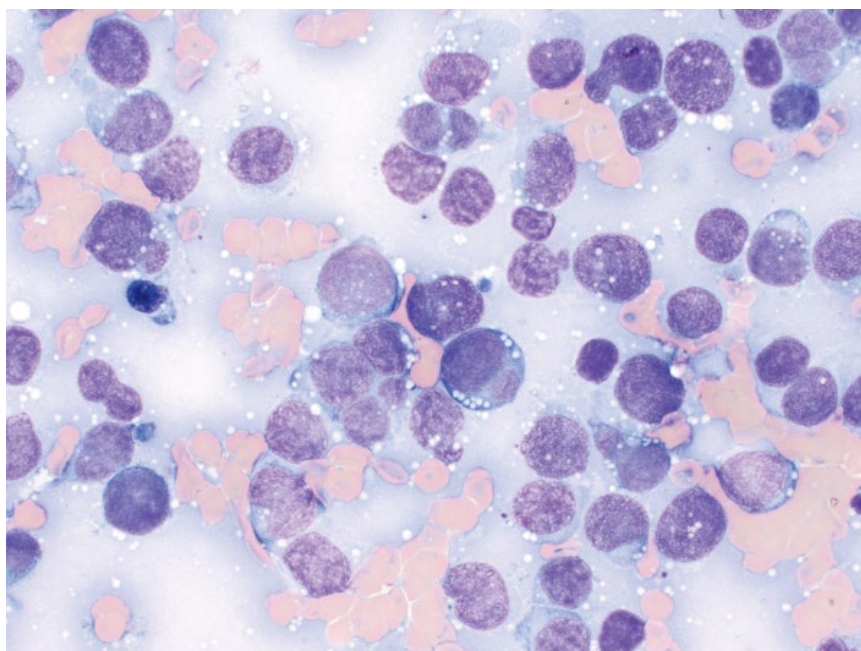


Figure 6.25 Rhabdomyosarcoma (embryonal), dog, 50× objective.

nucleoli. Anisocytosis/anisokaryosis are mild and N/C ratios are low.

6.3.1.2 Clinical Considerations

- Rare tumors. Dog > cat.
- Most commonly reported in the larynx [36, 37].
- DDX = granular cell tumor and oncocytoma.

6.3.1.3 Prognosis

Good. Dogs with laryngeal rhabdomyomas have long survival times, with no evidence of recurrence or metastatic disease [36].

6.3.2 Rhabdomyosarcoma

6.3.2.1 Cytologic Features

Cytologic appearance of rhabdomyosarcomas is highly variable based on the degree of differentiation of the cells. Rhabdomyoblasts (in embryonal rhabdomyosarcomas) are round, individualized cells with a small volume of medium-blue cytoplasm that contains fine clear vacuoles. Nuclei frequently are indented or bilobed (Figure 6.25). These rhabdomyoblasts may be difficult to differentiate from lymphoma (see Chapter 4). More differentiated rhabdomyosarcomas have a polygonal appearance with abundant medium-blue cytoplasm that may have fine pink granules and perinuclear clearing (Figure 6.26). Nuclei are ovoid and have prominent single nucleoli. Linear cells with nuclei in rows (strap cells) and cytoplasmic striations may be seen in very well-differentiated tumors.

6.3.2.2 Clinical Considerations

- Rare tumors. Dogs > cats.
- Mostly single, but may be multiple masses [38].
- Predilection sites = oral cavity, urinary bladder, vagina, skin [38–40].
- Locally invasive with low to moderate metastatic potential (regional lymph nodes, lungs, spleen). Local recurrence may occur [38, 39].

6.3.2.3 Prognosis

Variable survival times are reported, but prolonged survival is possible in the absence of metastatic disease, even with recurrence of the tumor [39].

6.3.3 Leiomyoma

6.3.3.1 Cytologic Features

Leiomyomas exfoliate variably well, and comprise well-differentiated spindle cells seen individually and in aggregates. The cells have a scant volume of pale cytoplasm forming bipolar tendrils and wisps, and elongated nuclei with finely granular chromatin and small basophilic nucleoli (Figure 6.27). Anisocytosis/anisokaryosis are mild and N/C ratios are high. May look similar to fibromas or gastrointestinal stromal tumors (compare to Figures 3.40 and 8.16).

6.3.3.2 Clinical Considerations

- Benign neoplasms of smooth muscle origin in dogs and cats.
- Predilection sites = vagina, uterus, gastrointestinal tract.

Figure 6.26 Rhabdomyosarcoma (differentiated), dog, 50× objective. Many cells have a faint pink granular appearance to their cytoplasm.

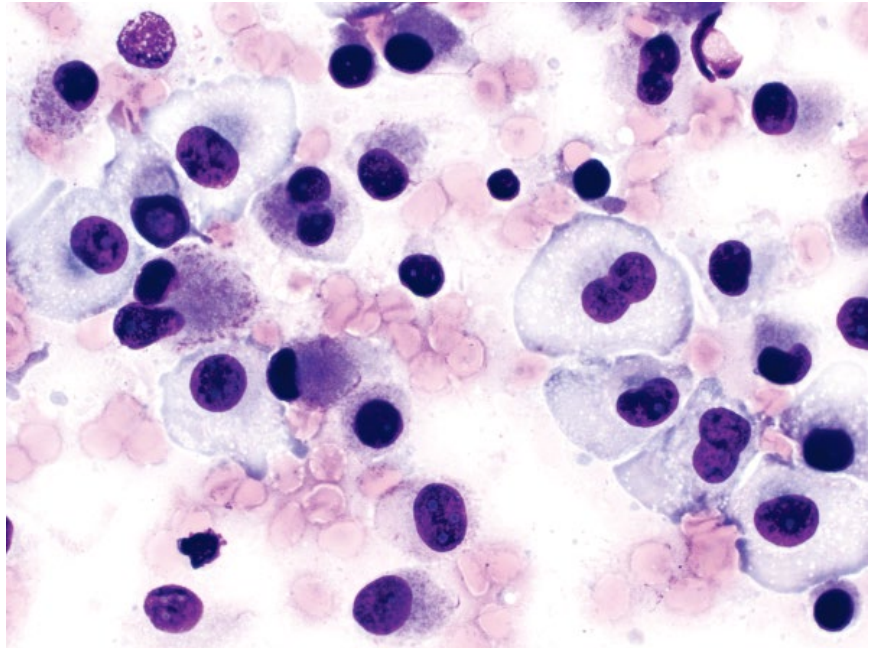
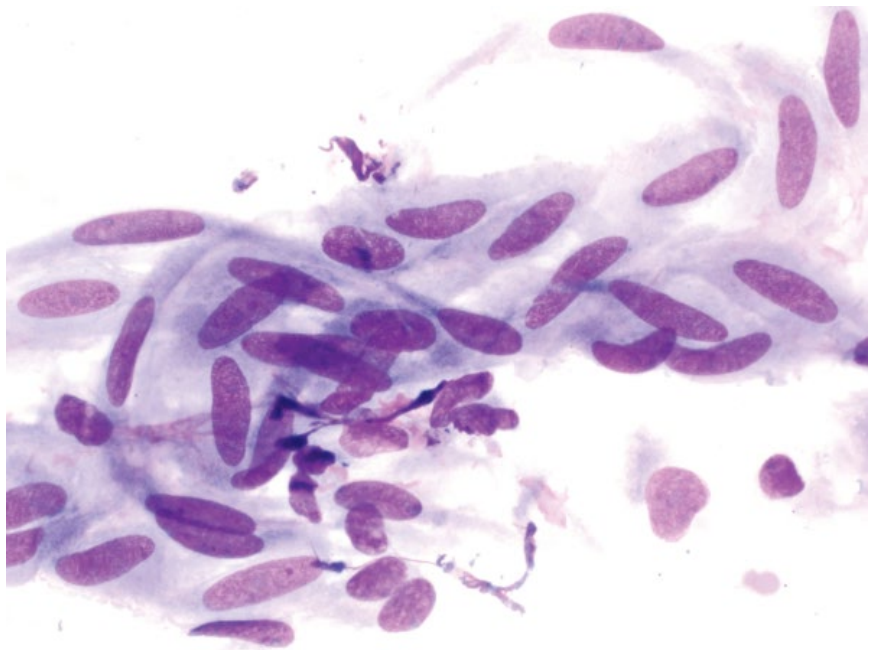


Figure 6.27 Leiomyoma, dog, vagina, 50× objective.



- Usually small, solitary, and well-encapsulated. Vaginal leiomyomas often are pedunculated.

6.3.3.3 Prognosis

Excellent. Vaginal leiomyomas may spontaneously regress after ovariectomy [41].

6.3.4 Leiomyosarcoma

6.3.4.1 Cytologic Features

Leiomyosarcomas exfoliate variably well in loose aggregates and individually. They comprise plump spindle cells with a moderate volume of medium-blue cytoplasm

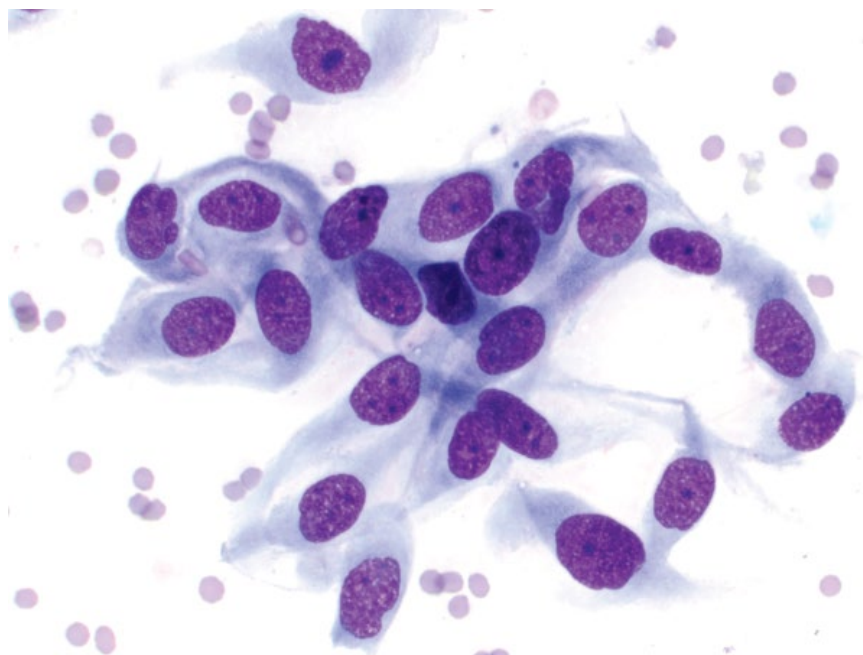


Figure 6.28 Leiomyosarcoma, cat, stomach, 50× objective.

forming short bipolar tapering ends, and may contain fine clear vacuoles. Nuclei are ovoid with coarsely granular chromatin and prominent basophilic nucleoli. Anisocytosis/anisokaryosis are variable, and N/C ratios are moderate to high (Figure 6.28).

6.3.4.2 Clinical Considerations

- Malignant tumors arising from smooth muscle cells.
- Older dogs and cats.
- Predilection sites = gastrointestinal tract (see Chapter 8) > spleen, genitourinary tract, liver, blood vessel walls and subcutaneous tissues [42–44].

- May be associated with paraneoplastic syndromes such as hypoglycemia and nephrogenic diabetes insipidus [42].

6.3.4.3 Prognosis

Variable, based on location. Neoplasms in the liver have a grave prognosis, with 100% metastatic rate [43]. The metastatic rate for other abdominal locations is approximately 50%, and dermal tumors are not reported to metastasize [42, 45]. Surgical excision may be curative, and moderate to long-term survival is possible with surgical removal, even with concurrent metastatic disease [42].

References

- 1 Spodnick, G.J., Berg, J., Rand, W.M., *et al.* (1992) Prognosis for dogs with appendicular osteosarcoma treated by amputation alone: 162 cases (1978–1988). *J. Am. Vet. Med. Assoc.*, **200** (7), 995–999.
- 2 Knecht, C.D., Priester, W.A. (1978) Musculoskeletal tumors in dogs. *J. Am. Vet. Med. Assoc.*, **172** (1), 72–74.
- 3 Burton, A.G., Johnson, E.G., Vernau, W., *et al.* (2015) Implant-associated neoplasia in dogs: 16 cases (1983–2013). *J. Am. Vet. Med. Assoc.*, **247** (7), 778–785.
- 4 Hillers, K.R., Dernell, W.S., Lafferty, M.H., *et al.* (2005) Incidence and prognostic importance of lymph node metastases in dogs with appendicular osteosarcoma: 228 cases (1986–2003). *J. Am. Vet. Med. Assoc.*, **226** (8), 1364–1367.
- 5 Boerman, I., Selvarajah, G.T., Nielen, M., *et al.* (2012) Prognostic factors in canine appendicular osteosarcoma – a meta-analysis. *BMC Vet. Res.* 2012;8:56. doi: 10.1186/1746-6148-8-56. Last accessed May 1, 2017.
- 6 Liptak, J.M., Dernell, W.S., Ehrhart, N., *et al.* (2004) Canine appendicular osteosarcoma: diagnosis and palliative treatment. *Compend. Contin. Educ. Pract. Vet.*, **26**, 172–183.
- 7 Waltman, S.S., Seguin, B., Cooper, B.J., *et al.* (2007) Clinical outcome of non-nasal chondrosarcoma in dogs: thirty-one cases (1986–2003). *Vet. Surg.*, **36** (3), 266–271.
- 8 Dernell, W.S., Straw, R.C., Cooper, M.F., *et al.* (1998) Multilobular osteochondrosarcoma in 39 dogs: 1979–1993. *J. Am. Anim. Hosp. Assoc.*, **34** (1), 11–18.

- 9 Liu, S.-K., Dorfman, H.D., Hurvitz, A.I., *et al.* (1977) Primary and secondary bone tumours in the dog. *J. Small Anim. Pract.*, **18** (5), 313–326.
- 10 Hidaka, Y., Hagio, M., Uchida, K., *et al.* (2006) Primary hemangiosarcoma of the humerus in a Maltese dog. *J. Vet. Med. Sci.*, **66** (8), 895–898.
- 11 Trost, M.E., Inkelmann, M.A., Galiza, G.J., *et al.* (2014) Occurrence of tumours metastatic to bones and multicentric tumours with skeletal involvement in dogs. *J. Comp. Pathol.*, **150** (1), 8–17.
- 12 Wesselhoeft-Albin, L.A., Berg, J., Schelling, S.H. (1991) Fibrosarcoma of the canine appendicular skeleton. *J. Am. Anim. Hosp. Assoc.*, **27**, 303–309.
- 13 Schultz, R.M., Puchalski, S.M., Kent, M., *et al.* (2007) Skeletal lesions of histiocytic sarcoma in nineteen dogs. *Vet. Radiol. Ultrasound*, **48** (6), 539–543.
- 14 Craig, L.E., Julian, M.E., Ferracone, J.D. (2002) The diagnosis and prognosis of synovial tumors in dogs: 35 cases. *Vet. Pathol.*, **39** (1), 66–73.
- 15 Matus, R.E., Leifer, C.E., MacEwen, E.G., *et al.* (1986) Prognostic factors for multiple myeloma in the dog. *J. Am. Vet. Med. Assoc.*, **188** (11), 1288–1292.
- 16 Patel, R.T., Caceres, A., French, A.F., *et al.* (2005) Multiple myeloma in 16 cats: a retrospective study. *Vet. Clin. Pathol.*, **34** (4), 341–352.
- 17 Hanna, F. (2005) Multiple myelomas in cats. *J. Feline Med. Surg.*, **7** (5), 275–287.
- 18 Cooley, D.M., Waters, D.J. (1998) Skeletal metastasis as the initial clinical manifestation of metastatic carcinoma in 19 dogs. *J. Vet. Intern. Med.*, **12** (4), 288–293.
- 19 Bubenik, L.J. (2005) Infections of the skeletal system. *Vet. Clin. North Am. Small Anim. Pract.*, **35** (5), 1093–1109.
- 20 Bergh, M.S., Peirone, B. (2012) Complications of tibial plateau levelling osteotomy in dogs. *Vet. Comp. Orthop. Traumatol.*, **25** (5), 349–358.
- 21 Muir, P., Johnson, K.A. (1992) Anaerobic bacteria isolated from osteomyelitis in dogs and cats. *Vet. Surg.*, **21** (6), 463–466.
- 22 Lewis, D.D., Goring, R.L., Parker, R.B., *et al.* (1987) A comparison of diagnostic methods used in the evaluation of early degenerative joint disease in the dog. *J. Am. Anim. Hosp. Assoc.*, **23** (3), 305–315.
- 23 Scharf, V.F., Lewis, S.T., Wellehan, J.F., *et al.* (2015) Retrospective evaluation of the efficacy of isolating bacteria from synovial fluid in dogs with suspected septic arthritis. *Aust. Vet. J.*, **93** (6), 200–203.
- 24 Clements, D.N., Owen, M.R., Mosley, J.R., *et al.* (2005) Retrospective study of bacterial infective arthritis in 31 dogs. *J. Small Anim. Pract.*, **46** (4), 171–176.
- 25 Marchevsky, A.M., Read, R.A. (1999) Bacterial septic arthritis in 19 dogs. *Aust. Vet. J.*, **77** (4), 233–237.
- 26 Allison, R.W., Little, S.E. (2013) Diagnosis of rickettsial diseases in dogs and cats. *Vet. Clin. Pathol.*, **42** (2), 127–144.
- 27 Theodorou, K., Leontides, L., Siarkou, V.I., *et al.* (2015) Synovial fluid cytology in experimental acute canine monocytic ehrlichiosis (*Ehrlichia canis*). *Vet. Microbiol.*, **177** (1–2), 224–227.
- 28 Rondeau, M.P., Walton, R.M., Bissett, S., *et al.* (2005) Suppurative, nonseptic, polyarthropathy in dogs. *J. Vet. Intern. Med.*, **19** (5), 654–662.
- 29 Smee, N.M., Harkin, K.R., Wilkerson, M.J. (2007) Measurement of serum antinuclear antibody titer in dogs with and without systemic lupus erythematosus: 120 cases (1997–2005). *J. Am. Vet. Med. Assoc.*, **230** (8), 1180–1183.
- 30 Colledge, S.L., Raskin, R.E., Messick, J.B., *et al.* (2013) Multiple joint metastasis of a transitional cell carcinoma in a dog. *Vet. Clin. Pathol.*, **42** (2), 216–220.
- 31 Jansen, N.W., Roosendaal, G., Wenting, M.J., *et al.* (2009) Very rapid clearance after a joint bleed in the canine knee cannot prevent adverse effects on cartilage and synovial tissue. *Osteoarthritis Cartilage*, **17** (4), 433–440.
- 32 Vail, D.M., Powers, B.E., Getzy, D.M., *et al.* (1994) Evaluation of prognostic factors for dogs with synovial sarcoma: 36 cases (1986–1991). *J. Am. Vet. Med. Assoc.*, **205** (9), 1300–1307.
- 33 Liptak, J.M., Withrow, S.J., Macy, D.W., *et al.* (2004) Metastatic synovial cell sarcoma in two cats. *Vet. Comp. Oncol.*, **2** (3), 164–170.
- 34 van Kuijk, L., van Ginkel, K., de Vos, J.P., *et al.* (2013) Peri-articular histiocytic sarcoma and previous joint disease in Bernese Mountain Dogs. *J. Vet. Intern. Med.*, **27** (2), 293–299.
- 35 Klahn, S.L., Kitchell, B.E., Dervisis, N.G. (2011) Evaluation and comparison of outcomes in dogs with periarticular and nonperiarticular histiocytic sarcoma. *J. Am. Vet. Med. Assoc.*, **239** (1), 90–96.
- 36 Meuten, D.J., Calderwood Mays, M.B., Dillman, R.C., *et al.* (1985) Canine laryngeal rhabdomyoma. *Vet. Pathol.*, **22** (6), 533–539.
- 37 Dunbar, M.D., Ginn, P., Winter, M., *et al.* (2012) Laryngeal rhabdomyoma in a dog. *Vet. Clin. Pathol.*, **41** (4), 590–593.
- 38 Brockus, C.W., Myers, R.K. (2004) Multifocal rhabdomyosarcomas within the tongue and oral cavity of a dog. *Vet. Pathol.*, **41** (3), 273–274.
- 39 Avallone, G., Pinto da Cunha, N., Palmieri, C., *et al.* (2010) Subcutaneous embryonal rhabdomyosarcoma in a dog: cytologic, immunocytochemical, histologic, and ultrastructural features. *Vet. Clin. Pathol.*, **39** (4), 499–504.
- 40 Kuwamura, M., Yoshida, H., Yamate, J., *et al.* (1998) Urinary bladder rhabdomyosarcoma (sarcoma

- botryoides) in a young Newfoundland dog. *J. Vet. Med. Sci.*, **60** (5), 619–621.
- 41 Sathya, S., Linn, K. (2014) Regression of a vaginal leiomyoma after ovariohysterectomy in a dog: a case report. *J. Am. Anim. Hosp. Assoc.*, **50** (6), 424–428.
- 42 Cohen, M., Post, G.S., Wright, J.C. (2003) Gastrointestinal leiomyosarcoma in 14 dogs. *J. Vet. Intern. Med.*, **17** (1), 107–110.
- 43 Kapatkin, A.S., Mullen, H.S., Matthiesen, D.T., *et al.* (1992) Leiomyosarcoma in dogs: 44 cases (1983–1988). *J. Am. Vet. Med. Assoc.*, **201** (7), 1077–1079.
- 44 Miller, M.A., Ramos-Vara, J.A., Dickerson, M.F., *et al.* (2003) Uterine neoplasia in 13 cats. *J. Vet. Diagn. Invest.*, **15** (6), 515–522.
- 45 Liu, S.M., Mikaelian, I. (2003) Cutaneous smooth muscle tumors in the dog and cat. *Vet. Pathol.*, **40** (6), 685–692.

7

Hepatobiliary

7.1 Liver

7.1.1 Normal Hepatocytes

7.1.1.1 Cytologic Appearance

Normal hepatocytes may exfoliate in large numbers, unlike cells from many other normal tissues. They are seen mostly in cohesive sheets, and have a large volume of pale-blue cytoplasm. The cytoplasm may contain lipofuscin pigment, especially in older patients (see section 7.1.15). Nuclei are round, centrally located, and have granular to reticulated chromatin with single, prominent, centrally located nucleoli. Anisocytosis/anisokaryosis are mild (Figure 7.1). Binucleation may be seen in low numbers of cells, especially in older patients. Rectangular, crystalline nuclear inclusions may also be seen, and are of no clinical significance (Figure 7.2).

7.1.2 Vacuolar Hepatopathy (Non-lipid)

7.1.2.1 Cytologic Appearance

Accumulation of glycogen or water in the cytoplasm of hepatocytes gives them a lacy/feathery vacuolar appearance with poorly defined areas of clearing (Figure 7.3). Nuclei mostly stay centrally placed.

7.1.2.2 Clinical Considerations

- Dogs > cats.
- Most commonly associated with exposure to exogenous or endogenous corticosteroids (steroid hepatopathy) [1].
- Also non-specific change with hepatocellular damage (hypoxia, drug/toxin exposure, inflammation, proliferation, etc.).

7.1.2.3 Prognosis

Generally good, but variable based on underlying cause.

7.1.3 Vacuolar Hepatopathy (Lipid)

7.1.3.1 Cytologic Appearance

Lipid appears as coarse, clear vacuoles of varying size within the cytoplasm. Small numbers may be present, or

(as in feline hepatic lipidosis) they may be abundant and distend the cytoplasm of hepatocytes, pushing the nuclei to the periphery and making hepatocytes almost unrecognizable (Figures 7.4 and 7.5).

7.1.3.2 Clinical Considerations

- Small lipid vacuoles may represent a non-specific marker of hepatocellular dysfunction.
- Cats > dogs.
- Feline hepatic lipidosis:
 - Overweight/obese cats at increased risk
 - Disease preceded by inappetence/anorexia and may be associated with many underlying conditions [2].
 - Associated with increased liver enzymes; however, GGT is commonly within the reference interval [3].

7.1.3.3 Prognosis

Variable, based on the presence of underlying disease. Recovery rates can be high in primary feline hepatic lipidosis with appropriate therapy [3].

7.1.4 Nodular Hyperplasia

7.1.4.1 Cytologic Appearance

Hepatocytes in nodular hyperplastic lesions may be indistinguishable from normal cells (or even hepatomas; see section 7.1.5), and histopathology is required for definitive characterization. Mild crowding of cells can be seen, and mild, non-lipid vacuolar changes frequently are present multifocally (Figure 7.6).

7.1.4.2 Clinical Considerations

- Older dogs > cats [4, 5].
- May be single, but usually multiple, small (typically 2–3 cm or less), well-demarcated nodules.
- There is good correlation between cytologic and histopathologic analysis of hepatic masses, particularly benign processes such as nodular hyperplasia [6].

7.1.4.3 Prognosis

Excellent.

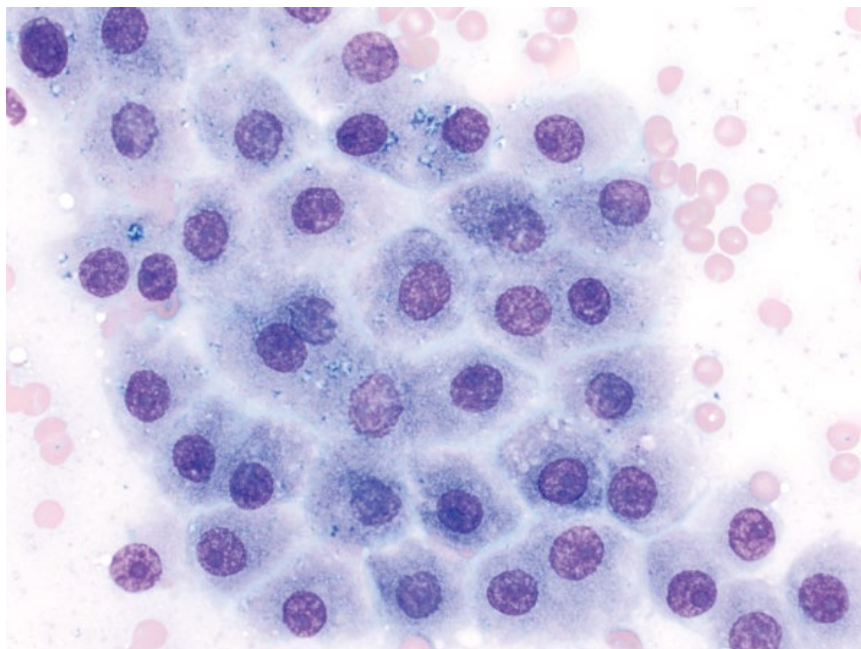


Figure 7.1 Normal hepatocytes, dog, 50x objective.

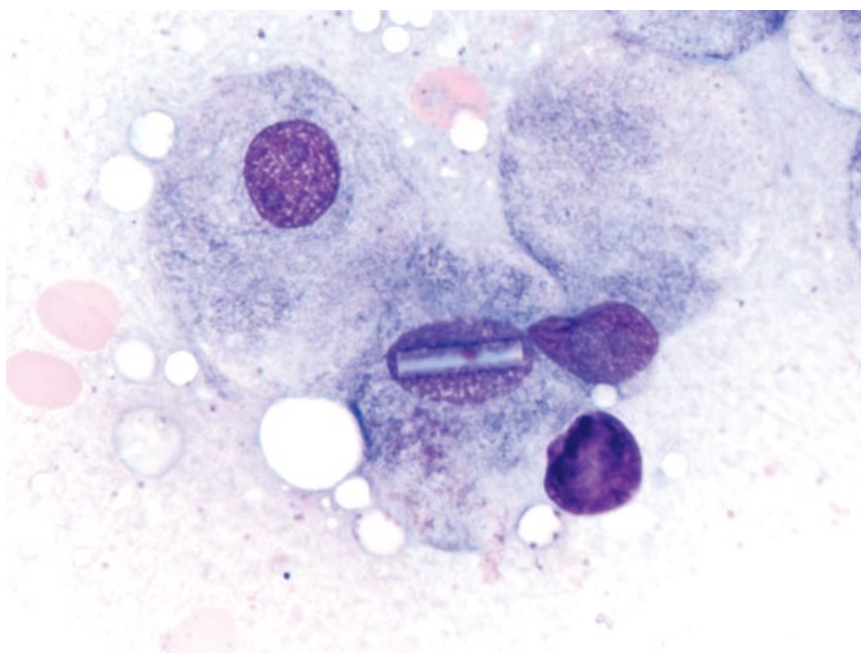


Figure 7.2 Normal hepatocytes, dog, 100x objective. Note the rectangular crystalline structure within the nucleus.

7.1.5 Hepatoma

7.1.5.1 Cytologic Appearance

Hepatomas comprise sheets of well-differentiated hepatocytes; however, relative to normal hepatocytes they frequently have a mildly decreased volume of cytoplasm that is more basophilic, and may have non-lipid vacuolar changes (Figure 7.7). There is an increasing degree of anisocytosis/anisokaryosis and cell piling relative to normal cells and those in nodular hyperplastic nodules.

7.1.5.2 Clinical Considerations

- Usually a single mass (compared to nodular hyperplasia) involving one liver lobe, and often large (ranging from 2 to >10cm).
- More common than hepatocellular carcinomas [7].
- Histopathology is required for definitive differentiation, especially from well-differentiated hepatocellular carcinomas (see section 7.1.7).

7.1.5.3 Prognosis

Excellent.

Figure 7.3 Non-lipid (glycogen) vacuolar hepatopathy, dog, 50× objective.

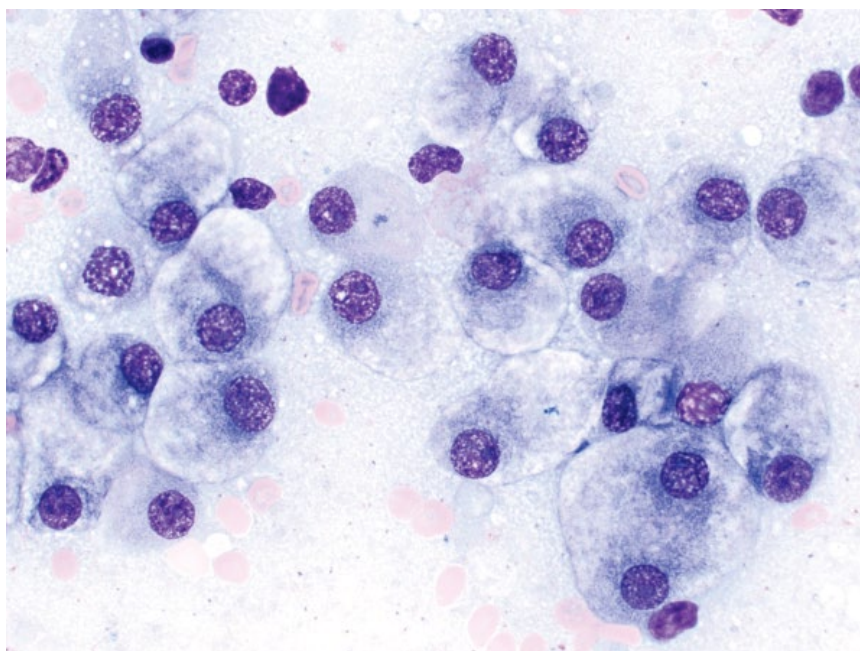
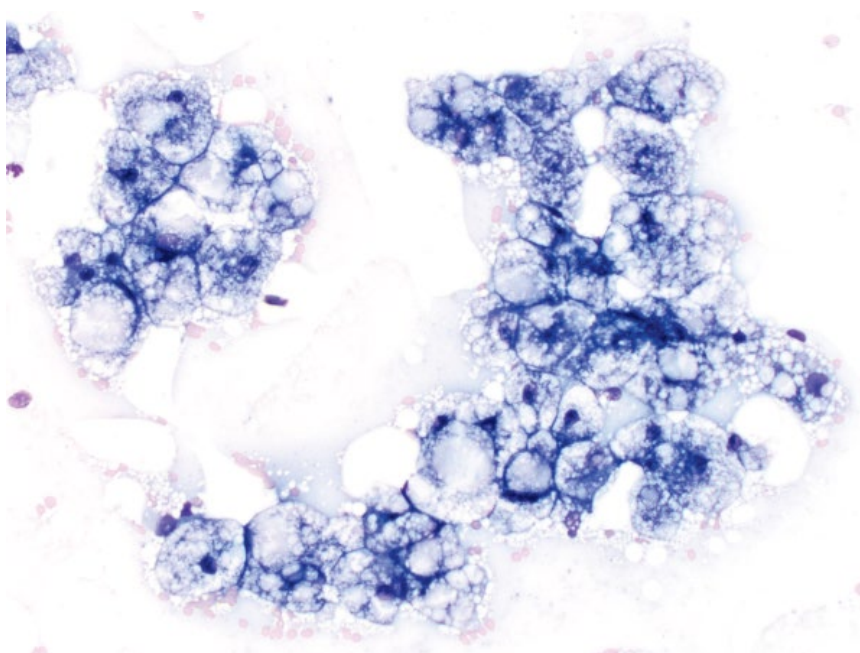


Figure 7.4 Hepatic lipidosis, cat, 20× objective.



7.1.6 Hepatocellular Carcinomas

The morphologic appearance of hepatocytes in hepatocellular carcinoma (HCC) is highly variable. While highly anaplastic tumors are readily diagnosed as malignant, well-differentiated variants can be difficult to distinguish from benign processes, even with histopathology. The two ends of this diagnostic spectrum are discussed separately below to highlight morphologic and prognostic differences.

7.1.7 Hepatocellular Carcinoma (Well-differentiated)

7.1.7.1 Cytologic Appearance

Well-differentiated HCCs comprise sheets of well-differentiated hepatocytes that can be difficult to distinguish from hepatomas/nodular hyperplasia. Cytologic features reported to be useful in differentiating these from benign lesions include individualized hepatocytes, acinar or palisading arrangement of cells, and the presence

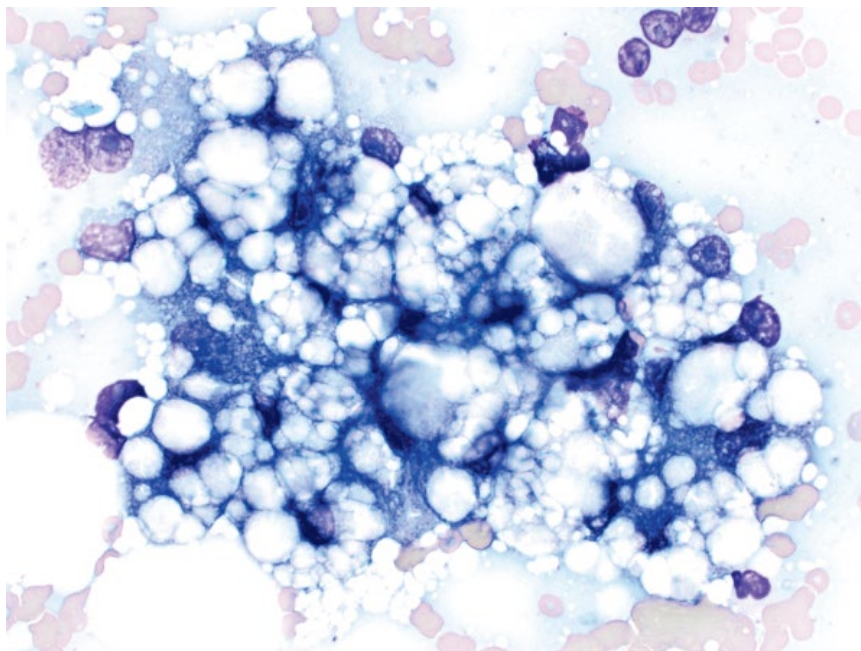


Figure 7.5 Hepatic lipidosis, cat, 50× objective.

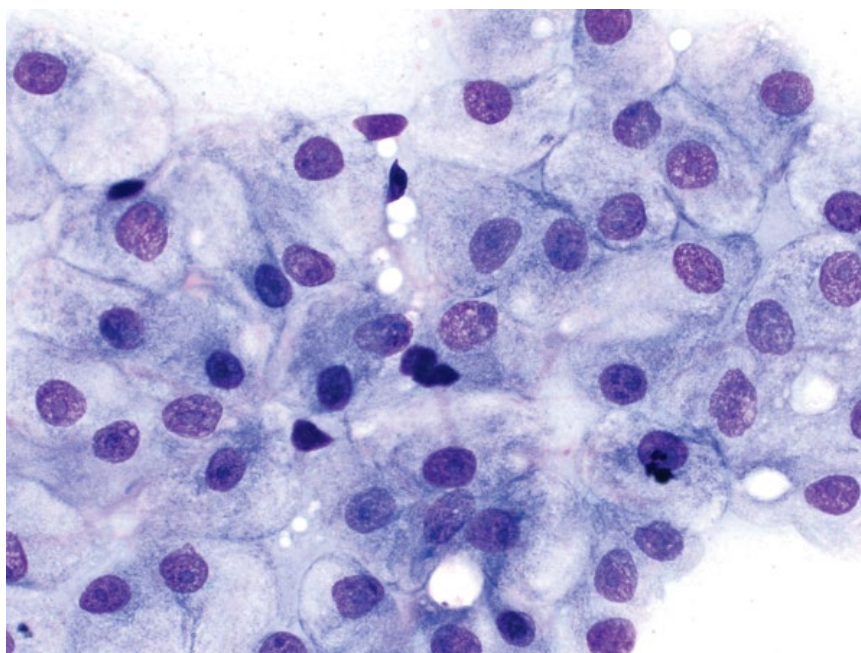


Figure 7.6 Liver, nodular hyperplasia, dog, 50× objective.

of capillaries [8]. When comparing these tumors to hepatomas, the cells frequently have higher N/C ratios, and a greater degree of anisocytosis/anisokaryosis (compare Figures 7.8 and 7.7).

7.1.7.2 Clinical Considerations

- Mostly associated with a trabecular subtype of HCC, and grossly appear as well-circumscribed, single lesions.

7.1.7.3 Prognosis

Good. Well-differentiated HCCs are almost always associated with solitary lesions that have low metastatic potential [9].

7.1.8 Hepatocellular Carcinoma (High-grade)

7.1.8.1 Cytologic Appearance

Anaplastic or high-grade HCCs comprise highly pleomorphic hepatocytes that frequently are seen

Figure 7.7 Hepatoma, dog, 50× objective.

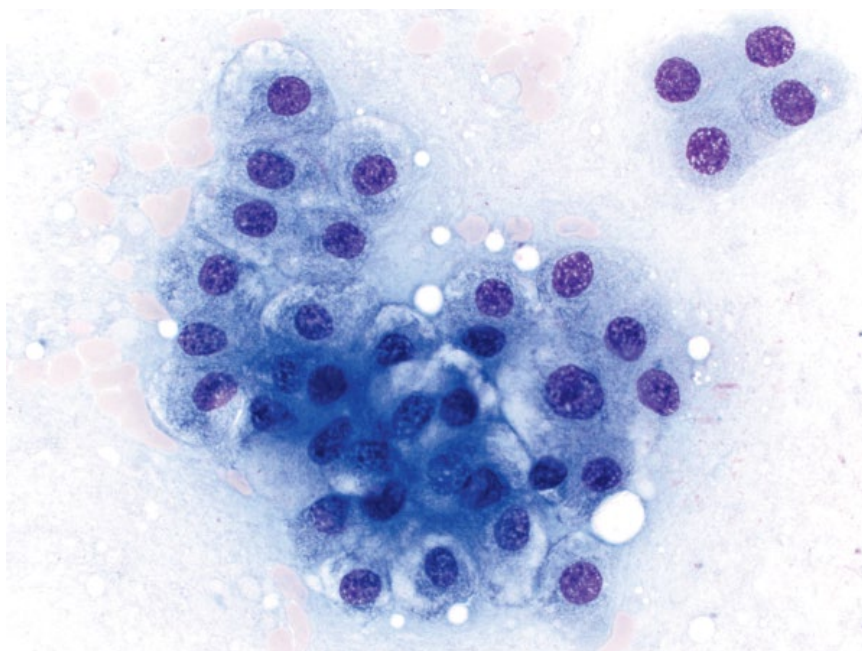
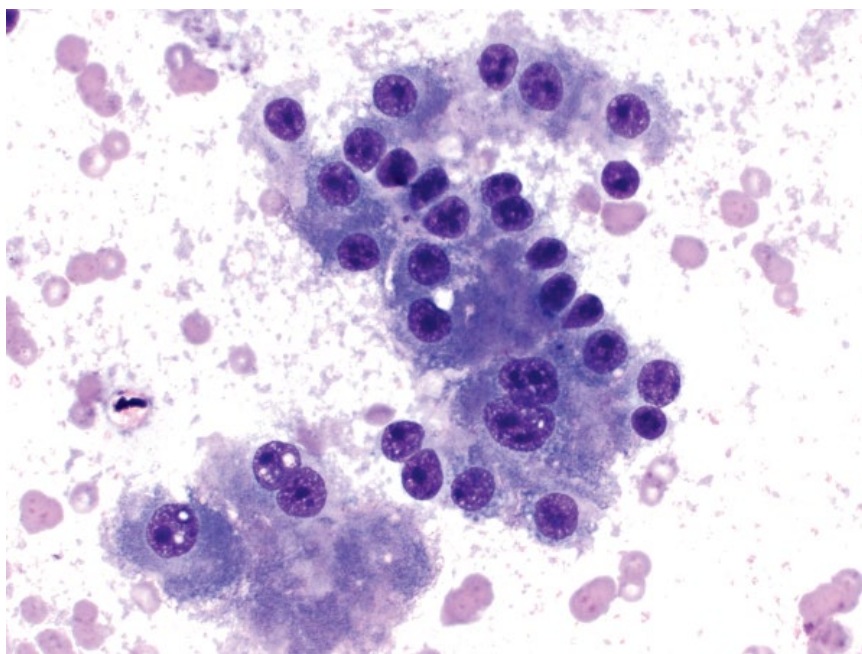


Figure 7.8 Hepatocellular carcinoma (well-differentiated), dog, 50× objective.



individually or are only loosely cohesive. They have a decreased volume of more deeply basophilic cytoplasm (high N/C ratios), and large nuclei with marked criteria of malignancy including anisokaryosis, karyomegaly, and multiple basophilic nucleoli of varying size and shape (Figure 7.9).

7.1.8.2 Clinical Considerations

- Three morphologic types exist: massive, nodular and diffuse, in decreasing order of frequency.
- Nodular and diffuse forms are more likely to have an anaplastic morphology, and a poor prognosis.

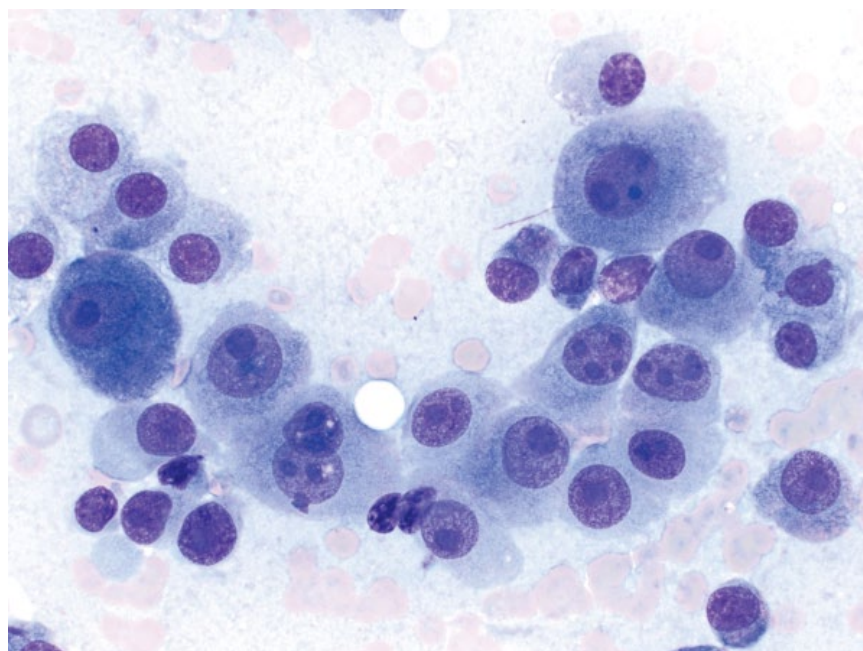


Figure 7.9 Hepatocellular carcinoma (high grade), dog, 50× objective.

- The left liver lobes are more commonly affected by massive HCC than the right lobes.
- Elevated ALT and AST may be seen, and if present confer a poorer prognosis.

7.1.8.3 Prognosis

Surgical excision for massive HCC in dogs provides excellent long-term control, whereas dogs treated conservatively had short survival times and were 15.4-fold more likely to die of tumor-related disease [10]. The prognosis for nodular and diffuse forms is poor due to lack of resectability and a high metastatic potential [9, 11].

7.1.9 Carcinoid (Hepatic)

7.1.9.1 Cytologic Appearance

Carcinoids have a classic neuroendocrine appearance, with sheets of epithelial cells that have poorly defined intercellular borders. They have a moderate volume of pale-blue cytoplasm, and round nuclei with finely stippled chromatin and variably prominent, single nucleoli. Anisocytosis/anisokaryosis typically are mild to moderate (Figure 7.10).

7.1.9.2 Clinical Considerations

- Rare tumors in dogs and cats [9, 12].
- Tend to occur at a younger age relative to other hepatobiliary neoplasms.
- All liver lobes usually affected. In dogs, about two-thirds are diffuse with small coalescing nodules, and one-third have a well-circumscribed nodular appearance [12].
- Carcinoid of the gallbladder has rarely been described [13].

7.1.9.3 Prognosis

Grave. Despite mild cytologic criteria of malignancy, these tumors have an aggressive biologic behavior, with an early, high metastatic rate to local lymph nodes and peritoneum, and less commonly to other distant locations [12].

7.1.10 Metastatic Neoplasia

7.1.10.1 Cytologic Appearance

A myriad of neoplasms may metastasize to the liver. Round-cell neoplasia (Figure 7.11) and carcinomas (Figure 7.12) are most common, but sarcomas may also be seen (Figure 7.13). Neoplastic mesenchymal cells should be differentiated from primary hepatic neoplasia (e.g., hemangiosarcoma or fibrosarcoma arising in the liver).

7.1.10.2 Clinical Considerations

- Metastatic carcinomas may be difficult to differentiate from primary hepatic neoplasms such as carcinoids and biliary carcinomas.

7.1.10.3 Prognosis

Poor.

7.1.11 Lymphoma (Large-cell)

7.1.11.1 Cytologic Appearance

Large-cell lymphomas typically exfoliate in large numbers, and may efface hepatic parenchyma. The cells have large nuclei, about two to three red blood cells in diameter, and have a variable volume of cytoplasm that may contain clear vacuoles (Figures 7.14 and 7.15).

Figure 7.10 Liver, carcinoid, dog, 50× objective.

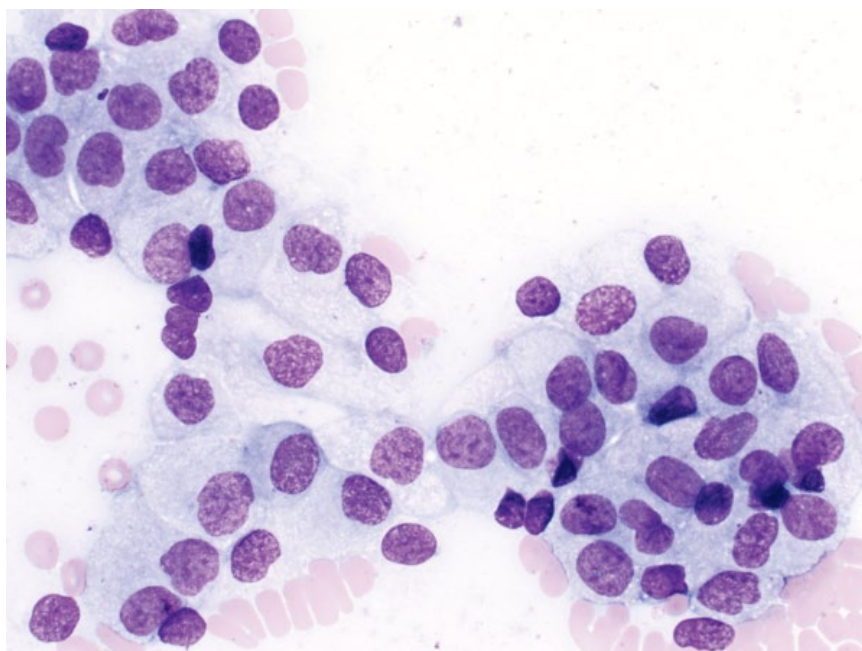
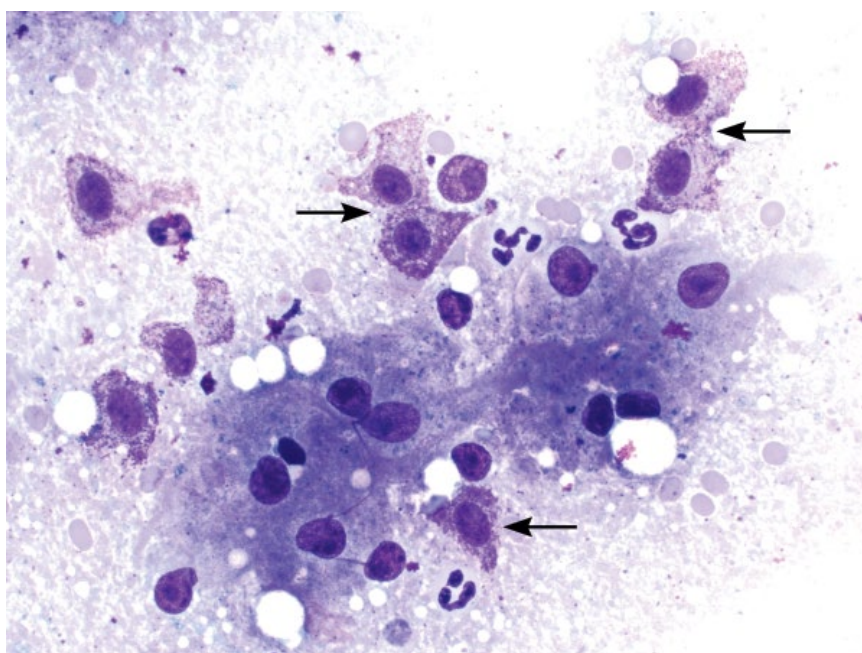


Figure 7.11 Liver, metastatic mast cell neoplasia, dog, 50× objective. Note the mast cells (arrows) centered around a sheet of hepatocytes.



7.1.11.2 Clinical Considerations

- Most commonly part of generalized disease, but may be primary [14, 15].

7.1.11.3 Prognosis

Variable, based on lymphoma type. Primary lymphomas of the liver carry a poor to grave prognosis [14].

7.1.12 Lymphoma (Small-cell)/Chronic Lymphocytic Leukemia (CLL)

7.1.12.1 Cytologic Appearance

Small-cell lymphoma and CLL may involve the liver. The cells have small nuclei, about one to 1.25 red blood cells in diameter, and a small cap of pale-blue cytoplasm that may contain azurophilic granules (Figure 7.16).

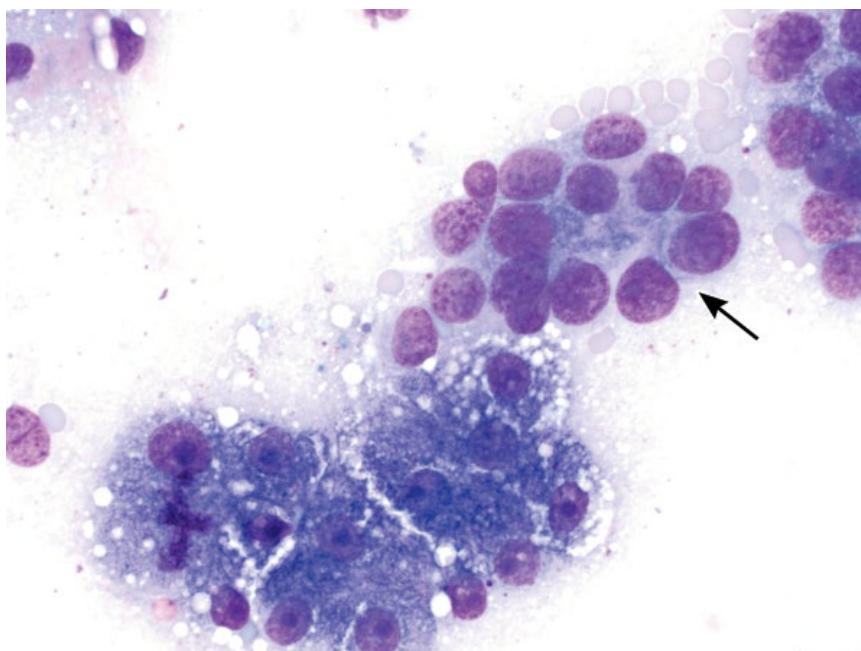


Figure 7.12 Liver, metastatic mammary carcinoma, cat, 50× objective. Note the acinar arrangement of the neoplastic cells (arrow) and the sheet of hepatocytes (lower left).

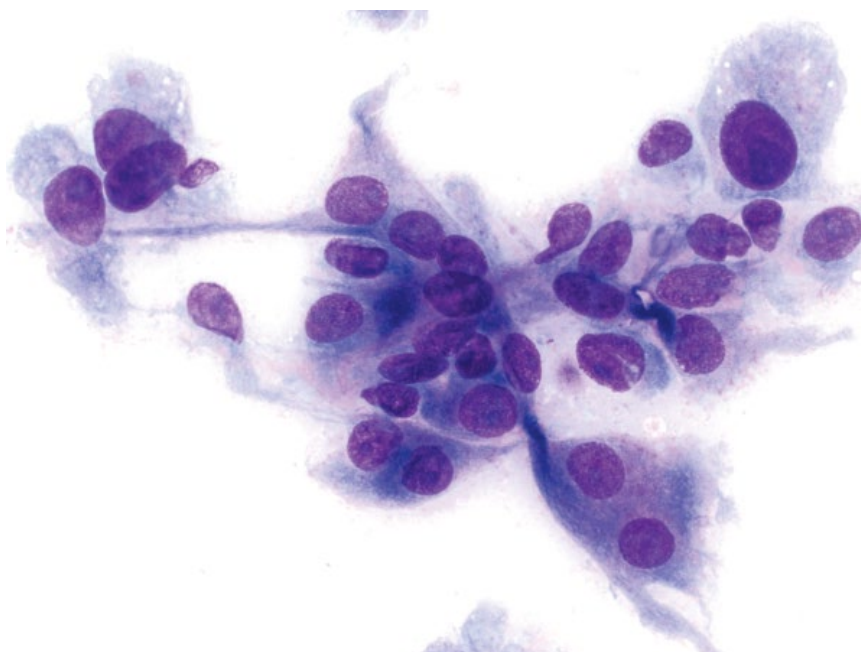


Figure 7.13 Liver, metastatic fibrosarcoma, dog, 50× objective.

The maturity of the cells can make differentiation from lymphocytic inflammation difficult (compare to Figure 7.17). Features of malignancy include monomorphism of the population, more open chromatin, prominent nucleoli, and typically a greater numbers of cells.

7.1.12.2 Clinical Considerations

- Affects middle-aged to older dogs and cats.
- Represents liver involvement in generalized disease [15].
- May be accompanied by mature lymphocytosis.

7.1.12.3 Prognosis

Generally good, with long survival times reported.

7.1.13 Inflammation: Lymphoplasmacytic

7.1.13.1 Cytologic Appearance

Increased numbers of lymphocytes (Figure 7.17) and plasma cells (Figure 7.18) are embedded in sheets of hepatocytes and scattered across the background. The population usually is heterogeneous, and the cells have

Figure 7.14 Liver, lymphoma (large cell), dog, 50× objective. Note the small cluster of hepatocytes (upper right corner).

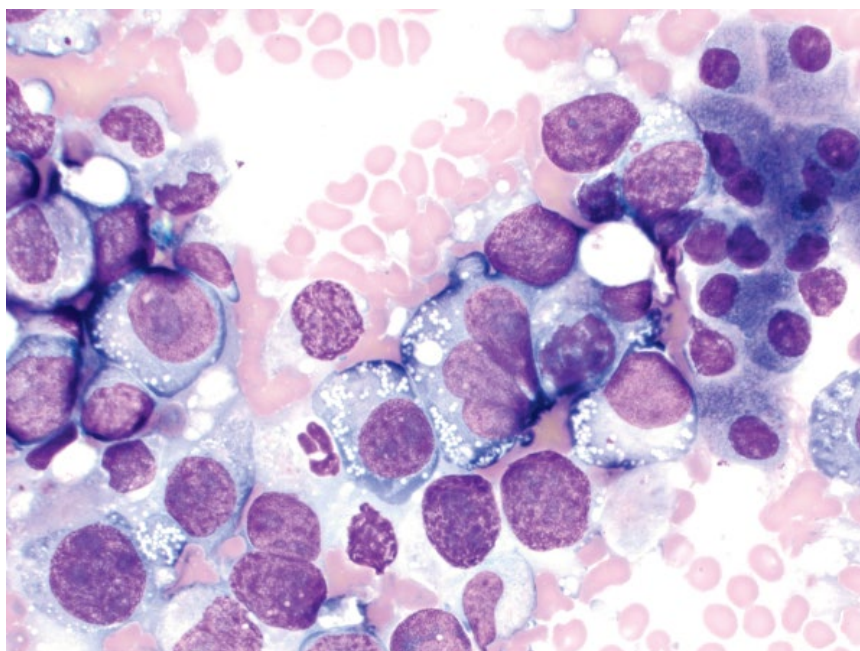
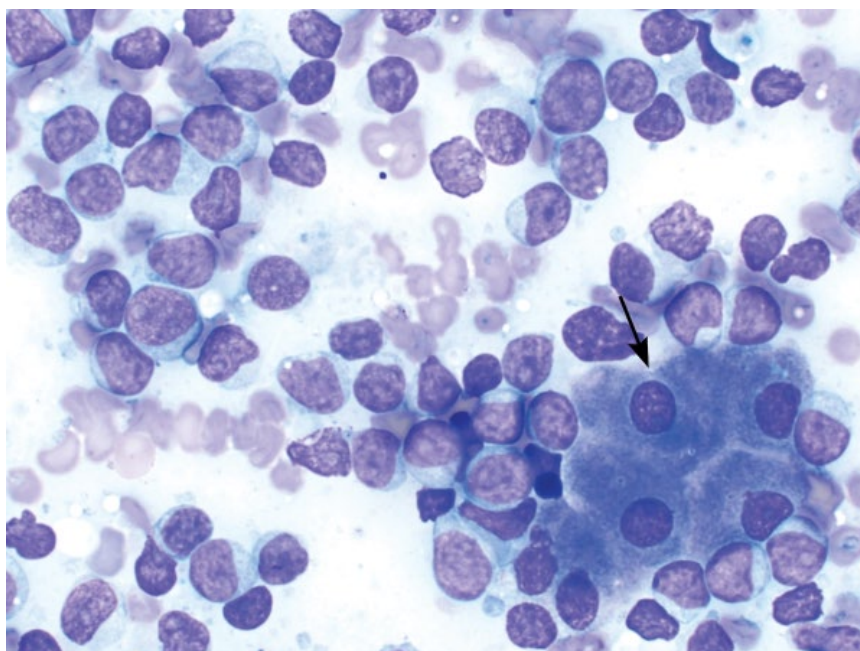


Figure 7.15 Liver, lymphoma (large cell), dog, 50× objective. Note the small cluster of hepatocytes (arrow).



mature, clumped chromatin, which can help differentiate from a neoplastic process, though this can be difficult (compare to Figure 7.16).

7.1.13.2 Clinical Considerations

- Inflammation may be primary (e.g., lymphocytic portal hepatitis/cholangiohepatitis in cats or chronic progressive hepatitis in dogs) or secondary to inflammation in adjacent organs (e.g., pancreatitis or gastroenteritis) [16, 17].

- Histopathology is required to assess location and extent of inflammation.

7.1.13.3 Prognosis

Variable, based on underlying cause.

7.1.14 Inflammation: Neutrophilic

7.1.14.1 Cytologic Appearance

Increased numbers of neutrophils associated with hepatocytes is consistent with neutrophilic inflammation.

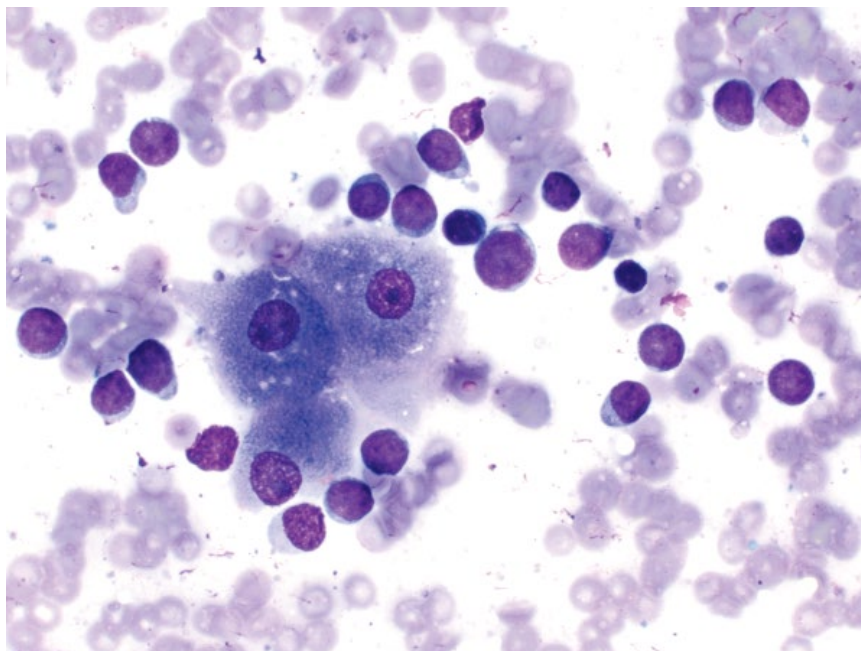


Figure 7.16 Liver, lymphoma (small cell), dog, 50× objective. Compare the smudged chromatin to the mature, clumped chromatin of inflammatory lymphocytes in Figure 7.17.

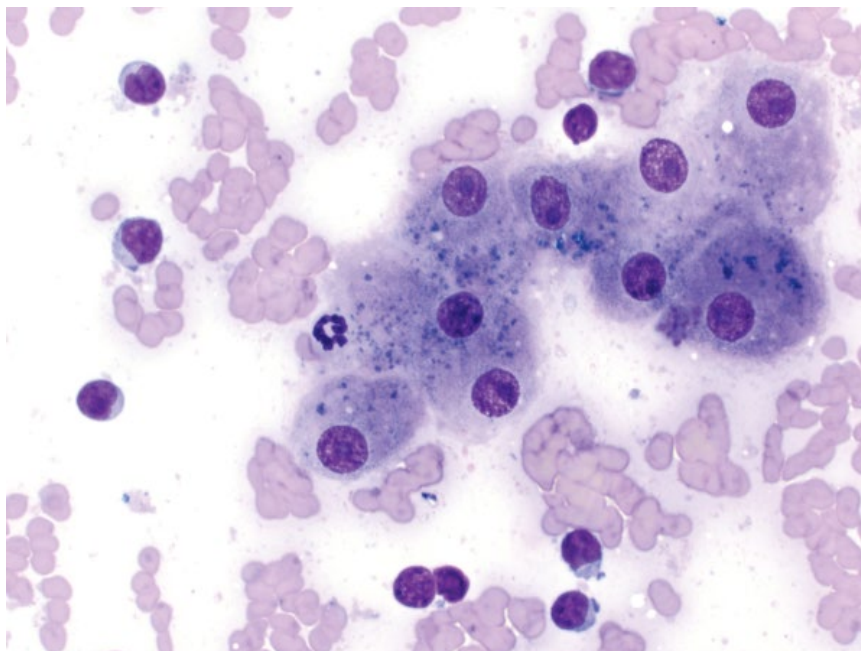


Figure 7.17 Liver, inflammation (lymphocytic), cat, 50× objective.

Finding neutrophils in aggregates across the slide, embedded within sheets of hepatocytes or with a left shift or degenerative changes, can help differentiate inflammation from blood-associated leukocytes (Figure 7.19).

7.1.14.2 Clinical Considerations

- Inflammation may be sterile, but investigation for infectious organisms is warranted (see Chapter 2).

- Histopathology is required to assess location of inflammation (e.g., hepatitis versus cholangitis) [16, 17].
- Absence of cytologic evidence does not rule out underlying inflammation [18].
- Cautious interpretation is warranted with concurrent neutrophilia if blood contamination is present.

7.1.14.3 Prognosis

Variable, based on underlying cause.

Figure 7.18 Liver, inflammation (lymphoplasmacytic), cat, 50× objective. Note the concurrent hepatic lipodosis.

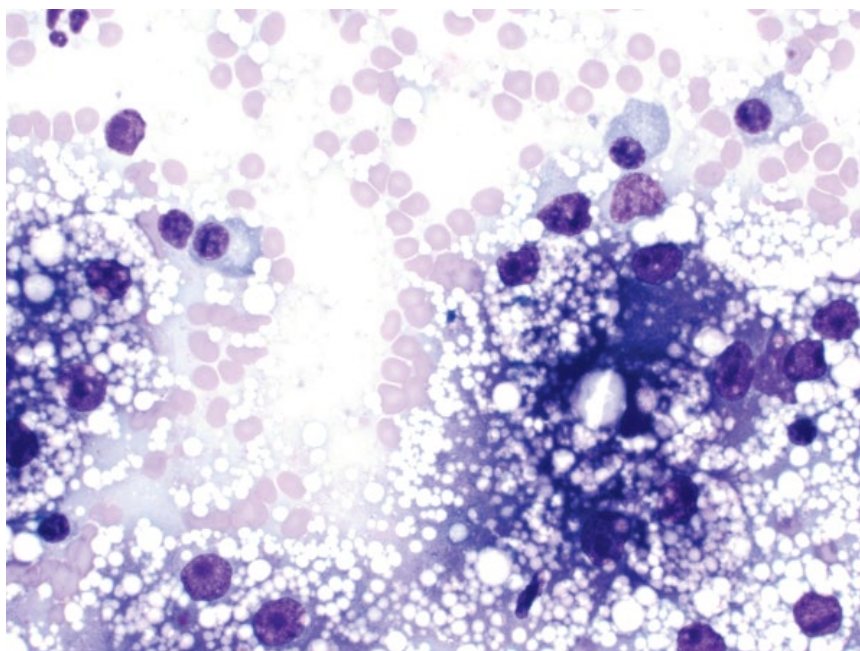
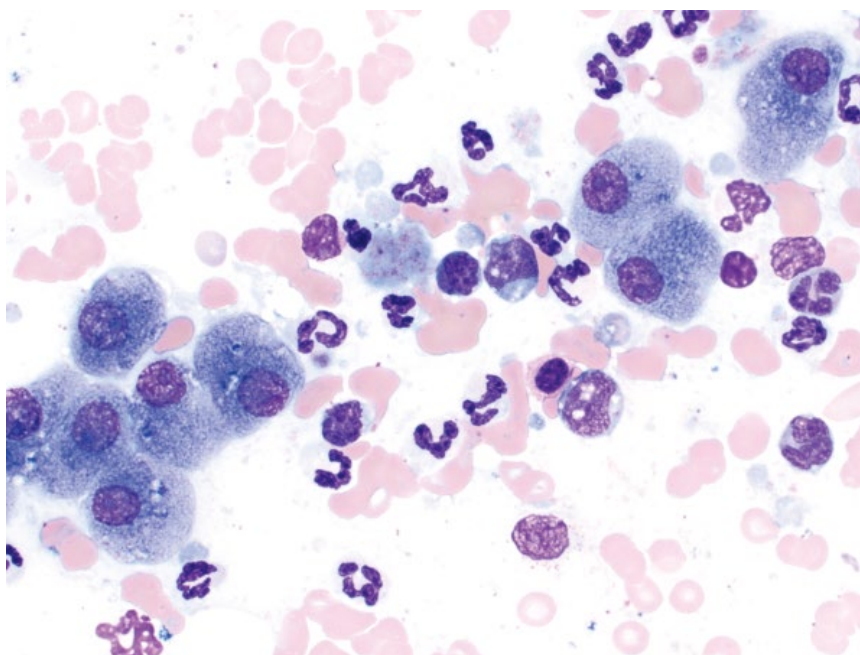


Figure 7.19 Liver, inflammation (neutrophilic), dog, 50× objective.



7.1.15 Lipofuscin Pigment

7.1.15.1 Cytologic Appearance

Lipofuscin pigment appears as variably chunky blue-green granular material within the cytoplasm of hepatocytes (Figure 7.20). It can be difficult to differentiate from bile (compare to Figure 7.21).

7.1.15.2 Clinical Considerations

- Most common pigment of hepatocytes, especially in older patients.

- Accumulates over time in lysosomes as a normal product of cellular aging.

7.1.15.3 Prognosis

Excellent – no pathologic significance.

7.1.16 Cholestasis/Bilirubin Pigment

7.1.16.1 Cytologic Appearance

Cholestasis manifests most commonly as green/black tubular structures coursing between hepatocytes,

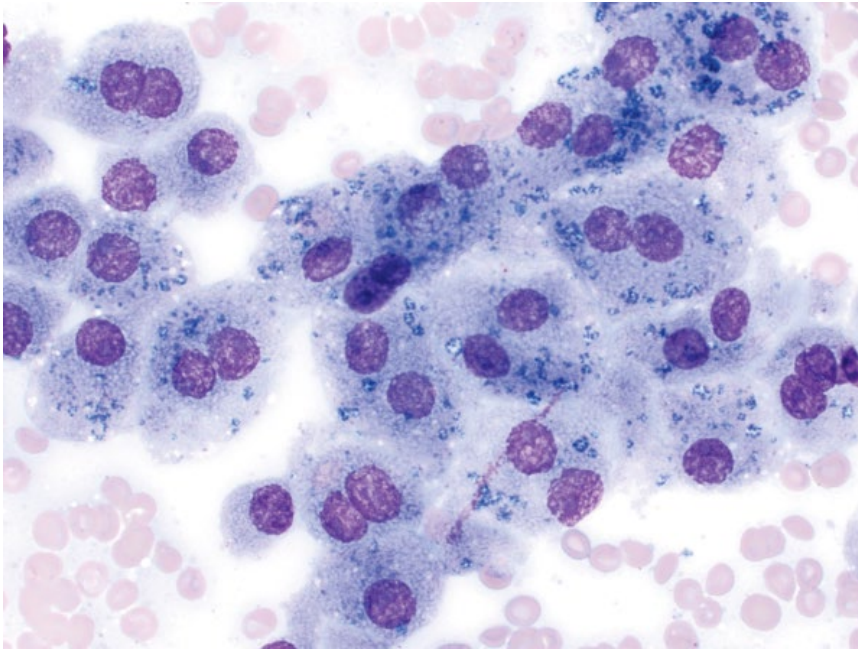


Figure 7.20 Lipofuscin pigment, dog, 50x objective.

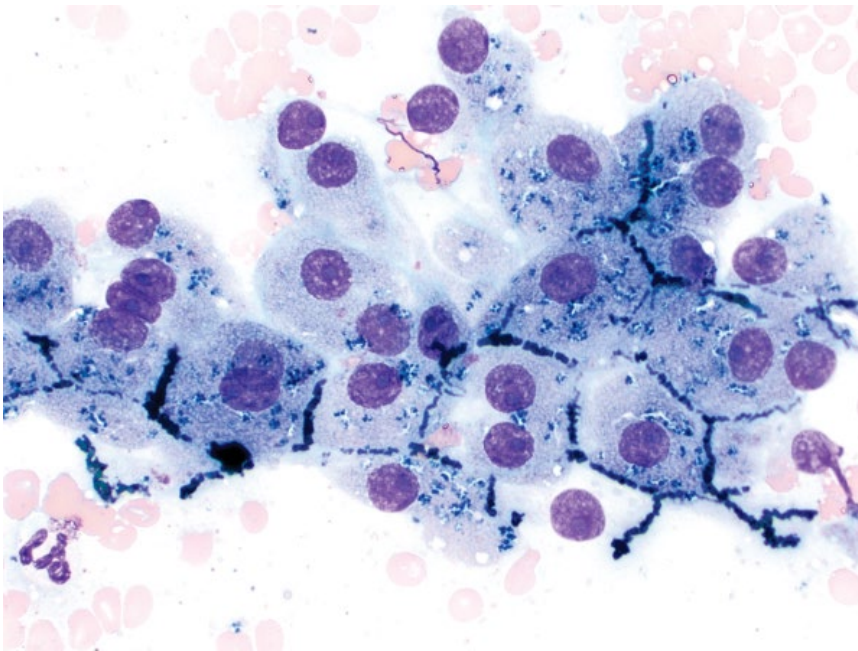


Figure 7.21 Cholestasis and bile pigment, dog, 50x objective. Note the green/black tubular structures coursing between hepatocytes (bile plugging of biliary canaliculi).

reflecting bile plugging of biliary canaliculi (Figure 7.21). Granular green/black pigment may also be seen within the cytoplasm of hepatocytes.

7.1.16.2 Clinical Considerations

- Disease may be prehepatic (hemolysis), hepatic (inflammation, neoplasia, etc.), or post-hepatic (bile duct obstruction).
- Cytologic changes may precede hyperbilirubinemia.

7.1.16.3 Prognosis

Variable, based on underlying cause.

7.1.17 Hemosiderin Pigment

7.1.17.1 Cytologic Appearance

Hemosiderin pigment appears mostly as golden brown, to occasionally brown/black, variably coarse granular material in the cytoplasm of hepatocytes (Figure 7.22).

Figure 7.22 Hemosiderin pigment, dog, 50x objective.

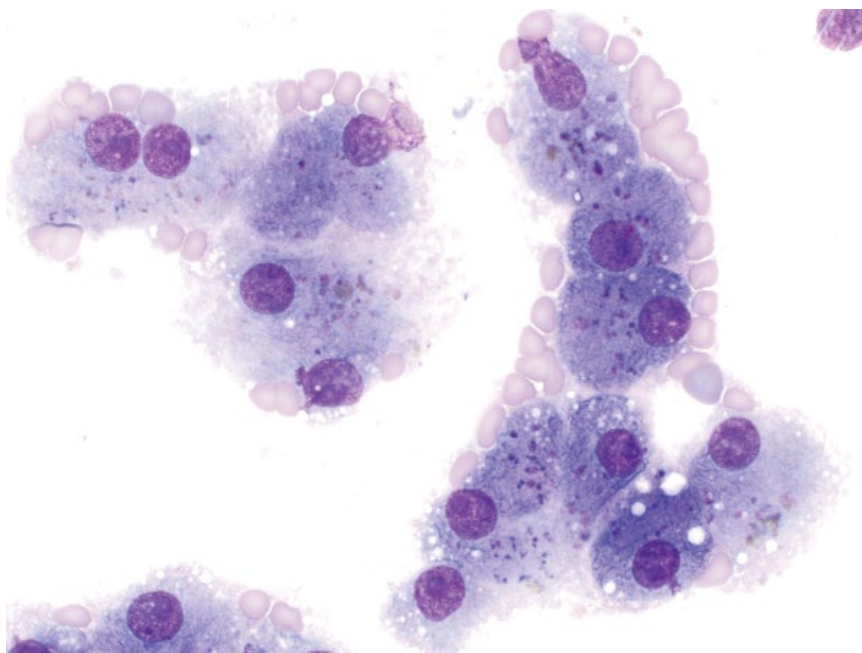
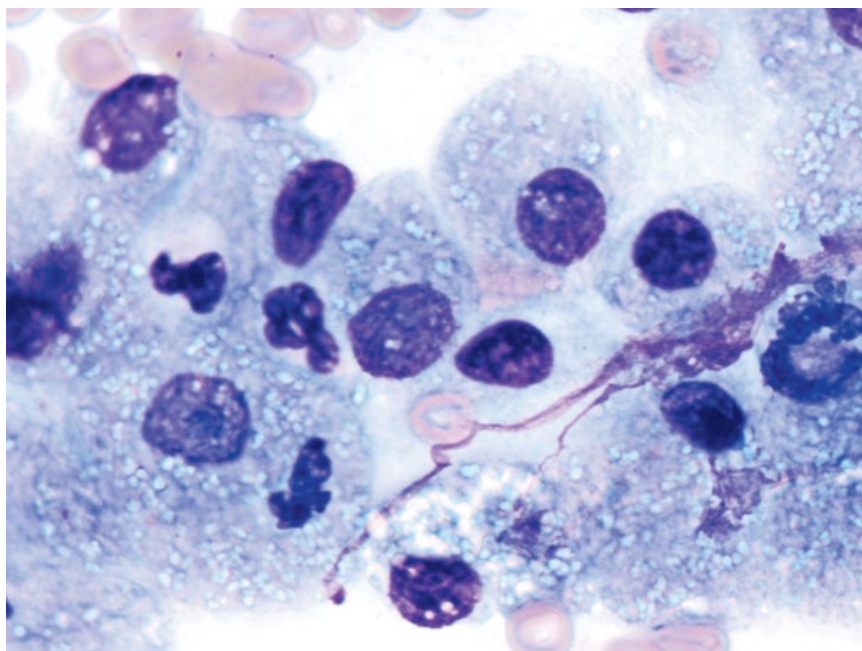


Figure 7.23 Copper pigment, dog, 100x objective.



It may be accompanied by evidence of erythrophagia or heme-breakdown pigment in macrophages in the liver.

7.1.17.2 Clinical Considerations

- May be associated with hemolytic diseases, repeat blood transfusions, or iron administration [19].

7.1.17.3 Prognosis

Variable, based on underlying cause.

7.1.18 Copper Accumulation

7.1.18.1 Cytologic Appearance

Copper pigment can be seen with routine cytologic stains as small, aquamarine crystalline aggregates in the cytoplasm of hepatocytes (Figure 7.23). It is best visualized with a 100x oil objective. Copper pigment can be confirmed with special stains such as rhodanine (Figure 7.24).

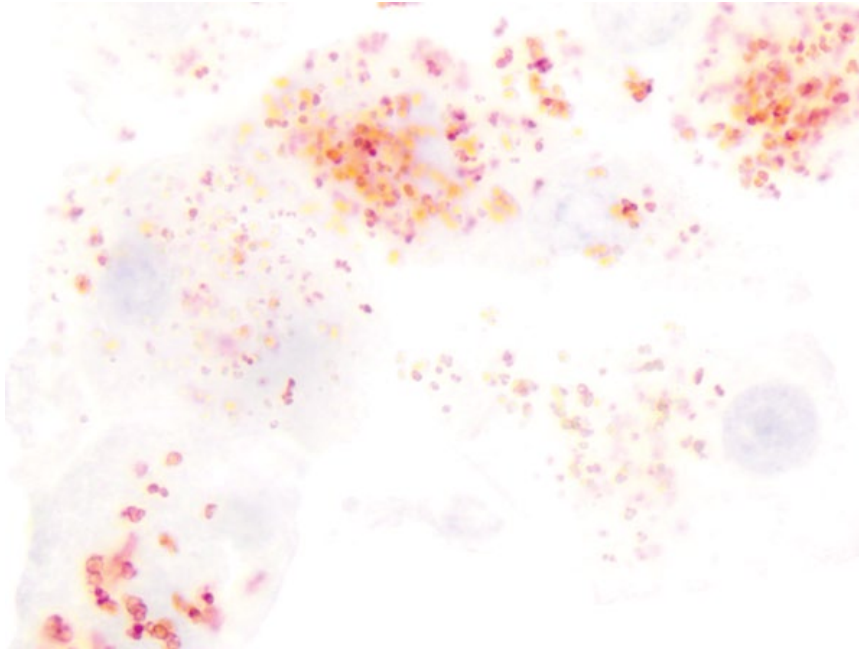


Figure 7.24 Rhodanine stain highlighting copper pigment in hepatocytes, dog, 100× objective. Same case as Figure 7.23.

7.1.18.2 Clinical Considerations

- Copper accumulation may be a primary cause of disease (copper storage disease) and Bedlington Terriers, Doberman Pinschers, Labrador Retrievers, Skye Terriers, Dalmatians and West Highland White Terriers are predisposed [20].
- Small amounts of copper can be seen secondary to cholestasis, chronic inflammation, or hepatic injury in both dogs and cats [21–24].
- Histopathology is required for definitive distinction between primary and secondary copper accumulation.

7.1.18.3 Prognosis

Variable. Copper storage disease may respond to therapy, but can cause fatal hepatic failure [25]. Accumulation secondary to cholestasis or inflammation may have a better prognosis.

7.1.19 Amyloid

7.1.19.1 Cytologic Appearance

Amyloid is seen as smooth to fibrillar, magenta extracellular material, intimately associated with hepatocytes (Figure 7.25).

7.1.19.2 Clinical Considerations

- Amyloid deposition may be localized or systemic (involving kidney, spleen, etc.) [26].
- Amyloid may accumulate due to a primary familial predisposition, or secondary to chronic, extrahepatic/systemic inflammation.
- Predisposed breeds = Shar Pei dogs and Abyssinian cats.

7.1.19.3 Prognosis

Variable, based on primary or secondary, organs involved, and ability to treat any underlying disease.

7.2 Biliary Tract

7.2.1 Biliary Hyperplasia

7.2.1.1 Cytologic Appearance

Hyperplastic biliary epithelium is seen as sheets of minimally pleomorphic cuboidal epithelial cells in papillary arrangements (Figure 7.26). The cells have a small to moderate volume of pale-blue cytoplasm that may contain clear vacuoles, and round nuclei with stippled chromatin and small nucleoli. Hyperplastic tissue cannot reliably be distinguished cytologically from normal tissue, which may be sampled incidentally during aspiration of the liver.

7.2.1.2 Clinical Considerations

- Biliary hyperplasia usually is seen secondary to cystic lesions or cholangitis/cholangiohepatitis.

7.2.1.3 Prognosis

Variable, based on the underlying cause of the hyperplasia, but generally good.

7.2.2 Bile Duct Adenoma/Biliary Cystadenoma

7.2.2.1 Cytologic Appearance

Bile duct adenomas/cystadenomas comprise sheets of cuboidal epithelial cells, often accompanied by pools of smooth blue mucinous material in the background (Figure 7.27). Cellular crowding often is seen, and

Figure 7.25 Amyloid, dog, 50x objective. Note the bright-purple, fibrillar amyloid material intimately associated with hepatocytes. Slide courtesy of Dr Ida Piperisova.

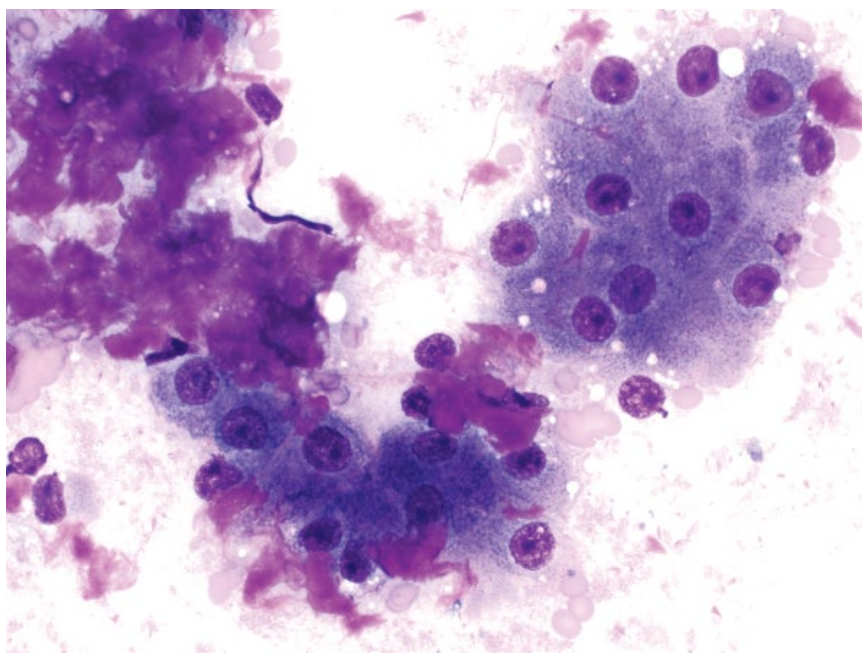
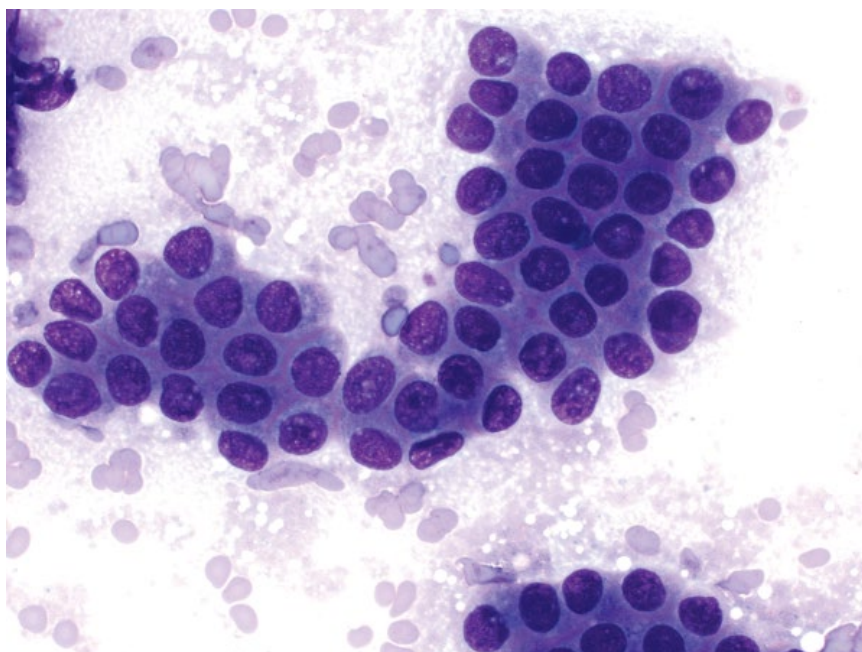


Figure 7.26 Biliary epithelial hyperplasia, cat, 50x objective.



anisocytosis/anisokaryosis and N/C ratios are increased relative to hyperplastic epithelium.

7.2.2.2 Clinical Considerations

- Cats > dogs, and male cats may be predisposed [27].
- Biliary cystadenomas may be single or multiple, and variably sized [27, 28].

- Non-cystic bile duct adenomas normally are small and solitary.
- Often incidental findings, but may cause compression of adjacent organs if large.

7.2.2.3 Prognosis

Excellent. Surgical excision (if required) is curative.

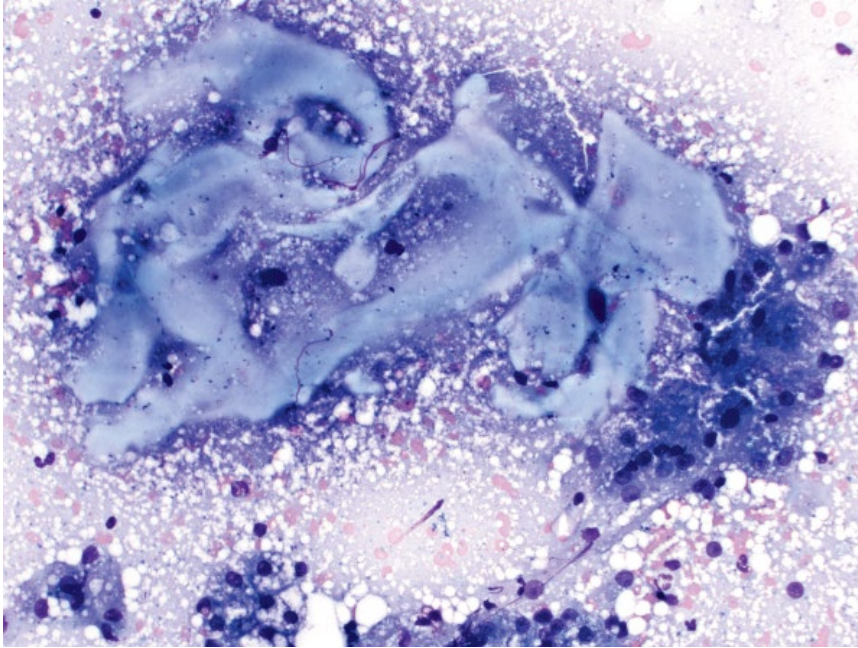


Figure 7.27 Biliary cystadenoma, cat, 20× objective. Note the abundant smooth blue mucinous material.

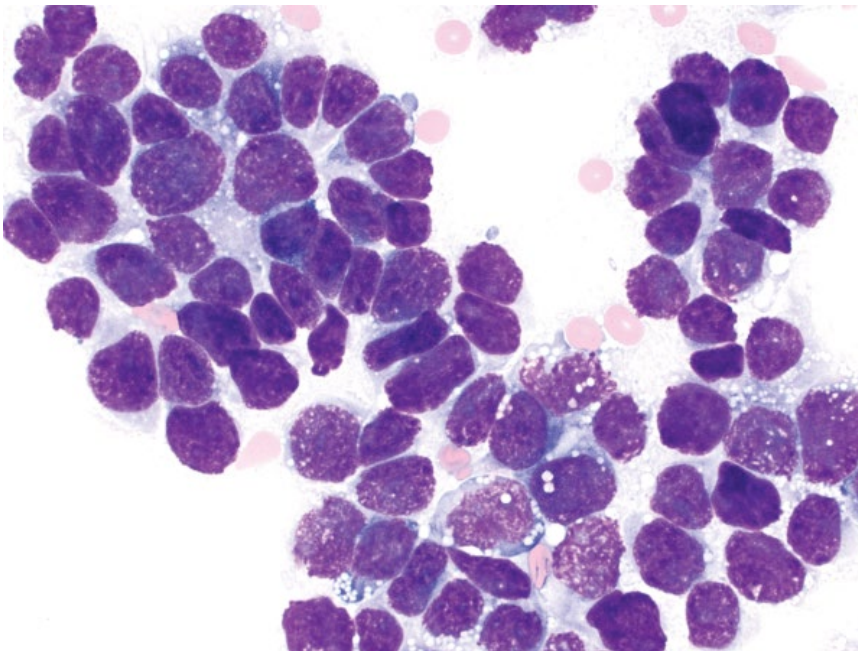


Figure 7.28 Bile duct carcinoma (cholangiocarcinoma), cat, 50× objective.

7.2.3 Bile Duct Carcinoma (Cholangiocarcinoma)

7.2.3.1 Cytologic Appearance


Bile duct carcinomas mostly are highly cellular, characterized by cohesive sheets of cuboidal epithelial cells, often in palisading or acinar arrangements (Figure 7.28). The cells have a small volume of medium-blue cytoplasm, which may contain small, clear vacuoles. Nuclei are round with clumped chromatin, and mostly single,

prominent, basophilic nucleoli. Anisocytosis/anisokaryosis are moderate to occasionally marked.

7.2.3.2 Clinical Considerations

- Most common malignant hepatobiliary tumor in cats [11].
- Massive, nodular and diffuse variants.
- Tumors may be intra- or extra-hepatic. Intra-hepatic tumors are more common in dogs, whereas there is an equal distribution in cats [7, 11, 29].

Figure 7.29 Bactibilia, dog, 50× objective. Numerous small, blue bacterial cocci are noted around aggregates of yellow/orange bile and pale-blue mucin.



7.2.3.3 Prognosis

Poor. Bile duct carcinomas are aggressive, highly metastatic malignancies.

7.2.4 Cholecystitis

7.2.4.1 Cytologic Appearance

Bile has a yellow/green appearance, and pale-blue mucinous material may also be present. Cholecystitis is associated with an overgrowth of infectious agents ± inflammatory cells. Bacteria is the most common infectious agent identified (bactibilia; Figure 7.29), but fungal and protozoal agents also have been reported [30–32].

7.2.4.2 Clinical Considerations

- Dogs and cats. Dachshunds may be over-represented [30].
- Presence of infectious agents more commonly found by cytology than microbial culture [31].
- Common bacterial isolates = *Escherichia coli*, *Enterococcus* spp. [30, 31].
- Cholecystocentesis associated with low complication rate [31].

7.2.4.3 Prognosis

Good with appropriate therapy. Gallbladder rupture and cholangiohepatitis can result if untreated [30, 33].

References

- 1 Sepesy, L.M., Center, S.A., Randolph, J.F., *et al.* (2006) Vacuolar hepatopathy in dogs: 336 cases (1993–2005). *J. Am. Vet. Med. Assoc.*, **229** (2), 246–252.
- 2 Center, S.A. (2005) Feline hepatic lipidosis. *Vet. Clin. North Am. Small Anim. Pract.*, **35** (1), 225–269.
- 3 Center, S.A., Crawford, M.A., Guida, L., *et al.* (1993) A retrospective study of 77 cats with severe hepatic lipidosis: 1975–1990. *J. Vet. Intern. Med.*, **7** (6), 349–359.
- 4 van Sprundel, R.G., van den Ingh, T.S., Guscetti, F., *et al.* (2013) Classification of primary hepatic tumours in the dog. *Vet. J.*, **197** (3), 596–606.
- 5 van Sprundel, R.G., van den Ingh, T.S., Guscetti, F., *et al.* (2014) Classification of primary hepatic tumours in the cat. *Vet. J.*, **202** (2), 255–266.
- 6 Lodi, M., Chinosi, S., Faverzani, S., *et al.* (2007) Clinical and ultrasonographic features of the canine hepatocellular carcinoma (CHC). *Vet. Res. Commun.*, **31** (Suppl. 1), 293–295.
- 7 Patnaik, A.K. (1992) A morphologic and immunocytochemical study of hepatic neoplasms in cats. *Vet. Pathol.*, **29** (5), 405–415.
- 8 Masserdotti, C., Drigo, M. (2012) Retrospective study of cytologic features of well-differentiated hepatocellular carcinoma in dogs. *Vet. Clin. Pathol.*, **41** (3), 382–390.
- 9 Patnaik, A.K., Hurvitz, A.I., Lieberman, P.H. (1980) Canine hepatic neoplasms: a clinicopathologic study. *Vet. Pathol.*, **17** (5), 553–564.
- 10 Liptak, J.M., Dernell, W.S., Monnet, E., *et al.* (2004) Massive hepatocellular carcinoma in dogs: 48 cases

- (1992–2002). *J. Am. Vet. Med. Assoc.*, **225** (8), 1225–1230.
- 11 Lawrence, H.J., Erb, H.N., Harvey, H.J. (1994) Nonlymphomatous hepatobiliary masses in cats: 41 cases (1972–1991). *Vet. Surg.*, **23** (5), 365–368.
 - 12 Patnaik, A.K., Lieberman, P.H., Hurvitz, A.I., *et al.* (1981) Canine hepatic carcinoids. *Vet. Pathol.*, **18** (4), 445–453.
 - 13 Lippo, N.J., Williams, J.E., Brawer, R.S., *et al.* (2008) Acute hemobilia and hemocholecyst in 2 dogs with gallbladder carcinoid. *J. Vet. Intern. Med.*, **22** (5), 1249–1252.
 - 14 Keller, S.M., Vernau, W., Hodges, J., *et al.* (2013) Hepatosplenic and hepatocytotropic T-cell lymphoma: two distinct types of T-cell lymphoma in dogs. *Vet. Pathol.*, **50** (2), 281–290.
 - 15 Aresu, L., Martini, V., Rossi, F., *et al.* (2015) Canine indolent and aggressive lymphoma: clinical spectrum with histologic correlation. *Vet. Comp. Oncol.*, **13** (4), 348–362.
 - 16 Gagne, J.M., Armstrong, P.J., Weiss, D.J., *et al.* (1999) Clinical features of inflammatory liver disease in cats: 41 cases (1983–1993). *J. Am. Vet. Med. Assoc.*, **214** (4), 513–516.
 - 17 Hirose, N., Uchida, K., Kanemoto, H., *et al.* (2014) A retrospective histopathological survey on canine and feline liver diseases at the University of Tokyo between 2006 and 2012. *J. Vet. Med. Sci.*, **76** (7), 1015–1020.
 - 18 Roth, L. (2001) Comparison of liver cytology and biopsy diagnoses in dogs and cats: 56 cases. *Vet. Clin. Pathol.*, **30** (1), 35–38.
 - 19 Bohn, A.A. (2013) Diagnosis of disorders of iron metabolism in dogs and cats. *Vet. Clin. North Am. Small Anim. Pract.*, **43** (6), 1319–1330.
 - 20 Hoffmann, G. (2009) Copper-associated liver diseases. *Vet. Clin. North Am. Small Anim. Pract.*, **39** (3), 489–511.
 - 21 Johnston, A.N., Center, S.A., McDonough, S.P., *et al.* (2013) Hepatic copper concentrations in Labrador Retrievers with and without chronic hepatitis: 72 cases (1980–2010). *J. Am. Vet. Med. Assoc.*, **242** (3), 372–380.
 - 22 Vince, A.R., Hayes, M.A., Jefferson, B.J., *et al.* (2014) Hepatic injury correlates with apoptosis, regeneration, and nitric oxide synthase expression in canine chronic liver disease. *Vet. Pathol.*, **51** (5), 932–945.
 - 23 Spee, B., Arends, B., van den Ingh, T.S., *et al.* (2006) Copper metabolism and oxidative stress in chronic inflammatory and cholestatic liver diseases in dogs. *J. Vet. Intern. Med.*, **20** (5), 1085–1092.
 - 24 Whittemore, J.C., Newkirk, K.M., Reel, D.M., *et al.* (2012) Hepatic copper and iron accumulation and histologic findings in 104 feline liver biopsies. *J. Vet. Diagn. Invest.*, **24** (4), 656–661.
 - 25 Noaker, L.J., Washabau, R.J., Detrisac, C.J., *et al.* (1999) Copper associated acute hepatic failure in a dog. *J. Am. Vet. Med. Assoc.*, **214** (10), 1502–1506.
 - 26 Flatland, B., Moore, R.R., Wolf, C.M., *et al.* (2007) Liver aspirate from a Shar Pei dog. *Vet. Clin. Pathol.*, **36** (1), 105–108.
 - 27 Adler, R., Wilson, D.W. (1995) Biliary cystadenoma of cats. *Vet. Pathol.*, **32** (4), 415–418.
 - 28 Nyland, T.G., Koblik, P.D., Tellyer, S.E. (1999) Ultrasonographic evaluation of biliary cystadenomas in cats. *Vet. Radiol. Ultrasound*, **40** (3), 300–306.
 - 29 Hayes, H.M., Jr, Morin, M.M., Rubenstein, D.A. (1983) Canine biliary carcinoma: epidemiological comparisons with man. *J. Comp. Pathol.*, **93** (1), 99–107.
 - 30 Lawrence, Y.A., Ruaux, C.G., Nemanic, S., *et al.* (2015) Characterization, treatment, and outcome of bacterial cholecystitis and bactibilia in dogs. *J. Am. Vet. Med. Assoc.*, **246** (9), 982–989.
 - 31 Peters, L.M., Glanemann, B., Garden, O.A., *et al.* (2016) Cytological findings of 140 bile samples from dogs and cats and associated clinical pathological data. *J. Vet. Intern. Med.*, **30** (1), 123–131.
 - 32 Neel, J.A., Tarigo, J., Grindem, C.B. (2006) Gall bladder aspirate from a dog. *Vet. Clin. Pathol.*, **35** (4), 467–470.
 - 33 Neer, T.M. (1992) A review of disorders of the gallbladder and extrahepatic biliary tract in the dog and cat. *J. Vet. Intern. Med.*, **6** (3), 186–192.

8

Digestive System

8.1 Salivary Glands

8.1.1 Salivary Gland (Normal)

8.1.1.1 Cytologic Features

Sample backgrounds contain streaming blue/purple mucin, distributing erythrocytes and cells in a prominent windrowing pattern. Salivary glandular epithelium exfoliates as tight, cohesive sheets of cells that have abundant foamy cytoplasm, and round, pyknotic nuclei (Figure 8.1). Anisocytosis/anisokaryosis are mild, and N/C ratios are low.

8.1.1.2 Clinical Considerations

- Often an incidental or inadvertent finding when sampling mandibular lymph nodes.
- Normal salivary epithelium may be present in cases of sialadenitis and salivary mucoceles (see Figure 8.5).
- May indicate idiopathic sialadenosis [1].

8.1.2 Salivary Gland Adenoma

8.1.2.1 Cytologic Features

Salivary gland adenomas exfoliate as cohesive sheets of cells with a papillary or acinar-like arrangement. The cells mostly are well-differentiated, which can make differentiating these from normal or hyperplastic tissue difficult. Features include crowded sheets (with cellular piling), higher N/C ratios, and less-vacuolated cells than normal epithelium (compare Figures 8.2 and 8.1).

8.1.2.2 Clinical Considerations

- Rare in dogs and cats; they comprise <5% of salivary tumors [2, 3].
- Histopathology is required for definitive diagnosis.

8.1.2.3 Prognosis

Excellent. May require surgical removal if causing clinical signs.

8.1.3 Salivary Gland Adenocarcinoma

8.1.3.1 Cytologic Features

Salivary gland adenocarcinomas exfoliate in cohesive sheets, and may retain a papillary or acinar-like arrangement. More anaplastic tumors lose features of salivary differentiation (Figure 8.3). They have a variable volume of deep-blue cytoplasm that may contain clear vacuoles. Nuclei are round with smudged chromatin and prominent basophilic nucleoli. Anisocytosis/anisokaryosis often are marked, and N/C ratios are high.

8.1.3.2 Clinical Considerations

- Most common salivary gland tumor in dogs and cats [3, 4].
- Found most frequently in the mandibular gland (cats) and parotid gland (dogs) [4].
- Clinical signs = palpable mass, halitosis, exophthalmos, Horner's syndrome.

8.1.3.3 Prognosis

Prognosis varies greatly in the literature; however, cats universally have a poorer prognosis than dogs. One study found long-term survival with surgery ± radiation therapy, but others report high metastatic rates and short survival times [4, 5].

8.1.4 Sialocele (Salivary Mucocele)

8.1.4.1 Cytologic Features

Sialoceles have a distinctive background that contains numerous pools of smooth, pale-blue/lavender mucinous

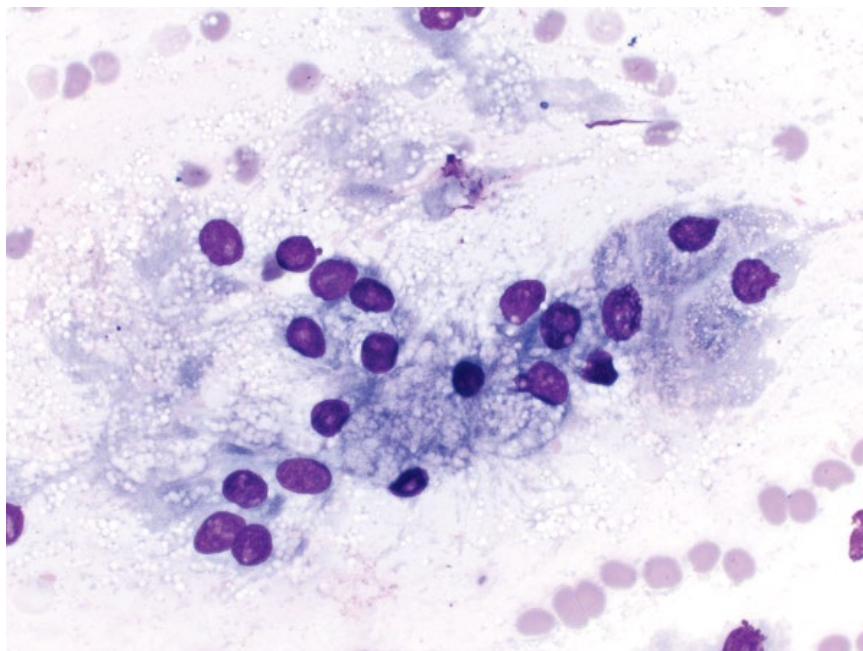


Figure 8.1 Normal salivary gland epithelium, dog, 50× objective.

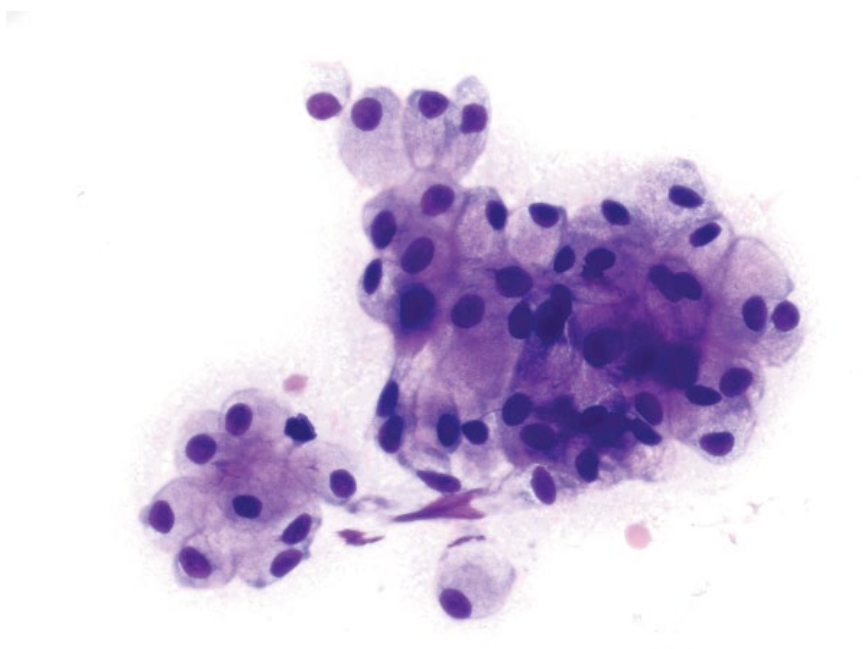


Figure 8.2 Salivary gland adenoma, dog, 40× objective. Slide courtesy of Dr. Connie Wu Siegfried.

material (Figure 8.4). Embedded within this material are inflammatory cells. Reactive macrophages usually predominate, and frequently contain hematoidin crystals (see Figure 8.4) or other heme-breakdown pigments. Neutrophils and small mature lymphocytes may also be present. Normal salivary gland epithelium is variably present.

8.1.4.2 Clinical Considerations

- Dogs > cats.
- Common in young dogs, but any age affected.
- Often secondary to trauma, less commonly to calculi, duct obstruction or idiopathic.
- Also may occur under the tongue (ranula) or in the pharynx [6].

Figure 8.3 Salivary gland adenocarcinoma, cat, 50× objective.

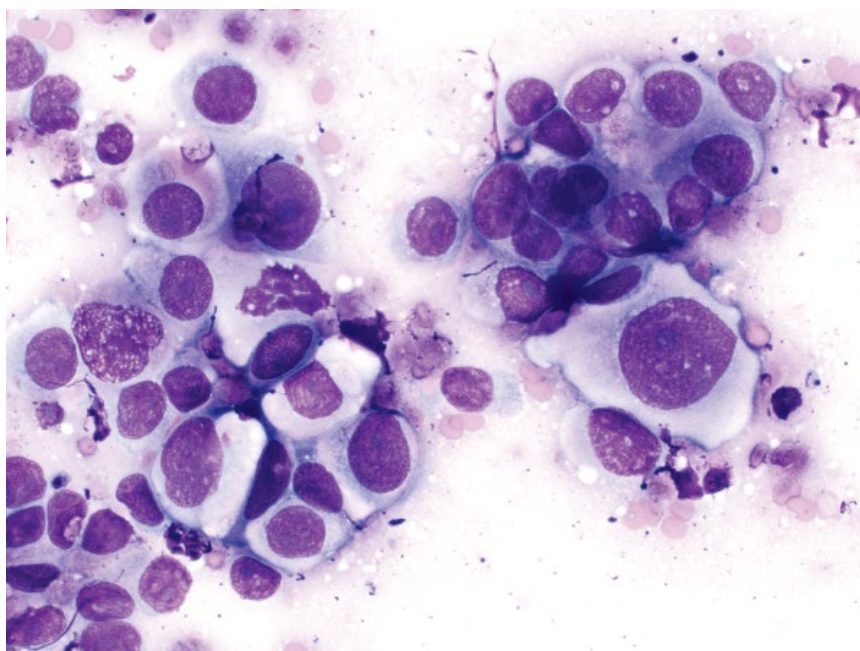
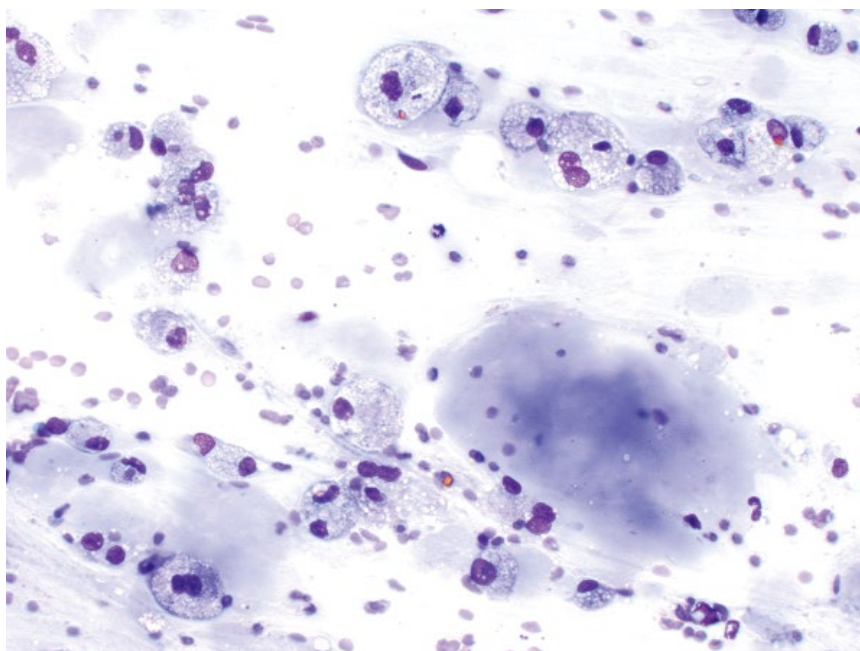


Figure 8.4 Sialoceles, dog, 20× objective.



8.1.4.3 Prognosis

Excellent. Some lesions are self-limiting. Surgical excision generally is curative, with low rates of recurrence [7].

8.1.5 Sialadenitis

8.1.5.1 Cytologic Features

Inflammation may be seen in the salivary gland in the absence of a cystic component, though variable amounts of mucin may still be seen (Figure 8.5). The types of

nucleated cells vary with the primary pathologic process, and may comprise neutrophils (more common in bacterial etiologies) or small mature lymphocytes (chronic, viral or immune mediated causes). Infectious agents may be present.

8.1.5.2 Clinical Considerations

- Responsible for ~25% of cases of salivary gland pathology in one study [3].

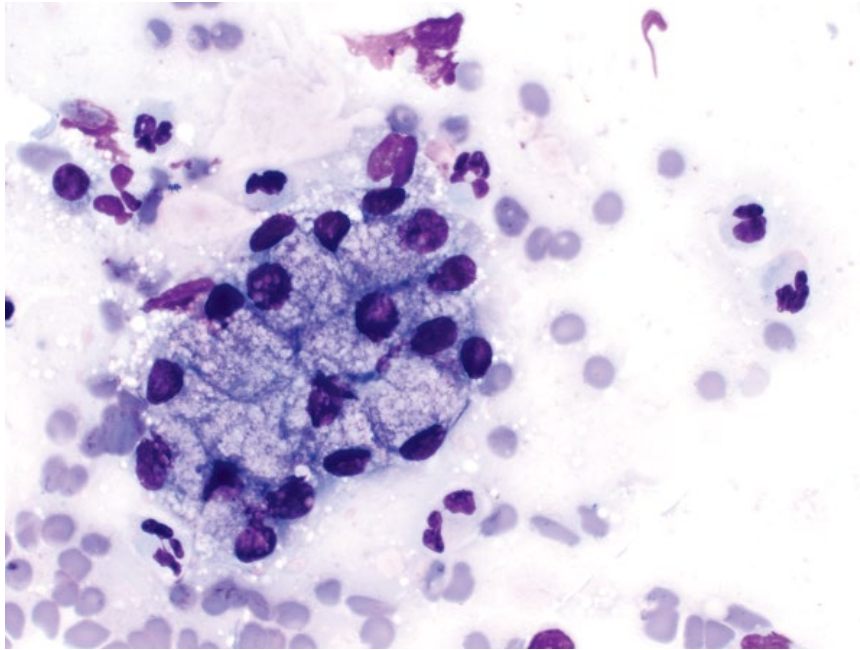


Figure 8.5 Sialadenitis, dog, 50× objective.

- May be primary (penetrating wounds, ascending infection from oral cavity, infarction) or secondary to systemic disease (e.g., viral) [8].

8.1.5.3 Prognosis

Generally good, based on underlying etiology of the inflammation.

8.2 Stomach/Intestines

8.2.1 Inflammation

8.2.1.1 Cytologic Features

Inflammatory lesions in the gastrointestinal tract are categorized by the predominant cell type. Lymphoplasmacytic inflammation is common, often associated with inflammatory bowel disease (IBD). The lymphoid population is mixed, with plasma cells often present (Figure 8.6), helping distinguish it from small-cell lymphoma (compare to Figure 8.7). Eosinophils may also be present in cases of IBD, but may also indicate underlying hypersensitivity disease, parasitic disease, neoplasia (e.g., mast cell neoplasia) or feline gastrointestinal eosinophilic sclerosing fibroplasia. When neutrophilic or granulomatous inflammation is present, careful assessment for infectious organisms is warranted (see Chapter 2 for details).

8.2.1.2 Clinical Considerations

- Cats and dogs. IBD more common in cats.
- May affect any age. IBD most common in middle-aged to older patients

- Clinical signs = vomiting, diarrhea, weight loss, lethargy.
- Histopathology required for definitive diagnosis.

8.2.1.3 Prognosis

Variable, based on etiology. IBD generally is associated with prolonged survival with appropriate therapy, though clinical signs may wax and wane [9].

8.2.2 Lymphoma (Small-cell)

8.2.2.1 Cytologic Features

Characterized by a monomorphic population of small lymphocytes, with nuclei about one to 1.25 red blood cells in diameter, and a unipolar cap of pale-blue cytoplasm (Figure 8.7). Relative to normal or reactive lymphocytes, they have more open chromatin and variably prominent nucleoli. Plasma cells generally are absent or seen in low numbers.

8.2.2.2 Clinical Considerations

- Cats >> dogs.
- Small intestine >> stomach. Other organs rarely concurrently involved [10].
- Diffuse thickening of intestine > discrete mass.

8.2.2.3 Prognosis

Good. Long-term remission and survival are common [11].

8.2.3 Lymphoma (Large-cell)

8.2.3.1 Cytologic Features

Discrete, round cells with large nuclei, ranging from two to four red blood cells in diameter, with finely stippled

Figure 8.6 Intestine, lymphoplasmacytic inflammation, cat, 100× objective.

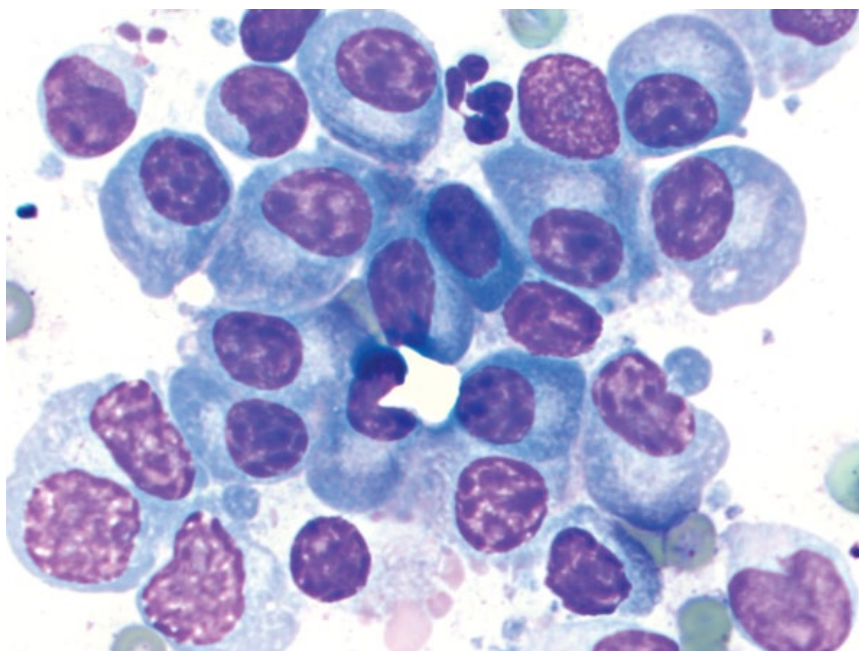
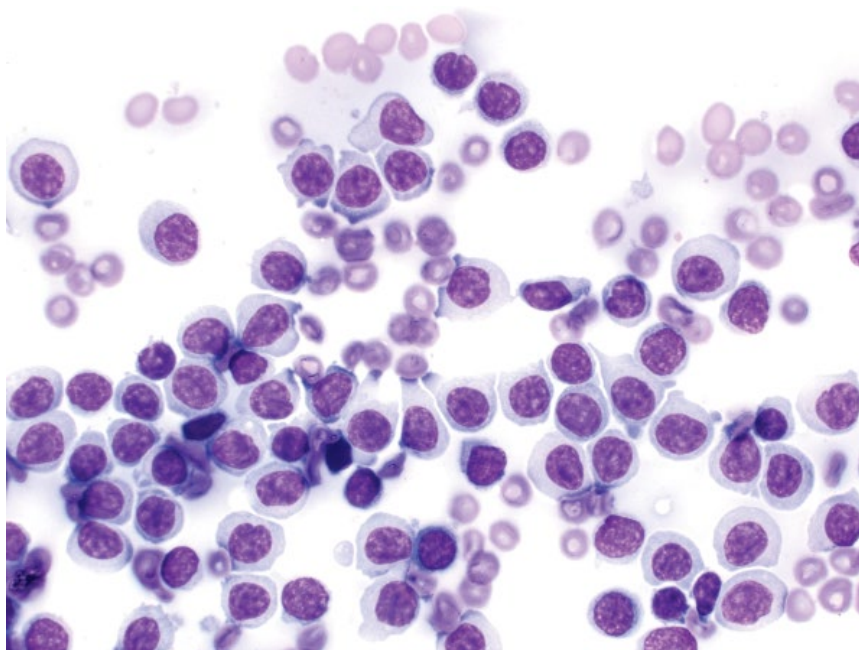


Figure 8.7 Intestine, lymphoma (small cell), dog, 50× objective.



chromatin and variably prominent nucleoli (Figure 8.8). The cells have a small to moderate volume of medium-blue cytoplasm that may contain vacuoles. Large granular lymphoma (LGL) contains variably chunky azurophilic granules in the cytoplasm (Figure 8.9).

8.2.3.2 Clinical Considerations

Cats

- Most frequent primary site of lymphoma [12].
- Discrete mass > diffuse thickening.

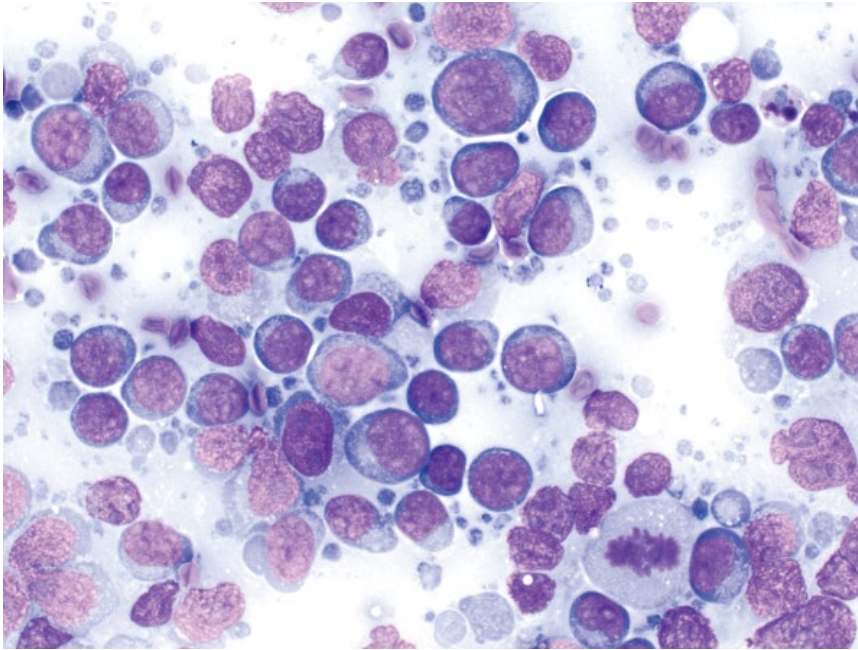


Figure 8.8 Intestine, lymphoma (large cell), dog, 50× objective.

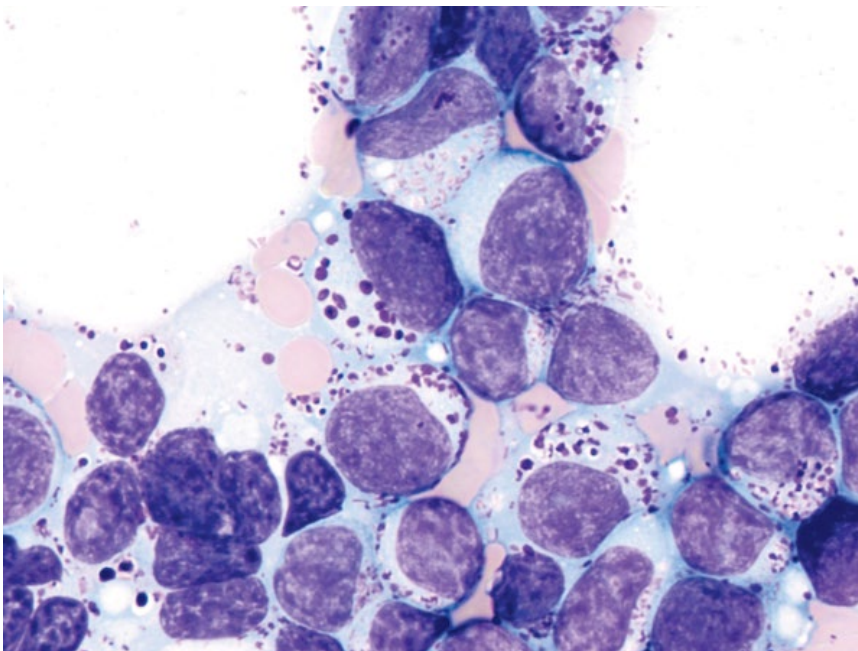


Figure 8.9 Intestine, lymphoma (large granular lymphoma; LGL), cat, 100× objective.

Dogs

- Primary disease less common than multicentric.
- Often affects multiple segments, but may be focal. Thickening of the wall, and mucosal ulceration common [13, 14].

8.2.3.3 Prognosis

Guarded to grave in both cats and dogs [15, 16]. LGL especially is rapidly progressive, poorly responsive to therapy, and carries a grave prognosis [17, 18].

8.2.4 Plasmacytoma

8.2.4.1 Cytologic Features

Extramedullary plasmacytomas of the gastrointestinal tract exfoliate as discrete round cells. Differentiation is variable, ranging from well-differentiated cells with a Golgi zone, and eccentric, round nuclei (Figure 8.10), to highly pleomorphic, seen in crowded sheets with multinucleation, and prominent nucleoli.

Figure 8.10 Colon, plasmacytoma, dog, 50x objective.

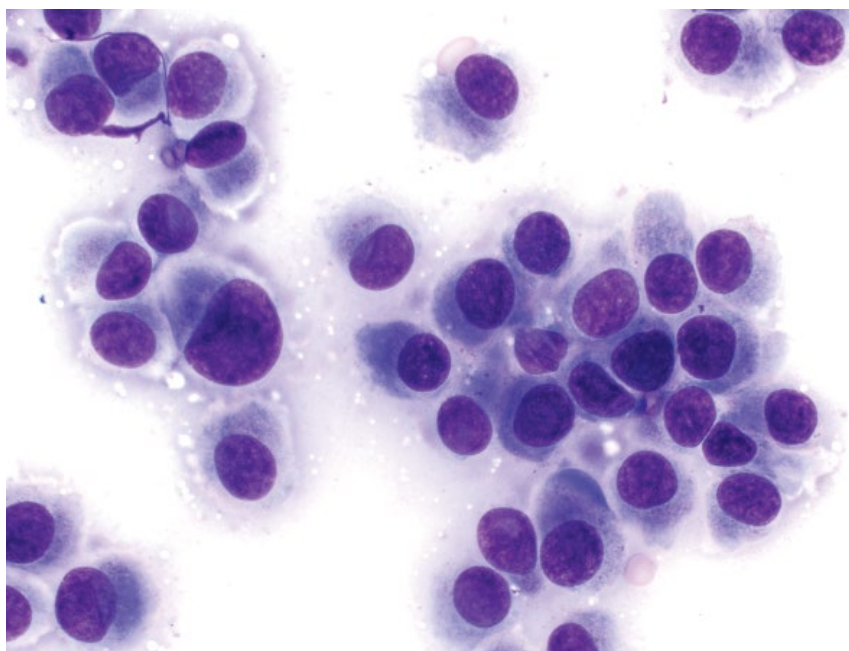
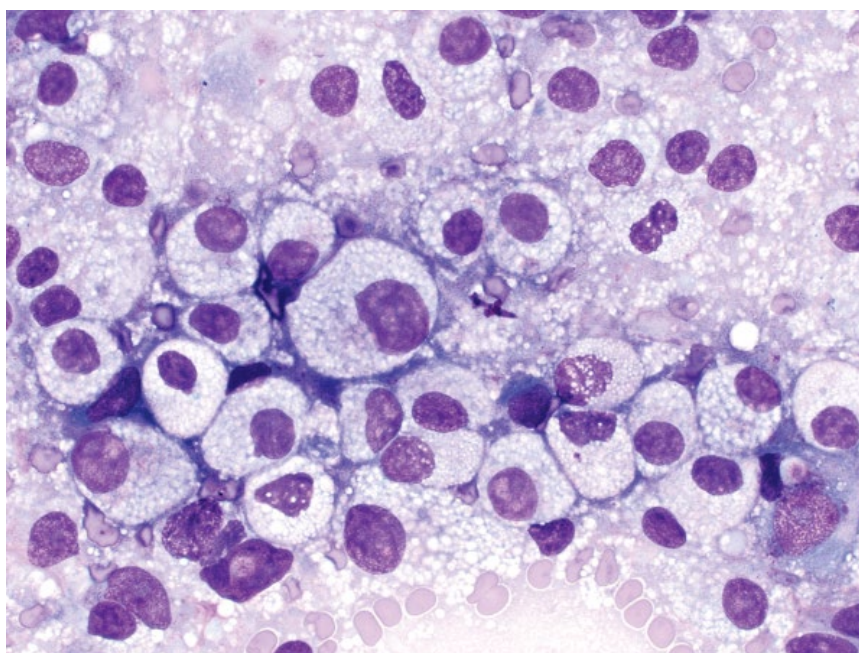


Figure 8.11 Intestine, mast cell tumor, cat, 50x objective.



8.2.4.2 Clinical Considerations

- Dogs > cats.
- Rectum and colon most common sites.
- Usually solitary, but multiple masses may occur [19].
- Clinical signs = tenesmus, hematochezia, rectal prolapse.

8.2.4.3 Prognosis

Generally good with complete excision of solitary tumors [19].

8.2.5 Mast Cell Neoplasia

8.2.5.1 Cytologic Features

Discrete, round cells are seen both individually and in crowded sheets. Mast cells in the gastrointestinal tract frequently are less well granulated than those from other organs, and the cytoplasm often contains clear vacuoles (Figure 8.11). Nuclei are round, centrally located, and have granular chromatin.

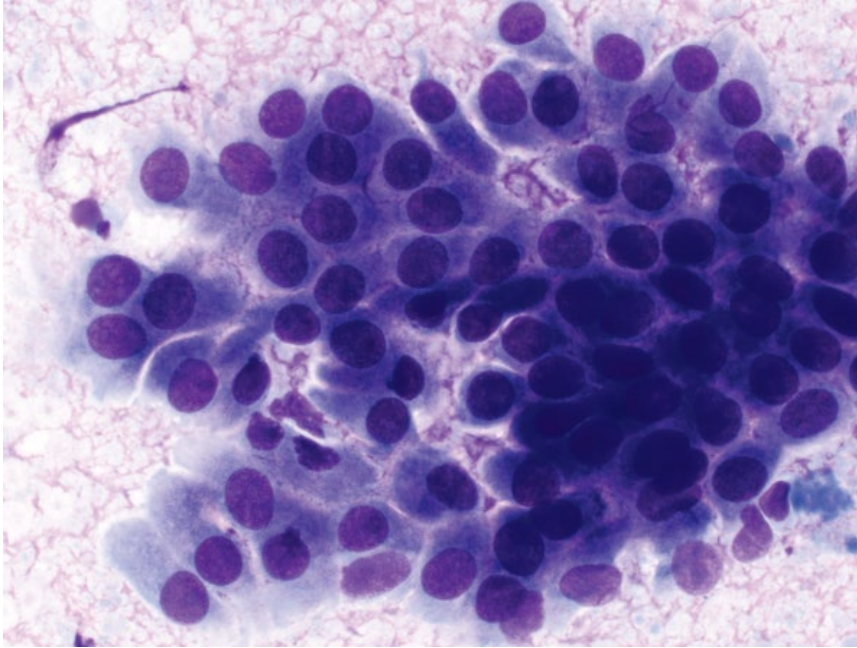


Figure 8.12 Colon, polyp, dog, 50× objective.

8.2.5.2 Clinical Considerations

- Cats > dogs. Third most common intestinal tumor in cats [20].
- Tumors mostly are in the intestine or ileoceocolic junction [21].
- Mostly focal tumors, rarely diffuse [21].

8.2.5.3 Prognosis

Guarded to poor, as metastatic disease is common [22].

8.2.6 Adenoma/Polyp

8.2.6.1 Cytologic Features

Adenomatous polyps exfoliate in organized, cohesive sheets, often with prominent intercellular borders. Cells are round to columnar, with a moderate volume of medium-blue cytoplasm (Figure 8.12). Nuclei are round, centrally to eccentrically placed, and have finely stippled chromatin with small or inapparent nucleoli. Anisocytosis/anisokaryosis are mild.

8.2.6.2 Clinical Considerations

- Most common in rectum (dogs) and intestine (cats).
- Solitary > multiple or diffuse [23].
- Clinical signs = hematochezia, tenesmus, rectal prolapse [23, 24].
- Histopathology required to differentiate adenomatous polyps from carcinoma *in situ*.

8.2.6.3 Prognosis

Generally good with surgical resection. Polyps >1 cm may be more likely to recur or undergo malignant transformation [24].

8.2.7 Adenocarcinoma

8.2.7.1 Cytologic Features

Neoplastic cells are seen in variably sized cohesive sheets that frequently are crowded or piled, with greater disorganization than polyps (compare Figures 8.13 and 8.12). The cytoplasm may contain vacuoles, which can be large and coarse, particularly in adenocarcinomas of the colon (Figure 8.14). Nuclei may be centrally or eccentrically placed. Anisocytosis/anisokaryosis are variable, but often moderate to marked.

8.2.7.2 Clinical Considerations

- Second most common neoplasm of the gastrointestinal tract in cats and dogs (behind lymphoma).
- Siamese cats predisposed [20].
- Most common in small intestine (cats) and the large intestine/colon (dogs) [25, 26].

8.2.7.3 Prognosis

Grave if untreated. Presence of metastatic disease is a poor prognostic factor [25].

Figure 8.13 Intestine, adenocarcinoma, cat, 50× objective.

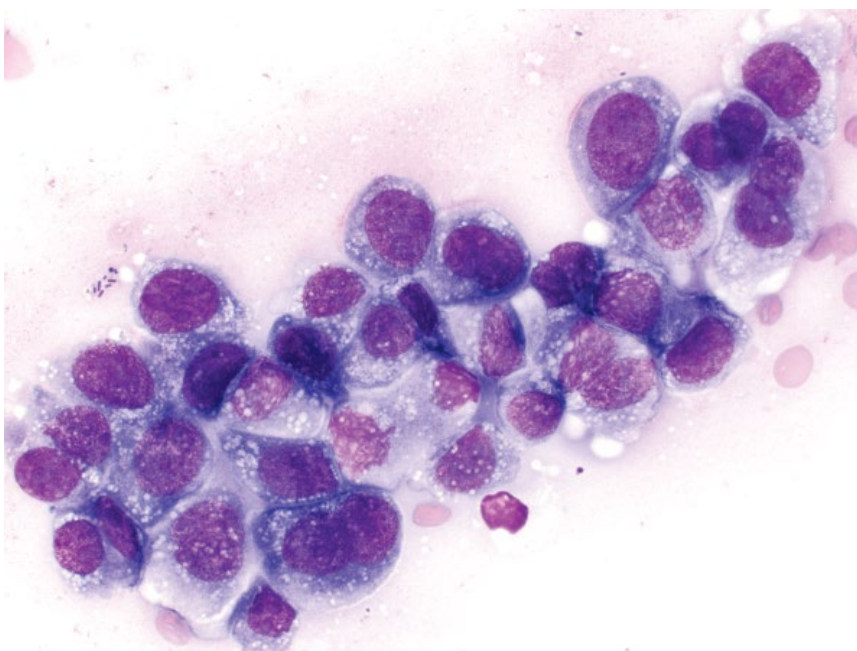
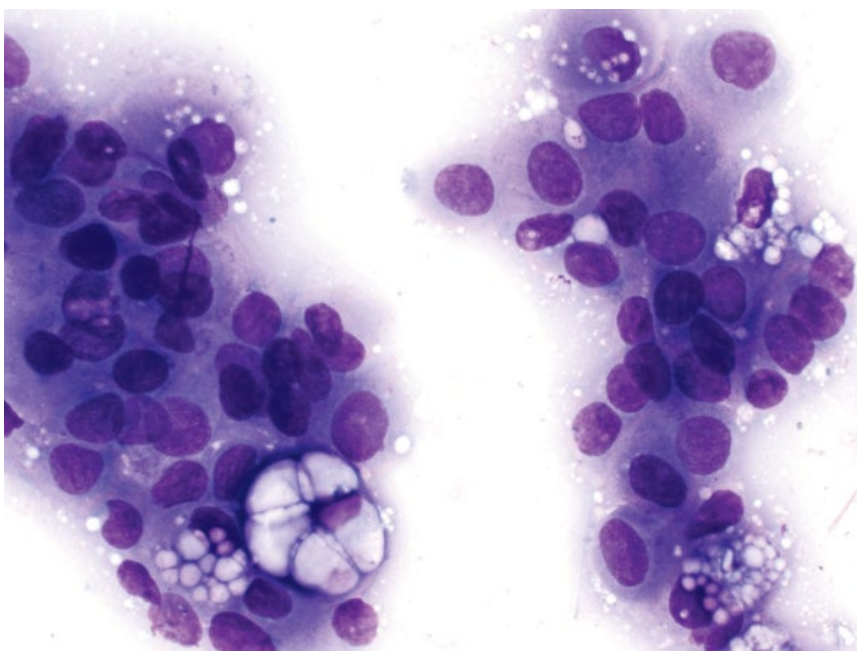


Figure 8.14 Colon, adenocarcinoma, dog, 50× objective.



8.2.8 Carcinoid (Intestinal)

8.2.8.1 Cytologic Features

Intestinal carcinoids exfoliate well in variably cohesive sheets, often with poor intercellular boundaries and many bare nuclei, which can help differentiate these

from adenocarcinomas (compare Figures 8.15 and 8.13). Intact cells are round, with a moderate volume of medium-blue cytoplasm. Nuclei are round, with finely stippled chromatin and multiple, small, basophilic nucleoli. Hyperchromasia is a common finding.

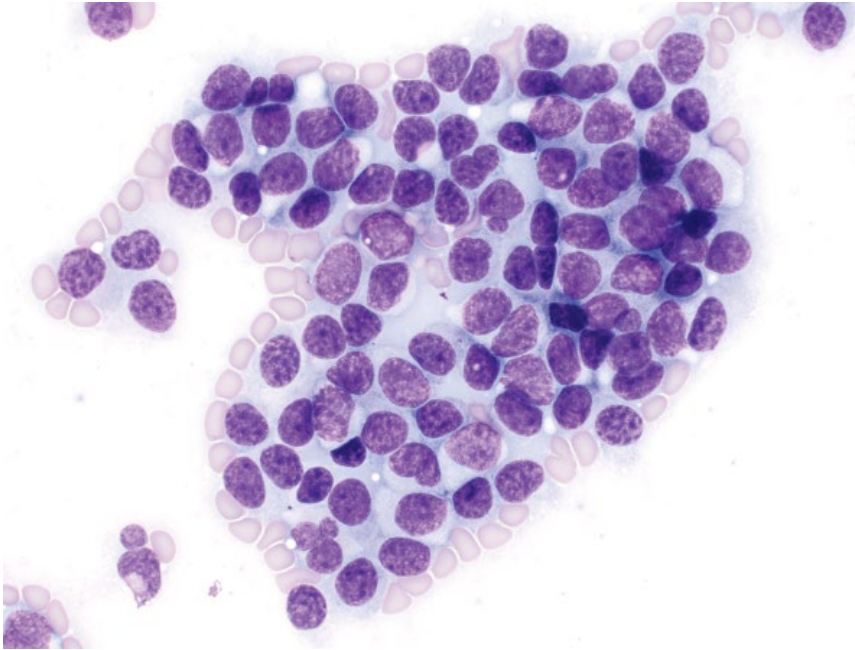


Figure 8.15 Intestine, carcinoid, dog, 50× objective.

Anisocytosis/anisokaryosis and N/C ratios generally are moderate.

8.2.8.2 Clinical Considerations

- Malignant tumors arising from enterochromaffin cells of the intestinal mucosa.
- May occur in the small or large intestine.

8.2.8.3 Prognosis

Guarded to poor. Tumors frequently metastasize, mostly to the liver [27]. Rectal location has a favorable prognosis in humans, and may also confer a better prognosis in dogs [28].

8.2.9 Gastrointestinal Stromal Tumor (GIST)

8.2.9.1 Cytologic Features

GISTs frequently are highly exfoliative, comprising spindle cells in tight, crowded aggregates. The cells have a scant volume of pale-blue cytoplasm forming long delicate tendrils and wisps. Nuclei are elongated or 'cigar-shaped' with coarsely granular chromatin and mostly inapparent nucleoli (Figure 8.16). Anisocytosis/anisokaryosis are mild and N/C ratios are high. GISTs appear cytologically similar to leiomyomas and leiomyosarcomas (compare to Figure 8.17), and require histopathology for definitive characterization.

8.2.9.2 Clinical Considerations

- Originate from interstitial cells of Cajal.
- Older patients (mean age 11 years) [29].

- Most common in the large intestine and cecum (>50% of cases), less common in small intestine and stomach [29, 30].
- Often clinically silent, but may cause vomiting, inappetence, melena.

8.2.9.3 Prognosis

Metastatic disease is seen in ~30% of cases, to the liver, abdominal cavity and spleen [29]. Patients without metastatic disease and surviving surgical removal can have a good prognosis [30].

8.2.10 Leiomyosarcoma

8.2.10.1 Cytologic Features

Leiomyosarcomas exfoliate variably well in loose aggregates and individually. They comprise plump spindle cells with a moderate volume of medium-blue cytoplasm forming short bipolar tapering ends, and may contain fine clear vacuoles. Nuclei are ovoid with coarsely granular chromatin and prominent basophilic nucleoli. Anisocytosis/anisokaryosis are marked, and N/C ratios are moderate to high (Figure 8.17). Well-differentiated tumors may mimic GISTs; however, leiomyosarcoma cells generally are more plump, and have greater criteria of malignancy (compare to Figure 8.16).

8.2.10.2 Clinical Considerations

- Malignant tumors arising from smooth muscle cells.
- Predilection for jejunum and stomach, but may affect any segment of gastrointestinal tract [30–32].

Figure 8.16 Colon, gastrointestinal stromal tumor (GIST), dog, 50× objective.

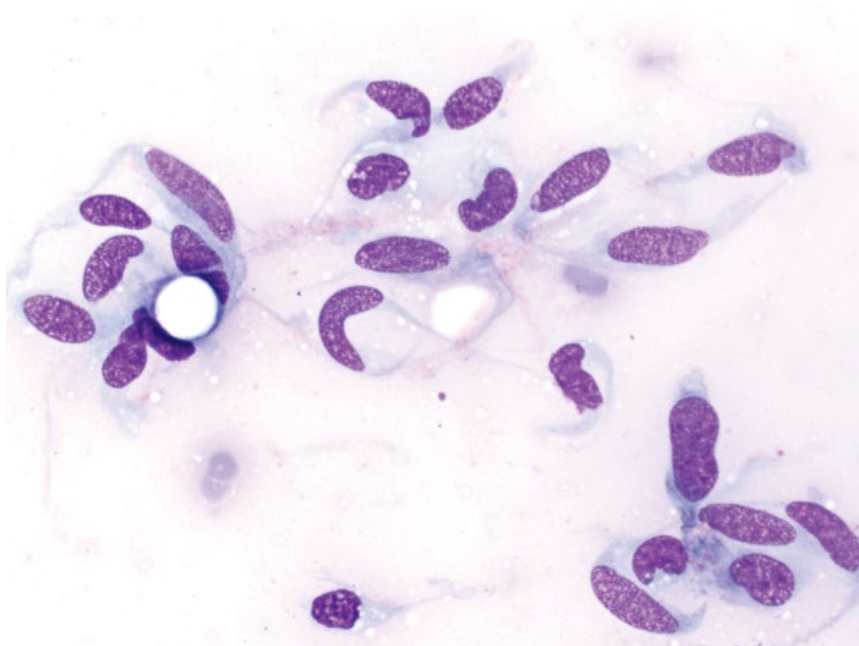
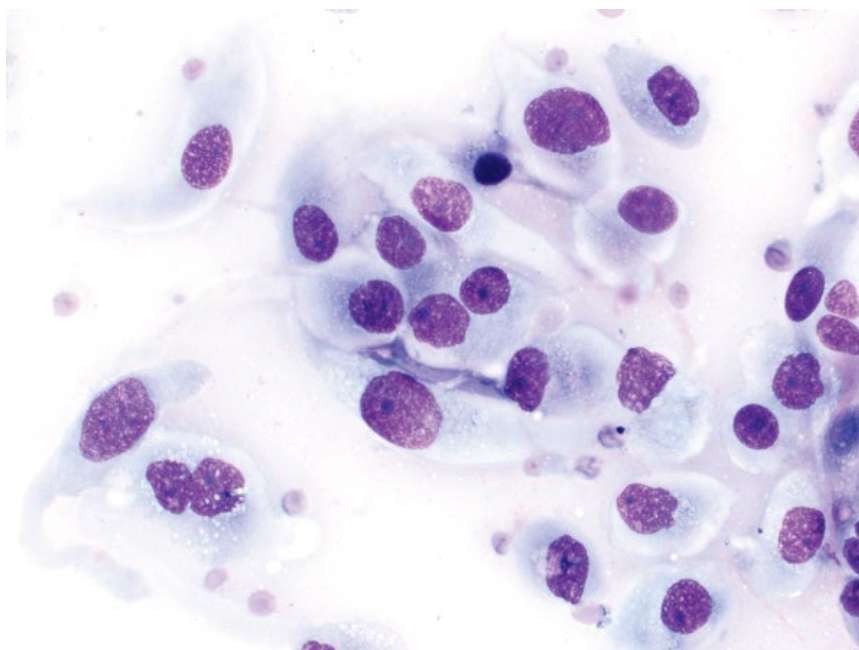


Figure 8.17 Stomach, leiomyosarcoma, cat, 50× objective.



- May be associated with paraneoplastic syndromes such as hypoglycemia and nephrogenic diabetes insipidus [32].

8.2.10.3 Prognosis

Variable. Long-term survival can be seen in dogs with surgical resection of masses, even in the presence of metastatic disease [32].

8.3 Feces

8.3.1 Normal

8.3.1.1 Cytologic Features

Normal flora within feces is predominated by a polymorphic population of mostly rod-shaped bacteria (Figure 8.18) [33]. Cocci should rarely be seen. Additionally, rare spiral bacteria and rare spore-forming

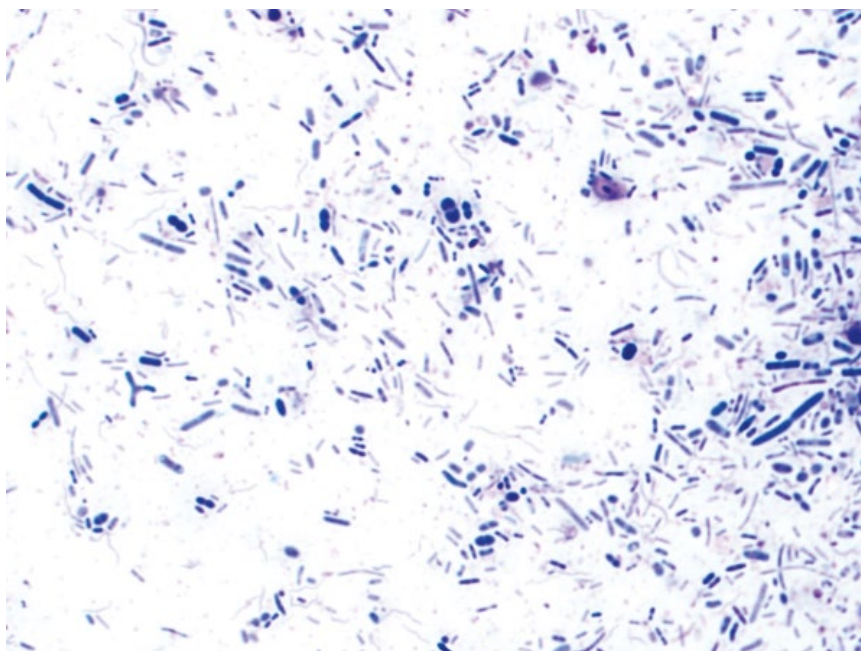


Figure 8.18 Feces, normal, dog, 100× objective. Note the mixed population of bacteria, dominated by rods.

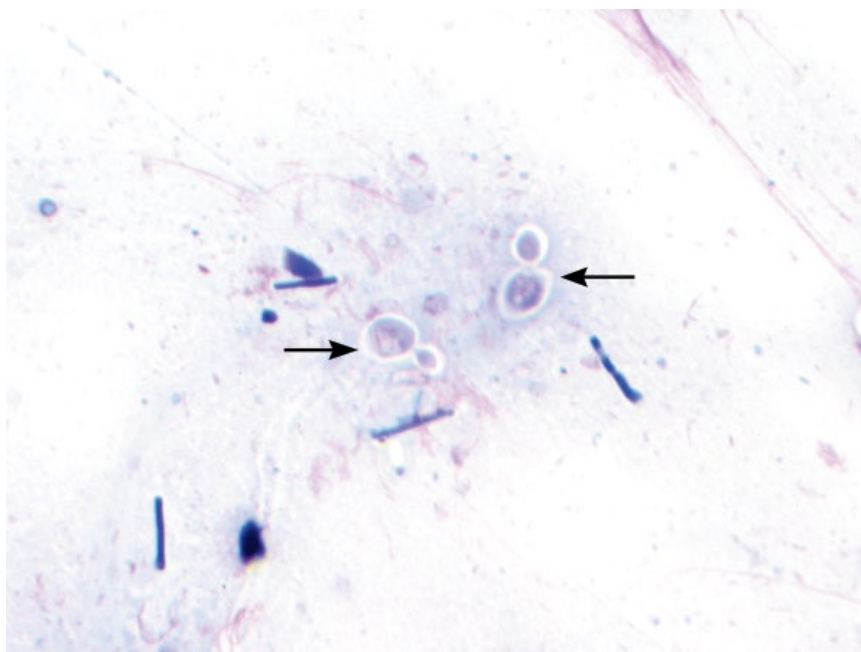


Figure 8.19 Feces, normal, dog, 100× objective. Small, encapsulated enteric yeast are seen (arrows), accompanied by rod-shaped bacteria.

bacteria may be present. Small enteric yeast (Figure 8.19) are common in low to moderate numbers, and *Cyniclomyces guttulatus* may be an incidental finding (see Chapter 2). Well-differentiated columnar epithelial cells may be present in samples from rectal scrapes.

8.3.2 Inflammation/Infection

8.3.2.1 Cytologic Features

Inflammatory cells may be seen in feces, indicative of gastroenteritis, or colitis (Figure 8.20). Evidence of infection may be seen by a monomorphic expansion

Figure 8.20 Feces, neutrophilic inflammation, dog, 50× objective.

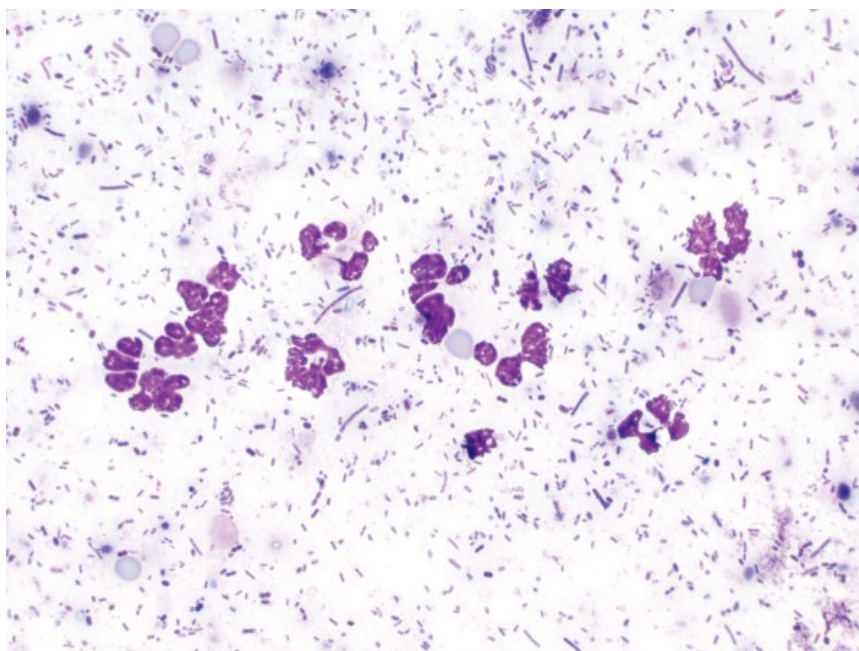
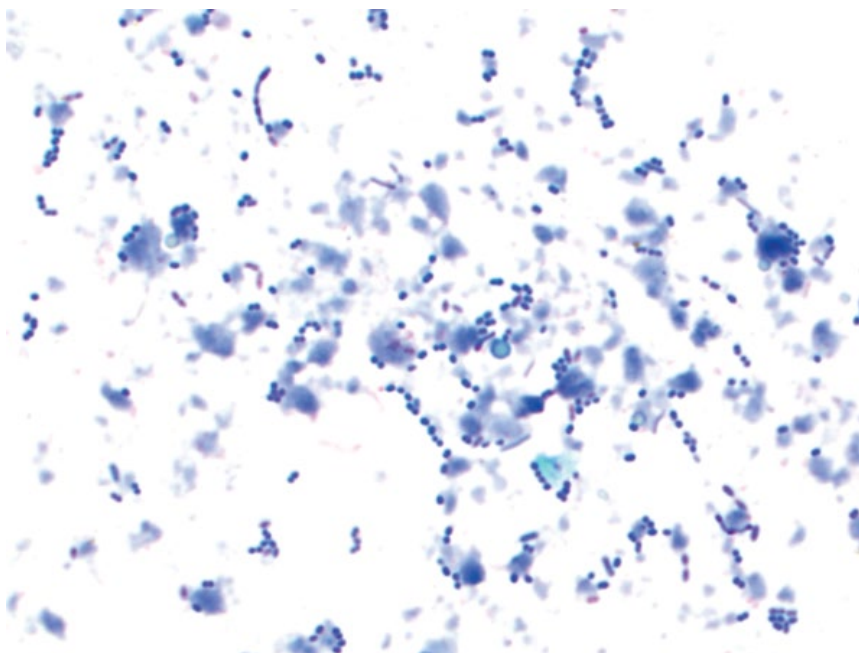


Figure 8.21 Feces, bacterial overgrowth (cocci), dog, 100× objective.



of bacteria (Figure 8.21), including spore-forming bacteria or spiral-shaped bacteria (e.g., *Clostridium* spp. and *Campylobacter* spp.; see Chapter 2 for details). Additionally, many important gastrointestinal pathogens may be identified, including protozoa (e.g., *Giardia*, *Cryptosporidium*), algae (e.g., *Prototheca*), or fungi (e.g., *Histoplasma*, *Pythiosis*). The reader is referred to Chapter 2 for details of these organisms.

8.3.2.2 Clinical Considerations

- Plasma cells and lymphocytes may be seen in cases of IBD.
- Bacterial overgrowth may be primary, or secondary to antibiotic therapy, exocrine pancreatic insufficiency, or IBD [34].

8.3.2.3 Prognosis

Variable, based on underlying cause of inflammation.

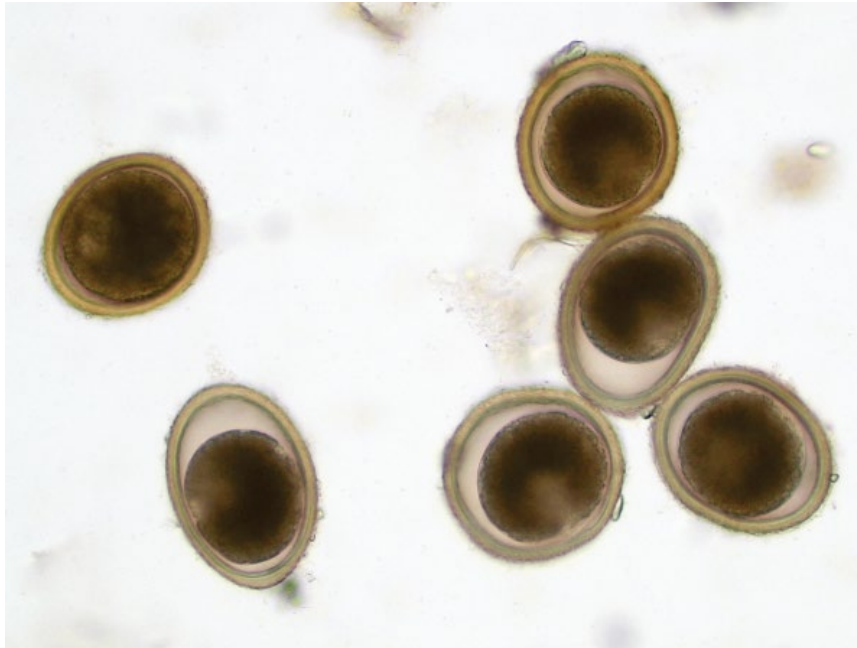


Figure 8.22 Feces, *Toxocara canis* (roundworm) ova, dog, 50× objective.

8.3.3 Parasite Ova: Roundworm

8.3.3.1 Cytologic Features

Eggs from round worms are round, and ~65–90 μm in diameter. They have a characteristic rough outer shell wall. Eggs passed in feces are unlarvated, and have a large, dark brown, round embryo (Figure 8.22).

8.3.3.2 Clinical Considerations

- Most common species = *Toxocara canis* (dog), *Toxocara cati* (cats), *Toxascaris leonina* (dog and cat)
- Zoonotic potential.

8.3.3.3 Prognosis

Good with treatment. Untreated *T. canis* can result in intussusception, obstruction or rupture of the intestines, and may be fatal. Pneumonia from parasite migration may also be fatal [35].

8.3.4 Parasite Ova: Hookworm

8.3.4.1 Cytologic Features

These eggs are ellipsoidal, ~50–75 μm in length \times 30–50 μm wide. They have a smooth, clear shell, and contain an embryo in the morula stage of development that may have variable divisions (Figure 8.23).

8.3.4.2 Clinical Considerations

- Dogs > cats. *Ancylostoma* spp. more common than *Uncinaria* spp. [36].
- Eggs detected in feces after onset of clinical signs [35].
- *A. caninum* associated with severe, possibly fatal anemia.
- Zoonotic potential.

8.3.4.3 Prognosis

Guarded. Poor without treatment.

8.3.5 Parasite Ova: Whipworm

8.3.5.1 Cytologic Features

Eggs are lemon-shaped with distinct bipolar plugs (Figure 8.24). Each egg contains a single cell. They generally are >75 μm in length.

8.3.5.2 Clinical Considerations

- Dogs > cats. Infection in cats rare and incidental.
- *Trichuris vulpis* common in dogs of all ages [36].
- Most canine infections are asymptomatic, but may cause intermittent mucoid diarrhea flecked with blood [35].

8.3.5.3 Prognosis

Excellent.

8.3.6 Parasite Ova: Tapeworm

8.3.6.1 Cytologic Features

Dipylidium caninum eggs often are seen in an egg capsule ~100–200 μm , that contains between five and 30 eggs (Figure 8.25). Individual eggs are round, ~30–50 μm diameter, and have a thick, radially striated embryophore, containing an embryo with three pairs of hooks (Figure 8.26).

8.3.6.2 Clinical Considerations

- Common in dogs and cats, but incidence is declining [37].
- Eggs do not consistently float, and may not be seen in fecal floats [38].

Figure 8.23 Feces, *Ancylostoma caninum* (hookworm) ova, dog, 100× objective. Note abundant blood in the background.

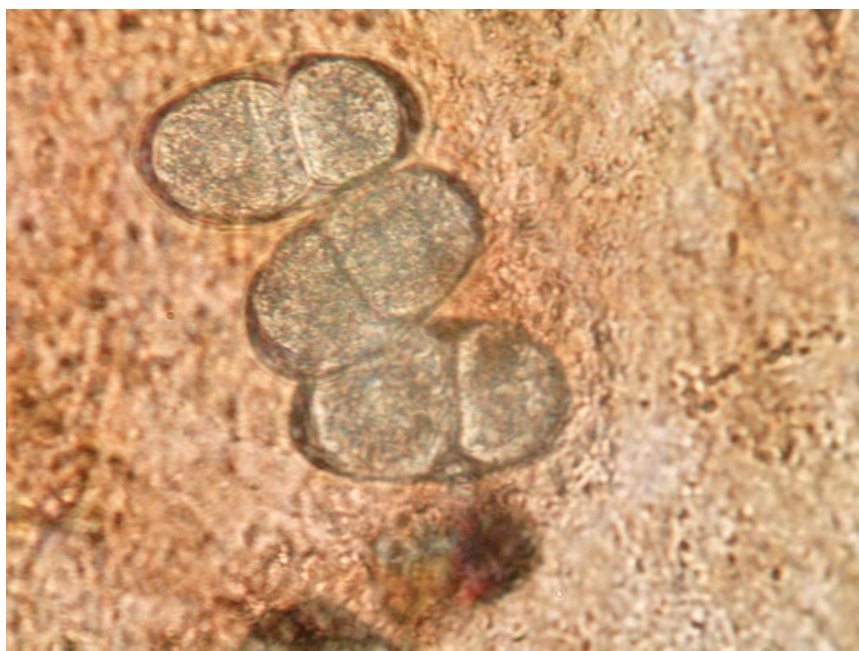
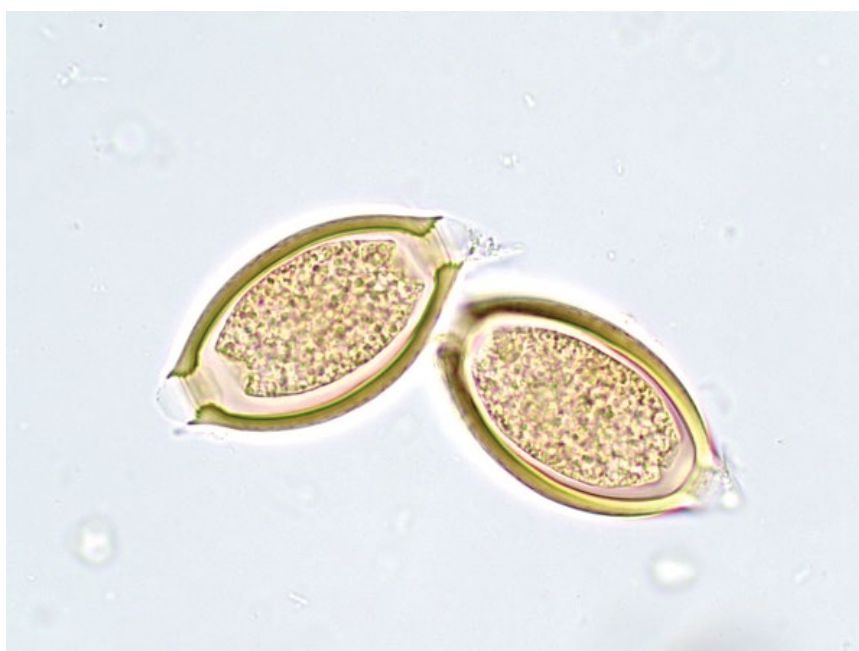
Figure 8.24 Feces, *Trichuris vulpis* (whipworm) ova, dog, 50× objective.



- Clinical disease rare. Perianal irritation most common.
- Zoonotic potential.

8.3.6.3 Prognosis

Excellent with therapy, including control of intermediate hosts (e.g., fleas).

8.3.7 Parasite Ova: Coccidia

8.3.7.1 Cytologic Features

Non-sporulated oocysts are detected in feces. These are ovoid, ~30–40 μm in length, and have a thin, double-layered outer wall encasing a small amount of clear cytoplasm and a single, or occasionally double, cell (sporont) (Figure 8.27).

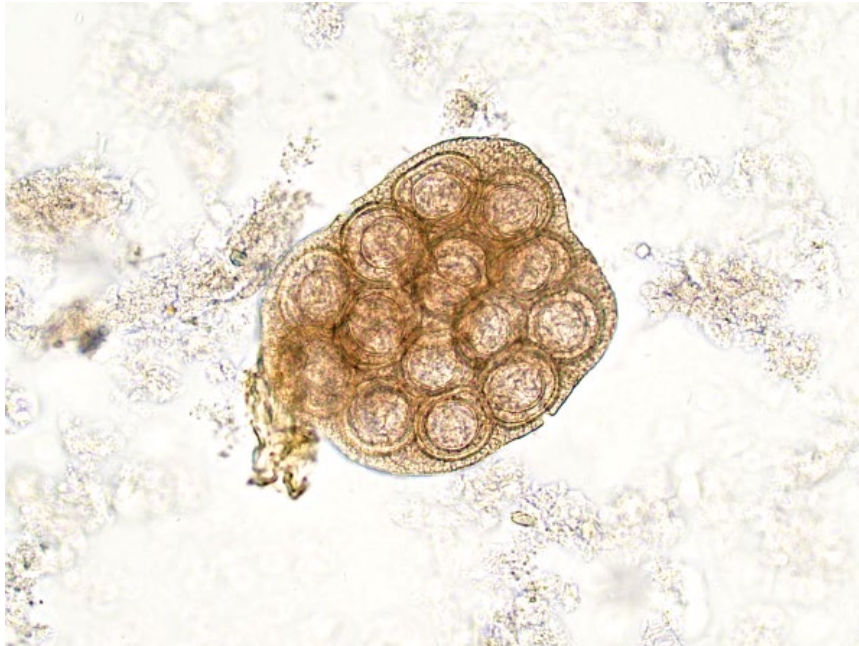

Figure 8.25 Feces, *Dipylidium caninum*, egg capsule, dog, 20× objective.

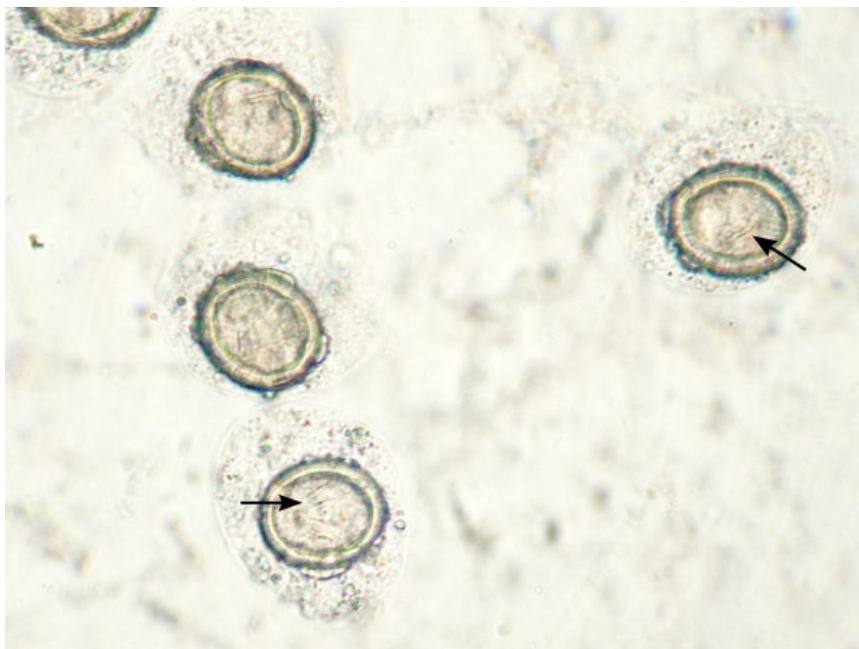


Figure 8.26 Feces, *Dipylidium caninum*, dog, 100× objective. Note individualized eggs that contain small hooks (arrows).

8.3.7.2 Clinical Considerations

- *Cytoisospora* spp. (formerly *Isospora*) common in young dogs and cats [39, 40].
- High prevalence in crowded or unsanitary environments.
- Disease may be subclinical or self-resolving.
- Clinical signs = diarrhea, weight loss, dehydration.

8.3.7.3 Prognosis

Excellent.

8.4 Pancreas

8.4.1 Pancreatic Nodular Hyperplasia

8.4.1.1 Cytologic Features

Nodular hyperplasia is characterized by cohesive sheets of epithelial cells with prominent intercellular borders, and cells do not overlap. Acinar or tubular arrangements are common. The cells have abundant cytoplasm that frequently contains fine clear vacuoles (Figure 8.28).

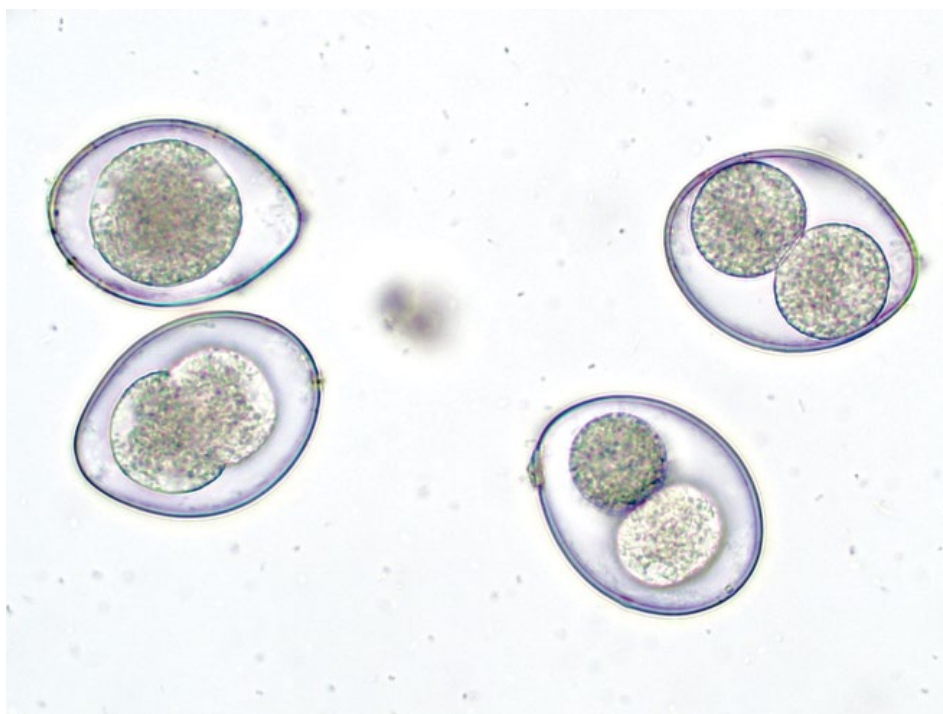


Figure 8.27 Feces, *Cytoisospora* spp. ova, cat, 100× objective.

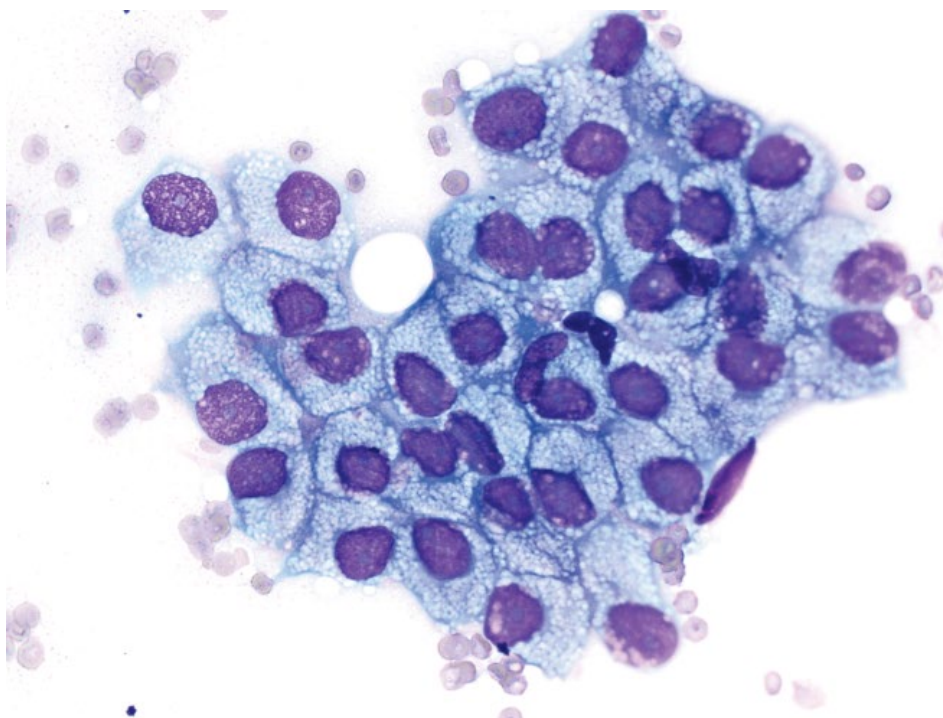


Figure 8.28 Pancreas, nodular hyperplasia, cat, 50× objective.

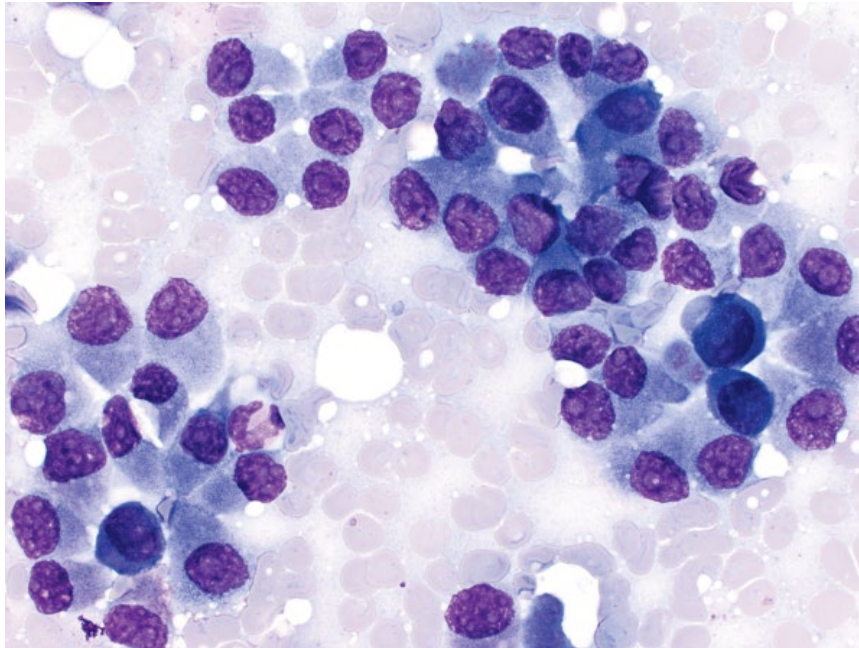


Figure 8.29 Pancreas, adenoma, dog, 50x objective.

Nuclei are round, with finely stippled chromatin and small basophilic nucleoli. Anisocytosis/anisokaryosis are mild and N/C ratios are low. Differentiation from adenomas or well-differentiated adenocarcinomas can be difficult (compare to Figure 8.29).

8.4.1.2 Clinical Considerations

- Common, incidental finding in older cats and dogs.
- Arise from hyperplasia of acinar cells of the exocrine pancreas.
- Mostly multiple nodules, though single masses may be present [41].
- Typically small lesions (<2 cm in cats) [41].

8.4.1.3 Prognosis

Excellent.

8.4.2 Pancreatic Adenoma

8.4.2.1 Cytologic Features

Pancreatic adenomas exfoliate in cohesive sheets of cuboidal to columnar cells that form acinar and tubular arrangements (Figure 8.29). The cells have a moderate volume of medium-blue cytoplasm, and round nuclei with single nucleoli. Anisocytosis/anisokaryosis are mild. These lesions may mimic well-differentiated adenocarcinomas (see section 8.4.3 for distinguishing features).

8.4.2.2 Clinical Considerations

- Rare tumors, less common than adenocarcinomas and nodular hyperplastic lesions.

- Usually solitary, solid and well-encapsulated.
- May be ductular or acinar in origin.

8.4.2.3 Prognosis

Good to excellent.

8.4.3 Pancreatic

Adenocarcinoma: Well-differentiated

8.4.3.1 Cytologic Features

Well-differentiated pancreatic adenocarcinomas often are highly cellular and exfoliate in acinar or tubular arrangements that can make them difficult to differentiate from adenomas or nodular hyperplasia (Figure 8.30). Reliable distinguishing features from benign lesions are established for humans, and include: nuclear enlargement; nuclear membrane irregularity; anisonucleosis; and nuclear crowding/overlapping [42]. These features are seen by comparing Figures 8.28 through 8.31, which highlight the increasing spectrum of malignancy in pancreatic masses.

8.4.3.2 Clinical Considerations

- May be ductular or acinar in origin.
- A single mass >2 cm in diameter is more likely to represent malignant neoplasia than benign hyperplasia in cats [41].
- Cytologic analysis of pancreatic masses correlates well with histologic analysis in human and veterinary medicine when performed by experienced cytopathologists [42, 43].

Figure 8.30 Pancreas, adenocarcinoma (well-differentiated), dog, 50× objective.

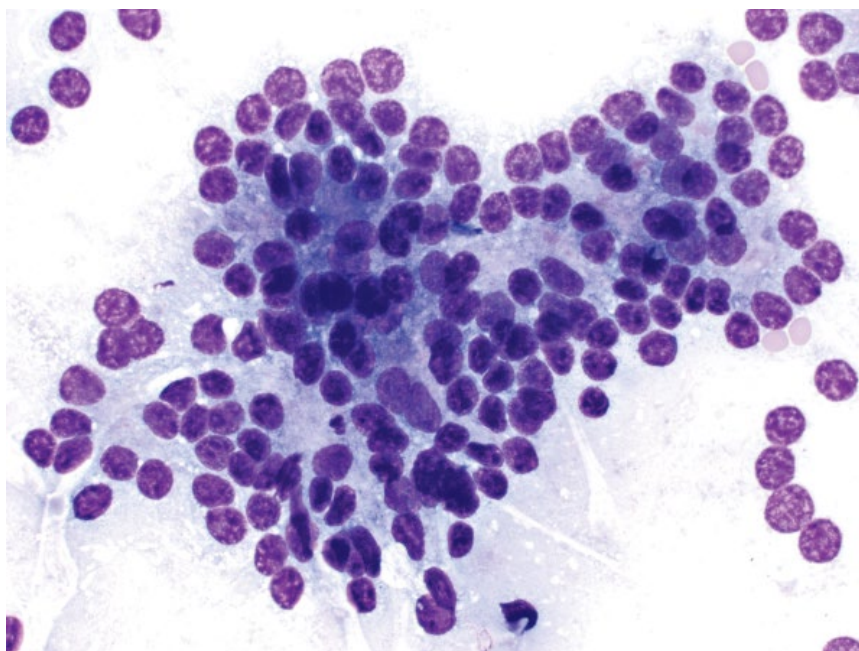
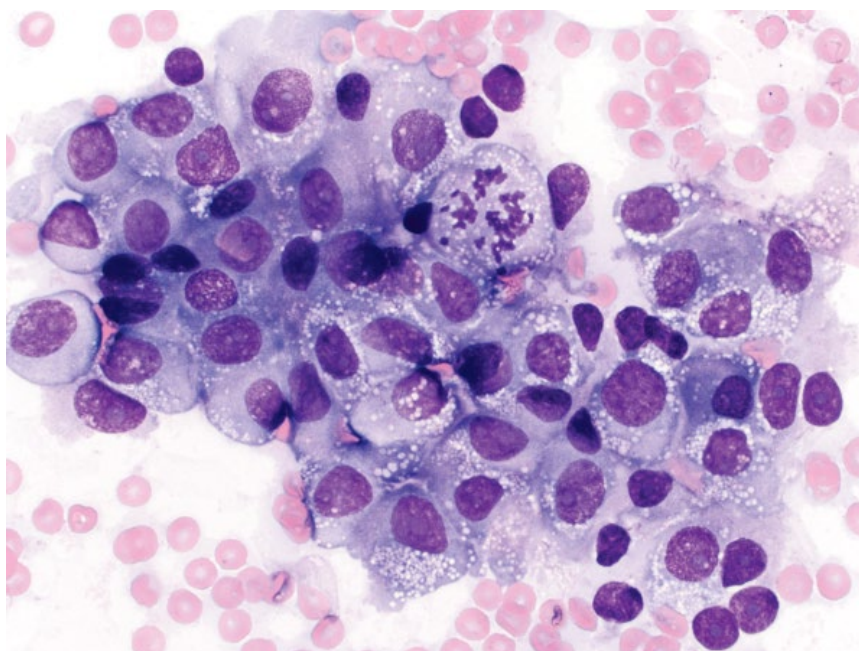


Figure 8.31 Pancreas, adenocarcinoma, (poorly differentiated), dog, 50× objective.



8.4.3.3 Prognosis

Poor to grave. Despite a well-differentiated appearance, 85% of dogs and cats have evidence of metastatic disease at the time of diagnosis, most commonly to the liver [44].

8.4.4 Pancreatic Adenocarcinoma: Poorly Differentiated

8.4.4.1 Cytologic Features

Poorly differentiated pancreatic adenocarcinomas have marked criteria of malignancy, and lose differentiating

features of pancreatic epithelium. Anisocytosis/anisokaryosis are marked, cells may dissociate from sheets, and mitotic figures often are seen (Figure 8.31).

8.4.4.2 Clinical Considerations

- May be ductular or acinar in origin.
- Can be seen as a single mass, or diffuse thickening of the pancreas.
- Older patients (mean age 9 and 10 years for dogs and cats, respectively) [44].

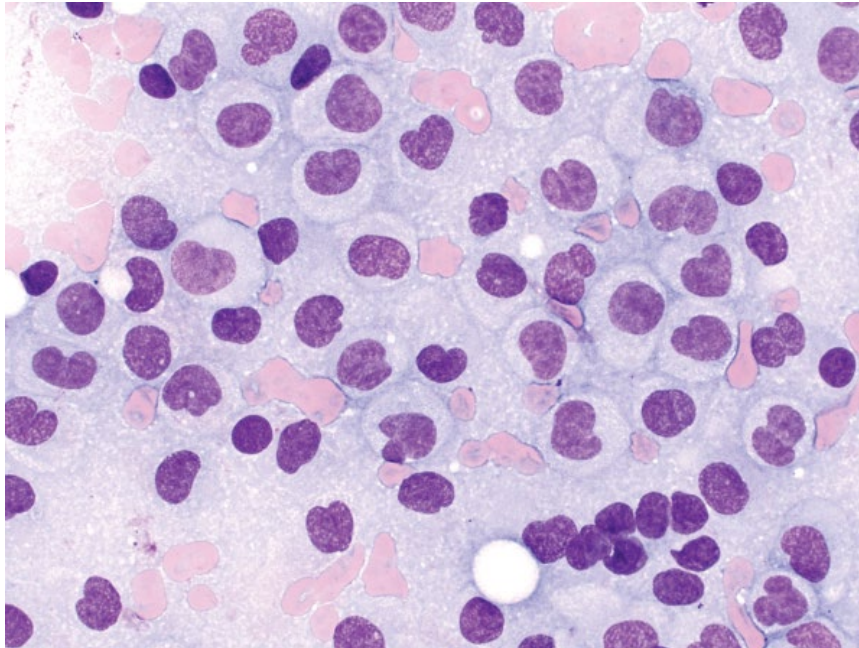


Figure 8.32 Pancreas, insulinoma, dog, 50× objective. Note the discrete cells with characteristic cleaved nuclei.

8.4.4.3 Prognosis

Prognosis is similar to well-differentiated carcinomas, and is poor to grave, with high rates of metastatic disease and short survival times.

8.4.5 Insulinoma (Pancreatic Beta Islet Cell Tumors)

8.4.5.1 Cytologic Features

Insulinomas frequently are highly cellular. However, many cells may rupture creating a homogeneous blue background with many bare nuclei, typical of tumors of neuroendocrine origin. Intact cells are seen individually and in loosely cohesive sheets. They are round, with a moderate volume of medium-blue cytoplasm. Nuclear features are distinctive, with many reniform, indented or cleaved variants (Figure 8.32). They have stippled chromatin with multiple small nucleoli. Anisocytosis/anisokaryosis are mild to moderate, and N/C ratios are moderate to high. They appear similar to other tumors of neuroendocrine origin of the pancreas (e.g., gastrinoma, glucagonoma, etc.).

8.4.5.2 Clinical Considerations

- Arise from neoplastic transformation of pancreatic beta cells.
- Dogs > cats, usually older patients.
- Often functional and associated with hypoglycemia despite a normal or elevated serum insulin concentration [45].
- Clinical signs = seizures, weakness and collapse [46].

- Metastatic disease present at time of diagnosis in ~50% of dogs, mostly in liver and lymph nodes [46].

8.4.5.3 Prognosis

Good short-term control is possible, but long-term prognosis is guarded to poor. Medical therapy alone, and distant metastatic disease are associated with a poor prognosis [46, 47]. Surgical therapy ± medical therapy may result in prolonged survival times [47].

8.4.6 Non-epithelial Neoplasia

8.4.6.1 Cytologic Findings

Non-epithelial pancreatic tumors are rare [41, 43]. Lymphoma is one of the most common neoplasms identified (Figure 8.33), with other reported neoplasms including gastric carcinoma and histiocytic sarcoma [48, 49].

8.4.6.2 Clinical Considerations

- Correlate findings with clinical patient.

8.4.6.3 Prognosis

Guarded to poor. Most non-epithelial neoplastic processes in the pancreas represent a wide dissemination of the underlying disease.

8.4.7 Pancreatitis

8.4.7.1 Cytologic Features

Samples usually contain both inflammatory cells and epithelial sheets. Inflammatory cells may comprise mostly non-degenerative neutrophils (acute pancreatitis)

Figure 8.33 Pancreas, metastatic large granular lymphoma, cat, 100× objective.

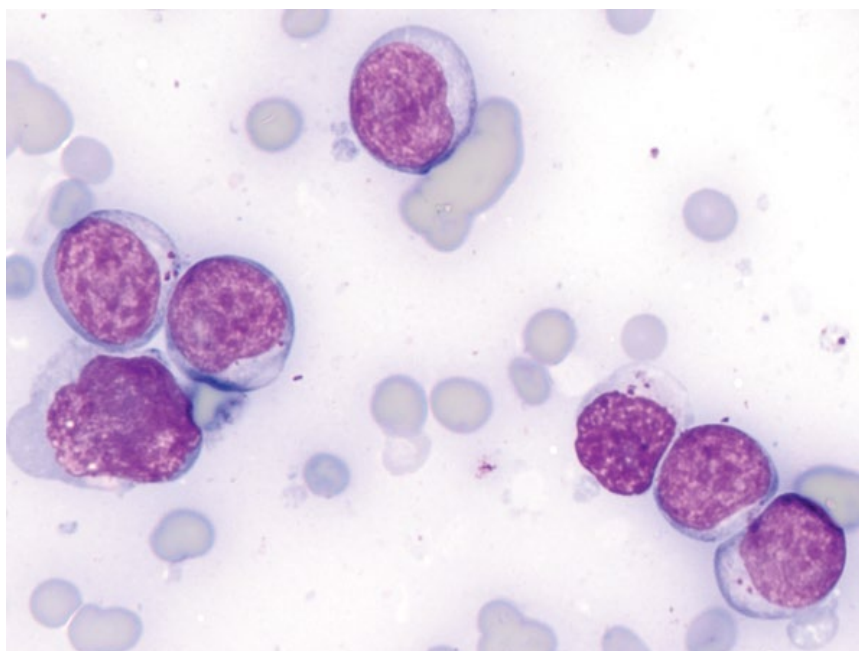
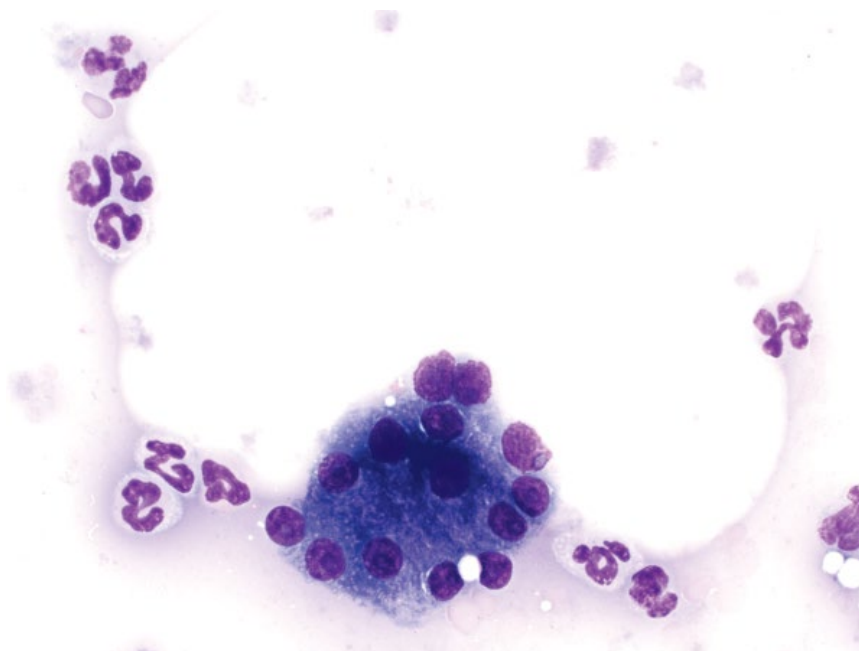


Figure 8.34 Pancreatitis, cat, 50× objective.



or lymphocytes/plasma cells (chronic pancreatitis). Epithelial cells generally are uniform, but they may have reactive changes such as a decreased volume of cytoplasm that is more basophilic (Figure 8.34).

8.4.7.2 Clinical Considerations

- Cytologic analysis of pancreatic inflammatory disorders correlates well with histologic analysis [43].

- Careful evaluation for any infectious organisms, and correlation with clinical and imaging findings is essential to differentiate neutrophilic pancreatitis from pancreatic abscesses (see section 8.4.8).

8.4.7.3 Prognosis

Variable, based on extent of inflammation and other comorbidities.

8.4.8 Pancreatic Abscess

8.4.8.1 Cytologic Features

Samples from pancreatic abscesses are dominated by variably degenerative neutrophils. Lesions may be sterile, or septic and, if present, intracellular bacteria confirm septic inflammation (Figure 8.35). Reactive macrophages and small mature lymphocytes also may

be present. Pancreatic epithelium may exfoliate and, if present, confirms pancreatic origin.

8.4.8.2 Clinical Considerations

- Rare in dogs and cats, and most develop as a sequela to pancreatitis.
- Most present as single masses, but infection may be diffuse [50].

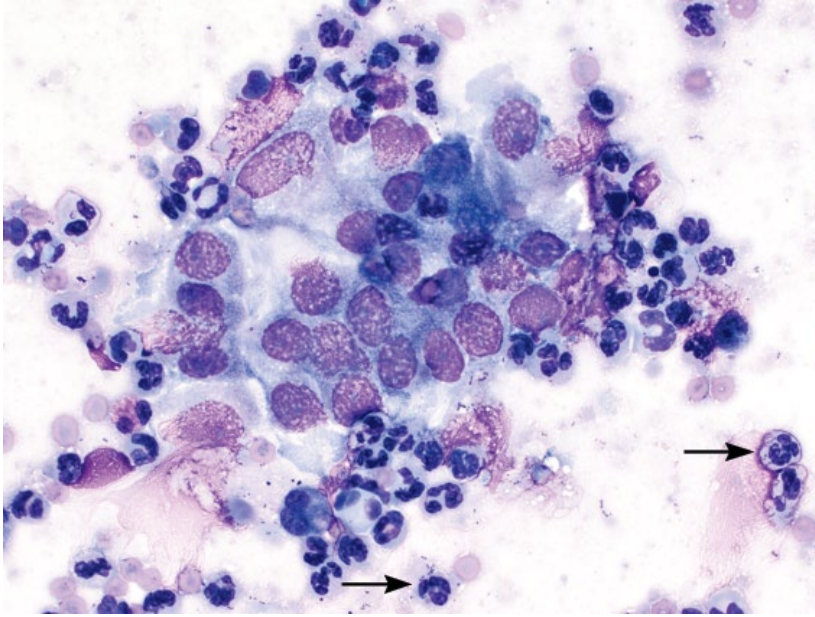


Figure 8.35 Pancreatic abscess, cat, 50× objective. Sheets of well-differentiated pancreatic epithelium are surrounded by neutrophils. Bacterial cocci are seen in the background and within neutrophils (arrows).

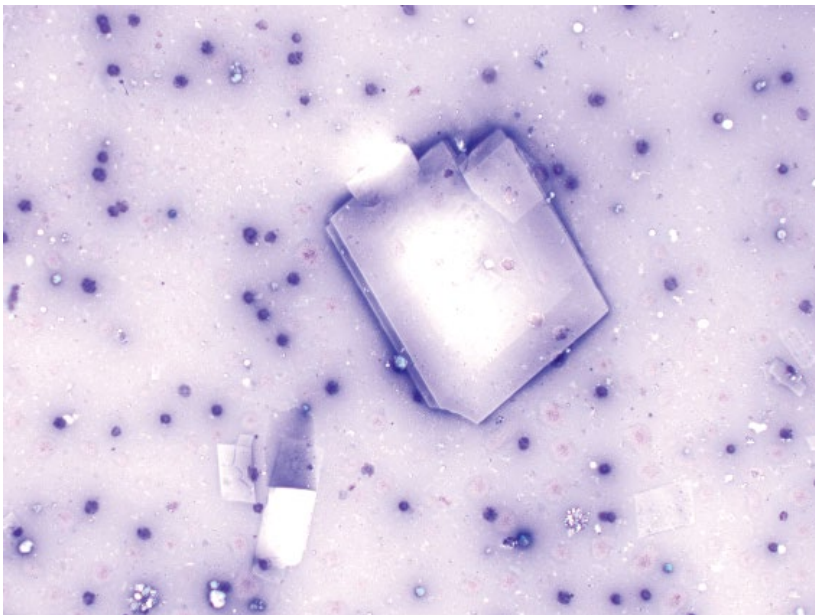


Figure 8.36 Pancreas, cyst, cat, 20× objective. Note the cholesterol crystals.

- Bacteria may not be seen, and microbial cultures frequently are negative [50, 51].
- Elevated BUN, ALP and rising HCO_3^- associated with poor outcome in dogs [50].

8.4.8.3 Prognosis

Guarded. Short-term mortality rates are high for dogs and cats (71% in a large retrospective study in dogs), but patients surviving surgery may do well [50–52].

8.4.9 Pancreatic Cyst

8.4.9.1 Cytologic Features

Pancreatic cysts appear similar to cystic lesions in other locations, and have a thick pink stippled to purple/blue proteinaceous background. Cellularity generally is low, and rare reactive macrophages or other inflammatory

cells may be seen. Abundant crystalline debris often is present in pancreatic cysts, and cholesterol crystals may be present (Figure 8.36).

8.4.9.2 Clinical Considerations

- Rare findings in dogs and cats [53].
- Most commonly pancreatic pseudocysts that contain pancreatic enzymes and debris. These likely form secondary to chronic pancreatitis.
- Congenital cysts are rare.
- Cytology useful to rule out other fluid-filled lesions (e.g., pancreatic abscess, cystic neoplasia).

8.4.9.3 Prognosis

Mostly good with drainage. Underlying disease likely more important for prognosis.

References

- 1 Boydell, P., Pike, R., Crossley, D., *et al.* (2000) Sialadenitis in dogs. *J. Am. Vet. Med. Assoc.*, **216** (6), 872–874.
- 2 Carberry, C.A., Flanders, J.A., Harvey, H.J., *et al.* (1988) Salivary gland tumors in dogs and cats: a literature and case review. *J. Am. Anim. Hosp. Assoc.*, **24**, 561–567.
- 3 Spangler, W.L., Culbertson, M.R. (1991) Salivary gland disease in dogs and cats: 245 cases (1985–1988). *J. Am. Vet. Med. Assoc.*, **198** (3), 465–469.
- 4 Hammer, A., Getzy, D., Ogilvie, G., *et al.* (2001) Salivary gland neoplasia in the dog and cat: survival times and prognostic factors. *J. Am. Anim. Hosp. Assoc.*, **37** (5), 478–482.
- 5 Volmer, C., Benal, Y., Caplier, L., *et al.* (2009) Atypical vimentin expression in a feline salivary gland adenocarcinoma with widespread metastases. *J. Vet. Med. Sci.*, **71** (12), 1681–1684.
- 6 Benamino, K.P., Birchard, S.J., Niles, J.D., *et al.* (2012) Pharyngeal mucoceles in dogs: 14 cases. *J. Am. Anim. Hosp. Assoc.*, **48** (1), 31–35.
- 7 Tsioli, V., Papazoglou, L.G., Basdani, E., *et al.* (2013) Surgical management of recurrent cervical sialoceles in four dogs. *J. Small Anim. Pract.*, **54** (6), 331–333.
- 8 Brown, N.O. (1989) Salivary gland diseases. Diagnosis, treatment, and associated problems. *Probl. Vet. Med.*, **1** (2), 281–294.
- 9 Jergens, A.E. (2012) Feline idiopathic inflammatory bowel disease: what we know and what remains to be unraveled. *J. Feline Med. Surg.*, **14** (7), 445–458.
- 10 Kiselow, M.A., Rassnick, K.M., McDonough, S.P., *et al.* (2008) Outcome of cats with low-grade lymphocytic lymphoma: 41 cases (1995–2005). *J. Am. Vet. Med. Assoc.*, **232** (3), 405–410.
- 11 Stein, T.J., Pellin, M., Steinberg, H., *et al.* (2010) Treatment of feline gastrointestinal small-cell lymphoma with chlorambucil and glucocorticoids. *J. Am. Anim. Hosp. Assoc.*, **46** (6), 413–417.
- 12 Gieger, T. (2011) Alimentary lymphoma in cats and dogs. *Vet. Clin. North Am. Small Anim. Pract.*, **41** (2), 419–432.
- 13 Couto, C.G., Rutgers, H.C., Sherding, R.G., *et al.* (1989) Gastrointestinal lymphoma in 20 dogs. A retrospective study. *J. Vet. Intern. Med.*, **3** (2), 73–78.
- 14 Ozaki, K., Yamagami, T., Nomura, K., *et al.* (2006) T-cell lymphoma with eosinophilic infiltration involving the intestinal tract in 11 dogs. *Vet. Pathol.*, **43** (3), 339–344.
- 15 Gouldin, E.D., Mullin, C., Morges, M., *et al.* (2015) Feline discrete high-grade gastrointestinal lymphoma treated with surgical resection and adjuvant CHOP-based chemotherapy: retrospective study of 20 cases. *Vet. Comp. Oncol.*, 2015 Sep 3. doi: 10.1111/vco.12166. Epub ahead of print. Last accessed May 1, 2017.
- 16 Frank, J.D., Reimer, S.B., Kass, P.H., *et al.* (2007) Clinical outcomes of 30 cases (1997–2004) of canine gastrointestinal lymphoma. *J. Am. Anim. Hosp. Assoc.*, **43** (6), 313–321.
- 17 Krick, E.L., Little, L., Patel, R., *et al.* (2008) Description of clinical and pathological findings, treatment and outcome of feline large granular lymphocyte lymphoma (1996–2004). *Vet. Comp. Oncol.*, **6** (2), 102–110.
- 18 Snead, E.C. (2007) Large granular intestinal lymphosarcoma and leukemia in a dog. *Can. Vet. J.*, **48** (8), 848–851.
- 19 Kupanoff, P.A., Popovitch, C.A., Goldschmidt, M.H. (2006) Colorectal plasmacytomas: a retrospective study of nine dogs. *J. Am. Anim. Hosp. Assoc.*, **42** (1), 37–43.

- 20 Risetto, K., Villamil, J.A., Selting, K.A., *et al.* (2011) Recent trends in feline intestinal neoplasia: an epidemiologic study of 1,129 cases in the veterinary medical database from 1964 to 2004. *J. Am. Anim. Hosp. Assoc.*, **47** (1), 28–36.
- 21 Laurenson, M.P., Skorupski, K.A., Moore, P.F., *et al.* (2011) Ultrasonography of intestinal mast cell tumors in the cat. *Vet. Radiol. Ultrasound*, **52** (3), 330–334.
- 22 Henry, C., Herrera, C. (2013) Mast cell tumors in cats: clinical update and possible new treatment avenues. *J. Feline Med. Surg.*, **15** (1), 41–47.
- 23 Valerius, K.D., Powers, B.E., McPherron, M.A., *et al.* (1997) Adenomatous polyps and carcinoma in situ of the canine colon and rectum: 34 cases (1982–1994). *J. Am. Anim. Hosp. Assoc.*, **33** (2), 156–160.
- 24 Seiler, R.J. (1979) Colorectal polyps of the dog: a clinicopathologic study of 17 cases. *J. Am. Vet. Med. Assoc.*, **174** (1), 72–75.
- 25 Green, M.L., Smith, J.D., Kass, P.H. (2011) Surgical versus non-surgical treatment of feline small intestinal adenocarcinoma and the influence of metastasis on long-term survival in 18 cats (2000–2007). *Can. Vet. J.*, **52** (10), 1101–1105.
- 26 Patnaik, A.K., Hurvitz, A.I., Johnson, G.F. (1980) Canine intestinal adenocarcinoma and carcinoid. *Vet. Pathol.*, **17** (2), 149–163.
- 27 Sako, T., Uchida, E., Okamoto, M., *et al.* (2003) Immunohistochemical evaluation of a malignant intestinal carcinoid in a dog. *Vet. Pathol.*, **40** (2), 212–215.
- 28 Sykes, G.P., Cooper, B.J. (1982) Canine intestinal carcinoids. *Vet. Pathol.*, **19** (2), 120–131.
- 29 Frost, D., Lasota, J., Miettinen, M. (2003) Gastrointestinal stromal tumors and leiomyomas in the dog: a histopathologic, immunohistochemical, and molecular genetic study of 50 cases. *Vet. Pathol.*, **40** (1), 42–54.
- 30 Russell, K.N., Mehler, S.J., Skorupski, K.A., *et al.* (2007) Clinical and immunohistochemical differentiation of gastrointestinal stromal tumors from leiomyosarcomas in dogs: 42 cases (1990–2003). *J. Am. Vet. Med. Assoc.*, **230** (9), 1329–1333.
- 31 Kapatkin, A.S., Mullen, H.S., Matthiesen, D.T., *et al.* (1992) Leiomyosarcoma in dogs: 44 cases (1983–1988). *J. Am. Vet. Med. Assoc.*, **201** (7), 1077–1079.
- 32 Cohen, M., Post, G.S., Wright, J.C. (2003) Gastrointestinal leiomyosarcoma in 14 dogs. *J. Vet. Intern. Med.*, **17** (1), 107–110.
- 33 Broussard, J.D. (2003) Optimal fecal assessment. *Clin. Tech. Small Anim. Pract.*, **18** (4), 218–230.
- 34 Minamoto, Y., Otoni, C.C., Steelman, S.M., *et al.* (2015) Alteration of the fecal microbiota and serum metabolite profiles in dogs with idiopathic inflammatory bowel disease. *Gut Microbes*, **6** (1), 33–47.
- 35 Epe, C. (2009) Intestinal nematodes: biology and control. *Vet. Clin. North Am. Small Anim. Pract.*, **39** (6), 1091–1107.
- 36 Little, S.E., Johnson, E.M., Lewis, D., *et al.* (2009) Prevalence of intestinal parasites in pet dogs in the United States. *Vet. Parasitol.*, **166** (1–2), 144–152.
- 37 Gates, M.C., Nolan, T.J. (2014) Declines in canine endoparasite prevalence associated with the introduction of commercial heartworm and flea preventatives from 1984 to 2007. *Vet. Parasitol.*, **204** (3–4), 265–268.
- 38 Conboy, G. (2009) Cestodes of dogs and cats in North America. *Vet. Clin. North Am. Small Anim. Pract.*, **39** (6), 1075–1090.
- 39 Barta, J.R., Schrenzel, M.D., Carreno, R., *et al.* (2005) The genus *Atoxoplasma* (Garnham 1950) as a junior objective synonym of the genus *Isospora* (Schneider 1881) species infecting birds and resurrection of *Cystoisospora* (Frenkel 1977) as the correct genus for *Isospora* species infecting mammals. *J. Parasitol.*, **91** (3), 726–727.
- 40 Litster, A.L., Nichols, J., Hall, K., *et al.* (2014) Use of ponazuril paste to treat coccidiosis in shelter-housed cats and dogs. *Vet. Parasitol.*, **202** (3–4), 319–325.
- 41 Hecht, S., Penninck, D.G., Keating, J.H. (2007) Imaging findings in pancreatic neoplasia and nodular hyperplasia in 19 cats. *Vet. Radiol. Ultrasound*, **48** (1), 45–50.
- 42 Lin, F., Staerckel, G. (2003) Cytologic criteria for well differentiated adenocarcinoma of the pancreas in fine-needle aspiration biopsy specimens. *Cancer*, **99** (1), 44–50.
- 43 Cordner, A.P., Sharkey, L.C., Armstrong, P.J., *et al.* (2015) Cytologic findings and diagnostic yield in 92 dogs undergoing fine-needle aspiration of the pancreas. *J. Vet. Diagn. Invest.*, **27** (2), 236–240.
- 44 Bennett, P.F., Hahn, K.A., Toal, R.L., *et al.* (2001) Ultrasonographic and cytopathological diagnosis of exocrine pancreatic carcinoma in the dog and cat. *J. Am. Anim. Hosp. Assoc.*, **37** (5), 466–473.
- 45 Siliart, B., Stambouli, F. (1996) Laboratory diagnosis of insulinoma in the dog: a retrospective study and a new diagnostic procedure. *J. Small Anim. Pract.*, **37** (8), 367–370.
- 46 Goutal, C.M., Brugmann, B.L., Ryan, K.A. (2012) Insulinoma in dogs: a review. *J. Am. Anim. Hosp. Assoc.*, **48** (3), 151–163.
- 47 Polton, G.A., White, R.N., Brearley, M.J., *et al.* (2007) Improved survival in a retrospective cohort of 28 dogs with insulinoma. *J. Small Anim. Pract.*, **48** (3), 151–156.
- 48 Lamb, C.R., Simpson, K.W., Boswood, A., *et al.* (1995) Ultrasonography of pancreatic neoplasia in the dog: a retrospective review of 16 cases. *Vet. Rec.*, **137** (3), 65–68.

- 49 Hayden, D.W., Waters, D.J., Burke, B.A., *et al.* (1993) Disseminated malignant histiocytosis in a golden retriever: clinicopathologic, ultrastructural, and immunohistochemical findings. *Vet. Pathol.*, **30** (3), 256–264.
- 50 Anderson, J.R., Cornell, K.K., Parnell, N.K., *et al.* (2008) Pancreatic abscess in 36 dogs: a retrospective analysis of prognostic indicators. *J. Am. Anim. Hosp. Assoc.*, **44** (4), 171–179.
- 51 Johnson, M.D., Mann, F.A. (2006) Treatment for pancreatic abscesses via omentalization with abdominal closure versus open peritoneal drainage in dogs: 15 cases (1994–2004). *J. Am. Vet. Med. Assoc.*, **228** (3), 397–402.
- 52 Son, T.T., Thompson, L., Serrano, S., *et al.* (2010) Surgical intervention in the management of severe acute pancreatitis in cats: 8 cases (2003–2007). *J. Vet. Emerg. Crit. Care*, **20** (4), 426–435.
- 53 VanEnkevort, B.A., O'Brien, R.T., Young, K.M. (1999) Pancreatic pseudocysts in 4 dogs and 2 cats: ultrasonographic and clinicopathologic findings. *J. Vet. Intern. Med.*, **13** (4), 309–313.

9

Urinary

9.1 Kidney

9.1.1 Normal

9.1.1.1 Cytologic Appearance

Normal renal epithelial cells are round, and may exfoliate individually or in small cohesive sheets. They have abundant clear to pale-blue cytoplasm, and may contain coarse clear lipid vacuoles, particularly in cats (Figure 9.1). Glomerular tufts of capillaries may also be sampled (Figure 9.2).

9.1.2 Pyelonephritis

9.1.2.1 Cytologic Appearance

Generally characterized by a marked inflammatory infiltrate. Degenerative neutrophils containing intracellular bacteria are most common. Granulomatous inflammation is associated with fungal and *Mycobacterium* infections. Sheets of renal epithelial cells also may be seen (Figure 9.3).

9.1.2.2 Clinical Considerations

- Usually secondary to ascending infection.
- *Escherichia coli* most common agent in dogs [1].

9.1.2.3 Prognosis

Variable, based on severity and any underlying kidney damage. Pyelonephritis can be fatal.

9.1.3 Renal Carcinomas

9.1.3.1 Cytologic Appearance

Renal carcinomas often exfoliate well, in cohesive sheets with variably prominent intercellular borders. Nuclei are round to polygonal with medium-blue cytoplasm that may contain small clear vacuoles. Nuclei are ovoid with finely granular chromatin and prominent, often multiple nucleoli. Anisocytosis/anisokaryosis vary from mild to moderate in well-differentiated tumors, to marked in anaplastic neoplasms. Renal carcinoma (Figure 9.4), adenocarcinomas (tubular and papillary) (Figures 9.5

and 9.6), and transitional cell carcinoma (Figure 9.7), among others are reported.

9.1.3.2 Clinical Considerations

- Most common primary tumor of the kidney.
- Unilateral or bilateral [2].
- Highly locally invasive (may invade vena cava) and high metastatic rate.
- *Note:* metastatic disease to kidneys is more common than primary renal neoplasia.

9.1.3.3 Prognosis

Guarded. All carcinoma types have similar clinical behavior. Nephrectomy for unilateral tumors with no evidence of metastatic disease may achieve moderate survival times [2]. Poor prognosis if surgery not performed/not possible.

9.1.4 Nephroblastoma

9.1.4.1 Cytologic Appearance

The epithelial component of nephroblastomas often exfoliates well as variably cohesive sheets of ovoid cells with a moderate volume of pale-blue cytoplasm. Bright-pink basement membrane-like material may be present (Figure 9.8). Nuclei are ovoid with finely clumped chromatin and small or inapparent nucleoli. Mitotic figures may be seen (Figure 9.9). Anisocytosis/anisokaryosis typically are mild to moderate (compared to renal carcinomas). Evaluation for areas of cohesion can be important to differentiate between loosely cohesive nephroblastomas and renal lymphoma (compare Figures 9.9 and 9.10).

9.1.4.2 Clinical Considerations

- Rare tumors of embryonal metanephric blastema with epithelial and mesenchymal components.
- Dogs > cats
- Patients often younger than those with renal carcinoma or sarcomas, and can be seen in dogs and cats <1 year of age [3].
- Solitary, unilateral tumors [2].
- May also be seen in the spinal cord (see Chapter 13).

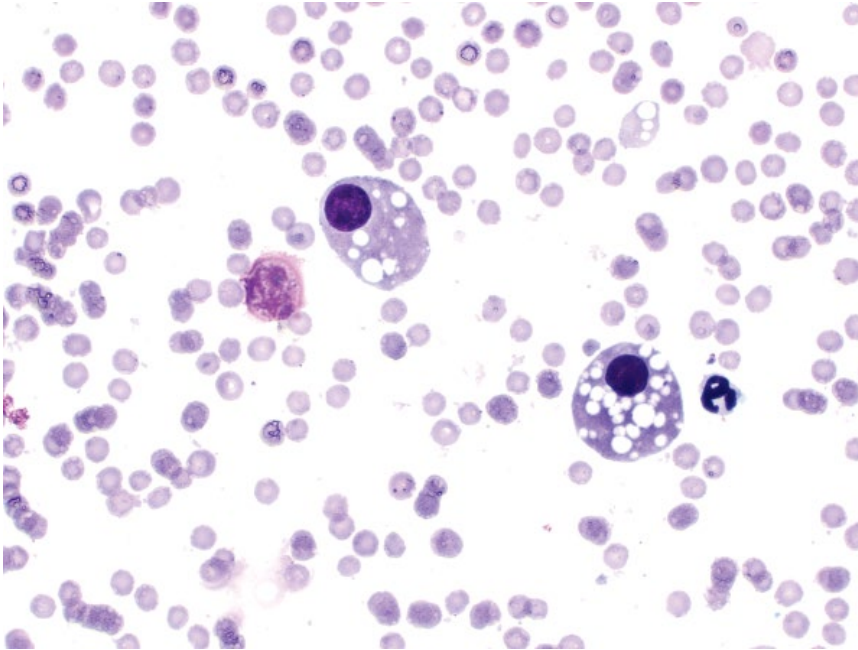


Figure 9.1 Normal renal tubular epithelial cells, cat, 50× objective. Note the coarse, clear lipid vacuoles in the cytoplasm.

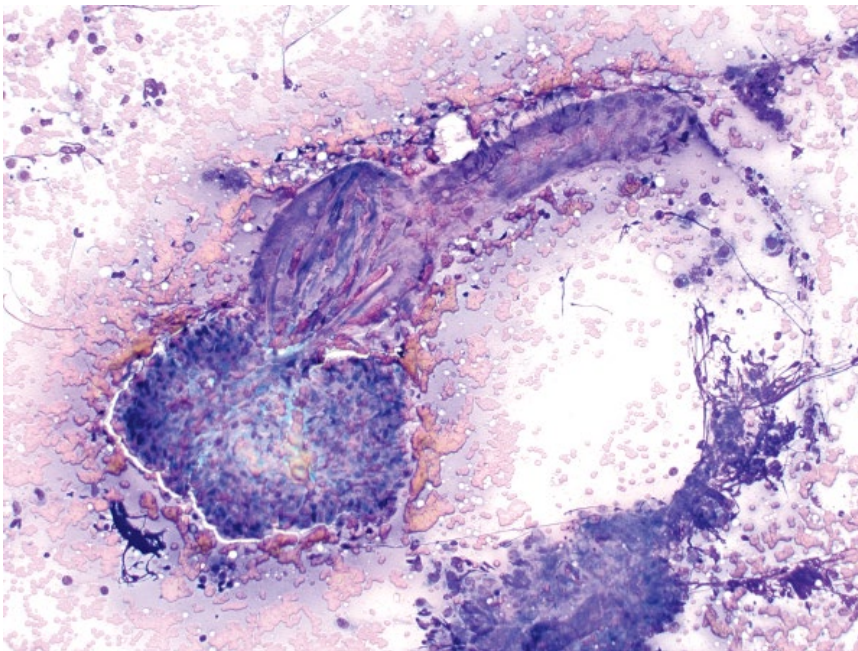


Figure 9.2 Glomerular tuft, cat, 10× objective. Note the linear renal tubule extending from the glomerular tuft.

9.1.4.3 Prognosis

Guarded to poor. Metastatic disease occurs early and widely, and survival times are short, even with surgery [2].

9.1.5 Lymphoma

9.1.5.1 Cytologic Appearance

Renal lymphomas often exfoliate in large numbers, comprising individualized cells with nuclei about two to three red blood cells in diameter, and finely stippled

chromatin. The cells have a moderate volume of medium- to deep-blue cytoplasm that frequently contains fine clear vacuoles (Figure 9.10).

9.1.5.2 Clinical Considerations

- Bilateral > unilateral [4].
- May be primary (more common in cats) or part of multicentric disease.
- Clinical findings = renomegaly, inappetence, weight loss, polyuria/polydipsia [5].

Figure 9.3 Pyelonephritis, dog, 50× objective.

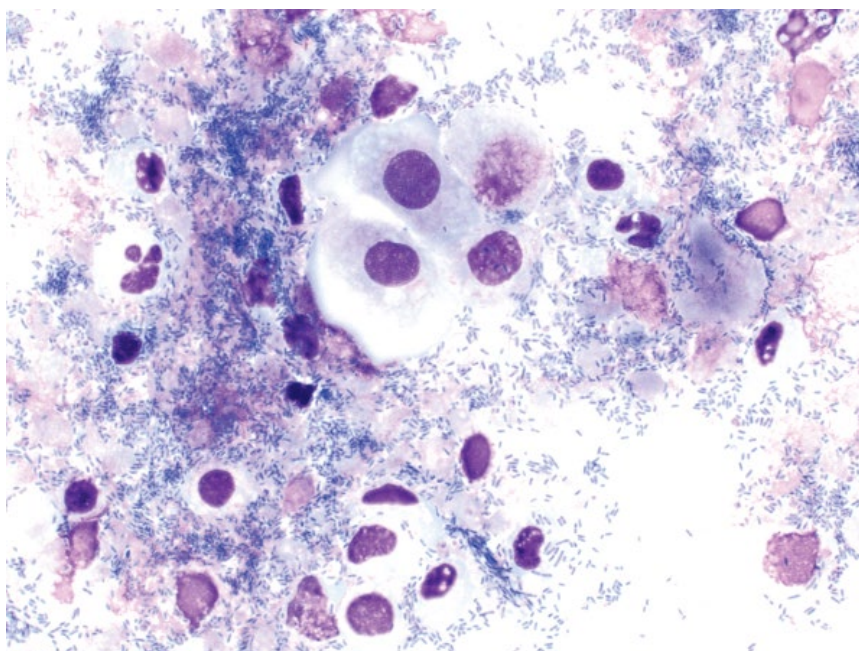
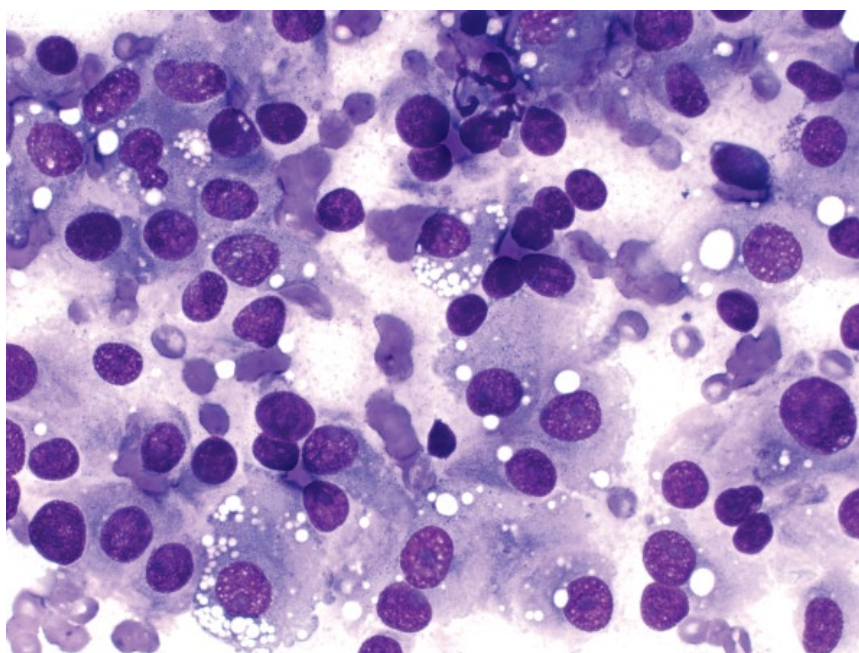


Figure 9.4 Renal carcinoma, dog, 50× objective.



9.1.5.3 Prognosis

Poor. Remission and survival times are short [5–7].

9.1.6 Renal Sarcomas

9.1.6.1 Cytologic Appearance

Sarcomas of the kidney exfoliate variably well, with cells seen individually or in aggregates. They have a small to moderate volume of cytoplasm forming bipolar tapering ends, and ovoid to elongated nuclei with granular

chromatin and prominent nucleoli. Anisocytosis/anisokaryosis usually are moderate to marked, and N/C ratios often are high (Figures 9.11 and 9.12).

9.1.6.2 Clinical Considerations

- Unilateral [2].
- Dogs > cats [2, 8].
- Hemangiosarcoma and renal sarcoma most common [2, 9].

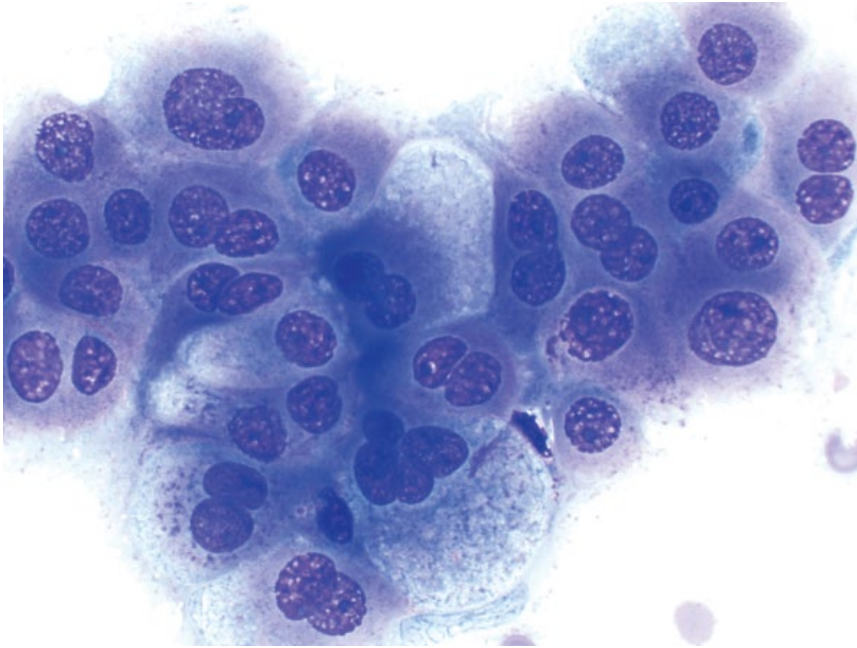


Figure 9.5 Renal adenocarcinoma (tubular), dog, 50× objective.

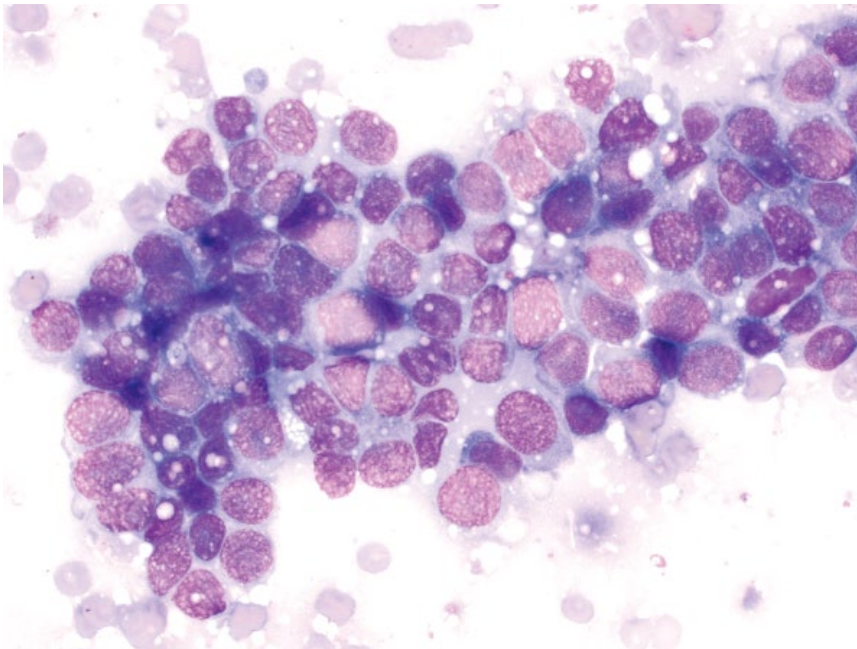


Figure 9.6 Renal adenocarcinoma (papillary), dog, 50× objective.

9.1.6.3 Prognosis

Guarded to poor. High rates of metastasis and short survival times reported [2].

9.1.7 Renal Cysts

9.1.7.1 Cytologic Appearance

Renal cysts have a thick proteinaceous background that may be pink, blue, or purple. Cholesterol crystals and

inflammatory cells – particularly reactive macrophages – often are present (Figure 9.13). Renal epithelial cells are variably present.

9.1.7.2 Clinical Considerations

- May be unilateral or bilateral.
- DDx = simple renal cysts, polycystic kidney disease, renal dysplasia, perinephric pseudocysts [10, 11].

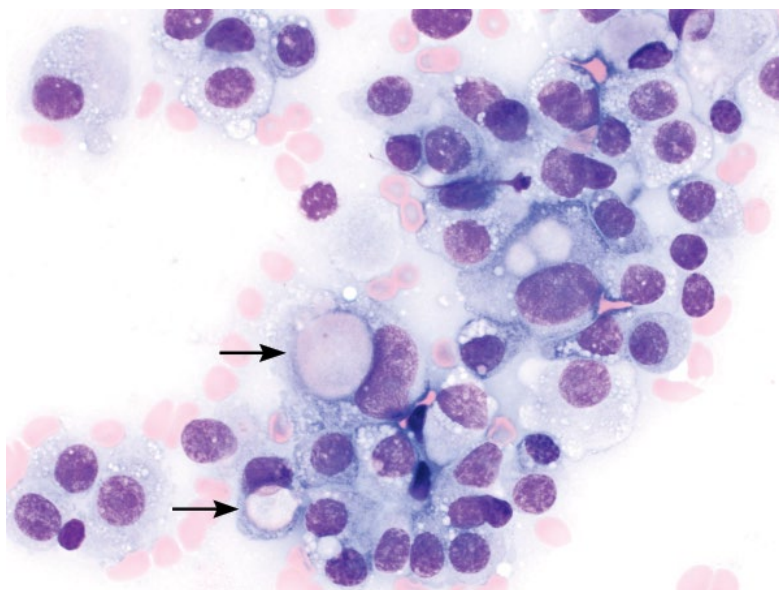


Figure 9.7 Renal transitional cell carcinoma, dog, 50× objective. Note the round, pink secretory material in the cytoplasm of some cells (arrows).

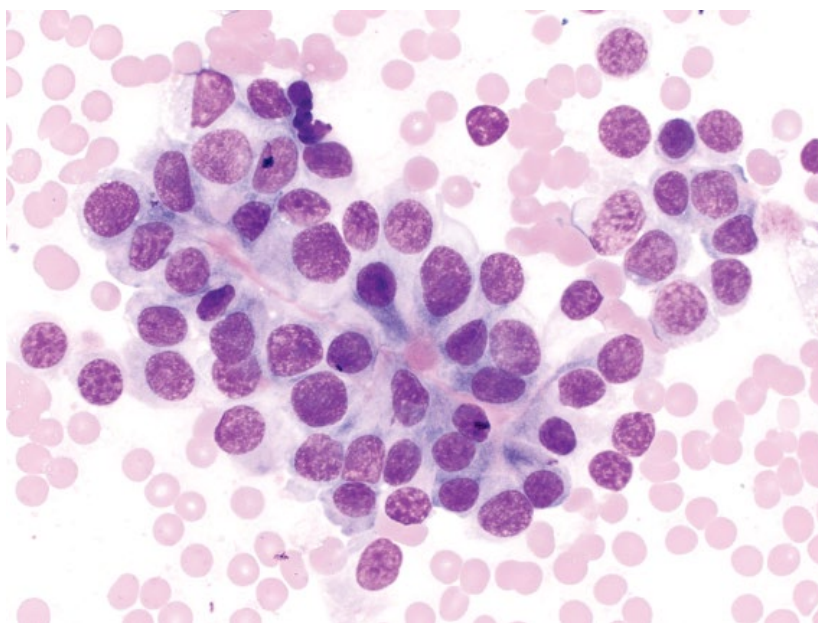


Figure 9.8 Nephroblastoma, dog, 50× objective. Note the bright pink basement membrane between cells.

9.1.7.3 Prognosis

Variable based on underlying cause. Simple renal cysts often are incidental; perinephric pseudocysts carry a good prognosis [10, 11].

9.2 Bladder

9.2.1 Hyperplastic Epithelium

9.2.1.1 Cytologic Appearance

Hyperplastic transitional epithelium can be highly pleomorphic, and may mimic neoplasia (compare Figures 9.14

and 9.16). It is normally seen secondary to inflammation (septic or sterile) or trauma/irritation (e.g., due to urolithiasis), and evidence of inflammation, infectious organisms or crystalluria frequently is present.

9.2.1.2 Clinical Considerations

- False-positive diagnoses of neoplasia may be made [12]. Always correlate with clinical/imaging findings, and histopathology may be required.

9.2.1.3 Prognosis

Excellent with treatment of the underlying inflammation/infection.

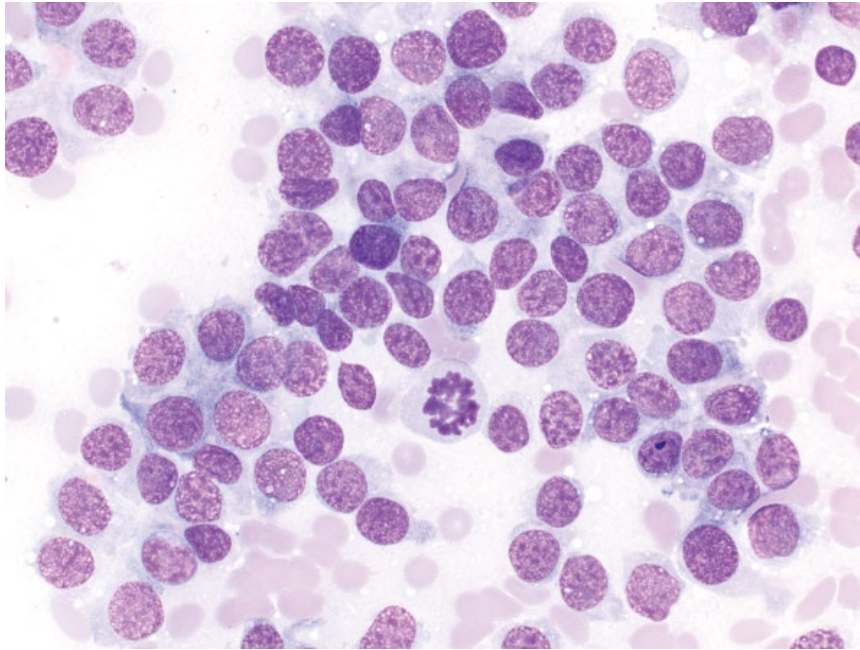


Figure 9.9 Nephroblastoma, dog, 50× objective. Cells are variably cohesive and mitotic figures are common (middle).

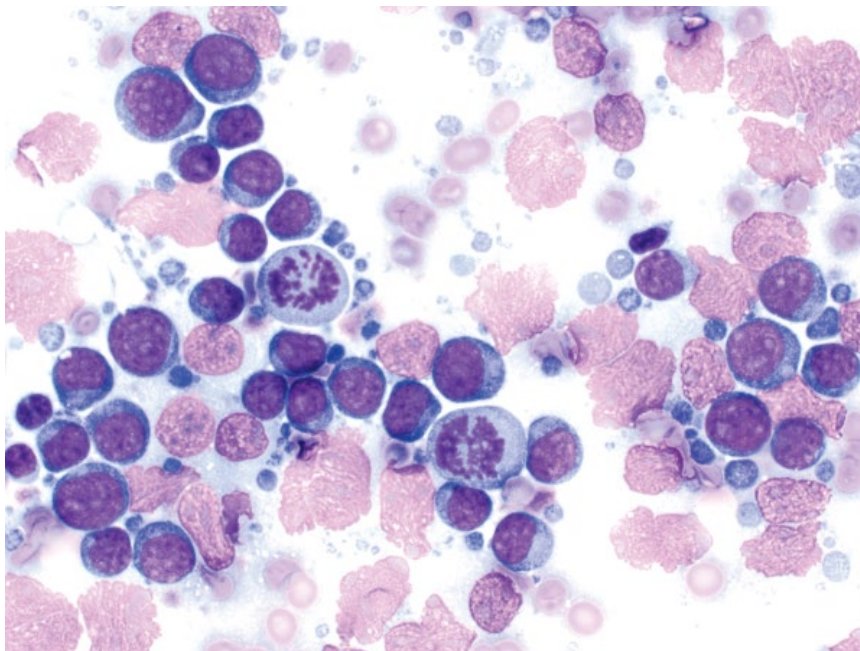


Figure 9.10 Renal lymphoma, dog, 50× objective.

9.2.2 Papilloma/Polyp

9.2.2.1 Cytologic Appearance

Papillomas and polyps exfoliate as cohesive sheets of monomorphic cells, in contrast to the gradient of pleomorphism seen with hyperplastic epithelium (compare Figures 9.15 and 9.14). Cells are round to polygonal, and have a moderate volume of pale-blue cytoplasm. Nuclei are ovoid, with finely granular chromatin and small or

inapparent nucleoli. Anisocytosis/anisokaryosis are mild, and N/C ratios are moderate to low.

9.2.2.2 Clinical Considerations

- Much less common than malignant tumors [13].
- May represent benign neoplasia or non-neoplastic hyperplasia (e.g., polypoid cystitis) [14, 15].
- Unknown if papillomas/polyps represent a pre-neoplastic lesion [15].

Figure 9.11 Renal sarcoma, dog, 50× objective.

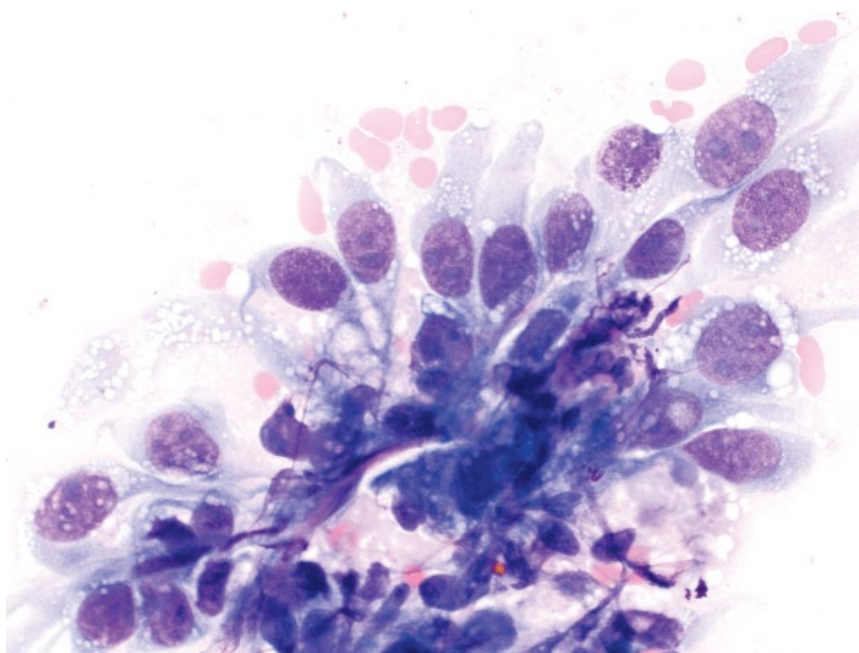
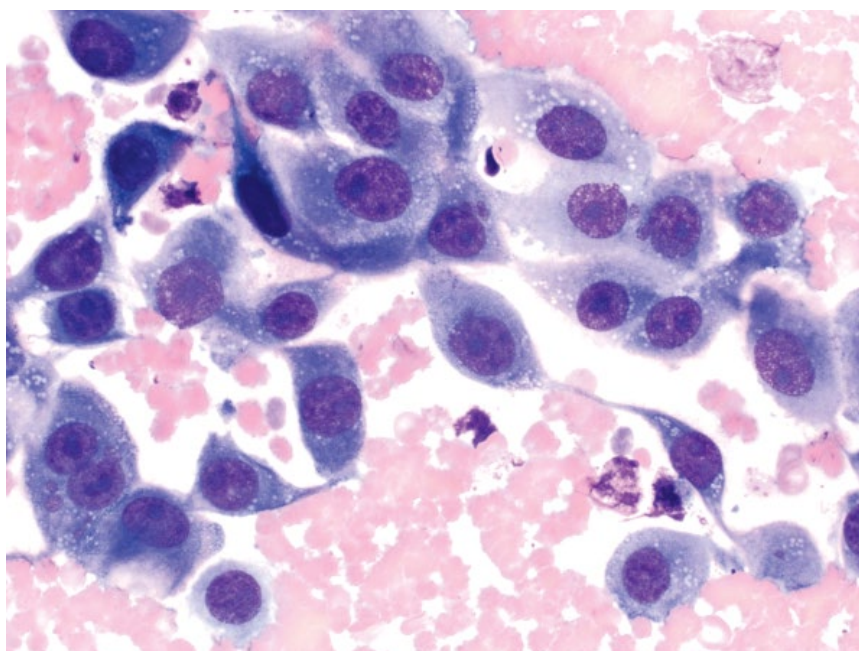


Figure 9.12 Renal hemangiosarcoma, dog, 50× objective.



9.2.2.3 Prognosis
Excellent.

9.2.3 Transitional Cell Carcinoma

9.2.3.1 Cytologic Appearance

Transitional cell carcinomas (TCC) exfoliate as sheets of epithelial cells that are round to polygonal. They have a variable volume of cytoplasm that frequently contains bright-pink, spherical inclusions of secretory material

(Figure 9.16). Nuclei are ovoid, with granular chromatin and often multiple, prominent nucleoli. Multinucleation is common. Anisocytosis/anisokaryosis are marked, and N/C ratios are variable.

9.2.3.2 Clinical Considerations

- Dogs >> cats. Most common bladder tumor in both species [16–18].
- Most often located in trigone region in dogs, but not in cats [19, 20].

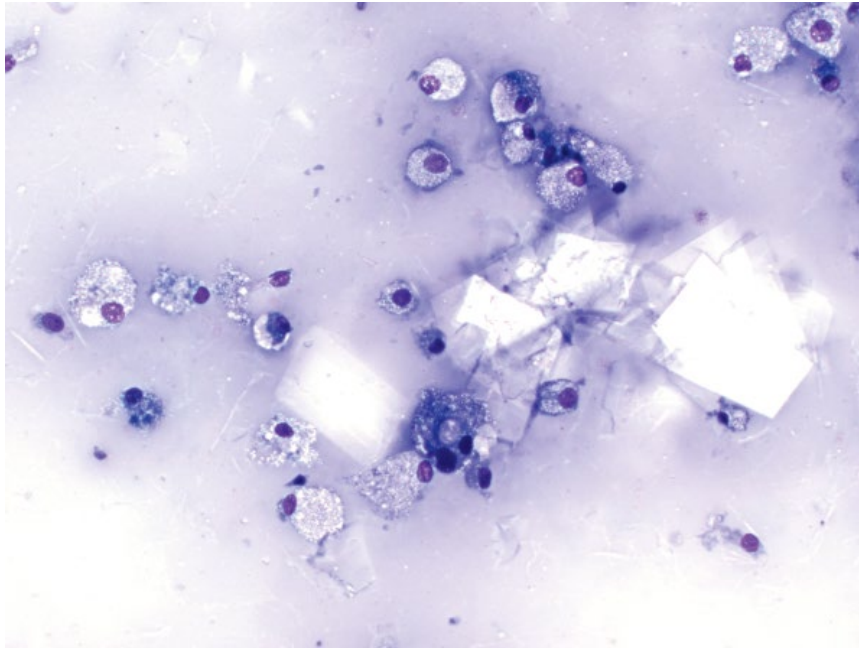


Figure 9.13 Renal cyst, cat, 20× objective. Note the large, rectangular, clear cholesterol crystals and reactive macrophages.

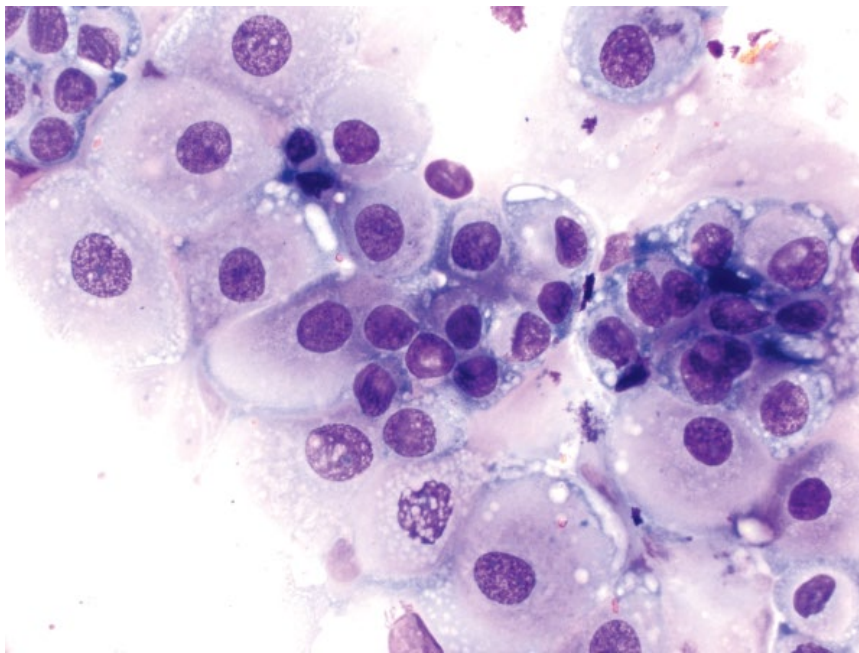


Figure 9.14 Bladder, transitional epithelial hyperplasia, dog, 50× objective.

- Predisposing factors = females, neutered animals, breeds = Scottish Terrier, Shetland Sheepdog, Beagle, Wire-haired Fox Terrier, West Highland White Terrier [19].

9.2.3.3 Prognosis

Guarded to poor [19–21]. Increased tumor size and presence of metastatic disease significantly decrease survival times [19].

9.2.4 Other Neoplasms

Other neoplasms that rarely affect the bladder include lymphoma (see Chapter 4), SCC (see Chapter 3),

rhabdomyoma/sarcoma, leiomyoma/sarcoma (see Chapter 6), and hemangiosarcoma (see section 9.1.6).

9.3 Urine

9.3.1 Normal/Hyperplastic Epithelium

9.3.1.1 Cytologic Appearance

Normal transitional epithelial cells are monomorphic, with minimal pleomorphism and low N/C ratios (Figure 9.17). Hyperplastic transitional epithelial cells can exfoliate into urine, and have increased pleomorphism

Figure 9.15 Bladder, polyp, dog, 50× objective.

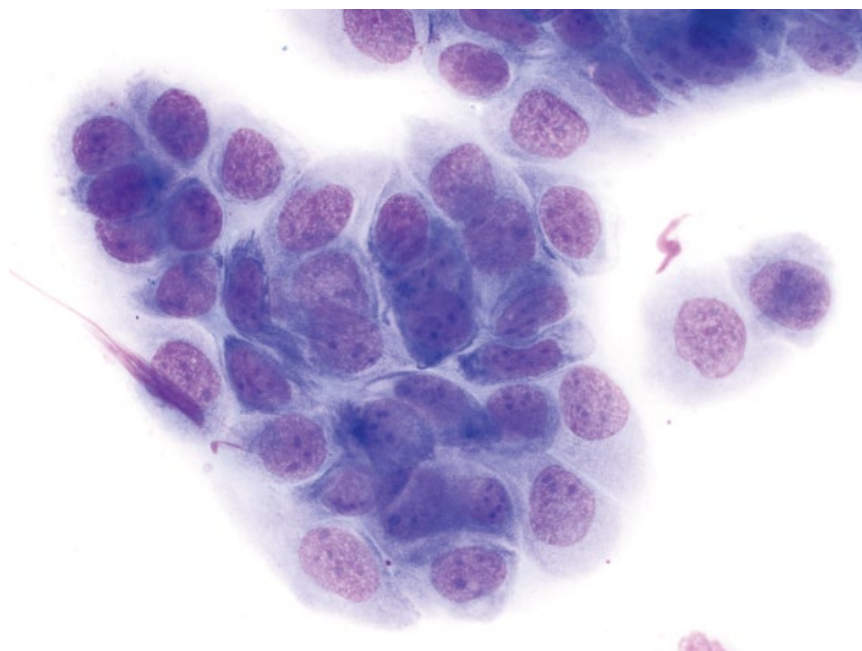
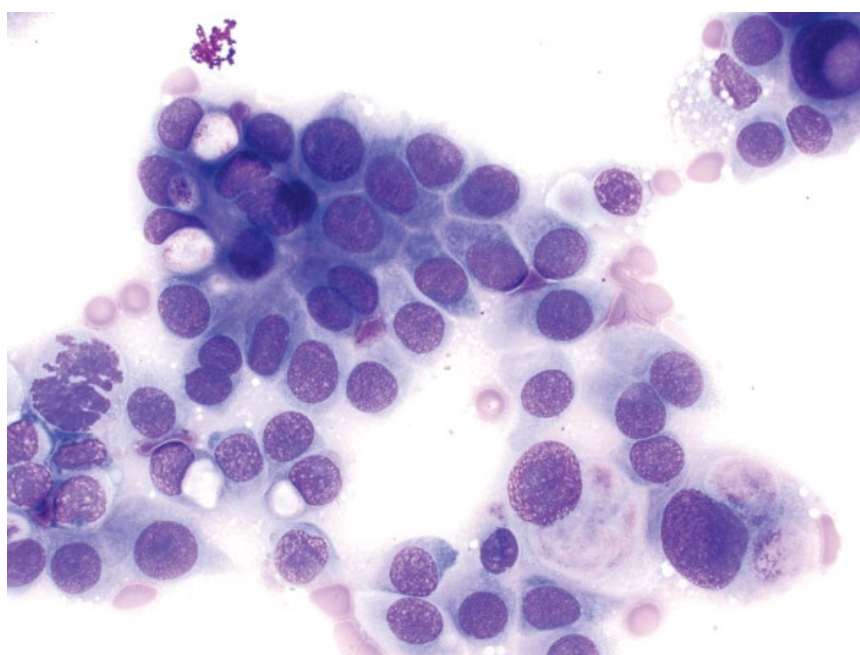


Figure 9.16 Bladder transitional cell carcinoma, dog, 50× objective.



that may mimic neoplasia (Figure 9.18). As described above, in section 9.2.1, they often are accompanied by evidence of inflammation, infectious organisms, or crystals.

9.3.1.2 Clinical Considerations

- False-positive diagnoses of neoplasia may be made [12]. Always correlate with clinical/imaging findings, and histopathology may be required.

9.3.1.3 Prognosis

Excellent with treatment of the underlying inflammation/infection.

9.3.2 Neoplastic Epithelium

9.3.2.1 Cytologic Appearance

Exfoliation of neoplastic cells into urine is uncommon, and differentiation from epithelial hyperplasia can be difficult. Neoplastic cells should have marked criteria

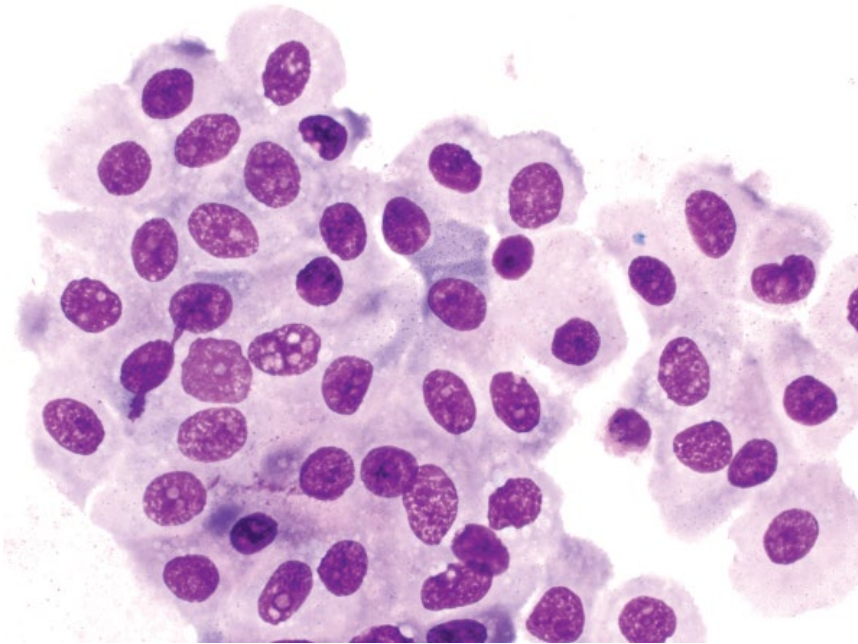


Figure 9.17 Urine, normal transitional epithelium, dog, 50× objective.

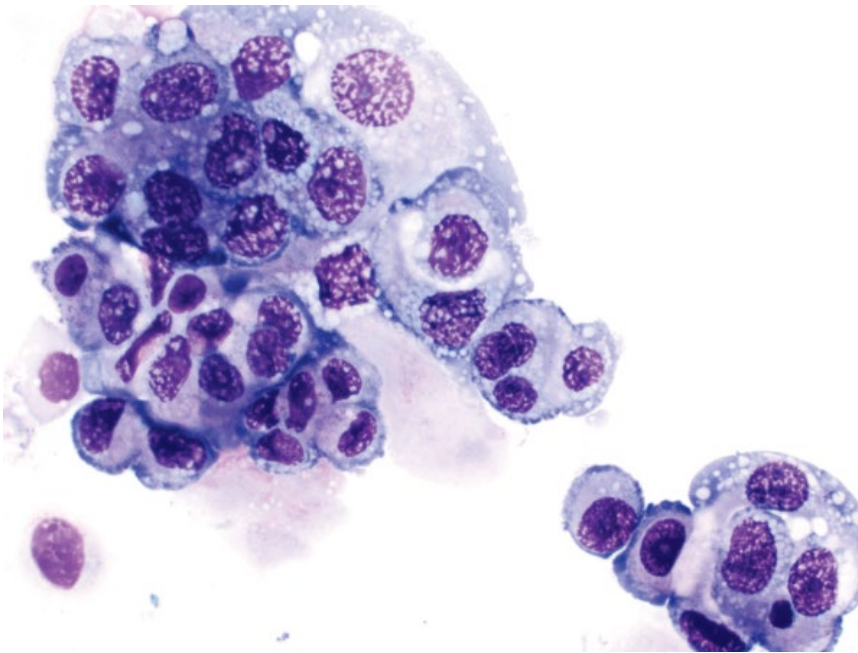


Figure 9.18 Urine, transitional epithelial hyperplasia, dog, 50× objective.

of malignancy, including marked anisocytosis/anisokaryosis, prominent nucleoli ± mitotic figures (Figures 9.19 and 9.20).

9.3.2.2 Clinical Considerations

- Atypical epithelial cells should be correlated with clinical and diagnostic imaging findings.
- Traumatic catheterization or direct aspiration of any masses is more reliable for diagnosis.

9.3.2.3 Prognosis

Poor.

9.3.3 Inflammation/Infection

9.3.3.1 Cytologic Appearance

Leukocytes should be seen in low numbers in normal urine (<3 per 40× objective field in a wet preparation). Neutrophils are most frequently seen, and may be

Figure 9.19 Urine, transitional cell carcinoma, dog, 50× objective.

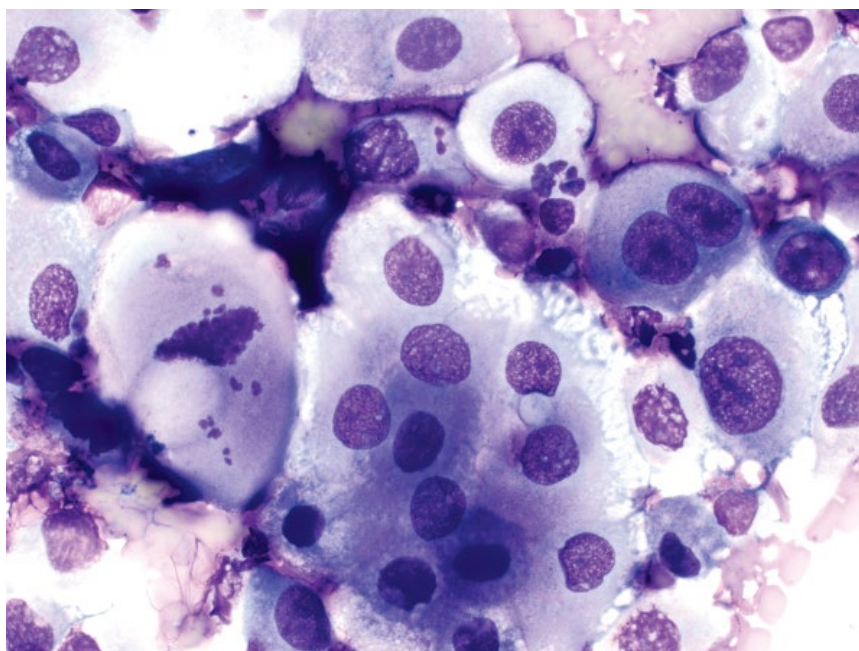
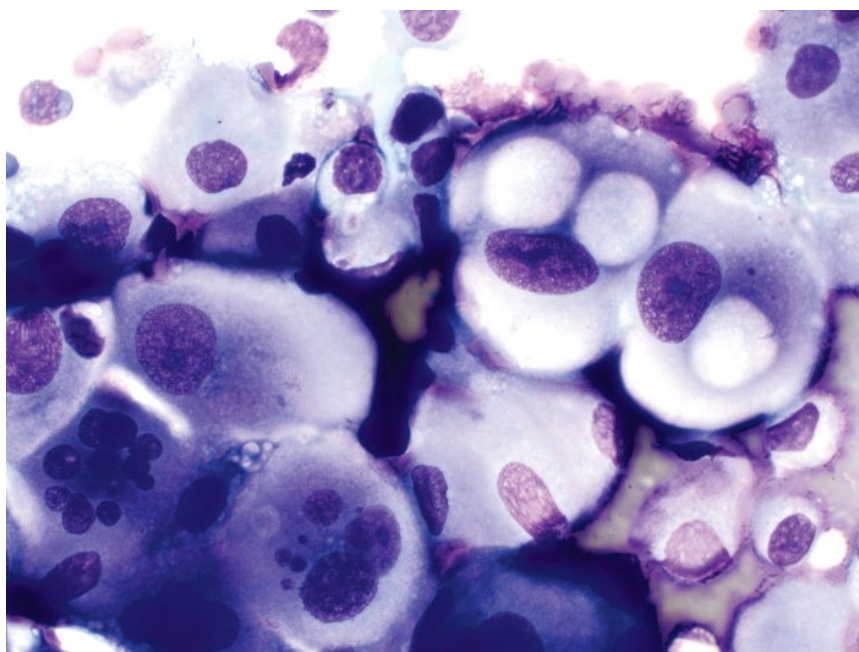


Figure 9.20 Urine, transitional cell carcinoma, dog, 50× objective.



associated with infectious organisms such as bacteria (Figure 9.21) or fungal agents (Figure 9.22).

9.3.3.2 Clinical Considerations

- Stained slides are recommended to most accurately evaluate infectious organisms [22, 23].

- Microbial culture and susceptibility testing is recommended even if bacteria are not seen.

9.3.3.3 Prognosis

Generally excellent, but variable with underlying cause of inflammation.

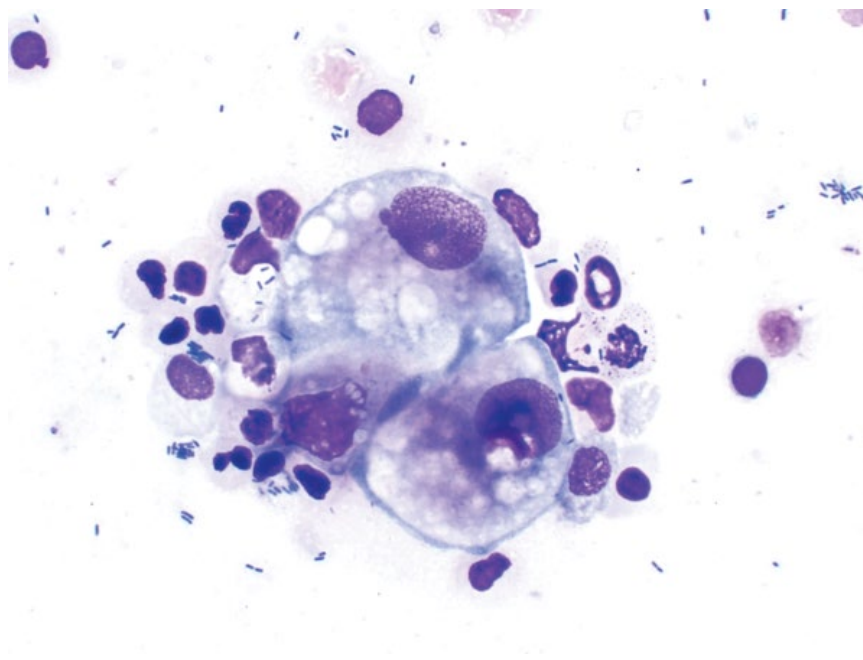


Figure 9.21 Urine, septic inflammation (bacteria), dog, 50× objective. Note bacteria within neutrophils and in the background.

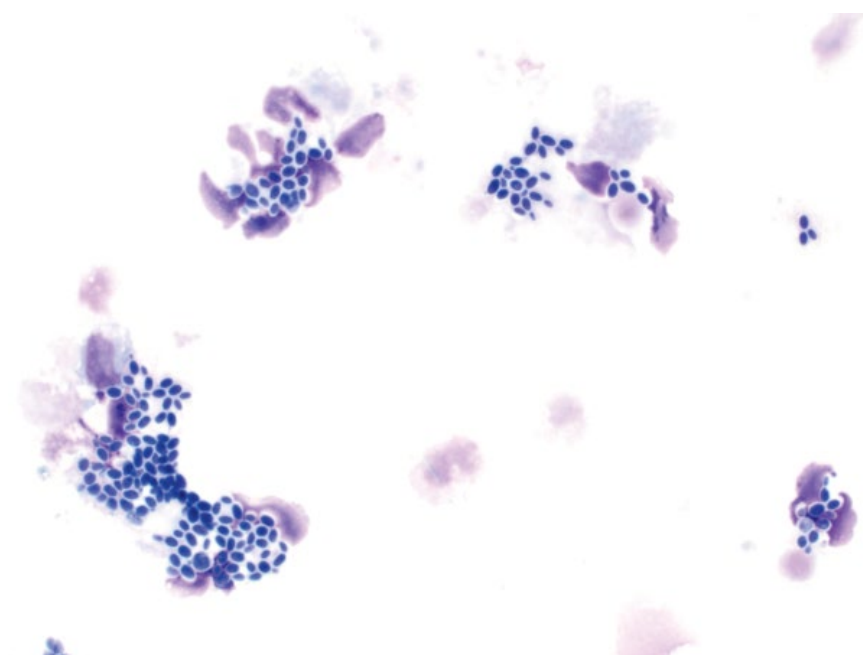


Figure 9.22 Urine, septic inflammation (*Candida* spp.), dog, 50× objective.

9.3.4 Capillaria Plica

9.3.4.1 Cytologic Appearance

Eggs from *Capillaria plica* (syn. *Pearsonema plica*) may be detected in urine samples. The eggs are lemon-shaped, with bipolar tilted terminal plugs (Figure 9.23).

9.3.4.2 Clinical Considerations

- Mostly incidental finding.
- Clinical signs (if present) = polyuria, pollakiuria, periuria, incontinence [24].


9.3.4.3 Prognosis

Generally excellent.

Figure 9.23 Urine, *Capillaria plica* ova, cat, 40x objective.

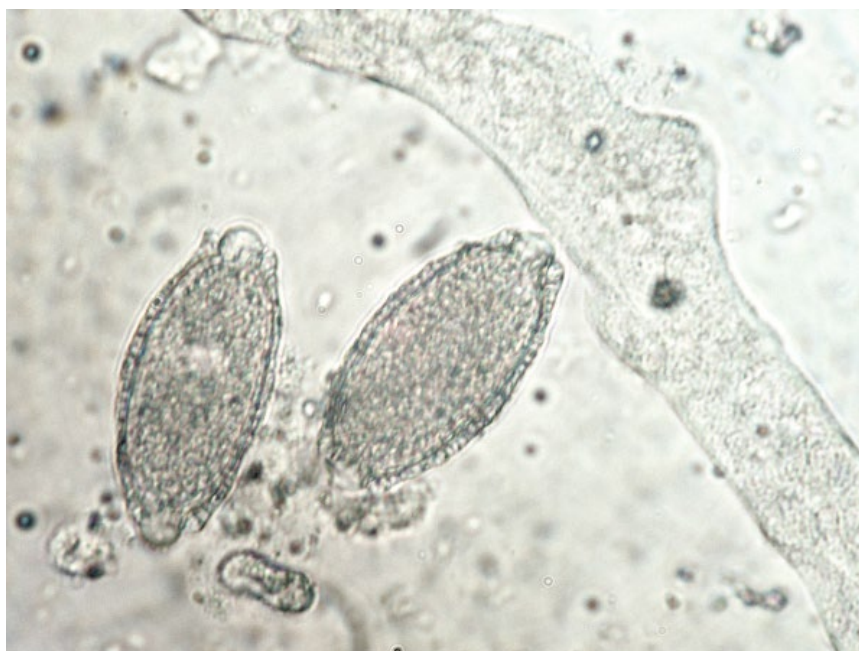

Figure 9.24 Urine, struvite crystals, dog, 50x objective.



9.4 Urinary Crystals

The shape of crystals (habit) often provides a strong indication of composition. However, this is not always the case, and mixed crystals are possible. The following section provides classic examples of common crystal shapes seen in the urine of cats and dogs.

9.4.1 Struvite

9.4.1.1 Cytologic Appearance

Struvite crystals are colorless, mostly rectangular, and often have a characteristic 'coffin-lid' appearance (Figure 9.24). Struvite crystals may also appear as linear, needle-shaped crystals.

9.4.1.2 Clinical Considerations

- pH = alkaline urine.
- May be incidental finding, and may form *in vitro* in refrigerated or stored samples [25].
- Variably associated with struvite urolithiasis. Uroliths are radio-opaque.
- May be associated with sepsis due to urease-producing bacteria (e.g., *Staphylococcus*, *Enterococcus*, and *Proteus* spp.), especially in dogs [26].
- Mostly seen in small or toy-breed dogs; females > males [27].

9.4.2 Calcium Oxalate Dihydrate**9.4.2.1 Cytologic Appearance**

Calcium oxalate dihydrate crystals are colorless, square, and have a characteristic cross pattern (Figure 9.25).

9.4.2.2 Clinical Considerations

- pH = mostly acidic urine.
- May form *in vitro* in refrigerated or stored samples [25].
- Often an incidental finding in clinically healthy patients.
- Breed predisposition = long-haired cats (e.g., Persian, Himalayan), and small breed dogs (e.g., Miniature Schnauzer, Shih Tzu, Yorkshire Terrier) [26].
- Uroliths not amenable to medical dissolution.
- High recurrence rate in dogs and cats [28, 29].

9.4.3 Calcium Oxalate Monohydrate**9.4.3.1 Cytologic Appearance**

These crystals are variably shaped. Elongated crystals reminiscent of fence-posts often are associated with cases of ethylene glycol toxicity, and may be accompanied by dumbbell and cross shapes (Figure 9.26). Crystals may also be associated with hypercalciuric or hyperoxaluric conditions, and generally are smaller, shorter, and broader (Figure 9.27).

9.4.3.2 Clinical Considerations

- pH = acidic > neutral or alkaline urine.
- In large numbers, suggests hypercalciuric or hyperoxaluric conditions.
- The elongated form is most commonly seen in ethylene glycol toxicity, forming 3–9 hours post exposure, and may persist for up to 18 hours [30].

9.4.4 Ammonium Urate**9.4.4.1 Cytologic Appearance**

Yellow/brown or amber crystals that are round to amorphous, with irregular spiny projections (Figure 9.28).

9.4.4.2 Clinical Considerations

- pH = mostly acidic urine
- Dogs > cats.
- Commonly associated with liver disease (e.g., portosystemic shunts) [31].

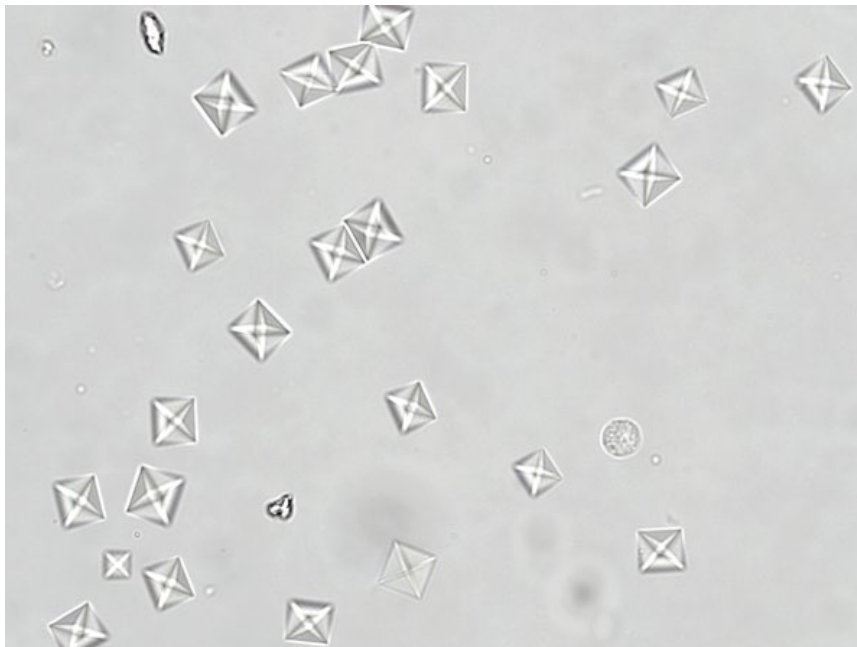


Figure 9.25 Urine, calcium oxalate dihydrate crystals, cat, 40× objective.

Figure 9.26 Urine, calcium oxalate monohydrate crystals, dog, 50× objective. Case of ethylene glycol toxicity. Slide courtesy of Dr Reema Patel.

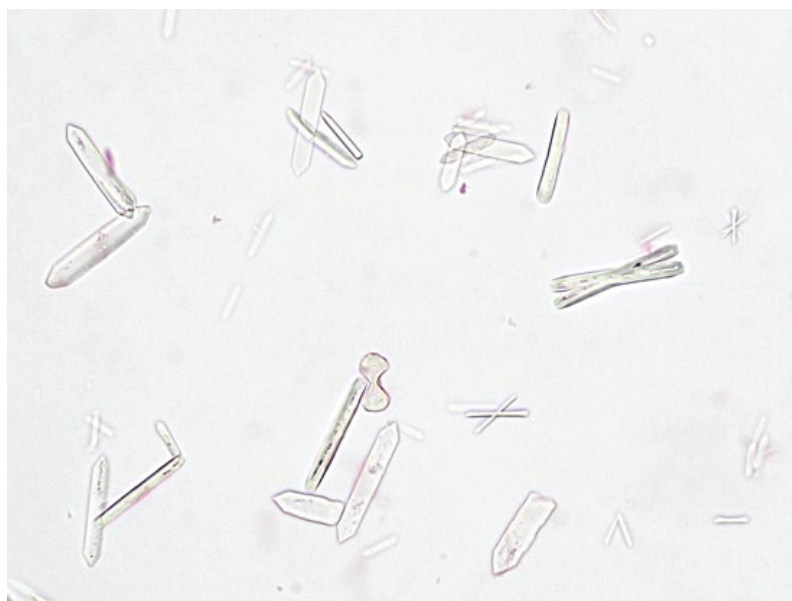
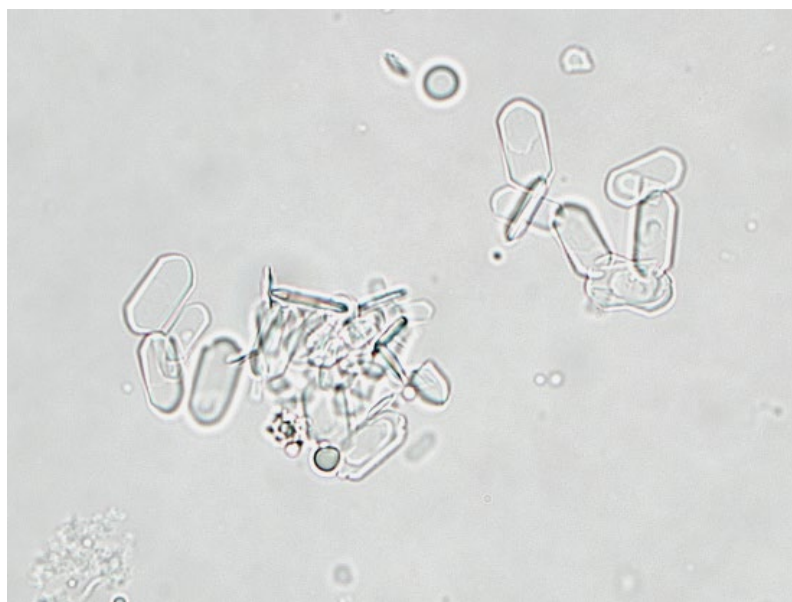

Figure 9.27 Urine, calcium oxalate monohydrate crystals, dog, 100× objective. Case of hypercalciuria. Note the small size and short nature of the crystals relative to those in Figure 9.26.



- Breed predisposition = Dalmatians, English Bulldogs [32].
- Medical dissolution possible (though not normally successful with untreated liver disease).

9.4.5 Uric Acid

9.4.5.1 Cytologic Appearance

Clear to yellow/brown, flat crystals that are diamond-shaped to six-sided (Figure 9.29). They may be seen individually or in aggregates. The crystals are birefringent under polarized light (Figure 9.30)

9.4.5.2 Clinical Considerations

- Similar to ammonium urate (see above).

9.4.6 Cystine

9.4.6.1 Cytologic Appearance

Cystine crystals are colorless, flat, hexagonal crystals that may be seen individually but frequently stack in aggregates (Figure 9.31).

9.4.6.2 Clinical Considerations

- pH = acidic urine.
- Dogs >> cats.
- Due to proximal tubular defect in amino acid absorption (cystine, lysine, and arginine) [33].
- Breed predisposition = Dachshunds, Basset Hounds, English Bulldogs, Irish Terriers [32, 33].

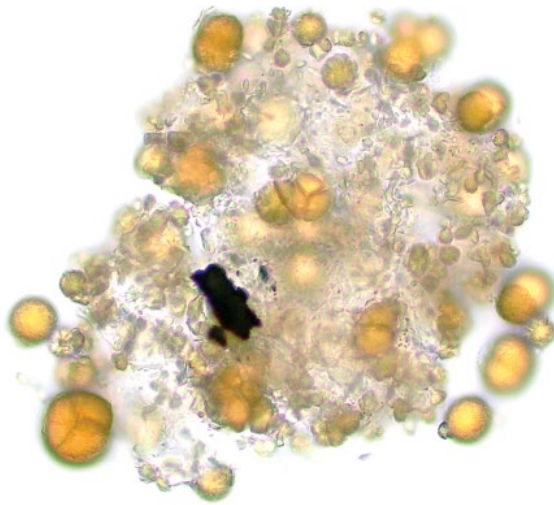


Figure 9.28 Urine, ammonium urate, dog, 50× objective.




Figure 9.29 Urine, uric acid crystals, dog, 20× objective. Slide courtesy of Dr Reema Patel.

- Uroliths frequently present and are amenable to medical dissolution.

9.4.7 Bilirubin

9.4.7.1 Cytologic Appearance

Needle-like crystals that are orange/amber, often seen in bundles and may be pinched in the middle (Figure 9.32).

9.4.7.2 Clinical Considerations

- pH = any
- May be seen in low numbers in concentrated urine from healthy male dogs.
- Indicate hemolytic or hepatobiliary disease.

9.5 Urinary Casts

9.5.1 Hyaline

9.5.1.1 Cytologic Appearance

Translucent and colorless, with parallel sides and rounded edges (Figure 9.33).

9.5.1.2 Clinical Considerations

- Comprised purely of mucoproteins (Tamm–Horsfall proteins) [34].
- Low numbers seen in normal/healthy patients (e.g., up to 2 per 10× objective field).
- Increased numbers may be seen secondary to fever, extreme exercise, renal disease, or diuresis.




Figure 9.30 Urine, uric acid crystals under polarized light, dog, 20× objective. Slide courtesy of Dr Reema Patel.




Figure 9.31 Urine, cystine crystals, dog, 20× objective. Note the spermatozoa in the background.

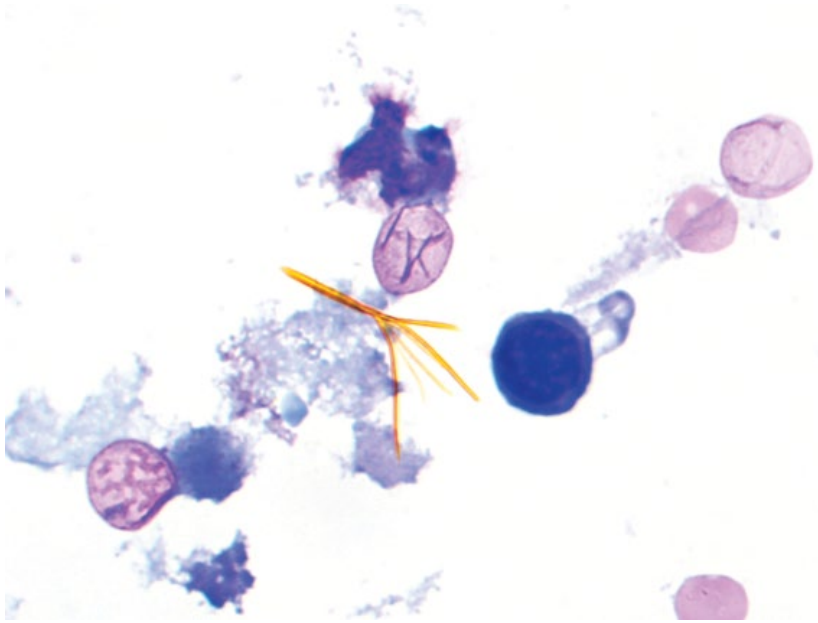


Figure 9.32 Urine, bilirubin crystals, dog, 100× objective.

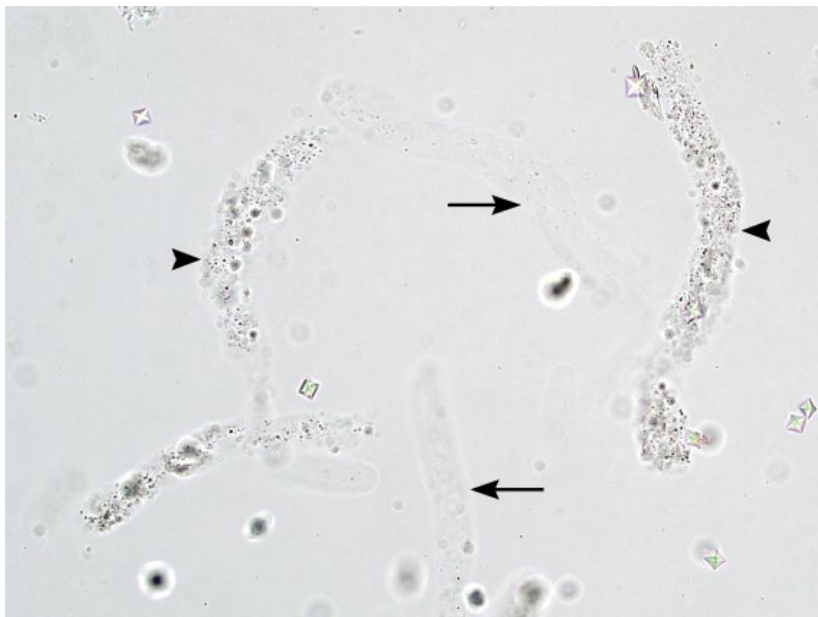


Figure 9.33 Urine, renal tubular casts, dog, 20× objective. Hyaline casts (arrows) are translucent and difficult to see. Note also the granular casts (arrowheads).

- Increased contrast often required to visualize (either lower microscope condenser or close iris diaphragm).

9.5.1.3 Prognosis

Generally good – correlate with any possible underlying cause.

9.5.2 Granular

9.5.2.1 Cytologic Appearance

Granular casts are tubular and have a variably coarse, grainy appearance (Figures 9.33 and 9.34).

9.5.2.2 Clinical Considerations

- Thought to represent degenerated epithelial casts [32].
- Low numbers of granular casts are considered normal, especially in concentrated urine (e.g., 1–2 per 10× objective field).
- Similar rule-outs as epithelial casts.

9.5.2.3 Prognosis

Variable, based on severity of underlying disease.

Figure 9.34 Urine, coarse granular cast, cat, 50× objective.

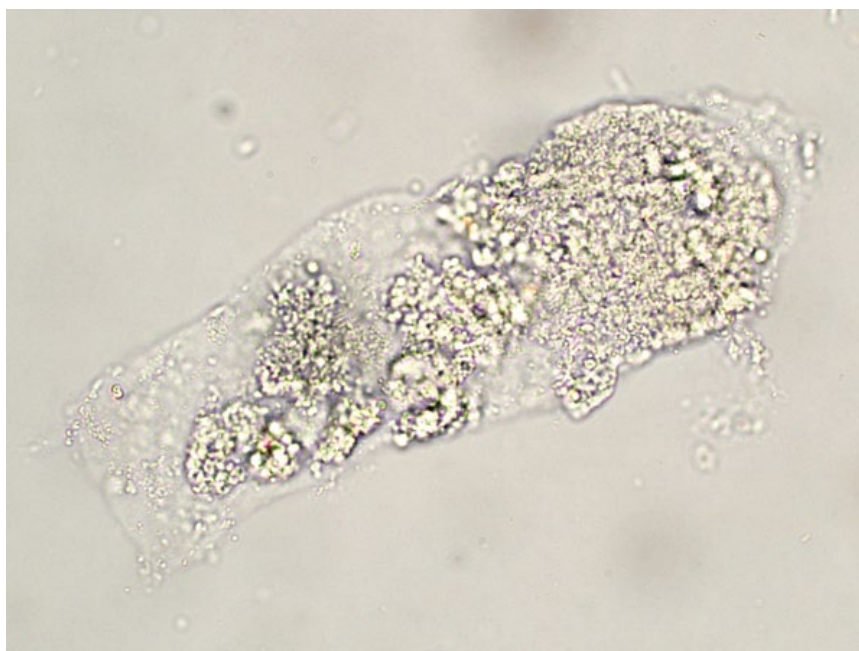
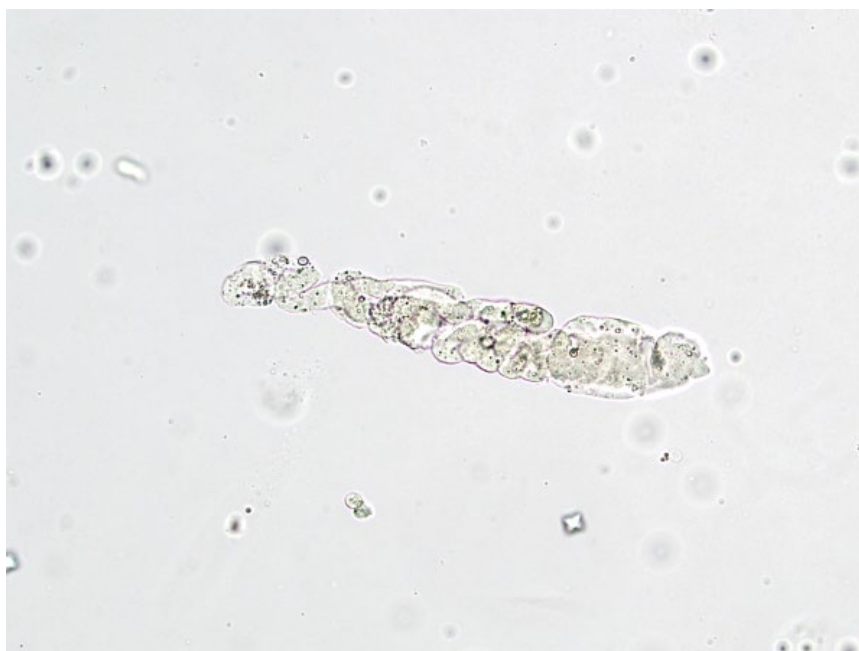
Figure 9.35 Urine, renal tubular cast (waxy), dog, 20× objective.



9.5.3 Waxy

9.5.3.1 Cytologic Appearance

Waxy casts may appear similar to hyaline casts, but generally are wider, have blunt squared ends, are more opaque, and often have fissures (Figure 9.35).

9.5.3.2 Clinical Considerations

- Considered the final stage of cast degeneration.
- Always considered pathologic and suggestive of chronic or prior renal tubular damage.

9.5.3.3 Prognosis

Variable, based on severity/extent of disease.

9.5.4 Cellular

9.5.4.1 Cytologic Appearance

Sloughed/dead epithelial cells may become entrapped in mucoproteins, and form epithelial casts. They are tubular, and contain numerous nuclei of epithelial cells arranged in palisading rows (Figures 9.36 and 9.37). Cellular casts may also include leukocytes and red

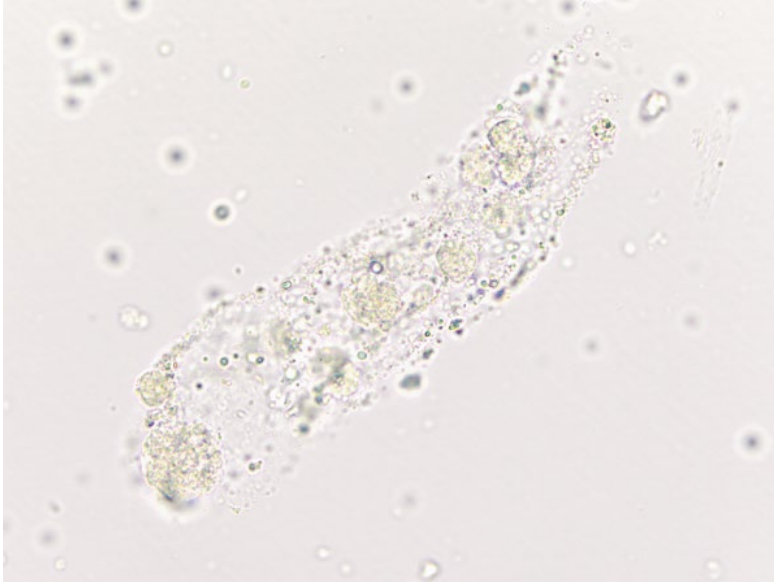

Figure 9.36 Urine, renal tubular cast (epithelial), cat, 50× objective. Note the epithelial cells trapped within the tubular cast.

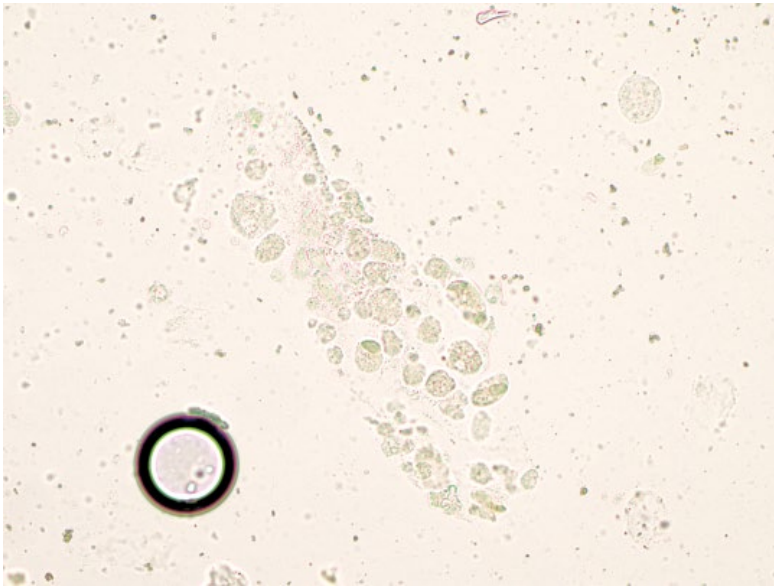


Figure 9.37 Urine, renal tubular cast (epithelial), cat, 20× objective. Renal tubular epithelial cells are seen in a tubular arrangement.

blood cells, indicating inflammation and hemorrhage, respectively.

9.5.4.2 Clinical Considerations

- Always considered abnormal, and seen secondary to renal tubular disease.
- Rule-outs may include renal ischemia/infarction or drug/toxin exposure.
- May be seen prior to changes in serum renal markers or altered renal concentrating ability [32, 35].

9.5.4.3 Prognosis

Variable, based on the severity of underlying disease.

9.5.5 Fatty

9.5.5.1 Cytologic Appearance

Fatty casts contain numerous, variably sized round, highly refractile lipid droplets (Figure 9.38).

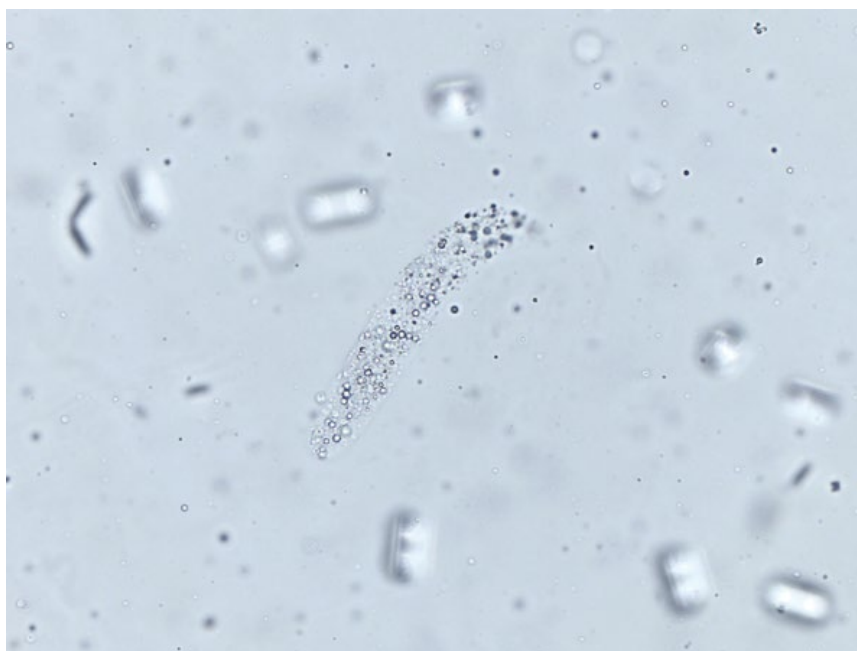9.5.5.2 Clinical Considerations

- May be an incidental finding in low numbers, especially in cats.
- Seen in disorders of lipid metabolism such as diabetes mellitus [32].

9.5.5.3 Prognosis

Generally good, but should be correlated with any underlying disease.

Figure 9.38 Urine, hyaline cast with entrapped lipid droplets, 40× objective. Photo courtesy of Dr Annalisa Hernandez.



References

- Wong, C., Epstein, S.E., Westropp, J.L. (2015) Antimicrobial susceptibility patterns in urinary tract infections in dogs (2010–2013). *J. Vet. Intern. Med.*, **29** (4), 1045–1052.
- Bryan, J.N., Henry, C.J., Turnquist, S.E., *et al.* (2006) Primary renal neoplasia of dogs. *J. Vet. Intern. Med.*, **20** (5), 1155–1160.
- Michael, H.T., Sharkey, L.C., Kovi, R.C., *et al.* (2013) Pathology in practice. Renal nephroblastoma in a young dog. *J. Am. Vet. Med. Assoc.*, **242** (4), 471–473.
- Taylor, A.J., Lara-Garcia, A., Benigni, L. (2014) Ultrasonographic characteristics of canine renal lymphoma. *Vet. Radiol. Ultrasound*, **55** (4), 441–446.
- Taylor, S.S., Goodfellow, M.R., Browne, W.J., *et al.* (2009) Feline extranodal lymphoma: response to chemotherapy and survival in 110 cats. *J. Small Anim. Pract.*, **50** (11), 584–592.
- Vail, D.M., Moore, A.S., Ogilvie, G.K., *et al.* (1998) Feline lymphoma (145 cases): proliferation indices, cluster of differentiation 3 immunoreactivity, and their association with prognosis in 90 cats. *J. Vet. Intern. Med.*, **12** (5), 349–354.
- Snead, E.C. (2005) A case of bilateral renal lymphosarcoma with secondary polycythaemia and paraneoplastic syndromes of hypoglycaemia and uveitis in an English Springer Spaniel. *Vet. Comp. Oncol.*, **3** (3), 139–144.
- Henry, C.J., Turnquist, S.E., Smith, A., *et al.* (1999) Primary renal tumours in cats: 19 cases (1992–1998). *J. Feline Med. Surg.*, **1** (3), 165–170.
- Locke, J.E., Barber, L.G. (2006) Comparative aspects and clinical outcomes of canine renal hemangiosarcoma. *J. Vet. Intern. Med.*, **20** (4), 962–967.
- Zatelli, A., Bonfanti, U., D'Ippolito, P. (2005) Obstructive renal cyst in a dog: ultrasonography-guided treatment using puncture aspiration and injection with 95% ethanol. *J. Vet. Intern. Med.*, **19** (2), 252–254.
- Ochoa, V.B., DiBartola, S.P., Chew, D.J., *et al.* (1999) Perinephric pseudocysts in the cat: a retrospective study and review of the literature. *J. Vet. Intern. Med.*, **13** (1), 47–55.
- Cannon, C.M., Allstadt, S.D. (2015) Lower urinary tract cancer. *Vet. Clin. North Am. Small Anim. Pract.*, **45** (4), 807–824.
- Norris, A.M., Laing, E.J., Valli, V.E., *et al.* (1992) Canine bladder and urethral tumors: a retrospective study of 115 cases (1980–1985). *J. Vet. Intern. Med.*, **6** (3), 145–153.
- Patrick, D.J., Fitzgerald, S.D., Sesterhenn, I.A., *et al.* (2006) Classification of canine urinary bladder urothelial tumours based on the World Health Organization/International Society of Urological Pathology consensus classification. *J. Comp. Pathol.*, **135** (4), 190–199.
- Martinez, I., Mattoon, J.S., Eaton, K.A., *et al.* (2003) Polypoid cystitis in 17 dogs (1978–2001). *J. Vet. Intern. Med.*, **17** (4), 499–509.
- Mutsaers, A.J., Widmer, W.R., Knapp, D.W. (2003) Canine transitional cell carcinoma. *J. Vet. Intern. Med.*, **17** (2), 136–144.

- 17 Walker, D.B., Cowell, R.L., Clinkenbeard, K.D., *et al.* (1993) Carcinoma in the urinary bladder of a cat: cytologic findings and a review of the literature. *Vet. Clin. Pathol.*, **22** (4), 103–108.
- 18 Schwarz, P.D., Greene, R.W., Patnaik, A.K. (1985) Urinary bladder tumors in the cat: a review of 27 cases. *J. Am. Anim. Hosp. Assoc.*, **21** (2), 237–245.
- 19 Knapp, D.W., Glickman, N.W., Denicola, D.B., *et al.* (2000) Naturally-occurring canine transitional cell carcinoma of the urinary bladder: a relevant model of human invasive bladder cancer. *Urol. Oncol.*, **5** (2), 47–59.
- 20 Wilson, H.M., Chun, R., Larson, V.S., *et al.* (2007) Clinical signs, treatments, and outcome in cats with transitional cell carcinoma of the urinary bladder: 20 cases (1990–2004). *J. Am. Vet. Med. Assoc.*, **231** (1), 101–106.
- 21 Rocha, T.A., Mauldin, G.N., Patnaik, A.K., *et al.* (2000) Prognostic factors in dogs with urinary bladder carcinoma. *J. Vet. Intern. Med.*, **14** (5), 486–490.
- 22 Swenson, C.L., Boisvert, A.M., Gibbons-Burgener, S.N., *et al.* (2011) Evaluation of modified Wright-staining of dried urinary sediment as a method for accurate detection of bacteriuria in cats. *Vet. Clin. Pathol.*, **40** (2), 256–264.
- 23 Swenson, C.L., Boisvert, A.M., Kruger, J.M., *et al.* (2004) Evaluation of modified Wright-staining of urine sediment as a method for accurate detection of bacteriuria in dogs. *J. Am. Vet. Med. Assoc.*, **224** (8), 1282–1289.
- 24 Basso, W., Spänhauer, Z., Arnold, S., *et al.* (2014) *Capillaria plica* (syn. *Pearsonema plica*) infection in a dog with chronic pollakiuria: challenges in the diagnosis and treatment. *Parasitol. Int.*, **63** (1), 140–142.
- 25 Albasan, H., Lulich, J.P., Osborne, C.A., *et al.* (2003) Effects of storage time and temperature on pH, specific gravity, and crystal formation in urine samples from dogs and cats. *J. Am. Vet. Med. Assoc.*, **222** (2), 176–179.
- 26 Bartges, J.W., Callens, A.J. (2015) Urolithiasis. *Vet. Clin. North Am. Small Anim. Pract.*, **45** (4), 747–768.
- 27 Okafor, C.C., Pearl, D.L., Lefebvre, S.L., *et al.* (2013) Risk factors associated with struvite urolithiasis in dogs evaluated at general care veterinary hospitals in the United States. *J. Am. Vet. Med. Assoc.*, **243** (12), 1737–1745.
- 28 Lulich, J.P., Osborne, C.A., Lekcharoensuk, C., *et al.* (2004) Effects of diet on urine composition of cats with calcium oxalate urolithiasis. *J. Am. Anim. Hosp. Assoc.*, **40** (3), 185–191.
- 29 Bartges, J.W., Kirk, C., Lane, I.F. (2004) Update: Management of calcium oxalate uroliths in dogs and cats. *Vet. Clin. North Am. Small Anim. Pract.*, **34** (4), 969–987.
- 30 Thrall, M.A., Dial, S.M., Winder, D.R. (1985) Identification of calcium oxalate monohydrate crystals by X-ray diffraction in urine of ethylene glycol-intoxicated dogs. *Vet. Pathol.*, **22** (6), 625–628.
- 31 Caporali, E.H.G., Phillips, H., Underwood, L., *et al.* (2015) Risk factors for urolithiasis in dogs with congenital extrahepatic portosystemic shunts: 95 cases (1999–2013). *J. Am. Vet. Med. Assoc.*, **246** (5), 530–536.
- 32 Callens, A.J., Bartges, J.W. (2015) Urinalysis. *Vet. Clin. North Am. Small Anim. Pract.*, **45** (4), 621–637.
- 33 Hoppe, A., Denneberg, T. (2001) Cystinuria in the dog: clinical studies during 14 years of medical treatment. *J. Vet. Intern. Med.*, **15** (4), 361–367.
- 34 De Loor, J., Daminet, S., Smets, P., *et al.* (2013) Urinary biomarkers for acute kidney injury in dogs. *J. Vet. Intern. Med.*, **27** (5), 998–1010.
- 35 Schentag, J.J., Gengo, F.M., Plaut, M.E., *et al.* (1979) Urinary casts as an indicator of renal tubular damage in patients receiving aminoglycosides. *Antimicrob. Agents Chemother.*, **16** (4), 468–474.

10

Respiratory

10.1 Nasal Cavity

10.1.1 Inflammation (Septic)

10.1.1.1 Cytologic Appearance

Septic rhinitis is characterized by large numbers of inflammatory cells, with neutrophils normally predominating in bacterial rhinitis (Figure 10.1), and macrophages seen with fungal, protozoal or algal infections, which may also be accompanied by eosinophils.

10.1.1.2 Clinical Considerations

- Primary rhinitis = fungal > bacterial [1].
- Fungal disease more common in young patients [2].
- Septic inflammation may be secondary to underlying neoplasia or foreign body [3].
- See Chapter 2 for details on infectious agents.

10.1.1.3 Prognosis

Highly variable, based on causative agent and whether septic inflammation is primary or secondary.

10.1.2 Inflammation: Lymphoplasmacytic Rhinitis

10.1.2.1 Cytologic Appearance

Lymphoplasmacytic rhinitis is the most common sterile inflammatory condition, and is associated with increased numbers of small mature and reactive lymphocytes with plasma cells (Figure 10.2).

10.1.2.2 Clinical Considerations

- Most common in large-breed dogs.
- Associated with mucoid nasal discharge and bilateral stertor [4].
- Bilateral >> unilateral, though discharge often only unilateral [5].
- May cause epistaxis [6].

10.1.2.3 Prognosis

Generally good, but a common cause of chronic nasal disease in dogs.

10.1.3 Normal/Hyperplastic Epithelium

10.1.3.1 Cytologic Appearance

Both, squamous and psuedostratified columnar epithelial cells are present in the nasal cavity. Hyperplasia may be seen secondary to inflammation, infection, chronic irritation, or adjacent neoplasia. Typically, these cells have a slightly decreased volume (higher N/C ratios) of more deeply basophilic cytoplasm, and may lack cilia (Figure 10.3). Anisocytosis/anisokaryosis generally are still mild, and few criteria of malignancy are seen.

10.1.4 Nasal Adenocarcinoma

10.1.4.1 Cytologic Appearance

Adenocarcinomas exfoliate in variably cohesive sheets. Well-differentiated tumors have prominent intercellular borders, while anaplastic tumors may be poorly cohesive, mimicking lymphoma, particularly in cats [7]. Cells mostly are round, with a moderate volume of medium-to deep-blue cytoplasm, and round nuclei with stippled chromatin and prominent nucleoli. Anisocytosis/anisokaryosis mostly are moderate to marked, and N/C ratios are high (Figure 10.4).

10.1.4.2 Clinical Considerations

- Dogs > cats. Most common nasal tumor in dogs [8].
- Mostly older patients, but reported in young dogs [3, 8, 9].
- Clinical signs = nasal discharge (often unilateral progressing to bilateral), epistaxis, sneezing, facial deformity.

10.1.4.3 Prognosis

Poor. Survival times are short without therapy [10]. Metastatic disease confers a grave prognosis [11].

10.1.5 Nasal Lymphoma

10.1.5.1 Cytologic Appearance

Nasal lymphoma often exfoliates well, and comprises individualized cells with round nuclei, stippled chromatin,

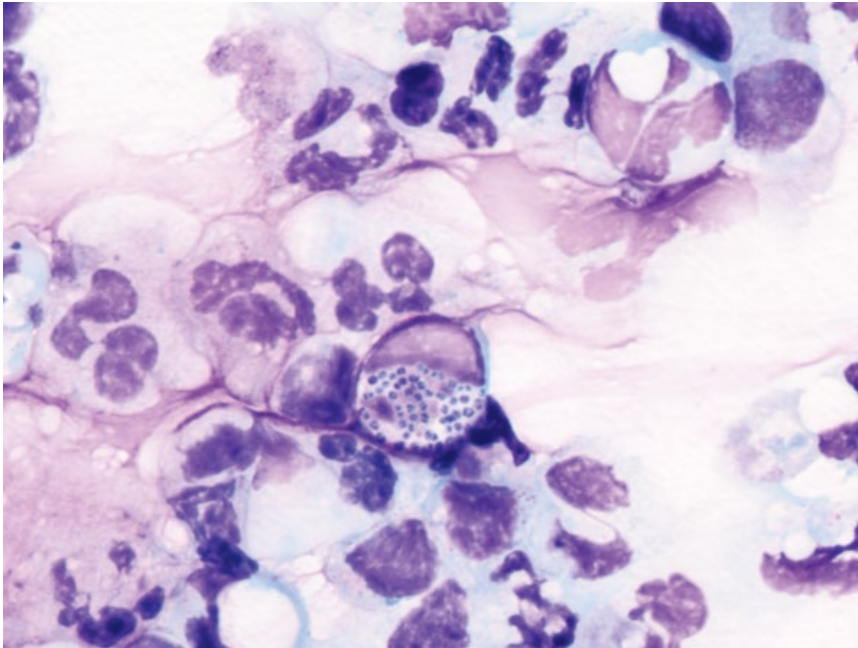


Figure 10.1 Bacterial rhinitis, dog, 100× objective. Note intracellular bacterial cocci within a degenerative neutrophil and smooth pink mucin in the background.

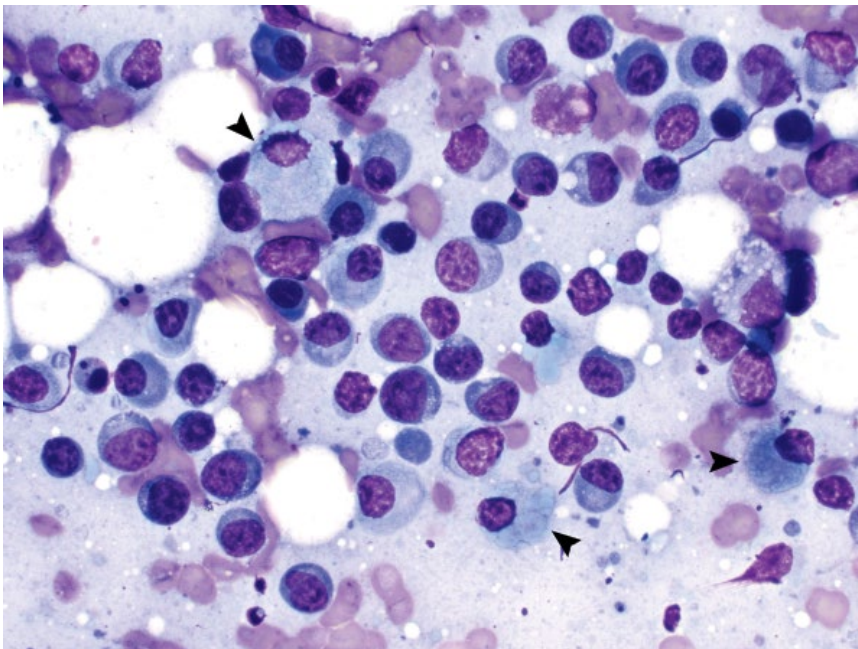


Figure 10.2 Lymphoplasmacytic rhinitis, dog, 50× objective. Lymphocytes, plasma cells and even Mott cells (arrowheads) are seen.

and variably prominent nucleoli. The cells have a small to moderate volume of medium- to deep-blue cytoplasm (Figure 10.5).

10.1.5.2 Clinical Considerations

- Cats > dogs. Most common nasal tumor in cats [12].
- Clinical signs = nasal discharge (unilateral or bilateral), sneezing, decreased appetite, and increased upper respiratory noise [12].

10.1.5.3 Prognosis

Guarded. Survival times generally short, even with therapy, though can be prolonged in cats [3, 13]. Anemia may be a negative prognostic factor in dogs [13].

10.1.6 Squamous Cell Carcinoma

10.1.6.1 Cytologic Appearance

Squamous cell carcinomas are characterized by variably cohesive sheets of cells ranging from polygonal to round.

Figure 10.3 Hyperplastic nasal epithelium, dog, 50× objective.

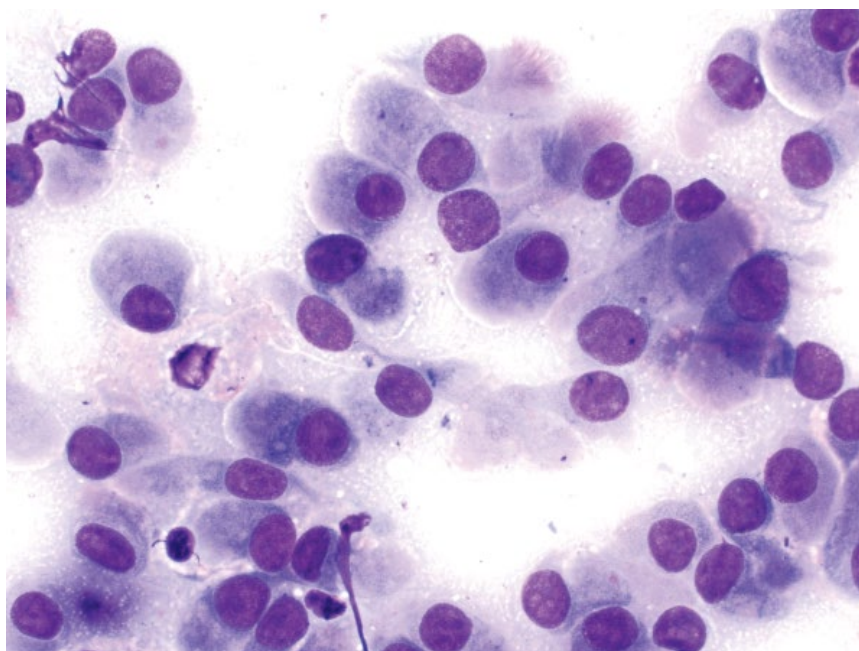
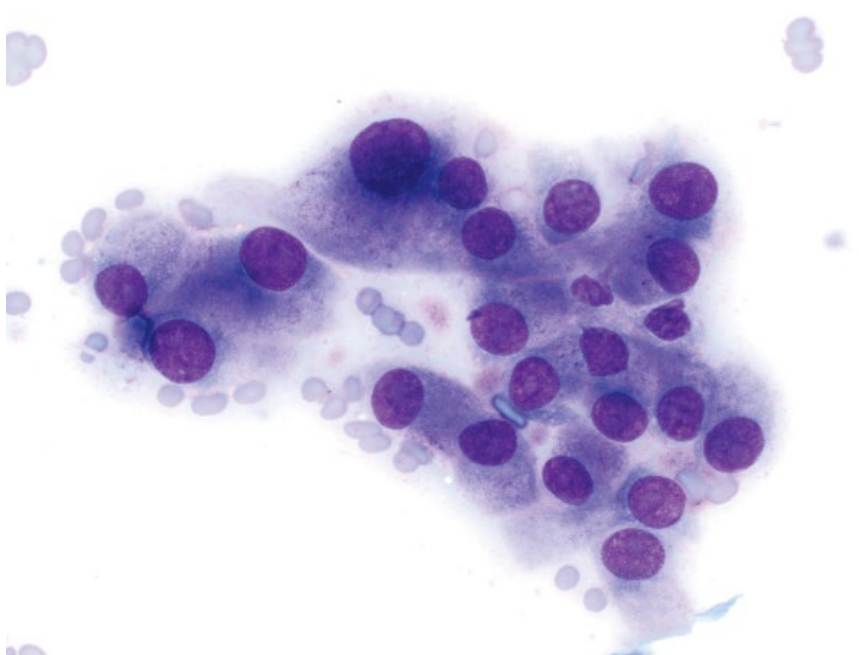


Figure 10.4 Nasal adenocarcinoma, cat, 50× objective.



The cells frequently have keratinized, bright-blue cytoplasm (Figure 10.6). Perinuclear vacuolation also is a common finding. Anisocytosis/anisokaryosis are marked. Tumors frequently are accompanied by neutrophilic inflammation.

10.1.6.2 Clinical Considerations

- Common in dogs and cats.
- Clinical signs= nasal discharge, epistaxis, sneezing, facial deformity, exophthalmos.
- Low metastatic rates [14].

10.1.6.3 Prognosis

Poor. Survival times are short, even with therapy, which generally is palliative [14, 15].

10.1.7 Chondrosarcoma

10.1.7.1 Cytologic Appearance

Chondrosarcomas are characterized by dense, metachromatic extracellular chondroid in which cells may be embedded, forming lacunae. Cells mostly are

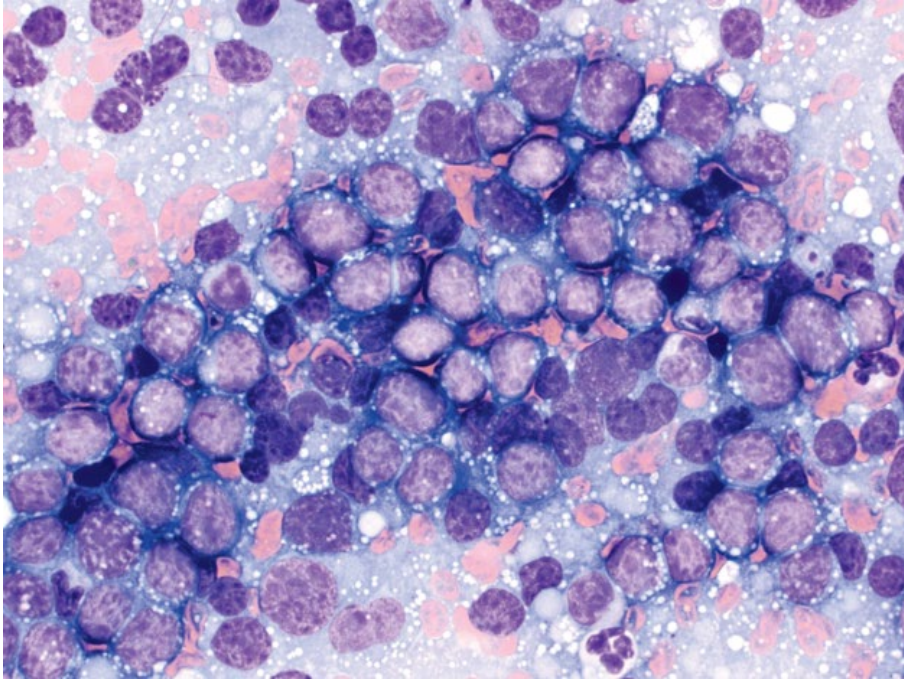


Figure 10.5 Nasal lymphoma, cat, 50x objective.

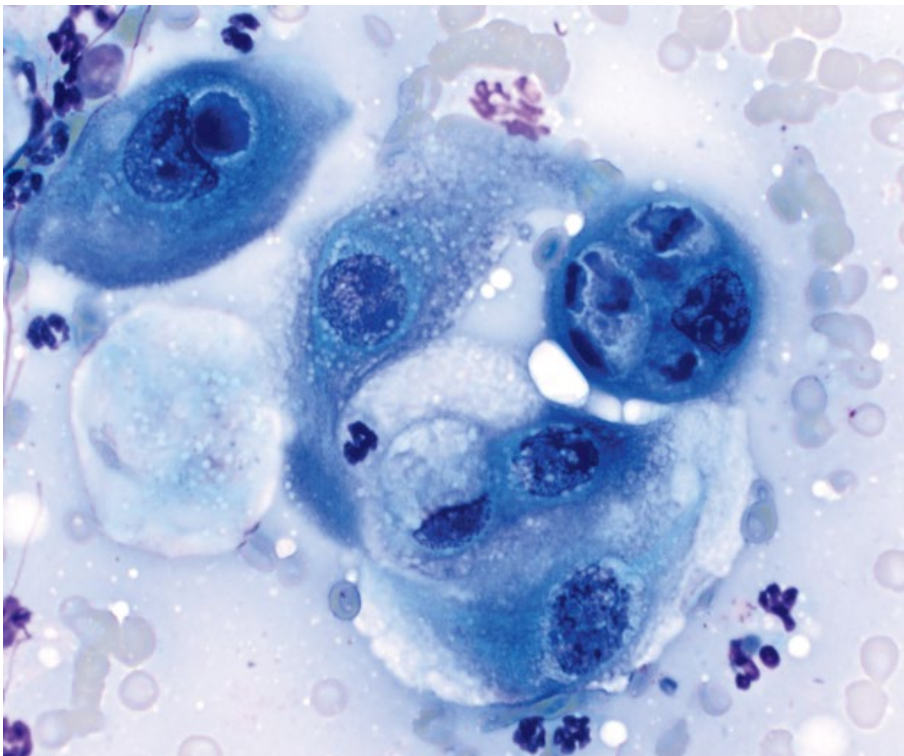
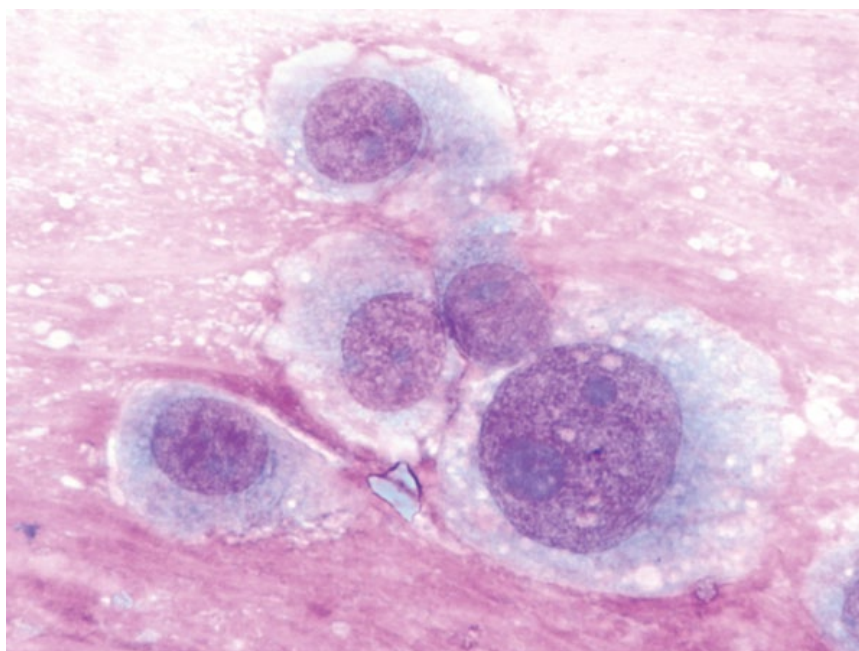


Figure 10.6 Nasal squamous cell carcinoma, cat, 50x objective.

Figure 10.7 Nasal chondrosarcoma, dog, 100× objective.



round but can be spindloid, and have pale-blue cytoplasm that contains pink granules (Figure 10.7). Nuclei are centrally placed, with finely stippled chromatin and multiple basophilic nucleoli.

10.1.7.2 Clinical Considerations

- Common non-epithelial nasosinual tumor.
- Unilateral ≈ bilateral [16].
- Metastasis rare, generally to lungs, but other organs reported [17].

10.1.7.3 Prognosis

Guarded. Prolonged survival times possible with appropriate therapy [18].

10.1.8 Fibrosarcoma

10.1.8.1 Cytologic Appearance

Fibrosarcomas exfoliate as spindloid cells seen individually or in aggregates, often associated with bright-pink extracellular matrix. The cells have a variable volume of cytoplasm forming tendrils and wisps, and may contain fine pink granules or vacuoles (Figure 10.8). Nuclei are ovoid to elongated, with finely granular chromatin and prominent nucleoli. Anisocytosis/anisokaryosis often are marked, and N/C ratios generally are high.

10.1.8.2 Clinical Considerations

- Dogs > cats
- Middle-aged to older patients.
- Paraneoplastic erythrocytosis reported in a dog [19].

10.1.8.3 Prognosis

Guarded. Moderate survival times possible with appropriate therapy [18].

10.1.9 Other Neoplasms

Numerous other neoplasms may rarely be seen in the nasal cavity, some of which include osteosarcoma (see Chapter 6), mast cell tumor (see Chapter 3), melanoma (see Chapter 3), and transmissible venereal tumors (see Chapter 3).

10.2 Lung

10.2.1 Hyperplastic Epithelium

10.2.1.1 Cytologic Appearance

Hyperplastic epithelium may be seen secondary to underlying inflammation, infection, hemorrhage, or neoplasia. Cells are variably pleomorphic, and criteria of malignancy such as high N/C ratios and increased anisocytosis/anisokaryosis may be seen (Figure 10.9). Care must be taken to distinguish between hyperplasia and neoplasia, which is not always possible, especially in the presence of inflammation.

10.2.2 Carcinoma (Bronchoalveolar and Adenocarcinoma)

10.2.2.1 Cytologic Appearance

Pulmonary carcinomas exfoliate as cohesive sheets of cuboidal to round cells, often seen in tubular or acinar-like arrangements. Degree of atypia is highly variable,

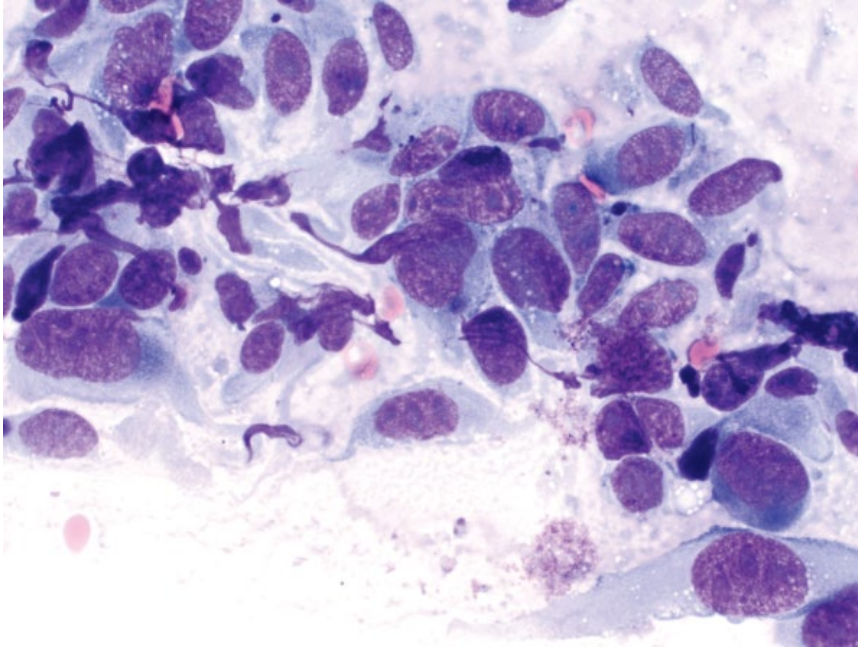


Figure 10.8 Nasal fibrosarcoma, dog, 50× objective.

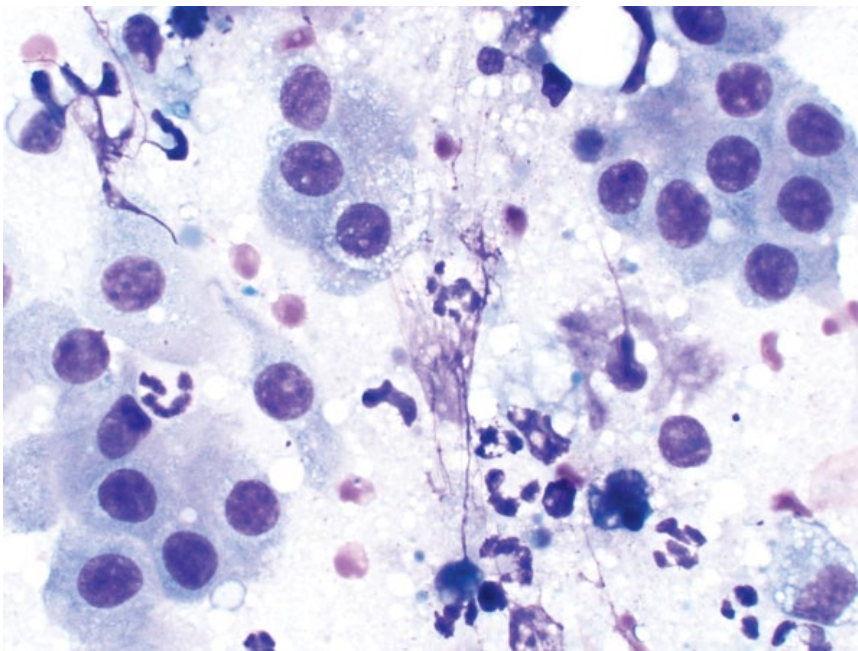


Figure 10.9 Lung, hyperplastic epithelium, dog, 50× objective. Note the concurrent inflammation.

ranging from well-differentiated (Figure 10.10) to pleomorphic (Figure 10.11). These tumors frequently are associated with a marked paraneoplastic inflammatory response. Note that metastatic carcinomas may appear cytologically similar.

10.2.2.2 Clinical Considerations

- Bronchoalveolar, adenocarcinoma, anaplastic, and adenosquamous reported.
- Most common = bronchoalveolar (dogs) and adenocarcinoma (cats) [20, 21].

- Mostly a solitary, well-defined nodule, but multiple nodules can be seen, and concurrent metastatic lesions may be present [22].
- Most common in caudal lung lobes [23, 24].
- Clinical signs frequently not present at time of diagnosis [25].

10.2.2.3 Prognosis

Guarded to poor. Poor prognosis with clinical signs present, metastatic disease and large tumor size [24–27].

Figure 10.10 Lung, carcinoma (well-differentiated), dog, 50× objective. Large sheets of cuboidal cells are arranged in tubular arrangements.

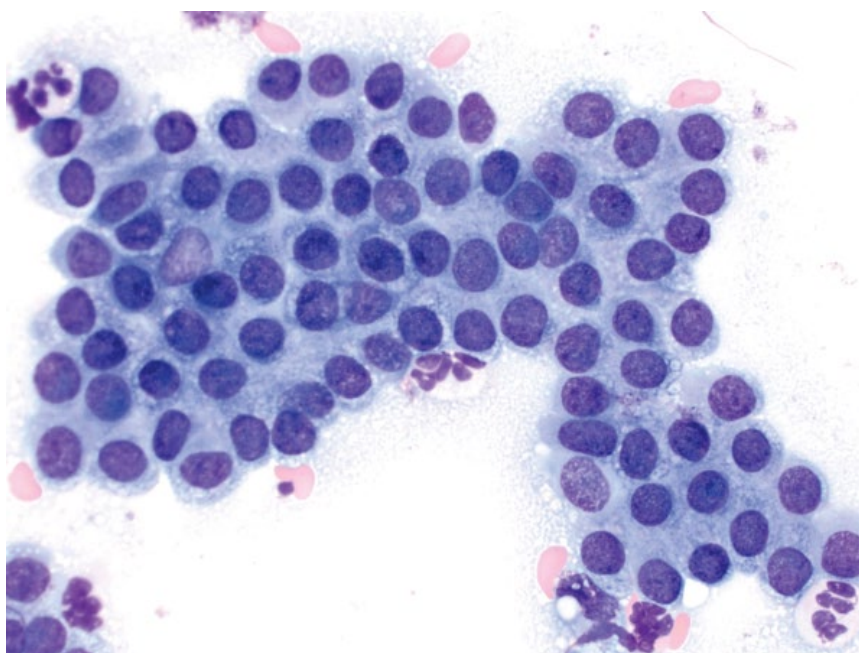
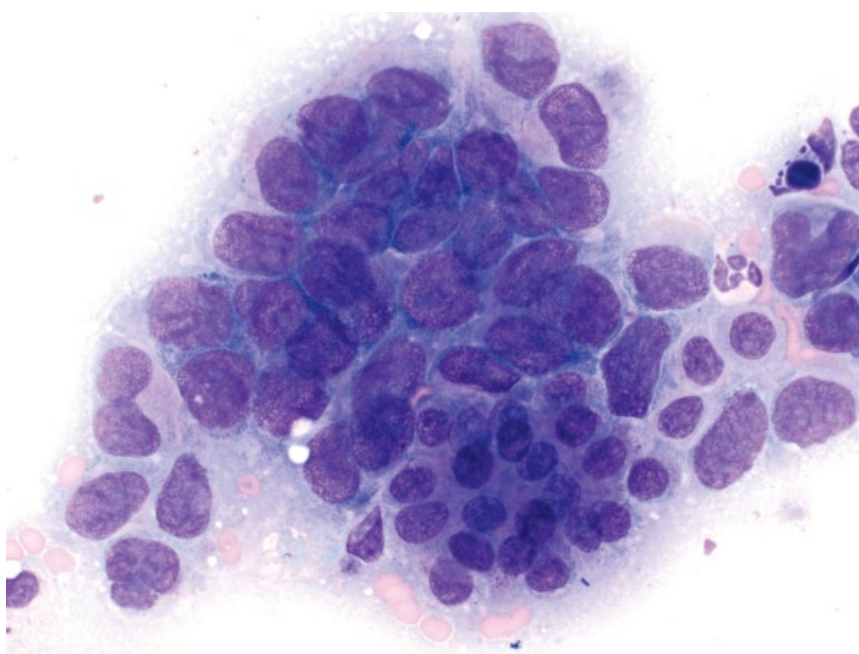


Figure 10.11 Lung, carcinoma (pleomorphic), dog, 50× objective.



10.2.3 Squamous Cell Carcinoma

10.2.3.1 Cytologic Appearance

Squamous cell carcinomas are characterized by variably cohesive sheets of cells ranging from polygonal to round. The cells frequently have keratinized, bright-blue cytoplasm (Figure 10.12). Perinuclear vacuolation also is a

common finding. Anisocytosis/anisokaryosis often are marked. Tumors frequently are accompanied by concurrent inflammation.

10.2.3.2 Clinical Considerations

- Mostly a solitary, well-defined nodule [23].

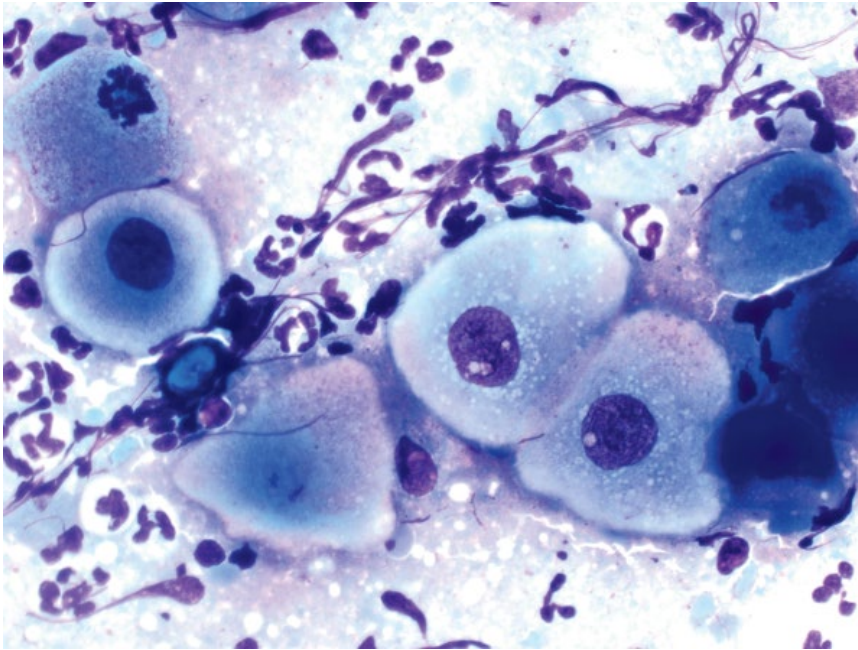


Figure 10.12 Lung, squamous cell carcinoma, dog, 50× objective.

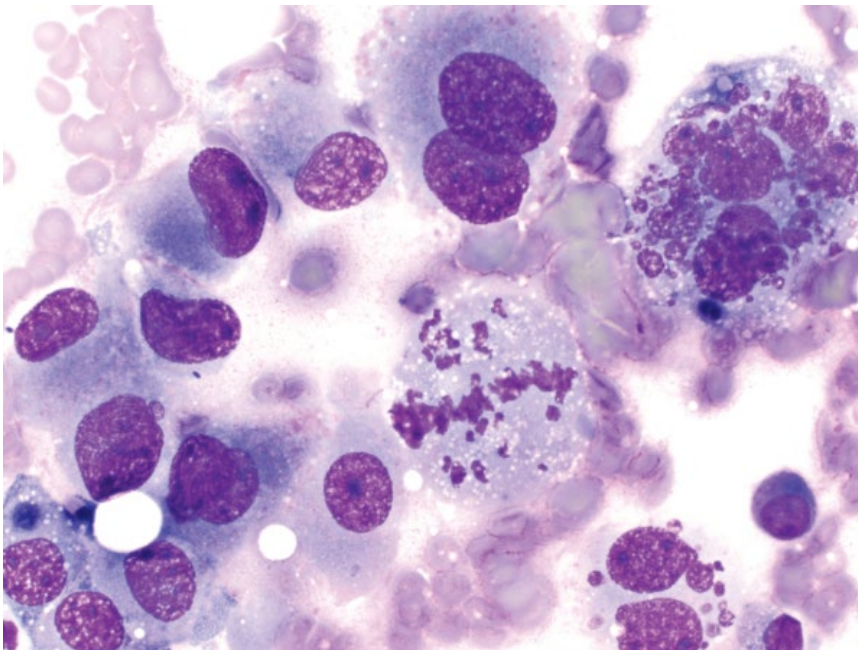


Figure 10.13 Lung, histiocytic sarcoma, dog, 50× objective.

10.2.3.3 Prognosis

Poor. High metastatic rates, and short survival times reported [24, 28].

10.2.4 Histiocytic Sarcoma

10.2.4.1 Cytologic Appearance

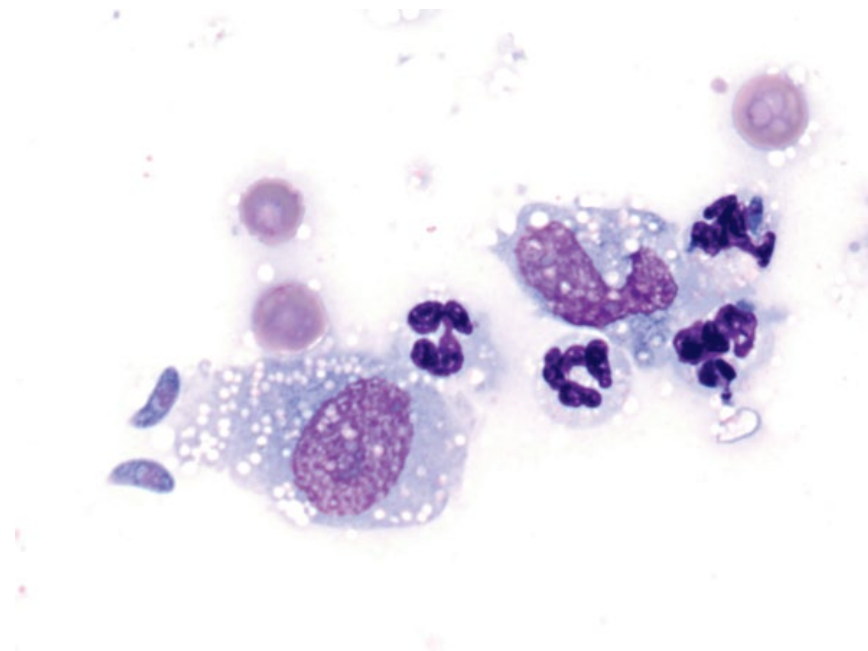
Histiocytic sarcoma is characterized by individualized cells with many criteria of malignancy, including marked anisocytosis and anisokaryosis, with karyomegaly a common finding. Multinucleation, nuclear fragmentation,

and hyperchromasia also are common (Figure 10.13). The cytoplasm is variably vacuolated.

10.2.4.2 Clinical Considerations

- Most common sarcoma in dog lungs [23, 29]. May reflect primary or disseminated disease.
- Significantly larger than other primary pulmonary tumors [23].
- Most commonly found in left cranial and right middle lung lobes [23].

Figure 10.14 Lung, *Toxoplasma gondii*, dog, 100× objective. Protozoal organisms are accompanied by mixed inflammatory cells.



10.2.4.3 Prognosis

Grave.

10.2.5 Inflammation/Infection

10.2.5.1 Cytologic Appearance

Inflammatory lesions in the lung frequently exfoliate well, and contain large numbers of leukocytes that may indicate underlying disease. Neutrophils often are associated with bacterial agents, macrophages are most common with fungal or protozoal agents (Figure 10.14), and eosinophils may be seen with fungal, protozoal, or algal organisms (see Chapter 2 for details).

10.2.5.2 Clinical Considerations

- Paraneoplastic inflammation is common with many neoplasms, especially pulmonary carcinomas and squamous cell carcinomas (see sections 10.2.2 and 10.2.3).

10.2.5.3 Prognosis

Variable, based on underlying cause.

10.3 Bronchoalveolar Lavage (BAL)/Transtracheal Wash (TTW)

10.3.1 Normal/Hyperplastic Airway Epithelium

10.3.1.1 Cytologic Appearance

The airways are lined by pseudostratified, columnar, ciliated, respiratory epithelium with goblet cells (Figure 10.15). Hyperplastic epithelial cells are cytologically similar to normal cells, but appear in

greater numbers. Hyperplastic cells may have decreased N/C ratios, increased cytoplasmic basophilia, and may not be ciliated.

10.3.1.2 Clinical Considerations

- Low numbers seen normally in BAL/TTW samples.
- Epithelial hyperplasia often associated with chronic inflammation or airway irritation.

10.3.2 Oropharyngeal Contamination

10.3.2.1 Cytologic Appearance

Well-differentiated, polygonal squamous epithelial cells with pyknotic or absent nuclei are considered contaminants from the oropharynx. These may be accompanied by normal oral bacterial flora such as *Simonsiella* spp. that have a characteristic appearance (Figures 10.16 and 2.42). They are rod-shaped bacteria and form striated stacks of bacteria.

10.3.2.2 Clinical Considerations

- Oropharyngeal flora may be present in cases of aspiration pneumonia [30].
- Microbial culture results may be invalid.

10.3.3 Mucus and Curschmann's Spirals

10.3.3.1 Cytologic Appearance

Mucus is seen in BAL/TTW samples as pools and streaming strands of material ranging from blue to pink. Curschmann's spirals are bright pink/purple, serpiginous spirals of mucus (Figure 10.17).

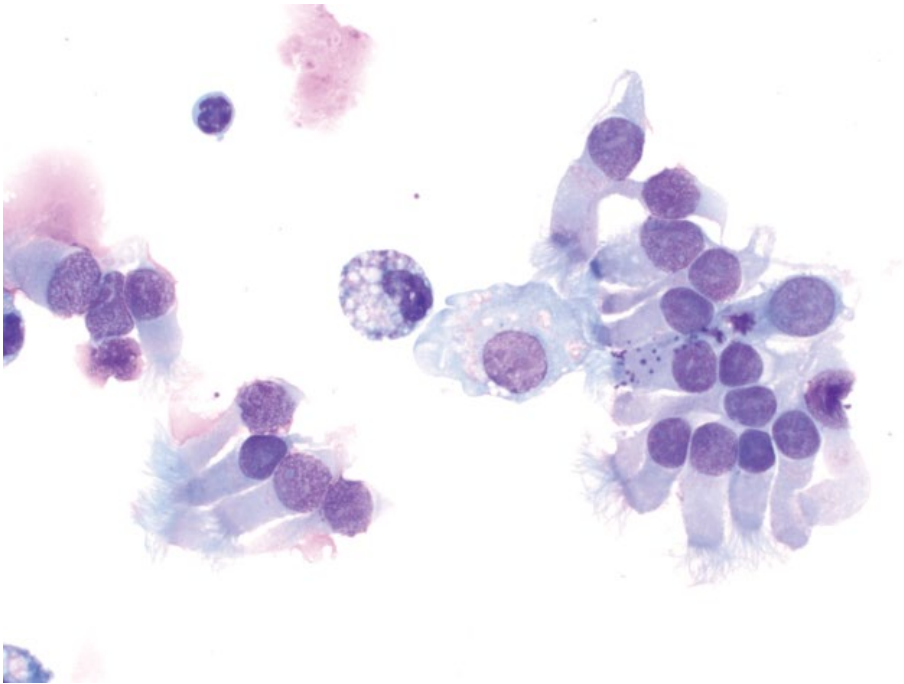


Figure 10.15 BAL, normal respiratory epithelium, dog, 50× objective. Note the purple granules of mucin in the cytoplasm of some cells.

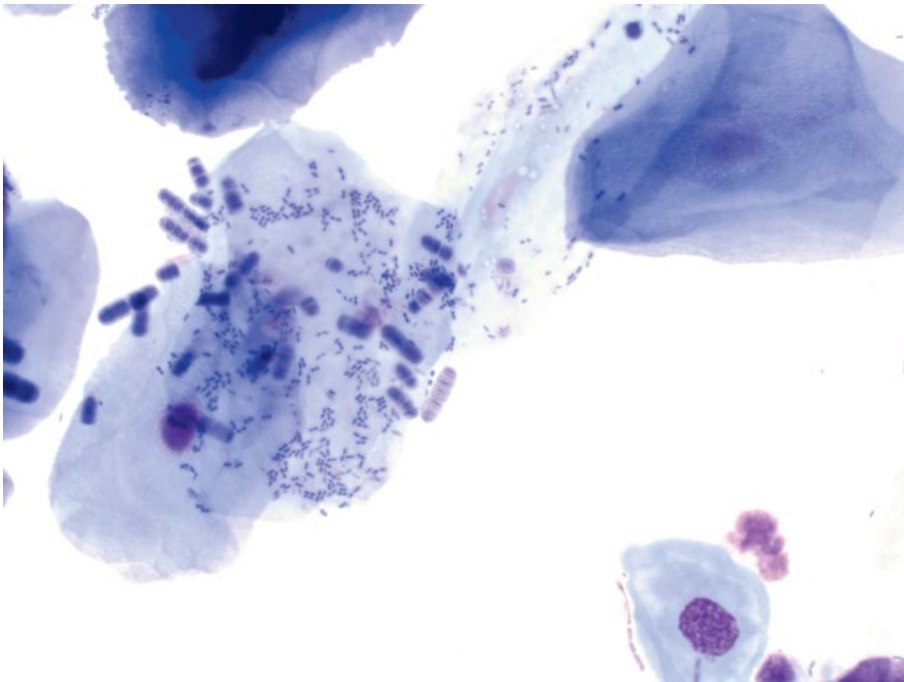


Figure 10.16 BAL, oropharyngeal contamination, dog, 50× objective. Squamous epithelial cells with adherent bacteria (*Simonsiella* spp. and coccobacilli).

Figure 10.17 BAL, Curschmann's spiral, dog, 50x objective.

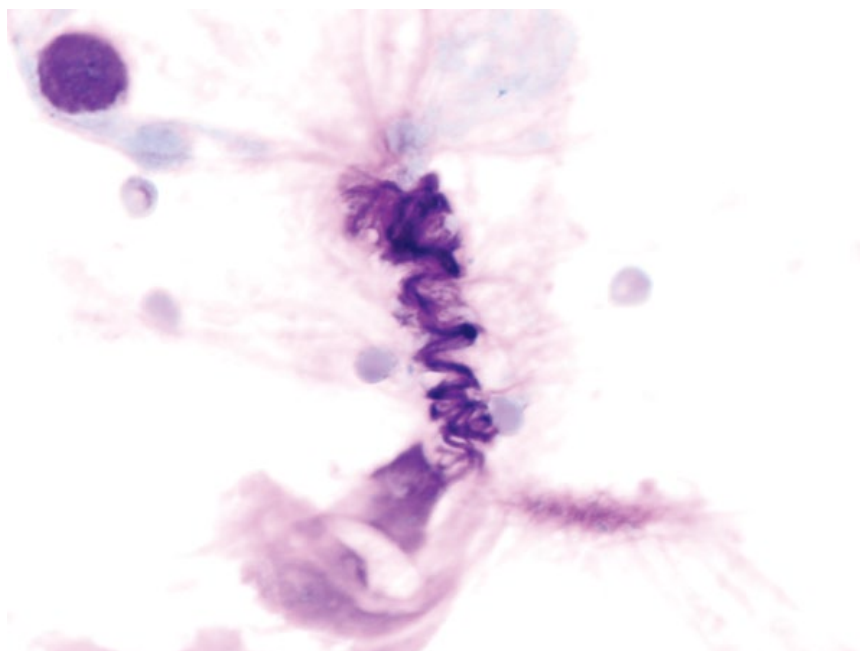
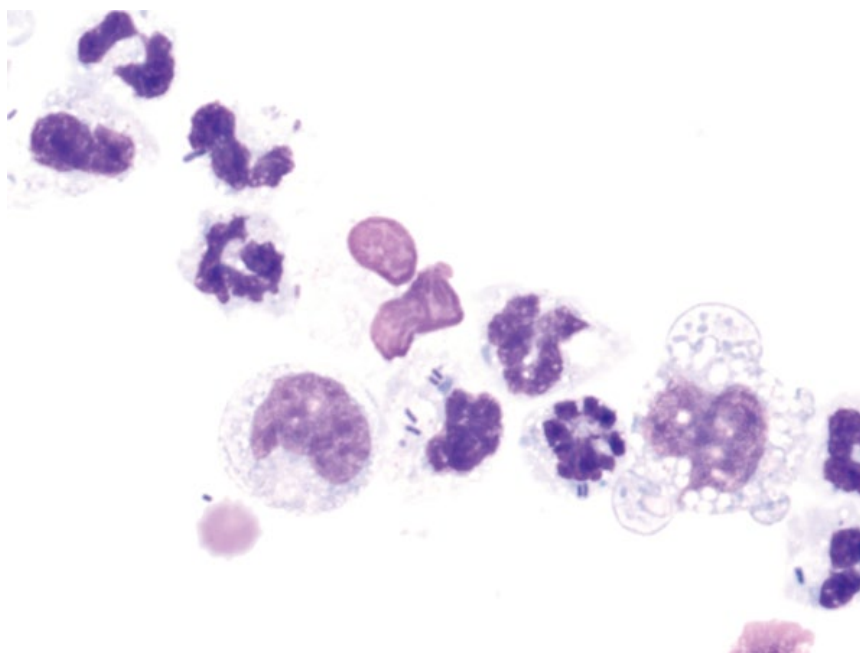


Figure 10.18 BAL, bacterial sepsis, dog, 100x objective.



10.3.3.2 Clinical Considerations

- A small amount of mucus is normal. Increased mucus may be seen secondary to inflammation, irritation or chronic airway disease.
- Curschmann's spirals represent mucous casts of bronchioles, associated with chronic or obstructive disease of the small airways.

10.3.4 Inflammation (Neutrophilic)

10.3.4.1 Cytologic Appearance

Neutrophils may appear similar to those in blood (non-degenerative) or may be degenerative, suggestive of infectious organisms (see Figure 10.18).

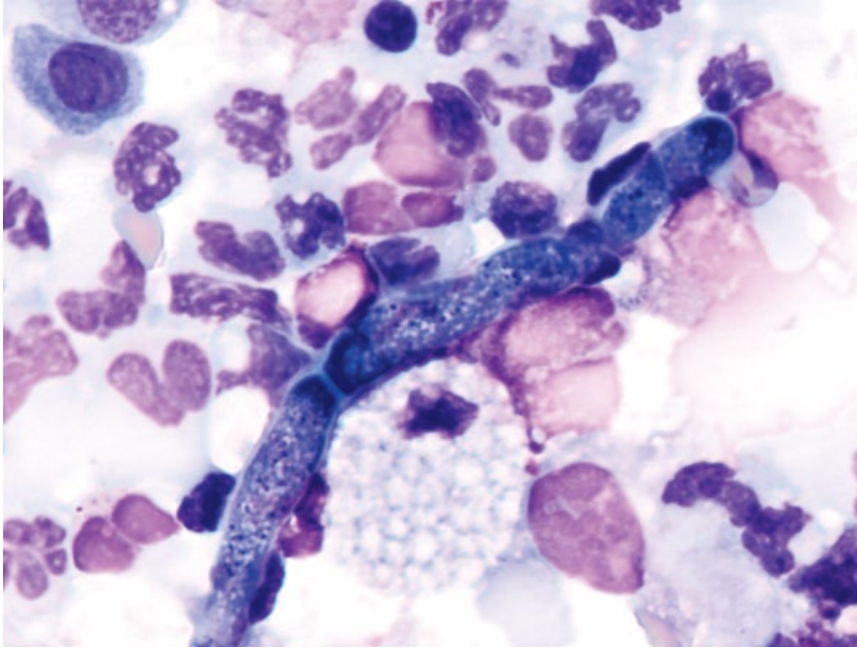


Figure 10.19 BAL, fungal sepsis, dog, 100× objective. Hyphae of *Conidiobolus* spp. are accompanied by a mixed inflammatory response.

10.3.4.2 Clinical Considerations

- Normal neutrophil % = ~5% in dogs and cats [31, 32].
- DDx = infectious disease (especially bacterial), aspiration pneumonia, obstructive/dynamic airway disease, trauma, neoplasia, foreign body reaction.
- May be seen in acute and chronic inflammation.
- Repeat BAL procedures may cause an increase in neutrophil % [30].

10.3.4.3 Prognosis

Variable, based on underlying/predisposing causes.

10.3.5 Infectious Agents

10.3.5.1 Cytologic Appearance

Many infectious organisms may affect the lungs. Common agents include bacteria (e.g., *Bordetella bronchiseptica*, *Mycobacteria*), fungi (e.g., *Cryptococcus*, *Blastomyces*, *Coccidioides*, *Pneumocystis*), parasites (*Aelurostrongylus abstrusus*, *Filaroides hirthi*), and protozoal agents (e.g., *Toxoplasma gondii*) (see Chapter 2 for details).

10.3.5.2 Clinical Considerations

- Presence of inflammation warrants close examination for infectious organisms. Figure 10.19 shows fungal hyphae in a BAL (*Conidiobolus* spp.) with mixed inflammation, while Figure 10.20 shows *Bordetella bronchiseptica* adhered to respiratory epithelial cilia (see Chapter 2 for details).

10.3.5.3 Prognosis

Variable, based on infectious agent present and extent of disease.

10.3.6 Inflammation (Eosinophilic)

10.3.6.1 Cytologic Appearance

Eosinophil granules vary greatly in color in BAL/TTW samples from bright pink (Figure 10.21) to brick-red or even brown. Eosinophil granules are rod-shaped in cats and round in dogs, but may coalesce to form large amorphous inclusions. Eosinophilic inflammation often is associated with increased mucus production.

10.3.6.2 Clinical Considerations

- Normal eosinophil % = ~4% in dogs and ~16% in cats (though normal counts up to 25% are reported in healthy cats) [31–33].
- DDx = allergic/hypersensitivity disease, infectious organisms (e.g., fungal, protozoal, *Mycoplasma*, or parasites such as lungworm).

10.3.6.3 Prognosis

Variable, based on underlying cause.

10.3.7 Inflammation (Granulomatous)

10.3.7.1 Cytologic Appearance

Macrophages normally predominate in BAL/TTW samples. Increased numbers and/or % indicate granulomatous inflammation. Multinucleation or reactive changes

Figure 10.20 BAL, *Bordetella bronchiseptica*, dog, 100× objective. Note the ciliotropic coccobacilli.

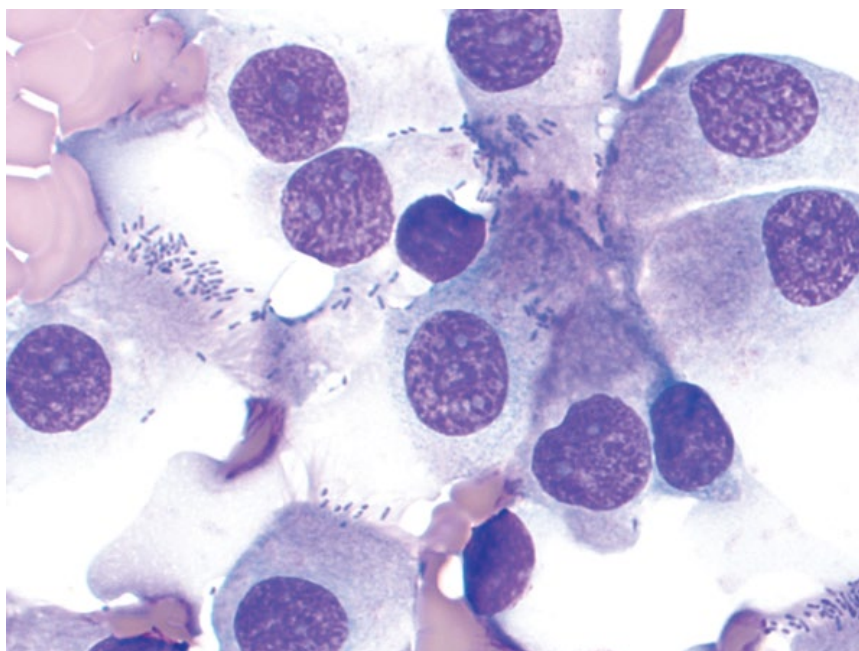
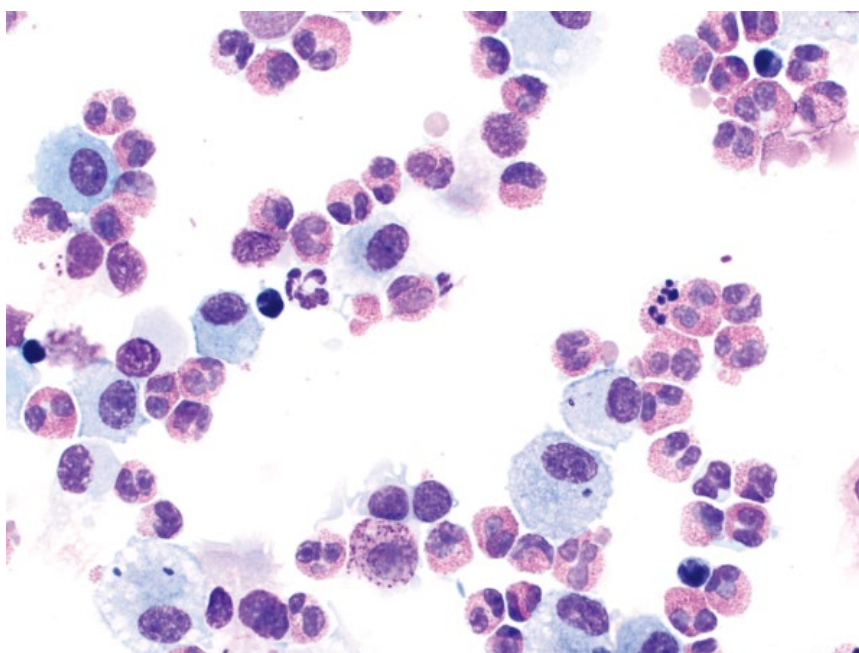


Figure 10.21 BAL, eosinophilic inflammation, dog, 50× objective.



(e.g., highly vacuolated or basophilic cytoplasm) also suggest inflammation (Figure 10.22).

10.3.7.2 Clinical Considerations

- Normal macrophage % = ~78% in dogs and ~71% in cats [31].
- DDx = chronic inflammation, irritation, or hemorrhage, infectious agents (e.g., fungi, *Mycobacteria*), foreign body/material reaction.

10.3.7.3 Prognosis

Variable, based on underlying/predisposing cause.

10.3.8 Inflammation (Lymphocytic)

10.3.8.1 Cytologic Appearance

Lymphocytic inflammation is characterized by a mixed population of lymphocytes, mostly dominated by small mature cells and plasma cells (Figure 10.23).

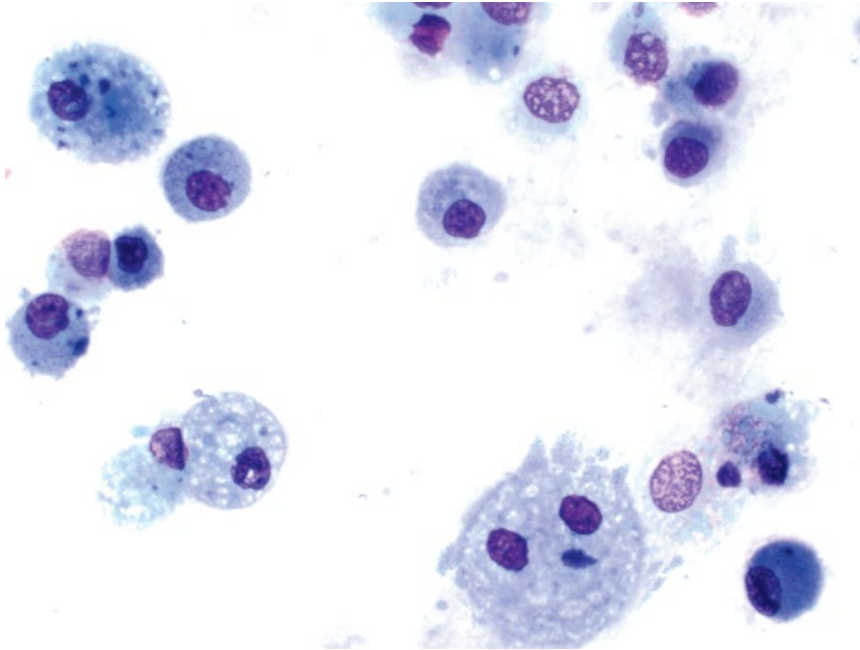


Figure 10.22 BAL, granulomatous inflammation, dog, 50x objective.

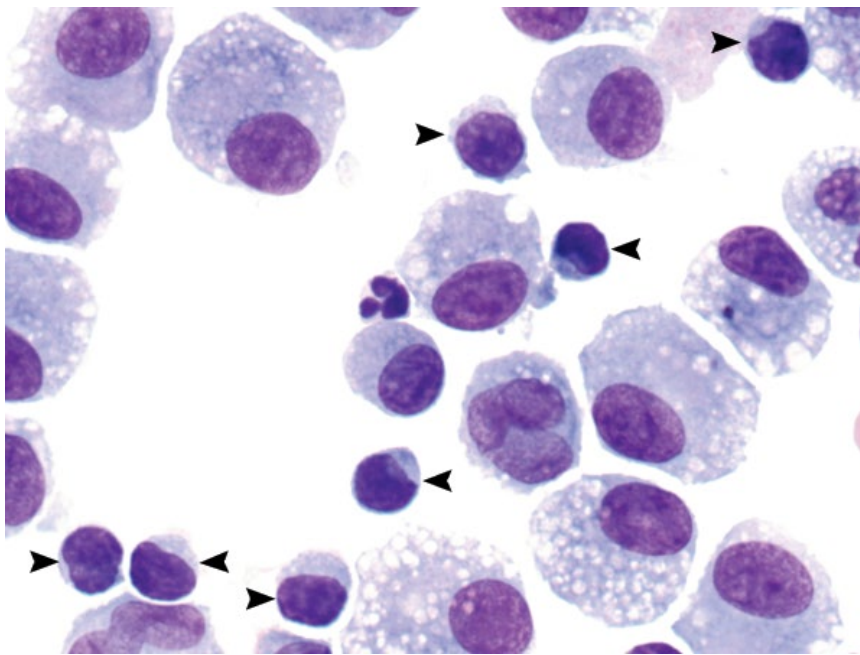


Figure 10.23 BAL, lymphocytic inflammation, dog, 100x objective. An increased percentage of small mature lymphocytes (arrowheads) are admixed with reactive macrophages and a single neutrophil.

10.3.8.2 Clinical Considerations

- Normal lymphocyte % = ~7% of cells in dogs and ~5% in cats [31].
- DDx = chronic inflammation/antigenic stimulation.

10.3.8.3 Prognosis

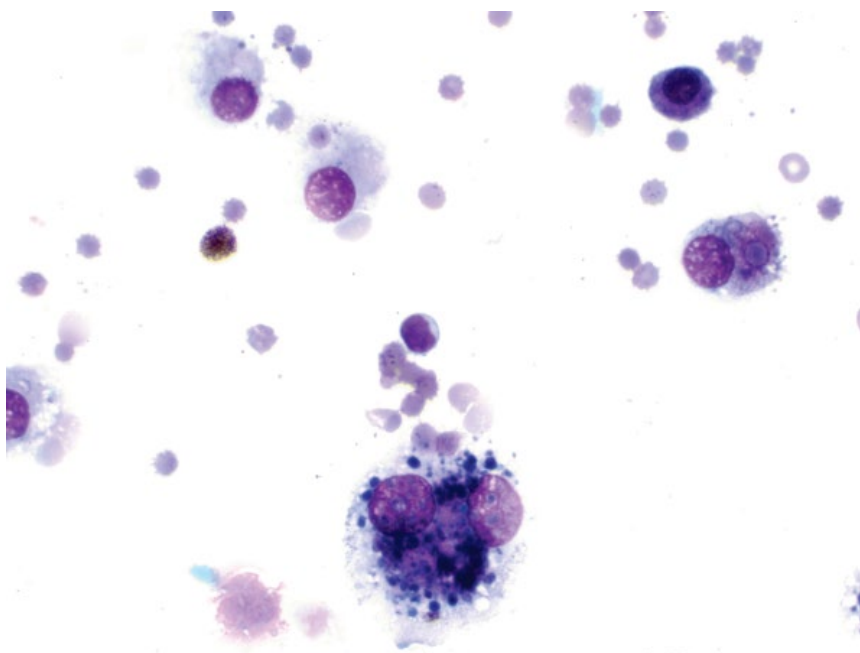
Variable, based on underlying/predisposing causes.

10.3.9 Hemorrhage

10.3.9.1 Cytologic Appearance

Blood should not be present in BAL/TTW samples. Erythrocytes may represent acute hemorrhage, and chronic hemorrhage is confirmed by the presence of macrophages that are erythrophagocytic or contain heme-breakdown pigment (hemosiderophages) (Figure 10.24).

Figure 10.24 BAL, hemorrhage, dog, 50× objective. Note erythrophagia and hemosiderin pigment within macrophages.



10.3.9.2 Clinical Considerations

- DDx = neoplasia, cardiac failure, rhinitis, asthma, bleeding diatheses, trauma, or inhaled irritants [34].

10.3.9.3 Prognosis

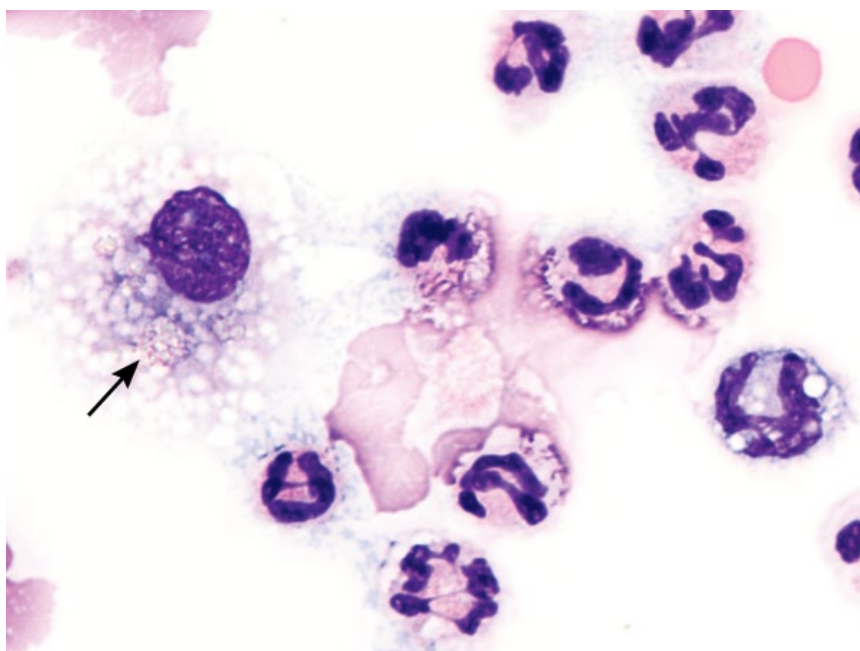
Variable, based on underlying/predisposing cause.

10.3.10 Foreign Material

10.3.10.1 Cytologic Appearance

Aspirated foreign material incites an inflammatory response, generally predominated by macrophages that ingest the material. Crystalline barium material is seen phagocytosed by macrophages in Figure 10.25.

Figure 10.25 BAL, foreign material (barium), dog, 100× objective. Crystalline barium material is phagocytosed by a macrophage (arrow).



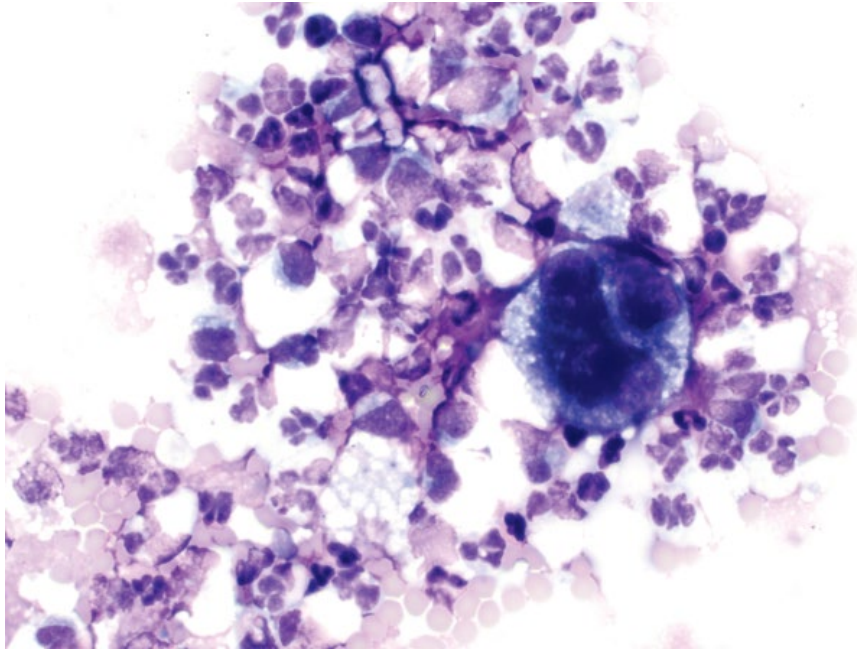


Figure 10.26 BAL, carcinoma, dog, 50× objective. A large, multinucleated carcinoma cell is accompanied by mixed inflammation.

10.3.10.2 Clinical Considerations

- Barium and sucralfate reported [35, 36].
- May be accompanied by evidence of hemorrhage or Curschmann's spirals.

10.3.10.3 Prognosis

Generally good, but dependent on type of material and extent of disease.

10.3.11 Neoplasia

10.3.11.1 Cytologic Appearance

Neoplastic cells from the lungs or airways may rarely be seen in BAL/TTW fluid samples, and appear

similar to the underlying neoplasm. Carcinoma cells are most commonly seen, with marked criteria of malignancy including anisocytosis/anisokaryosis (Figure 10.26).

10.3.11.2 Clinical Considerations

- Carcinomas must be distinguished from hyperplastic epithelium.
- Lymphoma is also occasionally seen in BAL samples [37].

10.3.11.3 Prognosis

Poor.

References

- 1 Meler, E., Dunn, M., Lecuyer, M. (2008) A retrospective study of canine persistent nasal disease: 80 cases (1998–2003). *Can. Vet. J.*, **49** (1), 71–76.
- 2 Plickert, H.D., Tichy, A., Hirt, R.A. (2014) Characteristics of canine nasal discharge related to intranasal diseases: a retrospective study of 105 cases. *J. Small Anim. Pract.*, **55** (3), 145–152.
- 3 Henderson, S.M., Bradley, K., Day, M.J., *et al.* (2004) Investigation of nasal disease in the cat – a retrospective study of 77 cases. *J. Feline Med. Surg.*, **6** (4), 245–257.
- 4 Lobetti, R. (2014) Idiopathic lymphoplasmacytic rhinitis in 33 dogs. *J. South Afr. Vet. Assoc.*, **85** (1), 1151.
- 5 Windsor, R.C., Johnson, L.R., Herrgesell, E.J., *et al.* (2004) Idiopathic lymphoplasmacytic rhinitis in dogs: 37 cases (1997–2002). *J. Am. Vet. Med. Assoc.*, **224** (12), 1952–1957.
- 6 Bissett, S.A., Drobatz, K.J., McKnight, A., *et al.* (2007) Prevalence, clinical features, and causes of epistaxis in dogs: 176 cases (1996–2001). *J. Am. Vet. Med. Assoc.*, **231** (12), 1843–1850.
- 7 Nagata, K., Lamb, M., Goldschmidt, M.H., *et al.* (2014) The usefulness of immunohistochemistry to differentiate between nasal carcinoma and lymphoma in cats: 140 cases (1986–2000). *Vet. Comp. Oncol.*, **12** (1), 52–57.
- 8 Avner, A., Dobson, J.M., Sales, J.I., *et al.* (2008) Retrospective review of 50 canine nasal tumours evaluated by low-field magnetic resonance imaging. *J. Small Anim. Pract.*, **49** (5), 233–239.

- 9 Lefebvre, J., Kuehn, N.F., Wortinger, A. (2005) Computed tomography as an aid in the diagnosis of chronic nasal disease in dogs. *J. Small Anim. Pract.*, **46** (6), 280–285.
- 10 Rassnick, K.M., Goldkamp, C.E., Erb, H.N., *et al.* (2006) Evaluation of factors associated with survival in dogs with untreated nasal carcinomas: 139 cases (1993–2003). *J. Am. Vet. Med. Assoc.*, **229** (3), 401–406.
- 11 Henry, C.J., Brewer, W.G., Jr, Tyler, J.W., *et al.* (1998) Survival in dogs with nasal adenocarcinoma: 64 cases (1981–1995). *J. Vet. Intern. Med.*, **12** (6), 436–439.
- 12 Little, L., Patel, R., Goldschmidt, M. (2007) Nasal and nasopharyngeal lymphoma in cats: 50 cases (1989–2005). *Vet. Pathol.*, **44** (6), 885–892.
- 13 Haney, S.M., Beaver, L., Turrel, J., *et al.* (2009) Survival analysis of 97 cats with nasal lymphoma: a multi-institutional retrospective study (1986–2006). *J. Vet. Intern. Med.*, **23** (2), 287–294.
- 14 Rogers, K.S., Walker, M.A., Helman, R.G. (1996) Squamous cell carcinoma of the canine nasal cavity and frontal sinus: eight cases. *J. Am. Anim. Hosp. Assoc.*, **32** (2), 103–110.
- 15 Gieger, T., Rassnick, K., Siegel, S., *et al.* (2008) Palliation of clinical signs in 48 dogs with nasal carcinomas treated with coarse-fraction radiation therapy. *J. Am. Anim. Hosp. Assoc.*, **44** (3), 116–123.
- 16 Patnaik, A.K., Lieberman, P.H., Erlandson, R.A., *et al.* (1984) Canine sinonasal skeletal neoplasms: chondrosarcomas and osteosarcomas. *Vet. Pathol.*, **21** (5), 475–482.
- 17 Hahn, K.A., McGavin, M.D., Adams, W.H. (1997) Bilateral renal metastases of nasal chondrosarcoma in a dog. *Vet. Pathol.*, **34** (4), 352–355.
- 18 Sones, E., Smith, A., Schleis, S., *et al.* (2013) Survival times for canine intranasal sarcomas treated with radiation therapy: 86 cases (1996–2011). *Vet. Radiol. Ultrasound*, **54** (2), 194–201.
- 19 Couto, C.G., Boudrieau, R.J., Zanjani, E.D. (1989) Tumor-associated erythrocytosis in a dog with nasal fibrosarcoma. *J. Vet. Intern. Med.*, **3** (3), 183–185.
- 20 Griffey, S.M., Kraegel, S.A., Madewell, B.R. (1998) Rapid detection of K-ras gene mutations in canine lung cancer using single-strand conformational polymorphism analysis. *Carcinogenesis*, **19** (6), 959–963.
- 21 D'Costa, S., Yoon, B.I., Kim, D.Y., *et al.* (2012) Morphologic and molecular analysis of 39 spontaneous feline pulmonary carcinomas. *Vet. Pathol.*, **49** (6), 971–978.
- 22 Marolf, A.J., Gibbons, D.S., Podell, B.K., *et al.* (2011) Computed tomographic appearance of primary lung tumors in dogs. *Vet. Radiol. Ultrasound*, **52** (2), 168–172.
- 23 Barrett, L.E., Pollard, R.E., Zwingenberger, A., *et al.* (2014) Radiographic characterization of primary lung tumors in 74 dogs. *Vet. Radiol. Ultrasound*, **55** (5), 480–487.
- 24 Maritato, K.C., Schertel, E.R., Kennedy, S.C. (2014) Outcome and prognostic indicators in 20 cats with surgically treated primary lung tumors. *J. Feline Med. Surg.*, **16** (12), 979–984.
- 25 McNiel, E.A., Ogilvie, G.K., Powers, B.E., *et al.* (1997) Evaluation of prognostic factors for dogs with primary lung tumors: 67 cases (1985–1992). *J. Am. Vet. Med. Assoc.*, **211** (11), 1422–1427.
- 26 Mehlhaff, C.J., Leifer, C.E., Patnaik, A.K., *et al.* (1984) Surgical treatment of primary pulmonary neoplasia in 15 dogs. *J. Am. Anim. Hosp. Assoc.*, **20** (5), 799–803.
- 27 Polton, G.A., Brearley, M.J., Powell, S.M., *et al.* (2008) Impact of primary tumour stage on survival in dogs with solitary lung tumours. *J. Small Anim. Pract.*, **49** (2), 66–71.
- 28 Moulton, J.E., von Tscharner, C., Schneider, R. (1981) Classification of lung carcinomas in the dog and cat. *Vet. Pathol.*, **18** (4), 513–528.
- 29 Bleakley, S., Duncan, C.G., Monnet, E. (2015) Thoracoscopic lung lobectomy for primary lung tumors in 13 dogs. *Vet. Surg.*, **44** (8), 1029–1035.
- 30 Andreasen, C.B. (2003) Bronchoalveolar lavage. *Vet. Clin. North Am. Small Anim. Pract.*, **33** (1), 69–88.
- 31 Hawkins, E.C., DeNicola, D.B., Kuehn, N.F. (1990) Bronchoalveolar lavage in the evaluation of pulmonary disease in the dog and cat. State of the art. *J. Vet. Intern. Med.*, **4** (5), 267–274.
- 32 Rebar, A.H., DeNicola, D.B., Muggenburg, B.A. (1980) Bronchopulmonary lavage cytology in the dog: normal findings. *Vet. Pathol.*, **17** (3), 294–304.
- 33 Padrid, P.A., Feldman, B.F., Funk, K., *et al.* (1991) Cytologic, microbiologic, and biochemical analysis of bronchoalveolar lavage fluid obtained from 24 healthy cats. *Am. J. Vet. Res.*, **52** (8), 1300–1307.
- 34 DeHeer, H.L., McManus, P. (2005) Frequency and severity of tracheal wash hemosiderosis and association with underlying disease in 96 cats: 2002–2003. *Vet. Clin. Pathol.*, **34** (1), 17–22.
- 35 Colledge, S.L., Messick, J.B., Huang, A. (2013) What is your diagnosis? Transtracheal wash fluid from a dog. *Vet. Clin. Pathol.*, **42** (2), 238–239.
- 36 Nuñez-Ochoa, L., Desnoyers, M., Lecuyer, M. (1993) What is your diagnosis? Transtracheal wash from a 2-year-old dog. *Vet. Clin. Pathol.*, **22** (4), 122.
- 37 Hawkins, E.C., Morrison, W.B., DeNicola, D.B., *et al.* (1993) Cytologic analysis of bronchoalveolar lavage fluid from 47 dogs with multicentric malignant lymphoma. *J. Am. Vet. Med. Assoc.*, **203** (10), 1418–1425.

11

Endocrine

11.1 Thyroid

11.1.1 Thyroid Adenoma

11.1.1.1 Cytologic Features

Thyroid adenomas comprise sheets of uniform, cuboidal to columnar epithelial cells, frequently arranged in palisading rows and acinar arrangements (Figure 11.1). Bright-pink colloid may be seen in the background, and bare nuclei are a common finding. The cells often lack prominent intercellular borders. They have a moderate volume of cytoplasm that may contain green/black pigment (tyrosine). Nuclei are centrally or eccentrically placed, and have stippled chromatin with small basophilic nucleoli. Anisocytosis/anisokaryosis are mild and

N/C ratios are low. Note that adenomatous hyperplasia appears cytologically similar.

11.1.1.2 Clinical Considerations

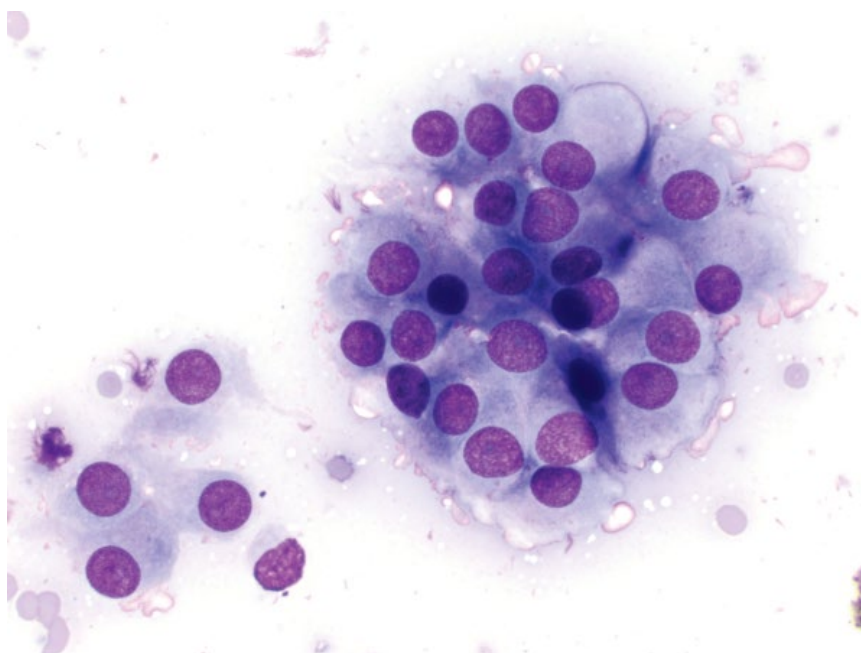
Cats

- Very common, and responsible for 97–99% of cases of hyperthyroidism [1].
- Rare in patients <8 years of age.
- 71–85% of cases of adenoma/adenomatous hyperplasia are bilateral [1, 2].

Dogs

- Less common than cats, usually small, clinically silent, and an incidental finding.

Figure 11.1 Thyroid adenoma, cat, 50x objective. Note the acinar arrangement of the cells, and the subtle pink colloid around the periphery of the cytoplasm.



11.1.1.3 Prognosis

Excellent.

11.1.2 Thyroid Adenocarcinoma**11.1.2.1 Cytologic Features**

Cytologic appearance of thyroid carcinomas is highly variable, ranging from well-differentiated (making them difficult to distinguish from adenomas; compare Figures 11.1 and 11.2), to markedly pleomorphic (see Figures 11.3–11.5). They frequently have a densely

bloody background, as carcinomas are more vascular than benign tumors [3]. The cells often form palisading rows or acinar arrangements, and bright-pink, smooth colloid may be seen in the background. Green/black tyrosine granules may be present in the cytoplasm.

11.1.2.2 Clinical Considerations**Dogs**

- The majority of clinically detectable tumors are carcinomas [4].

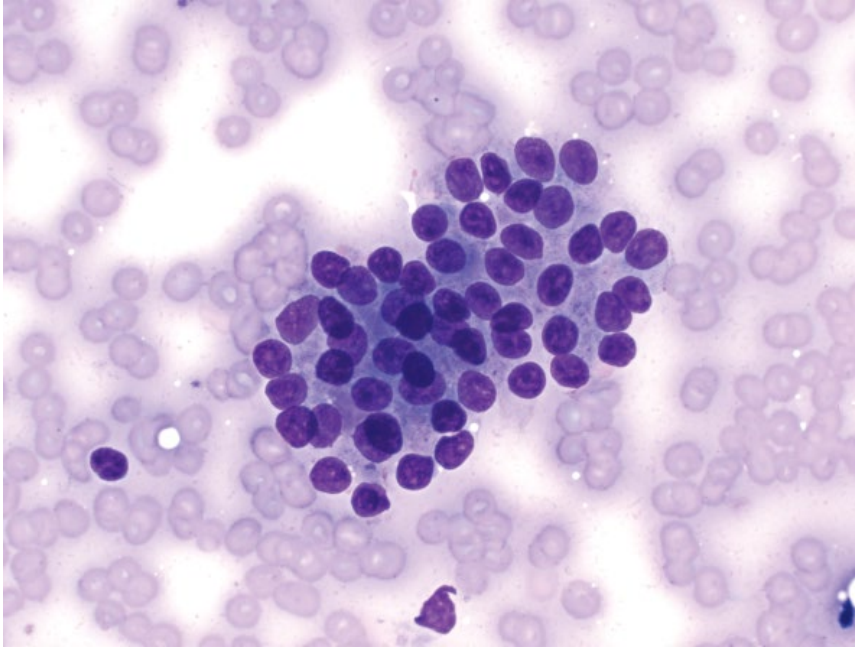


Figure 11.2 Thyroid adenocarcinoma (well-differentiated), dog 50× objective. The cells have mild criteria of malignancy, but note the high N/C ratios and cellular crowding.

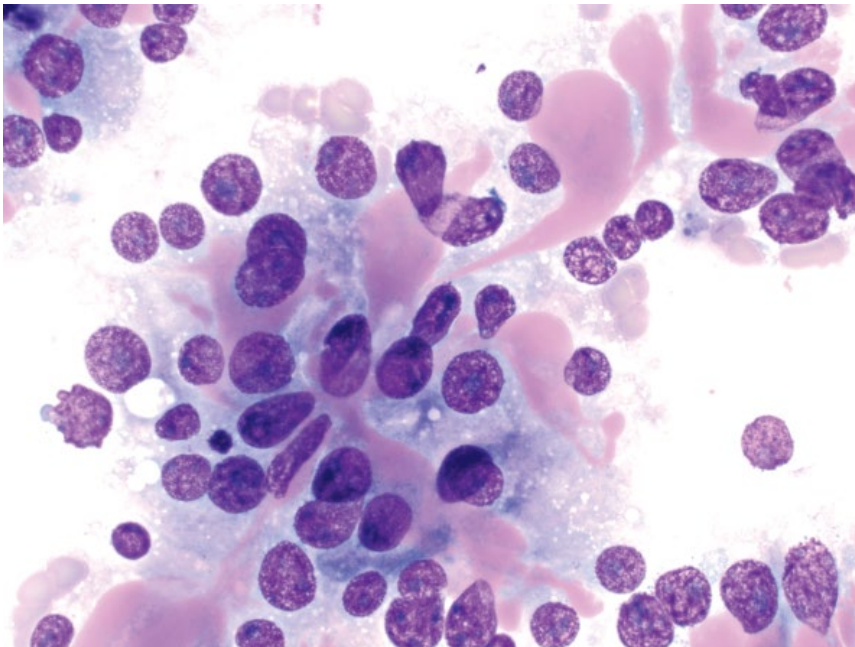


Figure 11.3 Thyroid adenocarcinoma, dog, 50× objective. There is abundant bright-pink colloid. Cells have indistinct intercellular borders and are disorganized.

Figure 11.4 Thyroid carcinoma, dog, 50× objective. Neoplastic cells are poorly cohesive and have marked anisokaryosis.

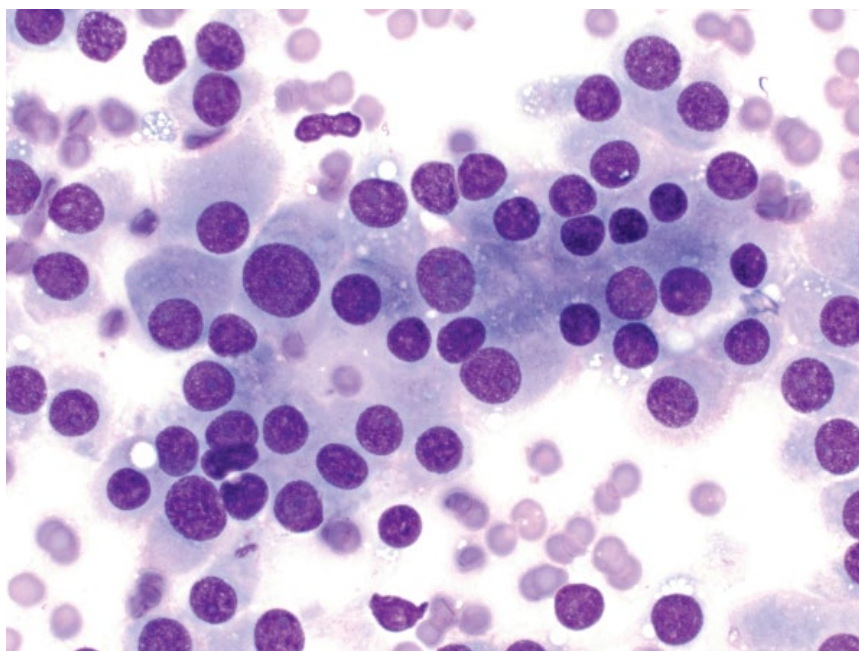
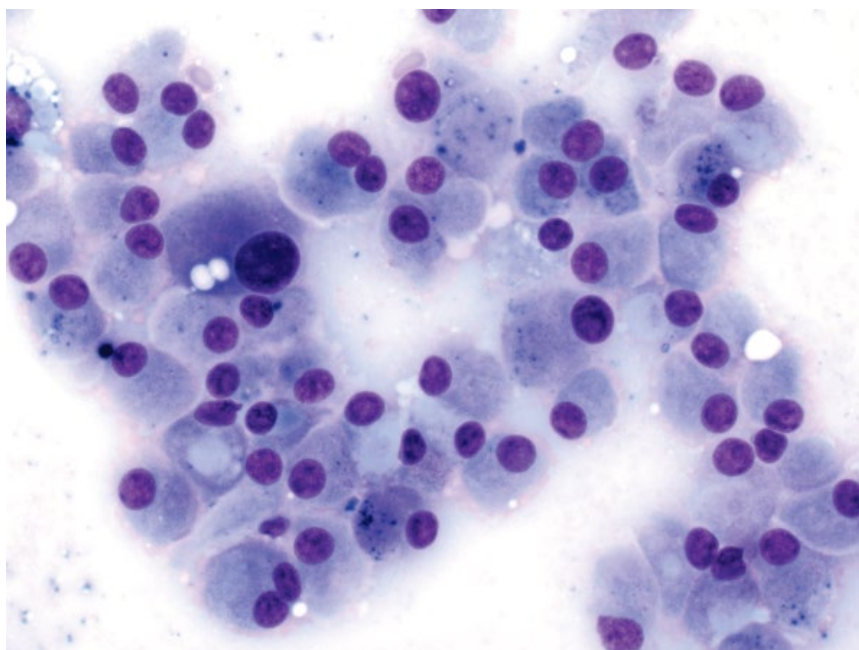


Figure 11.5 Thyroid carcinoma, dog, 50× objective. The cells are arranged in palisading rows and have marked anisocytosis/anisokaryosis. Green/blue tyrosine granules are seen in many cells.



- Most are non-functional.
- Seen mostly in older dogs. Boxers, Golden Retrievers, Beagles and Siberian Huskies are predisposed [4, 5].
- Good correlation between results of cytology and histopathology [6].
- Metastatic potential is linked to tumor size, and is 14% for tumors $\leq 20 \text{ cm}^3$, 74% for tumors $21\text{--}100 \text{ cm}^3$ and 100% in tumors $>100 \text{ cm}^3$ [5]. The lungs are the most common location for metastases.

- Metastasis is 16-fold more likely for bilateral tumors than unilateral.

Cats

- Uncommon. Seen in 1–3% of hyperthyroid cats [1], and non-functional carcinomas are rare.
- Metastatic disease to local lymph nodes and lungs is common.

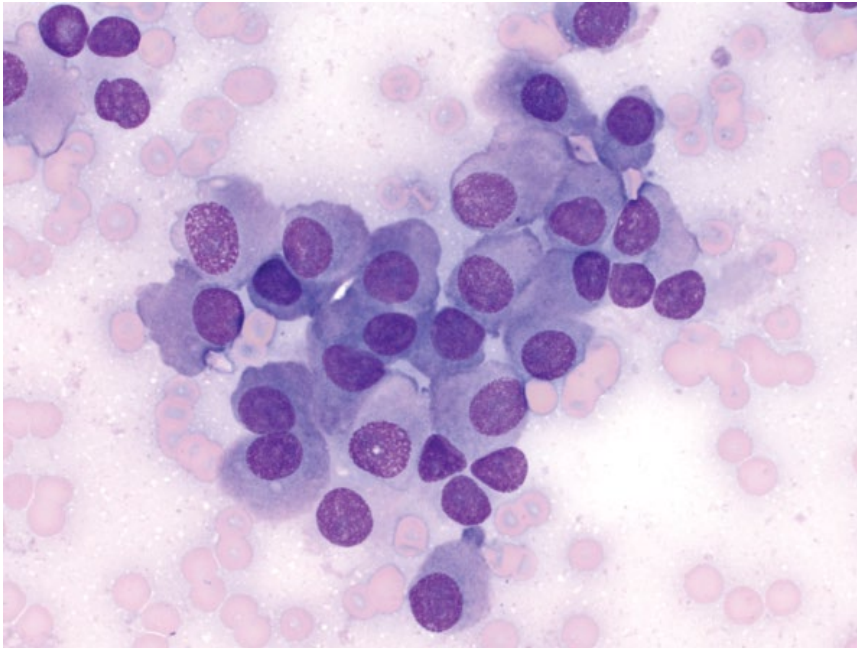


Figure 11.6 Thyroid C cell (medullary) carcinoma, dog, 50× objective. Note the faint pink granular appearance of the cytoplasm.

11.1.2.3 Prognosis

Variable, based on the presence of metastatic disease (poor prognosis when present) and invasiveness. Invasive tumors result in shorter survival times, even in the absence of metastatic disease at the time of diagnosis [7].

11.1.3 Thyroid C Cell (Medullary) Carcinoma

11.1.3.1 Cytologic Features

Thyroid C cell carcinomas often have a distinctive ‘plasmacytoid’ appearance, similar to those described in humans [8]. The cells are ovoid, with a moderate volume of pink granular cytoplasm (which may represent cytoplasmic calcitonin), and eccentrically placed nuclei that have finely stippled chromatin and single basophilic nucleoli (Figure 11.6). Anisokaryosis is moderate. The pink cytoplasm can make differentiating these tumors from carotid body tumors difficult (compare to Figure 11.9); however, the cytoplasm of carotid body tumors mostly has a more coarse granular appearance.

11.1.3.2 Clinical Considerations

- Derived from C cells of the thyroid.
- Rare in dogs, not reported in cats.
- Elevated calcitonin is used as a tumor marker in humans, but is not reported in dogs [9]. Hypocalcemia is an inconsistent finding [10, 11].

11.1.3.3 Prognosis

Less malignant potential than thyroid adenocarcinomas, a finding mirrored in human patients [9, 10]. In one study, 30% of surgically resected cases had at least one-year survival [10].

11.2 Parathyroid

11.2.1 Parathyroid Adenoma

11.2.1.1 Cytologic Features

Parathyroid adenomas comprise sheets of uniform cuboidal to columnar cells in palisading rows and acinar arrangements. They have a moderate volume of cytoplasm, which may contain eosinophilic material (see Figure 11.7) that has also been reported in parathyroid carcinomas [12]. Nuclei are round with granular chromatin and inapparent nucleoli. Tumors of parathyroid origin may appear similar to those of the thyroid, and can be difficult to distinguish without histopathology.

11.2.1.2 Clinical Considerations

- Derived from parathyroid chief cells.
- Rare tumors in dogs and cats.
- Adenomas are more common than carcinomas [13, 14].
- Frequently functional and associated with hypercalcemia.

11.2.1.3 Prognosis

Excellent.

11.2.2 Parathyroid Carcinoma

11.2.2.1 Cytologic Features

Parathyroid carcinomas can appear similar to adenomas. Increased anisokaryosis/anisocytosis and high N/C ratios generally are seen, as well as cellular crowding (compare Figures 11.8 and 11.7).

Figure 11.7 Parathyroid adenoma, dog, 50x objective. Cells are arranged in palisading rows. Note the smooth pink material in the cytoplasm of many cells.

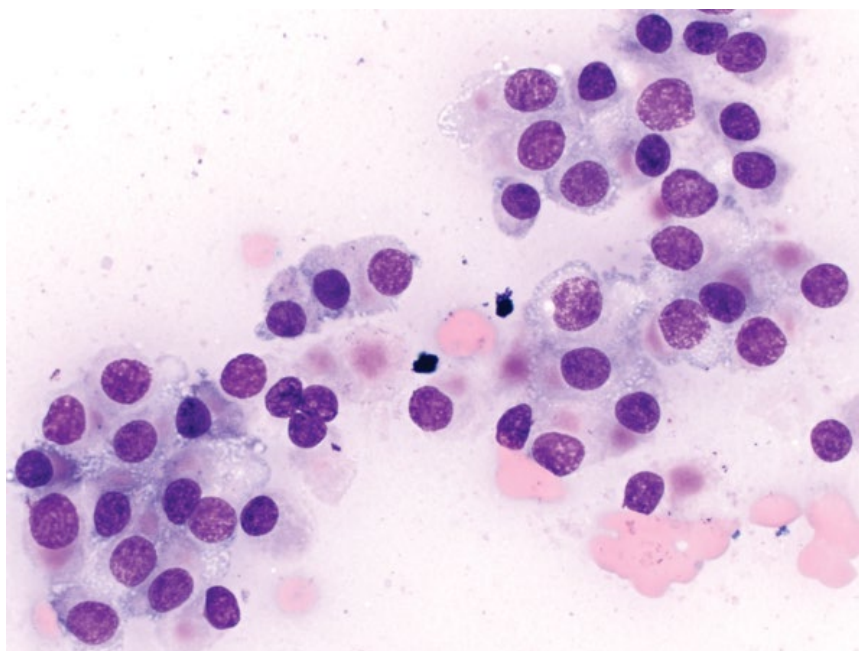
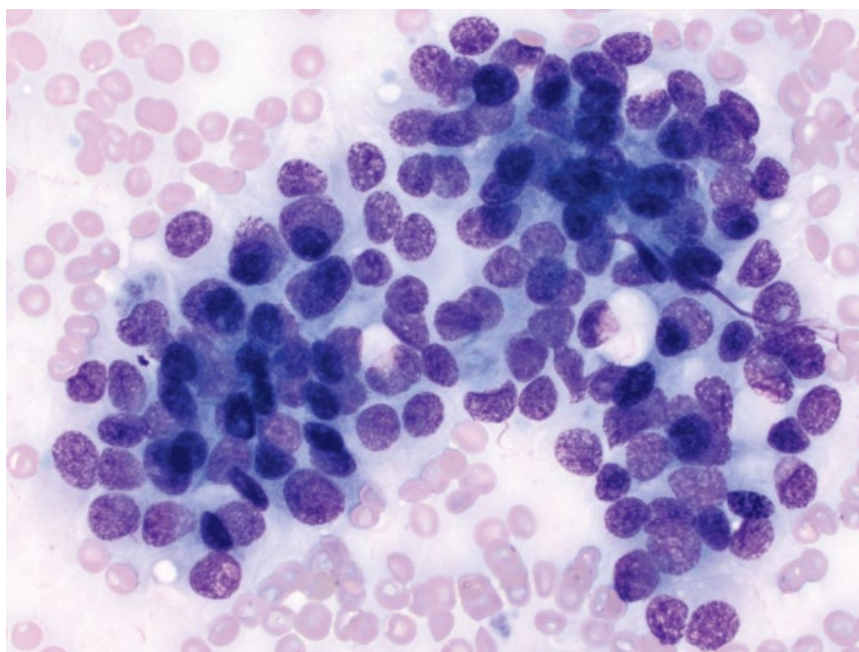


Figure 11.8 Parathyroid adenocarcinoma, dog, 50x objective. Cells are crowded, piled, and have high N/C ratios and moderate anisokaryosis.



11.2.2.2 Clinical Considerations

- Usually larger than adenomas, and may be palpable in cats, though rarely palpable in dogs [13].
- Frequently functional and associated with hypercalcemia.
- Metastatic disease, or recurrence after surgery is rare [15].

11.2.2.3 Prognosis

Good, with long-term survival reported after surgical excision [15].

11.3 Chemoreceptor Tumors

11.3.1 Chemodectomas

11.3.1.1 Cytologic Features

Chemodectomas often are highly cellular and have a moderate amount of pale-blue cytoplasm that frequently contains abundant, diffuse, pink granules that are helpful to distinguish them from thyroid/parathyroid tumors (Figure 11.9). Some tumors may lack pink granules (Figure 11.10), and special stains may be required for

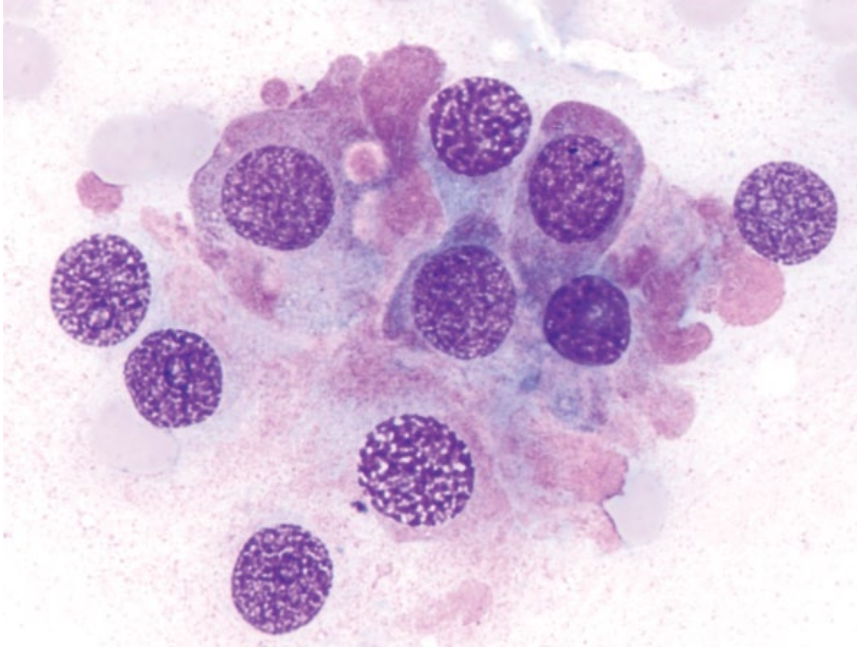


Figure 11.9 Carotid body tumor, dog, 100× objective. The cytoplasm contains many fine pink granules.

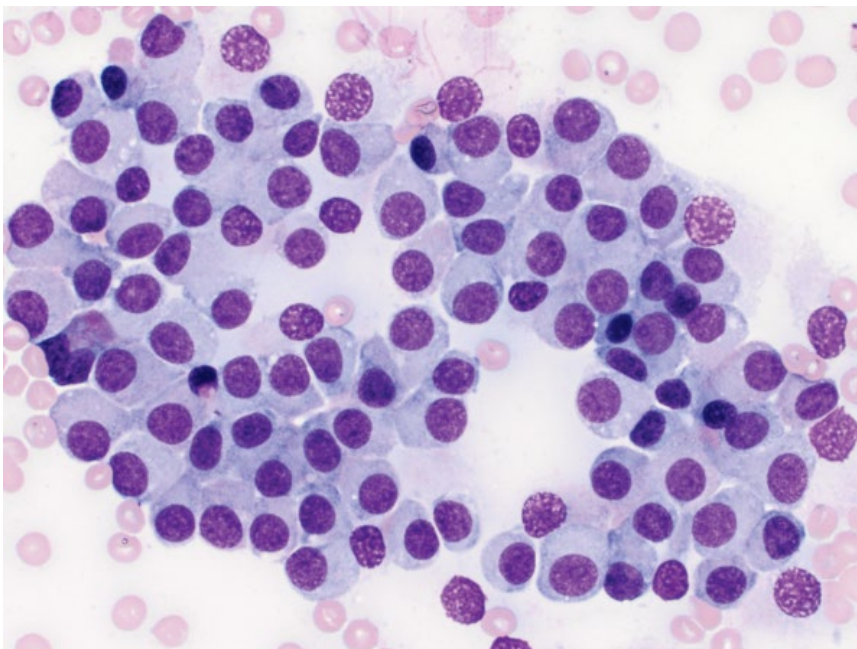


Figure 11.10 Carotid body tumor, dog, 50× objective. Cells are seen in loose sheets, and lack pink granules.

further assessment (Figure 11.11). Nuclei are round, with finely stippled chromatin and small basophilic nucleoli. Anisocytosis/anisokaryosis generally are mild.

11.3.1.2 Clinical Considerations

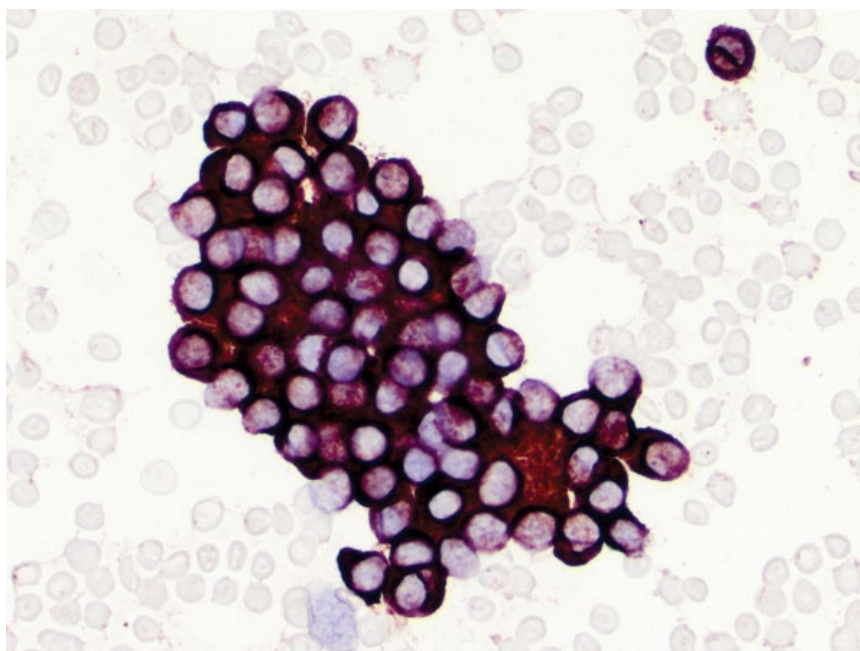
- Chemodectomas include aortic body tumors (more common) and carotid body tumors.
- Dogs >> cats

- There is an increased incidence of aortic body tumors in brachycephalic breeds [16].

11.3.1.3 Prognosis

Carotid body tumors frequently are locally invasive and have a propensity to metastasize widely [17]. Aortic body tumors often are benign with a low incidence of metastatic disease, but are associated with pericardial effusion, cardiac

Figure 11.11 Carotid body tumor, dog, 50× objective. Cell cytoplasm is staining strongly positive for synaptophysin (same case as Figure 11.10).



tamponade or heart failure. Dogs treated with pericardectomy had significantly longer survival times [18].

11.4 Adrenal Gland

11.4.1 Adrenocortical Adenoma

11.4.1.1 Cytologic Features

Adrenocortical adenomas often exfoliate as individualized, ovoid cells, but may also be seen in small sheets associated with capillaries (Figure 11.12). The cells have abundant pale blue/gray cytoplasm that contains numerous small, coarse, clear vacuoles. Nuclei are round, centrally located, and have reticulated chromatin with small, prominent, single nucleoli. Anisocytosis/anisokaryosis are mild, and N/C ratios are low (Figure 11.13). Hyperplastic nodules appear cytologically similar, and require histopathology for differentiation.

11.4.1.2 Clinical Considerations

- May be functional or non-functional.
- In a large retrospective study, adrenocortical adenomas were nearly fourfold more common than carcinomas [19].
- Extramedullary hematopoiesis can be seen in adrenal tumors (Figure 11.14), and is more likely to be present in adenomas than carcinomas [20].

11.4.1.3 Prognosis

Variable. Many tumors are incidental findings. Dogs surviving surgery for functional adrenocortical adenomas have an excellent prognosis [21].

11.4.2 Adrenocortical Carcinoma

11.4.2.1 Cytologic Features

Variably cohesive tumors comprising round to polygonal cells with variably vacuolated cytoplasm. The nuclei are round, centrally located with reticulated chromatin, and often with multiple, basophilic nucleoli. Relative to adenomas, adrenocortical carcinomas have higher N/C ratios, often contain fewer vacuoles, have a more basophilic cytoplasm, and greater nuclear atypia (compare Figures 11.15 and 11.13).

11.4.2.2 Clinical Considerations

- May be functional or non-functional (functional tumors are more common).
- Typically larger than adenomas, with tumors >2 cm more likely to be carcinomas [20].
- Metastatic disease is seen in approximately 50% of cases [20].

11.4.2.3 Prognosis

Variable. Prolonged survival times are reported in patients surviving surgery. Survival times are significantly decreased in the presence of metastatic disease [22].

11.4.3 Pheochromocytoma

11.4.3.1 Cytologic Features

Pheochromocytomas frequently exfoliate well, as papillary sheets of polygonal cells with abundant, distinctive eosinophilic granular cytoplasm (Figure 11.16). The nuclei are ovoid, with coarsely granular chromatin and small basophilic nucleoli. Anisokaryosis often is marked.

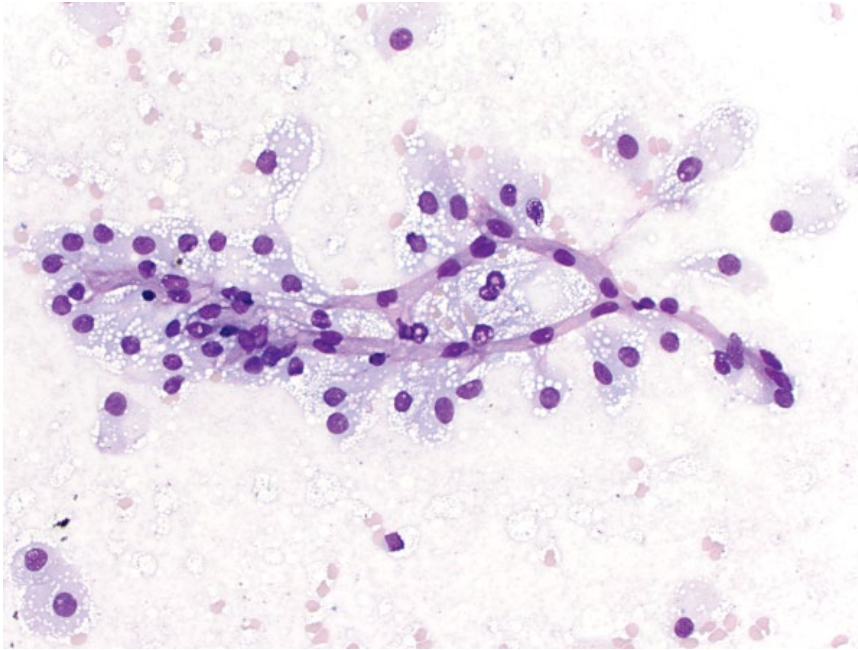


Figure 11.12 Adrenocortical adenoma, dog, 20x objective. Cells are emanating from linear capillaries.

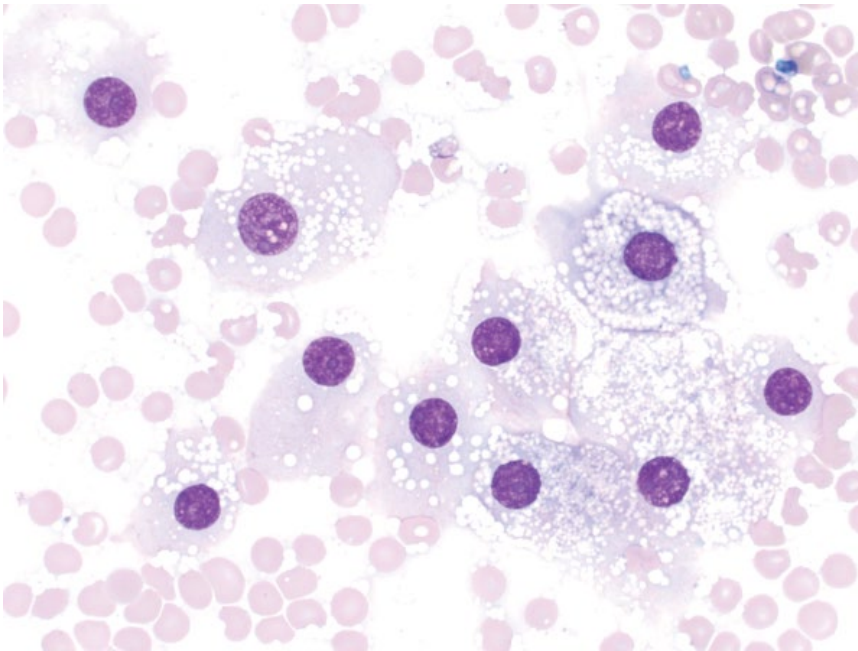


Figure 11.13 Adrenocortical adenoma, dog, 50x objective. The cells are uniform and have abundant vacuolated cytoplasm.

11.4.3.2 Clinical Considerations

- Arise from chromaffin cells of the adrenal medulla.
- Uncommon in dogs (middle aged to older). Rare in cats.
- Often incidental findings. A high frequency of concurrent neoplasia, including other endocrine origin, is reported [23].

- Metastatic disease is seen in up to 36% of cases, in local lymph nodes or widely disseminated [23, 24].

11.4.3.3 Prognosis

Highly variable based on tumor size, local invasion, or presence of metastatic disease. Patients without metastatic disease that survive surgical removal have a good prognosis.

Figure 11.14 Adrenocortical adenoma, dog, 50× objective. Note the erythroid precursors at the right of the photograph.

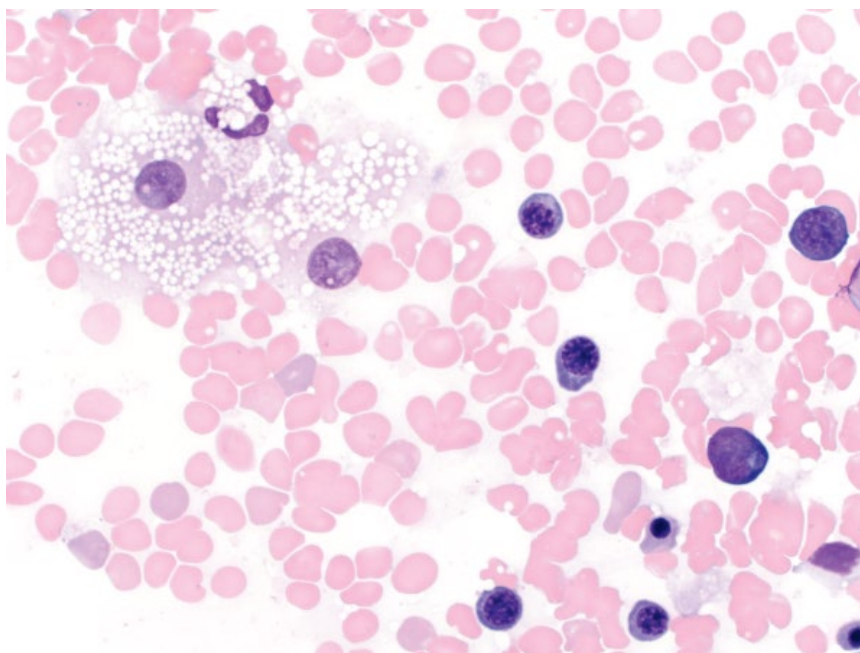
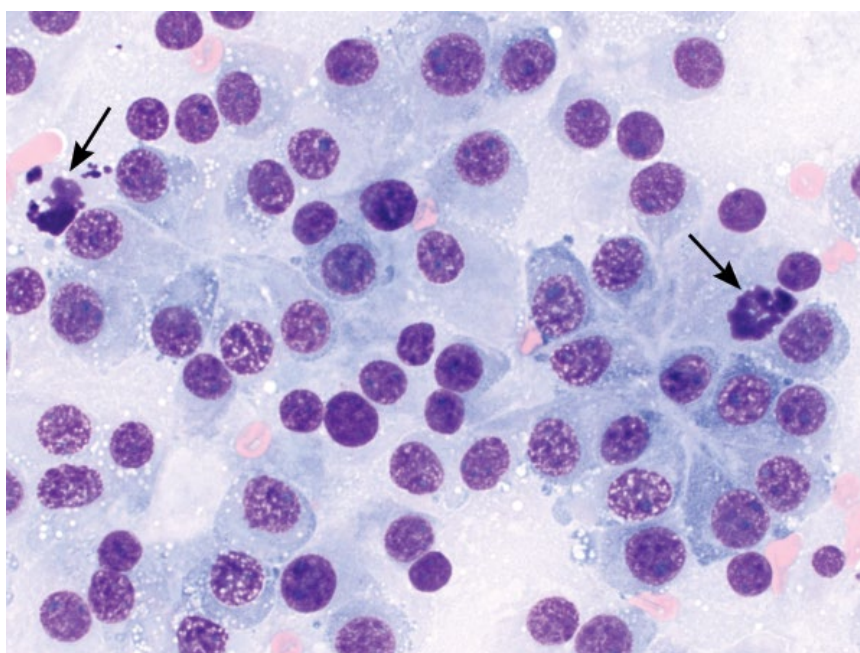


Figure 11.15 Adrenocortical adenocarcinoma, dog, 50× objective. The cells have high N/C ratios and are poorly vacuolated. Note the mitotic figures (arrows).



11.5 Pituitary Gland

11.5.1 Pituitary Carcinoma

11.5.1.1 Cytologic Features

Cells from pituitary carcinomas exfoliate individually and in variably cohesive sheets. The cells are round, with a moderate volume of medium-blue cytoplasm

that frequently contains fine clear vacuoles. Nuclei mostly are ovoid, but often are amoeboid or cleaved, and have very finely stippled, immature chromatin with multiple basophilic nucleoli. Anisocytosis/anisokaryosis are moderate to marked, and N/C ratios are moderate to high. These tumors frequently have a very high mitotic rate (Figure 11.17).

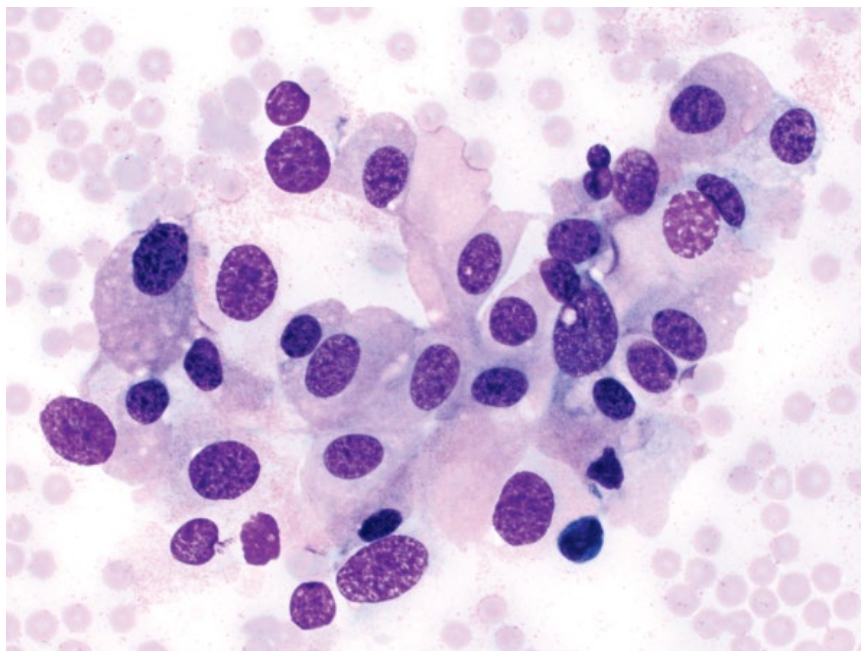


Figure 11.16 Pheochromocytoma, dog, 50× objective. The cells have characteristic faint pink cytoplasm, and prominent anisokaryosis.

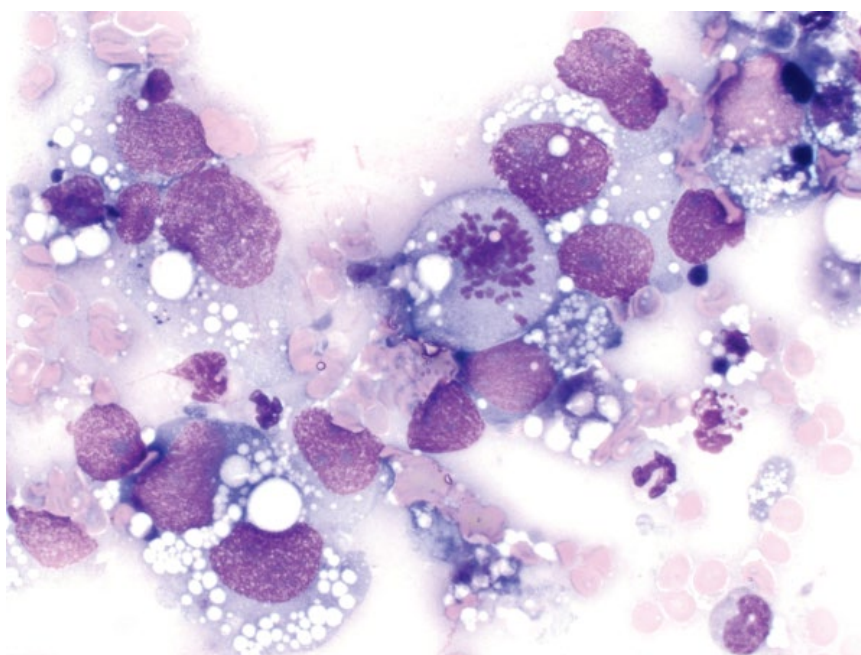


Figure 11.17 Pituitary carcinoma, dog, 50× objective.

11.5.1.2 Clinical Considerations

- Rare tumors in dogs and cats [25, 26].
- Typically older patients, but reported in a dog <1 year old [27].

- Less common than adenomas [25].
- Variable hormone production.

11.5.1.3 Prognosis

Poor.

References

- 1 Naan, E.C., Kirpensteijn, J., Kooistra, H.S., *et al.* (2006) Results of thyroidectomy in 101 cats with hyperthyroidism. *Vet. Surg.*, **35** (3), 287–293.
- 2 Peterson, M.E., Kintzer, P.P., Cavanagh, P.G., *et al.* (1983) Feline hyperthyroidism: pretreatment clinical and laboratory evaluation of 131 cases. *J. Am. Vet. Med. Assoc.*, **183** (1), 103–110.
- 3 Kent, M.S., Griffey, S.M., Verstraete, F.J., *et al.* (2002) Computer-assisted image analysis of neovascularization in thyroid neoplasms from dogs. *Am. J. Vet. Res.*, **63** (3), 363–369.
- 4 Wucherer, K.L., Wilke, V. (2010) Thyroid cancer in dogs: an update based on 638 cases (1995–2005). *J. Am. Anim. Hosp. Assoc.*, **46** (4), 249–254.
- 5 Leav, I., Schiller, A.L., Rijnberk, A., *et al.* (1976) Adenomas and carcinomas of the canine and feline thyroid. *Am. J. Pathol.*, **83** (1), 61–122.
- 6 Thompson, E.J., Stirtzinger, T., Lumsden, J.H., *et al.* (1980) Fine needle aspiration cytology in the diagnosis of canine thyroid carcinoma. *Can. Vet. J.*, **21** (6), 186–188.
- 7 Klein, M.K., Powers, B.E., Withrow, S.J., *et al.* (1995) Treatment of thyroid carcinoma in dogs by surgical resection alone: 20 cases (1981–1989). *J. Am. Vet. Med. Assoc.*, **206** (7), 1007–1009.
- 8 Mehdi, G., Maheshwari, V., Ansari, H.A., *et al.* (2010) FNAC diagnosis of medullary carcinoma thyroid: A report of three cases with review of literature. *J. Cytol.*, **27** (2), 66–68.
- 9 Melvin, K.E., Miller, H.H., Tashjian, A.H., Jr. (1971) Early diagnosis of medullary carcinoma of the thyroid gland by means of calcitonin assay. *N. Engl. J. Med.*, **285** (20), 1115–1120.
- 10 Carver, J.R., Kapatkin, A., Patnaik, A.K. (1995) A comparison of medullary thyroid carcinoma and thyroid adenocarcinoma in dogs: a retrospective study of 38 cases. *Vet. Surg.*, **24** (4), 315–319.
- 11 Patnaik, A.K., Lieberman, P.H., Erlandson, R.A., *et al.* (1978) Canine medullary carcinoma of the thyroid. *Vet. Pathol.*, **15** (5), 590–599.
- 12 Ramaiah, S.K., Alleman, A.R., Hanel, R., *et al.* (2001) A mass in the ventral neck of a hypercalcemic dog. *Vet. Clin. Pathol.*, **30** (4), 177–179.
- 13 Kallet, A.J., Richter, K.P., Feldman, E.C., *et al.* (1991) Primary hyperparathyroidism in cats: seven cases (1984–1989). *J. Am. Vet. Med. Assoc.*, **199** (12), 1767–1771.
- 14 Berger, B., Feldman, E.C. (1987) Primary hyperparathyroidism in dogs: 21 cases (1976–1986). *J. Am. Vet. Med. Assoc.*, **191** (3), 350–356.
- 15 Sawyer, E.S., Northrup, N.C., Schmiedt, C.W., *et al.* (2012) Outcome of 19 dogs with parathyroid carcinoma after surgical excision. *Vet. Comp. Oncol.*, **10** (1), 57–64.
- 16 Hayes, H.M. (1975) An hypothesis for the aetiology of canine chemoreceptor neoplasms, based upon an epidemiological study of 73 cases among hospital patients. *J. Small Anim. Pract.*, **16** (5), 337–343.
- 17 Obradovich, J.E., Withrow, S.J., Powers, B.E., *et al.* (1992) Carotid body tumors in the dog. Eleven cases (1978–1988). *J. Vet. Intern. Med.*, **6** (2), 96–101.
- 18 Ehrhart, N., Ehrhart, E.J., Willis, J., *et al.* (2002) Analysis of factors affecting survival in dogs with aortic body tumors. *Vet. Surg.*, **31** (1), 44–48.
- 19 Labelle, P., De Cock, H.E. (2005) Metastatic tumors to the adrenal glands in domestic animals. *Vet. Pathol.*, **42** (1), 52–58.
- 20 Labelle, P., Kyles, A.E., Farver, T.B. (2004) Indicators of malignancy of canine adrenocortical tumors: histopathology and proliferation index. *Vet. Pathol.*, **41** (5), 490–497.
- 21 Schwartz, P., Kovak, J.R., Koprowski, A., *et al.* (2008) Evaluation of prognostic factors in the surgical treatment of adrenal gland tumors in dogs: 41 cases (1999–2005). *J. Am. Vet. Med. Assoc.*, **232** (1), 77–84.
- 22 Massari, F., Nicoli, S., Romanelli, G., *et al.* (2011) Adrenalectomy in dogs with adrenal gland tumors: 52 cases (2002–2008). *J. Am. Vet. Med. Assoc.*, **239** (2), 216–221.
- 23 Barthez, P.Y., Marks, S.L., Woo, J., *et al.* (1997) Pheochromocytoma in dogs: 61 cases (1984–1995). *J. Vet. Intern. Med.*, **11** (5), 272–278.
- 24 Gilson, S.D., Withrow, S.J., Wheeler, S.L., *et al.* (1994) Pheochromocytoma in 50 dogs. *J. Vet. Intern. Med.*, **8** (3), 228–232.
- 25 Rissi, D.R. (2015) A retrospective study of skull base neoplasia in 42 dogs. *J. Vet. Diagn. Invest.*, **27** (6), 743–748.
- 26 Kimitsuki, K., Boonsriroj, H., Kojima, D., *et al.* (2014) A case report of feline pituitary carcinoma with hypercortisolism. *J. Vet. Med. Sci.*, **76** (1), 133–138.
- 27 Gestier, S., Cook, R.W., Agnew, W., *et al.* (2012) Silent pituitary corticotroph carcinoma in a young dog. *J. Comp. Pathol.*, **146** (4), 327–331.

12

Reproductive

Male

12.1 Testes

12.1.1 Normal Testicle

12.1.1.1 Cytologic Appearance

An appreciation of normal testicular cytology is important when interpreting pathologic changes. Readers are referred to the review in Ref. [1] for an excellent and comprehensive summary of normal testicular cytology. Cells from testicle aspirates can be grouped into three major categories: Sertoli cells; Leydig cells; and spermatogenic cells. Sertoli cells have large ovoid nuclei with finely stippled chromatin and single, prominent nucleoli (Figure 12.1). Leydig cells are seen rarely, and have abundant cytoplasm with numerous punctate, clear vacuoles (Figure 12.2). Spermatogenic cells include (from most immature to mature): spermatogonia, spermatocytes, early spermatids, late spermatids, and spermatozoa (Figures 12.1, 12.3, and 12.4). Spermatogonia are rare, and have characteristic parachromatin condensation causing a crescent shape. Spermatocytes have a characteristic cord-like chromatin pattern (Figure 12.1). Spermatids are most common. Early spermatids have a small to moderate volume of pale cytoplasm that contains small, clear vacuoles. Multinucleation is common. Late spermatids have progressively elongated nuclei with condensed chromatin and scant to absent cytoplasm (Figure 12.4).

12.1.2 Seminoma

12.1.2.1 Cytologic Appearance

Seminomas exfoliate well, comprising many large, individualized, discrete cells with a moderate volume of encircling, pale-blue cytoplasm. Nuclei are round, with very finely granular, immature chromatin, and multiple prominent basophilic nucleoli. Binucleation, multinucleation and mitotic figures often are present. Small mature lymphocytes may be seen (Figure 12.5).

12.1.2.2 Clinical Considerations

- Derived from germinal epithelium of the seminiferous tubules.
- Dogs >> cats.
- Gross appearance = variably sized, soft, bulging and cream-colored on cut surface [2].
- Increased risk in cryptorchid testes [3].
- Can be bilateral, and associated with other testicular tumors of different origin [4].
- Feminization syndrome is rare [5].

12.1.2.3 Prognosis

Generally good. In the absence of metastatic disease, orchiectomy is curative. Metastatic disease is uncommon for testicular tumors in general and, if present, seminomas tend to metastasize to inguinal or sublumbar lymph nodes, with wide dissemination reported rarely [2].

12.1.3 Sertoli Cell Tumor

12.1.3.1 Cytologic Appearance

These tumors exfoliate variably well and comprise round cells distributed individually and in loose aggregates, often with a palisading arrangement. The cells have a moderate volume of medium-blue cytoplasm that frequently contains characteristic coarse, clear vacuoles, which can be helpful to differentiate these tumors from seminomas (compare Figures 12.6 and 12.5). The nuclei are round, with coarsely granular chromatin, and prominent, single nucleoli. Anisocytosis/anisokaryosis generally are mild to moderate.

12.1.3.2 Clinical Considerations

- Derived from sustentacular cells of the seminiferous tubules.
- Dogs >> cats.
- Gross appearance = variably sized, firm, lobulated, white/gray [2].
- Increased risk in cryptorchid testes [3].

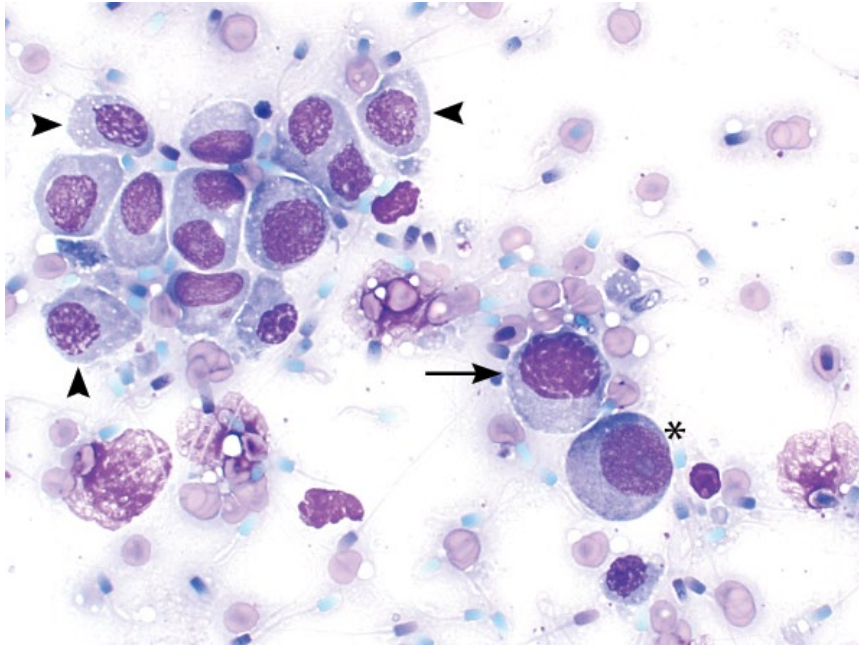


Figure 12.1 Normal testicle, cat, 50× objective. Sertoli cell (asterisk), spermatocyte (arrow), early spermatids (arrowheads) and spermatozoa in the background.

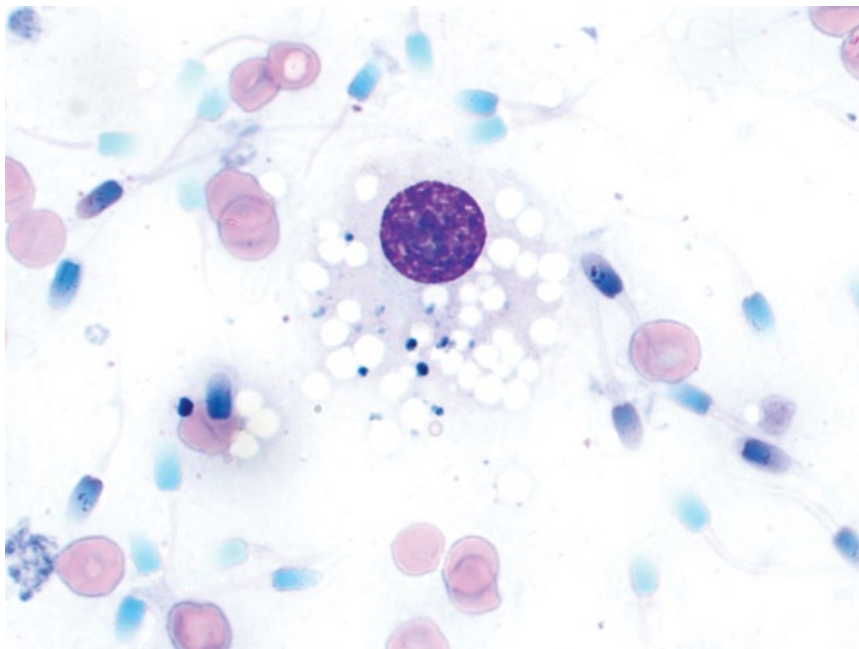


Figure 12.2 Normal testicle, cat, 100× objective. Leydig cell with cytoplasmic vacuoles and numerous spermatozoa in the background.

- Less common than seminomas and interstitial cell tumors [3, 4].
- May produce estrogen and be associated with feminizing syndrome. Clinical signs = bilaterally symmetrical alopecia, hyperpigmentation, gynecomastia, and bone marrow suppression.

12.1.3.3 Prognosis

Variable, based on the presence of metastatic disease and feminizing syndrome. Signs of feminization will resolve

with removal of the tumor [6]. Metastatic rate is low, and if absent, orchiectomy is curative.

12.1.4 Interstitial Cell Tumor (Leydig Cell Tumor)

12.1.4.1 Cytologic Appearance

Neoplastic cells are elongated, and may even appear spindloid, and often exfoliate centered around capillaries (Figure 12.7). They have a moderate volume of pale-blue cytoplasm that frequently contains numerous fine, clear

Figure 12.3 Normal testicle, cat, 50× objective. Early (arrows) and late (arrowhead) spermatids with many mature spermatozoa in the background.

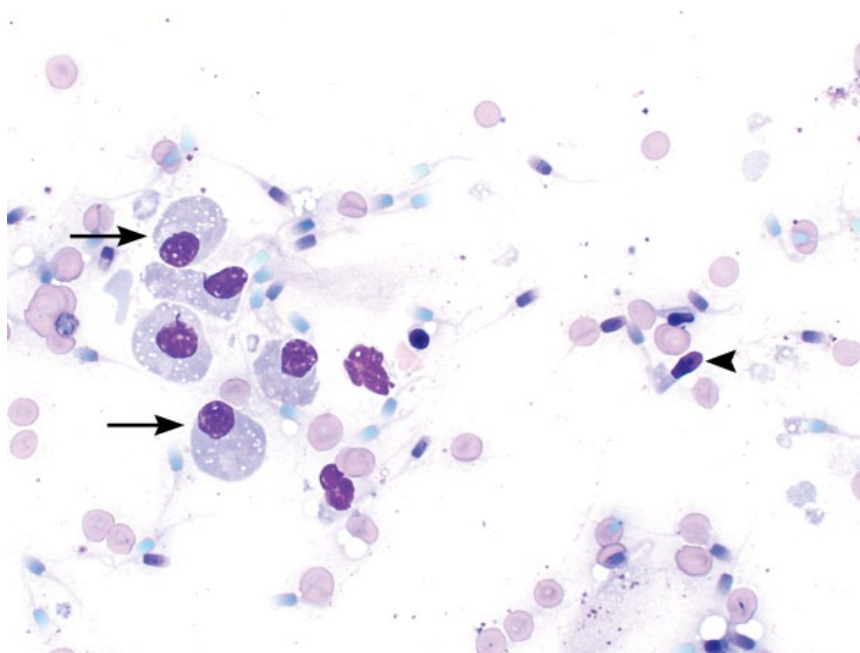
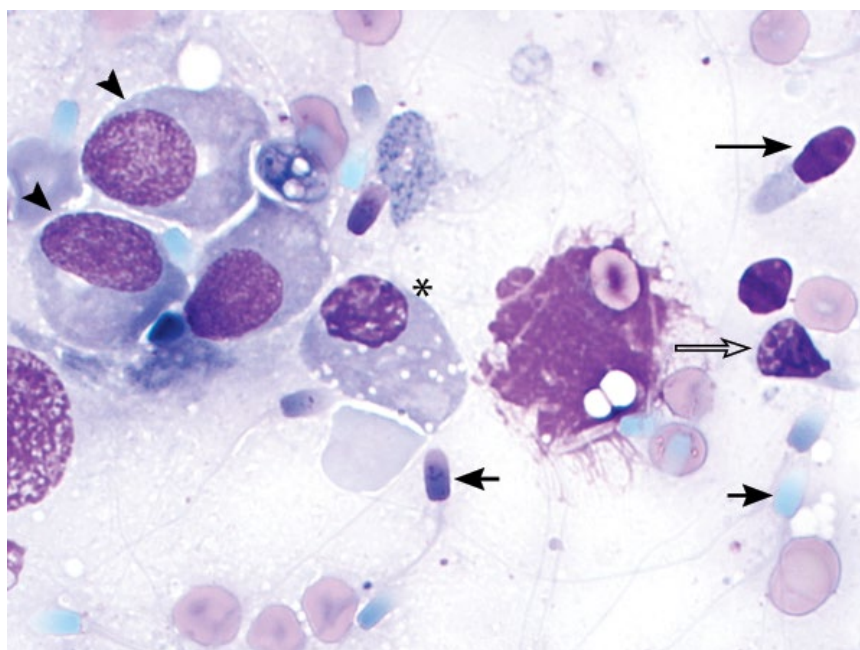


Figure 12.4 Normal testicle, cat, 100× objective. Stages of spermiogenesis: early spermatids (arrowheads), Golgi phase (asterisk), cap phase (open arrow), maturation phase (long arrow) and mature spermatozoa (short arrows).



vacuoles (Figure 12.8) compared to the coarse clear vacuoles in Sertoli cell tumors (see Figure 12.6). Nuclei often are eccentrically placed and have finely granular chromatin with small basophilic nucleoli. Anisocytosis/anisokaryosis generally are mild to moderate.

12.1.4.2 Clinical Considerations

- Derived from Leydig cells between seminiferous tubules.
- Dogs >> cats.

- Gross appearance = generally small, soft, bulging and yellow/orange on cut surface. Often contain cysts [2].
- Cryptorchidism is not a risk factor for development [3].
- Produce testosterone and are associated with an increased risk of perianal gland tumors and prostatic disease [2].

12.1.4.3 Prognosis

Good. Interstitial cell tumors have a very low metastatic rate, and orchiectomy mostly is curative.

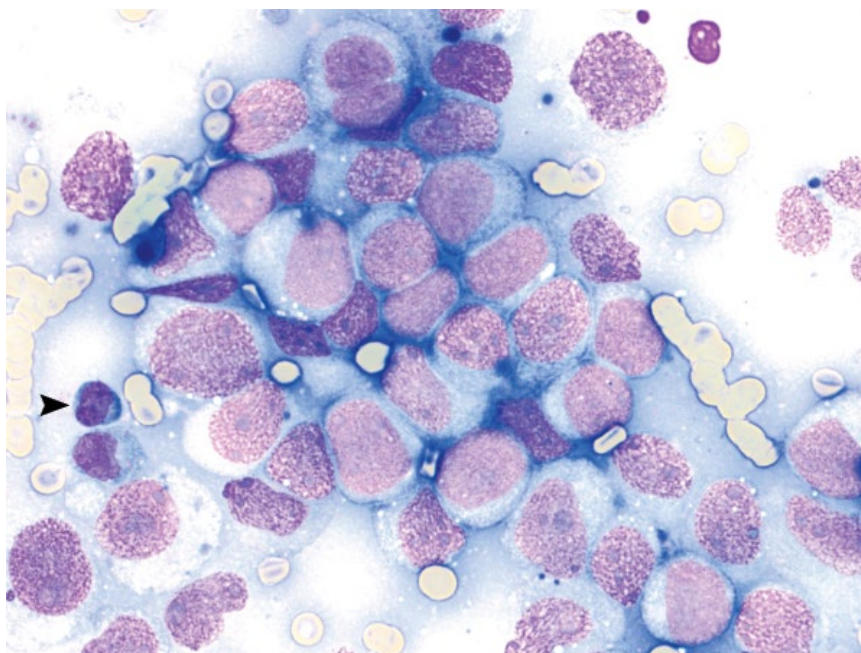


Figure 12.5 Seminoma, dog, 50× objective. Note the small mature lymphocyte (arrowhead).

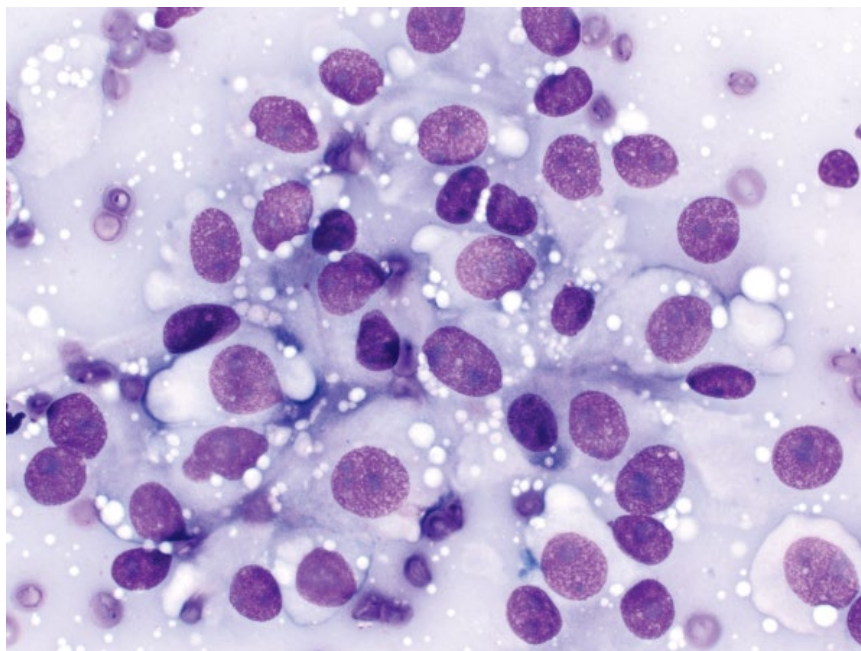


Figure 12.6 Sertoli cell tumor, dog, 50× objective. Note the coarse, clear vacuoles in the cytoplasm.

12.1.5 Orchitis

12.1.5.1 Cytologic Appearance

Orchitis is characterized by an inflammatory infiltrate, interspersed with variable numbers of spermatogenic precursor cells (Figure 12.9). Infectious agents such as bacteria, fungi, or protozoa may be seen.

12.1.5.2 Clinical Considerations

- *Brucella canis* is a common cause. *B. canis* has zoonotic potential.
- Other bacteria, *Blastomyces dermatitidis* and *Leishmania infantum* reported [7–9].
- Immune-mediated orchitis is reported [10].

Figure 12.7 Interstitial cell tumor, dog, 20× objective. Neoplastic cells radiate from central linear capillaries.

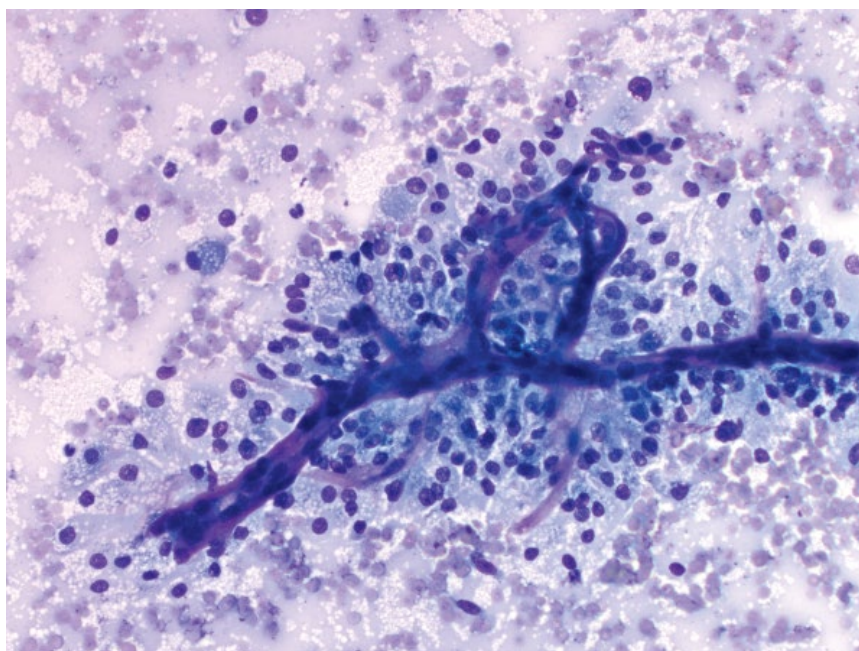
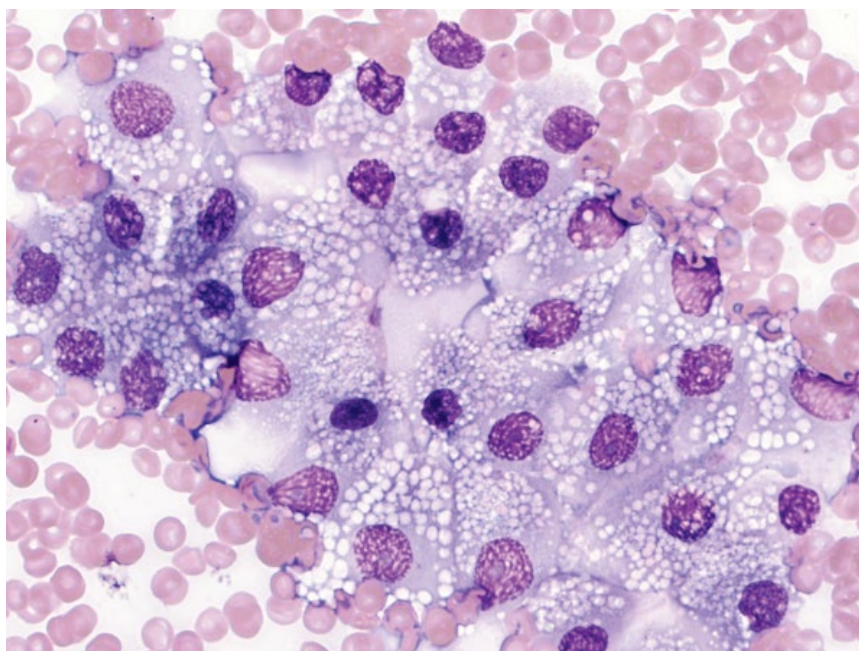


Figure 12.8 Interstitial cell tumor, dog, 50× objective. Note the fine clear vacuoles.



12.1.5.3 Prognosis

The prognosis for maintaining fertility is guarded in cases of acute orchitis, and poor for chronic orchitis.

12.2 Semen Analysis

The following section describes the morphologic characteristics of spermatozoa. Readers are referred to other excellent resources for a full description of semen analysis [11, 12].

12.2.1 Sperm Morphology

12.2.1.1 Cytologic Appearance

Spermatozoa morphology is shown in Figure 12.10.

Normal spermatozoa have a single, ovoid head, attached to a single, straight tail.

Primary morphologic changes occur during spermatogenesis and are considered more serious than secondary changes [13]. These changes include: double tail, tightly coiled tail, deformed head (including bent head or abnormal shape), proximal droplet, and double head.

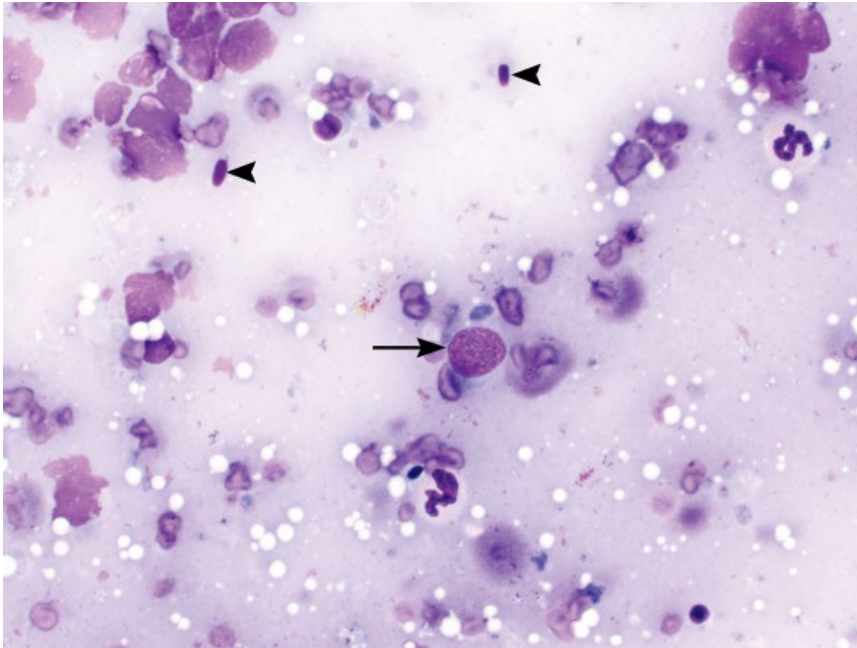


Figure 12.9 Orchitis, dog, 50× objective. Neutrophils are seen with scattered normal spermatogenic cells including spermatozoa heads (arrowheads) and an early spermatid (arrow).

Secondary morphologic changes occur during maturation or collection of samples and include: detached head, bent tail, distal coiled tail or distal droplet.

Normal semen should have <10% primary and <20% secondary abnormalities [13].

The samples should also be assessed for any evidence of inflammation (Figure 12.11).

12.2.1.2 Clinical Considerations

- Slides are best prepared using similar spreading techniques as when making a blood smear [11]. Diff-Quik® stains are adequate for analysis [14].
- At least 200 spermatozoa should be assessed on two separate slides. Assess spermatozoa in the middle third of the slides for optimal morphology.
- Aspiration of the testicle, if required, is a safe procedure, with no significant adverse side effects or effects on testicular function [15].

12.2.1.3 Prognosis

Fertility in dogs appears to be most adversely affected when the percentage of normal spermatozoa morphology drops below 60% [16]. *Note:* The morphologic assessment of spermatozoa is only one facet of assessing fertility.

12.3 Prostate

12.3.1 Benign Prostatic Hyperplasia (BPH)

12.3.1.1 Cytologic Features

BPH is characterized by sheets of uniform cells, with minimal anisocytosis and anisokaryosis. Cells have prominent intercellular borders and are cuboidal to polygonal, giving them a characteristic 'honey-comb' appearance (Figure 12.12). Nuclei have clumped, mature chromatin and mostly inapparent nucleoli.

12.3.1.2 Clinical Considerations

- Common in older, intact dogs.
- Prostate usually symmetrical, smooth and non-painful.
- Not a risk factor for subsequent development of carcinoma [17].

12.3.1.3 Prognosis

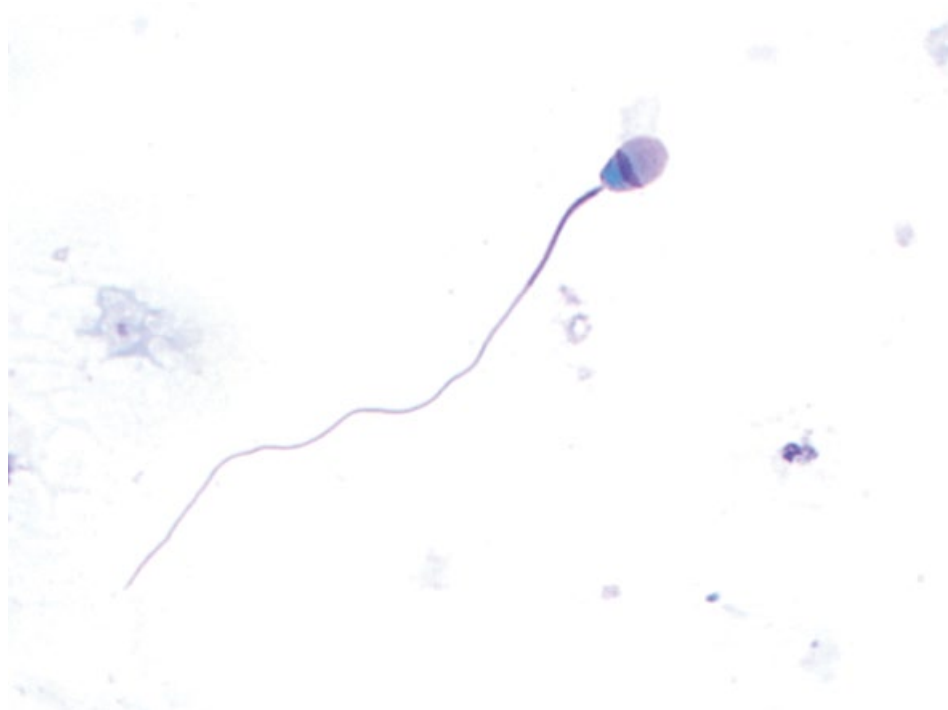Excellent.

12.3.2 Prostatic Carcinoma

12.3.2.1 Cytologic Features

Carcinomas exfoliate as sheets of cohesive cells, but differ from BPH in that the cells become more round/ovoid and have a variable amount of cytoplasm. Cell sheets also

(A)

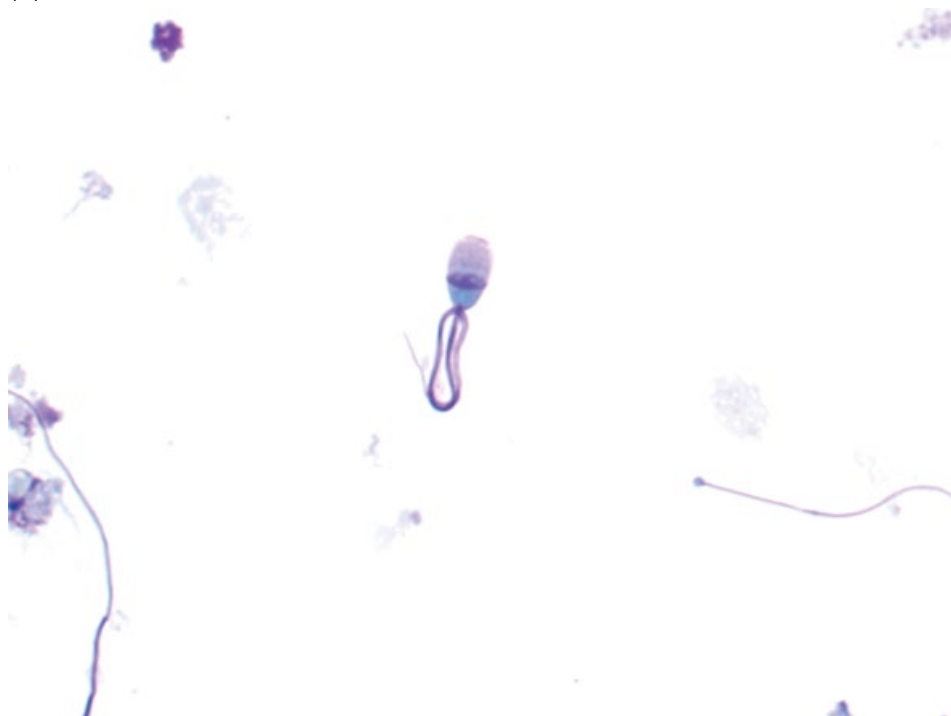


(B)

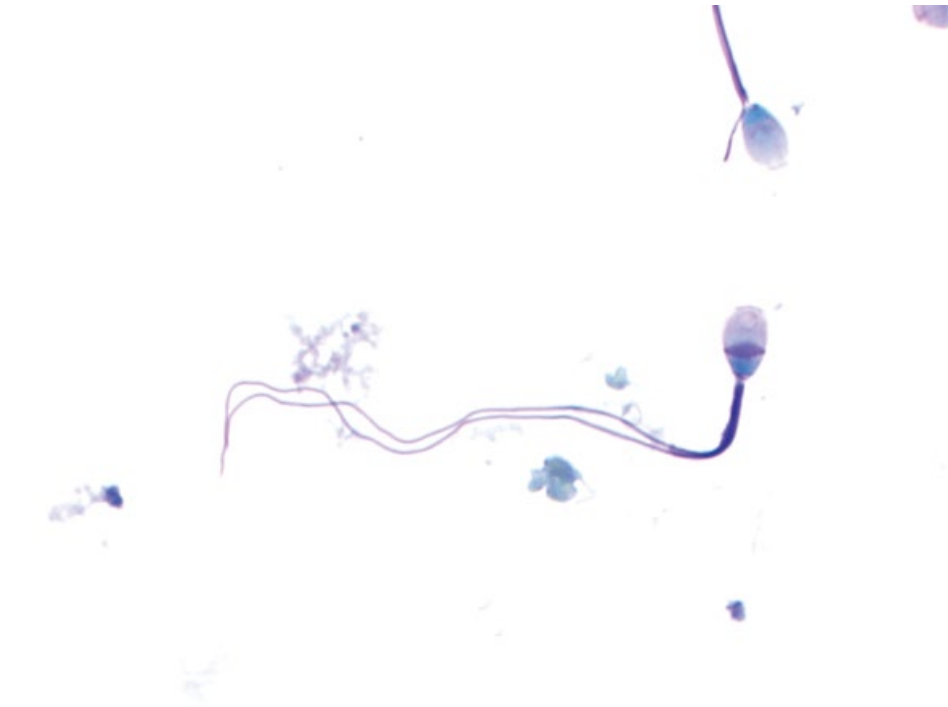

Figure 12.10 Sperm morphology. (A) Normal spermatozoon. (B) Double tail.

(C)



(D)

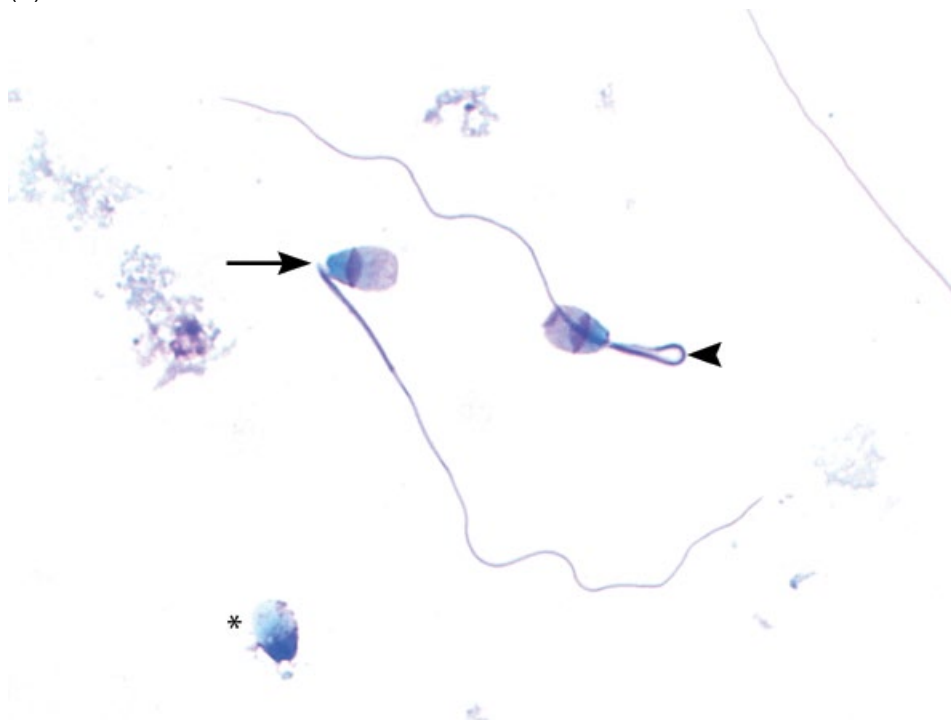
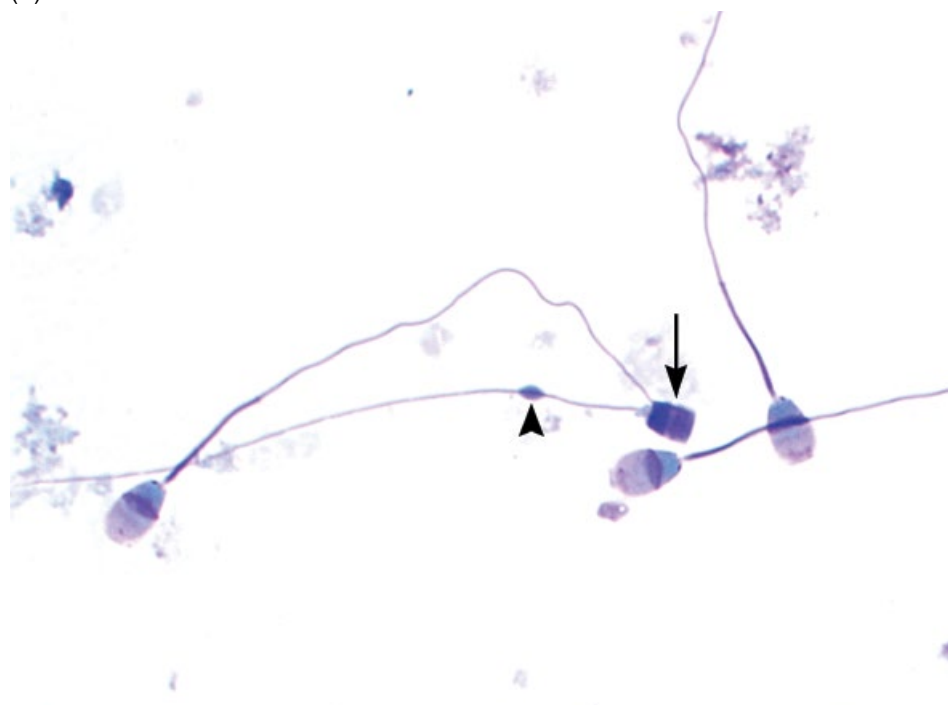


Figure 12.10 (Continued) (C) Tightly coiled tail. (D) Bent head (arrow), bent tail (arrowhead) and detached head (asterisk).

(E)



(F)

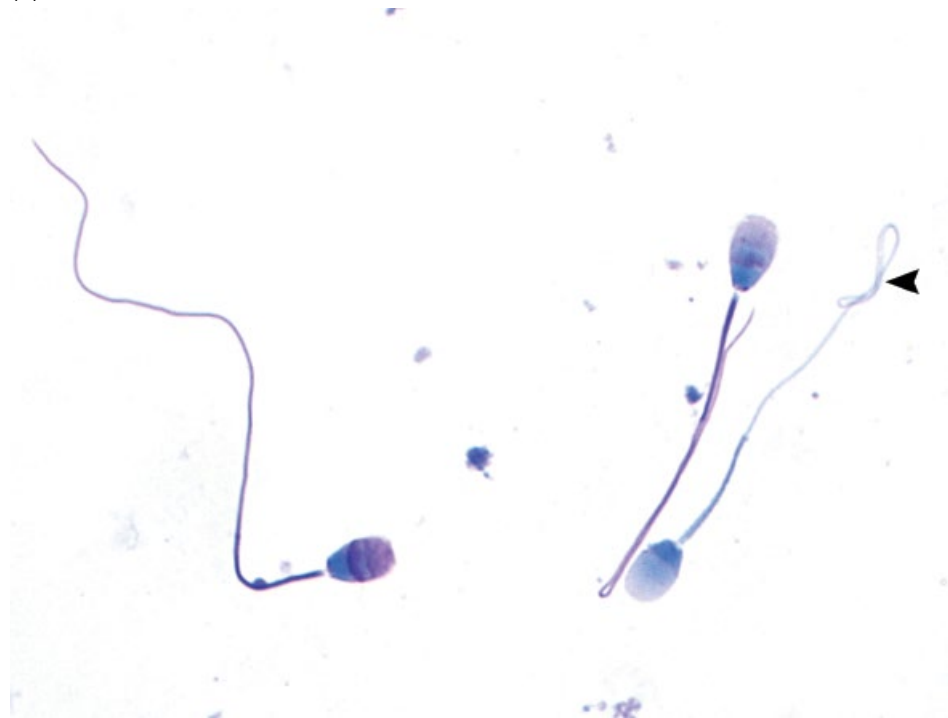


Figure 12.10 (Continued) (E) Abnormally shaped head (arrow) and a proximal droplet (arrowhead). (F) A spermatozoon is seen with a distal coil (arrowhead). The two other spermatozoa have bent tails.

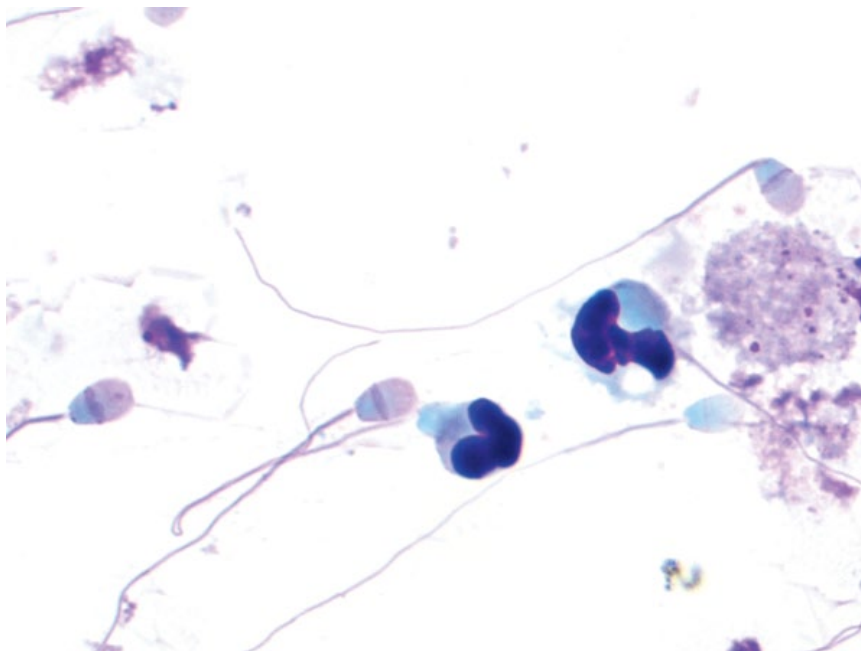


Figure 12.11 Neutrophilic inflammation, semen, dog, 100× objective.

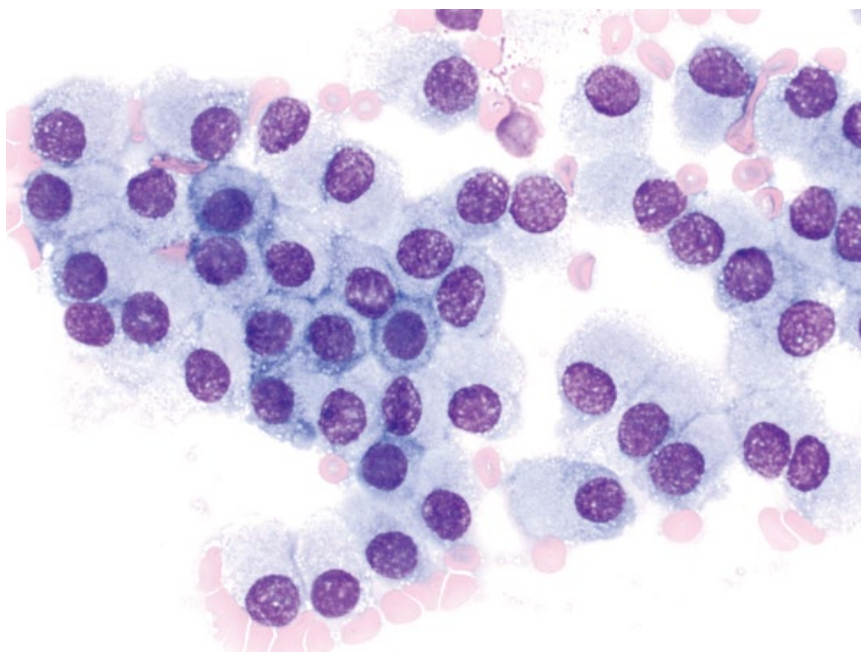


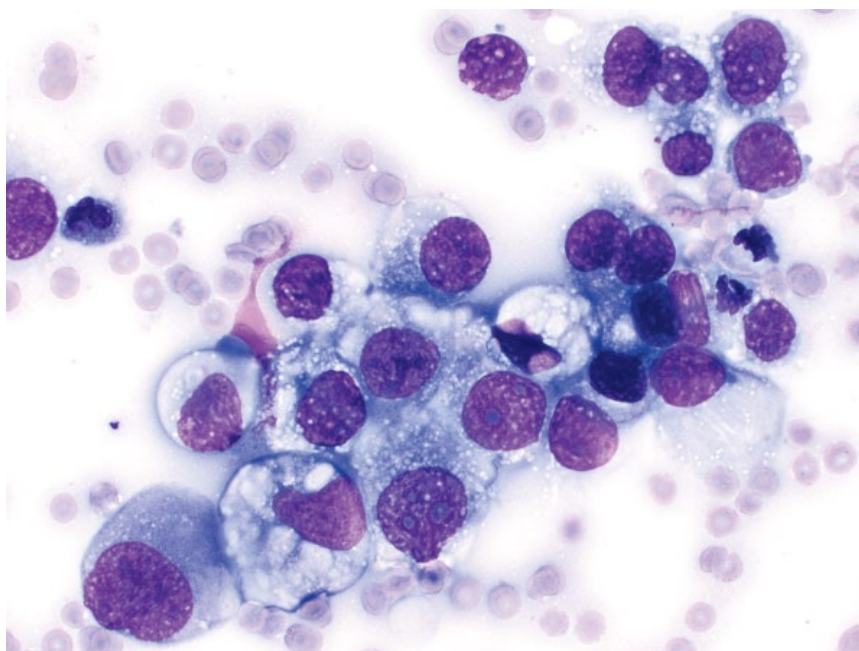
Figure 12.12 Benign prostatic hyperplasia, dog, 50× objective.

become more crowded and less uniform than those seen with BPH. Anisokaryosis is increased, nuclei have more open chromatin, and nucleoli become more prominent and numerous (compare Figures 12.13 and 12.12).

12.3.2.2 Clinical Considerations

- Dogs >> cats
- Castrated dogs at increased risk relative to intact dogs [18].

Figure 12.13 Prostatic carcinoma, dog, 50x objective.



- Frequently associated with mineralization and necrosis (see Figures 1.2 and 1.6), which may constitute the majority of the sample [19].

12.3.2.3 Prognosis

Poor. Locally aggressive and high metastatic rate.

12.3.3 Prostatic Transitional Cell Carcinoma (TCC)

12.3.3.1 Cytologic Features

Transitional cell carcinomas can be difficult to differentiate from prostatic carcinomas cytologically, and even histopathologically [20]. Although not pathognomonic for TCC, they frequently contain bright-pink secretory material within the cytoplasm (Figure 12.14). Criteria of malignancy frequently are marked, similar to those described for prostatic carcinoma.

12.3.3.2 Clinical Considerations

- Arise from prostatic urothelial cells.
- Castrated dogs at increased risk relative to intact dogs [18].

12.3.3.3 Prognosis

Poor. High metastatic rate.

12.3.4 Prostate: Squamous Metaplasia

12.3.4.1 Cytologic Features

Prostatic epithelial cells assume a more squamous appearance, and are large, angular and flattened, with abundant pale-/sky-blue cytoplasm consistent with keratinization. Nuclei are single, centrally located, and have stippled to variably clumped chromatin. Hyperplastic epithelium also may be seen (Figure 12.15).

12.3.4.2 Clinical Considerations

- Most commonly associated with increased concentration of estrogen, especially from Sertoli cell tumors [21].
- Also may be seen secondary to chronic inflammation/irritation.

12.3.4.3 Prognosis

Generally good with removal of the source of estrogen/irritation.

12.3.5 Prostatic Cyst

12.3.5.1 Cytologic Appearance

Cysts generally have a pink-stippled, proteinaceous background with a minimal amount of blood. Nucleated cells are seen in low numbers, and may include rare quiescent macrophages, non-degenerative neutrophils,

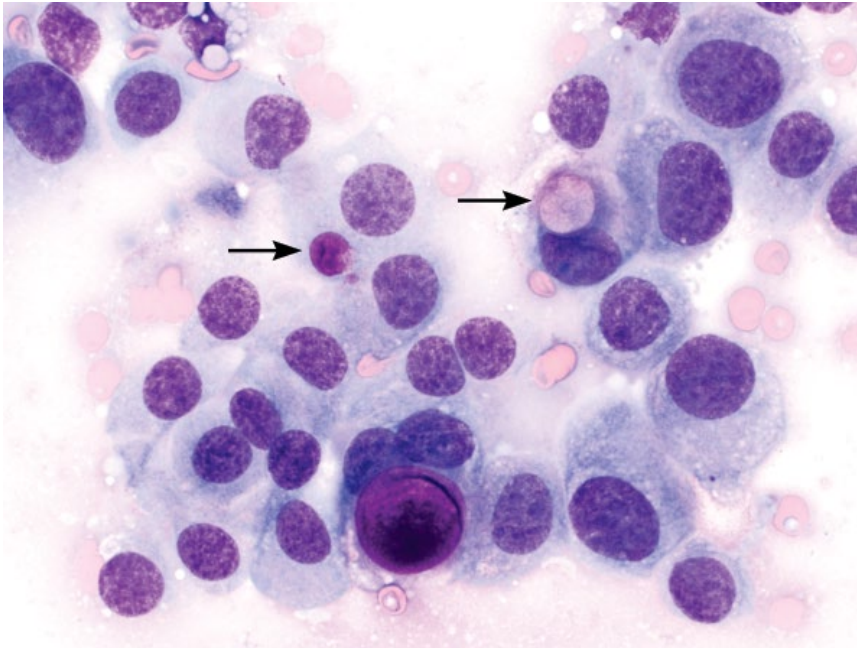


Figure 12.14 Transitional cell carcinoma, prostate, dog, 50× objective. Bright-pink secretory material is seen within the cytoplasm (arrows).

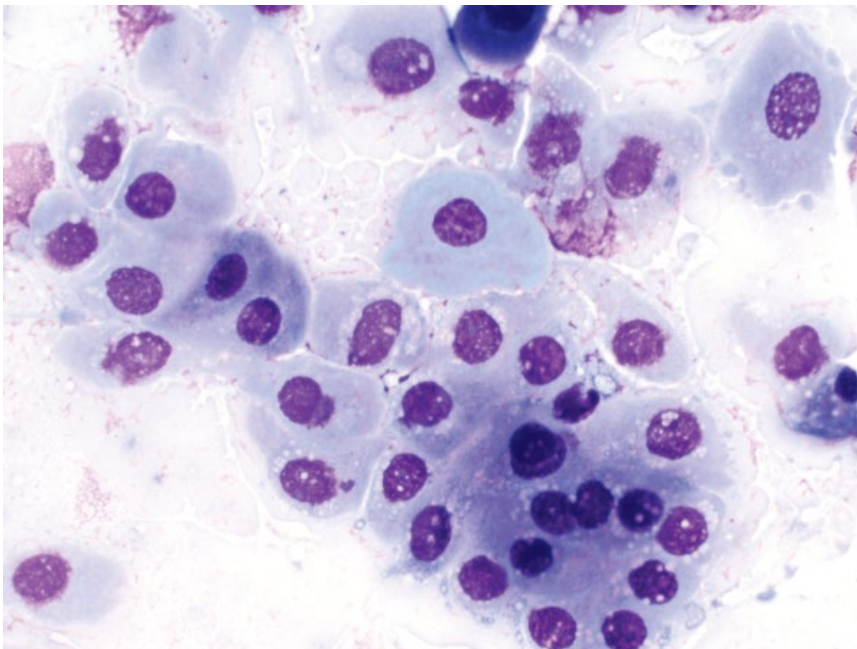


Figure 12.15 Squamous metaplasia, prostate, dog, 50× objective. Note the sky-blue appearance of the cytoplasm, consistent with keratinization.

and small mature lymphocytes. Mineralized material may be present (Figure 12.16).

12.3.5.2 Clinical Considerations

- Often associated with benign prostatic hyperplasia, and may be septic [22].
- May form within prostatic parenchyma (retention cysts) or outside prostate gland (paraprostatic cysts).

12.3.5.3 Prognosis

Good with appropriate therapy.

12.3.6 Septic Prostatitis

12.3.6.1 Cytologic Appearance

Septic prostatitis appears similar to septic inflammation elsewhere, with degenerative neutrophils predominating, often containing intracellular bacteria. Hyperplastic

Figure 12.16 Prostatic cyst, dog, 20× objective. Note the aggregates of refractile mineralized material, and a single macrophage (far left).

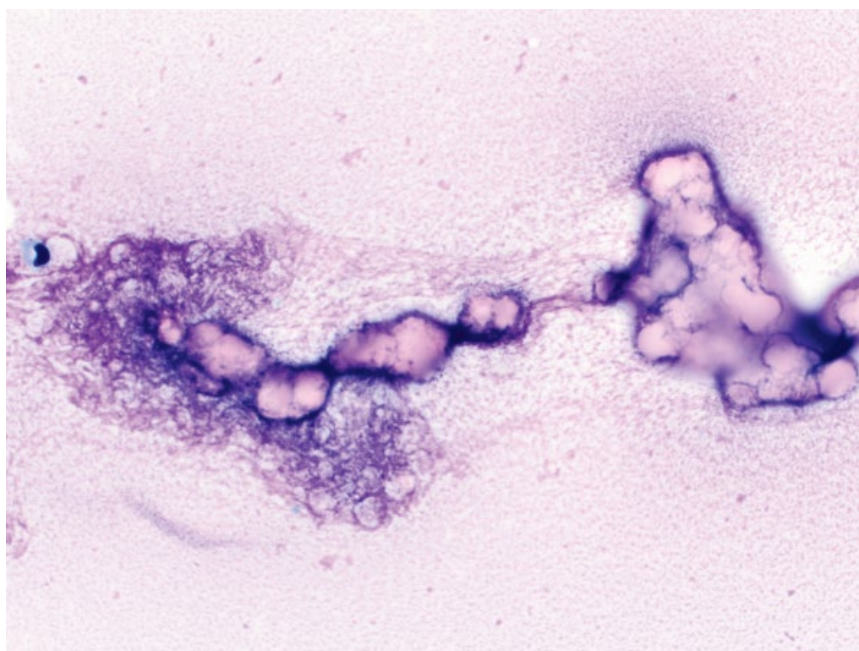
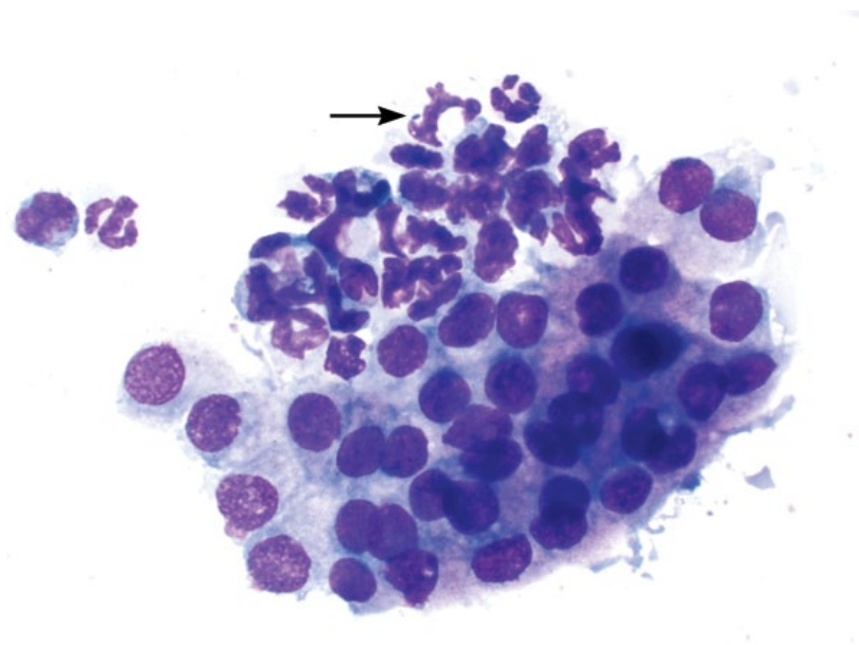


Figure 12.17 Septic prostatitis, dog, 50× objective. Degenerative neutrophils that contain rod-shaped bacteria (arrow) are intimately associated with hyperplastic prostatic epithelium. Slide courtesy of Dr Reema Patel.



prostatic epithelium may be present, and confirms the prostate as the source of the septic inflammation (Figure 12.17).

12.3.6.2 Clinical Considerations

- Intact > castrated dogs.
- Ascending infection from bladder > hematogenous spread [23].

- Predisposing factors = benign prostatic hyperplasia and prostatic cysts [24].
- Mostly aerobic bacteria (*Escherichia coli* most common). Anaerobic bacteria uncommon [25].

12.3.6.3 Prognosis

Generally good with appropriate therapy. Prolonged antibiotic therapy and castration often required [24].

12.4 Penis

The most frequent neoplasms affecting the penis include squamous cell carcinoma (SCC) and transmissible venereal tumor (TVT), and other tumors of the skin (prepuce). See Chapter 3 for details.

Female

12.5 Ovary

12.5.1 Dysgerminoma

12.5.1.1 Cytologic Appearance

Dysgerminomas are highly exfoliative, composed of discrete, large, round cells with a small to moderate volume of pale-blue/purple cytoplasm. Nuclei are ovoid to occasionally amoeboid, and have finely granular, immature chromatin with multiple basophilic nucleoli. Multinucleation and satellite nuclei are frequent, and many mitotic figures are present (Figure 12.18). Anisocytosis/anisokaryosis are moderate to marked.

12.5.1.2 Clinical Considerations

- Mostly older dogs and cats (>10 years), but have been reported in patients as young as 2 years [26, 27].
- Usually unilateral, frequently affecting the right ovary [26].

- Clinical signs mostly attributable to a space-occupying abdominal mass.
- Metastatic disease present in 10–33% of cases, in regional lymph nodes and widely disseminated [28, 29].

12.5.1.3 Prognosis

Good with surgical excision if no metastatic disease is present; however, prognosis is poor in the presence of metastases [26].

12.5.2 Granulosa Cell Tumor

12.5.2.1 Cytologic Appearance

Highly cellular, arranged in loose aggregates and often associated with streaming or pooling eosinophilic extracellular mucinous material (Figure 12.19). Cells are round to polyhedral, with a large amount of pale-blue cytoplasm that contains many punctate clear vacuoles. Nuclei are round, eccentrically placed, and have finely

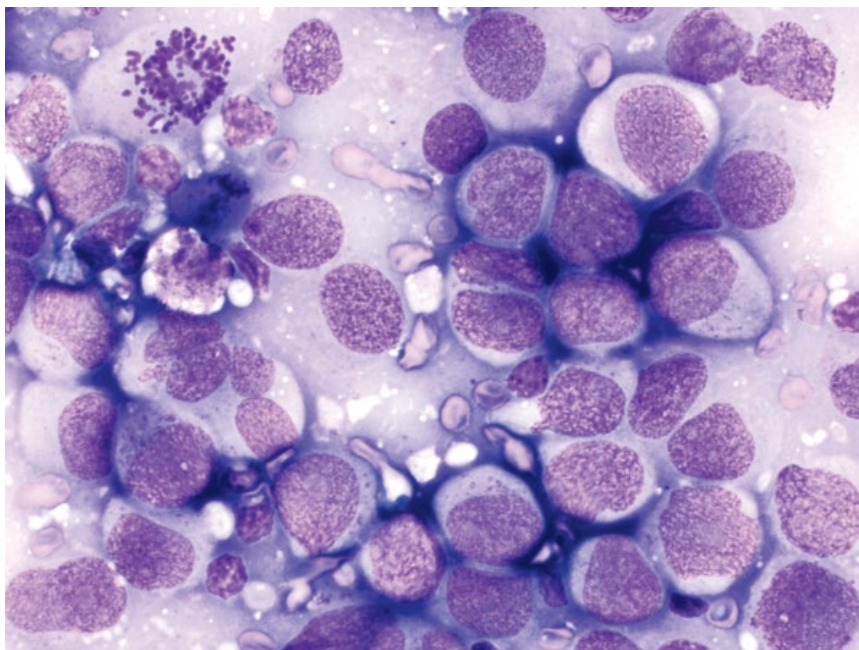
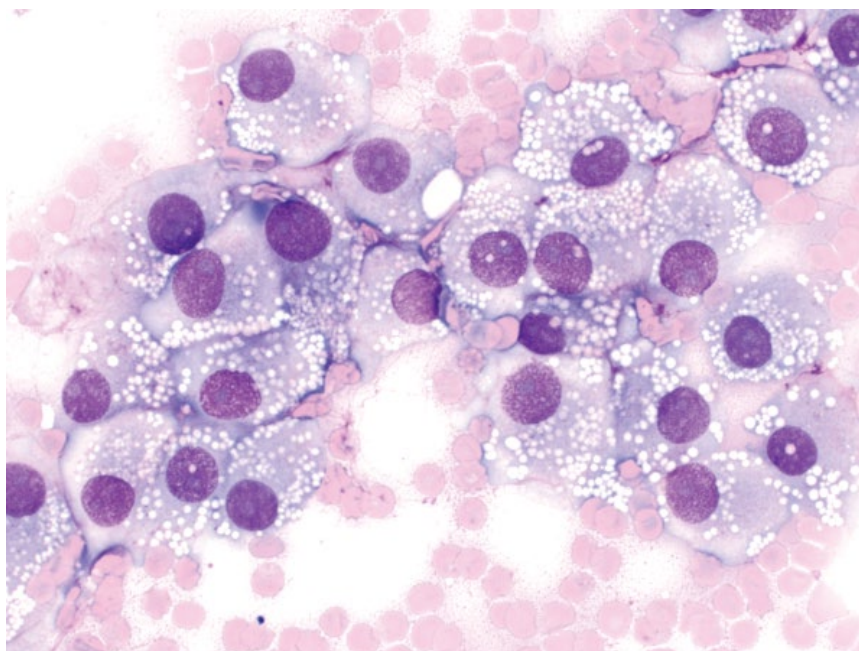


Figure 12.18 Dysgerminoma, dog, 50× objective. Note the mitotic figure (top left).

Figure 12.19 Granulosa cell tumor, dog, 50x objective.



stippled chromatin, with single, basophilic nucleoli. Anisocytosis/anisokaryosis are moderate to rarely marked, and N/C ratios are low.

12.5.2.2 Clinical Considerations

- Sex cord-stromal tumors.
- Constitute approximately 50% of ovarian tumors in dogs and cats [2].
- Most are functional and produce estrogen or progesterone, causing persistent estrus, vulvar swelling, pyometra, mammary gland hyperplasia, and/or myelotoxicity [30].
- Approximately 20% of tumors are malignant in dogs, 50% are malignant in cats, and the tumors metastasize widely [2, 29].

12.5.2.3 Prognosis

Surgical excision may be curative, but the prognosis is poor with evidence of metastatic disease, which is common.

12.5.3 Ovarian Adenoma

12.5.3.1 Cytologic Appearance

Ovarian adenomas comprise cohesive sheets of round epithelial cells that have a moderate to abundant amount of pale-blue cytoplasm. Nuclei are round, centrally located, and have coarsely granular chromatin with small nucleoli. Anisocytosis/anisokaryosis are mild, and N/C ratios are low (Figure 12.20).

12.5.3.2 Clinical Considerations

- Dogs > cats.
- Occur unilaterally.
- Often associated with cystic endometrial hyperplasia [31].

12.5.3.3 Prognosis

Excellent. Ovarian adenomas do not metastasize, and ovariectomy is curative [31].

12.5.4 Ovarian Adenocarcinoma

12.5.4.1 Cytologic Appearance

Ovarian adenocarcinomas also exfoliate as cohesive sheets. Relative to adenomas the cells often are crowded or piled and have high N/C ratios. Chromatin is more 'ropey,' and hyperchromasia of nuclei is often more prominent (compare Figures 12.21 and 12.20).

12.5.4.2 Clinical Considerations

- Dogs > cats.
- Most common ovarian tumor in dogs [31, 32].
- Papillary, tubular and undifferentiated variants.
- Unilateral involvement most common.

12.5.4.3 Prognosis

Guarded. Approximately 50% will metastasize, generally within the peritoneal cavity. A larger tumor size is linked to malignancy [31].

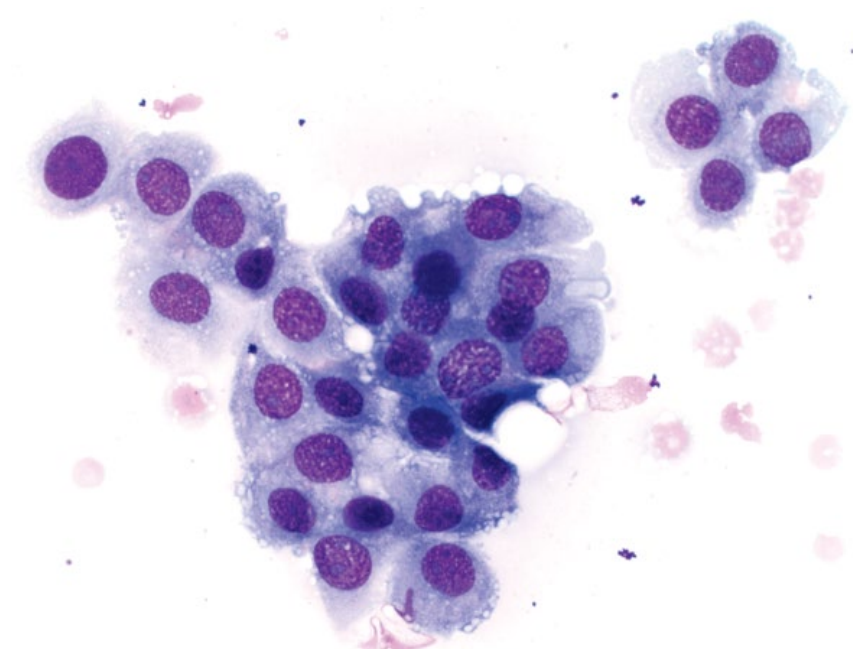


Figure 12.20 Ovarian adenoma, dog, 50× objective.

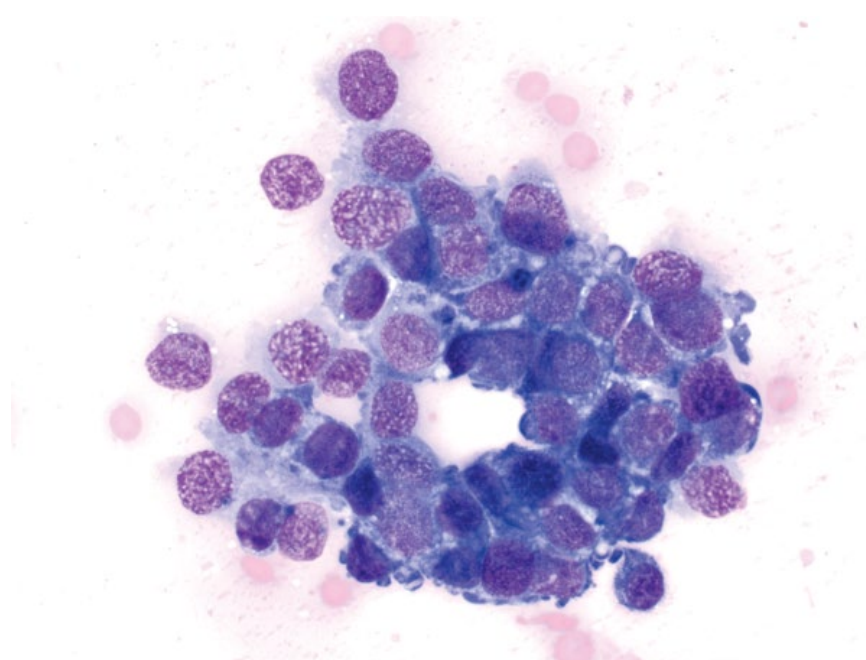


Figure 12.21 Ovarian papillary adenocarcinoma, dog, 50× objective.

12.5.5 Teratoma

12.5.5.1 Cytologic Appearance

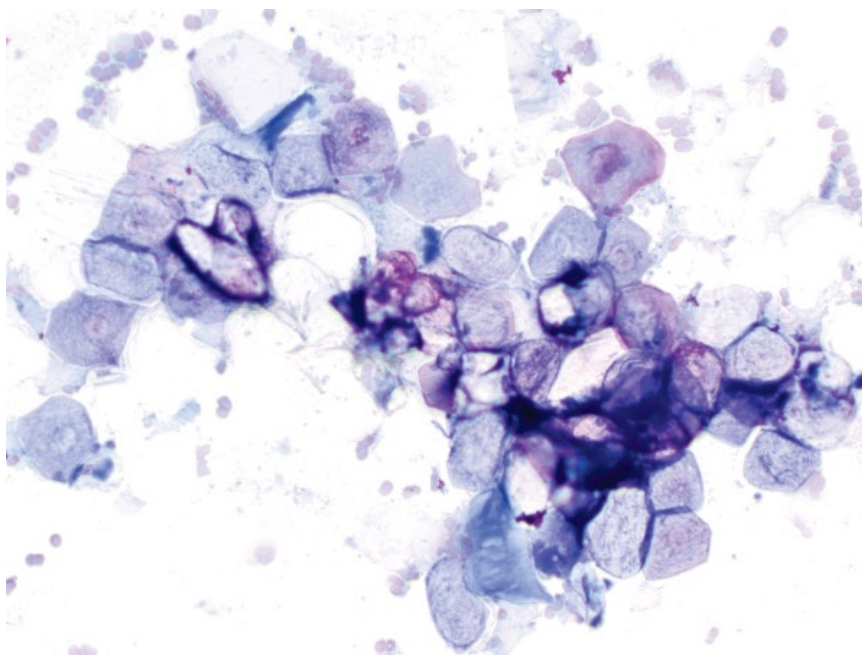
Teratomas arise from more than one germ cell layer (ectoderm, mesoderm, or endoderm), and as such their appearance is highly variable. Epithelial origin cells are most common, varying from poorly differentiated to well-differentiated (see squamous epithelial cells in

Figure 12.22). Hair shafts, cartilage/bone, muscle and nervous tissue may all be seen. These tumors often are cystic.

12.5.5.2 Clinical Considerations

- Rare in dogs and cats.
- Mostly young animals, but may be seen in older patients [33].

Figure 12.22 Teratoma, cat, 20× objective.



- Most commonly affect the left ovary. Extragonadal sites are rare [26].
- May be benign or malignant.

12.5.5.3 Prognosis

Good for benign tumors, but poor if metastatic disease is present [26, 34].

12.6 Mammary Glands

12.6.1 Benign Mammary Tumors

12.6.1.1 Cytologic Appearance

Epithelial origin: Hyperplastic lesions of ducts, and adenomas appear cytologically similar, and comprise variably sized sheets of uniform, cuboidal to round epithelial cells. Cell clusters frequently have a tubular (Figure 12.23) or papillary arrangement (Figures 12.24 and 12.25). Anisocytosis/anisokaryosis generally are mild; however, small clusters with increased atypia can be seen. N/C ratios are low to moderate. *Note:* Well-differentiated carcinomas can mimic benign lesions, and histopathology is required for definitive characterization of biologic behavior (compare to Figure 12.26).

Mesenchymal origin: Benign mesenchymal neoplasms are rare and usually seen in conjunction with an epithelial component (e.g., fibroadenoma).

12.6.1.2 Clinical Considerations

- Dogs > cats - malignant tumors more common in cats (see section 12.6.2).

- Usually small, well-encapsulated, firm.
- May be single or multiple, and other concurrent masses may not share biologic behavior [35, 36].

12.6.1.3 Prognosis

Good to excellent, with surgical excision generally curative.

12.6.2 Malignant Mammary Tumors

12.6.2.1 Cytologic Appearance

Epithelial origin: Mammary gland carcinomas often are highly pleomorphic, but can be well-differentiated (Figure 12.26). The cells often exfoliate in sheets that have a papillary or acinar arrangement. Nuclei range from round to amoeboid, and often have prominent basophilic nucleoli. Mitotic figures are common. Anisocytosis/anisokaryosis are marked, and N/C ratios are variable. Many variants are described that require histopathology for differentiation. Some of these include ductal (Figure 12.27), simple tubular (Figure 12.28), adenocarcinoma (Figure 12.29) and anaplastic (Figure 12.30) [37].

Mesenchymal origin: Cytologic appearance reflects the cell of origin. Osteosarcoma is most common (Figure 12.31), with chondrosarcoma, fibrosarcoma, and hemangiosarcoma also possible.

12.6.2.2 Clinical Considerations

Dogs

- Middle-aged to older, increased risk over time.
- Ovariohysterectomy is protective. Risk of tumor development increases from 0.5% to 26% in dogs with no estrous cycle, to the 3rd estrous cycle [38].

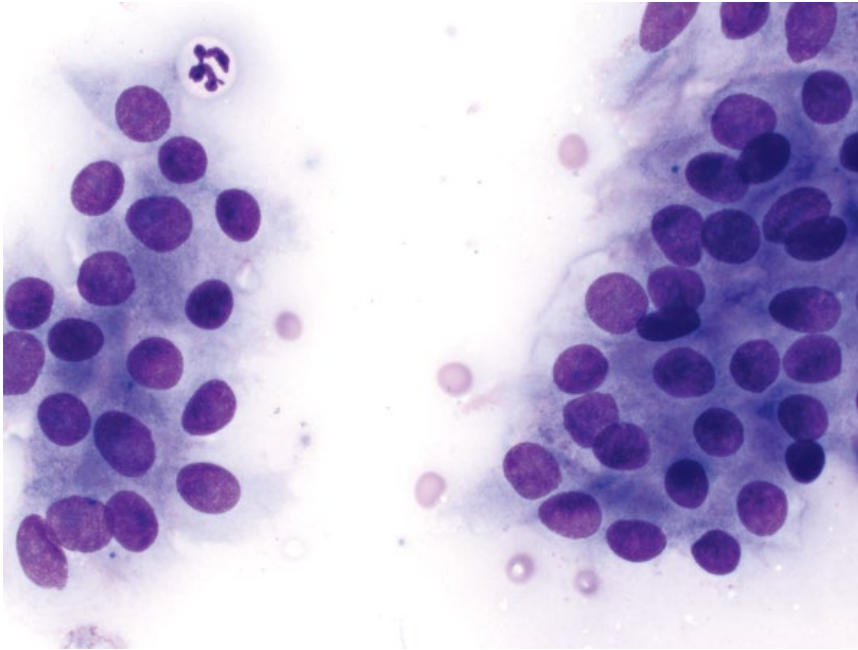


Figure 12.23 Tubular mammary adenoma, dog, 50× objective.

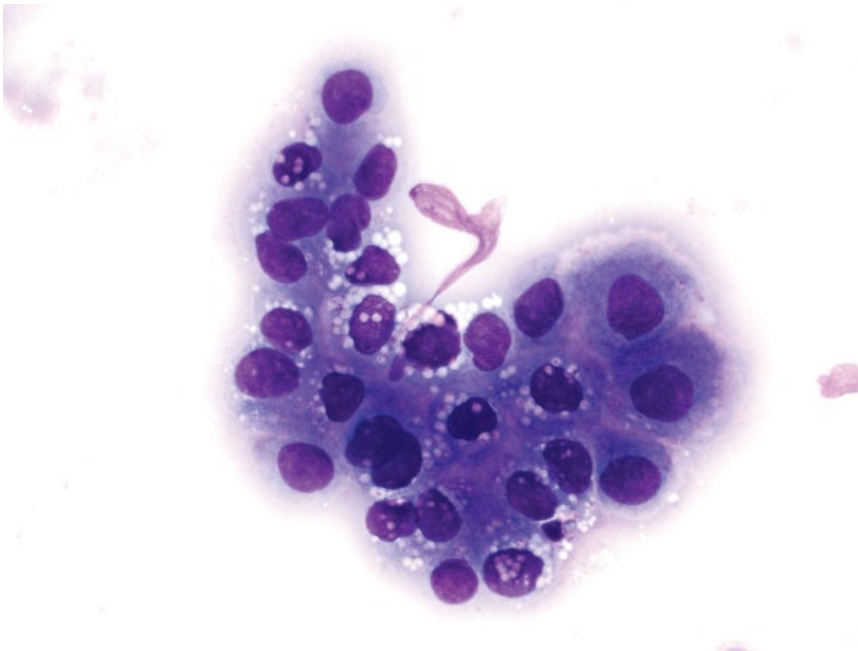


Figure 12.24 Papillary mammary adenoma, dog, 50× objective.

- Up to 70% of intact females have more than one tumor at diagnosis (benign or malignant) [35, 38].

Cats

- Middle-aged to older, increased risk over time.
- Siamese breed over-represented [36].
- Sevenfold higher risk in intact cats compared to spayed cats [39].
- Multiple tumors may be present at the time of diagnosis (benign or malignant) [36].

12.6.2.3 Prognosis

Variable. Low rates of lymphatic invasion and distant metastatic disease in dogs, but high in cats. Surgical excision of localized tumors may be curative. Important prognostic factors in both dogs and cats include: (i) tumor type (ductal carcinomas more aggressive); (ii) tumor size (tumors <3 cm in diameter have longer survival, tumors >3 cm in cats = poor prognosis); and (iii) lymph node involvement (poor prognosis if present) [40–42].

Figure 12.25 Papillary mammary adenoma, dog, 50× objective.

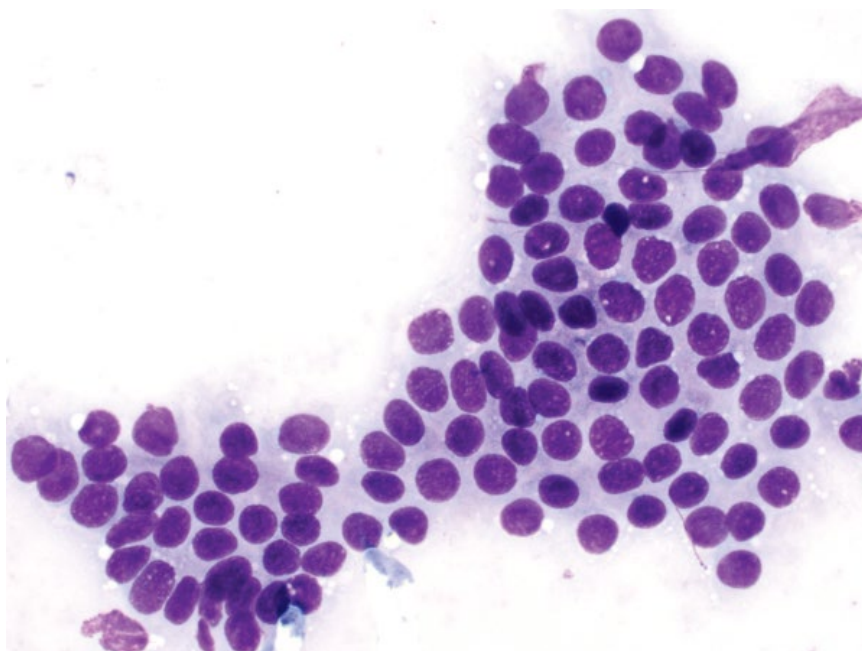
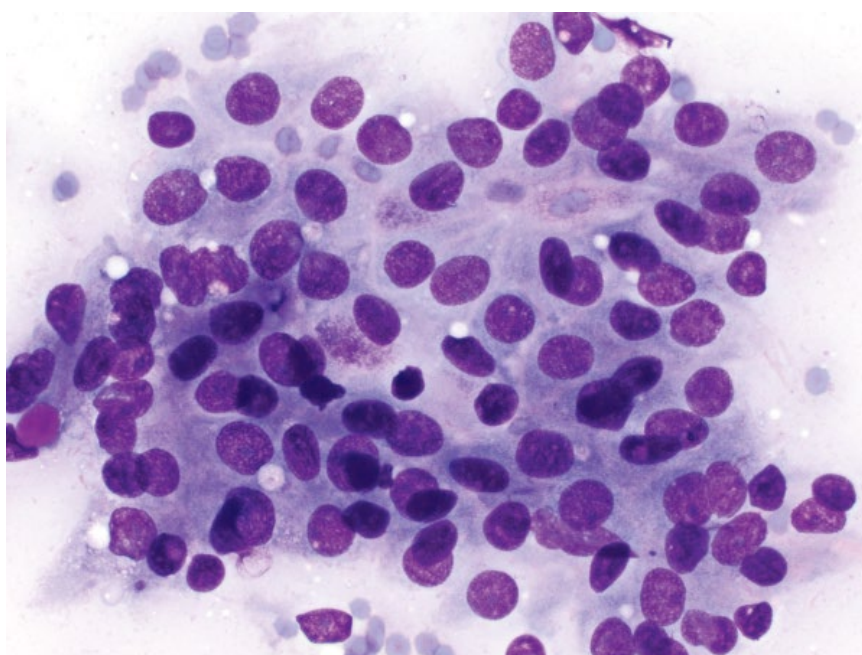


Figure 12.26 Mammary carcinoma (well-differentiated), cat, 50× objective.



12.6.3 Complex/Mixed Mammary Gland Tumors

12.6.3.1 Cytologic Appearance

Complex tumors contain an epithelial and a mesenchymal component (Figure 12.32), while mixed tumors involve an epithelial population with proliferation of cartilage ± bone ± adipose tissue (Figure 12.33).

12.6.3.2 Prognosis

Variable, based on tumor types involved. Carcinosarcomas (malignant epithelial and mesenchymal components) metastasize widely and carry a poor prognosis [39].

12.6.4 Mastitis

12.6.4.1 Cytologic Appearance

Samples frequently contain large numbers of inflammatory cells. Degenerative neutrophils containing intracellular bacteria are most common (Figure 12.34), with lesser numbers of macrophages and lymphocytes.

12.6.4.2 Clinical Considerations

- Mostly seen postpartum or in pseudopregnancy.
- Clinical signs = swollen, painful, warm glands ± discoloration of skin.

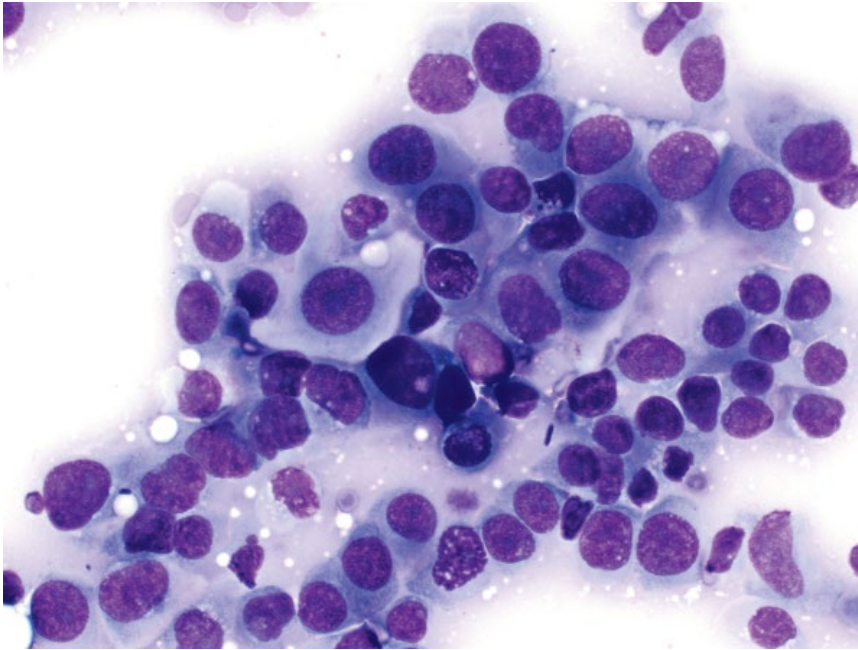


Figure 12.27 Mammary carcinoma (ductal), cat, 50× objective.

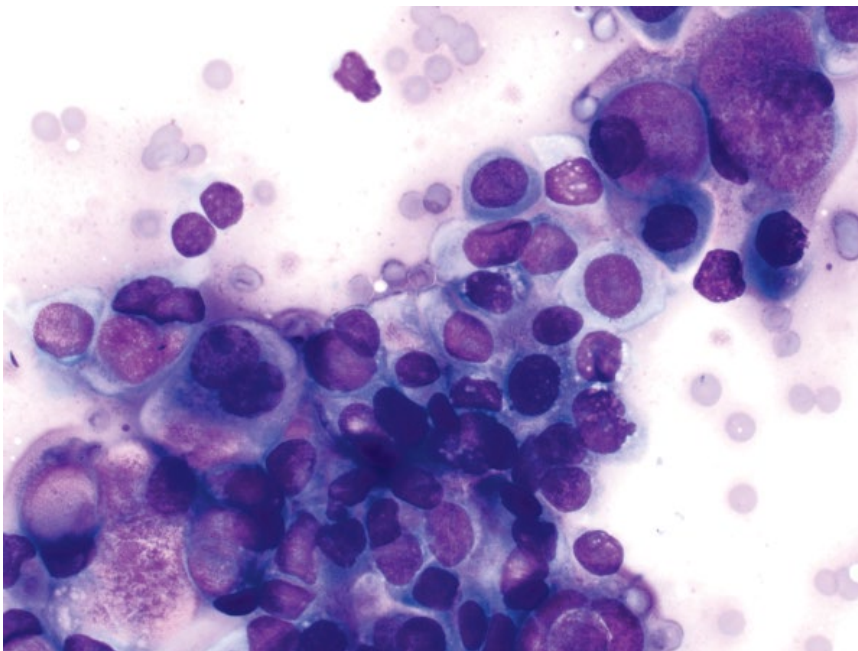


Figure 12.28 Mammary carcinoma (tubular), cat, 50× objective. Note the bright-pink secretory material within many cells.

- *Escherichia coli*, *Staphylococcus* spp. and *Streptococcus* spp. are most common bacterial isolates [43].
- Other infectious organisms (*Mycobacterium*, fungal agents, protozoa) rarely noted [44–46].

12.6.4.3 Prognosis

Mostly good with appropriate therapy. Abscessation or gangrenous mastitis may carry a more guarded prognosis.

12.7 Vaginal Cytology

The cells that need to be identified on vaginal cytology include basal cells, parabasal cells, intermediate cells, and superficial cells (Figure 12.35).

- 1) Basal cells = These cells are small, round, and have very high N/C ratios. They have a deep epithelial location, and are not routinely seen in vaginal cytology samples.

Figure 12.29 Mammary carcinoma (adenocarcinoma), dog, 50× objective. Note the vacuolated cytoplasm and multiple prominent nucleoli.

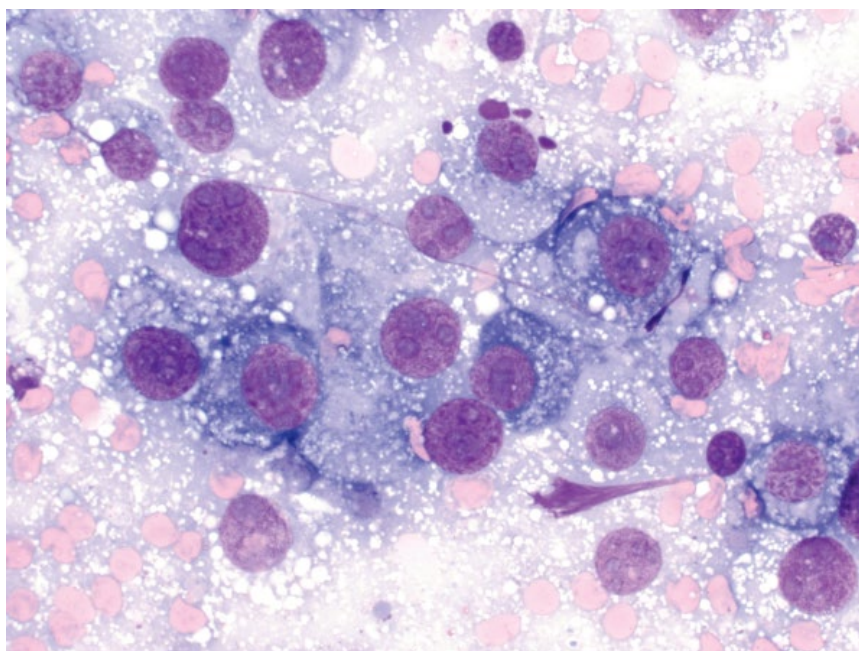
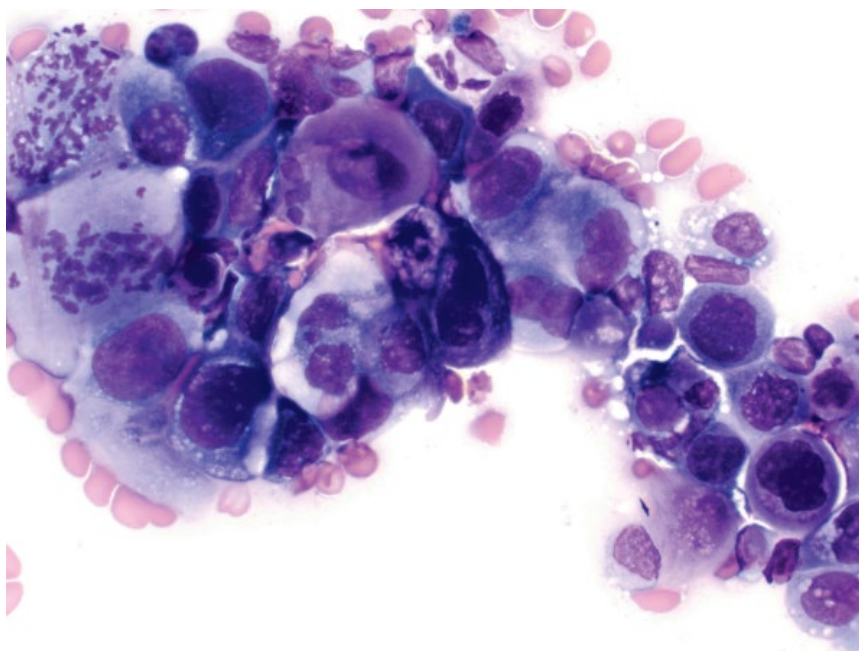


Figure 12.30 Mammary carcinoma (anaplastic), dog, 50× objective.



- 2) Parabasal cells = These cells are small and round, with high N/C ratios, and large nuclei with stippled chromatin.
- 3) Intermediate cells = These cells are ovoid with a more abundant volume of pale-blue cytoplasm. They have similar nuclei to parabasal cells, which are round with stippled chromatin.
- 4) Superficial cells = These cells are polygonal with abundant pale-blue cytoplasm. They can be anuclear,

or have small, pyknotic, round nuclei with condensed chromatin.

12.7.1 Anestrus

12.7.1.1 Cytologic Appearance

Anestrus in dogs is dominated by parabasal cells, admixed with occasional intermediate cells (Figure 12.36). Superficial cells and red blood cells are absent during

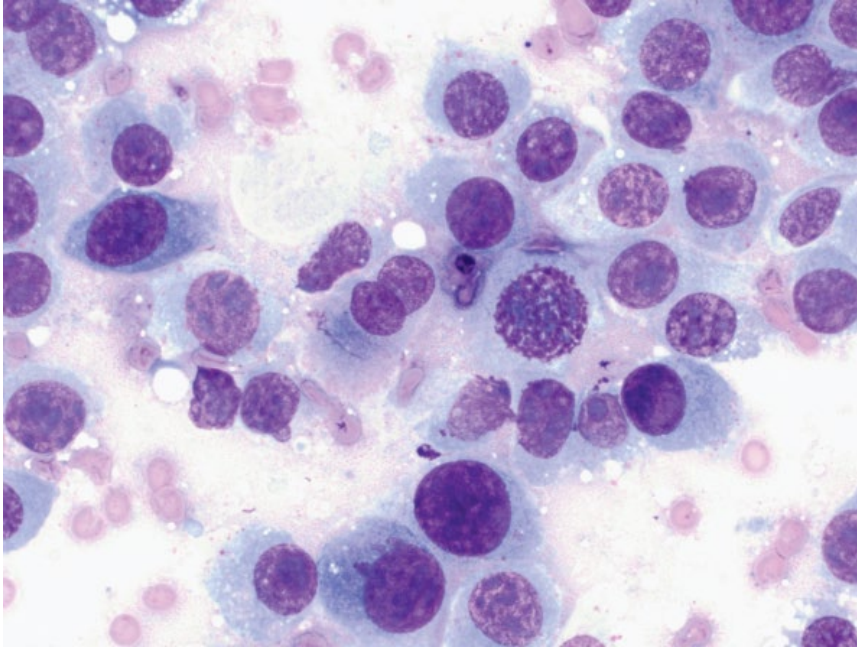


Figure 12.31 Mammary gland osteosarcoma, dog, 50× objective.

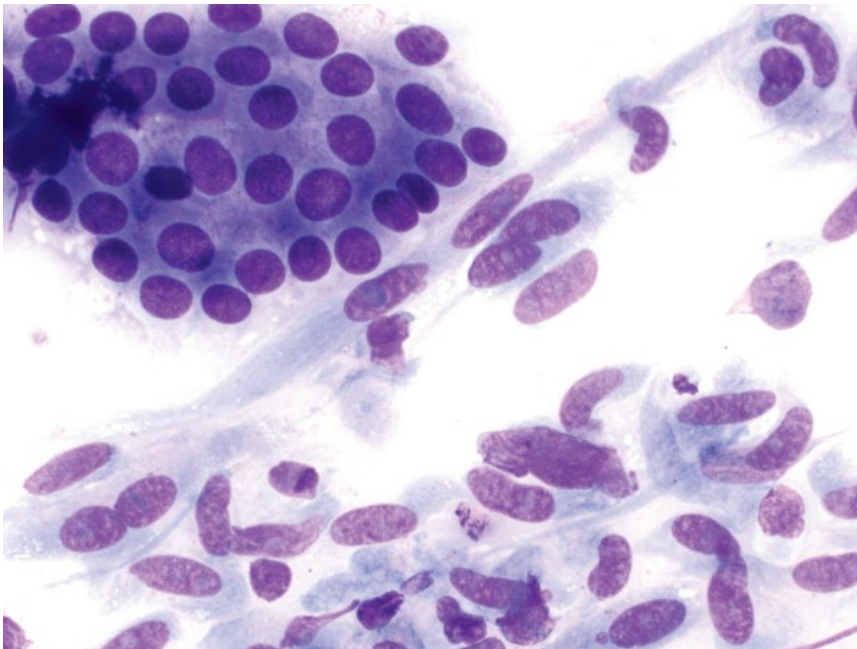


Figure 12.32 Benign complex mammary gland tumor, dog, 50× objective. Note the epithelial cells (top left) and mesenchymal cells.

anestrus. Rare neutrophils and extracellular bacteria may be present, but are most often absent. In cats, nucleated superficial cells may be seen [47].

12.7.1.2 Clinical Considerations

- Anestrus varies from 1 to 6 months.
- Associated with uterine involution and endometrial repair.
- Females not attractive to, or receptive to, males.

- No discharge, and the vulva is small.
- During late anestrus, progesterone concentrations are at their nadir ($<1 \text{ ng ml}^{-1}$) and estrogen is at basal levels ($\sim 2\text{--}10 \text{ pg ml}^{-1}$).

12.7.2 Proestrus

12.7.2.1 Cytologic Appearance

Increasing concentrations of estrogen lead to progressive cornification of the vaginal epithelium. As such, in addition

Figure 12.33 Mixed mammary gland tumor, dog, 50× objective. Note the sheet of epithelial cells adjacent to an island of deep metachromatic chondroid that contains embedded chondrocytes.

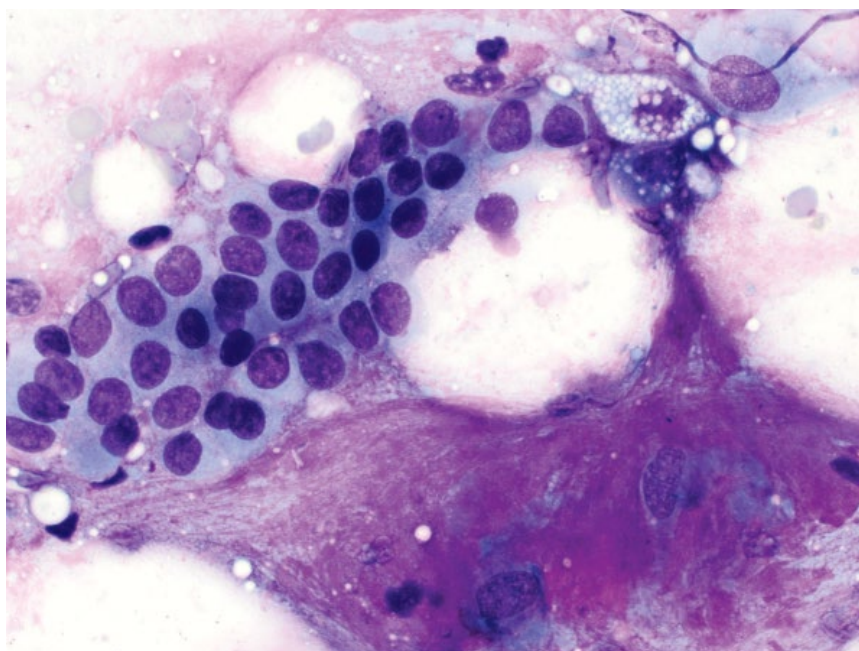
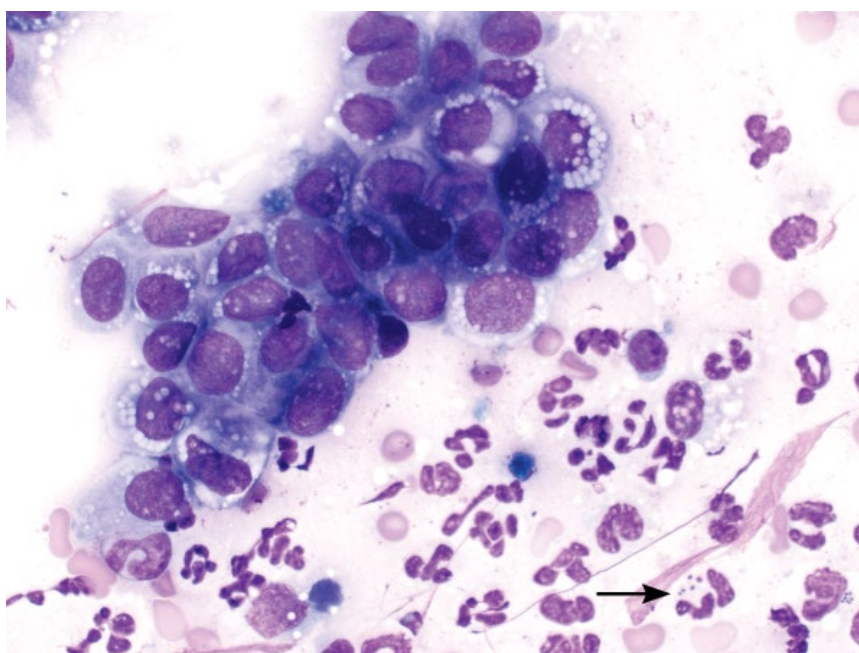


Figure 12.34 Mastitis, dog, 50× objective. Hyperplastic epithelial cells are accompanied by many variably degenerative neutrophils that contain intracellular bacteria (arrow).

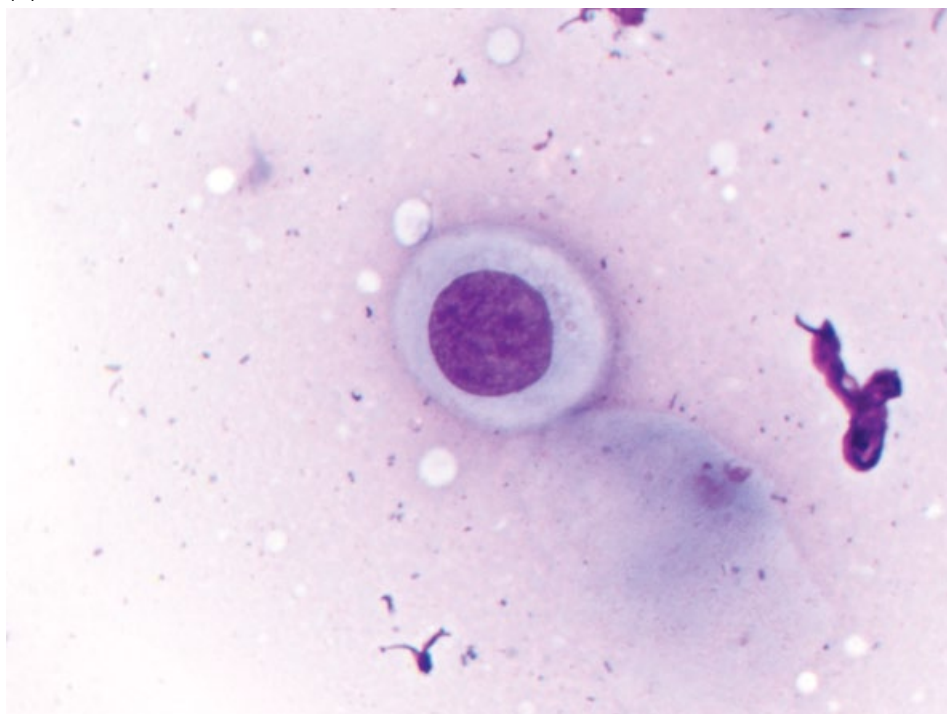


to intermediate and parabasal cells, proestrus is characterized by the presence of superficial cells, which constitute <50% of cells in early proestrus (Figure 12.37), and >50% of cells in late proestrus (Figure 12.38). An increasing estrogen concentration also results in capillary fragility, and erythrocytes generally are present in large numbers, accompanied by non-degenerate neutrophils ± extracellular bacteria.

12.7.2.2 Clinical Considerations

- Proestrus length is highly variable, ranging from 3 days to 3 weeks (mean = 9 days) [48].
- Females become attractive to males, but usually are not receptive.
- Vulva mildly enlarged ± serosanguinous or hemorrhagic discharge (dogs).

(A)



(B)

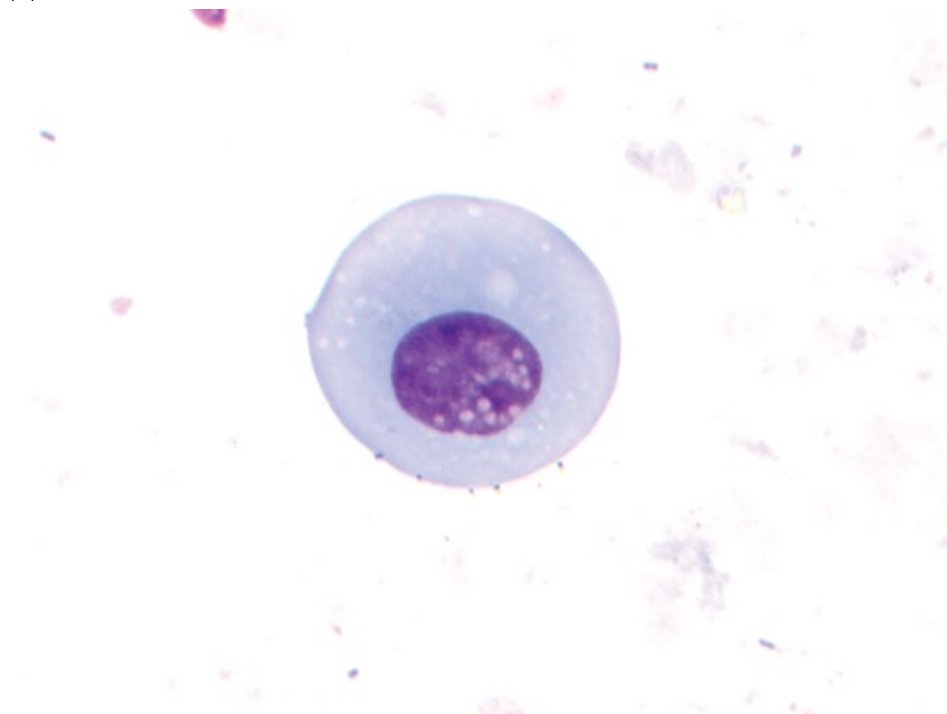
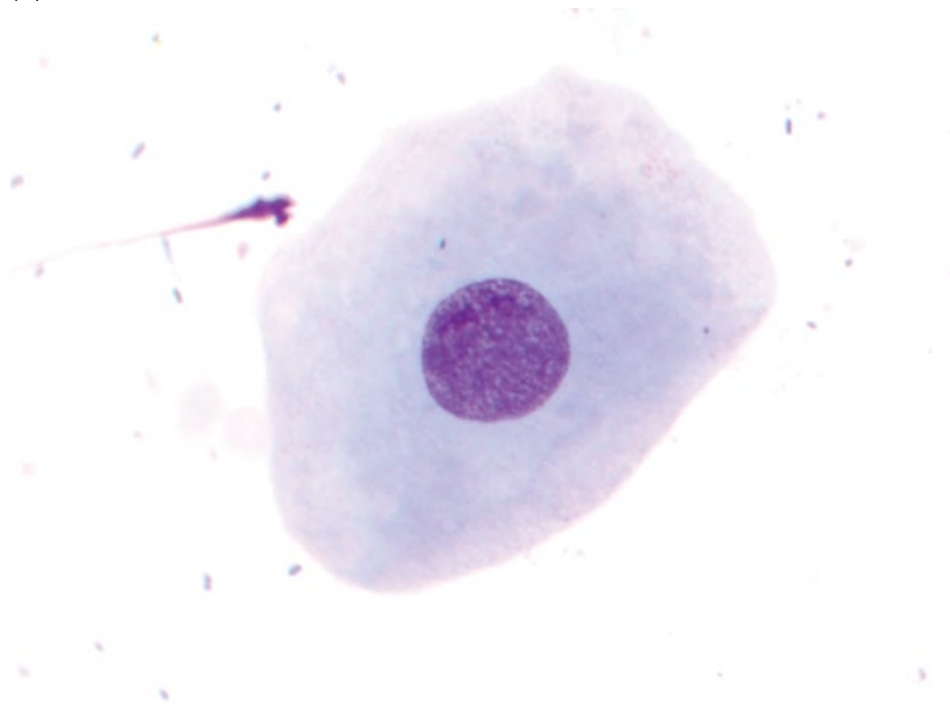


Figure 12.35 Normal vaginal epithelial cells. (A) Basal cell. (B) Parabasal cell.

(C)



(D)

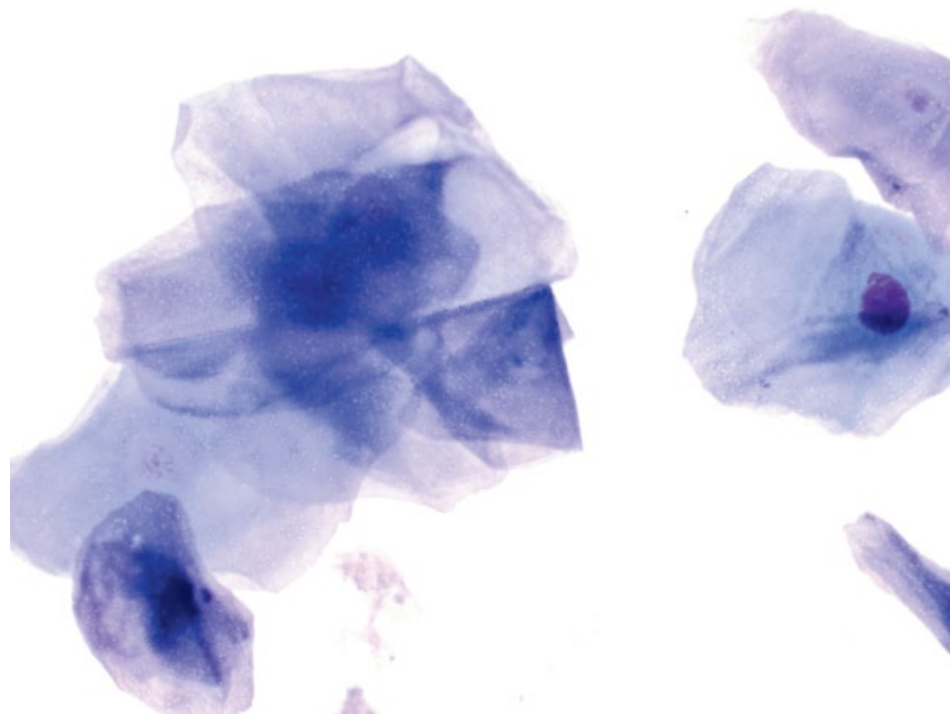


Figure 12.35 (Continued) (C) Intermediate cell. (D) Superficial cells.

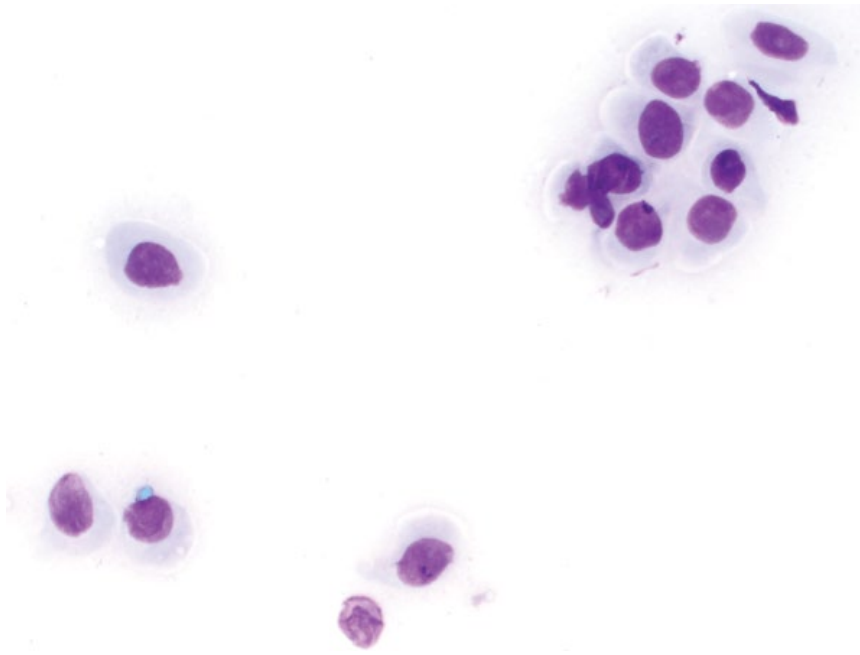


Figure 12.36 Vaginal cytology, anestrus, cat, 50x objective. Only parabasal cells are seen.

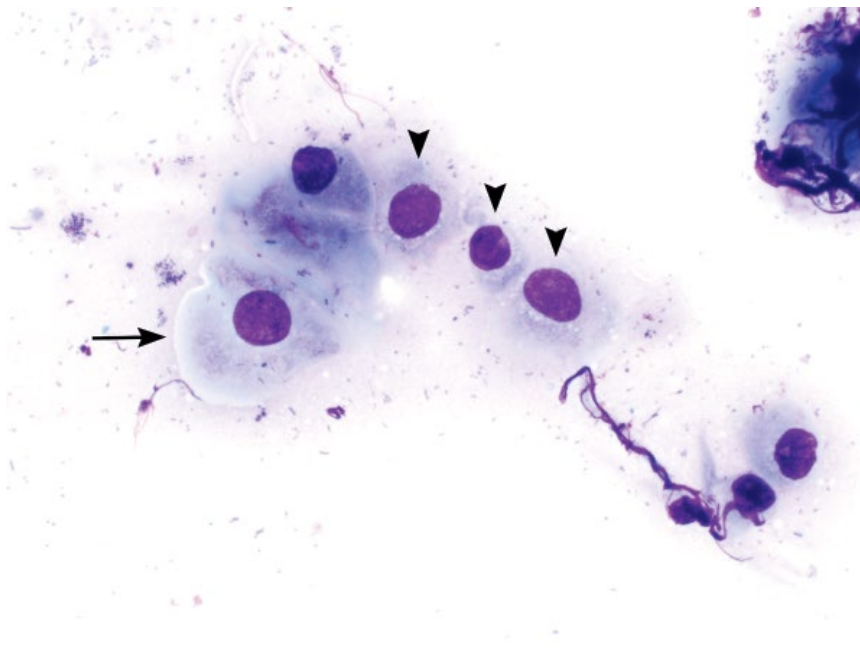


Figure 12.37 Vaginal cytology, early proestrus, dog, 50x objective. Parabasal cells (arrowheads) and a small superficial cell (arrow) are seen. Many extracellular bacteria are present.

- Estrogen levels peak during late proestrus ($\sim 50\text{--}100\text{ pg ml}^{-1}$), and progesterone concentration is low, but increases with the luteinizing hormone (LH) surge (to typically $>2\text{ ng ml}^{-1}$).

12.7.3 Estrus

12.7.3.1 Cytologic Appearance

In dogs, estrus is characterized by an almost exclusive population ($>90\%$) of superficial cells (Figure 12.39).

Neutrophils are absent, but extracellular bacteria may be present (Figure 12.40). In cats, anuclear superficial cells constitute 40–60% of the cells [49].

12.7.3.2 Clinical Considerations

- Females are receptive and passive toward males. *Note:* Both estrus behavior and cornification of epithelial cells may precede or follow the LH surge, and do not always correlate with the fertile estrus period.
- Estrus lasts 3 days to 3 weeks (mean = 9 days) [48].

Figure 12.38 Vaginal cytology, late proestrus, dog, 50× objective. Large superficial cells dominate, accompanied by many red blood cells and a neutrophil.

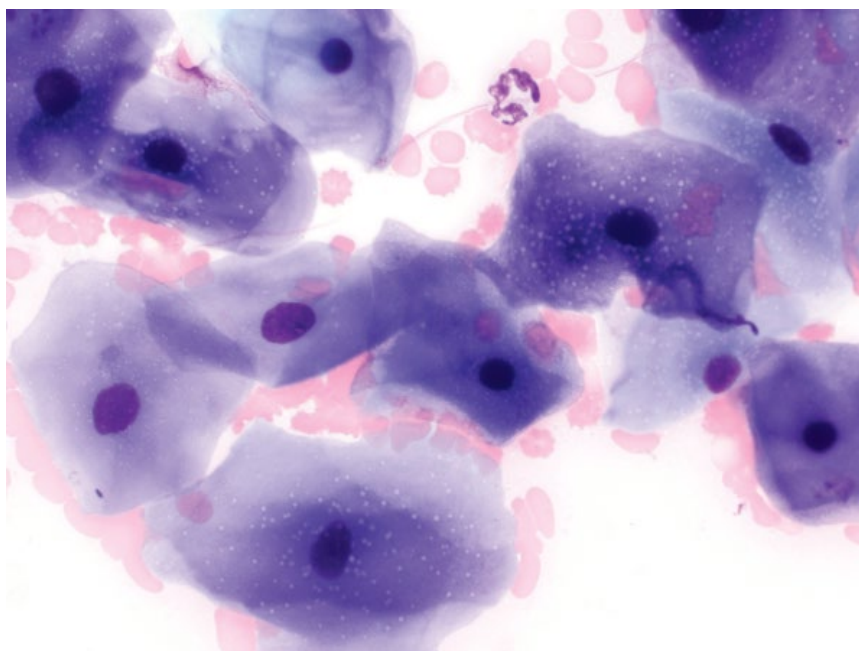
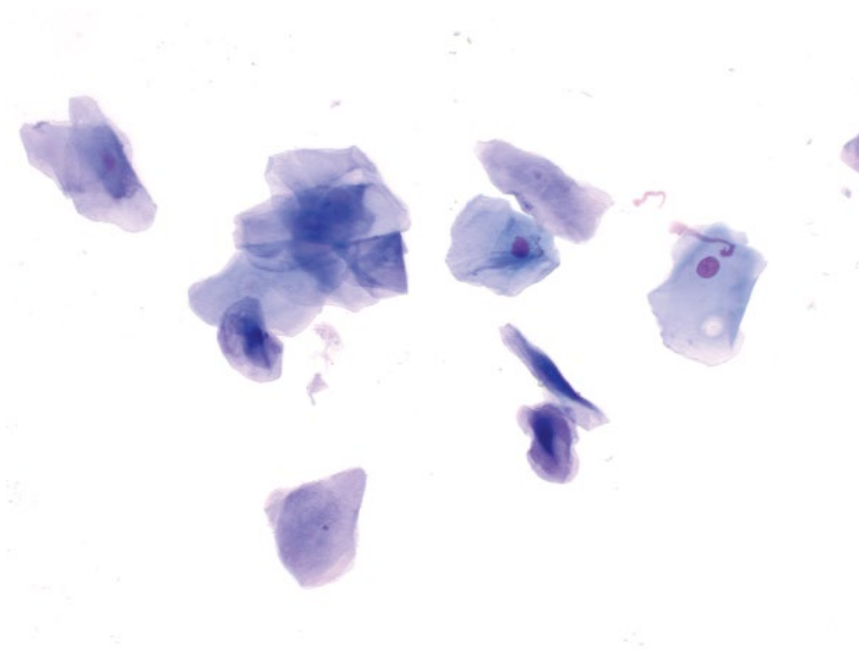


Figure 12.39 Vaginal cytology, estrus, dog, 20× objective.



- Vulvar enlargement is maximal (dogs).
- The serosanguinous/hemorrhagic discharge seen in proestrus tends to diminish.
- Estrogen levels drop precipitously after the LH surge, while progesterone increases (usually to 4–10 ng ml⁻¹ at ovulation).

12.7.4 Diestrus

12.7.4.1 Cytologic Appearance

During diestrus, there is a dramatic decrease in the percentage of superficial cells, and a return of intermediate and parabasal cells. Within 24 hours, superficial cells decrease from approximately 100% to 20–40% of the

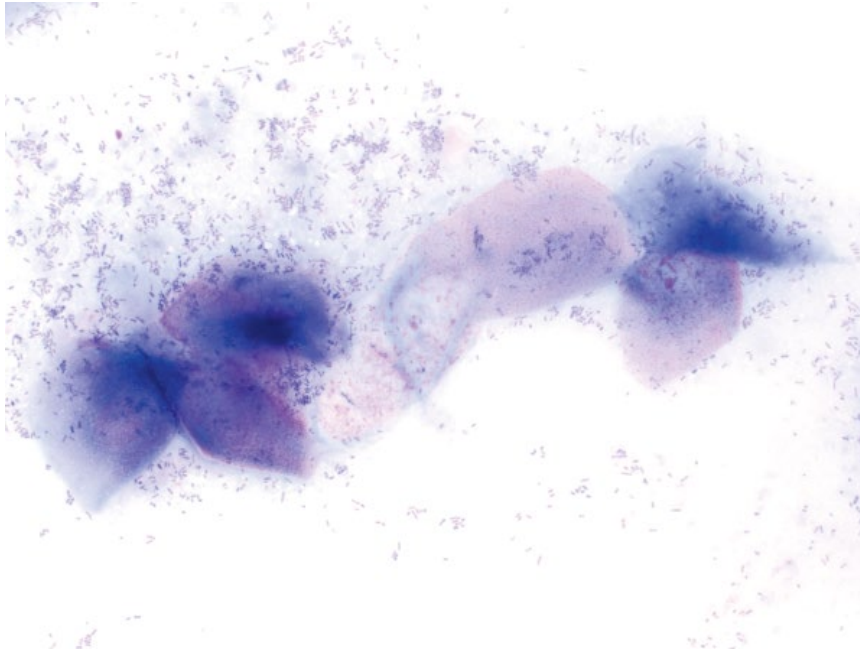


Figure 12.40 Vaginal cytology, estrus, dog, 50x objective. Note the abundance of extracellular bacteria, but absence of any neutrophils.

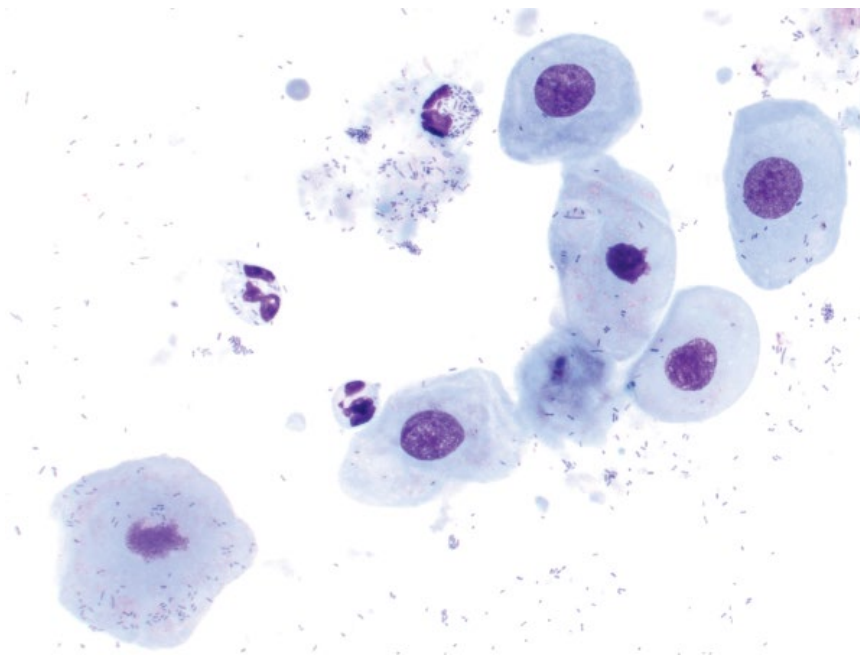


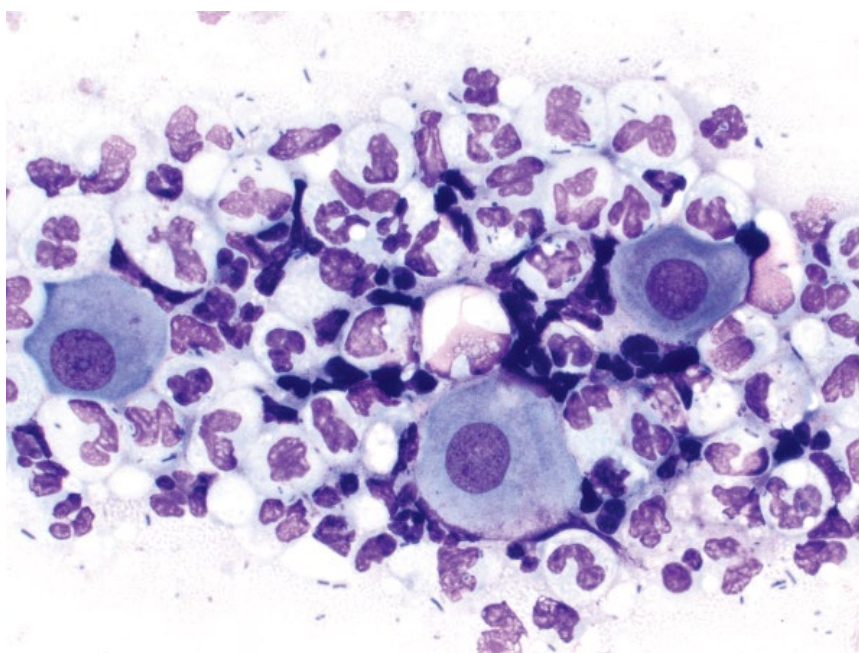
Figure 12.41 Vaginal cytology, diestrus, dog, 50x objective. Intermediate cells dominate, admixed with increased neutrophils and bacteria (both intracellular and extracellular).

population. Neutrophils often return during diestrus, and intracellular bacteria may be noted (Figure 12.41).

12.7.4.2 Clinical Considerations

- Females become refractory to breeding. Vulvar swelling and any residual discharge decreases.
- Breedings after the onset of diestrus rarely are fertile.
- Onset of diestrus is an accurate determinant of the time of ovulation, and hence can be used to estimate gestation length. In dogs, ovulation occurs 5–7 days prior to the onset of diestrus. Gestation time is therefore $57 \text{ days} \pm 1 \text{ day}$ from the onset of diestrus.
- Progesterone levels rise to a peak ($15\text{--}80 \text{ ng ml}^{-1}$), before progressively declining in late diestrus.

Figure 12.42 Vaginitis, dog, 50× objective. Vaginal epithelial cells are surrounded by abundant degenerative neutrophils that contain intracellular bacteria.



- Diestrus typically lasts 2–3 months in the absence of pregnancy.

12.7.5 Vaginitis/Metritis

12.7.5.1 Cytologic Appearance

Large numbers of neutrophils typically are seen that may be degenerative and contain intracellular bacteria (Figure 12.42). Squamous epithelial cells (anucleated or with pyknotic nuclei) may be seen.

12.7.5.2 Clinical Considerations

- Intracellular bacteria may be seen during diestrus normally – correlate with epithelial cell populations and clinical signs.

- Common aerobic bacterial isolates include *Escherichia coli*, beta-hemolytic *Streptococcus* and *Staphylococcus intermedius*, though microbial culture and susceptibility testing is recommended [50].

12.7.5.3 Prognosis

Generally excellent with appropriate antimicrobial therapy and treatment of any underlying predisposing causes. Prognosis for cases of pyometra is more guarded [51].

12.7.6 Neoplasia

Common neoplasms that affect the vagina include leiomyoma/leiomyosarcoma (see Chapter 6) and transmissible venereal tumor (TVT) (see Chapter 3).

References

- 1 Santos, M., Marcos, R., Caniatti, M. (2010) Cytologic study of normal canine testis. *Theriogenology*, **73** (2), 208–214.
- 2 McEntee, M.C. (2002) Reproductive oncology. *Clin. Tech. Small Anim. Pract.*, **17** (3), 133–149.
- 3 Liao, A.T., Chu, P.Y., Yeh, L.S., *et al.* (2009) A 12-year retrospective study of canine testicular tumors. *J. Vet. Med. Sci.*, **71** (7), 919–923.
- 4 Grieco, V., Riccardi, E., Greppi, G.F., *et al.* (2008) Canine testicular tumours: a study on 232 dogs. *J. Comp. Pathol.*, **138** (2–3), 86–89.
- 5 Lipowitz, A.J., Schwartz, A., Wilson, G.P., *et al.* (1973) Testicular neoplasms and concomitant clinical changes in the dog. *J. Am. Vet. Med. Assoc.*, **163** (12), 1364–1368.
- 6 Withers, S.S., Lawson, C.M., Burton, A.G., *et al.* (2016) Management of an invasive and metastatic Sertoli cell tumor with associated myelotoxicosis in a dog. *Can. Vet. J.*, **57** (3), 299–304.
- 7 Wanke, M.M. (2004) Canine brucellosis. *Anim. Reprod. Sci.*, **82–83**, 195–207.
- 8 Diniz, S.A., Melo, M.S., Borges, A.M., *et al.* (2005) Genital lesions associated with visceral leishmaniasis and shedding of *Leishmania* sp. in the semen of naturally infected dogs. *Vet. Pathol.*, **42** (5), 650–658.
- 9 Ober, C.P., Spaulding, K., Breitschwerdt, E.B., *et al.* (2004) Orchitis in two dogs with Rocky Mountain spotted fever. *Vet. Radiol. Ultrasound*, **45** (5), 458–465.

- 10 Davidson, A.P., von Dehn, B.J., Schlafer, D.H. (2015) Adult-onset lymphoplasmacytic orchitis in a Labrador retriever stud dog. *Top. Companion Anim. Med.*, **30** (1), 31–34.
- 11 Root Kustritz, M.V. (2007) The value of canine semen evaluation for practitioners. *Theriogenology*, **68** (3), 329–337.
- 12 Zambelli, D., Cunto, M. (2006) Semen collection in cats: techniques and analysis. *Theriogenology*, **66** (2), 159–165.
- 13 Freshman, J.L. (2002) Semen collection and evaluation. *Clin. Tech. Small Anim. Pract.*, **17** (3), 104–107.
- 14 Root Kustritz, M.V., Olson, P.N., Johnston, S.D., *et al.* (1998) The effects of stains and investigators on assessment of morphology of canine spermatozoa. *J. Am. Anim. Hosp. Assoc.*, **34** (4), 348–352.
- 15 Gouletsou, P.G., Galatos, A.D., Leontides, L.S., *et al.* (2010) Impact of fine or large needle aspiration on the dog's testis: in vitro ultrasonographic, bacteriological, gross anatomy and histological assessment. *Theriogenology*, **74** (9), 1604–1614.
- 16 Oettlé, E.E. (1993) Sperm morphology and fertility in the dog. *J. Reprod. Fertil. Suppl.*, **47**, 257–260.
- 17 LeRoy, B.E., Northrup, N. (2009) Prostate cancer in dogs: comparative and clinical aspects. *Vet. J.*, **180** (2), 149–162.
- 18 Bryan, J.N., Keeler, M.R., Henry, C.J., *et al.* (2007) A population study of neutering status as a risk factor for canine prostate cancer. *Prostate*, **67** (11), 1174–1181.
- 19 Bradbury, C.A., Westropp, J.L., Pollard, R.E. (2009) Relationship between prostatomegaly, prostatic mineralization, and cytologic diagnosis. *Vet. Radiol. Ultrasound*, **50** (2), 167–171.
- 20 LeRoy, B.E., Nadella, M.V.P., Toribio, R.E., *et al.* (2004) Canine prostate carcinomas express markers of urothelial and prostatic differentiation. *Vet. Pathol.*, **41** (2), 131–140.
- 21 Powe, J.R., Canfield, P.J., Martin, P.A. (2004) Evaluation of the cytologic diagnosis of canine prostatic disorders. *Vet. Clin. Pathol.*, **33** (3), 150–154.
- 22 Black, G.M., Ling, G.V., Nyland, T.G., *et al.* (1998) Prevalence of prostatic cysts in adult, large-breed dogs. *J. Am. Anim. Hosp. Assoc.*, **34** (2), 177–180.
- 23 Smith, J. (2008) Canine prostatic disease: a review of anatomy, pathology, diagnosis, and treatment. *Theriogenology*, **70** (3), 375–383.
- 24 Nizański, W., Levy, X., Ochota, M., *et al.* (2014) Pharmacological treatment for common prostatic conditions in dogs – benign prostatic hyperplasia and prostatitis: an update. *Reprod. Domest. Anim.*, **49** (Suppl. 2), 8–15.
- 25 Krawiec, D.R., Heflin, D. (1992) Study of prostatic disease in dogs: 177 cases (1981–1986). *J. Am. Vet. Med. Assoc.*, **200** (8), 1119–1122.
- 26 Greenlee, P.G., Patnaik, A.K. (1985) Canine ovarian tumors of germ cell origin. *Vet. Pathol.*, **22** (2), 117–122.
- 27 Fernández, T., Díez-Bru, N., Rios, A., *et al.* (2001) Intracranial metastases from an ovarian dysgerminoma in a 2-year-old dog. *J. Am. Anim. Hosp. Assoc.*, **37** (6), 553–556.
- 28 Herron, M.A. (1983) Tumors of the canine genital system. *J. Am. Anim. Hosp. Assoc.*, **19**, 981–994.
- 29 Stein, B.S. (1981) Tumors of the feline genital tract. *J. Am. Anim. Hosp. Assoc.*, **17**, 1022–1025.
- 30 McCandlish, I.A., Munro, C.D., Breeze, R.G., *et al.* (1979) Hormone-producing ovarian tumours in the dog. *Vet. Rec.*, **105** (1), 9–11.
- 31 Patnaik, A.K., Greenlee, P.G. (1987) Canine ovarian neoplasms: a clinicopathologic study of 71 cases, including histology of 12 granulosa cell tumors. *Vet. Pathol.*, **24** (6), 509–514.
- 32 Banco, B., Antuofermo, E., Borzacchiello, G., *et al.* (2011) Canine ovarian tumors: an immunohistochemical study with HBME-1 antibody. *J. Vet. Diagn. Invest.*, **23** (5), 977–981.
- 33 Yamaguchi, Y., Sato, T., Shibuya, H., *et al.* (2004) Ovarian teratoma with a formed lens and nonsuppurative inflammation in an old dog. *J. Vet. Med. Sci.*, **66** (7), 861–864.
- 34 Coggeshall, J.D., Franks, J.N., Wilson, D.U., *et al.* (2012) Primary ovarian teratoma and GCT with intra-abdominal metastasis in a dog. *J. Am. Anim. Hosp. Assoc.*, **48** (6), 424–428.
- 35 Sorenmo, K.U., Kristiansen, V.M., Cofone, M.A., *et al.* (2009) Canine mammary gland tumours: a histological continuum from benign to malignant: clinical and histopathological evidence. *Vet. Comp. Oncol.*, **7** (3), 162–172.
- 36 Hayes, H.M., Jr, Milne, K.L., Mandell, C.P. (1981) Epidemiological features of feline mammary carcinoma. *Vet. Rec.*, **108** (22), 476–479.
- 37 Goldschmidt, M., Peña, L., Rasotto, R., *et al.* (2011) Classification and grading of canine mammary tumors. *Vet. Pathol.*, **48** (1), 117–131.
- 38 Schneider, R., Dorn, C.R., Taylor, D.O. (1969) Factors influencing canine mammary cancer development and postsurgical survival. *J. Natl Cancer Inst.*, **43** (6), 1249–1261.
- 39 Dorn, C.R., Taylor, D.O., Schneider, R., *et al.* (1968) Survey of animal neoplasms in Alameda and Contra Costa Counties, California. II. Cancer morbidity in dogs and cats from Alameda County. *J. Natl Cancer Inst.*, **40** (2), 307–318.
- 40 Benjamin, S.A., Lee, A.C., Saunders, W.J. (1999) Classification and behavior of canine mammary epithelial neoplasms based on life-span observations in beagles. *Vet. Pathol.*, **36** (5), 423–436.

- 41 Chang, S.C., Chang, C.C., Chang, T.J., *et al.* (2005) Prognostic factors associated with survival two years after surgery in dogs with malignant mammary tumors: 79 cases (1998–2002). *J. Am. Vet. Med. Assoc.*, **227** (10), 1625–1629.
- 42 MacEwen, E.G., Hayes, A.A., Harvey, H.J., *et al.* (1984) Prognostic factors for feline mammary tumors. *J. Am. Vet. Med. Assoc.*, **185** (2), 201–204.
- 43 Biddle, D., Macintire, D.K. (2000) Obstetrical emergencies. *Clin. Tech. Small Anim. Pract.*, **15** (2), 88–93.
- 44 Murai, A., Maruyama, S., Nagata, M., *et al.* (2013) Mastitis caused by *Mycobacterium kansasii* infection in a dog. *Vet. Clin. Pathol.*, **42** (3), 377–381.
- 45 Ditmyer, H., Craig, L. (2011) Mycotic mastitis in three dogs due to *Blastomyces dermatitidis*. *J. Am. Anim. Hosp. Assoc.*, **47** (5), 356–358.
- 46 Park, C.H., Ikadai, H., Yoshida, E., *et al.* (2007) Cutaneous toxoplasmosis in a female Japanese cat. *Vet. Pathol.*, **44** (5), 683–687.
- 47 Mills, J.N., Valli, V.E., Lumsden, J.H. (1979) Cyclical changes of vaginal cytology in the cat. *Can. Vet. J.*, **20** (4), 95–101.
- 48 Olson, P.N., Husted, P.W., Allen, T.A., *et al.* (1984) Reproductive endocrinology and physiology of the bitch and queen. *Vet. Clin. North Am. Small Anim. Pract.*, **14** (4), 927–946.
- 49 Shille, V.M., Lundström, K.E., Stabenfeldt, G.H. (1979) Follicular function in the domestic cat as determined by estradiol-17 beta concentrations in plasma: relation to estrous behavior and cornification of exfoliated vaginal epithelium. *Biol. Reprod.*, **21** (4), 953–963.
- 50 Bjurström, L. (1993) Aerobic bacteria occurring in the vagina of bitches with reproductive disorders. *Acta Vet. Scand.*, **34** (1), 29–34.
- 51 Jitpean, S., Ström-Holst, B., Emanuelson, U., *et al.* (2014) Outcome of pyometra in female dogs and predictors of peritonitis and prolonged postoperative hospitalization in surgically treated cases. *BMC Vet. Res.* 2014;10:6. doi: 10.1186/1746-6148-10-6. Last accessed May 1, 2017.

13

Neurologic

13.1 Brain

13.1.1 Meningioma

13.1.1.1 Cytologic Appearance

Meningiomas exfoliate in variably tight aggregates that may be associated with pink extracellular matrix. Cells mostly are fusiform to stellate, but can be ovoid, and have a moderate volume of pale-blue cytoplasm (Figures 13.1 and 13.2). Nuclei are ovoid with finely granular chromatin and multiple prominent nucleoli. Round, prominent structures may be seen in the nucleus (nuclear pseudoinclusions) that represent projection of the cytoplasm into nuclear grooves (Figure 13.3) [1, 2]. Anisocytosis/anisokaryosis usually are moderate, and N/C ratios are variable.

13.1.1.2 Clinical Considerations

- Most common brain tumor of dogs and cats [3, 4].
- Affect older patients.
- Many subtypes in dogs, including psammomatous meningiomas that are associated with mineralized 'psammoma bodies' (Figure 13.4) [5].
- Mostly benign tumors, but metastatic disease does occur [3, 6].

13.1.1.3 Prognosis

Variable, based on treatment methods, but long-term survival is possible [6].

13.1.2 Astrocytoma

13.1.2.1 Cytologic Appearance

The cytologic appearance of astrocytomas varies with degree of differentiation of the neoplastic cells. Differentiated tumors comprise spindloid cells with scant cytoplasm forming long bipolar cytoplasmic processes, and elongated nuclei that have finely granular chromatin and small basophilic nucleoli (Figures 13.5 and 13.6) [1]. Anisocytosis/anisokaryosis are mild to moderate, and N/C ratios are high. Anaplastic variants

comprise round cells that may be difficult to differentiate from oligodendrogliomas.

13.1.2.2 Clinical Considerations

- Dogs > cats.
- Brachycephalic dog breeds appear over-represented [3].
- Clinical signs = mentation change, seizures, vestibular syndrome, and vision loss [3, 4].

13.1.2.3 Prognosis

Limited data are available. Prognosis without treatment is poor [7, 8].

13.1.3 Oligodendroglioma

13.1.3.1 Cytologic Appearance

Oligodendrogliomas often are associated with abundant coursing capillaries (Figure 13.7) [1]. Neoplastic cells are fragile, and many bare nuclei may be present. Cells are seen individually, and are ovoid, with a moderate volume of medium-blue cytoplasm. Nuclei are ovoid, eccentrically placed, and have coarsely granular chromatin with prominent nucleoli (Figure 13.8). The chromatin pattern, and the amount of cytoplasm, are most useful in differentiating from lymphoma (compare to Figure 13.9).

13.1.3.2 Clinical Considerations

- Dogs > cats.
- Brachycephalic dog breeds appear over-represented [3, 9].
- Clinical signs = seizures and mentation changes most common [3, 4].
- Neoplastic cells may be seen in cerebrospinal fluid (CSF) [10].

13.1.3.3 Prognosis

Limited data are available. Prognosis without therapy is poor, but long-term survival is reported with therapy [7, 11].

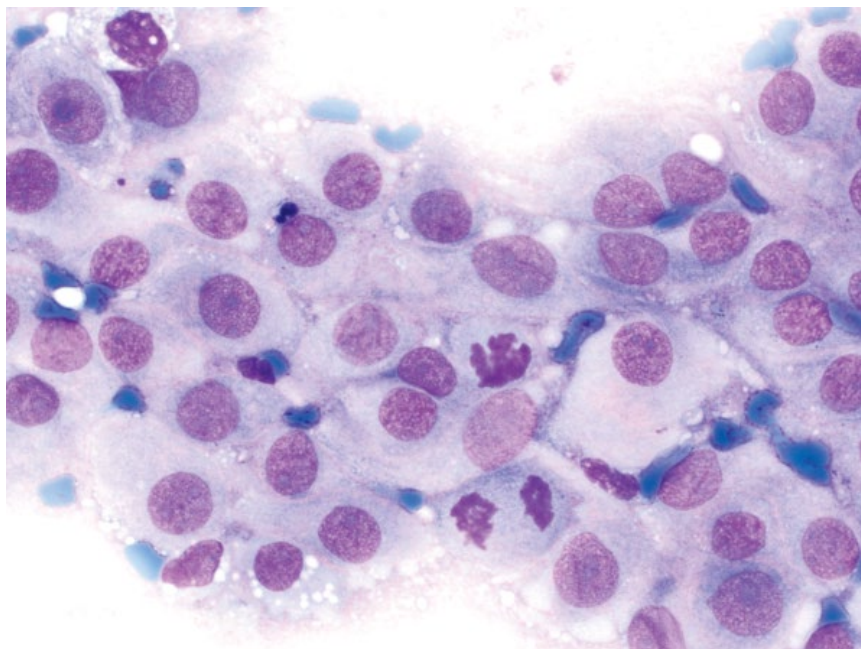


Figure 13.1 Meningioma, dog, 50× objective.

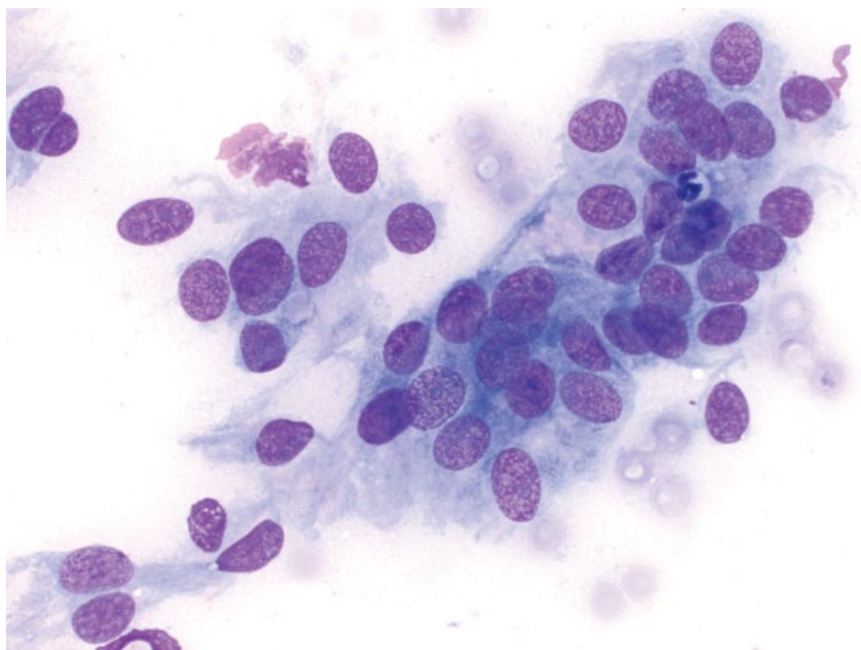


Figure 13.2 Meningioma, dog, 50× objective.

13.1.4 Lymphoma

13.1.4.1 Cytologic Appearance

Lymphoma of the central nervous system (CNS) appears similar to that in other organs, with an expanded population of discrete, round cells with round to indented nuclei approximately two to three red blood cells in diameter, and finely stippled, immature chromatin (Figure 13.9). Mitotic figures may be seen [1].

13.1.4.2 Clinical Considerations

- Cats > dogs. Second most common brain neoplasm in cats [4].
- May be primary or an extension of multicentric lymphoma.

13.1.4.3 Prognosis

Generally poor. Response rates to therapy are moderate to low, and survival times are short [4, 12, 13].

Figure 13.3 Meningioma, dog, 100× objective. Note the prominent nuclear pseudoinclusion (arrow) that should not be mistaken for a nucleolus.

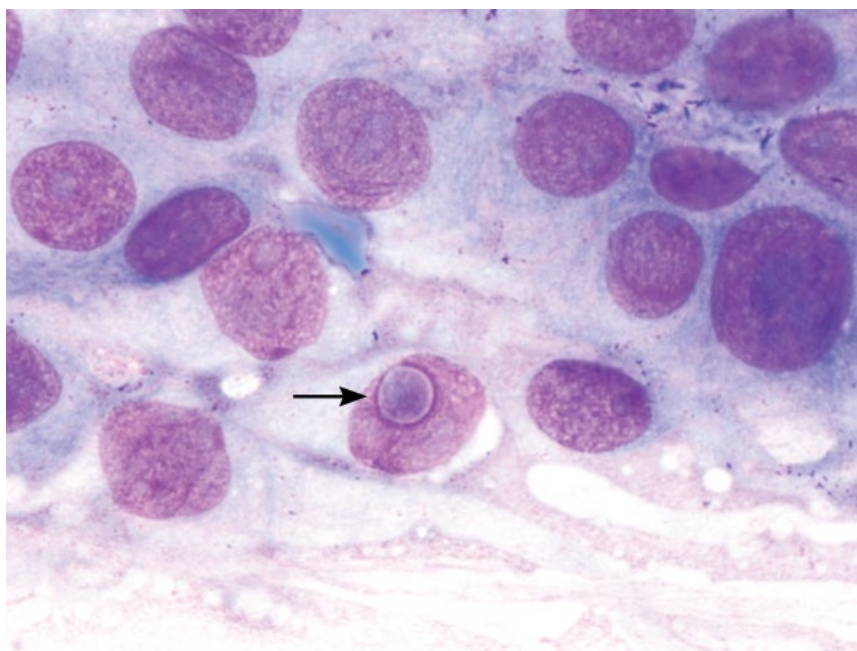
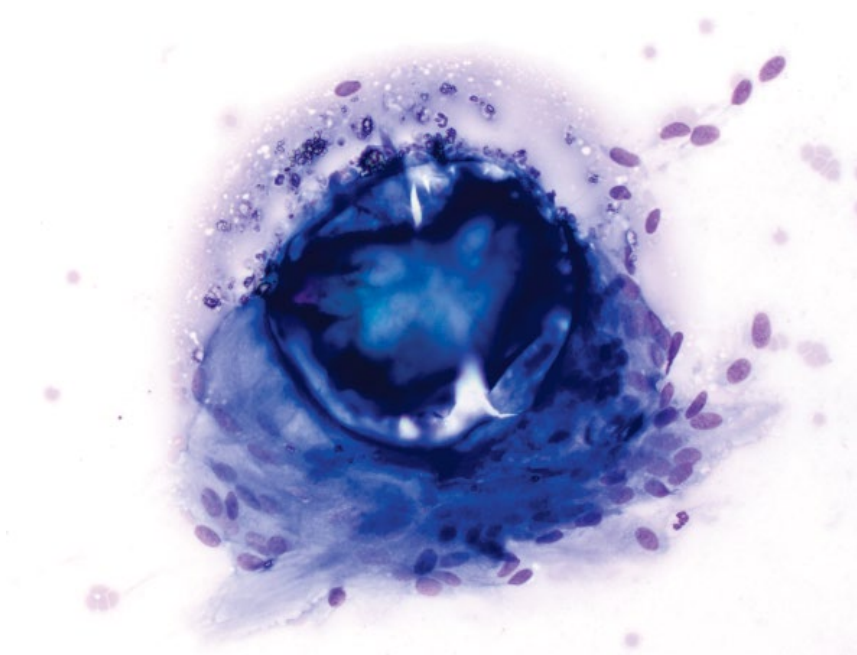


Figure 13.4 Psammoma body, psammomatous meningioma, dog, 20× objective. The psammoma body is refractile and mineralized, surrounded by neoplastic cells.



13.1.5 Primitive Neuroectodermal Tumors

13.1.5.1 Cytologic Appearance

Primitive neuroectodermal tumors (PNETs) mostly exfoliate in loosely cohesive sheets, and cells often are seen individually such that they may be difficult to differentiate from lymphoma. Compared to lymphoma, the cells often aggregate and tend to form vague palisading and acinar-like arrangements (compare Figures 13.10

and 13.9). They have ovoid nuclei with stippled chromatin and variably prominent nucleoli. Anisocytosis/anisokaryosis are mild to moderate, N/C ratios are high, and many mitotic figures usually are present [14].

13.1.5.2 Clinical Considerations

- Medulloblastomas and neuroblastomas are the most common PNETs [15].

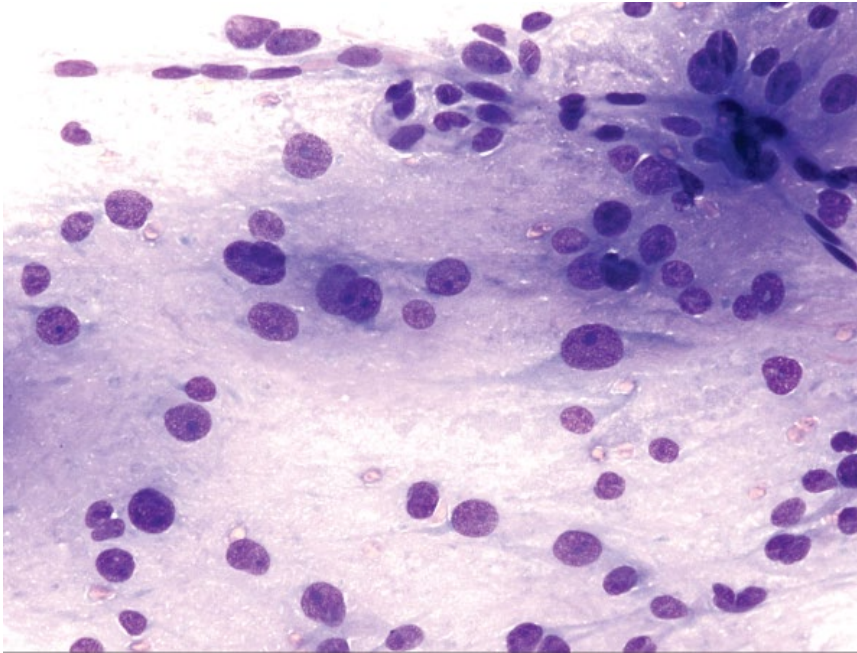


Figure 13.5 Astrocytoma, dog, 20× objective. Photograph courtesy of Dr Bill Vernau.

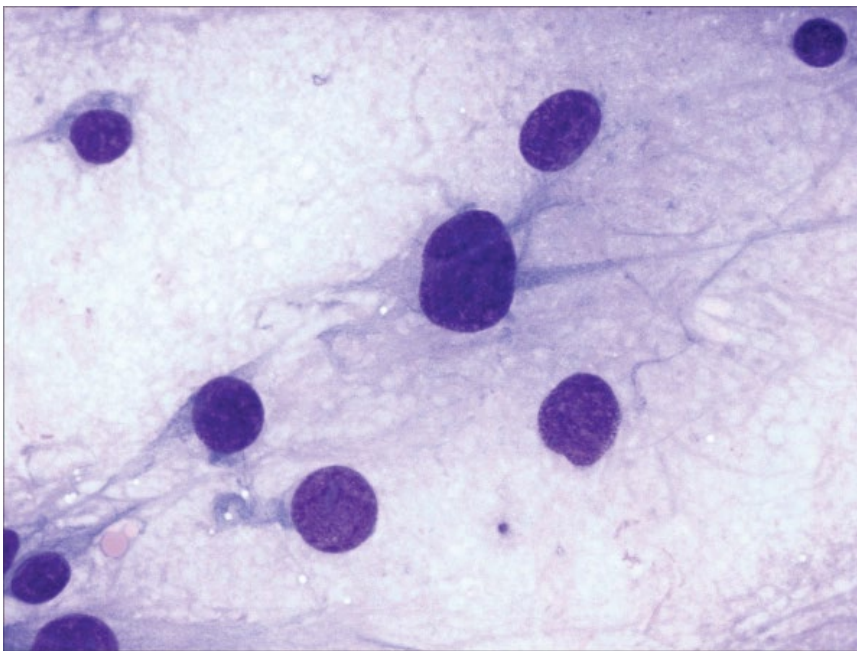


Figure 13.6 Astrocytoma, dog, 50× objective. Note the fine delicate tendrils of cytoplasm. Photograph courtesy of Dr Bill Vernau.

- Medulloblastomas most common in cerebellum [15].
- Dogs > cats. Rare in both.
- Typically affect younger patients.

13.1.5.3 Prognosis

Limited data are available, but prognosis generally is guarded to poor [14, 15].

13.1.6 Histiocytic Sarcoma

13.1.6.1 Cytologic Appearance

Histiocytic sarcoma is characterized by a population of large, atypical discrete cells. These cells are round, with a variable volume of medium-blue cytoplasm that often is vacuolated. Nuclei are ovoid to amoeboid, and have finely stippled chromatin with multiple prominent

Figure 13.7 Oligodendroglioma, dog, 20× objective. There are numerous capillaries coursing across the sample.

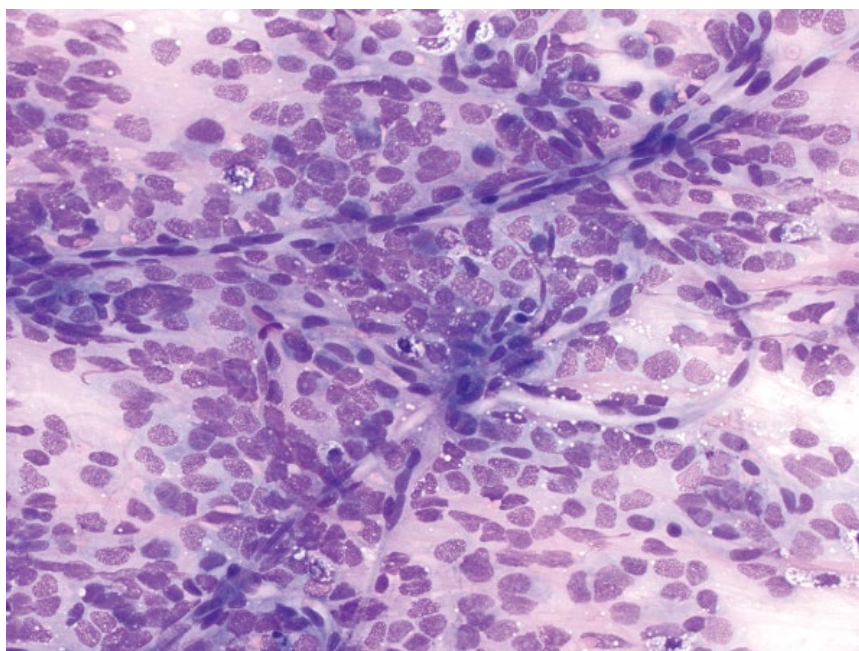
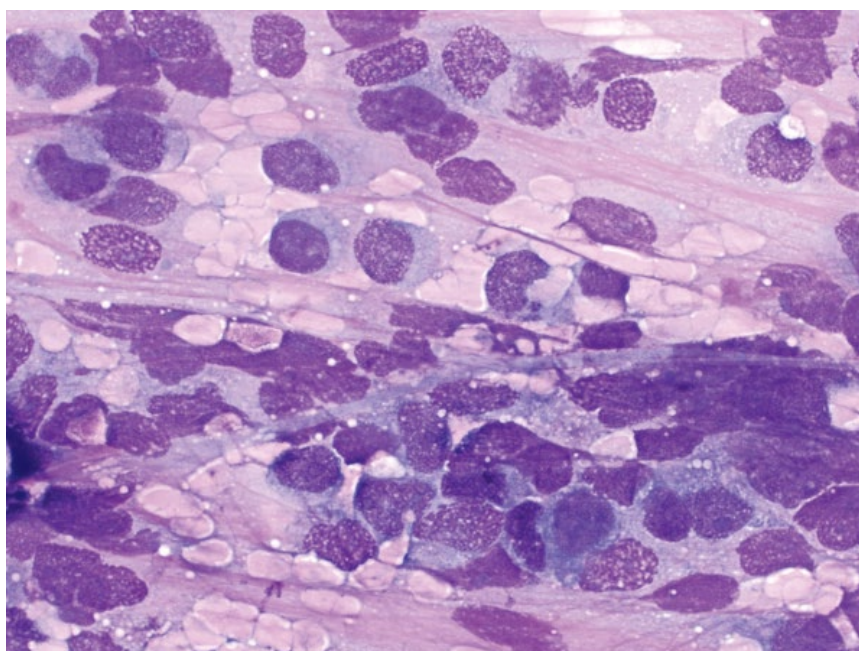


Figure 13.8 Oligodendroglioma, dog, 50× objective. Many cells are lysed. Intact cells are round and discrete.



nucleoli (Figure 13.11). Anisocytosis/anisokaryosis are marked, and N/C ratios are variable.

13.1.6.2 Clinical Considerations

- May be primary or an extension of disseminated disease [16].
- Predisposed breeds = Labrador Retrievers, Golden Retrievers and Pembroke Welsh Corgis [16].

13.1.6.3 Prognosis

Grave [16].

13.1.7 Choroid Plexus Papilloma

13.1.7.1 Cytologic Appearance

Choroid plexus papillomas comprise cohesive sheets of round cells with moderate to abundant amounts of mid-blue cytoplasm that contains a variable number of fine

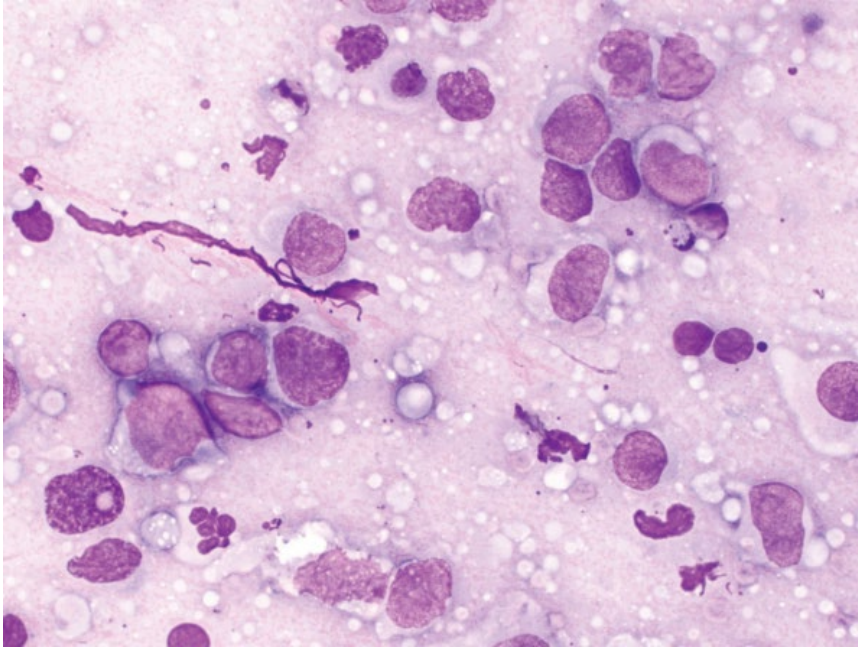


Figure 13.9 Lymphoma, dog, 50× objective.

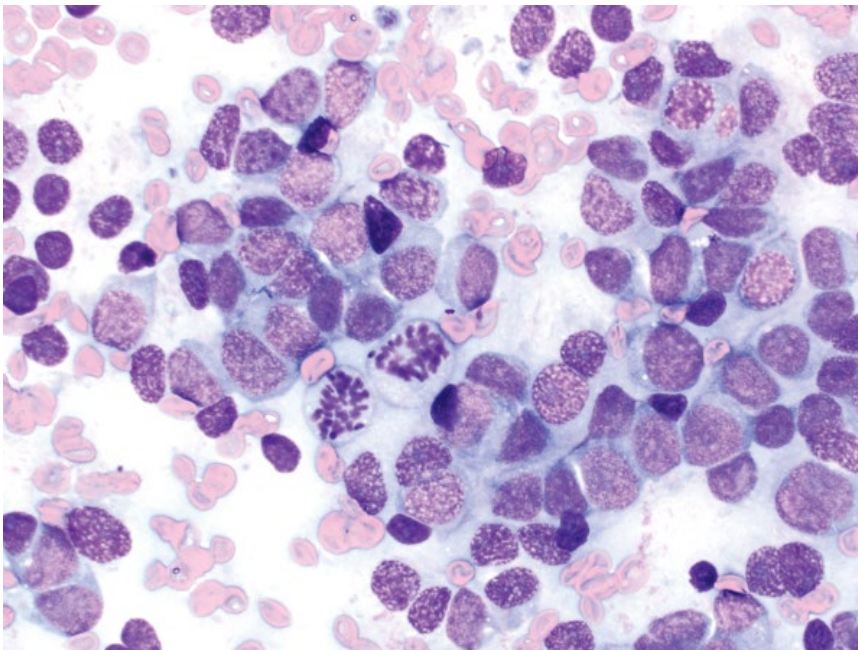


Figure 13.10 Primitive neuroectodermal tumor (neuroblastoma), dog, 50× objective.

pink granules (Figure 13.12). Nuclei are round to ovoid, eccentrically placed, and have small or inapparent nucleoli. Anisocytosis/anisokaryosis are mild, and N/C ratios are moderate to low.

13.1.7.2 Clinical Considerations

- Median age of 5 years in dogs [17].
- Clinical signs = mentation change, central vestibular disease, neck pain [3].
- Rarely locally invasive.

13.1.7.3 Prognosis

Limited data are available, but prognosis appears guarded to poor. Most patients have short survival times [7, 18]. Long-term survival rarely reported [19].

13.1.8 Choroid Plexus Carcinoma

13.1.8.1 Cytologic Appearance

Choroid plexus carcinomas also exfoliate in sheets, often in palisading rows (Figure 13.13). The cells have a small to moderate volume of mid-blue cytoplasm, and round

Figure 13.11 Histiocytic sarcoma, dog, 50x objective.

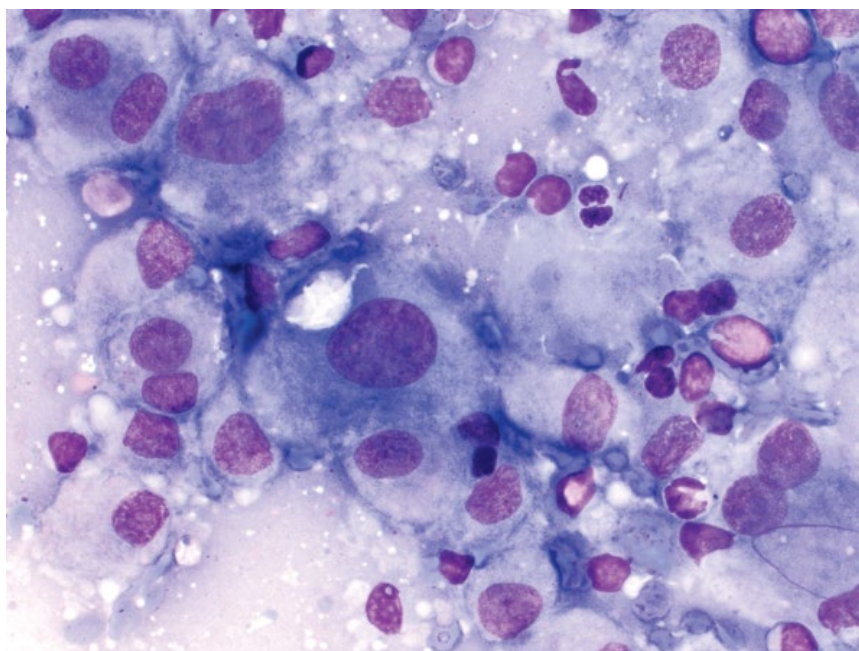
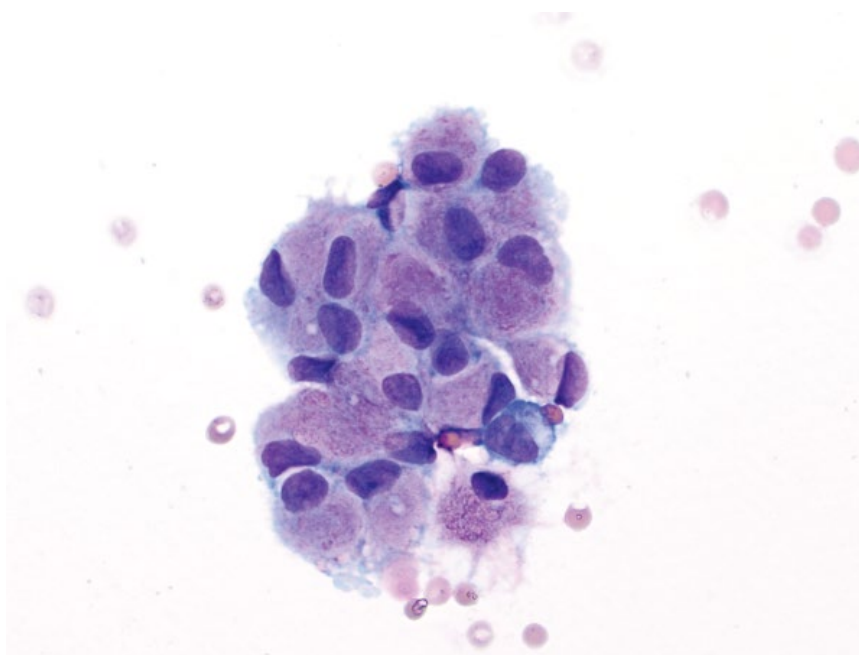


Figure 13.12 Choroid plexus papilloma, dog, 50x objective.



nuclei with coarsely granular chromatin and variably prominent nucleoli. Anisocytosis/anisokaryosis are mild to moderate, but N/C ratios are high.

13.1.8.2 Clinical Considerations

- Median age of 7 years in dogs [17].
- Clinical signs = mentation change, central vestibular disease, neck pain [3].
- Locally invasive tumors, which may metastasize within the brain, or less commonly to the spinal cord [17].

13.1.8.3 Prognosis

Limited data are available, but prognosis generally is poor [7, 18].

13.1.9 Ependymoma

13.1.9.1 Cytologic Appearance

Ependymomas exfoliate as tightly cohesive clusters, often in acinar-like arrangements (Figure 13.14). Cells have a moderate volume of medium-blue cytoplasm that may contain clear vacuoles. Nuclei are round, eccentrically

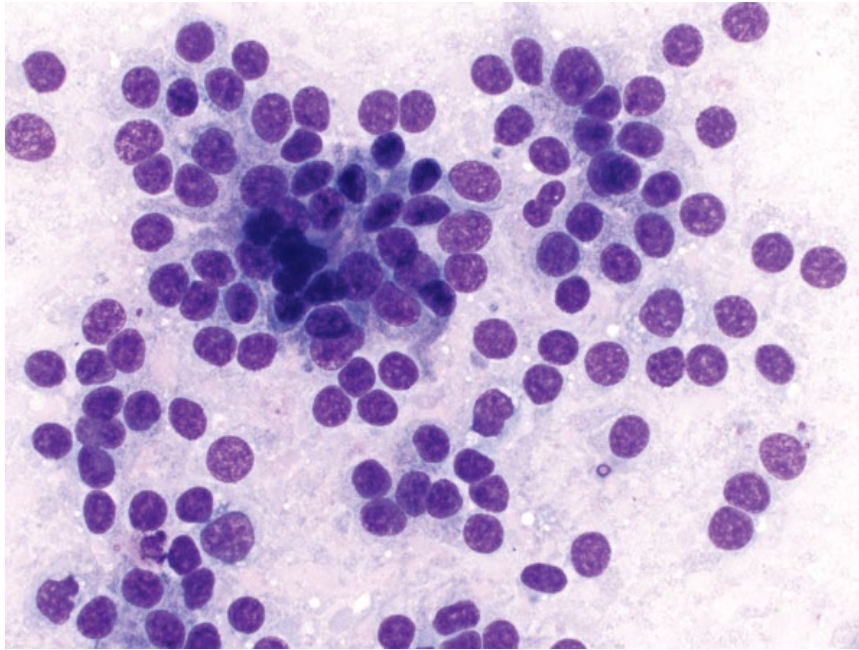


Figure 13.13 Choroid plexus carcinoma, dog, 50× objective.

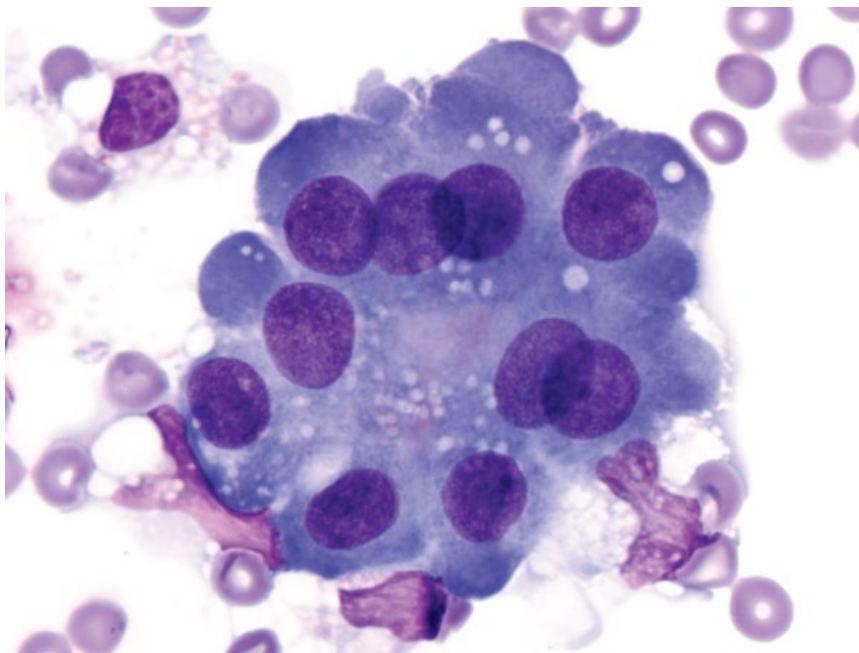


Figure 13.14 Ependymoma, dog, 100× objective.

placed, and have granular chromatin and single nucleoli. Anisocytosis/anisokaryosis are mild to moderate.

13.1.9.2 Clinical Considerations

- Rare in dogs and cats.
- May affect brain or spinal cord.
- Locally invasive and may metastasize via CSF [20].

13.1.9.3 Prognosis

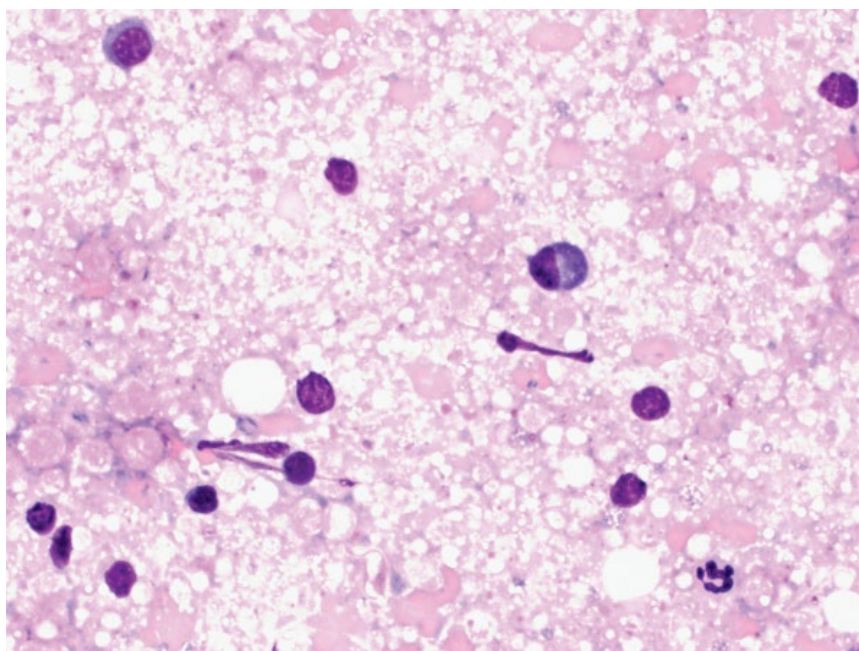
Limited data are available. Prognosis generally is poor for intracranial masses, but better for spinal lesions [20–22].

13.1.10 Encephalitis

13.1.10.1 Cytologic Appearance

Inflammatory lesions in the CNS are characterized by variable numbers of inflammatory cells (Figure 13.15). The type of cells may indicate the underlying cause, such as neutrophils in cases of bacterial disease, lymphoplasmacytic inflammation in sterile/immune-mediated inflammatory lesions or secondary to viral disease, and eosinophils secondary to parasitic, fungal, or protozoal agents.

Figure 13.15 Encephalitis, dog, 50× objective. Note the pink white matter in the background, and numerous small mature lymphocytes, a plasma cell, and a neutrophil.



13.1.10.2 Clinical Considerations

- Inflammatory mass lesions less common than neoplasia [23, 24].
- May be sterile or due to infectious agents.

13.1.10.3 Prognosis

Variable, based on underlying cause.

13.2.2.2 Clinical Considerations

- May be inadvertently sampled during CSF collection, or indicate underlying intervertebral disc disease if present in large amounts.

13.2.2.3 Prognosis

The presence of disc material does not affect prognosis – correlate with severity of underlying disease.

13.2 Cerebrospinal Fluid (CSF)

13.2.1 Normal CSF

13.2.1.1 Cytologic Appearance

Normal CSF has low cell and protein concentrations. Nucleated cell counts should be $<5 \text{ cells } \mu\text{l}^{-1}$ [25]. Protein concentration is $<25 \text{ mg dl}^{-1}$ for cisternal samples, and $<35 \text{ mg dl}^{-1}$ for lumbar samples [25]. Nucleated cells are seen in low numbers, and are dominated by quiescent macrophages, with low numbers of small mature lymphocytes (Figure 13.16). Neutrophils and eosinophils should be absent, or seen rarely if blood is present in the samples.

13.2.1.2 Clinical Considerations

- Grossly clear and colorless.
- Lack of cytologic abnormalities does not exclude pathology in the CNS, nor future involvement of CSF in disease.

13.2.2 Intervertebral Disc Material

13.2.2.1 Cytologic Appearance

Intervertebral disc material appears as variably sized, amorphous, smooth to fibrillar, deep magenta extracellular material (Figure 13.17).

13.2.3 Myelin-like Material

13.2.3.1 Cytologic Appearance

Myelin-like material may be sampled during CSF collection. It appears as variably sized aggregates of pale-pink, foamy material, often with internal circular structures giving a 'honeycomb' appearance (Figure 13.18).

13.2.3.2 Clinical Considerations

- Mostly an incidental finding in CSF samples.
- Larger amounts associated with intervertebral disc disease [26].
- No association with disease outcome.
- More likely to be seen in lumbar (than cerebrospinal) samples, and in small dogs ($<10 \text{ kg}$) [26].

13.2.3.3 Prognosis

Mostly excellent. May rarely be associated with myelomalacia, which carries a poor prognosis [27].

13.2.4 Surface Epithelial Cells

13.2.4.1 Cytologic Appearance

Surface epithelial cells may include ependymal, meningeal, and choroid plexus cells, which are seen individually or in small cohesive sheets. These cells may be round,

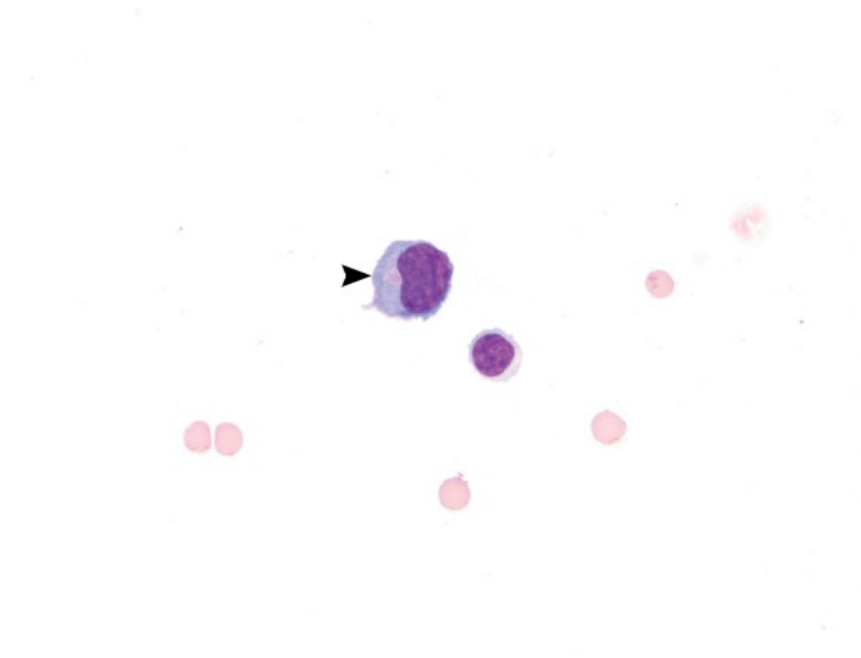


Figure 13.16 Normal CSF, dog, 50× objective. Low numbers of cells are seen on a clear background with a small amount of blood. A quiescent macrophage is seen (arrowhead) next to a small mature lymphocyte.

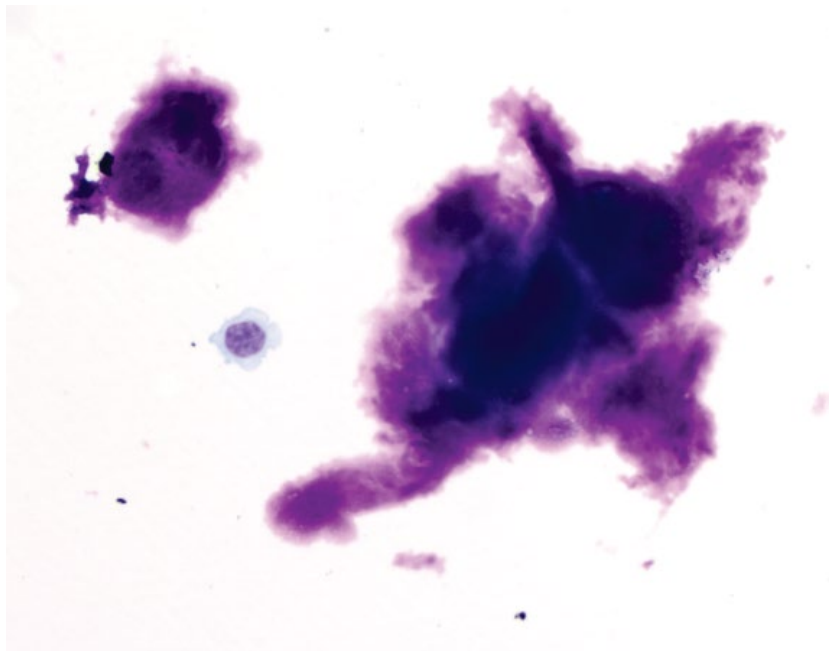


Figure 13.17 Intervertebral disc material, CSF, dog, 50× objective. Note the quiescent macrophage.

with a moderate volume of pink granular cytoplasm and eccentric nuclei (ependymal or choroid plexus origin; Figure 13.19), or more polygonal/spindloid with pale-blue cytoplasm and round/ovoid nuclei (meningeal origin; Figure 13.20). Anisocytosis/anisokaryosis are mild.

13.2.4.2 Clinical Considerations

- Uncommon, mostly an incidental finding [28].

13.2.4.3 Prognosis

Excellent.

13.2.5 Neutrophilic Inflammation

13.2.5.1 Cytologic Appearance

Neutrophils should be absent in CSF. Low numbers may be seen if blood contamination is present. A predominance of neutrophils confirms neutrophilic inflammation.

Figure 13.18 Myelin-like material, CSF, dog, 50x objective.

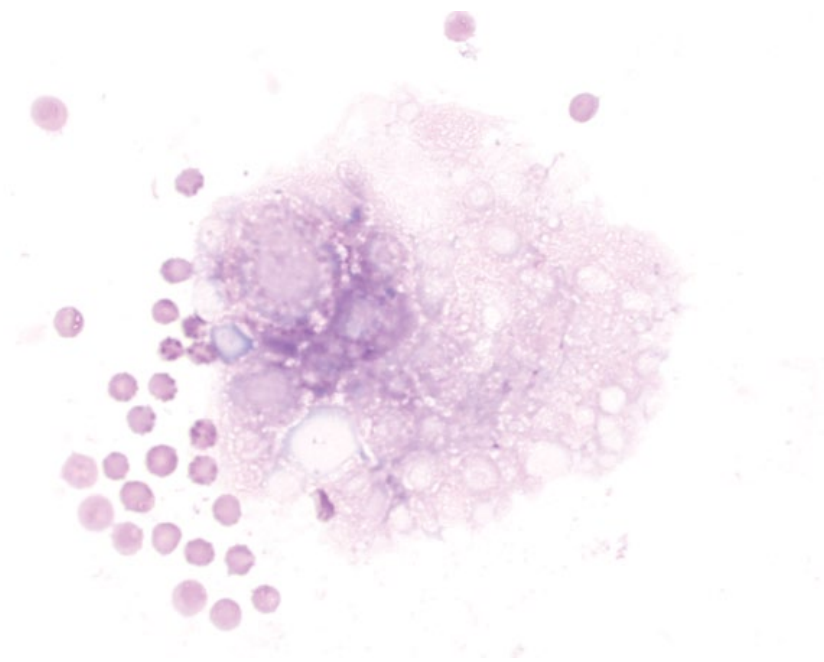
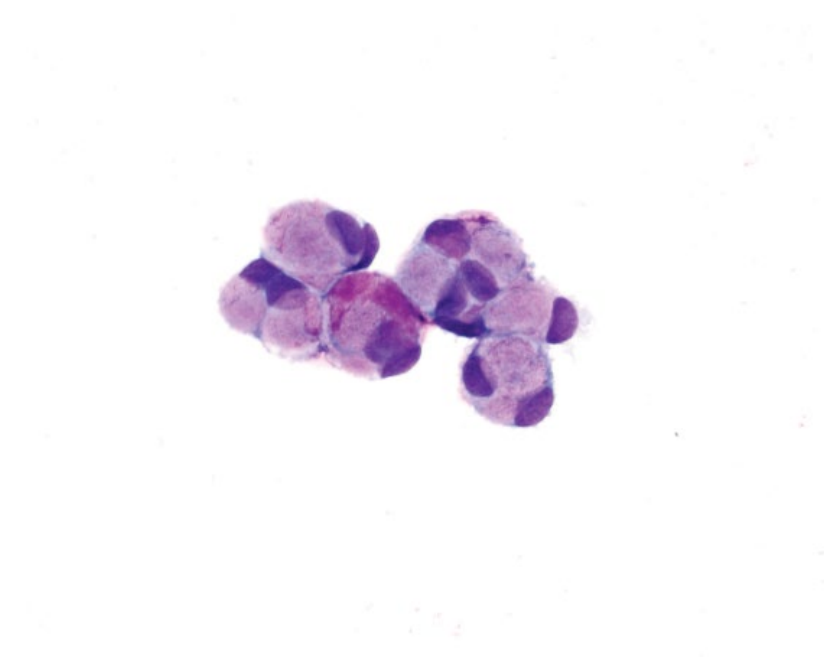


Figure 13.19 Surface epithelial cells, ependymal/choroid plexus origin, CSF, dog, 50x objective.



Neutrophils may be non-degenerative in sterile processes (Figure 13.21), or degenerative with infectious etiologies (Figure 13.22).

13.2.5.2 Clinical Considerations

- DDx = infectious meningitis, steroid-responsive meningitis-arteritis (acute), neoplasia, fibrocartilagenous emboli, trauma, and necrosis [16, 29–31].

13.2.5.3 Prognosis

Variable, based on underlying cause.

13.2.6 Eosinophilic Inflammation

13.2.6.1 Cytologic Appearance

Eosinophils should be absent in CSF. Mildly increased numbers of eosinophils may be seen in many inflammatory

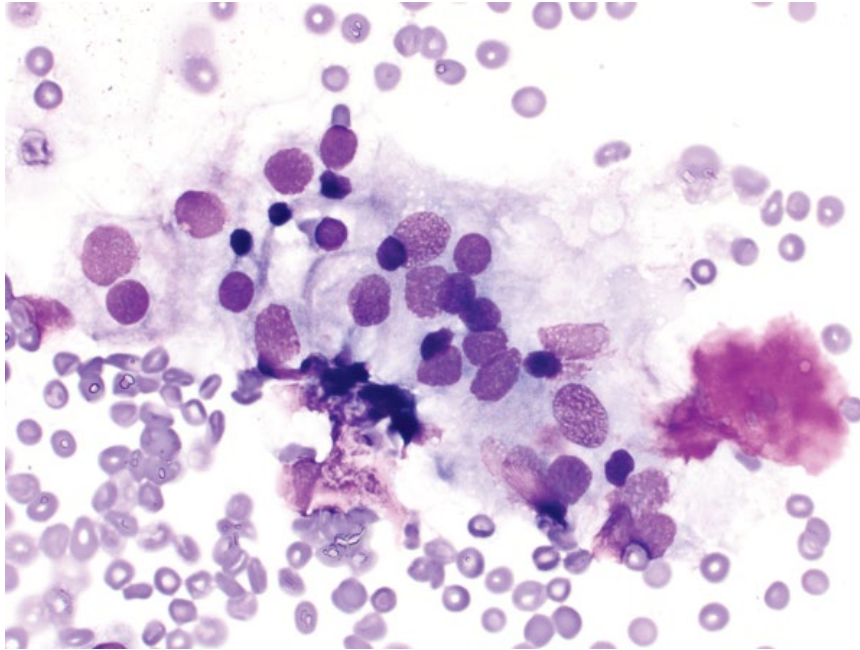


Figure 13.20 Surface epithelial cells, meningeal origin, CSF, dog, 50× objective. Note the small aggregate of intervertebral disc material on the right.

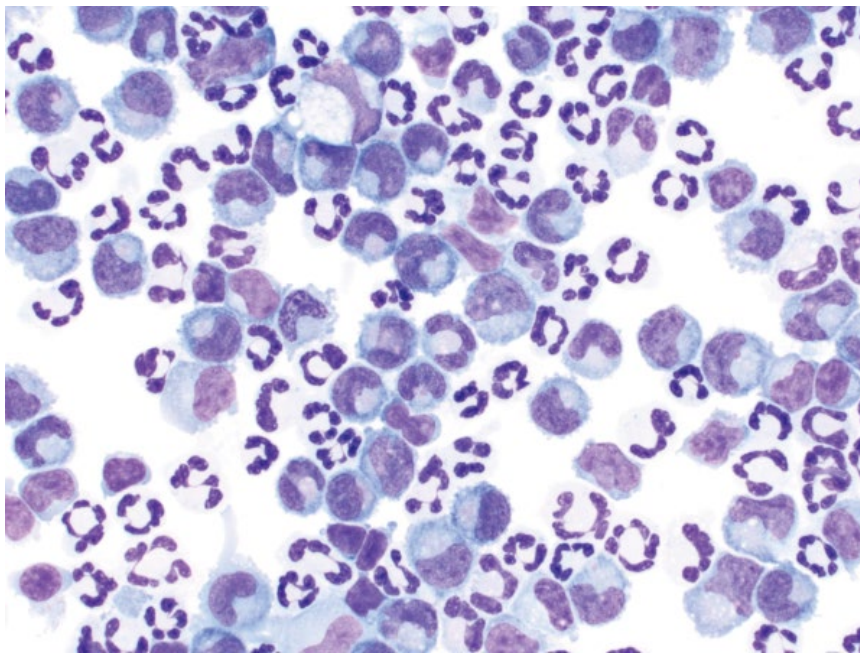


Figure 13.21 Neutrophilic inflammation (sterile), CSF, dog, 50× objective.

conditions. Eosinophils >10–20% are supportive of eosinophilic meningitis (Figure 13.23) [32, 33].

13.2.6.2 Clinical Considerations

- DDx = infectious agents (especially protozoa, fungal agents, algae, and migrating parasites), intervertebral disc extrusions, and idiopathic eosinophilic meningoencephalomyelitis [33].

13.2.6.3 Prognosis

Variable, based on underlying cause – infectious agents generally confer a poor prognosis [33, 34].

13.2.7 Lymphocytic Inflammation

13.2.7.1 Cytologic Appearance

Lymphocytes are present in low numbers in normal CSF. Lymphocytic inflammation is characterized by an

Figure 13.22 Neutrophilic inflammation (septic), CSF, dog, 100× objective. Note the variably shaped/sized bacterial rods in phagolysosomes of degenerative neutrophils.

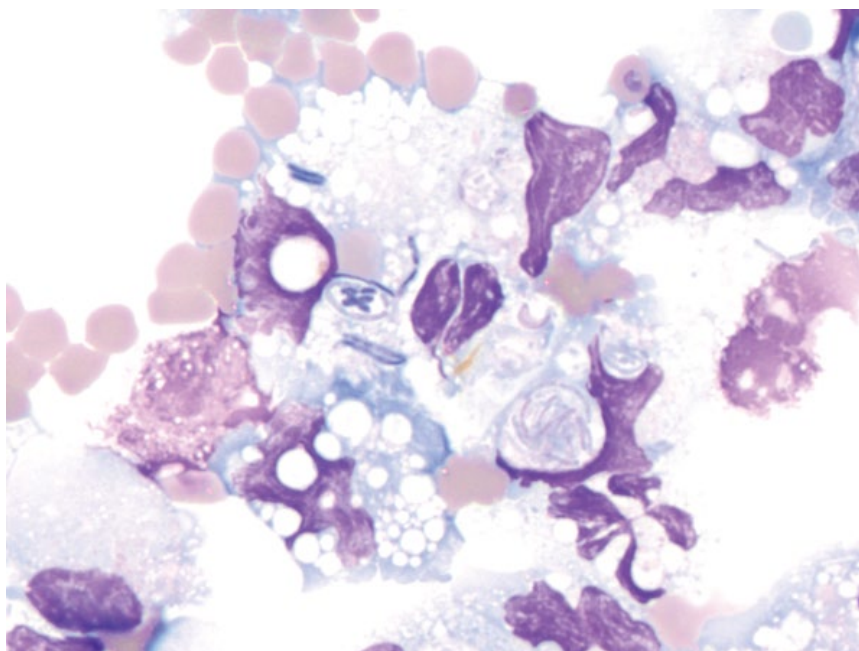
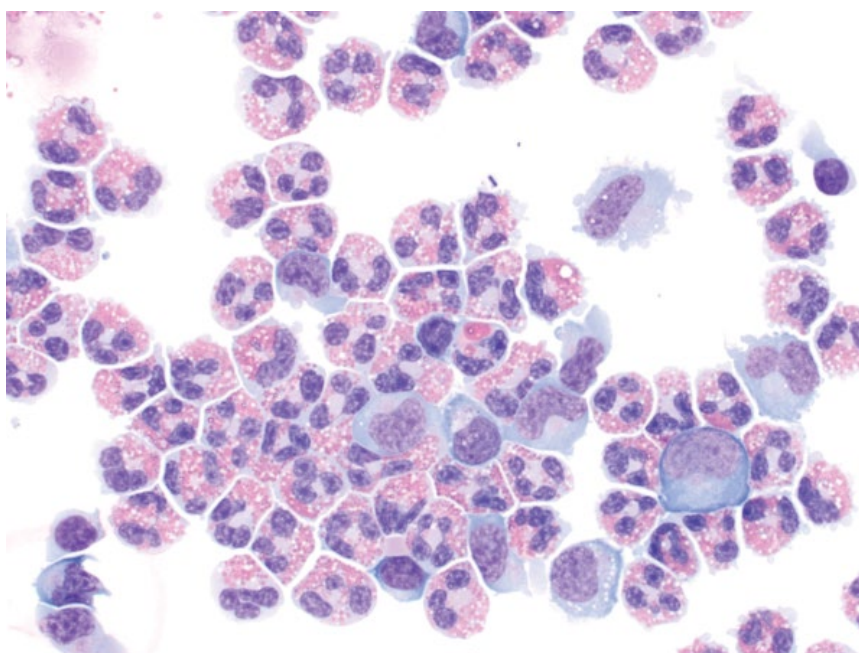


Figure 13.23 Eosinophilic inflammation (idiopathic eosinophilic meningoencephalomyelitis), CSF, dog, 50× objective.



increased number of heterogeneous lymphocytes, usually dominated by small mature cells, with lesser numbers of intermediate cells, reactive variants or plasma cells (Figure 13.24).

13.2.7.2 Clinical Considerations

- DDx = intervertebral disc disease (especially chronic), granulomatous/necrotizing meningoencephalitis, and infectious agents (especially viral) [35–38].

13.2.7.3 Prognosis

Variable, based on underlying cause.

13.2.8 Mononuclear Inflammation

13.2.8.1 Cytologic Appearance

Macrophages predominate in normal CSF; however, increased numbers may be seen in cases of mononuclear inflammation, frequently accompanied by reactive

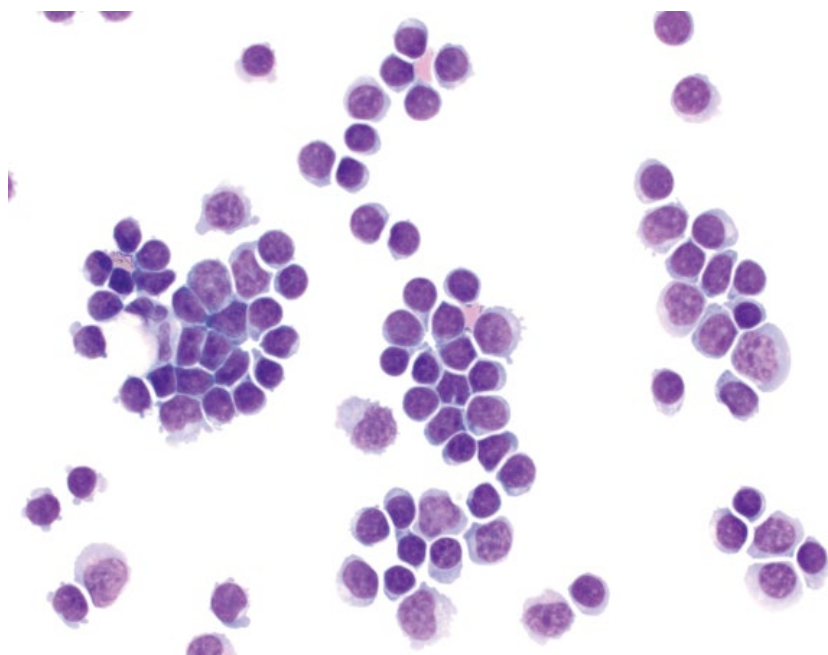

Figure 13.24 Lymphocytic inflammation, CSF, dog, 50× objective.

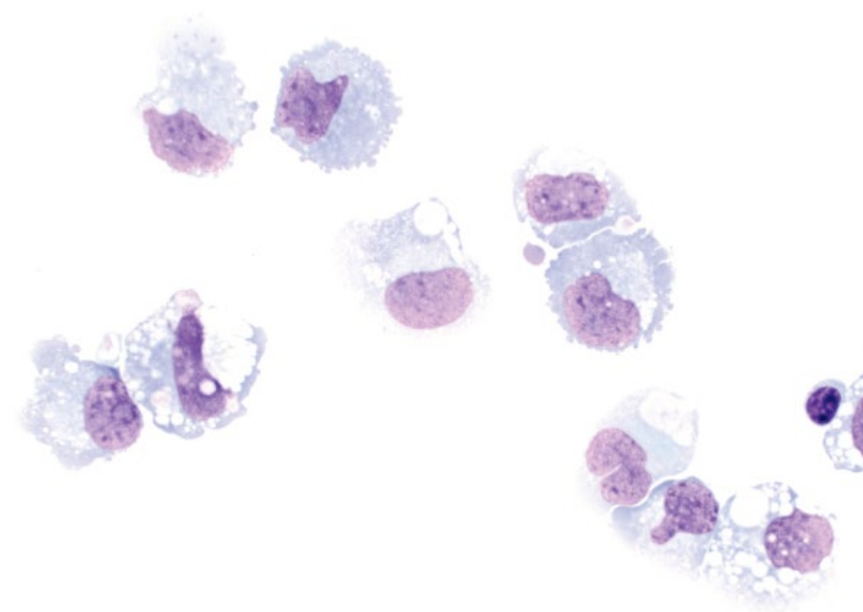


Figure 13.25 Mononuclear inflammation, CSF, cat, 50× objective.

changes such as an increased volume of vacuolated cytoplasm (Figure 13.25).

13.2.8.2 Clinical Considerations

- DDX = steroid responsive meningitis-arteritis (chronic), granulomatous meningoencephalitis (GME), infectious agents (e.g., fungal, feline infectious peritonitis), storage diseases [30, 39].

13.2.8.3 Prognosis

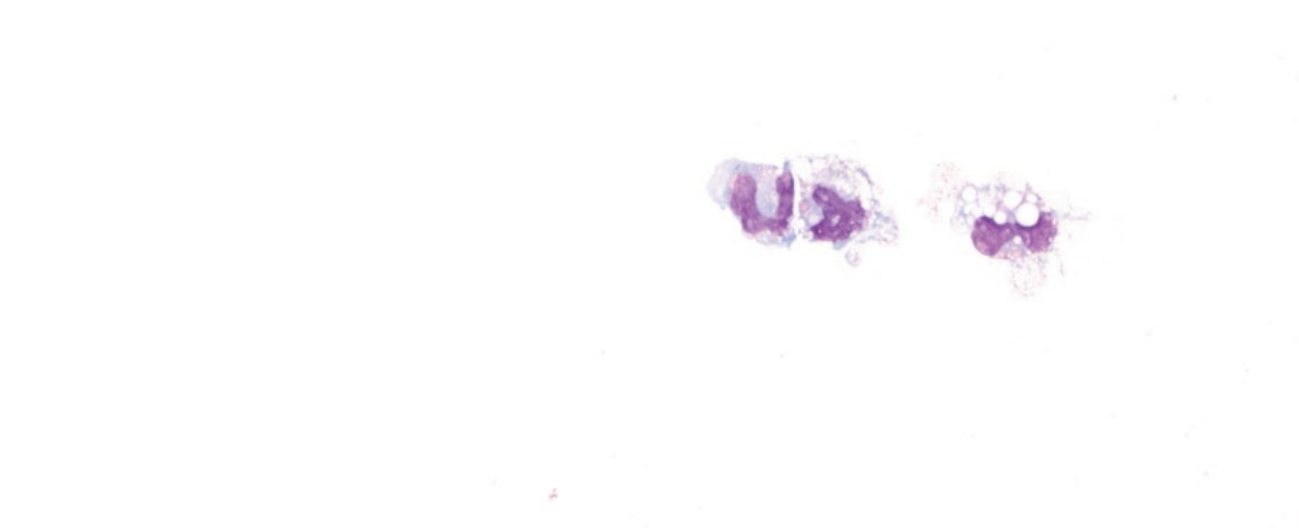Variable, based on underlying cause.

13.2.9 Mononuclear Reactivity

13.2.9.1 Cytologic Appearance

Macrophages predominate in normal CSF. In cases of mononuclear reactivity, these cells are present in normal numbers, but have reactive changes including

Figure 13.26 Mononuclear reactivity, CSF, dog, 50× objective. Macrophages are reactive, but are seen in low/normal numbers.



an increased volume of vacuolated cytoplasm (most common), or increased cytoplasmic basophilia (Figure 13.26).

13.2.9.2 Clinical Considerations

- Reactive macrophages are not associated with blood contamination of samples and are useful indicators of pathology [40].
- Non-specific but important marker of underlying disease. Can be seen secondary to inflammation, seizure activity, non-exfoliating neoplasia, vascular disease, necrosis, etc.

13.2.9.3 Prognosis

Variable, based on underlying cause.

13.2.10 Mixed Inflammation

13.2.10.1 Cytologic Appearance

Frequently, a mixture of inflammatory cells is present, without any obvious predominance of type (Figure 13.27). Combinations of increased lymphocytes, neutrophils, macrophages, and eosinophils are seen. Cell and protein concentrations usually are also increased.

13.2.10.2 Clinical Considerations

- DDx = granulomatous meningoencephalitis (GME), steroid-responsive meningitis-arteritis, intervertebral disc disease, ischemia, non-exfoliating neoplasia, etc.

13.2.10.3 Prognosis

Variable, based on underlying cause.

13.2.11 Hemorrhage

13.2.11.1 Cytologic Appearance

Erythrocytes should not be present in normal CSF. Pathologic hemorrhage may be acute or chronic. Chronic hemorrhage is confirmed with the presence of either erythrophagia or heme-breakdown pigments (e.g., hemosiderin) in macrophages (Figure 13.28). Acute hemorrhage may be pathologic or iatrogenic at the time of sampling, and is difficult to differentiate via cytology. Reactive changes in macrophages and lymphocytes are not associated with blood contamination, and may be helpful markers [40].

13.2.11.2 Clinical Considerations

- CSF grossly may appear yellow (xanthochromic).
- DDx = trauma (including intervertebral disc disease), degenerative conditions, inflammation, neoplasia.
- Blood contamination results in increased percentages of neutrophils and eosinophils, and an increased protein concentration [40].

13.2.11.3 Prognosis

Variable, based on underlying cause.

SPECIFIC DISEASES ASSOCIATED WITH CSF

13.2.12 Granulomatous Meningoencephalitis (GME)

13.2.12.1 Cytologic Appearance

GME is characterized by a variably mixed population of leukocytes, but most often is dominated by lymphocytes. Small mature lymphocytes are admixed with lesser

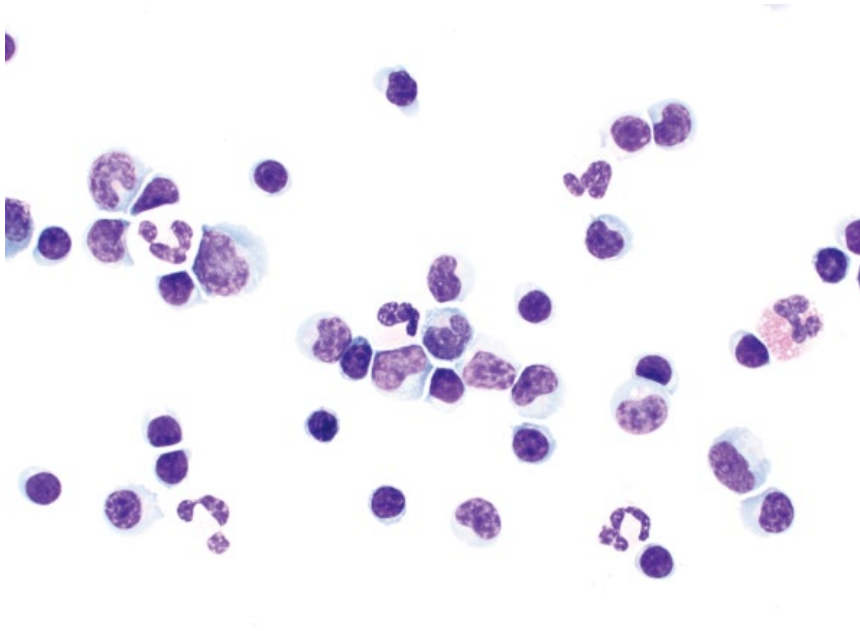


Figure 13.27 Mixed inflammation, CSF, dog, 50× objective. Note the mixture of inflammatory cells including macrophages, small mature lymphocytes, neutrophils, and an eosinophil.

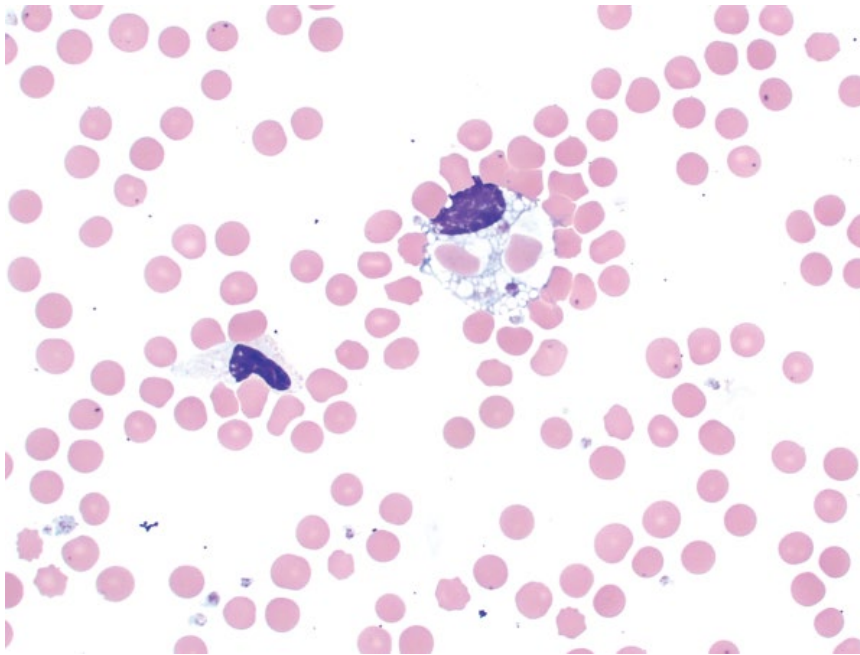


Figure 13.28 Hemorrhage, CSF, dog, 50× objective. Phagocytosed red blood cells are seen within a reactive macrophage. Note the neutrophil to the lower left.

numbers of intermediate-sized or reactive lymphocytes, and a variable number of non-degenerative neutrophils, macrophages, and even rare eosinophils (Figure 13.29).

13.2.12.2 Clinical Considerations

- Most common in toy and terrier breed dogs [36].
- Clinical signs = cranial nerve deficits, visual disturbances, seizures, and ataxia.
- DDx = necrotizing meningoencephalitis, necrotizing encephalitis.

13.2.12.3 Prognosis

Guarded to poor [36].

13.2.13 Feline Infectious Peritonitis

13.2.13.1 Cytologic Appearance

Feline infectious peritonitis (FIP) often manifests with changes in CSF. The fluid frequently has a very high protein concentration, associated with a medium to thick purple background. Reactive macrophages usually predominate; however, neutrophils may also predominate,

Figure 13.29 Granulomatous meningoencephalitis, CSF, dog, 50× objective.

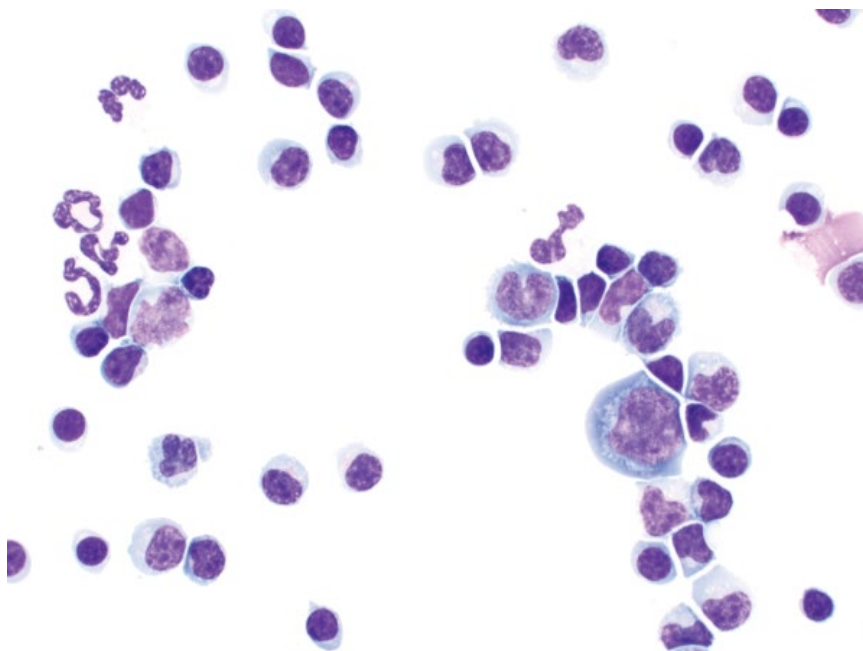
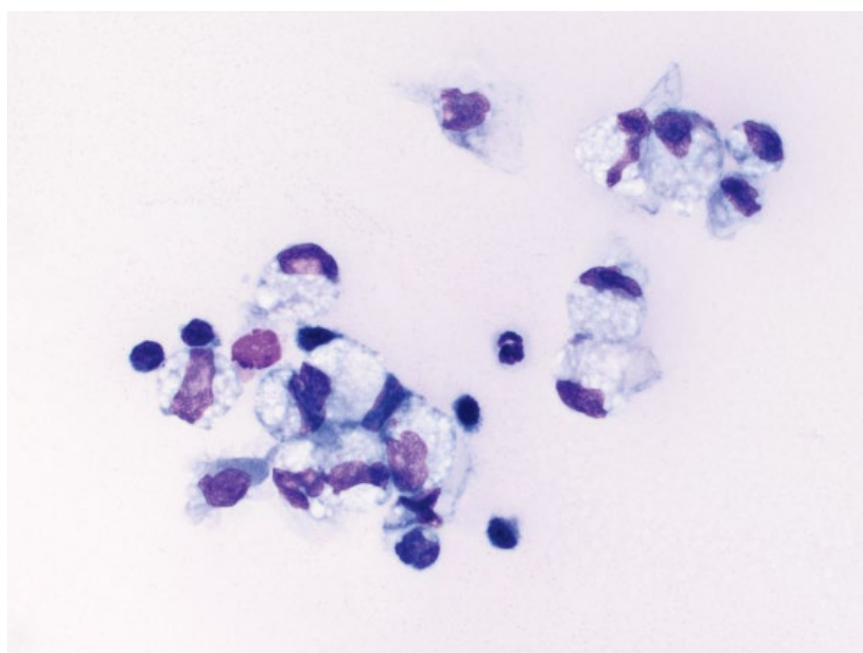


Figure 13.30 Feline infectious peritonitis (FIP), CSF, cat, 50× objective. Note the thick proteinaceous background; the protein concentration was 3212 mg dl⁻¹.



and small mature lymphocytes often are present (Figure 13.30).

13.2.13.2 Clinical Considerations

- Common cause of neurologic signs in young cats [41].
- Normal CSF analysis does not rule out underlying FIP [42].

13.2.13.3 Prognosis

Grave.

13.2.14 Septic Meningitis

13.2.14.1 Cytologic Appearance

Septic meningitis is associated with large numbers of inflammatory cells, the type of which often suggests the underlying organism. Bacterial meningitis is associated with neutrophilic inflammation, and bacteria often are present within degenerative neutrophils (see Figure 13.22). Fungal, protozoal, and algal infections are mostly associated with eosinophilic inflammation (Figure 13.31).

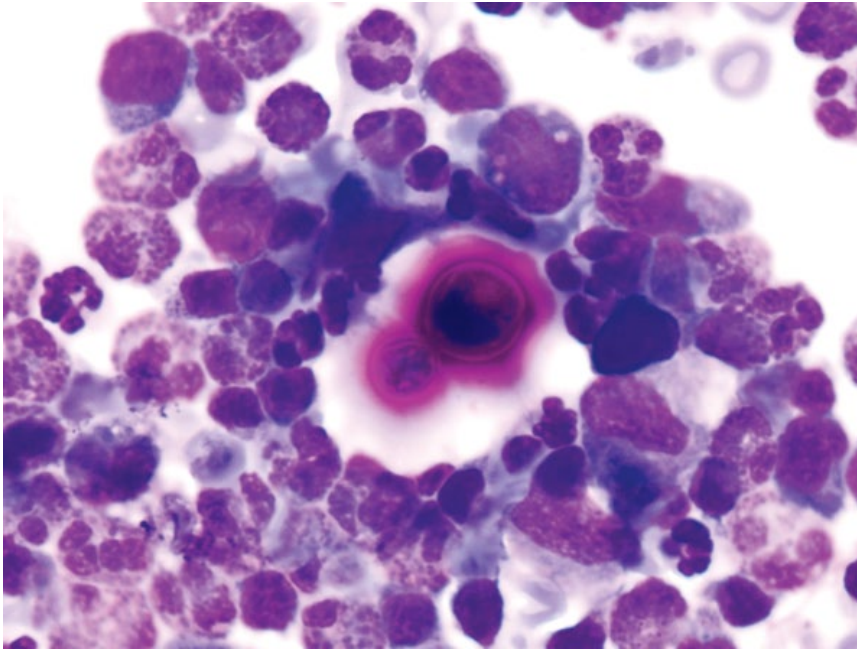


Figure 13.31 Septic meningitis (*Cryptococcus*), CSF, dog, 100× objective.

13.2.14.2 Clinical Considerations

- Clinical signs = cranial nerve deficits, mentation changes, conscious proprioception deficits, seizures [29].
- May result from hematogenous spread, extension from the middle/inner ear, or direct inoculation.

13.2.14.3 Prognosis

Variable, based on the stage and severity of disease, as well as the etiological agent. Fungal and protozoal agents tend to confer a worse prognosis than bacteria [29, 43].

NEOPLASIA AND THE CSF

13.2.15 Lymphoma

13.2.15.1 Cytologic Appearance

Lymphoma in the CSF exfoliates as discrete round cells that are large, with nuclei approximately two to three red blood cells in diameter. The nuclei may be round, indented, or have irregular borders. Chromatin is finely granular, nucleoli are prominent, and mitotic figures are common (Figure 13.32).

13.2.15.2 Clinical Considerations

- Dogs and cats.
- May be restricted to CNS or extension of generalized disease.
- Neoplastic cells do not always exfoliate into CSF, and absence does not rule out lymphoma [4].

13.2.15.3 Prognosis

Generally poor. Response rates to therapy are moderate to low, and survival times are short [4, 12, 13].

13.2.16 Histiocytic Sarcoma

13.2.16.1 Cytologic Appearance

Similar to other locations, histiocytic sarcoma cells are large and have marked atypia. Nuclei vary from ovoid to amoeboid, and multinucleation is common, as are mitotic figures. Anisocytosis/anisokaryosis are marked, and N/C ratios are variable. Importantly, histiocytic sarcoma frequently is accompanied by a mixed inflammatory response (Figure 13.33). Immunocytochemical stains may be required for definitive diagnosis (Figure 13.34).

13.2.16.2 Clinical Considerations

- Dogs >> cats.
- Often associated with concurrent inflammation, and neoplastic cells may not be seen [16].

13.2.16.3 Prognosis

Grave [16].

13.2.17 Choroid Plexus Carcinoma

13.2.17.1 Cytologic Appearance

Choroid plexus carcinomas may be seen in CSF as cohesive sheets (often in palisading rows) (Figure 13.35), or as

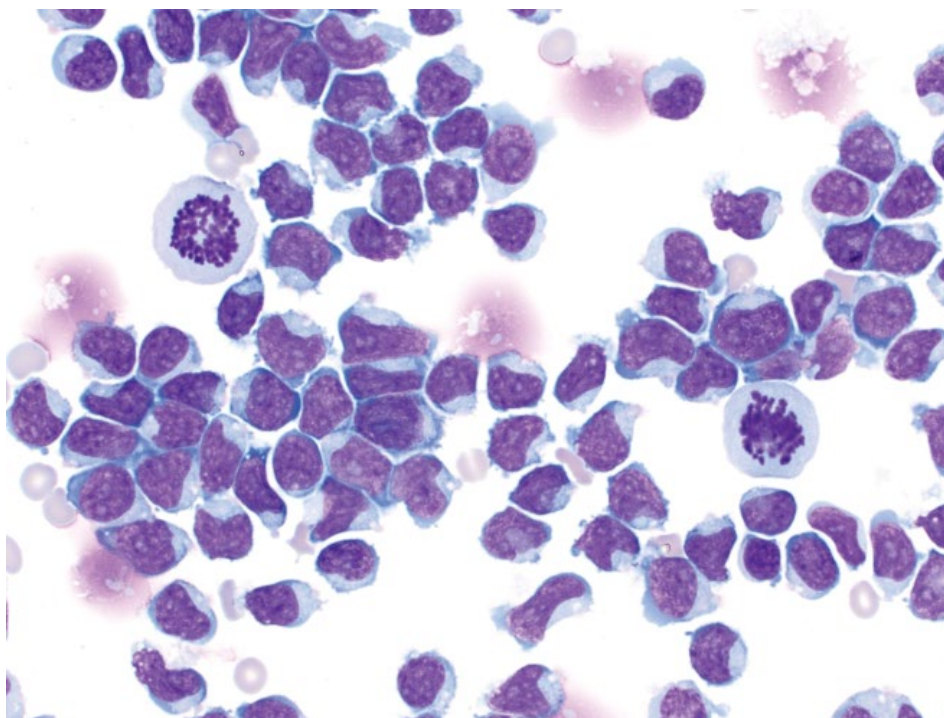


Figure 13.32 Lymphoma, CSF, dog, 50× objective.

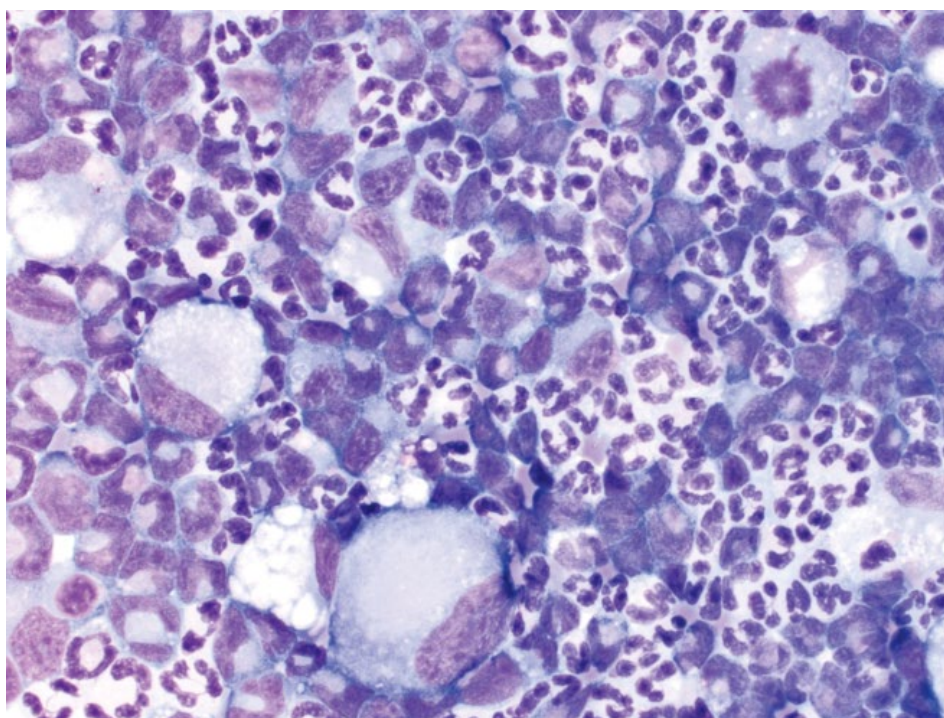


Figure 13.33 Histiocytic sarcoma, CSF, dog, 50× objective.

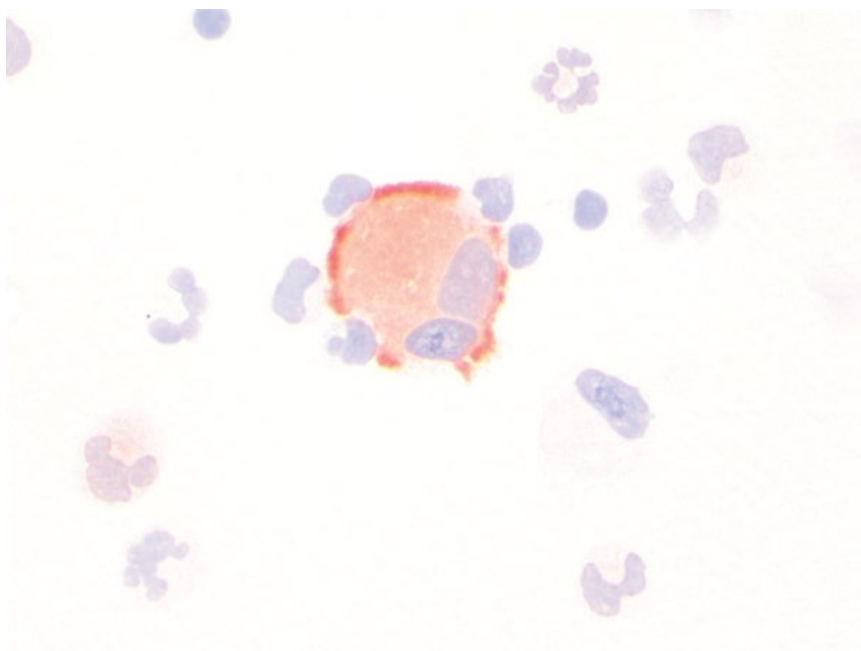


Figure 13.34 Histiocytic sarcoma, CSF, dog, CD1c stain, 50x objective. Same case as Figure 13.33.

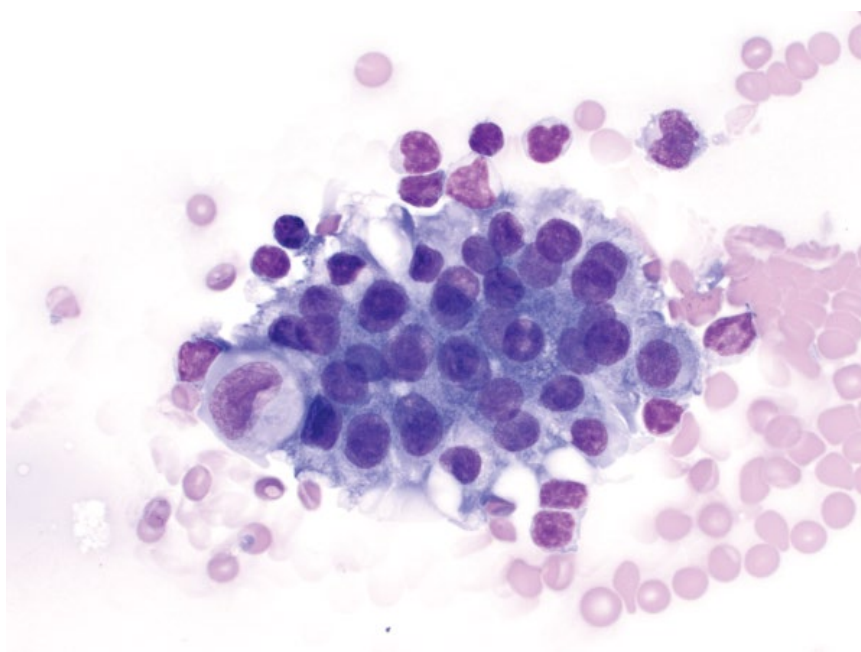


Figure 13.35 Choroid plexus carcinoma, dog, 50x objective.

individualized cells that are round, with a moderate volume of mid-blue cytoplasm, and round, eccentrically placed nuclei with granular chromatin and prominent nucleoli (Figure 13.36).

13.2.17.2 Clinical Considerations

- Choroid plexus carcinomas have higher CSF protein concentrations than papillomas. In one study, only carcinomas had protein $>80 \text{ mg dl}^{-1}$ [17].

Figure 13.36 Choroid plexus carcinoma, dog, 100× objective.

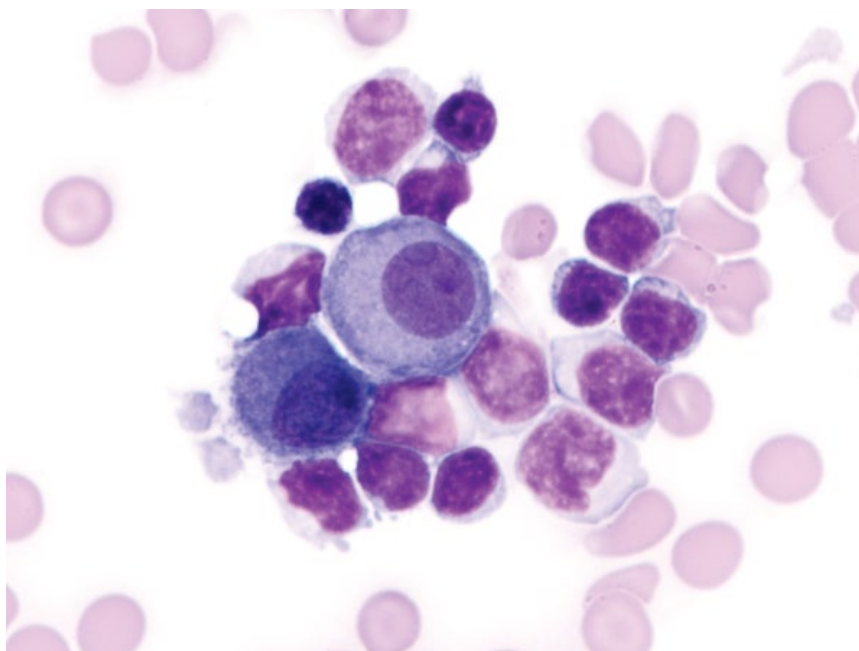
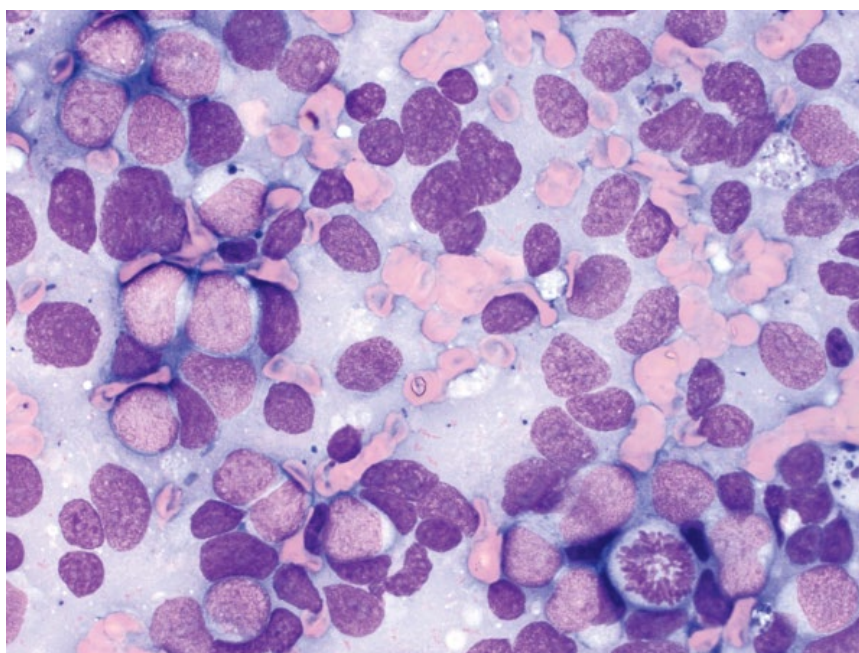


Figure 13.37 Nephroblastoma, spinal cord, dog, 50× objective.



13.2.17.3 Prognosis

Limited data are available, but the prognosis generally is poor [7, 18].

13.3 Spinal Cord

13.3.1 Spinal Cord Nephroblastoma

13.3.1.1 Cytologic Description

Similar to those in the kidney (see Chapter 9), spinal cord nephroblastomas exfoliate well, often as individualized

cells, and rarely in sheets (Figure 13.37). The cells are round, with ovoid to amoeboid nuclei and finely stippled chromatin. Nucleoli, when visible, are single. Many mitotic figures are seen. The cells have a small volume of pale-blue cytoplasm. These tumors can be difficult to differentiate from lymphoma (compare to Figures 13.9 and 13.32).

13.3.1.2 Clinical Considerations

- Rare tumors of young dogs (typically aged <4 years, but may be as young as 5 months) [44].

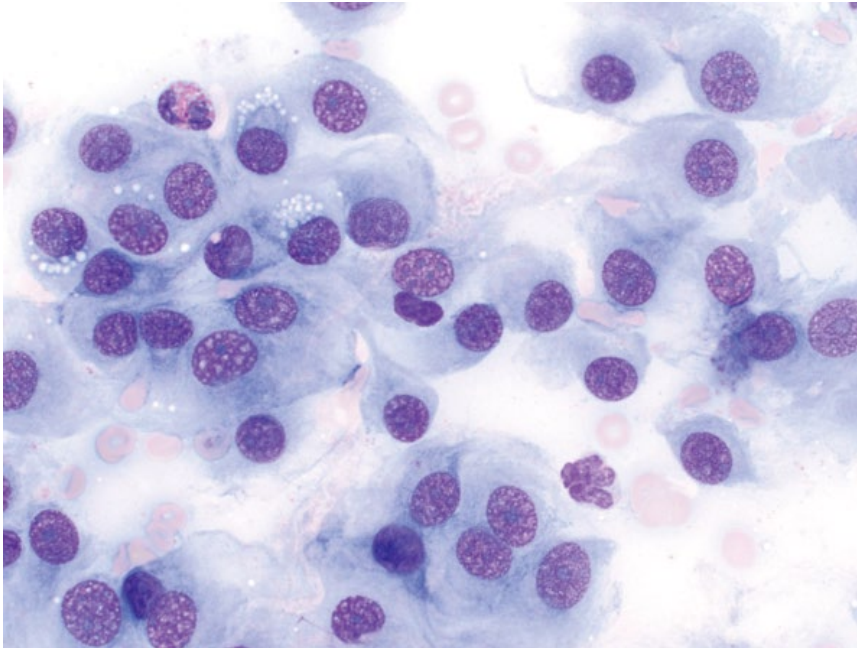


Figure 13.38 Nerve sheath tumor, spinal cord, dog, 50x objective.

- Breed predilection = Labrador Retrievers, Golden Retrievers and German Shepherds [44, 45].
- Progressive gait abnormalities most common clinical sign.
- Most common in the distal thoracic to early lumbar segments [44, 45].

13.3.1.3 Prognosis

Grave. Short survival times generally, even in patients undergoing surgery ± radiation therapy [45].

13.3.2 Nerve Sheath Tumor

13.3.2.1 Cytologic Appearance

These samples are variably exfoliative, with cells seen individually and in aggregates that may be associated with a bright-pink extracellular matrix. The cells are spindloid and plump, with a moderate volume of medium-blue cytoplasm that forms tendrils and wisps, and may contain clear vacuoles (Figure 13.38). Nuclei are ovoid, with coarsely granular chromatin and prominent nucleoli. Anisocytosis/

anisokaryosis are mild to moderate, and N/C ratios are moderate to high. These tumors can be difficult to differentiate from meningiomas; however, the presence of long delicate cytoplasmic wisps is more suggestive of nerve sheath tumors (compare to Figures 13.1 and 13.2).

13.3.2.2 Clinical Considerations

- This category includes schwannomas, neurofibromas, and neurofibrosarcomas.
- May be benign or malignant – histopathology required to assess malignancy.

13.3.2.3 Prognosis

Guarded to poor. Dogs with tumors close to the nerve root have short survival times [46].

13.3.3 Other Neoplasms

Other neoplasms that can affect the spinal cord include meningioma, ependymoma, and lymphoma, which are described earlier in this chapter.

References

- 1 Vernau, K.M., Higgins, R.J., Bollen, A.W., *et al.* (2001) Primary canine and feline nervous system tumors: intraoperative diagnosis using the smear technique. *Vet. Pathol.*, **38** (1), 47–57.
- 2 Harms, N.J., Dickinson, R.M., Nibblett, B.M., *et al.* (2009) What is your diagnosis: Intracranial mass in a dog. *Vet. Clin. Pathol.*, **38** (4), 537–540.
- 3 Snyder, J.M., Shofer, F.S., Van Winkle, T.J., *et al.* (2006) Canine intracranial primary neoplasia: 173 cases (1986–2003). *J. Vet. Intern. Med.*, **20** (3), 669–675.
- 4 Troxel, M.T., Vite, C.H., Van Winkle, T.J., *et al.* (2003) Feline intracranial neoplasia: retrospective review of 160 cases (1985–2001). *J. Vet. Intern. Med.*, **17** (6), 850–859.

- 5 Montoliu, P., Añor, S., Vidal, E., *et al.* (2006) Histological and immunohistochemical study of 30 cases of canine meningioma. *J. Comp. Pathol.*, **135** (4), 200–207.
- 6 Motta, L., Mandara, M.T., Skerriitt, G.C. (2012) Canine and feline intracranial meningiomas: an updated review. *Vet. J.*, **192** (2), 153–165.
- 7 Heidner, G.L., Kornegay, J.N., Page, R.L., *et al.* (1991) Analysis of survival in a retrospective study of 86 dogs with brain tumors. *J. Vet. Intern. Med.*, **5** (4), 219–226.
- 8 Kube, S.A., Bruyette, D.S., Hanson, S.M. (2003) Astrocytomas in young dogs. *J. Am. Anim. Hosp. Assoc.*, **39** (3), 288–293.
- 9 Rissi, D.R., Levine, J.M., Eden, K.B., *et al.* (2015) Cerebral oligodendroglioma mimicking intraventricular neoplasia in three dogs. *J. Vet. Diagn. Invest.*, **27** (3), 396–400.
- 10 Dickinson, P.J., Keel, M.K., Higgins, R.J., *et al.* (2000) Clinical and pathologic features of oligodendrogliomas in two cats. *Vet. Pathol.*, **37** (2), 160–167.
- 11 Tamura, M., Hasegawa, D., Uchida, K., *et al.* (2013) Feline anaplastic oligodendroglioma: long-term remission through radiation therapy and chemotherapy. *J. Feline Med. Surg.*, **15** (12), 1137–1140.
- 12 Taylor, S.S., Goodfellow, M.R., Browne, W.J., *et al.* (2009) Feline extranodal lymphoma: response to chemotherapy and survival in 110 cats. *J. Small Anim. Pract.*, **50** (11), 584–592.
- 13 Couto, C.G., Cullen, J., Pedroia, V., *et al.* (1984) Central nervous system lymphosarcoma in the dog. *J. Am. Vet. Med. Assoc.*, **184** (7), 809–813.
- 14 Thompson, C.A., Russell, K.E., Levine, J.M., *et al.* (2003) Cerebrospinal fluid from a dog with neurologic collapse. *Vet. Clin. Pathol.*, **32** (3), 143–146.
- 15 Steinberg, H., Galbreath, E.J. (1998) Cerebellar medulloblastoma with multiple differentiation in a dog. *Vet. Pathol.*, **35** (6), 543–546.
- 16 Mariani, C.L., Jennings, M.K., Olby, N.J., *et al.* (2015) Histiocytic sarcoma with central nervous system involvement in dogs: 19 cases (2006–2012). *J. Vet. Intern. Med.*, **29** (2), 607–613.
- 17 Westworth, D.R., Dickinson, P.J., Vernau, W., *et al.* (2008) Choroid plexus tumors in 56 dogs (1985–2007). *J. Vet. Intern. Med.*, **22** (5), 1157–1165.
- 18 Zaki, F.A., Nafe, L.A. (1980) Choroid plexus tumors in the dog. *J. Am. Vet. Med. Assoc.*, **176** (4), 328–330.
- 19 Itoh, T., Uchida, K., Nishi, A., *et al.* (2016) Choroid plexus papilloma in a dog surviving for 15 months after diagnosis with symptomatic therapy. *J. Vet. Med. Sci.*, **78** (1), 167–169.
- 20 Vural, S.A., Besalti, O., Ilhan, F., *et al.* (2006) Ventricular ependymoma in a German Shepherd dog. *Vet. J.*, **172** (1), 185–187.
- 21 Traslavina, R.P., Kent, M.S., Mohr, F.C., *et al.* (2013) Clear cell ependymoma in a dog. *J. Comp. Pathol.*, **149** (1), 53–56.
- 22 Ueno, H., Morimoto, M., Kobayashi, Y., *et al.* (2006) Surgical and radiotherapy treatment of a spinal cord ependymoma in a dog. *Aust. Vet. J.*, **84** (1-2), 36–39.
- 23 De Lorenzi, D., Mandara, M.T., Tranquillo, M., *et al.* (2006) Squash-prep cytology in the diagnosis of canine and feline nervous system lesions: a study of 42 cases. *Vet. Clin. Pathol.*, **35** (2), 208–214.
- 24 Koblik, P.D., LeCouteur, R.A., Higgins, R.J., *et al.* (1999) CT-guided brain biopsy using a modified Pelorus Mark III stereotactic system: experience with 50 dogs. *Vet. Radiol. Ultrasound*, **40** (5), 434–440.
- 25 Di Terlizzi, R., Platt, S. (2006) The function, composition and analysis of cerebrospinal fluid in companion animals: part I – function and composition. *Vet. J.*, **172** (3), 422–431.
- 26 Zabolotzky, S.M., Vernau, K.M., Kass, P.H., *et al.* (2010) Prevalence and significance of myelin-like material in canine cerebrospinal fluid. *Vet. Clin. Pathol.*, **39** (1), 90–95.
- 27 Fallin, C.W., Raskin, R.E., Harvey, J.W. (1996) Cytologic identification of neural tissue in the cerebrospinal fluid of two dogs. *Vet. Clin. Pathol.*, **25** (4), 127–129.
- 28 Wessmann, A., Volk, H.A., Chandler, K., *et al.* (2010) Significance of surface epithelial cells in canine cerebrospinal fluid and relationship to central nervous system disease. *Vet. Clin. Pathol.*, **39** (3), 358–364.
- 29 Radaelli, S.T., Platt, S.R. (2002) Bacterial meningoencephalomyelitis in dogs: a retrospective study of 23 cases (1990–1999). *J. Vet. Intern. Med.*, **16** (2), 159–163.
- 30 Lowrie, M., Penderis, J., McLaughlin, M., *et al.* (2009) Steroid responsive meningitis-arteritis: a prospective study of potential disease markers, prednisolone treatment, and long-term outcome in 20 dogs (2006–2008). *J. Vet. Intern. Med.*, **23** (4), 862–870.
- 31 De Risio, L., Adams, V., Dennis, R., *et al.* (2008) Association of clinical and magnetic resonance imaging findings with outcome in dogs suspected to have ischemic myelopathy: 50 cases (2000–2006). *J. Am. Vet. Med. Assoc.*, **233** (1), 129–135.
- 32 Kuberski, T. (1981) Eosinophils in cerebrospinal fluid: criteria for eosinophilic meningitis. *Hawaii Med. J.*, **40** (4), 97–98.
- 33 Windsor, R.C., Sturges, B.K., Vernau, K.M., *et al.* (2009) Cerebrospinal fluid eosinophilia in dogs. *J. Vet. Intern. Med.*, **23** (2), 275–281.
- 34 Duncan, C., Stephen, C., Campbell, J. (2006) Clinical characteristics and predictors of mortality for *Cryptococcus gattii* infection in dogs and cats of southwestern British Columbia. *Can. Vet. J.*, **47** (10), 993–998.
- 35 Windsor, R.C., Vernau, K.M., Sturges, B.K., *et al.* (2008) Lumbar cerebrospinal fluid in dogs with type I

- intervertebral disc herniation. *J. Vet. Intern. Med.*, **22** (4), 954–960.
- 36 Granger, N., Smith, P.M., Jeffery, N.D. (2010) Clinical findings and treatment of non-infectious meningoencephalomyelitis in dogs: a systematic review of 457 published cases from 1962 to 2008. *Vet. J.*, **184** (3), 290–297.
 - 37 Levine, J.M., Fosgate, G.T., Porter, B., *et al.* (2008) Epidemiology of necrotizing meningoencephalitis in Pug dogs. *J. Vet. Intern. Med.*, **22** (4), 961–968.
 - 38 Amude, A.M., Alfieri, A.A., Alfieri, A.F. (2007) Clinicopathological findings in dogs with distemper encephalomyelitis presented without characteristic signs of disease. *Res. Vet. Sci.*, **82** (3), 416–422.
 - 39 Johnsrude, J.D., Alleman, A.R., Schumacher, J., *et al.* (1996) Cytologic findings in cerebrospinal fluid from two animals with GM2-gangliosidosis. *Vet. Clin. Pathol.*, **25** (3), 80–83.
 - 40 Doyle, C., Solano-Gallego, L. (2009) Cytologic interpretation of canine cerebrospinal fluid samples with low total nucleated cell concentration, with and without blood contamination. *Vet. Clin. Pathol.*, **38** (3), 392–396.
 - 41 Bradshaw, J.M., Pearson, G.R., Gruffydd-Jones, T.J. (2004) A retrospective study of 286 cases of neurological disorders of the cat. *J. Comp. Pathol.*, **131** (2-3), 112–120.
 - 42 Boettcher, I.C., Steinberg, T., Matiassek, K., *et al.* (2007) Use of anti-coronavirus antibody testing of cerebrospinal fluid for diagnosis of feline infectious peritonitis involving the central nervous system in cats. *J. Am. Vet. Med. Assoc.*, **230** (2), 199–205.
 - 43 Griffin, J.F., Levine, J.M., Levine, G.J., *et al.* (2008) Meningomyelitis in dogs: a retrospective review of 28 cases (1999–2007). *J. Small Anim. Pract.*, **49** (10), 509–517.
 - 44 Brewer, D.M., Cerda-Gonzalez, S., Dewey, C.W., *et al.* (2011) Spinal cord neuroblastoma in dogs: 11 cases (1985–2007). *J. Am. Vet. Med. Assoc.*, **238** (5), 618–624.
 - 45 Liebel, F.X., Rossmeisl, J.H., Jr, Lanz, O.I., *et al.* (2011) Canine spinal neuroblastoma: long-term outcomes associated with treatment of 10 cases (1996–2009). *Vet. Surg.*, **40** (2), 244–252.
 - 46 Brehm, D.M., Vite, C.H., Steinberg, H.S., *et al.* (1995) A retrospective evaluation of 51 cases of peripheral nerve sheath tumors in the dog. *J. Am. Anim. Hosp. Assoc.*, **31** (4), 349–359.

14

Ocular and Special Senses

14.1 Eyes: Cornea

14.1.1 Normal Epithelium

Normal corneal epithelium from scrapings of the cornea comprises mostly intermediate squamous epithelial cells. These cells are polygonal, with abundant pale-blue cytoplasm that may contain a small amount of melanin pigment. The nuclei are round, centrally located, and have clumped chromatin with small or inapparent nucleoli. Anisocytosis/anisokaryosis are mild, and N/C ratios are low (Figure 14.1). Lesser numbers of basal squamous epithelial cells may be seen with deep scrapings.

14.1.2 Epithelial Hyperplasia/Dysplasia

14.1.2.1 Cytologic Appearance

Relative to normal corneal epithelium, hyperplastic or dysplastic epithelial cells generally have higher N/C ratios and deeper-blue cytoplasm. The nuclei often are larger, and have stippled chromatin and more prominent nucleoli. Anisocytosis/anisokaryosis are variable, ranging from mild to moderate (Figure 14.2).

14.1.2.2 Clinical Considerations

- Frequently accompany cases of chronic irritation/inflammation.

14.1.2.3 Prognosis

Good – hyperplastic changes will resolve with treatment of the underlying cause.

14.1.3 Squamous Cell Carcinoma

14.1.3.1 Cytologic Appearance

Squamous cell carcinomas of the cornea and conjunctiva mostly have marked criteria of malignancy. Cells have a variable volume of cytoplasm that frequently has a bright, sky-blue/hyalinized appearance consistent with keratinization. This is accompanied by large, immature nuclei that have prominent nucleoli (Figure 14.3). Anisocytosis/anisokaryosis are marked, and N/C ratios

are high. These features can overlap with dysplastic changes (see section 14.1.2), and histopathology is required for definitive diagnosis.

14.1.3.2 Clinical Considerations

- Rare on the cornea, more common arising from conjunctiva.
- Brachycephalic dogs predisposed [1].

14.1.3.3 Prognosis

Good with appropriate therapy. Metastatic potential is low [1].

14.1.4 Bacterial Keratitis

14.1.4.1 Cytologic Appearance

Bacterial keratitis generally is characterized by a neutrophilic infiltrate of variably degenerative neutrophils, with intracellular bacteria confirming bacterial sepsis (Figure 14.4). Bacteria may be present in the background only, or may be absent in cytologic samples. Often accompanied by epithelial hyperplasia.

14.1.4.2 Clinical Considerations

- Dogs > cats [2].
- Usually associated with concurrent ulceration (ulcerative keratitis).
- Common bacteria = *Staphylococcus*, *Streptococcus*, and *Pseudomonas* spp.
- Microbial culture and susceptibility testing is recommended to increase successful diagnosis [3].

14.1.4.3 Prognosis

Generally good with appropriate, early therapy, but variable based on severity of disease.

14.1.5 Fungal Keratitis

14.1.5.1 Cytologic Appearance

Fungal hyphae often are seen in dense mats, and close investigation of thick areas of corneal scrapes is warranted. Fungal hyphae have parallel sides, internal structure and

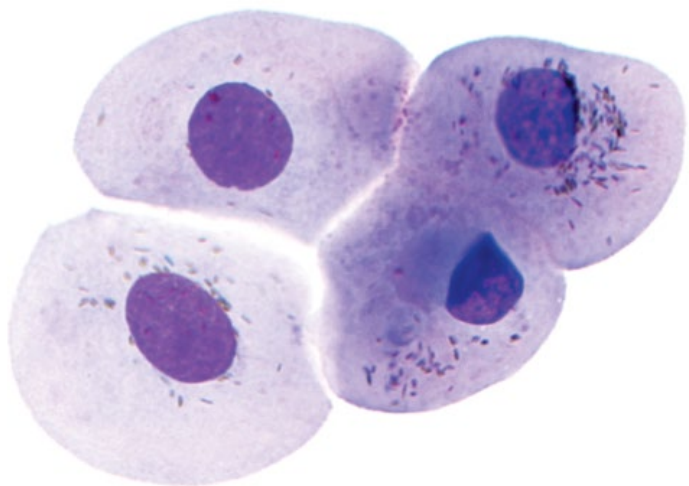


Figure 14.1 Normal corneal epithelium, dog, 100× objective. These cells contain a fine dusting of melanin pigment granules.

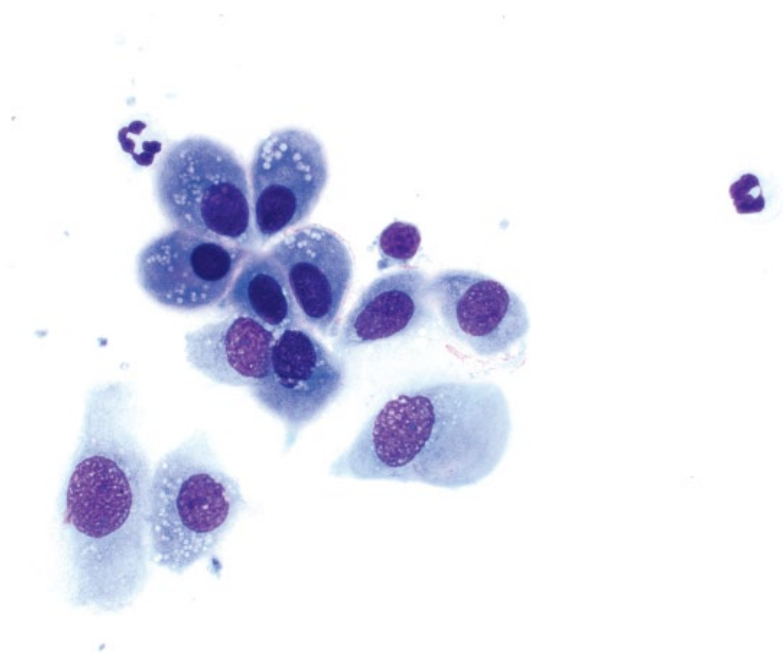


Figure 14.2 Corneal epithelial hyperplasia, dog, 50× objective. The cells have higher N/C ratios and more basophilic cytoplasm. Note the neutrophils in the background.

may be septated or branching (Figure 14.5). Inflammatory cells and epithelial hyperplasia are variably present.

14.1.5.2 Clinical Considerations

- *Aspergillus* spp. most common. *Candida* and *Fusarium* spp. also common [4].
- Predisposing factors = corneal trauma, prolonged use of antibiotics or corticosteroids, endocrinopathies [5].

14.1.5.3 Prognosis

Variable, based on severity of disease and underlying cause. Enucleation is sometimes necessary [5].

14.1.6 Eosinophilic Keratitis

14.1.6.1 Cytologic Appearance

Eosinophilic keratitis, or keratoconjunctivitis, is characterized by increased eosinophils, and numerous eosinophil

Figure 14.3 Corneal squamous cell carcinoma, dog, 50× objective. The cells have sky-blue, keratinized cytoplasm with immature nuclei. Criteria of malignancy are marked.

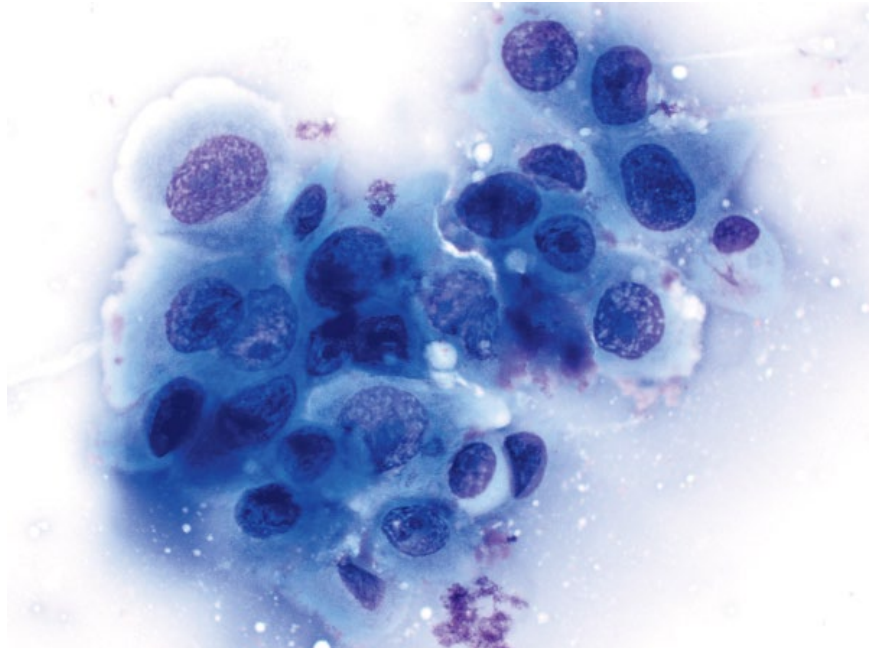
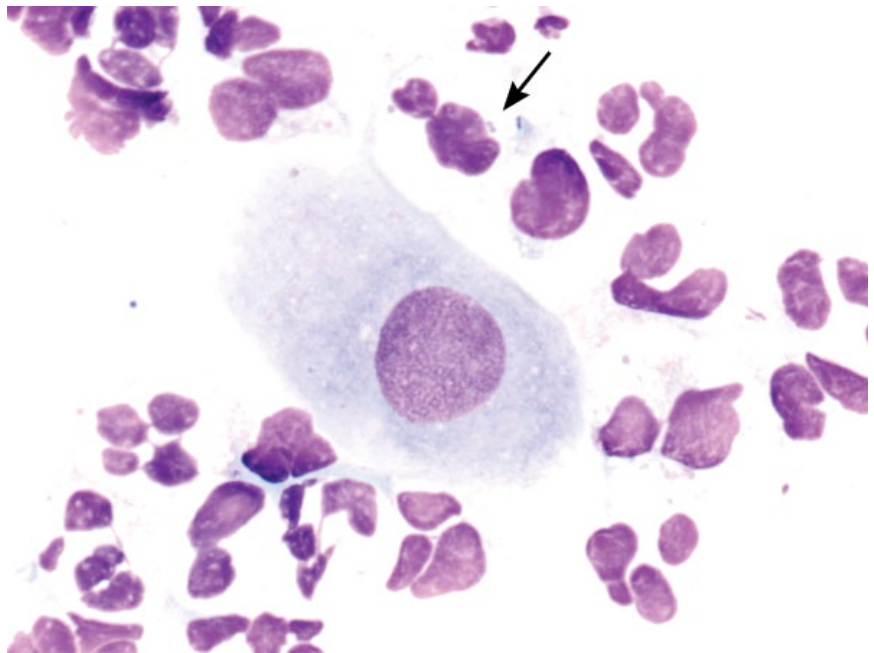


Figure 14.4 Bacterial keratitis, dog, 100× objective. Note the degenerative neutrophils that contain intracellular rod-shaped bacteria (arrow).



granules may be present in the background (Figure 14.6). Low numbers of other inflammatory cells, especially small mature lymphocytes, may be present.

14.1.6.2 Clinical Considerations

- Cats.
- Unilateral > bilateral [6].
- Grossly = pink/white infiltration with gritty, yellow material and most commonly affects the superotemporal quadrant [6–8].
- Often associated with Feline Herpes Virus 1 [6, 7].

14.1.6.3 Prognosis

Good with appropriate therapy, but recurrence is common [8].

14.1.7 Pigmentary Keratitis

14.1.7.1 Cytologic Appearance

In pigmentary keratitis, excessive melanin pigment accumulates within corneal epithelial cells. The melanin pigment is green/black and varies from fine elongated granules to coarse clumps (Figure 14.7).

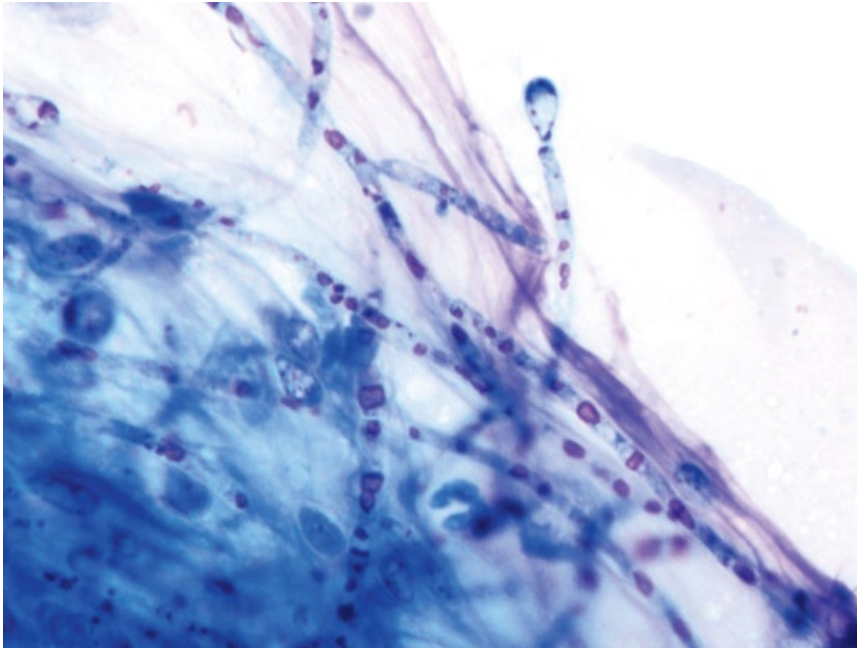


Figure 14.5 Fungal keratitis, dog, 100× objective. Fungal hyphae are seen in a large mat.

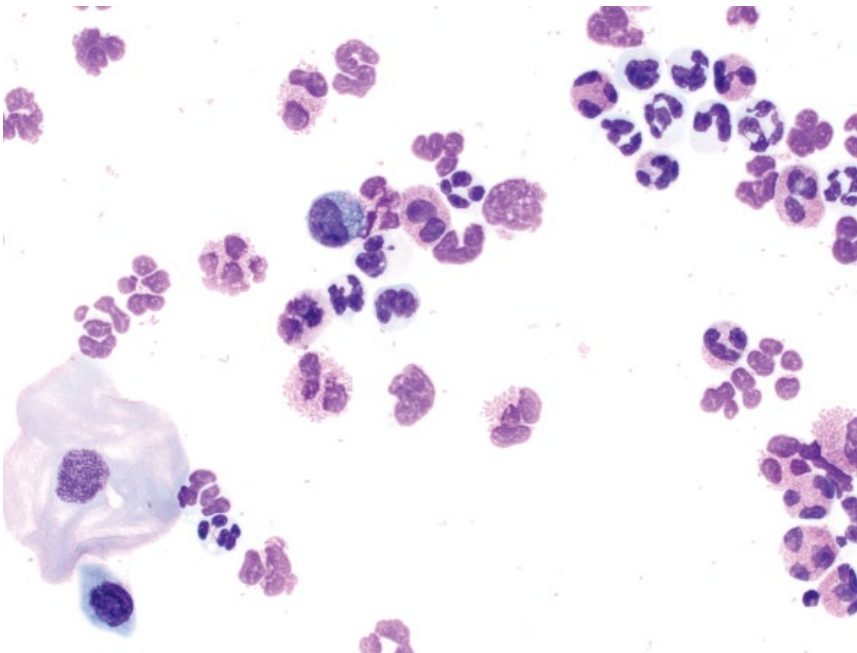


Figure 14.6 Eosinophilic keratitis, cat, 50× objective. A corneal epithelial cell is seen at the lower left.

14.1.7.2 Clinical Considerations

- Most common secondary to irritating stimuli (e.g., entropion, distichiasis, keratoconjunctivitis sicca, or chronic inflammation) [9].
- Common in Pugs, with or without predisposing stimuli [9].

14.1.7.3 Prognosis

Variable, based on the underlying cause.

14.2 Eyes: Conjunctiva

14.2.1 Inflammation

14.2.1.1 Cytologic Appearance

Conjunctivitis is most commonly neutrophilic in dogs and cats, but other inflammatory cells may be seen. Bacteria may be identified within neutrophils, or associated with epithelial cells such as *Chlamydia* (Figure 14.8) or *Mycoplasma* (Figure 14.9).

Figure 14.7 Pigmentary keratitis, dog, 50× objective. Abundant melanin pigment is noted, often in aggregates, associated with corneal epithelial cells. Three neutrophils are seen, and many coccoid bacteria are noted in the background.

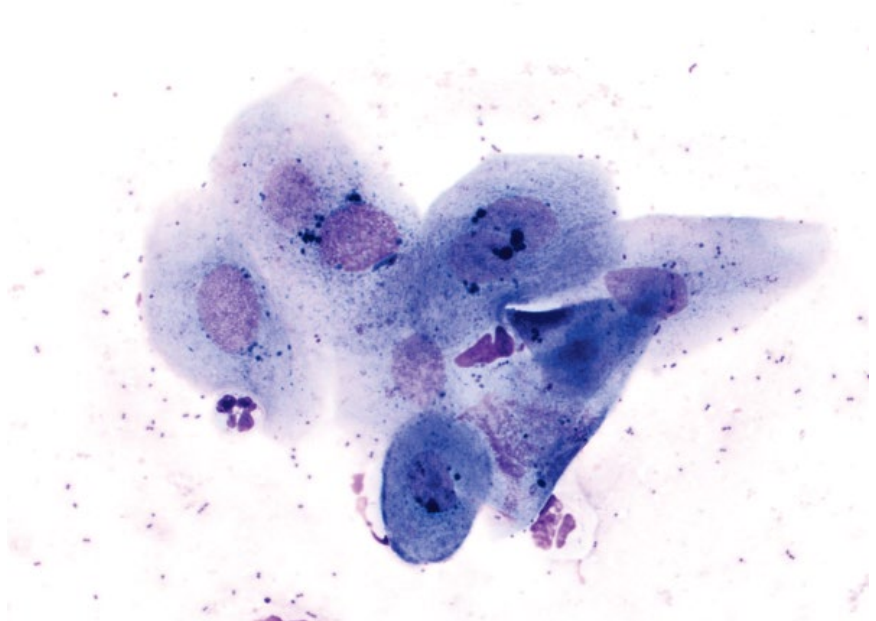
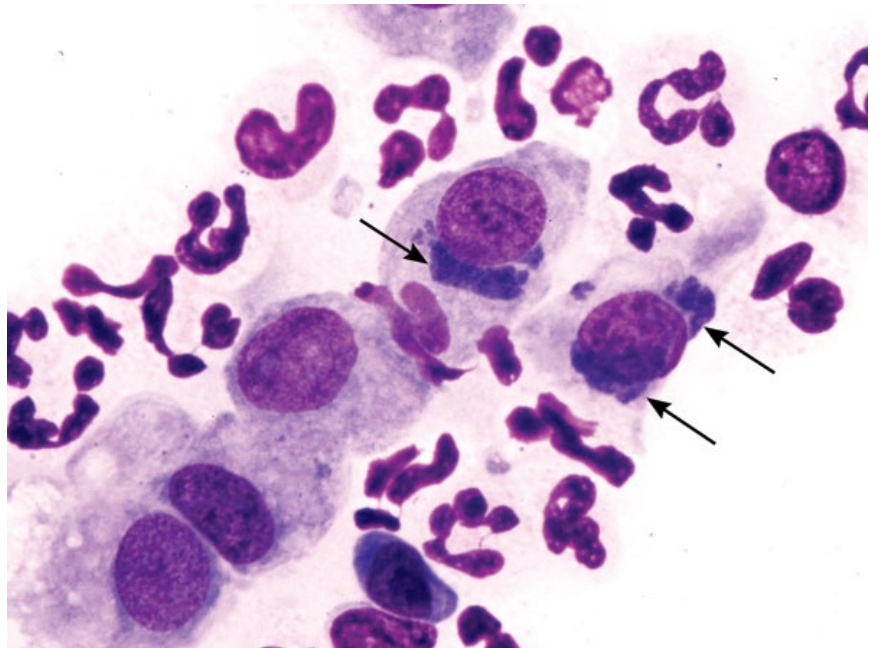


Figure 14.8 *Chlamydia felis* elementary bodies, conjunctiva, cat, 100× objective. Note the basophilic, perinuclear inclusions (arrows). Photo courtesy of Dr Bill Vernau.



14.2.1.2 Clinical Considerations

- May be primary or secondary, and sterile or infectious.
- DDx: (dogs) = viral (*Distemper*), bacterial, keratoconjunctivitis sicca, neoplasia, immune-mediated; (cats) = viral (herpesvirus), bacterial (*Mycoplasma*, *Chlamydia*), neoplasia [10].

14.2.1.3 Prognosis

Generally good, but variable based on underlying cause.

14.2.2 Neoplasia

Numerous neoplasms affect the conjunctiva, including squamous cell carcinoma (see section 14.1.3), melanoma,

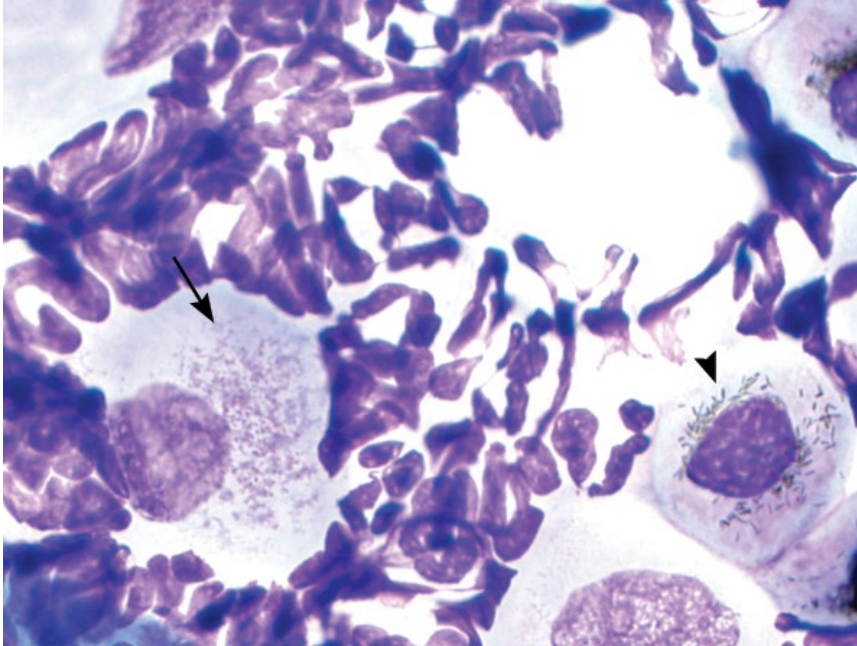


Figure 14.9 *Mycoplasma felis*, conjunctiva, cat, 100× objective. Fine, basophilic organisms are scattered over the surface of a squamous epithelial cell (arrow). Compare them to the melanin pigment in the cells on the right (arrowhead).

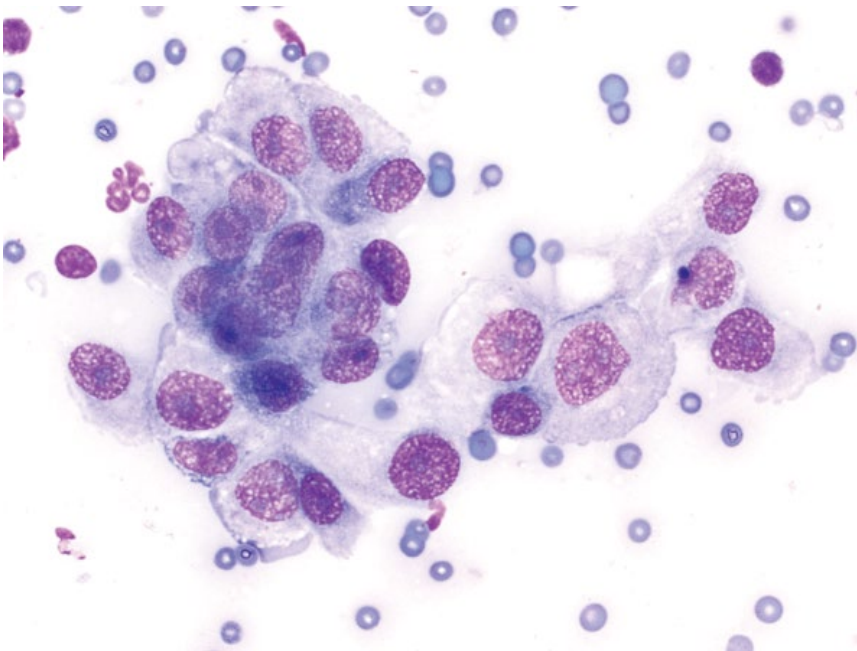


Figure 14.10 Ceruminous gland adenoma, dog, 50× objective.

mast cell tumor, papilloma (see Chapter 3) and lymphoma (see Chapter 4).

14.3 Ears

14.3.1 Ceruminous Gland Adenoma

14.3.1.1 Cytologic Features

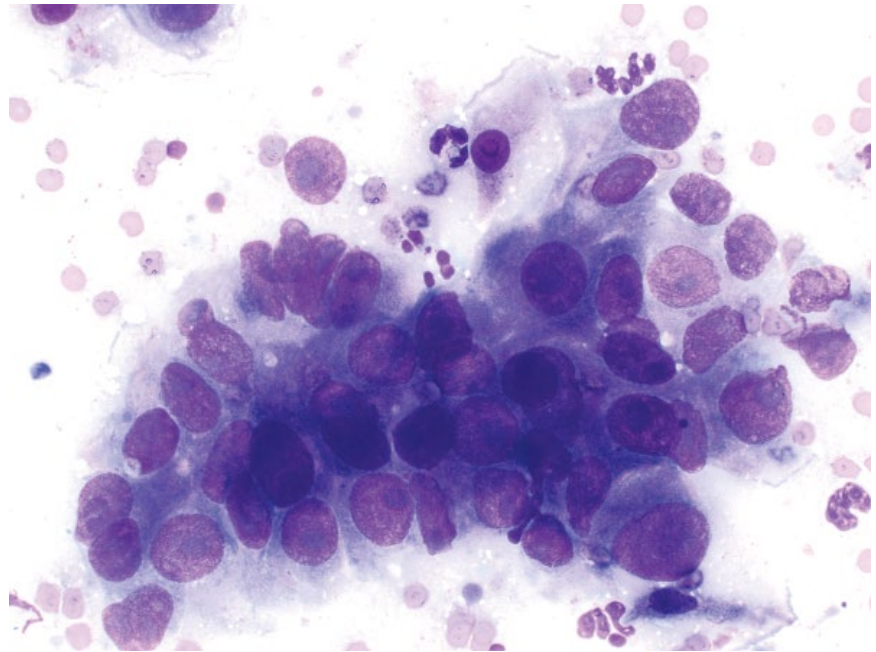
Ceruminous adenomas exfoliate in cohesive sheets of relatively uniform ovoid cells with pale-blue cytoplasm that may contain clear secretory material. Nuclei are

round, with granular chromatin and small basophilic nucleoli. Anisocytosis/anisokaryosis are mild, and N/C ratios are moderate to low (Figure 14.10). Cytologically similar to ceruminous cystic hyperplasia.

14.3.1.2 Clinical Considerations

- Typically exophytic, smooth, pedunculated masses that rarely ulcerate.
- Seen in older dogs (9 years) but cats typically younger than those with adenocarcinomas [11].
- Cocker Spaniels and Poodles appear predisposed.

Figure 14.11 Ceruminous gland adenocarcinoma, dog, 50× objective.



14.3.1.3 Prognosis

Excellent. Surgical excision is curative.

14.3.2 Ceruminous Gland Adenocarcinoma

14.3.2.1 Cytologic Features

These tumors comprise crowded sheets of ovoid to polygonal cells, often distributed in papillary or vague acinar arrangements. They have a variable volume of medium-blue cytoplasm that may be distended with clear secretory material. Nuclei are ovoid with finely stippled chromatin and prominent basophilic nucleoli. Anisocytosis/anisokaryosis are marked, and N/C ratios are moderate to high (Figure 14.11).

14.3.2.2 Clinical Considerations

- Most common malignant tumor of the ear canal in dogs and cats [11].
- Low metastatic rate, though metastatic potential increases over time. Tumors are locally aggressive and invasive [12].

14.3.2.3 Prognosis

Variable. Long-term survival is possible with appropriate local therapy. Metastatic disease confers a poor prognosis [11].

14.3.3 Otitis Externa (Bacterial)

14.3.3.1 Cytologic Features

Large numbers of bacteria are seen individually and as colonies in the background of the slide (Figures 14.12 and 14.13). Inflammatory cells are not always present, but sepsis is confirmed if intracellular bacteria are seen.

Note: Low numbers of bacteria can be normal. In general, mean bacteria counts of ≥ 25 in dogs and ≥ 15 in cats per 40× objective field are considered abnormal [13].

14.3.3.2 Clinical Considerations

- Dogs > cats.
- Bilateral > unilateral.
- Most common bacteria = *Staphylococcus pseudintermedius/intermedius* and *Pseudomonas aeruginosa* [14].
- Clinical signs = pruritus, head-shaking, otic erythema/discharge, malodor, pain.
- Underlying predisposing factors (e.g., ear anatomy, moisture) and primary causes (e.g., allergic dermatitis, parasites, foreign bodies, etc.) should be investigated [15].
- Heat-fixing slides does not improve sample quality for cytologic analysis [16].

14.3.3.3 Prognosis

Generally excellent, but may be complicated by underlying predisposing causes, and recurrence is common [17].

14.3.4 Otitis Externa (Fungal)

14.3.4.1 Cytologic Features

Otitis externa due to fungal agents (otomycosis) is most commonly associated with *Malassezia* spp. These are ovoid to bilobed organisms that stain intensely basophilic and may have a fine clear halo (Figure 14.14). *Note:* *Malassezia* may be seen normally in ears in low numbers. In general, mean *Malassezia* counts of ≥ 5 in dogs and ≥ 12 in cats per 40× objective field are considered abnormal [13]. Inflammatory cells are seen rarely.

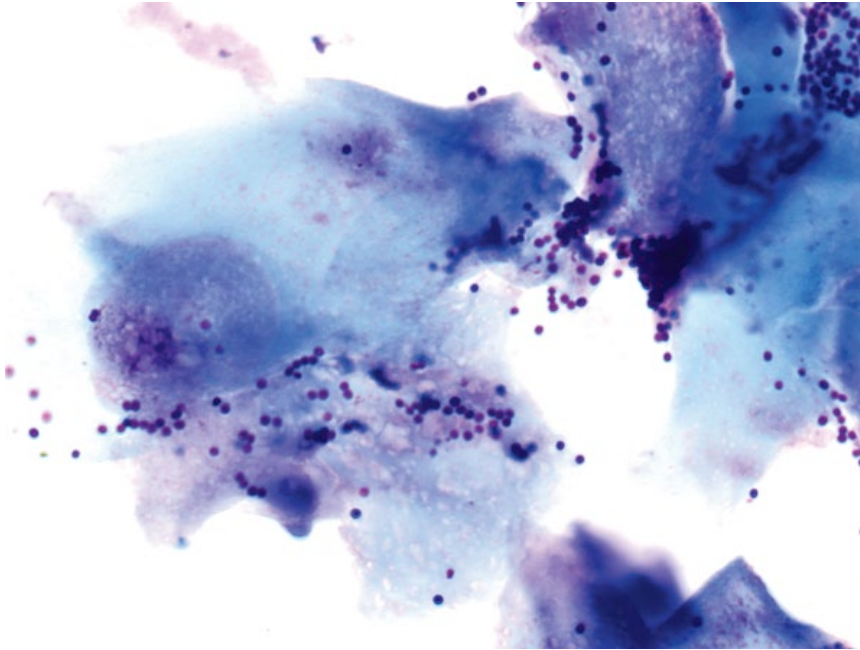


Figure 14.12 Bacterial otitis externa, dog, 100× objective. Colonies of bacterial cocci are noted, associated with squamous epithelial cells.

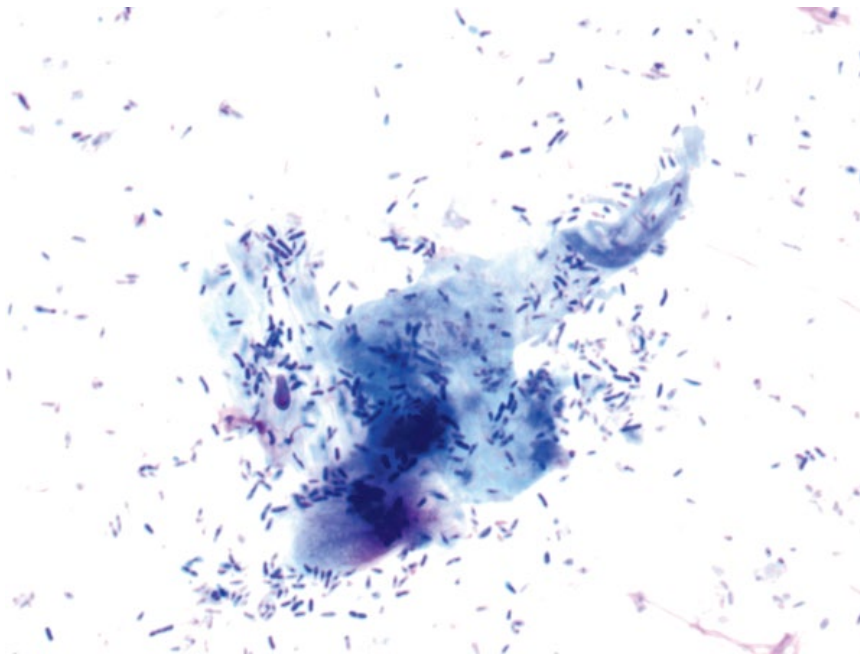


Figure 14.13 Bacterial otitis externa, dog, 100× objective. Colonies of bacterial rods are noted, associated with squamous epithelial cells.

14.3.4.2 Clinical Considerations

- Dogs > cats.
- Bilateral > unilateral.
- Underlying predisposing factors (e.g., ear anatomy, moisture) and primary causes (e.g., allergic dermatitis, parasites, foreign bodies, etc.) should be investigated [15].
- Most commonly due to *Malassezia pachydermatis*. Rarely associated with other fungal agents such as *Candida* and *Aspergillus* spp. [18].
- Heat-fixing slides does not improve sample quality for cytologic analysis [16, 19].

14.3.4.3 Prognosis

Generally excellent, but may be complicated by underlying predisposing causes, and recurrence is common [17].

14.3.5 Otitis Externa (Parasitic)

14.3.5.1 Cytologic Appearance

Otodectes cynotis is the most common cause of parasitic otitis externa. They have two anterior and two posterior pairs of legs (see Figure 2.45). Sometimes, only eggs of mites will be present, which are ovoid and ~200 μm long

Figure 14.14 Mixed fungal and bacterial otitis externa, dog, 50× objective. Numerous bilobed *Malassezia* organisms are seen, as well as bacteria.

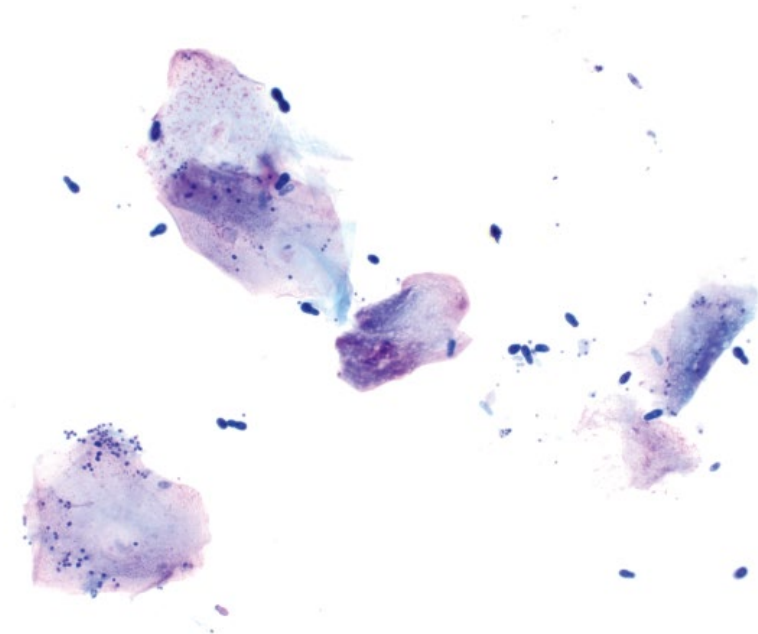
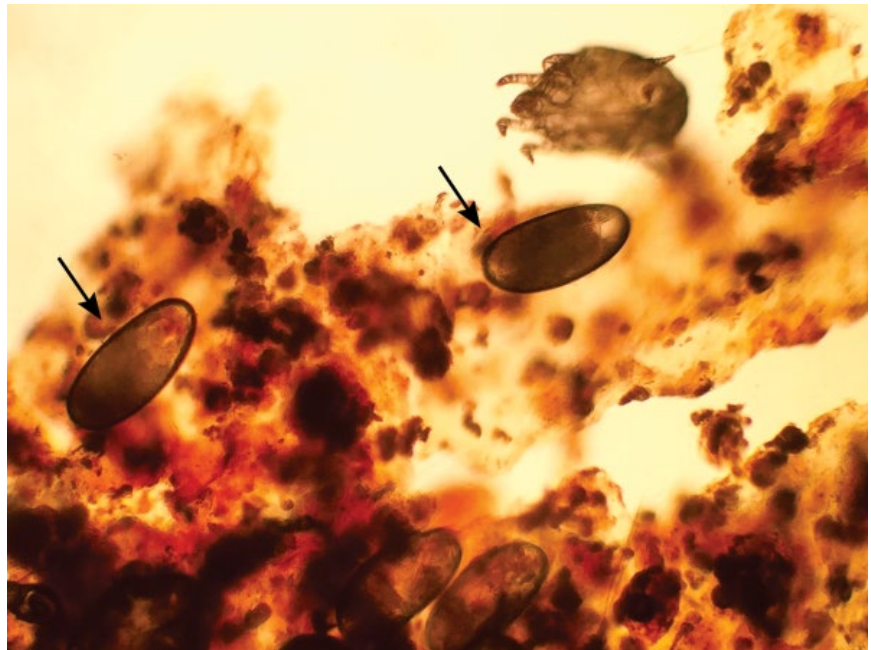


Figure 14.15 *Otodectes cynotis*, dog, 10× objective. Note the large elongated eggs (arrows). Photo courtesy of Dr Eric Franson.



(Figure 14.15). *Demodex* spp. and other mites are less common (Figure 14.16).

14.3.5.2 Clinical Considerations

- Common primary causes of otitis externa [15].
- Often associated with black, granular discharge.

- Clinical signs = head-shaking, ear scratching, ear droop.
- May be accompanied by neutrophilic inflammation and ceruminous discharge.

14.3.5.3 Prognosis

Excellent.

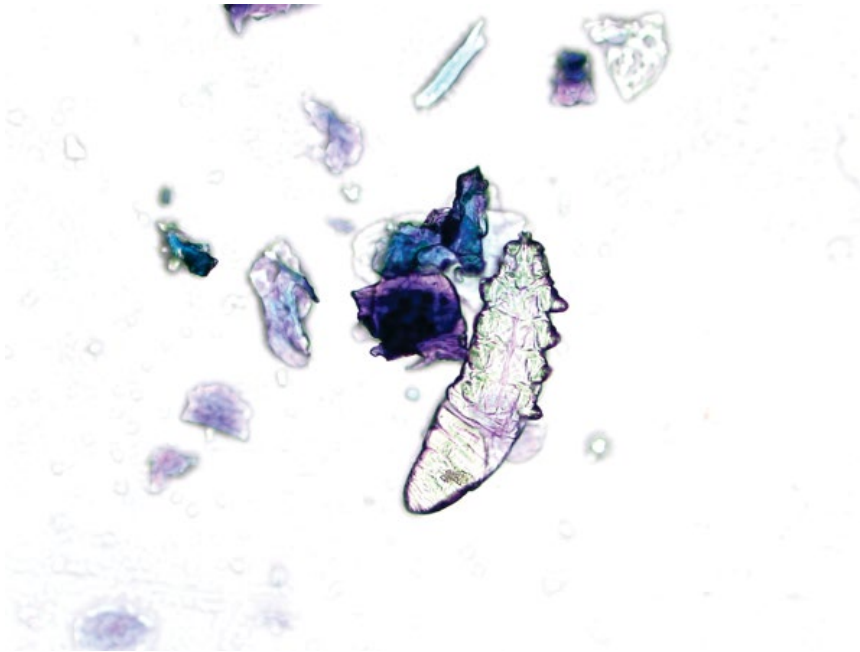


Figure 14.16 *Demodex* nymph, dog, 20× objective.

References

- 1 Dreyfus, J., Schobert, C.S., Dubielzig, R.R. (2011) Superficial corneal squamous cell carcinoma occurring in dogs with chronic keratitis. *Vet. Ophthalmol.*, **14** (3), 161–168.
- 2 Ollivier, F.J. (2003) Bacterial corneal diseases in dogs and cats. *Clin. Tech. Small Anim. Pract.*, **18** (3), 193–198.
- 3 Massa, K.L., Murphy, C.J., Hartmann, F.A., *et al.* (1999) Usefulness of aerobic microbial culture and cytologic evaluation of corneal specimens in the diagnosis of infectious ulcerative keratitis in animals. *J. Am. Vet. Med. Assoc.*, **215** (11), 1671–1674.
- 4 Andrew, S.E. (2003) Corneal fungal disease in small animals. *Clin. Tech. Small Anim. Pract.*, **18** (3), 186–192.
- 5 Scott, E.M., Carter, R.T. (2014) Canine keratomycosis in 11 dogs: a case series (2000–2011). *J. Am. Anim. Hosp. Assoc.*, **50** (2), 112–118.
- 6 Dean, E., Meunier, V. (2013) Feline eosinophilic keratoconjunctivitis: a retrospective study of 45 cases (56 eyes). *J. Feline Med. Surg.*, **15** (8), 661–666.
- 7 Nasisse, M.P., Glover, T.L., Moore, C.P., *et al.* (1998) Detection of feline herpesvirus 1 DNA in corneas of cats with eosinophilic keratitis or corneal sequestration. *Am. J. Vet. Res.*, **59** (7), 856–858.
- 8 Morgan, R.V., Abrams, K.L., Kern, T.J. (1996) Feline eosinophilic keratitis: a retrospective study of 54 cases (1989–1994). *Vet. Comp. Ophthalmol.*, **6** (2), 131–134.
- 9 Labelle, A.L., Dresser, C.B., Hamor, R.E., *et al.* (2013) Characteristics of, prevalence of, and risk factors for corneal pigmentation (pigmentary keratopathy) in Pugs. *J. Am. Vet. Med. Assoc.*, **243** (5), 667–674.
- 10 Peña, M.A., Leiva, M. (2008) Canine conjunctivitis and blepharitis. *Vet. Clin. North Am. Small Anim. Pract.*, **38** (2), 233–249.
- 11 London, C.A., Dubilzeig, R.R., Vail, D.M., *et al.* (1996) Evaluation of dogs and cats with tumors of the ear canal: 145 cases (1978–1992). *J. Am. Vet. Med. Assoc.*, **208** (9), 1413–1418.
- 12 Théon, A.P., Barthez, P.Y., Madewell, B.R., *et al.* (1994) Radiation therapy of ceruminous gland carcinomas in dogs and cats. *J. Am. Vet. Med. Assoc.*, **205** (4), 566–569.
- 13 Ginel, P.J., Lucena, R., Rodriguez, J.C., *et al.* (2002) A semiquantitative cytological evaluation of normal and pathological samples from the external ear canal of dogs and cats. *Vet. Dermatol.*, **13** (3), 151–156.
- 14 Oliveira, L.C., Leite, C.A., Brilhante, R.S., *et al.* (2008) Comparative study of the microbial profile from bilateral canine otitis externa. *Can. Vet. J.*, **49** (8), 785–788.
- 15 Rosser, E.J., Jr (2004) Causes of otitis externa. *Vet. Clin. North Am. Small Anim. Pract.*, **34** (2), 459–468.
- 16 Toma, S., Cornegiani, L., Persico, P., *et al.* (2006) Comparison of 4 fixation and staining methods for the

- cytologic evaluation of ear canals with clinical evidence of ceruminous otitis externa. *Vet. Clin. Pathol.*, **35** (2), 194–198.
- 17 Saridomichelakis, M.N., Farmaki, R., Leontides, L.S., *et al.* (2007) Aetiology of canine otitis externa: a retrospective study of 100 cases. *Vet. Dermatol.*, **18** (5), 341–347.
- 18 Goodale, E.C., Outerbridge, C.A., White, S.D. (2016) *Aspergillus* otitis in small animals – a retrospective study of 17 cases. *Vet. Dermatol.*, **27** (1), 3–8.
- 19 Griffin, J.S., Scott, D.W., Erb, H.N. (2007) *Malassezia* otitis externa in the dog: the effect of heat-fixing otic exudate for cytological analysis. *J. Vet. Med. A. Physiol. Pathol. Clin. Med.*, **54** (8), 424–427.

Index

A

Abdominal fluid *see* Body cavity fluids

Abscess

cutaneous 97, 98f

mammary gland 304

pancreatic 228–229, 228f

tooth root 174

Acantholytic cells, pemphigus foliaceus 101, 102f

Acid fast

Cryptosporidium spp. 48, 48f

Mycobacterium spp. 52

Nocardia spp. 53

Acral lick granuloma 97

Actinomyces spp. 52–54, 53f

Acute leukemia

erythroid 126, 127f, 134, 143f

granulocytic/monocytic 117f, 126f, 134, 141f–142f

lymph node infiltration 117, 117f

lymphoid 139, 144f

megakaryoblastic 134, 139, 143f

myeloid 117, 117f, 134

spleen 126, 126f–127f

Adenocarcinoma

adrenocortical 279, 281f

anal sac apocrine gland 83, 84f

ceruminous gland 347, 347f

intestinal 214, 215f

lung 259–260, 261f

mammary 301–302, 302f–305f

nasal 255, 257f

ovarian 299, 300f

pancreatic 224–226, 225f

parathyroid 276–277, 277f

perianal gland 23f, 83, 83f

renal 233, 236f

salivary 207, 209f

sweat gland 78, 78f

thyroid 274, 274f–275f

Adenoma

adrenocortical 279, 280f–281f

bile duct 202–203, 204f

ceruminous gland 346–347, 346f

intestinal 214, 214f

mammary 22f, 301, 302f–303f

ovarian 299, 300f

pancreatic 224, 224f

parathyroid 276, 277f

perianal gland 81–83, 82f

salivary 207, 208f

sebaceous 78, 79f

sweat gland 77–78, 77f

thyroid 273–274, 273f

Adipocytes *see* Lipoma

Adipose tissue, incidental 3, 10f

Adrenal gland 279–281

adenocarcinoma 279, 281f

adenoma 279, 280f–281f

extramedullary hematopoiesis 279, 281f

pheochromocytoma 279–280, 282f

Aelurostrongylus abstrusus 51, 51f

Algae 40–42

Alimentary tract *see* Intestines

Allergic disease

cutaneous 101, 101f, 347–348

respiratory 266, 267f

Amastigotes, in *Leishmania* 43, 44f, 148f

Amelanotic melanoma *see* Melanoma

Ammonium urate crystals *see* Urine, crystals

Amyloid

liver 202, 203f

spleen 130–131, 132f

Anal sac apocrine gland

adenocarcinoma 83, 84f

Anaphase 27, 29f

Anaplasma spp. 54, 55f, 177, 178f

Anaplastic mammary carcinoma 301, 305f

Anaplastic sarcoma with giant cells 25f, 91, 91f

Ancylostoma spp. 220, 221f

Anestrus, vaginal cytology 305–306, 310f

Anisocytosis 21, 22f

Anisokaryosis 21, 24f

Anisonucleosis 23

Antinuclear antibodies (ANA) 180

Aortic body tumor 278

Apocrine gland adenocarcinoma, anal sac 83, 84f

Apoptotic cells 3, 6, 7f, 17f

Arthritis

immune-mediated 177–178, 178f, 179f

osteoarthritis 176

septic 177, 177f

Arthrospores, *Dermatophyte* spp. 34, 36f

Artifacts

cell lysis 3, 7f

crystal formation 3, 5f

formalin 3, 9f

gel 3, 6f

glove powder/starch crystals 2, 4f

hemoglobin crystals 3, 8f

nuclear material 3, 6f

stain precipitation 3, 5f

Ascites *see* Body cavity fluids

Aspergillus spp. 40, 41f, 174, 342, 348

Astrocytoma 317, 320f

B

Bacteria

abscess 97, 98f

acid fast 48, 48f, 52–53

arthritis 177, 177f

bile 205, 205f

branching 53, 53f

cerebrospinal fluid 329f, 333–334

fecal flora 217–218, 218f

fluids 155–156, 156f, 161f

identification of 51–57, 53f–58f

osteomyelitis 174

otitis externa 347, 348f

pneumonia 266, 267f

prostatitis 296–297, 297f

rickettsial 54, 55f, 110–111, 111f, 177, 178f

spiral 55–57, 56f–57f, 217, 219

spore forming 54–55, 56f

vaginitis 313, 313f

Bactibilia 205, 205f
 Bare nuclei, artifact 3, 7f
 Barium, pneumonia 269, 269f
 Basal cell carcinoma 76–77, 77f
 Basal cells, vaginal cytology 304, 308f
 Basal cell tumor *see* Cutaneous basilar epithelial neoplasia
 Bence-Jones urine protein 127, 148, 174
 Benign mammary tumors 22f, 301, 302f–303f
 Benign neoplasia 21, 21f–22f
 Benign prostatic hyperplasia (BPH) 290, 294f
 Beta islet cell tumors *see* Insulinoma
 Bile duct adenoma 202–203, 204f
 Bile duct carcinoma 204–205, 204f
 Bile duct cystadenoma 202–203, 204f
 Bile peritonitis
 classic 159, 159f
 white bile 159, 160f
 Biliary epithelium 202, 203f
 Biliary hyperplasia 202, 203f
 Biliary tract 202–205
 Bilirubin
 concentration in body fluids 159
 crystals *see* Urine crystals
 pigment, hepatocytes 199–200, 200f
 Bladder 237–240
 hyperplasia 237, 240f
 papilloma/polyp 238–239, 241f
 transitional cell carcinoma 239–240, 241f
Blastomyces dermatitidis 35–36, 36f
 Body cavity fluids 155–167
 bile peritonitis 159, 159f–160f
 blood-to-fluid glucose difference 156
 cell concentration in 155
 cestodiasis 48–50, 49f–50f
 cholesterol-to-triglyceride ratio 160
 chylous effusion 159–160, 160f
 classification of 155–157
 exudate, eosinophilic 157, 158f
 exudate, high protein 157, 158f
 exudate, neutrophilic 156–157, 157f
 exudate, septic 155–156, 156f
 exudate, sterile 156–157, 157f
 feline infectious peritonitis 157
 fluid-to-serum creatinine ratio 161
 fluid-to-serum potassium ratio 161
 hemorrhagic 161, 162f
 histiocytic sarcoma 165–166, 167f
 lymphoma 164–165, 167f
 mesothelial hyperplasia 161–162, 162f–163f
 mesothelioma 22f–23f, 162–163, 164f–165f
 modified transudate 155

neoplastic 162–166, 164f–167f
 pericardial 155, 161, 165–166, 167f
 protein concentration in 155
 transudate 155, 156f
 triglyceride concentration in 159
 uroabdomen 160–161, 161f
 Bone 169–174
 chondrosarcoma 169, 171f
 fibrosarcoma 172, 173f
 hemangiosarcoma 170–172, 172f
 histiocytic sarcoma 172, 173f
 metastatic neoplasia 174–175f
 multilobular osteochondrosarcoma (MLO) 169–170, 171f
 multiple myeloma 172–174, 174f
 osteomyelitis 174, 175f
 osteosarcoma 19f, 26f–27f, 169, 170f
 Bone marrow 133–150
 acute leukemia 134, 139, 141f–144f
 aplasia 150
 chronic lymphocytic leukemia 147, 149f
 erythroid hyperplasia 142–143, 145f
 granulocytic/erythroid ratio (G/E ratio) 134
 granulocytic hyperplasia 141–142, 145f
 hemophagocytic histiocytic sarcoma 145–146, 146f
 hemophagocytosis 143–145, 146f
 histiocytic sarcoma 146–147, 147f
 hypoplasia 150, 151f
 inflammation/infection 147, 148f
 lymphoma 139, 144f
 metastatic disease 148–149, 150f–151f
 multiple myeloma 147–148, 149f
 normal 133–134, 135f–141f
Bordetella bronchiseptica 54, 54f, 266, 267f
 Bowel *see* Intestines
 Brain 317–325
 astrocytoma 317, 320f
 choroid plexus carcinoma 322–323, 324f
 choroid plexus papilloma 321–322, 323f
 encephalitis 324–325, 325f
 ependymoma 323–324, 324f
 histiocytic sarcoma 320–321, 323f
 lymphoma 318, 322f
 meningioma 317, 318f–319f
 neuroblastoma 319, 322f
 oligodendroglioma 317, 321f
 primitive neuroectodermal tumors (PNET) 319–320, 322f
 psammoma body, meningioma 317, 319f

Bronchoalveolar lavage (BAL) 263–270
 allergic disease 266
 bacteria 265–266, 265f, 267f
 curschmann's spirals 263, 265, 265f
 eosinophilic inflammation 266, 267f
 foreign material 269–270, 269f
 goblet cells 263, 264f
 granulomatous inflammation 266–267, 268f
 hemorrhage 268–269, 269f
 hyperplastic epithelium 263
 hypersensitivity 266
 infectious agents 266, 266f–267f
 lymphocytic inflammation 267–268, 268f
 macrophages 266–267, 266f, 268f–269f
 mucus 263, 265, 256f
 neoplasia 270, 270f
 neutrophilic inflammation 265–266, 265f
 normal epithelium 263, 264f
 oropharyngeal contamination 263, 264f
Brucella canis 288

C
 C cell carcinoma, thyroid 276, 276f
 Calcareous corpuscles 49, 50f
 Calcinosis circumscripta 98–99, 99f, 100f
 Calcinosis cutis 100
 Calcium oxalate crystals *see* Urine crystals
Campylobacter spp. 55–56, 56f
Candida spp. 38, 38f, 244f, 342
 Canine
 cutaneous mast cell neoplasia 19f, 63, 63f–65f
 histiocytoma 20f, 65–67, 67f
 lymphoma 112–114, 112f–113f
 sterile nodular panniculitis 95, 96f
 Cannibalism, cells in neoplasia 21, 23f, 162, 164f
Capillaria plica 244, 245f
 Capillaries 3, 9f–10f, 87f, 93f, 280f, 289f, 321f
 Carcinoid
 intestine 215–216, 216f
 liver 194, 195f
 Carcinoma *see also* Adenocarcinoma
 adrenal 279, 281f
 basal cell 76–77, 77f
 bile duct 204–205, 204f
 body cavity fluids 163–164, 165f–166f
 choroid plexus 322–323, 324f, 334, 336–337, 336f–337f

- clear cell adnexal 83–84, 84f
 hepatocellular 20f, 191–194, 193f–194f
 lung 259–260, 261f
 mammary 24f, 301–302, 303f–305f
 metastatic
 bone 174, 175f
 bone marrow 148–149, 150f–151f
 cutaneous 80, 81f
 liver 194, 195f–196f
 lung 270, 270f
 lymph node 117–118, 117f–120f
 spleen 129–130, 130f
 synovial fluid 180, 180f–181f
 parathyroid 276–277, 277f
 perianal gland 23f, 83, 83f
 pituitary 281–282, 282f
 prostatic 2f, 18f, 150f, 290, 294–295, 295f
 pulmonary 259–260, 261f
 renal 233, 235f–237f
 sebaceous 79–80, 80f
 squamous cell 80–81, 82f, 256–257, 258f, 261–262, 262f, 341, 343f
 thymic 133, 133f
 thyroid 274–276, 274f–275f
 thyroid C cell carcinoma 276, 276f
 transitional cell 24f, 239–240, 241f, 243f, 295, 296f
 Carcinoma *in situ* 214
 Carcinosarcoma, mammary gland 303
 Carotid body tumor 279, 278f–279f
 Casts, urinary *see* Urine casts
 Cell count
 body cavity fluids 155
 cerebrospinal fluid 325
 synovial fluid 175
 Cells, categorization 4–6
 Cellulitis *see* Panniculitis
 Central nervous system 317–338
 Cerebrospinal fluid (CSF)
 blood contamination of 331
 cell concentration 325
 choroid plexus carcinoma 334, 336–337, 336f–337f
 choroid plexus cells, incidental 325–326, 327f
 eosinophilic inflammation 327–328, 329f
 ependymal cells 325–326, 327f
 feline infectious peritonitis 332–333, 333f
 granulomatous
 meningoencephalitis 331–332, 333f
 hemorrhage 331, 332f
 histiocytic sarcoma 334, 335f
 infectious agents 329f, 333–334, 334f
 intervertebral disc material 325, 326f, 328f
 lymphocytic inflammation 328–329, 330f
 lymphoma 334, 335f
 meningitis-arteritis 327
 mononuclear inflammation 329–330, 330f
 mononuclear reactivity 330–331, 331f
 myelin-like material 325, 327f
 neoplasia 334–337
 neutrophilic inflammation 326–327, 328f
 normal 325, 326f
 protein concentration 325
 septic meningitis 329f, 333–334, 334f
 surface epithelial cells 325–326, 327f–328f
 xanthochromia 331
 Ceruminous gland
 adenocarcinoma 347, 347f
 Ceruminous gland adenoma 346–347, 346f
 Cestodiasis *see* Body cavity fluids
 Chemodectoma 277–279
 aortic body tumor 278
 carotid body tumor 278, 278f–279f
 Chemoreceptor tumors *see* Chemodectoma
Chlamydia spp, conjunctival 344–345, 345f
 Cholangiocarcinoma 204–205, 204f
 Cholangiohepatitis 197, 202, 205
 Cholangitis 198, 202
 Cholecystitis 205
 Cholestasis 199–200, 200f
 Cholesterol crystals 1, 1f, 74, 182f, 228f, 240f
 Cholesterol-to-triglyceride ratio *see* Body cavity fluids
 Chondroid 169, 171f, 307f
 Chondrosarcoma
 bone 169, 171f
 mammary gland 301
 nasal 257, 259, 259f
 Choroid plexus carcinoma
 brain 322–323, 324f
 cerebrospinal fluid 334, 336–337, 336f–337f
 Choroid plexus cells 325–326, 327f
 Choroid plexus papilloma 321–322, 323f
 Chronic lymphocytic leukemia
 bone marrow 147, 149f
 liver 195–196
 spleen 126, 127f
 Chylous effusion 159–160, 160f
 Ciliated epithelium, respiratory 263, 264f
 Clear cell adnexal carcinoma 83–84, 84f
Clostridium spp. 54–55, 56f
Coccidioides spp. 36–38, 37f
 Coccidiosis *see* *Cytoisospora* spp.
 Colitis 218–219, 219f
 Collagen, in keloidal fibromas 86, 87f
 Collagenolysis, in mast cell tumors 63, 63f
 Colloid, thyroid 273–274, 273f–274f
 Colon *see* Intestines
 Conjunctiva 344–346
 Chlamydia felis 344–345, 345f
 inflammation 344–345
 Mycoplasma felis 344–345, 346f
 neoplasia 345–346
 Copper pigment, in hepatocytes 201–202, 201f–202f
 Cornea 341–344
 bacterial keratitis 341, 343f
 eosinophilic keratitis 342–343, 344f
 fungal keratitis 341–342, 344f
 hyperplasia 341, 342f
 inflammation 342f
 normal epithelium 341, 342f
 pigmentary keratitis 343–344, 345f
 squamous cell carcinoma 341, 343f
 Corticosteroids, hepatopathy 189
 Cranial mediastinal mass
 chemodectoma 277–279
 lymphoma 133, 134f
 thymoma 131–132, 132f
 Creatinine, in body fluids 161
 Criteria of malignancy 21–27, 21f–27f
 Crown cells 87, 88f
Cryptococcus spp. 33, 34f, 334f
Cryptosporidium spp. 48, 48f
 Crystals
 ammonium urate 246–247, 248f
 background artifact 3, 5f
 barium 269, 269f
 calcium oxalate dihydrate 246, 246f
 calcium oxalate monohydrate 246, 247f
 cholesterol 1, 1f, 74, 182f, 228f, 240f
 cystine 247–248, 249f
 glove power 2, 4f
 hematoidin 1, 2f, 161–162, 162f, 164f, 208
 hemoglobin 3, 8f
 struvite 245–246, 245f
 uric acid 247, 248f–249f
 urinary 245–248
 CSF *see* Cerebrospinal fluid (CSF)

Curschmann's spirals 263, 265, 265f
 Cutaneous basilar epithelial neoplasia 74–75, 76f
 Cutaneous lymphoma 69–70, 69f
 Cutaneous metastatic carcinoma 80, 81f
Cynicomyces guttulatus 39–40, 40f, 218
 Cyst
 background 1
 Giardia lamblia 45–46, 47f
 infundibular/epidermal 74, 74f–76f
 kidney 236–237, 240f
 pancreas 228f, 229
 Pneumocystis spp. 38, 39f
 prostate 295–296, 297f
 synovial 180, 182f
 Cystadenoma, of bile duct 202–203, 204f
 Cystine *see* Urine crystals
 Cystitis *see* Urine, infection/inflammation
Cytauxzoon felis 44–45, 45f
Cytoisospora spp. 221–222, 223f
 Cytologic analysis of cells 1–30
 Cytologic artifacts 2–3, 4f–9f
 Cytoplasmic fragments 2, 3f

D

Degenerative joint disease 176–177, 180
 Degenerative neutrophils 5, 16f
Demodex spp. 57, 58f, 349, 350f
Dermatophyte spp. 34–35, 36f
 Diestrus, vaginal cytology 311–313, 312f
 Diff Quik® stain 63–64, 65f–66f, 113f, 290
Dipylidium caninum 220–221, 222f
 Döhle bodies 6, 16f
Dracunculus 51, 52f
 Dry-mount fecal cytology 217–219
 Dysgerminoma 298, 298f
 Dystrophic mineralization 99

E

Ear mites *see* *Otodectes cynotis*
 Ears 346–350
 ceruminous gland
 adenocarcinoma 347, 347f
 ceruminous gland adenoma 346–347, 346f
 otitis externa 347–350
 Ectoparasites 57–59
 Effusions *see* Body cavity fluids
Ehrlichia spp. 54, 177
 Encephalitis 324–325, 325f
 Endocrine tumors 273–282
 Endospores
 Clostridium spp. 54, 56f

Coccidioides spp. 37, 37f
Prototheca spp. 41, 42f
Rhinosporidium seeberi 42, 42f
 Enteritis 218–219, 219f
 Eosinophilic effusion 157, 158f
 Eosinophilic granuloma 101, 102f
 Eosinophilic inflammation
 body cavity fluids 157, 158f
 bronchoalveolar lavage 266, 267f
 cerebrospinal fluid 327–328, 329f
 cornea 342–343, 344f
 cutaneous lesions 101, 102f
 lymphadenitis 109–110, 111f
 Eosinophilic keratitis 342–343, 344f
 Eosinophilic meningoencephalomyelitis 327–328, 329f
 Eosinophils, identification of 4, 13f
 Ependymal cells 325–326, 327f
 Ependymoma 323–324, 324f
 Epidermal inclusion cyst *see* Infundibular/epidermal cyst
 Epithelial cells
 cerebrospinal fluid 325–326, 327f
 identification of 17, 18f
 Epithelioid macrophages 96
 Epithelioma, sebaceous 78, 79f
 Epitheliotropic lymphoma 69, 69f
 Erythrocytes
 body cavity fluids 161, 162f
 cerebrospinal fluid 331, 332f
 hemorrhage 1, 2f
 synovial fluid 180, 181f
 Erythroid precursors
 adrenal gland 281f
 bone marrow 135f–136f, 145f
 spleen 119–120, 121f–122f, 123f
 Erythroleukemia
 bone marrow 134, 143f
 spleen 126, 127f
 Erythrophagocytosis
 hemorrhage 2f, 181f, 332f
 histiocytic sarcoma 129f, 146f
Escherichia coli 205, 233, 297, 304, 313
 Estrogen
 bone marrow hypoplasia 150
 granulosa cell tumor 299
 sertoli cell tumor 286
 serum concentration 306–307, 310–311
 in squamous metaplasia, prostate 295
 Estrous cycle 301
 cytologic staging of 304–313
 Estrus, vaginal cytology 310–311, 311f–312f
 Ethylene glycol toxicity 246, 247f
 Extracellular matrix
 background 1–2, 3f

chondroid 169, 171f, 257, 259f, 307f
 colloid 273, 273f, 274, 274f
 osteoid 169, 170f
 Extramedullary hematopoiesis (EMH)
 adrenal gland 279, 281f
 spleen 119–120, 122f
 Extramedullary plasmacytoma
 cutaneous 70, 70f–71f
 gastrointestinal 212–213, 213f
 Exudate *see* Body cavity fluids
 Eyes 341–346
 conjunctiva 344–346
 cornea 341–344

F

Fatty cast, urinary 252, 253f
 Fatty liver *see* Hepatic lipidosis
 Fecal cytology 217–222
 bacteria 217, 218f
 bacterial overgrowth 218–219, 219f
 Campylobacter spp. 55–56, 56f
 Clostridium spp. 54–55, 56f
 Coccidia 221–222, 223f
 Cryptosporidium spp. 48, 48f
 Cynicomyces guttulatus 39–40, 40f
 Cytoisospora spp. 221–222, 223f
 Giardia spp. 45–46, 46f–47f
 hookworm 220, 221f
 inflammation 218–219, 219f
 normal 217–218, 218f
 parasite ova 220–223
 roundworm 220, 220f
 tapeworm 220–221, 222f
 trichomonads 47–48, 47f
 whipworm 220, 221f
 Feline
 eosinophilic keratitis 342–343, 343f
 hepatic lipidosis 189, 191f–192f, 199f
 visceral mast cell neoplasia 129, 130f
 Feline herpesvirus, conjunctival 343
 Feline immunodeficiency virus (FIV)
 lymphoma 114
 Toxoplasma gondii 43
 Feline infectious peritonitis (FIP)
 cerebrospinal fluid 332–333, 333f
 exudate 157
 Feline leukemia virus (FeLV)
 acute erythroid leukemia 134
 acute lymphoid leukemia 139
 bone marrow hypoplasia 150
 Cryptosporidium spp. 48
 lymphoma 114
 mediastinal lymphoma 133
 Feline mast cell neoplasia
 cutaneous 63–65, 66f–67f
 visceral 129, 130f
 FeLV *see* Feline leukemia virus (FeLV)

- Fibrocartilagenous emboli (FCE) 327
- Fibroma
cutaneous 21f, 85–86, 85f
keloidal 86, 87f
- Fibroplasia
reactive 84–85, 85f
reactive, in mast cell tumors 63, 64f
- Fibrosarcoma
bone 172, 173f
cutaneous 86, 86f
keloidal 86, 87f
metastatic 120f, 131f, 196f
nasal 259, 260f
- Filaroides hirthi* 50–51, 50f
- FIP *see* Feline infectious peritonitis (FIP)
- FIV *see* Feline immunodeficiency virus (FIV)
- Flame cell
identification 5, 15f
multiple myeloma 174, 174f
plasmacytoma 70, 71f
- Fluid-to-serum potassium ratio 161
- Fluids *see* Body cavity fluids;
Cerebrospinal fluid (CSF);
Synovial fluid
- Follicular cyst *see* Infundibular/
epidermal cyst
- Foreign body
cutaneous reaction 95, 97
nasal 255
- Formalin artifact 3, 9f
- Fungal agents 33–40
- Furunculosis 97
- G**
- Gallbladder 205
- Gamonts, *Hepatozoon* spp. 48, 49f
- Gastrinoma 226
- Gastritis *see* Intestines
- Gastrointestinal stromal tumor (GIST) 216, 217f
- Gastrointestinal tract *see* Intestines
- Gel, artifact 3, 6f
- Giant cells
anaplastic sarcoma with giant cells 25f, 91, 91f
macrophages, multinucleated 96f, 97f
osteoclasts 19f, 175f
- Giant cell tumor of soft tissue *see* Anaplastic sarcoma with giant cells
- Giardia* spp. 45–46, 46f
- Gliomas 317
- Glomerular tuft 233, 234f
- Glove powder crystals, artifact 2, 4f
- Glucose, in body cavity fluids 156
- Goblet cells 263, 264f
- Gram stain
Actinomyces spp. 53
Clostridium spp. 55
Helicobacter spp. 57
Mycobacterium spp. 52
Nocardia spp. 53
Simonsiella spp. 57
- Granular casts, urinary 250, 250f–251f
- Granular lymphoma 211, 212f
- Granulocytic/Erythroid ratio (G/E ratio) 134
- Granulocytic leukemia
bone marrow 134, 141f–142f
lymph node 117, 117f
spleen, 126, 126f
- Granulocytic precursors
bone marrow 133, 137f–139f
spleen 119, 122f
- Granuloma
acral lick 97
eosinophilic 101, 102f
- Granulomatous inflammation 96–97, 97f
- Granulomatous meningoencephalitis (GME) 331–332, 333f
- Granulosa cell tumor 6f, 298–299, 299f
- H**
- Hair follicular tumors *see* Cutaneous
basilar epithelial neoplasia
- Hair shaft fragments 75f
- Helicobacter* spp. 56–57, 57f
- Helminths 48–51
- Hemangioma 88–89, 89f
- Hemangiopericytoma 87, 87f–88f
- Hemangiosarcoma
bone 170–172, 172f
cutaneous 89, 90f
hemorrhagic effusion with 161
kidney 235, 239f
spleen 121–122, 123f–124f
- Hemarthrosis 180, 181f
- Hematoidin crystals 1, 2f, 161–162, 162f, 164f, 208
- Hematopoiesis *see* Extramedullary
hematopoiesis (EMH)
- Hemoabdomen 122, 123, 125, 161
- Hemoglobin crystals, artifact 3, 8f
- Hemophagocytic histiocytic sarcoma
bone marrow 145–146, 146f
spleen 129, 129f
- Hemorrhage
background 1, 2f
body cavity fluids 161, 162f
bronchoalveolar lavage 268–269, 269f
cerebrospinal fluid 331, 332f
iatrogenic 161, 180, 331
synovial fluid 180, 181f
- Hemorrhagic effusion 161, 162f
- Hemosiderin
chronic hemorrhage 2f, 111f, 162f, 269f
liver 200–201, 201f
- Hepatic disease *see* Liver
- Hepatic lipidosis 189, 191f–192f, 199f
- Hepatitis *see* Liver, inflammation
- Hepatocellular carcinoma 191–194
high-grade 20f, 192–194, 194f
well-differentiated 191–192, 193f
- Hepatocytes *see* Liver
- Hepatoid gland tumor *see* Perianal
gland adenoma
- Hepatoma 190, 193f
- Hepatosplenic lymphoma 125–126, 125f
- Hepatozoon* spp. 48, 49f
- Herpesvirus, conjunctival 343
- Histiocytic sarcoma *see also*
Hemophagocytic histiocytic
sarcoma
body fluids 165–166, 167f
bone 172, 173f
bone marrow 146–147, 147f
brain 320–321, 323f
cerebrospinal fluid 334, 335f–336f
criteria of malignancy 25f–27f
cutaneous 67–69, 68f
lungs 262–263, 262f
periarticular 182–183, 183f
spleen 128, 128f
synovial fluid 180, 180f
- Histiocytoma 20f, 65–67, 67f–68f
- Histoplasma capsulatum* 33, 35f
- Hodgkin's-like lymphoma 116–117, 116f
- Hookworm 220, 221f
- Hyaline cast, urine 248, 250, 250f
- Hygroma 97–98
- Hypercalcemia
anal sac apocrine gland
adenocarcinoma 83
lymphoma, large cell 113
lymphoma, lymphoblastic 115
lymphoma, mediastinal 133
multiple myeloma 127, 148, 174
parathyroid adenocarcinoma 277
parathyroid adenoma 276
thymoma 132
- Hyperchromasia, nuclear 23, 26f
- Hyperplasia
biliary 202, 203f
corneal 341, 342f
erythroid, bone marrow 142–143, 145f
granulocytic, bone marrow 141–142, 145f
liver, nodular 189, 192f
lung 259, 260f
lymph node 107, 108f–109f
mesothelial 161–162, 162f–163f

Hyperplasia (*cont'd*)

- pancreas, nodular 222, 224, 223f
- prostatic, benign 290, 294f
- respiratory epithelial 255, 257f
- spleen, nodular 118–119, 121f
- synovial 176
- thyroid, adenomatous 273
- transitional cell 237, 240f, 242f

Hypersensitivity reaction

- bronchoalveolar lavage 266
- cutaneous 101, 101f

Hyphae, fungal

- Aspergillus* spp. 40, 41f
- Candida* spp. 38, 38f
- Conidiobolus* spp. 266f
- keratitis 344f
- osteomyelitis 175f
- Pythium insidiosum* 40, 41f

Hypocellular, bone marrow 150, 151f

I

Iatrogenic hemorrhage

- cerebrospinal fluid 331
- hemorrhagic effusion 161
- synovial fluid 180

Idiopathic

- calcinosis cutis 100
- chylous effusion 159
- eosinophilic granuloma 101
- eosinophilic
 - meningoencephalitis 328, 329f
- pericardial effusion,
 - hemorrhagic 161
- sialadenosis 207
- sialocele 208
- xanthoma 94

Immune mediated polyarthritis

- (IMPA) 95, 177–178, 178f, 179f

Immunoglobulins

- flame cells 5, 15f
- mott cells 5, 15f
- ragocytes 177, 179f

Immunophenotype, lymphoma *see*

- Phenotype, lymphoma

In vitro artifacts

- background crystal formation 3, 5f
- cell lysis 3, 6f–7f
- formalin 3, 9f
- hemoglobin crystal formation 3, 8f
- urine crystal formation 246

Infectious agents 33–59

Infiltrative lipoma *see* Lipoma

Inflammation

- body cavity fluids 155–157
- brain 324–325, 325f
- bronchoalveolar lavage 265–268
- cerebrospinal fluid 326–330
- characterization, cells 4–6, 13f–16f

conjunctiva 344–345, 345f–346f

cornea 341–343, 342f

ears 347–350

feces 218–219, 219f

granulomatous 96–97, 97f

intestine 210, 211f

joint 177–178, 178f–179f

kidney 233, 235f

liver 196–198, 198f–199f

lung 260f, 263, 263f

lymph node 108–111, 110f–111f

mammary gland 303–304, 307f

nasal cavity 255, 256f

pancreas 226–228, 227f–228f

prostate 296–297, 297f

pyogranulomatous 96–97, 96f–97f

salivary gland 209–210, 210f

testicle 288–289, 290f

urine 242–243, 244f

vagina 313, 313f

Inflammatory bowel disease (IBD) 210

Inflammatory cells, identification 4–6, 13f–16f

Infundibular/epidermal cyst 74, 74f–76f

Injection site reaction 97

Insulinoma 226, 226f

Intermediate cells, vaginal

cytology 304–305, 309f

Interstitial cell tumor 286–287, 289f

Intervertebral disc material 325, 326f

Intestines 210–217

adenocarcinoma 214, 215f

adenoma 214, 214f

carcinoid 215–216, 216f

gastrointestinal stromal tumor

(GIST) 216, 217f

inflammation 210, 211f

leiomyosarcoma 18f, 216–217, 217f

lymphoma, large cell 210–212, 212f

lymphoma, small cell 210, 211f

mast cell neoplasia 213–214, 213f

plasmacytoma 212–213, 213f

polyp 214, 214f

Intracellular bacteria 98f, 111f, 156f, 228f, 256f, 297f, 307f, 312f, 313f, 343f

Ischemia 252, 331

Ischemic myelopathy *see*

Fibrocartilagenous emboli (FCE)

Islet cell tumors 226

Iso spor a see *Cytoisopora* spp.

J

Joint fluid *see* Synovial fluid

Joints 175–183

degenerative disease 176, 180

hemarthrosis 180, 181f

immune mediated disease 95, 177–178, 178f–179f

infection 177, 177f–178f

inflammation 177–178, 178f–179f

neoplasia

metastatic 180, 180f–181f

primary 181–183, 182f–183f

synovial cyst 180, 182f

systemic lupus erythematosus 179–180, 179f

Juvenile cellulitis 108, 110f

K

Karyolysis 5, 16f

Karyorrhexis 5, 16f

Keloidal fibroma/fibrosarcoma 86, 87f

Keratin debris

incidental 3, 11f

infundibular/epidermal cysts 74, 74f–76f

Keratinization 80–81, 82f, 257, 295, 296f, 341, 343f

Keratinocytes 101, 102f

Keratitis 341–344

bacterial 341, 343f

eosinophilic 342–343, 344f

fungal 341–342, 344f

pigmentary 343–344, 345f

Keratohyaline granules, squamous papilloma 80, 81f

Kerion 34, 36f

Kidney 233–237

carcinoma 233, 235f–237f

cyst 236–237, 240f

inflammation 233, 235f

glomerulus 233, 234f

lymphoma 234–235, 238f

nephroblastoma 233–234, 237f–238f

normal 233, 234f

pyelonephritis 233, 235f

sarcoma 235–236, 239f

transitional cell carcinoma 233, 237f

Kinetoplasts, in *Leishmania* spp. 43, 44f

L

Large granular lymphoma (LGL)

intestines 211, 212f

pancreas 227f

Large intestine *see* Intestines

Larynx

rhabdomyoma 183f

Leiomyoma 184–185, 185f

Leiomyosarcoma 18f, 185–186, 186f, 216–217, 217f

Leishmania spp. 43–44

amastigotes 43, 44f

bone marrow 148f

- Leukemia
 acute erythroid 126, 127f, 134, 143f
 acute granulocytic 117, 117f, 126, 126f, 134, 141f–142f
 acute lymphoid 139, 144f
 acute megakaryoblastic 134, 139, 143f
 acute myeloid 117, 117f, 134
 chronic lymphocytic 126, 127f, 147, 149f, 195–196
 lymph node infiltration 117, 117f
 spleen 126, 126f–127f
Leukocytes 13f–14f
Leydig cell tumor 286–287, 289f
Lipid, background 3, 10f–11f
Lipid droplets, fatty cast 253f
Lipidosis, hepatic 189, 191f–192f, 199f
Lipofuscin 199, 200f
Lipoma
 cutaneous 92, 92f–93f
 infiltrative 92
Liposarcoma 92–93, 93f–94f
Liver 189–202
 amyloid 202, 203f
 bile pigment 199–200, 200f
 carcinoid 194, 195f
 carcinoma
 high-grade 192–194, 194f
 well-differentiated 191–192, 193f
 cholangiohepatitis 197, 202, 205
 cholestasis 199–200, 200f
 copper pigment 201–202, 201f–202f
 cytoplasmic changes 189, 191f–192f
 hemosiderin pigment 200–201, 201f
 hepatic lipidosis 189, 191f–192f, 199f
 hepatoma 190, 193
 inflammation 196–198, 198f–199f
 lipofuscin pigment 199, 200f
 lymphoma
 large cell 194–195, 197f
 small cell 195–196, 198f
 metastatic disease 194, 195f–196f
 nodular hyperplasia 189, 192f
 normal 189, 190f
 nuclear inclusion 189, 190f
 steroid hepatopathy 189
 vacuolar hepatopathy 189, 191f–192f
Lubricant gel, artifact 3, 6f
Lung 259–263
 bronchoalveolar lavage of 263–270
 carcinoma 259–260, 261f
 histiocytic sarcoma 262–263, 262f
 hyperplasia 259, 260f
 infection 263, 263f
 inflammation 260f, 263, 263f
 parasites 50–52
 squamous cell carcinoma 261–262, 262f
Lungworm
Aelurostrongylus abstrusus 51, 51f
Filaroides hirthi 50, 50f
Oslerus osleri 51
Lupus erythematosus (LE) cells, synovial fluid 179, 179f
Lutenizing hormone (LH) 310–311
Lymph node 107–118
 eosinophilic lymphadenitis 109–110, 111f
 hyperplasia 107, 108f–109f
 infectious organisms 110–111, 111f
 leukemia infiltration 117, 117f
 lymphoma
 hodgkin's like 116–117, 116f
 large cell 3f, 111–114, 112f–113f
 lymphoblastic 114–115, 115f
 metastatic disease 117–118, 118f–120f
 mott cell differentiation 115–116, 116f
 small cell 114, 114f–115f
 neutrophilic lymphadenitis 108–109, 110f
 normal 107, 107f–108f
 reactive hyperplasia 107, 108f–109f
 salmon poisoning disease 55f, 110–111, 111f
Lymphadenitis
 eosinophilic 109–110, 111f
 neutrophilic 108–109, 110f
 septic 110f
Lymphocytes
 in bone marrow 134
 in bronchoalveolar lavage 268f
 in cerebrospinal fluid 325, 326f
 in histiocytoma 66, 68f
 identification of 5, 14f
 lymph nodes 107
 in seminoma 288f
 in synovial fluid 175
Lymphocytic inflammation
 bronchoalveolar lavage 267–268, 268f
 cerebrospinal fluid 328–329, 330f
 intestines 210
 liver 196–197, 198f
 nasal cavity 255
Lymphoglandular bodies *see* Cytoplasmic fragments
Lymphoid leukemia *see* Leukemia
Lymphoma
 B-cell 113, 116, 124
 body cavity fluids 164–165, 167f
 bone marrow 139, 144f
 brain 318, 322f
 cerebrospinal fluid 334, 335f
 cutaneous 69–70, 69f
 epitheliotropic 69
 hepatosplenic 125–126, 125f
 hodgkin's like 116–117, 116f
 intestinal 210–212, 211f–212f
 large cell 3f, 111–114, 112f–113f
 large granular 211, 212f, 227f
 liver 194–196, 197f–198f
 lymphoblastic 114–115, 115f
 marginal zone 124–125, 125f
 mediastinal 133, 134f
 mott cell differentiation 115–116, 116f
 nasal 255–256, 258f
 nodal 111–117
 renal 234–235, 238f
 small cell 114, 114f–115f, 126, 127f
 spleen 123–126, 124f–125f, 127f
 T-cell 4, 69, 109, 113, 114, 133
 thymic 133, 134f
Lymphoplasmacytic inflammation
 brain 324, 325f
 intestines 210, 211f
 liver 196–197, 199f
 nasal cavity 255, 256f
Lysis, of cells 3, 6f–7f
- ## M
- Macrophages
 alveolar 267
 body cavity fluids 155
 cerebrospinal fluid 325, 326f
 epithelioid 96
 granulomatous inflammation 96, 97f
 hemorrhage 1, 2f, 161, 162f, 181f
 identification of 4, 14f
 multinucleated 96, 96f–97f
 synovial fluid 175, 176f
 xanthoma 94, 94f
Magnesium ammonium phosphate crystals *see* Urine crystals, struvite
Malassezia spp.
 identification 38–39, 39f
 otitis externa 347–348, 349f
Malignancy, criteria of 21, 23, 21f–27f
Malignant fibrous histiocytoma *see* Anaplastic sarcoma with giant cells.
Malignant mammary tumors 24f, 301–302, 303f–306f
Malignant melanoma 21f, 73–74, 73f, 119f

- Mammary gland**
 adenocarcinoma 301, 305f
 adenoma 22f, 301, 302f–303f
 benign tumors 301, 302f–303f
 carcinoma 24f, 303f–305f
 carcinosarcoma 303
 complex tumor 303, 306f
 hyperplasia 301
 inflammation 303–304, 307f
 mastitis 303–304, 307f
 metastatic 175f, 196f
 mixed tumor 303, 307f
 sarcoma 301, 306f
- Marginal zone lymphoma** 124–125, 125f
- Mast cell neoplasia**
 bone marrow 149, 151f
 canine 19f, 63, 63f–65f
 cutaneous 63, 63f–67f
 diff-quick®, 63, 65f–66f
 eosinophilic inflammation in 63, 64f
 feline 63f–65f, 129, 130f, 213f
 fibroplasia in 63, 64f
 high-grade 63–64, 64f, 67f
 intestine 213–214, 213f
 metastatic 117, 118f, 129–130, 131f, 195f
 spleen 129–130, 130f–131f
 visceral 129, 130f
- Mast cells**
 allergic disease 101, 101f
 in bone marrow 149
 in hemangioma 89, 89f
 lymph nodes 117
 in thymoma 132
- Mastitis** 303–304, 307f
- Matrix** *see* Extracellular matrix
- Mediastinal lesions**
 chemodectoma 277–279, 278f–279f
 lymphoma 133, 134f
 thymic carcinoma 133, 133f
 thymoma 131–132, 132f
- Medulloblastoma** 319–320
- Megakaryoblastic leukemia** 134, 139, 143f
- Megakaryocytes**
 bone marrow 133, 140f–141f
 extramedullary hematopoiesis 122f
 identification of 140f–141f
- Melanocytoma** 71–73, 72f
- Melanoma**
 amelanotic 73, 73f, 119f
 benign 71–73, 72f
 malignant 21f, 73–74, 73f, 119f
 poorly melanotic 73, 73f, 119f
- Meningeal cells** 325–326, 328f
- Meningioma** 317, 318f–319f
- Meningitis**
 eosinophilic 327–328, 329f
 septic 327, 329f, 333–334, 334f
 steroid responsive meningitis-arteritis 327, 330–331
- Meningoencephalitis**
 granulomatous
 meningoencephalitis 331–332, 333f
 necrotizing
 meningoencephalitis 329, 332
- Merozoites, *Cytauxzoon felis*** 44, 45f
- Mesenchymal tissue cells**
 identification of 17, 18f–19f
 origin of 17
- Mesocetoides*** 48–50, 49f–50f
- Mesomycetozoea** 42–43
- Mesothelioma** 22f–23f, 162–163, 164f–165f
- Mesothelium**
 body cavity fluids 161–162, 162f–163f
 hyperplasia 161–162, 162f–163f
 identification of 3, 12f
 neoplasia *see* Mesothelioma
 normal 3, 12f
 reactive 161–162, 162f–163f
- Metamyelocytes** 138f, 141, 145f
- Metaphase** 27, 28f
- Metaplasia, squamous, prostate** 295, 296f
- Metarubricytes** 136f
- Metastatic disease**
 bone 174, 175f
 bone marrow 148–149, 150f–151f
 cutaneous 80, 81f
 joints 180, 180f–181f
 kidney 233
 liver 194, 195f–196f
 lymph nodes 117–118, 118f–120f
 pancreas 227f
 spleen 129–130, 130f–131f
- Metritis** 313, 313f
- Microsporium* spp.** 34
- Mineralization**
 calcinosis circumscripta 98–99, 99f
 dystrophic 99
 identification of 2, 4f
 infundibular/epidermal cysts 74, 75f
 prostatic carcinoma 295
 prostatic cyst 297f
 psammoma body 317, 319f
- Mites**
Demodex spp. 57, 58f, 349, 350f
Otodectes cynotis 59, 59f, 348, 349f
Sarcoptes scabiei 58, 58f
- Mitotic figures**
 atypical/bizarre 30f
 normal 27, 28f–30f
- Modified transudate** *see* Body cavity fluids
- Monocytic leukemia** 117f, 134, 142f
- Mononuclear inflammation**
 bronchoalveolar lavage 266–267, 268f
 cerebrospinal fluid 329–330, 330f
 synovial fluid 176, 176f
- Mononuclear reactivity**
 cerebrospinal fluid 330–331, 331f
 synovial fluid 176, 176f
- Mott cell**
 identification of 5, 15f
 lymph nodes 107
 lymphoma, differentiation in 115–116, 116f
 rhinitis 256f
 russell bodies 116f
- Mucin**
 biliary cystadenoma 202, 204f
 bronchoalveolar lavage 263, 265, 265f
 cholecystitis 205, 205f
 myxoma 90f
 myxosarcoma 91f
 nasal cavity 256f
 respiratory epithelium 264f
 salivary gland 207, 208f
 sialoceles 207–208, 209f
 synovial cyst 180, 182f
 synovial fluid 175, 176f
 white bile 159, 160f
- Mucocele, salivary** 207–208, 209f
- Mucus** 263, 265, 265f
- Multilobular osteochondrosarcoma (MLO)** 169–170, 171f
- Multinucleation**
 criterion of malignancy 21, 25f
 giant cells 25f, 91, 91f
 macrophages 96, 96f–97f
 osteoclasts 19f, 175f
- Multiple myeloma**
 bone 172, 174, 174f
 bone marrow 147–148, 149f
 spleen 126–127, 128f
- Muscle**
 skeletal muscle, normal 3, 12f
 tumors of 183–186, 183f–186f
- Mycobacterium* spp.** 51–52, 53f, 97, 233, 304
- Mycoplasma* spp.** 266, 344, 345, 346f
- Myelin, in cerebrospinal fluid** 325, 327f
- Myeloblasts** 137f, 141, 145f
- Myelocytes** 138f
- Myelofibrosis** 150

Myeloid leukemia *see* Leukemia
 Myeloid/erythroid (M/E) ratio *see*
 Granulocytic/Erythroid (G/E) ratio
 Myelolipoma 120–121, 122f–123f
 Myelomonocytic leukemia
 bone marrow 134, 142f
 lymph node infiltration 117f
 Myxoma 89–90, 90f
 Myxosarcoma 90–91, 91f

N

Nasal cavity
 adenocarcinoma 255, 257f
 chondrosarcoma 257, 259, 259f
 epithelial hyperplasia 255, 257f
 fibrosarcoma 259, 260f
 hyperplasia, epithelial 255, 257f
 infection 255, 256f
 inflammation 255, 256f
 lymphoma 255–256, 258f
 squamous cell carcinoma 256–257, 258f
 N/C ratios 21, 24f
 Necrosis 1, 2f
 Necrotizing cholecystitis 159
 Necrotizing meningoencephalitis (NME) 329, 332
 Nematodes 50–51
 Neoplasia *see also* specific tumor types
 benign 21, 21f–22f
 criteria of malignancy 21–27, 21f–27f
 malignant 21, 23, 21f–27f
 mitoses in 27, 28f–30f
Neorickettsia helminthoeca 54, 55f, 111, 111f
Neospora caninum 43, 43f
 Nephroblastoma
 renal 233–234, 237f–238f
 spinal 337–338, 337f
 Nerve sheath tumor 338, 338f
 Neuroblastoma 319–320, 322f
 Neuroendocrine tumor
 chemodectomas 277–279, 278f–279f
 hepatic carcinoid 194, 195f
 insulinoma 226, 226f
 intestinal carcinoid 215–216, 216f
 pancreas 226
 parathyroid tumors 276–277, 277f
 thyroid tumors 273–276, 273f–276f
 Neutrophilic inflammation
 abscess 97, 98f
 body cavity fluids 155–156, 156f–157f
 bronchoalveolar lavage 265–266, 265f
 cerebrospinal fluid 326–327, 328f
 conjunctiva 344, 345f–346f
 cornea 341, 342f–343f
 feces 218–219, 219f
 intestines 210, 211f
 kidney 233, 235f
 liver 197–198, 199f
 lymphadenitis 108–109, 110f
 pancreas 226–228, 227f–228f
 salivary gland 209–210, 210f
 semen 290, 294f
 synovial fluid 177–180, 177f–179f
 urine 242, 244f
 Neutrophils
 degenerative 5, 16f
 döhle bodies 6, 16f
 identification of 4, 13f
 karyolysis 5, 16f
 karyorrhexis 5, 16f
 pyknosis/pyknotic 17f
 toxic changes 5, 6, 16f
Nocardia spp. 52–54
 Nodular hyperplasia
 liver 189, 192f
 pancreas 222, 223f, 224
 spleen 118–119, 121f
 Nodular panniculitis, canine
 sterile 95, 96f
 Nose *see* Nasal cavity
 Nuclear fragmentation 21, 23, 26f
 Nuclear streaming 3, 6f
 Nuclear to cytoplasmic ratios (N/C ratios) 21, 24f
 Nucleoli, criteria of malignancy 23, 27f

O

Oligodendroglioma 317, 321f
 Oncocytoma 184
 Oocysts
 Cryptosporidium spp. 48, 48f
 Cystoisospora spp. 221–222, 223f
 Oomycetes 40, 41f
 Orchitis 288–289, 290f
 Oropharyngeal contamination 57, 58f, 263, 264f
Oslerus osleri 51
 Osteoarthritis 176
 Osteoblast 175f
 Osteoclast 19f, 175f
 Osteoid 169, 170f
 Osteomyelitis 174, 175f
 Osteosarcoma 19f, 26f, 27f, 169, 170f, 301, 306f
 Otitis externa
 bacterial 347, 348f
 fungal 347–348, 349f
 parasitic 348–349, 349f–350f
Otodectes cynotis 59, 59f, 348, 349f
 Ovary
 adenocarcinoma 299, 300f
 adenoma 299, 300f
 dysgerminoma 298, 298f
 granulosa cell tumor 6f, 298–299, 299f
 teratoma 300–301, 301f

P

Pancreas 222–229
 abscess 228, 228f
 adenocarcinoma
 poorly-differentiated 225–226, 225f
 well-differentiated 224–225, 225f
 adenoma 224, 224f
 beta islet cell tumor 226
 cyst 228f, 229
 inflammation 226–227, 227f
 insulinoma 226, 226f
 lymphoma 226, 227f
 metastatic neoplasia 226, 227f
 nodular hyperplasia 222, 223f, 224
 Pancreatitis 226–227, 227f
 exudate 157, 157f
 Panniculitis 95–96, 96f
 Papilloma
 bladder 238–239, 241f
 choroid plexus 321–322, 323f
 squamous 80, 81f
 Parabasal cells, vaginal
 cytology 304–305
Paragonimus kellicotti 51, 52f
 Parasites
 effusions 48–50, 49f–50f, 155
 identification 58f–59f
 ova 220f–223f
 Parathyroid adenocarcinoma 276–277, 277f
 Parathyroid adenoma 276, 277f
Pearsonema plica *see* *Capillaria plica*
 Pemphigus foliaceus 101–102, 102f
 Penis 298
Pentatrichomonas hominis 47
 Perianal gland adenocarcinoma 23f, 83, 83f
 Perianal gland adenoma 81–83, 82f
 Pericardial effusion
 hemorrhagic 161, 162f
 idiopathic 161
 neoplastic 165–166, 167f
 reactive mesothelial
 hyperplasia 162f–163f
 Perinuclear vacuolation 82f
 Peripheral nerve sheath tumor 87
 Peritonitis
 bile 159, 159f–160f
 feline infectious peritonitis 157
 parasitic 49f–50f, 50
 septic 155, 156f
 sterile 157, 157f

Perivascular wall tumors 87, 87f–88f
 Phenotype, lymphoma
 B-cell 113, 116, 124
 T-cell 4, 69, 109, 113, 114, 133
 Pheochromocytoma 279–280, 282f
 Pigmentary keratitis 343–344, 345f
 Pigments, hepatic 199–202, 200f–202f
 Pilomatricoma 75
 Piropasms, *Cytauxzoon felis* 45, 46f
 Pituitary carcinoma 281–282, 282f
 Plaque, eosinophilic 101
 Plasma cells *see also* Plasmacytoma and
 Multiple myeloma
 bone marrow 134, 147, 148f
 brain 324, 325f
 flame cells 5, 15f, 70, 71f, 174, 174f
 identification of 5, 14f
 intestines 210, 211f
 liver 199f
 lymph node 107, 108f–109f
 mott cells 5, 15f, 107, 256f
 nasal cavity 255, 256f
 spleen 118, 121f
 Plasmacytoma
 colon 212–213, 213f
 cutaneous 70, 70f–71f
 Pleural effusion *see* Body cavity fluids
Pneumocystis spp. 38, 39f
 Pneumonia 220, 263, 266, 266f
 Polyarthrititis 95, 177–178, 178f–179f
 Polyp
 bladder 238–239, 241f
 gastrointestinal 214, 214f
 nasal, *Rhinosporidium seeberi* 42
 Polypoid cystitis 238
 Potassium, in body cavity fluids 161
 Primitive neuroectodermal tumors
 (PNET) 319–320, 322f
 Proestrus, vaginal cytology 306–307,
 310f–311f
 Progesterone, concentration
 estrous cycle staging 306, 310–312
 granulosa cell tumor 299
 Promegakaryocytes 140f
 Promyelocytes 137f, 141, 145f
 Prophase 27, 28f
 Prorubricytes 135f, 142
 Prostate 290, 294–297
 benign hyperplasia 290, 294f
 carcinoma 2f, 18f, 150f, 290, 295, 295f
 cyst 295–296, 297f
 septic prostatitis 296–297, 297f
 squamous metaplasia 295, 296f
 transitional cell carcinoma 24f,
 295, 296f
 Protein concentration
 body cavity fluids 155
 cerebrospinal fluid 325

Prototheca spp. 40–41, 42f
 Protozoa 43–48
 Psammoma bodies, meningioma
 317, 319f
 Pseudohyphae, *Candida* spp. 38, 38f
 Pulmonary *see* Lung
 Pulmonary carcinoma 259–260, 261f
 cutaneous metastases 80, 81f
 Pyelonephritis 233, 235f
 Pyknosis/pyknotic cells 6, 7f
 Pyogranulomatous inflammation 96–97,
 96f–97f
 Pyometra 299, 313
 Pyothorax 155–156
Pythium insidiosum 40, 41f
 Pyuria *see* Urine, infection/
 inflammation

R

Rabies, vaccine reaction 98f
 Ragocytes 178, 179f
 Ranula 208
 Reactive fibrohistiocytic nodule 95, 95f
 Reactive fibroplasia 63, 64f, 84–85, 85f
 Reactive lymphoid hyperplasia 107,
 108f–109f
 Rectal
 adenoma 214
 carcinoid, prognosis in 216
 plasmacytoma 213
 prolapse 213, 214
 Rectum *see* Intestines
 Red blood cells *see* Erythrocytes
 Reed-Sternberg cells 116, 116f
 Renal
 carcinoma 233, 235f–237f
 cyst 236–237, 240f
 glomerulus 233, 234f
 lymphoma 234–235, 238f
 nephroblastoma 233–234, 237f–238f
 normal epithelium 233, 234f
 pyelonephritis 233, 235f
 sarcoma 235–236, 239f
 transitional cell carcinoma 233, 237f
 Reproductive system
 female 298–313
 male 285–298
 Respiratory tract 255–270
 Rhabdomyoma 183–184, 183f, 240
 Rhabdomyosarcoma 92, 184,
 184f–185f, 240
 Rhinitis 255, 256f
Rhinosporidium seeberi 42–43, 42f
Rickettsia spp.
 identification 54, 55f
 joints 177, 178f
 lymph nodes 110–111, 111f
 Ringworm *see* Dermatophyte spp.

Romanowsky stains 48, 63–64
 Round cell tumors, classification of
 17, 19f–20f
 Roundworm 220, 220f
 Rubriblasts 135f, 142–143, 143f
 Rubricytes 136f, 142
 Russell bodies, mott cells 116

S

Salivary gland 207–210
 adenocarcinoma 207, 209f
 adenoma 207, 208f
 inflammation 209–210, 210f
 mucocele 207–209, 209f
 normal 207–208f
 sialocele 207–209, 209f
 Salmon poisoning disease 54, 55f,
 110–111, 111f
 Sarcoma
 anaplastic sarcoma with giant cells
 25f, 91, 91f
 chondrosarcoma 169, 171f, 257,
 259f, 301
 fibrosarcoma 86, 86f, 120f, 131f,
 196f, 259, 260f
 hemangiosarcoma 89, 90f, 121–122,
 123f–124f, 170–172, 172f
 hemophagocytic histiocytic sarcoma
 129, 129f, 145–146, 146f
 histiocytic sarcoma *see* Histiocytic
 sarcoma
 keloidal fibrosarcoma 86, 87f
 leiomyosarcoma 18f, 185–186,
 186f, 216–217, 217f
 liposarcoma 92–93, 93f–94f
 metastatic
 liver 196f
 lymph node 120f
 spleen 131f
 synovial fluid 180f
 myxosarcoma 90–91, 91f
 osteosarcoma 19f, 26f, 27f, 169,
 170f, 301, 306f
 renal sarcoma 235–236, 239f
 rhabdomyosarcoma 92, 184,
 184f–185f, 240
 soft tissue sarcoma 86–88, 87f–88f
 synovial cell sarcoma 3f, 181–182, 182f
Sarcoptes scabiei 58, 58f
 Satellite nuclei 21, 25f
 Schizont, *Cytauxzoon felis* 44–45, 45f
 Scrapes
 corneal 341
 deep skin 57
 rectal 218
 Sebaceous adenoma 78, 79f
 Sebaceous carcinoma 79–80, 80f
 Sebaceous epithelioma 78, 79f

- Semen analysis 289–290, 291f–294f
 Seminoma 285, 288f
 Septic
 abscess 97, 98f
 arthritis 177, 177f
 body cavity fluids 155, 156f, 161f
 lymphadenitis 108, 110f
 mastitis 303–304, 307f
 meningitis 329f, 333–334, 334f
 pancreatic abscess 228, 228f
 prostatitis 296–297, 297f
 rhinitis 255, 256f
 urine 244f
 vaginitis 313, 313f
 Seroma 97–98, 99f
 Sertoli cell tumor 285–286, 288f
 Sialadenitis 209–210, 210f
 Sialadenosis 207
 Sialocele 207–209, 209f
Simonsiella spp.
 identification 57, 58f
 oropharyngeal contamination 263, 264f
 Skeletal muscle, normal 3, 12f
 Skin 63–102
 Skin surface debris 3, 11f
 Small cell lymphoma *see* Lymphoma
 Small intestines *see* Intestines
 Soft tissue sarcoma 86–88, 87f–88f
 Spermatozoa morphology 289–290, 291f–293f
 Spherules, *Coccidioides* spp. 36, 37f
 Spinal cord 337–338
 ependymoma 338
 meningioma 338
 nephroblastoma 337–338, 337f
 nerve sheath tumor 338, 338f
 Spindle cells, identification of 17, 18f
 Spleen 118–131
 amyloid 130–131, 132f
 chronic lymphocytic leukemia 126, 127f
 extramedullary hematopoiesis 119–120, 122f
 hemangiosarcoma 121–122, 123f–124f
 hemophagocytic histiocytic sarcoma 129, 129f
 histiocytic sarcoma 128, 128f
 hyperplasia, nodular 118–119, 121f
 leukemia 126, 126f–127f
 lymphoma
 hepatosplenic 125–126, 125f
 large cell 123, 124f
 marginal zone 124–125, 125f
 small cell 126
 mast cell neoplasia 129, 130f
 metastatic disease 129–130, 130f–131f
 multiple myeloma 126–127, 128f
 myelolipoma 120–121, 122f–123f
 nodular hyperplasia 118–119, 121f
 normal 118, 120f
Sporothrix schenckii 33, 35f
 Squamous cell carcinoma
 cornea 341, 343f
 cutaneous 80–81, 82f
 lung 261–262, 262f
 lymph node, metastatic 118f
 nasal 256–257, 258f
 Squamous metaplasia, prostate 295, 296f
 Squamous papilloma 80, 81f
 Stain precipitate 3, 5f
 Starch crystals, artifact 2, 4f
 Steatitis 95–96, 96f
 Sterile nodular panniculitis 95, 96f
 Steroid hepatopathy 189
 Steroid responsive meningitis-arteritis 327, 330–331
 Stomach *see* Intestines
 Strap cells 184
 Struvite crystals *see* Urine crystals
 Superficial cells, vaginal cytology 304–305, 309f
 Suppurative inflammation *see* Neutrophilic inflammation
 Surface epithelial cells, in cerebrospinal fluid 325–326, 327f
 Sweat gland adenocarcinoma 78, 78f
 Sweat gland adenoma 77–78, 77f
 Synovial cell sarcoma 3f, 181–182, 182f
 Synovial cyst 180, 182f
 Synovial fluid 175–180
 cell concentration 175
 degenerative joint disease 176, 180
 hemarthrosis 180, 181f
 immune mediated polyarthritis (IMPA) 95, 177–178, 178f, 179f
 inflammation 177–178, 178f–179f
 metastatic neoplasia 180, 180f–181f
 mononuclear inflammation 176–177, 176f
 mononuclear reactivity 176–177, 176f
 normal 175, 176f
 ragocytes 178, 179f
 rickettsial disease 177, 178f
 septic 177, 177f–178f
 systemic lupus erythematosus 179–180, 179f
 Systemic lupus erythematosus (SLE) 179–180, 179f
- T**
- Tachyzoites
 Neospora caninum 43, 43f
 Toxoplasma gondii 43, 44f, 263f
 Tamm-Horsfall proteins 248
 Tapeworm 220–221, 222f
 Telophase 27, 30f
 Teratoma 300–301, 301f
 Testes 285–289
 inflammation 288–289, 290f
 interstitial (Leydig) cell tumor 286–287, 289f
 normal 285, 286f–287f
 orchitis 288–289, 290f
 seminoma 285, 288f
 sertoli cell tumor 285–286, 288f
 Thoracic fluid *see* Body cavity fluids
 Thymic carcinoma 133, 133f
 Thymic lymphoma 133, 134f
 Thymoma 131–132, 132f
 Thyroid adenoma 273–274, 273f
 Thyroid C cell carcinoma 276, 276f
 Thyroid carcinoma 274–276, 274f–275f
 Thyroid medullary carcinoma *see* Thyroid C cell carcinoma
 Tissue cells, types 6, 17
 Total nucleated cell count
 body cavity fluids 155
 cerebrospinal fluid 325
 synovial fluid 175
 Total protein concentration
 body cavity fluids 155
 cerebrospinal fluid 325
Toxascaris leonina 220
 Toxic neutrophils 5, 6, 16f
Toxocara spp. 220, 220f
Toxoplasma gondii 43, 44f, 263f
 Transitional cell carcinoma
 bladder 239, 241f
 kidney 233, 237f
 prostate 24f, 295, 296f
 in urine 243f
 Transitional cell papilloma/polyp 238–239, 241f
 Transitional epithelium
 hyperplasia 237, 240f, 240–241, 242f
 normal 242f
 Transmissible venereal tumor (TVT) 70, 72f, 117, 119f, 259, 298, 313
 Transtracheal wash *see* Bronchoalveolar lavage
 Transudate *see* Body cavity fluids
 Traumatic catheterization, urethra 6f, 242
 Trichoblastoma 75, 76f
 Trichoepithelioma 75
 Trichomoniasis 47–48, 47f
Trichophyton spp. 34
Trichuris vulpis 220, 221f
 Triglycerides, in chylous effusion 159–160

Tritrichomonas foetus 47–48, 47f

Trophozoites

Giardia spp. 45–46, 46f

Pneumocystis spp. 38, 39f

Tumors *see also* specific tumor types

epithelial 17, 18f

mesenchymal 17, 18f–19f

round cell 17, 19f–20f

TVT *see* Transmissible venereal tumor

U

Ultrasound gel, artifact 3, 6f

Uncinaria spp. 220

Urine 240–253

Capillaria plica 244, 245f

epithelial cells 240–241, 242f

infection/inflammation 242–243, 244f

neoplastic cells 241–242, 243f

Urine casts 248–253

cellular 251–252, 252f

granular 250, 250f–251f

hyaline 248, 250, 250f

fatty 252, 253f

waxy 251, 251f

Urine crystals 245–248

ammonium urate 246, 248f

bilirubin 248, 250f

calcium oxalate dihydrate 246, 246f

calcium oxalate monohydrate

246, 247f

cystine 247, 249f

struvite 245–246, 245f

uric acid 247, 248f–249f

Uric acid crystals, urine 247, 248f–249f

Uroabdomen 160–161, 161f

V

Vaccination reaction 97, 98f

Vacuolar hepatopathy 189, 191f–192f

Vagina

inflammation 313, 313f

neoplasia 313

Vaginal cytology 304–313

anestrus 305–306, 310f

cell types 304–305, 308f–309f

diestrus 311–313, 312f

estrous cycle staging 304–313

estrus 310–311, 311f–312f

proestrus 306–307, 310, 310f–311f

Vaginitis 313, 313f

Venereal tumor, transmissible *see*

Transmissible venereal tumor (TVT)

Virus

canine distemper virus 345

feline herpesvirus 343, 345

feline immunodeficiency virus 43, 114

feline leukemia virus *see* Feline

leukemia virus (FeLV)

papilloma virus 80

parvovirus 150

W

Wart *see* Squamous papilloma

Waxy casts, urinary 251, 251f

Whipworm 220, 221f

White bile peritonitis 159, 160f

Windrowing

salivary gland 207, 208f

synovial fluid 176f, 178f, 181, 182f

X

Xanthochromia, of cerebrospinal fluid 331

Xanthoma 93–94, 94f

Y

Yeast, enteric 218, 218f

Z

Zoonoses

Bordetella bronchiseptica 54

Brucella canis 288

Campylobacter spp. 56

Cryptosporidium spp. 48

Dermatophytes spp. 35

hookworms 220

roundworms 220

Sporothrix schenckii 33

tapeworms 221

Toxoplasma gondii 43