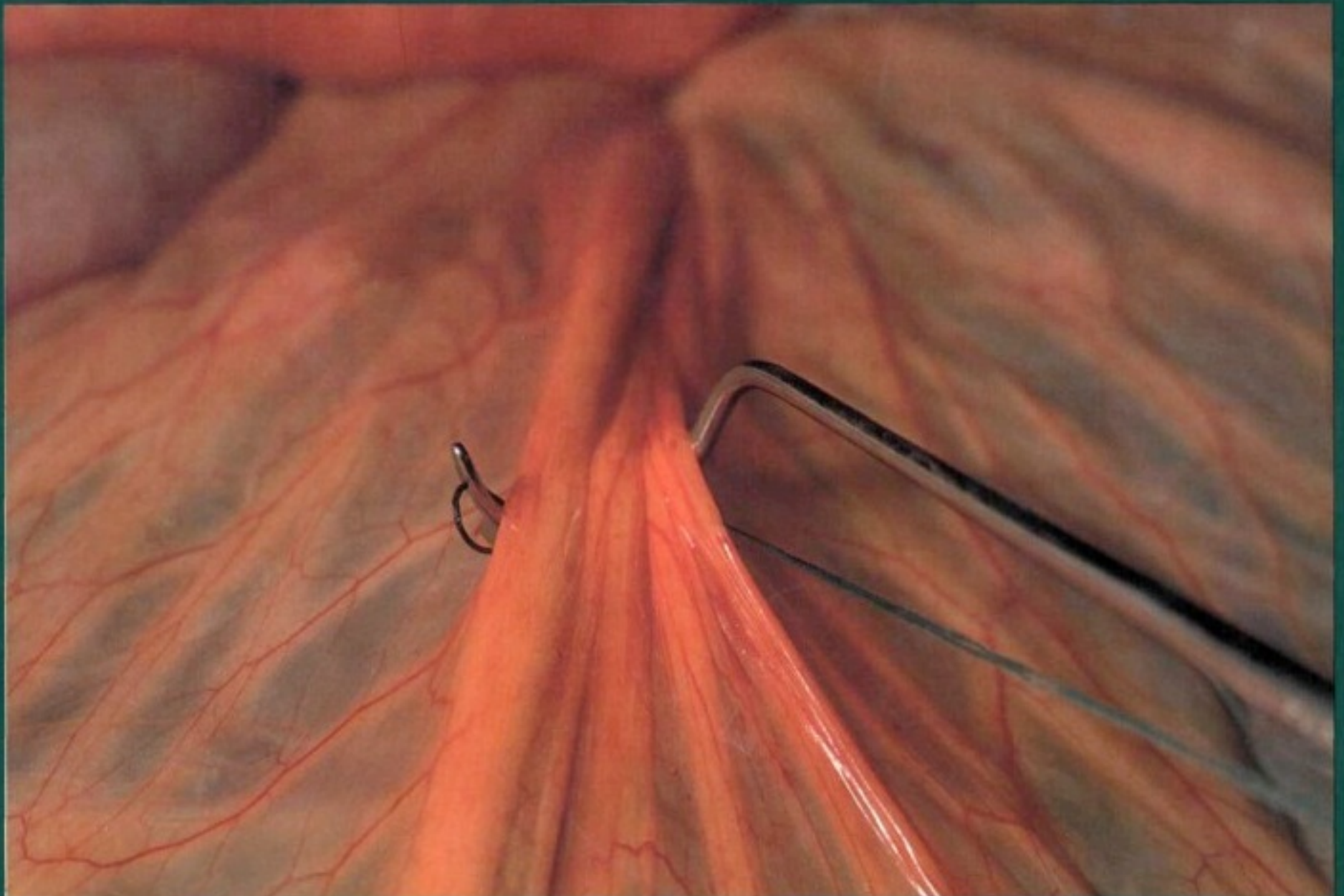


Atlas of large animal surgery

edited by

A. W. Kersjes, F. Németh and L. J. E. Rutgers

Williams & Wilkins



A colour atlas of large animal surgery

A colour atlas of large animal surgery

edited by

A. W. Kersjes, F. Németh and L. J. E. Rutgers

in collaboration with

E. C. Firth, P. Fontijne and M. A. van der Velden

Photography F. A. Blok

Wolfe Medical Publications Ltd

Copyright © Wetenschappelijke uitgeverij Bunge, Utrecht
Published by Wolfe Medical Publications Ltd, 1985
Printed by Koninklijke Smeets Offset BV, Weert
ISBN 0 7234 0852 1

For a full list of Wolfe Veterinary Colour Atlases, plus forthcoming titles,
please write to Wolfe Medical Publications Ltd., Wolfe House, 3 Conway
Street, London W1P 6 HE, England

All rights reserved. The contents of this book, both photographic and
textual, may not be reproduced in any form, by print, photoprint,
phototransparency, microfilm, microfiche, or any other means, nor may it
be included in any computer retrieval system, without written permission
from the publisher.

Design Bernard C. van Bercum GVN

AUTHORS

Dr. E. C. Firth
Professor, Department of General and Large Animal Surgery

P. Fontijne
Senior Lecturer, Department of Obstetrics, Gynaecology and A.I.

Dr. A. W. Kersjes
Professor and Chairman, Department of General and Large Animal
Surgery

Dr. F. Németh
Professor, Department of General and Large Animal Surgery

L. J. E. Rutgers
Lecturer, Department of General and Large Animal Surgery

Dr. M. A. van der Velden
Senior Lecturer, Department of General and Large Animal Surgery

Faculty of Veterinary Medicine
State University of Utrecht
Utrecht, The Netherlands

Preface

A thorough anatomical and pathophysiological knowledge of the condition and meticulous attention to surgical principles are the basis for all surgical procedures. Assuming these requirements are fulfilled, surgery is by its very nature a discipline which should be visualized. Modern visual aids are therefore playing an increasingly important role in the instruction of surgical techniques. This does not mean that textbooks will become redundant, but there is a trend toward more illustrations and less text, a tendency which underlies the preparation and publishing of this atlas.

The authors are of the opinion that it will be elucidating to students and veterinary surgeons to have available a full colour photographic atlas of the treatment of the most important surgical conditions. We have attempted to show the essential steps of each procedure, accompanied by pertinent but limited text. It often has been a challenge to find a balance between text and photographs and at the same time to meet the requirements of adequate description, within the limitations of the concept of this atlas.

This publication does not aim at replacing a textbook, and thus chapters on general surgical principles have been omitted. It is therefore assumed that the reader has knowledge of current concepts of, for instance, asepsis and antisepsis, instrumentation, suture materials and techniques, wound healing, principles of fracture repair, and supportive measures (fluid therapy, role of antibiotics, anti-inflammatory drugs etc.).

The surgical techniques are in most cases time-honoured and are used in the Department of General and Large Animal Surgery and the Department of Obstetrics, Gynaecology and A.I. at Utrecht. The majority of the presented techniques, especially those concerning the bovine species and other food animals, can be carried out in general practice. However, a number of advanced techniques which can not be performed without hospital facilities are included.

The editors are grateful to Prof. Dr. K. J. Dik and A. van der Woude, Department of Veterinary Radiology, for providing the radiographs. Realization of the book would not have been possible without help from fellow members of the Departments of General and Large Animal Surgery and Veterinary Anaesthesiology, particularly Dr. A. Barneveld, G. E. Bras, W. R. Klein and H. W. Merkens, who performed some of the depicted surgery. We also extend our thanks to Mrs. J. Th. Abels-van der Linden for typing the manuscript.

A. W. Kersjes
F. Németh
L. J. E. Rutgers

Contents

PREFACE

CHAPTER 1 THE HEAD 1

Poll

- 1-1 Disbudding and dehorning 2,3

Ear

- 1-2 Extirpation of aural fistula 4,5

Guttural pouch

- 1-3 Drainage and fenestration 6

Face

- 1-4 Trephination of the frontal sinus in cattle 7
1-5 Trephination of maxillary sinuses and repulsion of teeth in the horse 8,9

Mandible

- 1-6 Treatment of premaxilla and mandibular body fractures 10
1-7 Treatment of mandibular interdental space fracture 11

Mouth

- 1-8 Lingual mucosa resection in cattle 12

Eye

- 1-9 Suturing of eyelid laceration 13
1-10 Excision of the nictitating membrane 14
1-11 Enucleation of the eyeball 14,15

Nose

- 1-12 Treatment of nasolacrimal orifice atresia 16

CHAPTER 2 THE NECK 17

Muscles

- 2-1 Myectomy (Forssell) and accessory nerve neurectomy 18,19

Larynx and trachea

- 2-2 Laryngotomy - cricoarytenoidopexy and ventriculectomy 20,21
2-3 Laryngotomy - extirpation of subepiglottal cyst 22
2-4 Laryngotomy - in bovine necrotic laryngitis 23
2-5 Tracheotomy 24

CHAPTER 3 THE THORAX 25

- 3-1 Diaphragmatic herniorrhaphy 26,27
3-2 Treatment of fistulous withers 28

CHAPTER 4 THE ABDOMEN

Abdominal wall

- 4-1 Umbilical herniorrhaphy 30,31
4-2 Resection of urachal fistula 32,33
4-3 Ventral midline laparotomy 34,35
4-4 Flank laparotomy 36,37
4-5 Paramedian laparotomy 38

Gastro-intestinal system

- 4-6 Rumenotomy 39
4-7 Correction of left displaced abomasum 40,41
4-8 Correction of right displaced abomasum 42
4-9 Caecotomy in cattle 43
4-10 Enterectomy; side-to-side anastomosis 44,45
4-11 Enterectomy; end-to-end anastomosis 46
4-12 Jejunocaecostomy; end-to-side anastomosis 47
4-13 Correction of rectum prolapse 48,49
4-14 Treatment of atresia ani (et recti) 50

CHAPTER 5 THE UROGENITAL SYSTEM 51

The male urogenital system

- 5-1 Castration: open technique in the pig 52
5-2 Castration: closed technique in the goat 53
5-3 Castration: half closed technique in the horse 54,55
5-4 Castration: primary closure method in the horse 56,57
5-5 Vasectomy 57
5-6 Inguinal cryptorchidectomy in the horse 58,59
5-7 Abdominal cryptorchidectomy in the horse 60,61
5-8 Abdominal cryptorchidectomy: flank approach in the pig 61
5-9 Inguinal herniorrhaphy in the pig 62,63
5-10 Treatment of incarcerated inguinal hernia in the horse 64
5-11 Inguinal herniorrhaphy in foals 65

- 5-12 Management of evisceration after castration in the horse 66
- 5-13 Cystorrhaphy 67
- 5-14 Pararectal cystotomy 68
- 5-15 Urethrotomy 69
- 5-16 Removal of neoplasms of the bovine penis 70
- 5-17 Amputation of the equine penis 71
- 5-18 Circumcision (reefing) of the equine penis 72, 73
- 5-19 Retention suturing of the equine preputial orifice 73
- 5-20 Penis retraction operation in the horse 74, 75

The female urogenital system

- 5-21 Caesarean section in cattle 76, 77
- 5-22 Vestibuloplasty 78, 79
- 5-23 Perineal reconstruction after third degree laceration 80, 81
- 5-24 Episiotomy 82
- 5-25 Ovariectomy 82

CHAPTER 6 THE COMMON INTEGUMENT 83

Skin

- 6-1 Skin grafting 84, 85
- 6-2 Cryosurgery of sarcoids 86
- 6-3 Extirpation of acquired carpal bursa 87

Equine hoof

- 6-4 Treatment of pododermatitis 88
- 6-5 Extirpation of keratoma 88, 89
- 6-6 Management of penetrating wounds of the sole 90, 91
- 6-7 Treatment of canker 92
- 6-8 Treatment of thrush 93
- 6-9 Treatment of sand crack 93

Bovine digit

- 6-10 Treatment of pododermatitis 94
- 6-11 Treatment of heel abscess 95
- 6-12 Resection of the distal interphalangeal joint and navicular bone 96, 97
- 6-13 Amputation of digit 98
- 6-14 Resection of digital flexor tendons and digital synovial sheath 99

Mammary gland

- 6-15 Repair of teat lacerations 100
- 6-16 Repair of traumatic teat fistula 101
- 6-17 Management of congenital teat fistula 102
- 6-18 Management of teat obstructions 103
- 6-19 Amputation of the mammary gland 104

CHAPTER 7 THE MUSCULOSKELETAL SYSTEM 105

Muscles and tendons

- 7-1 Desmotomy of inferior check ligament 106
- 7-2 Desmotomy of medial patellar ligament 107
- 7-3 Sectioning of fetlock annular ligament 108
- 7-4 Tendon repair - carbon fibre implantation 109
- 7-5 Tibial neurectomy in spastic paresis 110, 111
- 7-6 Coccygeal myotomy 112
- 7-7 Amputation of the tail 113

Elbow

- 7-8 Plate osteosynthesis of ulna fracture 114, 115

Carpus

- 7-9 Arthrotomy in carpal bone fracture 116
- 7-10 Correction of valgus deviation 117

Femur

- 7-11 Plate osteosynthesis of supracondylar fracture 118, 119

Tibia

- 7-12 Plate osteosynthesis 120

Tarsus

- 7-13 Arthrotomy in osteochondrosis 121
- 7-14 Arthrodesis of the distal intertarsal joint in the horse 122, 123
- 7-15 Arthrotomy and curettage in septic bovine spavin 124

Metacarpus and metatarsus

- 7-16 Resection of fractured splint bone 125
- 7-17 Fracture treatment by the walking cast technique 126, 127
- 7-18 Sequestrectomy 128

Fetlock and phalanges

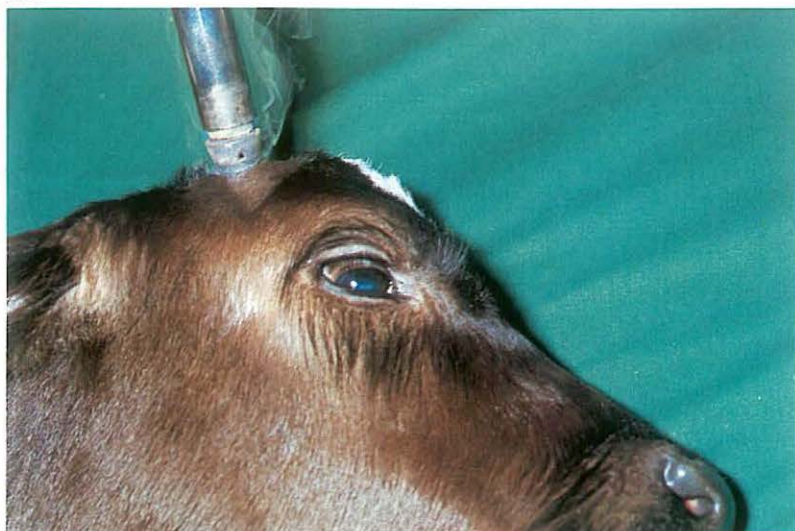- 7-19 Ostectomy of apical fracture of proximal sesamoid bone 129
- 7-20 Treatment of first phalanx fractures 130, 131
- 7-21 Arthrotomy of fetlock joint in chip fracture 132
- 7-22 Treatment of third phalanx fracture in the horse 133
- 7-23 Lag screw fixation of navicular bone fracture 134, 135
- 7-24 Posterior digital neurectomy 136

BOOK REFERENCES 138

INDEX 139

Chapter 1 The head

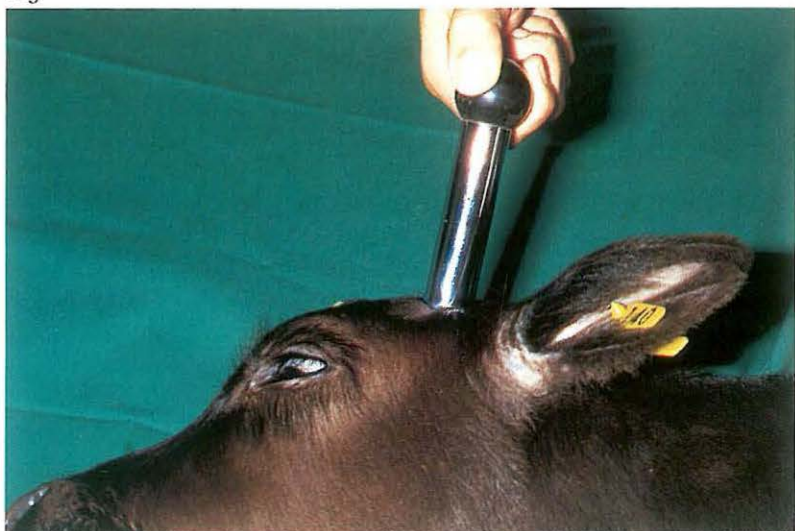001



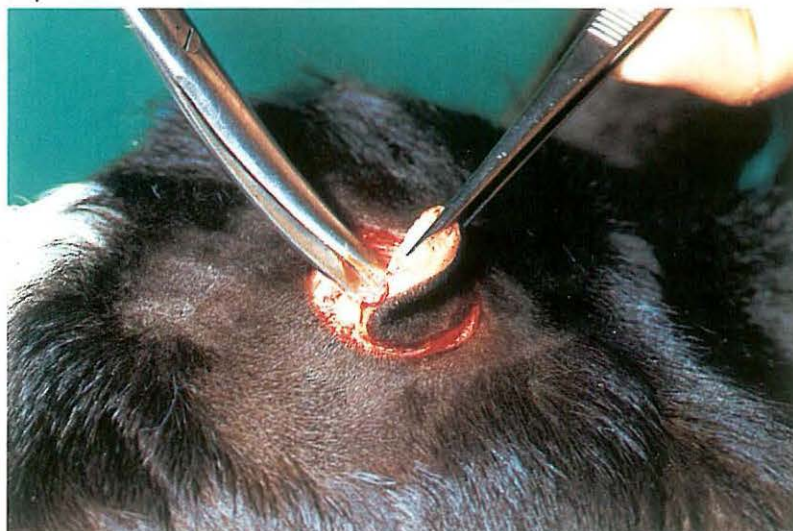
002



003



004



1-1 Disbudding and dehorning

Dehorning of cattle is necessary as soon as the herd is being kept in a loose-housing system. The animals are no longer able to gore each other and become much quieter. As dehorning of adult cattle may be fatiguing for the operator and the procedure may give rise to complications (e.g. sinusitis), disbudding of calves is preferable. Occasionally amputation of the horn is indicated for other reasons e.g. fracture of the bony core of the horn.

Surgery.

(1) Disbudding. Several methods are practised.

a The use of caustics should be discouraged as it may cause too little or too much tissue damage.

b The best method is removing the buds with a disbudding iron under local analgesia (cornual nerve block). The hot iron is rotated as it burns through the skin surrounding the bud [001]. The iron is then tilted, enabling the bud to be scooped out [002]. This method is recommended because

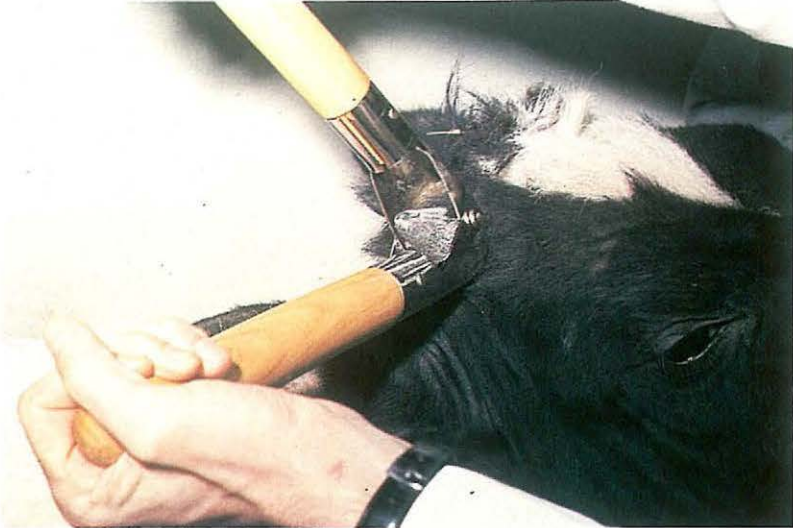haemorrhage does not occur and healing takes place within a few weeks leaving little or no scar.

c Surgical excision may be performed with Robert's dehorning trephine under local analgesia. The skin around the bud is incised by rotating the trephine [003], and although the instrument is designed for scooping out the bud, removal with forceps and scissors may be easier [004]. The wound produced is relatively large, and some haemorrhage is always present.

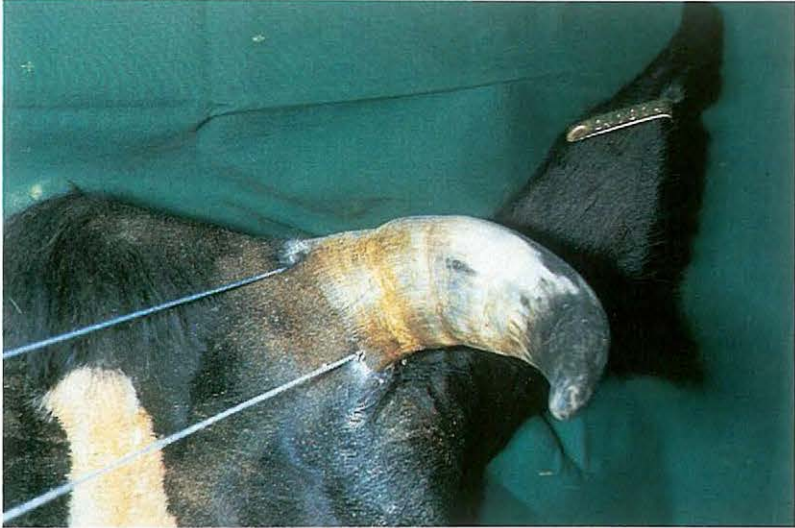(2) Dehorning. If horn growth is already present some kind of surgical amputation must be performed. Several instruments are available for this purpose (saws, shears, wire). Adult cattle, restrained physically and chemically, are dehorned standing, and surgery must be carried out under local analgesia. If regeneration of horn is to be avoided the amputation should include 1 cm of skin around the base of the horn.

Young cattle can effectively be dehorned with one of the smaller amputation devices (e.g. Barnes' dehorner [005]). For older animals, embryotomy wire is very suitable as it offers the greatest opportunity to con-

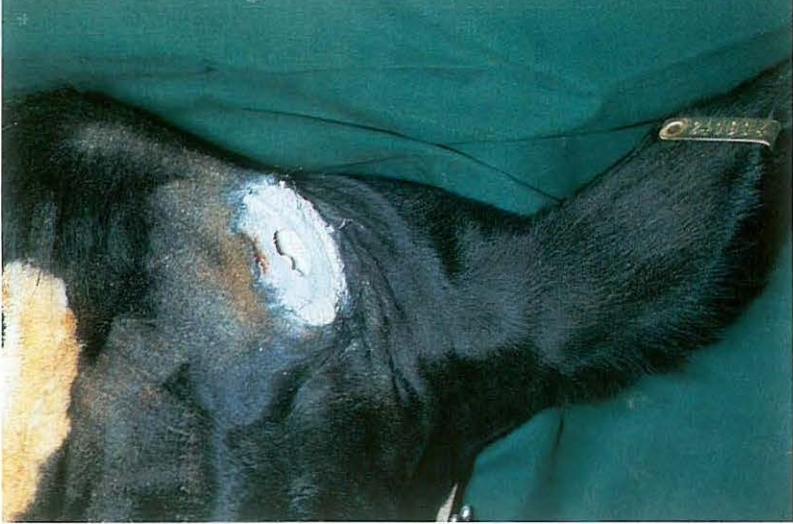005



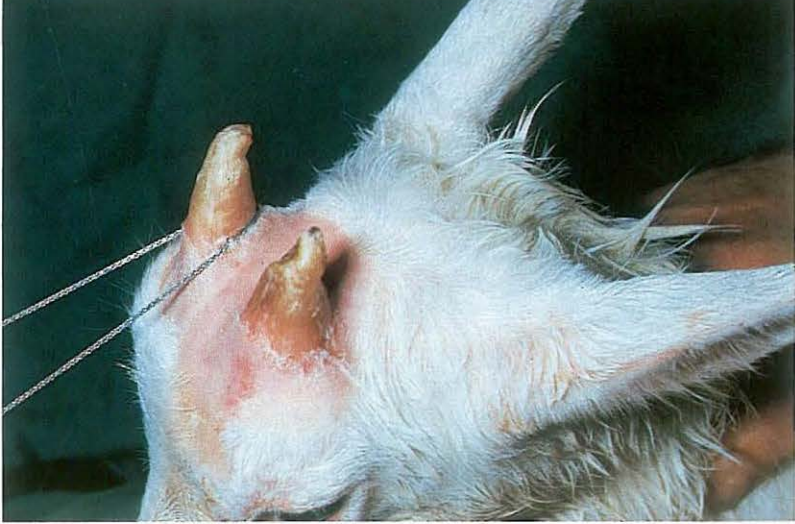006



007



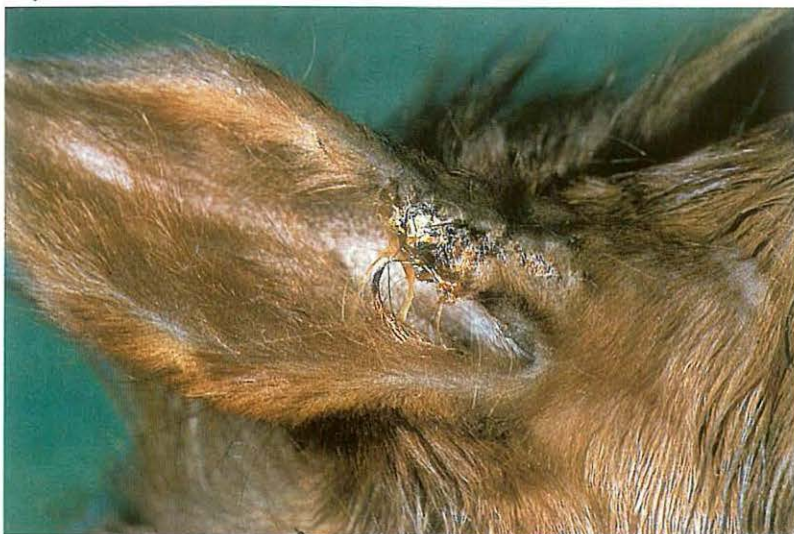008



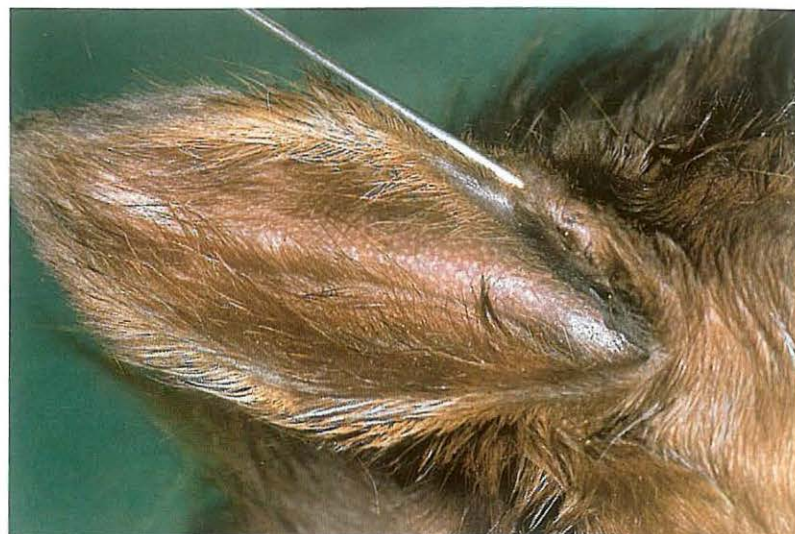trol the direction of the 'incision' [006]. As sawing is begun the wire is held in place at the horn base with a metallic object (e.g. scissors) to prevent the wire moving from the intended incision site. The sawing often generates sufficient heat to minimize haemorrhage [007]. If significant bleeding occurs haemostasis is best achieved with a point firing iron. Pneumatization of the bony core in animals over 6 months of age means that dehorning results in an open frontal sinus [007]. Dehorning of goats is occasionally requested. The different innervation should be noted: cornual branches of both lacrimal and infratrochlear nerves must be blocked. Suitable instruments include dehorning saw or embryotomy wire [008]. Amputation in adult goats should be considered carefully, because very large openings to the frontal sinuses result, necessitating prolonged aftercare. Complications following dehorning of adult cattle are rare. Because secondary haemorrhage may develop after fighting or rubbing the wound, a dehorned herd should be inspected regularly during the first half day post-

operatively. Sinusitis may also occur due to the opening of the frontal sinus. If the sinusitis becomes purulent, trephination may be indicated (see 1-4).

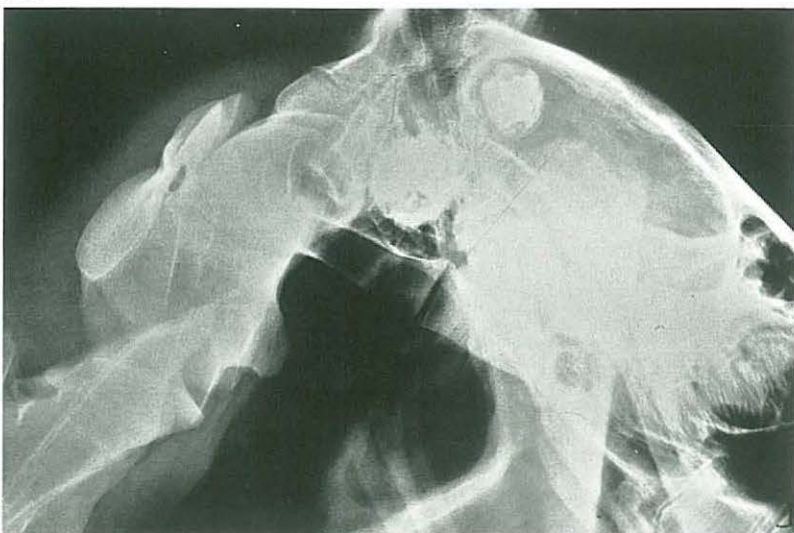
009



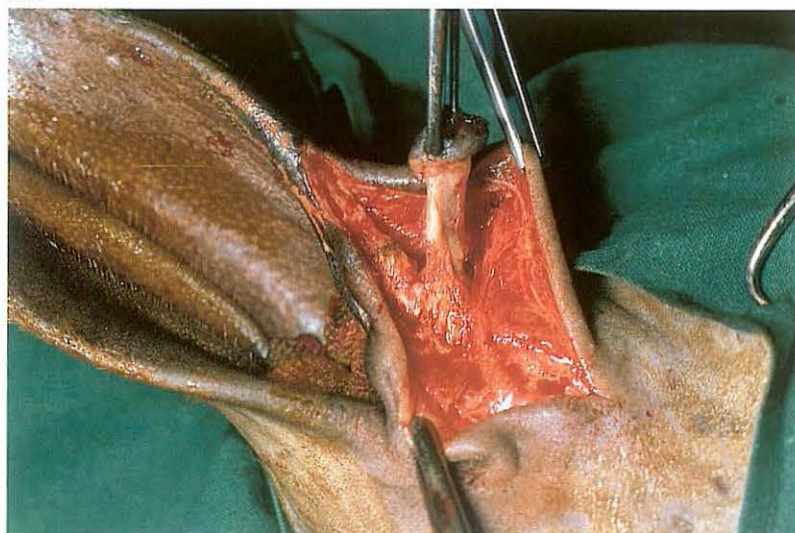
010



011



012



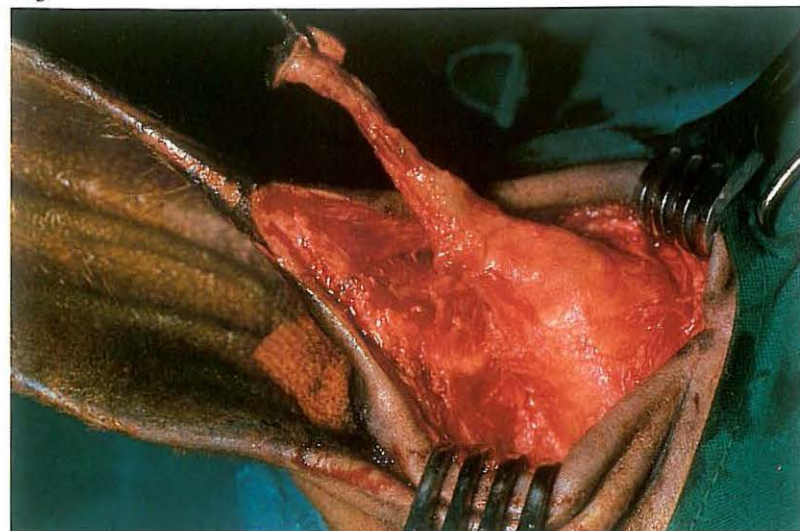
1-2 Extirpation of aural fistula

Ear fistula in the horse is most often caused by a dentigerous cyst. The opening of the tract is commonly located on the cranial border of the pinna, 1–3 cm from its base [009]. The cyst is usually attached to the temporal bone, under the temporalis muscle. In most cases the cyst contains one or more aberrant teeth, which may be detected by introducing a probe into the cyst [010], but in some cases only a cyst is present. Definitive diagnosis demands radiographic examination [011]. The only treatment is surgical. *Surgery.* Surgery is carried out with the animal in lateral recumbency under general anaesthesia. The external auditory meatus is packed with a sterile gauze plug, and a probe is inserted into the fistulous tract. A skin incision is made around the opening and extended along the border of the ear, immediately over the probe. The fistulous tract is dissected completely free from the surrounding tissue [012]. Opening of the fistulous tract and damage to the aural cartilage must be avoided. When the base of the fistula

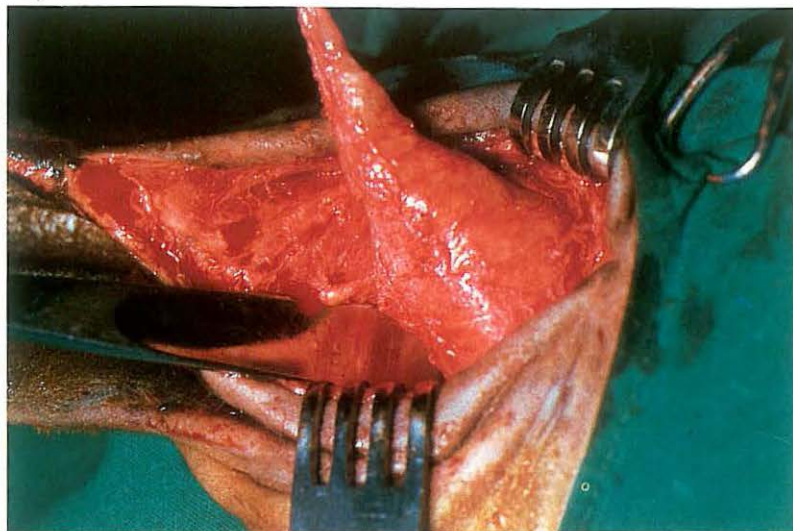
is reached the skin incision is extended over the cyst. Careful searching with the probe may give an accurate indication of the position and extent of the cyst. The temporalis muscle is bluntly dissected in the direction of its fibres; wound retractors facilitate exposure of the cyst and its contents [013]. The cyst is then bluntly dissected. If the tooth is firmly attached to the temporal bone it must be levered out using a chisel [014] and forceps [015]; in doing so care must be taken to prevent fracture of the temporal bone. Before closure, it must be established that all aberrant teeth have been removed.

The temporalis muscle and subcutaneous tissue are sutured with simple interrupted sutures of absorbable material, after a latex drain has been inserted. The skin is also sutured with simple interrupted sutures [016]. Systemic antibiotics are administered. The latex drain is removed on the second or third postoperative day and the skin sutures on the tenth postoperative day.

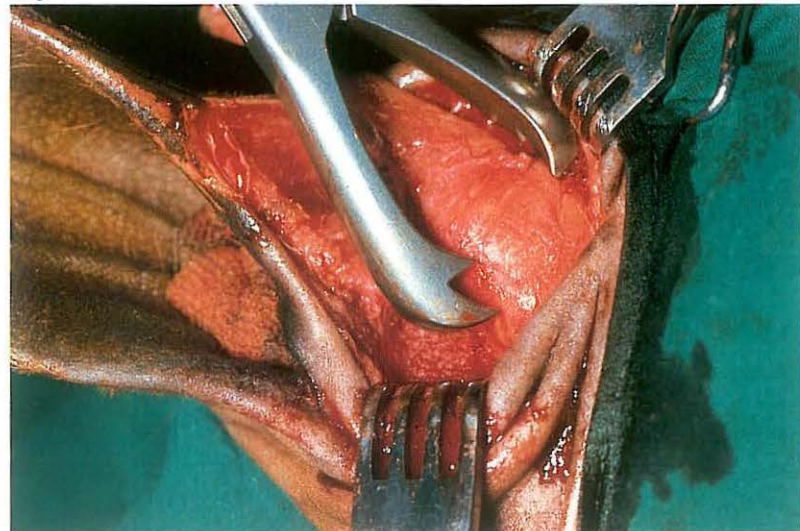
013



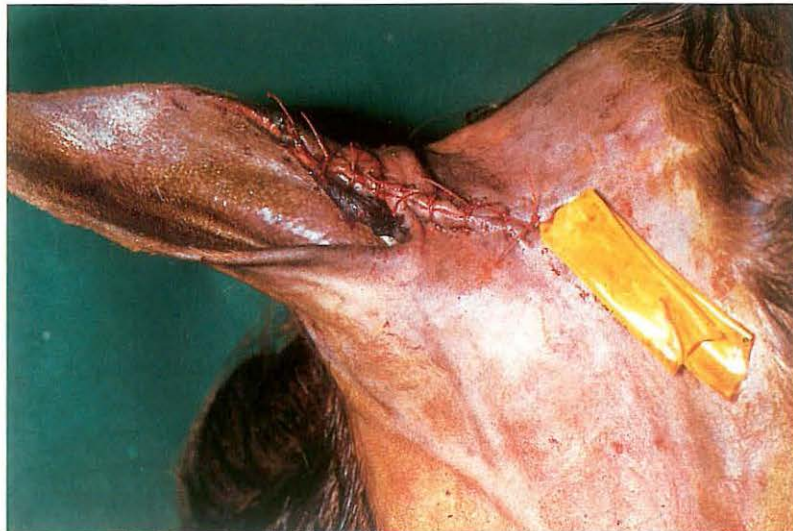014



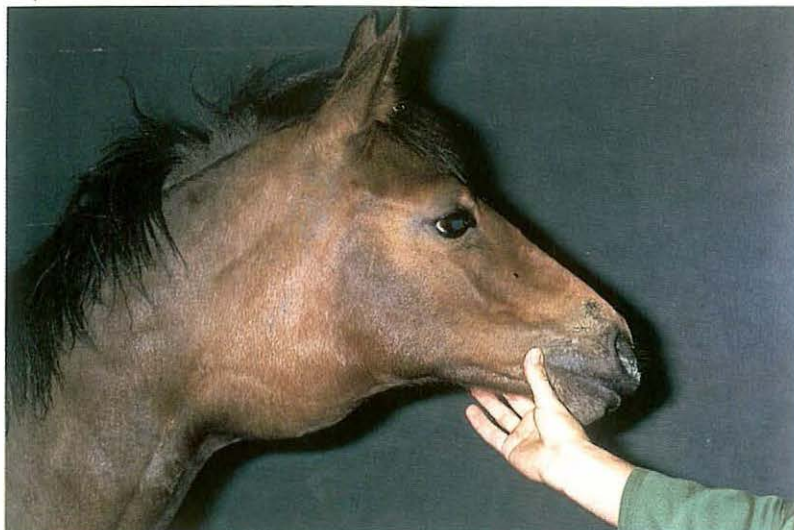015



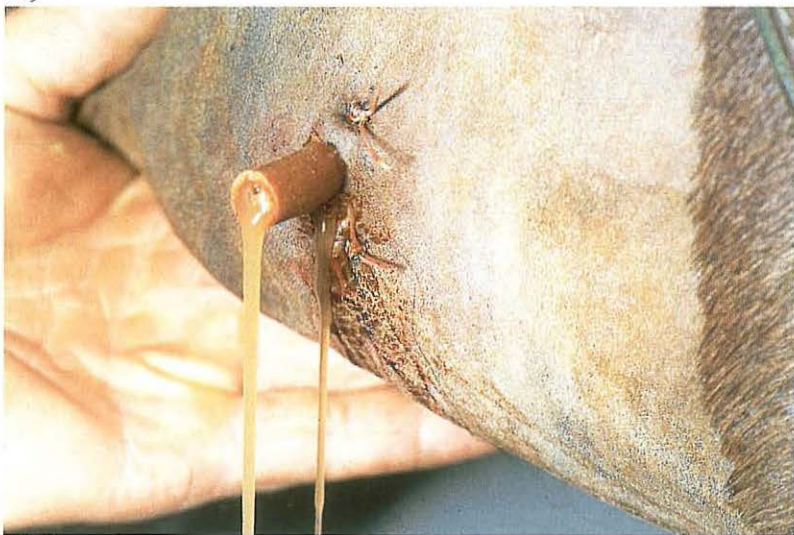016



017



019

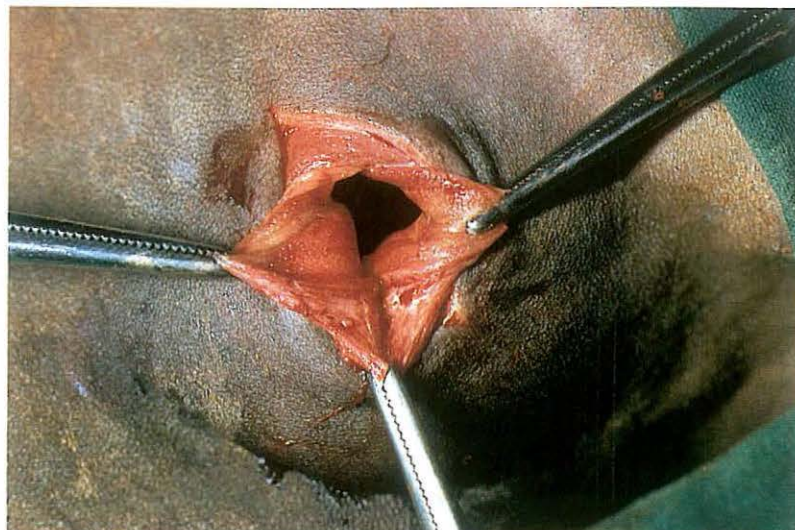


1-3 Drainage and fenestration

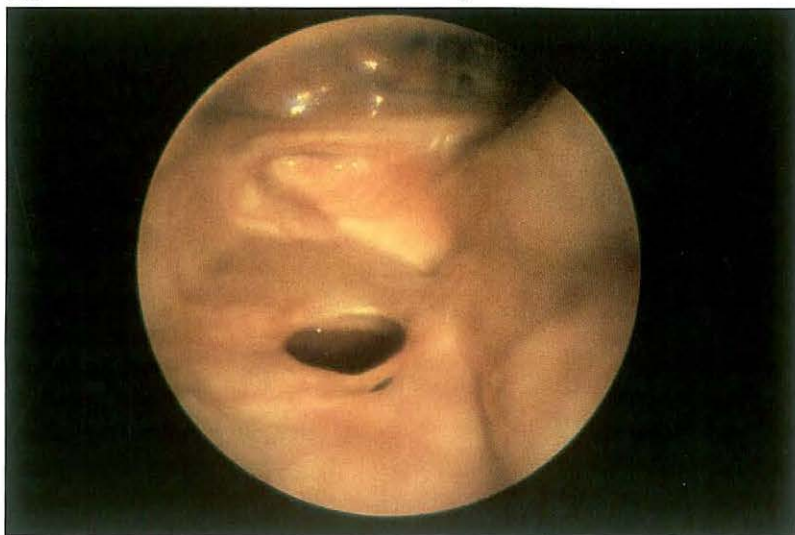Guttural pouch drainage is indicated in chronic empyema, chondroids and tympany, the latter of which is observed only in foals [017].

Surgery. Surgery is usually performed with the animal in lateral recumbency under general anaesthesia. The guttural pouch is commonly opened through Viborg's triangle, which is bounded by the linguofacial vein, the tendon of the sternocephalic muscle, and the vertical ramus of the mandible. A 3-5 cm incision is made dorsal and parallel to the vein through the skin and subcutaneous fascia. The connective tissue at the ventral border of the parotid is bluntly dissected, until the guttural pouch submucosa has been reached. A fold is carefully elevated as far as possible, and opened with scalpel or scissors [018]. If possible the wall of the guttural pouch is sutured to the edges of the skin wound. Abnormal contents are removed by flushing with a mild disinfectant. A rubber tube is inserted into the drainage opening, and fixed to the skin with sutures [019]. Postoperative flush-

018



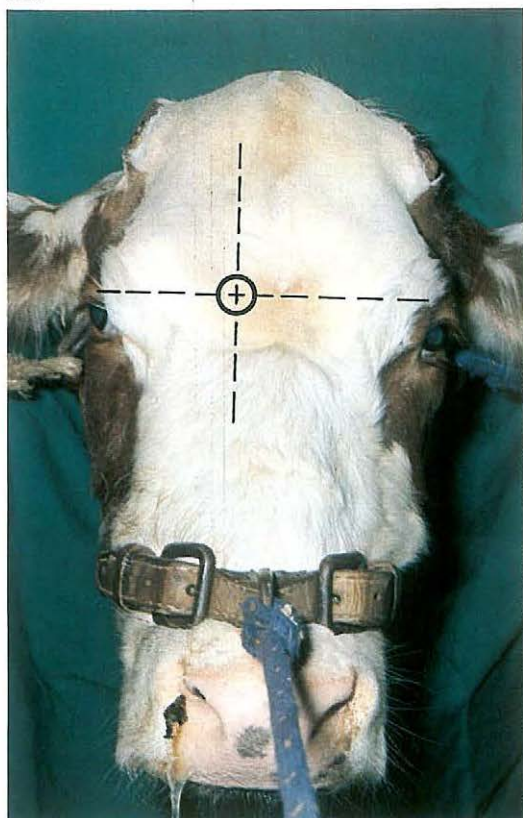
020



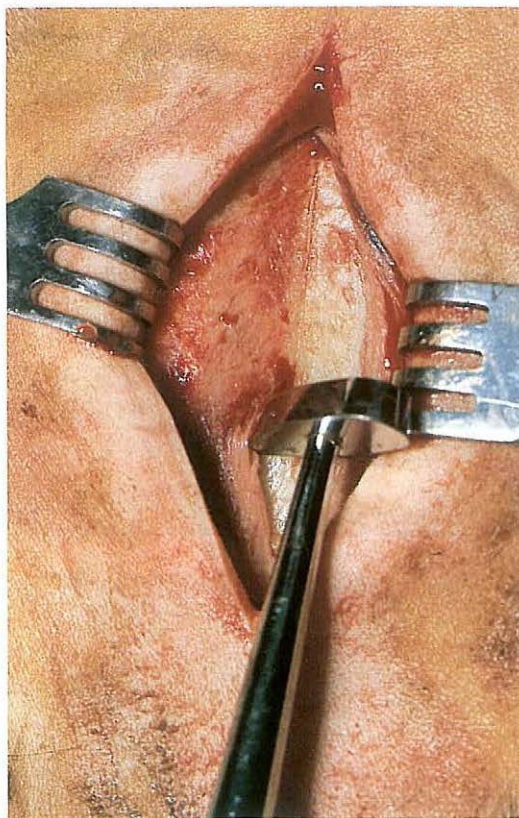
ing is carried out until exudation has ceased; during this period the tube is left in place.

In unilateral tympany the tympanic pouch is opened through Viborg's triangle, and a fenestration is made in the septum between the right and left guttural pouch, using long tissue forceps and scissors [020]. In bilateral tympany one pouch is opened, fenestration performed, and the mucous membrane flap (valve) at the outlet of the Eustachian tube of the opened pouch dissected. In both cases the opened guttural pouch is drained and flushed until exudation has ceased.

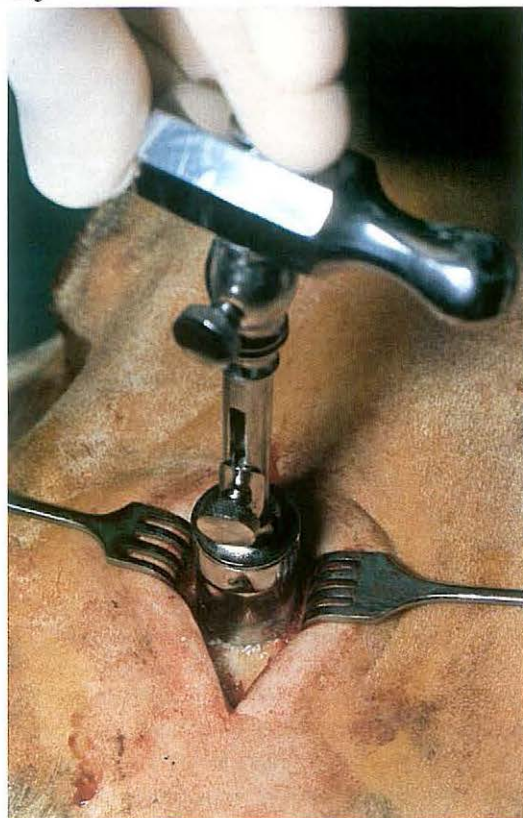021



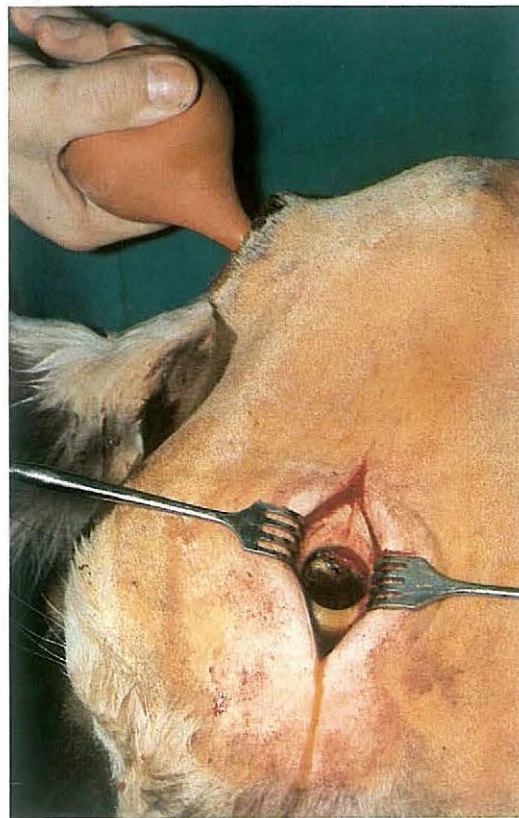
022



023



024



1-4 Trephination of the frontal sinus in cattle

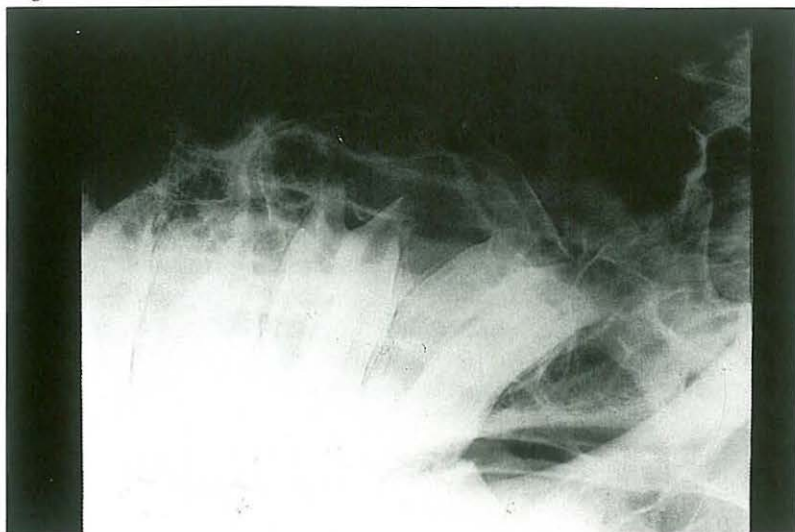
Trephination of the frontal sinus is indicated in chronic empyema, which in adult cattle is caused usually by infection of the sinus following dehorning or horn fracture. Initially the sinusitis is often confined to the caudal part of the sinus, but in long-standing cases the entire sinus may be involved. In the latter case drainage of the sinus is obtained by trephining 2 cm from the midline on a line passing through the centre of the orbits [021]. If the original opening to the sinus at the site of the dehorning wound is narrowed or closed by granulation tissue, it is enlarged or re-opened under cornual nerve block to facilitate adequate flushing of the sinus.

Surgery. Trephination is carried out on the standing animal under local analgesia. An approximately 5 cm long vertical incision is made through skin, subcutis and periosteum. The periosteum is dissected from the bone with a periosteal elevator [022] and drawn aside, together with the skin, with wound retractors. The point of the trephine is inserted into the bone. Trephination is performed by rotating the trephine [023]. After a circular groove has been cut into the bone, the point of the trephine is retracted, and trephination is continued through the full thickness of the bone. The disc is removed with a bone screw inserted into the hole made previously by the point of the trephine. Sometimes the disc must be levered out because it remains fixed to a bony sinus septum.

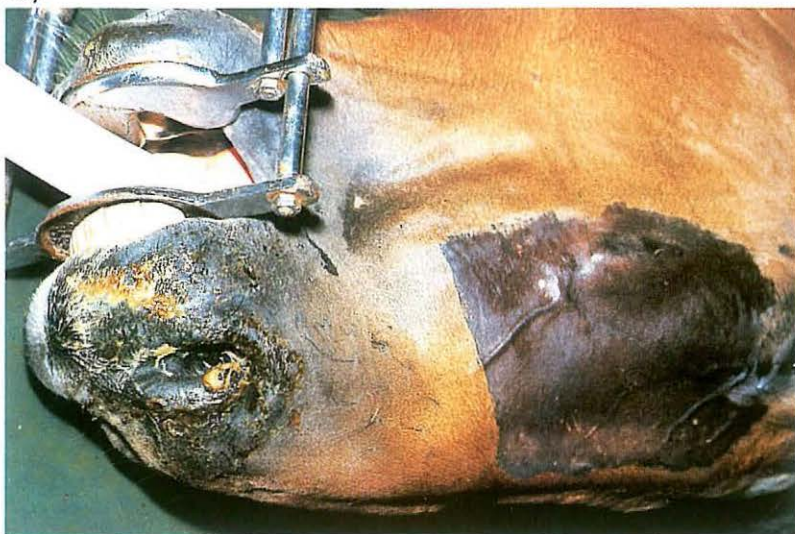To remove exudate and necrotic tissue the sinus is flushed thoroughly with a disinfectant solution [024].

To prevent premature closure of the openings they are packed with gauze bandage plugs. Post-operative flushing is repeated daily, until the sinus has healed, as evidenced by absence of purulent discharge.

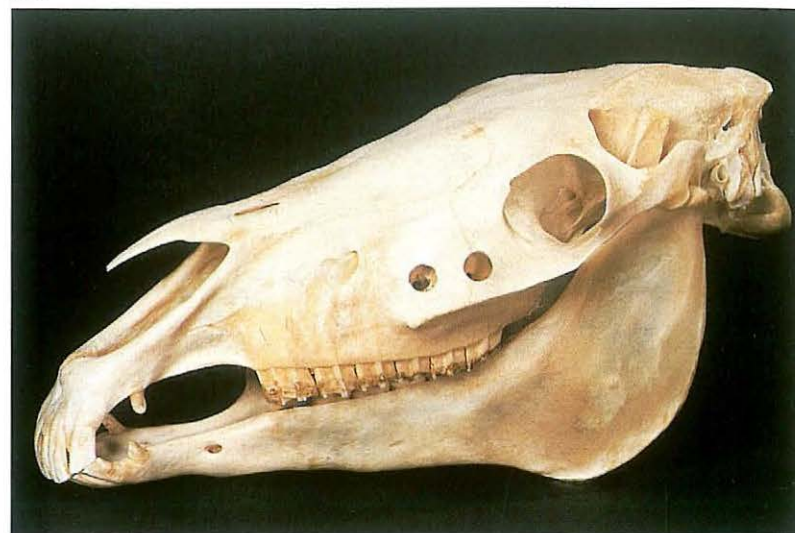025



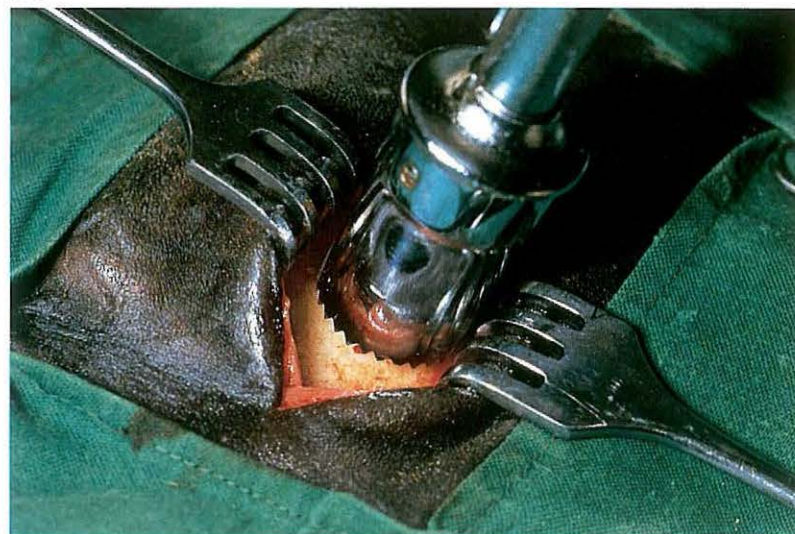027



026



028



1-5 Trephination of the maxillary sinuses and repulsion of teeth in the horse

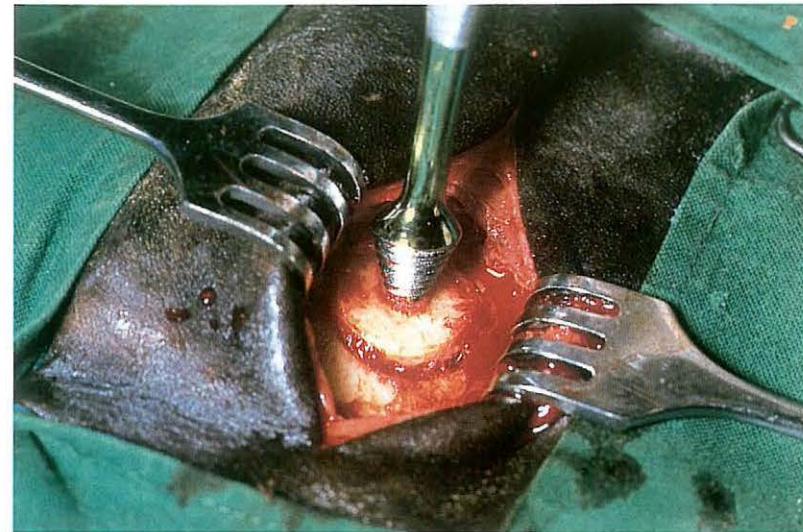
Trephination of the maxillary sinuses is indicated in cases of empyema, cysts or neoplasms, and for repulsion of upper molar teeth. Plate 025 represents a radiograph showing chronic alveolitis of the first upper molar. The rostral maxillary sinus is trephined about 2-3 cm dorsal to the rostral end of the facial crest; the caudal maxillary sinus is trephined 2-5 cm rostral to the medial canthus and 2-3 cm dorsal to the facial crest [026]. Care must be taken to avoid damage to the nasolacrimal duct.

Surgery. The operation may be carried out either on the standing animal under local infiltration analgesia, or on the recumbent animal [027] under general anaesthesia. In case of tooth repulsion general anaesthesia is required.

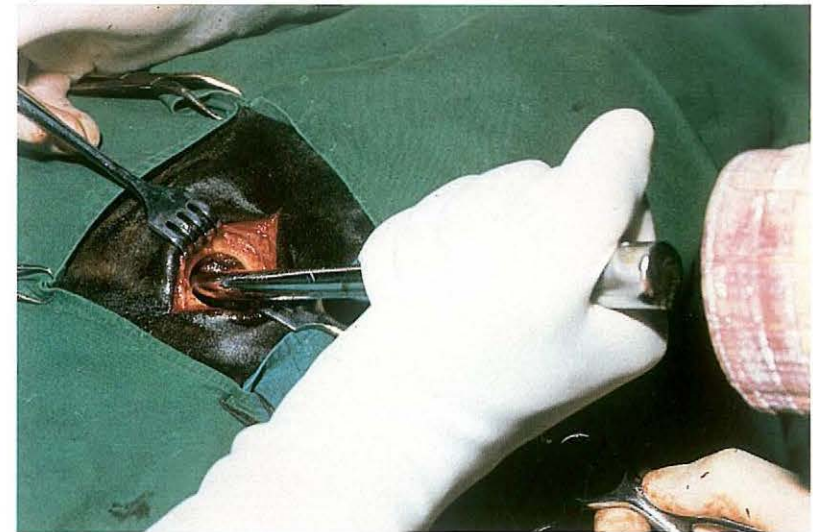
At the selected site an approximately 4 cm long incision is made parallel to the facial crest through the skin and subcutaneous tissue. Depending on

the site of surgery it may be necessary to retract the levator labii maxillaris muscle in order to expose the periosteum. The periosteum is then incised with a scalpel and separated from the bone with a periosteal elevator. The wound edges of the skin and periosteum are drawn aside with wound retractors [028]. Trephination is performed as described in 1-4. The disc is removed with a bone screw [029]. In empyema caused by alveolitis, the sinus is flushed and the affected tooth is carefully located. A punch is then introduced into the sinus and placed upon the roots of the tooth to be repelled. To prevent damage to adjacent teeth and the maxillary bone, the punch must be placed accurately; it may thus be necessary to enlarge the trephination hole with rongeurs. The tooth is repelled from its alveolus with firm, but careful, blows [030]. The course of repulsion is constantly checked by the surgeon's hand in the oral cavity. After removal the tooth is examined to determine if it is complete. Any tooth or bony fragments must be removed. Intra-operative radiography is recommended to ensure that no fragments remain. The sinus and alveolus are copiously flushed with a

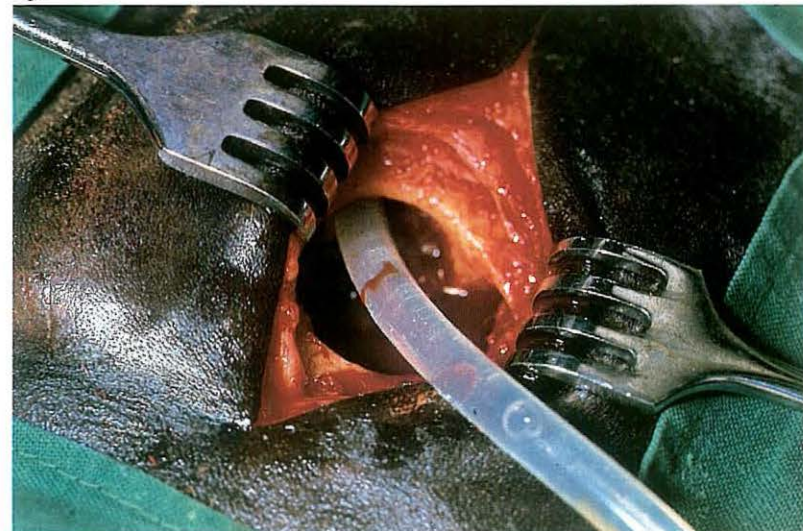
029



030



031

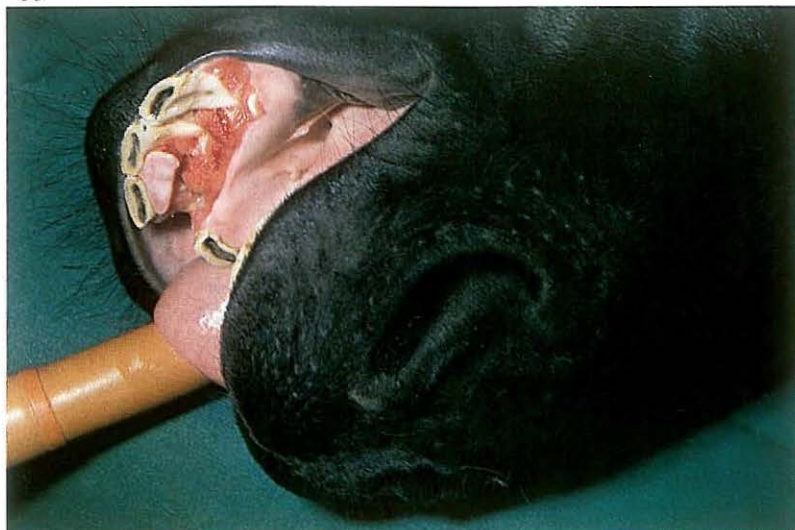

032

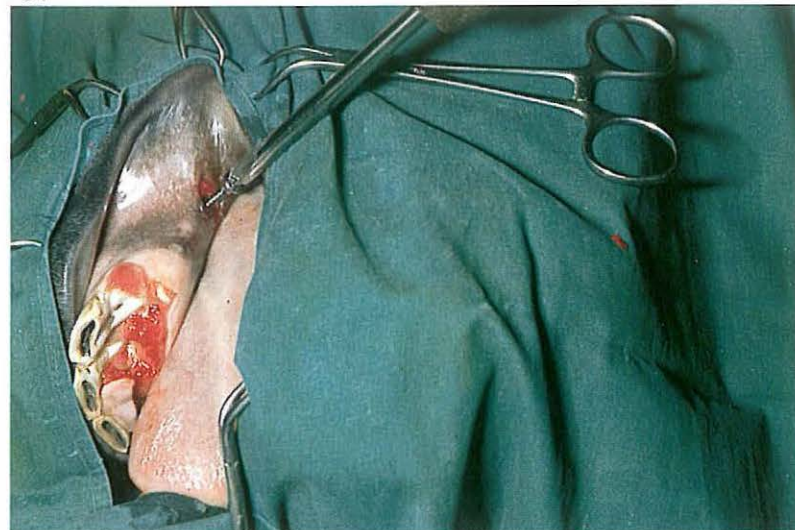


disinfectant solution [031]. The alveolus and trephination hole are then packed with povidone iodine soaked gauze bandage plugs [032]. Postoperatively the sinus and alveolus are repeatedly flushed after removal of both plugs. The plug placed in the alveolus after flushing must be somewhat smaller than the previous one, in order to enable granulation tissue to gradually fill the alveolus; the plugs in the trephination hole are of constant size. Only when the alveolus is closed off by granulation tissue and exudation in the sinus has ceased is the trephination hole allowed to close.

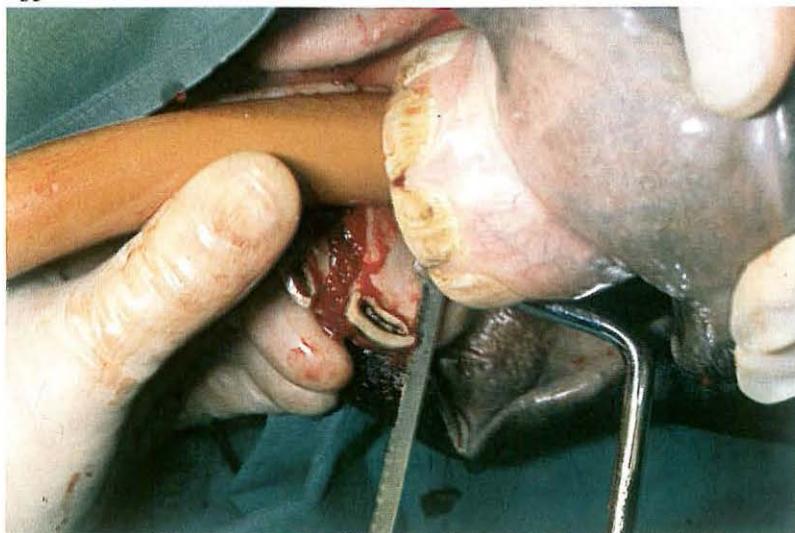
033



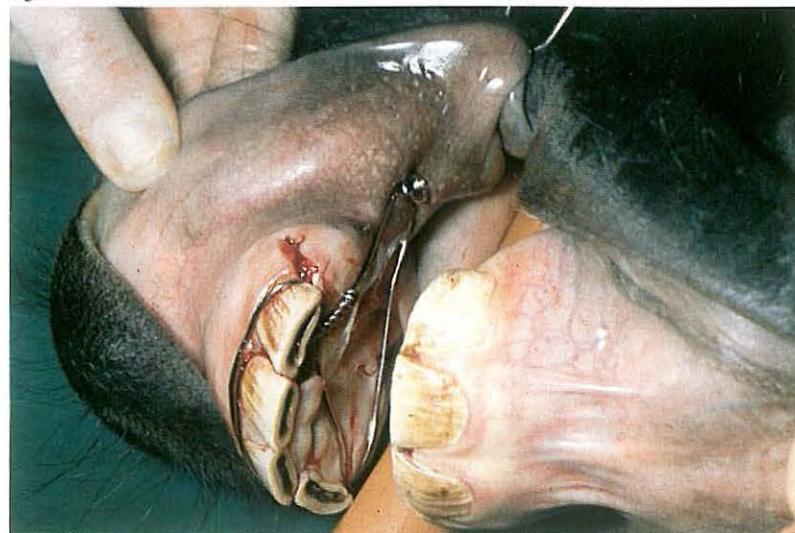034



035



036

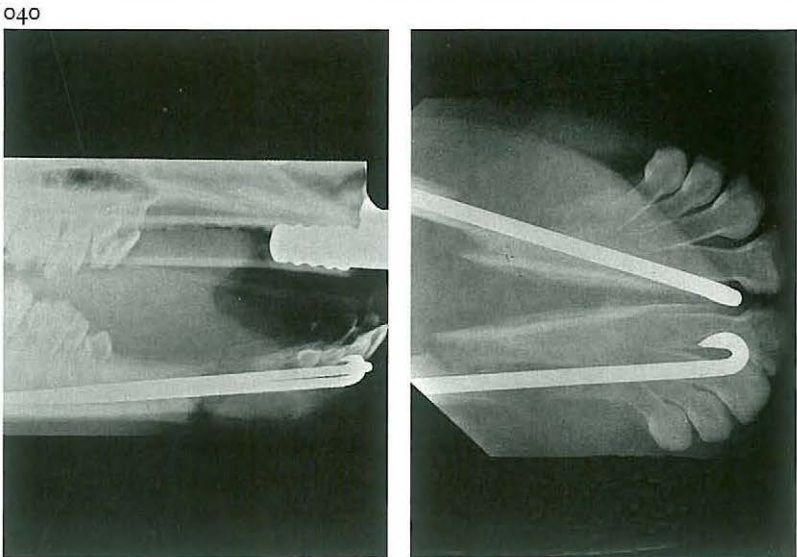
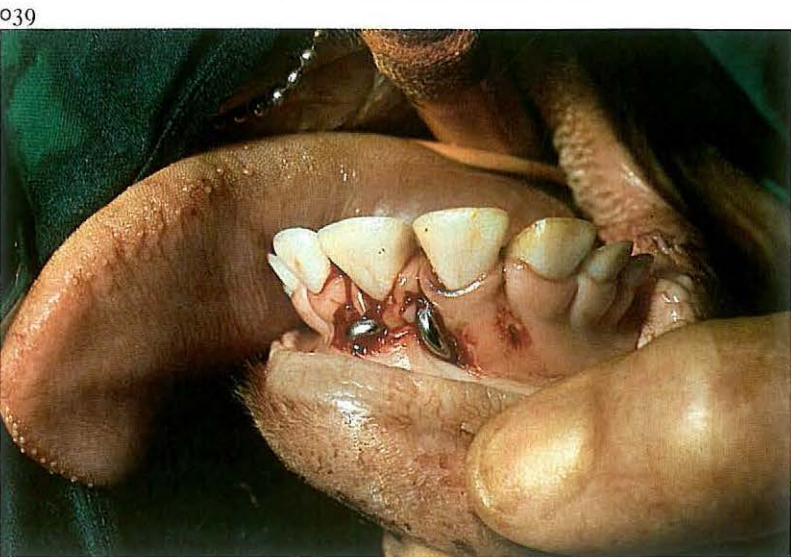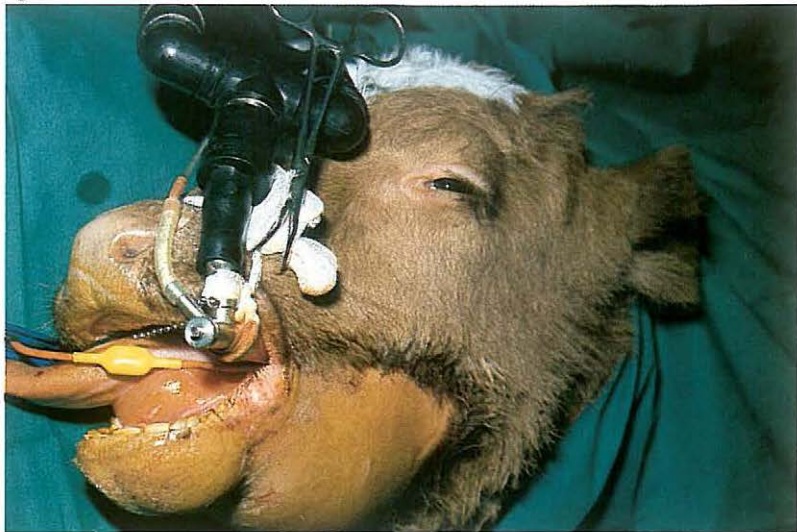

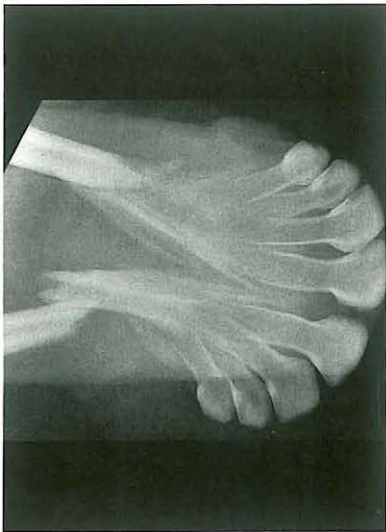
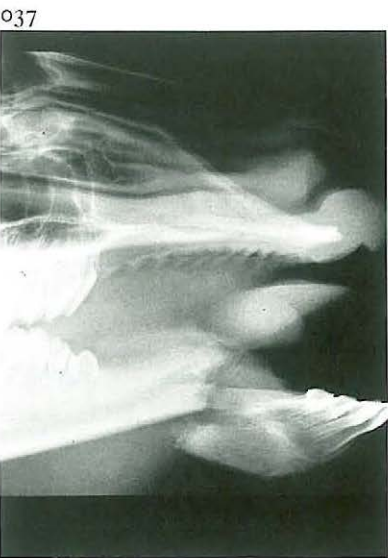1-6 Treatment of premaxilla and mandibular body fractures

Fractures of the maxilla and mandible have been observed in all large animals but occur most frequently in horses and cattle. Self-inflicted trauma and external violence are the most common causes. In horses, fractures involving the incisor teeth and a variable sized fragment of premaxilla or mandible occur frequently [033]. The deciduous teeth in young animals are frequently involved. Because these teeth have short roots the injury is often minor and of little consequence. Clinically, dislocation of the incisor teeth is obvious. The wound may be packed with feed if the animal has attempted to eat. Teeth may be loose, broken or missing.

Surgery. The operation should be performed in lateral recumbency under general anaesthesia. Debris and granulation tissue, if any, are removed and the wound is carefully cleansed and disinfected. The fragment should be fixed to the premaxilla or mandible by wiring the incisor teeth, but compression in a caudal direction may also be necessary. A canine tooth is used

for the caudal fixation, but if absent (as in this case) a cortical screw is placed in the intervalveolar space [034]. To prevent the wire from slipping off the teeth, grooves are made with a hack saw or file in the neck of both third incisors [035] and in the canine teeth. By tightening the stainless steel cerclage wire around the unfractured teeth the fragment is stabilised laterally, and additional stabilisation and compression is achieved by applying and tightening the wire around the canine tooth or the screw [036]. Postoperatively, there is usually no problem associated with prehension or mastication. Healing of the fracture takes place in 4-8 weeks depending on the age of the patient. After healing the wire must be removed.



1-7 Treatment of mandibular interdental space fracture

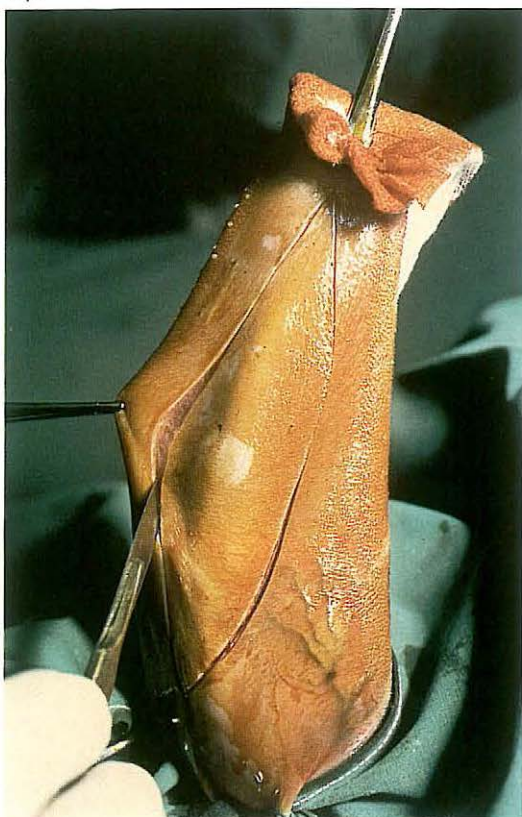Fracture in the interdental space is the most common fracture involving the horizontal rami of the mandible. The fractures may be unilateral or bilateral [037] and usually compound into the mouth. Unilateral interdental space fractures without severe dislocation heal spontaneously. Bilateral fractures of the interdental spaces cause dislocation of the rostral part [038], and require osteosynthesis.

Surgery. The operation should be performed with the patient in lateral recumbency under general anaesthesia. In this case intramedullary nailing was chosen because the rostral fracture fragment was too short for plating or transfixation.

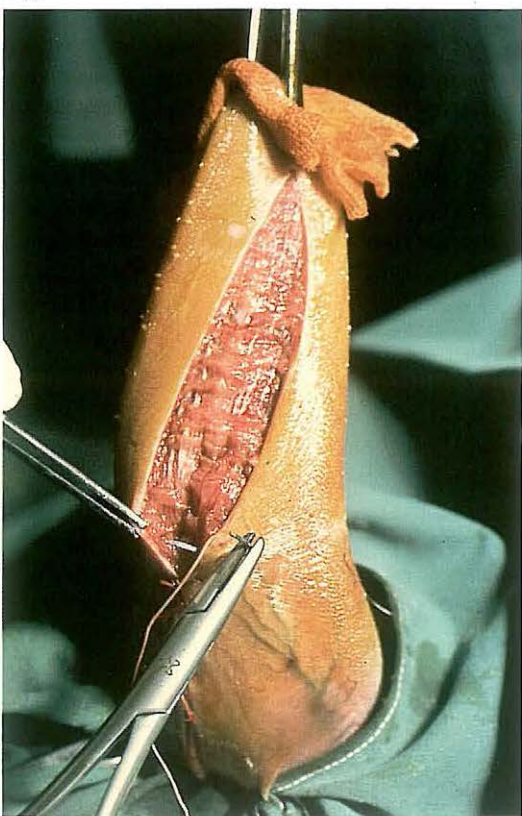
Implantation of the nails precisely in the mandibular rami without damaging the roots of the teeth demands radiographic monitoring during surgery to ensure accurate insertion of the drill. After reposition of the fracture a hole is drilled in each mandibular ramus beginning medioventral to the

two first incisor teeth or between the first and second incisor teeth. The two Rush nails, previously cut to the required length and contoured correctly, are inserted with a hammer and impactor [039]. It is important that the nails do not damage the roots of the premolars [040]. Postoperative feeding must be modified, but in sucklings nursing can be permitted. In the event of compound fracture bone sequestration often occurs, in which case purulent material usually escapes from draining tracts inside and/or outside the mouth. Sequestra must be removed, after which discharge ceases. Healing of the fracture takes place in 4-8 weeks depending on the age of the patient; implants may then be removed.

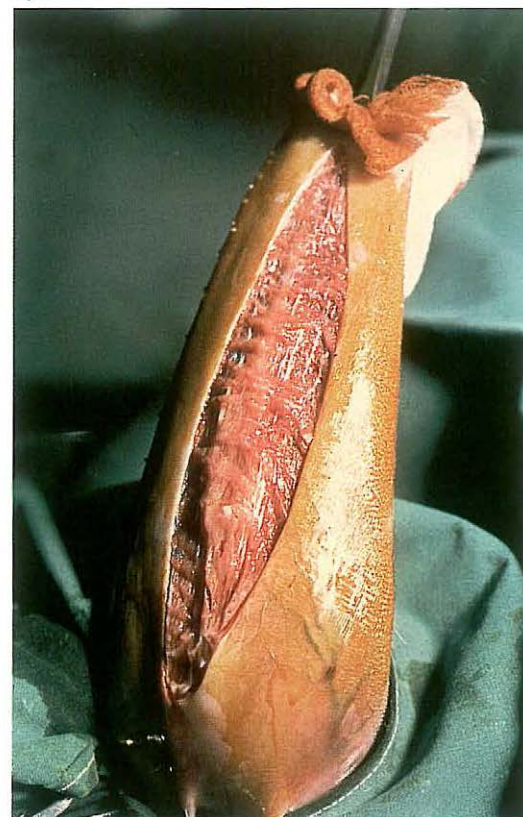
041



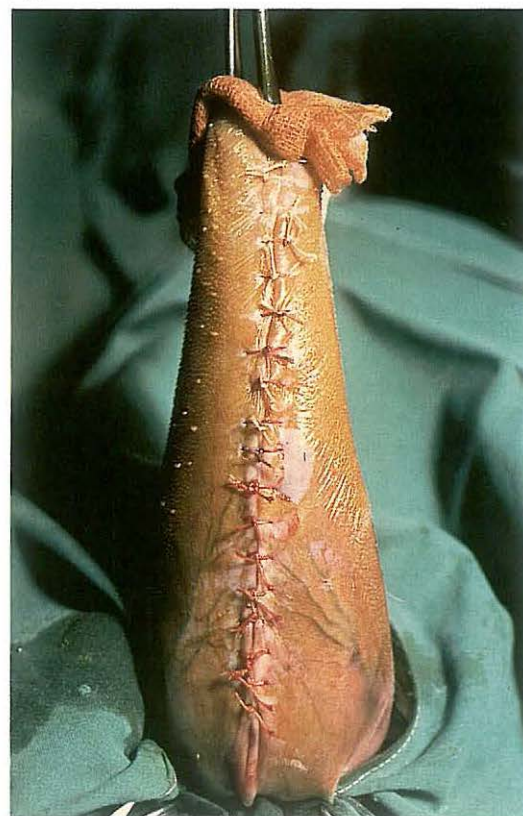043



042



044



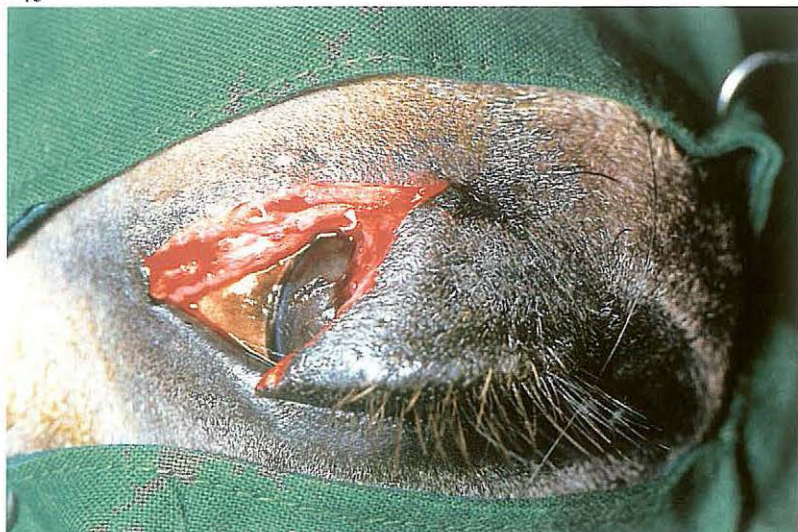
1-8 Lingual mucosa resection in cattle

Because of changes in housing facilities in the last ten years the problem of cattle which suck themselves or each other has increased. Numerous mechanical devices have been invented to prevent sucking. Because the herd may become restless due to the pain these devices inflict, and feeding and drinking may be impaired, surgical treatment is preferable.

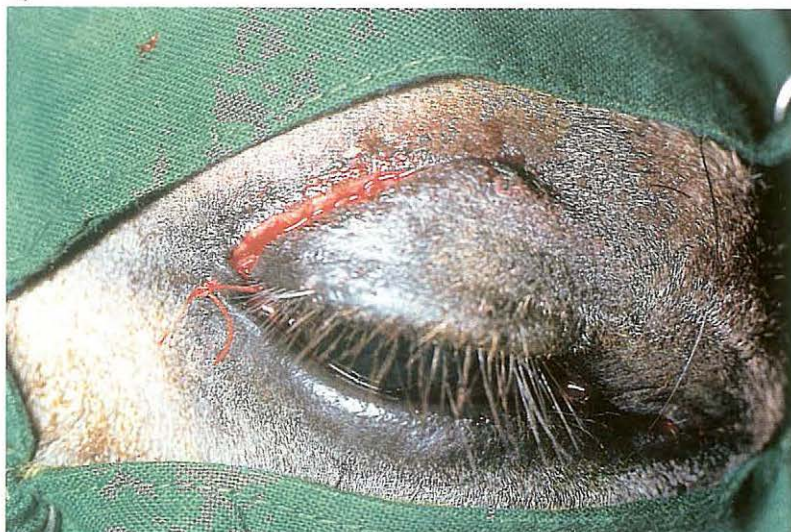Surgery. The patient is sedated and restrained in lateral recumbency. Traction on a modified sponge forceps applied to the tip of the tongue facilitates exposure of the ventral lingual surface. A tourniquet is placed around the base of the tongue as close to the frenulum as possible, and the operative area is submucosally infiltrated with local analgesic. The elliptical incision begins a few centimetres caudal to the tip of the tongue, ends just cranial to the attachment of the frenulum, and is about 5 cm wide at its widest part in adult cattle [041, 042]: it is important that sufficient mucosa is excised so that a convex shape of the dorsum of the tongue is produced after suturing is complete. The wound edges are apposed with single interrupted sutures of synthetic absorbable material. The sutures must include not only the mucosa but also some muscle to prevent tearing of the tissue by the sutures [043, 044].

For 12-24 hours postoperatively the patients receive only water. Nearly all animals will eat immediately thereafter, and show no major problems in prehension and mastication of food.

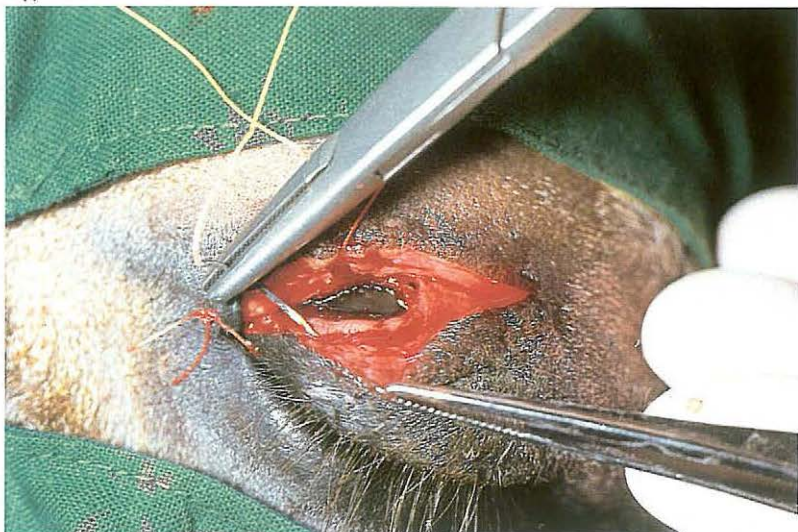
045



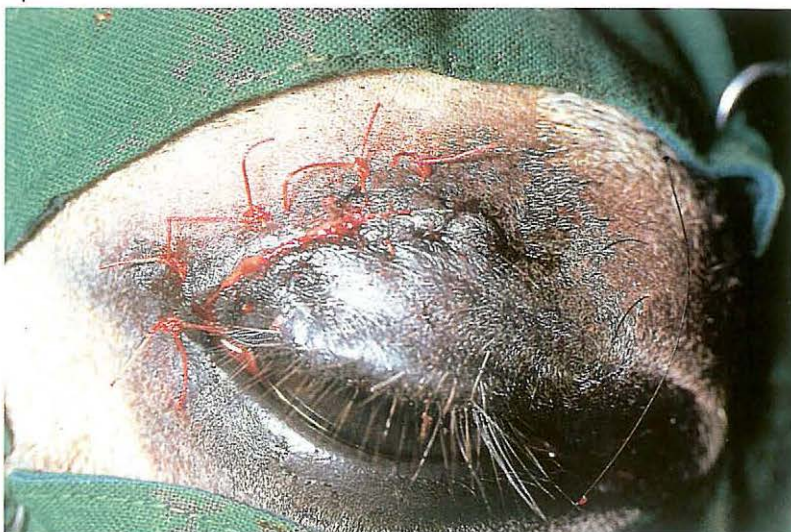046



047



048



1-9 Suturing of eyelid lacerations

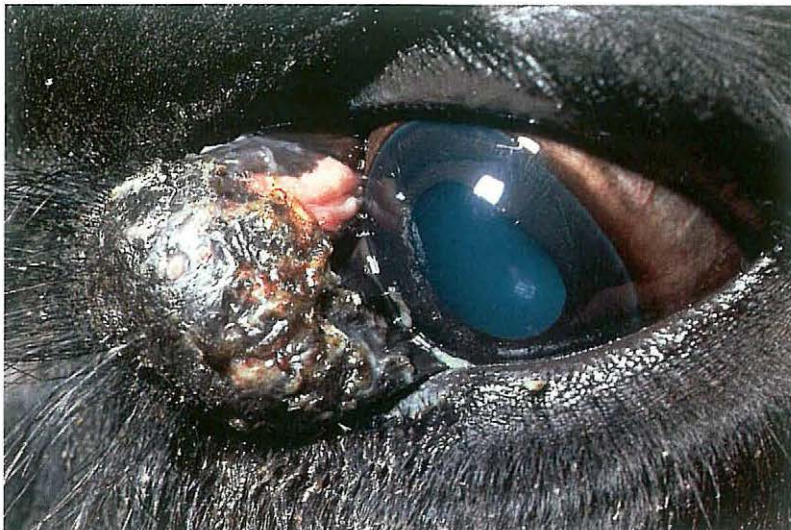Eyelid lacerations in horses are often full-thickness, i.e. involving skin, orbicularis oculi muscle and conjunctiva. Usually the upper eyelid is torn [045]. In cases of recent laceration re-apposition and careful suturing must be attempted.

Surgery. Treatment may be carried out either on the standing animal under local analgesia (infiltration or frontal nerve block), or on the recumbent animal under local analgesia or general anaesthesia. The wound and conjunctival sac are flushed with physiologic saline. Sharp superficial excision of the wound edges is then carried out with a scalpel, to produce fresh, bleeding surfaces. Suturing is begun at the site of the palpebral margin, where a simple interrupted suture is placed [046]. The remainder of the wound is then closed. Usually the conjunctiva is not sutured: in any case perforation should be avoided to prevent damage to the cornea. The orbicularis oculi muscle and skin are sutured together, either with interrupted vertical mat-

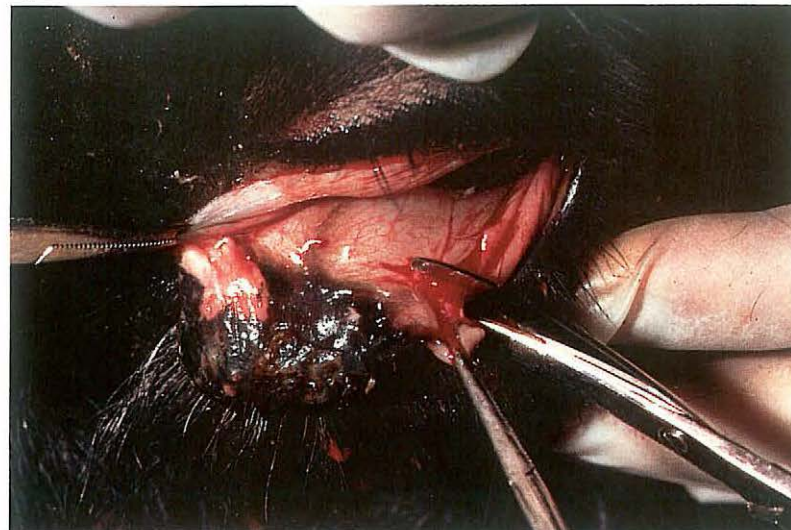
tress sutures or with deep simple interrupted sutures alternating with superficial simple interrupted sutures. The deep bites of the mattress suture involve the skin together with the orbicularis oculi muscle [047], and the superficial bites only the skin. Either absorbable or non-absorbable suture material may be used.

The sutures are left in place for at least one week [048]. During this period ophthalmic antibiotic ointment may be administered twice daily.

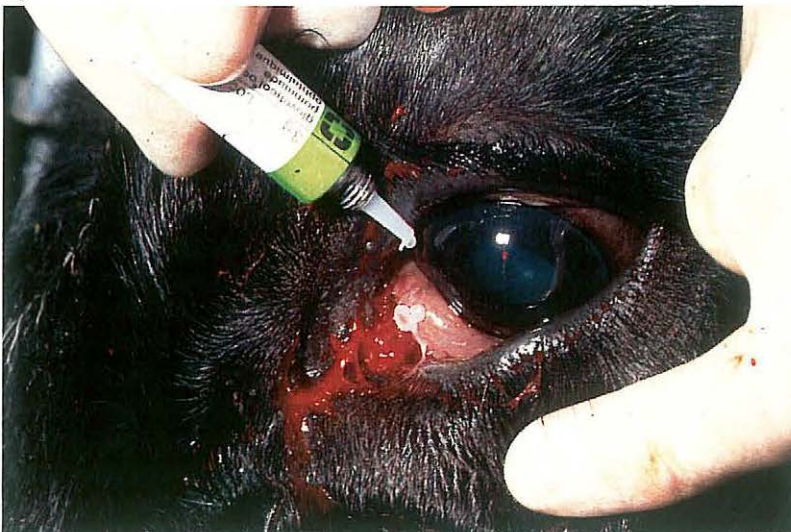049



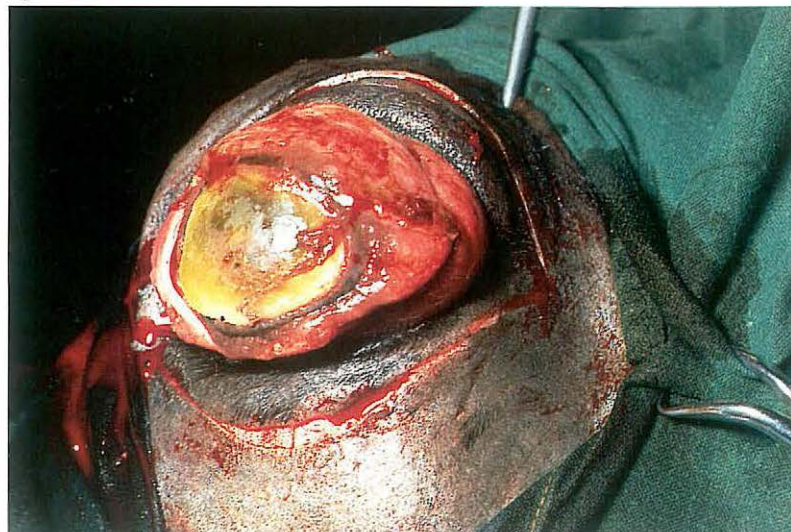050



051



052



1-10 Excision of the nictitating membrane

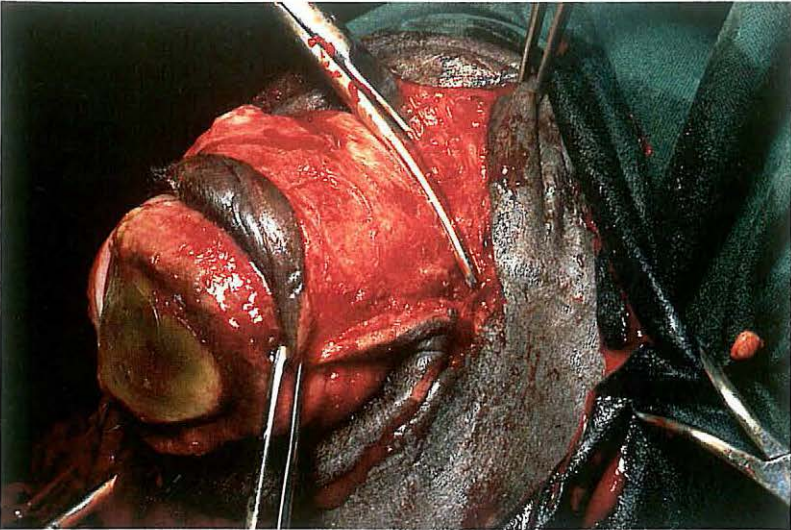
Surgery of the third eyelid is indicated in case of tumorous growth, which in horses and cattle usually involves squamous cell carcinoma. Small neoplasms can be removed leaving an intact nictitating membrane, but larger tumours require total excision [049].

Surgery. The operation is carried out on the standing or recumbent animal under local analgesia. The base of the third eyelid is infiltrated with a local analgesic after instillation of topical analgesic in the conjunctival sac.

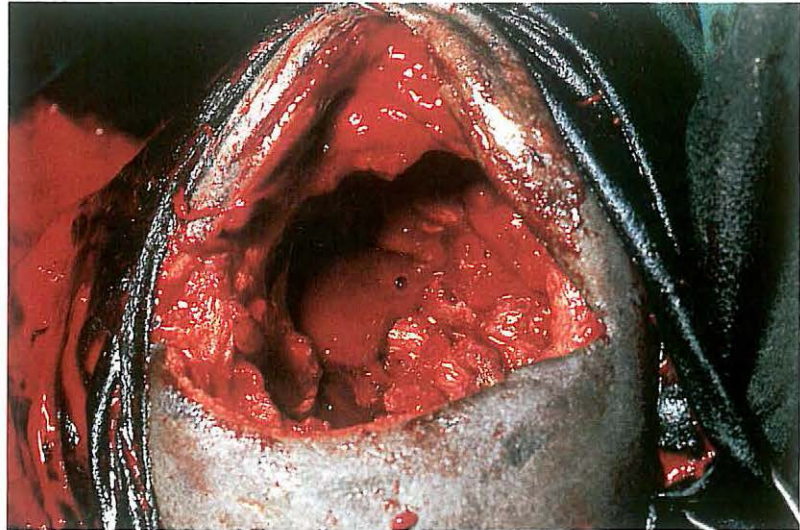
The nictitating membrane is held with a forceps and drawn from the conjunctival sac as far as possible. Complete excision deep to the cartilage is performed using a pair of curved blunt-pointed scissors [050]. Haemorrhage is controlled by pressure with a gauze swab soaked in 0.01 per cent adrenalin solution.

Ophthalmic antibiotic ointment is administered in the conjunctival sac for several days [051].

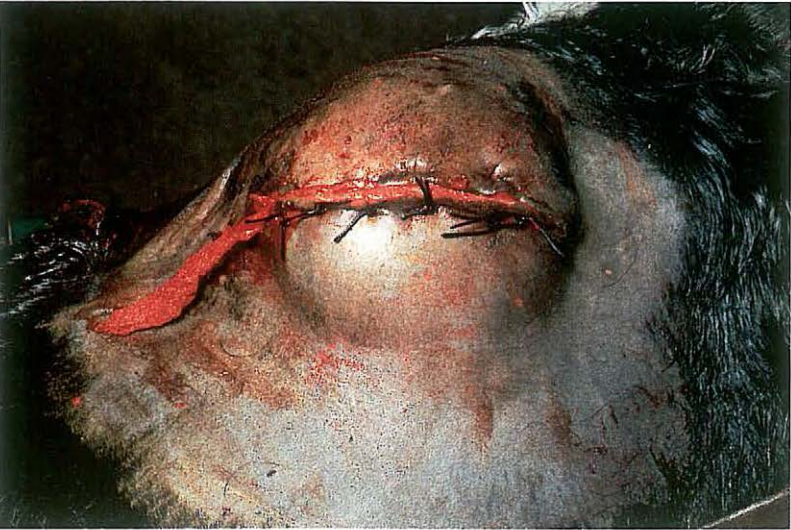053



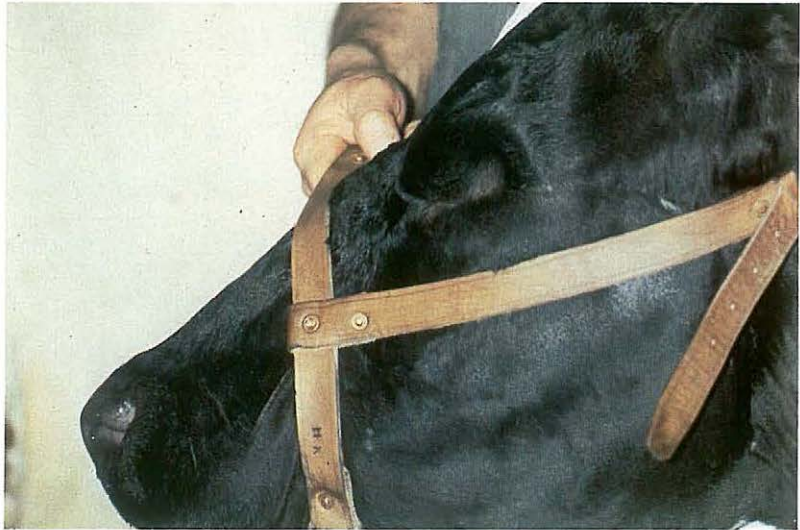054



055



056

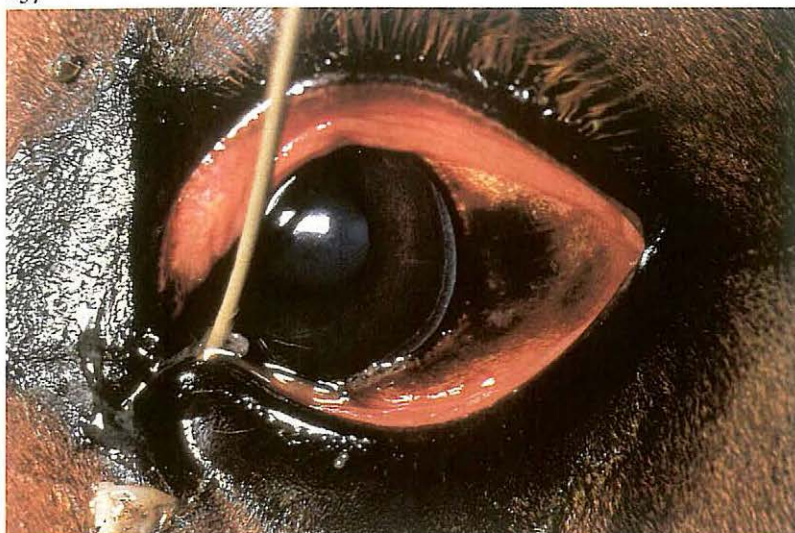

1-11 Enucleation of the eyeball

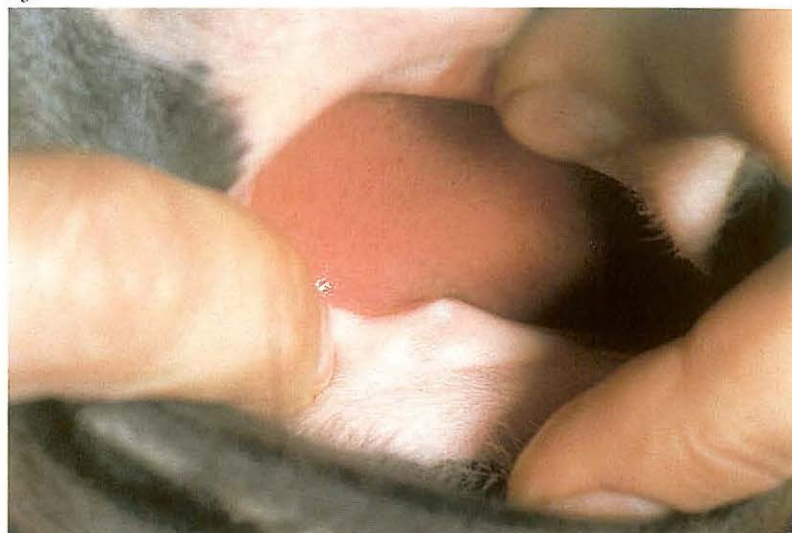Enucleation of the eyeball usually includes removal of the globe together with the bulbar and palpebral conjunctiva, the nictitating membrane and the lacrimal gland. The operation may be indicated in cases of eyelid or eyeball neoplasia, gross injuries of the eyeball (e.g. corneal rupture) and panophthalmitis [052].
Surgery. Surgery is carried out with the animal recumbent under either general anaesthesia, or under ophthalmic nerve regional analgesia and infiltration analgesia of the lower eyelid and medial canthus. If possible, the upper and lower eyelids are sutured together with a continuous suture. An elliptical incision, 0.5-1 cm from and parallel to the margin of the eyelids, is made through the skin and palpebral muscle [052]. By blunt dissection in the direction of the orbital ridge the orbit is entered [053]. The retrobulbar tissues and extra-ocular muscles are dissected bluntly and transected as close to the globe as possible. Finally the retractor bulbi muscle and en-

closed ophthalmic vessels and optic nerve are clamped with a curved crushing forceps and transected between forceps and globe. The eyeball is then withdrawn from the orbit [054]. The lacrimal gland is then removed. The forceps is removed; haemorrhage may be controlled either by vessel ligation or packing the orbit with sterile gauze bandages. The eyelids are sutured together with interrupted sutures, leaving a small opening medially for the gauze drain [055].
The gauze packing is removed after 2 to 3 days. Plate 056 shows the induced artificial ankyloblepharon several months postoperatively.

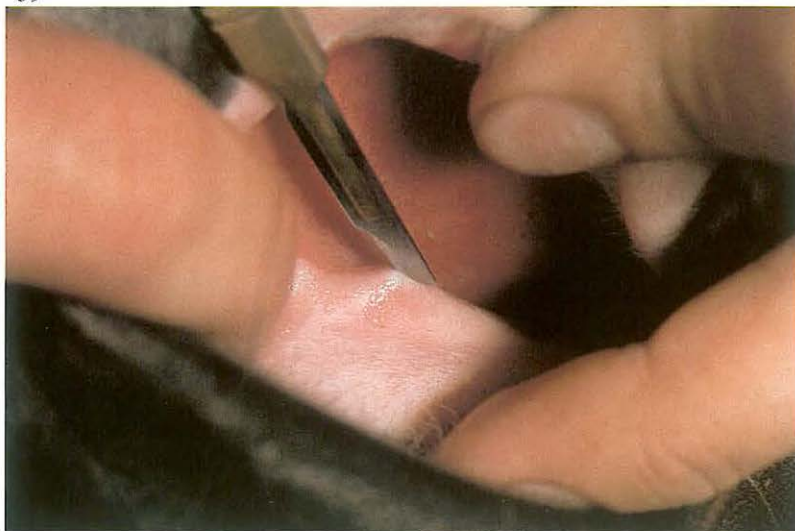057



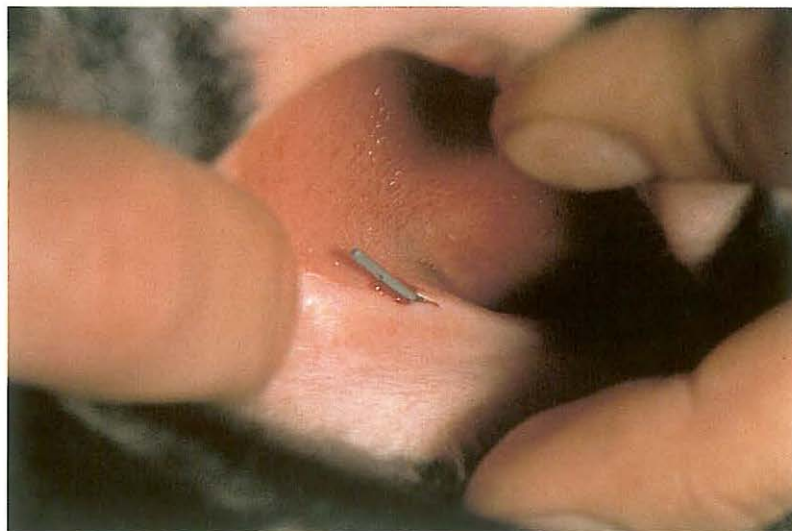058



059



060



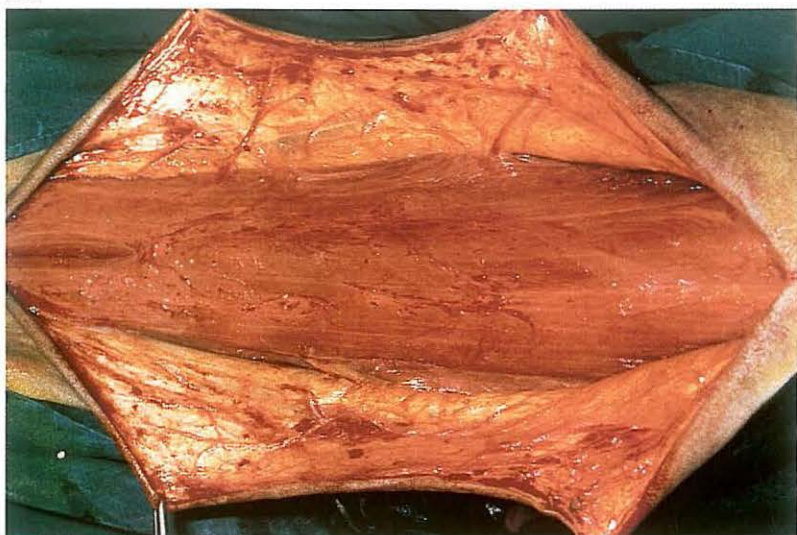1-12 Treatment of nasolacrimal orifice atresia

Atresia of the nasal opening of the tear duct may be the cause of chronic lacrimation in foals. In some cases the distal part of the duct is also absent. *Surgery.* Surgery is performed under general anaesthesia. A catheter is introduced into the lacrimal papilla of either the upper or lower eyelid [057]. The catheter is then advanced carefully down the tear duct, until the tip is palpable beneath the nasal mucous membrane [058]. The nasal mucosa and the mucosa of the blind end of the duct are incised over the tip of the catheter [059], after which the catheter is pushed through the opening created [060]. If accessible, the mucous membrane of the duct is sutured to the nasal mucous membrane with simple interrupted sutures of fine absorbable material. The catheter is then sutured to the skin in the nasal and eyelid regions, and left in place for at least two weeks. If suturing of the mucosal layers is impossible the catheter must be left in place for a longer period (3–4 weeks), after which time the wound edges have healed and the opening remains patent.

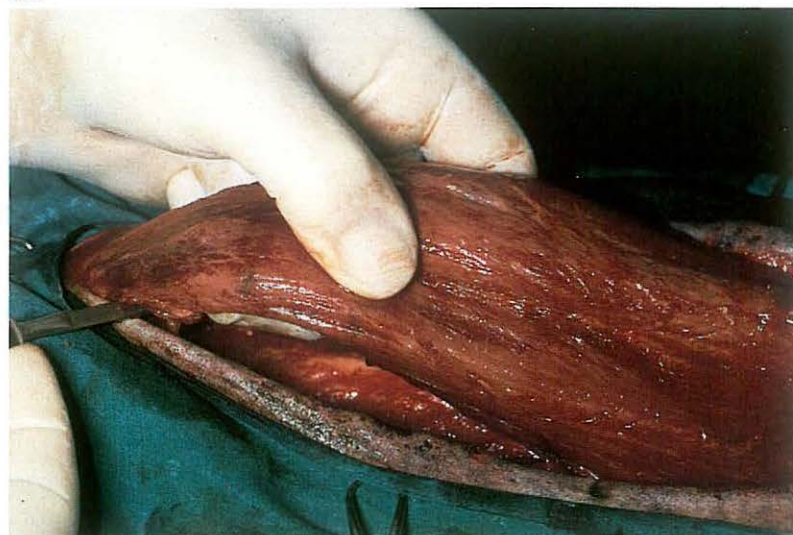
Postoperatively antibiotic ophthalmic ointments are administered into the conjunctival sac, and corticosteroids may be added for several days to reduce oedema and fibrosis around the created orifice.

Chapter 2 The neck

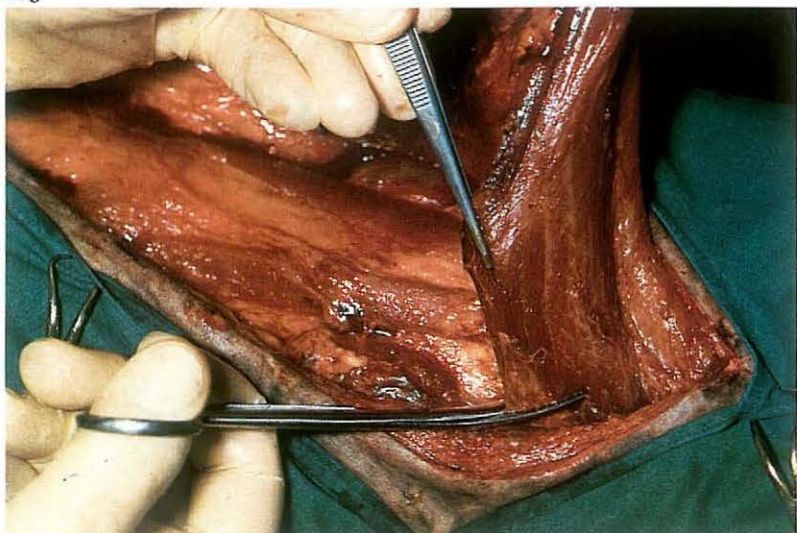
o61



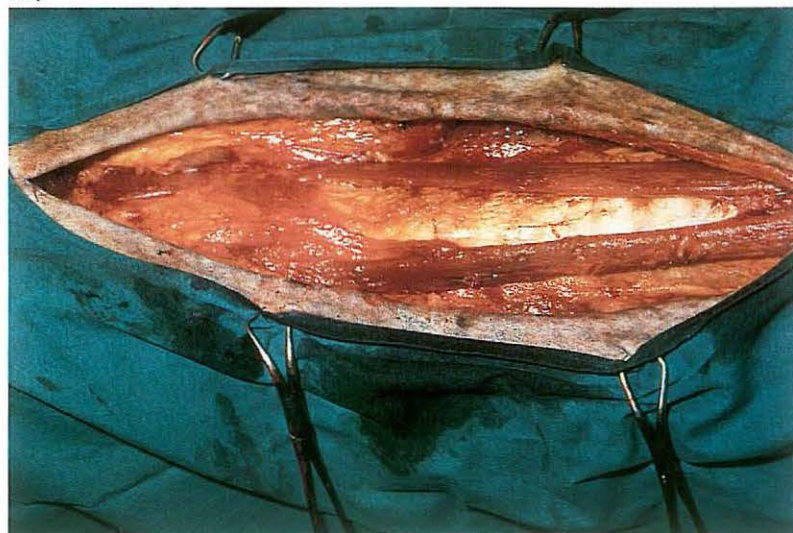
o62



o63



o64



2-1 Myectomy (Forssell) and accessory nerve neurectomy

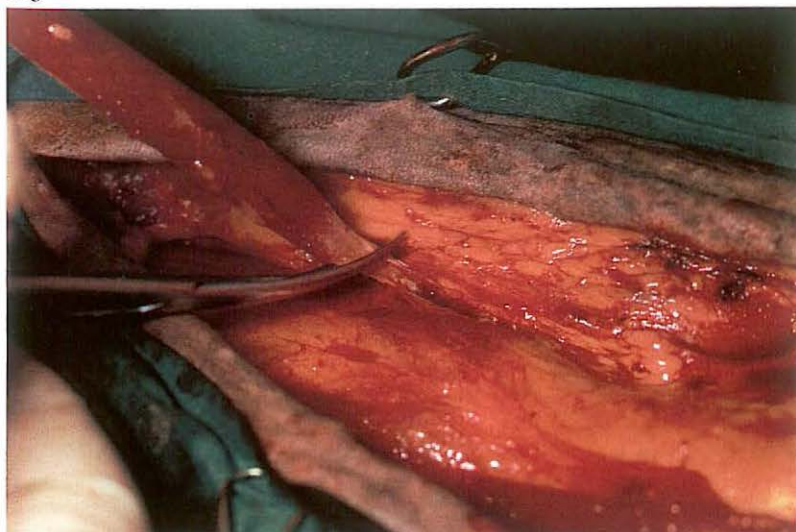
In crib-biting the horse grips a fixed object (e.g. manger) with the (upper)incisor teeth, arches the neck and attempts to swallow air; horses which succeed in swallowing air are called windsuckers. Some horses are 'free' windsuckers, these display the vice without cribbing. Initially non-surgical methods (cribbing strap, aversion therapy) may be used, but are often unsuccessful, and the owner requests surgical treatment. This consists of partial resection of the paired ventral neck muscles: sternohyoideus, omohyoideus, sternothyroideus and sternocephalicus. Instead of myectomy of the latter, neurectomy of the ventral branch of the accessory nerve may be performed.

Surgery. The horse is positioned in dorsal recumbency under general anaesthesia. Excessive extension of the neck should be avoided because of possible stretching of the recurrent nerve, the head should thus be resting at an angle of about 30°.

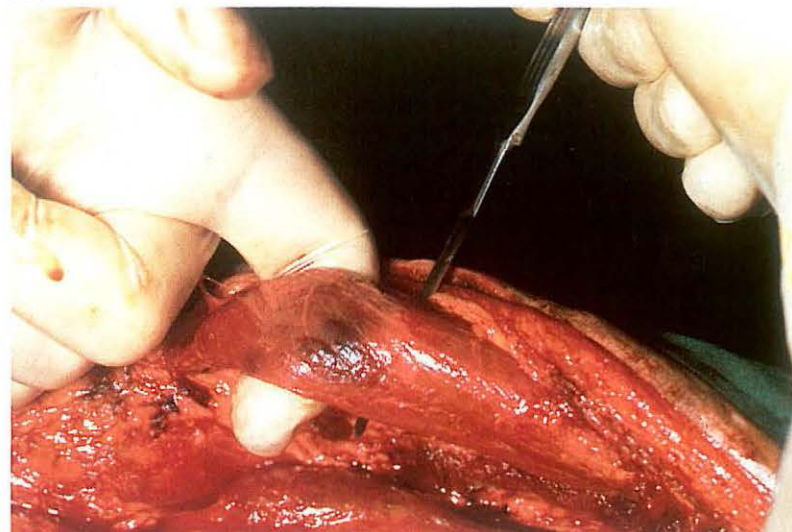
A midline skin incision of 30-40 cm is made from the hyoid bone caudally. The whole operation may be accompanied by considerable haemorrhage, and careful haemostasis is obligatory. The skin and subcutis are dissected and reflected laterally [o61]. The omohyoideus muscle is carefully separated from the jugular vein. The omohyoideus and sternohyoideus are transected near their insertions [o62] and reflected back to the caudal edge of the wound, whereafter the entire muscle section is removed [o63]. This exposes the cranial part of sternothyroideus [o64] which is easily dissected from the trachea and excised [o65]. Next the sternocephalicus is freed by blunt dissection after incising its sheath longitudinally. The muscle is transected at the caudal edge of the incision [o66], reflected cranially and severed through its tendon [o67].

Instead of sternocephalicus myectomy, denervation of the muscle may be performed. The purpose of neurectomy of the ventral branch of the accessory nerve is to diminish the post-operative deformity of the region. The nerve is located on the dorso-medial aspect and runs parallel with the

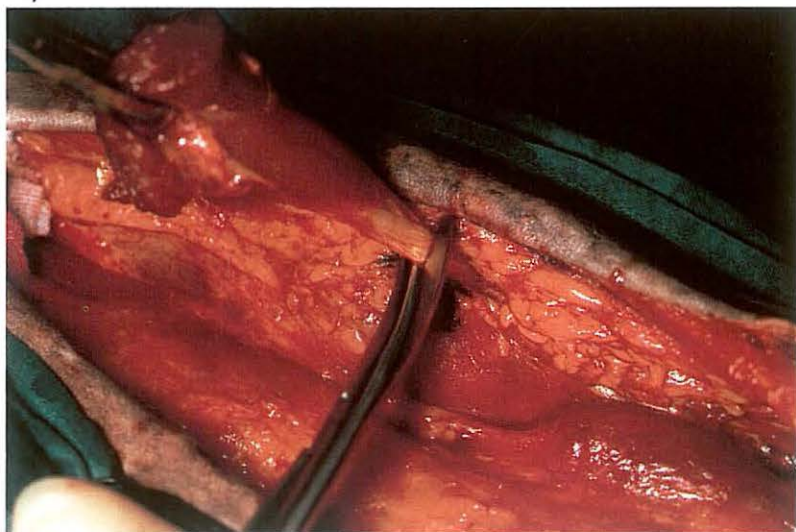
o65



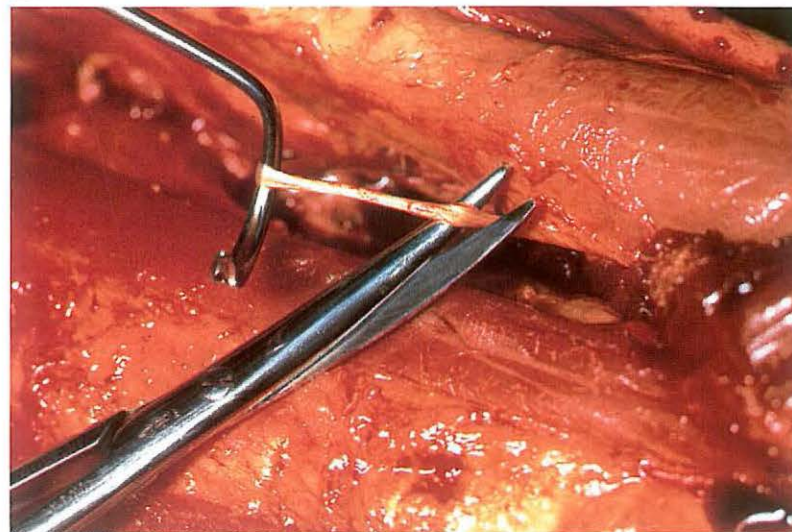
o66



o67



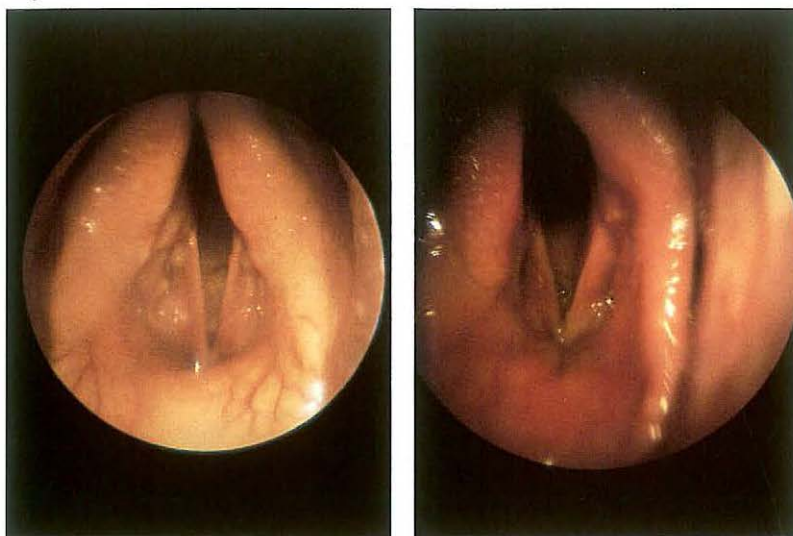
o68



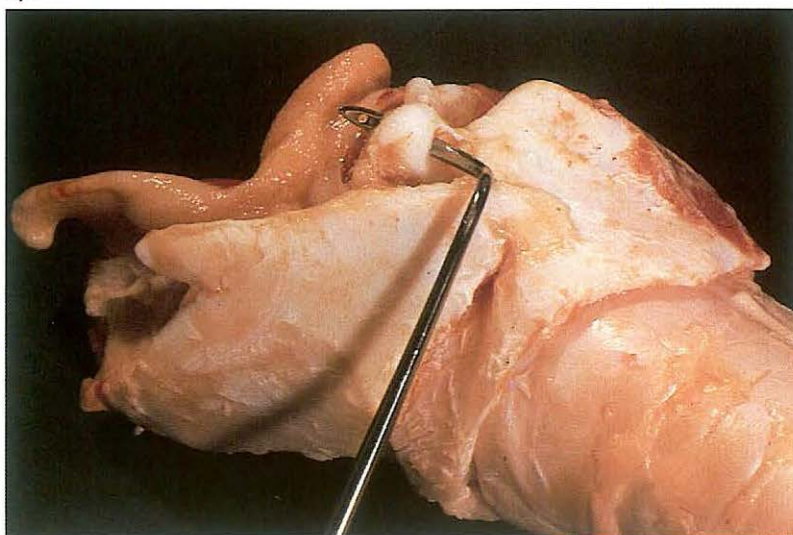
muscle. The neurectomy site is proximal to the entry of the nerve into the muscle; at least 3 cm are removed [o68]. The procedure may be carried out before or after myectomy of the other muscles. The skin is closed with interrupted mattress sutures. At both ends of the wound a drain is placed. Proper functioning of the drains must be checked twice daily, and they must not be removed before 3 days.

Postoperatively the horse is confined for about three weeks, and care is taken that the stall contains no objects that may be grasped with the incisors or on which the wound may be rubbed.

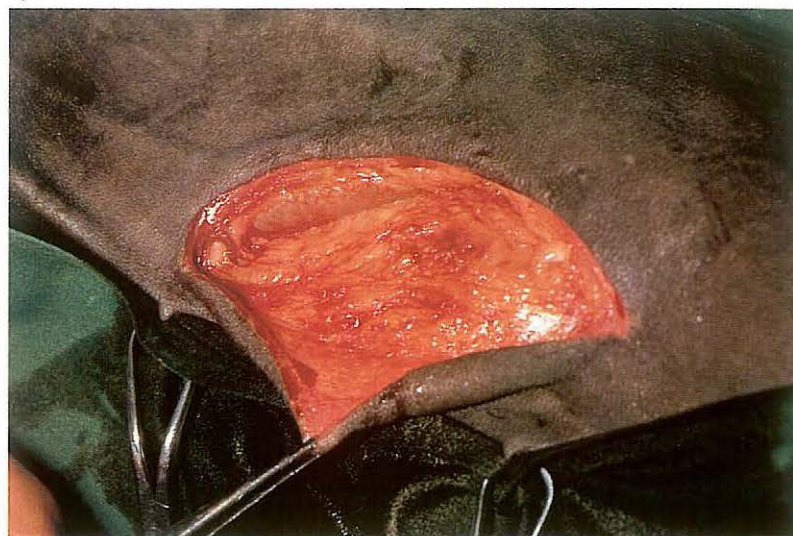
o69



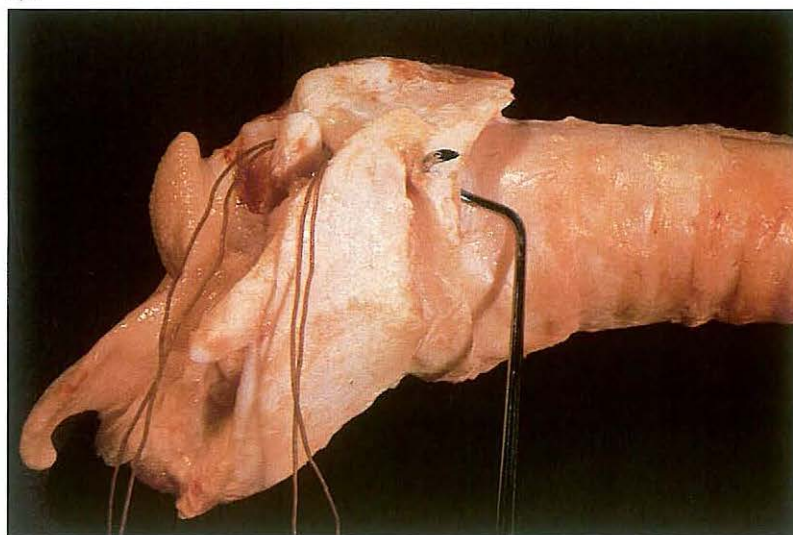
o71



o70



o72



2-2 Laryngotomy - cricoarytenoidopexy and ventriculectomy

Inspiratory dyspnoea due to laryngeal hemiplegia (roaring) is a common clinical sign in horses requiring surgical treatment to enlarge the reduced laryngeal lumen [o69A]. Many procedures to alleviate laryngeal hemiplegia have been utilized. Of the various techniques the combination of cricoarytenoidopexy with unilateral or bilateral ventriculectomy has given the best results. Instead of lycra, a double ligature of heavy-sized chromic catgut is preferred for the cricoarytenoidopexy.

Surgery. The horse is positioned in right lateral recumbency in general anaesthesia with the head and neck extended.

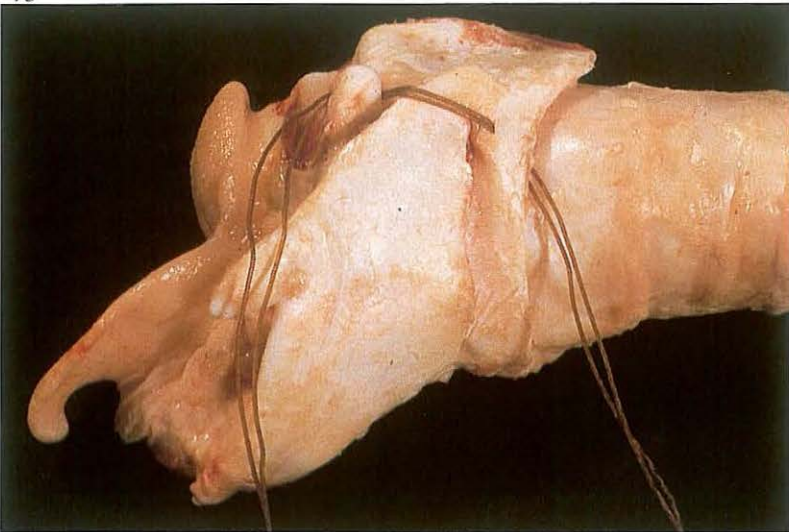
A 10 cm skin incision is made parallel and ventral to the linguofacial vein from the cranial border of the larynx to the second tracheal ring [o70]. Subcutaneous fascia is incised with a scalpel. The dorsolateral aspect of the larynx is approached by blunt dissection. The muscular process of the arytenoid cartilage is penetrated from medial to lateral with a pointed

Deschamp's needle [o71]. The double chromic catgut is threaded through the eye of the needle and pulled through the muscular process. The medial part of the ligature is brought under the cricoarytenoid muscle using the Deschamp's needle. The needle is then passed, from medial to lateral, through the caudal border of the cricoid cartilage, about 2 cm lateral to the median ridge. The needle passes through the cartilage, but not through mucous membrane into the laryngeal lumen. The needle emerges approximately 1 cm cranial to the caudal border of the cricoid [o72]. The medial part of the thread is threaded into the needle and pulled through the cricoid cartilage [o73]. The two ends of the ligature are tied [o74] with sufficient tension to fully retract the arytenoid cartilage; this can be checked by laryngoscopy [o69B].

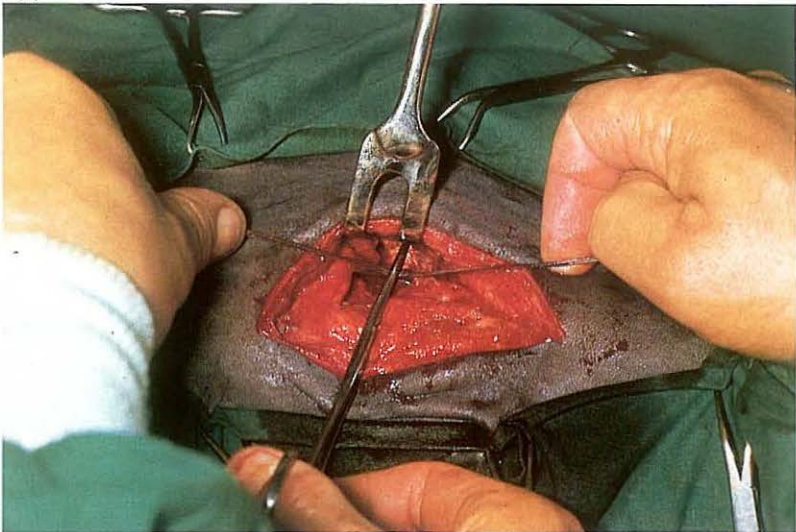
A vacuum drain is placed in the wound cavity. The subcutaneous and deep fascial tissues are closed with a simple continuous suture and the skin with interrupted sutures, using synthetic absorbable material.

The patient is then positioned in dorsal recumbency; the nose is supported

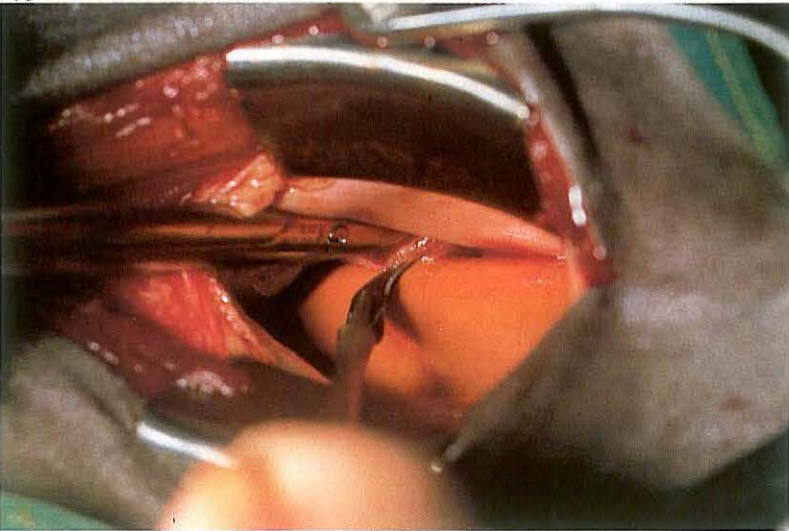
073



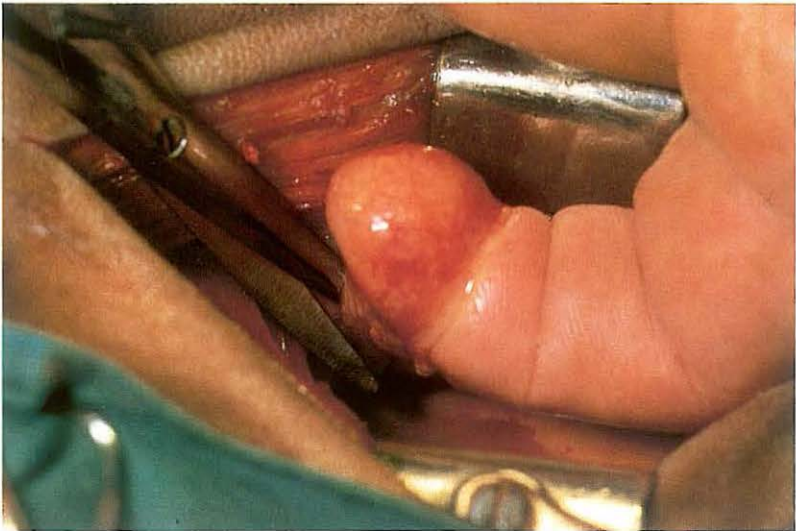
074



075

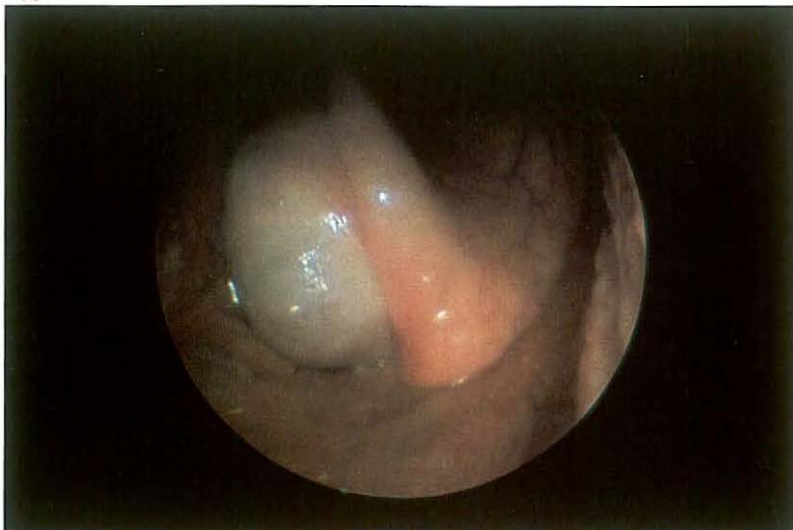

076

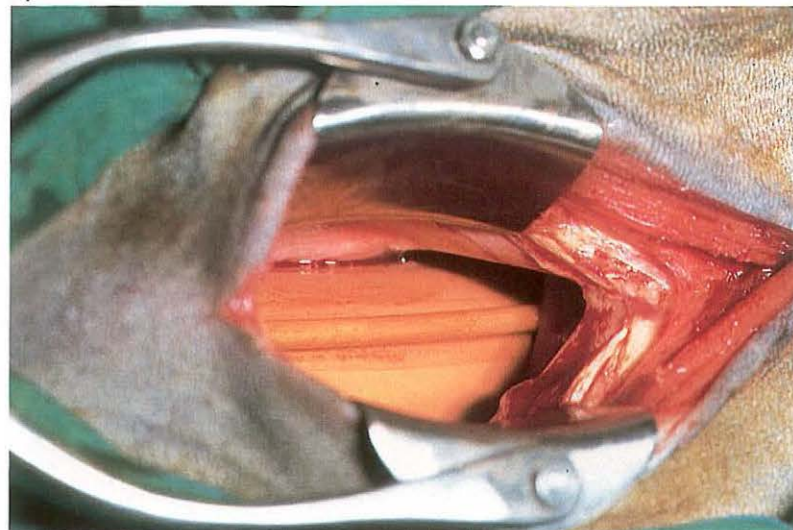


to prevent extreme extension of the neck. The laryngeal cavity is opened (see 2-3); the crycoid cartilage is not incised. The mucous membrane of the left laryngeal saccule is removed. The rim of the laryngeal saccule is incised on its caudal border [075] and the index finger is brought submucosally to free and then evert the mucous membrane. The everted mucous membrane is resected with scissors as close to the base as possible without damaging the adjacent cartilage [076]. To prevent foreign body aspiration during recovery and recuperation the skin is closed with a few non-absorbable interrupted sutures. If postoperative dyspnoea occurs a tracheotomy tube is inserted through the laryngotomy wound, or tracheotomy (see 2-5) is performed. Antibiotics are administered. The vacuum drain is removed after two to three days. The laryngotomy wound is cleansed daily and heals satisfactorily by second intention. The horse is confined to a box for 4 weeks. After two months at pasture the horse may be returned to training.

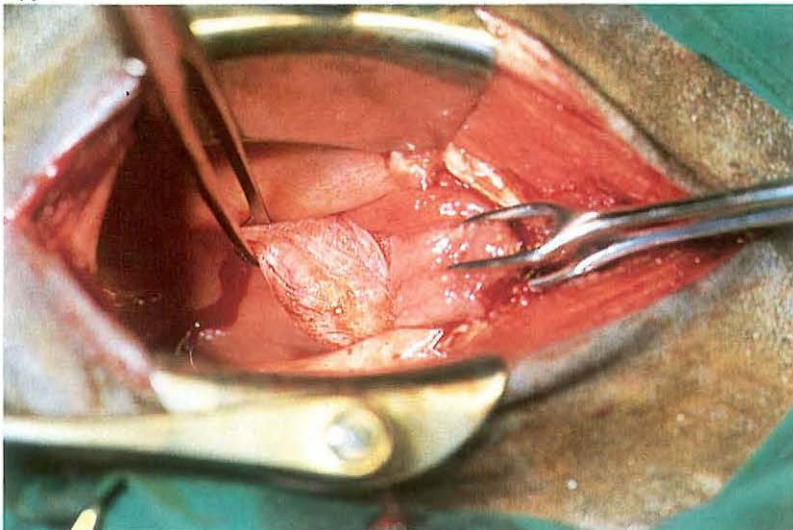
077



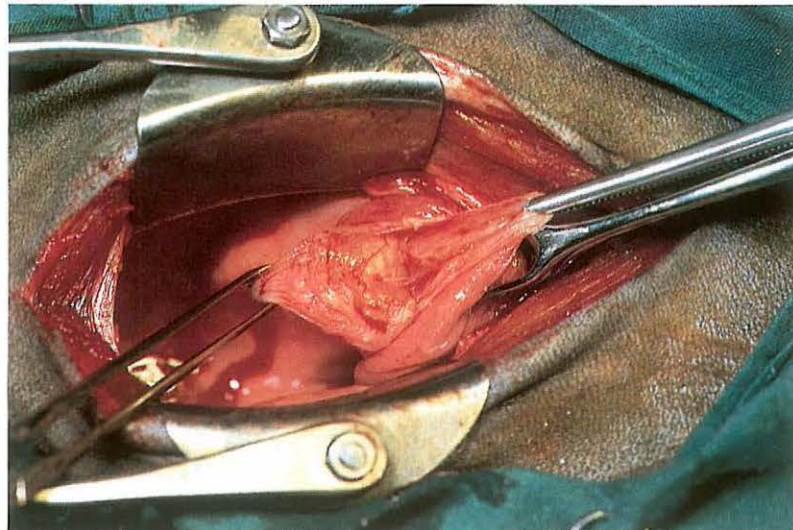
078



079



080



2-3 Laryngotomy - extirpation of subepiglottal cyst

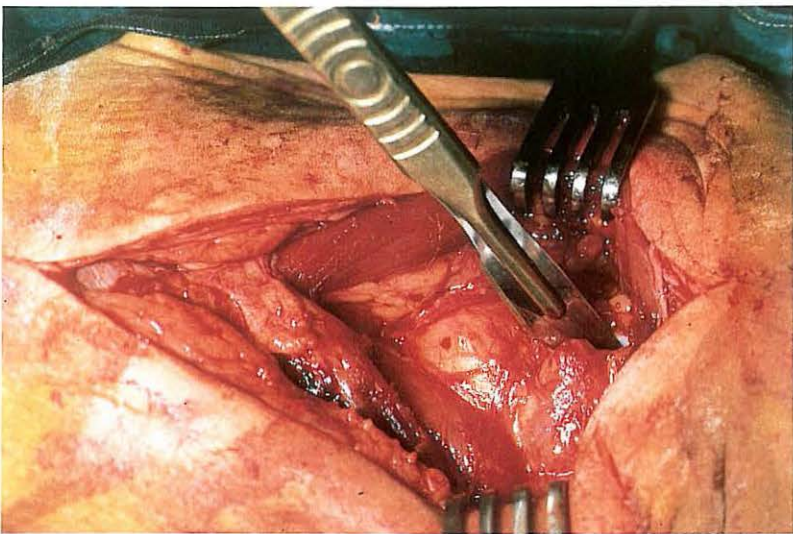
Inspiratory and/or expiratory noise at work and dyspnoea due to epiglottal lesions (subepiglottal cyst, abscess, and epiglottic entrapment) are occasionally observed in horses. To enable surgery in the area of the soft palate and epiglottis, a laryngotomy must be performed. The surgical technique for removal of a subepiglottal cyst is described here. Diagnosis is made by endoscopic examination [077].

Surgery. The patient is positioned in dorsal recumbency under general anaesthesia. A 10 cm midline incision is made over the larynx through the skin and through the midline junction of the sternohyoid muscles. The cricothyroid membrane is incised in the midline. In this condition, incision through ventral midline of the cricoid cartilage is necessary to gain space. A self-retaining wound retractor exposes the laryngeal cavity [078]. After the endotracheal tube has been removed exposure of the subepiglottal cyst is possible. The apex of the epiglottis is drawn caudad from the naso-

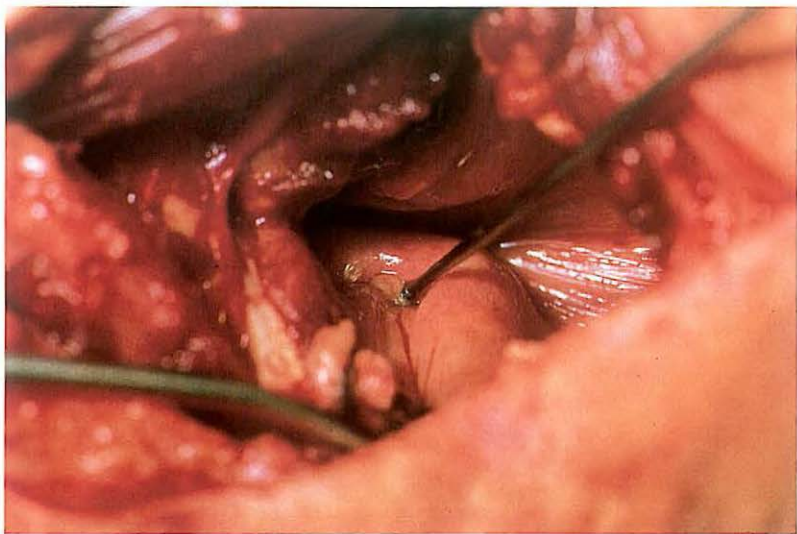
pharynx into the laryngeal lumen, thereby presenting the cyst on the ventral surface of the epiglottis in the surgical field. Traction on the epiglottis is accomplished by grasping the aryepiglottic fold, on the lateral wall of the pharynx between the base of the epiglottis and the arytenoid, with a sponge forceps. A Lakey traction forceps applied to the apex of the epiglottis retains it in position.

The mucosa surrounding the cyst is carefully grasped with Allis tissue forceps [079], incised and the cyst is then dissected bluntly from the surrounding tissue [080]. Excess mucosa may be excised. The wound is left open. Only the skin is closed with a few non-absorbable interrupted sutures. The laryngotomy wound heals by second intention. The patient is box rested for 4 weeks.

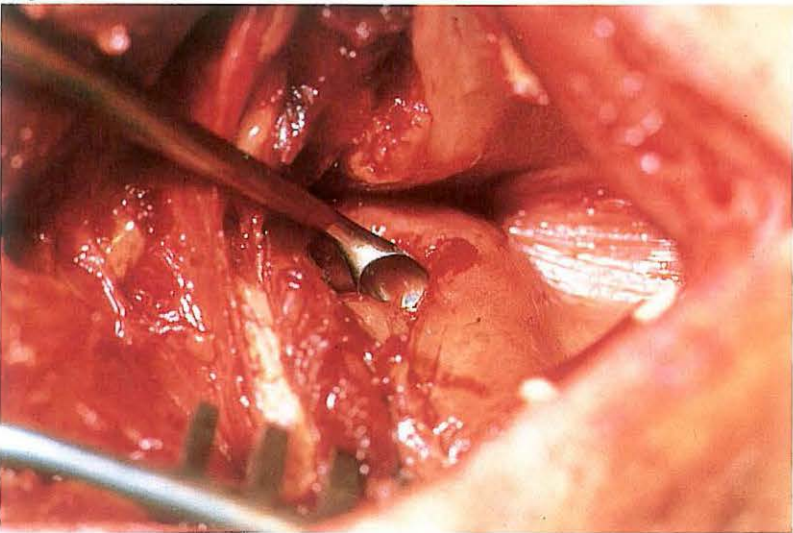
o81



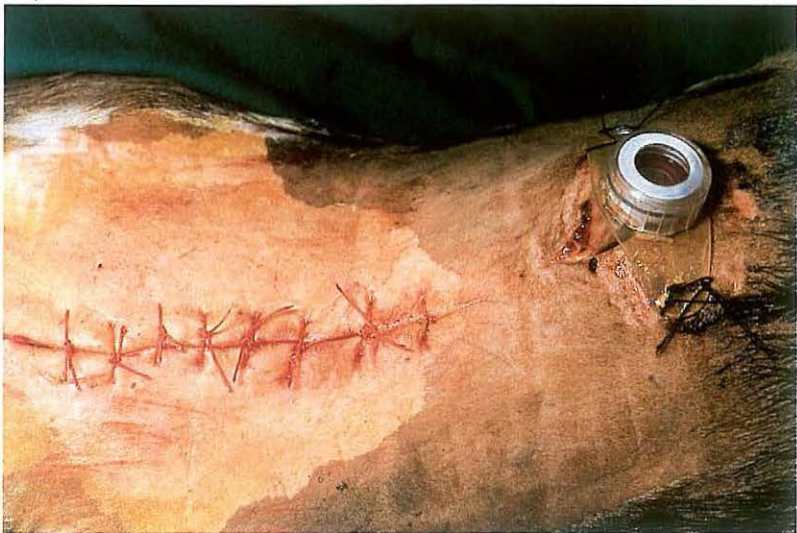o82



o83



o84



2-4 Laryngotomy – in bovine necrotic laryngitis

Necrotic laryngitis associated with calf diphtheria is the most important cause of laryngeal dyspnoea in young cattle. The results of medical treatment are often disappointing. The aim of surgical treatment is to excise necrotic cartilage and/or granuloma and produce a permanent widening of the glottis.

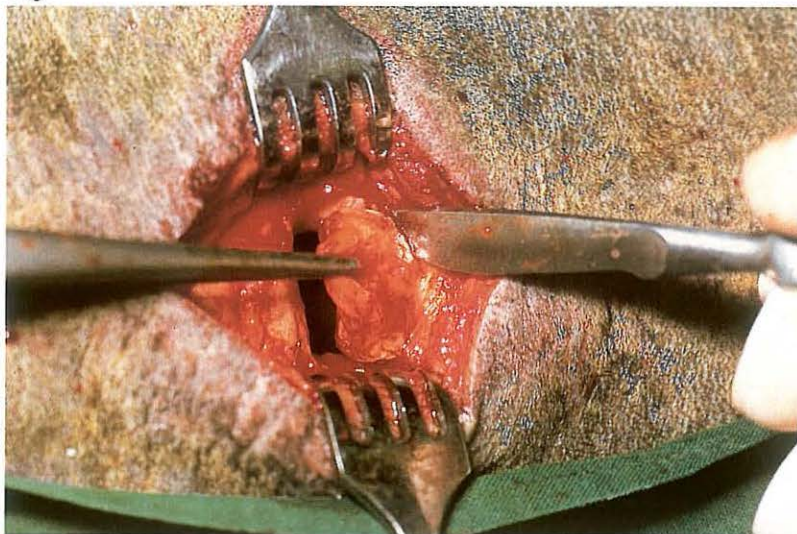Surgery. Prior to laryngotomy, a tracheotomy is performed (see 2-5). The patient is placed in dorsal recumbency under general anaesthesia, or under sedation in combination with local infiltration analgesia. If laryngeal intubation is impossible an endotracheal tube must be inserted via the tracheotomy wound. The inflated cuff prevents the passage of blood into the lungs during surgery.

The skin and subcutaneous tissue are incised in the midline and the sternohyoid muscles are separated. A midline incision is made through the cryothyroid ligament, thyroid cartilage and the first 2 tracheal cartilages

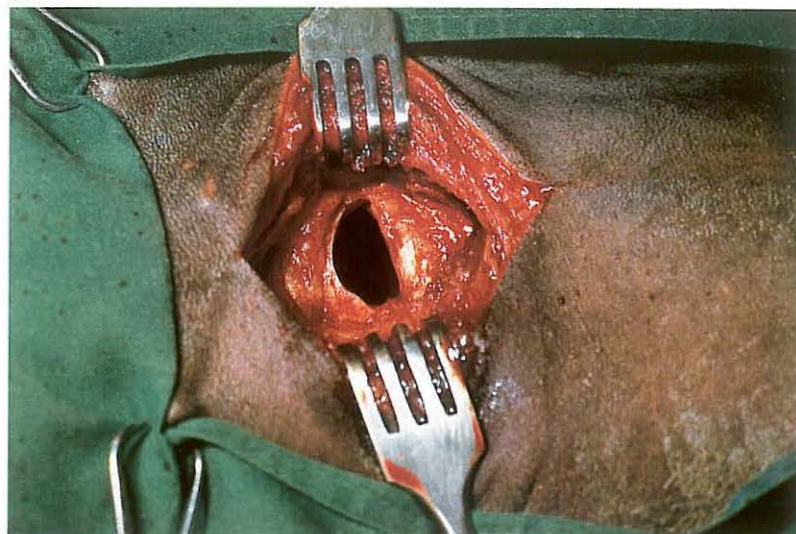
[o81]. (The thyroid cartilage is cut with a strong pair of scissors). Topical analgesia of laryngeal mucosa is necessary if general anaesthesia has not been used. The laryngeal cavity is exposed by means of Volkmann retractors. In most cases the necrotic lesions and granulomas are clearly visible. The depth of (a) possible fistulous tract(s) is determined with a probe [o82]. Necrotic debris, including cartilage sequestra, are removed by curettage [o83]. After cleaning the laryngeal cavity, the skin is closed with non-absorbable material in an interrupted pattern [o84].

Systemic antibiotics are administered. The tracheotomy tube is removed as laryngeal swelling reduces and has less effect on respiration.

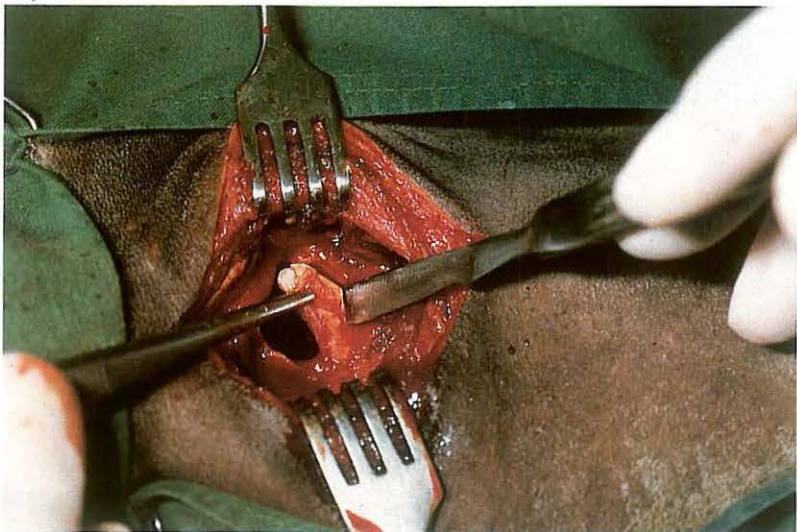
o85



o86



o87



o88



2-5 Tracheotomy

Tracheotomy is usually an emergency procedure and is indicated to relieve dyspnoea caused by acute nasal, laryngeal or proximal tracheal obstructions. Tracheotomy is also indicated prior to some operations on the nose, paranasal sinuses or larynx.

Surgery. Tracheotomy is usually performed on the standing animal under local infiltration analgesia, but may also be carried out on the recumbent patient. The head and neck of the animal are extended and an approximately 7 cm ventral midline skin incision is made in the cranial third of the neck at the level of the 4th–6th tracheal ring. After incising the thin cutaneous muscle in the midline, the longitudinal junction of the sternohyoid muscles is divided and the trachea exposed. The muscles and skin are spread with a wound retractor.

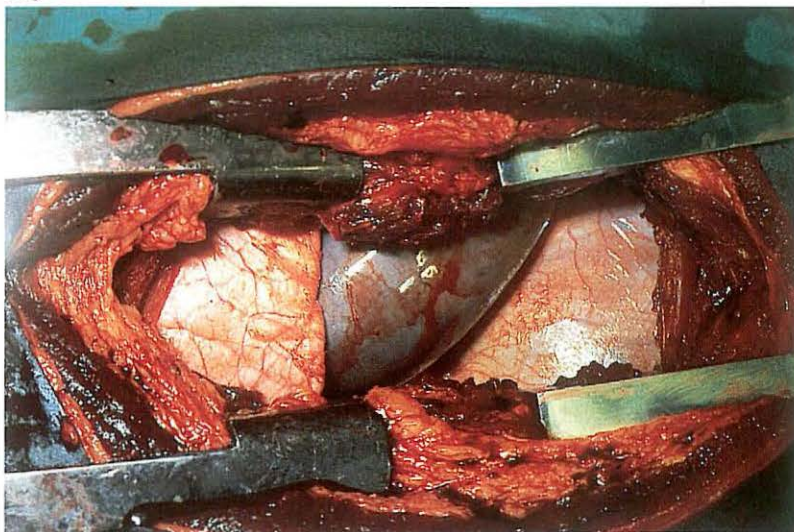
If temporary tracheotomy is indicated, a tracheal annular ligament is pierced with a scalpel and a tracheal tube (ovoid in cross-section) is inserted.

If the tracheotomy tube is to remain for a longer period, partial resection of a tracheal ring is performed. (1) A tracheal window is produced by partial resection of one tracheal ring [o85]. The disc to be removed is grasped with forceps. (2) To prevent the tracheal ring from collapsing, resection of a semi-disc of the tracheal rings proximal and distal to an incision through the annular ligament is recommended [o86, o87].

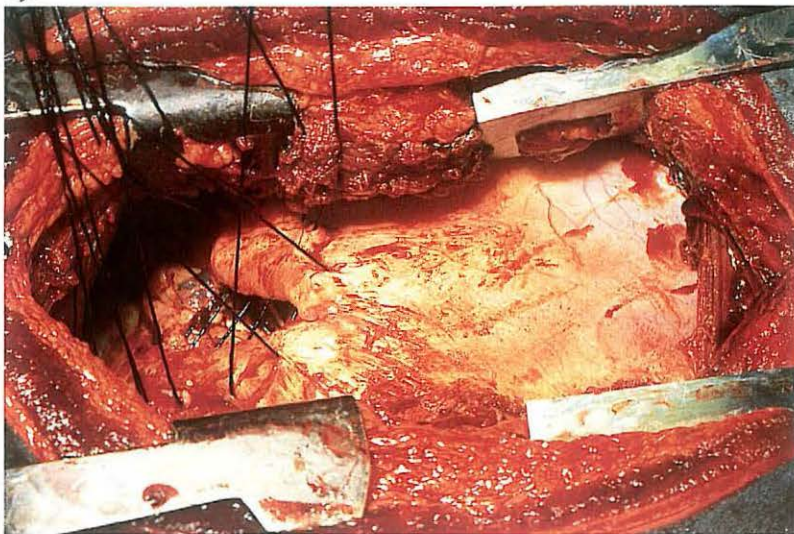
After tracheotomy a self-retaining tube is inserted [o88] and the skin edges are sutured around the tube in a simple interrupted pattern. Since there is considerable mucous secretion for the first few postoperative days, the tube must be cleaned frequently. Later on, when the discharge has reduced, air passage through the tube is checked daily, but the intervals of cleaning may be prolonged. After the tube is withdrawn, the tracheotomy wound heals by second intention.

Chapter 3 The thorax

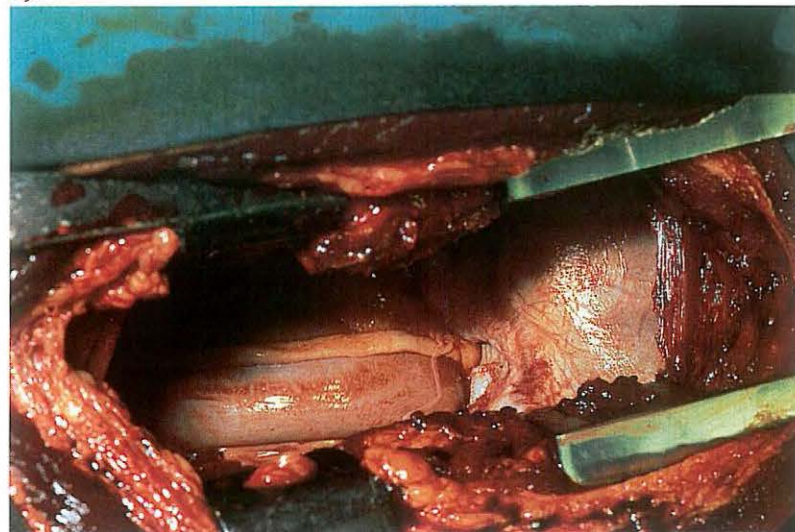
o89



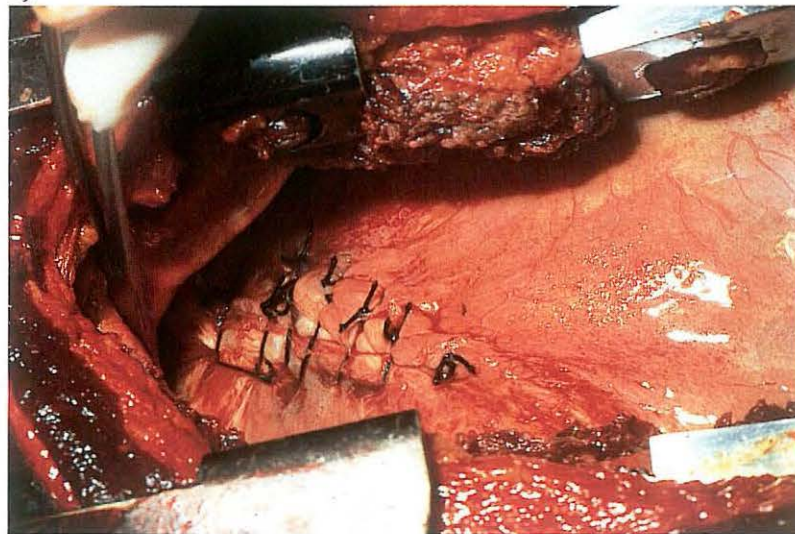
o91



o90



o92



3-1 Diaphragmatic herniorrhaphy

In large animal surgery thoracotomy is seldom used. Its main indication is diaphragmatic hernia, although the technique is occasionally used in cases of traumatic injury with or without foreign body penetration into the thorax, approach to the thoracic oesophagus, and experimental surgery.

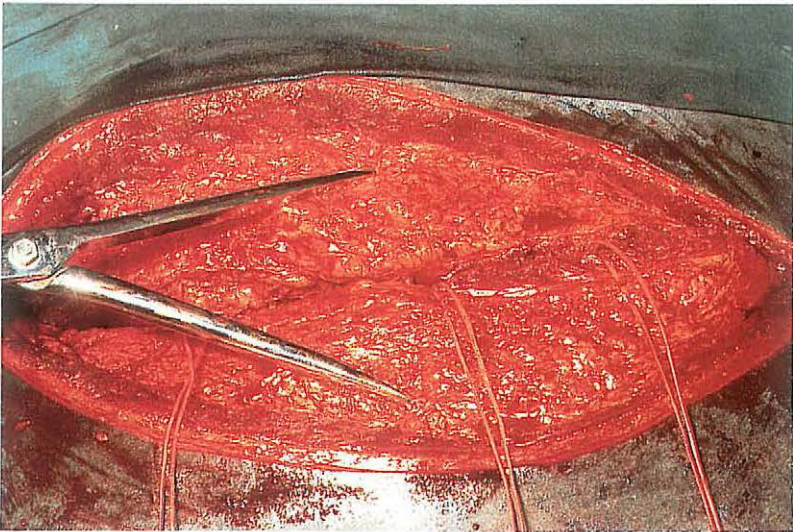
Surgery. The patient is placed in lateral recumbency under general anaesthesia with positive pressure ventilation.

The thorax is approached through the left or right 8th, 9th or 10th intercostal space, depending on the localisation of the hernia. Skin, subcutis, fascia, intercostal muscles and pleura are incised in the middle of the intercostal space. In young animals access to the thorax is facilitated by one or two rib retractors [o89]. In older animals, partial resection of one or two ribs may be necessary. Plate o89 shows a part of colon in the thorax of a horse, between the lung and diaphragm. After partial reposition of the intestine the diaphragmatic hernial ring is visible [o90].

A second surgeon, working through a laparotomy incision, may be needed to aid with reposition of the abdominal organs (intestines and liver) and in placing the sutures in the hernial ring. The hernia is closed by tying the pre-placed interrupted sutures of non-absorbable material [o91, o92].

When the diaphragmatic defect is extensive or can not be closed with sutures, closure is achieved using a synthetic mesh [o95, o96] (see also 4-1). Reposition of the ribs is done with the help of reposition forceps. The ribs are held in position by several interrupted sutures [o93]. Prior to tying the last two sutures of the intercostal muscles, air must be removed from the thorax by either evacuation or by inflating the lungs [o94]. Closure of the wound is completed by suturing of the fascia, subcutis and the skin with interrupted sutures of absorbable material. Systemic antibiotics are indicated. Intrathoracic drains are not routinely used, and postoperative complications have not arisen. Residual air in the thoracic cavity is resorbed within a few days.

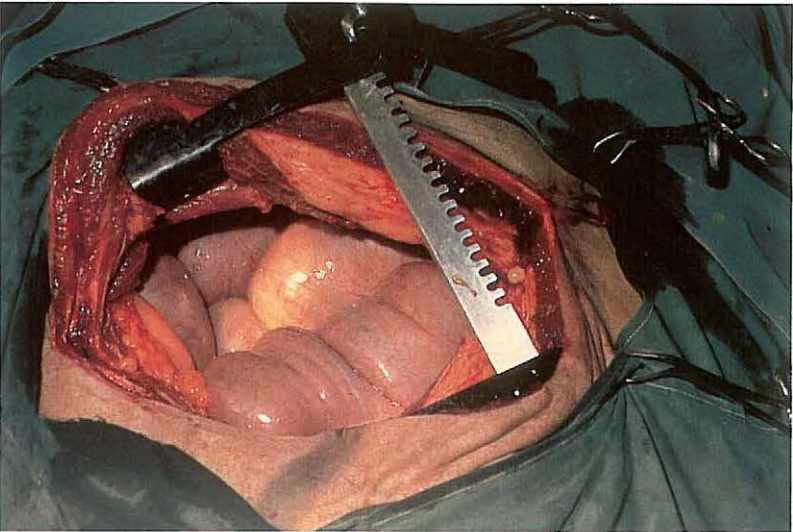
093



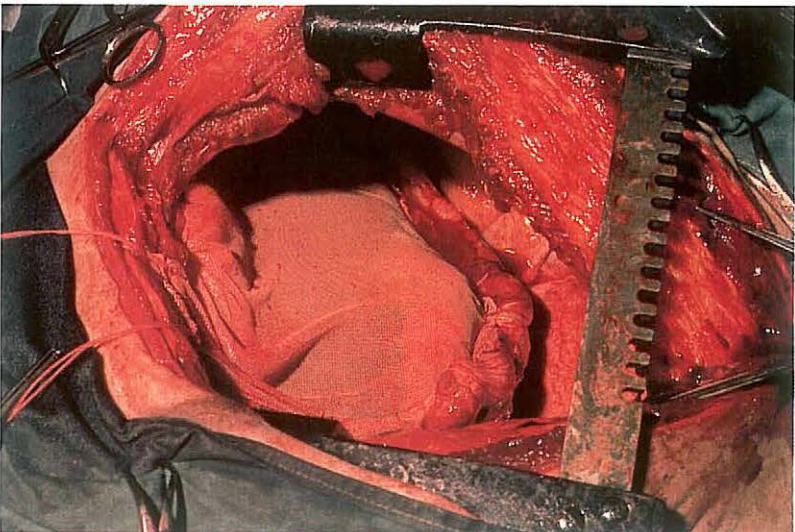
094



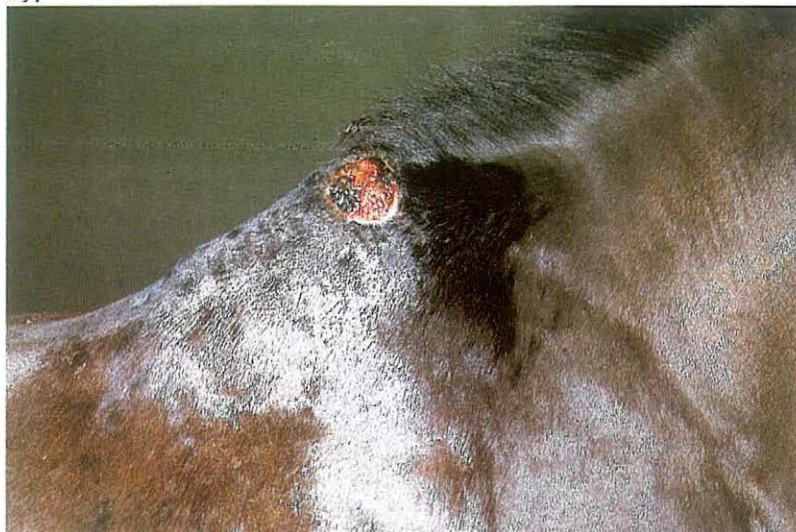095



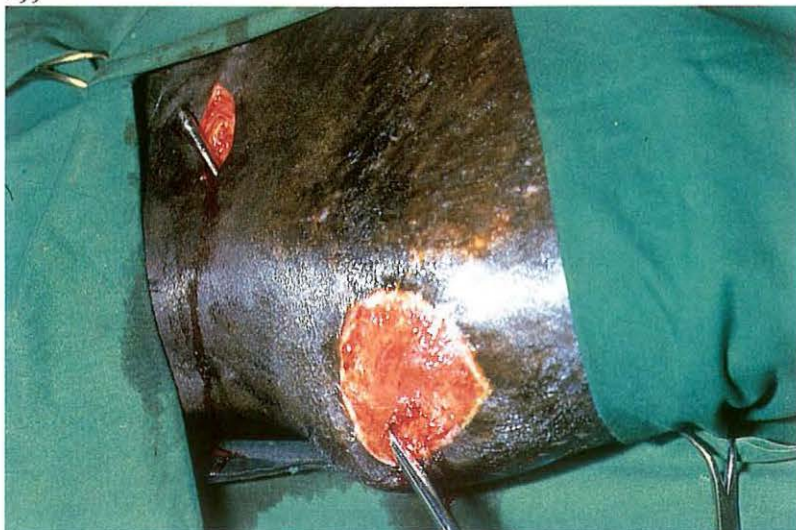
096



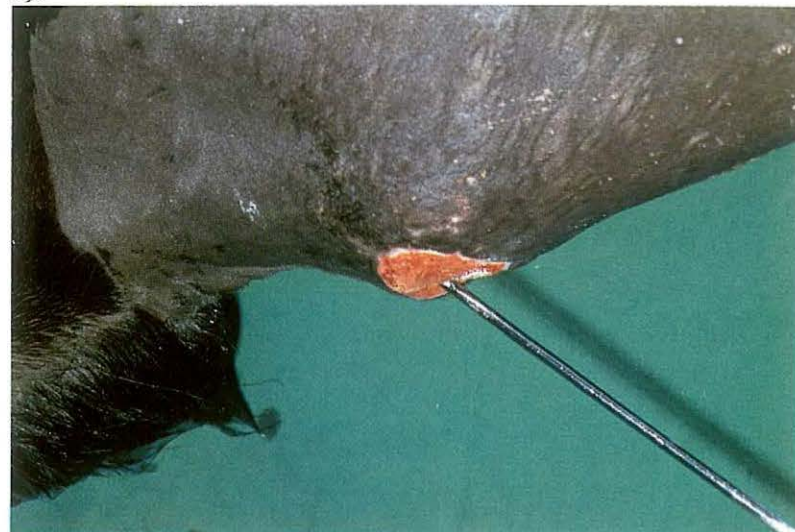097



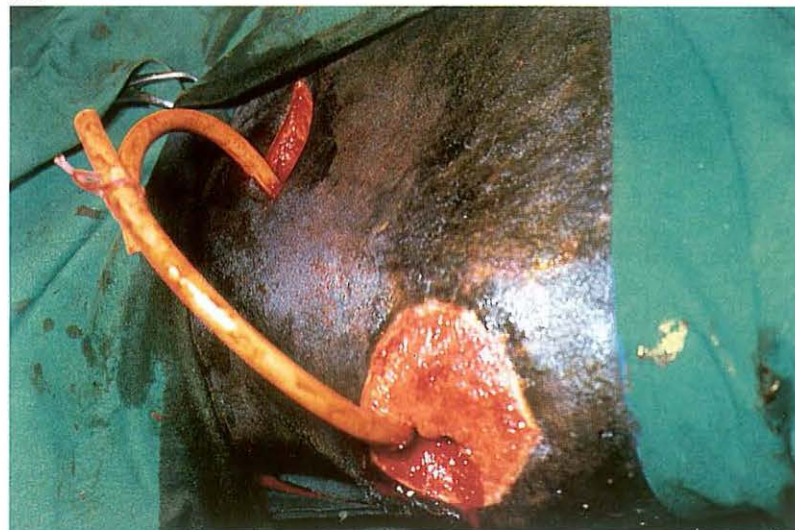
099



098



100



3-2 Treatment of fistulous withers

Infection of tissues in the region of the withers may be the result of traumatic injury, pressure necrosis of skin and underlying tissues due to ill-fitting saddles and/or prolonged riding [097], infection of the supraspinous bursa (e.g. Brucellosis) and invasion of the nuchal ligament with filariae (*Onchocerca* sp).

Pockets and compartments of exudate are formed between the tissues of the withers as inflammation extends. The tissues involved (ligament, bursa, spines of first thoracic vertebrae) and the depth and direction of the tracts may be identified with a probe [098, recumbent horse]; (contrast)radiography is an additional diagnostic aid. Surgical therapy consists of drainage of pockets and fistulous tracts.

Surgery. Short interventions and superficial incisions may be carried out on the standing animal under sedation and physical restraint. Drainage of deeper tissues demands recumbency and general anaesthesia. The general

principle of drainage should be followed: opening of pockets and counter-incision(s) at the lowest point to achieve drainage [099]. Transverse incisions over the withers must be avoided. Necrotic tissue, which may include the tips of spines, is removed, but excision should not be too radical. Drainage openings are kept open by gauze drains or rubber tubing [100] to allow daily irrigation with a mild disinfectant until exudation changes from a purulent to mucous character and finally ceases. Surrounding skin should be protected with vaseline ointment.

Anthelmintic drugs may be indicated, and systemic antibiotics are administered in cases of acute inflammation.

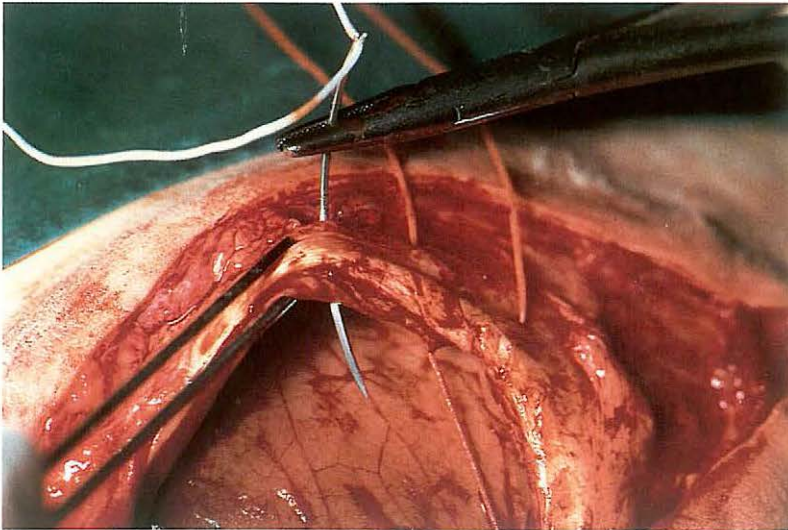
Treatment of fistulous withers is usually time-consuming: several surgical sessions may be necessary.

Chapter 4 The abdomen

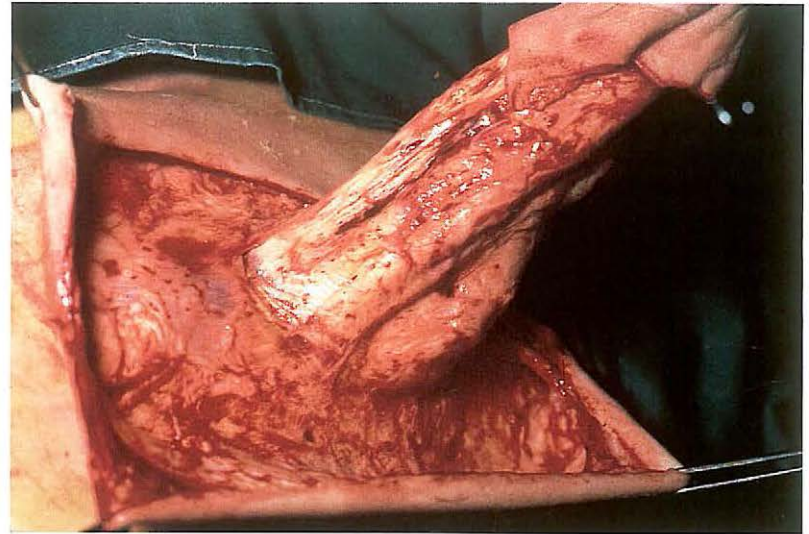
101



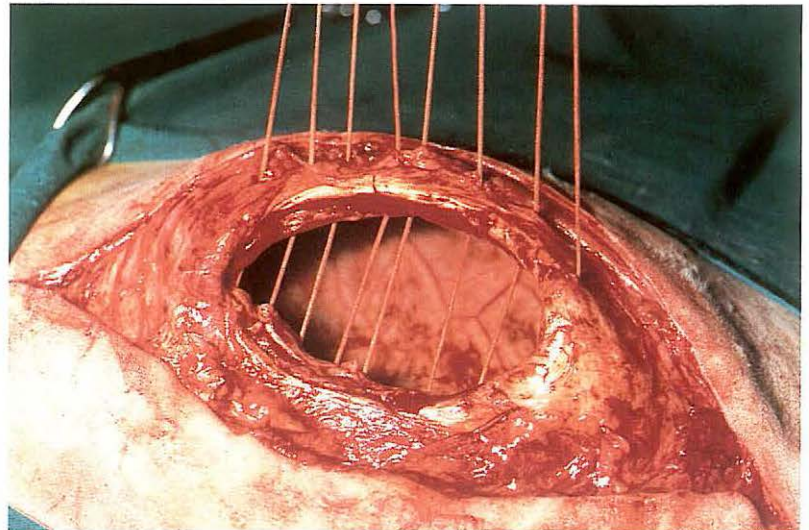
103



102



104



4-1 Umbilical herniorrhaphy

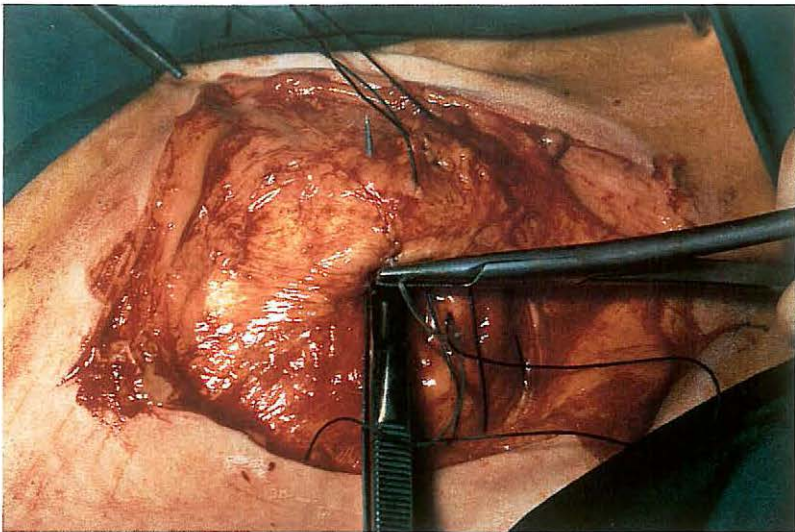
Umbilical hernias may occur in all domestic animals, especially pigs, cattle [101] and horses, and may be reducible or non-reducible. A hernia is reducible if the hernial contents can be returned into the abdomen. Hernias are non-reducible because of either adhesions between hernial contents and internal hernial sac (hernia accreta), or incarceration of viscera by the hernial ring (incarcerated hernia). If spontaneous recovery of the umbilical hernia does not occur, or in cases of incarcerated hernia, surgical correction is indicated.

Surgery. Herniorrhaphy is performed with the patient in dorsal recumbency under general anaesthesia (pig, horse) or epidural analgesia (anterior block) in combination with a field block cranial to the umbilicus (cattle). An incision, usually elliptical, is made through the external hernial (cutaneous) sac and dissection of the internal hernial sac is continued down to the hernial ring [102].

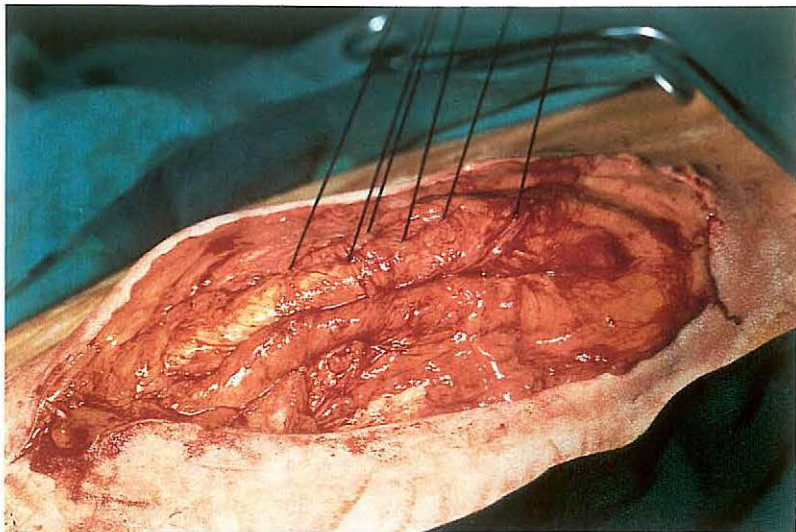
(1) Amputation of the internal hernial sac.

Amputation is indicated in cases of hernia accreta or incarcerated hernia. The internal hernial sac is carefully incised without damaging the hernial contents and amputated along the edge of the hernial ring using dissection scissors. The adhesions between hernial sac and hernial contents are separated and the hernial contents returned to the abdomen. If it is expected that the internal hernial sac can not be incised without damaging the hernial contents (usually in cases of incarcerated hernia), the abdomen is opened in the linea alba just cranial to the hernial ring, which is then enlarged using a blunt-pointed scalpel. If incarcerated viscera appear to be devitalized, the internal hernial sac is not separated from the hernial contents, but is removed together with the resected viscera at the time of enterectomy. The hernial ring is closed using horizontal mattress sutures, which perforate both abdominal wall and peritoneum [103, 104]. When all sutures have been inserted, steady traction is applied on all sutures to close the hernial ring, whereafter the sutures are tied. Non-absorbable suture

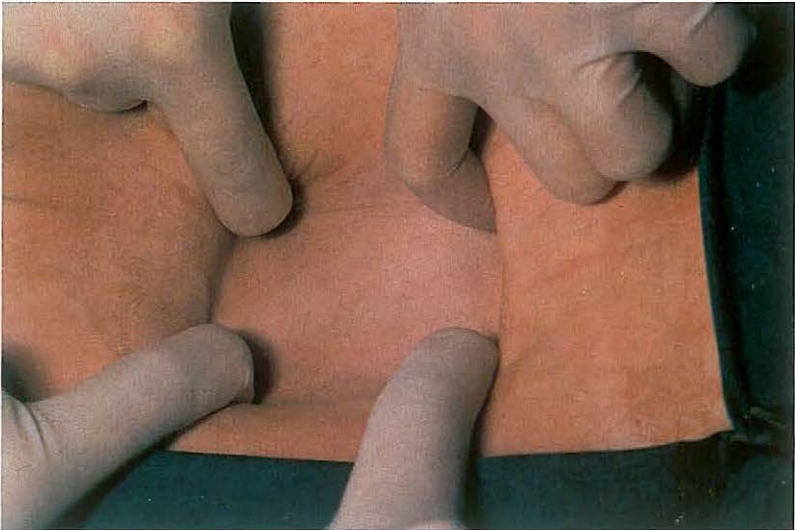
105



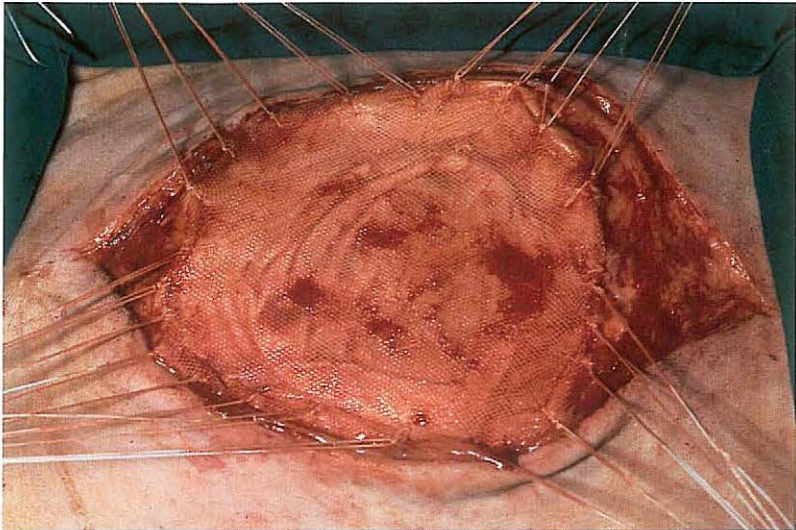
106



107



108



material or stainless steel is used. In horses with small hernias, use of synthetic absorbable suture material is preferable.

(2) Replacement of the internal hernial sac.

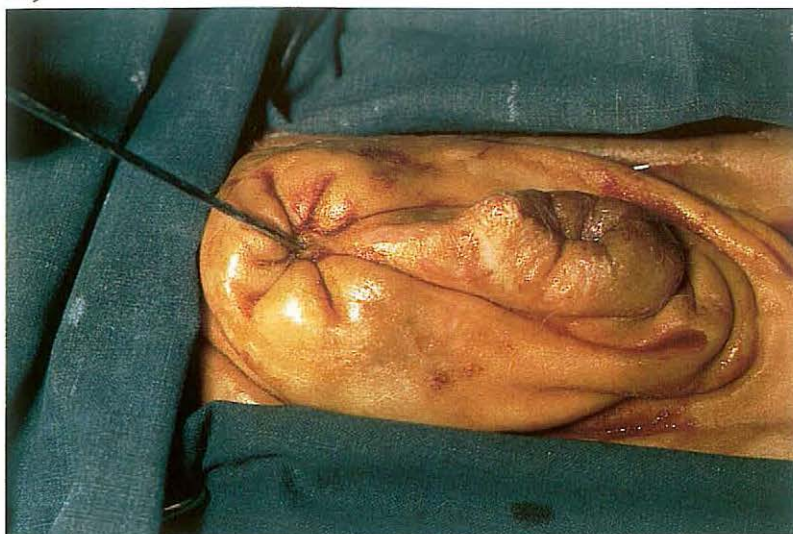
In cases of reducible hernia, the internal hernial sac is usually replaced into the abdomen. The hernial ring is then closed using horizontal mattress sutures. The needle is introduced into the hernial ring 1–2 cm from its edge and runs deeply through the ring without perforating peritoneum. The index finger or the handle of a thumb forceps can be used as a guide [105]. When all sutures have been inserted, they are tightened [106] and tied.

(3) Closure of the hernial ring using alloplastic material.

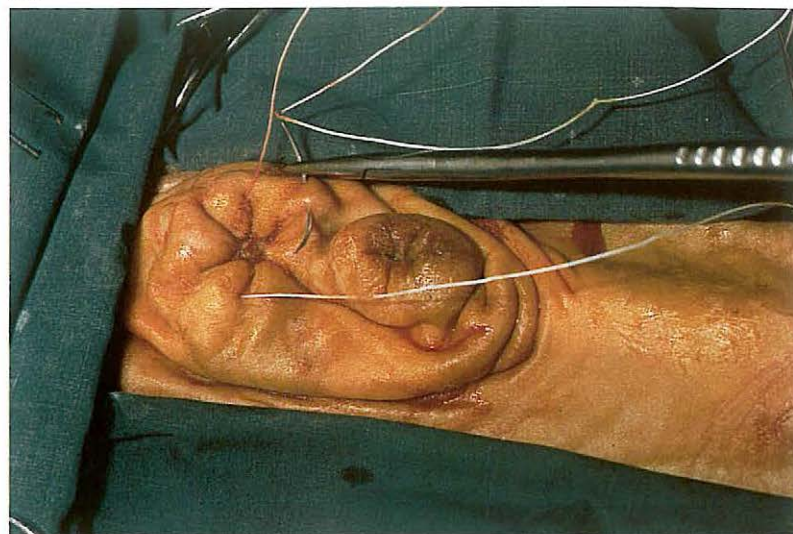
When the hernial ring is too large for closure with horizontal mattress sutures [107], repair may be successful when alloplastic meshes are used. If possible, the internal hernial sac should be left intact. The mesh is cut 2 cm larger than the hernial ring and the edges are sutured to the hernial ring with simple interrupted sutures (non-absorbable material), without perforating the peritoneum [108].

In all three techniques, subcutaneous tissues are sutured in a continuous pattern, in which the ridge of the closed hernial ring or the central part of the mesh is included to obliterate dead space. The skin is closed using simple interrupted sutures. In female cattle and horses, a belly bandage is recommended for support and to prevent excessive oedema. Tension on the wound edges of large hernias may be reduced by restricting dietary intake pre- and postoperatively.

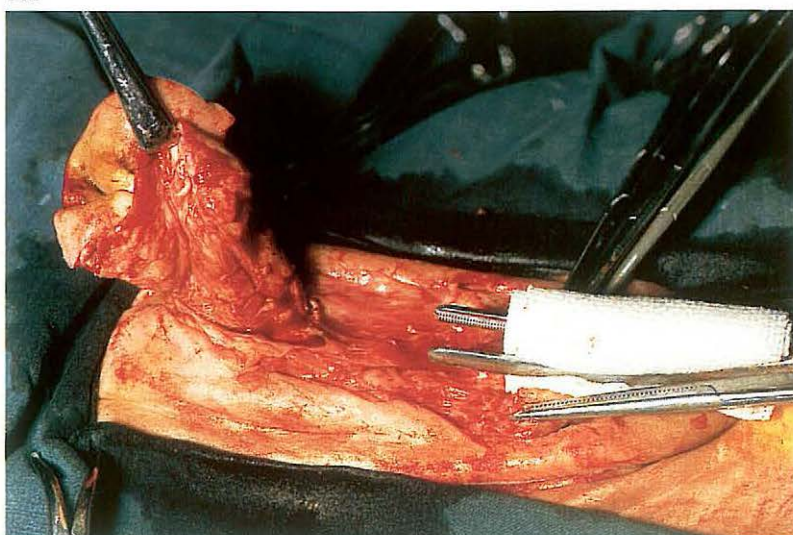
109



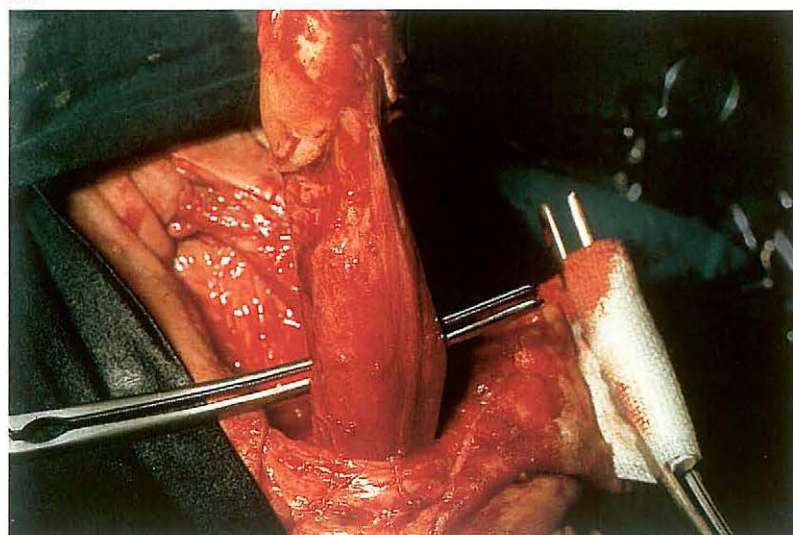
110



111



112



4-2 Resection of urachal fistula

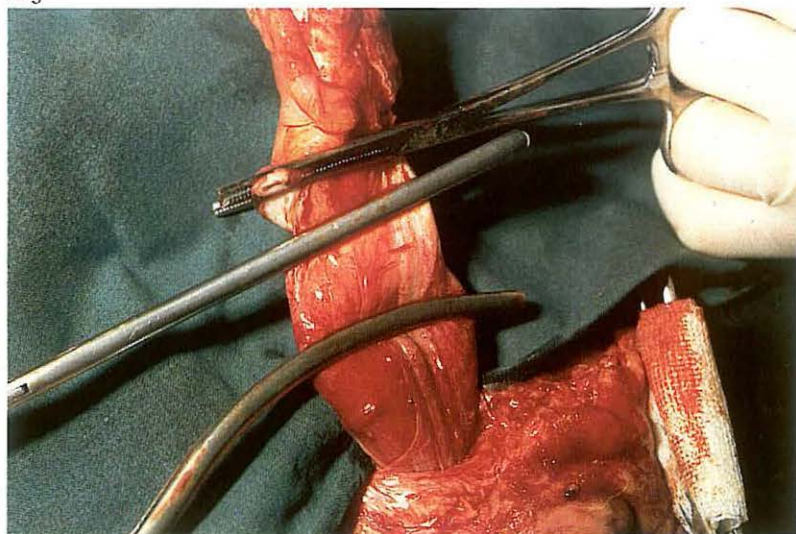
Infection of the umbilical cord in calves may cause inflammatory processes involving the umbilical vessels, urachus, bladder or liver. Chronic cases may result in urachal abscessation, and surgical treatment is indicated. Abscessation of the urachus frequently results in urachal fistula, in which case purulent exudate is visible at the umbilicus. In this bull calf [109], the fistula opening is visible cranial to the preputial orifice. The direction and depth of the fistula can be determined with a probe [109]. Urachal fistulas course caudo-dorsally towards the bladder, and are frequently accompanied by umbilical hernia.

Surgery. Resection of urachal fistula is performed under caudal epidural analgesia (anterior block) in combination with a field block cranial to the umbilicus. The calf is restrained in dorsal recumbency with the legs tied in an extended position. To prevent contamination of the operative area by the urachus, a purse-string suture is placed around the fistula opening

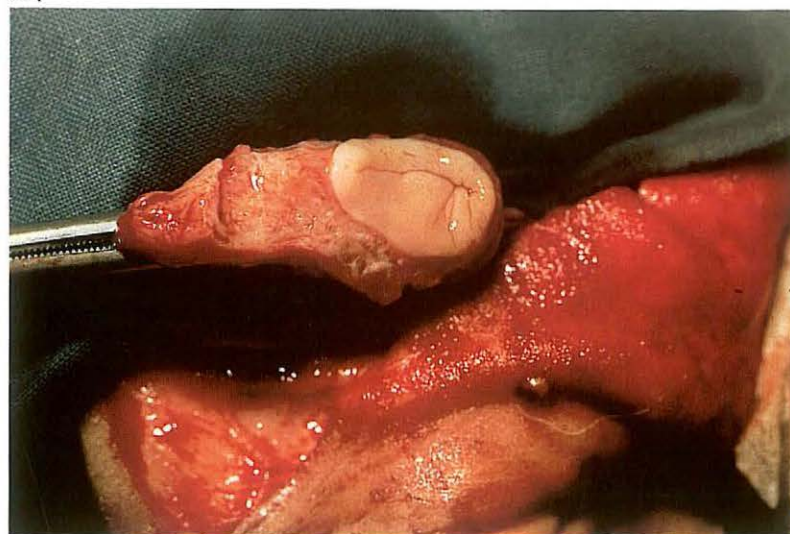
[110]. An intestinal clamp is placed over the preputial orifice to avoid possible contamination by urine. An elliptical skin incision is made around the umbilicus and is extended parapreputially. To facilitate dissection of the affected umbilical cord, the cranial part of the prepuce is freed from the underlying tissues. Traction is applied to the periumbilical skin, using a tenaculum forceps. The umbilical cord is dissected towards the abdominal body wall [111]. The abdominal cavity is entered by incising in the midline cranial to the umbilical cord, and after digital exploration, the body wall directly adjacent to the umbilical cord is excised.

Urachal fistulas often extend to the serosa of the bladder, in which case partial cystectomy is indicated. In order to gain access to the bladder it may be necessary to extend the laparotomy wound caudally. The umbilical cord is dissected from peritoneum and/or greater omentum towards the bladder [112]. The distinction between the affected urachus and the bladder is clearly visible [112]. Intestinal clamps are placed on the apex of the bladder and the urachus [113], and the apex is transected between the two

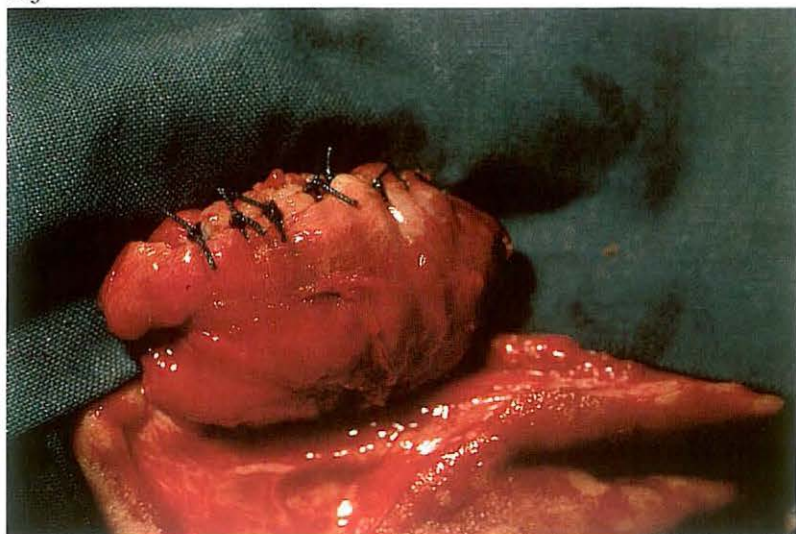
113



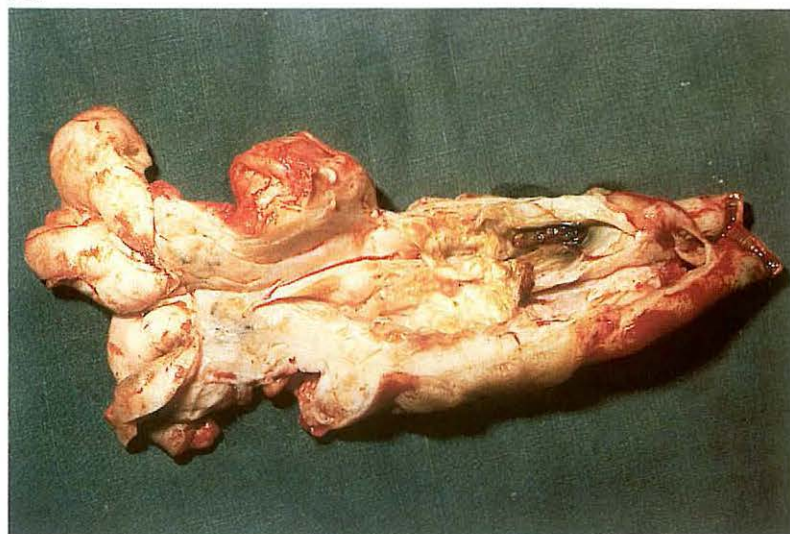
114



115



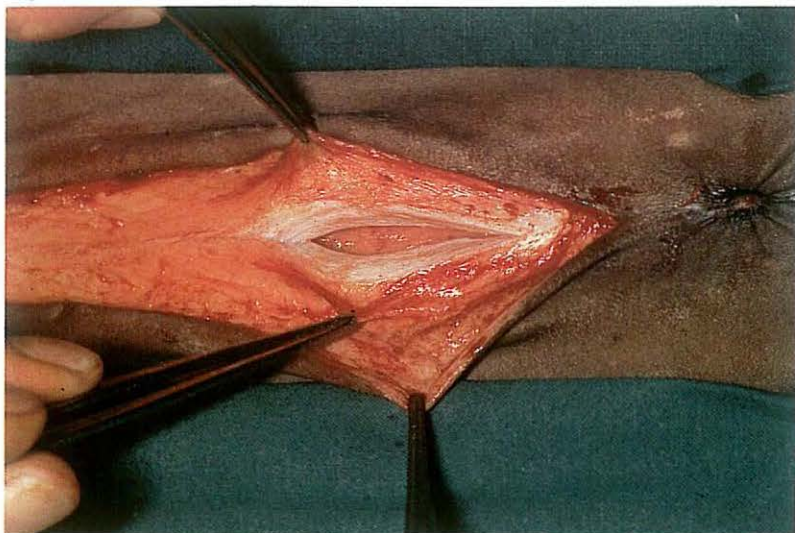
116



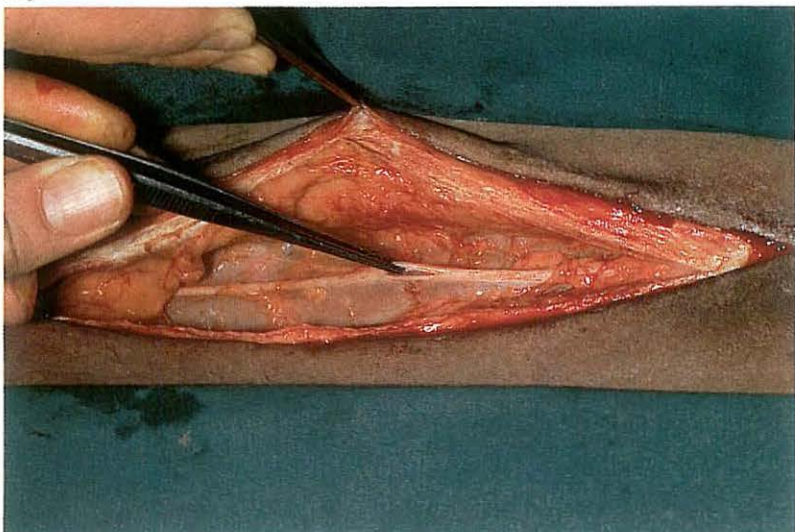
clamps. Plate 114 shows the incised bladder, the mucosa of which appears to be normal. The bladder is closed with a Schmieden intestinal suture, and oversewn with a Lembert seromuscular suture in a continuous or simple interrupted pattern [115] using absorbable material. Finally, the abdominal wall is sutured as described for umbilical herniorrhaphy (see 4-1). Because surgery has taken place in a possibly heavily contaminated area, systemic antibiotics should be administered.

Plate 116 shows the severely enlarged urachus, which has been incised longitudinally. The umbilicus is visible on the left and the resected apex of the bladder on the right. The lumen of the urachus is necrotic and contains purulent exudate.

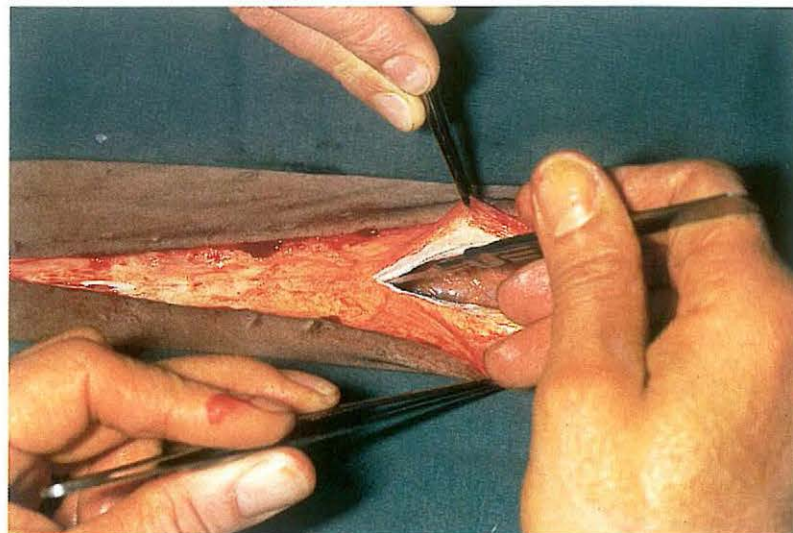
117



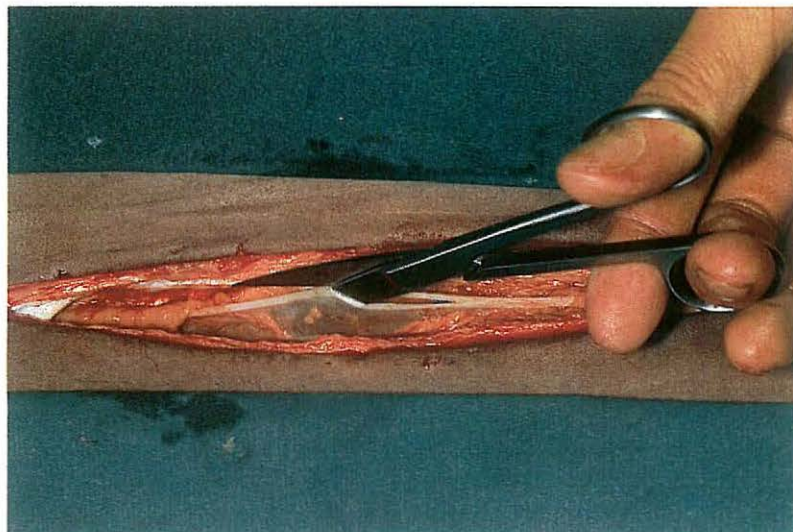
119



118



120



4-3 Ventral midline laparotomy

Laparotomy in the linea alba is the method of choice in abdominal surgery in horses. Abdominal exploration and exposure of the intestines are easily performed through a ventral incision. The paramedian and flank approach should be considered only for specific indications e.g. bilateral abdominal cryptorchidism (see 5-7), caesarian section. The incision through the linea alba may be umbilical (through the navel), pre-umbilical and post-umbilical, depending on the location of the abdominal disorder. The advantage of the median incision is the ease of extension craniad or caudad, if necessitated by the abdominal situation.

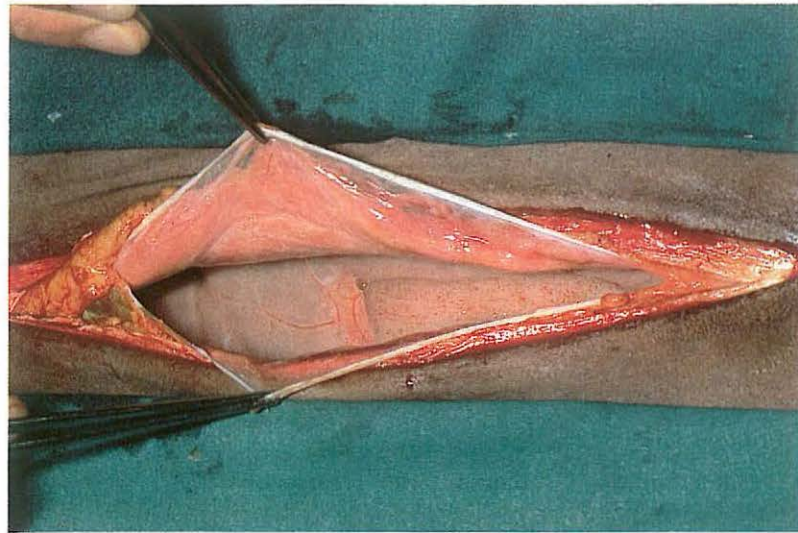
Surgery. The animal is placed in dorsal recumbency under general anaesthesia. The legs must be tied with the forelimbs extended and the hindlimbs slightly abducted and flexed.

The skin and subcutis is incised over the desired length, followed by a small incision precisely through the linea alba [117]. After palpation of the

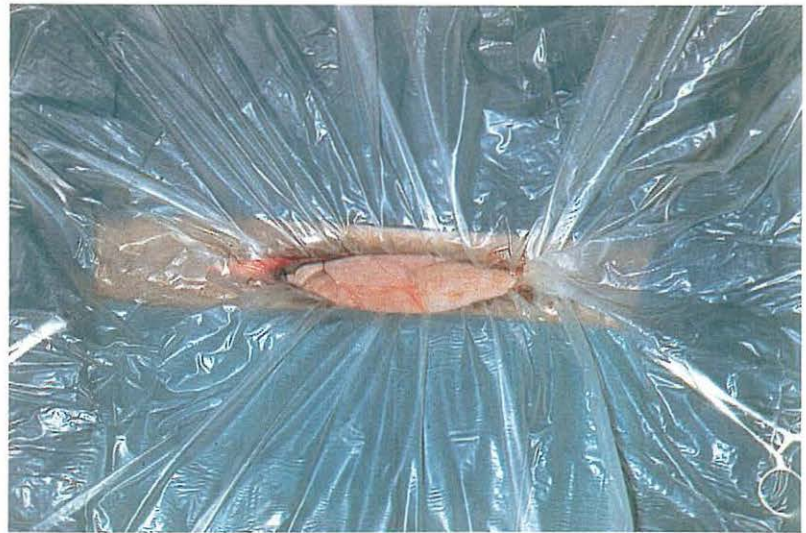dorsal aspect of the linea alba with the index finger this incision is extended, using a blunt-pointed scalpel [118]. Blunt dissection of the retroperitoneal adipose tissue reveals the round ligament (lig. teres hepatis). The ligament is incised [119] and then split with the fingers or blunt scissors [120]. The split round ligament [121] later functions as a reinforcement of the peritoneum and prevents tearing out of the sutures. The wound edges and viscera to be exteriorised are protected by introducing the ring of a sterile plastic drape into the abdomen and spreading the drape over the ventral abdominal wall [122].

The wound is closed by suturing the distinct layers, preferably with synthetic absorbable material. The peritoneum is closed in a simple continuous pattern [123]; the linea alba with simple interrupted sutures [124] or in a simple continuous pattern with double-stranded material of maximum strength; a simple continuous suture closes the subcutis and apposes this layer to the linea alba; finally the skin is sutured with simple interrupted or horizontal mattress sutures. Systemic antibiotics are usually indicated.

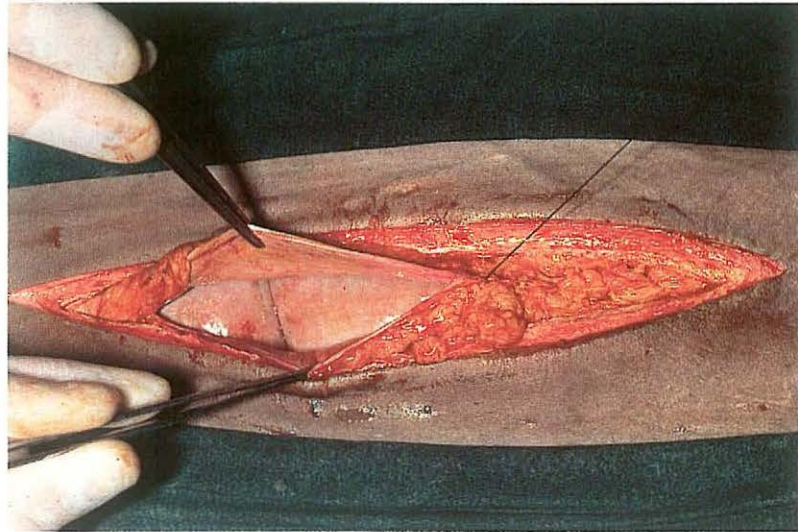
121



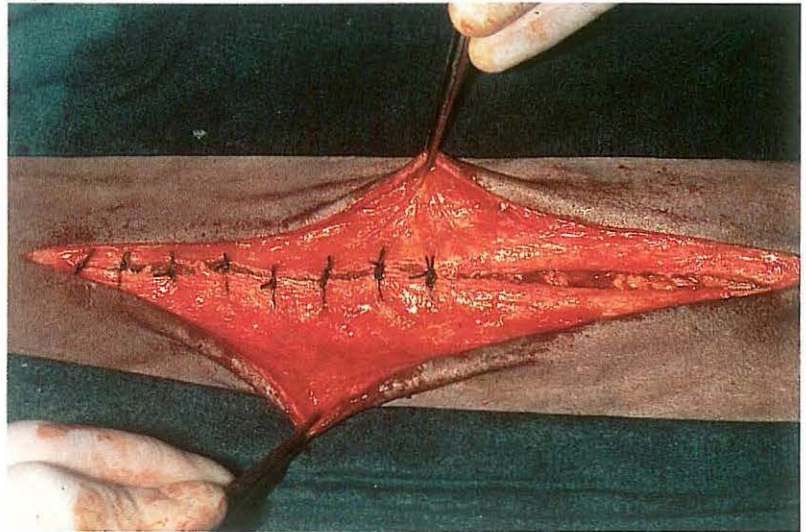
122



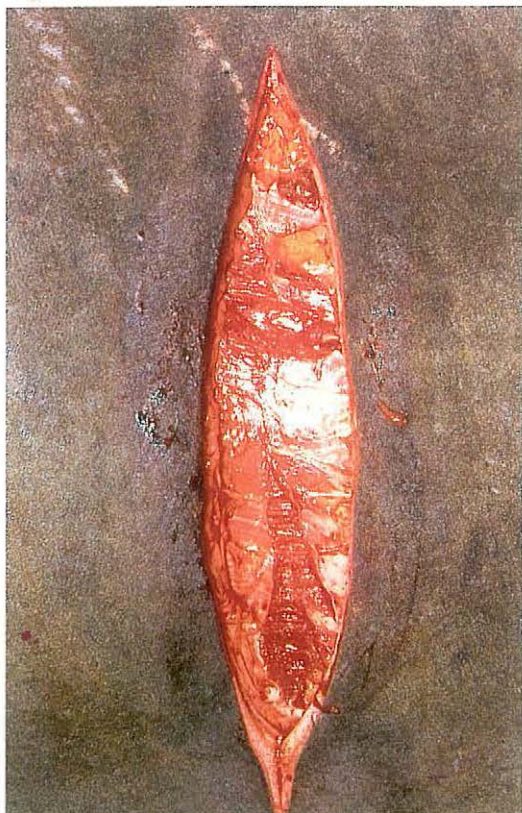
123



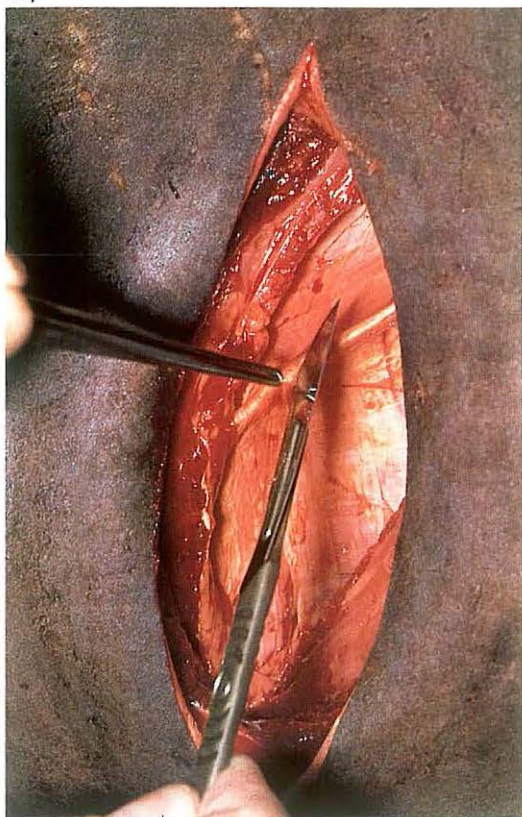
124



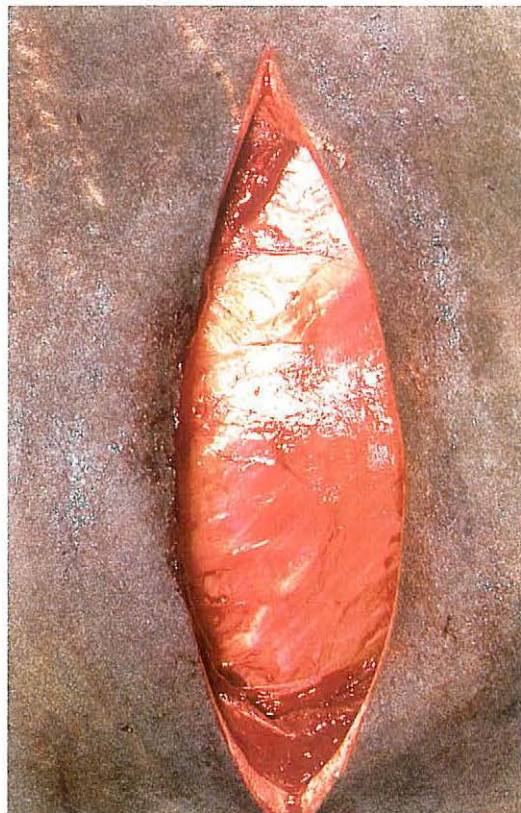
125



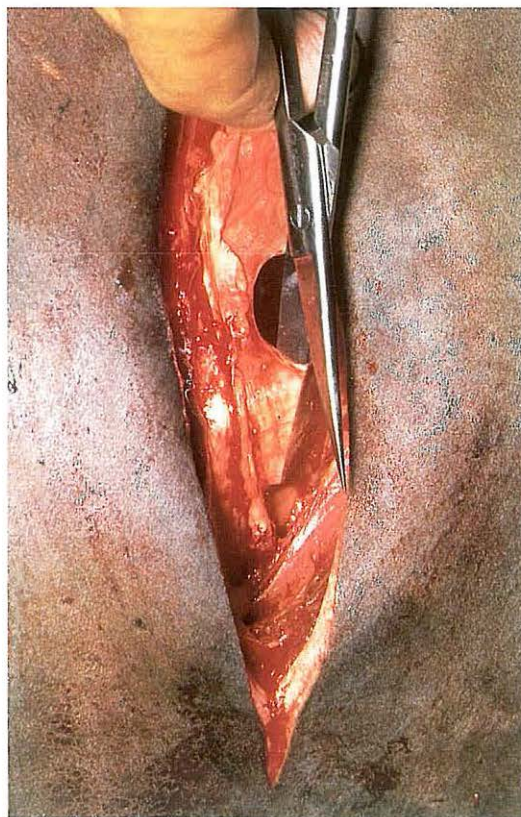127



126



128



4-4 Flank laparotomy

Laparotomy in cattle is most often carried out through a flank incision. The choice between the left or right flank, the selection of the specific site and the type of incision depend upon the procedure to be performed and, in some cases, on the preference of the surgeon.

Surgery. Flank laparotomy is carried out in the standing animal. Local analgesia is achieved by either infiltration, inverted L field block, or para-vertebral nerve block.

(1) Left flank.

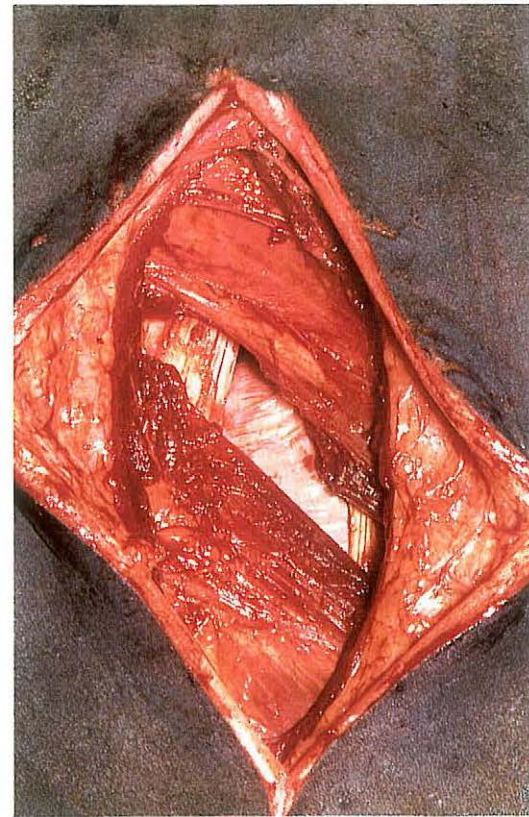
The standard method for left flank laparotomy is the 'through-and-through' incision. A vertical skin incision is made ventral to the lumbar transverse processes [125]. The external [126] and internal oblique muscle are transected in the same direction. Bleeding vessels may be clamped with haemostats or ligated. The transversus muscle is then carefully incised vertically [127]. The transversalis fascia and peritoneum are elevated and lifted with thumb forceps, and incised with a scalpel; care must be taken not to incise underlying viscera. The incision is enlarged dorsally and ventrally with scissors [128]. Each incision in the separate layers of the abdominal wall is shorter than the preceding one.

The wound is closed in three or four layers. The peritoneum and transversalis fascia are closed together with the transversus muscle using a simple continuous suture. The oblique muscles are closed together using simple interrupted sutures. Either absorbable or non-absorbable suture material may be used for these sutures. If the laparotomy is carried out in the lower part of the flank the subcutis, which is more prominent there, is sutured in a simple continuous pattern with absorbable suture material. Finally the skin is closed, using simple interrupted sutures with non-absorbable suture material.

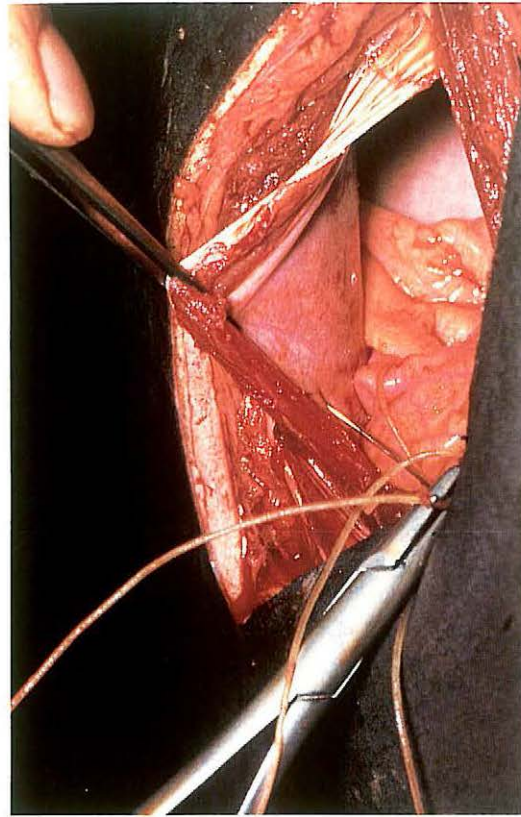
(2) Right flank.

Right flank laparotomy is usually executed by performing either a 'true grid' or a 'modified grid' incision. In both methods a 15–20 cm skin incision is made vertically. In case of a 'true grid' incision the external oblique muscle is split in the direction of its fibres (caudo-ventrally), while in case of a 'modified grid' incision this muscle is incised vertically. Both the internal oblique muscle and the transversus muscle are split in the direction of their fibres (i.e. cranio-ventrally and vertically respectively). The transversalis fascia

129



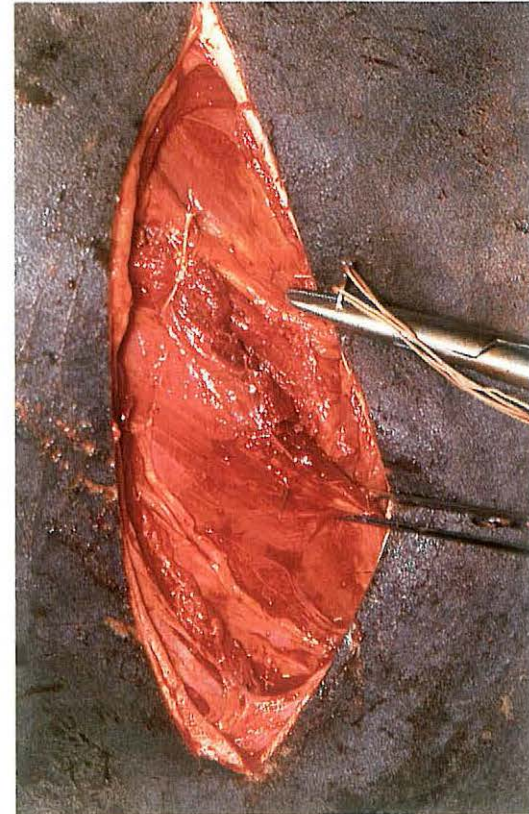
130



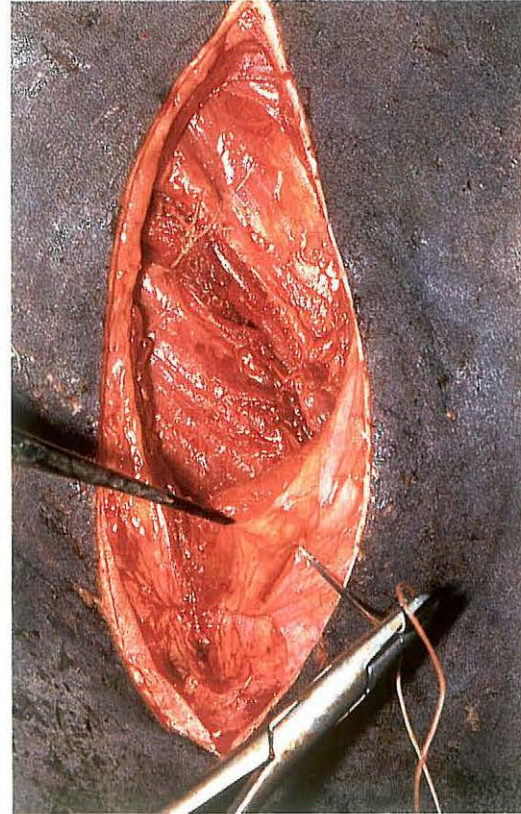
and peritoneum are incised vertically as described for left flank laparotomy. Plate 129 shows a 'modified grid' incision.

The right flank laparotomy wound is always closed in four separate layers. Peritoneum, transversalis fascia and transversus muscle are sutured together in a simple continuous pattern [130]. The internal oblique muscle is sutured with two or three simple interrupted sutures [131]. The external oblique muscle is also closed with simple interrupted sutures, the number of which depends upon the direction of muscle incision: in a 'true grid' incision two or three sutures are sufficient, while in a 'modified grid' incision more sutures must be placed [132]. The skin is closed with simple interrupted sutures.

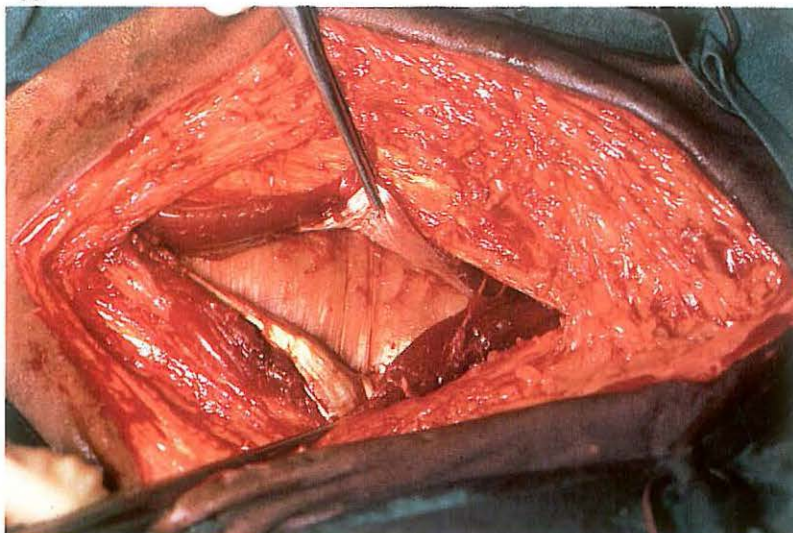
131



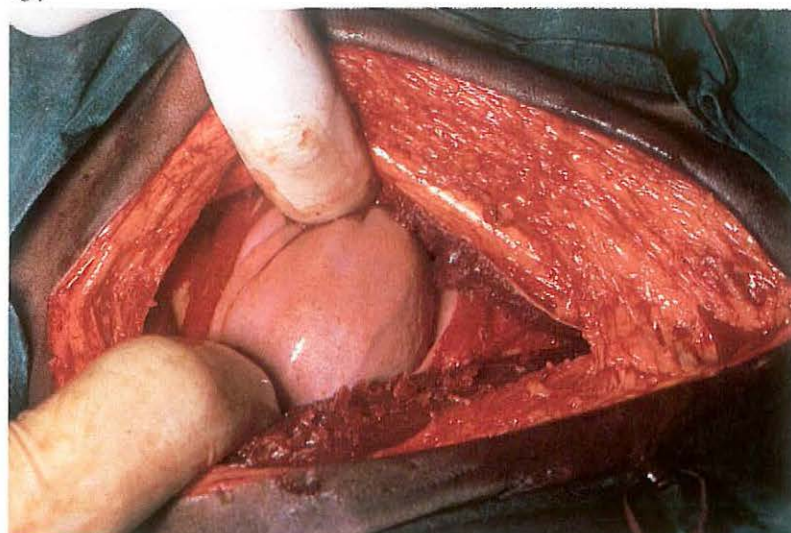
132



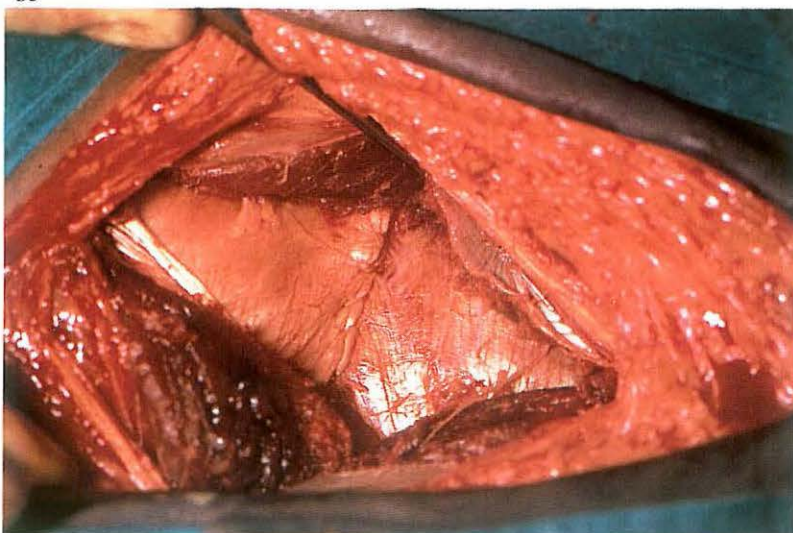
133



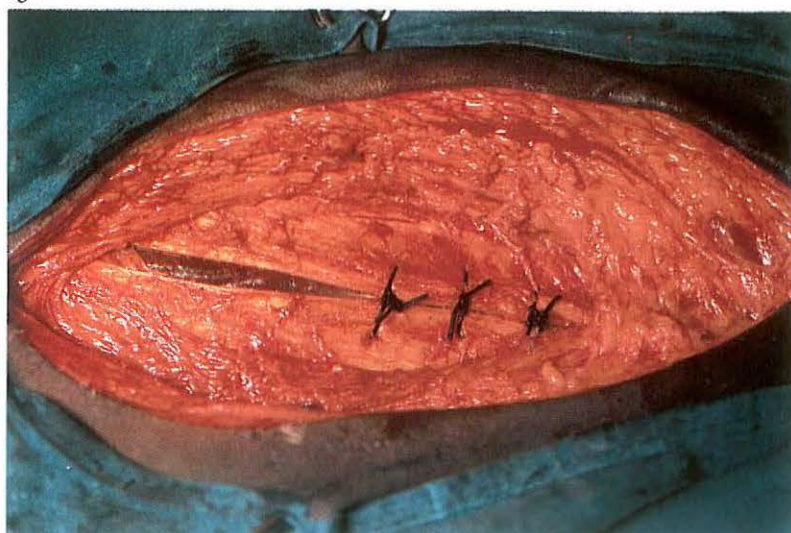
134



135



136



4-5 Paramedian laparotomy

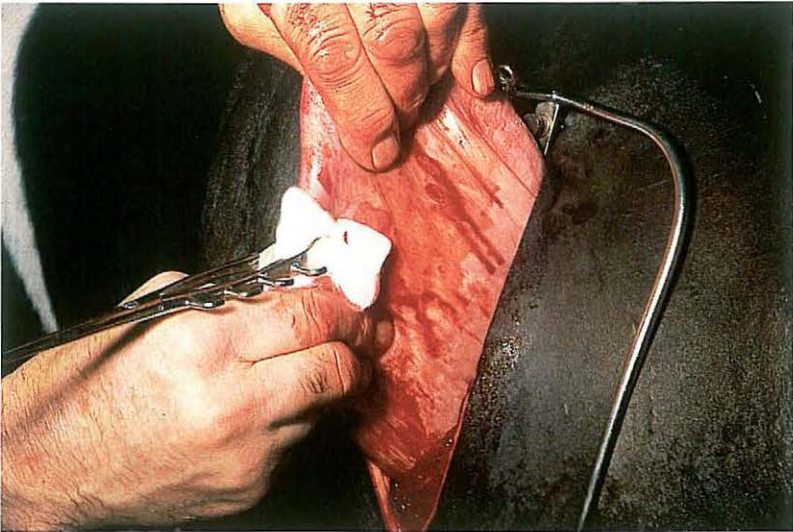
The main indications for paramedian laparotomy are abomaso- and omentopexy in bovine left or right abomasal displacement, cystic surgery and abdominal cryptorchidectomy in horses (see 5-7). Paramedian parapreputial laparotomy in the horse is discussed here.

Surgery. The paramedian laparotomy is performed under general anaesthesia with the horse in dorsal recumbency. A 15 cm skin incision is made caudally from the level of the preputial orifice, 7-10 cm lateral and parallel to the midline. The abdominal tunic (tunica flava) and the closely adherent ventral sheath of the rectus abdominis muscle are incised in the same direction. The underlying rectus muscle is split in the direction of its fibres by blunt dissection [133]. Subsequently, the internal (dorsal) rectus sheath is incised at right angles (i.e. along its fibres) to the skin incision, after which the peritoneum is bluntly split in the same direction [134].

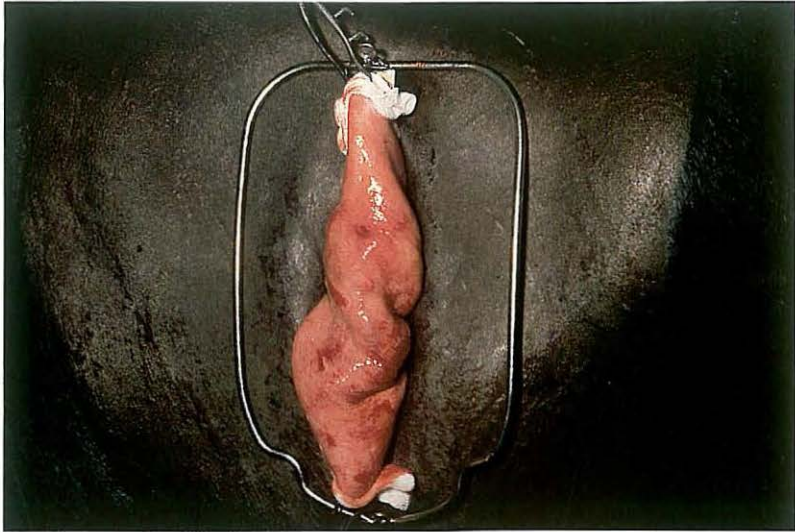
The wound is closed in four separate layers using synthetic absorbable

suture material. Peritoneum and internal rectus sheath are sutured together in a simple continuous pattern [135]. The rectus muscle and external rectus sheath are sutured together using simple interrupted sutures [136]. Finally, subcutis and skin are closed with continuous and simple interrupted sutures respectively.

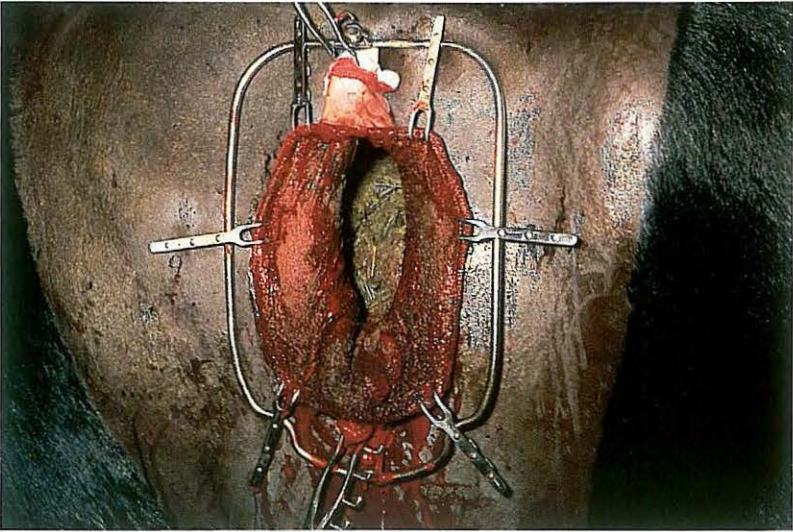
137



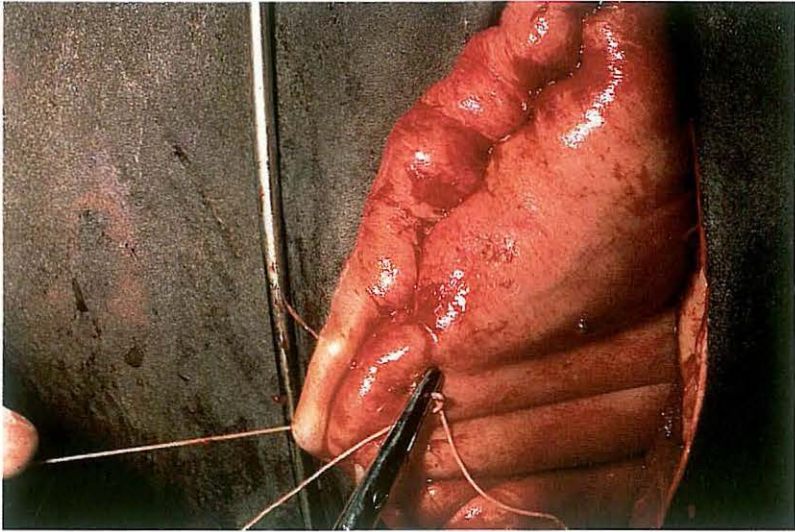
138



139



140

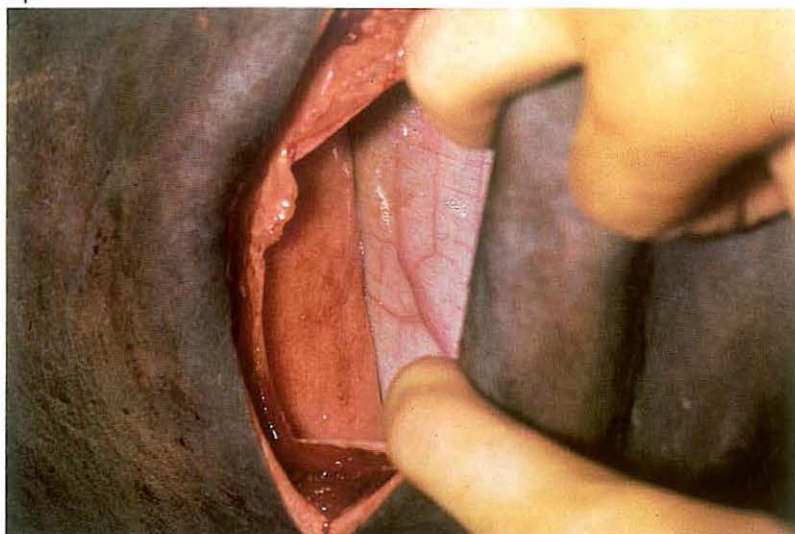


4-6 Rumenotomy

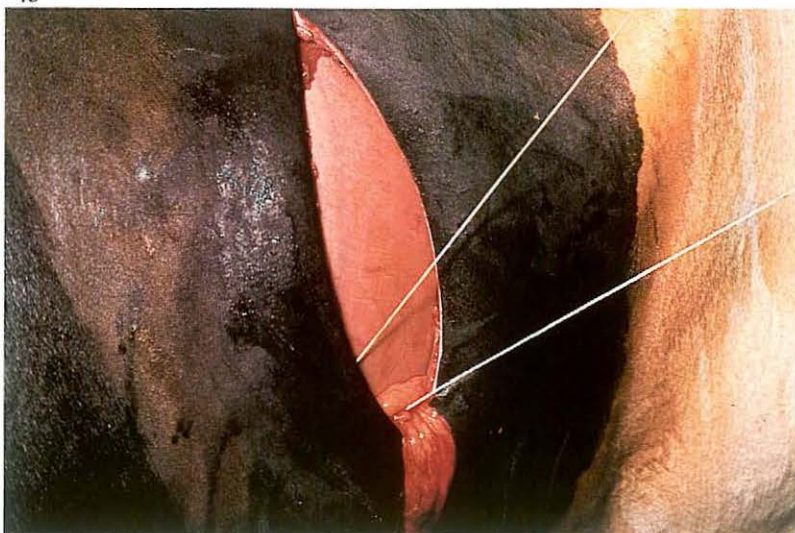
Rumenotomy is indicated for the removal of penetrating foreign bodies (traumatic reticuloperitonitis), neoplasms (papillomas at the site of the cardia) or abnormal ruminal ingesta (plastic, rope, toxic plants). *Surgery.* Laparotomy is performed in the upper left flank (see 4-4). The abdomen is explored for the presence and extent of peritonitis and other possible disorders. To prevent peritoneal contamination by ruminal contents, Weingart's apparatus is used. The fixation frame is inserted into the dorsal commissure of the skin wound. A fold of the wall of the dorsal ruminal sac is drawn outside the skin incision [137] and fixed with two rumen forceps, first in the lower and then in the upper eye of the frame [138]. The ruminal wall is now incised, beginning ventrally; as the incision is lengthened Weingart hooks are placed through the full thickness of the rumen wound edges and attached onto the frame [139]. Ruminal contents are now visible, and abnormal ingesta can be removed. In cases of reticuloperitonitis all

penetrating and loose foreign bodies must be removed from both the reticulum and the rumen. Ingesta is removed from the edges of the rumen wound by flushing. The two lowest hooks are removed and a Schmieden suture or a continuous seromuscular suture (Lembert or Cushing) is begun. As suturing progresses dorsally the other hooks are removed. The first suture line is oversewn with a continuous seromuscular suture [140]. Either absorbable or non-absorbable material may be used. The rumen fold is replaced in the abdomen, after which the Weingart frame is removed and the laparotomy wound closed (see 4-4). Administration of antibiotics is indicated. Dietary measures are taken routinely.

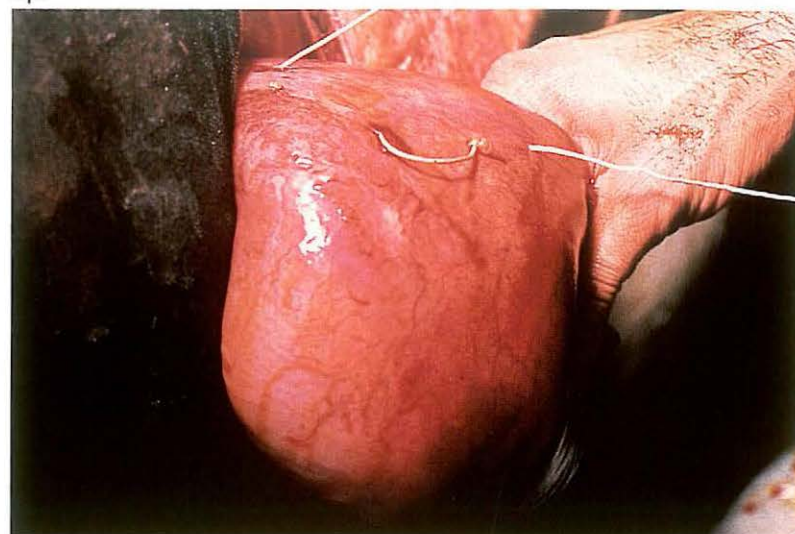
141



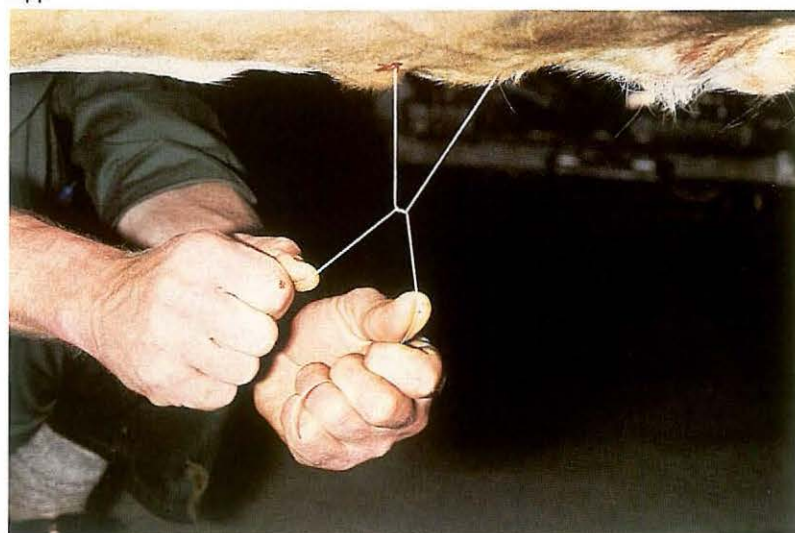143



142



144



4-7 Correction of left displaced abomasum

Procedures used for correction of left displaced abomasum include omentopexy through the left or right flank, and omentopexy or abomasopexy by right paramedian laparotomy. In addition to these methods techniques of percutaneous abomasopexy have been developed.

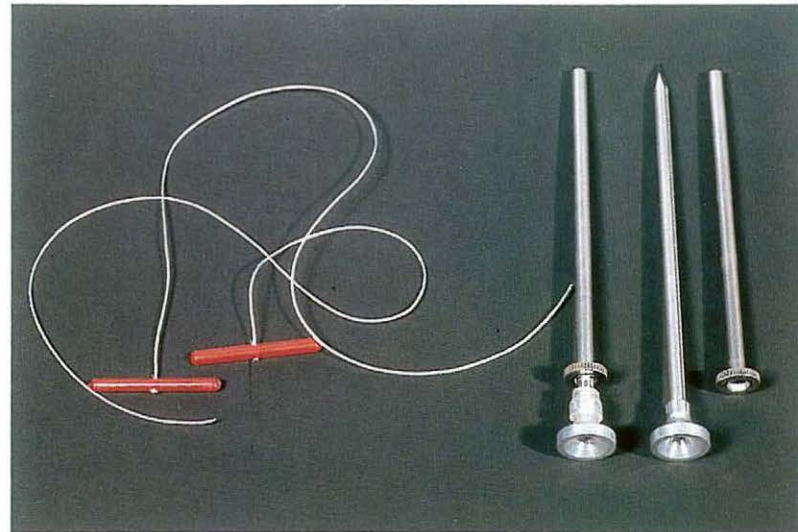
Surgery. The Utrecht method (left flank laparotomy and omentopexy) and percutaneous abomasopexy using a bar suture are discussed here.

(1) Utrecht method.

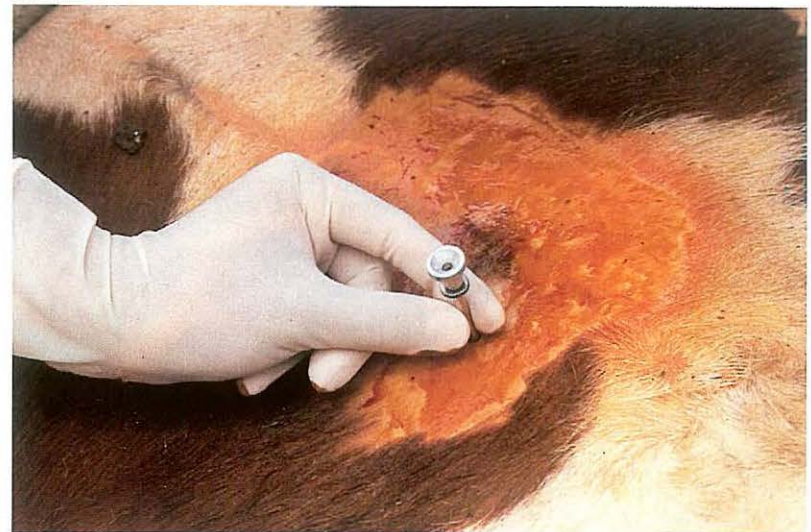In the standing animal left flank laparotomy (see 4-4) is carried out one handbreadth behind the last rib and about 20 cm ventral to the lumbar transverse processes. In most cases the abomasum appears directly in the laparotomy wound [141]. With the right hand and forearm some pressure is applied on the greater curvature in the direction of the xiphoid to expel gas and achieve partial replacement. Only if distension is excessive, is gas aspirated with a needle affixed to a long tube; the puncture opening is closed with a seromuscular purse-string suture.

At the level of the 11th-12th rib, a fold of the greater omentum is grasped and pulled into the laparotomy wound. A two metre long heavy thread of non-absorbable suture material with a needle at both ends is then passed a few times through this fold over a length of about 10 cm close to its attachment to the abomasum [142]. Care must be taken to avoid blood vessels. The abomasum is pushed ventral to the ruminal antrum into its normal position. Both ends of the thread still protrude from the laparotomy wound [143]. The needles, shielded by the hand, are taken separately along the left abdominal wall to the ventral midline and inserted through the abdominal wall about 10 and 15 cm cranial to the umbilicus respectively. The mattress suture is drawn tight and tied on the outside of the body by an assistant [144]. Care must be taken that no other structures are interposed in the omentopexy area. The laparotomy wound is closed as described in 4-4. Postoperative dietary measures are routinely taken. The fixation suture and skin sutures are removed on the tenth postoperative day.

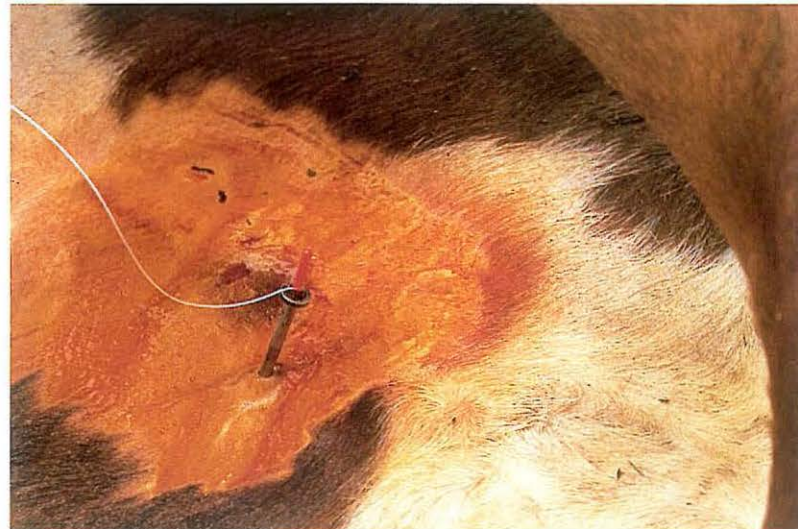145



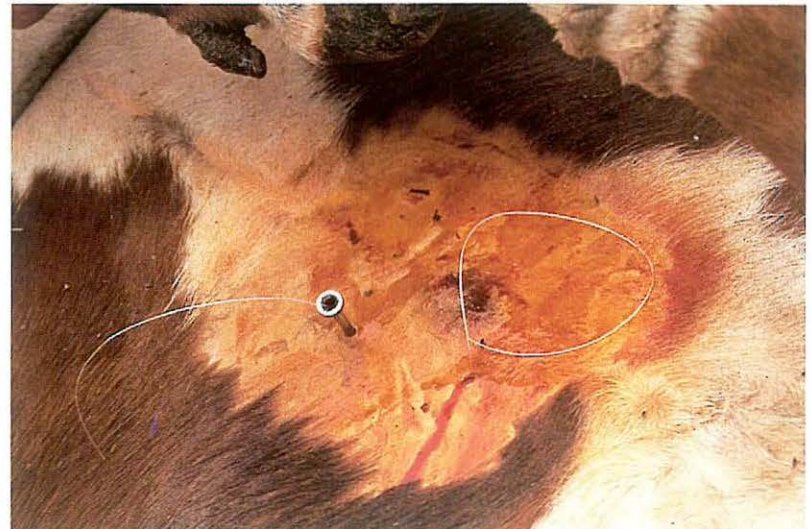
146



147



148

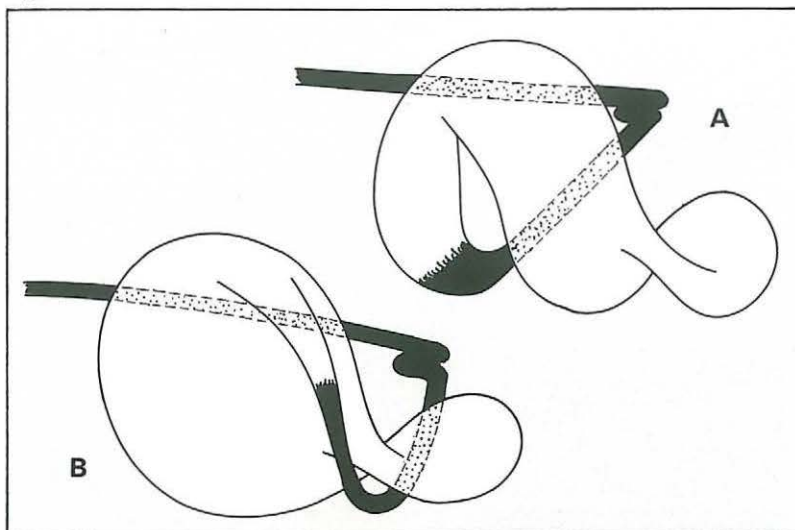


(2) Percutaneous abomasopexy using a bar suture.

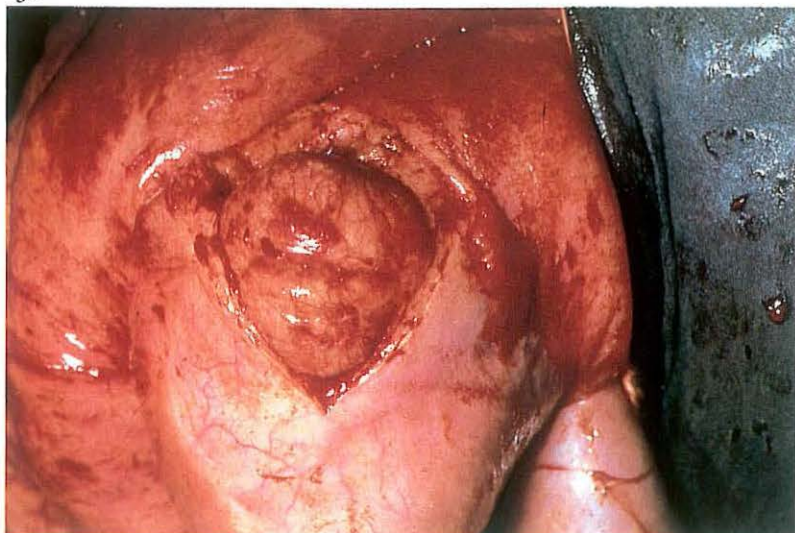The cow is cast, restrained in right lateral recumbency, and then carefully rolled into dorsal recumbency. Percussion and auscultation of the body wall between the umbilicus and xyphoid for detection of a 'ping' reveals the location of the abomasum and the site of trocarization. In the region of the loudest 'ping', usually on the right side of the ventral midline, a 4 mm diameter trocar-cannula [145] is inserted through the abdominal wall into the abomasum, avoiding the subcutaneous abdominal vein [146]. The trocar is then removed with the cannula left in place. Perforation of the abomasum is suggested by the distinctive odour of escaping abomasal gas, and is confirmed by determination of a pH of 2-3 in aspirated content. A bar suture [145] is placed in the cannula [147] and pushed into the abomasal lumen with the trocar. The cannula and trocar are then removed, leaving the suture in place. In a similar manner, a second suture is placed about 7 cm from the first [148]. Prior to removal of the second cannula, abomasal gas is allowed to escape. The sutures are tied loosely. The cow is rolled into left lateral recumbency and allowed to stand.

Postoperative care consists of dietary measures. After about 10 days the sutures are cut close to the skin allowing the sutures to withdraw into the lumen of the abomasum.

149



151

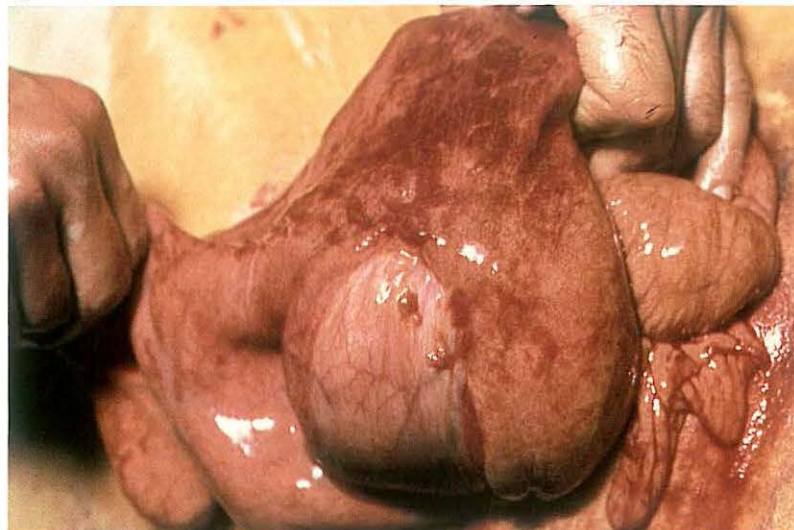

4-8 Correction of right displaced abomasum

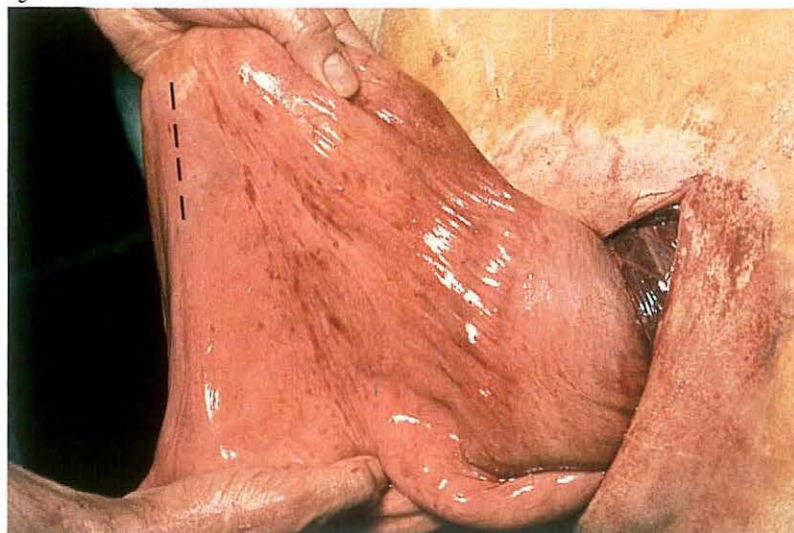
Right abomasal displacement always starts with a 'flexio', i.e. a displacement about a horizontal axis running cranio-caudally; the greater curvature of the abomasal corpus moves dorsally along the right abdominal wall [149A]. In many cases the flexio is followed by a 'rotation', i.e. the abomasum turns about an axis perpendicular to its greater curvature and running through a point halfway between the omaso-abomasal junction and the sigmoid curve of the duodenum; the pyloric part moves cranially along the right abdominal wall [149B].

Surgery. After right flank laparotomy one handbreadth behind the last rib (see 4-4) the abdomen is first explored to determine the type of displacement and to detect possible complications. If necessary the abomasum is punctured before reposition is started (see also 4-7). A flexio is corrected by pushing with the whole lower arm the greater curvature in a cranioventral direction along the right abdominal wall. If a flexio with rotation is present,

150



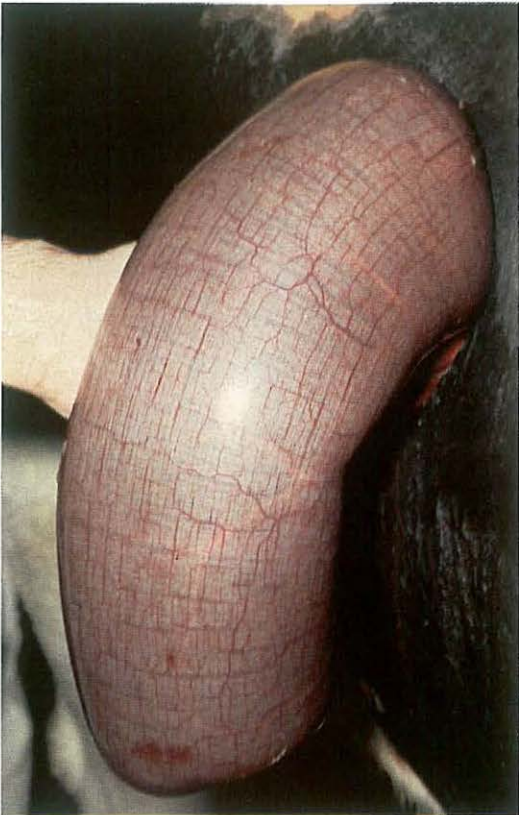152



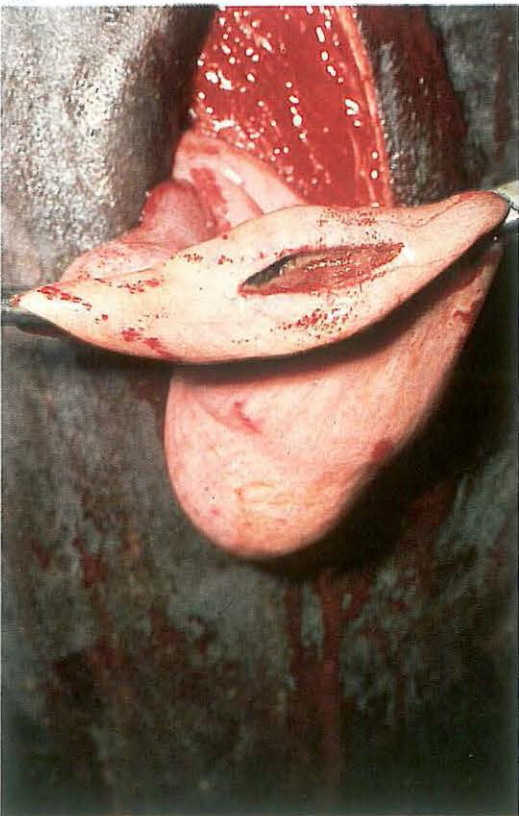
the abomasal corpus is first pushed in a cranial and ventral direction, after which the pyloric part is grasped and pulled caudally across the abdominal floor. In case of severe stasis of abomasal contents a pyloromyotomy may be performed. The pylorus is grasped and brought extra-abdominally [150]. An approximately 8 cm long incision is made through the serosa and muscularis of the pyloric region until the mucosa bulges along the entire length of the incision [151]. The pylorus is replaced into the abdomen. In order to prevent recurrence of the displacement a fold of the greater omentum about 20 cm caudal to the pylorus [152 - dotted line] is incorporated into the first layer of the abdominal wall closure, i.e. the simple continuous suture of the peritoneum and transversus muscle. The other muscular layers and the skin are sutured as described in 4-4.

Further supportive treatment, such as administration of fluids and electrolytes, is based upon the patient's general condition and biochemical findings.

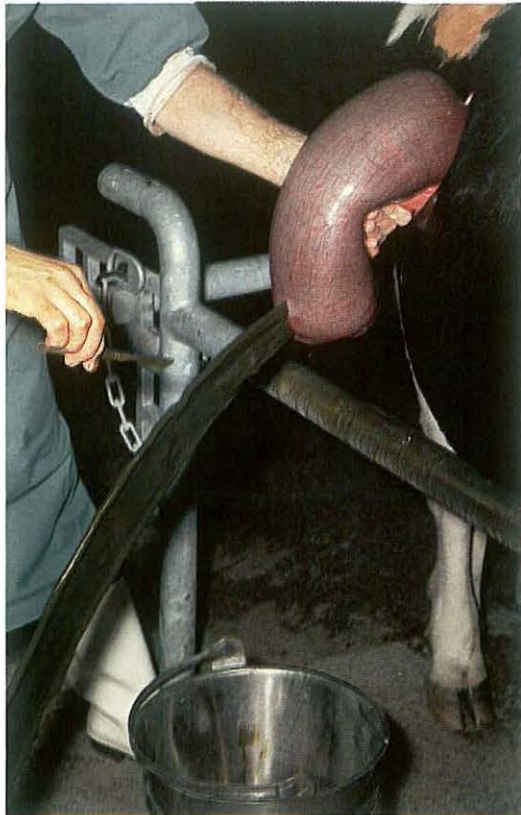153



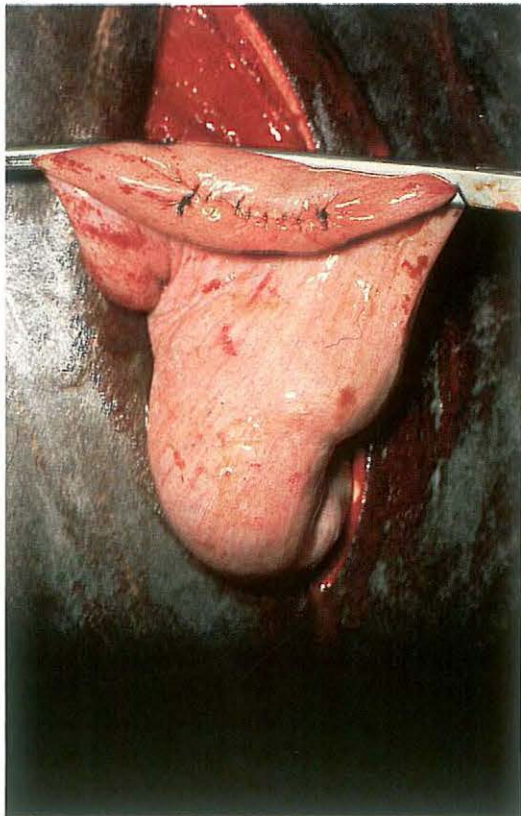
155



154



156

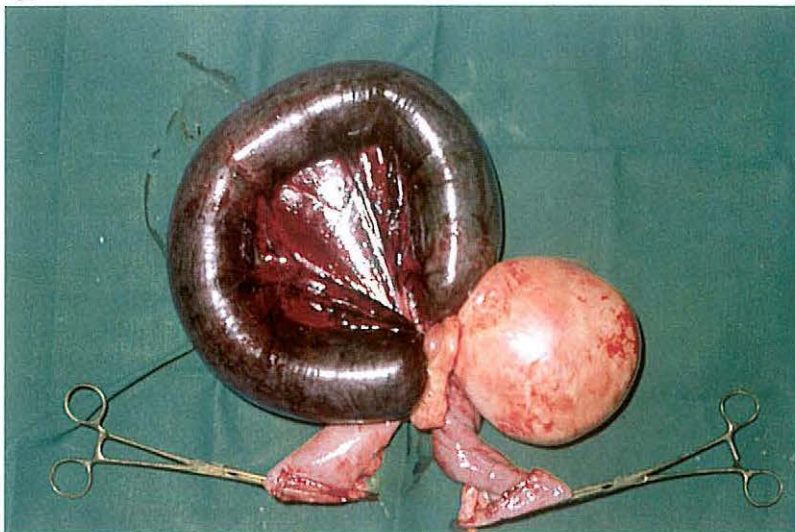


4-9 Caecotomy in cattle

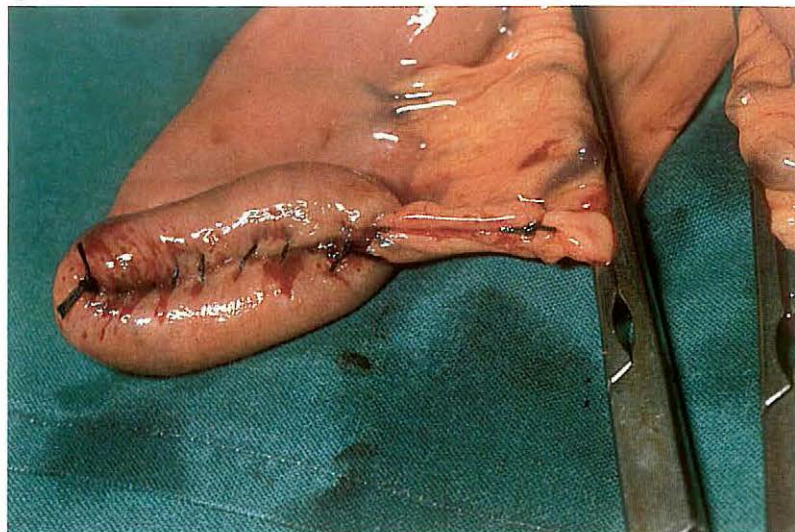
Caecotomy is indicated in cattle suffering from dilation and torsion of the caecum and ansa proximalis of the colon. In some cases only a dilation is present, but usually a torsion also occurs; this may be clockwise or counterclockwise seen from the animal's right side.

Surgery. Laparotomy is carried out on the standing animal in the caudal part of the right flank (see 4-4). The abdomen is explored to detect whether torsion is present or not; if present its direction is determined. The free part of the caecum is brought extra-abdominally and held in a ventral position [153], after which the caecal apex is incised to release ingesta [154]. The intra-abdominal part of the caecum and the ansa proximalis of the colon are also emptied as well as possible, by massaging the ingesta in the appropriate direction. An intestinal clamp is then placed proximal to the incision [155], which is closed by either a Schmieden suture oversewn with a continuous Lembert suture, or with two continuous Lembert sutures [156]. The surface of the caecal apex is flushed with physiologic saline. The caecum is replaced in the abdomen, and the reposition of the torsion is completed. The laparotomy wound is then closed (see 4-4). Antibiotic administration is optional. Dietary measures are routinely taken.

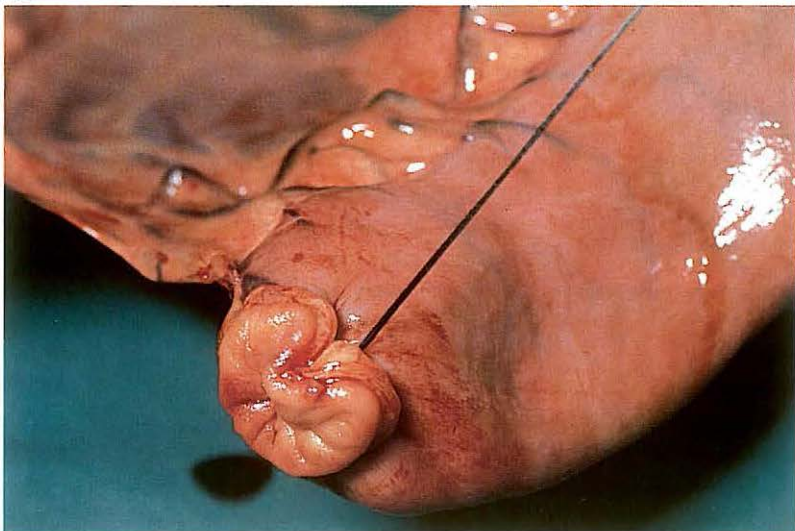
157



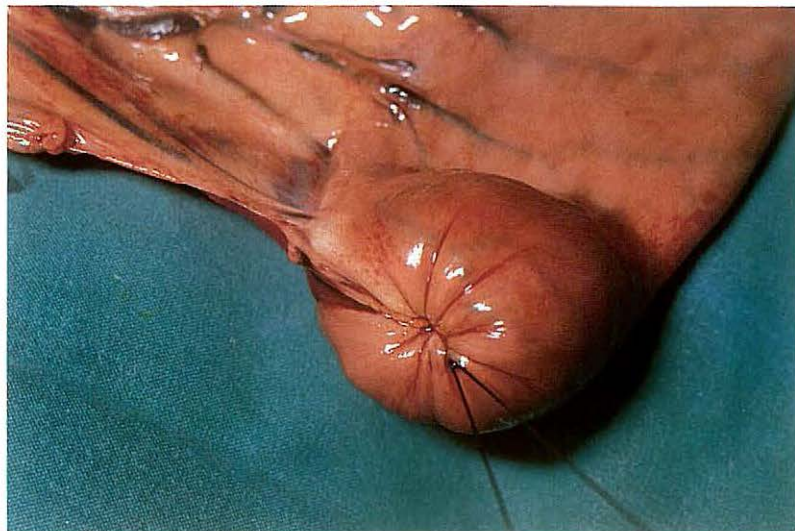
158



159



160



4-10 Enterectomy; side-to-side anastomosis

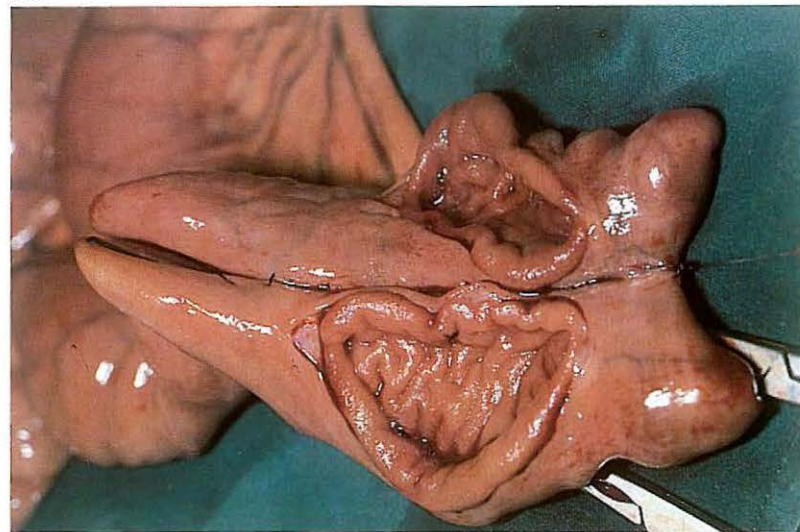
Enterectomy is indicated in cases of irreversibly compromised viability of the intestinal wall, which may be caused by incarceration, torsion, intussusception, strangulation by fibrous bands or pedunculated tumours, etc. Plate 117 shows strangulation of a jejunal loop by a pedunculated lipoma. In horses, side-to-side anastomosis of the jejunum is often preferred, to avoid postoperative stenosis.

Surgery. The operation is carried out with the animal in dorsal recumbency under general anaesthesia. A laparotomy is performed in the ventral mid-line (see 4-3). After correction of the primary disorder and emptying of the jejunum, the intestinal wall is examined for viability, in which special attention is paid to the state of circulation and motility. If enterectomy is required the affected gut is brought sufficiently extra-abdominally to allow resection through healthy tissue and to prevent peritoneal contamination from intestinal contents. After the extent of resection is determined, the

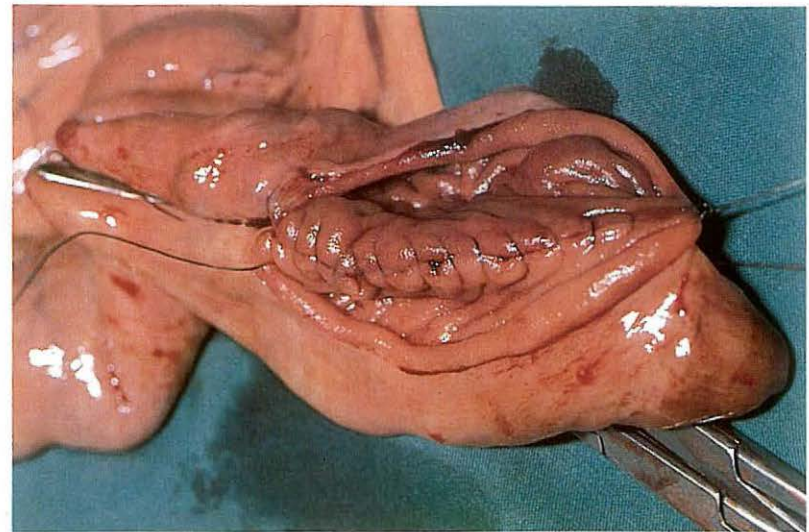
vessels of the adjacent mesentery are ligated; the mesentery to be removed is usually wedge-shaped. The blood supply of the proposed sites of resection must not be compromised. The affected intestine is isolated by carefully placing two pairs of intestinal clamps over adjacent bowel. The mesentery is transected distal to the ligatures, and the diseased gut is resected between the two clamps, both proximally and distally. After flushing with physiologic saline the remaining ends are closed using a Schmieden suture oversewn with a continuous Lembert suture, both with absorbable suture material [158]. An alternative method of resection is as follows: the intestinal loop to be resected is isolated from the remainder of the gut by ligatures instead of intestinal clamps. The gut is then transected between the ligatures [159]. The ligatures of the remaining ends are invaginated after which closure of the ends is performed with a sero-muscular purse-string suture [160].

The ends of the gut are now laid side by side with their stumps either in the same direction (anisoperistaltic = functional end-to-end anastomosis) or in

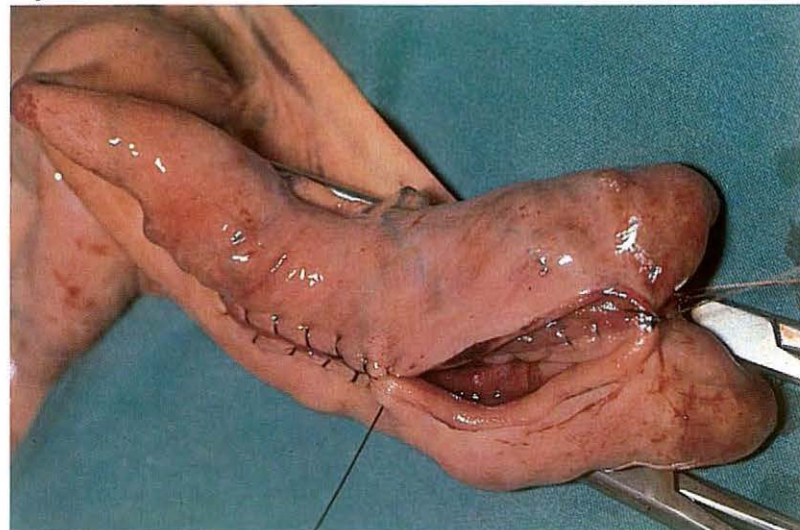
161



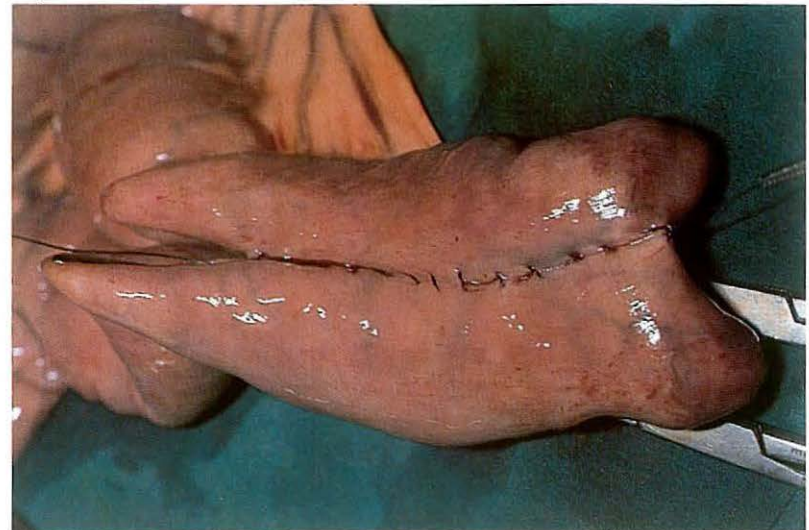162



163

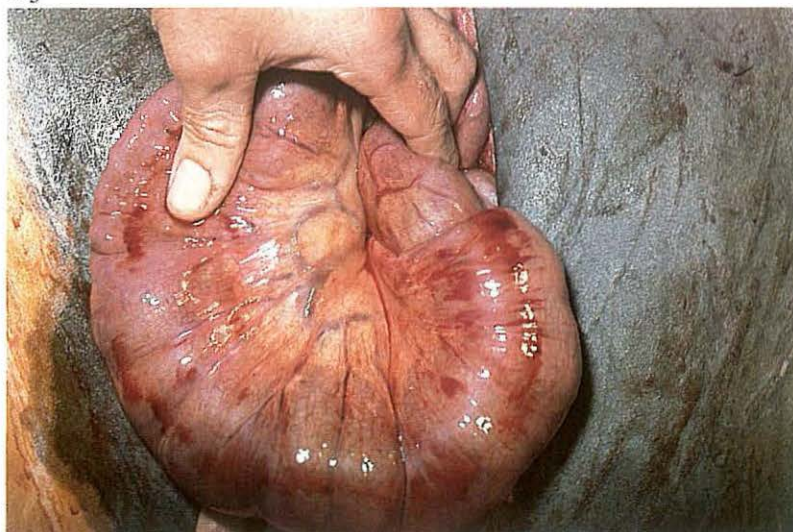


164

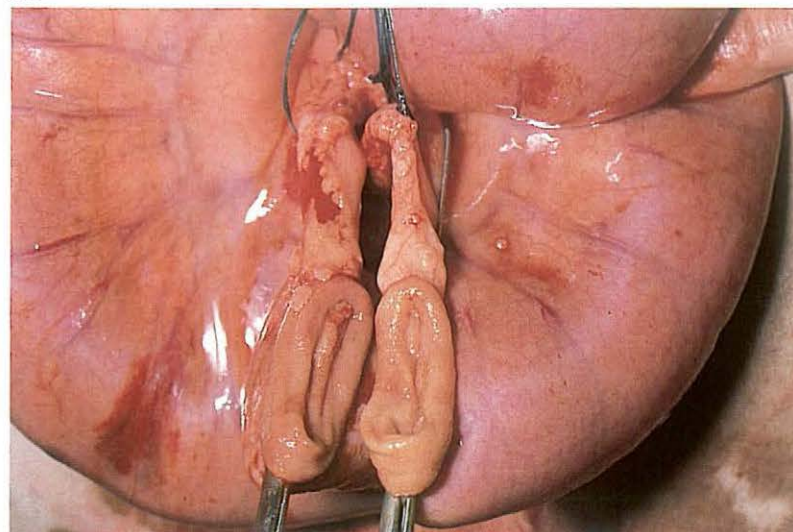


opposing directions (isoperistaltic). Intestinal content is milked back and isolated with intestinal clamps. The two apposed loops are sutured together with a continuous Lembert suture. They are then incised about 1 cm from and parallel to the Lembert suture. The incisions must be of equal length and shorter than the Lembert suture [161]. A simple continuous suture, including all layers of the intestinal wall, is started at one end of the incision, thus suturing together the wound edges on the luminal side of the Lembert suture [162]. On reaching the other end of the incision the continuous suture continues as a Schmielen suture [163], which is continued up to the origin of the simple continuous suture. The previously placed Lembert suture, with which the simple continuous suture is already oversewn, is now continued to oversee the Schmielen suture [164]. Absorbable suture material is used for both suture lines. After removal of the clamps the intestine is flushed again and the anastomosis is checked for patency and leakage. The mesentery is closed with interrupted sutures. The intestine is replaced into the abdomen and the laparotomy wound closed (see 4-3). Systemic antibiotics are indicated.

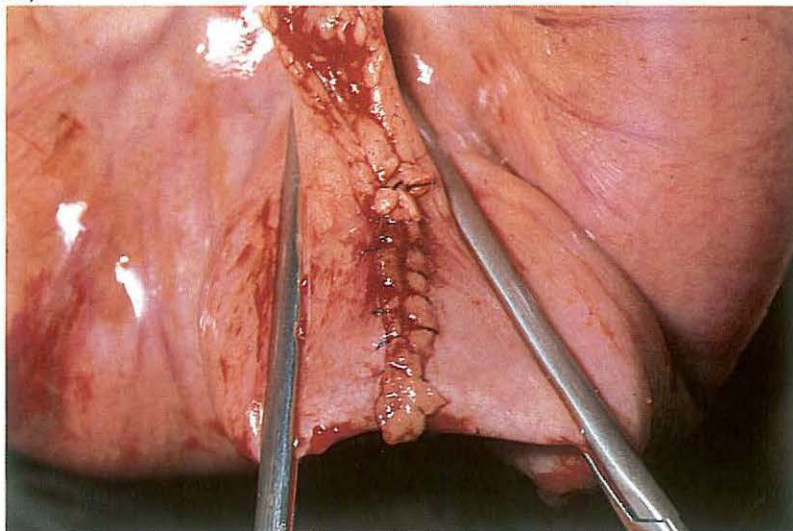
165



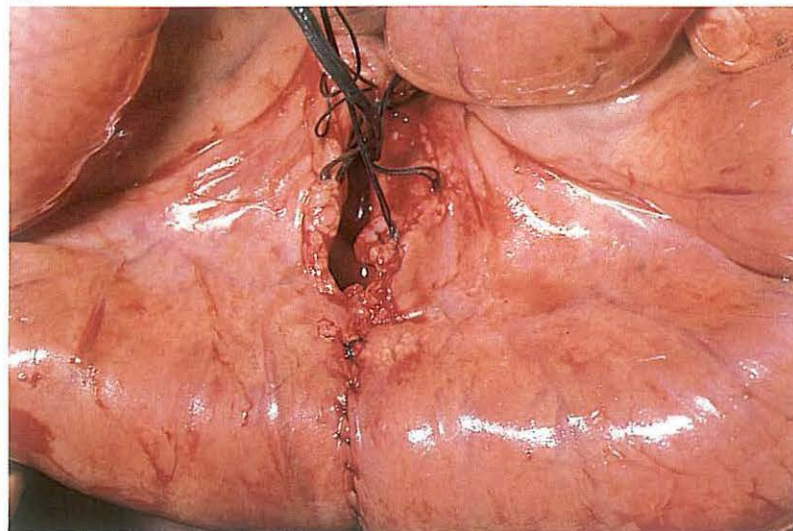
166



167



168



4-11 Enterectomy; end-to-end anastomosis

Intussusception [165] is the most frequent indication for small intestinal enterectomy in cattle, although other disorders which interfere with the viability of the intestinal wall may also necessitate resection. In cattle end-to-end anastomosis is usually performed.

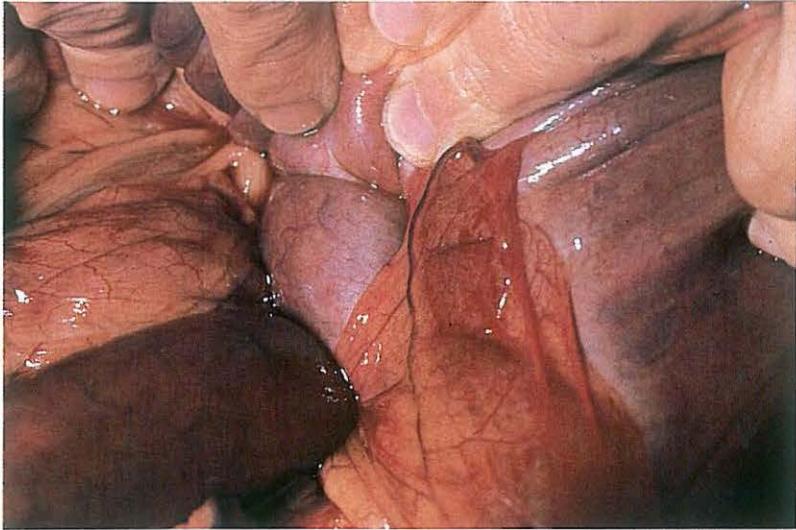
Surgery. A right flank laparotomy is carried out on the standing animal under local analgesia (see 4-4). The affected bowel is carefully exteriorized and the extent of the gut to be resected determined. After application of topical analgesia a V-shaped area of the adjacent mesentery, including the vessels, is ligated.

The diseased loop is then isolated from the remainder of the gut by intestinal clamps and resected with its mesentery. The viable ends are flushed with physiologic saline and apposed, with the lumina held toward the surgeon [166]. The adjacent halves of the two wound edges are sutured with a simple continuous suture perforating all layers of the intestinal wall. The

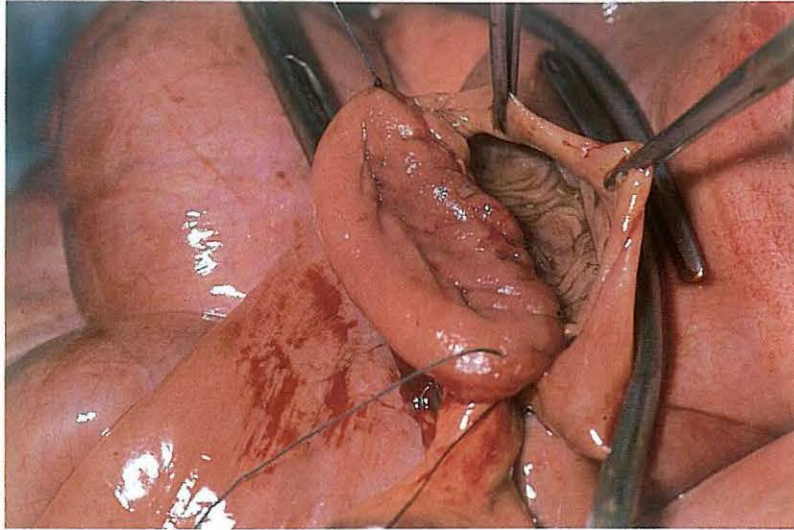
suture begins at the mesenteric border with the knot lying in the lumen of the gut. On reaching the antimesenteric border the lumina are apposed and the continuous suture continues as a Schmieden suture, with which the two other halves are sutured until the mesenteric border has been reached [167]. Using a continuous Lembert suture, the first suture line is completely oversewn [168]. Absorbable suture material is used for both suture lines. The clamps are removed and the anastomosis checked. The defect in the mesentery is closed by tying the long end of mesenteric ligatures lying opposite to each other. After replacing the intestine into the abdomen the laparotomy wound is closed (see 4-4).

Systemic antibiotics are administered and dietary measures are routinely taken.

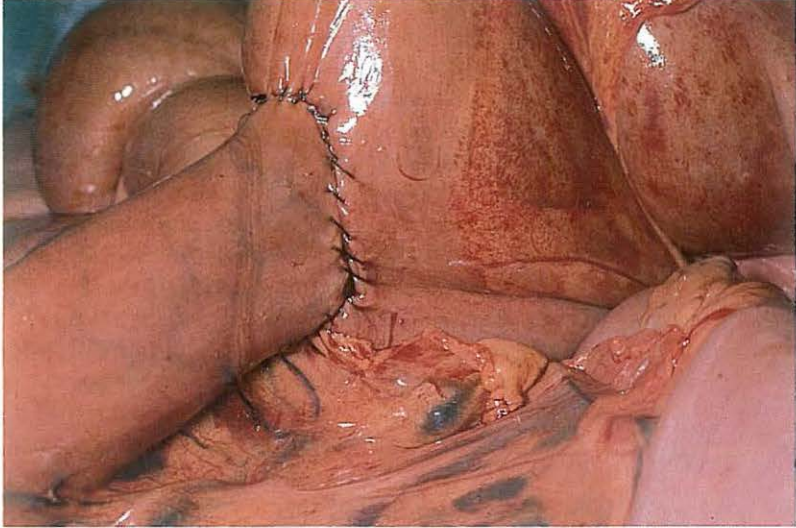
169



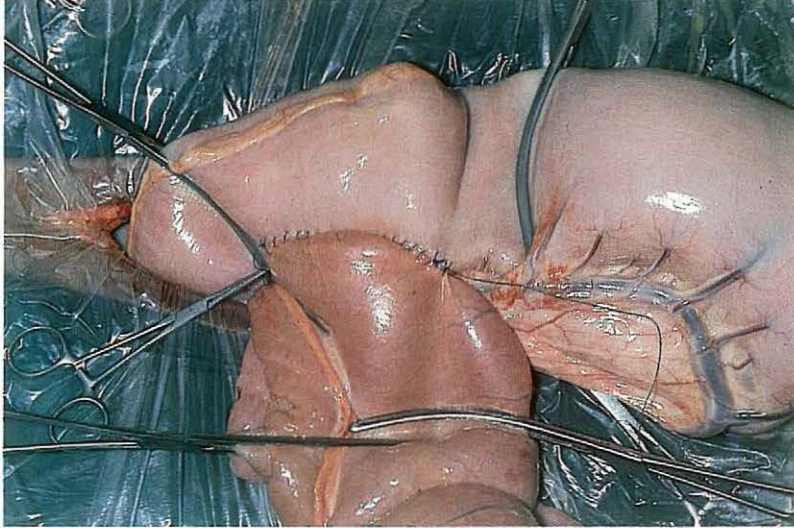
170



171



172



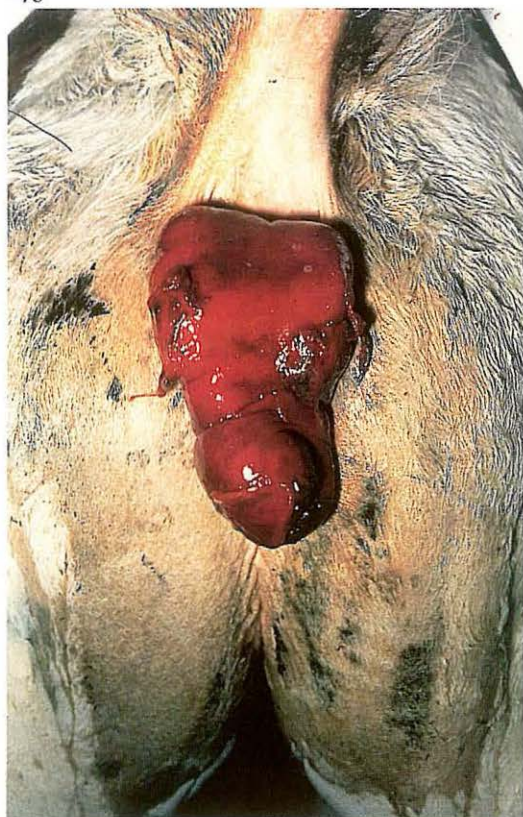
4-12 Jejunocaecostomy; end-to-side anastomosis

Obstruction of the ileum in horses is caused by ileocaecal intussusception [169], involvement of the ileum in internal or external hernias, or ileal ob-
stipation. Because the ileocaecal area is inaccessible, resection of the entire
ileum and sparing the ileocaecal valve is impossible. A new junction be-
tween the distal jejunum and caecum must therefore be created, and is
achieved by either end-to-side or side-to-side anastomosis.

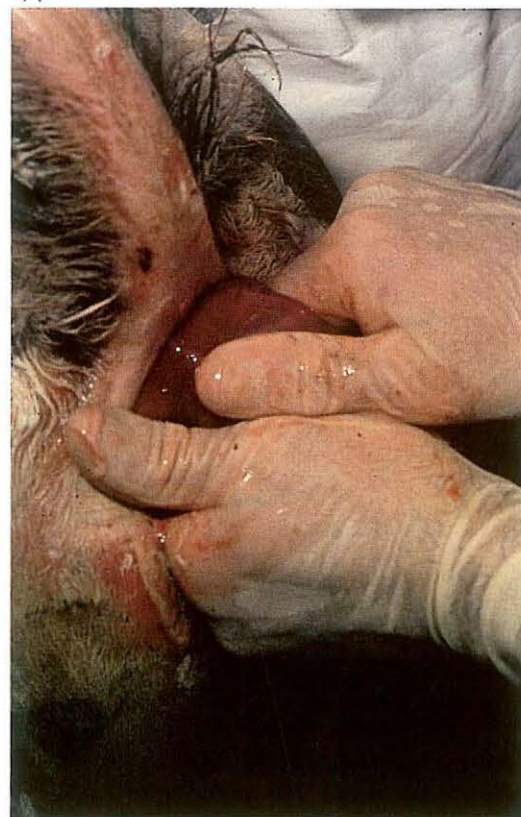Surgery. Treatment of ileocaecal intussusception by reduction alone rarely
succeeds. Usually the intussusceptum is left in place and jejunocaecostomy
is carried out. To perform an end-to-side anastomosis the jejunum is
transected as distally as possible, after which the distal stump (ileum) is
closed, as described in 4-10. The caecum is then exteriorized. A fold of the
wall about 20 cm distal to the ileocaecal valve is clamped off. Half the
circumference of the open end of the jejunum is sutured to this fold, using
a continuous Lembert suture placed 6-7 mm from the transected edge. The

caecal wall is then incised 6-7 mm from this suture line; the length of the
incision corresponds with the diameter of the jejunal end. The caecal and
jejunal edges are joined together using a simple continuous suture, which is
continued as a Schmielen suture [170], as in 4-10. The Lembert suture is
continued to oversewn the Schmielen suture line [171]. The free border of
the mesentery of the distal jejunum is sutured to the caecum to obliterate
the space between jejunum and caecum.
In ileum ob-
stipation and ileum muscular hypertrophy, a jejunocaecal by-
pass is performed, leaving the normal ileal pathway open [172]. The bypass
is created as a side-to-side anastomosis (see 4-10).

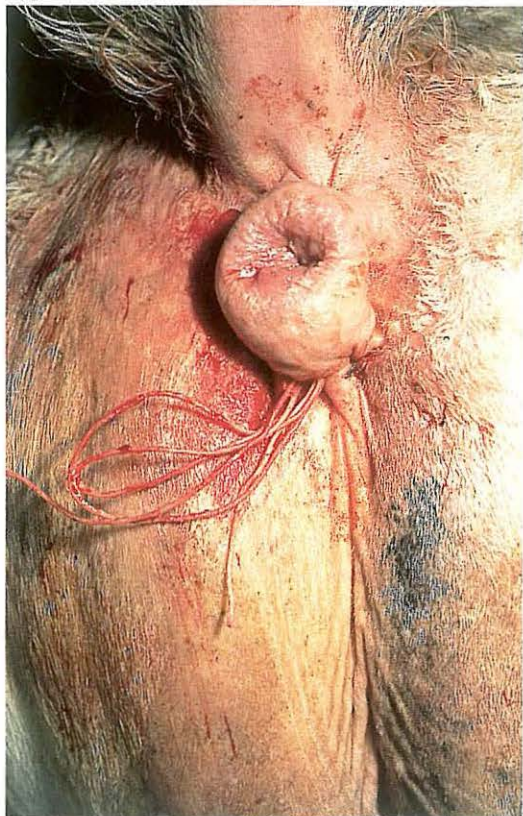
173



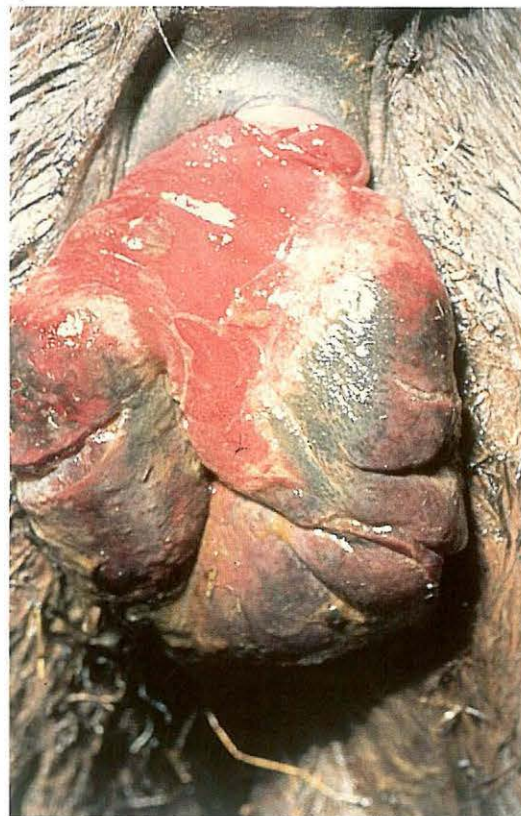174



175



176



4-13 Correction of rectum prolapse

Rectum prolapse involves either the rectal mucosa alone (incomplete prolapse) or the full thickness rectal wall (complete prolapse). Furthermore, the rectum prolapse may contain an intussusception of the rectum, colon or even small intestine.

Treatment depends on the degree of damage to the mucosal layers. Usually, manual reposition and suture retention of the prolapse can be carried out. However, amputation of the prolapse is indicated when reposition is impossible (because of severe swelling or adhesions) or when perforating injuries or necrosis of the mucosal layers are present [176]. In cases of extensive prolapse, the prognosis is guarded due to the possibility of accompanying mesocolon vascular damage; in this condition laparotomy should be considered for definitive diagnosis and possible treatment.

Surgery. Correction of rectum prolapse is performed under caudal epidural analgesia (posterior block) or general anaesthesia.

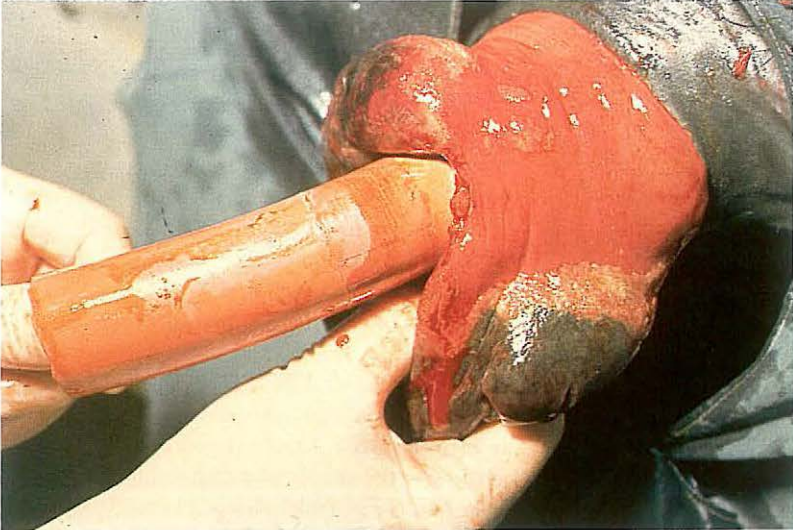
(1) Reposition and retention of the prolapse.

Reposition [173, foal] is achieved by careful massage of the prolapse using a vaseline-based ointment [174]. To aid retention of the replaced rectum, a purse-string suture is placed through skin and deep fascia around the anus [175]. Before tying the suture, liquid paraffin is administered rectally with a soft rubber tube to facilitate defaecation. The purse-string suture is then tied in a bow, so that it can be easily loosened and retied. The suture is tied such that two fingers can easily be passed through the anus, thereby allowing some defaecation.

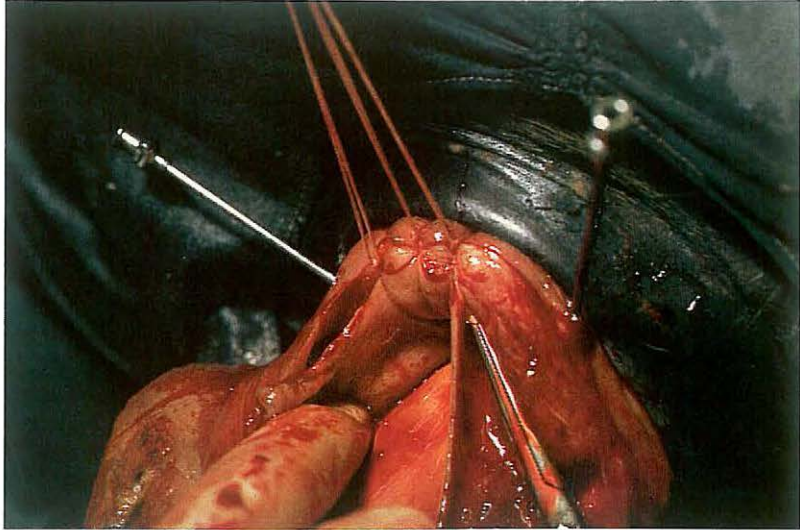
(2) Amputation of the prolapse.

Before resection ([176], horse), a probe is passed between the prolapse and the anal ring to ensure that intussusception is not present. Next, a suitably sized firm rubber tube is passed into the rectum [177]. As slight traction is applied to the prolapse, two long needles are thrust (one vertically, the other horizontally) through the prolapse and the tube. The needles must be close to the anal ring [178], so that healthy tissue is penetrated. The first quadrant of the prolapse is then resected just distal to the needles, and the outer and inner layers of the resected end of the rectum are sutured together, using simple interrupted sutures [178]. The second quadrant of the prolapse is then resected in a similar way [179]. After amputation and suturing of all

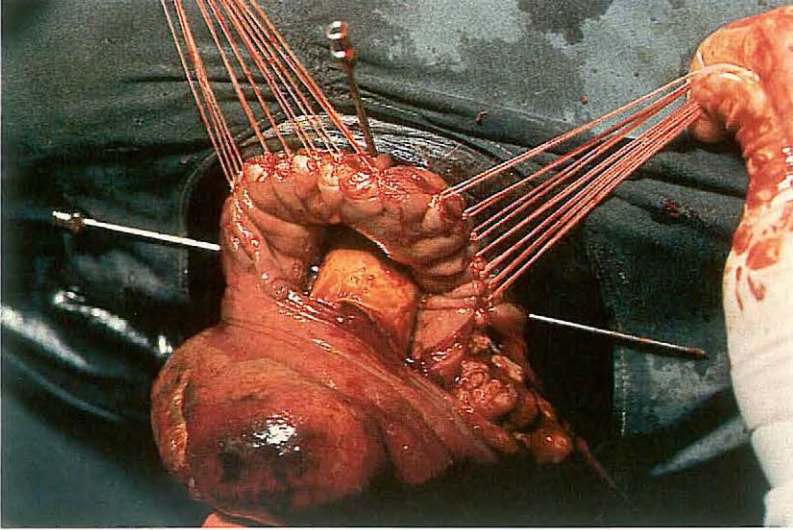
177



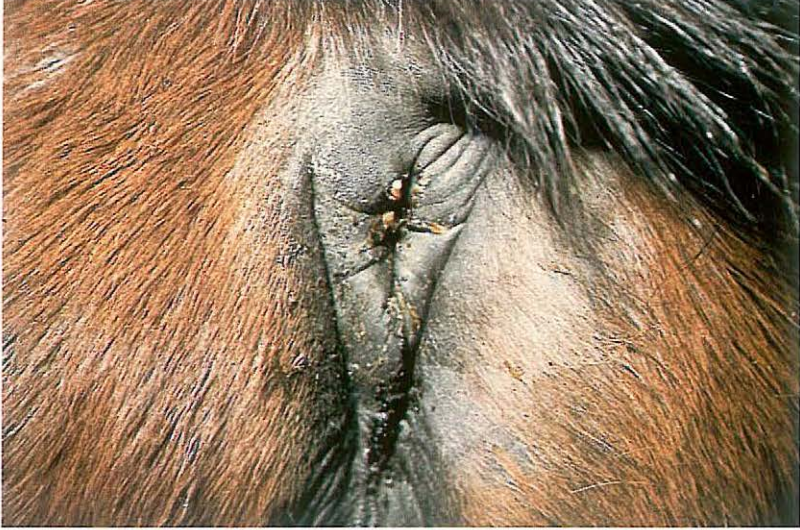178



179



180



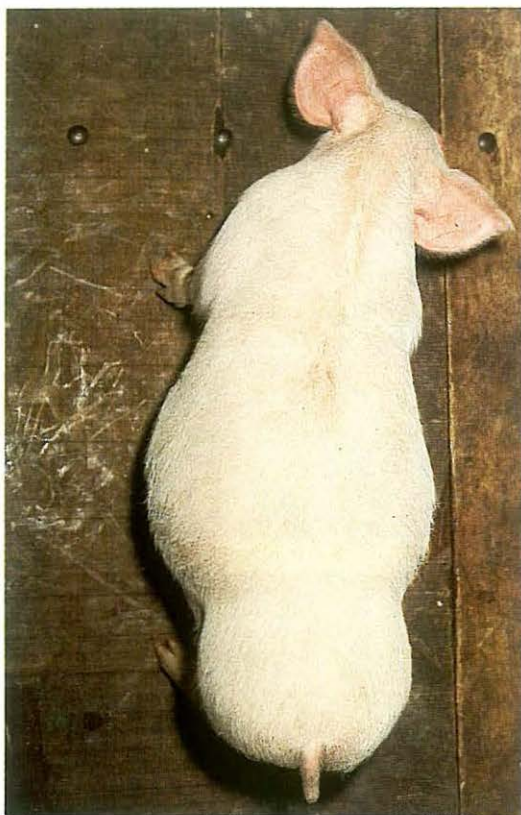
quadrants have been completed, the ends of the threads are cut off and the two needles and tube are removed. In most cases the stump retracts spontaneously. In those cases in which the stump remains slightly prolapsed, retention of the rectum is achieved by use of a purse-string suture as described above.

Dietary measures and/or liquid paraffin administered either by stomach tube and/or rectally may be used to facilitate defaecation.

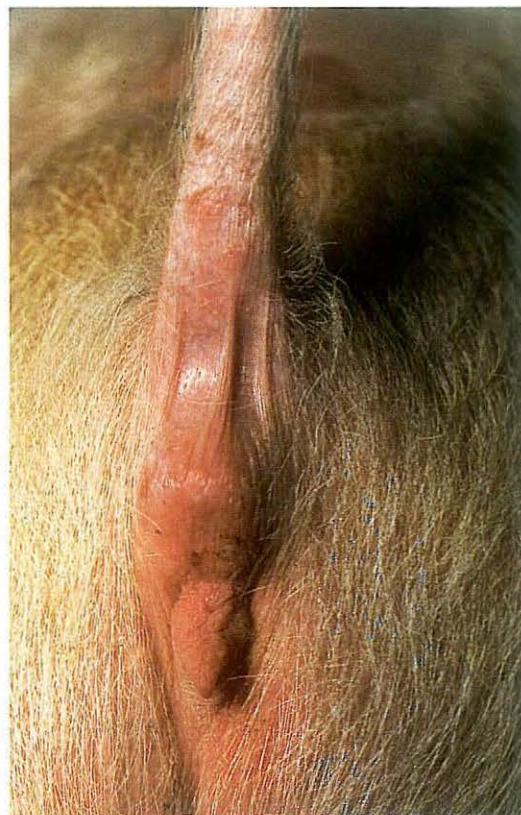
It may be necessary to loosen the purse-string suture twice daily to release faeces. The purse-string suture may be removed within 48-72 hours.

Plate 180 shows the situation on the tenth postoperative day.

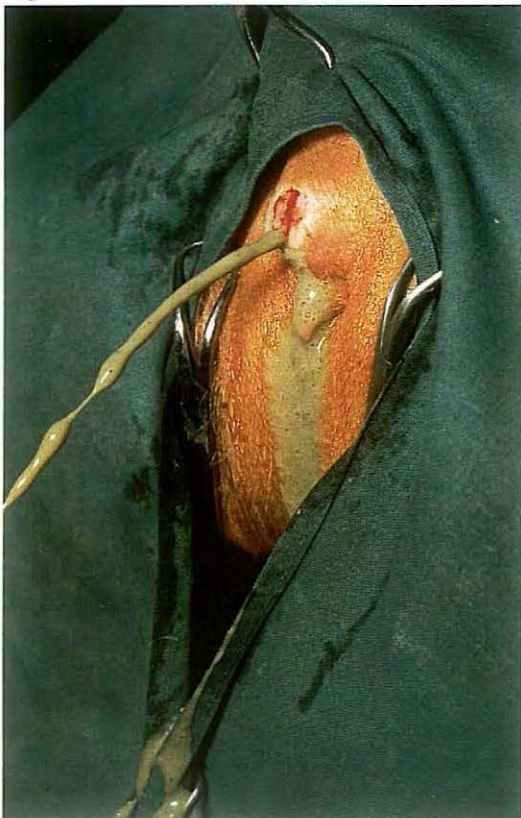
181



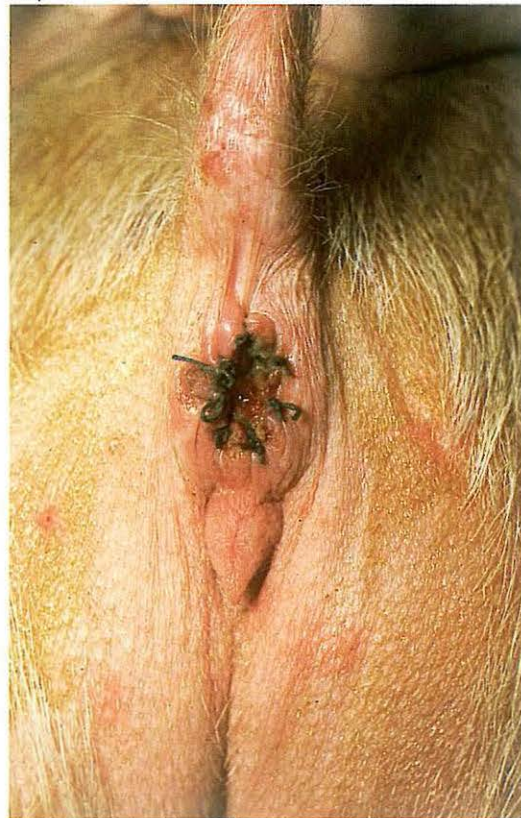182



183



184



4-14 Treatment of atresia ani (et recti)

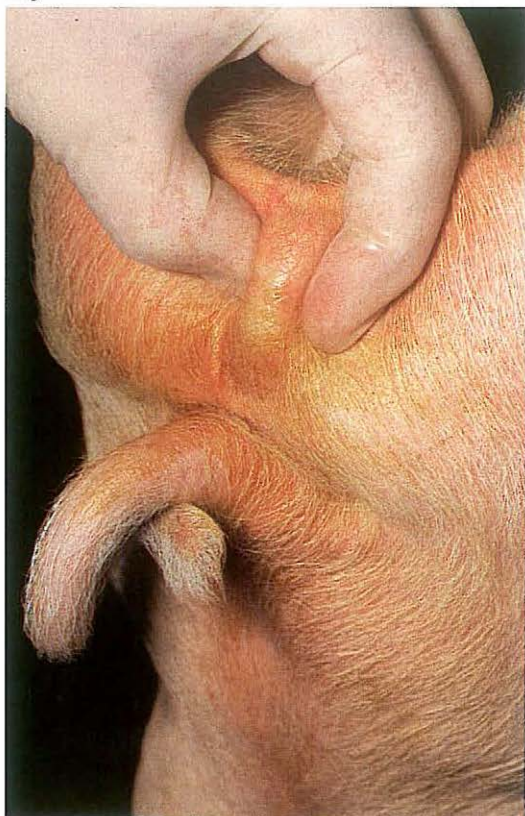Absence of the anal opening is observed often in the piglet and occasionally in other species. Affected piglets may be up to several weeks old without showing serious illness except progressive abdominal distension [181]. In female piglets even distension may not be evident because of the presence of a recto-vaginal fistula through which some evacuation occurs. In some cases there may be a swelling at the site of the anus [182].

Surgery. After local infiltration analgesia or epidural analgesia a circular piece of skin is excised over the anal site. Ideally the rectum should be sutured to the skin before the rectum is opened but often faeces are discharged immediately following the skin excision [183]. After sufficient evacuation of the bowel the rectal wall is apposed to the skin by interrupted sutures [184]. If the distal portion of the rectum is also atretic, deeper dissection is required to locate the blind end of the rectum. Gentle traction, assisted by pressure on the abdominal wall, should be used to draw the rectum caudad to the anus, where it is sutured to the skin.

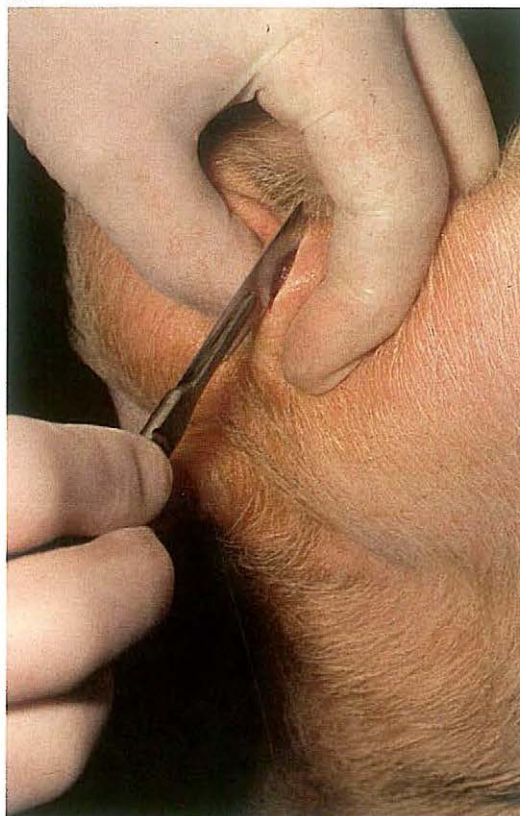
If too large a portion of the rectum is absent, creation of a preternatural anus via a laparotomy under general anaesthesia may be considered. Postoperatively a cicatricial stricture of the anal opening may develop.

Chapter 5 The urogenital system

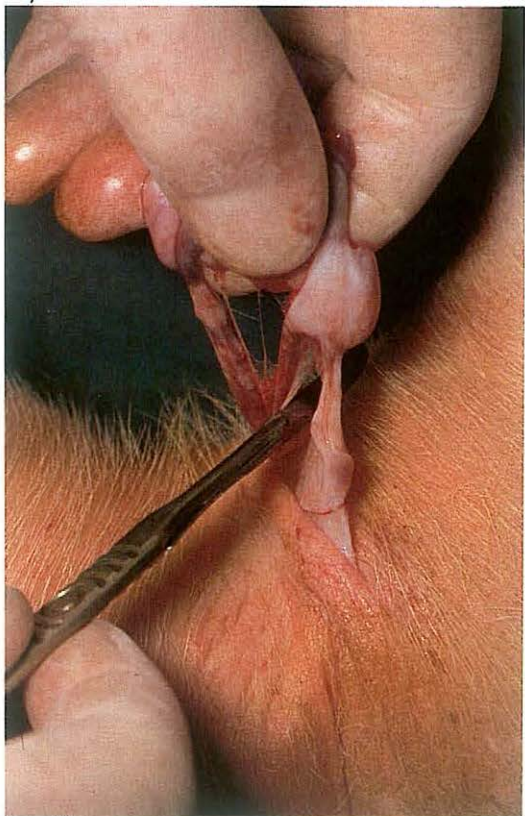
185



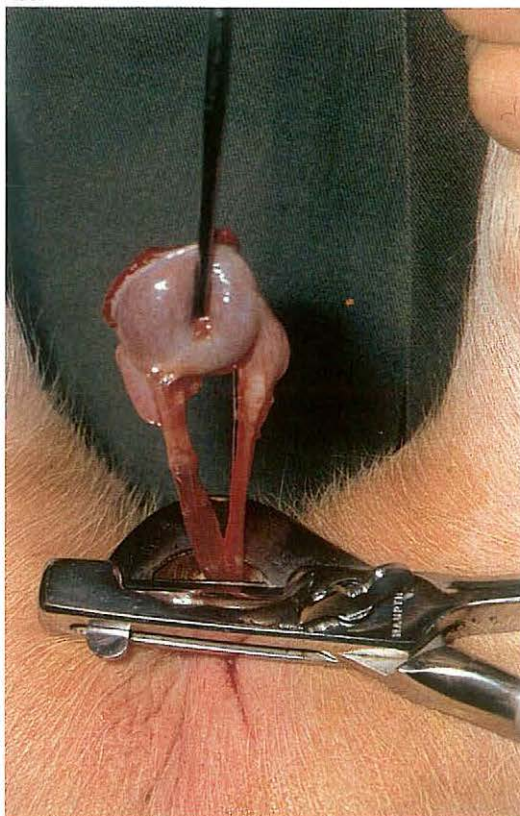
186



187



188

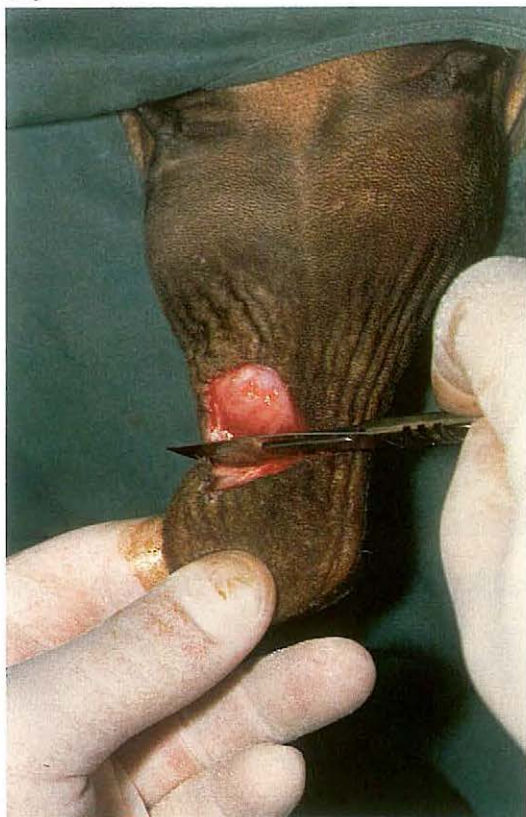

5-1 Castration: open technique in the pig

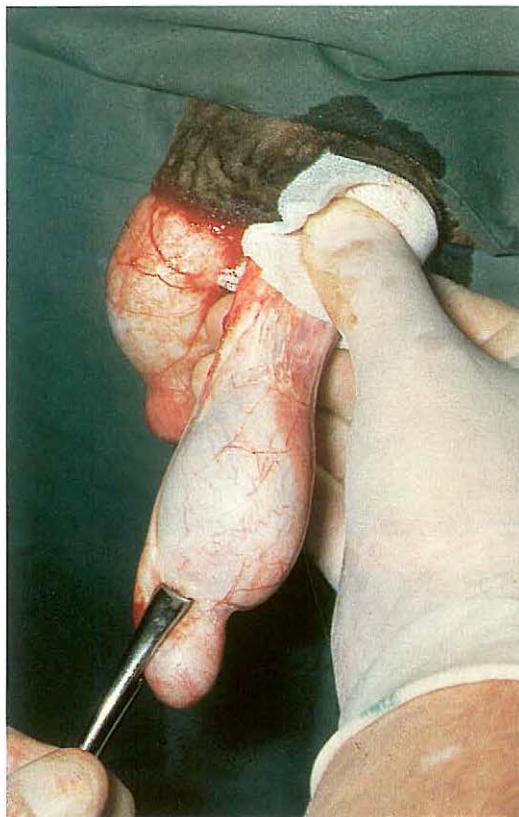
Piglets are usually castrated using the open technique, in which the vaginal cavity is left open after emasculation. It is clear that the open technique of castration is contraindicated in cases of inguinal or scrotal hernia. Piglets are generally castrated at the age of 3-6 weeks.

Surgery. Castration is performed under local analgesia of the scrotal skin and both testicles. An assistant holds the animal upside-down by the hindlimbs, with the piglet's back towards the surgeon. The testicle is pushed up into the scrotum with thumb and forefinger [185]. An incision is made into testicular tissue through scrotal skin, tunica dartos and vaginal tunic [186]. The exposed testicle is grasped with the fingers and the scrotal ligament is transected with a scalpel; the incision starts at the site of the mesorchium [187]. To prevent spermatic cord haemorrhage, ligation (with a catgut ligature) or crushing (with an emasculator, which crushes and cuts at the same time) of the spermatic cord is recommended. The emasculator is held as proximal as possible on the spermatic cord [188] for 10-15 seconds. The emasculator is then removed and the severed end of the cord retracts into the inguinal canal.

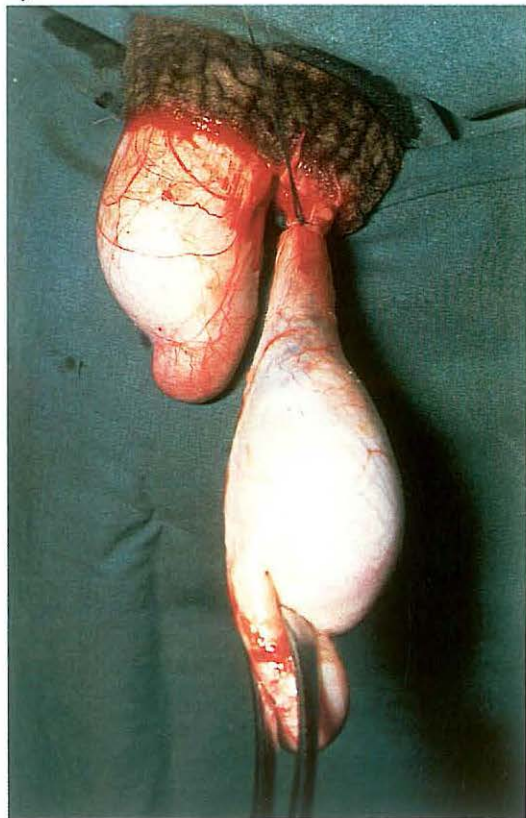
189



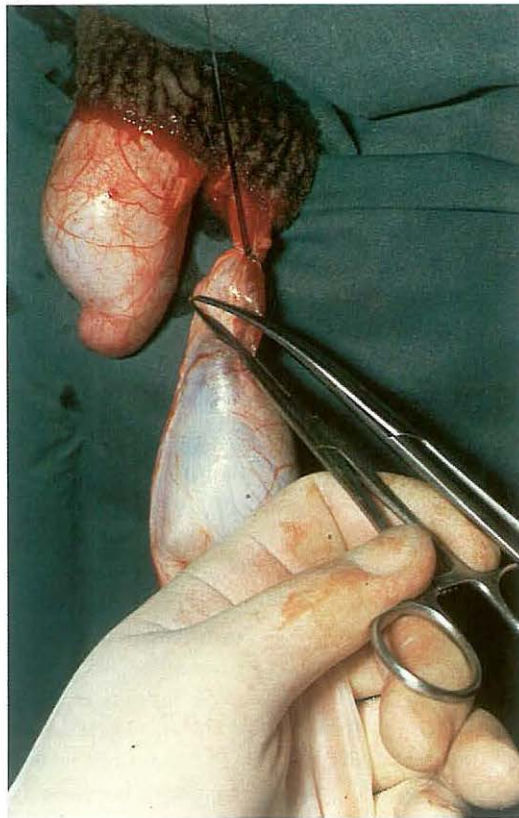
190



191



192



5-2 Castration: closed technique in the goat

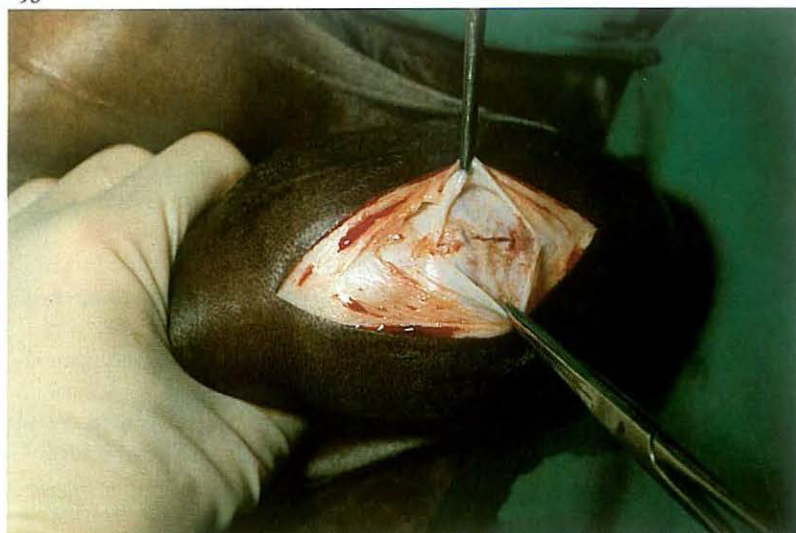Castration of goats is in general indicated to reduce the odour originating from the horn glands. Goats should be castrated after the age of six months, since urinary obstruction due to urethral calculi occur more often in young castrated goats.

Goats are usually castrated by the closed technique, in which the vaginal cavity is not opened. This is in contrast to the open castration technique, whereby the vaginal cavity is left open after emasculation (see 5-1).

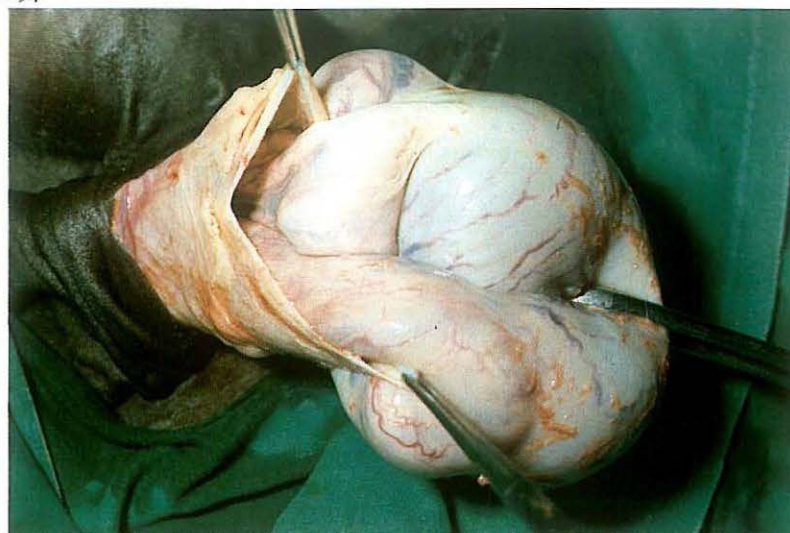
Surgery. An assistant restrains the goat in dorsal recumbency in his lap: the goat's head is held under one arm and the limbs grasped firmly together. The scrotal skin and both spermatic cords are locally infiltrated with suitable analgesic solution. The tip of the scrotum is tightly stretched distally and is amputated [189]. This allows both testicles to emerge into the incision. The testicle is grasped with a tenaculum forceps and the tunica dartos is stripped from the vaginal tunic with a gauze sponge [190]. The spermatic cord, covered by vaginal tunic, is then crushed by an emasculator or, as in this case, ligated with a ligature of absorbable suture material [191]. The spermatic cord is transected 1 cm distal to the ligature [192] and the stump checked for bleeding. The opposite testicle is removed in a similar manner.

Tetanus prophylaxis must be provided.

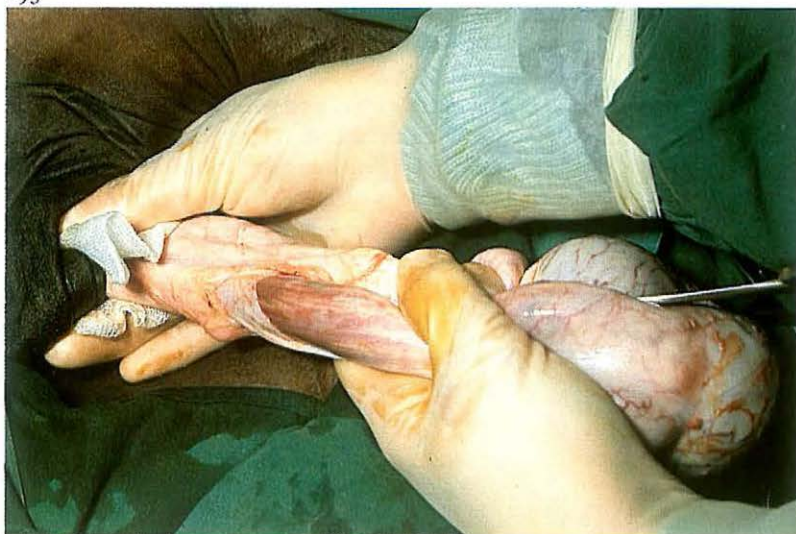193



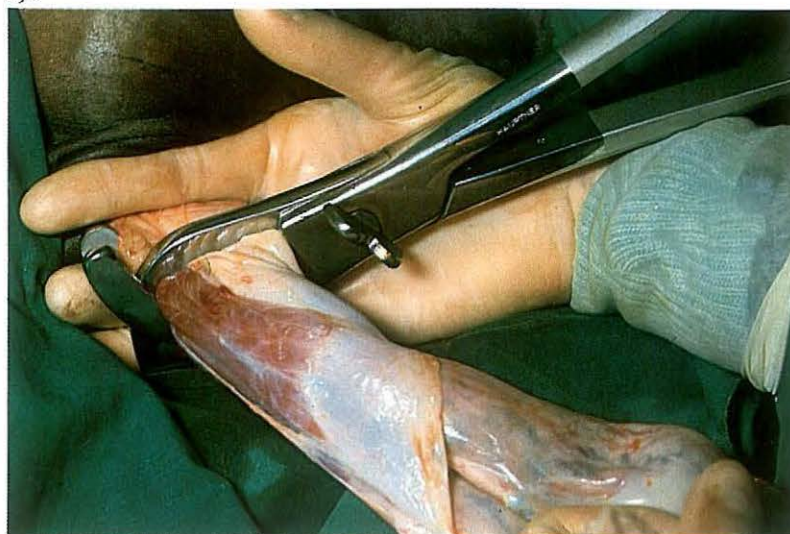194



195



196



5-3 Castration: half-closed technique in the horse

In the horse several methods of castration may be used: the open technique (see 5-1), closed technique (see 5-2), half-closed technique, which is discussed here, and the primary closure method (see 5-4).

The half-closed technique involves crushing and ligation of the spermatic cord enclosed in the vaginal tunic, with the testicle itself lying outside the opened vaginal tunic. Using this approach, the most serious postoperative complications such as intestinal eventration and spermatic cord haemorrhage are averted.

Surgery. Half-closed castration can be carried out in the recumbent or standing stallion.

(1) Half-closed castration in the recumbent stallion.

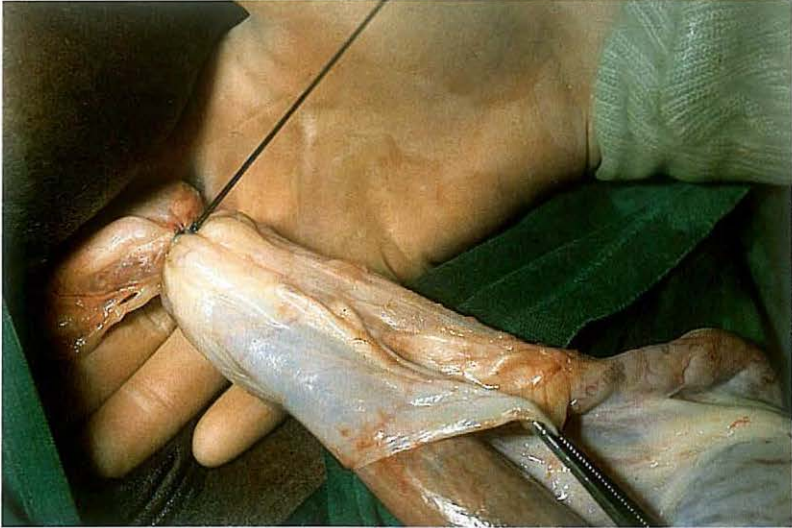
For a right-handed surgeon, the horse is positioned in left lateral recumbency. The right leg is pulled tightly against the chest and the foot tied at the level of the shoulder joint. Castration is performed under local infiltra-

tion analgesia or general anaesthesia. The left testicle is held in the scrotum with the left hand, so that the scrotal skin is tightly stretched. A 7–10 cm incision is made 1 cm lateral and parallel to the median raphe through skin and tunica dartos. A small incision is then made in the vaginal tunic and its edges are grasped with haemostatic forceps [193]. The incision is enlarged sufficiently to allow testicle and epididymis to emerge from the vaginal cavity [194], whereupon the exposed testicle is grasped with a tenaculum forceps. The tunica dartos is stripped from the vaginal tunic with a gauze sponge or blunt scissors [195]. The spermatic cord, covered by vaginal tunic, is then crushed with an emasculator [196]. A ligature of absorbable suture material is applied at the crush site [197]. The spermatic cord is transected 1–2 cm distal to the ligature and the stump checked for bleeding. The opposite testicle is removed in a similar manner.

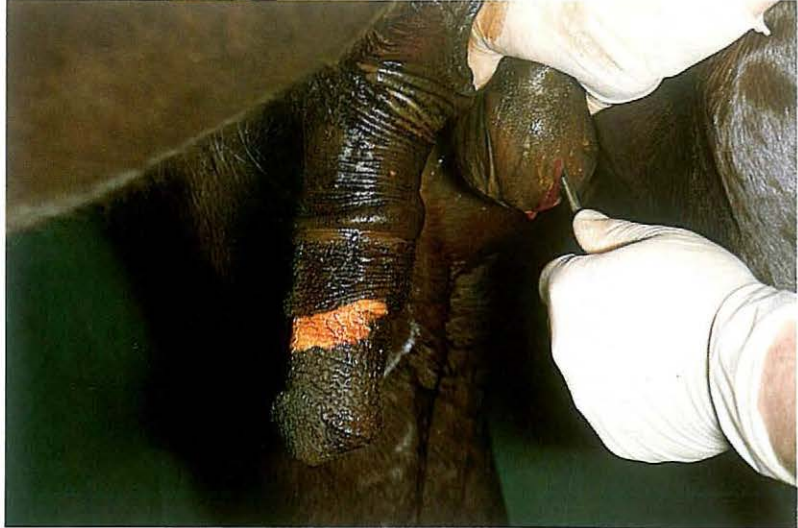(2) Half-closed castration in the standing stallion.

The technique is in principle similar to the half-closed castration in the recumbent stallion. Castration is performed under physical restraint and

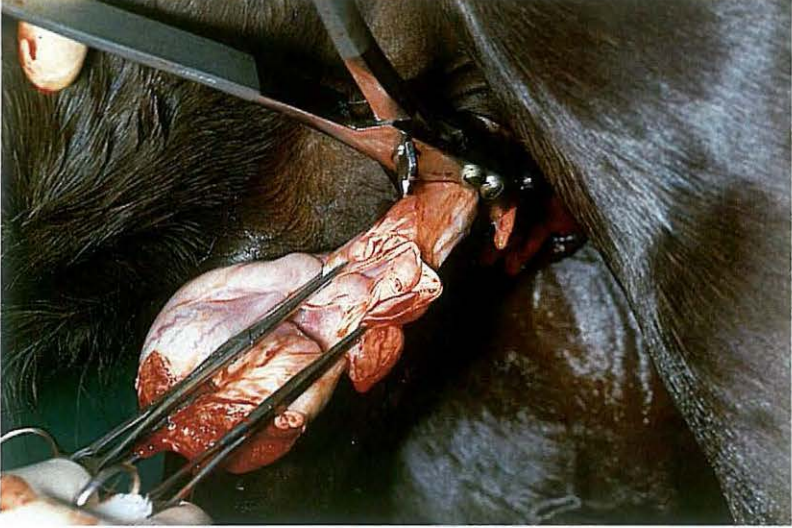
197



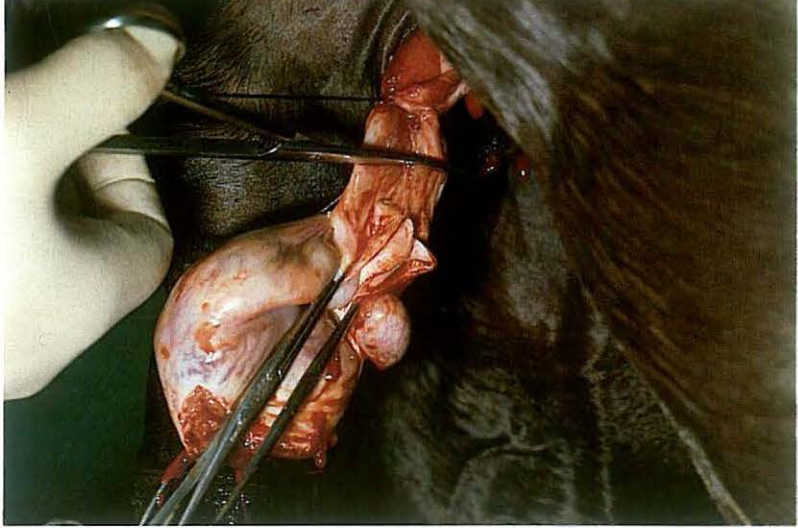
198



199

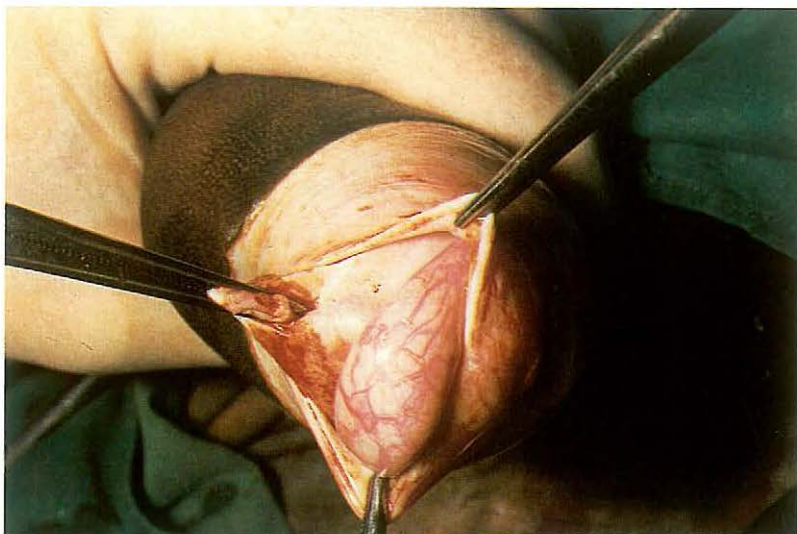


200

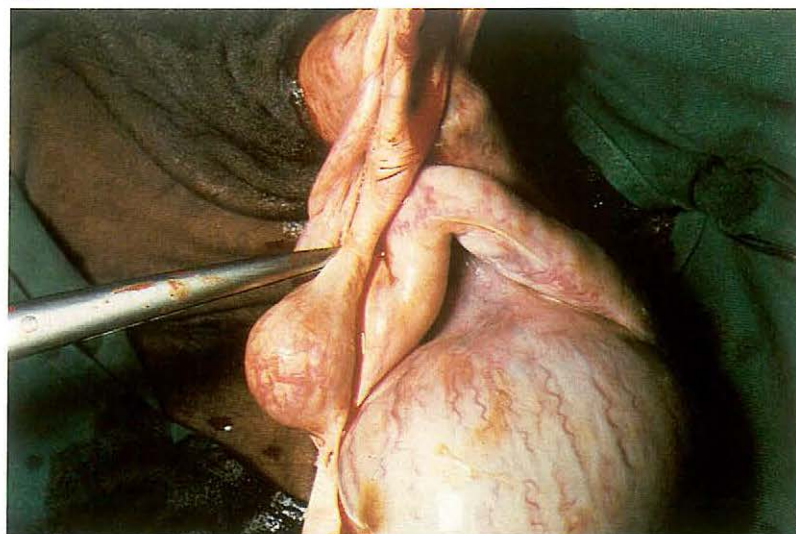


local infiltration analgesia, together with chemical restraint if necessary. The scrotum is grasped firmly with one hand just proximal to the testicle, so that the scrotal skin is tightly stretched. A 7–10 cm incision is made, beginning cranially, about 1 cm lateral and parallel to the median raphe through skin, tunica dartos and vaginal tunic into the testicular tissue [198]. The exposed testicle is grasped with a tenaculum forceps and the edges of the incised vaginal tunic are grasped with haemostatic forceps. The tunica dartos is stripped from the vaginal tunic with a gauze sponge and an emasculator is applied to the covered spermatic cord [199]. A ligature of absorbable suture material is applied at the crush site and the spermatic cord is transected 2 cm distal to the ligature [200]. The opposite testicle is removed in a similar manner. Tetanus prophylaxis is provided. Postoperative management consists of sufficient exercise to avoid scrotal and preputial oedema.

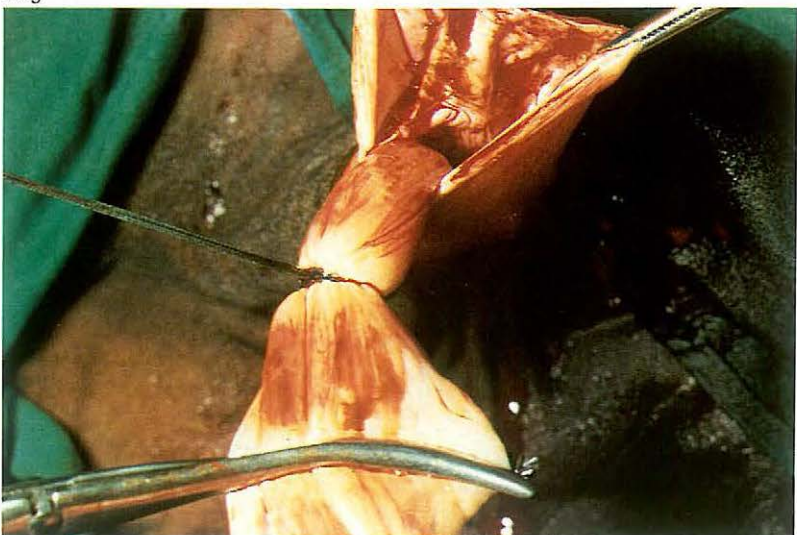
201



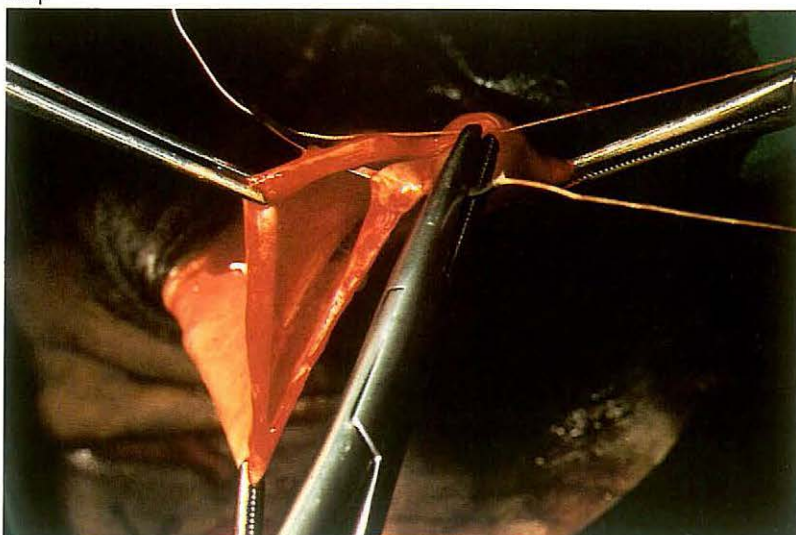
202



203



204



5-4 Castration: primary closure method in the horse

Castration in which primary closure of the scrotal wound is attempted should be carried out only under strictly aseptic conditions. The technique for the stallion is discussed here.

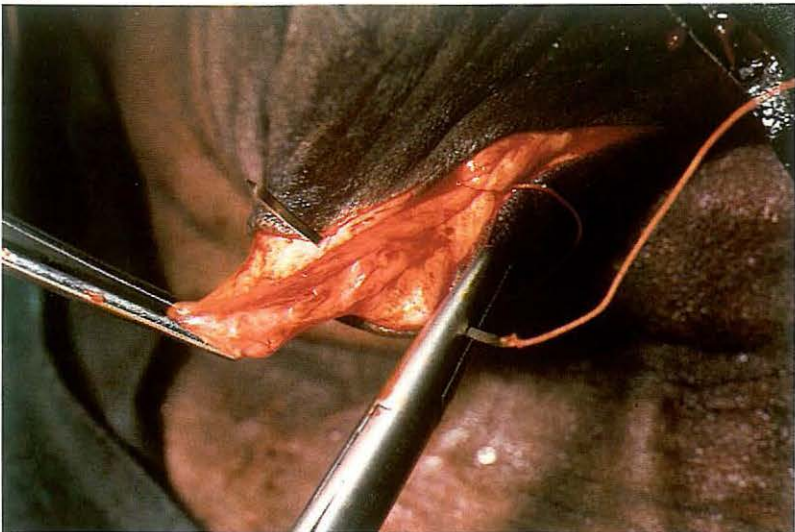
Surgery. Castration is performed under general anaesthesia with the horse in dorso-lateral recumbency. The uppermost leg is secured in flexion and abduction.

The testicle is grasped firmly in one hand, so that the scrotal skin is tightly stretched. A 7–10 cm incision is made through skin and tunica dartos in the caudal part of the scrotum, parallel to the median raphe. A small incision is then made through the vaginal tunic and its edges grasped with tissue forceps [201]. The incision is then enlarged sufficiently to allow testicle and epididymis to emerge from the vaginal cavity, whereupon the exposed testicle is grasped with a tenaculum forceps. The scrotal ligament is severed with dissection scissors [202], and the mesorchium is carefully torn from

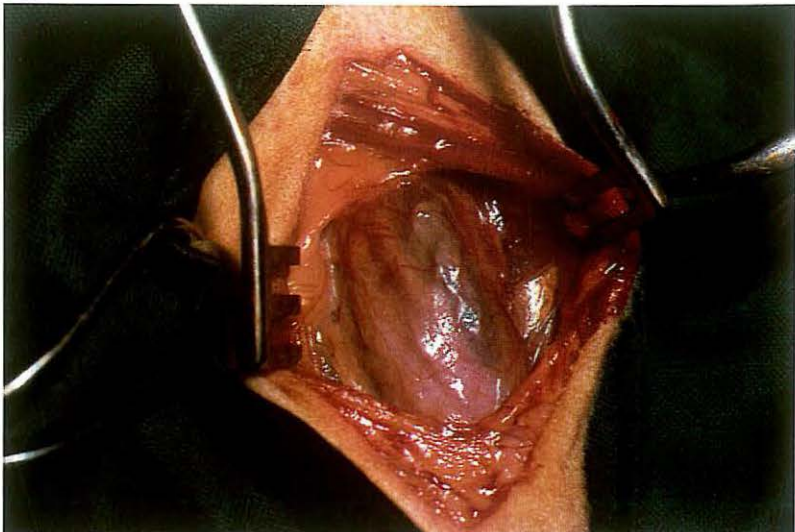
the vaginal tunic and the spermatic cord is ligated with absorbable suture material as proximally as possible. A peritoneum forceps is applied to the spermatic cord about 3 cm distal to the ligature [203] and the spermatic cord is transected between forceps and ligature. The stump and mesorchium are checked for bleeding. The wound is closed in three separate layers using synthetic absorbable suture material: the vaginal tunic [204] and tunica dartos [205] are sutured in a continuous pattern, and the skin with interrupted mattress sutures.

Aftercare consists of routine postcastration management.

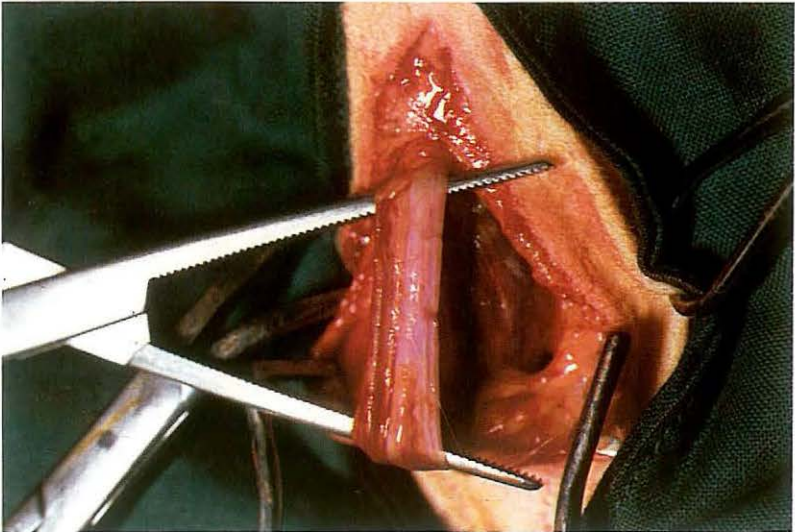
205



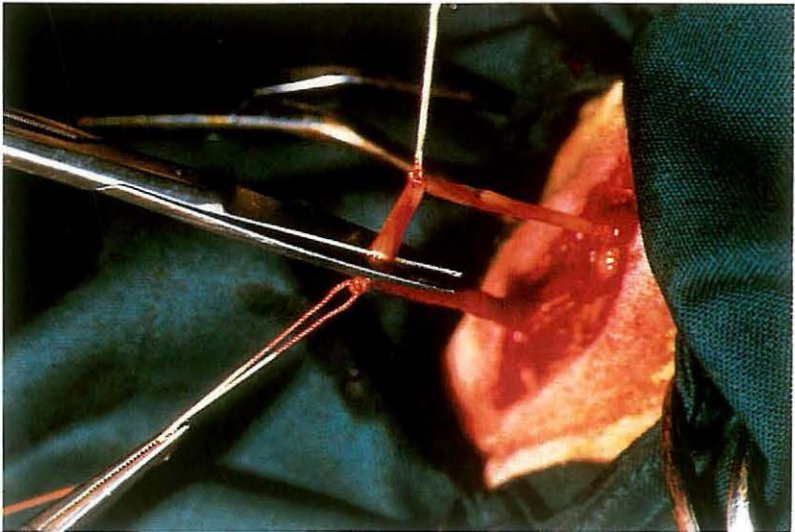
206



207



208



5-5 Vasectomy

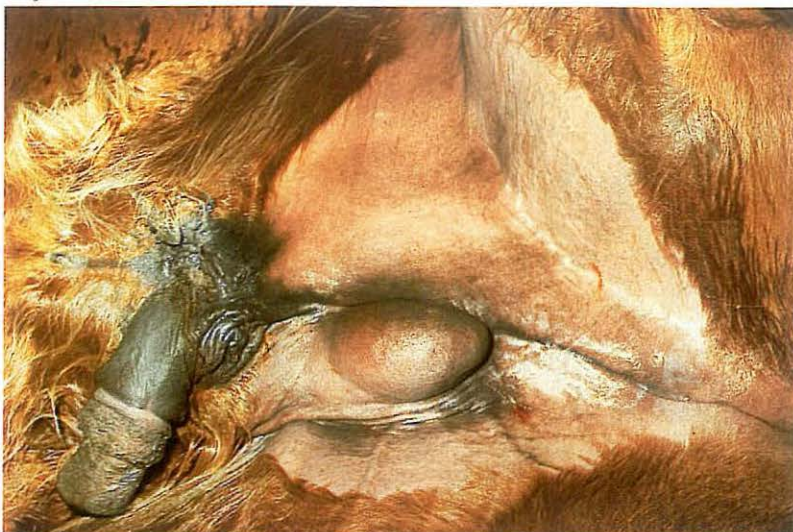
Vasectomy is indicated for production of heat detector (teaser) bulls or rams.

Surgery. The operation can be performed under local analgesia, with the animal either cast or standing.

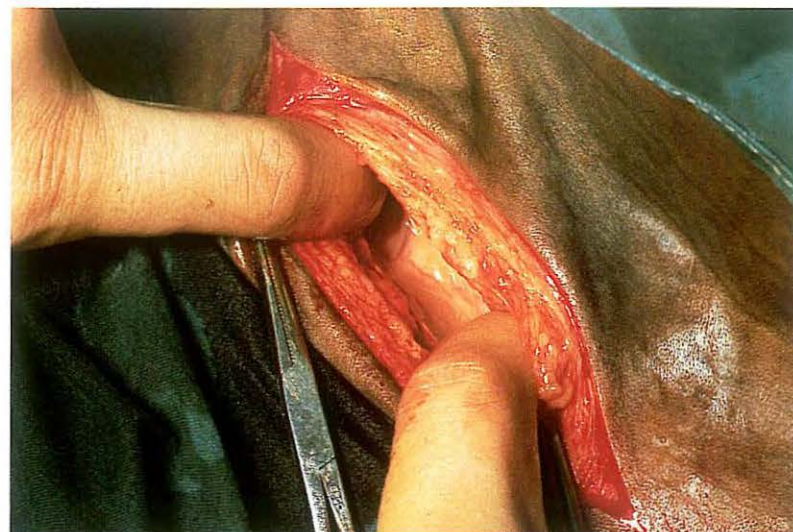
The spermatic cord is located. A 2-3 cm skin incision is made medially to reveal the vaginal tunic [206]. The ductus deferens is palpated as a firm, non-pulsating cord-like structure. After careful incision of the tunic, the ductus deferens is easily separated and exteriorized [207]. A segment of about 2 cm is removed and the incised ends are ligated [208].

It is not essential to suture the vaginal tunic, but the skin is closed with a few interrupted sutures.

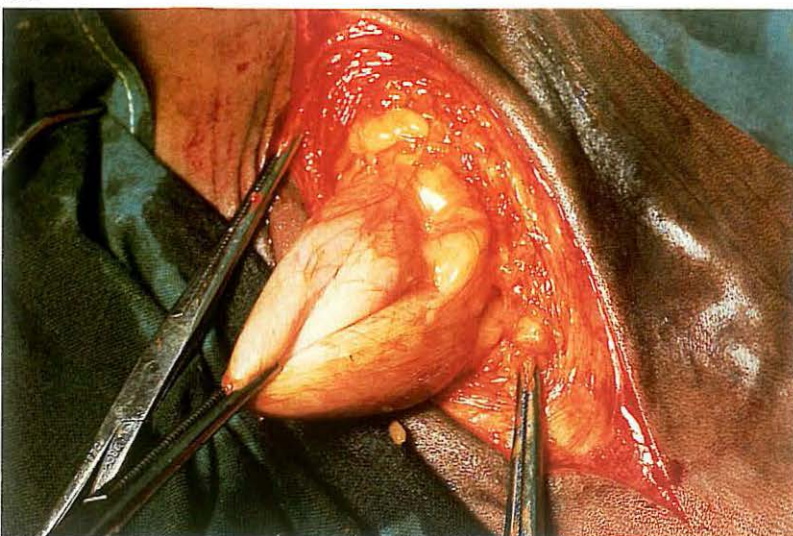
209



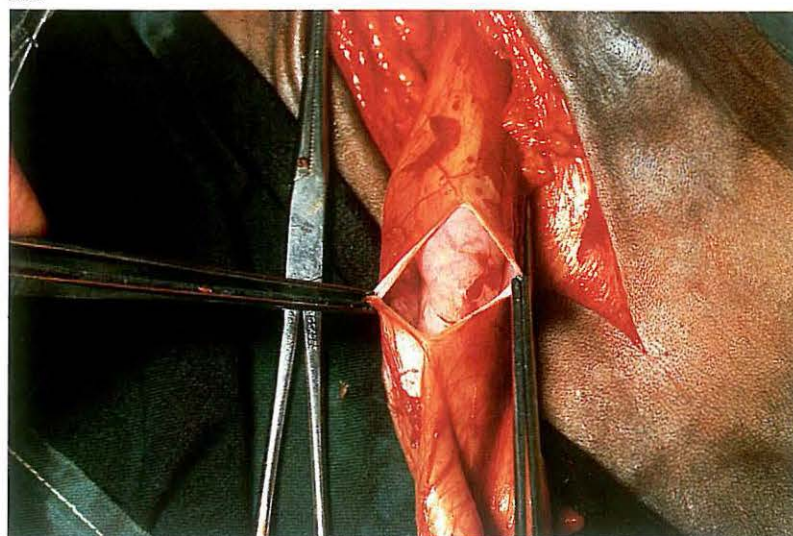
210



211



212



5-6 Inguinal cryptorchidectomy in the horse

Cryptorchidism may be classified into two main types: *a* testicle and epididymis retained between the internal inguinal ring and the scrotum ('high flanker'); *b* testicle and epididymis retained within the abdominal cavity (abdominal cryptorchid). In a partial abdominal cryptorchid, the epididymis descends into the inguinal canal with the testicle remaining in the abdominal cavity.

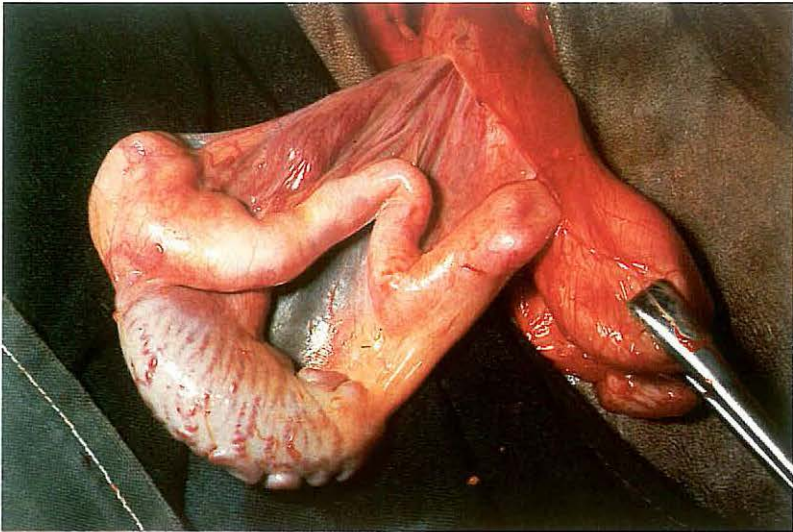
Inguinal cryptorchidectomy is discussed here.

Surgery. Surgery is performed with the patient under general anaesthesia and in dorso-lateral recumbency with the leg on the cryptorchid side up-permost and secured in flexion and abduction [209]. A 10 cm incision is made over the external inguinal ring through skin and scrotal fascia. Care should be taken to avoid trauma to the large vessels in this region. Blunt dissection of the connective tissue is continued towards the inguinal canal [210]. The testicle and epididymis, covered by vaginal tunic, may be en-

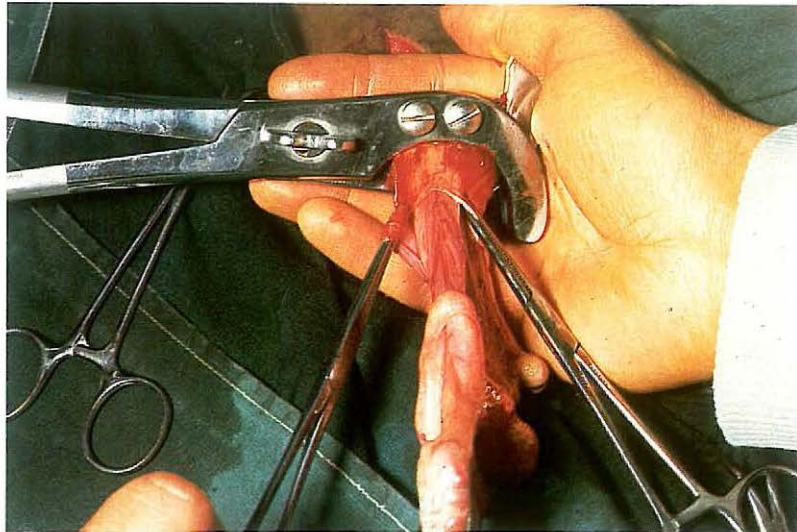
countered adjacent to the external inguinal ring or can be located in the inguinal canal. The vaginal tunic is grasped with forceps [211] and incised longitudinally [212]. The cryptorchid testicle (which is usually much smaller than the descended testis) and epididymis are then drawn outside the vaginal cavity [213]. Half-closed castration is then performed (see 5-3): the spermatic cord, covered by the vaginal tunic, is crushed [214], ligated and transected 2 cm distal to the ligature [215]. The stump is checked for haemorrhage and the long ends of the ligature cut. A sterile gauze or latex drain is placed in the wound and the skin is closed with simple interrupted sutures [216].

If the vaginal sac can be drawn sufficiently beyond the external inguinal ring, the closed technique or primary closure method of castration can be used instead of the half-closed method. Tetanus prophylaxis is provided. The drain is removed after 48 hours. Aftercare consists of routine post-castration management.

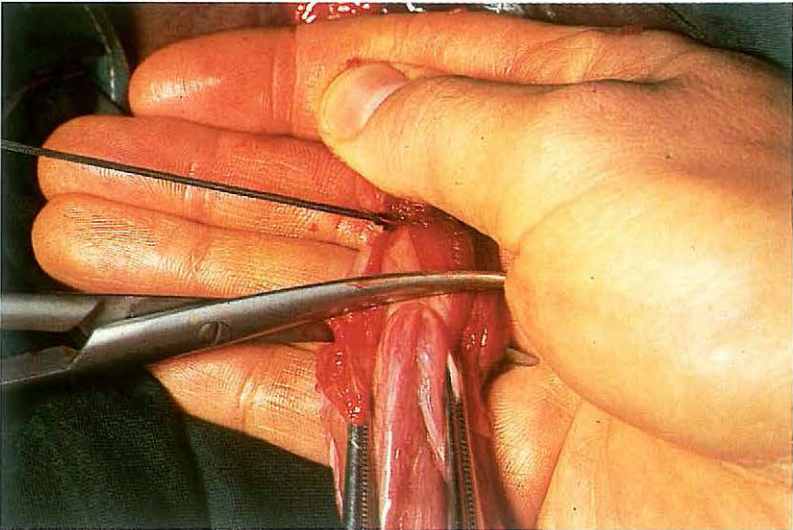
213



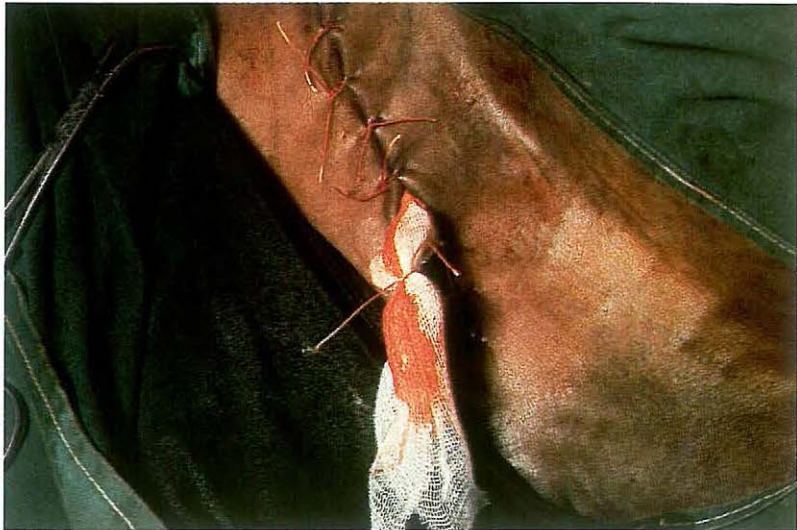
214



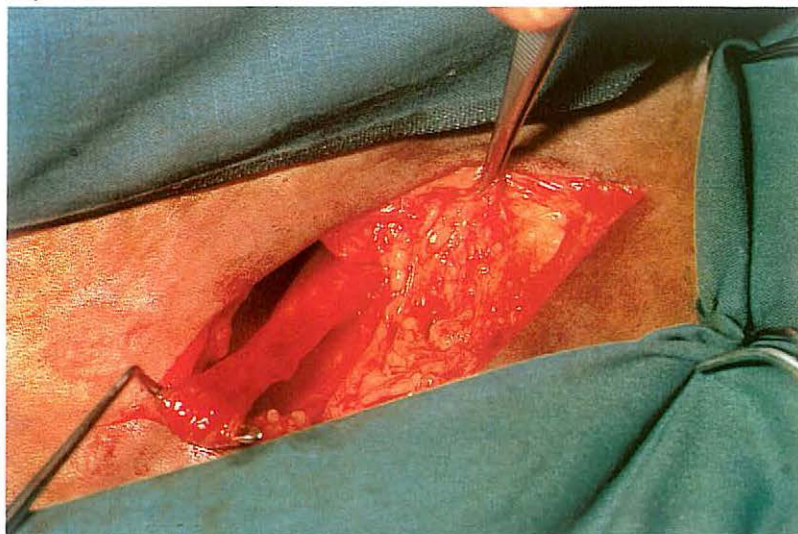
215



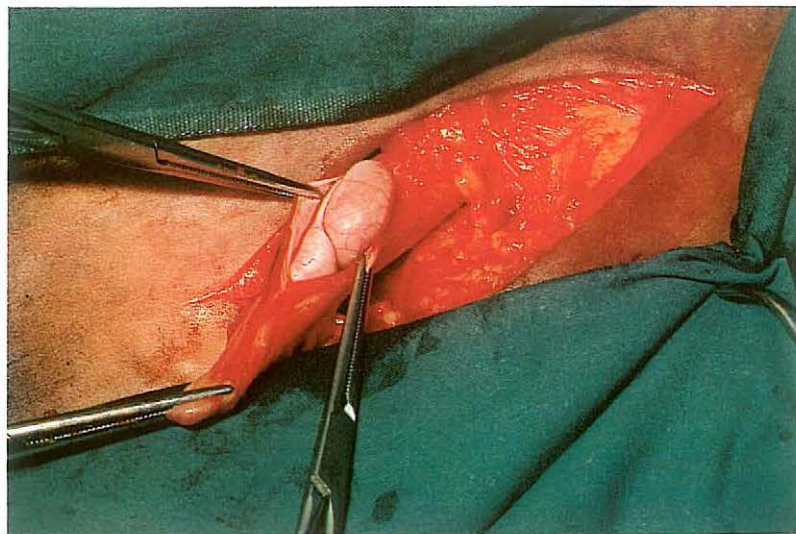
216



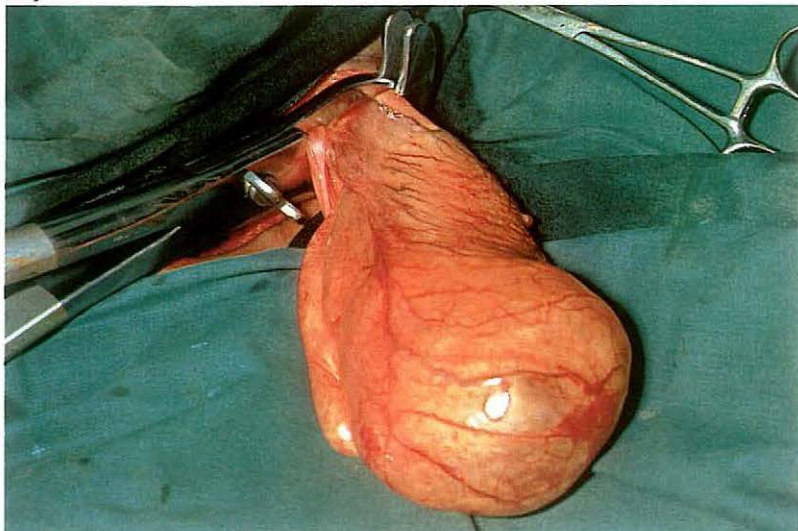
217



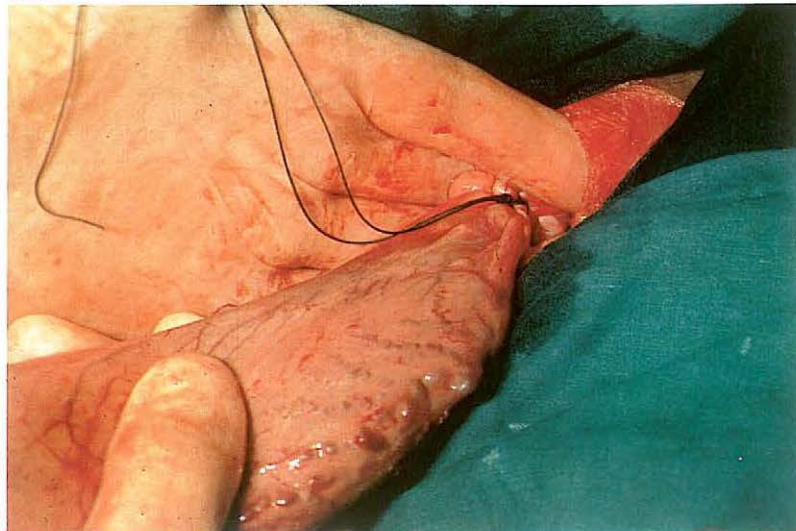
218



219



220



5-7 Abdominal cryptorchidectomy in the horse

The inguinal approach is most commonly used for abdominal cryptorchidectomy in the equine, while paramedian laparotomy is indicated for bilateral abdominal cryptorchid or grossly enlarged testicles.

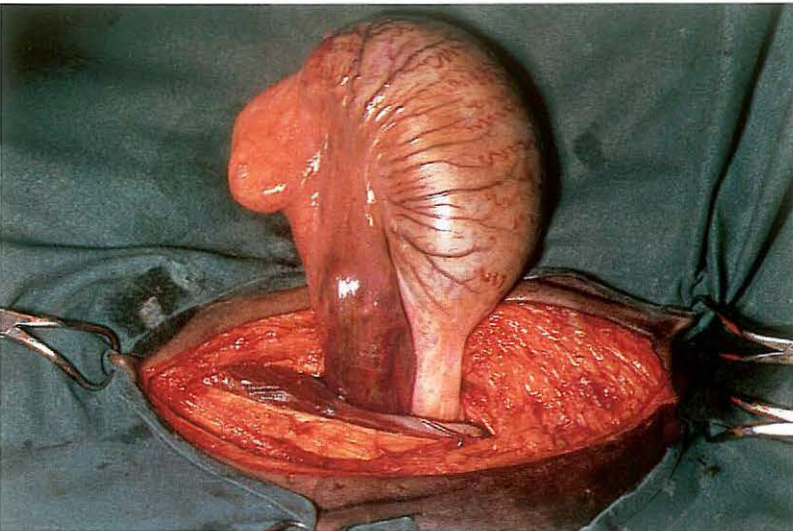
Surgery.

(1) Inguinal approach. The position, preparation and incision is as for inguinal cryptorchidectomy (see 5-6). Frequently, in an abdominal cryptorchid the extra-abdominal part of the gubernaculum can be located in the inguinal canal. Careful blunt dissection may allow visualization of this structure. By exerting moderate traction on the gubernaculum [217], the vaginal process can be drawn through the external inguinal ring. If the extra-abdominal part of the gubernaculum can not be recognized, dissection is continued and the vaginal process is searched for at the level of the internal ring. The vaginal process is then grasped with sponge forceps and withdrawn as far distally as possible. The vaginal process is then incised,

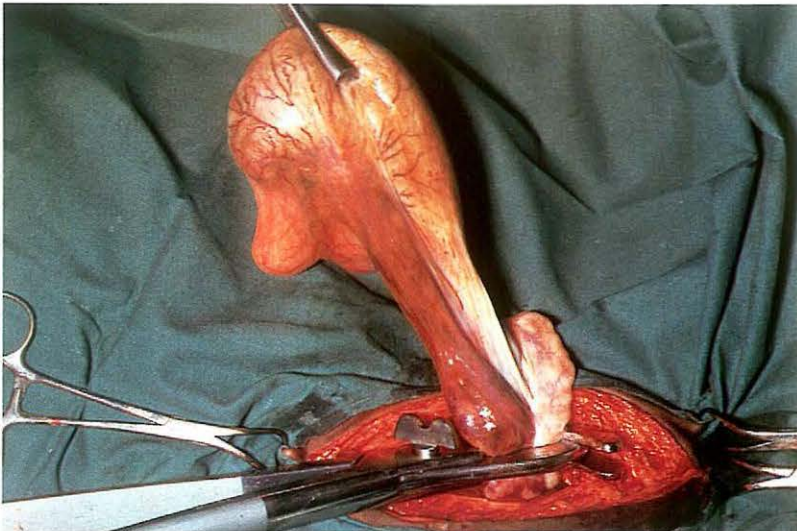
exposing the epididymis [218], which is grasped by forceps. Gentle traction is applied until the testicle is delivered. Cystic degeneration had caused enlargement and retention of this testicle [219].

When neither the extra-abdominal part of the gubernaculum nor the vaginal process can be recognized in the inguinal canal, the peritoneum is perforated at the level of the internal inguinal ring with the finger. One or two fingers (or even the entire hand) in the abdominal cavity search for the gubernaculum, epididymis, testicle or ductus deferens. After one of these structures has been recognized, it is brought into the inguinal canal, grasped with forceps and withdrawn further until both epididymis and testicle are exteriorized. The exposed spermatic cord is crushed [219], ligated [220] and transected 2 cm distal to the ligature. Suture closure of the external inguinal ring with simple interrupted or continuous sutures is recommended. A drain is placed in the wound and the skin is closed with simple interrupted sutures. Tetanus prophylaxis is provided. The drain is removed after 48 hours. Aftercare consists of routine post-castration management.

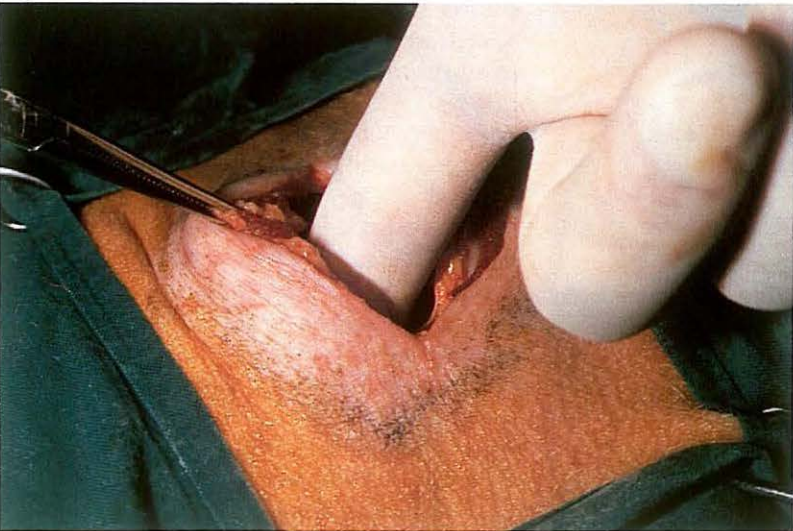
221



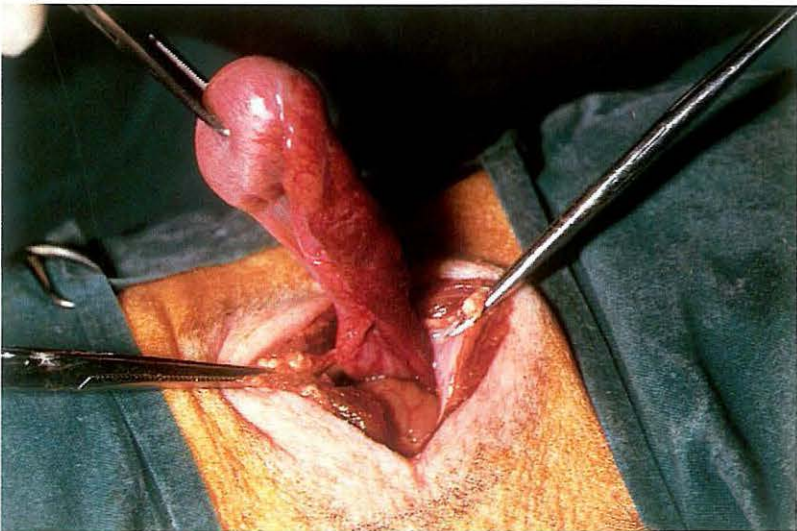
222



223



224



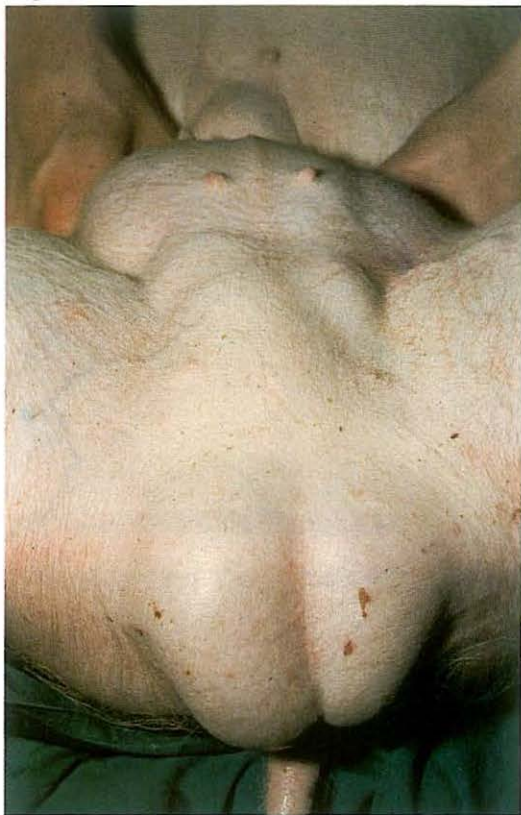(2) Paramedian approach. A paramedian parareputal laparotomy [221] is performed under general anaesthesia with the horse in dorsal recumbency (see 4-5). The surgeon's hand is introduced into the abdominal cavity and a search is made for the testicle. Most retained testicles are located close to the internal inguinal ring. The testicle is brought through the incision [222], and the exposed spermatic cord is crushed with an emasculator, ligated with absorbable suture material and transected 2 cm distal to the ligature. The laparotomy wound is closed in four separate layers (see 4-5).

5-8 Abdominal cryptorchidectomy: flank approach in the pig

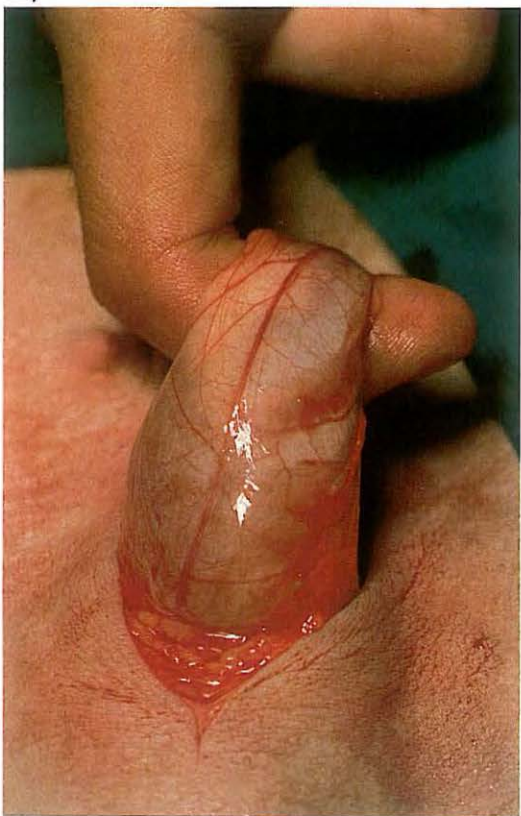Because cryptorchidism in the pig is usually abdominal, a lateral flank laparotomy is recommended in this species.

Surgery. The operation is done under general anaesthesia with the pig in lateral recumbency and the cryptorchid side uppermost. Flank laparotomy is performed, using a through-and-through incision (see 4-4). The forefinger is introduced into the abdominal cavity [223] and a search is made for the testicle, which usually can be found between the caudal pole of the kidney and the pelvic inlet. When the testicle has been located, it is delivered into the flank incision [224] and the spermatic cord is either ligated and transected, or severed with an emasculator. Peritoneum and all muscle layers are sutured together, using absorbable material in a simple interrupted pattern. The skin is then closed with interrupted sutures.

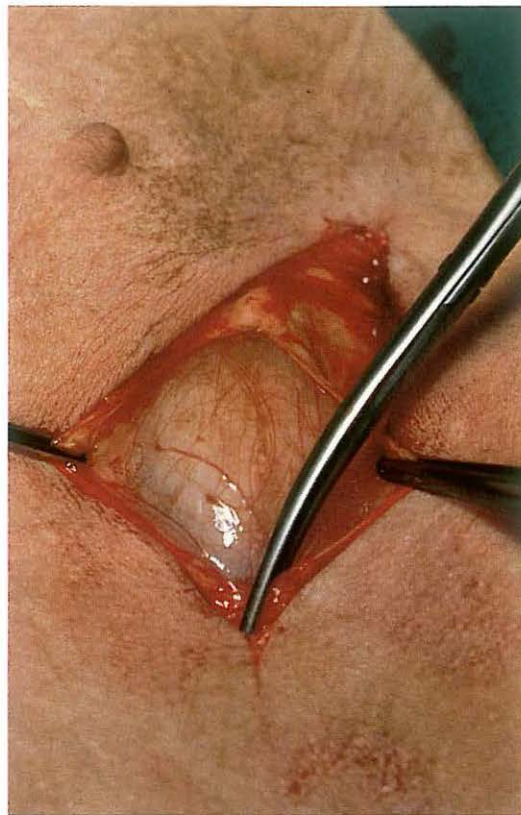
225



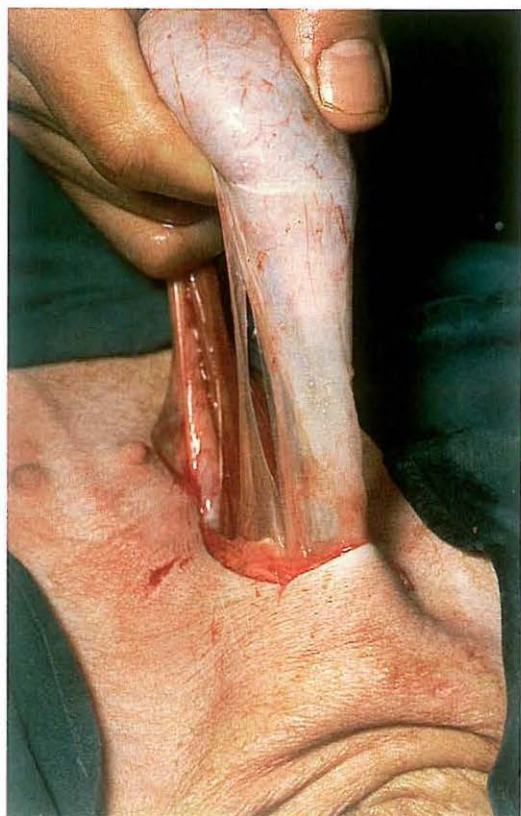227



226



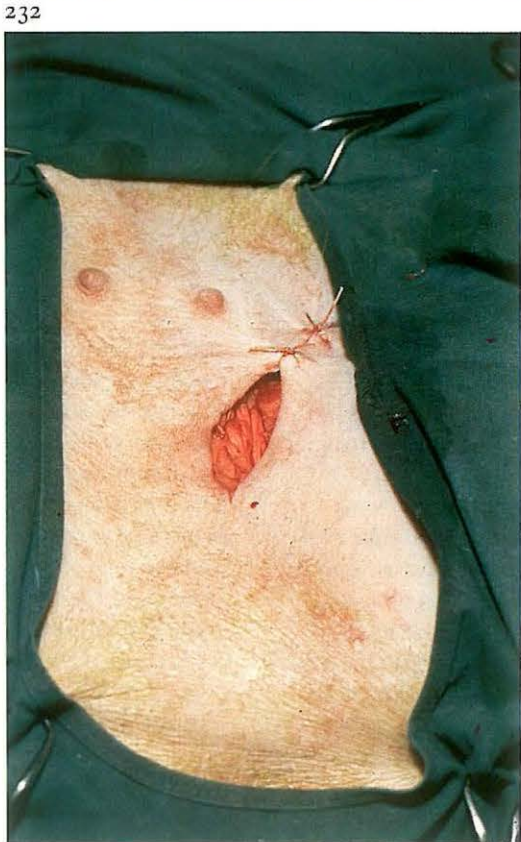
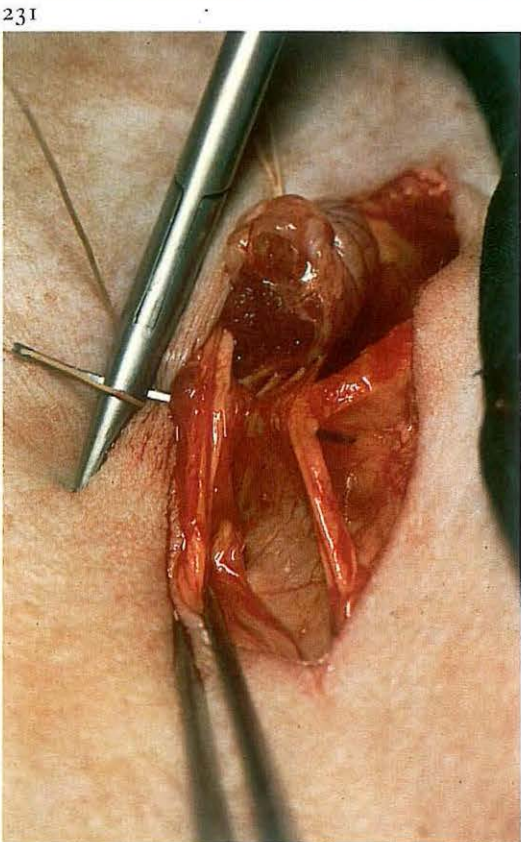
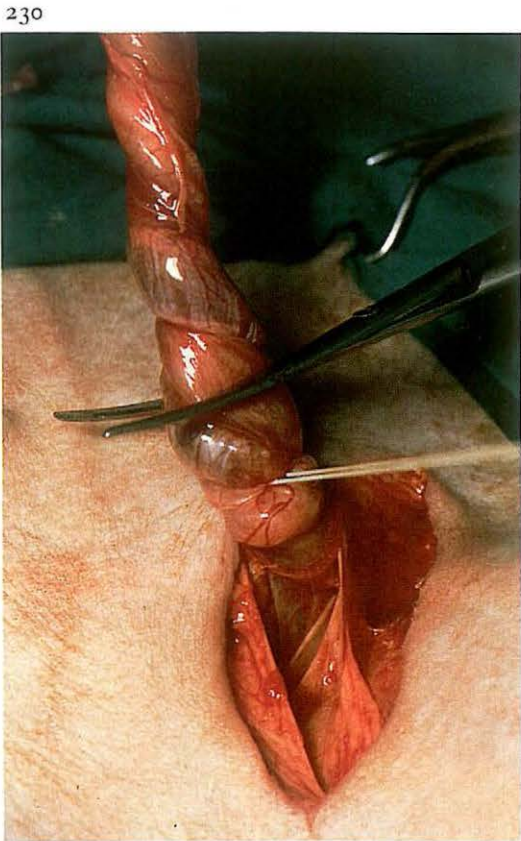
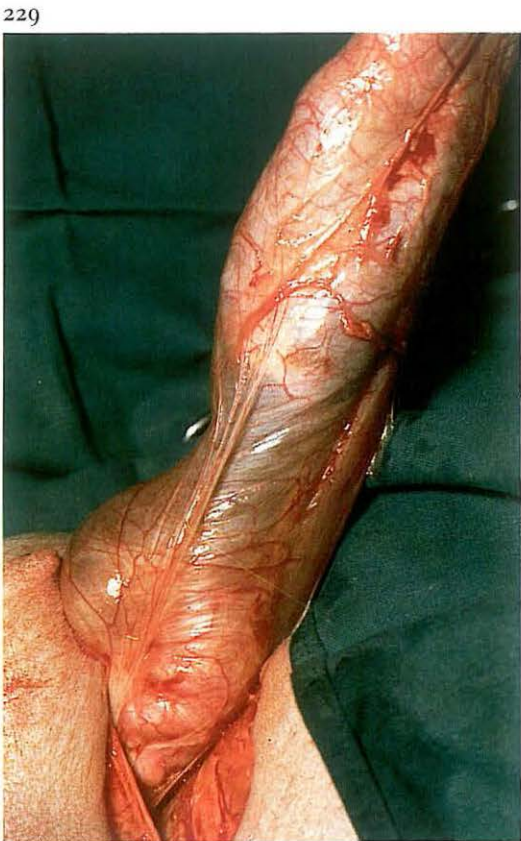228



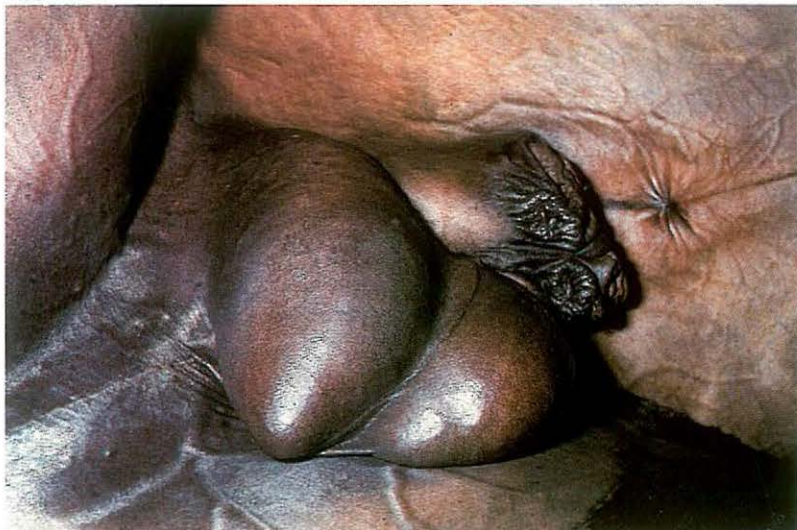5-9 Inguinal herniorrhaphy in the pig

Inguinal or scrotal hernias frequently occur in pigs and are often discovered at the time of castration. Inguinal hernias also occur in female pigs. In general, inguinal and scrotal hernias in pigs are reducible, and the visible swelling in the groin can be increased by applying slight pressure to the abdominal wall, which allows viscera to pass into the scrotum via the inguinal canal, uni- or bilaterally [225].

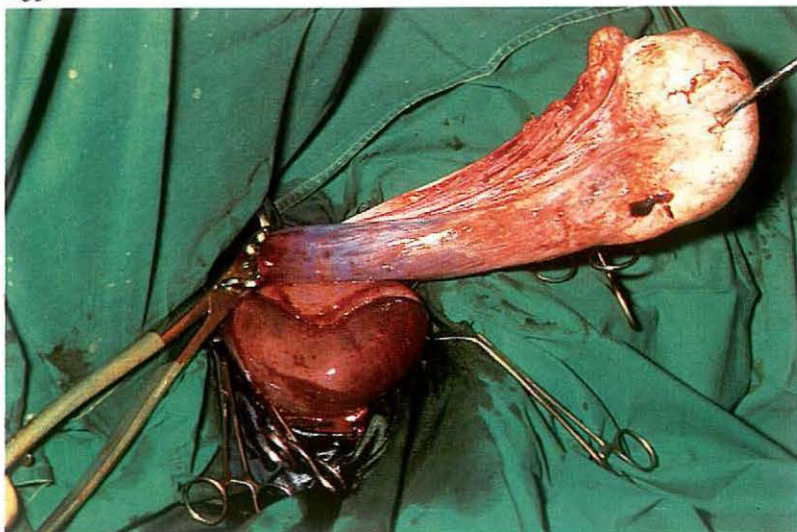
Surgery: Inguinal herniorrhaphy in pigs is performed under general anaesthesia. The pig is tied in dorsal recumbency. A 4 to 6 cm incision is made over the external inguinal ring through skin, subcutaneous tissue and scrotal fascia. The incision through the scrotal fascia must be done carefully, so that the vaginal tunic is not inadvertently incised: it is thus preferable to split the scrotal fascia with dissection scissors [226]. The spermatic cord, covered by the vaginal tunic, is loosened from the surrounding tissues by blunt dissection with the forefinger [227]. Steady traction is exerted on the tunic, testicle and spermatic cord to distract the scrotal fascia from the scrotal skin [228]. Small intestine can now be visualised through the vaginal tunic [229]. The hernial contents (intestine) are replaced into the abdomen by twisting the vaginal sac [230]. The vaginal sac and spermatic cord are ligated as close as possible to the external inguinal ring and the cord, covered by vaginal tunic, is transected approximately 1 cm distal to the ligature [230]. To prevent inguinal herniation, the size of the external inguinal ring is reduced. This is achieved by suturing the external inguinal ring in a simple continuous pattern using both ends of the spermatic cord ligature [231]. Finally, the skin incision is partly closed with simple interrupted sutures: the most ventral point is left open to allow drainage of exudate [232].



233



235

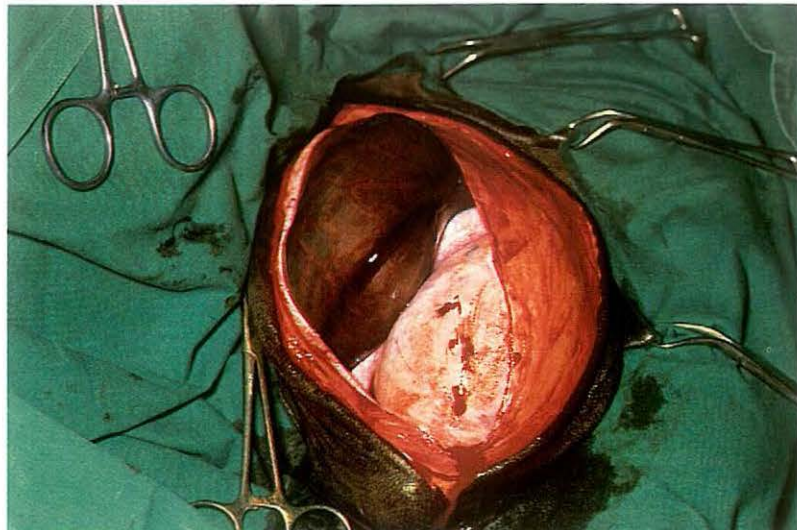


5-10 Treatment of incarcerated inguinal hernia in the horse.

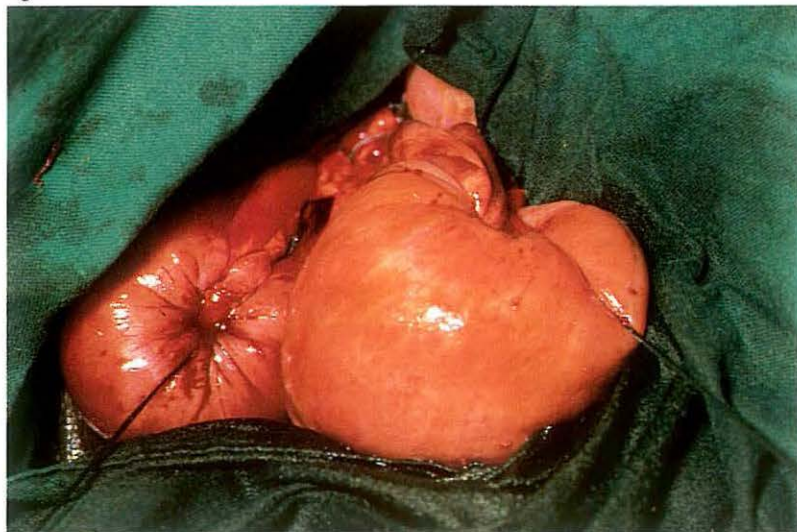
Incidence of incarcerated inguinal hernia is greatest in the equine [233]. Incarceration of herniated intestine (often ileum) is caused by the hourglass-like constriction of the vaginal tunic.

Surgery. Herniorrhaphy is carried out in the horse under general anaesthesia in dorso-lateral recumbency. The hindleg on the affected side is up-ermost and secured in flexion and abduction. A 15–20 cm skin incision is made from the external inguinal ring to the distal aspect of the scrotum. After carefully incising the vaginal tunic, the testicle and incarcerated intestine are exposed [234]. Testicle and epididymis are then drawn outside the vaginal cavity. The spermatic cord is crushed, ligated and transected 2 cm distal to the ligature [235]. If the bowel appears to be vital, replacement takes place through the vaginal cavity into the abdomen. If replacement is difficult, the hourglass-like constriction of the vaginal tunic is carefully incised in a cranial direction with a blunt-pointed scalpel. If the

234



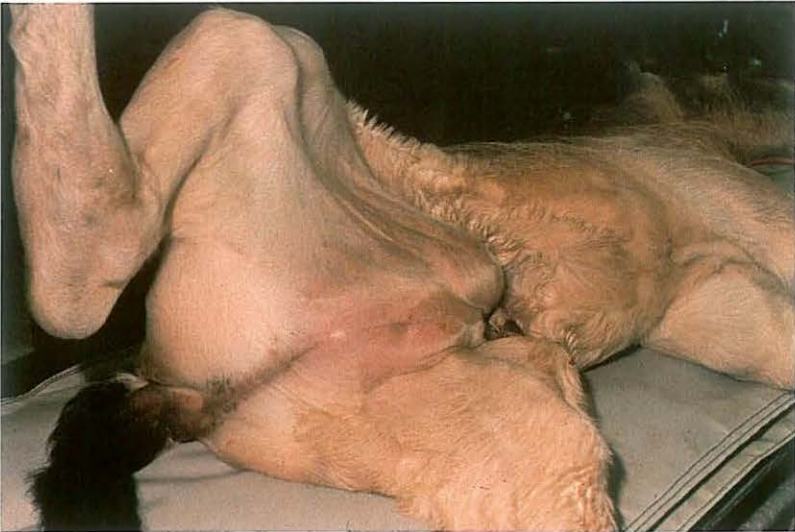236



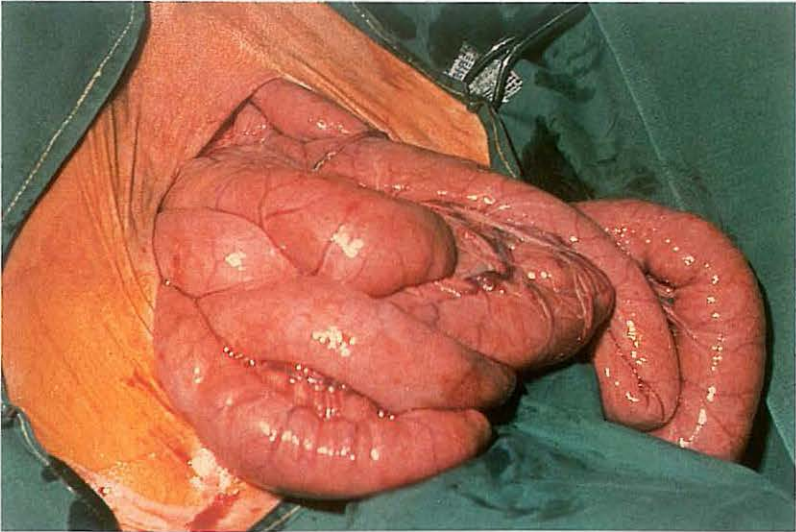
intestinal loop is necrotic [234], enterectomy (see 4-10) is performed, the remaining ends are closed [236] and replaced into the abdomen. If rupture of the devitalized loop is unlikely, the hernial contents are reduced before enterectomy. Resection and anastomosis is performed after ventral midline laparotomy (see 4-3).

The vaginal tunic is bluntly dissected, crushed, ligated and transected as proximally as possible. If the hourglass-like constriction of the vaginal tunic has been incised, suture closure of the external inguinal ring is recommended. A drain is placed in the wound and the skin is closed using simple interrupted sutures. Systemic antibiotics are administered and tetanus prophylaxis is provided.

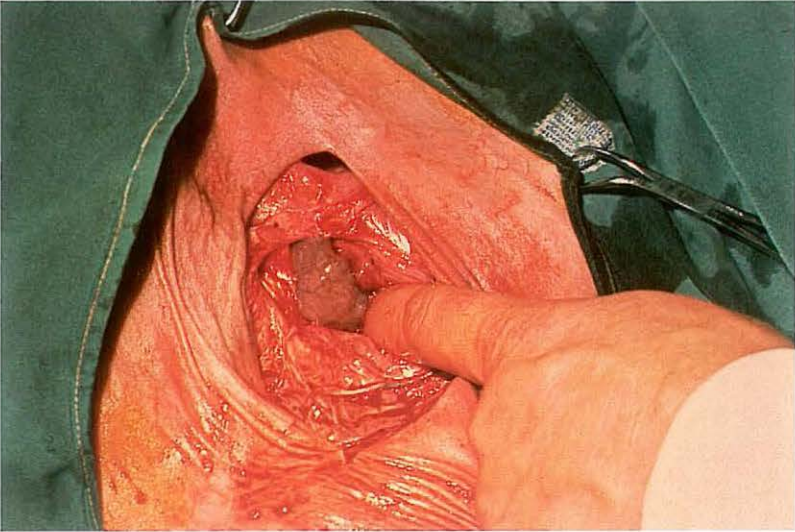
237



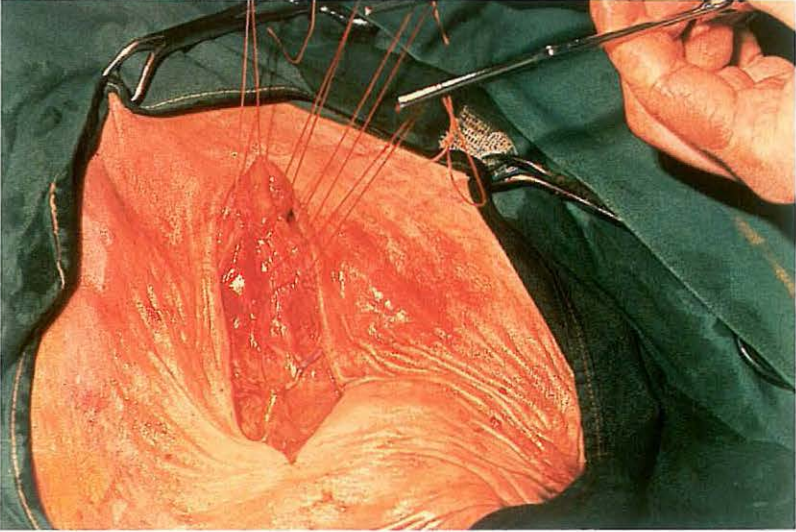
238



239



240



5-11 Inguinal herniorraphy in foals

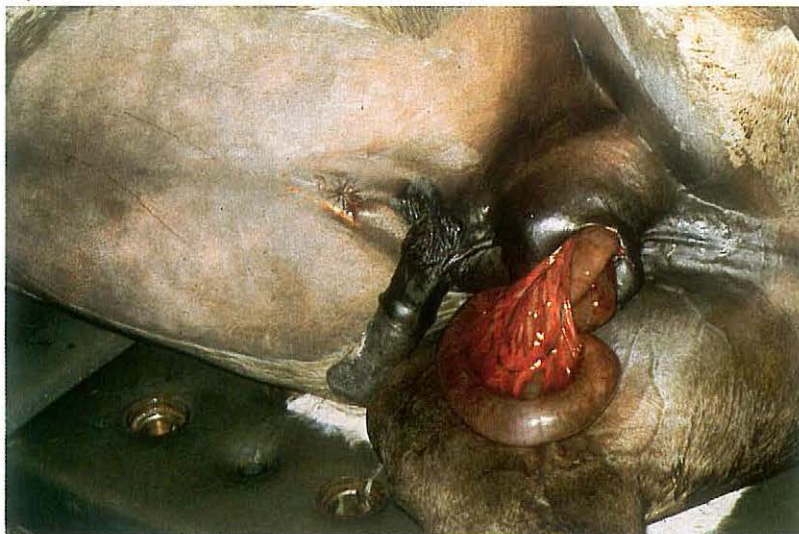
In male foals two types of inguinal hernia may be observed.

(1) Most frequently a true hernia is seen, i.e. a protrusion of intestine and/or omentum through the vaginal ring into the inguinal region. The contents are enclosed by the vaginal tunic. In persons this is called an indirect inguinal hernia. Only if spontaneous resolution has not occurred within a year or if clinical symptoms arise, is surgical correction indicated. The operative method is the same as is used in pigs (see 5-9).

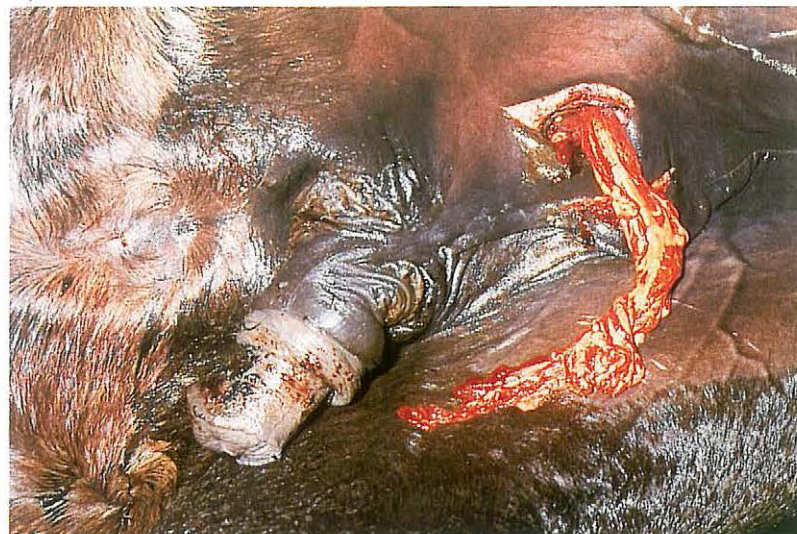(2) Less frequently the inguinal swelling is caused by the subcutaneous presence of intestines, sometimes called interstitial inguinal hernia or intestinal prolapse [237]. This may be due to *a* rupture of the vaginal tunic of an indirect inguinal hernia; *b* a direct inguinal hernia, i.e. herniation through the deep inguinal ring (outside the vaginal ring) into the inguinal canal; *c* rupture in the abdominal wall, usually cranial to the deep inguinal ring. In contrast to the indirect hernia, reduction of the contents is very difficult and immediate surgical intervention is indicated.

Surgery. Under general anaesthesia the animal is positioned in dorso-lateral recumbency with the hindleg on the affected side uppermost and secured in flexion and abduction. After incision of the skin over the external inguinal ring, protruding jejunal loops are usually visible [238]. The intestines, but not the testicle, are returned into the abdominal cavity [239]. If the hernia has occurred through the inguinal canal, unilateral castration is indicated. The hernial ring is closed with interrupted sutures [240], followed by suturing of the subcutis (continuous pattern) and then skin (interrupted). Drainage of the deeper regions of the wound with gauze or latex drains is recommended. Systemic antibiotics are indicated.

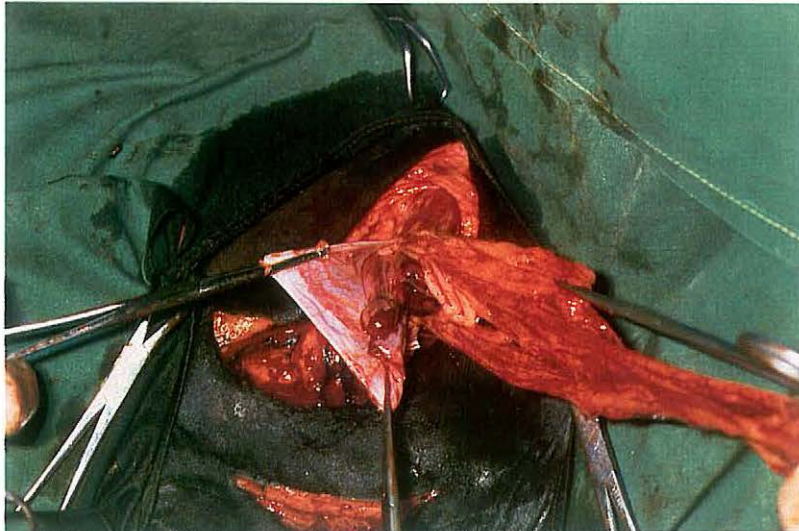
241



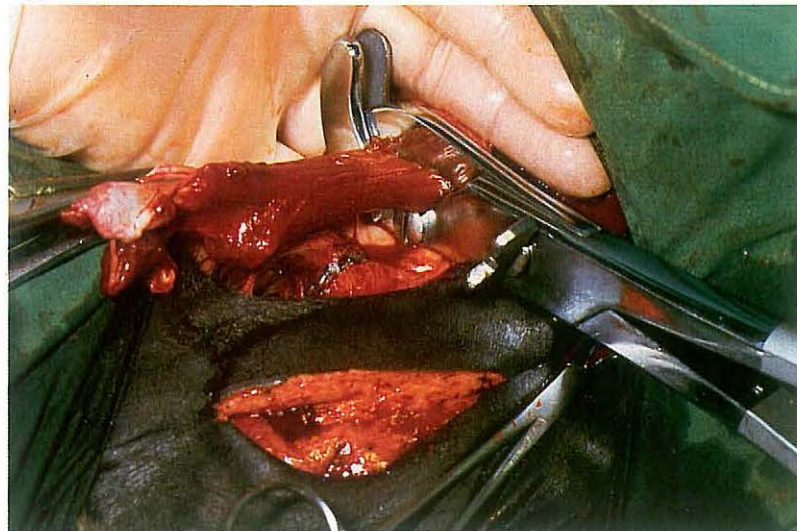
242



243



244



5-12 Management of evisceration after castration in the horse

Evisceration is the most serious complication following castration and the incidence is greatest when the open technique has been used. Evisceration may consist of either intestine [241] or omentum [242], and both conditions require emergency surgical intervention.

Surgery. Surgery is performed with the patient under general anaesthesia in dorso-lateral recumbency. The hindleg on the affected side is uppermost and secured in flexion and abduction. A skin incision is made from the external inguinal ring to the scrotal wound. The vaginal tunic is bluntly dissected from the scrotal fascia down to the external inguinal ring.

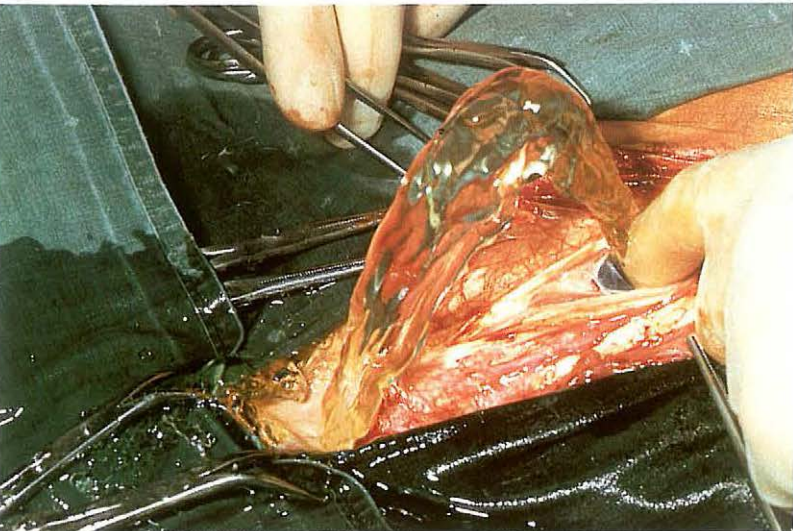
Plate 243 shows the spermatic cord stump and protruding omentum from the vaginal cavity. The omentum is drawn further exteriorly, ligated with absorbable suture material as proximally as possible, transected 2 cm distal to the ligature, and replaced into the abdomen.

In cases of intestinal evisceration, the exposed bowel is thoroughly cleansed

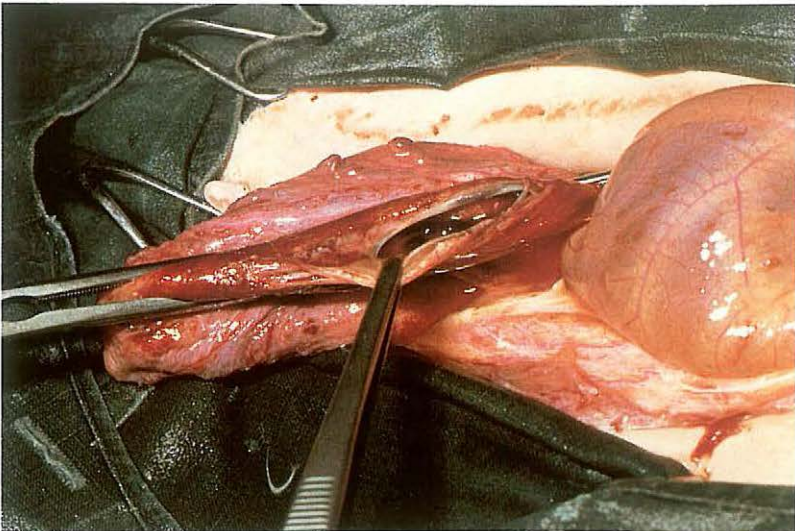
with physiological saline containing antibiotics and replaced into the abdomen. If the intestine appears to be devitalized, resection and anastomosis is indicated (see 5-10).

After replacement of omentum or bowel, the spermatic cord, covered with vaginal tunic, is crushed as proximally as possible [244]. A ligature of absorbable suture material is applied at the crush site and the spermatic cord is transected 2 cm distal to the ligature. A sterile gauze or latex drain is placed in the wound and the skin wound is partly closed using simple interrupted sutures. Systemic antibiotics are administered.

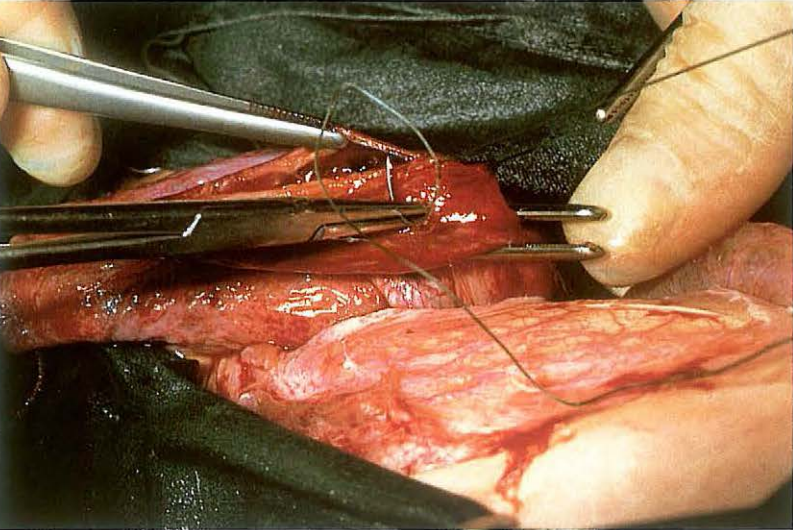
245



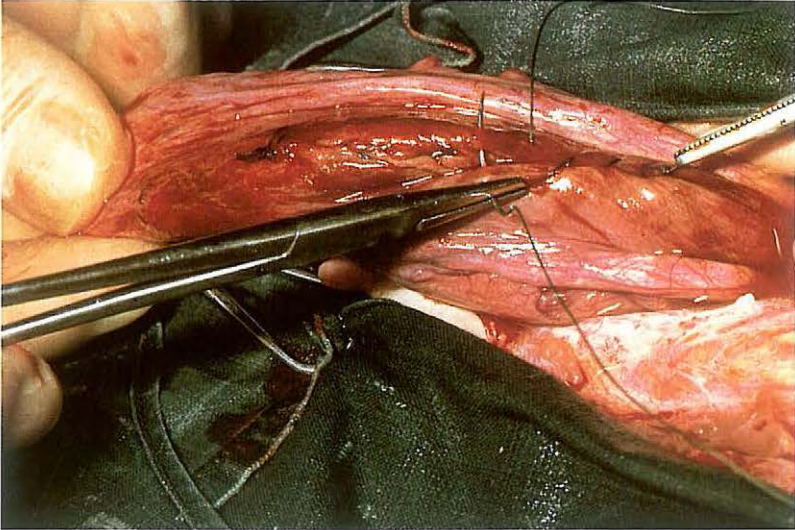
246



247



248



5-13 Cystorrhaphy

Rupture of the urinary bladder is observed primarily in male neonatal foals, occasionally in calves with urolithiasis, and rarely in mature animals. In foals the cause is attributed to external pressure on the distended bladder at parturition.

Surgery. Drainage of the accumulated urine by abdominocentesis before induction of anaesthesia is indicated in order to relieve respiratory distress. The animal is positioned in dorsal recumbency under (shallow) general anaesthesia.

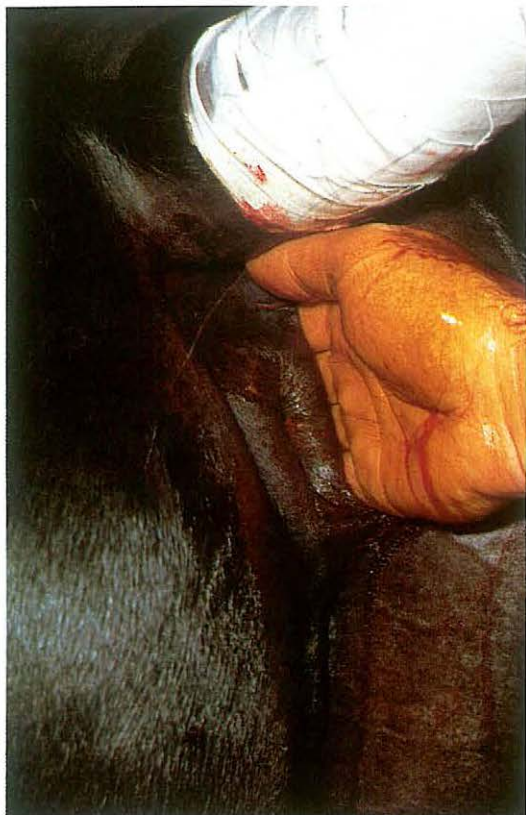A paramedian, parapreputial laparotomy is performed (see 4-5); in females, midline laparotomy is preferred. After incising the peritoneum further removal of urine should take place slowly to avoid hypovolaemic shock [245, calf].

The rent [246] is usually found in the dorsal surface of the bladder, but may also occur at the fundus. If necessary the edges of the tear are de-

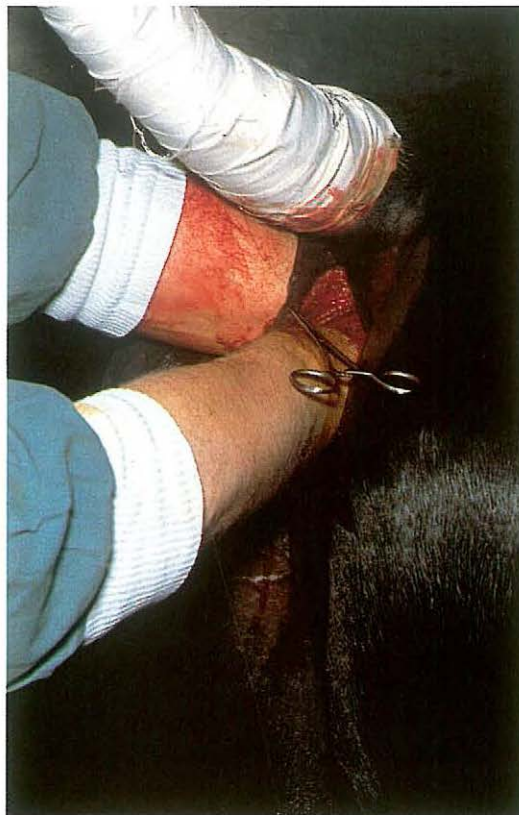brided. The rupture is closed in two rows of inverting continuous sutures i.e. Schmieden suture [247] and Lembert suture [248] using synthetic absorbable material. The abdominal cavity is cleansed by lavage and suction. Closure of the laparotomy wound is performed as described in 4-5.

To prevent urine retention the use of an indwelling catheter for about 3 days is desirable. (In case of urolithiasis the urethral obstruction must be removed, if necessary by urethrotomy.) Systemic antibiotics are indicated and should be continued until the catheter is removed.

249



250



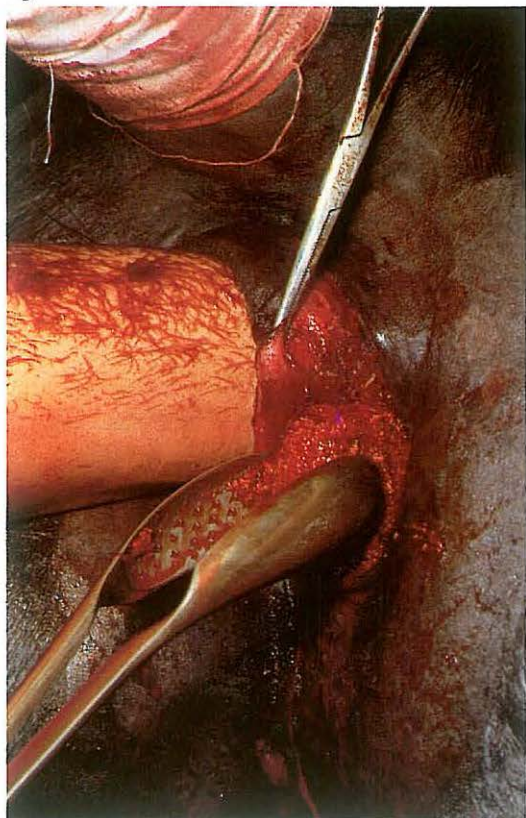
5-14 Pararectal cystotomy

In urolithiasis in male horses small vesical calculi may be removed through an ischial urethrotomy (see 5-15), but larger stones require removal via either laparocystidotomy or Gökel's pararectal approach to the bladder.

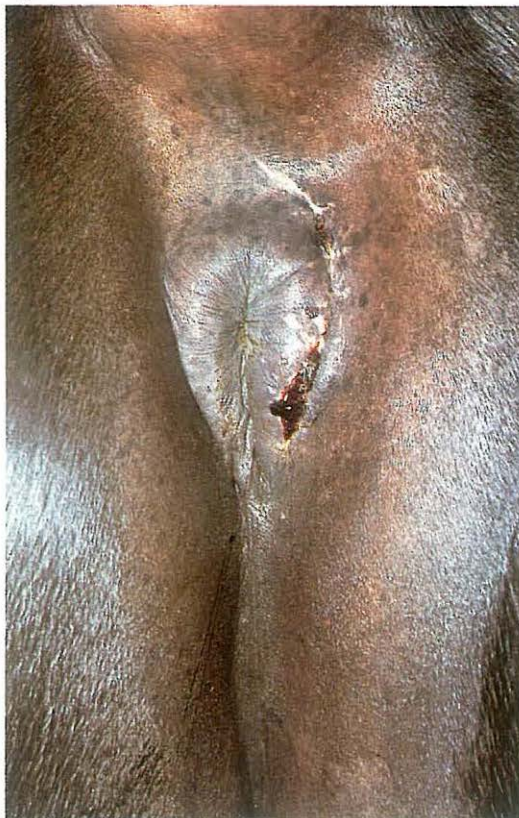Surgery. The operation is performed on the standing horse under caudal epidural analgesia (posterior block); supplementary perirectal infiltration analgesia may be needed. Physical protection and restraint is necessary to protect the surgeon from being kicked. The tail is bandaged and secured overhead. The rectum is emptied manually and the bladder evacuated by catheterization if necessary. Right-handed surgeons make a 10-15 cm vertical skin incision between the anus and the right semimembranous muscle. The incision is deepened by blunt dissection through the periproctal tissues along the rectal wall to the neck of the bladder [249]. The surgeon's (or an assistant's) free hand is introduced into the rectum and the calculus is forced into the bladder neck [250]. With the calculus so presented an incision is made in the retroperitoneal portion of the bladder wall with a pair of long half-pointed scissors. The cystotomy incision is enlarged and the calculus removed with a suitable forceps [251]. Gentle traction is often needed to free rough stones from the adherent vesical mucosa. After removal of the stone(s) the bladder is flushed with physiologic saline. The wound is loosely packed with hydrophilic gauze soaked in antiseptic solution: urine must be allowed to flow through the wound for several days. The wound heals by second intention. Systemic antibiotics are administered and analgesics are indicated if severe straining occurs.

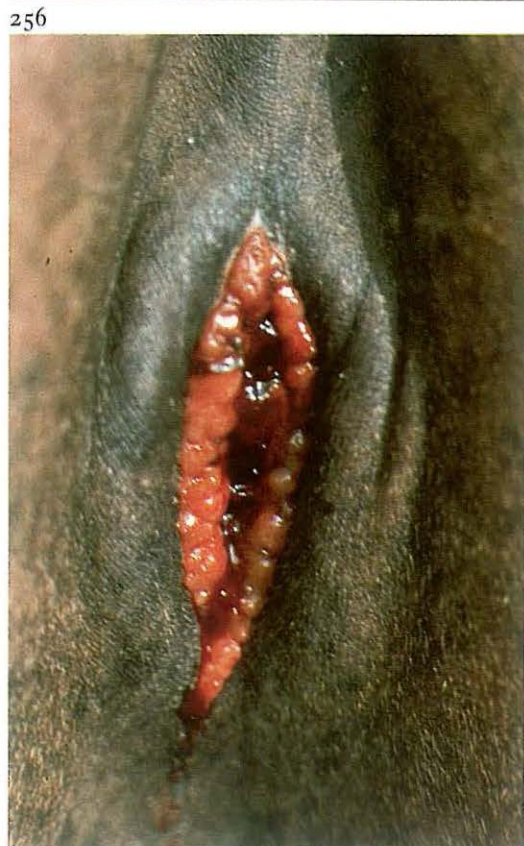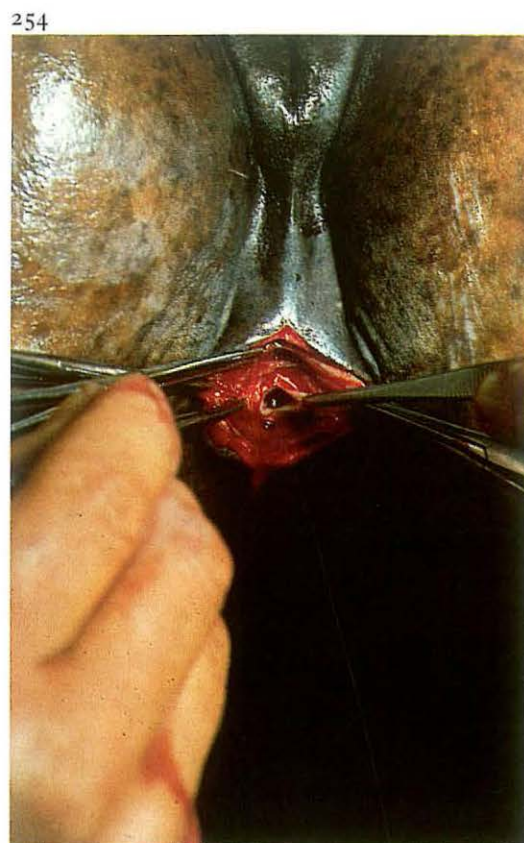
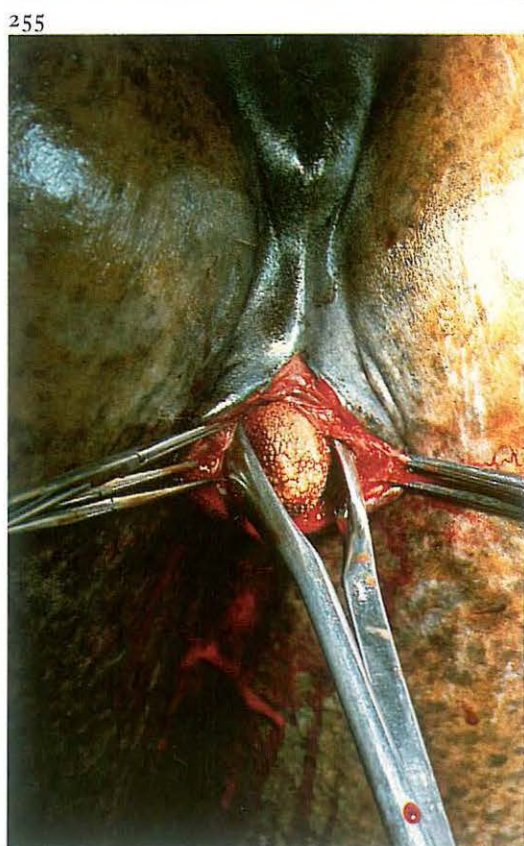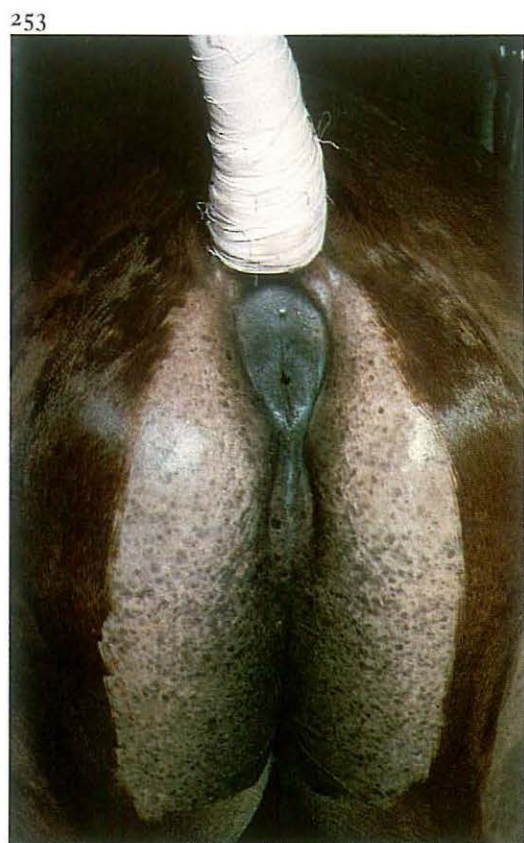The gauze drain is removed on the 3rd postoperative day; the flow of urine through the wound during micturition gradually diminishes and healing usually takes place in 7-14 days without complications [252].

251



252





5-15 Urethrotomy

Indications for performing an ischial urethrotomy are *a* urethral obstruction by calculi and *b* removal of small vesical calculi.

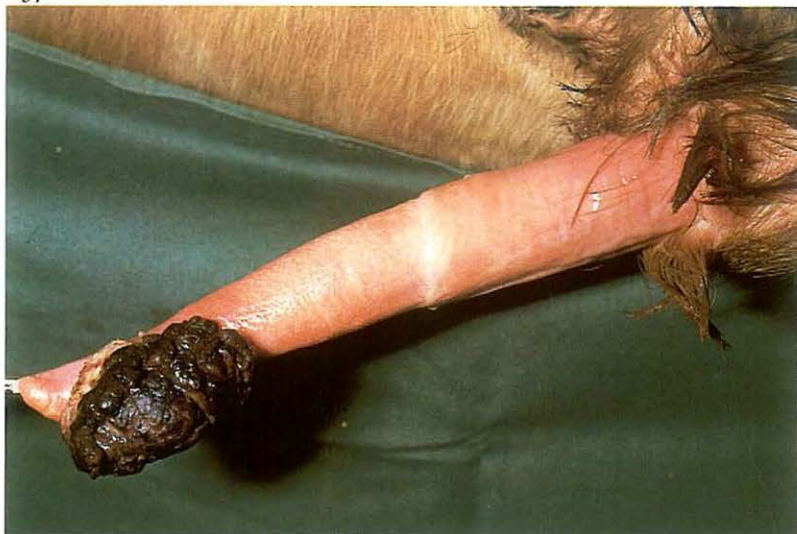Surgery. Ischial urethrotomy is most easily accomplished in the standing animal, because the incision must be made precisely in the perineal midline. In calves and goats an upright position is maintained by positioning the animal on a table in ventral recumbency, with the hindlegs hanging. Larger animals (in this case the horse) should be physically restrained, caudal epidural analgesia (posterior block) administered and the tail secured overhead [253]. Catheterization may facilitate location of the urethra.

In the perineal region a midline skin incision is made. Exact midline dissection is continued between the paired bellies of the retractor penis muscle through the bulbo-spongiosus muscle, corpus spongiosum and urethral mucosa into the urethra [254]. The urethral incision should be large enough to allow entry of a grasping forceps [255].

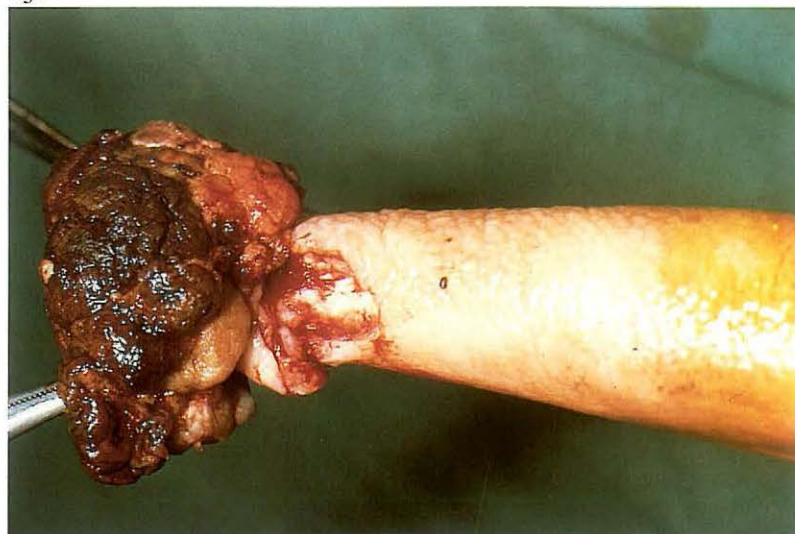
In cases of vesical calculi the forceps is introduced into the bladder and the free hand is passed into the rectum in order to guide the calculus into the forceps. Currently, removal of vesical calculi is usually carried out by means of a laparocystidotomy or by the pararectal approach (see 5-14), but urethrotomy is definitely indicated in cases of urethral calculi; the incision should be made as near as possible to the site of obstruction.

Postoperatively the bladder is thoroughly flushed. The wound heals by second intention [256]. In cases in which a chronic fistula is indicated (urethrostomy), the urethral mucosa is sutured to the skin and a temporary catheter inserted. Systemic antibiotics are optional.

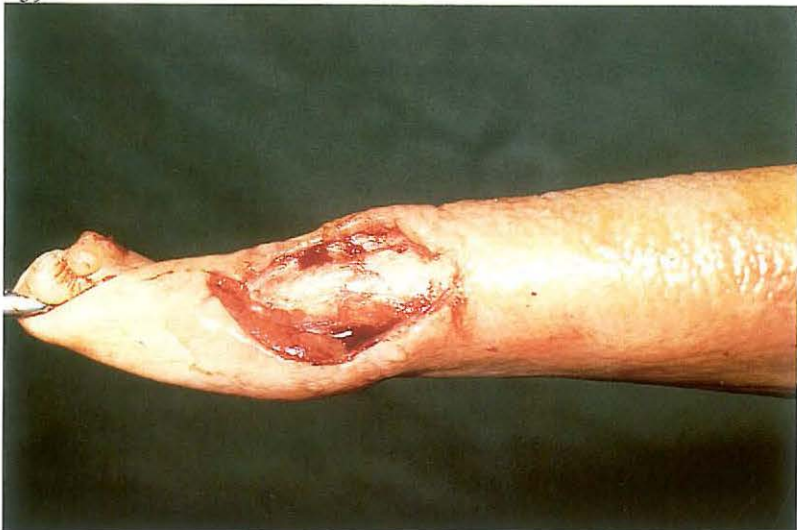257



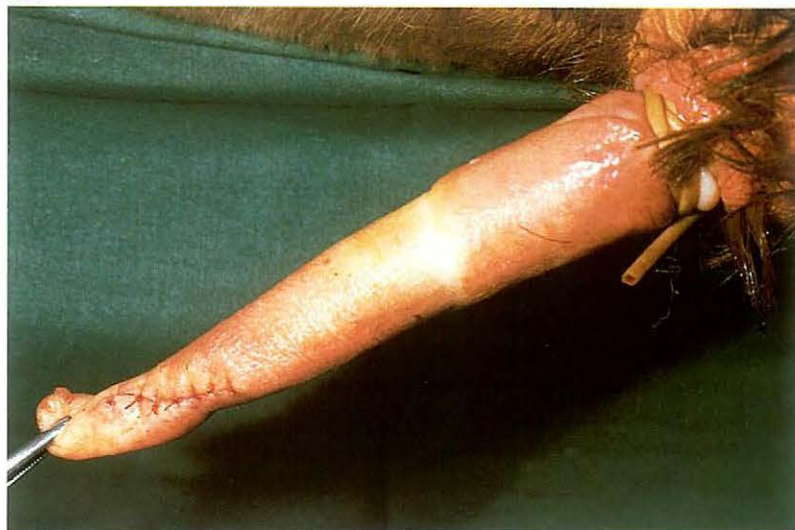258



259



260



5-16 Removal of neoplasms of the bovine penis

Neoplasms occur rather frequently in young bulls. Fibropapilloma is the most common type, malignant tumours are rarely seen. Fibropapillomas vary in size, they may be single or multiple and are usually located at the free portion of the penis [257]. In some cases the tumours may cause phimosis or paraphimosis.

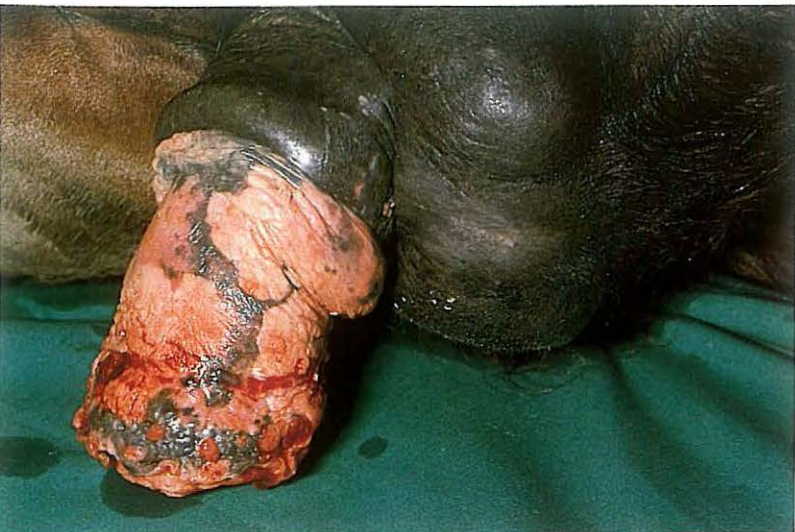
Surgery. The operation may be carried out in the cast or standing position. Tranquilization is needed to facilitate protrusion of the penis. Analgesia is achieved by a ring block proximal to the lesion. In the cast position general anaesthesia is preferred.

The neoplastic tissue is excised by dissecting through the penile epithelium at its base [258]. Bleeding vessels are ligated. Fibropapillomas often have a rather small base, and this facilitates uniting the wound edges [259]. Closure is performed with fine absorbable material, using interrupted sutures [260]. If the defect is large, the area is treated as an open wound with anti-

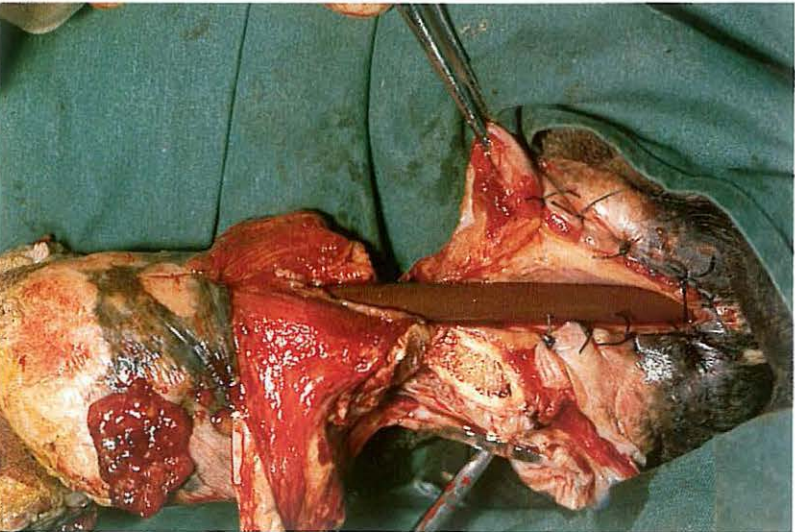
biotic ointment. Recurrence of the disorder is not unusual but may be reduced by vaccination with wart vaccine.

If the neoplastic growth is extensive and includes the urethra, amputation may be considered. As described in 5-17 a triangular area of tissue is excised and the urethral wall incised. The two edges of the urethra are now sutured to the penile epithelium. A ligature is placed distal to the base of the triangle. Amputation is completed by simple transection of the tumorous end of the penis distal to the ligature. If only the terminal free end of the penis is removed the bull may serve normally.

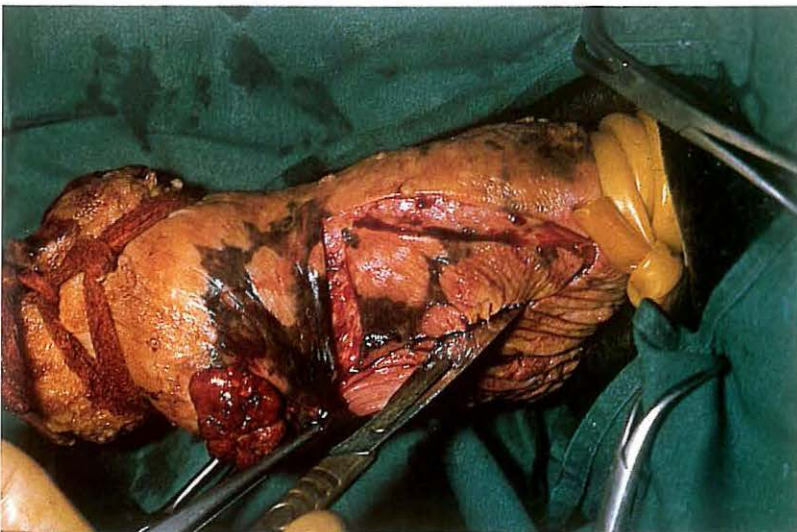
261



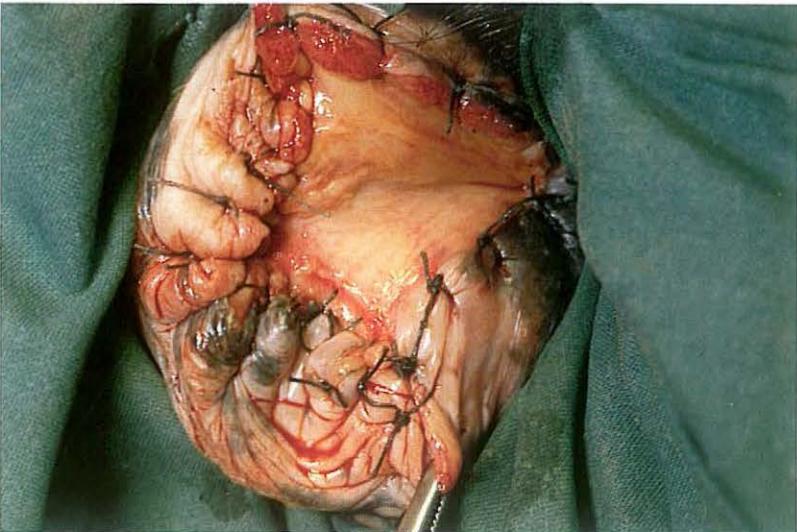
263



262



264



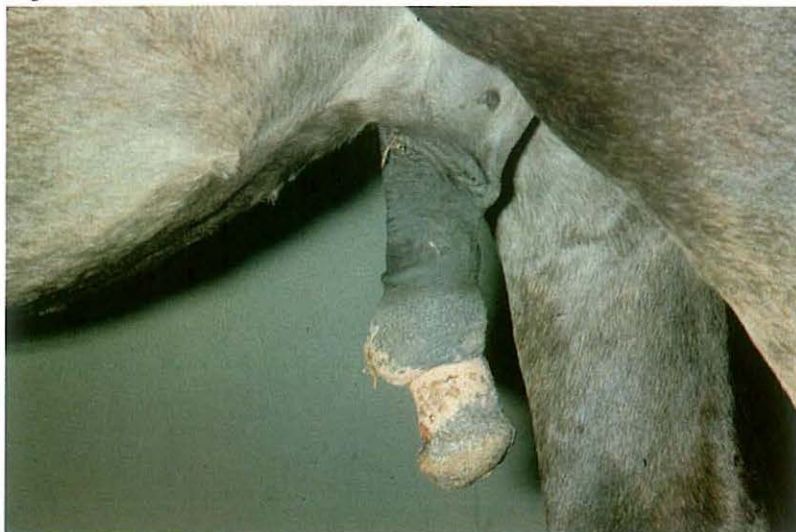5-17 Amputation of the equine penis

Indications for amputation of the penis in large animals are intractable paralysis of the penis, especially then accompanied by irreversible enlargement, and extensive neoplasia [261]. The operation is the ultima ratio where other means are impossible or have failed e.g. local tumour excision or Bolz' penis retraction operation (see 5-20).

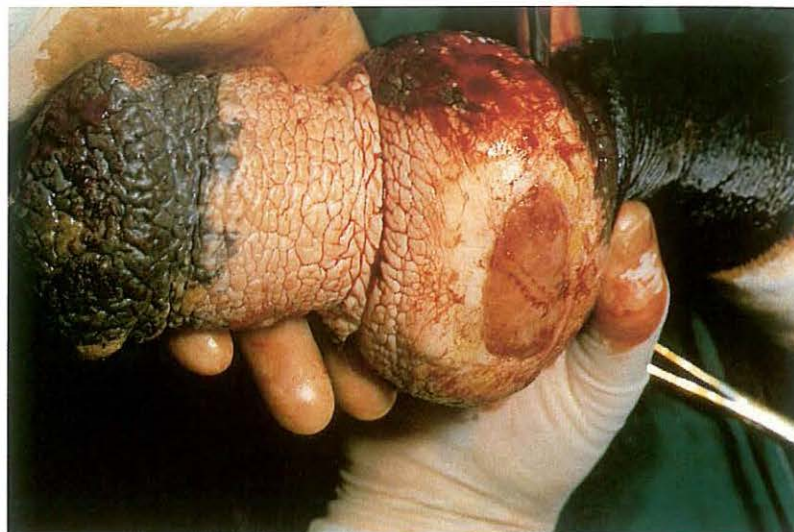Surgery. The animal is positioned in dorsal or lateral recumbency under general anaesthesia. After catheterization of the urethra a tourniquet is applied at a point which is determined by the indication for the operation, i.e. more distally in cases of glans tumours and as far proximal as possible in paralysis of the penis. The penis is drawn forward under moderate traction. A triangular skin incision, with the apex caudad, is made over the urethra. The incision is deepened and tissues (fascia, bulbospongiosus muscle and corpus spongiosum urethrae) are dissected from the intact urethra [262]. The urethra is then incised longitudinally, using the catheter as a guide.

The urethral mucosa is sutured to the penile epithelium in a simple interrupted pattern [263], starting at the apex of the incision. The amputation is completed by transecting the penis in an oblique (craniodorsad) plane [263]. The identifiable vessels are ligated and after removing the tourniquet the stump is closed by interrupted sutures which pass through urethral wall, tunica albuginea (twice) and skin [264]. Systemic antibiotics are advisable and tetanus prophylaxis is mandatory.

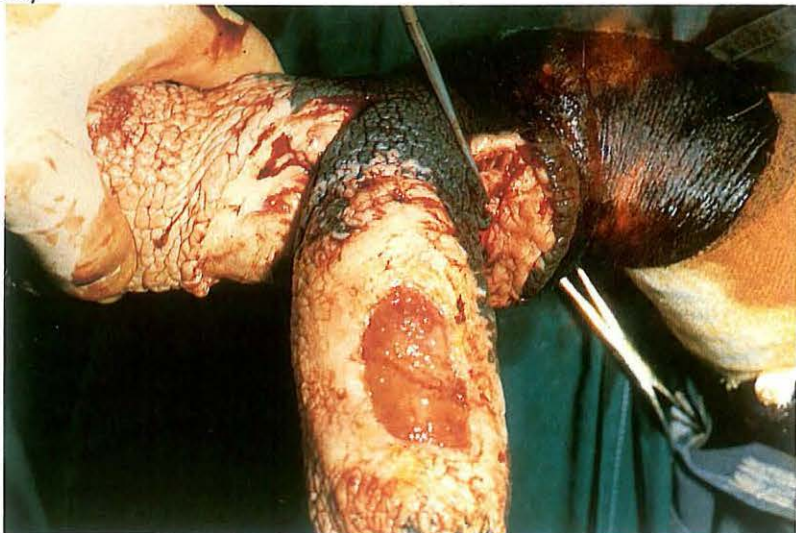
265



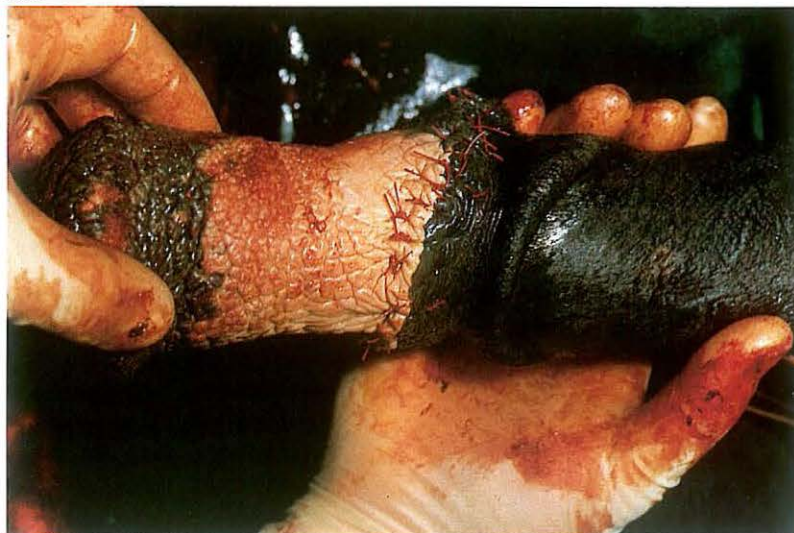266



267



268



5-18 Circumcision (reefing) of the equine penis

Chronic lesions (scar tissue, granuloma, neoplasia) of the inner segment of the prepuce may cause sufficient deformity and dysfunction to prevent retraction of the penis [265, 266]. If other treatments have failed and amputation is not indicated, a circumferential segment of prepuce may be resected.

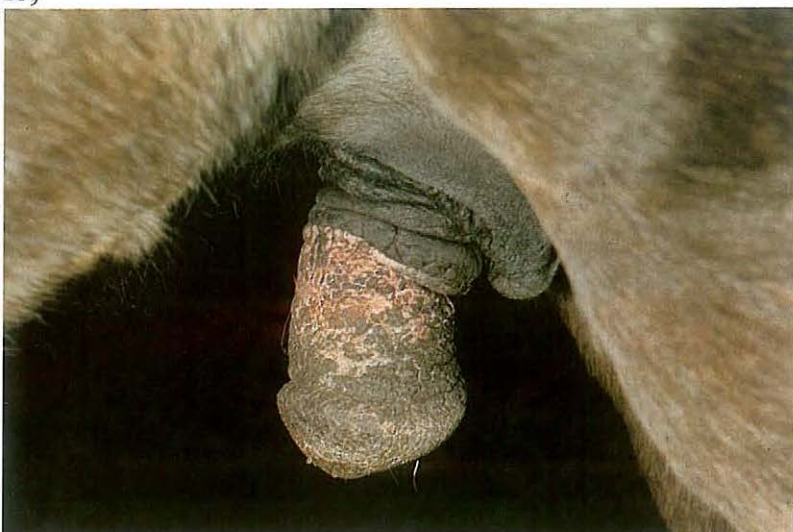Surgery. The horse is positioned in recumbency under general anaesthesia. Plate 266 shows the granuloma and chronic thickening of the internal part of the prepuce. To facilitate surgery a tourniquet may be used, as well as a catheter for identification of the urethra. A circumferential incision is made both cranial and caudal to the lesion. A third longitudinal incision connects the two previous incisions. The segment including the lesion is dissected free [267] and removed, avoiding the large dorsal penile arteries and veins which lie just outside the tunica albuginea.

The tourniquet is released to identify and ligate bleeding vessels. The skin

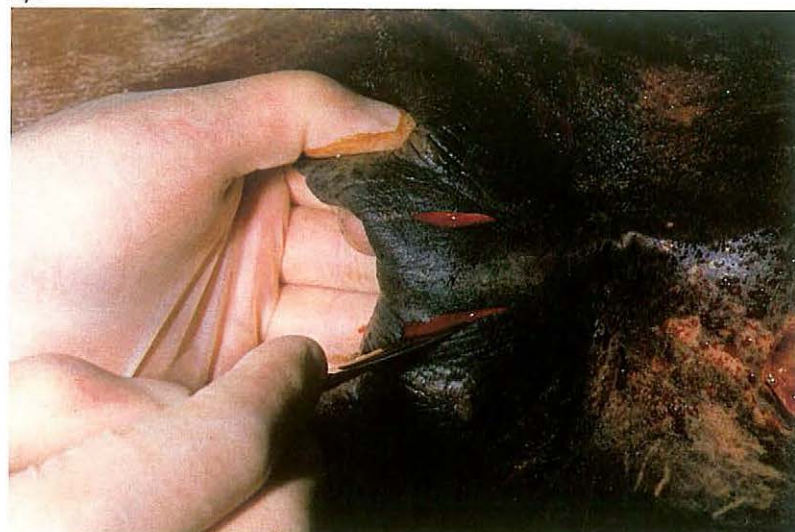edges are apposed and sutured in a mattress or simple interrupted pattern, using synthetic absorbable material [268]. Temporary retention of the penis by a subcutaneous purse-string closure of the preputial orifice (see 5-19) is recommended. Systemic antibiotics are administered and tetanus prophylaxis is provided. Stallions should be isolated from mares for at least 3 weeks. Regular exercise reduces postoperative oedema. Sutures are removed after 14 days.

Plate 269 shows the improvement in retraction of the penis.

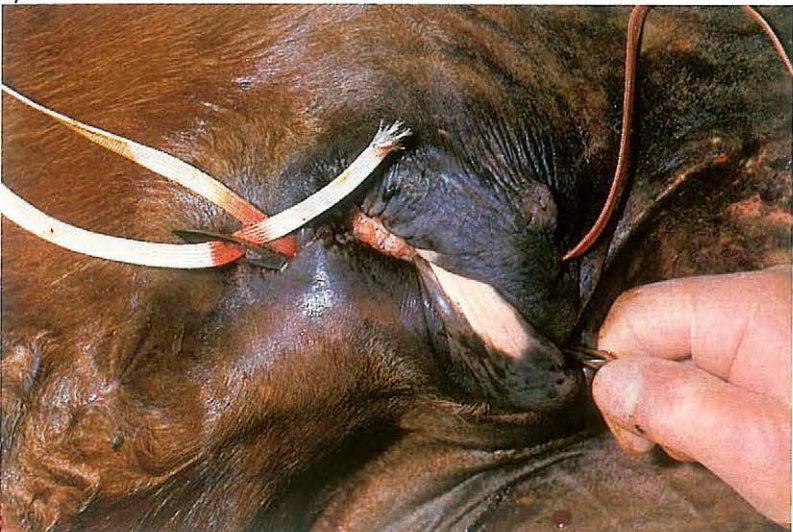
269



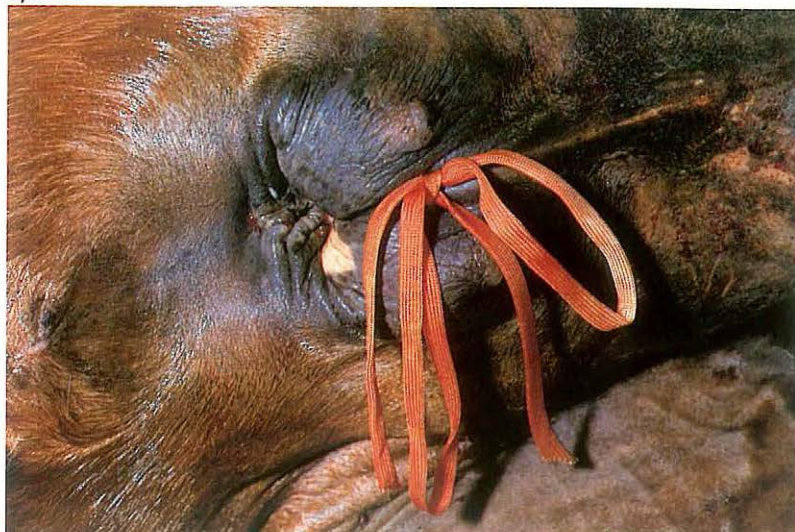270



271



272



5-19 Retention suturing of the equine preputial orifice

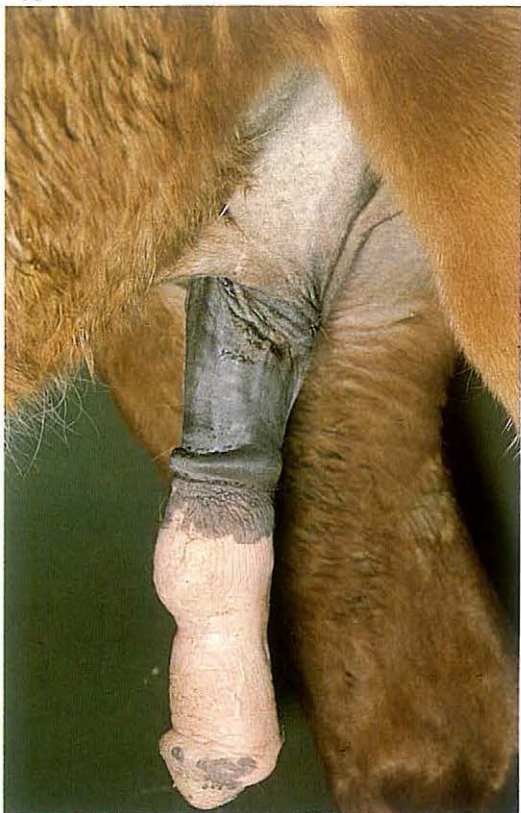Temporary retention of the penis in cases of traumatic injury followed by paraphimosis may be achieved by a buried purse-string suture analogous to Bühner's closure of the bovine vulva. Surgery must be preceded by reducing swelling by gentle massage and/or temporary application of rubber bandages, whereafter the penis and internal part of the prepuce can be returned to the preputial cavity.

Surgery. Surgery is best carried out in the recumbent horse under general anaesthesia. For the standing operation, local analgesia is achieved by infiltration, and physical restraint is necessary. Two stab incisions are made through the skin of the external prepuce [270] at the ventral commissure of the preputial orifice, 0.5–1 cm lateral to the raphe. One incision is made on the dorsal aspect. A Gerlach needle is inserted into one of the ventral incisions and pushed subcutaneously in the direction of the dorsal incision, under the guidance of the surgeon's hand in the orifice.

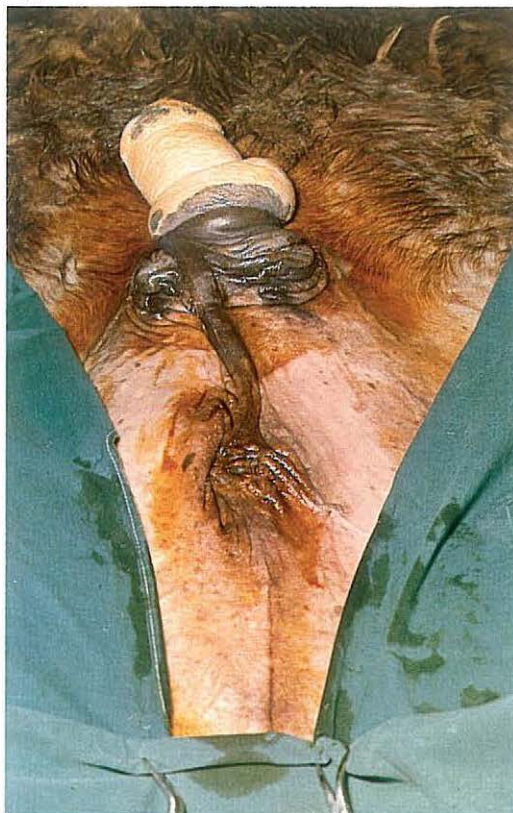After emerging at the dorsal incision, umbilical or Bühner vaginal tape is threaded through the eye of the needle and drawn through the ventral incision. The procedure is repeated on the other side [271]. The two free ends of the suture tape are tied ventrally, resulting in a buried loop dorsally [272]. After tying, the orifice must admit two to three fingers, so that urination is not hampered.

Systemic antibiotics are indicated and tetanus prophylaxis is provided. Postoperative hydrotherapy and regular exercise will help reduce swelling. The suture is usually removed after 1 week.

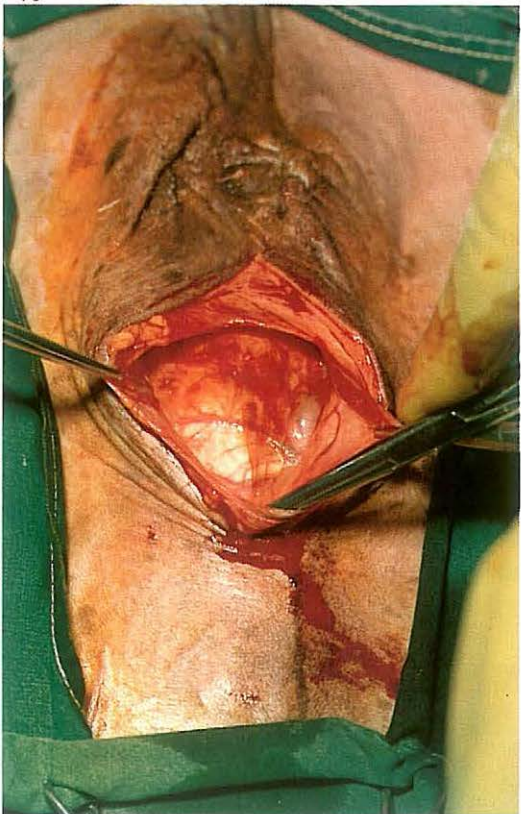
273



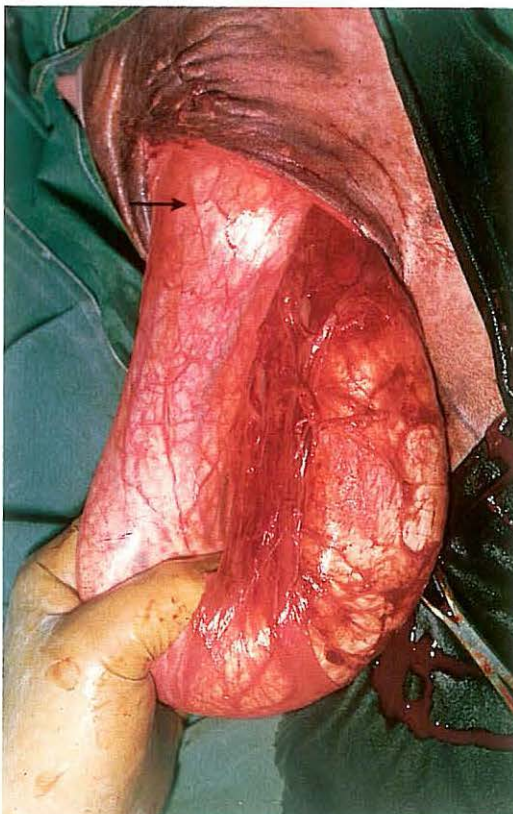
274



275



276



5-20 Penis retraction operation in the horse

In cases of paralysis or prolapse of the penis [273] which have not responded to initial therapeutic management (e.g. massage, hydrotherapy, reposition, support with a suspensory, or temporary retention by narrowing the preputial orifice, see 5-18), Bolz' penis retraction operation may be considered. The method is an alternative to amputation of the penis, but may be used only if *a* the horse is a gelding (stallions should be castrated some weeks before the retraction operation is carried out) and *b* the prolapse is uncomplicated by severe swelling due to oedema, fibrosis or inflammatory reactions.

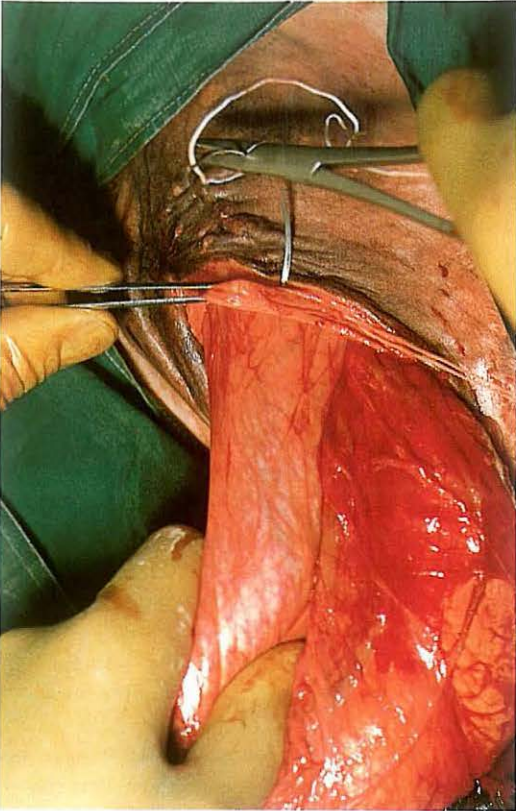
Surgery. The horse is positioned in dorsal recumbency under general anaesthesia [274]. It may be preferable to catheterize the penis for easy identification of the urethra. An approximately 10 cm long skin incision [275] is made in the midline just caudal to the castration scar. Subcutaneous tissue is bluntly dissected and the penis freed from the surrounding fascia. Injury to blood vessels should be avoided. The penis is gripped and retracted sufficiently to identify the annular swelling of the reflection of the inner prepuce [276, arrow].

Fixation of the penis may be performed in two ways: *a* by placing two heavy non-absorbable percutaneous sutures through the ring on each side of the midline incision and securing over tension buttons or bandage rolls; *b* by placing several heavy absorbable synthetic sutures through the reflection ring (without entering the preputial cavity) and the subcutaneous fascia [277, 278]. Retraction [279] usually causes a sigmoid curvature in the penis, but this abnormal situation causes no problems with blood supply and urination.

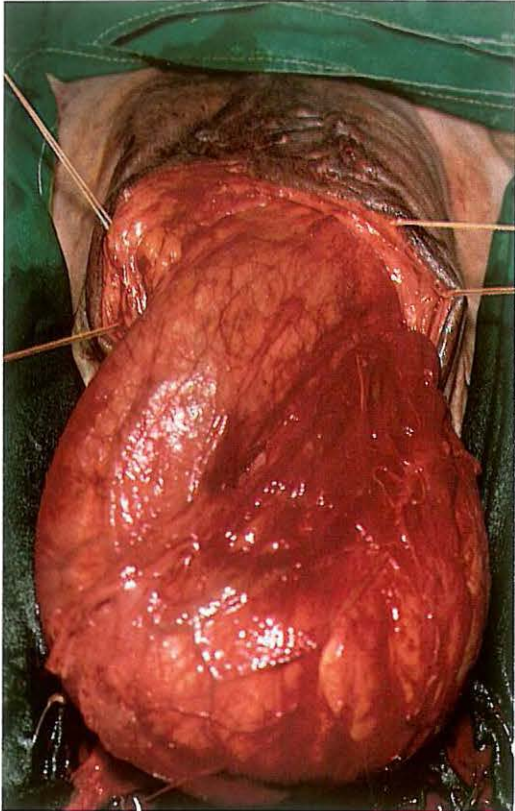
Fascia and skin are sutured separately with absorbable material. Temporary drainage of the wound is desirable. Tetanus prophylaxis is provided.

Regular postoperative exercise should be given to minimize oedema, but the horse should not be allowed in the company of mares for several weeks. If percutaneous retention sutures have been used, they should be removed together with the skin sutures after about two weeks. Plate 280 shows the situation a few weeks postoperatively.

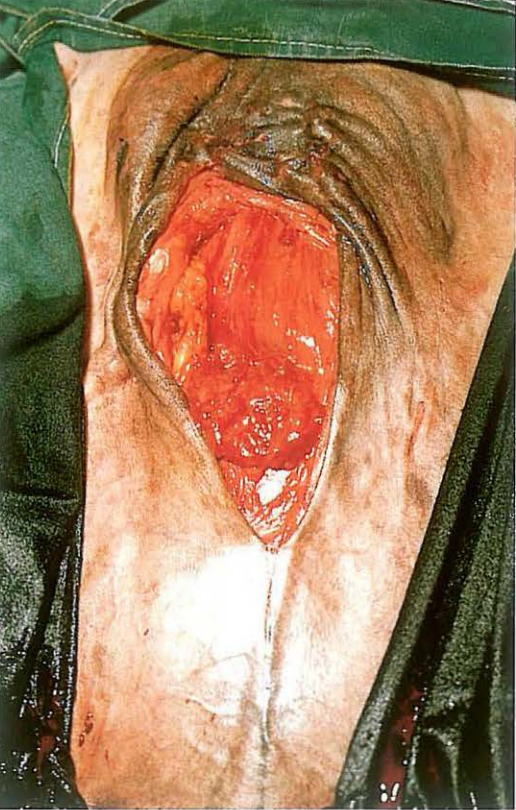
277



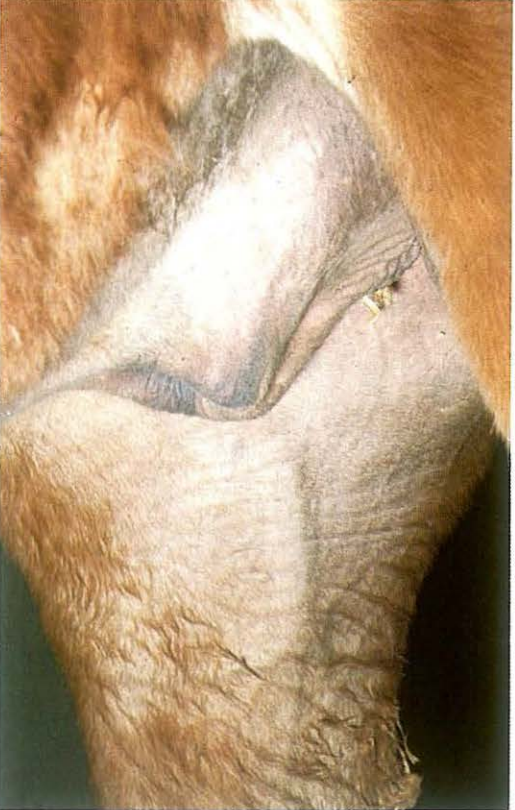278



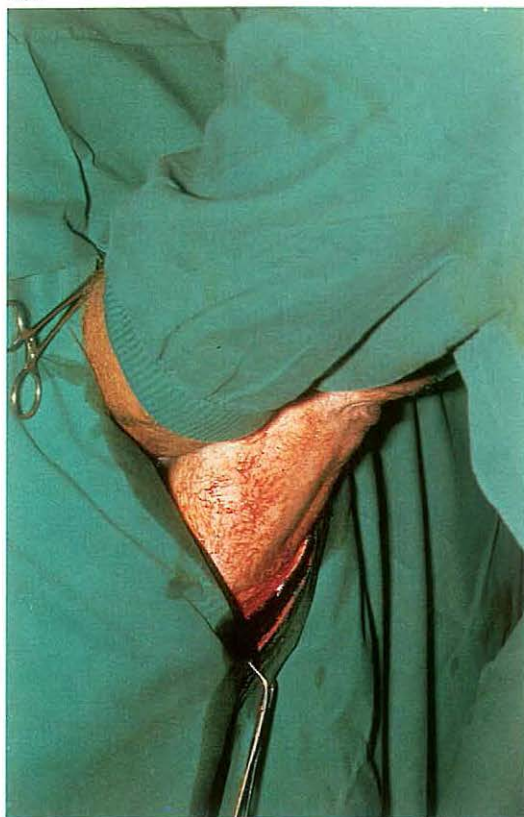279



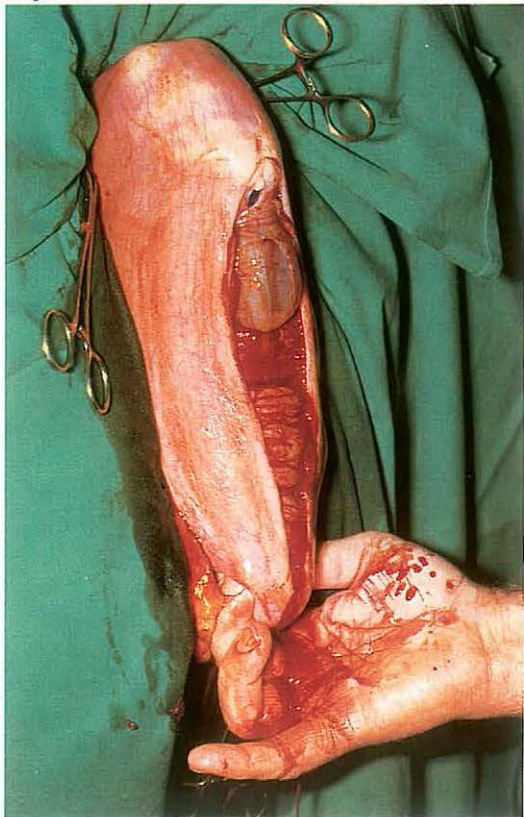
280



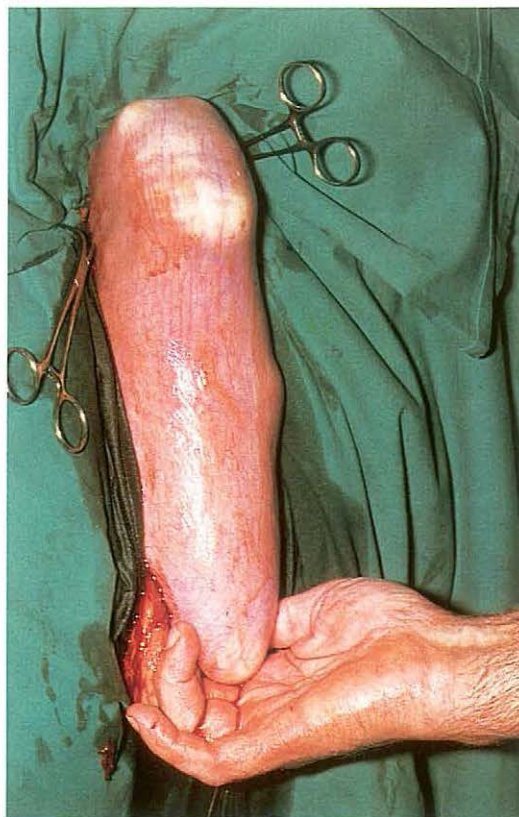281



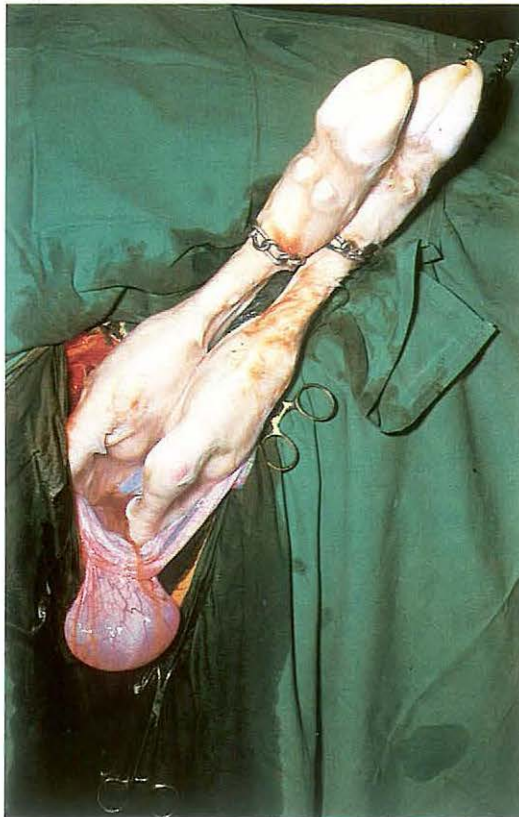283



282



284

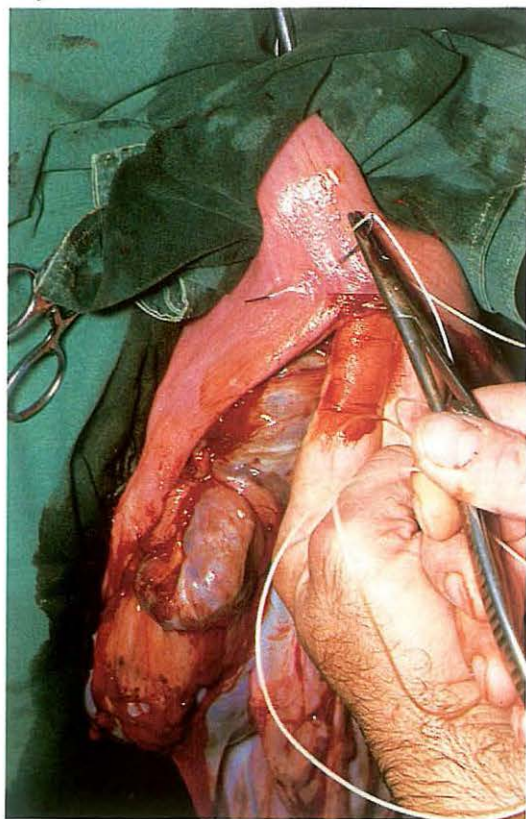


5-21 Caesarean section in cattle

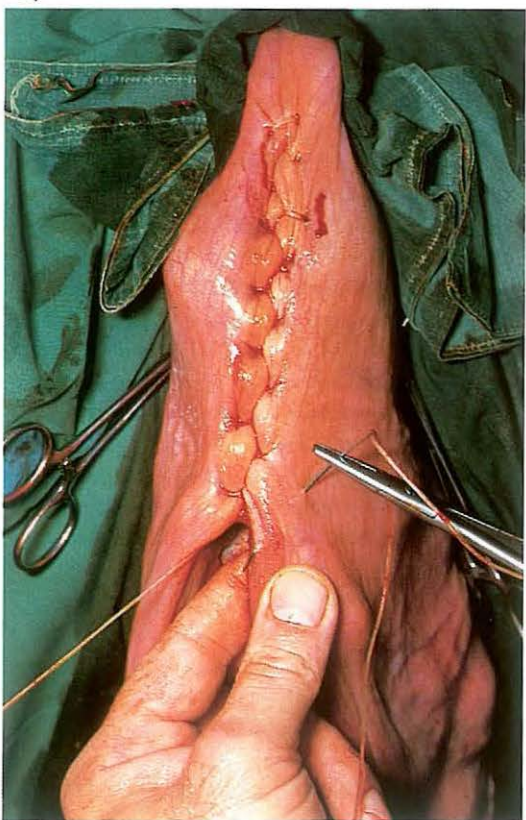Different techniques have been developed for caesarian section in cattle: flank, paramedian and midline approach in the recumbent animal, and right or left flank laparotomy in the standing position. Each method has certain advantages and disadvantages. Choice depends on the type of dystocia, breed and condition of dam and foetus, and in some cases on the preference of the surgeon. In many cases of dystocia, however, foetotomy is the method of choice. In dairy cattle, standing left flank caesarian section is most commonly carried out and is described here.

Surgery. In addition to paravertebral or infiltration anaesthesia, a caudal epidural analgesia (posterior block) is given to reduce abdominal straining. A vertical through-and-through incision of adequate length is made (see 4-4). If the apex of the gravid horn (left or right) is positioned in the right side of the abdomen, the uterus must be rotated, by bringing the right hand under the uterus, and grasping the dorso-medial surface of the tip of the horn. With the hand so placed, the uterus is rotated about 90° by pulling the apex under the uterus, which is elevated and pushed to the opposite side by the arm and elbow. The apex of the gravid horn is elevated and exteriorized: the right hand locates the foetal digits in the horn tip, follows the metatarsal bone and grasps the calcaneus. The left hand then grasps the tip of the horn from the medial side [281] and presents the tip of the horn into the wound. The calcaneus is brought into the ventral commissure of the wound with the right hand. [282]. The incision through the uterine wall along the greater curvature runs from 5 cm below the digits to the calcaneus, and is large enough to allow extraction [283]. (In cases of posterior presentation, the head is supported with the right hand, the uterus is exteriorized by traction on the metacarpus with the left hand, and an incision in the greater curvature is made over the metacarpus.) Sterile chains are applied to the limbs and the foetus is slowly extracted [284]. Thereafter the uterus is kept in position by means of sponge forceps: escaping placental fluids must not enter the abdominal cavity. The placental edges are excised. The uterus is closed with a modified Cushing suture (Utrecht method), using plain catgut. The suture begins about 2 cm from the upper end of the wound [285]. Oblique bites are used [286] so that the knot is

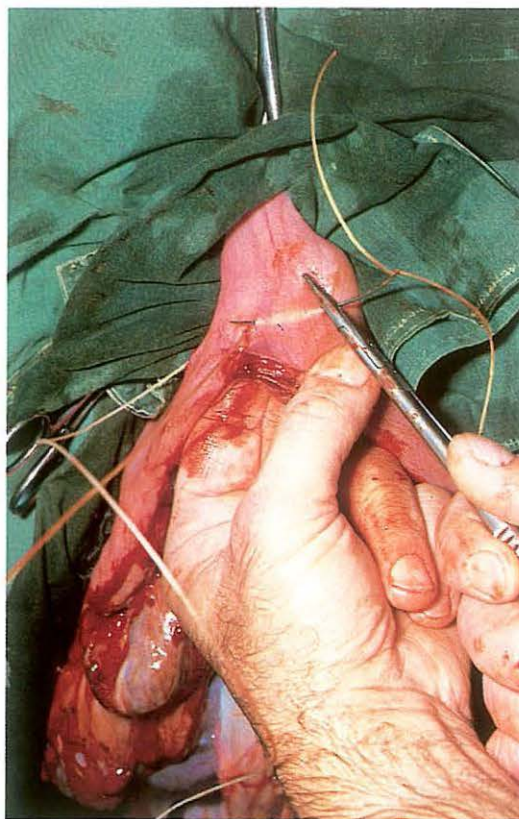
285



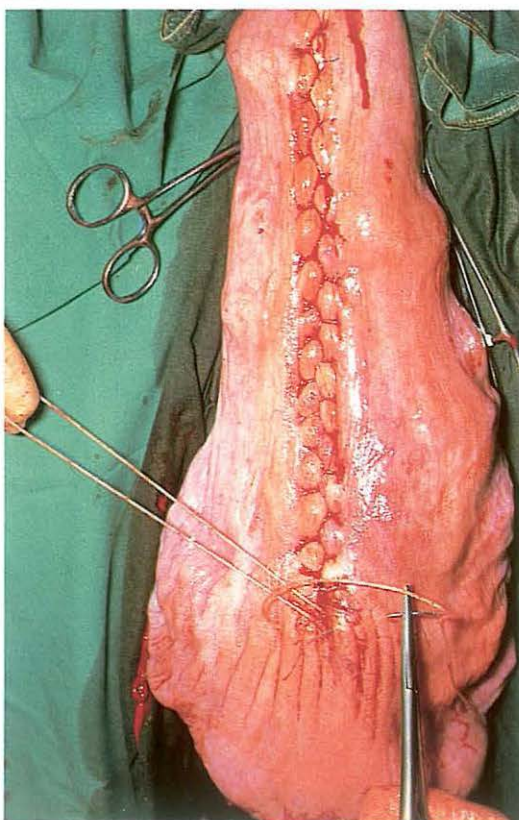
287



286

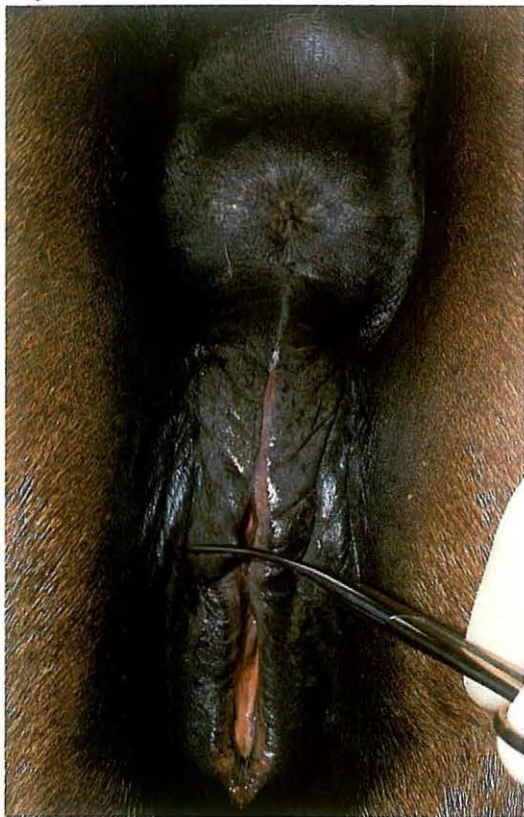

288

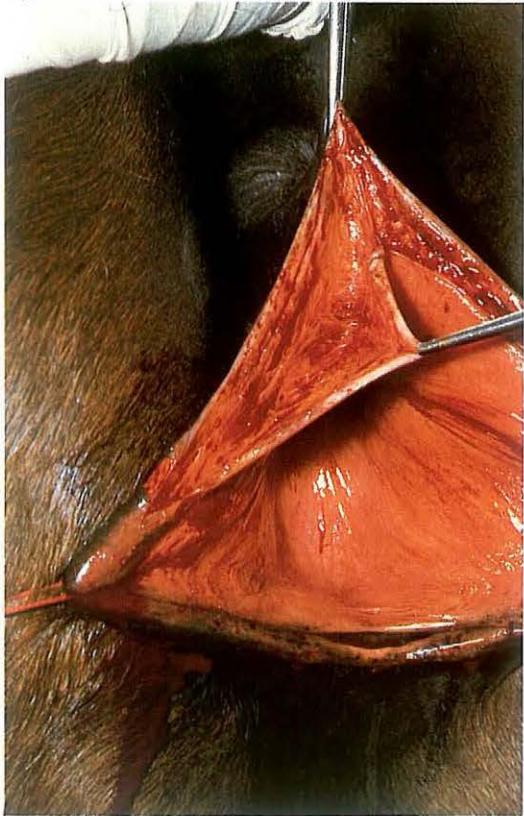


buried by the inverted tissue. The next bite begins about 2 cm from the incision edge and is directed at an angle of 45° to it [287]. The bite on the other side is placed similarly but is inserted some distance back from the emergence of the previous bite. It is important that each suture be pulled tightly following its insertion. This inversion suture prevents any leakage and leaves minimal exposure of suture material. Before closure is complete intrauterine tetracycline is administered. The final knot is buried in the same way as at the beginning of the suture line [288]. The uterus is replaced in the abdominal cavity, and oxytocin is given intramuscularly. The laparotomy wound is closed (see 4-4). Systemic antibiotics are administered. The placenta is normally expelled after 4 hours. Retention of the placenta is usually not treated: after about 10 days it is expelled as a necrotic mass. In some cases repeated intra-uterine application of tetracycline is necessary.

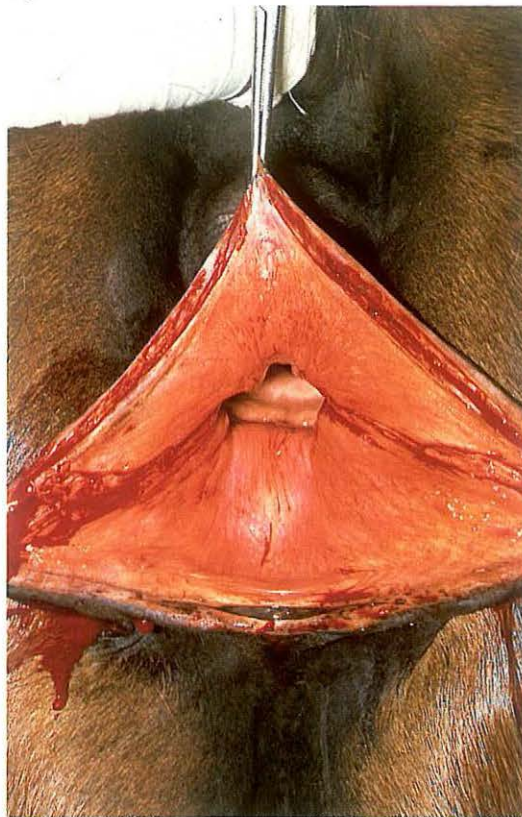
289



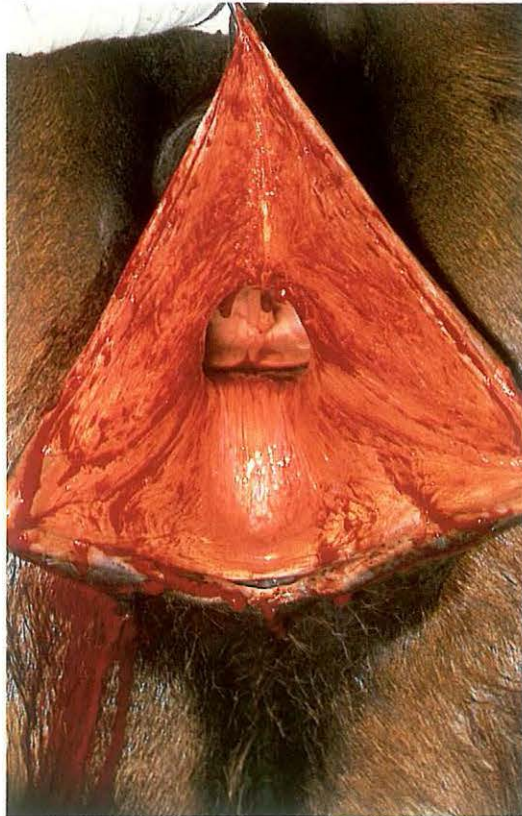
291



290



292



5-22 Vestibuloplasty

Pneumovagina is the involuntary aspiration of air, sometimes contaminated with faeces, into the mare's vagina, and results from faulty conformation and closure of the vulva and vestibulum. It is seen in mares of all ages, and may cause infection of the genital tract, and occasionally pneumometra.

The aim of vestibuloplasty is to reduce the vestibular introitus (vulvar cleft) by 30–50%, and to lower the vestibular roof. Infection should be treated pre-operatively.

Surgery. The mare is restrained in stocks, and the tail wrapped and tied to the side. The vestibular mucosa is flushed with a mild antiseptic. Analgesia is achieved by infiltration (using a fine needle) of the dorsal vestibular mucosa and the mucocutaneous junction of the upper vulvar cleft. Sedation may be indicated.

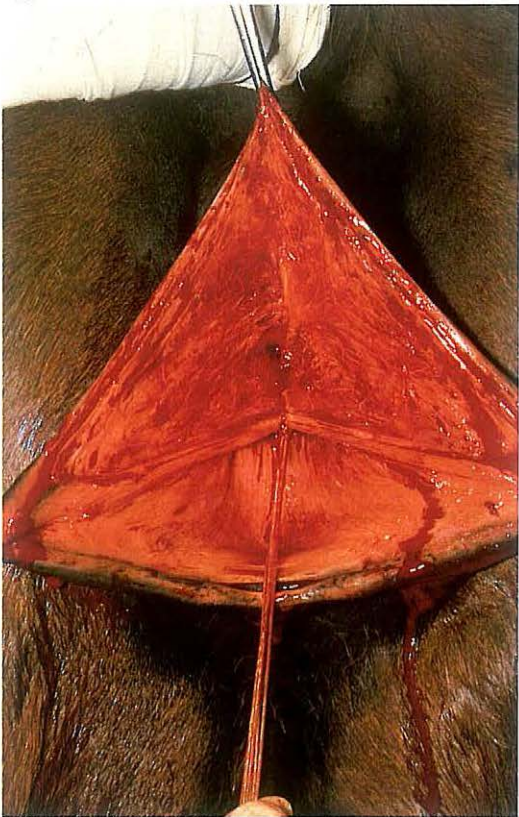Firstly, the site of the new dorsal commissure is marked on the lips with scissors [289]. If a scar of an old first- or second degree laceration is present, this site is at a point halfway between the dorsal and ventral vulval commissures.

In a non-ruptured vulva, the upper third of the vulvar cleft is closed, and the new dorsal commissure will be at the level of the floor of the bony pelvis.

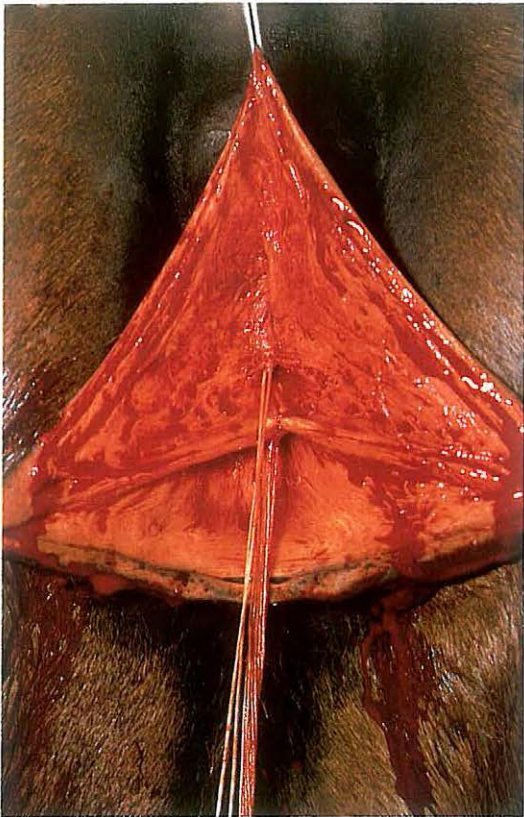
The vestibulum is exposed by retraction with a forceps in the dorsal commissure and two stay sutures in the vulval lips, placed just ventral to the scissor marks. Incision starts in the vestibular roof 3 to 6 cm caudal to the vestibulo-vaginal junction and runs caudally to the mark on the vulval lip. An identical incision is made on the other side. Finally the dorsal commissure and mucocutaneous junction of the labia are incised [290]. A double-triangular section of mucosa is then dissected submucosally from the dorsum and dorsolateral aspects of the vestibulum [291, 292]. The left and right horizontal wound edges are carefully apposed and sutured with absorbable material in a simple interrupted pattern, beginning cranially [293]. The knots are tied in the vestibular cavity. After 3–4 knots, simple interrupted sutures are placed dorsal to this suture line to appose the dissected surfaces [294]. Suturing is completed by alternate suturing of the mucosa and deeper layers [295]. The skin is closed with simple interrupted sutures of absorbable material [296].

Tetanus prevention is obligatory. Complete

293

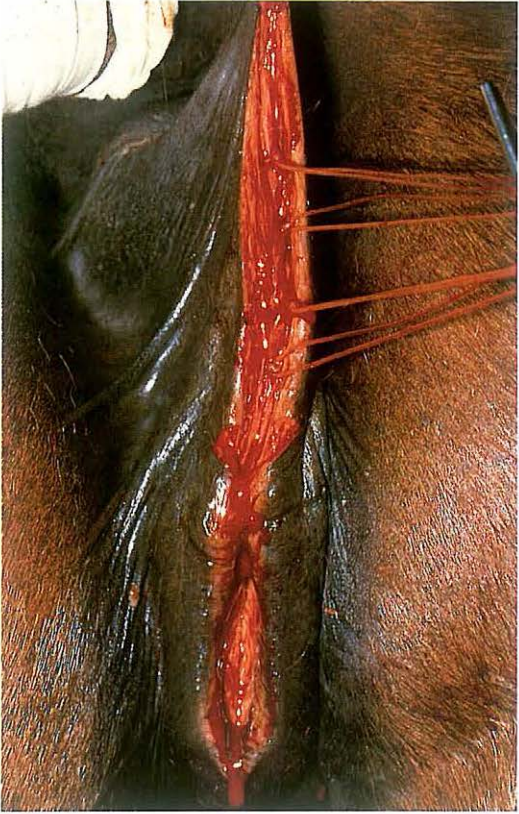

294

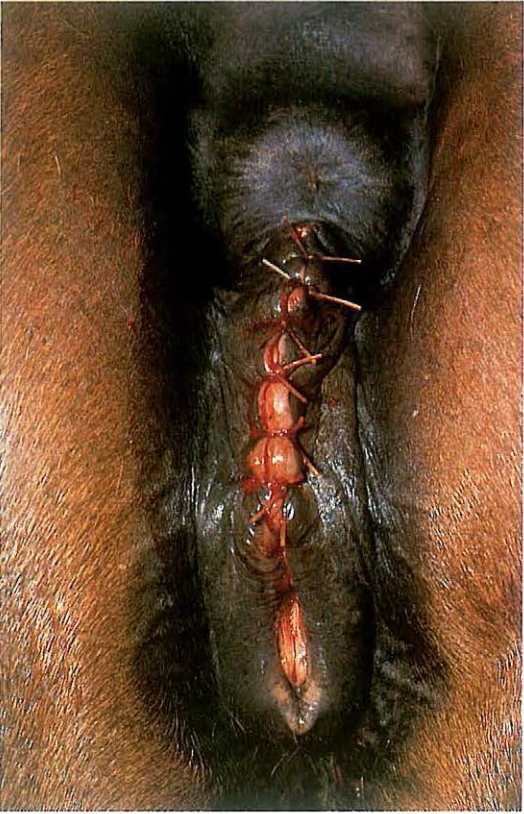

functional healing usually takes place in 4-8 weeks; during that time natural covering is prohibited. Episiotomy is necessary at parturition, to prevent irregular tearing of the vulva (see 5-24).

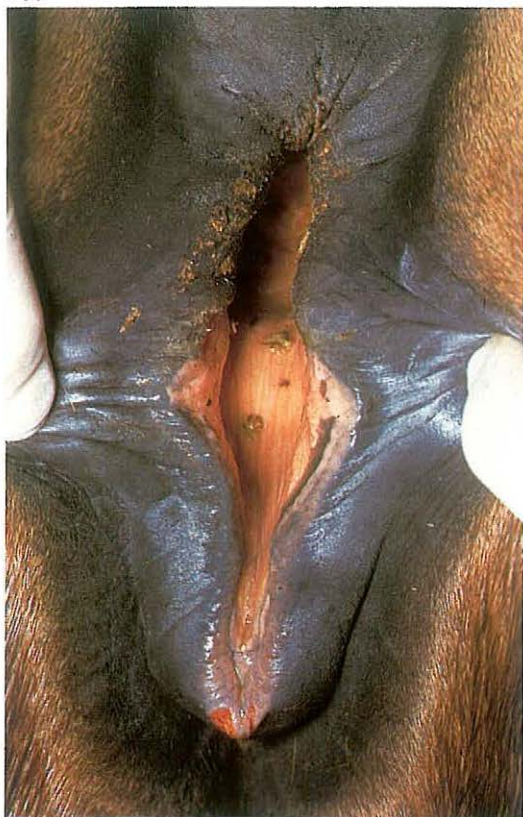295



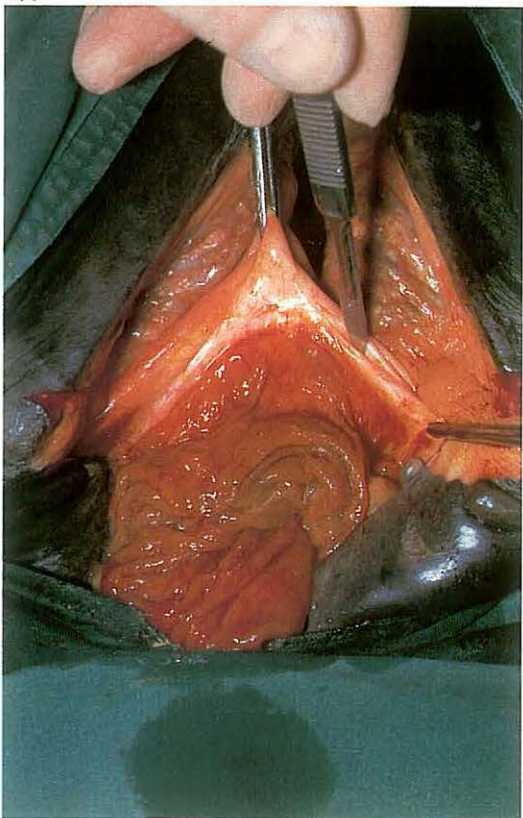
296



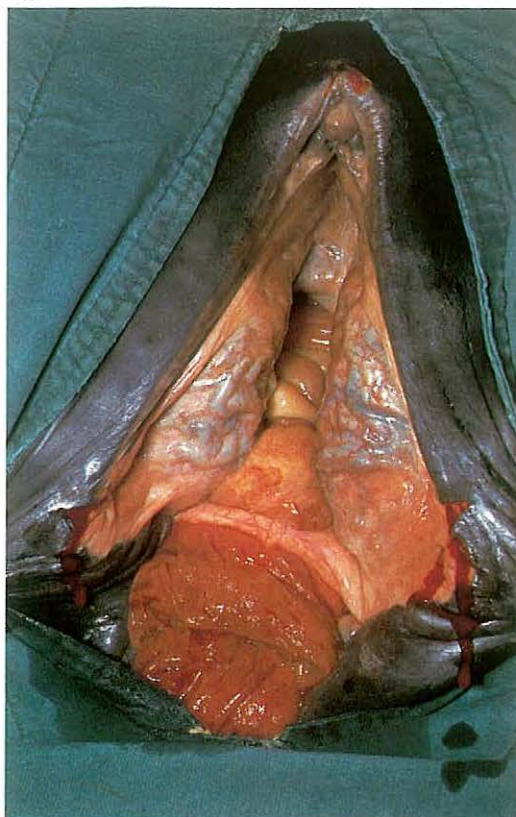
297



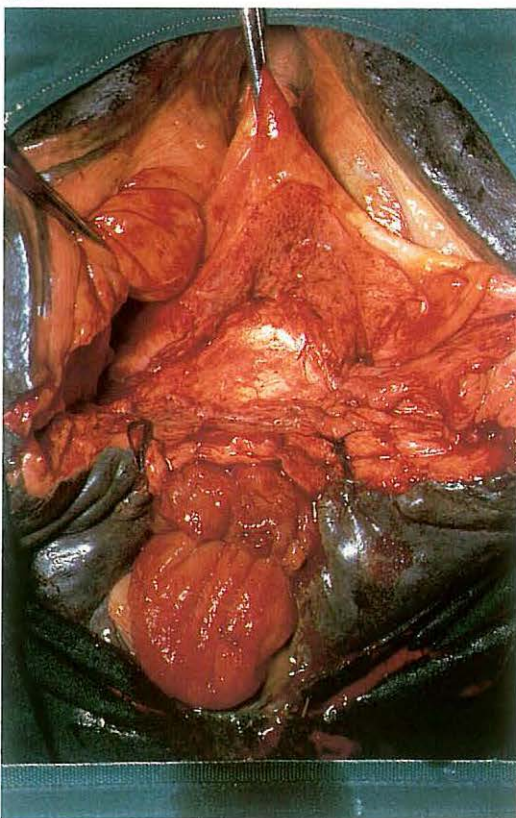
299



298



300



5-23 Perineal reconstruction after third degree laceration

Rupture of the perineal septum and body, vestibular walls, and rectum may occur during parturition at all ages, and is most common in the primiparous mare. The foal's forefoot or nose catches the vestibular roof caudal to the vaginovestibular junction. If unattended, the abdominal straining pushes the foot or nose through the vestibular roof and rectal floor. If the foal is born in this position, the perineum ruptures and a third degree laceration occurs. Immediate reconstruction is not recommended, because of contamination and oedema. Haemostasis, tetanus prevention, debridement, and systemic antibiotics are of importance directly following injury.

Surgical reconstruction is carried out after weaning of the foal, or healing by second intention (in case of a dead foal). Plate 297 shows the cloaca in the standing mare. Preoperative fasting for 9-10 days is necessary to ensure uneventful wound healing.

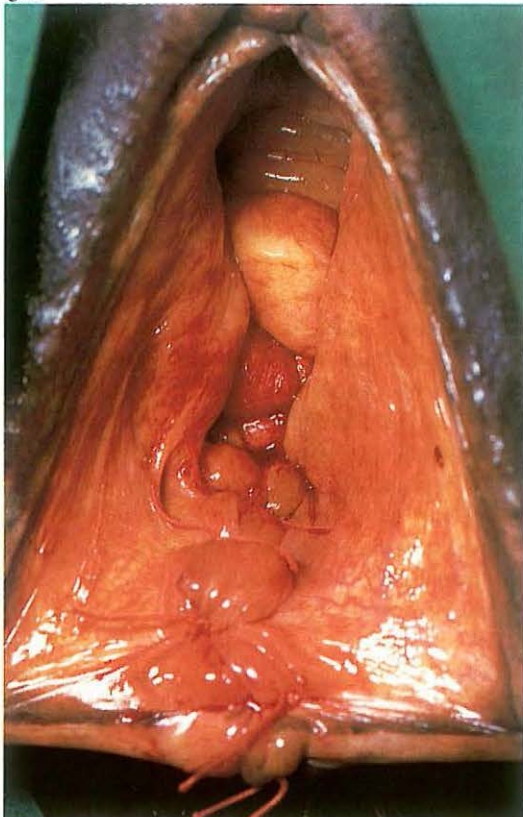
Surgery. Positioning in dorsal recumbency under general anaesthesia is preferred because surgery in the standing mare is difficult due to the depth of the injury and the need for sufficient exposure. The site of the new dorsal commissure is marked on the vulva, and retraction is effected by two stay sutures [298]. The operation consists of 3 phases.

(1) Incision of the rectovestibular septum and sidewalls is begun cranially, in the middle of the shelf remaining between vestibule and rectum. The dissection is extended caudally and horizontally along the junction of rectal and vaginal mucosa to the points marked on the vulva [299]: the dissection is extended sufficiently to create flaps of tissue which can be apposed and sutured without tension.

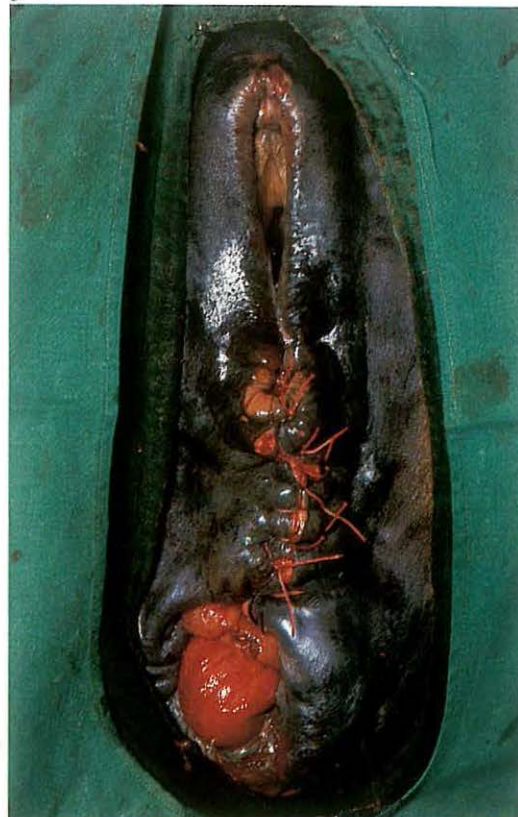
The next incisions run in the mucocutaneous junction of both vulval lips, from the mark to the anal sphincter, from where an incision runs cranially in the vestibular mucosa on both sides, at an angle of 30 degrees to the horizontal incision. The triangles of vestibular mucosa are resected.

(2) The most cranial edge of one lateral flap is apposed to the adjacent half of (the dorsal i.e. rectal part of) the 'frontal' flap, using absorbable synthetic material in a simple continuous pattern. The rectal mucosa is not included. The same

301



302

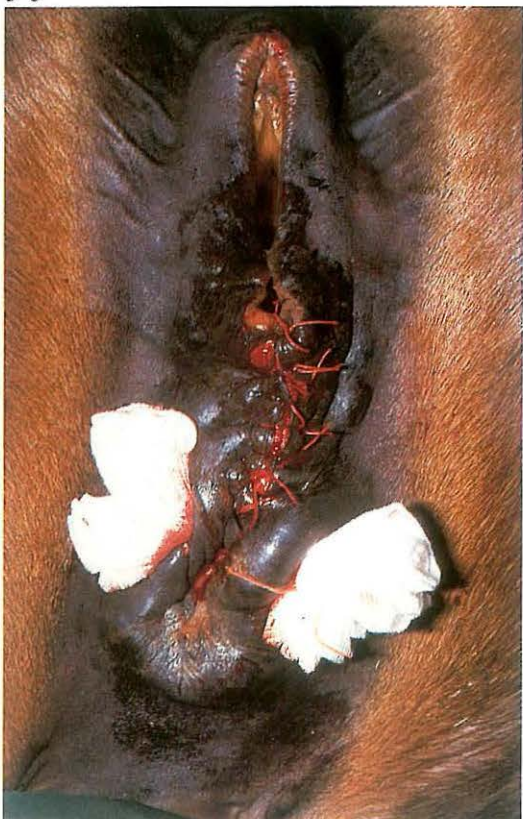

procedure is followed on the opposite side [300], and the continuous suture continues caudad, apposing the more caudal parts of both side flaps. The thus created Y-formed suture line is oversewn with a second continuous suture. The remaining part of the dissected surfaces of both lateral walls (vaginal side) are then apposed with layers of continuous sutures. The mucosa of the vestibular roof is then apposed and closed with everting interrupted sutures, using non-absorbable material [301].

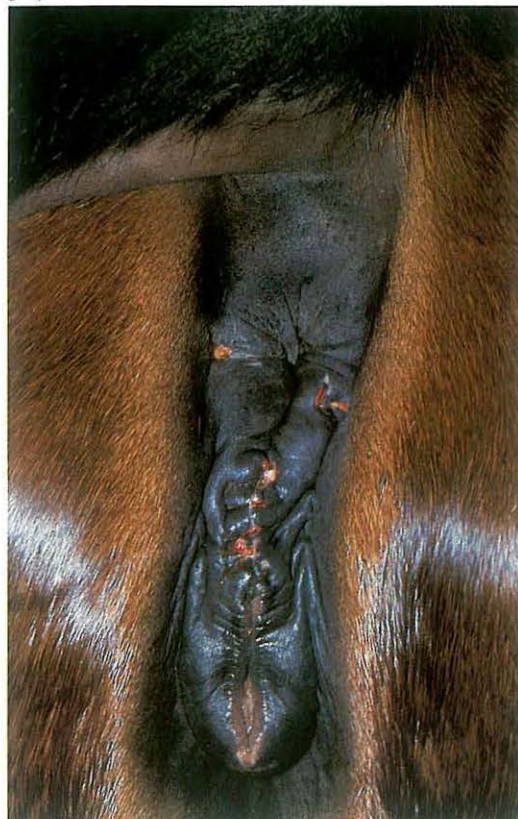(3) The perineum (perineal body) is reconstructed by suturing skin and subcutaneous tissue in a simple interrupted pattern, using non-absorbable material [302]. The anal sphincter is reconstructed with a large supporting mattress suture, which passes through muscle tissue and is tied over two surgical swabs [303].

Systemic antibiotics are administered and tetanus prophylaxis is obligatory. Fasting is continued for 4 days postoperatively, after which the mare is allowed small portions of hay, daily increasing to full rations by the tenth postoperative day. On the 6th postoperative day the supporting suture in the anus is removed. Perineal skin sutures and vestibular mucosa sutures are removed on the 10th [304] and 20th day respectively. If bacteriological examination of uterine mucus is negative 6 weeks postoperatively, natural covering is allowed. Just prior to the next parturition the vulvar cleft must be opened (see 5-24).

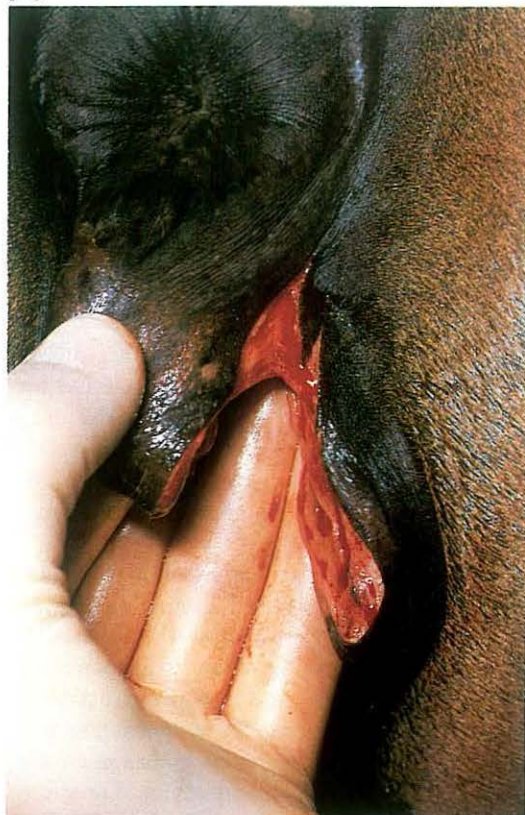303



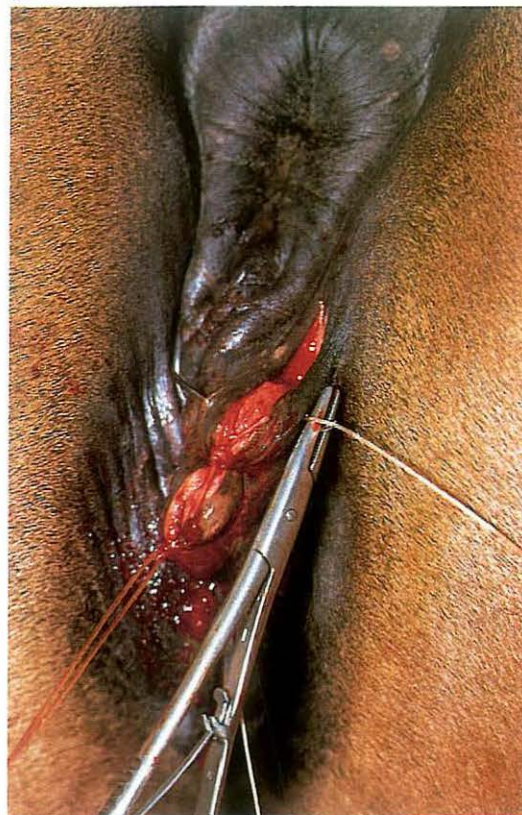
304



305



306



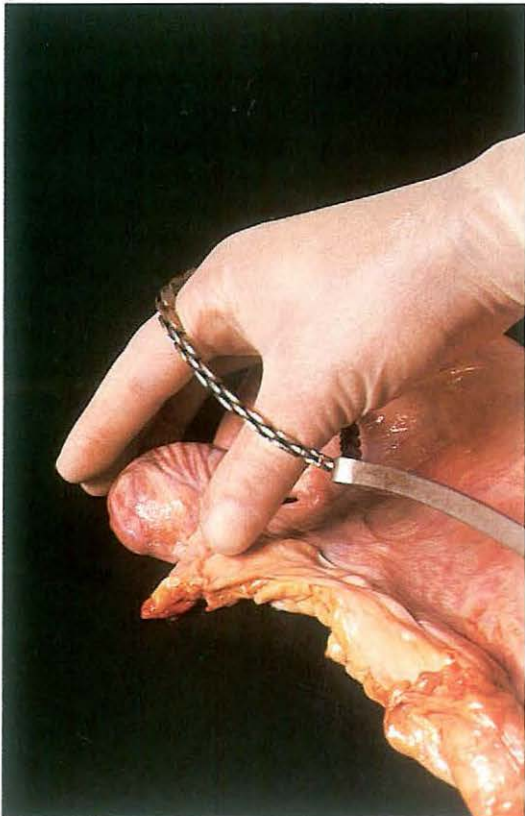
5-24 Episiotomy

Surgical widening of the vulvar cleft at parturition is sometimes indicated in primiparous mares and is very often necessary after vulval surgery (see 5-22, 5-23).

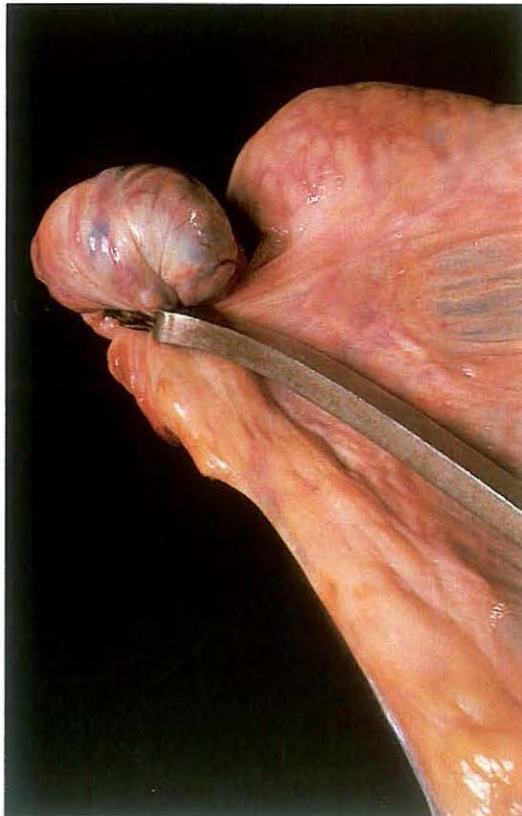Surgery. During parturition one vulvar lip is incised in a dorso-lateral direction beginning 3 cm below the dorsal commissure ([305] plate shows non-foaling mare). The incision through skin and vestibular mucosa is sufficiently long and deep to allow delivery. The wound must be sutured within 4 hours after parturition. The first suture is placed in the mucocutaneous junction. The wound edges are stretched by applying slight traction in a ventro-lateral direction. The other sutures are then placed in a simple interrupted pattern, penetrating all layers, including the vestibular mucosa [306].

Tetanus prophylaxis is provided.

307



308



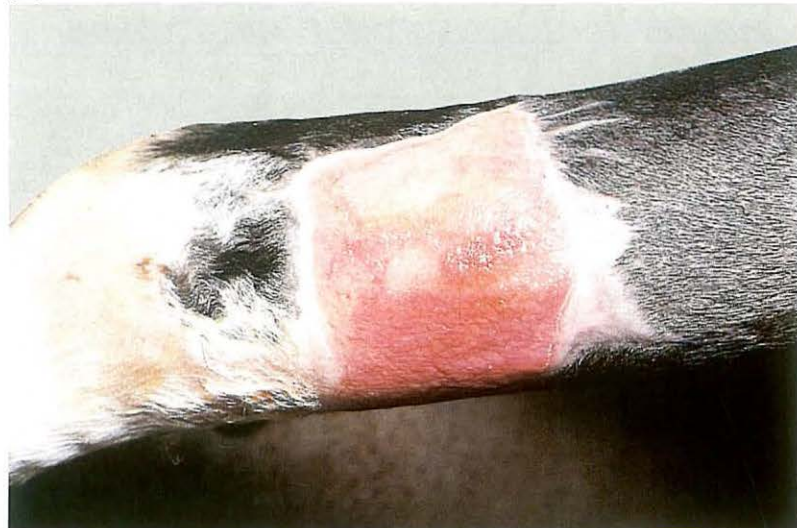5-25 Ovariectomy

Bilateral ovariectomy may be indicated in various types of nymphomania. A vaginal approach (colpotomy) is described here.

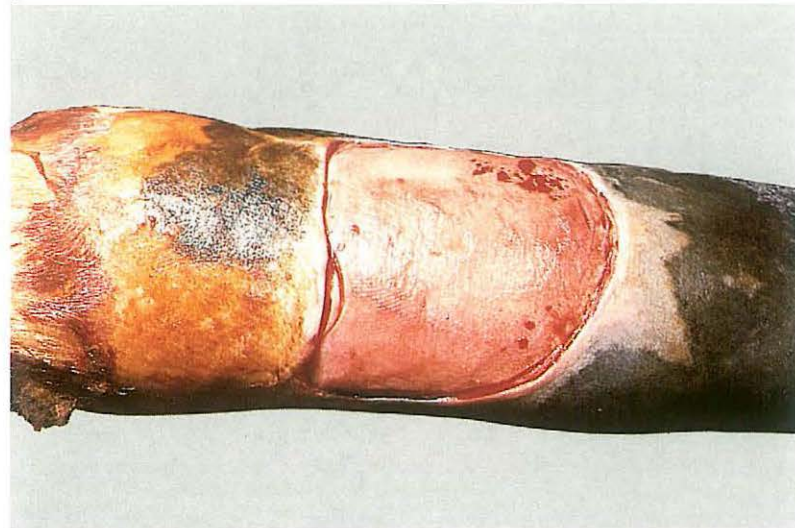
Surgery. The operation may be performed on the standing mare, but dorsal recumbency and general anaesthesia is preferred. Bladder and rectum are emptied and the vagina is prepared. The vaginal roof is stretched and thus lifted from the underlying rectum by displacing the cervix cranially with an instrument introduced through the vagina. A 5 cm incision is made through the dorso-lateral vaginal wall, 3 cm caudal to the cervix. After careful manual enlargement of the perforation, the ecraseur, with the loop of the chain covered by hand, is inserted and the ovary is brought into the loop [307], which is tightened around the mesovarium. The chain is tightened step by step, at decreasing intervals [308]. The vaginal wound heals by second intention. Systemic antibiotics are administered and tetanus prophylaxis is provided. During the first days the mare is kept standing to avoid the risk of eventration.

Chapter 6 The common integument

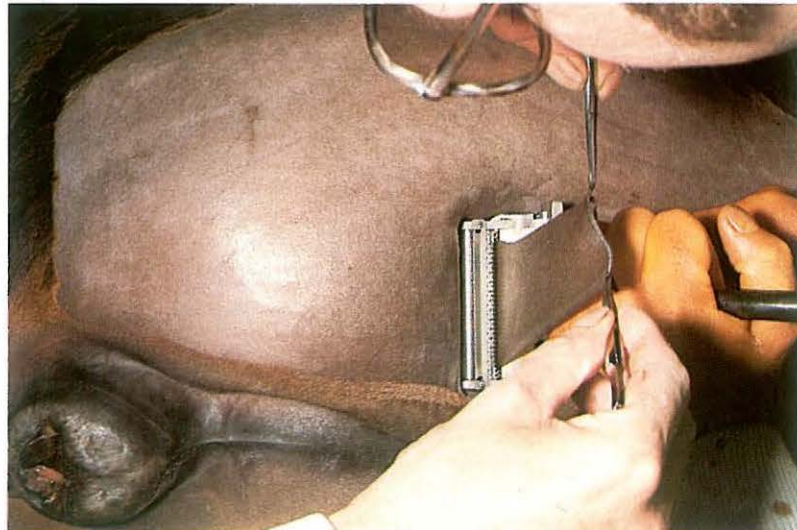
309



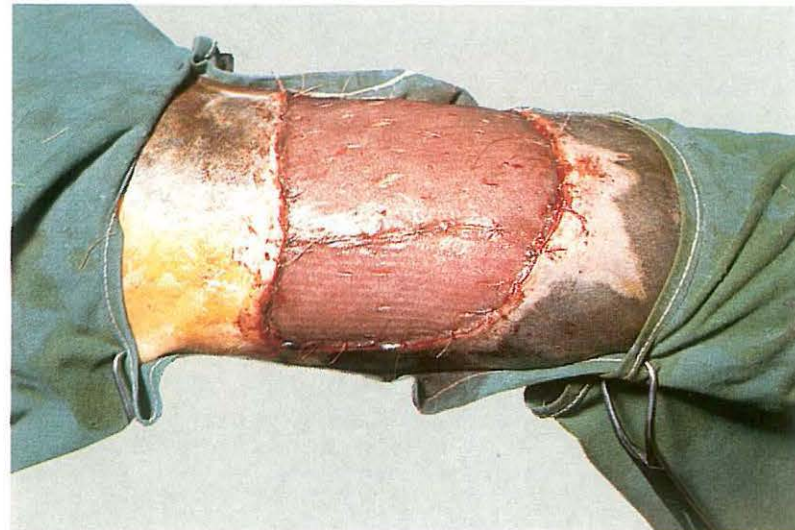
310



311



312



6-1 Skin grafting

Autologous skin grafting is often a very useful procedure in the treatment of accidental wounds in horses, especially larger granulomatous wounds of the lower legs. Various types of grafting techniques have been developed: most involve split thickness grafting (Thiersch) and pinch grafting (Braun's implantation technique).

(1) Split skin grafting.

The appropriate time for grafting is when the wound is in an advanced state of second intention healing, i.e. the surface should be covered with healthy granulation tissue [309]. The procedure requires recumbency and general anaesthesia. After preparation for sterile surgery, a superficial layer of granulation tissue is removed [310]. Bleeding is prevented by a tourniquet. A donor site (abdominal wall, caudal surface of the thigh) is prepared for surgery and a split thickness graft of about 0.5 mm thickness is harvested with a dermatome [311], after which the transplant is trimmed to

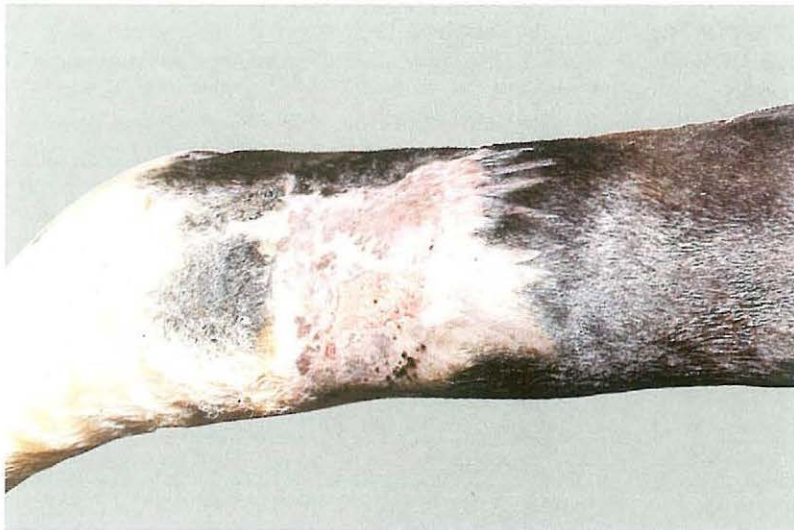shape and sutured to the wound edges. In larger wounds several grafts may be necessary to cover the surface. Small parallel incisions in the transplant allow some increase in area of the graft, exact fitting of the donor skin to the receptor site, and drainage of fluids [312]. The operation site is covered with sterile paraffin gauze and an elastic bandage, which is changed every 2–3 days for the first two weeks postoperatively. Excessive movement should be prevented by confinement in a small box. Systemic antibiotics are advisable.

Even when transplantation is not followed by complete adhering of the donor skin, the healing process, i.e. epithelialisation and contraction, is quickened considerably. The procedure usually leads to an acceptable cosmetic appearance without excessive scar formation [313].

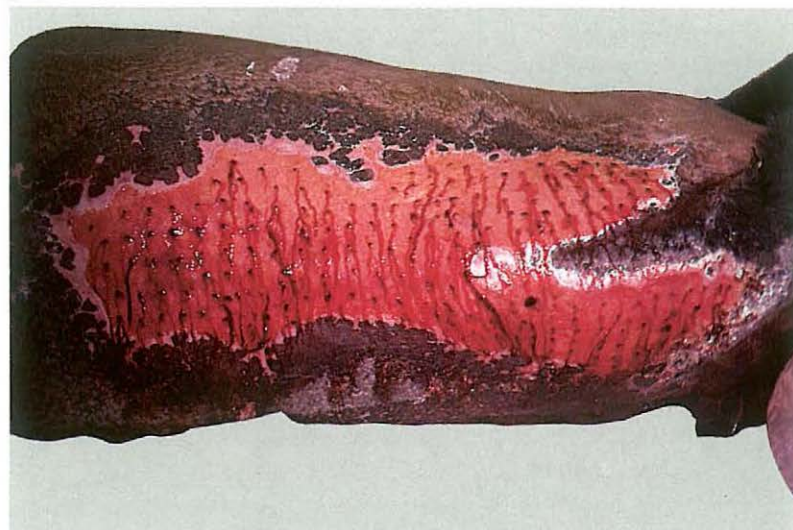
(2) Pinch grafting.

When bandaging is impossible and/or larger areas e.g. withers and back [314] must be covered, seed grafting may be preferred. The pinch grafts are harvested from a surgically prepared site using a biopsy punch or sim-

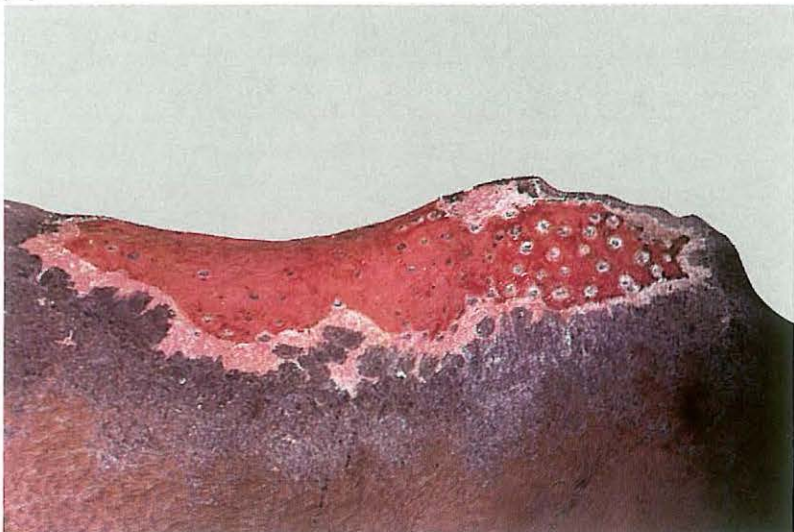
313



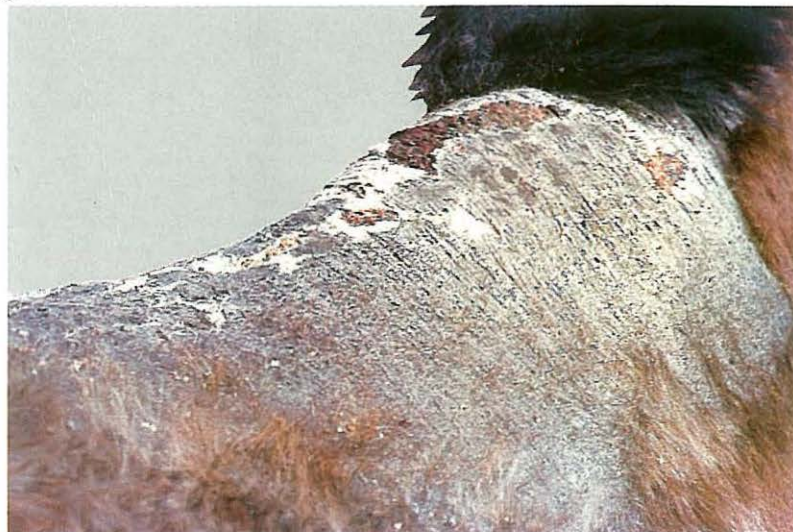314



315

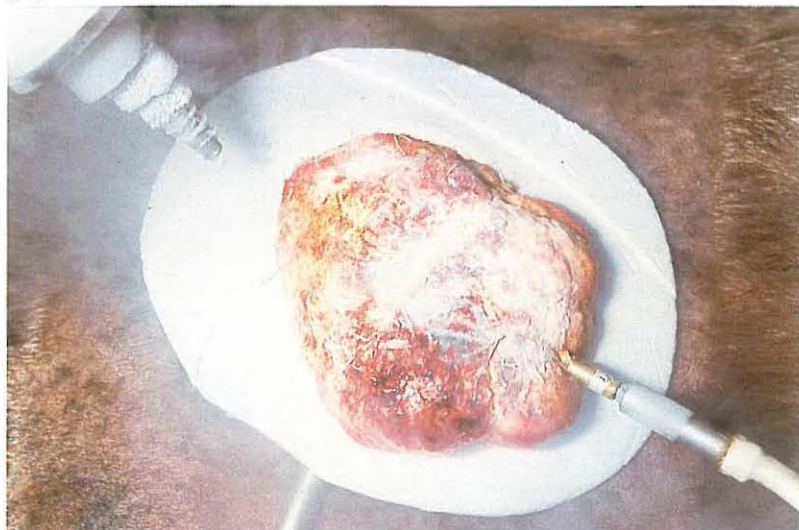


316

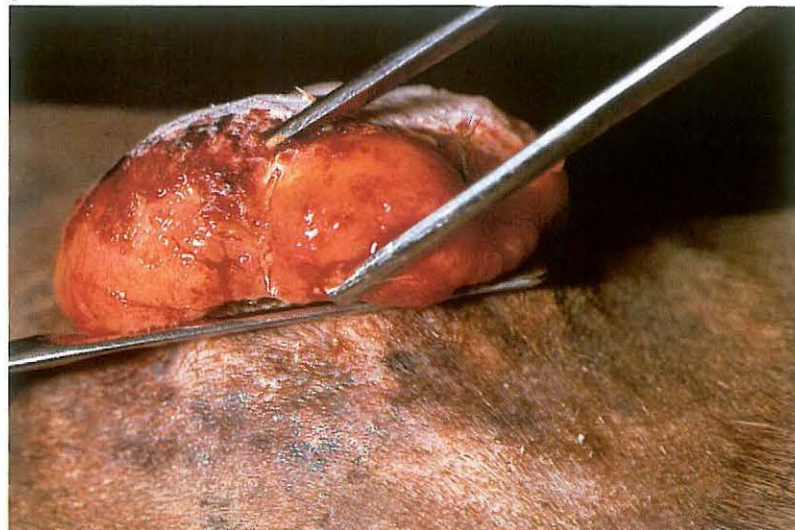


ply by excising a piece of skin elevated with forceps, so that a split skin seed of 4-6 mm² is obtained. These grafts are implanted in healthy granulation tissue, in stab incisions made at about 30° to the surface and to a depth of 4-5 mm. If movement can be prevented sufficiently, most seeds will take and epithelial islands become visible after a few weeks [315]. This technique usually controls granulation tissue, accelerates epithelialisation and may lead to complete skin cover of extensive wounds [316].

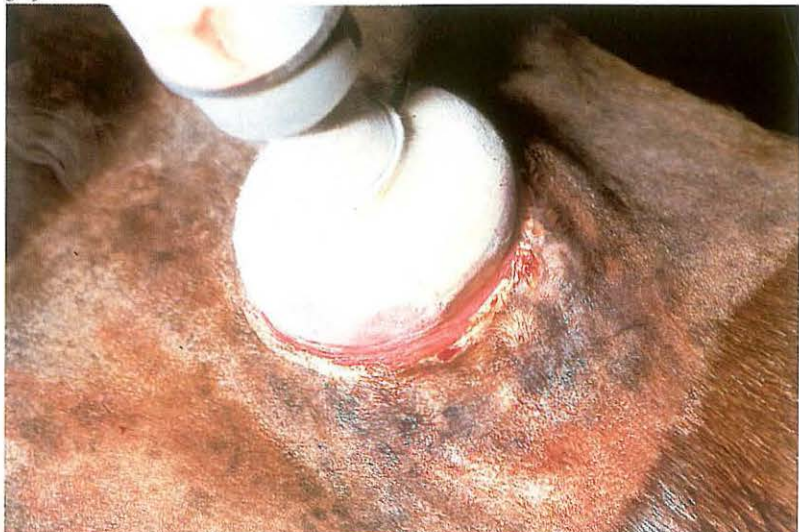
317



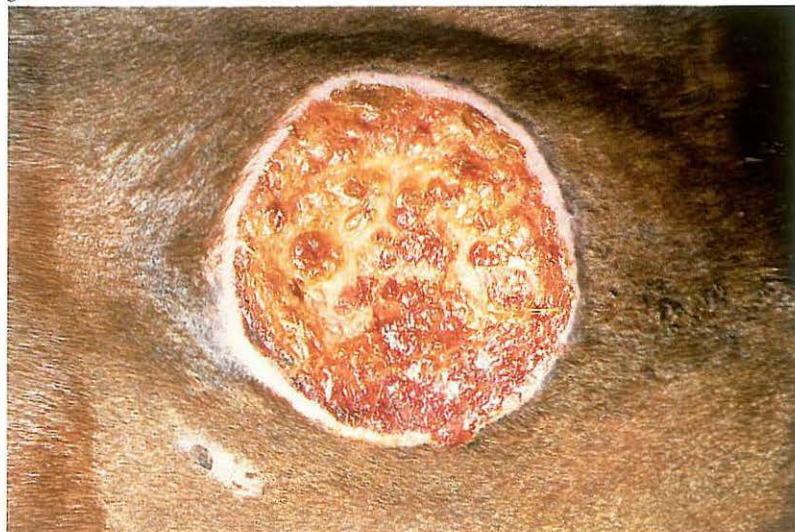318



319



320



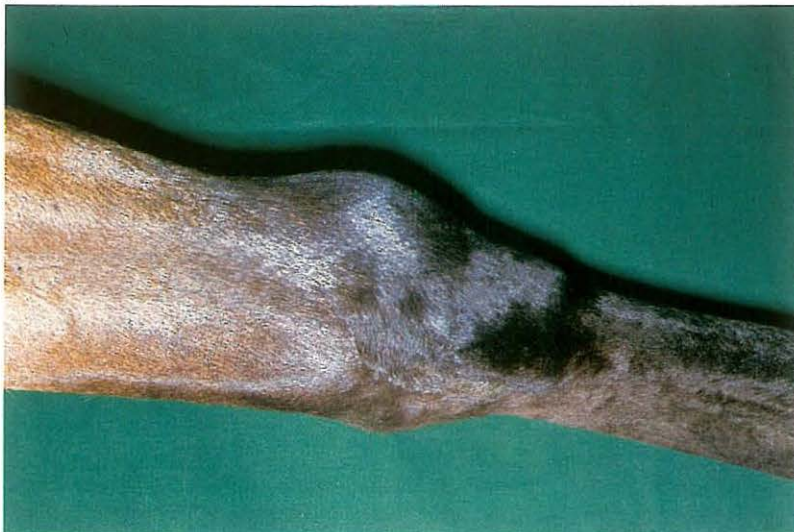6-2 Cryosurgery of sarcoids

Equine sarcoid is the most common tumour of the horse: it has a non-malignant character but recurrence is often observed after surgical excision. Far better results are obtained by destruction of tissue through freezing (cryonecrosis). Controlled freezing of tissue has the advantage of absence of haemorrhage, reducing the likelihood of dissemination of tumour cells. A disadvantage is the necrosis and subsequent sloughing of tissues. The cryonecrosis results from direct cellular damage (ice crystal formation, dehydration etc.) and anoxia due to destruction of blood vessels. Cryogens most often used include liquid nitrogen and nitrous oxide.

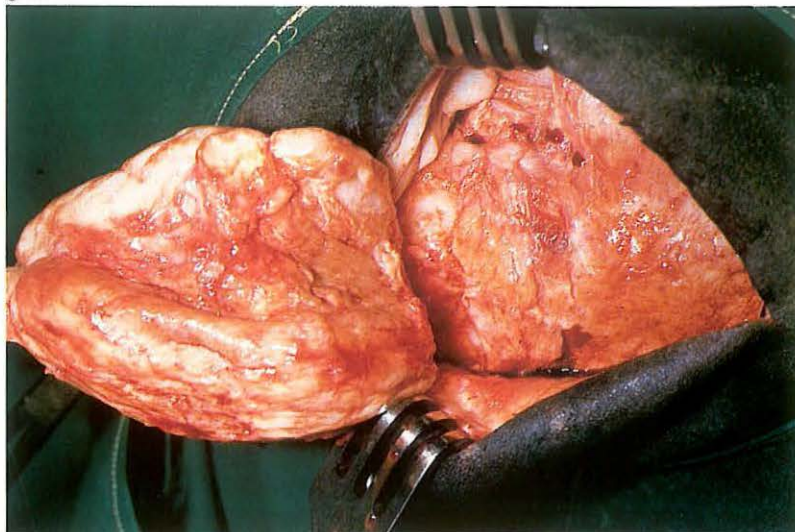
Surgery. Cryosurgery may be carried out under sedation and local analgesia, but recumbency under general anaesthesia may sometimes facilitate the procedure. Tissue should be frozen rapidly and this may be achieved by direct spraying of the tumour with liquid nitrogen [317]. The surrounding skin should be protected, e.g. by a styrofoam cup, cut to a fitting shape

[317]. The tumour is frozen to -20 to -30°C , the temperature is monitored by thermocouples in and deep to the 'iceball' [317]. The frozen tumour is then removed at the level of the surrounding skin [318], whereafter the base is frozen with a circulating contact probe [319]. A double freeze-thaw cycle is used. The larger tumours may need several sessions of cryosurgery, after each of which a layer of tissue will become demarcated over a period of weeks. The aftercare is usually minimal: the post-freezing oedema resolves quickly, and separation of the necrotic tissue occurs in 7–14 days [320]. The time needed for complete healing depends on the lesion. Scarring is minimal, but white hair will often grow at the site of the lesion.

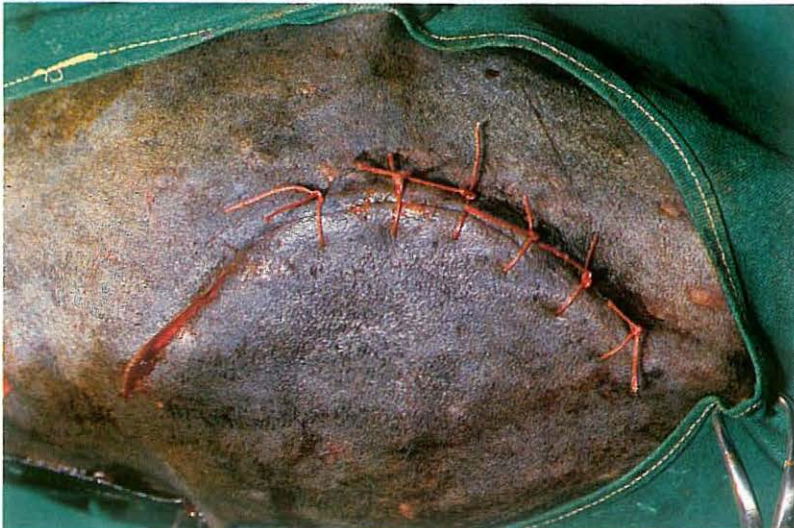321



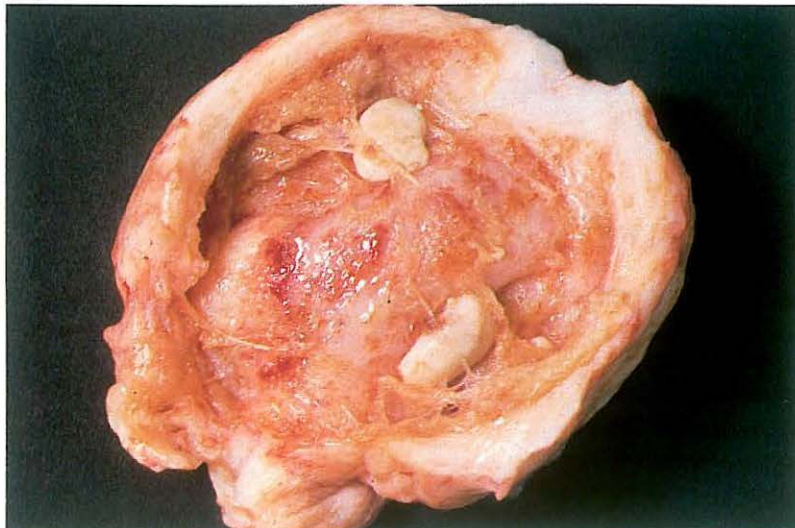
322



323



324



6-3 Extirpation of acquired carpal bursa

Subcutaneous acquired carpal bursa is localised on the cranial surface of the carpus [321] and is the result of (repeated) trauma. Rest, aspiration of the bursa, and administration of medicaments (e.g. corticosteroids) together with a firmly placed carpal bandage often produces unsatisfactory results. Surgical extirpation of the bursa is recommended if further treatment is requested.

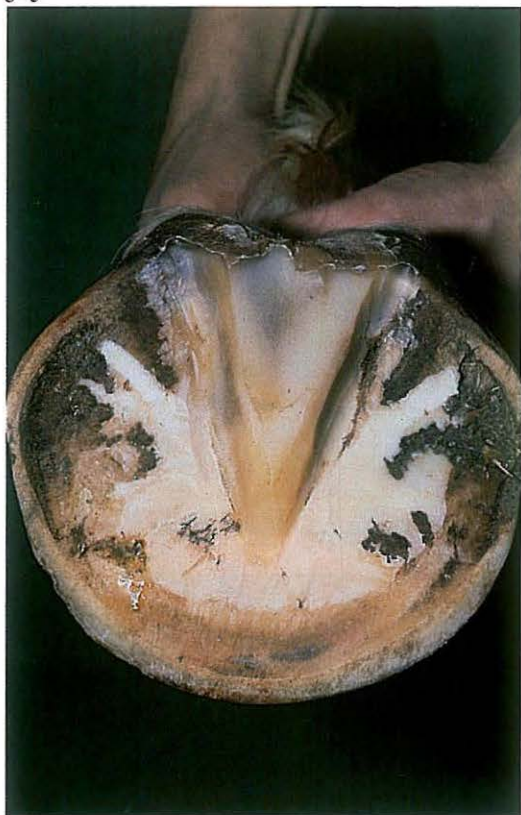Surgery. The patient is placed in right or left lateral recumbency under general anaesthesia, depending on the affected site. An Esmarch's bandage facilitates surgery. The carpus is slightly flexed and a curvilinear incision [323] is made through skin and subcutaneous tissue. On the dorsal surface of the bursa blunt dissection from the surrounding tissue is difficult. When the dissection plane is found on the edges of the bursa, separation of the capsule from the dorsal surface of the carpus may be simpler. The irregular borders of the bursa may be the cause of opening the bursa despite the

widest possible excision. To avoid opening of the flexor tendon sheaths or joint cavity care should be taken when dissecting the bursa from the dorsal surface of the carpus [322]. Plate 324 shows the bursa, opened after extirpation.

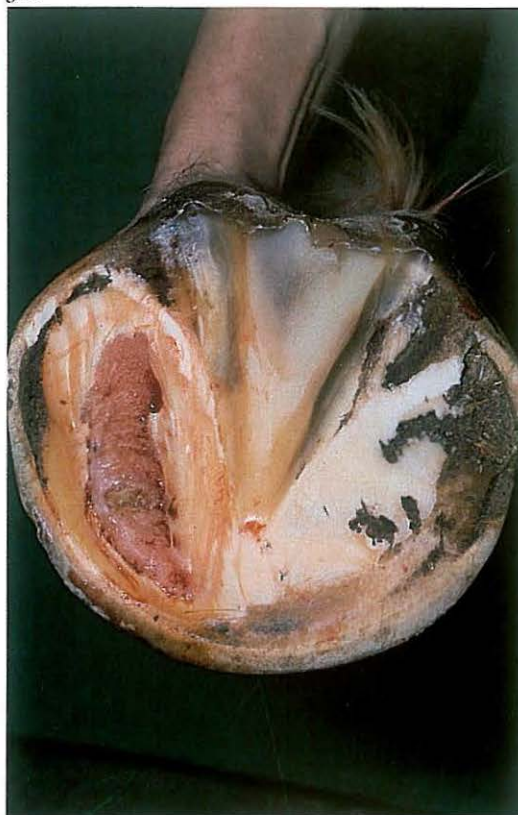After complete excision dead space is closed with simple interrupted sutures, subcutaneous tissue with continuous and the skin with interrupted sutures, using absorbable synthetic material [323]. A vacuum drain may be placed before closure of the dead space is complete. Systemic antibiotics are administered.

After surgery the limb is immobilized (plaster cast) in extension for about 3 weeks. The drain is removed 3 days postoperatively. The cast is replaced by firm bandaging for 3 weeks.

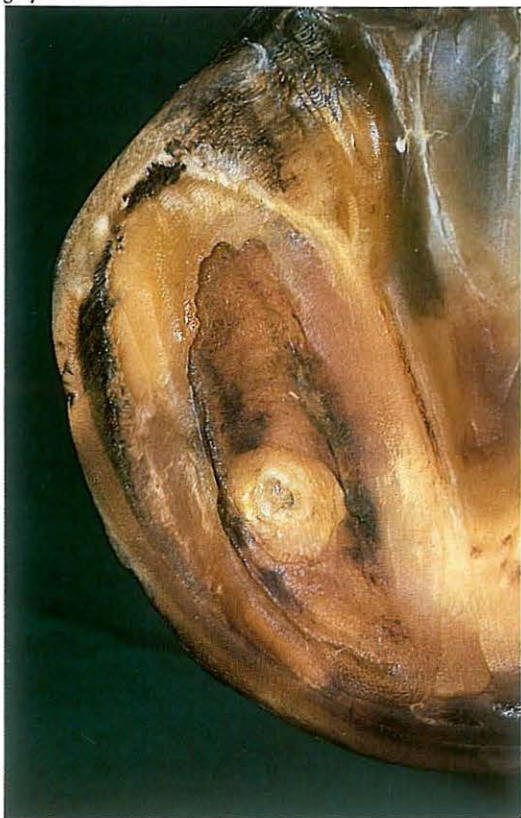325



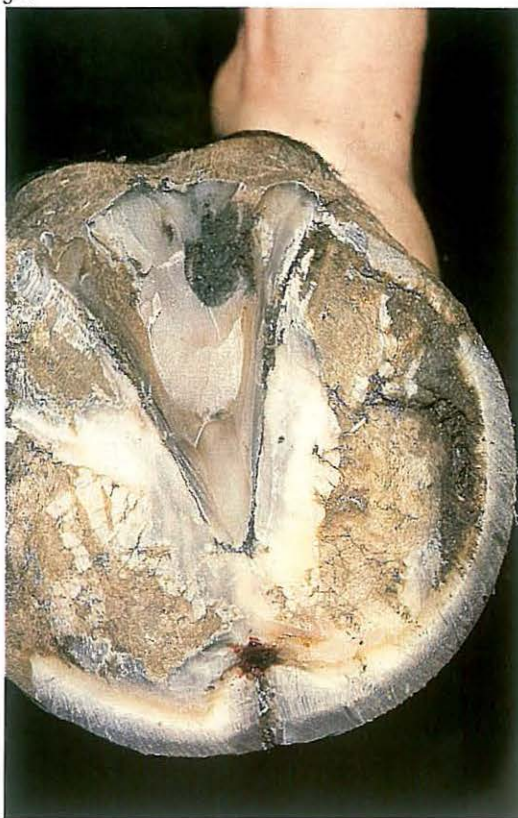326



327



328



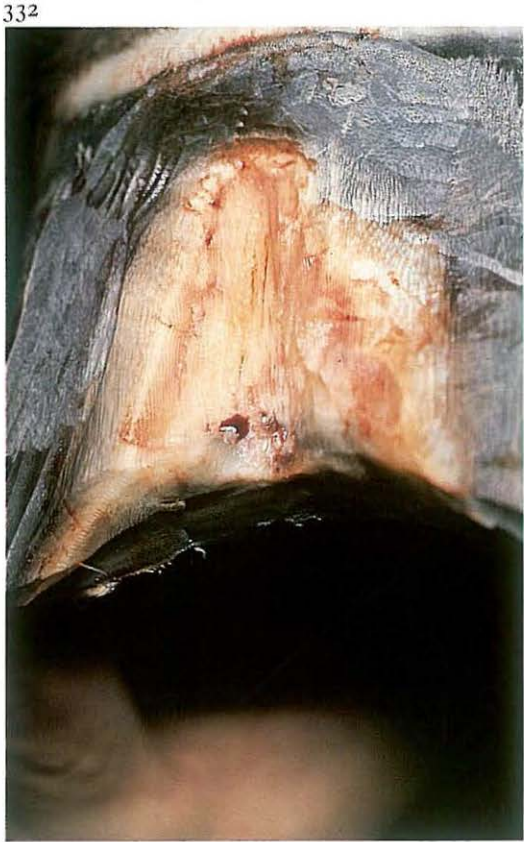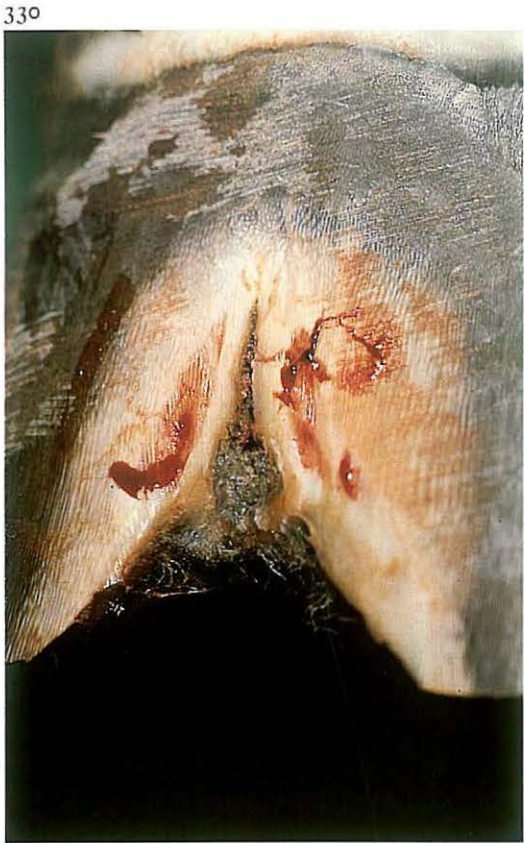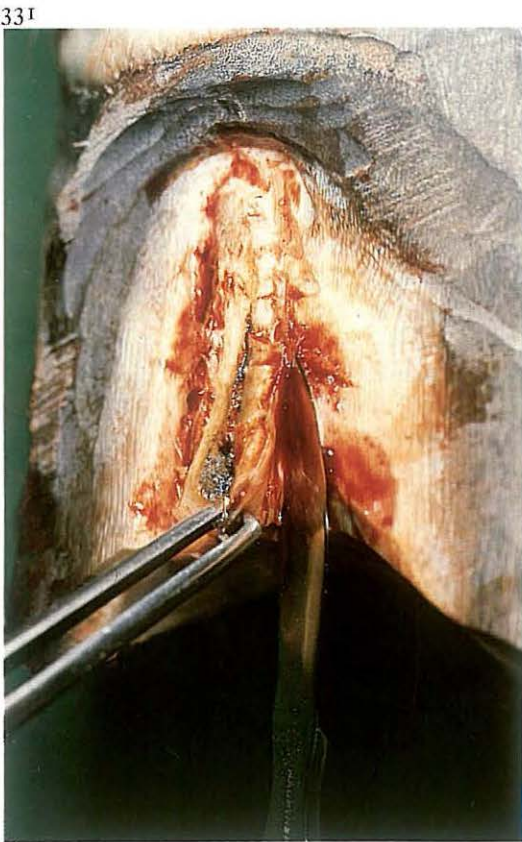
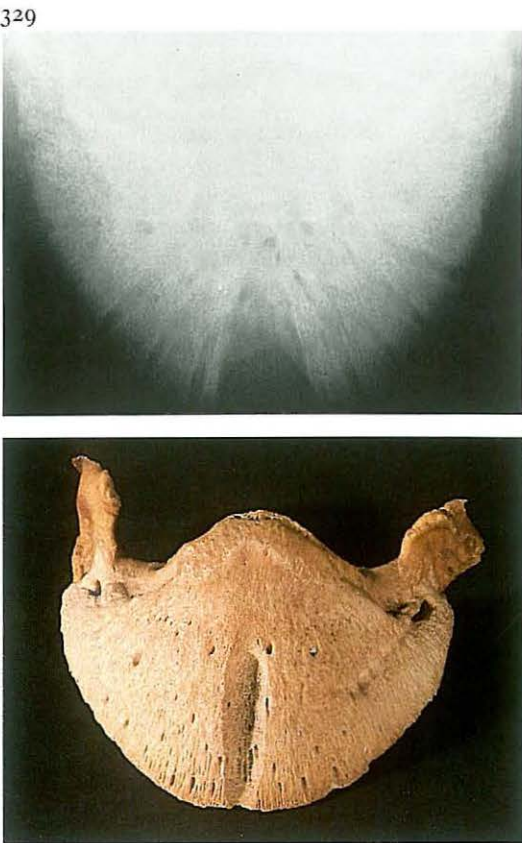
6-4 Treatment of pododermatitis

Septic pododermatitis may result from foreign body penetration, cracks in the white line or sole, local bruising (e.g. corns), or chronic laminitis. Trauma causes haemorrhage and/or necrosis of the pododerm, rendering it prone to bacterial infection. The result is severe pain caused by exudate under pressure between pododerm and sole. The foot of the affected leg may be swollen, due to oedema or extension of the septic process. Puncture wounds in the sole or cracks in the white line always result in a black dot or line at the site of initial injury [325]. A hoof tester is helpful in locating the involved area.

Surgery. Analgesia may not be required. The hoof is trimmed. When present the tract must be followed, if not the horn over the most painful spot must be removed. The (black) exudate is usually under pressure and has a putrid odour. Proper drainage may be achieved through a rather small opening of the undermined area, followed by applying a wet disinfecting cotton bandage for two days. Tetanus prophylaxis is provided.

If the patient remains very lame after this period and purulent exudate is still present, all undermined horn must be removed (under analgesia), even if this results in a large defect [326]. The edges of the defect are thinned and the wound should be dressed with disinfectant-soaked gauze and a waterproof pressure bandage. In this case healing was delayed due to bone sequestration, which made removal of necrotic material necessary [327].

Dressings are changed weekly. As soon as the defect is covered with newly formed horn, the hoof is shod with a sole protecting pad.



6-5 Extirpation of keratoma

A keratoma is an abnormal proliferative growth of the horn which develops on the inner aspect of the hoof wall [328]. The white line is deflected inward by the keratoma, which appears as a cylindrically shaped growth between the wall and laminar corium. The keratoma may extend a variable distance up the wall from the bearing surface towards the coronet.

When the keratoma increases in size lameness may gradually develop. Pressure of the keratoma results in localized atrophy of the pedal bone, which can be demonstrated by radiography [329]. Contamination through defects in the white line may result in secondary septic inflammation of the damaged sensitive laminae which usually leads to development of a fistulous tract [328]. Therapy consists of surgical extirpation of the keratoma.

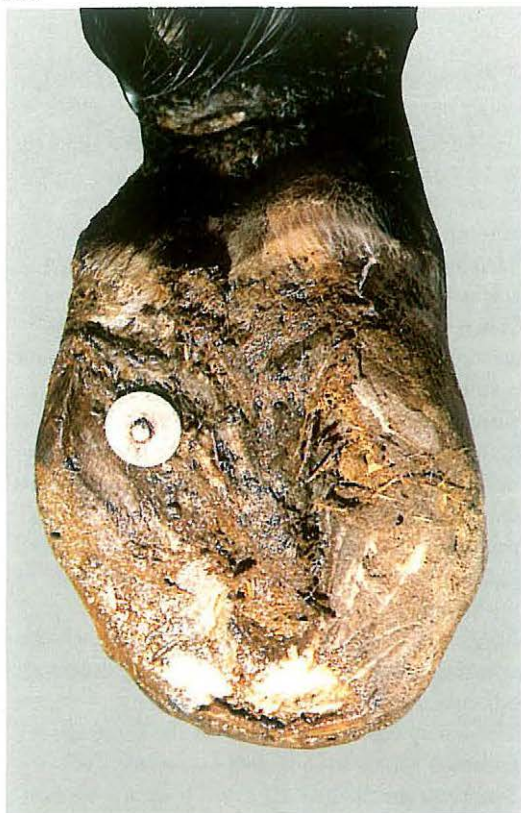Surgery. The operation can be performed on the standing horse under local analgesia or in lateral recumbency under general anaesthesia.

The horny wall on both sides of the keratoma is removed almost to the laminar corium [330].

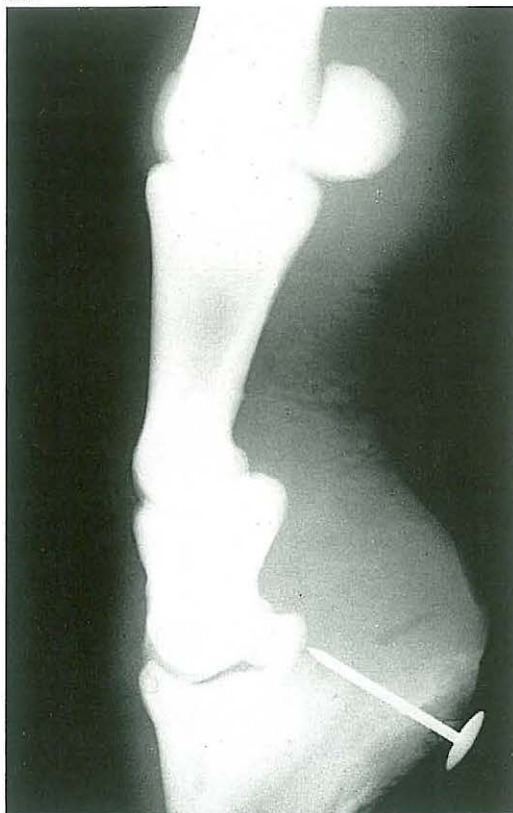The keratoma is then dissected from the corium [331,332]. If it is confirmed that the 'tumour' extends to the coronary band, removal may be achieved by grasping the distal border with a large pincer and reflecting it proximad. To prevent hoof wall movement as much as possible, a shoe with a clip on either side of the defect is used. The defect is dressed with a disinfectant and pressure bandage. The bandage is changed weekly.

Bandages are left off as soon as the thin layer of newly formed horn is sufficiently hard, but desiccation should be avoided to prevent cracking. The special shoe is used until the defect in the wall has grown out.

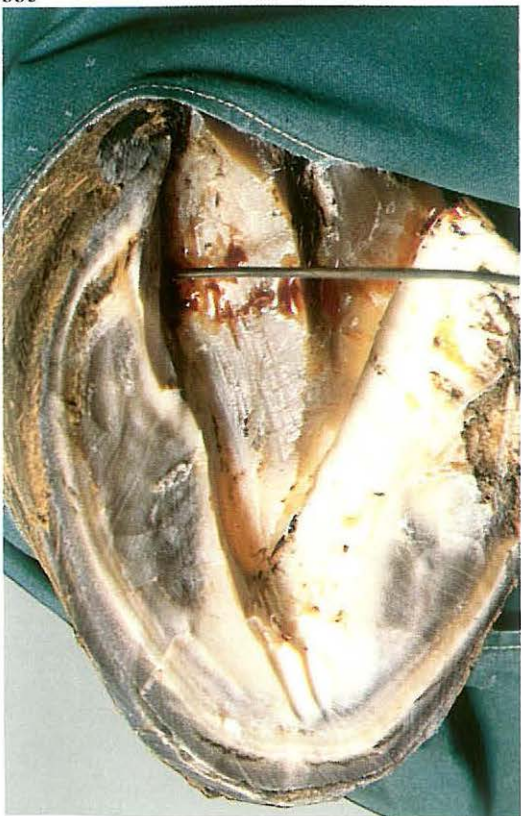
333



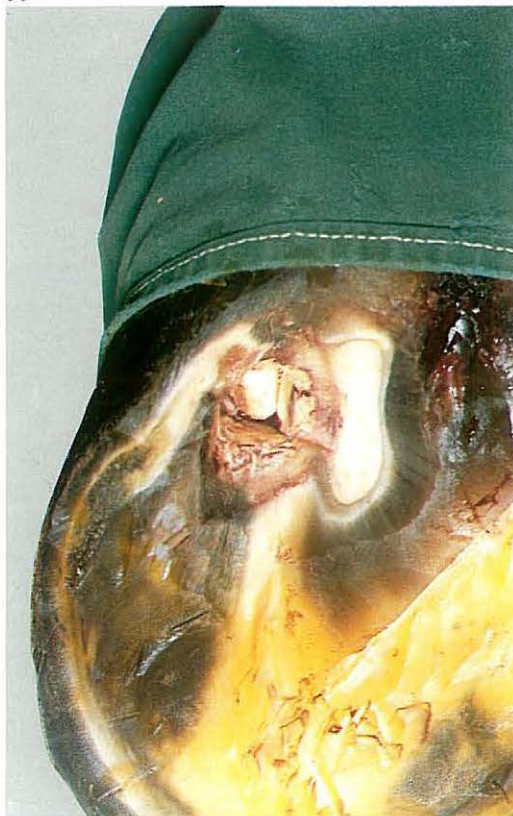334



335



336



6-6 Management of penetrating wounds of the sole

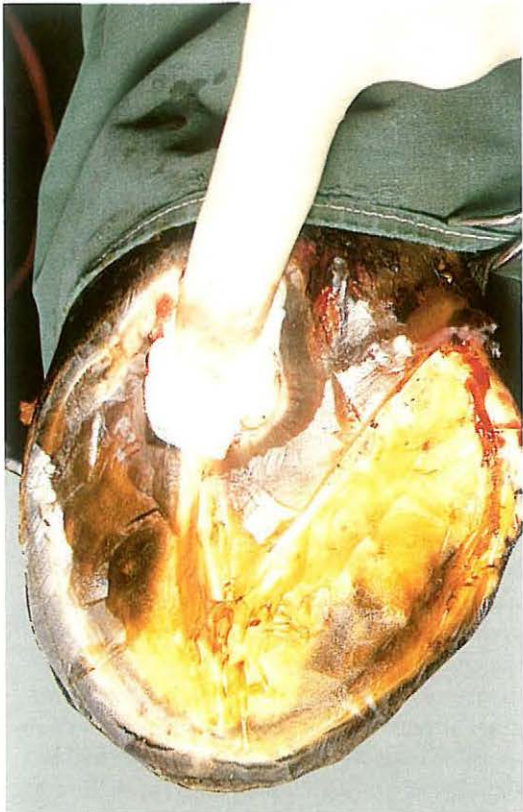Puncture wounds in the foot are quite common in horses and are caused by a variety of foreign bodies, such as nails and fragments of glass. These foreign bodies may penetrate to the third phalanx, which may result in an infectious pedal osteitis. Wounds in the middle third of the frog are most serious because of the possibility of puncture of the navicular bursa [333], and infectious arthritis of the coffin joint. The depth and direction of the tract can be determined by radiography [334] and exploration with a sterile probe [335].

Surgery. In the early stages, treatment consists of superficial drainage of the lesion, which is accomplished by wide trimming of the horny walls of the tract opening. The horn in the surrounding area should be thinned to prevent a prolapse of the pododermal tissue. The wound is then flushed, and a disinfectant bandage is applied. Tetanus prophylaxis is provided, and antibiotics are given systemically.

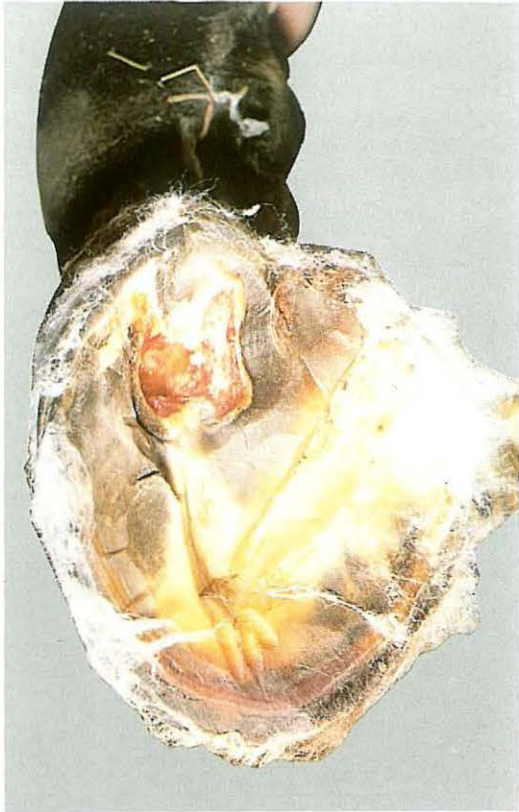If considerable improvement of lameness has not occurred within two days, surgery is indicated under local or general anaesthesia. In cases in which the navicular bursa is affected, drainage of the bursa should be performed. The foot is disinfected and the frog trimmed out. All necrotic tissue should be removed.

Drainage of the bursa is achieved by fenestration of the deep flexor tendon performed at the site of the tract (by excising a 'window' of 1 × 1 cm), the flexor surface of the navicular bone is now visible [336]. If the cartilage has been damaged, curettage of the navicular bone is carried out. The bursa is then flushed with sterile physiologic saline, containing antibiotics. The wound is packed with sterile surgical gauze [337]. The foot is kept under a sterile bandage and systemic antibiotics are administered as long as the bursa remains open. Five days postoperatively newly formed granulation tissue is visible [338]. After 18 days, a zone of new pododermal tissue has developed [339]. If the wound has granulated in completely, which means that the navicular bursa is closed, the bandage is replaced by a shoe with a removable steel plate. This permits prolonged treatment, if necessary. If the horse remains lame, due to inflammation of the deep flexor tendon, raising the heels of the shoe with calks to spare the tendon is recommended. After

337



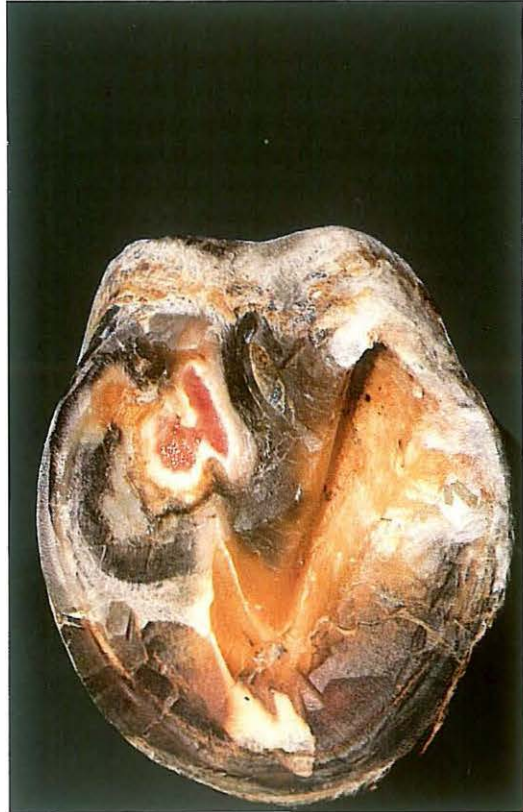338



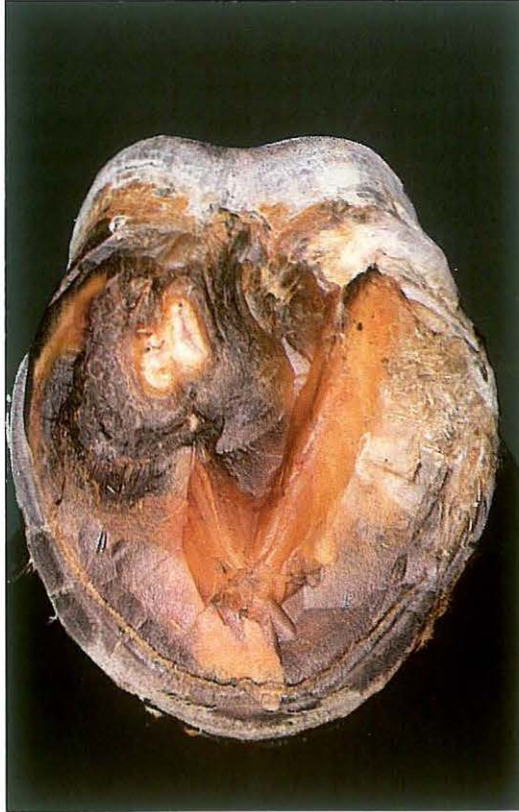40 days, epithelialisation is almost complete [340]. At this stage protective shoeing (shoe with a leather pad) is provided for a period of 4-6 weeks.

The prognosis of superficial puncture wounds and pedal osteitis is favourable. In cases of inflammation of the navicular bursa and infectious arthritis of the coffin joint, the prognosis is guarded and unfavourable respectively.

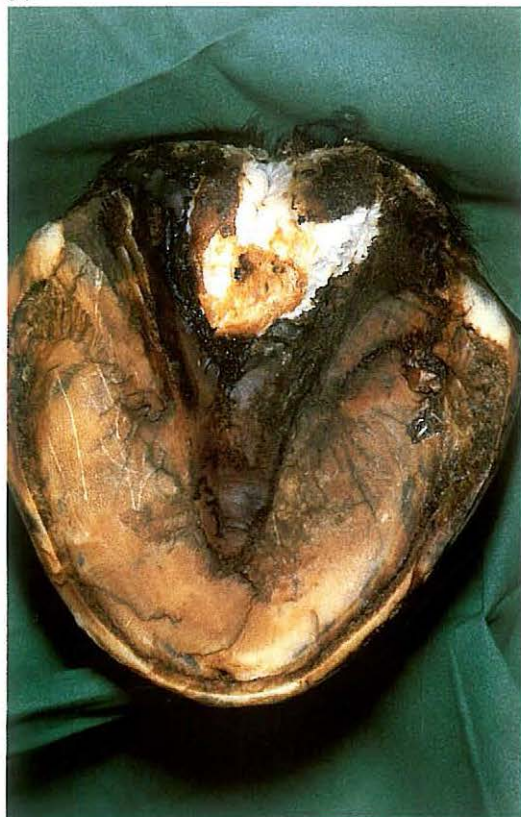339



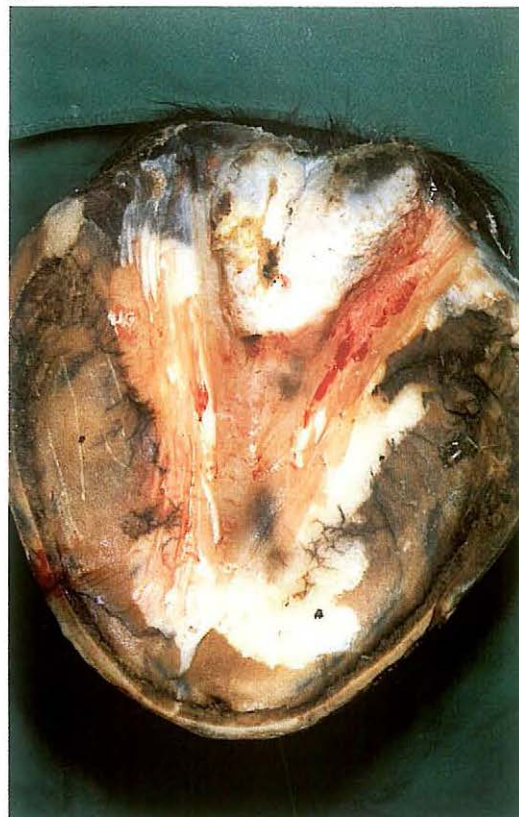340



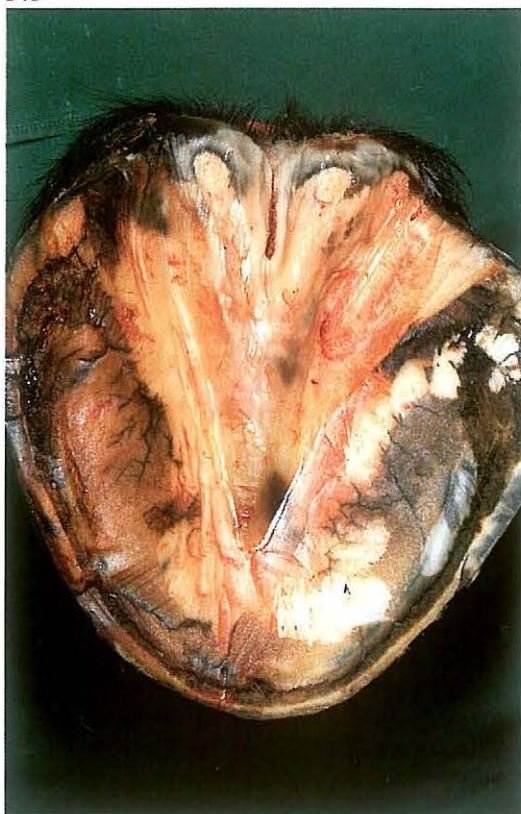
341



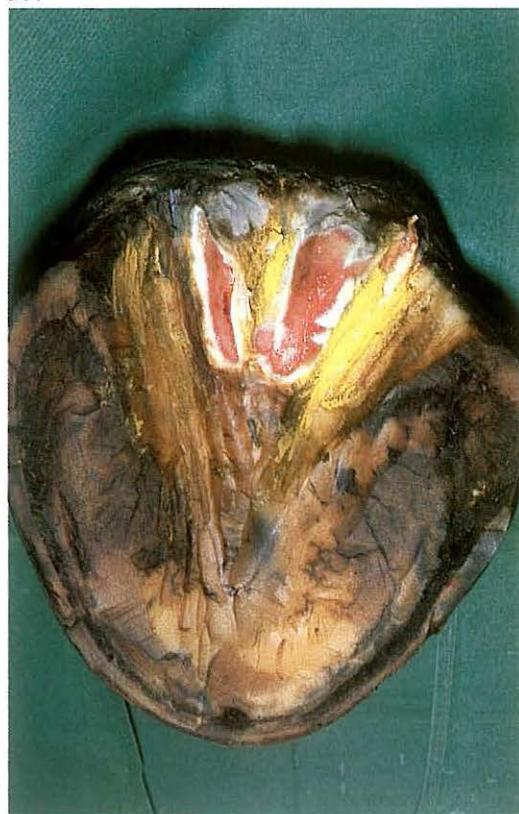342



343



344



6-7 Treatment of canker

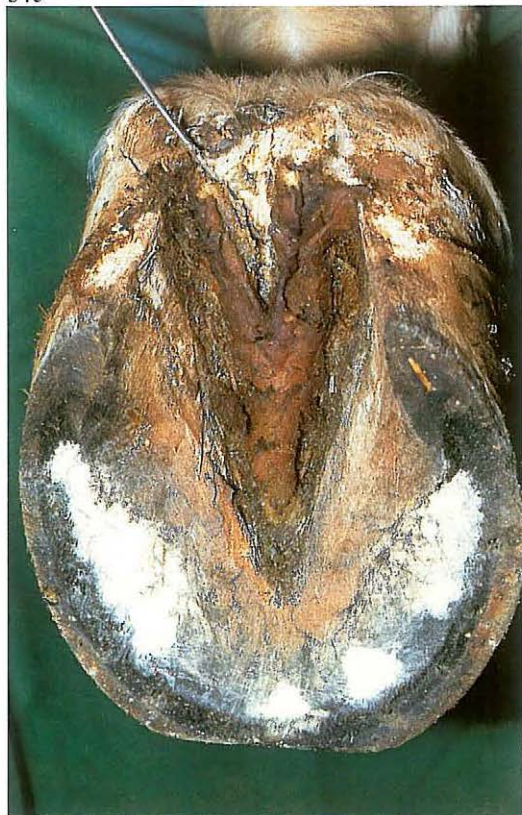Canker may be considered as a chronic hypertrophic pododermatitis, but also as parakeratosis because of the abnormality of the horn produced. The disease begins usually in the frog, but may extend to all other areas of the hoof. As lameness is not present initially, the lesions may be well advanced before they are detected. In severe cases the pododerm may show a cauliflower-like hypertrophy of foul-smelling weak caseous horn [341].

Aetiologically the disease is presumably related to unhygienic stabling and neglected foot care, and must be differentiated from thrush (see 6-8) and from so called chronic progressive pododermatitis. The latter has been seen especially in the fore feet of trotters and is associated with lameness.

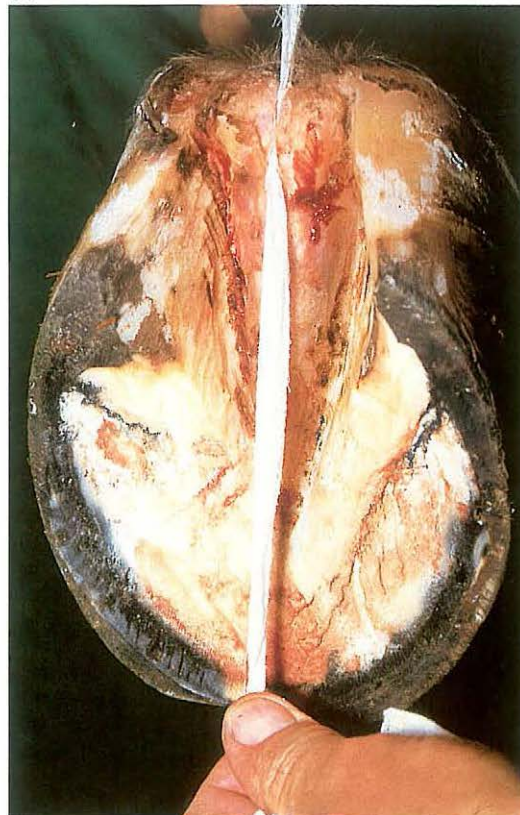
Surgery. The treatment of both canker and progressive pododermatitis is based on removal of the diseased tissue. Regional analgesia may be necessary if part of the hypertrophic pododerm must be removed. The procedure begins with removal of loose and abnormal horn, followed by thinning of the surrounding horn [342]. Severely affected pododerm is also removed [343]. Surgical removal of abnormal tissues is preferable to the use of caustic agents. Less hypertrophic pododerm may be left to the beneficial influence of a pressure bandage, which is necessary in all cases. Astringent and drying powders may be added to the bandage. In cases of extensive lesions a plaster cast may be used. Dressings should be changed once a week. Plate 344 shows the epithelialization of the treated area of the frog one week after surgery.

The treatment of canker may be time-consuming, but the prognosis is usually not unfavourable, although recurrence is possible. As a matter of course prevention lies in good hoofcare, including hygienic stabling.

345



346

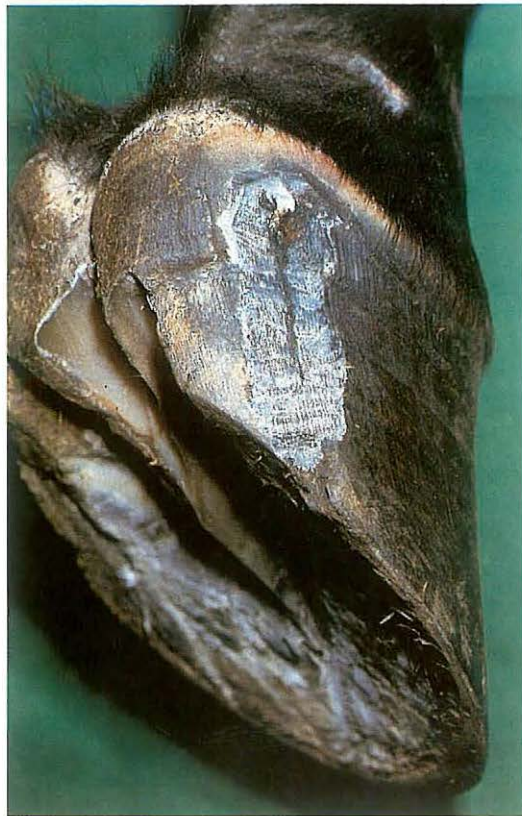

6-8 Treatment of thrush

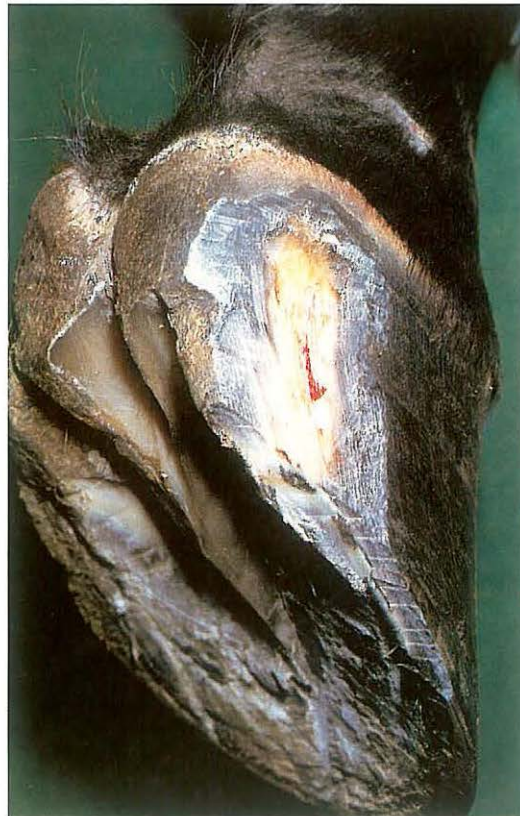Thrush is a degenerative condition of the frog, usually starting in the central sulcus and resulting from poor hoof care and unhygienic management. The affected areas are characterized by the presence of grayish-black degenerate horn [345] with a distinct odour.

Surgery. The hoof should be trimmed to normal conformation to achieve normal pressure on the frog; all affected and undermined horn should be removed and the surrounding horn trimmed. Thorough cleansing of the sulci [346] is followed by application of disinfectants and astringents. Deep sulci may be packed with cotton swabs soaked in the medication. Treatment should be continued until the frog is covered with normal horn. The prognosis is good, provided hoof care and stalling are improved.

347



348



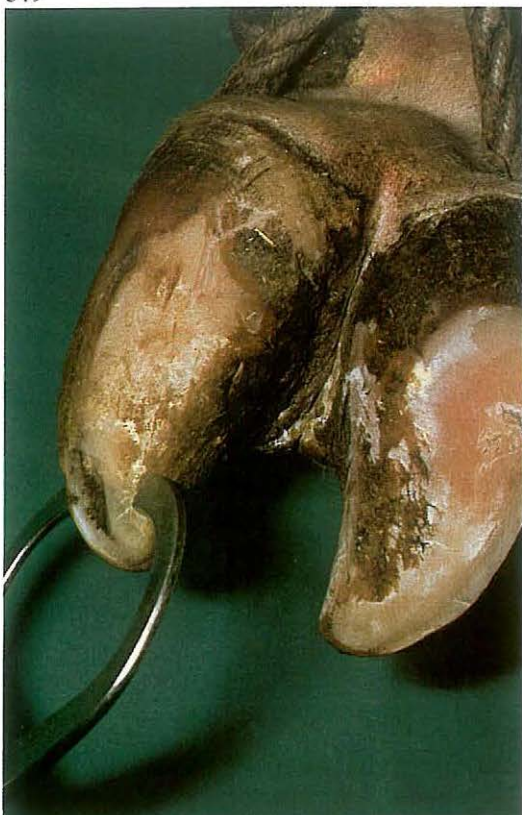6-9 Treatment of sand crack

Sand crack consists of a fissure (fracture) of variable length commencing at the coronet or at the bearing surface of the wall. The cracks are identified as toe, quarter or heel cracks depending on their location. Lameness may not be present, but it will develop if the crack extends into the sensitive laminae [347].

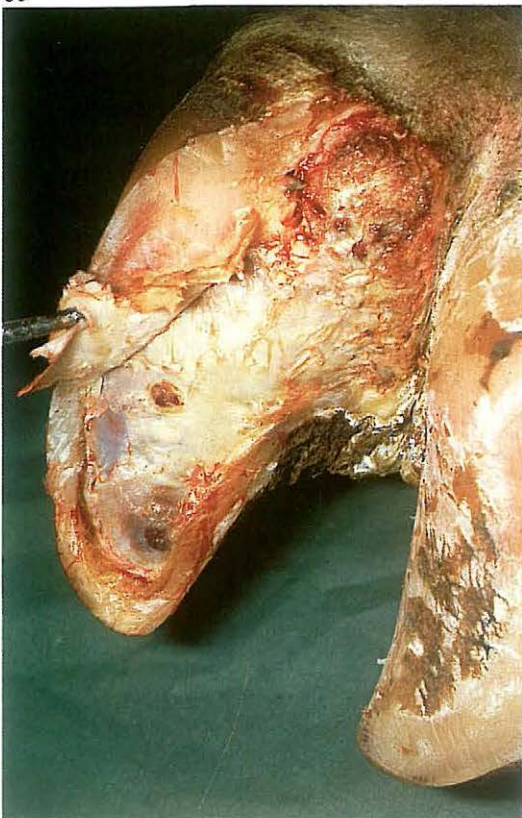Surgery. If the crack extends into the coronary band and/or into the sensitive laminae radical excision of the crack is the prime requisite. The operation can be performed under local regional analgesia. The horny wall on both sides of the crack is thinned with rasp and knife and the damaged sensitive laminae is removed. The bearing surface caudal to the crack should be trimmed approximately 0.5 cm shorter than the rest of the foot, so that it does not bear weight until the crack has grown out [348].

The defect is dressed with disinfectant and a pressure bandage is applied until the defect is covered by horn. Shoeing is beneficial to prevent recurrence (a full bar shoe is used in quarter crack).

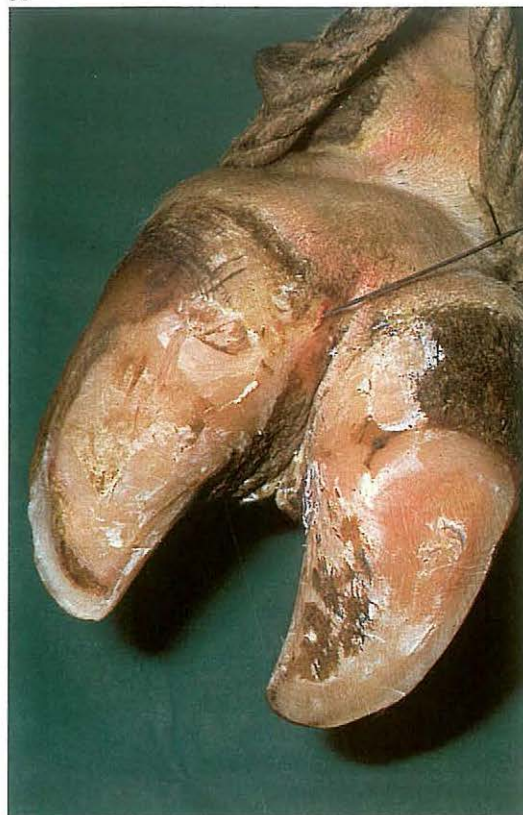349



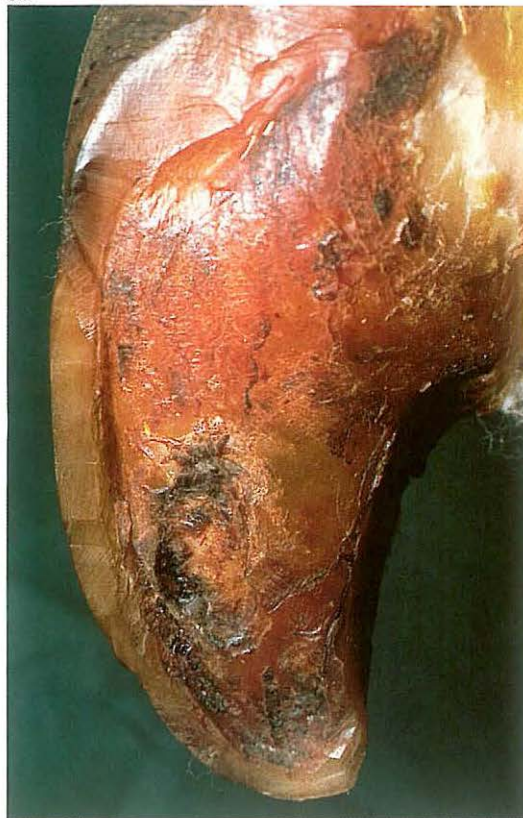351



350



352



6-10 Treatment of pododermatitis

Septic pododermatitis can result from foreign body penetration, or from generalised bruising which may follow irregular weightbearing and/or chronic laminitis.

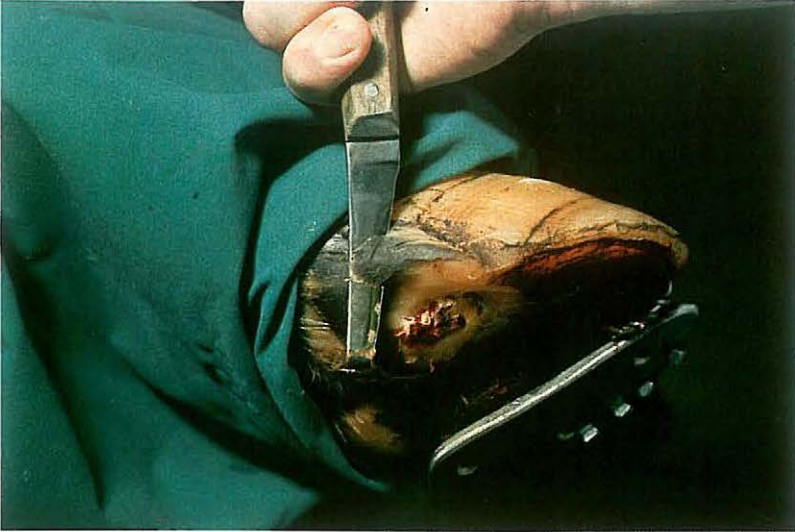Bruising causes haemorrhage and/or necrosis of the sensitive laminae; bacterial infection of the damaged sensitive laminae can occur primarily (in penetration trauma) or secondarily by contiguous or haematogenous infection. The result is serious lameness caused by pain brought about by exudate under pressure between sensitive laminae and sole [349]. The heel of the affected side may be swollen, because of extension of the septic process.

Surgery. Analgesia may not be required. When present, the tract must be followed along its full length [350]. All separated sole horn should be removed. If the affected area is small, horn trimming, dressing the defect with a disinfectant, and confining the animal on soft bedding or dry pasture for some days may be sufficient to allow healing. Often however the exudate has extensively under-run the horn. Because of the presence of necrotic pododerma this horn must be removed, even if a large defect results [351].

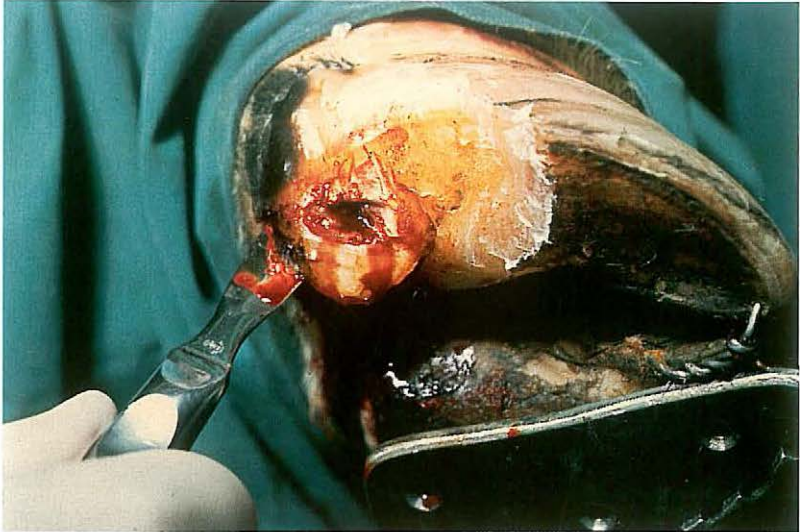
Necrotic material in deeper structures should be removed similarly, as in this case of bone sequestration of the pedal bone [352]. The defect should be dressed with disinfectant and packed with gauze, cotton wool, and a waterproof pressure bandage.

In cases of extensive inflammation and/or severe lameness, the sound digit is shod with a block to avoid damage to the affected digit and to facilitate healing. The dressing should be renewed after one week. Severe cases of bone infection may require prolonged treatment.

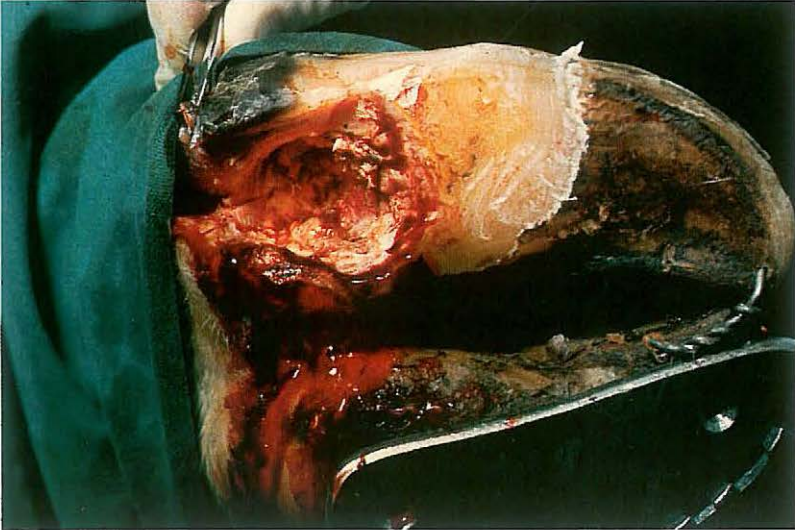
353



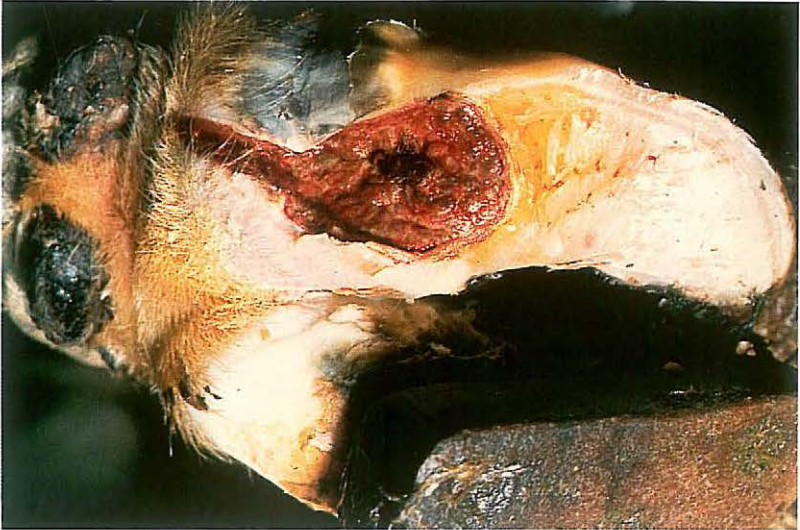354



355



356



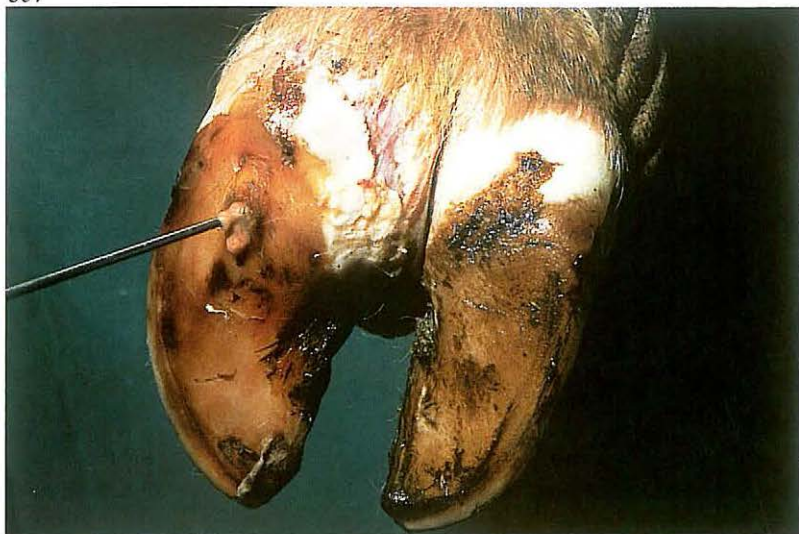6-11 Treatment of heel abscess

Abscessation of the heel results from necrotic pododermatitis, interdigital necrobacillosis, or puncture wounds of the heel, and causes prominent localised swelling of the whole heel extending over the coronet to the haired skin. The heel itself may be firm or fluctuating. The abscess is often deep-seated and associated with a purulent necrotic process originating in the sole, as in this case.

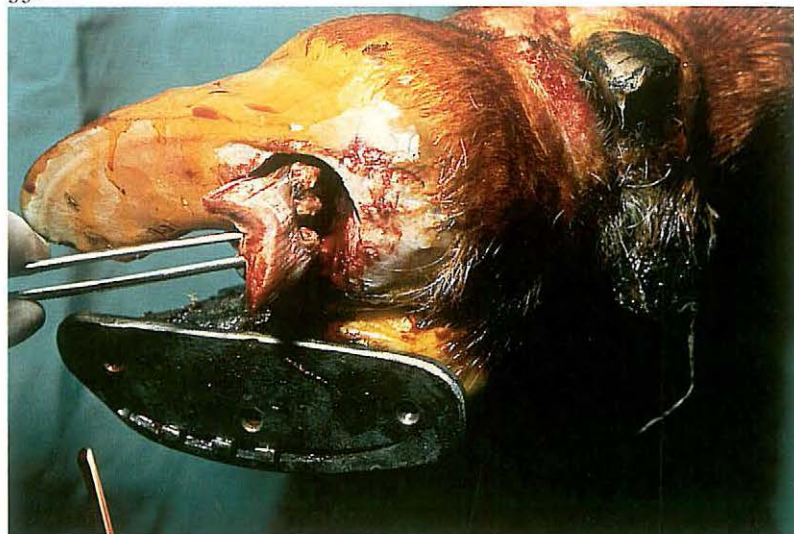
Surgery. The patient is restrained in standing or recumbent position. A tourniquet of rubber tubing is placed around the limb in the mid-metatarsal (metacarpal) region and local intravenous analgesia is administered. The horn of the heel is thinned [353]. An opening is made around the necrotic ulcer and an incision is made into the abscess [354]. Necrotic tissues and debris are removed from the cavity with a curette [355]. The sound digit is shod with a block to avoid damage to the operated digit and to facilitate healing [356].

If the deep flexor tendon has been destroyed by necrosis, the toes are wired together for about 6 weeks to prevent upturning of the operated digit. The abscess space is irrigated, packed with sterile gauze swabs soaked in povidone iodine, and bandaged for a few weeks. The shoe is removed after healing is complete. Complications such as extension of necrosis towards the pedal joint (causing septic arthritis) and/or towards the digital sheath (infectious tenosynovitis) may occur.

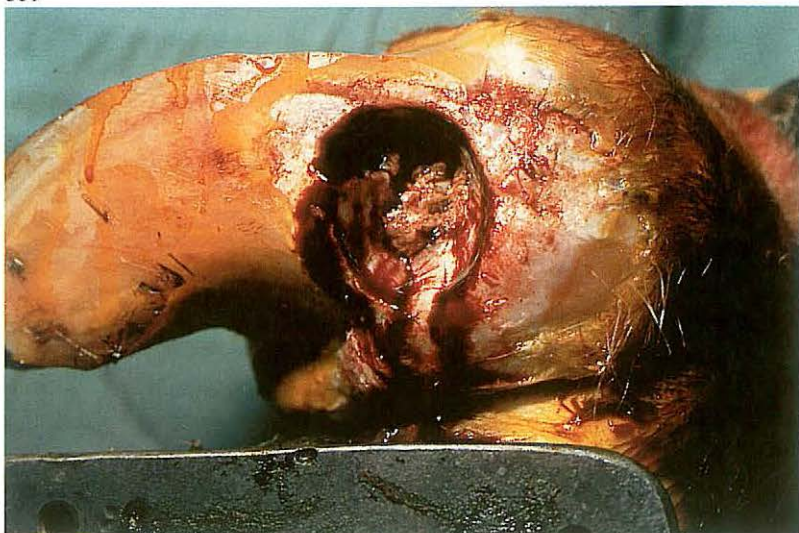
357



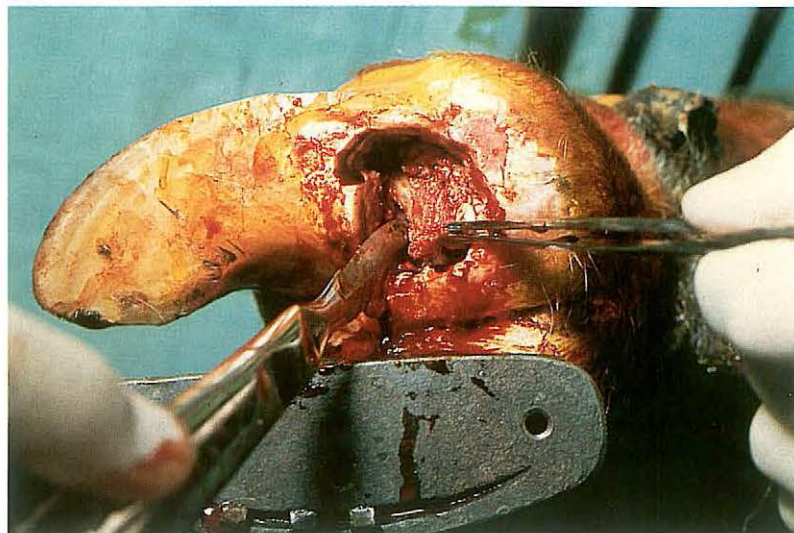
358



359



360



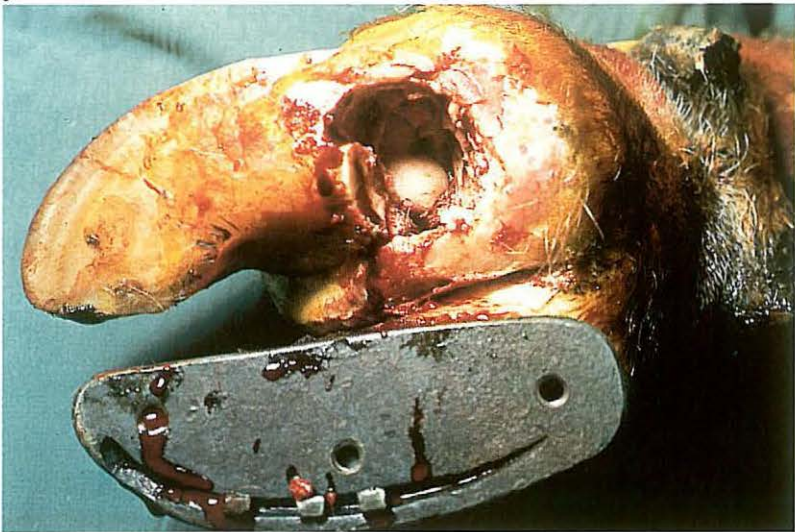
6-12 Resection of the distal interphalangeal joint and navicular bone

Purulent necrotic inflammation of the distal interphalangeal (pedal) joint is usually a complication of other diseases such as foreign body penetration, chronic necrotic pododermatitis [357], and interdigital necrobacillosis. When chronic arthritis of the pedal joint is present, or when structures of the joint (cartilage, subchondral bone, joint capsule) are necrotic and antibiotic therapy is unlikely to be successful, amputation of the digit (see 6-13) or resection of the pedal joint is indicated.

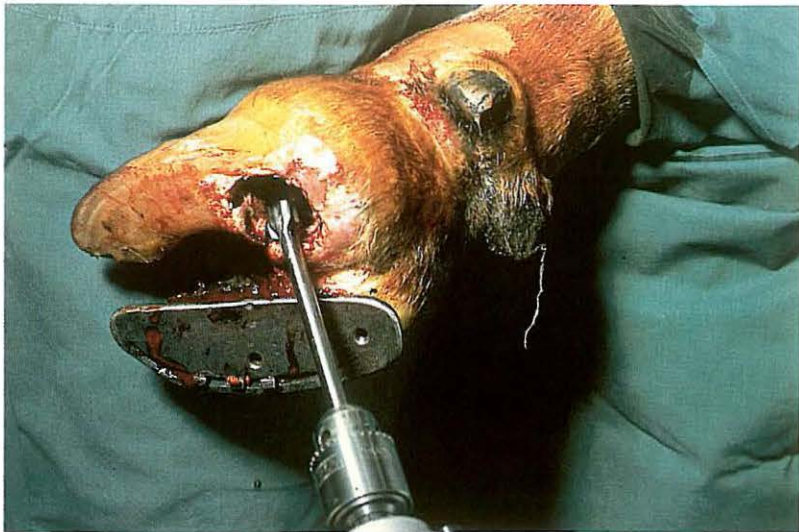
Surgery. The approach to the joint, dictated by the primary cause of the arthritis, is in most cases as described here; occasionally (e.g. following coronet wounds or extension of interdigital necrobacillosis) navicular bone resection is unnecessary, and the joint is approached from the dorsolateral or medial aspect respectively. The patient is restrained in lateral recumbency. A tourniquet of rubber tubing is placed around the limb in the mid-metatarsal (metacarpal) region and local intravenous analgesia is administered.

The joint is approached through a circular incision (about 3 cm diameter) in the sole of the hoof about 1 cm distal to the plantar (palmar) coronary border [358]. The remnants of the deep flexor tendon are resected using a scalpel; the partially necrotic navicular bone becomes visible [359]. The navicular bone is removed by sectioning the distal navicular ligament first and then the remaining navicular ligaments [360, 361]. Care must be taken not to penetrate the digital synovial sheath. All articular cartilage and subchondral bone of the pedal joint is removed with a 12 mm gouge driven by a low-speed electric drill [362]. With a scalpel a 2 cm diameter circular section of skin is excised just proximal to the coronet on the dorsolateral aspect [363]. It is important that all remaining necrotic tissue and the joint cartilage on the plantar aspect of the distal surface of the second phalanx are removed, using a curette. The cavity is dressed with antiseptic-soaked gauze drains [364]. The sound digit is shod with a block to avoid damage to the operated digit and to facilitate healing. Systemic antibiotics are administered.

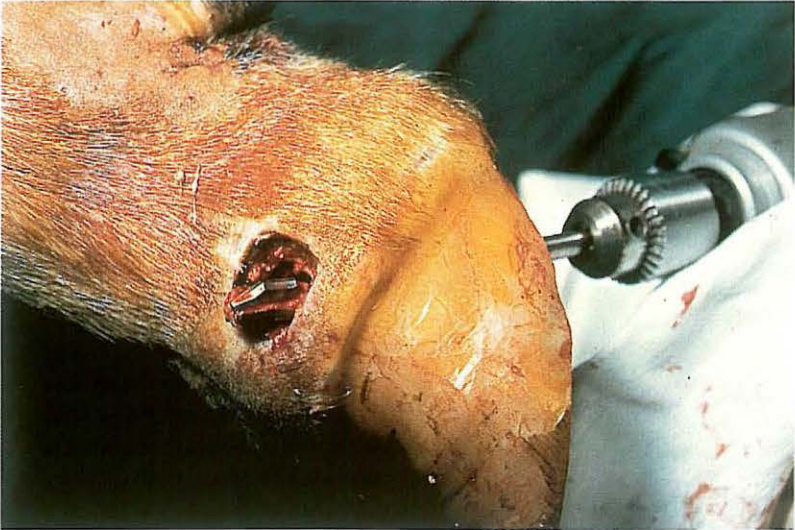361



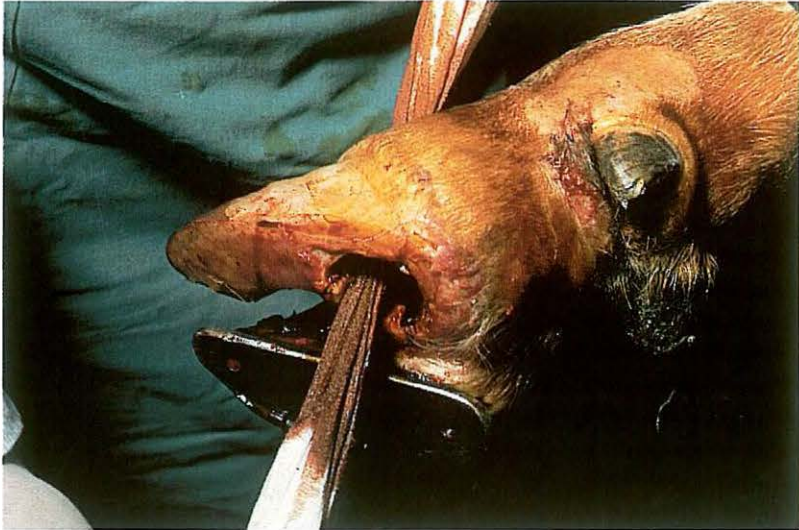362



363

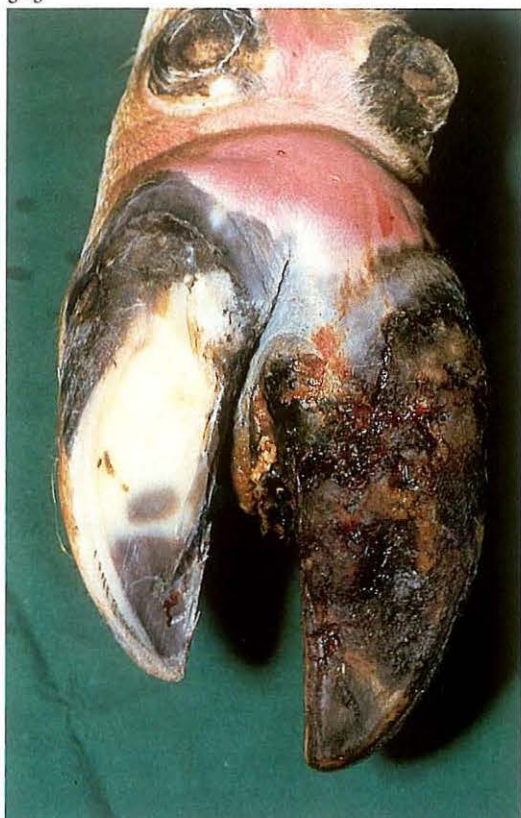

364

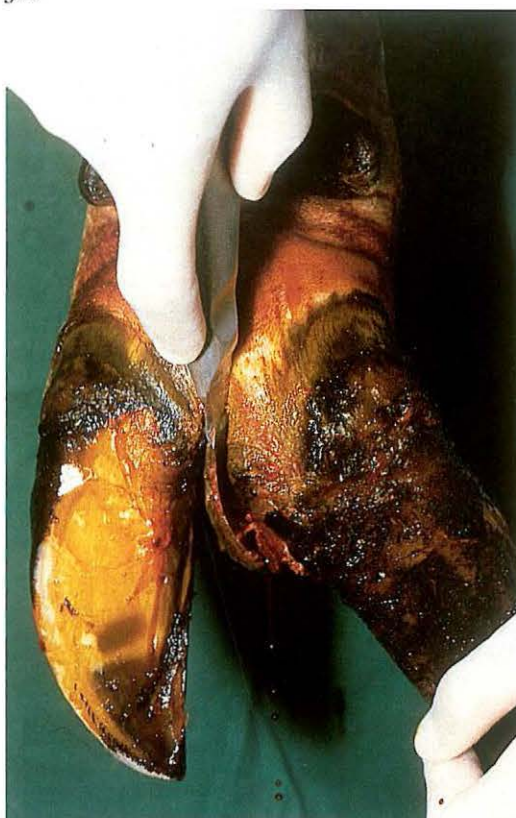

If the deep flexor tendon has been transected the toes must be wired together for 6 weeks to prevent upturning of the operated hoof. A firm bandage is applied, and is changed after 2 days and thereafter weekly for 3-4 weeks. When the bandage is renewed, the wound is cleaned and the drain changed. When new granulation tissue has filled the depths of the wound the drain is not replaced. The block is removed after about 6 weeks. If it appears (following navicular bone resection) that other parts of the joint are not necrotic, it may not be necessary to resect the entire joint: intra-articular antibiotics may be effective. The wound is filled with antibiotic-soaked gauze swabs and the digit is bandaged with sterile cotton. Systemic antibiotics are administered for 10 days. The wound must be dressed sterily till the joint capsule is closed by granulation tissue formation.

365



366



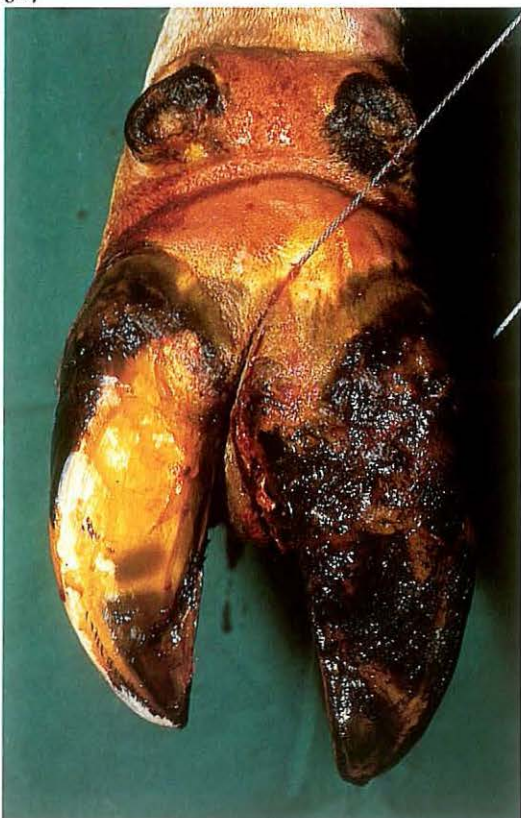
6-13 Amputation of digit

Digital amputation is indicated in cattle suffering from severe disorders of the digit such as purulent necrotic inflammation of the distal or proximal interphalangeal joint, or severe pedal trauma. Plate 365 shows a chronic necrotic pododermatitis, which has resulted in a purulent necrotic inflammation of the distal interphalangeal joint. Advantages of digital amputation in comparison with other surgical methods, are the simplicity of the technique and the relatively rapid return to normal general condition and milk yield.

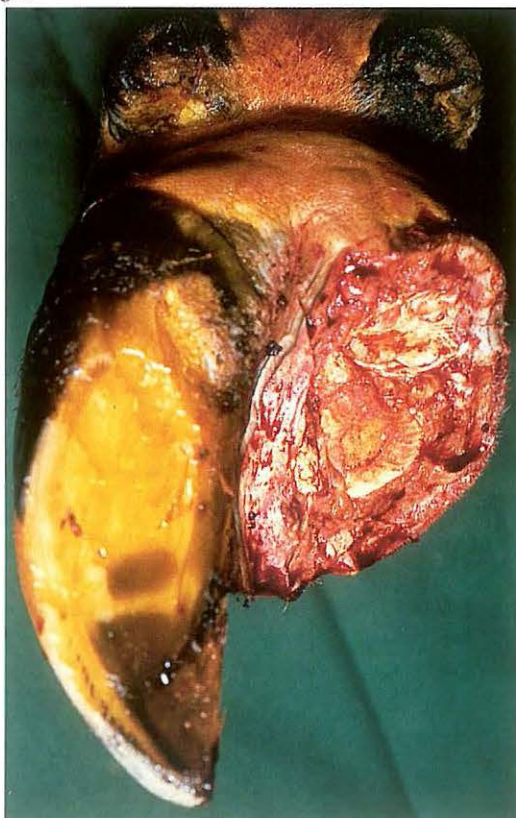
Surgery. The cow is restrained in a standing position with the limb elevated and secured. A rubber tourniquet is applied in the mid-metatarsal (metacarpal) region and local intravenous analgesia is administered. Using a scalpel, a 2-3 cm deep incision is made along the whole length of the interdigital space through skin, subcutaneous tissue and interdigital ligaments, as close as possible to the affected claw [366]. An embryotomy wire is inserted in the incision and the digit is sawn off, directing the wire towards a point 2-3 cm proximal to the abaxial aspect of the coronet [367]. The transection courses through the middle phalanx, flexor tendons, digital flexor synovial sheath and skin [368].

In cases of purulent necrotic inflammation of the proximal interphalangeal joint, the level of amputation is the distal third of the proximal phalanx. The embryotomy wire is inserted in the interdigital incision, and the transection plane runs from 1-2 cm proximal to the axial aspect of the proximal interphalangeal joint to a point 3-4 cm proximal to the joint space abaxially. The wound is dressed with povidone iodine soaked gauze, and a pressure bandage is applied. The first bandage is renewed after 2 days. The stump is checked for inflammatory processes, such as infection of the digital flexor synovial sheath. After 1-2 weeks no further dressing is required.

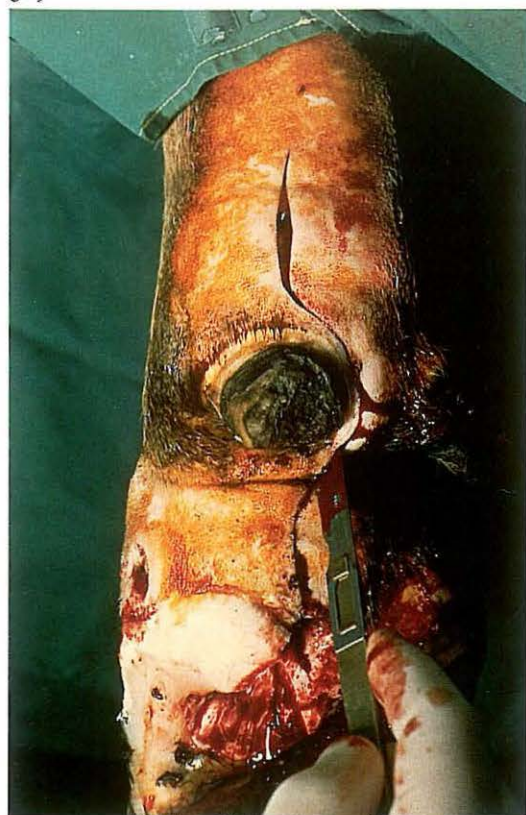
367



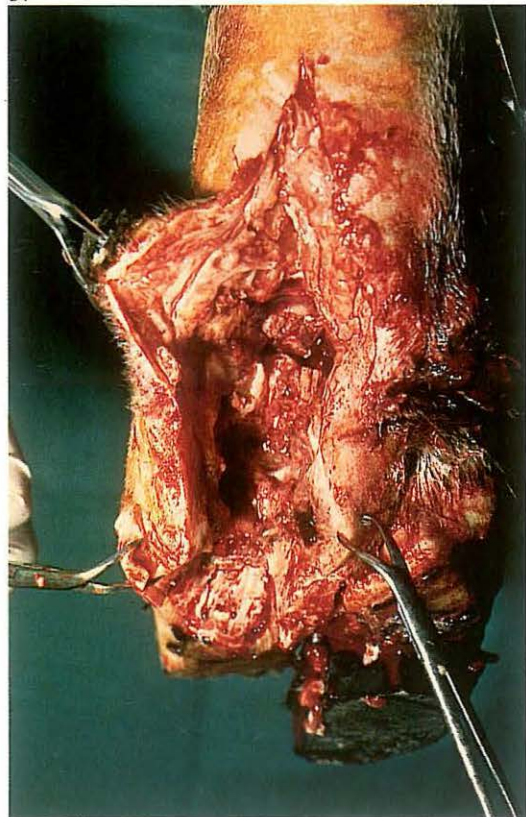
368



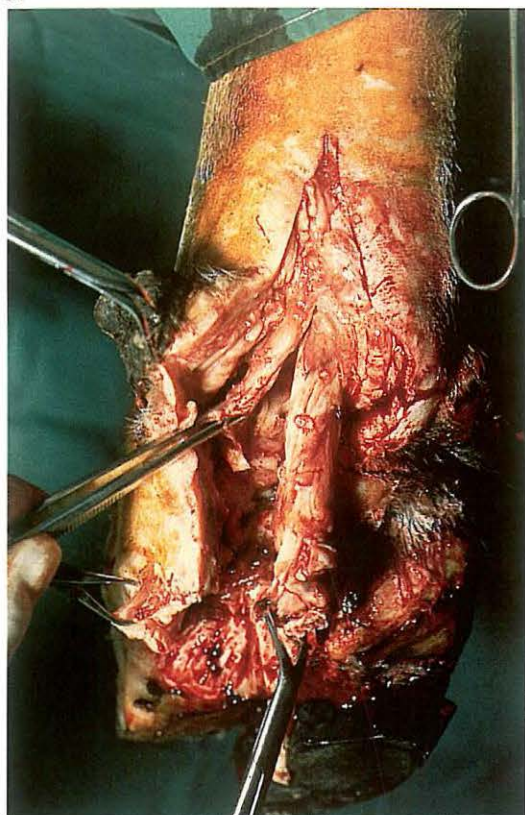
369



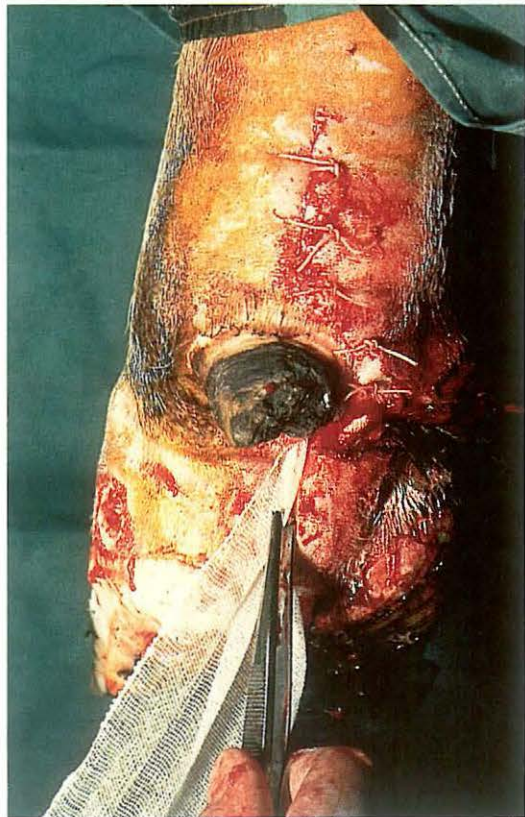
371



370



372



6-14 Resection of digital flexor tendons and digital synovial sheath

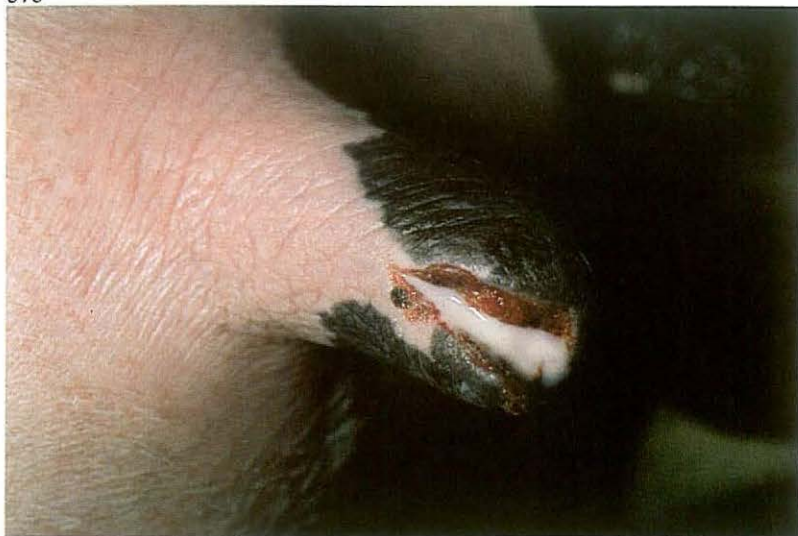Infection of the digital synovial sheath develops from *a* proximal extension of a sole lesion (navicular bursitis and pedal arthritis), *b* penetrating wound into the sheath or *c* haematogenous infection. If conservative therapy fails – the affected tendon and sheath being necrotic – excision of the necrotic structures is the prime requisite.

Surgery. The patient is placed in lateral recumbency. A tourniquet of rubber tubing is placed around the limb in the mid-metatarsal (metacarpal) region and local intravenous analgesia is applied. The skin and subcutaneous tissue over the tendon sheath are incised from the bulb (or sole ulcer) to a point about 5 cm proximal to the accessory digit, i.e. immediately distal to the bifurcation of the deep flexor tendon [369]. The sheath itself is then opened along its plantar (palmar) aspect. The superficial flexor tendon (which envelops the deep flexor at the level of the fetlock) is sectioned longitudinally; the deep tendon is transected adjacent to the bifurcation [370] and subsequently transected distally and removed. The superficial tendon is then likewise transected proximally and at its insertion at the second phalanx [371].

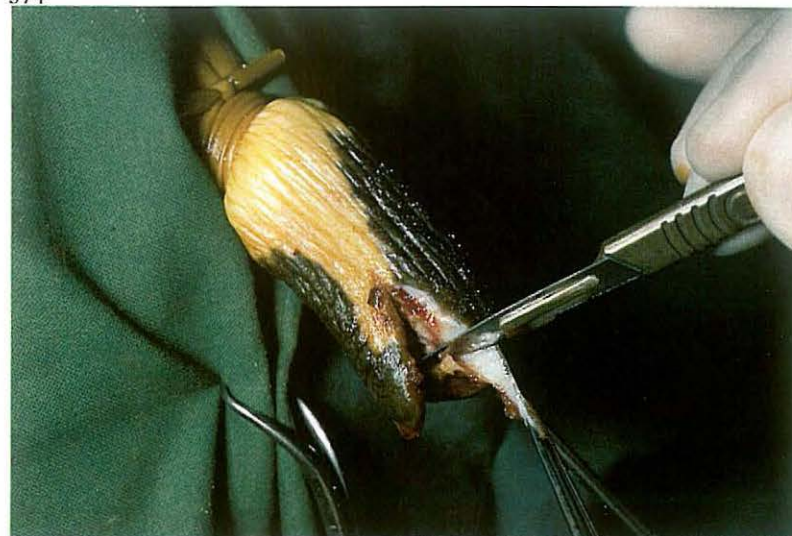
After all necrotic debris and tissue have been removed, the wound is dressed with povidone iodine soaked gauze and the skin is closed with interrupted sutures [372]; distally the wound remains open for drainage. The toes are wired together for about 6 weeks to prevent upturning of the affected digit, and the sound digit is shod with a block to avoid damage to the operated digit and to facilitate healing.

The digit is bandaged firmly. Systemic antibiotic administration is advisable. The bandage and drain are changed on the second postoperative day, and thereafter as needed.

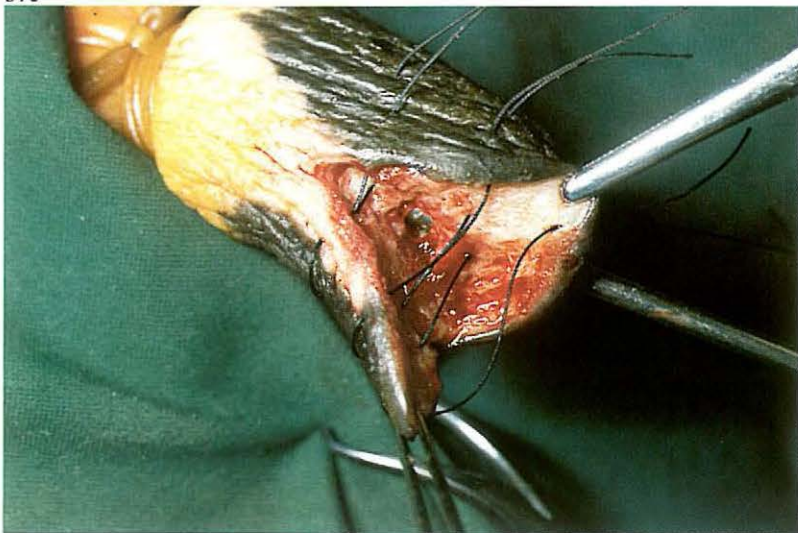
373



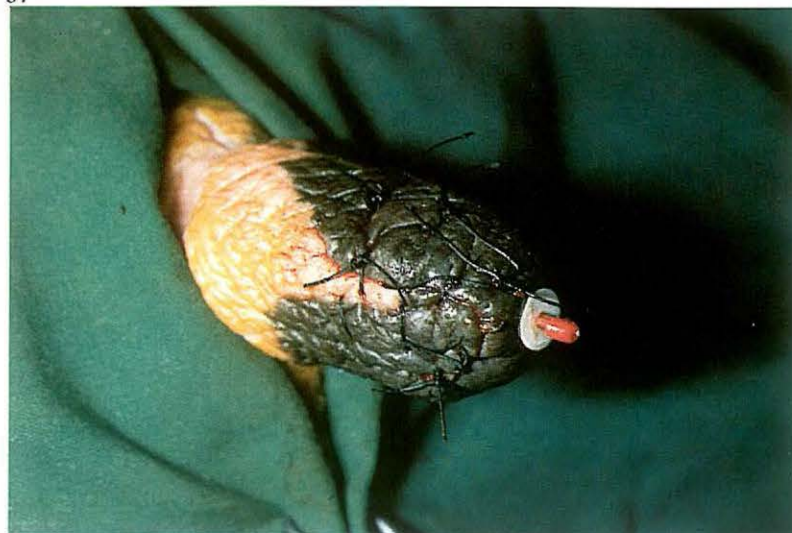374



375



376



6-15 Repair of teat lacerations

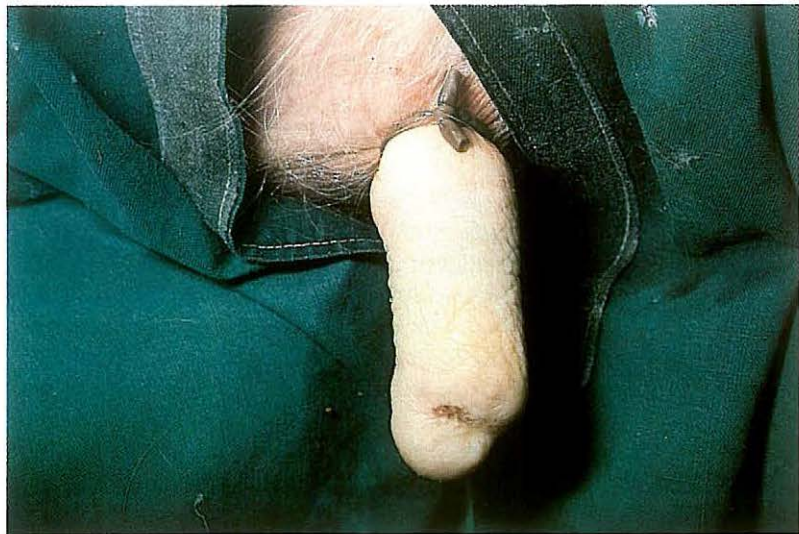Most teat lacerations occur in lactating cows. The two main types of laceration are non-perforating wounds, in which only the skin and muscular layers are involved, and perforating wounds, in which the teat sinus has been penetrated [373]. In both types of teat wound, healing by primary intention should be attempted, provided the wound is fresh and without extensive bruising or skin loss.

Surgery. Repair of teat lacerations is performed under local ring block analgesia at the base of the teat. A rubber tourniquet is applied to the teat base to prevent haemorrhage. The wound is debrided by excising a superficial layer from the wound edges [374]: all foreign material and devitalized tissue must be removed. Skin and muscular layers are then sutured using several vertical mattress sutures, which do not perforate the mucosa [375]. Simple interrupted sutures are placed between the vertical mattress sutures [376]. Fine atraumatic (absorbable or non-absorbable) suture material is

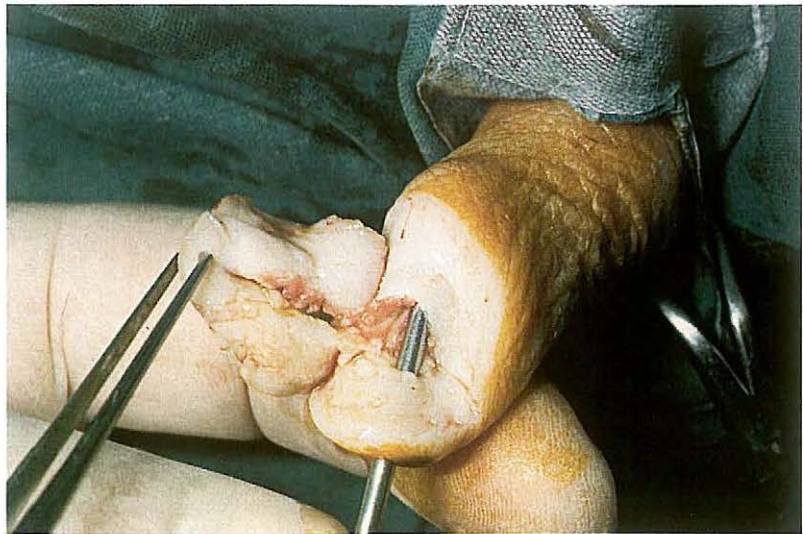
used. After removal of the tourniquet, antibiotics are administered into the affected teat and in high-lactating cows a self-retaining plastic teat canula is placed in the streak canal. The cap remains in the canula so that the antibiotics do not immediately flow out with the milk. The teat is bandaged with a slightly elastic bandage, which is fixed to the udder skin with two simple interrupted sutures.

Antibiotics are administered systemically. Postoperative management consists of daily checking of the udder. If obvious tension develops in the quarter, the canula cap is removed so that milk can flow out freely. Bandage, sutures and teat canula are removed on the tenth day. Because the streak canal does not close immediately after removal of the canula, administration of antibiotics is continued for another two days.

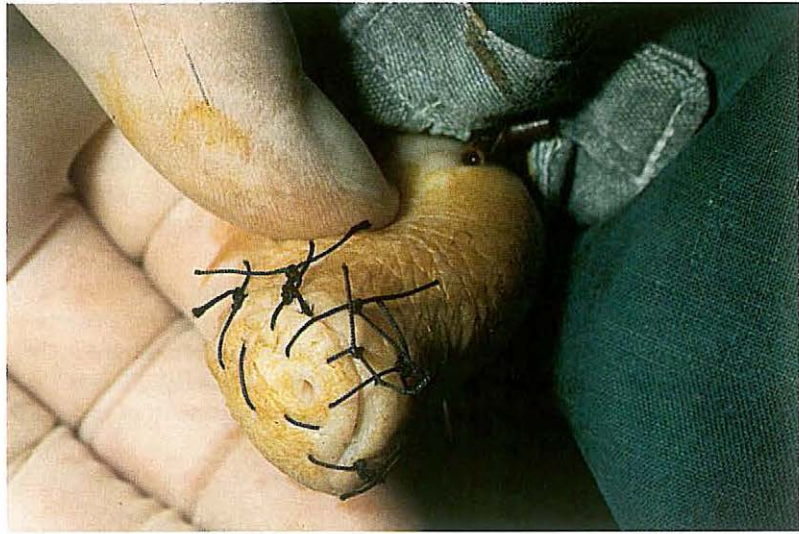377



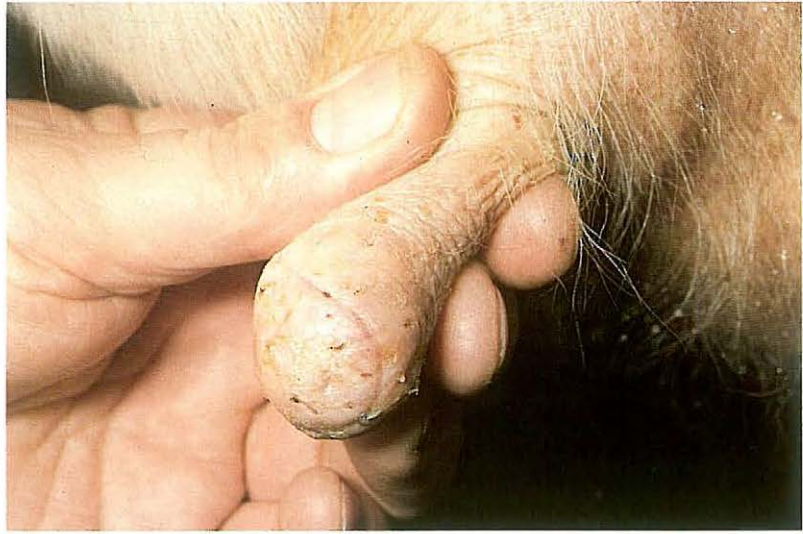378



379



380

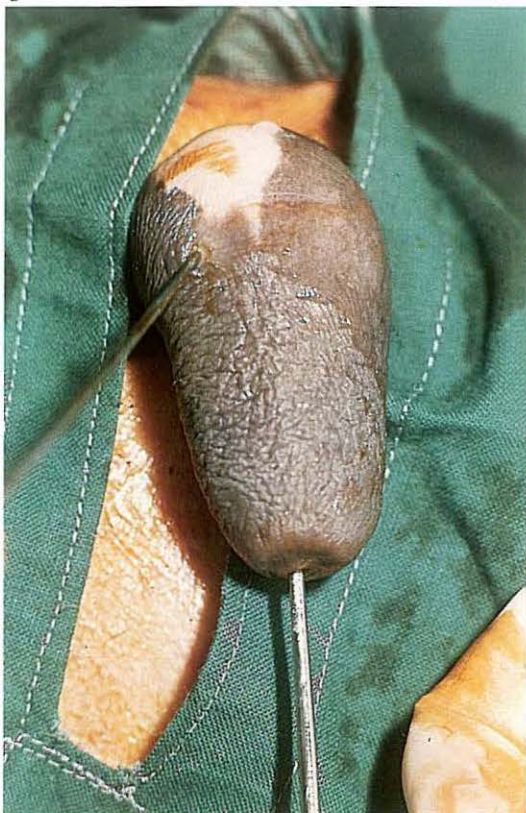

6-16 Repair of traumatic teat fistula

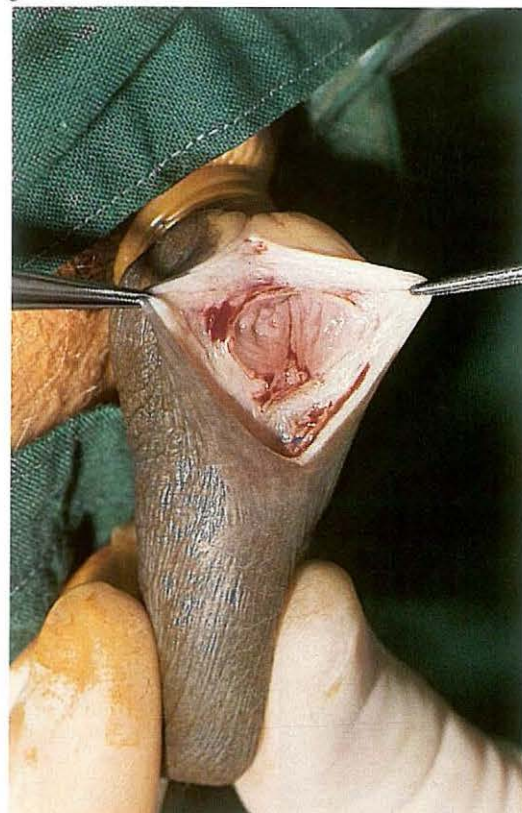When milk flows continually through a perforating teat wound, failure of wound healing results in a teat fistula [377]. Congenital teat fistula is associated with a supernumerary mammary gland (see 6-17). Treatment of a teat fistula consists of dissection of the fistula and subsequent suturing of the wound. It is preferable to operate after the cow has been dried off. *Surgery.* The operation is performed under local ring block analgesia at the base of the teat. A rubber tourniquet is applied to the teat base [377]. A milk canula is placed through the streak canal into the sinus, and an elliptical incision is made around the fistula. It is important that all scar tissue (in skin, muscular layers and mucosa) is removed to ensure primary intention healing [378]. After dissection, the fresh wound surfaces are apposed with several vertical mattress sutures and simple interrupted sutures [379] (see 6-15). Because of anticipated postoperative wound swelling, it is important to tie the sutures loosely to prevent wound edge necrosis. The tourniquet is

removed and long-acting antibiotics are injected into the teat sinus. In dry cows a self-retaining plastic teat canula is usually not used, although in cases of streak canal damage a teat canula may prevent stenosis during repair. The teat is bandaged with a slightly elastic bandage (see 6-15). Postoperative management consists of daily checking for mastitis. Plate 380 shows primary intention healing on the tenth postoperative day, after all sutures have been removed.

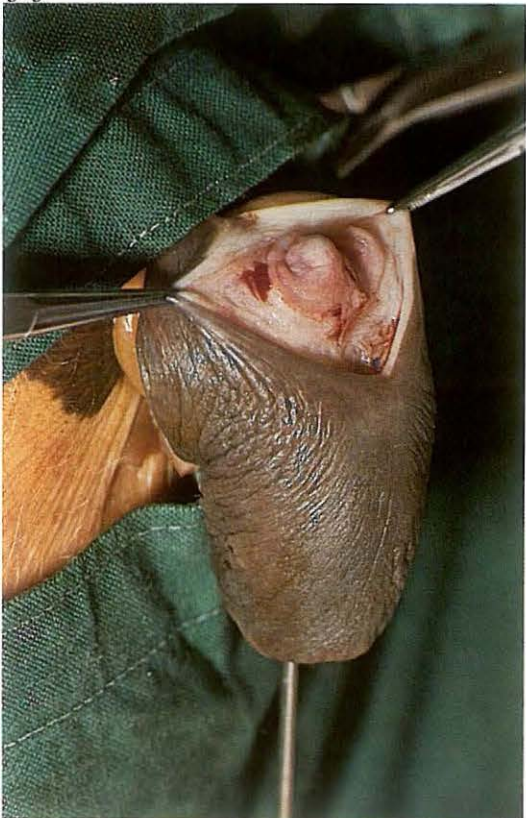381



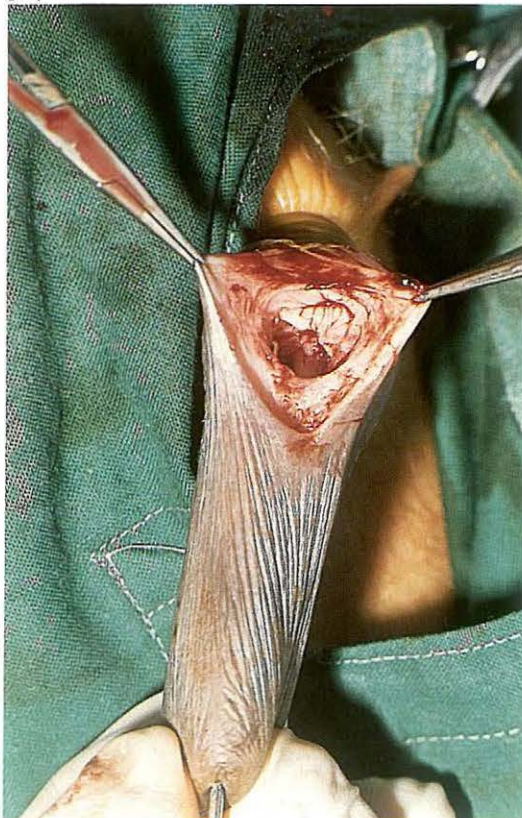382



383



384

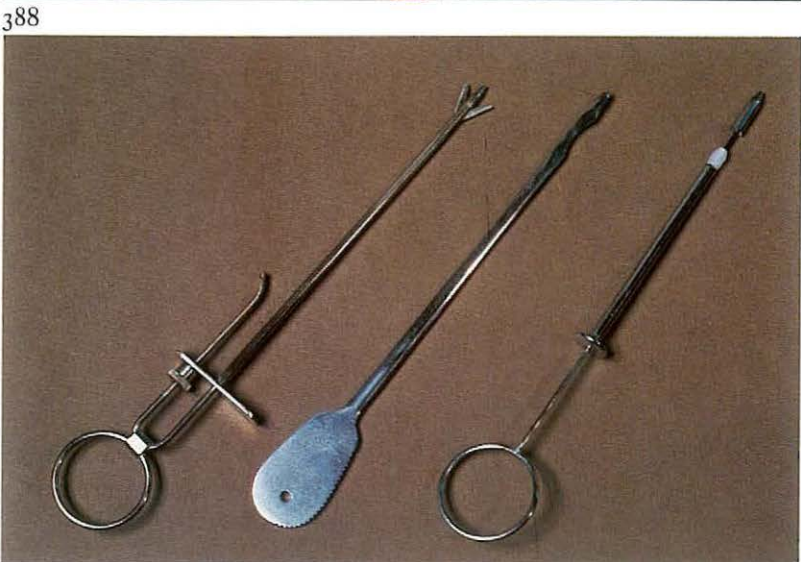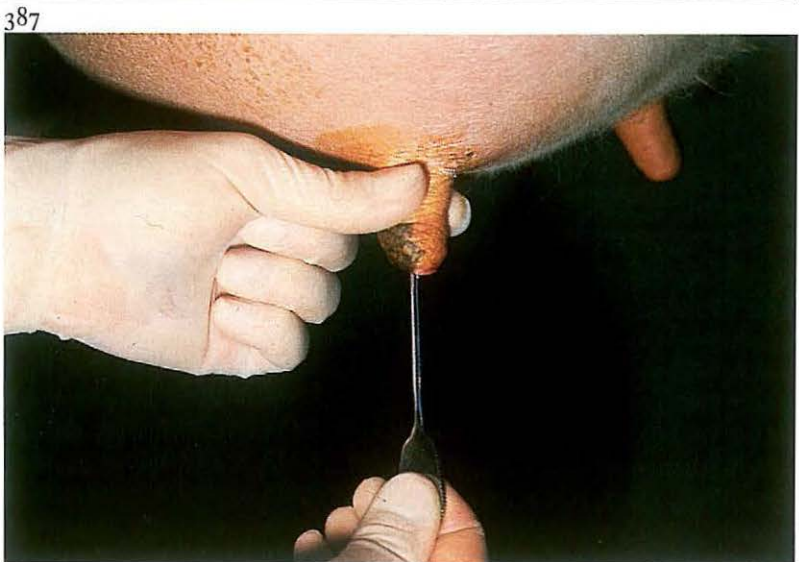
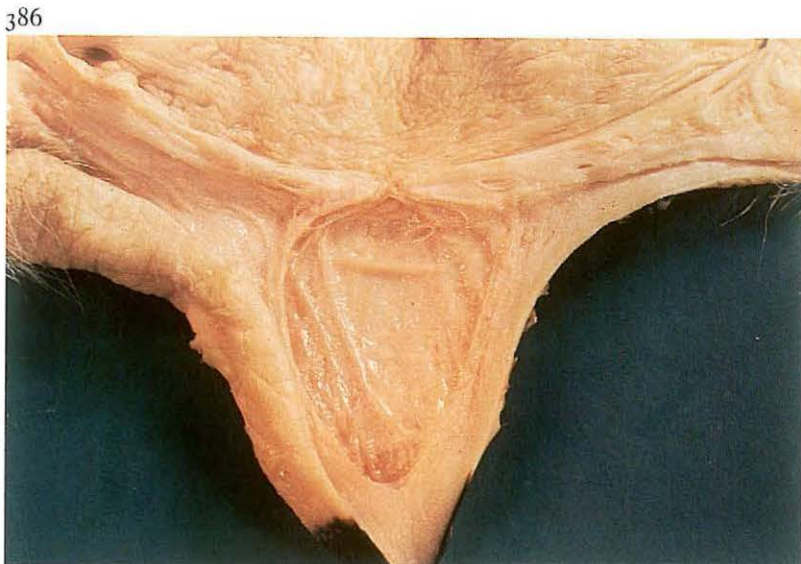

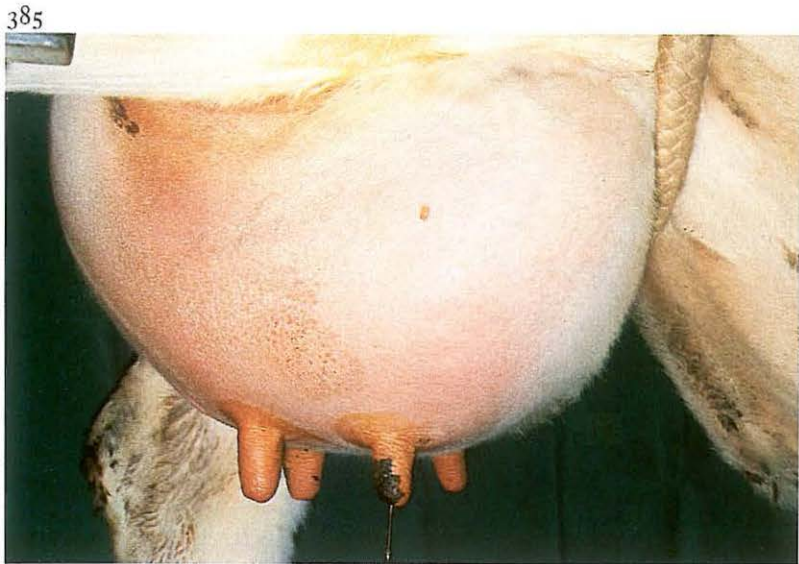
6-17 Management of congenital teat fistula

A congenital teat fistula is in general caused by the presence of a supernumerary mammary gland and is usually localized in the proximal part of the teat [381]. Milk flows through the fistula. Surgical correction is possible only when the lactiferous sinus of the supernumerary gland is situated close to the teat sinus.

Surgery. After local ring block analgesia at the base of the teat, a rubber tourniquet is applied. An elliptical incision is made around the fistula into the lactiferous sinus of the supernumerary gland. After dissection of the fistula, a fresh perforating teat wound is produced. In the depth of the wound, the mucosal membrane between the teat sinus and the sinus of the supernumerary gland is visible [382]. With a milk canula, brought through the streak canal into the teat sinus, the mucosal membrane is elevated into the wound [383]. By excising the membrane with scissors or scalpel, a connection is made between the two sinuses [384], and milk can drain from the supernumerary gland to the teat sinus. The wound is sutured using vertical mattress and simple interrupted sutures, loosely tied (see 6-15).

The tourniquet is removed and antibiotics are injected into the teat sinus. In lactating cows a self-retaining plastic teat canula is placed in the streak canal and the teat is bandaged (see 6-15). Postoperative management consists of prevention of mastitis.

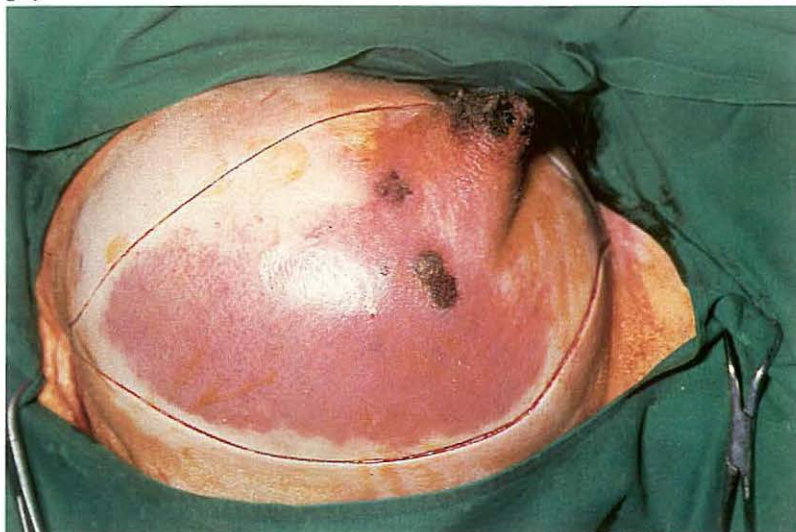

6-18 Management of teat obstructions

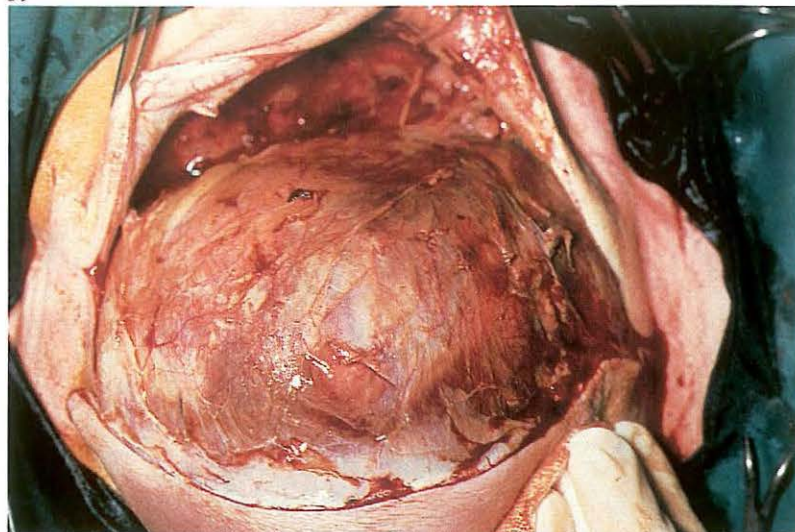
Teat obstructions in the cow may be congenital or acquired. Congenital obstruction at the base of the teat is caused by a completely closed annular fold of mucous membrane. Acquired basal obstructions develop during the dry period and are due to chronic inflammation of the annular fold. Localised obstructions in the teat sinus ('peas') may be due to local neoplasia or to chronic proliferative inflammation. Chronic inflammatory processes of the 'rosette of Fürstenberg' or the streak canal may also lead to stenosis. *Surgery.* In cases of basal teat obstructions the affected quarter is under considerable tension [385] and milk flow is absent. Plate 386 shows a congenital basal teat obstruction at the annular fold. The membrane is perforated with a milk canula. If there is no outflow of milk, the prognosis is unfavourable. If milk flow is present, Hug's teat knife [388, centre] is inserted through the membrane, which is then slit radially in three of four directions [387]. To ensure a permanent communication, it is recommended the

quarter is not milked completely for about ten days. In general the prognosis for a productive quarter is guarded, but in cases of thin membranes the prognosis is more favourable. 'Peas' are usually localized in the mid-teat region. Large lesions may require open teat surgery, but the smaller ones are removed from the wall (with Hug's teat knife, Hug's tumour extractor [388, right] or a curette) and massaged out. Cows with apical obstructions (traumatic or congenital) are usually presented as 'hard milkers'. The stenosis may be temporarily relieved by longitudinal radiate incisions of the sphincter or the fibrosed canal with a Danish teat knife [388, left] or by widening the opening with a teat dilator. A self-retaining teat canula prevents postoperative stenosis.

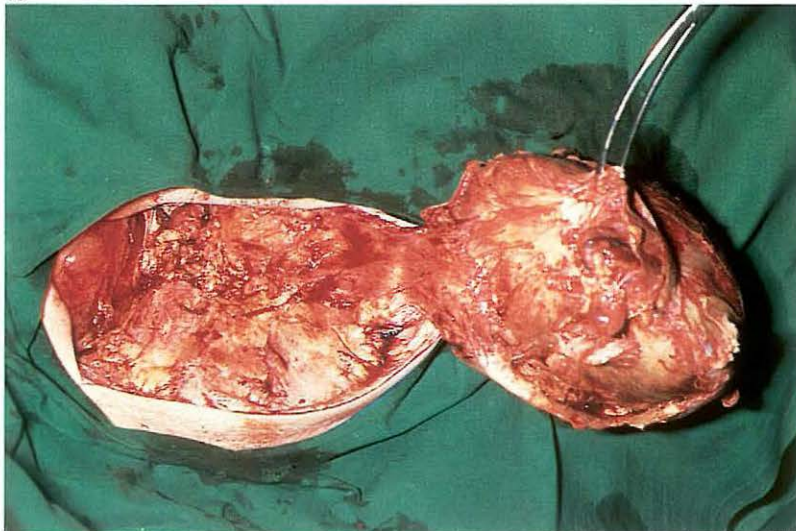
389



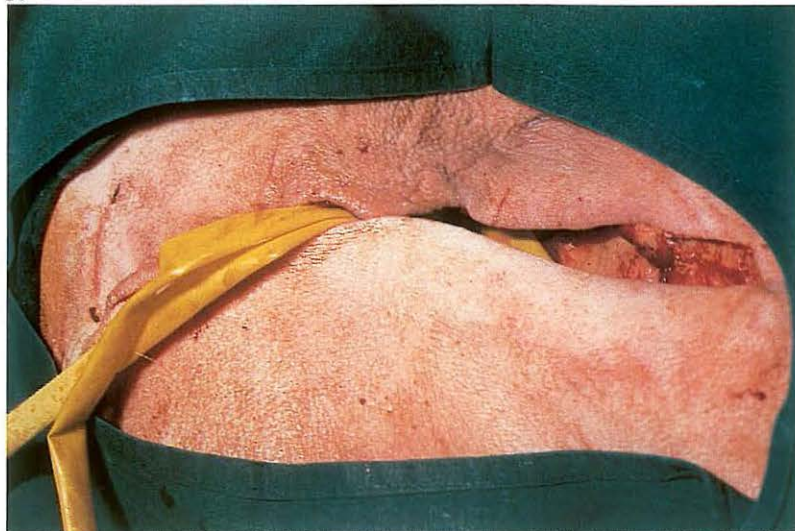
390



391



392



6-19 Amputation of the mammary gland

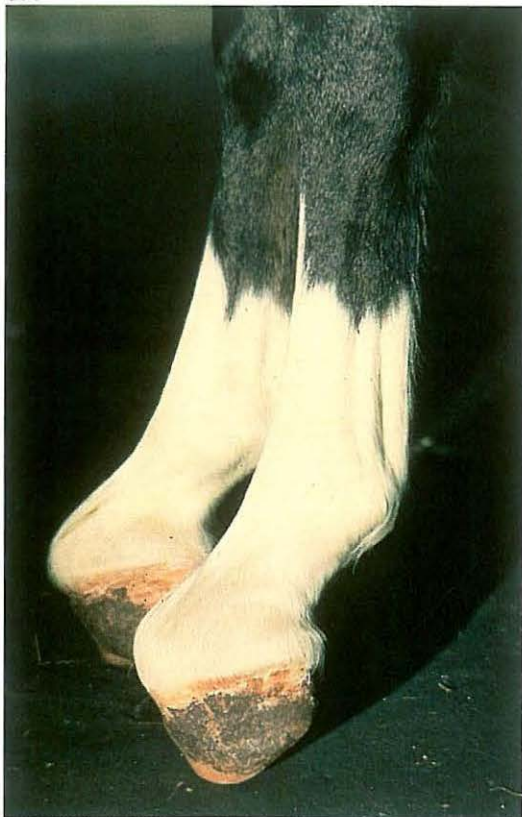The main indication for amputation of the mammary gland is a severe life-threatening mastitis, often seen in sheep and goats. Plate 389 shows an acute necrotizing mastitis in a ewe, characterised by a dark blue discoloration of the skin and a severely swollen right mammary gland.

Surgery. Amputation of the mammary gland is performed with the patient under epidural analgesia (anterior block) or general anaesthesia and in dorsal or dorso-lateral recumbency. An elliptical skin incision is made around the discoloured area [389], followed by dissection of the glandular tissue along the suspensory ligament medially and the lateral ligament laterally [390]. The gland is grasped with a tenaculum forceps and dissected from the body wall, beginning caudally. The major vessels (external pudendal artery and vein, ventral perineal artery and vein, and subcutaneous abdominal vein) are connected by numerous anastomoses, and double ligation is essential. The vessels are transected between the ligatures and dissection of

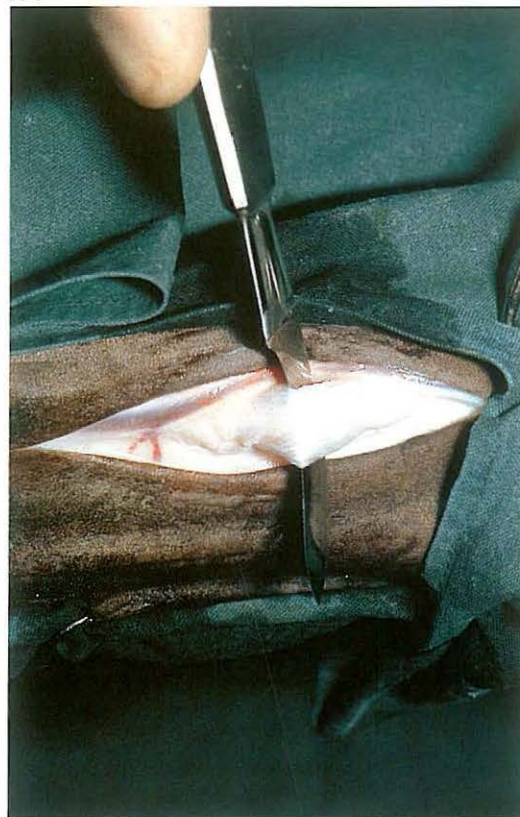the gland is continued craniad [391]. The large external pudendal artery, which enters the udder on the cranio-lateral aspect after passing through the inguinal canal, should be respected. After dissection of the mammary gland is complete, subcutis is sutured in a simple continuous pattern using absorbable suture material. Sterile gauze or latex drains are placed in the wound, one deeply, the other superficially [392], and the skin is closed with simple interrupted sutures. Systemic antibiotics are administered.

Chapter 7 The musculoskeletal system

393



394

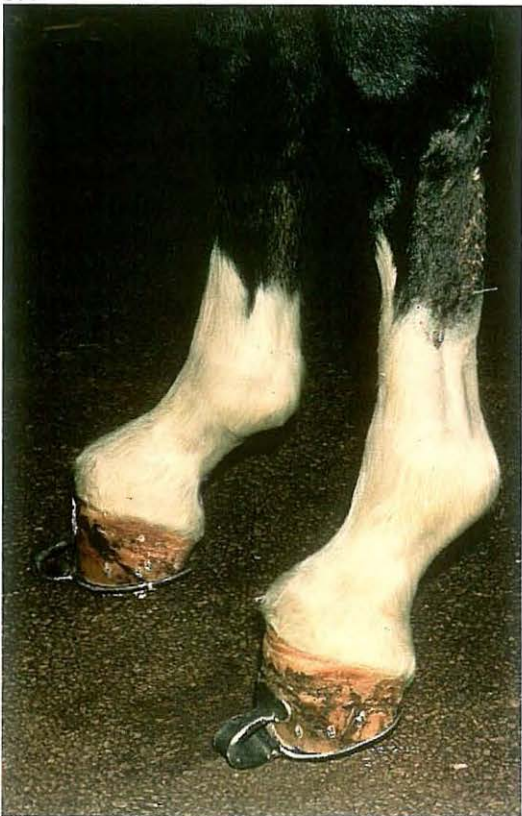

7-1 Desmotomy of inferior check ligament

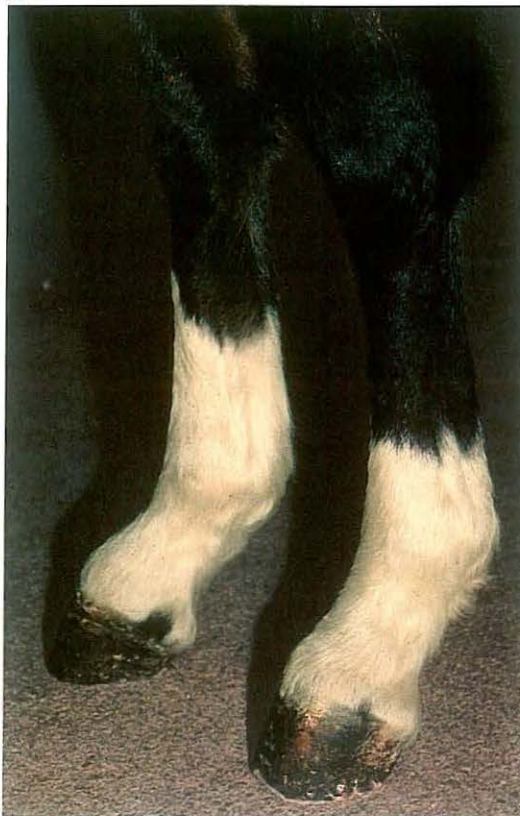'Contraction' of the deep flexor tendon in foals may be congenital or acquired [393]. In the latter case development may be associated with pain in the navicular bone/bursa, the suspensory apparatus, or other sites. Initially, treatment is aimed at gradual stretching of the 'contracted' muscle-tendon unit. If serious pain is still present, the stretching can only occur if analgesics are administered. The heel of the hoof is shortened as much as possible; the toe is kept long or is lengthened with the help of a shoe with an extended toe [395]. In severe cases, or if conservative therapy fails, desmotomy of the inferior check ligament is indicated to allow further lengthening of the muscle head.

Surgery. The patient is placed in lateral recumbency under general anaesthesia. The ligament is approached from the lateral aspect in the proximal third of the metacarpus or metatarsus. Skin, subcutis and deep fascia are incised in the groove between the deep flexor tendon and suspensory ligament. The ligament is separated from the deep flexor tendon with dissecting scissors and transected [394]. Fascia and skin are sutured with absorbable material, using a continuous and interrupted suture pattern respectively. The wound is dressed with an elastic bandage. Starting on the second postoperative day the patient is walked daily on a hard surface, and this exercise is increased gradually. The shoe with the extended toe [395] is removed when the position of the digit has improved satisfactorily [396]. Continued optimal hoof care is important.

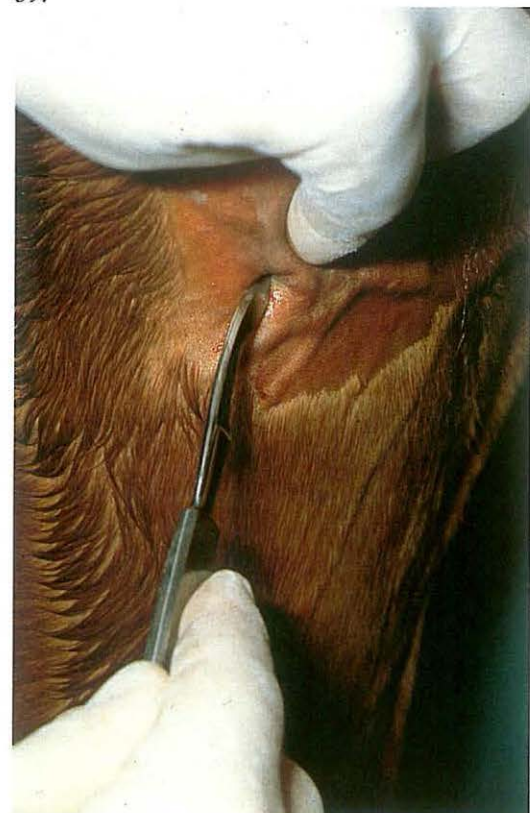395



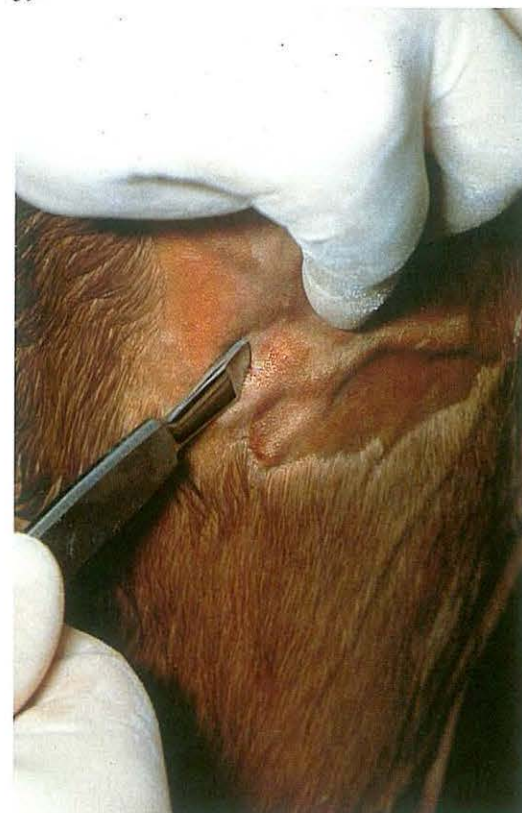396



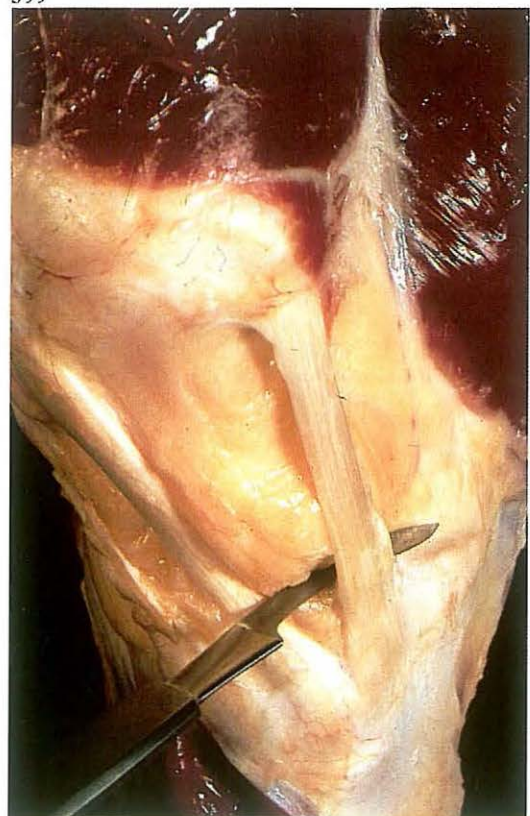
397



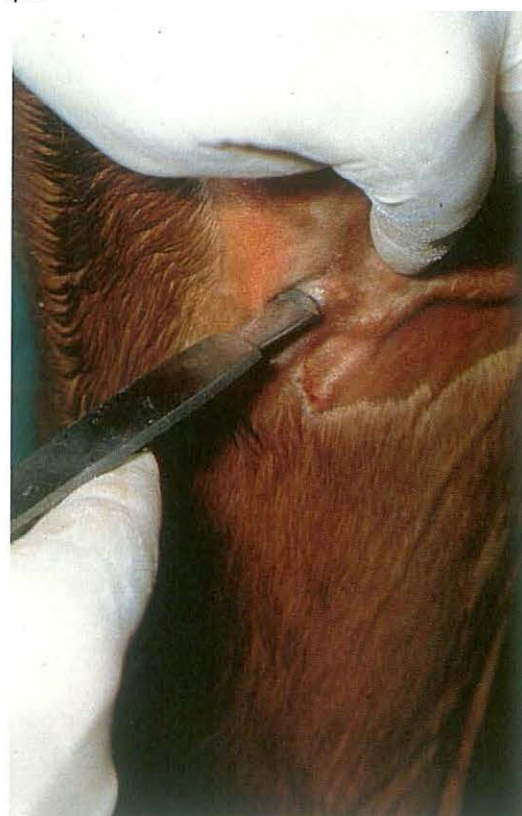398



399



400

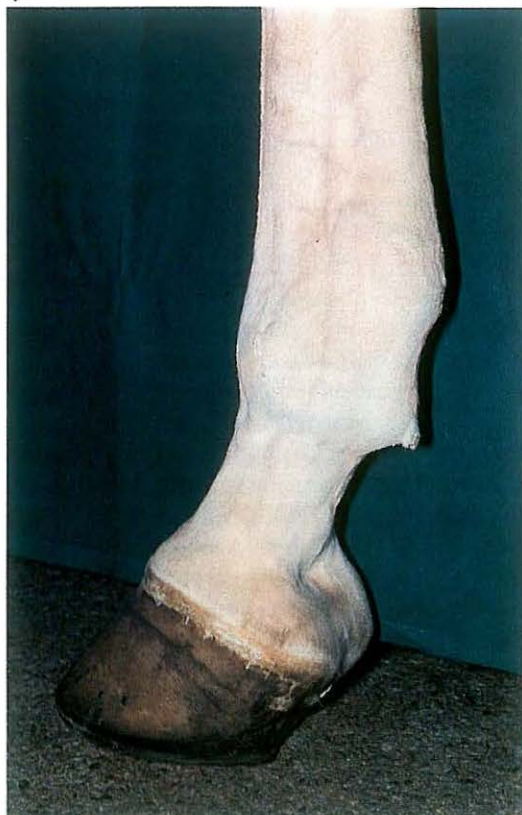


7-2 Desmotomy of medial patellar ligament

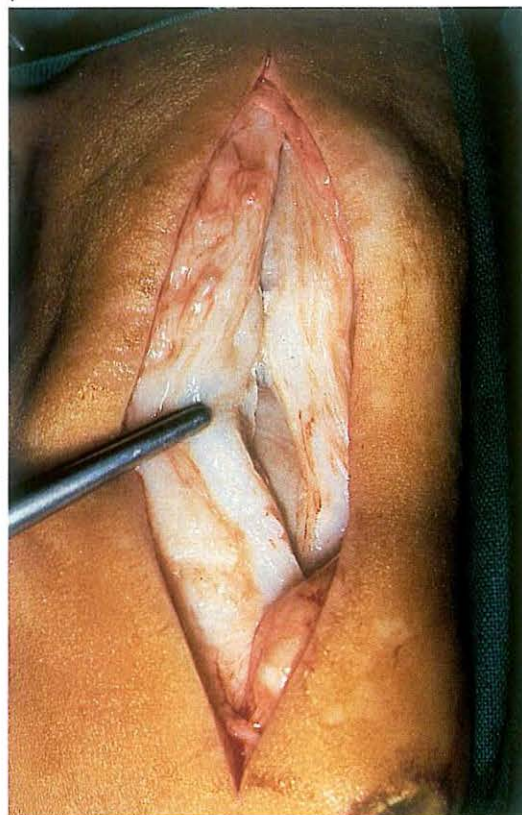Fixation of the patella may be persistent or temporary. Permanent fixation of the patella proximal to the medial trochlear ridge of the femur prevents flexion of the affected hind limb. In some cases (in standardbreds) there may be only a 'catching' of the patella during locomotion and the leg never truly locks in extension. The condition is commonly bilateral, although it may be worse in one limb. In all cases of persistent and intermittent fixation and 'catching' where conservative treatment (e.g. corrective trimming and shoeing) fails, surgical intervention is indicated.

Surgery. The medial patellar ligament is located and the skin and tissues around the insertion of the ligament to the tibia are infiltrated with local analgesic. Using a pointed tenotome a small skin incision is made just proximal to the tibial insertion of the medial patellar ligament, between the medial and middle patellar ligaments [397]. The tenotome is further introduced, caudal to the medial patellar ligament [398]; the blade is then turned so that the cutting edge is against the ligament [399]. The ligament is severed by a combination of a slight sawing movement of the tenotome and percutaneous pressure applied to the ligament with the forefinger [400]. There will be a distinct snap as the ligament is cut, and a definite cavity is palpable following transection. A single suture of absorbable material is sufficient to close the skin incision. In general both medial ligaments should be severed even if only one limb is involved, since the cause of this condition appears to be related to conformation; the other limb frequently becomes affected at a later date. Aftercare consists of 4-6 weeks' rest from work. To prevent the ends of the ligament reuniting prematurely, the patient is walked at hand daily from the first postoperative day, and the exercise is increased gradually.

401



402



7-3 Sectioning of fetlock annular ligament

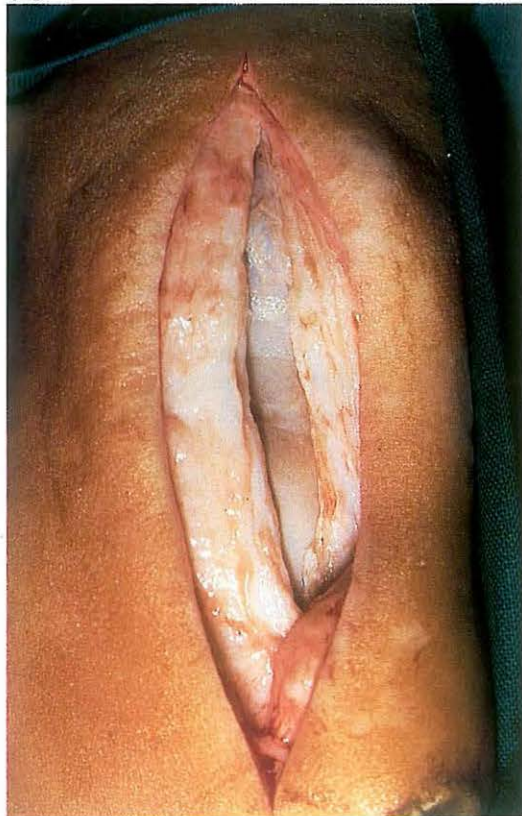Restriction of the free movement of the flexor tendons within the fetlock canal may result from swelling of the tendons (bowed tendon) or from constriction by the annular ligament. Direct injury to the annular ligament with subsequent inflammation, fibrosis, and constriction of the ligament, may result in lameness due to pressure on the superficial flexor tendon. Fluid distention and tendon swelling dorsal and ventral to the constricted annular ligament causes the characteristic notch in the caudal outline of the limb [401]. Therapy is sectioning of the annular ligament, if this is done in the caudal midline the digital sheath is not opened.

Surgery. The patient is placed in lateral recumbency under general anaesthesia. The use of an Esmarch's bandage facilitates surgery.

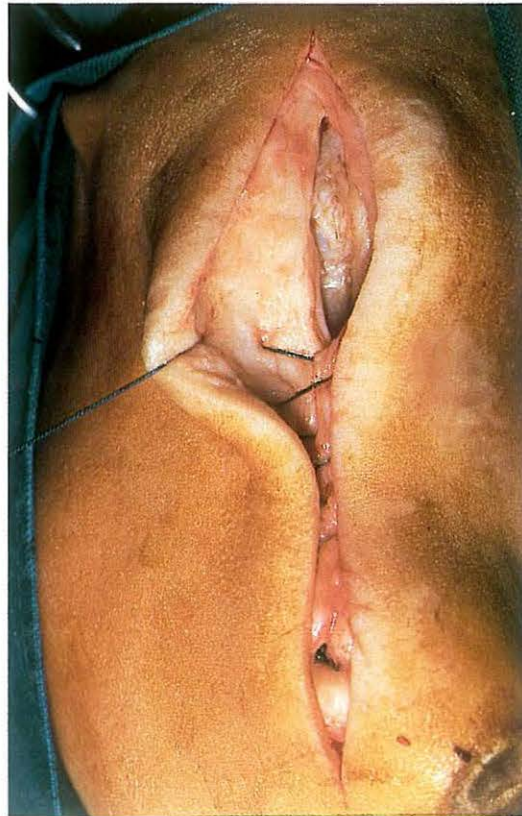An 8 cm skin incision is made about 1 cm from and parallel to the caudal midline over the annular ligament. The incision is continued through subcutaneous tissue and, in the midline, into the annular ligament [402]. The incision through the thickened annular ligament is extended to complete sectioning of the entire ligament [403].

The subcutaneous tissue is sutured in a continuous pattern with synthetic absorbable material [404] and the skin is closed with simple interrupted sutures. A sterile dressing is placed over the wound and a firm bandage is applied. The bandaging is maintained for 4 weeks. The patient is box rested for 3 weeks. The main criterion for returning the patient to work is the time necessary for healing of the superficial flexor tendon lesion.

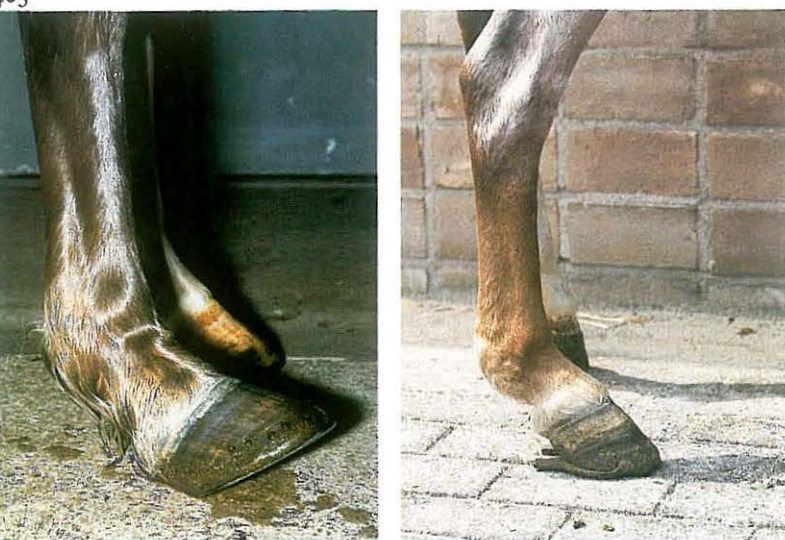403



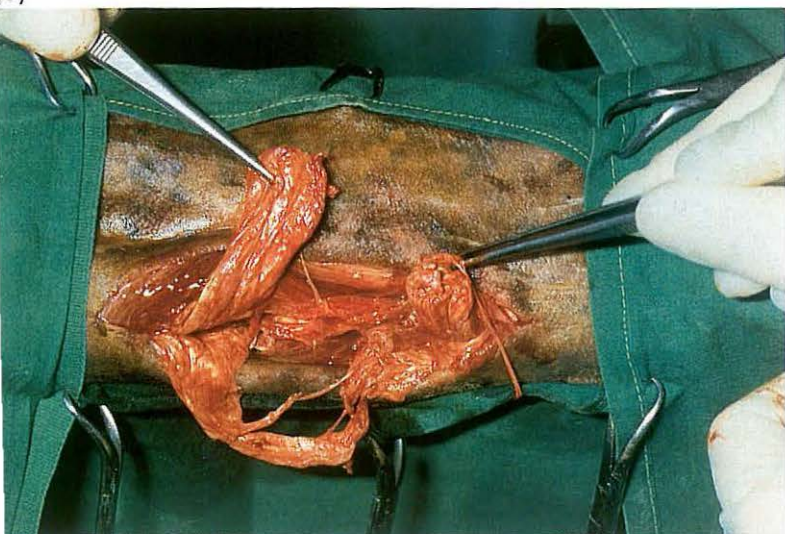404



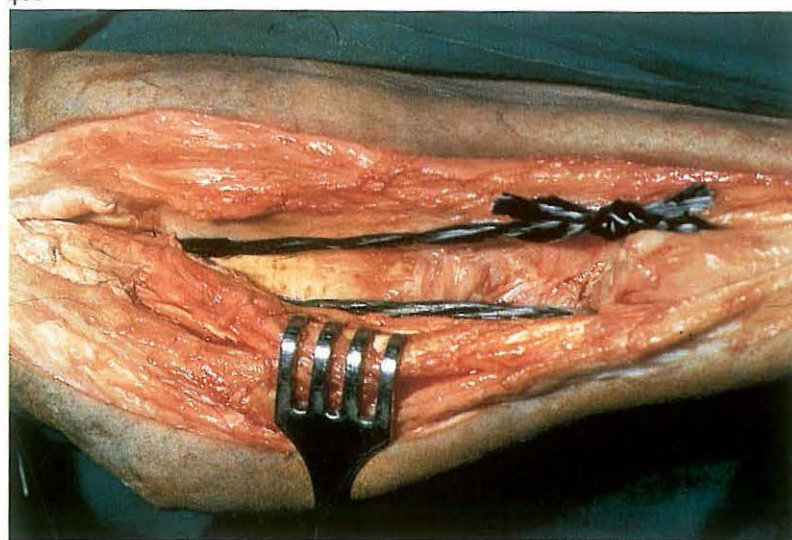
405



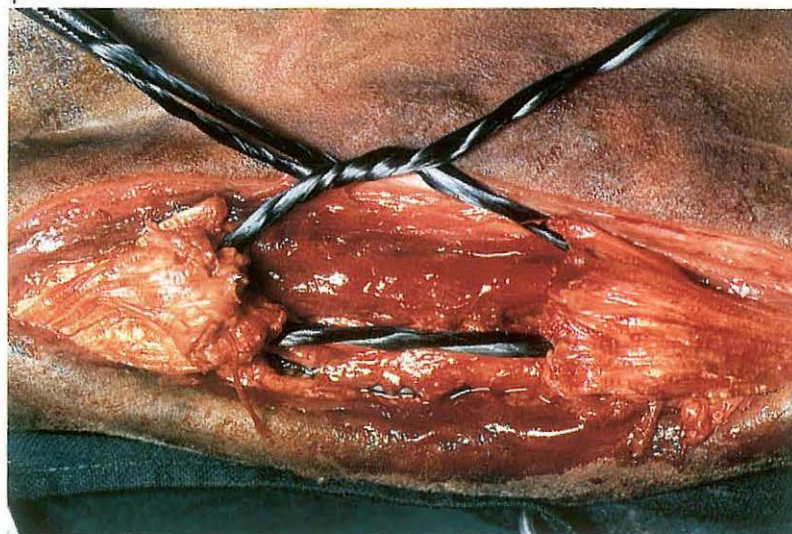
407



406



408



4 Tendon repair - carbon fibre implantation

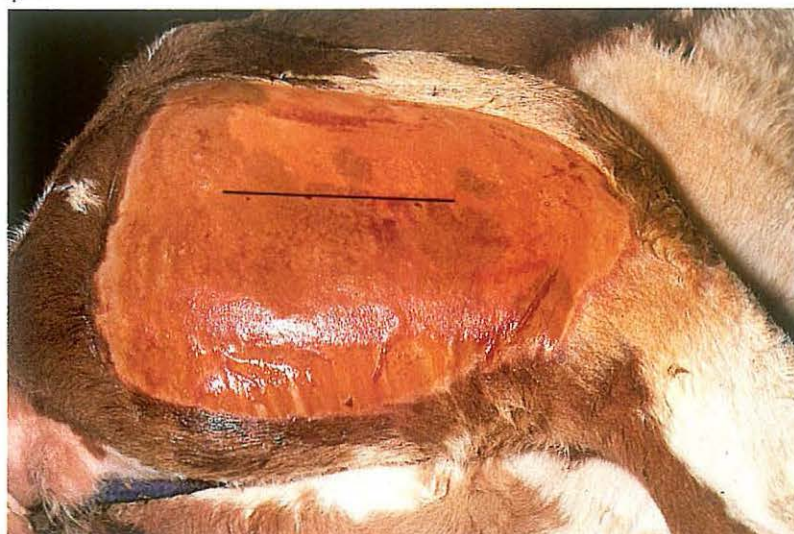Injuries of the digital flexor tendons are relatively common and can arise from (repeated) overloading or traumatic insult [405A]. Carbon fibre prostheses may be used to repair acute tendon rupture and also to bridge the defects which often remain in the tendon after conservative treatment. **Surgery.** The patient is positioned in lateral recumbency under general anaesthesia. An Esmarch's bandage may facilitate surgery. On the lateral aspect of the tendon, a longitudinal incision of about 15 cm is made through the skin, subcutaneous tissue and paratenon to expose the rupture site. In case of an unsatisfactorily healed rupture the inferior part of tendon and surrounding tissue is removed and the ends of the tendons are connected by carbon fibres [406]. In case of acute traumatic rupture, haematoma and severely damaged parts of both tendons are removed [407]. Vertical stab incisions are made in the tendon approximately 2 cm from each cut end. Sterilised carbon fibre bundles are passed through both tendon ends and tied together.

The carbon fibre bundle is pulled tight [406,408] so that the foot reaches a slightly flexed position. A vacuum drain is placed in the wound. The paratenon and subcutaneous tissue are closed separately in a simple continuous pattern and the skin with simple interrupted sutures, using synthetic absorbable material. Systemic antibiotics are administered. The wound is dressed with sterile gauze and the leg is cast in a slightly flexed position up to the level of the carpus or tarsus for about 6 weeks. After the plaster cast has been removed the limb is firmly bandaged for about 4 weeks. The hoof is shod by a shoe with extended branches. Plate 405B shows the result of case 405A, 5 months after surgery.

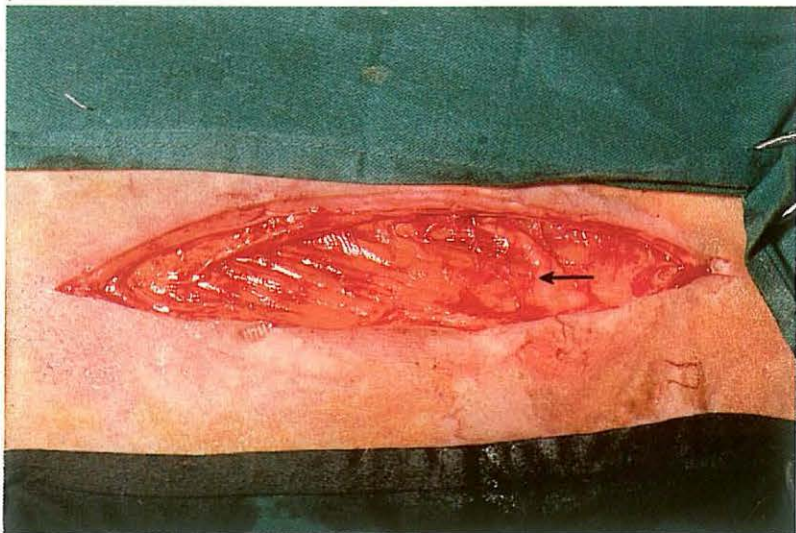
409



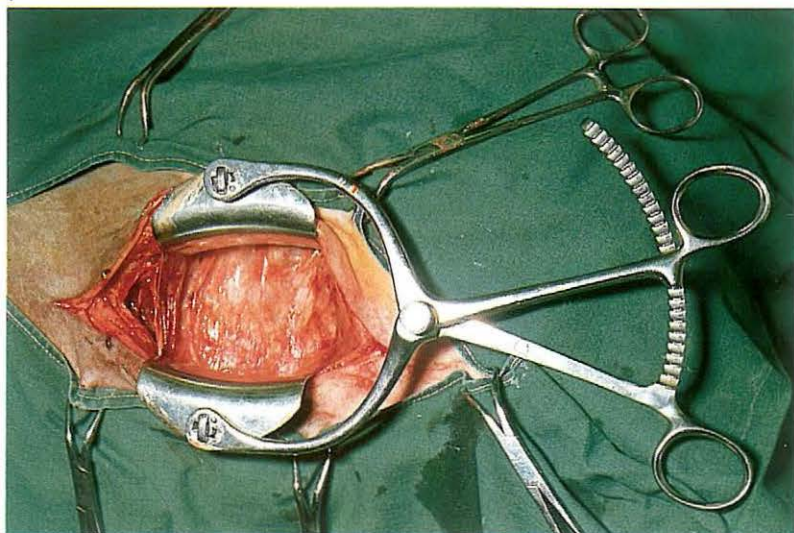
410



411



412



7-5 Tibial neurectomy in spastic paresis

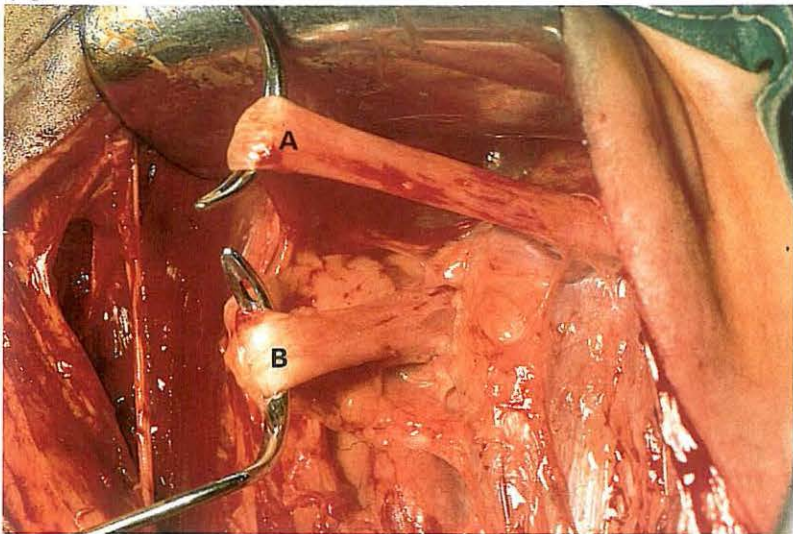
Spastic paresis in cattle is a progressive spastic lameness of one or both hindlimbs caused by increased muscular tone of the gastrocnemius (and to a lesser extent of other hindlimb muscles), due to a relative overstimulation of the γ -motor neurons of the tibial nerve [409].

Surgery. Surgical treatment consists of total or partial neurectomy of the tibial nerve. The operation is performed under caudal epidural analgesia (anterior block).

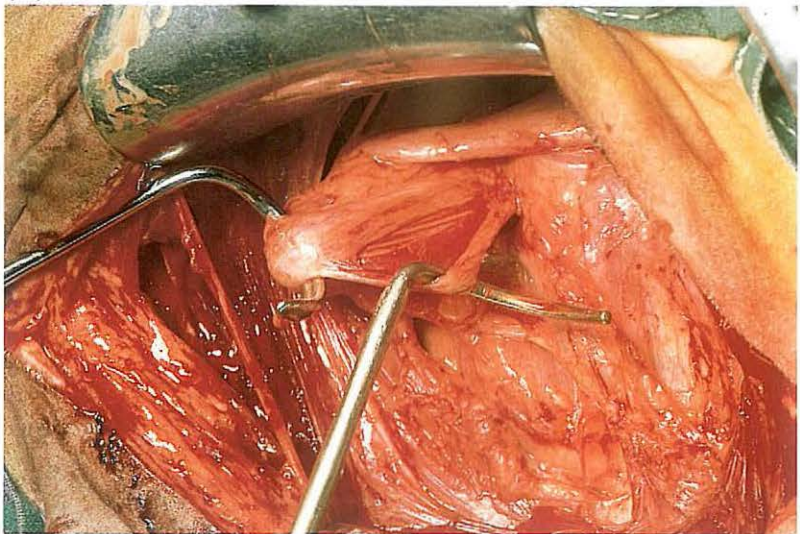
The site of the 15–20 cm skin incision is in the groove between the two heads of the biceps femoris, in the ventral half of the distance between the hip and knee [410]. It is recommended that this groove be marked on the standing animal, since it is much less obvious in the recumbent patient. After incising the skin and underlying gluteal fascia, a cutaneous branch of the tibial nerve is visible [411, arrow]. This branch courses between the two heads of the biceps femoris before emerging, and thus accurately indicates

the site of cleavage of the two heads of the biceps femoris, which are bluntly dissected and separated by a suitable wound retractor [412]. The peroneal nerve [413A] lies in the adipose tissue on the lateral aspect of the lateral head of the gastrocnemius. The tibial nerve [413B] is situated caudal to the peroneal nerve but the nerves can be reliably identified only by electrical or mechanical stimulation. Irritation of the peroneal and tibial nerves cause extension and flexion of the digit respectively. Depending on the animal's weight, a total or partial neurectomy of the tibial nerve is performed. Total neurectomy, in which a 3 cm segment of the tibial nerve is removed, is performed only in animals with a relatively low body weight. Partial neurectomy implies denervation of the gastrocnemius only. In this procedure the tibial nerve is divided into several bundles [414]. Electrical stimulation of the branches which innervate the gastrocnemius causes contraction of the Achilles tendon, without flexion of the digit. The branches which innervate the digital flexors are spared and only the branches supplying the gastrocnemius are transected [415]. The wound retractor is re-

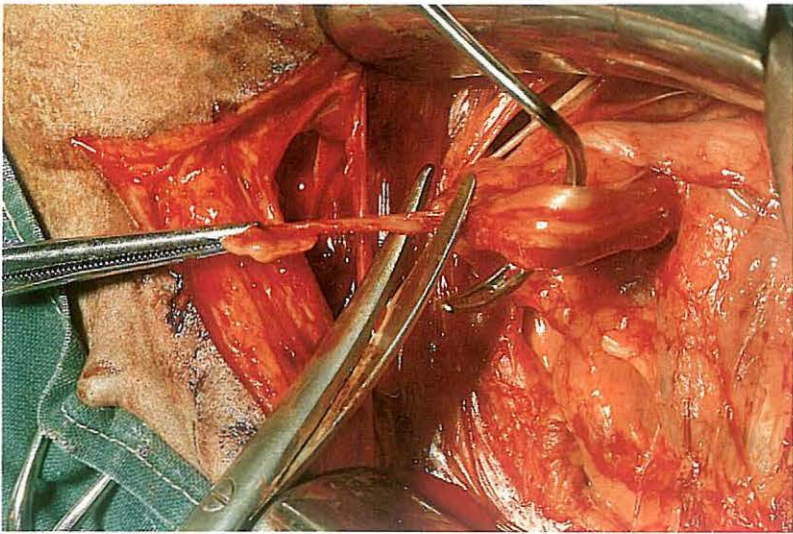
413



414



415

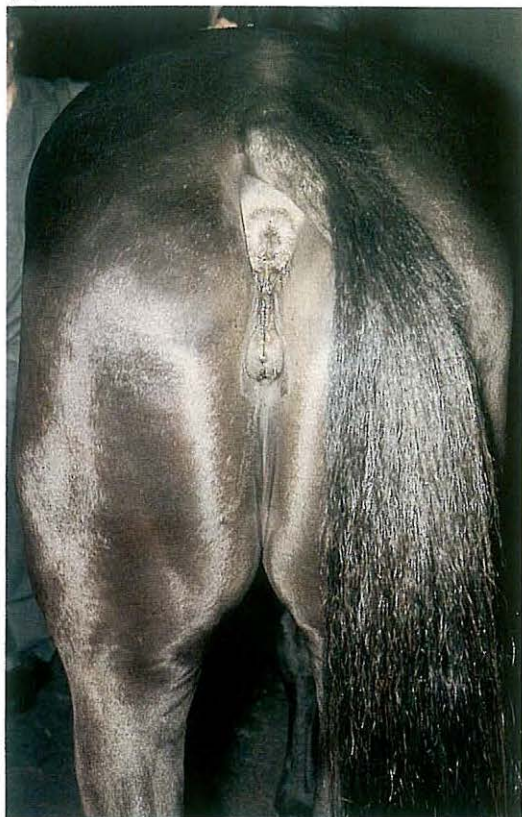

416

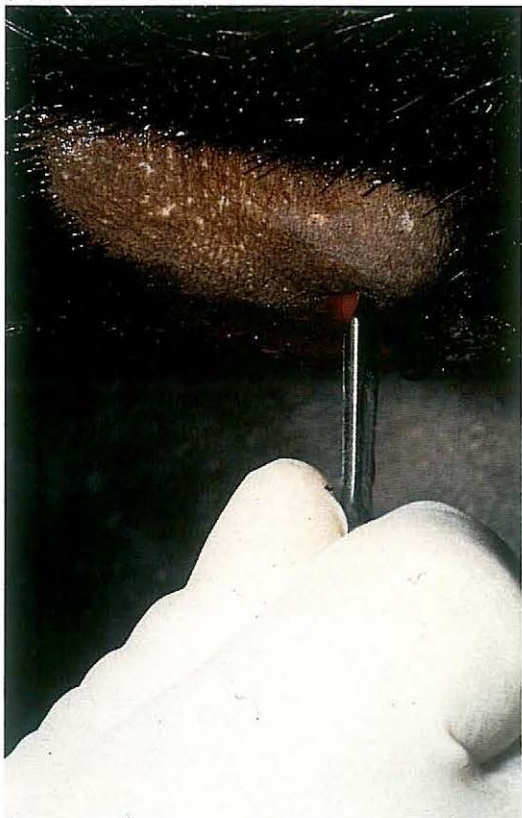


moved and the gluteal fascia is closed with a simple continuous suture, and the skin with simple interrupted sutures. Postoperatively, limited exercise should be given for several weeks. In most cases, total or partial neurectomy of the tibial nerve results in normal function of the hindlimb [416]. Very occasionally, rupture of the gastrocnemius muscle occurs.

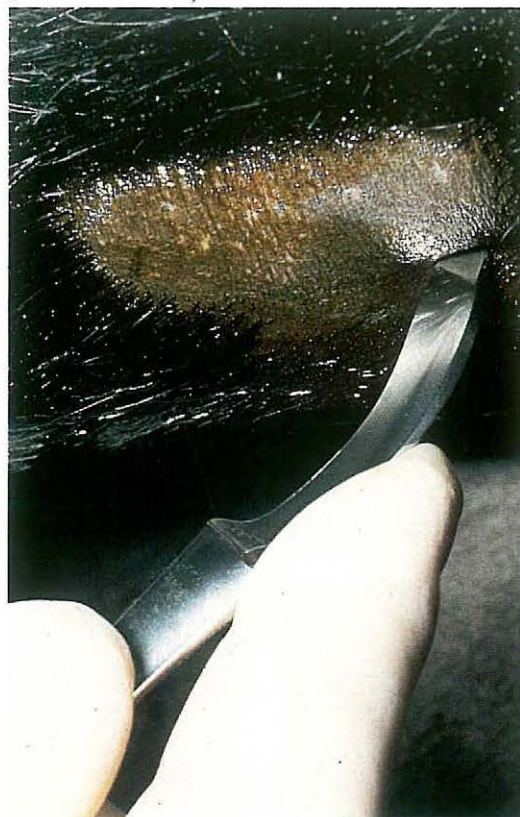417



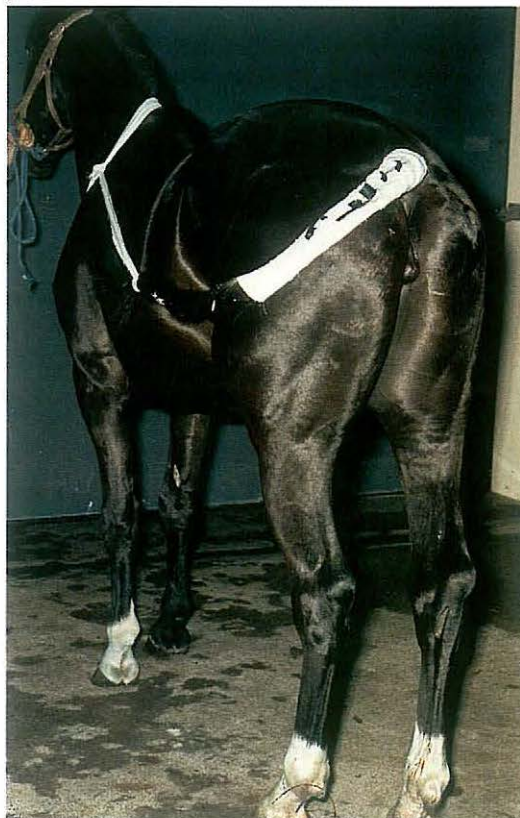419



418



420



7-6 Coccygeal myotomy

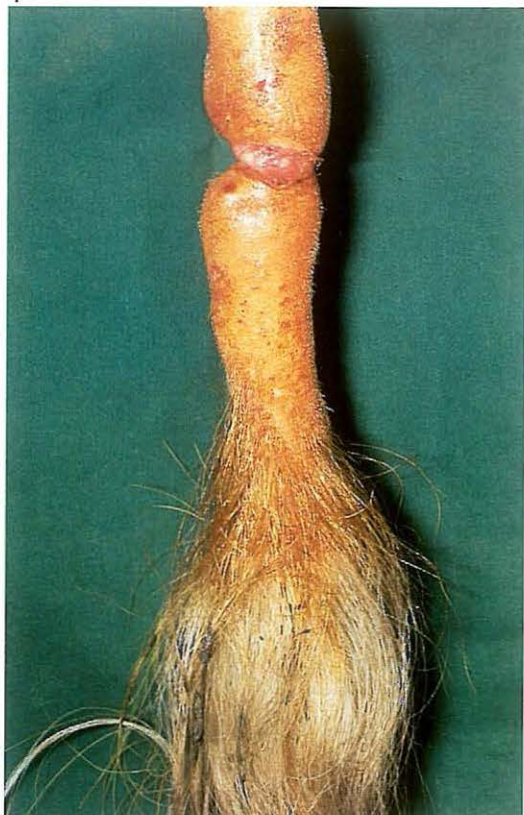
Cosmetic considerations may indicate severing of tail muscles in horses which carry their tail to the side [417].

Surgery. Physical restraint (including protection from kicking) and local infiltration analgesia is preferred to tranquilization and epidural analgesia, because the result of surgery should be judged immediately after the operation by hand-walking and trotting the horse.

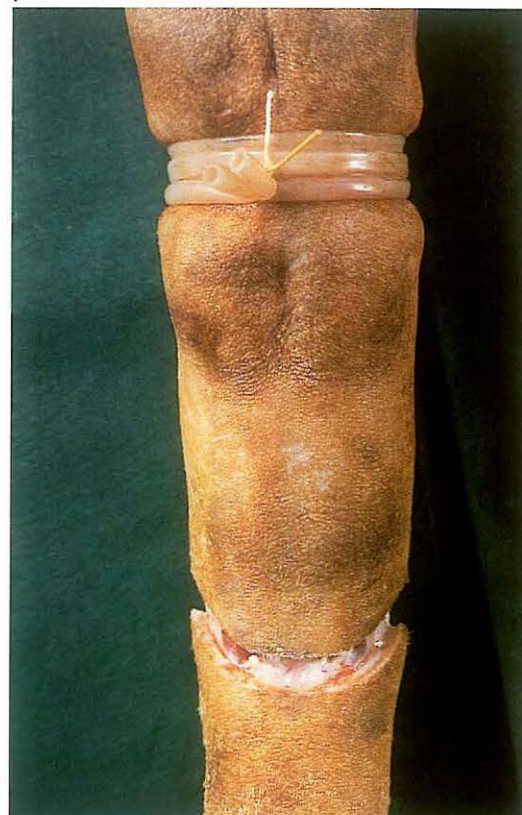The surgical area is located on the concave side (i.e. the same side as the direction of the deviation) of the base of the tail. A longitudinal stab incision is made with a pointed tenotome in the furrow between the dorsal and ventral coccygeal muscles [418]. The tenotome is inserted until the point contacts the lateral aspect of the vertebra, whereupon the cutting edge is rotated dorsally. The point is then advanced dorsally until it can be felt in the subcutaneous tissue, just lateral to the dorsal midline of the tail. The tenotome is carefully moved through a 90° arc so that the (lateral and medial) dorsal sacrococcygeus muscles are completely transected [419].

The skin incision is closed with a single suture. Postoperatively the tail should curve in the opposite direction. If this is not the case the tenotome should again be inserted in order to sever the remaining fibres of the dorsal coccygeal muscles. The tail is bandaged (braided with hair) and held drawn to the opposite side for one week [420].

421



422



7-7 Amputation of the tail

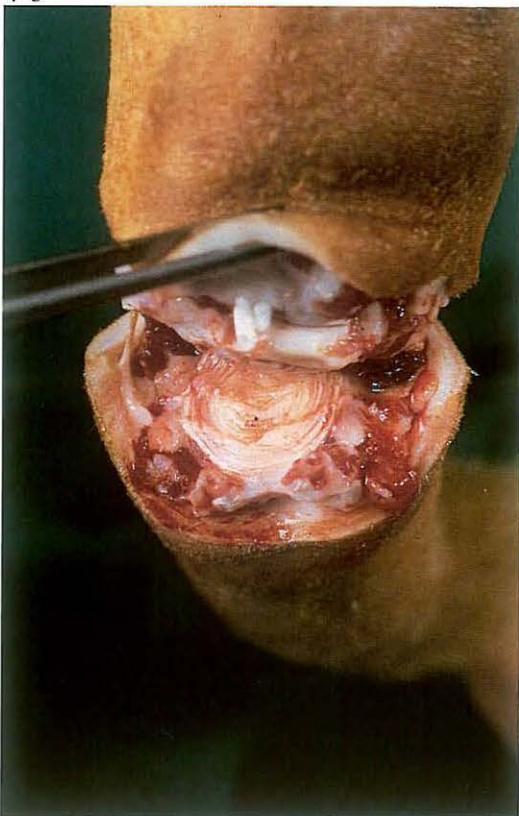
Docking may be indicated on medical grounds in case of injury, necrosis or neoplasms of the tail [421].

Surgery. Surgery is usually performed in the standing animal. Analgesia is achieved by infiltration or caudal epidural analgesia (posterior block). A tourniquet is placed proximally to the site of amputation. In horses the hairs are reflected forward. The exact point of disarticulation is determined by careful palpation of the tail as it is manipulated and/or by inserting a needle in an intervertebral space. Just distal to this site a dorsal and ventral curvilinear skin flap is created [422]. After reflecting one flap, disarticulation is performed by transection through the intervertebral disc [423].

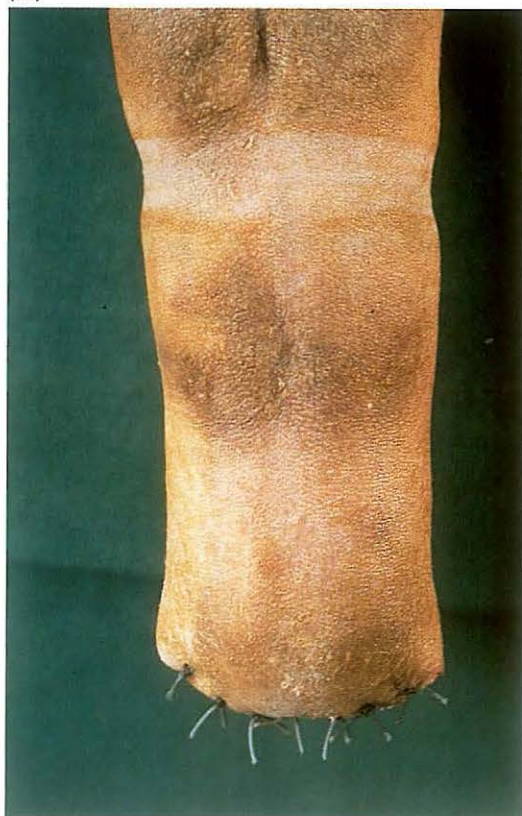Vessels are ligated. Haemostasis is checked by loosening the tourniquet.

The skin is closed with interrupted sutures [424].

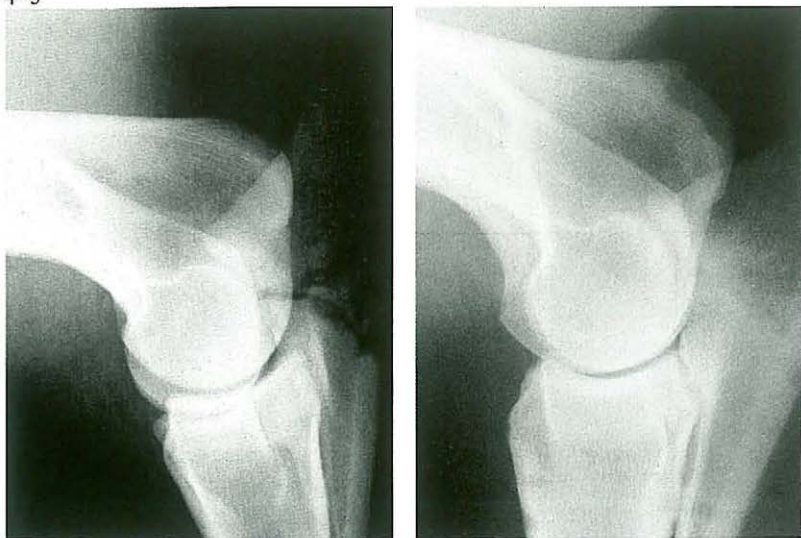423



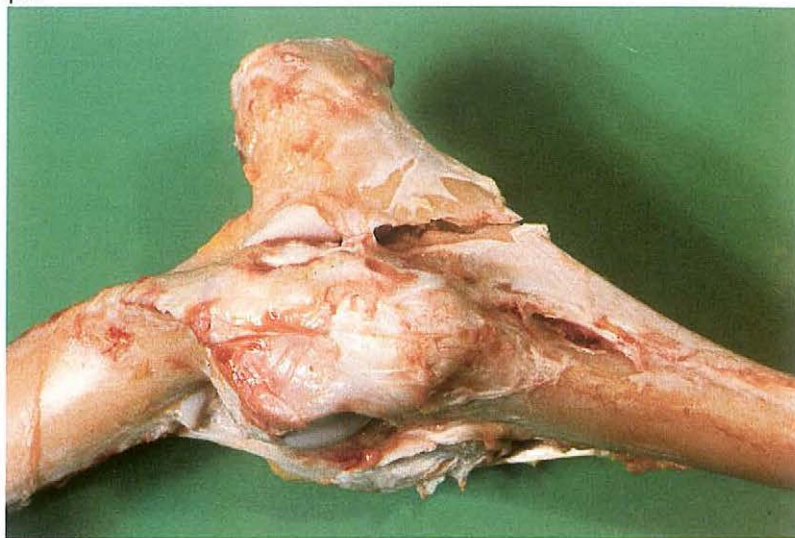
424



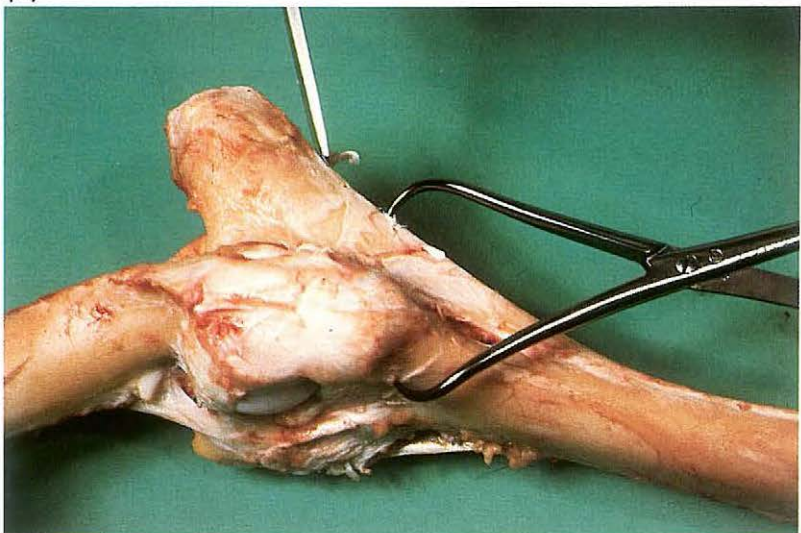
425



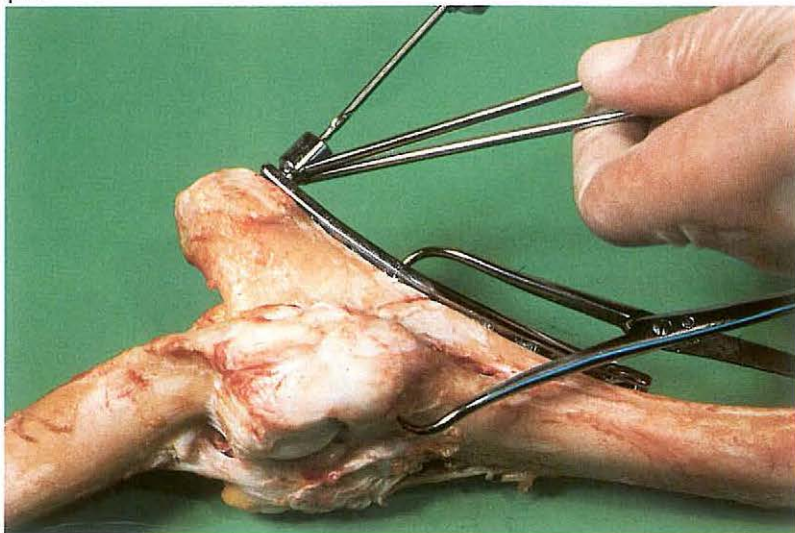
426



427



428



7-8 Plate osteosynthesis of ulna fracture

Fractures of the ulna occur due to external trauma to the elbow and are relatively common in younger horses. The most common fracture splits the ulna transversely through the semilunar notch and involves the elbow joint [425A, 426].

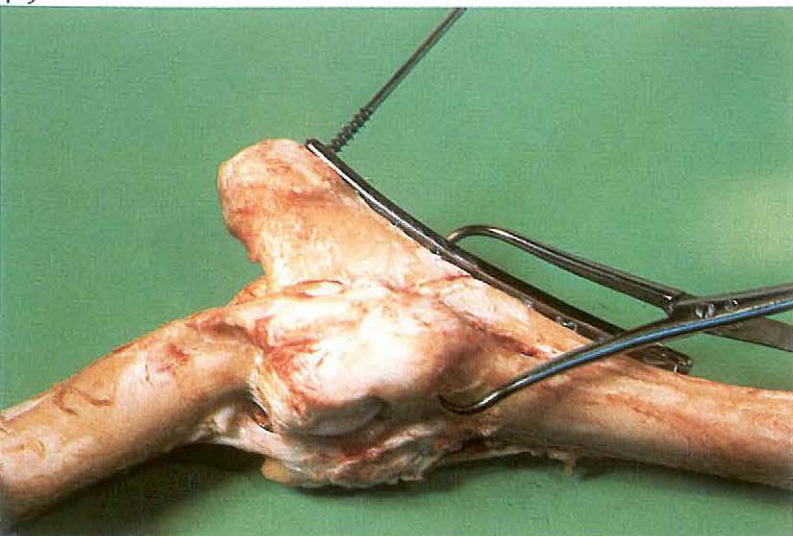
Displaced intra-articular fracture of the ulna must be accurately reduced and immobilized to prevent non-union and osteoarthritis. A contoured Dynamic Compression Plate (DCP), on the volar surface of the ulna, acts as a tension band fixation device.

Surgery. The patient is placed in lateral recumbency under general anaesthesia. The skin is incised from the olecranon to mid-radius on the latero-volar aspect; the proximal portion of the skin incision curves cranially so that it does not lie directly over the point of the olecranon. Approach to the caudo-lateral aspect of the ulna is between the muscle bellies of the ulnaris lateralis and the ulnar head of the deep digital flexor.

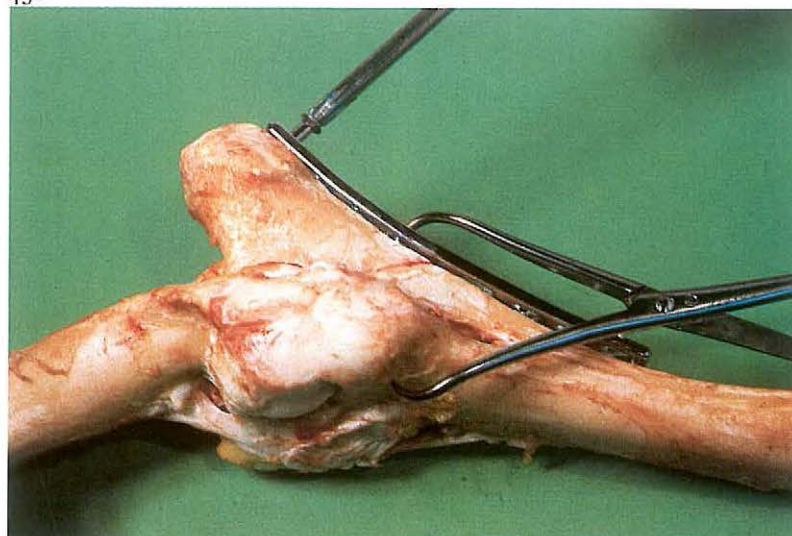
After reposition the fracture fragments are fixed with reposition forceps. The proximal fracture fragment is fixed to the distal part of the fracture with a DCP and cancellous and cortical screws. The length of the plate depends on the size of the patient. An 8 hole slender plate is used for demonstration of the technique of osteosynthesis. The sharp edge of the volar surface of the ulna is removed with a bone chisel to facilitate the placing of the plate [427]. The proximal fracture fragment is fixed to the plate with 2 or 3 cancellous screws. After drilling a hole with the 4.5 mm drill and drill guide [428], the cancellous tap is inserted through the first hole and the threads tapped [429]. The plate is loosely attached to the bone by inserting the first screw [430]. The second and third screws are placed, and all three are tightened. The other half of the compression plate has a screw hole design (with the exception of the hole closest to the fracture site) which permits the sliding of the plate and compression of the fracture during screw tightening.

The distal end of the ulna, together with the proximal end of the radius, is

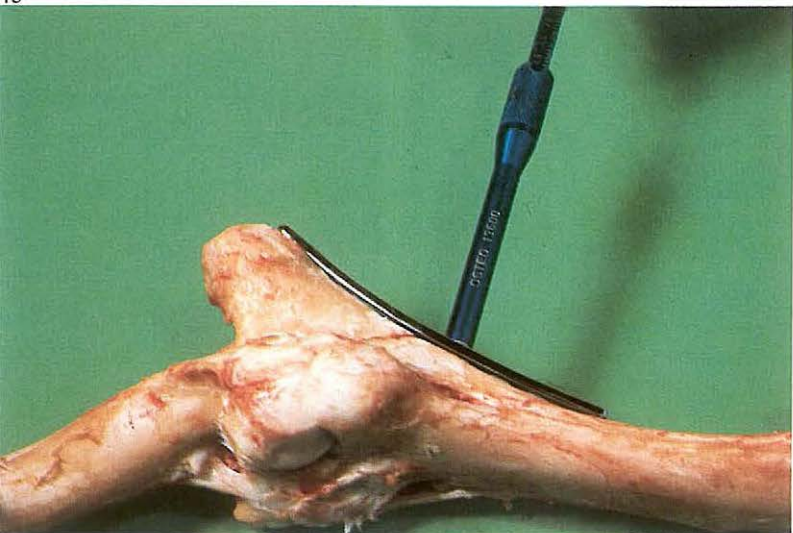
429



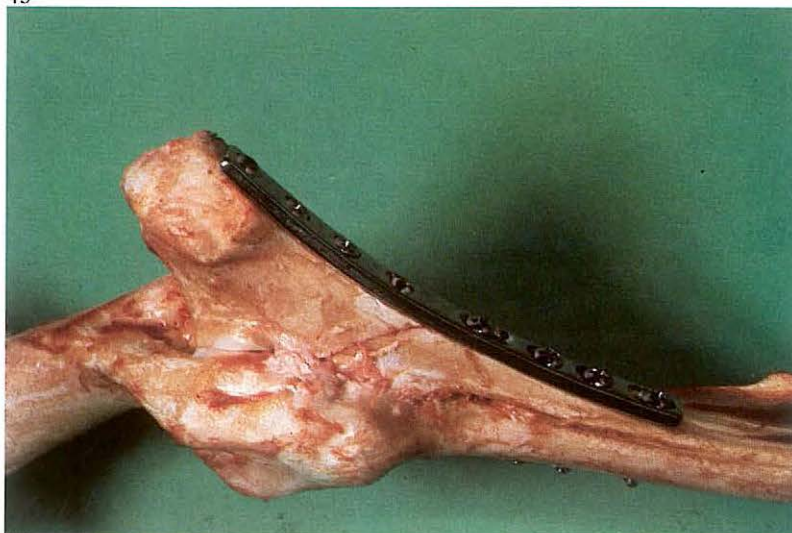430



431



432



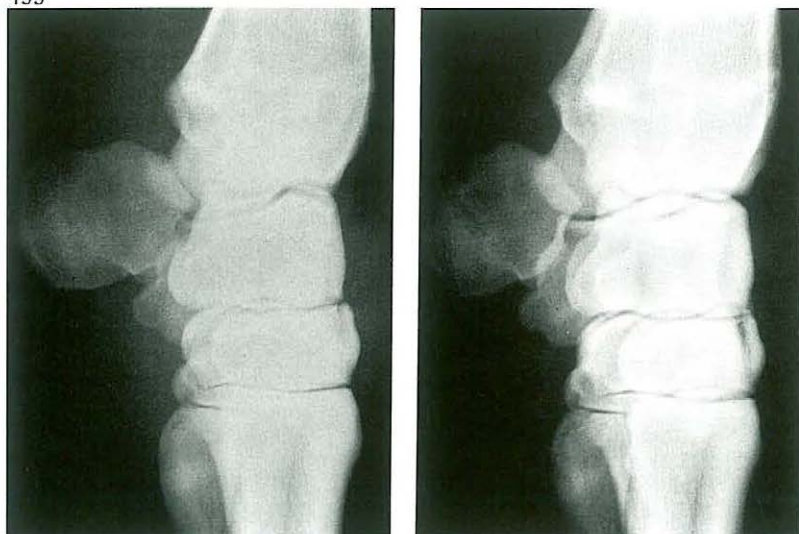
fixed to the plate with a cortical screw in the first screw hole – the adapting hole – near the fracture space. The other screws, the so-called load screws, are placed starting at the end of the plate. Holes for these cortical screws are drilled with the 3.2 mm drill and guide. To obtain fracture compression when tightening the screws, the screws are sited at the end of the oblong screw holes which is farthest from the fracture line. The plate is fixed to the bone with screws some 2 mm longer than measured [431] so that about $1\frac{1}{2}$ threads protrude on the opposite site of the radius [432].

Radiographic monitoring during surgery should be used for checking reduction and exact positioning of the screws in the olecranon. A vacuum drain is placed into the wound.

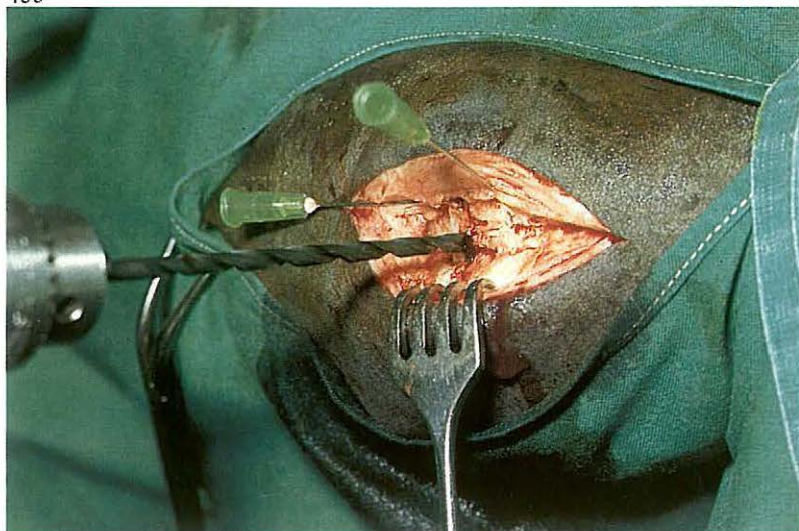
Muscle, fascia and skin are sutured with absorbable synthetic material in an interrupted suture pattern. Systemic antibiotics are administered. The drain is removed 2–3 days after surgery.

The patient is still rested until the fracture heals. Plate 425B shows the healed fracture after removing the plate.

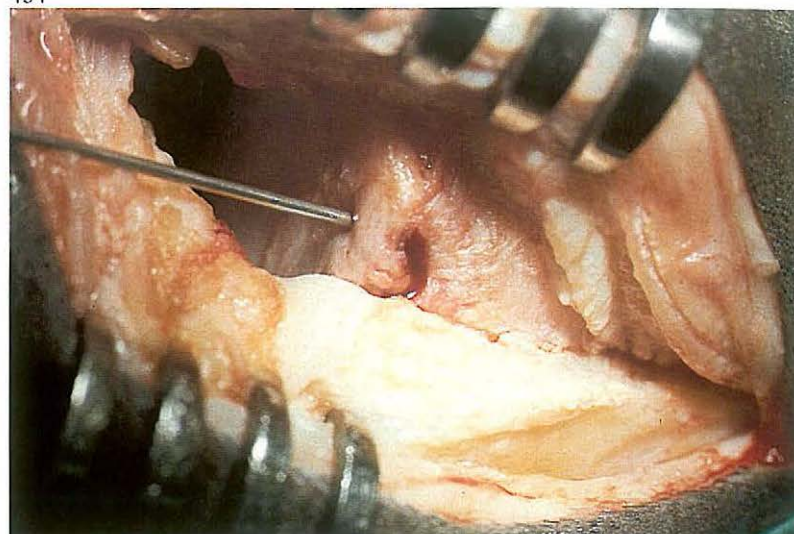
433



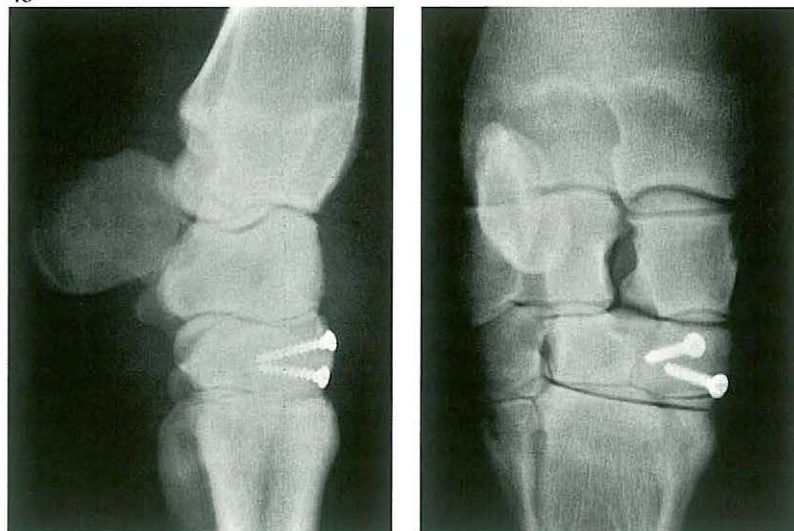
435



434



436



7-9 Arthrotomy in carpal bone fracture

Injuries of the carpal bones are common in horses, especially racing thoroughbreds. Radial carpal bone fractures are usually small chip fractures and third carpal fracture may result in a large slab, usually on the dorsal surface. When dislocation of the fragment is minimal, the fracture may be envisaged clearly only in oblique radiographs [433]. The only effective therapy for displaced fractures is surgical removal of the small fragments or fixation of the larger fragment.

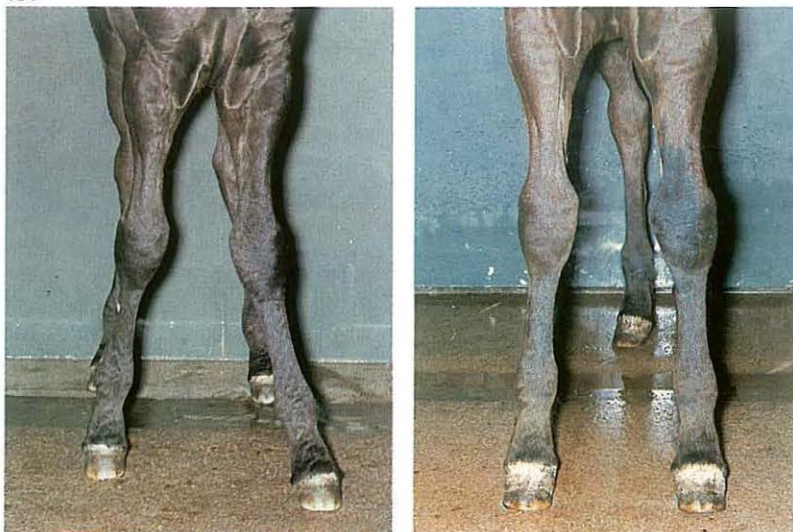Surgery. The horse is placed in right or left lateral recumbency under general anaesthesia, depending on the fracture site. The carpal joint is slightly flexed, and a vertical (curvilinear) incision is made through skin, subcutaneous structures and joint capsule, avoiding tendons and tendon sheaths. Retraction of the joint capsule is necessary to be able to envisage the exact reposition of the fragment and removal of possible debris [434]. The site and direction of the screws can be established using hypodermic needles

and intra-operative radiography. In this case the fragment of the third carpal bone was fixed with two 3.5 mm navicular lag screws [435]. The joint cavity is flushed with sterile physiological saline. The joint capsule (without penetrating synovial membrane), the dorsal carpal ligament (extensor retinaculum), subcutaneous fascia and the skin are sutured separately with absorbable synthetic material. The limb is firmly bandaged from hoof to mid-radius for about 3 weeks (a plaster cast is used only in exceptional cases). Systemic antibiotics may be given.

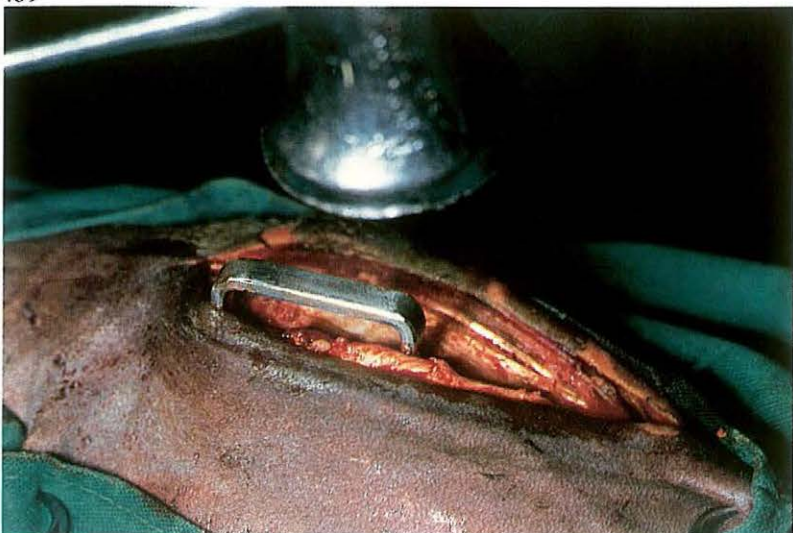Radiographic control is carried out during convalescence; plate 436 shows the situation 6 weeks postoperatively.

Prognosis depends on the possible development of carpal arthrosis.

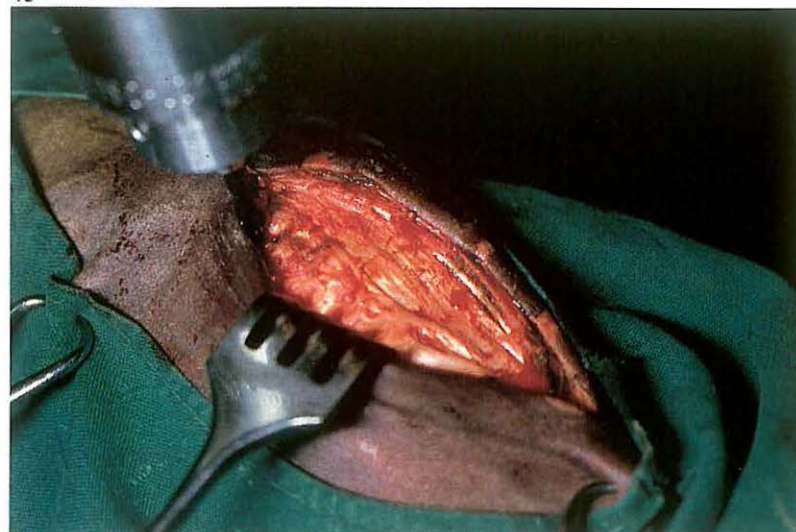
437



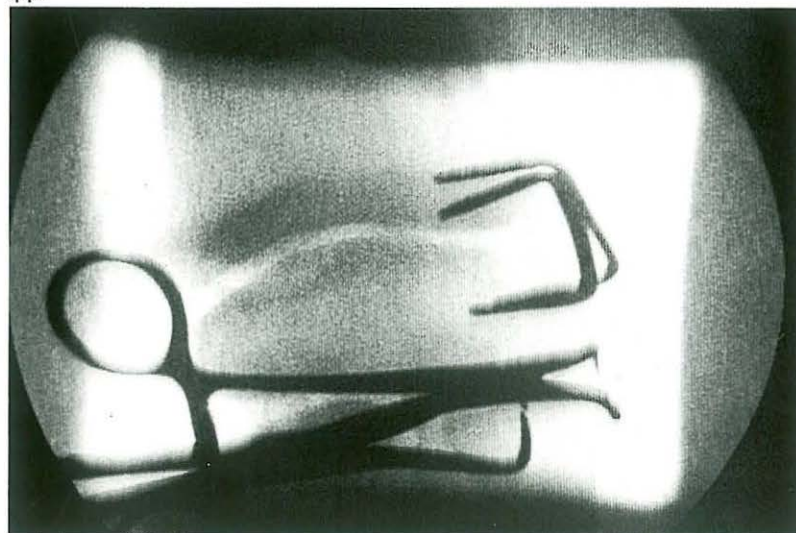
439



438



440



7-10 Correction of valgus deviation

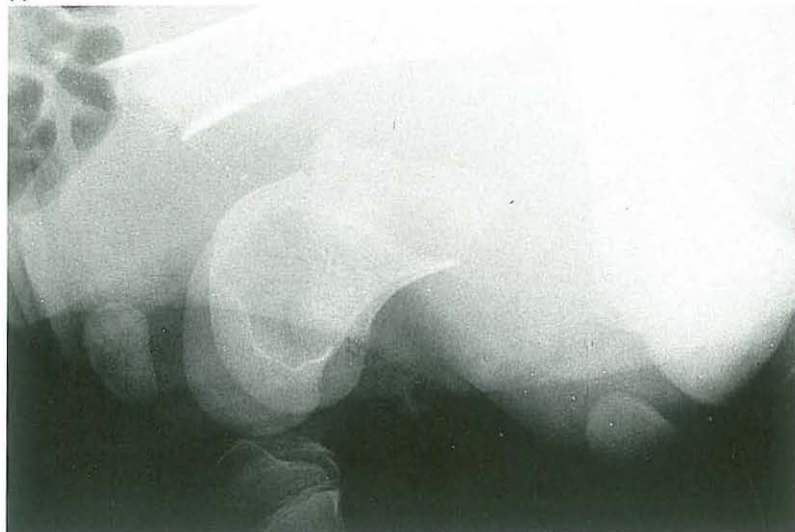Angular deformity is a common disorder afflicting the distal radius, tibia, and metacarpal/metatarsal bones in the young animal. One of the causes of the deformity is retardation of enchondral ossification on one side (in most cases the lateral side) of the growth plate. In this case the affected foal shows an abnormal curvature of the distal radius, causing the limb distal to that point to deviate laterally [437A]. If conservative treatment fails, surgical intervention is necessary. The aim is to reduce growth of the growth plate on the convex side by means of staples or screws and wire.

Surgery. The patient is placed in lateral recumbency under general anaesthesia. The use of an Esmarch's bandage and a pneumatic tourniquet facilitates the surgery. A 5 cm incision is made through skin, subcutaneous tissue and deep fascia from 2 cm proximal to the medial radial epicondyle to almost the level of the radiocarpal joint. The growth plate is located by using a hypodermic needle or by radiographic monitoring. The size of the

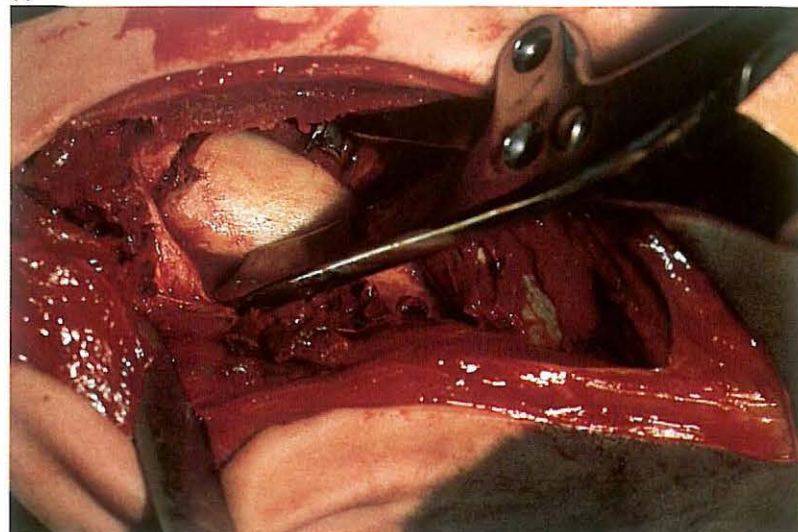
stainless steel staple depends on the size of the patient. Holes (3 mm diameter, 2.5 cm deep) are drilled through the unincised periosteum proximal and distal to the growth plate to accommodate the staple [438]. The staple is inserted with a hammer and driver [439]. The second staple is placed approximately 20 mm cranial or caudal to the first staple, and at an angle of some 30° to it [440].

The subcutaneous tissue and deep fascia are sutured in a continuous pattern with synthetic absorbable material, and the skin is closed with simple interrupted sutures. A sterile dressing is placed over the wound and an elastic bandage is applied for about 1 week. Exercise is limited to stall rest until the limb is completely straight [437B]. It is important to remove staples before overcorrection occurs.

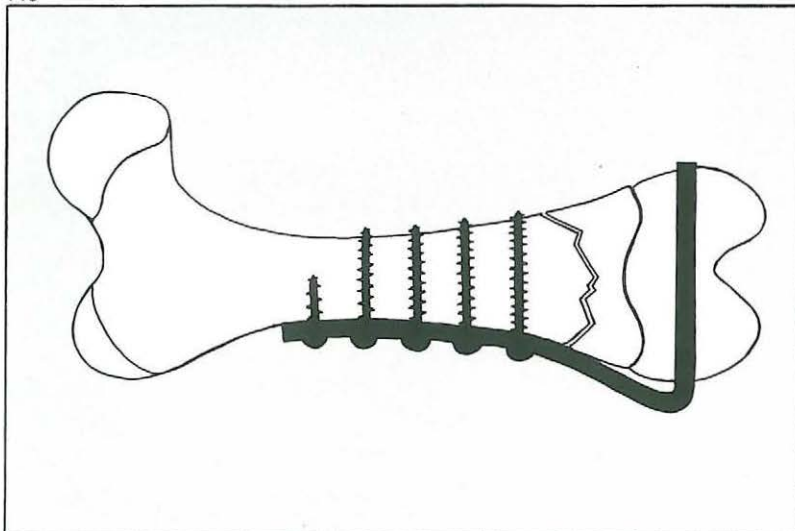
441



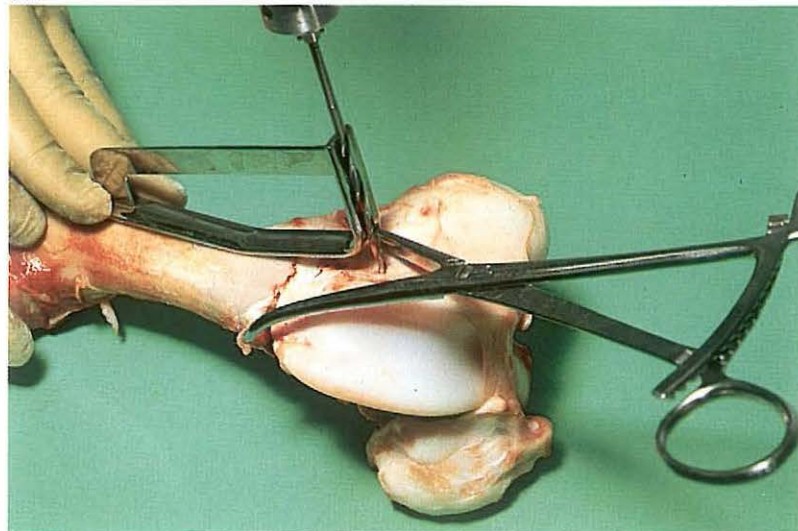
442



443



444



7-11 Plate osteosynthesis of supracondylar fracture

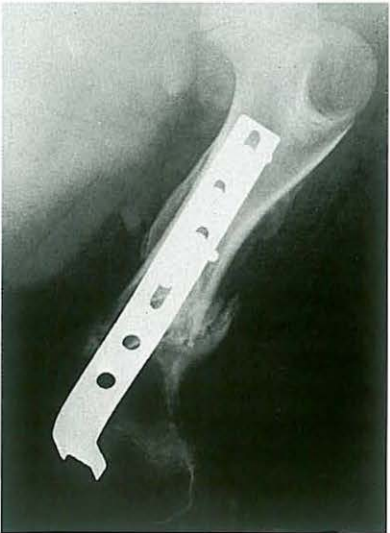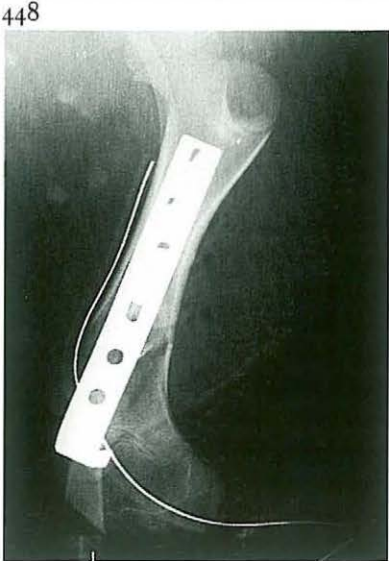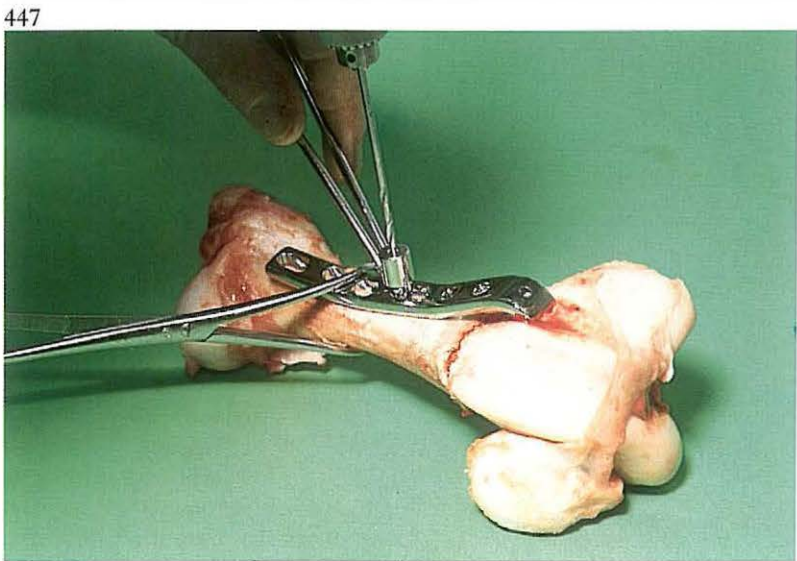
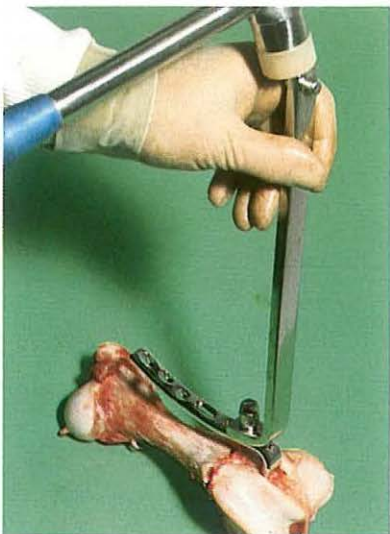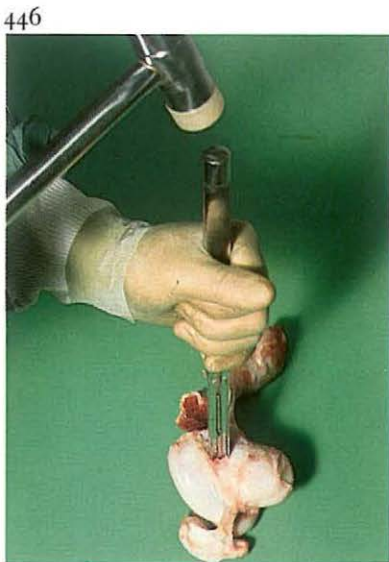
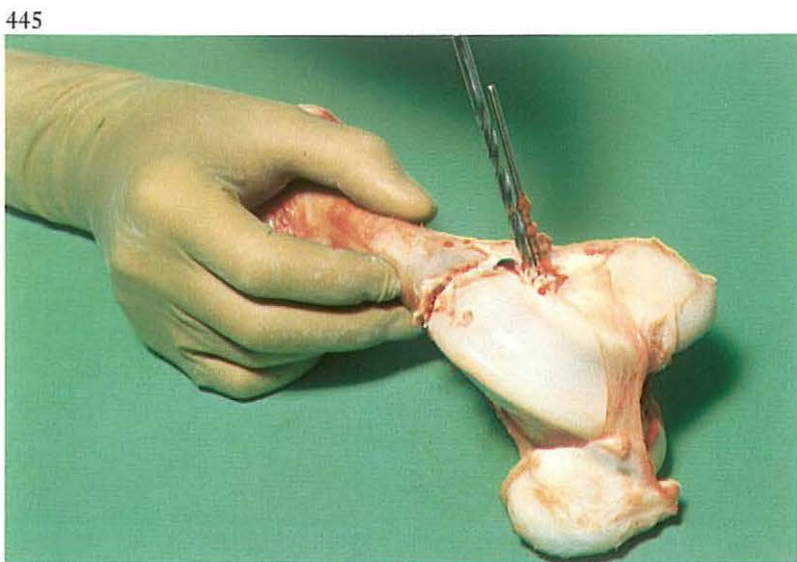
Supracondylar femur fractures occur in foals, ponies and newborn calves [441] (the latter are often delivered in posterior presentation with the help of a calf extractor).

Supracondylar femur fractures are not suitable for the usual osteosynthesis techniques, because of their form and the short, comparatively wide marrow cavity. It is possible, however, to treat supracondylar femur fractures in young animals, especially those with a low bodyweight, with condyle plates fabricated for human use [443].

Surgery. Open reduction is performed in lateral recumbency under general anaesthesia or caudal epidural analgesia (anterior block). After a suitable skin incision the tensor fasciae latae is separated from the biceps femoris. The vastus lateralis is split in the direction of its fibres. If the femoro-patellar joint capsule is not already ruptured, arthrotomy exposes the lateral surface of the lateral ridge of the trochlea.

Reposition with the help of reposition forceps [442] is possible only if dislocation of the fracture fragments and contraction of adjacent musculature is not severe. Reposition is more difficult or even impossible in fractures older than 48 hours. If reposition is impossible even after administration of muscle relaxants, the distal end of the proximal fracture fragment is shortened with rongeurs. Reduction of the fragments is maintained with reposition forceps [444].

The distal fracture fragment (condyle) is fixed to the proximal fracture fragment using a condylar plate (DCP) [443]. These plates are available with different angles, and the appropriate plate (usually with an angle of 90° , 95° or 100°) is chosen. With the help of the angle gauge, a Steinman pin or a drill is placed in the distal fracture fragment [444]. The purpose of this pin is to indicate the direction of the two drill holes [445] and to guide the chisel, which has a guide hole [446a]. The stem of the plate, the length of which depends on diaphyseal length, is contoured to the correct shape indicated by a bending template. The transverse part of the plate (the length

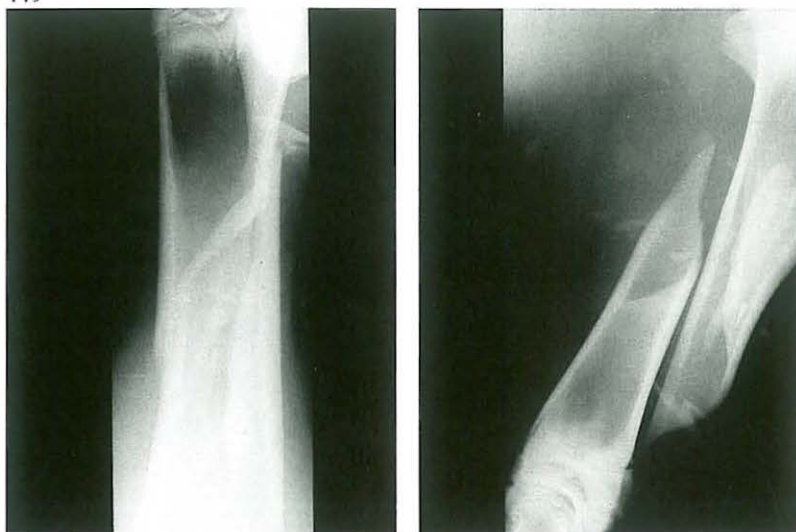

of which depends on epiphyseal diameter) is inserted using the impactor, which is temporarily attached to the plate [446B]. The stem of the plate is then fixed to the metaphysis and diaphysis using (cancellous and) cortical screws [447].

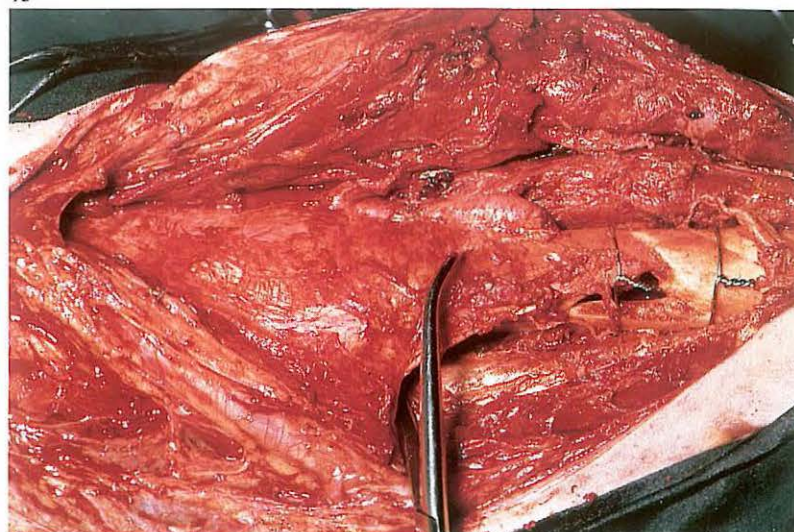
A vacuum drain is placed in the wound. The femoro-patellar joint capsule, muscle layers, subcutis and skin are closed separately with synthetic absorbable suture material. Systemic antibiotics are administered. Weight-bearing on the treated leg after recovery from anaesthesia is permitted. The drain is removed after 3 days.

Radiographic study is conducted immediately postoperatively [448A], and thereafter every 2 weeks. Because growth in the distal growth plate is stunted by the condyle plate, it is important to remove the plate as soon as sufficient callus has formed [448B].

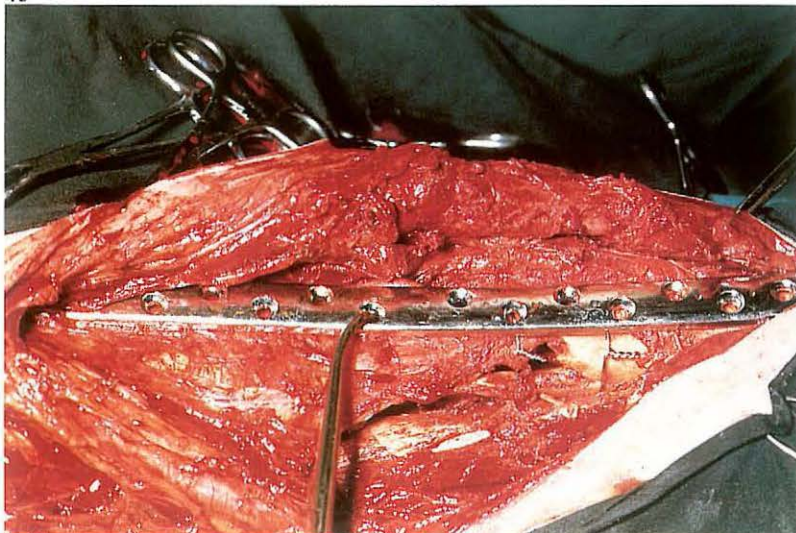
449



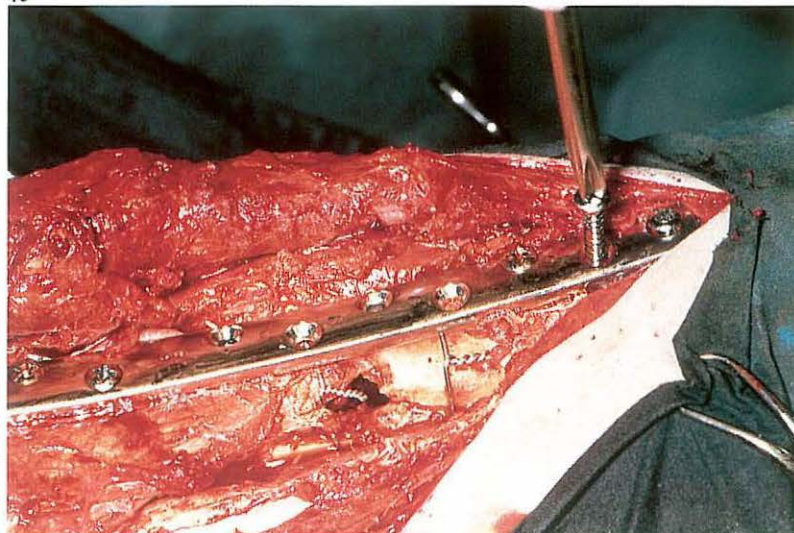
450



451



452



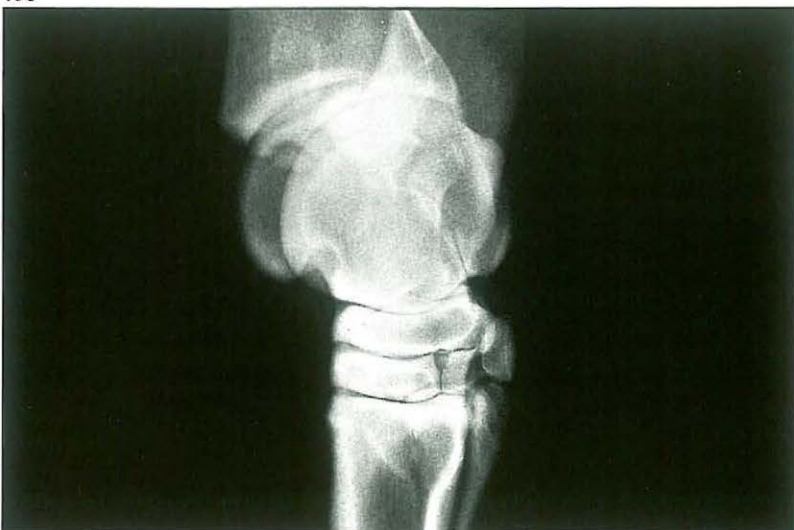7-12 Plate osteosynthesis

Plate fixation of long bone fractures of large animals is – since the walking cast technique (see 7-17) – used mainly in treating radius-ulna and tibia fractures and seldom in humerus and femur fractures. A tibial diaphyseal fracture in a calf [449] is used to show a plating technique that may be used. *Surgery.* The patient is positioned in lateral recumbency with the affected limb down. A curvilinear incision through skin and subcutaneous tissue is made on the medial aspect of the tibia. The convexity of the incision is directed caudally. The straight incision through the fascia is made carefully, avoiding the medial saphenous vein, artery and nerve. Deep fascia is dissected from the fractured tibia as far as both epiphyses. Blood clots are removed. After reposition of the fracture fragments and securing with a bone holding forceps, cerclage wiring is employed as a (temporary) fixation method prior to definitive stabilisation with plate and screws [450]. Long bone fractures of large animals require a broad plate. In general, the

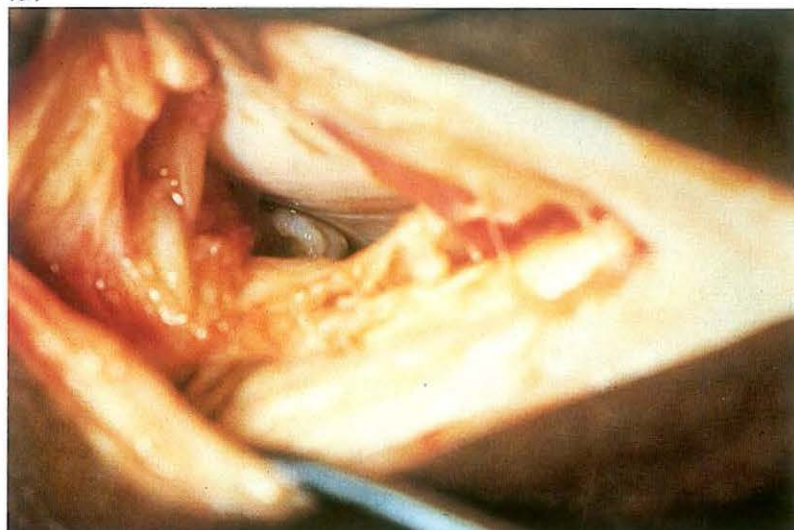
longest possible plate is used. Compression plate osteosynthesis is preferred. Compression is achieved with the help of the tension device or a Dynamic Compression Plate. The plate is contoured and then placed over the bone, secured with a bone holding forceps, and fastened with cortical bone screws [451, 452] (see also 7-8). Defects at the fracture site should be filled with cancellous bone graft. Before closing, a vacuum drain is put into the wound for 2–3 days.

Fascia, subcutaneous tissue and skin are closed with interrupted sutures using synthetic absorbable material. Systemic antibiotics are administered. In large animals osteosynthesis must in most cases be protected with a plaster cast or Thomas splint.

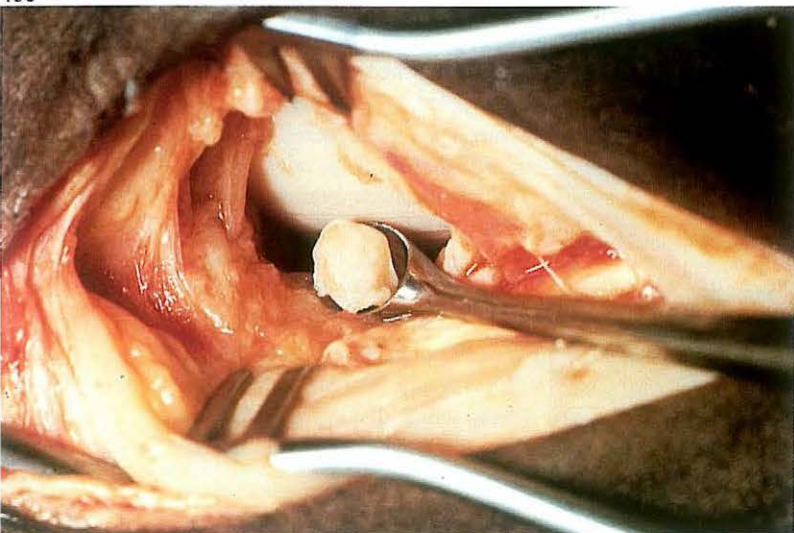
453



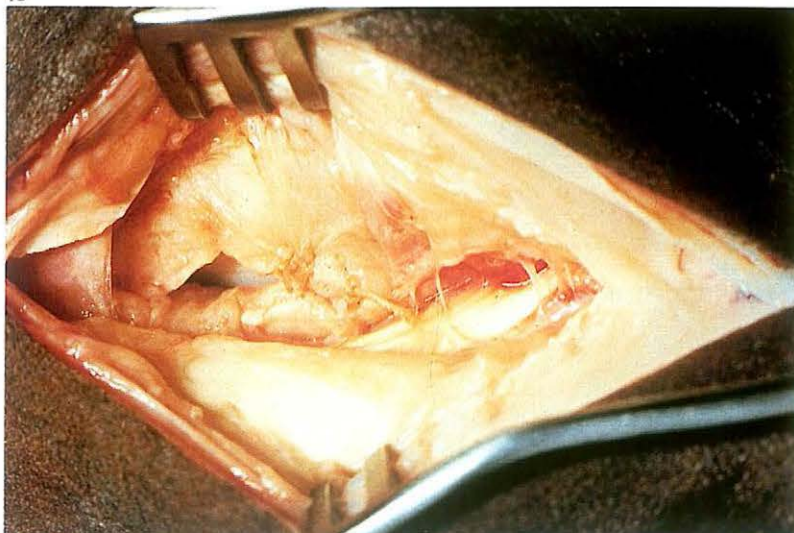
454



455



456



7-13 Arthrotomy in osteochondrosis

Tibio-tarsal joint arthrotomy in horses may be indicated in cases of chip fracture and osteochondrosis. Lameness and/or severe hydarthrosis may be indications for removal of osteochondrotic fragments and/or curettage of lesions.

Surgery. The tibio-tarsal joint can be approached from the craniolateral or craniomedial side. The craniolateral approach is indicated in case of osteochondrosis at the intermediate ridge of the tibia [453]. The horse is positioned in lateral recumbency under general anaesthesia with the affected leg uppermost.

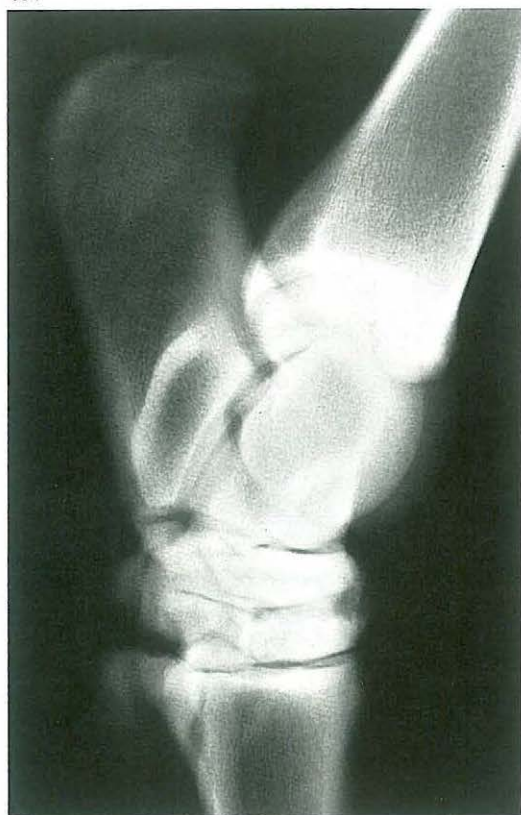
A 7 cm skin incision is made from the level of the lateral malleolus distally and runs lateral to the digital extensor tendon. Superficial and deep fascia are incised avoiding damage to blood vessels. The joint capsule is most easily entered just over the lateral trochlea of the talus. After retracting the wound edges and slight flexion of the joint the intermediate ridge becomes

visible [454]; suction of synovial fluid facilitates the exposure. Removal of osteochondrotic fragments is often accomplished using a Brun curette [455], but occasionally the fragment must be freed with the help of an osteotome. Subsequent curettage of the base of the lesion depends on the findings; flushing of the joint cavity is then obligatory.

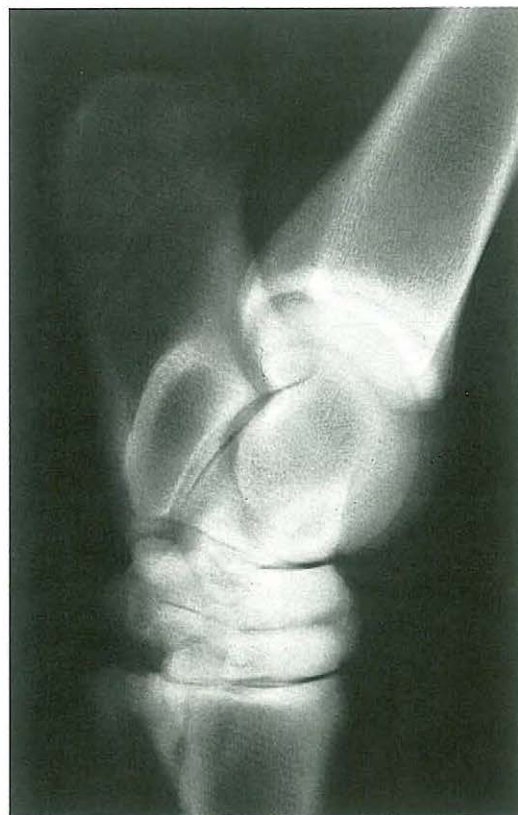
Closure is performed in four layers: the fibrous part of the capsule [456], deep fascia, subcutaneous fascia and skin, all in an interrupted pattern using synthetic absorbable material. A firm (possibly elastic) bandage is applied.

After 1 week the bandage is changed. In cases of severe postoperative joint distension, synovial fluid is aspirated.

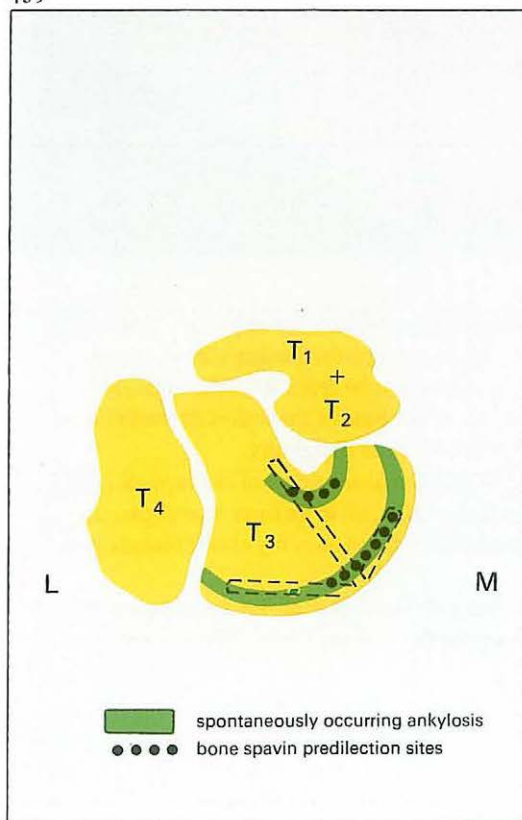
457



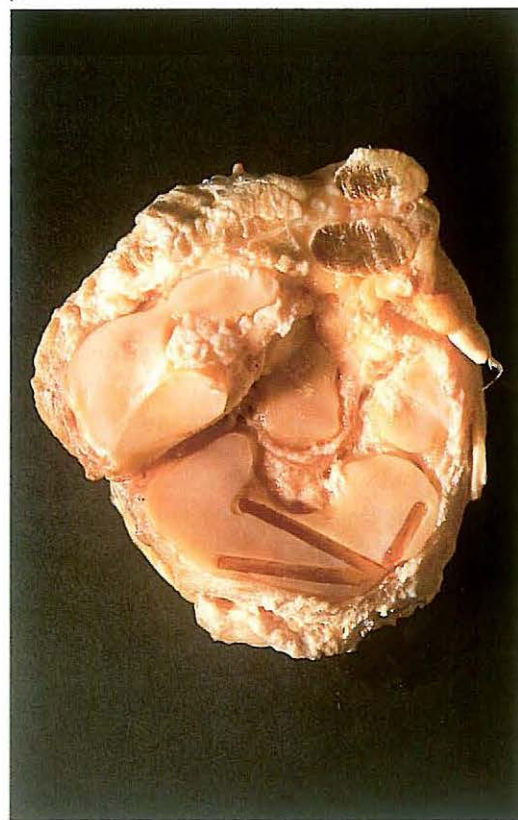
458



459



460



7-14 Arthrodesis of the distal intertarsal joint in the horse

Spavin is an osteoarthritis of the distal tarsal joints, in which the changes are localised to the central tarsal bone (Tc), third tarsal bone (T₃) and the proximal articular surface of the third metatarsal bone (Mt₃). Arthrodesis of the distal intertarsal joint (DIT) is one of the possibilities for treatment of bone spavin, and is especially indicated in cases in which the osteoarthritic changes are characterized mainly by osteolysis [457].

The principle of arthrodesis is that surgical destruction of parts of the joint surfaces of two apposing bones of a joint with restricted movement induces a rigid ankylosis, as shown in the radiograph of a DIT six months after arthrodesis [458]. In this operation the drilling of three holes destroys tissue only in the predilection sites of the frequently occurring spontaneous ankylosis [459, 460].

Surgery. The horse is anaesthetized in lateral recumbency with the affected limb down. A skin incision is made over the dorso-medial part of the DIT. Care should be taken to avoid the saphenous vein. A cunean tenectomy, in which 2–3 cm of the tendon is excised, is performed [461]. The DIT is identified by inserting four needles of different shape [462].

First needle: dorso-medial in the DIT at the site from which drilling will later begin.

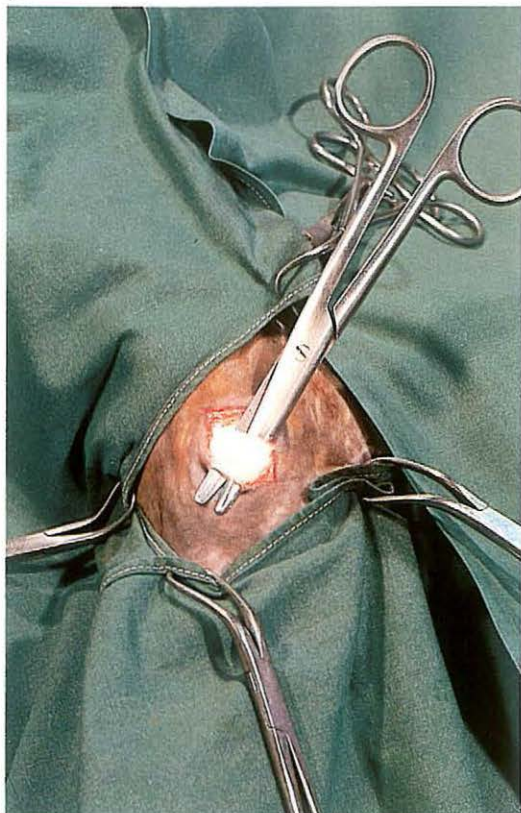
Second needle: medial in the DIT between Tc, T₃ and T₁+2.

Third needle: dorsal in the DIT just lateral to the midline.

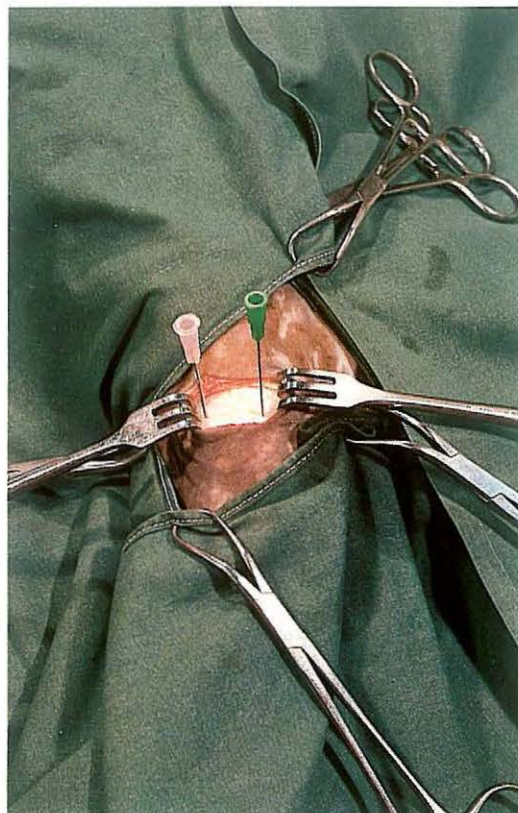
Fourth needle: lateral in the tarsal canal, between Tc, T₃ and T₄. Only by this careful marking of the joint space is it possible to drill accurately in the desired directions, especially since attainment of precision is complicated by the curvature of the joint surfaces, and because it is necessary that the drill penetrates the subchondral bone to a uniform depth. Taking intra-operative radiographs, or preferably fluoroscopic viewing with an image intensifier, is thus obligatory [464].

After marking is completed, the first needle is removed and a small incision (0.5 cm) is made through the ligaments and joint capsule. All drilling of the DIT is carried out through this incision. To reduce the chance of thermal necrosis and prematurely drilling too deeply, it is better

461



462

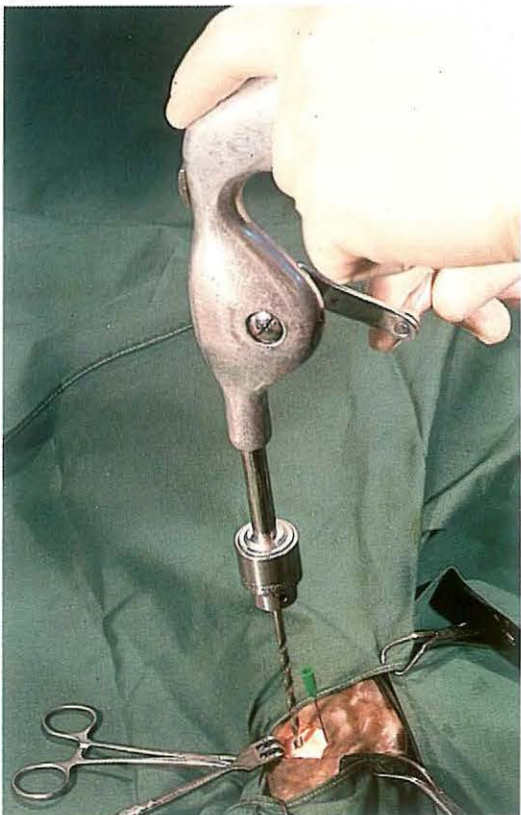


to use a manually operated drill than an electric or air drill [463]. The dorsal, medial and lateral needles determine the drilling direction of the dorsal, medial and plantar holes respectively. Extreme care should be taken to ensure that the drills do not emerge from the bone and damage the adjacent soft tissue.

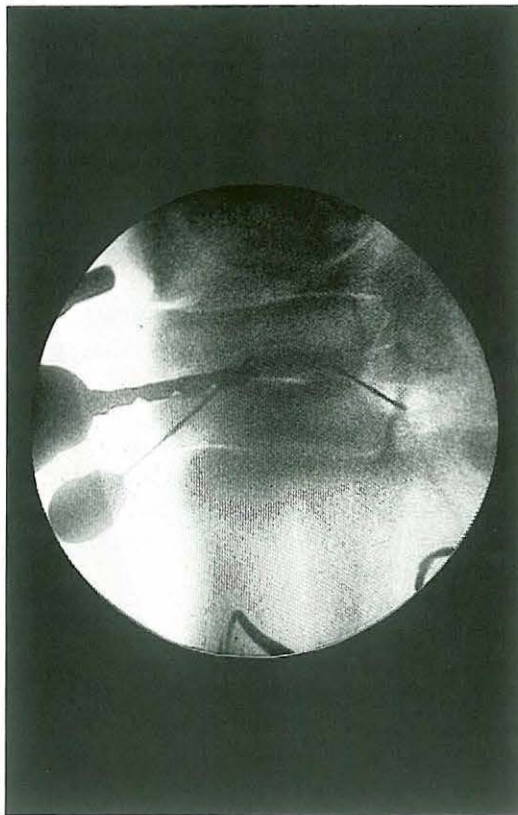When the drill bit (\varnothing 4.5 mm) is about 1 cm into the joint space, radiographic control is used to ensure correct positioning of the drill in the joint space. After drilling further to the desired depth, the drill holes are flushed with sterile physiologic saline. The wound is closed as follows: joint capsule and ligaments with one simple interrupted suture, subcutaneous tissue with continuous, and skin with interrupted sutures, all with synthetic absorbable suture material. Arthrodesis of the tarso-metatarsal joint is necessary only in cases in which this joint is involved. This operation can be performed through one incision, using similar identification and siting procedures. In horses with bilateral spavin both hocks are operated in the same surgery.

Six weeks box rest and four to five months at pasture are recommended.

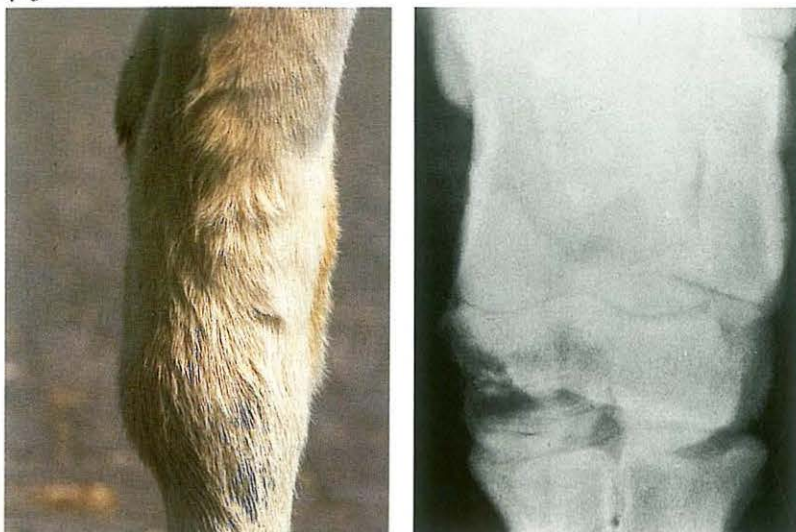463



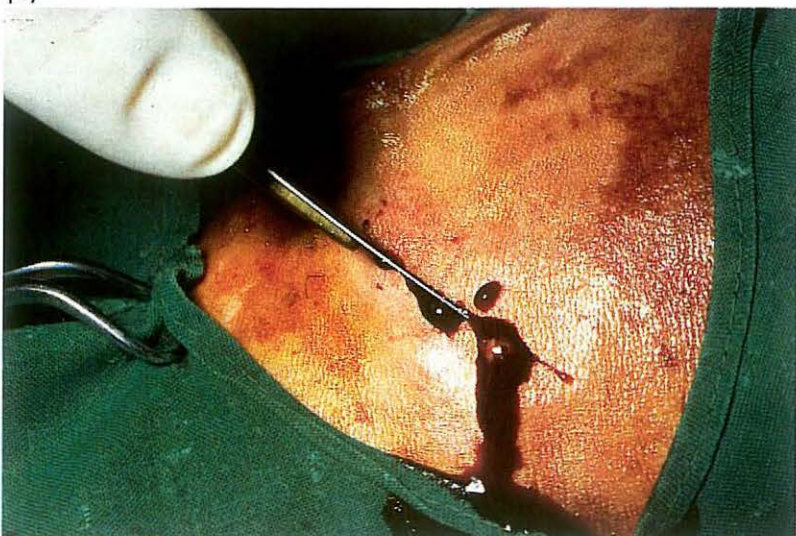
464



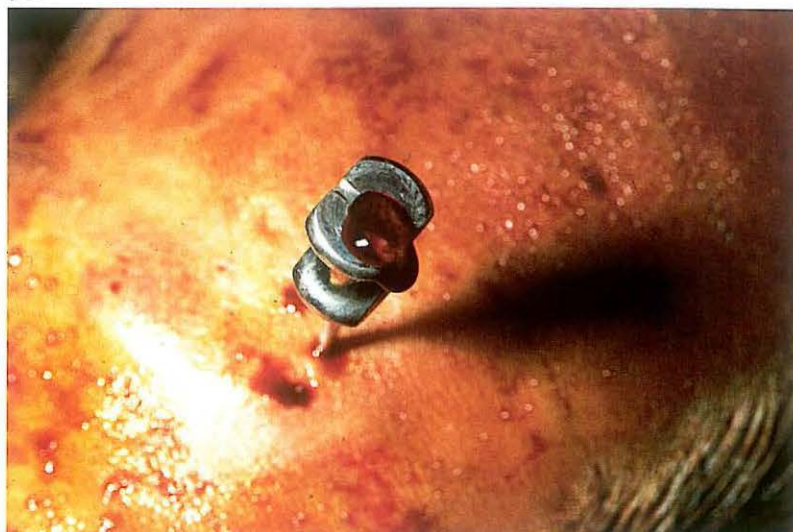465



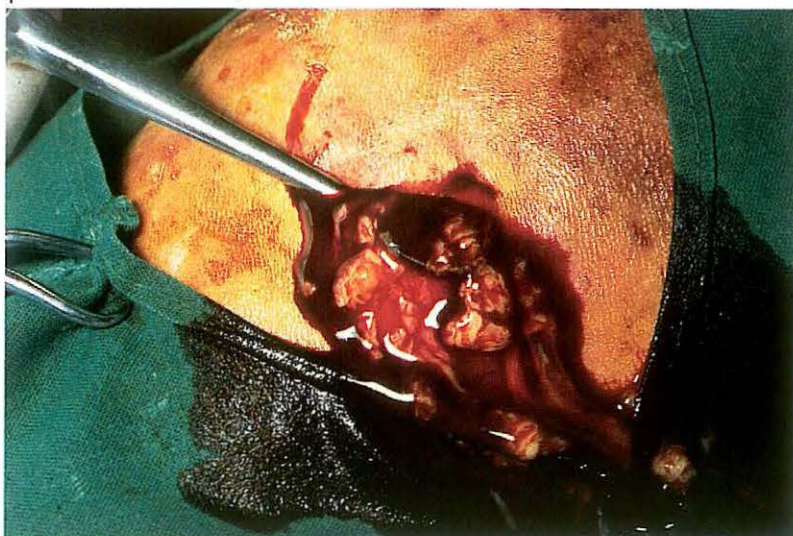
467



466



468



7-15 Arthrotomy and curettage in septic bovine spavin

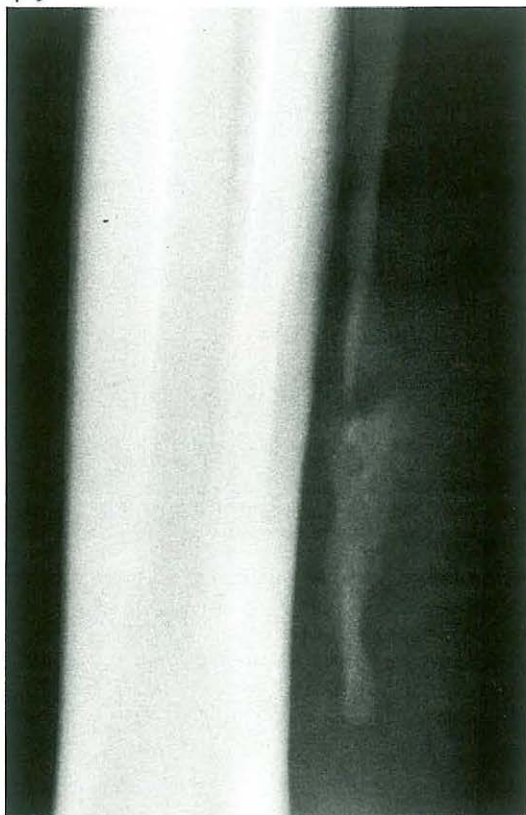
In cattle serious lameness of the hindleg may be caused by osteomyelitis of the centroquartal bone and the fused second and third tarsal bones. The distal intertarsal joint and/or the tarso-metatarsal joint may be involved in the process, which causes a painful localised swelling at the medial site of the distal tarsal joints [465A]. The osteomyelitis is caused by haematogenous (usually *Corynebacterium pyogenes*) infection, possibly in combination with local trauma. The result is necrosis and sequestration, and it is thus usually too late to expect antibiotic therapy to be successful. If radiography shows evidence of necrosis and/or sequestration [465B], surgery is indicated.

Surgery. The operation is performed with the patient in lateral recumbency, under general anaesthesia or regional intravenous analgesia. The correct site of incision may be ascertained by radiographic control or by aspiration of the process [466].

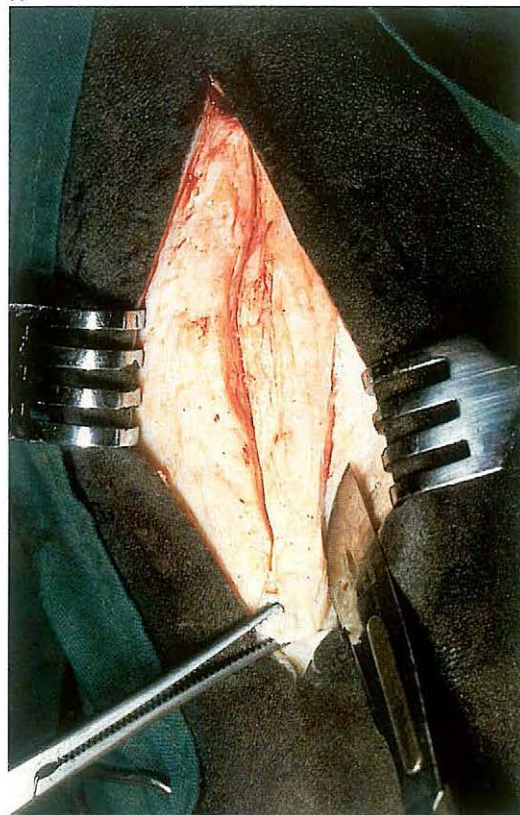
An incision is made directly over the process and the abscess opened [467]. Necrotic tissue (and if present) bone sequestrs are removed with a Brun curette [468]. The cavity is packed with gauze soaked in a disinfectant and the hock is bandaged firmly.

Antibiotics are administered systemically for about 10 days. The bandage and gauze drain are changed every second day. If postoperative lameness is severe, analgesics are administered. The prognosis is guarded, since further extension of the osteomyelitis may occur.

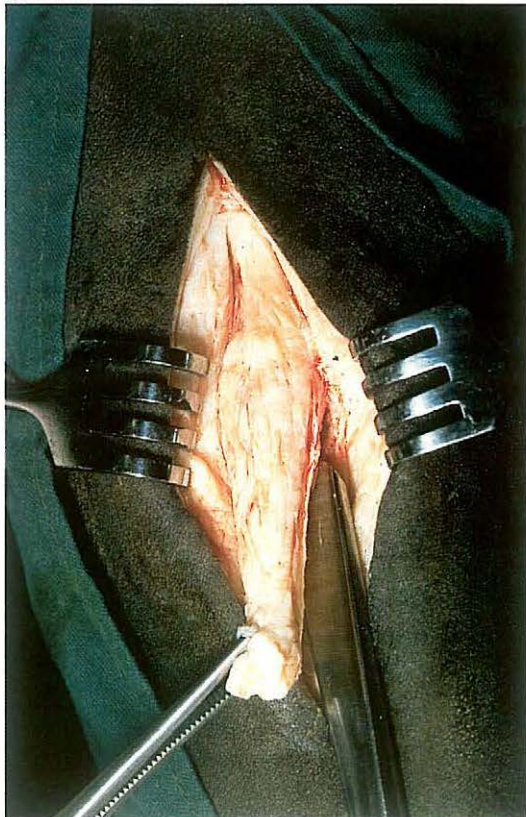
469



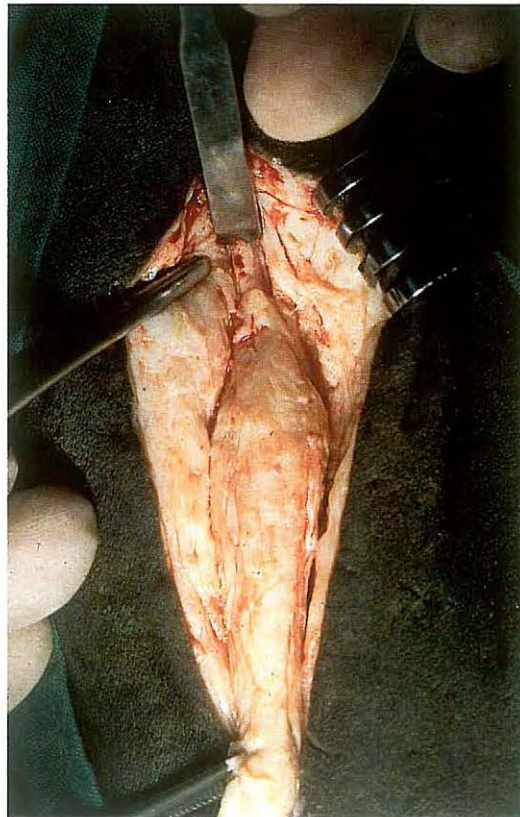
470



471



472



7-16 Resection of fractured splint bone

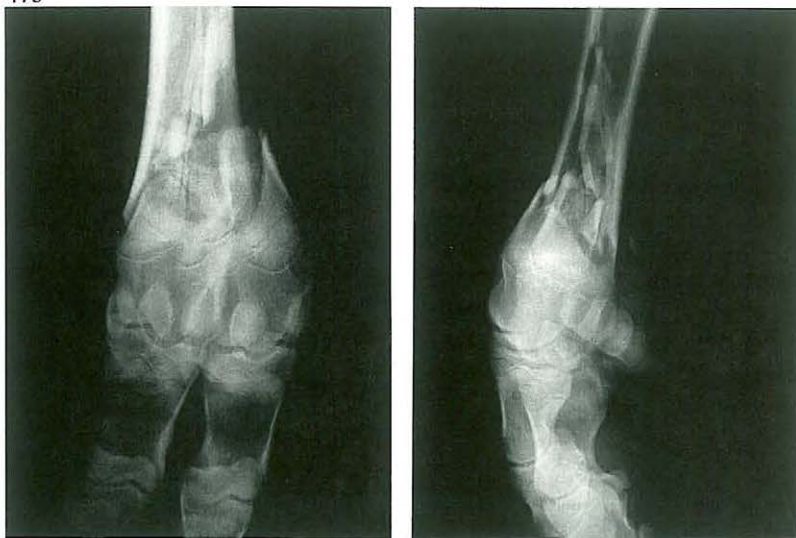Fracture occurs anywhere along the length of the splint bone but most often in standardbreds in the distal third of the bone. Trauma is the aetiology in most cases, but some distal fractures have been attributed to stress. This kind of stress is most common in trotters. The constant movement of the fracture fragments prevent healing and may result in non-union with superfluous callus formation [469], which may cause a (peri)-tendinitis of the suspensory ligament. Treatment consists of surgical removal of the distal fragment and the involved part of the proximal fragment.

Surgery. The operation should be performed with the horse in lateral recumbency under general anaesthesia. A skin incision, from the distal end of the bone to 3 cm proximal to the fracture site, is made over the cranial border of the affected splint bone. The periosteum-covered distal fracture fragment and the fracture site are dissected free [470,471]. The periosteum is separated from the distal end of the proximal fragment, which is transected with a chisel just proximal to the hard swelling around the fracture site [472]. The proximal segment should be carefully tapered with a chisel or suitably sized rongeurs to prevent subsequent irritation of the surrounding tissues. If possible, the periosteum is closed with fine synthetic absorbable material over the stump to reduce bone proliferation.

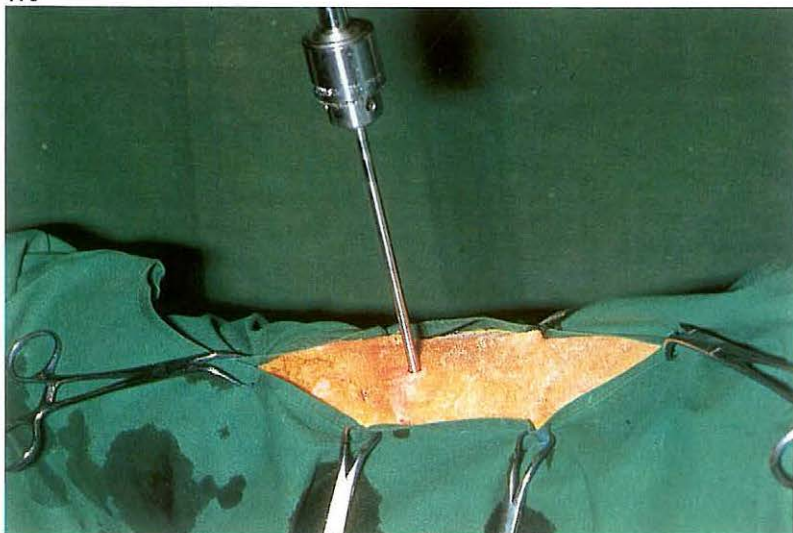
Deep fascia and subcutaneous tissue are sutured separately in a continuous pattern with absorbable material and the skin with simple interrupted sutures. The wound is dressed with a sterile firm (elastic) bandage for at least two weeks.

The patient is box rested for 4 weeks. Training can begin after 6 weeks if undisturbed healing, as evaluated by radiological examination, has taken place.

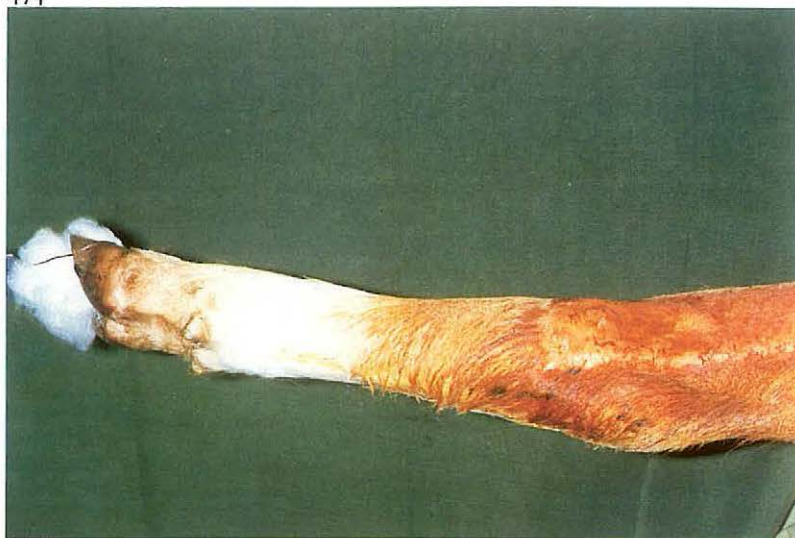473



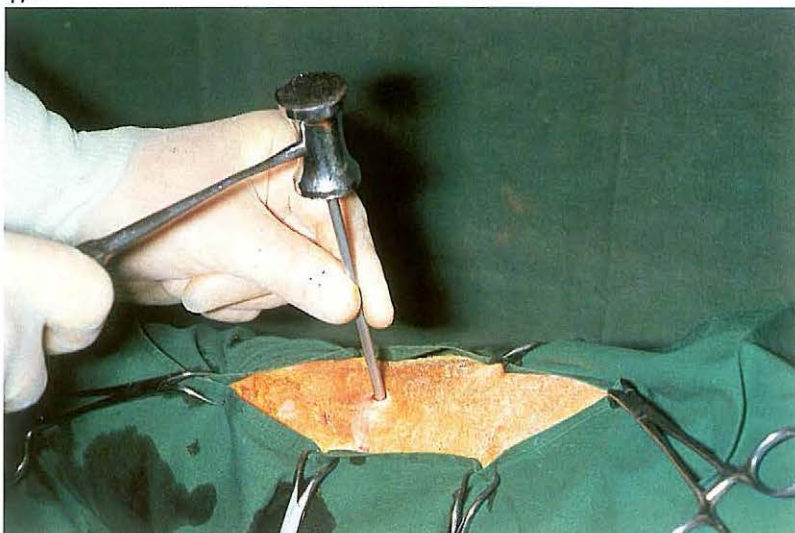475



474



476



7-17 Fracture treatment by the walking cast technique

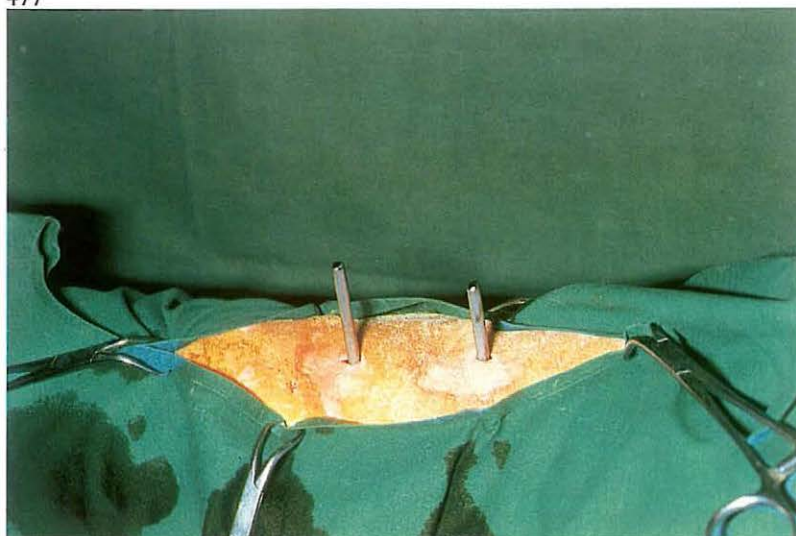
The walking cast technique is used in treating fractures of the distal radius and tibia, metacarpal/metatarsal bones and phalanges. This method is useful in treating comminuted fractures which can not be treated by other osteosynthesis techniques. It is also used where it is necessary to protect the digit from weightbearing (e.g. protection of osteosynthesis). The concept of the method is that two or three Steinmann pins, inserted proximal to the fracture site and connected to a U-shaped steel frame, allow the body weight of the patient to rest on the frame and thus relieve the fracture site. In distal radius and tibia fractures the pins are placed in the proximal radius and tibia, in cannon fractures in the distal radius or tibia, and in phalangeal fractures the pins are placed in distal metacarpus/metatarsus. One of four sizes of Steinmann pins can be used, depending on the weight of the patient: standard factory Vitallium® pins with a diameter of 3.96 mm or 4.76 mm and stainless steel pins of 6 or 8 mm diameter. The pins are cut

pre-operatively such that both ends will protrude approximately 2.5 cm outside the steel frame, the size of which depends on the weight of the patient. The cast and frame should reach to the elbow, stifle, carpal, or tarsal joint to prevent secondary fractures at the site of the proximal pin. The technique is demonstrated on a distal cannon bone fracture in a young bull [473].

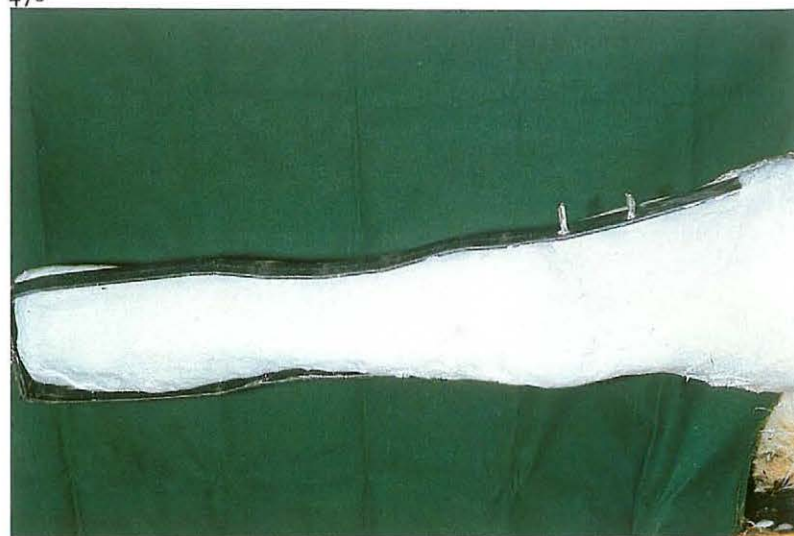
Surgery. Surgery is performed with the patient in lateral recumbency under general anaesthesia, or (for hindlimb fractures in cattle) under caudal epidural (anterior block) analgesia. A piece of steel wire is fixed to the hoof-wall, and traction can be applied to the limb if necessary to facilitate reduction [474]. The reduction is checked radiographically, as are the sites of pin placement.

After stab incisions, the holes are drilled through the distal part of the tibia [475]. The diameter of the drill is the same as the diameter of the pins. After the pins have been placed [476, 477], the frame is fitted and the sites where holes must be drilled in the frame are marked. The holes in the

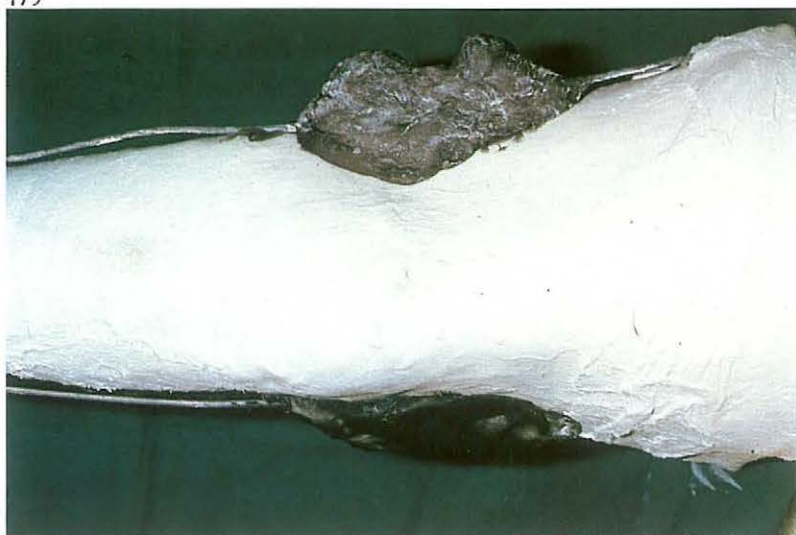477



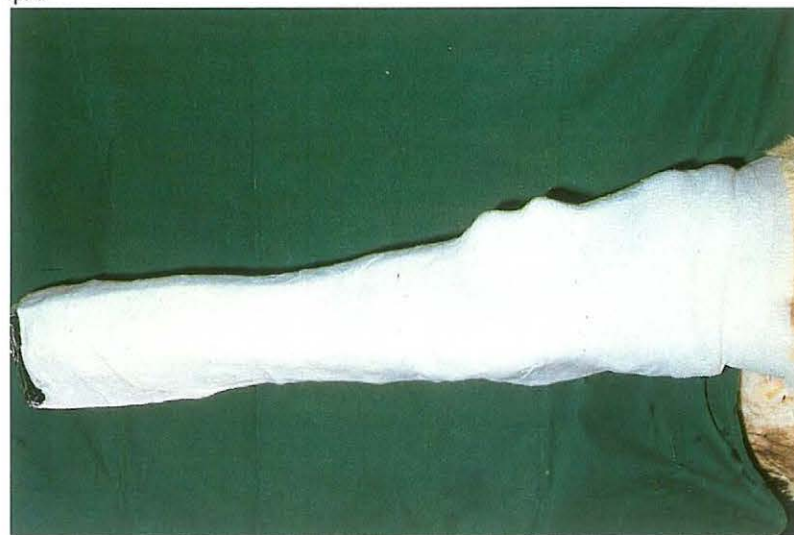478



479



480



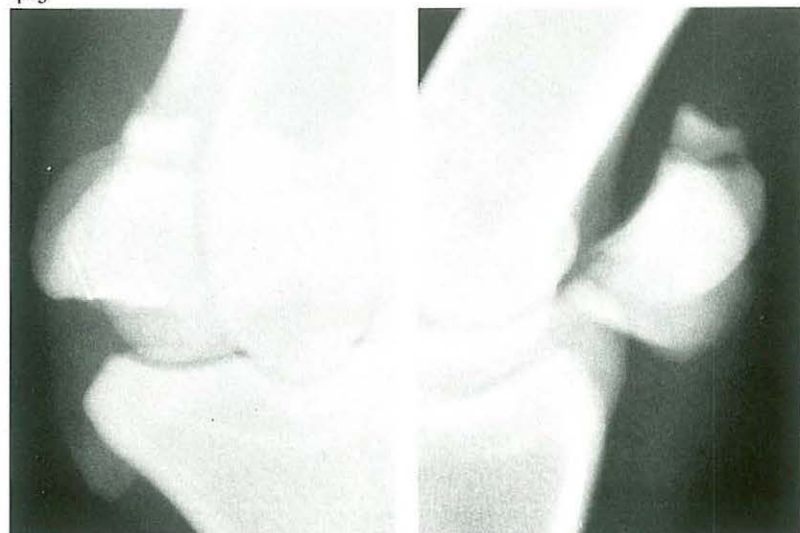
frame must be about 3 mm larger than the pin diameter to prevent torsion between pins and frame. If necessary, the skin wounds are closed with synthetic absorbable suture material, and covered with sterile tampons.

A sterile layer of cotton wool and gauze bandage are used as padding. A plaster cast approximately 3 mm thick is applied to the leg from hoof to stifle. The frame is moulded to the shape of the casted leg and placed on the pins [478]. The space between the pins and frame is filled with Technovit® to fasten the frame to the pins. The protruding ends of the pins are covered with Technovit® to protect the animal as well as the pins [479]. A second layer of plaster incorporates the frame and fixes it to the first layer. The distal part of the frame is not covered by the cast and the hoof is not fixed to the frame [480]. After hardening of the cast, the steel traction wire is cut. Systemic antibiotics are administered.

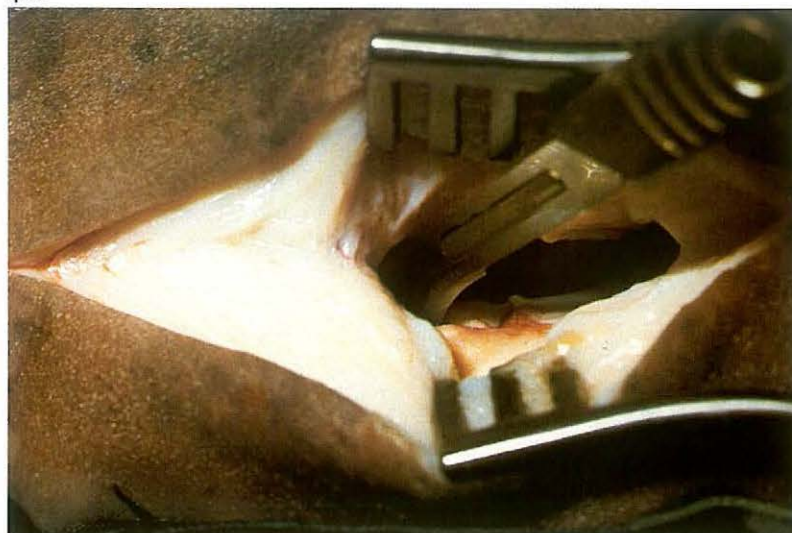
The patient is confined to stall rest during the healing period. The walking cast is not removed until X-ray control reveals that sufficient callus has been formed. There may be osteolysis around the pins, accompanied by

slight purulent secretion. The skin and subcutaneous wounds close some days after the pins have been removed. After removal of the cast the healed leg can be put in a supporting bandage.

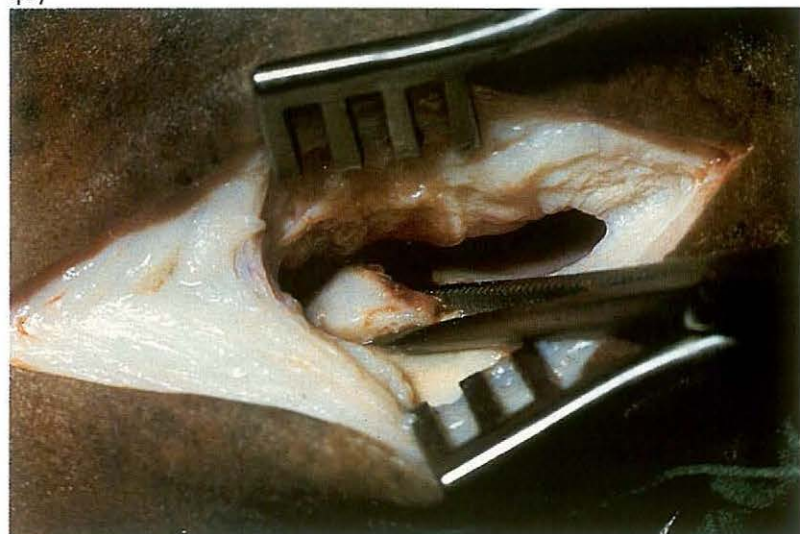
485



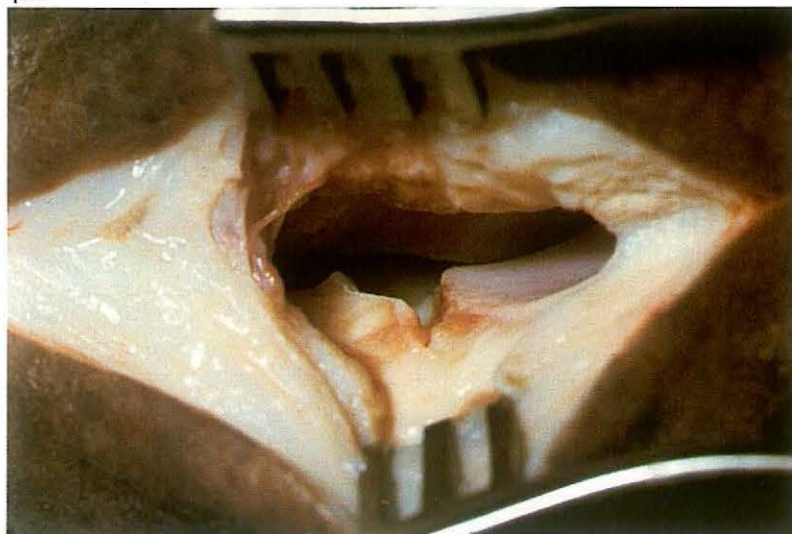
486



487



488



7-19 Osteotomy of apical fracture of proximal sesamoid bone

Fractures of the proximal sesamoids are most common in standardbreds and thoroughbreds and are classified as apical, midline or basilar fractures. Treatment consists of either lag screw fixation, plaster casting in slight flexion or removal of the fracture fragment. Apical fractures [485] involving one third or less of the bone are amenable to treatment by surgical resection of the fragment.

Surgery. The patient is placed in lateral recumbency, with the affected sesamoid bone uppermost, under general anaesthesia. An Esmarch bandage may facilitate surgery.

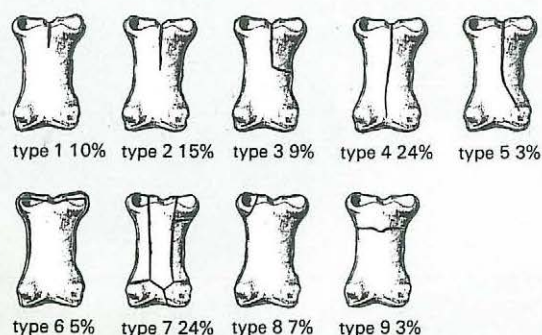
An incision approximately 5 cm long is made, between the caudal border of the third metacarpal (metatarsal) bone and the cranial border of the suspensory ligament from just below the button of the splintbone to the proximal border of the collateral sesamoidean ligament. The joint capsule is incised and a Weitlander retractor is positioned to facilitate exposure of the proximal sesamoid bone.

The fragment should be dissected free from its attachment to the suspensory ligament and intersesamoidean ligament using a hooked scalpel blade [486]. When the soft tissue attachments are severed, the fragment is removed with Ochsner forceps [487,488]. Flushing of the joint cavity may be indicated.

The fibrous capsule is closed with simple interrupted sutures of synthetic absorbable material. The subcutaneous tissue is closed in a simple continuous pattern using synthetic absorbable material, and the skin with simple interrupted sutures. A sterile dressing is placed over the incision, and a firm bandage is applied.

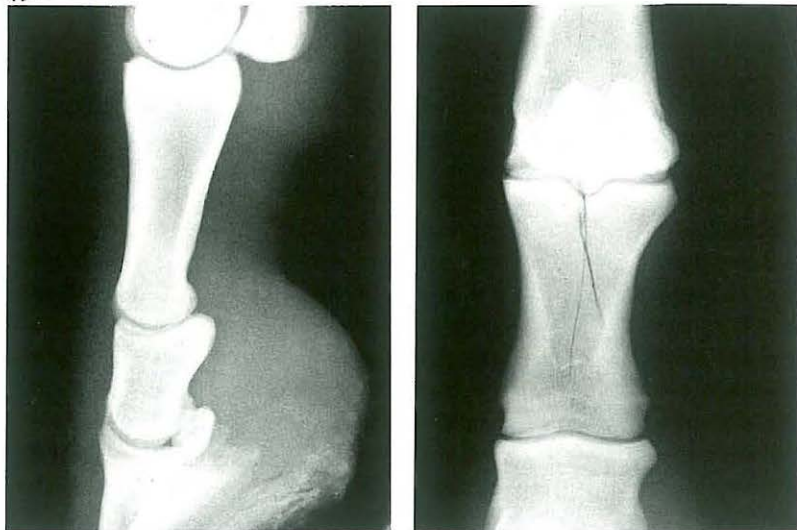
Aftercare consists of at least 3 weeks' bandaging and box rest. Training may begin after 6 weeks in some cases.

489




Classification of the different types of fractures and the frequency of occurrence (total 116 cases).

491

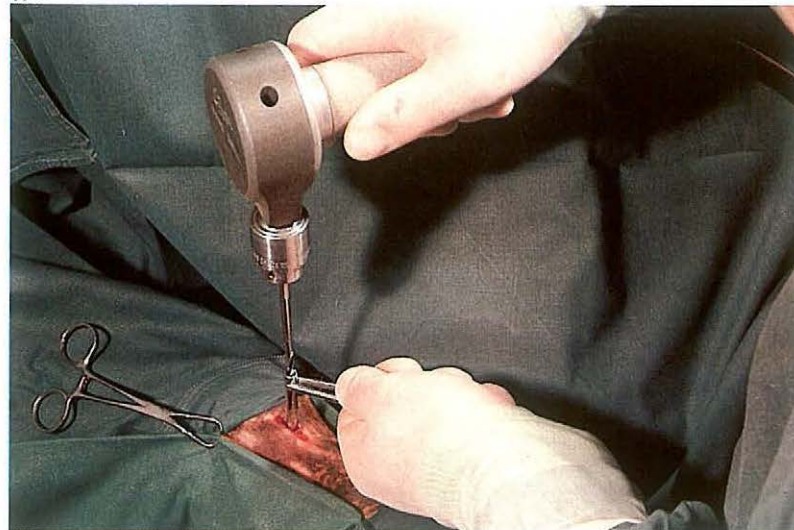


490



Indication for osteosynthesis

492



7-20 Treatment of first phalanx fractures

First phalanx fissures and fractures in horses are usually the result of injuries sustained during locomotion and may be classified into nine types [489]. There are two types of fissure (type 1 and type 2), which result from the effects of torsion of the sagittal ridge of the loaded metacarpus and metatarsus ('screwdriver effect'). The fracture types 3, 4 and 5 occur in the sagittal plane and may also result from the screwdriver effect. Type 6 is a fissure or fracture in the frontal plane; type 7 is a comminuted fracture, type 8 an avulsion fracture. Type 9 is a transverse fracture, and most often occurs in young foals, due to trauma caused by the mare. There are two possibilities for treatment of first phalanx fissures and fractures.

(1) Conservative treatment (non-surgical). Types 1 and 9 are treated by external fixation.

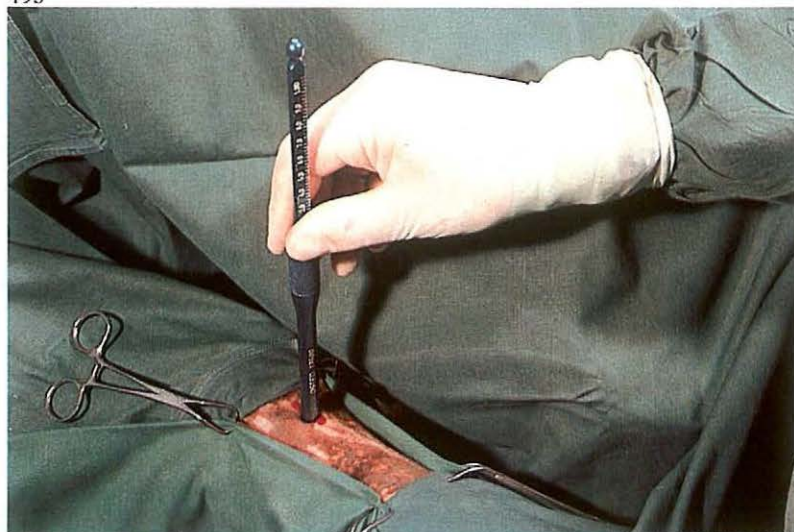(2) Surgical treatment (osteosynthesis). Relative indication for osteosynthesis means that the prognosis will not be much different in using either

osteosynthesis or conservative treatment [490], but osteosynthesis reduces the time of healing. Absolute indication for osteosynthesis means that the prognosis is significantly less favourable if the lag screw technique is not employed. Types 2 and 7 may be treated surgically (relative indication); lag screw fixation is used in type 2 fissures, whereas for type 7 the walking cast technique may be employed (see 7-17).

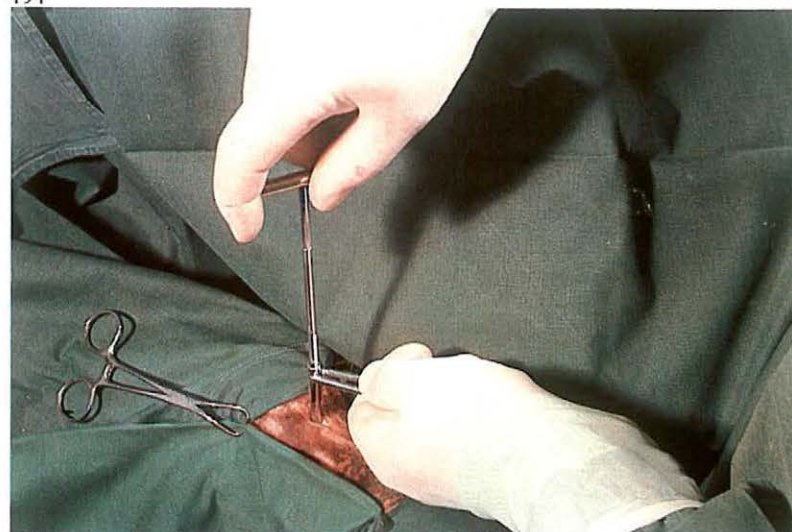
Types 3, 4, 5 and 6 have an absolute indication for lag screwing. In type 8 lag screwing is used only if the fragment is large enough; if the fragment is small, it is surgically removed.

Surgery. The lag screw technique, in this case for type 4 fracture [491], is carried out under general anaesthesia with the patient in lateral recumbency. At the site of insertion of the screw into the smaller fragment, an approximately 1.5 cm incision is made through the skin into the periosteum, which is then retracted. With the soft tissues protected by a drill guide, a 4.5 mm diameter hole is drilled through the smaller fragment [492]; this is referred to as the gliding hole. In the larger fracture fragment,

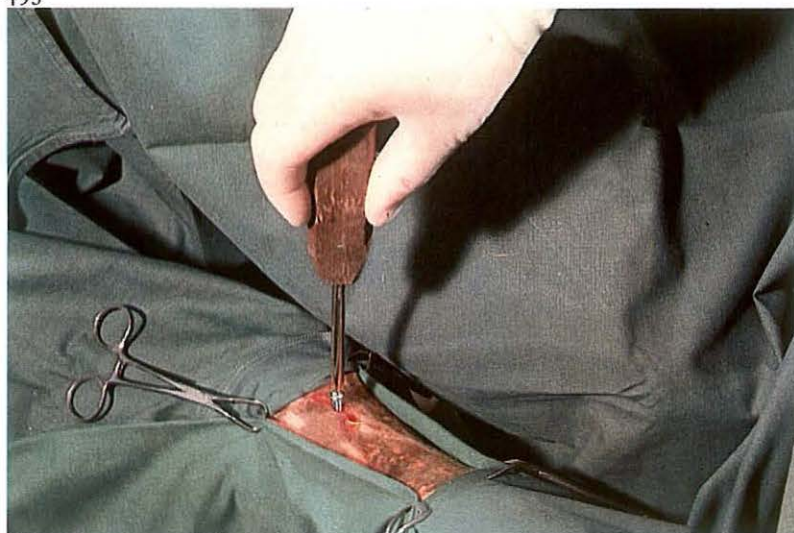493



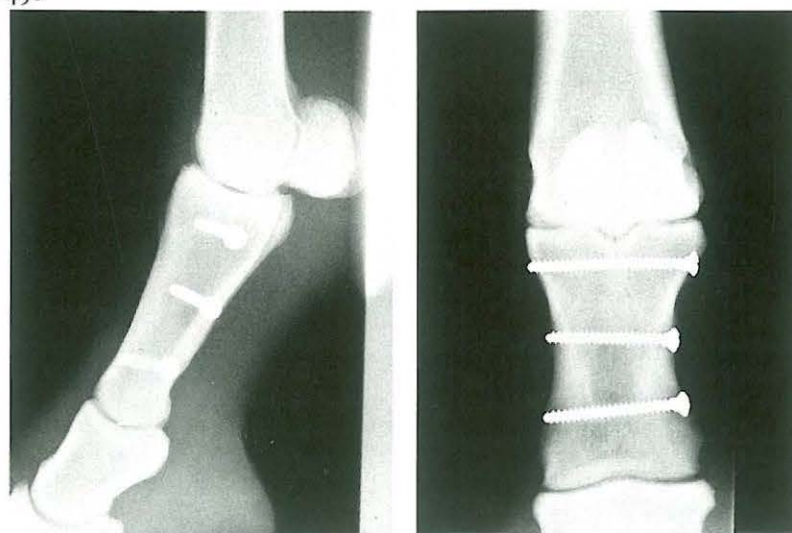494



495

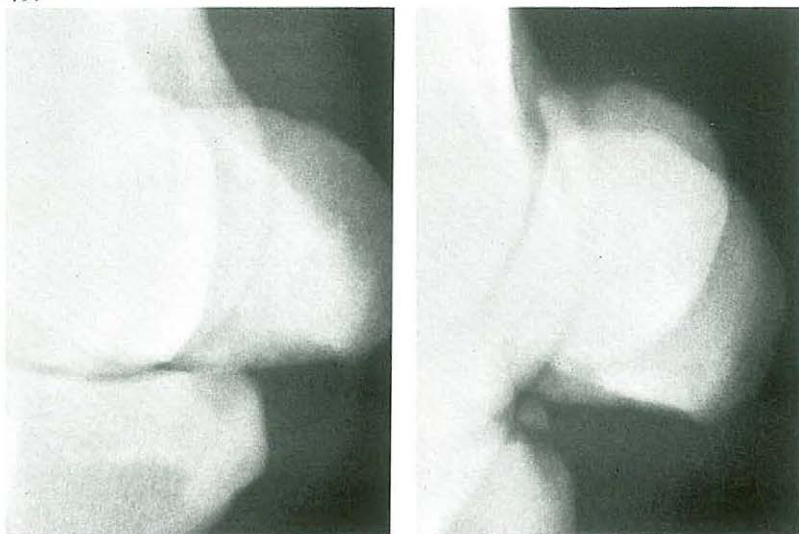


496

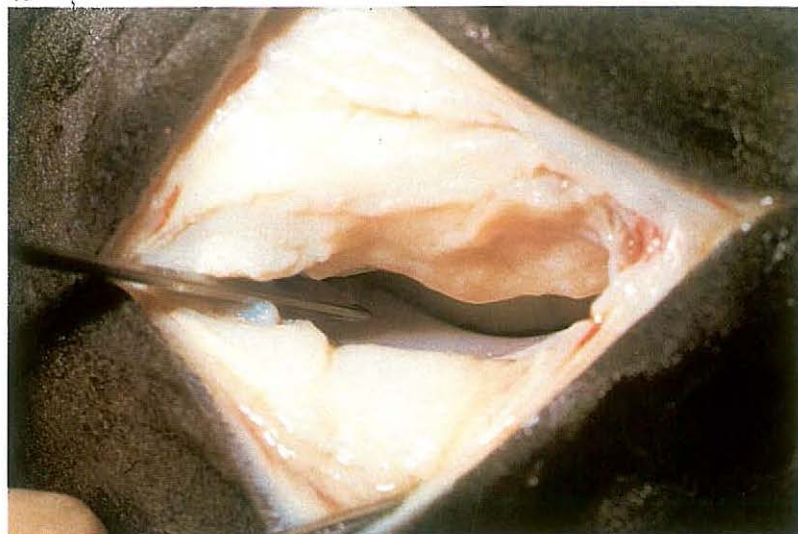


the thread hole is drilled, using a 3.2 mm drill guide placed in the gliding hole. The length of the cortex screw is determined with the depth gauge [493]. In the larger fragment the thread is cut using a tap [494]. After countersinking, the screw is screwed in [495]. The length should be such that $1\frac{1}{2}$ threads of the screw protrude on the cortex of the larger fragment. Radiographic monitoring during surgery should be used for exact positioning of the screws. The osteosynthesis is protected by an external fixation for about six weeks. The best chances for full functional recovery occur after contact healing with minimal or no callus formation [496]. Healing is radiographically visible at approximately eight weeks. Patients with comminuted fractures (type 7) remain lame and can be used only for breeding purposes.

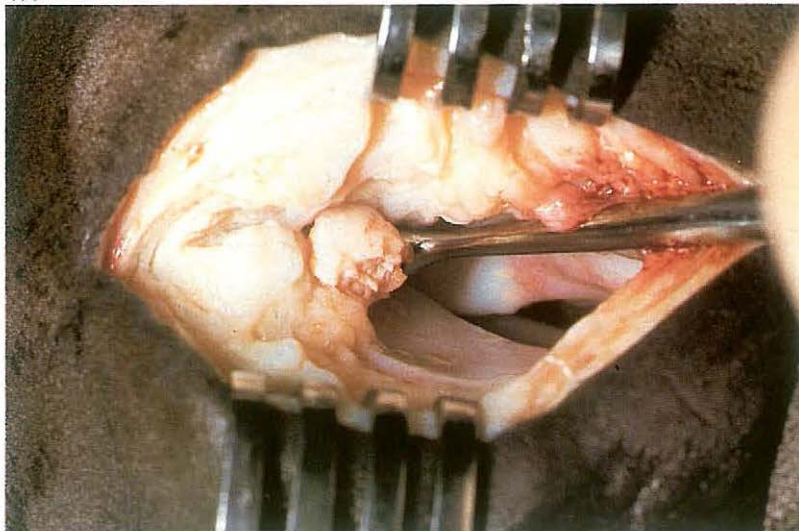
497



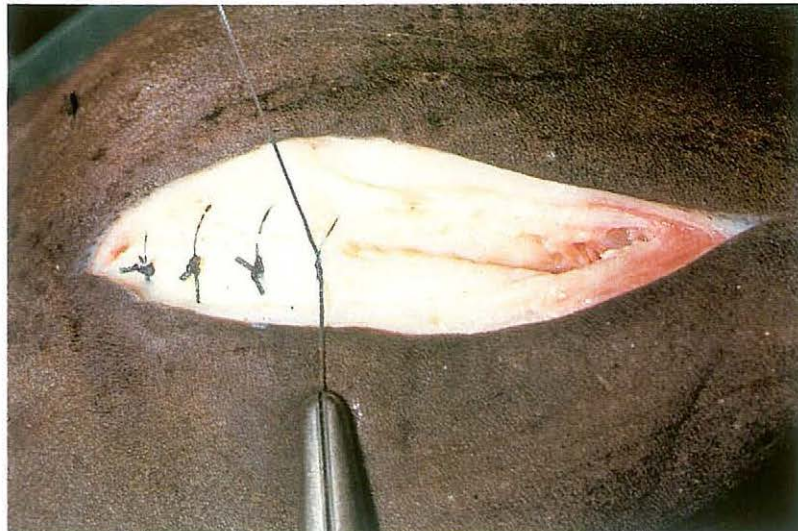
498



499



500



7-21 Arthrotomy of fetlock joint in chip fracture

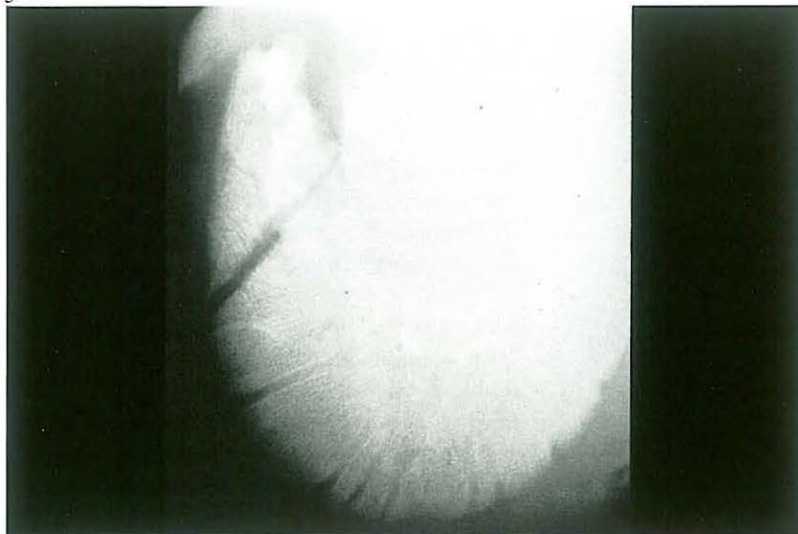
Arthrotomy of the fetlock joint is indicated in e.g. anterior or posterior chip fractures of the first phalanx, apex fracture, and basilar chip fracture of the proximal sesamoid bone. Arthrotomy to remove a posterior chip fracture of the first phalanx is presented here. The presence of such a fragment is often the cause of lameness. Radiographic examination shows a displaced bony fragment at the level of the base of the proximal sesamoid bone [497].

Surgery. The patient is placed in lateral recumbency with the affected side uppermost, under general anaesthesia. An Esmarch bandage may facilitate surgery. The joint is opened with the same technique used in the removal of the apical chip fracture of the proximal sesamoid bone (see 7-19) but in this operation the incision must be extended distally through the collateral sesamoidean ligament to provide exposure of the posterior distal joint cavity [498]. Wound retractors are positioned to facilitate exposure of the fragment. The fragment should be dissected free from the joint capsule

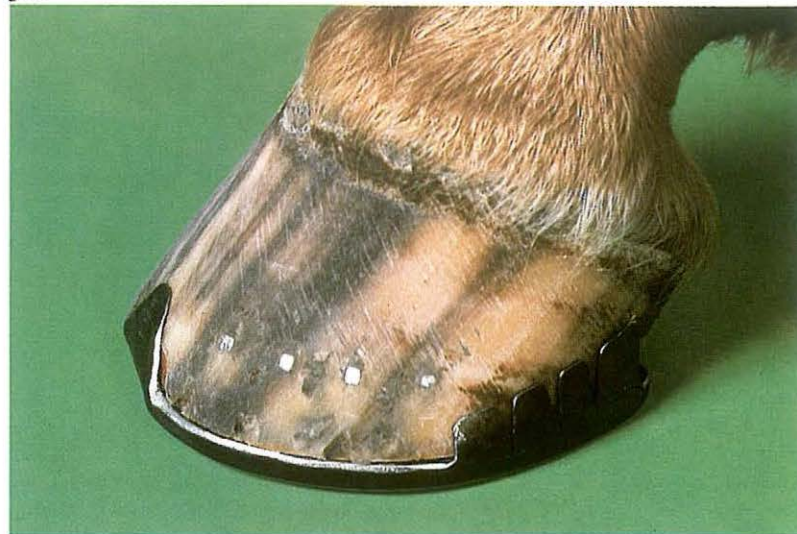using a hooked scalpel blade, after which the fragment is removed using Ochsner forceps or a Brun curette [499]. After removal of the fragment the joint cavity is flushed with sterile physiologic saline.

The fibrous capsule and the collateral sesamoidean ligament is closed with simple interrupted sutures using synthetic absorbable material [500]. The subcutaneous tissue is closed in a simple continuous pattern using synthetic absorbable material and the skin with simple interrupted sutures. A sterile dressing is placed over the incision, and the leg is firmly bandaged. Postoperative management is similar to that for removal of apical chip fracture (see 7-19).

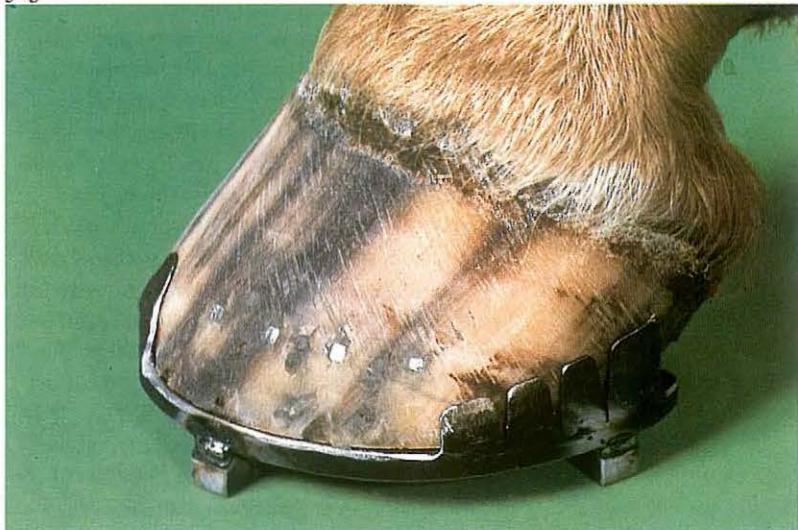501



502



503



504

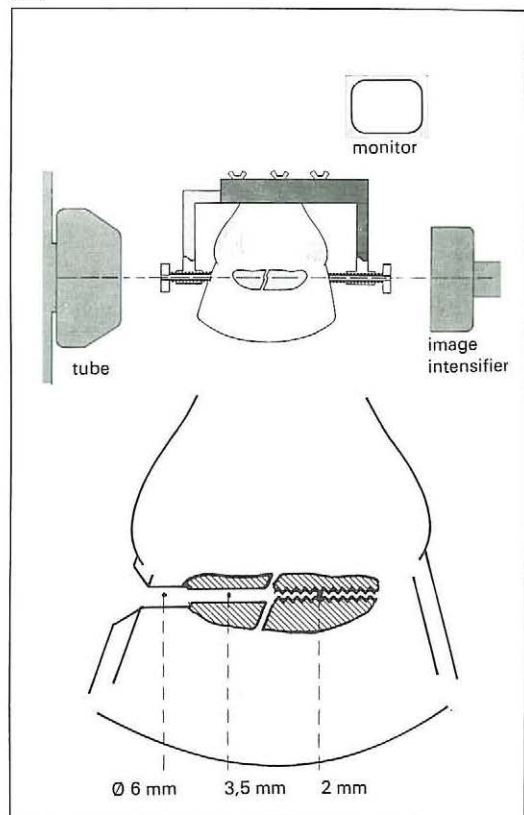


7-22 Treatment of third phalanx fracture in the horse

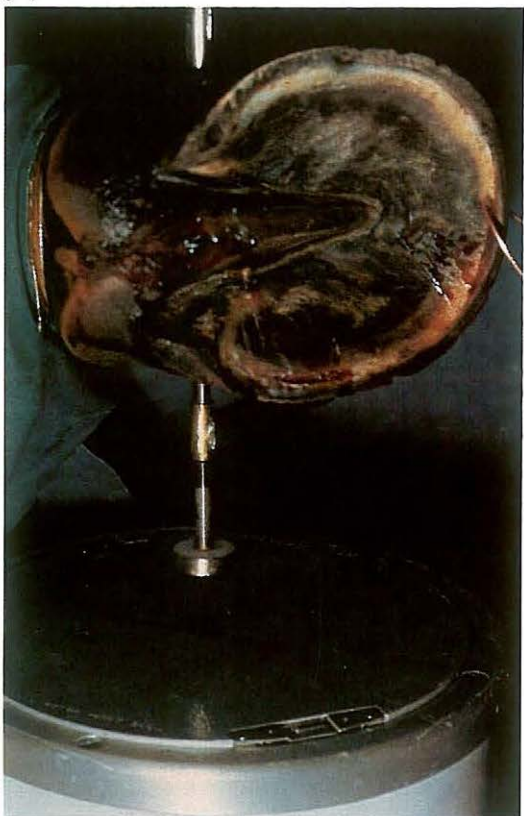Trauma is the predominant cause of fractures of the third phalanx. Wing [501], sagittal, and extensor process fractures are most common. Large and small extensor process fracture fragments may be treated by lag screw fixation and ostectomy respectively. The failure of bony union of wing and sagittal fractures is caused by continuous movement of the fracture fragments by expansion of the hoof. Therapy aims to immobilize the fracture fragments by preventing expansion of the hoof. Stability can be also achieved by lag screw fixation of the fracture fragments. Use of a lag screw may be considered in case of sagittal (intra-articular) fractures in older horses. Precise implantation of the screw demands a special guide apparatus (see 7-23) and radiographic monitoring during surgery. However, most fractures heal successfully with conservative treatment using a full bar shoe with quarter and heel clips [502]. Further reduction of hoof expansion can be achieved by applying a rigid cast over the clip shoe.

Four calks are used to prevent wear and tear to the cast [503,504]. Care is taken to leave the coronary band free of the cast to avoid pressure sores.


505



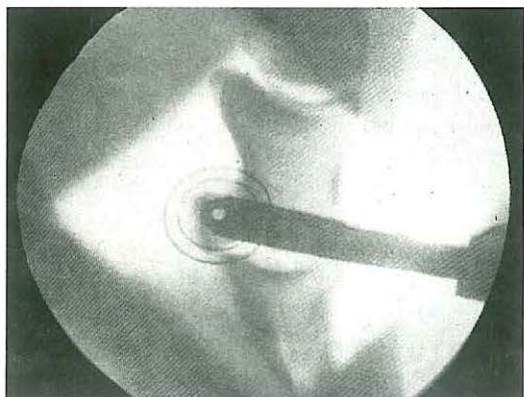
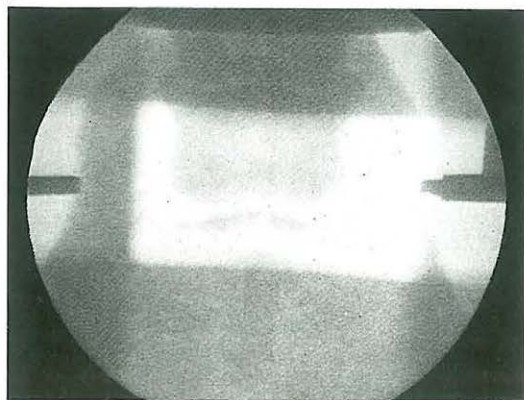
507



506



508

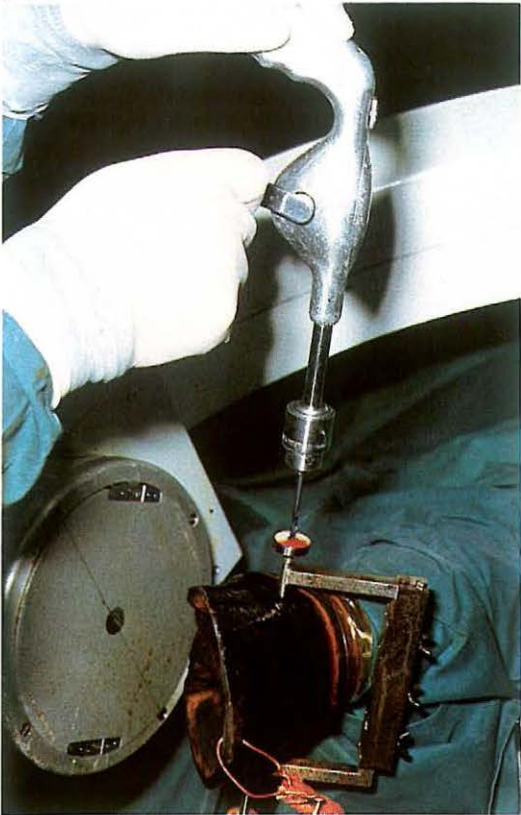


7-23 Lag screw fixation of navicular bone fracture

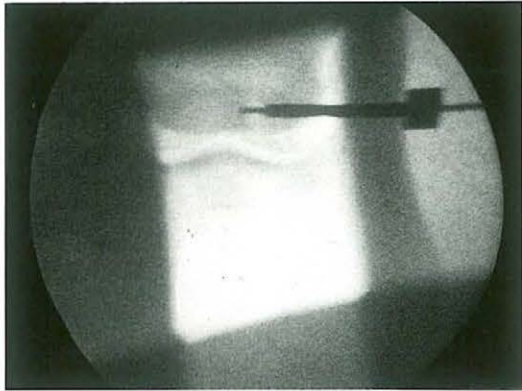
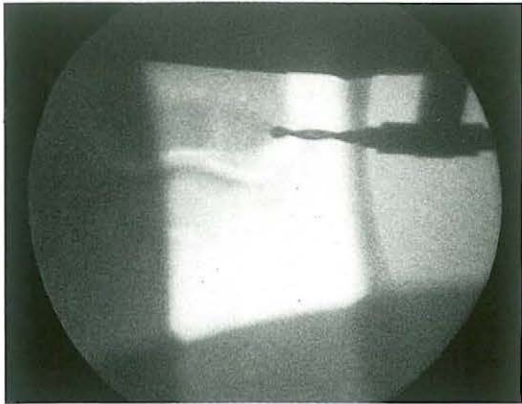
Navicular bone fractures in the horse occur infrequently. These fractures are presumably the result of sudden extreme unequal pressure from the second and third phalanges and deep flexor tendon upon the navicular bone. Osteoporosis as a result of severe navicular disease or local osteolysis may be predisposing factors. Most fractures are sagittal, located in the latero-central or medio-central area of the navicular bone, and are minimally displaced. Healing occurs mainly by fibrous callus of endosteal origin, resulting in permanent lameness. The failure of bony union of navicular fractures is caused by continuous instability of the fracture fragments. Stability can be achieved by lag screw fixation of the fracture fragments. Implantation of the screw precisely along the transverse axis of the navicular bone demands radiographic monitoring during surgery as well as a specially developed apparatus [505, 506] to ensure perfectly accurate insertion of the drill. With the help of two 3.5 mm threaded drill guides, the guide system can be fixed to the hoof. The screw on the drill guide is made of nylon, which is not radiopaque. A stainless steel ring around the nylon screw facilitates centering. *Surgery.* The horse is placed in lateral recumbency under general anaesthesia. By means of a latero-medial fluoroscopic view, the ends of the navicular bone are located and marked with hypodermic needles in the lateral and medial area of the hoof wall. The threaded drill guides of the guide apparatus are placed over the needles. The needles are removed and the position of the drill guides is adjusted, using latero-medial, dorso-palmar and caudal proximo-distal fluoroscopic views. Exact alignment of both drill guides along the transverse axis of the navicular bone is required [507, 508].

Through the 3.5 mm drill guide, a hole is drilled through the hoofwall, sensitive laminae, lateral cartilage or wing of P3, and through the navicular bone as far as the fracture line [509]. The progress of the drilling is monitored radiographically [510A]. With the 2 mm drill guide in the 3.5 mm guide, a hole is drilled into the other fragment of the navicular bone [510B]. The 3.5 mm drill is reinserted, and the hole in the tissue peripheral to the navicular bone is widened using a 6 mm flexible (intramedullary) reamer. The 3.5 mm hole in the navicular bone is countersunk.

509

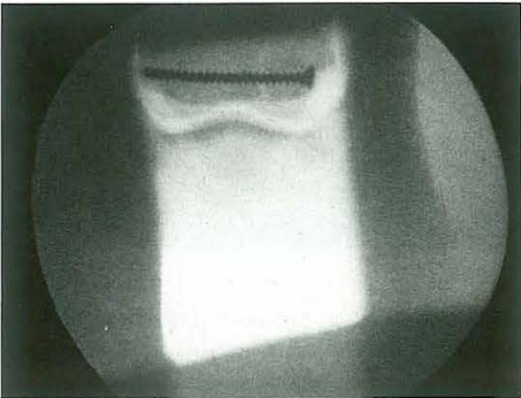


510

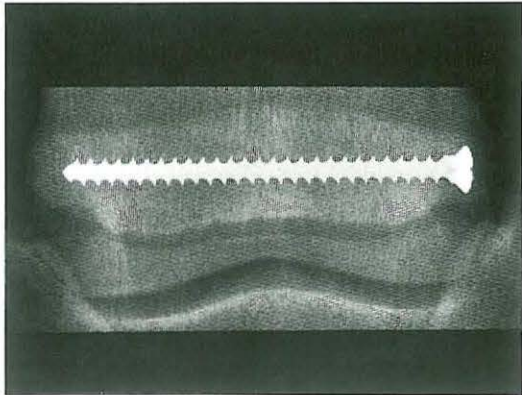
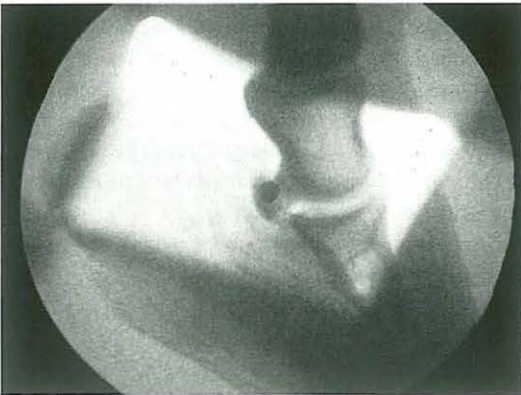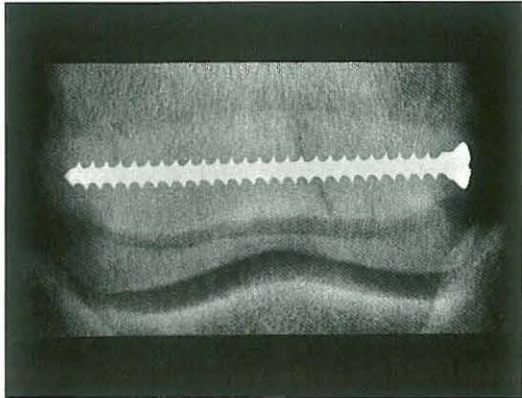


The lag fragment is tapped, and a cortical screw of suitable length (usually about 50 mm) is used to exert compression between the two fragments [511,512A]. Systemic antibiotics are administered. Postoperatively, bandages covering the coronary band and hoofwall are applied and the animal is box rested until the fracture is healed. Bony union of the fracture fragments is visible on radiographs taken approximately 6 weeks after surgery [512B].

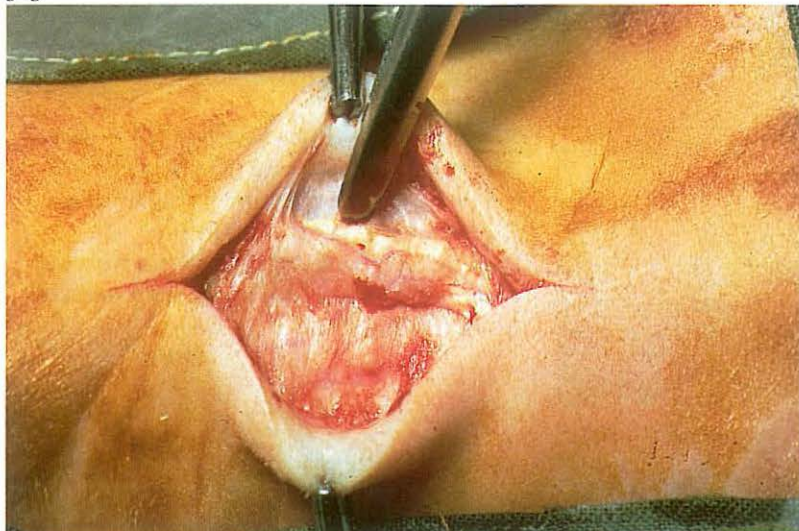
511



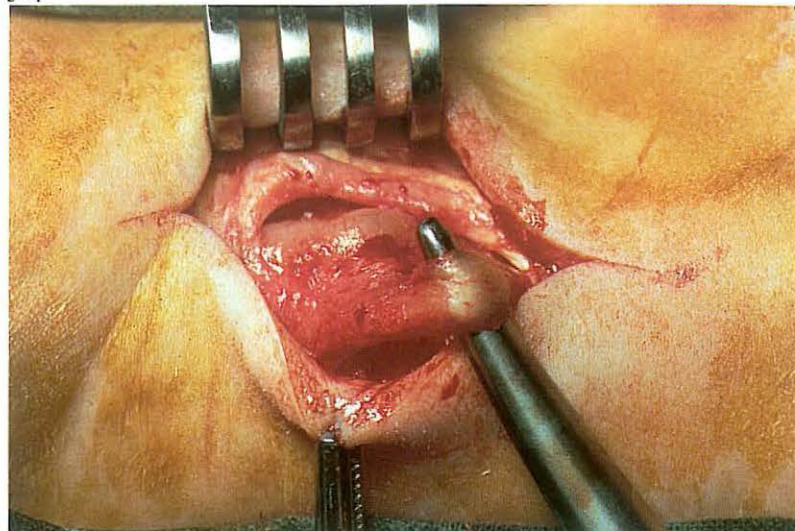
512



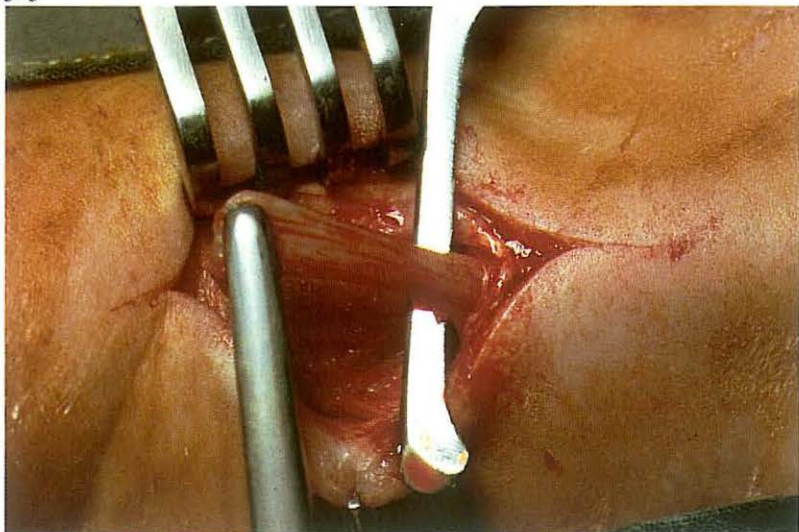
513



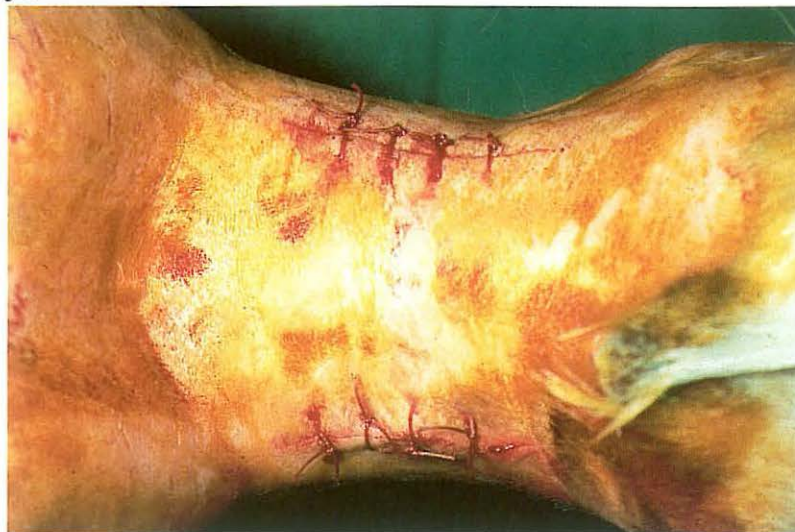514



515



516



7-24 Posterior digital neurectomy

Neurectomy of the posterior distal digital nerve is used in some cases of incurable disease in the caudal part of the hoof, e.g. navicular disease, navicular bone fracture, ossification of the lateral cartilages). Before neurectomy is considered, it should be established that palmar digital nerve block abolishes the lameness, because concurrent causes of chronic lameness e.g. ringbone, sesamoiditis, arthrosis of the fetlock joint, are contraindications for neurectomy.

Surgery. The horse is placed in lateral recumbency under general anaesthesia. The operation can also be performed on the standing horse with a regional nerve block proximal to the site of the operation. A skin incision of about 3 cm is made over the nerve, which lies just cranial and parallel to the digital flexor tendons. Subcutaneous fascia is dissected just caudal to the ligament of the ergot [513]. At this point the tissues may be separated by dissection scissors or by careful sharp dissection. It is imperative that the

least possible surgical trauma is inflicted. The nerve lies slightly caudal to the digital artery, and is separated from the artery using dissection scissors [514]. The nerve is then stripped of the surrounding fascia. One should positively identify the nerve (by careful observation of macroscopic characteristics) before transection. With tension applied, a sharp scalpel is used to cut the nerve in the proximal commissure of the incision [515]. The severed end retracts to its normal position proximal to the incision. The nerve is then severed at the distal end of the incision, removing about 2.5–3 cm of the nerve. The incision is closed with interrupted skin sutures [516]. A sterile pressure bandage is applied and left in place for 7 days. The surgical area is protected with bandages for two further weeks.

The horse can be put back to work after six to eight weeks' rest. The prognosis is generally fair but painful neuroma occasionally may develop.

Book references

- Adams, O. R., *Lameness in horses*. 3rd Ed., Philadelphia: Lea & Febiger, 1974.
- Berge, E. & M. Westhues, *Tierärztliche Operationslehre*. 29. Aufl., Berlin und Hamburg: Paul Parey, 1969.
- Bolz, W., O. Dietz, H. Schleiter & R. Teuscher, *Lehrbuch der speziellen Veterinärchirurgie*. 2. Aufl., Jena: Gustav Fischer Verlag, 1975.
- Dietz, O. & E. Wiesner, *Handbuch der Pferdekrankheiten für Wissenschaft und Praxis*. Jena: Gustav Fischer Verlag und Basel: S. Karger, 1982.
- Dyce, K. M. & C. J. G. Wensing, *Anatomie van het paard*. Utrecht: Bohn, Scheltema & Holkema, 1980.
- Dyce, K. M. & C. J. G. Wensing, *Anatomie van het rund*. Utrecht/Antwerpen: Bohn, Scheltema & Holkema, 1983.
- Frank, E. R., *Veterinary surgery*. 7th Ed., Minneapolis: Burgess Publishing Company, 1964.
- Greenough, P. R., F. J. MacCallum & A. D. Weaver, *Lameness in cattle*. 2nd Ed., Bristol: Wright, Sciencetechnica, 1981.
- Hickman, J. & R. G. Walker, *An atlas of veterinary surgery*. 2nd Ed., Bristol: John Wright & Sons Ltd., 1980.
- Mansmann, R. A., E. S. McAllister & P. W. Pratt (Eds), *Equine medicine and surgery*. Santa Barbara, Ca.: American Veterinary Publications, 1982.
- Milne, D. W. & A. S. Turner, *An atlas of surgical approaches to the bones of the horse*. Philadelphia, London, Toronto: W. B. Saunders Co, 1979.
- Oehme, F. W. & J. E. Prier, *Textbook of large animal surgery*. Baltimore: The Williams & Wilkins Co, 1974.
- Getty, R., *Sisson and Grossman's The anatomy of the domestic animals*. 5th Ed., Philadelphia, London, Toronto: W. B. Saunders Co, 1975.
- Turner, A. S. & C. W. McIlwraith, *Techniques in large animal surgery*. Philadelphia: Lea & Febiger, 1982.
- Walker, D. F. & J. T. Vaughan, *Bovine and equine urogenital surgery*. Philadelphia: Lea & Febiger, 1980.
- Wintzer, H. J., *Krankheiten des Pferdes*. Berlin und Hamburg: Paul Parey, 1982.

Index

- abdominal cryptorchidectomy
 - flank approach 61
 - inguinal approach 60
 - paramedian approach 61
- aberrant teeth 4
- abomasopexy, percutaneous 41
- abomasum
 - displacement of, left-sided
 - left flank omentopexy 40
 - percutaneous omentopexy 41
 - displacement of, right-sided,
 - right flank laparotomy 42
 - 'flexio' of 42
 - pyloromyotomy of 42
 - 'rotation' of 42
- accessory nerve, neurectomy of 18, 19
- anastomosis of intestine
 - side-to-side 44, 45, 47
 - anisoperistaltic 45
 - isoperistaltic 45
 - jejunocaecostomy 47
 - end-to-end 46
 - end-to-side 47
 - jejunocaecal bypass 47
- annular ligament of the fetlock, sectioning of 108
- ansa proximalis of colon, dilation and torsion of 43
- anus
 - atresia of 50
- atresia
 - of nasolacrimal orifice 16
 - ani (et recti) 50
- arthrodesis
 - of distal intertarsal joint 122, 123
 - of tarso-metatarsal joint 123
- arthrotomy
 - of carpal joint 116
 - of fetlock joint 129, 132
 - of intertarsal joint, distal 122, 123, 124
 - of tarso-metatarsal joint 123, 124
 - of tibio-tarsal joint 121
- bone(s)
 - carpal, fracture of 116
 - femur, supracondylar fracture of 118, 119
 - metacarpal/metatarsal
 - fracture of 126, 127
 - sequestration of 128
 - valgus deviation of 117
 - navicular
 - fracture of 134, 135
 - resection of 96, 97
 - phalanx
 - first, fracture of 126, 127, 130, 131, 132
 - second, fracture of 126, 127
 - third, fracture of 133
 - radius
 - fracture of 126, 127
 - valgus deviation of 117
 - sesamoid, apical fracture of 129
 - tibia
 - fracture of 120
 - valgus deviation of 117
 - ulna, fracture of 114, 115
- Braun's pinch skin grafting 84, 85
- Bolz' penis retraction operation 74, 75
- caecotomy 43
- caecum, dilation and torsion of 43
- caesarean section 76, 77
- canker 92
- carbon fibre, implantation in tendons 109
- carpal bone fracture 116
- carpal bursa, extirpation of 87
- carpal joint, arthrotomy of 116
- castration
 - closed technique 53
 - in cryptorchidism
 - inguinal 58, 59
 - abdominal 60, 61
 - half-closed technique 54, 55
 - in the recumbent stallion 54
 - in the standing stallion 55
 - in inguinal (scrotal) hernia 62, 63, 64, 65
 - open technique 52
 - primary closure method 56
- cattle
 - abomasal displacement
 - left-sided, correction of 40, 41
 - right-sided, correction of 42
 - anus, atresia of, see pig
 - caesarean section 76, 77
 - caecotomy 43
 - cystorrhaphy 67
 - dehorning 2, 3
 - diaphragmatic herniorrhaphy, see horse
 - digit
 - amputation of 98
 - digital flexor tendons, resection of 99
 - digital synovial sheath, resection of 99
 - heel abscess, treatment of 95
 - interphalangeal joint, distal, resection of 96, 97
 - navicular bone, resection of 96, 97

- disbudding 2, 3
- enterectomy, end-to-end anastomosis 46
- episiotomy, see horse
- eyeball, enucleation of 15
- eyelid laceration, see horse
- femur, supracondylar fracture, plate osteosynthesis of 118, 119
- flank laparotomy 36, 37
- laryngotomy, in bovine necrotic laryngitis 23
- mandibular body fracture, see horse
- mandibular interdental space fracture, treatment of 11
- mammary gland, amputation of, see sheep
- metatarsal bone fracture, treatment by walking cast 126, 127
- nictitating membrane, excision of 14
- paramedian laparotomy, see horse
- patellar ligament, medial, see horse
- penis
 - amputation of 70
 - removal of neoplasms 70
- rectum prolapse, see horse
- rumenotomy 39
- sequestrectomy 128
- sinus, frontal, trephination of 7
- skin grafting, see horse
- tail, amputation of 113
- tarso-metatarsal joint, arthrotomy and curettage of septic bovine spavin 124
- teat
 - fistula, congenital, management of 102
 - fistula, traumatic, repair of 101
 - lacerations, repair of 100
 - obstructions, repair of 103
- tibia fracture, plate osteosynthesis 120
- tibial neurectomy in spastic paresis 110, 111
- tongue, lingual mucosa resection 12
- tracheotomy, see horse
- ulna fracture, see horse
- umbilical herniorrhaphy 30, 31
- urachal fistula, resection of 32, 33
- urethrotomy, see horse
- ventral midline laparotomy, see horse
- cerclage wire 10, 120
- circumcision (reefing) of equine penis 72
- cloaca 80
- coccygeal myectomy 112
- colpotomy 82
- condylar plate (DCP) 118, 119
- cracks 88, 93
- crib-biting 18
- cricoarytenoidopexy 20
- cryosurgery 86
- cryptorchidectomy
 - abdominal 60, 61
 - inguinal 58, 59
- cryptorchidism
 - abdominal 58, 60, 61
 - inguinal ('high flanker') 58
 - partial abdominal 58
- cunean tenectomy 122
- cystectomy, partial 32
- cystorrhaphy 67
- cystotomy, pararectal 68
- dehorning
 - in cattle 2, 3
 - in goats 3
- dentigerous cyst 4
- desmotomy
 - of annular ligament of the fetlock 108
 - of inferior check ligament 106
 - of medial patellar ligament 107
- diaphragmatic hernia 26, 27
- diaphragmatic herniorrhaphy 26, 27
- digital flexor tendon
 - deep
 - 'contraction' of 106
 - fenestration of 90
 - resection of 96, 99
 - rupture of 109
 - superficial
 - resection of 99
 - rupture of 109
- digital synovial sheath
 - synovitis of 99
 - resection of 99
- disbudding, in calves 2
- Dynamic Compression Plate (DCP) 114, 115, 118, 119, 120
- ear fistula 4
- embryotomy wire 3, 98
- enterectomy 44, 46, 47, 48, 49, 64, 66
- enterotomy 43
- enucleation of eyeball 15
- episiotomy 82
- Eustachian tube 6
- evisceration
 - of intestine 66
 - of omentum 66
- eyeball, enucleation of 15
- eyelid
 - lacerations of 13
 - third (nictitating membrane) 14
- femur, supracondylar fracture of 118, 119
- fenestration
 - of guttural pouch 6
 - of deep flexor tendon 90, 91
- fibropapillomatosis, penis 70
- fistula
 - ear 4
 - recto-vaginal 50
 - teat 101, 102
 - urachus 32, 33
 - withers 28
- flank laparotomy, see laparotomy
- 'flexio' of abomasum 42
- flexor tendon, see digital flexor tendon
- fracture
 - of carpal bone(s) 116
 - of femur 118, 119
 - of mandible 10, 11
 - of maxilla 10
 - of metacarpal bone 126, 127
 - of metatarsal bone 126, 127
 - of navicular bone 134, 135
 - of phalanges 126, 127, 130, 131, 132, 133
 - of radius 126, 127
 - of sesamoid bone 129
 - of splint bone 125
 - of tibia 120, 126, 127
 - of ulna 114, 115
- frog
 - canker 92
 - pododermatitis of 88
 - puncture wounds of 90, 91
 - thrush 93
- Forssell's myectomy 18
- goat
 - castration, closed technique 53
 - dehorning 3
 - rumenotomy, see cattle
 - urethrotomy, see horse
- Gökel's pararectal cystotomy 68
- grid incision 36, 37
- guttural pouch
 - drainage of 6
 - fenestration of 6
- heel abscess 95
- hernia
 - accreta 30
 - diaphragmatic 26, 27
 - incarcerated 30, 64
 - inguinal (scrotal) 62, 63, 64, 65
 - interstitial 65

- non-reducible 30
- reducible 30, 62
- umbilical 30
- herniorrhaphy
 - diaphragmatic 26, 27
 - inguinal 62, 63, 64, 65
 - umbilical 30, 31
- hoof, see horse
- horse
 - accessory nerve, neurectomy of 18, 19
 - anus, atresia of, see pig
 - aural fistula, extirpation of 4, 5
 - castration
 - closed technique, see goat
 - half-closed technique 54, 55
 - open technique, see pig
 - primary closure method 56
 - carpal bone fracture, arthrotomy in 116
 - cricoarytenoidopexy 20, 21
 - cryosurgery of sarcoids 86
 - cryptorchidectomy
 - abdominal 60, 61
 - inguinal 58, 59
 - cystorrhaphy, see cattle
 - cystotomy, pararectal 68
 - diaphragmatic herniorrhaphy 26, 27
 - enterectomy
 - end-to-end anastomosis, see cattle
 - end-to-side anastomosis 47
 - side-to-side anastomosis 44, 45, 47
 - episiotomy 82
 - evisceration after castration, management of 66
 - eyeball, enucleation of, see cattle
 - eyelid lacerations, suturing of 13
 - femur, supracondylar fracture of, see cattle
 - fetlock annular ligament, sectioning of 108
 - fetlock joint, arthrotomy 132
 - Forssell's myectomy 18, 19
 - guttural pouch, drainage and fenestration 6
 - hoof
 - canker, treatment of 92
 - cracks, treatment of 93
 - keratoma, extirpation of 89
 - pododermatitis, treatment of 88
 - puncture wounds, management of 90, 91
 - thrush, treatment of 93
 - inferior check ligament, desmotomy of 106
 - inguinal herniorrhaphy 64, 65
 - intertarsal joint, distal, arthrodesis of 122, 123
 - jejunocaecostomy 47
 - laryngotomy
 - subepiglottal cyst, extirpation of 22
 - ventriculectomy 20, 21
 - mammary gland, amputation of, see sheep
 - mandibular body fracture, treatment of 10
 - mandibular interdental space fracture, see cattle
 - metacarpal/metatarsal bone fracture, see cattle
 - nasolacrimal orifice atresia, treatment of 16
 - navicular bone fracture, lag screw fixation of 134, 135
 - nictitating membrane, see cattle
 - ovariectomy 82
 - paramedian laparotomy 38
 - patellar ligament, medial, desmotomy of 107
 - penis
 - amputation of 71
 - circumcision (reefing) of 72
 - retraction operation (Bolz) 74, 75
 - perineal reconstruction after third degree laceration 80, 81
 - phalanx fracture
 - first, treatment of 126, 127, 130, 131
 - third, treatment of 133
 - posterior digital neurectomy 136
 - premaxilla fracture, treatment of 10
 - preputial orifice, retention suturing of 73
 - rectum prolapse, correction of 48, 49
 - sequestrectomy, see cattle
 - sesamoid bone fracture, ostectomy 129
 - sinus, maxillary, trephination of 8, 9
 - skin grafting 84, 85
 - splint bone fracture, resection of 125
 - tail, see cattle
 - teat, see cattle
 - teeth, repulsion of 8, 9
 - tendon repair, carbon fibre implantation 109
 - tibia fracture, see cattle
 - tibiotarsal joint, arthrotomy in osteochondrosis 121
 - tracheotomy 24
 - ulna fracture, plate osteosynthesis 114, 115
 - umbilical herniorrhaphy, see cattle
 - urethrotomy 69
 - valgus deviation, correction of 117
 - vestibuloplasty 78, 79
 - withers, treatment of fistula 28
 - ventral midline laparotomy 34, 35
- inguinal cryptorchidectomy 58, 59
- inguinal (scrotal) hernia
 - direct 65
 - incarcerated 64
 - indirect 65
 - interstitial 65
 - reducible 62
- inguinal herniorrhaphy 62, 63, 64, 65
- interphalangeal joint, distal, resection of 96, 97
- intertarsal joint, distal
 - arthrodesis of 122, 123
 - curettage of 124
- intestine
 - anastomosis 44, 45, 46, 47, 64, 66
 - enterectomy 44, 45, 46, 47, 48, 49, 64, 66
 - enterotomy 43
 - evisceration of 66
 - herniation of 26, 27, 30, 31, 62, 64, 65
 - prolapse of 48, 49, 65, 66
- intussusception
 - ileocaecal 47
 - jejunal 46
 - rectal 48
- jejunocaecostomy 47
- joint
 - carpal, arthrotomy of 116
 - fetlock, arthrotomy of 129, 132
 - interphalangeal, distal, resection of 96, 97
 - intertarsal, distal
 - arthrodesis of 122, 123
 - curettage of 124
 - tarso-metatarsal
 - arthrodesis of 123
 - curettage of 124
 - tibio-tarsal, arthrotomy of 121
- keratoma 89
- lag screw fixation
 - of carpal bone fracture 116
 - of first phalanx fractures 130, 131
 - of third phalanx fractures 133
 - of navicular bone fracture 134, 135
- laparotomy
 - flank, left 36
 - in abdominal cryptorchidism 61
 - in abomasal displacement, left-sided 40
 - for caesarean section 76, 77
 - for rumenotomy 39
 - flank, right 36, 37
 - in abdominal cryptorchidism 61
 - in abomasal displacement, right-sided 42
 - in intestinal disorders 43, 46
 - paramedian 38
 - in abdominal cryptorchidism 61
 - in urinary bladder disorders 67
 - ventral midline (linea alba) 34, 35
 - in abdominal disorders 44, 45, 47
- laryngeal hemiplegia 20

- laryngitis, necrotic 23
 laryngotomy
 - in bovine necrotic laryngitis 23
 - for extirpation of subepiglottal cyst 22
 - for ventriculectomy 20, 21
 linea alba, laparotomy 34, 35

 mammary gland
 - amputation of 104
 - supernumerary 102
 mandible, fracture of 10, 11
 maxilla, fracture of 10
 metacarpal/metatarsal bone
 - fracture of 126, 127
 - sequestration of 128
 - valgus deviation of 117
 muscle(s)
 - coccygeal, myotomy of 112
 - gastrocnemius, denervation of 110
 - omohyoideus, myectomy of 18
 - sacrococcygeal, myotomy of 112
 - sternocephalicus, myectomy of 18
 - sternohyoideus, myectomy of 18
 - sternothyroideus, myectomy of 18
 myectomy, Forssell 18, 19
 myotomy, coccygeal 112

 nasolacrimal orifice, atresia of 16
 navicular bone
 - fracture of 134, 135
 - resection of 96, 97
 navicular bursa
 - bursitis of 90, 91, 96, 97
 - drainage of 90, 91
 neurectomy
 - of accessory nerve 18, 19
 - of posterior digital nerve 136
 - of tibial nerve 110, 111
 nictitating membrane (third eyelid), excision of 14

 omentopexy
 - left flank 40
 - right flank 42
 omentum
 - evisceration (prolapse) of 66
 - omentopexy 40, 42
 osteochondrosis, tibiotarsal joint 121
 osteosynthesis
 - of carpal bone fracture 116
 - of femur (supracondylar) fracture 118, 119
 - of mandibular interdental space fracture 11
 - of navicular bone fracture 134, 135
 - of phalanx fractures 130, 131, 133
 - of premaxilla and mandibular body fractures 10
 - of tibia fracture 120
 - of ulna fracture 114, 115
 ovariectomy 82

 paramedian laparotomy, see laparotomy
 paraphimosis 72, 73
 pararectal cystotomy 68
 patella, fixation of 107
 patellar ligament, medial, desmotomy of 107
 penis
 - amputation of 70, 71
 - circumcision (reefing) of 72
 - fibropapilloma of 70
 - neoplasms of 70, 71
 - paralysis of 74
 - paraphimosis of 72, 73
 - retention of 73
 - retraction operation (Bolz) of 74, 75
 perineum, third degree lacerations (cloaca) of 80, 81
 phalanx
 - first, fracture of 126, 127, 130, 131, 132
 - second, fracture of 126, 127
 - third, fracture of 133
 pig
 - anus, treatment of atresia 50
 - castration, open technique 52
 - cryptorchidectomy, abdominal 61
 - herniorrhaphy
 - inguinal 62, 63
 - umbilical, see cattle
 - rectum prolapse, see horse
 plate
 - condylar (DCP) 118, 119
 - Dynamic Compression Plate (DCP) 114, 115, 118, 119, 120
 plate osteosynthesis
 - of femur (supracondylar) fracture 118, 119
 - of tibia fracture 120
 - of ulna fracture 114, 115
 pneumovagina 78
 pododermatitis
 - in cattle 94, 95, 96, 98
 - in horses 88, 90, 92, 93
 preputial orifice, retention suture of 73
 prolapse
 - of intestine 65, 66
 - of rectum 48, 49
 puncture wounds of the sole 88, 90, 91, 94, 95, 96
 pyloromyotomy 42

 radius
 - fracture of 120, 126, 127
 - valgus deviation of 117
 recto-vaginal fistula 50
 rectum
 - atresia 50
 - prolapse
 - amputation of 48, 49
 - complete 48
 - incomplete 48
 - reposition of 48
 - retention of 48
 reefing of equine penis 72
 rectovestibular septum, rupture of 80, 81
 repulsion of molar teeth 8, 9
 rumenotomy 39
 'rotation' of abomasum 42

 sarcoids, cryosurgery of 86
 sequestrectomy 128
 sesamoid bone, fracture of 129, 132
 sheep
 - anus, atresia of, see pig
 - flank laparotomy, see cattle
 - herniorrhaphy
 - inguinal, see pig
 - umbilical, see cattle
 - mammary gland, amputation of 104
 - rectum prolapse, see horse
 - rumenotomy, see cattle
 - urethrotomy, see horse
 - vasectomy 57
 sinus
 - frontal, trephination of 7
 - maxillary, trephination of 8
 skin grafting
 - pinch skin grafting (Braun) 84, 85
 - split skin grafting (Thiersch) 84
 spastic paresis 110, 111
 spavin (horse) 122
 spavin, septic (cattle) 124
 splint bone, fracture of 125
 subepiglottal cyst, extirpation of 22
 sucking in cattle 12

 tail
 - amputation of 113
 - coccygeal myotomy 112
 tarso-metatarsal joint
 - arthrodesis of 123
 - curettage of 124

- teat
 - fistula
 - congenital 102
 - traumatic 101
 - instruments
 - Danish teat knife 103
 - Hug's teat knife 103
 - Hug's tumour extractor 103
 - lacerations 100
 - obstructions
 - apical ('hard milker') 103
 - basal 103
 - mid-teat ('peas') 103
 - self-retaining teat canula 100, 101, 102, 103
 - wound 100, 101
- tendon
 - digital flexor, see digital flexor tendon
 - repair of 109
- tenectomy
 - cunean 122
 - flexor tendon 96, 99
- Thiersch split skin grafting 84
- thoracotomy 26
- 'through-and-through' incision 36
- thrush 93
- tibia
 - fracture of 120, 126, 127
 - osteochondrosis of 121
 - valgus deviation of 117
- tibiotarsal joint, arthrotomy of 121
- tongue, lingual mucosa resection 12
- tracheotomy 21, 23, 24
- trephination
 - of caudal maxillary sinus 8
 - of frontal sinus 7
 - of rostral maxillary sinus 8
- trephine 2, 7
- ulna, fracture of 114, 115
- umbilical cord, fistula of 32, 33
- umbilical hernia 30, 31
- umbilical herniorrhaphy 30, 31
- urachus, fistula of 32, 33
- urethrotomy 69
- urinary bladder
 - cystectomy, partial 32, 33
 - cystorrhaphy 67
 - cystotomy, pararectal 68
- urolithiasis 67, 68, 69
- uterus, caesarean section 76, 77
- Utrecht method (left flank omentopexy) 40
- Utrecht uterine suture 77
- vagina, pneumo- 78
- valgus deviation 117
- vasectomy 57
- ventral midline laparotomy, see laparotomy
- ventriculectomy 20, 21
- vestibuloplasty 78, 79
- vestibulum
 - episiotomy 82
 - rupture of 80, 81
- Viborg's triangle 6
- vulva, episiotomy 82
- walking cast, fracture treatment by 126, 127
- Weingart's apparatus 39
- windsucker 18
- withers, fistula of 28