
CONTRIBUTORS

Edward R. Eisner, DVM, DAVDC

Director of Services
Denver Veterinary Dental Service, P.C.
at Tender Care Veterinary Medical
Center
Owner and Consultant
Denver Veterinary Dental Consulting
Greenwood Village, Colorado
www.denervetdental.com

Patricia Frost Fitch, DVM, DAVDC

Visiting Instructor
Veterinary Medical Teaching Hospital
Oregon State University
Corvallis, Oregon;
Washington State University
Pullman, Washington;
Referral Veterinary Dentist
Animal Dental Services
Portland Oregon;
Owner
Veterinary Dental Consulting
La Center, Washington

Steven E. Holmstrom, DVM, DAVDC

Clinical Director
Animal Dental Clinic
San Carlos, California;
Instructor, Veterinary Technology
Department
Foothill College
Los Altos, California;
Owner and Consultant
Veterinary Dental Consulting
San Carlos, California
www.toothvet.info

Meghan Richey, DVM, MS, DACVA

Adjunct Assistant Professor
Emergency and Critical Care Medicine
Department of Veterinary Clinical
Sciences
Oklahoma State University
Stillwater, Oklahoma

**Frank J. M. Verstraete, DMV,
BVSc(Hon), MMedVet(Chir), DECVS,
DAVDC, DEVDC**

Professor and Service Chief
Dentistry and Oral Surgery
Department of Surgical and
Radiological Sciences
School of Veterinary Medicine
University of California
Davis, California;
Adjunct Assistant Professor
Department of Stomatology
Division of Oral Medicine, Pathology,
and Radiology
School of Dentistry
University of California
San Francisco, California

PREFACE

We have written the expanded third edition of *Veterinary Dental Techniques for the Small Animal Practitioner* in the same easy-to-read, easy-to-use chairside, procedure-friendly format as with the first two editions. Our goal has been to create an informative, updated, practical guide to dental materials and techniques in a wide spectrum of dental procedures that includes examination and charting, routine and advanced periodontal care, endodontic treatment, restorative dentistry, orthodontics, orthopedics, dental anesthesia, ergonomics, and operatory design. In the third edition we have invited guest authors, specialists in their own fields, for the maxillofacial fractures and anesthesia chapters. By so doing we aim to create an ideal book for veterinary students, technicians, seasoned general practitioners who wish to increase their dental knowledge of dental treatment planning and instrumentation, and veterinarians who are expanding their dental departments.

With the advent of the Internet, information may be exchanged rapidly. The reader is invited to contact the authors, by electronic mail, with any suggestions for future editions. The screen names are: Steve@Toothvet.info (Holmstrom), PatVancVDT@aol.com (Frost Fitch), and Dog2thdoc@aol.com (Eisner).

STEVEN E. HOLMSTROM, DVM, DAVDC
PATRICIA FROST FITCH, DVM, DAVDC
EDWARD R. EISNER, DVM, DAVDC

ACKNOWLEDGMENTS

We wish to thank Dr. Frank Verstraete and Dr. Meghan Richey for their contributions as the first guest authors in chapters for *Veterinary Dental Techniques for the Small Animal Practitioner*. The Third Edition also brings on a new illustrator, Jean Schroeter. We thank her for her contribution. Special thanks go to our former illustrator, Leo Hagstrom, for work in the first two editions. We thank Barron Hall and Richard Seidenberg, DVM, for their review of the second edition. We also wish to acknowledge the members of the American Veterinary Dental College, the Academy of Veterinary Dentistry, and the American Veterinary Dental Society for their contributions to the veterinary dental evolution and many techniques that are incorporated in this book.

We are grateful to the following dentists and hygienists who have contributed to our dental knowledge: Toby A. Burgess, DDS; Peter Emily, DDS; Keith Grove, VMD, DDS; Stephen John, DDS; Charles L. Neubauer, DDS; Robert Olson, DDS; Morgan Powell, DDS; Nick Sabbia, DDS; Dr. Barry Staley, DDS, DAVP; Judith Timchula, DDS; Walter E. Tweedie, DDS; Carol Weldin, RDH; and Laurie Holmstrom, RDH.

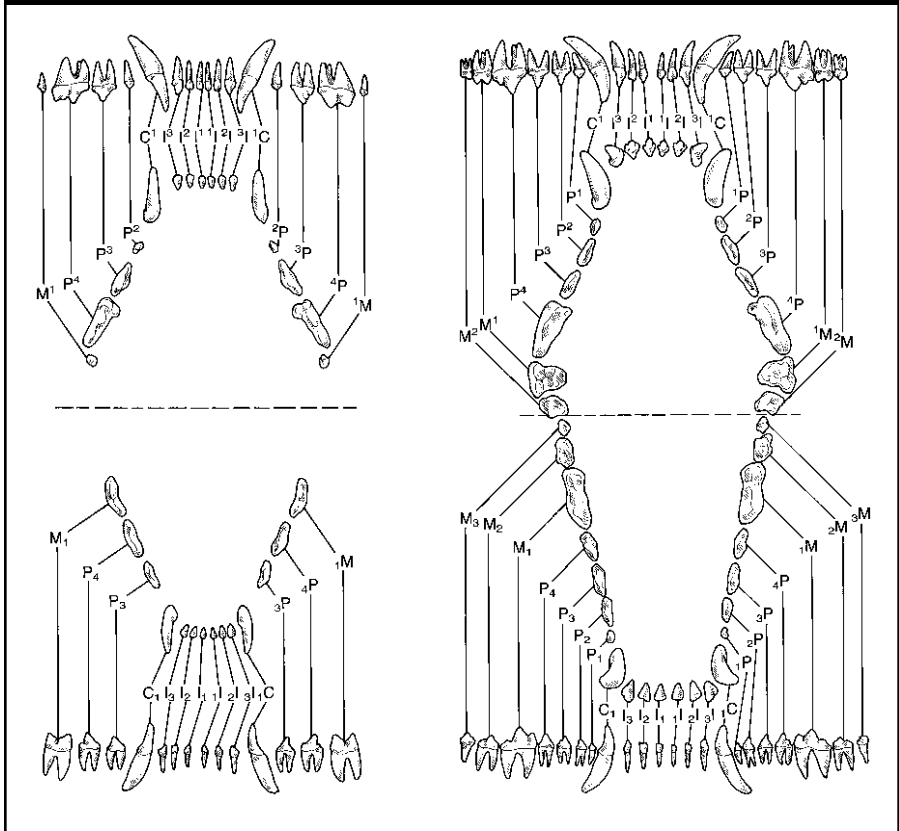
We also thank the American Dental Association and the state dental associations for their generosity in admitting interested veterinarians to their annual meetings and symposia. Without the sharing of knowledge, veterinary dentistry would not have progressed as rapidly.

Finally, we thank the many veterinary commercial entities that have supported the growth of veterinary dentistry and the veterinary practitioners whose continued interest in the field of veterinary dentistry is the real reason that this third edition of *Veterinary Dental Techniques* has been written. Your interest gives us the energy needed to provide you with an improved and updated text.

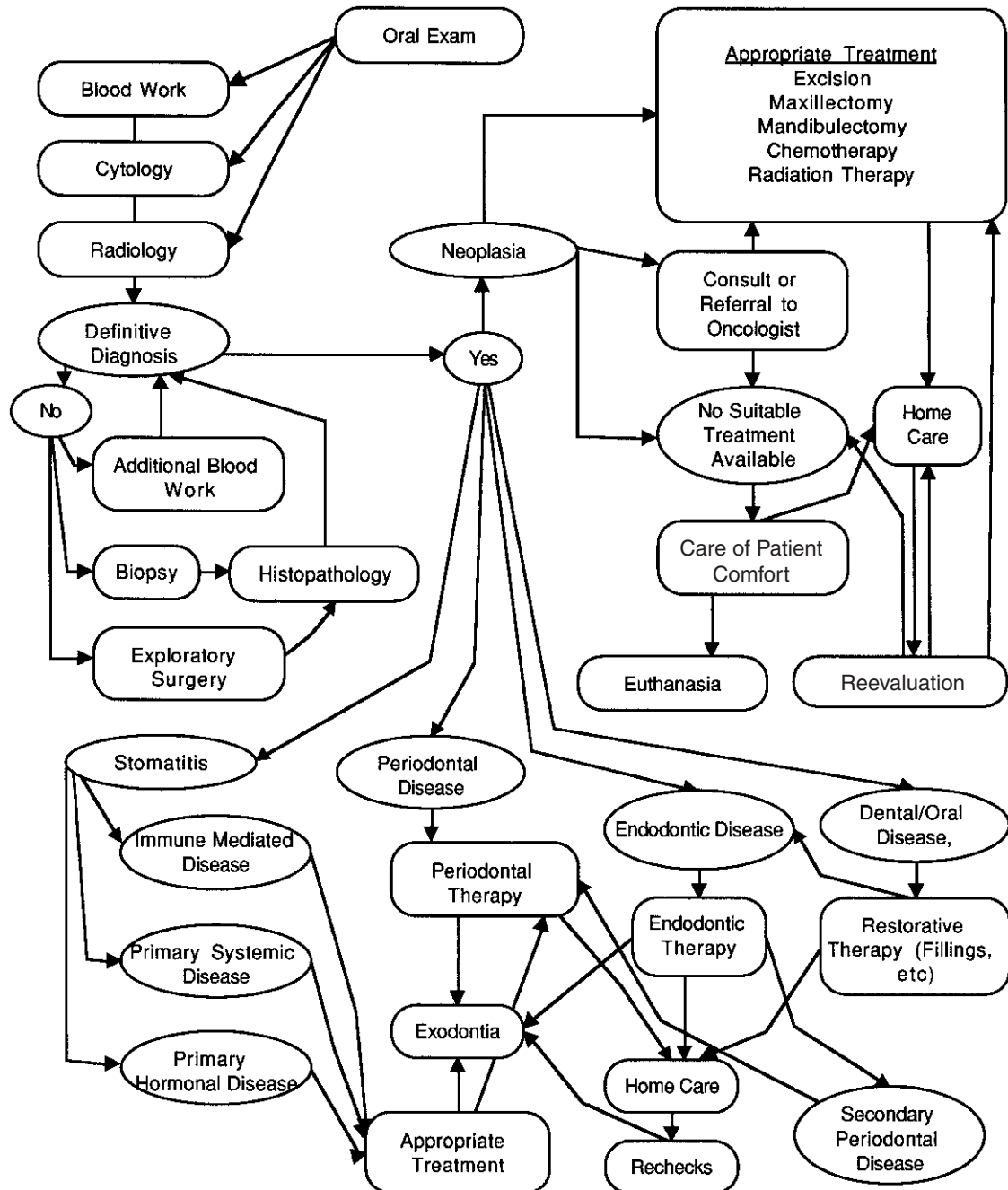
Chapter 1



DENTAL RECORDS



- Clear, concise, complete dental records are important for all patients undergoing oral and dental examination and treatment. Records are the most critical evidence that can be presented in court, at any level, as confirmation of accurate diagnosis and proper treatment. Good records are the best way to defend against unjustified malpractice claims. A standard of care does not require perfection, but rather a reasonable degree of skill, knowledge, and competence exercised by doctors under similar circumstances. As the level of veterinary dentistry rises during the twenty-first century, it behooves general practitioners either to develop an increased level of dental skill or at least to increase their knowledge to a point of being able to refer to an appropriate clinician a case in need of treatment.¹
- Written records are necessary to identify the patient; to record the patient's status before, during, and after treatment procedures; to document client acceptance or rejection of the treatment plan; to record therapy sequence, prognosis, results, and sequelae; to measure progress at successive appointments; to document consultations and referrals; and to provide ease of transfer to another practitioner.²
- Dental charts are a convenient conveyance for reducing the amount of writing, as well as increasing the visual comprehension. They serve well for the application of abbreviations and schematic treatment references of anatomic abnormalities, a patient's condition, performed periodontal, endodontic, and surgical therapy modalities, and for evaluating the response to treatment by comparison with charted information on recall visits. Good records are the best way to defend against unjustified malpractice claims.³ The paperless practice is a buzzword of the turn of the century, but to be a legally defensible record it should be unalterable. Too many "paperless" practices rely on invoice-driven programs, itemizing services performed or products sold, but not justifying the treatment administered or the products dispensed. Likewise, many records interchange the reason for patient presentation with the diagnosis, and they are not at all the same. A diagnosis (definitive diagnosis) is derived from a combination of history taken (subjective information), observations (objective data of signs, symptoms, or laboratory evaluations), and an assessment that rules out differential diagnoses suggested from objective data gathered. A diagnosis is justified by the historical and objective data; it is not necessarily what the client believes is the problem or the reason written in the clinician's schedule for the appointment.
- There is one other important legal aspect concerning records. Each entry in the dental record should be initialed by the person responsible for the entry. In computerized records, that means that a provider code should be entered and one should be assigned to all staff members.
- The American Veterinary Dental College (AVDC), in its Position Statement for Dental Health Care Providers,⁴ defines veterinary dentistry as "... the art and practice of oral health care in animals other than man. It is a discipline of veterinary medicine and surgery. The diagnosis, treatment, and management of veterinary oral health care is to be provided and supervised by licensed veterinarians or by veterinarians working within a university or industry." The AVDC has developed this position as a means to safeguard the veterinary dental patient and to ensure the qualifications of persons performing veterinary dental procedures. It is not a legal position, but one set by leaders of the veterinary dental profession. The practice acts of all but nine states in the United States legally consider tooth extraction a surgical procedure. Surgery alters the anatomy of the patient and, as such, should be performed by qualified doctors. The AVDC position accepts "that the following health care workers may assist the responsible veterinarian in dental procedures or actually perform dental prophylactic services while under direct, in-the-room supervision by a veterinarian if permitted by local law: licensed, certified, or registered veterinary technician, or a veterinary assistant with advanced dental training, dentist, or registered dental hygienist."⁴
- The AVDC supports the advanced training of veterinary technicians and assistants to perform additional ancillary dental services: taking impressions, making models, charting veterinary dental pathology, taking and developing dental radiographs, performing nonsurgical subgingival root scaling and debridement, providing that they do not alter the structure of the tooth (see Appendix.)
- The reader has the authors' permission to use the dental charts in this text in the course of practice.



TOOTH IDENTIFICATION SYSTEMS

General Comments

- A number of tooth identification systems have been used for dental records.
- In some systems a number is given to each tooth, whereas other systems use numbers and symbols to designate a tooth. The systems that use numbers alone are more readily adaptable for use with computers.
- This text uses the terms *type* to refer to primary (deciduous) or secondary (permanent) dentition and *function* to refer to the four common functional groups: incisor, canine, premolar, and molar.
- The two most commonly used identification systems in veterinary dentistry are the modified Triadan system and the anatomic system.
- Three other systems are described, used with varying frequency in countries other than the United States.

MODIFIED TRIADAN SYSTEM

General Comments

- The modified Triadan system has been described in numerous texts. Each tooth is given a three-digit number.^{5,6}
- The first number represents the quadrant, with the maxillary right quadrant being 1. Looking at a dental chart, the system is set up to reflect the clinician who is looking at the patient that is looking back at him or her. The quadrants seen on the chart, beginning with the maxillary right, are numbered sequentially in a clockwise fashion.
- For permanent teeth, the maxillary right quadrant is 1, the maxillary left quadrant is 2, the mandibular left quadrant is 3, and the mandibular right quadrant is 4. Quadrants for primary teeth are represented by 5, 6, 7, and 8, beginning again with the maxillary right quadrant as 5 and ending with the lower right as 8. The individual teeth are represented by two digits, with 01 being the first tooth from the midline and continuing distally along the arch to the last tooth. For dogs, the last number for secondary teeth is normally 10 for the upper arch and 11 for the lower arch.
- The rule of four and nine is used to simplify annotations among the various species.

Tooth 4 is always the canine tooth and tooth 9 is always the first molar, in either the maxillary or mandibular arch. For example, 504 represents the primary maxillary right canine tooth, and 309 represents the secondary mandibular left first molar. In species such as the cat, where the maxillary first premolar is missing, the teeth on the secondary maxillary right side are 101, 102, 103, 104 (105 is missing), 106, 107, 108, and 109. The teeth in the feline right secondary mandibular arch are 401, 402, 403, 404, 407, 408, and 409 (405 and 406 are missing). The numbers are not used when a tooth is normally missing in a species.

Advantages

- Easily adaptable for computer use if computer is not alphanumeric.
- Each tooth is assigned a number for individual identification.
- Easy to use in dealing with a single species or when records with anatomic charts printed on them are used.
- Once learned, this system is easier to say and write in records when describing teeth involved in pathology or treatment.
- If the rule of four and nine is used, this identification system is usable in a variety of mammals.

Disadvantages

- Difficult to remember if not used frequently.
- Tooth function is not identified by this system.

ANATOMIC IDENTIFICATION SYSTEM AND DENTAL SHORTHAND

General Comments

- Each tooth is given a letter corresponding to tooth function and type.
- Uppercase letters are used for secondary (permanent) teeth, and lowercase letters are used for primary (deciduous) teeth.

I = incisor	i = primary incisor
C = canine	c = primary canine
P = premolar	p = primary premolar
M = molar	

- Each quadrant of the mouth corresponds to a corner around the letter.
- Maxillary teeth are indicated by superscript numbers, and mandibular teeth are indicated by subscript numbers.
- Teeth on the patient's right are indicated to the right side of the letter, and teeth on the patient's left are indicated to the left side of the letter. In this system, unlike in most dental charts, the clinician and the patient are looking in the *same* direction; the patient's right teeth are noted on the right, and the left ones on the left in the chart.
- The teeth are numbered consecutively, for each functional group of teeth, starting from the midline. This number is placed in the appropriate corner around the letter. For example:

Superscript and subscript numerals for the teeth on the animal's right side are placed on the right side of the letter designating the functional group.

The permanent maxillary right central incisor is represented by the number 1 placed as a superscript on the right side of the uppercase letter I as: I¹.

Second and third secondary mandibular left premolars are represented by the numbers 2 and 3 placed as a subscript on the left side of the uppercase letter P as: _{3,2}P.

The primary maxillary left canine is represented by the number 1 placed as a superscript on the left side of the lowercase letter c as: ¹c.

Advantages

- Easy to learn because it is more self-explanatory than other systems.
- Identifies tooth function and type.
- The same tooth number is used for the corresponding tooth in different species.
- Several teeth can be listed, efficiently, with one letter: P^{1,2,3,4}.
- May be used with alphanumeric systems by placing "U" (upper) or "L" (lower) or "+" or "-" for maxillary or mandibular, before or after the tooth number.

The permanent upper right central incisor = IU1 or I+1 or UR11.

Second permanent lower left premolar = L2P or -P or LLP2.

Primary upper left canine = U1c or +1c.

The letters L or R may also be used: UR1C or UR1c.

Disadvantages

- May not be used with all computer systems without the above modifications.
- May be confusing to an uninformed reader as to whether reference is to patient's or observer's right or left.
- Is easier to use in written than oral form.

PALMER NOTATION SYSTEM

General Comments

- Each tooth is given a letter corresponding to its function.
- Capital letters are used for permanent teeth, and lowercase letters are used for primary teeth.
- The teeth are numbered consecutively within their functional group, and a symbol is used to denote the quadrant. Note that right and left are as viewed and do not indicate the patient's right and left.

P $\overline{2}$ = upper left second permanent premolar.

P $\overline{1}$ = lower left first permanent premolar.

C $\overline{1}$ = lower right first permanent canine.

Advantages

- Identifies tooth function and type.
- Easy identification of quadrant.

Disadvantages

- Not easily used with a computer.
- Difficult to use to describe tooth verbally.

NUMERICAL ORDER (UNIVERSAL TOOTH NUMBERING SYSTEM)

General Comments

- This system is commonly used in human dentistry and facilitates communication with this profession.

- Each permanent tooth is given a number 1 to 30 in the cat, 1 to 42 in the dog. Primary teeth are lettered (a to z in the cat; a to B in the dog).
- The teeth are numbered starting in the upper right quadrant with the last tooth and continuing with consecutive numbers around the arch to the opposite last upper left tooth. The lower arch is numbered starting from the last lower left tooth and continuing around the arch to the last lower right tooth.

Advantages

- Enables easy communication if both parties know the numbers and the system.
- Easily used with computers.

Disadvantages

- The same tooth from species to species will have a different number because of the differences in dental formulas.
- Difficult to remember all the numbers, especially if the system is used infrequently or if numerous species are treated.
- Does not identify tooth function.

HADERUP SYSTEM

General Comments

- This system numbers each tooth in a quadrant consecutively, starting at the midline.
- The upper or lower arch is indicated by a + or – next to the number, with + corresponding to the upper jaw and – to the lower jaw.
- The right or left is indicated by the side of the tooth on which the symbol is placed: +2 = left upper second incisor, 6– = right lower second premolar.

Advantages

- Readily usable with computerized records.
- Easier to use in oral communication than the anatomic system.

Disadvantages

- The practitioner must memorize the numbering for each species treated. This becomes cumbersome.
- Does not identify tooth function.
- All parties involved must know the system, and it is used infrequently.

Palmer	3	2	1	1	2	3
Triadan	103	102	101	201	202	203
Anatomic	1 ³	1 ²	1 ¹	1 ¹	2 ¹	2 ³
Universal	8	9	10	11	12	13
Haderup	3+	2+	1+	1+	2+	3+
Zsigmondy	3	2	1	1	2	3
Federali	1,3	1,2	1,1	2,1	2,2	2,3

Palmer	Triadan	Anatomic	Universal	Haderup	Zsigmondy	Federali		Federali	Zsigmondy	Haderup	Universal	Anatomic	Triadan	Palmer
C ₁	104	C ¹	7	4+	4	1,4		2,4	4	+4	14	1 ^C	204	C ₁
P ₁	105	P ¹	6	5+	5	1,5		2,5	5	+5	15	1 ^P	205	P ₁
P ₂	106	P ²	5	6+	6	1,6		2,6	6	+6	16	2 ^P	206	P ₂
P ₃	107	P ³	4	7+	7	1,7		2,7	7	+7	17	3 ^P	207	P ₃
P ₄	108	P ⁴	3	8+	8	1,8		2,8	8	+8	18	4 ^P	208	P ₄
M ₁	109	M ¹	2	9+	9	1,9		2,9	9	+9	19	1 ^M	209	M ₁
M ₂	110	M ²	1	10+	10	1,10	Right	2,10	10	+10	20	2 ^M	210	M ₂
M ₃	411	M ₃	42	11-	11	4,11	Left	3,11	11	-11	21	3 ^M	311	M ₃
M ₂	410	M ₂	41	10-	10	4,10		3,10	10	-10	22	2 ^M	310	M ₂
M ₁	409	M ₁	40	9-	9	4,9		3,9	9	-9	23	1 ^M	309	M ₁
P ₄	405	P ₄	39	8-	8	4,8		3,8	8	-8	24	4 ^P	308	P ₄
P ₃	407	P ₃	38	7-	7	4,7		3,7	7	-7	25	3 ^P	307	P ₃
P ₂	406	P ₂	37	6-	6	4,6		3,6	6	-6	26	2 ^P	306	P ₂
P ₁	405	P ₁	36	5-	5	4,5		3,5	5	-5	27	1 ^P	305	P ₁
C ₁	404	C ₁	35	4-	4	4,4		3,4	4	-4	28	1 ^C	304	C ₁

Federali	4,3	4,2	4,1	3,1	3,2	3,3
Zsigmondy	3	2	1	1	2	3
Haderup	3-	2-	1-	1-	2-	3-
Universal	34	33	32	31	30	29
Anatomic	1 ₃	1 ₂	1 ₁	1 ₁	2 ₁	2 ₃
Triadan	403	402	401	301	302	303
Palmer	13	12	11	11	12	13

ZSIGMONDY SYSTEM

General Comments

- This system uses a plus sign to identify quadrants. With the head of the patient facing the observer, visualize a horizontal line between the upper and lower jaws and a vertical line separating the right from the left side.
- The intersecting lines of this sign are used to show the corresponding quadrant. These are noted as viewed (not the patient's right or left).
- The permanent teeth are numbered consecutively in each quadrant, starting from the midline. The primary teeth are lettered consecutively, starting with the letter A for the first tooth from the midline.
5 = permanent upper right first premolar in the dog.
4 = permanent lower left canine in the dog.
B = primary upper left second incisor in the cat or dog.

Advantage

- Clearly defines maxillary versus mandibular quadrant and right versus left quadrant.

Disadvantage

- Inconsistent with other systems except, for example, the Palmer Notation System; in this system the tooth is identified by the observer's view of the tooth rather than by where the tooth is located in the patient's mouth.

FÉDÉRATION DENTAIRE INTERNATIONALE SYSTEM

General Comments

- This system identifies each quadrant by numbers 1 to 4 for permanent teeth and 5 to 8 for primary teeth: 1/5 = upper right

maxillary teeth, 2/6 = upper left maxillary teeth, 3/7 = lower left mandibular teeth, and 4/8 = lower right mandibular teeth.

- The teeth are numbered consecutively in each quadrant from the midline, with the corresponding quadrant number for the permanent or primary tooth in front of it separated by a comma.
- In the dog 1,1 = upper right maxillary permanent central incisor.
- In the cat 6,4 = upper left maxillary primary canine.

Advantages

- Easy identification of quadrant (upper maxillary or lower mandibular, left or right).
- Can be used easily with computerized records.

Disadvantages

- Difficult to learn.
- Does not identify tooth function.
- Not good for use with multiple species.

VETERINARY MEDICAL RECORDS

General Comments

- Written records must be dated, accurate, and readable, and they should be signed.
- In recording dental findings, written justification for treatment and procedures performed is necessary to substantiate a legal record. If that treatment is ever questioned, the record will reflect continuity of periodic treatment for various dental disorders.
- The medical record should contain the client's name, address, and telephone number(s) and the name, breed, age, and gender of the patient.
- Having a telephone number where the client can be contacted during a patient's dental procedure can be beneficial if additional abnormalities are found while the patient is anesthetized.

Client number _____

Pet Clinic Initial Oral Exam

Medical Alert

Owner _____ Patient _____ Date _____

Species _____ Breed _____ Sex _____ Date of Birth _____

Chief complaint _____

Past dental history _____

General medical history _____

Diet _____

Home oral hygiene _____

Other _____

Skull type:

- ☐ Brachycephalic
☐ Mesiocephalic
☐ Dolichocephalic
☐ _____

Oral Hygiene

- ☐ Plaque N S M H
☐ Calculus N S M H
 Normal Slight Moderate Heavy

Periodontal Exam

- | | | | | |
|---|---|---|---|---|
| <input type="checkbox"/> Inflammation | I | C | P | M |
| <input type="checkbox"/> Gingival Edema | I | C | P | M |
| <input type="checkbox"/> Pockets >3mm | I | C | P | M |
| <input type="checkbox"/> Pockets >5mm | I | C | P | M |
| <input type="checkbox"/> Recession | I | C | P | M |
| <input type="checkbox"/> Hyperplasia | I | C | P | M |
| <input type="checkbox"/> Mucogingival loss | I | C | P | M |
| <input type="checkbox"/> Tooth Mobility | I | C | P | M |
| <input type="checkbox"/> Further evaluation | I | C | P | M |

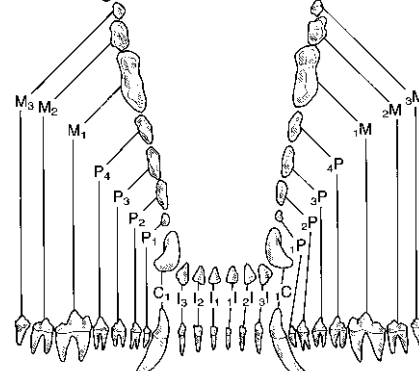
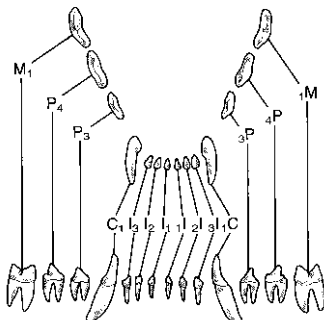
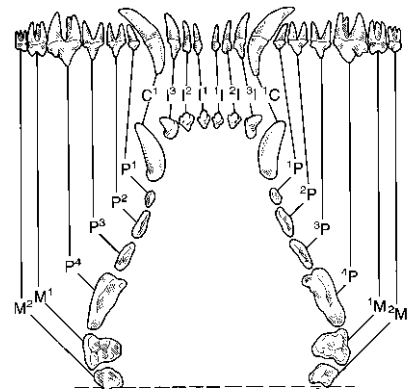
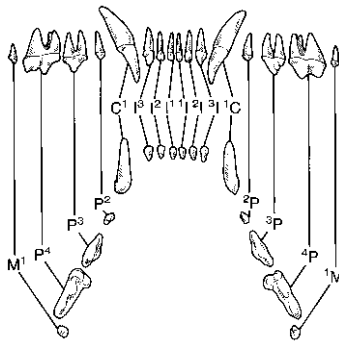
Incisor Canine Premolar Molar

Occlusion:

- ☐ Scissors
☐ Brachygnathic
☐ Prognathic
☐ Wry
☐ Level
☐ Crossbite
☐ Occlusal wear I C P M

Tooth Abnormalities

- | | | | |
|--|---|---|-------|
| <input type="checkbox"/> Ret. Primary | I | C | P |
| <input type="checkbox"/> Missing | I | C | P M |
| <input type="checkbox"/> Supernumerary | I | C | P M |
| <input type="checkbox"/> Caries | I | C | P M |
| <input type="checkbox"/> Resorptive | I | C | P M |
| <input type="checkbox"/> Injured | I | C | P M |



DENTAL RECORDS

General Comments

- Dental records also have legal ramifications and can consist of fill-in or check-off formats, dental anatomic charts, or a combination of these to provide efficient, shorthand recording.
- An adequate dental record provides subjective and objective information. It should contain enough information to justify the treatment performed and the materials used in that treatment, tooth by tooth. To provide an efficient record-keeping system, a chart should include a dental diagram with an abbreviation key so that abbreviations and diagrams, augmented by a brief description to clarify disease(s) and treatment protocols, can be read accurately by a person not in the field. An assessment of procedure(s) performed, interpretation of radiographs taken, a therapeutic plan, and a prognosis complete the functional dental record.
- Dental anatomic charts are important because three-dimensional objects are described that are often difficult to discuss in written terms. An anatomic chart facilitates the recording of sequential treatments. If repetitive and extensive treatment is performed, additional pages with ongoing notations permit treatment progress review at a glance.
- The type of record used will vary in each practice but should include patient and client identification, chief complaint, a general health history, dental history, tooth identification system used, specific findings, treatment plan, anesthetic drugs (with strengths or dosages and route of administration used), follow-up care recommended, radiographic interpretation, assessment of treatment, prognosis, documentation of discussions and consultations, missed appointments, or deviation from recommended follow-up, and documented informed consent. Additionally, it is particularly important to enter a recommended diagnostic procedure or therapy that is declined.
- Small labels, containing dental charts, are available from a variety of sources. These peel-off labels, although not as complete or adequate as full-page dental records, are better than no chart and will facilitate making notations when placed in the medical record.

INITIAL ORAL EXAMINATION

General Client and Patient Information

- This includes the names of the client and patient, date of examination, species, breed, gender, and date of birth (or age).

Chief Complaint

- Listing the chief complaint ensures that this client concern is addressed even though additional dental problems may be found upon examination.

Dental History

- This includes dates and descriptions of past dental problems, treatment(s) performed, and relative success of therapy.

General Medical History

- Knowing the general health of the patient is extremely important, because most dental procedures require general anesthesia. Physical, metabolic, immune, and endocrine abnormalities and ongoing medical treatment affect decisions when constructing a safe anesthesia protocol.

Diet

- The patient's current diet and amounts fed—whether moist or dry, prescription, commercial, or table scraps—should be recorded. Other treats fed and oral habits (fence chewing, bones, rocks, firewood collection, etc.) should be listed. Identifying types of chew and play toys available can also be helpful, because many can cause tooth damage (prepared cow hooves, tennis balls, hard plastic or nylon chews).

Home Oral Hygiene

- Home oral hygiene performed is noted, including the names of products used, frequency and manner of care (e.g., brushing, oral rinse, food or water additive, and

chewable or edible treats), and effectiveness and patient compliance.

Recording Specific Findings

- The head and oral cavity are examined systematically, and initial findings and abnormalities are recorded.
- The skull type (brachycephalic, mesocephalic, dolichocephalic, or variation) is noted.
- The face and jaw should be examined for symmetry, swellings, and any abnormalities of the salivary glands and regional lymph nodes.
- The occlusion and any occlusal wear are noted.
- The amount of plaque and calculus present in general is recorded.
- Tooth abnormalities, including retained primary teeth, missing teeth, and supernumerary teeth, should be noted. Other dental findings, such as carious lesions, resorptive lesions, dental trauma, and any other abnormalities, are noted by indicating the tooth involved and their location on the tooth.
- The periodontal status is recorded by noting gingival inflammation, gingival edema, significant periodontal pocket depth, gingival recession, gingival hyperplasia, attachment loss, and tooth mobility. Additional diagnostic evaluation that is recommended should be noted.
- Other oral disease, if present, is noted in the dental chart.
- The permanent initial record of dental findings is kept for future reference.
- In addition to dental tissue, the oral cavity in general should be examined for lesions. Lesions, if detected, may be described in a variety of different ways, but not limited to those in Table 1-1 (see also Oral Examination in Chapter 4).

Table 1-1 • WORDS TO DESCRIBE ORAL INFLAMMATORY DISEASE

Type categories	Descriptive term	Definition
Duration	Acute	Having a short course
	Chronic	Having a long, continued course
Physical appearance	Vesicular	Small, blister-like
	Bullous	Circumscribed, elevated lesion more than 5 mm in diameter
	Ulcerative	Loss of epithelial covering causing a gradual disintegration of tissues
	Proliferative	Growth by reproduction of similar cells
	Suppurative,	Inflammatory exudate formed within the tissues
	Fibrinous	Containing fibrous tissue, usually by degeneration
Severity	Hemorrhagic	Containing the elements of blood
	Mild	Appreciated only after careful observation
	Moderate	Readily apparent, but lacks visual and mental impact
	Severe	Immediate and forceful visual impact on viewer
Spread	Focal	Discrete and well circumscribed
	Multifocal	Well defined but numerous
	Diffuse	Substantial portion of affected region
Location of inflammation	Glossitis	Inflammation of the tongue
	Cheilitis	Inflammation of the lips
	Buccostomatitis	Inflammation of the inner cheek
	Pharyngitis	Inflammation of the pharynx
	Faucitis	Inflammation of the glossopalatine folds or angles of the mouth
	Palatitis	Inflammation of the palate
	Gingivitis	Inflammation of the gingiva
	Periodontitis	Inflammation of the periodontium

ANATOMIC CHARTING AND ABBREVIATED NOTATIONS

- Pathologic findings can be recorded on the anatomic chart. The chart is updated as the patient's condition changes. This becomes the continuing record of the patient's dental status.
- Symbols or letters to indicate a variety of abnormalities can be used on a dental anatomy chart to speed recording and allow a quick reference to all the abnormalities and treatments.
- Many symbols are in common usage in dentistry, or clinicians may develop their own.
- A key for symbols and letter abbreviations used should be available to eliminate confusion for others reading the record.
- The AVDC has adopted an extensive list of abbreviations and updated them in 2003⁷ (Table 1-2). The clinician can choose diagnoses and procedures most common in the practice and list these abbreviations and descriptions in an abbreviation key on the dental chart.

**Pet Clinic
Canine Dental Treatment Chart**

Right Side															Left Side																											
Buccal															Buccal																											
Occlusal															Occlusal																											
Palatal															Palatal																											
Lingual															Lingual																											
Occlusal															Occlusal																											
Buccal															Buccal																											
M2	M1	P4	P3	P2	P1	C1	I3	I2	I1	1I	2I	3I	1C	1P	2P	3P	4P	1M	2M	M2	M1	P4	P3	P2	P1	C1	I3	I2	I1	1I	2I	3I	1C	1P	2P	3P	4P	1M	2M			
110	109	108	107	106	105	104	103	102	101	201	202	203	204	205	206	207	208	209	210	M3	M2	M1	P4	P3	P2	P1	C1	I3	I2	I1	1I	2I	3I	1C	1P	2P	3P	4P	1M	2M	3M	
411	410	409	408	407	406	405	404	403	402	401	301	302	303	304	305	306	307	308	309	310	311																					

Remarks and Diagnosis: _____

Radiographic Evaluation and Assessment: _____

Treatment Summary and Plan: _____

Client Instructions: _____

Table 1–2 • AVDC APPROVED ABBREVIATIONS
ADOPTED BY BOARD OF DIRECTORS IN AUGUST 2003

All Abbreviations					
<i>Diagnosis</i>	<i>Procedure</i>	<i>Definition</i>	<i>Diagnosis</i>	<i>Procedure</i>	<i>Definition</i>
AB		abrasion		FX/R/WIR/ OS	osseous wire fracture repair of jaw
ANUG		acute necrotizing ulcerative gingivitis	GH		gingival hyperplasia/ hypertrophy
AT		attrition	GM		gingival mass
	B	biopsy	GM/EPA		acanthomatous ameloblastoma (epulis)
	B/E	biopsy excisional	GM/EPB		basal cell epulis
	B/I	biopsy incisional	GM/EPF		fibrous epulis
	BG	bone graft (includes placement of bone substitute or bone stimulant material)	GM/EPO		osseous epulis
CA		caries	GM/FS		fibrosarcoma
CFL		cleft lip	GM/MM		malignant melanoma
	CFL/R	cleft lip repair	GM/OS		osteosarcoma
CFP		cleft palate	GM/OT		other
	CFP/R	cleft palate repair	GM/SC		squamous cell carcinoma
CMO		cranio-mandibular osteopathy	GR	GP	gingivoplasty (gingivectomy)
	CBU	core build up		GTR	gingival recession
	CR	crown		IM	guided tissue regeneration
	CR/A	crown amputation		IMP	impression and model
	CR/BM	crown base metal		IO	implant
	CR/G	crown gold		IO/D	interceptive (extraction) orthodontics
	CR/L	crown lengthening		IO/D	deciduous tooth interceptive orthodontics
	CR/PFM	crown porcelain fused to metal		IO/P	permanent tooth interceptive orthodontics
	CR/P	crown preparation		IP	inclined plane
	CR/R	crown reduction		IP/AC	acrylic inclined plane
	CS	culture/susceptibility		IP/C	composite inclined plane
DT		deciduous tooth		IP/M	metal (lab produced)
DTC		dentigerous cyst		IP/WIR	inclined plane wire reinforced
E		enamel			laceration
E/D	E/D	enamel defect	LAC		laceration buccal (cheek)
E/H	E/H	enamel hypocalcification/ hypoplasia	LAC/B		laceration lip
EG		eosinophilic granuloma	LAC/L		laceration tongue
EG/L	EG/L	eosinophilic granuloma–lip	LAC/T		lymphocytic-plasmacytic stomatitis
EG/P	EG/P	eosinophilic granuloma–palate	LPS		malocclusion
EG/T	EG/T	eosinophilic granuloma–tongue	MAL		class I malocclusion (normal jaw relationship, specific teeth are incorrectly positioned)
FB		foreign body	MAL/1		class II malocclusion (mandible shorter than maxilla)
	F	flap			class III malocclusion (maxilla shorter than mandible)
	F/AR	apical repositioned gingival flap	MAL/2		base narrow mandibular canine tooth
	F/CR	coronal repositioned gingival flap	MAL/3		anterior crossbite
	F/LS	lateral sliding gingival flap			posterior crossbite
	F/RB	reverse bevel gingival flap			wry bite
	FGG	free gingival graft	MAL/BN		mandible
	FRE	frenoplasty (frenotomy, frenectomy)	MAL/AXB		mandibular fracture
FX		fracture (tooth or jaw)	MAL/PXB		maxilla
	FX/R	repair of jaw fracture	MAL/WRY		maxillary fracture
	FX/R/P	pin fracture repair of jaw	MN	OA	orthodontic appliance
	FX/R/PL	plate fracture repair of jaw	MN/FX	OA/A	adjust orthodontic appliance
	FX/R/S	screw fracture repair of jaw	MX	OA/BKT	bracket orthodontic appliance
	FX/R/WIR	wire fracture repair of jaw	MX/FX		
	FX/R/WIR/ C	cerclage wire fracture repair of jaw	OA		
	FX/R/WIR/ ID	interdental wire fracture repair of jaw			

Table 1–2 • AVDC APPROVED ABBREVIATIONS
ADOPTED BY BOARD OF DIRECTORS IN AUGUST 2003—*cont'd*

All Abbreviations					
<i>Diagnosis</i>	<i>Procedure</i>	<i>Definition</i>	<i>Diagnosis</i>	<i>Procedure</i>	<i>Definition</i>
	OA/BU	button orthodontic appliance	SLG		sublingual granuloma
	OA/EC	elastic (power chain)			“tongue-biter” lesions)
		orthodontic appliance	SN		supernumerary
	OA/I	install orthodontic appliance		SPL	splint
	OA/R	remove orthodontic appliance		SPL/AC	acrylic splint
	OA/WR	wire orthodontic appliance		SPL/C	composite splint
	OC	orthodontic/genetic consultation	SYM	SPL/WIR	wire reinforced splint
OM		oral mass	SYM/S		symphysis
OM/AD		adenocarcinoma		SYM/WIR	symphyseal separation
OM/FS		fibrosarcoma			wire repair of symphyseal separation
OM/LS		lymphosarcoma	T		tooth
OM/MM		malignant melanoma	T/A		avulsed tooth
OM/OS		osteosarcoma	T/FX		fractured tooth
OM/OT		other type oral mass	T/I		impacted tooth
OM/PAP		papillomatosis	T/LUX		luxated tooth
OM/SC		squamous cell carcinoma	T/NE		near pulp exposure
ONF		oronasal fistula	T/NV		non-vital tooth
	ONF/R	oronasal fistula repair	T/PE		pulp exposure
	OR	orthodontic recheck	T/V		vital tooth
OST		osteomyelitis	TMJ		temporomandibular joint
	PC	pulp capping		TMJ/C	temporomandibular joint condylectomy
	PC/D	direct pulp capping	TMJ/D		TMJ dysplasia
	PC/I	indirect pulp capping	TMJ/FX		TMJ fracture
	PRO	periodontal prophylaxis (examination, scaling, polishing, irrigation)	TMJ/L		TMJ luxation
	PSB	periodontal suprabony surgery		TMJ/R	reduction of TMJ luxation
PDI		periodontal disease index		TP	treatment plan
PD0		normal periodontium		TRX	tooth partial resection (e.g. hemisection)
PD1		gingivitis only		VP	vital pulp therapy
PD2		< 25% attachment loss		X	simple closed extraction
PD3		25-50% attachment loss		XS	extraction with tooth sectioning, non-surgical
PD4		>50% attachment loss		XSS	surgical (open) extraction of a tooth
PE		pulp exposure			
	PIB	periodontal intrabony surgery			
		periodontal intrabony surgery			
R	R	restoration of tooth	AB		Diagnosis Abbreviations
	R/A	restoration with amalgam	ANUG		abrasion
	R/C	restoration with composite			acute necrotizing ulcerative gingivitis
	R/I	restoration with glass ionomer	AT		attrition
			CA		caries
	RAD	radiograph	CFL		cleft lip
	RC	root canal therapy	CFP		cleft palate
	RC/S	surgical root canal therapy	CMO		cranio-mandibular osteopathy
	RC/APG	apexogenesis			culture/susceptibility
	RC/APX	apexification	CS		deciduous tooth
RL		root resorption lesion	DT		dentigerous cyst
	RPC	root planing—closed	DTC		enamel
	RPO	root planing—open	E		enamel defect
	RRX	root resection (crown left intact)	E/D		enamel hypocalcification/hypoplasia
RR		endodontic root resorption	E/H		eosinophilic granuloma
RRT		retained root tip	EG		eosinophilic granuloma—lip
RTR		retained tooth root	EG/L		eosinophilic granuloma—palate
	S	surgery	EG/P		eosinophilic granuloma—tongue
	S/M	mandibulectomy	EG/T		foreign body
	S/P	palate surgery	FB		fracture (tooth or jaw)
	S/X	maxillectomy	FX		
	SC	subgingival curettage			

Table 1–2 • **AVDC APPROVED ABBREVIATIONS**
ADOPTED BY BOARD OF DIRECTORS IN AUGUST 2003—cont'd

All Abbreviations					
<i>Diagnosis</i>	<i>Procedure</i>	<i>Definition</i>	<i>Diagnosis</i>	<i>Procedure</i>	<i>Definition</i>
GH		gingival hyperplasia/ hypertrophy	SN		supernumerary
GM		gingival mass	SYM		symphysis
GM/EPA		acanthomatous ameloblastoma (epulis)	SYM/S		symphyseal separation
GM/EPB		basal cell epulis	T		tooth
GM/EPF		fibrous epulis	T/A		avulsed tooth
GM/EPO		osseous epulis	T/FX		fractured tooth
GM/FS		fibrosarcoma	T/I		impacted tooth
GM/MM		malignant melanoma	T/LUX		luxated tooth
GM/OS		osteosarcoma	T/NE		near pulp exposure
GM/OT		other	T/NV		non-vital tooth
GM/SC		squamous cell carcinoma	T/PE		pulp exposure
GR		gingival recession	T/V		vital tooth
LAC		laceration	TMJ		temporomandibular joint
LAC/B		laceration buccal (cheek)	TMJ/D		TMJ dysplasia
LAC/L		laceration lip	TMJ/FX		TMJ fracture
LAC/T		laceration tongue	TMJ/LUX		TMJ luxation
LPS		lymphocytic-plasmacytic stomatitis			
MAL		malocclusion		Procedure Abbreviations	
MAL/1		class I malocclusion (normal jaw relationship, specific teeth are incorrectly positioned)	B		biopsy
MAL/2		class II malocclusion (mandible shorter than maxilla)	B/E		biopsy excisional
MAL/3		class III malocclusion (maxilla shorter than mandible)	B/I		biopsy incisional
MAL/BN		base narrow mandibular canine tooth	BG		bone graft (includes placement of bone substitute or bone stimulant material)
MAL/AXB		anterior crossbite	CFL/R		cleft lip repair
MAL/PXB		posterior crossbite	CFP/R		cleft palate repair
MAL/WRY		wry bite	CBU		core build up
MN		mandible	CR		crown
MN/FX		mandibular fracture	CR/A		crown amputation
MX		maxilla	CR/BM		crown base metal
MX/FX		maxillary fracture	CR/G		crown gold
OM		oral mass	CR/L		crown lengthening
OM/AD		adenocarcinoma	CR/PFM		crown porcelain fused to metal
OM/FS		fibrosarcoma	CR/P		crown preparation
OM/LS		lymphosarcoma	CR/R		crown reduction
OM/MM		malignant melanoma	F		flap
OM/OS		osteosarcoma	F/AR		apical repositioned gingival flap
OM/OT		other type oral mass	F/CR		coronal repositioned gingival flap
OM/PAP		papillomatosis	F/LS		lateral sliding gingival flap
OM/SC		squamous cell carcinoma	F/RB		reverse bevel gingival flap
ONF		oronasal fistula	FGG		free gingival graft
OST		osteomyelitis	FRE		frenoplasty (frenotomy, frenectomy)
PDI		periodontal disease index	FX/R		repair of jaw fracture
PD0		normal periodontium	FX/R/P		pin fracture repair of jaw
PD1		gingivitis only	FX/R/PL		plate fracture repair of jaw
PD2		< 25% attachment loss	FX/R/S		screw fracture repair of jaw
PD3		25-50% attachment loss	FX/R/WIR		wire fracture repair of jaw
PD4		>50% attachment loss	FX/R/WIR/ C		cerclage wire fracture repair of jaw
PE		pulp exposure	FX/R/WIR/ ID		interdental wire fracture repair of jaw
RL		root resorption lesion	FX/R/WIR/ OS		osseous wire fracture repair of jaw
RR		endodontic root resorption	GP		gingivoplasty (gingivectomy)
RRT		retained root tip	GTR		guided tissue regeneration
RTR		retained tooth root	IM		impression and model
SLG		sublingual granuloma ("tongue-biter" lesions)	IMP		implant

Table 1-2 • AVDC APPROVED ABBREVIATIONS
ADOPTED BY BOARD OF DIRECTORS IN AUGUST 2003—*cont'd*

[illegible]

Table 1–2 • **AVDC APPROVED ABBREVIATIONS**
ADOPTED BY BOARD OF DIRECTORS IN AUGUST 2003—cont'd

All Abbreviations					
<i>Diagnosis</i>	<i>Procedure</i>	<i>Definition</i>	<i>Diagnosis</i>	<i>Procedure</i>	<i>Definition</i>
	IO/P	permanent tooth interceptive orthodontics		PSB	periodontal suprabony surgery
	IP	inclined plane	PDI		periodontal disease index
	IP/AC	acrylic inclined plane	PD0		normal periodontium
	IP/C	composite inclined plane	PD1		gingivitis only
	IP/M	metal (lab produced) inclined plane	PD2		< 25% attachment loss
	IP/WIR	wire reinforced malocclusion	PD3		25-50% attachment loss
MAL			PD4		>50% attachment loss
MAL/1		class I malocclusion (normal jaw relationship, specific teeth are incorrectly positioned)	PIB		periodontal intrabony surgery
MAL/2		class II malocclusion (mandible shorter than maxilla)	RPC		root planing—closed
MAL/3		class III malocclusion (maxilla shorter than mandible)	RPO		root planing—open
MAL/BN		base narrow mandibular canine tooth	SC		subgingival curettage
MAL/AXB		anterior crossbite	Surgery and Extraction Abbreviations		
MAL/PXB		posterior crossbite	B		biopsy
MAL/WRY		wry bite	B/E		biopsy excisional
	OC	orthodontic/genetic consultation	B/I		biopsy incisional
	OR	orthodontic recheck	CFL		cleft lip
			CFL/R		cleft lip repair
			CFP		cleft palate
			CFP/R		cleft palate repair
			FX		fracture
			FX/R		repair of jaw fracture
			FX/R/P		pin fracture repair of jaw
			FX/R/PL		plate fracture repair of jaw
			FX/R/S		screw fracture repair of jaw
			FX/R/WIR		wire fracture repair of jaw
			FX/R/WIR/C		cerclage wire fracture repair of jaw
			FX/R/WIR/ID		interdental wire fracture repair of jaw
			FX/R/WIR/OS		osseous wire fracture repair of jaw
			ONF		oronasal fistula
			ONF/R		oronasal fistula repair
			S		surgery
			S/M		mandibulectomy
			S/P		palate surgery
			S/X		maxillectomy
			SPL		splint
			SPL/AC		acrylic splint
			SPL/C		composite splint
			SPL/WIR		wire reinforced splint
			SYM		symphysis
			SYM/WIR		wire repair of symphyseal separation
			TMJ		temporomandibular joint
			TMJ/C		temporomandibular joint condylectomy
			TMJ/R		reduction of TMJ luxation
			X		simple closed extraction
			XS		extraction with tooth sectioning, non-surgical
			XSS		surgical (open) extraction of a tooth

Remarks

- Miscellaneous remarks may be entered. Additional pages may be added, as necessary, to describe adequately or depict nonroutine procedures or surgery performed.

**Diagnosis, Treatment Plan,
Treatment Completed**

- A date, the tooth or teeth involved, radiographic assessment and number of films

taken, and treatment plan or options are entered. A “P” is placed in the column to denote a plan, or a “T” is placed to denote a treatment. The date may be written alongside the “P” to indicate a plan that has been followed with a treatment.

- Complications and follow-up may be recorded in this area.
- Discussions, consultations, and phone calls may also be documented in this section.

PERIODONTAL CHARTING

- Periodontal charting is a more specialized record of the periodontal status of each tooth. It can include evaluation of the various indices to quantitate gingival health, such as gingival bleeding and edema (gingival index), amount of plaque and calculus (plaque index or calculus index), probing depths, mobility, and attachment levels. These measurements are important in quantitating the degree of periodontitis present generally, as well as the involvement of individual teeth, and they allow for more detailed assessment of periodic treatment and home care hygiene. The level of the patient's periodontal disease is graded on a level with the most involved teeth, because it is their status that determines the recall interval for periodic care. This periodontal grade may fluctuate with successive treatments. It is a fairly subjective evaluation, and a patient may have a generalized stage and a local stage, such as generalized stage 2 with localized stage 4 for teeth 108 and 109. If the tooth or teeth responsible for an advanced grade of periodontal disease are extracted, the periodontal condition is then upgraded, because maintenance will be less complicated.

Periodontal Indices

- Anatomic changes in the periodontium, in response to disease, can be quantified by the use of various indices. Periodic charting helps to assess the severity of the pathologic process and can be used to evaluate success of treatment over time.
- Epidemiologic studies use indices in order to have a consistent evaluation of disease and to be able to compare data statistically.

Plaque Index⁸

Grade

- 0 = No plaque.
- 1 = Thin film of plaque at gingival margin visible when margin checked with explorer.
- 2 = Moderate amount of plaque at gingival margin. Interdental space is free of plaque. Plaque is visible to the naked eye.
- 3 = Heavy plaque accumulation at gingival margin. Interdental space filled with plaque.

Calculus Index⁹

- 0 = No calculus.
- 1 = Supragingival calculus extending only slightly below the free gingival margin.
- 2 = Moderate amount of supragingival and subgingival calculus or subgingival calculus only.
- 3 = Abundance of supragingival or subgingival calculus.

Gingival Index^{8,10}

Grade

- 0 = Normal gingiva. No inflammation, discoloration, or bleeding.
- 1 = Mild inflammation, slight color change, mild alteration of gingival surface, no bleeding on probing.
- 2 = Moderate inflammation, erythema, swelling, bleeding on probing or when pressure applied.
- 3 = Severe inflammation, severe erythema and swelling, tendency toward spontaneous hemorrhage, some ulceration.

Mobility¹¹

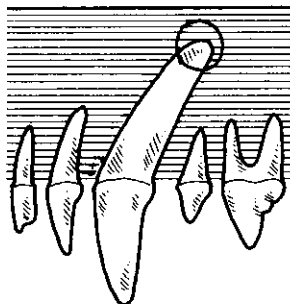
Degree

- I = Slight horizontal mobility (0.2 to 1.0 mm): represents the first detectable sign of movement greater than normal.
- II = Moderate horizontal mobility: movement of more than 1 mm.
- III = Marked mobility: movement of more than 1 mm in vertical, as well as horizontal, direction.

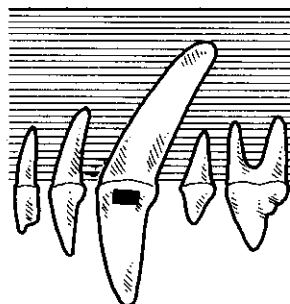
Furcation Exposure¹¹

Degree

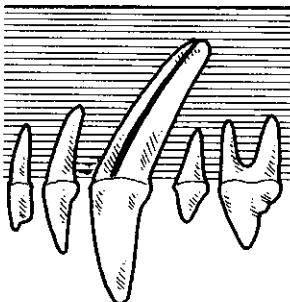
- 1 = Horizontal loss at the entrance to the furcation is less than one third of the width of the tooth.
- 2 = Horizontal loss at the entrance to the furcation exceeds one third of the width of the tooth but does not extend to the other side. Early radiographic changes may be seen.
- 3 = Horizontal "through-and-through" destruction of the supporting tissues in the furcation (periodontal probe can pass through the furcation to the other side).



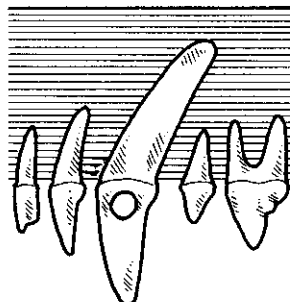
Periapical
pathology



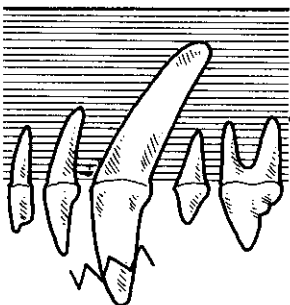
Restoration



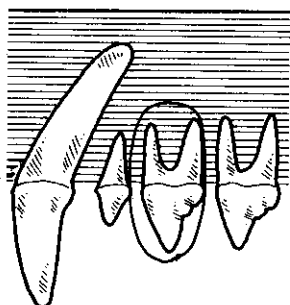
Root canal
treatment



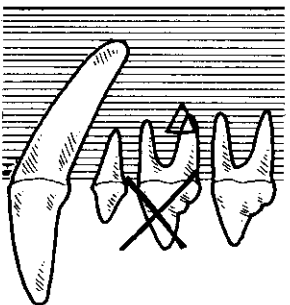
Caries



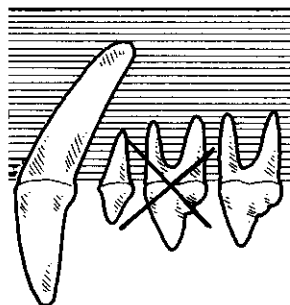
Fractured
crown



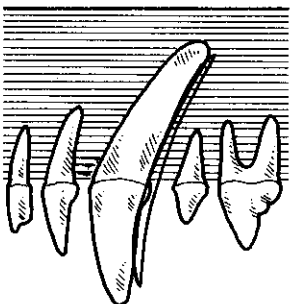
Missing
tooth



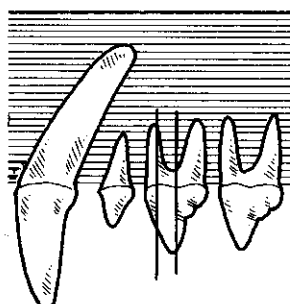
Retained
root



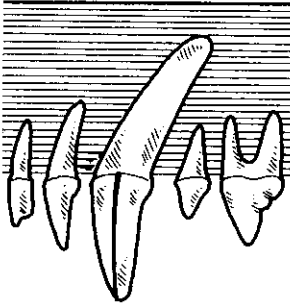
Extracted
tooth



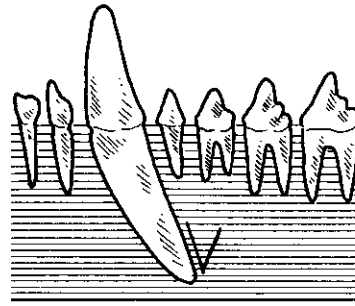
Retained
primary
tooth



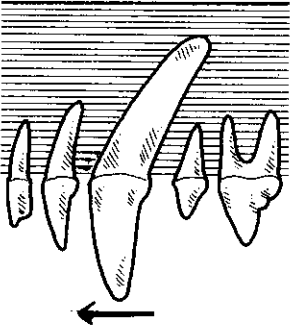
Planned
extracted
tooth



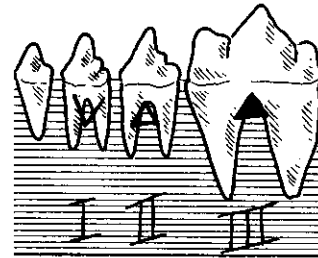
Posts



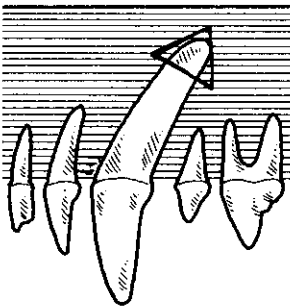
Frenula problem



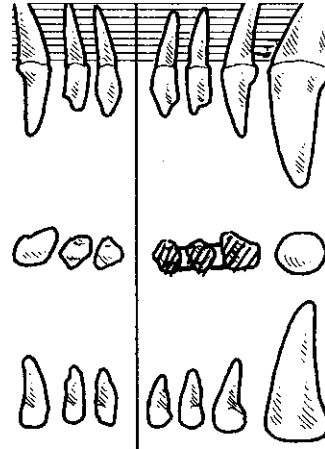
Malpositioned tooth



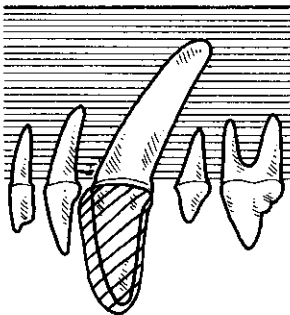
Furcation



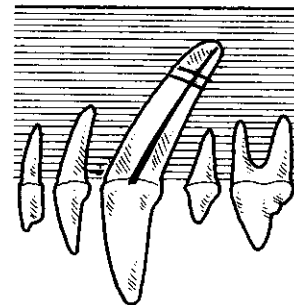
Apicoectomy



Bridge



Crown



Implant

SAMPLE DENTAL CHART WITH DISEASE

Various standard marks can be used to record conditions of the teeth and gums. The sample chart on the facing page shows many of these marks. The numbers of the following list refer to points on the chart.

1. Periapical disease is indicated by a circle around the root tip in the buccal view.
2. Fractured crown is indicated by a jagged line over the crown in all three views, with an attempt made to show the missing area.
3. Retained root is indicated by an X over the crown in the buccal, occlusal, or palatal (lingual) view and by drawing in the root portion retained in the buccal view.
4. Retained primary tooth is indicated by drawing in the tooth on the buccal view, including the root.
5. Cavities are indicated by an irregular circle on the appropriate views in the area of the lesion (do not fill in, because that indicates a restoration).
6. Missing teeth are indicated by a circle around the tooth in all three views.
7. Planned extractions are indicated by parallel lines over all three views.
8. Malpositioned teeth are indicated by an arrow in the direction of malposition in the appropriate views.
9. A need for a frenectomy is indicated by a V-shaped figure in the buccal view at the involved area.
10. An exposed furcation (class 1) is indicated by a V in the direction of the roots.
11. An open triangle denotes a class 2 furcation.
12. A filled-in triangle denotes a class 3 furcation.
13. A hatched line over the V indicates that a frenectomy has been performed.
14. Probing depth measurements can be recorded in the first row of boxes.
15. A line is drawn on the buccal view to show the level of the gingival margin. Combining the charted gingival margin line with the charted probing depth allows the practitioner to determine the level of gingival attachment. See the Periodontal Charting section in this chapter.
16. Root canal treatment is indicated by a solid line in the root canal (not in the pulp chamber) in the buccal view.
17. A restoration is indicated by filling in the area of restoration on appropriate views.
18. Extracted teeth or roots are indicated by an X over the tooth or root extracted in all three views.
19. Posts are indicated by a line in the pulp chamber (not in the root canal, which would indicate root canal therapy).
20. Apicoectomy is indicated by an open triangle around the apex.
21. A crown or cap is indicated by a circle around the coronal views. If porcelain, it is left clear; if metal, it is filled in with hatch lines.
22. A bridge is indicated by parallel lines connecting the involved crowns in the occlusal view.
23. An implant is indicated by a line in the root area, with perpendicular lines on the buccal view.
24. Pulp capping is indicated by a straight line across the crown and a solid rectangle in the coronal pulp chamber below the line.

INTRAORAL PHOTOGRAPHY

General Comments

- Oral photography is an important tool in veterinary dentistry. For years it has been used for legal protection and in the educational process. Some of the many uses for dental photography are for documentation of written and oral case studies and reports, peer review, self-evaluation, following the course of disease in cases, staff training, consulting with colleagues throughout the world, and educating clients and the general public. It can also be used for local and regional presentations to encourage referrals to one's area of special interest, for presentations at national and international conferences, and at universities for instructional purposes. It is important that these photographs be of good quality so that the viewer can appreciate the subject matter. General use cameras do not allow the photographer to get close-ups that focus on oral subject matter.
- Many types of cameras can be used for oral photography. The camera must be suited to the individual photographer. For those with little camera knowledge or little willingness to learn, a "point-and-shoot" camera may be the best choice. Experienced photographers may already have the equipment; with a few equipment modifications, they can get excellent results. Digital cameras are more versatile for convenient computer image storage and distribution, but basic camera knowledge serves as a foundation for all photography.

RANGE-FINDER CAMERAS

General Comments

- Both Kodak and Polaroid have close-up kits that use the fixed focus technique.
- These cameras have lenses that attach to the camera, with a frame in front that serves as an aiming mechanism to delineate quickly the area of the photograph and the distance.

Advantages

- Can be used by anyone.
- Are uncomplicated and modest in cost.

- Can have an instant print for use in a patient record or showing client pathology or treatment performed.
- Can record images of the lingual or palatal side of the teeth with an accessory mirror.

Disadvantages

- Polaroid cameras produce prints only, which are available instantly; Kodak camera models can produce both prints and slides.
- May be difficult to position camera in patient's mouth.

SINGLE LENS REFLEX CAMERAS

General Comments

- The term *single lens reflex (SLR)* indicates a viewing system in which mirrors used inside the camera allow the photographer to view the image through the lens before exposure of the film.
- As the camera shutter is opened, a mirror inside the camera swings out of the way, exposing the film.
- The state-of-the-art film camera is the single lens reflex, through-the-lens 35-mm camera (SLR-TTL).
- The camera is able to sense the light and deliver the correct amount of flash, time exposure, and size of the aperture (f-stop).
- These cameras can be equipped with motor drive, automatic ASA (film speed) setting, data backs, and automatic film loading.
- Usually these cameras provide excellent pictures.
- These automatic exposure systems are more expensive than the point-and-shoot cameras but are a very good value when considered as a recording and marketing instrument.

LENSES

- A lens of either approximately 50 or 100 mm will work well for close-up oral photography.
- The lens should have macro capabilities; that is, it should have the ability to focus down to 1:1 life-size images (if the subject is 10 mm, the image on the film is 10 mm).
- As the magnification increases, the image size on the film decreases (the 10-mm subject would be 5 mm on the film at 1:2 magnification or 1 mm at 1:10).

50 mm Lens

Advantage

- Less bulk.

Disadvantage

- Greater distortion.

100 mm Lens

Advantage

- A longer working length, and the photographs can be taken with the camera at a greater distance from the mouth.

Disadvantage

- More expensive than equivalent 50-mm macro lens, and longer, bulkier, and heavier.

LIGHTING SYSTEMS

- There are two types of close-up lighting systems: ring light and point light.

With ring light, the flash strobe circles the lens. Many have numerous on/off switches on the circumference of the ring that may be turned off singly or in multiples to produce desired shadows and greater subject definition.

With full ring light, there are no shadows, unless switches are purposely turned off or on, and it is best used for lighting the total subject.

Because ring light can eliminate shadows, when all switches are on, it also can eliminate contrast that is gained by the shadows. For that reason, small point lights are also available.

- Point light is best for cosmetic work when contrast and detail are desirable.
- There are systems that use both point light and ring light.
- In addition, many systems come with modeling lights to aid in focusing.

FILM

- There are two types of film: print film and slide film.

Print Film

Advantages

- Does not need a special viewer to look at it.
- Greater latitude of exposure.

Disadvantages

- Less detail.
- Without converting to slides, cannot be shown to a large audience.
- Image must be scanned for use with a computer.

Slide Film

Advantages

- Greater detail.
- Can be shown to a large audience.
- Image can be scanned into a computer.

Disadvantage

- Must be converted to prints or viewed with a special viewer (photographic loop or projector).

Combination Slide and Print Film

- PhotoWorks in Seattle.

Advantage

- Option of processing as print, slide, or on disk.

Film Speed

- Film speed is rated in ASA: the higher the ASA number, the faster the film.
- Fast film requires less exposure.
- Faster film has increased grain that decreases the detail as compared with slower ASA film.

Processing Date

- Due to color changes that occur in time, check the dating on the box of film and resist the temptation to buy "outdated" or "short-dated" film, regardless of the price "bargain."

MIRRORS

- Areas difficult to photograph may be visualized with dental mirrors.
- These mirrors are finely polished and yield excellent results.
- Care must be taken to retain their clean, smooth finish.
- To prevent moisture condensation, a mirror can be warmed slightly with a surgical lamp, warm water, or hair dryer before inserting into the patient's mouth.

DIGITAL CAMERAS

General Comments

- Digital cameras are becoming more reliable.
- Most digital cameras are combination still and video systems.
- As computers and software have become more sophisticated, many veterinary practices are incorporating photographs into patient records on a computer. It is the current wave of high technology. In many ways, digital cameras are more convenient than SLR cameras, and often are a less expensive setup. For photos to be used in a PowerPoint presentation, a camera setting of 2 megapixels (megs) will suffice. This also produces images of a good size to send as an e-mail attachment, such as when sending photos of radiographs for consultation. If publication of images is desired, such as in a journal, at least 3 megs usually will be required by the editor or publisher. It will take 3 megs to produce a 4 × 5-inch picture with 500 dots per inch (dpi). If you have a camera set at 3 megs (2,272 × 1,704), the image should be shrunk to approximately 30% of its size when sending it by e-mail, so that it will fit entirely on the viewer's screen.

Advantages

- Instant gratification—the image can be evaluated immediately for quality and retaken if necessary.
- Can be purchased with zoom and macro capabilities built into the camera, thereby requiring less gadgetry to deliver images of high quality.
- Many models are smaller, less bulky, and lighter weight than SLR macro setups.

- Instead of film, they operate with reusable image sticks or chips, small compact disks, or floppy disks.
- Images can be efficiently uploaded for computer storage.
- Images can be adjusted for size, quality, and composition, first with camera settings and then with computer imaging programs, thus eliminating the photography laboratory expense and time.

Disadvantages

- Digital photography is a new technology and requires patience and a learning curve.
- The technology is improving at a very rapid rate; newer and better cameras are available almost as soon as the newest model is purchased, and few people are interested in buying your old technology when you upgrade.
- For optimum use in practice, the office must be computerized and personnel using the camera should be computer literate.
- Cost will be similar to that of an SLR camera if publishable quality pictures are desired.
- Less expensive models will produce lesser quality color reproduction.

TAKING PHOTOGRAPHS

- Ensure that the subject is in the unobscured field of view.
- Pay strict attention to distracting factors, such as improper instrument technique, blood, dirty fingernails, matted hair, etc.
- If the patient's lips or tongue must be held back, it is best to do this mechanically or wear gloves so as not to distract from the subject matter.
- When working with slides, crop the slide to focus on the center object by using Mylar masking tape.
- With prints, distractions can be cropped out.
- With digital cameras, ring lights are available to create and eliminate shadows as desired. Zoom function and light adjustment are available to improve composition and light balance.
- To take a photograph, check the strobe to be sure it is operational.
- If the strobe is fitted with ring and point, make the appropriate selection.

- Choose the magnification and setting on the lens, or adjust custom settings in the digital camera.
- Set the shutter speed and f-stop.
- Move the camera back and forth until the image is in focus. Once the image is in focus, gently press the shutter trigger.

Additional Tips

- Setting the magnification rather than adjusting the focus standardizes the photographs and allows comparison of cases and standardization of photographic technique.
- A log should be kept in a notebook of settings used for slide or print film (pieces of paper tend to get lost in most offices) recording the date, patient, condition, f-stop setting, magnification (distance from subject), type of strobe (ring or point), and any other pertinent information.

DENTAL TERMINOLOGY

- A knowledge of dental terminology is important for understanding a technique or for discussing a case with another veterinarian, dentist, or student. It is also basic for accurately entering a finding or procedure in a record. A list of common dental and anatomic terms follows.¹²⁻¹⁴

GLOSSARY

Anatomic Terms

- Alveolar bone.** Cancellous bone directly surrounding the tooth roots.
- Alveolar crest.** The most coronal ridge of bone between two adjacent teeth or between the roots of a tooth.
- Alveolar mucosa.** Less densely keratinized gingival tissue covering the bone.
- Alveolus.** The cavity or socket in either jawbone that surrounds and supports the root of the tooth.
- Anterior teeth.** The canine and incisor teeth.
- Apex.** The terminal portion of the root.

Apical delta. The diverging branches of the root canal at the apical end of the tooth root.

Apical foramen. The opening(s) in the apex of the root through which nerves and vessels pass into the root canal.

Arch, dental. The dentition and alveolar ridge of either the maxilla or the mandible; sometimes called either the upper or lower arch.

Attached gingiva. The gingiva that extends apically from the free gingival groove to the mucogingival junction.

Attachment apparatus. The periodontal ligament, cementum, and alveolar bone that hold the tooth in place.

Canine tooth. Large, single-rooted tooth designed for puncturing, tearing, and grasping.

Carnassial tooth. Shearing tooth. Upper P4 and lower M1 in the dog and cat.

Cementoenamel junction. The junction at the neck of the tooth where the enamel and the cementum meet.

Cementum. A specialized calcified connective tissue covering the root surface and serving as attachment for the periodontal ligament from the bone to the tooth.

Cingulum. The ledge on the cervical third of the palatal surface of the crowns of the incisor teeth.

Col. The interdental connection between the junctional epithelia of any two adjacent teeth.

Crown. The portion of the tooth covered with enamel.

Cusp. The tip or pointed prominence on the occlusal surface of the crown.

Deciduous teeth. Teeth of primary dentition (baby teeth) that will be replaced by secondary (adult) teeth.

Dental arch. Formed by the curve of the crowns of the teeth in their normal position or by the residual ridge if the teeth are missing.

Dental quadrant. An upper or lower dental arch on one side of the patient.

Dentin. The main component of the tooth, consisting of multiple tubules that radiate from the pulp to the tooth's outer surface. The tubules contain sensory nerve fibers that register various degrees of pain. Harder than bone, dentin is covered by enamel on the crown and by cementum on the root.

Dentition. Natural teeth as a unit in the dental arches.

Diastema. The space between two adjacent teeth that are not in contact with each other in an arch.

Embrasure. The space between teeth occlusal to areas of contact of teeth.

Enamel. The hard, shiny outer layer of the crown, composed of hexagonal rods of hydroxyapatite crystalline components organized with their long axis approximately at right angles to the surface.

Epithelial attachment. The epithelium attaching the gingiva to the tooth.

Fauces. The arch between the pharyngeal and oral cavities, formed by the tongue, tonsillar pillars, and soft palate.

Free gingiva. Portion of the gingiva not directly attached to the tooth that forms the gingival wall of the sulcus.

Free gingival groove. On the surface of the gingiva, a slight concavity or line separating free from attached gingiva.

Free gingival margin. The unattached edge of the gingiva that lies against the tooth surface.

Furcation. The space between tooth roots where the roots join the crown.

Gingiva. The soft tissue surrounding the teeth.

Gingival sulcus. The normal space created between the free gingiva and the tooth.

Gnathic. Referring to the jaw.

Halitosis. Foul, offensive, or unpleasant breath.

Incisal edge. The cutting edge of the incisors.

Incisive papilla. The small protuberance palatal to the maxillary incisors. The nasopalatine ducts exit on each side of the incisive papilla.

Incisor. Small anterior tooth with a single root.

Infrabony pocket. A periodontal pocket whose base is apical to the crest of the alveolar bone.

Interdental. The area between the proximal surfaces of adjacent teeth in the same arch.

Interproximal. The area between adjacent surfaces of adjoining teeth.

Interradicular. The area between roots of multirooted teeth.

Juga. The prominent bulge of bone formed by roots in the alveolar process on the mandible, the premaxilla, and the maxilla.

Lamina dura. A radiographic term referring to the dense cortical bone forming the wall of the alveolus. The lamina dura appears on a radiograph as a bony white line next to the dark line of the periodontal ligament.

Lateral or accessory canal. The small canal branching from the root canal to the outer surface of the root, usually occurring in the apical third of the root.

Mental foramen. Openings in the lateral wall of the mandible through which nerves

and vessels pass to supply the tissues of the lip.

Molar. The large, multicusp tooth designed primarily for grinding.

Mucogingival junction. The line of demarcation where the attached gingiva and alveolar mucosa meet.

Neck (cervical line). The junction between the crown and root.

Odontoblast. The outer cells of the pulp that produce dentin throughout the life of the tooth and provide sensory innervation to the tooth.

Palate. The bone and soft tissue that separate the oral and nasal cavities.

Periodontal ligament. A network of collagenous fibers suspending the tooth in its alveolus attaching it to its supporting bone.

Periodontium. The supporting tissues of the teeth including the periodontal ligament, gingiva, cementum, and alveolar supporting bone.

Pockets, periodontal. An area of diseased gingival attachment, characterized by its loss of attachment and eventual damage to the tooth's supporting bone.

Posterior teeth. The premolar and molar teeth.

Premolar. The teeth distal to the canine and mesial to the molars that have one to three roots in the dog and cat.

Primary (deciduous) teeth. The first teeth to erupt; they are replaced by secondary (adult) teeth.

Prosthesis. An artificial replacement for a body part. In dentistry it is an appliance used either for esthetics or to maintain space when replacing a missing tooth or teeth.

Proximal surface. The surface of a tooth or cavity that is closest to the adjacent tooth.

Pulp. Soft-tissue component of the tooth consisting of blood, vascular tissue, nerve tissue, loose connective tissue, and cellular elements such as odontoblasts that form dentin.

Pulp canal. The central portion of the tooth which contains pulp.

Pulp chamber. The portion of the crown containing the pulp.

Root. The portion of the tooth apical to the crown and normally covered by cementum.

Root canal. Portion of the root containing the pulp.

Ruga palatina. The irregular ridges in the mucous membrane covering the anterior part of the hard palate.

Sectorial. The shearing action that designates the identification of carnivore dentition as seen in the carnassial teeth of the dog and cat between the maxillary fourth premolar and the mandibular first molar.

Sulcus. A groove. In veterinary dentistry it usually refers to the gingival sulcus present, in healthy patients with healthy gingiva, between the free gingiva and the surface of the tooth and extending around the tooth's circumference.

Suprabony pocket. A periodontal pocket, the base of which is above the level of the crestal alveolar bone.

Vestibule of oral cavity. The part of the oral cavity between the cheeks or lips and alveolar ridge.

Vital. Necessary to or pertaining to life.

Dental Positioning and Surfaces

Apical. Toward the apex.

Buccal. The surface of the tooth nearest the cheek (posterior teeth).

Coronal. Toward the crown.

Distal. Away from the midline of an imaginary line following the curve of the dental arches.

Facial. The surface of the tooth nearest the face. This term is awkward to apply to most veterinary patients because there is little delineation of face and cheek. Buccal and labial are more accurate.

Incisal. The biting surface of anterior teeth.

Interproximal. Between closest surfaces of adjoining teeth.

Labial. The surface of the tooth nearest the lips (anterior teeth).

Line angle. Imaginary line formed by the junction of two adjacent vertical surfaces or walls of a tooth.

Lingual. The surface of the tooth nearest the tongue.

Mandible. The bone that forms the lower jaw.

Maxilla. The bone that forms most of the upper jaw and contains the sockets of all the upper teeth except the incisors.

Mesial. Toward the midline along the curve of the dental arch.

Occlusal. The chewing surfaces of the caudal teeth.

Palatal. The surface of the tooth toward the palate.

Sublingual. The structures and surfaces beneath the tongue.

Dental Disciplines

Endodontics. The diagnosis and treatment of diseases that affect the tooth pulp and apical periodontal tissues.

Exodontics. The branch of dentistry that deals with extraction of teeth.

Oral surgery. Pertaining to surgery of the oral cavity.

Orthodontics. The branch of dentistry that deals with the guidance and correction of malocclusion of the juvenile teeth and adult tooth positioning.

Periodontics. The branch of dentistry that deals with the study and treatment of diseases of the tooth-supporting tissues.

Prosthodontics. The branch of dentistry that deals with the construction of appliances designed to replace missing teeth or other adjacent structures.

Restorative operative dentistry. The branch of dentistry that deals with restoring the form and function of teeth.

Oral Diseases and Conditions

Abrasion. The wearing away of tooth structure because of contact with structures other than teeth.

Anodontia. The absence of teeth.

Anterior crossbite. The orthodontic condition in which the maxillary-to-mandibular relationship is normal and in which canine, premolar, and molar occlusion is normal, but one or more mandibular incisors are anterior to the maxillary incisors.

Apexogenesis. The developmental portion of the maturation of a tooth in which the root attains its full length.

Attrition. The wearing away of teeth by continual tooth-against-tooth contact.

Avulsion. The loss of the tooth from its alveolus.

Brachygnathia. The lower jaw is markedly shorter than the upper jaw.

Calculus. Hard, mineralized plaque deposited on the tooth surface.

Caries. A demineralization and loss of tooth structure because of action of microorganisms on carbohydrates.

Cellulitis. A diffuse inflammation of loose connective tissue.

Dilaceration. An abnormally shaped root resulting from trauma during tooth development.

Edentulous. Without teeth.

Embedded tooth. A tooth that usually is covered in bone and that has not erupted into the oral cavity and is not likely to erupt.

Erosion. Loss of tooth structure by chemical or mechanical means not involving bacteria. The surface of the defect, unlike caries, is hard and smooth.

Facet. A flattened or worn spot on the surface of a tooth.

Faucitis. Inflammation of the glossopalatine folds or arches (fauces).

Fenestration (root). A window-like opening of bone and gingiva over the root.

Freeway space. The abnormal vertical space between the opposing mandibular and maxillary premolar cusps when the mouth is closed.

Fistula. An abnormal opening associated with underlying dental disease.

Fused teeth. The joining of two teeth in development in which they have developed from different tooth buds.

Gemini tooth. The partial division of a tooth bud attempting to form two teeth.

Gingival hyperplasia. A pathologic increase in the amount of gingival tissue in a normal cellular arrangement, resulting in a thickened enlargement of tissue.

Granuloma. Chronic inflammation of loose connective tissue.

Horizontal bone loss. Loss of crestal alveolar bone along an arch, usually secondary to periodontal disease.

Impacted tooth. An unerupted or partially erupted tooth that is prevented from erupting further by any structure.

Level bite (even bite). Occlusion in which the upper and lower incisors meet incisal edge to incisal edge.

Luxation (tooth). The displacement or partial displacement of a tooth from its alveolus.

Mesiodens. A supernumerary tooth appearing in the erupted or unerupted state between the two maxillary central incisors.

Odontalgia. Pain in a tooth.

Oligodontia. Reduced number of teeth.

Open bite. The failure of the upper and lower incisors to meet or overlap each other in the vertical dimension when the mouth is closed.

Oronasal fistula. An abnormal opening between the oral and nasal cavities.

Overbite. Layman's term for the upper jaw vertically overlapping the lower jaw.

Overjet. Horizontal projection of the maxillary anterior teeth in front of the mandibular anterior teeth such that the two arches do not touch.

Parulis. Abscess of the gingiva.

Periapical abscess. See periapical abscess.

Periapical lysis. Bone loss involving the apex and surrounding periapical periodontal tissues, visible by radiograph, that signifies apical pathology such as apical granuloma, periapical abscess, periapical cyst.

Pellicle. The thin film composed mostly of protein that continuously forms on the surface of teeth. It forms with or without bacteria and can be removed by abrasive action.

Periapical abscess (apical abscess or periradicular abscess). An abscess at the apical region of the root, involving the pulp and surrounding periapical tissues.

Periodontal abscess. An abscess involving the periodontium as a sequela of periodontal disease.

Plaque. A thin, sticky film covering the teeth, composed of bacteria and their byproducts, saliva, food particles, and sloughed epithelial cells.

Posterior crossbite. An abnormal occlusion in which one or more mandibular premolars or molars occlude buccal to their occlusal counterpart.

Pulpitis. Inflammation of the pulp, which may be reversible or irreversible.

Pulpitis, hypertrophic. A productive type of chronic inflammation that contains a mass of tissue protruding from a pulp exposure.

Pyorrhea. Antiquated term for discharge of pus from the periodontium.

Resorption. The loss of substance by a physiologic or pathologic process.

Reverse scissor bite. Occlusion in which all the lower incisors occlude anterior to, but are overlapping vertically and touching, the labial surfaces of the upper incisors. This is a prognathic condition.

Stomatitis. Inflammation of the soft tissues of the oral cavity.

Supernumerary tooth. An additional tooth of the same type as one already present.

Vertical bone loss. Bone loss at an angle acute to the horizontal plane along a root surface, forming an infrabony pocket.

Wry bite. A malocclusion in which the midline of the lower jaw does not oppose the midline of the upper jaw. The face and jaw are asymmetric in relation to each other.

Dental Treatment

Apexification. The process of induced apical development or closure by hard tissue deposition.

Apical repositioning. An oral surgical procedure that repositions the gingiva or bone toward the apex.

Apicoectomy. The retrograde surgical treatment of endodontic disease, by access to the apex, removing diseased tissue and sealing the canal.

Convenience form. Referring to the cornucopia-shaped root canal preparation, wider at the coronal end of the canal, that is shaped to remove all overhangs and indentations.

Creep, dynamic. The shifting of amalgam secondary to masticatory forces.

Creep, static. The slight expansion of amalgam after it has hardened.

Crown lengthening. An oral surgical procedure that entails movement of the gingiva apically and reduction of the alveolar crest. This procedure is performed as treatment of periodontal disease and in restorative crown therapy when additional crown surface area is required for cementation of an artificial crown.

Electrosurgery. The use of electrically generated, filtered, fully rectified waveform energy, generally 1.7 to 4.0 megahertz (MHz), to perform the controlled cutting of tissue. Lower frequencies cause more tissue alteration. Continuous-output waveform produces less tissue alteration in superficial tissue layers than full rectification waveform.

Electrocautery. The use of electrically generated full-wave energy to perform hemostasis. Causes more tissue alteration than continuous-output waveform.

Finish. The final smoothing of a surface restorative after it is installed.

Obturation. The act of closing or occluding. In root canal therapy, the filling and sealing procedure that follows root canal preparation.

Preparation, endodontic. The mechanical and chemical debridement and antiseptic preparation of the pulp canal, prior to obturation during endodontic treatment.

Preparation, restorative dental. The mechanical and chemical preparation of the tooth surface to receive a restoration.

Pulp cap, direct. A procedure that has covered exposed pulp by application of material directly to the pulp that stimulates repair of

the injured pulp tissue, and of other materials external to it that protect the pulp from external influences.

Pulp cap, indirect. A procedure that places a chemical, usually calcium hydroxide, over a thin layer of healthy or carious dentin to protect potentially exposed pulp from external irritants.

Pulpectomy. See root canal therapy, standard.

Pulpotomy. Surgical amputation of pulp material that is coronal to the cemento-enamel junction.

Radiosurgery. A procedure using a high-frequency radiowave of 3.0-4.0 megahertz (MHz), above AM and below FM frequencies, producing a pressureless, micro-smooth incision with hemostasis and minimum tissue alteration. A small metal wire electrode acts as the active plate, and a large metallic antenna plate acts as the passive one. It is the most advanced form of electrosurgery.

Retrograde root canal therapy. See apicoectomy.

Root canal therapy, retrograde. See apicoectomy.

Root canal therapy, standard. Complete pulpectomy (pulp removal) from the pulp chamber and root canal and the subsequent filling of the empty canal with chemicals or materials to seal the dentinal tubules and prevent infection from escaping from the tooth.

Root canal therapy, surgical. See apicoectomy.

Dental (Intraoral) Devices

Abutment. The tooth or implant that is used for the support or anchorage of a fixed or removable prosthesis or appliance.

Anchorage. The supporting base for orthodontic forces that are applied to stimulate tooth movement.

Articulator. The mechanical device that represents the orientation and movement of the temporomandibular joints; the mandible and maxilla are used to hold the maxillary and mandibular cast in the proper occlusal relationship.

Bite register. The impression made by closing the patient's mouth on a soft, imprintable sheet of material or compound used to align casts of the occlusion of the patient.

Cast. The replication of the teeth and tissues made from an impression.

Crown or cap. The dental prosthesis covering part or all of the crown of the tooth to restore its anatomy, function, and esthetics.

Helix. A loop or coil.

Impression. The negative replication (mold) of the teeth and tissues used to make a positive reproduction (cast).

Inlay. The prosthetic device that is cemented into a recessed preparation.

Onlay. The prosthetic device that is cemented to a minimally prepared tooth surface.

Orthodontic appliance. The oral device used to apply force to malpositioned teeth to provide tooth movement or to maintain tooth position.

PFM. Porcelain-fused-to-metal, referring to fabricated, esthetic dental crowns.

Prosthesis. An artificial replacement for a body part. In dentistry it is an appliance used either for esthetics or to maintain space when replacing a missing tooth or teeth.

Splint. An apparatus designed to prevent motion or displacement of displaced or movable teeth or bone.

Spot weld. To join together two metals by heating (but not melting) electronically and fusing (recrystallizing) in a small spot.

Dental Materials and Instruments

Amalgam. An alloy of mercury with one or more metals used for dental restorations and dies.

Anneal. To soften a metal by heating and then cooling it.

Baseplate wax. Thin sheets of high-quality wax used for a variety of dental and laboratory procedures.

Bracket. An orthodontic device that is cemented to a tooth that provides support for an arch wire.

Burnish. To draw (spread out) polish or to flatten a malleable metal through pressure using an instrument with rounded edges.

Button. A small metal or plastic device cemented to a tooth that serves for the attachment of an orthodontic elastic.

Cavity liner. The preparation used to seal dentinal tubules, reduce microleakage, and insulate pulp against shock from thermal changes.

Cement base. The insulating layer of cement placed in the deeper portion of a prepared cavity to insulate the pulp.

Crown or cap. The dental prosthesis covering part or all of the crown of the tooth to restore its anatomy, function, and esthetics.

Flux. The substance used to prevent oxidation on heated metals used for welding.

Formocresol. The chemical compound used to mummify the pulp tissue.

Glass ionomer. In the pure form, a mixture of polyacrylic acid and fluoroaluminosilicate glass that, when combined, is used as a cement or restorative material. Other agents have been added that change the characteristics of the material.

Impression. The negative replication (mold) of the teeth and tissues used to make a positive reproduction (cast).

Methyl methacrylate liquid and powder. An acrylic resin derived from methyl acrylic acid.

Monomer. In dentistry, a short-chain hydrocarbon (the liquid) to be mixed with the polymer (long-chain hydrocarbon) for fabrication of appliances and restorations.

Polymer. In dentistry, a long-chain hydrocarbon (the powder portion) to be mixed with the monomer (short-chain hydrocarbon, the liquid portion) for fabrication of appliances and restorations.

Pontic. Bridge. A device resembling a tooth spanning one or more missing teeth and suspended between the two adjacent teeth.

Pumice. Abrasive glass agent made from volcanic rock, used for smoothing and polishing.

Resin. A broad term used to indicate organic products that are soluble in ether or acetone but not soluble in water; further named according to their activation (light, chemical), chemical components (acrylic), or physical structure (filled, nonfilled).

Solder. A fusible metal alloy used in its molten state to mechanically join two metals together. Also, the process of soldering.

Spherical amalgam. Amalgam of particles that are in the form of a ball, globe, or sphere.

Sticky wax. A hard wax that breaks off easily and is useful for wires and materials in the dental laboratory.

Varnish. A solution of one or more resins that come from natural gums, synthetic resin, or rosin.

REFERENCES

1. Zinman EJ: Records and legal responsibilities. In Cohen S, Burns RC, editors: *Pathways of the pulp*, ed 8, St Louis, 2002, Mosby, pp 365-407.

2. Cohen S, Burns RC: *Pathways of the pulp*, St Louis, 1984, Mosby, p 302.
3. Carranza FA: Clinical diagnosis. In Newman MG, Takei HH, Carranza FA: *Carranza's clinical periodontology*, ed 9, WB Saunders, 2002, Philadelphia, pp 432-453.
4. AVDC Position Statement on Veterinary Dental Healthcare Providers, *J Vet Dent* 15(2):94, 1998. Adopted April 5, 1998, by Board of Directors of the American Veterinary Dental College and amended October 21, 1999, by the same Board removing the endorsement of the American Association of Equine Practitioners' Position Statement because of AVMA criticism regarding its wording.
5. Floyd MR: The modified Triadan system: nomenclature for veterinary dentistry, *J Vet Dent* 84:18, 1991.
6. Wiggs RB, Lobprise HB: Oral examination and diagnosis. In Wiggs RB, Lobprise HB, editors: *Veterinary dentistry: principles and practice*, Philadelphia, 1997, Lippincott-Raven, pp 87-103.
7. From the files of the Secretary and the website of the American Veterinary Dental College www.AVDC.org, April 2003, accessed October 2, 2003.
8. Rateitschak KH, Rateitschak EM, Wolf HF, Hassell TM: Epidemiology and indices. In *Color atlas of dental medicine 1: periodontology*, ed 2, Stuttgart, 1989, Georg Thieme Verlag, pp 33-40.
9. Listgarten MA, Lindhe J, Parodi R: The effect of systemic antimicrobial therapy on plaque and gingivitis in the dog, *J Periodontol Res* 14:65, 1979.
10. Loe H: The gingival index, the plaque index, and the retention index systems, *J Periodontol* 38(suppl):610, 1976.
11. Nyman S, Lindhe J: Examination of patients with periodontal disease. In Lindhe J, Karring T, Lang NP, editors: *Clinical periodontology and implant dentistry*, Munksgaard, 2000, Copenhagen, pp 383-395.
12. Zwemer TJ: *Boucher's clinical dental terminology*, St. Louis, 1982, CV Mosby.
13. Schroeder HE: *Oral structural biology*, New York, 1991, Thieme Medical Publishers.
14. *Dorland's dentistry speller*, Philadelphia, 1993, WB Saunders.

Appendix 1



**AMERICAN VETERINARY
DENTAL COLLEGE POSITION
STATEMENT REGARDING
VETERINARY DENTAL
HEALTHCARE PROVIDERS
(Adopted April 5, 1998, and
amended October 21, 1999).**

The American Veterinary Dental College (AVDC) has developed this position as a means to safeguard the veterinary dental patient and to ensure the qualifications of persons performing veterinary dental procedures.

1. Primary Responsibility for Veterinary Dental Care

The AVDC defines veterinary dentistry as the art and practice of oral health care in animals other than man. It is a discipline of veterinary medicine and surgery. The diagnosis, treatment, and management of veterinary oral health care is to be provided and supervised by licensed veterinarians or by veterinarians working within a university or industry.

2. Who May Provide Veterinarian-Supervised Dental Care

The AVDC accepts that the following health care workers may assist the responsible veterinarian in dental procedures or actually perform dental prophylactic services while under direct, in-the-room supervision by a veterinarian if permitted by local law: licensed, certified, or registered veterinary technician or a veterinary assistant with advanced dental training, dentist, or registered dental hygienist.

Operative Dentistry and Oral Surgery

The AVDC considers operative dentistry to be any dental procedure which invades the hard or soft oral tissue including, but not limited to, a procedure that alters the structure of one or more teeth or repairs damaged and diseased teeth. A veterinarian should perform operative dentistry and oral surgery.

3. Extraction of Teeth

The AVDC considers the extraction of teeth to be included in the practice of veterinary dentistry. Decision making is the responsibility of the veterinarian, with the consent of the pet owner, when electing to extract teeth. Only veterinarians shall determine which teeth are to be extracted and perform extraction procedures.

4. Dental Tasks Performed by Veterinary Technicians

This AVDC considers it appropriate for a veterinarian to delegate maintenance dental care and certain dental tasks to a veterinary

technician. Tasks appropriately performed by a technician include dental prophylaxis and certain procedures that do not result in altering the shape, structure, or positional location of teeth in the dental arch. The veterinarian may direct a technician to perform these tasks providing that the veterinarian is physically present and directly supervising the treatment and provided that the technician has received appropriate training.

The AVDC supports the advanced training of veterinary assistants to perform additional ancillary dental services: taking impressions, making models, charting veterinary dental pathology, taking and developing dental radiographs, performing nonsurgical subgingival root scaling and debridement, providing that they do not alter the structure of the tooth.

Tasks That May Be Performed by Veterinary Assistants (not Registered, Certified, or Licensed)

The AVDC supports the appropriate training of veterinary assistants to perform the following dental services: supragingival scaling and polishing, taking and developing dental radiographs, making impressions, and making models.

Tasks That May Be Performed by Dentists, Registered Dental Hygienists, and Other Dental Health Care Providers

The AVDC recognizes that dentists, registered dental hygienists, and other dental health care providers in good standing may perform those procedures for which they have been qualified under the direct supervision of the veterinarian. The supervising veterinarian will be responsible for the welfare of the patient and any treatment performed on the patient.

The AVDC understands that individual states have regulations that govern the practice of veterinary medicine. This position statement is intended to be a model for veterinary dental practice and does not replace existing law.

SELECTING THE APPROPRIATE DENTAL DELIVERY SYSTEM

A variety of equipment is available, which leads to the frequently asked question: "What type of dental equipment should I buy?" There are several factors to consider, depending on the individual practice. How much and what type of dentistry will be performed? How much space is available? How much capital is available to purchase the equipment? Is the practice prepared to equip for future department expansion, or just for the immediate needs?

When purchasing dental equipment, frequency of use, type of use, space available for equipment, and the cost should be evaluated before making a decision. For example, if endodontic therapy is to be performed, purchase of an air-driven unit is recommended. Other advanced level dental procedures also require specialized equipment.

After reviewing your own practice situation and goals, the equipment suited to your practice should become more apparent. The purchase of dental equipment provides an excellent return on investment.¹ The dental service is one of the most cost-efficient departments in the veterinary hospital.

A variety of dental instruments and supplies are needed, and selecting instruments that allow efficiency and effectiveness during dental procedures is a must. This includes having a variety of sizes of some instrument types in order to work with the different sizes of teeth and oral cavities that veterinarians encounter.

Suggested Minimum Instrument List

- This list contains the instruments necessary for doing dental cleanings, routine and surgical extractions, and basic periodontal procedures, in addition to the major equipment that will clean teeth, polish teeth, and section teeth for extractions.

Oral Examination

- Fine Shepherd hook explorer, calibrated probe.
- First Sight disclosing solution.
- Welch Allyn penlight for transilluminating teeth.

- Intraoral radiographic equipment and supplies.

Dental Prophylaxis

- Mini 5 Gracey curette 5/6 or 7/8.
- Columbia curette 4R/4L.
- Barnhart curette 5/6.
- Gracey curette 13/14.
- After Five curettes (for deep periodontal pockets).
- Short-shanked Gracey curettes (for cats and toy breeds).
- Morse 0-00 scaler for cats.
- Jaquette sickle scaler for dogs.

Basic Oral Surgery

- Number 3 scalpel handle.
- Scalpel blades: #11, #12, #15 or 15c.
- Canine large periosteal elevator Molt #4.
- Feline and small dog periosteal elevator Molt #2.
- Freer periosteal elevator.
- Miller 5-0 (3-mm) surgical bone curette.
- Apical elevator or root tip pick.
- Root tip forceps.
- Large and small breed extraction forceps.
- Adson-Brown thumb forceps.
- Five-inch needle holders.
- Iris scissors.
- La Grange scissors (for periodontal surgery).
- A combination of various sized luxators; a set of winged elevators, with or without small, medium, and wide elevators for extractions; small, medium, and large, left and right pennant-shaped elevators.
- Conical sharpening stone to sharpen luxators and winged elevators.
- Arkansas stone with oil to sharpen curettes and scalers.
- Burs: size 699L, 701L, 701LS, 702, #2, #4, #6, #8. Diamond burs for round burs are beneficial for bone removal and alveoloplasty.
- Suture material 4-0 absorbable, 5-0 for cats.

POWER EQUIPMENT

- When purchasing power equipment, the practitioner should consider the cost of the unit, intended location for the compressor and dental consoles, noise levels at the location, availability at the clinic for equip-

ment maintenance, and present and future dental caseload.

Features to Consider

Foot Pedal

Advantage

- Allows hands to work uninterrupted, rather than switching on and off manually.

Variable Speed

Advantage

- Allows for a broader range of work with more control.

Reverse Direction

Advantage

- Can reverse direction with caution to back out of wrapped-up hair.

Disadvantage

- A mandrel or screw-in prophy cup may become unscrewed if turned in the direction opposite to its design (snap-on prophy cups are available).

Accessories

- Prophylaxis angles are used to polish during prophylaxis, restorations, and other times when abrasives are used.
- Contra angles are used to change the angle of rotation of the device used on the teeth.
- Reduction contra angles are used to reduce speed at an angle.
- Acceleration contra angles are used to increase speed at which the device spins.
- Handpieces are used to create force and to hold contra angles, prophy angles, burs, and other instruments.

Uses

- Prophylaxis.
- Periodontics.
- Endodontics.
- Restorations.
- Exodontics.
- Orthodontics.

- Orthodontic laboratory.
- Oral surgery.
- Prosthodontics.

Electric Motor Handpieces

Comments

- These are handpieces with electric motors built in (Fig. 2-1).
- A control box connects the handpiece electrically.
- Speed range 3,000 to 30,000 rpm; with accelerating contra angles speed can be increased to 125,000 rpm. (These contra angles are expensive.)

Advantages

- Most cost less than air-driven units.
- Low maintenance.
- Portability.
- Small size.
- More torque.
- They are popular in Europe and gaining popularity in the United States in human practices due to decreased incidence of air embolism.

Disadvantages

- Handpiece and motor break down with heavy use.
- Except for models with accessories, inability to run water through handpiece as a coolant for dental tissue.
- Slow cutting speed.
- Increased torque creates more heat (potential thermal tissue injury).
- Some are cumbersome to use.

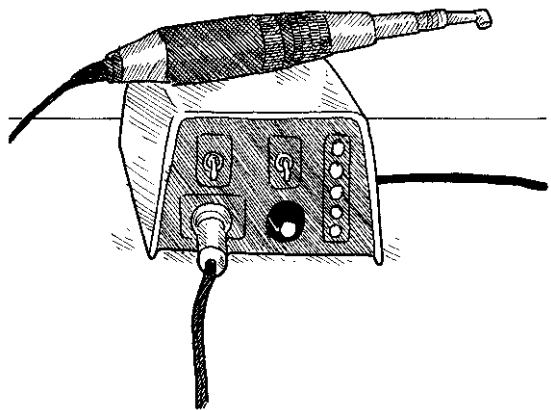


Fig. 2-1

Air-Driven Power Equipment

Comments

- Air-driven systems have three components: the air power source; the tubing, hoses, connectors, and controls; and the handpieces. They can be powered safely by an air compressor or by a tank of compressed carbon dioxide or nitrogen. Compressors are rated by horsepower (hp) and the ability to deliver a flow of air. Most dental handpieces require the compressor to maintain 30 to 40 pounds per square inch (psi) at a flow of 3 cubic feet per minute at the handpiece. The control section is an array of air and water switches, regulators (valves), and hoses that control the flow of air and water into the hoses and, in turn, into the handpieces. The control section can be a mobile stand, cart, wall-mounted extension arm, over-the-patient delivery system, or small counter-top unit.

Advantages

- Air acts as coolant to the handpiece.
- Water passes through the handpiece and acts as coolant and irrigant for the dental tissues.
- Longer life of the compressor and handpiece than electric motor-driven handpieces.
- Ability to run at higher speeds, than electric motor-driven handpieces, for rapid performance.
- Less torque than electric motor-driven systems and therefore less heat created at the cutting surface.
- Air-driven units generally come with an air and water syringe built into the unit that is used to provide irrigation and cooling, air drying, or both, improving visualization during dental procedures.
- Air compressor units are easier and less expensive to maintain than delivery systems powered by carbon dioxide or nitrogen.

Disadvantages

- Larger size than an electric delivery system.
- Noisy if not using a small “silent” compressor.
- More expensive than electric motor-driven units.
- Spray mist forms aerosol and may create a fomite problem.
- Accumulation of water in the oral cavity.
- Noise from a high-speed handpiece may contribute to hearing loss.

Variable Features

- These are features the practitioner should consider when purchasing these units.

Electric foot switches

Comment

- The electric foot switch compressor operates with an electrical circuit to turn the compressor on and off, and air is delivered directly to the handpiece without storage.

Advantage

- Require low horsepower and thus units at table side can be smaller.

Disadvantage

- Handpiece is either on full speed or off; there is no intermediate speed.

Air rheostat controls

Comments

- The compressor is turned on and off by a preset pressure switch and runs only to fill the storage tank.
- Compressors of less than $\frac{3}{4}$ hp are running more than they are off. This leads to overheating and temporary shutdown.
- If the practitioner’s intent is infrequent use, the smaller, chairside units work well.
- If frequent use or the use of multiple dental stations is anticipated, a larger, remote compressor with a storage tank is the best selection. A compressor of at least 1 hp is recommended if either two stations or a sonic air scaler is in use.

Advantage

- Wide variability in speeds.

Disadvantage

- Greater expense than electric foot-switch units.

Remote compressors

Comment

- Compressors can be located away from the dental operatory. This removes another space-consuming item from the dental operatory and allows for multiple station use from a single power source.

Advantages

- Can be used to power multiple stations.
- Many smaller, table-side compressor control units without compressors are compact, can be moved around, can be used at dif-

ferent locations, and can be stored out of the way.

- Removes compressor noise from working area.

Disadvantages

- Requires space for ventilation and cooling.
- Requires personnel safety considerations regarding noise level.
- Requires a location where compressor noise will not interfere with practice routine.
- Adherence to maintenance schedule is more at risk if compressor is outside the operatory.
- Pressure decreases with increasing distance from the dental delivery system. The remote compressor should be ideally within 50 feet of the dental operatory.

Table-side compressors

Comment

- Primary considerations for selection of a table-side compressor are space in the dental area, enough power and air storage for current and future use, and noise element for staff in the treatment area.

Advantages

- Can be stored in a different location when not in use.
- Can be moved easily.

Disadvantages

- Self-contained units may require additional in-line care and water filtration systems for restorative dentistry.
- Low power of some units translates into low volume of air flow and low air pressure.
- Excessive noise of some units.

Oil-free versus oil-containing compressors

Comments

- Air heats up as it is compressed, and this heat is transmitted to the compressor.
- Compressors are cooled by either air or oil.
- Air-cooled oil-free compressors do not have oil to check or change.
- As a general rule, oil-free compressors are noisier and more expensive than the oil-containing variety.
- To overcome the problem of monitoring oil level with a dipstick, several oil-containing models have view ports for observing the oil level.
- In-line filters to separate oil and water are recommended with all types of compressors.

“Whisper-quiet” compressors

Comments

- Traditional air compressors are fairly noisy.
- Very quiet refrigerator compressors have been converted from pumping refrigerator coolant to pumping air.
- These units are available in portable carts, portable cabinets, and countertop units.
- The single-unit compressor rates around ½ hp. If multi-station use or a sonic scaler handpiece is being considered, a double-unit 1-hp compressor should be considered.
- Because converted refrigerator compressors contain oil, the oil level must be monitored and changed according to the manufacturer’s recommendation.

Advantages

- Quiet compressor.
- Available tabletop models.

Disadvantages

- Most units contain oil, and oil levels must be maintained.
- Expensive.
- If used for long periods without stopping, some models may overheat and shut down until cool; this may take 30 to 60 minutes.

Air-Driven Alternatives Other Than by Air Compressor

Carbon dioxide

Comment

- Tanks can be rented from medical supply services and can be used, with a regulator gauge and quick disconnect couplings, to drive high-speed handpieces.

Advantages

- No maintenance.
- Saves the cost of an air compressor.
- Is not flammable.

Disadvantage

- Rental of tanks and ordering more carbon dioxide.

Nitrogen

Comments

- Nitrogen offers the same advantages and disadvantages as carbon dioxide; however, nitrogen is less expensive than carbon dioxide.

Caution

- Oxygen should not be used to power dental handpieces, because a spark could cause an explosion.

Delivery systems used in veterinary dentistry offer various combinations of accessories and handpieces. A typical top-of-the-line setup consists of two high-speed handpieces, one low-speed handpiece with a straight attachment, a prophylaxis angle, a contra angle, and a three-way air and water syringe. Other useful accessories frequently seen as attachments on the delivery system are a suction apparatus, a sonic scaler that can be substituted for one of the high-speed handpieces, fiberoptics for the handpieces, a bright light wand, and a curing unit for light-cure materials. Two styles of tubing for the handpieces are available: coiled and straight. The coiled tubing can be kept off the floor and out of the way more easily than the straight type but has much more operator-fatiguing drag and pull than the straight tubing.

Three-way syringes**Comments**

The three-way syringe is used for the following (Fig. 2-2, A):

- Flushing the oral cavity for better visualization.
- Rinsing chemicals off dental structures.
- Air-drying tooth structures during restorations and other procedures.
- Air-drying teeth to visualize calculus deposits that turn chalky when dry.²

Automatic switches and mechanical switching**Comments**

- Some units have switches that turn air on and off when handpieces are taken from or placed in their holders.
- Other units require mechanical switching by the operator.
- Automatic switches are desirable, but they present another potential mechanical failure problem.

Automatic drain valves**Comment**

- When pressure is released from the air storage tank, condensed water is released.

Advantages

- Valves require less maintenance because water is drained automatically.

- Compressor tank will last longer (decreases rust).

Disadvantages

- One more piece of equipment that may break down.
- Does not always work.

Oil-level indicators**Comment**

- A view port is located at the same level as the oil stored inside the compressor (Fig. 2-2, B).

Advantages

- Checking the oil level may be performed without the mess of a dipstick.
- The color of the oil may be inspected periodically.

Adjustable chairside air and water pressure controls**Comment**

- Some delivery systems have individual adjustable valves available for each handpiece.

Advantage

- More accommodating for the needs of different handpieces (e.g., a sonic scaler may require higher air pressure, which could be detrimental to certain prophylaxis angles on a low-speed handpiece). Manufacturer recommendations should be consulted for each handpiece.

Compressor Maintenance

- All compressors with air storage tanks require periodic drainage of condensation from the tank (Fig. 2-2, C).
- The last-stage regulator should be set between 30 and 40 psi (Fig. 2-2, D).
- The pressure in the tank may be 80 to 120 psi, depending on the brand.

Compressor Accessories

- Filters to filter out oil and water from the compressed air. These provide for drier air and less chance of bonding material failures.
- Dryers to dry the air.
- Water filters to filter the water before it enters the handpiece. Some locales have more impurities in the water than others. This can also affect procedural technical success.

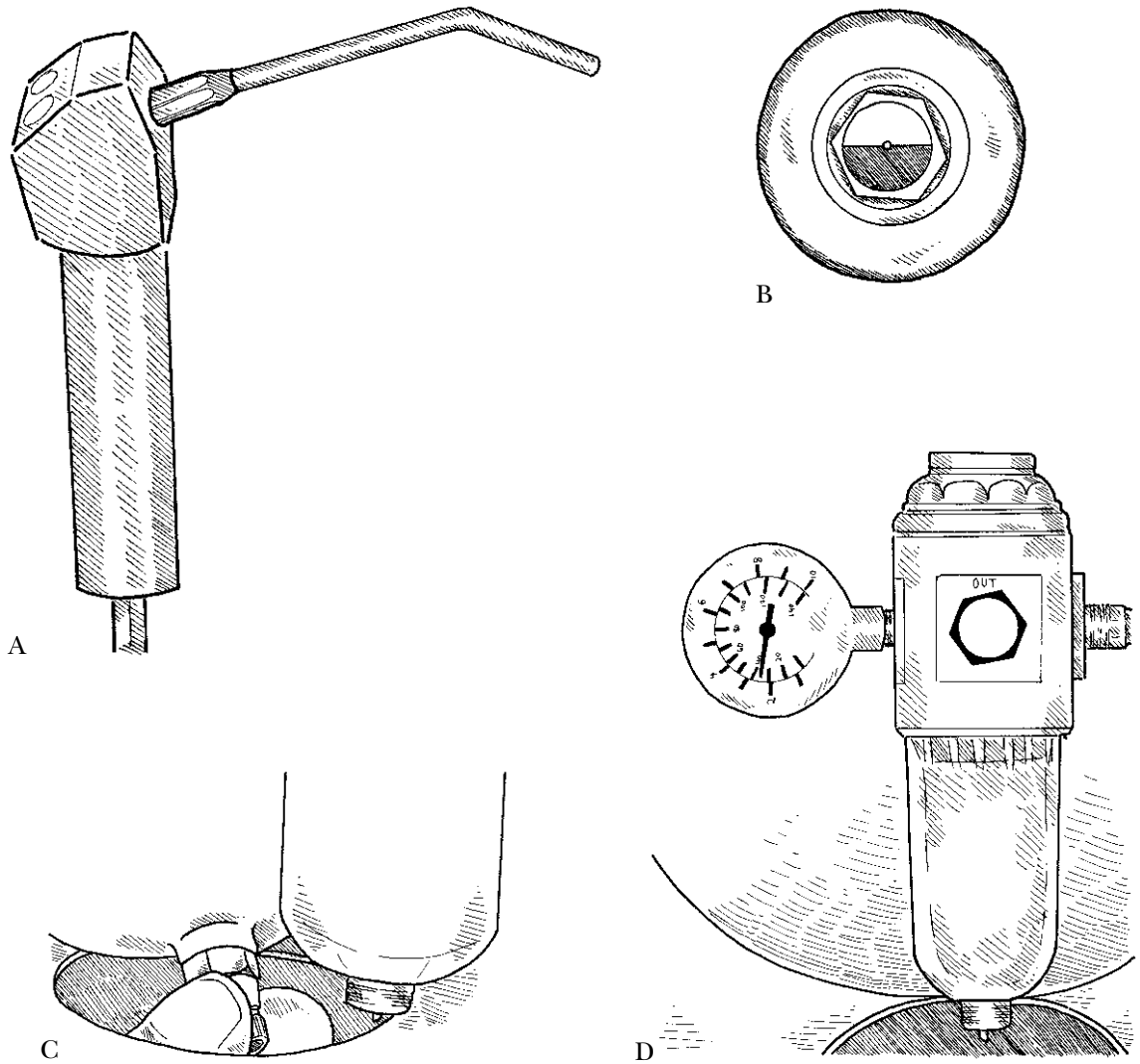


Fig. 2-2

Handpieces

- Handpieces enable the operator to work on teeth. They hold the mechanical cutting and finishing instruments used to modify tooth structure.
- Many types of handpieces are available, and they can be categorized into three basic types: low-speed, high-speed, and sonic scalers.

General maintenance

- A handpiece should never be turned on without a bur or “blank” inserted into the chuck to prevent damage to the chuck.
- Follow the manufacturer’s recommendations on handpiece lubrication and air pressure.
- Lubricant should be placed in the smaller of the two large holes (Fig. 2-3, *A* and *B*).

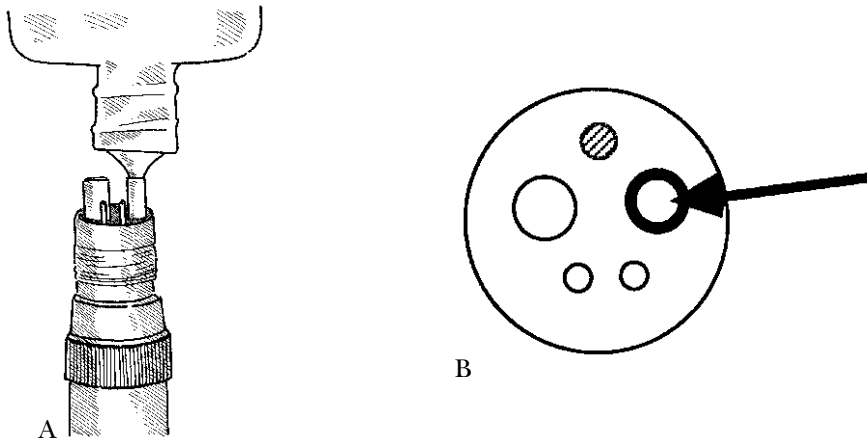


Fig. 2-3

Low-speed handpieces**Comments**

- Low-speed air-driven handpieces operate within 5,000 to 20,000 rpm. Low-speed handpieces have two kinds of connections with the contra angle, E-type and Doriot-type.
- The E-type handpiece has a quick release, pull-off end for E-type prophyl and contra-angle nose cones (Fig. 2-4).
- Doriot-type handpieces have a twist-and-lock end for Doriot-type prophyl and contra angles.
- Disposable prophyl angles and handpiece burs or diamond discs require a Doriot-type handpiece.

Uses

- They can be used for polishing with prophyl angles.
- Contra angles can be attached to allow use of burs, endodontic files, polishing discs, and other specialized instruments requiring slower speeds and higher torque.

Advantages

- High torque; less likely to “stall out.”
- Slower speed for cutting bone.

Disadvantages

- Low speed is a disadvantage when drilling into or sectioning teeth; increases working time and tissue heat.
- May shatter the tooth if the bur binds while cutting the tooth.
- May create thermal injury because of the slow speed and pressure between the bur and tooth surface (drilling pressure).
- Usually do not have water as a coolant and irrigant.

Autoclave option**Comment**

- Many of the newer low-speed handpieces can be autoclaved.

Advantage

- Increases rust resistance.

Maintenance

- Lubricate according to manufacturer’s instructions.
- If a heavy oil is used, spray with a light oil (WD-40) once every 2 weeks to help dissolve oil accumulations.
- Run the handpiece for 20 to 30 seconds after lubrication.
- Sterilize between patients.

Accessories: prophyl angles**Comments**

- Prophyl angles are used to polish teeth.
- There are two types of prophyl angle rubber cup attachments: snap-on and screw-on. Which to use is an individual preference, but it must match the attachment configuration of the end of the prophyl angle. Some prophyl angles accept either type of cup.

Circular action prophyl angles*Comments*

- These prophyl angles rotate 360 degrees.
- Metal models are manufactured, some to be disposed of when they break and some to be repaired.
- Plastic models are disposable and are designed for single use.

Advantages

- Circular prophyl angles tend to be inexpensive.
- The inexpensive models are usually replaced rather than repaired. They may last for a few months of use.

Disadvantages

- Require disassembling and lubricating.
- May “spit” oil, contaminating the prepared dental surface.
- May incur hair entanglement from the patient.

Oscillating prophyl angles*Comments*

- The oscillating prophyl angle oscillates back and forth 90 degrees.
- This style is a sealed unit. Now also available as a plastic disposable model (Twist2it, Flushing, NY).

Advantages

- This style does not require lubrication.
- Prophyl paste is not thrown because the cup does not spin.
- Hair does not become trapped around the cup.

Disadvantages

- Metal unit expensive to purchase.
- Repairs, if possible, may cost more than a new prophyl angle.

Maintenance of nonsealed prophyl*Angles*

- The prophyl angle can be disassembled and lubricated. There are usually two locations




Fig. 2-4

where the instrument can be opened for cleaning: the head and the cap. With most prophyl angles, only one method needs to be used.

Removal of head

Step 1—The head is unscrewed by turning it counterclockwise (Fig. 2-5, *A*).

Step 2—The gears are cleaned with WD-40 or other solvent (Fig. 2-5, *B*).

Step 3—The gears are lubricated with Prophyl Lube (Young Dental, Earth City, Mo.) or other appropriate light gear lubricant (Fig. 2-5, *C*).

Step 4—The head is replaced by screwing it on clockwise.

Removal of cap

Step 1—The cap is unscrewed by turning it clockwise (Fig. 2-5, *D*).

Step 2—The gears are cleaned with WD-40 (Fig. 2-5, *E*).

Step 3—The gears are lubricated with Prophyl Lube (Fig. 2-5, *F*).

Step 4—The cap is replaced by screwing it on counterclockwise.

Accessories: contra angles

- Specific contra angles can increase or decrease the revolutions per minute at the working end, change angulation, or provide 90-degree rotation. Typically, a 4:1 step-up contra angle is used in low-speed electric motor handpieces and increases the speed from 20,000 to 80,000 rpm. A typical down-step contra angle is a 10:1 reduction gear and is used to reduce the speed, for example, when employing spiral paste fillers or in dental prosthetic procedures.
- Contra angles use right angle (RA) or latch-type burs, which have larger diameter shanks than high-speed burs.
- Straight Doriot-type low-speed handpieces use handpiece (designated HP) burs, which are longer and even greater in diameter than RA bur shanks.

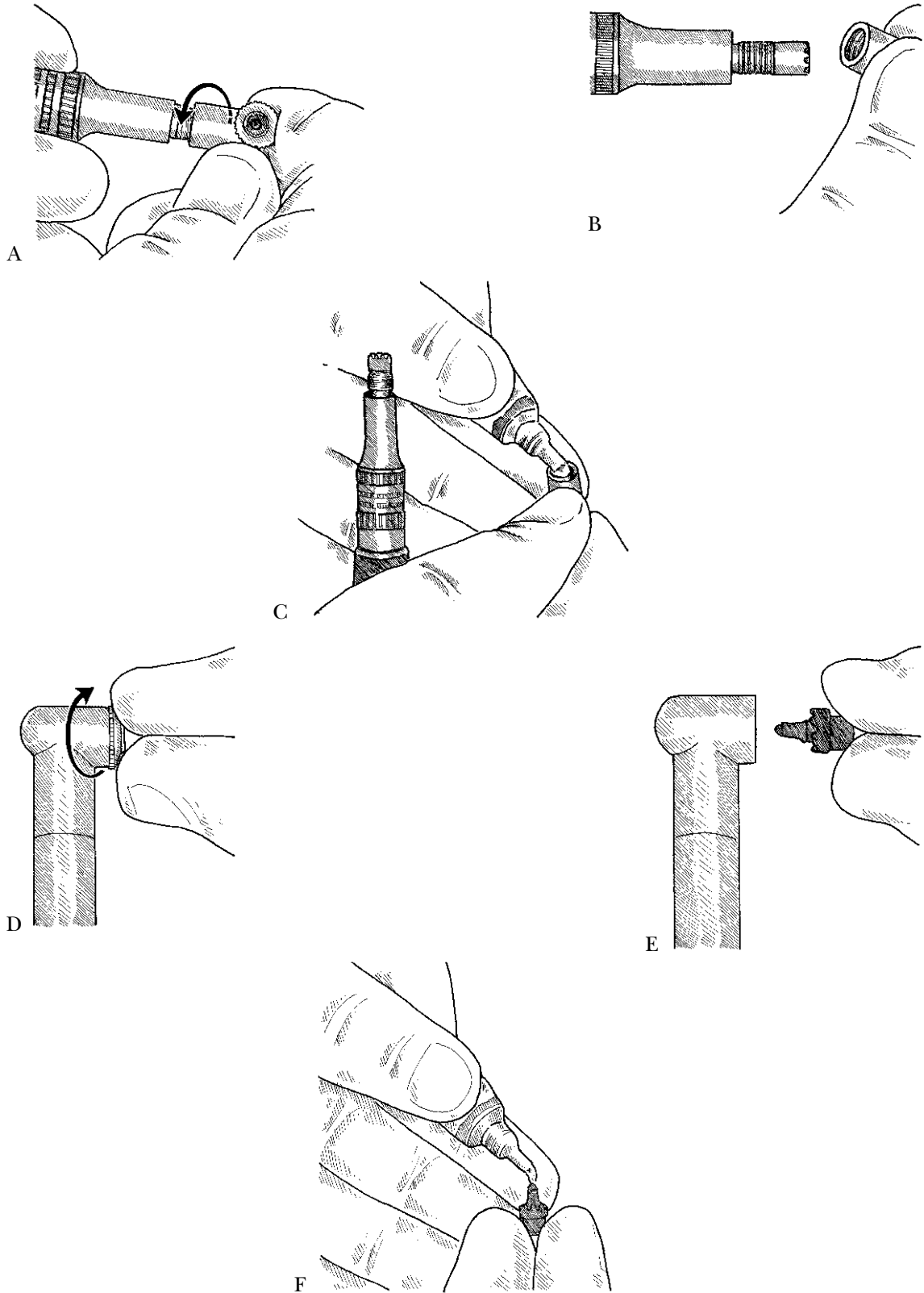


Fig. 2-5

Low-speed burs

- Burs are held by handpieces in three ways: straight, latch, and friction grip (FG).
- The straight bur (designated HP) (Fig. 2-6, *A*) fits directly into the straight low-speed handpiece.

Changing straight burs

Step 1—Twist the collar to open the chuck (Fig. 2-6, *B*). Proper position usually is noted by dots on the handpiece.

Step 2—Remove straight bur and replace with new bur (Fig. 2-6, *C*).

Step 3—Twist chuck latch collar to close, as noted by dots on the handpiece (Fig. 2-6, *D*).

Latch burs

- This type of bur, also called an RA bur (Fig. 2-6, *E*), fits into a contra angle that holds the bur in place.

Changing latch-type burrs

Step 1—Holding the contra angle with the bur facing away from the operator, pivot the latch lever to the right (Fig. 2-6, *F*).

Step 2—Remove old bur (Fig. 2-6, *G*).

Step 3—Replace with new bur, lining up the flat portion of the bur to slide all the way in (Fig. 2-6, *H*).

Step 4—Pivot the latch back, and slide handle to the left until it clicks into place parallel to the contra angle (Fig. 2-6, *I*).

- Although the FG bur can be used in appropriate low-speed handpieces, it usually is used in high-speed handpieces and is discussed in that section.

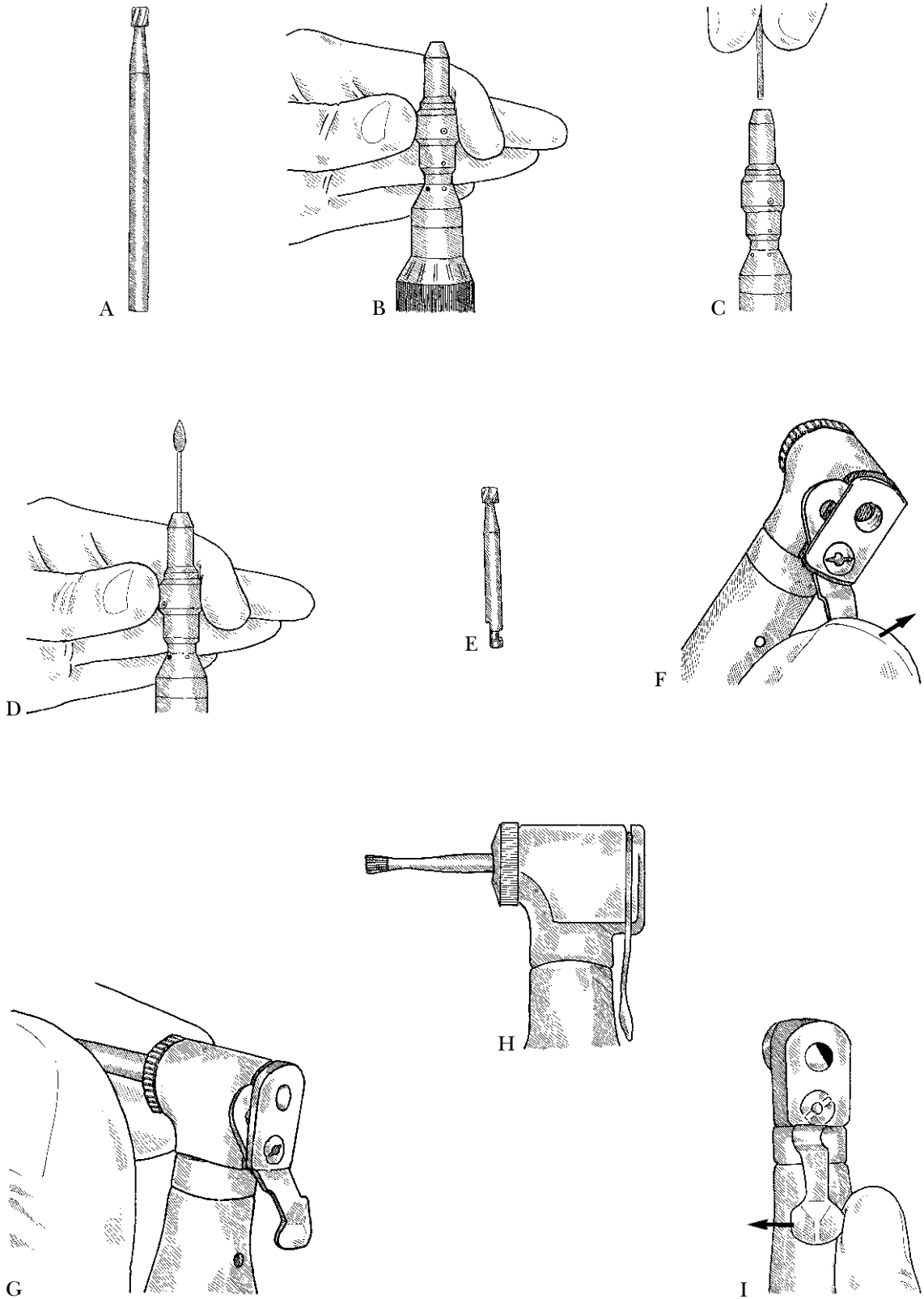


Fig. 2-6

Types of burs and drills

- Many types of low-speed burs are similar to high-speed burs.
- Some types of burs and drills are available for low speed use only.
- A bur converter is available, sold in packages of three, which allows FG burs to be used in latch contra angles (Fig. 2-7, *A*).

Gates Glidden drills*Comments*

- Have relatively long, narrow shafts with a flame-shaped boring head (Fig. 2-7, *B*).
- Have bands on the shaft to indicate sizes 1 through 6.
- Have (RA) and are used with latch-type contra angles.

Uses

- Expands the opening into the endodontic system for easier instrumentation and filling of the canal during root canal therapy.
- Tends to follow the path of a pre-existing hole.

Cautions

- If bound in the canal or bent, the drill will break, usually at the latch end of the shaft.
- Use with low-speed handpiece only.

- Breakage can be reduced by lubricating with a chelating material such as R-C Prep (Premier Dental Products, Plymouth Meeting, Penn.).

Peeso reamers*Comments*

- Have a longer, torpedo-shaped head and shorter shaft than the Gates Glidden drill (Fig. 2-7, *C*).
- Have bands on the shank to indicate sizes 1 through 6.

Uses

- Widens the diameter of a prepared root canal in preparation for a post (Fig. 2-7, *D*).
- May cut its own path (use with caution), not necessarily following the pulp chamber or root canal (Fig. 2-7, *E*).

Mueller bur

- The Mueller bur, like the Gates Glidden drill, has a long and narrow shaft, but the working end is that of a round cutting bur (Fig. 2-7, *F*).

Uses

- Is especially useful in performing pulpotomies on large canine teeth.
- Is usually supplied with a set of five burs numbered 1 through 5.

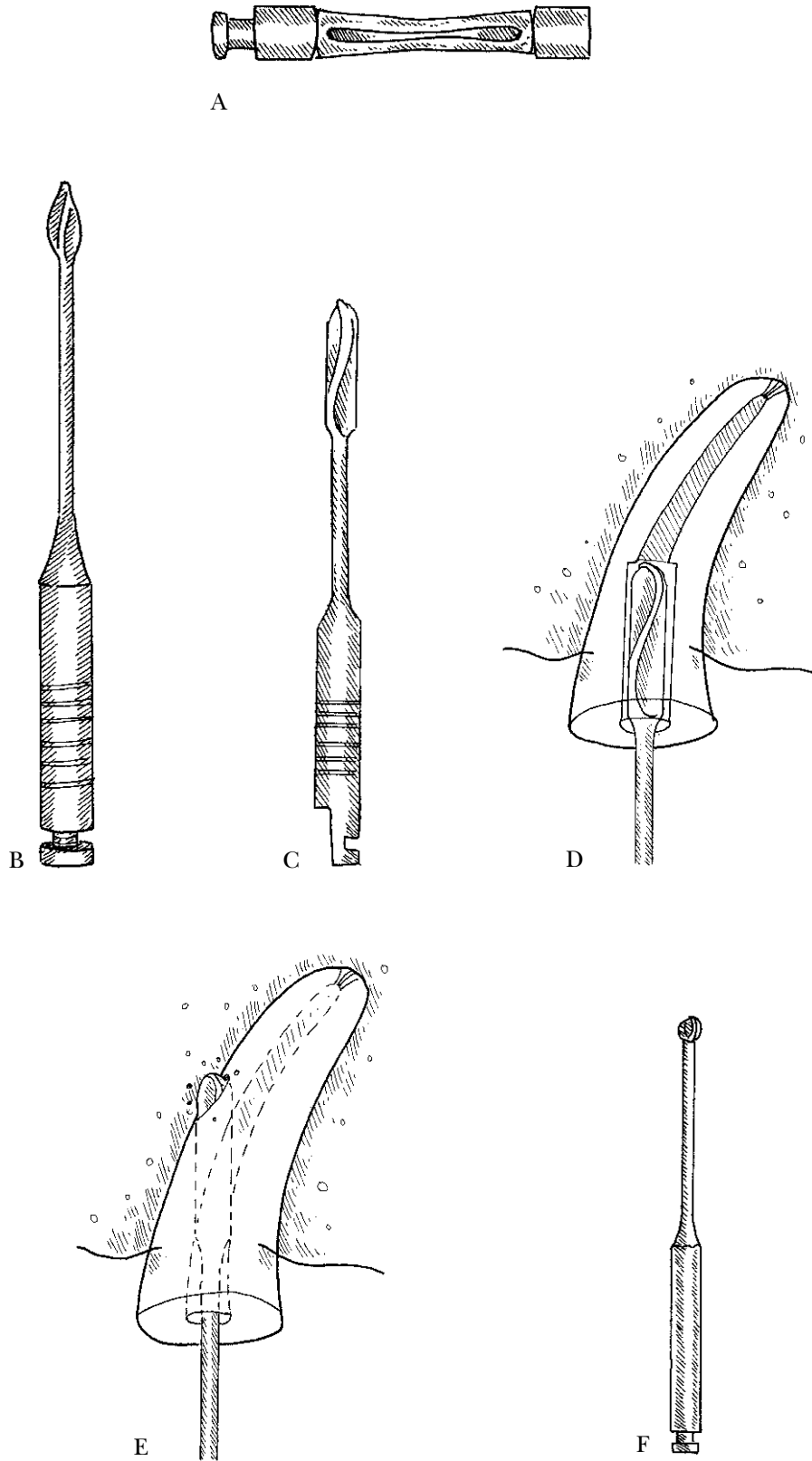


Fig. 2-7

Green stones**Comment**

- Green stones are silicon carbide abrasive stones in carefully controlled grits of various shapes and sizes.

Uses

- For finishing restorations and producing a moderately rough surface.
- For bulk removal of restorative material before the final finish.

White stones**Comment**

- White stones are dense aluminum oxide abrasives of fine texture. They come as RA or FG as pictured (Fig. 2-8, A).

Use

- For finishing composite restorations and producing a smooth surface.

Discs**Comments**

- Discs are flexible molded or cut paper, plastic, rubber, stone, porcelain, acrylic, or metal (Fig. 2-8, B).
- Discs are supplied in $\frac{1}{2}$ -, $\frac{5}{8}$ -, $\frac{3}{4}$ -, and $\frac{7}{8}$ -inch diameters.
- Discs may have their own shafts or may be held by a mandrel.
- Paper discs are prepared with sandpaper, cuttlebone, emery, or garnet finishes in extra fine, fine, medium, or coarse grits.
- Metal discs are either single sided or double sided, often with a diamond grit.

Uses

- For finishing restorations, occlusal adjustment, and cutting tooth and material.
- A diamond disc with disc protector can be used to reduce crown height when doing a crown reduction with a partial coronal pulpectomy technique (see Chapter 7).
- Shofu polishing disc and mandrel (Shofu Dental, San Marcos, Calif.) (Fig. 2-8, C).
- These come in flexible plastic color-coded sets (black, violet, green, and red) with grits becoming finer in that order. The discs come with the grit on either side and in two

diameters. They generally achieve a smoother restoration than the paper discs.

Wheels**Comment**

- Wheels composed of molded abrasive materials of phenolic resins or rubber with an abrasive come in various shapes and sizes (Fig. 2-8, D).

Uses

- For laboratory procedures, finishing, and polishing.

Mandrels**Comments**

- Mandrels attach to the low-speed handpiece with latch, straight, or FG burs.
- Mandrels hold discs or wheels by a pop-on, screw-on, or rod-type screw.
- Pop-on mandrel (Fig. 2-8, E).
- Screw-on mandrel (Fig. 2-8, F).
- Rod-type screw-on mandrel (Fig. 2-8, G).

Use

- Hold finishing materials.

Paste fillers**Comments**

- Paste fillers are attached to the reduction gear contra angle of the low-speed handpiece (Fig. 2-8, H).
- When rotated, they spin paste root canal filling material into the canal.
- Because of their reverse spiral, they work in the forward (clockwise) rotation.
- They are manufactured in various sizes and lengths.

Advantage

- Paste fillers auger root canal pastes or sealers apically into the canal, eliminating air bubbles.

Disadvantages

- May not fit into canal.
- Should use 10:1 reduction gear contra angles or may break spiral filler.
- Should have adequate diameter access to prevent binding and breakage.
- Should be replaced if become bent or weakened.

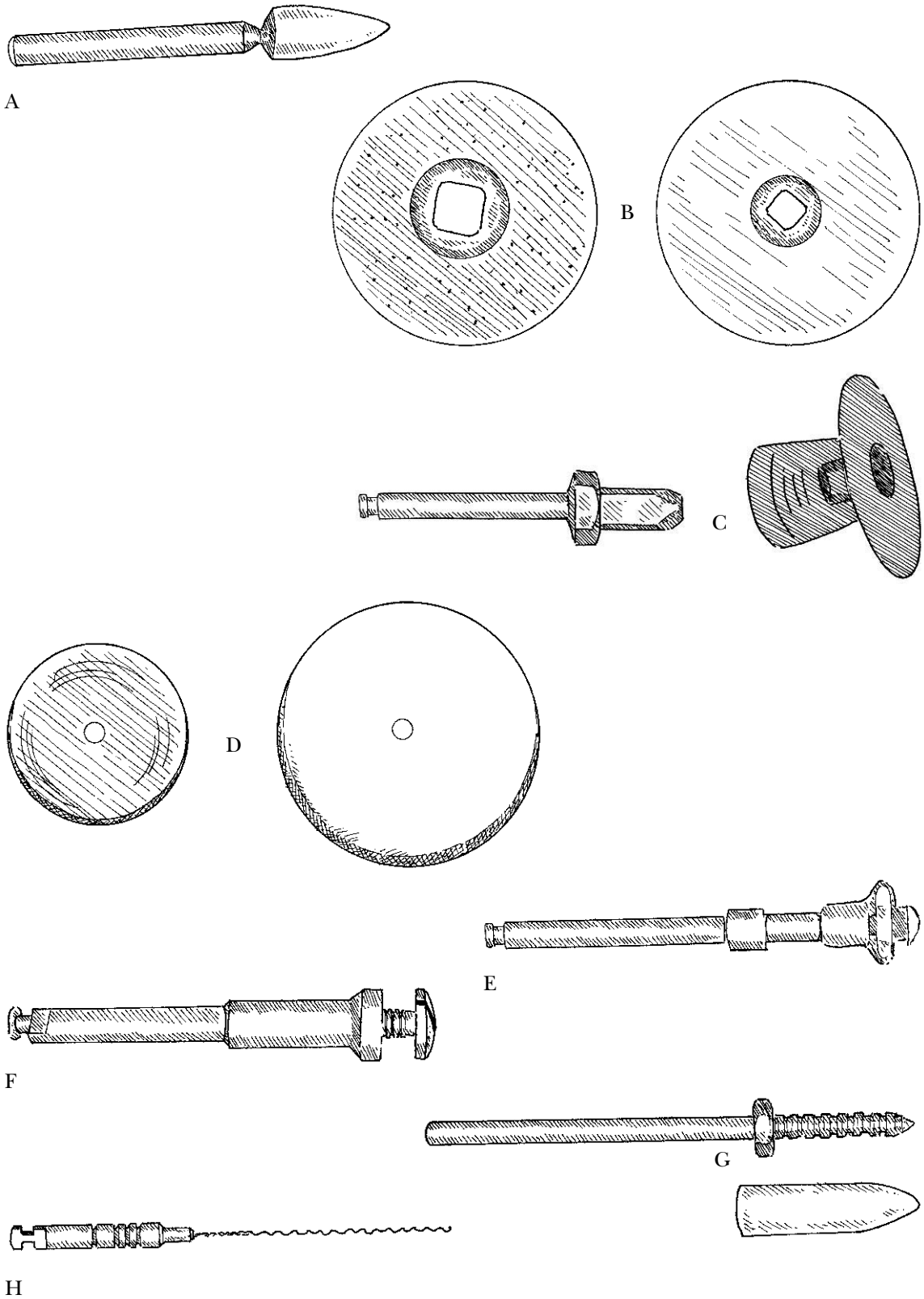


Fig. 2-8

High-speed handpieces

Comment

- High-speed handpieces rotate in the range of 200,000 to 400,000 rpm. Different makes of handpieces have various size heads. A pediatric size head is beneficial when working on preparing retrograde root canal sites and when working in general on cats or small dogs.

Uses

- Sectioning or otherwise cutting teeth, bone removal, endodontic access, cavity preparation, finishing restorations, and crown preparation.

Advantages

- High speed allows for rapid cutting of hard dental tissue.
- Water cooling protects dental tissue.
- Stalling due to low torque protects dental tissue from shattering.
- Less risk of thermal injury to tissues than with low-speed handpieces

Disadvantages

- Stalling may slow work. New and sharp burs lessen this problem.
- May create excessive heat or burning if inadequate water cooling or too much drilling pressure.
- Moisture or oil blown through the handpiece may destroy the turbine bearings.

Options

Wrenchless handpieces

Comment

- This feature allows bur exchange without using a chuck key. Push either button or latch at the back of the handpiece.

Advantage

- Speed in changing burs.

Disadvantage

- The push-button mechanism requires periodic replacement.

Fiberoptics

Comments

- Light is directed toward the operating field, which is particularly helpful when instrumenting caudal teeth.

- A light source provides light that is transferred by fiberoptics to the head of the handpiece.

Advantage

- Greater visualization of working area.

Disadvantages

- Bulbs can wear out.
- Models with flexible fiberoptic bundles require replacement of hoses, as the fibers break with repeated use.
- Additional expense.
- Electric source is necessary.

High-speed handpiece maintenance

- Lubricant must be used on a regular basis unless it is a sealed unit (more expensive). Follow the recommendations of the handpiece manufacturer for which spray or liquid lubricant to use. Oils are not recommended for most high-speed handpieces.
- The lubricant should be placed in the smaller of the two large holes (Fig. 2-9, A).
- Once a sealed high-speed handpiece is lubricated, it will need to be lubricated forever.

Changing FG burs

Overhead chuck key type

Step 1—Place chuck key over the head of the handpiece (Fig. 2-9, B).

Step 2—Rotate the chuck key knob counter-clockwise (Fig. 2-9, C).

Step 3—Remove old bur (Fig. 2-9, D); if there is resistance, gently push in on bur to loosen the chuck grip and then pull the bur out.

Step 4—Push new bur in until completely seated (Fig. 2-9, E). Caution: If the bur is not completely seated, the turbine bearings may be damaged.

Step 5—Rotate chuck key knob clockwise just until bur is snug (Fig. 2-9, F). Do not over-tighten.

Step 6—Before using bur, observe its rotation. A wobbling motion indicates a bent shaft, and the bur should be discarded to avoid damage to the chuck or the patient.

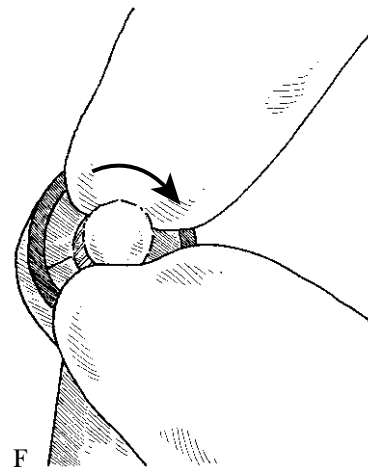
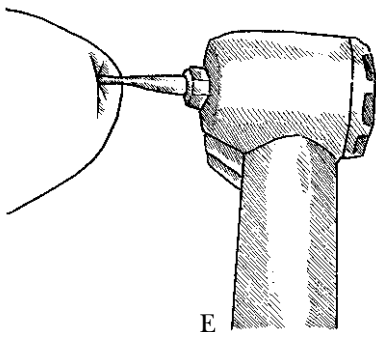
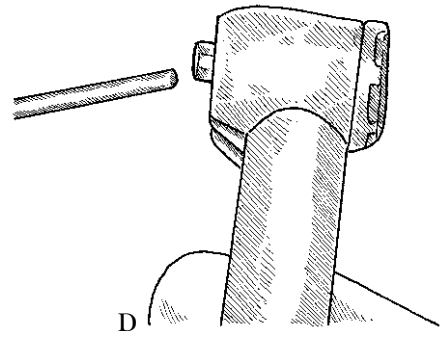
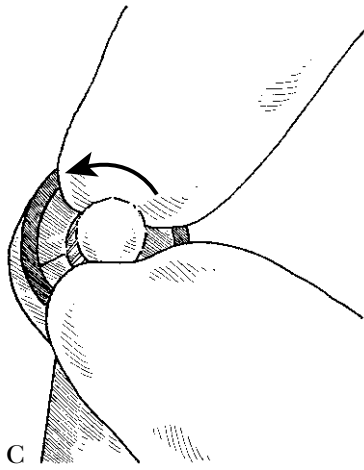
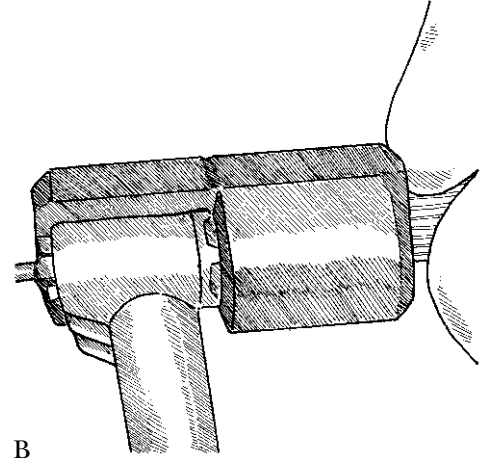
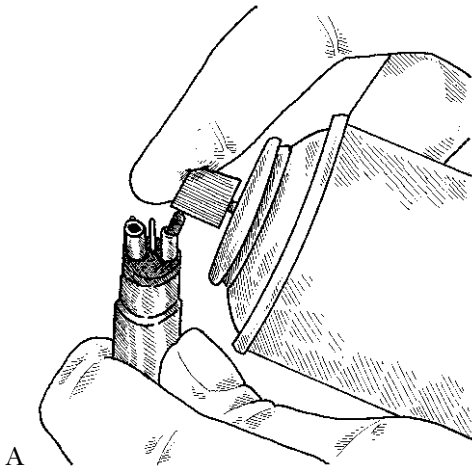


Fig. 2-9

Replacement of turbine cartridge

Signs of defective turbine cartridge:

- Chuck does not tighten around the bur.
- Increased noise or vibration.
- Roughness felt when spinning bur by hand, with turbine in or out of handpiece.
- Handpiece stops intermittently.
- Handpiece does not work.

Cap-style handpiece back

Step 1—Place “blank” bur in handpiece (Fig. 2-10, *A*). If bur that is in handpiece cannot be removed, proceed with caution to avoid cutting hands on bur.

Step 2—Place small metal ring (wrench) supplied with handpiece on cap of handpiece (Fig. 2-10, *B*).

Step 3—By rotating wrench counterclockwise, unscrew the handpiece cap and remove (Fig. 2-10, *C*).

Step 4—Press on blank or bur to remove turbine cartridge from handpiece head (Fig. 2-10, *D*).

Step 5—Place the new turbine cartridge into the handpiece head (Fig. 2-10, *E*).

Step 6—Align the new turbine cartridge with pin side up (Fig. 2-10, *F*). If the pin is not lined up with the slot, the turbine cartridge will not slide completely into the handpiece head (Fig. 2-10, *G*).

Step 7—Slide cartridge all the way into handpiece head (Fig. 2-10, *H*).

Step 8—Replace handpiece cap by twisting wrench clockwise (Fig. 2-10, *I*).

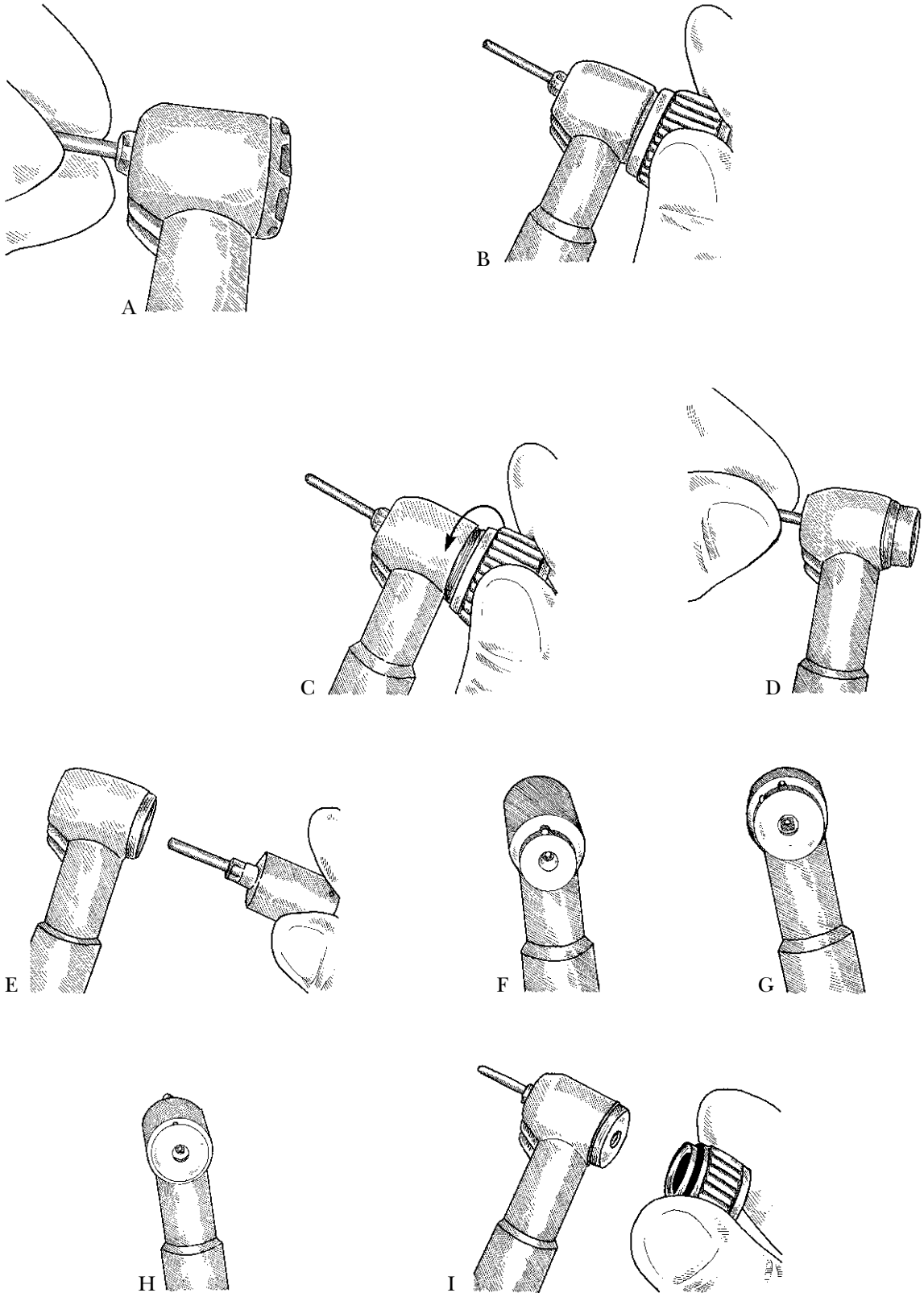


Fig. 2-10

Handpiece burs

- High-speed handpieces use FG burs.
- Only high-speed burs should be used with high-speed handpieces.
- There are three parts: shank, the portion that attaches to the handpiece; shaft, the portion from the shank to the head; and head, the working portion.
- Heads may be denoted as S (short) or L (long); if no letter, the head is standard length.
- Standard shanks are 19.0 mm long and 1.6 mm in diameter.
- Longer shanks are denoted as surgical length (Fig. 2-11, *A*). They are 25 mm long and 1.6 mm in diameter.
- The shanks of burs that fit into straight handpieces, designated in catalogs as HP, are 44.5 mm long and 2.35 mm in diameter. Low-speed latch burs that are designated RA in catalogs have regular shanks that are 22 mm long by 2.35 mm in diameter and are also supplied in surgical length with shanks 26 mm long by 2.35 mm in diameter (Table 2-1).
- Flutes can be manufactured plain, without fissure notches (Fig. 2-11, *B*), or cross-cut, with transverse notches (Fig. 2-11, *C*).
- Most cutting burs are six-fluted (have six cutting edges). Finishing burs have 10 to 30 flutes. The more flutes on the bur, the finer and smoother the finish on the tooth after treatment.
- Bur type refers to the shape of the head of the bur. Most shapes come in plain or cross-cut. Common shapes are round, cylinder (with or without fissures), taper (with or without fissures), pear, flame, inverted cone, and wheel.
- The tips of the bur can be cutting, non-cutting, square, or rounded. The non-cutting tip is used to cut straight sides without cutting the floor of a cavity preparation. The cutting tip may cut into the cavity floor. The square tip creates a 90-degree angle at the interface between the floor and the wall of a preparation. This may be difficult to fill with restorative material and creates a weaker breaking point at line angles. The round tip creates a rounded transition between the floor and wall. This interface is easier to fill and is less fragile.

Round burs

- Round burs come in sizes $\frac{1}{4}$, $\frac{1}{2}$, 1, 2, 3, 4, 6, and 8 (Fig. 2-11, *D*).

Uses

- The smaller burs ($\frac{1}{4}$ and $\frac{1}{2}$) can be used to create retentive grooves in tooth structure or to mark locations for larger low-speed bur placement. They can also be used as all-purpose cutting burs in smaller teeth, such as those in domestic cats and toy breed dogs.

Comments

- Bur tips as small as $\frac{1}{4}$ round may be easily bent or detached from the shank unnoticed by the clinician as they are installed in the handpiece or inadvertently bumped against a piece of equipment.
- The medium burs (#1, #2) can be used for initial cavity preparation and outline.
- The #2 and #4 burs are useful in creating endodontic access openings or pulpotomy procedures.
- The larger burs are used for bulk removal of dental tissue.
- Some round burs are designed to be placed parallel to the tooth, with the shank as a limit to marking cutting depth in crown preparation.

Fissure burs

- Model numbers are 556, 557, and 558.

Comment

- The sides of the head are parallel (Fig. 2-11, *E*).

Use

- They have straight, parallel sides that create parallel cavity sides.

Tapered-fissure burs

- Models are plain 168, 169, 169L, 170, 170L, 171, 171L, 172, 172L, and 173; cross-cut 699, 700, 701, 701L, 702, 702L, 703, and 703L.

Comment

- Their head is narrower at the tip than toward the shank (Fig. 2-11, *F*).

Uses

- These are general purpose burs that can be used for bulk removal of dental tissue, for sectioning teeth for extraction, and for endodontic access.
- When held perpendicular to a cavity preparation, they can be used to prevent an undercut.

Table 2-1 • BUR SHANK DIMENSIONS

Bur shank type	Short shank	Standard length	Surgical length	Shank diameter
Friction grip	16.0 mm (0.670")	19.0 mm (0.768")	36.0 mm (1.004")	1.6 mm (0.0630")
Straight handpiece	—	44.5 mm (1.772")	—	2.35 mm (0.0925")
Latch type	—	22.0 mm (0.886")	26.0 mm (1.023")	2.35 mm (0.0925")

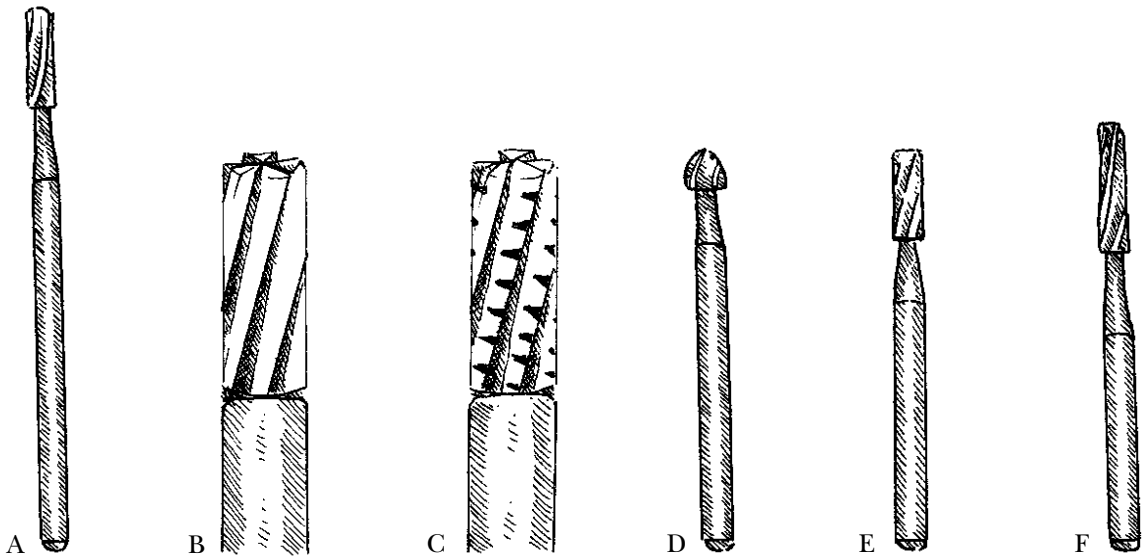


Fig. 2-11

Pear-shaped burs

- Models are 330, 331, 331L, and 332 (Fig. 2-12, A).

Uses

- These are general purpose burs that can be used for root canal access or undercutting dentin in cavity preparation.
- They create smoothly rounded internal line angles.

Flame burs

- Flame burs have a pointed tip and wider body that rounds toward the shank.

Inverted-cone burs

Models are 33-1/2, 34, 35, 37, 38, and 39.

Comment

- The head is wider toward the tip than toward the shaft (Fig. 2-12, B).

Uses

- Smaller burs are used to penetrate into root canals and to create a mechanical interlock in restoration preparations in the smaller teeth.
- Larger burs are used to undercut cavity preparations to create a mechanical interlock.

Special use burs**Rotopro bur**

- Formerly used for scaling teeth (Ellman International, Hewlett, NY) (Fig. 2-12, C).
- Frequency is 100,000 rpm at the working tip, depending on speed of air turbine and air pressure. These burs can create enamel and soft tissue damage and their routine use is no longer recommended.³
- Can be used to shape or remove dental acrylic material used as intraoral splints.

Multifluted finishing burs

- Come in a variety of shapes.
- Have 10 to 30 flutes; the more flutes, the smoother the finish.

Diamond burs

- These cut by grinding and can be used for cutting (Fig. 2-12, D) or finishing (Fig. 2-12, E). They come in many sizes and shapes. When used for bone removal and alveoloplasty, they leave a smoother edge and if used for sectioning teeth will cut more slowly than a carbide bur. Diamond burs commonly are used for crown preparation.
- Are manufactured by electroplating diamond grit onto a one-piece bur blank by either a nickel or chromium bonding material.
- Use natural or artificial diamonds.
- Use different grits of diamonds; commonly used are extra fine, fine, medium, and coarse.
- The more cutting surface area, the more friction and heat are generated. Diamonds generally produce more heat than cutting burs and the surface treated should be irrigated for cooling.

Bur accessories**Bur-cleaning brush**

- Bur-cleaning brushes clean the flutes of the bur but do not sharpen, or dull, the flutes (Fig. 2-12, F).
- The brush is used by brushing the bur without running the handpiece.

Diamond bur-cleaning stone

- The diamond bur-cleaning stone removes debris from the surface of the diamond bur (Fig. 2-12, G).
- Using the high-speed handpiece, the bur is run over a wet stone.

Bur block

- The bur block is used to store burs (Fig. 2-12, H).
- Many are magnetic to help keep the burs in place.
- Some bur blocks are autoclavable, and some are manufactured with a hinged cover.

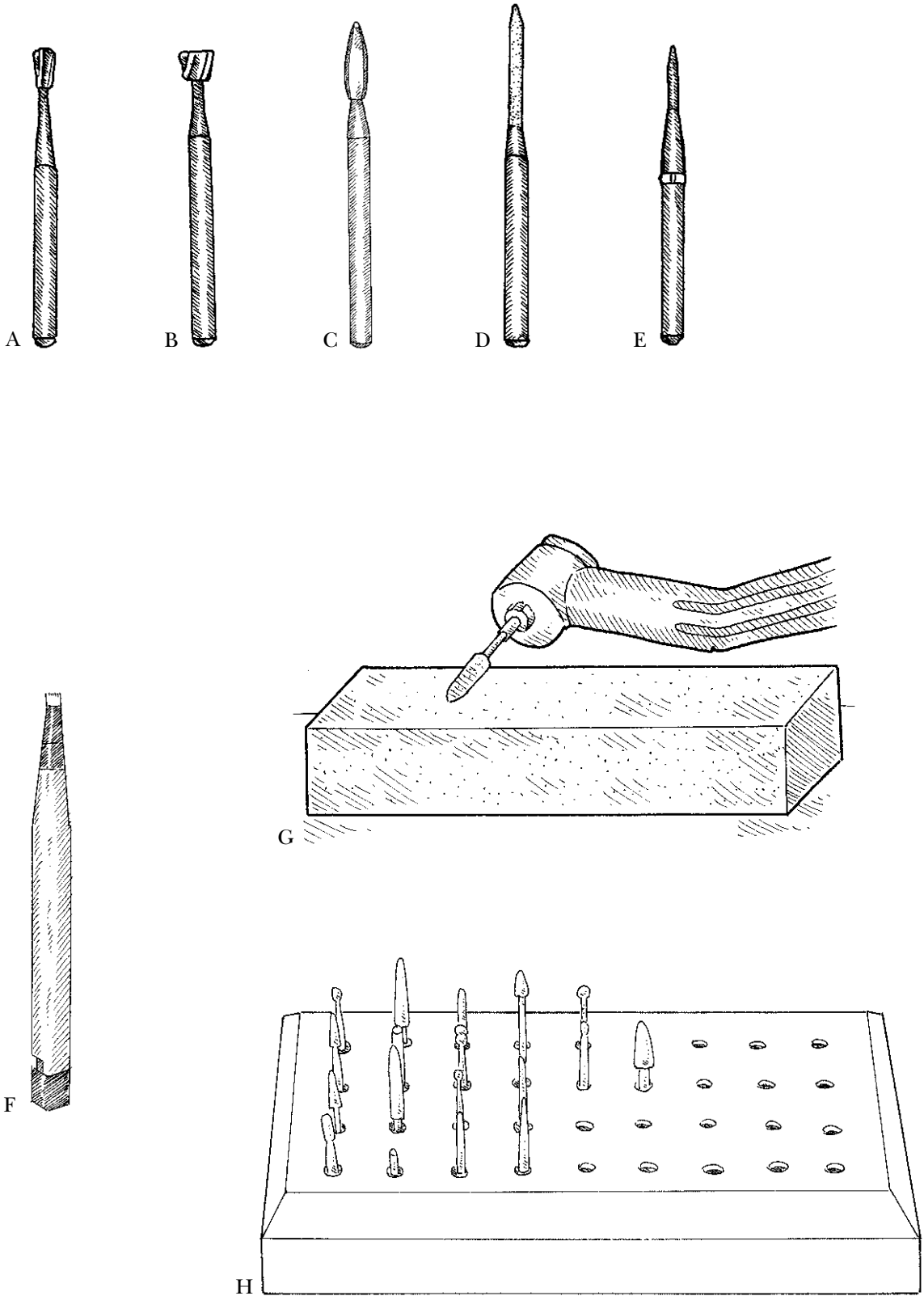


Fig. 2-12

DENTAL RADIOLOGY EQUIPMENT

Veterinary Medical Units

Comment

- Dental film may be exposed using 50 to 500 mA veterinary medical units.

Advantage

- No additional expense to the veterinary hospital required when using standard veterinary medical machines.

Disadvantages

- The patient must be moved between the dental area and radiology area during procedures.
- The flexibility of most veterinary medical units does not allow the radiographic head to move for optimal positioning. Thus, the patient must be repositioned for each radiographic view; that is more time consuming and difficult than moving the radiographic head alone.

Dental Radiographic Units

Comments

- They are usually low-milliamperage units suited for dental film exposure.
- Long or short cone options and wall-mounted or floor models are available in current models.

Advantages

- Dental radiology may be performed in the dental operatory.
- The veterinary medical radiographic unit is available for use by the rest of the hospital while the dental procedure is performed.
- A higher quality image is generated by parallel x-rays and a smaller focal spot than in most medical units.

Film Processing Systems

- Film may be processed either manually or with an automatic processor.

Manual Processing

- There are three types of manual developing solutions: standard veterinary dip tank, one-step rapid process, and two-step rapid process.

Standard veterinary dip tank solution

Comment

- The regular developer and fixing solutions that are normally used in manual processing of veterinary radiographic film may be used to develop dental film.

Advantage

- If the hospital is already using this system, these solutions are available at no additional cost.

Disadvantages

- Loss of detail.
- Longer processing time.

One-step rapid processing solution

Comment

- A single developing solution contains both developer and fixer to process the film in approximately 1 minute.

Advantage

- Single-step processing.

Disadvantages

- Loss of detail.
- "Greening" of processed film may occur several days after developing.

Two-step rapid processing solution

Comments

- A developing solution and a separate fixing solution designed to process film in approximately 1 minute.
- Come as concentrated solutions to be diluted or ready to use. Use in containers with air-tight lids to minimize oxidation between uses and prolong life of chemicals.

Advantages

- Provide high-quality developing and rapid processing.
- If used properly, create archival quality films that may be stored for years without loss of quality.

Automatic Processing

- There are two types of mechanical processing systems: the large-film automatic processors and the smaller dental processors.

Large-film processors

Comments

- Large-film automatic processors commonly are found in veterinary hospitals.

- Dental radiographic film may be taped to larger radiographic film and sent through the processor.
- A film mounting system designed to hold #2 and #4 dental films can be used to run films through most automatic processors (Film Tran, Bisco International, Hillside, Ill.).

Advantages

- In most practices, manual systems are best.
- If using mounts designed to go through processor, have dry films to read and film is already mounted for storage.

Disadvantages

- Risk loss of film in the processor.
- Must use leader film to attach the smaller film unless film mounts designed for radiographic processing are used.
- Possible damage to processor if improper tape is used.
- Requires more time to develop the film than manual methods.
- Cost of specific film mounts.

Small-film processors

Comment

- Small-film processors are designed to transport dental films through the processing solutions and the dryer.

Advantages

- Greater quality control.
- No need to use leader film or film mounts.

Disadvantages

- Expensive.
- Requires more time to process film than manual rapid process methods.
- Location of processing may be remote to the dental operatory, although countertop units are available.

Location of Processing

Dip tanks for darkrooms

Comment

- Tanks or containers may be used in the darkroom with rapid processing solutions to process the radiographs.

Advantages

- Inexpensive.
- Faster developing time than with traditional chemicals.

Disadvantages

- Less quality control than with mechanical processors.
- Personnel must leave the dental area to process the film.
- May create additional mess in the darkroom due to inadvertent spillage.

Chairside darkrooms

Comments

- Chairside darkrooms are small, portable, light-proof boxes that have hooded hand ports for processing the film in darkness. Because this process is manual, a special see-through safety filter plastic cover allows the operator to see the film and dip tanks. The cover does not allow low-level room light to affect the film. An amber or red safety filter is provided.
- If using the amber filter, it must be away from direct light or operator may see fogging of film. It may be necessary to move to another location or use the red filter. The amber filter is designed for Ultraspeed (D speed) film, and the red filter is designed for Ektaspeed (E speed) film.

Advantages

- Rapid process (usually less than 1 minute).
- Avoids tying up a darkroom.
- Can process films in dental operatory.

Disadvantages

- Use caution to avoid opening the lid accidentally and exposing the film during processing.
- The chemical containers are small, and the chemicals must be kept fresh.
- The amber filter will protect the film for a limited time and intensity of light.
- Must have space at table side or in the dental area.

Maintenance

- The frequency of chemical change depends on the number of radiographs processed, the amount of exposure to air, and the age of the chemicals.
- Close lids to unused chemicals.
- Replace damaged hand porthole diaphragms.
- Clean box with mild detergent and water.
- Do not damage the porthole sleeves with jewelry.
- Chairside darkrooms need to be used in subdued light areas. To test the location, place the chairside darkroom where you plan to use it. Open a film packet in the chairside darkroom. Lay the film on top of one of the jars and cover all but one portion of it. At 15-

to 30-second intervals, uncover another portion of the film until the last portion has been exposed for the set time interval. Develop the film in the normal fashion. After fixing, examine the film for fogging. If there is no fogging, it is safe to develop film at that location under the same light intensity conditions. If there is fogging, determine the length of time during which fogging developed and whether or not you can process films in less time at that location and light intensity. If the fogging occurred in a short time, the location or the amount of light needs to be changed.

LIGHTING AND MAGNIFICATION

Comments

- Whether doing detailed dental work or routine dental cleanings, adequate lighting is a must to see into the mouth, and magnification is often useful to improve visualization of dental lesions and performance during dental treatments.

Overhead Lighting

- There are several manufacturers of adjustable overhead lights.
- Some lights are on tracks and will provide an intense light that will cover the working area of the mouth.
- Some lights have variable brightness.

Advantages

- Is out of the way.
- Easily adjustable.
- Many models have lighter and smaller size lamps.

Disadvantages

- Need ceiling space.
- Banging head or dental x-ray unit if not pushed out of the way in a timely fashion.

Floor Model

- Many floor model lights are also available to provide additional lighting beyond regular room lighting. If a ceiling attachment isn't

workable over the dental table, a floor model may be necessary.

Advantages

- Can be used at various stations or tables in the clinic.
- Easily adjustable.

Disadvantages

- Take up additional floor space around dental work area.
- May be uncomfortably warm because closer to the operator.
- More likely to become an obstruction or head-bumping hazard.
- Electrical cord running on floor can be an obstruction or hazard.

Headlamp Light Source

- These small bright lights are worn on a headband or eyeglass frame, with or without optical magnification, to shine a bright light where ever the operator turns his or her head.

Advantages

- Portable.
- Does not take up ceiling space or floor space.
- Can easily direct light where desired by moving head and keeping hands in working area.

Disadvantages

- Models that don't use batteries require use of headband or glasses that are plugged into power source, which may limit movement in dental operatory.
- Headband style may become uncomfortable or glasses frame style may become undesirably heavy for some operators.
- Smaller area of illumination.

Fiberoptic Illuminated Handpiece

- High-speed handpieces have one or two bright lights located at the base of the cutting bur. These very effectively illuminate the exact portion of the tooth structure being altered. Some have the light bulb within the handpiece, and some have it located with the delivery system end of the handpiece tubing.

Advantages

- Pinpoint spotlighting of working area.
- Very bright illumination.
- Especially useful for aging clinician eyes and for treating caudal teeth.
- No encumbrance of wires, head gear, heavy glasses, patient positioning.

Disadvantages

- Small area of illumination.
- Increases the cost of handpieces and tubing.
- Additional light limited to use of high-speed handpiece only.
- Light bulbs, in some models, require changing and can be costly.

Magnification

- Magnification is extremely important in doing fine dental work and oral surgery. Several options are available from simple reading glasses to optical lenses attached to a glasses frame.

Reading Glasses

- These are inexpensive, available as half glasses or full glasses, and come in different powers (1.75× to 3×) to accommodate different visual needs.

Advantages

- Inexpensive.
- Can provide eye protection.
- Lightweight.

Disadvantages

- Higher magnification focal distance may be too close for ergonomic posture.
- May not provide sufficient magnification.
- Full-frame style alters distance vision unless glasses are removed. Limited peripheral vision.

Binocular Loupes and Lenses

- These lightweight plastic frames come in various styles. Some are flip-up lenses attached to plastic frames without lenses. Others are attached to a headband or glasses frames with an extension bar to vary the working distance.
- The frameless binocular lens style does not interfere with peripheral vision (1.75× to 3× magnification).

Advantages

- Flip-up models allow distance visibility easily, as well as lenses on extension bar.
- Lightweight.
- Inexpensive.
- Some styles can be worn over other glasses or safety glasses.

Disadvantages

- Some styles don't provide sufficient eye protection alone.
- Headband style can become uncomfortable for some operators.
- Styles with extension bar may require more head movement to get correct view.
- Extension bar can become loose and fail to hold position.

Optical Lenses

- These are small magnification lenses attached to the bottom of a glasses frame that give magnification when looking through the lenses for close-up work.
- Some models have a five-lens prismatic style giving 3.5×, 4.5×, or 5.5× magnification at working distances of 13, 16, 18, or 20 inches (High Q Dental, Scottsdale, Ariz.).

Advantages

- Provide eye safety as well as magnification. Some may come with light source. Some come with orange safety filter to protect eyes from cure lights.
- Smaller lenses allow for greater peripheral vision.
- Can be made to order with specifically desired working focal distance and magnification.

Disadvantages

- Greater expense.
- Cannot flip the lenses out of the way when not needed.
- Limited focal distance.

Magnifiers

- Handheld magnification devices allow magnification of flat surfaces such as radiographs, photos, or slides.

Advantage

- Allows magnification of radiographs, photos, etc.

Disadvantage

- Are not easily used while working in the mouth because they are handheld.

EQUIPMENT FOR PERIODONTICS**Sonic Scalers****Comments**

- Sonic scalers are used for gross calculus removal from teeth (Fig. 2-13, A).
- Inside most sonic scalers is a shaft that is connected to the air supply and tip.
- The vibration at the tip of the scaler is caused by air passing out of a hole in the shaft that spins a ring that encircles the shaft.
- The working tip has an elliptical type action similar to the stack-type inserts.
- A swivel attachment allows more freedom of movement.
- Frequency is 3,000 to 8,000 cycles per second at the working tip with an excursion of 1.0 to 1.5 mm.

Advantages

- Very little heat is created at the working tip when compared with some models of ultrasonic scalers.
- There is less chance of injuring the tooth with pulp hyperthermia.
- The user does not have to sharpen the instrument.
- The scaler performs a lavage function by irrigating and flushing while effecting calculus removal.
- A separate piece of equipment is not needed for tooth scaling when installed on a compressed air dental unit with high-speed and low-speed handpieces.

Disadvantages

- Conflicting reports exist regarding the relative strengths of the sonic and ultrasonic scaler. One study showed that some models of sonic scalers were as effective at calculus removal as ultrasonic scalers set at maximum power.⁴ However, another study claimed that the ultrasonic scaler cleared hard deposits of calculus faster.⁵ A 2000 review of studies comparing sonic, piezoelectric, and magnetostrictive scalers show nearly equivalent clinical results.⁶

- Some units must be cleaned and lubricated periodically.
- Sonic scalers have higher rates of breakdown than ultrasonic scalers.
- Sonic scalers with coiled tubing may have more fatiguing pull on operator's hand than lighter ultrasonic scaler handpieces.

Ultrasonic Scalers**Comments**

- The ultrasonic scaler has long been the mainstay of cleaning teeth in veterinary dentistry.
- Several types of ultrasonic scalers are available with several tip options for each type (Table 2-2).
- Numerous tips and inserts are available for magnetostrictive stack-type ultrasonic scalers (Table 2-3).
- Generally, the higher the frequency, the shorter the working time, and the smaller the excursion, the less trauma that is delivered to the surface of the tooth. Units come with either a foot pedal or handpiece activation and adjustments for tuning, power, and water spray.

Uses

- Removes gross calculus from the teeth.
- Ultrasonic periodontal debridement.
- Removes orthodontic bonding materials.

Advantages

- Rapid removal of tooth deposits.
- Durability.
- No need to sharpen instrument.
- Performs a lavage function by irrigating and flushing while effecting calculus removal.
- Broad tips available for heavy supragingival calculus removal, universal tips for general scaling.

Table 2-2 • TYPES OF ULTRASONIC SCALERS

Type of scaler	Type of action of working tip	Frequency (cps)	Excursion at tip (mm)
Magnetostrictive (Cavitron-like)	Figure-of-eight	25,000 or 30,000	0.8-1.1
Piezoelectric	Linear	≈45,000	0.2-0.4
Magnetostrictive ferrite rod	Circular	≈42,000	0.01-0.2

Table 2-3 • **ULTRASONIC SCALER TIPS (STACK-TYPE)**

Use and type	Parkell	Cavitron	Hu-Friedy
Supragingival beavertail	DBI25, DBI30	TFI-3, TFI-9	UI325K, UI330K
Supragingival universal	External water: DUE25, DUE30 or internal water: DUI25, DUI30	External water: 25KP-10, 30KP-10	External water: UI1025K, UI1030K or UI25KP10, UI30KP10
Subgingival straight	Internal water: DPI25, DPI 30 or external water: DPE25, DPE30	Internal water: slimline 25K or 35K SLI10S	Streamline internal water: UI25K100S, UK30K100S or After Five external water: UI25KSL10S, UI30KSL10S or After Five Plus: UI25KSF10S, UI30KSF10S
Subgingival curved	Internal water: left DPL25, DPL30 or right DPR25, DPR30	Internal water: slimline left 25K or 30K SLI10L, right 25K or 30K SLI10R	After Five external water: left UI25KSL10L, UI30KSL10L, right UI25KSL10R, UI30KSL10R or After Five Plus: left UI25KSF10L, UI30KSF10L or right UI25KSF10R, UI30KSF10R

- Newer models have optional micro tips (0.5 mm) for subgingival use and ultrasonic periodontal debridement.
- Some units can deliver medicated solutions subgingivally during scaling.

Disadvantages

- Heat production and possible injury to tooth with stack-type models.
- Expense of replacement tips, inserts, or rods.
- With improper use, can damage enamel.

Tip-Only Replacement**Comment**

- Some models are available in which only the tip needs to be replaced (Fig. 2-13, *B*). These are called piezoelectric scalers.

Advantage

- Replacement of piezo tips is about one half the cost of a whole leaf stack arrangement on a magnetostrictive unit.

Disadvantages

- Piezo tips, due to higher frequency of operation, suffer metal fatigue and require replacement twice as often as the magnetostrictive stack, although they are usually half the cost.
- May require entire handpiece to be repaired or replaced.

Rod or Stack Magnetostrictive Model Maintenance

- The nickel alloy leaves of the metal stack-type insert that come with Cavitron-like scalers should be inspected periodically for fracture and replaced if fractures are found (Fig. 2-13, *C*).

- The ferrite rod (Fig. 2-13, *D*) attached to the titanium working tip, although inexpensive and easy to replace, will break readily if dropped.
- The longevity of any of the tip parts for all the units can be increased by adjusting the power of the unit during the procedure and using only the energy required for that particular portion of the task. Some are self-tuning.

Calculus Removal Forceps**Comment**

- Calculus removal forceps are specially designed forceps used for the removal of gross calculus (Fig. 2-13, *E*).

Advantage

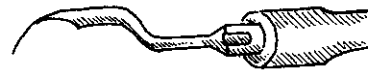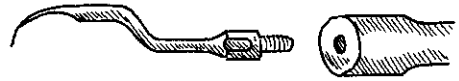- Quick removal of large pieces of gross calculus.

Disadvantages

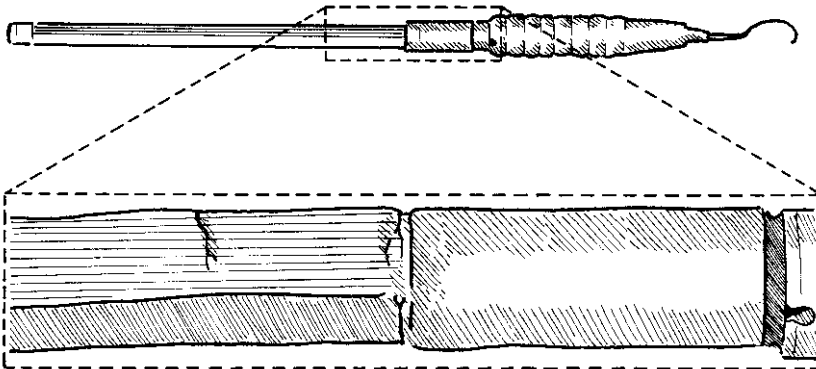
- Remove only large deposits of supragingival calculus (and are only one of the first steps of a complete and thorough prophylaxis).
- Can damage the crown, enamel, or gum tissue if used improperly.



A



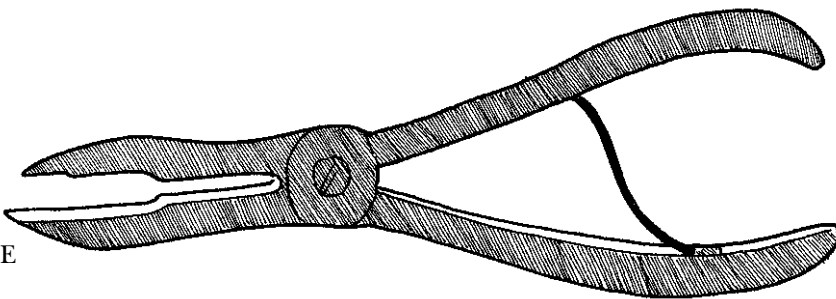

B



C



D



E

Fig. 2-13

Large Hand Instruments

Dental Hoe (Chisel)

Comment

- The working tip is a wide, chisel-like blade (Fig. 2-14, *A*).

Use

- Supragingival gross calculus removal.

Advantage

- Strong instrument.

Disadvantage

- For removal of large deposits only, not for removal of subgingival or small calculus and plaque.

Dental Claw

Comments

- The dental hoe and claw were once the mainstay hand instruments of veterinary dentistry.
- The claw is a large, thick, sickle-shaped universal scaler (Fig. 2-14, *B*).

Use

- To break off large pieces of supragingival gross calculus.

Advantage

- Removal of gross calculus in absence of sonic or ultrasonic scalers or calculus-removing forceps.

Disadvantages

- Slow speed.
- Some hand strength required.
- Potential damage to the tooth and gingival structures.

Fine Hand Instruments

- The selection of a particular curette or scaler is a matter of personal preference.
- If you do not like a particular instrument, do not replace it with the same one.
- Even if properly used and sharpened, these instruments need to be replaced periodically.
- Most veterinary tooth cleaning can be done with sonic or ultrasonic scalers.
- Hand instrument use should always follow mechanical scaling. Hand scalers are used to remove fine particles of calculus supragingivally, such as the developmental groove of carnassial teeth, while curettes can be used to remove fine calculus supragingivally and for subgingival scaling and root planing.
- Hand scaling requires special training to avoid fatigue and repetitive stress occupational injuries. A combination of hand scaling and mechanical scaling is desirable in veterinary medicine.
- Fine instruments are best stored in specific instrument trays, or protected by tip covers, to avoid damage to the working tips.

Options

Comments

- Curettes and scalers are made of carbon steel or stainless steel.
- Dry storage of dental instruments is an accepted procedure in human dentistry.

Carbon steel**Advantage**

- Carbon steel instruments maintain a sharper edge than stainless steel instruments, provided they are kept rust free.

Disadvantage

- Carbon steel instruments rust and become brittle if left for extended periods in water containing cold disinfecting solutions or if steam autoclaved without a rust inhibitor.

Stainless steel**Advantage**

- Stainless steel instruments are rust resistant.

Disadvantage

- Stainless steel instruments become dull if left in disinfecting solutions and do not maintain as sharp an edge as carbon steel.

Replaceable tips**Comment**

- Some manufacturers make hand instruments that have a cone socket handle and removable tips (Fig. 2-14, C).

Advantages

- The tips rather than the entire instrument are replaced when the tip is worn down or broken.
- The operator can select different tips for each end of the instrument and customize the instrument.

Disadvantage

- Instruments with replaceable tips are generally expensive to purchase initially.

Handle design and size**Comments**

- Handles for scalers and curettes come in various styles, weights, and widths.
- Some instruments have color-coded rubber grips or color-coded handles.
- Hollow #4 handles are lightweight and slightly wider than the standard #2 handle.
- Even wider handles are available from some manufacturers.

Advantages

- Color coding of grip or handle allows for quick identification of instrument.
- Rubber or textured grips minimize slipping and widen grip.
- Wider, lighter handles are more ergonomic to reduce hand strain and fatigue with frequently used instruments.

Disadvantages

- Rubber grips can degrade over time with repeated sterilization.

Single instrument or instrument kits**Comments**

- Several canine and feline instrument kits are available that include a probe-explorer, dental mirror, several scalers, and several curettes, sized for each species, in an autoclavable instrument tray.
- They may have color coding and guides for instrument use.

Advantages

- Good starting point to learn differences between types of instruments and where they are best used.
- Having the tray keeps them separate from other instruments and easily autoclavable.

- Get the variety of instruments necessary to work in all areas of the mouth.

Disadvantages

- May be greater initial cost than those in a practice want to purchase.
- May have instruments that an operator doesn't prefer.
- Quality may vary from individual instrument companies.

Scalers

Comments

- The blade of a scaler is triangular and tapers to a pointed tip, with two parallel cutting edges (Fig. 2-14, *D*).
- There are a variety of configurations of the working tip for use on different tooth surfaces and sizes.
- Having a selection of several types is useful in working on the different tooth sizes and shapes in veterinary dentistry.

Use

- Scalers are used for supragingival scaling. They are used in a pull stroke away from the gingiva.

Advantages

- The angulation of a scaler is convenient for supragingival scaling.
- The pointed tip may be used to remove calculus from grooves, pits, and fissures and interproximal areas (Fig. 2-14, *E*).

Disadvantage

- Because of the shape and sharp tip, the scaler should not be used below the gum line. It can distend and lacerate soft tissues.

Types

- Some instrument companies have their own identification systems and these are noted along with the more common instrument numbers and names.

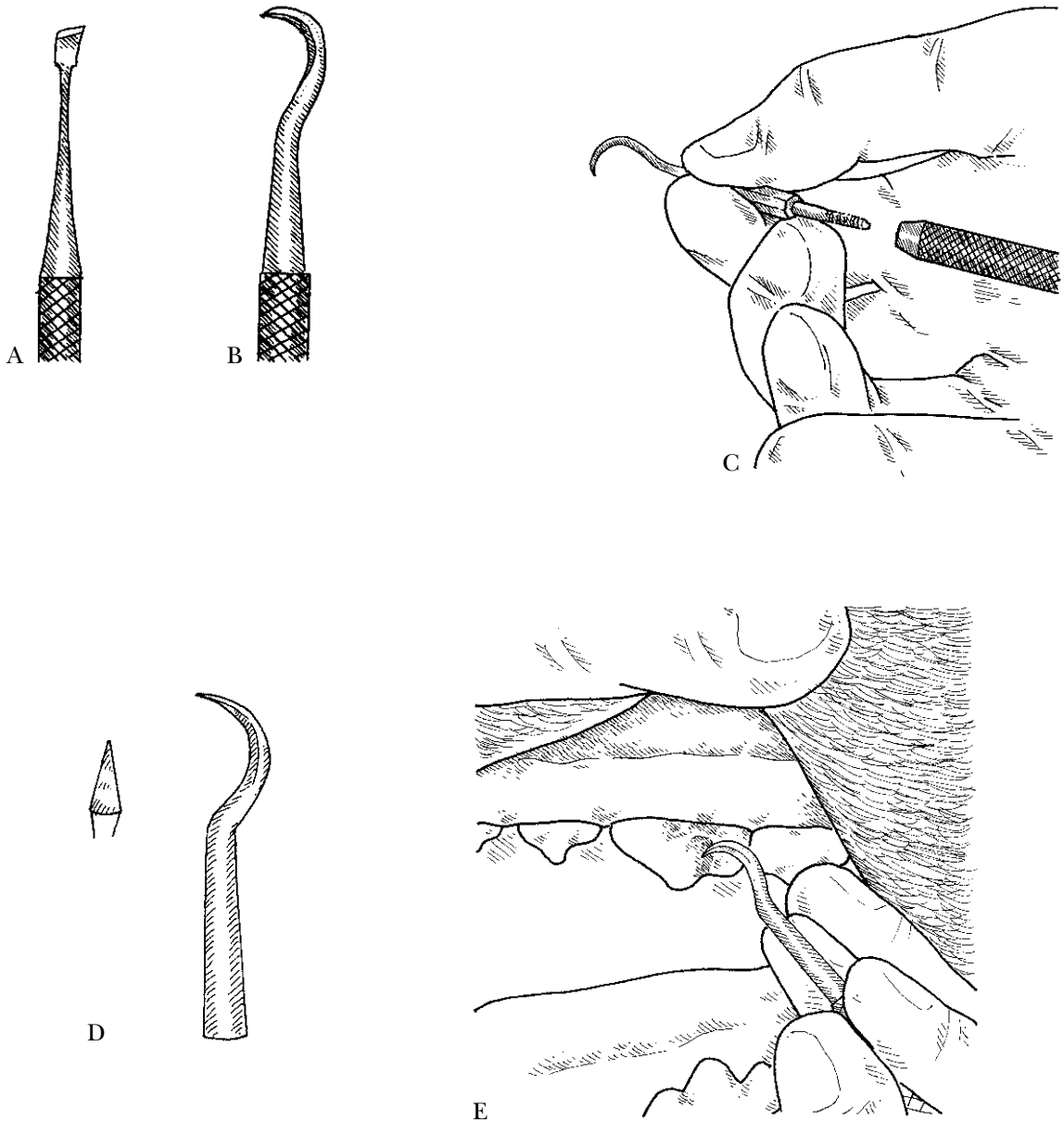


Fig. 2-14

Jacquette 2Y-3Y scaler (P4)

- Has medium blade, acute round angle at the blade, and no shaft; the blade is slightly longer than that of the Morse 0-00 (P series, Cislak Manufacturing, Glenview, Ill.) (Fig. 2-15, A).

N135 scaler (P5)

- Has medium shaft, thin blade with sharp curve, good for supragingival interproximal work between incisors or between maxillary fourth premolar and first molar (Fig. 2-15, B).

H6-H7 or N6-N7 scaler (P11)

- Long, sickle-shaped blade of medium thickness (Fig. 2-15, C).

Morse 0-00 scaler

- Has no angle; very thin, short blade; acute 90-degree angulation (Fig. 2-15, D).
- Good scaler for use on teeth of cats and small dogs.

Maintenance

- To remain functional, a scaler must be kept sharp. Sharp scalers fracture, cleave, and remove calculus; dull scalers ineffectively crush and burnish calculus.
- Ideally, hand instruments should be sharpened between each use.

Curettes**Comments**

- Curettes have two sharp working edges, a flat face, and a rounded back (Fig. 2-15, E). They consist of a blade, toe, terminal shank, shank, and handle (Fig. 2-15, F).
- Looking end-on, they have a half-moon shape.
- Short-shanked instruments are particularly useful in cats and small dogs. Long-shanked After Five (P46-P52) curettes are designed for periodontal pockets greater than 5 mm and are particularly useful on the palatal side of dog canines that have periodontal disease. Mini Five curettes (P19, P24, P26-P29) have a reduced blade length and are ideal for use in narrow periodontal pockets or on cats, because they also have a fine blade (After Five and Mini Five, Hu-Friedy Manufacturing, Chicago, Ill.; P series, Cislak Manufacturing).
- Curettes are double ended with the same blade type, one end going to the left and one going to the right, so that the instrument can be manipulated easily for accessing all sides of a tooth.
- Curettes are designed in universal or area-specific styles based on how the blade is attached to the terminal shank (Fig. 2-15, G). Universal instruments can be used on all teeth. In area-specific curettes of individual styles, as the numbers of the

curettes increase, their use is designed for teeth progressively farther back in the mouth. This does not necessarily hold true for universal instruments.

Uses

- Removing fine calculus and plaque above and below the gum line.
- Subgingival curettage and root planing.

Advantage

- The rounded tip and back are less traumatic to soft tissue than scalers, and adapt easily to root surfaces.

Disadvantages

- The rounded tip may not reach all gingival crevices.
- If used improperly, may break or cause tissue damage.

Types

Universal curettes

- Can be used throughout the mouth; thus, they are “universal.”
- Although the anatomy varies from humans to animals, this general concept is still valid.
- Either side of the blade can be used on the tooth surface, although the angulation of the

blade when placed on the tooth surface may vary between sides.

Columbia 13/14 curette (P10)

- Has short shank, medium-to-thin blade, and medium curve (Fig. 2-15, *H*).

Barnhart 5/6 curette (P8, smaller version P-36)

- Has short shank, medium blade, and small-to-medium curve (Fig. 2-15, *I*).

Columbia 3/4 curette

- Has medium shank, medium blade, and small-to-medium curve (Fig. 2-15, *J*).

Posterior curettes

- Have a longer terminal shank with more bends for interproximal access.

4R-4L curette (P37)

- Has a medium shank, medium blade, and medium curve, primarily for posterior teeth.

2R-2L curette

- Has a long shaft, medium blade, and medium curve; fits shape of canine teeth, primarily anterior teeth.

Barnhart 1/2 curette

- Has a long shaft, thin blade, and medium curve; good for root planing in tight fits.

Gracey curettes

- These curettes are area specific; 1-2, 3-4, (P-22) 5-6, 7-8, (P23) 9-10, 11-12, (P20) 13-14, (P21) 15-16, 17-18 (P22, P23, P20, P21).
- Lower numbers are for incisors and canines, while higher numbers for instruments used on caudal teeth.
- Only one side of the blade is used on the tooth surface, which is the lower side when viewed with the terminal shaft vertical and the working end viewed end on. This angulation allows for a flatter entry into periodontal pockets.

Periodontal files*Comments*

- Periodontal files are available in several shapes to be used for cleaning and smoothing root surfaces in periodontal pockets (HF 3/7, HF 5/11, HF 9/10, Cislak Manufacturing).

Advantage

- Can provide better cleaning and smoothing ability in deep narrow pockets and furcation areas.

Disadvantages

- Having another instrument in tray for specific use only.
- Difficult to sharpen, need to be replaced once dull.

Cleaning and care of scalers and curettes

Step 1—The instrument should be washed with a disinfectant soap to remove all debris.

Step 2—The instrument should be dried.

Step 3—The instrument is sharpened (see the following section, Sharpening Scalers and Curettes).

Step 4—The instrument is soaked in a disinfectant solution, autoclaved, dry sterilized, or gas sterilized.

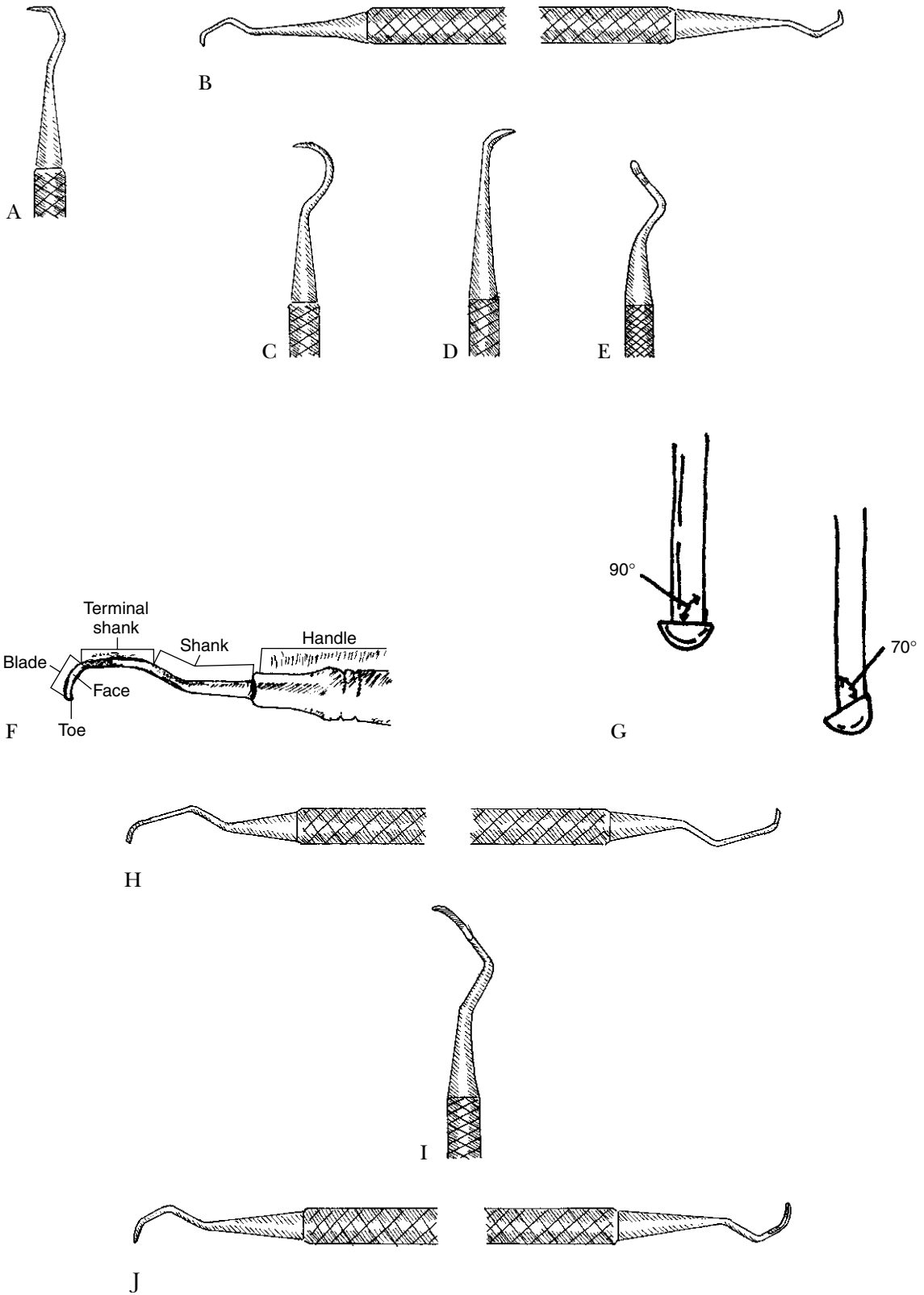


Fig. 2-15

Sharpening scalers and curettes**Objectives**

- Remove as little of the instrument as possible.
- Obtain sharp edge.
- Retain original design of the instrument.
- With scalers, both blade edges are sharpened. With universal curettes, one edge is sharpened as the cutting edge. Gracey or area-specific curettes have only the one cutting edge sharpened.

Materials: sharpening stones

- Sharpening stones are used to restore the cutting edge on a dull instrument without changing the original design of that instrument.⁷
- The coarser the stone, the faster the sharpening, and the rougher the edge.
- Fine stones are used for sharpening only slightly dull instruments and for finishing sharpening to remove rough edges or flash.
- Coarse stones are used for dull instruments and for reshaping.

Arkansas stones*Comments*

- Fine white stones.
- Used with oil.

Advantages

- Give a fine finish.
- Relatively little of the instrument is reduced.

Disadvantage

- May be slower, in performance, if used to recontour the instrument.

Maintenance

- Should be wiped clean after use.
- May be cleaned with routine soaps or detergents.
- May be autoclaved.

India stones*Comments*

- Fine or medium in coarseness.
- Used with oil.

Advantage

- Can sharpen excessively dull instruments.

Disadvantage

- May wear the instrument away excessively if used for routine sharpening.

Maintenance

- After use, should be wiped clean.
- May be cleaned with routine soaps or detergents.
- May be autoclaved.

Ceramic stones*Comments*

- Made from compressed glass.
- Used with water or dry.
- Fine to medium in coarseness.

Advantage

- Do not create mess, as does oil.

Disadvantage

- Expensive.

Moving flat stone technique**Advantages**

- Easiest technique to learn.
- Good visibility of sharpening surface.
- Sharpens side of instrument, maintaining strength (Fig. 2-16, A).

Disadvantage

- Some operators prefer stationary stone technique.

Materials

- Stone oil.
- Sharpening stone.

Technique for curettes

Step 1—A drop of oil is placed on an India or Arkansas sharpening stone (Fig. 2-16, B).

Step 2—The oil is distributed over the face of the stone by wiping with a tissue (Fig. 2-16, C).

Step 3—The instrument is held vertically over the side of a table with the edge to be sharpened down (Fig. 2-16, D) so that the face of the blade is parallel to the floor.

Step 4—The stone is placed so that the open angle between the face and stone is 110 degrees (Fig. 2-16, E). This creates a 70-degree angle between the face and side of the blade. The stone is drawn up and down to sharpen the blade while maintaining this angle.

Step 5—The sharpening sequence always ends on the downstroke so as not to leave a rough edge.

Step 6—The blade of the opposite tip is sharpened in a similar manner.

Step 7—With curettes the stone is brought around to the toe, continuing the up and down action for a few strokes, to keep the toe blunt.

Technique for scalers

Steps 1 through 3 are the same.

Step 4—The stone is placed against the side of the blade and moved up and down several times.

Step 5—The other side of the blade and the other working end are sharpened similarly.

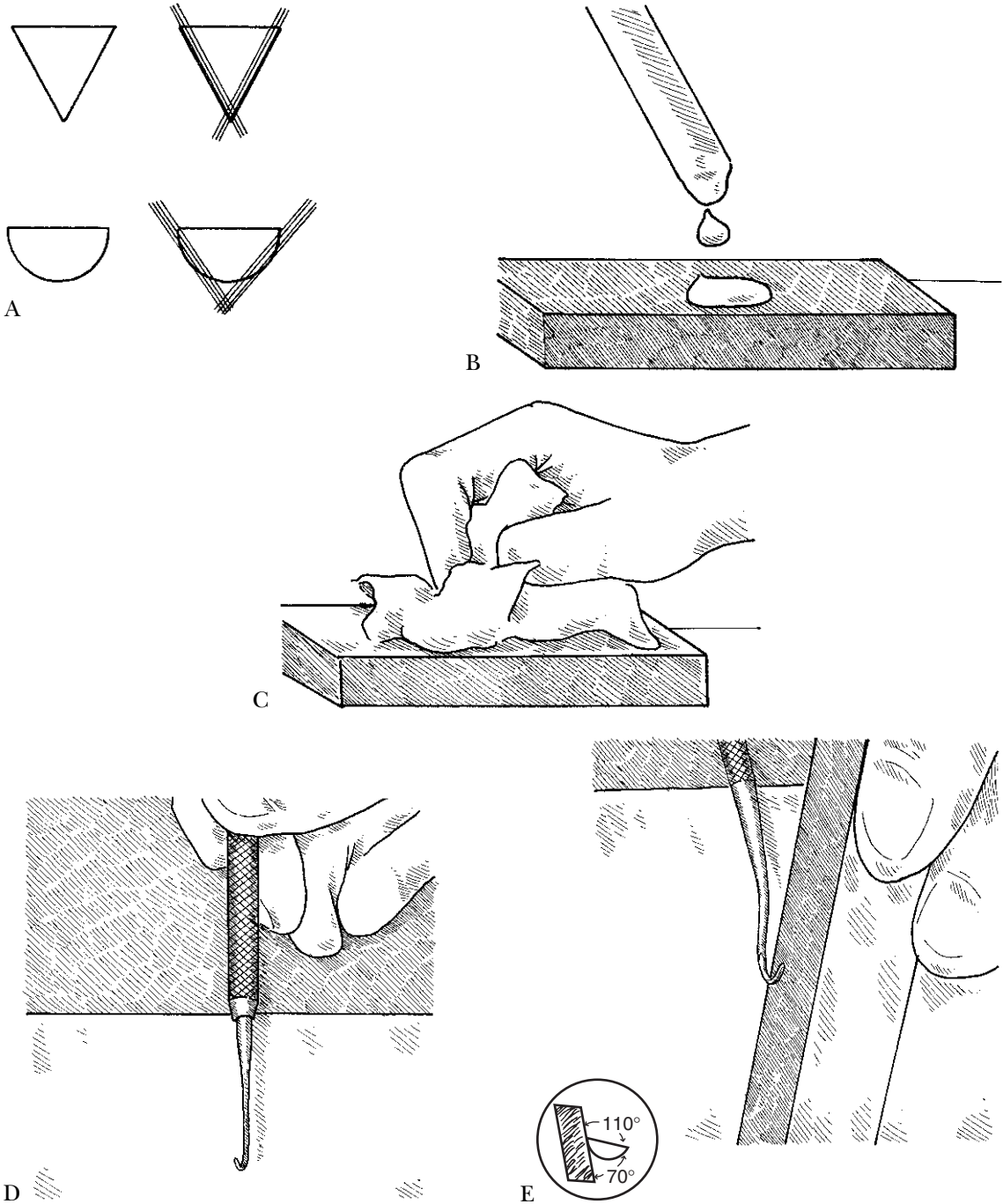


Fig. 2-16

Stationary flat stone technique**Comment**

- A sharpening aid with a stone and disc with guides for use with different scalers and curettes can make this technique consistent each time the instruments are sharpened (Premier Dental Products).

Advantage

- Once learned, may be the fastest technique to perform.

Disadvantage

- Takes time and practice to use this technique effectively.

Materials

- Stone oil.

Technique for curettes

Step 1—The stone is oiled as with other techniques.

Step 2—The stone is placed flat on a table and is held by hand (Fig. 2-17, A).

Step 3—The instrument is held in the opposite hand with a modified pencil grip (Fig. 2-17, B). The index finger and thumb hold the instrument while the middle, ring, and little fingers act as a guide and slide along the table. The blade to be sharpened is positioned with the face of the instrument opened at a 110-degree angle to the stone. The cutting edge is formed between the face and side of the blade, and that angle should be between 70 and 80 degrees. The instrument is moved back and forth on the stone while keeping the blade at this constant angle.

Technique for scalers

Steps 1 and 2 are the same.

Step 3—The scaler is held in the opposite hand with a modified pencil grip. The index finger and thumb hold the instrument while the middle, ring, and little fingers act as a guide and slide along the table. The side of the scaler to be sharpened is positioned so that the side of the tip is against the stone and moved back and forth several times.

Step 4—The other side of the blade and the other working end are sharpened similarly.

A variation of this technique is employed when a mechanical sharpening system is employed, such as the Rx Honing System (see below).

Conical stone technique**Advantage**

- Less skill is involved in using a conical stone.

Disadvantages

- Decreases the strength of the instrument by decreasing the body of the blade, whereas the other techniques remove sides but keep the thickness (Fig. 2-17, C, see Fig. 2-16, A).
- Changes the angle between the face and side of the blade of a curette.

Materials

- Stone oil.

Technique for curettes

Step 1—A small amount of stone oil is placed on the stone (Fig. 2-17, D).

Step 2—The stone is wiped with a tissue (Fig. 2-17, E).

Step 3—The stone is placed on the face of the instrument and is rotated and, at the same time, rubbed along the face toward the tip (Fig. 2-17, F). One to three rotations over the face of the blade are made to remove excess flash or uneven edges.

Technique for dental elevators (winged) and luxators

Step 1—A drop of oil is placed on the stone and wiped with a tissue.

Step 2—The concave side of the luxator or winged elevator is placed at a slight angle (30 degrees) to the stone, matching the diameter of the instrument tip to the width of the stone, and moved back and forth several times (Fig. 2-17, G). (For wider working tips, a cylindrical stone can also be used in a similar manner.)

Mechanical honing set: Rx honing system (Rx Honing Machine, Mishawaka, Ind.)**Comments**

- It uses a system of rotating flat stones of various coarseness and conical stones specially shaped that rotate on a mandrel.
- The system comes complete with video and written instructions and with stabilizing guides to ensure that hand instruments are held at the proper angle for maximum sharpening, and has accessories that enable the sharpening of scalers, curettes, elevators, luxators, scissors, biopsy punches, electric clipper blades, and knives.

Advantages

- Positioning devices keep sharpening uniform for each instrument type.
- Rapid sharpening.
- Ability to sharpen a variety of instruments easily.

Disadvantages

- Takes up more counter space.
- Cost.

For many people, instrument sharpening can be difficult and time consuming. Professional sharpening services are offered by many instrument companies and may prove to be economical alternatives to hand sharpening.

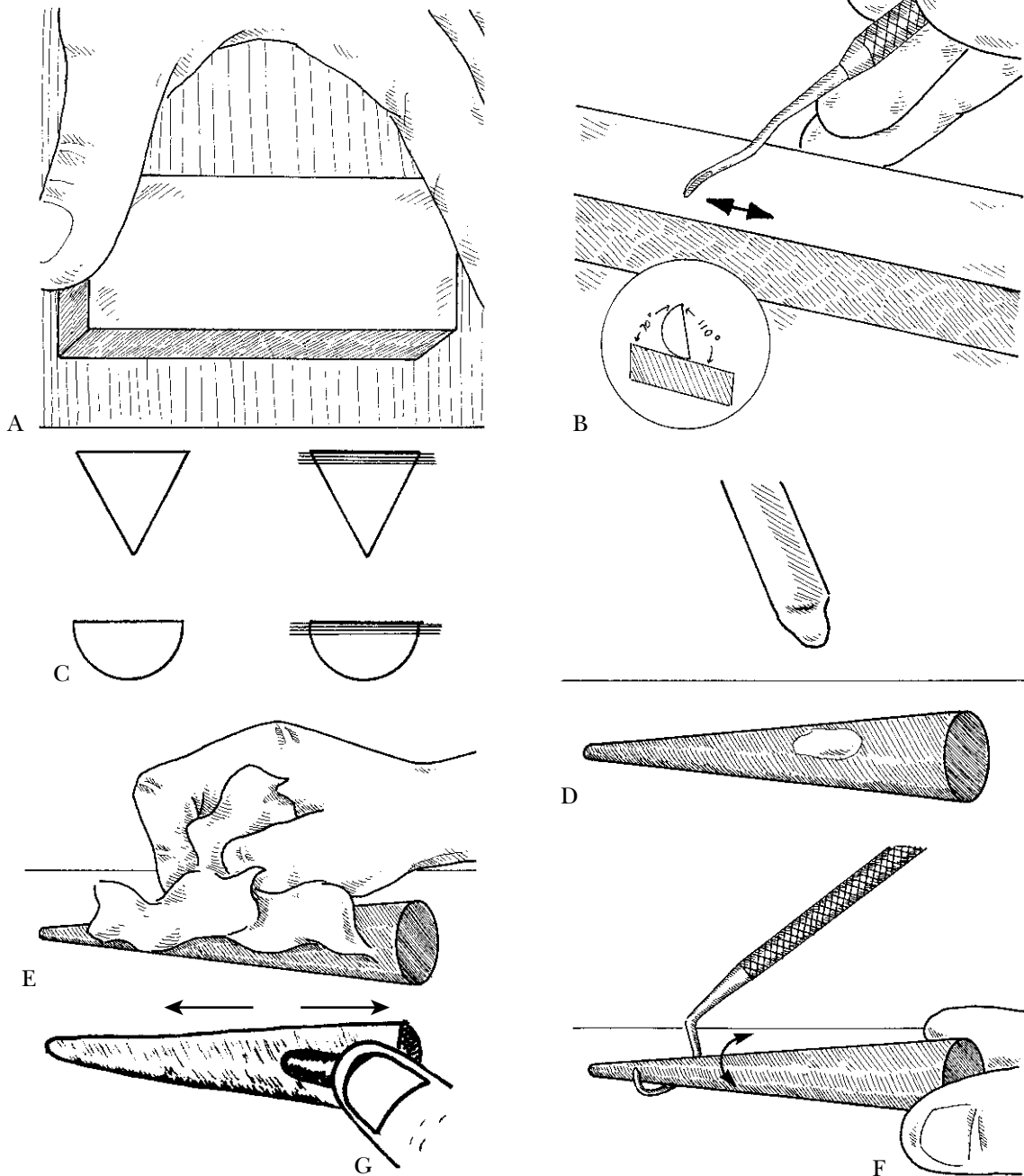


Fig. 2-17

Instruments for Periodontal Diagnosis

Periodontal Probes

Comments

- Are either notched, or have color-coded calibrated notches or bands. They may be single ended or double ended in combination with another type of probe or explorer.
- May be contra angled for more accurate reading on the distal side of teeth.

Use

- Measure gingival recession and periodontal pocket depth, allowing the evaluator to estimate epithelial attachment level.^{8,9}

Advantage

- Can be used to measure the degree of periodontal disease.

Disadvantage

- If used improperly, probes can damage epithelial attachment, especially because diseased tissues are more friable.

Types

Notched probes

Comments

- Are generally notched in millimeters.
- Are either flat or round; flat probes are easier to fit into a thin sulcus; round probes are easier to see at different angles.
- Goldman Fox and Williams probes have notches at 1-2-3-(skips 4)-5-(skips 6)-7-8-9-10 mm (Fig. 2-18, A).

Advantage

- The notch is a clear indication of depth. (The colored notch probes are easier to read than the plain probes. Intervals of 3 mm are easier to read accurately than 1-mm calibrations.)

Disadvantages

- May not be as easy to read as color-coded probes.
- Flat probes may be more susceptible to breakage.

Color-coded probes

Comments

- Have color-coded bands.
- Come in 10-, 11-, and 12-mm lengths.
- The 3-, 6-, 9-, and 12-mm readings are popular markings (Fig. 2-18, B).

Advantages

- The longer probes may record deeper pockets.
- Color-coded probes are often longer and easier to see at different angles than are the flat probes.

Disadvantage

- Color coding may wear off in time or when cleaned with ultrasonic cleaning machines; some probes are guaranteed never to lose color (Cislak Manufacturing).

World Health Organization pressure probe

- This probe mechanically closes a gap once 20 grams of pressure in the gingival sulcus occurs.
- The closure of the gap on the head of the instrument can be visualized by the person charting the patient (Fig. 2-18, C). Twenty grams of pressure should be sustained in a healthy gingival sulcus before bleeding occurs. This probe comes color coded in a variety of millimeter patterns.

Advantage

- Enables charting uniformity among staff members in measuring gingival bleeding indices.

Disadvantage

- Made of plastic and is more bulky than some of the metal instruments.

Periodontal Explorers

Comments

- Explorers are used to examine the tooth and detect abnormalities through the senses of touch and hearing.¹⁰
- Of the several types of explorers available, the most common is the Shepherd hook (#23) (Fig. 2-18, D).
- The #17 explorer is shown in Fig. 2-18, E. This explorer is particularly useful in determining the adequacy of a surface restoration preparation.

- The finer, more delicate tips allow greater tactile sensitivity.
- More flexible steel helps tactile sense.

Use

- Explorers are used subgingivally to detect calculus and supragingival and subgingival surface irregularities, to assess tooth mobility, to evaluate root smoothness,¹¹ to check for tooth caries, exposed pulp in worn or fractured tooth crowns, and to detect odontoclastic resorptive lesions supralingually and subgingivally.

Advantage

- Ability to easily detect decayed soft dental areas, open pulp chambers, subgingival calculus, and surface irregularities with minimal equipment.

Disadvantage

- Improper use may result in damaged tissue.

Mirrors

Comments

- Dental mirrors are usually attached to handles for easier access and extension.
- Some mirrors come with light sources attached.
- Mirrors are supplied in several diameters, most commonly from $\frac{3}{4}$ to $\frac{15}{16}$ inch. Some are very small, such as endodontic retrograde mirrors that can be as small as 2 mm (Fig. 2-18, *F*).

Uses

- Mirrors are used for direct vision of the far side of a tooth; for retraction of lips, cheeks, and tongue; and for illumination.
- Mirrors may be used for transillumination to detect caries.
- Large mirrors are used for intraoral photography in hard-to-visualize places.
- Patient saliva on the mirror or warming the mirror may prevent fogging.

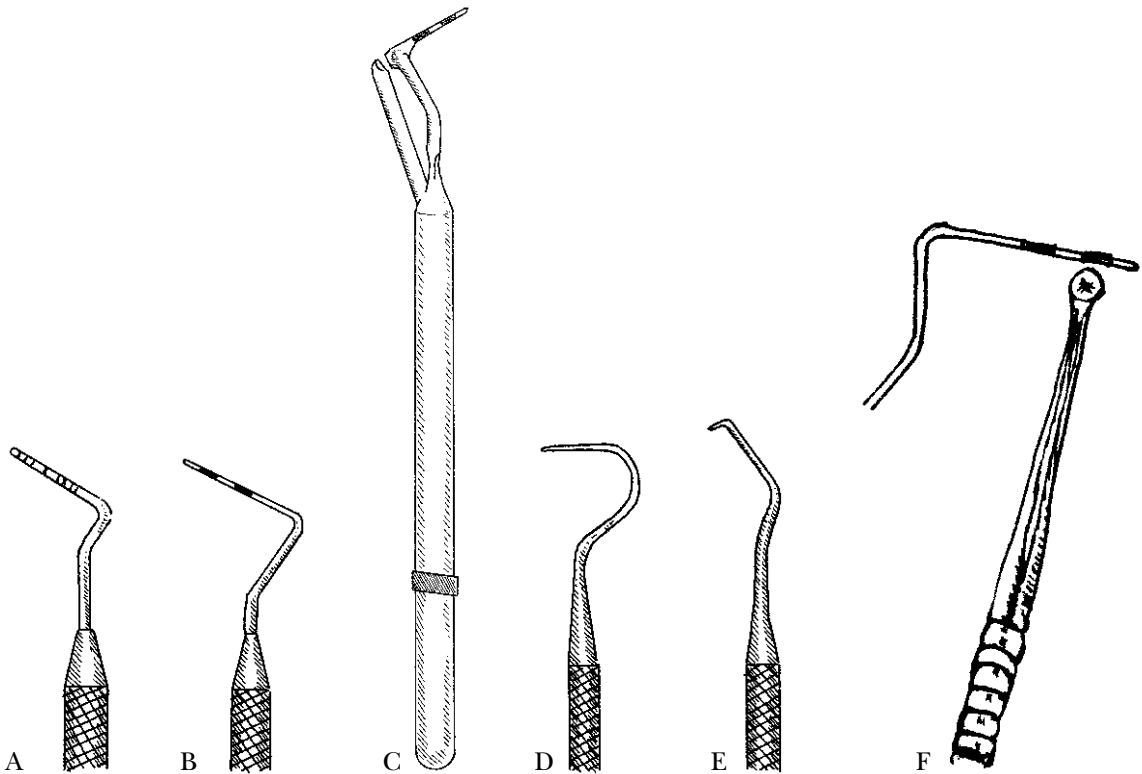


Fig. 2-18

Instruments for Periodontal Surgery

- With a few additional instruments, the general veterinary surgical pack can be adapted for periodontal surgery.
- Necessary instruments are periodontal knives, dental periosteal elevators, curettes, and chisels.
- These instruments should be as delicate as possible to allow atraumatic manipulation of tissues.
- Shorter, or even ophthalmic, needle holders, suture scissors, and thumb forceps will facilitate gentle handling of oral tissues.

Scalpel Blades

Comments

- Generally, smaller blades are more useful for periodontal surgery.
- A #3 scalpel handle is used with these blades.
- A 360-degree blade handle or round handle can also be used for easier manipulation in tight areas (Hu-Friedy Manufacturing; Cislak Manufacturing).

Types

Number 11

Comment

- The #11 blade has a sharp, triangular point (Fig. 2-19, A).

Uses

- Stab-type incisions.
- Delicate sulcular incisions, and to sever the epithelial attachment in extractions.

Advantage

- Sharp, pointed tip.

Disadvantage

- Pointed tip may not give as much control as other blades.
- The tip is also more delicate and subject to breakage.

Numbers 12 and 12B “hawk-billed”

Comments

- Both have hook-type tips.
- Number 12 has a cutting surface on the inner side only (Fig. 2-19, B).
- Number 12B has a cutting surface on both sides.

Uses

- Both may be used with a lifting (pulling) motion that places tension on the tissue, giving increased stability.
- Both provide interdental access.
- Number 12B may be used for pulling or pushing.

- Both may be used for flap, mucogingival, and graft operations; gingivoplasty; and gingivectomy.

Advantage

- Getting to distal surfaces that may not be otherwise easily reachable with #11 or #15C blades.

Disadvantage

- Tip may get locked in bone and be subject to breakage.

Number 15

Comment

- Thin blade (Fig. 2-19, C).

Uses

- Sulcular incisions, and in extractions to sever the epithelial attachment.
- Mucogingival surgery.

Advantages

- Finer blade than that of the larger small animal veterinary blade (#10).
- Costs less than #10 blade.

Disadvantages

- May break if used for heavy duty work.
- Becomes dull more quickly than #10 blade.

Number 15C

Comment

- Thinner, drop-point design, initially sharper blade than that of larger #15 (Fig. 2-19, D).

Uses

- Sulcular incisions, especially in the cat and small dog breed extractions, to sever the epithelial attachment.
- Feline and small dog breed mucogingival surgery.

Advantages

- Allows for finer work.
- Costs less than #15 blade.

Disadvantages

- May break if used for heavy duty work.
- Becomes dull more quickly than #15 blade.

Surgical Knives

Comment

- Various angles and shapes are available.

Use

- Periodontal surgery.

Advantages

- The angulation of the surgical knives gives flexibility and ease of cutting soft tissue.

- Thicker than scalpel blades; can be used for reflection.

Disadvantages

- The blades must be kept sharp, a skill that takes practice.
- Isolated storage must be provided for these delicate instruments.
- The blades can be damaged easily by inexperienced clinicians.

Types

Orban knife

Advantage

- Good for interproximal removal of tissue (Fig. 2-19, *E*).

Kirkland knife

Advantage

- Good for removal of large amounts of firm, fibrous tissue (Fig. 2-19, *F*).

Disadvantages

- Must be kept sharp.
- Cannot be used for fine, delicate procedures.

Maintenance: sharpening technique

Step 1—The sharpening stone is placed flat on a table and oiled as described in the earlier section titled Sharpening Scalers and Curettes.

Step 2—The edge of the blade is held at 15 to 25 degrees to the stone (Fig. 2-19, *G*). The wrist is rotated so that the blade edge moves along the stone to sharpen the tip.

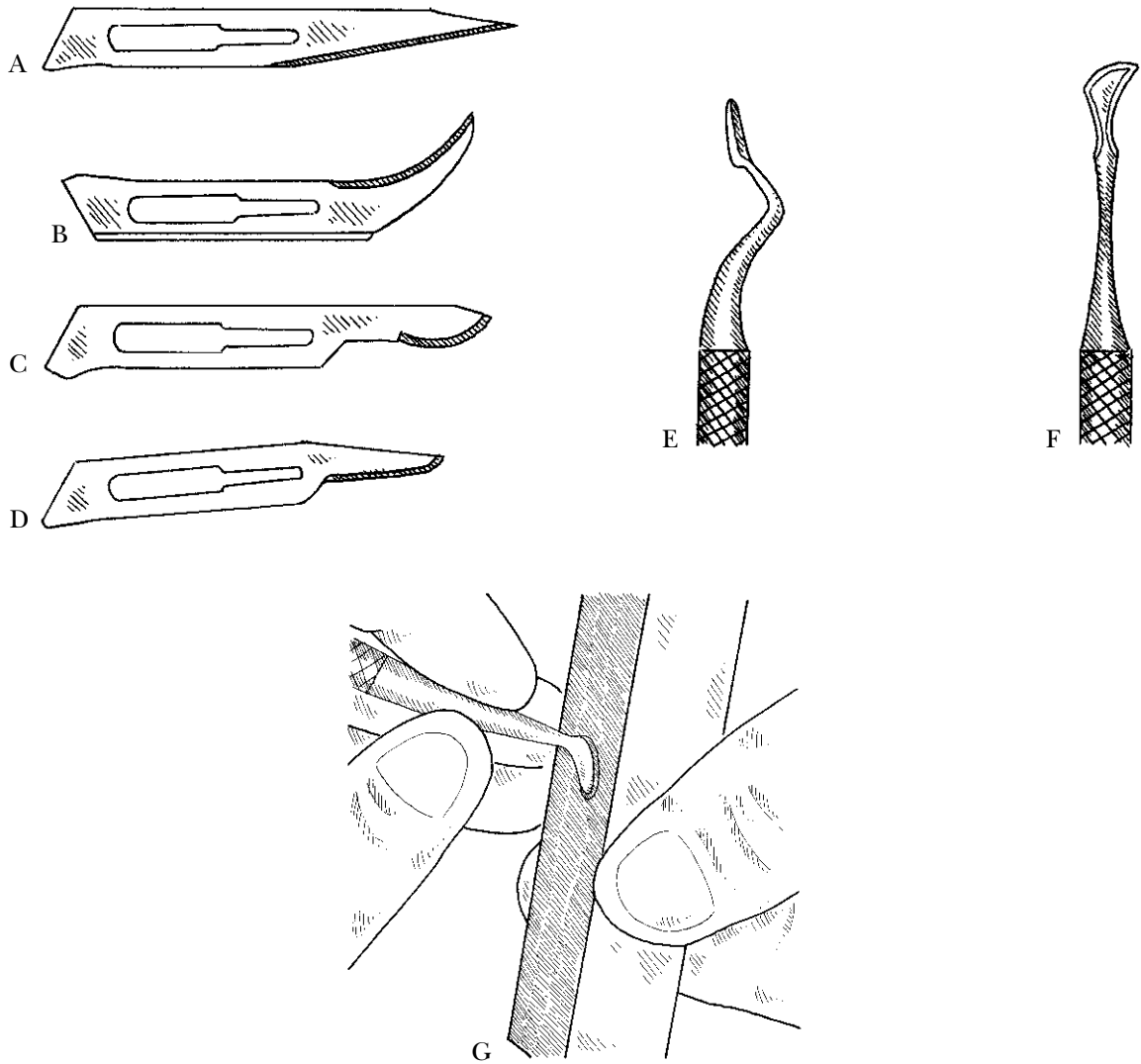


Fig. 2-19

Periosteal Elevators

Comment

- The blade shapes include rounded, straight, and sharp points.

Uses

- Reflect and retract mucoperiosteum after initial incision of gingival tissue.
- Elevate split-thickness or full-thickness mucogingival and palatal surgical flaps.
- Blade portion is used with the convex side against the soft tissue, reducing the chance for tearing or puncturing the gingiva.
- It is important to have several sizes of periosteal elevators for use in different size patients and types of procedures.

Types

- Molt #9 (EX-1) (Fig. 2-20, A)
- A #7 wax spatula looks similar to Molt #9 but is more delicate and achieves better access to the periodontal space. This small instrument is less expensive than the Molt #9, and the spoon-shaped end is a favorite to be used as a retractor to protect soft tissue from damage by cutting burs. The pointed end of either the #7 or #9 is used effectively to stretch and sever the periodontal fibers during extractions in medium and large dog breeds.
- Molt #4 (EX-21) (Fig. 2-20, B).
- Molt #2 (EX-20) (Fig. 2-20, C).
- Pritchard (PR-3) (Fig. 2-20, D).
- ST 7 (Sp-7 [Cislak Manufacturing]) (Fig. 2-20, E).
- Goldman Fox #14.
- Freer or mini Freer.
- EX 9 or EX 7 Feline Periosteal elevator (EX and PR series, (Cislak Manufacturing,)) (Fig. 2-20, F).

Maintenance

- Sharpening as with other sharp instrument.

Ochsenbein Periosteal Chisel

Comments

- These instruments have a sharp chisel shape blade at an angle to the handle (Fig. 2-20, G).
- Single or double ended.

Uses

- Useful for larger gingival, mucosal, and palatal flaps.
- Reshaping or removing bone.

Advantage

- Less aggressive than rongeurs or burs for bone removal.

Disadvantage

- Can tear tissue if not used properly.

Surgical Curettes

Comment

- Thicker and wider than other curettes, with a less flexible shank.

Use

- Removal of hard deposits, granulation tissue, necrotic cementum, and fibrous interdental tissue.

Advantage

- Stronger than other curettes; less likely to break.

Disadvantage

- Bulkier than other curettes; may not allow access into small areas.

Surgical Scissors

Goldman Fox #15

Comments

- Sharp-sharp scissors, with one serrated blade. Comes in straight or curved format.
- Curved format depicted here (Fig. 2-20, H).

Use

- Enlarging initial incisions, trimming tissues, and incising muscle attachments.
- Very useful in creating or expanding releasing incisions.

La Grange scissors

Comment

- Sharp-sharp scissors that have S-shaped, double-curved blade and handle (Fig. 2-20, I).

Advantage

- Better accessibility to osseous side of flap.

Tissue Retractors

Minnesota retractor

Comment

- Used for retraction of lips, tongue, or cheeks (Fig. 2-20, J).

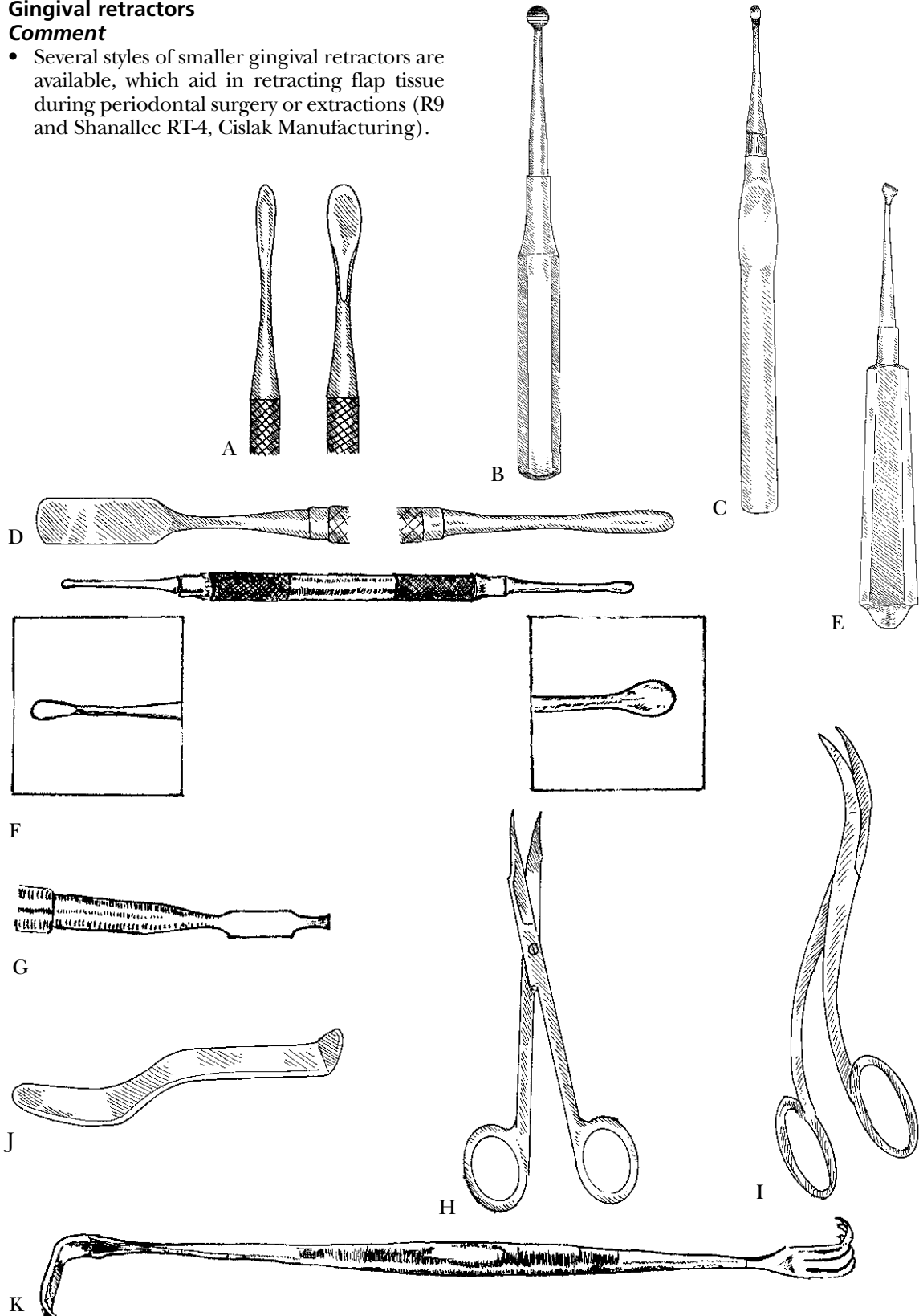
Senn retractor

Comment

- Comes with sharp or blunt teeth, single ended or double ended with a blunt blade opposing the rake end (Fig. 2-20, K).

Gingival retractors**Comment**

- Several styles of smaller gingival retractors are available, which aid in retracting flap tissue during periodontal surgery or extractions (R9 and Shanallec RT-4, Cislak Manufacturing).

**Fig. 2-20**

INSTRUMENTS FOR EXTRACTIONS

Surgical Elevator

Comment

- Surgical dental elevators are available in various sizes and shapes to fit different tooth sizes. Styles may vary, even within the same style of elevator. Some clinicians prefer serrations to be added either to the cutting edges of the tips or to the sides of the working end. Additionally, they may desire a diamond dust coating on the gouge surface. Dental instrument suppliers can provide these after-market modifications.

Use

- As different types of levers or gouges to stretch, cut, and tear the periodontal ligament and to displace the tooth root from its socket.

Disadvantage

- Because of these instruments' mechanical advantage, careful use is needed to avoid fracturing the crown or root, or causing expansion fractures of alveolar bone.

Comment

- Handles are available in various sizes and shapes. More control is provided with handles of larger diameter. Likewise, the shaft should ideally be short enough to allow the index finger to be close to the working end and the handle to fit completely within the closed hand.

Types

- Root elevators generally have a slightly thicker (not wider) working end than luxators, allowing for more twist and torque to be placed on the instrument without damaging the tip.
- Manufacturers vary the appearance of each instrument, even though they may use the same size number. The armamentarium should consist minimally of a thinner, short-shanked (#301s) (EX-5) (Fig. 2-21, *A*); a small (#301) (EX-4) (Fig. 2-21, *B*); a medium (#34) (EX-3) (Fig. 2-21, *C*); a large (#3) (Fig. 2-21, *D*); and a dog-leg style (#E46) (EX-12) (Fig. 2-21, *E*) elevator (Cislak Manufacturing).
- Smaller 2-mm-wide elevators are very useful in extracting smaller cat teeth.

Modifications of the 301s Elevator

- Bent (#301s Bent) (EX-5E) (Fig. 2-21, *F*) has been modified with an 80-degree bend to make entering the periodontal ligament space easier, avoiding interference with the opposite jaw.
- Notched (#301s-Modified Fork) (EX-5H) (Fig. 2-21, *G*) has been modified with a notch in the working tip. This notch creates a two-tipped fork that helps to prevent slippage on smaller dental alveolar ridges.
- Bent and notched (#301s Bent Fork) (EX-5EH) (Fig. 2-21, *H*) has been modified with an 80-degree bend and a notch (301 series, Dentalair, Fountain Valley, Calif.; EX series, Cislak Manufacturing).

Use

- Elevating very small teeth in crowded arches and loosening fractured retained roots of small teeth.

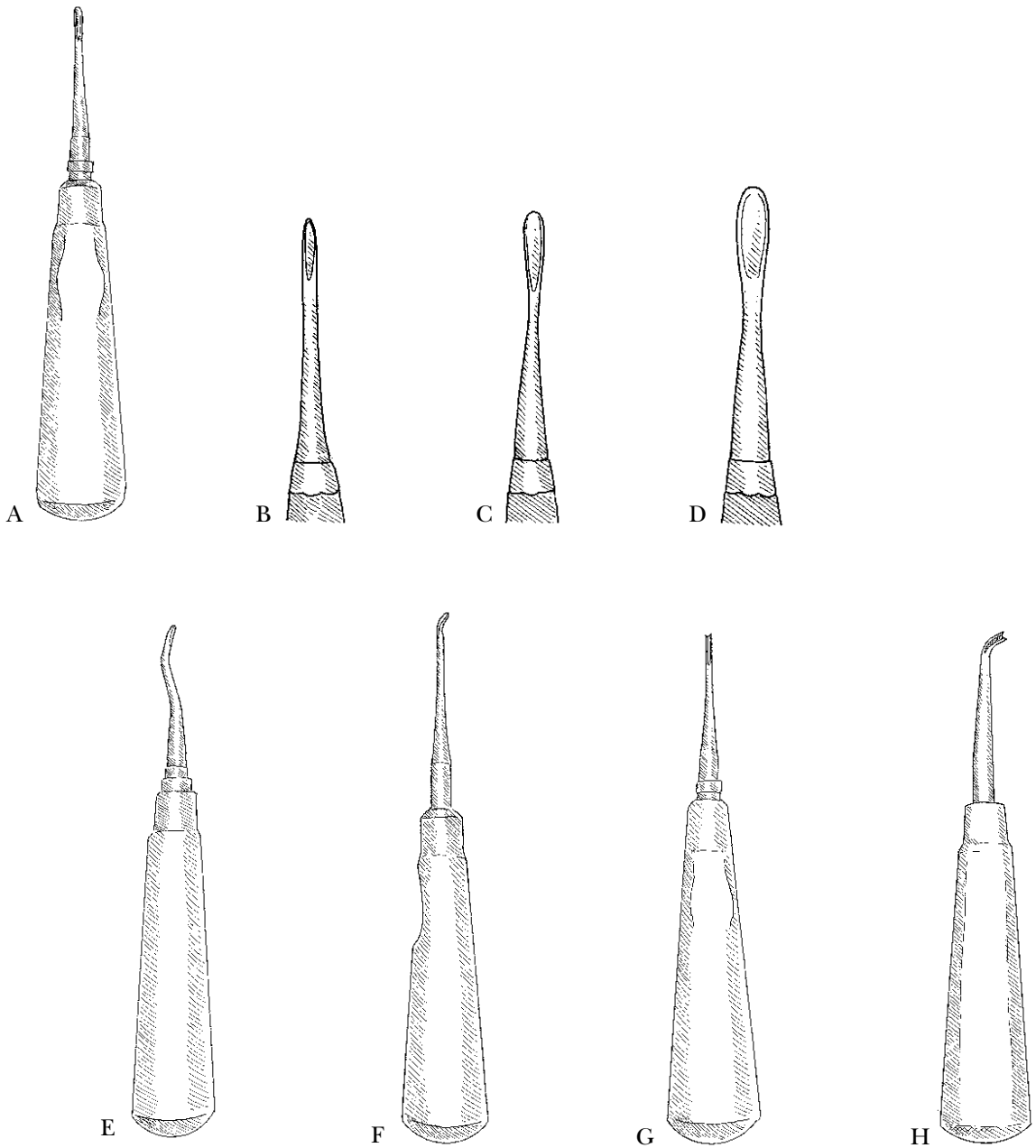


Fig. 2-21

Cryer Elevators

Comment

- Triangular (pennant or flag-shaped) working tip (Fig. 2-22, *A*). They are supplied in right and left pairs of small, medium, and large sizes by numerous distributors (EX 18, EX 17).

Uses

- Levering retained roots by extrusion, thus avoiding the risk of implosion fractures which may result, when using a straight elevator, in driving a root tip through a necrotic nasal plate and into the maxillary antrum or nasal passage.
- Especially useful in removing the palatal root of a trisected maxillary fourth premolar or the palatal root of the maxillary first molar.

Luxators

Comments

- Are similar to surgical elevators but have a slimmer (not wider) tip design (Fig. 2-22, *B*).
- They are used to cut the periodontal ligament, slide apically, and luxate the tooth.
- They are used in a circular cutting motion around the tooth root, different from the prying motion used with elevators.

Advantages

- Supplied in a variety of sizes and fit well into the periodontal space. Also come with a straight or angled working end.
- Broader working ends to encompass more of the root's circumference than can be done with the surgical elevator.
- Have thin, sharp edge for efficiently negotiating the periodontal ligament space.
- Have a large-diameter handle for a more ergonomic grip.
- Cat-size luxators (100C, Lux 2S, Lux 2C [Cislak Manufacturing]) are now available that fit around the small roots of feline premolars and molars as well as around smaller roots in the dog.
- Can be used in conjunction with elevators during extractions to create space for the elevator alongside the root.

Disadvantages

- They are not as strong as elevators, and do not replace surgical elevators. They break if improperly used and too much torque is applied.

- The more delicate, thinner instrument tip can be easily damaged with misuse.

Maintenance

- The working edges of winged elevators and luxators should be kept sharp.
- A conical stone is used to sharpen inside edges on the concave side of elevators (see section on sharpening).
- Instrument longevity and effectiveness is further enhanced by periodic professional sharpening and reconditioning by a company experienced in servicing surgical instruments.
- Frequency of this service varies with the amount and type of use, but annual care is recommended.

Fahrenkrug Elevators

- Designed to follow the curvature in teeth with curved roots (Fig. 2-22, *C*).
- Modified with a gently backward curved, gouge-shaped blade designed to help prevent elevator slippage (Fig. 2-22, *D*).
- Manufactured in 2-, 3-, and 4-mm sizes.

Advantages

- Blade is curved to follow most curved roots (canine and incisors).
- Useful in extracting retained deciduous canine teeth.

Disadvantages

- This elevator is a delicate instrument, which must be used with care.
- The long, double-bladed handle may be awkward for some.
- Longitudinal curve of the blade may not fit the alveolar shape of some teeth.

Winged Elevators

Comment

- These elevators have a winged blade and are available in 1.5-, 2.5-, 3.5-, and 4.5-mm working tip widths to be effective on different root circumferences (Fig. 2-22, *E*).
- They have a short shaft and large-diameter handles for comfortable use by clinicians with smaller hands.
- Can be used like a luxator or elevator.
- The working end should be sharpened periodically to keep the thinner tip sharp.

Advantages

- Winged blade conforms to root structure, having more circumferential contact, providing greater stability and instrument control.
- Design incorporates useful parts of both luxator and elevator.

Disadvantages

- Short vertical length of working tip can be damaged.
- If too much torque is placed on small teeth, lateral blades can create a root fracture.

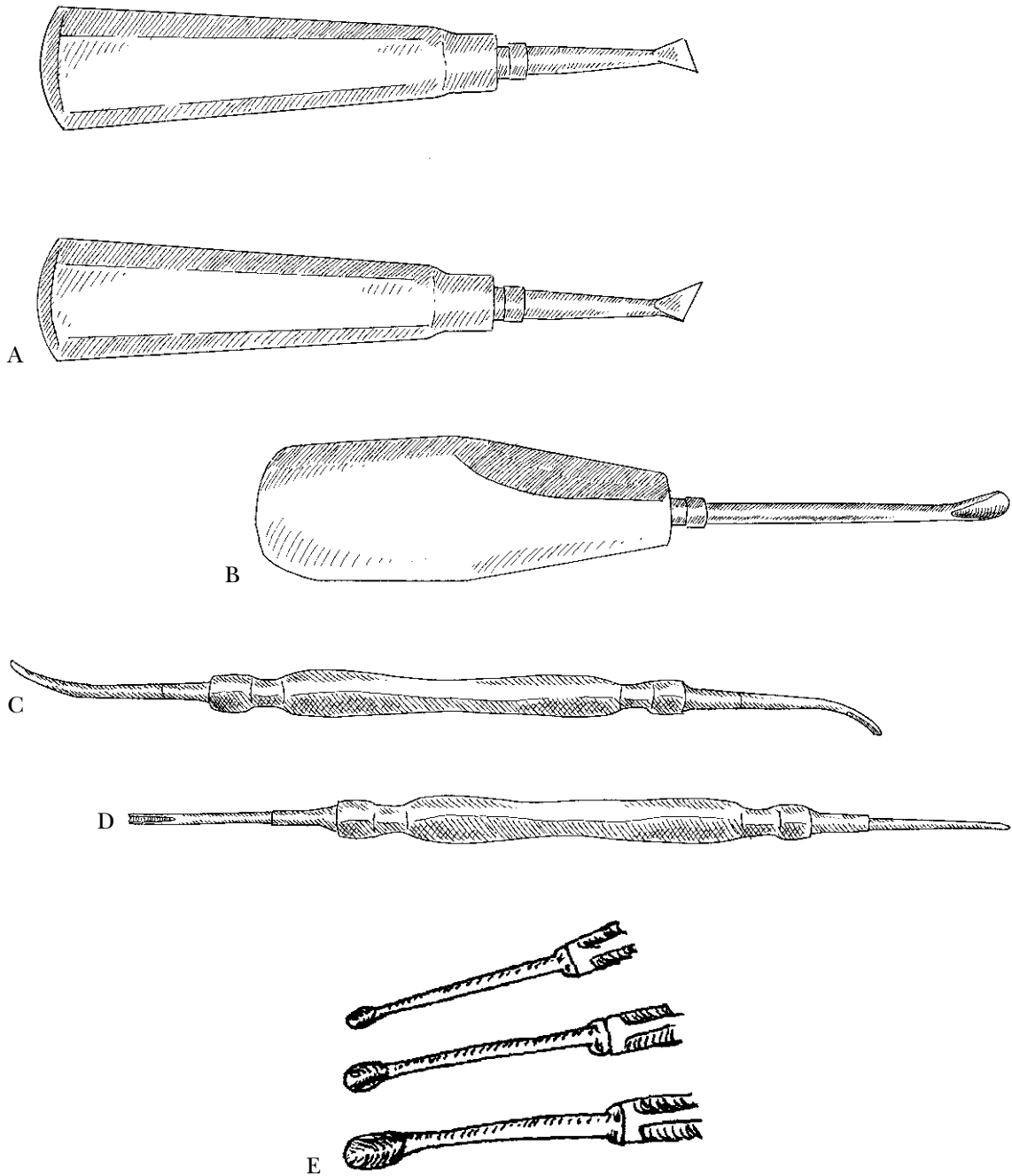


Fig. 2-22

Heidbrink Root Tip Pick

Comments

- Have narrow, sharp points (Fig. 2-23, A).
- Supplied in sets of three: straight (#1) and right and left angled (#2 and #3).
- Also supplied in either long narrow hexagonal handles with long shanks, or shorter wider handles with short-shanked working ends.

Uses

- Stretching and breaking the periodontal ligament.
- Retrieving fractured root tips by using a levering action.

Advantage

- Small size to retrieve fractured root tips.

Disadvantages

- Requires light touch to avoid alveolar perforation.
- May break the tip of the instrument if too much force is applied.

ED10-11 Root Tip Pick (WA-1, WA-2, or WA-3)

Comment

- Double ended (WA series, Cislak Manufacturing) (Fig. 2-23, B).

Uses

- Stretching and breaking the periodontal ligament.
- Extraction of retained root tips.

Advantage

- Small size.

Disadvantage

- Requires light touch to avoid alveolus perforation or instrument fracture.

Bone Curette

Comment

- There are two styles. One style has a spoonlike end that comes straight or angled as a double-ended instrument (EX 2 or EX 2F). The working ends come in different sizes (Fig. 2-23, C). The other style has the more traditional “ice cream scoop” tip that is heavier, and larger sizes can also be used when gathering cancellous bone for grafting (Fig. 2-23, D).

Use

- Debride alveolus after extraction.

Advantages

- The spoon curette is a little more flexible to use and less expensive than the scoop-style bone curette.
- Small sizes (2 to 3 mm [5-0 or 4-0]) of either style can easily remove granulation tissue and debris from the alveolus (Sontec Instruments, Englewood, Colo.).
- The scoop curette size 5-0 is small enough for most alveolar debridement.

Disadvantage

- May be too large for smaller cat dental alveoli, except for canine teeth (see the later section on excavator uses).

Extraction Forceps

Comments

- Many different varieties are available.
- Human dental extraction forceps can be used, but the human forceps often used in veterinary dentistry were designed to fit the wasp-waisted human incisor and generally derive their holding power on the carnivore tooth with a two-point (tips of jaws) grasp.
- Veterinary models fit the carnivore conical teeth better, by having more parallel jaws, and have longitudinal ribbing to provide better traction when gripping the tooth. They are associated with less rocking because they have a greater area of contact. Angled beaks facilitate removal of caudal teeth and roots. Small size is available for cats and small dogs, as well as large size for medium and large dog breeds.

Uses

- Gripping the tooth for removal during extraction.
- Removing gross calculus (not as efficient as a calculus removing forceps designed specifically for the task at hand).

Advantages

- Lifts a tooth out of alveolus.
- Allows gripping of tooth to allow gentle twisting and pulling action to remove tooth.

Disadvantages

- Because of this instrument's mechanical advantage, careful use is required to avoid fracturing the crown, root, or alveolar bone.
- Must use in alignment with tooth to avoid root fracture. Human incisor extraction forceps are more likely to fracture carnivore teeth when used for forceful extraction because of their two-point pressure.

Types

Small Breed Extraction Forceps

Comments

- The veterinary instrument beaks are more parallel than are the human incisor forceps often used by veterinarians and therefore are better adapted to conical carnivore teeth (Fig. 2-23, *E*).
- They are small forceps.

Advantages

- Small size fits most hands comfortably.
- Less force placed on small teeth during extraction.

Veterinary Large Dog Breed Extraction Forceps

Comments

- The beaks are more parallel than the human incisor forceps often used by veterinarians and therefore better adapted to the conical carnivore teeth (Fig. 2-23, *F*).
- These are large forceps.

Advantage

- May fit larger teeth better than human or cat extraction forceps.

Disadvantage

- May cause operator to "overpower" and fracture crown or root tip.

Human Extraction Forceps

Comment

- The grasping surfaces are concave to accommodate the bulge of the crown of human teeth and to grasp the crown down at the neck.

Disadvantages

- The concavity makes for poor contact with the conical teeth commonly encountered in veterinary dentistry.

- Grasping the tooth by the two points of the tips of the jaws only results in more pressure in small areas and creates intraoperative tooth fractures.

Root Tip or Fragment Forceps

Comment

- These forceps (Fig. 2-23, *G*) have fine, pointed, serrated grasping tips at a 45-degree angle to the handle. Newer modifications have jaws that are 1 mm wide (Fig. 2-23, *H*) (#4658 or Peet's forceps, Cislak Manufacturing; fragment forceps, CK Dental Specialties, Orange, Calif.).

Use

- These forceps are invaluable for grasping and removing root tips or fragments, as well as small delicate teeth such as feline incisors.

Advantages

- The fine tips allow them to reach deep into the alveolus to grasp and remove loosened root pieces.
- The forceps with a 45-degree angle is more adaptable than right-angled forceps.

Disadvantage

- The fine tips can become damaged with misuse.

SUTURE MATERIAL

General Comments

- The choice of suture material should be based on factors such as nature and goals of the procedure, length of time the material is to be in the oral cavity, and personal preference.
- Both absorbable and nonabsorbable materials may be used.
- There is no ideal suture material; all have advantages and disadvantages.
- Absorbable materials include: coated polyglactin 910 (Vicryl), polyglycolic acid (Dexon), polydioxanone (PDS), polyglyconate (Maxon), poliglecaprone 25 (Monocryl), and chromic gut.
- Nonabsorbable materials include silk (Perma-Hand), nylon (Ethilon), and polypropylene (Prolene).

Coated Polyglactin 910, Polyglycolic Acid, Polyglyconate

Advantages

- Degradation by hydrolysis.
- Good for procedures in which healing is rapid and the suture does not need to be functional for long periods.
- Does not require removal.
- Stays functional longer than chromic gut, for patients that might abuse the surgical site.

Disadvantage

- Requires extra knots or will untie.

Chromic Gut

Advantages

- Good for procedures when healing will be rapid and the suture does not need to be functional for long periods.
- Does not require removal.

Disadvantages

- Lasts a very short time in oral cavity.
- Degradation by proteolytic enzymes and phagocytic cells.
- Sometimes stimulates inflammatory response in tissue.

Poliglecaprone 25

Advantages


- Monofilament suture that pulls freely through tissue.
- Good knot security.
- Stays in mouth for longer time than chromic gut for major oral surgery procedures.
- Does not require removal.

Disadvantage

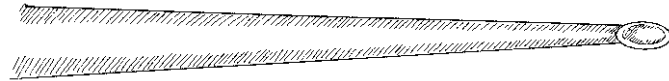- Clear color difficult to see in smaller suture size (5-0).



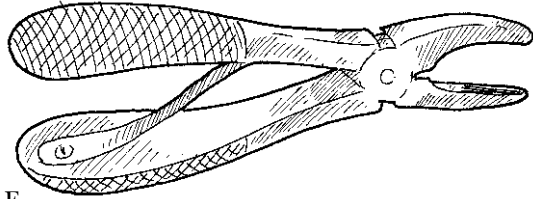
A



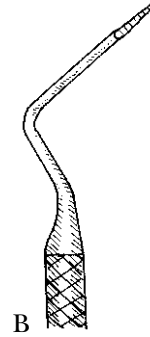
C



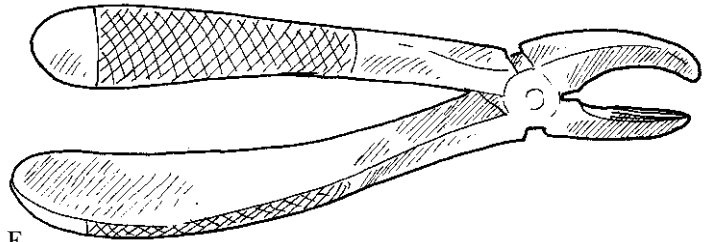
D



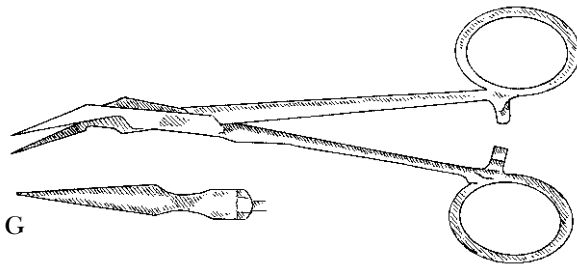
E



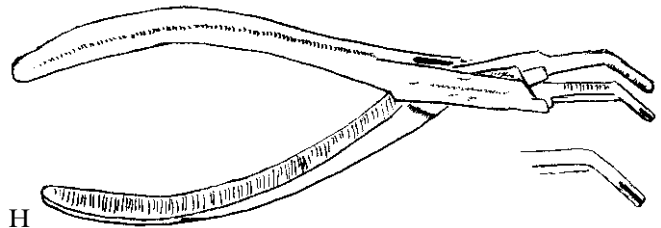
B



F



G



H

Fig. 2-23

Silk, Nylon, and Polypropylene

Advantages

- Good for surgeries requiring long-term tissue fixation support.
- Minimal tissue reaction.

Disadvantage

- Must be removed.

EQUIPMENT FOR ENDODONTICS

Cotton Pliers

Comment

- Cotton pliers (forceps) have two beaks and a handle; some are locking.

Uses

- Grasp materials to transfer them into and out of the oral cavity.
- Used in all phases of dentistry, including endodontics, orthodontics, and periodontics. Cotton pliers designed for endodontics have a longitudinal groove in each jaw to grasp absorbent points and gutta-percha points.
- Called endodontic point forceps, they are not intended to grasp tissue.

Endodontic Broaches

Comment

- Broaches are manufactured by notching the walls of a round blank (Fig. 2-24, A) and creating flared barbs. They are available in 22- and 47-mm lengths.

Uses

- Bulk removal of pulp tissue and other debris from the pulp chamber and root canal.
- Have been used to retrieve absorbent points lodged in the root canal; occasionally may aid in retrieval of a separated file tip.
- Should not be used to prepare the canal.
- Designed for single use only; however, may be cleaned intra-operatively by passing through rubber glove material.
- Made of soft iron and break easily when stressed.
- Should be used only in canals that have been instrumented at least to a size 25 file.

Endodontic Reamers and Files

Comments

- Reamers and files have two dimensions: length and diameter.
- Length is indicated by a millimeter notation.
- Typical lengths are 21, 25, 30, 31, 40, 49, 55, and 60 mm.
- The shorter files can be used for the incisors, premolars, and molars; the longer files are necessary for the canine teeth of dogs.
- The long Hedström files are available with a working length of the cutting flutes of 16 or 30 mm.
- Diameter is indicated by a number representing the diameter of the file at the working end (e.g., a #10 file is 0.1 mm, a #50 file is 0.5 mm, and a #100 file is 1.0 mm at the working end).
- Standard (International Standards Organization [ISO]) sizes are 06, 08, 10, 15, 20, 25, 30, 35, 40, 45, 50, 60, 70, 80, 90, 100, 110, 120, 130, and 140.
- ISO size files have handles that are color-coded for easy recognition: pink 06, gray 08,

lavender 10. Then, in repeating sequence, white, yellow, red, blue, green, and black for file sizes 15-40, 45-80, and 90-140.

- A pathfinder file with an orange handle is the smallest file used to locate and reach the working length of the canal.

Series 29 Files

- Series 29 file, a newer concept, is also available (Dentsply-Tulsa Dental Products, Tulsa, Okla.).
- These files are designed to produce a tapered funnel form, crown-down preparation quickly and efficiently without zipping, ledging, or perforating the canal. They conform to the new Series 29 standard, which maintains a constant 29% increase in tip diameters, thereby allowing a smooth, progressive enlargement of the canal from one file to the next.
- The rotary instruments come with a 0.04 or 0.06 taper, as well as the constant 29% increase in tip diameter.

Advantages

- Offers fewer instruments, which are better spaced within the useful range (ISO #10 to #60).¹² Usually, only three to five sizes of files are used in a root canal preparation.
- The 0.04 taper files have twice the taper of ISO files. This creates a greater funnel form of the root canal for ease in obturating the canal.
- Available in a variety of sizes from 00 to 11 in 21-, 25-, 30- and 40-mm lengths.
- Available in either stainless steel or nickel titanium.
- Especially advantageous in curved canals when using the flexible nickel titanium files.
- Especially useful in retreatment cases requiring bypassing ledges and for removing gutta-percha.

- Supplied as rotary instruments used in a controlled low-speed, high-torque rotary handpiece.
- File will unravel before breaking.

Disadvantages

- Requires a 6:1 reduction gear handpiece if rotary pieces are to be used.
- Desired speed is 300 to 375 rpm.
- Must remember to fully depress rheostat foot pedal; not designed for speed adjustment by foot pedal rheostat.
- If using rotary instruments, hand instruments are still needed initially and for measuring working length, larger canals, and longer canals. Hand instruments are often preferable at the apical end of the working length of the preparation.
- Does not reduce the need for irrigants during root canal preparation or, when using Gates Glidden drill, for additional cleaning and shaping.
- Rotary instruments require a light touch in order to avoid file separation.

Comment

- The clinician has better control and bends fewer files when using the shortest file possible.

Use

- Endodontics: root canal preparation.

Reamers

Comments

- Reamers are manufactured by twisting tapered and faceted wire to produce cutting edges, or flutes (Fig. 2-24, *B*).
- Reamers are used for filing and reaming.
- Filing with a reamer is accomplished by pushing and pulling the instrument within the pulp chamber of the tooth.

- When filing, flutes scrape against the wall, cutting and removing dentin.
- Reaming is twisting the file in a clockwise direction. With this movement, the flutes cut the walls and widen the canal, carrying the debris coronally, through the access site as the file is used in an auger motion.
- Reaming creates a round canal. Reamers can be used well in any portion of the canal.

Advantage

- Reamers are stronger than other files of the same dimensions.

Disadvantages

- Do not have the cutting ability of newer style files.
- Should not be turned counterclockwise while filing, which will weaken the file.

Kerr Files

Comments

- Kerr files, or K-files, are manufactured in the same manner as reamers but are twisted to a greater degree (in a tighter spiral) (Fig. 2-24, C).
- Because K-files cut when they are twisted as well as when they are pulled, they create a round canal apically and an oval canal coronally. They are best used to shape the apical third of the canal.
- The flutes are greater in number and more angulated than those of reamers.
- K-files may be used in reaming and filing.

Advantages

- They are stronger than Hedström files.
- K-files have a greater number of cutting edges and cut better than reamers.

Disadvantages

- K-files do not carry as much material out of the canal as reamers. This is called *carrier effect*.
- If twisted clockwise with too much torque, they will become lodged and then break.
- Once trapped in the canal, they will break even more easily if twisted counterclockwise.
- With continued twisting, they can penetrate the tooth apex if used with indiscretion.
- They are not as strong as reamers.

Hedström Files

Comments

- Hedström files are manufactured by cutting triangular pieces from tapered wire (Fig. 2-24, D); as such, they are weaker than either K-files or reamers because their core is supported by less metal.
- They do not provide a round shape to the canal because of their push-pull use. Because of this and their weakness, they are best used to shape the coronal two thirds of the canal.

Advantage

- Very sharp when new and cut better than reamers or K-files.

Disadvantages

- Used only in filing; should never be twisted and used for reaming.
- More prone to breakage than are K-files or reamers.
- Less flexible than K-files.

Maintenance: Cleaning Files and Reamers

- Many manufacturers recommend single-use applications. These instruments should be disposed of in proper waste containers, according to regulations dealing with “sharps.” Files tend to unravel with repeated use. If used more than once, files should be inspected continually. They should be discarded immediately when a shiny, weak spot is detected.
- Caution should be exercised not to stab oneself when handling files and reamers.

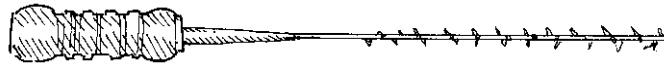Step 1—Disinfect files by soaking in chlorhexidine solution, diluted as recommended on bottle.

Step 2—Scrub file with a brush and submit to an ultrasonic cleaning cycle.

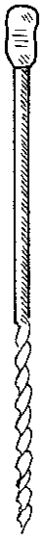Step 3—Disinfect again by soaking in chlorhexidine solution.

Step 4—Rinse. (An alternative approach is to use a bead sterilizer in place of steps 3 and 4 or to autoclave the files).

Step 5—Place in storage for next use.



A



B



C



D

Fig. 2-24

Accessories

File Organizers

Comments

- File organizers allow the orderly storage of endodontic files.
- Some organizers have containers for disinfectants (Fig. 2-25, *A*).
- Other models are autoclavable.

Advantage

- Allow an organized approach to file storage and arrangement for chairside use.

Disadvantages

- Vigilance must prevail to keep the organizer clean; it is difficult to keep sterile.
- The best system is to place only new files in the organizer when the file packages are opened. Files are destroyed after first use, thereby decreasing the incidence of file breakage or separation in the root canal.

Endo-Ring

Comment

- Endo-Ring is a plastic ring with ruler and replaceable sponge for intraoperative storage of files (Almore International, Portland, Ore.) (Fig. 2-25, *B*).

Advantages

- Provides orderly storage of files and reamers in use as well as for pastes, such as R-C Prep, by placing on the sponge (Premier Dental Products).
- Allows files that have been used to be separated from those in the organizer.
- Sponge on the Endo-Ring can be soaked in alcohol and used to clean files intra-operatively.

Disadvantage

- Care should be taken not to stab one's fingers when placing file in the sponge.

Maintenance

- The foam inserts are supplied in packs of 48 and are intended to be used once and discarded.
- The Endo-Ring and foam with or without files may be sterilized by steam or ethylene oxide sterilization.

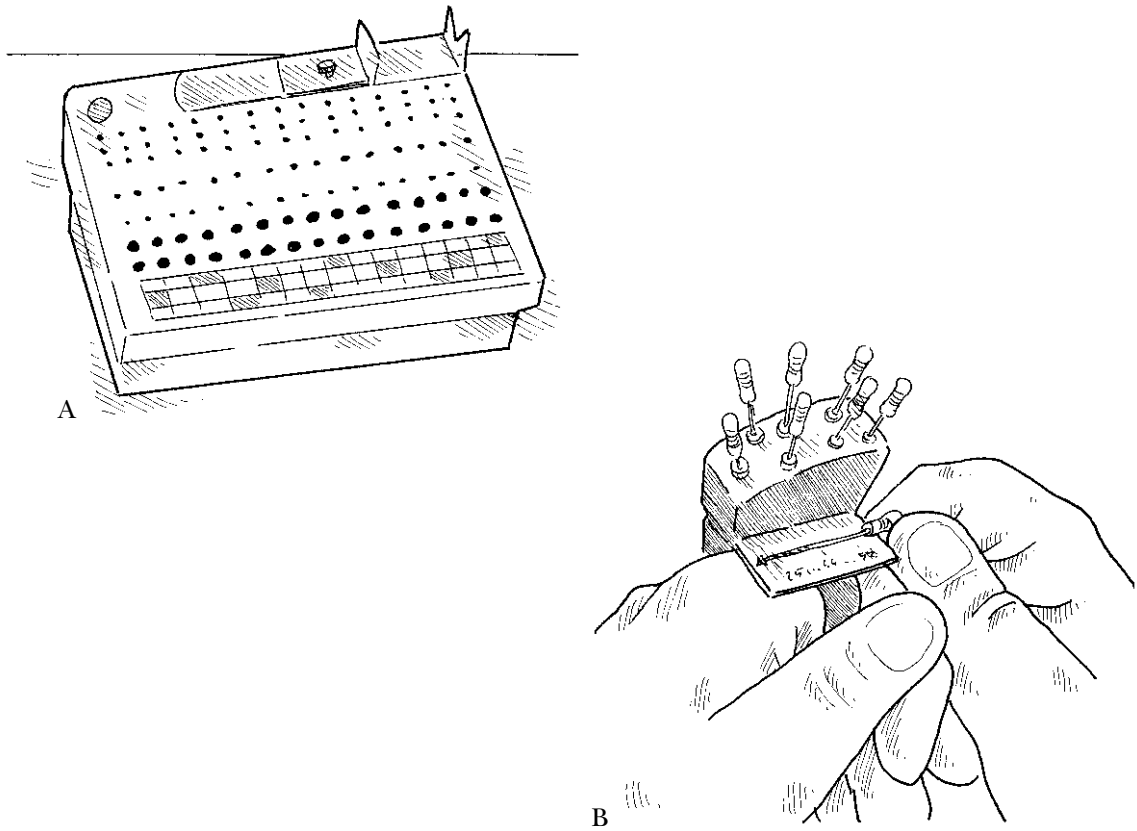


Fig. 2-25

Bead Sterilizer**Comment**

- This is a small sterilizer in which to place tips of instruments for sterilization (Fig. 2-26, A).

Advantage

- Allows relatively quick sterilization.

Disadvantages

- Only the tip of an instrument is sterilized.
- Additional expense and another item on the counter.

Automated Files**Comments**

- With the use of a special contra angle that oscillates at 30 or 90 degrees and files that fit into these contra angles, a canal can be filed with a low-speed handpiece.
- Automated files are used most successfully in short canals.

Advantages

- Less physical strength required than when filing manually.
- May speed preparation of canal.

Disadvantages

- Time consuming to change files.
- Less tactile sensitivity than with hand files.
- Possible perforation of apex, flaring at the apical end of the canal, or “zipping” of canal wall (see Chapter 7).
- Greater risk of breaking files.

Instruments for Filling the Canal**Lentulo Spiral Fillers****Comment**

- Spiral wire tip on round wire for use in 10:1 reduction contra angle.
- Come in 25-, 29-, and 60-mm lengths.
- Used for spinning endodontic sealing material down into canal.

Advantage

- Auger effect of spiral filler delivers sealer well into canal.

Disadvantages

- Cannot use in canals smaller than a size 25.
- Working end may break off in canal, especially with multiple uses or if used at too high a speed.

High-Pressure Syringes**Comments**

- A metal syringe with mechanical advantage that increases the pressure placed on the filling material to extrude it through a small opening.
- The pressure may be placed by a lever at the back of the plunger (Fig. 2-26, B).
- The pressure may be created by a screw at the back of the plunger (Fig. 2-26, C).

Advantage

- Material may be injected into small canals through a fine needle, as small as 30 gauge.

Disadvantages

- Special needles for these syringes have one-time use.
- Time is required to clean the syringe.
- Procedure is technique sensitive.

Maintenance

- E.L. Cor Solvent cleaning solution is used to clean the zinc-oxide-eugenol compounds (Lang Dental Manufacturing, Wheeling, Ill.).

Plugger**Comment**

- Pluggers come in various lengths and widths as straight pluggers or curved (Fahrenkrug) for larger canine teeth and have a blunt tip (Fig. 2-26, D).

Use

- Pushing the malleable gutta-percha into the root canal in the vertical condensation or compaction technique.

Advantage

- Helps gutta-percha to completely seal the apex of the root canal.

Disadvantage

- May seal incompletely the apical one third of the root canal if not used in conjunction with a warm gutta-percha technique.

Use

- Reaching into canals when intraoral access is limited.

Advantage

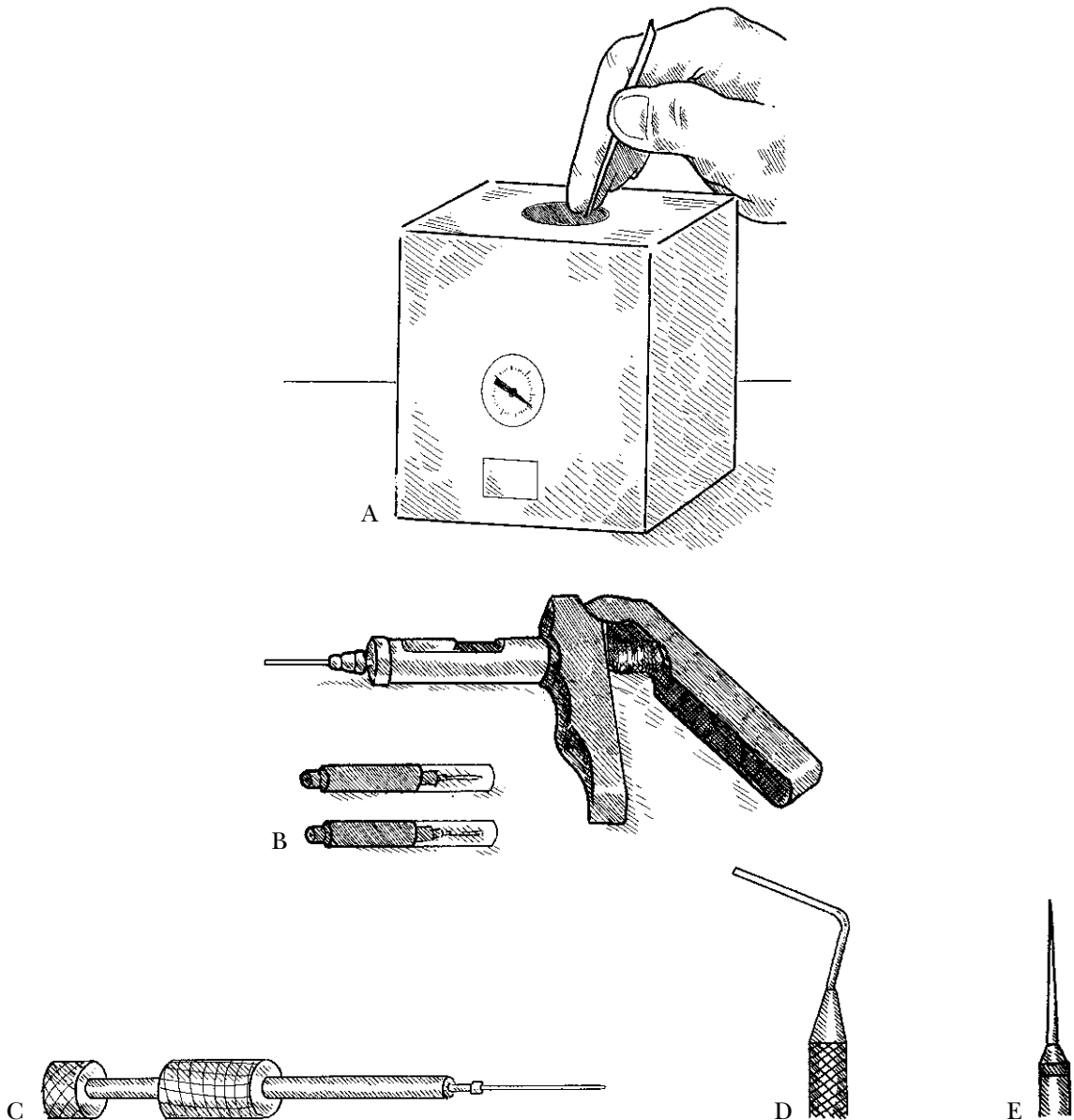
- Better tactile sense.

Finger Plugger or Finger Spreader**Comment**

- This is a short-shanked plugger or spreader with a handle similar to those of files or reamers (Fig. 2-26, *E*).

Disadvantage

- Short, sometimes hard to hold.

**Fig. 2-26**

Spreaders

Comment

- Spreaders are tapered, pointed, and sized according to original standardized sizes of gutta-percha (Fig. 2-27, A). A curved spreader is also available for use in large canine teeth (Fahrenkrug).

Advantage

- Condense gutta-percha laterally.

Disadvantages

- Excessive force in narrow canal could cause root fracture.
- Thinner tips can bend easily if too much force is used.

Holmstrom Plugger and Spreaders

Comments

- These are double-ended instruments with a spreader on one end and plugger on the other.
- They are 35 mm long, designed for use in longer canals and come in five widths.
- Plugger and spreader kits are available (Cislak Manufacturing).

Advantages

- Have both plugger and spreader in one instrument.
- Additional length advantageous in long canals.

Disadvantage

- Can bend easily if used with too much force or held improperly.

Electrically Heated Spreaders

Comments

- An electrical current passed through the spreader causes it to heat up (Fig. 2-27, B).
- There are two mechanisms for heat control in the Touch and Heat and System B equipment (Sybron Endo, Redmond, Wash.). One mechanism uses a series of electrical pulses to heat the element. The more frequent the pulse, the hotter the tip gets. The second mechanism is a rheostat that varies the current passing through the spreader. The latter

mechanism controls the temperature more accurately.

Touch and Heat System

Uses

- Warming and condensing gutta-percha.
- Cutting gutta-percha.

Advantages

- Warming gutta-percha speeds up the process of placement, particularly in large canals.
- When the spreader cools, it adheres to the gutta-percha and allows the gutta-percha to be removed. This is helpful when a canal requires repeated instrumentation.

Disadvantages

- There is a possibility of causing thermal damage to the tissue surrounding the tooth.
- Gutta-percha expands when warm and shrinks when cold.
- Temperature is not adjustable, which causes greater metal fatigue of the working tips.

System B

- Also by Sybron Endo, System B more accurately measures the temperature of the working end, allowing adjustments for different functions such as compaction, repeated instrumentation, and removal of improperly placed gutta-percha.

Advantages

- Its adjustability allows for more successfully using a warm gutta-percha technique, such as the continuous wave obturation technique.
- The heated tips do not fatigue as quickly as those of the Touch and Heat spreader because of the adjustability of the unit.

Disadvantage

- It costs more than the Touch and Heat spreader.

Warmed Gutta-Percha Carriers, Cannulas, and Syringes

Comment

- Cannulas of gutta-percha are warmed in a heating unit and then placed into a special syringe for injection into the canal (Obtura Corporation, Fenton, Mo.; Hygenic, Akron, Ohio) (Fig. 2-27, C).
- Carriers are plastic or titanium, sized obturators coated in gutta-percha that are

heated in an oven (Dentsply Maillefer, Tulsa, Okla.; Soft Core Texas, North Richland Hills, Tex.).

- Syringes of gutta-percha are warmed in a heating unit, and the softened gutta-percha is placed on a file and transferred into the canal (Hygenic).

Use

- Plasticized root canal filling.

Advantages

- Allows rapid filling of canals.
- Provide good three-dimensional filling of irregular canals.
- Gutta-percha covered carriers can be used in smaller canals than can SuccessFil, because obturators are supplied in sizes 20 to 100.
- SuccessFil technique has been reported to provide a greater apical seal than a heated lateral compaction method.¹³

Disadvantages

- Gutta-percha covered carriers come in 25-mm length only.

- Gutta-percha cannulas are not long enough for large canine teeth fills and need an access opening the size of a #70 endodontic file.
- Warmed gutta-percha procedures are technique sensitive and can be difficult to reinstrument.
- Cost of heating unit and cannulas, carriers, or syringes.

Gutta-Percha Removal Files

Comment

- Gutta-percha removal files are 21-mm files used in a low-speed handpiece that have a spiral vent.
- As gutta-percha is plasticized by frictional heat, it is removed from canal.

Advantage

- Allows for more complete removal of gutta-percha during repeated instrumentation.

Disadvantage

- If used with too much force may break in canal.

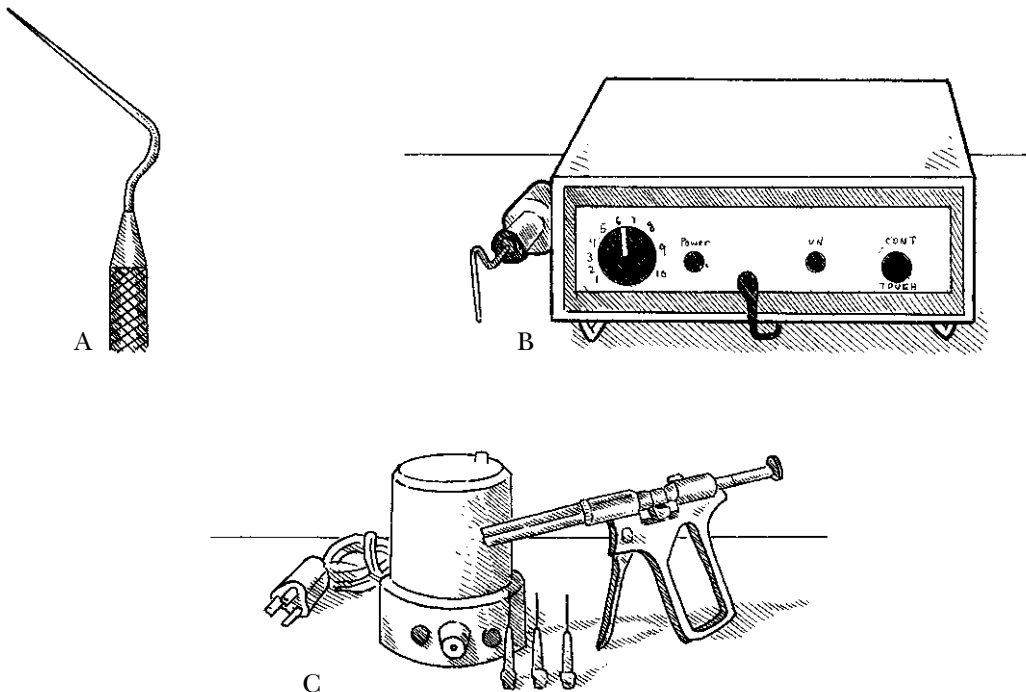


Fig. 2-27

RESTORATIVE EQUIPMENT AND INSTRUMENTS

Chisels

Comments

- The cutting edge of a chisel forms a one-sided acute angle to the working end. Chisels are different than osteotomes, which are angled equally and symmetrically from both sides of the working end tapering toward the vertical midline of the instrument.
- When double ended, one cutting edge is distal to the handle and is termed *reverse bevel*. The other end is termed *standard bevel* (Fig. 2-28, A). The reverse bevel is indicated on the instrument shaft by an indented ring (Fig. 2-28, B).
- Chisels come with a straight angle (Fig. 2-28, C), monangle (Fig. 2-28, D), biangle (Fig. 2-28, E), or triple angle (Fig. 2-28, F).

Use

- Reshaping and smoothing dental tissue.

Hatchets

Comments

- The cutting edge is parallel to the angle of the handle (Fig. 2-28, G).
- Chisels are supplied in a variety of widths, angled working ends, and styles.

Use

- Trimming and smoothing dental tissue, such as removing unsupported enamel rods or creating a bevel on cavity margins for composite restorations.

Excavators

Comments

- An excavator is a double-ended instrument (Fig. 2-28, H) with a flat, disclike working end with fine, cutting edges; working tips come in different diameters.
- They most commonly are supplied and inventoried with double-ended #33 blades and a smaller size with #31 blades.

Uses

- Removing carious dentin.
- Removing dental material from endodontic access sites.
- Debriding feline alveolar sockets after extraction.
- Excising gingival attachment around teeth of cats and small breed dogs.
- Convenient for delivery of restorative materials or small amounts of grafting implants to small places.

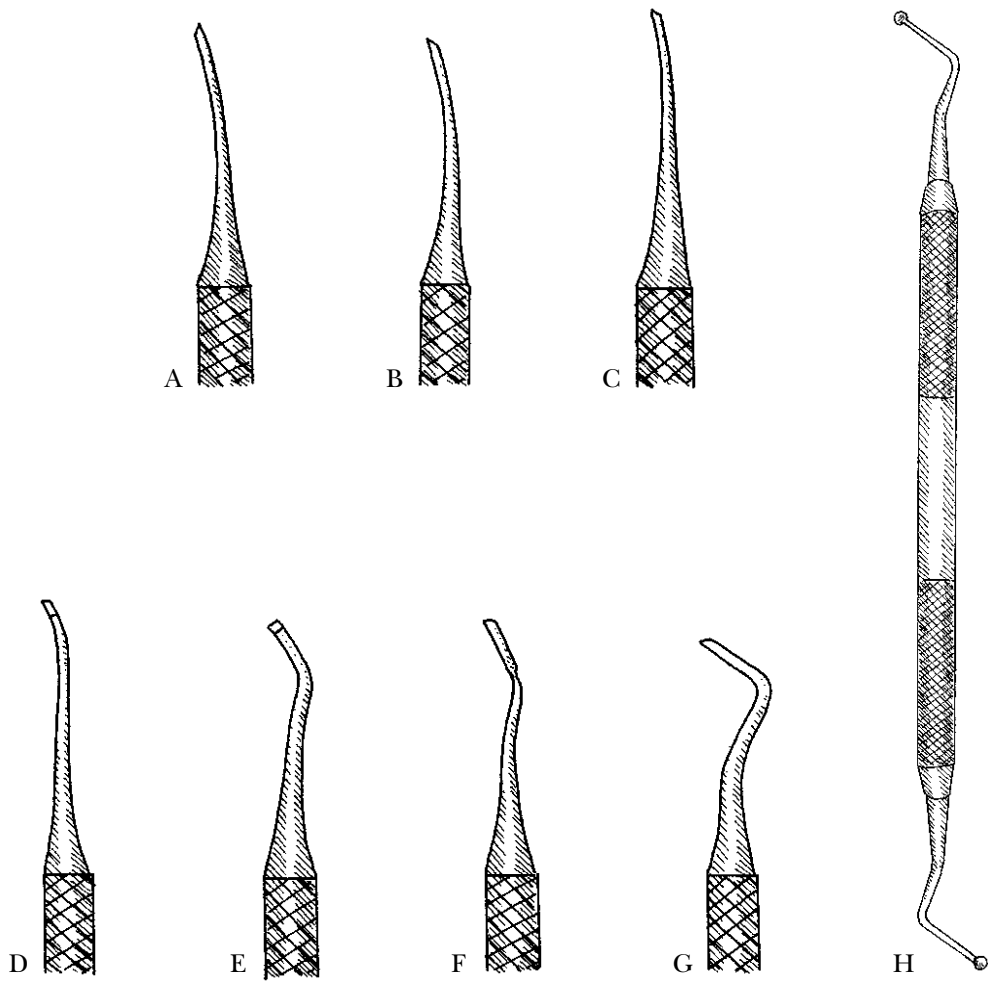


Fig. 2-28

Light-Cure Gun

Comment

- The high-intensity light-cure gun is used to start the photochemical reaction that sets (hardens) the light-cure dental materials.

Uses

- Curing light-cure restorative materials.
- Curing light-cure periodontal packs.
- Curing light-cure orthodontic resins.
- Curing light-cure calcium hydroxide.
- Curing light-cure rubber dams.

Advantages

- Light curing allows longer instrumentation time for easy shaping of the restoration and then rapid curing.
- Decreased polymerization shrinkage.
- Less mess.
- Many brands have several time interval settings.

Disadvantages

- Cost of light-cure gun.
- Special eyeglasses or shields needed to protect the eyes from the intense light.
- Maintenance: wands must be kept clean to ensure effective function.

Options

"Continuous On"

Comment

- Many guns turn off automatically, slowing the procedure down.

Advantage

- A gun with continuous on allows long curing times.

Disadvantage

- May cause breakdown of light filter if used frequently for long periods.

High-Energy Output

Comments

- Light-curing guns are manufactured with different light intensities.
- With some, the bulb will become weaker before it burns out.

Advantage

- Brighter lights penetrate for a greater depth of cure and faster curing times.

Disadvantage

- Greater risk of eye damage.

Fiberoptic Cord Versus Pistol Style

Comments

- Some light-cure guns have their light source in the control box and transmit the light via a long fiberoptic cord.
- Most newer models are of the pistol style.

Advantage

- Having the light source in a box allows for larger fans than can be hand held. This decreases the chance of bulb burnout caused by overheating with long exposures.

Disadvantages

- Fiberoptic cords are very delicate; small breaks in the fibers occur with use and decrease the output, making costly replacement necessary.
- Fiberoptic cords are thicker and harder to handle.

Accessories

Multiple Tips

Comment

- Some units come with optional tips in different sizes and shapes.

Advantages

- Multiple tips allow greater range of uses (such as restorative, light-cure orthodontic materials, light-cure periopacks, light-cure rubber dams).
- Using larger diameter tips (13 mm) reduces the chance of inadequate cure at the restoration margins.

Disadvantage

- Most guns come with only a small (8 mm) tip not efficient for all needs.

Maintenance

- Inspect filter (with light turned off) on a regular basis (Fig. 2-29, A).

- The filter should look like a blue-purple mirror (Fig. 2-29, *B*).
- Holes in filter indicate that dangerous wavelengths of light may be escaping (Fig. 2-29, *C*).
- Inspect the light bulb: black, discolored bulbs may need to be replaced.

Optic Shield for Tip

Comments

- Small plastic light shields fit over the fiberoptic tip (Fig. 2-29, *D*).
- Larger protective light shields that attach to the base of the light wand are also available, and still others can be ordered built into custom operating glasses for the operator.

- An accessory protective light shield strip can be fixed adhesively to the assistant's face shield.

Advantage

- The tip or wand shield is always with the light-curing gun.

Disadvantage

- The tip shield usually will not conform completely to shape of tooth; therefore, bright light escapes around the edges.
- Disadvantage to the wand base shield is that the operator will have to position his or her head behind the shield, and it does not protect the assistant's eyes.

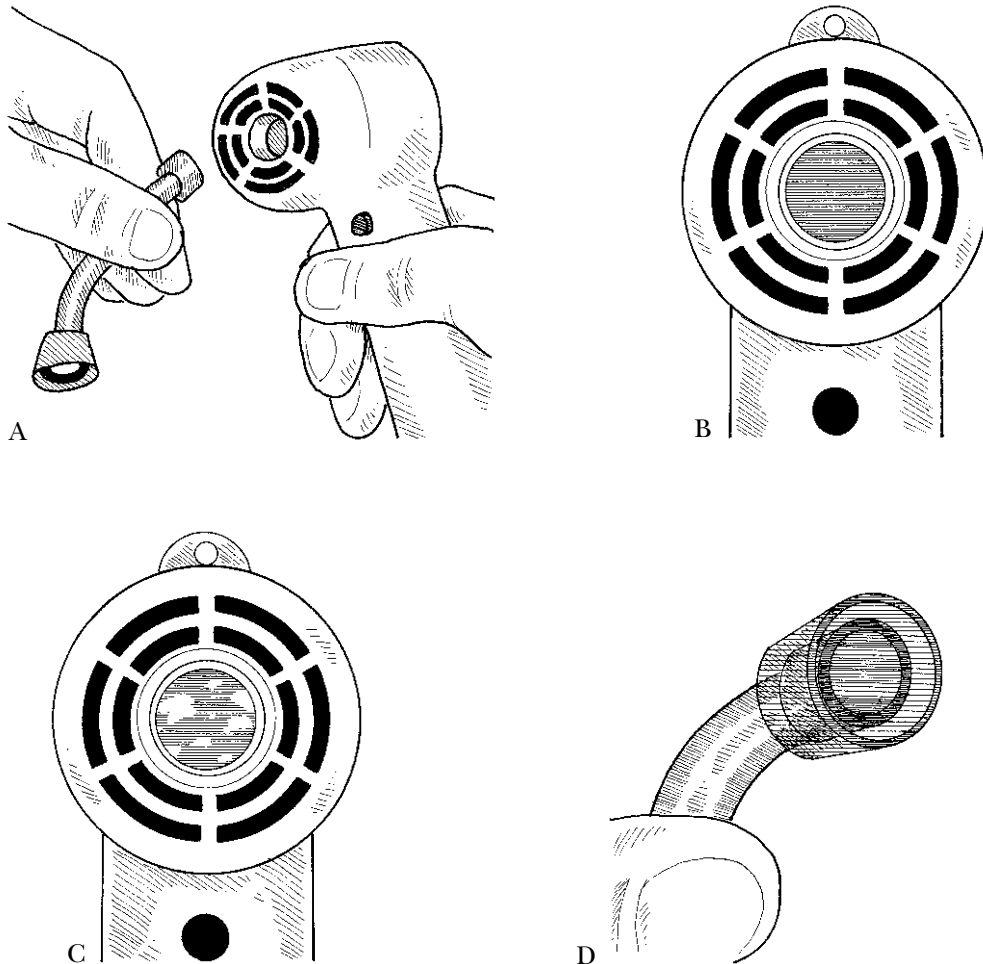


Fig. 2-29

Light Analysis Tool**Comment**

- This tool is used for checking intensity of the light output.

Advantage

- Daily monitoring of light ensures optimal curing, because some bulbs become dimmer before burning out.

Disadvantage

- Expense. Note: some models have built-in light analyzers.

Amalgamators**Comment**

- Amalgamators hold a capsule that contains amalgam or glass ionomer (Fig. 2-30, A).

Use

- Rapid mixing of glass ionomer and amalgam restorative material.

Advantages

- Thorough mixing of material.
- Helps prevent inconsistent mixing and environmental contamination.

Disadvantage

- As with all equipment, instructions must be followed. Mixing the ingredients for an improper period produces an inadequate product.

Amalgam Wells**Comment**

- An amalgam well is a small metal bowl that holds amalgam mixture before mixture is transferred to the cavity preparation.

Advantages

- No movable parts.
- Easily maintained.
- Stable design, resistant to tipping.

Amalgam Carrier

Comments

- The amalgam carrier transfers amalgam from amalgam well to restoration site (Fig. 2-30, *B*).
- Amalgam carriers and composite carriers look similar, but amalgam carriers have metal plungers that, if used with composite, may discolor it.
- Composite carriers have a nylon, plastic, or treated metal plunger (Cislak Manufacturing).

Advantage

- Transfers amalgam to the restoration site quickly.

Disadvantage

- Training is required; the operator and assistant must know not to compact the amalgam into the carrier. If this occurs, the carrier will jam, and amalgam cannot be removed easily from the carrier.

Maintenance

- Periodic cleaning with paper points or cotton swabs.
- Once a carrier is jammed with amalgam, the barrel can be reamed clean with careful use of an appropriately sized cutting bur.
- Replacement of plastic tips.

Retrograde Amalgam Carriers

Comment

- Retrograde amalgam carriers hold a smaller amount of amalgam and fit into smaller spaces (Fig. 2-30, *C*).

Uses

- Used in surgical root canal treatments and for depositing restorative material into limited access sites.
- Convenient for placing calcium hydroxide powder into pulpotomy access sites.

Advantages

- Small tip for placing amalgam into apical opening.

- One popular style is supplied in two convenient barrel diameters, $\frac{3}{64}$ and $\frac{5}{64}$ (Miltex, Bethpage, NY).

Disadvantage

- Limited to use in surgical root canal therapy or very small fillings.

Amalgam Condensers (Pluggers)

Comments

- Condensers are used to pack (condense) amalgam into and within the surface defect restoration prepared site (Fig. 2-30, *D*).
- A variety of sizes are available for different size restorations.

Use

- To condense the cold, molten amalgam into the undercut preparation so that it is a homogeneous, dense restoration without internal voids and with a tight seal at the surface margins.

Advantages

- By using different sizes and shapes, amalgam can be condensed into various sizes and shapes of cavity preparations.

- Performance can be improved over that of hand instruments by using an air-driven vibrating handpiece that comes with a variety of tips that condense the amalgam and burnish its surface (Teledyne-Getz, Elk Grove Village, Ill.).

Amalgam Carvers

Comments

- Various sizes and shapes have been designed to trim and shape amalgam (Fig. 2-30, *E*).
- If working with amalgam, the practitioner will accumulate a variety of carvers. These should be kept separate from the composite instruments and be used only for amalgam, both because of mercury contamination and to avoid discoloring the composite.

Advantage

- Rapid trimming of amalgam.

Amalgam Burnishers

Comments

- Smooth the surface of an amalgam restoration (Fig. 2-30, *F* and *G*).
- Beneficial when mixing amalgam by hand.

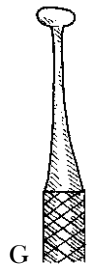
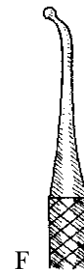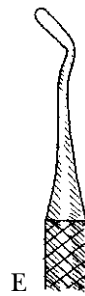
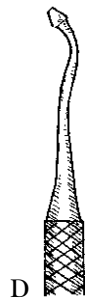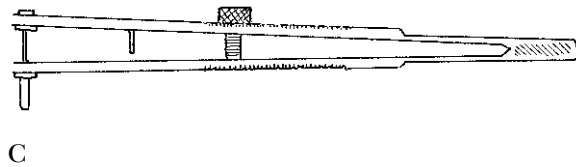
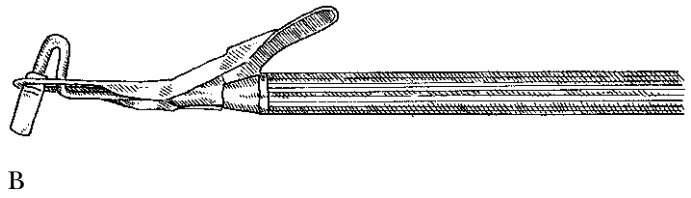
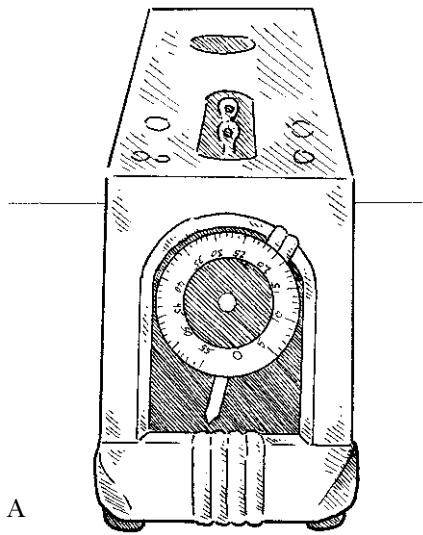


Fig. 2-30

Plastic Working (Filling) Instruments

Comments

- Plastic or metal instruments used to shape plastic restorative material before curing.
- Come in several sizes and shapes and are double ended or single ended. Double-ended instruments are often indicated as “de” or “D/E” in catalogs.

Advantage

- Made of a type of metal that does not leave a metal stain or discolor the restoration, or are stainless steel coated with titanium nitrate, anodized aluminum, or gold plating to give them a nonstick surface for composites.

Mixing Spatula

Comment

- Thin-blade metal spatula.

Use

- Mixing cements, sealers, restoratives, cavity liners, and impression materials.

Mixing Pads

Comment

- Either glass slabs or pads of waxed paper are used for mixing dental materials.

Uses

- Orthodontics.
- Restorations.
- Periodontics.
- Endodontics.
- Splint materials.

Types

Glass

Comments

- Glass slabs come in varying thicknesses and sizes.
- They may be cooled (e.g., stored in refrigerator) before use to provide longer working time for materials.

- This technique should not be performed in areas of high humidity.

Advantages

- Provides a smooth, sturdy working surface.
- Reusable.

Disadvantages

- Slab must be cleaned immediately after each mixing.
- Chemical residues may be present that could interfere with the mixing of the next chemical.

Paper

Comment

- Pad of wax-coated paper.

Advantage

- Disposable, one-time use; ease of cleaning: tear off and dispose of contaminated paper.

Disadvantages

- Must reorder and keep inventory.
- Some types of materials (glass ionomers) may pick up the wax coating on the paper pad.

Jiffy Tubes

Comments

- A jiffy tube is open wide at one end and drawn down to a fine delivery-tip point at the other end.
- The dental material is introduced into the open end, which is then pinched closed, forcing the material out of the fine delivery-tip point.

Use

- Restorative materials such as glass ionomers, liners.

Advantages

- Easy to use.
- Disposable; no clean-up after procedure.

Disadvantages

- Small size.
- A little messy in use.
- Requires more dexterity than with other products.

- Less control and pressure than with other restorative placement methods.

Curved-Tip Syringes

Comments

- Syringes with disposable curved tips (or needles) of several sizes and rubber plugs.
- The restorative material is pushed into the tubular base of the curved tip.
- The rubber plug is inserted.
- The syringe has a plunger on the shaft that advances the rubber plug into one of various size curved tips, forcing the material out of the tapered end (Centrix, Shelton, Conn.).

Use

- Placing restorative material.

Advantages

- Disposable delivery tips and rubber plugs.
- Can deliver with a fair amount of pressure.
- Creates a very fine, void-free, and controlled flow of restorative material.

Disadvantages

- Small volume of material that can be accommodated by the tip.
- Sets up quickly in the tubular tips.

Options

Plastic syringe

Advantage

- Less expensive than metal.

Disadvantage

- May be stained by materials.

Metal Syringe

Advantages

- More resistant to staining.
- Easier to clean than plastic syringe.

Disadvantage

- Slightly greater initial cost than plastic syringe.

Maintenance

- Cleaning with alcohol or other solvent.

EQUIPMENT AND INSTRUMENTS FOR ORTHODONTICS

Impression Trays

Comments

- Multiple sizes of impression trays are necessary (Fig. 2-31, A), because veterinary patients come in a variety of sizes and dimensions.
- Impression trays can be custom made by the practitioner or purchased as preformed trays.
- Styrofoam or paper cups should not be used. They do not provide enough stability.

Uses

- Orthodontics.
- Restorative and prosthetic dentistry (crowns and bridges).

Options

Custom Trays

Comment

- The practitioner may need to make custom trays to fit an individual patient because of the variations in width and length of a patient's mouth.

Disadvantages

- Time required to mix, shape, and cure the tray.
- Another skill to learn.
- For precision work (crowns and bridges), a tray should be made by the clinician and allowed to cure 24 hours before use to avoid distortion of the impression from polymerization (curing) of the impression tray.

Manufactured Trays

Comment

- Several companies manufacture trays that are shaped to fit dog and cat mouths.

Advantages

- Fit most patients.
- Fairly inexpensive.

Disadvantage

- Will not fit all patients; still need to have the ability to make custom trays, especially for the very large or wide mouth.

Maintenance

- Cleaning and disinfecting.

Trays Manufactured for Human Dentistry**Comment**

- Trays of various sizes and shapes are available for human dentistry.

Advantages

- Less expensive than veterinary version.
- Good when relatively small impression or an impression of only one tooth is required.

Disadvantage

- Will not fit the entire arch of most animal patients.

Accessory**Tray Adhesive**

- Improves the ability of the material to stick to the tray.

Rubber Mixing Bowls**Comment**

- Soft rubber bowls allow easy mixing and spatulation of alginate and dental laboratory stone materials (Fig. 2-31, *B*).

Advantages

- The flexibility of the bowl makes it easier to grasp and to position the material to be mixed.

- The bowls are easy to clean because once set up, alginate peels off the surface of the bowl, and once dried, laboratory stone also breaks free of bowl's surface.

Universal Cartridge Mixing and Delivery System**Comment**

- A pistol grip delivery system holds twin cartridge barrels to which are attached a single mixing tip designed to deliver consistently the correctly mixed two-part vinyl polysiloxane impression material into an impression tray.

Advantages

- Accurate mixture.
- Homogeneous mixture.
- Less mess.
- Sometimes short expiration dates.

Disadvantage

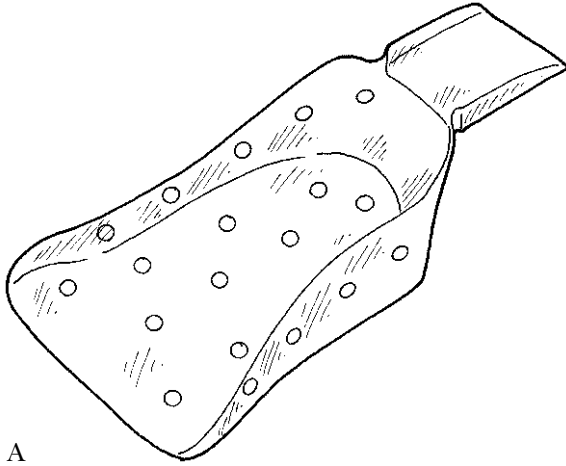
- Expensive.

Large Mixing Spatulas**Comments**

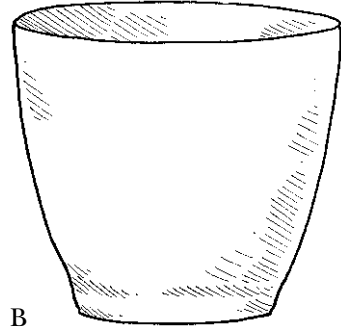
- Made of flexible plastic, nylon, or metal (Fig. 2-31, *C*).
- Also called *buffalo spatulas*.

Advantage

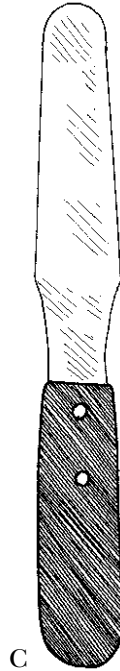- Convenient mixing of a large volume of material with the use of a large spatula and rubber bowl.



A



B



C

Fig. 2-31

Vibrators

Comments

- Vibrators aid in working with dental laboratory alginate and stone by removing bubbles or voids and facilitating flow of mixed material to the depth of the impression (Fig. 2-32, A).
- They are especially helpful for pouring model material into small impressions.

Uses

- Formation of uniform, homogeneous, void-free dental models for orthodontics.
- Formation of cast for crown and bridge restoration.

Advantage

- Without a vibrator, air bubbles may be trapped in the dental stone, particularly that of long, narrow canine teeth; these air bubbles may cause either model fracture or imperfections.

Maintenance

- The vibrator should be covered with a plastic bag or paper towel to prevent stone and plaster from damaging the unit.

Accessories

Model Trimmer

Comment

- An electric motor drives a circular grinding disc (Fig. 2-32, B). Water is circulated to remove ground plaster, and plaster residue is washed from the unit to a plaster trap beneath an adjacent sink's drain.

Use

- Trimming models for orthodontics and restorations.

Advantages

- Allows mounting of the model.
- Much more cosmetic appearance for client education.

Disadvantages

- Must be connected to plumbing and drain into sink. A plaster trap is recommended to prevent plugged pipes.
- Operation can be messy.
- Expensive.

Plaster Trap

Comment

- A receptacle to collect solids flushed down the drain (Fig. 2-32, C).

Advantages

- Prevents plumbing blockage.
- Is supplied with disposable liners.
- Can be installed by a household plumber.
- Can be purchased through dental supply distributors.
- Inexpensive.

Disadvantage

- Liner must be changed periodically, a messy chore.

Articulators

Comment

- Articulators are made of metal or plastic, with two flanges hinged together.

Use

- Hold casts of jaws in proper alignment during stages of prosthodontics or orthodontics.

Welders

Comment

- Compact, miniature arc welders solder or weld by electric current.

Use

- Allow veterinarian to custom make or repair orthodontic appliances in the office.

Advantages

- Increased control of the quality and design style of the appliance.
- Ability to perform table-side adjustments.

Disadvantage

- Expense and time required to learn to use this equipment.
- Not all veterinary dentists have the expertise.

Maintenance

- Replacement of carbon electrodes.

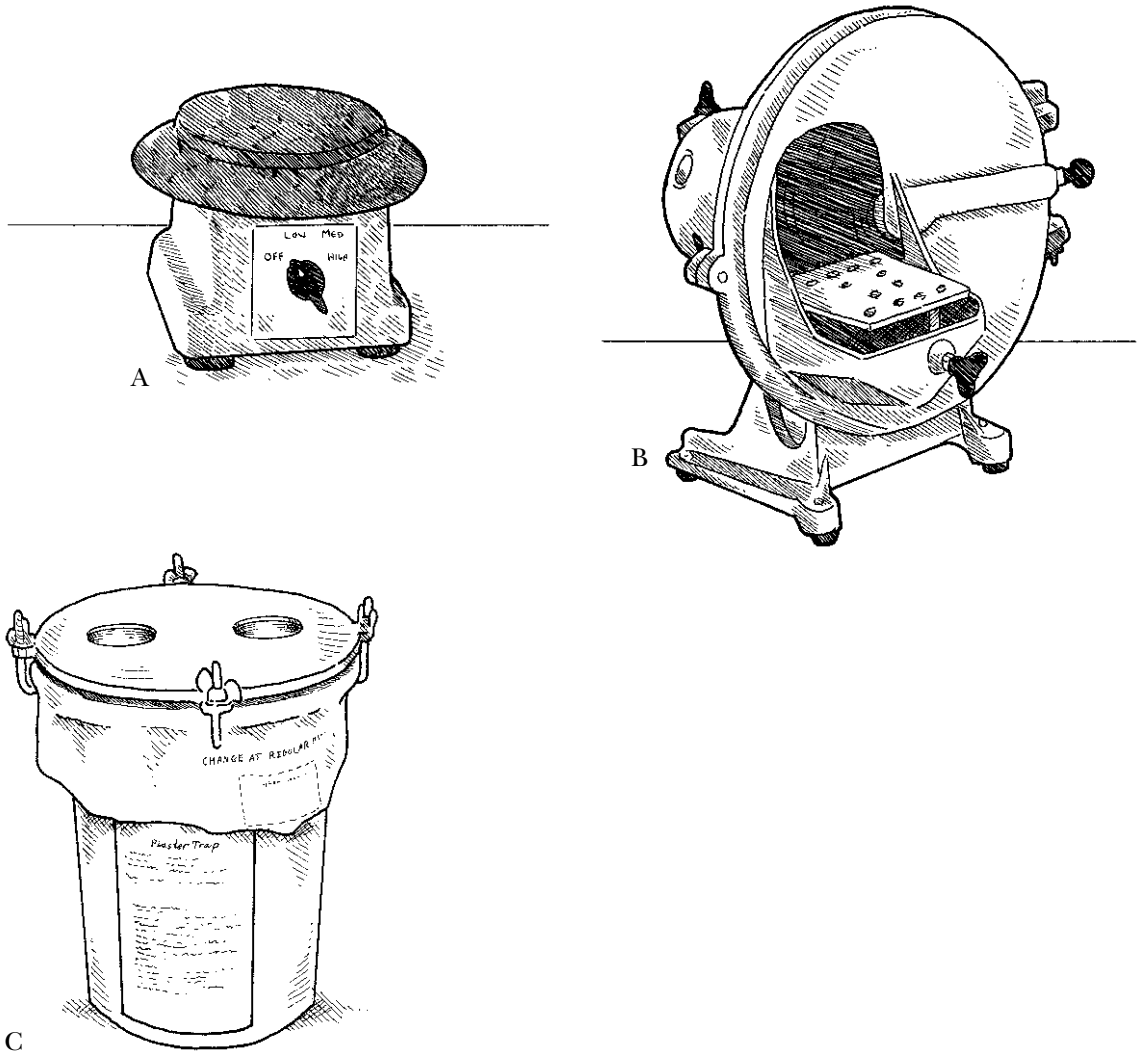


Fig. 2-32

Pliers

Comment

- Pliers are used to bend wire to create orthodontic appliances.

Uses

- Orthodontics.
- Oral orthopedic surgery.

Types

Howe Pliers

Comment

- Howe pliers are for holding wire and free-form wire bending (Fig. 2-33, *A*).

Use

- General use orthodontic pliers: may be used for gripping wire during placement or removal, seating bands, making adjustments to appliances, and other related tasks.

Bird Beak (Loop-Forming) Pliers

Comment

- Have one round tip for round bends and one flat tip for sharp, angular bends (Fig. 2-33, *B*).

Uses

- Bending orthodontic wire.
- Creating either a sharp or gradual wire bends.

Three-Prong (Triple-Beaked) Pliers

Comment

- Have a pair of prongs on one jaw and a single prong on the other jaw (Fig. 2-33, *C*). The single prong is centered to move between the paired prongs.

Uses

- Three-prong pliers bend by squeezing the wire between the pliers' jaws.
- Three-prong pliers are useful in adjusting wire, bending heavier orthodontic wire, and activating appliances.

Tweed Arch-Adjusting Pliers

Comments

- Have heavy, nonslip beaks (Fig. 2-33, *D*).
- Size limits use in the oral cavity; used mainly for laboratory work.

Use

- Holding and adjusting arch wires.

Tweed Loop-Forming Pliers

Comment

- Have various diameters at tip of one jaw (Fig. 2-33, *E*).

Use

- Forming loops.

Band- or Bracket-Removing Pliers

Comments

- Have a protective nylon cap over the longer beak; cap is placed on the crown of the tooth (Fig. 2-33, *F*).
- Shorter beak is a hooked, bladed jaw and is placed apical to the bracket or band to be removed. The pliers, when closed, will loosen and force the bracket or band coronally.
- Pliers may be used similarly to shear the remnants of the bonding cement off the tooth.

Maintenance

- The shorter hooked beak may require sharpening to provide better purchase on small bands.

Wire Cutters

Comments

- Wire cutters can be purchased from dental suppliers or local hardware stores less expensively than from orthodontic suppliers (Fig. 2-33, *G*).
- If they are not made of stainless steel, precautions should be taken to prevent rusting after cleaning.
- Orthodontic cutters are available in various styles and angulations for the wire cutting ends.

Accessories

Storage Trays

Comment

- For organization and visualization of instruments.

Boley Gauge**Comment**

- A caliper that is calibrated in millimeters (Fig. 2-33, *H*).

Use

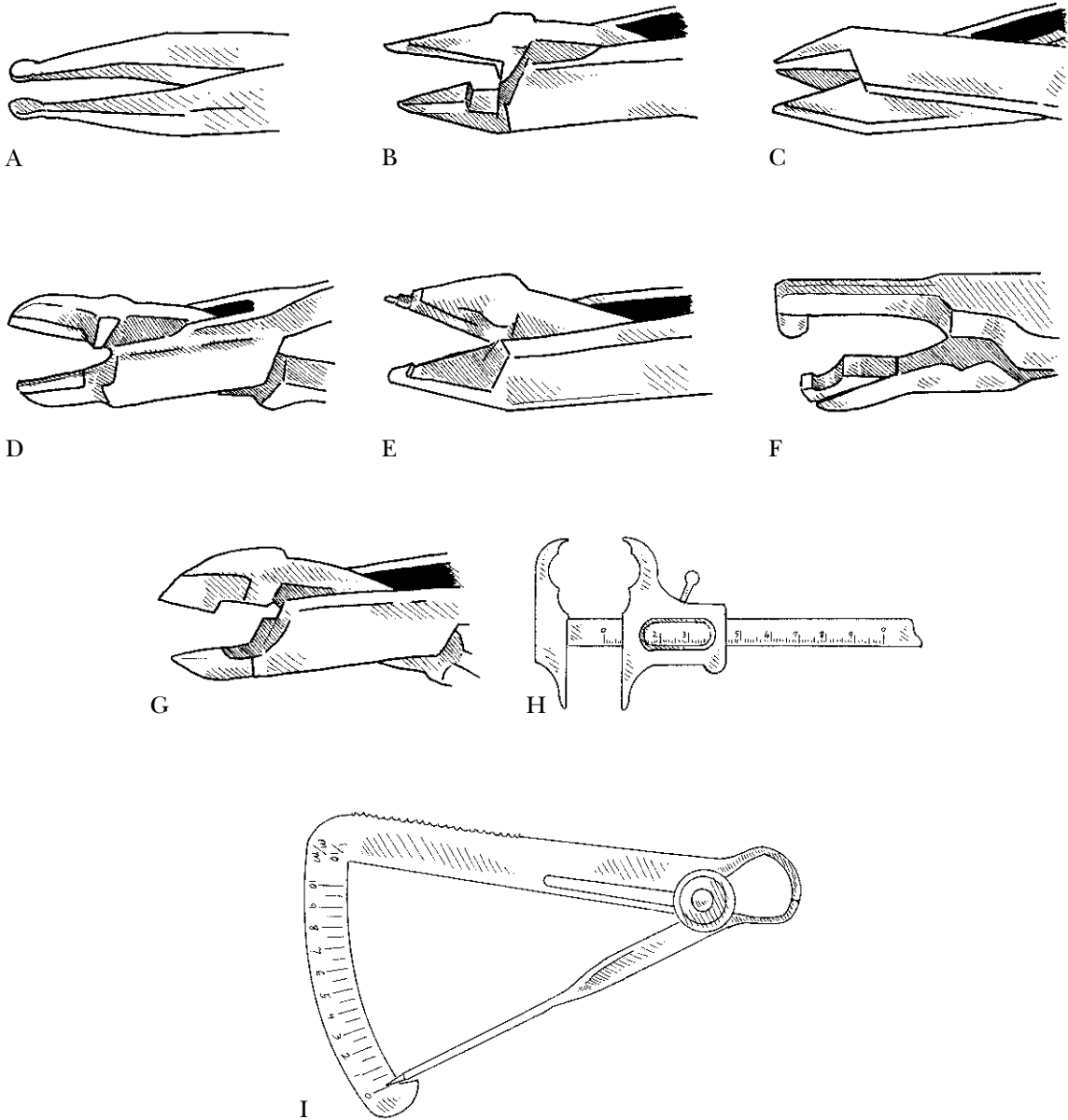
- Measurement of size of teeth.

Iwanson Spring Caliper**Comment**

- A caliper that is calibrated in millimeters (Fig. 2-33, *I*).

Use

- Measurement of teeth prepared for an artificial crown.

**Fig. 2-33**

Separating Endotracheal Tube

Comments

- It is often necessary to remove the endotracheal tube to check for occlusion when performing such procedures as crown therapy, orthodontics, and fracture repair.
- An alternative to removing the tube is to use a separating endotracheal tube such that the inserted portion of the tube remains in the mouth when the occlusion is checked quickly.
- Separating tubes are not available commercially and must be constructed by the user.

Advantage

- Quick and easy occlusal evaluation without the need to extubate.
- Can be replaced quickly.
- Reduced chance of trauma to the trachea.

Disadvantages

- Decreases the amount of area where the tube can be tied into the mouth.
- May be unintentionally disconnected within the mouth.

Constructing a Separating Endotracheal Tube

Step 1—Select two identically sized tubes (Fig. 2-34, *A*). One tube must have a functioning inflator cuff. The other tube is just a donor for parts.

Step 2—Carefully cut the functional tube 1 cm from the area where the cuff inflator hose joins the tube (Fig. 2-34, *B*).

Step 3—Remove the plastic connectors from the donor tube (Fig. 2-34, *C*). Cut off the wider portion that is inserted into the anesthetic hose and discard it (Fig. 2-34, *D*).

Step 4—Retain the smaller portion of the connector that inserts into the endotracheal tube and insert it, as a connector, between the two pieces of functional tube (Fig. 2-34, *E*).

Step 5—You now have a functional separating endotracheal tube that can be separated briefly to enable occlusal evaluation intraoperatively (Fig. 2-34, *F* and *G*).

Cautions

- The tube should be tied to the patient with the knot slid well down the functional endotracheal tube portion. Make sure the tube is well secured.
- To reduce the chance for complications, this arrangement should be used only to check for occlusion.
- The tube must be reconnected in a timely fashion or the patient will wake up.

REFERENCES

1. Williams CA: Dental equipment needs. Las Vegas, 1998, Western Veterinary Conference, pp 6-12
2. Grove K: Periodontal therapy. *Comp Cont Ed* 5:660-664, 1983.
3. Brine EJ, Manfra M, Pijanowski GJ, Siegel AM: Comparison of the effects of four different power scalers on enamel tooth surface in the dog. *J Vet Dent* 17(1):17-21, 2000.
4. Clinical Research Associates: *Sonic and ultrasonic scalers*, Provo, Utah, 1982, 6:1.
5. Loos B, Kiger R, Egelberg J: An evaluation of basic periodontal therapy using sonic and ultrasonic scalers. *J Clin Periodontol* 14:29-33, 1987.
6. American Academy of Periodontology: Position statement, sonic and ultrasonic scalers in periodontics. *J Periodontol* 71:1792-1801, 2000.
7. Hu-Friedy: *Smarten up, sharpen up*, Chicago, 1982, Hu-Friedy.
8. Parr RW, Pipe P, Watts T: *Periodontal maintenance therapy*, Berkeley, 1974, Praxis Publishing, pp 87.
9. Tholen MA: *Concepts in veterinary dentistry*, Edwardsville, Kan, 1983, Veterinary Medicine Publishing, pp 164.
10. Finkbeiner BL: Periodontal instruments. In Carter LM, Yaman P, editors: *Dental instruments*, St Louis, 1981, Mosby, p 4.
11. Hawkins BJ: *Periodontal disease therapy and prevention*, Philadelphia, 1986, WB Saunders, pp 835-849.
12. Miserendino LJ: Instruments, materials and devices. In Cohen S, Burns RC, editors: *Pathways of the pulp*, ed 6, St Louis, 1994, Mosby, pp 377-413.
13. Mendoza KA, Manfra M, Siegel AM, et al: Comparison of two heated gutta percha and seal techniques in canine teeth of dogs. *J Vet Dent* 17(2):69-74, 2000.

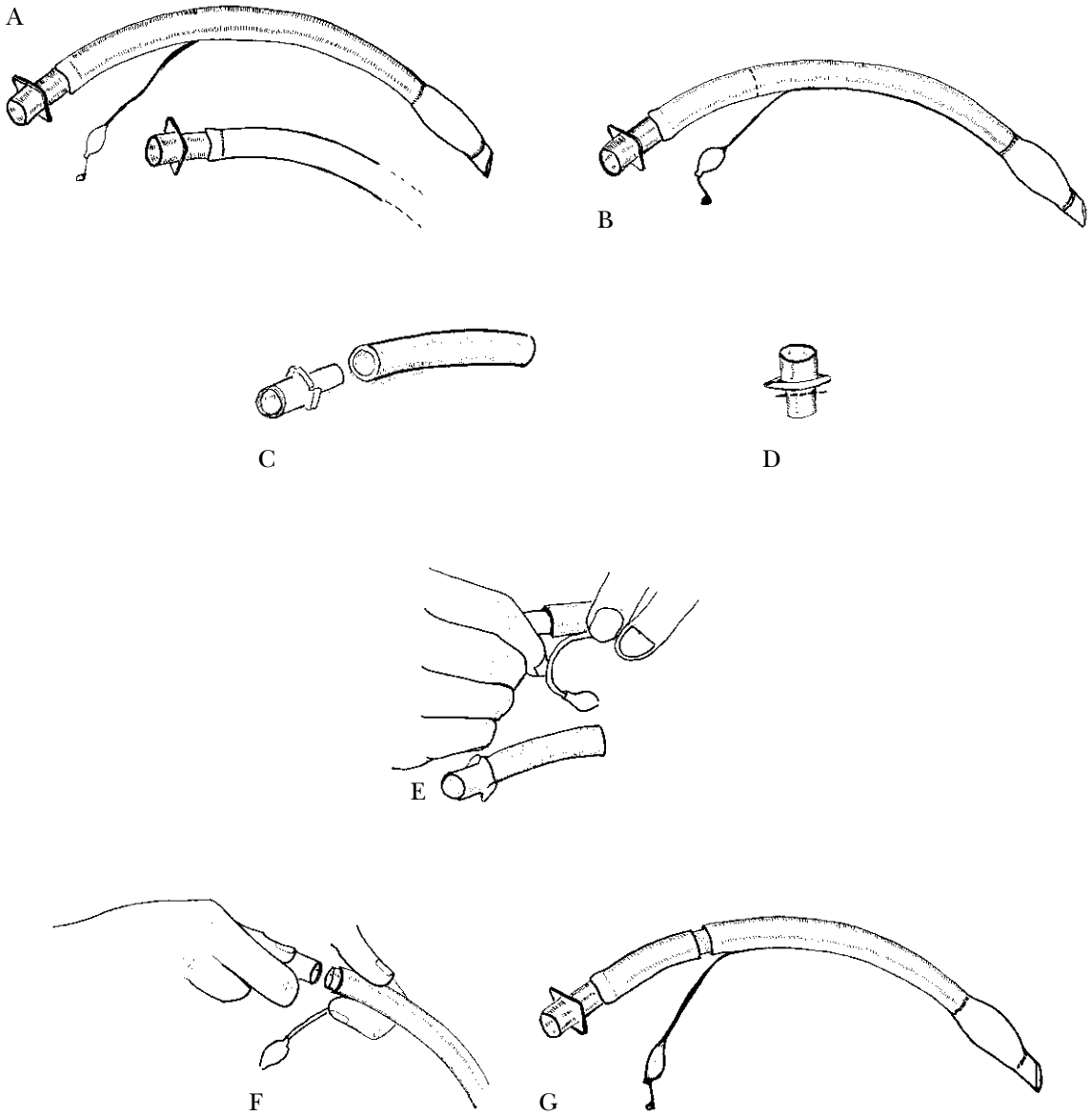
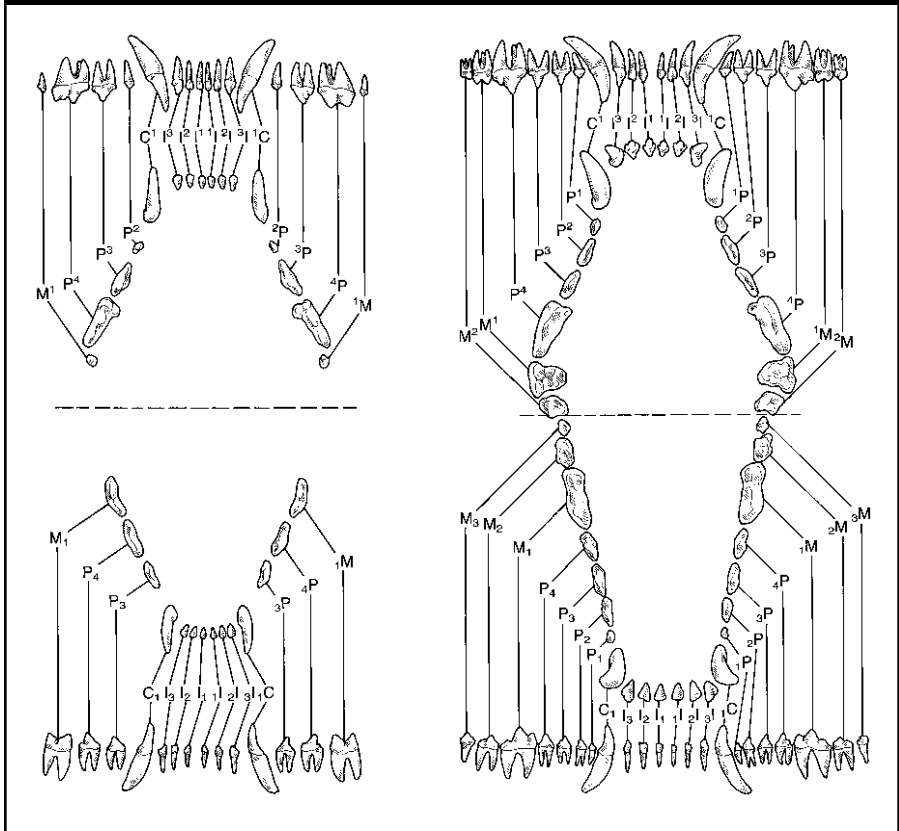


Fig. 2-34



DENTAL RADIOLOGY



In the United States during the 1970s, dental radiology was not incorporated routinely in the course of extractions and other procedures. During the 1980s, practitioners who were interested in performing at a more advanced level found that radiographs helped them. At first, the convenient method was to use the larger veterinary medical units in the office. As radiology was recognized as more useful, these enterprising veterinarians explored the practicality of purchasing human dental radiographic units. It quickly became apparent that a definitive diagnosis often was not made unless

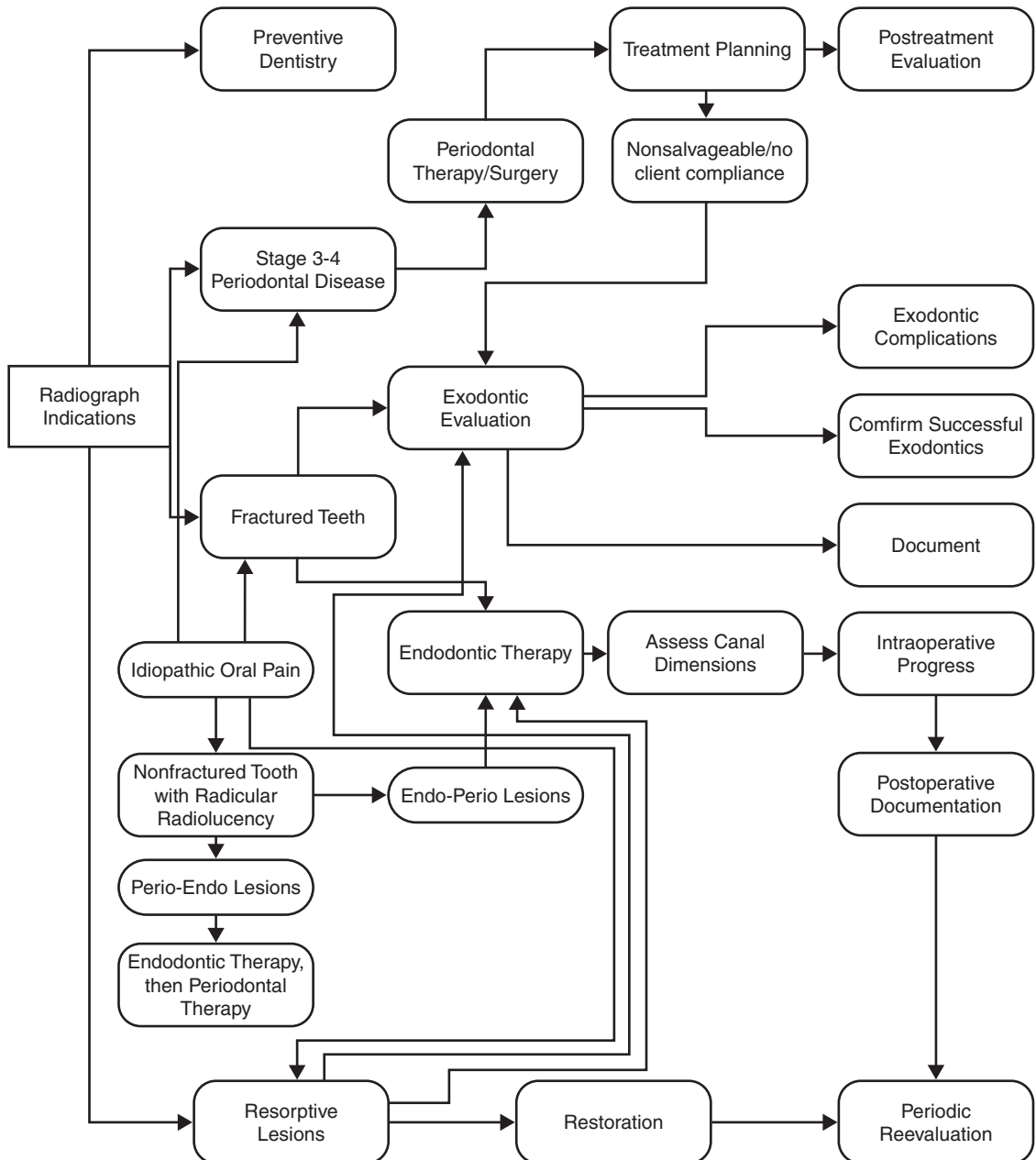
intraoral radiographs were taken. Dental radiography has now become an essential part of the veterinary dental diagnostic workup. The diagnostic yield of full mouth radiographs in feline and canine patients is high, and routine full mouth radiography is justified.^{1,2} These studies found that if disease existed, radiographs were clinically useful in 86.1% of the cases in the study (Tables 3-1 and 3-2). Follow-up radiographs may be required, and professional judgment should be used in determining the type, frequency, and extent of each radiographic examination.¹

Table 3-1 • **VALUE OF RADIOGRAPHS—NO CLINICAL FINDINGS PRESENT**

	<i>Dogs</i>	<i>Cats</i>
Incidental radiographic findings	41.7%	4.8%
Clinically important findings	27.8%	41.7%
Radiographs of no value	30.5%	53.6%

Table 3-2 • **VALUE OF RADIOGRAPHS—CLINICAL FINDINGS PRESENT**

	<i>Dogs</i>	<i>Cats</i>
Confirmational only	24.3%	13.9%
Additional findings	50.0%	53.9%
Clinically essential findings	22.6%	32.2%
No value	3.1%	0



NORMAL RADIOGRAPHIC ANATOMY¹⁻⁵

Normal and Abnormal

- Often, abnormalities observed on a radiograph can be confirmed or denied by examining a radiograph of the contralateral tooth or teeth.
- Bilateral symmetry suggests that the “pathological” finding may be a normal variant, the sequelae of a systemic condition, or a genetic condition.
- Periodic sequential radiographs often are indicated to evaluate the course of chronic disease.

Reading the Radiograph

- Before reading a radiograph, it is essential that the view box be clean and the fluorescent tubes be without black discoloration at the ends.
- A systematic approach should be taken when evaluating dental radiographs in order to interpret comprehensively and accurately everything on the film. It is helpful to orient the film so that it matches the orientation of the dental chart, with the cusps of the maxillary crowns pointing down and those of the

mandibular crowns pointing up. Additionally, films should be mounted so that the patient’s teeth on the right side are seen to the viewer’s left and the patient’s teeth on the left side are seen to the viewer’s right.

- Evaluate the technical quality of the film(s)
Step 1—Identify, in the radiographs, the presence of anatomical landmarks.

Step 2—Determine if all the necessary teeth and roots are visible.

- Identify pathology

Step 3—Start on one side of the radiograph and view each tooth, evaluating the normalcy of shape and radiopacity, as the examination progresses across the film.

Step 4—Evaluate the pulp chamber of every tooth for size and shape.

Step 5—Evaluate the level of the alveolar crestal bone surrounding the teeth and furcations, as well as the level and contour of interproximal crestal bone.

RADIOGRAPHIC FINDINGS

Structures Visible

- The following structures should be identified: crown, neck, pulp chamber, root canal, apex, periodontal space, dentinal wall, cortical bone, interradicular bone, furcation, and mandibular canal (Fig. 3-1).

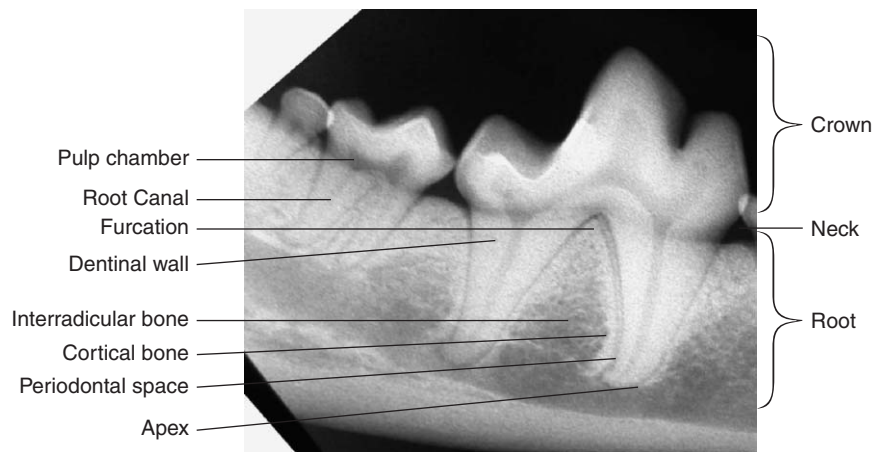


Fig. 3-1

Normal Young Patient

- In a young patient, the dentinal wall is thin and the pulp chamber is large.
- As the tooth develops, after apexogenesis is complete, odontoblasts that line the pulp chamber will produce secondary dentine. This will thicken the dentinal wall and reduce the size of the pulp chamber and root canal. The apex may be open, depending on the age of the patient.
- In the young patient, the dense cortical alveolar bone forming the wall of the socket appears radiographically as a distinct, opaque, uninterrupted, white line parallel to the long axis of the tooth root(s). This is known as the *lamina dura*.
- The radiolucent image between the lamina dura and the tooth root is the periodontal space and is known radiographically as the *lamina lucida*. It is occupied by the periodontal ligament.
- The trabecular pattern of interdental bone should also be studied (Fig. 3-2, A).

Normal Older Animal

- The dental radiograph of a healthy adult will show a decreased pulp canal size and increased dentinal wall thickness.
- With age, the lamina dura disappears.
- Generally, the width of the lamina lucida will become thinner.
- Although an apex is present, the apical delta or apical foramen usually is not seen.
- There may be thinning of the alveolar crest.

To summarize, the normal radiographic signs of aging are as listed below:

- Lengthening of the root
- Closure of the apical foramen.
- Progressive narrowing of pulp canal.
- Increasing density and coarseness of the trabecular pattern of supporting bone.
- More indistinct lamina dura.
- Narrowing of the lamina lucida, sometimes to the point of ankylosis.
- Slight regression of the alveolar crest (Fig. 3-2, B).

General Comment

- Dental radiology, using intraoral film, can be performed by all practitioners.

Indications

- In young patients, to evaluate the presence and nature of unerupted, embedded, impacted teeth or supernumerary teeth.
- During prophylactic or therapeutic teeth cleaning (periodontal debridement), to evaluate the extent of periodontal disease by measuring bone loss and to assist in treatment planning.
- In patients with a parulis (fistula), as a diagnostic tool.
- Intraoperatively, during endodontic therapy, to facilitate evaluation of therapy and to study radicular health and size before, during, and after endodontic therapy, including periodic reexaminations.
- In patients with visually missing teeth, to ascertain the condition, e.g. potentially impacted teeth or areas of spontaneous resorption in roots or unerupted teeth.
- In all types of dental and oral disease, to document and study the progress of therapeutic programs.
- In patients with discolored, worn, or fractured teeth, to evaluate pulp health and root end pathology.
- In cases in which neoplasia or metabolic disease is suspected, to evaluate the involvement of teeth and bone.
- In oral trauma, to evaluate the injury in detail.
- Before or during extractions, to evaluate root and supportive bone structure before extraction and to verify the complete removal of root tips or the location of retained root tips.
- Evaluation of suspected oral neoplasia.
- Evaluation of developmental anomalies.
- Evaluation of root changes seen with canine and feline resorptive lesions or true dental caries.

Contraindications

- Critically ill patients in whom the risk of anesthesia is so great that the risk of treatment will not be justified.
- Clients declining the service.

Objective

- To obtain a radiograph with fine detail that permits accurate interpretation of the patient's condition.

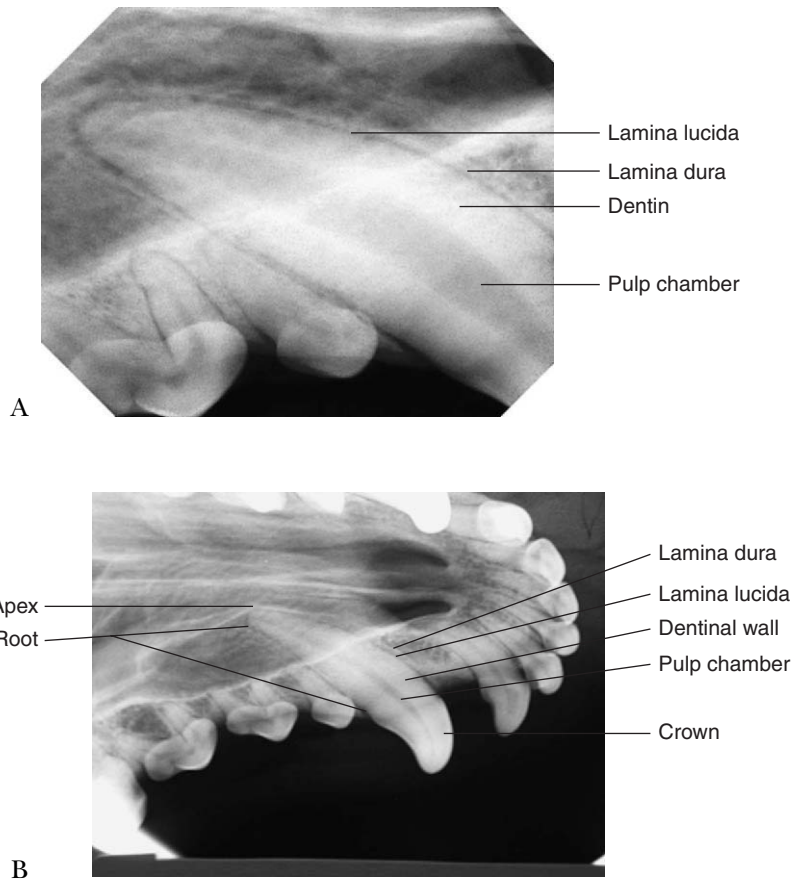


Fig. 3-2

Radiographic Units

Medical Radiographic Unit

- A medical radiographic unit can be used to obtain extraoral and intraoral films, but its use is limited due to the restricted movement of the radiographic head and because the unit is located distant from the dental operator, thus requiring the patient to be brought to the machine for each film desired.
- When a medical radiographic unit is used, having the ability to adjust the focal distance and angle of the head is preferred. A focal film distance of approximately 12 inches is preferred, coning down with an adjustable collimator, as appropriate, to reduce scatter.
- The parallel and bisecting angle techniques can be used with a medical radiographic unit. They require, with each film, repositioning the patient with foam wedges and sandbags to achieve the proper alignment with the primary beam.
- To achieve a bisecting angle technique of the caudal maxillary teeth, the patient is placed in sternal recumbency, with the nose supported so that planum nasale is parallel to the table surface. The patient is then rotated obliquely 45 degrees, dental film is placed intraorally, and the radiographic head is adjusted until the primary beam is directed appropriately over the area of interest (see the later section titled Bisecting Angle Technique). The opposite side is taken similarly by rotating the patient in the opposite direction. Anterior maxillary views using the bisecting angle technique are taken with the patient in sternal recumbency, as with the caudal maxillary views, with the film in the mouth. Preferably the radiographic head is tilted approximately 45 degrees, pointing ventrocaudally, and collimated to the appropriate dimensions. The primary beam should be approximately 45 degrees to the plane of the palate.
- Caudal mandibular views are taken on either side by placing the patient in lateral recumbency, with the film placed intraorally lingual to the mandibular teeth to be viewed. This is often a parallel view so the radiographic beam is centered over the area of interest and collimated to limit the x-rays to the space occupied by the film.
- To obtain a rostral oblique mandibular bisecting angle view, the patient is placed in dorsal recumbency with the top of the muzzle parallel to the table and then rotated obliquely 45 degrees. The film is placed intraorally, as close to parallel to the lingual surface of the

tooth as possible, and the positioning is adjusted until the beam is directed appropriately in a buccoventrolingual direction. The rostral mandibular bisecting angle view of both canines and incisors is taken similarly, with the patient in straight dorsal recumbency. The primary beam will be directed rostrodorso-caudally at an angle of approximately 20 degrees from vertical.

- Each medical radiograph unit will have different technique ranges. A starting point is 100 mA, 65 kilovolt peak (kVp) at $\frac{1}{10}$ second. When the kVp is too low, the result is low density with high contrast. The film will be light and the kVp or the time needs to be increased. When the kVp is too high, the result is high density and poor contrast. The film will be dark and the kVp or the time needs to be decreased. It is necessary to achieve a proper balance between kVp and mA. Practice with a study skull to try several combinations until the most desirable exposure is achieved.

Dental Radiographic Unit

- A dental radiographic unit can be purchased new (or sometimes used from dentists or from dental supply warehouses). It can be wall mounted in the dental area or mounted on a mobile floor stand. It has a compact, rotating, and swiveling tube head, with a multiple jointed cantilevered arm for maneuverability.
- Dental radiograph units are available, varying from 70 to 85 kVp and 7, 10, or 15 mA with several time-exposure capabilities. These units are very versatile and produce a more detailed image due to a smaller focal spot and a fixed focal distance.
- The newest dental radiograph machines are designed to use direct current instead of alternating current power to generate the x-ray beams. This gives greater contrast and less soft radiation to the tissues. These machines are digital and have a programmable keypad. Some of the keypads have diagrams of tooth types and large, medium, and small dog and cat options to choose from for the time exposure that is most appropriate.
- Suggested technique chart using Ultraspeed (type D) film with a 7-mA output and direct current generator.
- If using alternating current, increase time slightly. Upper fourth premolar will use the same technique as the upper molar (Tables 3-3 and 3-4).
- Current state health laws require and, hence, the newer machines have lead-lined or

Table 3-3 • 60 kV (MAXIMUM IMAGE CONTRAST)

	<i>Small dog or cat</i>	<i>Large dog</i>
Incisor	0.25 second	0.4 second
Canine	0.25 second	0.4 second
Premolar	0.32 second	0.5 second
Lower molar	0.4 second	0.63 second
Upper molar	0.5 second	0.8 second

Table 3-4 • 70 kV (MAXIMUM GREY LEVEL DEFINITION)

	<i>Small dog or cat</i>	<i>Large dog</i>
Incisor	0.125 second	0.2 second
Canine	0.16 second	0.25 second
Premolar	0.2 second	0.32 second
Lower molar	0.25 second	0.4 second
Upper molar	0.32 second	0.5 second

aluminum-lined cylindrical pointing devices to further reduce scatter radiation. This is an important feature to consider if purchasing a used machine. The ease of using a dental radiographic unit and its proximity to the procedure will encourage taking more radiographs, thereby providing a higher percentage of accurate diagnoses and a better service to the patient and client.

- Some machines have timers that are indicated in fractions of seconds. Other machines use “pulses” as an indication for time. One pulse equals $\frac{1}{60}$ second.

Materials

Film

- Intraoral radiographic film is inexpensive, small, and flexible, fitting well into the oral cavity and conforming to the area placed (Table 3-5). Intraoral film is nonscreen film, which provides greater detail than the larger high-speed cassettes used in most veterinary general medicine situations. Intraoral film can be processed in 1 to 2 minutes with fresh rapid developer and fixer solutions, and there is minimal loss of detail. It can also be processed in 2 to 4 minutes in dental automatic x-ray processors. Using this film, small areas of interest can be isolated and superimposition of anatomical structures avoided.

Table 3-5 • FILM SIZES

<i>Size</i>	<i>Measurement</i>	<i>Ultraspeed (type D)</i>	<i>Ektaspeed (type E)</i>
Periapical			
0	$\frac{7}{8} \times 1\frac{3}{8}$ inch	DF-54	EP 01
1	$\frac{15}{16} \times 1\frac{9}{16}$ inch	DF-56	EP 11
2	$1\frac{1}{4} \times 1\frac{7}{8}$ inch	DF-58	EP-21
Occlusal			
4	$2\frac{1}{4} \times 3$ inch	DF-50	EO-41

Each film packet has lead foil backing that reduces fogging and scattered radiation.

- Ultraspeed (D-speed) film is used most commonly because it provides greater detail and is less grainy, although it requires twice the exposure time as Ektaspeed (E-speed) film to produce a comparable image (Eastman Kodak, Rochester, NY). When taking radiographs of giant breed dogs with a dental radiographic unit, it may be helpful to use Ektaspeed film to achieve the x-ray penetration of thicker bone without increasing the exposure time. Kodak InSight⁶ Intraoral Dental Film (F-speed) reduces radiation dosage to a lower level than Ultraspeed or Ektaspeed. It also delivers excellent image quality because it provides better contrast and is therefore superior to the E-speed and D-speed films.⁶

Film Identification

- When taking intraoral radiographs, it is important to be able to identify easily which patient they belong to. Several methods of film identification can be used, depending on the clinician's preferences.

Identification Methods

- An indelible ink pen to mark the client and patient identification directly on the radiograph.
- A radiograph marking pen that writes in white to mark the client and patient identification on the dry film.
- A small press-apply radiopaque number that correlates in a log to a specific client and patient, placed on the outside of the film packet before film exposure.
- Plastic or cardboard film mounts that are made for the various film sizes are available through dental suppliers. Client and patient identification and other pertinent information can be written on the film mount. Pre-

sized punches are available to make cutouts for custom made cardboard holders.

- Small envelopes, with client and patient identification on the outside, to hold one or more films.
- Whole mouth surveys can be placed in proper orientation (see the following sections titled Whole Mouth Survey) and taped in 8½- by 11-inch plastic cover sheets for easy viewing and storage.

Identifying Right and Left Sides

- All intraoral films have a small depressed dimple in one corner of the film. It is visible and palpable on both the film and film packet. The side with the raised dimple is called the “dot” and faces the x-ray beam when the film is placed in the mouth.
- One technique is to place the dimple side of the radiograph on the patient’s right in the mouth. When the radiograph is mounted in normal alignment, as when the teeth are radiographed with the raised dot facing you, it will be easy to tell whether the tooth is on the right or left. This is only effective if the entire staff adheres flawlessly to the protocol.
- Identification is still possible for personnel who forget to be consistent with dimple position. To do this, the raised side of the dot is found and oriented so that the convex side of the dimple (the “dot”) faces the viewer while viewing the film. The film is placed in proper alignment with the maxilla or mandible (tooth crown appropriately down or up respectively). Next, the film is oriented with proper alignment of the teeth rostral to caudal. The orientation of the teeth on the film will match the patient’s chart, as seen when the clinician faces the patient that is, in turn, facing the clinician. The right side of the film will be the left side of the patient. In this way, the view that corresponds to the dental chart can be achieved by placing processed films in plastic mounts or plastic sheets, with the dot facing the viewer and with the films of the patient’s right side on the viewer’s left and films of the patient’s left on the viewer’s right, Incisor views are mounted, when the mount is so designed, in the middle. This will reduce charting errors when transposing information from the film to the chart.

Film Storage

- Individual film envelopes or envelopes holding film mounts can be placed in the patient record or stored in a separate radiographic filing system. The patient’s current dental films are stored with its past dental films, so that the course of its dental history can be accessed easily for review. Dental radiograph logs are helpful in retrieving past films, with number identification placed in the chart. To avoid losing these small dental films, it is best to file intraoral films separately and not with the large cassette-size radiographs of the same patient.

TAKING AN INTRAORAL RADIOGRAPH^{4,5,7-10}

General Comments

- Keep the distance from the subject to the film as short as possible.
- Use D-, E-, or F-speed film.
- The side of the film packet with the raised dot is placed facing the x-ray beam.
- Use a radiographic unit with as small a focal spot as possible.
- Collimate to the area of the subject needed.
- Process the film carefully after exposure.

Step 1—The patient is positioned appropriately for the radiograph to be taken.

Step 2—The intraoral film is placed in the proper position. As a supportive aid in positioning the film, a mouth gag, special film wedge, gauze sponge, or other object can be placed behind the film. A tongue depressor can be placed under occlusal size film to prevent bending of the film over the endotracheal tube in maxillary views if the patient is placed in sternal recumbency.

Step 3—The cylinder of the x-ray machine head is centered over the area of interest and placed as close as possible to the structure being evaluated and positioned for the study. If using a medical radiographic unit, a focal distance of 12 inches is maintained from the film to the surface of the collimator.

Step 4—The appropriate milliamperage, kilovolt peak, and time are selected.

Step 5—The film is exposed.

Step 6—The film is developed (see the later section entitled Radiographic Developing).

CAUTION: Personnel should adhere to state public health and Occupational Safety and Health Association (OSHA) safety regulations. This includes wearing exposure monitors, protective apparel, or being at a safe distance from the x-ray machine or standing behind a protective screen, as appropriate.

Whole Mouth Survey: Small Dog or Cat⁹

- Typical study includes:
One view: maxillary incisors and canines; anterior bisecting angle technique.
Two views (right and left): maxillary premolars and molars; lateral bisecting angle technique for each side.
One view: mandibular incisors and canines; anterior bisecting angle technique.
Two views (right and left): mandibular premolar and molar teeth; parallel technique for each side.
- Typically, six views may complete the study. Additional views and films may also be required, depending on the disorder involved. It is often helpful to take multiple views when questioning whether a finding is pathology or merely an artifact. Anterior oblique, posterior oblique, and occlusal views can be taken in addition to a whole mouth survey or individual study.
- The parallel technique is the most accurate, because it follows the principle of accurate shadow writing, in which the projected shadow of an object from a light source resembles the height of the object most accurately. If the angle between the film and the structure to be radiographed is greater than 15 degrees, then the x-ray beam should be directed according to the bisecting angle technique.

Whole Mouth Survey: Large Dog⁹

- Typical study includes:
One view: maxillary incisors and canines; anterior bisecting angle technique. Two views (right and left): maxillary rostral premolars and canine tooth; lateral bisecting angle technique for each side.
Two views (right and left): maxillary caudal premolars and molar teeth; lateral bisecting angle technique for each side. In dolichocephalic dogs, especially in large breeds such as the Collie or Borzoi, oblique bisecting angles are often needed to isolate and visualize well the right and left canine teeth alone. With these breeds, sometimes it is necessary to take two views, at slightly different angles, to accurately visualize the incisors in one film and the canines in the second film.
One view: mandibular incisors and canines; anterior bisecting angle technique.
Two views (right and left): mandibular anterior premolars and canine tooth; lateral bisecting angle technique for each side.
Two views (right and left): mandibular posterior premolar and molar teeth; parallel technique for each side.
- Typically, 10 views are required for large dogs, and additional views may be needed for giant and large dolichocephalic breeds.

Specific Intraoral Radiographic Techniques

Parallel Technique

Indications

- Radiographs to evaluate the posterior mandibular teeth, especially in large dogs, where the vestibule is deep.
- Evaluation of the facial maxillary complex and nasal cavity.
- Occlusal view of caudal maxillary or mandibular teeth.

Contraindications

- Any location where the film cannot be placed parallel to the structure being radiographed. If the angle between the film and the long axis of the structure is greater than 15 degrees, a bisecting angle technique should be used.
- Any area where other structures would be superimposed onto the film. An example might be when teeth are crowded and rotated, requiring a unique positioning technique.

Objective

- To take a radiograph when the long axis of the tooth or structure being evaluated is parallel to the radiographic film and perpendicular to the primary x-ray beam. The parallel technique is the most accurate, because it follows closely the principle of shadow writing.

Technique

- The film packet is placed parallel to and close to the structure being radiographed. The plane of the film should be parallel to the plane through the long axis of the structure (Fig. 3-3, *A*). In radiographing the teeth in the caudal mandible, the film needs to be placed so that the edge of the film can be felt below the ventral border of the mandible.
- The position-indicating device (cylinder) is centered over the desired teeth in the study to avoid cone-cutting.
- The head of the machine is placed as close to the film as is practical, and the x-ray beam should be perpendicular to the long axis of the structure being radiographed (Fig. 3-3, *B* and *C*).

Complication

- In many areas of the mouth, it is not possible to place a film parallel because of anatomical interference.

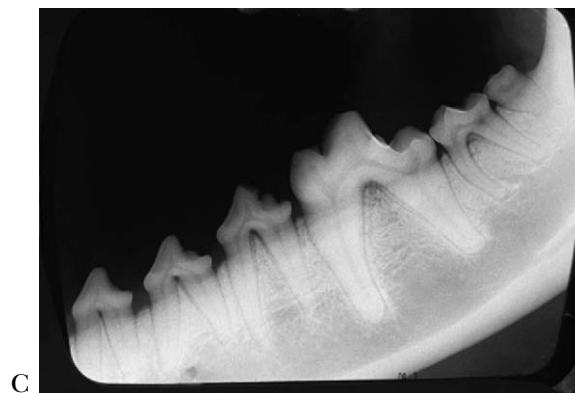
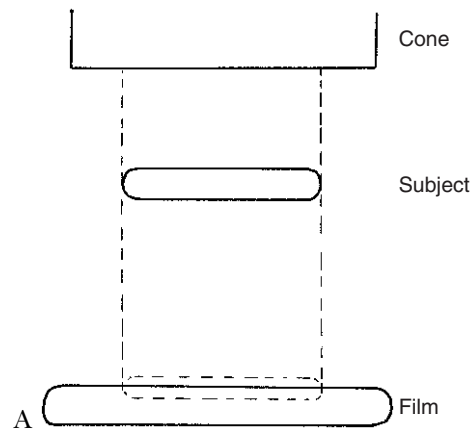


Fig. 3-3

Bisecting Angle Technique

General Comments

- Ideally, all exposures should be made using the parallel technique. However, in the mouth, few areas physically accommodate this technique. This is a more common problem than in people, because in cats and dogs the palate is not vaulted and the mandibular vestibule is often more shallow than in people.
- The bisecting angle technique is an application of the geometric principle of equilateral triangles: if two triangles share a side and both triangles have an equal angle at their apex, then the opposite sides are the same length.
- The caudal maxillary dentition is the most difficult to radiograph with intraoral techniques.

Indications

- Bisecting angle technique is used when parallel projections are not possible.⁹
- Posterior portion of the maxilla (Fig. 3-4, *A* and *B*).
- Anterior portion of maxilla, including incisors and canines (Fig. 3-4, *C* and *D*).
- Maxillary canines. The cone is positioned at 45 degrees from the anterior and 45 degrees from the lateral. This photograph illustrates the positioning of the cone from the lateral view (Fig. 3-4, *E*). The next photograph illustrates the position of the cone from the anterior view (Fig. 3-4, *F*).

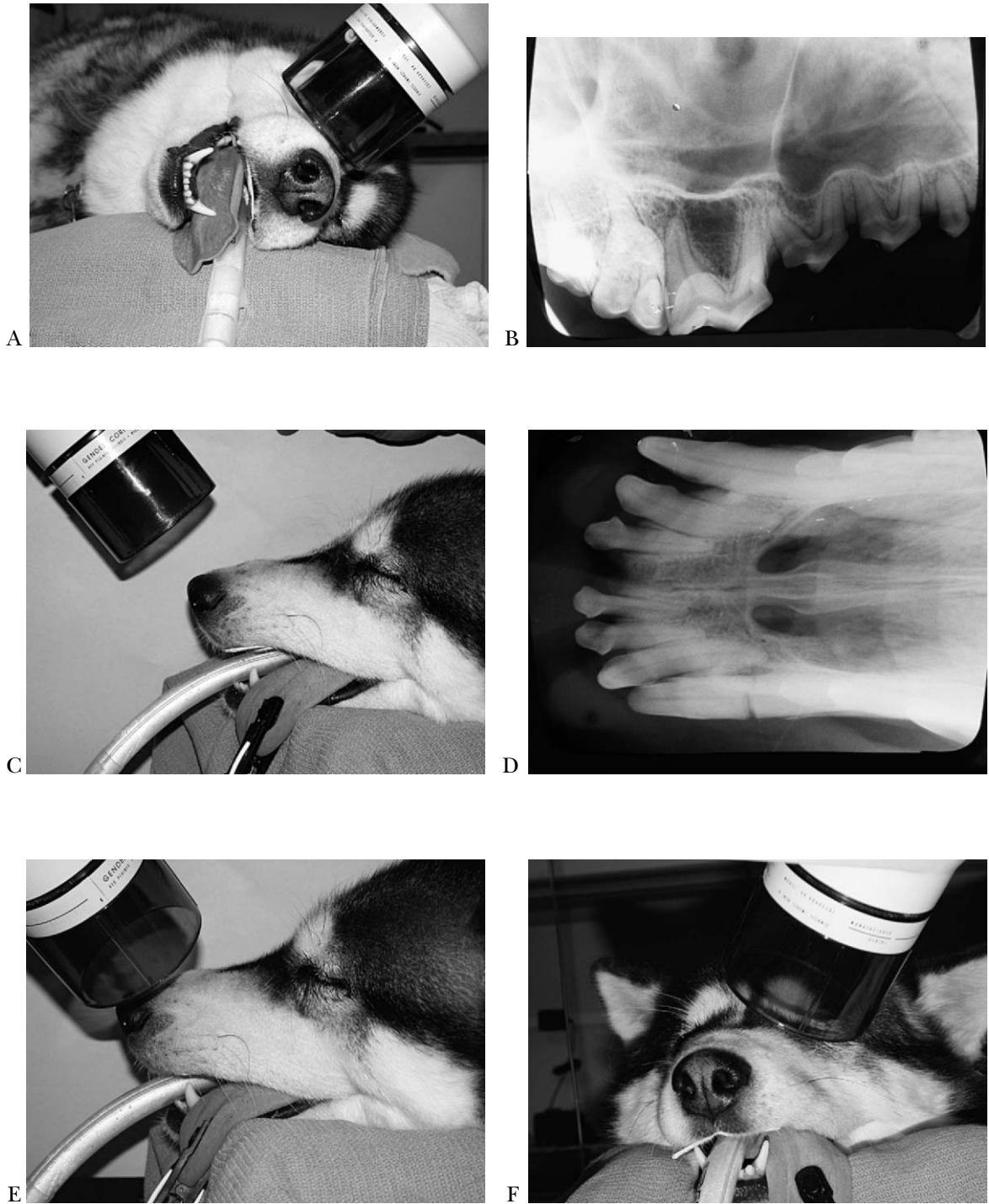


Fig. 3-4

- The resulting image isolates the canine tooth, and in this case the tooth has been fractured (Fig. 3-5, *A*).
- Mandibular incisors and canines (Fig. 3-5, *B* and *C*).
- Posterior portion of the mandible may be radiographed with the bisecting angle technique if the parallel technique cannot be achieved.

Advantage

- In developing a reproducible technique, the course of disease can be followed periodically by comparing periodic sequential radiographs taken with the same positioning technique.

Contraindication

- If parallel projections can be used, they are easier to produce and have less distortion.

Objective

- To obtain an accurate representation of the tooth.

Technique

- The angle formed between the radiographic film and the structure to be radiographed is created, and an imaginary line bisecting this angle is visualized (Fig. 3-5, *D*).
- The head of the machine is positioned so that the x-ray beam is perpendicular to the imaginary bisecting line. When learning this technique, it is often helpful to use props, such as three cotton tip applicators with one end taped so that the angle and bisecting angle can be created, to help visualize the proper radiographic projection.
- As a general rule, place the film parallel to the hard palate, being sure to catch the entire crowns of the teeth being studied, and aim the x-ray beam at a 45-degree angle to the hard palate on maxillary projections. The cone must be centered so that the caudal edge is level with the mesial root of the third premolar to ensure that the entire length of the maxillary canine roots are exposed in the rostral and rostral oblique views. The film must also be placed far enough in the mouth to avoid the cone visually cutting off the root ends.

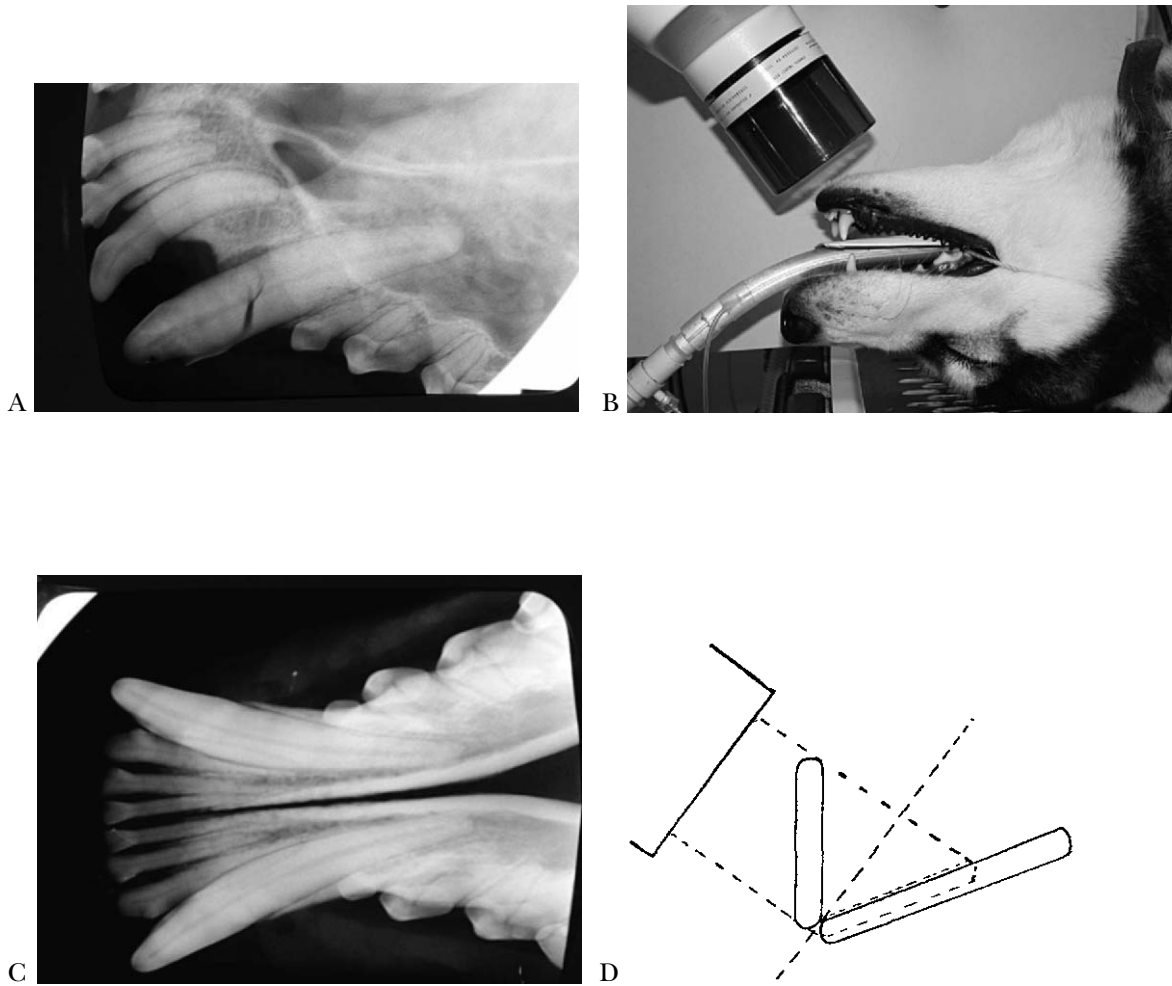


Fig. 3-5

Complications

- The most common problems are: (1) not achieving a true bisecting angle, (2) not aiming the x-ray beam perpendicular to the bisected angle, and (3) not aiming the primary beam at the intended target, the root end. This may create foreshortening (Fig. 3-6, *A*) or elongation (Fig. 3-6, *B*).
- Another error is to concentrate too much on the crown, placing the film too far out of the mouth and missing the apices of the roots. The radiograph should include at least 3 mm of periapical bone.

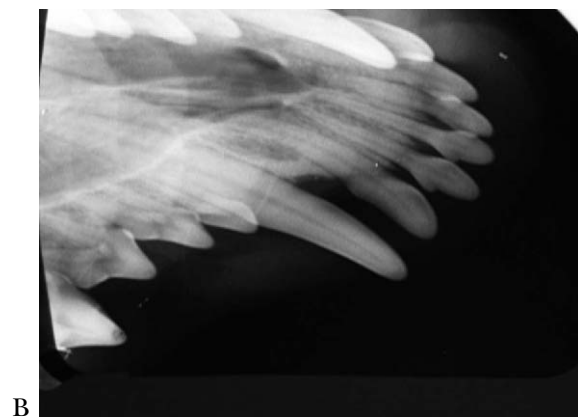
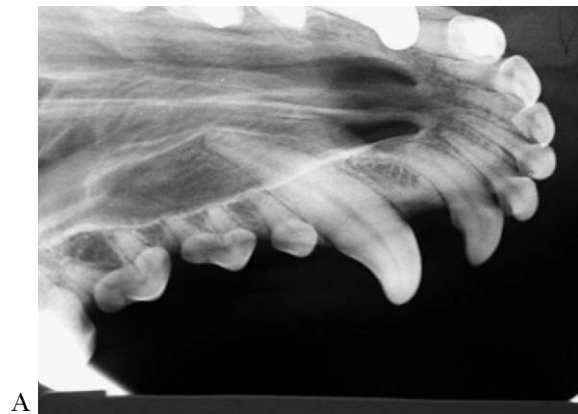


Fig. 3-6

Extraoral Use of Intraoral Film

- The extraoral technique can be useful when obtaining a radiograph of the caudal maxillary teeth.
- Superimposition of the opposite arch can be avoided and greater detail is obtained by placing the film just under the maxilla and by using nonscreen intraoral film, instead of using screened film in a high-speed cassette.
- The technique is also very useful in evaluating the maxillary fourth premolars in cats. In cats, the overlying zygomatic arch can cause obscuring of the fourth premolars by superimposition artifact.

Technique

- The patient is placed in a dorsolateral recumbency position, with the side of interest closest to the table.
- The mouth is held open as wide as possible with a radiolucent foam block or other object, such as a syringe case.
- The intraoral film is placed on the table beneath the area of interest.
- The mandible is lifted appropriately, to orient the plane of the quadrant parallel with the table top, with a roll of gauze or other padding.
- The goal is to make sure the side of interest is not obscured (Fig. 3-7, *A*).
- The x-ray beam is directed perpendicular to the film (Fig. 3-7, *B* to *E*). Films must be marked “right” or “left” because the raised dot rule of right and left is now reversed. Occlusal film (#4) can also be used for extraoral views and then orient with the raised side of the dimple away from viewer but film or mount still needs to be appropriately marked to reflect this alternative technique.

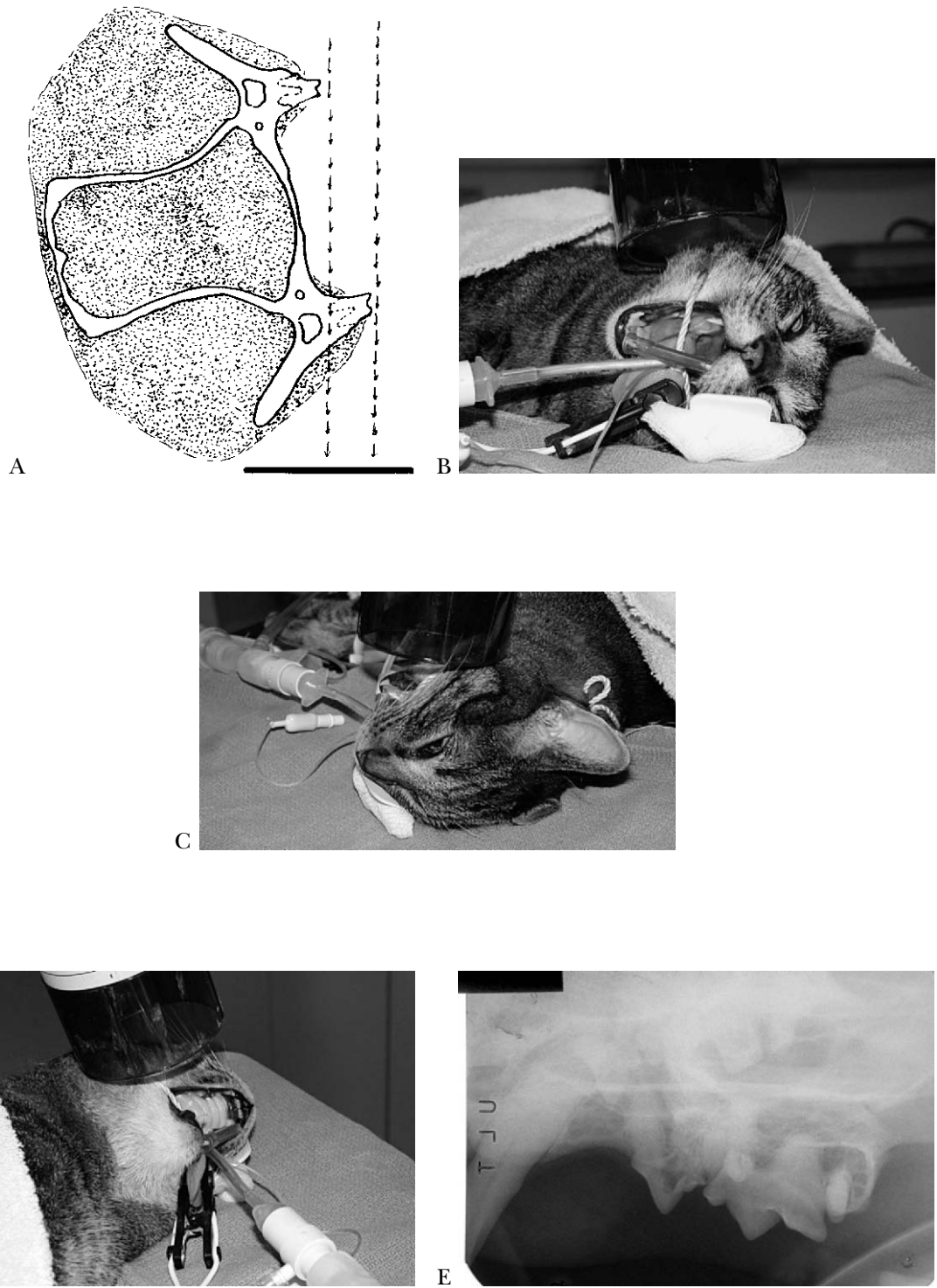


Fig. 3-7

Complications of Radiographic Technique

- Improper exposure settings.
- Limitations imposed by the radiograph machine.
- Placing the film incorrectly beneath the patient's mouth. The raised dot side of the film being placed down, away from the beam, will result in exposure through the lead barrier, creating a lighter exposure with a stippled, or tractor tread-like, appearance.
- Having the film placed improperly, so root ends are off the film, particularly in large dogs.
- Cone-cutting creates lack of exposure of desired tooth parts by not having the circumference of the cone centered directly over the desired area.
- Incorrect identification of right and left, either by the person mounting the film, or by the one taking and reading it. This problem is intensified when doctors mail or e-mail inadequately identified views for expert interpretation.
- Incorrect film placement or inaccurate aim of primary beam when placing small film extraorally.
- Inability to identify structures accurately, particularly when evaluating maxillary fourth premolar palatal and mesiobuccal roots. A second film is then taken, with the x-ray beam in either anterior or posterior oblique position. This creates an anterior oblique or posterior oblique projection. The structure that is more lingual (palatal root) will be

shadowed on the film closest to the direction the x-ray beam is coming from. The structure that is more buccal (mesiobuccal root) will be shadowed the farthest from the x-ray cone (Fig. 3-8, *A*). This phenomenon can be remembered by the "SLOB rule" acronym (same lingual, opposite buccal). Another word device is "facial farthest, lingual least." Diagrammed is the maxillary fourth premolar with anterior oblique (Fig. 3-8, *B*), lateral (Fig. 3-8, *C*), and posterior oblique (Fig. 3-8, *D*) views and root positions identified. *A*, mesiobuccal root; *B*, mesiopalatal root; *C*, distal root.

Radiation Safety

- To minimize radiographic exposure to personnel, it is best if the patient is anesthetized or heavily sedated so it can be positioned and the dental worker can leave the area or be a safe distance (usually 6 feet) from the tube head.
- If there is a need to take a radiograph of an awake patient, personnel should wear full protective covering, including aprons, thyroid protectors, eye shields, and gloves. A hemostat clamped to the film can be used to position the film in the patient's mouth if normal bite positioners are ineffective. The authors of this text do not recommend this technique, but newer dental radiographic units with lead-lined cylinders make awake radiograph positioning safer with less scattered radiation. A dosimeter badge or ring should be worn by personnel and monitored routinely.

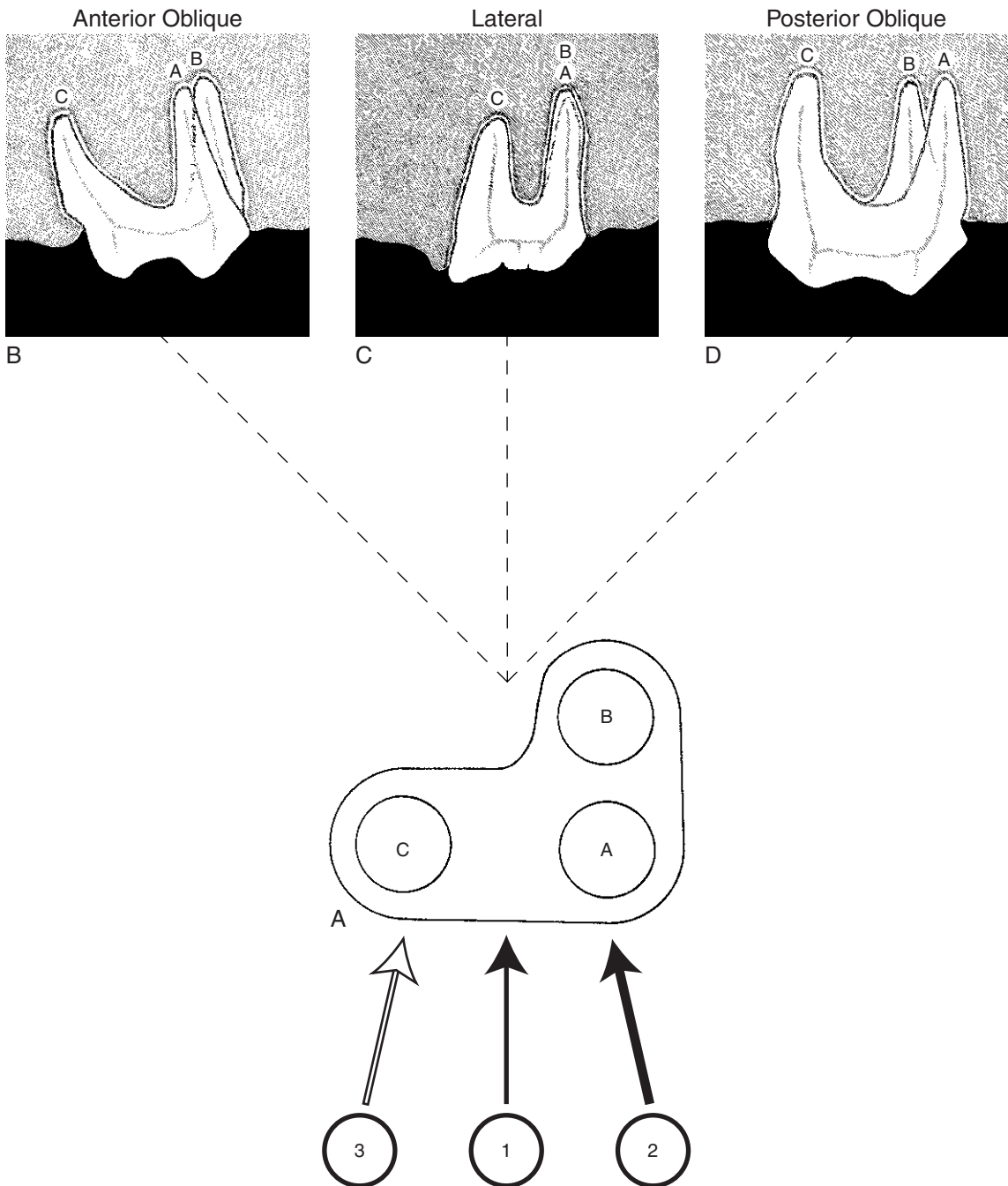


Fig. 3-8

Radiographic Developing

- There are four methods of developing the exposed film: standard manual developing, automatic processor developing, one-step rapid processing, and two-step rapid processing.

Standard Manual Developing

Comments

- The procedure is the same as for large high-speed cassette radiographic film.
- Specialized racks or holders may be used to hold the film(s) during the developing process (Fig. 3-9, A).

Advantage

- Additional equipment and materials are not required.

Disadvantages

- The biggest disadvantage is the slow developing time.
- The darkroom may not be close to the dental operator.

Automatic Processor Developing

Comments

- An automatic processor is used to develop, fix, and dry the film.
- The automatic processors used in veterinary medicine can be used but are unreliable without special care.
- Certain brands of human medical and dental automatic processors will develop all sizes of dental films (Fig. 3-9, B). The buyer should know their product's film size processing capabilities before purchasing.

Advantages

- Automatic processors provide constant, reliable developing and fixing, reducing human error.
- This method decreases operator time.
- A dry film is produced for viewing.

Disadvantages

- Unless the processor is designed to transport small films (Fig. 3-9, C), there will be difficulty with this method.
- Approximate developing time for each film is 4 minutes.

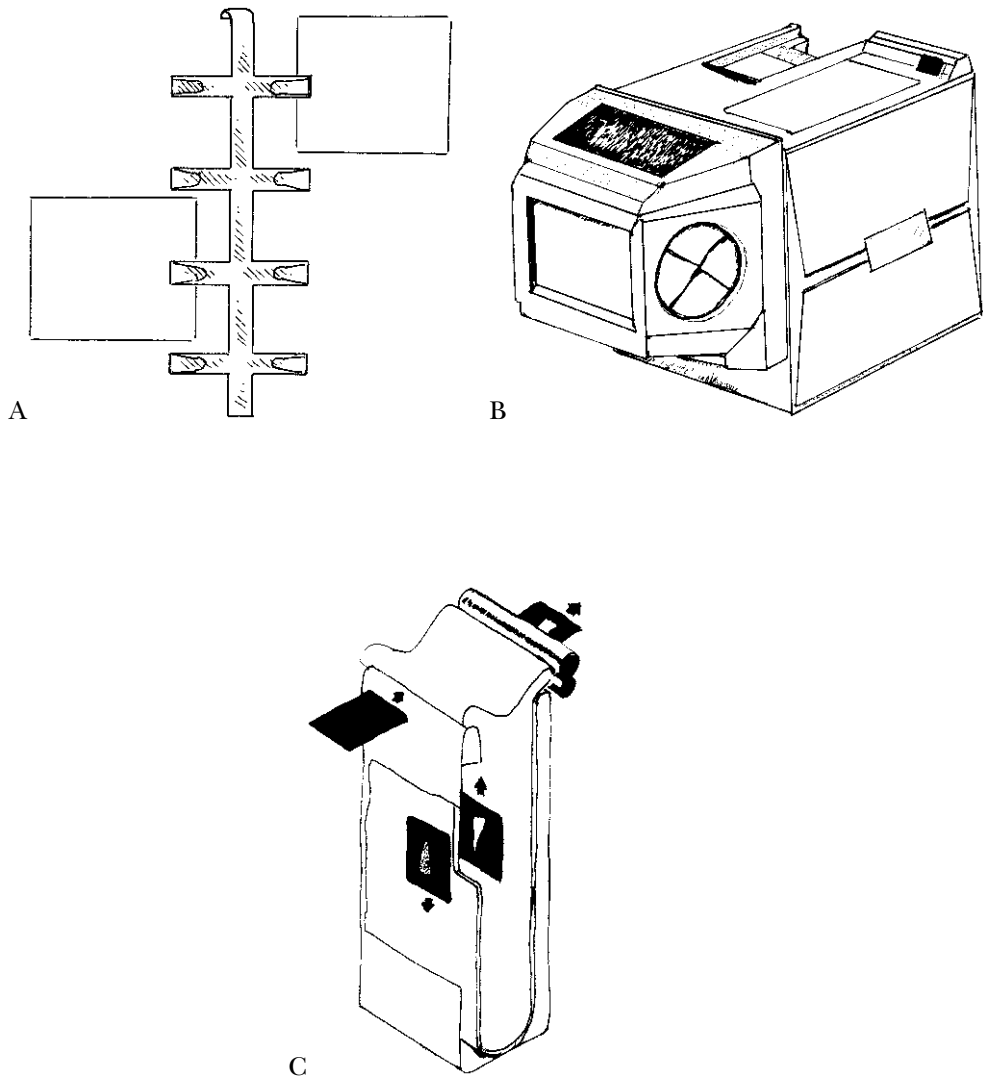


Fig. 3-9

Developing Dental Radiographs with a Veterinary Medical Film Automatic Processor

- Large 10- by 12-inch or 14- by 17-inch radiographic film can be used as a “leader” by taping the smaller dental film to it with a specific tape for this purpose. This tape is available at many camera stores.
- The large film is used to transport the dental film through the processors normally used in veterinary practices.
- This technique is discouraged because it is impractical and, if the dental film becomes dislodged, potentially damaging to the film processor. The tape often covers a critical part of the film, preventing accurate diagnostic viewing.
- Films to be developed can also be placed in film mounts specially designed with tape around the edge of the film opening, to secure the film as it passes through the processor attached to the mount.

Dental Automatic Processors

Technique

- Either in a darkroom, light-proof bag placed over the processor, or daylight loader with the processor, dental film is opened and placed in the processor.
- Caution must be exercised not to touch the unexposed film while being processed.

Processor Maintenance

- It is important that the processor be maintained according to the manufacturer’s recommendations.
- The level of developer and fixer should be checked daily, before use, and added to when appropriate.
- Many processors do not have a continuous flow of running water, and the water must be replaced daily with fresh clean water.
- Before processing, a “clean-up” film should be run through. Clean-up films should be replaced daily.
- For safety, the processor should be turned off each day.
- Periodically, the chemicals must be changed. To do this, the wash, fix, and developer tanks should be removed from the unit and emptied, cleaned, and dried. Next, the transport system is removed and immersed in hot water and cleaned as directed by the

manufacturer. The tanks and transport mechanism are replaced back to their prospective positions. Before clinical use, a clean-up film should be run through to check correct function.

One-Step Rapid Processing

Comment

- A special combination developing and fixing solution is used for this procedure.

Disadvantage

- Because developing and fixing are done by the same solution, detail is compromised; therefore, this process is not recommended.

Two-Step Rapid Processing

Comments

- Commonly, this is referred to as the “chairside darkroom” technique and equipment.
- This is the recommended processing technique for veterinary dentistry in general practices. Specialty practices with higher volume may benefit from employing automatic dental processors or digital radiographic technique.
- Separate solutions are designed for rapid developing and fixing of intraoral film.
- Single film clips are used to dip the film in each container. Multiple film hangers can be used to hold a single patient’s radiographs during the final rinse, so single clips can be used for additional films.
- At least four small containers are used.
- The containers are arranged as follows: one for developing solution, one for water rinse, one for fixing solution, and one or two for the final rinse.
- Small dip tanks may either be bought for this purpose, or empty clean unwaxed plastic or glass containers may be used. The containers should be tall enough to allow complete immersion of the larger #4 film. Tight-fitting lids should be used to seal the containers when the chairside darkroom is not in use to prolong the usefulness of the developer and fixer. Rinse water should be replaced between patients, and the chemicals should be replaced weekly.
- The dip tanks or containers may be housed in a darkroom or in a chairside darkroom (Fig. 3-10) (see Chapter 2).

- Chemicals become exhausted with use and must be changed frequently; 6 ounces of developer will develop 10 to 15 occlusal films or a greater number of smaller films.
- Disposal of chemicals after use should be done according to state health requirements. The lead packet insert can be saved for recycling.

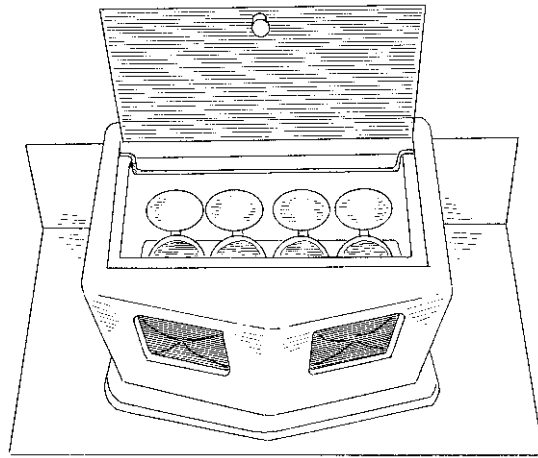


Fig. 3-10

Technique

Step 1—The solutions are stirred to mix.

Step 2—In a dark environment, the film packet is opened, and the film is removed from the packet and attached to a film clip (Fig. 3-11).

Step 3—The film is immersed in the developer, agitated to remove bubbles, and then no longer agitated. The amount of developing time depends on the solution used, the temperature, and the exhaustion state of the chemicals. The manufacturer's recommendations should be followed. The film is removed from the developing solution, with minimal drip-back into the developing tank.

Step 4—The film is placed into the water rinse, with continuous agitation for 30 seconds. .

Step 5—The film is transferred to the fixing solution and agitated intermittently during its fixing. Generally, fixing time is twice the developing time. For archival quality films, however, 10 minutes is recommended. (Archival quality refers to films that will maintain their image while in storage for the lifetime of the patient.)

Step 6—After the prescribed time for fixing by the manufacturer, the film is transferred into the final rinse. The fixing solution is allowed first to drip off the film back into the fixing tank. The film may be read at any time; however, it should be returned for a minimum of 10 minutes in a freshwater rinse (longer rinse time gives more assurance of removing all fixer from the emulsion). For archival quality, 30 minutes is recommended.

Step 7—The film can be air dried by hanging it on a single or multiple film hanger so that it will not touch adjacent films. Hair driers at low heat or specially designed film driers can be used to hasten the drying process. (Be sure to store films of each case together during the drying process, to avoid misidentification later.)

Complications

- Once the film is removed from the protective packet, processing should begin as soon as possible.
- Resist the temptation for prolonged viewing of the film between the developing and fixing stages.
- If Ektaspeed film is used, or if the unit is below a bright light source, a red filter should be placed over the amber filter.
- Old developing solution gives a "washed out" background and fogs the film. Developing solution oxidizes rapidly in open containers. Storage of solution in a container with a tight lid will prolong its life.
- If the films are not rinsed for a long enough time, they will turn brown as the remaining fixing solution oxidizes with age.
- The film should be removed from the protective paper. If the paper is left attached to the film, the film will not develop properly.
- Accidental exposure to light in the darkroom after the film is removed from the packet during developing creates an overall fogging or darkening of the film.
- Films touching during developing or fixing, films sticking together during processing, films being handled by fingers contaminated with solution, or film clips and fixing solution splashing together before developing will all cause artifacts on the processed film and should be avoided.
- Indentations on the film before processing, either by the operator's fingernail or the patient's tooth, will create dark line artifacts on the processed film.
- Insufficient fixing time will produce a yellowish brown film.
- If silver jewelry comes in contact with processing solutions, it may tarnish (evidence oxidation).

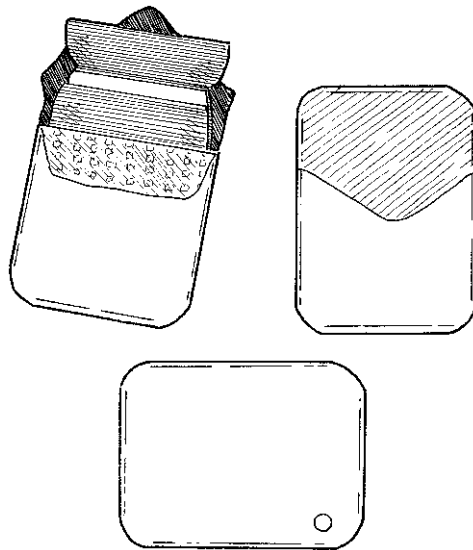


Fig. 3-11

DUPLICATING DENTAL RADIOGRAPHS

General Comments

- Radiographs are a record. They belong to the veterinary hospital and not to the client. Written medical records also belong to the veterinary hospital. The client has paid for and owns the information in the medical record and has the right to request copies of the medical record, but a potential problem arises when duplicate radiographs are requested.
- The nature of the problem varies, depending on the circumstances. Clients often claim they own the radiographs; in fact, they do not—they own the information gained by the interpretation. The ill will that often occurs between clients and clinics when clients are denied “their radiographs” may damage public relations.
- The clinic can send the original radiographs to a veterinarian of the client’s choice, requesting return of the film at an appropriate time. However, if the clinic wants to maintain possession of the films, several alternative approaches are available.
- It is appropriate to charge a fee for duplicate films.

Duplicating Techniques

Double-Loaded Film Packets

Comment

- This is the least expensive method of obtaining a duplicate radiograph. Radiographic film with two films per packet is available in Ultraspeed and Ektaspeed film (Table 3-6).

Table 3-6 • DOUBLE-LOADED FILM PACKETS

Type	Ultraspeed	Ektaspeed
Periapical		
0	DF-53	EP-02P
1	DF-55	EP-12P
2	DF-57	EP-22P
Occlusal		
4	DF-49	EP-42P

Advantages

- Results in a nearly perfect duplicate film.
- Easy to use.
- Efficient.

Disadvantages

- Additional dental film must be kept in inventory.
- Clinician must know ahead of time that duplicate film is desired.
- Film may be wasted, especially if repositioning and additional exposures are required to obtain diagnostic films.
- Film packets with two films per packet are more expensive than single film packets.

Single-Film Duplicator

- Single radiographs may be duplicated by means of a relatively inexpensive single-film duplicator (Mini-Ray Duplicator, Rinn, Model 72-1220 [Fig. 3-12, A], or Henry Schein, Catalog No. 100-7268).
- Duplicating film is also required (e.g., Kodak X-Omat, Catalog No. 158-6460).
- This system works well for duplicating individual dental radiographs, one at a time. The duplicator will accept size #0, #1, #2, and #3 films (not size #4 [occlusal] film).

Technique

- The duplicator holds one 9-volt battery. In the darkroom, the lid is lifted, the film to be duplicated is placed on the small light table inside the duplicator, and the duplicating film is placed on top of the duplicator.
- The lid is closed, and the activating button is pushed. The button turns on a light beneath the small light table and turns it off automatically after the film has been duplicated.
- The exposed duplicating film can then be developed in the usual manner. If using a chairside darkroom, that unit also must be placed in the darkroom before the film is exposed (Fig. 3-12, B).

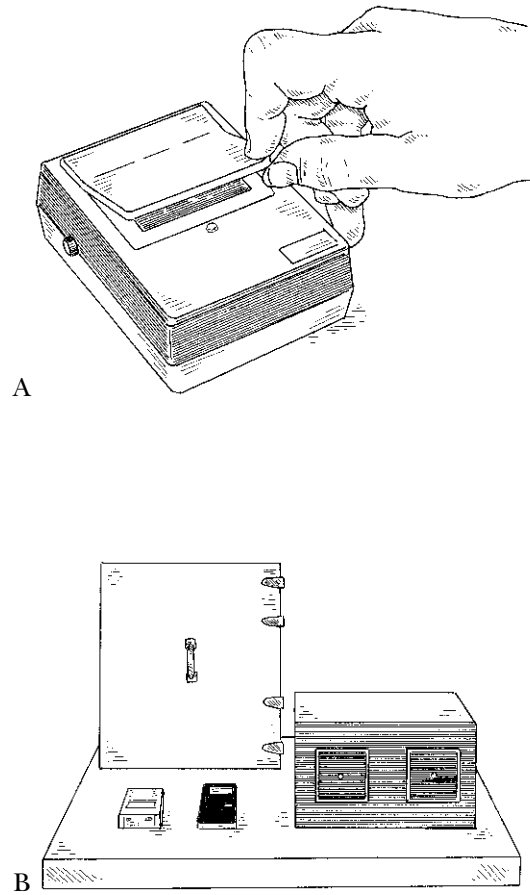


Fig. 3-12

Advantages

- Quick and easy for single films of sizes 0 to 3.
- Relatively inexpensive.

Disadvantages

- Tedious process if a radiographic survey of 6 to 12 films needs to be duplicated.
- Occlusal film, which is too large for the duplicator, is used with regularity in veterinary practice.

Panoramic Film Duplicator

- A system similar to that of the single-film duplicator, but larger, made by Rinn (Fig. 3-13).
- Kodak film can be used (X-Omat, Catalog No. 121-582I).

Technique

- Similar to that of single-film duplicator, but several films can be duplicated at the same time.

Advantages

- Reproduces film up to $5\frac{7}{8}$ by $12\frac{5}{8}$ inches.
- Accommodates five #2 films or three #4 (occlusal) films.

Disadvantage

- Cost of unit can be several times that of the single film duplicator.

Professional Medical Film Duplicating System

- If duplicating larger cassette radiographs is desired, a radiographic duplicating system for large-cassette medical radiographic film is available.

Technique

- Similar to those of single-film and panoramic duplicating systems, with ability for several dental films to be placed on the glass at one time.

Advantages

- The system works very well.
- Multiple dental films can be duplicated at the same time.

Disadvantage

- Cost of unit.

Economy Duplicating System Using a Printer-Proofers

- This is an additional way to duplicate either large-cassette or dental radiographs satisfactorily and relatively inexpensively.

Uses in Veterinary Dental Department

- Sending duplicated films to referring source or in matters of dispute.
- Marketing: providing duplicates for client, relieving a possible source of contention with clients who want films.
- Serving as an additional client service and source of revenue for general practices and dental departments.

Materials

- Eighteen-inch ultraviolet light (black light) wall-mounted 42 inches from the working surface.
- Electrical connection with pull string or wall switch.
- Printer-proofers (a 10- by 12-inch glass hinged to cover a soft parallel surface of similar size) available at photographic supply stores.
- Duplicating film (e.g., Agfa Curix Duplicating Film; Kodak Omat, Catalog No. 161-8909, both from radiographic supply distributors).
- Darkroom with film safe and flat working space.

Setup

- The black light tube is mounted horizontally 42 inches above the flat working space.
- The printer-proofers is positioned in front of the technician.
- The films to be duplicated are laid out in order, to one side, with all the lights off.
- The closed box of duplicating film is placed for easy access.

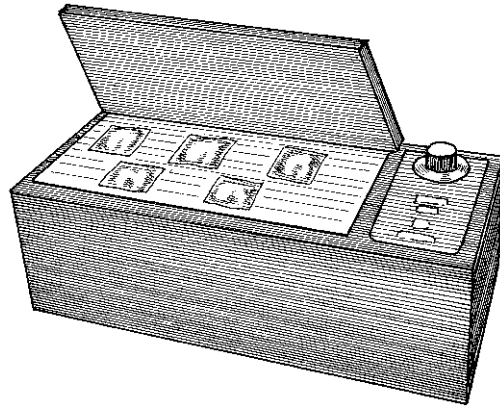


Fig. 3-13

Technique

Step 1—In the darkroom, the printer-proofer glass is lifted so that a piece of 10- by 12-inch duplicating film can be placed with its emulsion side (lighter, pinker, shinier) facing up on the soft bottom surface of the printer-proofer. In the dark, the correct film position can be achieved by the technician who will feel semicircular notches in the corner, on the edge of one of the short sides of the film. The duplicating film is oriented with these notches in the upper right corner when laid in the printer-proofer.

Step 2—Dental films, or the portion of a 14- by 17-inch film to be duplicated, is laid directly on top of the sheet of duplicating film because, in this case, the light source is above the unit (Fig. 3-14).

Step 3—The glass cover is brought down atop the two layers of film, and the black light is turned on to expose the film for exactly 5 seconds.

Step 4—The glass cover is lifted and the exposed duplicating film is removed and developed, either manually or in an automatic processor, in the usual manner.

Advantages of the Printer-Proofer

- Duplicating 6 to 12 films in 5 seconds is more efficient than duplicating the films individually.
- The system can duplicate the larger medical radiographs routinely taken in veterinary hospitals, so is capable of processing the films from whole skull and temporomandibular joint studies.
- The system can be installed more economically and requires little equipment.
- The detail is quite adequate for useful communications with other veterinarians.
- The duplicating service creates goodwill.
- It is to the clinician's advantage to be able to duplicate large-cassette film for referral cases or for clients seeking second opinions.
- It is appropriate to charge a fee for duplicate films.
- The service reduces the importance of whether or not the distributed film will be returned to the hospital of origin.

Disadvantage

- Duplicated (second-generation) films are not quite as high in quality as first-generation films.

Taking a Digital Photograph of the Radiograph

- This is discussed in the next section.

Digital Radiology

General Comment

- There are four ways that radiographs can be converted to digital images: digitally photograph the conventional radiograph, scan the conventionally taken radiograph, use a phosphorus sensor, and use a CCD (charged coupled device)/CMOS (complementary metal-oxide semiconductor) sensor. All of these have a variety of advantages and disadvantages (and expense).

Digital Cameras

Comment

- Digital cameras are a cost-effective method of converting conventional radiographs to digital images.

Advantages

- Cost less, as compared with phosphorus sensor and CCD/CMOS sensor.
- Speed—image is seen in seconds.
- Can be stored on hard drive with patient record.
- Can be printed for copies.
- Can be used for large and small films.

Disadvantages

- Is a second-generation image (conventional radiograph is first).
- Must go through the developing process with the radiograph that is being photographed.

Equipment

- Digital camera.
- Computer.
- View box.

Technique

- The strobe for the camera must be turned off.
- The camera is set on macro setting.
- If possible, set the camera to black and white (don't forget to reset it when you are finished).

- A cardboard template or mask with a hole the size of the film can be cut out to prevent extraneous light from the view box, to avoid an abnormal camera exposure.
- The radiograph is placed on a view box.
- The photograph is taken.
- The digitalized image can be transferred to a computer for storage or manipulation.
- Generally, the digital image should be converted to black-and-white format to avoid discoloration caused by artificial lights.

Complications

- May not appear as black and white unless it is converted.
- Loss of detail, often offset by enlargement.

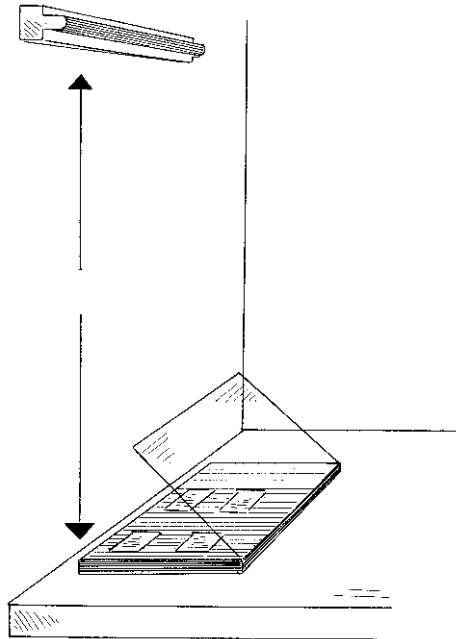


Fig. 3-14

Scanning

Comments

- Similar to taking a digital photograph, scanning produces a copy of the original radiograph.

Advantage

- Inexpensive once the computer and scanner are purchased.

Disadvantages

- Is a second-generation image.
- Must go through the developing process with the radiograph that is being scanned.
- Requires a scanner connected to a computer and back light.
- Requires time to achieve correct back lighting.

Equipment

- Scanner, computer.
- Backlight positioned above the scanner (or scanner with built-in backlight capability).

Technique

- To do this, the scanner must be able to “back-light” the radiograph. Some image enhancement is possible with digital cameras and scanners (zooming in, zooming out, changing contrast and darkness). The digital files are transferred easily from computer to computer both by disk and via the Internet. They can be used for client education, referral letters, and such.

Phosphorus Sensors

- Both phosphorus sensors and CCD/CMOS sensor technology eliminate the need for darkrooms and chemicals.
- The phosphorus sensor uses an image plate that can be reused.
- The size of the plate can vary from small periapical films to larger panoramic sizes.
- After exposure with a conventional dental radiographic unit, the plate is placed in a scanner and transmitted to a computer.

Advantage

- The image can be manipulated, is good for client education, is easily transferred, and

requires less radiation per image than conventional radiology and therefore is safer for the patient.

Disadvantages

- The image is not instant; it must be scanned to view.
- This requires more steps than does the CCD/CMOS technology.
- The initial cost is in the \$10,000 to \$20,000 range. Expense occurs, not only for new equipment, but also possibly creates the need to update peripheral computer hardware and software to be compatible.
- A new computer skill to be learned and taught to the staff.

CCD-CMOS Sensors

- The CCD and CMOS.
- Sensors use a sensor plate that is attached to a computer.

Advantages

- Image is immediately displayed on the computer.
- Errors in positioning and exposure can be corrected immediately, without waiting for film processing.
- Computer storage makes retrieval and storage of the image easier than for conventional film.
- Image can be adjusted for better visualization. For example, the image can be enlarged, rotated, the contrast changed, and the image reversed.

Disadvantages

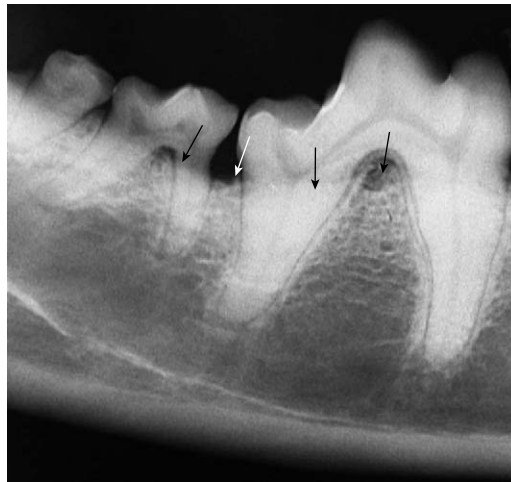
- Sensors are initially expensive (cost); however, over time they are less expensive than film-based radiology.
- At this time sensors are supplied only in periapical film size (#2).

RADIOGRAPHIC DIAGNOSTICS

- All radiographic findings must be correlated with clinical signs. Artifacts, overlying structures, and other abnormalities may interfere with a correct diagnosis.

Periodontal Disease^{11,12}

- A less sharp or distinct alveolar crest caused by resorption of bone (Fig. 3-15).
- Increased width of the lamina lucida caused by a widening of the periodontal space.
- Loss of radiopacity of the lamina dura caused by resorption of bone.
- Destruction of alveolar bone caused by the presence of suprabony or infrabony pockets with corresponding horizontal or vertical bone loss.

**Fig. 3-15**

Endodontic Disease^{11,12}

- Radiolucent area around the apex of the root, accompanied by loss of periodontal detail, caused by inflammation or infection around the apex (Fig. 3-16, *A*, *arrows*).
- There may be a difference in the size of the pulp canals when comparing the tooth being examined with adjacent teeth and contralateral teeth (Fig. 3-16, *B*, *arrows*). This indicates pulp death of the tooth, with the wider canal, at a younger age.
- Periapical sclerosis may be seen with chronically inflamed or infected pulp.

Lesions That Involve Both the Endodontic Systems and Periodontic Systems

There are three classes of combined endodontic and periodontal disease.

- Class 1 is a lesion that starts in the endodontic system and spreads to the periodontium.
- Class 2 is a lesion that starts in the periodontium and spreads to the endodontic system.
- Class 3 is a fusion of independent periodontic and endodontic lesions.

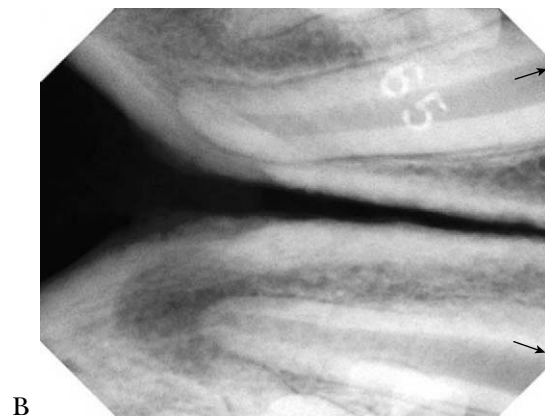
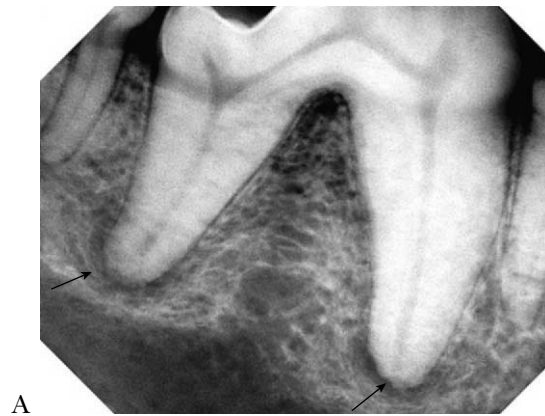


Fig. 3-16

Class 1 Lesion: Endoperiodontal Disease

- This lesion has started out as a fractured cusp. The resultant infection in the pulp has spread to the periodontium (Fig. 3-17, A).
- Using the SLOB rule, and moving the cone head caudally, it was determined that the lesion was on the mesiobuccal cusp (Fig. 3-17, B).

Class 2 Lesion: Perioendodontic Disease

- The pathology has begun in the periodontium and has progressed to involve the pulp.
- Complete breakdown of alveolar bone around the periodontium and apex in a dog with a fractured mandible (Fig. 3-17, C).
- Small breed patients that have perioendodontic lesions of the mandibular first molar are at risk for the occurrence of spontaneous mandibular fractures (Fig. 3-17, D).

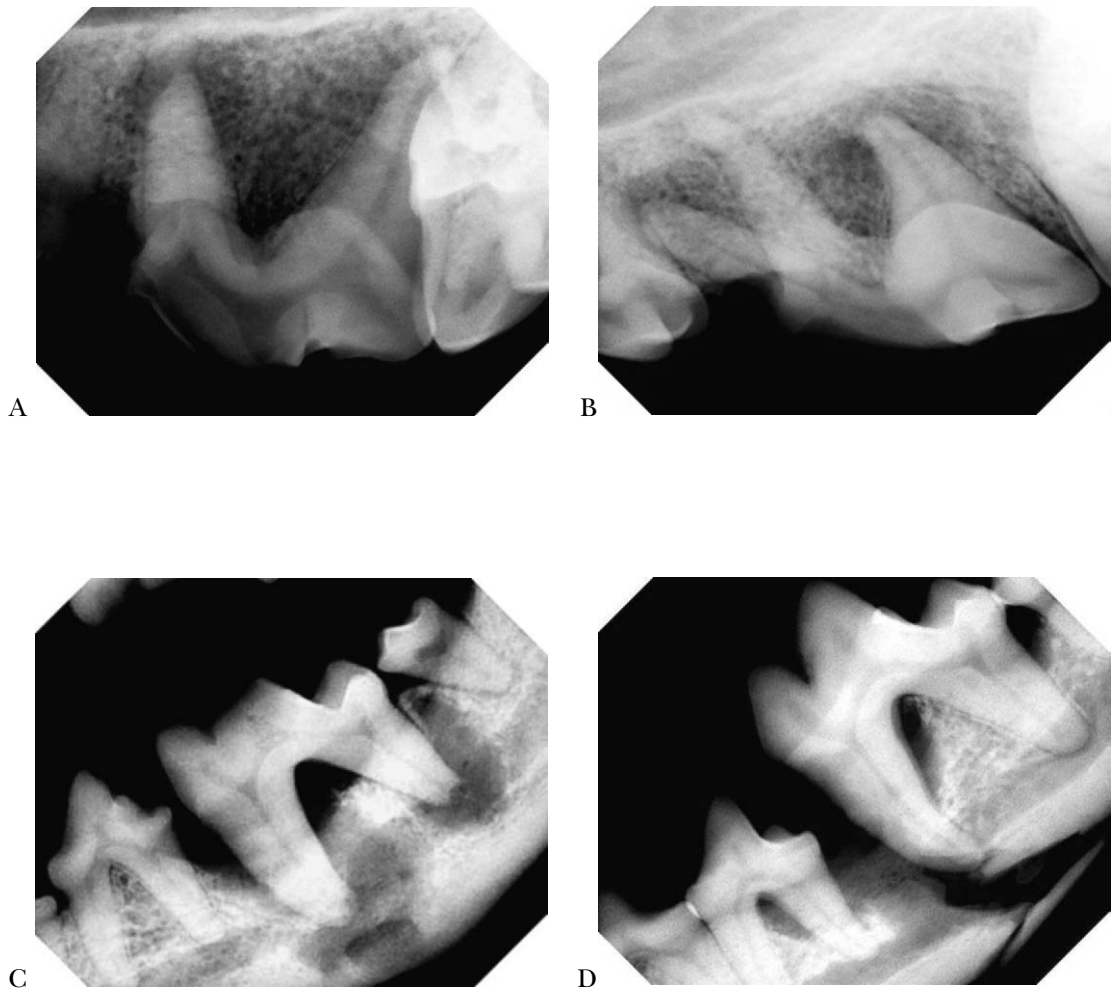


Fig. 3-17

Resorptive Lesions

Feline

- Feline resorptive lesions are classified into two classes, type I and type II.¹⁰

Type I Resorptive Lesion

- Includes periodontitis. It demonstrates radiographically external resorption of the crown or root, or both, including periodontal bone loss and possible periapical changes. The entire crown and root should be extracted. Crown amputations should not be performed on these teeth as a method of extraction (Fig. 3-18, *A*).

Type II Resorptive Lesion

- Is accompanied only by focal gingivitis; no periodontal bone loss, no periapical lysis, no faucitis.
- Roots show evidence of radiographic root replacement (loss of lamina dura and lamina lucida and loss of opacity in root structure) and no periodontal space. Here crown amputation is indicated. The mandibular third premolar is undergoing replacement resorption. The mandibular fourth premolar does not have any lesions and the mandibular first molar is completely resorbed (Fig. 3-18, *B*).
- In this case, the crowns were amputated but the abscessed roots were not extracted. The result left the patient symptomatically worse than before treatment. Extraction of the roots resolved the signs of pain (Fig. 3-18, *C*).

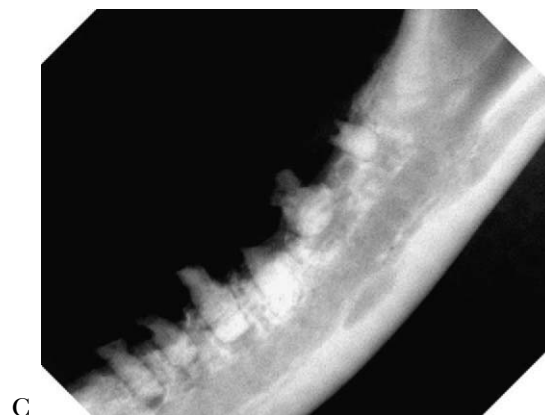
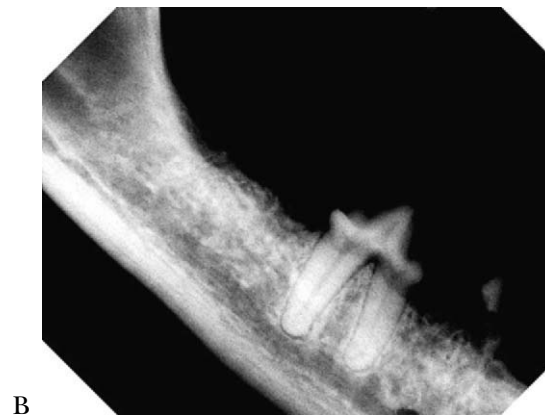
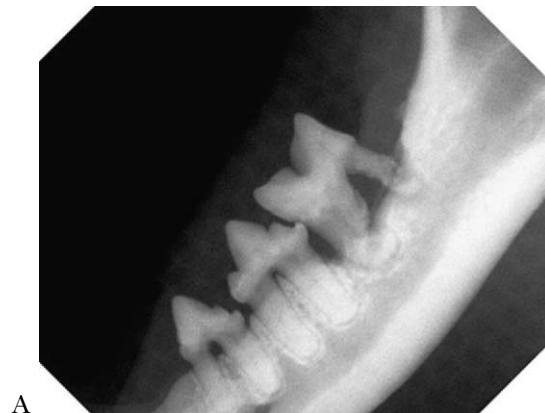
Fig. 3-18

CHECKLIST FOR SUBMITTING RADIOGRAPHS

- Various organizations may require dental radiographs for evaluation. In addition, following these recommendations will help in receiving the best possible feedback when submitting the radiographs for consultation. The following is intended as a guide to assist in self-evaluation of radiographs (Boxes 3-1 and 3-2).

Box 3-1 • FULL MOUTH DENTAL SURVEY

All teeth to be evaluated are clearly visible.
Radiographs are well positioned.
The maxillary cheek teeth should have the roots facing upward and the crowns downward.
The mandibular cheek teeth have the crowns facing upward and the roots downward.
Maxillary incisors have the roots facing upward and the crowns downward.
Mandibular incisors have the roots facing downward and crowns upward.
When viewing the right side of the mouth, the anterior teeth are on the right side.
When viewing the left side of the mouth, the anterior teeth are on the left side of the radiograph.
Proper angulation has been used.
There is no foreshortening or elongation.
Visualization of all roots and apices is adequate.
Exposure and developing technique are adequate.
No artifacts appear on the film.
Contrast and density of the radiograph are correct.

Box 3-2 • TEMPOROMANDIBULAR JOINT RADIOGRAPHS⁹

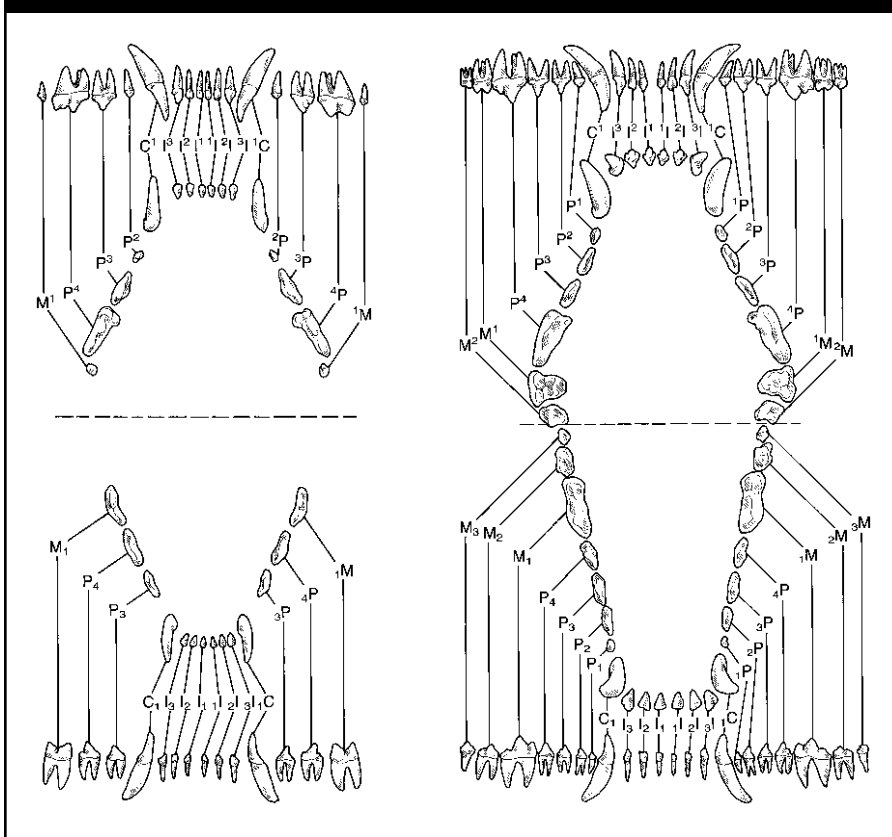
All four views are included and properly labeled (ventrodorsal, open mouth, and right and left lateral oblique).
The films are properly labeled with a right or left marker.
On the lateral views, the endotracheal tube must not be superimposed over the temporomandibular joint (TMJ).
The TMJ studied is to be the joint closest to the film; it is to be isolated from the contralateral TMJ, without using excessive ventral or cranial rotation.
On the ventrodorsal and the open mouth views, the TMJs are to be visible.
Exposure and developing technique must be adequate.
No artifacts appear on the film.
Contrast and density of the radiograph must be correct.

REFERENCES

1. Verstraete JM, Kass PH, Terpak CH: Diagnostic value of full mouth radiology in cats, *Am J Vet Res* 59:692-695, 1998.
2. Verstraete JM, Kass PH, Terpak CH: Diagnostic value of full mouth radiology in cats, *Am J Vet Res* 59:686-691, 1998.
3. White SC, Heslop EW, Hollender LG, et al: Parameters of radiologic care: an official report of the American Academy of Oral and Maxillofacial Radiology, *Oral Surg Oral Med Oral Pathol Oral Radiol Endod* 91:498-511, 2001.
4. Mulligan TW, Aller MS, Williams CA: *Atlas of canine and feline dental radiography*, Trenton, NJ, 1998 Veterinary Learning Systems..
5. DeForge D, Colmery BH III: *An atlas of veterinary dental radiology*, Ames, Iowa, 2000, Iowa State Press.
6. Ludlow JB, Platin E, Mol A: Characteristics of Kodak Insight, an F-speed intraoral film, *Oral Surg Oral Med Oral Pathol Oral Radiol Endod* 91(1):120-129, 2001.
7. Gracis M, Harvey CE: Radiographic study of the maxillary canine tooth in mesaticephalic dogs, *J Vet Dent* 15(2):73-78, 1998.
8. Gracis M: Radiographic study of the maxillary canine tooth of four mesaticephalic cats, *J Vet Dent* 16(3):115-128, 1999.
9. Eisner ER: Oral-dental radiographic examination technique, *Vet Clin North Am Small Anim Pract* 28(5):1063-1087, 1998.
10. Dupont GA, DeBowes LJ: Comparison of periodontitis and root replacement in cat teeth with resorptive lesions, *J Vet Dent* 9(2):71-75, 2002.
11. Gorrel C: Radiographic evaluation, *Vet Clin North Am Small Anim Pract* 28(5):1089-1110, 1998.
12. Goren AD, Lundeen RC, Deahl ST II, et al: Updated quality assurance self-assessment exercise in intraoral and panoramic radiography. American Academy of Oral and Maxillofacial Radiology, Radiology Practice Committee, *Oral Surg Oral Med Oral Pathol Oral Radiol Endod* 89(3):369-374, 2000.



DENTAL PROPHYLAXIS AND PERIODONTAL DISEASE STAGES



GENERAL COMMENTS

- The deleterious effects of untreated dental disease on the rest of the body have long been recognized.
- The oral examination and prophylaxis are basic to good dentistry. A thorough dental prophylactic treatment is a critical step in preventing and treating periodontal disease.
- To perform high-quality professional periodic periodontal care, it is imperative that a general anesthetic be administered when dogs and cats have their teeth cleaned. When general anesthesia is not administered, caudal teeth cannot be cleaned adequately, the lingual side of all the teeth are inaccessible, and the all-important subgingival tissues, both buccal and lingual, are at risk for incomplete care and tissue damage. This applies to both dogs and cats. Additionally, only the most docile animals will submit to sharp instruments being introduced subgingivally and the patient, as well as the person handling these instruments, is at risk for injury. If sharp instruments or mechanical instruments are not employed subgingivally in routine prophylactic dentistry, an incomplete service and a poor value is being delivered to the consumer and patient.

ORAL EXAMINATION

General Comment

- Perform the examination in a routine that is followed every time.¹ A thorough examination is facilitated by a bright light source and even with magnification, if necessary. Often only a cursory examination is possible in the awake patient. Once the patient is anesthetized, a more complete oral examination is possible.

Indications

- Awake cooperative patients receiving a physical examination.
- All patients undergoing general anesthesia.

Contraindication

- Uncooperative conscious patients that will not allow examination without risk to the examiner.

Objective

- Thorough examination of all oral and dental structures for evidence of abnormality or disease.

Materials

- Periodontal probe and explorer.
- Mouth gag.
- Adequate light source.
- Magnification.

Technique

Step 1—The head, muzzle, and nostrils are observed and examined. Check for asymmetry and lymph node enlargement. In the awake patient, note any pain on palpation.

Step 2—The lips are lifted; starting rostrally, and buccal and labial surfaces of the teeth and gingiva are examined.

Step 3—Working caudally, the mandibular and maxillary teeth, cheek tissues, and salivary gland ducts are evaluated. If crown wear or fractures are noted, a dental explorer can be used to determine if the pulp horn is open. Other dental abnormalities such as resorptive lesions and caries can be confirmed with use of the dental explorer (Fig. 4-1). More specific periodontal probing is performed while the patient is under general anesthesia, either before or after the teeth have been cleaned, in the patient brought in for dental treatment.

Step 4—The contralateral side of the mouth is examined in a similar fashion.

Step 5—Once the external examination of the lips and the buccal surface of the teeth and gingiva is completed and the clinician has gained familiarity with the patient, the mouth is opened.

Step 6—The lingual and palatal gingival tissues are examined. The lingual, palatal, interproximal, and occlusal surfaces of the teeth are evaluated. The examiner's thumb can be placed in the diastema behind the maxillary canine tooth so that the thumb pushes on the hard palate as an aid in keeping the mouth open. In the awake patient, visualization is limited.

Step 7—The tongue and floor of the mouth are examined. This area may be visualized more easily by pushing up on the skin beneath the tongue on the ventral portion of the mandible posterior to the symphysis.

Step 8—The hard and soft palates are examined.

Step 9—The pharyngeal area and tonsils are examined. In tolerant animals, a finger can be placed over the base of the tongue for better visualization of the oral pharynx.

- A mouth gag should be used only for a short time to prevent undue tension on the temporomandibular joint.
- The clinician should use caution to prevent being bitten.

Complications

- The patient may require general anesthesia if it will not submit otherwise to examination.

Follow-Up

- An initial treatment plan is formed after the oral examination.

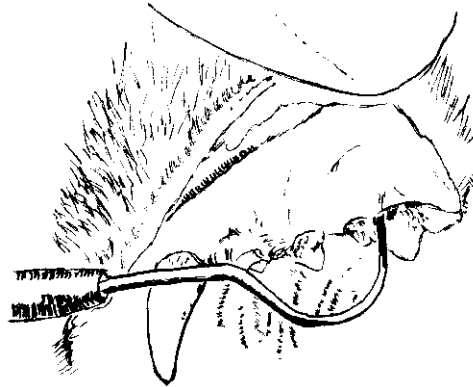


Fig. 4-1

PERIODONTAL DISEASE

Causes of Periodontal Disease

- The tissue degradation process appears to be driven by subgingivally advancing plaque, acute inflammation, and prostaglandin-induced bone resorption.² Plaque bacteria are area specific, with some attaching to the root surface, some to the epithelial lining of the sulcus or pocket, while others become loosely adherent to the sulcus wall in the gingival crevice. The loosely adherent plaque has been found to have more pathogenic potential and contains the endotoxins produced from gram-negative bacteria.³ Other bacteria actually penetrate into the gingival tissues.
- The host response, bacterial actions, and bacterial endotoxins all participate to help damage and, in the worst case scenario, destroy the periodontium.
- Page⁴ likened the area of periodontal disease to a battleground destroyed in the process of the battle.

Stages of Periodontal Disease

Comments

- Periodontal disease is divided into grades or stages for the purpose of treatment planning and evaluation of patient progress. In reality, a given stage of periodontal disease is fairly subjective; what matters is the overall evaluation of a combination of factors that includes plaque, calculus, gingival inflammation, gingival recession, and bone loss. The number of classification systems for grading periodontal disease are in excess of 18 in human dentistry. One treatment schedule was based on the predominant cell types in the connective tissue of the marginal gingiva.⁵ Periodontal pocket measurement was used in another.⁶ Harvey and Emily⁷ proposed a six-stage system. A five-stage system (0 to 4) described by Wiggs and Lobprise⁸ includes normal, gingivitis, and then three stages of periodontal disease based on percentage of bone loss.
- This text uses a system with a clinical approach. Healthy is defined as the *absence of disease* and therefore is not assigned a

grade. Likewise, once a tooth is extracted, although disease may be present, the intact periodontium is missing and, therefore, the missing tooth is not graded. There may be more than one stage present in a patient's mouth at one time or present even within a tooth with multiple roots, in which one root has advanced periodontal disease and the other(s) are normal. Although the site of the extracted tooth, itself, is not graded, the overall patient periodontal status may be upgraded once the disease process is inactivated. Periodontal disease typically waxes and wanes cyclically as it periodically becomes exacerbated and a currently inactive condition becomes active again.

A Healthy Periodontium

- The healthy gingiva has a knifelike margin (Fig. 4-2, A and B). The line of the gingival margin flows smoothly from tooth to tooth, called *smooth topography*.
- Radiographically, alveolar crestal bone is seen close to the neck of the tooth. The distance may vary proportionately with the greatly differing size of veterinary patients.

Stage 1: Early Gingivitis

- There is a redness of the gingiva at the crest of the gingival margin and a mild amount of plaque and calculus (Fig. 4-2, C and D).
- There is loss of visualization of the fine blood vessels at the gingival margins.
- Radiographically, there is no change from that of a healthy periodontium.
- The condition is reversible with treatment.

Stage 2: Established or Chronic Gingivitis

- Stage 2 is similar to stage 1, but there is an increase in inflammation, including edema and subgingival plaque development. Amounts of supragingival plaque and calculus are increased (Fig. 4-2, E and F). The line of gingival margin topography has started to become irregular but is still intact. Root exposure has not yet occurred.
- Radiographically, there is little noticeable change.
- The condition is reversible with treatment.

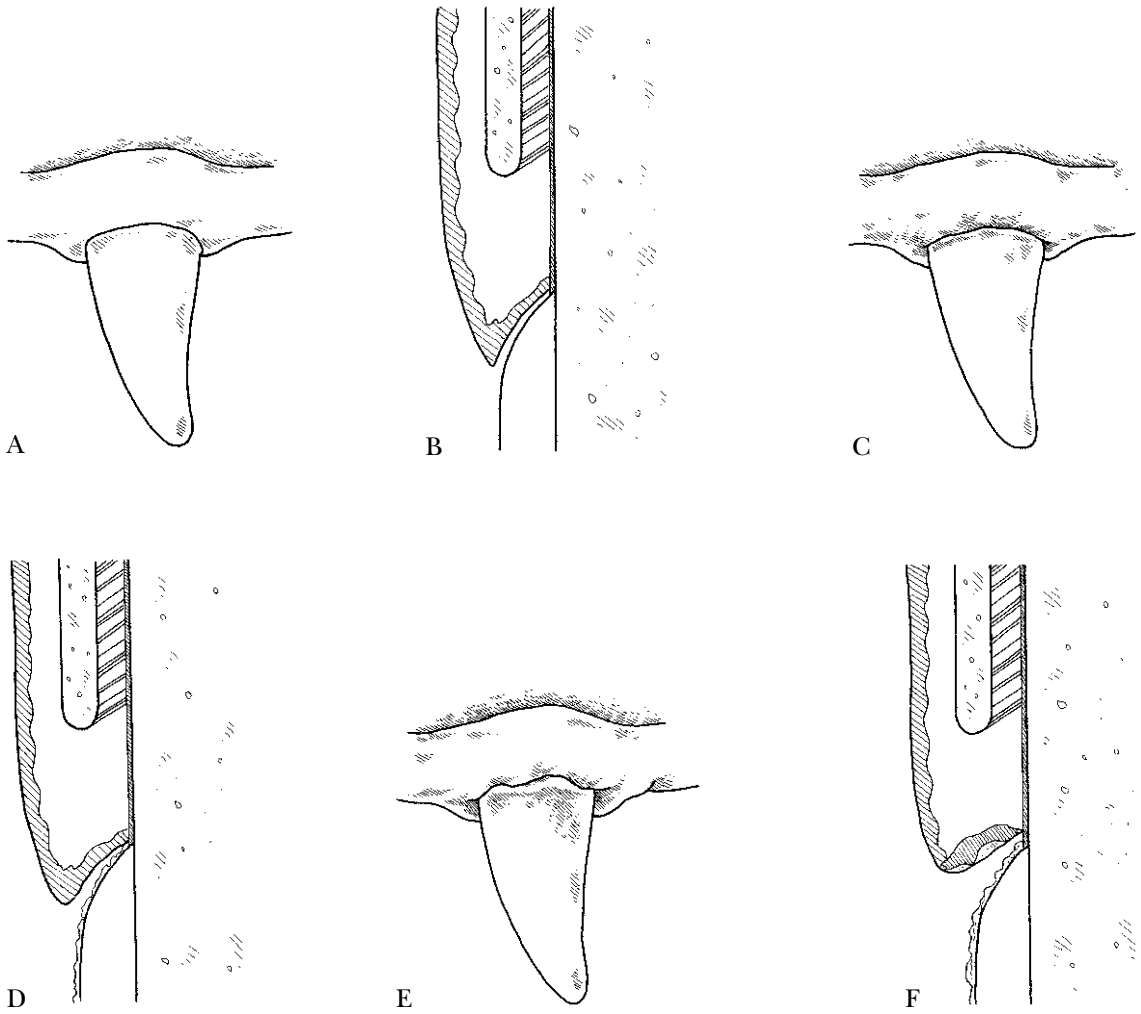


Fig. 4-2

Stage 3: Early Periodontitis

- Stage 3 is an incipient periodontal disease stage, with gingivitis, edema, beginning pocket formation, and increasing amounts of plaque and calculus supragingivally and subgingivally. The gingiva bleeds on gentle probing (Fig. 4-3, *A* and *B*). The gingival topography no longer flows smoothly from tooth to tooth, because there may be either mild gingival recession or gingival hypertrophy.
- Radiographically, subgingival calculus may be noted, and a rounding of the alveolar crestal bone at the cervical portion of the

tooth can be seen on careful examination at the earliest of stage 3. Up to 30% of the tooth root may be affected by either vertical or horizontal bone loss.

Stage 4: Established Periodontitis

- Some of the signs that may be associated with stage 4 are severe inflammation, deep pocket formation, gingival recession, easily recognized bone loss, pus, and tooth mobility. The gingiva usually bleeds easily on probing (Fig. 4-3, *C* and *D*).

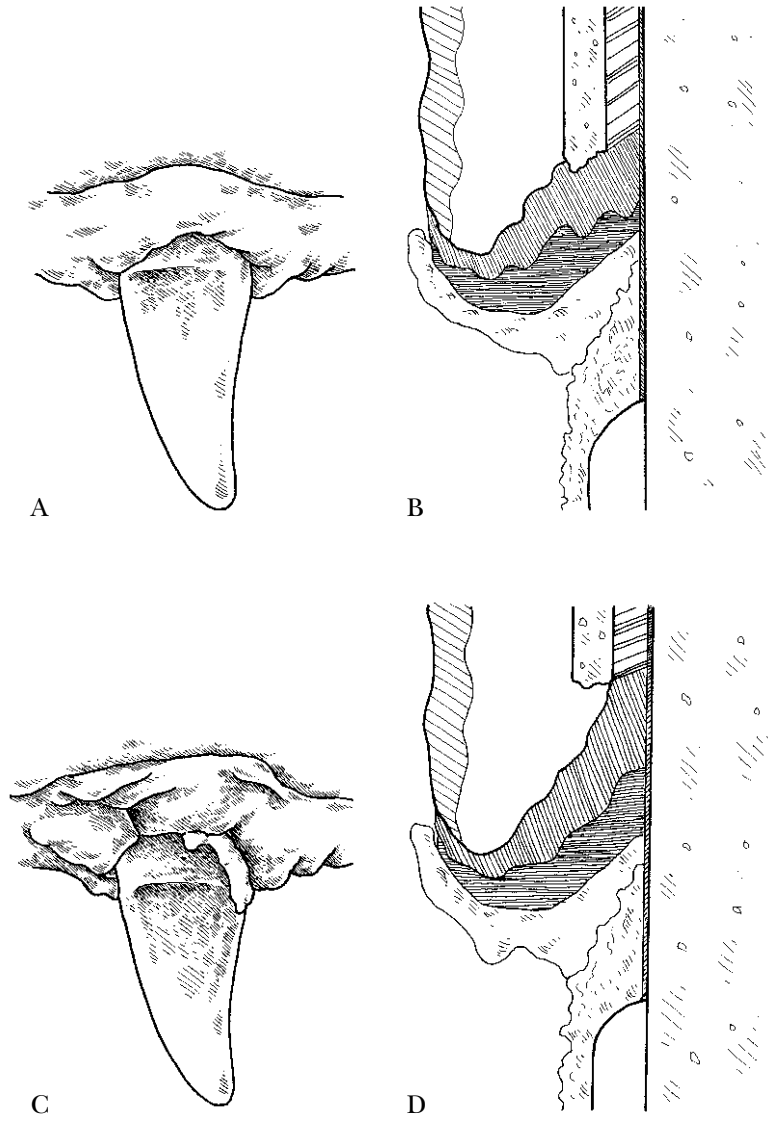


Fig. 4-3

- Radiographically, subgingival calculus and vertical or horizontal bone loss of 30% or greater of the root length are noted.
- There are two types of pocket formation, suprabony (Fig. 4-4, *A*) and infrabony pockets (Fig. 4-4, *B*). These are differentiated by the location of the bottom of the pocket with respect to the adjacent alveolar bone. Infrabony pockets have the depth of the pocket apical to the level of the alveolar bone and are associated with radiographically identifiable vertical bone loss. Suprabony pockets have the fundus of the pocket superficial to the height of the alveolar bone and are associated with horizontal bone loss radiographically. The different pocket types often require different treatment approaches, to be covered in Chapter 5.
- Some variations in the typical clinical picture of periodontitis exist.

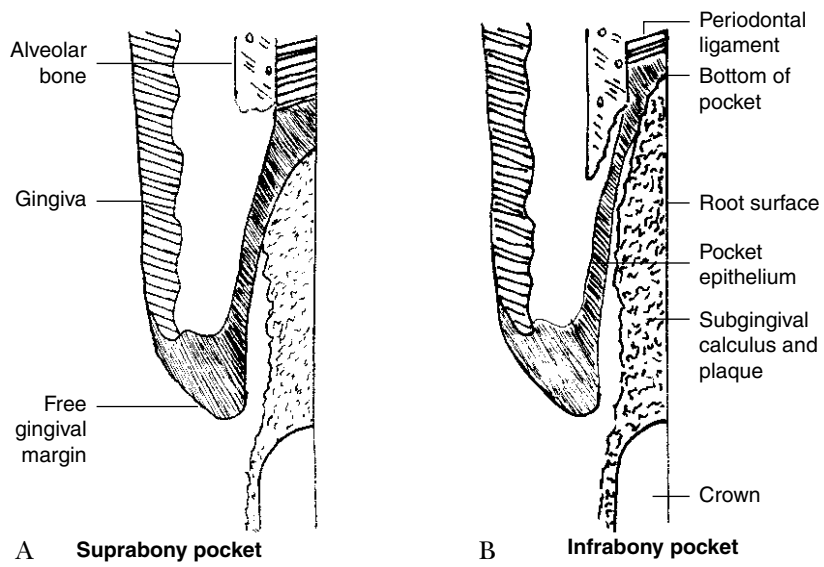


Fig. 4-4

Juvenile Gingivitis or Periodontitis

- Seen in young cats and dogs often after eruption of permanent teeth. They may have marginal gingival inflammation, gingival hyperplasia, or true periodontitis with bone loss secondary to the inflammation.

Chronic Ulceroproliferative Paradental Stomatitis

- This variation can be seen in immuno-compromised dogs and cats. They may have ulcers of the mucosa above areas of dental deposits out of proportion to the amount of deposit present. The gingiva is very friable, and there is often loss of attached gingiva. The condition can be very painful and the animals may suffer from decreased appetite, drooling, lack of grooming, and general discomfort. Feline leukemia virus (FeLV) and feline immunodeficiency virus (FIV) can be associated with these cases in cats. Hypothyroidism should be ruled out in dogs. Maltese dogs have an increased incidence of this form of periodontitis.⁹ Large breed dogs such as the German shepherd can also be affected. Spirochetes and other pathologic oral bacteria are often involved. Many cases require frequent dental cleanings, as well as long-term medical treatment, for control, along with home oral hygiene. Refractory cases often require extraction of affected teeth to control the inflammation.

Chronic Ulceroproliferative Fautitis, Gingivitis, and Stomatitis in Cats

- This variation is seen in cats. Typically the entire caudal aspect of the mouth, fauces, and oropharyngeal area will be inflamed, proliferative, and ulcerated. Histopathologic studies usually show a predominance of lymphocytes and plasmacytes along with varying degrees of polymorphonuclear cells. These cats experience significant pain and often will become anorexic. Their blood study results often are negative for FeLV and FIV. Some may be from households with more than one cat, and feline calicivirus (FCV) usually can be isolated from the tissues; however, in another study, inoculation

of cats with FCV from infected cats did not produce chronic oral disease.¹⁰ Cats should be tested for Bartonella and, if positive, treated appropriately. Disease in these cats is often refractory to usual dental cleaning and medical treatment successful in other periodontal disease cases, and caudal or even full mouth extractions may be required to resolve the disease (see Chapter 6).

Dental Resorptive Lesions

- These odontoclastic resorptive lesions are most frequently seen in cats; however, they can be diagnosed in dogs as well. They often cause a localized gingivitis. Tactile evaluation of the tooth with an explorer will demonstrate varying degrees of coronal and root destruction. External resorption without replacement resorption of the root structure can be seen with periodontal bone loss and gingival pocket formation along with the tooth defect. These are classified differently than other resorptive lesions that are associated with minimal gingivitis. No periodontal bone loss and replacement resorption or ankylosis of the roots is seen radiographically.¹¹

Autoimmune Disease

- Pemphigus vulgaris and bullous pemphigoid cases often have oral lesions that may appear similar to those of periodontitis. Often a distinguishing factor is that lesions are found in the oral mucosa, mucocutaneous junctions in the mouth, and elsewhere. Biopsy and histopathology are necessary to confirm and distinguish the two diseases. Autoimmune diseases will not be responsive to thorough dental cleaning and respond decreasingly well to intermittent courses of antibiotic therapy. Corticosteroid administration, in addition to dental cleaning, is the usual treatment.

Periodontal Treatment Planning

- Different areas of the mouth can be affected with different stages of periodontal disease at the same time. Each area should be treated accordingly.
- Patients with early gingivitis (stage 1) should receive hand or mechanical scaling and

polishing supragingivally and subgingivally (above and below the gum line).

- Advanced gingivitis (stage 2) should be treated with supragingival and subgingival mechanical and hand scaling, tooth polishing, oral irrigation, optional fluoride treatment, and home care instruction.
- Early periodontal disease (stage 3) should be treated with thorough calculus removal supragingivally and subgingivally, polishing, systemic antimicrobial treatment, ultrasonic periodontal debridement or root planing, and gingival curettage, oral irrigation, optional placement of a perioceutic formulation, and home care on a regular basis. Poor-risk patients with greater bone loss or those with an owner who does not perform regular home care may require extractions in order to maintain a healthy mouth.
- Established periodontal disease (stage 4) should be treated with thorough scaling, ultrasonic periodontal debridement, subgingival curettage, root planing, polishing, oral irrigation, systemic antimicrobial treatment, perioceutic treatment of deep pockets, gingival flap surgery, and other periodontal therapeutic modalities, as indicated (see Chapter 5). Teeth with significant mobility or with severe bone loss around one or more roots should be extracted. An intensive home care program is necessary if compromised teeth are to be salvaged. If the owner lacks this commitment or the patient's health status is poor, many teeth with stage 4 disease may require extraction to maintain a healthy mouth.
- Once periodontal disease reaches stage 3 or 4, a simple dentistry, dental (sic), or "prophy"

(sic) treatment, as commonly perceived by many veterinary practices, will not be sufficient to stabilize the infectious disease (Table 4-1).

DENTAL PROPHYLAXIS

General Comments

- A thorough dental prophylaxis program consists of supragingival and subgingival gross calculus and plaque removal, fine hand scaling, polishing, diagnostic studies, oral irrigation, charting, and home care instruction. The goal of dental prophylaxis is to remove or disrupt the composition of the bacterial plaque and its associated endotoxins, along with elimination of plaque retentive deposits and surfaces over the tooth and root surfaces to promote a healing response.¹²
- The procedure should be performed with the patient under general anesthesia and intubated with the cuff inflated. Adequate anesthetic monitoring, to maintain body temperature, and packing of the pharyngeal area are important for safety when performing dental procedures.
- Steps for a thorough prophylactic procedure are presented below in order of application. Some clinicians choose to do step 5 (diagnostic procedures, charting, and radiology) first, before cleaning the teeth, to record various periodontal indices on the dental chart and take dental films when indicated. Calculus and prophy paste may be seen on

Table 4-1 • TREATMENT AND PREVENTION PROTOCOLS FOR PERIODONTAL DISEASE

Procedure	Healthy	Stage 1	Stage 2	Stage 3	Stage 4
Scaling*	No	Possible	Yes	Yes	Yes
Polishing	Yes	Yes	Yes	Yes	Yes
Oral irrigation†	Yes	Yes	Yes	Yes	Yes
Ultrasonic periodontal debridement	No	No	Possible	Yes	Yes
Subgingival curettage	No	No	No	Yes	Yes
Root planing	No	No	No	Yes	Yes
Optional fluoride therapy§	No	No	No	Yes	Yes
Perioceutic	No	No	No	Yes	Yes
Gingival flap surgery	No	No	No	Possible	Yes
Splinting	No	No	No	No	Possible
Extraction†	No	No	No	Possible	Yes

*Subgingival and supragingival scaling.

†Chemical irrigation with chlorhexidine.

‡Extraction for periodontal disease.

§Application of fluoride gel or foam.

dental radiographs and may interfere with interpretation.

- Time needed for a thorough prophylactic treatment for an uncomplicated case is 30 to 60 minutes. Procedure time increases as patient size increases and when a routine cleaning becomes a more complex periodontal treatment.

Step 1: Gross Calculus Removal

General Comments

- Gross calculus is removed by using calculus-removing forceps, ultrasonic or sonic scalers, hand scalers, and curettes.
- Large accumulations of supragingival calculus are removed from the buccal, lingual, palatal, and interproximal surfaces of the teeth.
- Removal of gross calculus alone is not a complete prophylactic dental procedure and is of minimal therapeutic value. Gross calculus removal is, however, an important step in providing visualization and access to the smaller deposits and stains, as well as evaluating tooth mobility in patients with periodontal disease.

Objective

- To prepare efficiently for the subsequent steps of removing smaller accumulations of calculus and plaque.

Calculus-Removing Forceps

Indication

- Expedient removal of large, thick pieces of calculus.

Contraindication

- Fractured teeth with unstable fragments in which the entire fragment, along with the calculus, should be removed.

Basic Principle

- Rapid but uncontrolled removal of calculus.

Materials

- Calculus-removal forceps.
- Extraction forceps, if no calculus-removal forceps are available.

Technique

- The long jaw of the forceps is placed over the cusp of the crown, and the shorter cutting-edged jaw apical to the calculus to be removed.
- The jaws are closed by squeezing the handles together, and the calculus is loosened from the tooth.
- Extraction forceps may also be used in this manner, although less efficiently (Fig. 4-5).

Complications

- Fracturing the crown.
- Tearing gingival tissue.
- Luxating or extracting the tooth.
- Damaging enamel.

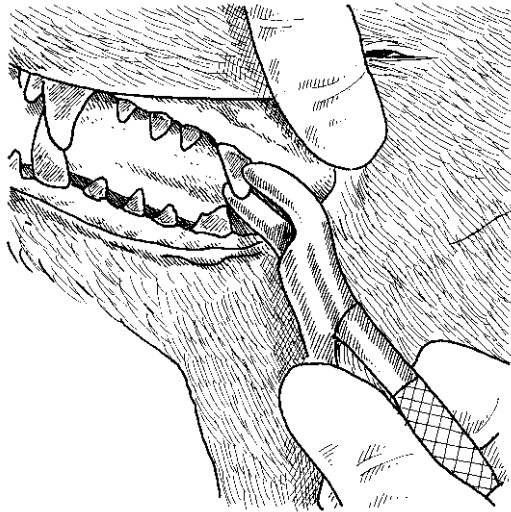


Fig. 4-5

Power Instrumentation: Ultrasonic Scalers

General Comments

- There are three basic styles of ultrasonic scalers: piezoelectric, magnetostrictive with a stack, and magnetostrictive with a ferrite rod.
- The magnetostrictive units with a stack-type insert tend to create more heat at the working tip than the other styles. They are all designed to be used with a fine-mist water spray around the tip.
- The pot (stack) should be inspected carefully at regular intervals for small fatigue fractures in one or more of the nickel alloy leaves (see Chapter 2).
- If performed properly, ultrasonic scaling is a safe method for removing large amounts of calculus rapidly.
- For gross calculus removal, the broad blade insert or tip or universal tip can be used supragingivally. Only the universal or microtips are to be used subgingivally.
- The correct angulation of the working end of the scaler is necessary for efficient and safe use. Numerous tip styles have unique modes of action at the working tip. Different styles have variable lengths of the tip that are active and different dimensions of the tip excursion. Generally, the side of the tip is most effective and least likely to cause damage if the handle is held parallel to the tooth surface (Fig. 4-6, A) rather than perpendicular to it¹³ (Fig. 4-6, B). The handpiece is held so that the working end is between the thumb and index finger, with the handle coming up over the web between the thumb and index finger. A feather-light grip is maintained, to avoid fatigue.
- To avoid damaging the tooth surface, the pressure applied should be less than approximately 50 grams (the weight of two aspirin tablets).

Indication

- Removal of gross calculus from supragingival surfaces.

Materials

- Ultrasonic scaler with water source.
- Broad or universal tip.

Technique

Substep 1—Handpiece is grasped with a modified pen grasp, using a finger fulcrum for control.

Substep 2—The terminal active portion on the side of the tip of the instrument is used (Fig. 4-6, C).

Substep 3—Rapid, broad overlapping strokes are made over the tooth surface. The strokes should start at the edge of the calculus to free it more readily. The tip should be moving continually to avoid thermal injury to the underlying pulp. With the stack-type scaler, only 10 to 15 seconds should be spent on one tooth at a time. The power setting, unless the unit has auto-tuning, should be set as low as efficiently possible so as to reduce metal fatigue of the working tip. The water spray should, at the same time, be adjusted to adequately cool the tip and effectively wash away calculus debris for better visualization.

Substep 4—The teeth are scaled systematically so that all tooth surfaces are cleaned. With the patient in lateral recumbency, the buccal surfaces of the teeth in the quadrants closest to the technician and inner surfaces of the teeth in the quadrants closest to the table are scaled to take advantage of optimum visibility and efficiency. Tips or inserts are changed alternately to continue scaling subgingivally safely and effectively. Hand positioning and rests can be used as demonstrated with the sonic scaler shown on pp. 192 to 195. The first side can be completed with fine scaling by hand instrument, subgingival scaling, charting, and polishing, with subsequent oral irrigation, and then the patient is positioned on its opposite side and all the steps of the cleaning process are repeated. If a patient is placed in dorsal recumbency, each step can be completed around the entire mouth with the patient in the same position.

Complications

- Inadequate water spray or lingering at one spot on the tooth may cause thermal injury to the pulp.
- Etching of the enamel because of excessive pressure or using the instrument tip rather than the side of the working end.

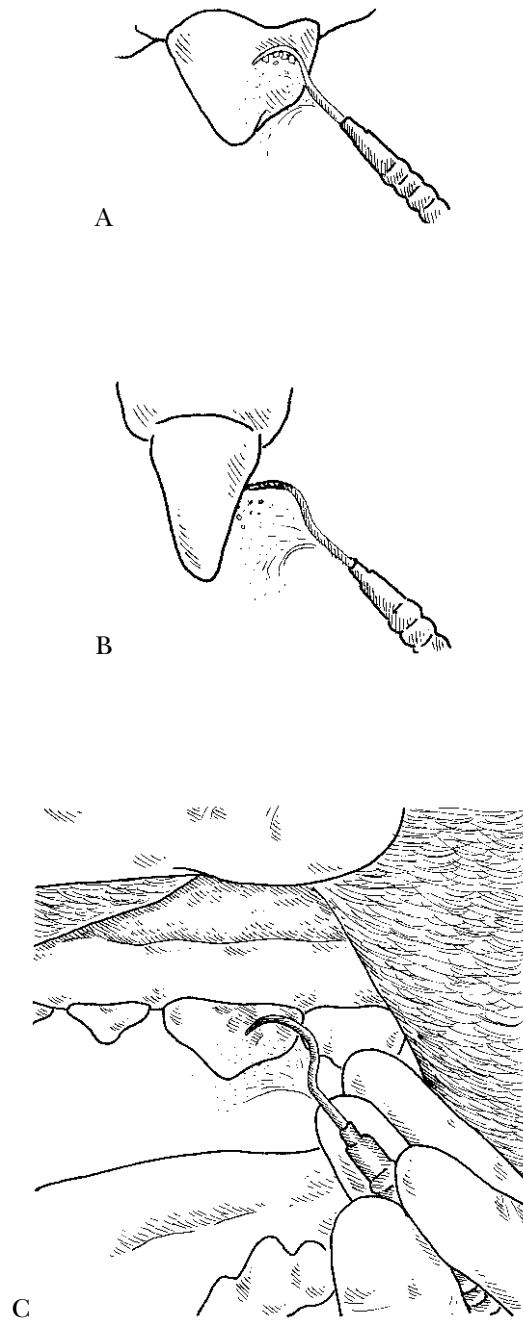


Fig. 4-6

- Premature metal fatigue necessitating frequent replacement of pot stacks or working tips due to higher than necessary power settings.
- Increased working time due to using a tip with fatigue fractures in the stack.

Aftercare: Follow-Up

- Fine calculus removal with hand scalers and curettes, and subgingival scaling.
- Polishing and subgingival irrigation.

Ultrasonic Instrumentation: Magnetostrictive with Ferrite Rod

General Comments

- The instrument is used in a manner similar to that of other ultrasonic handpieces (42:12, IM3, Vancouver, Wash.; Odontoson M, Odonto-Wave, Fort Collins, Colo.).
- The properties that are similar to those of a piezo transducer allow the ferrite rod unit to generate an exceptionally high frequency of 42,000 cycles per second (cps).
- The ferrite ceramic rod should be inspected periodically for tightness at its attachment to the working end. If the performance of the handpiece appears reduced, the transducer may have become loosened.
- The scaler tip moves in a circular fashion, so any side of the tip is active.

Technique

- The unit can be attached to the water supply system of a dental unit or other pressurized water system.

- Because of the design of the scaler tip, the water is delivered directly down the tip of the working end.
- The water bottle can be filled with an anti-microbial solution, and the scaler tip may be used to administer deep root therapy.
- The external tubing and scaler tips may be sterilized to reduce the risk of cross contamination or persistent biofilm.
- The on/off switch is in the handpiece, which is more ergonomically beneficial than using a foot pedal switch (see Chapter 13).
- Either the broad-tipped or universal insert is used first, set at a higher power to remove the heavier calculus deposits. It is moved with broad, sweeping strokes over the tooth's crown, with the tip positioned facing the gingiva. Because about 13 mm of the probe-like tip is active, more of the tip can be placed on the tooth. Next, either the universal or the periodontal insert is used with short overlapping strokes to remove residual coronal calculus, and the periodontal insert can be used to perform delicate subgingival debridement at a reduced power setting. General technique is the same as per magnetostrictive scaler description above.

Disadvantages

- Similar to those of other ultrasonic scalers.
- Fragile ferrite rods.

Maintenance

- All removable parts are autoclavable: tips, handpiece and cord, irrigation lines.

Ultrasonic Instrumentation: Piezoelectric

General Comments

- The unit operates with an electromagnetic transducer that allows it to operate at 40,000 cps, thus reducing operator time. The scaler tip moves in a linear manner (back and forth), rather than in a figure-of-eight motion as do magnetostrictive stack units. One model has a variety of tips available: three universal tips, six periodontal tips, and a variety of crown removing, as well as amalgam condensing, tips and an endodontic ultrasonic file handpiece (Amdent, Denta-laire, Fountain Valley, Calif.).
- The unit utilizes a water spray, either from an independent source or from the hospital main water supply, for irrigation and as a coolant.
- Working tips are changed by unscrewing the tip with a specific wrench and replacing it with a new tip. Subgingival tips are available for use in pockets and a ball tip for use in furcations.

Technique

- The handpiece is held and used in a manner similar to that of the stack model of magnetostrictive ultrasonic scalers.
- A broad tip is used first for heavy calculus removal, with broad sweeping strokes performed over the crown surface. Only the last 3 mm of the tip vibrates. Smaller or subgingival tips are then used for fine and subgingival scaling and ultrasonic debridement, with short overlapping strokes at a lower power setting.

Complications

- Because of their high frequency, the tips suffer metal fatigue fractures and need replacement approximately twice as often as do the magnetostrictive stacks, but tips are generally half the cost, resulting in similar economics.

Power Instrumentation: Sonic

General Comments

- Less heat is created by sonic scalers than by some ultrasonic scalers.
- Sonic scalers require compressed air to operate.
- Sonic scalers produce minimal heat, decreasing the incidence of thermal injury to the pulp.
- Sonic scalers can be used subgingivally because of minimal heat production. The tip, however, operates with a wider excursion than ultrasonic scaler tips and thus has the potential to create more soft tissue irritation when used subgingivally.
- Sonic scalers produce vibrations of 3,000 to 8,000 cps, and therefore procedures may take longer than with ultrasonic scalers.

Indication

- Removal of gross calculus from supragingival and (with caution) subgingival surfaces.

Materials

- Dental station with compressed air.
- Compressor of at least 1 horsepower, to avoid overheating.
- Sonic scaler handpiece and tip(s).

Technique

- A systematic approach is recommended.
- The finger rest will vary from tooth to tooth and operator to operator.

Step 1—The labial surface of the maxillary canine tooth is scaled with a sonic scaler, using extended-reach finger rests (Fig. 4-7, *A*).

Step 2—The buccal surfaces of the maxillary premolars and molars are scaled using standard finger rests (Fig. 4-7, *B*).

Step 3—The palatal surfaces of the maxillary incisors are scaled using extended-reach finger rests (Fig. 4-7, *C*).

Step 4—The palatal surface of the maxillary canine is scaled using standard finger rests (Fig. 4-7, *D*).

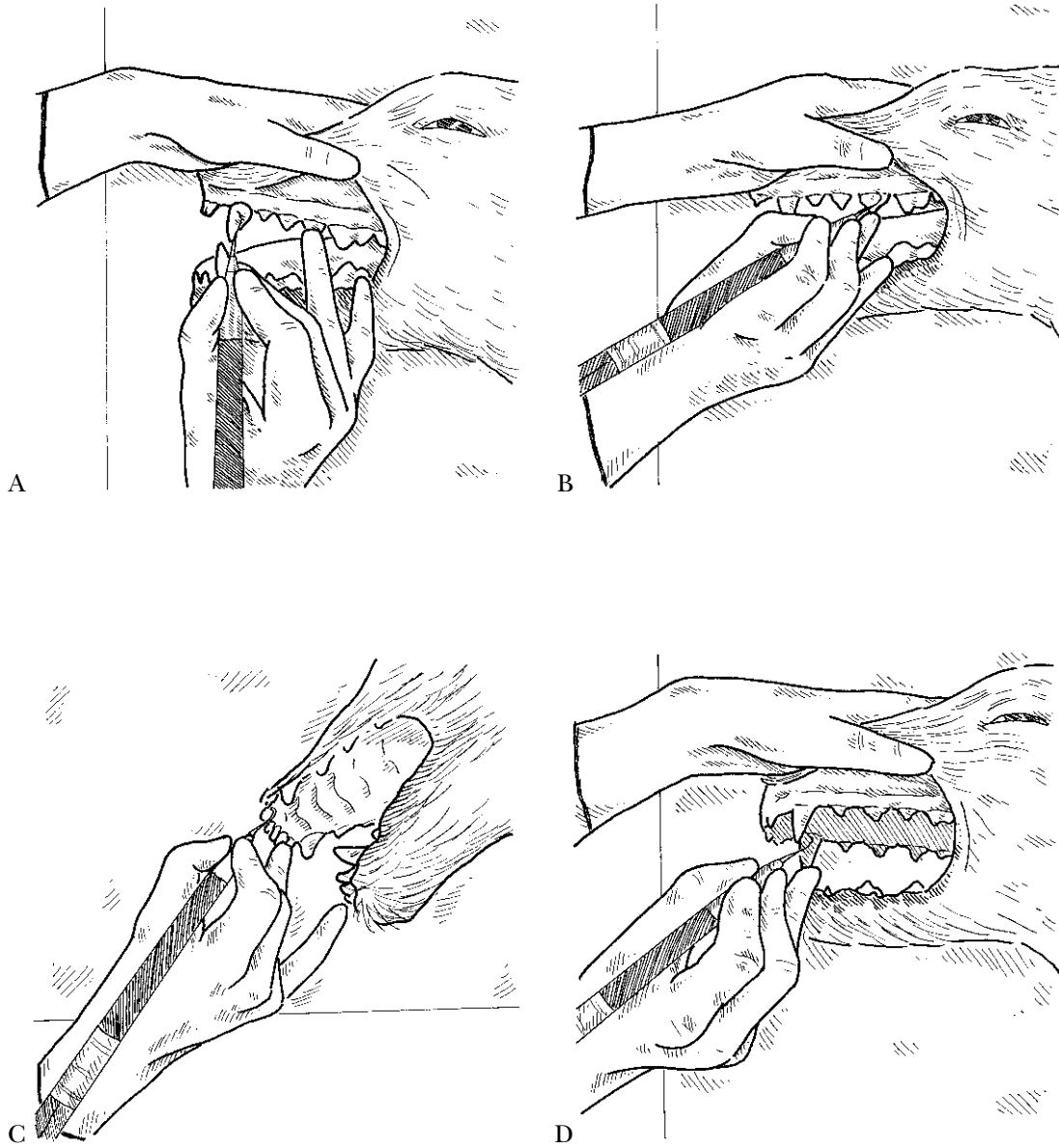


Fig. 4-7

Step 5—The palatal surfaces of the maxillary premolars and molars are scaled using an extended grasp (Fig. 4-8, *A*).

Step 6—The labial surface of the mandibular canine is scaled using standard rests on the incisor (Fig. 4-8, *B*).

Step 7—The lingual surfaces of the mandibular incisors are scaled using standard rests (Fig. 4-8, *C*).

Step 8—The lingual surfaces of the mandibular premolars and molars are scaled using extended rests (Fig. 4-8, *D*).

Complications

- Etching enamel.
- Soft tissue injury if used too aggressively subgingivally.

Disadvantage

- Sonic instruments move more slowly, which translates to procedures taking longer.

Aftercare: Follow-Up

- Same as that with ultrasonic scalers.

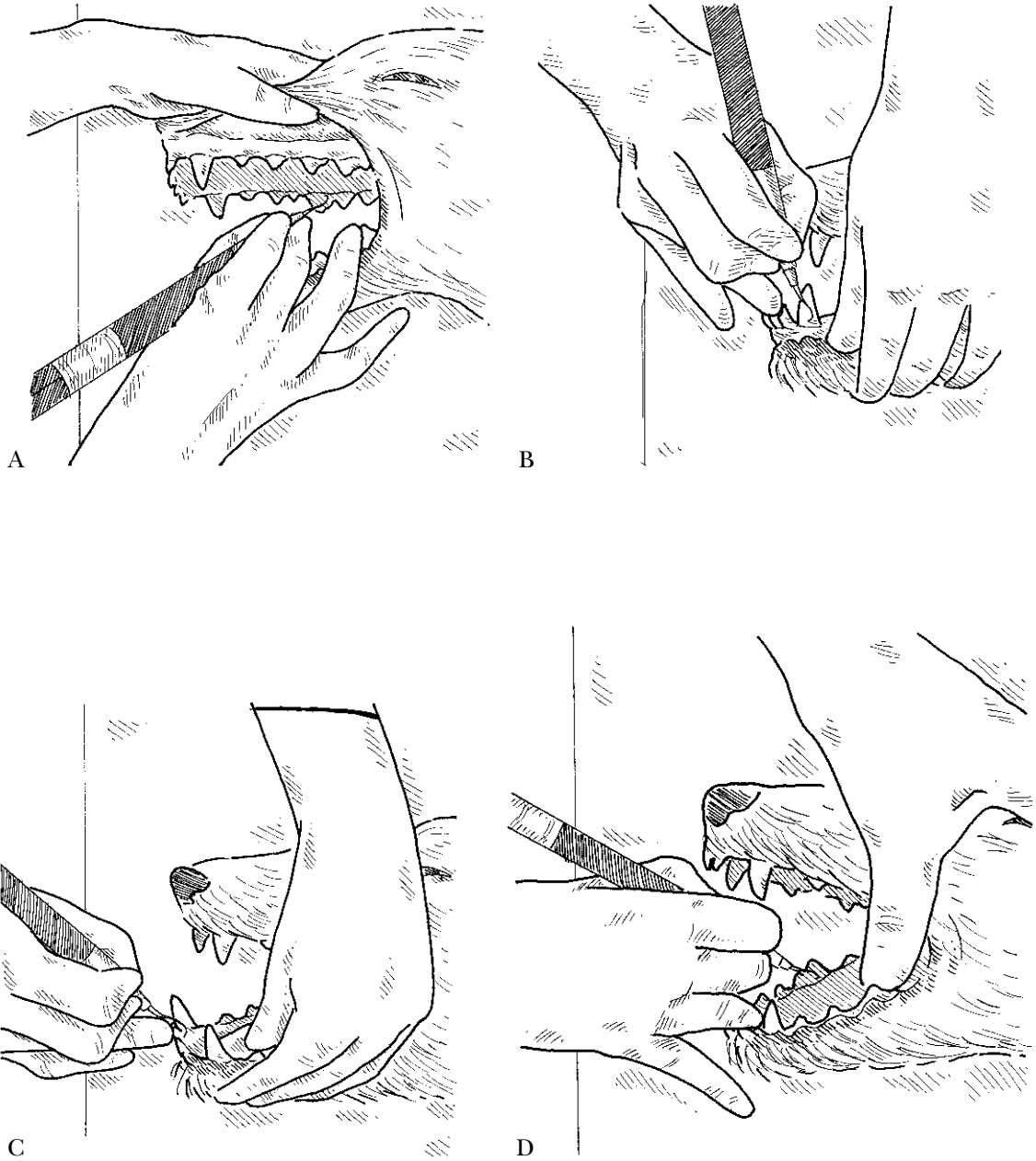


Fig. 4-8

Scalers and Curettes

Indications

- Scalers are used for removal of gross calculus above the gumline.
- Curettes are used for fine calculus and plaque removal above and below the gumline.
- Hand scalers and curettes are useful in areas that may be difficult to reach with power instrumentation. Even if mechanical scaling is done to remove the majority of tooth deposits, hand instrumentation is necessary in all prophylactic procedures to completely remove residual dental deposits.

Materials

- Hand scalers and curettes of choice.

Techniques

- Instrument holding techniques, use of finger rests, and proper instrumentation.

Hand instrument holding techniques

- Scalers and curettes are designed to be used with a modified pen grasp for greater control and effectiveness of the working end (Fig. 4-9, *A*).
- A pen grasp should be avoided (Fig. 4-9, *B*).
- The modified pen grasp is achieved by first holding the instrument between the thumb and index finger, with the remaining fingers held straight (Fig. 4-9, *C*).
- The remaining fingers are then moved over so that they are to the side of and slightly on top of the index finger. The instrument remains held by the tips of the fingers (Fig. 4-9, *D*).

Finger rests

- Fine-instrument control is necessary in order to clean teeth without causing tissue injury.
- A large variety of finger rests may be used in each situation.
- Hand size, position of operator in relation to patient, and type of instrument determine the finger rest.

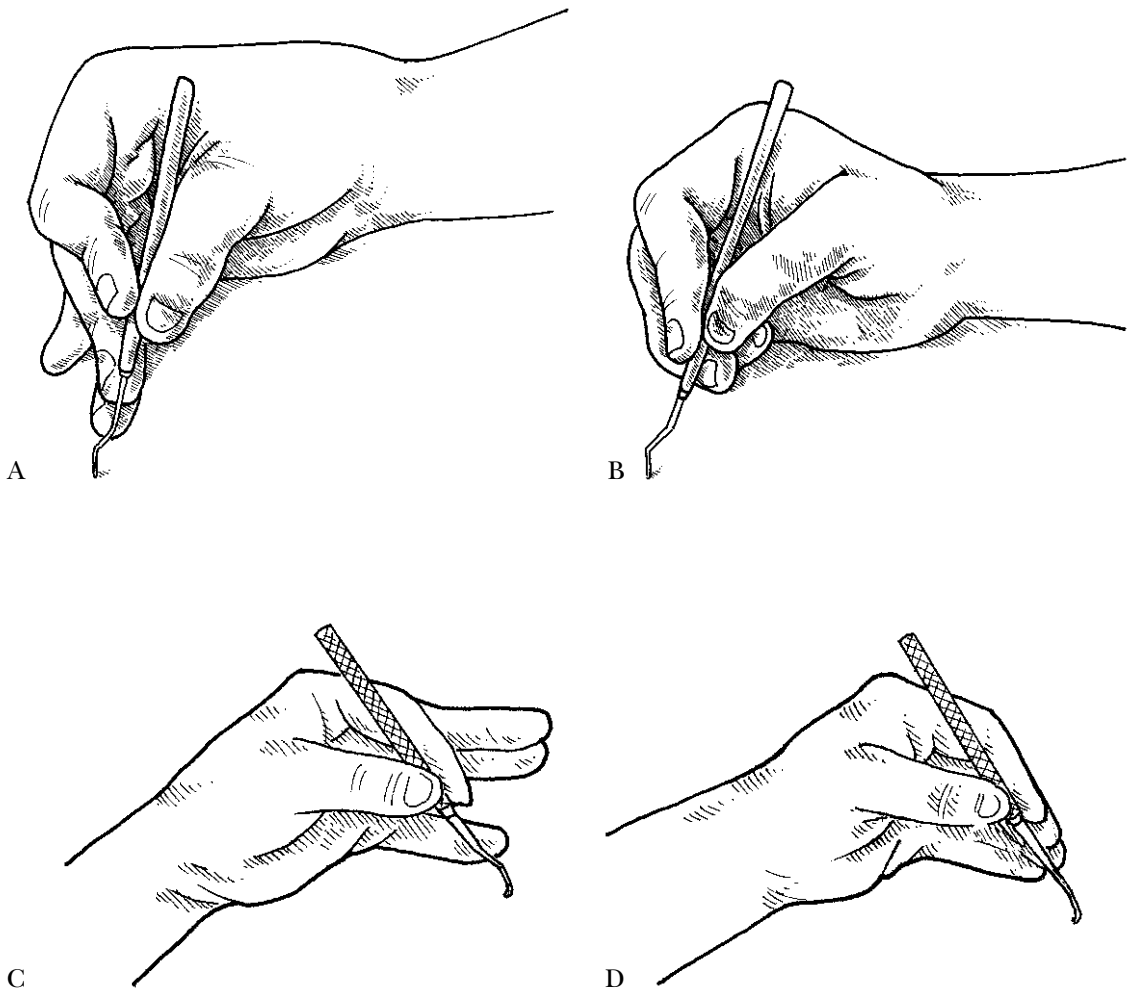


Fig. 4-9

Standard position

- The middle or the fourth (ring) finger is placed against the tooth being scaled or the proximal (adjacent) tooth. This finger becomes the fulcrum to effect power for the working stroke.
- The instrument is placed on the tooth to be scaled (Fig. 4-10, *A*).
- The wrist is rotated while keeping the fingers straight, as the blade of the instrument is made to move, following the contour of the tooth (Fig. 4-10, *B*).

Cross-arch rest

- The fulcrum finger is placed on a tooth in the opposite arch (Fig. 4-10, *C*). This often is done when working in smaller areas or on smaller patients.

Open or extended grasp

- The middle and ring fingers are allowed to separate (Fig. 4-10, *D*).
- This technique is used when the finger rest (fulcrum) cannot be near the work area, such as when scaling the more distal teeth.

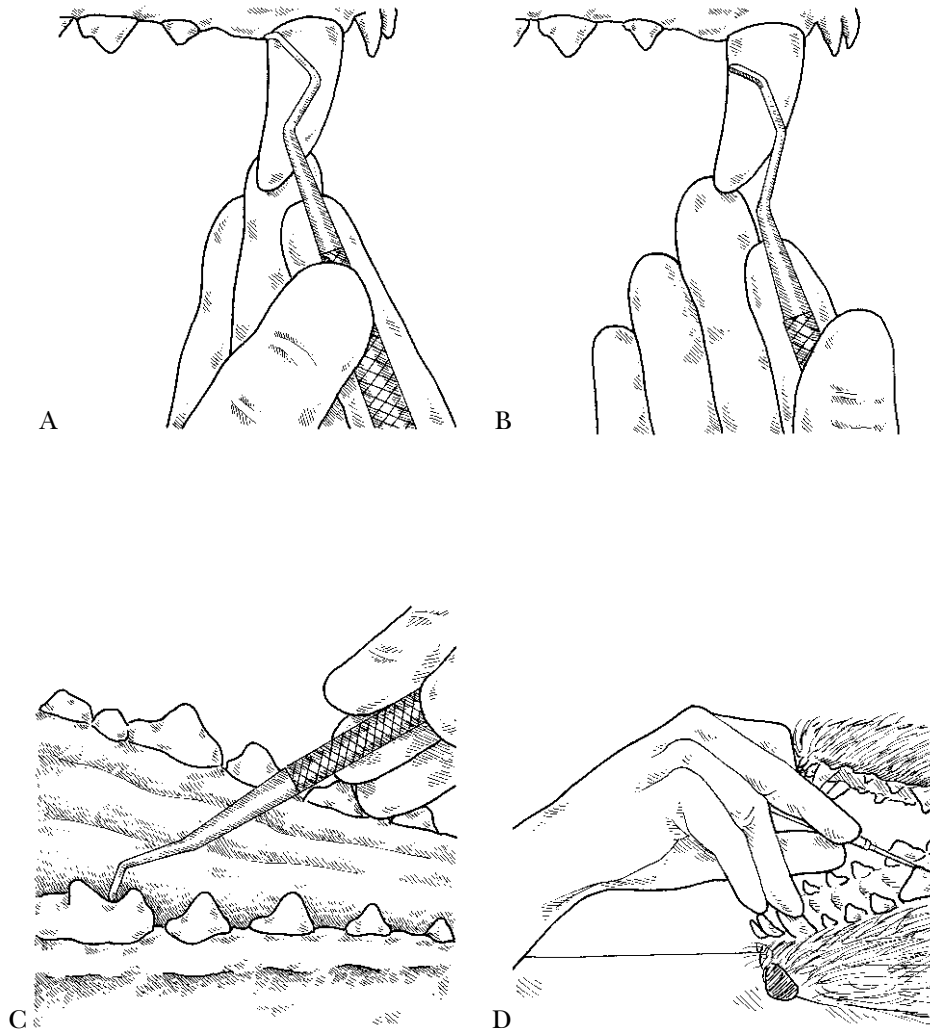


Fig. 4-10

Long reach

- The instrument is grasped farther toward the middle of the handle (Fig. 4-11, *A*). This is an alternative when working at the back of the mouth.
- This technique reduces the amount of instrument control and strength of stroke at the working end.
- A fulcrum is still used, to provide as much stability as possible.

Secondary rest

- The hand not holding the instrument is used as a rest for the fulcrum (Fig. 4-11, *B*).

Working techniques

- When using a scaler, the blade of the instrument is placed so that the face of the working end is at a 70- to 80-degree angle to the tooth surface (Fig. 4-11, *C* and *D*).
- With scalers, either edge can be used for scaling.
- Calculus is removed with a pull stroke of the instrument. The instrument should follow

the contour of the tooth and should maintain the 70- to 80-degree angle as the pull stroke is made toward the cusp of the tooth from the gingival margin.

- The tip of the instrument may be used for removing calculus from pits and fissures; the developmental buccal groove of the maxillary fourth premolar is a good example of a site where these deposits typically occur. The tip of small scalers can also be used to clean the labial groove found on feline canine teeth.
- Chisel scalers (sometimes called a *hoe*) can be useful in removing large accumulations of calculus initially. They are used in a pull or push stroke away from the gingival margin.
- Old style veterinary broad claw-shaped scalers should not be used subgingivally because they may distend and lacerate tissues. Scalers designed for use on people and newer veterinary hand scalers are not as broad as the older style, but their sharp tips may still lacerate the delicate subgingival tissues.

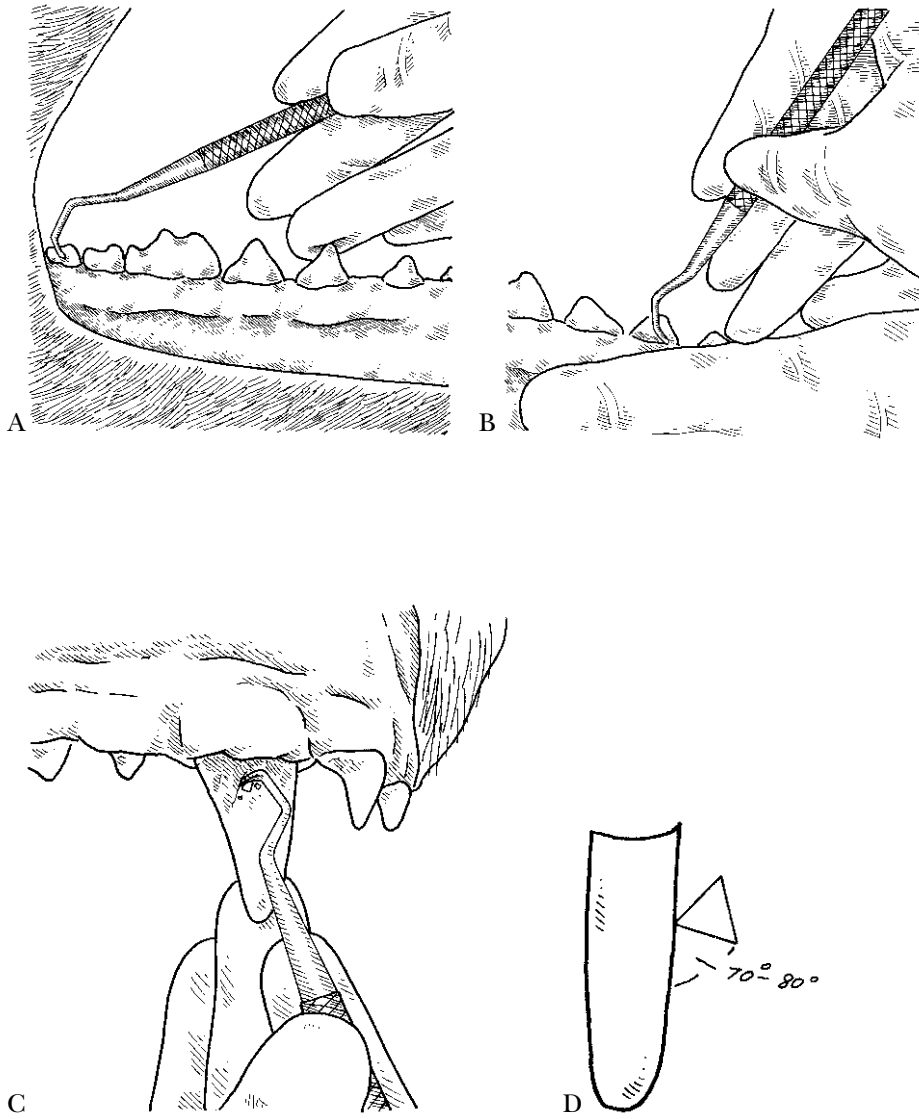


Fig. 4-11

- Curettes may be used supragingivally in a manner similar to that of scalers, in a pull stroke. They are not designed to be used on heavy calculus, because the fine blade will dull rapidly or break. Curettes, because of their blunt toe, can also be used more safely for subgingival plaque and calculus removal, root planing, and subgingival curettage. Although curettes have two cutting edges, only one edge is used. With universal and area-specific curettes, the working tip is placed on the tooth crown so that the terminal shank area is close to the tooth and the face of the curette is not easily visualized (Fig. 4-12, A). The blade is at an angle of 70 to 80 degrees to the tooth surface. If the curette is placed with the incorrect side on the tooth surface, the terminal shank will come up off the tooth surface and the face of the curette will be easily visualized (Fig. 4-12,

B). Used in this manner, the curette will be ineffective in removing calculus. Universal curettes can be used effectively anywhere in the mouth. Area-specific curettes have unique bends in their shanks. Generally, the straighter the shank, the more anterior in the mouth the instrument is to be used. Instruments with a greater number of bends allow the curette to be used effectively at the distal aspect of caudal teeth.

Complications

- Scratching or macro-etching the enamel or dentin.
- Inadvertently removing restorative material from previously filled teeth.
- Gingival lacerations, abrasions, tears, and damage to the sulcus.

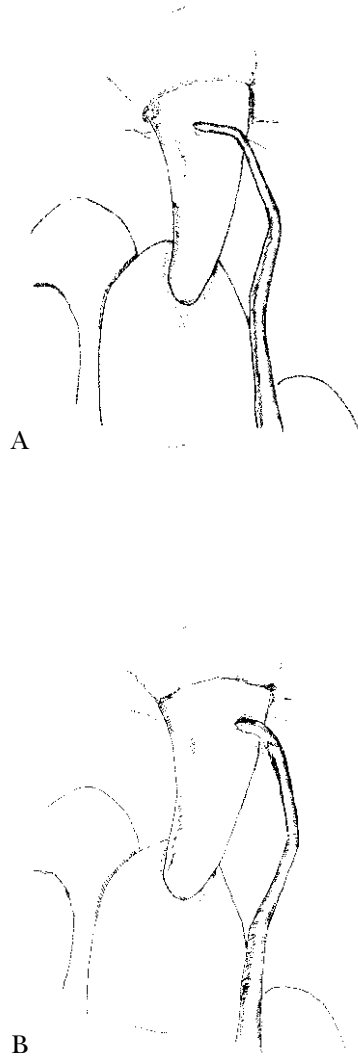


Fig. 4-12

Step 2: Closed Subgingival Plaque and Calculus Removal

General Comments

- If subgingival calculus remains, only a cosmetic benefit and no health benefits have been accomplished.
- Newer ultrasonic units, with thinner working tips and directed water spray and that can be used more safely for subgingival scaling, are available. The water spray lavages the sulcus or pocket to reduce further the number of plaque bacteria and remove loosened calculus. In some models, an antimicrobial solution can be placed in the lavage water. Cavitation or acoustic streaming is a phenomenon created by the ultrasonic vibration of the working tip in the sulcus or pocket, causing an increased cleansing effect.¹⁴ After subgingival scaling with an ultrasonic or sonic scaler, curettes are used to do the finishing touches manually. If thin, ultrasonic tips are unavailable, curettes must be used for all of the subgingival scaling.
- Sharp instruments are necessary for this procedure.
- Periodontal pockets, abnormal pocket epithelium, rough tooth surface, and necrotic cementum may necessitate root planing, subgingival curettage, and periodontal surgery.

Indications

- Removal of calculus below the gingiva when pocket depth is less than 5 mm.

- If periodontal pocket depth is greater than 5 mm, surgical treatment may be indicated.
- Ultrasonic periodontal debridement may also be effective in some pockets greater than 5 mm (see Chapter 5).

Contraindications

- Severe systemic disease.
- Increased bleeding time.

Objective

- Removal of all subgingival calculus, plaque, and endotoxins.

Materials

- Curettes of operator's choice.
- Thin-tipped ultrasonic tips or inserts.

Technique for Use of Curettes

Step 1—The angle of the face is positioned nearly parallel to the tooth surface (closed position) (Fig. 4-13, A). The curette is held with a modified pen grasp and introduced gently to the bottom of the sulcus or pocket (Fig. 4-13, B).

Step 2—The bottom of the sulcus or pocket is encountered and should feel soft and resilient (in contrast to the hard and firm feeling of calculus on the tooth surface).

Step 3—Once the sulcus fundus is reached, the curette is rotated so the face of the working end is at a 70- to 80-degree angle to the tooth surface (Fig. 4-13, C). Plaque and calculus are removed, by the cutting edge, with a pull stroke (Fig. 4-13, D).

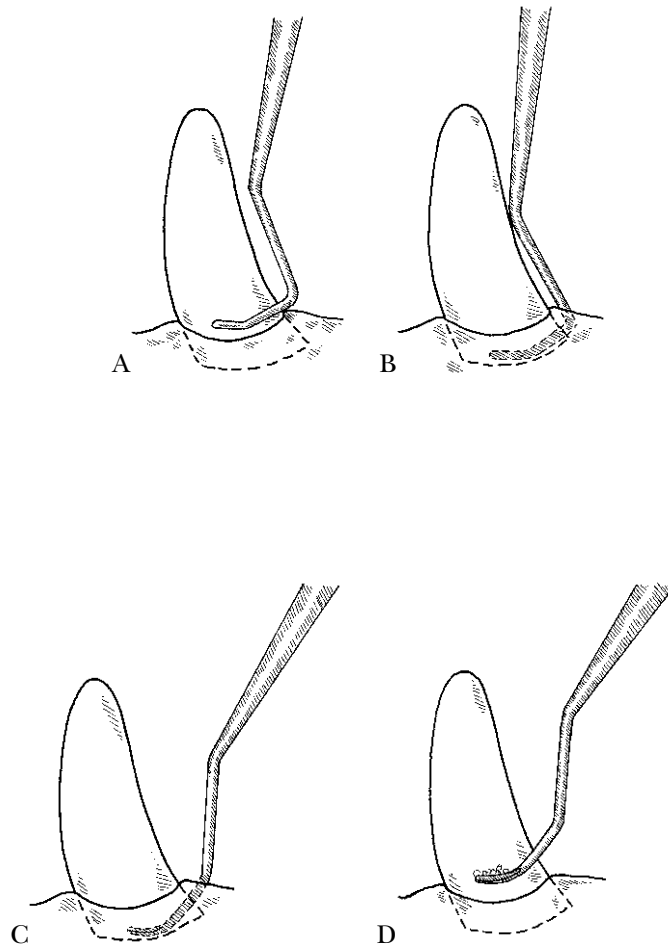


Fig. 4-13

Step 4—Repeated strokes are taken in different directions—vertical stroke (Fig. 4-14, *A*), oblique stroke distad (Fig. 4-14, *B*), oblique stroke mesiad (Fig. 4-14, *C*), and horizontal stroke (Fig. 4-14, *D*). Pressure on the instrument tip is applied more heavily at first and then gradually lighter and lighter—until the sulcus or pocket is clean and smooth.

- It may be necessary to start at an edge of the subgingival calculus and systematically remove portions of the calculus until the sulcus is clean.

Technique for Using Ultrasonic Scaler for Subgingival Therapy

Step 1—Select an appropriate subgingival tip and place it on or in the handpiece.

Step 2—Decrease the power setting to a lower setting on the unit.

Step 3—With short, overlapping strokes, direct the tip of the unit into the sulcus or pocket with a feather-light touch, around each tooth, in a systematic way (Fig. 4-14, *E*).

Step 4—Follow the use of the ultrasonic scaler with that of a curette to complete the process delicately.

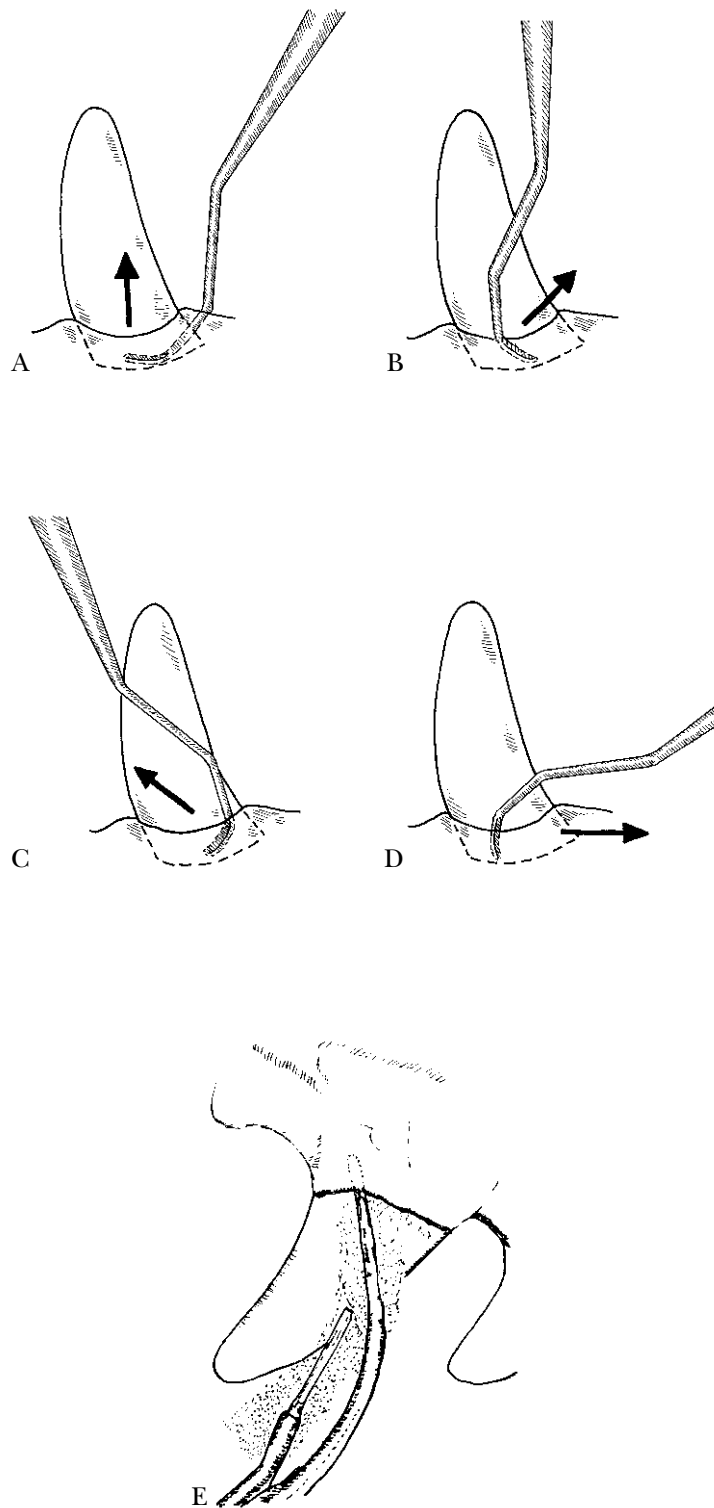


Fig. 4-14

Complications

- The affected, friable gingiva may become lacerated (Fig. 4-15, A).
- The epithelial attachment may be torn (Fig. 4-15, B). If too much force is applied to the tip when inserting it to depth, ultrasonic tips may tear the epithelial attachment, as well.
- The tooth surface may be roughened or macro-etched (Fig. 4-15, C).
- Ultrasonic scalers remove less cementum, which is preferable, and allow greater healing.¹⁵

Aftercare: Follow-Up

- Polishing, fluoride treatment if indicated, and final irrigation.
- Routine home care; see pp. 222 to 231.
- Reexamination in 14 to 21 days.
- Evaluation under general anesthetic in 3 to 12 months, depending upon stage of periodontal disease and level of home care recommended and applied.

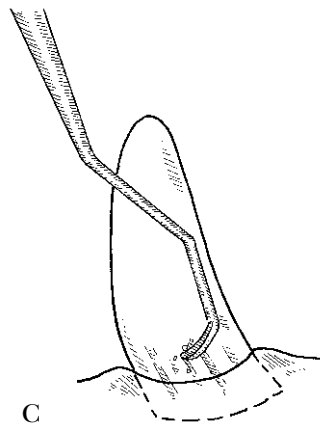
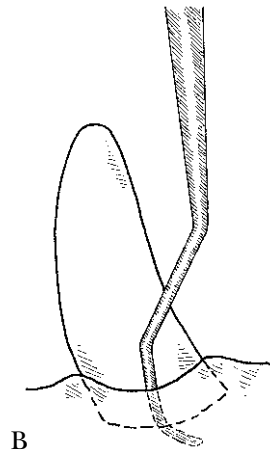
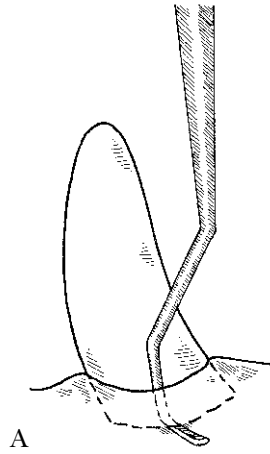


Fig. 4-15

Step 3: Detection of Missed Calculus and Plaque

Objective

- To ensure removal of all calculus and plaque.

Techniques

- Air drying, disclosing solutions, explorers, and periodontal probes are used to detect plaque and calculus.

Air Drying

General Comments

- Calculus is more visible when dry.
- Calculus appears chalky on the enamel surface after it is air dried.
- Subgingival calculus is a dark brown-black and can be seen at the cemento-enamel junction or on the root surface.
- This method works well during the prophylactic procedure on a tooth-by-tooth inspection after scaling. For examining the entire mouth, staining techniques are preferable.

Indication

- Rapid detection of calculus and plaque that may not be visible otherwise.

Contraindication

- May not be as effective as using a disclosing solution.

Materials

- Compressed air from a three-way syringe or other air source.

Technique

- Air is directed toward the gingival sulcus to lift the free gingival margin gently for greater visibility and to dry the tooth surface (Fig. 4-16, A).
- Calculus remnants are then removed with hand instruments.

Disclosing Solutions

General Comment

- Stains are not retained on the surfaces of clean teeth.

Indication

- Disclosing solution can help detect plaque that may otherwise be unnoticed.

Contraindication

- White or light-colored dogs, because overflow may stain the hair coat temporarily.

Materials

- One-stage disclosing solution, which stains plaque and calculus one color.
- Two-stage disclosing solution, which stains recently formed plaque a different color from long-standing plaque and calculus.
- Fluorescein stain, which may be observed in light or ultraviolet light.
- First Sight swabs (Virbac Animal Health, Fort Worth, Tex.), a plaque disclosing solution in a disposable, dry swab. No stains, no mess; apply in examination room and demonstrate dental deposits. Use following a prophylactic procedure to identify missed deposits.

Technique

Step 1—A small amount of disclosing solution is applied to a cotton-tipped applicator, or a presoaked swab is removed from its wrapping.

Step 2—The disclosing solution is applied to the teeth (Fig. 4-16, B).

Step 3—The oral cavity is rinsed with water to remove nonadherent disclosing solution from enamel (Fig. 4-16, C).

Step 4—The disclosing solution stains the plaque and calculus. The stain does not adhere to clean enamel or dentin (Fig. 4-16, D).

Step 5—Stained calculus and plaque are then visualized and removed using techniques described above.

Complications

- Staining gingiva and hairs. However, because disclosing solutions are water soluble, staining is temporary and is washed away in several days by eating and drinking.

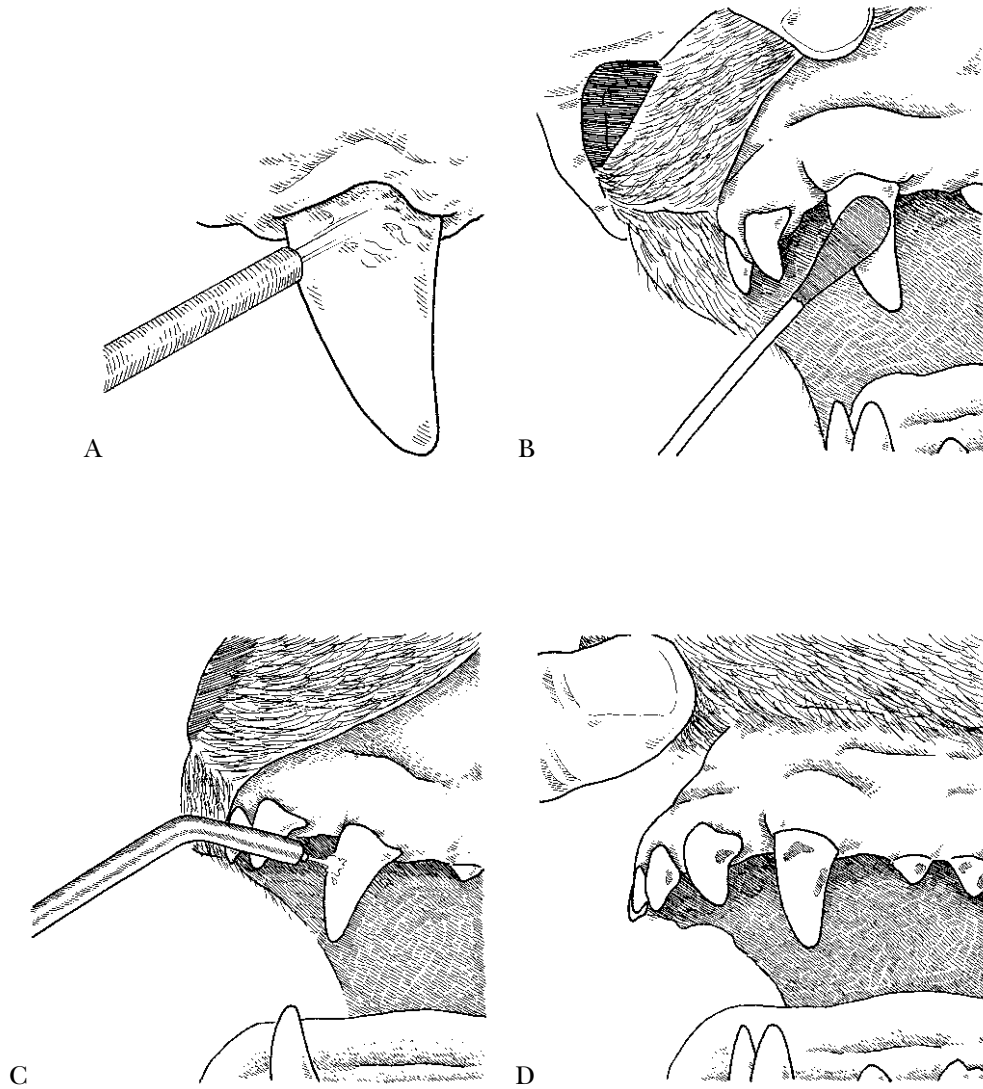


Fig. 4-16

Step 4: Polishing

General Comments

- Slow speed should be used.
- The polisher should spend only a short time on each tooth to avoid thermal injury to the tooth.
- Adequate supply of prophy paste is used to reduce friction, as lubrication for polishing.
- A light pressure minimizes thermal injury and tooth damage. Softer rubber tips are available, which flare with less pressure.
- If the teeth are not polished, the slightly rough surface facilitates prompt recurrence of bacterial plaque formation.

Indication

- After every professional tooth scaling.

Contraindications

- With some restorative materials, alternative prophy pastes should be used.
- With some restorative materials, polishing should be avoided until curing is complete.

Objective

- Smoothing the tooth surface and removing residual plaque.

Materials

- Dental delivery system (electrical or air-powered).
- Prophylaxis angle (an oscillating prophylaxis angle creates less heat, does not tangle hair, and does not sling paste).
- Prophylaxis cup.
- Prophylaxis paste supplied in bulk or individual containers.
- Prophylaxis paste dish.

Technique

Step 1—A small amount ($\frac{1}{2}$ teaspoon) of prophylaxis paste is placed in a prophylaxis paste dish (Fig. 4-17, A).

Step 2—A rubber prophylaxis cup is dipped into the prophylaxis paste dish (Fig. 4-17, B).

Step 3—The prophylaxis paste is transferred to the surface of the teeth to be polished (Fig. 4-17, C).

Step 4—A liberal amount of prophylaxis paste is used on each tooth surface to act as a lubricating and polishing compound (Fig. 4-17, D).

Step 5—The rubber prophylaxis cup is applied lightly to the tooth surface and turned at a slow speed (2,000 to 4,000 rpm) (Fig. 4-17, E). The edge of the cup can be flared slightly to polish subgingivally.

Step 6—The tooth surface and sulcus are rinsed thoroughly (Fig. 4-17, F).

- Coarse or supercoarse (“stain remover”) prophylaxis paste is available to assist in cleaning hard-to-clean enamel. When using coarse prophylaxis paste, more enamel is removed. A fine prophylaxis paste should be used after the coarse paste, to make the surface as smooth as possible.

Complications

- Thermal injury to the pulp.
- Wrapping patient’s hair in the cup with the rotating prophylaxis cup. Children’s “banana” hair clips can be used to keep hair out of the operating field. The patient’s face may be “toweled in” to prevent hair entanglement and prophylaxis paste from being splattered into the eyes. Oscillating prophylaxis angles rather than rotating prophylaxis angles, although more expensive, are also available.
- With air polishing, potential injury to soft tissues if not protected or getting powder into eyes or nose of patient or operator if not protected.

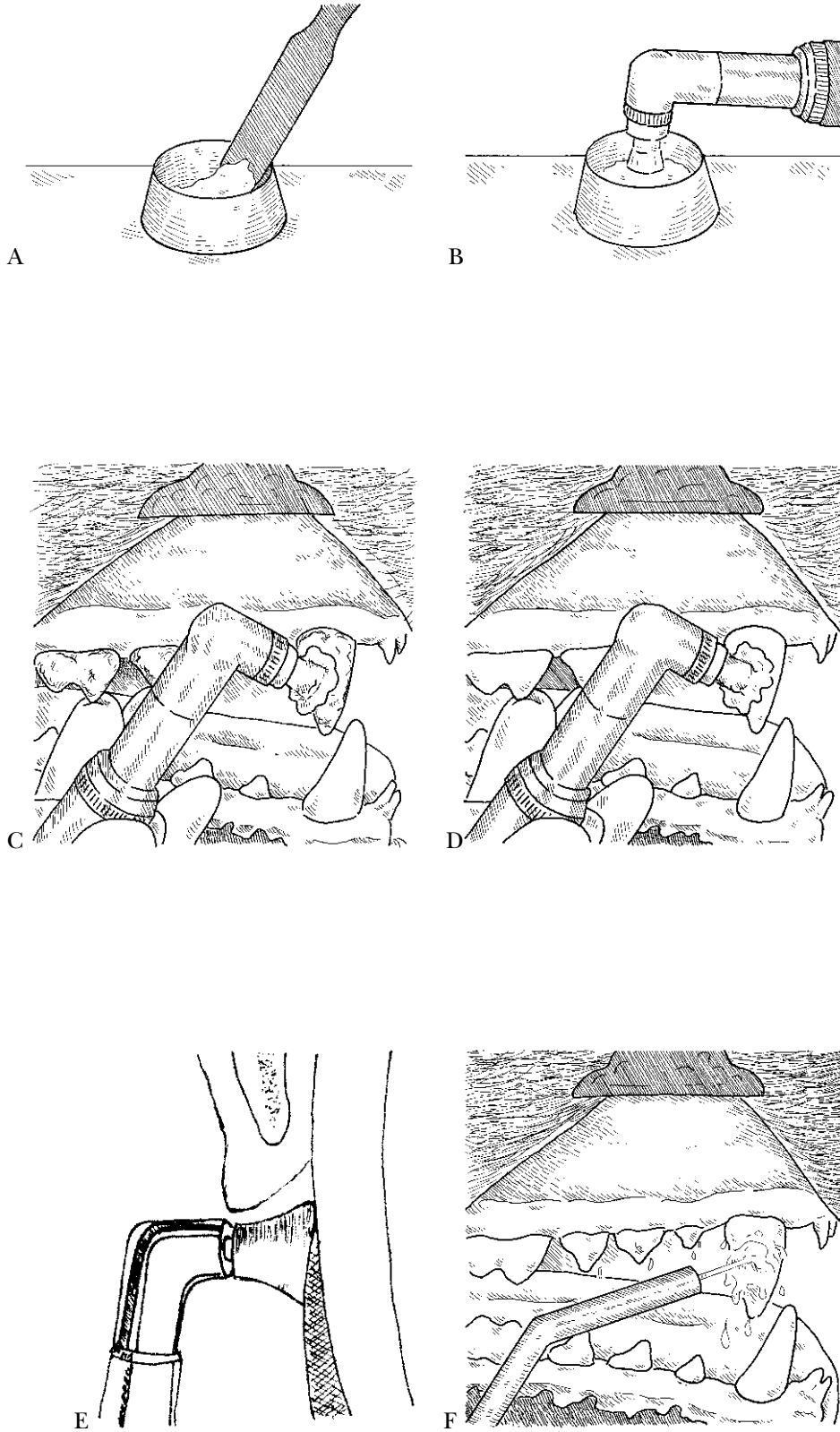


Fig. 4-17

Air Polishing

Comments

- Polishing and stain removal can also be accomplished by using an air polishing unit that sprays powdered sodium bicarbonate against the tooth surface. It is very quick; however, the pressurized spray can damage the soft tissues if they are not well protected.
- Air polishing can be accomplished by separate polishing units (Prophy-Jet, Dentsply Professional, York, Penn.), attachments to an ultrasonic scaler (Cavitron Jet, Dentsply Professional), or a handpiece attachment to a dental unit (Air Max, Satelec, Cherry Hill, NJ).
- Operator eye and respiratory shielding protection is a must for safety purposes.
- Patient eye protection is also important.

Technique

Step 1—Soft tissues are protected with gauze.

Step 2—The spray opening is directed at a slight angle to the tooth surfaces.

Step 3—The power is activated and the spray is passed over the tooth surfaces.

Step 4—Protective gauze is moved to another portion of the mouth, and the process is repeated until all tooth surfaces have been air polished.

Step 5—The mouth is rinsed with water to remove dried powder.

Advantages

- Cleans and polishes teeth rapidly without damaging them.
- Attaches to the high-speed handpiece air line or ultrasonic unit (Cavitron Jet or Air Max).

- Provides good access to the lingual and palatal surfaces, crevices, and fissures of the teeth.
- Provides access to exposed root surfaces.
- Removes stains.

Disadvantages

- Can be messy.
- Must protect soft tissue from abrasion.
- Careful cleaning is necessary to avoid obstruction of instrument.
- Must take particular care to protect eyes of operator and patient.
- Additional cost.

Step 5: Diagnostic Procedures

Periodontal Probing and Exploring

General Comments

- Periodontal probing and exploring are important diagnostic procedures.
- Some clinicians may choose to do this step first and then take radiographs of any problem areas before cleaning and polishing the teeth.
- Thorough treatment of any pocket more than 5 mm in depth may require periodontal surgery.
- The double-ended periodontal probe or explorer is one of the most important diagnostic instruments for the veterinary dentist.
- The delicate, sharp tip of an explorer may be moved along the tooth surface at the gingival margin to detect tooth irregularities and deposits. By percussion, the tip can be used to detect dentinal softening of carious lesions, enamel and dentin defects associated with resorptive dental lesions, patency of pulp chambers in fractured or worn teeth, and sensitivity.

Indications

- To examine dental structures.
- To detect periodontal pockets, roughened tooth surfaces, and calculus deposits.

Objectives

- To assess periodontal health and to monitor and evaluate periodically the progress of therapy.
- To detect dental pathology.

Materials

- Periodontal probe of operator's choice (see pp. 86-87).
- Double-ended explorer or probe.

Technique

Step 1—The probe is inserted gently, parallel to the long axis of the tooth to the bottom of the gingival sulcus or periodontal pocket (Fig. 4-18, *A*). Deep pockets are detected and measured (Fig. 4-18, *B*).

Step 2—The probe is “walked” along the entire wall of the tooth (do not drag the probe), measuring the depth of the sulcus or pocket, testing in at least six places (mesiobuccal, midbuccal, distobuccal, mesiolingual/mesiopalatal, midlingual/midpalatal, and distolingual (distopalatal) around the tooth's circumference (Fig. 4-18, *C*).

Step 3—Abnormal pocket depths are recorded in the dental record. Gingival recession and attachment loss may also be measured and noted in the chart, according to departmental policy.

Step 4—The explorer tip is used to evaluate any surface irregularities such as crown fractures, enamel cracks, or resorptive lesions. These abnormalities are also noted on the chart.

Step 5—Other abnormalities seen, such as missing teeth, supernumerary teeth, and discolored teeth, are noted in the chart.

Complication

- Perforation of floor of gingival sulcus from too much pressure. This can happen easily, because in the fundus of an unhealthy sulcus, the tissue is more friable than in the fundus of healthy tissue.

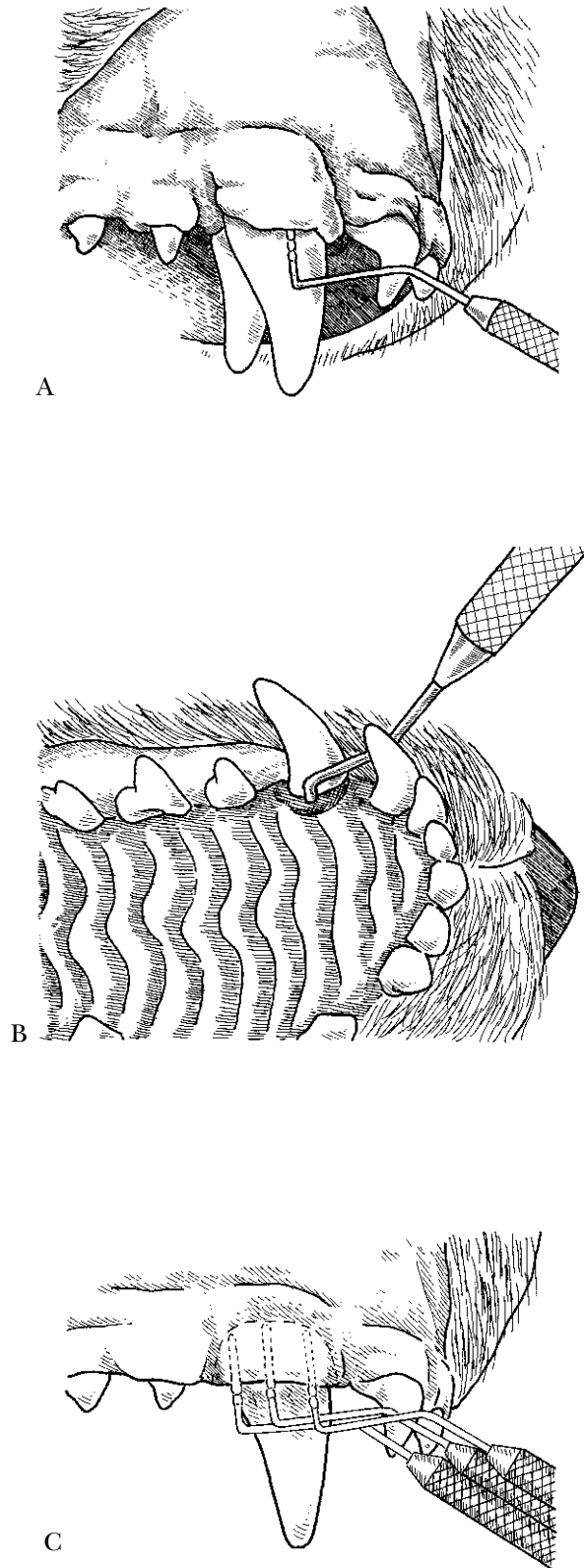


Fig. 4-18

Dental Radiology

Indications

- Radiographs are taken to evaluate the dental and bony structure for evidence of anatomic variations, periodontal disease, endodontic pathology, resorptive pathology, traumatic injury, or metabolic imbalance.
- Intraoral dental radiology enables the clinician to find dental disease that can be missed easily during physical examination or that is detectable only by radiographic means (see Chapter 3).

Biopsy and Histopathology

General Comments

- Oral diagnostic methods frequently show lesions or conditions that are not diagnosed readily with probing and radiographs. In these situations, histopathologic testing of the tissues, whether gingival, lingual, osseous, or dental, is helpful in determining a diagnosis and subsequent treatment plan. Biopsy and histopathology are also helpful to confirm a diagnosis.

Indications

- Presence of unusual gingival mass, growth, or inflammatory response.
- Oral mass, growth, or swelling.
- Radiographic bone or tooth changes not consistent with periodontal disease or other known dental process.
- Lingual lesions.

Objective

- To acquire a representative tissue sample for histopathologic study.

Materials

- Blade #15 or #15C and blade handle.
- Sharp-sharp scissors.
- Thumb forceps.
- Osteotome and mallet, dental bur, and cutting disc with protector.
- Periosteal elevator.
- Needle holders.
- Biopsy jars.
- Fine absorbable suture.

Techniques

- The two basic techniques are incisional and excisional. Depending upon the location and size of the lesion, the biopsy procedure may take the form of an elliptical incision, gingivectomy, wedge biopsy, or en bloc biopsy.

Technique for incisional biopsy

Step 1—For generalized lesions, an area is selected that appears representative of the process that will, if possible, include some adjacent normal tissue.

Step 2—A #15 blade or periodontal scissors is used to remove the tissue sample. If the pathology extends into hard tissue, an osteotome, cutting disc, or other bone-cutting instrument should be used to ensure that the active part of the process is included in the specimen. The sample is placed in the appropriate medium for submission to a clinical pathology laboratory.

Step 3—If appropriate, fine absorbable sutures are placed to close the defect in a simple interrupted or cruciate pattern.

Technique for excisional biopsy

- Localized small gingival or mucosal lesions may be removed in their entirety for histopathologic study.

Step 1—With a #15 or #15C blade, an elliptical incision is made around the lesion, including an adequate margin of normal tissue.

Step 2—Any tissue tags or connective tissue strands are cut with a sharp scissors to loosen the specimen. Holding the sample with thumb forceps is avoided, if possible, so as not to damage the tissue.

Step 3—The specimen is placed in the formalin jar, and the gingival or mucosal incision is closed with fine absorbable suture material in a simple interrupted or cruciate pattern.

Gingivectomy

- See Chapter 5.

Wedge biopsy

- With larger masses, only a small but deep specimen is removed initially for histopathologic analysis, to determine the appropriate definitive treatment options.

Step 1—A #15 blade is used to make a cut into the mass a few millimeters from the edge of the lesion.

Step 2—The blade is used to create another cut a few millimeters away and preferably including some normal margin tissue.

Step 3—The two cuts are joined, creating a triangular, wedge-shaped specimen with the blade or sharp-sharp scissors, and the specimen is removed and placed in a formalin jar for laboratory submission.

Step 4—Hemorrhage is controlled with pressure and the edges of the wedge are sutured together, if possible, with fine absorbable suture in an interrupted pattern.

En bloc biopsy

- Lesions often encompass a tooth or teeth. Extraction of teeth may disrupt the specimen interpretation. Removal of the tooth or teeth and surrounding abnormal tissue is done to obtain a representative biopsy specimen and to eliminate the tooth.

Step 1—A #15 blade is used to outline the cuts in the gingiva and mucosa to remove the tooth or teeth and abnormal tissue, including normal tissue margins.

Step 2—The cuts are deepened to the bone to fully outline the specimen.

Step 3—A small bone chisel, osteotome, or dental bur is used to cut the bone and or dental tissue. Low-speed burs with sterile water irrigation create less spray.

Step 4—A bone chisel or periosteal elevator is used to loosen the specimen from the surrounding tissue, and the specimen is placed in formalin.

Step 5—Hemorrhage is controlled, and remaining tooth portions are removed using described techniques (see Chapter 6).

Step 6—Releasing incisions are made, as necessary, in the buccal mucosal tissue to create and raise a released soft tissue flap. This flap is advanced until it can cover the defect without tension, and the edges are sutured to the gingiva and mucosa with fine absorbable sutures in an interrupted pattern.

Step 6: Oral Irrigation

General Comments

- Ultrasonic and sonic scaling provides irrigation during the cleaning procedure to remove loose calculus and reduce bacterial numbers.
- After polishing, rinse the mouth with water from the air-water syringe on a dental unit or with a curved tip syringe or sink sprayer to remove residual pumice, calculus, blood, and fibrotic debris. One-time subgingival irrigation with antimicrobial rinses has not been shown to be beneficial in the long term, because the crevicular fluid eliminates any irrigants quickly.¹⁶ An oral rinse with 0.12% chlorhexidine prior to dental cleaning has been shown to reduce the number of bacteria aerosolized.¹⁷

Indication

- To remove debris after every prophylactic dental service.

Contraindications

- Drug sensitivity.
- Mobile teeth.

Objective

- To flush all debris from the sulcus or pocket and coat the clean sulcus surfaces with antimicrobial substance.

Materials

- Air and water syringe.
- Curved tip syringes.
- Alternative rinsing solutions may include water or 0.12% chlorhexidine solution.

Technique

Step 1—The air-water syringe is used, pressing both buttons to create a complete rinse of the mouth. Alternatively, a curved tip syringe may be used (Fig. 4-19).

Step 2—Rinsing is continued until all debris, prophy paste, and blood are removed from the mouth.

Complication

- Failure to irrigate thoroughly.

Optional Fluoride Treatment

Comments

- Fluoride is taken up by dental tissue and can increase enamel strength and decrease dentinal sensitivity. It is used most commonly for caries prevention in human dentistry. Caries are an infrequent occurrence in veterinary patients, so the need for a fluoride treatment is less. Most prophy pastes have a small amount of fluoride. Specific fluoride products may be up to 1.64% to 2% stannous or sodium fluoride.

Indications

- Dentinal sensitivity.
- Gingival recession with root exposure.
- Enamel hypoplasia.
- Early feline resorptive lesion (stage 1).

Materials

- Fluorofoam.
- Fluoride gel.
- Fluoride rinse.

Technique

Step 1—All previous steps are completed and the teeth are air dried.

Step 2—The fluoride preparation is placed on the tooth surfaces.

Step 3—According to the product directions, the preparation is left on for the recommended time and then either wiped off or rinsed off.

Advantages

- Benefits of fluoride if needed.
- Gives a pleasant aroma to mouth.

Disadvantages

- One additional step to do.
- Potential for fluoride toxicity.
- Not needed in all cases.

Use of Antimicrobial Agents

Comments

- Antimicrobial agents often are indicated in the treatment of periodontal disease. Systemic antibiotics can be given preoperatively in older animals with stage 2 or greater disease, or in younger animals with other predisposing health issues, such as cardiac or other

metabolic disease, immune disease, or endocrine imbalance. Recommendations for administration vary, from 1 hour prior to a dental cleaning to protect the patient from bacteria released into the bloodstream during a dental treatment, to several days prior to treatment in cases of established periodontal disease, to reduce the numbers of gingival bacteria present at the time of treatment. Continued antibiotic therapy after dental treatment depends upon the extent of disease present. Patients with stage 3 and 4

disease most often will benefit from several days of additional antibiotic treatment.

- Preoperative rinses with an antimicrobial solution can also be beneficial in reducing the bacteria aerosolized during ultrasonic treatment and in reducing oral odors during the cleaning procedure.
- When there is active periodontal disease, subgingival delivery of a perioceutic formulation into periodontal pockets is another way of administering antibacterial agents topically (see Chapter 5).

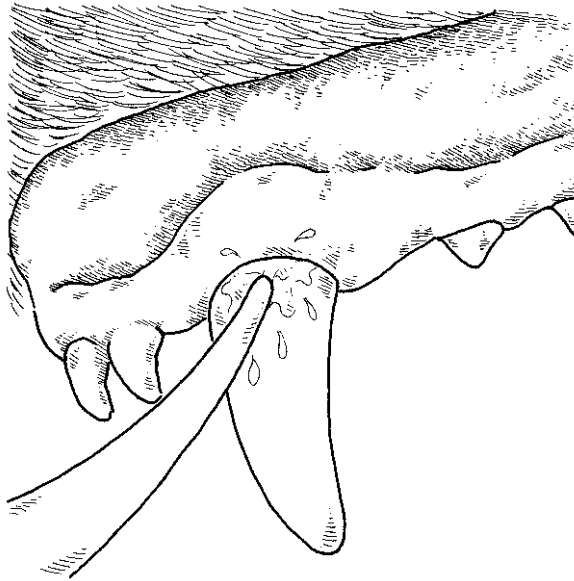


Fig. 4-19

Step 7: Home Care Instruction

General Comments

- The veterinarian has traditionally assumed complete responsibility for managing the dental patient. Currently, more clients are willing to assume supportive responsibility for daily dental hygiene of their pets, in order to increase the interval between professional dental care appointments necessary to maintain good oral health and to decrease the number and frequency of costly anesthetic procedures and professional care. At the time of the physical examination, a frank discussion to evaluate client commitment and patient cooperation in home care procedures will help the practitioner create a successful treatment plan. Matching the degree of commitment with the appropriate home care advice will lead to greater cooperation and success in client compliance. If the client is unwilling, or if the patient will not allow dental home care, extraction of diseased teeth is indicated rather than performing advanced level periodontal procedures, because the latter will require client commitment to ongoing home and professional care. Home care is most often successful when started with a puppy or kitten, before dental disease occurs.
- The client's commitment should be determined. Then the client should be shown appropriate techniques for providing the home care necessary to maintain clean teeth and a healthy mouth. After prophylaxis, teeth stay clean for only a short time without such care.
- Not all patients are willing to submit to, nor are clients capable of providing, home care. Too much enthusiasm on the part of the health care professional, in presenting the home care procedure, can actually drive a client away from the clinic or hospital and can even weaken the bond between owner and pet.
- Another equally important consideration is the patient's temperament. Clients and handlers should be advised of the potential personal risks involved in home care.
- A member of the staff should spend time reviewing brushing and home care techniques with the client. Time spent in staff training will enhance client rapport and increase the chances of successful therapy.
- Clients should be educated regarding the early signs of oral infection and encouraged to return for further instruction when such signs are noticed. Some clients may assume they are doing a great job, giving them a false sense of security, which can lead to unintentional progressive periodontal disease. To enhance the effectiveness of the home care program, it is advisable to schedule periodic recall appointments for oral examination, evaluation, and client encouragement.
- Handouts are beneficial in reinforcing the need for brushing and home care.
- A release consultation is important. The consultation may be conducted either by the doctor or by a trained staff member at the time the patient is picked up after the procedure.
- The client should be informed of the extent of dental disease, the type of home care necessary, and the need for professional follow-up. It is helpful to review the patient's dental chart and radiographs with the client at this time.
- Visual aids such as wall charts, models, case radiographs, and photo albums enable staff members to be more effective in communicating with the client.
- A written evaluation and prognosis, with suggestions for a maintenance plan, should be sent home at the time of the exit consultation, when the patient is released from the clinic. The importance of the written report is exemplified when the primary caregiver at home is not the person who arrives for the pet and pays the bill. The veterinarian's advice needs to reach the primary caregiver.
- Some products have been accepted by the Veterinary Oral Health Council and will display the acceptance seal. This acceptance indicates that the product has been reviewed and has been shown to be effective in plaque or calculus removal or prevention (www.vohc.org).
- Home care can be either active or passive; that is, the client can perform such activities as brushing or can rely on other more passive methods, such as feeding treats and foods that decrease the formation of plaque and calculus.

Active Home Care**Indication**

- To remove and delay formation of plaque and prevent formation of calculus.

Contraindications

- Unruly or dangerous patient.
- Inability to perform or disinterest of client.

Materials

- For demonstrations, the patient, a demonstrator dog or cat, or plastic or plaster models can be used to show brushing techniques.

Technique

- The two major methods of plaque control are mechanical and chemical.

Mechanical Devices

- Toothbrush.
- Various sizes and designs of toothbrushes are available in the veterinary market for dogs and cats.
- Toothbrushes designed for human use are also available in supermarkets and vary from neonatal to adult size.
- A fine-bristle toothbrush is recommended.
- A three-headed tooth brush (Triple Pet Toothbrush, Oxyfresh Worldwide, Coeur d'Alene, Idaho) is available, which can be used on larger dogs to access all tooth surfaces at once. A twin-head tooth brush is also available (Petosan AS, Bergen, Norway).

Advantages

- Readily available.
- Most effective method of removing plaque.

Disadvantages

- Some clients lack the manual dexterity required to brush animal teeth effectively.
- Many brushes are too large for small breed dogs and cats.

Mechanically Powered Toothbrush**Advantage**

- Easy to use.

Disadvantage

- Noise and mechanical action may frighten the patient.

Rubber Finger Brush**Advantages**

- Easier to use for some clients.
- Can be more effective than a gauze sponge.

Disadvantages

- Fingers in the mouth expose operator to a greater chance of being bitten.
- Not as abrasive as a bristle toothbrush.

Gauze Sponge

- May be wrapped around a cotton-tipped swab for ease of application.
- Gauze sponges with chemical plaque inhibitors can be used to rub the tooth surfaces (DentAcetic Wipes, DermaPet, Potomac, Md.).

Advantage

- Easy to use.

Disadvantages

- Fingers are in the mouth, exposing client to greater risk of being bitten.
- Greater expense.
- May not be as thorough as a brush beneath the gumline.
- Patient may object to taste or odor of some gauze-based products.

Water Pick

- Water picks should be used on low power.

Advantages

- Can be directed toward problem areas or areas that are hard to reach.
- May not be as painful as the application of a brush or gauze immediately following periodontal therapy.
- Useful in cases of sensitive, infected gingiva where brushes may cause patient discomfort.
- Useful around splinted incisors or areas of exposed furcations.

Disadvantages

- Messy.
- Patient may not tolerate it.
- Not designed to be introduced directly into sulcus; can cause transient bacteremia.

Types of Dentifrices

- Various chemical agents have been proposed for the removal and prevention of plaque in humans and animals. Generally, dentifrices operate in one of three ways: (1) by abrasion—these products contain either a calcium or a silicate ingredient, (2) by oxidation—these products contain an oxidizing agent designed to be inhospitable to anaerobic bacteria, (3) by various chemical ingredients designed to promote gingival health—such as zinc ascorbate.

Powders**Advantages**

- Powders have an abrasive quality that can vary with size, structure, and composition.
- Powders can be made into a paste.
- Patients help to distribute the powder to the palatal and lingual surfaces of their teeth with their tongues.

Disadvantages

- Powders are messy.
- Particles may be inhaled accidentally.
- Particles can accidentally contaminate the eyes and cause irritation.
- Clients tend to give more prophylactic credit to the patient's tongue than they should, resulting in less home care than believed.

Liquids**Advantages**

- Have a variety of delivery systems ranging from spray to water pick-type reservoirs.
- Can irrigate hard-to-reach areas.

Disadvantages

- Messy.
- Cannot be used easily with toothbrushes unless fairly viscous.
- Some animals avoid sprays or mechanical devices directed into their mouths. The result is less than desired effectiveness, and possibly a pet that runs and hides or one that even challenges its owner in a threatening manner.

Sprays**Advantage**

- Sprays are quick and easy to use.

Disadvantages

- The hissing noise may startle the patient.
- Sprays may accidentally contaminate the eyes, causing irritation.

Pastes**Advantages**

- Carried well by toothbrushes to the surface of the teeth.
- Provide good abrasive action.
- Adhere well for application.
- Often flavored for better acceptance.
- Can be distributed to the palatal and lingual surfaces of the teeth by the tongue.

Disadvantages

- Products designed for people will be swallowed and may cause gastric irritation in the pet.
- May stick to muzzle hairs or vibrissae.
- Clients need education to realize that brushing does not replace periodic professional care.

Gels**Advantages**

- Carried well by toothbrushes to the surface of the teeth.
- Adhere well for application.
- Often flavored for better acceptance.

Disadvantage

- May stick to muzzle hairs or vibrissae.

Products**Sodium or potassium pyrophosphate**

- When present in dog biscuits, may inhibit plaque and supragingival calculus formation.

Sodium hexametaphosphate 1% acetic acid

- In gauze wipes helps freshen breath, clean teeth and may reduce plaque and calculus accumulation (DentAcetic Wipes, DermaPet). Also comes as a gel.

Saliva substitutes

- Helpful in patients with xerostomia.
- Has some fluoride in formulation (Xero-lube Scherer, GelKam International, Dallas, Tex.).

Enzymatic

- Marketed in gels, pastes, spray, and impregnated pads (CET: Toothpaste, Virbac Animal Health; Biotene Veterinarian Enzymatic Antimicrobial Oral Treatment, Pet King Brands, Westmont, Ill., Enzadent, Vet Solutions, Fort Worth, Tex.).

Advantages

- Antiplaque; augments salivary peroxidase system.
- Flavored products available for pets.

Disadvantage

- Not as effective in plaque inhibition as chlorhexidine or fluoride.

Sanguinaria-based

- Marketed as paste and rinse (Viadent, Vipont Pharmaceuticals, Canton, Mass.).

Advantage

- Possible antiplaque agent.

Disadvantage

- Flavoring.

Chlorhexidine

- Marketed as a rinse and gel (Nolvadent, Fort Dodge Animal Health, Fort Dodge, Iowa; CET oral hygiene rinse and CET oral hygiene gel, Virbac Animal Health).

Advantages

- A premixed solution of chlorhexidine is recommended over dilution of a concentrated chlorhexidine.
- True antimicrobial agent.
- Antiplaque.
- Chlorhexidine adheres very well to the tissues, prolonging the contact time.

Disadvantages

- Bad aftertaste.
- Hampers ability to taste for a short time.

- Black or brown staining of protein pellicle may become noticeable after prolonged use by dedicated clients (can be polished clean).

Zinc ascorbate

- Marketed as a spray and as a viscous solution (Maxiguard, Oral Hygiene Gel, Addison Laboratories, Fayette, Mo.).

Advantages

- Supports collagen synthesis.
- Reduces odor.

Disadvantage

- Some patients object to the spray but will usually accept the gel.

Stabilized chlorine dioxide based (Oxygene)**Advantages**

- Easy to use (Pet Oral Hygiene Solution and Pet Gel, Oxyfresh Worldwide, Couer d'Alene, Idaho.)
- Oxidizes volatile sulfur compounds that cause malodor.
- Inhospitable to anaerobes.
- Neutral flavor is particularly acceptable to cats.
- Supplied as a solution, may be added to drinking water for dogs or cats.
- Supplied as a gel, may be brushed onto the teeth.
- Gel form also contains aloe vera as a soothing agent and to support healing of oral tissues; can be applied immediately after periodontal procedures or oral surgery for a soothing effect.

Disadvantage

- Less effective plaque control agent.

Fluoride based

- Marketed as gel or liquid (GelKam International).

Advantages

- Antibacterial.
- Inhibits plaque formation.
- Reduces surface tension of tooth surfaces.
- Reduces dental hypersensitivity.

Disadvantages

- May be toxic in large doses.
- May combine with other fluoride sources to cause toxicity.

Types of fluoride

- Stannous.

- Monofluorophosphate.
- Sodium fluoride.

Barrier sealant

- Waxy, hydrophobic material wiped on teeth after a dental prophylaxis and for weekly home care that creates an environment where bacteria cannot colonize. Waxy layers are sloughed daily exposing new protective layers (ProVSeal, Veterinary and Animal Health Solutions, Vancouver, Wash.).

Advantages

- Only needs to be applied to teeth once or twice a week.
- Reportedly provides protection for up to 8 days.
- Odorless, invisible, and tasteless.

Disadvantages

- Less effective than daily brushing.
- Client still has to get into the mouth to apply with sponge swab.
- Is extremely difficult to apply.

Brushing technique

- Start slowly and gently when first working with patient. This is a training process that

can take several weeks to master and achieve acceptance from the pet. Instruct the pet owner first to lift the lip and rub the front teeth. Owner should reward the pet at each session. Next time rub more teeth, extending the service caudally to the premolars and then the molars. After the process has become less awkward, for both the owner and the pet, the owner should introduce the brush and brush one tooth, then progressively more teeth, until the patient is in acceptance with full mouth brushing.

- It may be helpful to hold the muzzle with the free hand to control head movement and chewing while brushing the teeth.

Step 1—Dentifrice is applied to the brush (Fig. 4-20, *A*).

Step 2—The brush is placed at a 45-degree angle to the tooth wall (Fig. 4-20, *B*).

Step 3—A circular, sweeping motion, rotating the brush handle with the emphasis on the portion of the stroke away from the gumline, is used to brush plaque from the sulcus (Fig. 4-20, *C*).

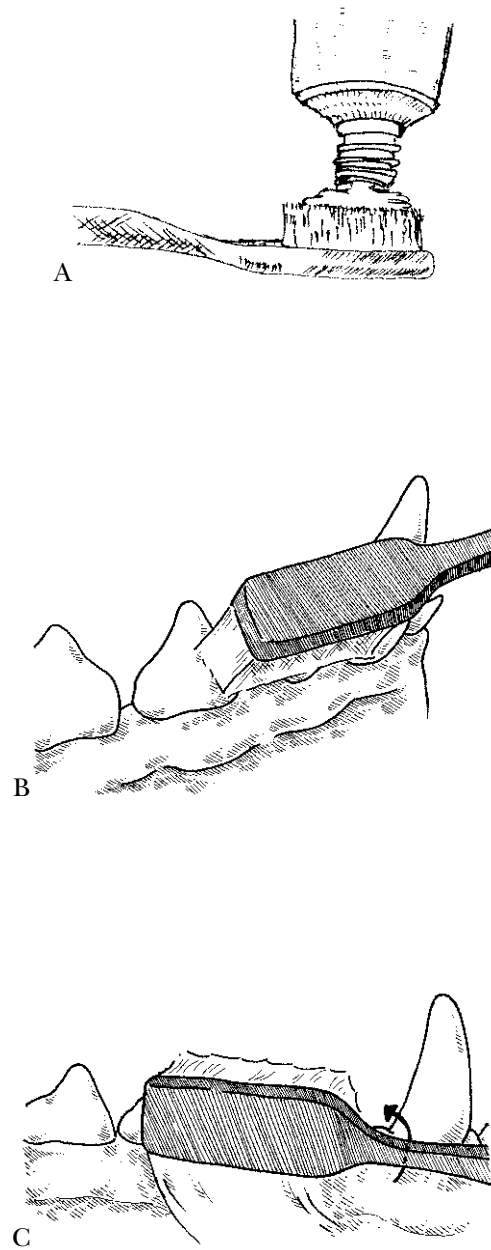


Fig. 4-20

Wiping technique

Step 1—The dentifrice may be placed on a cotton-tipped applicator (Fig. 4-21, *A*). The teeth may be wiped with a gauze sponge or manufactured wipe (Fig. 4-21, *B*), or the teeth may be wiped with a gauze sponge wrapped around a cotton-tipped applicator (Fig. 4-21, *C*) if gingiva is sensitive or bleeds easily.

Step 2—To provide safe access with a brush or wipe to the lingual or palatal surface, a hard rubber toy may be placed in the patient's mouth, and the mouth is held closed onto the toy with the opposite hand, thus keeping the mouth open while the teeth are brushed (Fig. 4-21, *D*).

Complications

- The client should be advised of the dangers of being bitten or scratched.
- Client-caused iatrogenic oral trauma may occur because of poor technique.
- Failure to respond to conventional therapy may be a sign of (1) systemic disease, (2) metabolic imbalance, (3) nutritional imbalance, (4) organ compromise, (5) viral infection, (6) bacterial or spirochete infection, (7) vitamin deficiency, and (8) immune deficiency.
- Calculus left subgingivally may lead to periodontal abscess.

Passive Home Care**Indication**

- Patient will not allow brushing.
- Client unable or unwilling to brush or to use active home care techniques, but desires to help pet's oral health.

Products**Dental diets**

- Various manufacturers with claims to prevent, control, or remove plaque, calculus, and stain have created diets; many of these claims are unsubstantiated.
- To establish a standard for the evaluation of diets, the American Veterinary Dental College

created the Veterinary Oral Health Council (VOHC).

- The VOHC exists to provide an objective means of recognizing commercially available products that meet preset standards of effectiveness in controlling accumulation of dental plaque and calculus (tartar) in dogs and cats.¹⁸
- The current list of VOHC approved products is available at: www.vohc.org.
- Diets with mechanical control of plaque and tartar (accepted by the Veterinary Oral Health Council):
 - New and Improved Prescription Diet Feline t/d (Hill's Pet Nutrition Inc., Topeka, Kan.)
 - New and Improved Prescription Diet Canine t/d Original Bites (Hill's Pet Nutrition Inc.)
 - New and Improved Prescription Diet Canine t/d Small Bites (Hill's Pet Nutrition Inc.)
 - Science Diet Oral Care Diet for Dogs (Hill's Pet Nutrition Inc.)
 - Science Diet Oral Care Diet for Cats (Hill's Pet Nutrition Inc.)
 - Friskies Feline Dental Diet (Friskies Petcare Co., Glendale, Calif.)
- Diets with chemical control of tartar:
 - Iams Chunk Dental Defense Diet for Dogs (Iams Company, Dayton, Ohio).
 - Eukanuba Adult Maintenance Diet for Dogs (Iams Company).

Comments

- Studies have been performed comparing food formulated to reduce the accumulation of dental substrates with commercially available dry foods.¹⁹⁻²¹ These studies conclude that dogs and cats consuming a diet formulated to reduce plaque and calculus had less plaque and calculus after 6 months. This resulted in significantly less plaque accumulation and gingival inflammation and improved gingival health.
- Hexametaphosphate is a calculus inhibitor. Studies show a decrease in calculus accumulation.

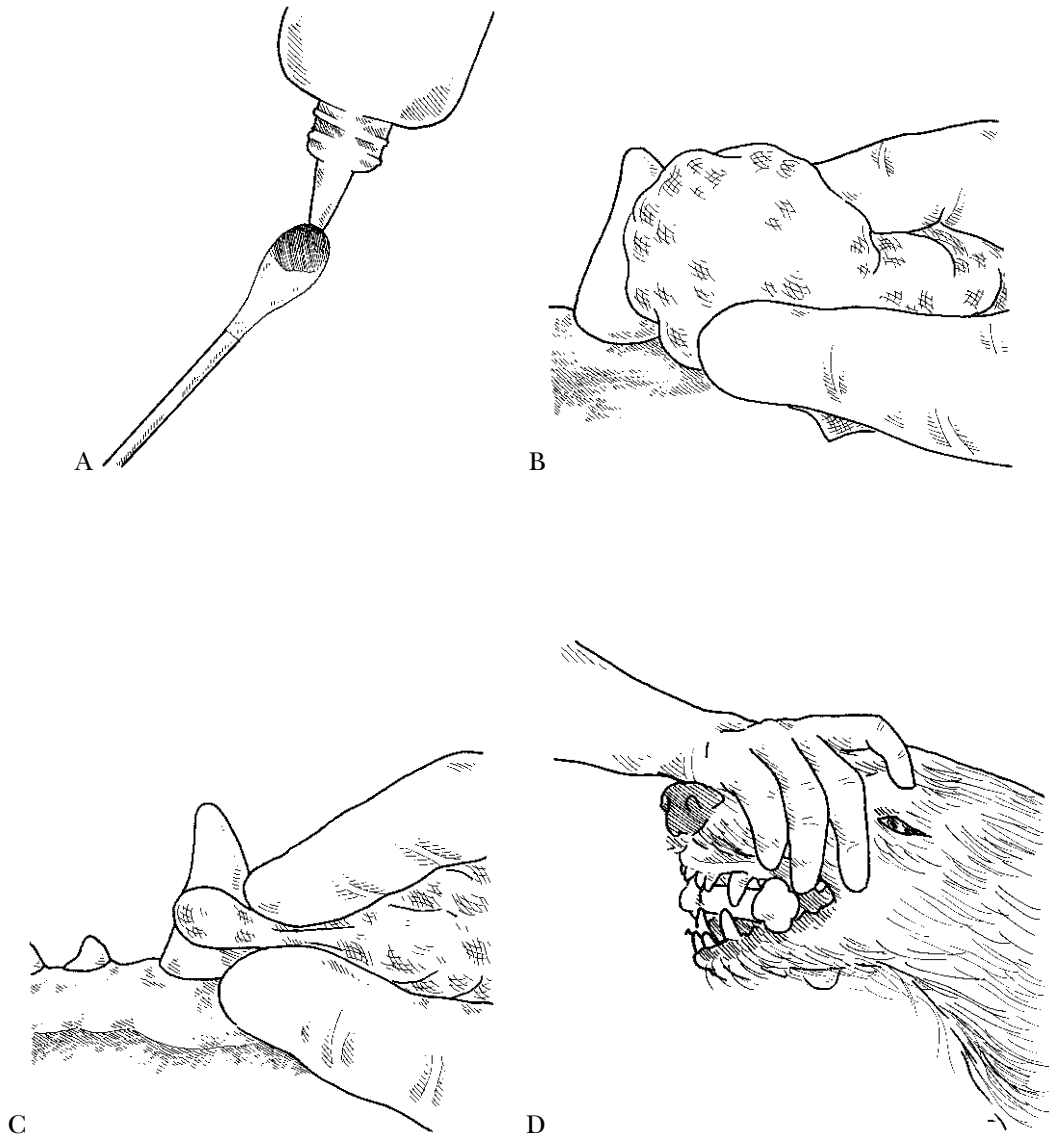


Fig. 4-21

Advantages

- Proven reduction in calculus formation.
- Patient acceptance.
- Does not rely on client compliance, which may be a significant problem with many clients and patients.²²

Disadvantages

- Patient may not chew on all surfaces; areas will be missed.
- These diets do not replace a professional health care program. Plaque and calculus will still form and periodic professional care will still be necessary.

Tartar control biscuits

- Treat type products are available to help control tartar.
- Heinz Tartar Check Dog Biscuit, Small Size (Heinz Pet Products, Pittsburgh, Penn.)
- Heinz Tartar Check Biscuit, Large Size (Heinz Pet Products)

Comment

- Biscuits are coated with hexametaphosphate as a calculus inhibitor. Treated biscuits are shown to have more benefit than conventional dog biscuits.²³

Advantages

- Proven reduction in calculus formation.
- Clients like to give dog treats, so there is greater compliance than with other oral hygiene methods.

Disadvantages

- Potential for weight gain if fed too many treats.
- Patient may not chew on all surfaces; areas will be missed.
- These treats do not replace a professional health care program. Plaque and calculus will still form, and periodic professional care will still be necessary.

Rawhide chewing products

- Chew-eez (Friskies PetCare). VOHC Approved, Helps Control Tartar category
- CET oral hygiene chews (Virbac Animal Health).
- HMP Rawhide Dental Maintenance System (Leather Goods, Bedford Park, Ill.), a 2-week program of chewable, digestible products.

Comments

- Studies have shown that chewing rawhide reduces plaque and rate of calculus formation

in dogs.^{24, 25} There was an improvement in the gingival indices, and the animals had improved oral health.

- Another study has shown that the addition of sodium hexametaphosphate, a calcium sequestrant, to the rawhide resulted in a reduction in calculus formation of about 42%.²⁶
- Flatter rawhide chews generally will not damage teeth during routine chewing. Larger, thicker rawhide chews may damage teeth if the animal chews aggressively before the rawhide is softened up.

Advantage

- May be useful for clients who will not brush and beneficial for patients who will not be brushed.

Disadvantages

- The client should be cautioned to monitor the patient so as to prevent ingestion of the product with little or no chewing (could result in a foreign body gastrointestinal tract obstruction).
- Patients may not chew with all dental surfaces; professional care and monitoring is necessary.

Non-rawhide chewing products

- Dentabone (Master Foods, Inc., Vernon, Calif.)
- Greenies (S&M Nu Tec, Kansas City, Mo.).

Other chew treats and toys

- Gummabone (Nylabone Products, Neptune, NJ).
- Havaball (StellarPets, Louisville, Colo.).
- Kong toys (Kong Company, Golden, Colo.).

Comment

- Chew toys that have some flexibility should be recommended, such as the toys listed above which will not damage teeth. Many chew toys or treats on the market can cause tooth fracture of the carnassial teeth, resulting in the need for extraction or endodontic therapy.

Advantage

- Provide chewing exercise without tooth trauma.

Disadvantage

- Do not have the abrasive action of rawhides and other abrasive chew treats.

Home Care Plans by Condition and Ability

Healthy Patient Dental Health Maintenance Program

- These patients, who are not critically ill, should be started on a tooth-brushing routine.
- Starting with flavored water or flavored toothpaste is fine.
- In young adult patients, treatment should be performed at least 3 times weekly, along with chewing activity on rawhide-like chewies. Additional chewing exercise with safe chew toys and dental diets can be beneficial.

Dental Intermediate Health Care Category

- These patients have had chronic gingivitis and need to have plaque prevention more intensively than healthy patients.
- They should begin with flavored water or flavored toothpaste.
- Home care should be performed 4 to 5 days a week to be effective.
- Additionally, fluoride may be recommended at least twice a week if gingival recession or resorptive lesions exist.
- Additional chewing exercise with safe chew toys and the use of dental diets and plaque-retarding medicated treats can be beneficial.

Dental Advanced Care Category

- These are patients with periodontal disease that have lost tooth-supporting bone. They often have just had some type of periodontal therapy.
- These patients are put on a routine of twice-daily rinses or brushings with a chlorhexidine solution.
- After 2 weeks, the patient may be maintained at least once a day with a fluoride gel, fluoride animal toothpaste, or one of the products that promotes gingival health.
- Patients with advanced periodontal disease may require daily brushing products to be alternated monthly between an antimicrobial product and a wellness product (see Chapter 5).
- In geriatric patients with stage 4 periodontal disease, the use of intermittent antibiotic therapy may be beneficial in supporting overall medical health²⁷ (see Chapter 5).

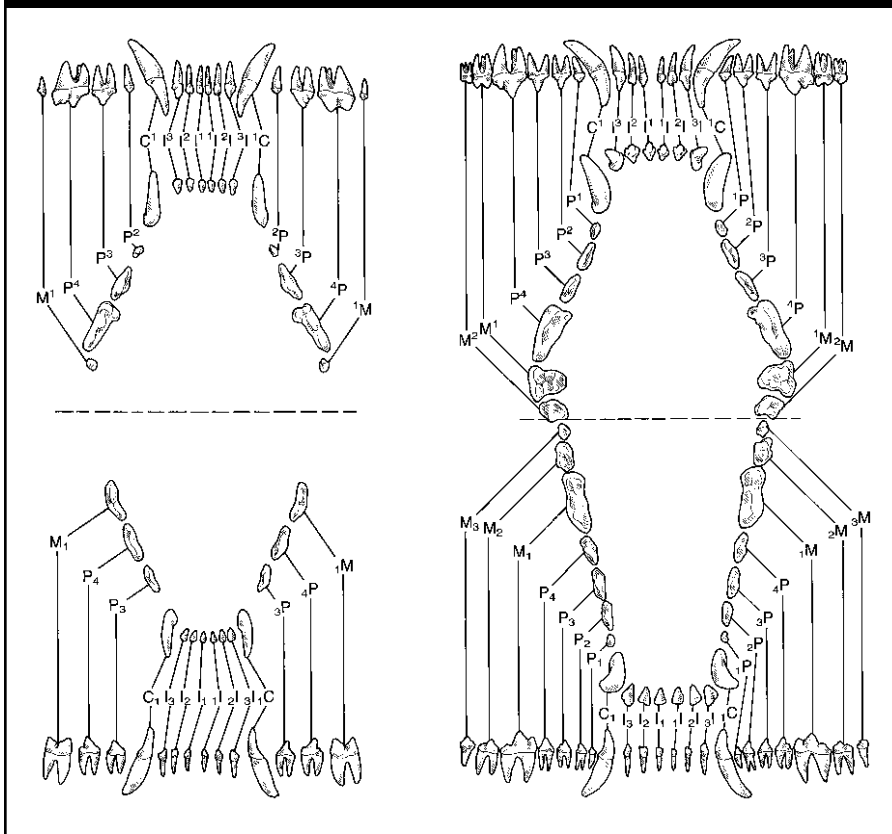
REFERENCES

1. Fagan DA: *Diagnosis and treatment planning*, Philadelphia, 1986, WB Saunders, pp 785-799.
2. Page RC, Schroeder HE: *Periodontitis in man and other animals*, New York, 1982, Karger, pp 158.
3. Fine DH, Tabak L, Oshrain H, et al: Studies in plaque pathogenicity I. Plaque collection and limulus lysate screening of adherent and loosely adherent plaque, *J Periodontol Res* 13(1):17-23, 1978.
4. Page RC: Keynote speech to the Academy of Veterinary Dentistry, Cincinnati, 1987.
5. Suzuki JB: *Diagnosis and classification of the periodontal diseases*, Philadelphia, 1988, WB Saunders, pp 195-216.
6. Tholen MA: *Concepts in veterinary dentistry*, Edwardsville, Kan, 1983, Veterinary Medicine Publishing Company, p 102.
7. Harvey CE, Emily PP: *Small animal dentistry*, St Louis, 1993, Mosby, pp 102-103.
8. Wiggs RB, Lobprise HB: *Veterinary dentistry, principles and practice*, Philadelphia, 1997, Lippincott-Raven, pp 197-199.
9. Wiggs RB, Lobprise HB: *Veterinary dentistry, principles and practice*, Philadelphia, 1997, Lippincott-Raven, pp 200-201.
10. Ruebel GH, Hoffman DE, Pederson NC: Acute and chronic faucitis of domestic cats, *Vet Clin North Am Small Anim Pract* 22:1347-1360, 1992.
11. DuPont GA, DeBowes LJ: Comparison of periodontitis and root replacement in cat teeth with resorptive lesions, *J Vet Dent* 19(2):71-75, 2002.
12. Young NS, O'Hehir TE, Woodall I: Periodontal debridement. In Woodall I, editor: *Comprehensive dental hygiene care*, St Louis, 1993, Mosby.
13. Parr RW, Green E, Madsen L, et al: *Subgingival scaling and root planing*, San Francisco, 1975, University of California, p 90.
14. Walmsley AD, Walsh TF, Laird WR, Williams AR: Effects of cavitation activity on the root surface during ultrasonic scaling, *J Clin Periodontol* 17:306-312, 1990.
15. Drago MR: A clinical evaluation of hand and ultrasonic instruments on subgingival debridement. 1. With modified and unmodified inserts, *Int J Periodontics Restorative Dent* 12:310-323, 1992.
16. Greenstein G: The Role of supra- and subgingival irrigation in the treatment of periodontal diseases, *The American Academy of Periodontology Position Paper* pp 1-18, 1995.
17. Logothetis DD, Martinez-Welles JM: Reducing bacterial aerosol contamination with a chlorhexidine gluconate pre-rinse, *J Am Dent Assoc* 126:1634-1639, 1995.
18. Anonymous. Purpose and History. www.vohc.org. Accessed January 15, 2004.
19. Logan EI: Oral cleansing by dietary means: results of six-month studies. In Proceedings of a Conference on Companion Animal Oral Health, Lawrence, Kan, 1996.
20. Harvey CE, Anderson JG, Miller BR: Longitudinal study of periodontal health in cats. In Proceedings of a Conference on Companion Animal Oral Health, Lawrence, Kan, 1996.
21. Logan EI: Oral cleansing by dietary means: feline methodology and study results. In Proceedings of a Conference on Companion Animal Oral Health, Lawrence, Kan, 1996.

22. Miller BR, Harvey CE: Compliance with oral hygiene recommendations following periodontal treatment in client-owned dogs, *J Vet Dent* 11:18-19, 1994.
23. Stookey, GK, Warrick JM, Miller LL. Sodium hexametaphosphate reduces calculus formation in dogs. *Am J Vet Res*, 56:913-918, 1995.
24. Lage AL, Lausen N, Tracy R, et al: Effect of chewing rawhide and cereal biscuit on removal of dental calculus in dogs, *J Am Vet Med Assoc* 197:213-219, 1990.
25. Goldstein GS, Czarnecki-Maulden GL, Vener ML: Beefhide strips in the maintenance of dental health, *Proc Vet Dent* 81:94, 1994.
26. Stookey GK, Warrick JM, Miller LL, et al: Reducing calculus formation in dogs with HMP-coated rawhide, *Proc Vet Dent* 65:95, 1995.
27. Hamlin RL: A theory for the genesis of certain chronic degenerative diseases of the aged dog, small animal scope, Kalamazoo, Mich, 1991, Upjohn Company, p 1.



PERIODONTAL THERAPY AND SURGERY



GENERAL COMMENTS

Many improvements in periodontal therapy have become available to us in recent years, and technology seems to be escalating. Advances in periodontal treatment include newer approaches in:

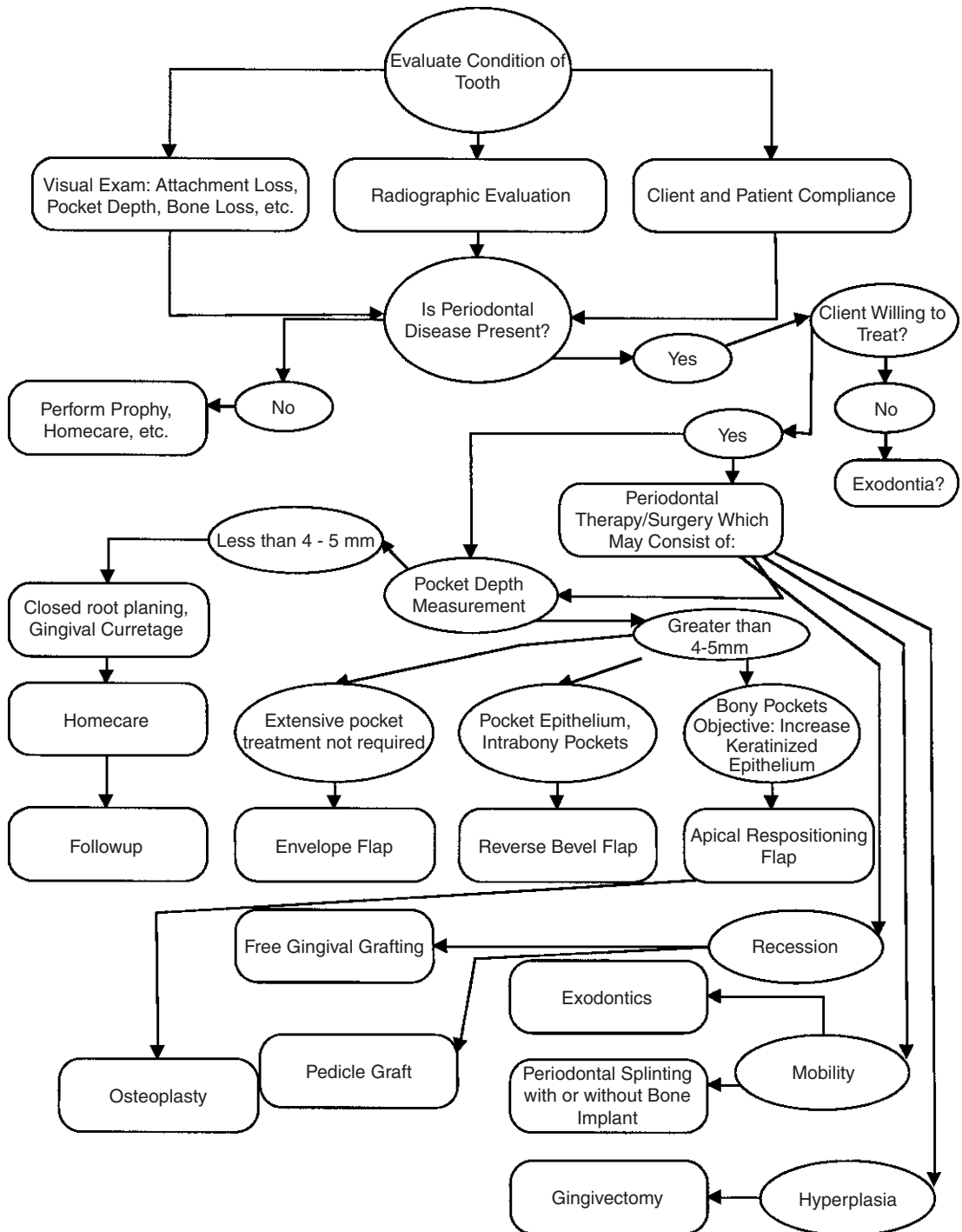
- Professional prophylaxis (recall intervals, chlorhexidine brushing before prophylactic treatment, ultrasonic subgingival instrumentation, home care advice regarding disruption of flora).
- Root surface therapy.
- Local delivery systems (bioadhesive tablets, subgingival biodegradable syringe applied and implant products).
- Collagen stabilization (doxycycline).
- Painless pocket reduction and gingival flap preparation by laser instrumentation.
- Osseous regeneration and augmentation (guided tissue regeneration, GTR), bone grafts, bioactive implants, enamel matrix derivatives).
- It is important not to discard traditional effective modalities as we incorporate newer techniques.
- Patients with foul breath and advanced periodontal disease are often brought in for teeth cleaning. In these cases, more than dental prophylaxis or a simple cleaning is necessary to restore gingival health. The additional treatment may be broadly termed *periodontal therapy*. Client communication in this case is important: the client should understand that the patient's condition has progressed beyond gingivitis to periodontitis and the treatment will not be a simple teeth cleaning, but periodontal therapy. Treatment for this patient will, therefore, take additional time, most likely require aftercare and follow-up, and will result in higher fees. Because of this, it is advisable to perform a preliminary examination, provide the pet owner with a written fee estimate, and establish with the owner the level of care desired. In this way a tentative treatment plan, anticipated expenses, and prognosis can be communicated to the client. The written information presented to the client should also include the possible need for extraction of teeth that can't be salvaged.
- In otherwise healthy patients that have grade 3 and 4 periodontal disease and in medically compromised patients that have grades 2 to 4 periodontal disease, antibiotics should be started before periodontal therapy

or surgery to establish a blood level.¹⁻³ Preferred treatment is an antibiotic by injection 1 hour before surgery.

- A broad spectrum bactericidal antibiotic such as ampicillin or amoxicillin may be used in most cases. Some cases require treatment with antibiotics selective for gram-negative organisms, such as cephalosporin-based agents, enrofloxacin, or combinations of antibiotics. Clindamycin hydrochloride (Antirobe) and amoxicillin trihydrate/clavulanate potassium (Clavamox) have been used successfully in the oral cavity. Cephalexin and metronidazole are also commonly used antibiotics effective in orofacial conditions in dogs and cats.⁴ Tetracycline has been added to the list of drugs used for periodontal therapy by respected researchers.⁵
- Antibiotics are an adjunct to treatment and prevention of secondary infections, not a cure for periodontitis, although it is often a disease associated with infection.
- Periodontal bacterial plaque is the leading cause of periodontal disease (gingivitis and periodontitis). Plaque-retentive areas (the periodontal pocket) should be eliminated, or at least reduced, to help prevent further periodontal breakdown.

SYSTEMIC DISEASE AND PERIODONTAL INFECTION

- One concept that has been a bit misunderstood in veterinary dentistry is "the theory of focal infection." Perhaps we would be more comfortable thinking of it as the "theory of distant infection." Current concepts in human dentistry today, of "periodontal diseases as localized entities affecting only the teeth and supporting apparatus, is oversimplified and in need of revision. Rather than being confined to the periodontium, periodontal diseases may have wide-ranging systemic effects . . . periodontal infection may act as an independent risk factor for systemic disease and may be involved in basic pathogenic mechanisms of these conditions. Furthermore, periodontal infection may exacerbate existing systemic disorders."⁶
- Historically, Hippocrates is said to have reported the cure of arthritis after removal of a tooth.⁷
1912: Frank Billings, MD, introduced the concept of focal infection to American physicians.^{8,9}



1920: C. Edmund A. Kells (founder of dental radiography) initiated reasoning that began to prevail, claiming that indiscriminate extraction of teeth to cure focal infections was “the crime of the age” and recommended that dentists refuse to operate upon physicians’ instructions to remove teeth needlessly.¹⁰

- This seems to be the crux of the problem. The initial concept in human medicine was that illness in various parts of the body could be cured by extracting teeth and performing tonsillectomies, but this could not be supported statistically. Nevertheless, systemic health is affected by chronic periodontal infection. In humans, a negative impact of oral infection on systemic health has been documented, from the entry of oral microorganisms or their products into the bloodstream. Research cites that bacteremia is common, and gingival inflammation can be the source of significant microbial entry into the bloodstream.¹¹ Additionally, the pathogenesis of bacterial pneumonia in adult people primarily involves aspiration of bacteria that colonize the oropharyngeal region into the lower respiratory tract and failure of the host defense mechanisms to eliminate the contaminating bacteria, which subsequently multiply and cause infection.¹² Gram-negative bacilli, such as enteric species and *Pseudomonas aeruginosa*, can be cultured from the subgingival flora of patients with periodontal disease.¹² Bacterial migration can be provoked by mastication and oral hygiene procedures. The extent to which bacteremia of oral origin occurs appears to be related directly to the severity of gingival inflammation.¹¹ This concept represents a

distinct mechanism by which these bacteria may gain access to the systemic circulation. Researchers of human dentistry report that there is little doubt that, under certain circumstances, microorganisms can move from one area of the body to another to establish their customary pathology in another locale.¹³ They cite that “bacteria metastasize to the heart, brain, kidney, liver, joints, gastrointestinal tract, and skin from other areas of the body, including the mouth. The pathways for the dissemination of infection are by direct spread or by blood or lymphatic metastasis of the infecting organisms, their toxic products, or tissue immunologic reactions to the organisms or their products.”¹⁴ Research in veterinary medicine is sparse on this subject, but cases of distant infection that originated in the mouth have been cited,¹⁵ and evidence is strong that the same phenomenon seen in people is seen also in animals.¹⁶

Objectives

- Periodontal therapy has three principal objectives: (1) pocket reduction or elimination of the soft and bony lesions, (2) eradication or arrest of the periodontal lesion, with correction or cure of the deformity created by it, and (3) alteration in the mouth of the periodontal climate that was conducive or contributory to allowing periodontal disease to become established, creating a more biologically sound environment.¹⁷ We cannot cite one pocket depth for all cats and dogs as being the point at which a periodontal depth is considered pathologic. In a domestic cat 1.0 mm is an abnormally deep gingival sulcus and,

whereas 2 to 3 mm might be the outside limit for a normal gingival sulcus depth in a medium to large breed dog, 4.0 mm might be considered normal in a St. Bernard. To keep normalcy in perspective, the healthy gingival attachment is found in very close proximity (within 1.0 mm) of the cemento-enamel junction. Attachment measurements greater than this should be noted as attachment loss, and treatment for this pathologic condition should be planned accordingly.

ROOT PLANING: CLOSED TECHNIQUE

General Comments

- Root planing is the process whereby residual embedded calculus and portions of the necrotic cementum are removed from the roots to produce a clean, hard, smooth surface that is free of endotoxin.¹⁸
- The objective, whether performed with specially manufactured thin ultrasonic periodontal tips (described later in this chapter) or by hand instrumentation, is to render the root surface biologically acceptable to the soft tissue wall of the periodontal pocket without causing unnecessary loss or damage to hard or soft tissues.

Indications

- Calculus on root surface.
- Gingival recession with calculus on root surface.

- Roughening of root surface.
- Presence of periodontal pocket of less than 5 mm in the dog and 1 to 2 mm in the cat. This does depend on relative tooth size and normal sulcus depth.
- Closed root planing can be performed in patients with pocket depths greater than 5 mm, but it is better to perform open techniques so that treatment can be more definitive.

Contraindications

- Pockets deeper than 4 to 5 mm; because of the inability to access the base of the pocket, the subgingival bacterial plaque cannot be removed. When this is the case, open flap surgery should be considered.
- Nonsalvageable teeth.
- General health considerations (life-threatening disease, a patient with overall critical health).

Equipment

- A selection of curettes (a sharp instrument is important). It may be necessary to sharpen the instrument during the procedure to ensure a sharp edge at all times, to prevent burnishing the calculus, which creates a greater nidus for periodontal disease.
- Hoe.
- Explorer for detection of subgingival calculus and root irregularities.
- Periodontal files.
- Thin periodontal tips for ultrasonic scalers (see Table 2-3 in Chapter 2).

Technique

- The patient should receive a preoperative antibiotic if pus is present in the pocket or if the patient has any other systemic disease.
- A routine, systematic approach should be used on each quadrant and on each tooth. Specific curettes are selected because of their ability to reach to the depth of the pocket and adapt to the tooth surface.
- The blade of the instrument is inserted gently in the closed position; that is, the face of the instrument moves parallel to the tooth (Fig. 5-1, A). This allows the positioning of the curette apical to the calculus (often called the *exploratory stroke*).
- The blade of the curette is positioned against the root surface (adaptation) and opened (Fig. 5-1, B).
- The opened blade of the curette is withdrawn from the pocket in an oblique manner while applying pressure (known as the *working stroke*) (Fig. 5-1, C).
- Root planing is performed using a curette with overlapping strokes in horizontal, vertical, and oblique directions (also known as *cross-hatching*) (see the later section on gingival curettage). This may require additional cleaning strokes after all calculus has been removed, to obtain a smooth surface, being careful not to gouge the root surface. Subgingival root scaling becomes root planing after deposits have been removed from the surface and the scaling technique is employed to smooth the root surface.
- Cross-hatching creates an optimally smooth surface while maintaining root anatomy.
- As root planing is being performed, an assessment must be made, using a dental explorer, regarding the nature of the dental deposits and tooth surface. This evaluation determines how much pressure and in what direction the working strokes should be made. Closed root planing by curette is a complex and precise coordination of visual, mental, and manual skill that makes subgingival instrumentation one of the most difficult of all dental skills. The success of the procedure rests on the operator's familiarity with and choice of instrument for each periodontal site, the maintenance of that instrument, and the skill with which the surfaces are debrided as atraumatically as possible.
- The object of calculus removal is to fracture it cleanly away from the tooth surface, not to

shave, wear down, or smooth the deposit (referred to as *burnishing*).

Complications

- Deposit cannot be removed. The solution is to reposition the blade to remove less calculus per stroke, change the angle and direction of pull of the instrument, change instrument, or sharpen the instrument. Too little pressure can cause the instrument to glance over the deposits and to smooth down the deposits rather than remove them. As these deposits become smoother, they also become harder to detect and remove.
- The surface is still rough after planing. The solution is to check the instrument for sharpness and replane or, if too much force has been applied causing an uneven root surface known as *ruffling*, to use light, smooth strokes.
- Failure to plane the root in the apical portion of the pocket leaves bacterial plaque and causes an increase in periodontal pocketing and subsequent periodontitis and bone loss.
- Some root surfaces do not lend themselves to thorough root planing, including the maxillary first and second molar. In this case, careful instrument selection and adaptation is important. Failing to do this, it is better to perform a periodontal flap procedure or extract the tooth.
- Hemorrhage may limit visibility. Limited visibility may require the use of pressure, water irrigation, and suctioning during the procedure.
- It may be difficult to access the root surface, particularly in areas of exposed furcations that may be large enough to allow accumulation of plaque and calculus, but too small and inaccessible to permit thorough root planing. Microultrasonic instruments may be the solution, due to their thinner tips and type of movement.
- Overuse of instrumentation and aggressive instrumentation cause damage to the gingival fibers or periodontal ligament at the apical end of the pocket.

Aftercare: Follow-Up

- Routine home care (see Chapter 4).
- Antibiotics.

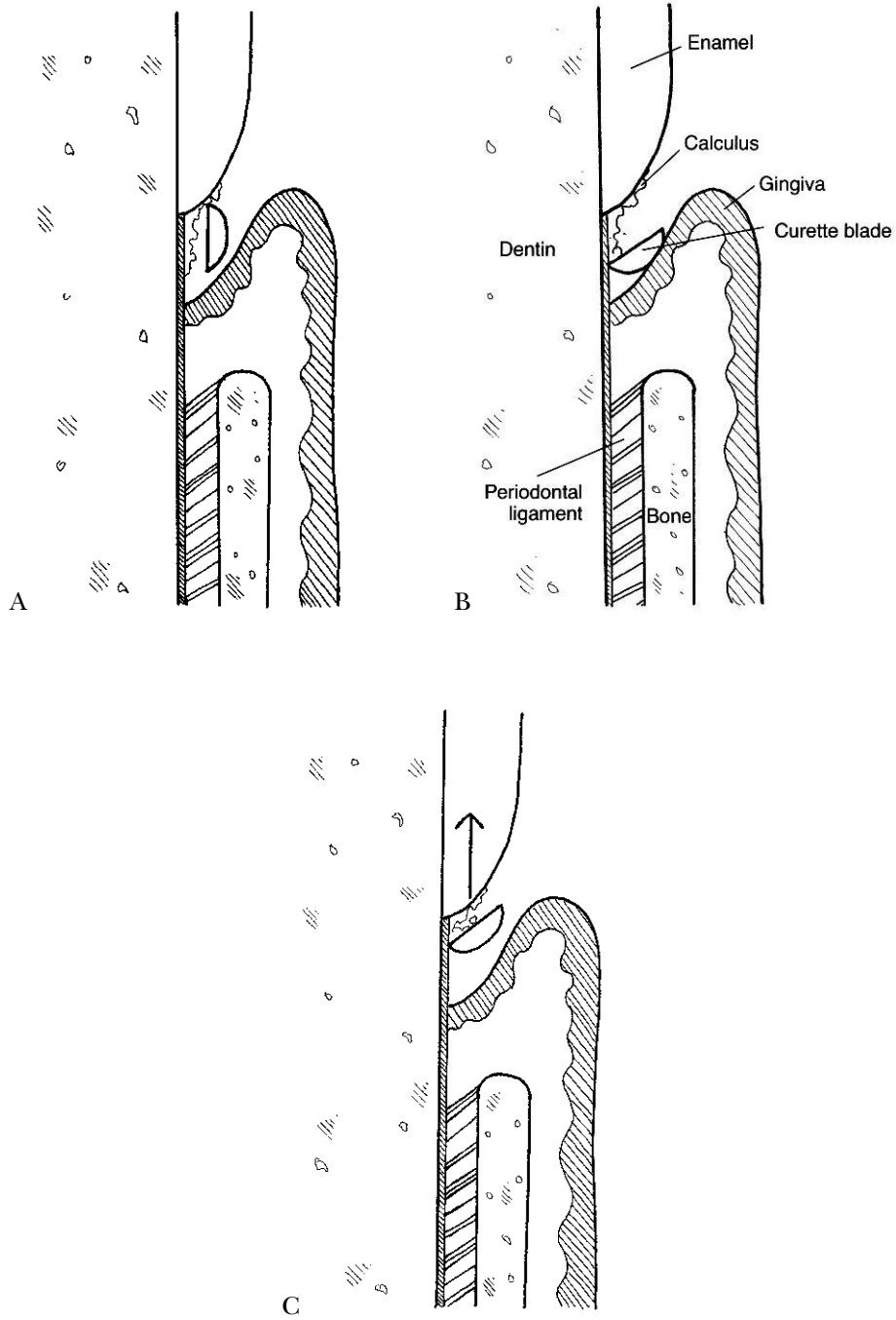


Fig. 5-1

GINGIVAL CURETTAGE

General Comments

- Treatment of the gingival soft tissues.
- Promotes optimal reattachment, resulting in reduced depth of the periodontal pocket.
- Usually is performed in conjunction with root planing; called *coincidental curettage* when performed adjacent to teeth being root planed.
- Pocket epithelium and infiltrated subepithelial connective tissues are removed without reflecting flaps, that is, without direct vision of the surfaces to be treated.

Indications

- Removal of sulcular epithelium, inflammatory infiltrate, subgingival bacteria, and invasive bacteria.
- Debridement of a periodontal abscess.

Contraindications

- Generally, pockets more than 4 mm deep and furcation areas that may not be accessible.
- Nonsalvageable teeth.
- General health considerations that need to be addressed before dental therapy.
- Uncomplicated periodontal disease.

Objective

- Elimination of the microorganisms that elicit gingival inflammation and of diseased or infiltrated tissues.^{18,19}

Equipment

- Ultrasonic scaler with periodontic tip.
- Curette (sharp instruments are important).

Technique

- Performed after root planing.

- Performed with the curette held in the reverse position from normal scaling; this places the blade against the soft tissue for epithelial removal (Fig. 5-2, A).
- A finger against the gingiva may be used to support gingival tissue during curettage (Fig. 5-2, B).
- Curette is pulled along the tissues and around the pocket wall, debriding pocket epithelium.
- Gingival tissues are irrigated with a chlorhexidine or fluoride solution.
- Gentle compression applied for several minutes to aid readaptation of tissues to the teeth and to control hemorrhage.

Complications

- Excessive destruction of the gingiva.
- Deepening of the periodontal pocket may be caused by placing the curette too deeply into the pocket and tearing or cutting the periodontal ligament or perforating the junctional epithelium at the base of the pocket (Fig. 5-2, C).
- Plaque or calculus left in the pockets—the superficial and coronal tissue heals, and the pocket shrinks and tightens, trapping mineralized bacterial plaque and calculus and resulting in increased chronic lysosomal release, tissue breakdown, bone loss (periodontitis), and possible abscess, which further prevents healing (Fig. 5-2, D). As part of the process, the tissues should be irrigated with water or an antimicrobial irrigant to cleanse the area further.
- Formation of a thick blood clot, which may hinder the adaptation of the gingival tissues to the teeth. Applying gentle pressure until hemorrhage stops may help avoid this.

Aftercare: Follow-Up

- Reexamination in 7 to 14 days; possible open surgical techniques.
- Open surgical techniques will be necessary if the gingiva does not respond to this conservative treatment.
- Long-term therapeutic planning to maintain oral health.

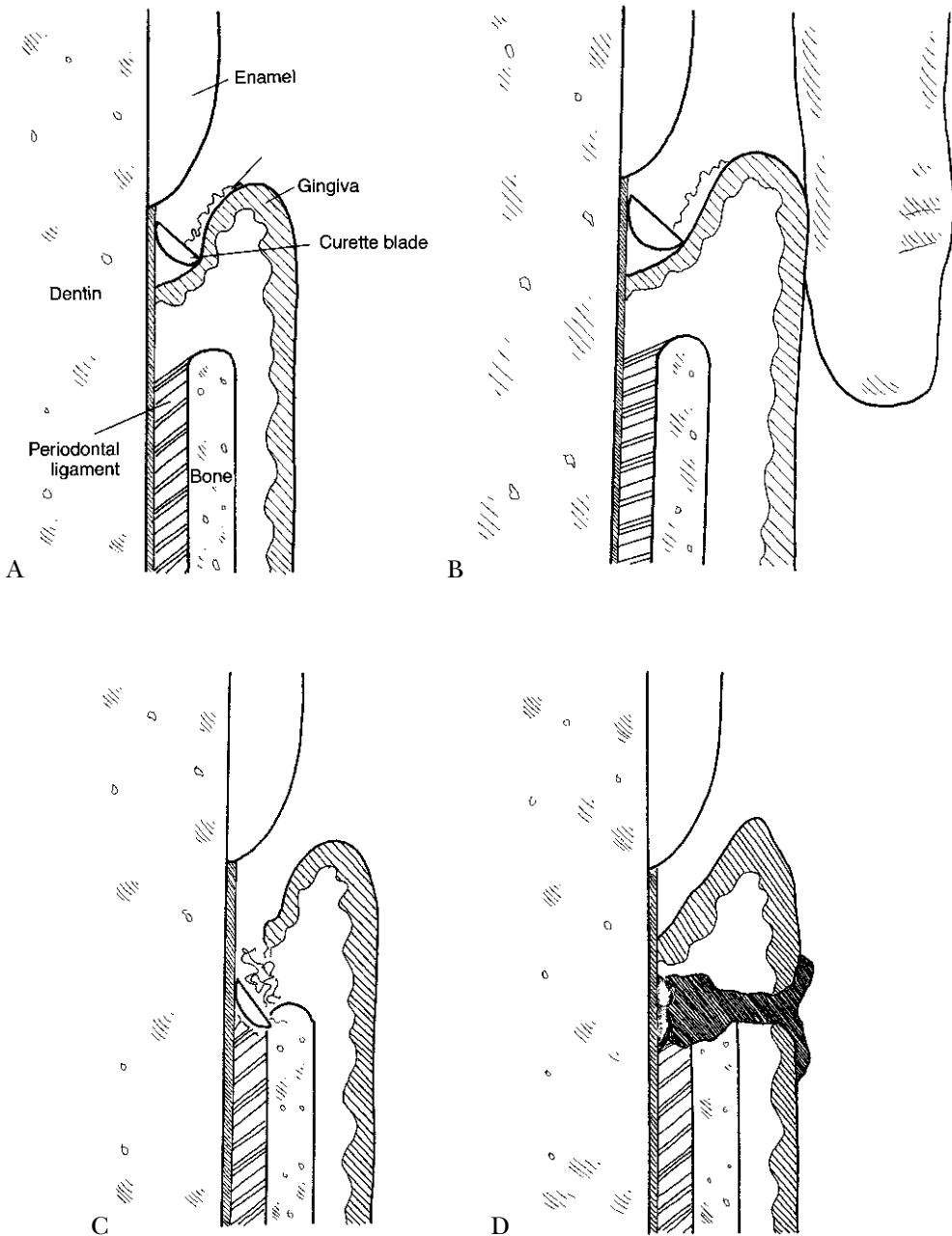


Fig. 5-2

ULTRASONIC PERIODONTAL DEBRIDEMENT

General Comments

- There has been a paradigm shift from the traditional emphasis on treatment of the tooth and root surface in periodontal therapy to a focus on establishing and maintaining healthy periodontal tissues.
- Removing bacterial plaque and endotoxins and removing plaque-retentive deposits and surfaces are the main goals of periodontal debridement.²⁰
- If plaque is removed thoroughly, periodontal tissues heal in spite of residual calculus deposits.
- This procedure may involve three phases: supragingival debridement, subgingival debridement, and plaque removal.
- This procedure removes less cementum than manual root planing with curettes; this creates less dentinal hypersensitivity and less chance of overinstrumentation and gouging of tooth and root surfaces.
- The long slender tips allow removal of bacteria to the apical limit of the pocket.
- Specialized tips can be used in and around furcations to improve removal of bacterial colonies and calculus, especially in the dome areas of furcations, previously inaccessible.
- This procedure can be performed in pockets greater than 4 mm in a closed fashion.
- This procedure can be performed as an adjunct to open procedures.
- This procedure can be performed more quickly and more effectively, with less anesthesia time and with less effort, than manual root planing.
- It is less technically demanding than root planing with curettes.
- Antimicrobial irrigants (dilute chlorhexidine or povidone-iodine solutions) can be added to the water source of some ultrasonic scalers to aid in plaque reduction and reduction of bacterial aerosolization.
- Ultrasonic bactericidal debridement combines the cavitation effect of the instruments destroying or lysing bacterial cell walls with the antimicrobial lavage.

Indication

- Subgingival dental plaque and calculus.

Contraindications

- Nonsalvageable teeth.
- Depends on general health considerations of the patient (systemic disease and patient's overall health).

Equipment

- Sonic scaler with long, thin periodontal tip.
- Ultrasonic scaler with specialized thin, micro tips, or inserts (see Chapter 2).
- Probe.
- Explorer.
- Curettes.

Technique

- The patient's mouth is lavaged with a dilute chlorhexidine solution to reduce external bacterial counts.
- Supragingival calculus and plaque are removed with the broad tips and with light, rapid sweeping motions over the surface of the crown.
- The ultrasonic or sonic scaler is fitted with the long, thin periodontal tip. The power setting is reduced and tuned properly, and the water spray is adjusted.
- The instrument tip is used similarly to a probe, placed in the sulcus or pocket parallel to the long axis of the tooth surface.
- The side of the tip of the instrument is used with a paintbrush-like motion over the root surface in diagonal strokes. The pressure is very light and rapid strokes are used (also referred to as *feather-light touch*).
- Removal of subgingival calculus starts coronally and works apically, using the end of the tip in a gentle tapping motion against the calculus to shatter and remove it.
- After calculus removal, the tip is used in a broad sweeping motion in the sulcus or pocket, to remove bacteria from the tooth surface. The instrument tip must touch every square millimeter of root surface; therefore, overlapping or cross-hatching strokes are most desirable.
- A curette or explorer is used to evaluate the smoothness of the root surface, because these delicate instruments provide an excellent tactile evaluation.
- High-speed suction should be used, if available, to remove water buildup and reduce

aerosolization. If suction is unavailable, the patient's head should be tipped down over a grate or laid on a towel to keep water from collecting under the patient.

Aftercare: Follow-up

- Follow routine home care instructions (see Chapter 4).
- Recall is scheduled according to the severity of the condition.

PERIOCEUTIC TREATMENT

General Comments

- A periocutic agent is a medication designed to be delivered into a periodontal pocket for local treatment of periodontal disease.
- Doxycycline has been found to provide local control of the microorganisms prevalent in periodontal disease.
- The need for continued home care and professional care at regular intervals should be stressed to the client.

Indication

- Patients with periodontal pockets equal to or greater than 4 mm; for treatment after root planing or periodontal debridement therapy.

Contraindications

- Lack of thorough periodontal therapy.
- Age less 1 year, because tetracycline products may cause discoloration of teeth.

Objective

- To infuse the material into the periodontal pocket to allow for a 2- to 4-week release of antibiotic into the periodontal pocket.

Materials

- Doxycycline 8.5% (Doxirobe, Pfizer, New York, NY). This product comes in a packaged pouch with two syringes and a 23-

gauge, 1-inch blunt cannula. Once mixed, the product becomes a solution of doxycycline hyclate equivalent to 8.5% doxycycline activity.

- Plastic working instrument.

Technique

- Periodontal therapy with root planing or periodontal debridement should be performed. The root surface and pocket should be completely free of calculus, plaque, and other debris. The product should be applied only after the teeth and pocket are clean.

Step 1—The two syringes are locked together.

Step 2—Beginning with syringe A, express the contents into syringe B, mixing the product by pushing the syringes back and forth approximately 100 times until the contents are mixed completely.

Step 3—Deliver all of the contents of the syringes, and remove syringe B from A and replace with the supplied 23-gauge cannula.

Step 4—Gently place the cannula 1 to 2 mm below the gingival margin of the tooth to be treated, and inject the mixture while moving the cannula in the pocket. The pockets should be filled to the gingival margin.

Step 5—Lavage with a few drops of water supragingivally to hasten the solidification of the material.

Step 6—As the material hardens, the product that is exposed supragingivally may be pressed into the pocket with a plastic working instrument or back of a curette.

Complication

- Loss of the material out of the pocket; in this case, the material may be tapped into place with a plastic working instrument.

Aftercare: Follow-Up

- Because the product is biodegradable, removal is not required.
- Continued home care is important.

PERIODONTAL SURGERY

- Various modalities may be employed when performing periodontal surgery. The time-

honored and traditional modality of scalpel surgery, using various sizes and shapes of scalpel blades, is the most commonly used modality. Electrosurgery and radiosurgery have been used frequently in recent years. More recently, laser surgery has been touted as a “painless” surgical technique and a way to perform high-technology surgery. There are pros and cons for each modality. Laser units are expensive and, in the opinion of the authors, in most instances do not offer significant advantage over scalpel and electrosurgical techniques to justify the increased cost to the clinic and the client. Surgical procedures in this text will be described with scalpel surgery, because that is what is employed in most veterinary offices. Readers who prefer other surgical modalities should substitute the use of scalpel with that of their own instruments. Following are brief descriptions of the three modalities and the advantages and disadvantages of each.

Sharp Dissection

- Scalpels, periodontal knives, periosteal elevators, excavators, bone curettes, and scissors are the most common sharp instruments used in periodontal surgery. They work well, are easily handled by general practitioners, and are the instruments favored by the majority of veterinary clinicians.

Instruments

- Examples of typical sharp instruments for soft tissue periodontal surgery are:
Scalpel: #3 handle, #15 and #15C scalpel blades.
Periodontal knives: Kirkland, Bucks, and Orban.
Periosteal elevators: Molt #2, #4, #9, and Freer elevators.
Scissors: sharp-sharp iris scissors (Goldman Fox).

Advantages

- Clean, neat incision.
- Inexpensive.
- Convenient.
- Fast, first intention healing.

Disadvantages

- More bleeding than with other techniques.

Electrosurgery and Radiosurgery

- Compared with electrosurgery, electrocautery uses low frequency, low wattage, and low heat, which creates incandescent heat, causing a third-degree burn that is harmful to tissues and can cause bone loss.
- Electrosurgery uses a frequency of 2.0 MHz or higher. Radiocautery uses higher frequency (3.0 to 4.0 MHz) and is relatively atraumatic.²¹ Fully rectified filtered waveform is used for cutting soft tissue with a pure continuous flow of high-frequency energy to provide micro-smooth cutting. There is minimal amount of lateral heat, and it can be used close to bone. Partially rectified waveform is used for coagulation of soft tissue, desensitizing dentin and cementum from cervical erosions, bleaching endodontically treated teeth, and drying and sterilizing endodontic canals.²²

Instruments

- Electrosurgical unit: Ellman International (Hewlett, NY) and Summit Hill Laboratories (Tinton Falls, NJ) supply the popular units in veterinary oral surgery.
- Electrosurgical tips: fine wire, small ball, straight and right-angle rod, small and large loop.
- Forceps: Adson Brown.

Advantages

- Permits any degree of rapid hemorrhage control.
- Prevents seeding of bacteria into the incision site.
- Controls hemorrhage during incision.
- Flexible electrodes are available to conform to surgical site. Activated electrodes are sterile.
- Improved field of view with hemorrhage control.

Disadvantages

- Unpleasant odor.
- May disturb other electrical devices, such as electrocardiograph machine, radio, pacemaker.

- Caution required near volatile chemicals and gases.
- May cause skin burns.
- Bone loss.

Laser Use in Periodontal Surgery

General Comments

- The lasers most commonly used in human periodontal dentistry are the carbon dioxide (CO₂) and the neodymium:yttrium-aluminum-garnet (Nd:YAG).²³ Diode lasers are also used in veterinary dentistry.

General Objectives

- Atraumatic, bloodless, nonpainful surgery with a more rapid recovery to former activity than with other surgical techniques.
- Destroy viruses, bacteria, and fungi.
- Decrease seeding of malignant cells, by sealing lymphatic vessels.

Reported Veterinary Dental Uses

- In cats with severely inflamed gums. Resurfacing of the gingiva to shrink the swollen gum tissues and reduce inflammation, using 2 watts continuous mode or, preferably, a superpulsed mode.
- Gingivectomies to reduce pocketing.
- Cats with very superficial feline odontoclastic resorptive lesions (FORLs), but no radiographically seen root resorption, are treated with superpulsed mode, or even continuous mode. Use caution to avoid charring the tooth and pitting the enamel or dentin. Use 2-watt setting after first painting the tooth with a thin layer of stannous fluoride. In most cases the procedure slows progression of the FORLs and improves the patient's comfort level.
- Incisional and excisional biopsies. Initially the laser is used in a cutting or focused mode, held perpendicular to the tissue, and used to follow the surgical outline. A tissue forceps is then used to raise a border of the outline, and the lesion is undermined with the laser in an elliptical fashion. The surgical site is left to granulate.
- Partial or full ablation of small, slightly raised benign lesions. Use CO₂ in a defocused mode for papillomas, fibromas, pyogenic granulomas, and hyperkeratotic lesions of the buccal mucosa and tongue.

- Gingival hyperplasia. A focused cutting mode is used much as a scalpel to perform a gingivectomy.

Advantages

- Less bleeding than with scalpel surgery. It seals the blood vessels as it cuts.
- Reportedly less pain because the nerve endings are sealed.
- Also seals lymphatic vessels as it cuts.

Precautions and Disadvantages

- Healing is delayed when compared with healing after conventional scalpel gingivectomy.²³
- Avoid reflecting the beam on instrument surfaces, because it could injure adjacent tissues and eyes of operator.
- Respected periodontal authorities in human dentistry are concerned regarding its efficacy: "At present, the use of lasers for periodontal surgery is not supported by research and is therefore discouraged. The use of lasers for other periodontal purposes, such as subgingival curettage is equally unsubstantiated and is also not recommended."²³

Equipment

Carbon dioxide laser

- Not a solid state laser; it consists of mirrors and gases (AccuVet NovaPulse 20-watt CO₂ surgical laser, ESC Sharplan, Norwood, Mass.).
- Hemostasis provided while cutting.
- Cuts optically, but coagulates thermally, producing some char. Wipe away the char with a wet physiologic saline solution (PSS) gauze to reduce slough.
- Less pain than scalpel or electrosurgery. It seals nerve endings, vessels, and lymphatic structures.
- Completely absorbed by water, but not by hemoglobin or oxyhemoglobin. Will never go through a wet sponge (this is good), but function is compromised in hemorrhagic conditions.
- Tip sizes 0.3, 0.4, 0.8, and 1.4 and scanner 3.0 mm for ablation.
- Can be used for any soft tissue surgery that you can reach with the tip.
- Models supplied in 12-watt, 20-watt, and 20-watt superpulse.
- Less zone of necrosis than diode laser.
- Cannot fit down an endoscope.

Diode laser

- Produces laser light when electrical current is passed through the diode chips (Vetroson, 810NM, and 815NM Twilite model, Summit Hill Laboratories, Tinton Falls, NJ).
- Flexible fiber fits down an endoscope. May be used in all areas of the body. Trim fiber before use.
- Solid state; no maintenance.
- Cuts and coagulates optically, not thermally, producing less charring.
- Can be used with or without contact with the tissue. Has more the feel of using a scalpel.
- Hemostasis provided as it cuts.
- Fibers and handpieces can be sterilized for sterile use.
- Laser is absorbed by water, hemoglobin, and oxyhemoglobin.
- Works in moist environment.
- Tabletop unit is more compact than CO₂ laser setup.

Nd:YAG laser

- Nd:YAG and diode lasers create deeper penetration.
- Nd:YAG was developed first but has been replaced in veterinary dentistry, for the most part, by the CO₂ and diode laser units.

A Final Thought About Lasers

- Martindale reported that BioLase developed the Waterlase, based on water technology, and predicts that it will replace all of the above, because each operates within specific but different wavelengths and works best in specific tissue and moisture environments. Early in 2002 the U.S. Food and Drug Administration sanctioned Waterlase for both soft and hard tissue work in root canals and jaw surgery. It has the advantage that it does not shoot a laser directly onto the tooth or gums. Instead, the beam energizes a spray of water droplets, which blasts the surface and scours away diseased or decayed tissue. It can switch between soft and hard tissue wavelengths.
- Laser technology is in a rapid state of development. As with computer technology, one can spend money continually to remain on the cutting edge, no pun intended, and few will be willing to buy your outdated equipment.

MANDIBULAR FRENOPLASTY (FRENECTOMY OR FRENOTOMY)

Indications

- Gingival recession or pocket formation and detached gingiva on the distal side of the lower canine teeth, enhanced by the presence of the frenulum.
- As an aid to treatment of tight lip in the Shar Pei dog.
- As an aid to treatment of cheilitis adjacent to the lower canine teeth.

Contraindication

- Bleeding disorders.

Objective

- To minimize food accumulation in the anterior portion of the mouth and to improve self-cleaning of this area.

Equipment

- Number 10, 15, or 15C scalpel blade and handle.
- Sharp-sharp scissors.
- Absorbable suture 4-0 or 5-0.
- Needle holder, thumb forceps.

Technique

Step 1—The attachment of the frenulum to the mandibular gingiva near the first premolar is cut horizontally with scissors or scalpel (Fig. 5-3, *A*).

Step 2—The incision is extended with sharp or blunt dissection into the frenulum to relieve the pull of the muscular attachments. The lip will relax laterally when the attachments have been severed completely (Fig. 5-3, *B*). A diamond shape is created by the cut surfaces.

Step 3—A suture is placed to bring the mesial and distal edges together (Fig. 5-3, *C*). Several simple interrupted, absorbable sutures are placed to prevent reattachment (Fig. 5-3, *D*).

Step 4—The root surfaces of the canines should be planed smooth and polished.

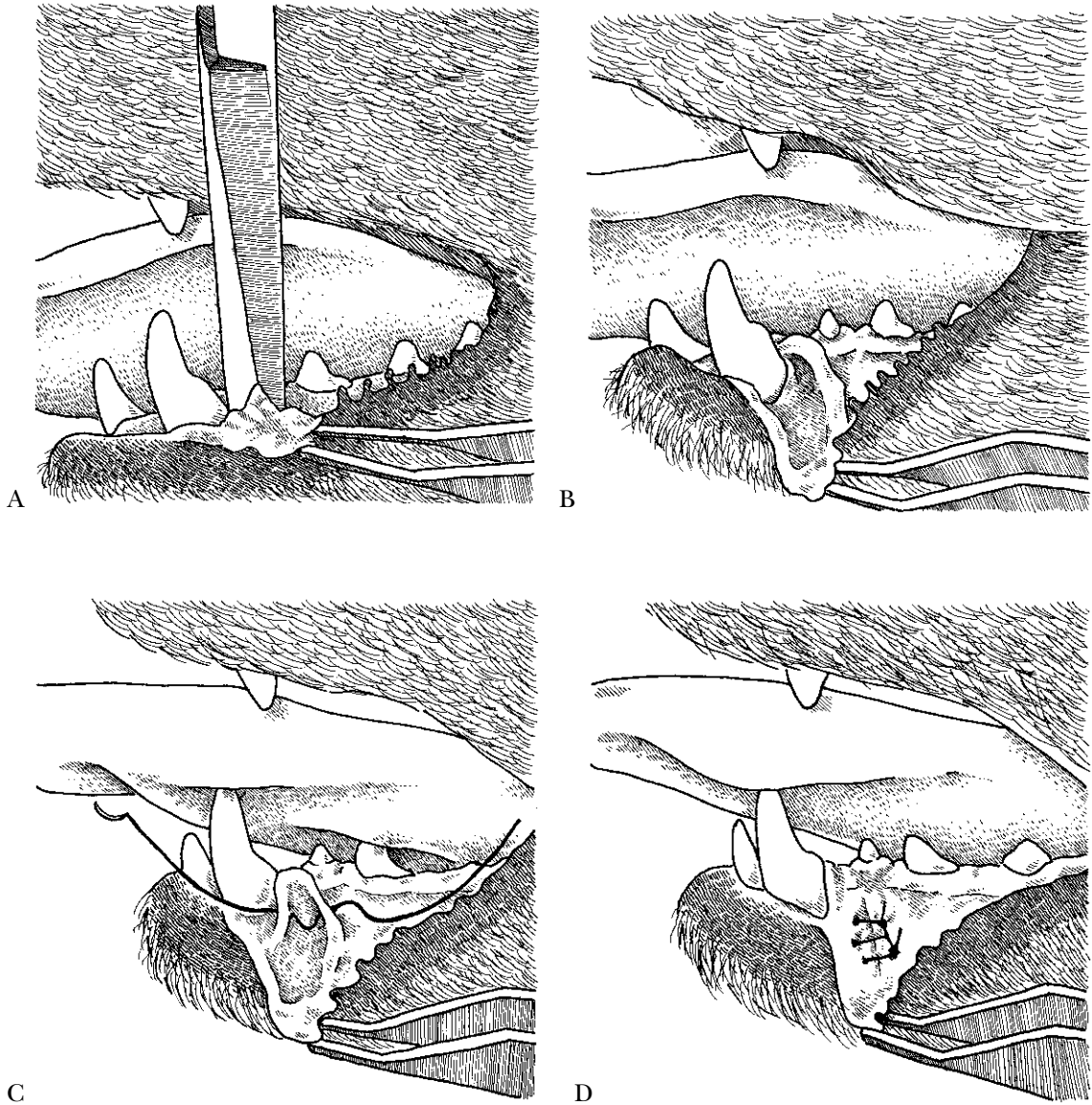


Fig. 5-3

Postsurgical Care

- Twice daily oral flushing with 0.12% chlorhexidine to keep the area clean for 2 weeks.
- Home oral hygiene to minimize progression of periodontitis.

Complications

- Hemorrhage (usually limited) caused by transection of the mental artery or vein; may be avoided by careful blunt dissection after the initial incision.
- Reattachment of frenulum if not sutured.
- Infection.

GINGIVECTOMY

General Comments

- Careful case selection is necessary. Gingivectomy is performed only in patients that will have at least 2 mm of attached gingiva remaining after the procedure.
- This procedure is not used for treatment of deep periodontal pockets or as part of routine prophylaxis.
- Reepithelialization takes place at the rate of 1 mm per day.

Indications

- Removal of excessive gingival tissue in cases with hyperplastic tissue.
- Incisional or excisional gingival biopsy.
- Reduction of suprabony periodontal pockets.

Contraindications

- Minimal or absent attached gingiva.
- Horizontal or vertical bone loss apical to the mucogingival junction.

Objective

- To remove excessive gingival tissue to achieve a clean tooth and root surface, and

a thin beveled gingival margin with pyramid-shaped or knifelike interdental tissue (papilla).

Equipment

- Number 12, 15, or 15C scalpel blade with handle, with or without gingivectomy knives, such as Kirkland or Orban.
- Periodontal probe.
- Electrosurgery and radiosurgery equipment (see p. 244).
- Wet compresses to control hemorrhage.
- Hemostatic agents.
- Cone-shaped rough diamond bur.

Technique

Step 1—The pocket's depth and contour are determined by inserting either a probe or a bleeding point forceps to the depth of the pocket at several areas around the tooth (Fig. 5-4, A). The probe can be walked around the tooth, providing six pocket readings. Use caution so as not to perforate the junctional epithelium.

Step 2—The corresponding depth is measured on the outside of the gingiva using the probe (Fig. 5-4, B).

Step 3—A bleeding point is made by closing the gingivectomy marking forceps (bleeding point forceps), with the tip of a probe, by placing the probe perpendicular to the gingiva and applying slight pressure to make a small hole (Fig. 5-4, C), or by using a small-gauge needle to create the bleeding point. These points are made along the contour of the pocket and are used as a guide for the gingivectomy. The gingivectomy is made at an angle apical to the bleeding point to create a beveled margin. At least 1 mm of healthy, attached gingiva must be present apical to the base of the incision.

Step 4—Using the scalpel blade or electrosurgery blade, the gingiva is excised by cutting below the bleeding points with the blade held at approximately a 45-degree angle, with the tip of the blade toward the tooth crown (Fig. 5-4, D).

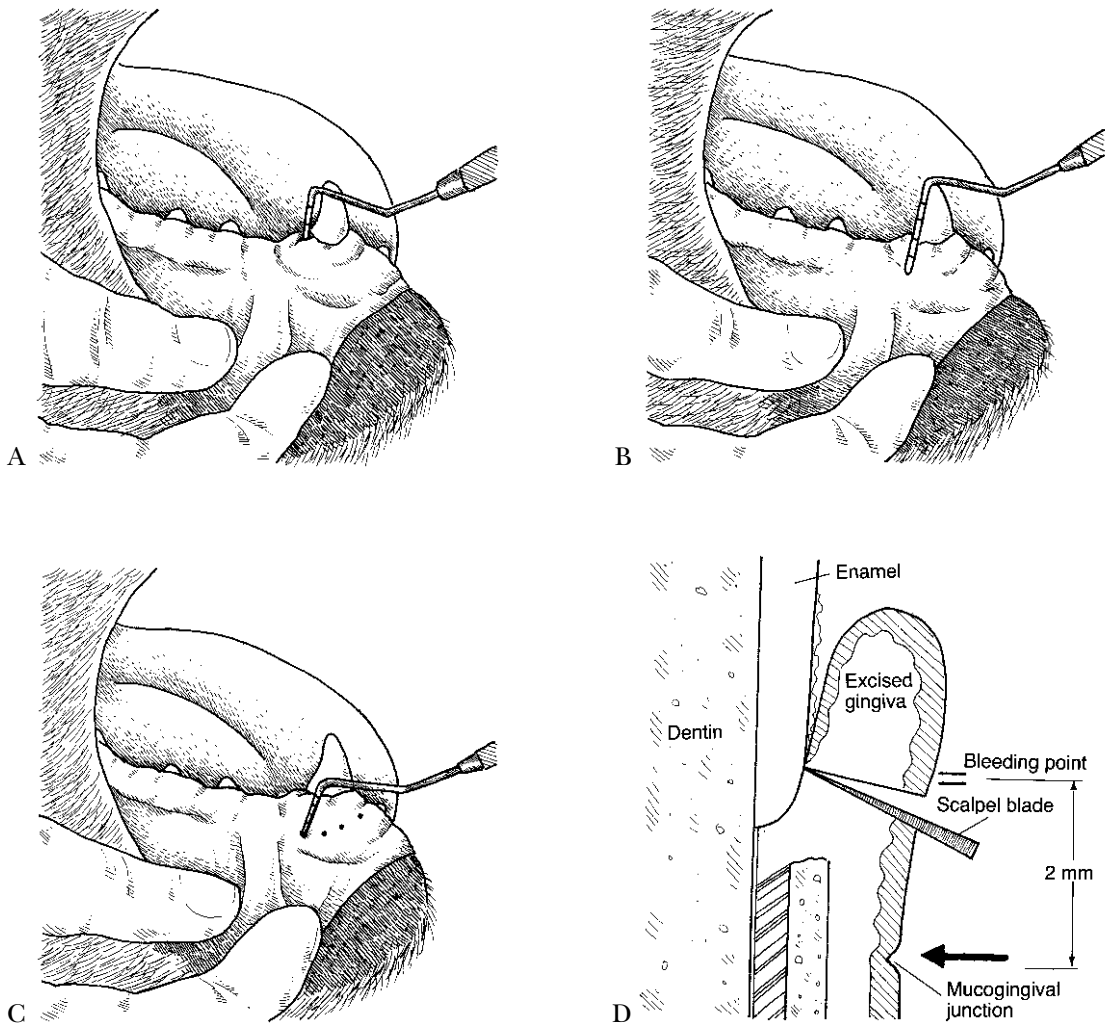


Fig. 5-4

Step 5—The ends of the excision should be tapered into the surrounding gingiva to create the normal scalloped contour, particularly if several adjacent teeth are treated (Fig. 5-5, *A*).

Step 6—Gingival tags can be removed with the blade or a sharp curette. An Orban interproximal gingivectomy knife can be used to incise through the papilla between the lingual and buccal-labial aspects.

Step 7—The exposed tooth and root surface can now be scaled and planed smooth (Fig. 5-5, *B*). Even when thorough root planing has been performed before surgery, a surprising amount of calculus may be discovered after the gingivectomy procedure.

Step 8—Hemorrhage is controlled by applying pressure with wet gauze pads or hemostatic agents. The authors of this text have had little luck maintaining periodontal dressings on canine and feline patients. Properly used, electrosurgery may simplify the procedure by controlling hemorrhage more quickly, allowing better visualization of the surgical field.

Postsurgical Care

- Most patients eat normally following surgery. Soft food can be fed initially, if necessary.
- Twice daily oral rinses with a 0.12% chlorhexidine solution for 2 weeks, by the client at home, to keep the oral cavity clean.
- Broad spectrum oral antibiotics for 1 week.
- Reexamination after 14 to 21 days.
- Follow-up with home oral hygiene and periodic professional dental prophylaxis or periodontal therapy, as appropriate, for the extent of periodontal disease present.

Complications

- Inadequate beveling of the gingival margin, leaving a blunted gingival margin.
- Burning the gingival tissue by using too high a setting on an electrosurgery unit. Anticipate a 1-mm sloughing of tissue even with a normal setting.
- Poor healing, if electrosurgery is performed on unhealthy tissue.
- Not leaving a 2-mm margin of attached gingiva. This promotes potential cleft formation or further gingival retraction. Less keratinized gingival tissue potentiates subsequent bone or root exposure.
- Tip of electrosurgery unit touching root surface, especially in small breeds and cats. This can lead to necrosis or thermal injury to the pulp.

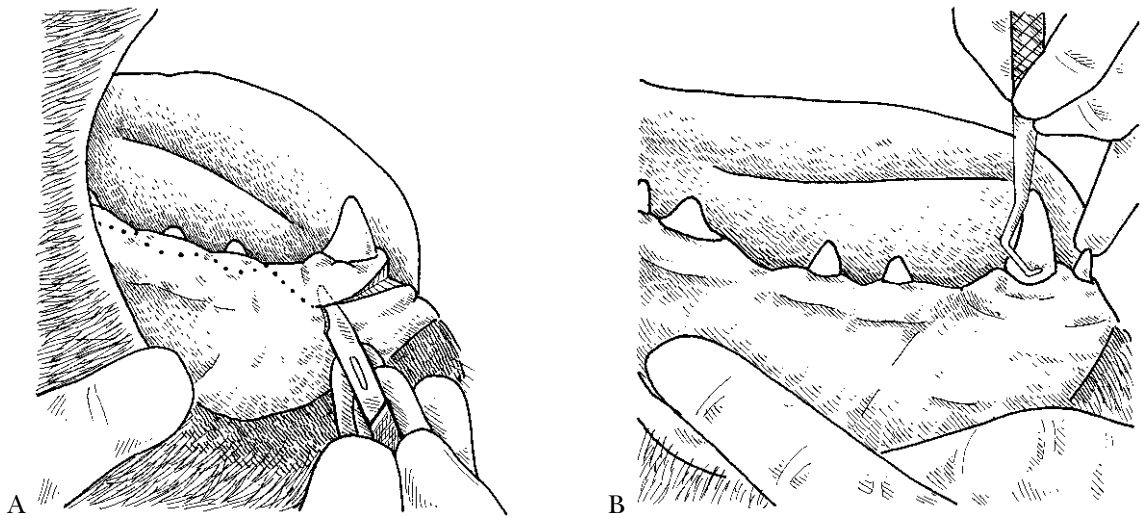


Fig. 5-5

GINGIVOPLASTY

General Comments

- Gingivoplasty is the procedure of surgically recontouring or remodeling the gingival surface.¹⁸
- Gingivectomy is one form of gingivoplasty. Gingivoplasty usually refers to procedures performed on hyperplastic areas without pseudopockets, whereas gingivectomy refers to procedures performed on hyperplastic areas with pseudopockets.

Indication

- Gingival hyperplasia in interdental areas.

Contraindication

- Narrow or absent attached gingiva.

Objective

- To create a physiologic contour of the gingiva.

Equipment

- Same as for gingivectomy.

Technique

- Gingivoplasty is often performed at the same time as gingivectomy.

Step 1—Using the scalpel blade or electro-surgery blade or loop, the gingiva is excised by cutting with the blade held at approximately a 45-degree angle, with the tip of the blade toward the crown.

Step 2—The marginal edge of the excision should be tapered into the surrounding gingiva to create the normal scalloped contour, particularly if several adjacent teeth are treated. An electrosurgery loop is used in a light superficial sweeping motion on the surface of hyperplastic gingiva, much as a sculptor would use a knife to gradually reduce the surface bulk of a clay model.

Step 3—Gingival tags can be removed with the blade or a sharp curette.

Step 4—Hemorrhage is controlled by applying pressure with wet gauze pads or hemostatic agents.

Complications

- See the preceding section, Gingivectomy.

Aftercare: Follow-Up

- See the preceding section, Gingivectomy.

PERIODONTAL FLAP TECHNIQUES

Open Flap Curettage or Envelope Flap

General Comments

- Open flap curettage can provide pocket reduction and reattachment by creating access to subgingival calculus and removal of fibrotic pocket epithelium.
- Generally, it is performed after evaluation of initial therapy.

Indications

- Local areas with suprabony pocket depths greater than 4 mm where extensive removal of pocket tissue is not required.
- To create better visualization and access for a reparative procedure.

Contraindications

- Poor health status of patient.
- Extensive periodontitis requiring additional exposure and visualization.
- Deep periodontal pockets requiring osteoplasty.

Objective

- To gain access to root surfaces for removal of subgingival calculus and necrotic cementum.
- To gain access to furcation pathology

Equipment

- Number 11, 12, 15, or 15C scalpel blade and handle.
- Appropriate sizes of dental periosteal elevators.

- Absorbable suture 4-0 or 5-0.
- Needle holder, thumb forceps, and scissors.
- Sharp curettes.

Technique

Step 1—The blade is inserted into the pocket with the tip directed toward the alveolar bone (Fig. 5-6, *A*), and the epithelial attachments are cut (Fig. 5-6, *B*; the *arrow* points to the mucogingival junction.) This is a reverse bevel incision with the intent of removing sulcular epithelium.

Step 2—The gingiva is elevated with the periosteal elevator positioned lingually-palatally and labially-buccally (Fig. 5-6, *C*) without exposing the crestal alveolar bone (Fig. 5-6, *D*).

Step 3—The exposed root surfaces are planed until they are smooth and hard (Fig. 5-6, *E*).

Step 4—The area is flushed with 0.2% chlorhexidine solution.

Step 5—The flap is repositioned and sutured with interrupted sutures placed interdentally (Fig. 5-6, *F*).

Postsurgical Care

- Twice daily oral flushing with 0.12% chlorhexidine solution for 2 weeks.
- Antibiotics as necessary.
- Home oral hygiene after healing, to minimize future plaque accumulation.
- Follow-up examinations, as necessary, to monitor healing.

Complications

- Inadequate treatment in areas of more extensive periodontitis.
- Bone loss with bony lesions that need osteoplasty.

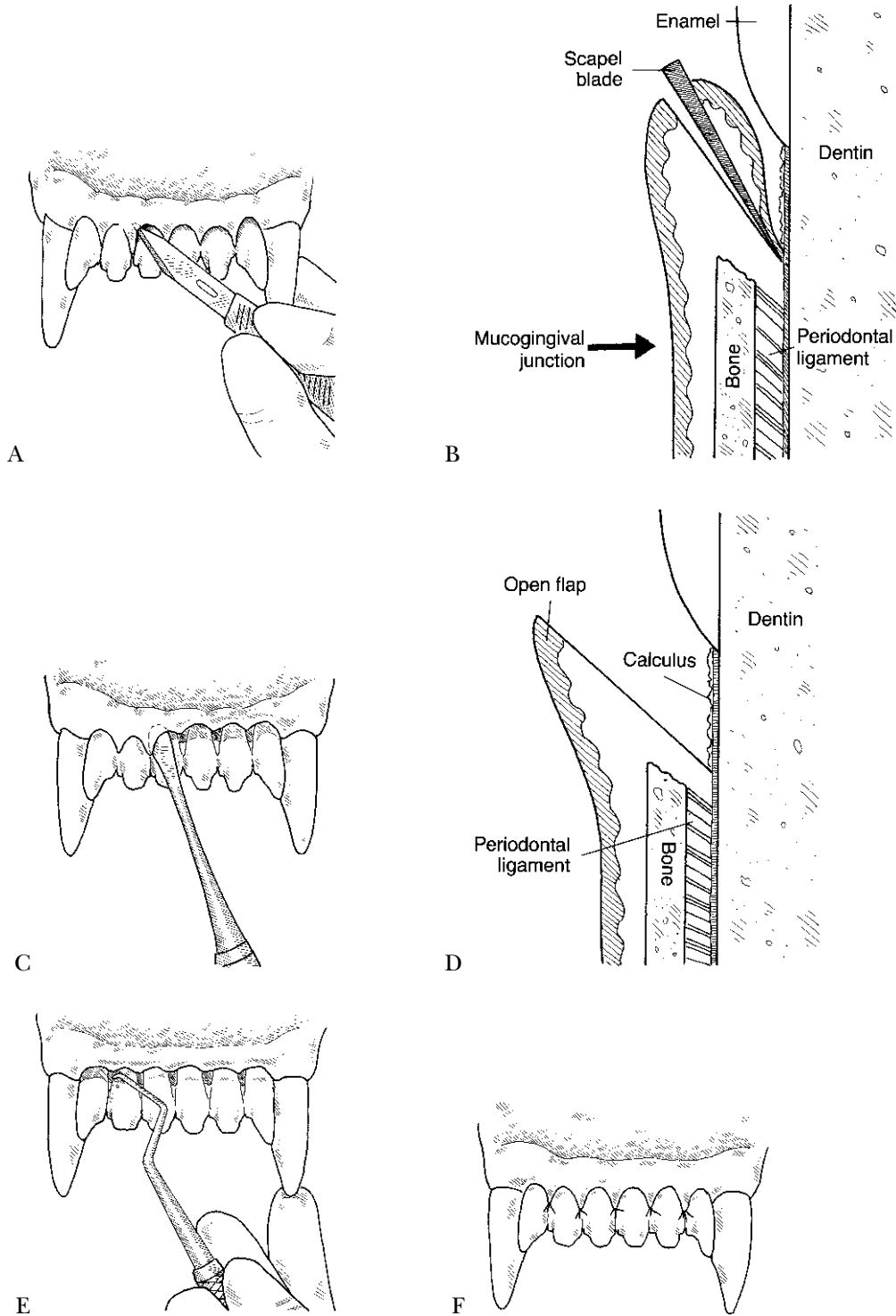


Fig. 5-6

Canine Teeth: Palatal or Lingual Surface Flap Technique

General Comments

- Periodontal disease often is found on the palatal or lingual surface of the canine teeth.
- This area may be difficult to clean with closed techniques.

Indications

- Periodontal pockets greater than 4 mm on the palatal or lingual surface of canine teeth.
- To provide access for correction of osseous defects with or without grafting.

Contraindications

- Loose teeth where salvage is not desired.
- Signs of severe oronasal fistulation (nasal discharge, sneezing, nasal penetration of probe, or presence of solution in nares after irrigation of pocket).
- Secondary mandibular osteomyelitis.

Objective

- To allow access to the palatal or lingual root surface of canine teeth for planing, removal of granulation tissue, and bony correction.

Equipment

- Number 11, 12, 15, or 15C scalpel blade and handle.
- Appropriate sizes of dental periosteal elevators.
- Absorbable suture 4-0 or 5-0.
- Needle holders, thumb forceps, scissors.
- Curettes.
- Numbers 2 and 4 round burs.

Technique

Step 1—The gingiva mesial and distal to the canine tooth is incised to the bone (Fig. 5-7, *A*). To gain more access, the incision is extended palatally and then caudally in a U-shaped exposure (Fig. 5-7, *B*).

Step 2—A reverse bevel incision is made to the level of the alveolar crest on the palatal or lingual surface (Fig. 5-7, *C*).

Step 3—The periosteal elevator is used to elevate the full-thickness gingival flap off the bone to expose the depth of the pocket (Fig. 5-7, *D*). (The collar of tissue is removed if a reverse bevel incision was made.)

Step 4—Hemorrhage is controlled with wet compresses and direct pressure.

Step 5—Subgingival calculus, granulation tissue, and debris are removed with a curette (Fig. 5-7, *E*).

Step 6—The exposed root surface is planed smooth and adjacent bone scraped with a curette.

Step 7—The area is flushed with 0.12% chlorhexidine solution.

Step 8—The desired bony corrections are made as indicated (see the sections on Osteoplasty and Guided Tissue Regeneration and Bone Grafting).

Step 9—The gingiva is repositioned apically to the crest of bone and tooth junction, tightly against the tooth surface, and sutured with interrupted sutures to the buccal gingiva (Fig. 5-7, *F*).

Postsurgical Care

- Oral antibiotics as necessary.
- Initially, oral flushing and swabbing; later, gentle brushing of the palatal or lingual tooth surface to prevent plaque buildup.
- Recheck in 3 months, with the patient under general anesthesia, including a follow-up radiograph. Periodic periodontal treatment as required.

Complications

- Puncturing into the nasal cavity during instrumentation. If only a small opening is created, it may be possible to continue with the procedure and allow the defect to granulate and ossify as periodontitis heals.
- Inadequate healing of tissue, with progression of periodontitis and oronasal fistula formation or mandibular bone loss and infection.

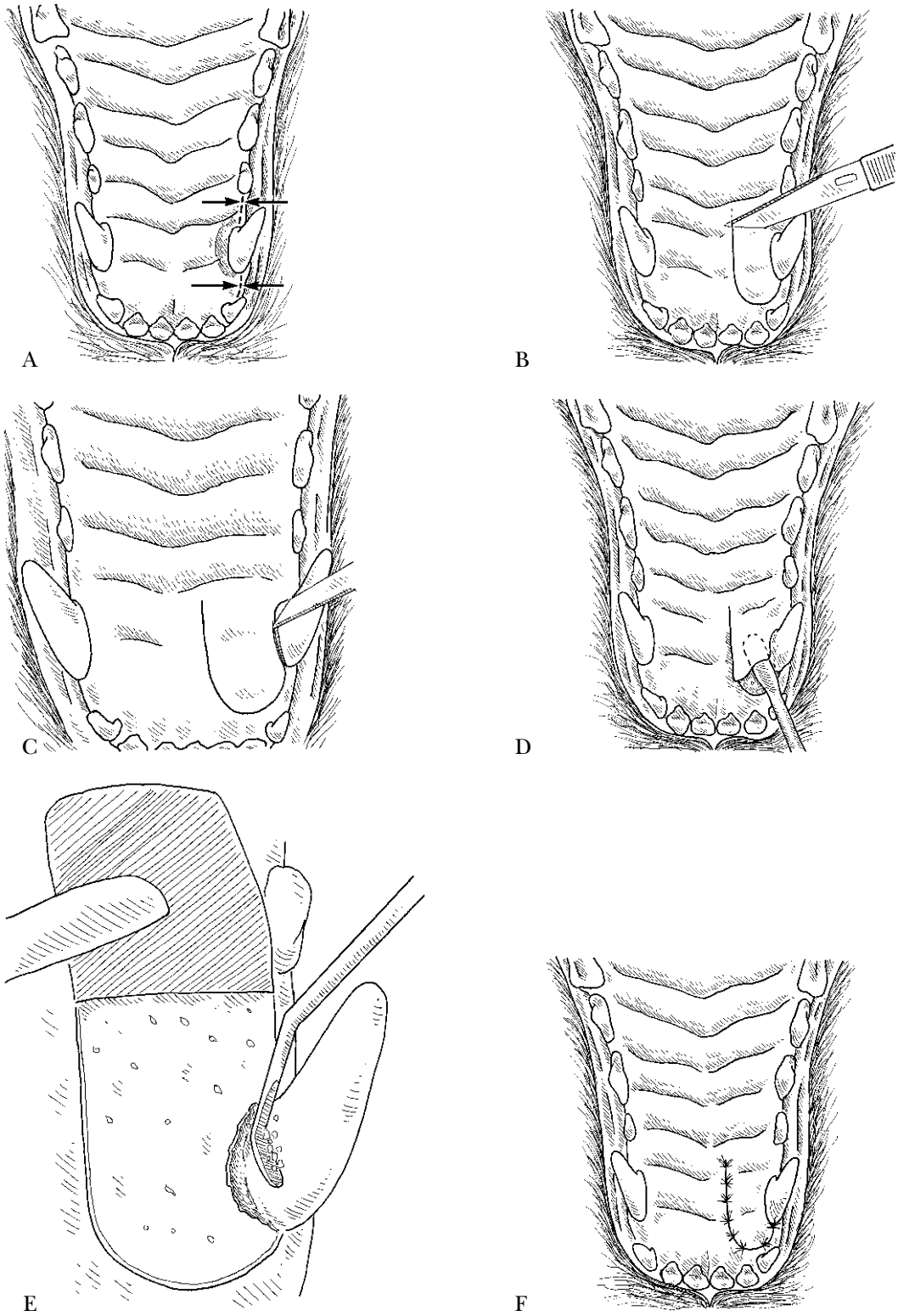


Fig. 5-7

Internal Bevel Releasing Flap Surgery (Modified Widman Flap)²⁴

General Comments

- Reverse bevel releasing flap surgery is performed to remove diseased pocket epithelium and to gain access for root planing.
- Reverse bevel releasing flap surgery is performed when it is desired, to maintain all of the keratinized tissue of the free pocket margin and to position the free pocket margin apically to have an adequate margin of attached gingiva after surgery.
- As with all gingival surgery, the surgery is performed from line angle to line angle. The line angle is an anatomic landmark on the tooth that represents the corner where two vertical walls of the tooth meet. In Fig. 5-8, *A*, *a* shows an interradicular incision and is incorrect, *b* shows a midfacial (radicular) incision and is incorrect, *c* shows an interproximal incision and is incorrect, and *d* shows a line angle incision and is correct.
- Releasing incisions are not always necessary and should not be used indiscriminately.

Indications

- Teeth that have pocket depths greater than 4 mm.
- Periodontal pockets that have not responded to conservative treatment.
- Infrabony pocket formation with vertical bone loss and osseous defects in areas with sufficient attached gingiva.
- To reposition keratinized tissue apically for pocket reduction and increase the zone of attached gingiva.

Contraindications

- Deep pockets with minimal attached gingiva.

- Poor client compliance with home oral hygiene and recall dental prophylaxis.
- Brittle health status of patient.

Objective

- To gain access to root surfaces of teeth with deep periodontal pockets (>4 mm) to remove subgingival calculus and diseased cementum, to remove diseased pocket epithelium and inflammatory infiltrate, and to correct osseous defects.

Equipment

- Number 11, 12B, 15, or 15C scalpel blade and handle.
- Sharp curette or scaler.
- Absorbable suture 4-0 or 5-0.
- Number 2 or 4 round bur for osteoplasty.
- Needle holder, tissue forceps, scissors.
- Appropriate sizes of dental periosteal elevators.

Technique

Step 1—Starting at the line angle of the healthy tooth mesial or distal to the operative area,²⁵ a reverse bevel incision is made, extending through the top of the free gingival margin (Fig. 5-8, *B*). The blade is directed toward the alveolar bone, leaving the pocket epithelium and thin collar of marginal tissue around the teeth, starting and ending at healthy gingiva. A scalloped incision is made, following the contour of the roots, with the highest point of contour at the interproximal area (Fig. 5-8, *C*).

Step 2—Vertical releasing incisions can be made, if necessary, on one or both sides of the affected area to permit better access to the root surface and alveolar bone (Fig. 5-8, *D*).

Step 3—The flap is elevated with a periosteal elevator (Fig. 5-8, *E*). If minimal bony correction is needed, the flap can be elevated just to expose that portion of the alveolar crest.

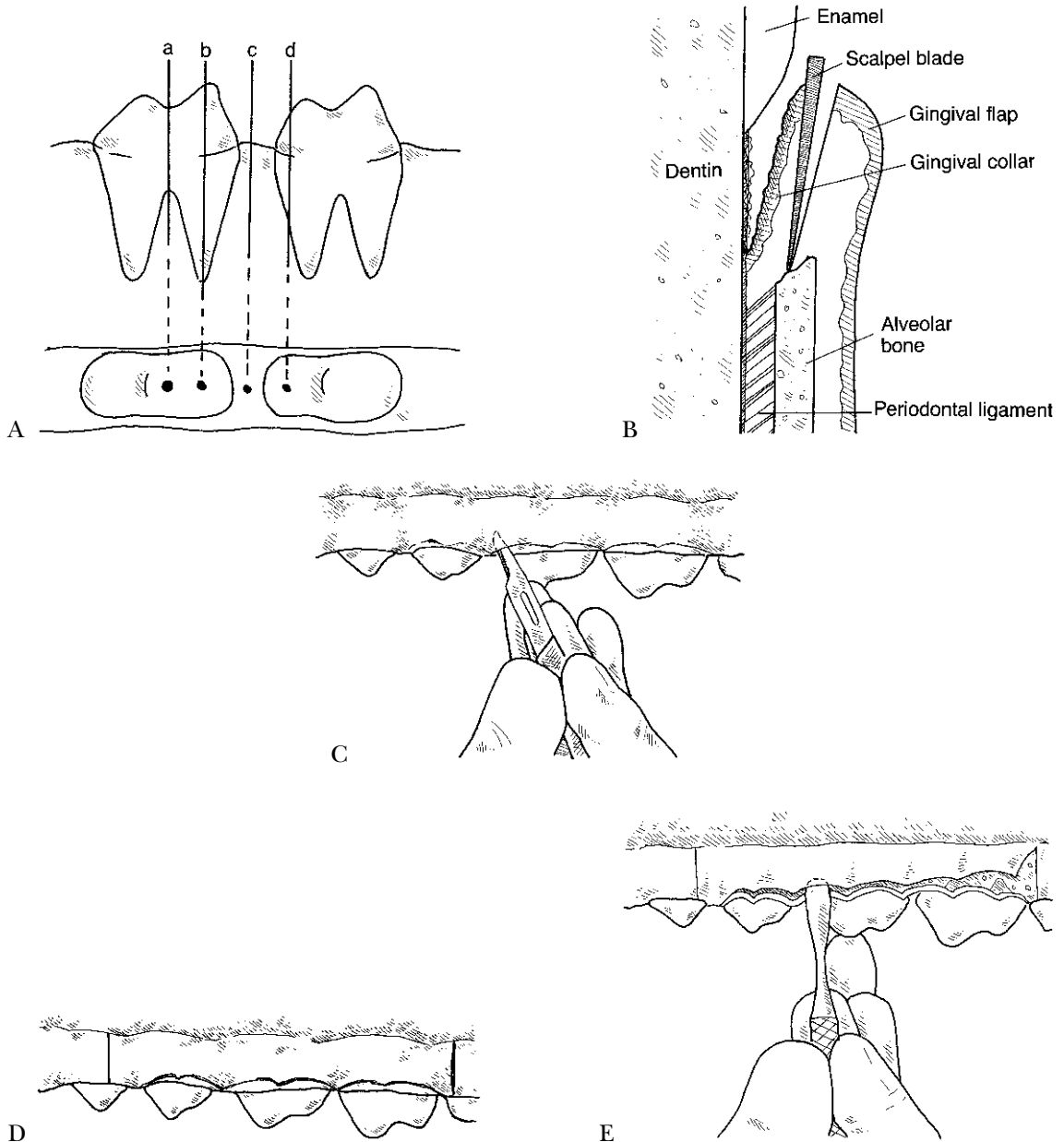


Fig. 5-8

Step 4—The collar of marginal tissue is removed by incising the attachments, with the scalpel blade placed in the sulcus horizontally at the base of the pocket. Affected tissue is removed from the root surface with a sharp scaler or curette (Fig. 5-9, *A* and *B*).

Step 5—The flap is retracted, and the root surfaces are planed smooth with sharp curettes (Fig. 5-9, *C*).

Step 6—Osseous defects and necrotic bone are removed with small round burs in a low-speed or high-speed handpiece, accompanied by saline irrigation.

Step 7—The area is flushed with a 0.12% chlorhexidine solution.

Step 8—The flap is repositioned, being sure that the bone margin is covered, and sutured interdentally with 4-0 or 5-0 absorbable suture (Fig. 5-9, *D*). The releasing incisions are sutured with interrupted sutures.

Postsurgical Care

- Soft food is recommended for 1 week.
- Oral antibiotics, continued as necessary.
- Daily oral flushing with 0.12% chlorhexidine solution for 2 weeks.
- After healing, home oral hygiene to minimize further plaque accumulation.
- Frequent follow-up examinations and periodic periodontal therapy accompanied by radiographic examination to monitor healing progress.

Complications

- Infection.
- Dehiscence.
- Inadequate coverage of alveolar bone margin due to excessive cutting of tissue.
- Greater pocket formation if soft tissue sutured too high on the root surface.

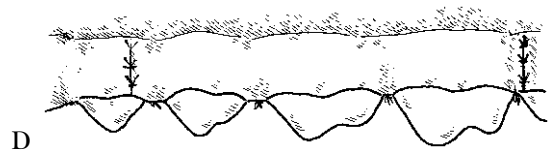
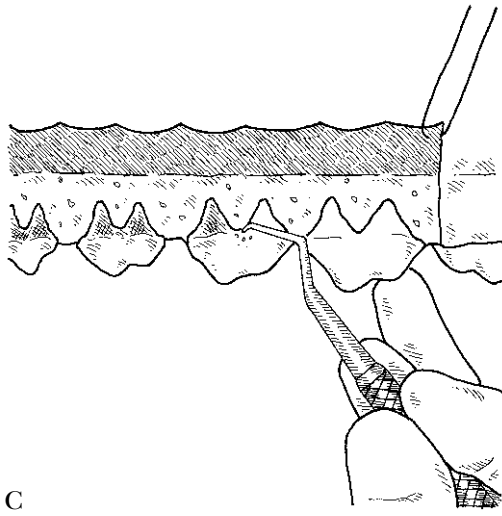
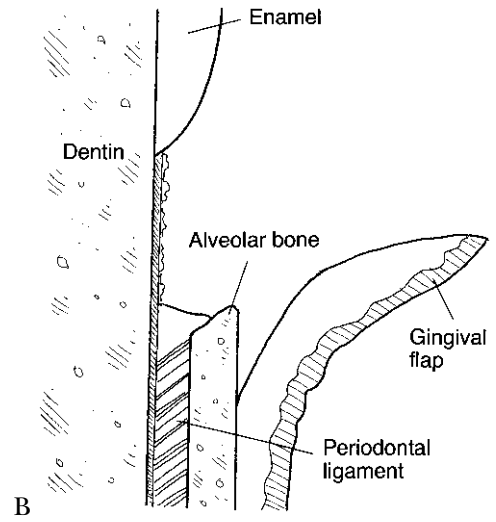
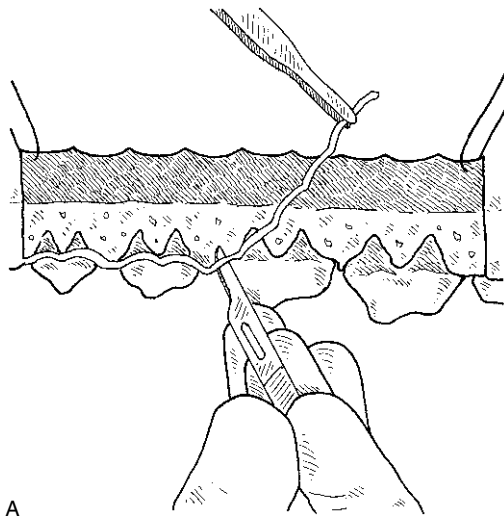


Fig. 5-9

Apically Repositioned Flap Surgery

General Comments

- When performing apically repositioned flap surgery, the gingiva is retracted, the periodontal pocket depth is reduced, and the soft tissue is reattached apical to its original location. Possibly, this exposes a furcation or dentin but permits better cleaning of the tooth and access for osteoplasty. The zone of attached gingiva may be preserved.

Indication

- Areas with pocket depths greater than 5 mm where a reverse bevel flap is contraindicated; when there are pockets with minimal attached tissue so that the intent is to move the keratinized free gingival margin apically over bony surface.

Contraindications

- Loose teeth.
- Poor client compliance with home oral hygiene or recall prophylaxis.
- Lack of keratinized free gingiva or attached gingiva to move apically.
- Poor health status of patient.

Objective

- To decrease pocket depth in areas with deep infrabony pockets, bringing the free gingival margin just coronal to the level of the alveolar bone to allow for better self-cleaning of affected areas and to preserve the zone of attached gingiva.

Equipment

- Number 11, 12, 15, or 15C scalpel blade with handle.
- Appropriate sizes of dental periosteal elevators.
- Absorbable suture 4-0 or 5-0.
- Needle holders, thumb forceps, scissors.
- Burs, as necessary, for osteoplasty, ostectomy.
- Sharp curettes for root planing.

Technique

Step 1—The blade is used to create a reverse bevel incision around the involved teeth (Fig. 5-10, *A*), and the epithelial attachments

are cut buccally and palatally or lingually and interproximally (Fig. 5-10, *B*). If inadequate attached gingiva is present, a sulcular incision is made to preserve the attached gingiva.

Step 2—Vertical releasing incisions are made in the healthy gingiva mesial and distal to the involved teeth (Fig. 5-10, *C*).

Step 3—A full-thickness flap is elevated apically with a periosteal elevator to expose the alveolar bone for about 3 to 4 mm; then a split-thickness flap is elevated apically, leaving periosteum so the apically repositioned flap can be sutured to it (Fig. 5-10, *D*).

Step 4—Sharp bony edges, irregular bone margins, or necrotic alveolar bone margins are removed with round burs and saline irrigation (Fig. 5-10, *E*) (see the section on Osteoplasty). Tooth-supporting bone is not removed.

Step 5—Granulation tissue and pocket lining are removed from the gingiva by curettage, and the root surfaces are planed (Fig. 5-10, *F*).

Step 6—The surgical area is flushed to remove debris with sterile saline or 0.12% chlorhexidine solution.

Step 7—The gingiva is repositioned just coronal to the alveolar bone level and sutured (Fig. 5-10, *G*) with vertical mattress sutures, tacking down to the periosteum apically and securing the coronal full-thickness portion to the lingual tissue (Fig. 5-10, *H*).

Step 8—The vertical releasing incisions are sutured with interrupted stitches. A fold of redundant tissue may be present and will reconform during healing.

Postsurgical Care

- Daily oral flushing with 0.12% chlorhexidine solution for 2 weeks.
- Return to routine home oral hygiene after first week.
- Follow-up periodic periodontal therapy, as necessary, to continue oral health.
- Soft food is recommended for 1 week.
- Oral antibiotics should be continued, as necessary.

Complications

- Infection.
- Dehiscence.
- Inadequate coverage of alveolar bone due to excessive cutting of tissue.
- Greater pocket formation if soft tissue sutured too high coronally on tooth surface and not at bony crest.

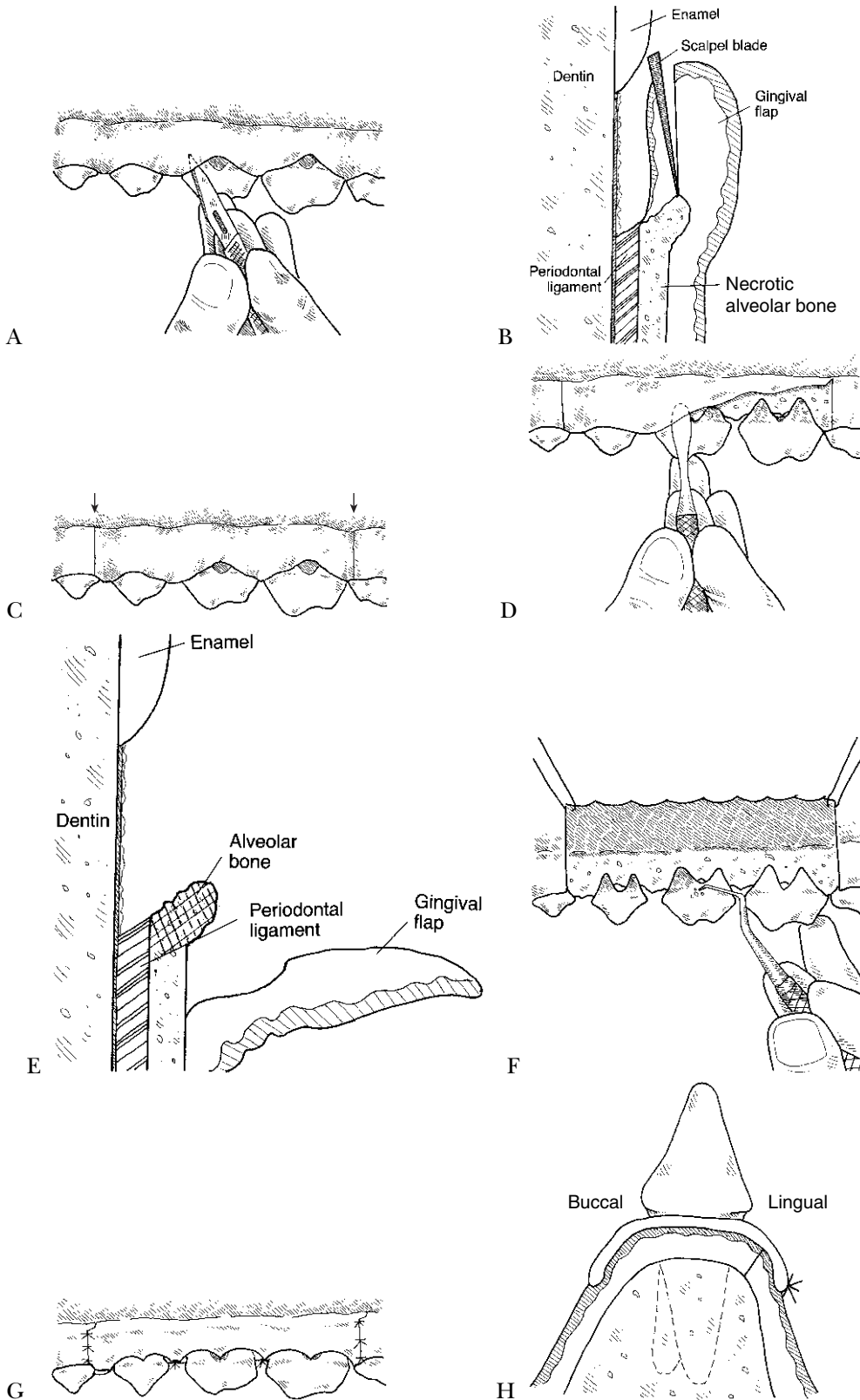


Fig. 5-10

Citric Acid

- Citric acid may be applied to the root structure after any root planing procedure, to enhance reattachment of gingival tissues.²⁶
- Following root planing, a citric acid solution that has a pH of 1.0 is applied to the dentin for 3 minutes, then rinsed.
- Citric acid may be purchased at a pharmacy or through dental supply houses. It is mixed with sterile water to form a superconcentrated solution.
- There is debate as to the effectiveness of citric acid treatment.

Periodontal Dressings

- Periodontal dressings are applied after periodontal surgery to protect gingival tissues.
- Lack of patient acceptance and lack of adequate adhesive areas limits their use.
- One product that does seem to stay in place fairly well is a light-cured liquid dam (Paint-on Dam, Den-Mat Corporation, Santa Maria, Calif.).

SOFT TISSUE GRAFTING TECHNIQUES

Pedicle Graft

General Comments

- The pedicle graft uses adjacent attached gingival tissue to reestablish gingiva that has been lost.
- An area of exposed tissue from the donor site will heal by second intention.

Indication

- For use in an area with gingival cleft formation that has an adjacent edentulous area or sufficient border of attached gingiva (Fig. 5-11, A).

Contraindications

- Loose tooth.
- Unrealistic client expectations.

Objective

- To establish a functional margin of attached gingiva in areas of cleft formation associated

with periodontal disease, combined periodontal and endodontic lesions, and frenula pull.

Equipment

- Number 11, 15, or 15C scalpel blade and handle.
- Appropriate sizes of dental periosteal elevators.
- Absorbable suture 4-0 or 5-0.
- Needle holders, thumb forceps, scissors.
- Sharp curettes.

Technique

Step 1—The teeth are scaled and polished.

Step 2—A beveled incision is made along the gingival margin of the defect to remove diseased epithelial lining (Fig. 5-11, B). The side adjacent to the graft is beveled externally, with the side away from the graft beveled internally. When treating a mandibular canine tooth, the graft should be taken mesial (anterior) to the canine tooth to avoid the mandibular frenulum.

Step 3—The exposed root surface is planed smooth with a curette, and the area is flushed with dilute chlorhexidine.

Step 4—A vertical incision is made at approximately $2\frac{1}{2}$ times the cleft width from the midline of the gingival border apically to match the length of the cleft (Fig. 5-11, C). The object is to create the donor graft $1\frac{1}{2}$ times the size of the recipient width. A horizontal releasing incision is made along the midline of the gingiva to the depth of the periosteum.

Step 5—The portion of the graft adjacent to the cleft is elevated to the depth of the bone for the width of the cleft with a periosteal elevator, and the portion of the graft away from the cleft is elevated only to the level of the periosteum. This increases the blood supply and leaves periosteum over the exposed bone for granulation tissue formation.

Step 6—The graft is rotated over the cleft and sutured to the free gingival margin with interrupted sutures (Fig. 5-11, D). The sutures are placed approximately 1.5 mm apart and are tied so that the margins are overlapped.

Step 7—The gingival edge away from the cleft is sutured to adjacent gingiva and periosteum. A cruciate (figure-X) or mattress-type suture may be placed to add additional support (Fig.

5-11, E). Care should be taken not to create much pressure with the suture material. Step 8—A periodontal dressing can be applied to protect the area for a few days.

Postsurgical Care

- Antibiotics as necessary.
- Pain medication as necessary.
- Remove periodontal dressing if still in place after 2 to 3 days.
- Twice daily oral rinsing with 0.2% chlorhexidine solution for 2 weeks.

- Continued daily home oral hygiene.
- Follow-up and periodic periodontal therapy as necessary to maintain oral health.

Complications

- Strangulation of gingival tissue by placing sutures too closely or tightly.
- Dehiscence, with failure to reform margin of attached gingiva.
- Exposure of bone with necrosis by elevating flap full thickness in area away from cleft.

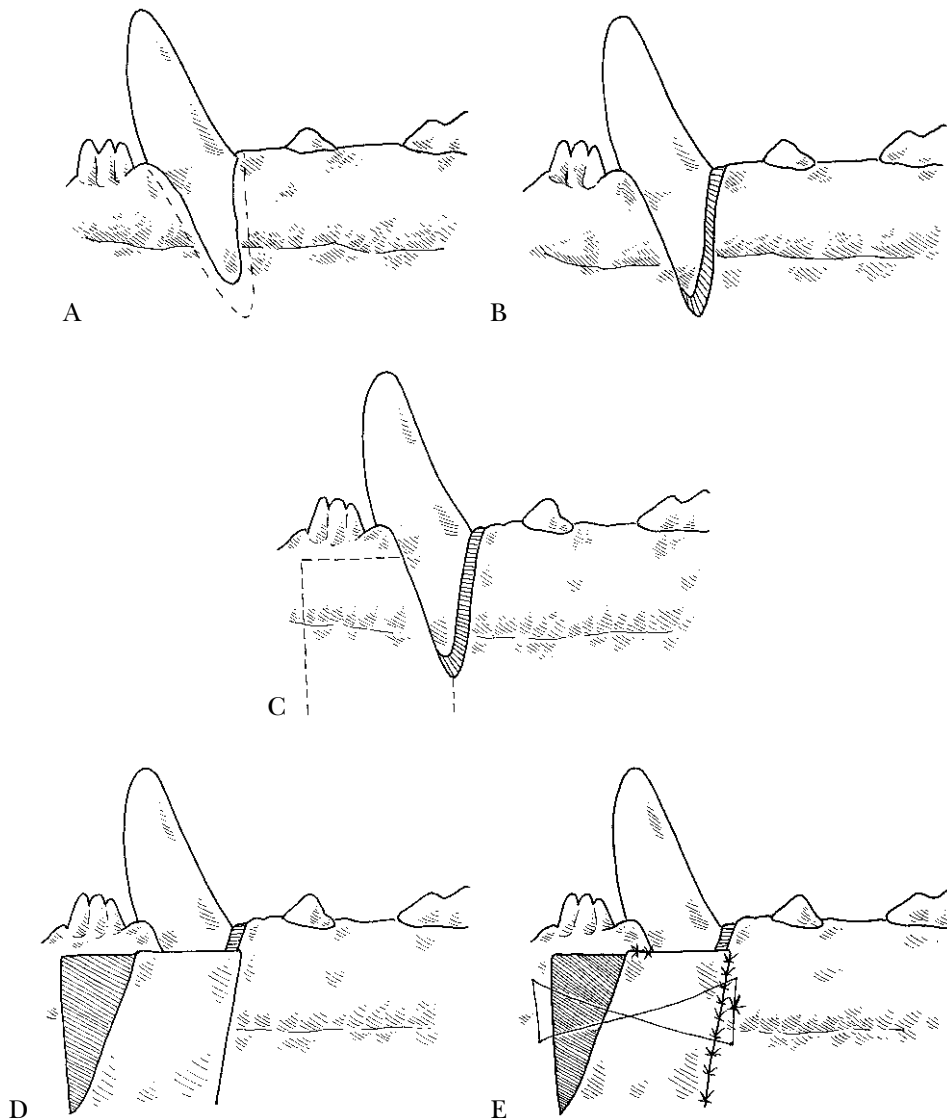


Fig. 5-11

Free Gingival Graft

General Comment

- If gingival defect is related to endodontic disease, endodontic disease must be treated first.

Indications

- Individual teeth, with deep gingival cleft formation close to or beyond the mucogingival junction, that are otherwise healthy (Fig. 5-12, A).
- When adjacent gingival tissue that could be used to cover the defect is insufficient.

Contraindications

- Poor client compliance with aftercare or unrealistic client expectations.
- Systemic disease.
- Untreated and uncontrolled periodontal disease.
- Other dental disease; some gingival defects are caused by endodontic disease.

Objective

- To reestablish a border of keratinized attached gingiva around a tooth that has a deep gingival cleft, to retain the tooth, and to create 2 mm of attached gingiva, which means that approximately 4 to 5 mm of keratinized tissue will be needed to make up the free gingiva and attached gingiva.

Equipment

- Number 11, 15, or 15C scalpel blade.
- Template made from a small piece of paper or metal foil.
- Absorbable 5-0 polyglycolic suture with swaged-on taper-point needle or poligle-caprone 25 (Monocryl, Ethicon).
- Small periosteal elevator.
- Needle holder, thumb forceps.
- Periodontal dressing.

Technique

Step 1—The recipient site is treated by scaling and planing the exposed root surface. A reverse bevel incision is made around the gingival margin to remove pocket epithelium (Fig. 5-12, B).

Step 2—A 3- to 4-mm recipient bed for the graft is created by removing all the soft tissue down

to the level of the periosteum in a rectangular pattern around the defect (Fig. 5-12, C). The bed should extend beyond the root surface sufficiently to allow for shrinkage during healing. Hemorrhage is controlled with a wet gauze and pressure.

Step 3—A donor area is selected where attached gingiva is sufficient, such as the area above the maxillary canine tooth or buccally by the mandibular first molar. The size of the recipient site can be measured, or a template can be made by using a small piece of aluminum foil.

Step 4—The template is placed on the donor area, and the outline is traced with a #15C blade (Fig. 5-12, D). Care should be taken to leave the periosteum intact and not expose root or bone.

Step 5—The donor incisions are deepened with the blade to the level of the periosteum.

Step 6—A corner of the donor tissue is elevated with the blade, leaving periosteum (split thickness) (Fig. 5-12, E), and tagged with a 5-0 suture with a swaged-on taper-point needle as a holder and marker.

Step 7—The remainder of the graft is elevated with the blade while tension is gently placed on the suture until the graft is free (Fig. 5-12, F).

Step 8—The graft is placed over the recipient bed (gingival side up), and pressure is applied for several minutes to help create a seal and force out air and blood between the donor and recipient tissue.

Step 9—The edges of the graft are sutured to the surrounding gingiva with interrupted sutures, spaced 2 mm apart (Fig. 5-12, G), using 5-0 absorbable suture with a swaged-on taper-point needle.

Step 10—Sling sutures are placed across the donor tissue and anchored on either side in solid tissue. Alternatively, or additionally, a periodontal dressing is placed over the graft site to protect it for the first few days.

Postsurgical Care

- Removal of the periodontal dressing in 2 to 3 days if the dressing is still present.
- Appropriate antibiotic therapy.
- Suture removal in 10 days if using non-absorbable suture.
- Soft food for 10 to 14 days.
- Twice daily oral flushing with 0.12% chlorhexidine solution for 2 weeks.
- Home oral hygiene after healing to minimize progression of periodontal disease.

Complications

- Sloughing of the graft from rough handling, poor adaptation of tissues, or patient abuse.
- Sutures placed too tightly or closely, creating loss of blood supply.
- Bone necrosis at donor site if insufficient periosteum left for healing.
- Inadequate home care, leading to recurrence of pocket / cleft formation.

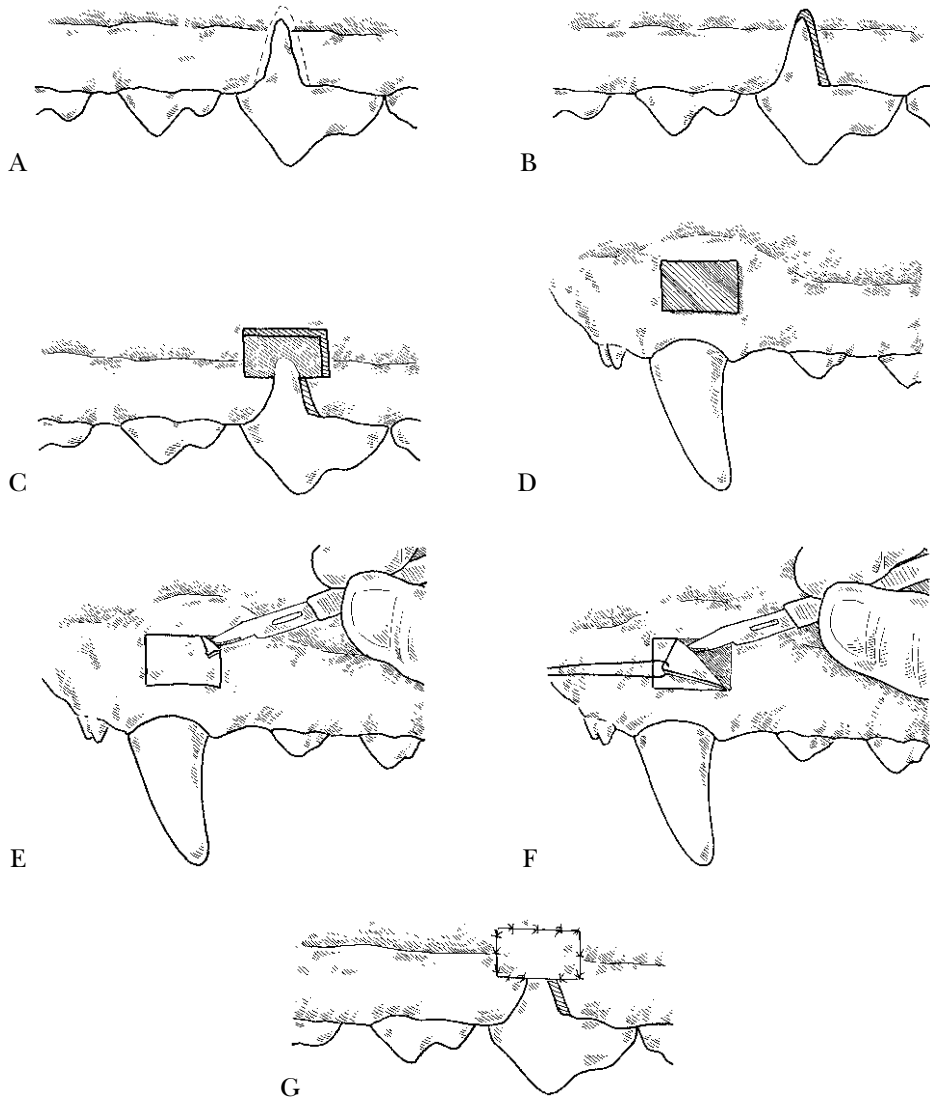


Fig. 5-12

MANAGEMENT OF DEFECTS IN BONE

General Comments

- Osseous surgery techniques are performed according to the type of lesion present and the wishes and compliance of the client.
- Management of bony defects by elimination of bony pockets provides an environment for better gingival healing around periodontally affected teeth that have supporting bone loss.
- Bony defects are further classified according to the number of remaining bony walls.
- Three-wall defect most commonly occurs in the interdental area, also called an *infrabony defect* (Fig. 5-13, A). A palatal pocket of the maxillary canine tooth is a three-wall defect if the pocketing is found only on the palatal aspect. A three-wall defect has three remaining bony walls. This condition has the best prognosis for treatment.
- Two-wall defect is the most common defect and occurs in the interdental area (Fig. 5-13, B). A palatal pocket, together with a mesial or distal pocket, of the maxillary canine tooth is a two-wall defect.
- One-wall defect occurs interdentally (Fig. 5-13, C). This defect has the worst prognosis.
- A defect that is continuous 360 degrees around the tooth is called a *cup defect* and carries the worst prognosis.
- Osteoplasty is the technique that removes or recontours nonsupporting bone.
- Ostectomy is the technique that removes tooth-supporting bone.

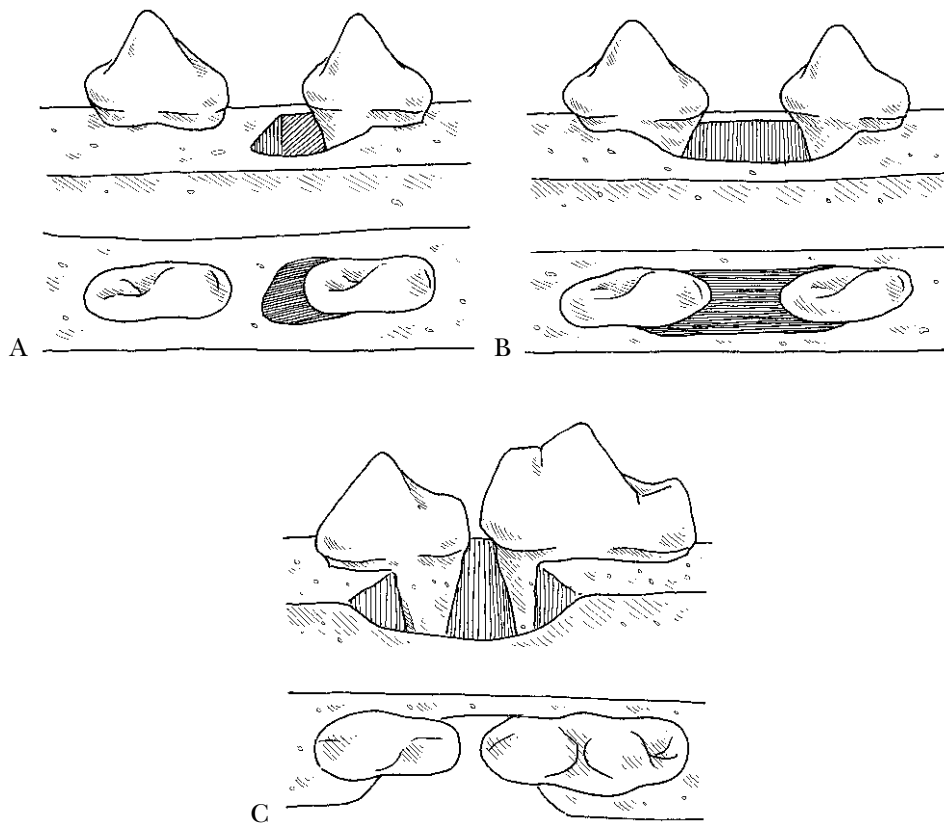


Fig. 5-13

Management Techniques

- Induce regrowth of bone by grafting.
- Hemisect a multiroot tooth, and extract one severely affected root while preserving the remaining root with appropriate endodontic procedure.
- Attempt to maintain pocket by frequent scaling, root planing, and plaque control. In pockets greater than 4 mm and in furcation areas, all of the subgingival plaque cannot be removed, and the disease process will progress.
- Attempt to maintain pocket with ultrasonic debridement combined with chemotherapeutic agents such as chlorhexidine. This may arrest the disease process; however, a refractory pocket may remain.
- Extract the tooth.

Osteoplasty

Indications

- Infrabony defect in which the base of the periodontal pocket is apical to the level of the crest of the alveolar bone, resulting in sharp irregular bone contours.
- Need for thinning of bony ledges and establishing a scalloped contour to allow for periodontal flap closure.
- Irregular alveolar margins after extracting teeth.
- Leveling indicated for interdental crater formation.
- Ramping (smoothing) furcation ledges where periodontitis has caused bone loss in the furcation.

Contraindications

- Poor health status of patient.
- Lack of client commitment to aftercare.
- Inexperienced clinician.

Objectives

- To remove ragged alveolar bone, to improve bony contour in areas with periodontal disease so as to allow adaptation of the surgical flap, to improve healing, and to improve ability to maintain oral hygiene.
- In periodontally created one-walled or two-walled bony defects: to allow adaptation of a

surgical flap with a parabolic flow, with the highest point in the interproximal area.

Equipment

- Materials for flap surgery.
- Number 1, 2, or 4 bur in a handpiece.
- Sterile saline.
- Small (3 mm) bone rongeurs (postextraction).

Technique for Osteoplasty or Ostectomy

Step 1—A full-thickness flap is prepared with a reverse bevel incision as described on pp. 254 to 255 (Fig. 5-14, A).

Step 2—Granulation tissue is removed, and the roots are planed and smoothed thoroughly with curettes.

Step 3—Sharp edges and ledges of alveolar bone are removed and contoured as needed with a round bur in a handpiece, accompanied with saline irrigation (Fig. 5-14, B). Minimal bone removal is desired, trying to make the parabolic architecture with the highest point interproximally (Fig. 5-14, C).

Step 4—Irregular alveolar margins are recontoured in areas of tooth extractions.

Step 5—Surgical area is lavaged with sterile saline.

Step 6—The gingiva is replaced over bone margin and sutured interdentally (Fig. 5-14, D and E).

Postsurgical Care

- Periodontal dressing if desired.
- Antibiotics as indicated.
- Twice daily oral flushing with 0.12% chlorhexidine solution for 2 weeks.
- Home oral hygiene.
- Follow-up management or recall for periodic periodontal therapy.

Complications

- Excessive bone removal with loss of attachment. Supporting bone should not be removed (ostectomy).
- Excessive heat produced if inadequate irrigation or too high a speed is used, with resulting bone necrosis.
- Inadequate bony contour or furcation ramping with poor gingival adaptation and poor healing or dehiscence.

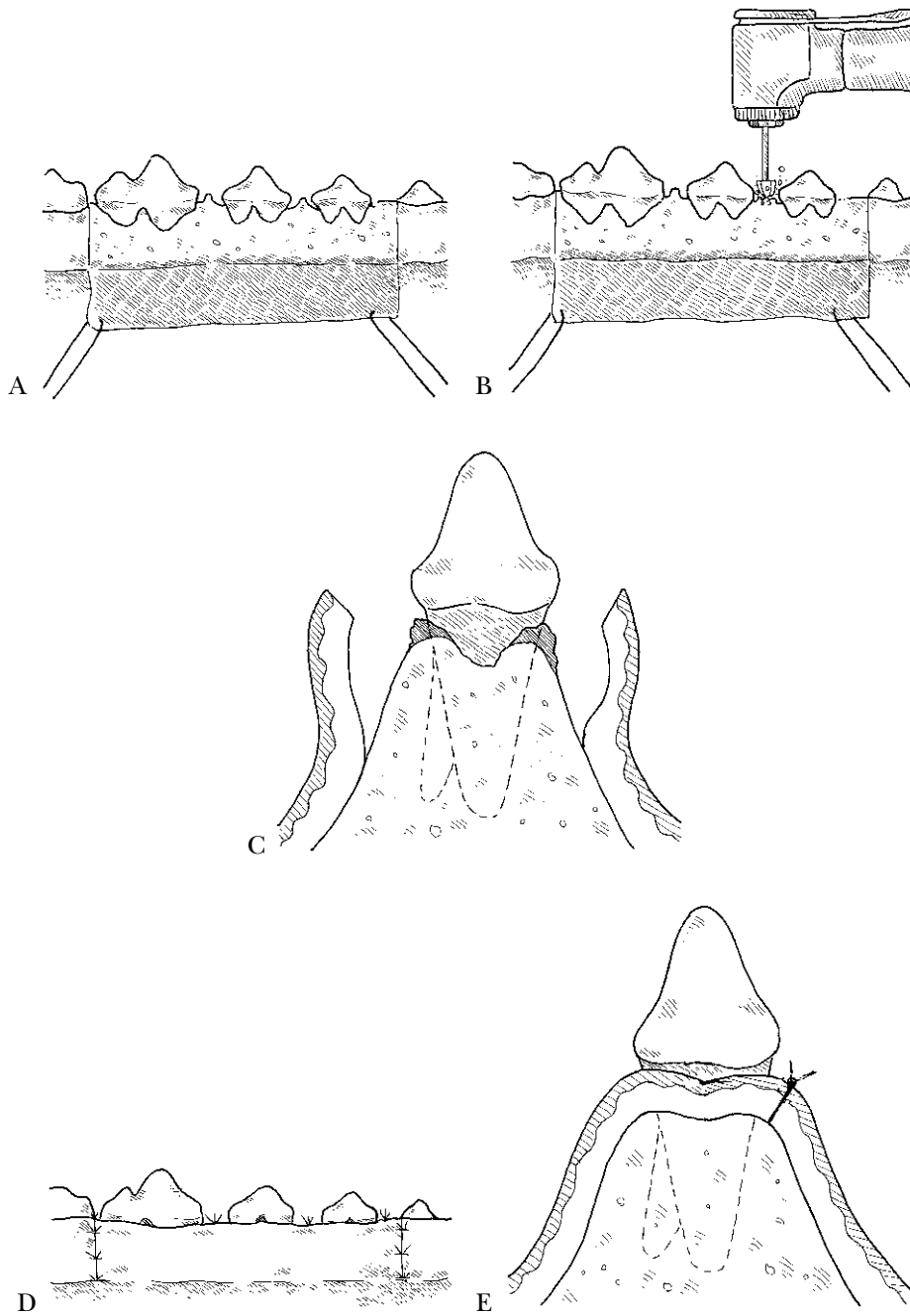


Fig. 5-14

Guided Tissue Regeneration and Bone Grafting

Bone Grafting

General Comments

- The value of veterinary bone grafting in the treatment of teeth with periodontal disease varies. Occasional bone reformation has been reported following thorough root planing and curettage after flap surgery in humans without the use of a filling material in bony defects, but it is not predictable.¹⁸ In another report, spontaneous bone regeneration was reported in a number of animal experiments (Waerhaug and Randers-Hansen 1966, Polson et al. 1976, Karring et al. 1982, Nman et al. 1982). These experiments involved both bone within the alveolus and the alveolar bone crest. When bone that had been resorbing because of occlusal trauma was relieved of its continual trauma, bone was deposited not only on the walls of the alveolus, normalizing the width of the periodontal space, but also on the alveolar crest, regaining its normal height. This bone regeneration did not always occur when there was untreated plaque-associated pathology in the soft tissue.¹⁹ If these procedures are to be successful, client compliance with follow-up and maintenance is extremely important.
- Bone grafting can be performed in conjunction with osteoplasty to enhance new bone formation.

Indications

- Two-wall or three-wall defects in which bone regeneration is desirable to maintain periodontal health of a tooth.

Contraindications

- Severely loose teeth.
- Poor health status of patient.
- Lack of client compliance with or patient acceptance of aftercare.
- Furcation invasion.
- Poor crown-to-root ratio.

Objective

- Regeneration of bone around periodontally affected teeth with bone loss, using autologous bone graft or synthetic implant material.

Equipment

- Autogenous cancellous bone taken from edentulous area.
- Hydroxyapatite Pro Osteon 200, (formerly Interpore 200 [Interpore/Cross International, Irving, Calif.])
- HTR (Biopiant, South Norwalk, Conn.).
- Consil (Nutramax Laboratories).
- Gore-Tex (WL Gore & Associates, Flagstaff, Ariz.).
- Calcium carbonate.
- Materials for periodontal flap surgery.
- Round # $\frac{1}{2}$ or #330 pear bur in handpiece.

Technique

Step 1—A full-thickness periodontal flap is created with a reverse bevel incision to expose the defect (Fig. 5-15, A).

Step 2—The bony pocket is debrided, and the root surface is planed smooth (Fig. 5-15, B).

Step 3—Lateral bony projections or irregularities can be smoothed with an appropriately sized round bur in a handpiece, with saline irrigation (Fig. 5-15, C).

Step 4—The bony pocket walls are fenestrated with a # $\frac{1}{2}$ or #330 bur in a slow-speed handpiece, to a depth of 1 to 2 mm in several places to ensure release of bone-forming elements.

Step 5—Bone grafting material is mixed with saline or blood to form a paste and is packed into the defect to the height of the remaining bone (Fig. 5-15, D).

Step 6—The gingival flap is replaced immediately and sutured interdentally (Fig. 5-15, E and F).

Step 7—Optionally, periodontal dressing is placed over the graft site.

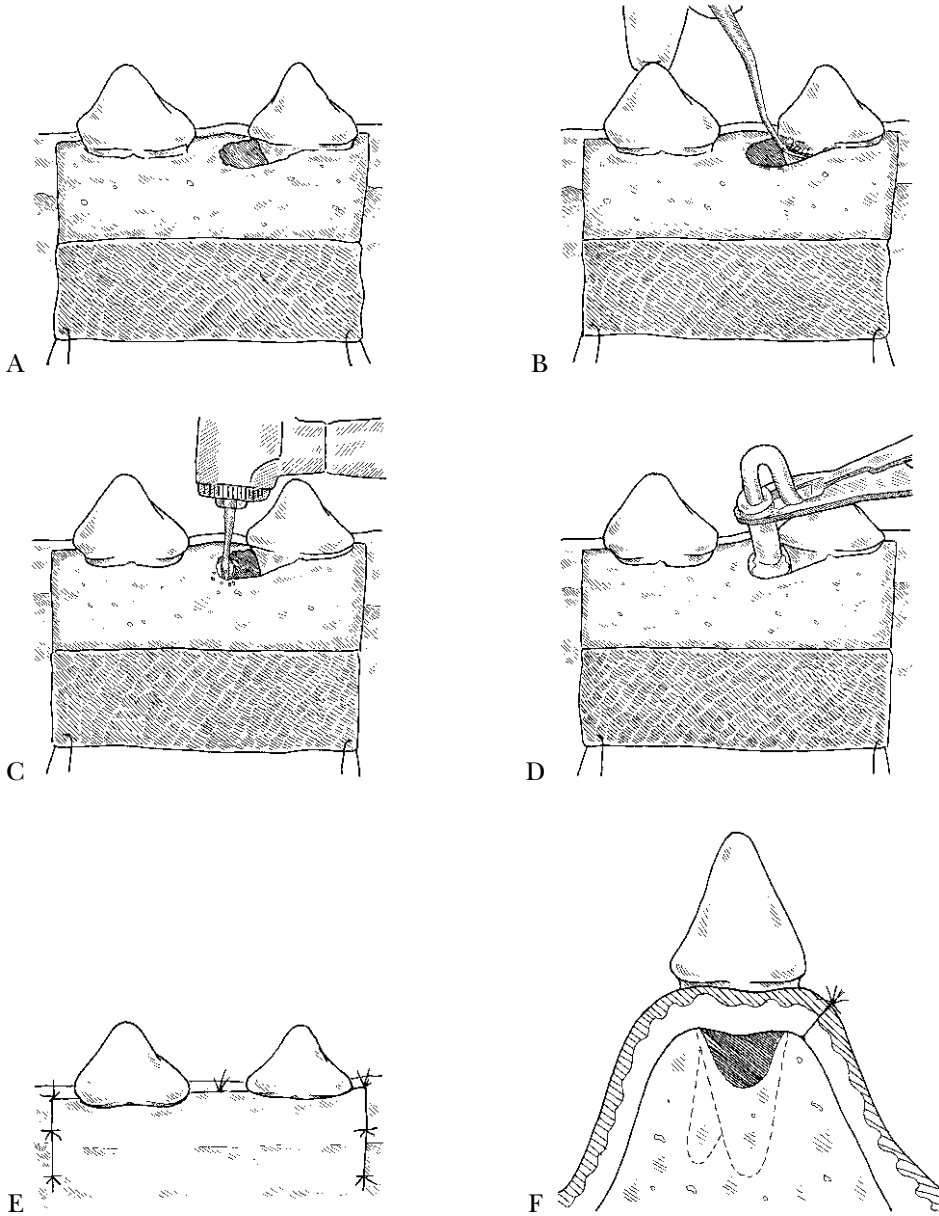


Fig. 5-15

Postsurgical Care

- Appropriate antibiotics.
- Periodontal dressing removed after 7 days if still present.
- Twice daily oral flushing with 0.12% chlorhexidine for 2 weeks.
- Follow-up plaque control; radiographs at 3- to 6-month intervals.

Complications

- Infection.
- Dehiscence.
- Progression of periodontal defect and bone loss.

Guided Tissue Regeneration**Indications**

- Three-wall defects, two-wall to three-wall defects, funnel-shaped defects greater than 5 mm deep, and class 2 furcation with or without a vertical component.

Contraindications

- Client's inability to perform home care.
- Loose teeth.

- Oral or systemic disease considerations.
- Oronasal communication present.

Objective

- Exclusion of gingival epithelium and connective tissue from the root surface to allow formation of a periodontal ligament.

Equipment

- Periodontal surgical instruments.
- Gore-Tex (WL Gore & Associates).
- Shield (THM Biomedical).

Technique

Step 1—Periodontal flap surgery is initiated; root planing and curettage are performed.

Step 2—A membrane that will extend a minimum of 4 mm apical to defect is selected. The membrane should overlap the lateral borders 2 to 3 mm over the entire defect. The collar should be at or apical to the cemento enamel junction.

Step 3—The material is placed and secured tightly to the tooth by a sling suture.

Step 4—The flaps are adapted with simple interrupted interdental sutures. The flaps should be full thickness to avoid tissue necrosis.

Postsurgical Care

- Antibiotic therapy for 1 week postoperatively.
- Commercially available chlorhexidine rinses or gels.
- If a nonresorbable material is used, it must be removed in 4 to 6 weeks, without disturbing the lining material.
- Periodic periodontal therapy, as indicated, to maintain oral health.

PERIODONTAL SPLINTING

General Comments

- Periodontal splinting is only semi-permanent, at best, to immobilize teeth and improve gingival health; it does not provide long-term stabilization.¹⁸
- These techniques can be used with a dental acrylic or with a composite resin.
- Caution must be exercised if a groove is cut in the tooth. Sensitivity or infection of the pulp chamber may result.

Indications

- Mobile incisors with solid adjacent teeth.
- All six incisors are slightly mobile and can be stabilized as a unit.

Contraindications

- Client is unwilling to provide adequate home care or to return for frequent, periodic professional care.
- Teeth with inadequate (less than 20%) bone support remaining.
- Single incisor without adjacent teeth.
- Periodontal and endodontic involvement of a nonstrategic tooth.
- Traumatized primary teeth, while the jaw is still growing.
- Small breeds with root proximity problems caused by thin interseptal bone.

Objectives

- To stabilize teeth (most commonly incisors) loosened, secondarily, by bone loss.
- To improve healing after periodontal treatment or surgery.
- To preserve cosmetic function.

Equipment

- A 0.010 ligature wire for figure-of-eight or Stout interdental wire support technique.
- Fine square orthodontic arch wire for lingual splint technique.
- Minikin pins for lingual splint technique (Whaledent International, New York, NY).
- Light-cure composite resin.
- Dental acrylic.
- How wire-bending pliers.
- Small wire-cutting pliers.
- Finishing burs.
- Optional: Ribbond (Ribbond, Seattle, Wash.).
- ProTemp II, ProTemp Garant (ESPE America, Norristown, Penn.),²⁷ or MaxiTemp (Henry Schein, Melville, NY). These materials are a combination of a composite resin and dental acrylic. The ProTemp Garant and the MaxiTemp come in a mixing syringe, and the ProTemp II is in separate tubes that are hand mixed. This material can be placed directly on the teeth or over spot etching, as an alternative to using composite resin or acrylic material.

Techniques

- Several techniques can be used, depending on the materials available, time needed for stabilization, and cosmetic appearance desired.

Figure-of-Eight Wiring Technique

Step 1—A #1/2 or #1 round bur is used in a high-speed handpiece to create a shallow, enamel groove circumferentially around each tooth at the middle of the crown (Fig. 5-16, A). Remove a thin layer of enamel only. Do not enter the pulp chamber. (This step is optional if cosmetic appearance is not critical or splinting is temporary.)

Step 2—A 0.010 ligature wire is placed in a figure-of-eight pattern around the teeth, stabilized in the grooves, and tightened (Fig. 5-16, B).

Step 3—The teeth are prepared by acid etch technique.

Step 4—A dental acrylic or a light-cure composite resin is layered over the wires and grooves and is shaped and cured (Fig. 5-16, C). When using dental acrylic, a fine camel's hair or Getz brush (Teledyne-Getz, Elk Grove Village, Ill.) is dipped into the liquid (monomer) and then into a small amount of the powder (polymer). This small amount of mixed acrylic is placed over the ligature wire. This step is repeated until the acrylic covers all the wire and the interproximal areas. It will take several minutes to harden.

Step 5—The acrylic or composite resin can be smoothed and shaped with finishing burs or sandpaper discs (Fig. 5-16, D).

Step 6—The occlusion should be checked and any areas of interference adjusted.

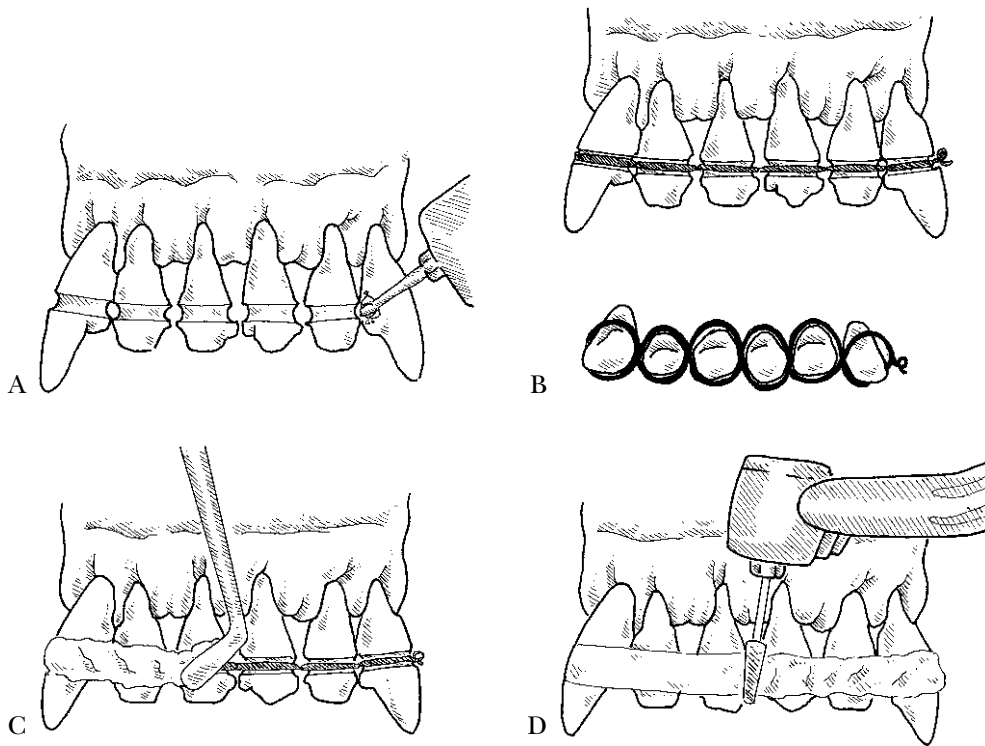


Fig. 5-16

Lingual Wire or Pin Stabilization

- If cosmetics are important, this is the preferred technique.
- Step 1—A # $\frac{1}{2}$ or #1 round bur is used to make a shallow enamel groove across the lingual aspect of the incisors coronal to the cingulum (Fig. 5-17, *A*). Do not enter the pulp chamber.
- Step 2—If an arch wire is to be used, it is shaped to conform to the lingual aspect of the incisors and fitted in the groove. The wire is cut and set aside.
- Step 3—The teeth are prepared with acid etch preparation. Do not etch exposed dentin.
- Step 4—The wire is placed in the groove (Fig. 5-17, *B*).
- Step 5—If Minikin pins are to be used, a small amount of composite resin or dental acrylic is placed in the groove first, and the pins are placed to overlap an interproximal space (Fig. 5-17, *C*).
- Step 6—Composite resin material or dental acrylic is placed over the wire or pins and cured as necessary (Fig. 5-17, *D*). The material is shaped and smoothed (Fig. 5-17, *E*), and occlusion is checked and adjusted. The interdental spaces are left open.

Postsurgical Care

- Daily home oral hygiene.
- Frequent, periodic periodontal therapy as required to maintain oral health; the frequency is dependent on client commitment.
- Removal of the splint, if temporary, when the teeth have stabilized.

Complications

- Chipping of acrylic or composite and loosening of the teeth. If chipped or fractured, dental acrylic can be repaired by adding powder and liquid to the splint. Acrylic is less brittle than the composite resin, but it is more porous and will harbor more bacteria.
- Exposed wire, leading to an appearance that is not pleasing cosmetically.
- Progression of periodontal disease, necessitating extraction.
- Endodontic involvement caused by perforating pulp chamber or thermal injury.

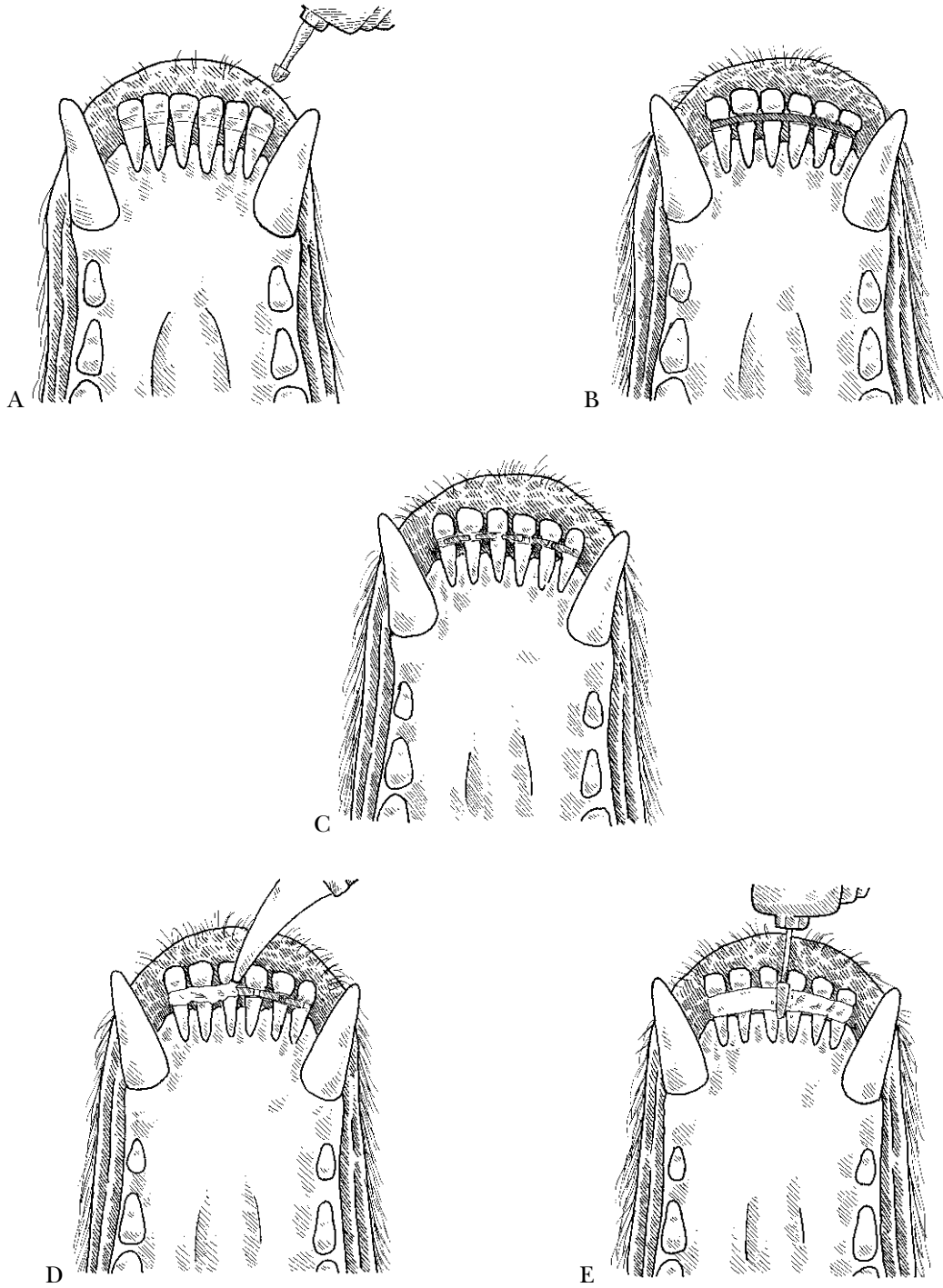


Fig. 5-17

Ribbon

- This is a bondable, reinforced ribbon material that can be used to splint periodontally involved incisors.
- It comes in 2-, 3-, 4-, and 9-mm widths. Special scissors are required to cut it, and cotton gloves must be worn to avoid oil contamination from the clinician's skin.
- A template of tin foil is used to measure the length of material needed to lay on the lingual aspect of the incisors.
- The Ribbon is cut to length with the special scissors and coated with filled bonding resin. It needs to be protected from ambient light.
- The teeth to be stabilized are prepared for bonding. Unfilled resin is placed on the teeth, and a thin layer of composite resin is placed with a Centrix syringe.
- Ribbon is placed on the resin material, compressed with a cotton-gloved finger, and adapted to the teeth.
- Excess composite material is removed, and each tooth is light-cured 30 to 40 seconds lingually-palatally and labially.
- Additional resin can be placed to create a smooth splint surface.
- The splint is smoothed and finished using conventional composite technique.

Maryland Bridge Splinting

- The Maryland Bridge is used commonly in restorative therapy. This appliance can provide a long-term solution.
- The bridge must be manufactured by a dental laboratory.
- The bridge may allow retention of a suspended artificial tooth (Fig. 5-18).

Technique

Step 1—Closed or open periodontal therapy is performed as necessary, during the first anesthetic procedure, when more than one is necessary to complete the treatment.

Step 2—An impression is taken. If the teeth are excessively mobile, they may be bonded together temporarily for support.

Step 3—The bridge is manufactured by a dental laboratory.

Step 4—The bridge is cemented in place during the second anesthetic procedure.

- The bridge should be at least 2 to 3 mm above the gingiva to reduce chance of irritation and to provide space for cleaning beneath.

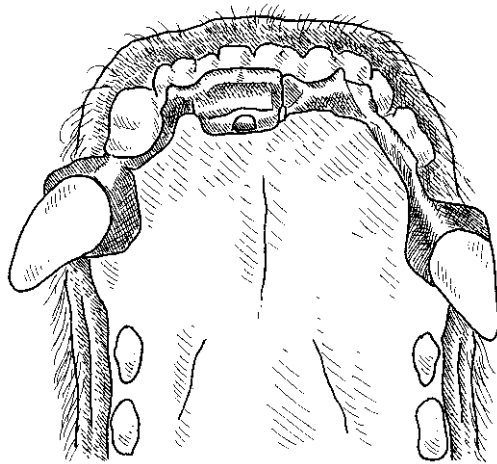


Fig. 5-18

Tight Lip Surgery in the Shar Pei Dog

General Comments

- Tight lip in the Shar Pei dog is a condition in which the vestibule of the lower lip is excessively shallow.
- The lip is drawn against the mandibular incisor teeth.
- This may cause trauma to the lip and lingual displacement of the mandibular incisors.
- The client should be advised of possible genetic impact inherent in this problem. Before surgery, appropriate consent, absolving the clinician of complicity to commit fraud, should be signed, and the client should be advised to remove the animal from the breeding line. The importance of this is that surgery is aimed at changing the heritable anatomy and, should the dog be shown, bred, or sold, surgery could be judged to be purposefully covering up a genetic defect, rather than simply attempting to improve oral health.

Indication

- Tight lip in the Shar Pei dog.

Contraindications

- Lack of client compliance or patient acceptance of aftercare.
- Suspicion of pending fraudulent action by the owner.

Objective

- To relieve lip tension and draw the inferior lip ventrally.

Equipment

- Equipment for periodontal flap surgery.
- Polydioxanone 2-0 suture.

Techniques

- Two techniques are offered here; the first is more basic, the second is a more involved surgical procedure.

Technique #1

Step 1—A ventral incision approximately 2 cm long is made in a craniocaudal direction over the mandibular symphysis (Fig. 5-19, A).

Step 2—The skin is undermined in a craniodorsal direction (Fig. 5-19, B).

Step 3—A suture is passed as far dorsally as possible toward the lip, taking an anchoring bite of tissue in order to pull the lip ventrally (Fig. 5-19, C).

Step 4—The suture is tacked down to the periosteum as far caudally as possible on the mandibular symphysis (Fig. 5-19, D).

Step 5—The suture is tightened. This should draw the lip ventrally. Additional sutures may be placed (Fig. 5-19, E).

Step 6—The skin is secured with fine nylon suture.

Postsurgical care

- Broad spectrum antibiotics.
- Daily home oral hygiene.
- Skin suture removal in 10 to 14 days.

Complications

- This procedure works best for prepubertal dogs with a mild condition but is often insufficient for more advanced conditions or in adult dogs.
- Breakdown of suture if a sufficient anchor for the suture is not taken, or if the patient is not restricted from self-destructive oral behavior.
- Infection (sterile technique should be used).

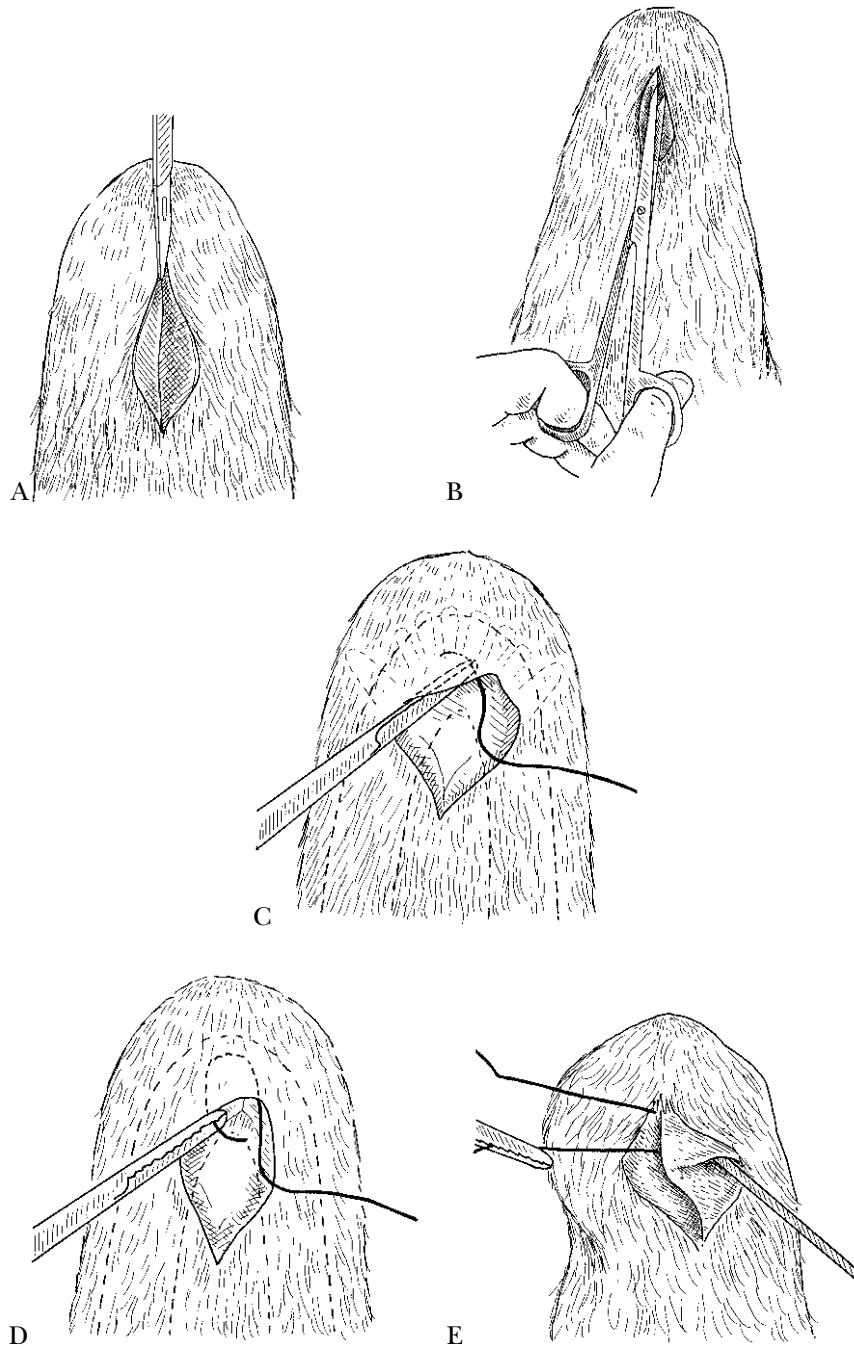


Fig. 5-19

Technique #2. Vestibule Deepening

- This more advanced procedure has been borrowed from oral surgeons of the 1960s and adapted for animals during the 1990s by Dr. Robert B. Wiggs. It works well, but success depends on careful and experienced case assessment and operator skill. Illustrations are from the text *The Veterinarian's Companion for Common Dental Procedures* by Lobprise and Wiggs.²⁸

Indications

- Prepubertal dogs, usually “meat-mouth” Shar Pei, when the edematous inferior lip physically and tightly covers the rostral teeth dorsally, forcibly tipping them lingually, inhibiting rostral growth of the mandible (Fig. 5-20, A to D).

Description of procedure

- The vestibule deepening procedure involves releasing the inferior lip by incising the mucosa and periosteum, undermining, then resuturing each layer in a manner to relieve the pressure on the rostral teeth and mandible. The procedure will allow for a mandibular catch-up and an uprighing of the mandibular incisors and canines, if necessary.
- Genetic impact plays a part in the predisposition to this problem, but the breed appears to have a genetic incidence of short mandibles separate from the “tight lip” syndrome. Therefore, not all class II malocclusions will self-correct following surgical intervention.
- Treatment planning includes properly estimating the extensiveness of the tissue release necessary to correct the problem. This is the art of the science. Some conditions involve the lip encroaching only on the incisors, while in some the lip also encroaches on the mandibular canines, and in some the mandibular first premolars are affected, as well.

Three levels of treatment

1. Incisor encroachment: rostral vestibule deepening.
 2. Incisor + canine encroachment: extend incision to include frenulum.
 3. Incisor + canine + first premolar encroachment: extend incision around to the sides.
- The condition is an uncomfortable one for the dog.
 - Dogs eat sloppily and they bite the lip.

- The condition hinders and alters the normal development of the mandible and dental occlusion.
- The standard for the breed states “. . . teeth have a strong meeting in a scissors bite. Deviation from a scissors bite is a major fault.”²⁹
- Ethical considerations: not every dog is entitled to a perfect bite, but every dog deserves a comfortable occlusion. The veterinarian should provide relief; ethically, the dog owner should not register the dog for a conformation class in an American Kennel Club dog show, where the rules mandate disqualification for dogs that have had their heritable anatomy altered.²⁶
- Glucocorticoids and diuretics will reduce the edema temporarily but may affect the overall skeletal development adversely.
- A more permanent solution is desirable.
- The procedure requires surgical skill but few instruments. Intraoperative injectable support is administered with antibiotics, antiinflammatory agents, pain medication, and intravenous fluids. Postoperative care includes oral broad spectrum antibiotics and pain medication for 1 week. The procedure is described step by step.

Equipment

- Number 3 scalpel handle.
- Number 15C scalpel blade.
- Molt #2 and #4 periosteal elevators.
- Iris scissors.
- Needle holder.
- Adson Brown forceps.
- Absorbable suture (3-0 Vicryl).
- Suction unit and tip.
- Gauze pads 3 × 3 inches.
- Sterile drapes and gloves.

Procedure

Step 1—Patient is positioned in sternal recumbency for best symmetric surgical access to rostral mandibular lip and dentition. Pathologic lip tension is evaluated. As necessary, a template may be used to demonstrate the extent of the planned incision. Two Bachaus towel clamps may be fastened to the lip at the level of the left and right canine to help retract the lip and expose the surgical access. A preoperative schematic of tight lip syndrome shows the encroachment of the lower lip on the mandibular incisors (Fig. 5-21, A).

Step 2—A releasing incision is made with a #15C scalpel blade, from canine to canine

(or frenulum to frenulum, or even more caudally as necessary) (Fig. 5-21, *A*). The tissue plane is found by blunt dissection, and a buccal mucosal flap is raised from below the mucocutaneous junction of the lip. Its base is the mucogingival line (Fig. 5-21, *B*).

Step 3—The buccal mucosal flap is then left while an incision is made along the mucogingival line, again with a #15C scalpel blade, and a full-thickness periosteal flap is raised (Fig. 5-21, *C* and *D*, *upper arrow*). Its base will be farther ventrocaudal (Fig. 5-21, *D*, *lower arrow*).

Step 4—The first flap, the mucogingival flap, will be folded ventrally for placement against mandible to be sutured into the depth of the vestibule, once the recipient tissue beds are ready (Fig. 5-22, *A* and *B*, *lower arrow*).

The flaps are freed with the aid of iris scissors and #2 and #4 Molt elevators. Adson Brown forceps help in tissue handling, and the use of suction is a must.

Step 5—Parallel mattress sutures (3-0 Vicryl) are placed in the apex of the mucosal flap, and the incision at the mucogingival line and the tissues are brought into apposition (Fig. 5-22, *A*). The periosteal flap is then brought forward and sutured to the edge of the incision on the inside of the lip so that it covers the mucosal flap donor site (Fig. 5-23, *A* and *B*, *upper arrow*). The procedure is now complete. The inferior lip should rest naturally in its surgically adjusted position. (Fig. 5-23, *A*) and is more ventral than seen in Figs. 5-20, *B* and *C*, and 5-21, *B*.

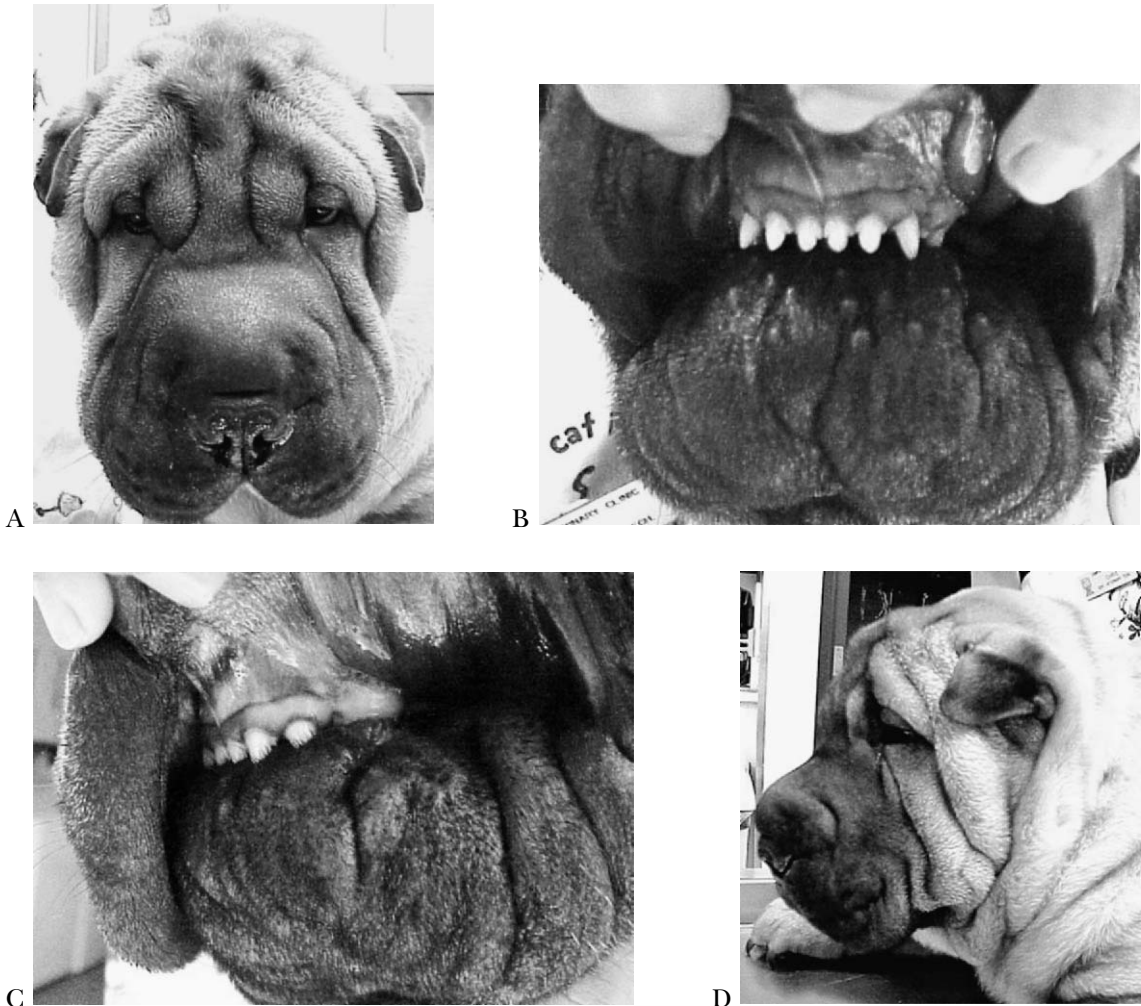


Fig. 5-20

Postoperative care

- The pet owner should not handle the lower lip more than necessary.
- Broad spectrum antibiotics should be administered orally for 1 week, along with pain-relieving medication.
- Only softened food should be fed and no hard treats, soft or hard chew toys, or oral play should be allowed for 3 weeks, while the surgical site heals.

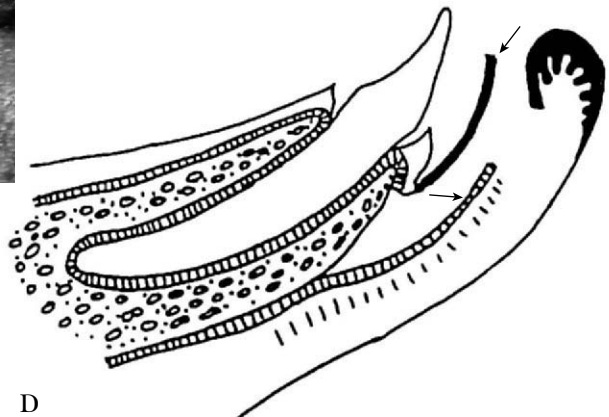
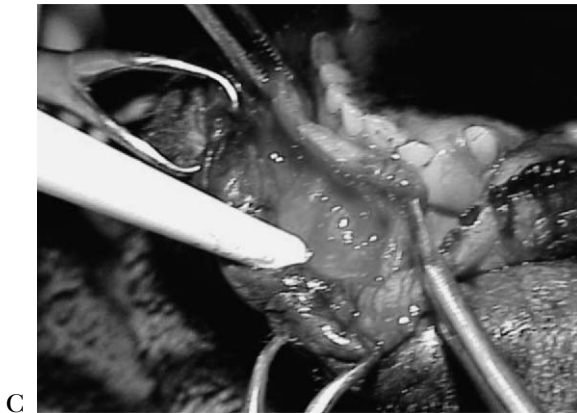
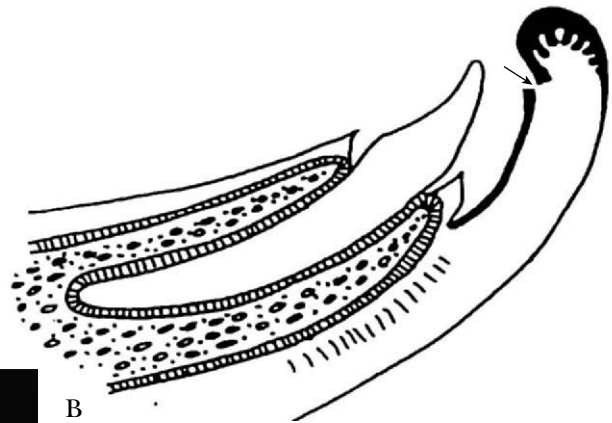
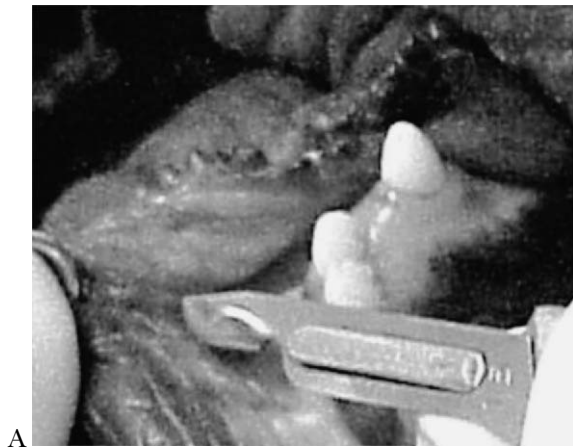

Fig. 5-21

Drawings used by permission from Lobprise HB, Wiggs RB: *The Veterinarian's Companion For Common Dental Procedures*, Lakewood, Colo, 2000, AAHA Press, 800-883-6301.

General considerations

- Cases with the best results are those caught early, and the most success is in dogs whose condition is corrected by the time they are 5 months of age.
- In the case of an overjet, results should be seen during the first month or two if the mandible is going to experience a growth catch-up.

- Recheck in 1, 2, and 4 weeks and again at 1 year of age.

Complications

- Dehiscence.
- Infection.
- Minimal or no improvement due to either inadequate case assessment or genetic impact.

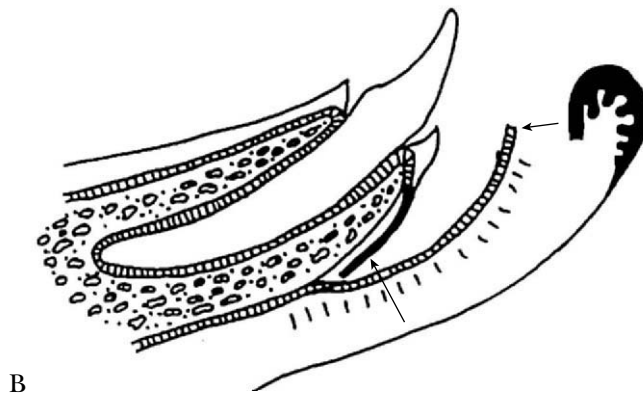
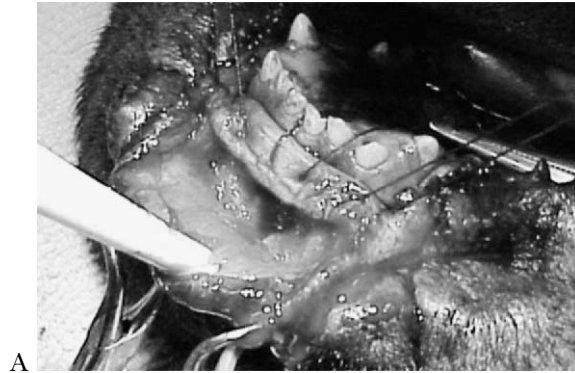

Fig. 5-22

Drawings used by permission from Lobprise HB, Wiggs RB: *The Veterinarian's Companion For Common Dental Procedures*, Lakewood, Colo, 2000, AAHA Press, 800-883-6301.

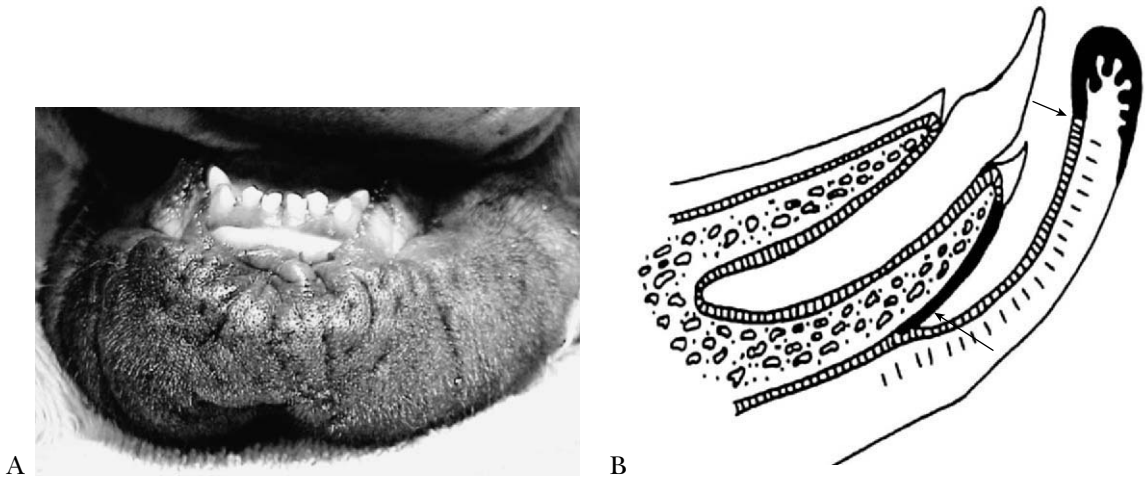


Fig. 5-23

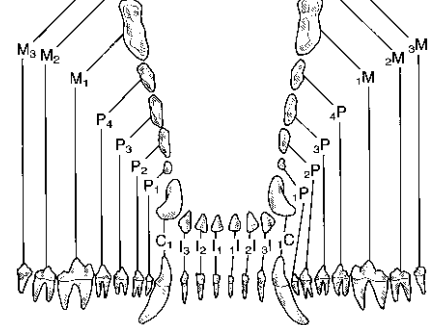
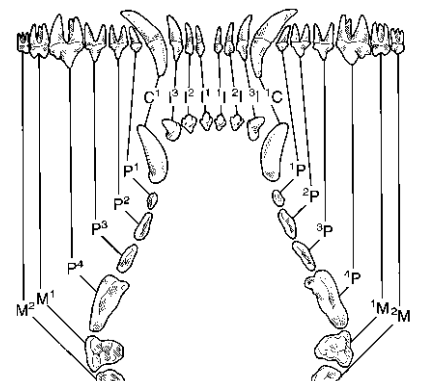
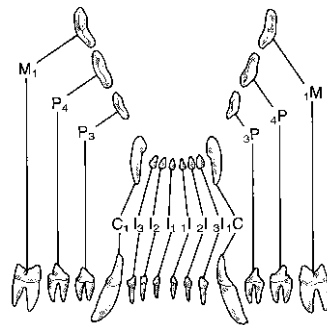
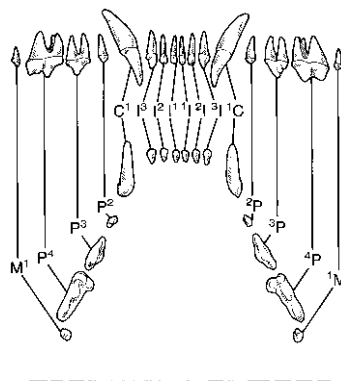
Drawings used by permission from Lobprise HB, Wiggs RB: *The Veterinarian's Companion For Common Dental Procedures*, Lakewood, Colo, 2000, AAHA Press, 800-883-6301.

REFERENCES

1. Grove K: Periodontal therapy, *Comp Cont Ed* 5:660-664, 1983.
2. Grove TK: Periodontal disease, *Comp Cont Ed* 4: 564-570, 1982.
3. Mealey BL, Klokkevold PR, Otomo-Corgel J: Periodontal treatment of medically compromised patients. In Newman MG, Takei HH, Carranza FA, editors: *Carranza's clinical periodontology*, ed 9, Philadelphia, 2002, WB Saunders, pp 527-550.
4. Verstraete JM: Use of antibiotics and antimicrobials in the orofacial trauma patient, *EVDS Forum* 10:8-11, 2001.
5. Harvey CE, Thornsberry C, Miller BR: In Proceedings, Symposium sponsored by Pfizer Animal Health: a systems approach to antibiotic therapy: special patients, common infections, Western Veterinary Conference, Las Vegas, Feb 21, 1996, pp 21-26.
6. Mealey BL, Klokkevold PR: Periodontal medicine. In Newman MG, Takei HH, Carranza FA, editors: *Carranza's clinical periodontology*, ed 9, Philadelphia, 2002, WB Saunders, pp 229-244.
7. Francke OC: William Hunter's oral sepsis and American odontology, *Bull Hist Dent* 21(2):73-79, 1973.
8. Billings F: Chronic focal infections and their etiologic relations to arthritis and nephritis, *Arch Int Med* 9: 484-498, 1912.
9. Billings F: *Focal infection: the Lane medical lectures*, New York, 1916, Appleton.
10. Kells CE: The x-ray in dental practice: the crime of the age, *J Nat Dent Assoc* 7:241-272, 1920.
11. Silver JG, Martin AW, McBride BC: Experimental transient bacteraemias in human subjects with varying degrees of plaque accumulation and gingival inflammation, *J Clin Periodontol* 4:92-99, 1977.
12. Committee on Research, Science and Therapy 1998 report to the American Academy of Periodontology: Periodontal disease as a potential risk factor for systemic diseases, *J Periodontol* 69:841-850, 1998.
13. Pallasch TJ, Wahl MJ: The focal infection theory: appraisal and reappraisal, *J Calif Dent Assoc* 28:194-200, 2000.
14. Deplian GJ, Olsen I, Tronstad L: Systemic disease caused by oral microorganisms, *Endo Dent Traumatol* 10(2):57-65, 1994.
15. Withrow SJ: Dental extraction as a probable cause of septicemia in a dog, *J Am Anim Hosp Assoc* 15:345-346, 1979.
16. DeBowes LJ, Mosier D, Logan E, et al: Association of periodontal disease and histologic lesions on multiple organs from 45 dogs, *J Vet Dent* 13:57, 1996.
17. Zwemer TJ: *Boucher's clinical dental terminology*, ed 3, St Louis, 1982, Mosby, p 299.
18. Rateitschak KH, et al: *Color atlas of periodontology*, Stuttgart, 1986, Georg Thieme.
19. Lindhe J, Nyman S: Occlusal therapy. In Lindhe J, Karring T, Lang NP, editors: *Clinical periodontology and implant dentistry*, ed 3, Copenhagen, 2002, Munksgaard, pp 711-726.
20. Woodall IR: *Comprehensive dental hygiene care*, ed 3, St Louis, 1993, Mosby, p 592.
21. Sherman JA: Principles and theory of radiosurgery. In *Oral radiosurgery*, ed 2, London, 1997, Martin Duntz Ltd, pp 1-8.
22. Sherman JA: Waveform types and properties. In *Oral radiosurgery*, ed 2, London, 1997, Martin Duntz Ltd, pp 9-14.
23. Carranza FA: Gingivectomy technique. In Newman MG, Takei HH, Carranza FA, editors: *Carranza's clinical periodontology*, ed 9, Philadelphia, 2002, WB Saunders, pp 749-753.
24. Carranza FA, Takei HH: The flap technique for pocket therapy In Newman MG, Takei HH, Carranza FA, editors: *Carranza's clinical periodontology*, ed 9, Philadelphia, 2002, WB Saunders, pp 774-785.
25. Fedi PF Jr: *The periodontic syllabus*, Philadelphia, 1985, Lea & Febiger, p 115.
26. Lindhe J: *Textbook of clinical periodontology*, Copenhagen, 1985, Munksgaard-Saunders, 1985.
27. Emily P: Noninvasive mandibular fracture repair. Proceedings of the tenth annual veterinary dentistry forum, Houston, Oct 31-Nov 3, 1996, pp 39-40.
28. Illustrations by Wiggs RB with permission from Lobprise HB, Wiggs RB: Oral surgery. In *Common dental procedures*, Lakewood, Colo, 2000, AAHA Press, pp 71-92.
29. Special guide to the AKC Breed Standards, *Dog World* July:164, 2001.



EXODONTICS



GENERAL COMMENTS

- Teeth should not be sacrificed unnecessarily. In years past, when veterinary dentistry was taught in veterinary curricula, exodontics was one of the primary subjects. Students learned how and where to trephine and repel equine teeth. Entire books were devoted to equine dentistry, such as L.A. Merillat's *Animal Dentistry and Disease of the Mouth* published in 1911 by Alexander Eger. As the usefulness of the horse in industry declined, equine dentistry was not emphasized as much in the veterinary curriculum. As current practitioners endeavor to render good dental care for their patients, they should bear in mind that exodontics is the area of dentistry they should practice as infrequently as possible. Most veterinarians are sensitized to the term *euthanasia* and do not like to perform such a procedure wantonly. It may be helpful to use the term *euthanasia* interchangeably with the word *extraction*. That way, every time a tooth euthanasia, or "toothanasia," is performed, more sensitivity will be manifest, and the practitioner will look for other, more positive alternatives.
- When extractions are indicated, however, many animals will have greatly improved oral health and a better quality of life if extractions are performed properly.
- Teeth normally are held in the alveolar bone by the periodontal ligament. When teeth are removed, the periodontal ligament must be stretched and then broken or torn. If this is accomplished properly, without the complication of an expansion fracture of the alveolus, the rest of the extraction process is atraumatic.
- Preoperatively, the practitioner should consider the advisability of a preanesthetic hematologic database, as well as other laboratory tests indicated by history or preprocedural medical examination.
- The client's approval should be obtained for the extent of treatment, potential complications, the cost anticipated by the clinician, and a plan of action in the event that unanticipated pathology is discovered during the procedure.
- Extractions are performed while the patient is under general anesthesia.
- Additionally, local anesthesia should be considered, to decrease the amount of anesthetic medication needed to maintain a surgical plane of anesthesia and for intraoperative and postoperative relief of pain (see Chapter 12).
- A radiograph should be taken before extractions to evaluate health of the alveolar bone, visibility of the periodontal ligament, variations in root anatomy, presence of ankylosis as seen by decreased visibility of periodontal space, sclerosis as seen by increased density of alveolar bone, or root resorption. This information helps determine the justification for, complexity of, and treatment modality for the intended extraction.

- Good accessibility and exposure to the surgical site may require changing the patient's position during the procedure.
- Good visibility facilitates the procedure. Bright lighting, magnification, suction, use of an air-and-water syringe, and relative position of the clinician and patient are all factors affecting visibility.
- Buccal gingival flaps are used appropriately to improve visibility and to expedite atraumatic access to and removal of solid teeth requiring extraction.
- The patient should be under a general anesthetic. A secured endotracheal tube with inflated cuff and gauze packed at the back of the pharynx will help prevent blood and debris from entering the airway and esophagus. A pad or towel beneath the head will cushion the head from pressure during the procedure. Ophthalmic ointment in the eyes will protect them from drying, and a drape or cloth covering the face will protect the face from soiling and the eyes from the operative light, foreign objects, and debris.
- A #11 scalpel blade is used to sever the epithelial attachment circumferentially around the tooth. A sharp elevator of appropriate size and curvature should be used to match the curvature of the root of the tooth intended for extraction. The elevator is grasped with the butt of the handle seated in the palm of the clinician's hand, and the index finger is placed as close to the tip as possible to protect the tissues in case of instrument slippage.
- The patient's head needs to be supported properly. During maxillary tooth extractions, the patient's head is cradled over the bridge of the maxillary bone with the palm of the free hand. With small dogs and cats, the entire head may be cradled in the palm of the hand during caudal maxillary tooth extractions.
- During mandibular tooth extractions, the jaw can be cradled in the palm of the free hand, or the individual side can be grasped between the thumb and forefinger. This support helps prevent jaw fracture by neutralizing pressure applied during extraction. It also helps prevent facial nerve damage, due to pressure on the head, if the head is resting on a hard table.
- Gentle tissue handling is important to minimize trauma and to allow rapid healing of both hard and soft tissues.
- After extraction, the socket is debrided thoroughly, and rough alveolar bone edges are smoothed.
- Any exposed bone is covered by tension-free soft tissue and sutured.
- Most states consider extractions as surgery and permit only licensed veterinarians to perform exodontia. A minority of states (nine states in 2003) also allow veterinary technicians to perform extractions. The American Veterinary Dental College, in a position statement dated April 5, 1998,¹ has taken the position that only licensed veterinarians may perform extractions.

Indications

- As a general principle, with permission from the client, any diseased tooth that is not contributing to function is a likely candidate for extraction.²
- Persistent primary teeth (Fig. 6-1, *A*, *arrow*). Two homologous teeth should never be in the mouth at the same time. If a practitioner identifies an adult tooth erupting and the primary tooth is not exfoliating naturally, it is time to extract the primary tooth.
- Interceptive orthodontics. Primary teeth are extracted when the mandible or the facial maxillary structures are not developing appropriately and a malevolent interlock exists, interfering with normal jaw development. Supernumerary teeth (Fig. 6-1, *B*, *arrow*) are extracted when they cause crowding or interfere with occlusion and periodontal health.
- Malocclusion or malpositioned teeth, if orthodontics, occlusal equilibration, or other corrective techniques are declined by the client.
- Periodontal disease, if the periodontium cannot be restored, or if the client does not commit to a combination of the necessary home and periodic professional care (Fig. 6-1, *C*, *arrow*).
- Nonvital teeth, or fractured crowns with pulp exposure when root canal therapy will be unsuccessful due to extensive periapical abscess formation (Fig. 6-1, *D*), or if the client declines endodontic treatment.
- Teeth that have structural damage, for which restoration is not feasible because of the extent, type of destruction, or for economic factors.
- Retained roots or sequestered bone at fistulated, former extraction sites.
- Teeth experiencing internal or external resorption, if treatment is not possible (Fig. 6-1, *E*).
- Teeth in a fracture line that interferes with bone fracture repair or healing. Teeth in a fracture line may or may not require extraction.^{2,3}
- Teeth involved with, or surrounded by, oral neoplasia.
- Dental or oral disease, when the client desires a possibly less expensive but definitive treatment. Note: extraction is not necessarily the easiest or least expensive method of treatment. An example of a time-intensive extraction would be an otherwise healthy, stable canine tooth or carnassial tooth that has been recently fractured. The procedure becomes more time intensive and expensive if the extraction would leave the mandible severely weakened, thus requiring a protective bone graft.
- Impacted or embedded teeth, or ones involved with developmental root end cysts or tumors.

Contraindications

- Poor health, when the patient may not safely tolerate the procedure or general anesthesia.
- Malignant conditions, when the patient is undergoing radiation or chemotherapy that would inhibit healing.
- Bleeding disorders that cannot be controlled.
- Patients on medications that may cause prolonged bleeding times (e.g., aspirin, anticoagulants, and chemotherapy).

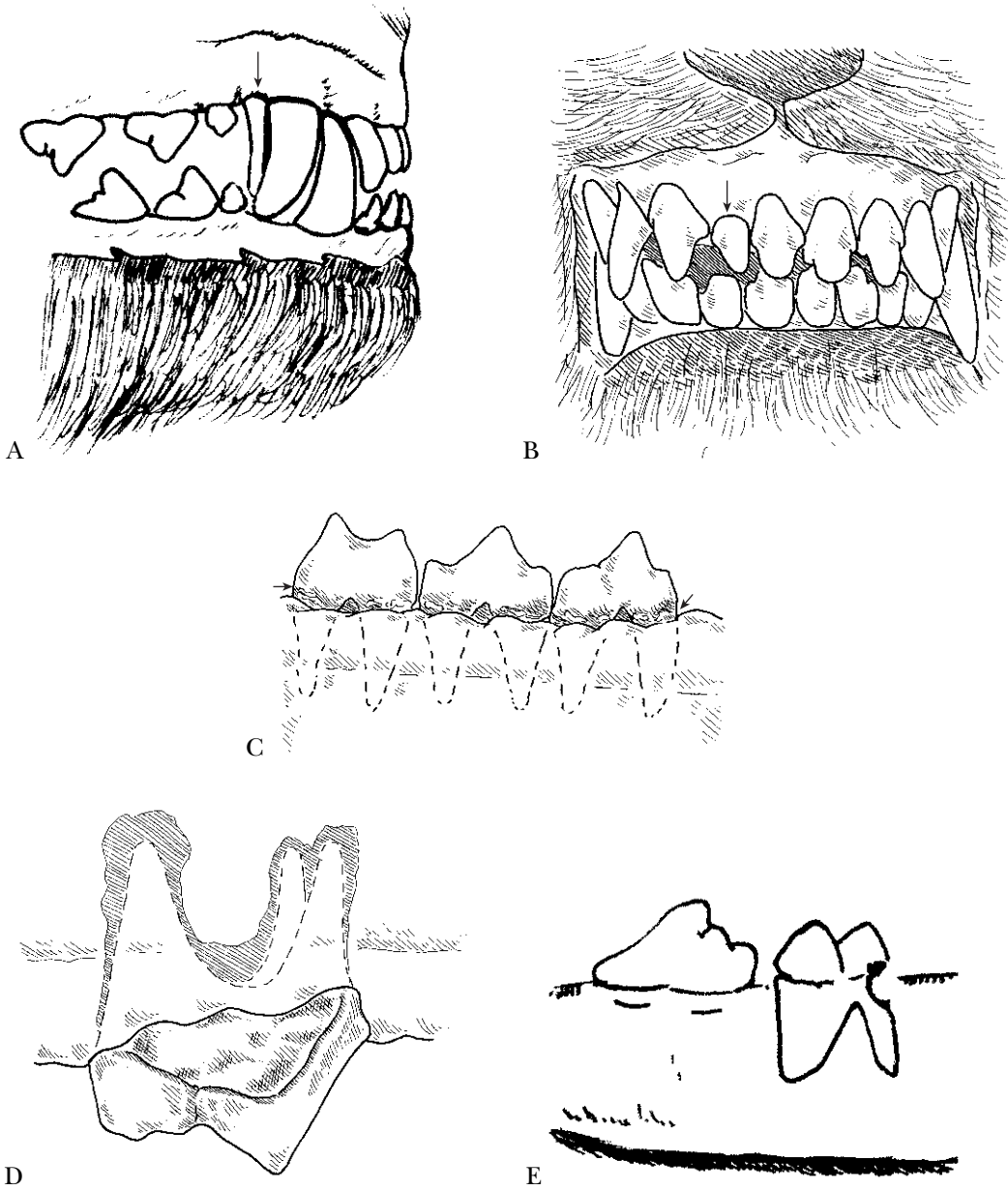


Fig. 6-1

Objectives

- Controlled force should be used when extracting teeth. Patience is prudent for successful extractions.
- A smooth, unimpeded pathway of removal should be obtained.
- A tooth should be extracted completely, with as little trauma to the oral tissues and bone as possible.
- All the tooth's roots should be extracted, unless there is ankylosis of roots and no sign of infection or inflammatory disease. This is especially true in cats.
- A scalpel blade is used first to sever the epithelial attachment to the tooth. Surgical elevators are used as levers to break down the periodontal ligament. Three basic types of lever are involved⁴:
A first-class lever, with a fulcrum between the resistance and the force (Fig. 6-2, *A* and *B*).
A lever that is a wedge (Fig. 6-2, *C* and *D*).
A lever that is a wheel and axle (Fig. 6-2, *E* and *F*).
- If the tooth root has not been displaced by the surgical elevator, extraction forceps are used to lift the tooth out of the socket after the periodontal ligament has been torn free.
- If it does not lift out easily with extraction forceps, elevation should be continued.

Materials

- See Chapter 2, Dental Equipment and Care, for details of specific instruments.

Canine Extraction Pack

- Scalpel handle and #11 and #15 or #15C blades.
- Number 4 or 6 round bur; 701L, 557L, 1557L, or 1558L cross-cut cutting burs in a low-speed or high-speed handpiece with irrigation.
- Surgical elevators, winged elevators, or luxators of various sizes.
- Periosteal elevators, several styles and sizes
- Soft tissue retractor (Senn).
- Extraction forceps (for small and large breeds).

- Bone or spoon curette (5-0).
- Three-millimeter bone rongeur or bone rasp.
- Tissue forceps.
- Needle holders.
- Scissors.
- Gauze pads.
- Suture material: 3-0, 4-0, and 5-0 resorbable suture, reverse-cutting needle or taper swaged-on needle.
- Monocryl (poliglecaprone 25, Ethicon, Somerville, NJ), Vicryl (polyglactin 910, Ethicon), Dexon II (polyglycolic acid, U.S. Surgical, Norwalk, Conn.), Maxon (Davis & Geck, Manati PR), chromic catgut.
- Surgical extraction pack (in addition to those items in the nonsurgical pack).
- Root-tip picks.
- Apical elevator.
- Root-tip forceps.
- La Grange surgical scissors.
- Bone wax.
- Consil (Nutramax Laboratories, Inc., Edgewood, Md.), or Collaplug (Zimmer Dental, Carlsbad, Calif.).
- Pro Osteon 200 (formerly Interpore 200 [Interpore/Cross International, Irving, Calif.]); it is supplied both as blocks and granules and is resorbable.

Feline Extraction Pack

- Scalpel handle with #11 and #15 or #15C blade.
- Small excavator.
- Number 7 wax spatula, Molt #2 periosteal elevator, or EX9C (Cislak Manufacturing, Glenview, Ill.).
- Root elevators: 301S or other feline elevators, 2-mm elevator, 3-mm curved luxator, 100C (Cislak).
- Winged elevators #1, #2, and #3.
- Apical elevator.
- Numbers 330, 2, 4, 699, and 701 cutting burs with low-speed or high-speed handpiece with irrigation.
- Small breed extraction forceps.
- A pair of 5½-inch needle holders.
- Iris scissors.
- Adson Brown or fine tissue forceps.
- Chromic catgut suture 4-0 or 5-0 on reverse-cutting or taper swaged-on needle.
- Monocryl 5-0 with P-3 swaged reverse-cutting needle.

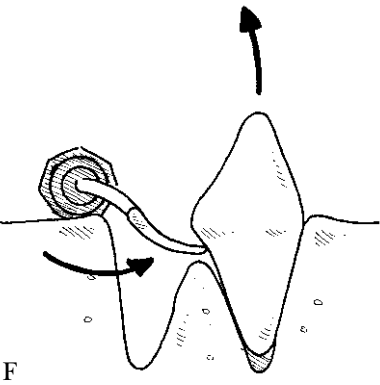
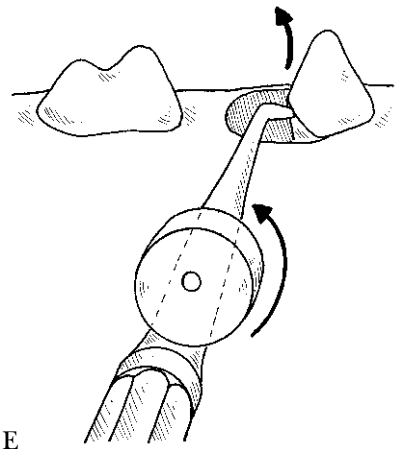
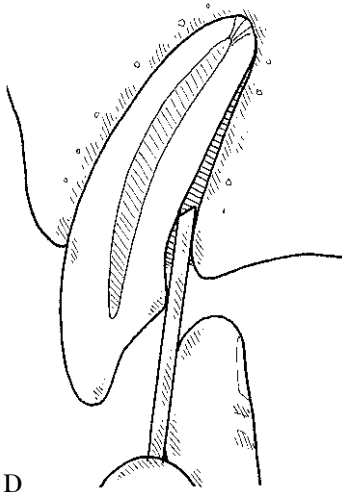
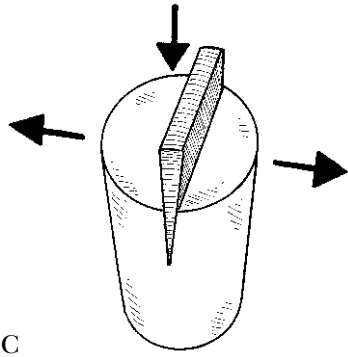
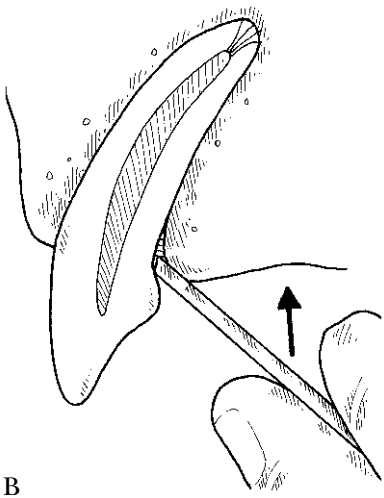
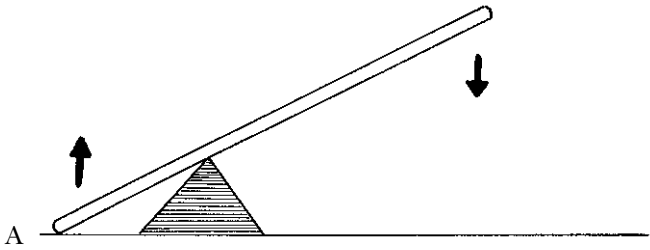


Fig. 6-2

SIMPLE EXTRACTION OF SINGLE-ROOTED TEETH

Incisors, First Premolars, and Mandibular Third Molars

Technique

Step 1—A radiograph is taken, and the tooth is evaluated for root structure, periodontal ligament health, and surrounding bone (Fig. 6-3, *A*).

Step 2—The gingival attachment is incised by inserting a #11 scalpel blade into the sulcus and severing the gingival attachment circumferentially around the tooth (Fig. 6-3, *B*). Luxators and winged elevators can be used to cut the periodontal ligament. They are placed in the periodontal ligament space and with apical pressure, while encircling the root, the periodontal ligament is cut and the instrument advanced apically.

Step 3—A surgical elevator, or Molt #9 periosteal elevator, is used to break down the periodontal ligament by alternately stretching and compressing it. The tip of the elevator is inserted between the tooth and the alveolar crest at a slight angle to the tooth, with the concave side facing the tooth. This utilizes the elevator as a wedge lever. The instrument is forced apically, then rotated slightly until tension is exerted on the periodontal ligament. This position is held for 5 to 10 seconds. The elevator is gently moved around the circumference of the tooth in this fashion and gradually advanced apically (Fig. 6-3, *C*). Loosening of the tooth in the socket will be noticed as the periodontal ligament is stretched and torn. Hemorrhage

from the torn periodontal ligament will assist in elevating the root.

- Alternately placing the elevator mesially and then distally, while maintaining rotation as well as apical pressure on the tooth, will result in further stretching and tearing of the remaining periodontal attachments. At this time the elevator can often be used as a first-class lever to lift the tooth out of the socket (Fig. 6-3, *D*). A notch can be made at the neck of the tooth with a bur, to gain additional purchase when using the elevator as a first-class lever (Fig. 6-3, *E*).
- The luxator can also be placed as a wedge lever; then rather than twisting or torquing the instrument against the tooth, the handle is moved side to side to create a cutting action at the luxator tip.

Step 4—The loosened tooth is grasped with extraction forceps as close to the gum line as possible. The tooth can be rotated slightly on its long axis with a steady pull to remove the tooth from its socket. Note: do not use force. If the tooth is not easily displaced, continue elevating it with either the wedge or first-class lever technique, intermittently using the extraction forceps, if necessary.

Step 5—The extracted tooth should be examined to ensure that the entire root has been extracted. If the root has broken into pieces, a radiograph is indicated to determine the number of fragments and where they are located.

Step 6—If there were retained fragments, additional radiographs, as necessary, including a postoperative radiograph, are taken to confirm that the entire root has been removed.

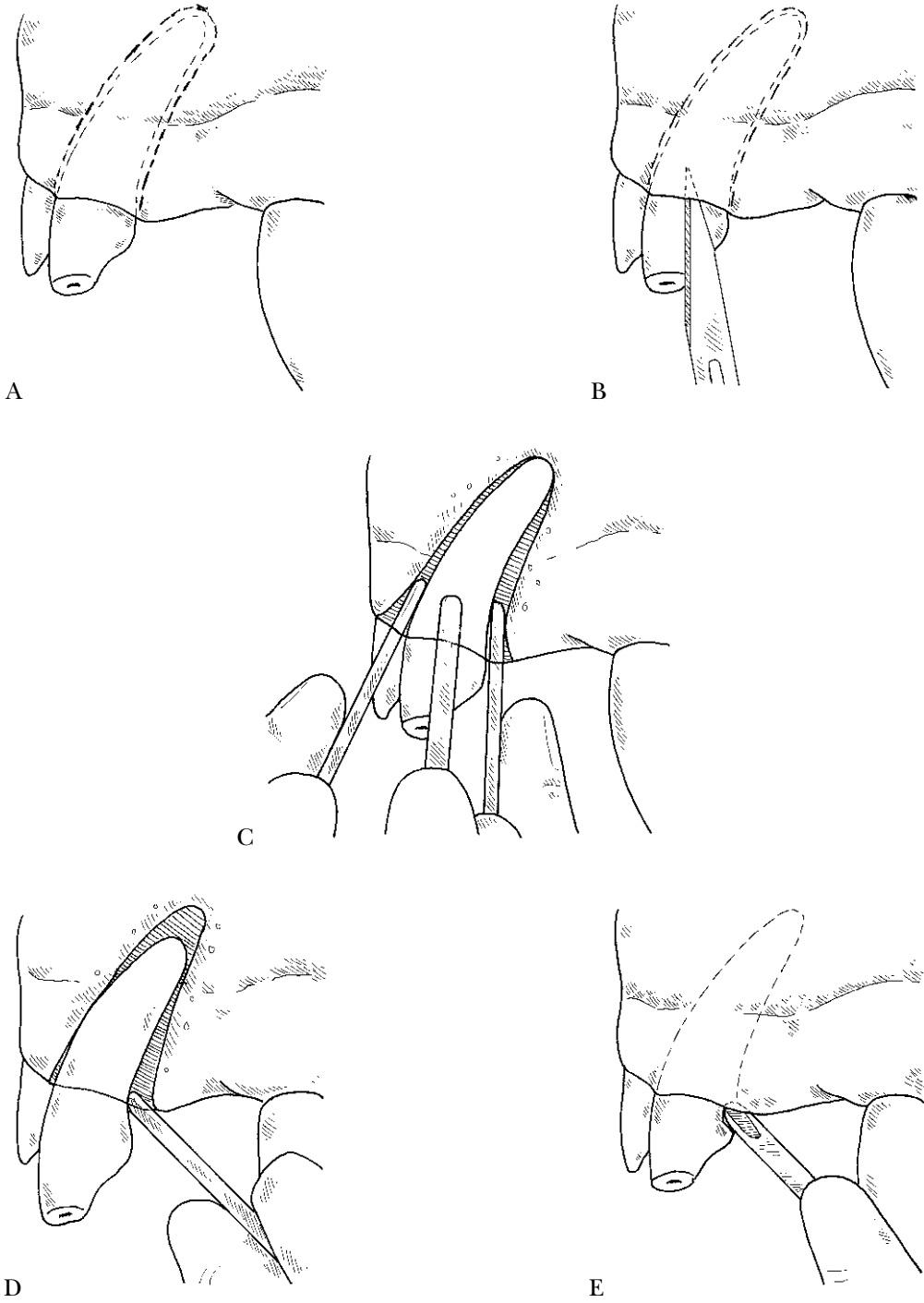


Fig. 6-3

Step 7—The alveolus is debrided with a spoon- (Fig. 6-4, *A*) or bone curette (Fig. 6-4, *B*) to remove any infected granulation tissue, debris, pus, and necrotic bone. The curette is placed at the apex and a scraping, pulling motion is used from the apex toward the rim of the socket.

Step 8—The crest of the alveolar bone may need to be reduced to facilitate suturing. This can be done by using a rongeur (Fig. 6-4, *C*), a bone rasp, or a round bur with water spray. This step is performed to increase chances of primary tissue apposition, prevent fenestrations of soft tissue by sharp bony edges, and hasten the autoosseous remodeling period.⁵

Step 9—The extraction site is lavaged gently with saline or dilute chlorhexidine or povidone-iodine solution. A blood clot is left in the alveolus. A syringe with an 18-gauge needle creates adequate pressure.

Step 10 (Optional)—If enhanced healing is desired, various products may be used. The alveolus can be packed with synthetic bone graft material (Consil, Nutramax Laboratories Inc.) or autogenous bone, as indicated. Tetracycline powder was once recommended for placement in extraction sites.⁶ This treatment modality has, in most cases, been replaced by debridement and irrigation with physiologic saline solution or dilute solutions of antimicrobial agents such as chlorhexidine or iodine.

Step 11—Digitally compress the extraction area with gauze. This helps collapse the alveolar socket, reduce hemorrhage, and appose gingival tissues. Suturing may not be necessary after this step when extracting very small teeth and if minimal damage has occurred to the periodontal tissues.

Step 12—The gingiva is best sutured using a reverse-cutting or a taper needle and 3-0 or 4-0 absorbable suture material (Fig. 6-4, *D*).

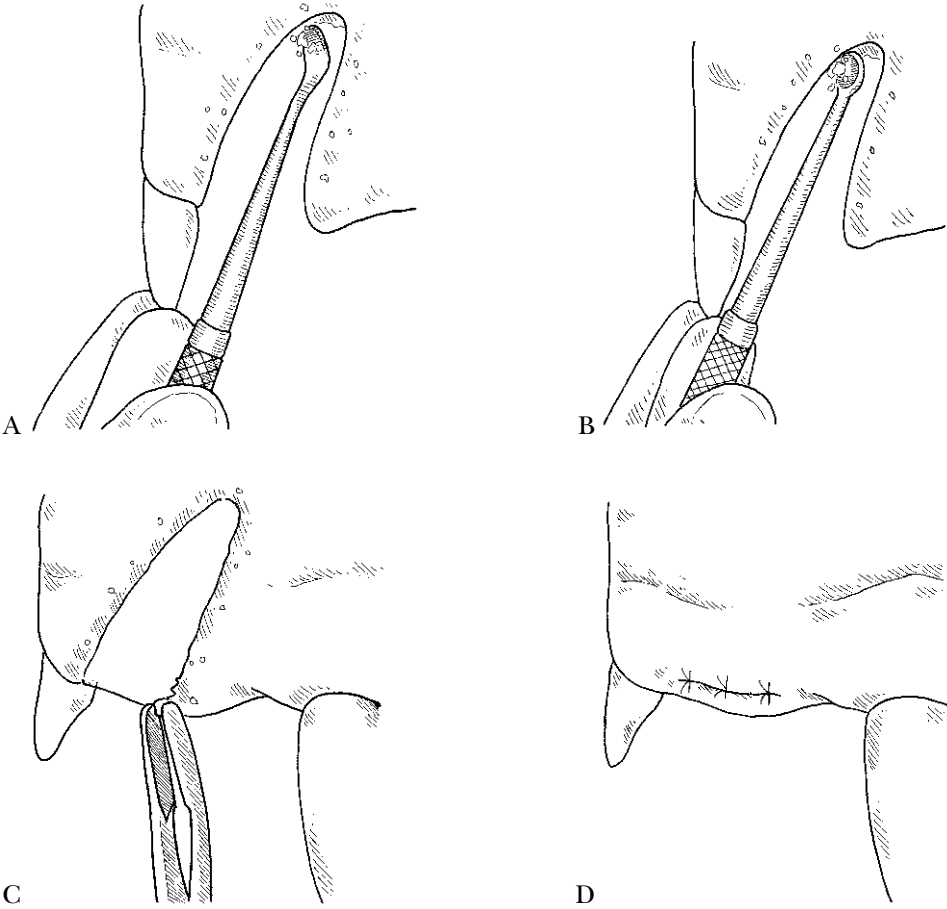


Fig. 6-4

NONSURGICAL EXTRACTION OF TEETH WITH MULTIPLE ROOTS

- The multirooted teeth in the dog are the maxillary second, third, and fourth premolars; maxillary first and second molars; mandibular second, third, and fourth premolars; and mandibular first and second molars.
- In the cat: the multirooted teeth are the maxillary third and fourth premolars; mandibular third and fourth premolars; and mandibular first molar.

General Comments

- If the multirooted tooth is first sectioned to provide “multiple” single roots, its extraction is no more difficult than that of multiple single-rooted teeth. A simple envelope flap may be raised to provide access to the tooth furcation for sectioning.

Indications

- Premolars and molars that are partially mobile secondary to periodontal disease or advanced periapical abscess formation (Fig. 6-5, *A*). These may include the maxillary fourth premolar and the upper and lower first and second molars.
- Retained primary premolars.
- Extraction of crowded or rotated premolars in a brachycephalic dog to preserve the periodontal health of adjacent teeth.
- Advanced root resorption.

Contraindications

- Solid teeth with abnormal root anatomy, ankylosis, or resorption that may lead to retained root fragments, excessive tissue damage, jaw fracture, or other complications (see the later section titled Surgical Extraction Technique).

Objective

- To extract a multirooted tooth completely and cover the resultant socket, as atraumatically as possible.

Materials

- Canine or feline extraction pack.
- High-speed or low-speed handpiece.

Technique

Step 1—The gingival attachment is incised around the tooth with an elevator or scalpel blade (Fig. 6-5, *B*).

Step 2—A radiograph is taken and evaluated to determine whether the tooth can be extracted easily. If it can, it is extracted using those techniques and principles of the simple single-root extraction, with elevation proceeding around each root until the remaining periodontal attachments are loosened.

- If the tooth is mobile, the roots are not seen on radiograph to be unfavorably shaped or oriented, the elevator can be placed in the furcation perpendicular to the long axis of the tooth to gain good purchase, and coronal pressure is applied to remove the tooth, providing the roots are not divergent or hooked. Care must be taken that all gingiva has been cut away from the tooth. If extraction forceps are used, each root must be loosened completely before extraction. Minimal twisting is used to remove the tooth. This reduces the risk of root fracture. If elevation cannot be performed easily, the tooth should be sectioned, separating each root.

Step 3—Using a periosteal elevator, the gingiva is elevated from the tooth and retracted, unless gingival recession is significant (Fig. 6-5, *C*).

Step 4—A cross-cut fissure bur is used in either a high-speed or low-speed handpiece to section the tooth. Sectioning is performed taking the shortest, straightest pathway, starting from the furcation and cutting coronally (Fig. 6-5, *D*). This leaves each root separate and isolated. A water spray is used during sectioning to avoid heat necrosis of adjacent teeth and bone.

Step 5—Each root is elevated as in a simple single-root extraction (Fig. 6-5, *E*). The elevator can also be placed perpendicular to the long axis of the tooth at the furcation between the roots, and rotated slightly and held for 5 to 10 seconds to distract and

loosen the roots (Fig. 6-5, *F*). Each root is loosened progressively, using adjacent roots for leverage when possible. If one root is

more solid, the other root(s) can be removed first to allow easier elevation along the interradicular surface of the solid root.

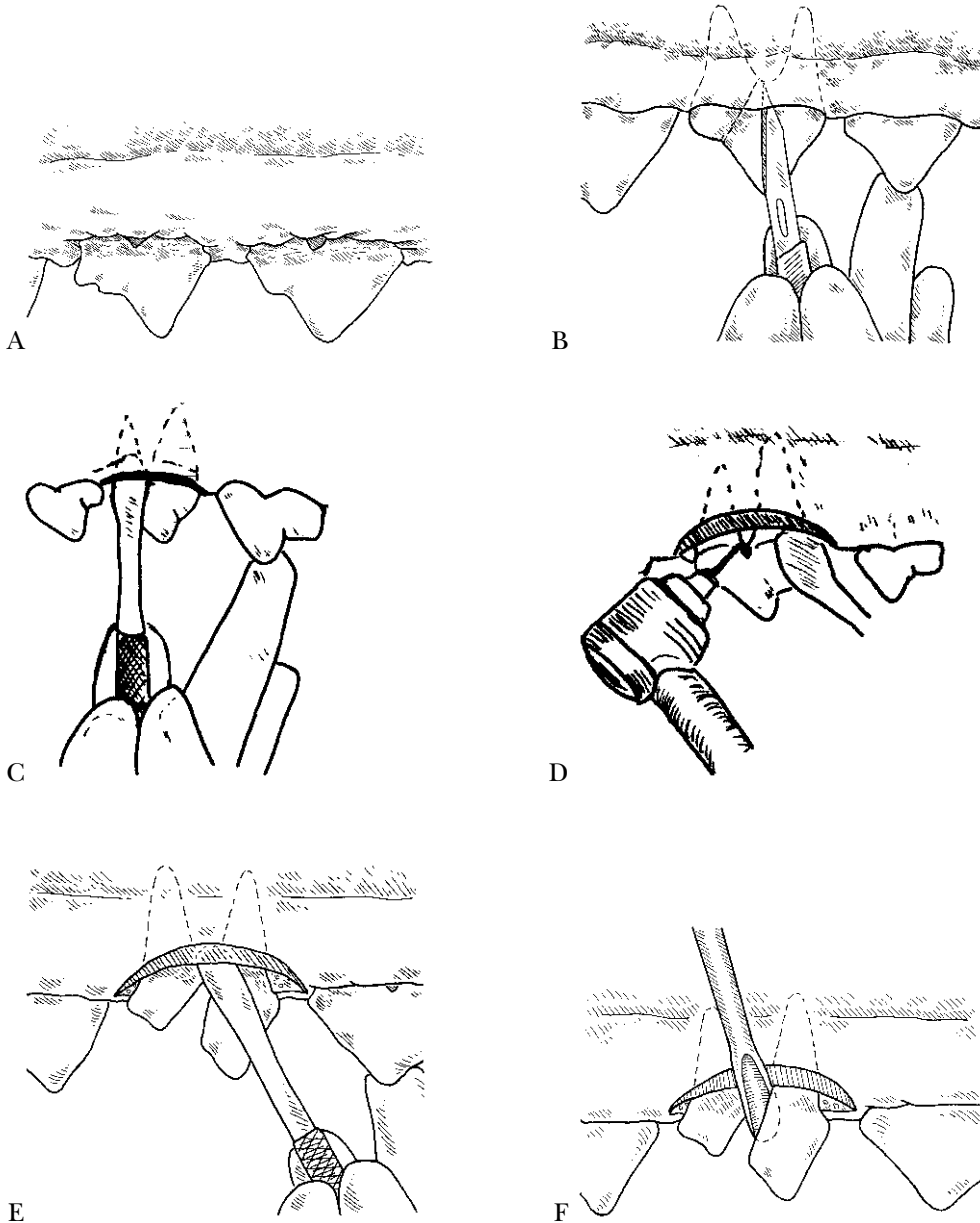


Fig. 6-5

Step 6—Once all roots are mobile in the sockets, each is extracted using extraction forceps (Fig. 6-6, *A* and *B*).

Step 7—The extraction segments are examined, and if the entire root cannot be accounted for, a radiograph should be taken, any remaining fragments identified and removed, and a postoperative radiograph taken.

Step 8—The alveolus is curetted and debrided of necrotic or infected tissues.

Step 9—Irregular edges of the alveolar crest are smoothed using a rongeur, bone rasp, or bur in a handpiece (Fig. 6-6, *C*).

Step 10—The extraction site is lavaged with saline or a dilute chlorhexidine or povidone-iodine solution.

Step 11 (Optional)—The socket can be packed with synthetic bone or polylactic acid granules or cube as discussed in the single-root technique.

Step 12—The extraction site is digitally compressed with gauze to promote coagulation.

Step 13—The gingiva is sutured, tension-free, over the extraction site with 3-0 or 4-0 absorbable suture (Fig. 6-6, *D*).

Step 14—Postoperative radiographs are taken.

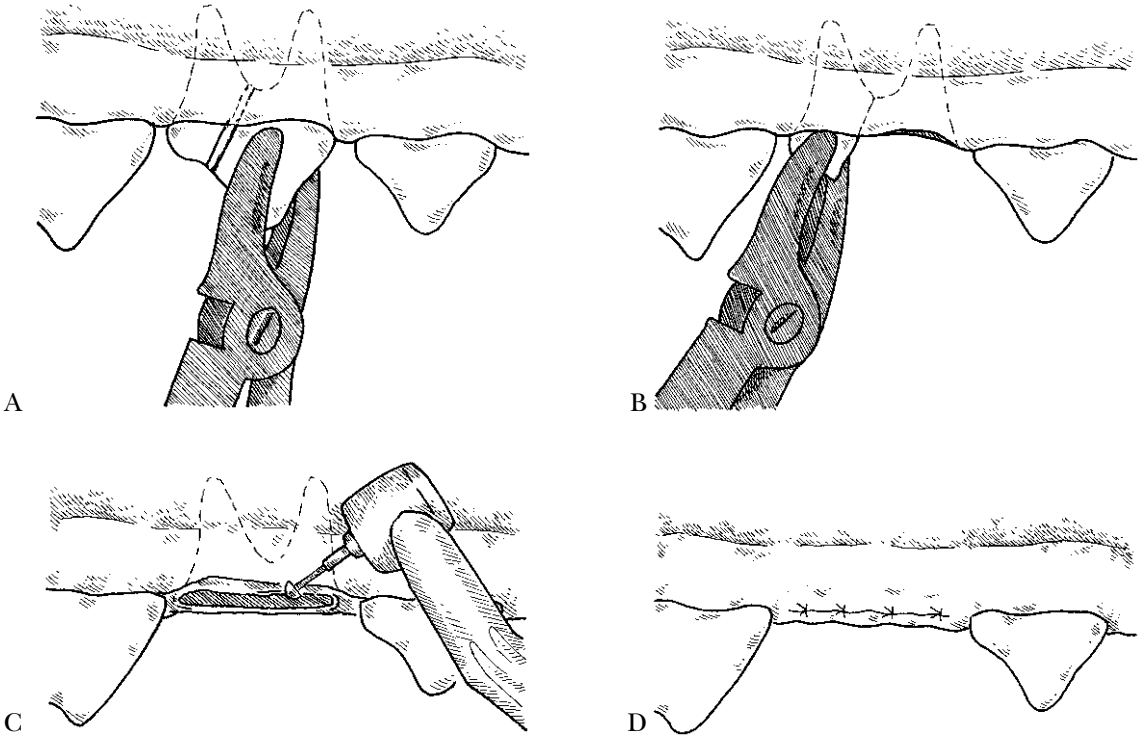


Fig. 6-6

Maxillary Fourth Premolar

Additional Considerations

- The gingival attachment is separated, starting from the furcation and cutting coronally, and each root is separated using a cross-cut fissure bur in a handpiece (Fig. 6-7, *A*).
- The palatine root is separated by cutting in the fissure created by the base of the large mesiobuccal cusp and the palatine cusp.
- The mesiobuccal and distal roots are separated by cutting between the two large cusps in a straight line from the furcation (Fig. 6-7, *B*).

Complications

- Slippage of the instrument penetrating the infraorbital artery. The index finger must be kept on the tip of the elevator to prevent the instrument from slipping.
- Fractured retained root tips should be recovered as a surgical extraction.

Maxillary First and Second Molar in the Dog

Additional Comments

- Each root is separated, using a cross-cut fissure bur in a handpiece.

- The mesial and distal roots are separated by cutting coronally, starting at the furcation and cutting toward the cusps (Fig. 6-7, *C*).
- The palatine root is separated from the rest of the tooth by cutting with a cross-cut fissure bur in the distomesial fissure created by the mesiodistal cusps and the palatine cusp (Fig. 6-7, *D*).

Complications

- Root-tip fracture is more likely if the periodontal ligament is strongly attached and the roots are not extracted individually.
- Root fracture is a more common occurrence during extraction of ankylosed teeth.
- Fracture of a root if the tooth is not sectioned completely.
- Misdirecting and inappropriately separating one of the roots or damaging adjacent structures.
- Instrument slippage and damage to ocular structures. This must be avoided at all costs. The index finger should be applied to the tip of the elevator to maintain instrument control.

Surgical Extraction Technique

General Comments

- This technique is used for difficult extractions in which tooth size, number of roots, root

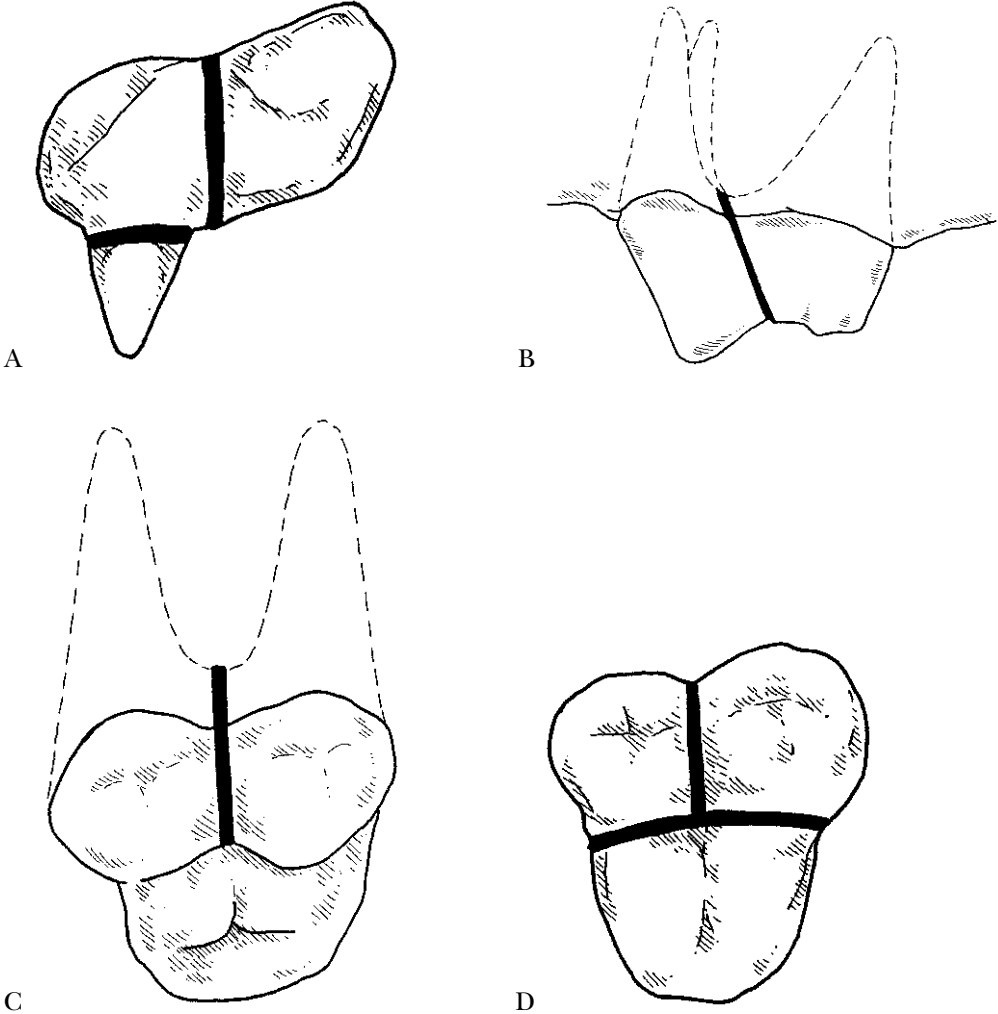


Fig. 6-7

anatomy, or pathology seen on preoperative radiographs indicate potential for complications or increased difficulty in extraction.

- The process is more involved and should not be used if simple elevation will suffice. Surgical extraction techniques, however, can expedite difficult extractions and will save time by reducing the frequency of root fracture, providing better exposure, better access for root elevation, and improved postoperative healing as a result of a less traumatic procedure.

Indications

- Larger, solid, single or multirooted teeth that require extraction, when simple elevation techniques are insufficient for adequate removal.
- Generally, the canine teeth and carnassial teeth in the dog affected by endodontic or early periodontal disease, where other treatment options are not feasible or declined by the client.
- Maxillary canine tooth extraction due to periodontal disease extending into the nasal cavity.
- Solid teeth with divergent roots or curved root ends.
- Teeth with ankylosed roots.
- Root fracture.
- Abnormal root anatomy.
- Feline or canine teeth undergoing external odontoclastic resorption.

Objective

- To create a buccal gingival flap and remove alveolar bone, as necessary, to facilitate complete extraction of the tooth with minimal trauma.

Materials

- Canine or feline extraction pack.
- High-speed or low-speed handpiece with cutting burs.
- Irrigation capabilities.
- Magnification and bright lighting beneficial.

Technique

Step 1—A radiograph is taken and evaluated prior to extraction.

Step 2—The gingival attachment around the tooth is incised with a scalpel blade or surgical knife (Fig. 6-8, A). A small excavator can be used in cats.

Step 3—A buccal mucoperiosteal (full-thickness) flap is created over the tooth with one or more vertical releasing incisions. Cuts making the releasing incisions should be made with a single motion, down to the bone. Apically diverging releasing incisions are made over healthy tissue one tooth mesial and distal to the tooth to be extracted (Fig. 6-8, B). This permits adequate circulation to the flap. (In cats with multiple extractions, the entire quadrant may be exposed with one large gingival flap.)

Step 4—It may be necessary to elevate the flap apical to the end of the juga (bony prominence covering the root). The flap should be elevated carefully from the buccal bone, mesial to distal, with a periosteal elevator (Fig. 6-8, C). The lingual or palatal gingival tissue should be elevated as an envelope flap to expose the alveolar crest.

Step 5—A cutting bur with water cooling is used to reduce the level of the alveolar bone buccally, mesially, and distally as necessary, as much as 1 to 2 mm in a cat or 3 to 5 mm in a dog (Fig. 6-8, D). The bone height in the coronal furcation area can be reduced, also. With canine teeth, the outline of the juga is cut through the bone with the bur. The entire buccal apical surface of the root does not always have to be exposed. This osseous cut frees the buccal plate from the rest of the facial bone. An elevator can be used to remove the detached bony plate (see p. 314).

Step 6 (Optional)—If desired, a ledge can be drilled into the tooth at the rostral and caudal aspect of the tooth, at the junction of the alveolar crest and the root. This allows for elevator purchase for dislocating and extruding the intended root from its alveolus.

Step 7—If the tooth is multirooted, it should be sectioned as described on p. 302 and illustrated in Fig. 6-8, E.

Step 8—An elevator can now be used as a wedge around the mesial, lingual, or palatal and distal surfaces, as in a simple extraction, to stretch the periodontal ligament or break the ankylosis of the root structure. Remember to hold the elevator with a slight rotating, torquing force for 10 to 30 seconds wherever it is placed. Note: do not use the elevator

vertically between crown pieces. This may lead to root fracture or a distraction mandibular fracture. The fingers of the other hand should support the mandible while elevating each mandibular root.

Step 9—The elevator can be placed perpendicular to the long axis of the tooth at the

furcation area between roots and between the mesial or distal root and the adjacent tooth as a wheel-and-axle lever or as a first-class lever to gradually stretch the periodontal ligament. Finesse and patience while freeing each root will help achieve a successful extraction.

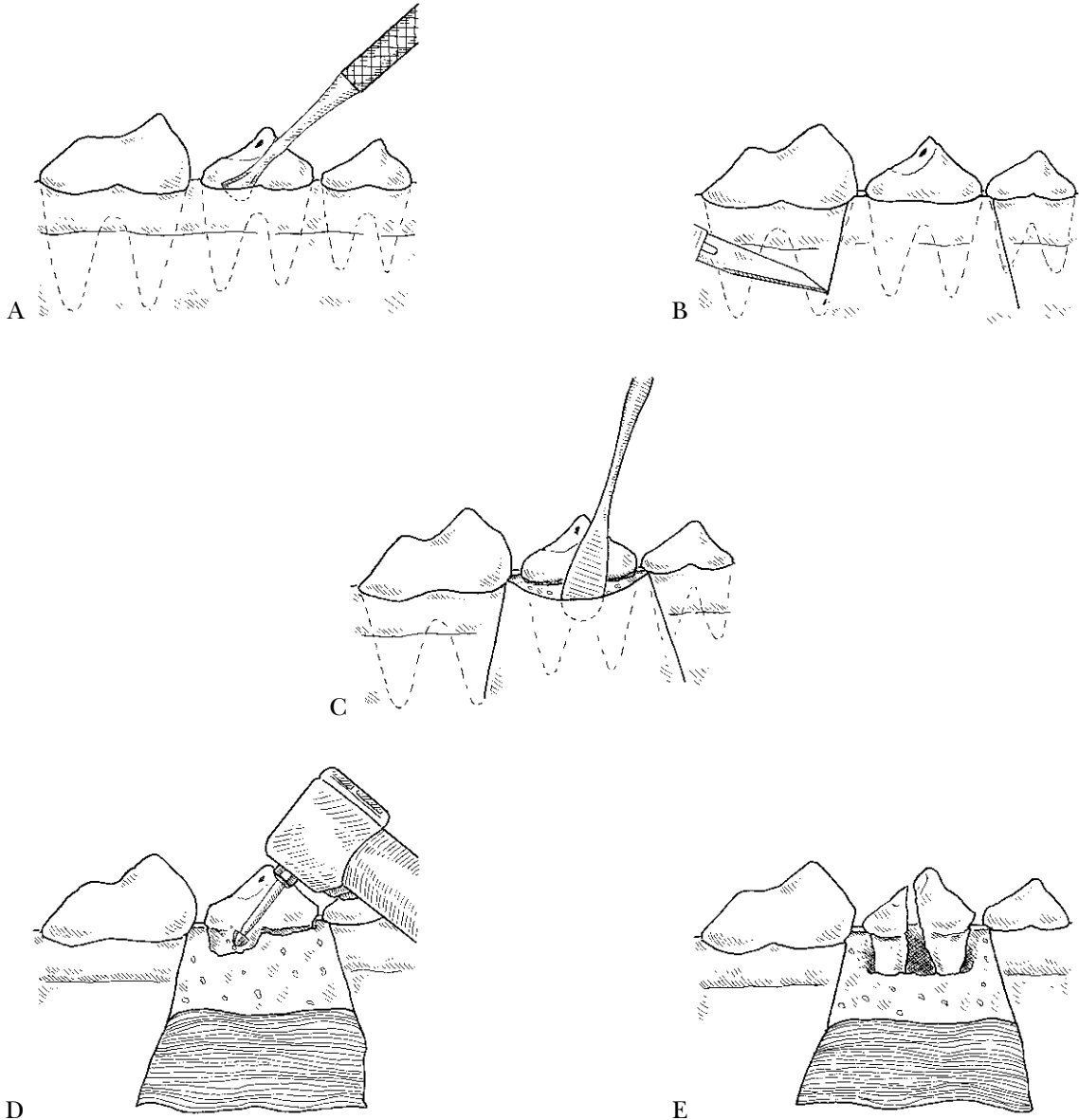


Fig. 6-8

Step 10—As the tooth is loosened, the elevator is moved apically until the roots are freed sufficiently that they are either displaced by the elevator or are easy to grasp and extract with an extraction forceps.

- Caution: with maxillary canine teeth, care is taken not to lever the crown of the tooth too far buccally. This leverage could cause an implosion fracture to an unhealthy nasal bone plate at the apical end of the palatal alveolar wall. If this bone is damaged, an oronasal fistula may result.

Step 11—If the loosened root is not displaced coronally by the elevator, an extraction forceps is used to grasp the crown piece as far apically as possible. Traction is applied while the tooth root is rocked in an intermittent twisting motion on its long axis, with a prolonged torque pressure at the end of each twisting action, until it is extracted. If this action does not readily extract the tooth, further use of the elevator is required as in steps 8 and 9.

Step 12—A radiograph is taken to confirm successful extraction.

Step 13—The alveolus is debrided gently with a spoon curette or similar instrument to remove granulomatous tissue, pus, and debris as in a simple single-tooth extraction.

Step 14—Any sharp bony projections are smoothed using a bur (Fig. 6-9, A), rongeur, or bone rasp. The alveolar crest also may be reduced further, if needed, to facilitate suturing.

Step 15—The surgical area is lavaged with sterile saline or a dilute chlorhexidine or povidone-iodine solution.

Step 16—Synthetic bone, such as Consil, can be placed in the sockets, as appropriate. If the extraction site is free from infection, it can be packed with a carved polylactic acid cube or granules to increase bone fill and reduce hemorrhage. The cube should be carved with a new scalpel blade to match the shape of the void.

Step 17—The elasticity of the flap is increased by making an incision in the periosteum of the flap. The flap is raised and held with a tissue forceps while a #15C scalpel blade, or smaller, is used on the exposed underside of the flap to incise the periosteal layer across the entire base of the flap. The tissue will be released as the inelastic layer of periosteum is cut, and the flap can then be advanced without resistance or tension (Fig. 6-9, B).

Step 18—Gingival margins are shaped appropriately with a fine scissors, and the flap is placed in position. One corner of the flap is sutured first (Fig. 6-9, C), placing additional sutures 2 to 3 mm apart and 2 to 3 mm from the gingival edges, approximating the gingival margins over the socket(s) and up each vertical releasing incision (Fig. 6-9, D). If extra flap tissue is present at the next corner it can be excised. Absorbable 3-0 or 4-0 suture is adequate. Sometimes 5-0 suture is preferable in the cat or small dog breeds.

Complications

- Fracturing the root(s) due to too much force or improper leverage of the elevator.
- Deep fracture of the buccal bone if the overlying bone was not adequately removed.
- Causing an oronasal fistula as the maxillary canine tooth is extracted by creating an implosion fracture between the alveolus and the nasal cavity.
- Fracturing the mandible by using improper elevation technique, such as by removing too little bone, by supplying too little digital support beneath the operative site, or by using an elevator to facilitate sectioning the crown.
- Alveolitis.

Aftercare: Follow-Up

- Pain should be controlled medically and by offering softened food if warranted (see Chapter 11). Frequently, veterinarians are unable to recognize or diagnose pain in patients. It may be better to err on the cautious side and administer pain-relieving drugs if they are not contraindicated. Softened food is less traumatic to the freshly sutured gingiva. The newly sutured tissue should also be spared by instructing the client to withhold hard treats, chew toys, and oral play while the tissue heals.
- The client should be instructed to rinse the extraction site at least once daily.
- Antibiotics should be administered.
- The patient should be examined by the doctor in 10 to 14 days to evaluate healing.
- Periodontal dressings may be applied to protect the healing soft tissue.

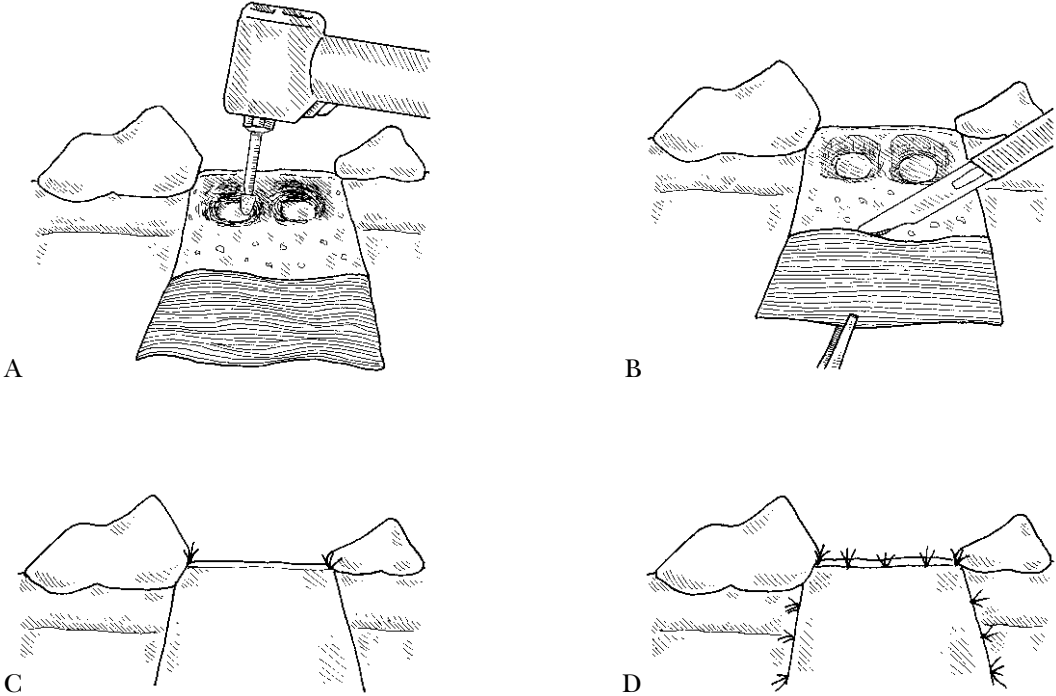


Fig. 6-9

Canine Tooth Extraction

General Comments

- Extraction takes one of two forms, depending on how well the tooth is attached. If the attachment has been weakened sufficiently to allow some mobility, the tooth may be extracted in a manner similar to that of any single-rooted tooth. If the attachment is solid, as with normal periodontium, it is less traumatic and requires less procedure time to raise a gingival flap and remove the buccal plate of bone.

Indications

- Same general indications as on p. 308.
- Reducing the biting potential of a vicious dog or cat, if endodontic treatment involving coronal reduction and pulp capping are declined by the owner.

Contraindications

- With a fractured mandible or complex maxillofacial fracture, postponement of extraction(s) may be advisable.

- In small breed dogs with periodontal disease involving the mandibular canine teeth, it may be preferable to stabilize the teeth by way of periodontal therapy, if there is still solid bone supporting the tooth (see Chapter 5).

Technique

- See the section on nonsurgical extraction technique for an easily extracted tooth, pp. 298 to 301.
- See the section on surgical extraction technique for a tooth firmly in bone requiring extraction, pp. 306 to 311.

Maxillary Canine

Step 1—The epithelial attachment is incised (Fig. 6-10, *A*).

Step 2—One or more releasing incisions are made (Fig. 6-10, *B*).

Step 3—The flap is elevated with a periosteal elevator (Fig. 6-10, *C*).

Step 4—The juga or the coronal portion of the juga is outlined and cut with a cutting bur (Fig. 6-10, *D*).

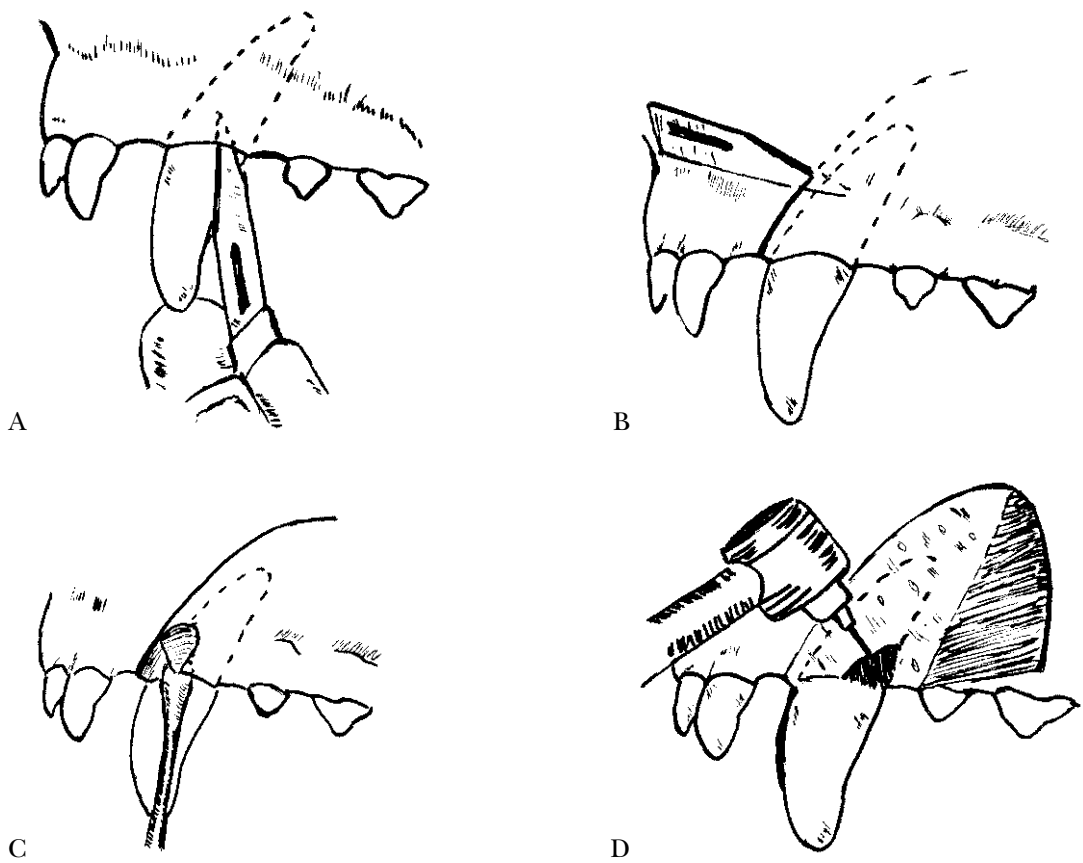


Fig. 6-10

Step 5—The buccal plate is elevated with a periosteal elevator or root elevator (Fig. 6-11, *A*).

Step 6—Root elevators are used as a wedge lever around the mesial, palatal, lingual, and distal root surfaces to stretch and tear the remaining periodontal ligament, loosening the tooth (Fig. 6-11, *B*). Luxators or winged elevators can be used initially to cut the periodontal ligament by applying apically directed pressure sequentially on progressive surfaces around the root's circumference, creating space to place the elevator. The elevator can then be placed in the space created and additional torque and twist can be placed against the root. These steps can be repeated as the process moves apically to loosen the root.

Step 7—Once the tooth is loosened, extraction forceps are placed as far apically as possible; using gentle rotation clockwise and counter-clockwise, the tooth is removed with an extrusionally directed force (Fig. 6-11, *C*).

Step 8—A spoon curette is used to remove granulomatous tissue and debris (Fig. 6-11, *D*).

Step 9—Any rough alveolar edges are smoothed with a cutting bur (Fig. 6-11, *E*), and the extraction site is lavaged.

Step 10—The gingival margin is trimmed, and the fresh edges of the buccal gingival flap are sutured appositionally in place (Fig. 6-11, *F*).

Mandibular Canine Tooth Extraction⁷

- Two approaches may be used.
- The primary complication associated with surgical extraction of the mandibular canine tooth is fracture of the rostral mandible.

Buccal Approach

- Similar to the maxillary canine tooth extraction, a flap is lifted, bone removed, and tooth extracted.

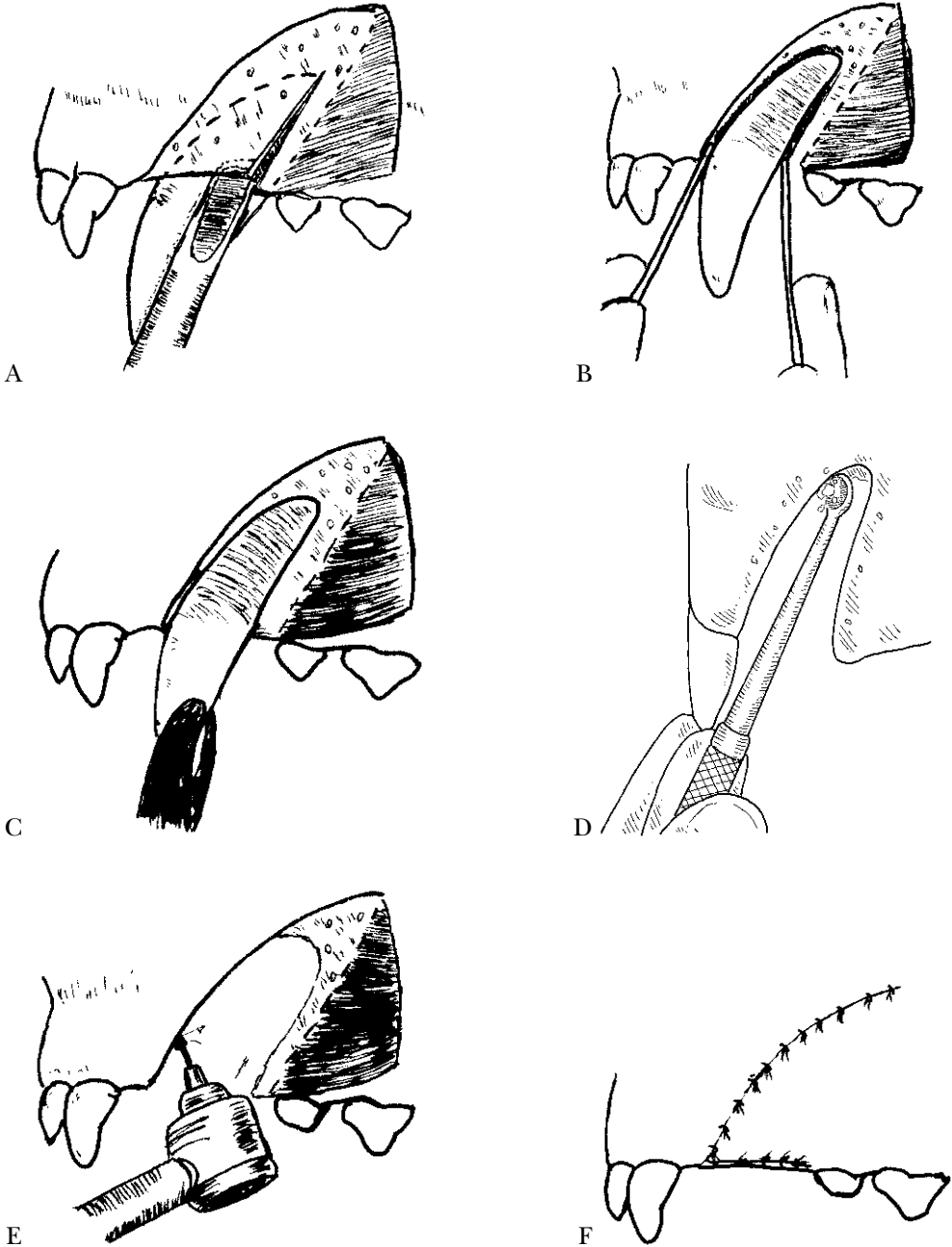


Fig. 6-11

Lingual Approach

Step 1—An incision is made with a #15 blade from the midline at the level between the mandibular first and second premolar, along the gingival attachment to the canine tooth, and lingually just behind the lateral incisor (Fig. 6-12, *A*).

Step 2—A mucoperiosteal flap is raised with an appropriate size and shaped periosteal elevator (Fig. 6-12, *B*).

Step 3—A high-speed handpiece and a round or pear-shaped bur is used to remove the lingual alveolar bone away from the lingual distal wall of the canine tooth (Fig. 6-12, *C*).

Step 4—The tooth is elevated from the tooth socket (Fig. 6-12, *D*).

Step 5—The gingiva is sutured.

Complication of Mandibular Canine Tooth Extraction

- Tongue hanging out of the mouth.

Description

- The mandibular rostral teeth serve, among other functions, as a basket to contain the tongue when it is relaxed. When lower canines are extracted, the tongue may not be held in the mouth all the time and periodically loll out of the oral cavity and downward.

Treatment

- Discuss this possibility with client before extraction; this discussion may provide a reason to perform alternative treatment.
- An osseous integrated prosthetic implant will provide the patient with a new tooth to help contain the tongue.
- Cheiloplasty may be attempted, but success and healing are difficult to achieve.

Complication of Maxillary Canine Tooth Extraction

- Trapping upper lip between gum and mandibular canine tooth

Description

- After extraction of the maxillary canine tooth, the maxillary lip may be caught and pinched between the mandibular canine and gingiva of the maxilla, which may be very uncomfortable for the patient and result in a chronic traumatic lesion.

Treatment

- Coronal reduction and pulp capping of offending mandibular canine tooth.
- Extraction of the mandibular canine tooth.

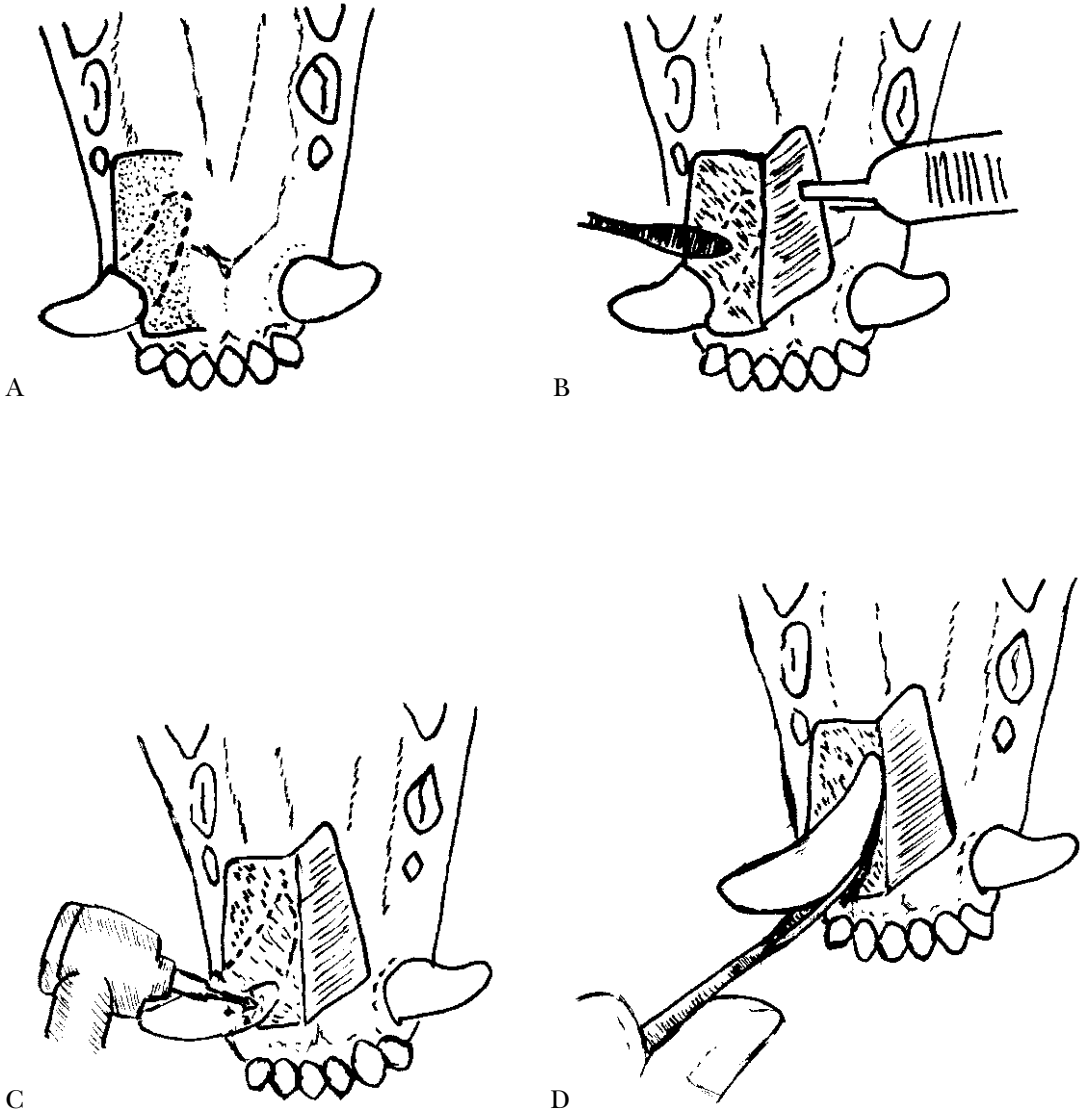


Fig. 6-12

General Extraction Complications

- Complications include expansion fracture of the socket, fractured or broken root tips, hemorrhage, endocarditis, secondary infections, mandibular fracture, implosion fracture of the maxillary nasal plate and resultant oronasal fistula, oronasal fistula as a result of necrotic alveolar bone being removed with the tooth, soft tissue trauma by the remaining opposing tooth, alveolitis, laceration of gingival tissue, retained root fragment, sequestered fractured bone plate, and inability to extract.⁸
- Additional complications less frequently encountered include trauma to adjacent tissues, osteitis, and osteomyelitis.

Fractured Socket

Description

- The alveolar bone is fractured in the process of extracting the tooth⁸ (Fig. 6-13, *A*).

Treatment

- Fragments that are unstable or exposed should be dissected and removed before the gingiva is closed.
- Lightly pack synthetic bone grafting or scaffolding implant material in the socket, shaped to the size of the extracted root, if in solid rather than granular form, and suture the gingiva. Note: in the case of an oronasal fistula secondary to extraction, care must be taken that implant material is not packed into the nasal passage.

Fractured or Broken Root Tips

Description

- A portion of the root is fractured and not extracted with the rest of the tooth.
- Can be a result of improper extraction technique, ankylosis, or spontaneously resorbing or necrotic roots/root ends.

Treatment

- See this chapter, pp. 306 to 311, on Surgical Extraction Technique.

Hemorrhage

Description

- Bleeding from the extraction site.
- May be caused by careless technique, over-instrumentation, handpiece bur perforation into the maxillary sinus or mandibular canal, or a bleeding disorder.

Treatments

Soft Tissue Hemorrhage

Pressure

- Pressure applied, with gauze sponge, swab, or dental cotton roll, directly to the extraction site to allow a clot to form (Fig. 6-13, *B*).

Cold Pack

- Application of cold compresses made from ice wrapped in a gauze sponge can reduce blood flow sufficiently to allow a clot to form and, at the same time, retard postoperative swelling (Fig. 6-13, *C*).

Ligation

- Ligation of bleeding vessels.

Electrocautery

- Most effective in controlling hemorrhage from small vessels. Caution must be exercised not to cause tissue necrosis.

Primary Closure of Site

- Suturing soft tissues over the extraction site with fine suture. Note: controls only minor seepage. Do not use for extensive hemorrhage; see other techniques.

Aids for Coagulation

- Floseal Matrix Hemostatic Sealant (Baxter Healthcare Corporation, Deerfield, Ill.) may be swabbed onto extraction site to serve as a matrix for clot formation.
- Synthetic bone products such as Bioplant HTR-24 (Septodont, New Castle, Del.), Consil (Nutramax Laboratories, Inc.), Osteon 200 (formerly Interpore 200 [Interpore/Cross International]) packed into extraction site to serve as matrix for clot formation and then aid in formation of new bone; cube form carved by clinician and placed in socket (Fig. 6-13, *D*); granular form inserted into socket by syringe (Fig. 6-13, *E*) or mixed to a paste with sterile saline and delivered on the blade of an excavator or placement instrument.
- Hemablock (Abbott Animal Health, North Chicago, Ill.) supplied as small bioinert polysaccharide beads. It accelerates clotting for fast control of bleeding sites. It is “puffed” onto or into the site from its applicator tube. Light pressure is applied for 30 seconds.
- Gelfoam (Pharmacia Division of Pfizer, New York, NY) packed into extraction site to serve as matrix for clot formation. Note: the product should be installed in clean sites that have adequate backing and should not be forced into the nasal passage, where they may cause blockage and discomfort.

Hemorrhage of Bone

Crushing Bone

- Rongeurs may be used to crush bone.

Packing with Gauze

- The socket may be packed with gauze, a coagulation-enhancing material such as

Gelfoam or Surgicel, or a biodegradable orthopedic implant.

Sterile Bone Wax

- Sterile bone wax may be placed in the alveolus onto the surface of the bleeding bone.

Endocarditis

Description

- If the tooth being extracted is abscessed or severely affected by periodontal disease, a transient bacteremia should be expected. It will tend to localize in a distant area of inflammation.^{9,10}

Treatment

- If anticipated, pretreatment with an appropriate antibiotic is warranted.

Secondary Infections

Description

- Secondary infections create osteomyelitis or suppurative arthritis.
- Although infrequently diagnosed as direct sequelae of extractions, secondary infections, of which the practitioner should be aware, can occur.
- Signs include fever, reluctance or inability to eat, resistance to examination, depression, lack of healing, and foul oral odor.

Treatment

- Radiographs, antibiotics, and surgical intervention may be necessary to assess and to treat cases of osteomyelitis, to debride diseased bone, and to cover exposed bone protectively with soft tissue.

Mandibular Fracture

Description

- The severity of bone damage can be evaluated with one or more preoperative radiographs (Fig. 6-13, *F*). If severely infected or thin bone is found, advise the client of an increased possibility of an iatrogenic jaw fracture. The amount of force used in extractions must be controlled. Sectioning multirooted teeth is essential, and surgical extraction may be indicated in these situations to minimize placing undue stress on weakened bone.
- A diseased mandible, once fractured, is often difficult to repair. It may never heal completely or be as strong as it once was. Fortunately, small dogs with caudal mandibular fractures can often function quite satisfactorily with a fibrous union of the jaw.

Treatment

- It is best to prevent an iatrogenic fracture. But when one occurs, perform a complete extraction, including debridement and irrigation of the extraction site, and suture the gingiva to cover voids and exposed bone. Postoperatively, treat the patient with parenteral antibiotics.
- If only one side is affected, the contralateral side will give sufficient stability for fibrous union of the fracture to occur. If the fracture is bilateral, a tape muzzle may be adequate to support the jaw while the bone infection heals and a fibrous union is formed. Stabilization can often be achieved with interdental wiring alone or in conjunction with extraoral splinting techniques. Bone plating often works well, but it is more invasive (see Miniplate and Screws Fixation in Chapter 10). Partial mandibulectomy is a last resort if other methods are unsuccessful or not possible.

Oronasal Fistula

Description

- A communication between the oral and nasal cavity may be present, or it may be created iatrogenically in the process of extraction.
- There is only a thin plate of bone between the tooth and nasal cavity.^{11,12}

Treatment

- It is important to explain, in writing, the possibility of such a complication to client before extracting one or more teeth.
- See p. 329.

Opposing Tooth Traumatizing Extraction Site or Lip

Description

- This most often occurs when a maxillary canine is extracted. The adjacent lip or cheek is not held away from the gingiva, as it was formerly by the maxillary canine, and the mandibular canine strikes it. The canine may only pinch the lip or may puncture or lacerate the lip.

Treatment

- The occlusion of the opposing tooth must be changed. This can be done by:
Reducing the offending tooth coronally to a level that does not trap the lip. If the pulp chamber is exposed, it will be necessary here to install a pulp cap (filling) to insulate the pulp and also to protect it from infection (see Pulp Capping, Chapter 7).
Orthodontically moving the offending tooth so that it no longer impinges on the soft tissue.
Extracting the offending tooth.

Alveolitis: Painful Socket

Description

- This is due to inflammation or infection of the empty socket after extraction.

Treatment

- Best to prevent at time of extraction by debriding necrotic and infected tissues, allowing enough bleeding for clot formation, and suturing the socket closed.
- Antibiotic therapy after extraction.
- Irrigation.

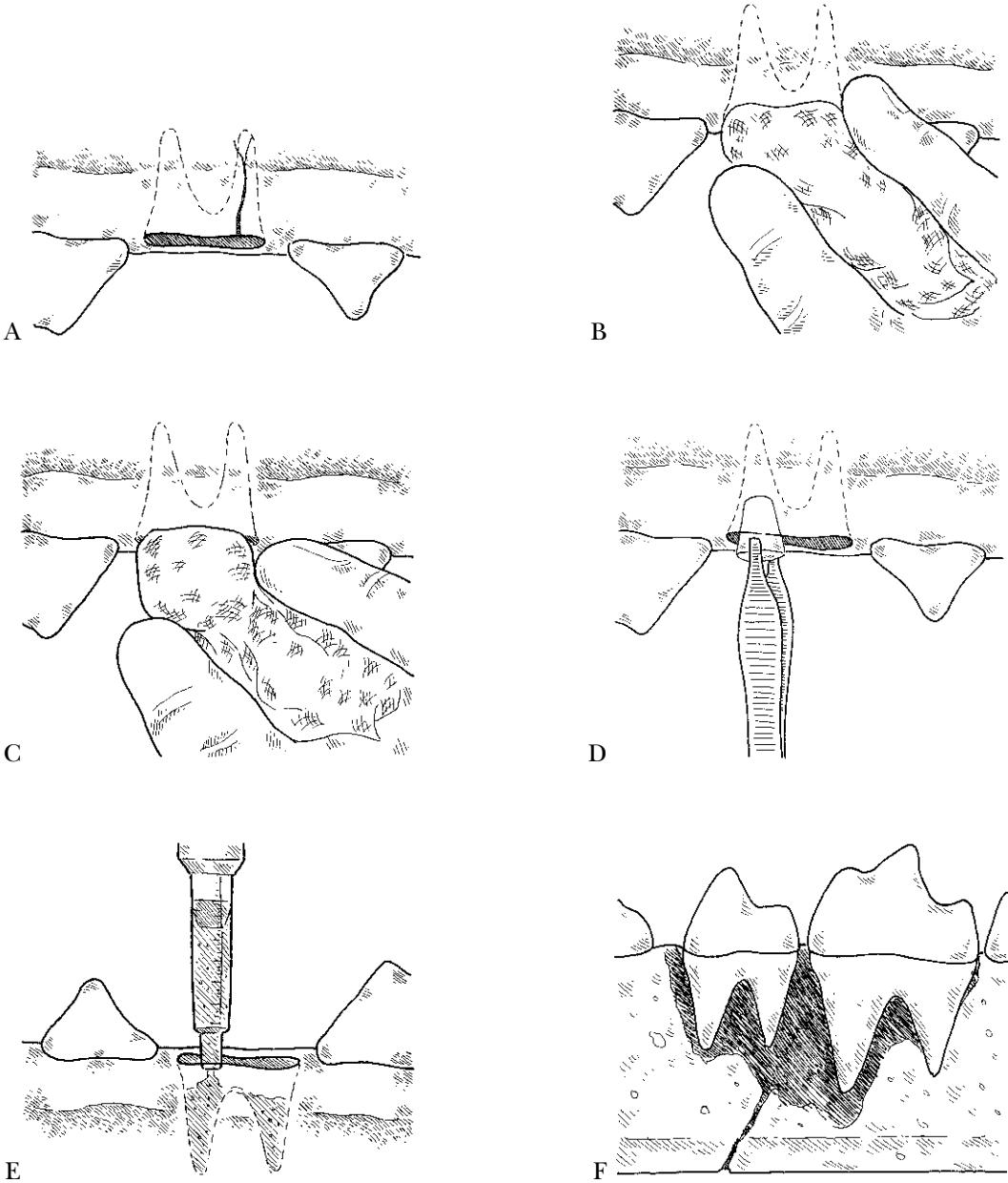


Fig. 6-13

Laceration of Gingival Tissue

Description

- Laceration may occur as the tooth is extracted, if the gingival attachment is not severed completely, or as a result of excessive over-instrumentation in the elevation technique.

Treatment

- Reparative suturing of the traumatized gingiva.
- Preventing the complication by completely severing the epithelial attachment and using a gentle elevation technique.

Ankylosis

Description

- Periodontal ligament space is not visible on radiograph.
- There is no tooth movement when pressure is applied with the elevator.

Treatment

- If there is no radiographic or clinical evidence of either periodontal or endodontic infection, the ankylosed tooth may be left in place.
- If infection is present, the root is removed by rongeur or surgical obliteration.

Large Tooth Surface

Description

- There may be a tooth root surface so large that the practitioner is unable to exert enough force with the elevator to stretch or break down the periodontal ligament.

Treatment

- See Surgical Extraction Technique, pp. 306 to 311.

Aftercare: Follow-Up

- The client should be instructed to rinse the area of extraction daily with a water-based commercial mouthwash such as CET oral rinse (Virbac, Fort Worth, Tex.), Pet Oral Hygiene Solution (Oxyfresh, Coeur d'Alene,

Idaho), Listerine, chlorhexidine, or an iodine solution.

- Appropriate oral antibiotics and pain medications are dispensed.
- The patient should be examined 10 to 14 days postoperatively by the doctor to determine whether healing is progressing normally or further treatment is indicated.
- The patient should be allowed only a softened diet, and no hard treats, soft or hard chew toys, or oral play during the healing period.

Dental Radiology

- Any time it is suspected that a fragment of root has been left behind, a radiograph should be taken. It is better to find a piece of root at the time of extraction than to be forced into a surgical revision.
- The practitioner should weigh the risk associated with leaving a portion of the root in the socket against the damage that may occur to tissue while extracting the retained portion of root. If there is no infection at the site and circulation to the root tip appears intact, it may be an acceptable risk to leave the root tip in place.¹³ In such cases, client communication is of the utmost importance so that there is no chance for them to be exposed to a surprising revelation at a later date.
- However, if the clinician's assessment of this is incorrect, a complication, resulting in sequestration and fistulation, may occur. It is best to be conservative and remove any root tips of questionable soundness. Clients hate surprises and anticipate "one-stop shopping" in cases of extraction.
- A fractured root that is left in the socket should be noted on the dental record, and possible complications and need for follow-up should be discussed with the client and the conversation noted in the record.

DENTAL PULVERIZATION

General Comments

- Occasionally, patients have dilacerated roots or retained root tips that are not easily removed by standard techniques. These teeth may be so ankylosed that they cannot be extracted with elevators and extraction

forceps. In these cases, a high-speed handpiece and a pear-shaped, round, or cross-cut fissure bur in standard length or surgical length may be used to pulverize the remaining root fragment. There are severe potential complications with this procedure, and it must be done with great care.

- The root tip is much harder than bone, and the bur tends to slip off and penetrate the bone. The root tip has a different tactile feel and drilling sound than when pulverizing bone.
- Other ways to differentiate the root tip from the alveolar bone is that the root tip does not bleed but adjacent bone does, and the root tip is white while adjacent bone is a darker shade.

Indication

Pulverization is performed as a last resort when it is difficult to extract with elevators as a result of resorbing or ankylosed root ends.

Objective

- Remove the entire retained or ankylosed root fragment.

Materials

- Instruments to separate gingival attachment.
- High-speed handpiece with water cooling.
- Numbers 330, 2, 4, 701L, and 701L surgical length shank FG burs.
- Magnification, additional light, forced air and water spray, or suction may improve visualization.

Technique

Step 1—A radiograph is made to evaluate the size and length of the root.

Step 2—The gingival attachment is cut with a blade, creating an envelope flap, and the crown of the tooth is cut off at the gingival line.

Step 3—The bur is used to remove the root structure carefully. Short periods of drilling should be used to prevent overheating of tissues and allow for visualization of progress.

Step 4—A radiograph is taken to show that the entire root has been removed. Several radiographs may need to be taken intraoperatively until removal is complete.

Complications

- The air from a high-speed handpiece may invade subcutaneous tissue planes, causing subcutaneous emphysema or, worse, it may invade the alveolar circulation, causing a fatal air embolism.^{13,15-17} There is sufficient risk to justify the use of the pulverization technique sparingly.
- Penetration into adjacent structures such as nasal passages, sinus, and infraorbital or mandibular canal.
- Imploding a root fragment into nasal passages, sinus, or mandibular canal.
- Overheating tissue. Irrigate copiously to keep the tissues cool. The smell of burning bone or the sight of blackened bone can signal future problems of bone necrosis and delayed healing of extraction sites.

Aftercare: Follow-Up

- Reexamine in 7 to 10 days to evaluate healing.
- Antibiotics and medications for pain relief should be prescribed.

CROWN REMOVAL ONLY WITH INTENTIONAL ROOT RETENTION

General Comments

- In cats with odontoclastic resorptive lesions, type 2, where there is radiographic evidence of replacement resorption without periodontal bone loss or periapical changes, it is possible to remove the crown only and a small portion of the roots with this technique.^{13, 14}
- A similar technique can be used in dogs with similar resorptive type lesions that are found in older dogs where the roots are radiographically disappearing secondary to replacement resorption.
- This technique allows for removal of the portion of the tooth that is creating discomfort for the patient and allows the resorption process to complete without

creating the potential complications of full root pulverization described above.

Indications

- Feline or canine teeth with radiographic evidence of replacement resorption and the presence of a coronal defect/lesion.

Contraindications

- Radiographic evidence of periodontal disease or periapical changes.
- Cats with chronic gingivostomatitis, feline leukemia, or feline immunodeficiency viral diseases.

Objective

- To remove the entire crown of the tooth using a high speed bur to eliminate a source of pain for the patient.

Materials

- Instruments to separate gingival attachment.
- High-speed handpiece with water cooling.
- Numbers 330, 2, 4, FG burs

- Magnification, additional light, forced air and water spray, or suction may improve visualization.
- Needle holders, scissors.
- 4-0 or 5-0 absorbable suture.

Technique

Step 1—A radiograph is taken to evaluate the root for presence of resorption and absence of other changes before continuing with the procedure.

Step 2—A #11, 15, or 15C blade is used to incise the gingival attachment around the entire tooth.

Step 3—A small periosteal elevator is used to reflect an envelope flap to just expose the alveolar bone on both sides of the tooth. In teeth with gingival overgrowth into the crown lesion, a vertical releasing incision(s) may need to be made on the buccal surface to prevent tearing of the tissue.

Step 4—The bur is directed perpendicular to the tooth crown at the level of the alveolar crest, and the crown of the tooth is resected.

Step 5—The bur is next directed down into the root remnant to remove any residual crown pieces and a small portion of the coronal root to allow for clot formation and primary closure of the gingival tissue. Any rough bone edges are also smoothed.

Step 6—The gingiva is carefully closed over the exposed root remnants with two interrupted sutures.

Complications

- Tearing of the gingival tissue, making it difficult to obtain primary closure.
- Incomplete removal of the entire crown of the tooth, leading to persistent irritation.
- Incomplete closure over the roots, leading to incomplete healing and persistence of inflammation from exposed roots.
- Root remnant infection from inappropriate choice of treatment with root pathology.

Aftercare: Follow-Up

- Reexamine in 7 to 10 days to evaluate healing.
- Antibiotics and medications for pain relief should be prescribed.

EXTRACTION OF RETAINED ROOT-TIP FRAGMENTS

General Comment

- Root-tip fragments may occur due to trauma, cavities, resorption of the crown, or as a complication of extraction (Fig. 6-14, A).

Indication

- If the root-tip fragment can be visualized clearly or is accompanied by periapical lysis or regional gingivitis, it should be extracted.

Contraindication

- If the risk of tissue damage is greater than the advantage gained by extraction, then the root fragment may be left and monitored closely. When bone is healthy around a root

tip, the risk of complications is less if only a small piece of root is left than if there is pathology involved, such as periapical disease or fistulation.

Objective

- Removing the entire root tip without excessive damage to adjacent tissues.

Materials

- Same as for single-root and multiroot extractions.
- The fine root-tip picks are particularly effective (apical elevator, Heidbrink #1).
- Root-tip forceps.
- Fragment forceps.
- Magnification, additional light, forced air and water spray, and suction for improved visualization.

Techniques

- Of the several techniques for removing root tips, pulverization (Fig. 6-14, *B*) (see p. 323) and surgical extraction (see pp. 306 to 311) have been described.
- Root-tip picks can be used as a wedge to expand bone and tease the root fragment out of the socket or coronally (Fig. 6-14, *C*).
- In a multirooted tooth, the interradicular septum can be opened with a bur on a high-speed handpiece to break down one wall of the alveolus. The root fragment may then be

avulsed into the created space and grasped with a root-tip forceps.

- A trough can be cut adjacent to the retained root tip with a cutting bur to allow insertion of a root-tip pick or apical elevator. Using the instrument in a lever or wheel-and-axle action will prevent perforating the apex with the instrument or pushing the root tip apically. Buccal bone can be removed to visualize the root tip, and with a levering action the root tip is forced coronally with a root-tip pick or apical elevator, so it can be grasped with a root-tip forceps.
- An oversized endodontic file can be used to retrieve the root fragment by inserting the file into the root canal and twisting to lock the file in place. With the aid of a root-tip pick, the root tip may then be retrieved by pulling on the endodontic file.
- A postextraction radiograph is taken to verify complete removal of the root fragment.

Complications

- Repelling the tooth fragment into the nasal cavity, sinus, or mandibular canal.
- Creating tissue damage (nerve, bone, or vascular).
- Additional hemorrhage.
- Leaving a root fragment.
- Persistent infection.

Aftercare: Follow-Up

- Monitor the healing process.
- Same instructions regarding oral behavior as for other extractions.

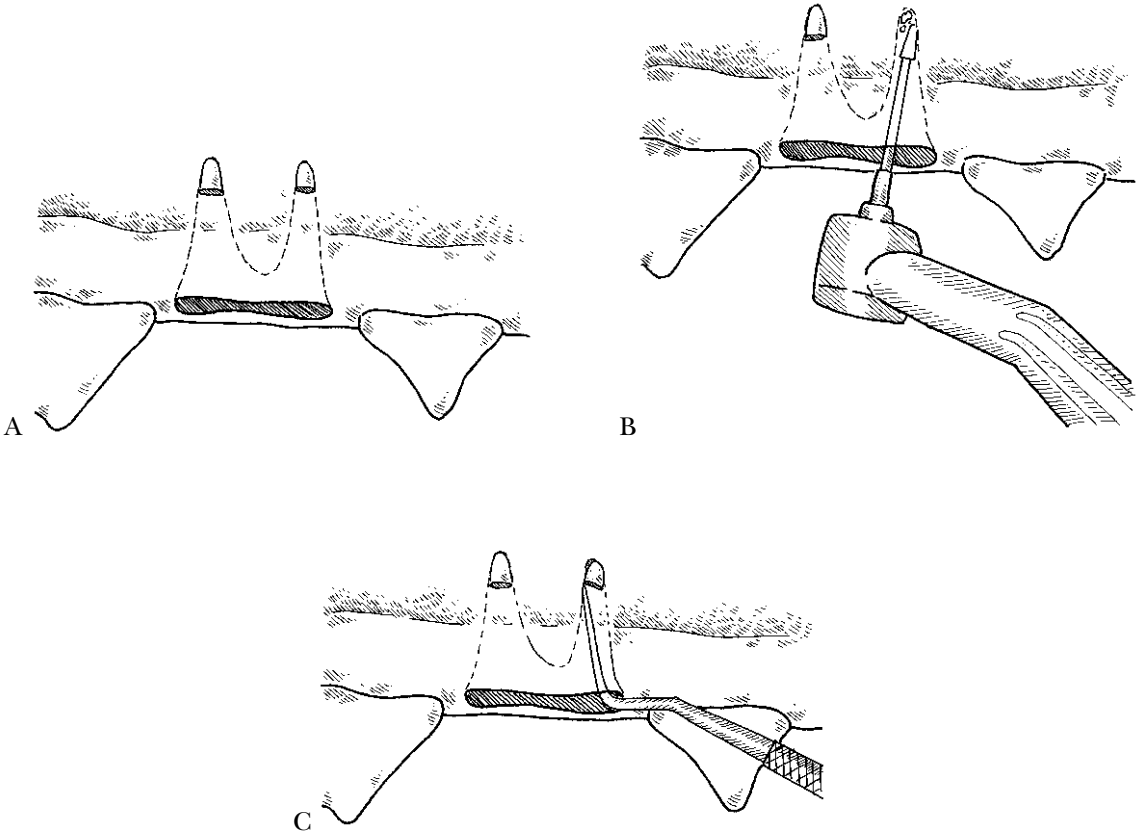


Fig. 6-14

EXTRACTION OF PRIMARY TEETH

General Comments

- The roots of primary teeth (deciduous, baby) are longer, thinner, and more delicate than those of the secondary (permanent, adult) teeth; therefore, they are more easily fractured.
- When the primary maxillary canine persists, the secondary tooth erupts mesial to the primary tooth.
- When the primary mandibular canine persists, the secondary tooth erupts lingual to the primary tooth.
- Retained primary incisors are found labial to their secondary counterparts.
- Retained premolars are found mesial or buccal to their secondary counterparts. The exact location or identification of unerupted secondary teeth can be confirmed by radiograph.

Indications

- When the adult tooth is erupting and the primary tooth has not been lost.
- As soon as the adult tooth is noticeable, whether it has erupted through the gingiva or is pre-emergent.
- If mandible and maxillofacial complex are not developing properly, primary teeth may in some cases be extracted to allow independent growth of the two jaws (see Chapter 9).
- When there is pulpal death of the primary tooth (gray and opaque).
- When a primary tooth has been fractured.
- Whenever there are two teeth, one primary and the other secondary, of the same kind in the same location at the same time, regardless of the age of the patient.

Objective

- Remove the primary tooth and root without damaging the adult tooth or other oral structures.

Materials

- Scalpel blades #11 and #15C.
- Number 301s root elevator or 3-mm luxator, 2- to 3-mm winged elevator, 100C luxator, or Fahrenkrug elevator (see Chapter 2).
- Hypodermic needle: 18 gauge.
- Small breed extraction forceps.
- Needle holder.
- Absorbable suture 3-0 or 4-0.
- Gauze pads.

Technique

Step 1—Take a radiograph of the tooth to be extracted to identify the shape, length, and morphology of the roots. The radiograph also identifies the location of unerupted secondary teeth so that injury to them can be avoided.

Step 2—Using a #11 scalpel blade, sever the epithelial attachment around the tooth to be extracted.

Step 3—Using a fine, sharp elevator or an 18-gauge needle as a wedge lever, elevate around the tooth. With primary teeth, it is important to elevate to the point that the periodontal ligament is broken and the tooth is free in the alveolus. Keep the elevator on the surfaces away from the permanent tooth as much as possible. When performing interceptive orthodontics in young puppies, avoid deep apical elevation of the primary tooth, thereby preventing damage to the permanent tooth bud.

Step 4—For solid, retained primary canine teeth, it may be beneficial to make a small incision in the attached gingiva over the distobuccal aspect to reduce risk of fracturing the root. One or two sutures with resorbable material are placed for closure.

Step 3—Extraction forceps are used to lift the tooth out of the socket. Rotational forces should not be used, because they often result in root fracture.

Step 4—A radiograph is taken if any doubt exists that the entire root was extracted, and if root fragments are seen, they are retrieved.

Complication

- Fracture of the root, which may be prevented by taking more time, using small enough elevators, and avoiding too much leverage. The newly erupted unstable permanent tooth should not be used as a fulcrum.

Aftercare: Follow-Up

- Monitor healing.
- Monitor eruption of the adult tooth.
- Monitor occlusion as the face and jaw develop.

ORONASAL FISTULA REPAIR

General Comments

- Oronasal fistulae can occur associated with any of the maxillary teeth.
- Severe periodontal disease creating a palatal pocket and loss of the bone on the palatal side of the root may be noted when (1) a probe is inserted deeply into an infrabony

pocket, (2) radiographically, or (3) by irrigation of the pocket, resulting in irrigant dripping out of the nostril. Clients may report chronic sneezing or snuffling with a unilateral or bilateral serous nasal discharge in patients. Dachshunds, poodles, and other small breed dogs are often affected with oronasal fistulae secondary to periodontal disease. Endodontic disease, evidenced by periapical lysis and abscess, can also lead to an oronasal fistula.

- If an oronasal fistula is created by an extraction, it should be repaired.
- Traumatic avulsion of a canine tooth can create an oronasal fistula.
- Ideally, the repair should place an epithelial layer in the oral and nasal cavities.
- The flap must not have any tension on it after it is sutured in place.
- The suture line should not be over a void.
- Frequent irrigation of the surgery site and pressure with moistened gauze provides visibility and controls hemorrhage.

Indication

- A communication between the oral and nasal cavities.

Contraindication

- Severely infected tissue; best to wait to perform reparative surgery until after a course of antibiotics or until 7 to 10 days after an initial extraction stage.

Materials

- Oral surgery pack.

Techniques

Single-Flap Technique: Buccal Mucoperiosteal Sliding (Advancement) Flap

- Used for fistulae where attached gingiva remains, providing a strong suture base. If the fistula is large or chronic, with no remaining attached gingiva, then the double-flap technique is recommended.

Step 1—The margins of the fistula are debrided of necrotic and epithelialized tissue (Fig. 6-15, *A*). The nasal cavity should be inspected for pus and foreign material and irrigated with sterile saline if debris is present.

Step 2—Releasing incisions are made with a #11 or #15C scalpel blade (Fig. 6-15, *B*). The mesial incision is started at the gingival ridge, mesial to the fistula, and continued apically into the elastic buccal mucosa. The distal incision is started at the gingival ridge, in the area of the mesial line angle of the first premolar, and continued apically, past the mucogingival line and into the buccal mucosa. The incisions should be diverging apically to ensure adequate circulation. The cuts creating this full-thickness flap are made in one pass, to the bone, and include the periosteum.

Step 3—A reverse bevel incision is made at the buccal edge of the fistula, connecting the releasing incisions. The palatal margin may be elevated slightly with a blade to facilitate suturing (Fig. 6-15, *C*).

Step 4—The gingival flap, with its periosteum, is elevated apically with a broad periosteal elevator, such as a #2 or #4 Molt elevator (Fig. 6-15, *D*). Enough tissue should be elevated for the flap to be placed over the fistula without spontaneous retraction. This ensures that there will be no tension when the sutures are placed.

Step 5—As necessary, to obtain tissue release, the periosteum is incised mesiodistally on

the underside of the flap at its base with a #15 or #15C blade (Fig. 6-15, *E*).

Step 6—The alveolar crest may need to be reduced for better positioning of the flap.

This can be done with a small rongeur, rasp, curette, or high-speed cutting bur.

Step 7—As conditions indicate, synthetic bone, a synthetic scaffold, or bone graft may be packed into the oronasal fistula before suturing.⁶ This is contraindicated if there is no backing on the nasal wall.

Step 8—The flap edge is trimmed, placed over the defect, and sutured with 3-0 or 4-0 resorbable suture on a reverse-cutting or taper swaged-on needle (Fig. 6-15, *F*). Suturing is started at one corner, and additional sutures are placed 2 to 3 mm apart and 2 to 3 mm from the gingival edge, closing across to the palatal tissue and up each releasing incision. It is helpful to use a small periosteal elevator to elevate the gingival edge of the palatal tissue and attached gingiva to which the flap will be sutured. Excess tissue at the next corner can be excised to avoid gaps which could lead to dehiscence. Do not crush the tissue with sutures tied too tightly. Sutures are passed from the donor flap tissue to the recipient tissue at the margin of the fistula.

Double-Flap Techniques

- Double-flap surgery is more complicated and usually is used for large defects where no attached gingiva remains or when the single-flap technique has failed.¹⁸
- This procedure provides an epithelial surface toward the nasal cavity and provides greater support for the buccal flap.
- The mesial, distal, and buccal epithelial margins of the fistula are debrided and scarified with a #15C blade or #12 fluted bur. The palatal margin is not debrided.
- Frequent irrigation of the surgery site and pressure with moistened gauze provide visibility and control hemorrhaging.

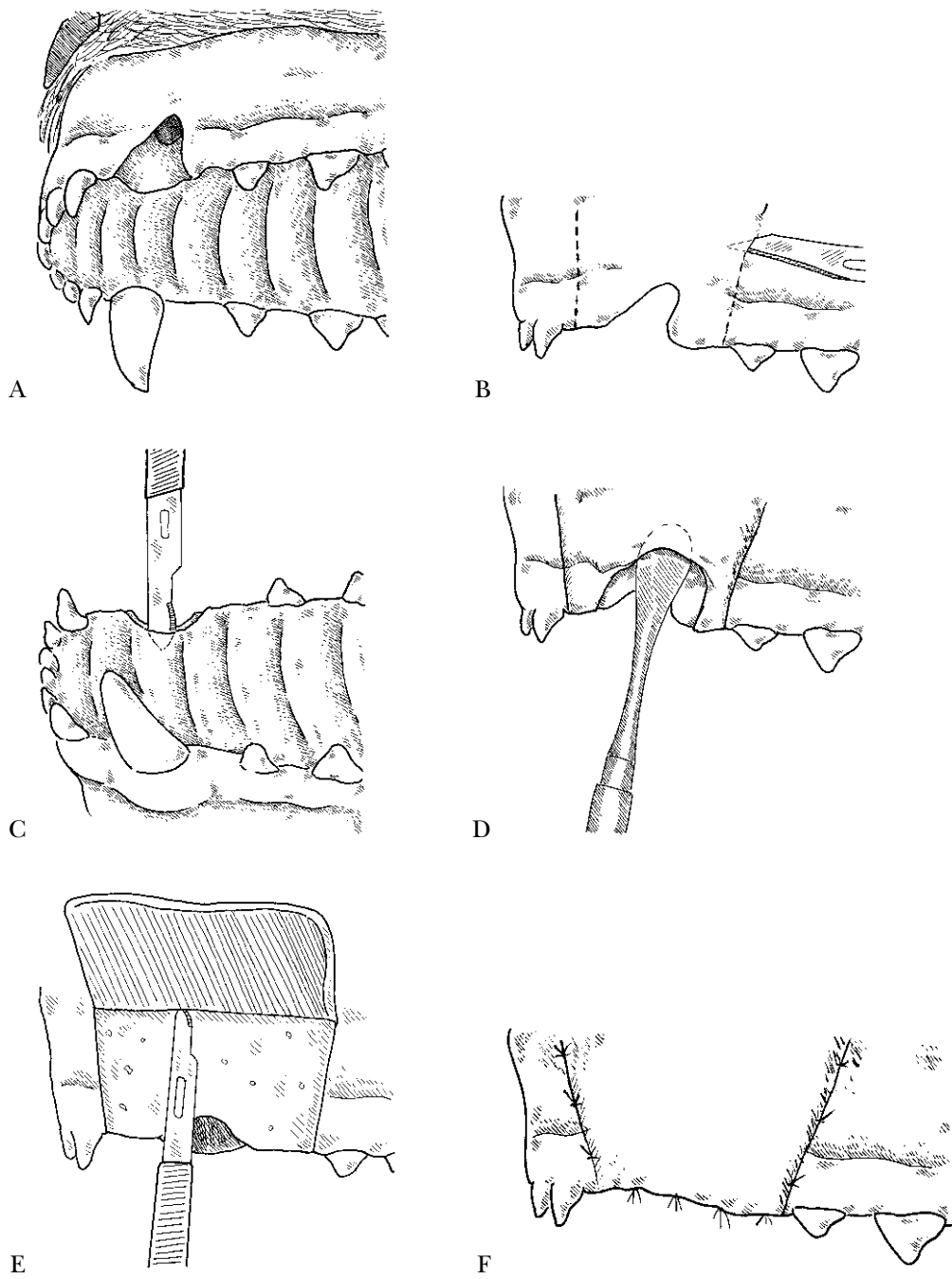


Fig. 6-15

Double-Flap: Palatal Inverted and Buccal Sliding Flaps

Step 1—A full-thickness palatal flap is created by making parallel incisions from mesial and distal borders of the fistula to or past the midline on the palate, where they are converged and connected to form a graceful arc (Fig. 6-16, *A*). This must create a flap large enough, when inverted (folded over its base), to fit over the fistula and, after suturing, to have no tension on the suture lines. Raising this palatal flap will create significant hemorrhage as the rostral palatine artery is transected. With careful dissection it may be possible to ligate the artery. Direct pressure with a moistened gauze will also control hemorrhage.

Step 2—The palatal flap is based at the medial edge of the fistula and is elevated, in full thickness, with a sharp periosteal elevator to the margin of the fistula, exposing the palatal bone (Fig. 6-16, *B*). It is inverted to cover the fistula. This inversion places the epithelium of the flap in contact with the nasal passage (Fig. 6-16, *C*). The flap is then returned to its donor site and kept moist while the buccal flap is raised.

Step 3—After raising the buccal sliding flap, using 3-0 or 4-0 absorbable suture, the palatal flap is again folded back and sutured to the mucosa at the edges of the fistula. Simple interrupted or cruciate stitches are customarily employed (Fig. 6-16, *D*).

Step 4—The buccal mucoperiosteal flap, with releasing incisions, is placed over the sutured palatal flap and also the palatal donor site. And is sutured to the margins (Fig. 6-16, *E*), as described on pp. 330 to 331. If the defect and donor site are too large to be covered, a labial mucosal rotational flap is created, with its apex also to or across the midline and based caudal to the fistula. It is rotated and placed over the sutured palatal flap and so that it also covers the palatal donor site, and is sutured to the defect margins. Sutures are placed between the buccal flap and the underside of the palatal flap.

- Note: The palatal defect will heal by second intention if not covered by mucosa.
- Any epithelialized tissue that is covered by the flap should be scarified with a blade or bur to allow first intention healing.

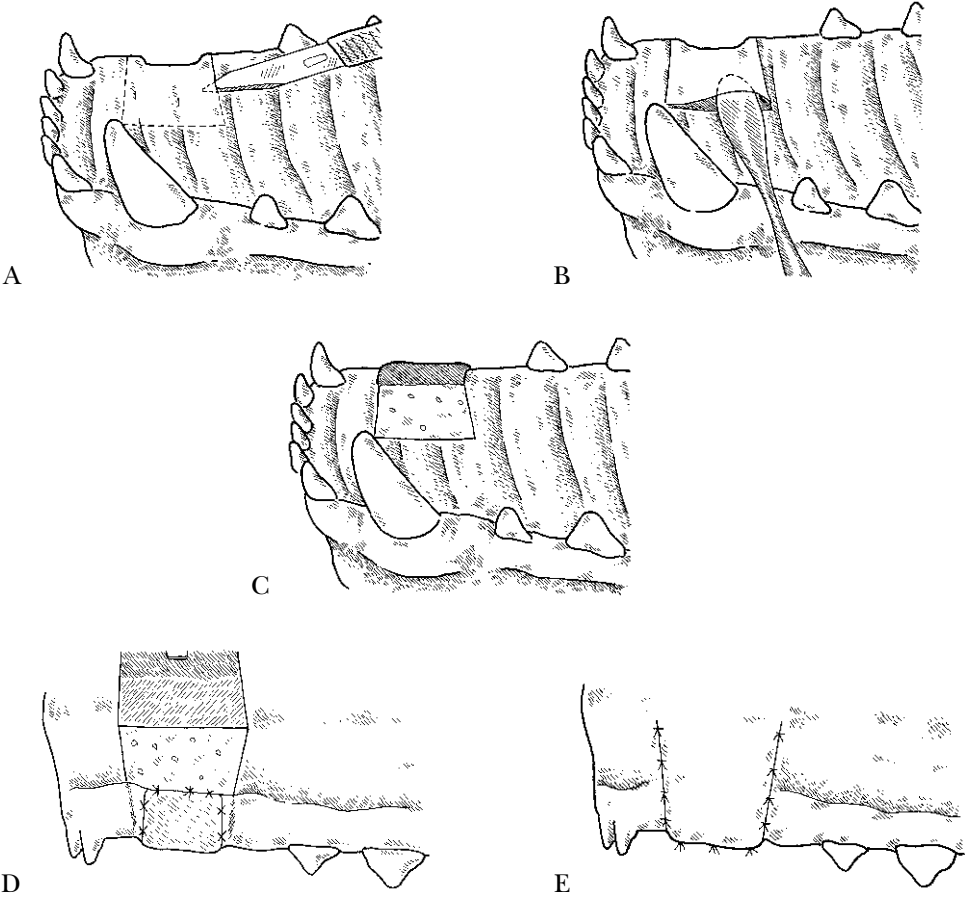


Fig. 6-16

Double-Flap: Palatal and Labial Buccal Pedicle Flap

Step 1—A palatal flap is created using the preceding steps 1 to 3.

Step 2—A partial thickness pedicle flap is created by making an incision along the mucogingival junction from the area of the distal edge of the juga, extending mesially to create a flap long enough to completely cover the donor site of the palatal flap (Fig. 6-17, *A*). This may be past the midline in dolichocephalic and toy breeds. It is imperative that this initial flap is large enough to cover the defect without tension. A sterile template may need to be cut to ensure that this flap will be large enough. A second incision is made, and a pedicle flap with its width $1\frac{1}{2}$ times the diameter of the fistula is created. This incision is made parallel to the initial releasing incision on the mucogingival junction. A third incision is made perpendicularly, connecting the two releasing incisions.

Step 3—Starting at the rostral end (Fig. 6-17, *B*), the flap is elevated (Fig. 6-17, *C*). Any epithelialized tissue that may be covered eventually by the flap should be scarified with a blade or bur to provide a first-intention healing bed.

Step 4—The pedicle flap is sutured over the palatal flap and palatal defect using simple interrupted sutures of absorbable 3-0 or 4-0 material on a reverse-cutting or taper swaged-on needle (Fig. 6-17, *D*). When fixing the buccal pedicle flap to the palate, the sutures will strengthen the repair if they include both flaps.

Step 5—The edges from the two releasing incisions are sutured together (Fig. 6-17, *E*).

Complications

- Potential complications should be written on the informed consent form, and the client told before extracting teeth that poor healing and dehiscence are possible complications.
- With any gingival flap technique, the client should also be informed that infection is a possibility.

- Persistent bleeding may occur if unhealthy tissue is insufficiently debrided or if a coagulopathy exists.
- Oronasal fistulas can be associated with any of the maxillary teeth, including in multiple sites; all must be addressed to alleviate symptoms.

Aftercare: Follow-Up

- Maintain the patient on a broad spectrum oral antibiotic for 10 days.
- Area may need cleansing, but this can disturb the healing process. Using a water irrigation device or water spray bottle may be beneficial.
- The doctor should recheck the patient at 2- to 3-day intervals if quiet convalescence, client compliance, or technique is in question. It is better to troubleshoot complications early than to wait until a surgical revision is necessary after the surgery has failed completely.
- The client should be advised against putting tension on the graft site by pulling on the patient's lip while cleansing the area or while examining the surgical site.
- A soft food diet should be provided and access to chew toys, hard treats, and oral play withheld for 2 weeks.
- An Elizabethan collar may be necessary, initially, to keep the dog from pawing or rubbing at the surgery area.

IMPACTED, UNERUPTED, OR EMBEDDED TEETH

General Comments

- An impacted tooth is one whose path of eruption is physically blocked or impaired.
- If the opposing tooth is erupted, impaction should be suspected, and if the contralateral tooth is erupted, impaction is almost certain.

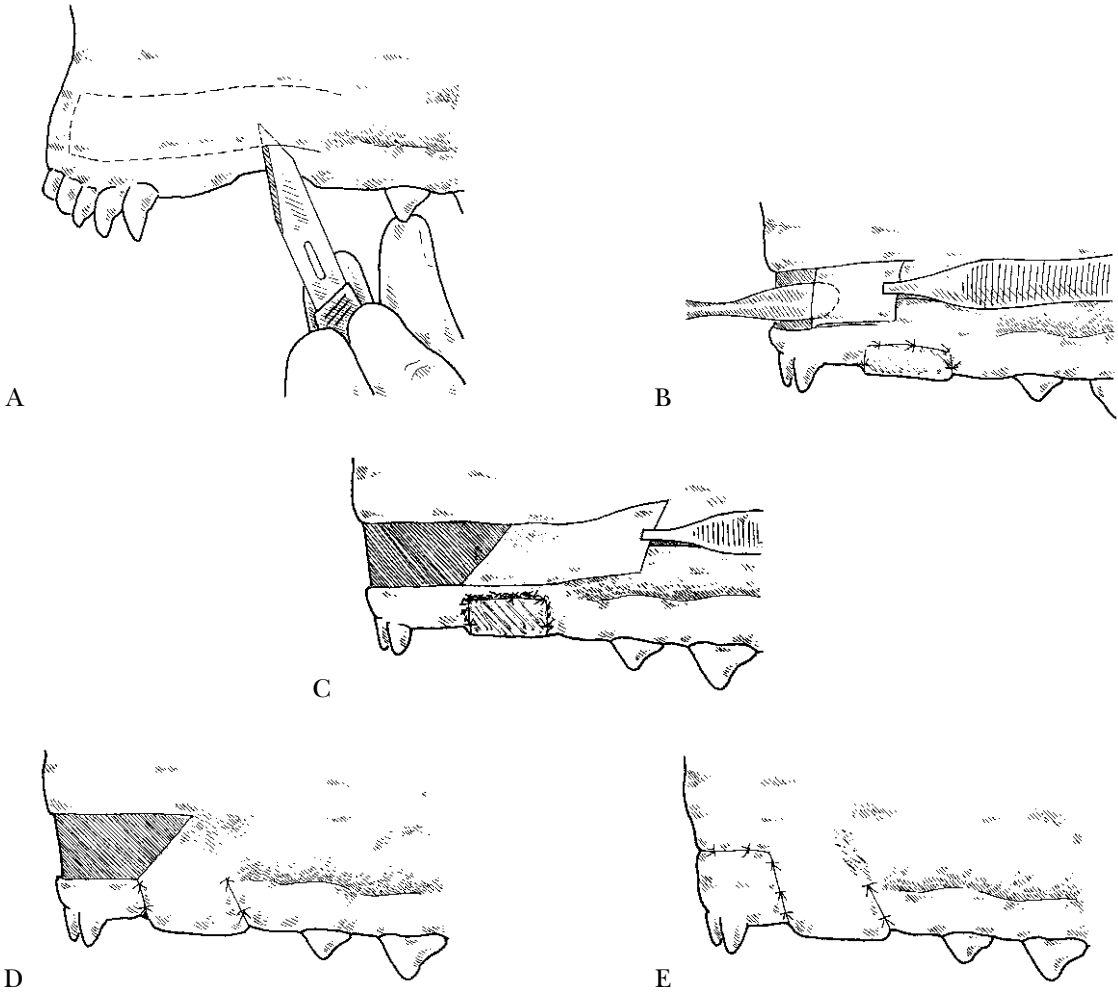


Fig. 6-17

- If a tooth is expected to erupt, it is called an *unerupted tooth*. Frequently, this is determined by clinically noting progress in the eruption process. If the eruption process has ended and the tooth is located beneath the mucosa, it is called an *embedded tooth*. This term usually is applied to teeth associated with some abnormality, such as gingival fibromatosis (gingivae fibrosa), supernumerary teeth, mesiodens, or pathologic states.

Indications for Extraction

- To avoid complications such as infection (pericoronitis), pressure necrosis, and follicular pathologic processes such as odontogenic cysts and neoplasms.
- To definitively treat infection or disease due to impaction.
- To assist in maintaining occlusion and comfort.
- Most impacted teeth should be removed.
- Note: if a tooth is embedded, an alternative to extraction is mandibulotomy; attach an eruption device to the embedded tooth and fix it, via its chain and a power cord, to an orthodontic labial arch wire. If this procedure is indicated or desired, and the clinician either does not have the equipment or experience, he or she may need to refer the case to a specialist.

Contraindications for Extraction

- Before the root has developed sufficiently to be certain that there is a problem.
- If there is an increased risk of injuring an adjacent significant structure (nerve tissue, vascular tissue, other teeth).
- When the patient's general health is not good enough to tolerate the procedure.

Objective

- Extraction with minimal damage to other oral structures.

Materials

- Canine or feline extraction pack.

Technique

Step 1—A radiograph is taken to identify the location of the impacted tooth (Fig. 6-18, A).

Step 2—A mucoperiosteal buccal flap is raised over the tooth as described on pp. 308 to 309 (Fig. 6-18, B).

Step 3—The bone covering the tooth is removed with a bur and high-speed handpiece (Fig. 6-18, C). This creates access to the crown and root surfaces.

Step 4—The tooth may be sectioned for a stepwise removal of the tooth and to create space for elevation and instrumentation (Fig. 6-18, D).¹⁹

Step 5—Once visualization is obtained, the remaining tooth structure can be displaced, elevated, and extracted (Fig. 6-18, E).

Step 6—A dental radiograph is taken to document what has been done.

Step 7—The site is closed using simple interrupted suture as described on pp. 310 to 311.

Complications

- Delayed healing due to improper closure or poor flap design.
- Damage to adjacent structures or fracture of the mandible when too much bone is removed or improper extraction technique is employed.
- Infection of soft tissue or bone.
- Oronasal or oroantral fistula may be created iatrogenically.

Aftercare: Follow-Up

- Standard postsurgical follow-up.

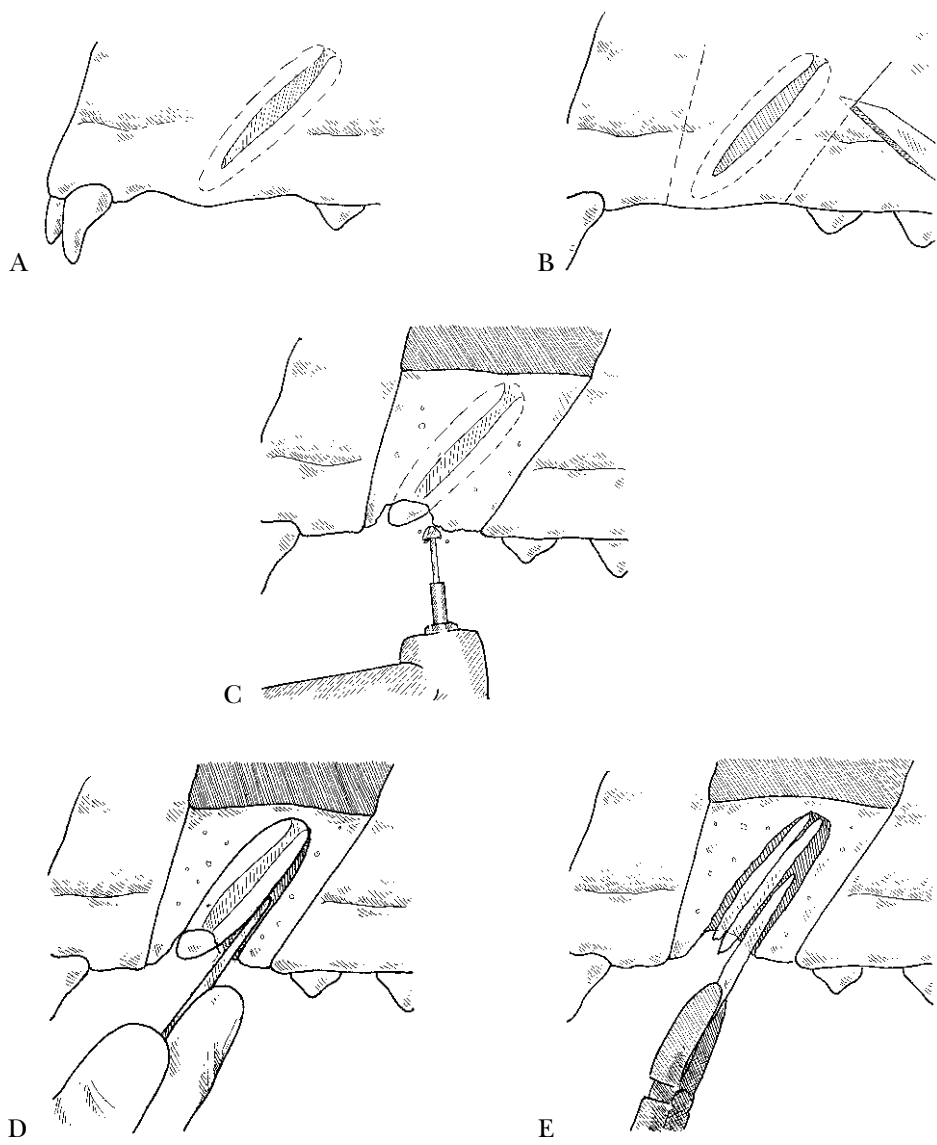


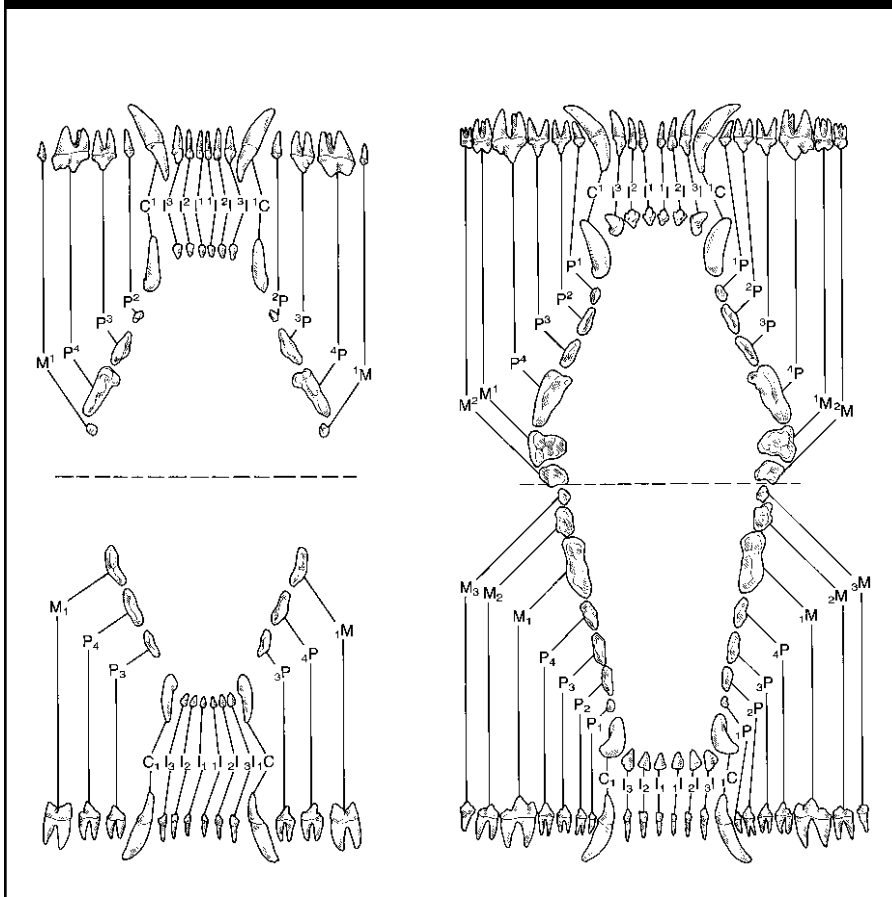
Fig. 6-18

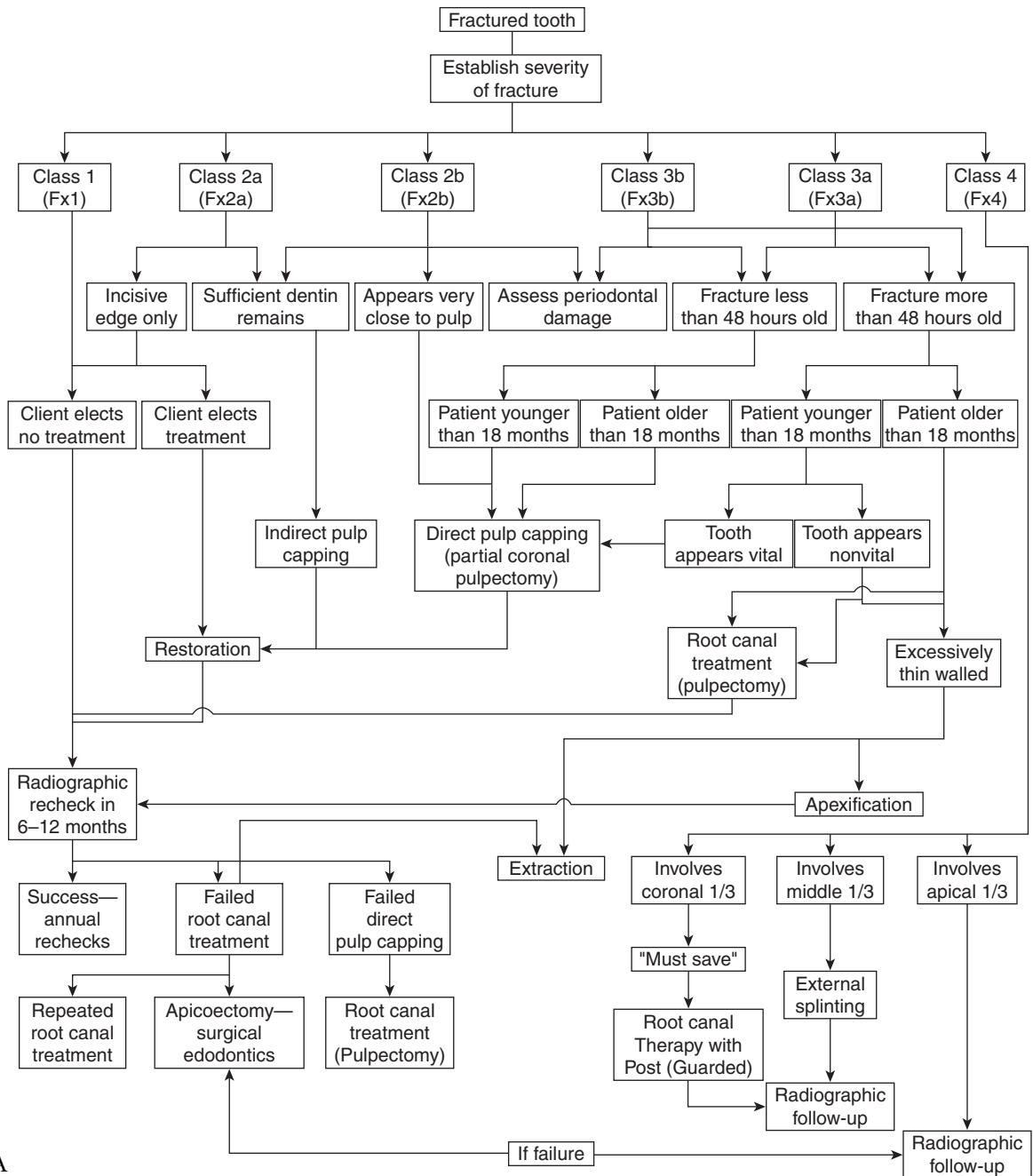
REFERENCES

1. Harvey CE, editor: Veterinary Dental News Position Statement of the American Veterinary Dental College, *J Vet Dent* 15:94, 1998.
2. Waite DE: Principles of exodontia. In: Waite DE, editor: *Textbook of practical oral and maxillofacial surgery*, Philadelphia, 1987, Lea & Febiger, pp 81-91.
3. Schloss AJ, Manfra Marretta S: Prognostic factors affecting teeth in the line of mandibular fractures, *J Vet Dent* 7:7-9, 1990.
4. Peterson LJ, et al: *Contemporary oral and maxillofacial surgery*, St Louis, 1988, Mosby.
5. Marett SM, Tholen M: Extraction techniques and management of associated complications. In Bojrab MJ, Tholen M, editors: *Small animal oral medicine and surgery*, Philadelphia, 1989, Lea & Febiger, pp 75-95.
6. Mulligan TW: *Oral/nasal fistula repair*, New Orleans, 1988, Nabisco.
7. Smith MM: Surgical extraction of the mandibular canine tooth in the dog, *J Vet Dent* 18(1):48-49, 2001.
8. Dorn AS: *Complications of dental extractions*, Chicago, 1989, Surgical Forum.
9. DeBowes LJ, Mosier D, Logan E, et al: Association of periodontal disease and histological lesions in multiple organs from 45 dogs, *J Vet Dent* 13(2):57-60, 1996.
10. Withrow SJ: Dental extraction as a probable cause of septicemia in a dog, *J Am Anim Hosp Assoc* 15:345-346, 1979.
11. Verstraete JM: *Self-assessment color review of veterinary dentistry*, Ames, Iowa, 1998, Iowa State University Press, pp 77-78.
12. Gracis M, Harvey CE: Radiographic study of the maxillary canine tooth in mesaticephalic dogs, *J Vet Dent* 15(2):73-78, 1998.
13. DuPont G: Crown amputation with intentional root retention for advanced feline resorptive lesions—a clinical study, *J Vet Dent* 12:9-13, 1995.
14. Dupont GA, DeBowes LJ: Comparison of periodontitis and root replacement in cat teeth with resorptive lesions, *J Vet Dent* 19(2):71-75, 2002.
15. Carr GB: Surgical endodontics. In Cohen S, Burns RC, editors: *Pathways to the pulp*, ed 6, St Louis 1994, Mosby pp 531-567.
16. Michael AH, Miserendino LJ: Instruments and materials. In Cohen S, Burns RC, editors: *Pathways to the pulp*, ed 4, St Louis, 1987, Mosby pp 397-440.
17. Rickles NH: A possible case in a human and an investigation in dogs of a death from air embolism during root canal therapy, *J Am Dent Assoc* 67:397-404, 1963.
18. Eisner ER: Nonsurgical and surgical tooth extraction and oronasal fistula repair. Part I, *Canine Pract* 21:12-15, 1996; Part II, *Canine Pract* 22:5-9, 1997.
19. Pedersen GW: *Oral surgery*, Philadelphia, 1998, WB Saunders, pp 69-71.



ENDODONTICS



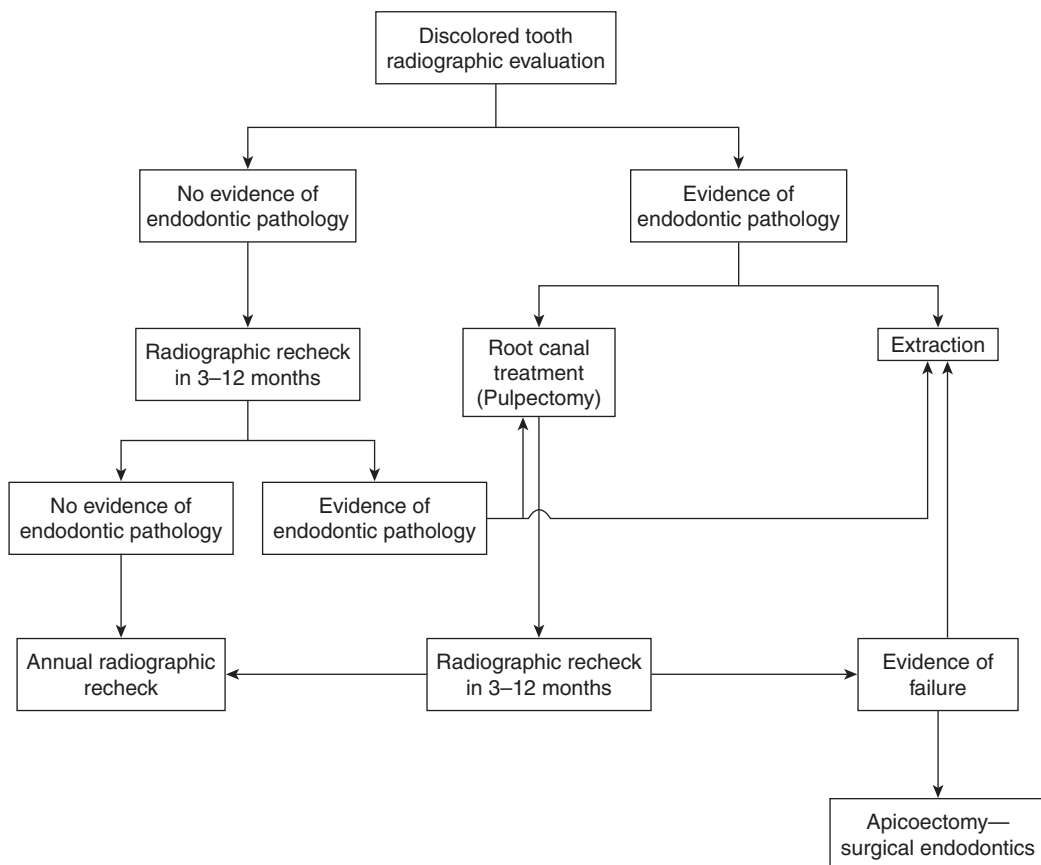


A

GENERAL COMMENTS

- The pulp is the innermost part of the tooth. The functional cells of the pulp are the odontoblasts, which produce dentin throughout the life of the tooth, creating a progressively thickened dentinal wall. Dental pulp consists of blood vessels and nerves that support the odontoblasts and provide internal sensory and metabolic function to the interior of the teeth.¹⁻⁴
- The objective of endodontic therapy is to maintain a vital tooth or, failing that, to

alleviate discomfort and infection from the tooth and periapical tissues by obliteration of the root canals.⁴⁻⁹ It may also be considered preventive treatment in a patient without symptoms when a dead tooth is treated to prevent subsequent abscess, bone lysis, and possible infections and invasion into other areas. The ultimate goal is to salvage the tooth and, in doing so, the therapy should be as least invasive and remove as little structural tooth substance as is possible while returning the tooth to its former form and function.⁴



B

Standard of Care

- As stated in Chapter 1, the best prophylaxis for malpractice is good records. Records are the single most critical evidence that can be presented in court at any level, as confirmation of accurate diagnosis and proper treatment. A standard of care does not require perfection, but rather a reasonable degree of skill, knowledge, and competence exercised by doctors under similar circumstances. As the level of veterinary dentistry rises during the twenty-first century, it behooves general practitioners to either develop an increased level of dental skill or at least increase their knowledge to a point of being able to refer a case in need of treatment to an appropriate clinician. Today the locality rule, which provides for different standards in different communities, is becoming rapidly outdated. The trend today, because of advances in continuing education, nationally published literature, internet communication, and increased availability of transportation of patients, is to move toward state standards for generalists and to national standards for veterinary specialists, including those who are not but advertise themselves as such.

Indications for Endodontic Therapy

- When either injury or a carious infection exposes either the pulp chamber or the root canal.
- When a pulp injury results in hemorrhage or necrosis in a closed pulp canal.
- When a pulp abscess or periapical abscess is present.
- When iatrogenic pulp exposure occurs during a restorative or endodontic procedure.
- When periodontal infection results in an ascending pulpal infection.
- When interrupted and incomplete tooth root development has occurred.
- When enamel or dentin fractures are present, they need to be evaluated radiographically and by transillumination, then treated as necessary to prevent bacterial pulp invasion.

Justifications for Endodontic Therapy

- People often do not perceive that their pet is in pain when a tooth has been damaged. Animals often do not exhibit pain once pulp death has occurred^{4,10,11} until periapical pathology occurs.
- Shortly after pulp has become exposed in a fractured tooth, the exposed dentinal tubules become sealed by a smear layer of tooth debris, plaque, or dirt, making the patient more comfortable until a pulpal or periapical abscess occurs. Only initially, after a fracture, when the tubules are open and the pulp is exposed, does the patient exhibit signs of pain. The pain is a result of fluid pressure changes experienced either through open dentinal tubules or direct pulp exposure.¹²

Signs of Endodontic Pain¹³

- Flinching when the tooth is percussed.
- Shearing or macerating food only on the side of the mouth opposite to the one with the injured tooth or teeth.
- Drooling on the injured side (pain causes increased salivation).
- Increased plaque and calculus on the injured side.
- Refusal of hard treats or chewing them only on the opposite side of the mouth.
- Sensitivity may be noticed during tooth-brushing or oral palpation.
- Reluctance to accept or carry favorite objects.
- Temperament becomes more irritable, especially if the patient is handled about the mouth or sometimes even petted on the top of the head.
- Hunting dogs may refuse training dummies.
- Utility dogs may refuse their dumbbells.
- Apprehensive dogs may either hesitate to bite or bite and release repetitively.
- Loss of concentration or attention to task.
- Reduced sense of smell, due to nasal infection.
- Moaning, which might be mistaken for arthritis, when the animal stands up.
- Inexplicable circling toward the injured side.

Additional Signs a Tooth Has Abscessed

- An oral malodor may be observed.
- A swelling may be seen superficially, approximating the area of the tooth's affected root.
- A fistulous drainage might be detectable at the mucogingival line.
- History may reveal social banishment because of odor or temperament.
- In fractured teeth, or ones in which the pulp is otherwise exposed, pathogenic bacteria will descend eventually into the pulp canal and cause either an abscess in the canal or periapically by extension of the infection. Periapical infection may lead to osteomyelitis and bone loss, weakening the mandible and predisposing it to fracture, or through necrotic bone, weakening the nasal plate and predisposing to oronasal fistula and chronic rhinitis by way of any of the maxillary teeth.^{4,11,13}

Advantages of Endodontic Treatment

- Efficient procedures to perform.
- Less invasive and less traumatic than surgical extraction.
- More esthetically pleasing to an owner than surgical extraction.
- Cost of root canal therapy, even if more than surgical extraction, is a good value because of reduced postoperative pain and a stronger mandible or maintained facial structure as compared to the opposite with extraction.
- Well-performed procedures are highly successful.
- Affected teeth are preserved in form and function.

Challenges of Endodontic Treatment

- To overcome potential lack of equipment, knowledge, or clinical experience.
- Requires a certain amount of inventoried supplies, equipment, continuing education, staff training, and client education.

Differential Diagnoses

- Ophthalmic disease, if an animal is rubbing its eye.
- Bee sting, if acute swelling is on face, muzzle, or jaw.
- Respiratory disease, if a unilateral nasal discharge is present.
- Allergies, if sneezing is reported.
- Digestive or systemic disease, if the patient is reluctant to eat or if food is dropped from the mouth.
- Uremia, in the presence of halitosis.
- Renal and pancreatic disease, when polydipsia and polyuria are reported.
- Primary endocrine, metabolic, or periodontal infection as primary causes of jaw fractures which might be secondary pathologic fractures.

Algorithm Outline for Endodontic Pathology

Following is an algorithm outline for endodontic treatment planning of teeth in which the pulp has been compromised.

Nonfractured Tooth

- I. No visible, radiographic, or detectable change requires no treatment.
- II. No visible change, but hypersensitivity of tooth.
 - A. Obtain further history and subjective information, and diagnostic tests, if history and symptoms indicate the need.
 1. Duration of symptoms: hours, days, weeks, months, years?
 2. Nature of discomfort: look for some or all of the following behavioral signs:
 - a. Rubs face on inanimate objects, or paws at face.
 - b. Refuses hard treats, or breaks them with the teeth only on one side of mouth.
 - c. Eats dry food more slowly, or eats only canned or softened food.
 - d. Hyperptyalism.

- e. Irritable temperament when petted on the head or touched near or on certain teeth.
- f. Aimless, incessant circling behavior.
- B. Diagnostic tests: standard root canal therapy if pulp compromise is indicated by any of the following tests:
 1. Radiographs: periapical lucency, internal pulp resorption, or root end resorption.
 2. Percussion: hypersensitivity of the tooth in question, compared with adjacent teeth.
 3. Transillumination: tooth is opaque when backlighted in a darkened room.
 4. Pulp testing: hypersensitivity.
- C. Discolored crown.
 1. Patient less than 2 years old: radiographic observation and follow-up.
 - a. At such a time when the pulp dies or abscesses, then either extract or perform apexification and follow-up radiographs, as necessary, followed by standard root canal therapy.
 2. Patient is more than 2 years old.
 - a. If just the coronal end of crown is discolored, take a radiograph and transilluminate. If apical end of crown is translucent and there is no radiographic evidence of pathology, then reevaluate annually.
 - b. If whole crown is discolored or if apical end of crown is discolored, perform standard root canal therapy or extraction.

Fractured Tooth

- Basrani classification, which takes into account the extent of tooth damage).²
 - I. Class A1 (crown: enamel only).
 - A. Client elects no treatment: take radiographs in 6 months.
 - B. Client elects treatment: restore the defect and recheck, take radiograph in 9 to 12 months.

- II. Class A2a (crown: enamel and dentin).
 - A. Client elects no treatment: take radiographs in 6 months.
 - B. Client elects treatment.
 1. If sufficient dentin remains (>0.5 mm) between defect and pulp, place indirect pulp cap with restoration, and take a radiograph in 9 to 12 months.
 2. If insufficient dentin remains (<0.5 mm) between defect and pulp, place pulp cap with restoration and take a radiograph in 9 to 12 months.
- III. Class A2b (crown, enamel, dentin, and pulp exposed).
 - A. Fracture is less than 48 hours old.
 1. Patient is less than 18 months old: perform vital pulpotomy (direct pulp cap procedure).
 2. Patient is more than 18 months old:
 - a. Pulp cap performed if tooth is mostly intact and risk of failure, and needing root canal procedure in future is worth opting for chance of salvaging tooth as vital.
 - b. Standard root canal therapy indicated unless service or sporting dog with mostly intact canine or carnassial tooth.
 - B. Fracture is more than 48 hours old:
 1. Patient is less than 18 months old:
 - a. Tooth appears vital: perform vital pulpotomy (direct pulp cap technique).
 - b. Tooth appears nonvital:
 - i. Excessively thin-walled: perform extraction.
 - ii. Or, if sufficiently important to salvage: perform apexification, followed by monthly radiographs and repeated treatment, and then standard root canal therapy unless treatment unsatisfactory, then extraction.
 2. Patient is older than 18 months old
 - a. Standard root canal therapy is indicated.

- IV. Class B (root fracture).
- A. Involving coronal one third of root.
 1. Extraction.
 2. Or, if in “must save” category: standard root canal therapy with post (guarded prognosis).
 - a. If procedure fails, then extraction.
 - B. Fracture involves middle third of root.
 1. Extraction.
 2. Or, if in “must save” category: standard root canal therapy with external splinting (guarded prognosis) with radiographic follow-up, and then surgical root canal therapy or extraction if procedure fails.
 - C. Fracture involves apical third of root.
 1. Extraction.
 2. Or if in “must save” category: standard root canal therapy with follow-up radiographs and if procedure fails, then surgical root canal therapy.
- V. Class C (fracture involving both crown and root).
- A. Extraction.

INDIRECT PULP CAPPING

General Comments

- Indirect pulp capping is indicated when a cavity or restorative preparation occurs within 1 to 2 mm of the pulp.
- During deep-decay cavity preparation, a layer of carious dentin can be left over the pulp. This layer will be sterilized with the application of calcium hydroxide, as shown by Aponte, Hartsook, and Camp in the 1960s (still valid information).¹⁴ Pulpitis of deep cavity preparation, secondary to chemical or thermal burns, can be partially prevented by application of cavity varnish, liners, or a base preparation to the tissue closest to the pulp.¹⁵ This is a highly controversial topic in human dentistry in which investigators found that even a double layer of Copalite did not prevent bacterial leakage and growth on cavity walls.¹⁶

Indications

- Deep-cavity preparations where the pink hue of pulp is seen shining through the dentin.
- Extensive crown restorations on vital teeth.

Contraindications

- Direct pulp exposure.
- Nonvital tooth restorations.
- Radiographic evidence of periapical or apical pathology.
- Radiographic evidence of a root fracture.
- Radiographic evidence of a tooth with periodontal disease that is not salvageable.

Objective

- A protective layer of calcium hydroxide or glass ionomer is placed, as a lining base, in a vital tooth as a covering, on the floor of a restorative preparation or cavity preparation close to the pulp tissue, to protect the pulp from thermal or chemical insult and to prevent sensitivity.

Materials

- Base material to cover the nearly exposed pulp. For many years, a fast-setting calcium hydroxide preparation such as Life (Kerr Corporation, Romulus, Mich.) or Dycal (Dentsply International, York, Penn.) has been recommended. Recently, glass ionomers, such as Ionoset Microspand (DMG Hamburg, distributed by Foremost Dental Manufacturing, Darby-Spencer-Mead, or Burns Veterinary Supply, Farmers Branch, Tex.), have been used and may be the preferred material to use as a base.
- Injection syringe or plastic working instrument.
- Materials, instruments, and equipment needed to prepare and complete a cavity preparation or restoration (see Chapter 8, Restorative Dentistry).

Technique

Step 1—The mechanically prepared cavity preparation or restoration site is irrigated with sterile saline to remove dentinal debris and is air dried (Fig. 7-1, *A*).

Substep 1—A dentin tooth conditioner is applied to the dentinal surface with a Getz brush for the manufacturer's recommended time, rinsed with water, and air dried (Fig. 7-1, *B*).

Substep 2—For deep-cavity preparations, it is desirable to use a calcium hydroxide and glass ionomer cavity liner. A minimum layer 1 mm deep should be placed. The calcium hydroxide should be placed first. The tooth conditioner can be used superficial to the calcium hydroxide product to prepare the dentinal walls for the glass ionomer. If possible, avoid getting the liner on the walls of the cavity coronally in the area of the final restoration.

Step 2—The cavity liner is applied to the fundus of the cavity or restorative preparation in a thin layer, using a Getz brush or plastic working instrument (Fig. 7-1, *C*), and is allowed to dry. Bonding of the final restoration will be inhibited if the liner coats the walls of the cavity preparation (Fig. 7-1, *D*). If the walls are coated inadvertently, they should be prepared again.

Substep 1—When using a light-cured glass ionomer liner, the material is cured with a visible light gun for the prescribed length of time (Fig. 7-1, *E*).

Step 3—In deep restorations, another layer of a glass ionomer can be placed to reduce the thickness of the final restoration (Fig. 7-1, *F*). This reduces the polymerization shrinkage that occurs as the restoration material cures.

Step 4—The restorative procedure is continued (Fig. 7-1, *G*), as described in Chapter 8.

Postoperative Care

- Follow-up radiographs at 6 and 12 months to evaluate pulp chamber size and evidence of apical abscess formation by comparison with other teeth.

Complications

- Entering pulp chamber during cavity preparation.
- Not allowing enough room for the final restorative material. The surface restorative needs to be thick enough for the patient to benefit from its abrasion-resistant and impact-absorbing attributes.
- Covering the walls of the preparation with the liner.
- Losing restorative material due to poor retention.
- Imperfect margins in finished restoration resulting in marginal leakage.

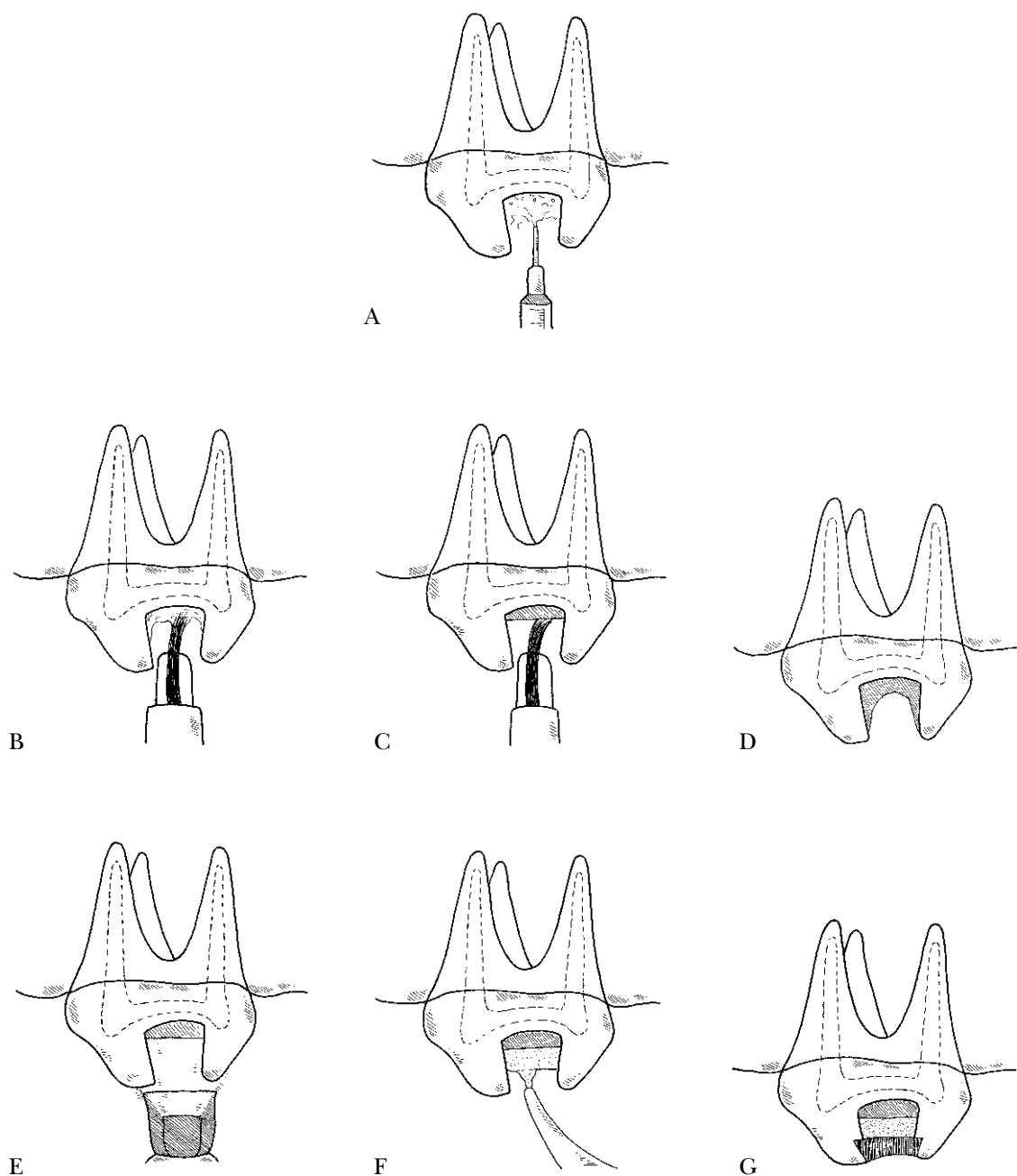


Fig. 7-1

INDIRECT PULP CAPPING: CROWN THERAPY

General Comments

- Due to rules about altering heritable anatomy in most dog show organizations, ceramic crown installation should not be performed on dogs intended to be entered in conformation-type dog shows.
- It is the best treatment to prevent further damage to the crown.
- A full-coverage crown (Fig. 7-2, A) or half-coverage crown (Fig. 7-2, B) may be placed to afford protection to the tooth to prevent chipping or further wear.

Indications

- Teeth that have fractures that have not exposed the pulp chamber.
- Teeth that have had excessive wear from such activities as carrying or chewing tennis balls or chewing on hard objects.

Contraindications

- Direct pulp exposure or radiographic evidence of apical disorder, in which case endodontic therapy should be performed first.
- Animals intended for show might have a metal crown, but not a porcelain-fused-to-metal or a high-impact ceramic crown. Although unfounded medically, animals may be disqualified from certain show events if they have crowns.
- In smaller teeth, the amount of structural tooth that would need to be removed in order for a fabricated crown to fit properly might severely weaken the tooth, subjecting it to fracture at the crown's margin.

Objective

- To prevent further trauma and wear.

- To regain grasping function in service, competitive obedience, hunting, or field trial dogs.
- Cosmetics in certain instances.

Materials and Technique

- See Chapter 8.

VITAL PULPOTOMY AND DIRECT PULP CAPPING

General Comment

- In patients younger than 18 months, it is frequently desirable to achieve additional dentin formation to increase the strength of a tooth that has been fractured. For recent fractures, vital pulpotomy with direct pulp capping is the treatment of choice. The technique will be the same, but the difference between a vital pulpotomy and a direct pulp cap is that in a direct pulp cap, a portion of healthy pulp is removed to make room for the restorative materials. In a vital pulpotomy, it is unhealthy pulp that is removed. A vital pulpotomy is also referred to as a *partial coronal pulpectomy*. Patients that have received this treatment should be monitored closely with radiographs to observe changes in pulp health. Root canal therapy is indicated if death of the pulp is evident on follow-up examination.

Indications

Vital Pulpotomy

- Fractured tooth crowns with pulp exposure of less than 2 weeks' duration in patients younger than 18 months.
- Fractured tooth crowns with pulp exposure of less than 48 hours' duration in patients older than 18 months.

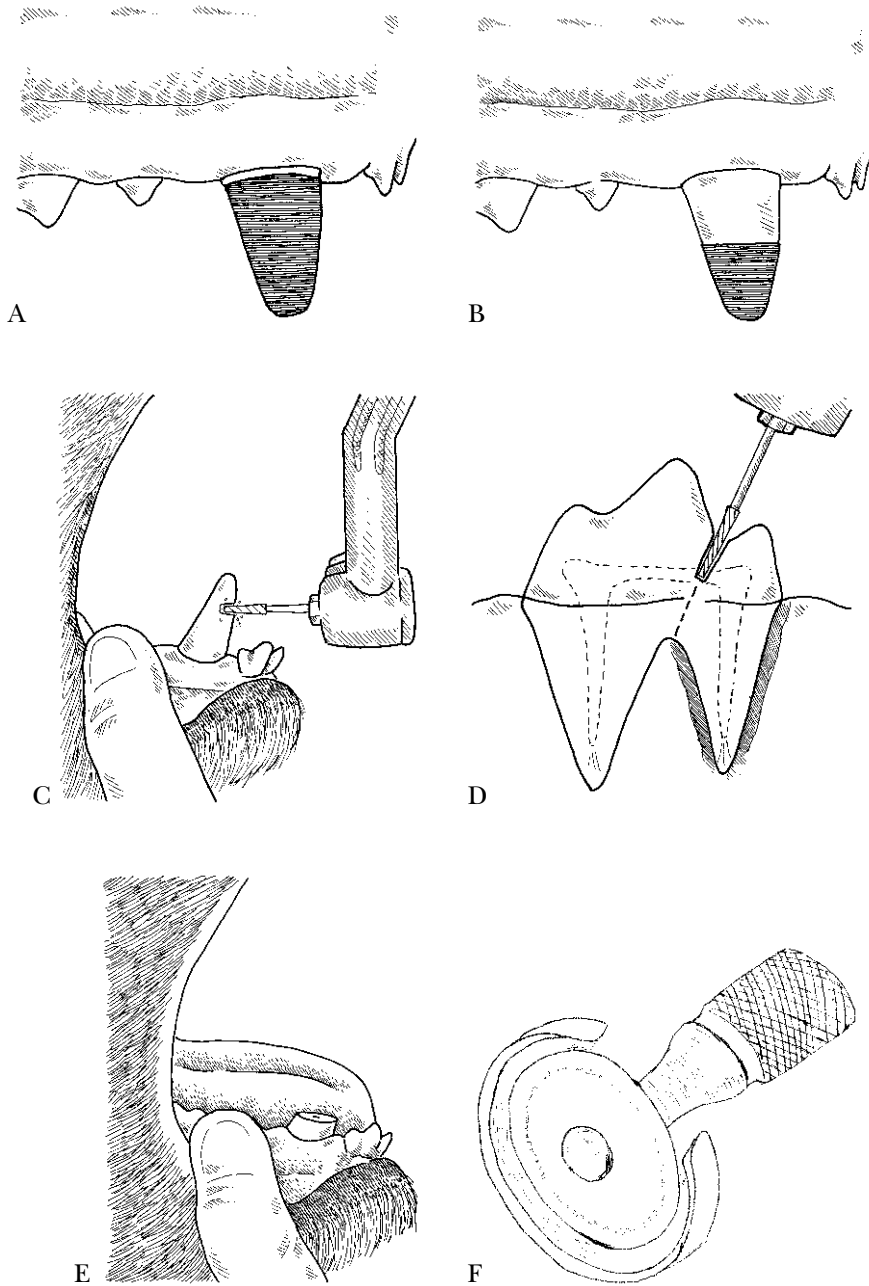


Fig. 7-2

Direct Pulp Cap

- Disarming animals by shortening the crowns of teeth used for biting.
- In patients with malocclusion, to shorten any tooth crowns so as to eliminate interference with other teeth or soft tissues.
- Accidental exposure of pulp during deep-cavity or restorative preparation.
- Hemi-section of vital multirooted teeth with extraction of one diseased or injured root when the remaining roots and crown are salvageable. This situation might occur with a purebred show dog of a breed whose standard calls for full dentition, thus making it desirable to save a portion of a tooth to prove its presence.

Contraindications

- Pulp death.
- Pulp exposure longer than 2 weeks in patient of any age.
- Fractures of the primary teeth. This procedure can be performed on primary teeth but is usually not cost effective when compared with extraction.
- Severely traumatized or grossly contaminated pulp when the pulp is unlikely to survive.

Objective

- Protect the pulp by stimulating dentinal repair with secondary dentin by using calcium hydroxide, as an irritant, directly on the pulp tissue and placing a restoration over the pulp access site.

Materials

- Number 701L cross-cut, tapered-fissure bur or diamond disc, accessorized with a disc guard to protect the adjacent soft tissues, for shortening the crown.
- Number 2 or 4 round bur in high-speed handpiece.
- Sterile saline.
- Sterile absorbent points.
- Dycal (Dentsply International).
- Calcium hydroxide paste (HypoCal, Ellman, Hewlett, NY; Pulpdent paste, Pulpdent Corporation, Watertown, Mass.) or calcium hydroxide powder.

- Retrograde amalgam carriers, sizes $\frac{3}{64}$ and $\frac{5}{64}$ inch.
- Intermediate filling material (Life, Dycal, IRM2 [Dentsply] glass ionomer base materials).
- Injection syringe.
- Restorative material of choice is discussed in Chapter 8.

Technique

Step 1—The oral cavity, particularly the tooth to be treated, is disinfected with an antiseptic solution (0.12% chlorhexidine). Aseptic technique is used throughout the procedure. If a sterile delivery system is not built into the handpiece system, coolant can be delivered by an assistant using a sterile solution in a syringe sprayed on the site.

Step 2—A #701L cross-cut, tapered-fissure bur in a high-speed or low-speed handpiece with sterile physiological saline or sterile water cooling is used to amputate a tooth crown (Fig. 7-2, C) or hemisect a multirooted tooth (Fig. 7-2, D). (When disarming animals, the canine teeth are shortened to the level of the adjacent incisors) (Fig. 7-2, E). A $\frac{3}{4}$ -inch diameter double-sided diamond disc, with a disc guard to protect the adjacent soft tissue, is another option (Fig. 7-2, F).

Step 3—A bur approximately equal in size to the diameter of the pulp chamber (round, pear, or tapered-fissure) is used in a high-speed handpiece to remove the coronal portion of the pulp from the amputated tooth, removing 5 mm of the pulp from the remaining endodontic system (Fig. 7-3, A).

Step 4—Hemostasis may be achieved using sterile saline lavage and the blunt end of multiple sterile, dry, paper points. Leaving a paper point in place for 2 to 3 minutes is often sufficient to control hemorrhage. In cases with persistent hemorrhage, lavage with a local anesthetic solution containing epinephrine¹⁷ or 20% ferric sulfate (Viscostat, Pulpdent) can be used. Caution should be used if employing a halothane (Fluothane) anesthetic agent. If hemorrhage continues, the coronal portion of the canal should be inspected to be sure all pulp tissue coronal to the area cleaned out in step 3 has been removed. Any filaments of inflamed pulp left may cause continued bleeding.^{14,17,18} Excessive hemorrhage at an exposure site or during the

procedure indicates severe inflammation, and treatment adjustment should be considered, either changing the therapy to pulpectomy or to extraction.¹⁴ A coating of calcium hydroxide powder on the paper point may also help control hemorrhage (Fig. 7-3, *B*).

Step 5—When bleeding is controlled, calcium hydroxide paste is applied over the exposed pulp for a depth of 1 to 2 mm using the applicator syringe provided (Fig. 7-3, *C*). The paste is tamped against the pulp stump with the blunt end of a sterile paper point. If using a calcium hydroxide powder, a sterile retrograde amalgam carrier can be used to gently place a layer of powder against the pulp. More recently mineral trioxide aggregate (MTA) (ProRoot, Dentsply Tulsa Dental, Tulsa, Okla.) has been advocated

because of its retention and resistance to leakage. MTA is a compound somewhat similar to Portland cement. It is mixed with water or physiologic saline and applied directly to the pulp with an amalgam plugger or other suitable instrument. It has been used successfully and is recommended by the manufacturer for use in vital pulpotomies, direct pulp caps, and retrograde root canal therapy.

Step 6—An intermediate filling material, such as glass ionomer, is placed over the calcium hydroxide paste (or MTA) with an injection syringe or jiffy tube and is allowed to cure (Fig. 7-3, *D*).

Step 7—The pulpal access (cavity) opening is prepared (Fig. 7-3, *E*) for the desired filling material, and the restoration is completed (Fig. 7-3, *F*).

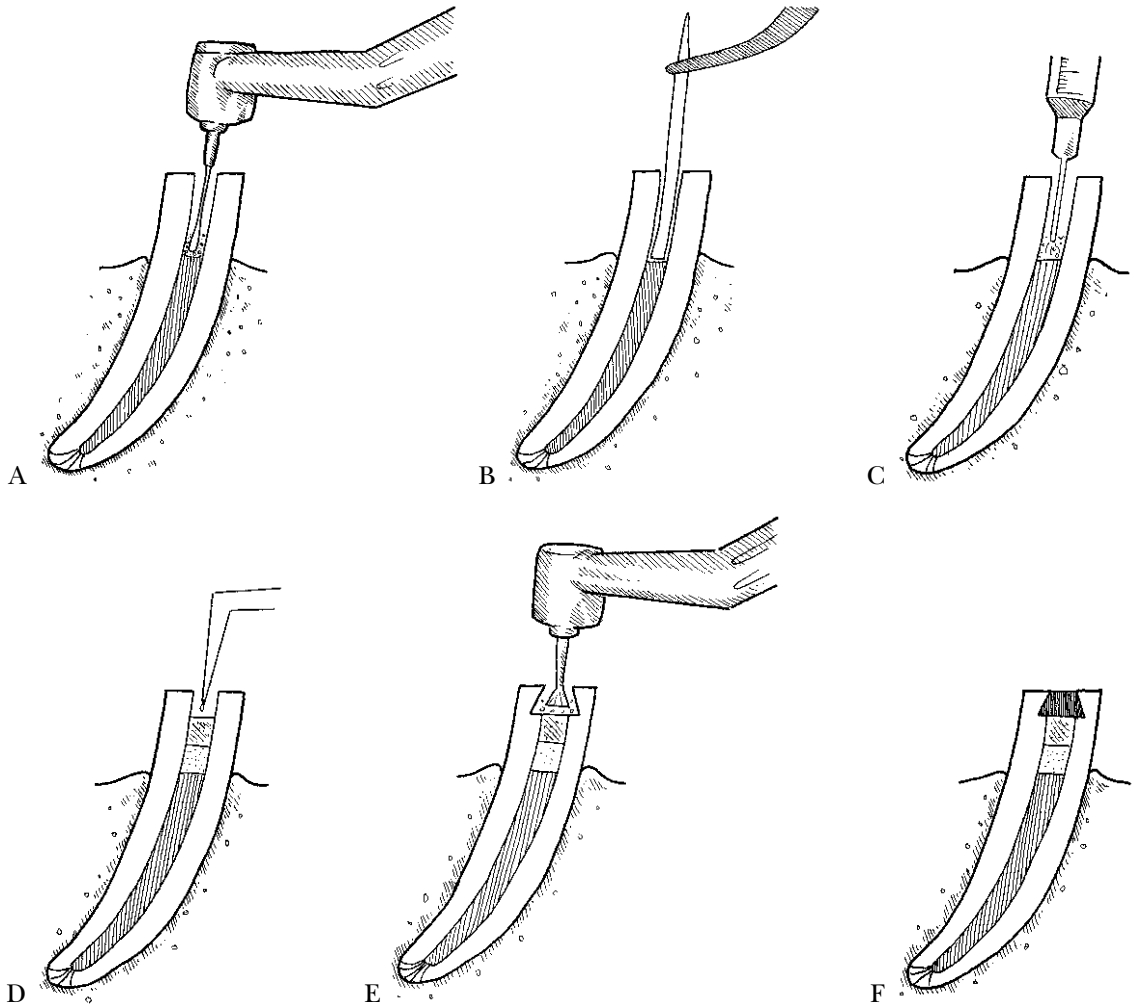


Fig. 7-3

Postsurgical Care

- Postoperative antibiotics should be administered for 7 days.
- Radiographic follow-up at 6 months and 12 months, or at appropriate intervals, is necessary to detect pulp death and subsequent apical changes indicating the need for root canal therapy. (Compare with contralateral tooth.)

Complications

- Inaccurate history resulting, in reality, in an older injury and more extensive pulp infection than initially assessed.
- Loss of restorative material with possible contamination of pulp.
- Tooth discoloration due to hemorrhage from pulp seeping into dentinal tubules coronal to pulp amputation. (Bleeding through intermediate filling material necessitates redoing the procedure.)
- Pulp death, which may lead to apical abscess formation.
- Pulpitis, which causes pain and may be difficult to detect.
- Internal resorption of the pulp chamber or root canal.

DIRECT PULP CAPPING WITH DENTAL ADHESIVES

General Comments

- Studies have shown that tissue responses after direct pulp capping may be caused by bacterial infiltration rather than directly by material toxicity.¹⁸
- The advantage of this technique is that it may provide a superior biologic seal due to the increased amount of resin contact.

Indications, Contraindications, Objectives

- Same as for calcium hydroxide technique in preceding section.

Materials

- In addition to those listed in calcium hydroxide technique in preceding section:
- Acid etch gel.
- Dentin adhesive.
- Unfilled and filled light-cured resin.
- Light-cure gun.

Technique

The coronal portion of the tooth is prepared as in the preceding section. Hemostasis is obtained, and this technique begins after step 5.

Step 6—Provisionally cover the exposed pulp with a calcium hydroxide paste with a sterile materials application syringe. This material is applied to protect the pulp during the next step and must not be skipped.

Step 7—A 37% phosphoric acid gel (contained in the composite resin kit) is applied for 20 seconds.

Step 8—After 20 seconds, the gel is wiped onto the enamel for a brief 10 seconds and then rinsed off with sterile saline.

Step 9—The area is blotted dry.

Step 10—The entire preparation, including enamel, dentin, and pulp tissue, is treated with the dentinal primer for approximately 5 seconds, followed by 5 seconds of air drying.

Step 11—A light-cured unfilled resin is applied and activated.

Step 12—The filled resin is applied.

- See Chapter 8 for further information on composite dental restoration.

Postsurgical Care

- Postoperative antibiotics for a minimum of 7 days.
- Pain medication for 3 days.
- Radiographic follow-up at 6 months and 12 months or, if no problem is perceived, at appropriate routine prophylactic recall appointment intervals.

Complications

- A dead tooth may result from any vital pulp capping procedure.
- The risks should be explained to the client before treatment: (1) the tooth injury may be older or more severe than it was thought to be, (2) the undetectable overwhelming infectious organisms might have contaminated the pulp, and (3) the patient may further insult and injure the tooth with inappropriate oral behavior.

APEXIFICATION, APEXOGENESIS, HARD TISSUE FORMATION

General Comments

- Apexification is the process of stimulating the formation of a closed apex with hard tissue when a necrotic pulp is present in an incompletely developed young permanent tooth, whether delayed by infectious or noninfectious process.
- Apexogenesis describes the completion of normal developmental root lengthening in young, permanent vital teeth.
- Typically a pulp canal is cleaned and filled with a temporary paste to stimulate the formation of calcified tissue at the apex.¹⁴

Calcium hydroxide paste is the traditional medicament and may require intermittent replacement during the healing period if there is no radiographic evidence of hard tissue formation. After radiographic evidence of apical closure is seen, the temporary filling material is removed and a standard root canal procedure performed with gutta-percha.

- Hard tissue formation is usually seen in 3 to 6 months.
- Length of time to apexification has not been documented in dogs but can take 6 to 24 months in humans.^{14,19} Osteoid or cementoid is the calcified material that forms over the apical foramen secondary to this process, as identified by investigators.²⁰⁻²² The treatment is a definite challenge, both in technique and in achieving recall compliance with clients. The prognosis is guarded in immature animals due to the fragility of the thin tooth wall that is subject to fracture upon minimal trauma.

Indications

- Fractured tooth crowns with severely traumatized or necrotic pulp in animals with a weak or absent apical seal (less than 18 months of age).
- Root perforations caused by over-instrumentation during endodontic therapy.

Contraindications

- Mature teeth with injured pulp and a solid apex do not need apexification; standard root canal therapy is the treatment of choice and is highly successful.
- Inability of client to return for follow-up radiographs and completion of root canal therapy.

Objective

- To induce closure of the apex of the root canal or formation of a calcified barrier at the apex to allow for future obturation of the canal.

Materials

- Calcium hydroxide paste (Pulpdent Paste, HypoCal).
- Lentulo spiral paste filler.
- Endodontic files and stops.
- Sterile water or saline.
- Sterile paper points.
- Needle and endodontic syringe.
- Sterile cotton pellets.
- Fast-setting cement base (Dycal, Life, IRM2) or glass ionomer base material (see Chapter 8).
- Restorative material of choice.

Technique

Step 1—A radiograph is taken to examine development of root length and apical closure.

Step 2—Access to the pulp chamber is made per standard endodontic treatment (see Coronal Access to the Pulp Chamber).

Step 3—A small file is placed in the canal to the approximate apical limit, and the tooth is radiographed again to determine a working length of the files, optimally to within 2 mm short of the apex, thus preventing injury to the periapical or apical tissues (Fig. 7-4, A).

Step 4—The root canal is filed and shaped in a standard manner (described in the section Cleaning and Shaping the Canal), using only sterile water or saline for irrigation (Fig. 7-4, B).

Step 5—The canal is dried, using the blunt end of sterile paper points (to avoid perforation into the apex) (Fig. 7-4, C).

Step 6—The canal is filled with calcium hydroxide paste, using a spiral filler with a stop at the working length (Fig. 7-4, D) or a sterile needle with an endodontic syringe.

Step 7—The calcium hydroxide paste is forced to the apex by placing a cotton pellet over the paste and using a blunt plugger to condense it apically (Fig. 7-4, E). The cotton pellet is removed with an endodontic file or broach.

Step 8—The calcium hydroxide paste is removed 3 mm from the access area, and a fast-setting base is placed over the paste (Fig. 7-4, F).

Step 9—A restoration is placed according to standard techniques.

Postoperative Care

- Follow-up radiographs are taken every 3 months to evaluate apical closure or root healing.
- When the desired hard tissue formation or apical closure is seen, the calcium hydroxide paste is removed, the canal is irrigated with sterile saline, and the canal is dried. Obturation can be completed using a technique to fill a larger canal adequately (chloropercha, inverted cone, or thermoplasticized gutta-percha technique).

Complications

- Restoration may need to be replaced; use restorative material that can be removed with the least damage to the tooth.
- Chronic abscess formation or drainage due to the thin wall of the tooth.
- Perforation of the apical seal obtained when refiling the canal.
- Further fracture of tooth due to thin-walled root structure.

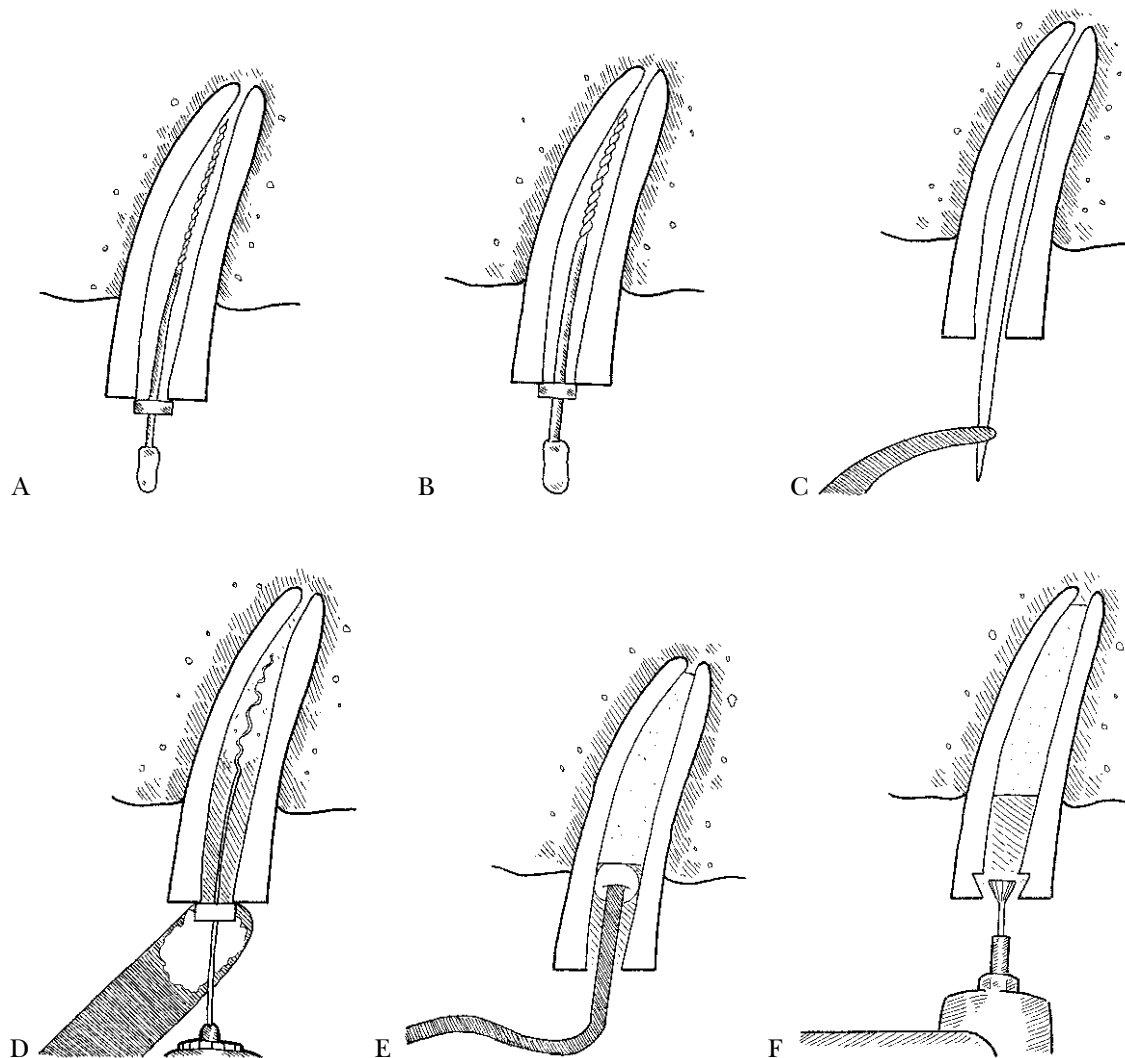


Fig. 7-4

NONSURGICAL ROOT CANAL THERAPY: STANDARD, NORMOGRADE, AND PULPECTOMY

General Comments

- When the tooth pulp has been traumatized, the pathogenesis culminates in apical root end resorption and abscess formation in the surrounding osseous tissue.²³⁻²⁵
- The theory of standard root canal therapy is that if the source of the infection (the root canal) is cleaned, the body will eliminate any residual escaped periapical infection.
- Bacterial pulpal infection can occur in an intact tooth. When a systemic infection occurs, microorganisms can ascend through the apical delta to contaminate the pulp canal (anachoresis).
- Patients requiring root canal therapy may exhibit a variety of signs.
- Patients may be asymptomatic.^{26,27}
- Patients may show signs such as fever, localized facial edema, a draining tract out of the skin or orally, drooling, reduced biting pressure (some trainers report attack dogs bite and release as they bite—*typewriting*), or reluctance to eat (they may pick up food, start to chew, and then drop the food). Other clients report patients licking in the air, circling, or displaying other stress patterns. Trained tracking dogs or dogs used for their sense of smell may lose their ability to perform their tasks; other service dogs may lose their concentration.

Indications

- Fractured crown with pulp exposure (Fig. 7-5, *A*).
- Worn tooth with pulp exposure (Fig. 7-5, *B*).
- Deep carious lesion with pulp exposure (Fig. 7-5, *C*).
- Discolored tooth with pulp death (Fig. 7-5, *D*).
- Teeth that are opaque when transilluminated.
- Reimplantation of avulsed or luxated tooth.
- Radiographic evidence of periapical bone lysis.

Contraindications

- Fractured primary teeth.
- Teeth with an incomplete apex. Studies have

shown, however, that the apex may close as early as 10 months of age.²⁸

- In adult teeth of animals younger than 18 months, when the pulp chamber is large and dentin layer is thin.
- Fractured crown with vertical root fracture.
- Tooth with internal resorption, creating a thin wall.
- Old animals with inaccessible or sclerosed root canals.
- Severe apical changes involving more than one third of the root.
- Crown root fractures.
- Severe wear that has involved the periodontium and external resorption.
- Patients severely affected with systemic disease such as heart disease, diseases that slow healing such as diabetes, and terminal cancer.

Objective

- To remove diseased or necrotic pulp tissue and achieve a hermetic seal at the apex to preserve a tooth. Root canal therapy consists of three basic procedures: (1) accessing the pulp canal, (2) cleaning and shaping the canal, and (3) obturating (filling) the canal. Each of these procedures will be covered as for a preparatory treatment, before restoring the tooth surface (see Chapter 8). Following are guidelines to adapt these general principles to individual tooth types.

Coronal Access to the Pulp Chamber and Root Canal

General Comments

- The coronal access (perforation and entry to the pulp canal) is the first step in root canal therapy. The access may already be present, in the case of a fractured tooth, or may need to be created.

Objectives

- To obtain straight-line access to the apical (toward the apex) third of the root canal, which will permit free instrumentation of the canal and preservation of as much tooth structure as possible.
- To create a cornucopia-shaped convenience form that is widest at the access site and permits shaping the access to the width of the

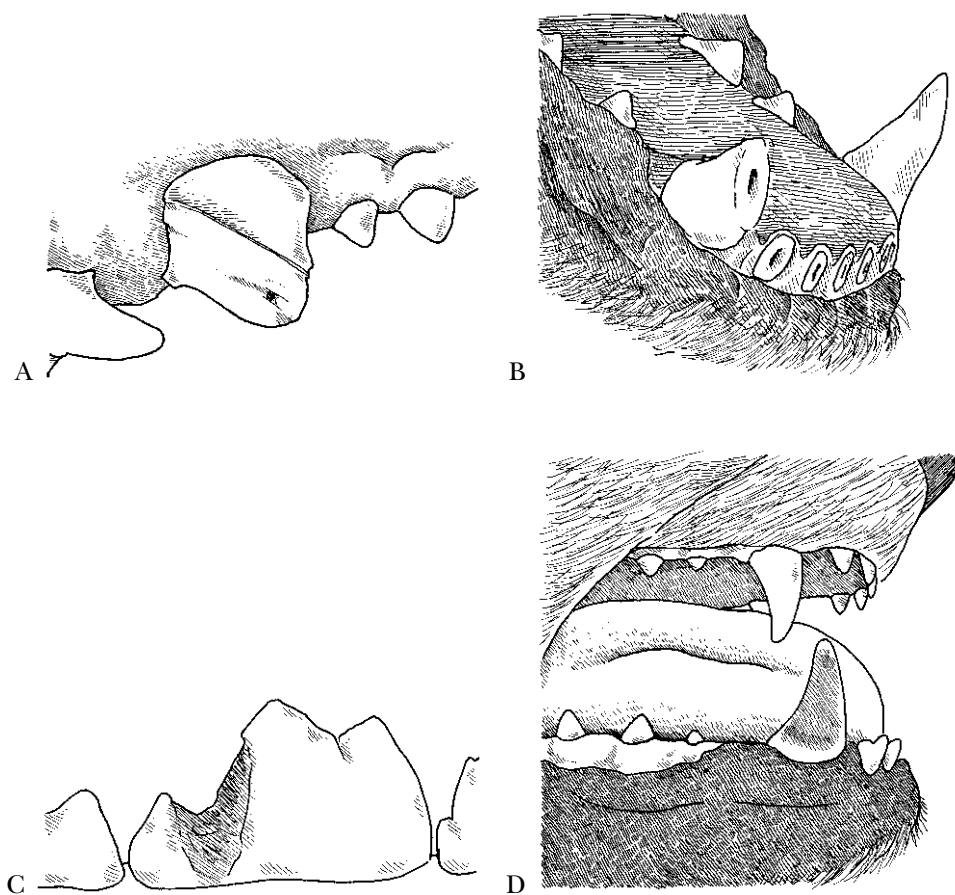


Fig. 7-5

pulp chamber, so that there are no overhangs of the root canal roof and the coronal walls to deflect the instruments during preparation.

Materials

- Number 2 or 4 round bur, #330 pear bur, or #701 or #701L cross-cut tapered-fissure bur for high-speed or low-speed handpiece.
- Endodontic explorer (DG-16).
- Intraoral radiographic film.
- Orifice widener (optional).
- Gates Glidden drills.

Technique

Step 1—A preoperative radiograph is taken to identify landmarks, to evaluate canal size and position, and to confirm the treatment plan.

Step 2—Evaluate the tooth clinically to determine root angulation, cusp position, and surface anatomy to help determine appropriate position and angulation of the access site. (Access in specific teeth is outlined later in this chapter under specific tooth types.)

Step 3—The oral cavity is disinfected with 0.2% chlorhexidine solution.

Step 4—Using the desired cutting bur, a hole is drilled through the enamel layer with the bur positioned perpendicular to the tooth surface, so as to minimize “wandering” of the bur tip. This step is eliminated if an open fracture site allows straight-line access to the apex (Fig. 7-6, A).

Step 5—Once the enamel has been perforated, the bur is repositioned and aligned parallel with the root canal, and the access site continues to be developed (Fig. 7-6, B).

Step 6—The access site is deepened until the pulp chamber is entered. When using a high-speed handpiece, a reduced resistance and a higher pitched drilling noise are noted when the pulp chamber is penetrated (Fig. 7-6, C).

Step 7—The access can be enlarged, using a #701L bur or Gates Glidden reamer, and shaped to expose the entire width of the pulp chamber, removing ledges so as to appropriately accommodate the endodontic files that will be introduced to debride the root canal (Fig. 7-6, D).

Complications

- Removal of too much dentin at the cervical margin weakens tooth structure and may

lead to postoperative traumatic fracture of the crown (Fig. 7-6, E).

- Incorrect alignment of the bur with the root canal may lead to perforation of the cervical area or wall of the root (Fig. 7-6, F).
- Inability to achieve pulp exposure (especially the palatal root of maxillary carnassial tooth).
- Ledge formation leading to excessive stress or bending of files during filing (Fig 7-6, G).
- A dull bur may burn the enamel or dentin, causing thermal necrosis and discoloration.
- A bur breaking and blocking the canal, preventing complete apical debridement.
- Anatomic abnormalities interfering with root access or complete root canal debridement.

Cleaning and Shaping the Canal

Objective

- To debride the root canal, by removing all pulp tissue and necrotic or softened dentin, and to shape it in preparation for obturation. Endodontic files are used for this purpose, and the canal is disinfected with disinfectant irrigating solutions.

Materials

- Endodontic files and reamers with rubber endodontic stops: 45-mm K-files (Brasseler USA, Savannah, Ga.) are minimal length for canine teeth in dogs; K-files 60 mm and Hedström files are available for larger patients.
- Broaches.
- Intraoral radiographic film.
- Syringes with blunt-end 27-gauge irrigation needles.
- Sodium hypochlorite solution (household bleach). See discussion below under Irrigation.
- EDTA (ethylenediamine tetraacetic acid) preparation (RC Prep, Premier Dental Products, Plymouth Meeting, Penn; REDTA Solution, Roth International, Chicago, Ill.; Endodilator, Union Broach Dental Products, Division of Moyco Industries, York, Penn.).
- Absorbent (paper) points.
- Ruler, measuring device, or endodontic ring.
- Dressing forceps.
- Gates Glidden drills.
- Peeso reamers.

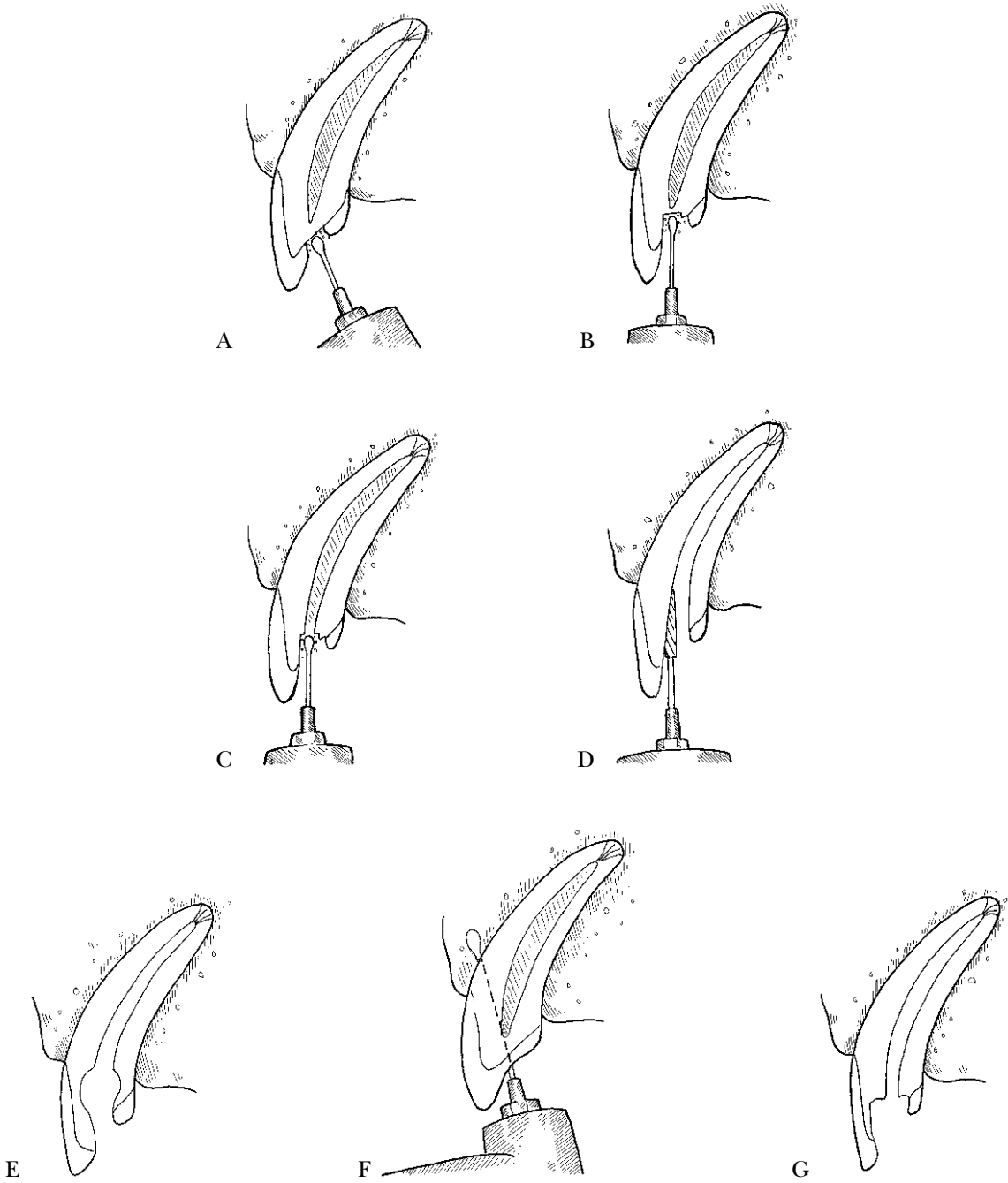


Fig. 7-6

Technique

Step 1—Length determination. A small-diameter endodontic file (usually size 10, but 06 and 08 sizes are available) with preplaced endodontic stop is inserted into the root canal 2 mm short of the estimated canal length, as determined from a preoperative radiograph (Fig. 7-7, *A*).

Step 2—Radiograph. A radiograph is taken to verify the file depth (how far the file has penetrated) and the working length (how far the file should penetrate). This apical stop indicates that the pulp canal does not extend beyond the file. The ideal working length is 1 mm short of the apex. The canal usually needs to be instrumented further, and the file may be inserted farther and additional radiographs taken until the working length is achieved. Once the working length is achieved, the endodontic stop is moved down the shaft of the file until it contacts the crown, with the file fully inserted. The length is noted (Fig. 7-7, *B*) and recorded. To provide consistency as to the measurement, the stop should be perpendicular to the file.

- In small canals, the liberal use of a chelating agent (RC Prep) alternated with sodium hypochlorite may help open up the canal, by softening the necrotic dentin, to allow more complete debridement and access for smaller pathfinder files.
- Subsequent files are fitted with endodontic stops at the predetermined file length (Fig. 7-7, *C*). If the file is not close to the desired depth, it is instrumented further, and a repeat radiograph is taken until the correct length is achieved. Canal preparation should not be considered complete until the master apical file is at least size 25. This will then permit size 15 to 20 filling materials, lightly buttered with sealer, to reach the apex of the canal.²⁹

Step 3—Filing. The canal is cleaned and shaped using the files in an appropriate manner:

- Hedström files: push-pull only (Fig. 7-7, *D*).
- K-files: push-pull, or push-rotate clockwise 90 degrees and pull (Fig. 7-7, *E*).
- Reamers: push-pull, or push-rotate past 90 degrees to carry debris to the access site with an auger action.
- The files are used in sequential order, with each file being inserted to the predetermined length and drawn against the sides of the canal in all directions until it moves freely.

Substep 1—An EDTA preparation (RC Prep) can be used to help soften the dentin and to lubricate the files by placing a small amount in the canal with a curved tip syringe or, if using a bulk supply, by placing a small amount of material on an EndoRing sponge and running the tips of the files through the material before entering the canal. When using these products, make sure all of the chemical is removed from the canal in the filing and irrigating process.

Step 4—Pulp tissue removal. Once the working length has been prepared with at least a size 25 file, any residual pulp tissue is removed from the canal by inserting the largest broach that will fit loosely in the apical third of the canal, twisting 90 degrees and pulling it out with attached pulp tissue (Fig. 7-7, *F*).

- This step can be repeated several times with a clean broach.
- In large canals, two or three broaches can be placed and rotated simultaneously to ensnare the pulp tissue.
- While treating the same patient, pulp material may be removed from the broach by passing it through a rubber glove or rubber dam. Broaches are made of soft iron and fatigue and break easily if forced into a tight canal space. They are intended to be disposable and should be appropriately discarded as sharps after use.

Step 5—Irrigation. The canal is irrigated and lubricated between file sizes, using a syringe with a blunt-tipped needle. The needle is inserted into the canal so that it does not bind. Irrigating solutions used are sodium hypochlorite and EDTA (RC Prep) preparations (Fig. 7-8, A).

- Sodium hypochlorite in its full strength is 5.25% (household bleach). Most veterinarians dilute the 5.25% concentrate 1:2 or

1:3 with water or physiologic saline solution for periapical safety,^{15,30} but it does reduce the antibacterial and organic dissolving properties of the solution, which works best at full strength.^{17,31,32} To reduce risk of accidental burning of the periapical tissues, it is best to alternate irrigating with sodium hypochlorite and physiologic saline solution, ending with the saline.

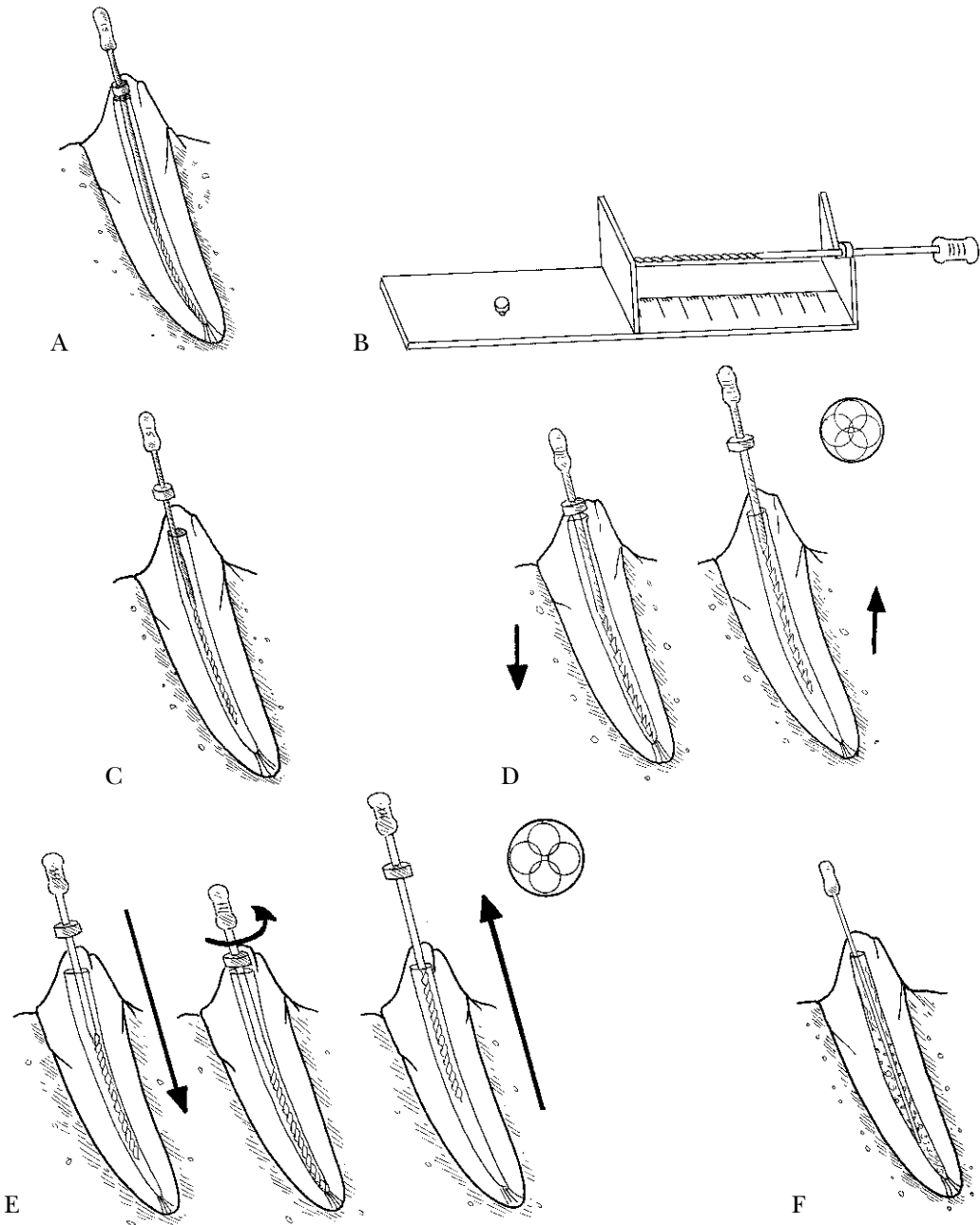


Fig. 7-7

- RC Prep is urea peroxidase and EDTA. It lubricates the files and acts as a chelating agent, softening the necrotic dentinal wall in the root canal so that the canal can be debrided more easily.

Step 6—Recapitulation. Periodically, a smaller file should be inserted to remove any dentinal filings that may have been packed into the apical portion of the canal by larger files used previously (Fig. 7-8, *B*).

Step 7—Shaping. By using standard (rigid core technique), step-back (which creates a tapered, flared, serial, telescoping, funnel shape), or crown-down (which also creates a tapered, flared, serial, telescoping, funnel

shape) technique, the canal is shaped wider at the crown and tapered to a narrower diameter apically, like a cornucopia.

Substep 1—Standard technique (Fig. 7-8, *C*) (ideal for straight, narrow canals). This technique is used to prepare a canal that has the same size, shape, and taper as a standardized instrument. Each size file is placed to its working limit as the canal is cleaned and shaped (Fig. 7-8, *D* to *F*).

- Cleaning and shaping continue until clean, white dentinal filings are seen on two to three successive file sizes (Fig. 7-8, *G*), and the next size file binds before reaching the working length (Fig. 7-8, *H*).

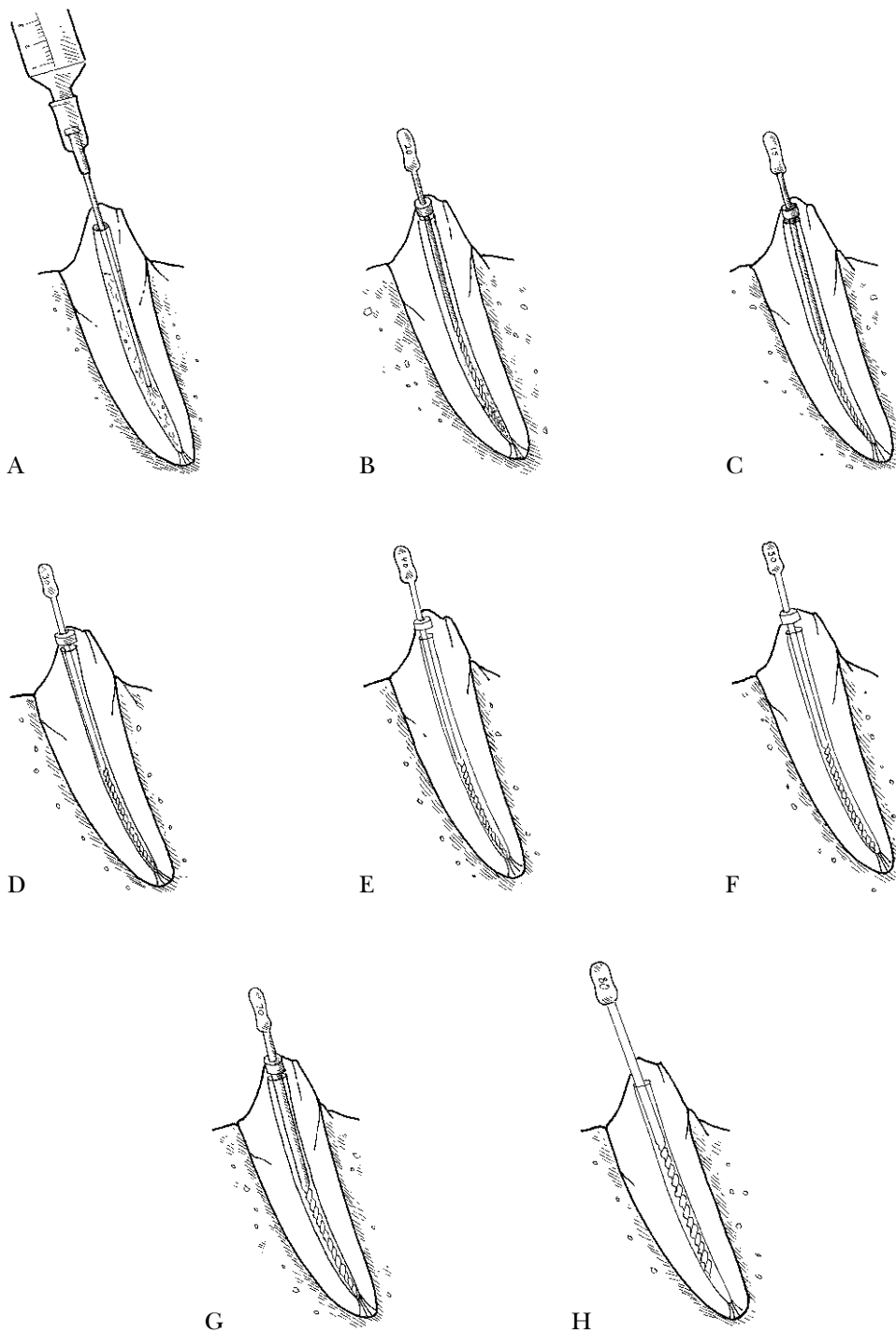


Fig. 7-8

Substep 1—Step-back technique (Fig. 7-9, *A* to *D*). Filing is started in the standard manner until the first file that binds at the apical limit is reached. Filing is continued in the standard sequential manner, increasing the file size one to two sizes larger. Next, the tapered or funnel shape is created by placing the stop on subsequently larger file sizes 1.0 to 1.5 mm closer to the file tip to create a working length for that file shorter than the previous file length. For curved canals or large-diameter canals, a sweeping motion is made with the file along one side of the canal at a time to create a smooth, tapered canal.

- A Gates Glidden drill can be used to complete the taper in the coronal third of the root canal.

Substep 1—Crown-down technique. This technique is useful in narrow canals where difficulty, due to binding of the shaft of the file, is encountered while attempting to penetrate with files to the apex. Filing is started, with a larger file first, to open the coronal end of the canal (Fig. 7-9, *E*). In addition, a Gates Glidden drill may be used to open the coronal portion of the canal. Filing is continued, using progressively smaller files

(Fig. 7-9, *F* and *G*). The result may be a ledged canal (Fig. 7-9, *H*), which may be smoothed by filing with additional small files. Small Hedström files may be useful in this step.

Substep 2—Between each step-back file and the last full-length file, a smaller file is used to clean accumulated debris from the terminal portion of the canal. This is called *recapitulating*.

Substep 3—Each time file size is changed, the root canal is irrigated with sodium hypochlorite.

Step 8—Disinfection. The canal is irrigated with sodium hypochlorite. A final irrigation with physiologic saline is advisable in the event that irrigating solution seeps into the periodontal or periapical space.

Step 9—Drying. The canal is dried by successively inserting absorbent points (paper points) into the canal with endodontic forceps (Fig. 7-9, *I*). The canal is dry when an absorbent point remains dry after insertion into the canal. When wet, the absorbent point has a grayish appearance, as compared with the whiteness of a dry absorbent point. The canal is now prepared to be obturated with a root canal sealer and a filling material of choice.

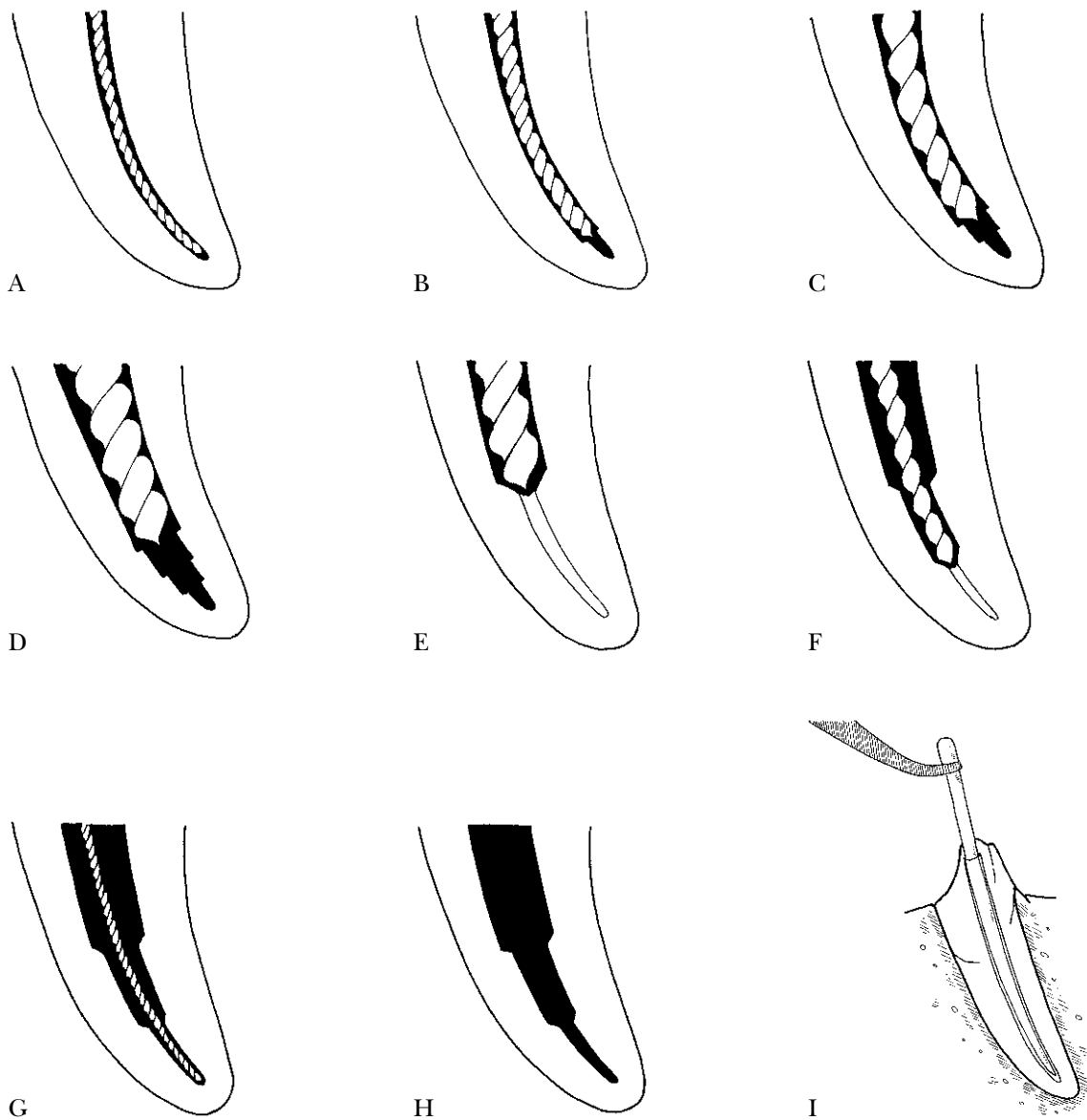


Fig. 7-9

Complications

- Improper access and filing technique or abnormal anatomy may result in a number of complications.
- The endodontic file may end up in a variety of incorrect positions. Transportation occurs when the file starts to widen the canal in the apical region (Fig. 7-10, A). If filing in this direction continues, a ledge may be formed (Fig. 7-10, B). Finally, a perforation may result when the file exits the wall of the canal (Fig. 7-10, C). The file may perforate through an apical foramen. If filing continues, a larger apical opening is created; this is known as a *zip* (Fig. 7-10, D).³³⁻³⁵
- A root that has been perforated with a file and the perforation treated should be evaluated and documented radiographically, because it may subsequently require retrograde filling (see p. 406).
- Separating (breaking) a file in the canal may occur. If the canal is clean and the file seals the apex, one option is obturation with paste, leaving the broken file in place. If the file tip is lodged short of the apex but can be bypassed, the endodontic therapy can proceed as originally planned. If this is not possible, a retrograde filling is the best way to ensure success.
- To prevent breaking files in the pulp chamber, the safest practice would be to use a new set of files in every case. However, in veterinary practice, this often is not economically feasible. In every instance files should be discarded when acute bends, deformation, or reverse twists (unraveling) are noted. Endodontic files should be treated as sharps and disposed of according to local regulations.
- Incomplete filing may be performed. Leaving remnants of pulp tissue or contaminated dentin will lead to failure, with pain, persistent bleeding, and apical abscess formation, and will require a repeat root canal procedure or a retrograde filling (see p. 406).
- Inadequate shaping leads to difficult or incomplete obturation. The canal should be reshaped with Gates Glidden drills or larger files.

Persistent Pulp Hemorrhage

General Comments

- For a successful procedure, the root canal must be completely dry before obturation.
- When performing a root canal treatment on teeth with fresh fractures, persistent hemorrhaging may occur. This is almost always from one of two causes: (1) over-instrumentation (perforation) or (2) under-instrumentation (some pulp remains).
- If hemorrhage does not stop with irrigation, but you are certain you have not over-instrumented or under-instrumented, attempt dry blotting or use a hemostatic agent (Viscostat, Pulpdent) on an absorbent point or calcium hydroxide powder on an absorbent point that has been moistened with saline, which is then inserted into the canal. An alternative method is to mummify the bleeding vessels with a formaldehyde preparation (formocresol). A temporary surface restoration is installed, and the final filling is completed at a second visit, 1 to 2 weeks later.

Indication

- Persistent hemorrhage after complete filing of a canal in a freshly fractured tooth.

Contraindications

- Open apex.
- Fractured root (class B fracture).

Objective

- To treat persistent apical hemorrhage during root canal therapy by fixing residual apical vessels with formocresol.

Materials

- Formocresol (Formo-Cresol, Sultan Chemists, Englewood, NJ).
- Cotton pellet.
- Temporary cavity material (Cavit G, Premier Dental Products).

- Sterile saline.
- Sterile paper points.

Technique

Step 1—The canal is irrigated with sterile saline and dried (Fig. 7-10, *E*) with sterile paper points (Fig. 7-10, *F*).

Step 2—A paper point or small cotton pellet is dipped in the formocresol solution, blotted dry, and placed into the canal with a dressing forceps (the paper point can be cut shorter, as necessary, to fit entirely into the canal) (Fig. 7-10, *G*).

Step 3—The access opening is sealed with a temporary cavity filling (Fig. 7-10, *H*).

Postoperative Care

- The patient is anesthetized again in 1 to 2 weeks. The temporary filling material is removed with a cutting bur, and the paper point or cotton pellet is removed with a broach or small file. The canal can now be obturated as desired.

Complications

- Failure of the client to return when requested, with subsequent irritation of apical tissues by formocresol and eventual abscess formation.

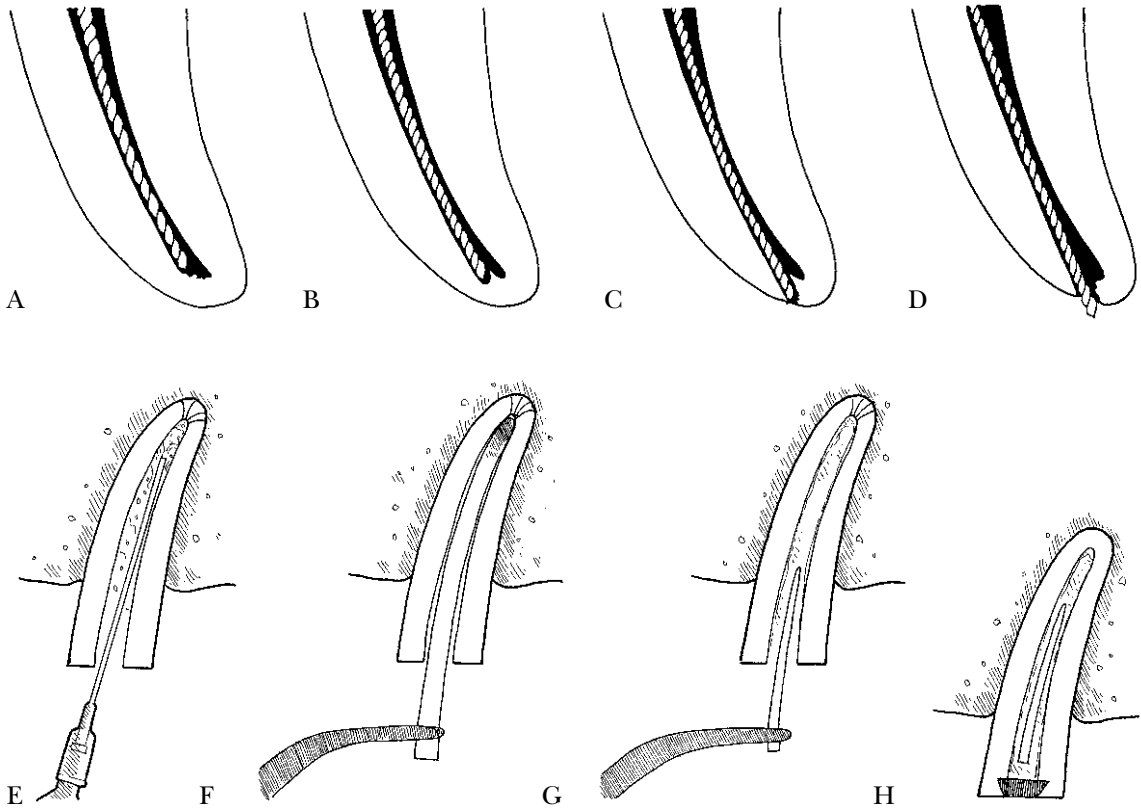


Fig. 7-10

Rotary Filing Technique

General Comments

- The use of mechanical rotary instruments to open and file the canal has advantages versus the use of conventional manual instrumentation. Rotary-type instrumentation allows for more complete cleaning of the canal, with less operator fatigue, and often results in a more efficient procedure.
- The major disadvantages of this technique are the expense of the instrumentation and its extreme technique sensitivity. Shortcuts, taken by busy clinicians, will predispose to separated files and all that is associated with that complication. Very low speed is required—no more than 350 rpm. Most low-speed handpieces turn at approximately 3,000 rpm. Therefore, a 10:1 or greater reduction gear is needed.
- Taper Series 29.04 (ProFile 0.04 Taper Series 29, Tulsa Dental Products, Tulsa, Okla.). This instrument set provides a consistent 29% increase in file size as opposed to the International Standards Organization (ISO) files that increase at first as much as 50% (10 to 15) and later 10% (100 to 110).
- This series of files gives more sizes of files in the smaller range, where it is needed most, and fewer in the larger range where it is not as important.
- The Taper Series 29 can be ordered for manual use as well as in rotary format.

Advantages

- There are fewer files in a Taper Series 29 set than in an ISO set.
- Using the Taper Series 29 is a more efficient use of time.

Materials

- Standard endodontic materials (Table 7-1).
- ProFile 0.04 Taper Series 29 rotary instruments.
- Contra-angle and low-speed handpiece (air or electric) capable of no more than 350 rpm; 150 to 300 rpm is preferred.
- RC Prep (essential for lubrication while using rotary files).
- Irrigation solution, syringe, and needles.
- Quantec-ETM Endodontic System with Quantec or K-3 files (Analytic Endodontics, Glendora, Calif.).
- This rotary file system also uses a very slow speed endodontic reducer contra angle. These files do not cut at the tip, but are shaping instruments, employed after the working length is established. They are designed to debride the coronal two thirds of the root canal and should be used with a lubricant, such as RC Prep.

K-3 Files

- Three-fluted.
- All have the same taper.
- Sizes 15 to 60.
- There are fewer files (three total) to use than with the Quantec files, which is more efficient.
- They require fewer passes than the Quantec files.
- They are stronger than the Quantec files (larger core diameter), but they are stiffer.

Quantec Files

- Two-fluted.
- Varying taper, all with a size 25 tip.

Table 7-1 • COMPARABLE FILE SIZES

0.04 Taper size	2	3	4	5	6	7	8	9	10
ISO equivalent	0.129	0.167	0.216	0.279	0.360	0.465	0.600	0.775	1.00
Closest ISO file size	10	15	20	30	40	50	60	80	100

ISO, International Standards Organization.

- There are more files (ten total) and they should all be used in a standard sequence.
- Length varies from 17 mm to 25 mm.
- They are not as strong as K-3 files but are more flexible.

Root Canal Preparation

Technique: Premolar and Incisor Teeth

Step 1—A size 08 or 10 manual K-file is used to open the canal to the apex, and radiographs are taken.

Step 2—Depending on the size of the canal, additional, sequentially larger hand files are introduced, just to the point of the file actually working the canal. The last file size is noted.

Step 3—RC Prep is applied to a #5 Taper Series 29 rotary file, and the file is used to open the coronal half of the canal halfway down the canal.

Step 4—Continuing to use the RC Prep on the file and continuing to clean the file, sequentially larger taper files are used to taper and shape the coronal half of the canal.

Step 5—Once the coronal half is opened, the equivalent file size three sizes larger than the last hand file size is selected and used to shape approximately three fourths of the canal. Liberal use of RC Prep is encouraged to lubricate the file and soften the necrotic dentin in the canal. For example, if a #20 ISO file was the last hand file, a #7 Taper Series 29 rotary file is used. In no case should the file be forced into the canal.

Step 6—The next smaller taper file size is connected, and approximately seven eighths of the canal is opened. Using the above example, a #6 file is used.

Step 7—The next size smaller taper file is used to the apex. Using the above example, a #5 file is used.

Step 8—The next smaller taper file (approximately the same size as the hand file) is used to smooth and complete the shape of the canal. Hand files and irrigation are used as necessary to ensure complete removal of dentinal filings.

Complications

- Breakage of the file can occur. This can be caused by a variety of reasons: running a handpiece too fast or with too much pressure,

lack of irrigation, lack of intraoperative cleaning of the file, or overuse of a fatigued file.

- To prevent breakage, the rotary file must be run slowly. The little dot on the shaft of the file should be visible as the file spins. If the dot is not visible, the speed is too fast.
- The file should not be in the canal for more than 5 seconds.
- Discard the file after using in no more than six canals.
- If binding occurs, an evaluation must be made as to the cause. In the initial opening of the coronal portion of the canal, it may be necessary to step back a size and reopen. In the crown-down phase, if binding occurs, opening the canal with hand instruments or further opening of the coronal portion of the canal may be necessary.

Obturation

General Comment

- Obturation is the sealing and filling of the prepared root canal. The goal is to obtain a three-dimensional seal, particularly of the apical one third of the canal. The reason for this is that, in the mature canine and feline tooth, not only does the apex contain multiple small foramina for vascular and neural communication, but often one or more small lateral vascular canals connect the periodontal space with the pulp in the apical third of the root.³⁶ Standard root canal therapy is considered a clean procedure. It is not a sterile procedure, because bacteria exist in the dentinal tubules of a patient with an infected tooth, and we cannot reach these bacteria with our treatment. The theory is that if the endodontist can contain the infection within the canal, the patient will clean up any residual infection that has escaped periapically. By disinfecting the canal, opening the dentinal tubules and then sealing the bacteria in those dentinal tubules, as long as the apical delta and any lateral canals are likewise sealed, the clinician has done the job.

Contraindications

- Persistent hemorrhage (see p. 366).
- Open apex (see p. 353).
- Fractured root(s) with displaced fragment(s).

Objective

- To fill the entire root canal system and any accessory canals completely and densely with nonirritating inert material, resulting in a fluid-tight seal.

Materials

- All materials may not be needed, depending on the method used.
- Root canal sealer. Many types are available. Traditionally, zinc oxide and eugenol (ZOE) has been used in veterinary dentistry. Other reduced-eugenol, augmented ZOE products or those that do not contain eugenol are ThermaSeal (Tulsa Dental Products), AH26 (LD Caulk/Dentsply, Milford, Del.), Can-a-Seal (Henry Schein, Melville, NY), Nogenol (GC America, Fuji Products, Alsip, Ill.), Pulp Canal Sealer EW and Sealapex, Grossman's cement (Kerr Corporation), and KetacEndo (ESPE America, Norristown, Penn.).
- Gutta-percha points.
- Root canal pluggers or condenser.
- Root canal spreaders.
- Endodontic point forceps.
- Source of heat.
- Glass slab.
- Mixing spatula.
- Spiral fillers.
- Files.
- Chloroform.
- Oil of eucalyptus.
- Alcohol in dappen dish.
- Heated gutta-percha applicator.
- Electrically heated plugger.
- ZOE applicator.

Obturing Techniques

Application of Sealer Alone

- In any filling technique, the root canal sealer is placed in the canal first. The choice

of product is by individual preference. ZOE, either United States Pharmacopeia or incorporated into a product, is the traditional sealer. Concern has been expressed about eugenol slowing or inhibiting the ability of composite restorations to set up. Therefore, many reduced-eugenol or noneugenol products have been developed.

- The root canal sealer is mixed, according to directions, to a thick consistency and placed in the canal, using one of the following methods:

Step 1—A spiral paste filler with a reduction gear on a low-speed handpiece is loaded with the paste and inserted into the canal to depth, activated, and moved slowly in and out to distribute the paste along the canal walls.

Step 2—Using a file two to three sizes smaller than the largest file to reach the apical limit, the file is placed in the sealer paste, inserted into the canal to the apical limit, rotated counterclockwise to coat the walls, and withdrawn. More paste is added, and the file is pumped in and out while being rotated counterclockwise until the walls and the apex are coated (Fig. 7-11, A).

Step 3—The sealer paste can be injected into the canal using pressure with a syringe and blunt-end needle that is small enough not to fit snugly into the canal (Fig. 7-11, B).

Step 4—The sealer paste can be placed on the master gutta-percha cone after sizing and inserted into the canal with the cone.

Advantages

- Improved apical seal.
- Bacteriostatic.
- Radiopaque.

Disadvantages

- Some toxicity to tissues if sealer is forced periapically.
- Soluble when exposed to oral or tissue fluids; therefore, if used as the only obturator, may wash out and fail.

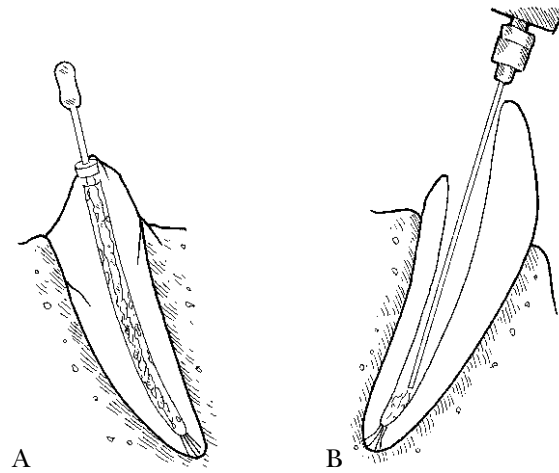


Fig. 7-11

Spiral Filling or Injection

- A ZOE mixture is spatulated on a glass slab until smooth, and the consistency is such that a strand of material is suspended when the spatula is elevated off the slab 1 to 2 cm (Fig. 7-12, *A*).

Spiral filling technique

Step 1—A spiral filler is placed in a reduction gear contra angle on the low-speed handpiece. Spiral fillers come in assorted sizes; one is chosen that can be inserted to the apical limit of the canal without binding.

Step 2—The tip of the spiral filler is loaded with the ZOE mixture (Fig. 7-12, *B*), and the spiral filler is placed in the canal to its apex.

Step 3—The rotary movement is activated, and the spiral filler is moved carefully back and forth in the canal without completely withdrawing it. Because its spiral is a backward twist, it unloads the sealer to fill the canal with paste. A spatula with additional paste on the tip is held near the access opening to continuously “feed” paste onto the paste filler while it delivers sealer into larger canals (Fig. 7-12, *C*).

Step 4—When the canal is full, paste will be extruded out of the access opening(s) as the filler is moved toward the apex (Fig. 7-12, *D*). The low-speed handpiece with reduction gear must be set to rotate in forward direction (clockwise) to provide a proper filling action.

Complications

- Binding and breaking the spiral filler in the canal may occur if the spiral filler is too large in relation to the canal diameter.
- Abnormally shaped canals may be inadequately filled or contribute to instrument breakage.

Injection technique

Step 1—A small syringe is loaded with the ZOE paste or other sealer, and a blunt-end or notched-end needle is placed in the canal to the apical limit. The needle is withdrawn slowly as the paste is injected into the canal (Fig. 7-12, *E*).

Step 2—Injection guns have cannulas of premixed root canal sealer for injecting the paste into the canal under pressure (Kerr Corporation; Endoseal System, Centrix, Shelton, Conn.).

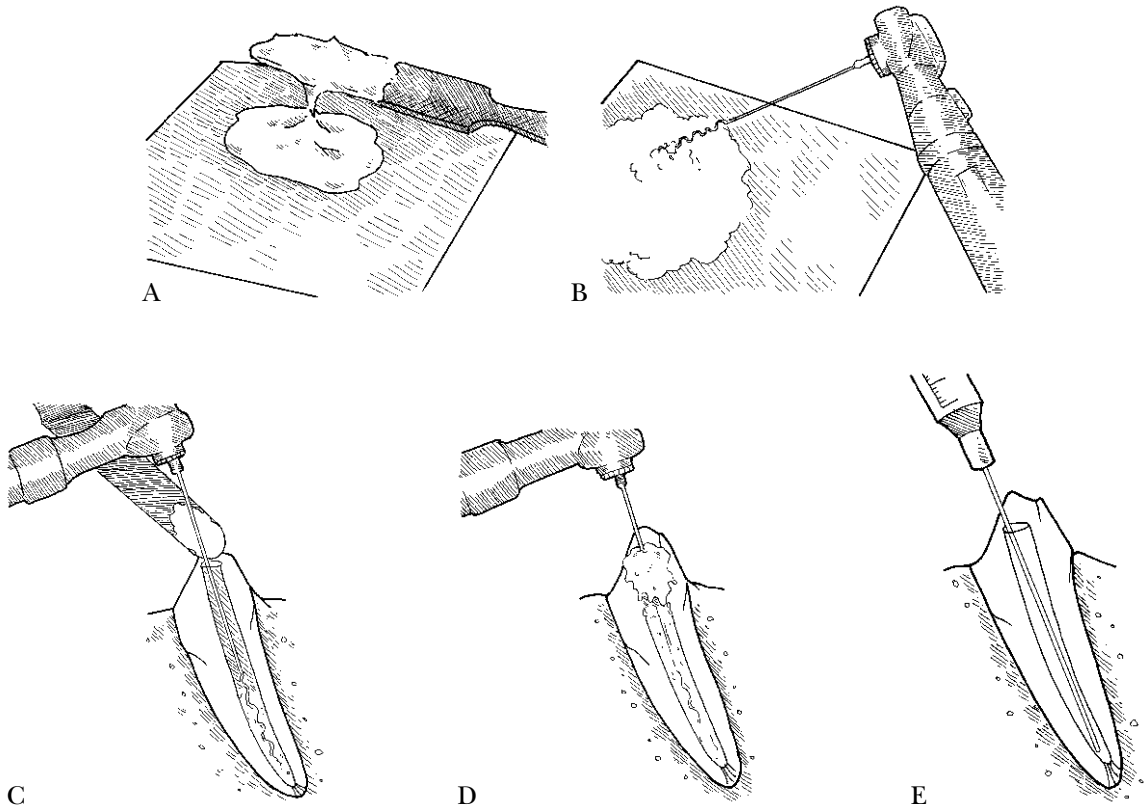


Fig. 7-12

- Pressure syringes can be used (Fig. 7-13, *A*), also. They can be loaded with spatulated sealer and will deliver the paste to the canal apex via specially supplied needles of appropriate diameter. The sealer, like the above systems, is delivered as the delivery needle is withdrawn (Pulpdent Corporation, Watertown, Mass.).
- Root canal sealer is loaded into hub of needle that is then threaded onto the syringe barrel (Fig. 7-13, *B*).
- Needle is placed 2 mm from apical stop in prepared canal.
- One quarter turn of wrench delivers root canal sealer to apex.
- Needles are disposable; plunger is cleaned with solvent.

Advantages

- Delivery needles: 18, 25, 27, and 30 gauge.
- Faster fill technique.
- Fewer materials needed.

Disadvantages

- Potential for inadequate fill, air bubbles, accessory canals not filled.
- Without a denser filling material such as gutta-percha present, ZOE may be resorbed at the apex, losing the fluid-tight seal.
- Shrinkage of ZOE paste, after setting, leading to microleakage if the paste is used as the only obturator.

Application of Solid Filling Material

General comments

- Many types of techniques have been devised to fill the root canal with solid filling material.
- Due to the variety of situations, each practitioner should have many techniques available.
- A three-dimensional fill is desired.

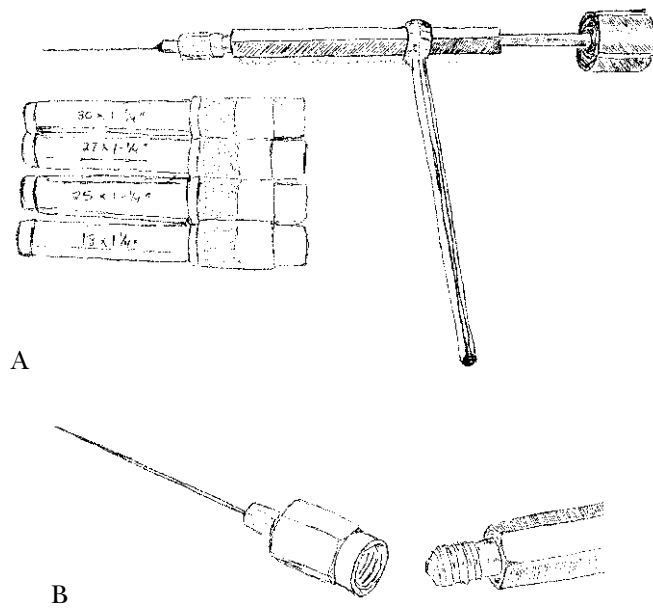


Fig. 7-13

Obturation: single-cone technique

- A dry gutta-percha or silver cone equal to the size of the last file used during instrumentation is selected. If the cone comes from a sterile container, it may be placed in the canal to the apex (Fig. 7-14, *A*). There should be a little resistance or tug-back felt when removing it. If nonsterile cones are used, the cone should be placed in sodium hypochlorite to disinfect it before inserting it into the canal.
- A radiograph is taken with the point in place to check for fit and fill. The entire canal should be filled. When the appropriate fit is achieved, the gutta-percha point can be marked at the coronal access by pinching with the endodontic forceps (Fig. 7-14, *B*). If a stiffer gutta-percha point is desired, the point may be soaked in alcohol before insertion.
- A root canal sealer is placed in the canal as a liner using the method described in the section Obturating Techniques.

- The point is cut off at the pinch mark, placed in the canal, and gently compacted vertically with a plugger or condenser until the pinch mark is at the desired level and the endodontic point fits snugly to the apical end of the canal (Fig. 7-14, *C*).

Advantages

- Provides a dense filling material at the apex to provide a longer-term success rate.
- Can provide sufficient fill in smaller, shorter canals prepared with standard technique.

Disadvantages

- Inadequate procedure in larger, longer canals because only the apical 2 to 3 mm of canal is solidly filled.
- Single-cone technique has greater amount of leakage than techniques that condense gutta-percha.
- Difficult to force smaller gutta-percha point (less than size 30) to the apical limit; alcohol helps stiffen gutta-percha.

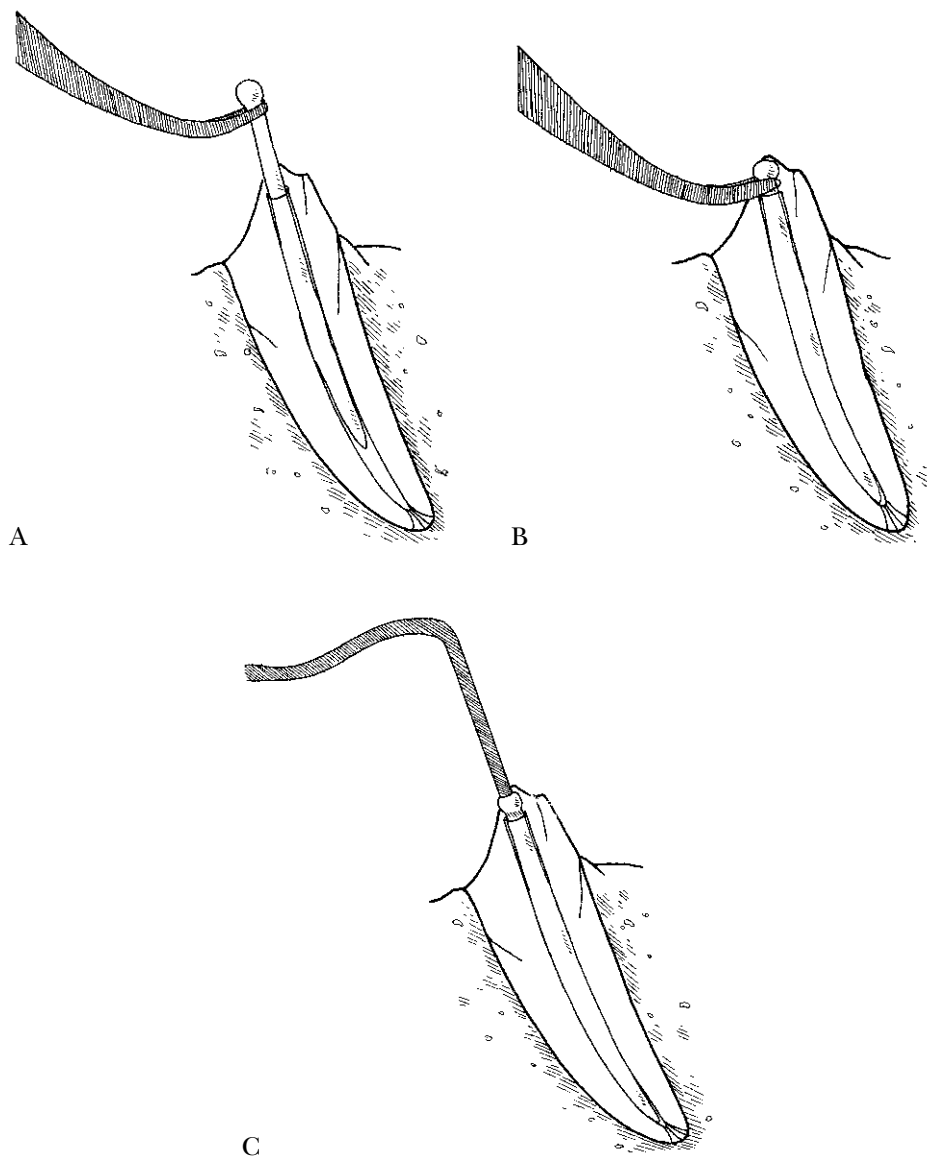


Fig. 7-14

Cold lateral condensation

- The canal is shaped into a cornucopia-shaped convenience form³⁸ in either a step-back or a crown-down technique, creating a flare of the coronal limit of the canal.
- A root-canal spreader is chosen that can be inserted to within 1 to 2 mm of the working length of the canal alongside the master cone (Fig. 7-15, *A*). Larger files or reamers can be used as spreaders in longer canals. The spreader must not be wider than the canal, because it may cause excessive lateral force and an expansion fracture of the root.
- A standardized gutta-percha point (master cone) is chosen and placed in the root canal for a snug fit to the apical limit of the canal (Fig. 7-15, *B*). Use a point the same size as or one size smaller than the last file used. This will provide space for both the sealer and the master apical point. The length of the point is marked by pinching the cone with endodontic point forceps at the level of the access hole.
- Root-canal sealer is placed in the canal as described previously.
- The master cone is placed in the canal to the predetermined length.
- A root canal spreader is inserted along the master cone to within 1 to 2 mm of the working length with apical pressure only (Fig. 7-15, *C*). This seats the gutta-percha point to the apical stop.
- The spreader is rotated on its axis clockwise and counterclockwise several times, laterally condensing the malleable gutta-percha, and

is then removed. The gutta-percha will retain its compressed state for a minute or so.

- An accessory gutta-percha point slightly smaller than the spreader is placed immediately in the space created by the spreader.
- These two steps are repeated until it is impossible to insert an accessory cone farther than 2 to 3 mm into the canal (Fig. 7-15, *D*).
- The excess gutta-percha is removed with a heated instrument below the access opening (Fig. 7-15, *E*).
- A radiograph is taken to confirm a complete fill.

Advantages

- Provides more complete obturation of canal with inert filling material.
- Places gutta-percha in apical stop during condensation to prevent overfill.

Disadvantages

- More time is required.
- A variety of gutta-percha sizes and spreaders is needed. Additional veterinary-length spreaders must be added to the inventory to reach desired limit in longer canals.
- Vertical root fracture may occur if excessive lateral force is applied.

Complications

- Splitting of root by over-instrumentation.
- Inadequate filling of canal by under-instrumentation.
- Old gutta-percha becoming hard and brittle and no longer being compressible and malleable.

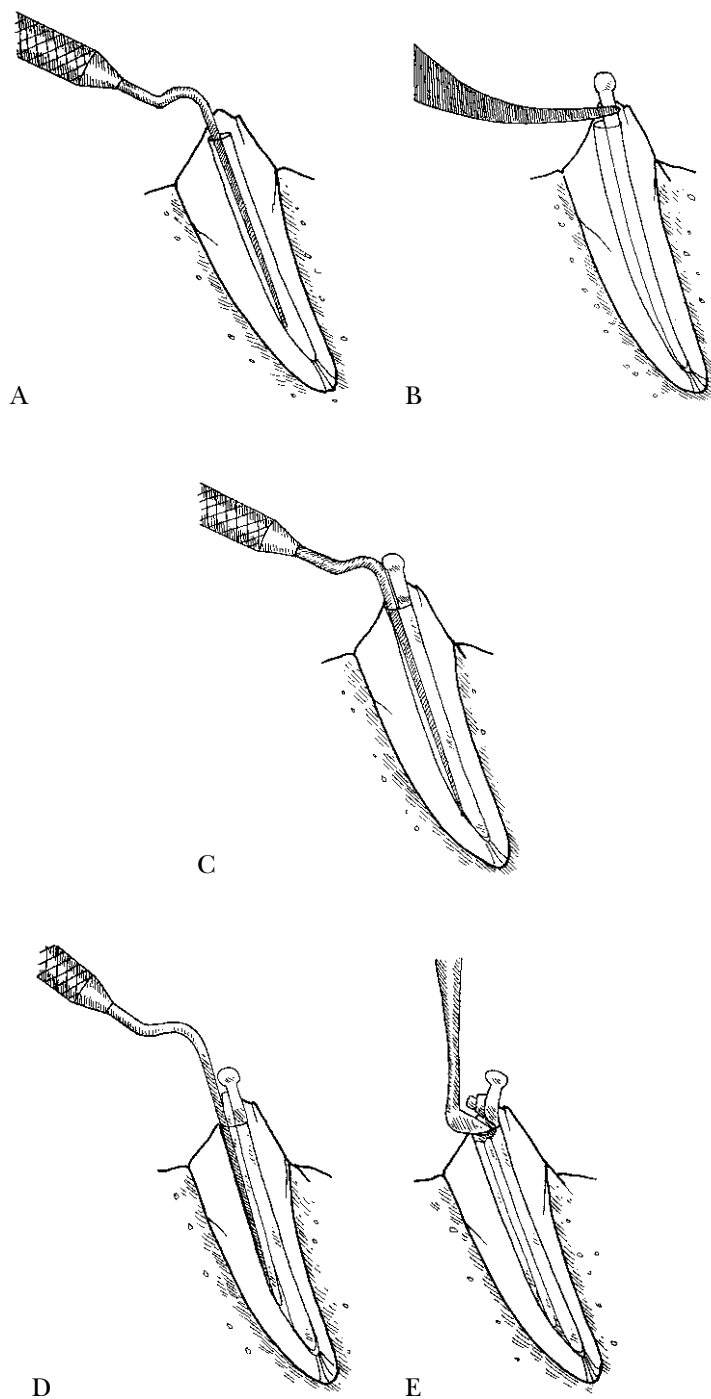


Fig. 7-15

Warm lateral condensation

- This technique uses the same instruments as cold lateral condensation. In addition, a heated carrier is used to soften the gutta-percha to allow further condensing of gutta-percha against the canal walls.
- The canal is prepared and shaped in either a step-back or a crown-down technique with coronal flare.
- A master cone is fitted, and sealer is applied to the canal, followed by the master cone (Fig. 7-16, *A*). Several accessory points are placed, as in the cold lateral condensation technique.
- Either an electrically heated instrument (Touch and Heat, Analytic Technology Corporation, Redman, Wash.) or a hand instrument, such as a spreader, is warmed in a flame (Fig. 7-16, *B*) and is inserted into the gutta-percha in the canal (Fig. 7-16, *C*). If it is a hand instrument, it is rotated and moved up and down continuously to keep it from sticking to the gutta-percha and dislodging it as the spreader is removed. An electrically heated spreader (Touch and Heat) simplifies this technique and is simply advanced with

gentle apical pressure, compressing the previously inserted gutta-percha.

- A cold endodontic spreader is inserted into the space created, compresses the softened gutta-percha laterally, and is removed (Fig. 7-16, *D*).
- An accessory point is inserted, and the process is repeated until the canal is full (Fig. 7-16, *E*).
- The excess gutta-percha is removed with a heated instrument below the coronal access opening (Fig. 7-16, *F*).
- A radiograph is taken to confirm the fill.

Advantages

- A denser fill, with elimination of irregularities caused by accessory canals, lateral canals, or filing procedure, is achieved.
- The microleakage potential is reduced.

Disadvantages

- Time consuming.
- Accidental removal of gutta-percha from canal with heated carrier (avoided with proper technique and experience).
- Flame-heating of spreaders causes loss of temper and weakens instrument.

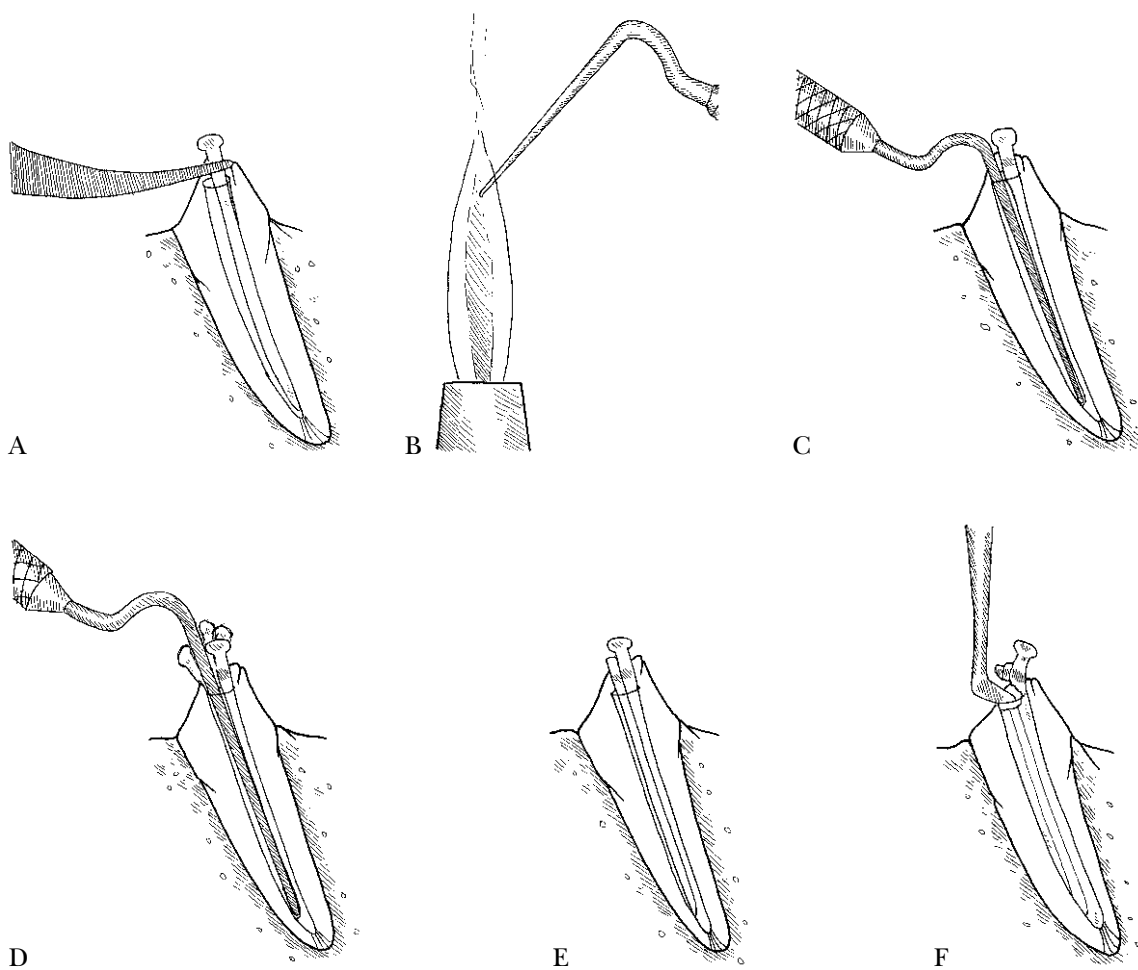


Fig. 7-16

Vertical condensation

- After placement of a single cone in the canal, a root canal plugger or condenser is used against the end of the point to push it apically.
- As a complete filling technique, a set of pluggers with depth markings is required, and the canal is prepared in step-back technique (Fig. 7-17, *A* to *C*). The pluggers should reach

the desired length and be wide enough to cover as large an area of gutta-percha as possible at the desired depth.

Step 1—A master cone is fitted, the canal is lined with sealer, and the master cone is seated (Fig. 7-17, *D*) as described in the section on the single-cone technique.

Step 2—The coronal portion of the cone is removed with a hot instrument (Fig. 7-17, *E*).

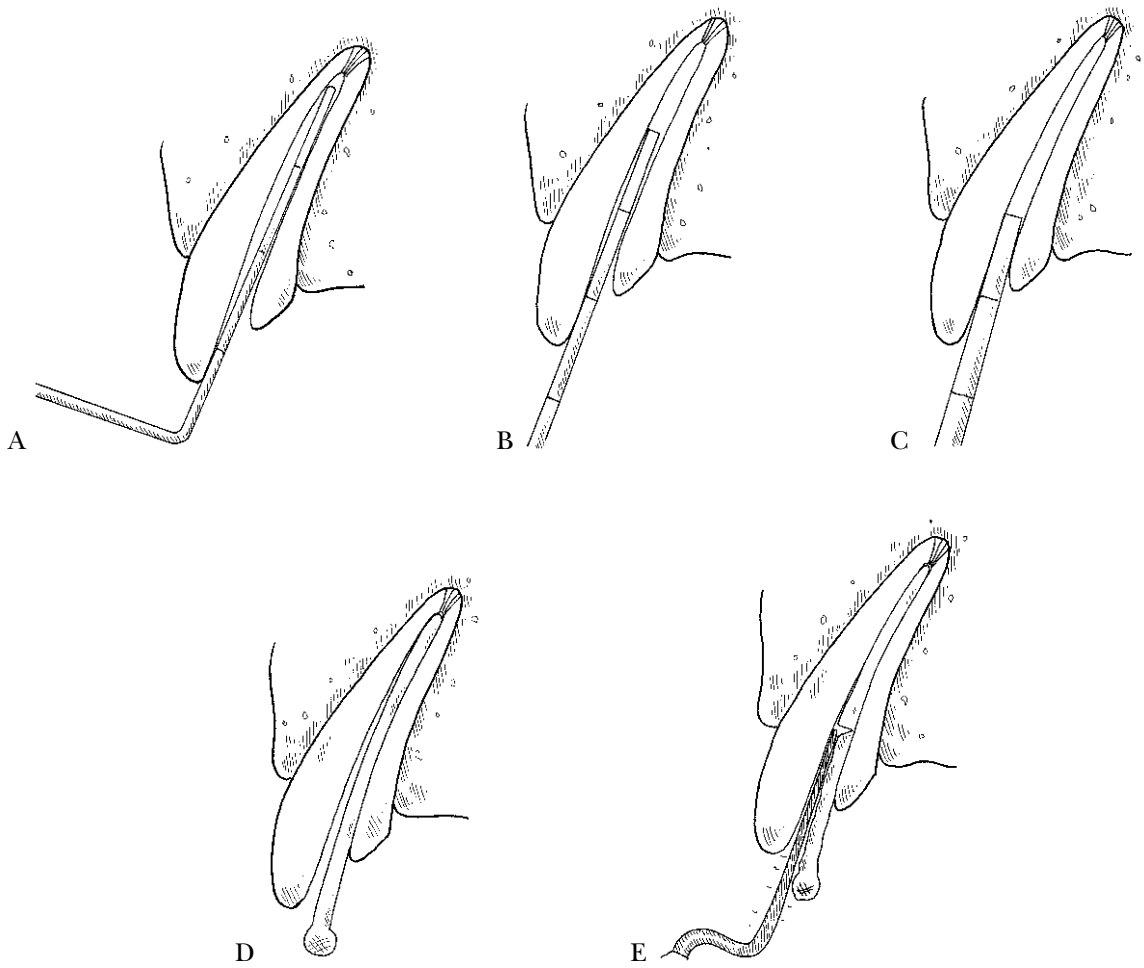


Fig. 7-17

Step 3—A heat carrier (spreader or plugger) is warmed in a flame, inserted into the coronal third of the root canal, with the gutta-percha, and removed (Fig. 7-18, A). (Some gutta-percha will be removed with the instrument.)

Step 4—A cold plugger of the appropriate length and width is inserted, and the gutta-percha is condensed apically (Fig. 7-18, B).

Step 5—An additional piece of gutta-percha, 3 to 4 mm in length and matching the width of the canal, is inserted into the canal (Fig. 7-18, C), and the process is repeated until the canal is full (Fig. 7-18, D).

- As an alternative to gutta-percha points, 4- to 5-mm increments of plasticized gutta-percha can be inserted into the canal with a special device (see p. 395) and condensed apically with an appropriate size plugger for the entire fill or in addition to a master cone.

Advantages

- Complete obturation of canal apex and accessory and lateral canals is achieved.
- Commercial sets of assorted double-ended plugger-spreaders that are sized for large canine teeth are available (Cislak Manufacturing, Glenview, Ill.).

Disadvantages

- Time consuming.
- Requires variety of pluggers and spreaders and is more complicated technically.
- Greater chance of overfill.

Lateral and vertical condensation

- The two previous techniques are used together to achieve complete fill of the canal.

Advantage

- Complete obturation of canal with gutta-percha.

Disadvantage

- Time consuming.

Warm vertical and lateral compaction (continuous wave technique)

- This technique uses a newer, upgraded, electrically heated set of pluggers and spreaders (System B, Analytic Technology Corporation; Analytic Endodontics, Glendora, Calif.) than the Touch and Heat

unit, together with one of the rotary file systems (Quantec-ETM Endodontic System with Quantec or K-3 files) (see Rotary Filing Technique previously in this chapter).

- This protocol is similar to the cold vertical and lateral condensation technique, but efficiency is gained by more rapid shaping of the coronal two thirds of the root canal and the intermittent use of thermostatically controlled heated pluggers and spreaders.

Advantages

- Better fill, especially into the apical delta and lateral canals.
- Fewer voids (underfill).
- Can self-correct some underfilled conditions.
- Thermostatically controlled temperature.
- Very useful for large, young canals and ones irregularly shaped.

Disadvantages

- Technique sensitive (there is a definite learning curve).
- Equipment and replacement tips are expensive.
- The heated tips will not fit into canals of smaller than size 70 diameter.
- The longest heated tips are 22 mm and of limited use in long canals.

Chloropercha-eucapercha technique

- This technique uses chloroform or warm oil of eucalyptus as a solvent to soften gutta-percha and allow its condensation into canal irregularities.
- Several large standardized gutta-percha points are placed in the solvent to produce a thick paste, similar in consistency to that of ZOE. This paste is used as a sealer with a master cone and lateral condensation technique.

Advantage

- The softened gutta-percha can be forced into fine, tortuous canals.

Disadvantages

- Chloroform is a hazardous material and should be used with caution.
- Chloroform is a reported carcinogen; however, this does not appear to be a problem in the amounts used.
- Gutta-percha is less solvent in oil of eucalyptus.

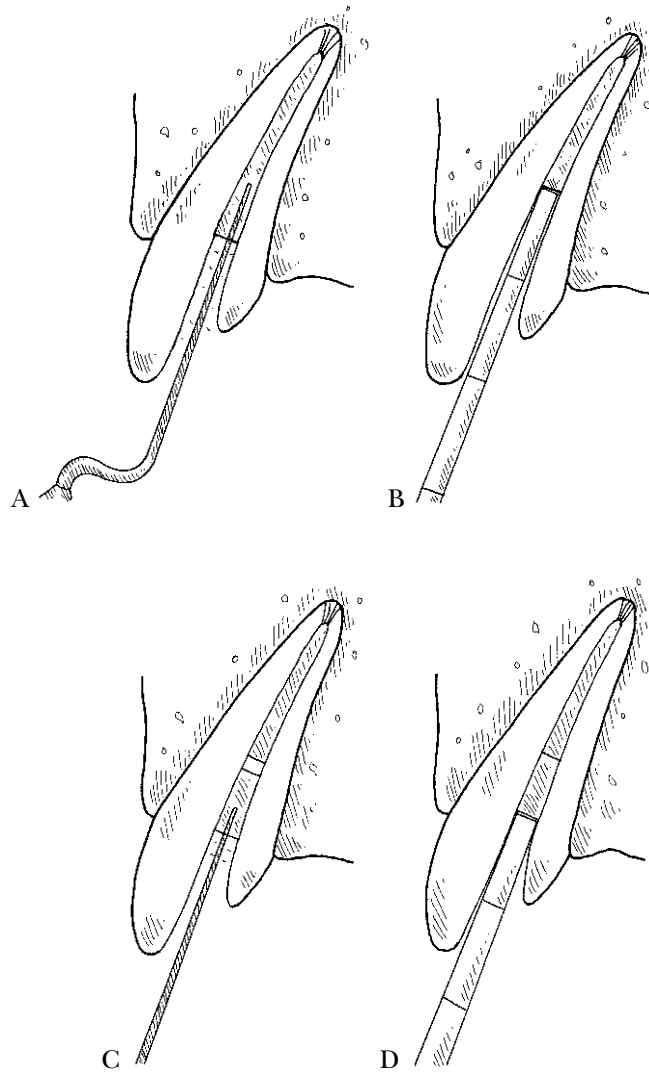


Fig. 7-18

Softened gutta-percha condensation (chloroform dip technique)

- This technique is useful when the apex is open or the apical portion of the canal is irregular (Fig. 7-19, *A*).
- A master cone is fitted that stops 2 to 4 mm short of the apex (Fig. 7-19, *B*). A pinch mark is made with dressing forceps at the desired working length, as determined by radiographs.
- The apical 2 to 3 mm of the master cone is dipped in chloroform for 1 to 2 seconds (Fig. 7-19, *C*).
- Fluothane may be used in place of chloroform to soften gutta-percha.
- The canal is wet with irrigant (sodium hypochlorite or saline) to prevent sticking to the walls. The cone is inserted into the canal and is tamped apically with a plugger until it reaches the working length (Fig. 7-19, *D*). (The cone can be removed, dipped in chloroform, and retamped until the working length is achieved; make sure it is reinserted in the same direction each time.) Confirm

the fill with a radiograph. The cone can be 1 mm short of the working length.

- The shaped cone is removed and is allowed to dry for several minutes.
- The apical third of the cone is coated with sealer, and the cone is reinserted into the canal to the set length (Fig. 7-19, *E*).
- The canal is filled using lateral condensation; each accessory point is coated with sealer before insertion (Fig. 7-19, *F*).
- A radiograph is taken to confirm the fill.

Advantage

- Adequate apical seal obtainable in irregularly shaped canals.

Disadvantages

- Chloroform is a hazardous material and should be used with caution.
- Chloroform is a reported carcinogen; however, this does not appear to be a problem in the amounts used.
- Shrinkage of the gutta-percha as the chloroform evaporates may lead to microleakage.

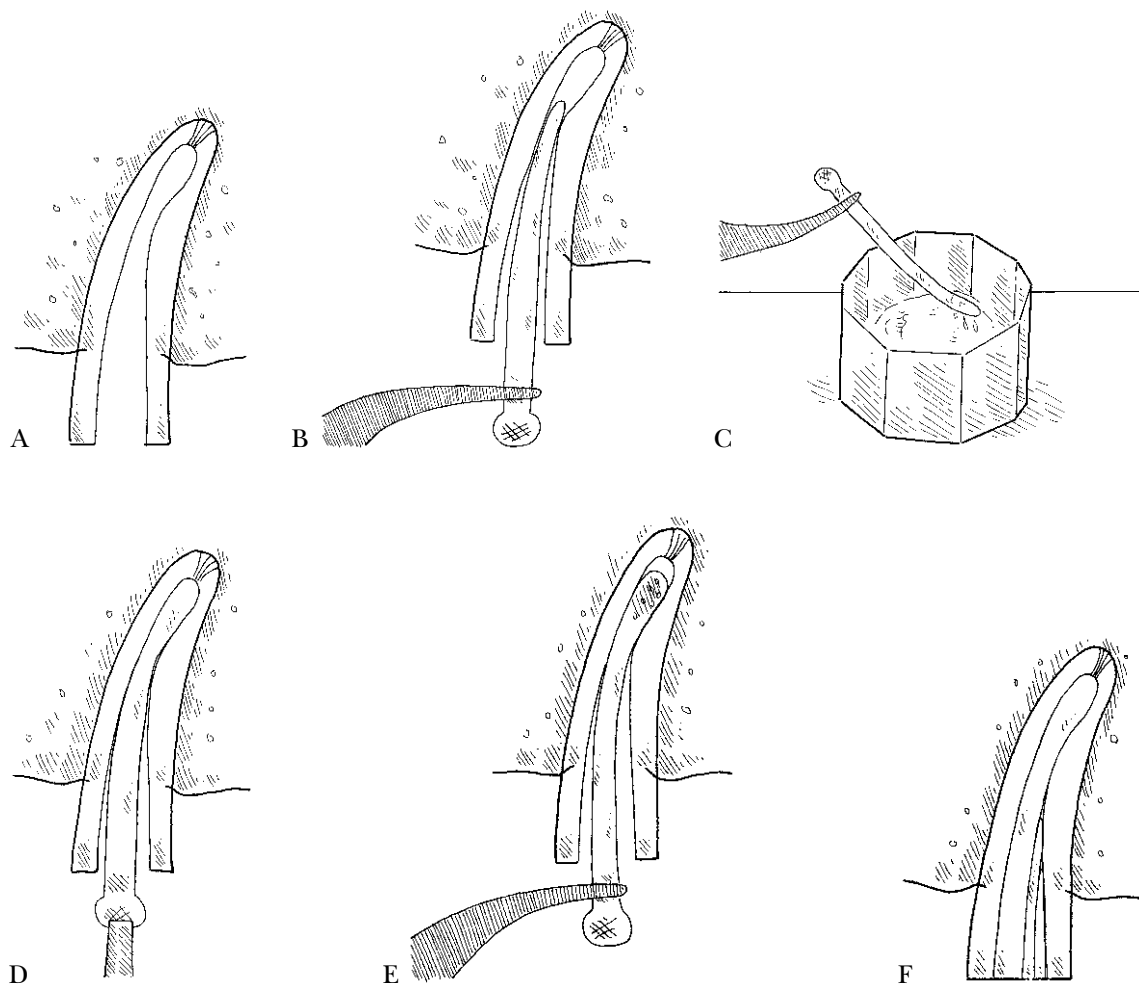


Fig. 7-19

Custom-point fill

- A custom-point fill is used in canals that are larger than the largest standardized gutta-percha available.
- Several large cones are softened in a flame (Fig. 7-20, *A*).
- The softened points are rolled into a cone shape between two glass slabs (Fig. 7-20, *B*).
- When the point is the approximate size of the canal, it is cooled in water and trial fitted (Fig. 7-20, *C* and *D*). The process is repeated until the cone fits 1 to 2 mm from the apex.
- The custom cone is used as the master cone, and either the warm or cold lateral

condensation technique is used to fill the canal completely.

Advantage

- Allows obturation of large canals.

Disadvantages

- Time consuming rolling gutta-percha to proper size.
- Gutta-percha must be softened sufficiently to minimize seams or apical voids, and it is difficult to remove them all with this technique.

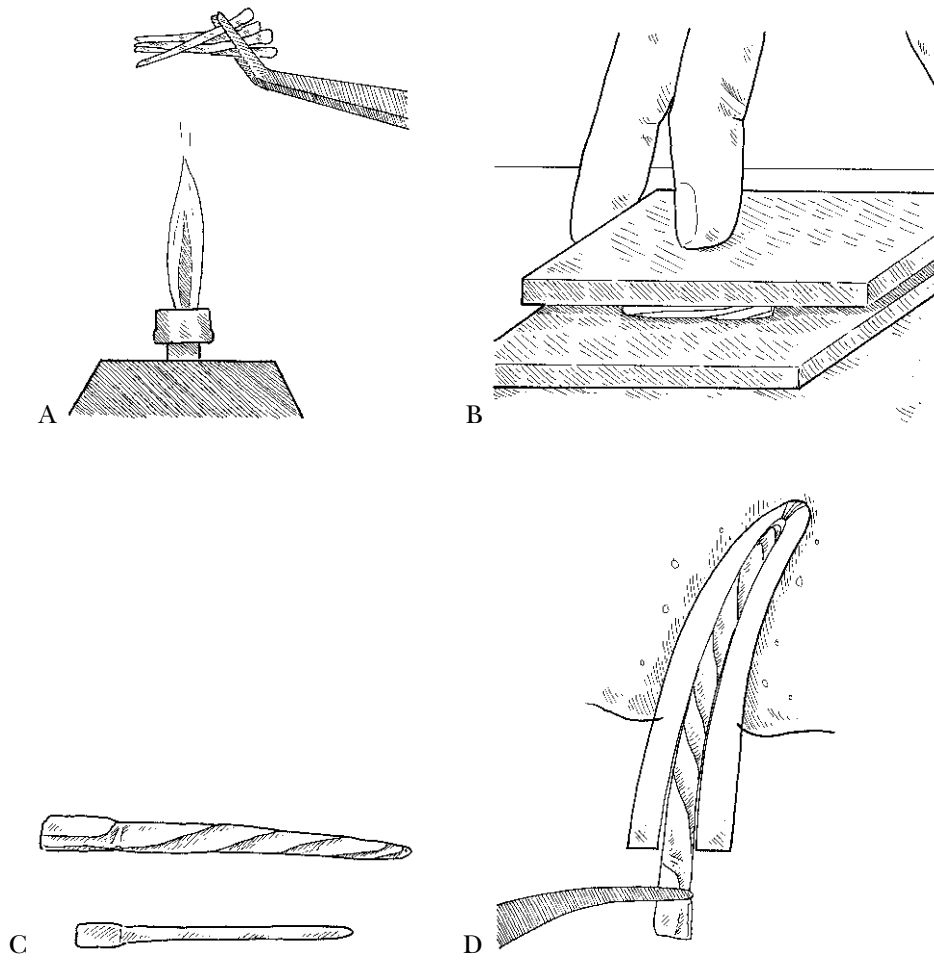


Fig. 7-20

Thermomechanical condensation (McSpadden method)

- A McSpadden compactor, which looks like a Hedström file but with reverse flutes, is used in a low-speed handpiece and is inserted alongside a master gutta-percha cone placed 1 to 2 mm short of the apex. The compactor chops up the gutta-percha, thus plasticizing it and forcing it apically and laterally.
- A master cone is fitted in the canal, which has been prepared either in a step-back or crown-down technique, 1.5 mm short of the apex (Fig. 7-21, *A*).
- The McSpadden compactor selected is the same size as the last file that came 1.0 to 1.5 mm from the apex. The working length is marked on the compactor.
- The master cone is coated with sealer and is inserted into the canal.
- The compactor is inserted alongside the cone until resistance is felt and is rotated at maximum speed (Fig. 7-21, *B*).
- After 1 second, the compactor is advanced apically to the predetermined length and is withdrawn slowly while rotating.
- Accessory points can be dipped in sealer and placed alongside the master cone and a larger compactor used until the canal is full (Fig. 7-21, *C*).
- A radiograph is taken to confirm the fill.

Advantage

- Rapid condensation technique, forcing softened gutta-percha into canal irregularities.

Disadvantages

- Breakage of compactor tip may occur in canal.
- Heat generation.
- Compactor not being long enough for use in canine teeth.

Broken-instrument technique

- If an instrument tip is broken inside the canal and cannot be retrieved, and an apical seal can be achieved, the tip can be left, lodged in place, and a filling technique used to fill around it if the canal has been cleaned completely (Fig. 7-21, *D*).
- The instrument breakage should be noted in the chart, the client informed of the complication, and follow-up radiographs should be taken at 6 months, or earlier if further complications are noted.

Advantage

- Do not have to remove a broken file tip.

Disadvantages

- If the canal is not prepared adequately, the procedure may fail.
- If a larger file tip is broken, it may not allow fill around it, necessitating an apicoectomy with retrograde filling.

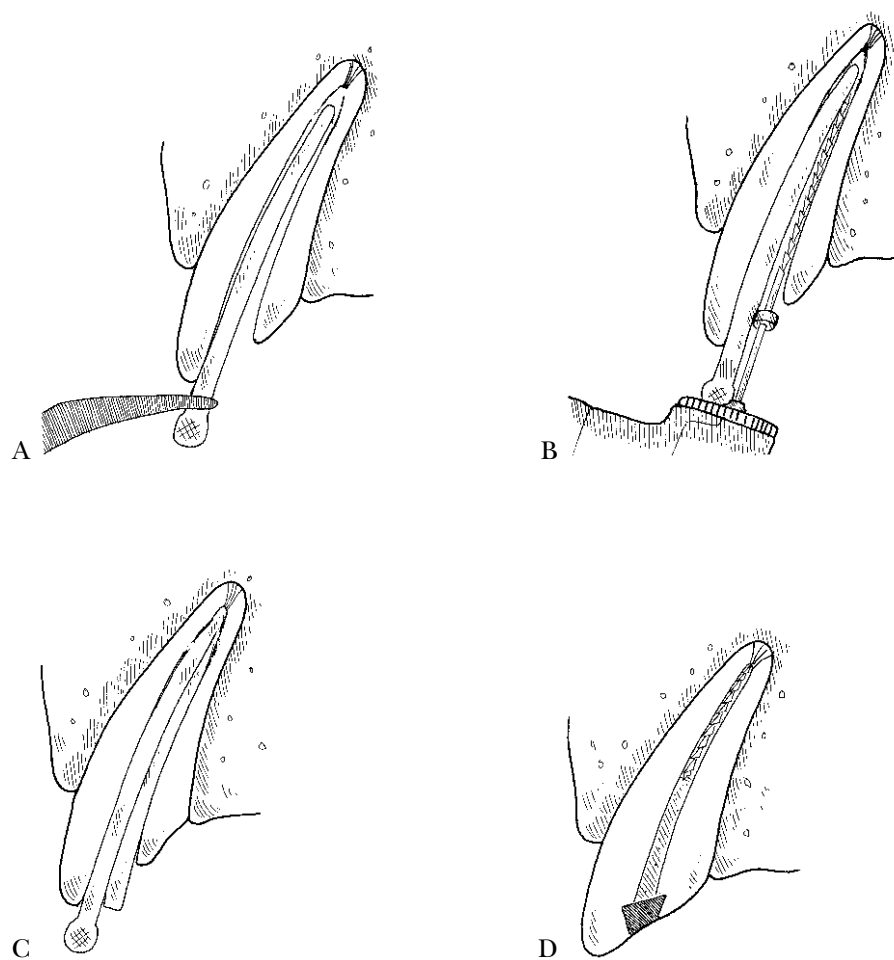


Fig. 7-21

Inverted cone technique

- Some canals may have a wider apical portion that makes them difficult to fill with standard size cones (feline canine teeth).
- Root canal sealer is placed as previously described.
- A gutta-percha cone is placed with the larger, rounded end toward the apex (Fig. 7-22, *A*).
- Using lateral or vertical condensation techniques, the remaining canal is filled with accessory gutta-percha points (Fig. 7-22, *B*).
- KetacEndo (ESPE America) used as a sealer in feline canine teeth can eliminate the need for accessory points in many canals.

Advantage

- Allows fill of atypical root canals using standard gutta-percha and root canal sealer.

Disadvantage

- Time consuming.

Orthograde amalgam technique

- This technique can be used when trying to fill a large open canal, as in an immature canine

tooth, to provide greater strength for future restorations.³⁹

- Amalgam is mixed and placed in the canal with an amalgam carrier (Fig. 7-22, *C*).
- The amalgam is condensed vertically with custom-made amalgam condensers (Fig. 7-22, *D*). (Condensers must be sized to reach the length and width of the canal.)
- These two steps are repeated until the canal is full.

Advantage

- Makes a stronger tooth when dentinal development is minimal.

Disadvantages

- Amalgam can be extended beyond apex if apical development is incomplete.
- Technique discolors tooth.
- Amalgam may expand and fracture tooth.
- Condensing instruments of adequate length are needed for a complete fill.

Thermoplasticized gutta-percha

- Trifecta/UltraFil System, Obtura II System.

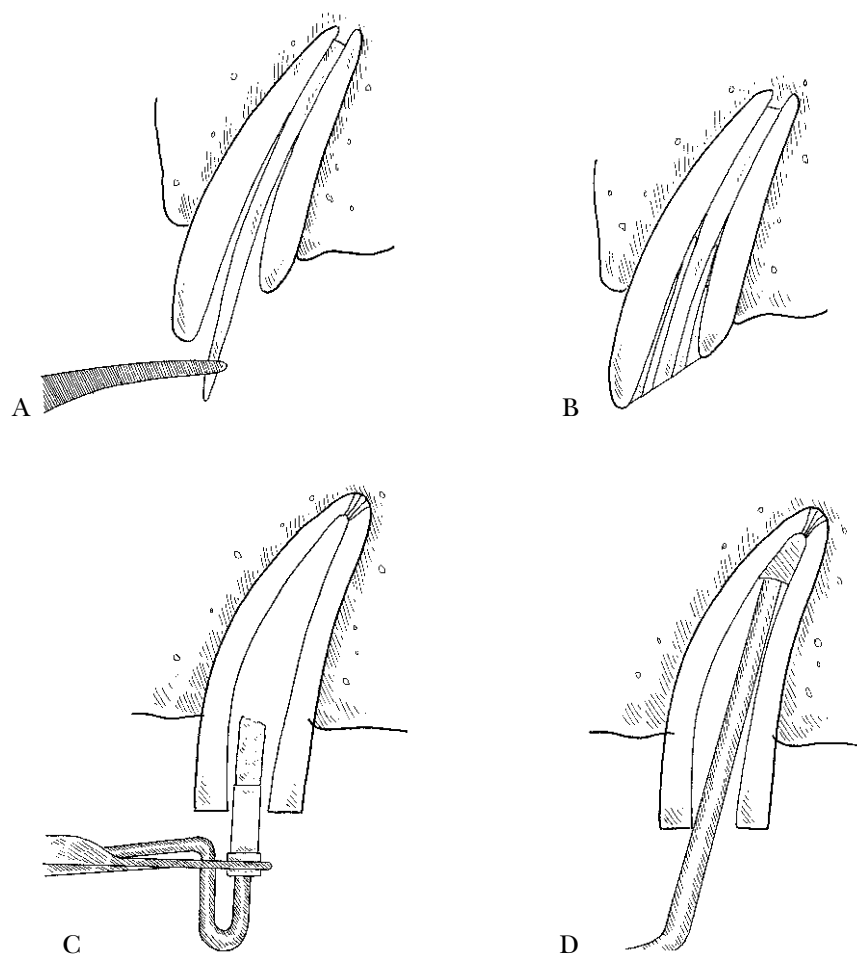


Fig. 7-22

Heated gun technique

- A special device (UltraFil System, Coltene/Whaledent, Mahwah, NJ; Obtura II, Obtura Corporation, Fenton, Mo.) is used to heat gutta-percha, which is injected into the canal with a pressurized syringe. The canal must be filed to a size 60 or 70 to allow the needle to be inserted near the apex. Cannules are supplied, loaded with gutta-percha of different levels of flowability. The more flowable gutta-percha is preferred.
- Root canal sealer is placed in the canal with a file or spiral filler.
- A cannule of gutta-percha is heated and loaded into the syringe.
- The needle (22 gauge) of the cannule is placed in the canal to within 1 mm of the apex.
- Melted gutta-percha is injected slowly into the canal as the needle is withdrawn (Fig. 7-23, *A*).
- In longer canals, a few millimeters of gutta-percha are placed in the canal (Fig. 7-23, *B*). After cooling for 20 to 30 seconds, a root canal plugger is used to push the gutta-percha apically (Fig. 7-23, *C*).
- This step is repeated until the canal is full (Fig. 7-23, *D*).
- Final condensation is performed with a root canal plugger to ensure an apical seal (Fig. 7-23, *E*).
- Excess gutta-percha is removed from the access opening with a heated instrument (Fig. 7-23, *F*).

Advantages

- Rapid filling method in larger canals.
- Can fill accessory or lateral canals.

Disadvantages

- Not applicable in small canals because the cannule needle is equivalent to a size 60 file.
- Needle of cannule not long enough for most canine teeth; must be combined with the vertical condensation technique to fill long teeth completely.

Heated syringe technique**General comments**

- This system employs a heater to heat gutta-percha in a syringe (SuccessFil Obturation System, Coltene/Whaledent). The gutta-percha is then transferred to either a titanium core carrier or a sterile endodontic K-file with endodontic stop to be inserted into the canal. The SuccessFil syringe may be reheated and used until empty.

Advantage

- A good, solid fill of the canal can be obtained.

Disadvantages

- Moderate expense for start-up and for materials.
- Learning curve to work with material.
- Can be time consuming on larger canals.

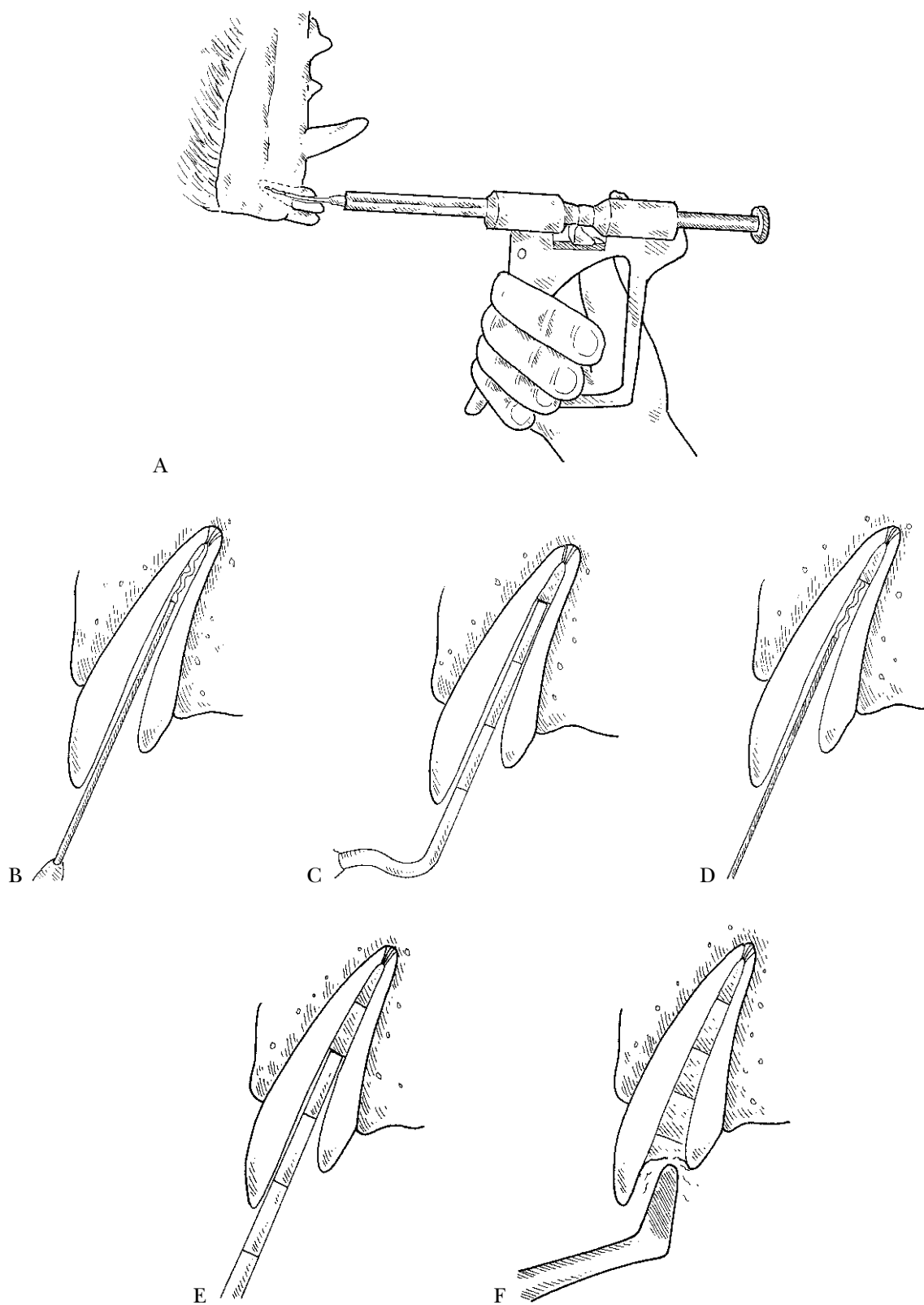


Fig. 7-23

Technique

- This technique has two options: leaving the file in the canal with the gutta-percha or removing the file after the gutta-percha is placed. The latter is the most commonly used.

Step 1—The syringe of gutta-percha is warmed in the heating unit (Fig. 7-24, A).

Step 2—A clean file, two to three sizes smaller than the last file used to reach the apex, is selected.

Step 3—Sealer is placed in the canal by one of the above-described methods.

Step 4—The selected file is inserted into the end of the syringe of warm gutta-percha and, while the plunger is pressed simultaneously, the file is withdrawn to create a thin, tapered coating of gutta-percha on the file (Fig. 7-24, B).

Step 5—The file is inserted quickly into the canal to the working length.

Substep 1—The file is held in place while the gutta-percha cools slightly. The file is then twisted counterclockwise and withdrawn, leaving the gutta-percha in place. A plugger is used to condense the softened gutta-percha apically. Additional gutta-percha can be placed and condensed until the canal is filled adequately.

Substep 1—An alternative method is to place a rubber stopper on the file before coating the file with gutta-percha. After the file is placed in the canal, the rubber stopper is placed against the tooth, and the file is withdrawn, keeping the gutta-percha in the canal. The gutta-percha is then condensed with a plugger.

Step 6—A radiograph is taken to confirm the desired fill.

- In large canals, this technique can be combined with using a cannule of warm gutta-percha injected to fill the coronal portion of the canal.

Complications

- May result in apical voids and coronal fill if too much material is placed on carrier.
- Gutta-percha may cool and not be taken to the working length if the insertion is too slow.
- Removing the gutta-percha with the file. Can be avoided by waiting a few seconds until gutta-percha has cooled; then twist the file out.

Obturation with Thermafil**General comments**

- The Thermafil (Tulsa Dental Products) system uses a plastic carrier to which a rubber stopper and thermally plasticized gutta-percha have been applied.
- After standard endodontic preparation, the gutta-percha on the carrier is warmed, and the carrier is inserted into the treated canal.
- After taking a radiograph to evaluate proper fill, the carrier is cut off and left in the canal.
- Thermafil is available either in specific carrier sizes or in an assortment of sizes.
- The carrier sizes are from standard file size 20 to 140.

Advantages

- Thermafil allows filling of narrow, medium-length canals where using standard gutta-percha techniques may be difficult.
- Thermafil provides a good apical seal.
- Although relatively rare in the dog and cat, if lateral canal or apical canals are present, Thermafil provides introduction of gutta-percha into these secondary canals.

Disadvantages

- Currently, the carriers are manufactured only in 25-mm lengths; therefore, canals longer than 25 mm cannot be treated. Longer lengths may be manufactured.
- The carriers are expensive, and using the system is moderately technique sensitive.

Technique

- Before beginning, the oven that will heat the plastic gutta-percha carrier must be turned on and allowed to warm up.

Step 1—The endodontic obturator is selected by using a size verification kit (Tulsa Dental Products; LD Caulk/Dentsply). From the kit, a carrier blank of the same size as the largest file used to the full working length is selected. The blank carrier is disinfected in a 5.25% sodium hypochlorite solution for 1 minute, followed by a rinse in 70% alcohol.

Step 2—The carrier blank is inserted to the working length. The carrier blank should fit without forcing. If it does not fit to the apex, either the canal must be reworked or a carrier blank the next size smaller must be selected and tried. A radiograph is taken to ensure proper fit to the apex.

Step 3—The same size plastic endodontic obturator as fits the canal properly is selected (Fig. 7-24, *C*) and placed in the oven (Fig. 7-24, *D*). The carrier should be warmed for 5 to 8 minutes before being inserted into the canal.

Step 4—As the endodontic obturators are warming, ThermaSeal is spatulated (ThermaFil, Tulsa Dental Products; Densfil, LD Caulk/Dentsply). The material may be

placed in the canal by coating gutta-percha points and swabbing the canal.

Step 5—Once heated, the endodontic obturators are inserted into the canals, being careful to make as direct an insertion as possible.

Step 6—Once inserted, radiographs are taken to confirm obturation to the apex of all canals.

Step 7—The endodontic obturators are cut with a heated instrument.

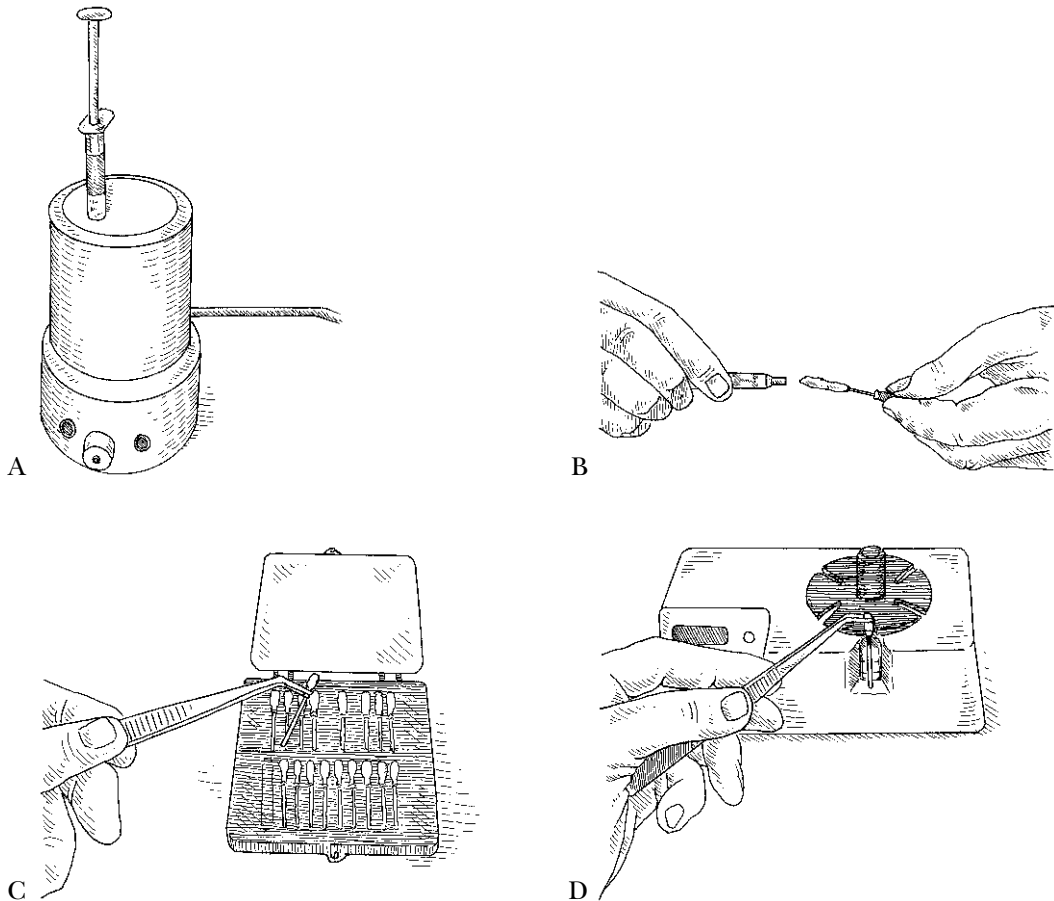


Fig. 7-24

Complications

- It may not be possible to insert the endodontic obturator to the apex. In this case, the obturator should be reheated and reinserted, another obturator should be chosen and heated, or another method of filling the canal should be selected.
- In the maxillary fourth premolar, where the mesiobuccal and palatal roots come together, it is best to fill one canal, take radiographs, cut the obturator with a heated instrument, and then fill the other canal. Otherwise, the obturator from the first canal may prevent a direct insertion of the obturator for the second canal.

Additional filling techniques**Comments**

- Additional techniques are available, but they are not recommended by the authors. They are included to list their advantages and disadvantages.
- Paste injection system.
- Tubli-seal (Kerr Corporation).

Advantages

- Easy.
- Fast.

Disadvantages

- Overfill of canal is possible.
- Sets up fast and may be difficult to remove, if necessary, such as if post space or repeated instrumentation is needed.
- May fill the coronal end and leave an apex open.

Solid fillers

- Silver points.

Advantages

- Do not shrink.
- Do not encourage bacterial growth.
- Nonirritating.
- Radiopaque.
- Easily introduced.
- Can be used more effectively than gutta-percha in straight canals less than a 25 file size.

Disadvantages

- Difficult to remove.
- Rigid and often do not match canal shape.
- Not suited for curved canals.
- Corrosion may release cytotoxic silver and staining.

Removal of gutta-percha

- The following techniques may be used to remove gutta-percha:
 1. An instrument may be used to heat the gutta-percha and remove it from the pulp chamber.
 2. Endodontic files may be used to refile the canal.
 3. Chloroform, fluothane, or rectified turpentine oil may be introduced into the canal to soften it. Rectified turpentine oil has the advantage that it is not carcinogenic.

Restoration of Coronal Access

- All residual gutta-percha and sealer should be removed from the coronal access area. This can be accomplished with an excavator or a bur on a high-speed or low-speed handpiece. An alcohol-impregnated small cotton ball may help remove ZOE sealants.
- A base of glass ionomer or other suitable material is placed over the gutta-percha ends.
- The access site is restored using a technique discussed in Chapter 8.

Postoperative care

- Recommend soft food for 48 hours.
- Follow-up radiographs are recommended at 6 months, 1 year, 2 years, and 5 years.
- Oral antibiotics for a minimum of 1 week should be prescribed.
- Pain-relieving medication should be prescribed for 3 days.
- Minimize aggressive chewing activity. Patients should be allowed to chew only items softer than the teeth.

Complications of nonsurgical endodontics

- The primary complication of a nonsurgical endodontic procedure is failure of the

procedure related to improper operator assessment or technique.

- The patient may be asymptomatic; therefore, radiology is an important tool to enable subsequent diagnosis of a failed treatment.⁴⁰
- Veterinary dentists should radiograph annually the site of endodontic treatment for up to 5 years to determine the success of previous treatment. In a 5-year (mean 13 months) retrospective radiographic study of 127 roots in 67 dogs, a failure rate for standard root canal therapy performed by skilled veterinary dentists was 6%, which is similar to that found in human dentistry.⁴⁰ Failure was declared in cases in which (1) periapical bone lysis or root resorption developed subsequent to endodontic treatment, (2) a preexisting lesion had increased in size, or (3) if preoperative root resorption appeared to continue after endodontic treatment.
- The radiograph may demonstrate that the lesion has remained the same, has enlarged, or has diminished in size only slightly and total healing has not occurred. If the condition appears no worse or the radiographic lucency is diminished (more opaque), and there are no clinical signs of pain or exacerbation of the condition, it may be considered stable or healing at the time of inspection.
- Common causes of procedure failure are incomplete obturation and inadequate apical seal, pathologic or iatrogenic root perforation, and broken instruments in the canal.
- Other causes of failure are root end resorption, coexistent periodontal-periapical lesions, and endodontic disease in adjacent teeth.

Variations with Individual Tooth Types

Incisors

Access opening

- If the crown is fractured or worn (Fig. 7-25, *A*), the opening to the pulp canal can be enlarged with an appropriate size round or pear-shaped bur in a high-speed or low-speed handpiece.
- If the crown is intact, the access hole can be made on the lingual surface between the crown tip and the cingulum (Fig. 7-25, *B*). The bur is directed toward the center of the tooth along the long axis to avoid perforation of the root.

Filing and irrigation of the canal

- Smaller and shorter files are used to clean and prepare incisor canals. The root of the third maxillary incisor curves dramatically, and it may be necessary to prebend files to reach the apex (Fig. 7-25, *C* and *D*).

General comment

- Incisor teeth can be treated relatively quickly. In small dogs it may be difficult to enter the canals of the central incisors and #06 and #08 files may be necessary, initially, to start filing. Generally, the canal is filed to size 35 to 40 for the average size dog.

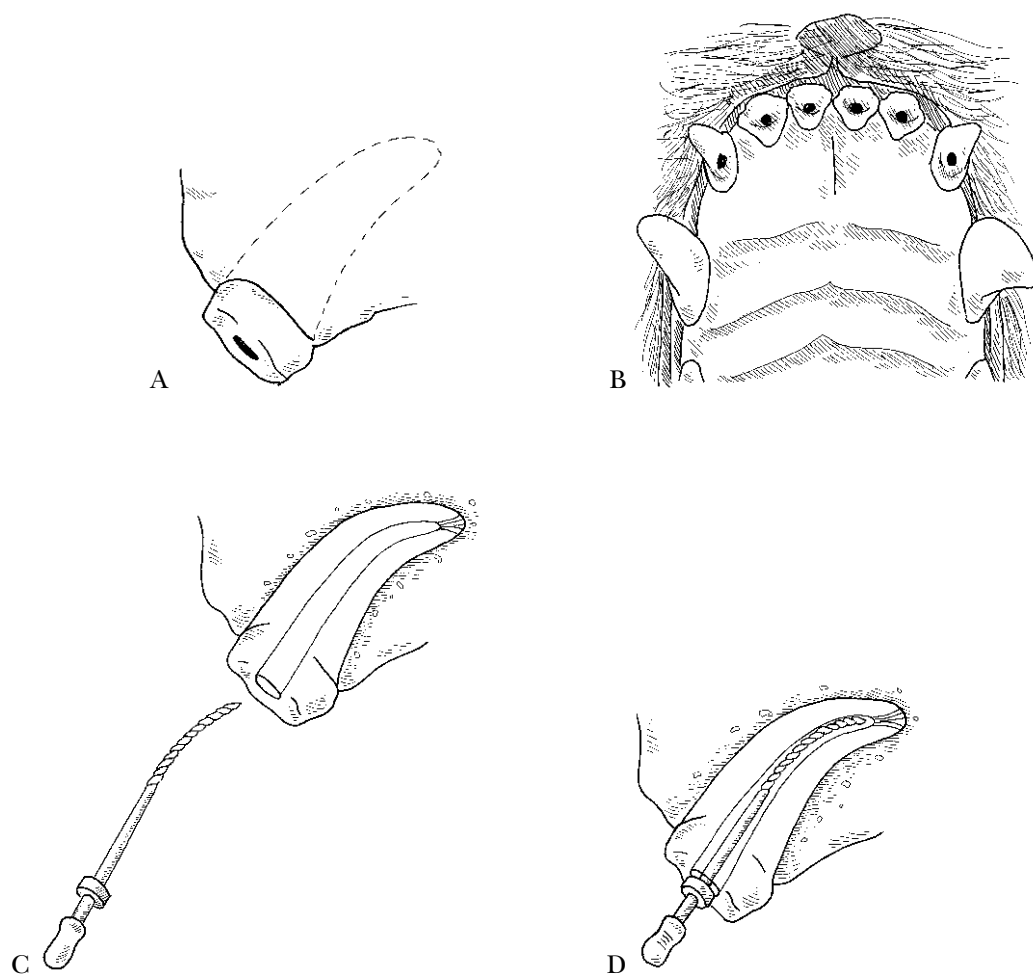


Fig. 7-25

Canine teeth

Access opening

- An access hole can be made at the fracture site by enlarging the pulp canal opening with a #2, #4 round, or #330 pear-shaped bur in a high-speed or low-speed handpiece (Fig. 7-26, A). This access may be sufficient in fractured teeth with little remaining crown. An additional access hole is made on the mesial surface of the tooth 2 to 3 mm coronal to the gingival margin, in a line with the root canal visualized on a preoperative radiograph in intact teeth or in teeth with incisal crown fractures, to allow complete instrumentation of the entire canal length without undue bending of files. The access hole begins with an initial cut made through the enamel and perpendicular to it (Fig. 7-26, B). The bur is next directed apically to penetrate the pulp chamber while being in a straight line with the apex (Fig. 7-26, C).
- Access holes should be just large enough to allow unimpeded instrumentation.

Filing and irrigation

- Filing and irrigation are completed as described on p. 360. Files or reamers 40- to 60-mm long are necessary to reach the apex in large dogs.⁴¹ In dogs with smaller canals, it is beneficial to enlarge the coronal portion of the canal with a Gates Glidden drill on a low-speed handpiece to eliminate binding the shaft of the larger files.
- Alternating between file types can be beneficial in completing the instrumentation

and ensuring a clean canal. Reamers work well throughout the canal length, whereas K-files are best used in the apical third of the canal; Hedström files are preferably used to shape the coronal two thirds of the canal.

- Wide pulp canals in younger dogs necessitate circumferential filing to remove all pulp remnants and softened dentin.
- In one study of 353 sequential endodontic treatments, the average canal diameter was found to range from size 25 × 23 mm in small dogs to 50 × 36 mm in large dogs.⁴¹

Filling techniques

- The techniques most commonly used are spiral filling, lateral condensation with multiple gutta-percha points, combinations of lateral and vertical condensation with standard gutta-percha, and thermoplasticized gutta-percha techniques.
- Large canals in young dogs can be filled with amalgam or Core Paste (Den-Mat, Santa Maria, Calif.).
- Longer plugger-spreader instruments designed for use in canine teeth are available (PLG/SP50, PLG/SP65, PLG/SP90, Cislak).
- In long, narrow canals better filling of the apex can be achieved by warming 5-10 mm of the tip of a gutta-percha point with a Touch and Heat. Holding the gutta-percha point in one hand the instrument is circled around the tip of the gutta-percha without touching it. This effectively softens the tip while the remaining gutta-percha remains stiff.

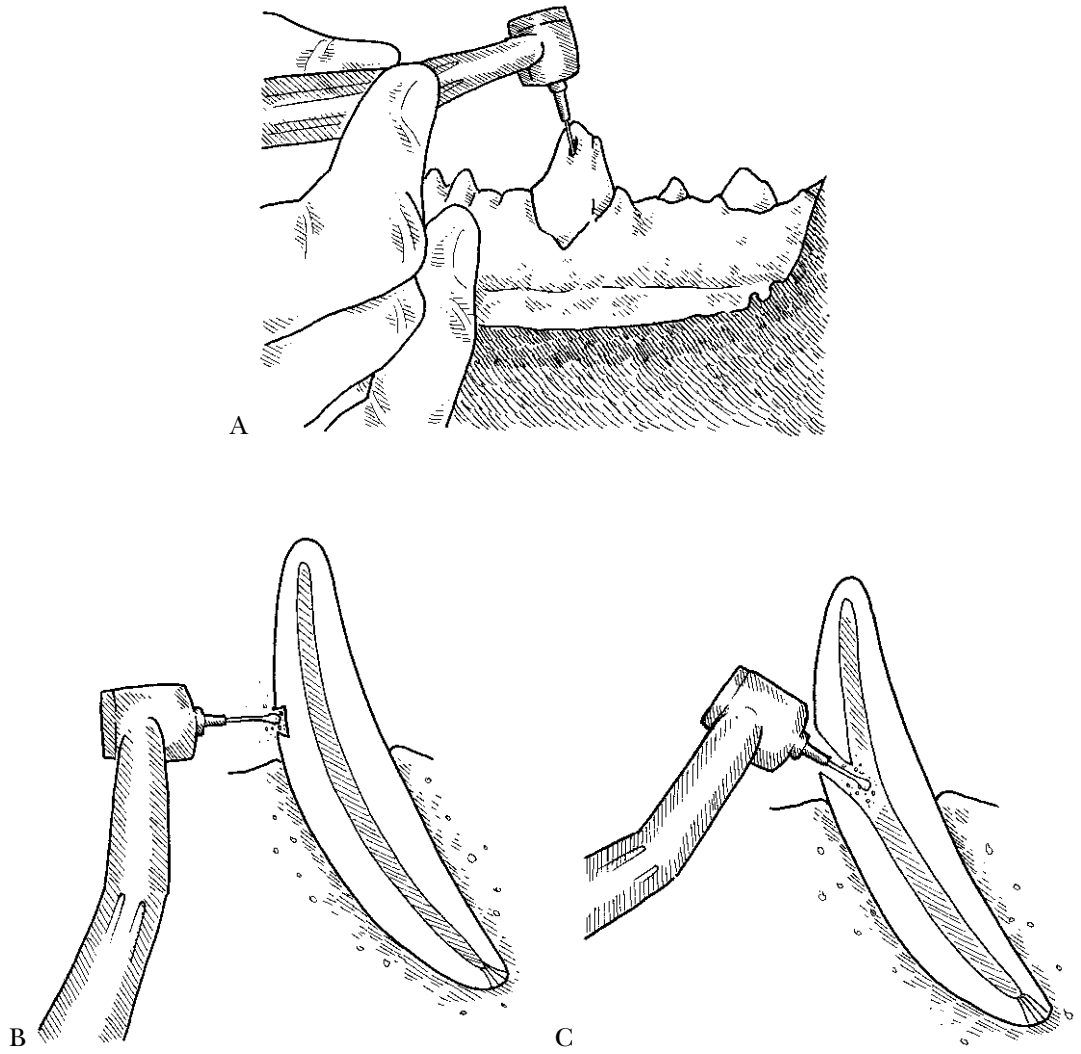


Fig. 7-26

Teeth with two roots

Access openings

- Openings need to be made into each root (Fig. 7-27, A). Premolars can be accessed from the fracture site, if large enough; otherwise, a separate hole is drilled into the crown over each root. The least amount of tooth structure as possible should be removed in making the access. Some authors advise opening the common pulp chamber liberally to allow removal of pulp tissue. The risks of using a single access site to instrument a two-rooted tooth are incomplete debridement and root-wall perforation when filing, and creating voids when filling.
- In a mandibular molar, access is made into the mesial root by drilling a hole just lingual to the small developmental fissure on the buccal surface of the tooth (Fig. 7-27, B). The distal root is accessed by a hole drilled in the center of the occlusal surface. Comparing the anatomic features with those in a radiograph helps determine the proper site and angle of the access hole.
- The roots may be filed sequentially or simultaneously (Fig. 7-27, C).

Teeth with three roots

Maxillary fourth premolar

Access to mesiobuccal root

- The mesiobuccal root can be accessed by drilling a hole at the point of intersection of a line approximately two thirds the distance between the developmental groove and buccomesial line angle at the waist of the tooth, and one fourth the distance from the gingival margin to the full length of the normal cusp tip. If the cusp is missing, the distance is approximated by comparing the injured tooth with the contralateral one.

Palatal root

Transcoronal approach^{41,42}

- The palatal root can be accessed through the hole discussed above by directing the file toward the palatal root (Fig. 7-27, D).
- The access to the palatal root can vary from a site in the chamber floor to a site in the chamber wall. It is helpful to visualize externally the palatal cusp and visible portion of the root. The access site may also be enlarged to provide better visualization of the chamber while locating the access to the palatal root.

Three access-hole approaches

- The palatal root can also be accessed by drilling directly over the palatal cusp close to the notch created by the large cusp surface. This is more difficult, particularly in older dogs and in larger dogs.
- A third approach to the palatal root is to create a groove between the mesial root access hole and the palatal cusp across the surface of the tooth. In difficult cases, this will allow visualization of the common pulp chamber, and the files can then be directed into the palatal root, but it does require removal of an increased amount of tooth structure.
- Occasionally, in older or small dogs, the palatal root cannot be filed to the apex due to partial calcification of the canal. If there is no periapical disorder visible and further filing cannot be accomplished with additional use of chelating agents, a clinician may choose to file and fill the canal to the depth reached, after which the canal should be monitored closely. This may be preferable to root amputation.

Palatal root amputation

- If the palatal root cannot be accessed or if root perforation occurs in attempts to locate the canal, the palatal root may need to be sectioned and removed to help prevent procedural failure. The resultant exposure to the pulp chamber is then filled with a restorative.
- One potential problem is that when the palatal root is amputated, its buttressing effect will be lost and the tooth will be weaker and more subject to fracture.⁴²⁻⁴⁴

Access to distal root

- The distal root access hole is drilled two thirds of the distance between the distal surface of the tooth and the developmental groove, and halfway from the gingival margin to the distal cusp.⁴² These holes are made large enough to allow free, straight-line instrumentation of all the canals in the maxillary fourth premolar.

Maxillary molar teeth

- Access sites in the three-rooted molar teeth are best made on the occlusal surface, in the center of each of the three cusps, after evaluation of preoperative radiographs and study models.

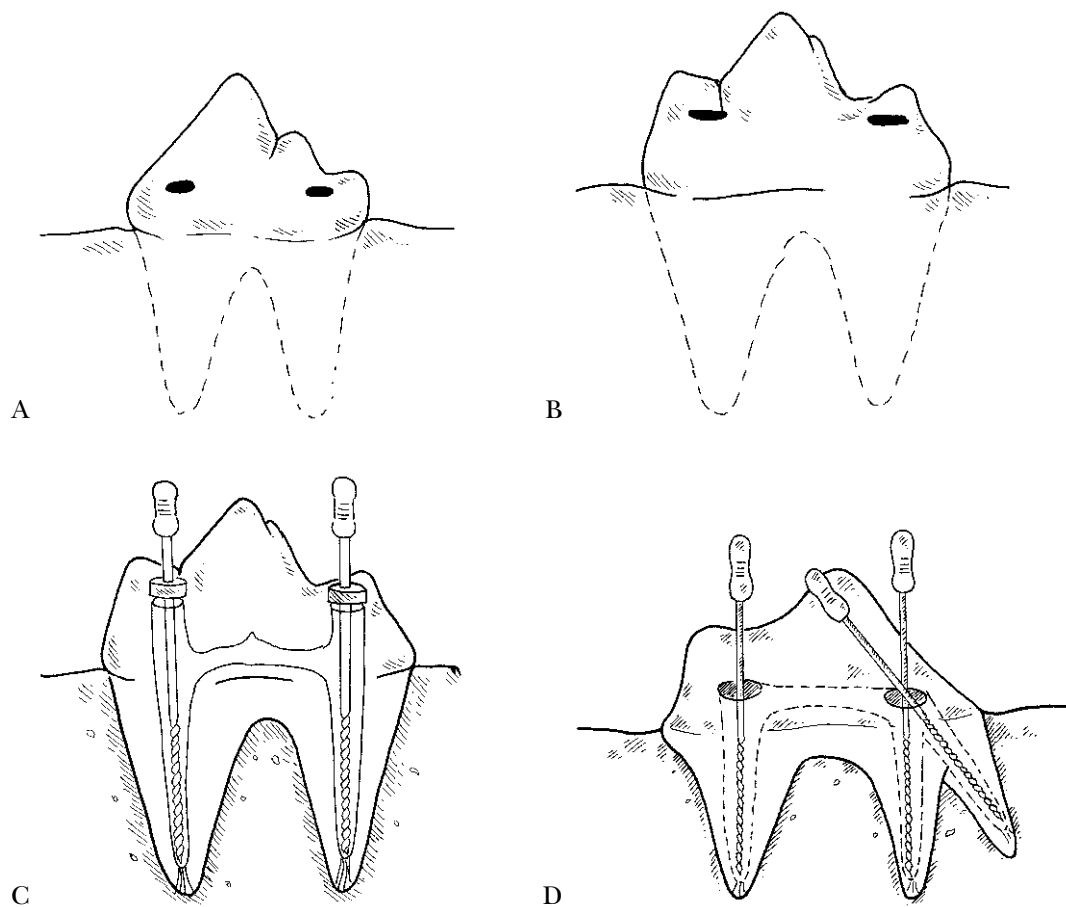


Fig. 7-27

Filing and irrigation

- Filing and irrigation of all three roots are completed using 21- to 30-mm files, as described throughout this chapter. The distal root is generally larger and may often be filed to size 80. The mesiobuccal root averages size 30 to 35 and the palatal root size 25 to 30.⁴¹

SURGICAL ENDODONTICS: APICOECTOMY WITH RETROGRADE FILLING

General Comments

- There are a few complicated situations in which only surgery can salvage the tooth.^{12,44,45} The success of surgical root canal therapy is improved when standard root canal therapy is performed first, whether performed as one-stage or two-stage procedures.^{12,44,46-48}
- The prognosis for successful surgical root canal therapy is very good, as long as attention is paid to detail, the tissues are instrumented adequately, and the materials are used in accordance with the manufacturer's instructions.^{49,50}
- The teeth most commonly requiring apicoectomy are the maxillary and mandibular carnassial and canine teeth.^{35, 36, 45, 46, 48-54}
- A surgical root canal treatment can be successful only if the basic tenets of canal cleaning and shaping have been accomplished.
- All roots should be treated in multirrooted teeth.
- It is very difficult to access surgically the palatal root of the upper fourth premolar. It

can be resected and extracted, as necessary, to salvage the tooth. If it is filled adequately, and it is not the reason for the surgical decision, it may be left in place.

- Using a study skull to reference anatomic features, with preoperative radiographs, is very often a helpful clinical aid.

Indications

- A tooth with an open apex and concomitant periapical infection that does not respond to standard endodontic treatment.
- Apical perforation during endodontic treatment that subsequently leads to clinical failure.
- A separated endodontic file tip embedded in the root canal or wall, which interferes with complete preparation and filling of that canal and subsequently leads to clinical failure.
- Failure of a standard root canal procedure resulting in clinical failure (underfill, overfill, root perforation, etc.). May need to retreat standard root canal therapy first, if canal is underfilled.
- Coronal approach impossible (narrow canals, aberrant canal formation, pulp stones, or calcified canal).
- Horizontal fracture of root tip.

Contraindications^{4,49}

- Retreatment is possible.
- Brittle health status of patient; high risk of anesthesia.
- Anatomic limitations.

- Procedure is beyond the skill level of available professionals.
- Complex root and crown structure that impedes standard root canal therapy.
- Excessively weak or damaged roots.
- Advanced periodontal disease of that tooth.
- Necessity to remove excess bone in the mandible, which may further weaken the mandible.
- Unidentifiable cause of root canal treatment failure.

Objective

- To ensure a seal of the root canal system at the apex by exposing the apical area and sealing the canal with a retrograde filling.

Materials

- Instruments and materials for standard root canal therapy.
- Number 10, 15, or 15C scalpel blade with #3 scalpel handle.
- Magnification (loupes, telescopes, or other sources).
- Good light source (fiberoptic handpiece, headlamp).
- Periosteal elevator (Molt 2, 4, and 9).
- Senn retractors.
- Number 701L, $\frac{1}{2}$, 2, 4, $33\frac{1}{2}$, or 34 bur.
- Small (3 mm) bone rongeurs.
- Dental excavators #31 and #33.
- Lucas #75 curette.
- Bone curette, oval or round (5-0 = 2 mm).
- Dressing forceps.
- Sterile physiologic saline.

- Retrograde amalgam or composite carriers ($\frac{3}{64}$ inch and $\frac{5}{64}$ inch).
- If amalgam technique is used: amalgam plugger and carver, zinc-free amalgam, amalgamator, amalgam well.
- Retrograde pluggers, left and right.
- Retrograde endodontic mirror (3 mm).
- If amalgam technique is not used: IRM, MTA, or Super EBA cement (ethoxybenzoic acid, Henry J. Bosworth Co., Skokie, Ill.).
- 4-0 absorbable suture material with swaged-on taper needle.
- Needle holders, scissors, thumb forceps.
- Cotton pellets.
- Hemostatic agent.
- Bone wax.
- Suction with sterile tips.

Technique

Step 1—Standard root canal therapy is performed first. (Retreatment and refilling of the canal may be first treatment option if failure is due to inadequate obturation, etc.)

Step 2—The mouth is disinfected with 0.2% chlorhexidine, and aseptic technique is employed.

Step 3—The tooth apex is located by feeling the bulge of the root (juga) beneath the alveolar mucosa and is exposed by incising the soft tissue superficial to the apex with a semilunar incision. The incision is made through the periosteum. The area can be infiltrated with lidocaine with epinephrine to enhance hemostasis.

Substep 1—A preoperative radiograph is taken to locate the apex.

Access Sites

- Access to the maxillary canine tooth is made with a curved incision starting mesial to the root in the alveolar mucosa, extended distally to the level of the distal root of the second premolar, with the ventral depth of the curve at the coronal third of the root (Fig. 7-28, *A*).
- Access to the maxillary fourth premolar is made with a semilunar incision through the alveolar mucosa starting at the level of the third premolar and extending distally to the first molar, with the depth of the curve at the coronal third of the root. (Do not disturb the infraorbital nerve exiting above the mesiobuccal root or the distal root of the third premolar.) An approximation of the apical locations can be made when it is realized that the mesiodistal width of the tooth approximately equals the distance from the gingival margin to the apex. It can be visualized as a square.⁴³
- Access is made to the first mandibular molar either intraorally, on the buccal mucosa, with a semilunar incision starting at the level of the fourth premolar and continuing distally to the second molar, with the depth of the curve at the coronal third of the root (Fig. 7-28, *B*), or through a ventral approach to the ramus of the mandible.
- Access to the mandibular canine teeth is made through a ventral approach to the mandible (Fig. 7-28, *C*).

- The maxillary canine tooth is used as an example for a surgical root canal.

Substep 2—An incision is made through the alveolar mucosa and periosteum over the tooth to be treated (Fig. 7-28, *D*).

Step 4—The gingiva and periosteum are reflected (Fig. 7-28, *E*). The bulge (juga) superficial to the root is palpated, and the apical area is determined by comparing with the file length used in preparation of the canal to locate the apex. Soft-tissue retractors are used to increase visualization. Avoid tearing the flap by using a sharp periosteal elevator and elevating a full-thickness flap including mucosa, fascia, and periosteum. Partial-thickness flaps are not recommended due to reduced healing capabilities caused by interrupted blood supply and reduced flap strength.

Step 5—The bone is drilled away, with a feather motion, using the side of the cutting bur, in a small circle encompassing the apex, to expose the distal 4 mm of the root with a high-speed #2, #4 round, #701L cross-cut fissure, or #330 pear-shaped bur with accompanying sterile saline irrigation. If a draining fistula is present, the bone will be soft and can be removed with a rongeur or bone curette (Fig. 7-28, *F*). If difficulty is encountered in reaching the apex, a surgical length cross-cut fissure or tapered-fissure bur may help. The buccal bone plate is often very thin. A light touch and paintbrush feather-light strokes with the cutting bur are recommended.

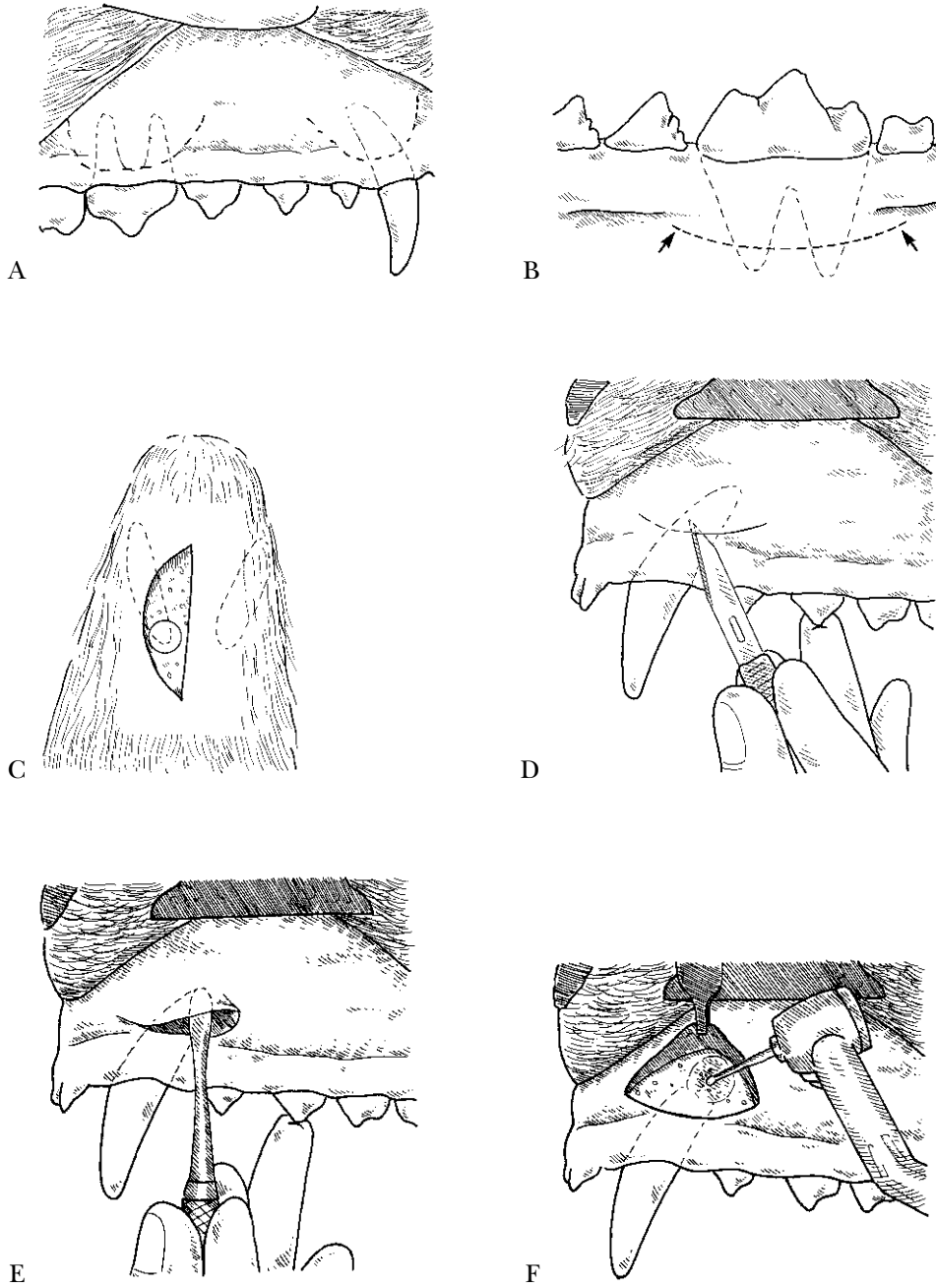


Fig. 7-28

Step 6—The necrotic tissue in the apical area is removed from the bone with a surgical excavator or sharp curette (Fig. 7-29, A).

Step 7—The apex is resected at a 10- to 45-degree angle to the long axis of the tooth with a #701L tapered-fissure or #331L bur in a high-speed handpiece with sterile saline irrigation (Fig. 7-29, B). The closer toward the 10-degree angle one gets, the less chance there is of residual necrotic material remaining medial to the remaining root material.⁵⁵ Necrotic apical material is removed so that solid hard root material is seen at the cut surface. More than 4 mm of root tip may need to be removed. The cut angle creates an oval opening of the pulp canal and exposes the standard root canal filling material. The apex should always be removed in a surgical root canal procedure, because the terminal portion of a normal canine or feline root canal usually develops apically into the apical delta where multiple, usually at this time necrotic, fine vascular and neural elements enter and exit.

Step 8—The surgical site is flushed liberally with sterile saline to remove debris.

Step 9—Hemorrhage is controlled by packing the area around the apex with sterile cotton pellets soaked in a hemostatic agent or by using bone wax, and visualization is enhanced by using suction equipment. Cotton pellets should be counted when inserted and again when removed, to avoid leaving foreign material in the surgical site.

Step 10—The opening into the canal is undercut with a #33½ or #34 inverted cone bur to make adequate retention for the filling (Fig. 7-29, C). This preparation should extend 2 to 3 mm coronally into the canal.

Step 11—The periapical area is flushed, dried, and repacked with cotton pellets or bone wax to keep the area dry and to allow entrapment of excess filling material (Fig. 7-29, D). The cotton pellets or bone wax are removed before closure.

- Many filling materials have been proposed to seal the apex. Amalgam has been used for years,^{11,21,56,57} and zinc-free amalgam has been recommended because of the moist environment in which the restorative material is placed. Recent studies have shown that amalgam is only 75% effective in preventing microleakage due to corrosion.⁵² Currently, materials providing a better seal are available. IRM2 (LD Caulk) has a milder tissue reaction than ZOE, compares favorably with other retrofilling materials, and is

delivered easily with a Centrix syringe.⁵¹ Ethoxybenzoic acid, another reinforced ZOE cement, has 37% aluminum oxide added, making it stronger and 95% effective against microleakage. It is also deliverable with a Centrix syringe. MTA has cavity adaptation similar to Super EBA.⁵⁸ The above materials have varying results and data can be found in the literature to support them all.^{58,59}

Step 12—If amalgam is used, the amalgam is mixed in an amalgamator, placed in the opening with the retrograde amalgam carrier (Fig. 7-29, E), and condensed in place with a small plugger. If IRM2 or Super EBA cement is used, as stated above, it is mixed and placed into the opening with a Centrix syringe.

Step 13—The filling material is carved smooth with a carver and allowed to set.

Step 14—The hemostatic packing is removed, and the area is flushed with sterile saline or 0.2% chlorhexidine.

Step 15—The gingival flap is closed with interrupted sutures, using 3-0 or 4-0 absorbable suture material (Fig. 7-29, F).

Step 16—A postoperative radiograph is taken to verify the seal.

Postoperative Care

- Oral antibiotics for a minimum of 1 week; in some cases, 1 to 2 months.
- Pain medication for 5 days.
- Follow-up radiographs at 6 months, and annually thereafter for 5 years.
- Softened food and no hard treats, chew toys, or oral play for 2 weeks to avoid tearing out sutures.
- The owner should apply cold compresses to the surgical site during the first 24 hours and warm moist compresses thereafter, 3 times a day, until all postsurgical swelling subsides.

Complications

- Drilling into nasal cavity around maxillary canine. This generally will heal with the closure of the flap.
- Perforation of maxillary sinus while amputating the palatal root of the maxillary fourth premolar.
- Injury to infraorbital nerve or hemorrhage during access to buccomesial root of upper carnassial tooth.
- Hemorrhage or injury to the mandibular division of the trigeminal nerve during access

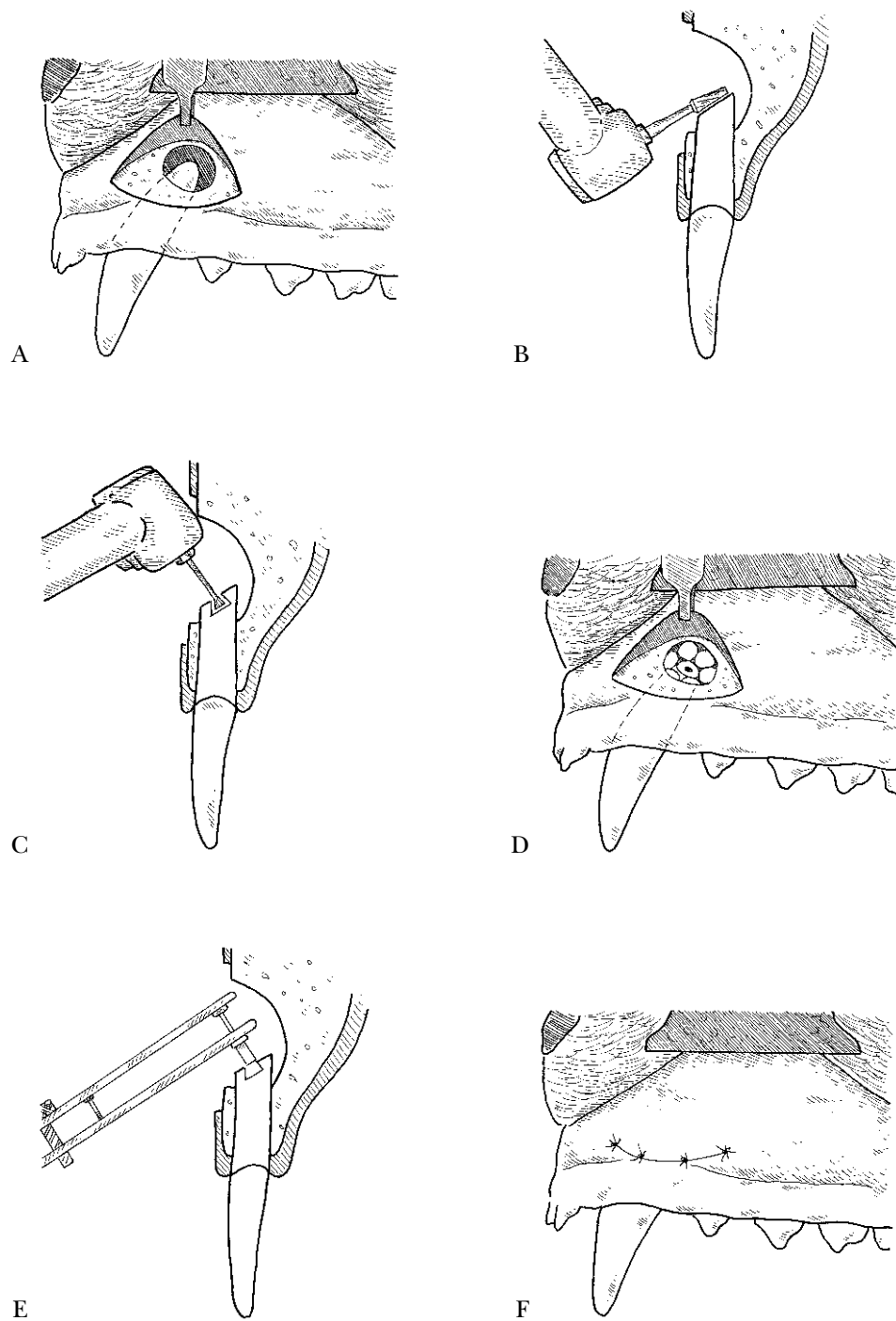


Fig. 7-29

Table 7-2 • PERIODONTAL AND ENDODONTIC RELATIONSHIPS

Condition	Signs	Treatment
Primary endodontic	Fistula Drainage into mucosa Normal crestal bone	Standard root canal therapy
Primary endodontic with secondary periodontal disease	Lysis of periodontal ligament Pocket formation J-shaped radiographic lesion	Standard root canal therapy Periodontal therapy
Primary periodontal	Lost crestal bone Normal apical region	Periodontal therapy
Primary periodontal with secondary endodontic disease	Mobility Loss of crestal bone Apical lysis Increased periodontal ligament loss	Periodontal flap Endodontic therapy
Combined endodontic and periodontic disease	Facial swelling Lateral swelling adjacent to apex	Endodontic treatment followed by periodontic treatment Poor prognosis

to the apices of the mandibular premolars or molars. Infection may also spread along this nerve.⁴⁶

- Dislodging or marginal leakage of retrograde filling due to inadequate preparation, placement, condensation, or finishing.
- Infection.
- Recurrent swelling or drainage due to persistent necrotic tissue or foreign material.
- Subcutaneous emphysema.
- Air embolism⁶⁰ (rare).
- Postoperative swelling and pain secondary to crushing injuries by retractors.

PERIODONTAL-ENDODONTIC RELATIONSHIPS

Comments

- The practitioner must consider the overall relationship and involvement of the periodontal and endodontic systems. Disease can originate inside the canal and spread to the periodontal tissues; conversely, disease can arise in periodontal structures and result in disease of the pulp.
- Table 7-2 may be helpful in defining the condition, signs, and treatment.

REFERENCES

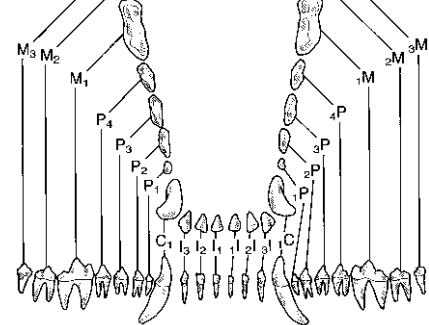
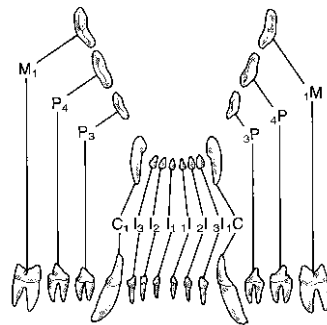
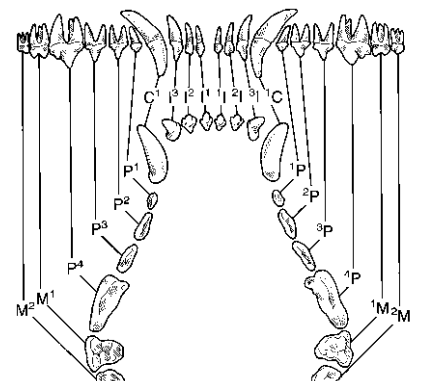
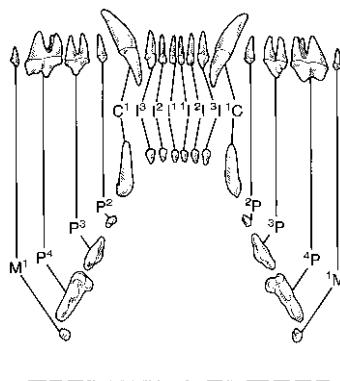
1. Emily P, Tholen MA: Endodontic therapy. In Bojrab MJ, Tholen MA, editors: *Small animal oral medicine and surgery*, Philadelphia, 1990, Lea & Febiger, pp 158-193.
2. Ross DL: The oral cavity. In Kirk RW, editor: *Current veterinary therapy VI*, Philadelphia, 1977, WB Saunders, pp 921-923.
3. Wiggs RB, Lobprise HB: Oral anatomy and physiology. In Wiggs RB, Lobprise HB, editors: *Veterinary dentistry: principles & practice*, Philadelphia, 1997, Lippincott-Raven, pp 55-86.
4. Wiggs RB, Lobprise HB: Basic endodontic therapy. In Wiggs RB, Lobprise HB, editors: *Veterinary dentistry: principles & practice*, Philadelphia, 1997, Lippincott-Raven, pp 280-324.
5. Ross DL: Veterinary dentistry. In Ettinger SJ, editor: *Textbook of veterinary internal medicine*, ed 1, Philadelphia, 1975, WB Saunders, pp 1047-1067.
6. Harvey CE, O'Brien JA, Rossman LE, Stoller NH: Oral, dental, pharyngeal, and salivary gland disorders. In Ettinger SH, editor: *Textbook of veterinary internal medicine*, ed 2, Philadelphia, 1983, WB Saunders, pp 1126-1190.
7. Harvey CE: Oral, dental, pharyngeal, and salivary gland disorders. In Ettinger SJ, editor: *Textbook of veterinary internal medicine*, ed 3, Philadelphia, 1989, WB Saunders, pp 1203-1254.
8. West-Hyde L, Floyd M: Dentistry. In Ettinger SJ, editor: *Textbook of veterinary internal medicine*, ed 4, Philadelphia, 1995, WB Saunders, pp 1097-1123.
9. Eisner ER: Endodontic and restorative dentistry. In Ettinger S, Feldman E, editors: *Textbook of veterinary internal medicine*, ed 5, Philadelphia, 2000, WB Saunders, pp 1135-1142.
10. Mulligan TW: Endodontics. In Kirk RW, editor: *Current veterinary therapy X*, Philadelphia, 1989, WB Saunders, pp 454-459.

11. Ross DL, Meyers JW: Endodontic therapy for canine teeth in the dog, *J Am Vet Med Assoc* 157(11):1713-1718, 1992.
12. Markowitz K: Tooth sensitivity: mechanisms and management, *Compend Contin Educ Dent* 14(8): 1032-1045, 1993.
13. Eisner ER: Standard root canal therapy: the pre-operative examination and root canal access, *Vet Med* 88(1):42-52, 1993.
14. Camp JH, Barrett EJ, Pulver F: Pediatric endodontics: endodontic treatment for the primary and young, permanent dentition. In Cohen S, Burns RC, editors: *Pathways of the pulp*, ed 8, Philadelphia, 2002, Mosby, pp 797-844.
15. Grossman LI, Oliet S, del Rio CE: Disease of the dental pulp. In Grossman LI, Oliet S, del Rio CE, editors: *Endodontic practice*, ed 11, Philadelphia, 1988, Lea & Febiger, pp 573-77.
16. Syngcuk K, Trowbridge H, Suda H: Pulpal reaction to caries and dental procedures. In Cohen S, Burns RC, editors: *Pathways of the pulp*, ed 8, Philadelphia, 2002, Mosby, pp 573-600.
17. Grossman LI, Oliet S, del Rio CE: Preparation of the root canal: equipment and technique for cleaning, shaping, and irrigation. In Grossman LI, Oliet S, del Rio CE, editors: *Endodontic practice*, ed 11, Philadelphia, 1988, Lea & Febiger, pp 179-227.
18. Heitmann T, Unterbrink G: Direct pulp capping with a dentinal adhesive resin system: a pilot study, *Quintessence International* 26:765-770, 1995.
19. Kleier DJ, Barr ES: A study of endodontically apexified teeth, *Endod Dent Traumatol* 7:112, 1991.
20. Camp JH: Continued apical development of pulpless permanent teeth after endodontic therapy, masters thesis, Bloomington, 1968, Indiana University School of Dentistry.
21. Ham JW, Patterson SS, Mitchell DF: Induced apical closure of immature pulpless teeth in monkeys, *Oral Surg* 33:438, 1972.
22. Steiner JC, Dow PR, Cathey GM: Inducing root end closure of nonvital permanent teeth, *J Dent Child* 35:47, 1968.
23. Rubin LD, Maplesden DC, Singer RR: Root canal therapy in dogs, *Vet Med Small Anim Clin* 73:593-589, 1978.
24. Ridgeway RL, Zielke DR: Nonsurgical endodontic technique for dogs, *J Am Vet Med Assoc* 174:82-85, 1979.
25. Ruddle CJ: Cleaning and shaping the root canal system. In Cohen S, Burns RC, editors: *Pathways of the pulp*, ed 8, Philadelphia, 2002, Mosby, pp 231-291.
26. Goldstein GS, Anthony J: Basic veterinary endodontics, *Comp Cont Ed* 12:207-217, 1990.
27. Grossman LI, Oliet S, del Rio CE: Microbiology. In Grossman LI, Oliet S, del Rio CE, editors: *Endodontic practice*, ed 11, Philadelphia, 1988, Lea & Febiger, pp 234-241.
28. Wilson GJ: Implications to the time of apical closure in relation to tooth fracture in dogs, *Aust Vet Pract* 26: 65-75, 1996.
29. Eisner ER: Standard root canal therapy: preparing and filling the root canal, *Vet Med* 88(3):252-262, 1993.
30. Visser CJ: The use of bleach and hydrogen peroxide in endodontics irrigation, *J Vet Dent* 5:3-4, 1988.
31. Harrison JW: The effect of dilution and organic matter on the antibacterial property of 5.25% sodium hypochlorite, *J Endod* 7:323, 1981.
32. Dumsha TC, Gutmann JL: Armamentarium and instruments in nonsurgical root canal treatment. In Dumsha TC, Gutmann JL: editors: *Clinician's endodontic handbook*, Hudson, Ohio, 2000, Lexi-Comp, pp 79-89.
33. West JD, Roane JB, Goering AC: Cleaning and shaping the root canal systems. In Cohen S, Burns RC, editors: *Pathways of the pulp*, ed 6, Philadelphia, 1994, Mosby, pp 179-219.
34. Grossman LI, Olivet S, Del Rio CE: Preparation of the root canal. In Grossman LI, Oliet S, del Rio CE, editors: *Endodontic practice*, ed 11, Philadelphia, 1988, Lea & Febiger, pp 179-228.
35. Ruddle CJ: Nonsurgical endodontic pretreatment. In Cohen S, Burns RC, editors: *Pathways of the pulp*, ed 8, Philadelphia, 2002, Mosby, pp 875-929.
36. Lyon KF: Endodontic therapy in the veterinary patient, *Vet Clin North Am Small Anim Pract* 28(5): 1203-1236, 1998.
37. Gutmann JL, Witherspoon DE: Obturation of the cleaned and shaped root canal system. In Cohen S, Burns RC, editors: *Pathways of the pulp*, ed 8, Philadelphia, 2002, Mosby, pp 293-364.
38. Korzen BH: Endodontic treatment of the adult tooth. In Levine N, editor: *Current treatment in dental practice*, Philadelphia, 1986, WB Saunders, pp 184-193.
39. Fahrenkrug P, Shipp AD: Prosthodontics. In Shipp AD, Fahrenkrug P, editors: *Practitioners' guide to veterinary dentistry*, Beverly Hills, Calif, 1992, Dr. Shipp's Laboratories, pp 95-116.
40. Kuntsi-Vaattovaara H, Verstraete FJM, Kass PH: Results of root canal treatment in dogs: 127 cases (1995-2000), *J Am Vet Med Assoc* 220(6):775-780, 2002.
41. Eisner ER: 353 Sequential canine and feline endodontic cases: a retrospective study in a suburban veterinary practice, *J Am Anim Hosp Assoc* 28(6):533-538, 1992.
42. Eisner E: Transcoronal approach to the palatal root of the maxillary fourth premolar in the dog, *J Vet Dent* 7:14-15, 1990.
43. Eisner ER: Performing surgical root canal therapy in dogs and cats, *Vet Med* 90:648-661, 1995.
44. Harvey CE, Emily PP: Endodontics. In Harvey CE, Emily PP, editors: *Small animal dentistry*, Philadelphia, 1993, Mosby, pp 157-212.
45. Eisner ER: Endodontics in small animal practice: an alternative to extraction, *Vet Med* 87(5):418-434, 1992.
46. Eisner ER: Performing surgical root canal therapy in dogs and cats. In Proceedings of the Eleventh Annual American College of Veterinary Surgeons Symposium (29th Annual Surgery Forum, 36th Annual Scientific Meeting), 2001, pp 474-477.
47. Carr GB: Surgical endodontics. In Cohen S, Burns RC, editors: *Pathways of the pulp*, ed 6, Philadelphia, 1994, Mosby, pp 531-567.
48. Wiggs RB, Lobprise HB: Advanced endodontic therapies. In Wiggs RB, Lobprise HB, editors: *Veterinary dentistry: principles & practice*, Philadelphia, 1997, Lippincott-Raven, pp 325-350.
49. Eisner ER: Principles of endodontic surgery. In Verstraete FJM, ed: *Oral and maxillofacial surgery in dogs and cats*, Oxford, UK, 2004, Elsevier Science (in press).
50. Eisner ER: Apicoectomy techniques. In Verstraete FJM, editor: *Oral and maxillofacial surgery in dogs and cats*, Oxford, UK, 2004, Elsevier Science (in press).
51. Holmstrom SE, Frost P, Eisner ER: Endodontics. In Holmstrom SE, Frost P, Eisner ER, editors: *Veterinary dental techniques*, ed 2, Philadelphia, 1998, WB Saunders, pp 255-318.

52. Kim S: Endodontic microsurgery. In Cohen S, Burns RC, editors: *Pathways of the pulp*, ed 8, Philadelphia, 2002, Mosby, pp 683-725.
53. Matthew IR, Frame JW: Surgical endodontics. In Pedlar J, Frame JW, editors: *Oral and maxillofacial surgery*, Philadelphia, 2001, Churchill Harcourt International, pp 71-87.
54. Carr GB: Surgical endodontics. In Cohen S, Burns RC, editors: *Pathways of the pulp*, ed 6, Philadelphia, 1994, Mosby, pp 531-567.
55. Sngcuk K: Endodontic microsurgery. In Cohen S, Burns RC, editors: *Pathways of the pulp*, ed 8, Philadelphia, 2002, Mosby, pp 683-725.
56. Taylor RA, Raymond P: Endodontia in the dog. *Vet Med Small Anim Clin* 67:1197-1200, 1972.
57. Lawer DR: Root canal with retrograde amalgam filling. *Cal Vet*, Mar 1979, pp 11-15.
58. Felton D: Long term effects of crown preparation on pulp vitality. *J Dent Res* 68(special issue 1009), 1989 (abstract 1139).
59. Spanberg L: Instruments, materials, and devices. In Cohen S, Burns RC, editors: *Pathways of the pulp*, ed 8, Philadelphia, 2002, Mosby, pp 521-572.
60. Grossman LI, Oliet S, del Rio CE: Endodontic surgery. In Grossman LI, Oliet S, del Rio CE, editors: *Endodontic practice*, ed 11, Philadelphia, 1988, Lea & Febiger, pp 289-312.



RESTORATIVE DENTISTRY



GENERAL COMMENTS

- Teeth are restored in an attempt to return the tooth to normal function and to normal appearance. In veterinary dentistry, this service most commonly is needed after endodontic therapy has been performed. Other restorative situations may arise from local enamel defects or hypoplasia, dental caries, feline dental resorptive lesions, and more advanced services such as fabricated crowns or prosthetic devices.
- Direct restorations are applied directly to the tooth. Indirect restorations involve laboratory manufacture of products such as metal, porcelain, or ceramic crowns, inlays, or onlays.

CLASSIFICATION OF LESIONS

- Various classification systems have been designed to communicate the extent of a dental lesion. One of the early classification systems was developed by G.V. Black. Black's system classifies cavities based on the location of the lesion.
- Cavities, here, refer to defects in the tooth surface from any cause, such as a carious lesion, fracture, or abrasion.

Classification by Location of Lesion

- Class I—Cavities beginning in structural defects in a tooth's pits and fissures (occlusal surface) (Fig. 8-1, *A*).
- Class II—Cavities in the proximal surfaces of premolars and molars (Fig. 8-1, *B*).
- Class III—Cavities in the proximal surfaces of the incisors and canines that do not involve damage to and restoration of the incisal angle (Fig. 8-1, *C*).
- Class IV—Cavities in the proximal surfaces of the incisors and canines that involve the removal and restoration of the incisal angle (Fig. 8-1, *D*).

- Class V—Cavities that are not pit cavities in the gingival third of the crown of the labial, buccal, palatal, or lingual surfaces of the teeth (Fig. 8-1, *E*).
- Class VI—Defects on the incisal edges of anterior teeth or the cusp tips of posterior teeth (Fig. 8-1, *F*).

Caries Classification

- Although the G.V. Black classification system can be used to localize what part of the tooth is affected, further description of the type of caries may be more helpful in veterinary dentistry. True caries is a bacterial decay of tooth structure caused when bacteria digest fermentable carbohydrates and produce various acids that diffuse into the tooth.¹ Caries are recognized by their dark discoloration and softened enamel and dentin. Identification of caries with a dental explorer is performed when the tip of the explorer sticks in the softened tooth structure. Caries can lead to tooth sensitivity as they penetrate the dentin, and the pulp will become inflamed and then infected as lesions deepen, even to the point of pulp penetration. General types of caries are: smooth surface caries, pit fissure caries, dentin caries, and cervical or root caries.¹
- Treatment of early-stage caries can be performed by debridement of the carious material with a small excavator or dental bur in a low-speed handpiece. Cavity preparation and restorative techniques as described in this chapter are used to restore the tooth structure. Radiographic evaluation is necessary to determine if advancement and infection of the pulp leading to periapical changes has occurred prior to treatment, and monitoring of the pathology, with intraoral radiographs, is done annually.
- Advanced lesions with extensive crown damage and endodontic involvement are treated best by extraction.

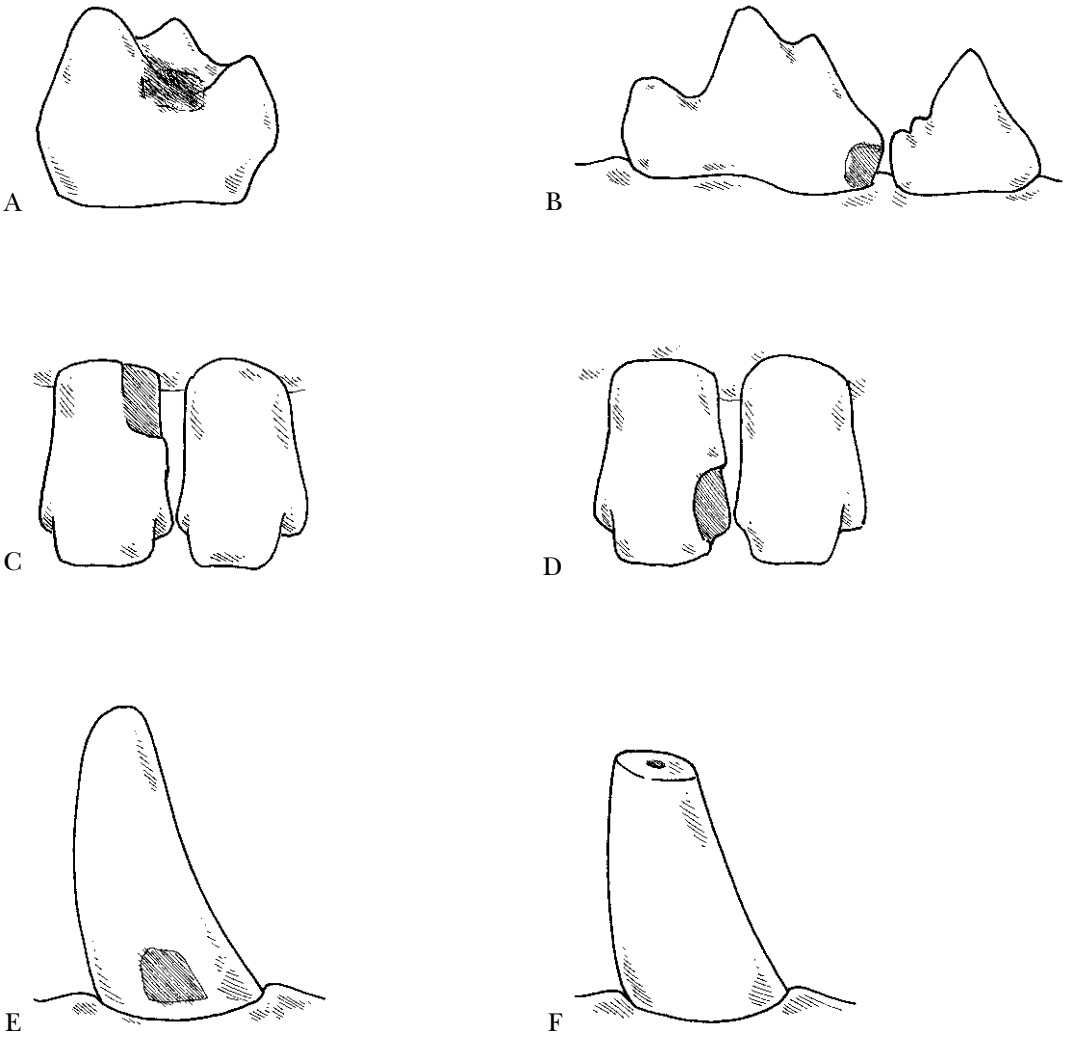


Fig. 8-1

Classification by Extent of Fracture

- Although Black’s system classifies cavities by location, the system does not classify the extent of the lesion or identify crown fracture description. Basrani developed a classification system that accomplishes this goal² (Table 8-1); however, this system does not distinguish between tooth fractures that go below the gingival margin. In this text we use a more practical system, based on the severity of the injury. Crown fractures can occur as a result of collisions with vehicles, hooved animals, being hit accidentally by a swinging object, catching hard objects, reckless participation in animal sports events such as Flyball or Ringsport tournaments, or chewing hard objects.
- The fracture classification system described in this text simplifies describing the extent of the fracture according to the dental tissue

exposed. We have named this classification the Fracture Severity Index (Table 8-2).

Class 1

- A Class 1 fracture is a “chip” fracture that has caused only the loss of, or damaged only, enamel (Fig. 8-2, A). The fracture is charted by the symbols FX1 and a jagged line over the area of the fracture.

Treatment

- In the dog, observe radiographically every 6 months to 1 year; at the next periodic dental care appointment, smooth the damaged enamel margins to prevent enamel stripping. If injury is acute, application of a pit and fissure sealant or a fluoride-containing varnish is appropriate, to prevent progressive disease. Root canal therapy is indicated if there is any sign of pulp death or periapical pathology.

Table 8–1 • FRACTURE CLASSIFICATION (BASRANI²)

Class A1	Crown fracture, enamel only
Class A2a	Crown fracture, enamel and dentin
Class A2b	Crown fracture into enamel, dentin, and exposing the pulp tissue
Class B	Crown fracture involving the root only
Class C	Crown and root fracture involving crown and root

Table 8–2 • FRACTURE SEVERITY INDEX

Class 1	FX1	Fracture into enamel only
Class 2a	FX2a	Fracture into enamel and dentin only; no pulp exposure or root involvement
Class 2b	FX2b	Fracture into enamel and dentin with root involvement; no pulp exposure
Class 3a	FX3a	Fracture into enamel, dentin, and with pulp exposure; no involvement of root
Class 3b	FX3b	Fracture into enamel, dentin, and with pulp exposure and root involvement
Class 4	FX4	Fracture of the root only; crown intact

- In the cat and other small carnivores, root canal therapy is recommended; most chip fractures are caused by enough trauma to these small teeth that trauma will lead to pulp death and apical abscess formation. Also, the pulp may be exposed but not visibly noticed, due to the small tooth size.
- If on the cusp, crown therapy may prevent further damage.

Class 2a

- A class 2a fracture involves both enamel and dentin in the crown of the tooth but has not exposed the pulp chamber, and is considered uncomplicated (Fig. 8-2, *B*). The fracture is charted by the symbols FX2a and a jagged line over the area of the fracture.

Class 2b

- A class 2b crown-root fracture involves enamel and dentin and has not exposed the pulp chamber, but the fracture extends below the gumline (Fig. 8-2, *C*). The fracture is charted by the symbols FX2b and a jagged line over the area of the fracture.

Treatment

Dog

- If injury is acute, application of a pit and fissure sealant or a fluoride-containing varnish is appropriate, to prevent progressive disease, along with odontoplasty to blend in fracture edges.

- If enough dentin remains, indirect pulp capping and restoration with a glass ionomer, composite resin, or crown therapy. Radiograph annually, because pulp death can occur from the initial trauma, through bacterial contamination of the exposed dentinal tubules, or through continued indiscriminate oral behavior.
- If very close to the pulp, direct pulp capping or root canal therapy followed by glass ionomer, composite resin, or crown therapy is indicated.

Cat

- Root canal therapy should be performed, followed by glass ionomer, composite resin, or crown therapy.

With Class 2b fractures that go below the gumline, additional periodontal procedures may be necessary to maintain periodontal health (see Chapter 5).

This type of fracture may require no treatment or may require endodontic, periodontic, restorative treatment, or combinations of the three types of treatment.

Class 3a

- A Class 3a fracture has broken through enamel and dentin and has exposed the pulp chamber, a complicated fracture. Only the crown is involved. The fracture is charted by the symbols FX3a and a jagged line over the area of the fracture.

Class 3b

- A class 3b crown-root fracture involves enamel and dentin, has exposed the pulp chamber, and extends below the gumline (Fig. 8-2, *D*). The fracture is charted by the symbols FX3b and a jagged line over the area of the fracture.

Treatment**Young animal (younger than 1½ years)**(Fig. 8-2, *E*)

- Vital pulpotomy, followed by glass ionomer, composite resin, or amalgam restoration if the fracture is less than 2 weeks old. If the procedure is successful after 6 months, crown restoration may be performed. If unsuccessful at 6 months, root canal therapy or extraction is indicated.
- Extraction or root canal therapy, restoration with amalgam or composite resin, and reinforced crown techniques if the fracture is open longer than 2 weeks (prognosis guarded; see Chapter 7, Endodontics, p. 350).

Older animal (older than 1½ years)(Fig. 8-2, *F*)

- Vital pulpotomy, if pulp exposed less than 48 hours and the bleeding is a healthy color and consistency.
- Root canal therapy followed by glass ionomer, composite resin, amalgam, or

crown restoration if pulp is exposed longer than 48 hours.

- For Class 3b fractures additional periodontal treatment, along with the above choices, may be needed to maintain periodontal health (see Chapter 5). Extraction may be the treatment of choice if there is extensive involvement of the root that compromises the tooth's periodontal health.

Class 4

- A class 4 fracture involves the root only (Fig. 8-2, *G*). The fracture is charted by the symbols FX4 and a jagged line over the area of the fracture.

Treatment

- If the fracture is in the coronal third of the root, root canal therapy followed by a post in the endodontic system of both pieces of the tooth may be attempted (prognosis guarded for long-term stability).
- If the fracture is in the middle third of the root, extraction is the best option in most cases.
- If the fracture is in the apical third of the root, a surgical root canal and extraction of the apical fragment often can be performed successfully.

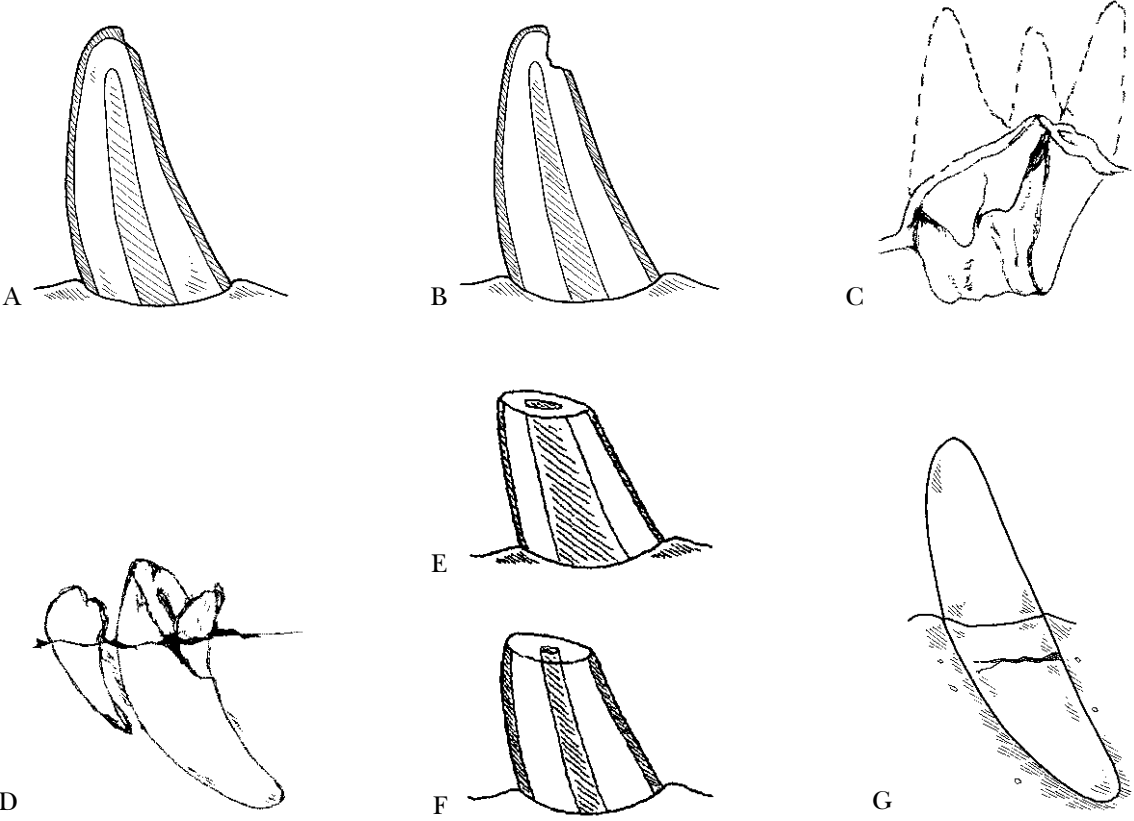


Fig. 8-2

GENERAL RESTORATIVE TECHNIQUES

Cutting Techniques

- Cut away from the enamel. When doing a crown preparation, cut with the bur approximately parallel to the long axis of the tooth, in a counterclockwise rotation around the circumference of the tooth (the bur is rotating clockwise) (Fig. 8-3).
- The choice of bur shape will determine the type of margin to be created.
- When drilling into teeth, intermittent pressure is applied. The period is two counts with pressure on to one count with pressure off, to limit heat generation and maintain bur speed.
- The operator should be aware of the change in audible pitch in the handpiece as an indication of changing bur pressure being applied to the tooth surface. A higher pitch indicates a higher speed and less pressure, which is desirable.
- The enamel layer in dogs and cats is significantly thinner than occlusal enamel surfaces in man (<0.1 to 0.3 mm in the cat and <0.1 to 0.6 mm in the dog).³ This means most crown preparations and cavity preparations will expose the dentin layer to allow room for a strong restoration.

Cavity Preparation Techniques

- The outline of the preparation is made using a round bur or a tapered-fissure bur to a depth of at least 1.5 mm.
- Macroretention is created using an inverted-cone or pear-shaped bur.
- Additional retention can be created by making retention grooves in the base of cavity walls (intersection of wall and floors) with a round bur of appropriate size.
- The walls and floors may be smoothed with dental chisels or hatchets.
- Any carious dentin or poorly supported tooth structure should be removed.

RESTORATIVE MATERIALS

General Comments

- Many types of dental materials have evolved.
- The ideal material for restorative work would form a chemical bond to the enamel and dentin, would not distort after placement, would not break or fatigue, would have high impact strength, would have the same coefficient of expansion as dental structures, would match the tooth color, and would wear at the same rate as the teeth. Restorative materials have been improved greatly during recent years but, unfortunately, the ideal material does not yet exist.⁴
- Given the different functions of different teeth and the areas to be restored, obtaining the best results from the materials available requires familiarity with the properties of each material.
- Restorative materials should be chosen according to the functional needs anticipated, so as to maximize the desirable properties and minimize the undesirable properties of the material.
- The restorative materials and techniques discussed in this chapter can be classified as composite resins, glass ionomers, amalgams, and fabricated crown restorative materials.
- It is important to store restorative materials correctly. An improper storage environment can destroy the material rapidly. The first thing one should do when receiving a material is to note the expiration date and read the package insert, paying particular attention to use and storage.
- Simplified, restorative dentistry can be broken down into five steps:
 1. Preparation of the surface.
 2. Placement and curing of the bonding agent.
 3. Placement and curing of the restorative agent.
 4. Shaping of the restoration.
 5. Smoothing of the restoration.

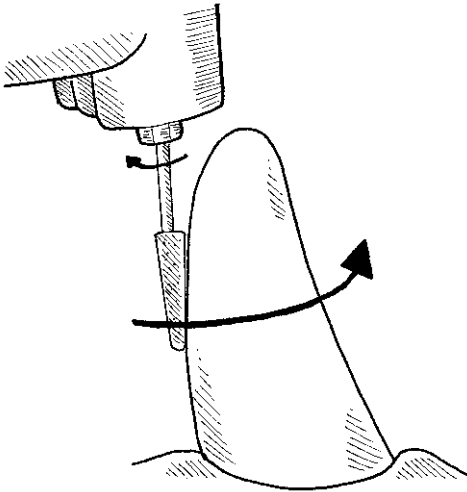


Fig. 8-3

Composite Resins

General Comments

- As in many industries, dentistry has been changed dramatically by the development of synthetic polymers.
- Composite resins are polymers created by a series of chemical reactions combining large numbers of similar smaller molecules (monomers) into a compound of high molecular weight.⁵ The organic polymer matrix is made up of either bisphenol A-glycidyl methacrylate (Bis-GMA) or urethane dimethacrylate (UDMA).⁶
- Throughout the “life” of the material, polymerization continues. It is a continuous reaction that is never entirely complete.
- The polymerization reaction is activated either chemically or by a visible blue light with a wavelength range of 468 to 480 nm.⁶
- Chemical-cure composite resins usually come as two components that, after mixing, cause molecules to join and the material to harden.
- Composite resins can be classified generally as filled or unfilled.
- Unfilled resins do not have fillers; they flow readily, are translucent, and are used to coat “cavity” preparations before application of the filled resins and are applied as a final coat to penetrate microcracks and minimize wear.⁶ The unfilled resins are applied to prevent microleakage and to promote the attachment of the restorative material to the tooth.
- Acid-etching a tooth surface creates effective microprojections and therefore micro-retention of unfilled resin when applied to the tooth’s crystalline structure.
- The filled resins contain fillers and are more viscous, opaque, harder, and wear better than unfilled resins.
- The filled resin is bonded onto the unfilled resin.
- Fillers added to the filled resins give them hardness, strength, color, resistance to temperature change, wearability, and control of polymerization shrinkage.⁷
- Composite resins contain at least 60% (usually 70% to 80%) inorganic filler (quartz, lithium, or silica) by weight.
- The filler particles are described according to size: (1) conventional (20 to 35 μm), (2) intermediate or macrofilled (1 to 5 μm), (3) microfilled (equal to or less than 0.04 μm), and (4) hybrid (containing either a conventional or an intermediate particle, in addition to a microfilled particle).⁷
- The conventional and macrofilled compounds are more resistant to fracture and can be safely exposed to more abrasive and concussive wear and tear than can microfilled restorative materials.
- Two disadvantages of the macrofilled compounds are a decreased ability to be finely polished, because of larger particle size, and that they become pitted with wear.
- Microfilled compounds polish to a very smooth surface; however, their disadvantage is that they are less strong and so tend to fracture more easily. Therefore, they are best used in areas with less exposure to wear and trauma.
- In an attempt to reach a compromise between the microfilled and macrofilled qualities, hybrid compounds were developed to combine smoothness with durability. Hybrids may be microhybrids designed for use in classes III, IV, and V lesions or posterior hybrids designed more for classes I and II lesions with greater durability.
- Flowable composites have lower filler content and lower modulus of elasticity and are therefore more flexible. They can be injected into a defect and are used as a sandwich layer between the tooth and a hybrid composite resin or in areas of low wear. They have high polymerization shrinkage and low wear resistance.

- Compactable composites have the strength and resistance to wear of amalgam, can be manipulated (packed or condensed) like amalgam, and are esthetic like a standard composite resin. They have low polymerization shrinkage and can be cured to a greater depth than other composite resins.⁸
- Pit and fissure sealants are generally unfilled or lightly filled resins with low viscosity and good wetting properties. They are applied after the enamel surfaces are etched; the sealant is then applied and cured. They are most effective in low-wear areas and protect from decay by sealing small pits and fissures in caries-prone teeth. They may be applied usefully to the maxillary molar surfaces if early staining is noticed. Some products also release fluoride.
- Both filled and unfilled resins are available that cure by either chemical reaction or light exposure. Light-cure products allow greater working time for placement and shaping.
- Polymerization of composite resins creates shrinkage that may exceed the bond between the composite and the enamel or dentin. Bond failure can lead to microleakage, leading to marginal staining, secondary caries, and sensitivity in a vital tooth.
- Shrinkage can be reduced by placing small amounts of material at a time and curing between increments. With light curing, newer methods are being applied with new light guns. These methods include ramp, pulse, or step-up techniques to reduce shrinkage.⁹ Composite resins come in various tooth shades for cosmetic appearance. The shades may vary among products, so it is important to use the shade guide provided with the restorative material to attain the best color match. Checking the color match in natural light is preferable.
- Some products require use of a bonding agent or primer before application of the

unfilled resin adhesive in order to improve bonding to the tooth structure. Newer systems are a one-step etch and primer combination, followed by the adhesive or a primer and lightly filled resin adhesive combination used after etching. Many types of systems are used for bonding agents. The practitioner should refer to the instructions on the restorative kit for specific instructions.

- Care should be used with unfilled resins or bonding agents in order to apply only a thin film to the tooth.

Indications

- Restoration of a damaged tooth crown.
- Restoration of access holes after endodontic therapy.
- Bonding wires used for fracture repair and splinting teeth if other, more durable, materials are not available.

Contraindication

- Damage in patients who chew rocks, bones, and other hard objects. Their surface defects should be restored with a stronger material.

Materials

- Flour pumice.
- Prophyl cup.
- Dental handpieces.
- Mixing pad.
- Mixing spatula.
- Centrix syringe.
- Brushes and sponges.
- Acid-etch materials.
- Bonding agent.
- Composite resin restorative material.
- Plastic working instrument.
- Light-curing gun (light cure).
- Smoothing and polishing materials.

Technique

- Although many different applications and variations of chemical and light-cure restorations exist, the following example is a step-by-step method for placement on a two-rooted tooth that has undergone endodontic therapy.

Step 1—Preparation of the Surface

- Preparation of the surface is identical for chemical-cure and light-cure restorations.
- Substep 1—Prepare the filling site, considering the following:
- All unsupported enamel should be removed using a handpiece and bur, chisel, or sharp curette (Fig. 8-4, *A* and *B*). A beveled edge will increase bonding surface area at the margins of the restoration except on occlusal surfaces.
 - Margins should be made at sites least susceptible to caries.

- The preparation may include deep grooves on the side or base for retention.
- The border of the preparation should not terminate on cusps.¹⁰
- If zinc oxide–eugenol was used as a sealer during the endodontic procedure, the access opening should be cleared of residual sealer by using alcohol or other clearing agent applied to cotton pellets or gauze, so as not to interfere with the surface bonding process and to have a nonzinc-eugenol base material in place. In deeper restorations, a base layer of calcium hydroxide, glass ionomer, or a flowable composite may be placed first.

Substep 2—Clean the surface using a prophylactic cup and flour pumice (not prophylactic paste, which may contain fluoride and glycerin) (Fig. 8-4, *C*).

Substep 3—Wash the surface with water and air dry (Fig. 8-4, *D*).

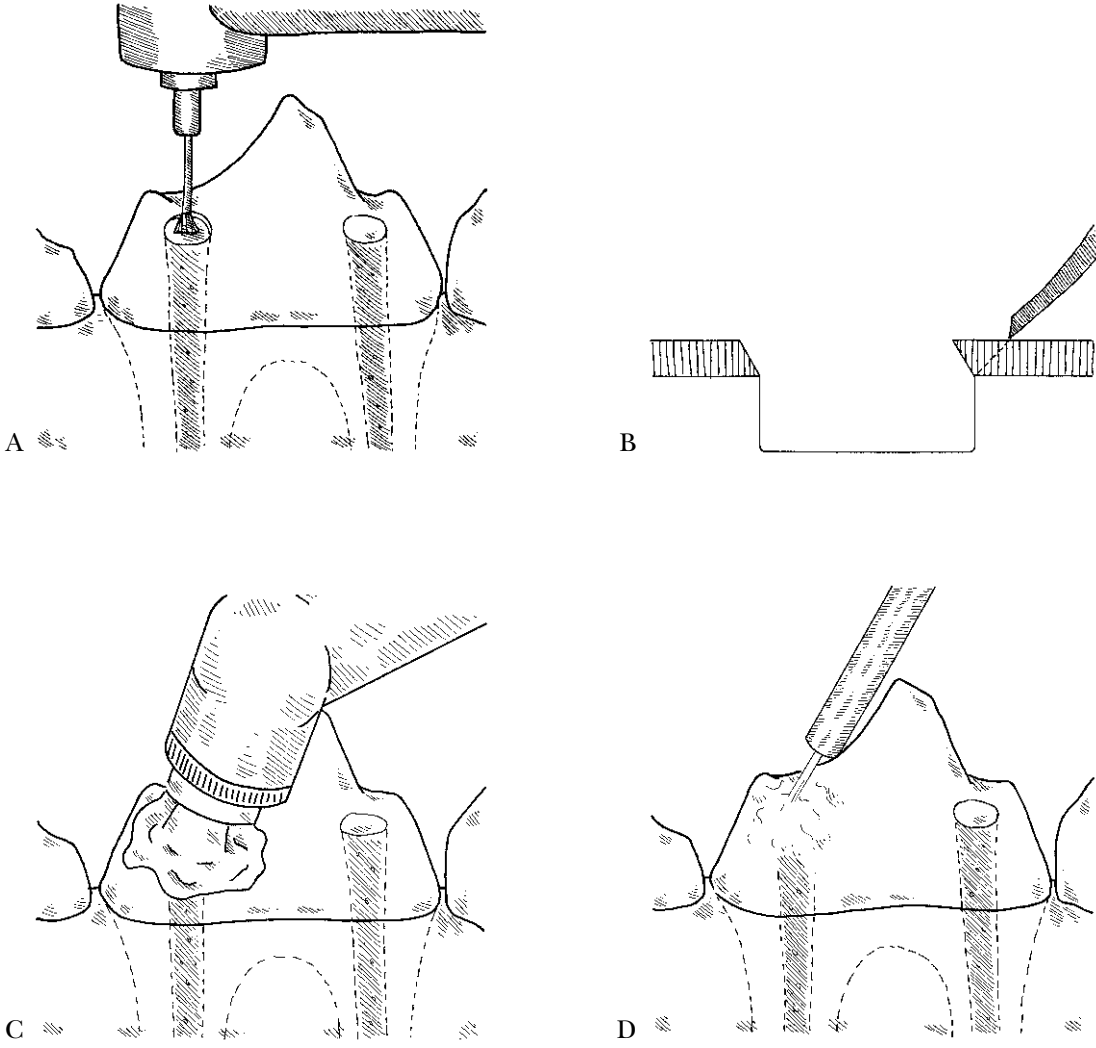


Fig. 8-4

Substep 4—Acid-etch the enamel with 38% to 50% phosphoric acid solution or gel for 15 to 20 seconds, according to manufacturer's instructions. Either a sponge (Fig. 8-5, *A*) or a brush (Fig. 8-5, *B*) may be used. Gel etchant can be placed with a small blunt needle and does not need to be applied with a brush or sponge.

- Some authorities promote a “total etch” technique, in which both the enamel and dentin are etched, to improve bonding.
- On nonvital teeth, dentin can be etched along with enamel, using phosphoric acid gel.
- On vital teeth, a dentin conditioner, which is a lesser concentration of etching gel (10% to 38% acid), can be used to etch the dentin for 10 to 15 seconds only.

Substep 5—Wash the surface with water for 10 to 20 seconds (Fig. 8-5, *C*).

Substep 6—Air dry the surface (5 seconds) (Fig. 8-5, *D*).

- The area to be restored should have a chalky white appearance; if it does not, the surface should be etched again.
- The amount of drying depends on the particular product used. Some require the chalky white dryness. Others recommend blot drying only by using cotton pellets, paper points, gauze, or a 2-second period of air drying, so as not to desiccate the tooth and result in less satisfactory bonding.
- It is important to keep the surface free from chemicals, saliva, blood, and other contaminants that interfere with bonding.
- Contamination is the most common reason for restorative failure.
- Another common reason for failure is incomplete coverage by the cure light.
- If contamination occurs, the surface should be prepared again, although a shorter etching time may be used.

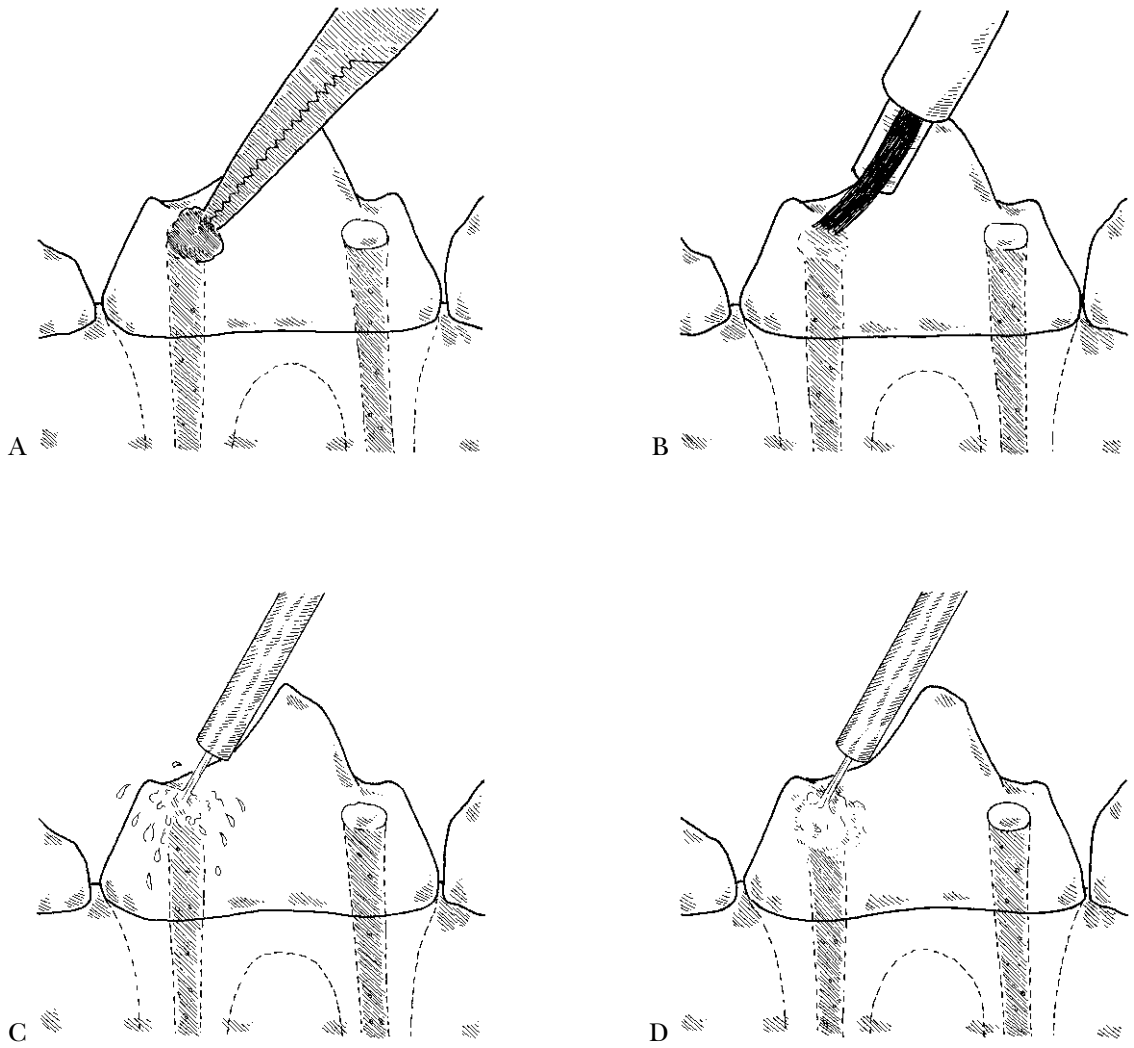


Fig. 8-5

Step 2—Application of the Bonding Agent: Chemical Cure (Light-Cure Gun Not Available)

- The following procedure is for applying a chemical-cured bonding agent followed by applying a chemical-cured restorative resin.
- These steps vary with the manufacturer (Table 8-3). Some first apply a dentin primer to enhance bonding of the unfilled resin; others mix the dentin primer chemical with the unfilled resin.

Substep 1—Drop(s) of bonding agent solution A are placed in a dappen dish (Fig. 8-6, *A*).

Substep 2—Bonding agent solution B is added to the same dappen dish (Fig. 8-6, *B*). Exact proportions of the two solutions are determined by the manufacturer's recommendations. The solutions are mixed with a brush (Fig. 8-6, *C*).

Substep 3—A thin coat of bonding agent is applied to the prepared surface (Fig. 8-6, *D*).

Substep 4—A gentle stream of air is blown over the surface to minimize the thickness and eliminate pooling of the bonding agent. (Some manufacturers recommend repeating these two steps.) The dentin surface should appear shiny.

Substep 5—The unfilled resin is placed on a brush (Fig. 8-6, *E*) and is brushed onto the tooth (Fig. 8-6, *F*).

Substep 6—A gentle stream of air is directed onto the unfilled resin-covered tooth surface to thin the layer of resin and to eliminate pooling.

Table 8-3 • BONDING AGENTS

Chemical-Cured Bonding Agents

Product	Manufacturer
Bonding Agent Self Cure	Dentsply Caulk
Etch-Prep	Henry Schein
Clearfil New Bond	Kuraray America
Encore Bond	Centrix

Dentin Bonding Agents

Product	Manufacturer
All Bond 2	Bisco
Clearfil Line Bond 2V	Kuraray America
DenTASTIC	Pulpdent
Gluma Solid Bond	Heraeus Kulzer
OptiBond	Kerr
OptiBond FL	Kerr
Scotchbond Multi Purpose	3M ESPE
Tenure	Den-Mat
Syntac	Ivoclar Vivadent
One Up Bond F	Morita
ProBond	Dentsply Caulk
PermaQuick	Ultradent
Wet Bond	Mirage Dental
	Systems/Chameleon Dental Products

Dual-Cure Bonding Agents

Product	Manufacturer
Scotchbond Multipurpose Plus	3M ESPE
DenTASTIC Uno Duo	Pulpdent
Clearfil Photo Bond	Kuraray America
OptiBond Solo Plus Dual Cure	Kerr
Prime & Bond NT	Dentsply Caulk
Multibond	Centrix
Bond-It	Pentron Clinical Technologies

Single-Step Bonding Agents

Product	Manufacturer
DenTASTIC Uno	Pulpdent
Excite Advanced Adhesive Technology	Ivoclar Vivadent
OptiBond Solo Plus	Kerr
One-Step	Bisco
One-Step Plus	Bisco
Single Bond	3M ESPE
Syntac Single Component	Ivoclar Vivadent
Gluma Comfort Bond	Heraeus Kulzer
Clearfil SE Bond	Kuraray America
Tenure, UniBond	Den-Mat
Xeno	Dentsply Caulk
PQ1	Ultradent
Prime One	Mirage Dental
	Systems/Chameleon Dental Products
Bond-1	Pentron, Clinical Technologies

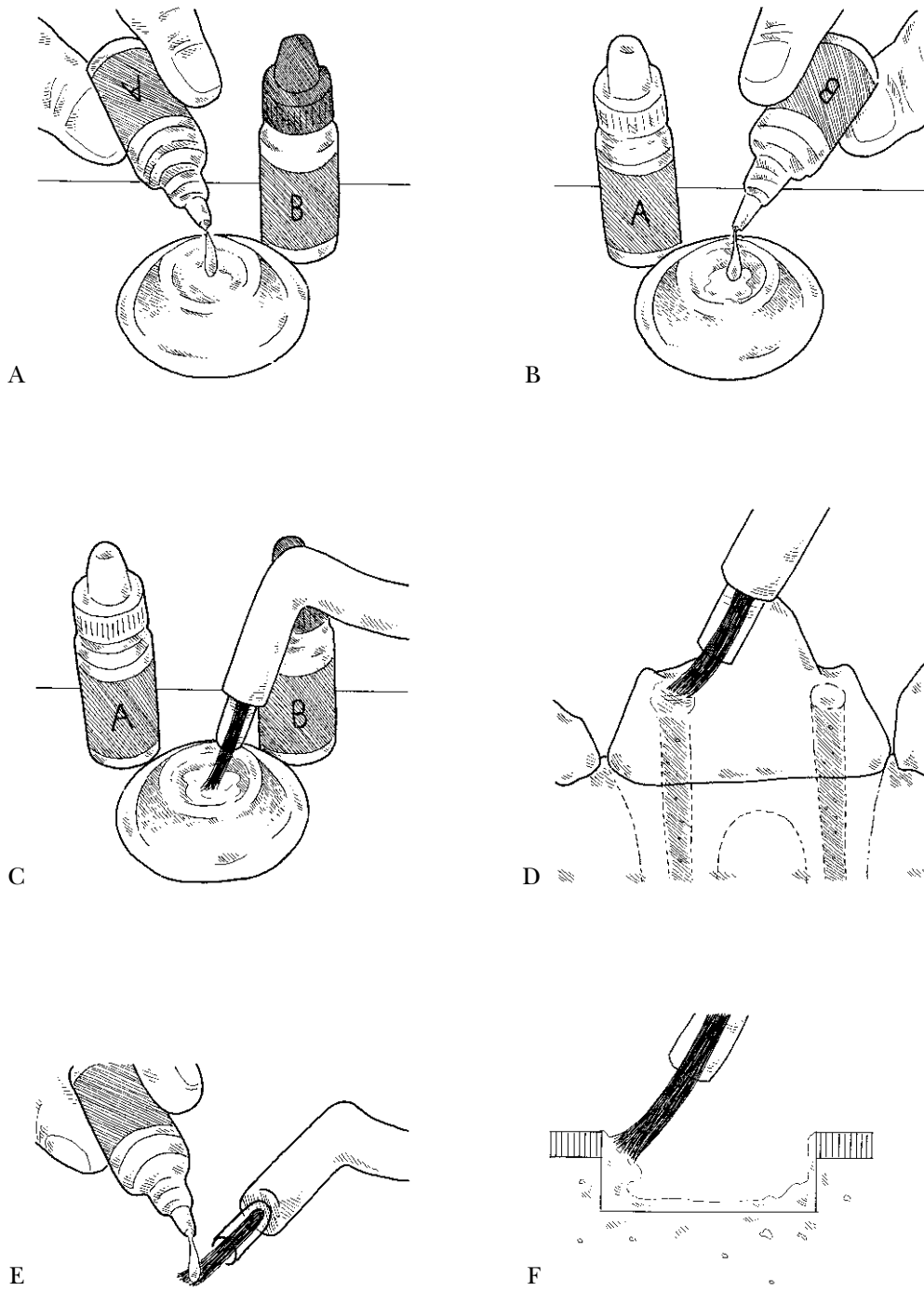


Fig. 8-6

Step 3—Application of the Restorative Agent: Chemical Cure (Light-Cure Gun Not Available)

- The chemical-cured, filled resin (Table 8-4) is mixed as directed by the manufacturer.
- Substep 1—Equal portions of the filled resin are placed on a mixing slab (Fig. 8-7, *A*).
- Substep 2—The restorative material is mixed in a figure-of-eight motion using a plastic spatula.
- The mixing should be thorough and take 15 to 20 seconds.

Substep 3—The mixed resin is transferred to the site with a plastic filling instrument (Fig. 8-7, *B*).

- The material may also be transferred to the site by using an injection syringe (Centrix II Syringe, Centrix, Shelton, Conn.).
- The injection syringe is loaded by scooping the material into the wide end of the plastic tip from either the spatula or the glass slab (Fig. 8-7, *C*).
- The rubber plunger is placed in the plastic tip behind the restorative material (Fig. 8-7, *D*).
- The material is injected into the restoration site (Fig. 8-7, *E*).
- The cavity preparation is made to overfill slightly. The composite resin is allowed to harden, usually within 2 to 6 minutes.

Substep 4 (Optional)—A Mylar strip is placed over the site to conform the material better to the tooth shape and to compact the material, lessening the chance of leaving an internal void (Fig. 8-7, *F*).

Step 2—Application of the Bonding Agent: Light Cure (Light-Cure Gun Available)

- The following procedure is for applying a light-cure bonding agent, followed by applying a light-cure restorative resin.

Table 8-4 • **CHEMICAL-CURED COMPOSITE RESINS**

Conventional Fillers	
<i>Product</i>	<i>Manufacturer</i>
Concise	3M ESPE
Composite/radiopaque	Henry Schein
Hybrid Fillers	
<i>Product</i>	<i>Manufacturer</i>
P10	3M ESPE
Marathon (hybrid)	Den-Mat
CR Hybrid	Centrix
Bisfil II	Bisco
Core Materials	
<i>Product</i>	<i>Manufacturer</i>
Clearfil Core	Kuraray America
Core Paste	Den-Mat
Encore	Centrix
Core Material	Henry Schein
CompCore	Premier

Substep 1—The dentin primer is applied with a brush to the prepared surface.

Substep 2—The dentin primer is air dried for 5 seconds or pat dried with a cotton pellet or paper point.

- The manufacturer's directions should be followed. In most cases complete desiccation of dental tissues should be avoided.

Substep 3—A thin coat of bonding resin (unfilled resin or adhesive) is applied to the prepared dentin and enamel surface.

Substep 4—The bonding resin is light cured for 10 to 20 seconds.

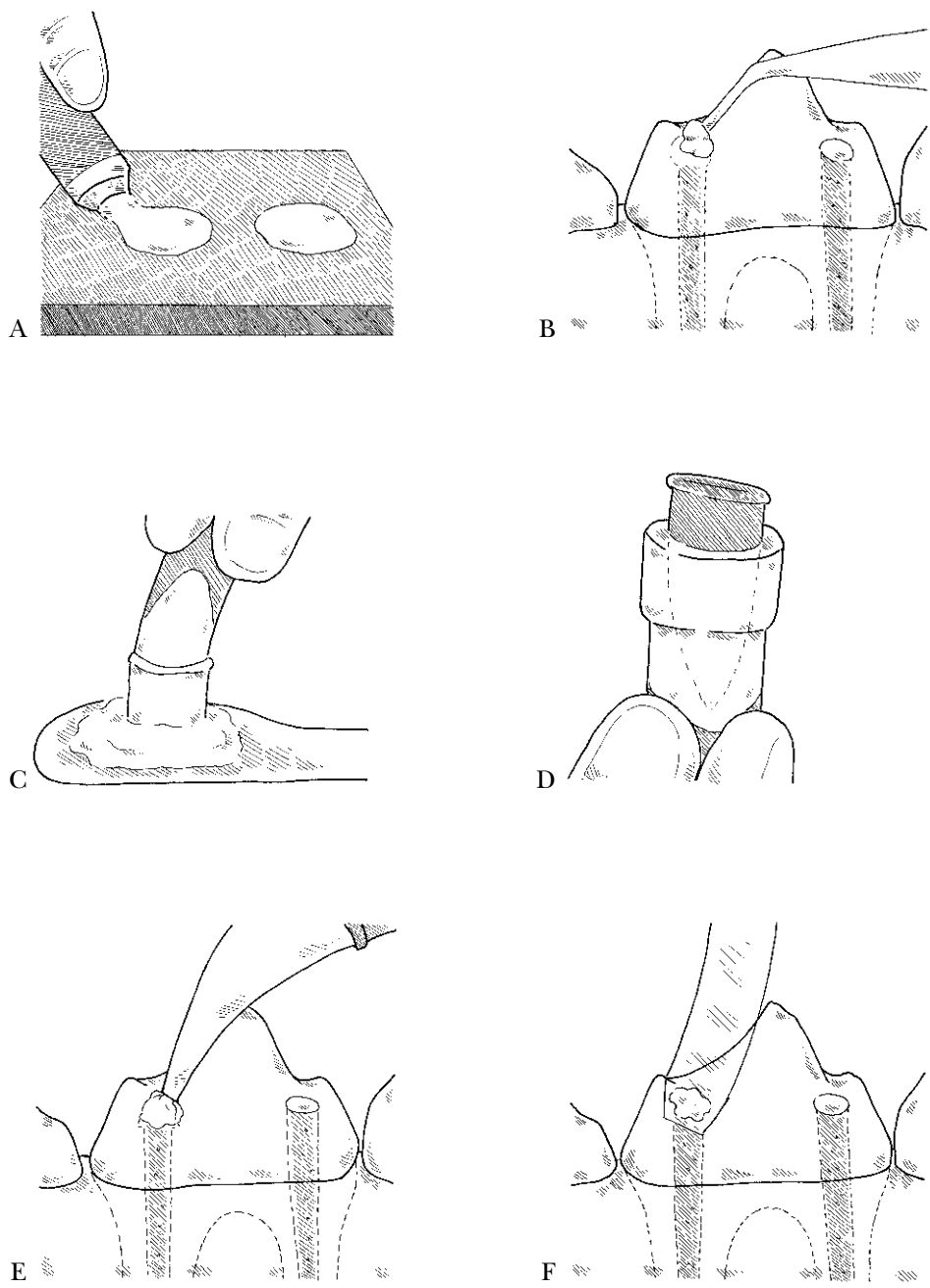


Fig. 8-7

Step 3—Application of the Restorative Agent (Light-Cure Gun Available)**General comments**

- Some light-cure products require mixing (substeps 1 and 2); others may be used directly without mixing (Table 8-5). Generally, light-cure products come either in a syringe or in a preloaded syringe tip.
- Dual-cure materials cure by both light and chemical reactions.
- The unfilled resin may also need light curing before application of the filled resin.
- An advantage of light-cured restorative materials is the increased time for shaping the filled resin before hardening it with the light gun.

Table 8-5 • **LIGHT-CURE RESTORATIVE MATERIALS**

Light-Cure Microfil Composites	
Product	Manufacturer
Durafill VS	Heraeus Kulzer
Amelogen Microfil	Ultradent
Renamel Microfil	Cosmedent
Esthet-X Micro Matrix Restorative	Dentsply Caulk
HelioProgress	Ivoclar Vivadent
Filtek A110	3M ESPE
Micronew	Bisco
Virtuoso Sculptable	Den-Mat
Light-Cure Hybrid Composites	
Product	Manufacturer
Charisma	Heraeus Kulzer
Tetric	Ivoclar Vivadent
Herculite XR	Kerr
Herculite XRV	Kerr
Prodigy	Kerr
Amelogen Universal	Ultradent
Z100	3M ESPE
Filtek Z250	3M ESPE
Prisma APH	Dentsply Caulk
Prisma TPH	Dentsply Caulk
Clearfil ST Opaquer	Kuraray America
Clearfil AP-X	Kuraray America
Renew	Bisco
Aelite LS	Bisco
Versalite	Centrix
True Vitality	Den-Mat
Vit-I-escence Syringes	Ultradent
Simile	Pentron Clinical Technologies

Flowable Composites

Product	Manufacturer
Aeliteflo	Bisco
Tetric Flow	Ivoclar Vivadent
Starflow	Danville Materials
Esthet-X Flow	Dentsply Caulk
Flow-It	Pentron Clinical Technologies
Filtek Flow	3M ESPE
Flow Line	Heraeus Kulzer
Heliomolar Flow	Ivoclar Vivadent
Point 4 Flowable	Kerr
Revolution Formula 2	Kerr
PermaFlo	Ultradent
PermaFlo DC	Ultradent
Flows-Rite	Pulpdent
Versaflo	Centrix
Virtuoso Flowable	Den-Mat

Table 8-5 • **LIGHT-CURE RESTORATIVE MATERIALS—cont'd**

Compactable Composites	
Product	Manufacturer
Pyramid	Bisco
Filtek P-60	3M ESPE
SureFil	Dentsply Caulk
Alert	Pentron Clinical Technologies
Prodigy Condensable	Kerr
Solitare 2	Heraeus Kulzer
Heliomolar HB	Ivoclar Vivadent
Virtuoso Packable	Den-Mat
Compomers	
Product	Manufacturer
F2000	3M ESPE
Dyract AP	Dentsply Caulk
Dyract Flow	Dentsply Caulk
Compoglass F	Ivoclar Vivadent
Light-Cure or Dual-Cure Composite Core Materials	
Product	Manufacturer
Clearfil Photo Core	Kuraray America
Core Restore 2	Kerr
Encore Supercure	Centrix
FluoroCore	Dentsply Caulk
HardCore	Pulpdent
ParaPost, ParaCore	Coltene/Whaledent
HardCore	Pulpdent
Bisfil Core	Bisco
Bis-Core (dual cure)	Bisco

Light-cure technique

Substep 1—The filled resin is dispensed from the syringe onto a plastic working instrument (Fig. 8-8, *A*). Some products come with small ampules of filled resin and an injection syringe. This material can be deposited directly into the cavity preparation.

Substep 2—The filled resin is applied to the prepared surface (Fig. 8-8, *B*).

Substep 3—The restorative material is shaped with a plastic working instrument.

- A small amount of unfilled resin on a plastic filling instrument can be used to help shape the filled resin and prevent sticking.

Substep 4 (Optional)—For some sites, a Mylar strip can be drawn taut over the site to compact the material more densely and conform it more exactly to the tooth shape.

Substep 5—The filled resin is hardened with a light-cure gun (Fig. 8-8, *C*). Hold the tip of the light source within 3 to 4 mm of the surface and cure the restorative material for 30 to 70 seconds, according to the manufacturer's instructions. The time necessary will vary depending on the darkness of the shade, the thickness of the restoration, the product used, and the strength of the cure light. The thickness of restorative material should be no more than 2 mm at a time without curing to minimize polymerization shrinkage. Large restorations may need to be cured from several directions and have smaller increments placed in sequential layers and cured incrementally to minimize polymerization shrinkage.

Dual-cure technique

Substep 1—Equal portions of the filled resin are placed on a slab.

Substep 2—The restorative material is spatulated to a homogeneous consistency.

Substep 3—The mixed resin is transferred to the site with a plastic filling instrument or injection syringe.

Substep 4—The restorative material is shaped with a plastic working instrument.

Substep 5 (Optional)—A Mylar strip is pulled tightly over the filling material.

Substep 6—The restorative material is cured with a light-cure gun. With a dual-cure product, any areas of the restorative material not cured by the light will harden chemically, as well.

- Additional 2-mm layers of restorative material can be placed, and cured one layer at a time, on top of the material to provide thicker restorations.

Complications and cautions

- It is important when using light-curing units, to use appropriate protective glasses or shields to protect the dental health care provider. The assistant should also protect his or her eyes from the light to avoid retinal damage.
- Light-activation techniques require that light emission be close to the restoration (less than 4 mm).
- To ensure a full cure, cure the filled resin for a minimum of 40 to 60 seconds.

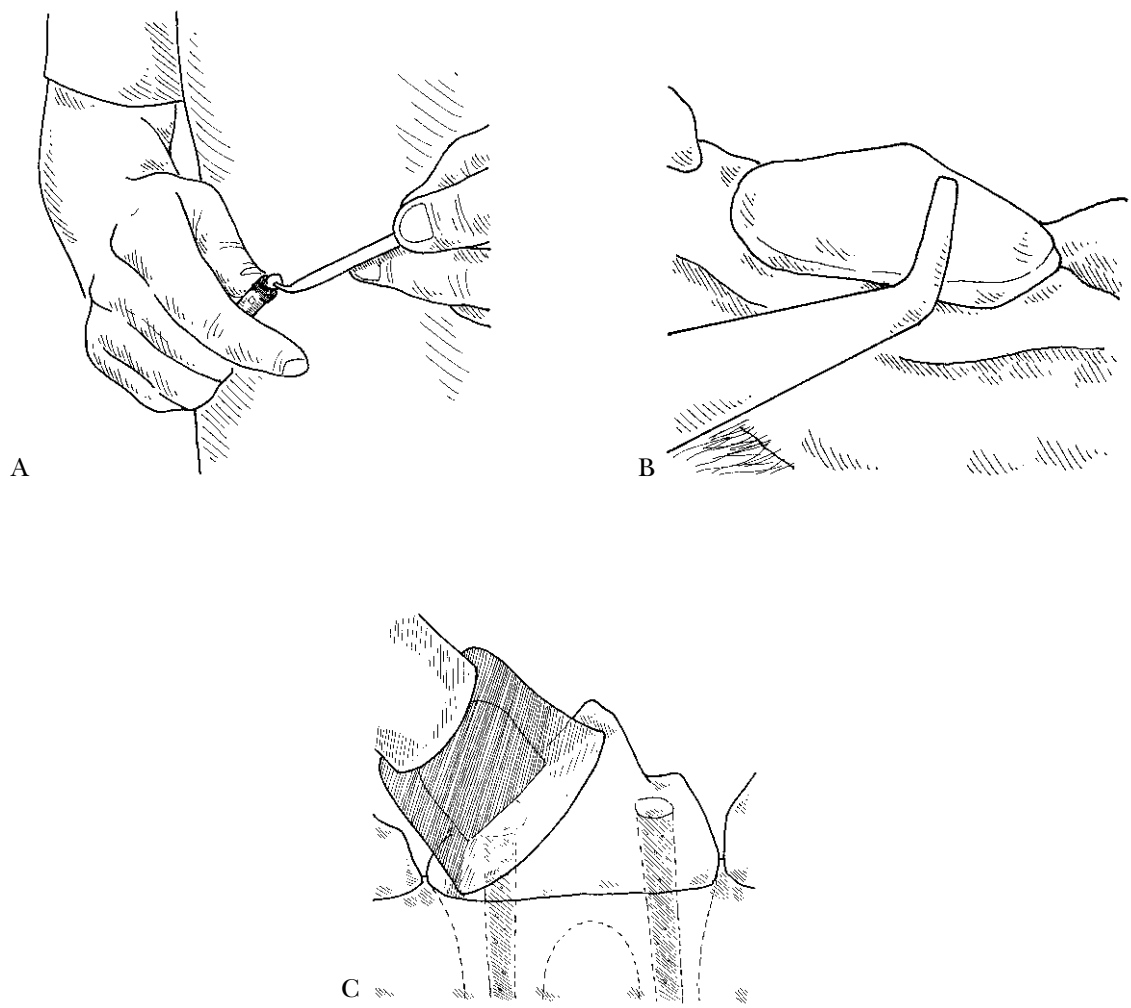


Fig. 8-8

Step 4—Shaping the Hardened Restoration

- The material is shaped with finishing diamond burs, a sequence of 12, 16, and 30 fluted-blade carbide finishing burs, or fine-particle stones (Fig. 8-9) (see pp. 56 to 57).

Step 5—Smoothing the Restoration

- The restoration is smoothed with abrasive discs, strips, or fine-particle stones.

Abrasive discs

Description

- Plastic or stiff-paper circular discs are attached to a mandrel and rotated by a contra angle and low-speed handpiece.
- Paste lubricants and polishing agents are available to aid in smoothing and are applied by using a prophylaxis cup.

Advantages

- Supplied in various grits and materials.
- Quick reduction of tooth surface.
- Inexpensive.

Disadvantage

- Being circular, the discs may not fit into all contours of the restorative surface.

Finishing strips

Description

- Thin plastic sanding strips.

Advantage

- Useful in cone-shaped teeth, such as canine teeth, to smooth the surface rapidly.

Disadvantage

- Do not fit into all spaces.

Nonadhesive strips

Description

- Do not contain adhesive to hold particles. This decreases the number of particles that break free and re-adhere to the strip, becoming captured particles.
- Captured particles have the potential to damage the surface being finished by leaving deep grooves.
- Thin, flexible strips to smooth the tooth surface.

Advantages

- Easy interproximal access.
- Readily contour to conform to the shape of the tooth.
- After the surface is smoothed with discs or strips, a final polishing step can be performed using aluminum oxide polishing paste in a soft rubber cup at low speed. A final light cure of 40 seconds will further harden the surface. A last application of unfilled resin over all etched surfaces and the restoration is recommended to increase wear resistance and fill any microcracks on the composite resin surface.⁶

Complications

- Microleakage is recognized by a black line between the restorative material and the tooth, occurring some time after restoration.
- In the case of vital teeth, sensitivity can result from microleakage.
- The three main factors that cause microleakage are (1) poor technique, (2) shrinkage of the restorative material occurring with polymerization, and (3) inability of the resin to bond chemically to the tooth structure.
- Acid-etching may cause dentinal sensitivity in vital teeth. Etching dentin, when performed, should be done with the milder acids identified as dentin conditioners and for shorter times.
- Loss or damage to restoration from detrimental oral habits of the patient or poor bonding technique of the clinician.

Product Options

Repair of Defective Composite Resin Restorations¹¹

General comments

- The trauma of use may cause defects in the composite resin restoration.
- The overall strength of the repair may not be as strong as the original restoration.

Indication

- Fractured composite resin restoration.

Contraindication

- Fracture of a tooth that may require more than conservative restoration.

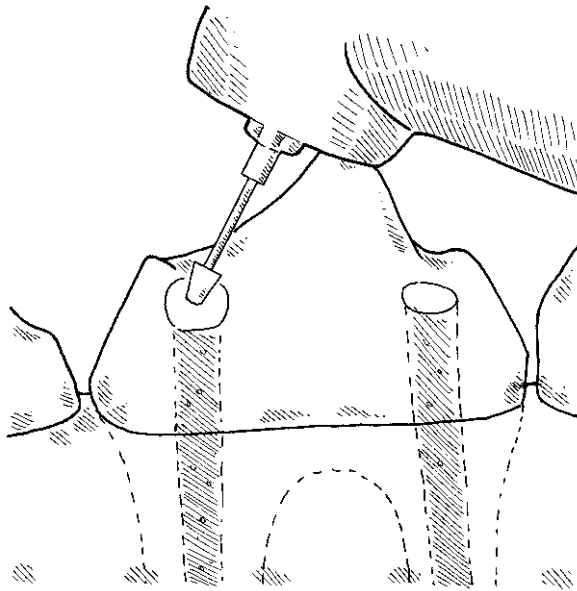


Fig. 8-9

Materials

- Same as those with composite restorations.

Technique

- Step 1—The restoration is probed to discover any defects that may not have been visualized.
- Step 2—A water-cooled, inverted-cone carbide bur is used to remove defective resin. A slight undercut may aid retention.
- Step 3—A coarse diamond bur is used to roughen the entire surface of the remainder of the restoration to eliminate superficial resin that has been exposed to the oral environment.
- Step 4—A phosphoric acid gel is spread over the entire preparation for 30 seconds, rinsed with water for 30 seconds, and air dried.
- Step 5—An unfilled resin is applied over the surface and blown gently with compressed air to a thin layer. The unfilled resin is light-cured, if required.
- Step 6—The filled resin is mixed, placed in an injection syringe, and injected uniformly into the restorative site.
- Step 7—The resin is allowed to cure. If using a light-cure restorative material, the curing light is held from the side in an attempt to cure from the restorative margins first.
- Step 8—The surface is re-contoured and smoothed as described on p. 438.

Glass Ionomers

General Comments

- Glass ionomers are sold in kits that may contain powder (in various shades), liquid, measuring scoops, varnish, etching agent, and mixing pads.
- They are easy to use and are less technique sensitive than composite restorative materials.
- The powder is an aluminosilicate glass.
- The anhydrous form contains acid in the powder.
- The hydrous form contains acid in the liquid.
- When the powder and liquid are mixed together, chemical reactions bond the restorative material to tooth structure and harden the compound.
- Light-cure and dual-cure glass ionomer restorative materials are available.
- Glass ionomers can be classified as type I (luting-sealing) cement or type II (for lining, restorative site, or core restoration) (Table 8-6).

Table 8-6 • **GLASS IONOMER RESTORATIVE MATERIALS**

Type I: Luting or Cementing	
<i>Product</i>	<i>Manufacturer</i>
CX-Plus GlasIonomer Cement	Shofu
Fuji I	GC America
FujiCEM	GC America
Ketac-Cem	3M ESPE
Vivaglass Cem	Ivoclar Vivadent
GlassLute	Pulpdent
Type II: Core	
<i>Product</i>	<i>Manufacturer</i>
Ketac Silver Applicap	3M ESPE
Ketac-Silver Maxicap	3M ESPE
Miracle Mix	GC America
Fuji II LC Core Material	GC America
EMKA Silver	Henry Schein
CoreShade	Shofu
Vitremer Core Buildup	3M ESPE
GlassCore	Pulpdent
Type II: Lining	
<i>Product</i>	<i>Manufacturer</i>
FujiPlus	GC America
Fuji Lining LC	GC America
Ketac-Bond	3M ESPE
Ketac-Bond, Applicap	3M ESPE
Vitrebond	3M ESPE
RelyX	3M ESPE
GlassLine	Pulpdent
Type II: Restorative	
<i>Product</i>	<i>Manufacturer</i>
Fuji II	GC America
Fuji II LC	GC America
Fuji IX GP	GC America
Ketac-Fil Applicap	3M ESPE
Ketac-Molar Applicap	3M ESPE
Photac-Fil Quick Applicap	3M ESPE
Geristore	Den-Mat
GlassFill	Pulpdent

- Type I glass ionomers are fine grained and are used for cementing (luting) crowns, bridges, and other castings.
- Type II glass ionomers are used as restorative materials.
- Type II glass ionomers are coarser than type I and therefore are not suitable for cementing.
- Restorative glass ionomers can be used as a base or as the sole restorative agent.
- Glass ionomers are biocompatible and do not require placement of obtunding base

material to protect the pulp, except in case of direct pulp exposure.

- Nonencapsulated forms are mixed with a spatula and pad.
- The encapsulated form requires a special instrument to break the internal separation between the liquid and powder, an amalgamator to mix the compound, and a special syringe to apply the mixture.
- A consideration with glass ionomer compounds is their lack of wearability. In an attempt to increase wearability, called *abrasive resistance*, some manufacturers have added metals to the mixture. Most commonly, silver is added; gold, copper, and zinc have been suggested as possible alternatives.
- After mixing nonencapsulated forms, the material is either transferred to an injection syringe and squeezed into the prepared cavity or is installed with a plastic placement instrument.
- With chemical-cure restorative materials, the surface should be protected from loss or gain of moisture by applying a varnish or light-cure sealant.
- Once hardened, the surface can be smoothed with a diamond finishing bur while being irrigated with copious amounts of water.
- The restoration should not be smoothed with a carbide bur.
- If water is not used, cocoa butter can be used as a lubricant.
- Without a lubricant, the material will over-heat, desiccate, and weaken.
- Glass ionomer restorative materials have the advantage of forming a chemical bond as well as a mechanical bond to enamel and dentin.
- Glass ionomers release fluoride slowly, which can be an advantage when cementing orthodontic bands or as a base underneath composite resin restorations.
- The expansion coefficient is the same as that of the tooth.

Indications

- Type I glass ionomers are used well for cementing (luting) crowns, onlays, and orthodontic appliances.
- Type II lining glass ionomers are used as a restorative foundation upon which other

materials, such as composite resins, are applied.

- Core glass ionomers are used as a base or for building up material around a post to support a laboratory-fabricated crown.
- Type II can also be used as a sandwich, in combination with light-cure composites, to reduce the amount of light-cure restorative agent required and to decrease the potential for polymerization shrinkage. The glass ionomer is placed in contact with the tooth, at the base and walls of the restorative preparation, and cured. It is then acid-etched along with the enamel for 15 seconds, rinsed, and dried. The composite resin is placed superficially as previously described.
- Type II glass ionomers are ideal for repairing odontoclastic resorptive lesions^{12,13} and for filling root canal access sites on nonocclusal areas.
- In some products, glass ionomer has also been added to mostly composite resin mixtures (compomers). These products are harder than pure glass ionomer; however, they have little inherent tooth-bonding properties left and require a bonding agent, as do the pure composite resins. They have been used successfully in repair and restoration of some crown root fractures.¹⁴

Contraindication

- Because these materials are less durable than other restorative materials, glass ionomers are not recommended on high-wear surfaces.

Materials

- Small excavator or curette.
- Power equipment (air-driven preferred).
- Glass or treated paper mixing slab.
- Spatula.
- Centrix syringe or Jiffy tube.
- Glass ionomer.
- Placement instrument(s).
- Glass ionomer varnish or unfilled resin.
- Light-cure gun (if using light-cure glass ionomer product).
- Finishing diamond or white stone bur.
- Coconut butter or polishing paste.

Technique for Restoration After Root Canal Therapy

- If used as a base below a composite resin, only steps 1 to 3 will apply.

Step 1—Preparation of the Surface

Substep 1—In most situations, cavity preparation will be the same as a standard preparation for composite resins (Fig. 8-10, A).

- In the treatment of nonocclusal class V lesions, the creation of an undercut may not be necessary.

Substep 2—The surface is cleaned by using a prophylaxis cup filled with flour pumice because many polishes contain fluoride, essential oils, or glycerin that would interfere with the bonding of the restorative material.

- Etching or conditioning of nonvital dentin, to remove the smear layer that forms during preparation, is controversial. If a conditioner is supplied with the restorative kit, it should be used according to the manufacturer's instructions.

Substep 3—The cavity is dried lightly with an air source or blotted dry with paper points. Do not desiccate.

Substep 4—The cavity preparation agent (usually a mild acid) is applied (Fig. 8-10, B) if required.

Substep 5—After 15 seconds the cavity preparation agent is washed off with water (Fig. 8-10, C).

Substep 6—The area is dried lightly.

- As opposed to composite resin techniques, it is important that the cavity not be “bone dry.” Although there should be no pools of water in the preparation, the area should not have the chalky white appearance of a completely dried tooth.
- If accidentally overdried, the preparation should be rehydrated with water.
- Once the area has been prepared, it is important to prevent contamination. If contaminated, the area must be prepared again.

Step 2—Application of the Bonding Agent

- In this case, it is the glass ionomer applied in step 3. If a compomer is being used, apply the bonding agent as described under the composite resin material section.

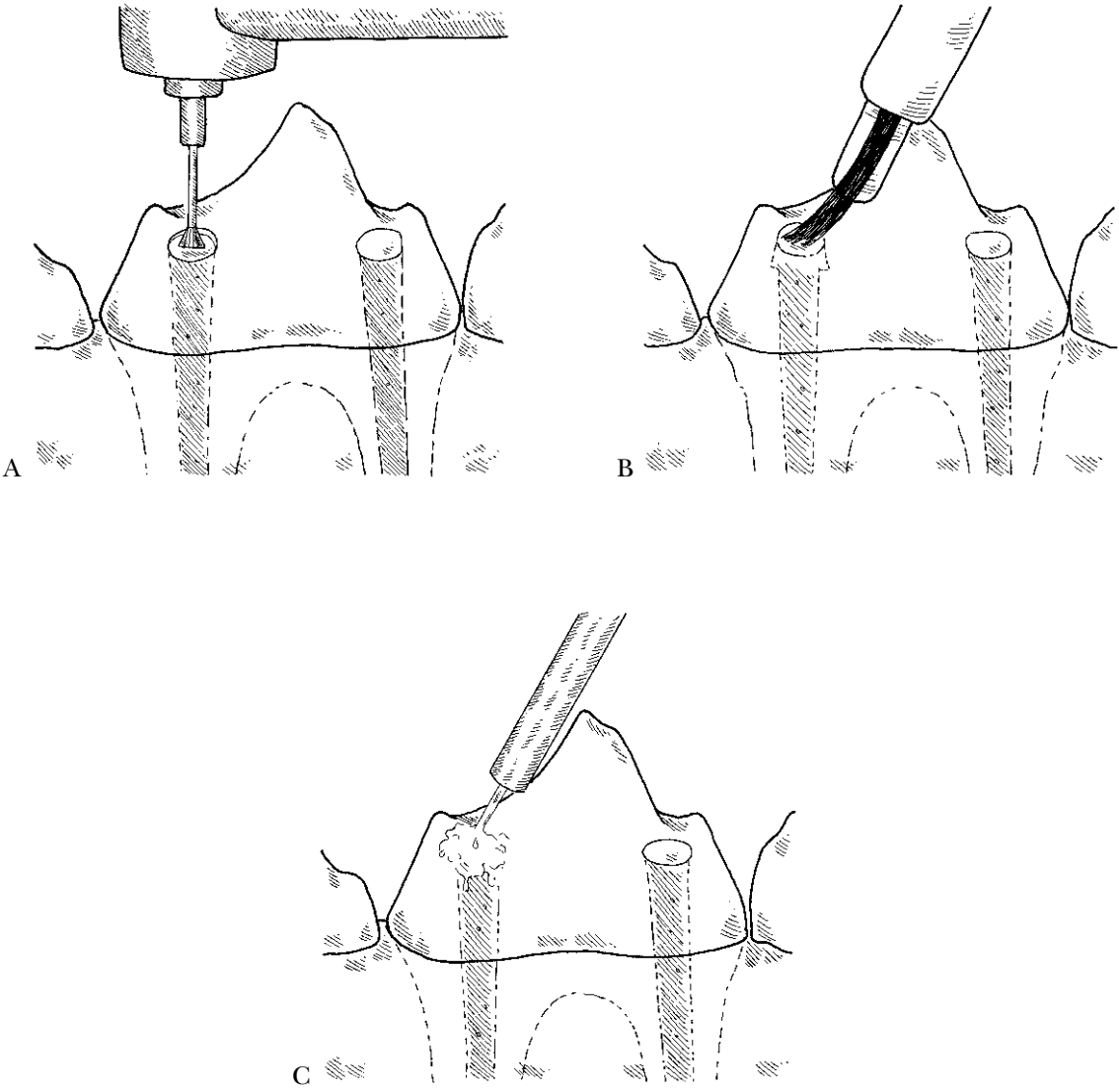


Fig. 8-10

Step 3—Application of the Glass Ionomer

- Glass ionomer restorative material is mixed quickly, following the manufacturer's instructions. Although the ratios may vary from product to product, and the amounts may vary from case to case, the following substeps apply.

Substep 1—The powder is “fluffed” (shaken) with the lid closed, and level scoops of the powder are measured and placed, preferably onto a heavy glass slab (Fig. 8-11, *A*).

Substep 2—The appropriate number of drops of liquid are dripped out; avoid air bubbles that may distort the measurement (Fig. 8-11, *B*).

Substep 3—The powder is divided in half, and one of the halves is divided again (Fig. 8-11, *C*).

Substep 4—One half of the total powder is pulled into the liquid and is mixed rapidly (Fig. 8-11, *D*).

Substep 5—One fourth of the powder is then pulled into the liquid (Fig. 8-11, *E*), and subsequently the other one fourth is mixed in (Fig. 8-11, *F*). A figure-of-eight motion, with the spatula at an acute angle, 10 degrees to the mixing slab, is used to mix the glass ionomer into a homogeneous state (Fig. 8-11, *G*). Use of a chilled glass slab will extend the working time. The mix should have a puttylike consistency and a glossy appearance.

- Once the material is applied to the cavity, manipulation should be limited.

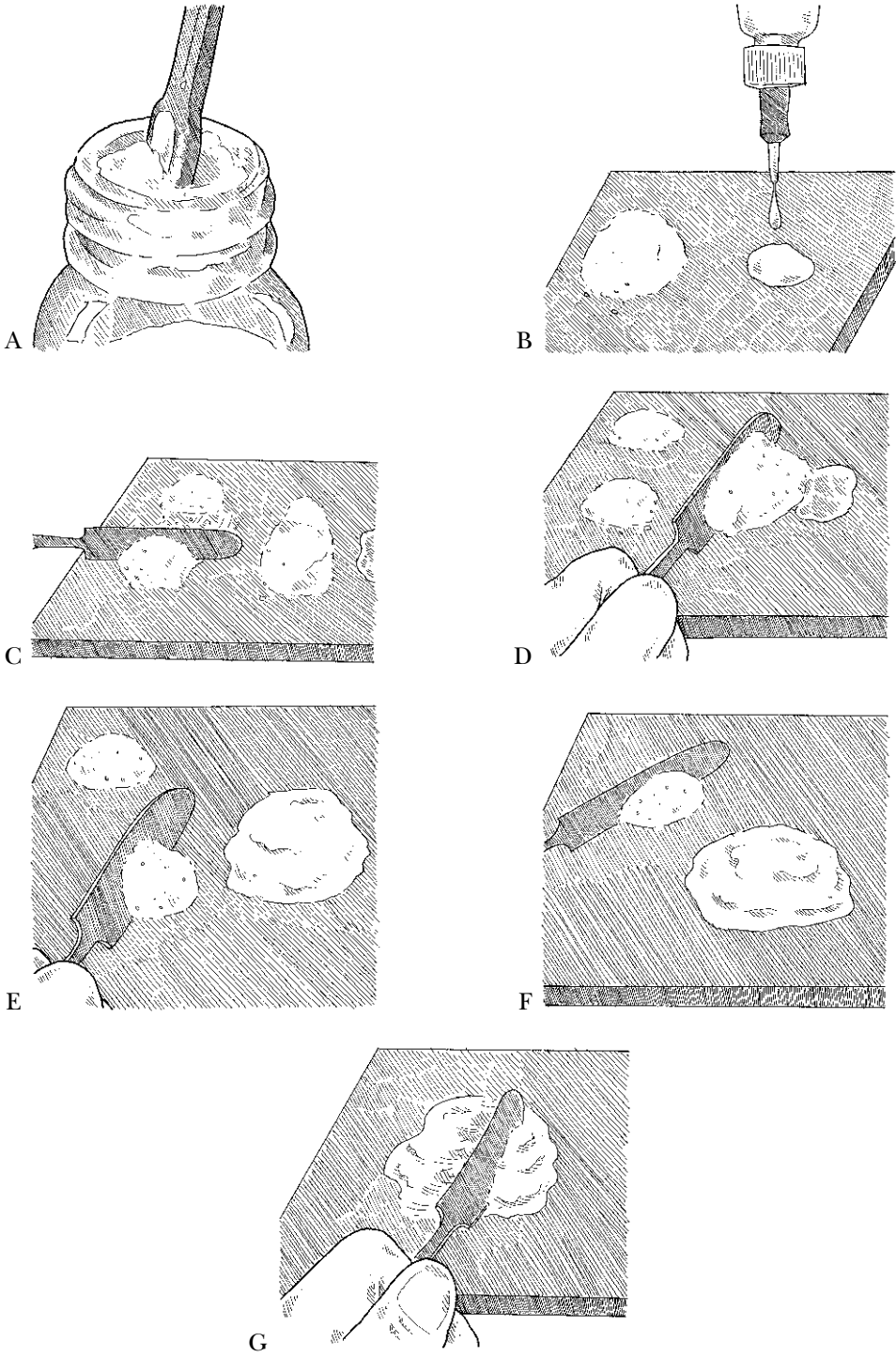


Fig. 8-11

Substep 6—The glass ionomer material can be placed with a plastic filling instrument or the mix may be loaded into the curved tip of a Centrix injection syringe (Fig. 8-12, *A*).

Substep 7—The tip is pushed down over the plug (Fig. 8-12, *B*). The tip and plug are loaded into the syringe.

Substep 8—The restorative material is injected uniformly into the defect to be filled (Fig. 8-12, *C*).

Substep 9—The glass ionomer is cured for the recommended time with a light-cure gun if using a light-cured product.

Step 4—Shaping the Restoration

Substep 1 (Optional)—While the glass ionomer is setting, it is covered with a Mylar strip to

prevent moisture contamination (Fig. 8-12, *D*). A condenser may be applied over the Mylar strip to help to better conform the restorative material to the tooth structure (Fig. 8-12, *E*).

Substep 2—The overfilled edges of the material (flashing) are painted with a varnish (Fig. 8-12, *F*). If a Mylar strip is not used, the surface of the restorative material should be coated with a layer of varnish after it begins to harden.

- Alternatively, the liquid component of a light-cure resin can be painted on to protect the glass ionomer as it sets.

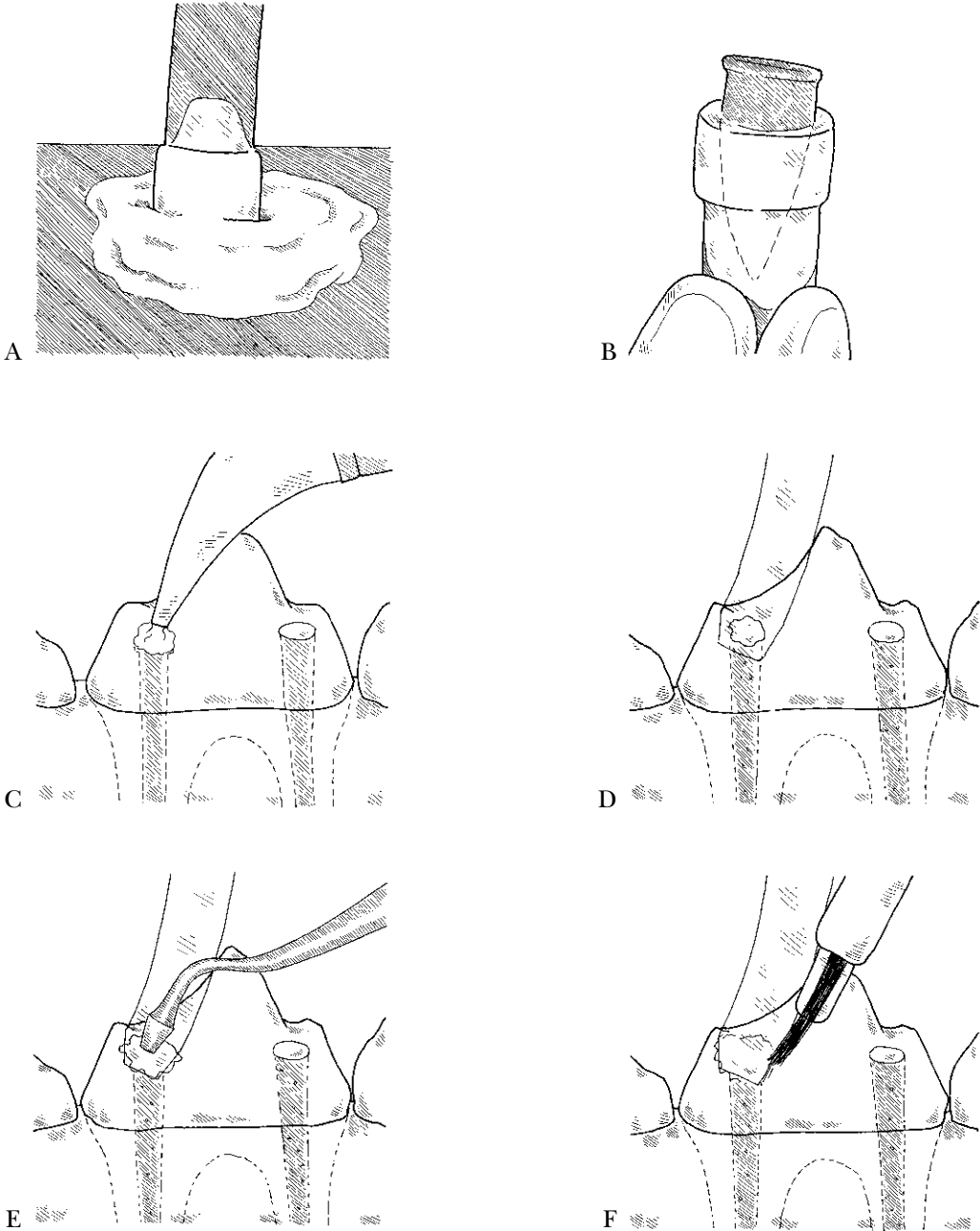


Fig. 8-12

Step 5—Smoothing the Restoration

Substep 1—The restoration is carved with a fine diamond bur and coated with cocoa butter or lubricant as directed by the glass ionomer manufacturer (Fig. 8-13, A).

Substep 2—The cocoa butter is wiped from the tooth (Fig. 8-13, B).

Substep 3—A coat of varnish or the liquid portion of a light-cure resin is applied as a final protective coat (Fig. 8-13, C). A light-cure glass ionomer does not need the final application of varnish or unfilled resin to be applied to its surface.

Complications and Cautions

- The tooth conditioner may cause dentinal sensitivity, because it is a form of acid-etch.
- It is important that the glass ionomer material be applied before the mixture loses its shiny appearance and, thus, its adherent quality. If this loss occurs, a new batch of material should be mixed.
- If the glass ionomer restoration crazes, cracks, or falls out, it is usually a problem of moisture (Fig. 8-13, D). Water contamination as well as overdrying can cause these problems.
- Many of the newer glass ionomer hybrids that are light-cure products contain resin, which protects them from the moisture problems of the pure glass ionomers. These may not be as technique sensitive as the pure glass ionomer materials. They may not need cocoa butter or other protectants while being shaped and smoothed.

Feline Odontoclastic Resorptive Lesions

Etiology

- The pathogenesis of odontoclastic resorptive lesions on feline teeth is not fully understood. It is known that stem cells are attracted to the cemental surface and clastic activity is activated by cytokines. It is unclear what initiates the cytokine release and stem cell attraction.¹⁵
- There is a correlation between hypervitaminosis D and resorptive lesions.¹⁶ Hypervitaminosis D may be a major cause of resorptive lesions, but it is likely that there are other factors that cause this disease.
- Research shows that these lesions tend to start at the gingival margin or subgingivally and progress apically and coronally. A study

comparing central point of lesions in cats showed canine teeth to have a center point generally located apical to the cemento-enamel junction.¹⁷ These lesions have been called cervical line lesion, odontoclastic resorption, neck lesion, feline neck lesion, feline caries, feline odontoclastic resorptive lesion, and cavities (and facetiously “catvities”).

Signs

- They often are covered with hyperplastic gingiva and may not be detectable without using an explorer to probe for irregularities of the tooth surface.
- The patient usually shows signs of discomfort and pain when the lesions are probed.
- This discomfort is sometimes even evident when the patient is under deep, plane II surgical anesthesia.
- The lesions may be found on any of the teeth, but molars and premolars are most frequently involved, followed by the canine teeth.
- The exposed dentinal tubules may be covered with calculus, especially in the molar and premolar teeth, which protects them from pain.
- Lesions are found on the buccal and lingual or palatal surfaces.
- The lesions seem to be progressive, and many teeth in a patient may be affected, showing different stages of destruction at the time of examination.
- Lesion incidence increases with the age of the patient.
- In early stages, lesions can be so small that they are difficult to detect.
- As lesions progress, they enlarge, encompassing more and more of the root and crown.
- In advanced lesions, an overhang of enamel may be found, with the underlying dentin missing.
- Radiographs often show the affected teeth to be demineralized much more dramatically than is apparent on visual examination. Affected roots often are undergoing resorption and replacement with osteoid tissue.
- Some teeth have external resorption with evidence of periodontal bone loss, and others have normal bone level yet show varying degrees of replacement resorption of the root structure.
- The incidence of periapical changes seen radiographically with resorptive lesions is

very low.¹⁸ Teeth that show evidence of periodontal bone loss, periapical changes, or associated advanced chronic gingivostomatitis should be extracted. They are considered type 1 lesions.¹⁹ Teeth with shallow lesions just penetrating the dentin may be candidates for restoration. Teeth with lesions that radiographically show the presence of root replacement resorption are not candidates

for restoration. These teeth can be extracted, using a crown amputation and intentional root retention technique, provided that they are radiographically free of endodontic disease and periapical pathology and that there is no evidence of chronic ulcerative gingivostomatitis or feline leukemia virus. These are type 2 lesions.¹⁹

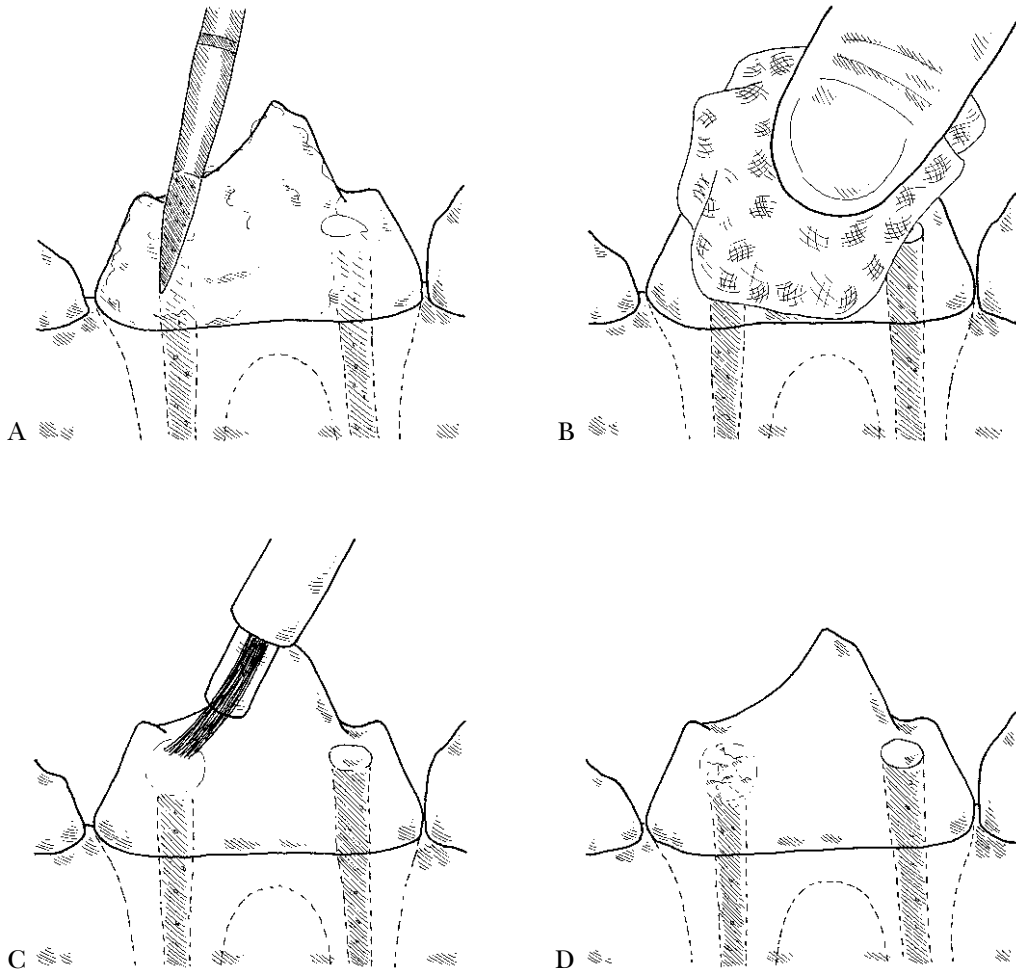


Fig. 8-13

Treatment Protocol

Technique for restoration of feline odontoclastic resorptive lesions

Step 1—Before restoration is attempted, the tooth should be examined carefully to determine the amount of involvement (Fig. 8-14, A).

- A radiograph is a very important part of this evaluation.
- It is inappropriate service to restore a tooth whose roots are already being resorbed, because the underlying pathology will continue to progress after restoration therapy.
- The following classification system of feline resorptive lesions based on extent of tooth involvement is in common use.¹⁵

Stage 1—Abrasions or shallow cementum or enamel defects that do not enter the dentin.

Stage 2—Erosions that progress into the dentin through enamel or cementum. May see normal root structure or early replacement resorption starting on radiographs. Periodontal bone loss may be present in type 1 lesions.

Stage 3—Erosions that extend into the root canal.

Stage 4—Chronic resorptive lesions resulting in extensive loss of crown or root structure. There may be radiographic evidence of periodontal disease or replacement resorption with ankylosis of the root.

Stage 5—An advanced lesion, where crown has already been lost, with radiographic evidence of root fragments. Some roots may be intact, while others may have already undergone replacement resorption.

- The following system can be used to plan treatment.

Stage 1—Thorough dental prophylaxis, dental radiographs of all teeth, and follow-up home care. Recheck in 6 to 12 months with radiographic examination.

Stage 2—Thorough dental prophylaxis, dental radiographs of all teeth, possible surgical gingivectomy, glass ionomer restoration if the lesion is shallow and involves a major tooth with healthy roots. These lesions can also be filled with a flowable composite resin and a dentin bonding agent that releases fluoride. Recheck in 6 to 12 months with radiographic examination. The condition may continue to develop in other parts of the tooth. Restoration of these teeth is “buying time.”

- If no periodontal bone loss or endodontic changes are present and restoration isn’t performed, a crown amputation with intentional root retention extraction may be performed to eliminate the dental pain.
- Type 1 lesions include periodontitis with radiographic bone loss and a periodontal ligament space. These teeth should not have a crown amputation performed and should be extracted to eliminate dental pain.¹⁹

Stage 3—Thorough dental prophylaxis, dental radiographs of all teeth, and possible surgical gingivectomy, root canal therapy, and glass ionomer restoration or extraction and alveoplasty, depending on quality of root structure, periodontal status, and importance of tooth for function.

Stage 4—Dental radiographs of all teeth and extraction and alveoplasty followed by supportive care. Type of extraction depends on whether type 1 or type 2 lesion.

- A type 2 lesion is accompanied only by focal gingivitis; no periodontal bone loss, no periapical lysis, no gingivostomatitis. Type 2 root lesions show radiographic root replacement signs and no periodontal ligament space; here crown amputation is indicated. Type 1 lesions require complete extraction.

Stage 5—Generally no treatment is necessary unless radiographs and examination reveal small remnants of tooth crown that are causing irritation.

Step 2—Clean the lesion of plaque and hyperplastic gingiva; remove any soft dentin that may be present by curettage (Fig. 8-14, B). This is often difficult to do without penetrating the pulp chamber.

- If the pulp chamber is penetrated iatrogenically, extraction should be performed.

Step 3—The lesion may be isolated by packing retraction cord into the sulcus (Fig. 8-14, C). If necessary to maintain a dry field and access to subgingival lesions, a gingival flap may be elevated for better exposure and treatment.

Step 4—The lesion is cleaned with a prophylactic cup and pumice. This removes debris from the cavity surface (Fig. 8-14, D).

Step 5—The lesion is rinsed and dried, and either a glass ionomer restorative material, or a dentinal bonding agent and flowable composite resin, is placed.

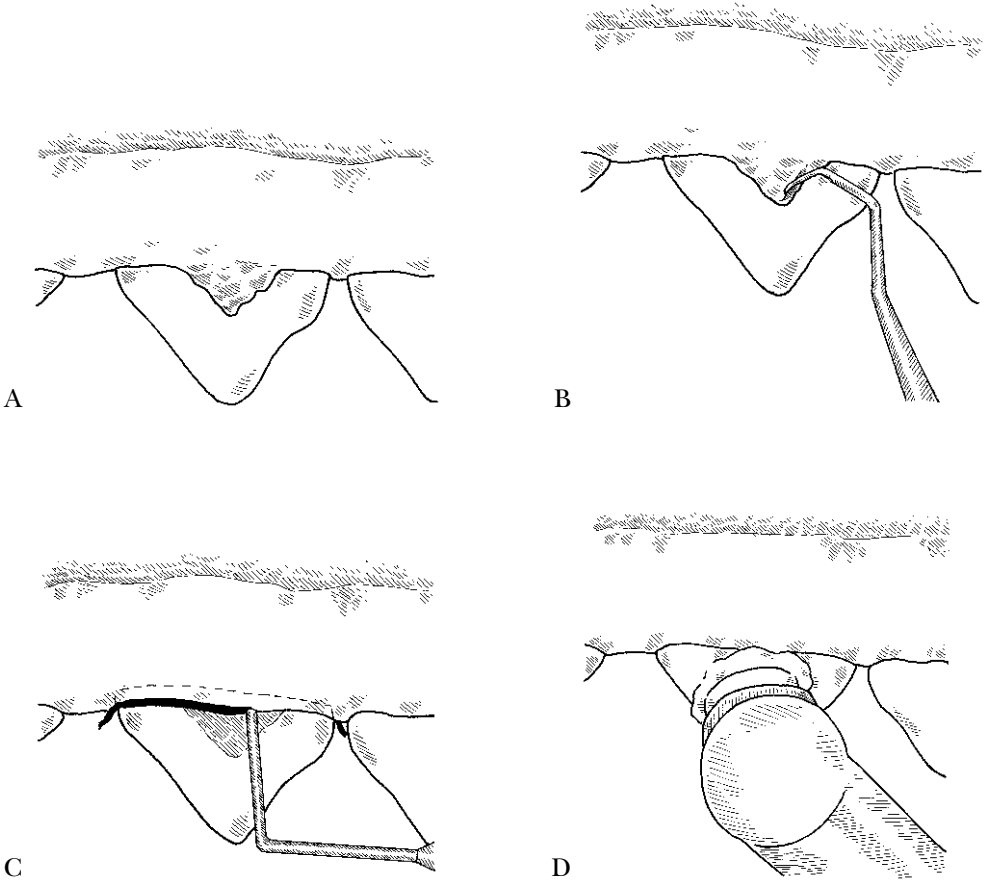


Fig. 8-14

Placing a glass ionomer restorative agent

Substep 1—A dentin conditioner is applied to the lesion with a brush (Fig. 8-15, *A*) and, following the manufacturer's instructions, either actively scrubbed or left passively to perform on the surface.

Substep 2—The dentin conditioner is washed thoroughly from the tooth surface (Fig. 8-15, *B*), and the tooth is dried lightly (slightly damp is permitted).

Substep 3—After mixing, the glass ionomer is inserted into an injection syringe and

delivered into the defect (Fig. 8-15, *C*) or applied with a small plastic filling instrument.

Substep 4—A Mylar strip is placed over the glass ionomer and tooth (Fig. 8-15, *D*). Pressure is placed on the Mylar strip with an instrument such as a condenser, curette, or explorer (Fig. 8-15, *E*).

Substep 5—The “flashing” (glass ionomer that has overflowed the prepared defect margin) is coated with varnish or a light-cured unfilled resin (Fig. 8-15, *F*).

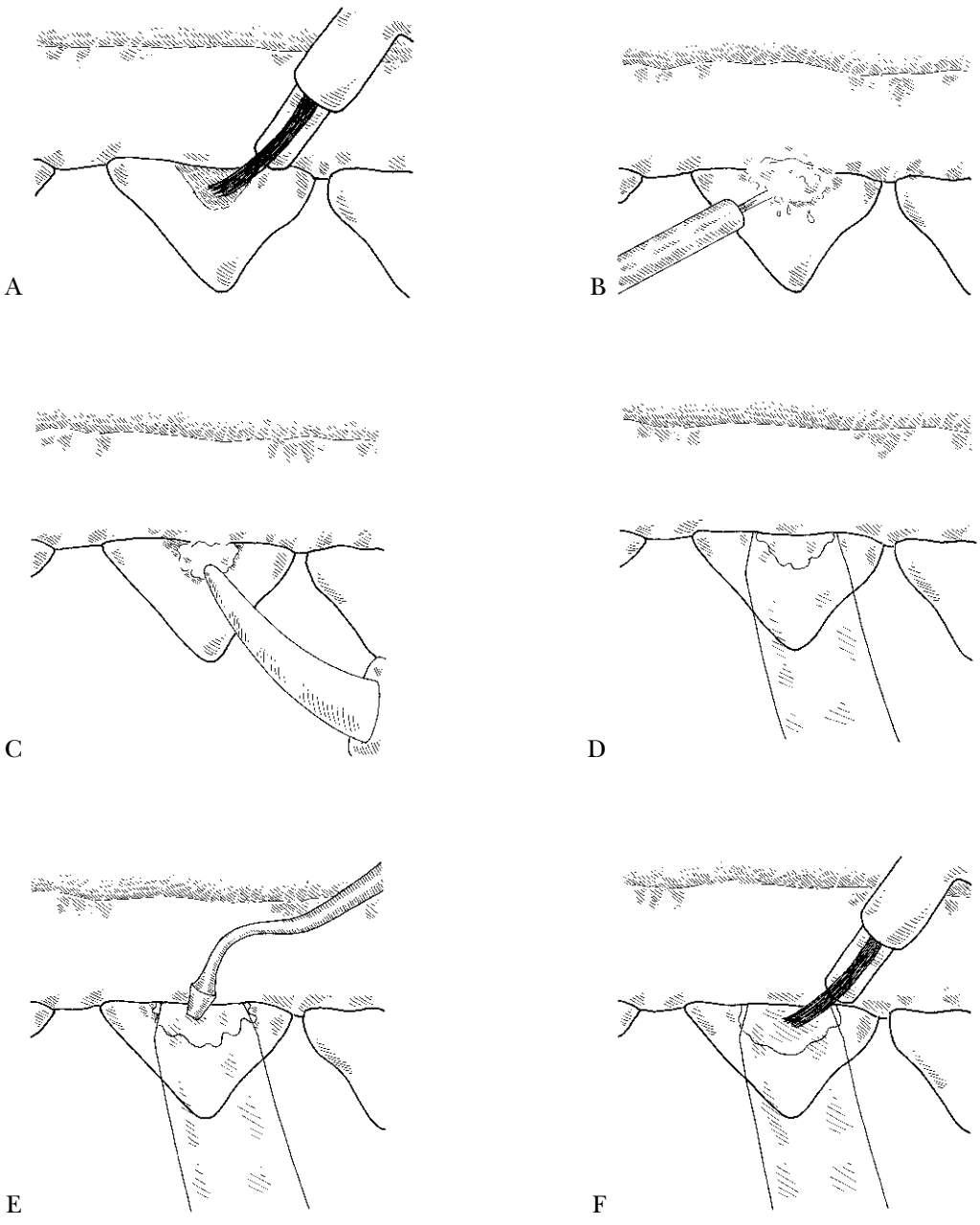


Fig. 8-15

Substep 6—When the glass ionomer is hard (after 2 to 3 minutes), the Mylar strip is removed, and the excess glass ionomer is trimmed away, leaving a smooth surface and blended margin (Fig. 8-16, A).

Substep 7—Excess material is wiped away from the surface (Fig. 8-16, B).

Substep 8—The glass ionomer is recoated with varnish or light-cured unfilled resin (Fig. 8-16, C).

- Alternative Step 5—An alternative restorative method is to use a flowable, light-cured glass ionomer material (Vitrebond, 3M ESPE, St. Paul, Minn.). The lesion is prepared as in steps 1 to 4. The lesion is rinsed and dried but should not be overdried.

Substep 1—The glass ionomer material is mixed as directed. Using a small ball-end placement instrument, a small amount of the glass ionomer material is flowed into the defect.

Substep 2—The material is light-cured for the prescribed time. Deeper lesions can be filled and cured in layers.

Substep 3—The restoration margins are finished and smoothed.

Step 6—Home care will assist in maintaining the patient's oral health.

- Amalgam does not serve to strengthen the tooth as do composite resin materials.
- Amalgam itself is not bonded to the tooth and therefore, if used alone, requires a mechanical interlock to keep it in place, involving a dentinal undercut or pin and post placement.
- Mercury is a poison, and direct contact with skin should be avoided.
- Amalgam seals by corrosion, and a black oxidized edge will be seen around the filled area at a later date. Because black discoloration is normal, clients should be advised of its future appearance. Painting a varnish over the area to be restored before amalgam placement can reduce discoloration.
- To reduce marginal leakage and seal the dentin, an unfilled resin can be placed and cured prior to placement of the amalgam.
- Newer amalgam bonding systems will create a chemical bond between dentin and amalgam (Amalgambond Adhesive System, Parkell, Farmingdale, NY; Clearfil Liner Bond 2V, Kuraray America, New York, NY; ScotchBond Multipurpose Dental Adhesive, 3M ESPE).
- This reduces microleakage, decreases post-operative sensitivity in vital teeth, and some release fluoride (DenTASTIC Amalgam Bonding Kit, Pulpdent, Watertown, Mass.).

Amalgam

General Comments

- Amalgam is a metal alloy of mercury and silver that may also contain copper, zinc, tin, and other metals.
- Amalgam, separately contained in a prepared capsule with mercury, is mixed with amalgamators, which are mechanical mixing devices, until the two ingredients are homogeneous. The capsule is placed in the amalgamator, and when the machine is turned on the mercury alloy material is mixed by a metal or plastic ball within the capsule that serves as the pestle.
- Depending on the alloy, it usually takes from 10 to 30 seconds to mix the amalgam. Follow the manufacturer's recommendation.
- Amalgam is an easy material to work with; it is strong and able to withstand years of wear. Often the tooth will wear around an amalgam restoration, leaving amalgam protruding beyond the worn tooth structure.

Indications

- Surface restoration.
- Core build-up for crown.

Contraindications

- Restorations where cosmetics are important.
- Very small teeth that will be weakened by an undercut macropreparation.

Materials

- Amalgam in capsule.
- Amalgamator.
- Amalgam carrier.
- Amalgam condensers.
- Amalgam burnishers.
- Amalgam carvers.
- Amalgam finishing cups.
- Amalgam well.
- Cavity varnish, amalgam bonding agent, or unfilled resin material.

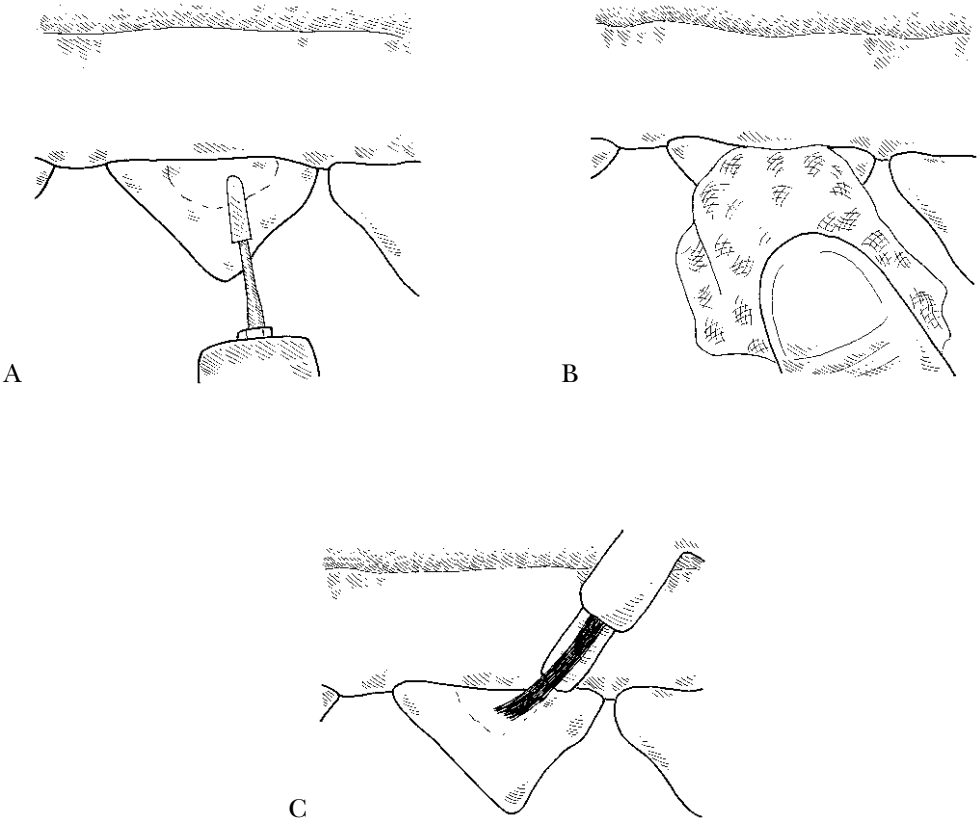


Fig. 8-16

Technique**Step 1—Preparing the Surface**

Substep 1—The outline and retention of the cavity are prepared using a diamond or carbide bur (Fig. 8-17, *A*).

Substep 2—Unsupported enamel is chiseled along the margins to remove the enamel overhangs (Fig. 8-17, *B*).

Substep 3—In areas within 1 mm of the pulp, resinated calcium hydroxide is placed (Fig. 8-17, *C*) (see Chapter 7, pp. 345 to 347).

Substep 4—In deep restorations, a liner of glass ionomer may be placed (see the preceding section on glass ionomers).

Step 2—Sealing Dentinal Tubules of Vital Teeth

- A cavity varnish or dentin adhesive is placed (Fig. 8-17, *D*).
- Dentin adhesives significantly reduce microleakage around amalgam restorations.²⁰
- Use only a thin layer over all surfaces, and allow to dry or light-cure, if required, before placing the amalgam. Some amalgam bonding agents are designed to be wet when the amalgam is placed.

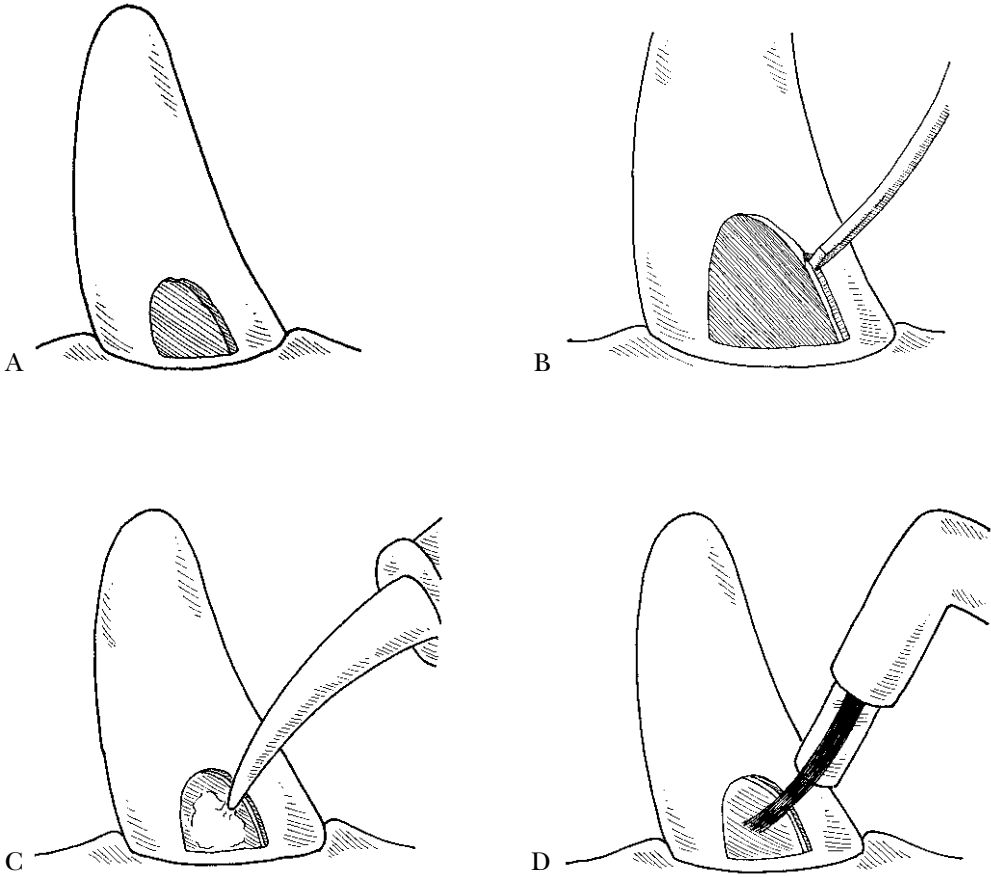


Fig. 8-17

Step 3—Placing Restorative Material

Substep 1—The amalgam capsule is activated according to the manufacturer's instructions.

Substep 2—The amalgam is triturated at the time and speed directed by the manufacturer.

Substep 3—The mixed amalgam pellet is placed in an amalgam well (Fig. 8-18, *A*). Properly prepared amalgam should appear shiny and moist. Over-mixed amalgam appears chalky and flaky and does not condense. Under-mixed amalgam appears not to be homogeneous.

Substep 4—An amalgam carrier is loaded with amalgam from the well (Fig. 8-18, *B*).

- Caution should be used not to compact the amalgam in the carrier. If it becomes compacted, it may be necessary to replace the carrier tip or use a sharp, pointed instrument to dig out the amalgam.

Substep 5—Amalgam is placed in the prepared restoration site (Fig. 8-18, *C*).

Substep 6—The first layer of amalgam is condensed with pressure (Fig. 8-18, *D*). Smaller condensers are used during the early filling stage, and larger condensers are used for final condensing. Condensing reduces the amount of residual mercury in the final restorative material, and strength of the restoration improves with lower mercury-to-alloy ratios.²¹

Substep 7—Subsequent layers are condensed. It is important when condensing each layer to eliminate voids. Mechanical vibrating contra angles and tips are available that efficiently compact and condense the restoration, layer by layer. A slight overfill is desired; this is reduced during the next step.

Step 4—Carving Amalgam

- The final anatomic form is created with an amalgam carver. While carving, the operator should carve from tooth surface into the restoration to avoid “scooping” out the amalgam.

Step 5—Burnishing

- The surface of the amalgam is burnished with a burnisher (Fig. 8-18, *E*).

- Burnishing renders the restoration more corrosion resistant.
- The surface is rubbed lightly until it takes on a velveteen or satin appearance.⁷
- When burnishing, the instrument is directed from the restorative surface to the tooth surface.²² The restoration ideally should be polished when completely set 24 hours after placement (Fig. 8-18, *F*). With fast-setting amalgams, polishing can be completed at the time of installation, once the restorative material has hardened.

Complications

- Microleakage resulting in penetration of bacteria, bacterial products, soluble ions, and saliva into the gap between the restoration and the cavity walls.
- Microleakage resulting in pulp irritation, inflammation, and necrosis.
- Inherent characteristics of the material, such as the lack of chemical adhesion (unless bonding agents are used), differences in the coefficients of thermal expansion between the amalgam restoration and tooth structure, and the dimensional changes and surface texture of the amalgam after insertion into the prepared cavity—leading to microleakage or tooth fracture.
- Inadequate condensation resulting in voids along the cavity margins and in the restorative material.
- Overtrituration (mixing) resulting in overcontraction.
- Overmixing causing amalgam to set before it is placed in the cavity preparation.
- Undertrituration resulting in high-setting expansion and increased corrosion. If undermixed, the material will be dull and grainy, leading to a weak and rough surface with free mercury.
- Delay in placing the amalgam into the restoration, resulting in a partial setting of the amalgam and weakening of the restoration. Varying with the product and amount of trituration, the amalgam begins to solidify in 1 to 5 minutes.
- Careless placing of lining material on the walls, reducing macroretention of the amalgam with the tooth structure.²⁰

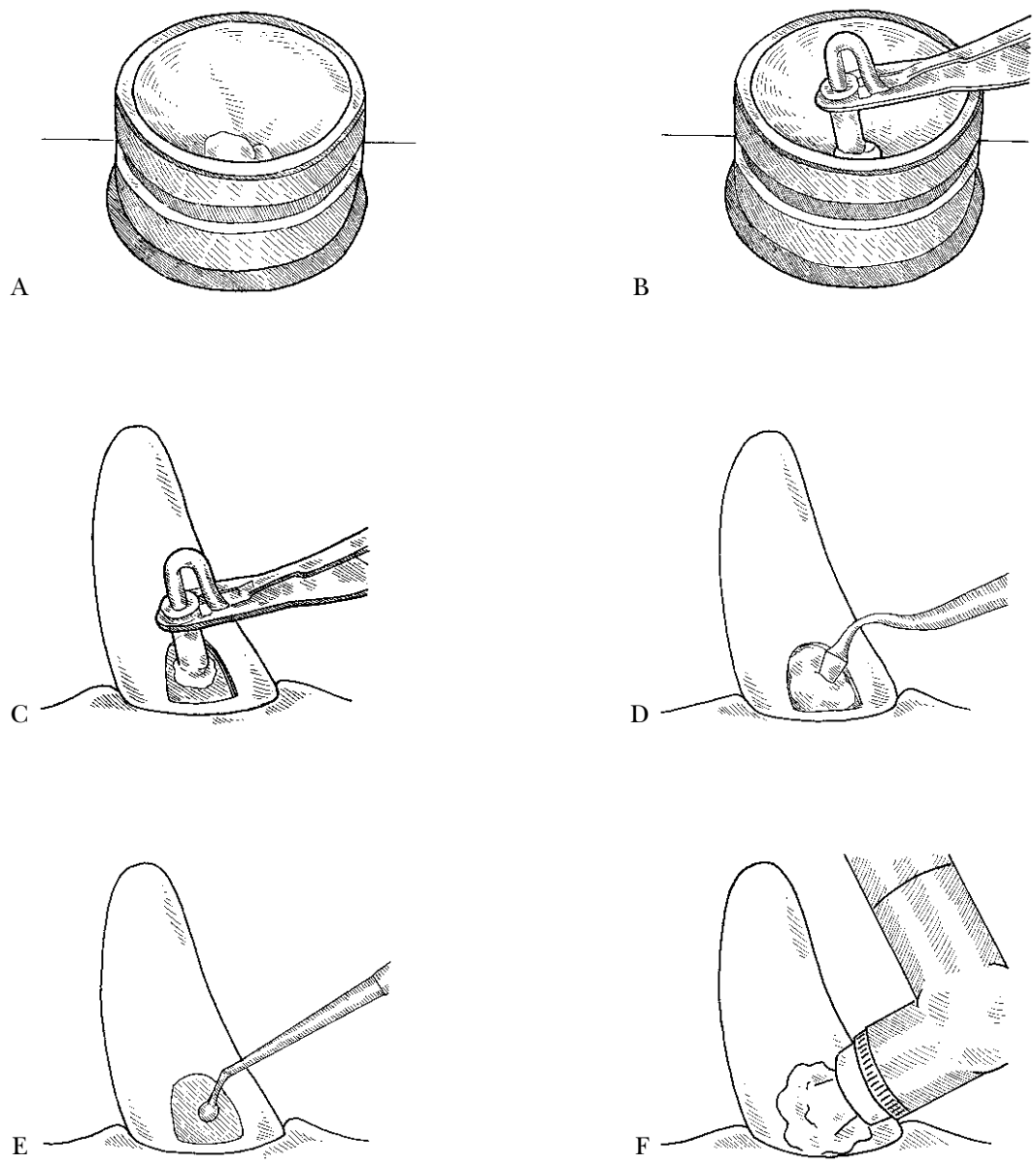


Fig. 8-18

PIN RESTORATION

General Comments

- A pin-retained buildup is formed with pins placed in the dentin and covered with amalgam, composite, or a glass ionomer.
- A buildup may be part of a final restoration or as a core buildup for crown placement.
- If a minimal buildup is needed, the pin-retained buildup method may be used.
- In general, pins strengthen retention but weaken the tooth so, when used, the least number of pins necessary (minimum of two) should be used. They should be placed at least 2 mm from each other, the other walls, and the pulp. At least 1.5 mm of restorative material should cover the pin.²²

Advantage

- Provides additional retentive surface.

Disadvantages

- Pins weaken tooth structure.
- Restoration will not withstand much tangential or shear force.

Materials

- Power equipment.
- Low-speed handpiece.
- TMS pin kit (Minikin, Coltene/Whaledent, New York, NY).

Technique

Step 1—Appropriate endodontic or restorative preparation is performed (Fig. 8-19, A).

Step 2—With a low-speed handpiece and bur that comes with the Minikin kit, a hole is drilled in the dentin with one pass (Fig. 8-19, B).

- A small indentation in the dentin surface can be made with a $\frac{1}{4}$ round bur before drilling the hole, to prevent wandering of the drill bit during initiation of the drilling.

Step 3—The pin is loaded into the pin instrument.

Step 4—The pin self-taps and is threaded into the predrilled hole (Fig. 8-19, C).

Step 5—When the pin is set, the pin will break off at the precut location (Fig. 8-19, D).

Step 6—A restoration is placed (chemical or light-cure composite resin, glass ionomer, or amalgam) with a previously described technique (Fig. 8-19, E).

Complications

- Caution must be used for vital teeth not to perforate into the pulp tissue; this may lead to sensitivity, infection, and failure. If perforation occurs, a small amount of calcium hydroxide may be placed in the hole, followed by the permanent restoration. The hole should not be used for the pin.
- Caution must be used to avoid perforation into the periodontal ligament space. If this should occur, a small amount of calcium hydroxide should be placed in the hole, and that hole should not be used for the procedure. Radiographs should be taken postoperatively and at 6-month intervals, so that early detection and treatment planning can be made if complications arise.
- When drilling, caution must be used to make the hole as close to the size of the drill as possible (avoid drill wobble).
- Stripped threads in drilled holes will lead to an unstable pin, and the hole should not be used.

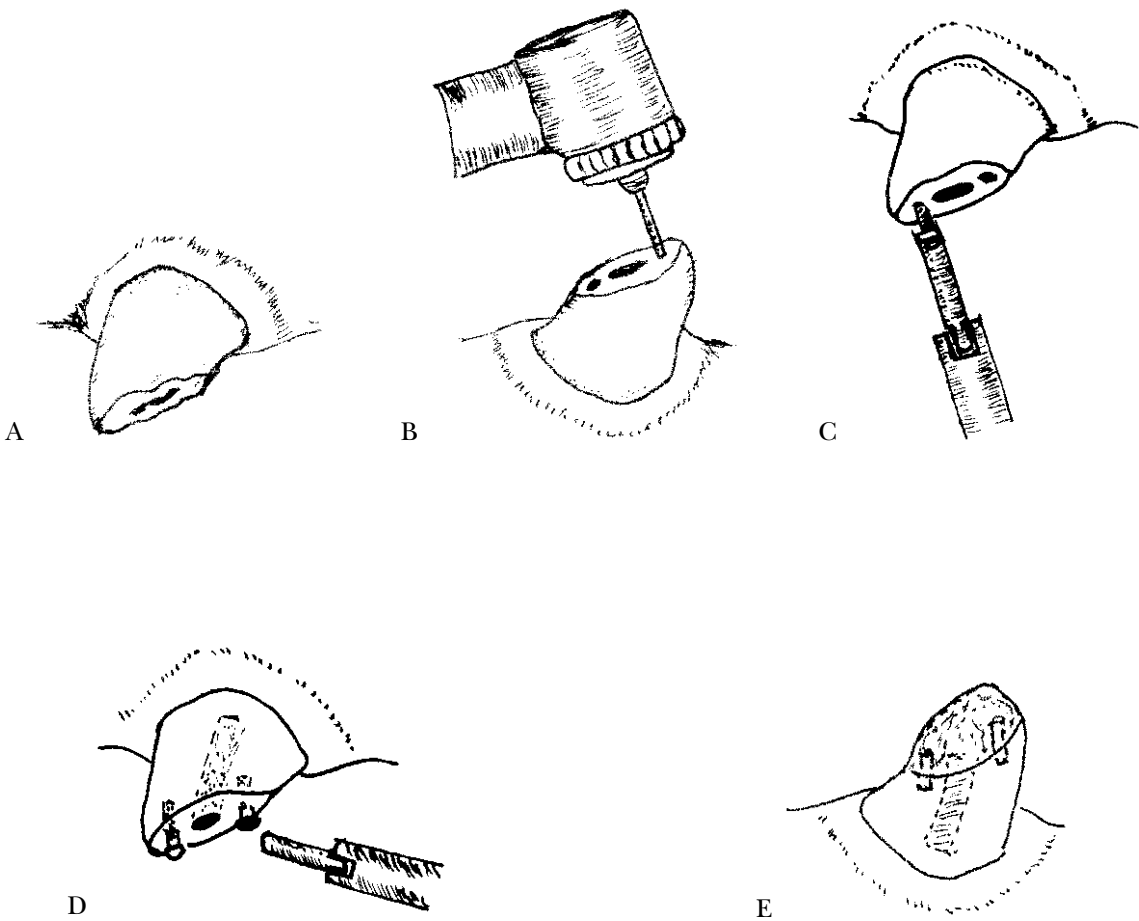


Fig. 8-19

CROWN THERAPY

Crown: General Technique

General Comments

- A crown (“cap”) is a device that replaces the function and structure of a damaged tooth and protects the portion of the tooth that remains.
- A crown can be made to match closely the function and appearance of the tooth.
- The decision to place a crown is determined after careful consideration of the patient’s lifestyle and the client’s wishes. Working dogs that damage their teeth performing their duties, sporting dogs, Ringsport or shutzhund dogs all place damaged teeth at a greater risk for further injury and a crown is often warranted. Other patients in situations where dental abuse will continue and tooth preservation is a high priority will benefit from metal crowns.²³ Crown preparation involves removal of tooth structure, further weakening the tooth if a crown cannot be retained.
- Crown preparation entails additional anesthesia, laboratory costs, and expense to the client.
- The replacement crown is called a *full crown* if it covers the entire crown of the tooth.²⁴
- The replacement crown is called a *partial crown* if it covers only a portion of the tooth’s crown.
- The material that the crown is made of affects its appearance.
- The margin of the crown is the edge that interfaces with the margin of the tooth preparation.
- Maintenance (conservation) of tooth structure is the primary concern in crown preparation design. It is unwise to remove more tooth structure than is absolutely necessary for creating retention and integrity; at the same time, enough tooth structure must be removed to create adequate space for the restoration. The goal is to have the final restoration the same dimensions as the original unbroken tooth unless specifics of the case dictate otherwise.
- The preparation should be designed with a parallel technique of the walls and a 6-degree vertical taper to increase the resistance of the crown to dislodgment.
- Canine teeth in dogs and cats do not lend themselves to parallel technique as readily as do most human teeth, because canine

teeth in dogs and cats are conical and not boxlike, as they are in humans.

- Parallelism may be accomplished by “stair-stepping” the preparation between the mesial and the distal surfaces in canine teeth. However, this is seldom necessary.
- Greater retention is achieved when most of the available surface area of the prepared axial wall of the tooth is in contact with the cast restoration.
- A minimum of 4 to 6 mm of available sound tooth structure is necessary for crown retention.
- The restoration must have adequate occlusal clearance or it will strike other teeth.
- The margin of the restoration must facilitate good hygiene and not create areas for plaque and debris to accumulate; at the same time, it should be accessible so the veterinarian can finish it and the client can maintain it.
- Ideally, the margin placement is on the enamel surface 1 to 2 mm coronally from the free gingival margin. This is more readily accomplished when aesthetics are not a primary concern.
- If aesthetics are of paramount importance, subgingival placement of the margin is necessary.

Indications

- Enamel hypoplasia or aplasia (dental structures are intact, pulp is vital).
- Fractured teeth with damaged pulp and lost vitality; performed after endodontic therapy.
- Undamaged pulp: pulp vital but additional protection desired.
- When deterioration or damage has left an unstable or inadequate supragingival portion of the crown structure and the damage is not reparable by other methods.
- To protect a damaged tooth from further trauma or deterioration.

Contraindications

- Thin wall structure; always take a radiograph before performing a crown preparation.
- Nonvital teeth that have not received endodontic therapy.
- Endodontically treated tooth when practitioner is unsure of success.
- Dogs that abuse their teeth with indiscriminate oral habits or service dogs that display reckless disregard for their well-being during oral aggression training.

Objective

- To protect the tooth and to improve the cosmetics and function of the tooth.

Materials

- A crown of semiprecious metal. The least expensive material is silver colored. Generally, the cost of the metal is the smaller portion of the cost to fabricate a crown in relation to the labor cost.
- A premium gold alloy contains a greater percentage of gold; when the percentage is greater than 40%, the alloy produces a gold-colored crown. Crowns with 30% or less gold in the alloy are silver in color.¹³
- A crown made of a gold alloy is more malleable, resulting in easier fabrication and placement, but softer and more subject to wear and traumatic damage.
- A tooth-colored crown can be made by fusing porcelain to a metal shell or by using porcelain alone. Porcelain by itself is extremely fragile, and its use is limited.²⁵
- Porcelain fused to metal can be used to create aesthetic restorations. The preparation for this method requires removal of more tooth structure than does a metal crown, thus further weakening the tooth.
- Newer ceramic materials (Inceram, Vident, Brea, Calif.; Cerinate, Den-Mat, Santa Maria, Calif.) are available for cosmetic crowns; however, they have yet to be shown to have the durability and longevity of porcelain and metal.²⁶

Technique

- (1) Evaluation for preparation, (2) tooth reduction and margin preparation, (3) taking an impression and casting, (4) manufacture of temporary crown (optional), (5) laboratory orders and manufacture of crown, and (6) cementation of crown.
- The many alternatives and methods that can be used must be selected case by case.

Step 1—Evaluation for Preparation

- The occlusal edge or surface is evaluated for reduction to allow space for the metal in the crown.
- Potential contact surfaces such as between lower canine teeth and upper canine teeth and third incisors, distal surface of the maxillary fourth premolars and mesial

surface of maxillary first molars, or the palatal aspect of the maxillary fourth premolars with the mandibular first molars should be evaluated so sufficient tooth is reduced to allow for the thickness of the crown material and a resultant atraumatic occlusion after the fabricated crown is installed.

- Anticipated wear determines space requirements and crown thickness.
- Allow a minimum of 1.5 mm of space for the areas of increased wear potential and 1 mm of space for the areas of little or no wear potential.^{24,27,28}
- The incisor, premolar, and molar teeth that have occlusal surfaces require additional space allowance on the occlusal surface.
- The canine and premolar teeth without an actual occlusal surface usually require little reduction for space allowance but do require reduction and beveling of any sharp or thin edges.

Step 2—Tooth Reduction and Margin Preparation

- A gingival retraction cord is placed with a cord packer. The purpose of the cord is to isolate the gingiva from the tooth surface. Avoid wrapping the gingival cord in the bur while preparing the tooth surface.
- A tapered coarse diamond bur is used for initial reduction (Table 8-7).
- Either a chamfer or a shoulder, depending on the preference of the laboratory and the clinician, is created at the gingival edge of the preparation. Bur shape selection will determine the type of margin created.
- The margin should be placed either 1 mm above or 1 mm below the free gingival margin to reduce the incidence of gingivitis.

Axial reduction

- The tooth structure is removed by axial reduction along the long axis of the tooth. The bur is held nearly parallel to the tooth axis.
- The tooth surface should be reduced in the attempt to create walls that are nearly parallel with a 6-degree slope.
- Undercuts should be avoided, and when looking at the preparation from the coronal surface, the absence of undercuts is ensured when the entire prepared surface can be visualized.
- If possible, reduction should be made in one pass, moving in a counterclockwise direction around the tooth. For metal crowns, reduc-

Table 8-7 • **DIAMOND BURS FOR CROWN THERAPY**

Type	Use
Tapered flat end	Creates flat shoulder
Long, thin round end	Creates chamfer
Long shank with flame tip	Modifies shoulder preparation
Curettage, 55-degree bevel	Creates shoulder with bevel
12-mm flame	Creates feather
Stip-tipped	Periodontal use for curettage

tion of 0.5 to 1.0 mm of tooth structure is necessary.

- A level margin all around the tooth should be maintained.
- A stair-step reduction of the canine tooth may be necessary to maintain parallel walls when the full length of the crown is present (Fig. 8-20, A).

Margins

Chamfer

Description

- A chamfer is a type of margin created by removing structure to leave a gradual transition to the uncut surface (Fig. 8-20, B). This may be accomplished first by gross reduction with a tapered, round-end coarse diamond bur, and then by creating a finish line with a tapered medium or fine diamond bur with a round end.

Advantage

- This type of margin allows for a slip joint and is a good design for gold restorations.

Disadvantages

- More difficult to design clearly.
- Not a good design for a porcelain or a porcelain-fused-to-metal (PFM) restoration because it does not give enough support to the edge of the porcelain.

Shoulder joint

Description

- A shoulder joint is a butt joint (Fig. 8-20, C). It is created at the same time as axial reduction, using a tapered-cylinder flat-end bur.
- This margin must be used for porcelain restoration to give adequate support to the edge of the restoration.

- A shoulder with an internal bevel is created at the same time as axial reduction, using a tapered-cylinder pointed bur (Fig. 8-20, D).

Advantages

- The biggest advantage of this margin is that a definite finish line is created.
- For the beginner, the shoulder is created more easily.
- The diameter of the bur is an easy means by which to measure the amount of reduction performed.

Disadvantage

- Difficult to seal definitively.

Shoulder with external bevel

Description

- The shoulder is trimmed with a flame-shaped or beveled-cylinder diamond bur (Fig. 8-20, E).

Advantage

- Creates a better margin.

Disadvantage

- A steady hand is necessary to avoid destruction of the shoulder.

Feather, full bevel, occult, or chisel margins

Description

- These finishes all taper to a fine point at varying levels. This can lead to more difficult crown preparation by the lab and distortion during handling.
- They are created by using a beveled-end bur or fine-pointed diamond bur.

Advantages

- Allow for some micromovement of the crown under stress.
- Easy margin to create.

Disadvantages

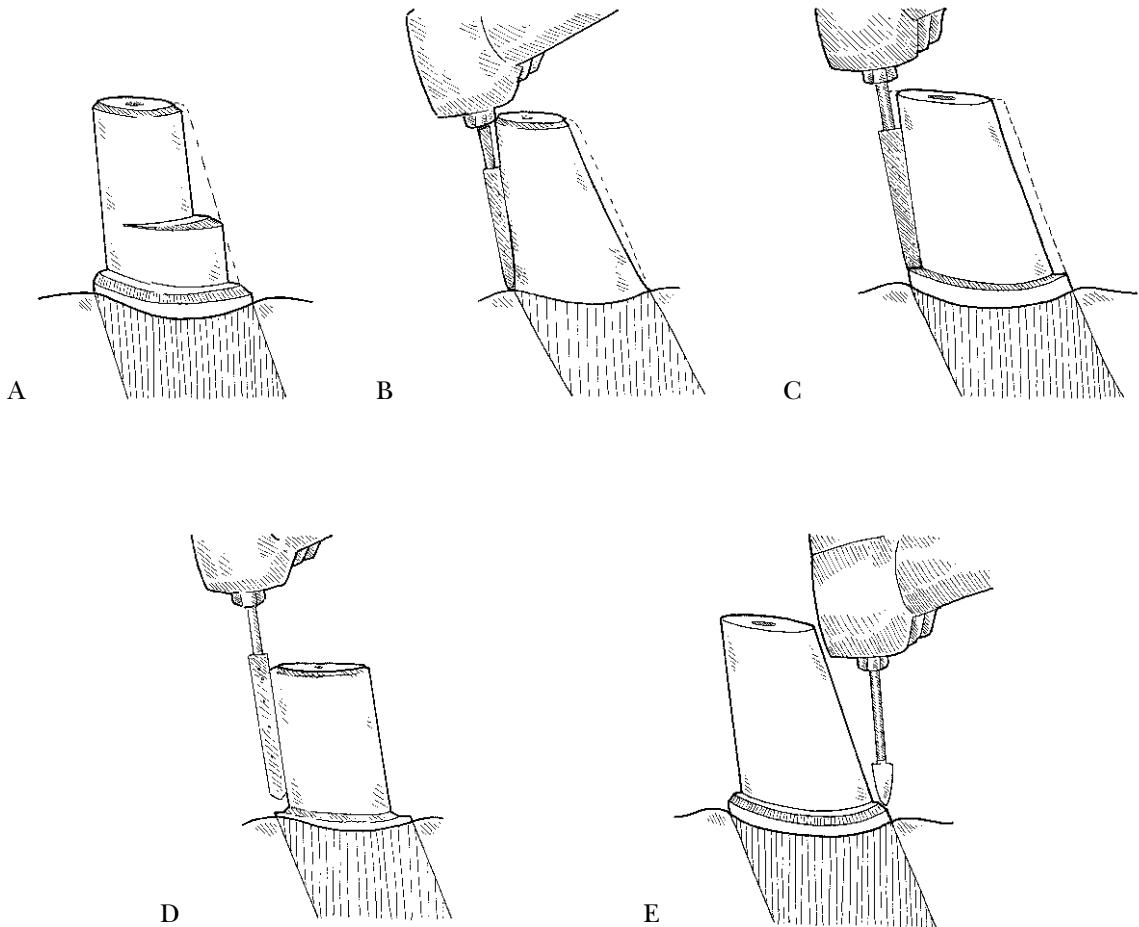
- Difficulty waxing up crown margins.
- May lead to insufficient tooth reduction and oversized crown, leading to tooth contact with adjacent teeth.

Additional comments

- A metal cast crown requires a circumferential, axial reduction of 1 mm.
- A crown of PFM requires a reduction of 1.5 to 2.0 mm to allow additional space for the porcelain.

Minimal preparation techniques

- There are times when reduction of the crown of less than 1 mm can take place.
 - This can occur when the teeth will not be hitting opposing teeth.
- Placing a crown without considering the occlusion may lead to patient discomfort and tooth wear. It makes no sense to save one tooth with crown therapy and cause damage to another tooth in so doing.

**Fig. 8-20**

Step 3—Taking an Impression and Casting

General comments

- Several types of materials are available for taking impressions for crowns. The alginate impressions, as used for making study models for orthodontics, do not show enough detail for crown fabrication. Full-mouth alginate impressions are taken to make casts that can be articulated to help in the laboratory creation of the crown to ensure proper design. A bite registration is included.
- Quadrant impression trays, small custom-made trays, or even large syringe caps can be used when taking an impression with a rubber-base material of a tooth that has had a crown preparation. The impression should include the tooth on either side of the prepared tooth.

Rubber base

Description

- These materials are rubber-like in nature and contain large molecules with weak interaction among them. These molecules are joined together at certain points to form a three-dimensional network.⁴
- The three kinds of commonly used rubber-based materials for taking impressions are polysulfide rubber, Siloxane polymers, and vinyl polysiloxane polymers.

Polysulfide rubber

Description

- An impression material supplied as a two-part system, containing a base and a catalyst.

Use

- Impressions for crown, bridge, implant crown.

Advantage

- Good working time (although may be too long for many).

Disadvantages

- Requires thorough mixing.
- Lack of a “snap set”; curing progresses slowly.
- Impressions should be poured after 15 minutes and before 72 hours.
- Messy; unpleasant odor.

Siloxane polymers

Use

- Crowns and bridges.

Advantage

- Accurate representation of the prepared tooth.

Disadvantage

- Poor ability of dental stone to “wet and flow” into the impression.

Vinyl polysiloxane polymers

Description

- These are silicone addition-type impression materials.
- These impression materials are usually available in different consistencies: light, medium, and heavy body.

Use

- Impressions for crown and bridge.

Advantages

- Accurate reproduction of detail.
- Dimensional stability; prevents longer delay before pouring stone casts.
- Excellent elasticity; enables recovery from undercuts.
- Good tear strength reduces likelihood of impression damage.
- Come in premeasured cartridges with mixing gun and tip.

Disadvantage

- Decreased “wetability”; stone does not flow as readily into the impression.

Materials

- Orthodontic trays for full-mouth impressions.
- Small tray for specific tooth impression. (A 12- or 20-cc syringe cap is often adequate for most crown prep impressions.)
- Impression material of choice.
- Large paper mixing pads.
- Mixing bowl for alginate.
- Large spatulas.
- Bite registration material or wax.

Technique

- The crown is prepared as previously described.
- The retraction cord is pulled from the gingival sulcus just before taking the impression.
- With any material used for the specific crown impression, full-mouth alginate impressions and stone casts are made, as well as a bite registration taken.

Step 1—Tray adhesive is painted into the impression tray to be used for the crown

prep impression. Equal parts of the material, supplied in tubes, are placed on a paper pad.

Step 2—The material is mixed thoroughly.

- Note: alternatively, but more expensively, convenient premeasured materials may be purchased in tandem cartridges. The contents are joined by a mixing tip, which leads to an intraoral tip. The cartridges are placed in a dispensing gun, which delivers the material through the mixing tip and the intraoral tip to the crown site.

Step 3—If not using the cartridges, the material is placed in an impression tray.

Step 4—The filled tray is placed over the prepared tooth.

Step 5—Once set, the impression material is removed with a snapping movement from the mouth and the cast is poured.

Variation in technique with vinyl polysiloxane polymers

Step 1—The light-bodied material is mixed and placed in a curved-tip syringe or, if supplied in premeasured cartridges, it is mounted into the dispensing gun.

Step 2—The light-bodied material is injected around the prepared tooth and into the subgingival area.

Step 3—Equal amounts of the medium-bodied material are placed on the mixing pad, are mixed, and are placed in the impression tray or, if supplied in premeasured cartridges, can be injected directly into the impression tray.

Step 4—The filled tray is placed over the light-bodied material covering the prepared tooth.

Step 5—Once the impression material is set, the tray and impression material are removed, and a cast is poured in standard fashion.

Advantage

- The light-bodied material will create an impression of even greater detail.

Complications

- Organic contaminants on the teeth, possibly causing roughness to the impression or bubbles and voids.
- Roughness caused by desiccation of teeth before the impression is taken.
- Inadequate working time caused by incorrect base-to-accelerator ratio, with excess catalyst or when ambient temperature and humidity are too high.
- Prolonged setting time caused by incorrect base-to-accelerator ratio, poor storage conditions, or use of outdated materials.

- Poor mixing techniques resulting in an uneven mix, causing uneven curing that may cause distortion, loss of detail, or roughness of the impression, as well as bubbles or voids.
- Distortion caused by poor adhesion of impression material to tray; may be avoided by using the tray adhesive that comes with many impression materials.
- Distortion, from partial polymerization, caused by excessive delay in seating the tray in the mouth.
- Distortion and loss of detail due to movement of the tray after it is seated in position.
- Excessive bulk of material possibly causing marked thermal contraction on cooling, thus causing distortion.
- Loss of detail or roughness caused by removing the tray before full setting of the impression material.
- Prolonged removal of the tray from the mouth possibly causing prolonged stress, with distortion and loss of detail of the impression.
- After impression taken, distortion avoided by placing tray down with impression material up.
- Care must be taken to make sure material is completely set before removal from the mouth.

Putty-wash technique with no preformed tray

Comments

- This technique may be useful in very large impressions for which custom trays are not available.
- The technique takes advantage of the variation between the consistency and viscosity of the vinyl polysiloxane materials and their ability to work together.
- Certain latex gloves may inhibit the set of the material, so a small amount should be tested with the gloves to be used.
- This technique, as with most impression techniques, must be performed on a patient intubated and under general anesthesia.

Advantages

- Impressions can be made of very large patients.
- Impressions do not require a tray.

Disadvantage

- May have some distortion due to lack of a tray.

Technique

Step 1—Following the manufacturer's instructions, the putty is mixed by gloved hands. The material is kneaded until a uniform, streak-free color is obtained.

Step 2—The impression material is spread out over one hand.

Step 3—The impression material is inserted in the mouth, over the teeth and gums, and held in place with hands until set up.

Step 4—When hard, the material is removed from the mouth.

Step 5—With an automix cartridge, the extra-light material is injected into the tooth impressions of the already set-up impression.

Step 6—The material is reintroduced into the mouth, seated, and allowed to set up.

Step 7—The model is poured as with previous techniques.

- For a crown preparation impression, one can also use a large syringe cap filled with putty that has an indentation made for the tooth. This is filled with the light-body material from the automix cartridge and the light material is also placed around the tooth and sulcus. The tray with the putty is placed over the tooth and held still until hardened.

Hydrocolloid-alginate**Description**

- A two-part process is performed: first, the impression material is warmed and injected around the tooth; second, as the injected material cools and solidifies, an alginate mixture is mixed, placed in a tray, and placed over the solidified material.

Use

- Impressions for crowns.

Advantage

- Superior reproduction of the crown preparation.

Disadvantage

- Requires a boiler pot to heat the hydrocolloid.

Equipment

- Boiler pot and thermometer.
- Impression trays.
- Cohere reversible hydrocolloid (Gingi-Pak, Camarillo, Calif.).
- Large-gauge injection needles.
- Rubber bowl.
- Large spatula.
- Type II alginate (irreversible hydrocolloid).

Technique

Step 1—The syringe containing the hydrocolloid material is placed in the boiling pot, and the water is brought to a boil for 5 minutes.

Step 2—The temperature in the pot is reduced to a constant 140° F to 150° F for a minimum of 10 minutes before use.

Step 3 (Optional)—The teeth may be sprayed lightly with a preimpression release agent.

Step 4—A large-gauge injection needle (which comes with the hydrocolloid) is placed on the syringe, and the material is injected around the prepared tooth.

Step 5—Type II alginate is mixed in a rubber bowl and placed in the impression tray.

Step 6—A standard alginate irreversible hydrocolloid impression is made (see Chapter 9, Orthodontics, pp. 508 to 511).

Step 7—Once set, the alginate with the hardened hydrocolloid around the tooth is removed from the mouth, and standard casts are poured.

Complication

- Care should be taken not to burn the oral cavity by using inadequately tempered hydrocolloid (too hot).

Bite registration**General comment**

- Bite registration allows the dental laboratory to place the models in proper articulation to avoid creating occlusal interference.

Indications

- Crown and bridge.
- Orthodontics.

Objective

- To obtain an accurate representation of the occlusion.

Materials

- Vinyl polysiloxane.
- Bite wax.

Technique

Step 1—The patient's vital signs are checked and anesthetic stability is confirmed.

Step 2—After all other impressions are made, the patient is extubated. The tongue may be rolled gently back over itself and placed in the pharynx. The patient should be observed to make sure that breathing is normal.

Step 3—The impression material of choice (a self-mixing injection-type vinyl polysiloxane sets rapidly and removes operator error in mixing) is placed over the canine and incisor teeth.

- If using a chemical-curing material, curing may be hastened by using a hair dryer.
- If using bite wax, the wax may be warmed with warm water or with the hair dryer and then placed between the incisors.

Step 4—The mouth is closed to a point of normal closed occlusion, with the registration material between the upper and lower teeth. The mouth is opened, and the bite registration material is removed carefully.

Step 5—The tongue is placed back in the normal position, and the patient is recovered from anesthesia or, if another procedure is to be performed, reintubated.

Complications

- Respiratory obstruction with the tongue.
- Inaccurate impression.
- Recovery from anesthesia before impression material sets.
- Time for material to set may be decreased by the bite registration material being warmed.

Considerations for making casts for crowns and bridges**Material complications**

- Poor cleaning of the impression before pouring the cast may cause an inferior, rough, or chalky cast.
- Excess water in the impression may cause a distorted cast.
- Premature removal of the cast from the impression may cause the cast to break.
- Poor mixing or casting technique may cause bubbles or an inferior cast.
- Contamination of the impression surface or dental stone powder may cause a rough cast.
- Incorrect water-to-powder ratio for the dental stone may cause distortion of the cast. A hard laboratory stone material is preferred to plaster of Paris.
- The stone model may be toughened to reduce tooth breakage while in laboratory transit by applying Stone Die and Plaster Hardener (George Taub Products & Fusion, Jersey City, NJ) after the model is dry.

Step 4—Fabrication of Temporary Crown (Optional)**General comments**

- The prepared tooth may be protected until the final cast restoration is returned from the laboratory and placed.
- In veterinary patients, this step can make the difference between a successful restoration and a failure, because patients and clients respond variably to instructions about protecting the prepared tooth.
- A temporary restoration must be strong enough to remain in place for the time needed.
- The client should be able to clean around the temporary restoration to prevent soft tissue inflammation or deterioration of the periodontal health, which could interfere with placement of the final restoration.

Direct acrylic technique

Step 1—An alginate impression of the prepared tooth and of the surrounding area is taken (Fig. 8-21, *A*).

Step 2—After unseating the impression, a round-ball carbide bur is used to carve some of the alginate away from the impression of the prepared tooth (Fig. 8-21, *B*).

Step 3—The alginate is filled with a thin mix of acrylic (Fig. 8-21, *C*).

Step 4—The tooth and surrounding gingiva are lubricated with petroleum jelly (Fig. 8-21, *D*), and the alginate with the acrylic is seated in the mouth (Fig. 8-21, *E*).

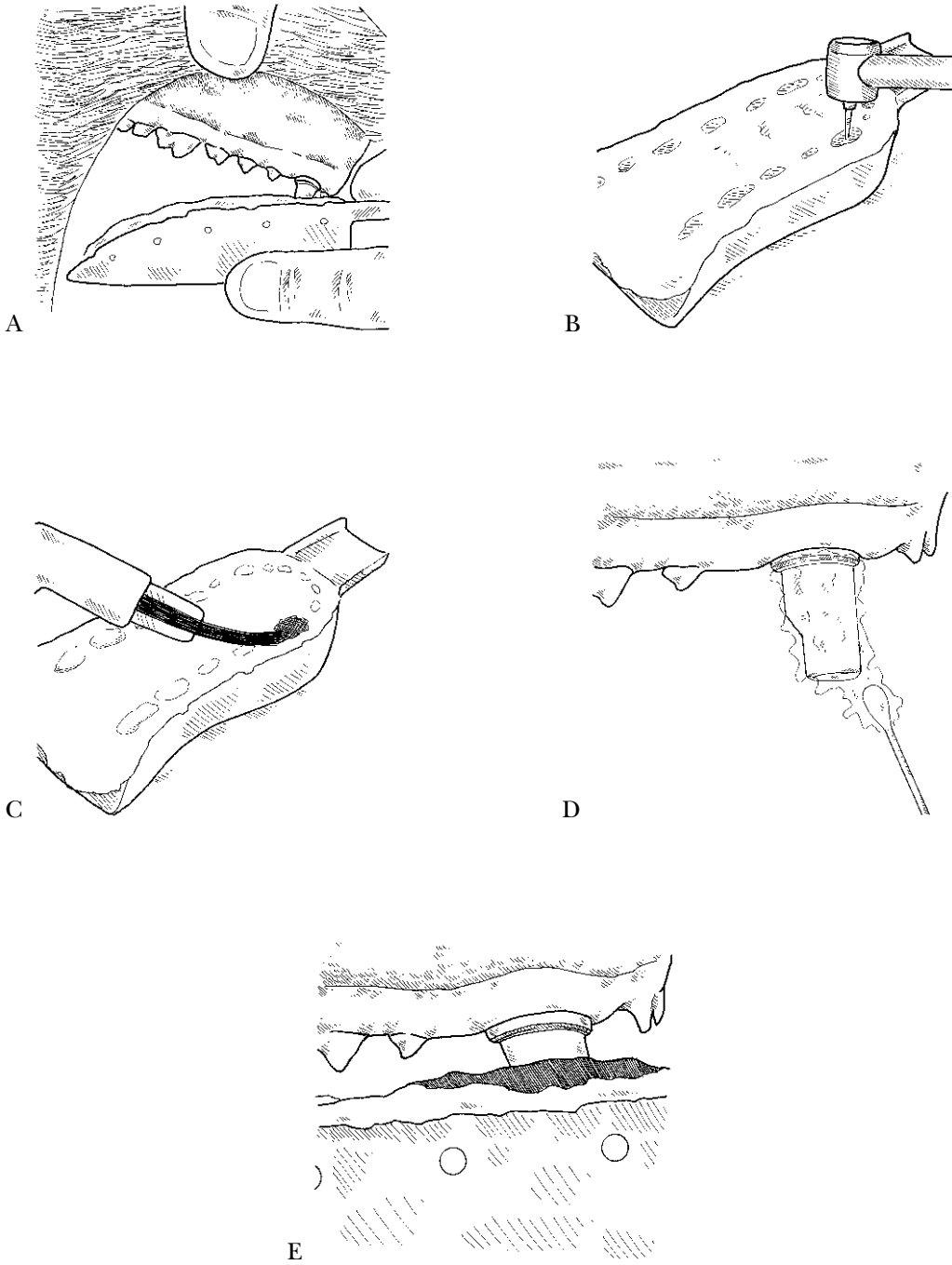


Fig. 8-21

Step 5—When the acrylic has hardened, the alginate is removed, and the acrylic casting is removed from the alginate (Fig. 8-22, A).

Step 6—The casting is trimmed and shaped with acrylic burs in a slow-speed handpiece (Fig. 8-22, B).

Step 7—The acrylic casting is trial fitted and trimmed again or shaped as needed.

- Because the primary function of the temporary restoration is to protect the prepared tooth, it is usually better to make it smaller so the patient will not place as much pressure or force on it.

Step 8—Once it fits properly, the restoration can be smoothed with sanding discs and polished with wet pumice on a wheel.

Step 9—A zinc oxide–eugenol temporary cement is applied to cement it in place (Fig. 8-22, C). The restoration is cemented in place (Fig. 8-22, D).

- A temporary crown can also be made directly on the tooth by first smoothing the surface with pumice, rinsing, and drying the pre-

pared tooth. The surface is acid-etched for 15 seconds, rinsed, and air dried. A self-cure temporary crown material with automix cartridge and injection tips (ProTemp Garant, 3M ESPE; Maxi-temp, Henry Schein, Melville, NY) is placed on the tooth surface in a thin layer and allowed to harden. It can be smoothed with finishing burs.

Advantage

- The temporary crown can protect the crown preparation while waiting for the crown cementation.

Disadvantages

- Takes additional time.
- May be dislodged and lose the advantage of tooth protection.

Complications

- Loss of temporary crown.
- False sense of security by client allowing patient to participate in undesirable oral activity.

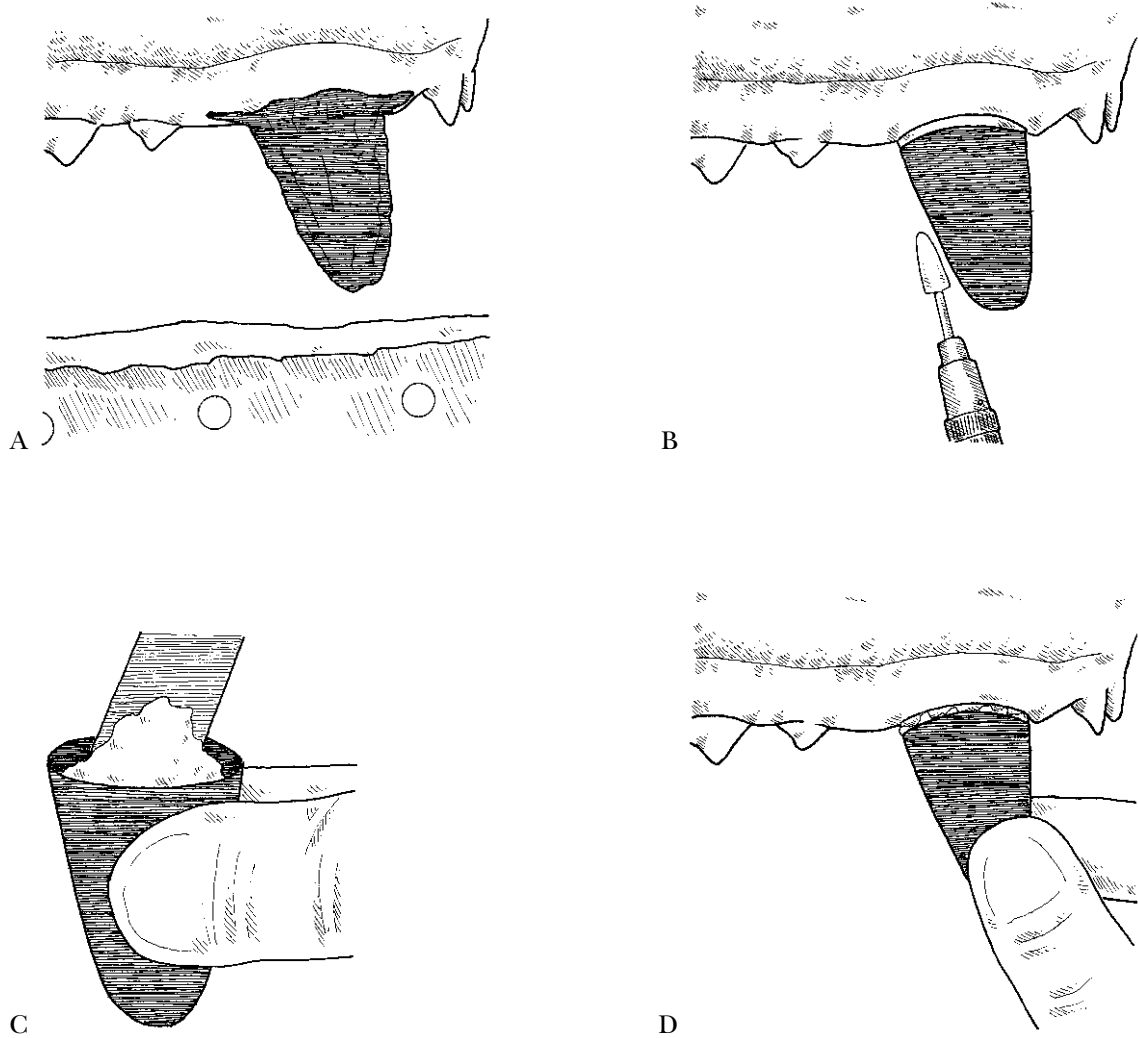


Fig. 8-22

Step 5—Laboratory Order and Manufacture of Crown

- A written laboratory prescription is sent with the model castings and bite impression registrations.
- The prescription should include type of material to be used for the crown and color with a shade guide.
- Sandblast etching of the inside of the crown or other preparation, depending upon cementation material requirements, should be requested.
- The model and new crown are returned from the dental laboratory (Fig. 8-23, *A*).

Step 6—Trial Placement of the Crown

Substep 1—The temporary crown and temporary filling material are removed carefully so the shape of the preparation is not altered (Fig. 8-23, *B*). The surface is cleaned with a curette (Fig. 8-23, *C*).

Substep 2—The crown or dowel core are checked for proper fit by trial seating on or in the tooth (Fig. 8-23, *D*).

Substep 3—If there is any binding, the casting is removed, brushed with polishing rouge dissolved in chloroform, and reseated. Alternatively, occlusal chalk may be sprayed into the crown and the crown fit over the tooth (Fig. 8-23, *E*).

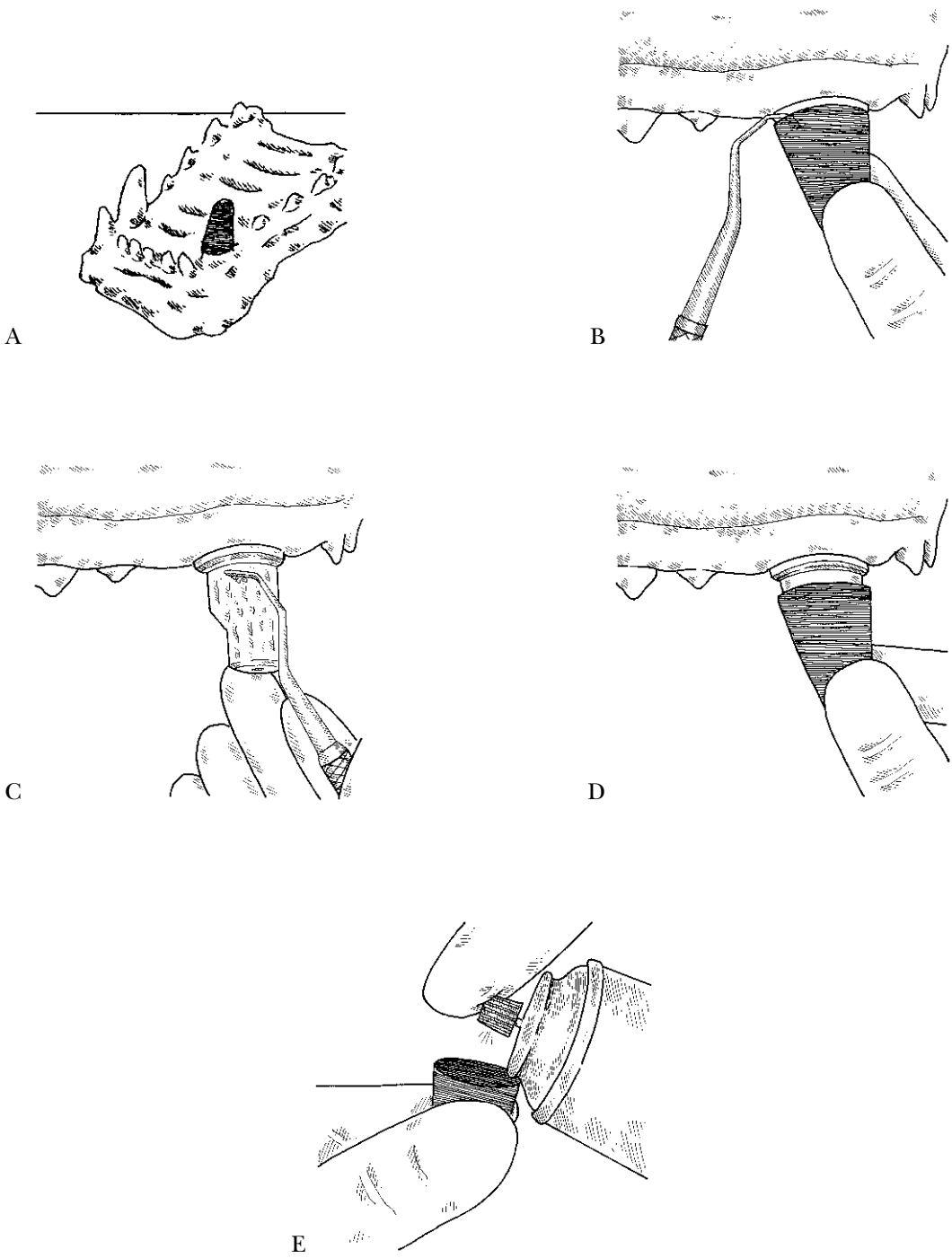


Fig. 8-23

Substep 4—The casting is removed, and the teeth are examined for residue. Residue (*arrow*) indicates the areas that are binding (Fig. 8-24, *A*).

Substep 5—Carefully remove some interior crown material or exterior tooth structure from these spots with a bur and retest (Fig. 8-24, *B*).

- This process is repeated until the casting seats properly and all the rouge is removed.
- The fit should be snug, and the margins should be smooth.
- Margins are examined with an explorer by pointing the tip toward the gingiva and sliding it down the crown onto the root.
- If the explorer slides over the interface smoothly, the crown fits properly.
- This procedure is repeated in several places around the tooth.
- Clean the inside of the crown with a prophylaxis brush with flour pumice (Fig. 8-24, *C*).
- Clean the tooth with a prophylaxis brush (Fig. 8-24, *D*).

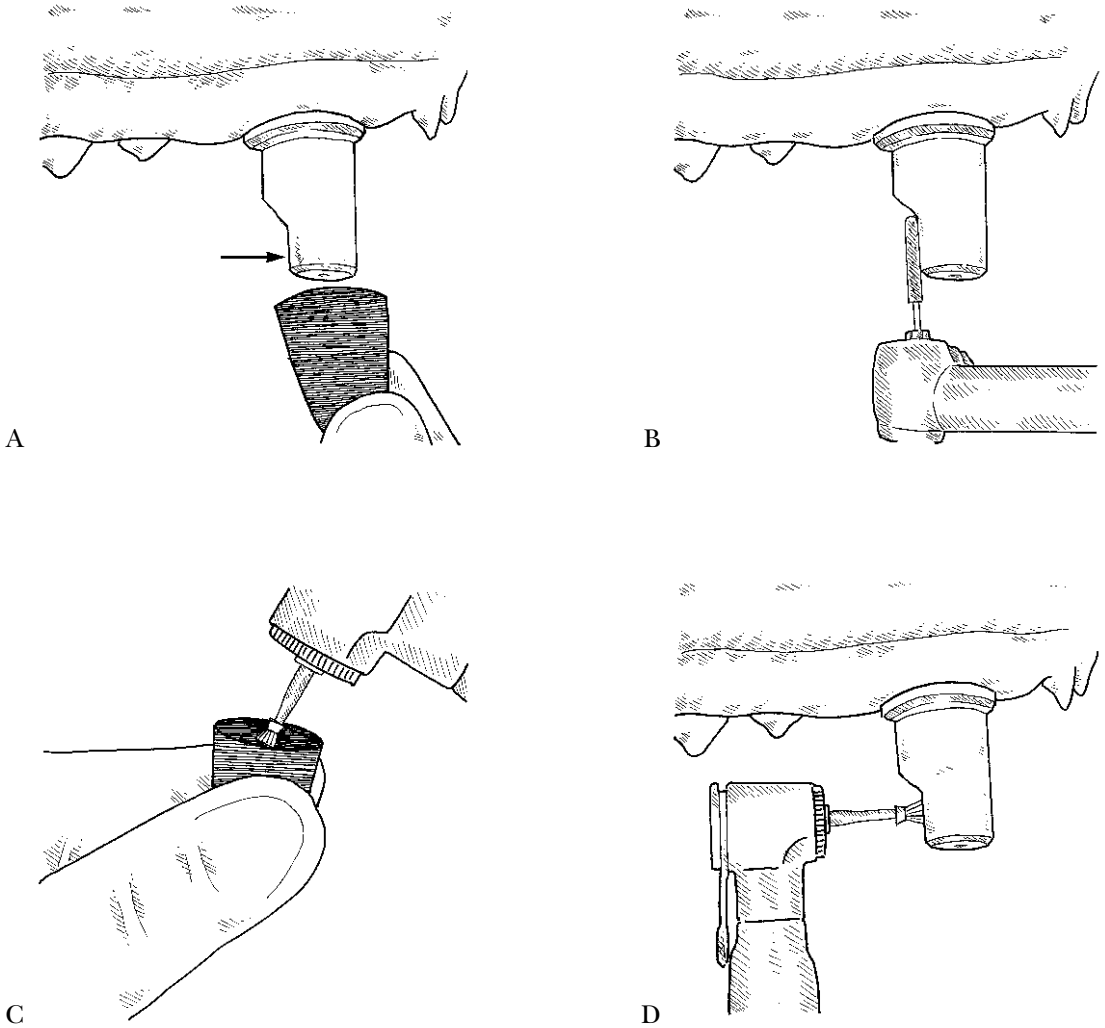


Fig. 8-24

Step 7—Cementation of Crown

Technique

Substep 1—The prepared tooth crown is rinsed well with water (Fig. 8-25, *A*).

Substep 2—The prepared tooth crown is dried according to the type of cement used (Fig. 8-25, *B*). Some cements require the surface to be bone dry, whereas others (glass ionomers) require a slight amount of moisture (see the following section). Any etching and bonding agent is placed if required by the choice of cement.

Substep 3—The manufacturer's directions are followed in mixing the cement (Fig. 8-25, *C*).

Substep 4—The cement is placed in the crown with a spatula (Fig. 8-25, *D*).

Substep 5—The crown is seated and held in place firmly until the cement hardens (Fig. 8-25, *E*).

Substep 6—Excess cement is trimmed from the crown (Fig. 8-25, *F*).

Cementation materials for crowns

- Most dental cements have a similar background, and their basic chemistry is derived from a powder, either zinc oxide or aluminum silicate, and a liquid, either phosphoric acid or polyacrylic acid.²⁹
- Cements are also made from composite resins.

Zinc phosphate

Description

- A mixture of zinc oxide and phosphoric acid.
- This cement has been used for a long time in human dentistry.

Use

- Luting cement for seating permanent prosthesis, crown, or bridge.

Advantage

- One of its primary advantages, excellent thermal insulation, may not be applicable in veterinary medicine, because most veterinary patients are not fed food that has a wide range of temperatures.

Disadvantage

- Very poor adhesive properties limit its use to temporary crowns or techniques that use mechanical retention.

Zinc oxide–eugenol

Description

- A mixture of zinc oxide and eugenol.

Uses

- As a temporary luting agent for crowns and bridges or as a temporary filling material.
- As a root canal sealant.

Advantage

- Soothing effect on the pulp.

Disadvantage

- Poor retentive and other physical properties limit its use in veterinary dentistry.

Zinc polycarboxylate

Description

- The liquid is an aqueous solution of polyacrylic acid and copolymers; the powder is zinc oxide with some magnesium or stannous oxide.
- Stannous fluoride may be added to increase the strength of the cement.

Use

- Luting crowns (very clean metal casting required for adhesion of cement to crown).

Advantage

- Adhesion to tooth structure.

Disadvantage

- Short working times.

Glass ionomer

Description

- The glass ionomer cements have been modified to provide radiopacity and handling properties suitable for lining or cementing purposes.

Advantages

- Cariostatic activity.
- Bonds to dentin.
- High strength.

Disadvantages

- Dental hypersensitivity reported in humans; may be avoided by using proper technique.
- In vital teeth, pulp sensitivity and possible necrosis caused by chemical irritation from the material and leakage may be a problem.³⁰
- Glass ionomers initially have a low pH.

Complications

- The tooth should not be overdried, but rather dried with a gentle stream of air or simply blotted dry with a gauze pad or cotton pellet.

- Observe mixing ratios recommended by the manufacturer; otherwise, excessive free acid will remain in the tooth structure and cause sensitivity.
- Avoid excessive hydraulic pressure by creating channels in the crown for excess cement to flow out or by seating the crown with a slow, steady pressure when cementing it in place.
- Prevent contamination with saliva or water during the early setting stages by using varnish, cocoa butter, or light-cure bonding agent on the marginal surface.
- If recommended with the particular luting agent, use a dentin conditioner before placement.

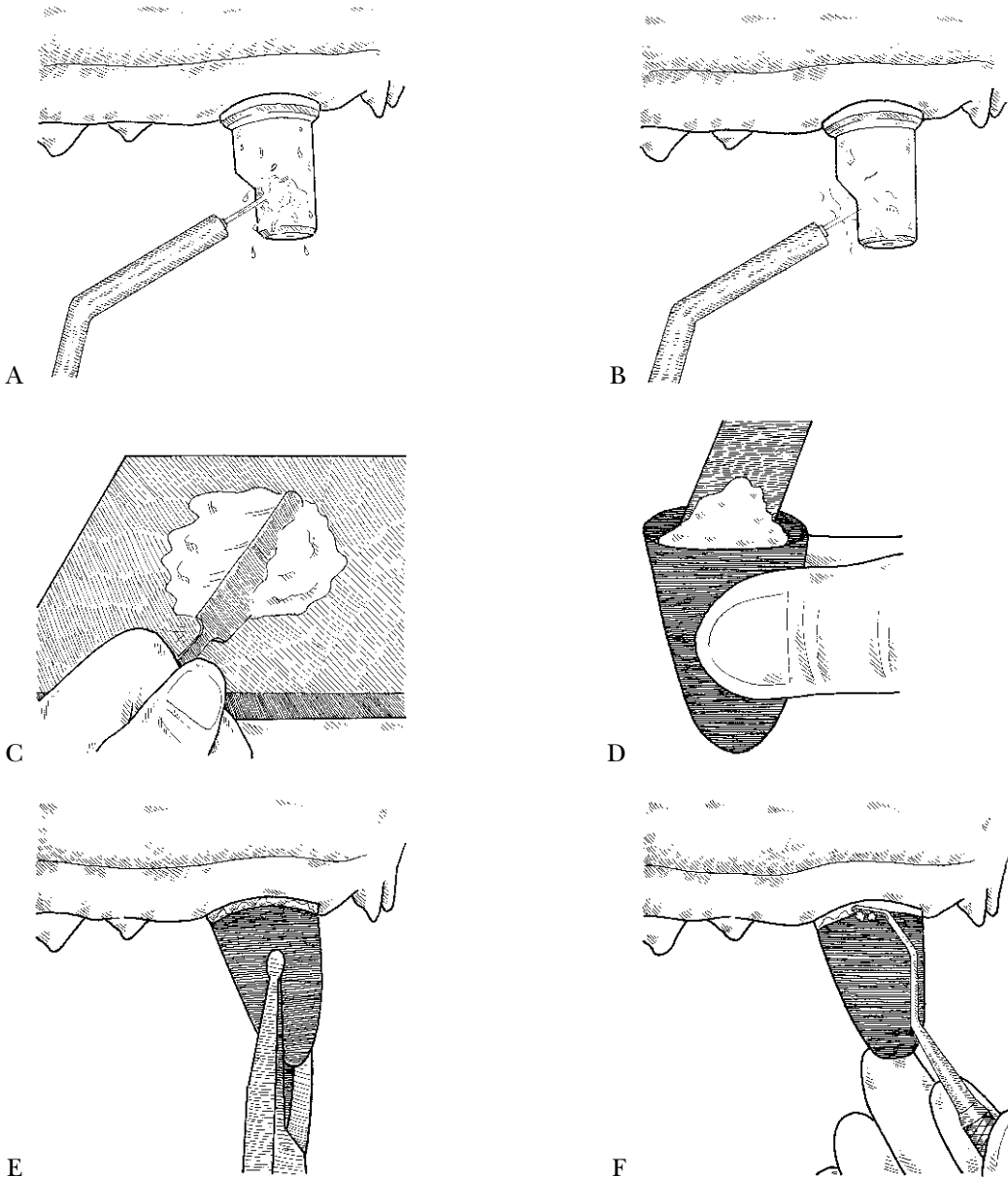


Fig. 8-25

Composite resin cements

Description

- Some of the newer composite resin cements (Panavia-21 and Panavia F, Kuraray America; CB Metabond, Parkell, Farmingdale, NY) bond chemically to metals, porcelain, tooth enamel, and dentin.
- Panavia 21 sets in an oxygen-free environment, allows one-step direct bonding to dentin and cut enamel without acid-etching.
- Panavia F is a dual-cure, fluoride-releasing, antibacterial, self-adhering, and self-etching resin cement used for cementing porcelain, metal, and composite crowns, bridges, inlays and onlays, and amalgam bonding, as well as endodontic, prefabricated posts, cast posts, and cores.
- Sand blasting, tin plating, or electrolytic etching of the inside surface of the crown will create a retentive surface.

Advantage

- Virtually insoluble in water.
- High tensile and good compressive strength.
- Have been used successfully on crown cementation of working dogs.³¹

Disadvantages

- Irritating to pulp; therefore, pulp must be protected by calcium hydroxide if used on a vital tooth.
- Poor manipulative characteristics; limited working times.

Complications

- Avoid acids, alcohol solutions, or pure alcohol when placing the crown on a vital tooth.
- When the cement is dry, do not remove any residual cement with sonic or ultrasonic scalers, because doing so may destroy the molecular structure of the cement, weakening the bond and causing loss of the crown.
- Use spatula, hand scaler, or curette to remove excess cement.
- If the tooth is damaged to a degree that little structure remains, the surface area is increased with additional cuts of box shapes or grooves, or a combination of the two, in the wall of the tooth.
- Teeth with shortened coronal height may be built up using a dowel-core technique or post-retained buildup, or the crown can be lengthened surgically.
- Although preservation of tooth structure is important, enough space must be created to

allow for the thickness of the metal. If the metal is too thin, the restoration will flex or bend under occlusal forces, and the restoration will deteriorate or fail. Bulk can be added at margins where rigidity and reinforcement are needed.

Special Situations

Crown-Dowel-Core Buildup

General Comment

- The minimum distance for dowel length is equal to the crown length.

Indication

- If the crown to be prepared has little remaining retentive surface area, a dowel-core buildup is necessary.

Contraindications

- Vertical root fractures.
- Teeth with inflammatory resorption.
- Teeth subject to excessive forces.

Objective

- To build up a crown to enable stable restoration of the tooth with support beneath the fabricated crown.

Materials

- Crown preparation instruments and materials.
- Peeso reamers.

Technique

- Before axial preparation, the root canal chamber is prepared.
- Step 1—The endodontic filling in the coronal portion of the canal is removed (Fig. 8-26, A). Ideally, two thirds to three fourths of the length of the canal is used for the post or core (Fig. 8-26, B).
- The natural curve of the canine tooth usually precludes access to the desired depth of two thirds to three fourths of the length of the root.
 - The preparation is extended to the greatest length possible in a straight line.
 - If the dentinal wall at the curve is thick, reduction of this area can lengthen the preparation.

- Care is exercised to avoid penetration through the root wall.
- Initially, Peeso reamers are used to remove the gutta-percha and to enlarge the canal.
- Peeso reamers have a flexible shank and easily follow the gutta-percha.
- The graduated sizes of Peeso reamers offer gradual canal enlargement.
- In mature teeth, the walls are shaped parallel to aid in retention.
- If increased length is required, or the canal is larger than the Peeso reamers, a tapered fissure bur is used.
- Undercuts are carefully avoided.

Step 2—A contra bevel is placed around the periphery of the occlusal portion of the tooth (Fig. 8-26, *C*).

Step 3—Axial reduction, as with crown preparation previously described.

Step 4—The post is trial fitted (Fig. 8-26, *D*); there should be no wobble. In long canals, a K-wire or other stainless steel pin should be used and bent to conform to the length of the canal. In this situation, the pin will conform to the natural canal, rather than a track drilled by the Peeso reamer. If using a K-wire or stainless steel pin, it should be notched and grooved with a bur for venting and retention.

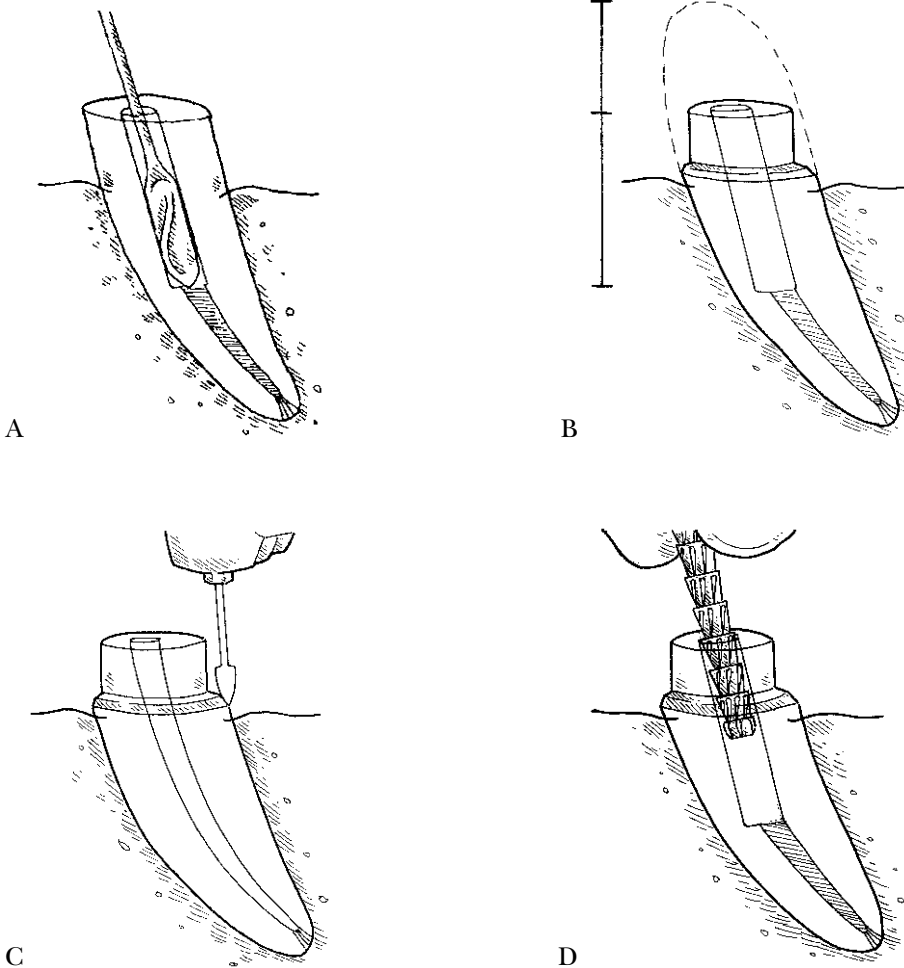


Fig. 8-26

Step 5—The cement is mixed and placed on the post (Fig. 8-27, A).

Step 6—The post is placed in the canal and held until the cement sets (Fig. 8-27, B).

Step 7—Core material is mixed according to the manufacturer's instructions and is placed over the post and tooth (Fig. 8-27, C).

Step 8—Once the core material has set, a standard crown preparation is performed (Fig. 8-27, D).

- The axial preparation of these teeth is much the same except fewer, if any, "stair steps" are needed.
- The margin is formed around the tooth, and the axial reduction is performed.

Complications

- Perforation while preparing the root canal for dowel; the treatment is to seal the perforation with calcium hydroxide paste.³²
- Perforation of the root canal; happens mostly on the mesial side of the tooth curvature.

Crown: Cast Dowel Core

- A dowel core is a custom-cast post and coronal buildup.
- One of the strongest methods of crown replacement is the use of a dowel-core casting.
- Ideally, the dowel should be two thirds to three fourths the length of the root and should leave no less than 3 mm of the endodontic filling material at the apex of the tooth.
- The path of insertion becomes important when placing the crown.
- The path of insertion is the line that coincides with the long axis of the preparation. Note: this is not necessarily equal to the long axis of the tooth.
- The crown will be placed on the prepared tooth along this line, and no other oral structures can restrict the placement of the crown along this line.
- The path of insertion must always be determined before starting the preparation.
- Any retentive grooves or boxes must be oriented in the same direction as the path of insertion.
- The path of insertion of the dowel core and that of the crown do not necessarily need to be the same. The canal is prepared with a Peeso reamer as previously described.

Step 1—The prepared canal is lubricated with a small Peeso reamer and cotton ball covered with petroleum jelly.

Step 2—A plastic sprue, notched or roughened to prevent it from pulling out of the final acrylic pattern, is trimmed to fit into the canal to the apical limit of the dowel preparation.

Step 3—Acrylic is mixed in a dappen dish to a thin consistency.

Step 4—The acrylic is placed in the prepared canal without any voids.

Step 5—A plastic sprue is seated in the canal, and the acrylic is added as needed to encompass the bevel on the occlusal margin of the preparation.

Step 6—As the acrylic reaches a pliable polymerization stage, the pattern is moved in and out of the canal to prevent it from locking.

Step 7—After the acrylic is polymerized, the pattern is removed, and the dowel is inspected for voids and adequate extension into the canal.

Step 8—If needed, another mix of the acrylic can be used to finish the dowel.

Step 9—When the acrylic has polymerized, it is seated, and more acrylic is placed on the tooth around the sprue.

- This acrylic becomes the foundation for the buildup.

Step 10—The pattern is seated in the tooth and shaped to fit the pulp chamber or root canal.

Step 11—The final reduction should closely replicate the desired final form of the dowel.

- An alternative method of obtaining an accurate representation of the canal is to coat the canal with K-Y jelly by coating an absorbent point with it and inserting it into the canal. Then, coat the plastic sprue with polyvinyl Siloxane impression material and insert it into the canal, removing it after it sets. The procedure can then be resumed at step 9.

- The prosthodontic laboratory will use this pattern to cast the post or dowel.

Step 12—The post dowel and core are seated in the tooth, and the gingival retraction cord is placed in the gingival sulcus.

Step 13—An impression is taken.

- When the impression material has set, it is removed and examined.
- The margin of the preparation must be reproduced accurately and free of flaws.
- The pattern (dowel and core) and impression are sent to a prosthodontic laboratory for preparation of the final castings.

Step 14—Temporary cavity filling material is placed in the coronal orifice of the endodontic canal to protect it until the castings are returned from the laboratory.

Step 15—After the custom dowel and crown are returned from the laboratory, the castings are inspected for fit as with the crown technique.

Step 16—The cement is mixed and placed in the canal and on the dowel.

Step 17—The dowel casting is seated slowly, allowing excess cement to escape, and is held firmly in place until the cement has hardened.

Step 18—Excess cement is removed from the margin.

Step 19—The cast crown is trial seated.

Step 20—The same process of checking fit, precision fitting, and cementing is repeated with the crown casting.

- A variation of the custom cast dowel and core to create greater stability and retention of a crown is to have the crown with post as one unit. The canal is prepared as previously described with Peeso reamers. A plastic sprue is placed in the canal and a light-bodied polyvinyl Siloxane material is used to obtain the impression of the canal and crown prep. A stone cast is made from the impression, and the lab manufactures a one-unit crown with post. This is trial fitted and cemented as previously described.

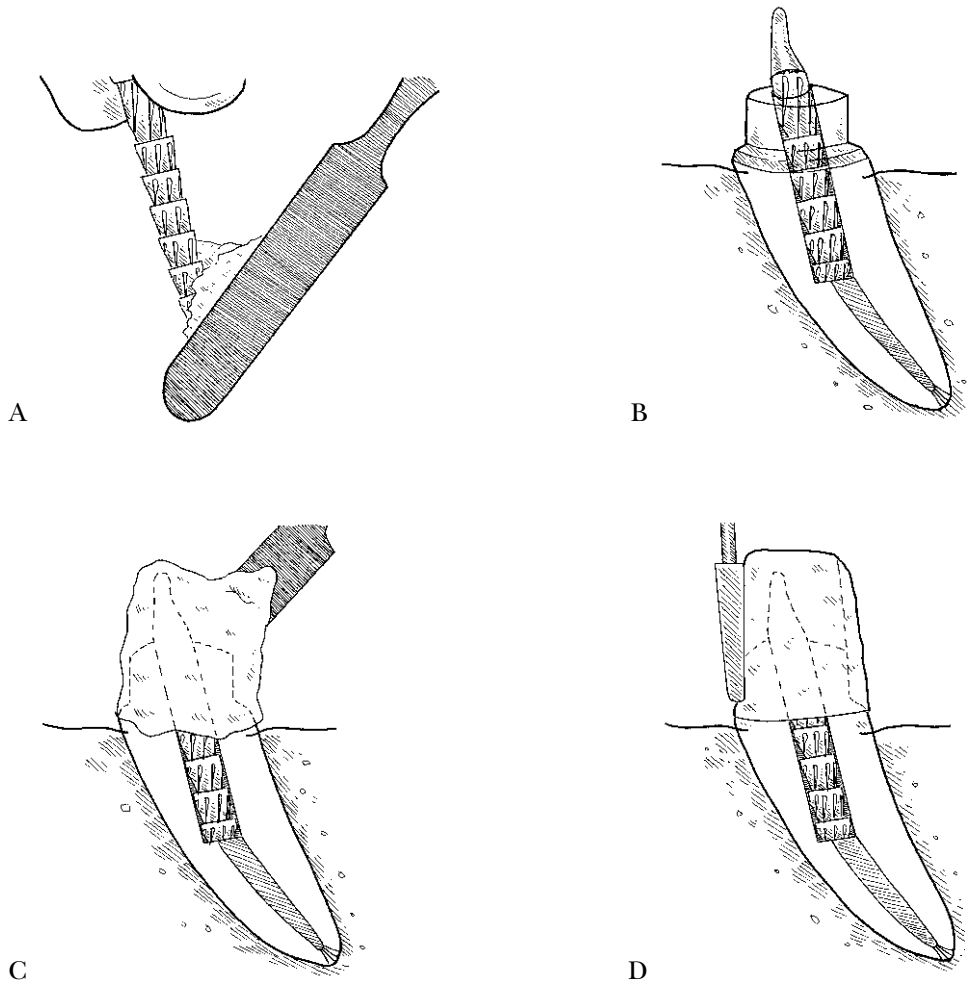


Fig. 8-27

Advantages

- Greater retention than with just the crown surface area when the remaining tooth crown is short or shaped to reduce retention.
- Is more time efficient than the custom dowel and core technique.

Disadvantages

- With the post as part of the crown unit, excessive force on the tooth may cause fracture of the root below the crown.

Surgical Crown Lengthening³³

General Comments

- When teeth are fractured at or near the level of alveolar bone, insufficient crown length may prevent enough retentive surface from being available.
- By decreasing the root length and increasing the crown length, retention may be obtained.
- Type I (gingivectomy) and type II (apically repositioned flap and osteoplasty) are the most common types of crown-lengthening procedures.
- Maintenance of the biologic width, consisting of the gingival sulcus, junctional epithelium, and connective tissue attachment (approximately 1 mm each), is important in these procedures to avoid inflammation, crestal bone resorption, and gingival recession.
- A 2- to 3-week delay between type II crown lengthening and crown preparation is recommended to allow evaluation of the gingival margin after healing.

Indications

- Tooth fractured at, near, or below gingival crest.
- Tooth fractured below alveolar crest.
- Inadequate retentive coronal surface.
- Gingival tissue overlying coronal surface.

Contraindications

- Patient will place excessive force on the teeth.
- General health of patient does not allow multiple anesthetic procedures.

Objective

- To expose more tooth surface for crown retention, 6- to 7-mm crown height desired.

Materials

- Materials previously described for crown preparation.
- Oral surgical pack.
- Diamond burs for bone removal.

Technique Type I

- See Gingivectomy, Chapter 5.

Technique Type II

Step 1—The tooth and surrounding tissues are examined for pockets, the depth of keratinized gingiva is measured, and the tooth and surrounding area are “sounded” with an explorer to determine the level of bone and extent of fracture (Fig. 8-28, *A*).

Step 2—An inverse-bevel or sulcular scalloped incision with mesial and distal releasing incisions is performed as necessary (Fig. 8-28, *B*) as described in Chapter 5, Periodontal Therapy, pp. 254 to 255. The gingival collar, if present, is removed.

Step 3—Using both high-speed handpiece with a diamond bur and hand instrumentation, alveolar bone is removed carefully from around the tooth to expose the apical level of the tooth necessary to create the desired retention height (Fig. 8-28, *C*).

Step 4—The bone is smoothed and reshaped so that it tapers into the root surface.

Step 5—The elevated flap is repositioned apically and sutured in place with absorbable suture (Fig. 8-28, *D*). One or more tacking sutures can be placed to ensure apical repositioning of the flap.

Step 6—The crown margins are prepared, built up if necessary, and finished in routine fashion with impressions and bite registration. (This step can be delayed for 2 to 3 weeks to allow healing prior to crown preparation.)

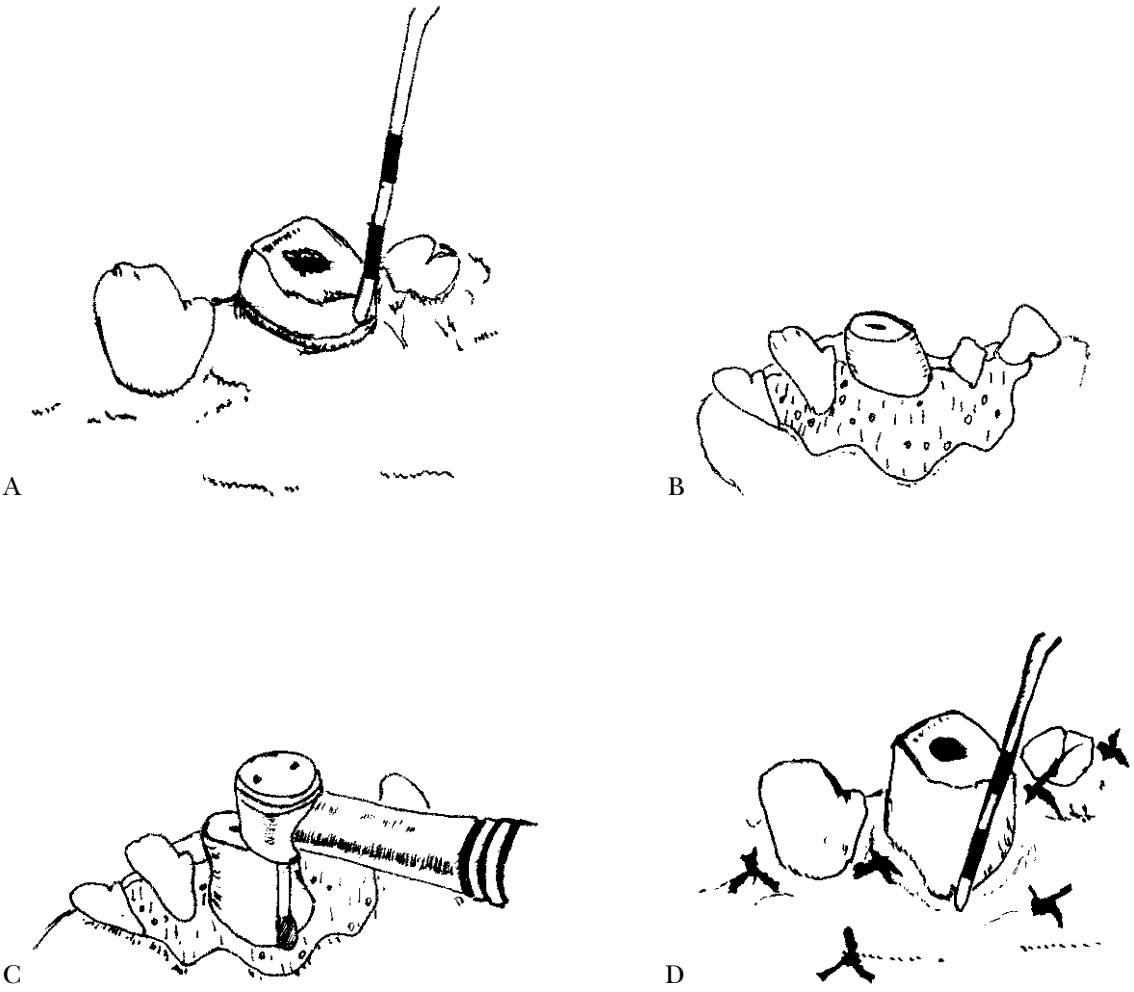


Fig. 8-28

Special Teeth

Canine Teeth

- With intact canine teeth there is adequate surface area for retention, and minimal preparations can be made to remove just enough tooth tissue to eliminate undercuts and prepare a finish margin supragingivally.

Step 1—Axial reduction is started on the mesial surface. The surface is reduced to the desired amount, and a straight surface is created.

Step 2—The labial and lingual surfaces are reduced until the prepared surfaces approach the 6-degree taper.

Step 3—The distal surface can be prepared minimally so as to create a margin and, at the same time, eliminate any undercuts present, thus providing maximal support for the restoration (Fig. 8-29).

Step 4—The final margin is finished by creating a bevel at the edge of the shoulder.

- This is best done with a flame-shaped diamond bur, using the beveled end of the bur as a gauge for cutting the tooth.
- The bur is held parallel to the tooth, and the beveled end is moved around the shoulder.
- The final bevel on the tooth is approximately the same size as the beveled end of the bur.

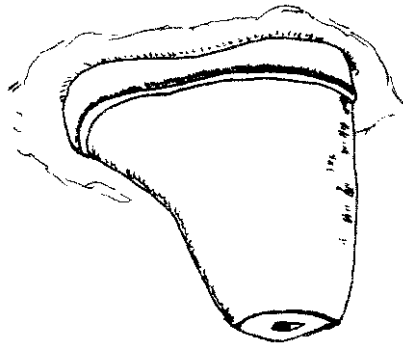


Fig. 8-29

Molars and Premolars

- The technique used for molars and premolars is similar to that used for canines and incisors.

Step 1—A tapered diamond bur is used for occlusal and axial preparation of premolars and molars.

- Occlusal reduction is performed only in areas that are actually in occlusion.
- Those surfaces or areas in occlusion with the opposing tooth need to be reduced sufficiently to allow 1.0 to 1.5 mm of clearance between the restoration and the opposing tooth.
- Sharp edges of cusps are reduced and beveled to facilitate the casting process in the laboratory.
- Axial reduction is created with a diamond bur and is initiated by creating a margin of choice

at the gingival edge. A supragingival margin is preferred (Fig. 8-30, *A*). It may be necessary to place the buccal or lingual margin subgingivally when the loss of tooth structure involves the subgingival area. The remaining surface margins can be placed supragingivally.

Step 2—When the axial reduction is adequate, the edge of the shoulder is beveled with a flame-shaped diamond bur if a shoulder with external bevel margin is desired. When adequate tooth structure is available, the tooth is ready for impressions at this point for manufacture of the final crown (Fig. 8-30, *B* and *C*).

- Retention is achieved with creation of parallelism and reduction for space requirements of the crown.
- An adequate approximation of parallelism is easily achieved on the lingual–buccal axis.

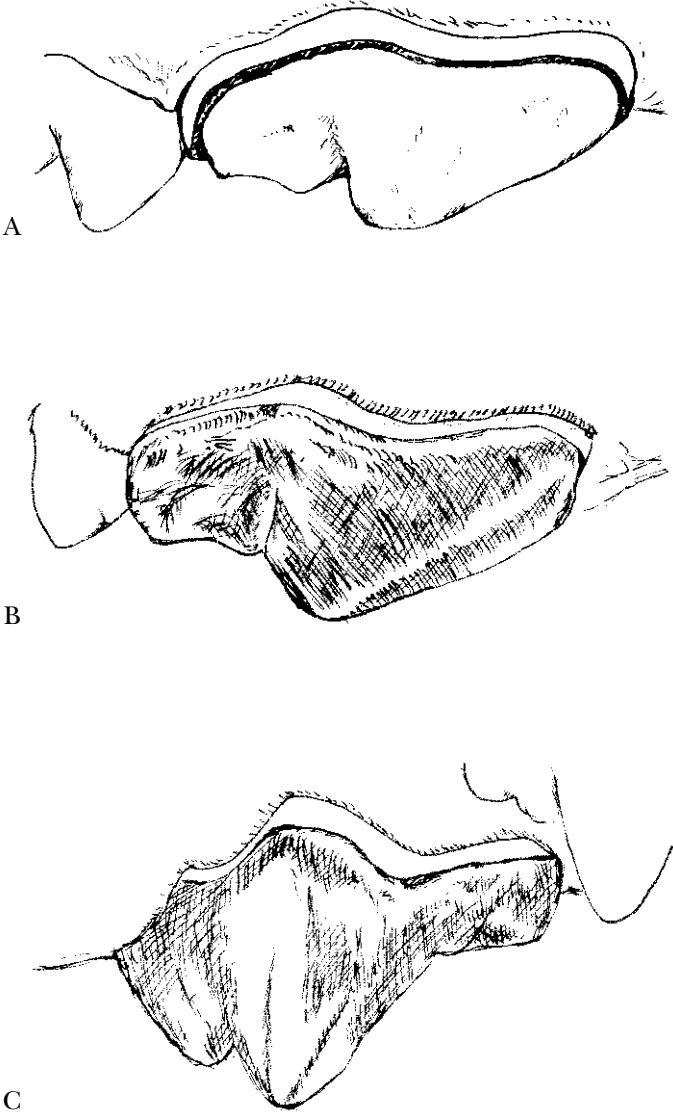


Fig. 8-30

- In teeth with little crown remaining, standard preparation may not be adequate for crown retention (Fig. 8-31, *A*).

Step 3—Additional retention is achieved in endodontically treated teeth by preparing the pulp canals, beginning with removal of the gutta-percha with a Peeso reamer to a depth at least equal to the height of the crown so that they may receive fabricated endodontic crown posts (Fig. 8-31, *B* and *C*).

- The canals are prepared with a flat-end tapered diamond bur so the “line of draw” coincides with the long axis of the prepared tooth (Fig. 8-31, *D*).
- As the bur is moved from one canal to the next, it is held steady so each canal is prepared parallel to the other.

Step 4—The coronal edge of the canal is expanded (beveled outward) to prevent binding as the restoration is seated.

- The remainder of the preparation is identical to that of preparations in canine teeth (Fig. 8-31, *E* and *F*).

Gingival Retraction

Description

- The gingiva may be retracted away from the tooth by using a gingival retraction cord.
- The cord may be precoated with a hemostatic agent or may be dipped into the hemostatic agent.

Use

- Crown therapy.
- Adhesive restorations close to gingiva.
- Hemorrhage control.

Advantage

- Allows better visualization and working space.

Disadvantage

- May occasionally interfere with working space.

Materials

- Gingicord, GingiAid (Gingi-Pak).
- Cord packer.

Technique

Step 1—The appropriate size cord is chosen for the sulcus and desired space and is cut to the length of the gingiva to be packed.

Step 2—The cord is packed into the gingival sulcus with one or two Gingicord packers of appropriate size for the patient.

Complications

- Care should be taken not to cut the gingiva.
- Hemorrhage may be controlled by pinpoint electrocautery.

Die Stone

Description

- A harder stone is created by mixing gypsum stone with water, letting the mixture set and dry, and then grinding it again. Die-stone hardener can then be painted on the model to make the molded teeth even harder.

Use

- Restorations.

Advantages

- The stone is harder; gives a better chance to remove from the impression without fracture.
- When mixed in proper weight-to-volume proportions as directed by the manufacturer, it is more accurate.

Materials

- Mixing bowl.
- Spatula.
- Scale.
- Syringe or measuring cup to measure volume.
- Vibrator.

Technique

- Mix according to instructions in Chapter 9, pp. 512 to 515.

Improving Metal-to-Cement Adhesion

- Roughening the inside of a metal crown surface may improve cement adhesion to the metal. This may be accomplished in the office by using a Micro-etcher (Danville Engineering, San Ramon, Calif.).
- Diamond roughening is not a good way to roughen the crown.
- Chemical etching is messy, possibly dangerous, and not a good technique.

- The prosthodontic laboratory or an in-house set-up (Danville Engineering) may be able to sandblast the crown or bridge. In this case,

the restoration may be returned in a liquid environment. The crown is protected in this environment until ready for cementation.

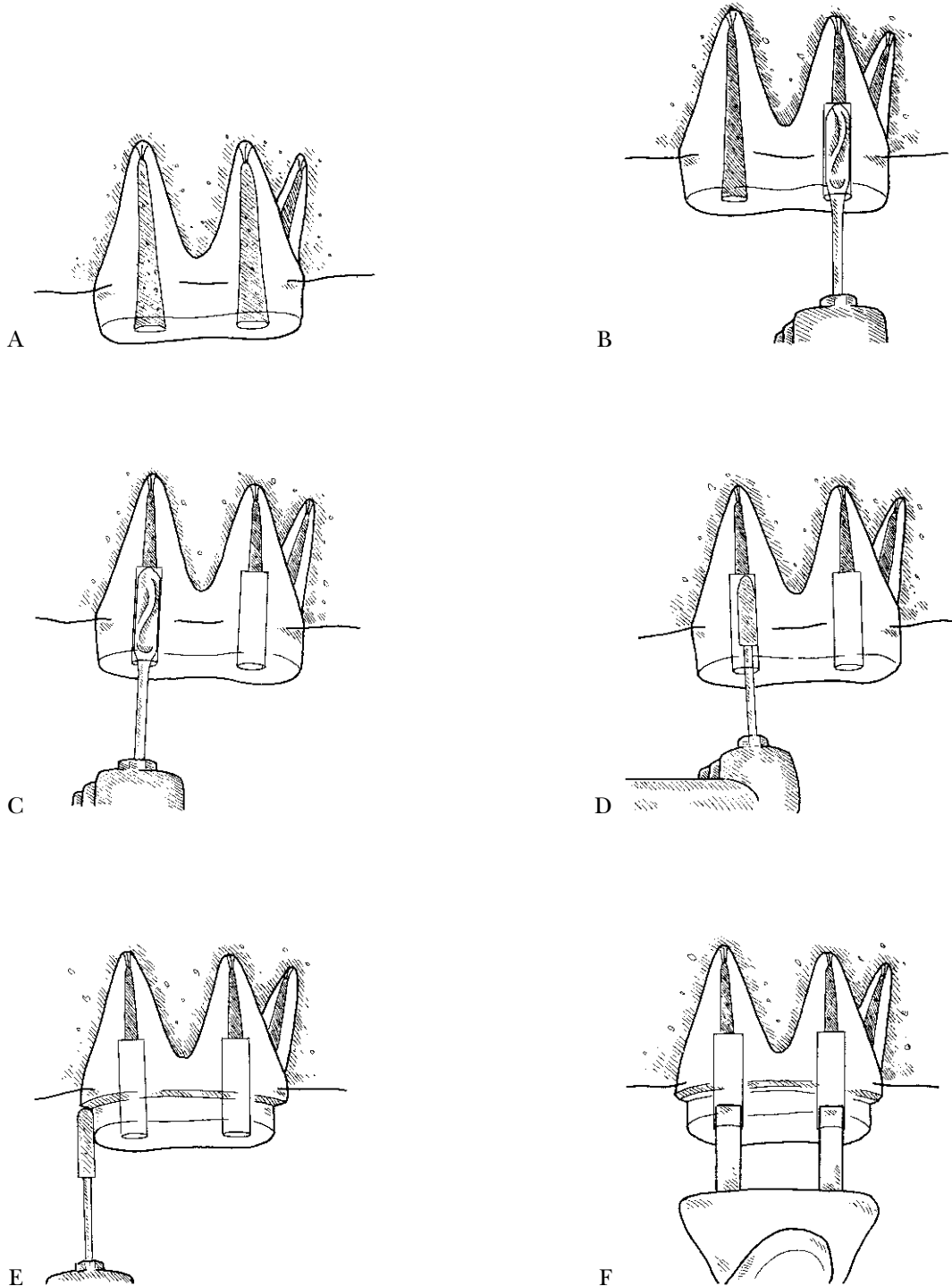


Fig. 8-31

Restorations Over Vital Teeth

General Comments

- Restorations placed over vital teeth require special considerations so that the pulp tissue is not damaged at the time the restoration is placed or at a later date.
- Lining and base cement materials are used in restorative dentistry as pulp-protection agents (Table 8-8).
- Liners and bases provide insulation under metallic restorative materials and a chemical barrier under plastic restorative materials.

Calcium Hydroxide

Description

- Calcium hydroxide lining cements are used commonly to promote pulp protection and healing.

Advantage

- The alkaline environment encourages remineralization and antibacterial activity.

Disadvantages

- Low-strength properties, leading to a weak structure.
- High solubility, leading to resorption of the material.

Resin-based calcium hydroxide

Description

- Calcium hydroxide is incorporated into a resin base.

Advantage

- Easy to use.

Table 8-8 • LINING/BASE MATERIALS

Calcium Hydroxide Cements	
Product	Manufacturer
Dycal	Dentsply Caulk
Life	Kerr
Cavitec	Kerr
Preline	Henry Schein
Pulpdent Cavity Liner	Pulpdent
Prisma VLC Dycal	Dentsply Caulk
Handi-Liner Kit	Mizzy
UltraBlend Plus	Ultradent
Glass Ionomer Liners	
Product	Manufacturer
Vitrebond	3M ESPE
Ketac-Bond	3M ESPE
Fuji Lining LC	GC America
XR Ionomer	Kerr
GlasIonomer Base Cement	Shofu
GlassLine	Pulpdent
Hydroxyapatite Liner/Bases	
Product	Manufacturer
Lime-Lite	Pulpdent
Delite	Kerr

Disadvantage

- Little is known of its relative properties and clinical performance.

INDIRECT RESTORATIONS

- An indirect restoration is one that has been fabricated by an outside laboratory.

Indications

- Teeth with large defects that require extensive restoration.
- Desire to use materials that require fabrication beyond the scope of the clinic's facilities or the clinician's expertise.

Examples

- Full-coverage or partial coverage metal or PFM crowns described on the previous pages.

Onlays

Inlays

- In addition to the metal and PFM materials, very tough, impact-resistant and abrasion-resistant composites have been developed: In-Ceram and Zirconium, In-Ceram and All-Ceram (Vident).

Uses

- Reconstruction of large carious buccal slab fracture defects.
- Reconstruction of distal canine cage-biter defects.
- Full-coverage crowns.

Clinical Tips

- Rubber-base impressions of the tooth to be restored and of the two adjacent teeth, along

with full-mouth laboratory stone models and wax bite registers, are requested by most laboratories.

- For crown preparation, a flat-end diamond bur is preferred. Consult with your laboratory for the technician's preference in tooth preparation design for specific restorations.
- For onlay preparation, a 45-degree bevel, diverging from the dentin to the surface of the enamel margin, is preferred. As with any indirect restoration, all undercuts should be avoided.
- A good crown cement is recommended for installation.

Advantages

- Can be used on vital as well as nonvital teeth.
- Can use stronger restorative materials than available to the clinician for direct, in-house use.
- Can reconstruct teeth to original size and shape, which would not be possible by direct restorative techniques.
- Onlays will support and strengthen the crown beneath the fabricated restoration, as a splint would support a long bone.

Disadvantages

- More than "one-stop shopping" for the client, requiring two stages and general anesthetics.
- Expense. Laboratory charges will be similar to those for metal and PFM crown fabrication.

Three-Quarter Crown Preparation³⁴

General Comment

- This is a protective procedure to strengthen the tooth and prevent further crown trauma to canine teeth with distal abrasion from cage-biter syndrome (Fig. 8-32, *A*). This is seen when dogs are kenneled and chew on fencing or metal bars or experience separation anxiety. The excessive wear on the teeth can lead to crown fracture with aggressive play, training, or bite work, leading to pulp exposure. The pulp generally does not become infected, because the wear occurs over a period of time and the tooth puts down reparative dentin in response to the wear. Radiographs should be taken initially to verify vitality of the tooth. Nonvital teeth will need a root canal treatment prior to preparation for the three-quarter crown. A full crown would also protect the tooth and requires removal of more natural tooth structure, further weakening the tooth.

Indications

- Canine teeth with distal crown wear weakening the tooth crown.

Contraindications

- Patients whose aggressive chewing behavior cannot be controlled with modifications in behavior, fencing type, or other interventions.

Objective

- To protect the tooth or teeth from further wear and possible crown fracture with pulp exposure in dogs that have the potential for continued oral trauma.

Materials

- Flame-shaped diamond burs.
- White stone bur.
- Detailed impression material of choice.
- Alginate impression material.
- Impression trays: full mouth and individual tooth.

- Tray adhesive.
- Bite registration material.
- Die stone casting material.
- Composite resin cement.

Technique

Step 1—If the wear extends close to the gingival margin or subgingivally, a type I crown-lengthening procedure (gingivectomy) is completed to expose greater surface area and create an adequate margin.

Step 2—The defect margins are prepared with a flame-shaped or tapered fine diamond bur to create a feathered margin 3 to 5 mm from the defect and staying 1 to 2 mm from the gingival margin (Fig. 8-32, *B*). The preparation will incorporate approximately three fourths of the crown diameter, with the mesial surface left untouched (Fig. 8-32, *C*).

Step 3—The cusp tip is reduced slightly (2 mm) and the margins around the cusp tip are contoured with the bur to create a feather margin (Fig. 8-32, *D*).

Step 4—The defect is prepared by scaling and then smoothing with a white stone.

Step 5—A detailed impression is made of the tooth as previously described.

Step 6—Whole-mouth alginate impressions and a bite registration are made. Stone casts are made and sent to the lab with the request for a three-quarter metal crown. The patient is recovered and training or chewing controlled to protect the preparation until the next appointment.

Step 7—The three-quarter crown is trial fitted and margins checked for smoothness.

Step 8—The three-quarter crown is cemented in place with a resin cement, and excess is removed with a scaler or curette before the cement hardens (Fig. 8-32, *E* and *F*).

Complications

- Continued excessive chewing with loss of crown or tooth fracture.
- Poor-fitting crown leading to microleakage around margins.

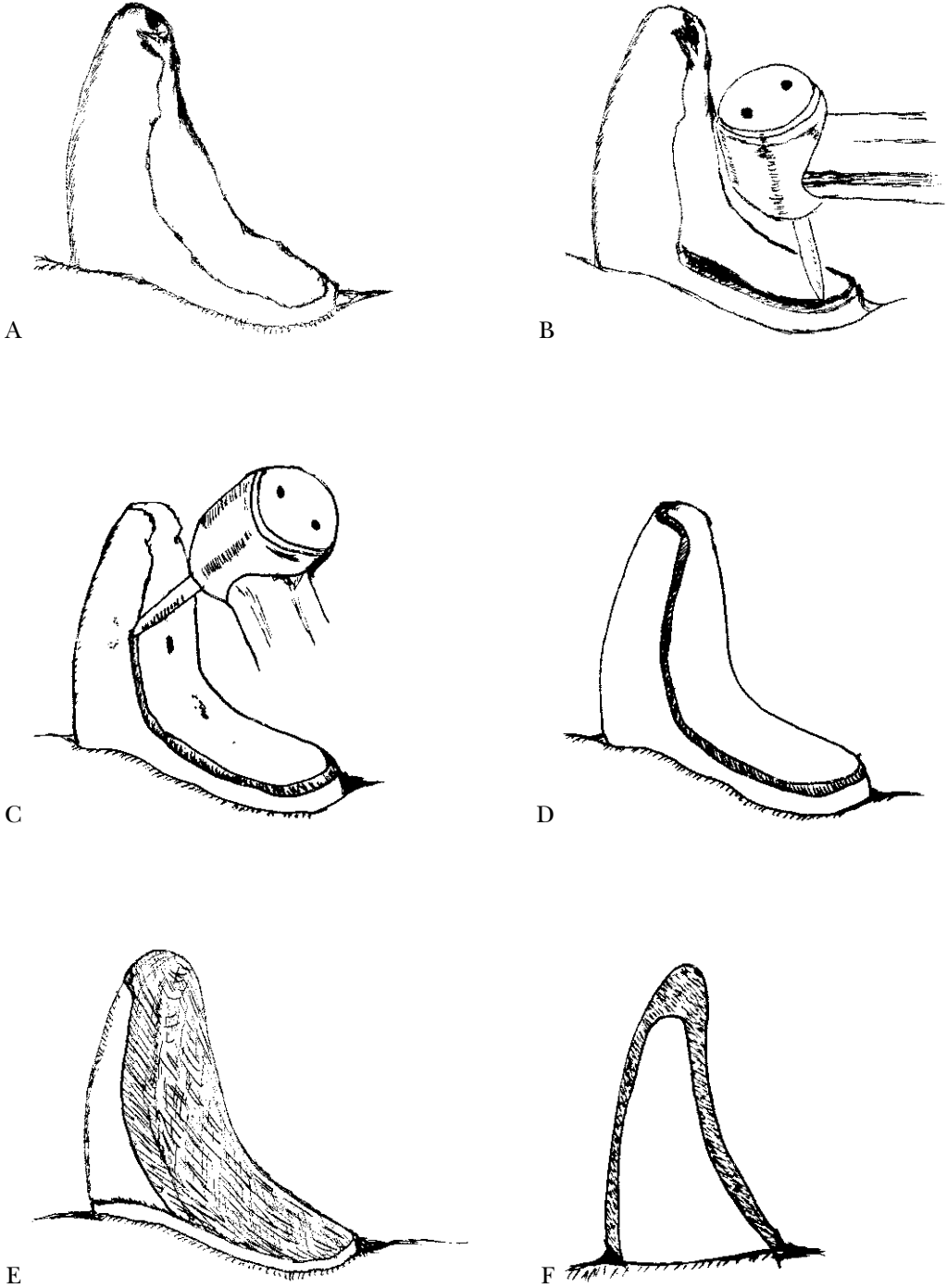


Fig. 8-32

BLEACHING OF NONVITAL TEETH

General Comment

- Stained teeth may be whitened by using concentrated hydrogen peroxide solutions.

Indication

- Bleaching of intrinsically discolored, nonvital teeth.

Contraindication

- The following procedure is not to be used on vital teeth.

Materials

- Hydrogen peroxide 35% (active and walking techniques) (Superoxol, Moyco Union Broach-Thompson, Montgomeryville, Penn.).
- Peroxyborate monohydrate (walking technique).

Techniques^{35,36}

Active Technique

Step 1—Root canal therapy is performed; a liner is placed over the gutta-percha in the root canal to prevent penetration of the hydrogen peroxide into the apex.

Step 2—The gingiva is coated with petroleum jelly.

Step 3—A rubber dam is placed over the tooth.

Step 4—A clamp is placed.

Step 5—The rubber dam is ligated with floss.

Step 6—The pulp chamber and surface of the tooth are acid-etched for 60 seconds with phosphoric acid.

Step 7—The pulp chamber is rinsed thoroughly with water for 1 minute and dried.

Step 8—Cotton pellets or paper points are saturated with 35% hydrogen peroxide.

Step 9—The saturated paper points or cotton pellets are placed in and around the tooth. Alternatively, the cotton pellets or paper points may be placed in the canal before saturating the canal with hydrogen peroxide.

Step 10—Heat is applied to the tooth surface with a heating unit, Touch 'N Heat unit, or

hair dryer. Heat should be applied to each surface for 60 seconds.

Step 11—The pellets and cotton points are replaced several times, for a total of four to six cycles.

Step 12—If bleaching is obtained, the pulp chamber is rinsed thoroughly for at least 1 minute with water and dried with paper points.

Step 13—The coronal portion of the canal and the access site are restored.

Walking Technique

Steps 1 through 11—The tooth is prepared as in the active technique.

Step 12—Peroxyborate monohydrate is mixed with 30% hydrogen peroxide to form a thick paste.

Step 13—The paste is placed in the pulp chamber, leaving space for the temporary filling material.

Step 14—A cotton pellet is placed over the paste.

Step 15—The access opening is sealed with a glass ionomer or zinc phosphate base.

Step 16—The patient is returned for re-examination and replacement of the walking paste as needed.

Step 17—Once the tooth is bleached, a restoration is placed.

Complications

- Leakage of hydrogen peroxide under the rubber dam.
- Irritation or burning of the gingiva.
- Safety goggles must be worn at all times during bleaching procedures by all staff in the dental area; extremely caustic agents are used.

Aftercare

- Tooth-whitening pastes may be beneficial in keeping the tooth bleached.

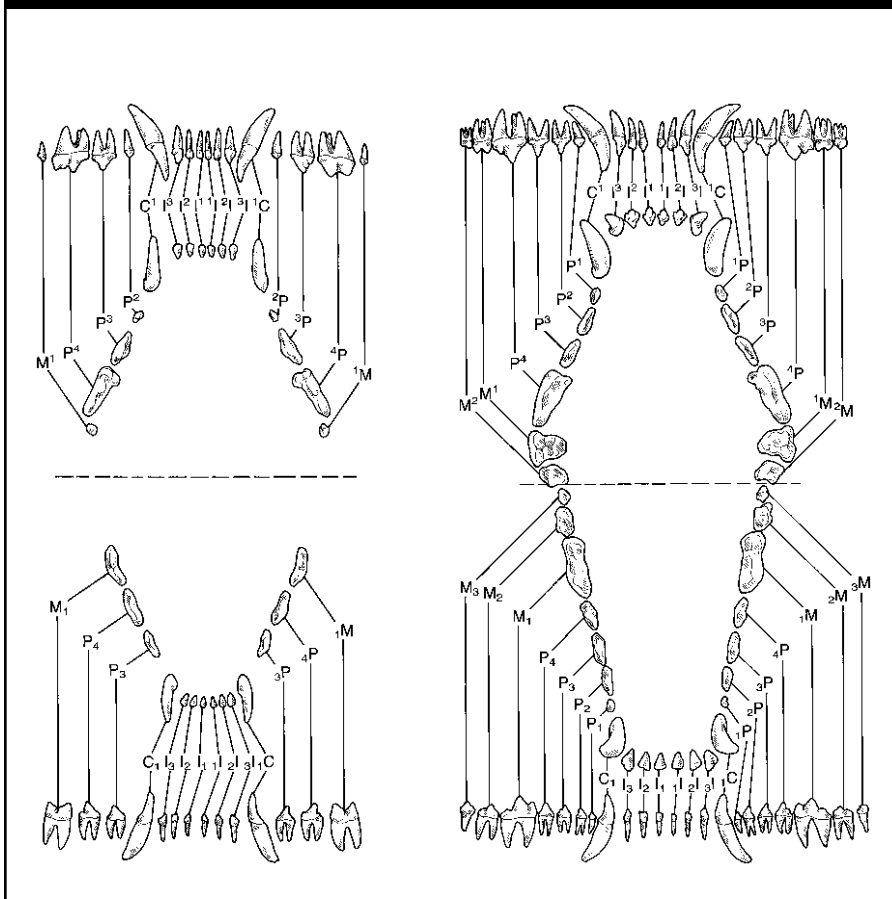
REFERENCES

1. Hale F: Dental caries in the dog, *J Vet Dent* 15(2):79-83, 1998.
2. Basrani E: *Fractured teeth*, Philadelphia, 1985, Lea & Febiger.
3. Crossley DA: Tooth enamel thickness in the mature dentin of domestic dogs and cats—preliminary study, *J Vet Dent* 12(3):111-113, 1995.

4. Phillips RW: *Skinner's science of dental materials*, ed 8, Philadelphia, 1982, WB Saunders, p 646.
5. Zwemer TJ: *Boucher's clinical dental terminology*, ed 3, St Louis, 1982, Mosby.
6. O'Brien WJ: Polymeric restorative materials: composites and sealants. In: *Dental materials and their selection*, ed 2, Carol Stream, Ill, 1997, Quintessence Publishing, pp 97-113.
7. Leinfelder KF, Lemons JE: *Clinical restorative materials and techniques*, Philadelphia, 1989, Lea & Febiger, p 359.
8. Brannan R: Restorative dentistry. Proceedings of the Veterinary Dental Forum, 2000, pp 74-78.
9. DuPont G: The bonded composite restoration. Proceedings of the Veterinary Dental Forum, 2001, pp 57-60.
10. Tholen M: Veterinary restorative dentistry: basic principles, *Vet Med Small Anim Clin* 12:1875-1880, 1983.
11. Croll TP: Repair of defective class I composite resin restorations, *Quintessence International* 21(9):695-698, 1990.
12. Eisner ER: Chronic subgingival tooth erosion in cats, *Vet Med* 84:378-387, 1989.
13. Emily P: Restoring feline cervical erosion lesions, *Vet Forum* 10:22-23, 1988.
14. DeForge DH: Use of a resin-ionomer in crown-root fracture repair of a canine tooth of a dog, *J Vet Dent* 14(1):11-14, 1997.
15. Lyon KF: Subgingival odontoclastic resorptive lesions, *Vet Clin North Am* 22:1417-1432, 1992.
16. Reiter AM: Evaluation of serum concentrations of calciotropic hormones in cats with feline odontoclastic resorptive lesions (FORL). Proceedings of Seventeenth Annual Veterinary Dental Forum, San Diego, Calif, Nov 6-9, 2003, pp 161-163; and Proceedings of the World Veterinary Dental Congress, Kyoto, Japan July 11-13, 2003.
17. Harvey CE, Orsini P, McLahan C, et al: Proceedings of the Veterinary Dental Forum, 2000, pp 142-144.
18. Lommer MJ, Verstraete FJ: Prevalence of odontoclastic resorptive lesions and periapical radiographic lucencies in cats: 265 cases 1995-1998, *J Am Vet Assoc* 217(12):1866-1869, 2000.
19. DuPont GA, DeBowes LJ: Comparison of periodontitis and root replacement in cat teeth with resorptive lesions, *J Vet Dent* 19(2):71-75, 2002.
20. Ben-Amar A: Reduction of microleakage around new amalgam restorations, *J Am Dent Assoc* 119:725-728, 1989.
21. O'Brien WJ: Dental amalgams in dental materials and their selection, Carol Stream, Ill, 1997, Quintessence Publishing, pp 187-201.
22. Marzouk MA, Simoton AL, Gross RD: *Operative dentistry*, St Louis, 1985, Ishiyaku.
23. Hale F: Proceedings of the Veterinary Dental Forum, 2000, pp 70-73.
24. Shillingburg HT, Sumiya H, Fisher DW: Preparations for cast gold restorations, *Die Quintessenz* 16, 25, 31, 147, 1974.
25. Craig RG, O'Brien WJ, Powers JM: Gold and nonprecious alloys. In Craig RG, Wataha JC, Powers JM, editors: *Dental materials: properties and manipulation*, ed 6, St Louis, 1996, Mosby, pp 214-229.
26. *CRA Newsletter*; vol 27, issue 5, May 2003.
27. Johnson JF, Phillips RW, Dykema RW: Modern practice in crown and bridge prosthodontics, Philadelphia, 1971, WB Saunders, pp 59, 374.
28. Coelho DH, Rieser JM: *A complete fixed bridge procedure*, New York, 1963, New York University Press, pp 29, 38.
29. Seluk LW: *Successful glass ionomer techniques*, Palo Alto, 1989, Shofu Dental Corporation.
30. Smith DC, Ruse ND: Acidity of glass ionomer cements during setting and its relation to pulp sensitivity, *J Am Dent Assoc* 119:654-657, 1986.
31. Van Foreest A, Roeters J: Evaluation of the clinical performance and effectiveness of adhesively bonded metal crowns on damaged canine teeth of working dogs over a two-52 month period, *J Vet Dent* 15(1):13-19, 1998.
32. Fahrenkrug P: Crowns: indication, preparation, proceedings. Meeting of the Academy of Veterinary Dentistry and the American Veterinary Dental College, New Orleans, 1989.
33. Hale FA: Crown lengthening for the mandibular and maxillary canine teeth in the dog, *J Vet Dent* 18(4):219-221, 2001.
34. Luskin IR: Three-quarter crown preparation, step-by-step, *J Vet Dent* 18(2):102-105, 2001.
35. Golden AL: *Vital and non vital bleaching techniques*, New Orleans, 1988, Nabisco.
36. Wiggs RB, Lobprise HB: *Veterinary dentistry principles and practice*, Philadelphia, 1997, Lippincott-Raven.



ORTHODONTICS



The word *orthodontics* often is equated with unethical veterinary practices. Certainly, orthodontic manipulation can be used for unethical purposes. However, orthodontic treatment should not be performed to deceive show judges, prospective owners, or buyers of offspring. The veterinarian who performs the procedures should not, inadvertently, become part of a treatment that will result in a deceptive act. The goal is to provide the patient with a pain free, functional bite. Regaining normal, cosmetic occlusion may be the end result of the treatment and is in itself not the result of unprofessional treatment. It is what the owner does with the animal that has had its heritable anatomy altered that determines the ethical or unethical behavior.

OCCLUSAL EVALUATION

- Occlusal (bite) evaluation involves more than just the relationship of the incisors to each other and the number of teeth. The entire mouth and dentition are used to evaluate occlusion properly.

Step 1—Observe the symmetry of the head, face, and dentition.

- The midpoints of the mandibular and maxillary dental arches should be in alignment with the midsagittal plane of the head.

Step 2—Count the teeth.

- All teeth should be present.

Canine Dental Formula

Primary (Deciduous)

$$2 \left(i \frac{3}{3} c \frac{1}{1} p \frac{3}{3} \right) = 28$$

Secondary (Adult)

$$2 \left(I \frac{3}{3} C \frac{1}{1} P \frac{4}{4} M \frac{2}{3} \right) = 42$$

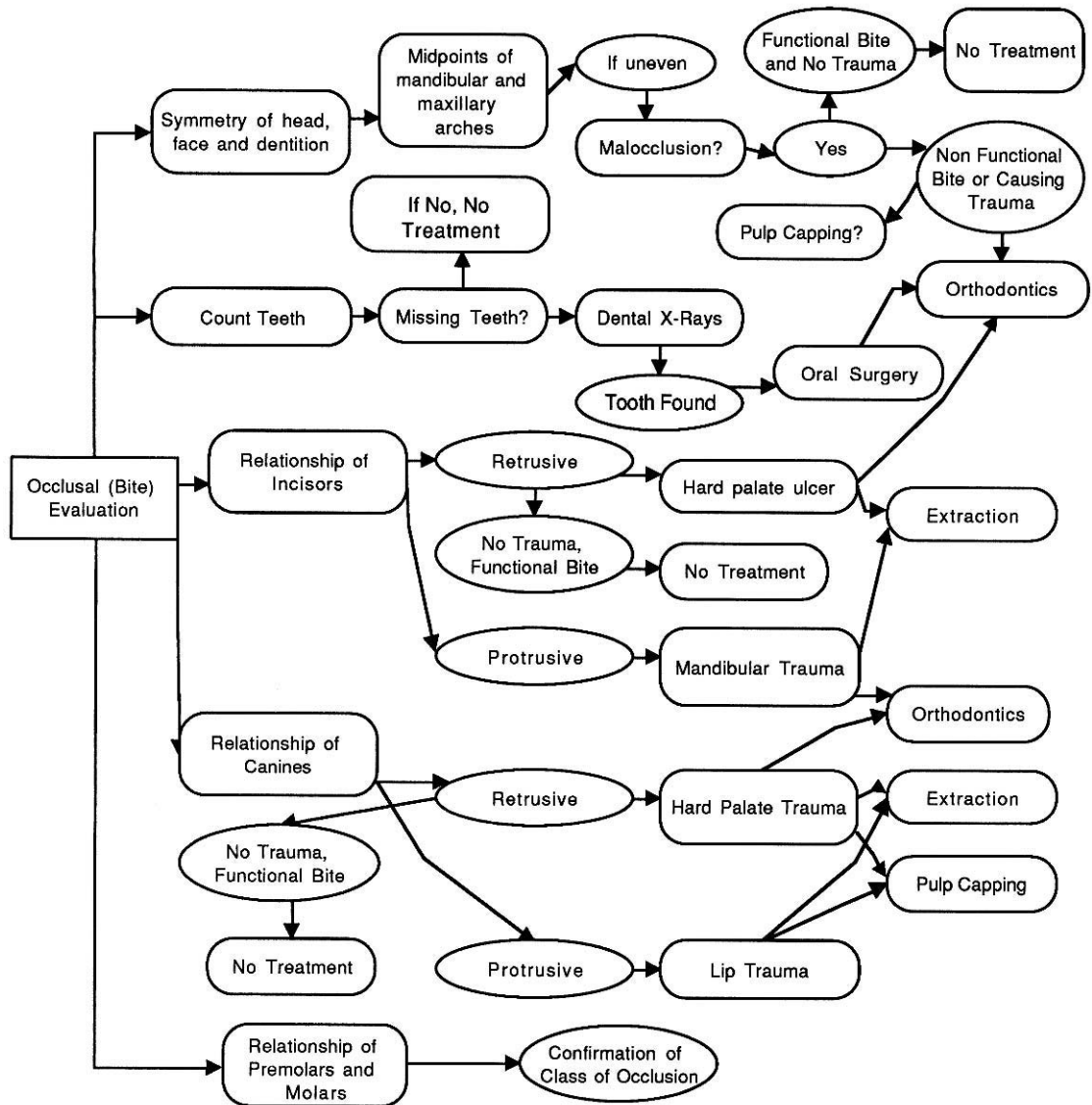
Feline Dental Formula

Primary (Deciduous)

$$2 \left(i \frac{3}{3} c \frac{1}{1} p \frac{3}{2} \right) = 26$$

Secondary (Adult)

$$2 \left(I \frac{3}{3} C \frac{1}{1} P \frac{3}{2} M \frac{1}{1} \right) = 30$$



Step 3—Evaluate the occlusion of the incisors (Fig. 9-1, A). The normal head type in feral dogs is the mesocephalic head as seen in the German shepherd. The line of the teeth is seen as a smooth, symmetrical curve not broken by rotated or misplaced teeth. All other relationships, for scientific purposes, must be considered to be in malocclusion to a greater or lesser degree.¹ The normal incisor occlusion has the large cusps of the lower incisors occluding near the cingulum on the lingual side of the upper incisors (Fig. 9-1, B). The large cusps of the central incisors should be centered with each other. The second and third incisors lose their centered relationship, and the large cusp of the third mandibular incisor should be in the interproximal space between the second and third maxillary incisors.

Step 4—Observe the relationships of the canine teeth (Fig. 9-1, C).

- The mandibular canine tooth should occlude buccal to the gingiva of the maxilla and should be equidistant between the maxillary canine tooth and the maxillary third incisor. The relationship of the mandibular canine to

the maxillary canine and third incisor is called the *dental interlock*. An abnormal dental interlock often signals a current or pending abnormal maxillary-mandibular occlusal relationship.

- This is the most reliable reference point in the mouth.²

Step 5—Observe the relationship of the premolars (Fig. 9-1, D).

- The large cusp on the lower fourth premolar should divide the space between the upper third and fourth premolars, the central cusp pointing interproximally between the two teeth.

Step 6—Observe the occlusal plane of the upper and lower arches (Fig. 9-1, E).

- The premolars should interdigitate from the second premolars back to the cusps of the upper fourth premolar, and there should be overlapping of the cusp tips.
- The molars should occlude to allow the cusps to function in crushing.
- The premolars and molars should be aligned mesial to distal in a smooth curve, with none of the teeth rotated.

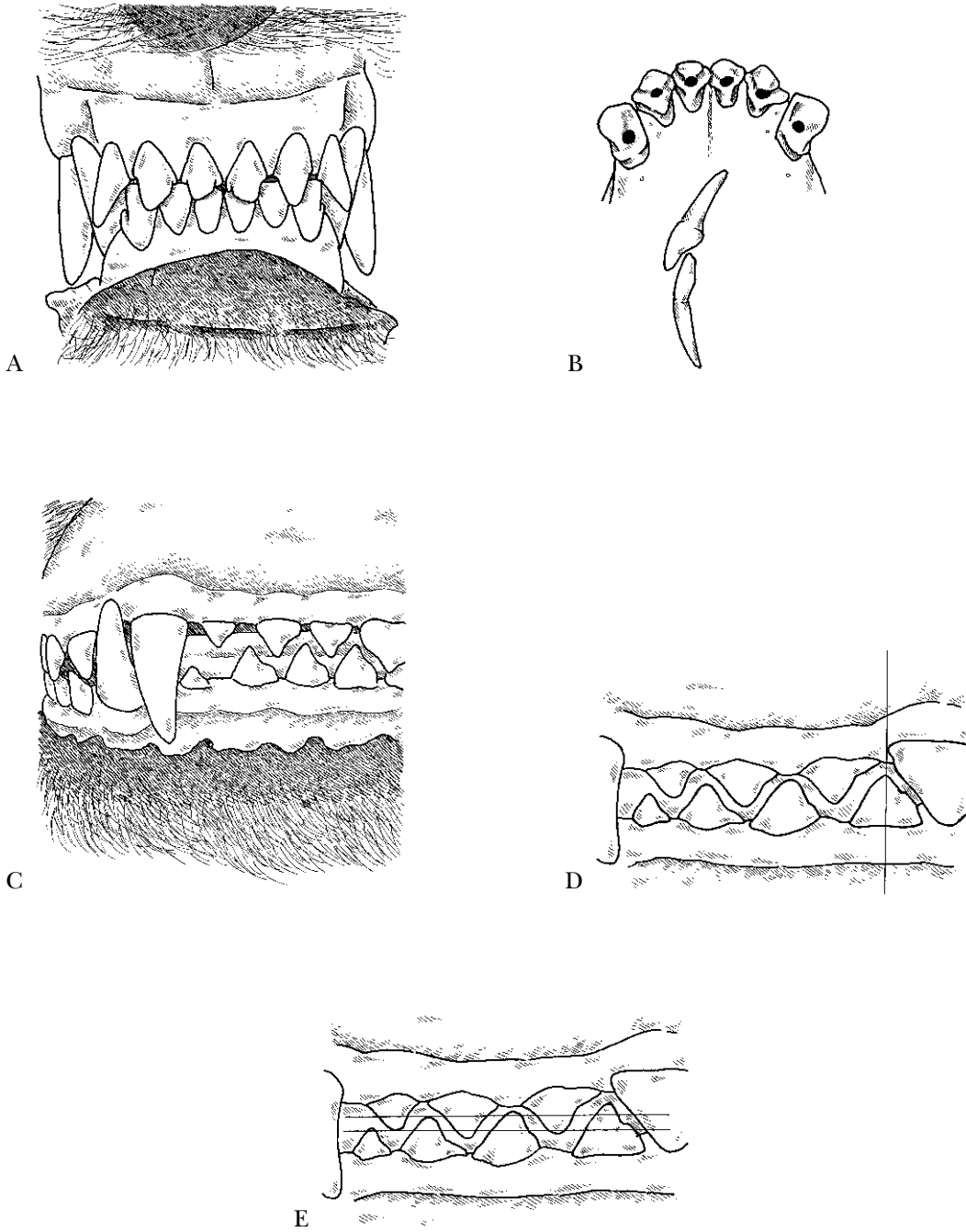


Fig. 9-1

Classes of Occlusion

Normal

- Scissor bite: normal occlusion pattern in which the lower incisors occlude on the cingulum on the palatal surface of the upper incisors. The upper and lower premolars are in an anisognathic, shearing relationship with the maxillary teeth buccal to the mandibular teeth. The upper and lower arches are symmetrical.

Abnormal Occlusion

Class 1

- Patients with class 1 malocclusion have generally normal occlusion with one or more teeth out of alignment or rotated. It may occur in any one of four basic formats: (1) a shift in the interdigitating relationship of the maxillary and mandibular premolars, (2) an anterior (or may be also thought of as an incisor) crossbite (see below), (3) a base narrow mandibular canine tooth or teeth, and (4) posterior crossbite of the premolars or molars.
- Anterior crossbite: a common abnormal occlusion in which one or more of the mandibular incisors are anterior to the maxillary incisors (Fig. 9-2, A, *arrow*) and, most importantly, the rest of the teeth occlude normally.
- Base narrow or lingually displaced canine teeth: one or both of the cusps of the mandibular canine teeth are displaced lingually and occlude on the hard palate (Fig. 9-2, B). Similar trauma may also occur in class 2 malocclusions.
- Rostrally angled maxillary canine teeth: these can be unilateral or bilateral and are most frequent in the Shetland sheepdog. The maxillary canine tooth erupts at an angle creating interference with the mandibular canine tooth, whereas the rest of the occlusion is generally normal. This occlusion is also known as *lance tooth* or *spear tooth* and can be seen in other breeds and in cats.

Class 2

- Patients with class 2 occlusion have the mandibular premolars and molars positioned caudal (distal) to the normal relationship (Fig. 9-2, C and D). This occlusion is also known as *mandibular brachygnathism*, *overjet*

(often called *overshot* by breeders), *retrusive mandible*, or *distal mandibular excursion*.

- The difference between the often incorrectly used terms *overbite/underbite* and *overjet/underjet*, is that the suffix “*bite*” refers to the vertical overlapping of the maxillary over the mandibular teeth, whereas the suffix “*jet*” refers to the horizontal projection of the maxillary or mandibular teeth beyond the opposite arch.³

Class 3

- Patients with class 3 occlusion have the mandibular premolars and molars positioned rostral (mesial) to the normal relationship (Fig. 9-2, E). This occlusion is also known as *prognathism*, *undershot*, *underjet* (called *underbite* by breeders), *protrusive mandible*, or *mesial mandibular excursion*. A level bite (often called an *even bite* by breeders) is a mild form of class 3 malocclusion. A reverse scissor bite is a class 3 occlusion that is a little more pronounced. In that case, the incisal edges of the maxillary incisors make contact with the lingual surface of the mandibular incisors. A true underjet is one in which the mandibular incisors are rostral to the maxillary incisors and not in contact with them.
- Level bite: an abnormal occlusal pattern in which the maxillary and mandibular incisors occlude cusp to cusp (edge to edge). This is a very punishing malocclusion, resulting in premature wear to the incisors, a predisposition to inflammatory periodontal problems (secondary to occlusal trauma) and, to a lesser extent, endodontic disease.

Unclassified

- Wry bite: an abnormal occlusion caused by a difference in lengths of the two halves of the mandible and maxilla. This abnormal occlusion is reported to be genetically created and can result in a variety of jaw relationships. It is characterized by asymmetry of the head in which the midline of the maxilla does not align with the midline of the mandible. The asymmetry may be found in either the maxilla or the mandible, or both. In a wry bite, when evaluating occlusion, a clinician may find a normal scissor incisal occlusion, a normal dental interlock, and normal premolar interdigitation on one side of a dog or cat, while the opposite side is afflicted with an underjet or overjet, a malevolent dental interlock, and an abnormal premolar inter-

digitation. If that patient is then appraised from a frontal view, the face will be seen to be asymmetrical, with the midsagittal plane not truly occurring between both the maxillary and mandibular first incisors. Clinically, this is

a very heritable and undesirable occlusion. Among English Bulldog breeders, a wry bite refers to a bowed or twisted hemimandible, not the wry bite described above.

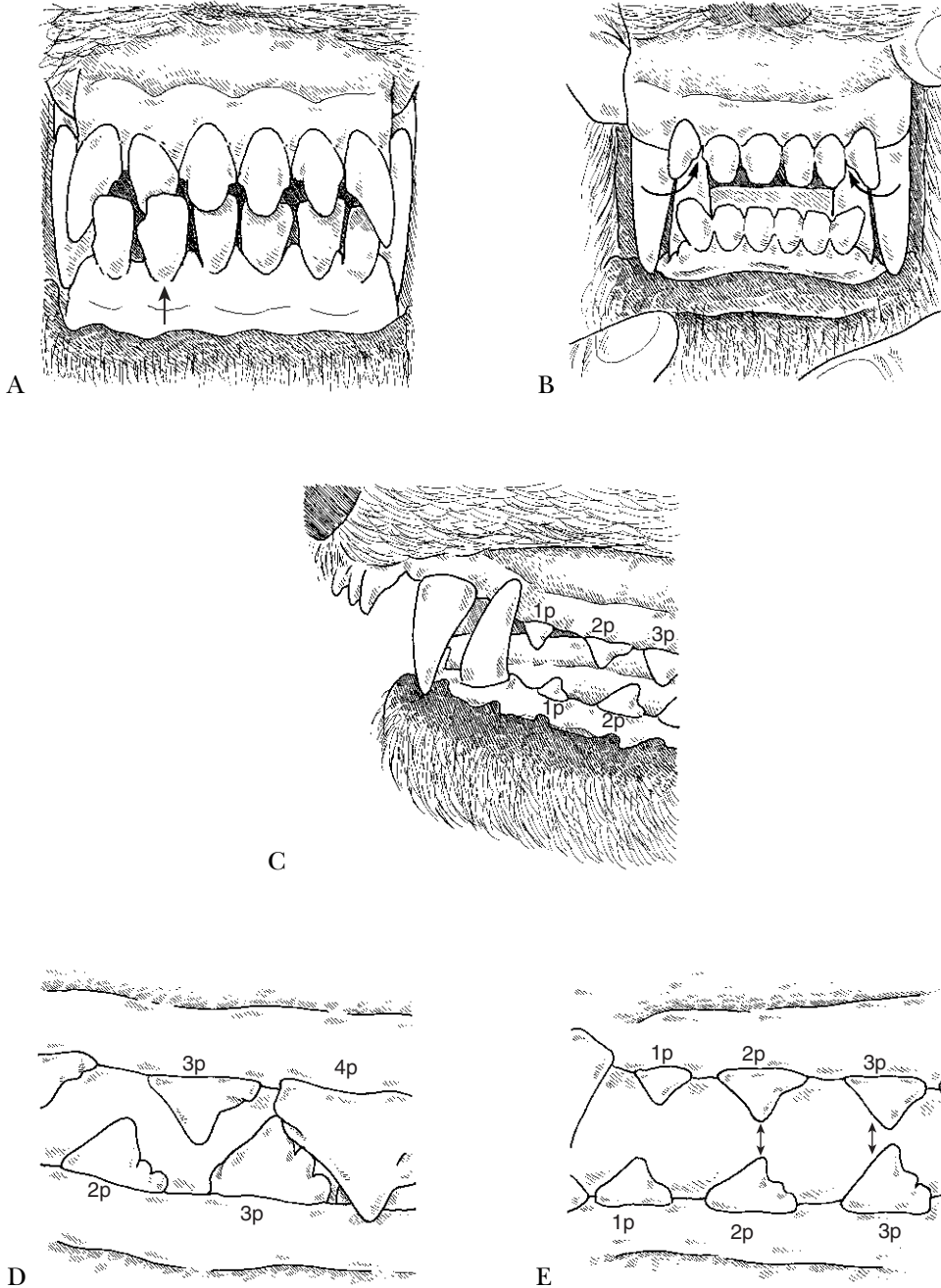


Fig. 9-2

Orthodontic Fundamentals

- Tooth roots are held in the alveolus by the periodontal ligament (PDL), which attaches to the cementum on the tooth and the alveolar bone of the dental arch.
- Osteoclasts and osteoblasts occur in the alveolar bone.
- Forces applied to the crown of the tooth are transmitted by the PDL to the bone.
- Stretching the PDL applies a pull on the alveolar bone and stimulates the osteoblasts to deposit new bone.
- Compressing the PDL and compressing the periodontal space applies compressive pressure to the alveolar bone and stimulates osteoclasts to resorb bone.
- The magnitude of the force applied to the crown of the tooth is critical. If the force exceeds the capillary blood pressure in the PDL, then the PDL will necrose or hyalinize and become cell free. When this happens, remodeling of bone in the acellular area must be accomplished by cells derived from adjacent healthy bone. This causes a delay in the orthodontic movement process.
- Types of movement are created by the way the force is applied to the tooth:

Tipping: one part of the tooth moves a greater distance and direction than another (Fig. 9-3, *A*) (requires light force).

Translation or bodily movement: all parts of the tooth move the same distance in the same direction in the same amount of time (Fig. 9-3, *B*) (requires twice the force of tipping).

Rotation: tooth is rotated around its axis (Fig. 9-3, *C*) (requires light force).

Intrusion: tooth is moved into the alveolus (Fig. 9-3, *D*) (requires the greatest amount of force).

Extrusion: tooth is moved out of the alveolus (Fig. 9-3, *E*) (requires the least amount of force).

- Duration of the force also influences the response. The three classes of duration are:
Continuous: force gradually diminishes (but does not reach zero) between adjustments.
Interrupted: force is reduced to zero between adjustments.

Intermittent: force drops to zero when a removable appliance is removed and is regained when the appliance is replaced.

- Anchorage is resistance to unwanted tooth movement.⁴ The object is to create a platform from which an orthodontic force may be exerted that will move the active tooth and only minimally move the anchorage tooth or teeth (unless one also wants to move the anchorage).
- Once tooth movement has been accomplished, the tooth or teeth must be maintained in their desired positions; in veterinary orthodontics this is usually 2 to 4 weeks. This is known as the *retention period*.

Legal and Ethical Considerations

Before accepting a patient for orthodontic correction, the client should be advised of the potential legal and ethical implications of these procedures. A release, approved by the practitioner's attorney, should be signed by the client. The following release is a sample only.

Agreement and Consent for Orthodontics

The correction of malocclusions in animals has moral, ethical, and legal implications. In addition, the rules of many breed clubs and organizations state that any animal that has had its heritable anatomy altered is subject to disqualification from showing in conformation classes.

Because many orthodontic conditions are inherited, we strongly recommend that such animals treated for orthodontic conditions not be used for breeding purposes. Such an animal should be neutered, rendering it incapable of being shown in conformation classes.

We believe that all pets are entitled to a comfortable, functional bite. There is nothing wrong with the correction of an acquired malocclusion, but the doctor and clinic staff will not be an accomplice to fraud.

My signature authorizing treatment indicates that I have read and understand the above information.

Signature of Client/Owner and Date

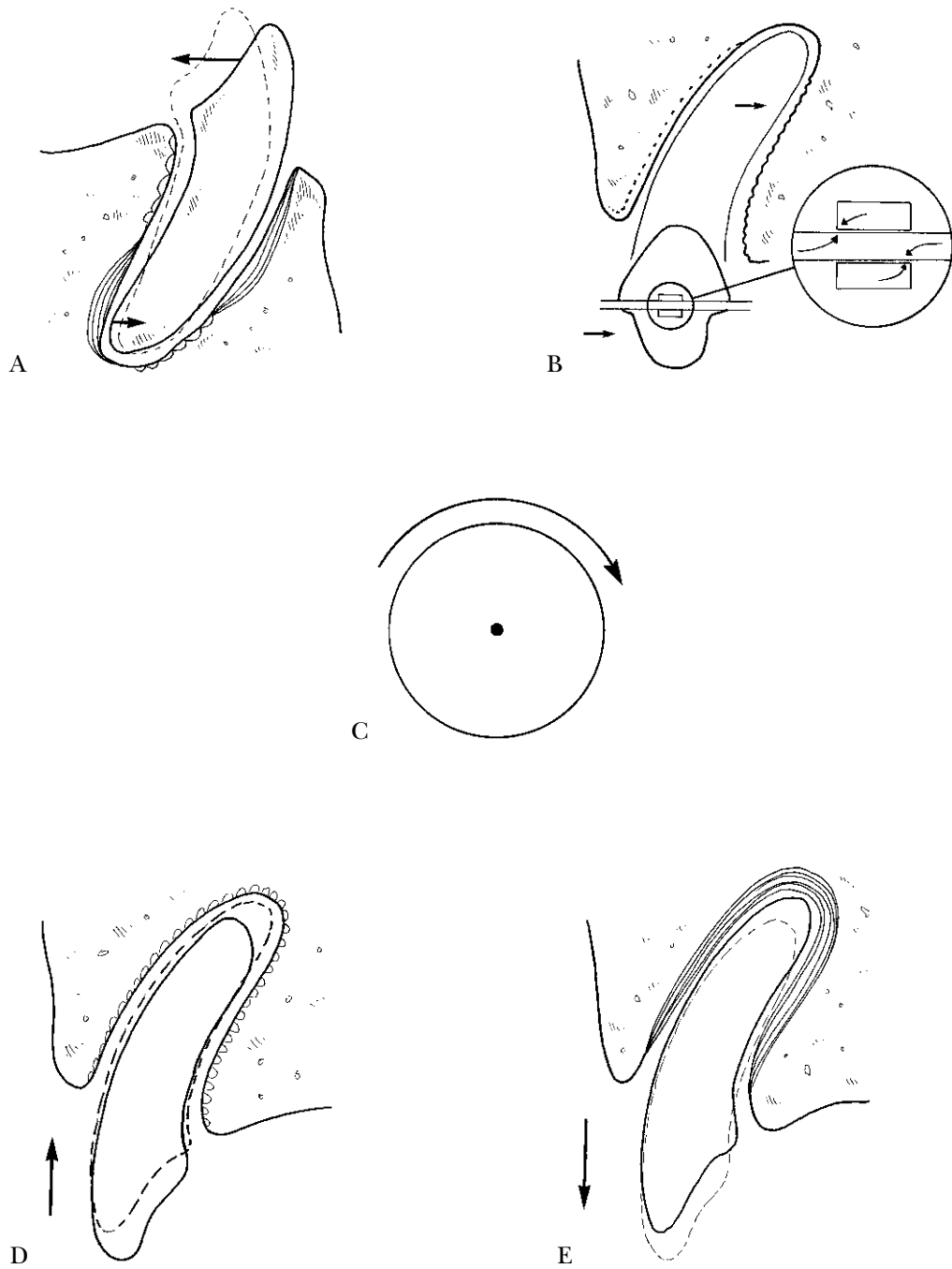


Fig. 9-3

GENERAL ORTHODONTIC TECHNIQUES

Making an Impression Tray

General Comment

- There are several styles of fabricated impression trays of various sizes designed for use in cats and dogs. Human impression trays have been used but do not allow access to the caudal teeth, which are important when evaluation of the entire occlusion is desired and when making models that are to be placed on an articulator for the proper occlusal relationship.

Indication

- When a preformed impression tray is not available or is not of the correct size for the patient.

Contraindication

- Do not use soft, flexible materials that will allow distortion of the alginate before pouring of the casts.

Materials

- Formatray (Kerr Corporation, Orange, Calif.).
- Easy Tray (Oral Dynamics, Seattle, Wash.).
- Hydroplastic (thermomalleable material) custom molded material.

Technique

Step 1—Follow manufacturer's instructions for preparing material. You may soften material with warm water or mix powder and liquid (Formatray).

Step 2—Shape material to desired form on model or in patient's mouth.

Step 3—Allow to harden.

Step 4—Trim rough edges before use.

Complications

- Material sets too quickly.
- Acetone odor of Formatray is very strong.

Creating the Impression

General Comments

- A good impression and model are necessary for many dental procedures.
- It allows a practitioner to study and measure the oral architecture, to confer with a colleague or laboratory, and to fabricate prostheses and appliances.
- It is an excellent medical record.
- An impression must be an accurate representation of the structure studied.
- Sedating the patient heavily or submitting the patient to general anesthesia is required for making accurate impressions.

Indication

- Any time a model is needed for study, treatment planning, or appliance fabrication.

Contraindication

- Uncooperative patient or patient unable to undergo general anesthesia.

Materials

- Impression tray (do not use Styrofoam cups, cut soft plastic bottles, and the like as trays because they are too unstable).
- Alginate.
- Set of three bowls and spatulas.
- Room temperature water.
- Bite registration material.

Technique

Step 1—Select an impression tray that fits over all the teeth loosely (Fig. 9-4, A).

Step 2—The alginate is "fluffed" by gently rolling or shaking the container. The powder is allowed to settle to avoid a particle dust cloud when the container is opened (dustless alginate is available).

Step 3—The alginate is measured into the mixing bowl with the measuring spoon provided with the alginate (Fig. 9-4, B). The amount will depend on the size of the tray used. Experiment until you know how much alginate a particular tray size needs

(generally two to three scoops for small breeds or anterior teeth only, and four to six scoops for a full tray). The alginate is placed in the rubber mixing bowl (Fig. 9-4, *C*).

Step 4—Water is measured with the container provided with the alginate (Fig. 9-4, *D*). If tap water is too cold or too hot, water is used from a storage flask at room temperature to

avoid variations in setting time caused by water temperature. Water temperature affects the setting speed of the alginate; warmer water increases setting time, and colder water decreases it. All the water is poured into the bowl with the alginate at the same time (Fig. 9-4, *E*).

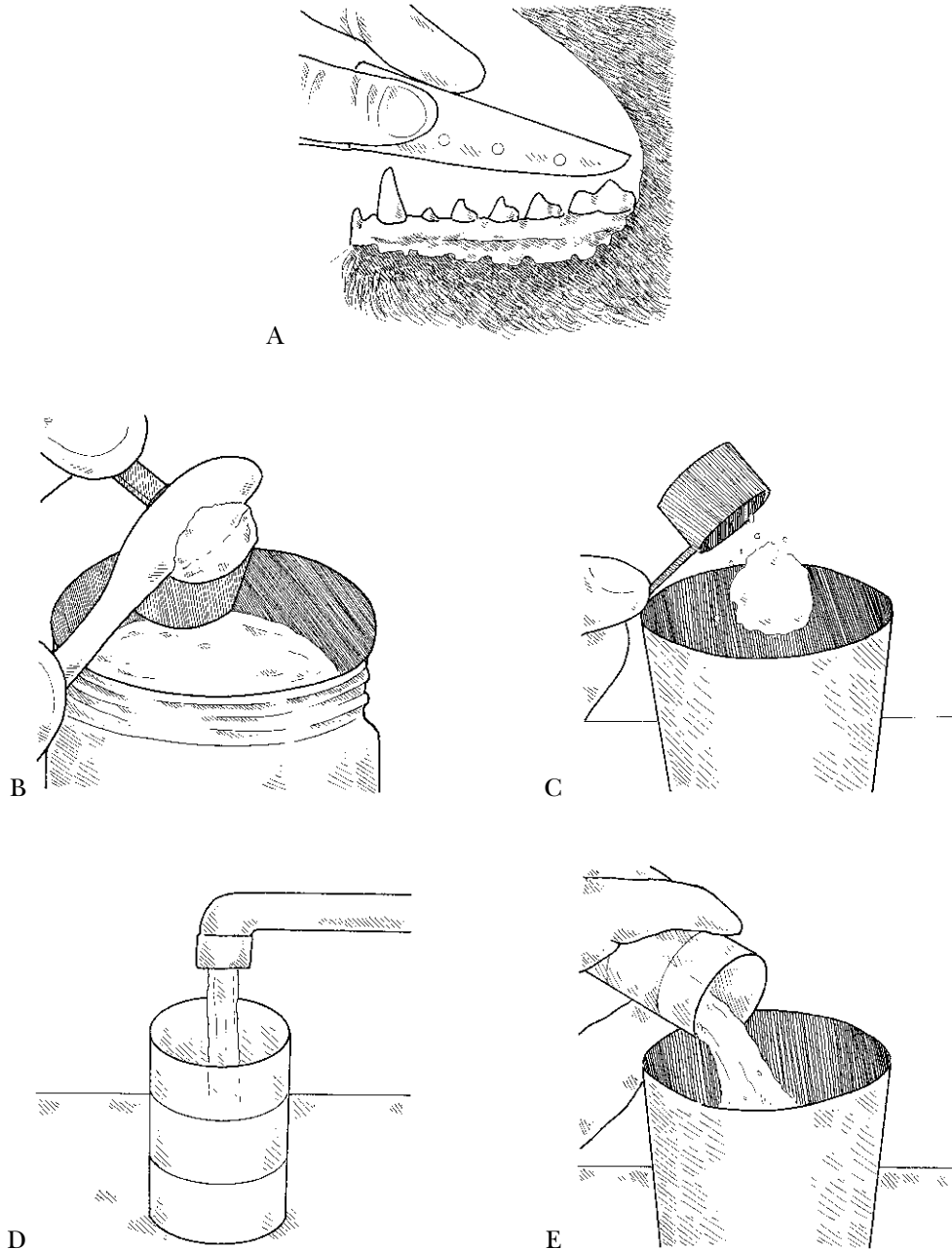


Fig. 9-4

Step 5—The alginate and water are mixed with the spatula (Fig. 9-5, *A*). Incorporate all the powder first by mixing in the center of the bowl. Smooth the mix by spatulating the mixture against the sides of the bowl (Fig. 9-5, *B*). The bowl is held in one hand, and the spatula is used to spread the mixture vigorously onto the sides of the bowl. Turn the bowl while spatulating to get a more homogeneous mixture. The entire mixing procedure should be completed in 30 to 45 seconds. The mixing is finished when all the lumps are removed and the consistency is homogeneous.

Step 6—The alginate is placed in the tray; any air bubbles or voids are removed (Fig. 9-5, *C*).

- The surface is smoothed and lightly dampened with water.

Step 7—With the patient in sternal recumbency for the maxilla and dorsal recumbency for the mandible, the tongue is rolled back into the pharynx and the lips are held back. While the patient's mouth is held open, the tray with the alginate is placed carefully in the mouth (Fig. 9-5, *D*). Contact with the teeth is made first in the caudal portion of the mouth, and the tray is rocked forward gently to incorporate the teeth in the anterior portion of the mouth (Fig. 9-5, *E*).

- Once the tray is in position, it is held steady until the alginate has set. The amount of time depends on the alginate used and the temperature of the water (usually 3 to 7 minutes).
- The setup is tested by pressing a finger on exposed alginate. When the finger does not stick or leave an indentation, the alginate has set.

Step 8—The tray with the alginate is removed from the mouth by firmly snapping the tray off the teeth (Fig. 9-5, *F*).

- The impression is examined for voids, flaws, or bubbles. If there is an imperfection in the impression in a critical area, the impression should be retaken. If the model is not going to be poured immediately, wrap the alginate and tray in a damp paper towel (Fig. 9-5, *G*). (Do not soak the tray and alginate in water because it will absorb water and distort the impression.) For accurate representation, laboratory stone should be poured into the alginate impressions within 30 minutes.

Step 9—Bite registration is critical for helping the dental laboratory determine the proper relationship of the two jaws so as to be able

to manufacture an appliance or a crown. To record the correct articulation after the impressions are made and just before the patient is awakened, the patient is extubated, and the bite registration is taken. A sheet of bite wax, which is often made of beeswax, is softened in warm water, placed in the mouth, and the patient is made to bite down on it. As an alternative to the bite wax, special bite impression registration materials are available that can be injected into the occlusal space.

Complications

- Inadequate mixing will leave lumps and voids in the alginate. To prevent this, mix the alginate thoroughly.
- Too thin a mixture will not have enough body and will tend to run out of the tray and not stay around the teeth. Follow the manufacturer's instructions on the mix and adjust only if necessary, adding small increments.
- Too firm a mixture will not conform to the teeth and mouth well and, thus, will provide poor detail. Correct by creating a thinner mix.
- If the tray is not filled properly, voids (bubbles) may be incorporated into the impression. Fill the tray completely and smoothly.
- Bubbles can be trapped when the tray is placed in the mouth. To prevent bubbles, slowly seat the tray, caudally to rostrally.
- Movement while the alginate is setting will cause distortion. Because movement usually is caused by the patient, adequate sedation or general anesthesia is suggested.
- The alginate may tear when removed from the mouth. This is especially a problem in the mandibular canine teeth, which are splayed at their coronal end. If the canines are severely divergent and cause tearing, slow removal of the impression, as well as a slight rotational movement as opposed to snapping the impression material off the teeth, may help prevent tearing. A minimal tear may not cause distortion and can be corrected on the model later.
- Alginate will become distorted if the water content changes between the time when the impression is taken and when the model is poured. Alginate will become distorted, also, if the tray is not solid.

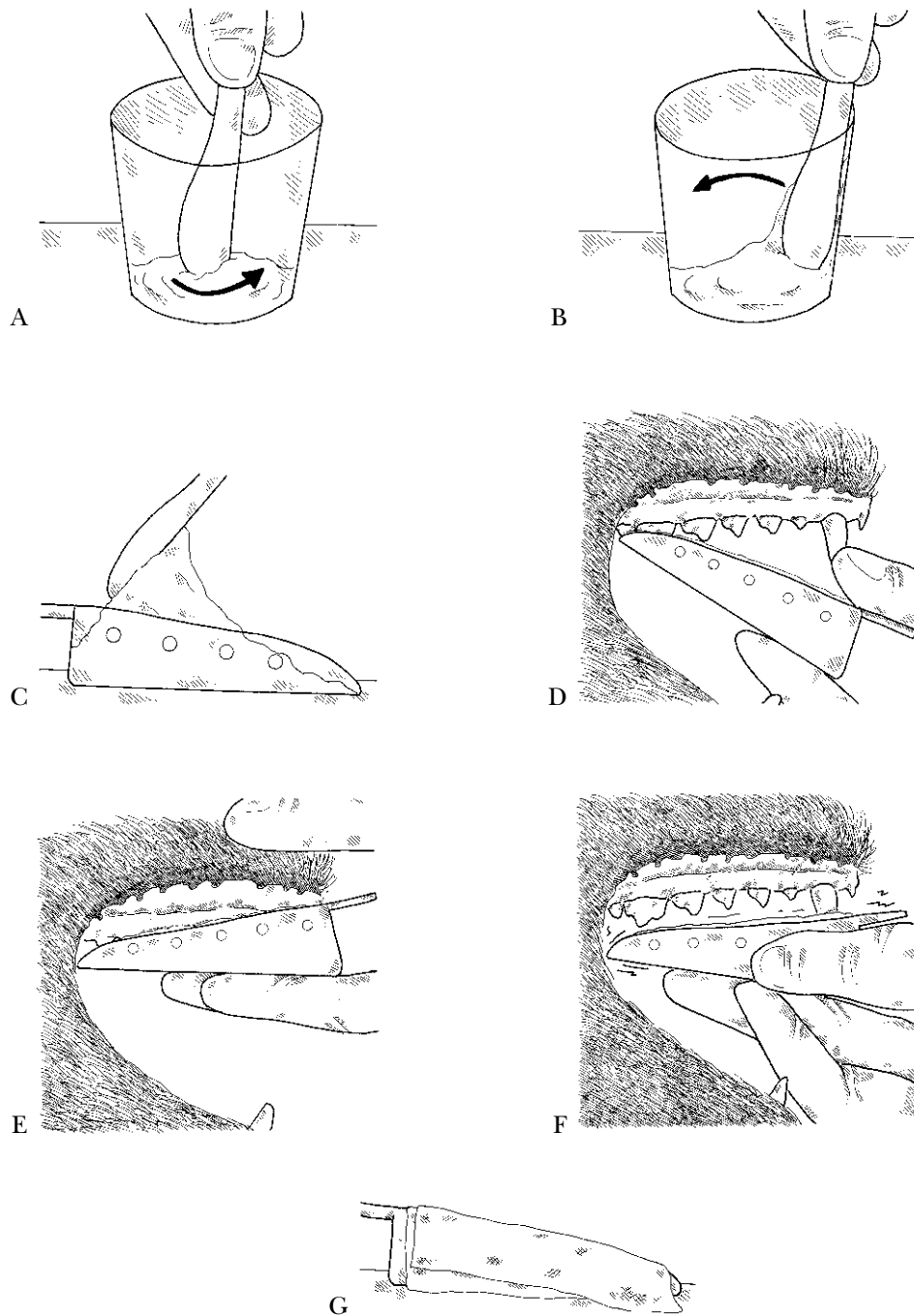


Fig. 9-5

Making a Model

General Comment

- Once the impression is made, a cast model should be poured as soon as possible.

Indications

- The model is used as part of the medical record.
- With a model, oral structures can be evaluated separate from the patient, orthodontic bite evaluation can be made, and a treatment plan can be created for orthodontic appliances or crown and bridge fabrication.
- The model or a copy of the model may be used to fabricate appliances or may be used in oral surgery for production of an acrylic splint.
- The model may be used to facilitate communication with colleagues or laboratory personnel.
- The model may be used as a visual aid in discussing the case with the client, showing the indicated treatment and how the appliance will function.
- The model may also be used for forensic documentation and evaluation.

Materials

- An accurate impression.
- Die stone. There are several types of plaster and dental stone, depending on the fabrication process. Type II plaster has low strength and hardness and often is used as the base for models. Type III dental stone has moderate strength and often is used for fabrication of dentures. Type IV stone (die stone) has high strength and hardness with minimal setting expansion and is the preferred stone in veterinary dentistry. Type V stone has high strength and a high setting expansion and is for use with alloys.
- Mixing bowl and spatula.
- Vibrator.
- Scale.

Technique

- It is often beneficial to mix a small amount of stone with a more fluid consistency first to allow flowing of the stone into the indentations made by the teeth when placed on the vibrator. When these areas are filled, a second, thicker batch of stone can be used for the rest of the model.

Step 1—The water is measured and placed in the bowl (Fig. 9-6, A).

Step 2—The stone is measured, ideally by weighing (Fig. 9-6, B), and added to the water all at once.

Step 3—Mixing is started in the center of the bowl (Fig. 9-6, C). After all the water is incorporated into the stone, the mixture is spatulated on the sides of the bowl to remove air bubbles and to remove lumps of unmixed powder. The bowl is turned, and spatulation is performed in one direction to minimize bubbles.

Step 4—The bowl with the stone can be placed on the vibrator during this process to help remove air bubbles (Fig. 9-6, D).

Step 5—The impression is rinsed gently with water. Excess water is removed with compressed air.

Step 6—An edge of the tray with the impression is placed on the vibrator (Fig. 9-6, E).

- A small amount of mixed liquid stone is placed in the center of the impression with a small spatula.
- With the aid of the vibrator, the stone is made to flow into the depressions created by the teeth. Take enough time to allow the stone to move into the voids without trapping air. This is the most critical part of the process. With the impression resting on the activated vibrator, a small cylindrical applicator stick may be used to stir the liquid stone material in each tooth depression, to aid in removing bubbles.
- For smaller teeth, a disposable brush may be used to place a small amount of mixed stone into the individual tooth impressions; avoid bubble formation, especially at the cusps of the teeth.

Step 7—After the stone is spread into the intricacies of the impression and any air bubbles have been vibrated out, the vibrator can be turned off, and additional stone of a thicker consistency is placed on the impression to make the model thick enough to minimize fragility (Fig. 9-6, F).

- Two options are available to make the base of the stone. The first layers of stone that fill in the impression tray can be allowed to harden slightly, and additional stone or plaster is placed on this first layer to create a base as described below. If sufficiently thick stone is used, a one-step model and base can be made without waiting for the stone to set initially.

Step 8—The impression is placed, with the stone in it, on a flat surface and allowed to set for 10

to 15 minutes (Fig. 9-6, G). Additional stone can now be added to the model to create a base. Start by mixing another batch of stone or plaster the same way as previously described.

- Place a layer of the stone onto the bottom of the hardened stone (Fig. 9-6, H). It can be shaped to form a flat base, or the pre-hardened model can be placed upside down

onto a block of plaster on a glass slab or countertop and leveled. Excess stone can be removed before it hardens to provide a shaped model when removed from the impression tray, if a model cutter is not available. The stone should be allowed to set for at least 45 minutes.

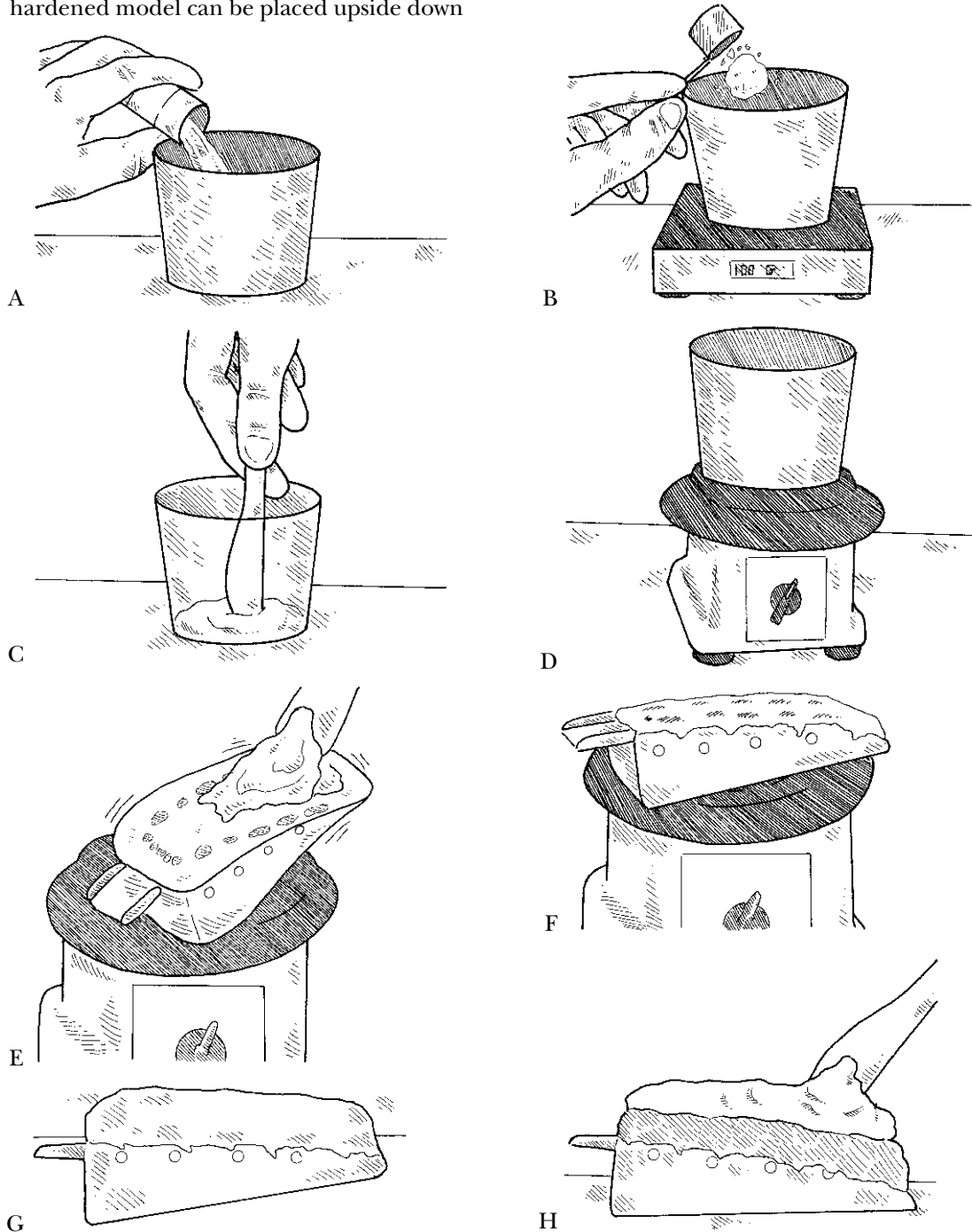


Fig. 9-6

Step 9—The hardened stone is removed from the alginate impression after 45 to 60 minutes (Fig. 9-7, A), usually after the model has cooled following the exothermic cycle of setting. If the alginate is too dry, separation is more difficult. A laboratory knife can be used to free the margins. The model is separated gradually upward from the alginate. Do not rock the model, because this may lead to fracture of a canine tooth on the model (Fig. 9-7, B).

- Another technique is to remove the impression tray first. With the stone down and the alginate on top, a sagittal wedge of alginate is removed with a laboratory knife from the center of the impression. Transverse cuts are then made so that the alginate can be removed segmentally with the knife.

Step 10—After the alginate is removed from the models, the edges of the stone can be trimmed with a model trimmer. The models are placed in occlusion with the bite registration in place, and the caudal aspect and sides of the models are placed against the moving trimmer wheel to align the caudal edges of the upper and lower models. To realign the models, they can be placed on their caudal aspect and gently slid together.

Step 11—Label the model with the patient's and client's name, date made, and the clinic's name. It is also helpful to identify, for the laboratory, on opposing arches and teeth cusps, places of occlusal contact. This can be accomplished with a Sharpie marker pen.

Complications

Incorrect Mix Ratios

- The stone will not flow if the mixture is too thick. Correct by using a thinner mixture, but changing the proportions from the manufacturer's instructions may cause distortion. A swab stick may be used to stir the thinner mix to help it fill the cusps of the teeth.
- Too thin a mixture will be weak and not as dimensionally stable. Correct by mixing more thickly.

Inadequate Mixing

- Lumps of unmixed stone will be found in the mix. Mix more thoroughly.

Air Bubbles

- Mixing can incorporate air into the stone mixture. Correct by spatulating against the sides of the bowl.
- Air can be trapped in the intricacies of the impression. This usually happens when the stone is placed in the impression too rapidly and is not allowed to flow into the small voids of the impression. Correct by placing small amounts of stone on the impression and allowing it to spread slowly, using the vibrator.
- In deep voids, such as those made by the canine teeth, a small amount of water left in the void will aid in prevention of trapping air.

Flexible Trays

- Allow the impression to become distorted before the stone is poured or set.

Desiccation of the Alginate

- The time between taking the impression and pouring the stone is too long. The stone should be poured quickly after the impression is taken. Wrapping the impression in a damp paper towel until it is poured or when sent to a dental laboratory will diminish this distortion. If the impression is sent to a laboratory before the stone is poured, the alginate wrapped in a damp paper towel should then be placed in a plastic bag until picked up by the laboratory. This will allow the delay of pouring the stone.

Fracturing of Crowns on Model Teeth

- This often is caused by trying to remove the stone from the impression too early (Fig. 9-7, B). Be patient. Even the most patient practitioner will break a crown occasionally as the model is removed from the impression. Most of the time the fractured piece can be placed back in position and cemented. Allow the model and fragment to dry completely. Cut the impression material away from divergent mandibular canines to reduce the incidence of these teeth being broken at the time of removal of the impression material.
- After the model is dry, the fractured piece can be repaired either with a glass ionomer cement or with polymethacrylate (Fig. 9-7, C and D).

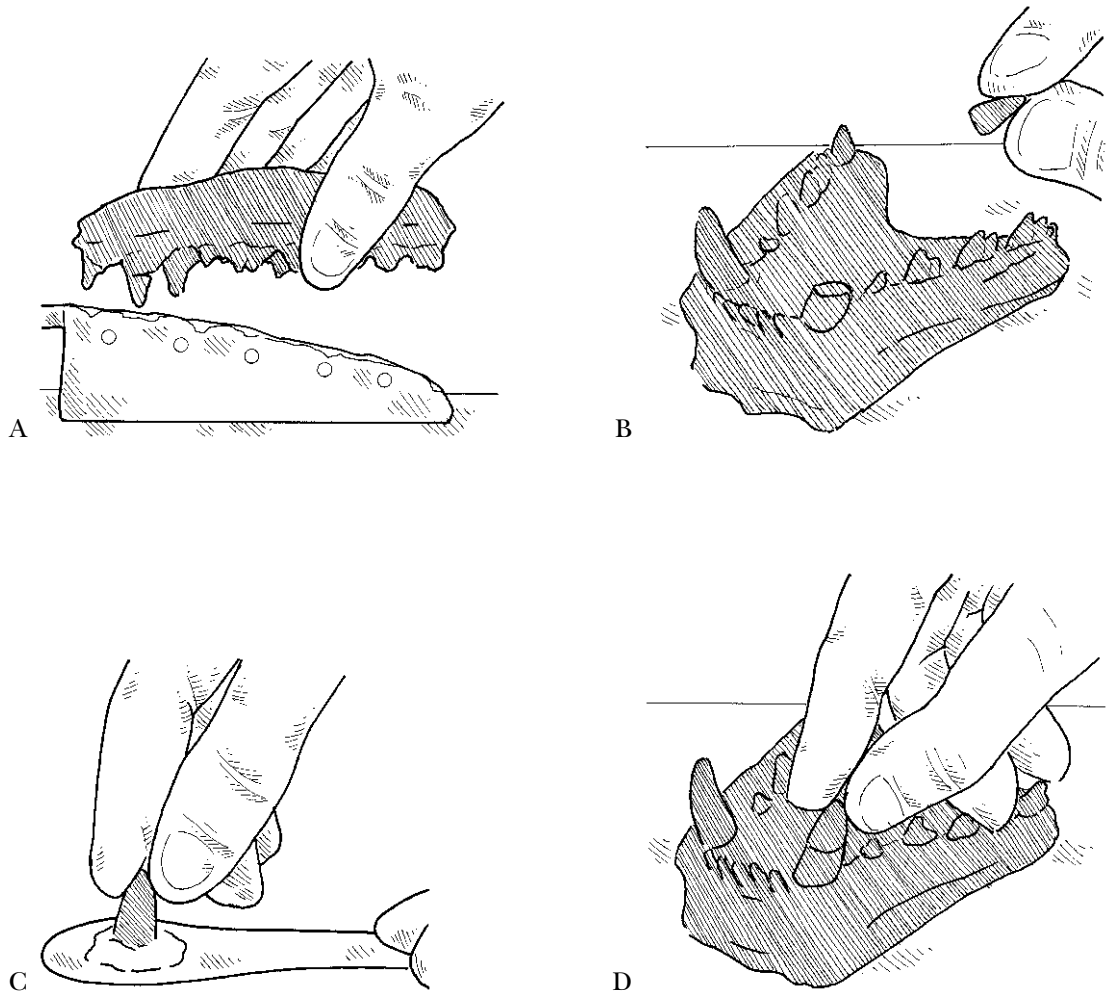


Fig. 9-7

- For very long teeth with narrow diameters, a small piece of orthodontic wire (24 to 26 gauge) may be placed in the impression before pouring the model. This will support the teeth and will help prevent fracture.
- The dry model may also be coated with a liquid model hardener to reduce breakage during shipment and handling.

Direct Bonding of Bands, Brackets, and Buttons

General Comments

- Brackets or buttons are bonded to teeth to attach devices for applying forces to achieve orthodontic movement.
- Bands can be used alone for attachment of elastics or arch wires, or are incorporated into an appliance for fixation to the teeth.

Indications

- Attachment of fixed or removable acrylic or metal appliances.
- Attachment of lingual or labial arch wires.
- Attachment of acrylic or metal appliances.
- For orthodontic movement with elastics.

Contraindication

- Patients that cannot be orally controlled or that chew on hard objects.

Materials

- Bands, brackets, or buttons.
- Orthodontic bracket-bonding cement, such as Unite (Unitek, Monrovia, Calif.) or Durelon carboxylic cement (3M ESPE, St. Paul, Minn.) or a dual-cure or light-cured composite resin with bonding agent.
- Spatula.
- Bracket forcep or college pliers (to transport the bracket).
- Band pusher or a hemostat forcep (to put pressure on the bracket while the cement sets).

- Hand scaler (to remove excess cement).
- Flour pumice, prophyl cup.

Technique

Step 1—The teeth that are to have brackets attached are scaled to remove any calculus (Fig. 9-8, *A*).

Step 2—A flour pumice is used to polish and remove any plaque (Fig. 9-8, *B*).

- Do not use prophyl paste, because it may contain fluoride, waxes, essential oils, and glycerin that may inhibit the bond.

Step 3—The bracket or button is chosen and trial placed on the tooth (Fig. 9-8, *C*). The baseplate should fit the contour of the tooth. If it does not fit, three-pronged pliers are used to bend the bracket or button baseplate to conform to the tooth surface.

Step 4—Phosphoric acid etching gel is placed on the tooth to etch the surface for 30 to 60 seconds (Fig. 9-8, *D*). The time depends on the acid concentration and whether the active or passive technique is used. With the active technique, the operator scrubs the tooth surface with a sponge or brush and acid-etches for a prescribed time. The passive technique allows the phosphoric acid to coat the tooth undisturbed for a prescribed time. Whether the active or passive technique is used depends on the manufacturer's instructions for the bonding agent. These instructions should be followed.

Step 5—Using a three-way syringe, water is used to rinse off the acid (Fig. 9-8, *E*). It is best to make sure rinsing is complete by rinsing for 20 to 30 seconds.

Step 6—The tooth is dried using air from the three-way syringe (Fig. 9-8, *F*) or from a handheld hair dryer on a low setting. For the bond to be solid, it is critical that this air be free of moisture and oil. For this reason, it is safest for the clinician to wear procedure gloves when handling the bracket.

- At this point the area on which the bracket will be placed should have a dull, chalky appearance.

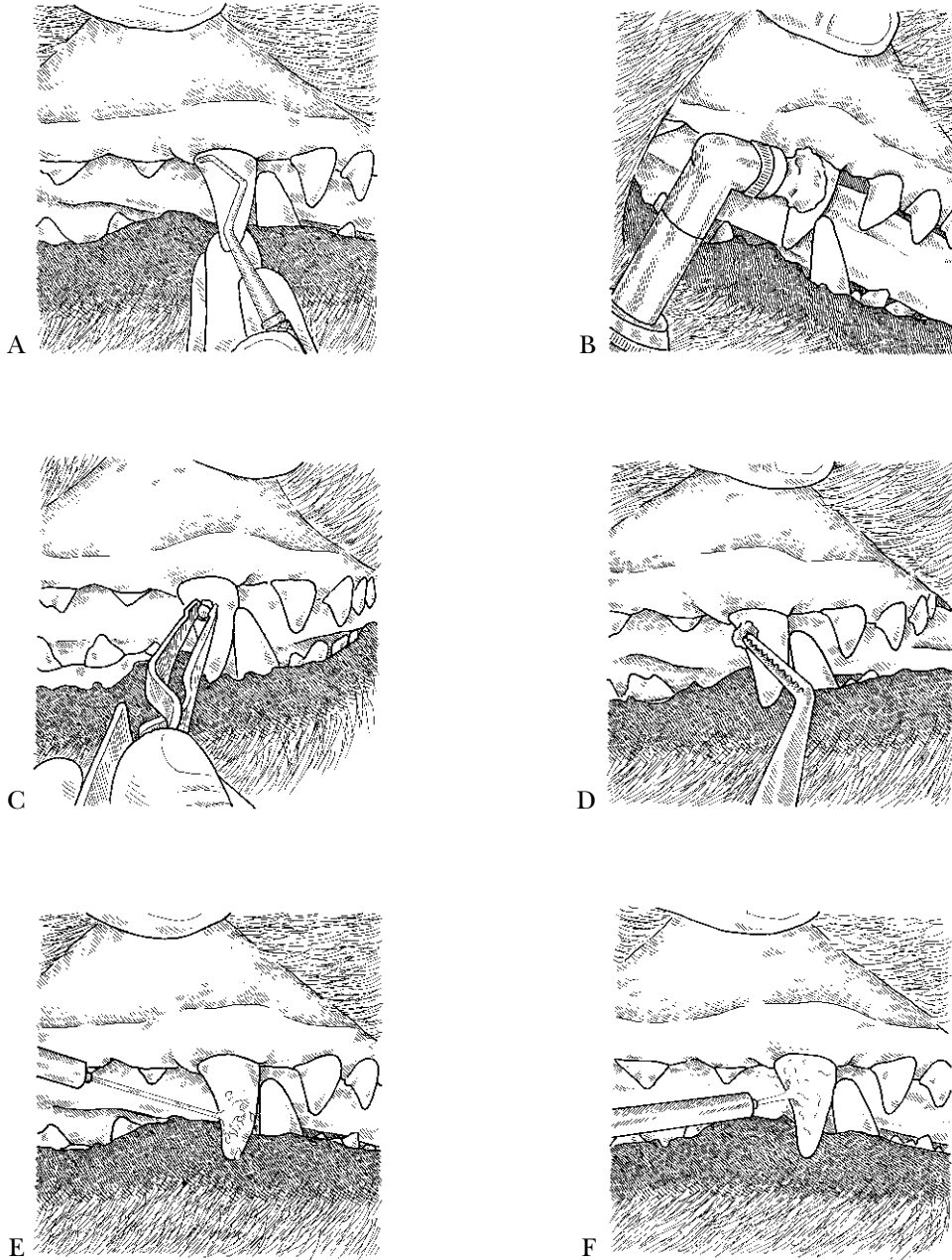


Fig. 9-8

- If contamination of the prepared tooth surface occurs from saliva, blood, oil, or other substance, the preparation should begin again from step 2, but reducing the etching time by 75%.

Step 7—The unfilled bonding agent is mixed and applied to the surface of the tooth (Fig. 9-9, A) and to the baseplate of the button or bracket (Fig. 9-9, B).

Step 8—The filled bonding agent is mixed (Fig. 9-9, C) and is placed on the back side of the bracket (Fig. 9-9, D). (Each manufacturer has specific instructions on the way its products should be mixed and handled. These materials are very technique sensitive.)

Step 9—The bracket is placed on the tooth in the position desired and pressed firmly against the tooth so that some of the bonding agent exudes around the edges of the bracket (Fig. 9-9, E).

Step 10—Excess bonding agent is removed with a hand scaler before it has set (Fig. 9-9, F). An ultrasonic scaler might vibrate the bracket loose. Wait to put a force on the bracket until the bonding agent has had the required time to finish polymerizing (Fig. 9-9, G). The time is stated in the package insert of the bonding agent.

- Test the strength of the bond by putting pressure on the bracket with college pliers. If the bond is not sufficient, it is preferable to test it and to rebond it while the patient is under anesthesia than to have the procedure fail, requiring a subsequent visit and additional anesthetic.²

Complications

Brackets or Buttons Come Off When Force First Applied

- Usually, directions were not followed meticulously.
- The tooth was not clean, etched, and absolutely dry.
- The base of the bracket did not conform to the contour of the tooth.

Brackets or Buttons Come Off Later

- Oral abuse, such as chewing on hard objects, can shear brackets or buttons off. Also, long hair, carpet yarn, or strings tangled on the appliance will pull them off. Improper placement of buttons or brackets may result in occlusal interference with the appliance and displacement of the bracket.

- Clients must be advised to protect their investment: during the time of orthodontic treatment, the patient must not be allowed to chew on hard objects. It may be necessary for the patient to wear a cloth muzzle when not monitored.

Discoloration of Tooth When Brackets Are Removed

- This happens when the brackets are not kept clean; cleaning the brackets is one of the reasons for the practitioner to schedule visits for monitoring the patient.
- Using cements that are not customarily used for orthodontics may cause tooth staining.

Excess Tension Placed on Active Tooth With Elastic Apparatus Attached to Brackets (or Increased Amount of Pressure or Frequency of Adjustments)

- Pulpitis. The client has changed the elastics and has applied too much pressure on the active tooth.
- Pain and irritability, noted by patient pawing at face or rubbing face on wall or carpet or displaying other neurotic signs. Client or clinician has applied too much tension on the active tooth.

Aftercare

- Periodic, timely progress examinations will be needed to evaluate tooth movement and to ensure that proper oral hygiene is being performed. The interval depends on the treatment, progress of the active tooth, and client/patient compliance with restricted oral activity.

Removing Buttons and Brackets

- When the treatment is completed, edgewise brackets are removed easily by squeezing the flanges of the bracket with How pliers, snapping the bracket from the tooth. It is best to use orthodontic cements because they are designed to yield before stripping the enamel off the tooth.
- Buttons can be removed by grasping the protruding button with a pliers and gently applying torque to release the bond to the tooth.
- The residual cement is removed with a hand scaler, and the tooth is cleaned with an ultrasonic scaler and polished with a fluoride prophylaxis paste.

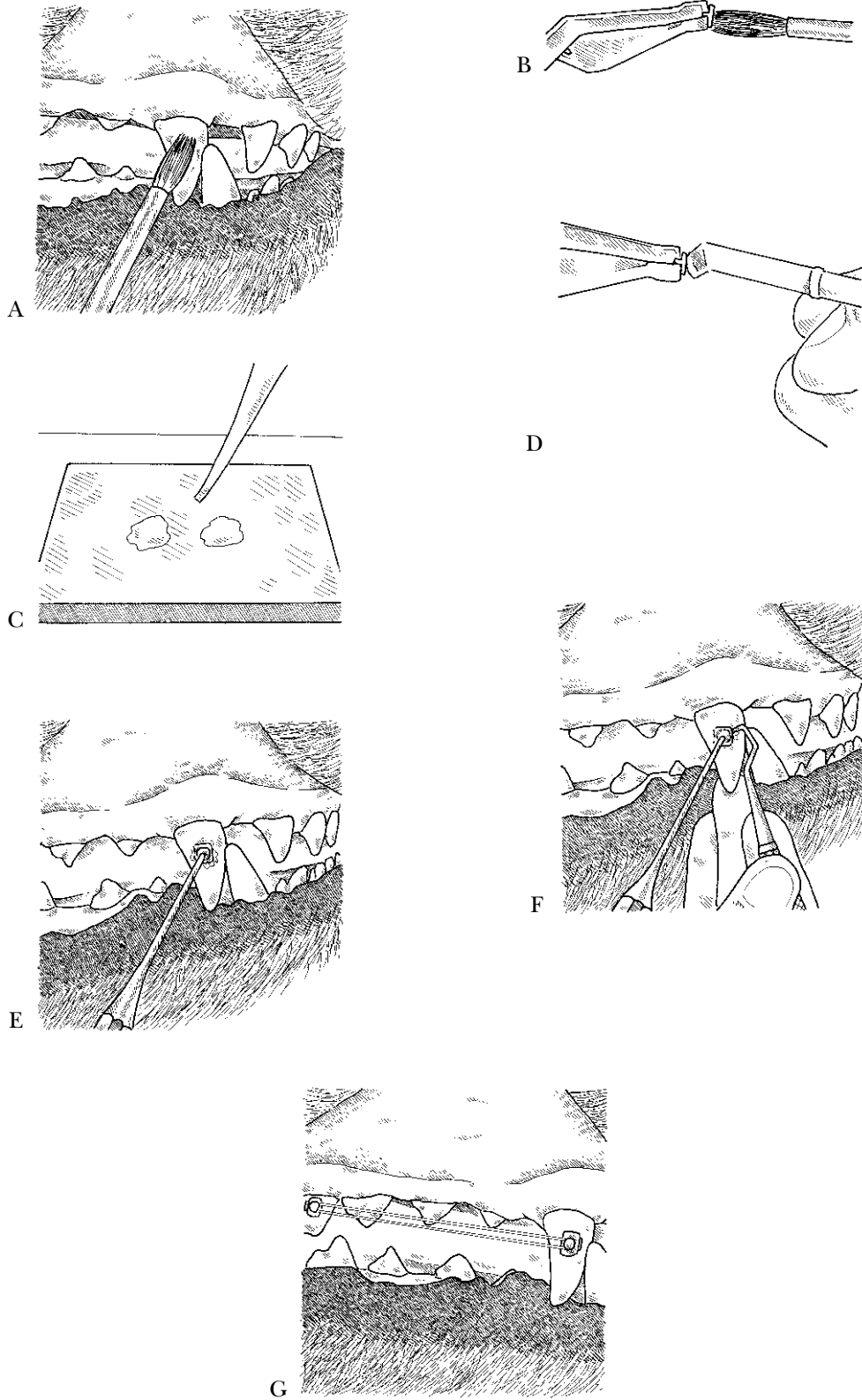


Fig. 9-9

ORTHODONTIC APPLIANCES

Making Bands

General Comments

- Orthodontic bands may be used as alternatives to buttons or brackets.
- Because orthodontic bands wrap around the entire tooth, they provide more bonding surface area and mechanical retention and are more durable than buttons and brackets.
- The bands may have brackets, buttons, pegs, or hooks soldered to them, or bands may be incorporated into arch wires.

Indications

- Orthodontic tooth movement.
- Lingual or labial arch wires.
- Attachment of acrylic or metal appliances.

Contraindication

- Poor client or patient compliance with oral hygiene.

Materials

- Patient's dental model.
- Band material. Suggested sizes: 0.150×0.003 inch, 0.150×0.004 inch, 0.180×0.005 inch, and 0.180×0.006 inch.
- Flux. This should be a flux recommended for orthodontic work.
- Silver solder.
- Gas torch.
- Orthodontic welder (optional).
- Orthodontic bonding material or luting cement (acrylic, composite resin, zinc oxide–eugenol, or glass ionomer).

Technique

Step 1—A dental stone model is manufactured as previously described in this chapter.

Step 2—The band material is contoured to conform to the tooth shape on the model at the location where the band will be placed.

Step 3 (Optional)—The band material is clamped with hemostats to secure its shape and is removed from the model. The band material may be spot (“tack”) welded to hold

it in place. The band material is replaced on the model.

Step 4—The ends of the band material are bent along the portion of the band circling the tooth.

Step 5—Excess band material is trimmed and removed.

Step 6—Flux is applied to the band in the area to be soldered.

Step 7—The band is soldered.

- Arch wires or buttons may be soldered or welded onto the band.

Step 8—The tooth to be banded is prepared for button or bracket placement.

Step 9—The orthodontic bonding cement is mixed and applied to the inside of the band (Fig. 9-10, A).

Step 10—The band is placed over the crown of the tooth to be banded (Fig. 9-10, B).

Step 11—The band is seated firmly with pliers (Fig. 9-10, C) or a band pusher. Excess cement is removed with a curette.

Complications

- Excess heat applied to the band may melt and destroy the band.
- Poor cementing technique may cause the band to detach from the tooth or may create voids that lead to microleakage, causing decay beneath the band, observed as a black stain in the tooth enamel when the band is removed.

Removing Bands

- Bands can be removed by using band-removing pliers, which have a narrow edge that catches the apical edge of the band, while the opposite jaw has a cup that is placed on the tooth's cusp. The pliers are squeezed, the cement seal is broken, and the band is dislodged. Excessive force may damage the tooth. It may be necessary to cut cast bands with a diamond bur.

- Remnants of cement are removed with a hand or ultrasonic scaler, sonic scaler, or finishing bur (glass ionomer cements are more easily removed than composite luting cements). Some crown cements may have more bonding strength than desirable.

- The tooth is polished with a fluoride prophylaxis paste.

Indirect Bonding of Brackets

General Comment

- Allows precise placement of brackets on teeth.

Indications

- Correction of rotated teeth.
- Placement of an edgewise appliance.

Contraindications

- Inadequate home care.
- Oral abuse by the patient.

Materials

- Brackets.
- Silicone high-viscosity and low-viscosity impression material.
- Alginate.
- Die stone.
- Laboratory knife.
- Water-soluble adhesive.
- Bonding material.

Technique

Step 1—Impressions are taken and models are made as previously described.

Step 2—The bracket location is marked on the model with a pencil (Fig. 9-10, *D*).

Step 3—A line is drawn to mark the long axis; the exact location of bracket is determined on these two lines (Fig. 9-10, *E*).

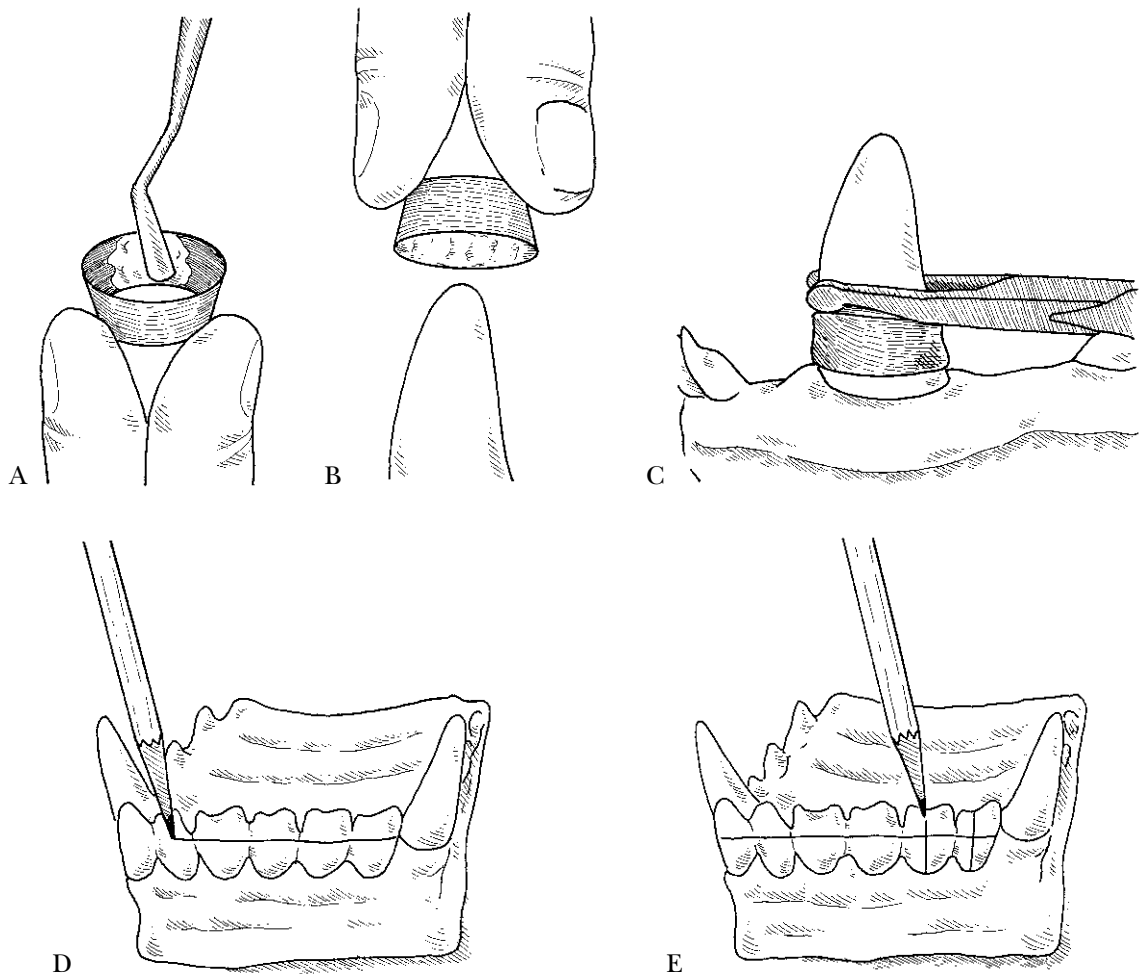


Fig. 9-10

Step 4—A small dot of water-soluble adhesive is applied to the marked bracket location, and the brackets are placed on the model (Fig. 9-11, *A*).

Step 5—Proper orientation of the brackets is checked.

Step 6—A low-viscosity silicone impression material is mixed.

Step 7—The material is applied around each bracket (Fig. 9-11, *B*).

Step 8—A high-viscosity material is mixed and applied.

Step 9—Impression material is peeled away from model, leaving brackets in position in the impression (Fig. 9-11, *C*).

Step 10—The tooth surface is prepared (see p. 516).

Step 11—Bonding material is mixed and applied to the base of the brackets (Fig. 9-11, *D*).

Step 12—Impression material with brackets is placed on patient in proper position; brackets are pressed against the teeth (Fig. 9-11, *E*).

Step 13—After bonding material has set, impression material is removed, and a wire is placed as needed (Fig. 9-11, *F*).

Complications

- Incorrect placement of brackets.
- Removal of brackets with impression material.

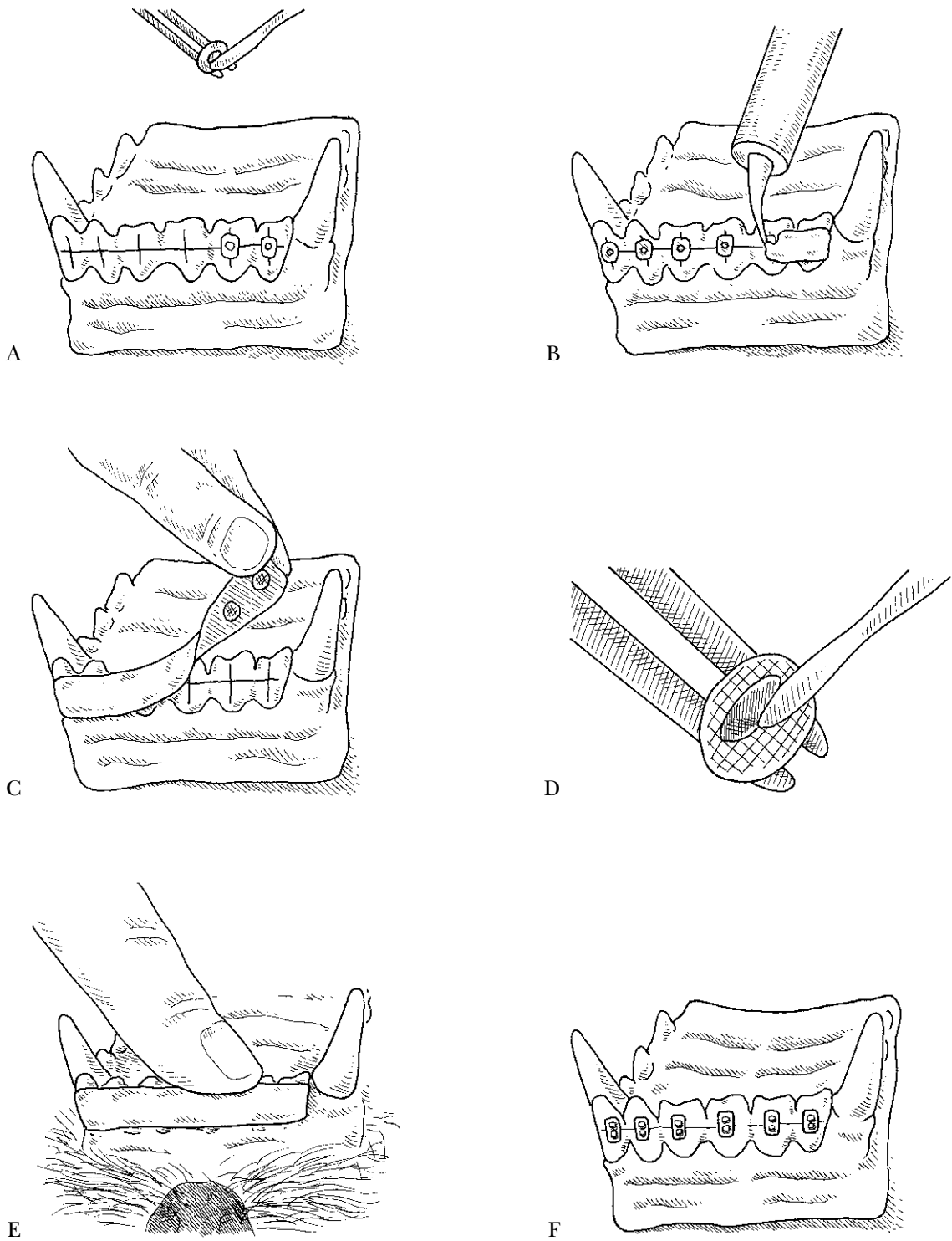


Fig. 9-11

Orthodontic Wire

General Comments

- Orthodontic wire diameter is measured in thousandths of an inch. The higher the number, the greater the cross-sectional area and relative rigidity of the wire.
- The annotation 188 indicates that the wire consists of 18% chromium, 8% nickel, and the rest iron.
- Elgiloy wire also contains cobalt and molybdenum. The ends of the wire have paint on them to indicate various wire characteristics: (1) red paint indicates greater spring in the wire, but that the wire is brittle, and therefore no sharp bends should be made, (2) green paint indicates good spring temper, but the wire should not be used for welding or soldering, (3) yellow paint indicates the wire is ductile, that it has good spring, and that it bends easily, and (4) blue paint indicates the wire has soft and regular temper, can be soldered, and can be welded with low heat.
- All Elgiloy wire can be heat treated to increase spring quality.
- Proportional limit, a property of wire, is the ability to return to its original position when it is bent and released. If pressure continues to be applied, the wire will reach a stress point and not return to its original position because permanent deformation has occurred.
- The bird-beak pliers are a universal pliers in orthodontics. The conical tip creates a uniform curvature, and the pyramid tip bends or adjusts loops at sharp angles. The actual bends are made by applying pressure with fingers.

Techniques

- To cut the wire, it should be held in one hand, grasping and controlling both ends as

the cut is made. The cutters should be held firmly in the other hand (Fig. 9-12, *A*).

- To create a smoothly curved arch, the wire is held with the pliers in one hand, and the thumb or index finger is drawn over the wire against the conical tip in a downward motion (Fig. 9-12, *B*). Repeating the process will draw the curve tighter.
- To create a right-angle bend, the wire is held in the bird-beak pliers, and the wire is bent over the pyramid tip.
- Smaller bends and loops are made with the conical beak, with the position of the wire on the cone determining the diameter of the loop.

Soldering Techniques

General Comment

- Flux protects metal and solder from oxidation.

Technique

- In this technique, a smaller wire will be soldered to a larger one.
- Step 1—Place flux on tip of the smaller wire (Fig. 9-12, *C*).
- Step 2—The wire is heated by bringing it to the top of the flame (Fig. 9-12, *D*).
- Step 3—Solder is touched to the wire, and the solder is fed from a coil to make a ball of solder and flux 2 mm in diameter (Fig. 9-12, *E*).
- Step 4—To weld the wires together, the larger one is held in flame and heated (Fig. 9-12, *F*).
- Step 5—The wire with solder is then touched near the larger wire. The solder should flow toward the flame (Fig. 9-12, *G*).
- Step 6—Excess solder can be removed with a bur or with a rubber wheel in a handpiece.

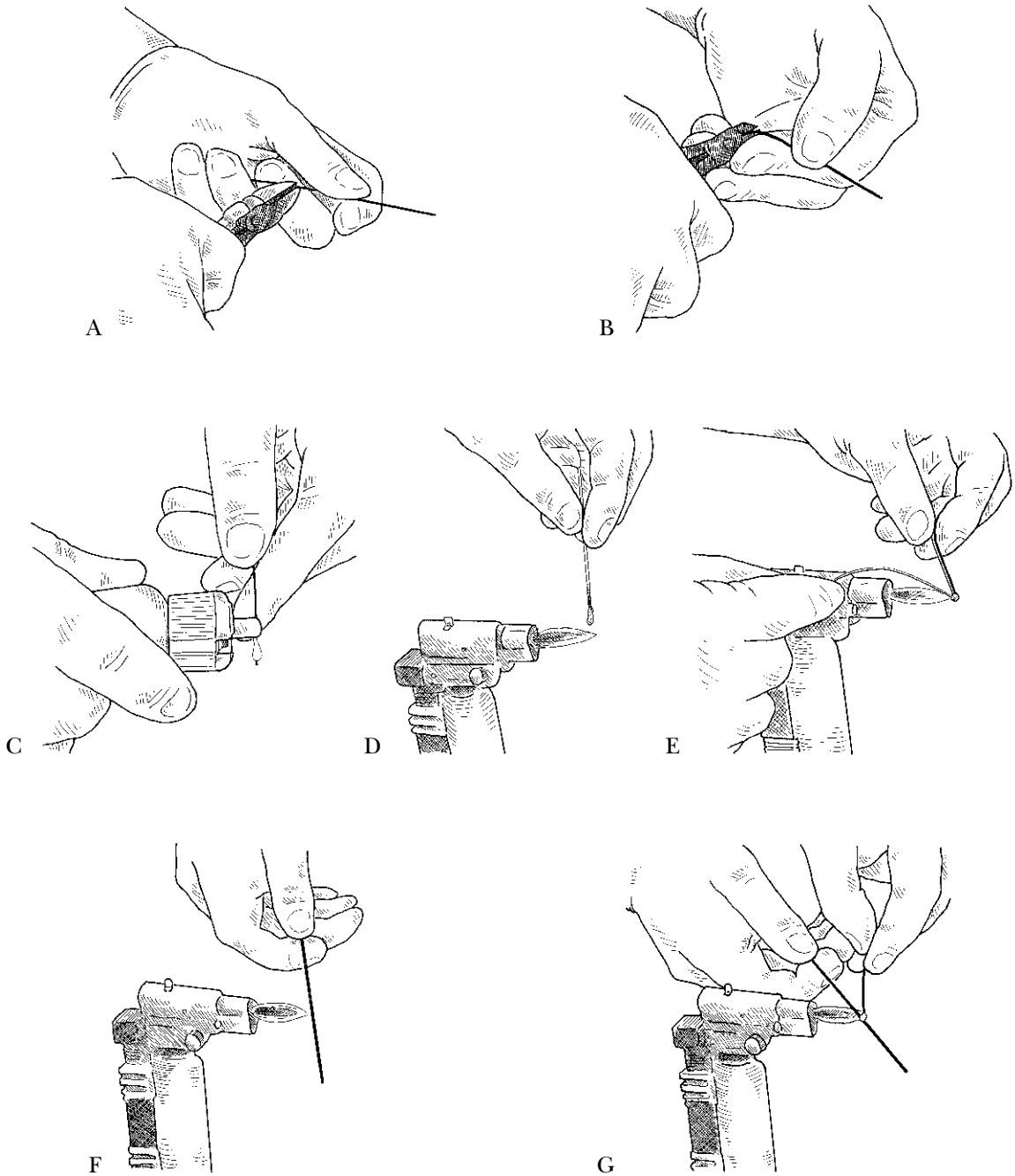


Fig. 9-12

Complications

- Overheating the wire to cherry red causes it to be annealed and destroys its spring temper, making it unsuitable for holding or working arch functions.

Making Acrylic Appliances

General Comment

- An acrylic appliance may be fabricated either by a dental laboratory or by the practitioner.^{5,6}

Indications

- Orthodontic tooth movement.
- Splinting of avulsed teeth.
- Splinting of oral fractures.

Contraindications

- Severely infected areas.
- Uncooperative patients that may not allow oral hygiene.

Materials

- Cast dental model, as previously described. It is recommended that a second “working model” be manufactured, whether by taking a second impression on the patient, by pouring two models from the first impression, or by

taking an impression of the first model and pouring a second model from this impression.

- Tinfoil substitute: material to inhibit bonding of acrylic to the working model.
- Rope wax.
- Sticky wax.
- Dental acrylic (denture-type material).
- Ruby laboratory burs.
- Wax carving instrument.
- Propane or alcohol torch.

Technique (Beginning)

Step 1—The area on the model where the appliance will be built is coated with the tinfoil substitute and is allowed to dry (Fig. 9-13, *A*).

Step 2—Rope wax, used to fabricate a retaining wall to contain the poured acrylic, is placed around the area for which the appliance is to be manufactured (Fig. 9-13, *B*).

Step 3—Any wires, such as finger springs or retaining wires, are bent and placed on the model in the desired position (Fig. 9-13, *C*).

Step 4—Sticky wax is placed by heating a wax carving instrument and dipping it into the hardened wax so the wax melts onto the instrument (Fig. 9-13, *D*) and flows onto the model and wire (Fig. 9-13, *E*). When the wax cools, it will harden and hold the wire in the desired position.

Step 5—The acrylic is placed onto the model.

- Three techniques are used to place the acrylic onto the model.
- Any one or all of the techniques may be used.

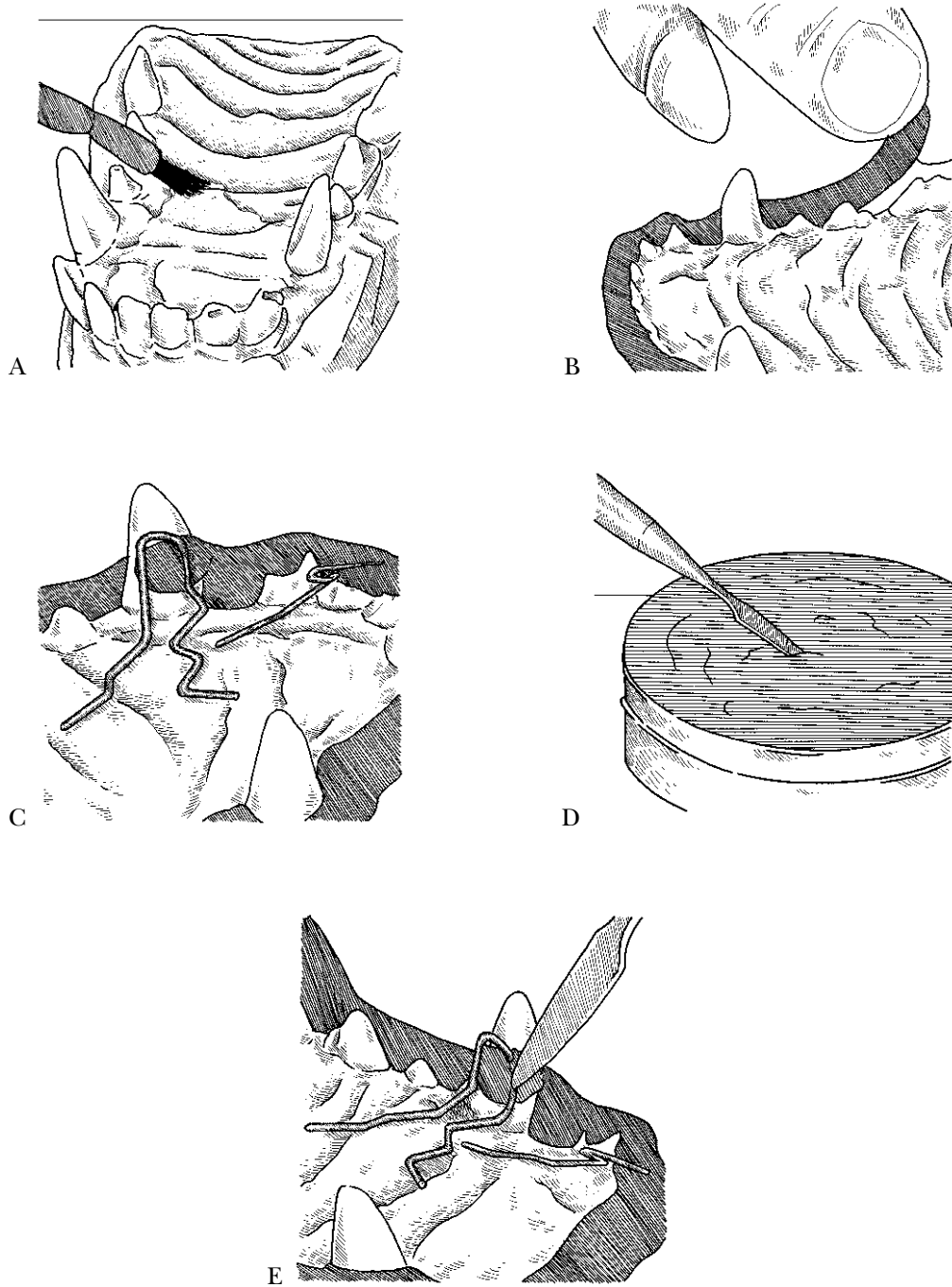


Fig. 9-13

Alternative 1: "Salt and Pepper" Technique

Step 1—A light coating (1 to 2 mm) of the acrylic powder (polymer) is sprinkled from the container onto the model in the area contained by the rope wax (Fig. 9-14, *A*).

Step 2—Drops of the acrylic liquid (monomer) are dropped onto the powder (Fig. 9-14, *B*). The powder will undergo a color change as the polymer is wetted (the color depends on the brand and shade).

Step 3—Additional polymer and monomer are added to build up the appliance as desired (Fig. 9-14, *C*).

Alternative 2: Mixing Technique

Step 1—The powder is placed in a paper cup (Fig. 9-14, *D*).

- The rubber bowl used for alginate should not be used, because the acrylic will destroy the bowl.
- Special glass or flexible bowls are made for this use.

Step 2—The liquid is added, according to the manufacturer's directions (Fig. 9-14, *E*).

Step 3—The liquid and powder are mixed with a spatula (Fig. 9-14, *F*).

Step 4—The mixture is poured onto the model (Fig. 9-14, *G*).

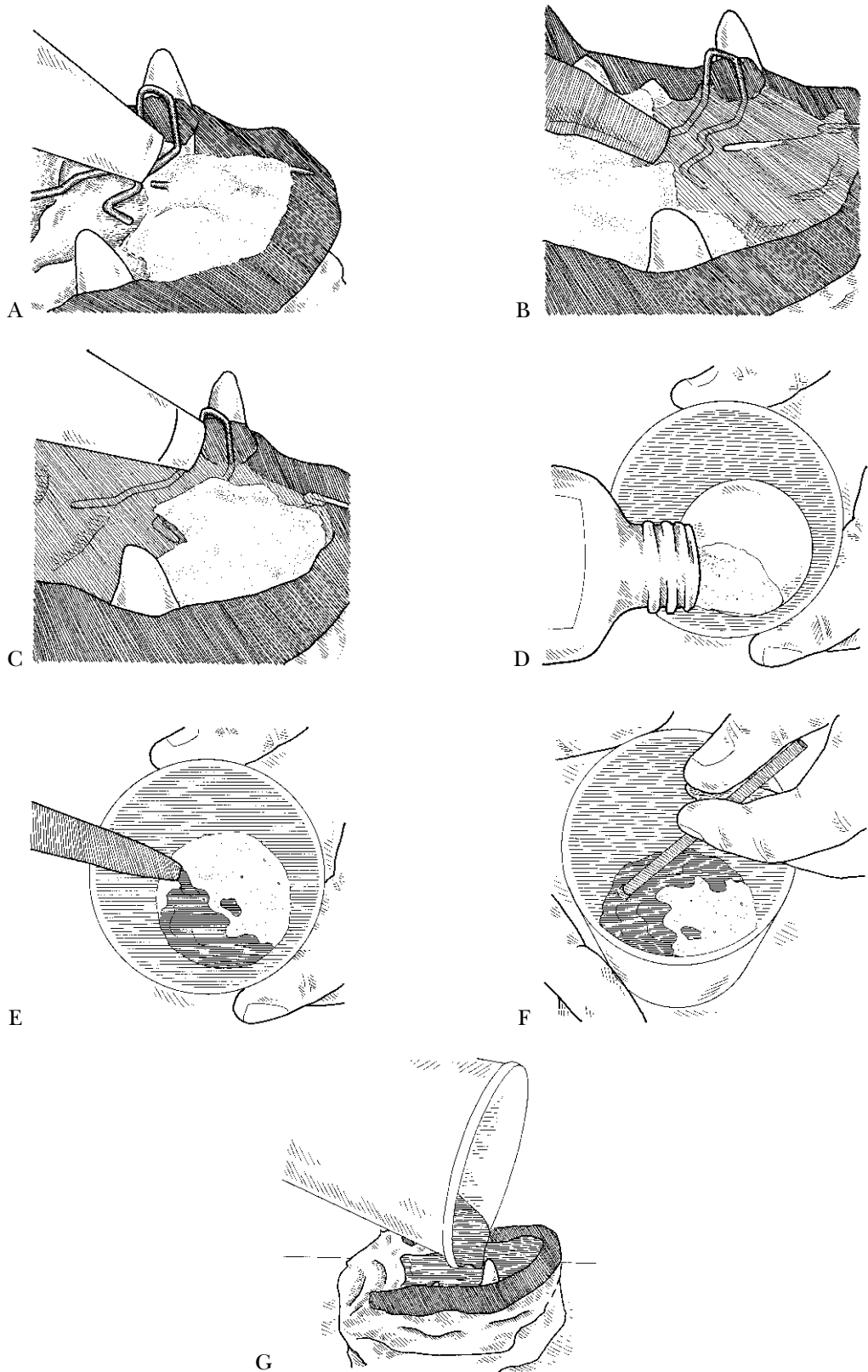


Fig. 9-14

Alternative 3: Brush Technique

Step 1—The polymer and monomer are each placed in dappen dishes (Fig. 9-15, A).

Step 2—A brush is dipped into the polymer (Fig. 9-15, B) and then dipped into the monomer (Fig. 9-15, C) to obtain a small amount of acrylic on the brush tip. The polymer absorbs the liquid monomer.

Step 3—The paste of acrylic is carried and placed on the model in the desired location (Fig. 9-15, D).

- The brush technique allows a precise placement of the dental acrylic.

Technique: Conclusion

Step 6 (Optional)—The model and appliance are placed in a pressure pot, and then pressure and heat are applied to eliminate air bubbles and to make a stronger appliance. Acrylic cured in this manner is more transparent.

Step 7—Once hardened, the appliance is removed from the model.

Step 8—With a laboratory bur and low-speed handpiece, the appliance is trimmed and shaped.

Step 9 (Optional)—The appliance is smoothed with a polishing wheel.

Complications

Appliance Sticking to Model

- Failure to apply adequate amount of tinfoil substitute or releasing agent.

Breakage of Appliance

- The appliance is too thin or needs reinforcing wires.

Breakage of Model

- Breakage of the model while manufacturing the appliance almost always occurs; therefore, a working model should be used. It is helpful to keep a duplicate model at the clinic in these cases.

INTERCEPTIVE ORTHODONTICS

General Comments

- The face and the jaw grow independently during development, usually at the same rate.

- The right and left sides of the face and jaw grow independently, usually at the same rate.
- The maxilla and mandible each exhibit intermittent, incremental, segmental growth spurts.
- The “dental interlock” formed by the mandibular teeth occluding (locking) with the maxillary teeth usually inhibits the independent growth and development of the bony structures of the jaws. Occasionally, one of the segmental growth spurts is denied because of other developmental demands. This denial can possibly be caused by an infection, parasitism, or other dramatic stress during fetal, neonatal, or early growth development.
- By interfering with this lock, the bony structures are more readily allowed to grow independently of each other and more closely reflect genetic programming.
- Interfering primary teeth may be extracted (interceptive orthodontics) to allow the mandible and facial-maxillary complex to grow independently.
- It is important to understand that interceptive orthodontics allows for a facial or mandibular growth catch-up, if it will; it does not stimulate such catch-up development.
- A primary tooth may be extracted to create space for an adult tooth to erupt unimpeded.

Indications

- Abnormal occlusion in a young patient before the eruption of the adult teeth. Treatment is started as early as possible to allow the longest time for correction to occur before the secondary teeth erupt.
- Retained deciduous teeth. Any primary tooth that is not lost by the time its homologous adult tooth has begun to erupt should be extracted.⁷⁻⁹ There should never be two teeth of the same type in the same place at the same time.

Technique

Step 1—The bite is evaluated, and the desired movement identified. For example, in a patient with a class 2 occlusion, the mandible needs to be longer.

Step 2—Any primary tooth that is inhibiting or would inhibit the desired growth catch-up is extracted. Extract each complete tooth and root; do not damage the developing permanent tooth bud.

- In this situation it is better to extract any primary tooth that the clinician believes might be hindering growth than to err by extracting too few teeth.

Complications

- If the entire root is not extracted, eruption of the adult tooth may be hindered or its eruptive pathway altered.

- Careless extraction techniques may damage the adult tooth.
- Choosing to wait and watch will reduce the available catch-up time of the short jaw before the adult teeth erupt.
- Incorrect assessment by clinician.
- Genetic predisposition will win out over interceptive orthodontics in determining treatment results.

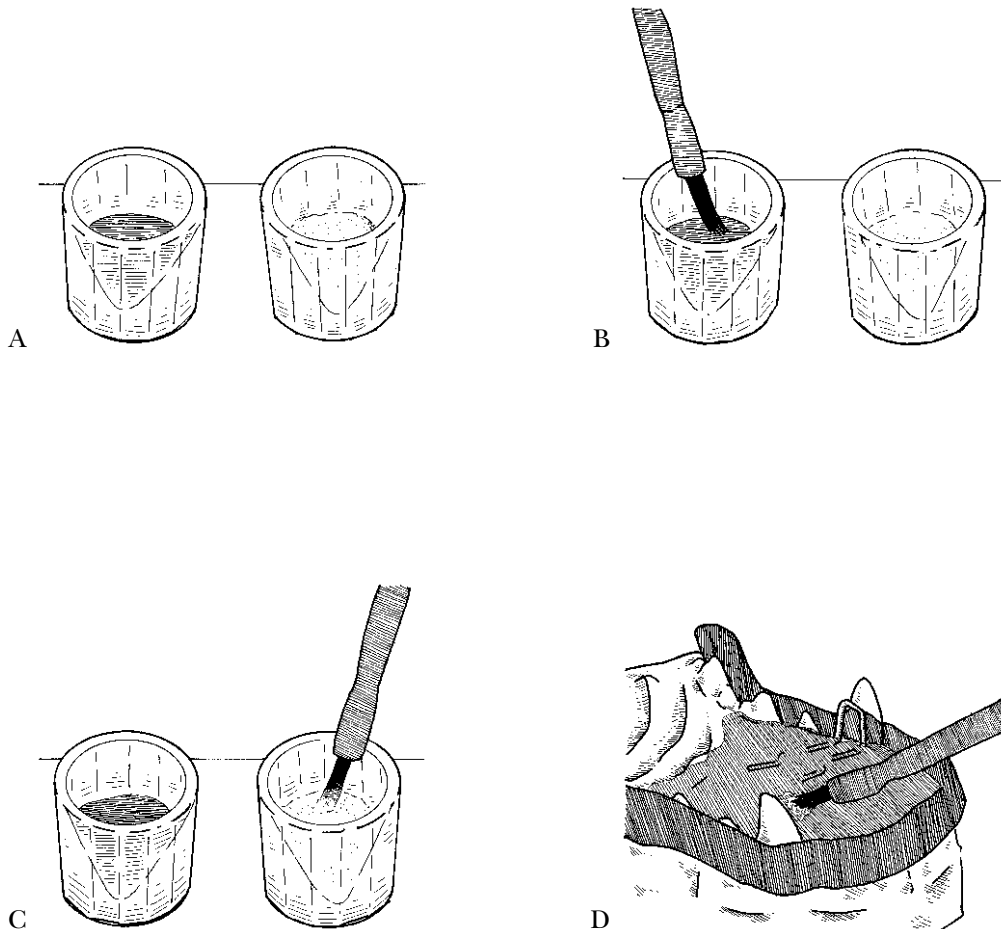


Fig. 9-15

ORTHODONTIC APPLIANCES

- Many types of orthodontic appliances exist; each is custom-made for the patient.

General Indications

- To correct a malocclusion that is causing or may lead to discomfort or tooth loss.
- Orthodontic adjustment also has a cosmetic value that, with due considerations to ethical implications, may be desirable.

General Contraindications

- Ankylosis of teeth.
- Severe periodontal disease associated with teeth in the area of treatment.
- Untrained or unsupervised patients.
- Patients whose indiscriminant oral behavior cannot be controlled.
- Clients who will not comply with oral hygiene or oral hygiene examinations.
- Cases in which periodic monitoring during treatment cannot be maintained.
- Fraudulent intentions.

Specific Appliances

Direct Orthodontics

General Comments

- The movement of a tooth or teeth with elastics or “power chain or cords” attached to the teeth by orthodontic buttons, brackets, or bands.
- Use of orthodontic buttons bonded to a tooth to secure an elastic is a straightforward way to achieve simple movement of a single tooth or possibly a small group of teeth, such as the lower incisors.
- Force vectors are determined by the coronal location of the button placed on the anchor tooth and on the tooth to be moved (active tooth). These forces must be evaluated carefully while placing the buttons so as to guide the movement properly. More coronally located appliances will effect more leverage and change the pivoting fulcrum point on the tooth.
- The anchor tooth or teeth must be composed of one or more roots on one or more teeth so that the radicular surface area is greater than that of the active tooth or teeth.¹⁰

Objective

- To achieve tooth movement (usually bodily or tipping) using force created by elastics.

Indications

- Minor displacement of teeth.
- Rostral displacement of maxillary canines.
- Rostral tipping or displacement of mandibular canines.
- To tip mandibular incisors caudally when angled in labioversion.
- To tip maxillary incisors labially when in palatoversion.

Contraindications

- Periodontal disease in the treatment area.
- See general contraindications to orthodontic appliances.

Materials

- Orthodontic buttons.
- Preferred orthodontic button: Ormesh Curved Lingual Pad with button (Ormco Corporation, Glendora, Calif.).
- Micro brackets (GAC, Central Islip, NY).
- Flour pumice.
- Prophyl cups.
- Orthodontic bonding material.
- Scaler or curette.
- Bracket-holding forceps or cotton pliers.
- Band pusher or a hemostatic forcep.

- Orthodontic elastics of various sizes and strengths.
- Power cord (Ormco Corporation, Glendora, Calif.) or Masel chain.
- Scissors.

Technique

- Buttons are bonded to the teeth as previously described.
- One or more buttons are placed on the anchor teeth. One deciding factor involves the need for the anchor root(s) to have more total surface area than the root(s) of the active teeth. It may be necessary to unite more than one tooth by buttons and ligature wire to create an appropriate anchor.
- Another button is placed on the tooth to be moved or as support for the elastic across the lower incisors.
- Elastic (Masel) chain, power cord, or orthodontic elastics of appropriate size are placed between the buttons to create the desired force on the teeth to be moved.
- The initial force on the teeth is determined by the strength of the elastic or by the number of links between the teeth when using Masel chain.
- The exact force to be used depends on the type of power chain, age of patient, size of tooth, which tooth is to be moved, and other factors. The best guideline is to start with a light force and increase the force at subsequent visits if the desired movement is not being obtained.

Displaced maxillary canines

- Occasionally (most often in Shetland sheepdogs) the maxillary canine is angled rostrally (rostraversion, spear tooth, lance tooth), causing interference with the mandibular canine (Fig. 9-16, A).
- The maxillary canine can also be displaced mesially; this pattern may be associated with a retained primary tooth. This may occur alone or in conjunction with lingually displaced mandibular canines or with one or both mandibular canines in labioversion.
- The anchor teeth are the maxillary fourth premolar and first molar. Additional anchorage and force on the canine tooth can be created by bonding a button to the lingual surface of the mandibular first molar and the palatal surface of the maxillary canine tooth and attaching an elastic chain with light tension.
- The button on the canine tooth must be placed in a location to create the appropriate tipping movement. Consideration should also be given to any rotational pull that a specific bracket placement may create. In an angled tooth, the button initially may be placed closer to the tip of the tooth for more tipping action to move the crown into position. As the crown becomes more perpendicular, the button can be replaced to the midtooth area to achieve a bodily movement into normal position.
- When using an elastic chain between the anchor teeth and the maxillary canine tooth, the distance between the fourth premolar and the canine tooth buttons is reduced by one fourth the number of links as the starting tension. The client or clinician can adjust the tension by one link at subsequent visits until the tooth is in correct position.
- Place a ligature wire between the buttons on the fourth premolar and first molar to create a more solid anchorage and prevent either mesial or extrusional displacement of the maxillary fourth premolar.

Advantages

- Direct orthodontics (no outside laboratory involved).
- Less expensive way to move teeth.
- Tolerated well by the patient.

- Elastic size or chain length can be adjusted easily as the orthodontic adjustment progresses.

Disadvantages

- Buttons can be displaced by chewing on hard objects.
- Possible poor evaluation of the stability of the anchor. This can result in mesial displacement, extrusion, and possible rotation of the fourth premolar if it alone is used as the anchor tooth. The total surface area of the roots of the anchor must exceed that of the root(s) of the active tooth.

Rostrally displaced mandibular canines

- Seen occasionally where one or more of the lower canines is tilted forward, often interfering with the maxillary lateral incisor and causing displacement or wear of that tooth.
- For anchorage, buttons are placed in the midtooth area of the canines and buccally or lingually on the third and fourth mandibular premolars or lingually on the lower molar.
- Orthodontic elastics, or elastic chain, is stretched between the buttons to create a light force (Fig. 9-16, B).
- The elastics are changed and the size adjusted as tooth movement occurs.
- Chain elastic can be adjusted by decreasing the number of links between the buttons to increase the pull or by increasing the number of links to decrease the pull. Chain elastic can be replaced as necessary.

Advantages

- Simple, less expensive movement of a displaced canine tooth.
- Tolerated well by the patient.

Disadvantages

- Dislodgment of the buttons.
- Pain and tooth damage possible by too much force placed on teeth with elastics (moving an active tooth too fast or moving the anchor teeth).
- Difficult to place buttons on small teeth in toy breeds or cats.

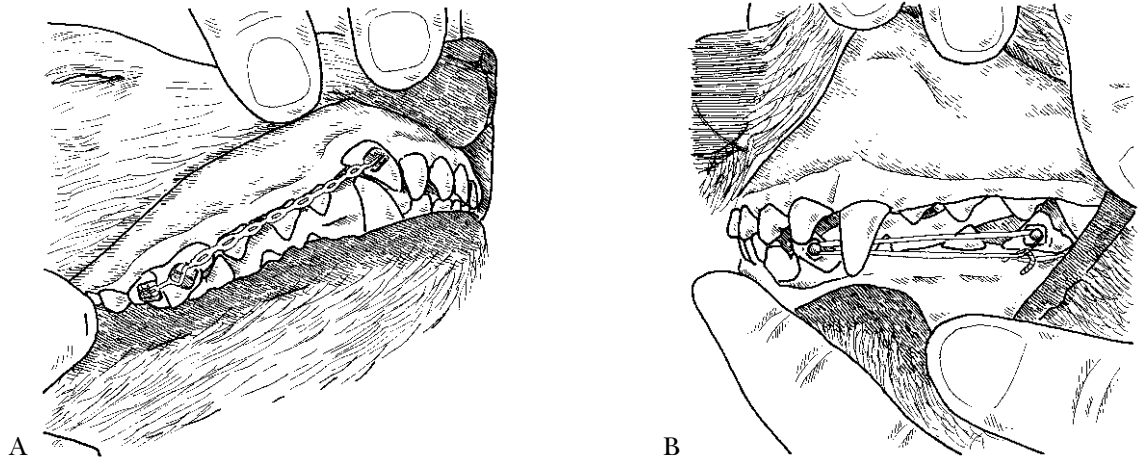


Fig. 9-16

Caudal movement of lower incisors

- In patients with anterior crossbite, some of the mandibular incisors can be moved caudally, either as a lone procedure or in conjunction with the simultaneous movement of the upper incisors labially, to achieve a scissors occlusion.
- Buttons are placed on the buccal surface of the lower canines and on each of the second incisors.
- An appropriate size orthodontic elastic, power cord, or Masel chain is stretched across the incisors from canine to canine (Fig. 9-17, *A*).
- Another variation of this technique places small brackets on the second or third lower incisors (Fig. 9-17, *B*). An orthodontic elastic or elastic cord is placed around both canines. The two strands of elastic stretched between the canine teeth are brought in front of the incisors and are secured in the slot of the brackets. Small amounts of bonding material can be placed on the canines and central incisors to help keep the elastic from slipping.
- The buttons or brackets secure the elastics and keep them from slipping apically onto or beneath the gingiva.
- Little force is needed to create the desired movement.
- These techniques should not be used until the permanent canines have a developed root as verified radiographically (when the patient is about 7 months of age); otherwise, these teeth are not secure enough to use as anchor teeth, and they may themselves be displaced. If the procedure is performed too early, the active teeth themselves may even be dislodged.

Advantages

- Less expensive method of moving teeth.
- Casts to design an appliance are not needed.
- Can be applied easily.

Disadvantages

- Buttons can be dislodged.
- Can create excessive crowding of teeth or may displace the canines if too much force is used.
- Does not allow for a retainer period to keep teeth in position. Elastic may be replaced with stainless steel wire placed between the buttons to maintain desired position.
- Inadequate frequent monitoring can lead to undesirable results very quickly.

Complications

- Early removal of buttons, requiring replacement with another anesthetic procedure.
- Noncompliance of clients to maintain oral hygiene, with gingival irritation secondary to debris or hair wrapped around buttons.
- Sliding of elastic either caudal to the incisors or apically, onto or beneath gingiva. This is usually corrected by creating a ledge on central incisors with bonding material to hold the elastic in place.
- Improper application of elastic by the client; excessive force on teeth, and undesirable movement or crowding may be the result.
- If there is insufficient space distal to the third incisors to allow caudal movement of the incisors, crowding and loss of the curve in the rostral arch can occur.

Aftercare and End of Treatment for Elastic Chains

- Home oral hygiene; keeping the buttons and elastics free of hair, lint, and other debris.
- Recheck appointments every 7 days to monitor home hygiene and tooth movement.
- Replacement of exhausted elastics or Masel chain, on a regular basis, when indicated.
- Softened food, no chew toys, no hard treats, and no oral play.
- Removal of the buttons or brackets is accomplished easily using pliers. Squeeze the prongs together on brackets or use band-removing pliers for buttons or bands.
- Patient is anesthetized, the excess bonding material is removed with the band-removing pliers or an ultrasonic scaler, and the teeth are polished with a fluoride-containing pumice.
- Occasionally, the band-stabilizing brackets or composite ledges may have to be cut with a high-speed handpiece and cutting bur after orthodontic movement is complete. Eye protection should be worn.

Arch Wires

General Comments

- Arch wires may be placed on the maxillary or mandibular teeth on either the palatal-lingual or labial surface.
- Arch wires are held in place by either bands or brackets, usually attached to the canine teeth.

Objective

- Arch wires using various activating forces, including those created by loops, arches, and finger springs, create tooth movement.

Indications

- Anterior crossbite, moving maxillary incisors rostrally.
- Anterior crossbite, moving mandibular incisors caudally.
- Movement of one or more teeth.
- Depressed mandibular central incisors.¹¹
- Attachment for eruption device on an embedded tooth.

Contraindications

- Teeth so small that wire cannot be maintained in proper position.
- General orthodontic appliance contraindications.

Materials

- Patient's dental model.
- Laboratory fabricated arch wire.

- Orthodontic wire, welder, and solder, if practitioner is capable of fabrication in office.
- Brackets and bands, if not incorporated into appliance.
- Orthodontic bonding material.
- Flour pumice.
- Rubber cups.
- Scaler or curette.

Technique: General

- The technique of manufacturing the arch wire is beyond the scope of this text. This text begins with a fabricated arch wire.
- Many types of configurations can be used with the arch wire.
- The arch wire, with incorporated bands, is applied as described in the brackets or band bonding technique earlier in this chapter.
- Brackets are bonded to the tooth first, and the arch wire is fitted and secured with ligature wire (if an arch wire is being used by itself).

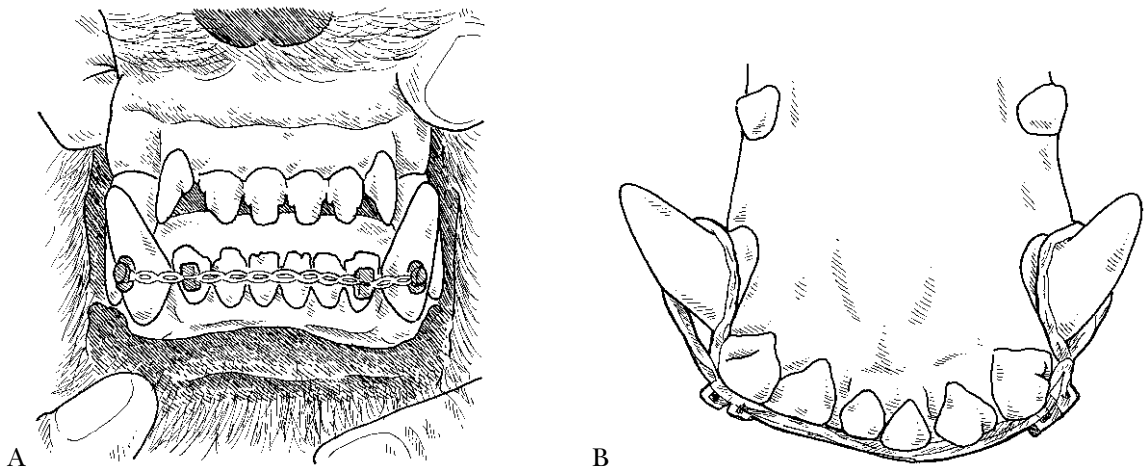


Fig. 9-17

Arch wire elastics

- An arch wire is designed to come across the labial or lingual surface of the mandibular or maxillary incisors and is welded to bands that encircle the canine teeth.
- The arch wire forms the desired position for forward or caudal movement of the teeth.
- The arch wire has small hooks approximating the location of each incisor, allowing a small elastic to be placed between the arch wire and the button on the tooth to be moved.
- Buttons or brackets are first bonded onto the teeth to be moved.
- The appliance is bonded to the canines as previously described.
- Once the bonding material is set, elastics are placed between the bracket on the tooth and arch wire (Fig. 9-18, A). The strength of elastic is measured in ounces and is calibrated at approximately twice the diameter of the elastic. For example, a $\frac{3}{8}$ -inch light elastic has 3 ounces of force when stretched to a length equaling twice its diameter, which is $\frac{3}{4}$ inch.

- A combination of arch wire, bands, and elastics or power chain can be used to pull teeth into proper position (Fig. 9-18, B and C).
- The elastics should be changed at appropriate intervals by the client.

Advantages

- Less expensive appliance to make than expansion devices.
- Can achieve rapid movement of teeth.
- Easy to keep clean.

Disadvantages

- Can cause irritation of upper lip.
- Client must be able and committed to change small elastics.
- Buttons or brackets can be dislodged.
- Arch wire can be bent.
- Arch wire design has to allow space for lower canines to come into normal position.
- Requires a compliant patient and a dextrous owner committed to either managing the adjustments or making frequent visits to the clinic.

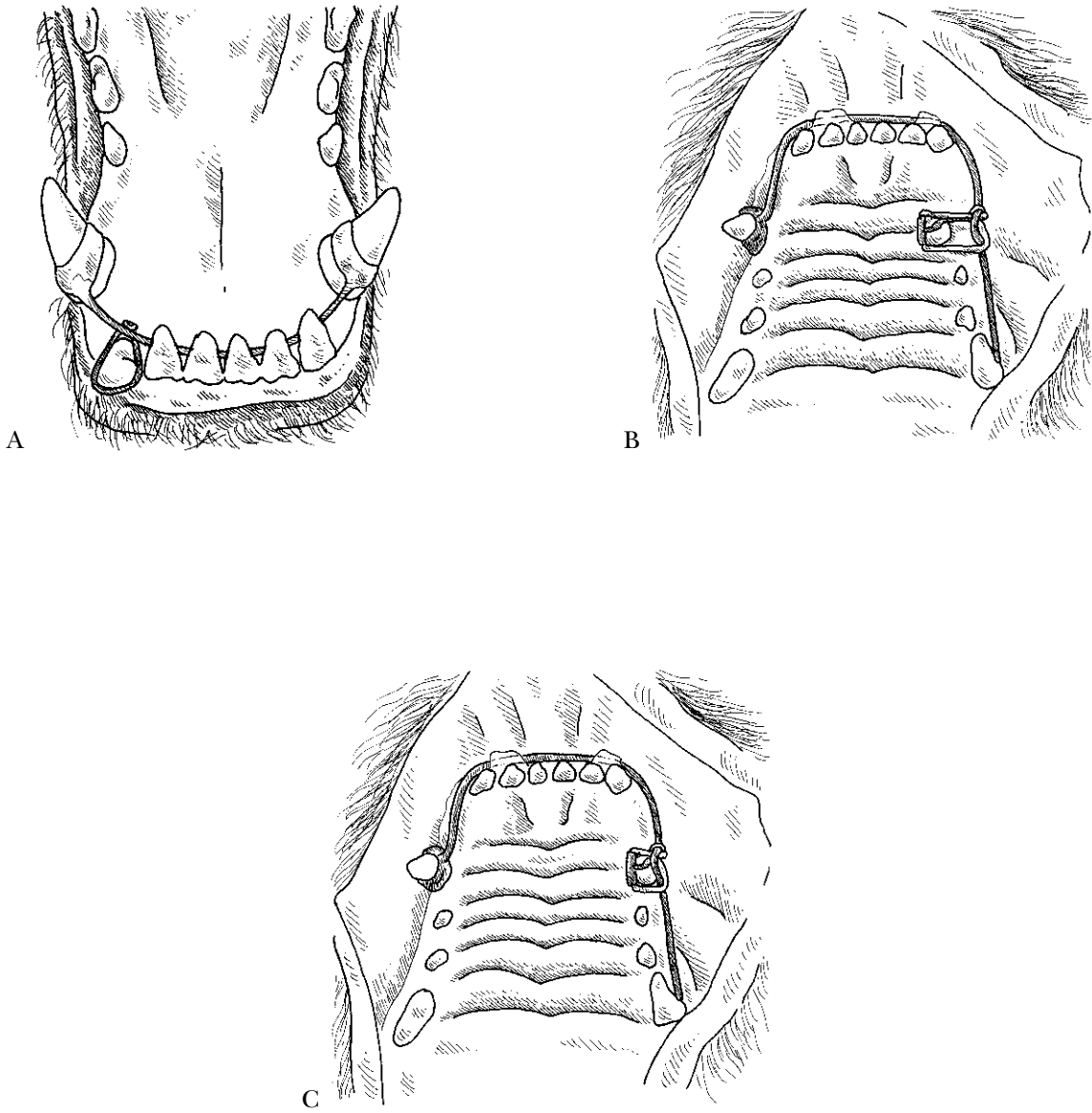


Fig. 9-18

Arch wire finger springs

- Bands are placed around the canine teeth, which are linked together with an arch wire that has finger springs soldered onto it, to create the desired tooth movement.
- This appliance can be designed to move a single tooth or several teeth.
- This appliance can be adapted for use in the maxilla or mandible, moving incisors forward or caudally.
- The appliance is trial fitted, and the finger springs are adjusted with three-prong or appropriate orthodontic pliers so the spring pressure will move the teeth to their desired positions (Fig. 9-19, *A*). A slight over-adjustment should be anticipated; however, additional adjustments may be made later on recheck visits.
- The appliance is cemented to the canines, using the technique described on pp. 516 to 521.
- The active finger spring wires are tucked behind the upper incisors, against their palatal surface (Fig. 9-19, *B*). A small ledge of composite resin or bonding material can be placed on the lingual surface of the incisors to keep the wire from slipping over the incisal edge and forward, off the teeth.

Advantages

- Simple appliance to design.
- Less expensive than expansion devices.
- Easy to keep clean.

Disadvantages

- Spring wires get caught in hair, blankets, and carpet and can become hazardous to the patient and damaging to the treatment.
- Laceration of lips or tongue from bent or broken wires.
- Potentially broken teeth.

Labial arch wires

- A labial arch wire uses a retention device (usually bands) connected by an arch wire that lies on the labial surface of the teeth (Fig. 9-19, *C*).
- Springs are formed by loops in the anterior diastema between the canine and lateral incisor.
- Closing these loops gradually with pliers over time creates the desired force to move the teeth.
- This type of arch wire can be used for an anterior crossbite by tipping the mandibular incisors lingually if there is a space between the incisors and canine teeth.

Advantages

- Easy appliance to design and place.
- Well tolerated by the patient.
- Can act as its own retainer when the desired tooth position is reached.
- Easy to keep clean.

Disadvantages

- Cannot be used in dogs with very small incisors.
- Wire can be bent or dislodged by oral abuse.

Complications

- Breakage of finger springs.
- Bending of finger springs.
- Hair and carpet getting caught in wires.
- Loss of appliance.

Aftercare

- Rechecks every 10 to 14 days.
- Elastics, finger springs, or loops adjusted as needed to maintain orthodontic force.
- After retainer period, the appliance is removed using band-removing pliers.
- Excess cement is removed with band-removing pliers or an ultrasonic scaler, and the teeth are polished with fluoride-containing pumice.

Expansion Devices**General Comments**

- Expansion screws, acrylic plate, and arch wire may be used to tip teeth labially.
- Small expansion screws can be placed in acrylic appliances or attached to wires and bands to create gradual movement of the teeth by adjusting the screw that directs an orthodontic force on the teeth to be moved.
- These screws come in various sizes and with various expansion capabilities.
- Practitioners can either create their own appliances with acrylic or wires and bands or send the patient's models to a laboratory to have one fabricated.
- Either removable or fixed appliances can be designed.
- Removable appliances (usually maxillary) are designed with wire loops that lie along the palatal surface of the canines and lateral incisors. Brackets or buttons are bonded to the buccal or labial surface of these teeth near the gingival margin, and small elastics

are placed over the wire on the appliance and button or bracket to hold the appliance in place.

- Removable appliances are removed for eating and allow for easier cleaning and more complete oral hygiene.
- Fixed appliances are designed with bands that are cemented in place around the canine teeth and are not as easily dislodged.

Objective

- Actively create gradual tooth movement using an expansion device that places an orthodontic force on the teeth to be moved.

Indications

- Anterior crossbite, maxillary appliance.
- Lingually displaced mandibular canines.

Contraindication

- See general orthodontic appliance contraindications.

Materials

- Worm gear.
- Expansion screws (Unitek #440-160 MidPalatal Suture Expansion Screw, Unitek Corporation, Monrovia, Calif.).
- Orthodontic wire, suggested sizes: 0.016 inch, 0.020 inch, 0.022 inch, 0.028 inch, 0.032 inch, 0.036 inch, and 0.040 inch.
- Buttons or brackets.
- Orthodontic cement or bonding material.
- Flour pumice.
- Rubber cups.
- Patient's models.
- Laboratory fabricated appliance.
- Adjusting key.

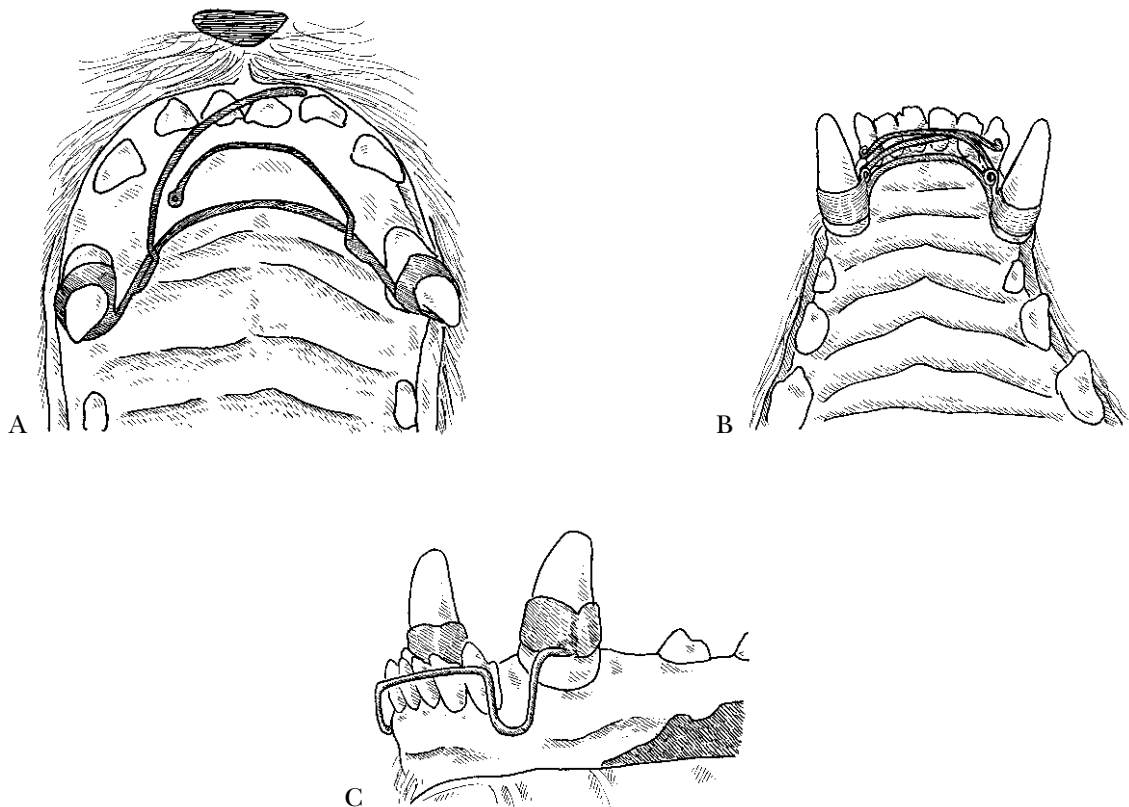


Fig. 9-19

Techniques

Maxillary acrylic or metal appliance for anterior crossbite

- An appliance is designed with the expansion screw placed rostral to caudal embedded in an acrylic shoe (Fig. 9-20, A) or in a separated fabricated metal shoe. The shoe is cut so the front half of the screw is in a section of acrylic that will move separately against the incisors to be pushed forward.
- This can be a removable (Fig. 9-20, B) or fixed appliance.
- The expansion screw is adjusted using a small wire key in the hole at the center of the expansion screw that expands the screw, thus putting an increased pressure on the teeth to be moved.
- The screw is adjusted by the client, who turns the key once every 4 days. Each 90-degree turn of the screw moves the active tooth 0.25 mm.
- When the teeth have moved into occlusion, the appliance is left in place for an additional 4 to 6 weeks for the retainer period.

Advantages

- A strong device that does not have loose wires that can be bent or catch on hair or other objects.
- Can be designed as a removable appliance for easy cleaning.
- Well tolerated by the patient.
- Creates a more uniform, controlled tooth movement.

Disadvantages

- Movable shoe may slip over the incisal edge of the active incisors, especially small incisors. A shoe that fits well against the cingulum of the incisors to be moved, incorporated into the acrylic, can help prevent this.
- More expensive to manufacture than arch wire.
- Client must successfully manage the home oral hygiene.
- Client must be able to make adjustments with wire key, and the patient must also be compliant.
- An overzealous or impatient client may create pain and tooth damage in the patient.

Lingually displaced mandibular canines

- This common occlusion problem usually is caused by retained primary canines that do not allow the adult teeth to come into position outside the maxillary arch. It may also occur by malpositioned secondary canine tooth buds. The same kind of trauma can be seen when confronted with structurally narrow mandibles, either unilateral or bilaterally. In a condition treated similarly, the mandibular canines are oriented properly, but a class 2 malocclusion results in the cusps of these teeth traumatizing the palate. It is a skeletal, structural problem, but it is treated orthodontically to relieve discomfort.
- The pressure caused by the indentation of the mandibular canines on the hard palate can lead to periodontal disease of the maxillary canines, pain, necrosis of the palatal tissue, potentially an oronasal fistula, and an irritable temperament.

Methods of correction

Removable device¹²

General comments

- This treatment method uses a rubber ball or rubber chew toy.

Advantages

- Does not require anesthesia.
- Increases the bond between the patient and client.
- Retention period is not necessary, because the natural occlusion will hold the teeth in place.

Disadvantages

- Requires patient and client cooperation.
- May delay other corrective procedures to the point that they become more difficult.

Indication

- Young patient, less than 8 months of age.

Contraindications

- Retrusive mandibles where there is no space for the mandibular canines to fit.
- Diastema between the maxillary lateral incisor and maxillary canine is closed.

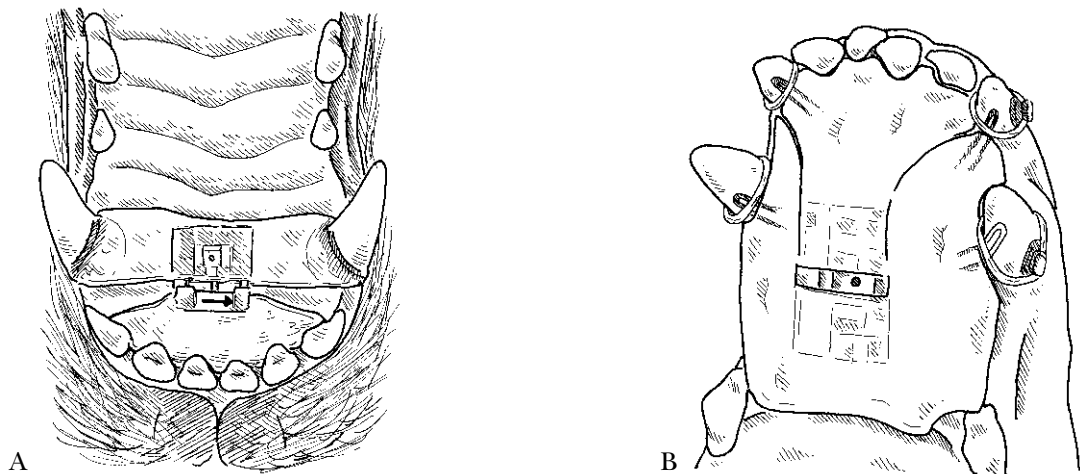


Fig. 9-20

Technique

- Photographs should be taken at the start of treatment to document progress. Movement can be slow and the photograph can help the practitioner and client evaluate movement.
- The correct toy size is one that sits between and just behind the canine teeth and the diameter is slightly larger than the distance between the canine teeth (Fig. 9-21, A).
- The intent is for the toy to apply lateral pressure to the canine teeth while the patient plays.
- The toy should be hard rubber, deforming slightly when chewed.
- Active play for 15 minutes, 3 times a day, is minimum; longer and more frequent periods are recommended.
- A 1-week learning phase with 2 weeks additional time before any movement is likely to be seen. If no movement is seen after 3 weeks, alternative treatment methods should be considered.

Complications

- A toy that is too small may not be effective (Fig. 9-21, B).
- The patient may choke on the toy if it is too small.
- A toy that is too small will not touch both canine teeth at the same time.
- Patient holds the toy between its carnassial teeth rather than the canine teeth. In this case, a larger toy that could cause some mesial tipping of the canine teeth is necessary.
- A too-soft toy results in destruction of toy and possible choking.

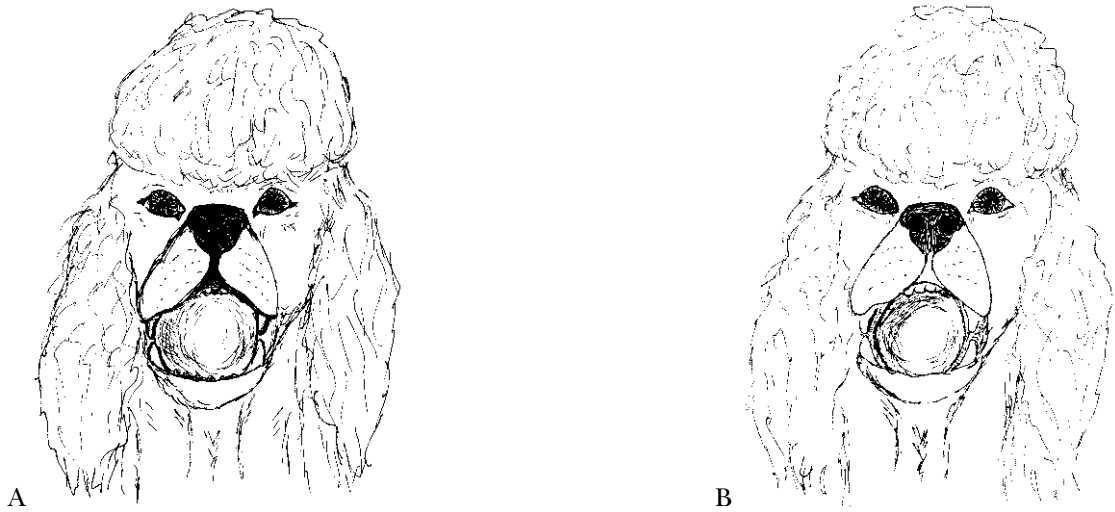


Fig. 9-21

Expansion screw

- The expansion screw is placed in a wire support structure with bands around the mandibular canines (Fig. 9-22, A).
- This device can be used effectively when both canines need to be moved out and are located in their normal relationship mesial to distal.
- Variations on the device, such as a wire arm alongside the premolars or placed at an angle between the canines, have been used to achieve movement of a single canine without shifting position of the other.
- The device is cemented to the canines, using the technique described on pp. 516 to 521.

Advantages

- Easily designed to create desired movement.
- Well tolerated by the patient.
- Easy to keep clean.
- Cannot be removed easily by the patient.

Disadvantages

- Tongue may make adjustments difficult.
- Client must be able to make the screw adjustments.
- This device will not change mesial-distal position of the canine tooth.
- The size of the patient may limit the device's use if there is not enough expansion to achieve desired tooth position.
- Appliance can be dislodged by indiscriminate oral behavior.
- In larger dogs, the splaying of the mandibular canines may be too extreme to allow installation of this appliance, because the expansion screw may not be long enough. This complication can be overcome with an appliance designed as a Maryland Bridge piece, with metal wings resting on the lingual surface of the canines and custom bands that can be installed and cemented to encircle the anchor tooth and its wing.

Omega or "W" wire

- An omega or "W" wire is an orthodontic wire bent in the form of the Greek letter ω or W (Fig. 9-22, B). Loops designed in the bends of the W create an expansion action of the outer arms when activated.
- The wire is soldered to bands around the canines and can be used to move lingually displaced canine teeth.

- The appliance is trial-fitted, and the outer arms are activated with three-prong pliers to extend to the desired position of the teeth while the appliance is free from the canines.
- The wire and bands are cemented to the teeth as previously described, collapsing the expanded W. This creates the force to move the teeth into position.

Advantages

- Easily designed appliance.
- Can be made to fit any size mouth.
- Easy to clean around appliance.

Disadvantages

- Cannot control force as easily; may move teeth too fast.
- Force created may not be sufficient to achieve desired movement.
- Can be dislodged or bent by heavy chewing on hard objects.
- Does not have a retainer function as readily as expansion screw device.

Complications

- Noncompliance of client with home oral hygiene.
- Dislodgment or breakage of appliance.
- Alveolar bone necrosis from rapid movement of teeth.
- Premature removal of appliance, with teeth drifting back; appliance should be left in place for adequate retainer period.
- Patient discomfort if force is too great.

Aftercare

- Home oral hygiene; daily flushing around appliance.
- Expansion screw adjustments should be made every 3 to 4 days. (Each turn of the key expands the screw 0.25 mm; therefore, four turns equals 1 mm of expansion.)
- Recheck examinations every 10 to 14 days to monitor home oral hygiene and tooth movement.
- Retaining period, provided by inactivating the W wire, for 5 to 6 weeks to prevent regression.
- Appliance is removed with band-removing pliers, excess cement is removed with band-removing pliers or an ultrasonic scaler, and the teeth are polished with a fluoride-containing pumice.

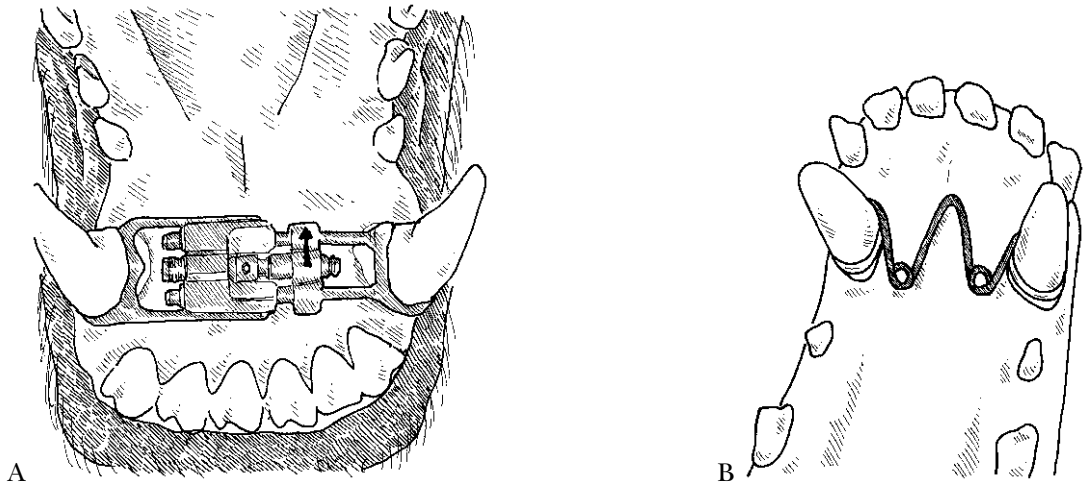


Fig. 9-22

Inclined Plane

General Comments

- Inclined planes are designed of acrylic or cast metal to guide a tooth into a new movement, using normal occlusal forces. Every time the patient closes its mouth, the teeth come in contact with the inclined plane and are directed into the desired position. Orthodontically, this is an intermittent active force, the force being applied more strongly and more frequently by more orally oriented animals.
- The appliance can be used for a variety of tooth movements but is used most commonly for lingually displaced mandibular canines. It has also been designed to move incisors rostrally or caudally.
- The inclined plane can be designed to allow forward or caudal canine movement along with buccal movement of the teeth.
- A telescoping inclined plane can be fabricated with a stabilizing transpalatal bar, consisting of a rod from one canine anchor fitting into a sleeve from the other canine anchor. This is useful when working with young, growing patients, to passively allow palatal expansion during treatment.
- Desired tooth position can be achieved readily with the inclined plane design.
- The device creates an intermittent force between times of rest and mastication.
- The time necessary to create the desired movement depends on the level of the patient's oral activity, amount of time arches are in occlusion, and angulation of incline.
- The more acute the angle, the faster the tipping movement and decreased tendency to create intrusion.
- Age of the patient is a factor: the younger the patient, the softer the supporting bone and the faster the movement.
- Another factor is the extent of oral activity of the patient.
- In mild cases of lingual displacement the palatal gingiva can be used as an inclined plane (see below, Gingival Wedge).
- An inclined plane should be created on both sides of the appliance even if only one tooth orientation needs to be adjusted. This provides stabilization and prevents shifting of the mandible and stress on the temporomandibular joint that may be created if only one canine is to be moved.

Objective

- To direct the tooth into a desired position by using normal occlusal forces.

Indications

- Lingual displacement of one or both mandibular canines (mandibular cuspid linguoversion.)
- Caudal displacement of maxillary incisor.

Contraindications

- See general orthodontic appliance contraindications.

Materials

- Patient's models.
- Laboratory designed inclined plane device.
- Orthodontic cementing materials.
- Flour pumice.
- Rubber cups.

Techniques

Acrylic

Indirect palatal acrylic appliance

- An inclined plane can be designed and made of dental acrylic, using the dental models in the office or at a dental laboratory, to fit against the hard palate.
- The appliance can be removable or fixed.
- The removable appliance is attached with elastics placed over buttons bonded to the buccal surface of the canines and lateral incisors, and wires are incorporated into the acrylic that lies along the palatal surface of those teeth.
- The fixed appliance is designed with bands around the maxillary canines and is cemented in place as previously described.
- The inclined plane can be reshaped, as necessary, in the mouth with an acrylic bur in a low-speed handpiece.
- Periodic adjustments are not needed with this device, because the design of the inclined plane is to create the intermittent patient-activated force necessary to move the tooth into position during natural occlusal activity.

Advantages

- Acrylic material allows for office adjustments, if necessary, during the course of treatment, without removing the appliance.

- Less expensive than cast metal appliance.
- Can be designed as a removable appliance for easy cleaning.
- No concern with heat production during curing of acrylic.
- Can create a smoother finish on appliance.

Disadvantages

- Client must maintain good home oral hygiene.
- Appliance must be designed to allow expansion between the maxillary canines for placement of the device and growth in the young patient.
- Requires an additional visit and anesthetic to take impressions for models.
- Acrylic may be fractured by active chewing on hard objects (this occurs more often in large dogs).
- Palatal mucosal irritation with fixed appliances.

Direct acrylic full palatal appliance

General comments

- Designing the acrylic inclined plane in the patient's mouth eliminates the need for a dental laboratory. It eliminates an additional anesthetic session to obtain impressions. It provides, therefore, a more rapid initiation of treatment and decreased cost to the client and risk to the patient.¹³
- The appliance can be remodeled as desired and made with minimal expense.

Advantages

- Requires only one anesthetic session to place appliance and one to remove it.
- Less expensive than cast metal or laboratory fabricated appliance.
- Acrylic can be adjusted in the office if necessary.

Disadvantages

- Covers the palate, with potential for mucosal irritation and necrosis.
- Does not allow for maxillary growth.
- Can be damaged or dislodged by the patient's oral abuse.
- Unless a nonexothermic acrylic, such as Tokuso Rebase (Tokuyama), or an acrylic composite combination such as Protemp Garant (ESPE America, Morristown, Penn.) or Maxitemp (Henry Schein, Melville, NY) is used, significant heat is produced during the curing period that may damage the soft tissues or the pulp tissue.

Materials

- Acrylic material (see comment above).
- Rubber prophyl cups.
- Utility wax strips.
- Low-speed and high-speed drills.
- Acrylic finishing burs.
- Nonfluoride paste or pumice.
- Etching gel.
- Assorted Dura white low-speed polishing stones (flame and pointed cone).

Technique

- Step 1—The patient is anesthetized, intubated, and placed in dorsal recumbency; the back of the pharynx is packed with gauze.
- Step 2—The anterior maxillary teeth are scaled and polished with the nonfluoride pumice.
- Step 3—All surfaces of the teeth are etched with a 37% phosphoric acid etching gel for 30 seconds and then rinsed and dried with oil-free and moisture-free air.
- Step 4—A wax strip dam ($\frac{3}{16}$ inch or greater in diameter) is formed around the anterior teeth at the gingival level.
- Step 5—The powder is placed to a depth of $\frac{1}{4}$ inch within the wax dam, and the liquid is placed drop-wise directly on the powder.
- Step 6—Additional acrylic can be applied by repeating the process.
- Step 7—Before the acrylic sets, the patient is extubated, and the jaws are occluded to create indentations that will serve as starting points for the inclined plane. The patient is reintubated.
- Step 8—Using a bullet-shaped acrylic bur in a high-speed handpiece, an inclined groove is cut into the acrylic from the starting indentations to a point that will be the end point of the movement desired.
- Step 9—The fine adjustments of angulation and direction can be achieved on the inclined plane with a white stone in a low-speed handpiece.
- Step 10—The acrylic shavings are rinsed periodically, and the gauze is exchanged at the back of the mouth.
- Step 11—The wax strip is removed, and all the surfaces of the appliance are smoothed and polished meticulously with a low-speed white stone.

Bilateral direct acrylic inclined plane

- This technique uses acrylic that is molded around the maxillary incisors and canine teeth on either side of the mouth to form an inclined plane to redirect the displaced mandibular canines.

- The two sides are separate to allow for continued maxillary development and easier oral hygiene.

Materials

- Flour pumice.
- Rubber prophyl cups.
- Low-speed handpiece.
- Acrylic cutting burs.
- Finishing burs.
- Finishing stones.
- Etching gel.
- Light-cure acrylic sheets (Triad VLC, Dentsply) or self-curing bisacryl composite material (Protemp Garant, ESPE America).
- Light-cure gun.

Technique

Step 1—The patient is anesthetized, intubated, and placed in dorsal recumbency.

Step 2—The maxillary lateral and intermediate incisors and canine teeth are scaled and polished with flour pumice and rinsed.

Step 3—The incisors and canines are spot etched for 30 seconds with the etching gel. They are rinsed with water and dried with oil-free and moisture-free air.

Step 4—The acrylic material is placed and shaped by hand to form an inclined plane anchored around and between the lateral and intermediate incisors and canine teeth on each side of the maxilla (Fig. 9-23, *A*). The acrylic material should not be in contact with the soft tissues.

Step 5—The patient is extubated to check the occlusion of the mandibular incisors on the inclined surface (Fig. 9-23, *B*). The mandibular canines should meet the incline at a 20-degree angle from parallel.¹⁴ The angle is adjusted as necessary, and the patient is reintubated. The slope of the incline can be directed mediolateral, or rostrocaudal and mediolateral, as necessary, to direct the lower canines into proper alignment.

Step 6—If using the light-cured acrylic (Fig. 9-23, *C*), the acrylic is light-cured in overlapping sections for 60 seconds each. If a self-curing acrylic is used, it is allowed to harden.

Step 7—The patient is extubated, and the occlusion is reevaluated and adjusted with acrylic burs if necessary, and the patient is reintubated.

Step 8—The acrylic is trimmed and smoothed with finishing burs and stones in a low-speed handpiece with irrigation (Fig. 9-23, *D*).

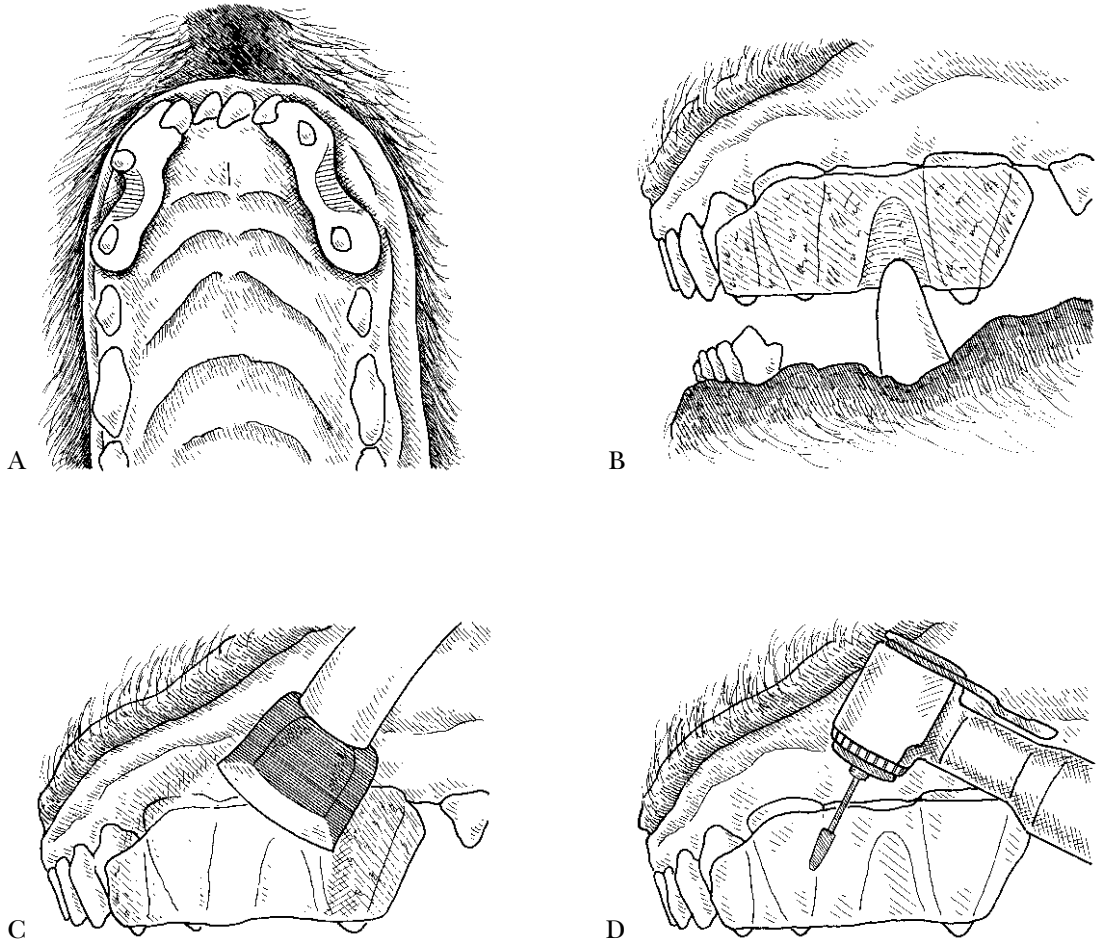


Fig. 9-23

Cast metal

- A cast metal inclined plane is designed in an appliance with a stabilizing telescoping bar across the hard palate and bands around the maxillary canines (Fig. 9-24, A).
- The metal telescoping inclined plane can be designed to direct the teeth in a number of directions (rostral and buccal, or caudal and buccal) (Fig. 9-24, B).
- The appliance is trial fitted and cemented in place as previously described.

Advantages

- The telescoping bar allows for easy placement and continued maxillary growth of the patient.
- The appliance is not in direct contact with the hard palate and is easier to keep clean.
- The appliance is well tolerated by the patient.
- Because it has greater appliance strength, it is less likely to be damaged by larger patients.
- Some adjustments can be made by adding composite to the lingual surface of the lower canines to allow further lateral movement.

Disadvantages

- Adjustments in design require removing and remaking the appliance.
- Discoloration of inside of mandibular canines from contact with some types of metal or cement.
- Wear on the tips of mandibular canines if appliance is poorly designed or in place for a long time.
- Teeth must be fully erupted before taking the impression to manufacture the appliance.
- Inclined planes can also be made with metal bands and telescoping part and acrylic for the inclined plane. This reduces wear on the canine cusp and allows for adjustment without removing the appliance, if necessary.

Complications: All Techniques

- Premature removal of appliance prevented by using appropriate cementing material and technique.
- Inadequate appliance design creating incorrect movement or undesired movement; have accurate models and bite impressions for laboratory to work with.
- Inadequate home care by client, leading to gingival irritation.
- Orally inappropriate behavior by patient, resulting in foreign objects being wedged between appliance and mouth.

- Palatal mucosal irritation. If present, resolves quickly after appliance is removed, but has been known to result in mucosal necrosis.
- Restriction of maxillary growth in younger patients if left in place for extended time (full-palate appliance).
- Fracture or loss of appliance.
- Premature limitation of movement. If the acrylic plate is too thick over a prominent incisive papilla, canine movement will be stopped when the lower incisors come in contact with the plate.
- Acrylic material harboring bacteria and serving as a reservoir for infection.
- Staining of the teeth from etching and microleakage under the appliance.
- Wear of canine teeth against appliance.

Aftercare: All Inclined Planes

- An Elizabethan collar may be necessary for the first few days the appliance is in place to prevent self-trauma from the patient trying to remove it.
- A curved-tip syringe with dilute chlorhexidine solution should be used two or three times daily to flush all gingival or appliance margins.
- Provide softened food and allow no chew toys, hard treats, or oral play while appliance is in place.
- Recheck examinations every week to monitor oral hygiene and tooth movement. Length of treatment depends on the age of the patient and the degree of movement necessary. Teeth may be moved with a well-designed appliance in as few as 7 to 10 days.
- When teeth are in desired position, the appliance is removed using band-removing pliers. Excess cement is removed from the teeth with band-removing pliers or an ultrasonic scaler, and the teeth are polished with a fluoride-containing pumice.

Gingival Wedge: Gingivoplasty of the Anterior Diastema

- A wedge can be created in the gingival tissue anterior to the maxillary canine, using electrosurgery or a scalpel blade to remove a traumatically caused superficial pocket of palatal tissue, to direct minimally displaced mandibular canines laterally¹⁵ (Fig. 9-24, C).
- This technique can be used in patients whose teeth are still erupting, to allow the teeth to

come into normal position by the time eruption is complete.

Advantages

- Not necessary to take impressions and make models to correct the malocclusion.
- Easily performed by a general practitioner without additional dental equipment.
- Use in a young patient allows early correction of teeth.
- “One-stop shopping” for the client.

Disadvantages

- Only effective if mandibular canines are minimally displaced.
- Excessive use of electrosurgery may damage gingiva and create additional sloughing.
- Overaggressive surgery may create permanent change in gingival contour.

Maryland Bridge

- A cast metal appliance that uses a variety of forces (expansion screw, elastics) to achieve the desired movement.¹⁶

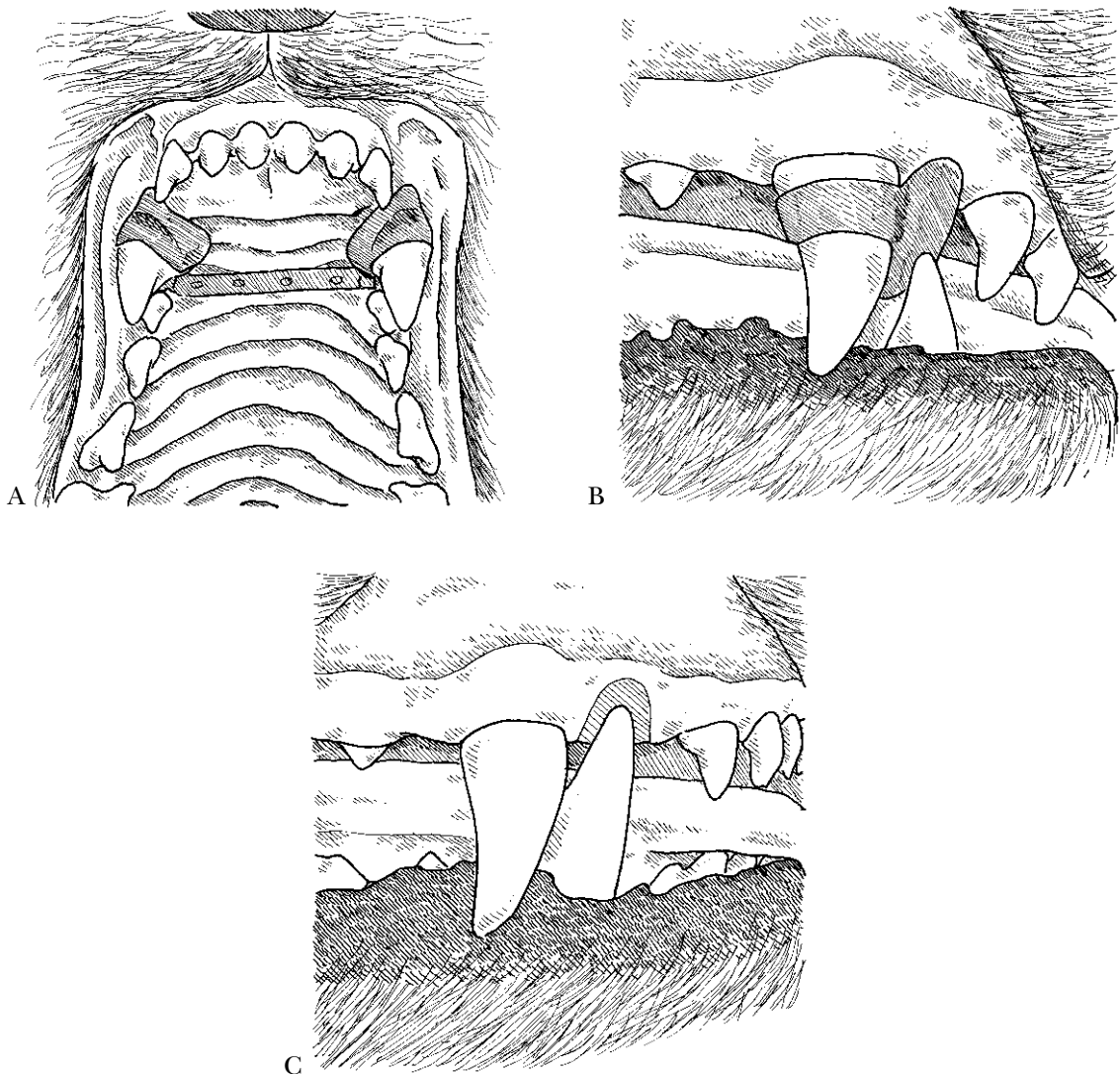


Fig. 9-24

- The Maryland Bridge uses broad coverage of the lingual or palatal surface of the canines (metal “wings”), along with cast metal partial crown covers to attach the appliance, creating more surface area for cementation and therefore better retention of the appliance in the mouth.
- Additional circumferential bands over the wings provides additional retention.
- The wings, cast crown covers, and band areas cemented in place using a Maryland Bridge adhesive or similar luting cement (Comspan, LD Caulk/Dentsply, Milford, Del.; Panavia, J Morita, Tustin, Calif.).
- These appliances are very durable in the mouth and are not broken or dislodged easily.

Objective

- To improve retention of an orthodontic appliance to achieve movement of teeth through the use of increased surface contact for cementation.

Indications

- Patients with chewing habits that require a sturdy appliance.
- Patients who have broken or removed their other appliances.
- Additional cementation security.

Contraindications

- Poor client compliance with follow-up care and rechecks.
- Inability of client to adjust expansion screws or replace elastics as necessary.
- Periodontal disease of the affected teeth, weak supportive bone.

Materials

- Patient’s models.
- Laboratory fabricated appliance.
- Maryland Bridge adhesive or luting cement.
- Flour pumice.
- Rubber prophyl cups.
- How pliers.
- Scaler or curette.

Technique

Maxillary appliance for anterior crossbite

- The appliance is cemented to the maxillary canines and incisors, following the directions of the cementing product.
- An expansion screw is designed into the appliance to create gradual forward movement of the incisors.

Advantages

- A stronger appliance is beneficial in large dogs that are more likely to break an acrylic appliance.
- There are no wires, buttons, or brackets to be dislodged or caught in hair, chew toys, or other objects.
- The open design of the cast metal appliance allows for easy cleaning of the hard palate area and less chance of irritation from deficiencies in home oral hygiene.

Disadvantages

- Increased expense of appliance.
- Must use special luting cements for proper retention.
- Lack of availability; not all laboratories make this style appliance.

Mandibular Appliance for Anterior Crossbite

- This appliance is cemented to the mandibular canines using the appropriate luting cement and following the instructions included with that particular cement.
- This appliance is designed to use orthodontic elastics across the front of the lower incisors to tip them caudally.
- The elastics are anchored on small hooks incorporated into the canine wings and through a notch in the incisor crown covers (Fig. 9-25).
- The elastics are changed daily, and the strength of elastic is adjusted as the teeth move into position.

Advantages

- Secure appliance to achieve caudal tipping of the lower incisors.
- Improved attachment and elastic holding to keep the appliance in place and to prevent gingival damage from slippage.
- Mandibular appliance may be used in conjunction with the maxillary appliance to achieve the desired occlusion in patients with severe anterior crossbite.

Disadvantages

- Increased expense of appliance.
- Must use special luting cements for proper retention.
- Lack of availability; not all laboratories make this style appliance.

Complications

- Noncompliance of the client to return for rechecks.
- Discoloration of teeth under wings if cement leaks, staining the tooth surfaces.
- Removal of appliance, although rarely, by patient.

- Must have enough distal room between incisors and lower canines to allow uniform movement of incisal arch without crowding.

Aftercare

- Adjusting elastics or expansion screw as necessary and recheck examination every 2 weeks to monitor tooth movement.
- Removing appliance after proper retainer period. It may be necessary to cut the bands with a diamond bur to facilitate removal. Using an ultrasonic scaler over the wings may help to fracture the cement for removal with band-removing pliers.
- Remaining cement is removed with band-removing pliers or an ultrasonic scaler.

Delayed Eruption in Young Animals^{17,18}

General Comments

- Eruption of the teeth occurs in two stages. During the intraosseous first stage, the overlying bone and primary tooth, if present, resorb. The supraosseous second stage starts as the crown erupts above the alveolar crest.

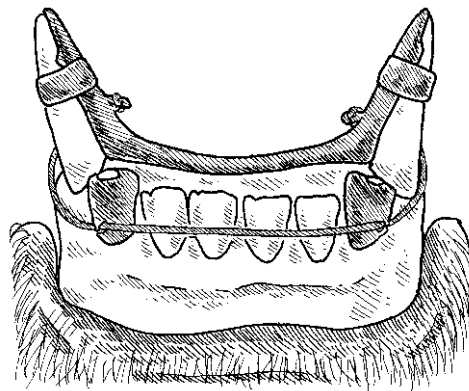


Fig. 9-25

- The eruption process is a very complex process and can be disrupted by genetic abnormalities, traumatic events, retained primary teeth, fibrous tissue, or thickened bone, and numerous other local and systemic causes.¹⁹

Operculectomy

Indications

- Tooth impaction in young patient.
- Unerupted tooth in young patient.

Contraindications

- Inability to take dental radiographs.
- Failure of teeth to develop and be noted on dental radiographs.

Technique

Step 1—Dental radiographs are taken to evaluate the presence and position of the tooth.

Step 2—Mesial and distal releasing incisions are made (Fig. 9-26, *A*).

Step 3—A full-thickness mucoperiosteal flap is lifted on both the lingual and buccal surfaces (Fig. 9-26, *B*).

Step 4—Any fibrous tissue covering the crown is excised with a #15 scalpel blade (Fig. 9-26, *C*).

Step 5—Any bone covering the crown is removed carefully with rongeurs (Fig. 9-26, *D*).

Step 6—The flap releasing incisions are sutured, keeping the coronal portion of the flap open (Fig. 9-26, *E*).

Complications

- Damage to the enamel of the crown. For this reason, rongeurs are used rather than a high-speed handpiece.

ORTHODONTIC EXTRUSION

Indications

- Impacted or embedded teeth.
- Partly erupted teeth.

Contraindications

- Dilacerated teeth that are severely malformed.

Technique

Step 1—Dental radiographs should be taken prior to treatment.

Step 2—Mandibular and maxillary impressions are taken.

Step 3—If the tooth is embedded, a surgical approach is made to expose the tooth.

Step 4—The model is poured and appliance manufactured. This appliance will have a tower with a hook such that force can be applied to the tooth to be extruded.

Step 5—The appliance is cemented in place. A button or bracket is applied to the tooth to be extruded. Appropriate force is applied with power cord, power chain, or elastics.

Step 6—The patient is rechecked at appropriate intervals until the appliance is removed.

Complications

- Dislodging of the appliance. This can be partly avoided by the removal of toys and confinement of the patient so that its activity can always be monitored.
- The client should be warned that if the appliance is dislodged, the appliance can be destroyed, swallowed, or cause choking.
- Bending of the tower.
- Misdirection of extrusion. The direction of the extrusion can be controlled by multiple hooks on the tower.
- Malocclusion of tower with canine teeth. For this reason, bite registration and a model of the opposite jaw must be correlated prior to placement of the appliance.

Alternative Appliances

- A number of different appliance designs can be used for this type of orthodontic correction. If dealing with an incisor tooth, a much simpler appliance may be designed, using brackets and arch wire as the anchor to a button or bracket on the tooth.²⁰

ORTHODONTIC LABORATORY PRESCRIPTION

- If a dental laboratory is used, a prescription should accompany the models.
- The prescription should order the type of appliance, the material to be used, and the color or shade of material, as appropriate.
- By drawing on the dental chart, the practitioner can indicate the anchorage and type of force to be applied.

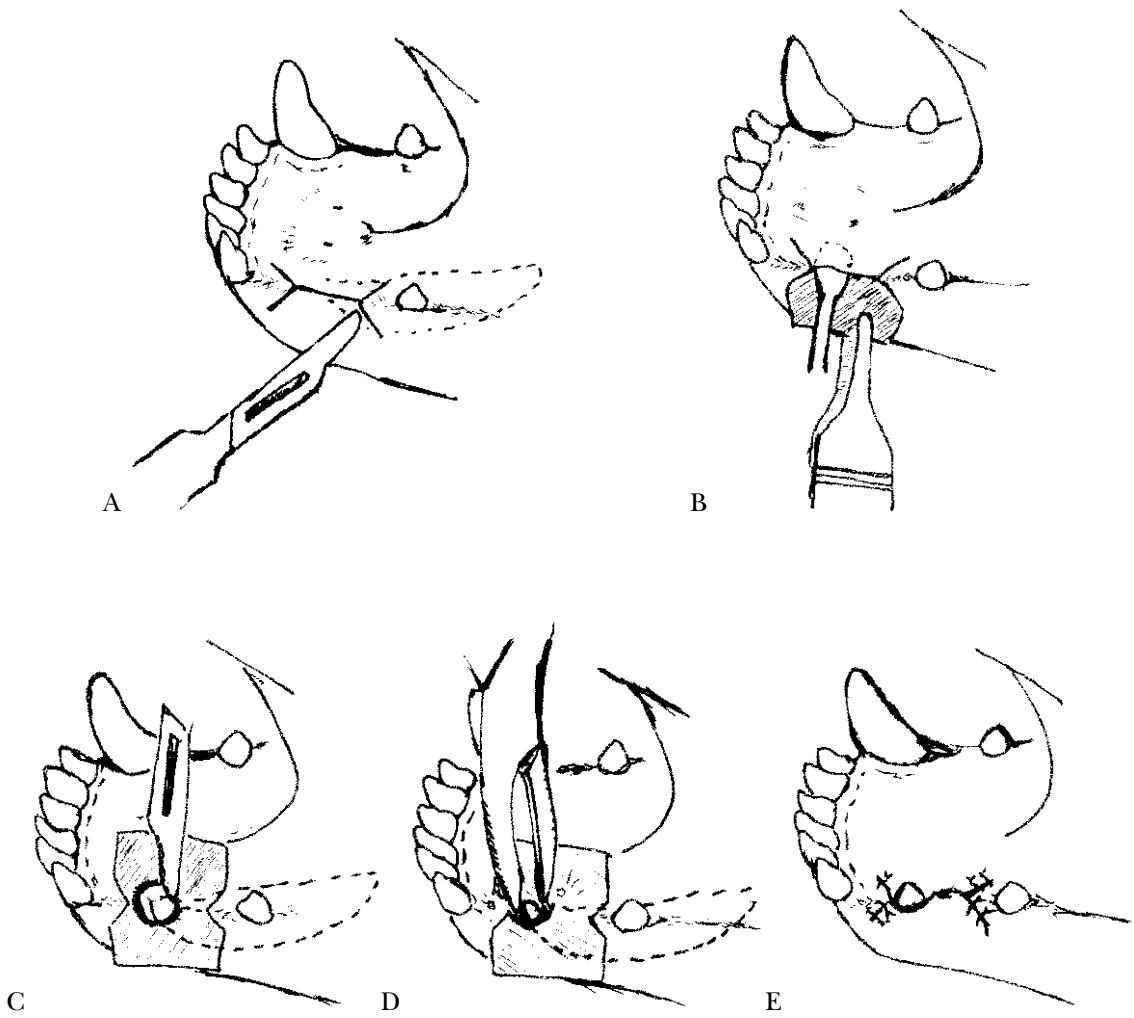
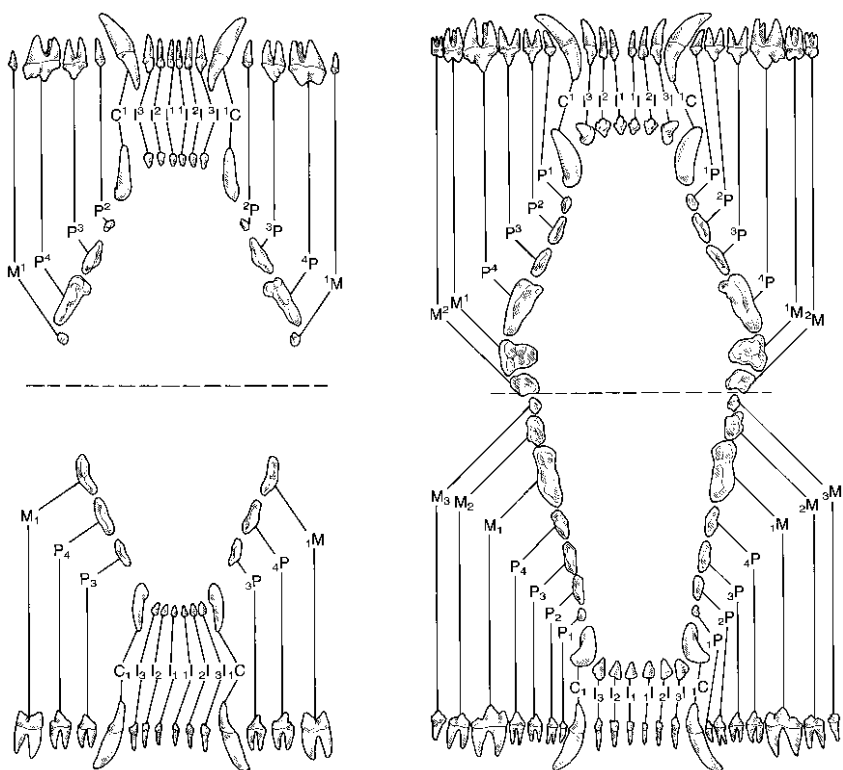


Fig. 9-26

- The laboratory cannot guess the intent of the clinician; the clinician must describe in writing and drawings exactly what kind of appliance is to be fabricated, its dimensions and its placement specifications. The laboratory should not be used as an instructor, but a place that fills the prescription for the doctor. In most cases where an appliance “doesn’t work,” one should look inward to determine what went wrong.

REFERENCES

1. Eisner ER: *Bites, breath and benevolent breeding*, Denver, 1997, published by author.
2. Ross DL: *Orthodontics for the dog: bite evaluation, basic concepts, and equipment*, Philadelphia, 1986, WB Saunders, pp 955-966.
3. Zwemer TJ, editor: Alphabetical listing of terms. In *Boucher's clinical dental terminology*, ed 3, St Louis 1982, Mosby pp 1-327.
4. Proffit WR, Fields HW: The biologic basis of orthodontic therapy. In *Contemporary orthodontics*, St Louis, 2000, Mosby, pp 296-325.
5. Wiggs RB: Orthodontics. Paper given at American Veterinary Dental Society Annual Meeting, St Louis, 1989.
6. Goldstein GS: The removable orthodontic appliance. Paper given at American Veterinary Dental Society Annual Meeting. Washington, DC, 1988.
7. Weigel JP, Dorn AS: Disease of the jaws and abnormal occlusion. In Harvey CE, editor: *Veterinary dentistry*, Philadelphia, 1985, WB Saunders, pp 106-122.
8. Ross D: Veterinary dentistry. In Ettinger SJ, editor: *Veterinary internal medicine*, Philadelphia, 1975, WB Saunders, pp 1053-1054.
9. Eisenmenger E, Zetner K: Abnormalities in dentition and change of teeth. In *Veterinary dentistry*, Philadelphia, 1985, Lea & Febiger, pp 48-67.
10. Proffit WR: Mechanical principles in orthodontic force control. In *Contemporary orthodontics*, St Louis, 1986, Mosby, pp 246-269.
11. Ross DL: *Common veterinary orthodontic indications: identification and classifications of needs*, New Orleans, 1988, Nabisco.
12. Verhaert L: A removable orthodontic device for the treatment of lingually displaced mandibular canine teeth in young dogs, *J Vet Dent* 16(2):69-75, 1999.
13. Luskin I: Veterinary dentistry 1994 Proceedings. Philadelphia, 1994.
14. Hale FA: Orthodontic corrections of lingually displaced canine teeth in a young dog using light-cured acrylic resin, *J Vet Dent* 13:69-73, 1996.
15. Goldstein GS: *Bite plates: removable and fixed*, New Orleans, 1988, Nabisco.
16. Beard GB: *Interceptive orthodontics for prevention: Maryland Bridges for correction*, New Orleans, 1988, Nabisco.
17. Stapleton BL, Clarke LL: Mandibular canine tooth impaction in a young dog—treatment and subsequent eruption: a case report, *J Vet Dent* 16(3):105-108, 1999.
18. Surgeon TW: Surgical exposure and orthodontic extrusion of an impacted canine tooth in a cat: a case report, *J Vet Dent* 17(2):81-85, 2000.
19. O'Connell AC, Torske KR: Primary failure of tooth eruption: a unique case, *Oral Surg Oral Med Oral Pathol Oral Radiol Endod* 87(6):714-720, 1999.
20. Kamakura S, Matsui K, Katou F, et al: Surgical and orthodontic management of compound odontoma without removal of the impacted permanent tooth, *Oral Surg Oral Med Oral Pathol Oral Radiol Endod* 94(5):540-542, 2002.



ANATOMY AND BIOMECHANICS

- The mandible and maxilla differ from the rest of the skeleton in that they contain teeth. Most of the dorsal two thirds of the body of the mandible is occupied by dental roots. The ventral third includes the mandibular canal, containing the inferior alveolar nerve and associated blood vessels. Ventral to the mandibular canal there is only a single layer of dense cortical bone.
- The lower jaw consists of two mandibles, joined at the symphysis, which consists of a fibrocartilaginous pad between the slightly irregular bony surfaces.¹ The symphysis remains a true joint throughout life in the dog and cat. The term *symphyseal separation* is therefore more accurate than symphyseal fracture. The mandible consists of a body, which is the tooth-bearing part, and a ramus, which is the caudal, non-tooth-bearing part.² The body of the mandible is often referred to incorrectly as the *horizontal ramus*. The ramus of the mandible contains three prominent processes: the coronoid process, on the dorsal aspect, the condylar process caudally, and the angular process caudoventrally.
- The term *maxillary fractures* in veterinary oral surgery often refers to fractures involving the incisive, palatine, zygomatic, frontal, and nasal bones, in addition to the maxillary bone proper.
- The temporal, masseter, and medial pterygoid muscles are responsible for closing the mouth. Because the muscular insertions are located on the caudal part of the mandible, this part in particular will be lifted when a fracture of the body of the mandible has occurred. The relatively small digastric muscle is responsible for opening the mouth. The static force exerted by this muscle, together with that of the geniohyoid and mylohyoid muscles and the force of gravity, tends to pull the rostral fragment of a fractured mandible in a caudoventral direction. Because of the forces exerted by the masticatory muscles, the direction of the fracture line determines whether a fracture is relatively stable (Fig. 10-1, A) or unstable (Fig. 10-1, B).^{3,4}
- The forces exerted on the mandible are also exerted on the maxilla. However, the distribution of these forces is much different, and it is generally accepted that the maxilla is subject to much less strain.

INITIAL MANAGEMENT

- Concurrent injuries to the head and other body parts are common. The patient should be fully examined in accordance with accepted clinical practice regarding trauma cases. Concomitant injuries may be life threatening and may require postponing definitive repair of the maxillofacial fracture.
- The diagnosis of a fracture of the mandible usually can be made by inspection and palpation. The nature and extent of the fracture can be further assessed by gentle palpation once the patient is under anesthesia prior to surgical treatment.
- Radiologic examination using dental film is indicated to visualize the fracture site and to diagnose concomitant dental trauma. Fractures involving the ramus or condylar process of the mandible and maxillary fractures are visualized best using computed tomography.
- Most maxillofacial fractures are of traumatic origin. Pathologic fractures associated with neoplasia occur occasionally. Relatively more common, however, are fractures of very weakened mandibles associated with severe periodontitis. Radiography is essential to recognize pathologic fractures.
- Fracture of the mandible is a most painful condition because of the inherent sensitivity of facial tissues. To lessen the patient's discomfort and to prevent further damage to the soft tissues, the fracture should be reduced temporarily and immobilized as soon as possible. Gross reduction can be obtained by gentle palpation using the occlusion of the canine teeth as a guide. A simple tape muzzle is then applied to maintain reduction (see further).^{5,6} This may be combined with a surgical technique for nutritional support, such as an esophagostomy tube, especially if the patient is in unstable condition and if it is unclear when definitive repair will be possible.

PRINCIPLES OF MAXILLOFACIAL FRACTURE REPAIR

- The management of fractures of the mandibular body should be aimed at the restoration of normal occlusion. The correct interdigitation of teeth is essential. It is imperative that the occlusion be inspected and taken as a guide during surgical repair of mandibular and maxillary fractures.

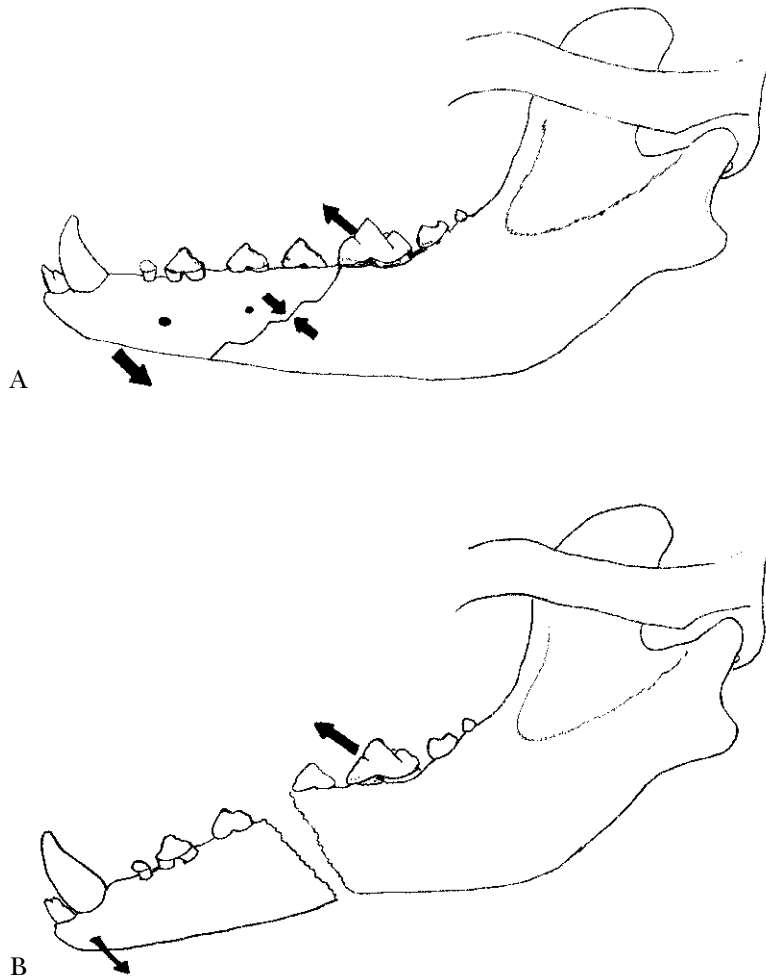


Fig. 10-1

- An important goal in the management of maxillofacial fractures is to restore normal function as soon as possible after the traumatic insult.
- Most mandible fractures in the dog are open to the oral cavity and inevitably contaminated. The prophylactic use of antibiotics in compound fractures has been shown to be of value in preventing infectious complications in humans.⁷ Removing devitalized tissue will enhance healing and may, to a large extent, prevent later complications.⁸ The surgical debridement of soft tissues should be very conservative, because the blood supply and healing capacity of oral tissues are excellent. Small loose pieces of bone should be removed if they do not contribute to stability of the repaired fracture. If they are retained, it is important to preserve their soft tissue attachments and to ensure that they are rigidly fixed.
- A tooth involved in a fracture line may be luxated and loose. In that case, the tooth should preferably be removed. If the tooth is not mobile, it usually is left in place, because it will contribute to the stability of the fracture fixation. If a tooth involved in the fracture line is retained, it should be monitored carefully for any subsequent evidence of periodontal or endodontal lesions, and appropriate treatment should be instituted as soon as this is recognized.^{9,10}
- During surgical repair of maxillofacial fractures, the surgeon should be aware of the teeth and other anatomic structures and make every effort to avoid iatrogenic damage.
- Severe dental disease, periodontal disease in particular, may have a marked effect on the amount and density of the jaw bone.¹⁰ The quality and amount of bone available are important factors in selecting orthopedic implants in maxillofacial surgery.
- Many maxillofacial fractures in dogs and cats can be managed conservatively, but many patients would benefit from skillful surgical intervention to achieve a more rapid return to normal function and to minimize the risk of malocclusion. Contraindications for surgical repair include a deciduous dentition, because it is nearly impossible to use implants without damaging the developing tooth germs.

ANESTHETIC MANAGEMENT AND POSITIONING FOR MAXILLOFACIAL FRACTURE REPAIR

General Comment

- The importance of checking the occlusion during surgical repair of mandibular fractures has already been mentioned. The presence of an oral endotracheal tube makes this impossible. However, intubation with a cuffed endotracheal tube to prevent aspiration is highly recommended during any oral surgery. Passing the endotracheal tube through a pharyngotomy incision satisfies both requirements.^{3,11}

Indications

- Pharyngotomy endotracheal intubation is indicated for all maxillofacial fracture repair procedures, with the exception of mandibular symphysis separation.
- The pharyngotomy can be converted into a pharyngostomy by replacing the endotracheal tube with a feeding tube on completion of the maxillofacial fracture repair.

Materials

- Long, curved forceps such as bile duct forceps.
- Wire-reinforced endotracheal tubes (Bivona Medical Technologies, Gary, Ind.).

Technique

- Step 1—With the patient under general anesthesia, the index finger is placed caudodorsal to the angle of the mandible and caudomedial to the hyoid apparatus, and a small skin incision is made over the finger (Fig. 10-2, A).
- Step 2—The finger is replaced by a long curved forceps, which is pushed through the pharyngeal wall and overlying tissues (Fig. 10-2, B).
- Step 3—The wire-reinforced endotracheal tube is grasped with the forceps and drawn into the pharynx (Fig. 10-2, C).

Step 4—The endotracheal tube is directed into the trachea (Fig. 10-2, *D*).

Step 5—Two pieces of adhesive tape are placed around the proximal end of the endotracheal tube and it is sutured to the skin (Fig. 10-2, *E*).

Patient Positioning

- Dorsal recumbency is indicated for the repair of most mandibular fractures, with the exception of fractures involving the condylar process, where lateral recumbency is preferred. The oral cavity can be lavaged with copious amounts of chlorhexidine gluconate solution. With the surgical drapes fixed to the upper lips, it is possible to check the occlusion during mandibular fracture repair (Fig. 10-2, *F*).

- Sternal recumbency is indicated for mandibular fracture repair using an intraoral acrylic or composite splint.

Complications

- Damage to the salivary glands and neurovascular structures at the pharyngotomy site. This can be avoided by careful blunt dissection with the long curved forceps.
- Endotracheal tube may collapse when bent; hence the use of a wire-reinforced tube.

Aftercare

- When extubation is indicated, the tube is removed and the pharyngotomy opening is left to heal by second intention.

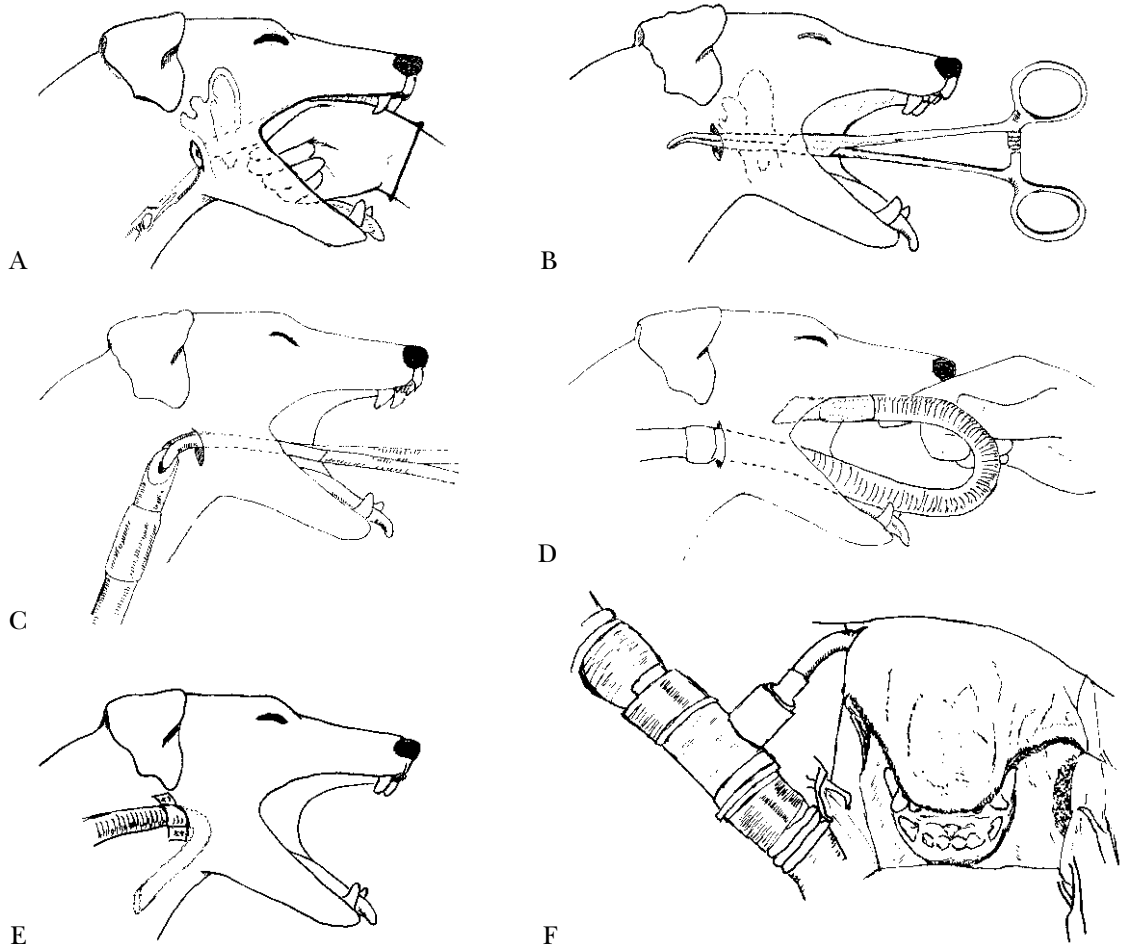


Fig. 10-2

TAPE MUZZLE FOR MAXILLOFACIAL FRACTURE STABILIZATION

Indications

- The use of a tape muzzle is well established in the treatment of mandibular fractures.^{5,6,12} By closing the mouth in occlusion, the fracture fragments are brought into alignment and some immobilization is achieved.
- This method is very useful in the first aid treatment of maxillofacial fractures.
- It is also indicated for the definitive treatment of stable and minimally displaced fractures, especially in patients with a deciduous dentition.
- The use of a tape muzzle can be considered as means of additional support in cases in which internal fixation did not achieve optimal stabilization.
- Tape muzzles can also be very useful in providing enough stability in cases of pathologic mandibular fractures caused by severe periodontitis, if surgical repair is not elected, in order to achieve a functional fibrous union.

Contraindications

- Unstable fractures with malocclusion.
- Respiratory distress due to epistaxis or blood clots in the nose.

Materials

- Semiporous tape, 1/2-, 1-, and 2-inch widths, depending on the size of the patient.

Technique

Step 1—The first strip of tape (adhesive side out) is applied around the muzzle; tape wide enough to encompass most of the patient's muzzle is used (Fig. 10-3, A).

Step 2—Two strips of tape, stuck together, are passed behind the ears and attached to the adhesive surface of the first strip (Fig. 10-3, B).

Step 3—A strip of tape, adhesive side in, secures the tape loop to the first strip of tape around the muzzle (Fig. 10-3, C).

Step 4—In brachycephalic dogs and cats, an additional double strip of tape, from the dorsum of the nose over the frontal region, is helpful (Fig. 10-3, D).

- A possible variation includes an additional piece of tape applied as a throat latch and attached by threading it around the cheek portion of the retaining piece of tape and passing it ventrally beneath the throat.
- A 5- to 10-mm gap is left for the tongue to allow the patient to lap liquefied food. Alternatively, the mouth can be closed completely and the patient fed through a pharyngostomy, nasogastric, esophagostomy, or gastrostomy tube.
- A commercially available nylon muzzle may be an acceptable substitute provided it fits snugly.

Complications

- Heat prostration.
- Dyspnea in brachycephalic patients is possible while the mouth is being maintained in a nearly closed position.
- Dermatitis can occur underneath the tape as a result of food and saliva accumulation.
- Aspiration pneumonia may occur if the patient vomits.
- The patient may dislodge the tape muzzle.

Aftercare

- Aftercare includes daily cleaning of the muzzle and underlying skin.
- An Elizabethan collar or taping the front feet is indicated if the patient tries to remove the muzzle.
- Depending on the nature of the fracture and the age of the patient, the tape muzzle can be removed after 2 to 8 weeks if used as a definitive method of stabilization.

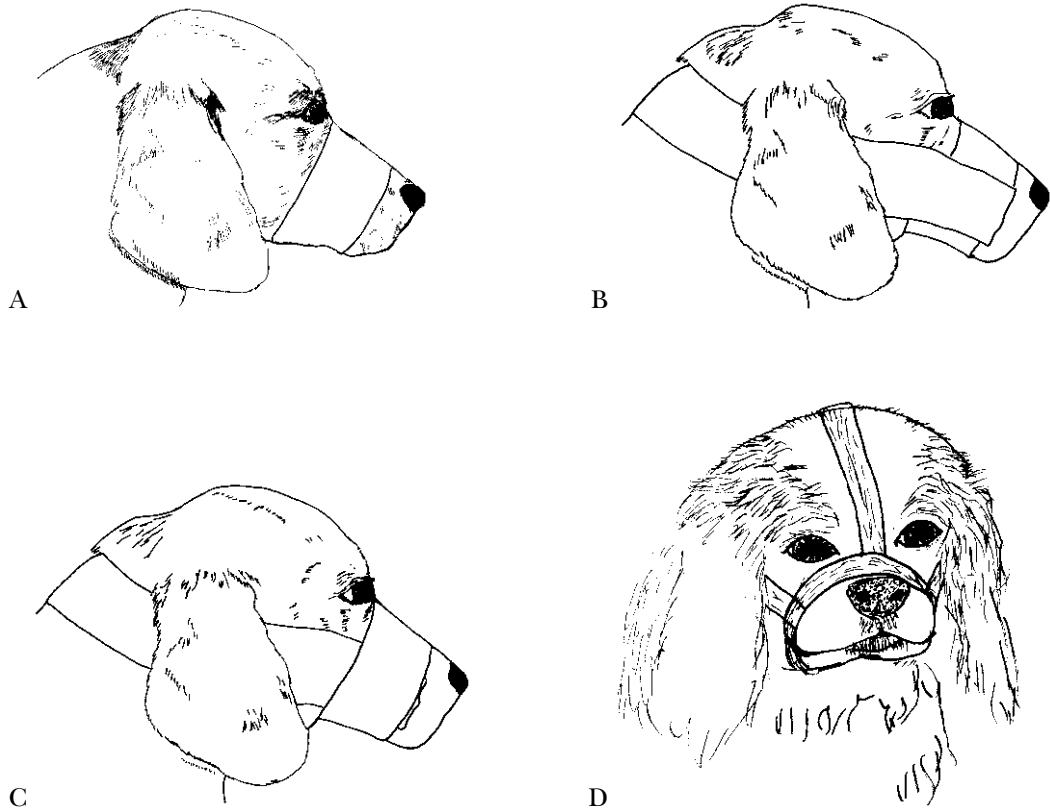


Fig. 10-3

SYMPHYSEAL SEPARATION REPAIR: CERCLAGE WIRING TECHNIQUE

General Comment

- Symphyseal separations are more common in cats than in dogs.
- Symphyseal separations are often accompanied by less obvious fractures of the ramus or condylar process.

Indications

- Traumatic separation of the mandibular symphysis.

Contraindications

- Loss of integrity of the mandibular symphysis due to osteomyelitis or neoplasia.

Objective

- A wire loop is passed between the soft tissues and bone around both mandibles distal to the canine teeth to stabilize the symphyseal separation.¹³

Materials

- Wire-twisting forceps (WT121C, Hu-Friedy, Chicago, Ill.).
- Wire-cutting scissors (S5095, Hu-Friedy).
- Orthopedic wire, 22 gauge.
- Large hypodermic needle, 14 to 18 gauge.

Technique

Step 1—The wire is passed into the bore of the needle at the hub to make sure the wire fits through the needle (Fig. 10-4, *A*).

Step 2—A 10-mm incision is made at the ventral midline, and the needle is inserted through the skin of the mandible and passed along the surface of the bone, directed dorsally to the buccodistal side of the canine (Fig. 10-4, *B*). The bevel of the needle should be facing the bone, thereby avoiding damage to the mental nerve with the sharp needle tip.

Step 3—The needle is grasped with wire-twisting forceps while the wire is pushed up through the needle (Fig. 10-4, *C*). The needle is removed, leaving the wire between the bone and skin and exiting both at the access and exit sites.

Step 4—The needle is reinserted at the ventral midline into the skin of the mandible and directed dorsally to the buccodistal side of the opposite canine, in a fashion similar to that of the first insertion (Fig. 10-4, *D*).

Step 5—The wire is inserted into the bore at the tip of the needle (Fig. 10-4, *E*).

Step 6—The needle is removed, leaving a loop of wire behind. On the dorsal aspect, the wire remains exposed to the oral cavity.

Step 7—Reduction is achieved and digitally maintained while the wire is tightened, using a wire-twisting forceps or small orthopedic wire twister, observing the standard guidelines for effective wire tightening (Fig. 10-4, *F*).

Step 8—The wire is trimmed so that approximately $\frac{1}{4}$ inch or four twists remain.

Step 9—The wire is not bent in order not to decrease the tension. The skin wound edges are approximated to cover the wire twist and sutured with two to three single, interrupted sutures.

Complications

- Overtightening may cause the wire to break or to necrose bone.
- Malocclusion due to incorrect alignment before the wire is tightened; this can be prevented by evaluating the occlusion and the mandibular incisive plane as the wire is tightened.
- Canine malocclusion in the presence of correct incisor realignment is suggestive of a concomitant caudal mandibular fracture.
- Some symphyseal joint mobility may remain and is clinically acceptable.

Aftercare

- Skin sutures can be removed after 10 days. Oral cavity fluids and bacteria may wick along the surface of the wire, resulting in a small draining tract at the ventral aspect of the chin. A 0.05% chlorhexidine gluconate solution can be used as an oral antiseptic rinse and to keep the skin wound area clean.

- The wire is removed after 4 to 6 weeks, and the mandibular symphysis is checked for stability.
- The wire is removed under general anesthesia: the wire loop is cut in the oral cavity using wire-cutting scissors. The two strands are straightened. The wire twist is grabbed through the draining tract opening or through a small stab wound and the wire pulled gently using wire-twisting forceps.

Variations

- Many variations on the simple cerclage wire technique have been described, such as placing the wire knot on the lateral aspect of

the mandible.¹⁴ Variations have also been described for cases in which fractures of parts of the incisive section of the mandible occurred in addition to the symphyseal separation during the traumatic incident.¹³ Interdental wiring techniques, augmented with and held in place by acrylic or composite resin, may be advantageous in cases in which incisors or canine teeth were luxated or avulsed in the process.¹⁵ In the case of a comminuted fracture with multiple small bone fragments and luxated teeth, a partial mandibulectomy can be performed.¹⁶

- Invasive techniques, such as screw fixation or a transverse pinning are not indicated, because of the unavoidable dental trauma associated with these techniques.

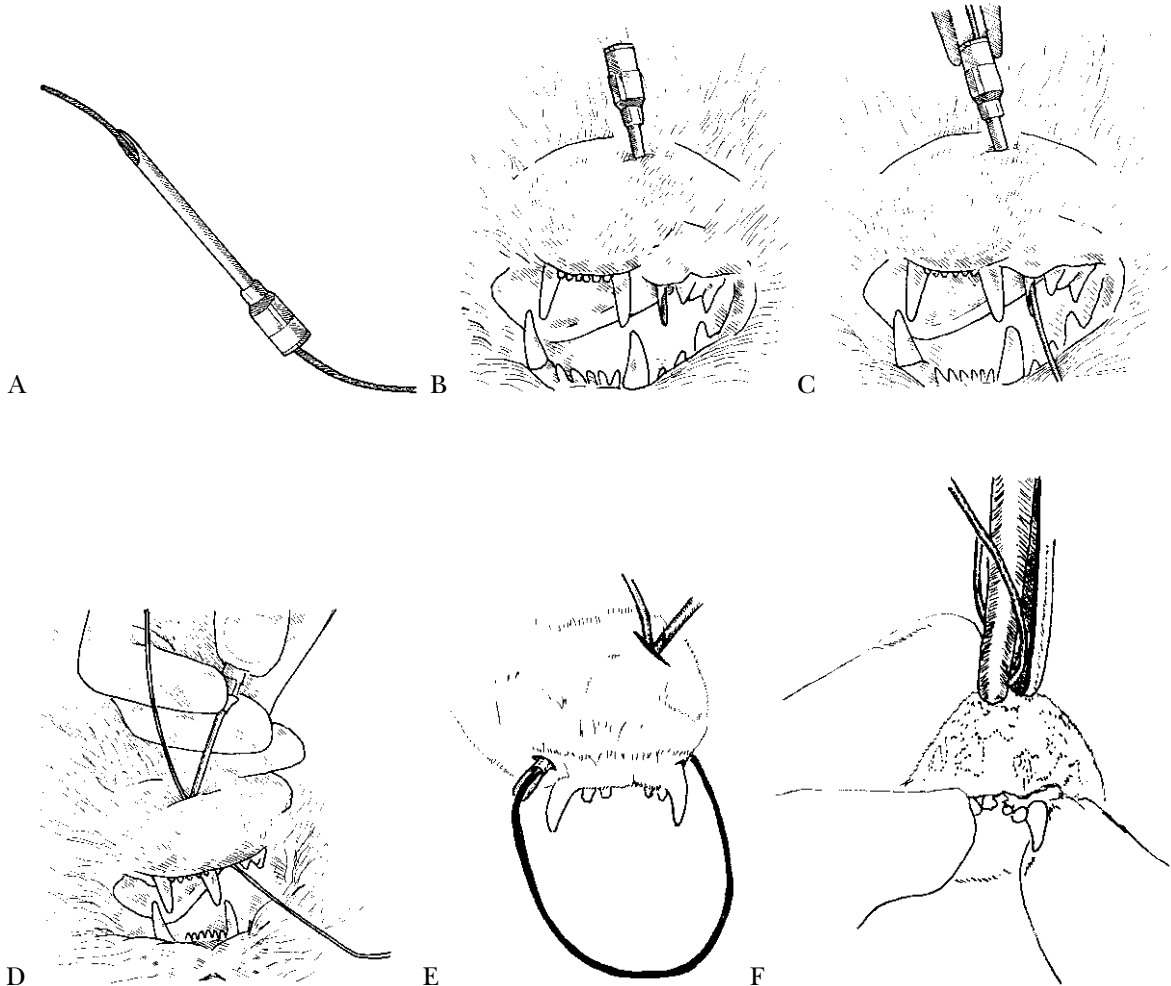


Fig. 10-4

FRACTURES OF THE BODY OF THE MANDIBLE

Methods of Repair

- A wide variety of surgical and nonsurgical methods have been described for the

treatment of fractures of the body of the mandible in the dog and cat. An in-depth discussion of the advantages, disadvantages, and technical details of each are not within the scope of this text. The following protocol is suggested (Fig. 10-5).

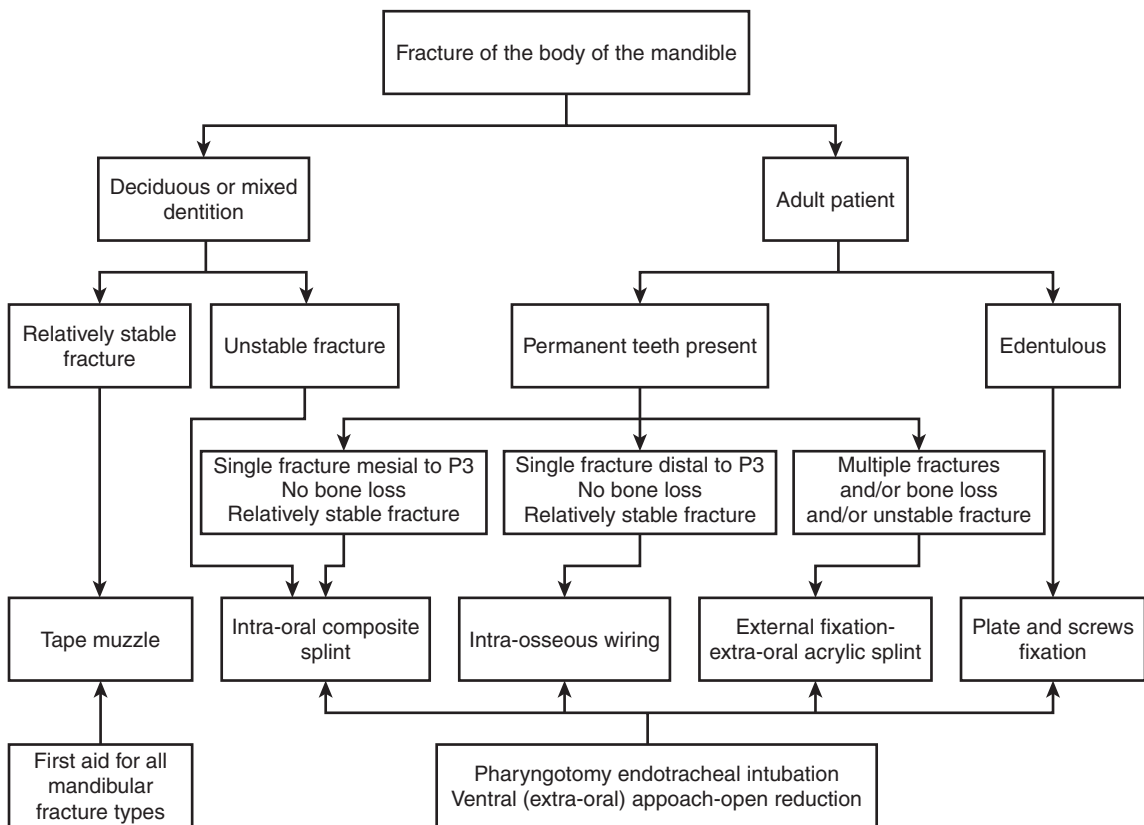


Fig. 10-5

Surgical Approach to the Body of the Mandible

- With the patient in dorsal recumbency, the standard ventral approach to the body of the mandible is simple and affords excellent exposure.¹⁷ The incision is made through the skin overlying the ventral edge of the mandible, from the level of the canine tooth to as far caudally as necessary for adequate exposure of the fracture site. Subcutaneous tissue and platysma are incised and the soft tissues reflected on both sides of the mandible. Care should be taken to avoid traumatizing the mental nerves and blood vessels rostrally, and the facial vein caudally (Fig. 10-6).
- On completion of the procedure, the soft tissues are apposed over the bone and implants and sutured.

INTRAORAL SPLINTS

General Comments

- The use of an intraoral acrylic splint in the management of maxillofacial fractures in small animals is well established.^{4,18-20} The original technique involved making an impression and from that a cast model of the dentition.⁴ An acrylic splint is then made on the model, after which it is installed in the mouth of the patient. Alternatively, and more practically, acrylic or a composite restorative material may be cast directly in the oral cavity to create an intraoral splint.¹⁸⁻²⁰
- The indirect fabrication of the cast is a longer procedure and is best suited to a team approach. Bone movement at the fracture site before, during, and after the impression is taken may complicate the installation of the splint. The additional length of anesthesia time is also a consideration.

- The composite restorative material offers the advantage of ease of application, lack of exothermic reaction, and absence of toxic fumes associated with acrylic monomers.

Indications

- Relatively stable fractures of the mandible mesial to the first molar, or preferably mesial to the third premolar.
- Maxillary fractures with relatively little displacement.
- Luxated or subluxated teeth²¹ (see further).

Contraindications

- Insufficient number of sound teeth on both sides of the fracture line.
- Unstable fractures and fractures with a missing bone fragment.

Materials for Intraoral Acrylic Splint: Direct Technique

- Flour pumice (not prophyl paste).
- Prophyl angle and rubber prophyl cups.
- Cold-cure acrylic (Jet Denture Repair Acrylic, Lang Dental, Wheeling, Ill.). Alternatively, a light-cure acrylic (Triad VLC, Dentsply-Trubyte, York, Penn.) may be used, which offers the advantage that there is less heat production, but which is time consuming to apply because of the long curing time.
- Petroleum jelly.
- Low-speed handpiece with acrylic cutting laboratory burs 75-080, 78-060 (Brasseler USA, Savannah, Geo.).
- Surgical or orthodontic wire; the gauge ranges from 14 to 26, depending on patient and tooth size.

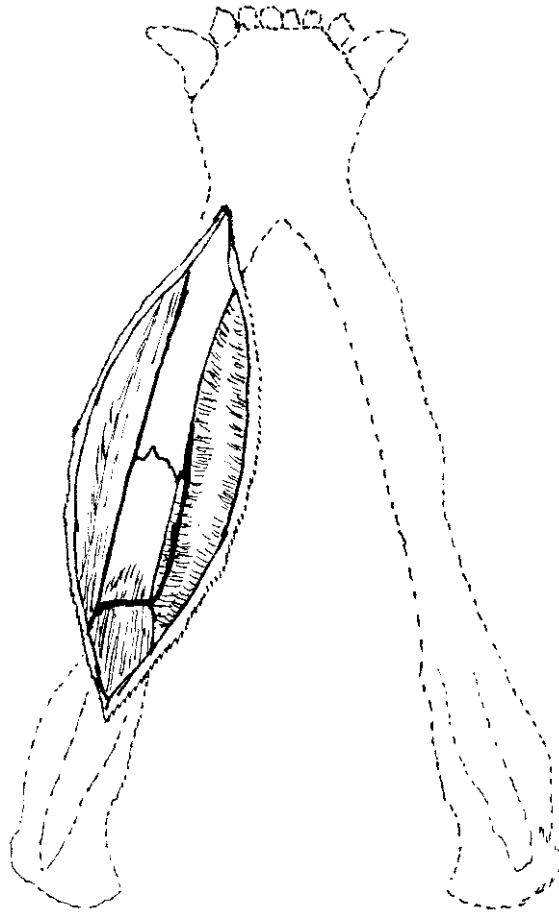


Fig. 10-6

Intraoral Acrylic Splint: Direct Technique

Step 1—Appropriate radiographs are obtained, misalignments are corrected, and other treatment is performed as indicated (Fig. 10-7, *A*). The tooth surfaces should be clean.

Step 2—The patient is placed in sternal recumbency. The coronal surface of the teeth (usually the canines and larger premolars) may be used for retention of the splint along with wiring techniques. The bonding sites are identified: the bulk of a mandibular splint should be on the lingual aspect of the teeth included, while a maxillary splint should primarily be created on the buccal aspect, in order to prevent or minimize occlusal interference.²² Teeth are scaled and then polished with a slurry of flour pumice (Fig. 10-7, *B*). The oral cavity is rinsed well.

Step 3—The bonding sites are acid-etched (see Chapter 9, Orthodontics).

Step 4—Wire is bent from tooth to tooth to act as a support for the acrylic (Fig. 10-7, *C*); alternatively, a wiring technique can be used (see further).

Step 5—A light coat of petroleum jelly is applied to exposed soft tissue surfaces (avoid the previously placed wire) and the coronal surfaces of the teeth on the opposite jaw. Boxing wax can also be applied on the buccal and lingual gingiva to prevent the acrylic from running off.

Step 6—A thin layer of the acrylic powder is applied (Fig. 10-7, *D*).

Step 7—The liquid monomer is dripped onto the powder (Fig. 10-7, *E*).

Step 8—Additional powder and liquid are alternately applied until the appliance has been built up for sufficient strength (Fig. 10-7, *F*).

Step 9—The appliance is trimmed and smoothed.

Step 10—The oral cavity and appliance are inspected for stability and occlusion.

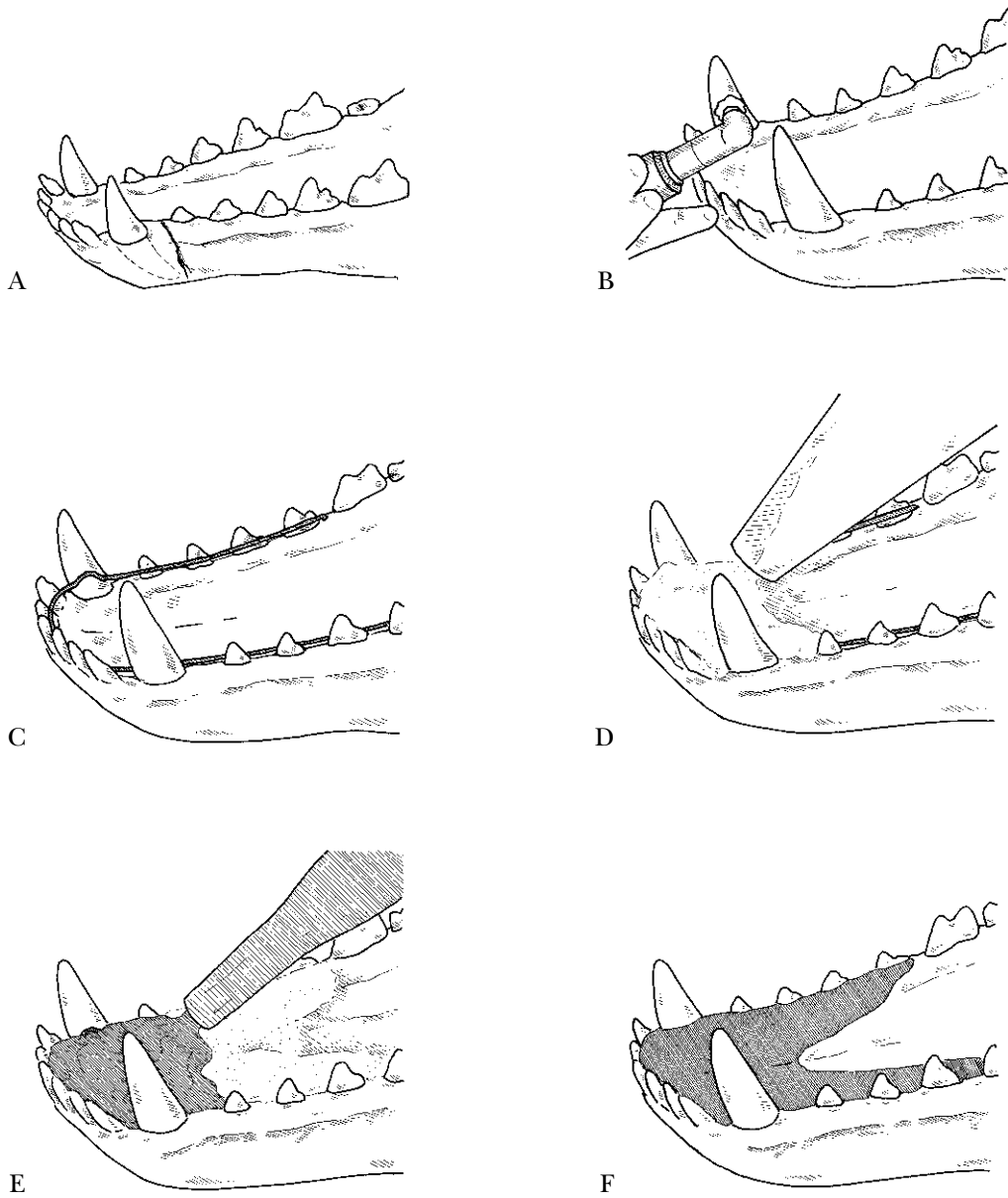


Fig. 10-7

Materials for Intraoral Composite Splint

- Flour pumice (not prophyl paste).
- Prophyl angle and rubber prophyl cups.
- Self-curing, composite temporary restorative material (Fig. 10-8, A) (Protemp Garant, ESPE, Plymouth Meeting, Penn.).
- Low-speed handpiece with acrylic cutting laboratory burs 75-080, 78-060 (Brasseler USA).

Technique for Intraoral Composite Splint

Step 1—Appropriate radiographs are obtained, misalignments are corrected, and other treatment is performed as indicated. The tooth surfaces should be clean.

Step 2—The patient is placed in sternal recumbency. The coronal surface of the teeth (usually the canines and larger premolars) may be used for retention of the splint along with wiring techniques. The bonding sites are identified: the bulk of a mandibular splint should be on the lingual aspect of the teeth, while a maxillary splint should primarily be created on the buccal aspect, in order to prevent or minimize occlusal interference.²² Teeth are scaled and then polished with a slurry of flour pumice. The oral cavity is rinsed well.

Step 3—The bonding sites are acid-etched (see Chapter 9, Orthodontics).

Step 4—The composite temporary restorative material is applied using an automix delivery system (Fig. 10-8, B).

Step 5—The appliance is trimmed and smoothed.

Step 6—The oral cavity and appliance are inspected for stability and occlusion.

Materials for Intraoral Acrylic Splint: Indirect Technique

- Flour pumice (not prophyl paste).
- Prophyl angle and rubber prophyl cups.
- Impression trays.
- Alginate impression material.
- Rubber bowl.
- Spatula.
- Die stone.
- Rope wax.
- Dental acrylics.
- Low-speed handpiece with laboratory burs.

- Soft stainless steel orthopedic wire.
- Orthodontic wire, 0.016 to 0.040 inch.
- Orthodontic cement.

Intraoral Acrylic Splint: Indirect Technique

Step 1—Appropriate radiographs are obtained, misalignments are corrected, and other treatment is performed as indicated.

Step 2—The proper impression tray is selected, alginate is mixed, and an impression is obtained (see Chapter 9, Dental Orthodontics). The fracture should be reduced when the impression is made; otherwise the model has to be sectioned to obtain proper alignment and subsequently luted with wax.

Step 3—A stone model is poured (see Chapter 9, Orthodontics).

Step 4—An outline of the splint is created on the model with rope wax (see Chapter 9, Dental Orthodontics).

Step 5—Bonding sites for wiring the appliance in place are identified.

Step 6—Wire is bent from tooth to tooth to act as a support for the acrylic.

Step 7—A thin layer of the acrylic powder is applied.

Step 8—The liquid monomer is dripped onto the powder from a dropper bottle.

Step 9—Additional powder and liquid are applied alternately until the appliance has been built up for sufficient strength.

Step 10—The appliance is trimmed and smoothed.

Step 11—The appliance is trial fitted and inspected for fit.

Step 12—The previously identified bonding sites are cleaned, polished with flour pumice, and acid-etched for 15 to 30 seconds with phosphoric acid gel or solution; then they are rinsed with water for 30 seconds and air dried.

Step 13—The appliance is refitted.

Step 14—Orthodontic cement is applied to the appliance and etched teeth to cement the appliance in place. Alternatively, the splint is held in place by circummandibular or interdental wires.^{4,23}

Complications

- Cold-curing acrylic causes a considerable exothermic reaction, which may damage the

underlying tissues. This is avoided by using small increments of acrylic. Once curing is started, the appliance may be cooled with water spray. This may cause discoloration of the material.

- Care should be taken that the acrylic does not flow into the fracture gaps, because this may impair healing.
- Sharp edges may be formed at the margins.
- Inflammation may occur secondary to food being trapped between the appliance and gingiva. This generally will resolve, without treatment, a few days after the appliance is removed.
- The appliance may break or become dislodged, in which case the procedure needs to be repeated.

Aftercare

- Aftercare includes regular cleaning of the oral cavity to limit the negative effects of food accumulation underneath the splint. Clients should be encouraged to flush the mouth and appliance twice daily with 0.05% to 0.12% chlorhexidine gluconate solution. A water pick may be used to aid in cleaning the oral cavity.
- The splint typically is removed after 6 weeks, after radiographic evaluation of the healing fracture site. The appliance is removed with band-removing pliers or a high-speed drill.
- Following removal of the appliance, routine periodontal treatment is indicated to prevent long-term periodontal complications.²²

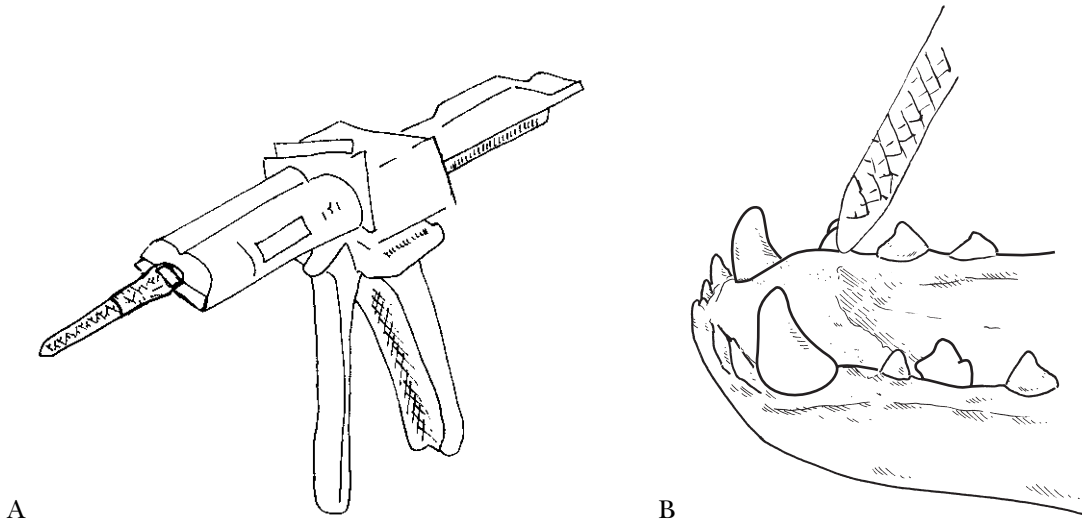


Fig. 10-8

INTERDENTAL WIRING

General Comments

- Various techniques for wiring an individual dental quadrant or arch have been described for man²⁴ and have been adapted for use in the dog.^{4,12} These techniques, such as the Risdon and ivy loop techniques, can be demonstrated easily on osteologic specimens but are clinically not so easy to apply. The conical shape of the crown of dog's teeth, with the widest diameter at the base of the crown, invariably leads to wire slippage. On specimens these wires are located just underneath the cementoenamel junction. In the live animal, however, this would mean gross interference with the periodontium. It has been recommended to notch the dental substance at the base of the crown to overcome wire slippage.⁴ These irregularities, however, interfere with the normal gingival contour and may lead to rapid plaque and calculus accumulation later in life.
- From a biomechanical point of view, interdental wiring is not indicated for unstable fractures, because the distracting forces would not be counteracted.
- The Stout multiple-loop wiring technique has become popular for use in combination with intraoral acrylic or composite splinting.^{10,25} Intraoral acrylic splints that are wire-reinforced are stronger than those that use either interdental wire or acrylic alone.²⁵

Indications

- Fixation and reinforcement of intraoral acrylic or composite splints used for maxillofacial fracture repair.
- Interdental wiring rarely is indicated as a sole method of fracture fixation.

Contraindications

- Fractures where more stable methods of fixation are required.
- Patients with poor periodontal health.

Materials

- Wire-twisting forceps (WT121C, Hu-Friedy, Chicago, Ill.) or Howe serrated-tip pliers (WBP110, Hu-Friedy).
- Wire-cutting scissors (S5095, Hu-Friedy).
- Orthopedic wire, 22 to 26 gauge.

Technique for Stout Multiple-Loop Wiring

- Step 1—A length of wire is cut and prestretched to improve its handling characteristics (Fig. 10-9, A).
- Step 2—One end of the wire is passed along the buccal surfaces of the teeth to be stabilized.
- Step 3—The other end is passed around the distal tooth at the interdental space to the lingual aspect (Fig. 10-9, B).
- Step 4—This end is passed back to the buccal surface at the next interdental space under the buccal wire, and looped over the buccal wire and back lingually through the same interdental space (Fig. 10-9, C).
- Step 5—The loop formed is twisted tight while the ends of the wire are held taut in place along the teeth (Fig. 10-9, D).
- Step 6—This process is repeated until all the teeth to be stabilized are encircled with the wire and their loops are tightened (Fig. 10-9, E).
- Step 7—The loop twists are bent flat against the tooth surface and can be covered with a dental acrylic or composite restorative material or embedded in an intraoral splint (Fig. 10-9, F).

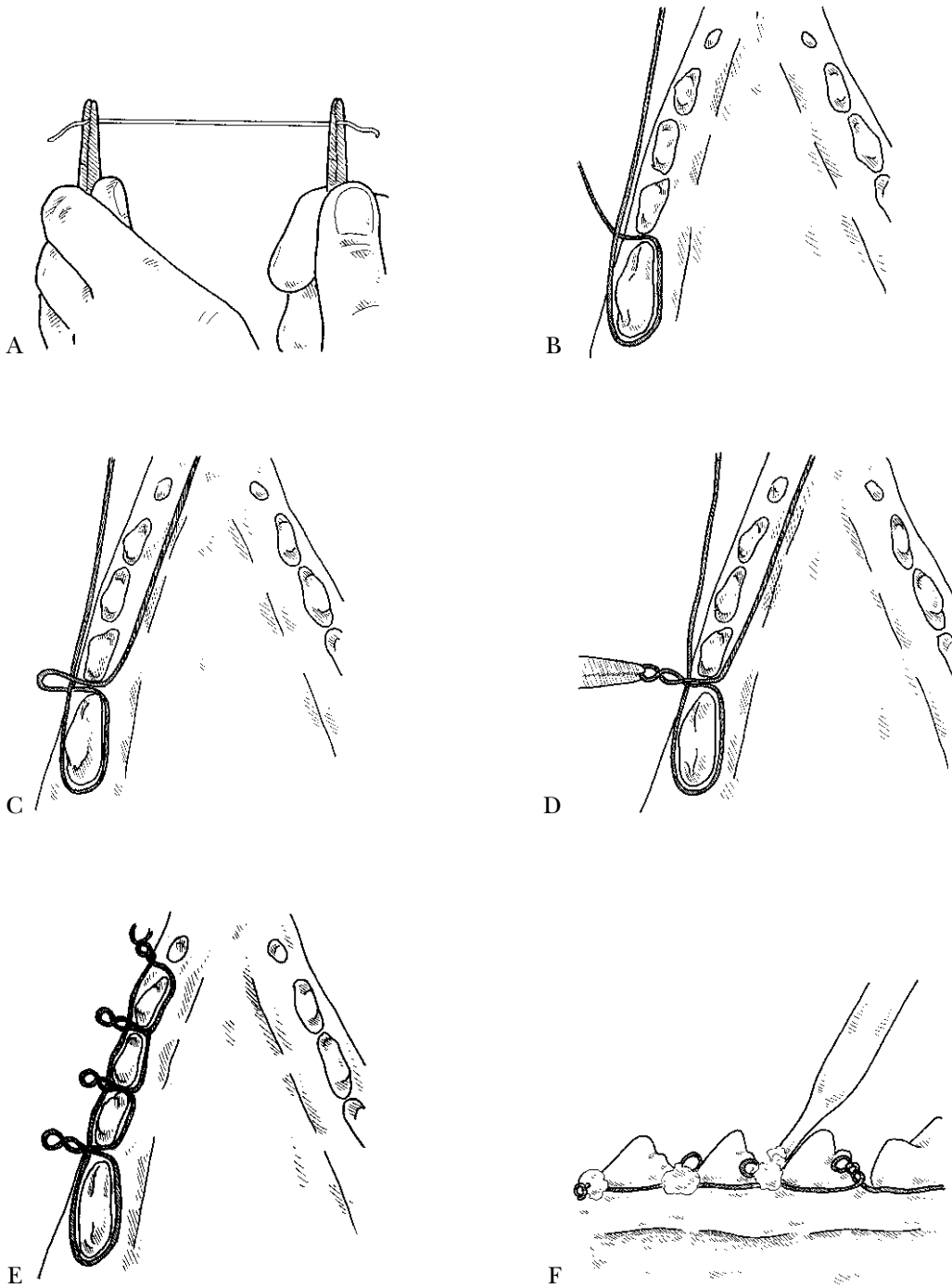


Fig. 10-9

Technique for Ivy Loop Wiring

Step 1—A length of wire is cut, and a loop is formed in the middle (Fig. 10-10, *A*). The ends are twisted together once.

Step 2—The free ends are passed buccally to palatally-lingually in the interdental space between the two teeth to be stabilized at the gingival margin (Fig. 10-10, *B*).

Step 3—One free end is passed rostrally and around the mesial aspect of the first tooth at the interdental space (Fig. 10-10, *C*).

Step 4—The other free end is passed caudally and around the distal aspect of the second tooth at the interdental space (Fig. 10-10, *D*). This wire is passed through the preformed loop rostrally and is twisted tight with the other free end (Fig. 10-10, *E*).

Step 5—The loop can be tightened further, and the twisted ends can be bent to lie flat against the tooth surface.

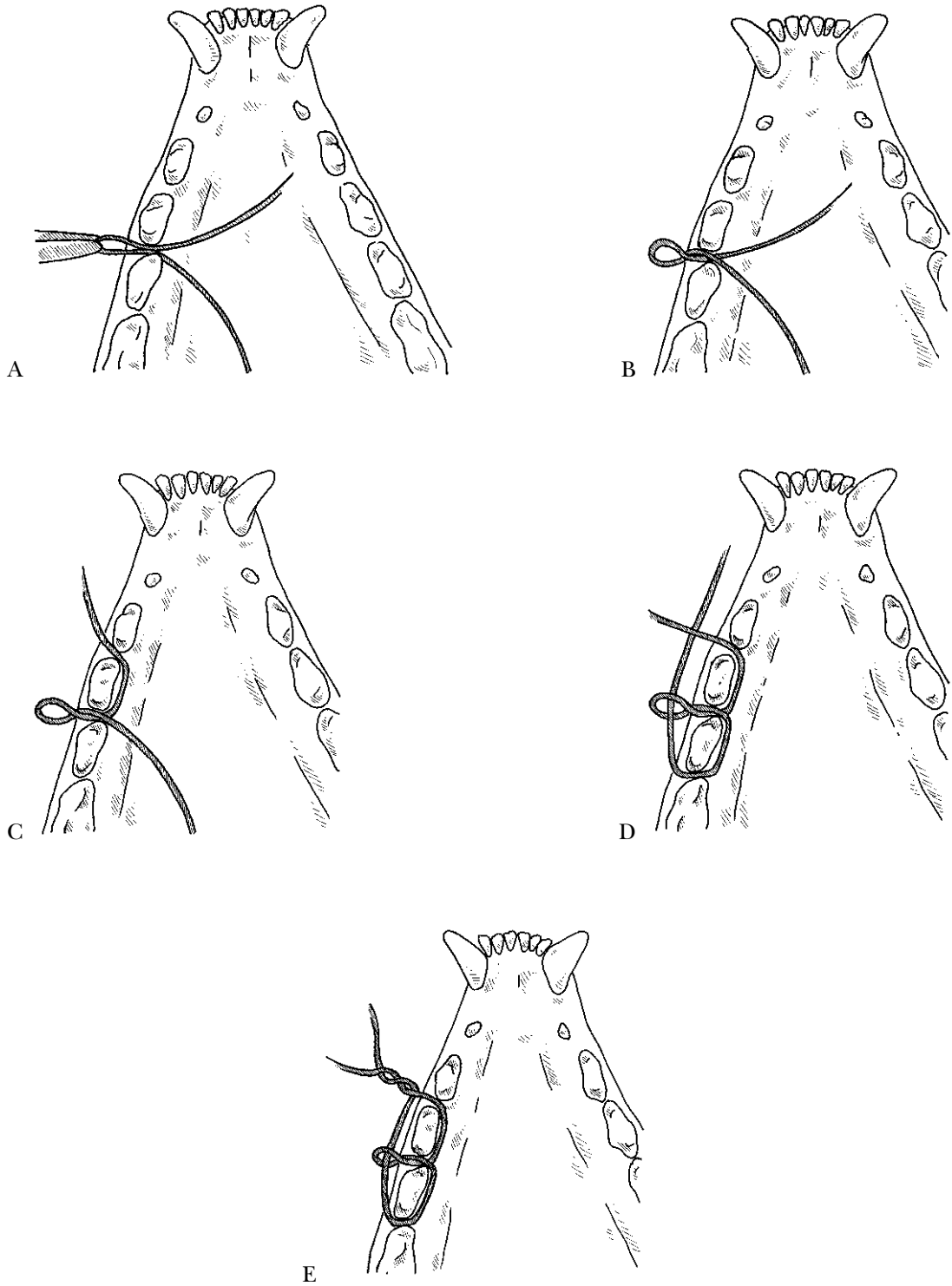


Fig. 10-10

Technique for Risdon Wiring

Step 1—A length of wire is passed around the anchor tooth selected on each side of the jaw so that the midpoint is on the palatal-lingual surface and equal lengths protrude on the buccal surface (Fig. 10-11, *A*).

Step 2—The free ends of the wires on each side of the head are twisted together for their entire length (Fig. 10-11, *B*).

Step 3—The twisted strands from each side are brought together at the midline and are twisted together (Fig. 10-11, *C*).

Step 4—Secondary wires are wrapped around the individual teeth in each arch and are twisted around the twisted master wire (Fig. 10-11, *D*).

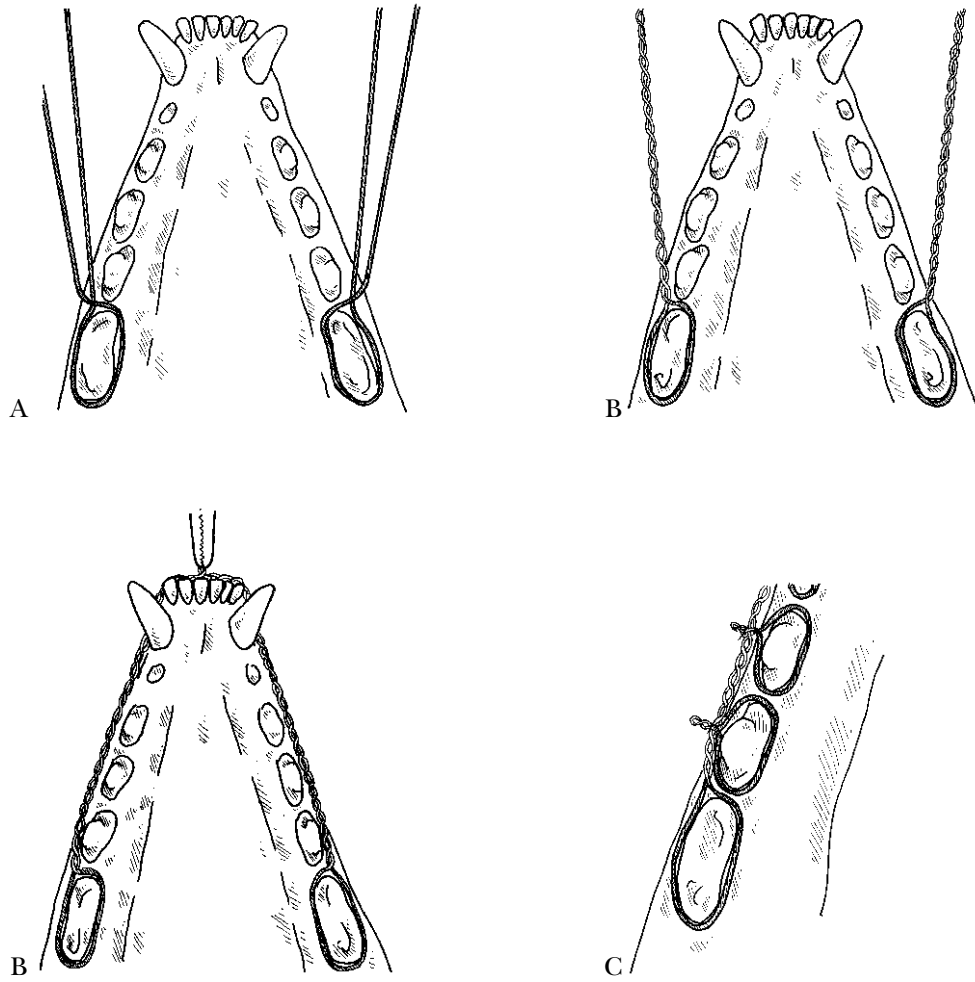


Fig. 10-11

INTRAOSSEOUS WIRING

General Comments

- A wide variety of intraosseous wiring techniques, also known as *interosseous* or *interfragmentary wiring*, have been described.²⁶

Indications

- Intraosseous wiring techniques are acceptable for the treatment of single, relatively stable mandibular fractures without bone loss, provided they are applied correctly.

Contraindications

- Unstable, comminuted, or bilateral fractures.
- Poor bone quality, as in geriatric patients with severe periodontitis.
- Fractures in patients with deciduous dentition.

Materials

- Good quality orthopedic wire: the wire should be soft and flexible. Orthodontic wire, with its inherent stiffness, is not indicated. Excessive manipulation and kinking of the wire should be avoided. Kinked wire is difficult to pass through the drill holes and the kinks make it impossible to maintain even tension. Recommended sizes for toy breeds are 24 gauge, going up to 18 gauge for large breeds.¹²
- Wire-twisting forceps (WT121C, Hu-Friedy).
- Wire-cutting scissors (S5095, Hu-Friedy).

Technique

- Antibiotic prophylaxis is indicated, because maxillofacial fractures often are open and therefore contaminated, the trauma associated with the surgical repair, and the presence of orthopedic implants.
- After adequate exposure of the fracture site through the standard ventral approach, the fracture fragments are reduced anatomically and normal occlusion restored.
- Drill holes should be planned bearing in mind the nature of the fracture (stable versus unstable), position of the mandibular canal and dental roots, and the biomechanics of the wiring pattern envisioned.

- A stable, well interdigitating fracture can be managed using a single wire (Fig. 10-12, A). The wire should be placed somewhere between perpendicular to the fracture line and parallel to the long axis of the body.^{8,26}
- Most commonly, however, two wires are used, preferably at an angle to each other (Fig. 10-12, B). Another good pattern is a triangular configuration, where two holes are made in the caudal segment and one in the rostral segment (Fig. 10-12, C).^{4,27} A hole should not be drilled too close to the fracture line nor in weakened bone. This is especially the case on the dorsal aspect of the mandibular body because of concurrent periodontitis.
- It often is indicated to place a hole through the mandibular canal. The mandibular canal is surrounded by dense cortical bone, providing excellent support for wire. To avoid damage to the neurovascular structures while drilling through the canal, a small Kirschner wire (K-wire) can be used instead of a conventional drill bit. The K-wire, with its smooth surface, will push the neurovascular structures out of the way and not traumatize them the way a drill bit would.
- Dental roots should be avoided when choosing drill sites, because trauma to these structures may result in devitalization of the tooth.
- An intraosseous wire should be secured as tightly as possible. Even tension should be maintained while twisting the wire.²⁶ Bending over the knot may decrease the tension somewhat, but it usually is indicated in order to prevent undue soft tissue irritation because of sharp protruding wire ends.

Complications

- Iatrogenic damage to the teeth and neurovascular structures.
- Overtightening the wire in poor-quality bone may cause the wire to cut through the bone.
- Loose wires result in instability of the fracture fragments which, in turn, leads to delayed healing. In addition, a loose wire often becomes a nidus of infection.
- Erosion of the alveolar mucosa overlying wire knots and sharp ends may occur, which leads to contamination of the fracture site.
- Poorly conceived wire placement may result in an unstable fixation.

Aftercare

- Nonabrasive food and chew toys are indicated while the fracture heals.
- Maxillofacial fracture repair typically is evaluated radiographically at 6 weeks post-operatively, unless clinical signs indicate possible complications sooner.
- Once the fracture is considered clinically healed, the wires should be removed, using the same surgical approach.

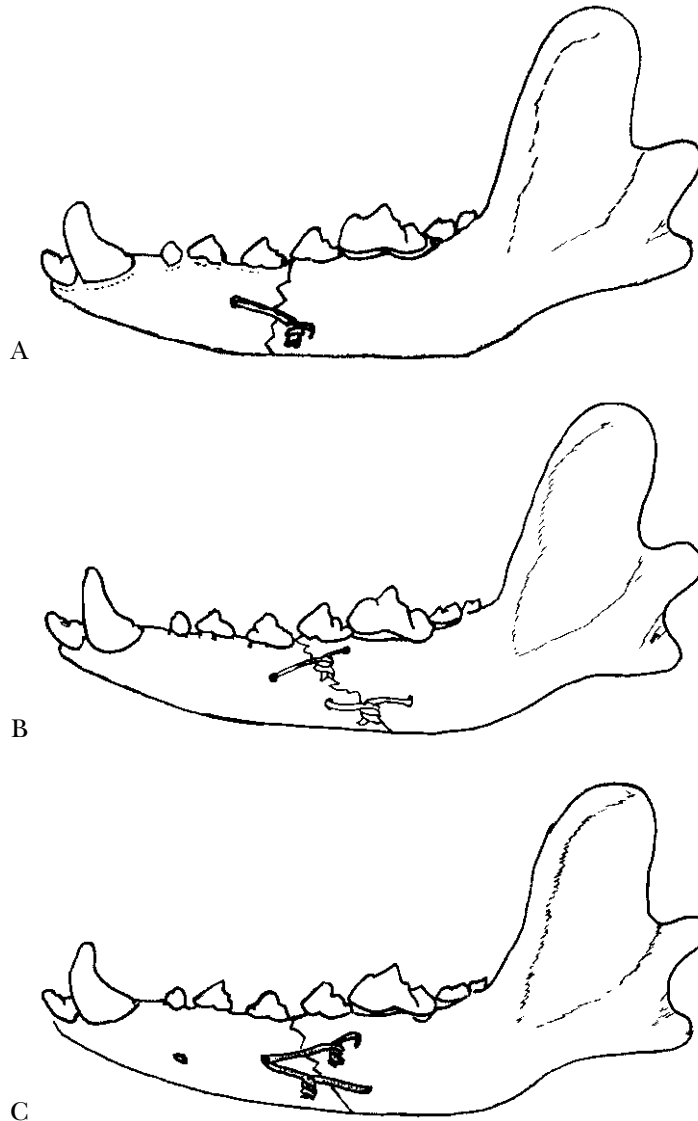


Fig. 10-12

EXTERNAL FIXATION

General Comments

- The full Kirschner-Ehmer apparatus is very stable, but cumbersome and difficult to apply to the mandible.^{12,28} Replacing the metal connecting bar with a mass of acrylic greatly facilitates placing the pins and connecting them, without compromising strength.²⁹
- Techniques using percutaneously placed K-wires connected by acrylic have become widely accepted in the management of maxillofacial fractures in dogs.³⁰

Indications

- External fixation affords excellent fracture stabilization, even in patients with multiple fractures, severe comminution, and missing fragments.^{29,30}

Contraindications

- Fractures that can be managed effectively using less involved techniques.
- Fractures in patients with deciduous dentition.

Materials

- Threaded or smooth K-wires (1.0 to 2.0 mm) (Synthes USA, Paoli, Penn.).
- Custom impression tray material (Formatray, Kerr; Romulus, Mich.), dental acrylic (Jet Denture Repair Acrylic, Lang), polymethyl methacrylate bone cement (Simplex P, Howmedica Osteonics, Rutherford, NJ), or hoof acrylic (Technovit, Jorgensen Laboratories, Loveland, Colo.).
- Catheter-tip syringe, 60 ml.
- Silicone tubing.

Technique

- Antibiotic prophylaxis is indicated, because maxillofacial fractures often are open and therefore contaminated, because of the trauma associated with the surgical repair, and because of the presence of orthopedic implants.

Step 1—After open or closed reduction, at least two K-wires are placed on either side of the fracture line. The pins must be slightly angled, especially if the splint is placed on only one mandible (Fig. 10-13, A). This example shows the use of external fixation for the repair of a bilateral fracture with closed reduction.

Step 2—Silicone tubing is placed over the external pin ends, leaving about 10 mm between the tubing and the skin (Fig. 10-13, B).³¹

Step 3—While normal occlusion is maintained, the tube is filled with dental acrylic or custom impression tray material, using a 60-ml catheter-tip syringe (Fig. 10-13, C). Polymethyl methacrylate bone cement or hoof acrylic can be used for the same purpose.³¹⁻³³

Step 4—Once the acrylic has set hard, the syringe is removed (Fig. 10-13, D).

Step 5—The silicone tube is not removed, because it offers some protection for the hard acrylic bar (Fig. 10-13, E).

- Care should be taken to avoid causing dental trauma when placing the pins; this is especially difficult in the canine-incisor area, and an intraoral splint is preferable for fractures involving this area. Alternatively, an interdental pin embedded in an intraoral splint in the canine-incisor area may be connected to the external fixation connecting bar.³²
- Although threaded pins may offer advantages from an orthopedic standpoint,¹⁸ smooth pins conceivably cause less trauma to the neurovascular structures in the mandibular canal than threaded pins, if inadvertently placed there.
- The pins should engage only in one mandible and not cross the intermandibular space, even in the case of a bilateral fracture, to avoid interference with tongue movement.
- A commonly used variation is to bend the pin ends and include them in an acrylic mold.^{30,33}

Complications

- Iatrogenic damage to the teeth and neurovascular structures.
- The external fixation device can be dislodged inadvertently (e.g., if it catches a door ledge).
- Pin loosening.
- Pin tract osteomyelitis and ring sequestrum.³⁴
- Lip dermatitis if food and saliva are allowed to accumulate between the external fixation device and the skin.

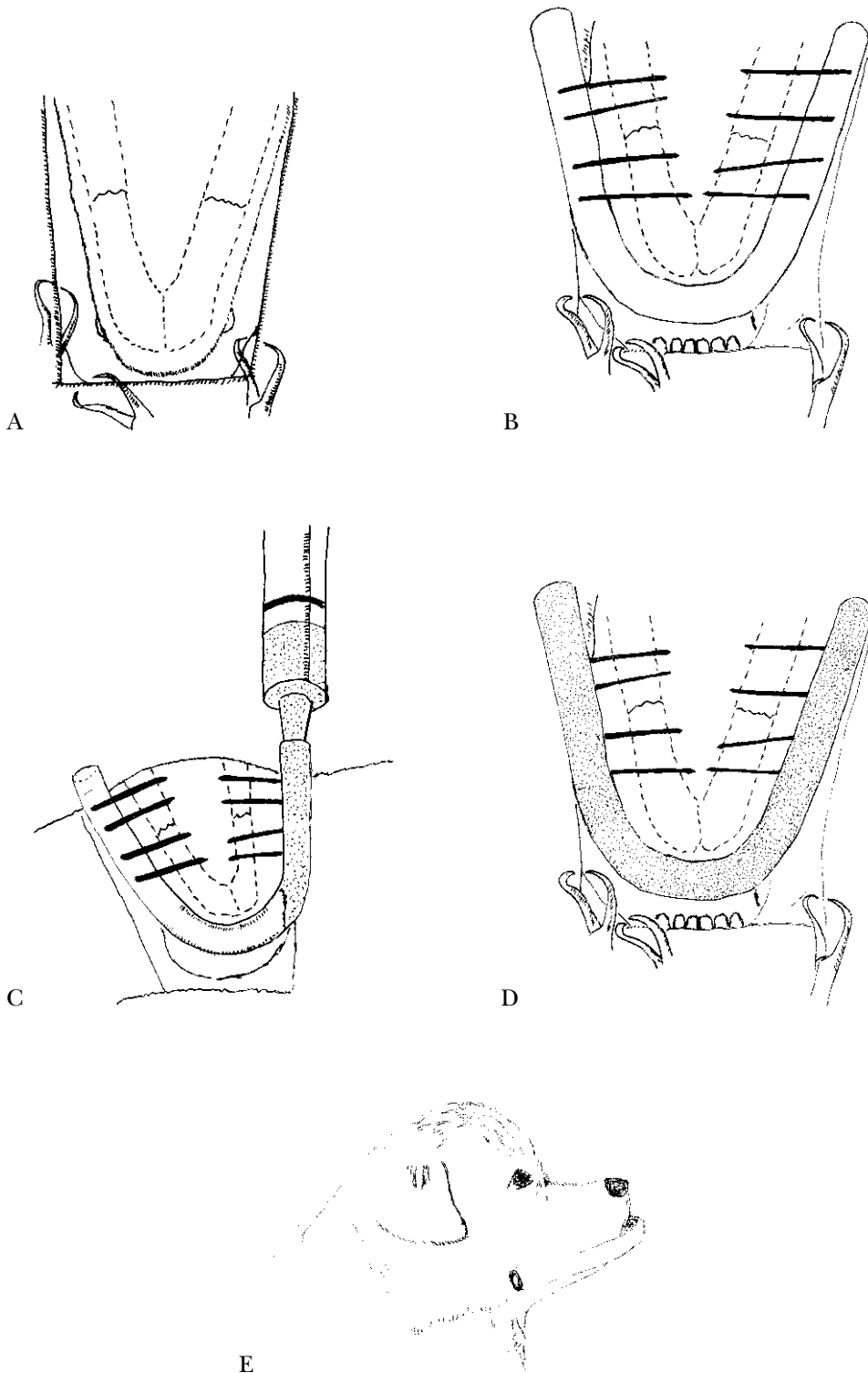


Fig. 10-13

Aftercare

- Aftercare includes daily cleaning of the lips and splint to prevent food and saliva accumulation between the skin and splint.
- Maxillofacial fracture repair typically is evaluated radiographically at 6 weeks post-operatively, unless clinical signs indicate possible complications sooner.
- Once healing has occurred, the pins can be cut between the acrylic and the skin and removed after removal of the splint. Alternatively, the acrylic bar can be cut in segments to allow pin removal.^{22,30}

MINIPLATE AND SCREWS FIXATION

General Comments

- Bone plating is a method by which rigid internal fixation and thus a rapid return to normal function is achieved. However, there are some distinct problems with this method if used on the mandibular body. A plate in a ventrolateral position is biomechanically relatively unstable, and screws are likely to cause damage to the neurovascular structures in the mandibular canal. The dorsolateral aspect is theoretically the position of choice for a plate because of its biomechanical advantage. The amount of bone available for screw insertion is very limited, and trauma to the dental roots and erosion of the alveolar mucosa can occur easily.³⁵
- Because of the difficulty in avoiding dental roots and mandibular canal, and an increased awareness of the importance of dental complications, plate fixation has not been recommended recently for mandibular fracture repair in dogs and cats, except for edentulous mandibles.^{22,35}
- A recent development in human and veterinary maxillofacial fracture repair is the use of miniplates.^{36,37} Maxillofacial miniplates and screws offer more versatility and have been used with good success for fixation of mandibular, maxillary, and other maxillofacial fractures. The contouring of these small titanium plates is much easier than with standard orthopedic plates, and a wide variety of plate designs and sizes are available. The self-tapping screws can be placed in a monocortical or bicortical fashion. These

features make it easier to place the plates in biomechanically advantageous positions, yet avoid important anatomic structures.³⁶

- The main disadvantage of miniplate fixation is the cost associated with the special instruments required and the variety of implants. In addition, special training is required to use this system.

Indications

- Fractures of edentulous mandibles.
- Multiple maxillofacial fractures with major fragment displacement in older patients (Fig. 10-14).
- Nonunion of mandibular fractures, requiring rigid internal fixation and bone grafting.

Contraindications

- Fractures that can be managed effectively using less involved techniques.
- Fractures in patients with a deciduous dentition.

Materials

- The miniplate system consists of a wide variety of titanium plates and matching screws, both in a number of sizes, and special instruments to place these implants (Synthes USA).

Complications

- Iatrogenic damage to the teeth and neurovascular structures.
- Implant failure.
- Osteomyelitis.

Aftercare

- Maxillofacial fracture repair typically is evaluated radiographically at 6 weeks post-operatively, unless clinical signs indicate possible complications sooner. Repeated follow-up examinations often are required, because this system typically is used in problem cases.
- Once healing has occurred, the implants can be removed. Implant removal is recommended in young animals and optional in older patients.

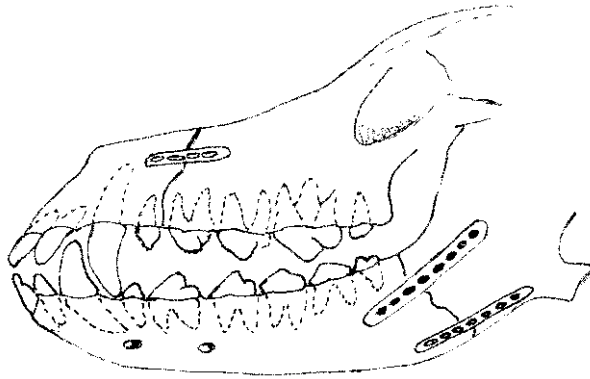


Fig. 10-14

MANAGEMENT OF CAUDAL MANDIBULAR FRACTURES

General Comments

- Fractures of the midportion of the ramus of the mandible are seen occasionally in the dog and cat.^{12,38,39} The surrounding muscle mass usually prevents gross displacement of the fragments and provides sufficient stabilization, in combination with a tape muzzle.
- Unstable fractures can be managed using intraosseous wiring techniques or miniplating.^{30,36,40} The ramus of the mandible lends itself fairly well to plate and screw fixation, especially in relatively larger patients and if miniplates are available, because of the absence of dental roots (see pp. 586 to 587). However, the bone in the masseteric fossa is very thin and care should be taken not to strip the screw holes.
- Highly comminuted fractures in this area are an indication for maxillomandibular fixation, for example by means of bonding the canine teeth (see pp. 592 to 593).⁴¹
- Fracture of the angular process and coronoid process are seen uncommonly, usually in combination with other ramus fractures. Displacement tends to be minimal because of the surrounding muscle mass.
- Fractures involving the condylar process are seen occasionally in the dog but more commonly in the cat.^{38,39,42} Careful radiographic examination of the temporomandibular joints in cats with maxillofacial injuries is indicated.⁴³
- The condylar process may be fractured in a sagittal plane (intracondylar), or the fracture may be subcondylar. Fractures of the retroarticular process, mandibular fossa, and

zygomatic process of the squamous part of the temporal bone may occur, also.⁴³

Indications

- The indications for surgical treatment versus nonsurgical treatment are summarized in the flow chart (Fig. 10-15).
- Fractures of the condylar process treated conservatively may heal by bony union or as a pain-free and functional nonunion.^{8,42} Conservative treatment of minimally displaced subcondylar and pericondylar fractures without joint surface involvement is therefore justifiable.
- Intraarticular fractures, however, are likely to result in temporomandibular joint arthrosis and possible ankylosis; the latter complication is characterized by a progressive inability to open the mouth.^{44,45} It is controversial whether this justifies performing a condylectomy at the time of diagnosis of an intraarticular fracture, or to wait for arthritic changes to develop and to perform the condylectomy at that stage.^{46,47}
- Condylectomy is also indicated for chronic temporomandibular luxation.

Contraindications

- Unstable trauma patients.

Materials

- Straight handpiece (KaVo INTRAFlex LUX 2 2313 LN, KaVo America, Lake Zurich, Ill.), osteotomy burs (#166 bone cutter bur, round all-port bone cutter bur, Brasseler USA).
- Osteotome, bone rongeur, bone file (Synthes USA).

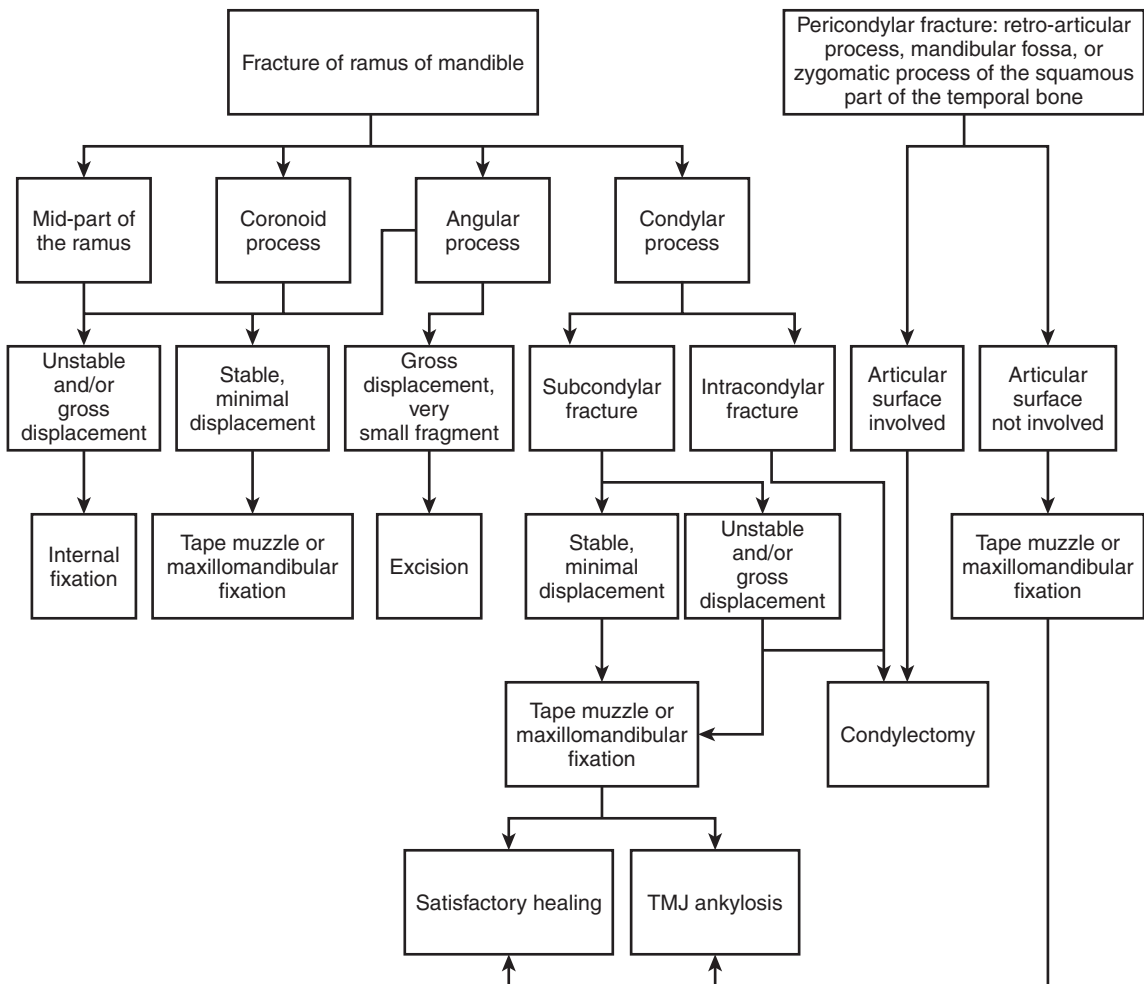


Fig. 10-15

Technique: Condylectomy

Step 1—The condylar process can be exposed through a lateral approach.¹⁷ The origin of the masseter muscle is incised on the ventral border of the zygomatic arch and the muscle retracted in a rostroventral direction (Fig. 10-16, A). Care should be taken to avoid the nearby neurovascular structures.

Step 2—The temporomandibular joint is found on the caudal aspect of the zygomatic arch. The joint capsule is incised craniolaterally, and the condylar process partly visualized by manipulating the mandible (Fig. 10-16, B).

Step 3—In case of a subcondylar fracture, the condylar process is lifted out by gentle traction and careful blunt dissection on the medial aspect of the joint capsule. If the condylar process is intact or partly intact, it can be separated from the rest of the mandible using a surgical handpiece with an osteotomy bur, an osteotome, or a bone rongeur, followed by careful blunt dissection on the medial aspect of the joint capsule (Fig. 10-16, C).

Step 4—The meniscus, which usually remains attached to the mandibular fossa, is left in place unless it is detached by the traumatic insult.

Step 5—The caudal aspect of the ramus of the mandible should be palpably smooth; if necessary, it can be smoothed using a surgical handpiece with a round bur, a small bone rongeur, or a bone file (Fig. 10-16, D).

Step 6—The aponeurosis of the masseter muscle is sutured to the periosteum on the ventral border of the zygomatic arch (Fig. 10-16, E). Platysma and skin are closed in separate layers.

Step 7—Postoperative radiographs are obtained to verify that the condylectomy was complete and that the caudal aspect of the ramus of the mandible is smooth.

Complications

- Severe hemorrhage can occur if sharp dissection is used on the medial aspect of the joint capsule, resulting in trauma to the maxillary artery or one of the major branches located on the medial aspect of the temporomandibular joint.
- There is generally a temporary malocclusion following a unilateral condylectomy. Mild

osteoarthritic changes may occur in the opposite joint.^{47,48}

- Malocclusion following a bilateral condylectomy may be more severe and longer lasting. Nutritional support may be indicated.
- An ankylosis may develop following a condylectomy. This is especially common when the condylectomy was performed to treat an already existing ankylosis.⁴⁷

Aftercare

- During the immediate postoperative period, soft food and pain management are indicated. Thereafter the patient should be stimulated to use its jaws actively. This can be achieved by feeding large kibble and providing chew toys. Antiinflammatory medication may be considered.
- Postoperative nutritional support may be indicated for patients with a bilateral condylectomy.
- For patients who underwent a condylectomy for the treatment of ankylosis, physical therapy is indicated to prevent ankylosis.

MAXILLOMANDIBULAR FIXATION: LONG-TERM MOUTH CLOSURE

General Comments

- A number of methods besides tape muzzling are available for long-term mouth closure, in order to achieve reduction and stabilization of the fracture fragments by maintaining the normal dental interlock. The use of intraoral screws and elastic bands for the more caudally located fractures in dogs has been described.⁴⁹ Screws are placed on the sides of both maxillae and mandibles. Elastic bands passed over the screw heads pull the mandible into occlusion. The bands can be removed easily should an emergency occur. Alternatively, a wire loop can be passed through holes drilled in the furcation bone of the maxillary fourth premolar and mandibular first molar on both sides.⁵⁰ The same technique has been used in the cat, as well as a wire loop placed transversely through both maxillae and mandibles.^{51,52}
- The above techniques have largely been replaced by composite bonding of the canine teeth, especially in cats and small dogs,

because the composite bonding technique is much less traumatic.⁴¹

- The advantages of this technique are that no further damage is caused to the teeth or other tissues of the oral cavity, the complications associated with tape muzzling (e.g., lip dermatitis) are avoided, and the technique can be applied in patients with poor bone quality.

Indications

- Highly comminuted fractures of the body and especially the ramus of the mandible are an indication for maxillomandibular fixation.⁴¹
- Stable periarticular and subcondylar fractures (see Fig. 10-15).

Contraindications

- Fractures that are amenable to other methods of fixation.
- The limiting factor of the composite bonding technique is that it does require three to four intact canine teeth.

Materials

- Flour pumice (not prophyl paste).
- Prophyl angle and rubber prophyl cups.
- Acid-etch materials.
- Self-curing, composite temporary restorative material (Protemp Garant, ESPE).
- Direct band remover with and without pad (Ormco, Orange, Calif.).




Fig. 10-16

Technique: Composite Bonding of the Canine Teeth

Step 1—The canine teeth are polished with pumice, acid-etched, and aligned (Fig. 10-17, A). If palpable, the fracture fragments are reduced.

Step 2—The teeth subsequently are covered with the composite restorative material, leaving the mouth open approximately 10 mm. Occlusion is maintained while the composite sets. (Fig. 10-17, B)

- A variation on this technique includes inserting small parapulpal pins (TMS-pins, Whaledent) into the four canine teeth and subsequently embedding them, and bonding the teeth with the composite restorative material.⁵³⁻⁵⁵ On removing the composite bridge, the pins, which are made of an inert metal alloy, are cut flush with the enamel surface.
- Another variation is based on incorporating periodontal splinting material (Masel, Bristol, Penn.) into the composite bridge.^{18,55}

Complications

- A rapid return to normal function is not achieved; for a considerable period the patient cannot open the mouth, so special measures have to be taken to feed the patient. Thermoregulation is compromised because panting is not possible. Vomiting poses a particular hazard if these methods are used. The postoperative period is especially hazardous, because respiratory complications cannot be dealt with easily.
- Maxillomandibular fixation will not always result in the necessary stabilization.

Aftercare

- Six weeks after application, the composite can be removed if healing has occurred. This is done with orthodontic band removers and the high-speed handpiece and should be done very carefully to avoid dental trauma, because the material is tooth-colored.

MIDLINE PALATAL FRACTURE OR SEPARATION

General Comments

- Isolated palatal fractures mainly occur as midline clefts, often seen as part of the high-rise syndrome in cats, but rarely in dogs.^{56,57}
- This injury occurs mostly in young patients, in which case it is a separation of the interincisive suture, or the median palatine sutures of the palatine processes of the maxillary bones and of the palatine bones, rather than a true fracture.¹ For this separation to occur, sutures in other parts of the maxillofacial skeleton have to stretch, as well.
- Narrow defects may heal without surgical management.^{22,57} Alternatively, and if the defect is wide, this injury can be managed easily and effectively by surgical means.
- Provided the patient is stable, the benefit of surgical treatment may outweigh the risk inherent in leaving this injury to heal by second intention. Occasionally this healing does not take place and a persistent oronasal fistula results; the latter condition is far more difficult to manage.
- The term *high-rise syndrome* describes the injuries sustained, mainly by cats, falling at least two stories.^{56,57} A cat usually falls in a splayed-leg position and lands on all four limbs; the head then bounces against the landing surface. As a result, the following maxillofacial injuries may be present: (1) soft tissue facial abrasions and avulsion of the lower lip, (2) dental fractures, (3) mandibular fractures, in particular symphyseal separation, (4) temporomandibular joint luxation and fracture of the condylar process, and (5) midline palatal fracture or separation.

Indications

- Traumatic midline palatal fracture or separation in patients whose general condition is stable enough to undergo general anesthesia.

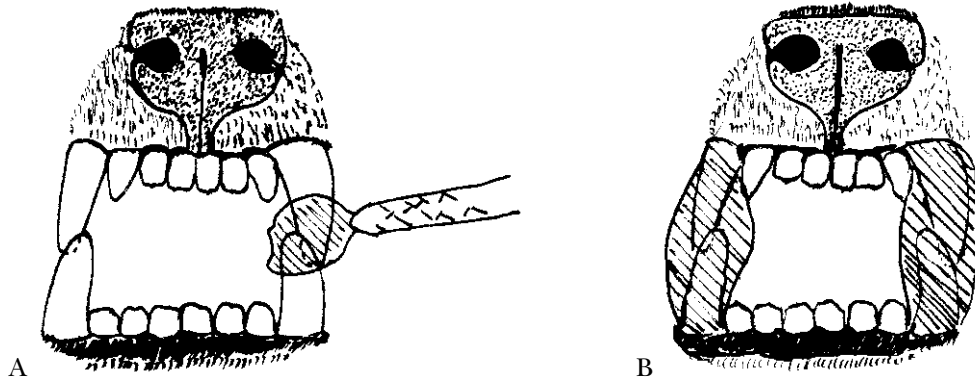


Fig. 10-17

Contraindications

- Unstable trauma patients.

Technique

Step 1—Soft tissue debridement is performed. Flushing and suctioning the nasal cavity is indicated if large blood clots are present (Fig. 10-18, A).

Step 2—The displaced bony structures can be approximated by gentle digital pressure (Fig. 10-18, B).

Step 3—This is followed by primary closure of the torn palatal soft tissues in a simple interrupted pattern, using fine, synthetic, monofilament absorbable suture material (Fig. 10-18, C).

- If the separation of the interincisive suture is associated with considerable displacement, a cerclage wire may be placed interproximally between the third incisors and canine teeth, with the wire twist exposed on the dorso-buccal aspect, in order to avoid contact with the mandibular canine (Fig. 10-18, D).^{3,26}

Complication

- Wound dehiscence, resulting in an oronasal fistula.

Aftercare

- If a cerclage wire was used, it must be removed when healing is complete, which typically is after 3 to 4 weeks.

MANAGEMENT OF PERIODONTAL TRAUMA

General Comments

- The following injuries to the periodontal tissues have been recognized⁵⁸:

Concussion.

Subluxation.

Intrusive luxation.

Extrusive luxation.

Lateral luxation.

Exarticulation (or avulsion).

- Concussion and subluxation are very discrete injuries to the periodontal ligament that are rarely diagnosed in veterinary dentistry.
- An intrusive luxation occurs when the tooth is forced into its alveolus. This is virtually only possible in the maxilla where a tooth can be pushed into the nasal cavity.
- In an extrusive luxation, the tooth has loosened and come slightly out of the alveolus. The injury causing the tooth to come out completely is called an *exarticulation* (also often referred to as an *avulsion*).
- The most common type of periodontal trauma is a lateral luxation. This is a displacement of a tooth in a direction other than axially and is accompanied by comminution or fracture of the alveolar socket.

Indications

- Luxated and exarticulated teeth, most commonly the canine teeth, can be repositioned and splinted.

Contraindications

- Grossly contaminated teeth or teeth affected by severe periodontitis.
- Unwillingness to commit to follow-up treatment, including root canal treatment.

Materials

- First aid storage media for avulsed teeth: Hank's balanced salt solution (emergency tooth preservation kit, Save-a-Tooth, SmartPractice, Phoenix, Ariz.), milk, or saline (in order of preference).⁵⁹
- Flour pumice (not prophyl paste).
- Prophyl angle and rubber prophyl cups.
- Wire-twisting forceps (WT121C, Hu-Friedy) or Howe serrated-tip pliers (WBP110, Hu-Friedy).
- Wire-cutting scissors (S5095, Hu-Friedy).
- Orthopedic wire, 22 to 26 gauge.
- Acid-etch materials.
- Self-curing, composite temporary restorative material (Protemp Garant ESPE), cold-cure acrylic (Jet Denture Repair Acrylic, Lang Dental), or a light-cure acrylic (Triad VLC, Dentsply-Trubyte).

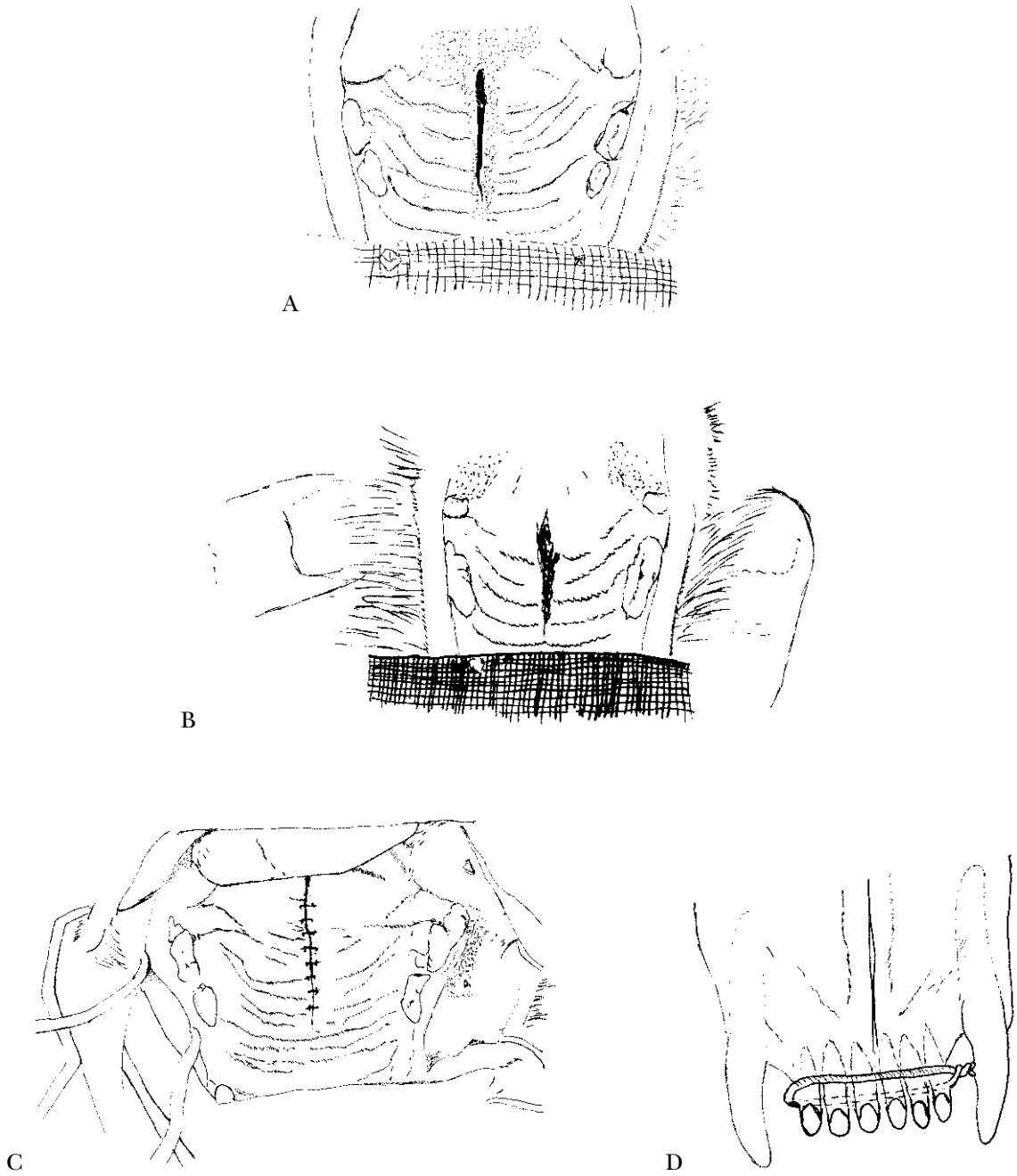


Fig. 10-18

Technique

- Prereplantation treatment of an avulsed tooth is critical to the outcome of the replantation. The tooth should be placed immediately in a suitable solution and handled very carefully in order to avoid damage to the periodontal ligament cells. Prophylactic antibiotics are indicated.^{59,60}
 - Various techniques for splinting luxated and avulsed teeth exist. The repair of a laterally luxated canine using a figure-of-eight wiring technique embedded in a composite or acrylic splint is illustrated.²¹
- Step 1—The laterally luxated tooth (the right maxillary canine is this example) is repositioned gently, following gentle rinsing of the periodontal defect on the palatal aspect (Fig. 10-19, A). Lacerated gingiva can be sutured if indicated.
- Step 2—The teeth are scaled and polished with flour pumice.
- Step 3—The wire is looped from the mesial aspect of the stable canine (Fig. 10-19, A) to the distal aspect of the injured canine (Fig. 10-19, B, *arrow*).
- Step 4—The wire is looped in a buccomesial direction around the injured canine and a buccodistal direction around the stable canine (Fig. 10-19, C, *arrows*).
- Step 5—The wire is directed from the distal aspect of the stable canine toward the mesial aspect of the injured canine (Fig. 10-19, D, *arrows*).
- Step 6—The two ends of the wire are joined together and are twisted on the buccodistal surface of the injured canine, and the ends are folded mesially against the tooth (Fig. 10-19, E).
- Step 7—The wire and teeth are rinsed, and the teeth acid-etched.
- Step 8—Dental acrylic or composite, or both, are placed over the wire, teeth, and palate (Fig. 10-19, F).
- Step 9—Any rough surfaces are smoothed; then the appliance is polished.

Complications

- Inflammation may occur secondary to food being trapped between the appliance and gingiva. This generally will resolve, without treatment, a few days after the appliance is removed.
- The wire and appliance may break or become dislodged.
- The prognosis following replantation is guarded because of the high incidence of root resorption. The success of replantation depends on the length of time the tooth has been out of the alveolus, the status of development of the apex, and the viability of the periodontal ligament on the root surface.
- The pulp is devitalized following a luxation or exarticulation, which is clinically evidenced by crown discoloration and radiographic changes.

Aftercare

- Aftercare includes regular cleaning of the oral cavity to limit the negative effects of food accumulation under the splint. Clients should be encouraged to flush the mouth and appliance twice daily with 0.05% to 0.12% chlorhexidine gluconate solution. A water pick may be used to aid in cleaning the oral cavity.
- Splinting for an extended period leads to a higher incidence of root resorption and should preferably not exceed 10 days.⁶¹ If extensive bony damage has taken place, the splint can be left for a longer period.⁶⁰
- Root canal treatment is indicated within 20 days following replantation.^{59,61}

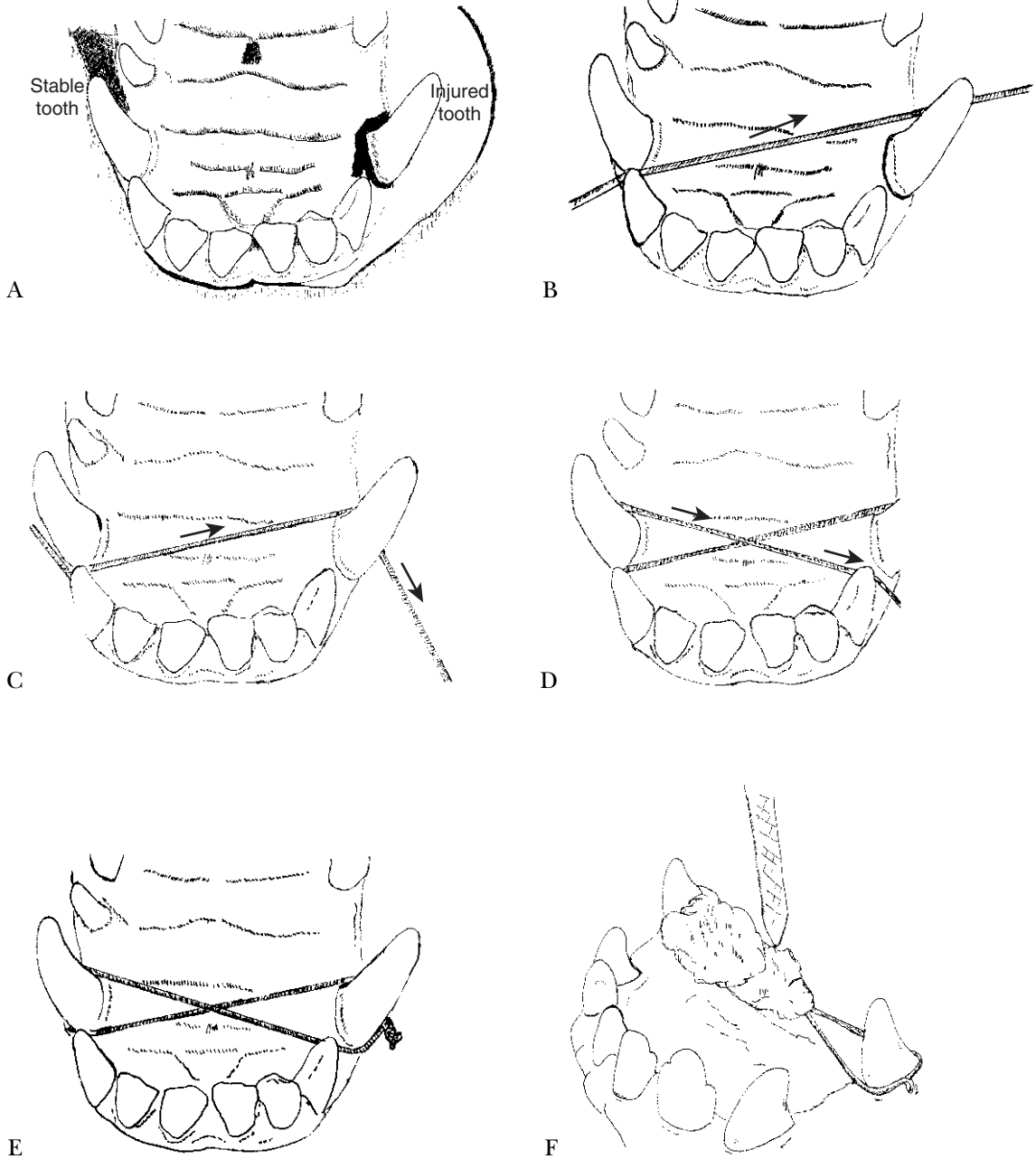


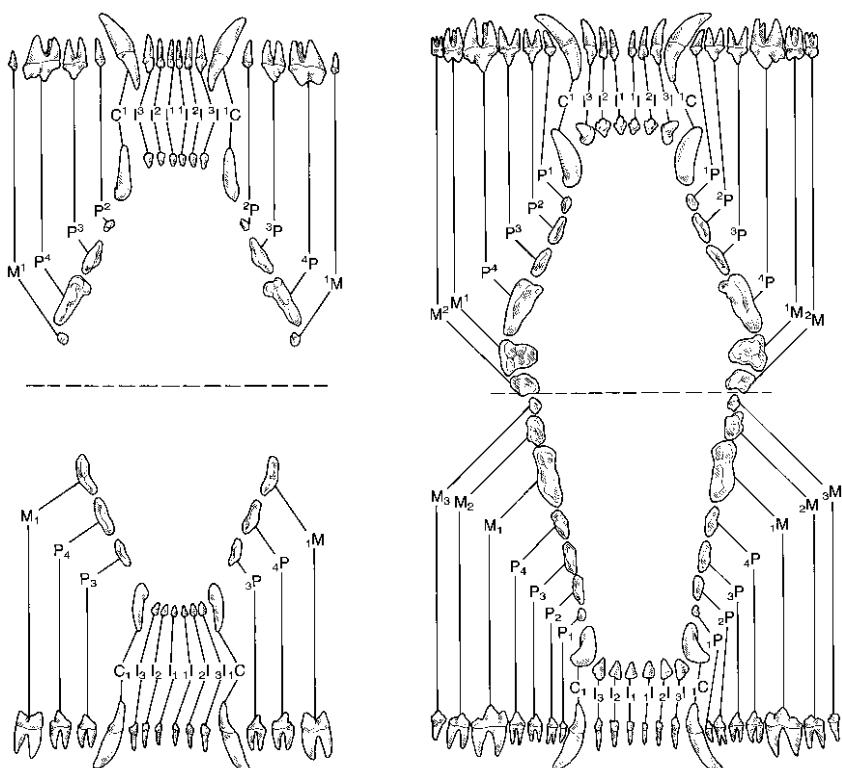
Fig. 10-19

REFERENCES

1. Evans HE: The skull. In Evans HE, editor: *Miller's anatomy of the dog*, ed 3, Philadelphia, 1993, WB Saunders, pp 128-166.
2. Anonymous: *Nomina anatomica veterinaria*, ed 4, Zurich and Ithaca, 1994, World Association of Veterinary Anatomists.
3. Rudy RL, Boudrieau RJ: Maxillofacial and mandibular fractures, *Semin Vet Med Surg Small Anim* 7:3-20, 1992.
4. Tholen MA: *Concepts in veterinary dentistry*, ed 1, Edwardsville, Kan., 1983, Veterinary Medicine Publishing Company.
5. Howard PE: Tape muzzle for mandibular fractures, *Vet Med Small Anim Clin* 76:517-519, 1981.
6. Withrow SJ: Taping of the mandible in treatment of mandibular fractures, *J Am Anim Hosp Assoc* 17:27-31, 1981.
7. Zallen RD, Curry JT: A study of antibiotic usage in compound mandibular fractures, *J Oral Surg* 33:431-434, 1975.
8. Chambers JN: Principles of management of mandibular fractures in the dog and cat, *J Vet Orthop* 2:26-36, 1981.
9. Shields Henney LH, Galburt RB, Boudrieau RJ: Treatment of dental injuries following craniofacial trauma, *Semin Vet Med Surg Small Anim* 7:21-35, 1992.
10. Smith MM, Kern DA: Skull trauma and mandibular fractures, *Vet Clin North Am Small Anim Pract* 25: 1127-1148, 1995.
11. Hartsfield SM, Gendreau CL, Smith CW, et al: Endotracheal intubation by pharyngotomy, *J Am Anim Hosp Assoc* 13:71-74, 1977.
12. Weigel JP: Trauma to oral structures. In Harvey CE, editor: *Veterinary dentistry*, ed 1, Philadelphia, 1985, WB Saunders, pp 140-155.
13. Schebitz H, Kostlin R, Matis U, et al: Zur Kieferfraktur beim Hund—Frakturen im Bereich der Pars incisiva mandibulae und des Proc. alveolaris ossis incisivi, *Kleintierpraxis* 28:285-292, 1983.
14. Hinko PJ: A method for reduction and fixation of symphyseal fractures of the mandible, *J Am Anim Hosp Assoc* 12:98-100, 1976.
15. Legendre L: Use of maxillary and mandibular splints for restoration of normal occlusion following jaw trauma in a cat: a case report, *J Vet Dent* 15:179-181, 1998.
16. Lantz GC, Salisbury SK: Partial mandibulectomy for treatment of mandibular fractures in dogs: eight cases (1981-1984), *J Am Vet Med Assoc* 191:243-245, 1987.
17. Piermattei DL: The head. In Piermattei DL, editor: *An atlas of surgical approaches to the bones and joints of the dog and cat*, ed 3, Philadelphia, 1993, WB Saunders, pp 32-43.
18. Davidson JR, Bauer MS: Fractures of the mandible and maxilla, *Vet Clin North Am Small Anim Pract* 22:109-119, 1992.
19. Spellman G: Reduction of fractures of the mandibular symphysis using acrylic splints with circummandibular wiring, *Vet Med Small Anim Clin* 67:1213-1215, 1972.
20. Lantz GC: Maxillary splint rod for the repair of selected facial fractures, *J Am Anim Hosp Assoc* 20:905-910, 1984.
21. Gracis M, Orsini P: Treatment of traumatic dental displacement in dogs: six cases of lateral luxation, *J Vet Dent* 15:65-72, 1998.
22. Manfra Marretta S, Schrader SC, Matthiesen DT: Problems associated with the management and treatment of jaw fractures, *Probl Vet Med* 2:220-247, 1990.
23. Ross DL: Anterior mandibular fracture fixation. In Bojrab MJ, editor: *Current techniques in small animal surgery*, ed 1, Philadelphia, 1975, Lea & Febiger, pp 363-364.
24. Williams JL: *Rowe and Williams' maxillofacial injuries*, ed 2, Edinburgh, 1994, Churchill Livingstone.

25. Kern DA, Smith MM, Grant JW, et al: Evaluation of bending strength of five interdental fixation apparatuses applied to canine mandibles, *Am J Vet Res* 54:1177-1182, 1993.
26. Rudy RL: Fractures of the maxilla and mandible. In Bojrab MJ, editor: *Current techniques in small animal surgery*, ed 1, Philadelphia, 1975, Lea & Febiger, pp 364-375.
27. Eisner ER: Stabilization of an unfavorable oblique caudal mandibular fracture with triangular transosseous wiring, *J Vet Dent* 7:23-25, 1990.
28. Renegar WR, Leeds EB, Olds RB: The use of the Kirschner-Ehmer splint in clinical orthopedics. Part I. Long bone and mandibular fractures, *Compend Contin Educ Pract Vet* 4:381-392, 1982.
29. Willer RL, Egger EL, Hestand MB: Comparison of stainless steel versus acrylic for the connecting bar of external skeletal fixators, *J Am Anim Hosp Assoc* 27: 541-548, 1991.
30. Piermattei DL, Flo GL: Fractures and luxations of the mandible and maxilla. In Piermattei DL, Flo GL, editors: *Handbook of small animal orthopedics and fracture repair*, ed 3, Philadelphia, 1997, WB Saunders, pp 659-675.
31. Stampely AR, Lawrence D: Acrylic external skeletal fixation in the treatment of complex mandibular fractures, *Canine Pract* 18:15-19, 1993.
32. Cook WT, Smith MM, Markel MD, et al: Influence of an interdental full pin on stability of an acrylic external fixator for rostral mandibular fractures in dogs, *Am J Vet Res* 62:576-580, 2001.
33. Fossum TW: *Small animal surgery*, St Louis, 1997, Mosby.
34. Kantrowitz B, Smeak D, Vannini R: Radiographic appearance of ring sequestrum with pin tract osteomyelitis in the dog, *J Am Anim Hosp Assoc* 24:461-465, 1988.
35. Verstraete FJM, Ligthelm AJ: Dental trauma caused by screws in internal fixation of mandibular osteotomies in the dog, *Vet Comp Orthopaed Traumatol* 5:104-108, 1992.
36. Boudrieau RJ, Kudisch M: Miniplate fixation for repair of mandibular and maxillary fractures in 15 dogs and 3 cats, *Vet Surg* 25:277-291, 1996.
37. Harle F, Champy M, Terry BC: *Atlas of craniomaxillofacial osteosynthesis: miniplates, microplates, and screws*, Stuttgart and New York, 1999, Thieme.
38. Umphlet RC, Johnson AL: Mandibular fractures in the cat. A retrospective study, *Vet Surg* 17:333-337, 1988.
39. Umphlet RC, Johnson AL: Mandibular fractures in the dog. A retrospective study of 157 cases, *Vet Surg* 19:272-275, 1990.
40. Brinker WO, Olmstead ML, Sumner-Smith G, et al: Fractures of the head. In Brinker WO, Olmstead ML, Sumner-Smith G, Prieur WD, editors: *Manual of internal fixation in small animals*, ed 2, Berlin, 1998, Springer-Verlag, pp 194-201.
41. Bennett JW, Kapatkin AS, Manfra Marretta S: Dental composite for the fixation of mandibular fractures and luxations in 11 cats and 6 dogs, *Vet Surg* 23:190-194, 1994.
42. Salisbury SK, Cantwell HD: Conservative management of fractures of the mandibular condylar process in three cats and one dog, *J Am Vet Med Assoc* 194:85-87, 1989.
43. Ticer J, Spencer CP: Injury of the feline temporomandibular joint: radiographic signs, *Vet Radiol* 19:146-156, 1978.
44. Lantz GC: Temporomandibular joint ankylosis: surgical correction of three cases, *J Am Anim Hosp Assoc* 21:173-177, 1985.
45. Sullivan M: Temporomandibular ankylosis in the cat, *J Small Anim Pract* 30:401-405, 1989.
46. Egger EL: Skull and mandibular fractures. In Slatter DH, editor: *Textbook of small animal surgery*, ed 2, Philadelphia, 1993, WB Saunders, pp 1910-1921.

47. Lantz GC, Cantwell HD, VanVleet JF, et al: Unilateral mandibular condylectomy: experimental and clinical results, *J Am Anim Hosp Assoc* 18:883-890, 1982.
48. Tomlinson J, Presnell KR: Mandibular condylectomy—effects in normal dogs, *Vet Surg* 12:148-154, 1983.
49. Nibley W: Treatment of caudal mandibular fractures: a preliminary report, *J Am Anim Hosp Assoc* 17:555-562, 1981.
50. Lantz GC: Interarcade wiring as a method of fixation for selected mandibular injuries, *J Am Anim Hosp Assoc* 17:599-603, 1981.
51. Lewis DD, Oakes MG, Kerwin SC, et al: Maxillary-mandibular wiring for the management of caudal mandibular fractures in two cats, *J Small Anim Pract* 32:253-257, 1991.
52. Umphlet RC: Interarcade wiring: a method for stabilization of caudal mandibular fractures and temporomandibular joint luxations in the cat, *Comp Anim Pract* 1:16-18, 1987.
53. Zetner K: Die Behandlung von Kieferfrakturen der Katze mit der Parapulpärstift-Composite-Brücke, *Kleintierpraxis* 32:1-44, 1987.
54. Zetner K: Treatment of jaw fractures in small animals with parapulpal pin composite bridges, *Vet Clin North Am Small Anim Pract* 22:1461-1467, 1992.
55. Holmstrom SE, Frost P, Eisner ER: *Veterinary dental techniques for the small animal practitioner*, ed 2, Philadelphia, 1998, WB Saunders.
56. Gordon LE, Thacher C, Kapatkin A: High-rise syndrome in dogs: 81 cases (1985-1991), *J Am Vet Med Assoc* 202:118-122, 1993.
57. Whitney WO, Mehlhaff CJ: High-rise syndrome in cats, *J Am Vet Med Assoc* 191:1399-1403, 1987.
58. Andreasen JO, Andreasen FM: *Textbook and color atlas of traumatic injuries to the teeth*, ed 3, Copenhagen, 1994, Munksgaard.
59. Trope M: Clinical management of the avulsed tooth, *Dent Clin North Am* 39:93-112, 1995.
60. Barrett EJ, Kenny DJ: Avulsed permanent teeth: a review of the literature and treatment guidelines, *Endod Dent Traumatol* 13:153-163, 1997.
61. Kinirons MJ, Boyd DH, Gregg TA: Inflammatory and replacement resorption in reimplanted permanent incisor teeth: a study of the characteristics of 84 teeth, *Endod Dent Traumatol* 15:269-272, 1999.



There is a vast amount of information about anesthesia that is beyond the scope of this book in terms of the nuances, idiosyncrasies, and precautions, that should be investigated more thoroughly by the reader. This chapter is intended to serve as a user-friendly guide to some convenient anesthesia protocols, routes of administration, and management suggestions before, during, and after operative dentistry on the small animal patient.

GENERAL ANESTHESIA

General Comments

- General anesthesia is a necessary part of most dental procedures to provide immobility required for safe and total access to the oral cavity.
- Dental patients are usually categorized, according to the American Society of Anesthesiologists (ASA) classification, as class I or II (normal patient or patient with mild systemic disease; see below). An exception to this may be the geriatric patient or the patient that is immunologically or metabolically compromised.
- Safe anesthesia protocols are available, even for young puppies and kittens, so they can be placed under general anesthesia for various dental procedures such as interceptive orthodontic extractions.
- General anesthesia is often a major concern of the client, particularly when multiple sessions are required.
- A significant portion of the cost of any dental procedure is generated by anesthesia, supportive measures during anesthesia, and preoperative laboratory evaluations.
- Monitoring the physiologic changes that occur during anesthesia, such as hypothermia, hypotension, and cardiorespiratory depression with appropriate intervention, will help to ensure a safer anesthesia session.
- With proper attention to their physiologic needs, healthy geriatric patients or patients with mild systemic diseases can be anesthetized safely. These patients can be treated for their dental disease and will benefit from improved oral health.
- Anesthesia records should include administration time, route, and duration of anesthetic drugs; dosages used; fluids administered; catheter type, size, and location; endotracheal tube size; monitoring parameters; and vaporizer settings and oxygen and

nitrous oxide flow rates. The anesthesia record should continue until the patient can maintain sternal recumbency unassisted.

- Charting heart rate, respiratory rate, and any other parameters monitored is a necessity. Any anesthesia complication or excessive delay in recovery should be noted so that future anesthesia protocols can be adjusted (Table 11-1).
- To reduce the incidence of aspiration during anesthesia, food should be withheld for 12 hours prior to induction of anesthesia, except to prevent hypoglycemia in young patients and diabetics. Water should be available to the patient until the morning of the procedure.

Chart: American Society of Anesthesiologists (ASA) Classifications¹

ASA I: a normal patient with no organic disease.

ASA II: a patient with mild systemic disease.

ASA III: a patient with severe systemic disease limiting activity but not incapacitating.

Table 11-1 • **EXAMPLE OF A SIMPLE ANESTHETIC RECORD**[illegible]

ASA IV: a patient with incapacitating disease that is a constant threat to life.

ASA V: a moribund patient not expected to live 24 hours with or without surgery.

- Age is not a factor in assigning risk. While many healthy older patients may have early organ dysfunction, it poses no greater risk than to a young patient with equivalent organ dysfunction. Patient evaluation prior to anesthesia includes (1) signalment (species, breed, age, and sex), (2) a complete physical examination, (3) the chief complaint, and (4) the medical history.

Preprocedure Workup

- The decision to perform preanesthetic laboratory workups, and the degree of comprehensiveness of such workups, will vary based on several factors including the laboratory capability of the practice, the age of the patient, the physical examination findings, the anxiety level of the client over the procedure, and even the timing of the procedure. Remember that normal laboratory values do not ensure a safe, successful anesthetic episode but rather are screening for problems in one of three categories: (1) immediate life-threatening problems, (2) problems necessitating changes in the anesthesia protocol, and (3) problems that are more longstanding that will require follow-up subsequent, and unrelated, to the anesthesia. Most problems identified will fall in category 3 and less often in category 2. Rarely will a life-threatening problem be identified solely by laboratory values.
- A basic preanesthesia profile should include packed blood cell volume (PCV), total blood protein or solids value, and urine specific gravity. Other tests may be added based on the patient evaluation. It is often recommended that young healthy patients have a PCV; total protein, blood glucose, and blood urea nitrogen levels; and a urine specific gravity performed. Older patients or those with significant findings in their initial physical examination should have a complete blood count and chemistry profile performed as a minimal database. Additionally, tests for thyroid function, feline leukemia, and feline immunodeficiency virus (for cats), complete urinalysis, electrocardiogram, ultrasonographic examinations, and thoracic radiography should be scheduled, depending on the patient's condition and the client's permission.

- Other considerations for determining the anesthesia protocol include weight, temperament, procedure to be performed, length of anticipated procedure, concurrent diseases (e.g., epilepsy, heart disease, kidney disease, liver disease, endocrine disease, gastrointestinal disease, or bleeding disorders), medications administered previously or concurrently, previous anesthesia experiences, and dietary history.²

Preanesthetic Medications

Comments

- Preanesthetic medications are used to reduce the anxiety level of the patient, provide preemptive analgesia, reduce the amount of induction and maintenance drugs and, on occasion, to reduce the volume of secretions.
- These drugs usually are given intramuscularly 10 to 30 minutes prior to the induction of general anesthesia.
- In select instances they can be administered intravenously immediately before the induction agent. This route should *not* be used for routine administration of premedication due to the possibility of rapid changes in cardiorespiratory function. Dosages should be reduced by at least 50% when these drugs are administered intravenously.
- Intravenous administration in compromised patients may cause a more profound effect than desired; it is preferable to administer these drugs intramuscularly.
- Dosages provided here are for young, healthy patients; older or debilitated patients will require reduced dosages.

Anticholinergic Agents

Comments

- To maintain heart rate and hence cardiac output in patients receiving vagotonic drugs, such as α_2 -agonists and opioid agonists, patients who may be subject to strong vagal reflexes, or those patients whose cardiac output is heart rate dependent, such as very young patients, patients with significant cardiac disease (i.e., hypertrophic cardiomyopathy), procedures in the oropharynx, or inadvertent application of ocular or carotid pressure.
- To help reduce the volume of salivary secretions.

- Two commonly used drugs are atropine and glycopyrrolate.
- The use of these drugs has declined with the introduction of others that either maintain heart rate or have minimal effects on heart rate. The blanket use of these drugs often results in tachycardia and a reduction of cardiac output. As such, these drugs should be used only if indicated.

Atropine

- Dosage: cat or dog, 0.01 to 0.04 mg/kg IM or SC.^{3,4}

Advantages

- Short onset time.
- Can be given intraoperatively to increase heart rate if a significant sinus bradycardia or second-degree atrioventricular (AV) block develops.
- Indicated in emergency or crisis situations.

Disadvantages

- Duration of 30 to 90 minutes.
- Can cause sinus tachycardia or even transient second-degree AV block.

Glycopyrrolate

- Dosage: cat or dog, 0.01 to 0.02 mg/kg IM or SC.^{3,4}

Advantages

- Less effect on heart rate than atropine.
- Lasts longer than atropine (2 to 3 hours).

Disadvantages

- May take 30 to 45 minutes to reach peak effect following IM administration.
- More expensive than atropine.
- Indicated as a prophylactic anticholinergic agent rather than as an emergency drug.

Tranquilizers and Sedatives

Comments

- Reduce nervousness, reduce the amount of induction agent required to allow intubation, smooth the transition to and from general anesthesia, and reduce the amount of anesthetic drug required to maintain anesthesia.
- Classified as major tranquilizers (phenothiazine derivatives such as acepromazine), minor tranquilizers (benzodiazepines such as diazepam [Valium]), and sedative-

hypnotics (α_2 -adrenoreceptor agonists such as xylazine).

Phenothiazine Derivatives

Comments

- The α -adrenoreceptor blockers, +/- anti-histaminergic, +/- antidopaminergic, depending on chemical structure changes.
- Major tranquilizer, produces calming effect, although patient is still rousable and responsive.
- Most commonly used drug in this class is acepromazine. Others include chlorpromazine, prochlorpromazine, and trimeprazine, to name a few.

Acepromazine

- Dosage: cat or dog, 0.01 to 0.1 mg/kg IM, SC, or IV.
- In the dog, as the dosage is increased there is a concomitant increase in magnitude of adverse or undesirable effects. If increased sedation is desired, it is recommended that opioids be administered with the acepromazine to prevent excessive vasodilation, hypotension, and hypothermia associated with increased dosages of acepromazine.
- Dogs with quiet, calm temperaments and older dogs will require only the low end of the dosage range in order to achieve adequate sedation.
- In the cat, one often fails to see any outward clinical signs of sedation. However, significant cardiovascular and central nervous system (CNS) depression is present, just as in the dog, despite the lack of obvious signs.

Advantages

- Produces a calming effect on most patients.
- Inexpensive.
- Can be protective against cardiac arrhythmias related to catecholamine release.

Disadvantages

- Caution must be exercised when used in compromised patients due to vasodilation with resultant hypotension and a relative hypovolemia.
- Peripheral vasodilation potentiates hypotension and hypothermia.
- Requires biotransformation in the liver; can have a prolonged effect in some patients, especially when used at higher dosages.
- No analgesic effect.

- Antidopaminergic effect can result in lasting behavioral changes when used at higher dosages.

Benzodiazepines

Comments

- Minimal cardiorespiratory depression.
- Muscle relaxation.
- Amnesiac.
- GABA-nergic (gamma aminobutyric acid [GABA] is an inhibitory CNS neurotransmitter).
- Disinhibition occurs in approximately 25% of veterinary patients, with resultant transient excitation following intravenous administration. Most common in young adult, normal, healthy patients.
- Most commonly used drug in veterinary medicine is diazepam. Midazolam (Versed) and zolazepam (found in Telazol) are other benzodiazepines used in veterinary medicine. Unlike diazepam, these and other benzodiazepines are water soluble.

Diazepam

- Dosage: cat or dog, 0.1 to 0.5 mg/kg IV or IM.^{3,4}
- Note: midazolam is a water-soluble benzodiazepine that is very similar to diazepam and, as such, may be substituted for diazepam if necessary.

Advantages

- Minimal central nervous system or cardiovascular depression.
- Produces muscle relaxation.
- Antiseizure activity.
- When combined with a dissociative agent (i.e., ketamine or tiletamine), can be used as a combination induction agent or to provide short-term anesthesia.
- When used with an opioid medication, provides good sedation and tranquilization in older or quieter patients.
- Can be reversed by flumazenil if necessary.

Disadvantages

- When administered intramuscularly it can provide unpredictable absorption due to its poor solubility in water.
- Rapid intravenous injection can lead to hypotension and bradycardia due to the propylene glycol vehicle.
- Minimal to no outward signs of sedation in normal, healthy, young adult dogs and cats.

Alpha₂ Adrenoreceptor Agonists

Comments

- Drugs in this group are sedative-hypnotics and will result in a quiet to minimally responsive patient. As the dosage is increased, a state resembling hypnosis can be achieved such that the patient is essentially unresponsive to external stimuli. However, anesthesia is not achieved, even at high dosages.
- Significant cardiorespiratory depression can occur with the drugs in this class. Manipulation of chemical structure has reduced this effect in many of the newer drugs. Bradycardia and peripheral vasoconstriction are the most common undesirable effects.
- Alpha₂ receptor activation prevents release of norepinephrine from the presynaptic nerve terminal, with a resultant lack of stimulation of postsynaptic neurons.
- To date, all α_2 agonists also have α_1 activity, although the relative α_2 -to- α_1 activity varies significantly among the drugs in this class.
- Because of the profound cardiac depression, it is recommended these drugs be administered intramuscularly whenever possible.
- Specific antagonists are available for each drug. Due to differences in α_2 -to- α_1 activity by both the agonists and the antagonists, one should be sure the antagonist is appropriate for the agonist.

Xylazine

- Dosage: dog, 0.5 to 1 mg/kg IM; cat, 0.25 to 0.5 mg/kg IM.

Advantages

- Provides profound sedation alone or in combination with opioids.
- Used in conjunction with ketamine to provide chemical restraint resembling anesthesia and may be suitable for minor procedures.
- Provides excellent analgesia.
- Provides good muscle relaxation.
- Specific antagonist is available (yohimbine).

Disadvantages

- Emesis.
- Profoundly vagotonic, resulting in bradycardia that can be prevented with the use of an anticholinergic agent. Bradycardia is due to a direct cholinergic effect as well as activation of the baroreceptor response.
- Gastrointestinal stasis and ileus are common due to its cholinergic effect.

- Profound vasoconstriction occurs due to α_1 activation, resulting in an increase in the systemic vascular resistance.
- The ratio of α_2 -to- α_1 activity is 160:1, indicating a significant α_1 effect in addition to the desired α_2 effect.
- Use of α_2 -antagonists other than yohimbine may not reverse cardiovascular or gastrointestinal effects.
- Several studies have demonstrated a significant hypoxemia without hypercapnia.
- Not recommended for use in debilitated or older patients.

Medetomidine

- Dosage: dog, 1 to 40 $\mu\text{g}/\text{kg}$ IM; cat, 5 to 40 $\mu\text{g}/\text{kg}$ IM.

Advantages

- Higher α_2 -to- α_1 activity reduces many of adverse effects.
- Longer duration of effect than xylazine.
- Bradycardia is a physiologic response due to the baroreceptor response to vasoconstriction (α_1) as opposed to a cholinergic effect.
- Sedative effects are dose responsive.
- Few to no effects at receptors other than α -adrenoceptors.
- Profound analgesia and muscle relaxation.
- When used in combination with opioids or dissociatives, there is a significant dosage reduction in medetomidine.
- Significant minimum alveolar concentration (MAC)-sparing effect and induction dosage requirements when used as a premedicant.
- Specific antagonist is available (atipamezole).

Disadvantages

- The α_1 effect is long lasting.
- Emesis may occur.
- Sudden arousal, especially when working around the patient's head, can occur, with the potential for bites to occur.
- Peripheral vasoconstriction results in peripheral cyanosis, especially when higher dosages are administered.

Opioids

Comments

- Opioids used as a preanesthetic medication provide analgesia as well as sedation (synergistic when used in combination with a sedative-tranquilizer).
- Administering opioids as preanesthetic medication can reduce dramatically the

amount of anesthetic agent required to maintain anesthesia.

- Morphine, oxymorphone, and hydromorphone (opioid agonists) produce greater pain relief, but also greater sedation.
- Meperidine (Demerol) is significantly less potent than morphine, oxymorphone, or hydromorphone and has a short duration of action (2 to 3 hr). It is the only opioid that causes vagolytic and negative inotropic effects at clinically used dosages.⁵ As such, it should be used cautiously in debilitated patients, as well as in those with hypothyroidism or hyperthyroidism, severe renal insufficiency, and adrenocortical insufficiency. It also causes significant histamine release and therefore should not be administered intravenously.
- Fentanyl is a very short-acting opioid agonist that causes significant bradycardia and respiratory depression when administered intravenously or intramuscularly.
- Buprenorphine is a partial opioid agonist (μ). It provides adequate analgesia for most moderately painful procedures. The duration of action is dose dependent and can range from 2 to 10 hours, depending on amount used. Onset of effect ranges from 30 minutes following intravenous administration to 1 hour following intramuscular administration. Buprenorphine causes minimal sedation or other adverse effects associated with opioids, even when used at high dosages. Due to the lack of sedation and longer onset time, its use as a premedicant is limited.
- Butorphanol, a mixed agonist-antagonist, is an adequate analgesic for short-term (1 to 2 hours) relief of mild pain. It is quite useful for its sedative effects.

Dosages

- Morphine: dog, 0.5 to 1.0 mg/kg IM, IV, or SC q 4 to 6 hr^{3,4}; cat, 0.1 to 0.5 mg/kg IM or SC q 4 to 6 hr.
- Note: when administered intravenously, morphine must be given slowly to prevent histamine release.
- Oxymorphone: dog, 0.05 to 0.2 mg/kg IM, IV, or SC q 4 to 6 hr; cat, 0.05 to 0.1 mg/kg IM, IV, or SC q 4 to 6 hr.
- Hydromorphone: dog, 0.1 to 0.2 mg/kg IM, IV, or SC q 2 to 3 hr.
- Meperidine: cat or dog, 2 to 5 mg/kg IM or SC⁴ q 2 to 3 hr. **Do not administer intravenously due to significant histamine release.**
- Fentanyl: 5 to 10 $\mu\text{g}/\text{kg}$ IM or IV q 15 to 60 min or 0.3 to 0.7 $\mu\text{g}/\text{kg}/\text{min}$ as a continuous-rate infusion.

- Butorphanol: cat or dog, 0.1 to 0.2 mg/kg IM, IV, or SC^{3,4} q 1 to 2 hr.
- Buprenorphine: cat or dog, 5 to 40 µg/kg IM or IV q 2 to 10 hr. Duration is dose dependent. Example: 5 µg/kg = 2 to 3 hr, 40 µg/kg = 10 to 12 hr.

Advantages

- Provide analgesia.
- Provide sedation (except buprenorphine).
- Can be given with sedative-tranquilizer for additional sedation.
- Reduce other anesthetic requirements.
- Do not depress myocardial contractility.
- Can be reversed with an opioid antagonist such as naloxone.

Disadvantages

- May cause sinus bradycardia when used at higher dosages (applies to opioid agonists only).
- May cause respiratory depression when used at higher dosages.
- May cause panting and flatulence.
- Can create startle response with loud or sharp noises.

Neuroleptanalgesia

Comments

- Combines a tranquilizer or sedative (i.e., neuroleptic) with an opioid (i.e., analgesia) as a preanesthetic medication.
- Two examples of combinations and dosages follow. However, there are many other combinations.

Dog

- Acepromazine 0.02 to 0.05 mg/kg SC or IM.
- Morphine 0.5 mg/kg SC or IM.

Cat or dog

- Acepromazine 0.02 to 0.05 mg/kg SC or IM.
- Butorphanol 0.1 to 0.2 mg/kg SC or IM.

Advantages

- Provides analgesia.
- Provides sedation.
- Reduces amount of induction agent required.
- Good for aggressive or anxious patients.
- Provides sedation for quiet inductions.
- Opioid effect can be reversed; the effects of some tranquilizers and sedatives can be reversed.

Disadvantages

- Attention must be paid to the dosages of each drug used. Synergism results in reduced dosage requirements, especially of the sedative-tranquilizer.
- Onset times of the two drugs may not coincide.
- Reversal of the opioid may result in renarcotization later due to longer duration of the opioid than that of the antagonist.
- Combining acepromazine with morphine may not inhibit the emetic effect of the morphine.
- Combining two vagotonic drugs (e.g., an opioid agonist and an α_2 -agonist) can result in profound or significant bradycardia.

Induction Drugs

Comments

- Induction drugs are used to induce unconsciousness in a smooth, struggle-free manner.
- These drugs generally are administered intravenously to effect to allow intubation.
- Adverse effects of these drugs are dosage dependent; therefore, techniques which minimize the induction dosage requirement are desirable.
- Because these drugs have induced anesthesia, intubation of the trachea is necessary to protect the airway from debris and to provide ventilatory support.

Barbiturates

Thiopental sodium

- Dosage: dogs and cats, 5 to 15 mg/kg IV, to effect.
- Available commercially in 1 g bottles to dilute to a final desired concentration. For example, to make a 5% solution, 20 ml of diluent is added to 1 g of sterile powder.
- A 2.0% or 2.5% solution is recommended for use in smaller or older dogs.⁴
- A 1.25% solution is recommended for use in cats, toy dogs, or unstable patients.⁴

Advantages

- Inexpensive.
- Rapid, smooth induction.
- Good relaxation for intubation.
- Short acting.
- Recovery from anesthesia is due to redistribution of the drug from the brain to other tissues.

Disadvantages

- Requires redistribution from the brain to fat and muscle for termination of effect. Repeated doses can result in prolonged recoveries due to saturation of muscle and fat.
- Requires hepatic transformation for final elimination from the body.
- Can cause severe tissue necrosis if injected perivascularly (in greater than 2% solutions).
- Can cause hypotension, arrhythmias, and apnea if given too rapidly.
- Rate of onset affected by patient's cardiac output and acid-base status.

Dissociative Agents**Ketamine**

- Dosage: cat, 5 to 30 mg/kg IM or IV.⁴
- Dog: not recommended to be used alone due to high incidence of seizures.
- Often given intravenously with diazepam as an induction agent (5 mg/kg ketamine and 0.25 mg/kg diazepam) in dogs and cats.

Advantages

- Relatively inexpensive.
- Minimal effect on cardiac output and blood pressure in the normal patient.
- Causes immobility due to dissociation from the environment.
- No tissue reaction if accidentally given extraveneously.
- Useful in combination with another agent for short periods of chemical restraint.

Disadvantages

- Causes increased salivation. Low doses of anticholinergic agents can be given before use.
- Causes central nervous system excitement in dogs, with a strong possibility of seizures.
- Renally excreted in cats (unchanged), hepatic biotransformation in dogs and in cats if renal excretion is not possible.
- Poor analgesic when used at induction dosages.
- Muscle rigidity often excessive, requires use of sedative-tranquilizer to provide muscle relaxation.
- Despite common misconceptions, pharyngeal and ocular reflexes, while present, are not protective.
- Is painful if given extraveneously, especially in cats.

Propofol**Comments**

- A safe, short-acting anesthetic agent that is milky white, for intravenous injection.^{8,9,11}

- Dosage: cat or dog, 1 to 4 mg/kg IV with sedation; 4 to 8 mg/kg without sedation. Given to effect.^{3,4,13}

Advantages

- Short duration of anesthesia.
- Can be given as repeated injections or continuous infusion due to minimal accumulation of the drug in the dog.
- Rapid recovery (approximately 15 to 30 minutes until patient is standing unaided) without residual effect.

Disadvantages

- Causes profound and significant respiratory depression when given rapidly. Preoxygenation is strongly recommended.
- Does not contain preservatives; not suitable for storage beyond 6 hours after opening vial; strict aseptic procedure must be followed to prevent inadvertent contamination of vial after opened.
- Reports of myoclonic activity during induction, especially in sight hounds. This incidence is reduced with the use of adequate premedication prior to induction.¹²
- It is a substituted phenolic compound. As such, use in cats as repeated injections or continuous-rate infusion can result in prolonged recoveries due to decreased rate of metabolic clearance.

Induction Agent and Drug Combinations**Ketamine and Diazepam**

- Dosage: cat or dog, 5 mg/kg of ketamine and 0.25 mg/kg of diazepam (0.5 cc of each drug per 20 lb or 10 kg). Mix in same syringe just prior to induction, and administer as a slow intravenous bolus, to effect.
- Alternative method: do not mix the drugs and administer each drug independently in $\frac{1}{4}$ -dose increments at 10- to 30-second intervals until patient can be intubated.

Advantages

- Relatively wide therapeutic index compared with other induction drugs.
- No tissue necrosis if inadvertently injected perivascularly.
- Same as individual drugs.

Disadvantages

- Can produce apnea.
- Patient may have rough, hyperactive recovery from ketamine.

- Difficult to titrate to effect due to longer delay in onset of anesthesia when compared with other induction drugs.

Tiletamine and Zolazepam

- Dehydrated mixture of 500 mg of tiletamine and 500 mg of zolazepam (Telazol). Reconstituted with 5 ml of sterile water for a final concentration of 50 mg/ml of each drug, or 100 mg/ml of tiletamine-zolazepam.
- Dosage: cat or dog, 0.5 to 2 mg/kg IV, 2 to 6 mg/kg IM.

Advantages

- Similar to ketamine and diazepam combination.
- Relatively wide therapeutic index.
- No tissue necrosis if inadvertently injected perivascularly.
- Small volume of injectate.

Disadvantages

- Same as ketamine and diazepam.
- Cats eliminate the tiletamine faster than the zolazepam. Dogs eliminate the zolazepam faster than the tiletamine. Recoveries in dogs are often rough and excited due to residual tiletamine.
- Higher dosages produce a transient central blindness in dogs.
- Recovery time is prolonged as dosage increases.

Oxymorphone and Diazepam

- Other opioids may be used in place of oxymorphone if oxymorphone is not available.
- Midazolam may be used in place of diazepam.
- Dosages:
Oxymorphone cat or dog, 0.1 to 0.2 mg/kg IV.
Hydromorphone 0.1 to 0.2 mg/kg IV.
Morphine 0.25 to 1 mg/kg IV slowly.
Fentanyl 5 to 10 µg/kg IV.
Diazepam or midazolam 0.1 to 0.2 mg/kg IV.

Advantages

- Cardiovascular stability.
- Minimal respiratory depression.
- Titrate each drug to effect.
- Good analgesia.
- Good muscle relaxation.
- Good in older or sick dogs.

Disadvantages

- Cannot mix diazepam with the opioids in the same syringe due to incompatibility of

diazepam with other drugs. Two separate syringes must be used.

- Intravenous catheter is necessary to titrate to effect.
- Bradycardia possible due to intravenous opioid administration.
- Vasodilation and hypotension are possible due to propylene glycol vehicle of diazepam or histamine release from rapid intravenous administration of morphine.
- Not very effective in normal healthy patients.
- Clinical signs of anesthetic induction (e.g., sudden loss of muscle tone, drop of head) do not occur, making titration to intubation the end point.

Medetomidine, Ketamine, and Butorphanol

- For use in cats only. Not recommended for use in dogs.
- Dosage: for intramuscular administration, 30–40 µg/kg medetomidine (Domitor) and 0.2 mg/kg butorphanol and 5 mg/kg ketamine, mixed in same syringe. For intravenous administration, 25 µg/kg medetomidine and 0.25 mg/kg butorphanol and 2.5 mg/kg ketamine.
- Dosages should be adjusted downward for patients that are not normal, healthy adult cats.

Advantages

- Intramuscular dosages provide anesthesia sufficient for most invasive procedures.
- Intravenous dosages provide anesthesia sufficient for efficient intubation.
- All three drugs may be mixed in one syringe for injection.
- Good analgesia due to the α_2 -adrenergic agonist (medetomidine), κ -opioid agonist (butorphanol), and NMDA (N-methyl-D-aspartate) antagonist-dissociative agent (ketamine).
- Rapid onset of effects following intramuscular administration.
- Medetomidine can be reversed rapidly with atipamezole (Antisedan).
- Good to excellent muscle relaxation.

Disadvantages

- Painful on intramuscular injection due to ketamine and butorphanol.
- Not suitable for older or less stable patients.
- If medetomidine is reversed before ketamine has been eliminated, overt dissociative effects will be seen.
- Cannot titrate to effect.

- Medetomidine is not approved for use in cats.

Thiopental Sodium and Propofol

- Dosage: 3 mg/kg propofol and 7.4 mg/kg thiopental IV.
- The thiopental dosage is an equal volume of 2.5% thiopental to the propofol.

Advantages

- Reduces the amount of each drug needed for intubation.
- Decrease in cardiorespiratory depression, because this effect is dosage dependent for each drug.
- Less likelihood of tissue necrosis from perivascular injection.
- “Stretches” the number of doses per bottle of propofol.
- Titrate to effect.

Disadvantages

- Rapid administration will result in apnea and cardiovascular depression.
- Solution must be used within 6 to 8 hours due to the lack of preservative in the propofol.
- Repeated doses can result in rough recoveries due to accumulation of the thiopental.
- Requires intravenous catheter.

Thiopental Sodium and Diazepam

- Dosage: cat or dog, thiopental sodium 10 mg/kg and diazepam 0.2 to 0.5 mg/kg IV.⁴
- Give each drug separately intravenously; start with one half dose thiopental sodium, then flush with saline, follow with one half dose diazepam, and flush. Repeat the sequence with one-fourth doses until patient is relaxed enough to permit intubation.

Advantages

- Smooth induction.
- Lower dosages of thiopental sodium given for decreased undesirable cardiovascular effects.
- Patient relaxed for intubation.
- Smooth recovery.

Disadvantages

- Slower induction when administering drugs alternately and waiting for effect.
- Requires intravenous catheter.

Propofol and Diazepam

- Dosage: cat or dog, 4 mg/kg propofol and 0.2 to 0.5 mg/kg diazepam IV.⁴
- Administered similarly to above combination, with similar advantages and disadvantages. One effective protocol, with or without a preanesthetic agent, is to use 4 mg/kg propofol and 0.3 mg/kg diazepam IV and administer slowly in separate syringes in the following format: (1) place an intravenous catheter, (2) inject one fourth of the propofol dose, flush with saline, (3) inject one half of the diazepam dose, and flush with saline; (4) then if necessary, inject one half of the remaining propofol dose, flush with saline, (5) follow as necessary with one half to all of the remaining diazepam dose, flush with saline, and (6) intubate. Additional propofol may be administered if necessary.⁷

Inhalant Anesthetic Agents

- Intubation of the airway is a must in any patient that is anesthetized adequately for a dental procedure. Even patients anesthetized with dissociative-based combinations (e.g., ketamine, tiletamine-zolazepam) may swallow occasionally or even move, yet lack the ability to protect their airways during anesthesia. Dental procedures require that copious amounts of water be introduced into the oral cavity and oropharynx. In addition, debris such as calculus, teeth, and blood also enter the oral cavity. The suddenness and force of the water stream used is such that often fully conscious patients may have water enter their airway, even with the resultant cough and gag reflex initiated in a timely manner. Obviously, the anesthetized patient is at greater risk due the time it takes to initiate such reflexes, if the reflexes are even present.
- Intubation can be accomplished with either a cuffed or uncuffed endotracheal tube, including Cole tubes. A properly inflated cuff is often not sufficient to prevent water from passing beyond it. Therefore, the oropharynx should be packed with a large gauze (i.e., 4 × 4 for a large dog), laparotomy sponge, or surgical towel. The number of packing materials should be recorded as they are introduced to ensure that all packing is removed when the procedure is complete. If a cuffed endotracheal tube is used, the cuff should be inflated only to the point at which air cannot leak around the tube when 15 to 20 cm H₂O pressure is applied to the airway via the anesthesia circuit as described below.

Excessive inflation may cause damage to the tracheal lining. Damage to the trachea, leading to tracheitis, may also be caused if the endotracheal tube is not detached from the anesthetic hose whenever the patient is rolled to a new position.

Step 1—Close the pop-off valve prior to inflating cuff.

Step 2—Gently squeeze the reservoir bag until circuit manometer reads 15 to 20 cm H₂O pressure.

Step 3—Listen at patient's mouth for any air leakage, or observe fall in manometer from 15 to 20 cm H₂O pressure.

Step 4—Attach an air-filled 3- to 5-cc syringe to the pilot balloon and slowly add air to the cuff while repeating steps 2 and 3.

Step 5—Stop adding air when there is no leak detected at 15 to 20 cm H₂O pressure.

Step 5—Open the pop-off valve.

- After approximately 15 to 30 minutes of anesthesia, the cuff should be checked for adequacy by repeating steps 1 to 3 above. As anesthetic maintenance is reached, the trachealis muscle relaxes, and the seal between the cuff and the trachea often becomes inadequate.
- Overinflation of a cuff is more hazardous than underinflation. Tracheal mucosal necrosis or tracheal rupture is possible. Airway obstruction is also possible due to collapse of the endotracheal tube walls by the excessive cuff pressure, or bulging of the cuff over the end of the endotracheal tube.
- Also, for orthodontic and crown procedures during which the occlusion must be checked multiple times during the procedure, a modified endotracheal tube may be used (see Chapter 2).

Advantages

- Extubation and reintubation is not required.
- Speed.

Disadvantages

- Must make sure that the tube is tied in well; you do not have much tube to recover if it is inadvertently forced down the trachea.
- Patient can wake up and struggle with tube in place.
- Risk of extubation or accidental loss of the endotracheal tube into the trachea is present. To prevent such a risk, a simple pharyngotomy can be performed quickly and allowed to heal by second intention.

Halothane

Advantages

- Rapid induction and recovery.
- Can be used for mask or chamber induction.

Disadvantages

- Can cause ventricular arrhythmias due to decrease in arrhythmogenic dosage of epinephrine.
- Taken up by body fat.
- Produces dose-dependent respiratory and cardiovascular depression.
- Requires some hepatic metabolism (25%).³
- Blocks the baroreceptor reflex. Reflex tachycardia from vasodilation-induced hypotension does not occur. Premedication with an anticholinergic agent is often necessary.
- Halothane-induced hepatitis has been reported.
- While all of the hydrocarbon anesthetics can cause arrhythmias associated with the use of epinephrine, the dose of epinephrine that causes arrhythmias is lower with halothane.

Isoflurane

Advantages

- Can be used for mask or chamber induction.
- Because it is somewhat less soluble in blood and tissue than halothane, isoflurane provides a slightly faster induction and recovery than halothane.
- Minimal hepatic metabolism (less than 1%).³
- Causes fewer incidences of cardiovascular depression and arrhythmias than halothane.
- Respiratory rate is slowed, but alveolar minute ventilation is maintained when used at appropriate concentrations.

Disadvantages

- Causes hypotension at high concentrations.
- Causes dose-dependent cardiovascular and respiratory depression.
- Pungent odor makes mask and chamber inductions unpleasant for patient.

Sevoflurane

Advantages

- Less soluble than isoflurane or halothane.
- More rapid induction and faster recovery from anesthesia when used as sole agent.
- No odor.
- Can be used for mask or chamber induction.
- No metabolism required for elimination.

Disadvantages

- Less potent than isoflurane or halothane, so higher dial settings are needed and more agent is used.
- Rapid recovery results and no postoperative analgesia unless analgesic drugs have been administered. Use of analgesics may slow rate of recovery from anesthesia.

Desflurane**Advantages**

- Very rapid induction and recovery due to its high insolubility in blood.
- Can be used for mask or chamber induction.

Disadvantages

- Odor is unpleasant and can cause laryngospasm when administered by mask or chamber.
- Very low potency, necessitating relatively high dial settings and resultant use of large quantities of the agent.
- Requires heated, pressurized vaporizer due to high degree of volatility.

Mask or Chamber Induction**Comments**

- Gas anesthetic agents such as halothane, isoflurane, sevoflurane, or desflurane can be used after preanesthetic medication by application of a mask or chamber box to induce anesthesia.
- High oxygen flow rates (3 to 5 lpm) are necessary to facilitate delivery of adequate concentrations to the patient in a timely fashion.
- When induced with a mask, the patient should be preoxygenated before the anesthetic agent is introduced in increments until intubation can be performed.
- When using a chamber for induction, it is not necessary to preoxygenate the patient or gradually increase the dial setting. The vaporizer dial should be turned to its maximum output setting and the patient observed. The patient is quickly removed from the chamber once the patient has lost its ability to right itself. Additional anesthetic is then administered via mask until the patient can be intubated.
- These techniques are not appropriate for patients that are vomiting or have compromised respiratory function.

Advantage

- Chamber induction can be used for smaller patients that cannot be safely restrained for intravenous induction.

Disadvantages

- Difficult to use on larger patients that are harder to restrain during induction phase.
- Uses more anesthetic agent.
- Adverse cardiorespiratory effects are more likely due to the necessarily higher concentrations of drugs. Cardiorespiratory depression can be significant.
- Time available to attempt intubation is very short. Additional agent must be administered by mask when patient begins to resist attempts to intubate, until a deeper plane of anesthesia is achieved. This is not as much of a problem if the patient is premedicated with a sedative.
- Rate of induction is very slow. Rapid control of the airway is not possible.
- A high degree of waste gas contamination and exposure to those in the immediate and surrounding area. Exposure will exceed levels acceptable by Occupational Safety and Health Administration standards.
- Stage II (involuntary excitement) is often prolonged and causes release of catecholamines.
- Apnea is common due to unpleasant odor of agent. Normal ventilation is necessary for delivery of the agent to the lungs; apnea results in prolonged induction times.
- Mask induction may cause discomfort and patient resistance with some dental pathology cases, such as maxillofacial fractures or periapical abscesses.

Monitoring**General Comments**

- Monitoring the patient during the anesthesia period is becoming the standard of practice and is necessary in order to provide safe anesthesia.
- No single method is completely adequate or accurate; therefore, it is best to monitor more than one body system during anesthesia.¹⁴
- Heart rate, respiratory rate, eye position, palpebral reflex, blood pressure level and character, mucous membrane color, and capillary refill time should be monitored by an assistant and charted at regular, frequent intervals (see Table 11-1). The assistant should assess anesthesia depth based on these findings.

- Adjustments in anesthesia depth should be made, as needed, to keep patient at an adequate depth of anesthesia for the procedure. Excessive or inadequate depth should be avoided.

Pulse Oximeter

Comments

- The oximeter can be used on the tongue, lip, pinna, vulva, rectum, prepuce, or toe web.
- A reading of 99% to 100% is expected when a patient is receiving supplemental oxygen.¹⁵

Advantages

- Can be placed in areas away from the mouth.
- Various models available, some able to monitor additional parameters.
- Noninvasive method for monitoring arterial oxygenation.

Disadvantages

- Oximeter is dislodged easily when patient is moved.
- Skin pigmentation, icterus, vasoconstriction, and patient movement will result in abnormal readings.

- Only measures the saturation of the hemoglobin. Familiarity with the oxygen-hemoglobin dissociation curve is necessary to make inference regarding P_{aO_2} and assessment of adequate oxygenation.

Blood Pressure Monitor

Comments

- Arterial blood pressure is determined by preload, heart rate, stroke volume, and peripheral vascular resistance.
- Most preanesthetic agents and all general anesthetic agents affect these parameters and cause hypotension.
- Blood loss decreases venous return (preload) and stroke volume, causing a decrease in blood pressure.
- Blood pressure may be measured directly or indirectly.
- Direct measurement requires placement of an arterial catheter and an aneroid manometer or pressure transducer connected to an electronic monitor.
- Indirect blood pressure monitoring uses external equipment to determine blood pressure in a peripheral artery.
- Blood pressure may be measured indirectly by using either Doppler or oscillometric methods (Table 11-2).

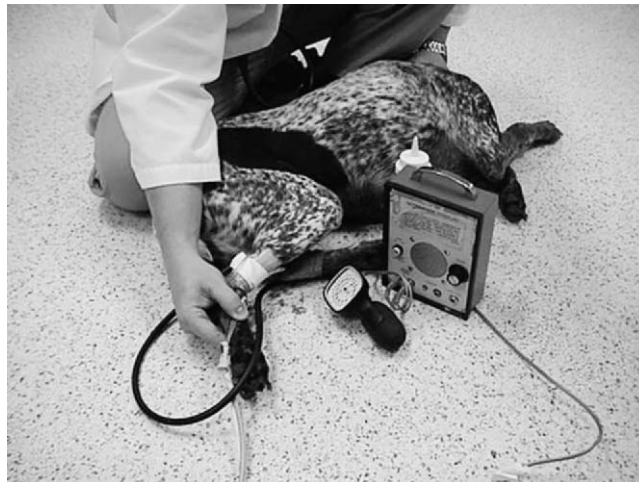

Fig. 11-1

Table 11-2 • **BLOOD PRESSURE MONITORS (NONINVASIVE, OR INDIRECT)**

Brand name	Address	Type
Model 811, 811-BTS	Parks Medical Electronics, 19460 SW Shaw, Aloha, OR 97007 800-547-6427	Doppler
CAT Doppler, PD1, PD1v	Thames Medical, Thames House, 16 Brook Barn Way, Goring by Sea, Worthing, West Sussex, BN12 4DW, England Tel: +44 1903 522911	Doppler
Vet-Dop	VMS Inc, PO Box 6005, Lincoln, NE 68506 800-895-2269	Doppler
Memoprint	Jorvet, 1450 N Van Buren Ave, Loveland, CO 89538 800-525-5614	Oscillometric
Dinamap 8100	Various used equipment suppliers	Oscillometric
Cardell 9301V, Cardell Plus 9302V	Sharn Veterinary, 12706 Casey Rd, Tampa, FL 33624 866-447-4276	Oscillometric
V60046	SurgiVet, N7 W22025 Johnson Rd, Suite A, Waukesha, WI 53186 888-745-6562	Oscillometric
LifeWindow 6000, Digstation, Digimax 5500	Digicare Biomedical Technology, 6879 Vista Pkwy N, West Palm Beach, FL 33411 561-689-0408	Oscillometric
BP-3, BP-2, VMS5/VMS6	VetSpec, 224 Brown Industrial Pkwy, Suite 101, Canton, GA 30114 800-599-2566	Pressure plethysmography

Doppler blood pressure measurement

- Parks Doppler applied and positioned to patient (Fig. 11-1).
- Doppler blood pressure measurement uses a small piezoelectric crystal placed over an artery.
- This crystal emits an ultrasonic pulse that is reflected back from moving tissues (i.e., blood) at a slightly different frequency.

- This shift in tone is converted to an audible tone.
- A mean arterial blood pressure above 60 to 70 mm Hg, or systolic pressure of 100 mm Hg, in an anesthetized patient is necessary to ensure adequate tissue perfusion.^{6,16}
- Pressure readings should be taken frequently so trends can be followed.
- A blood pressure cuff is placed on an extremity proximal to an artery. The cuff is then attached to a pressure gauge and a pump. The appropriately sized cuff will have a width of approximately 40% of the circumference of the extremity.
- The piezoelectric crystal (probe) is placed over the artery. Generous amounts of ultrasonography gel is used between the artery and the probe. Clipping the hair over the area will reduce the amount of noise and improve the ability to hear the pulse.
- Air is pumped into the cuff, occluding the artery until flow is not longer detectable by the Doppler probe.
- As the pressure in the cuff is released, blood again begins to flow through the artery.
- Systolic pressure is determined when flow is first heard or the needle on the gauge oscillates.
- The point at which the flow is continuous and no longer changes is considered to be an estimate of diastolic pressure.
- The problem most frequently encountered is the inability to hear the pulse due to inadequate volume settings on the unit.
- Systolic pressure is determined easily; however, diastolic is more difficult to determine. Mean arterial pressure is even more difficult (often impossible) to determine.

Oscillometric instruments

- The commonly used name for these instruments is *Dinamap*. Other manufacturers make oscillometric instruments, however, with other trade names.
- A cuff is placed around an extremity and the instrument inflates the cuff at predetermined intervals. As the unit releases the cuff pressure, it detects movement of air within the cuff caused by arterial wall movement beneath the cuff.
- Systolic, mean, and diastolic blood pressure and heart rate are computed and displayed.

Blood pressure measurements**Advantages**

- Arterial blood pressure is the first parameter to increase in response to an increase in sympathetic outflow.
- Out of the way of the oral cavity.
- Provide reading of pulse rate and rhythm.
- Can monitor cardiovascular response to anesthetic adjustments.

Disadvantages

- Inaccurate readings in small or very hypotensive patients (oscillometric).
- Requires someone to manually inflate and deflate the cuff (Doppler).
- Doppler probe can be dislodged when patient is repositioned.
- Arterial blood pressure is one of the last physiologic parameters to change during cardiovascular failure or collapse.

Respiratory Monitors**Comments**

- Adequate respiratory function is essential to maintain adequate tissue oxygenation and carbon dioxide elimination; therefore, respiratory monitoring is important.
- Most of these monitors have an attachment to the endotracheal tube that measures each respiration via a thermistor which detects flow of warm air from the patient.
- Can be preset to sound an alarm if a flow does not pass over thermistor during a user-determined interval. Some models also produce an audible beep with each respiration. The respiratory rate should be a minimum of 8 to 12 breaths per minute.¹⁵

Advantages

- Can be used easily on a patient of any size.
- Provides early recognition of changes in respiratory rate.
- Monitor is not in the way of the dental procedure.

Disadvantages

- Does not measure depth of respiration or adequacy of alveolar ventilation.
- User must determine desired frequency of breaths per minute.
- Very shallow respirations may not be detected by thermistor.

Capnography and Capnometry**Comments**

- Adaptor attaches to endotracheal tube and small amounts of airway gas are sampled to determine the PCO_2 .
- P_{ETCO_2} is the PCO_2 of the gas at the very end of respiration. It is (or is supposed to be) the gas from the alveoli.
- P_{ETCO_2} is an estimation of P_{ACO_2} which is a reflection of P_aCO_2 . Therefore P_{ETCO_2} is a noninvasive method of determining P_aCO_2 .
- P_{ETCO_2} is 5 to 10 mm Hg *less* than P_aCO_2 due to diffusion of carbon dioxide across the alveolar capillary membrane.
- Capnography is a graphic display of the PCO_2 throughout the entire respiratory cycle, from breath to breath.
- Capnometry is a digital display of the highest number during each respiratory cycle. This number is P_{ETCO_2} . At very low respiratory rates, PCO_2 values during the breath may also be displayed.

Advantages

- Provides information regarding adequacy of alveolar ventilation.
- Earliest indicator of decline in cardiac function.
- Monitors are often combined with pulse oximetry units.
- Capnography provides information regarding type of breath (e.g., bronchoconstriction, airway obstructions, disconnections from the anesthesia circuit), as well as the inspired PCO_2 .
- Increases in P_iCO_2 are indicative of rebreathing of carbon dioxide. This is most frequently due to expired carbon dioxide absorbent but is also due to inadequate fresh gas flows when using a non-rebreathing system.
- Apnea alarm.

Disadvantages

- Attaches to endotracheal tube, so there is additional equipment in the working field.
- Requires in-line filter or maintenance of unit to prevent condensation from entering the unit.

Electrocardiographic Monitor**Comments**

- Alligator clamps, needles, electrode pads, or stainless steel sutures are attached to the skin near the elbows and flanks or stifles, to provide connections for the leads to provide continuous electrocardiograph (ECG) and cardiac rhythm readings.

Advantages

- Monitors heart rate and rhythm (normal QRST) (Fig. 11-2).

Fig. 11-3: Example of a second-degree AV block. Notice the third P wave of the strip is not followed by a QRS complex. Without an ECG this would sound or feel the same as sinus arrhythmia or sinus pause.

Fig. 11-4: Example of a VPC (ventricular premature complex). Notice that the complex is wider and more bizarre than the normal complex and that there is no P wave present (paper speed = 50 mm/sec).

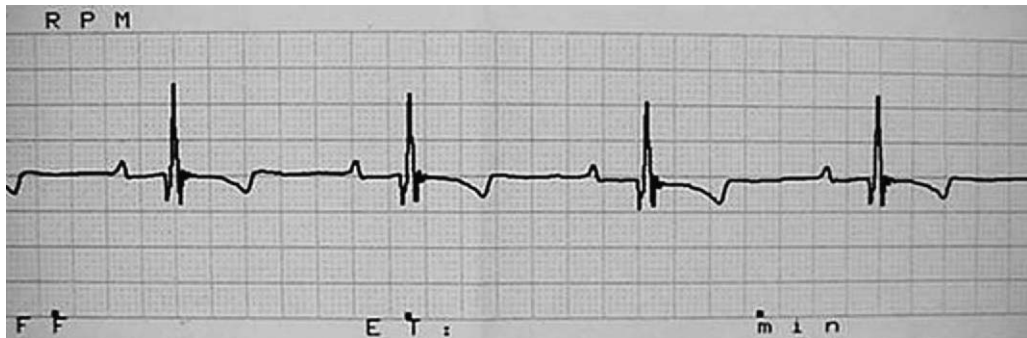

Fig. 11-2

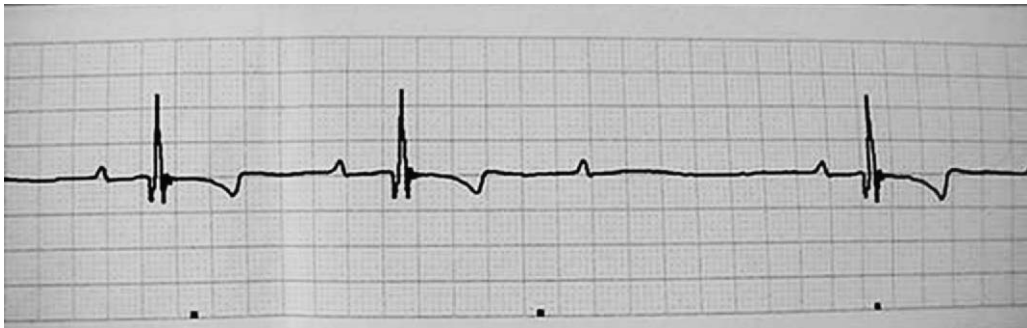


Fig. 11-3

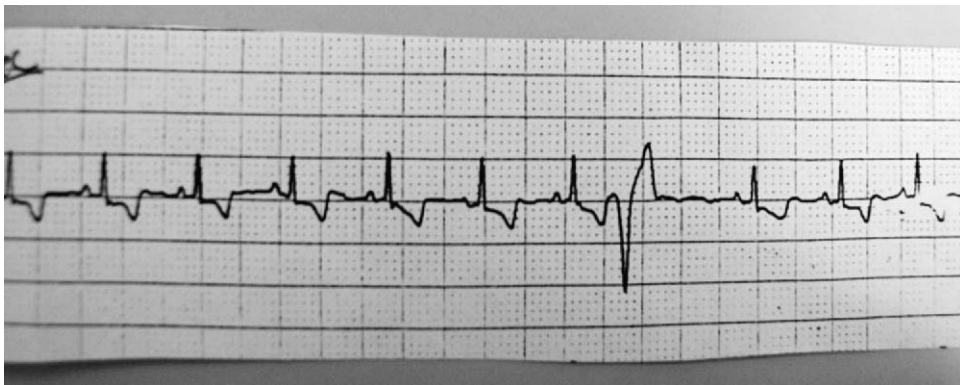

Fig. 11-4

Fig. 11-5: Example of ECG alterations due to hyperkalemia. The serum potassium level of this patient was 8 mEq/L. Notice the lack of P waves, the slow rate (paper speed = 50 mm/sec), and wide, bizarre ventricular complexes.

Fig. 11-6: Example of ST segment depression. This is commonly seen when myocardial oxygen delivery is inadequate.

Fig. 11-7: Example of EMD (electromechanical dissociation). Electrical complexes are present, albeit abnormal. The tracing was obtained during a thoracotomy, and no mechanical activity of the heart was observed despite the electrical activity recorded.

- Monitor and cables are distant from work area.

Disadvantages

- Good electrical contact is necessary between patient skin and electrode to prevent interference from other electrical systems (e.g., electrocautery).
- Must be able to discern normal variations and artifacts from true abnormalities in conduction.

- Only monitors electrical activity as opposed to mechanical activity; therefore, can have a normal ECG yet have a serious reduction in cardiac performance or even failure.
- Clamps or needles may be dislodged when the patient is repositioned.

Esophageal Heart Monitor

Comments

- A probe is inserted orally into the esophagus to a level near the heart, and it transmits the heartbeat audibly on an amplifier.
- Normal heart rates for dogs during anesthesia should range between 60 and 140 beats per minute; for cats, between 80 and 160 beats per minute.¹⁵
- Bradycardia can be caused by increased vagal tone, excessive anesthesia depth, hypothermia, hypoxia, hypertension, or hyperkalemia.
- Tachycardia can be caused by the anesthesia being too light, and the patient responds to painful stimuli, hypotension, hypoxia, hypercarbia, or hyperthermia.

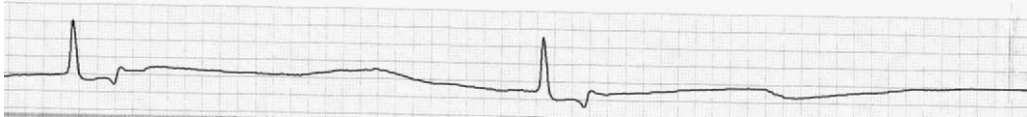


Fig. 11-5

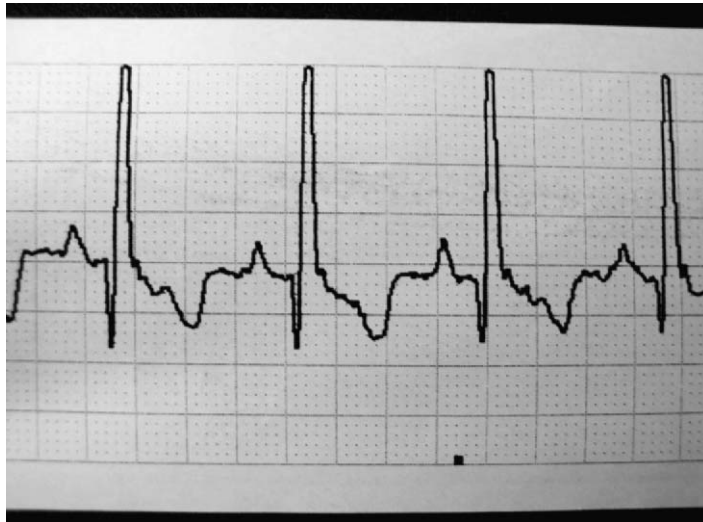

Fig. 11-6

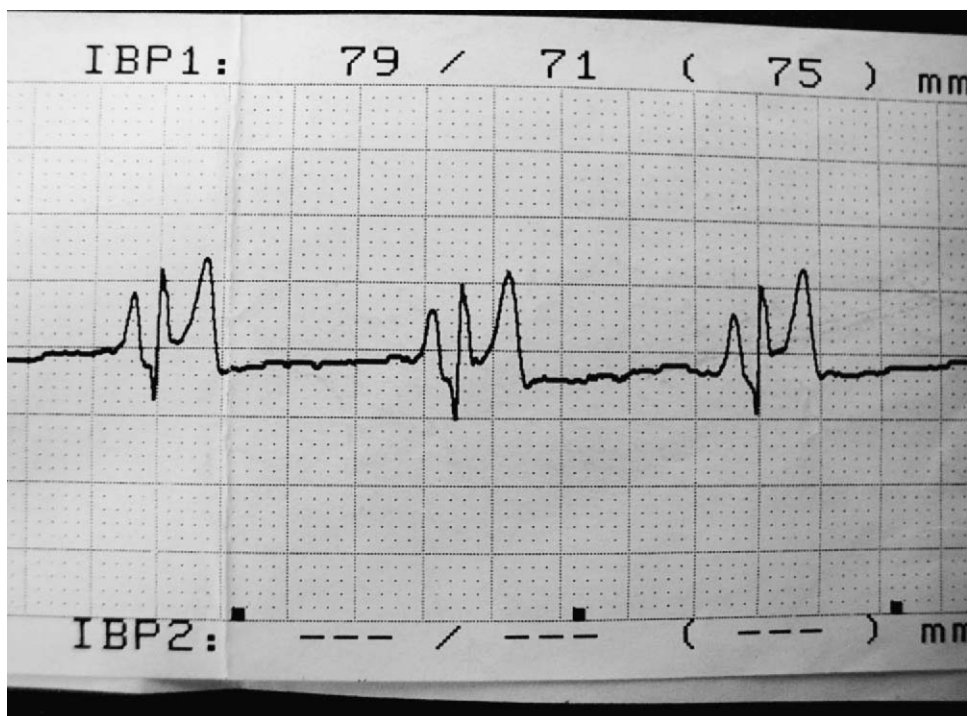


Fig. 11-7

Advantages

- Audible heartbeat confirms mechanical function of the heart.
- May also hear breath sounds.
- Changes in rate or quality of the sounds are detected easily and quickly.
- Minimally technical in operation.

Disadvantages

- Places an additional tube in the patient's mouth during a dental procedure.
- Secondary noise can be distracting when patient is moved or tube is moved.

Temperature Monitor**Comments**

- Hypothermia is common during anesthesia because the vasodilatory effects of anesthetic drugs cause an increase in radiation losses, inspiration of cold dry gasses, loss of heat through evaporative losses (respiratory as well as any body cavity openings), and lack of muscle activity to generate heat.
- The patient's body temperature changes can alter the response to anesthesia. Hypothermia is often a problem with prolonged procedures.
- Prevention of hypothermia can be accomplished easily by using a circulating water heating pad or forced warm air blowers. Further conservation of body heat can be achieved by covering the patient's body with a towel or blanket. This conservation can be enhanced further if the towel has just been removed from a clothes dryer.
- Wrapping small dogs and cats in bubble wrap or a plastic bag will also help retain body heat.
- Administering warm oral flushing solutions, keeping the patient as dry as possible during dental procedures, and maintaining the ambient temperature at a level suitable to maintain the patient's temperature are also very helpful.
- Hypothermia is the most common temperature change that occurs during anesthesia.
- Hypothermia is most severe in small, short-coated pets, but also occurs in large, heavy-coated dogs.
- Malignant hyperthermia is an extremely rare, potentially fatal complication that can occur during inhalant anesthesia.
- Body temperature can be monitored with a standard rectal mercury thermometer or by

using rectal or esophageal probes that record body temperature.

Body Changes with Hypothermia

- Hypothermia is defined as a body temperature below 100° F.
- Prolonged recovery from anesthesia.
- Bradycardia that may not be responsive to anticholinergic therapy.
- MAC reduction (less anesthetic required to provide anesthesia).
- Hypotension.
- Shivering results in a significant increase in oxygen demand.

Body Changes with Hyperthermia

- Hyperthermia is defined as a body temperature above 104° F.
- Extremely rare under anesthesia.
- Tachycardia.
- Increased respiratory rate.
- Metabolic alterations (electrolytes, acid base balance).

Changes in Anesthesia Status During Procedure**Problem: Anesthesia Plane too Light**

- Increased blood pressure reading.
- Increased respiratory and heart rate.
- Movement of eyes, jaw, or limbs.

Correction

- Check anesthetic level in vaporizer. To add additional agent, turn the oxygen flow off. Vaporizer may be left on.
- Increase vaporizer setting.
- Check equipment circuit for new or obvious leaks or disconnects.
- Ensure proper placement of endotracheal tube. Endobronchial intubation is common in small patients when endotracheal tubes have not been trimmed to a shorter length.
- Increase oxygen flow rate.
- Have the vaporizer calibration checked by a certified service technician if problem persists.

Problem: Anesthesia Plane too Deep

- Decreased heart and respiratory rate.
- Lowered blood pressure.

Correction

- Decrease vaporizer setting, or turn it to off.
- Increase oxygen flow rate.
- Evacuate reservoir bag into scavenger system.
- Increase fluid rate to offset hypotension.
- Assist patient's ventilation.

Additional Considerations for General Anesthesia

- A properly sized endotracheal tube with an inflated cuff should be used in dental and oral surgery patients to aid in preventing aspiration of water, blood, and calculus debris.
- Packing the oropharynx will ensure that debris will not fall into the airway and inadvertently become lodged between the trachea and the endotracheal tube.
- The head should be positioned slightly lower than the level of the carina (bifurcation of the primary bronchi), to assist in preventing fluid and debris from entering the airway.
- The endotracheal tube cuff should be inflated with enough air to prevent leakage of air around the cuff when the circuit is pressurized to 10 to 20 cm H₂O. Excessive air in the cuff will cause ischemic damage to the tracheal mucosa.
- Careful attention must be paid to maintaining an open pop-off valve. The pop-off valve must be reopened after testing the endotracheal tube cuff or ventilating the patient.
- The endotracheal tube should be secured to the patient to prevent accidental extubation. This can be accomplished with gauze ties, rubber bands, or used intravenous tubing.
- It may be desirable for patients undergoing major oral surgery, such as fracture repair, where intraoperative evaluation of occlusion is necessary, to have the endotracheal tube exit through a pharyngotomy incision in order to keep the oral cavity clear.
- It is appropriate during any anesthesia period for intravenous fluids to be administered. With older, more "brittle" patients, therapy is started several hours before the procedure and continued after the procedure until they are alert, stable, and able to stand on their own.

Pain Management

General Comments

- Pain recognition and management is becoming an important part of dental treatment.
- Animals have an evolutionary stoicism. In the wild, if an animal appears sick or injured, it may be eliminated by the group or attacked by predators¹⁷; therefore, patients can be adept at hiding behaviors that indicate pain. This seems to be the case with dental disease. Often when it is quite advanced, many patients exhibit minimal signs of discomfort.
- There is significant variation among individuals, species, and breeds in the response to painful stimuli.
- Pain is expressed by a change in behavior: vocalization, aggression, shivering, restlessness, reluctance to move or eat, guarding or avoidance of touch, and increased salivation.
- Dilated pupils, tachycardia, hypertension, possible increase in respiratory rate, cardiac arrhythmias, and hyperglycemia are also seen in patients with symptoms of pain.¹⁸
- Control of pain is important physiologically. (1) As pain increases, there is increased sympathetic nervous system stimulation with a catecholamine release; this can lead to vasoconstriction and tachycardia, which can increase the cardiac workload. (2) Pain results in decreased gastrointestinal motility. (3) Pain stimulates the release of antidiuretic hormone, which can lead to changes in body fluid balance. (4) Pain increases the level of patient stress, with potential negative effects on healing and the immune system. These can be related to decreased water and food consumption.¹
- Preventing and managing pain associated with dental procedures is humane.
- Preventing and managing pain associated with dental procedures is cost effective.
- Preventing and managing pain associated with dental procedures is expected and even assumed by most owners.
- The goal of pain management is to reduce the ongoing pain stimuli and thereby reduce the patient's response.
- It is most beneficial to the patient to administer analgesics before onset of pain.¹⁹ This leads to an increased use of opioids as preanesthetic medications, which also reduces the amount of general anesthetic needed. Before the patient reaches consciousness (when inhalant anesthetic is

discontinued) is the preferred time for administration of an injectable analgesic, for control of postoperative pain, and allows for a smaller dose to be given.

- When major oral manipulation is anticipated, regional blocks are beneficial in managing pain during anesthesia and immediately postoperatively.
- Regional blocks can reduce the dosage requirement of the initial postoperative opioid analgesics.
- There are four times for pain management: preoperative, intraoperative, immediately postoperative, and dispensed for home administration by owner. Preoperative medications that include opioids can reduce pain before and during dental procedures. More complete pain relief can be obtained with regional or local analgesia that will continue into the postoperative period, depending on duration of action of drug used (see Chapter 12).

Postoperative and Owner-Administered Pain Management

Comments

- There has been hesitation in using postoperative opioids because of the lack of approved drugs for use in cats and dogs for pain control; other reasons are short duration or inconsistency of duration of action of some drugs, expense, and the potential for abuse of class II drugs.^{6,17}
- Providing dispensed or prescribed pain medication after involved dental procedures allows a client to participate in the pet's recovery and satisfies the need to reduce perceived or real pain.

Drugs

Aspirin

- Dosage: dog, 10 to 25 mg/kg orally 2 to 3 times per day.⁵
- Cat, 40 mg (half of a baby aspirin) orally q 2 to 3 days.

Comments

- Aspirin is a commonly used nonsteroidal antiinflammatory drug (NSAID) that reduces pain, inflammation, and fever.
- Aspirin also decreases platelet aggregation.
- Not recommended for patients with liver, renal, or respiratory disease; gastrointestinal ulceration; hypoalbuminemia; bleeding

disorders; or for patients taking corticosteroids or other NSAIDs.²⁰

Advantages

- Inexpensive.
- Can be given orally.
- Decreases inflammation.
- Convenient over-the-counter medication.

Disadvantages

- Good only for mild pain relief.
- Adverse effects can be seen even at low dosages in some patients.
- Not recommended for patients with renal disease.

Carprofen

- Carprofen (Rimadyl) is an NSAID with increased specificity for the COX2 enzyme responsible for inflammation.
- Dosage for dogs is 2 mg/kg by mouth every 12 hours.
- Supplied in 25-, 75-, and 100-mg scored caplets, in bottles of 100 or 250 caplets.

Advantage

- Relieves pain and inflammation.

Disadvantages

- This drug is not approved for use in cats in the United States.
- Hepatopathies have been noted. It is advisable to evaluate liver function before using this product.
- NSAIDs have been associated with renal and gastrointestinal toxicity.
- Patients at greatest risk for complications are those on concomitant diuretic therapy and those with renal, cardiac, or hepatic dysfunction.
- This drug should be used with caution in conjunction with other antiinflammatory drugs, such as corticosteroids and other NSAIDs.

Opioids

- Opioids interact with specific receptors in the CNS to inhibit pain signal transmission from the dorsal root zone of the spinal cord, inhibiting the pain impulse transmission in the neurologic pathways.
- A number of oral and injectable drugs are available.

Butorphanol

Comments

- The use of the large animal formulation (Torbugesic, 10 mg/ml) makes adminis-

tration more convenient and cost effective. Torbutrol (0.5 mg/ml) and Torbugesic SA (2 mg/ml) are also available.

- Duration of analgesia is short, varying from 1 to 2 hours in most patients.
- Dosage: cat or dog, 0.1 to 0.2 mg/kg SC, IM, or IV.

Advantages

- Good for mild pain.
- Minimal cardiorespiratory depression.

Disadvantages

- Oral form undergoes extensive first-pass metabolism, which significantly reduces its bioavailability and hence actual effectiveness.
- Short duration of pain relief, often only 1 to 2 hours.
- Stings on injection.

Oral formulation of Torbugesic injectable with corn syrup²¹

Small patient: 4 to 9 lb

- Torbugesic 1.5 ml of the large animal strength (10 mg/ml) may be mixed with 2 oz (60 ml) corn syrup and administered orally at a dosage of 1 ml/5 lb. This gives a concentration of 0.25 mg/ml butorphanol.

Medium-sized patient: 10 to 19 lb

- Torbugesic 3 ml of the large animal strength (10 mg/ml) may be mixed with 2 oz (60 ml) of corn syrup and administered at a dosage of 1 ml/10 lb. This gives a concentration of 0.5 mg/ml.

Large patient: 20+ lb

- Torbugesic 6 ml of the large animal strength (10 mg/ml) may be mixed with 2 oz (60 ml) of corn syrup and administered at a dosage of 1 ml/20 lb. This gives a concentration of 1 mg/ml.

Buprenorphine

- Comes in 1-ml ampules; concentration is 0.3 mg/ml (i.e., 300 µg/ml).
- Dosage: 0.005 to 0.04 mg/kg (i.e., 5 to 40 µg/kg), IV or IM.

Advantages

- Good for mild to moderate pain.
- Duration is dosage dependent: 5 µg/kg provides 2 to 3 hours of analgesia, while 40 µg/kg provides 10 to 12 hours of analgesia.
- Parenteral administration.

- Can be administered orally in cats (sublingually, buccally, or just squirt into mouth) with resultant excellent bioavailability and effectiveness.

Disadvantages

- Comes in ampules only.
- Class III drug.

Codeine

- Dosage: dog, 0.5 to 1 mg/kg orally every 6 to 8 hours.⁵
- Can be special ordered by itself or used in a preparation with acetaminophen or aspirin in dogs.

Advantage

- Good for mild pain.

Disadvantages

- Class III drug.
- May cause vomiting.
- Poor bioavailability in dogs compared with man.

Meperidine hydrochloride

- Dosage: cat or dog, 2 to 10 mg/kg SC or IM.^{6,18}

Advantage

- Good for mild pain.

Disadvantages

- Short duration of 1 to 2 hours.
- Class II narcotic.
- Significant histamine release when administered intravenously.

Morphine

- Dosage: cat, 0.05 to 0.1 mg/kg; dog 0.5 to 1.0 mg/kg SC, IM, or IV.⁵
- Available in oral forms.

Advantages

- Least expensive opioid.
- Moderate duration of 4 hours.
- Gold standard of opioid analgesics.

Disadvantages

- May cause vomiting.
- May cause sedation.
- Class II drug.

Oxymorphone and hydromorphone

- Dosage: dog, 0.1 to 0.2 mg/kg; cat 0.05 to 0.2 mg/kg SC, IM, or IV.^{6,18}

Advantages

- Effective for severe pain.
- Can be used with tranquilizer for neuroleptanalgesia.

Disadvantages

- More expensive than morphine.
- Class II drug.
- Variable duration of 1 to 3 hours.
- Oxymorphone may be difficult to obtain.
- Can cause respiratory depression.
- Can cause excitation and increased reactivity to environmental noise.

Fentanyl transdermal patches (Duragesic)

- These are small patches that adhere to the skin of an area that has been clipped of hair.
- The patch may be placed anywhere on the patient.
- Dosage is 2 to 4 µg/kg/hr.
- Duragesic 25 has 2.5 mg fentanyl and is released at a rate of 25 µg/hr. This size is used for cats and dogs up to 25 lb.
- Duragesic 50 has 5 mg fentanyl and is released at a rate of 50 µg/hr. This size is used for cats and dogs up to 50 lb.
- There are also 75- and 100-mg patches with release rates of 75 and 100 µg/hr. Due to inconsistent absorption from the 100-mg patch, it is recommended to combine patch sizes when dosages greater than 100 µg/hr are desired.
- When less than an entire patch is needed, part of the stiff backing from the patch may be removed to expose only the fractional portion of the patch needed. This is often necessary in cats and small dogs. For example, a 5-kg patient requires 10 to 20 µg/hr. Uncovering one half of a 25 µg/hr patch will, in theory, provide 12.5 µg/hr. *Never* cut the patch itself.

Advantages

- Easy to apply.
- Provides continuous low-level analgesia for 72 or more hours.
- If adverse effects occur, patch can be removed and drug is eliminated rapidly.
- No absorption of the drug from the gastrointestinal tract.

Disadvantages

- Need to clip hair to place patch (metatarsal area makes patch less noticeable).
- For best effect, patch needs to be placed 24 hours before pain stimulus in the dog; cats need only 4 to 6 hours.

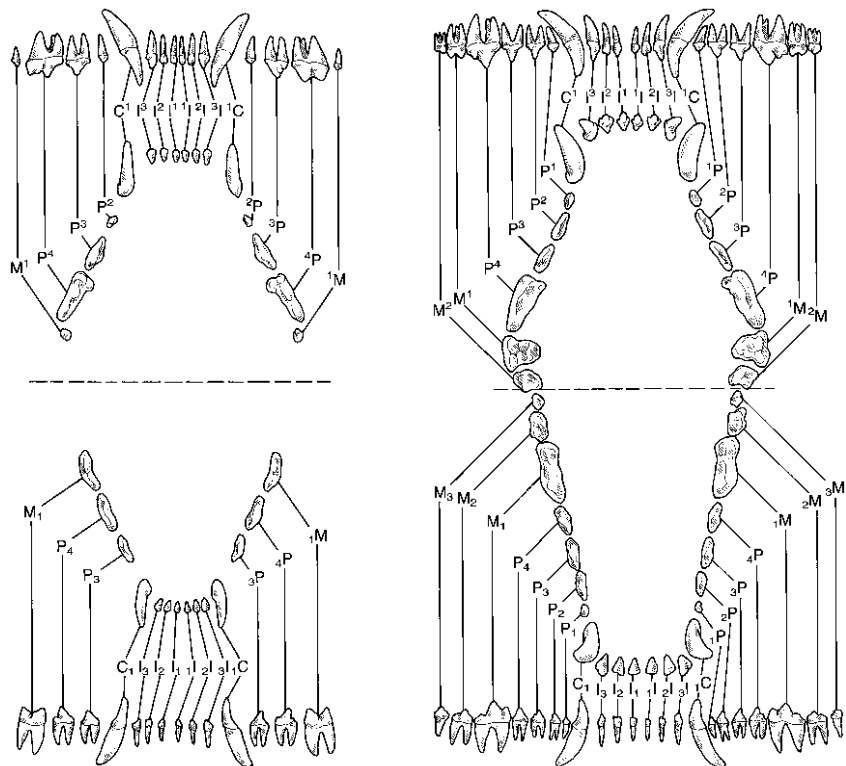
- Patch can be displaced or ingested. Fentanyl is easily absorbed from the mucous membranes of the mouth, so ingestion by toddlers who may suck on the patch is a risk.
- Class II drug.
- Significant interpatient variability in blood levels and response, especially in dogs.

REFERENCES

1. Paddleford RR: *Manual of small animal anesthesia*, New York, 1988, Churchill Livingstone.
2. Muir W, Hubbell J: *Handbook of veterinary anesthesia*, St Louis, 1989, Mosby.
3. Hellyer PW: General anesthesia for dogs and cats, *Vet Med* 4:314-325, 1996.
4. Pasco PJ, Ilkiw J: *Small animal anesthesia protocol sheet*, Davis, Calif, 1995, Veterinary Medical Teaching Hospital, University of California.
5. Plumb DC: *Veterinary drug handbook*, pocket ed, White Bear Lake, Minn, 1991, Pharma Vet Publishing.
6. McCoy D: Practical use of narcotic analgesics in small animals, *Trends Magazine* February/March 1995, p 3941.
7. Yin S: Anesthesia. In Yin S: *Small animal veterinary handbook*, Davis, Calif, 1994, CattleDog Publishing, pp 1.0-1.9.
8. Thurman IC, Tranquilli WI, Benson GI: *Lumb and Jones veterinary anesthesia*, ed 3, Philadelphia, 1996, Lea & Febiger/Williams & Wilkins, pp 232-234.
9. Morgan DWT, Legge K: Clinical evaluation of propofol as an intravenous anaesthetic agent in cats and dogs, *Vet Rec* 124:31-33, 1989.
10. Weaver BMQ, Raptopoulos D: Induction of anaesthesia in dogs and cats with propofol, *Vet Rec* 126:617-620, 1990.
11. Ko JCH, et al: Propofol: a new intravenous anesthetic, *Vet Tech* 16:734-737, 1995.
12. Smedile LE, Duke T, Taylor SM: Excitatory movements in a dog following propofol anesthesia, *J Am Vet Med Assoc* 32:365-368, 1996.
13. Smith JA, Gaynor JS, Bednarski RM, Muir WW: Adverse effects of administration of propofol with various preanesthetic regimens in dogs, *J Am Vet Med Assoc* 202:1111-1115, 1993.
14. McCurnin D: Surgical patient monitoring: Is it part of practice management? *Vet Prod News* 3:16, 1996.
15. Jones JL: Noninvasive monitoring techniques in anesthetized animals, *Vet Med* 4:326-336, 1996.
16. Paddleford RJ: The case for routine intraoperative blood pressure monitoring, *Vet Clin North Am* 22:444-445, 1992.
17. Hustead D: Pain, analgesia: the relief of pain and suffering: a DVM's responsibility in controlling patient suffering, Fort Dodge Animal Health, Feb 1993.
18. Raffe M: How to effectively manage pain in seriously ill patients, *Vet Forum* 3:26-40, 1995.
19. Carroll GL: How to manage perioperative pain, *Vet Med* 4:353-357, 1996.
20. Lewis L, Small D: A review of pain with potential therapy, *Vet Forum* 12:28-31, 1995.
21. Mooney J: Henry Schein handout.



REGIONAL AND LOCAL ANESTHESIA



GENERAL COMMENTS

- Local dental nerve blocks can be performed in conjunction with general anesthesia for greater pain relief and reduced general anesthetic levels during oral surgery procedures.
- Local anesthetics will also provide a level of early postoperative analgesia.

Advantages of Local Anesthesia

- Provides pain relief during the procedure and postoperatively.¹
- Reduces general anesthetic requirements, thus reducing anesthesia gas consumption.
- Decreases the chance of vagally mediated reflex bradycardia.
- If pain is prevented before it is perceived, the amount of other types of pain medication needed can be reduced.

Disadvantages

- Can add additional time to procedure.
- Potential nerve injury.
- Some patients may paw at mouth after waking.
- Patient may bite its tongue after waking.

LOCAL ANESTHETIC AGENTS

- Longer-acting anesthetics, such as 0.5% bupivacaine, can provide analgesia for 6 to 10 hours.
- Lidocaine 2% without epinephrine gives a shorter duration (less than 2 hours).
- Mepivacaine 2% provides a moderate duration (4 hours).¹
- Onset time for analgesia is longer with the longer acting agents such as bupivacaine. The onset time for bupivacaine is often as long as 30 minutes, whereas the onset time for lidocaine is only a few minutes. For this reason, it is common to use a 50-50 mixture of long-acting and short-acting local anesthetic agents.
- Local anesthetic agents may be purchased in carpules, which contain 1.8 cc, or in larger multi-dose bottles.
- Local anesthetic agents enter and occupy ion channels in the nerve cell membrane, preventing depolarization and the conduction of pain impulses.

Location for Blocks

- Regional blocks are introduced at the nerve foramen and create anesthesia of the regional teeth and associated soft tissues.
- Local blocks are accomplished by injecting anesthetic into the periodontal space or gingiva surrounding the tooth. Local blocks provide anesthesia only for the limited area directly perfused by local infiltration.
- Blocks can be performed on the infraorbital, mandibular, and mental nerves.

Dosage

- Total maximum dosage of bupivacaine for cats and dogs is 2 mg/kg.³ The total dosage for lidocaine for the dog is 5 mg/kg and 1 mg/kg for the cat.
- Toxic doses are additive. If a mixture of two local anesthetic agents is being used, it is recommended the maximum dosages be reduced by 50% to prevent inadvertent overdosage.
- Bupivacaine is potentially cardiotoxic; therefore, the lowest possible dosage should be used, which should not exceed 2mg/kg as a total cumulative dosage.
- A 5-kg cat could tolerate 10 mg of bupivacaine, or a total of 2 cc (just over one carpule). Generally 0.25 cc per site is adequate.
- A 30-kg dog could tolerate 60 mg of bupivacaine. Generally 1 cc per site is adequate.

Instrumentation

- A 1.5-inch 27-gauge needle, on a dental anesthetic syringe, is designed to be used with the anesthetic carpule and works most effectively.
- Alternatively, a 1-ml syringe with a 27-gauge hypodermic needle can be used to withdraw the anesthetic from the carpule and infiltrate it into the site.
- Regional anesthetic can reduce the level of general anesthetic required.
- With practice, nerve blocks can be performed accurately and can be very efficacious.
- First the carpule is placed in the syringe (Fig. 12-1, A).
- The plunger is pressed to fix its harpoon in the carpule. Next, the needle is screwed into the syringe (Fig. 12-1, B).

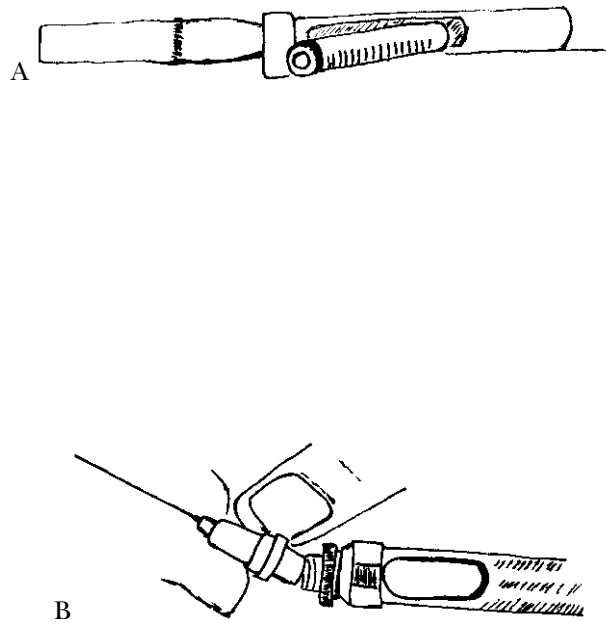


Fig. 12-1

Caution

- Always aspirate before injecting to make sure needle is not in a blood vessel.
- Calculate total dosage prior to starting injections.

Technique⁴⁻⁷**Area: Maxillary Nerve Block, Caudal**

- Also known as the *caudal infraorbital nerve block* (Fig. 12-2).

Area Blocked

- Maxillary bone.
- Maxillary molars.
- Maxillary fourth premolars.

Location

- The injection site is located where the infra-orbital nerve enters caudorostral to the maxillary foramen.
- The injection site in the dog is dorsal to the last maxillary molar at the ventral-most junction of the zygomatic bone on the maxilla.
- Advance the needle tip to the pterygopalatine fossa, and inject anesthetic adjacent to the nerve.
- This provides anesthesia to all the ipsilateral maxillary teeth.
- This block is used infrequently, because there are many large vessels, nerves, and globe located in this region.

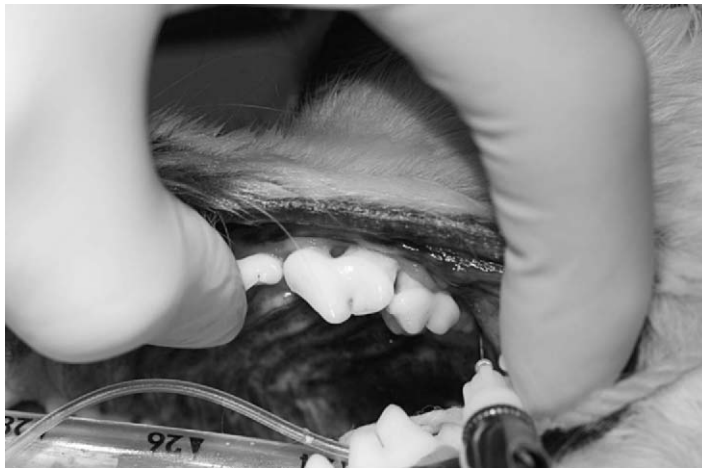

Fig. 12-2

Infraorbital Nerve Block**Area Blocked**

- Dependent on amount of anesthetic injected.
- Bone and soft tissue of the anterior maxilla.
- The infraorbital nerve block desensitizes the ipsilateral maxillary incisors, canine, first two premolars, and the soft tissues.
- Deep infiltration may block the maxillary fourth premolar (Fig. 12-3, A to C).

Location

- The injection site is located at the rostral end of the infraorbital canal.
- The infraorbital canal foramen can be palpated dorsal to the distal root of the third maxillary premolar.

Technique

- Holding the syringe parallel to the palate, advance the needle into the ventral aspect of the canal approximately 0.5 to 1.0 cm, and inject anesthetic adjacent to the nerve.
- For deep infiltration advance the needle carefully along the bottom of the canal for 1 cm. While holding pressure over the foramen with the index finger, aspirate and inject the local anesthetic.

Caution

- This may cause a transient neuropathy.

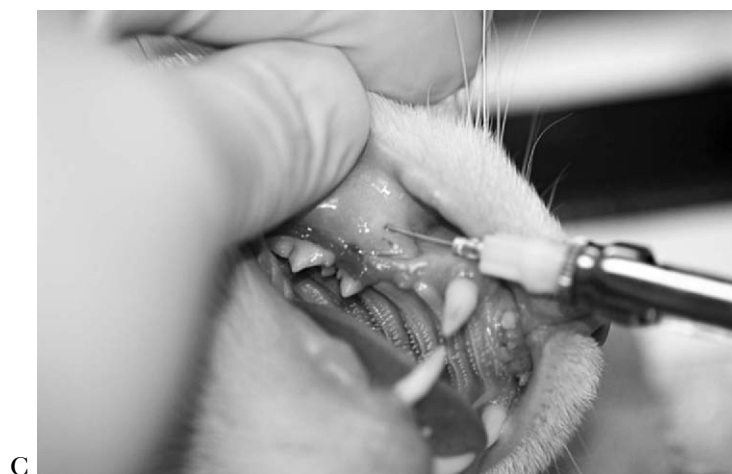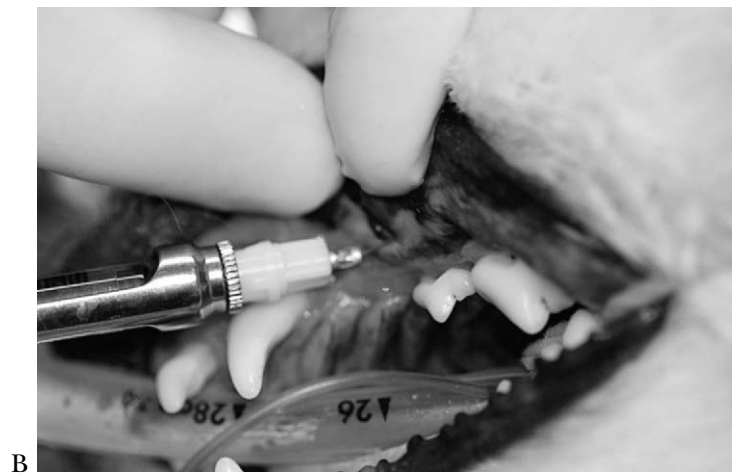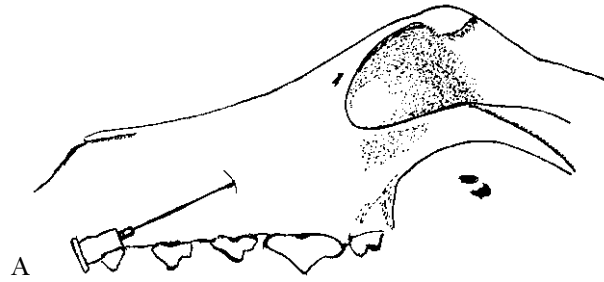


Fig. 12-3

Mandibular Alveolar Nerve Block

- A dog is shown in Fig. 12-4, *A*. A cat is shown in Fig. 12-4, *B* to *D*.
- Also known as the *inferior alveolar nerve block*.

Area Blocked

- All teeth in the mandible, including the soft tissue.

Location

- May be approached intraorally or extraorally.

Intraorally

- The mandibular foramen is palpated on the lingual surface, two thirds of the distance from the third molar, in the dog (see illustration) to the angular process of the mandible.
- In the cat, the injection site is halfway between the first molar and angular process.
- The needle is inserted intraorally on the lingual surface.

Extraorally

- The injection site is on the lingual surface of the mandible.
- Palpate the notch of the caudal ventral mandible and then palpate the mandibular foramen on the lingual surface of the mandible.
- The needle should be directed along the lingual surface of the mandible to the mandibular foramen.

Caution

- This may anesthetize the glossopharyngeal nerve (cranial nerve IX) and patient may traumatize (bite) its tongue.
- Less likely to anesthetize other structures if anesthetic delivered as close to inferior alveolar foramen as possible.

Mental Nerve Block**Area Blocked:**

- Tissues and teeth rostral to the site of injection.

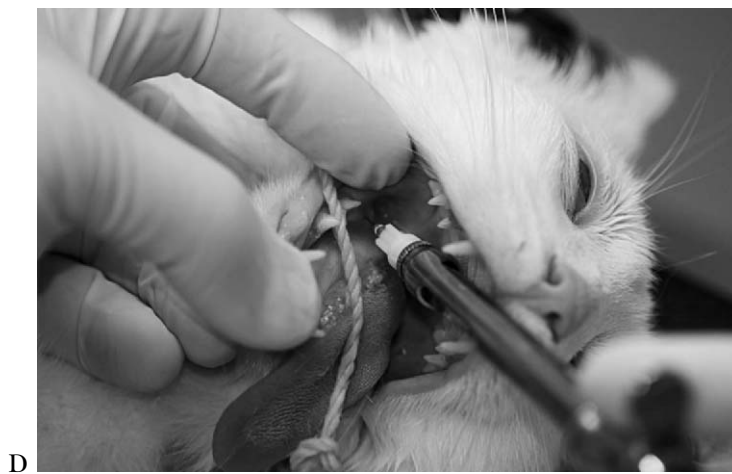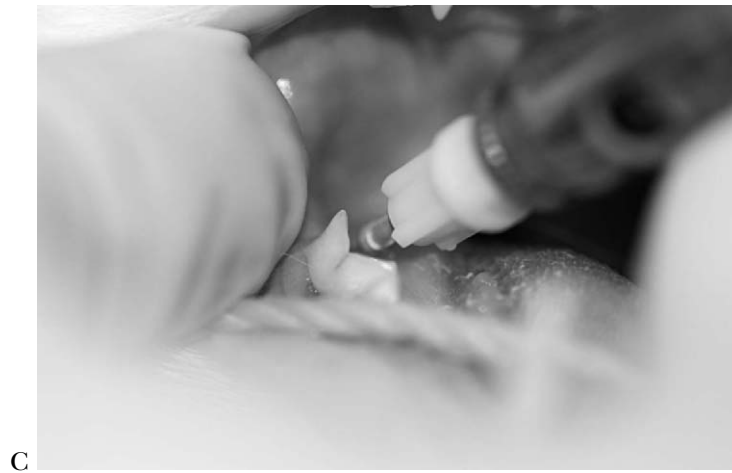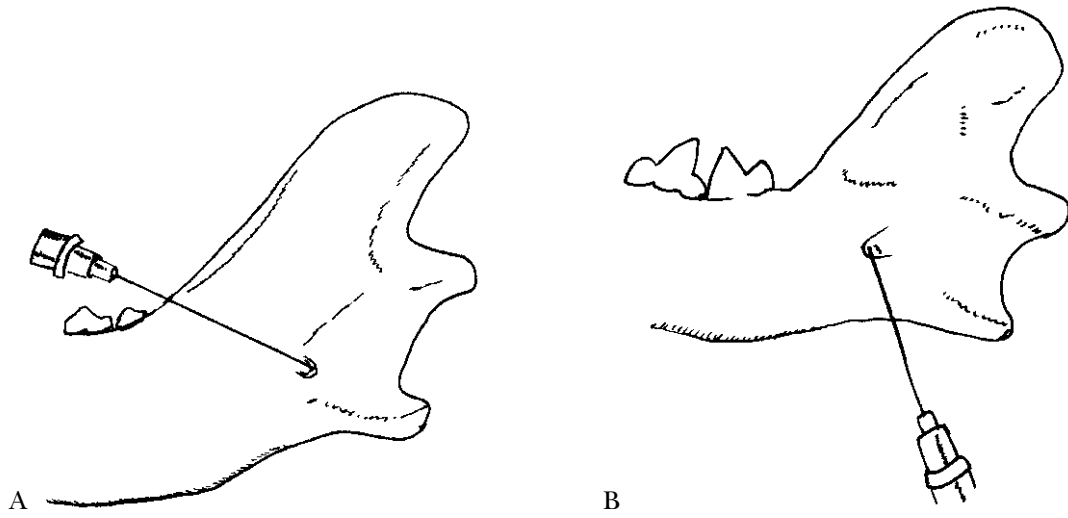


Fig. 12-4

Location

- The mental nerve block desensitizes the ipsilateral mandibular incisors, canine tooth, first two premolars, and associated soft tissues (Fig. 12-5, *A to C*).
- Use the middle mental foramen; it is the largest of the three foramina.
- It is palpated ventral to the mesial root of the second premolar.

Technique

- The needle is inserted 0.5 to 1.0 cm and the anesthetic is injected adjacent to the nerve.

CONCLUSION

- Local anesthesia, administered in conjunction with general anesthesia, will provide pain relief to the patient during dental surgery and for several hours after the procedure.
- Local anesthesia can also enhance the effect of preprocedural systemic narcotic pain relief.
- When preventing pain before its perception by the patient, subsequent surgical pain can be lessened.
- Post-surgically, medicine for pain relief should still be dispensed to ensure the patient's comfort at home.

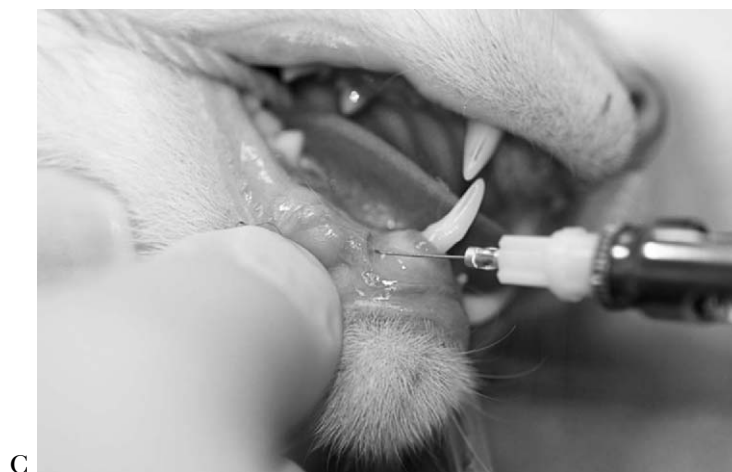

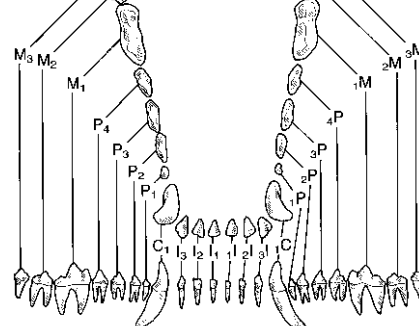
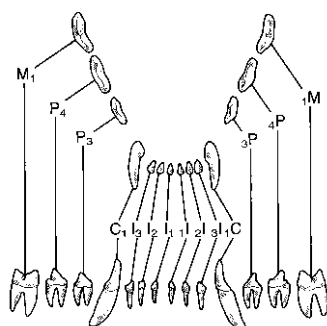
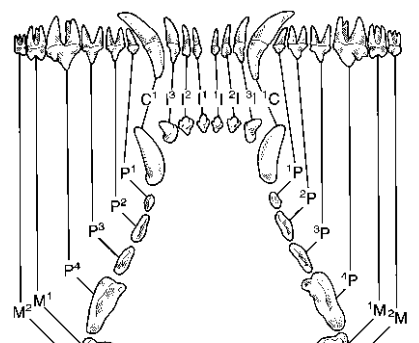
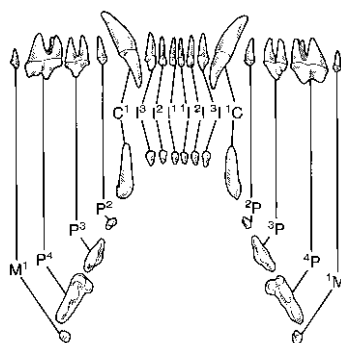
Fig. 12-5

REFERENCES

1. Lantz GC: Regional anesthesia for dentistry and oral surgery, *J Vet Dent* 20:181-186, 2003
2. Paddleford RR: *Manual of small animal anesthesia*, New York, 1988, Churchill Livingstone.
3. Pasco PJ, Ilkiw J: *Small animal anesthesia protocol sheet*, Davis, Calif, 1995, Veterinary Medical Teaching Hospital, University of California.
4. Tholen M: *Concepts in veterinary dentistry*, Philadelphia, 1984, Lea & Febiger.
5. Hustead D: Pain, analgesia: the relief of pain and suffering: a DVM's responsibility in controlling patient suffering, February 1993, Fort Dodge Animal Health.
6. Goldstein G: Regional nerve blocks offer pain relief for dental procedures: DVM best practices, *DVM Magazine*, August 2002, pp 28-30.
7. Beckman B, Legendre L: Regional nerve blocks for oral surgery in companion animals, *Compendium*, June 2002, pp 439-444.



GENERAL HEALTH SAFETY AND ERGONOMICS IN THE VETERINARY DENTAL WORKPLACE



- The purpose of this chapter is to make veterinarians and veterinary technicians aware of general work-related hazards and present practical suggestions and references for improving the health and productivity of staff in daily practice.
- Workers in the dental operatory should be protected from harm while completing their assigned tasks.
- Three federal agencies provide primary guidelines for worker safety: the Occupational Safety and Health Administration (OSHA), the National Institute for Occupational Safety and Health (NIOSH), and the Centers for Disease Control (CDC).
- All three agencies provide free or low-cost information via printed guidelines and web sites.
- OSHA requires the employer to post information about work-related hazards via a standardized poster in an area easily accessible to workers (see suggested readings at the end of this chapter).
- The areas of concern for the dental veterinary worker are physical hazards, chemicals, and biologic and blood-borne pathogens.
- A basic office safety plan will review potential for physical, chemical, and biologic hazards on a regular basis, develop specific safety protocols, and hold periodic inservice training sessions.

PHYSICAL HAZARDS

- Prevention of harm from physical hazards includes emergency protocols, radiation protection, and training in effective ergonomics.
- This chapter features specific information on the cause and prevention of common musculoskeletal disorders associated with dental workers.
- Emergency protocols include adequate exit signs, fire extinguishers, and evacuation plans that meet local fire standards.
- Physical hazards include arrangement of equipment cords, overhead lights, cabinets, and other fixtures.
- A simple “walk-through” may be used to evaluate the potential for tripping, head injuries, and the like.
- Floor surfaces should be easy to clean yet provide adequate traction.

- Supply storage planning minimizes the size and weight of objects placed above shoulder height or below knee level. For example, store larger and heavier items between knee and chest height.

CHEMICAL HAZARDS

- A significant chemical hazard involves anesthetic gases.
- Scavenging systems are used to reduce total exposure to gases.
- Monitoring badges will measure exposure to selected gases.
- Due to potential risks to the fetus, workers are responsible to promptly inform the employer of pregnancy and consult with their physician regarding specific precautions.

BIOLOGIC HAZARDS

- Biologic hazards include aerosolized fomites and the blood, mucus, and excretions of animals undergoing treatment.
- Workers may be exposed to biologic hazards through cuts and scratches, particularly at the cuticles and fingertips. The mucous membranes of the eyes, nose, and mouth also provide a portal for infection. Although veterinary personnel are exposed primarily to animal and equipment hazards, they are also susceptible to human communicable disease from coworkers and clients.
- Summary of recommended personal safety procedures in the veterinary dental setting follows.

Handwashing and Hand Care

- Frequent handwashing throughout the work day is the single most effective action to protect the worker. Handwashing will reduce greatly the potential for infection and cross-contamination. Use warm or cool water and mild antimicrobial hand soap. Nails should be kept well trimmed, and loose or torn cuticles protected until healed.
- Provide easily accessible handwashing stations. Ideally, foot or electronic controls reduce cross-contamination at the faucet handles.

Personal Protective Equipment

Gloves

General Comments

- Use high-quality, low-protein examination or surgical grade gloves to protect against open sores or infection of the nailbeds and cuticles.
- Avoid prepowdered gloves to reduce development of latex allergies.
- Nonlatex gloves (nitrile) are available.

Indications

- Protection against some, but not all, chemicals.
- Protect against biologic and blood-borne pathogens.
- Provide a sterile barrier.

Complications

- Gloves that fit too snugly across the palms and knuckles may contribute to musculoskeletal disorders.

- May not protect against all chemicals.
- May puncture, rendering them useless.

Safety Glasses

General Comments

- The routine use of safety glasses with side shields or wing shields or full-face shields mounted on headbands should be used for eye protection.
- May also provide magnification (Fig. 13-1).

Indications

- To protect the eyes from fomites, biologic debris, and broken burs.

Disadvantages

- Airborne particles may still enter eyes.
- Fogging of glasses can be relieved by making sure mask has a good fit and by using commercial defog solutions.

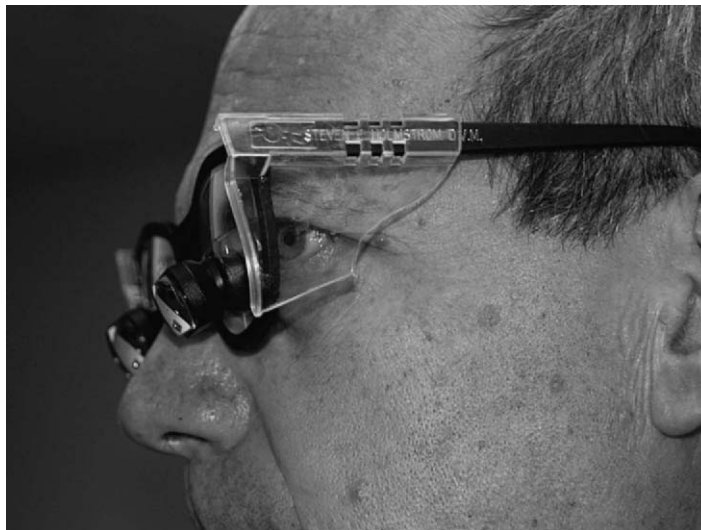

Fig. 13-1

Face Mask**General Comments**

- Surgical or other appropriate head cap and well-fitting pleated or molded face mask will protect respiratory passage and hairline.
- Surgical masks are not as effective as respirator masks (Fig. 13-2).

Indications

- To protect the mouth, nose, and lungs from fomites and biologic debris.

Technique

- Should fit well around face; leaks can render ineffective.
- A loose mask will cause fogging of glasses.

Disadvantages

- May cause eyeglass fogging.
- Requires getting used to the feeling that breathing seems restricted.

Gown**General Comments**

- A clinic jacket or smock used only in the dental operatory to reduce transfer of fomites as infective agents.
- Ideally jackets or smocks should cover the arms, neck, and necktie.

Indications

- All dental procedures.
- Sterile gowns for procedures in which sterility is necessary.

Technique

- Install hooks or storage space for gowns, jackets, and smocks in the dental department for dental-only outerwear.

Disadvantages

- Added time to change clothes.

Footwear**General Comments**

- Footwear should fit securely, have a cleanable surface, and provide a nonskid sole.
- Sandals do not give enough protection, and exposed breaks in the skin add risk of infection.

Technique

- If worker likes to wear sandals outside of work, adequate footwear should be stored at the clinic for wearing while at work.

Disadvantages

- None.

Ear Plugs**General Comments**

- Ear plugs may be necessary if the sound frequency or nature of the tasks reaches damaging decibel levels.
- Both the National Institute for Occupational Safety and Health (NIOSH) and Occupational Safety and Health Administration (OSHA) agree that impact or impulse noise should not exceed 140 dB. The two agencies do not, however, agree on the number of hours for allowable exposure (see Table 13-1).
- Dental activities that fall below the range of risking hearing injury include background dental office noise, 50 dB; air from an air/water syringe, 59 dB; laboratory handpiece, 72 dB; stone mixer or denture polisher, 74 dB.
- Dental activities that, if of sufficient continuous duration, increase the risk for significant hearing loss in some individuals include ultrasonic scaler, 80 dB; low-speed handpiece, 82 dB; sonic scaler, 84 dB; high-speed handpiece, 85 dB; model trimmer or vibrator, 87 dB; high velocity evacuation, 90 dB.

Indications

- The high frequency of dental high-speed handpieces and ultrasonic scalers may be detrimental to hearing.

TABLE 13-1 • CURRENT THRESHOLD STANDARDS FOR NOISE LEVELS

<i>Duration per day (hr)*</i>	<i>NIOSH-dBA levels</i>	<i>OSHA-dBA levels</i>
8	85	90
6	86	92
4	88	95
3	89	97
2	91	100
1.5	92	102
1	94	105
0.5	97	110
0.125	103	115

Data from the CRA Newsletter, vol 20, issue 9, Sept 2003.

* NIOSH recommends that for every 3 decibel increase in sound energy level, the maximum permitted exposure time be decreased by 50%. OSHA recommends that the maximum permitted exposure time be decreased by 50% for every 5 decibel increase in sound energy level.

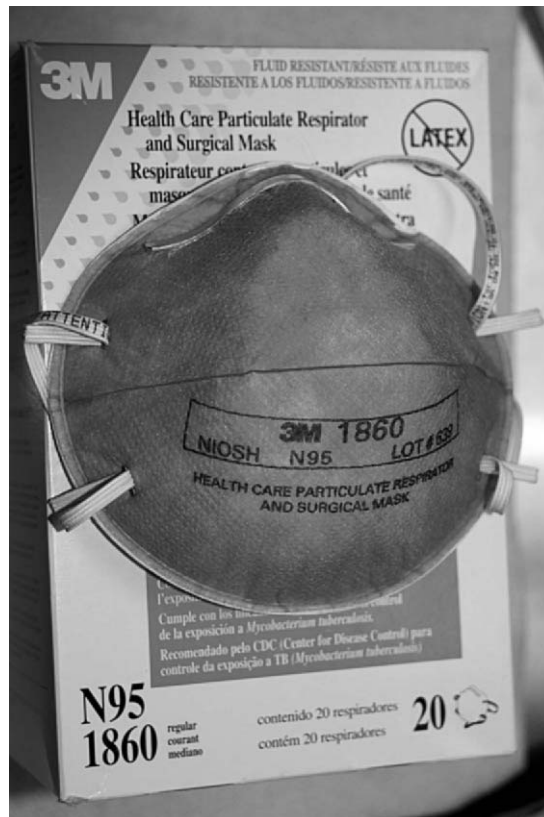


Fig. 13-2

Technique

- Ear plugs should be worn by all personnel within the known sound radius of harmful frequencies.

Disadvantages

- Permanent hearing loss from exposure to harmful sound.

Radiographic Monitoring Badges**General Comments**

- Every worker in an area where radiographic equipment is used should wear a badge to monitor exposure to x-rays.
- To be effective, the badge should be worn only by the individual named on it.
- Badges should be kept out of sunlight and away from heat sources.
- Monitoring companies can provide monthly or quarterly reports of exposure.

Indications

- Radiation protection includes a quality assurance schedule for periodic inspection (and where required, a certification stamp) of radiographic equipment.

Technique

- Training for all personnel authorized to use radiographic equipment includes personal protection procedures, office protocols for appropriate exposure settings, methods of reducing exposure to the central beam, and the process for identification of pregnancy status to the employer.

Complications

- Badges can be washed inadvertently, destroying the data.
- Loss of badge.
- Inadequate compliance wearing and submitting badges for reporting purposes.

Clinic Equipment***Eyewash Station*** (Fig. 13-3)

- Should be installed in the approximate area of potential harm.
- Hot water should be turned off at the station.

Indications

- When eye(s) are exposed to biologic or chemical irritants.

Technique

- The victim should lean over the station, preferably with the assistance of a healthy coworker, presenting the exposed eyes over the faucet. Rinse the eyes for the OSHA-indicated period, according to the nature of the eye insult.

Disadvantages

- Victim unfamiliar with the washing technique.
- Inadequate wash time.
- Wrong procedure for the eye insult.

Sharps Container**General Comments**

- Careful handling of sharps include using color-coded (usually red) rigid, puncture-resistant and leak-proof containers for disposal of used sharps (endodontic files, anesthetic needles, burs, scalpel blades, and suture needles).
- The disposal of full sharps containers is governed by the laws in force for the state or country.
- In the United States, Environmental Protection Agency (EPA) requirements dictate that the clinic is responsible for decontamination before disposal.
- Contaminated sharps are picked up and incinerated by an approved biohazard waste handler.

Indications

- Hypodermic needles.
- Files.
- Scalpel blades.
- Burs.
- Suture needles.
- Used hygiene instruments (curettes, scalers, probes).

Technique

- Recapping of needles should be avoided; place directly in sharps container.
- Do not transfer contents of sharps container.

Disadvantages

- Sharps containers are dangerous when overfilled.



Fig. 13-3

Safe Use of Chemicals and First Aid for Spills

- OSHA mandates office training that explains the safe use of potentially harmful chemicals and materials in a work setting.

Material Safety Data Sheets

- The most important resource is a well organized Material Safety Data Sheet (MSDS) file including information on safe use, management of spills, and first aid for emergency exposures.
- Manufacturers and supply houses are required to provide MSDSs for all materials they sell.
- The employer, in turn, is then responsible to provide access to training in the location and use of MSDS reference materials.
- MSDS information may also be contracted via a commercial service that includes a convenient 24-hour, 7 day per week, toll-free telephone number providing universal access to first aid and management information for every marketed chemical.
- Effective use of MSDS requires knowledge of the format and terminology it contains.
- This information must be included in office safety update sessions.
- Potentially toxic chemicals commonly found in veterinary dental practice include concentrated forms of commonly used surface disinfectants; acids; free mercury that may be present from the manipulation of dental amalgam; radiographic processing chemicals; acids, resins, and catalysts from restorative kits; and sodium hypochlorite.

ERGONOMICS

Rationale for Ergonomics in Veterinary Dental Practice

- Ergonomics is derived from two Greek words: *ergon* meaning work and *nomoi* meaning natural laws.
- The frequency of veterinary prophylactic and periodontal disease treatment procedures exposes veterinary technicians to repetitive motions which, in turn, produce repetitive stress syndrome.
- Reducing stress and maintaining the productive level of trained reliable workers is a significant benefit to the practice.

Defining Ergonomics and Cumulative Trauma Disorder

- Ergonomics is a body of knowledge about the application of human characteristics and limitations to workplace design and work techniques. Ergonomic design applies this knowledge to the design of tools, machines, equipment, and work processes. The ergonomist advocates the adjustment of work settings and tasks to human needs.
- The most common occupational hazards for the dental worker are ergonomic. Work-related musculoskeletal disorders or cumulative trauma disorders are injuries affecting the muscles, joints, nerves, and vascular blood supply systems when aggravated by work-related ergonomic hazards such as poor posture or malfunctioning equipment. Symptoms include loss of grip strength, tingling in the fingertips, numbness of hand and forearm, and sustained pain unrelieved by rest, ice, or heat.
- Cumulative trauma disorders occur as the result of tasks being repeated on a regular basis to a point of fatigue and muscular exhaustion.
- Incidence of musculoskeletal disorders may be reduced through personal factors such as posture, fitness, and effective instrumentation techniques; and engineering factors such as ergonomic design of instruments, effective use of ultrasonic devices, and design of tables and operator chairs.

Risk Factors in Veterinary Work Settings

- Neck, arm, and hand pain can be caused by poor posture, excessive pinch-grasping of hand instruments, and poorly designed or maintained workstations.
- Veterinary technicians are at higher risk of musculoskeletal injury when repetitive motions are combined with forceful movements, awkward postures, and insufficient recovery time.
- The human body was not designed to maintain the same body position or engage in repetitive motions for extended periods. Veterinary prophylaxis of animal teeth demands very controlled and fast-paced motions, while the technician maintains a hunched fixed posture for 20 to 40 minutes. This leads to cumulative trauma of the musculoskeletal system. In addition, demands of the job include awkward lifting, long

periods of standing on hard surfaces, and restraint of reluctant animal patients.

- The nature of the work environment involves high-intensity activity with detailed and sometimes delicate or difficult procedures being performed on anesthetized patients, where time is always a factor and this in itself can create a stressful situation.

Major Categories of Musculoskeletal Disorders

- Following are major musculoskeletal disorders most commonly encountered in

dentally related work activities, their anatomic locations and related symptoms. A physician should be consulted if any symptoms are noted.

Carpal Tunnel Syndrome (Fig. 13-4)

Area affected

- Median nerve in wrist and hand where the nerve passes beneath the transverse carpal ligament (*arrow*).

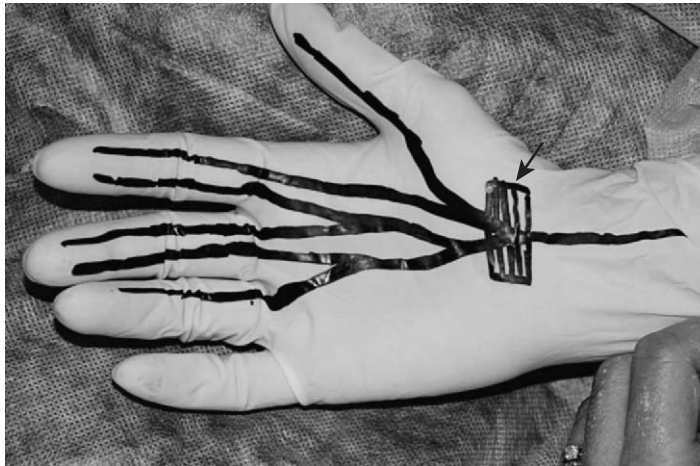


Fig. 13-4

Cause

- Repeated wrist flexion, especially with the fingers in the pinch position.
- Swelling of the tendons that line the carpal tunnel causes median nerve compression.
- The result is a median nerve neuropathy at the wrist.
- Multifactorial (Table 13-2).

Symptoms

- Tingling, pain, or numbness in the thumb, index finger, the middle finger, and half of the ring finger.
- Symptoms may occur in the back of the hand and in the palm and may be more severe during sleep. Temperature sensitivity and loss of strength may also result.

Prevention and treatment

- See Table 13-2 for comprehensive discussion of strategies.

Table 13-2 • CARPAL TUNNEL SYNDROME: DENTAL HYGIENE OCCUPATIONAL RISK FACTORS

Risk checklist

Are you scheduling more than two consecutive root planing appointments?
 Are you scheduling more than two consecutive large breed patients?
 Within an appointment, are you repeating same hand motion or posture for prolonged periods (e.g., scaling for 30-45 minutes, then doing other procedures)?
 Do you use ultrasonic or sonic scalers infrequently or not at all?

Operator posture

Are your shoulders elevated?
 Is one higher than the other?
 Are your wrists flexed or extended during scaling?

Operator-to-patient position

Are your elbows elevated more than 30 degrees?
 Is your back bent, and is your head unsupported by your spine?

Are you using a constant, pinching grasp during both exploring and working strokes?
 Are your instrument handles smooth?

What is the diameter of your instruments?
 Are your instrument handles hexagonal?
 Are the cords on your handpieces short or curly?
 Are your handpieces unbalanced?
 Are your gloves ill-fitting?

Is your operatory cold, or is there a cold air vent directed toward you?
 Are your instruments cold when you use them?
 Do you wash your hands with cold water?

Preventive strategies**Repetitiveness**

Allow sufficient time to treat the needs of the patient.
 Regulate the total number and scheduling of patients requiring hand-intensive motions.
 Alternate debridement and root planing within the same procedure.
 Vary hand-intensive activities by interspersing procedures such as radiographs, selective polishing with debridement, and root planing.
 Use very sharp instruments.
 Shorten the patient's recall interval.
 Maximize use of ultrasonic scalers.

Posture

Relax your shoulders: keep them even and parallel to the floor.
 Resist elevating elbows above 30 degrees.
 Avoid prolonged ulnar deviation.
 Reduce wrist flexion and extension: keep wrist in a neutral position with the hand and arm straight (patient height will help control this).
 Use full-arm strokes rather than wrist or finger action.

Force

Use minimal pressure in instrument grasp.
 Increase pressure with grasp only when deposits are engaged or during the early stages of root planing.
 Use instruments of adequate weight.
 Select instrument handles that are serrated or textured.

Mechanical Stresses

Choose larger diameter, round instrument handles.
 Use contra-angled instruments in various treatment areas if they help maintain neutral wrist position.
 Avoid heavy and unbalanced handpieces.
 Select contra-angled rather than right-angled prophyl angles.
 Avoid short and curled cords or retractable cords that pull on the wrist.
 Wear properly fitted gloves.

Temperature

Avoid cold drafts and air exhaust, especially on cold hands.
 Work in warm rooms or wear warm clothing.
 Use warm water to wash hands; maintain 77-degree finger temperature.
 Exercise hands for muscle warm-up and to relax muscles between patients.

Ulnar Nerve Entrapment at the Wrist: Guyon's Canal Syndrome (Fig. 13-5)

Area affected

- Ulnar nerve in the wrist and hand.

Cause

- The ulnar nerve passes under a ligament between two small wrist bones in the palm (*arrows*).
- The tunnel formed by the bones and ligaments is called *Guyon's canal*.
- The ulnar nerve supplies sensation to the little finger and half of the ring finger.

Symptoms

- Decreased hand strength.
- Numbness and tingling in the same ring and small fingers.

Prevention and treatment

- Wrist splint.
- May require surgery.

Ulnar Nerve Compression at the Elbow: Cubital Tunnel Syndrome

Area affected

- Ulnar nerve at elbow, forearm, and hands.
- The nerve runs inside of the elbow, running through a passage called the *cubital tunnel*.
- This is the same nerve that causes pain and tingling when the "funny bone" is hit.

Cause

- Repetitive motions of the lower arm.
- Leaning on the elbows for long periods.
- Sleeping with elbow bent.

Symptoms

- Tingling, pain, or numbness in the little finger, half the ring finger, and the ulnar side of the hand and forearm.
- Weakness of the hand.

Prevention and treatment

- Placing elbow on an elbow pad to minimize chronic irritation of the ulnar nerve.
- Change working habits; do not lean on elbow.
- Surgery.

Thoracic Outlet Syndrome

Area affected

- Neurovascular compression affecting shoulder, arm, and hands.

Cause

- Working with elbow above shoulder.
- Compression of arteries and nerves in the arm at the thoracic outlet.

Symptoms

- Tingling or numbness in the fingers and hands.
- Atrophy of the hand muscles.
- Weakness of the hands.
- Pale or bluish hands.
- Chronic pain or tired arm sensation.

Preparation and treatment

- Proper patient positioning.
- Proper instrument technique.
- Stretching and strengthening to improve posture, for example weight training for the back.
- Weight loss if overweight.

Raynaud Syndrome

Area affected

- Vascular compression in the hands and fingers.

Cause

- Genetic; also inflammation from improper technique.

Symptoms

- Tingling or numbness in the hands and fingers, which can lead to loss of control.
- Sensitivity to cold.
- Pale or bluish hands, especially after exposure to cold.

Preparation and treatment

- Same as for carpal tunnel syndrome.

Tenosynovitis

Area affected

- Connective tissue or sheath of any tendon overused or injured.

Cause

- Stressing the sheath.

Symptoms

- Pain, especially when the hand or arm is used.
- Inflammation or swelling may occur.

Preparation and treatment

- Alternating function.

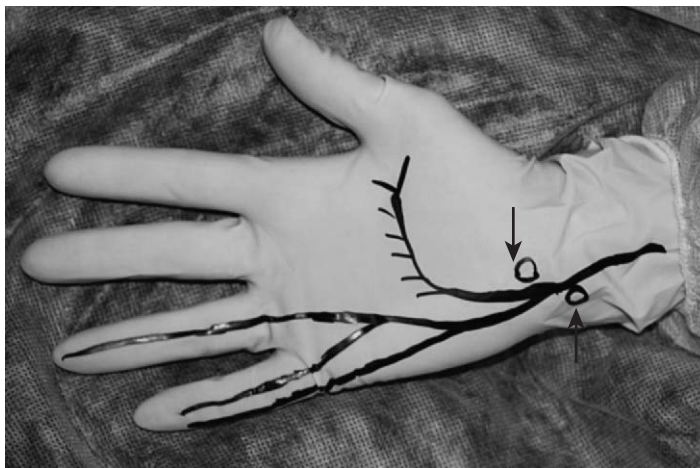

Fig. 13-5

De Quervain Disease**Area affected**

- Connective tissue at base and side of thumb.

Cause

- Wrist deviation with side-to-side motion and repetitive use of the thumb.
- Inflammation of the tendon sheaths of the two tendons that run through the tunnel on the wrist just above the thumb.

Symptoms

- Aching and weakness in thumb.
- Muscle atrophy.

Prevention and treatment

- Avoid repetitive thumb flexion in combination with wrist deviation.
- Use power grip hold instead of using the thumb, when possible.
- Wrist and thumb static splint.
- Medical options.

Stenosing Tendinitis: Trigger Finger**Area affected**

- Connective tissue in the shoulder, elbow, forearm, or fingers.

Cause

- Tendon entrapment in the hand that usually affects the thumb, middle finger, and ring finger.
- Grasping dental instruments.

Symptoms

- Painful snapping or triggering of the digit during active motion.

Preparation and treatment

- Proper technique.
- May require locking finger in flexion or extension.
- Surgery.

Rotator Cuff Tendinitis**Area affected**

- Connective tissue in the shoulder.

Cause

- Slumping shoulders.
- Lifting elbows above shoulders.

Symptoms

- Pain, often intense, or tenderness in the shoulder.
- Muscle weakness.

Prevention

- Posture.
- Technique.
- Medical treatment.

Lateral Epicondylitis: Tennis Elbow**Area affected**

- Connective tissue on the outside of the elbow.

Cause

- The wrist extensors are the muscles that pull the wrist upward.
- Some of the forearm muscles are attached by tendons to the lateral epicondyle.
- Overusing the muscles that extend the elbow and extend the wrist upward.

Symptoms

- Pain and tenderness when making a fist, gripping an object, or turning the forearms down with the elbows and wrists in extension.

Prevention

- Prevent overuse.

Medial Epicondylitis: Golfer's Elbow**Area affected**

- Connective tissue at the inside of the elbow.

Cause

- The wrist flexor muscles join one another and attach to the common flexor tendon that attaches to the medial epicondyle.
- Forceful and repetitive bending of the wrist and digits cause small ruptures of the muscles and common flexor tendon.

Symptoms

- Pain and tenderness at the inside of the elbow, radiating along the back of the forearm.

Prevention

- Frequent microbreaks (short rest periods).
- Limiting repetitive grasping and pulling.
- Increasing forearm and hand strength.

Neck and Spine Pain

Area affected

- Neck and spine.

Cause

- Improper positioning and posture (Fig. 13-6).

Symptoms

- Neck muscles cramping.
- Middle to lower back pain.
- Limited ability to turn head.

Prevention

- Proper positioning of practitioner and patient (Fig. 13-7).
- Use of magnification to reduce forward head movement.

Prevention and Reduction of Work-Related Musculoskeletal Disorders

- Effective ergonomics in the veterinary dental care setting may be divided into four categories: posture, equipment, administrative procedures, and personal factors.

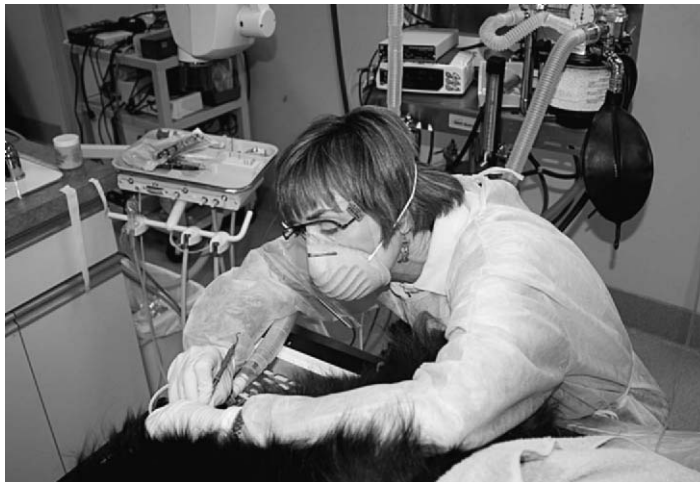

Fig. 13-6

Posture: Using Neutral Body Positioning (Fig. 13-7)

General comment

- Neutral position is an ideal position that minimizes the extension or flexion of the spine, arms, legs, neck, fingers, and other body parts. It is generally believed that the more a joint deviates from neutral, the greater the risk of injury.
- The following are neutral positions for the torso and spine, neck, back, upper arm, forearm, and hand.

Torso and Spine While Seated

Position

- Keep trunk and head erect.
- Head weight rests evenly over spine.
- Forearms and thighs are parallel to floor.
- Seat height is adjusted so that heels of feet are resting on the floor or a step. Legs are spread apart to form a tripod with the chair base.
- Avoid perching on edge of chair, wearing high heels.

Neck

Position

- Head is tilted not more than 15 degrees forward.
- Line of sight is as close to horizontal as possible.
- Avoid head tipped too far forward or tilted to one side.
- The neutral shoulder: shoulders form an even line parallel with floor.
- Avoid hunched or elevated shoulders (carrying tension in the shoulders).

Back

Position

- Leaning forward from the waist or hips not more than 20 degrees.
- Avoid leaning to the side; avoid hunched or curved back.

Upper Arm

Position

- Upper arms hang in a vertical line parallel to long axis of torso.
- Avoid holding elbows more than 20 degrees away from side of body.
- Avoid “flying wings” (elbows held away with shoulders elevated).

Forearm

Position

- Forearms parallel to floor.
- Avoid angles of less than 60 degrees between forearm and upper arm.

Hand

Position

- Wrist held with little finger side slightly lower and wrists aligned with forearm.
- Avoid:
- Hand held with little finger side higher than thumb side.
- Deviation of wrist toward the little finger (ulnar deviation).
- Hand and wrist bent up (extension) or down (flexion).

Posture

- Positioning of the veterinarian or technician is stated in relation to the treatment area and patient.
- The dental healthcare worker should use neutral positioning techniques.
- Establish seated position with hip angle at 90 degrees and elbow angle at 90 degrees when hands are in the treatment area.
- This position usually will require using an adjustable stool with adequate back support and footrest ring, due to the height and lack of adjustment of the typical veterinary treatment table.
- The dental healthcare worker should be able to face the animal treatment area with a minimum of deviation.
- The patient treatment area should be at the approximate height of the bent elbow.
- Maintain head balanced over torso, upper arms, and elbows not more than 20 degrees away from body, back against stool's back support, full weight supported on stool seat, and feet supported on floor or foot ring. Avoid excessive forward flexing of head and neck.
- Move the patient to accommodate vision for the technician rather than continuing to hunch the back or overflex neck in order to see intraoral areas.
- Do not underestimate the difficulty of changing ingrained habits of positioning and posture. It will require sustained conscious effort on the part of the technician and friendly reminders from supervisors and coworkers to retrain muscle habits.

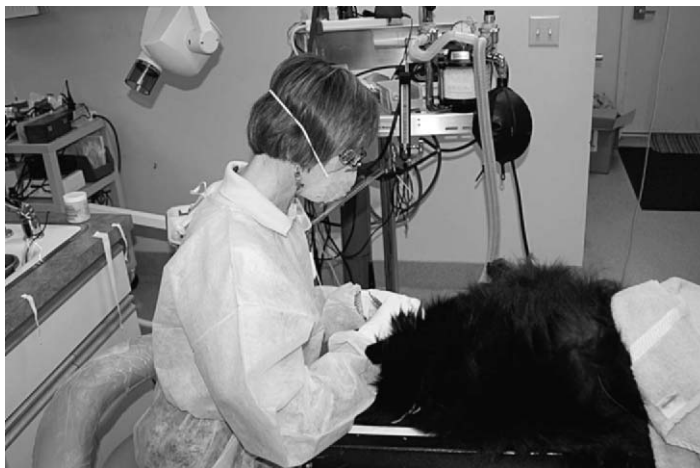

Fig. 13-7

Evaluating Workplace Equipment Risk Factors

Chairs

- Five legs for maximum stability.
- Height adjustment sufficient to allow practitioner neutral positioning of upper arms.
- Foot ring or footrest for seating used with standard-height veterinary treatment tables.
- Front edge of seat has waterfall shape with rounded front edge.
- Seat depth allows technician to make full use of stool back (usually 15 to 16 inches).
- Seat backrest is adjustable in vertical and horizontal positions and with an angle between 85 and 100 degrees to the plane of the chair seat.

Tables

- Clinic tables used as operatory work surfaces should ideally be adjustable vertically (Fig. 13-8). Alternatively, an adjustable chair and foot support should be provided.

Equipment Positioning

- Arrange equipment and controls to avoid excessive forward or sideways adjustment, not exceeding 20 inches radius from patient's head.

Handpiece Controls

- Controls for suction and water spray should be pressed easily or twisted with minimal pinching.
- Ergonomic design considerations for low-speed handpieces include swivel connections, short length, with balanced weight and straight, smooth cords.
- Curly cords contribute to considerable force against the technician's wrists and forearms.

Hand Instruments

- The primary consideration in ergonomic design for hand instruments is in the handle.
- Large-diameter (3/8-inch), size #4 or larger hollow handles.
- Many designs are now available in contoured and silicon-padded versions.
- Instruments are also available in bent-shank designs to facilitate access to posterior areas.
- Maintaining sharp instrument edges is a critical factor in reducing work-related musculoskeletal disorders.
- Sharp edges are essential to reduce excessive pinch and grasp force.
- Alternating between ultrasonic and hand instruments during the procedure helps to reduce fatigue.

Ultrasonic scalers

- Using ultrasonic scaling devices is a routine treatment modality for periodontal procedures in veterinary dental practice.
- Effective use of this procedure is likely to be the single most protective measure available to reduce musculoskeletal disorders for veterinary technicians.
- Use a very light grasp and fulcrum.
- Apply the side of the tip with light brushlike strokes.
- Avoid applying the point of the tip to the surface of the dentition.
- A variety of insert designs are available.
- The technician should have access to training in selection of inserts and safe effective application that achieves two key objectives: efficient, effective debridement of dental surfaces and minimal iatrogenic damage to soft and hard tissues.



Fig. 13-8

Administrative Factors

- Schedule periodic breaks for stretching, hydration, and personal needs. See Table 13-3 for selected exercises.
- Use job rotation to maintain alertness and reduce muscle fatigue. This also reduces potential problems if job-dedicated staff are absent due to vacations, maternity leave, and other reasons.
- Alternate difficult procedures on larger animals with shorter and less taxing procedures.
- Arrange staffing to provide sufficient assistance with anesthetic monitoring, suction, charting, and clean-up.

Table 13-3 • EXERCISES TO REDUCE OPERATOR FATIGUE AND INCREASE STRENGTH

Area of body	Purpose	Directions
Back	Stretch and strengthen lower back muscles	<ol style="list-style-type: none"> 1. Lie on the floor, pull knees up to chest, and wrap arms around knees. 2. Hold for a count of 3, release arms, resist arching back, and slowly straighten legs. 3. Perform 5 repetitions.
	Stretch out trunk muscles	<ol style="list-style-type: none"> 1. Stand with arms straight down along body. 2. Laterally flex back on one side and then the other. 3. Perform 5 repetitions.
	Increase natural flexibility of lower spine	<p><i>Extension:</i></p> <ol style="list-style-type: none"> 1. Extend back by bending backward with arms held over head for balance. 2. Hold in position for a count of 2 and straighten. 3. Perform 5 repetitions. <p><i>Flexion:</i></p> <ol style="list-style-type: none"> 1. Sit on a chair or stool, lean forward and arch back, with arms hanging toward the floor. 2. Hold in position for a count of 2 and straighten. 3. Perform 5 repetitions.
Upper back and shoulders	Stretch pectoral muscles	<ol style="list-style-type: none"> 1. Stand facing a corner of a room, approximately 2 feet from the corner. 2. Place palms of both hands on side walls in front of shoulders at shoulder height. 3. Lean toward corner, supporting your weight with your hands. 4. Hold for a count of 3, return to original position. 5. Perform 3 repetitions.
	Stretch upper back and pectoral muscles	<ol style="list-style-type: none"> 1. Clasp hands behind head (not neck). 2. Pull elbows back to squeeze shoulder blades together. 3. Hold for a count of 3, then relax. 4. Perform 3 repetitions.
	Encourage stability of upper back and shoulder muscles	<ol style="list-style-type: none"> 1. Lift shoulder blades, squeeze shoulder blades together, lower shoulders, and then relax. 2. Perform 3 repetitions.
	Relax shoulder muscles	<ol style="list-style-type: none"> 1. Roll shoulders backward, or in a clockwise direction, in circles, for 5 circles.
Neck	Stretch scalene muscles	<p>These stretches should be completed on one side and then reversed to stretch the muscles on the other side of the neck.</p> <ol style="list-style-type: none"> 1. Sit on a chair or stool, with the lower back supported. 2. Grasp the edge of the chair with the right hand. 3. Place head toward the left shoulder, then slightly rotate head to the right. 4. Pull head toward the left shoulder, then rotate head slightly to the right. 5. Hold for a count of 6, and repeat 3 times.
	Stretch upper trapezius muscles	<ol style="list-style-type: none"> 1. Sit on a chair or stool, with the lower back supported. 2. Grasp the edge of the chair with the right hand. 3. Facing forward, turn head halfway to the left. 4. With the left hand on the back of head, pull head forward and down in a diagonal direction. 5. Hold for a count of 6, and repeat 3 times.

Table 13–3 • EXERCISES TO REDUCE OPERATOR FATIGUE AND INCREASE STRENGTH—*cont'd*

Area of body	Purpose	Directions
Neck	Stretch levator scapulae (maintains erect head and neck posture)	<ol style="list-style-type: none"> 1. Sit on a chair or stool, with the lower back supported. 2. Place right hand on left knee. 3. Drop chin to chest. 4. Drop left ear to left shoulder, rotate head slightly to the left. 5. Hold for a count of 6, and repeat 3 times.
Wrist	Encourage gliding of radial, median, and ulnar nerves.	<p>Stretches should be completed with one arm and then repeated with the opposite arm.</p> <ol style="list-style-type: none"> 1. Extend right arm, elbow straight, palm up, out in front of the body. 2. Flex wrist so the palm of the hand is facing the head. 3. Extend the wrist by dropping fingers toward the floor. 4. Bend and drop the elbow to the side of the body. 5. Perform 3 repetitions. <p>Or:</p> <ol style="list-style-type: none"> 1. Extend the arm, elbow straight, palm up, out to the side of the body. 2. Rotate the arm backward. 3. Stretch the neck by leaning the left ear toward the left shoulder. 4. Perform 3 repetitions. <p>Or:</p> <ol style="list-style-type: none"> 1. Flex wrist, bend elbow, and raise hand so that fingers are against the forehead. 2. Extend wrist so that wrist is against the forehead, and slowly straighten elbow until the arm is extended in front of the body. 3. Perform 3 repetitions. <p>Or:</p> <ol style="list-style-type: none"> 1. Raise arm to the side, flex wrist, and raise hand to form a 90-degree angle at the elbow. 2. Rotate arm backward. 3. Stretch the neck by leaning the left ear toward the left shoulder. 4. Perform 3 repetitions.

Personal Factors: Additional Preventive Strategies for the Veterinary Dental Care Worker

- Everyone has unique predisposing personal factors that will affect their susceptibility to musculoskeletal disorders and their individual “hardiness” on the job.
- Key factors include individual overall health, effective immune system, chronic disease such as diabetes, individual physique, personal fitness (especially upper body strength in the case of females), and past injuries from sports and auto accidents.
- Hobbies intended for relaxation may contribute to physical susceptibility to musculoskeletal disorders. Particularly bad hobbies include extensive use of computers, biking, needlework and, ironically (considering the recommendations for fitness), weight lifting. Sleep habits may contribute to musculoskeletal disorders, if the individual routinely sleeps with bent wrists.
- Each person has a responsibility to maximize his or her individual health and fitness for both work and overall enjoyment of daily living. Modifiable factors include nutrition, adequate consumption of plain water, weight control, general fitness, and a lifestyle that allows for daily relaxation and stress relief.

Strategies for Prevention of Back Pain

- In several published surveys of dental workers, when symptoms from all body areas are tabulated, low back disorders outrank all upper body complaints.
- It is common to observe a positive response of 60% to 70% for persistent back pain among dentists and other dental workers.
- Risk factors include past injuries, overweight and poor abdominal muscle tone, and static working posture that places the trunk leaning forward over 20 degrees for two thirds of the treatment hour.
- Unsafe lifting also contributes to both acute and chronic back pain.
- Equipment placement is essential to reduce back stress.
- If the treatment table cannot be adjusted, it is essential to have an easily adjusted operator stool or chair with a footrest.
- The treatment table surface must have sufficient knee-hole space to allow the operator

to maintain a distance of 16 to 20 inches of working distance between the clinician’s face and the patient’s oral cavity.

- Operator chairs should provide lumbar back support adjustable to the correct height for the operator.
- Effective posture habits include sitting as straight as possible; avoid sideways deviation over 15 degrees.
- Alternate sitting with standing. While standing, place one foot on a low footrest (about 6 inches high) to relieve pressure on lumbar spine.
- Keep equipment within 20 inches’ reach, or use an assistant.
- Consider visual magnification systems (dental scopes or loupes). Low-power magnification of 2× to 3× provides a versatile depth of field.
- Microbreaks and microstretches at 15- to 20-minute intervals. Stretch and relax the affected body parts for 10 seconds.
- Lift safely, starting with planning the lift. Place legs apart at shoulder width; use a slight bend at the knees; tighten stomach muscles; face the load, keep yourself aligned (do not twist sideways to grab heavy loads); hold load close to body; use leg muscles to provide the major lifting force. Store heavy items between knee and shoulder height.

DESIGNING THE DENTAL OPERATORY

General Comments

- Every operatory will vary, depending on the room size available, number of anticipated procedures, types of procedures performed, and the preferences of the individual practitioner.
- It is vital to have a clear vision of your goal and to know or have access to knowledgeable advice regarding your remodel.
- Particular attention should be given to the requirements of the procedure table, stools, dental radiograph unit, handpiece delivery system(s), ultrasonic scalers, lighting, storage of instruments and materials, and other equipment.
- The more equipment that is mounted on the ceiling or wall or (off the floor), the less crowded the operatory area will be.

Procedure Table

- Tables can be adjustable and movable (Fig. 13-9, no. 1), or they can be fixed (Fig. 13-10, no. 1, Fig. 13-11, no. 1). The working level of a fixed table can be designed for either sitting or standing. Sitting is more ergonomic. If fixed, a footrest may be advisable for individual use so that the healthcare provider's thigh is horizontal, thus relieving lower back stress. The height of adjustable tables can be changed to provide reduced fatigue for various operators performing a sequence of different procedures.
- Quick disconnects and electrical receptacles mounted on the table base may help free the operator of some line "spaghetti."
- A raised edge around the table top will prevent fluid run-off, from either the patient or the handpiece.
- NOTE. If multiple tables are planned, if at all possible design the room to have them at least 60 inches apart to allow for multiple people working at each table and to provide access by an additional person to the counter or sink between the tables. Less available space does not mean your plan won't work, but it will present a reduction in efficiency.

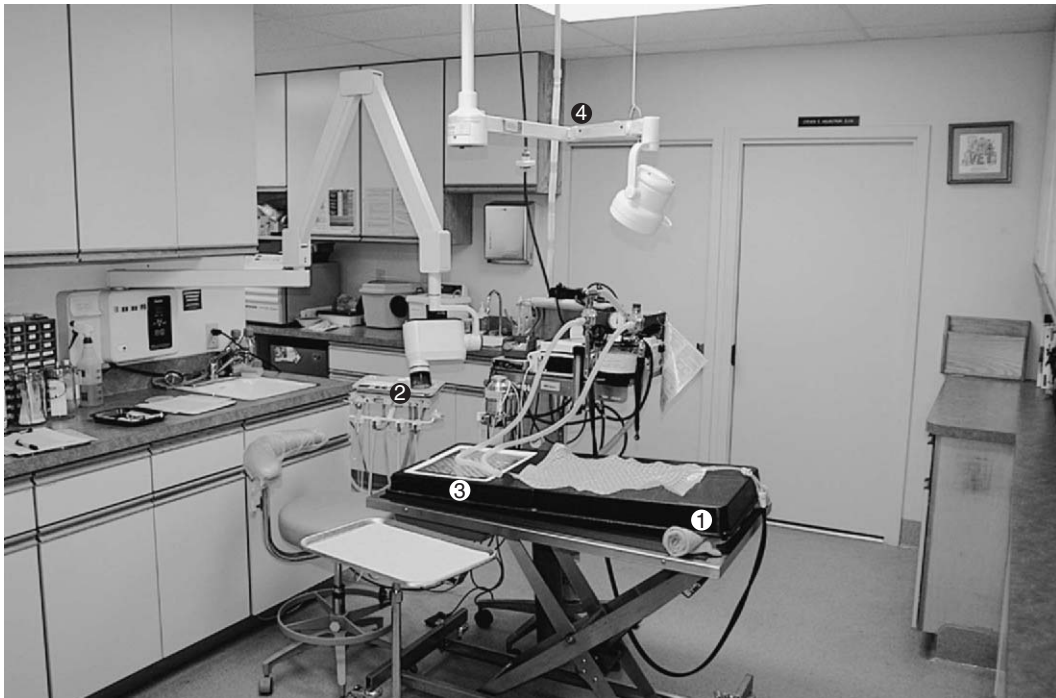

Fig. 13-9

Chairs/Stools

- Should be adjustable.
- Ergonomically, should have a back rest, the operator sitting deep into the seat.
- Ideally should have a foot plate to reduce lower back strain.

Delivery System/Handpiece Station

General Comment

- For purposes of this chapter, we discuss an air-driven system.

Mobile Units/Carts

Advantages

- Can be used in more than one place.
- Many are self-contained with a mounted silent air compressor.

Disadvantages

- May crowd the space around the operating area.
- Cords and tubes get in the way.
- Need large enough compressor/compressed air storage unit for anticipated needs.

Fixed Units

May be attached to a table, mounted on the wall or on a pole, or be an over-the-patient system (Figs. 13-9 to 13-11, no. 2).

Advantages

- Less in the way (smaller).
- Can have remote air compressor (less noise).
- Remote air compressors can serve multiple stations.

Disadvantage

- Usually a more expensive installation.

Dental Radiograph Unit

Portable (Floor Model)

Advantage

- Sometimes fits best in the existing operator(-ies).

Disadvantages

- They are not quite as stable as the wall-mounted unit.
- Often more expensive because of the cost of the base.

Wall-Mounted

General considerations

- Should be situated so that personnel can stand 6 feet away. May need second wall switch.
- Decide on the voltage to power the unit; 110v is common, whereas 220v requires additional wiring.
- Decide on an AC or DC radiographic unit. The DC systems cost more but may have less soft radiation due to the AC (alternating current) 60Hz waveform and have smaller tube heads. The DC systems take the voltage from the wall source and convert it to both high voltage and high frequency before it goes to the tube head. Since the tube head has no transformer in it, it is lighter and more compact.

Advantages

- Very stable.
- Less expensive than mobile unit.

Disadvantages

- May need to buy optional extension arm to achieve desired reach to the end of a single table or two tables.
- If more than two tables are used, more than one fixed radiograph unit will most likely be necessary.

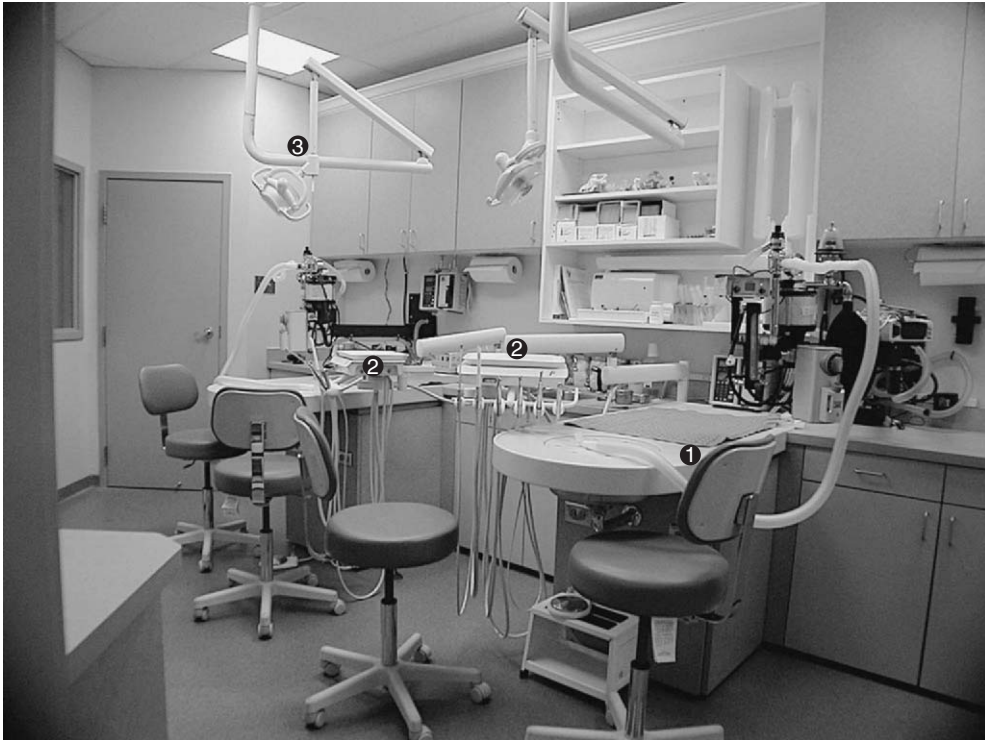

Fig. 13-10

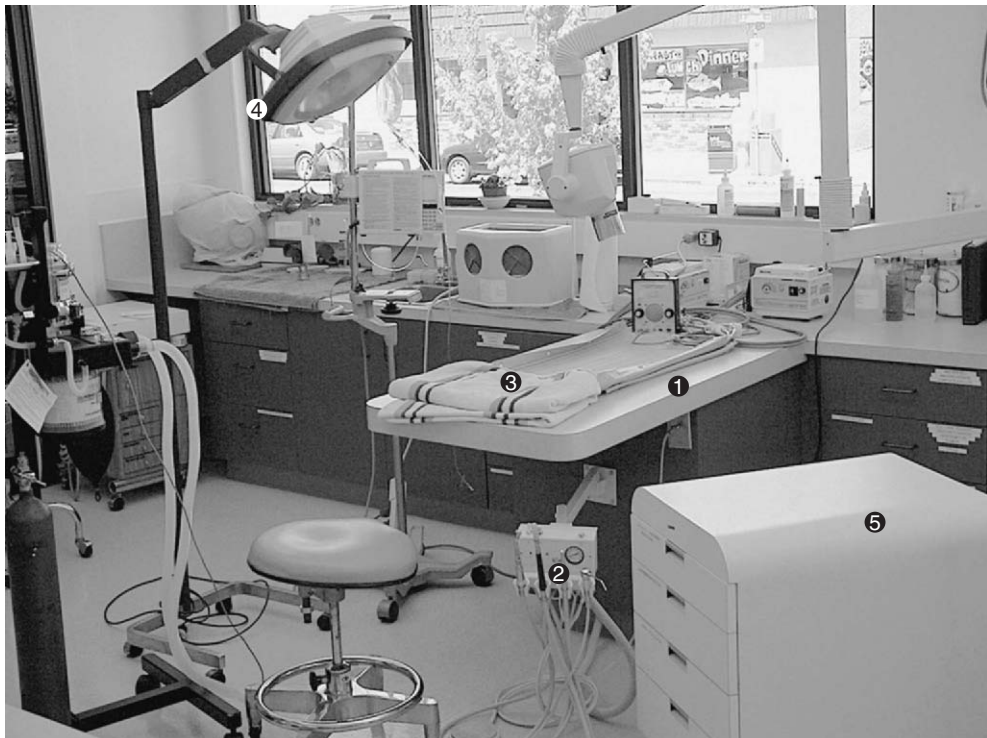

Fig. 13-11

- The wall needs to be reinforced to account for the unit's cantilevered weight as it is extended across the table.

Wet Sinks

General Considerations

- Intended use.
- Dental procedures generate water. This water must be removed by towels, portable sinks, or fixed sinks.
- Towels are an economical solution; however they must be changed often, and the patient will be wetter than with other methods (Fig. 13-11, no. 3) Wet towels may result in hypothermia if not frequently changed.
- Portable sinks (Fig. 13-9, no. 3) can be placed on top of the table. They are removed for cleaning and draining.
- Fixed sinks are usually associated with a fixed table. They require additional expense for installation but generally require less cleanup.
- At least one company (dbl.7, Windsor, Colo.) makes an adjustable table with a fixed sink, the best of both worlds. It is expensive and requires more space than some clinics have allotted for the dental operator; 48-inch and a 60-inch tables are available.
- General-use fixed sinks in a treatment room should be accessible to all who need to use them. Personnel at the dental table should not be inconvenienced nor interfere with its use.
- Dental-only fixed sinks should have a plaster trap mounted beneath the pea trap to prevent plumbing problems from impression materials, laboratory model stone, burs, files, and other debris going down the drain. Some method should be planned for cleaning the dental table or its individual sink if it is located at the patient's "head-end." A recoilable spray hose works well.
- If a table without drainage is used, arrangements need to be made for a water-collecting tray or using absorbent towels beneath the patient's head. It is best if the head is not resting in bacteria-laden debris.

Visualization of the Treatment Field

General Considerations

- The goal is visibility of the teeth, mouth, and deeper into the oral pharynx during procedures.

Ceiling Fixtures

- Consider daylight florescent panels, either 2' × 4' or 2' × 2', depending on the room.
- A 9-foot ceiling is less confining and provides cleaner air, especially in small rooms. It also works better for ceiling-mounted procedure lights.

Ceiling and Wall-Mounted Procedure Lights

NOTE: Some are supplied with more than one intensity setting. (Fig. 13-9, no. 4, Fig. 13-10, no. 3).

Advantage

- Less in the way.

Mobile Floor Procedure Lights (Fig. 13-11, no. 4)

Advantages

- Can be used elsewhere.
- Can be used to augment fixed procedure light illumination.

Disadvantages

- Cords and the lamp itself add to the clutter around the table.

Headband-Mounted Lights and Operating Glasses-Mounted Lights

Advantage

- Provide excellent visualization of the oral cavity.

- Provide lighting, even with low-speed handpieces, or when incisions and suturing are being performed.

Disadvantages

- Some are heavy and uncomfortable.
- Most require battery packs to be worn or must be attached to an electrical or fiberoptic source.

Fiberoptic Handpieces

Advantage

- Provide excellent visualization wherever the handpiece is used.

Disadvantages

- Only on high-speed handpieces.
- May require being attached to electrical source.

Anesthesia Units

General Considerations

- F circuits and Bain circuits are constructed with two concentric tubes. The inner tube is the supply tube and the outer tube is the expiration tube.

Advantages

- The expiration warms the gas supply, reducing the amount used.
- One less hose added to the equipment around the patient's mouth.
- Space for mounting monitors, infusion pumps, and intravenous fluids should be planned.

Mobile Carts

Advantages

- May travel with the patient, if moved.
- Can be used elsewhere in the hospital.

Disadvantage

- More clutter in the area of the procedure.

Wall-Mounted

Advantage

- Less in the way than mobile units.

Disadvantages

- Advisable to have cantilevered extension arm to reduce length of patient delivery and expiration hose.
- A typical anesthetic vaporizer setup, without monitors, weighs approximately 60 lbs. Its weight is increased every foot that it is cantilevered toward the patient's head; therefore, at the end of a typical 3-foot arm the unit's stress on the wall-mount is 180 ft-lbs.
- A stout device and wall reinforcement is required.

Under-the-Table Mounts

Advantage

- Less in the way than a mobile unit.

Disadvantage

- May reduce operator(s) leg space.

Cabinets and Storage

General Considerations

- Again, a vision of the level of service to be provided now and in the future is important.
- Always plan for more counter and storage space than you think you will need.
- Mobile storage/procedure carts can be used to augment fixed storage areas and provide supplies closer to the procedure (Fig. 13-11, arrow 5).
- Enough counter space for:
Computer, monitor, and telephone, as desired.
Sharpening station.

Anesthetic monitors.
 Cold trays.
 Chairside or automatic processor, or laptop computer for digital radiography.
 Radiographic viewbox.
 Ultrasonic scalers.
 Procedure equipment, instruments, and supplies.
 Any dental or microscopic laboratory equipment or procedures contemplated.
 Working space for mixing cements and other materials.
 Laying the dental record for charting.
 Emergency drugs.

- Enough cabinet storage space for:
 Easy access for procedures.
 Long-term storage to have all dental supplies centrally located.
 Convenient refrigerator space for supplies that benefit from such storage.

CONCLUSION

- There are well-documented risks and hazards related to veterinary dental practice.
- There are effective and established methods of reducing or preventing work-related injuries that are cost effective.
- Ergonomics and safety contribute to the general productivity and positive environment of the veterinary clinic.
- Numerous resources are available through published and internet sources to meet the legal requirements for staff training and accident prevention.
- Although veterinary care presents many potential physical, biologic, and chemical hazards, there are effective methods to promote a safe and satisfying work environment.

SUGGESTED READINGS

- CRA (Clinical Research Associates) Newsletter: Clinicians' guide to dental products and techniques, vol 27, issue 9, Sept 2003.
- Holmstrom SE, Frost P, Eisner ER: Ergonomics and general health safety in the dental workplace. In *Veterinary dental techniques*, ed 2, Philadelphia, 1998, WB Saunders.
- Liskiewicz ST, Kerschbaum WE: Cumulative trauma disorders: an ergonomic approach for prevention, *J Dent Hyg* 71:162, 1997.
- Michaiaik-Turcotte C: Ergonomic strategies for the dental hygienist. I, *J Pract Hyg* March/April, 2000.
- Murphy DC, editor: *Ergonomics and the dental care worker*, Washington, DC, 1998, American Public Health Association, pp 2005-2605.
- Nield-Gehrig J: *Periodontal instrumentation for the practitioner*, Baltimore, 1999, Lippincott, Williams & Wilkins.
- Stitik TP, Conte M, Foye P, Schoen D: An analysis of cumulative trauma disorders in dental hygienists, *J Pract Hyg* 9:19, 2000.

WEBSITES (accessed November 17, 2003)

- A Patient's Guide to Carpal Tunnel Syndrome at <http://www.sechrest.com/mmg/cts/ctsintro.html>
- American Back Society at <http://www.americanbacksoc.org>
- Hand Surgery Center at <http://www.handsurgeon.com/cubital.html>
- Organization for Safety and Asepsis Procedures (OSAP) at www.osap.org
- Occupational Safety and Health Administration (OSHA) at <http://www.osha.gov>
- Society of Ergonomics, links page at <http://www.ergonomics.org.uk>
- RDH—the national Magazine for Dental Hygiene Professionals, monthly column: The Comfort Zone by Anne Guignon, RDH, MPH. Past columns may be accessed through her web site: www.ergosonics.com.
- SmartPractice fitted gloves at www.smartpractice.com



MANUFACTURERS AND SOURCES OF DENTAL MATERIALS

3M ESPE Dental Products Division

Bldg. 260-28-09
3M Center
St. Paul, MN 55144
(800) 634-2249; (651) 733-1110
FAX: (800) 782-0956
www.3mespe.com
Products: Many dental products

3M Unitek Corp.

2724 S. Peck Rd.
Monrovia, CA 91016
(800) 423-4588; (800) 634-6300
FAX: (800) 328-2360
www.3m.com/unitek
Products: Orthodontic supplies

Abbott Animal Health

1401 N. Sheridan Rd. Bldg. A1
North Chicago, IL 60064-6316
(888) 299-7416
FAX: (847) 938-0659
www.abbott.com
Products: Hemabloc

Addison Biological Laboratory, Inc.

507 N. Cleveland Ave.
Fayette, MO 65248
(800) 331-2530; (660) 248-2215
FAX: (660) 248-2554
www.addisonlabs.com
Products: Home dental care products, MaxiGuard Gel, OraZn

Almore International, Inc.

PO Box 25214
Portland, OR 97298
(800) 547-1511; (503) 643-6633
FAX: (503) 643-9748
www.almore.com
Products: Dental products, clip-on loupes, fracture finders

Arista Surgical Supply, Inc.

67 Lexington Ave.
New York, NY 10010
(800) 223-1984; (212) 679-3694
FAX: (212) 696-9046
www.aristasurgical.com
Products: Dental and surgical instruments

Aseptico, Inc.

8333 216th St. SE
Woodinville, WA 98072
(800) 426-5913; (360) 487-3157
FAX: (360) 668-8722

www.aseptico.com

Products: Dental supplies and equipment

Astra/Zeneca Pharmaceutical Products, Inc.

50 Otis St.
Westborough, MA 01581
(800) 225-6333; (508) 366-1100
FAX: (508) 366-7406
www.astrazeneca.com
Products: Surgical face masks, pharmaceuticals

AVLS

3838 N. 63rd St.
Lincoln, NE 68507
(800) 444-3634; (800) 733-2857
FAX: (402) 466-3501
Products: Client education aids, staff clinical education training, in-house publication services

Bioplant, Inc.

20 N. Main St.
South Norwalk, CT 06854
(800) 432-4487; (203) 899-0466
FAX: (203) 899-0278
www.bioplanthtr.com
Products: Bioplant HTR implant materials

Bisco Dental Products

1100 W. Irving Park Rd.
Schaumburg, IL 60193
(800) 247-3368; (847) 534-6000
FAX: (800) 959-9550
www.bisco.com
Products: Bonding, restorative, and composite materials; curing lights; endodontic instruments and supplies; operating instruments and accessories

Bosworth Co.

7227 North Hamlin Avenue
Skokie IL 60076-3999
(800) 323-4352; (847) 676-3400
FAX: (847) 679-2080
www.bosworth.com
Products: Cements and endodontic sealants

Brasseler USA, Inc.

1 Brasseler Blvd.
Savannah, GA 31419-9598
(800) 841-4522; (912) 925-8525
FAX: (912) 921-7568
www.brasselerusa.com
Products: Burs, files, diamonds, instruments

Buffalo Dental Manufacturing Co.

99 Lafayette Dr.
Syosset, NY 11791

(800) 828-0203; (516) 496-7200

FAX: (516) 496-7751

www.buffalodental.com

Products: Orthodontic bowls, knives, spatulas, vibrators, bench engines, vacuum formers, burs, handpieces

Burns Veterinary Supply

Nationwide Office

1900 Diplomat Dr.

Farmers Branch, TX 75234

(800) 922-8767; (972) 620-9941

FAX: (972) 620-1071

www.burnsvet.com

Products: Veterinary distributor; dental products and equipment

Butler Co.

5600 Blazer Parkway

Dublin, OH 43017

(800) 848-5983; (614) 761-9095

FAX: (614) 761-9096

www.wabutler.com

Products: Complete veterinary supply distributor; dental products and equipment

Cameron-Miller, Inc.

3949 S. Racine Ave.

Chicago, IL 60609

(800) 621-0142; (773) 523-6360

FAX: (773) 523-9495

Products: Electrosurgery equipment

Carolina Biologicals

2700 Yourk Road

Burlington, NC 27215

(800) 334-5551

FAX: (800) 222-7112

www.carolina.com

Products: Catalog of numerous medical teaching materials, including animal skulls and dental teaching models

C.D.M.V. Centre Dist. Med. Vet.

2999 Ave. Choquette

St. Hyacinthe

Quebec, CANADA J2S 6H5

(800) 668-2368; (450) 771-2368

FAX: (450) 773-4370

Products: Complete veterinary supply distributor; dental products and equipment

Centerpulse Dental (Calcitek)

1900 Aston Ave.

Carlsbad, CA 92008

(800) 854-7019; (760) 929-4300

FAX: (888) 225-2483

www.calcitek.com; www.centerpulse.com

Products: Dental implants

Centrix, Inc.

770 River Rd.

Shelton, CT 06484

(800) 235-5862; (203) 929-5582

FAX: (203) 929-6804

www.centrixdental.com

Products: Centrix syringe, bonding agents, impression materials, curing lights

Charles Brungart, Inc. (CBI)

3625 N. Andrews Ave.

Oakland Park, FL 33309

(800) 654-5705; (954) 561-8597

FAX: (954) 563-1124

Products: Electric motor-driven handpieces, nitrogen air-driven dental equipment (NITAIR), air scalers, ultrasonic scalers, dental instrument design and manufacture

Cislak Manufacturing, Inc.

1866 Johns Dr.

Glenview, IL 60025

(800) 239-2904; (847) 729-2904

FAX: (847) 729-2447

www.cislak.com

Products: Hand instruments, feline elevator kit, sharpening aids, full-service dental supplier

CK Dental Specialties, Inc.

1407 N. Batavia, Suite 110

Orange, CA 92867

(800) 675-2537; (714) 639-6990

FAX: (714) 639-6991

Products: Disposable products, surgical supplies, endodontic instruments and supplies, operating instruments and accessories, ultrasonic equipment

Colgate Oral Pharmaceuticals

One Colgate Way

Canton, MA 02021

(800) 225-3756; (617) 821-2880

FAX: (617) 828-7330

www.colgate.com

Products: Viadent mouthwash and gingival flush, Gel-Kam stannous fluoride gel

Coltene/Whaledent

235 Ascot Parkway

Cuyahoga Falls, OH 44223

(800) 221-3046; (330) 916-8800

FAX: (330) 916-7077

www.coltenewhaledent.com

Products: Many dental products, Successfil, Hygenic products

Columbia Dentoform Corporation

34-24 Hunters Point Avenue
Long Island City, NY 11101
(800) 688-0662; (718) 482-1569
FAX: (718) 482-1585
www.columbiadentoform.com
Products: Teaching models

Confi-Dental Products Co.

416 S. Taylor Ave.
Louisville, CO 80027
(800) 383-5158; (303) 665-7535
FAX: (303) 666-4320
www.confidental.com
Products: Glass ionomers and composite restorative materials

Cosmedent, Inc.

401 N. Michigan Ave., suite 2500
Chicago, IL 60611
(800) 621-6729; (312) 644-9586
FAX: (312) 644-9752
www.cosmedent.com
Products: Bonding agents, composites, hybrids, instruments, polishing discs, polishing strips, cups, points, polishing pastes

Cottrell, Ltd.

5450 Joliet St.
Denver, CO 80239-2003
(800) 843-3343; (303) 799-9401
FAX: (303) 799-9408
www.gocertol.com
Products: Dental disinfectants and sterile packs

Danville Engineering

2021 Omega Rd.
San Ramon, CA 94583
(800) 827-7940; (925) 838-7940
FAX: (925) 838-0944
www.danvilleengineering.com
Products: Etcher and dust box

Darby Dental Supply Co., Inc.

865 Merick Avenue
Westbury, NY 11590
(800) 448-7323; (516) 683-1800
FAX: (800) 239-3272
www.darbydental.com
Products: Complete mail order dental line (also available through Burns Veterinary Supply, owned by Darby)

dbl.7

PO Box 696
Windsor, CO 80550
(800) 939-6287
FAX: (970) 667-4467
www.dbl7.com
Products: Variable height portable tables

Del Monte Pet Products

PO Box 80
Pittsburgh, PA 15230-0080
(800) 252-7022
FAX: (412) 222-4123
www.heinzpet.com; www.delmonte.com
Products: Pet foods, chew treats

Den-Mat Corp.

2727 Skyway Dr.
Santa Maria, CA 93455
(800) 433-6628; (805) 922-8491
FAX: (805) 922-6933
www.denmat.com
Products: Restorative products, bonding agents, composites, glass ionomers, curing lights, impression materials

Dentalaire

17165 Newhope St., Suite J
Fountain Valley, CA 92708
(800) 866-6881; (714) 540-9969
FAX: (714) 540-9947
Products: Air compressors, portable delivery systems, complete dental supplies; handpiece repair

Dental Enterprises

795 S. Jason St.
Denver, CO 80223
(800) 466-1466; (303) 777-6717
FAX: (303) 777-6726
Products: Complete line of new and used dental equipment

Denticator International, Inc. (See Young Dental Manufacturing, LLC)

Dentsply Caulk

38 W. Clarke Ave.
Milford, DE 19963
(800) 532-2855; (302) 422-4511
FAX: (302) 422-3480
www.caulk.com
Products: Restoratives, impression materials

Dentsply Friadent CeraMed

12860 W. Cedar Dr., Suite 110
Lakewood, CO 80228

(800) 426-7836
 FAX: (303) 989-5669
www.dentsply.com
Products: Implants and grafting

Dentsply Gendex Division

901 W. Oakton St.
 Des Plaines, IL 60018
 (800) 800-2888; (847) 640-4800
 FAX: (847) 640-6165
www.gendexxray.com
Products: Dental radiograph machines and processors, intraoral cameras

Dentsply Maillefer

5100 E. Skelly Dr., Suite 300
 Tulsa, OK 74135
 (800) 924-7393; (918) 493-6598
 FAX: (800) 924-7389
www.maillefer.com
Products: Endodontic hand files, gutta-percha, burs, supplies

Dentsply Professional

1301 Smile Way
 York, PA 17404-0807
 (800) 989-8826
 FAX: (717) 767-8252
www.dentsply.com
Products: Ultrasonic scalers, preventive handpieces and burs

Dentsply/Rinn Division

1212 Abbott Dr.
 Elgin, IL 60123-1819
 (800) 323-0970; (847) 742-1115
 FAX: (847) 742-1122
www.rinncorp.com
Products: Radiographic supplies

Dentsply Tulsa Dental Products

5001 E. 68th Street, Suite 300
 Tulsa, OK 74136
 (800) 662-1202; (918) 493-6598
 FAX: (918) 493-6599
www.tulsadental.com
Products: Rotary endodontic instruments and supplies

DermaPet

8909 Iverleigh Ct.
 Potomac, MD 20854
 (800) 755-4738; (301) 983-8387
 FAX: (301) 365-0191
www.dermapet.com
Products: Oral home care products, Dentacetic Tooth Gel and Wipes

Designs for Vision, Inc.

710 Koehler Avenue
 Ronkonkoma, NY 11779
 (800) 345-4009; (631) 585-3300
 FAX: (631) 585-3404
www.designsforvision.com
Products: Magnifying operative telescopes; branch offices nationally

Dr. Shipp's Dental Laboratory

6910 N. Camino Martin #120
 Tucson, AZ 85741
 (800) 442-0107; (520) 579-8722
 FAX: (520) 844-1811
www.drshipp.com
Products: Dental models, full-service dental supplies

Eastman Kodak Co. Dental Division

343 State St.
 Rochester, NY 14650-1122
 (800) 933-8031; (716) 724-5631
 FAX: (585) 724-3384
www.kodak.com/go/dental
Products: Intraoral and panoramic radiographic film and supplies, digital camera

Easy Tray, Inc. (See Kerr Corp.)

Products: Custom trays

Ellman International, Inc.

1135 Railroad Ave.
 Hewlett, NY 11557
 (800) 835-5355; (516) 569-1482
 FAX: (516) 569-0054
www.ellman.com
Products: Radiosurgical instruments, nylon and metal splint materials, apex locator, handpieces

Elsevier (W.B. Saunders Co.)

170 S. Independence Mall West 300E, Suite 300
 Philadelphia, PA 19106
 (800) 523-1649; (215) 238-7832
 FAX: (215) 238-8483
Products: Dental publications

Engler Engineering Corporation

1099 East 47th Street
 Hialeah, FL 33013
 (800) 445-8581; (305) 688-8581
 FAX: (305) 685-7671
www.engler-engineering.com
Products: ultrasonic scalers

Ethicon, Inc.

425 Hoes Lane
 PO Box 6800

Piscataway, NJ 08855
(877) 384-4266; (800) 255-2500
FAX: (732) 562-2212
www.ethicon.com
Products: Suture, surgical hemostat

Fort Dodge Animal Health
800 Fifth St. NW
Fort Dodge, IA 50501
(800) 685-5656; (515) 955-4600
FAX: (800) 846-8626
www.wyeth.com
Products: Nolvasan antimicrobial solution, Torbugesic SA, Torbutrol, Etogesic

GAC International, Inc.
185 Oval Drive
Islandia, NY 11749
(800) 645-5530; (631) 582-5700
FAX: (631) 582-5704
www.gacintl.com
Products: orthodontic supplies; national sales staff

G.C. America Inc.—Fuji Products
3737 W. 127th St.
Alsip, IL 60603
(800) 323-7063; (708) 597-0900
FAX: (800) 323-7063
www.gcamerica.com
Products: Dental cements, restorative materials, impression materials

George Taub Products
277 New York Ave.
Jersey City, NJ 07307
(800) 828-2634; (201) 798-5353
FAX: (201) 659-7186
Products: Dental products

Gingi-Pak
4820 Calle Alto
PO Box 240
Camarillo, CA 93011-0240
(800) 437-1514; (805) 484-1051
FAX: (805) 484-5076
www.gingi-pak.com
Products: Gingival packing cord, instruments, impression materials

Harpers Leather Goods, Inc.
6901 W. 65th St.
Bedford Park, IL 60638
(888) 542-7737; (708) 496-0399
FAX: (708) 496-3032
www.harperpet.com

Products: Rawhide chew toys (H.M.P. Rawhide Dental Maintenance System)

Harry J. Bosworth
7227 Hamlin Ave.
Skokie, IL 60076
(847) 679-3400
FAX: (847) 679-2080
www.bosworth.com
Products: Super EBA, impression materials

Henry Schein, Inc.
135 Duryea Rd.
Melville, NY 11747
(800) 520-2702; (631) 843-5500
FAX: (631) 843-5665
www.henryschein.com
Products: Complete supply of veterinary and dental products

Heraeus Kulzer, Inc.
99 Business Park Dr.
Armonk, NY 10504
(800) 343-5336; (914) 273-8600
FAX: (914) 273-5211
www.heraeus-kulzer-us.com
Products: Bonding agents, cements, composite resin products, impression materials

High Q Dental
6302 East Aster Dr.
Scottsdale, AZ 85254
(800) 775-3433; (480) 905-0614
FAX: (480) 905-0794
www.highqdental.com
Products: Magnification glasses, lights

Hills Pet Nutrition, Inc.
400 S.W. Eighth Ave.
Topeka, KS 66603
(800) 548-8387; (785) 354-8523
FAX: (785) 368-5523
www.hillspet.com
Products: Dog and cat food beneficial to dental hygiene

Hu-Friedy Manufacturing Co., Inc.
3232 N. Rockwell St.
Chicago, IL 60618
(800) 483-7433; (773) 975-6100
FAX: (773) 975-1683
www.hu-friedy.com
Products: Scalers, curettes, probes, dental instruments, endodontic instruments and supplies

The Iams Co.

7250 Poe Ave.
Dayton, OH 45414
(800) 535-8387 Veterinary line; (800)
525-4267 Customer service
www.iams.com
Products: Pet foods with Dental Defense
System

IDEXX Laboratories

One IDEXX Dr.
Westbrook, ME 04092
(800) 551-0998; (207) 856-0300
FAX: (207) 856-0625
www.idexx.com
Products: Laboratory equipment

iM3, Inc.

12606 N.E. 95th St., Suite C-150
Vancouver, WA 98683
(800) 664-6348; (360) 254-2981
FAX: (360) 254-2940
Products: Air-driven dental system

Interplak/Lanmark Group

527 Industrial Way, W
Eatontown, NJ 07724
(800) 633-6363; (732) 389-4500
FAX: (732) 389-4998
www.interplak.com
Products: Rotoplus

Interpore Cross International

181 Technology Drive
Irving, CA 92618-2402
(800) 722-4489; (949) 453-3200
FAX: (949) 453-3225
www.interpore.com
Products: Synthetic bone graft materials
(formerly Interpore 200, now Pro-osteon
200)

Ivoclar Vivadent, Inc.

175 Pineview Dr.
Amherst, NY 14228
(800) 533-6825; (716) 691-0010
FAX: (716) 691-2285
www.ivoclarvivadent.us.com
Products: Restorative materials and other
dental products

J. Morita USA, Inc.

9 Mason
Irvine, CA 92618
(888) 566-7482; (949) 581-9600
FAX: (949) 581-8811
www.jmoritausa.com

Products: Composite resins, dental adhesives,
restorative materials, radiograph machines,
video imaging system

Jansen Pharmaceuticals

1125 Trenton-Harbourt Rd.
PO Box 200
Titusville, NJ 08560
(800) 526-7736; (609) 730-2000
FAX: (609) 730-2461
www.duragesic.com/
Products: Fentanyl patch (Duragesic)

Jeneric/Pentron Clinical Technologies, LLC

53 N. Plains Industrial Rd.
Wallingford, CT 06492
(800) 551-0283; (203) 265-7397
www.jeneric.com
Products: Dental materials, composites,
bonding agents

Johnson and Johnson Oral Health Products

199 Grandview Road
Skillman, NJ 08558-9418
(800) 224-6513; (908) 874-2915
FAX: (908) 874-2546
rcitren@pcus.jnj.com
Products: Fluoride and other oral health
products

Jorgensen Laboratories, Inc.

1450 N. Van Buren Ave.
Loveland, CO 80538
(800) 525-5614; (970) 669-2500
FAX: (970) 663-5042
www.jorvet.com
Products: Dental instruments

Journal of Dental Research

American Association of Dental Research
1619 Duke Street
Alexandria, VA 22314
(703) 748-0066
FAX: (703) 548-1883
www.dentalresearch.org
Product: dental journal

**KBA Veterinary and Animal Health
Solutions**

12013 N.E. 99th St., Suite 1670
Vancouver, WA 98682
(626) 852-9742
Products: Barrier sealant, ProVSEAL

Kensey Nash (THM Biomedical, Inc.)

55 E. Uwchlan Ave.
Exton, PA 19341

(800) 524-1984; (610) 524-0188
 FAX: (610) 524-0265
www.kenseynash.com
Products: Surgical dressing material, bioresorbable barrier membrane, polylactic acid granules

Kerr Corp.
 1717 West Collins
 Orange, CA 92867
 (800) 537-7123; (714) 516-7400
 FAX: (714) 516-7635
www.kerrdental.com
Products: Composites, impression materials, amalgam, laboratory products, endodontic instruments

Kilgore International, Inc.
 36 W. Pearl St.
 Coldwater, MI 49036
 (800) 892-9999; (517) 279-9000
 FAX: (517) 278-2956
www.kilgoreinternational.com
Products: Educational models

Kong Company
 16191-D Table Mountain Parkway
 Golden, CO 80403-1641
 (303) 216-2626
www.kongcompany.com
Products: Rubber chew toys

Kuraray America, Inc.
 101 E. 52nd St., 26th Floor
 New York, NY 10022
 (800) 879-1676; (212) 986-2230
 FAX: (212) 867-3543
www.kurarayamerica.com
Products: Bonding agents, cements, restorative materials

Lang Dental Manufacturing Co., Inc.
 175 Messner Dr.
 PO Box 969
 Wheeling, IL 60090
 (800) 222-5264 (LANG); (847) 215-6622
 FAX: (847) 215-6678
www.langdental.com
Products: Acrylics

Lares Research, Inc.
 295 Lockheed Ave.
 Chico, CA 95973
 (800) 347-3289; (530) 345-1767
 FAX: (530) 345-1870
www.laresdental.com
Products: Handpieces, lasers

Lee Pharmaceuticals
 1434 Santa Anita Ave.
 South El Monte, CA 91733
 (800) 950-5337; (626) 442-3141
 FAX: (626) 443-5161
www.leepharmaceuticals.com
Products: Restoratives and other dental materials

Lifelearn
 MacNabb House
 University of Guelph
 Ontario N1G 2W1
 (800) 375-7994
 FAX: (519) 767-1101
www.lifelearn.com
Products: Audiovisual dental educational materials

Lightspeed Endodontics, Inc.
 403 E. Ramsey, Suite 205
 San Antonio, TX 78216
 (800) 817-3636; (210) 495-4942
 FAX: (210) 495-4945
www.lightspeedusa.com
Products: Apex locators, endodontic instruments and supplies, handpieces

Lippincott Williams & Wilkins
 530 Walnut St.
 Philadelphia, PA 19106-3621
 (215) 521-8300
 FAX: (215) 521-8902
www.lww.com
Products: Dental texts

Macan Engineering & Manufacturing Co.
 1564 N. Damen Ave.
 Chicago, IL 60622
 (773) 772-2000
 FAX: (773) 772-2003
Products: Electrosurgery equipment

Masel Enterprises
 2701 Bartram Rd.
 Bristol, PA 19007-6892
 (800) 423-8227; (215) 785-1600
 FAX: (215) 785-1680
www.maselortho.com
Products: Orthodontic instruments, materials, wire-splinting products

Matrix Medical, Inc.
 145 Mid County Dr.
 Orchard Park, NY 14127
 (800) 847-1000; (716) 662-6650
 FAX: (716) 662-8440

www.matrixmedical.com

Products: Dental compressors, anesthesia, emergency care products

Medidenta International, Inc.

39-23 62nd St.

Woodside, NY 11377

(800) 221-0750; (718) 672-4670

FAX: (718) 565-6208

www.medidenta.com

Products: Endodontic instruments, handpieces

Microcopy

3120 Moon Station Rd.

Atlanta, GA 30144

(800) 235-1863; (770) 425-5715

FAX: (770) 423-4996

www.neodiamond.com

Products: X-ray developer, portable darkrooms

Miltex Instrument Co., Inc.

700 Hicksville Rd.

Bethpage, NY 11714

(800) 645-8000; (516) 349-0001

FAX: (866) 854-8400

www.miltex.com

Products: Dental and surgical instruments, endodontic instruments, pulp testers, other supplies

MinXray, Inc.

3611 Commercial Ave.

Northbrook, IL 60062

(800) 221-2245; (847) 564-0323

FAX: (847) 564-9040

www.minxray.com

Products: Portable radiographic equipment

Mirage Dental Systems/Chameleon Dental Products

200 N. 6th St.

Kansas City, KS 66101

(800) 366-0001; (913) 281-5552

FAX: (913) 621-7012

www.miragecdp.com

Products: Bonding agents, composite resin products

Mizzy, Inc.

616 Hollywood Ave.

Cherry Hill, NJ 08002

(800) 333-3131

FAX: (609) 663-0381

Products: Cements (Flecks Zinc Phosphate Cement)

Moyco Union Broach Thompson Dental Products (See Miltex Instrument Co., Inc.)

Products: Apex locators, endodontic instruments and supplies, dental instruments

Nephron Dental Supply

2919 S. Alaska St.

Tacoma, WA 98409

(800) 426-3603; (253) 383-1002

FAX: (253) 383-2751

www.nephrondental.com

Products: Hand instruments and dental products

Nestle-Purina Pet Care

Checkerboard Square

St. Louis, MO 63164

(800) 222-8387; (314) 982-1000

FAX: 314-982-4274

Products: Pet food, chew products, Chew-eez

Nutramax Laboratories, Inc.

2208 Lakeside Blvd.

Edgewood, MD 21040

(800) 925-5187; (410) 776-4000

FAX: (410) 776-4009

www.nutramaxlabs.com

Products: Consil, a synthetic bone graft material; Cosequin

Nylabone Products

PO Box 427

Neptune, NJ 07754

(800) 631-2188; (732) 988-8400

FAX: (732) 988-5466

www.nylabone.com

Products: Home-care chewing aids

Obtura Spartan

1663 Fenton Business Park Court

Fenton, MO 63026

(800) 344-1321; (636) 343-8733

FAX: (636) 343-5794

www.obtura.com

Products: Warm gutta-percha equipment, ultrasonic equipment

Odonto-Wave

1136 Stuart St., Suite 4207

Fort Collins, CO 80525

(800) 368-5776

FAX: (888) 368-4787

www.odonto-wave.com

Products: Ferrite rod ultrasonic scaler, electrosurgical equipment

OMNI Oral Pharmaceuticals

1500 North Florida Mango Rd., Suite 1
West Palm Beach, FL 33409
(800) 445-3386; (561) 689-1140
FAX: (561) 689-1159

www.omnipharma.com

Products: Fluoride gels, chlorhexidine rinse, prophyl angles

Orascopic Research/Kerr Sybron Dental Specialties

3225 Deming Way
Middleton, WI 53562
(800) 369-3698; (608) 831-2555
FAX: (608) 831-2004

www.orascopic.com

Products: BodyGuard Seating System (loupes, lights, stools), zeon illuminator

Ormco Corp.

1717 W. Collins Ave.
Orange, CA 92867
(800) 854-1741; (714) 516-7400
FAX: (800) 317-6012

www.ormco.com

Products: Orthodontic supplies

Osada, Inc.

8436 W. Third St., Suite 695
Los Angeles, CA 90048
(800) 426-7232; (323) 651-0711
FAX: (323) 651-4691

www.osada.com

Products: Dental supplies and equipment

OSHA

D. C. Dept. of Employment Services
950 77 P Street NE
Washington, DC 20002
(202) 576-6339

FAX: (202) 576-7579

Product: Govern federal occupational safety standards

Oxyfresh Worldwide, Inc.

1301 West Lakewood Drive
Coeur d'Alene, ID 83814
(800) 333-7374; (208) 292-1200
FAX: (208) 292-1400

www.oxyfreshww.com

Products: Home-care products

Parkell, Inc.

155 Schmitt Blvd.
Farmingdale, NY 11735
(800) 243-7446; (631) 249-1134
FAX: (631) 249-1242

www.parkell.com

Products: Impression materials, bonding materials, electrosurgical units, ultrasonic scalers

Pascal Co., Inc.

2929 N.E. Northrup Way
Bellevue, WA 98009
(800) 426-8051; (425) 827-4694
FAX: (425) 827-6893

www.pascaldental.com

Products: Dental products

Patterson Dental Supply, Inc.

1031 Mendota Heights Rd.
St. Paul, MN 55120
(800) 328-5536; (615) 686-1600
FAX: (615) 686-9331

www.pattersondental.com

Products: Dental supplies

PCVET

31 South 2nd Avenue
Highland Park, NJ 08904
(877) 872-8391
FAX: (732) 247-0121

www.pcvetusa.com

Products: veterinary dental computer software

Pearson Dental Supply

13161 Telfair Ave.
Sylmar, CA 91342
(800) 535-4535; (818) 362-2600
FAX: (818) 833-7700

www.pearson-dental.com

Products: Vibrators, amalgamators, dental materials, equipment, supplies

Pelton & Crane

11727 Fruehauf Dr.
Charlotte, NC 28273
(800) 659-6560; (704) 588-2126
FAX: (800) 659-7255

www.pelton.net

Products: Chairs, lights, stools, cabinetry

Pfizer Animal Health

812 Springdale Dr.
Exton, PA 19341
(800) 733-5500
www.pfizer.com

Products: Clavamox (antibiotic), Antirobe (antibiotic), Doxirope gel (periosteal)
(Gelfoam is supplied by the Pharmacia Division of Pfizer)

Precision Ceramics Dental Laboratory

9591 Central Ave.
 Montclair, CA 91763
 (800) 223-6322
Products: Full-service dental
 laboratory

Premier Dental Products Company

1710 Romano Dr.
 PO Box 4500
 Plymouth Meeting, PA 19462
 (888) 773-6872; (610) 239-6000
 FAX: (610) 239-6171
 www.premusa.com
Products: Restoratives, cements, dental
 supplies

Pro-Dentec

267 East Main
 Batesville, AR 72501
 (800) 228-5595; (870) 698-2300
 FAX: (870) 793-5554
 www.prodentec.com
Products: World Health Organization Sensor
 Probe

Pro Vet/American Vet

2010 Ackerman Rd.
 San Antonio, TX 78219
 (800) 872-3867; (210) 661-9500
 FAX: (800) 441-4412
 www.provet.com
Products: Pharmaceuticals, equipment

Pulpdent Corp.

80 Oakland St.
 Watertown, MA 02471
 (800) 343-4342; (617) 926-6666
 FAX: (617) 926-6262
 www.pulpdent.com
Products: Dental products

Quintessence Publishing Co., Inc.

551 N. Kimberly Dr.
 Carol Stream, IL 60188-1881
 (800) 621-0387; (630) 682-3223
 FAX: (630) 682-3288
 www.quintpub.com
Products: Human dental publication

Ribbond, Inc.

1402 3rd Ave., Suite 1030
 Seattle, WA 98101-2118
 (800) 624-4554; (206) 340-8870
 FAX: (206) 382-9354
 www.ribbonbond.com
Products: Splinting materials

Richmond Dental Co.

1100 Hawthorne Lane
 Charlotte, NC 28231-9912
 (800) 277-0377; (704) 376-0380
 FAX: (704) 342-1892
 www.barnhardt.net
Products: Cotton pellets and products

Rocky Mountain Orthodontics

650 W. Colfax Ave.
 Denver, CO 80204
 (800) 525-6375; (303) 592-8200
 FAX: (303) 592-8209
 www.rmortho.com
Products: Orthodontic supplies

Roth International Ltd.

669 W. Ohio St.
 Chicago, IL 60610
 (800) 445-0572; (312) 733-1478
 FAX: (312) 733-7398
 www.rothendo.com
Products: Endodontic sealers and irrigants

Rx Honing Machine Corp.

1301 E. Fifth St.
 Mishawaka, IN 46544
 (800) 346-6464; (574) 259-1606
 FAX: (574) 259-9163
 www.business.michiana.org/rxhoning
 Sharpening equipment

SS White/Burs, Inc.

1145 Towbin Ave.
 Lakewood, NJ 08701
 (800) 535-2877; (732) 905-1100
 FAX: (732) 905-0987
 www.sswwhiteburs.com
Products: Burs

Saber Dental Studios

803 W. College Ave.
 Waukesha, WI 53186
 (800) 365-3210; (262) 542-5100
 FAX: (262) 542-1717
 www.saberdentalstudio.com
Products: Full-service dental laboratory chromium
 cobalt metal crowns, expansion screw devices

Satelec, Inc., USA

130 Gaither Drive, Suite 100
 Mount Laurel, NJ 08054
 (800) 289-6367; (856) 222-9988
 FAX: (856) 222-4726
 www.satelecusa.com
Products: Air Max air polisher, apex locator,
 ultrasonic scalers

Schick Technologies

30-00 47th Avenue, 5th Floor
Long Island City, NY 11101
(888) 472-4425; (718) 937-5765
FAX: (718) 937-5962
www.schicktech.com

Sensor Devices, Inc.

407 Pilot Court, Suite 400A
Waukesha, WI 53187
(414) 524-1000
FAX: (414) 524-1009
Products: Diagnostic monitors

Septodont, Inc. (Confi-Dental)

245 C Quigley Blvd.
New Castle, DE 19720
(800) 872-8305; (302) 328-1102
FAX: (302) 328-5653
www.septodontusa.com
Products: Local anesthetics, cements, endodontic instruments and supplies

Shofu Dental Corp.

1225 Stone Dr.
San Marcos, CA 94069
(800) 827-4638; (760) 736-3277
FAX: (760) 736-3276
www.shofu.com
Products: Burs, cements, finishing discs

Shor-Line, Schoer Manufacturing Co.

511 Osage Ave.
Kansas City, KS 66105
(800) 444-1579; (913) 281-1500
FAX: (913) 281-5339
www.shor-line.com
Products: Scalers, compressors, tables

Sirona USA, Inc.

1200 A Westinghouse Blvd.
Charlotte, NC 28273
(800) 659-5977; (704) 587-0453
FAX: (704) 587-9394
www.sirona.de
Products: Radiographic machines and accessories, operatory chairs

S & M Nu Tec, LLC

1501 Burlington, Suite 201
Kansas City, MO 64116
(877) 468-5695
FAX: (816) 221-8928
www.kissablepets.com
Products: Dental health treat, Greenies

Sontec Instruments

7248 South Tucson Way
Englewood, CO 80112
(800) 821-7496; (303) 790-9411
FAX: (303) 792-2606
www.sontecinstruments.com
Products: Hand instruments

Spectrum Surgical Instruments Corp.

4575 Hudson Dr.
Stow, OH 44224
(800) 444-5644
FAX: (330) 686-4555
www.spectrum surgical.com
Products: Dental instrument packs, dental instruments

Star Dental Products

1816 Colonial Village Lane
Lancaster, PA 17601
(866) 383-4636, press 2; (610) 725-8004
FAX: (610) 725-9894
www.dentalez.com
Products: Titan-S sonic scaler, handpieces

Suburban Surgical Co., Inc.

275 Twelfth St.
Wheeling, IL 60090
(800) 323-7366; (708) 537-9320
www.suburbansurgical.com
Products: Compressors, handpieces, tables

Sullivan-Schein Dental

135 Duryea Rd.
Melville, NY 11747
(800) 472-4346; (800) 372-4346; (516) 843-5500
FAX: (516) 843-5696
www.henryschein.com
Products: Full line of dental instruments, supplies, equipment

Sultan Chemists, Inc.

85 W. Forest Ave.
Englewood, NJ 07631
(800) 637-8582; (201) 871-1232
FAX: (201) 871-0321
www.sultanchemists.com
Products: Pharmaceuticals and endodontic sealants

Summit Hill Laboratories

Tinton Falls Business Center
One Sheila Dr.
Tinton Falls, NJ 07724

(800) 922-0722; (732) 933-0800
 FAX: (732) 933-0055
 E-mail: summithilllab@aol.com
Products: Scalers, electrosurgery units, anesthetic machines, diode laser, portable dental units

Surgitel/General Scientific Corp.
 77 Enterprise Dr.
 Ann Arbor, MI 48103
 (734) 996-9200
 FAX: (734) 662-0520
www.surgitel.com
Products: Magnification loupes and light systems

Sybron Endo/Analytic Technology Corp.
 15233 N.E. 90th St.
 Redmond, WA 98052
 (800) 428-2808; (425) 883-2445
 FAX: (425) 882-3128
www.sybronendo.com
Products: Touch 'N Heat, System B, apex locator, other dental products

Tanaka Dental
 5135 Golf Rd.
 Skokie, IL 60077
 (800) 325-5266; (847) 679-1610
 FAX: (847) 674-5761
Products: Dental laboratory products, shading kits

Temrex Corp.
 PO Box 426
 Selmer, TN 38375
 (800) 645-1226; (901) 645-4415
 FAX: (901) 645-8394
Products: Cements, bleaching etchants, filling materials, composite resin products, impression materials

TVC Laboratories
 6709 E. 38th Ave.
 Denver, CO 80207
 (800) 898-7144; (303) 320-0324
 FAX: (303) 320-0334
Products: Crowns and orthodontic appliances

Twist2it, Inc.
 39-23A 62nd St.
 Flushing, NY 11377
 (877) 776-7497; (718) 672-4234
 FAX: (718) 396-4500
www.twist2it.com
Products: Prophylaxis angles and kits

Ultradent Products, Inc.
 505 W. 10200 South
 South Jordan, UT 84095
 (800) 552-5512; (801) 572-4200
 FAX: (801) 572-0600
www.ultradent.com
Products: Tissue management products, impression trays, precomposite materials, sealant materials, gingival packing cord, hemostatic solution

Ultrasonic Services, Inc.
 PO Box 2009
 Bellaire, TX 77402-5653
 (800) 874-5332; (713) 665-4949
 FAX: (713) 665-4984
www.usiultrasonic.com
Products: Ultrasonic repair, magnetostrictive dental scalers

Unimed/Unident
 3095 Kerner Blvd., Suite G
 San Rafael, CA 94901
 (800) 835-3003; (415) 459-0367
 FAX: (415) 459-0553
www.unimedusa.com
Products: General dental supplies

Union Broach (See Miltex Instrument Co., Inc.)

U.S. Surgical
 150 Glover Ave.
 Norwalk, CT 06856
 (203) 845-1000
www.ussurgical.com
Products: Suture (Dexon II)

Veterinary Health Care Communications
 8033 Flint
 Lenexa, KS 66214
 (800) 255-6864; (913) 492-4300
 FAX: (913) 492-4157
www.vetmedpub.com
Products: Veterinary dental books and journals

Vetoquinol USA, Inc.
 101 Lincoln Ave., 2nd Floor
 Buena, NJ 08310
 (800) 267-5707; (856) 697-5115
 FAX: (856) 697-7288
www.vetoquinol.com; www.evscopharm.com
Products: Stomadhax, Bioadhesive Patch

Vetsonics

990 Lane Ave. #120

Chula Vista, CA 91914

(888) 949-5500; (619) 421-7694

Products: Ultrasonic scaler (Klaw), dental unit

Vident

3150 E. Birch St.

Brea, CA 92821

(800) 828-3839; (714) 961-6200

FAX: (714) 961-6299

www.vident.com

Products: Inceram indirect restoratives

Virbac Animal Health

3200 Meacham Blvd.

Fort Worth, TX 76137

(800) 338-3659

FAX: (817) 831-8327

www.virbac.co.uk

Products: Oral health home care products, CET

VSSI, Inc.

208 W. Central

Carthage, MO 64836

(800) 299-9525; (417) 358-4466

FAX: (417) 358-4716

www.vetproducts.com

Products: Dentistry wet tables

W.L. Gore & Assoc., Inc.

Medical Products Division

PO Box 2400

Flagstaff, AZ 86003

(800) 437-8181; (928) 779-2771

www.goremedical.com

Products: Guided tissue regeneration products, orthopedic devices

Waltham USA, Inc.

3250 East 44th St.

Vernon, CA 90058

(800) WALTHAM

www.walthamusa.com

Products: Chew products (DentaBones), videos

Water Pik Technologies, Inc.

1730 E. Prospect Rd.

Fort Collins, CO 80553

(800) 525-2020; (970) 484-1352

FAX: (800) 289-4389

www.professional.waterpik.com

Products: Alginate, cements, trays, jiffy tubes, subgingival irrigator, prophylaxis cups

Welch Allyn, Inc.

4341 State Street Rd.

Skaneateles Falls, NY 13153

(800) 535-6663; (315) 685-4245

FAX: (315) 685-3361

www.welchallyn.com

Products: Cameras, lights, monitoring devices

Whip Mix Corp.

361 Farmington Ave.

Louisville, KY 40217

(800) 626-5651; (502) 637-1451

FAX: (502) 654-4512

www.whipmix.com

Products: Quick-setting dental stone

Young Dental Manufacturing, LLC

13705 Shoreline Court East

Earth City, MO 63045

(800) 325-1881; (314) 344-0010

FAX: (314) 344-0021

www.youngdental.com

Products: Prophylaxis paste, fluoride, instruments

Zimmer Dental

1900 Ashton Avenue

Carlsbad, CA 92008

(800) 854-7019; (760) 929-4300

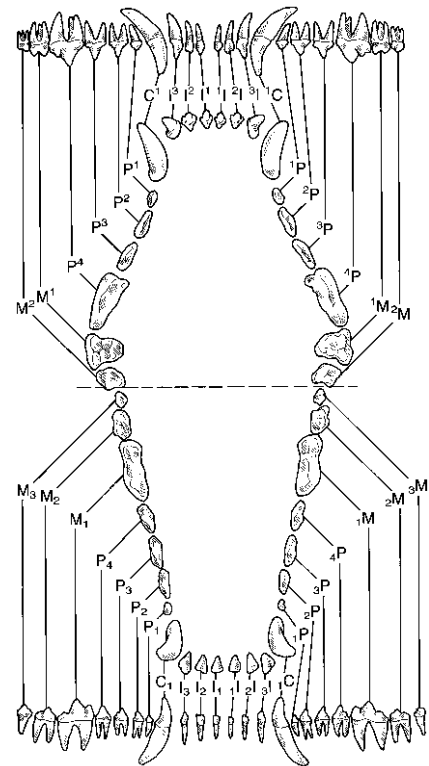
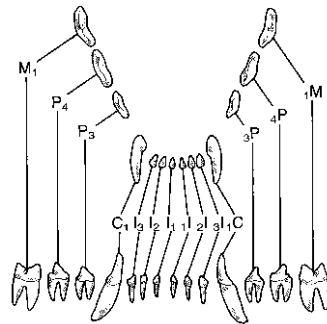
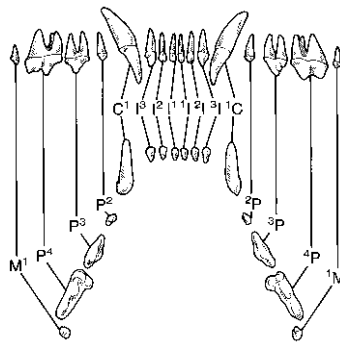
FAX: (888) 225-2483

www.Sulzerdental.com

Products: dental implants, hemostatic materials (Collaplug)



INDEX



A

Abbreviations approved by AVDC, 14t–18t
 Abnormal occlusion, 504
 Abscessed tooth, signs of, 343
 Accessories
 burs, 52–54, 58 (*See* Burs)
 contra angles, 50
 discs, 56
 fiber optics in, 58
 Gates Glidden drills, 54
 green stones, 56
 mandrels, 56
 paste fillers, 56
 Peeso reamers, 54
 prophy angles, 48–50
 wheels, 56
 white stones, 56
 Acepromazine, 604, 607
 Acid-etching, 438
 Acrylic technique, 470–472
 Adhesives in direct pulp capping, 352–353
 Air drying in calculus detection, 210
 Air polishing, 214–215
 Air rheostat controls, 42
 Air-driven power equipment, 42. *See also* Compressors
 alternatives to compressors, 43–44
 drain valves, 44
 handpieces in (*See* handpieces)
 oil-level indicators in, 44
 switching, automatic and mechanical, 44
 three-way syringes, 44
 Alginate impressions, 466
 Algorithm in endodontics, 343–345
 Alpha adrenoreceptor agonists, 605
 Alveolar bone necrosis, 546
 Alveolitis, 320
 Amalgam
 amalgamators, 116
 burnishers, 118
 carriers, 117
 carvers, 118
 condensers (pluggers), 118
 materials and indications in, 454
 placing restorative material in, 458
 preparing the surface for, 456
 restoration, 420
 wells, 116
 American Society of Anesthesiologists (ASA)
 classifications, 602
 American Veterinary Dental College (AVDC) statement
 on dental providers, 38
 Anatomy
 charting of, 12–13
 definition of terms used in, 29–31
 identification system for, 4–5
 of maxillofacial fractures, 560
 radiographic, 134
 Anchorage in orthodontics, 506
 Anesthesia
 general
 anticholinergic agents in, 603–604
 ASA classifications, 602
 capnography and capnometry, 614–615
 changes during procedure, 620–621
 electrocardiograph monitor in, 615–618
 esophageal heart monitor in, 618
 general comments, 602
 induction agent and drug combinations, 608–610
 induction drugs, 607–608
 inhalant anesthetic agents, 610–611

Anesthesia—cont'd

 mask or chamber induction, 611–612
 monitoring for, 612–614
 neuroleptanalgesia, 606–607
 pain management and, 621–624
 pre-anesthetic medications, 603
 pre-procedure work-up, 602–603
 temperature monitor(s) in, 618–620
 tranquilizers and sedatives, 604–606
 local agents
 dosage for, 626
 infraorbital nerve block, 630
 instrumentation for, 626
 location for blocks, 626
 mandibular alveolar nerve block, 632
 maxillary nerve block, 628
 mental nerve block, 632–634
 management with maxillofacial fractures, 562–563
 units in dental operatory, 663
 Angular process, 560
 Ankylosis
 in exodontics, 322
 of roots, 296
 Anterior crossbite, 504
 appliances for, 554–555
 Anticholinergic agents, 603–604
 Antimicrobial agents, 220–221
 Apexification, 353–355
 Apexogenesis, 353–355
 Apically repositioned flap surgery, 262
 Apicoectomy, 23
 with retrograde filling, 406–412
 Aplasia, 462
 Appliances. *See* Orthodontics, appliances
 Arch wires, 536–540
 Arkansas stones, 82
 Articulators in orthodontic equipment, 124
 Aspiration in local anesthesia, 628
 Aspirin, 622
 Atipamezole, 605
 Atropine, 603
 Autoimmune disease(s), 184
 Automatic film processing, 66–67
 Automatic processor developing, 154–155
 one-step, 156
 processor maintenance, 156
 two-step, 156–157
 Avulsion in periodontal trauma, 594
 Axial reduction, 463–464

B

Bands in orthodontics, 516, 520
 Barbiturates, 607
 Barnhart curettes, 79
 Barrier sealant type dentifrices, 226
 Basrani's fracture classification system, 344, 418
 Bead sterilizer(s), 108
 Benzodiazepines, 604
 Bevel margins, 464
 Bilateral direct acrylic inclined plane, 549–550
 Binocular loupes, 69
 Biologic hazards in workplace, 638–644
 Biomechanics in maxillofacial fractures, 560
 Biopsies, 245
 in prophylaxis, 218–219
 Bird-beak pliers, 524
 Bis phenol A-glycidyl methacrylate (Bis-GMA), 424
 Bisecting angle technique in radiography, 144–148
 Bite registration, 468
 Black's system of lesion classification, 416

- Bleaching of non vital teeth, 496
- Blood pressure monitor(s), 613–614, 620t
- Bodily movement in orthodontics, 506
- Bonding agents, 430
- Bone
 - curette, 98
 - defects management, 268–275
 - grafting, 272–274
 - hemorrhage, 319
 - plating, 586
- Brackets in orthodontics, 516
- Bridge, 23
- Broaches, 102
- Broken-instrument technique in obturation, 390
- Brush acrylic appliance technique, 530
- Brushing technique, 226–227
- Buccal approach to canine tooth extraction, 314
- Buccal gingival flaps, 293
- Buccal Mucoperiosteal Sliding Flap, 330
- Buccal sliding flap technique, 332
- Bupivacaine, 626
- Buprenorphine, 606, 623
- Bur block, 64
- Burnishing, 238
 - of amalgam, 458
- Burs, 52–54, 58
 - accessories for, 64
 - diamond, 64
 - fissure, 62
 - flame, 64
 - handpiece, 62
 - inverted-cone, 64
 - pear-shaped, 64
 - rotopro, 64
 - round, 62
 - shank dimensions, 63t
- Butorphanol, 606, 607, 609, 623
- C**
- Calcium hydroxide lining cements, 492
- Calculus. *See also* Prophylaxis
 - index, 20
 - removal forceps, 72, 186–187
- Canine teeth
 - crown therapy in, 486
 - extraction of, 312–316
 - variations in endodontics, 402
- Cap. *See* Crown therapy
- Capnography, 614–615
- Capnometry, 614–615
- Caprofen, 622
- Carbon dioxide laser, 245
- Carbon dioxide use in power equipment, 43
- Carbon steel instruments, 75
- Caries, 22
 - classification of, 416
- Carpal tunnel syndrome, 645–647
- Cast dowel core, 482–484
- Cast metal inclined plane, 552
- Casting in crown therapy, 466–469
- Caudal infraorbital nerve block, 628
- Caudal mandibular fractures, 588–590
- Cavity preparation techniques, 422
- CCD-CMOS sensors, 166
- Ceiling fixtures in dental operator, 662
- Cementation of crown, 478–480
- Centers for Disease Control (CDC), 638
- Ceramic stones, 82
- Cerclage wiring technique, 566–567
- Cervical caries, 416
- Chair side darkrooms, 67
- Chairs/stools in dental operator, 660
- Chamfer margins, 464
- Cheilitis, 246
- Cheiloplasty, 316
- Chemical hazards in workplace, 638
- Chemical-cured
 - bonding agents, 430
 - composite resins, 432
- Chew treats and toys in home care, 230
- Chisel(s), 112
 - margins, 464
- Chlorhexidine, 225
- Chloroform dip technique in obturation, 386
- Chloropercha-eucapercha technique, 384
- Chlorpromazine, 604
- Chronic gut, 100
- Chronic ulceroproliferative faucitis, 184
- Chronic ulceroproliferative paradental stomatitis, 184
- Circular action prophyl angles, 48
- Citric acid, 264
- Classes of lesions. *See* Lesions, classification of
- Clinic equipment and safety, 642–643
- Coagulation aids, 319
- Codeine, 623
- Coincidental curettage, 240
- Cold lateral condensation in obturation, 378
- Columbia cures, 79
- Compactable composites, 425, 435t
- Compomers, 435t
- Composite bonding of canine teeth, 592
- Composite resin(s), 424–439
 - application of bonding agent in, 430–431, 432
 - application of restorative agent in, 432–433, 434
 - cements, 480
 - light-cure restorative materials, 435t
 - materials and indications in, 425
 - preparation of surface in, 426–429
 - shaping and smoothing restoration, 438
- Compressors
 - “whisper-quiet,” 43
 - accessories for, 44
 - air rheostat controls in, 42
 - electric foot switches in, 42
 - maintenance of, 44
 - oil in, 43
 - remote, 42–43
 - table-side, 43
- Condylar process, 560
- Condylectomy, 588, 590
- Conical stone technique, 84
- Consil, 310
- Continuous wave technique in obturation, 384
- Contra angles, 50
- Coronal access
 - in root canal therapy, 356–358
 - restoration of, 399
- Coronoid process, 560
- Cotton pliers, 102
- Cross-arch rest in scalers and cures, 198
- Crosshatching, 238
- Crown therapy, 462–492
 - general technique, 462–480
 - cementation of, 478–480
 - evaluation for preparation, 463
 - laboratory order and manufacture, 474
 - manufacture of temporary crown, 469–473
 - taking an impression and casting, 466–469
 - tooth reduction and margin preparation, 463–465
 - trial placement, 474–477

Crown therapy—cont'd
 special situations in, 480–492
 canine teeth in, 486
 crown-dowel-core buildup, 480–482
 die stone, 490
 dowel core casting, 482–484
 gingival retraction, 490
 molars and premolars in, 488–490
 restorations over vital teeth, 492
 surgical crown lengthening, 484
 Crown(s), 23
 fracture of, 22
 removal of with root retention, 323–325
 Crown-dowel-core buildup, 480–482
 Crown-down technique, 364
 Cryer elevators, 96
 Cubital tunnel syndrome, 648
 Cumulative trauma disorder(s), 644–658. *See also* Ergonomics
 Curettes, 78–80
 in gross calculus removal, 196–203
 sharpening of, 82–83, 84
 surgical, 92
 technique for sub gingival plaque, 204–206
 Custom-point fill in obturation, 388
 Cutting techniques in restorative dentistry, 422

D

De Quervain disease, 650
 Delivery system in dental operatory, 660
 Dental automatic processors, 156
 Dental claw, 74
 Dental devices, 33–34
 Dental disciplines, 31
 Dental hoe (Chisel), 74
 Dental interlock, 502
 Dental materials and instruments, 34
 Dental operatory design, 658
 anesthesia units in, 663
 cabinets and storage in, 663–664
 chairs/stools in, 660
 delivery system/handpiece station in, 660
 lighting in, 662–663
 procedure table in, 659
 radiograph unit in, 660
 wet sinks in, 662
 Dental positioning and surfaces, 31
 Dental radiographic units, 66
 Dental radiology. *See* Radiographs
 in prophylaxis, 218
 Dental records, 10. *See also* Records
 Dental terminology, 29–34
 Dental treatments, 33
 Dentifrices, 224–230
 Dentin bonding agents, 430
 Dentin caries, 416
 Desflurane, 611
 Desiccation of alginate, 514
 Developing radiographs. *See* Radiographs
 Diagnosis abbreviations, 15t–16t
 Diamond burs, 64
 for crown therapy, 464
 Diazepam, 604, 608, 609, 610
 Die stone in crown therapy, 490
 Diet
 in dental records, 10
 in home dental care, 228–231
 Digital cameras, 164–165
 in intraoral photography, 28
 Digital radiology, 164
 Dinamap instruments, 614

Diode laser(s), 245, 246
 Direct acrylic full palatal appliance, 549
 Direct acrylic technique, 470–472
 Direct orthodontics, 532–536
 Direct pulp cap, 350
 Disciplines in dentistry, 31
 Disclosing solutions, 210
 Discs, as equipment accessories, 56
 Dissociative agents, 607
 Distal mandibular excursion, 504
 Dog(s), whole mouth survey in, 141
 Doppler blood pressure measurement, 613–614
 Dorsal recumbency, 563
 Double-flap oronasal fistula techniques, 330–334
 Double-loaded film packets, 160
 Dowel core casting, 482–484
 Doxycycline, 243
 Drain valves in power equipment, 44
 Dual-cure bonding agents, 430
 Dual-cure composites, 435t
 Dual-cure technique, 436
 Duplicating techniques, 160–166
 Duragesic, 624

E

Ear plugs in protective equipment, 640–642
 Electric foot switches, 42
 Electric motor handpieces, 41
 Electrocardiograph monitor, 615–618
 Electrocautery, 244, 318
 Electrosurgery, 244
 Elgiloy wire, 524
 Elizabethan collar, 552
 Embedded teeth in exodontics, 334–337
 Emergency protocols in workplace, 638
 En bloc biopsy, 219
 Enamel hypoplasia, 462
 Endo-Ring, 106
 Endocarditis, 319
 Endodontic disease, radiographic diagnosis of, 168
 Endodontic-periodontal relationships, 412
 Endodontics, 339–345
 algorithm outline for, 343–345
 apexification, apexogenesis, hard tissue formation, 353–355
 apicoectomy with retrograde filling, 406–412
 equipment for
 automated files, 108
 bead sterilizer, 108
 broaches, 102
 cotton pliers, 102
 Endo-Ring, 106
 file organizers, 106
 gutta-percha, 110–111
 high-pressure syringes, 108
 lentulo spiral fillers, 108
 pluggers, 108
 finger, 109
 Holmstrom, 110
 reamers and files, 102–104
 spreaders, 110
 finger, 109
 Holmstrom, 110
 indications and justifications for therapy, 342
 indirect pulp capping, 345–347
 crown therapy, 348
 non surgical root canal therapy, 356–396
 complications of, 399
 vital pulpotomy and direct pulp capping, 348–352
 dental adhesives in, 352–353

- Endoperiodontal disease, 170
 Endotracheal tubes in orthodontics, 128
 Envelope flap, 254–255
 Enzymatic dentifrices, 225
 Epicondylitis, 650
 Equipment safety. *See* Ergonomics; Safety in veterinary dentistry
 Equipment, dental
 in endodontics (*See* Endodontics, equipment for)
 in periodontics (*See* Periodontics)
 power, 40–65 (*See also* power equipment)
 radiology, 66–68
 selecting of, 40
 Ergonomics. *See also* Dental operatory design
 administrative factors in, 656
 cumulative trauma disorder(s) in, 644–658
 definition of, 644–658
 exercises to reduce fatigue/increase strength, 656t–657t
 personal factors in, 658
 rationale for, 644
 workplace equipment risk factors, 654
 Eruption delays, 555–556
 Esophageal heart monitor, 618
 Euthanasia, 292
 Even bite, 504
 Exarticulation, 594
 Excavators, 112
 Excisional biopsy, 218–219
 Exodontics, 292–297
 canine tooth extraction, 312–316
 crown removal with root retention, 323–325
 extraction of primary teeth, 328–329
 extraction of retained root-tip fragments, 325–327
 general extraction complications, 318–322
 impacted, unerupted, or embedded teeth, 334–337
 non surgical extraction of teeth with multiple roots, 302–306
 oronasal fistula repair, 329–334
 pulverization, 322–323
 simple extraction of single-rooted teeth, 298–301
 surgical extraction technique, 306–311
 Expansion devices in orthodontics, 540–547
 Exploratory stroke, 238
 Explorers, periodontal, 86–87
 External fixation of maxillofacial fractures, 584–586
 Extraction, 292
 in restorative dentistry, 420
 of tooth or fragments (*See* Exodontics)
 Extraction instruments
 bone curette, 98
 extraction forceps, 99
 Heidbrink root tip pick, 98
 root tip or fragment forceps, 100
 surgical elevator, 94–97
 Extraoral use of intraoral film, 148–151
 Extrusion in orthodontics, 506
 Extrusive luxation in periodontal trauma, 594
 Eyewash stations in workplace, 642
- F**
 Face mask in protective equipment, 640
 Fahrenkrug elevators, 96
 Feather margins, 464
 Federation dentaire internationale system, 8
 Feline dental treatment chart, 21
 Feline odontoclastic resorptive lesions (FORLs), 245, 448–450
 Fentanyl, 606
 Fentanyl transdermal patches, 624
- Fiberoptic handpiece(s), 68–69, 663
 Fiberoptics in equipment accessories, 58
 Fibromas, 245
 Fibrotic pocket epithelium, 254
 Figure-of-eight wiring technique, 276–277
 Files in endodontic equipment, 102–104
 automated, 108
 organizers for, 106
 Fillers, 432
 Filling techniques for canine teeth, 402
 Film
 in dental radiography, 139–140
 in intraoral photography, 27
 Film processing systems, 66–68
 Finger rests in scalers and curettes, 196
 Finger springs in arch wires, 540
 Finishing strips, 438
 Fissure burs, 62
 Flame burs, 64
 Flap techniques in periodontal therapy, 254–264
 Flat stone sharpening technique, 82–84
 Floseal Matrix Hemostatic Sealant, 319
 Flowable composites, 435t
 Fluoride based dentifrices, 225
 Fluoride treatment(s), 220–221
 Foot pedals in dental equipment, 41
 electric foot switches, 42
 Footwear in protective equipment, 640
 Force in orthodontics, 506
 Fracture severity Index, 418–421
 Fragment forceps, 100
 Free gingival graft, 266–267
 Frenectomy or frenotomy, 246–248
 Frenula problem, 23
 Furcation, 23
 Furcation exposure, 20
- G**
 Gates Glidden drills, 54
 Gauze sponge in home care, 223
 Gelfoam, 319
 Gels in dentifrices, 224
 General anesthesia. *See* Anesthesia
 Gingival biopsy, 248
 Gingival cleft formation, 264
 Gingival curettage, 240–241
 Gingival hyperplasia, 245
 Gingival index, 20
 Gingival recession, 246
 Gingival retraction, 490
 Gingival retractors, 93
 Gingival tissue laceration, 322
 Gingival wedge, 552–553
 Gingivectomy, 248–251, 252
 Gingivitis, 178–179
 juvenile, 184
 Gingivoplasty, 252–253
 of anterior diastema, 552–553
 Glass ionomers
 application of bonding agent in, 442
 cements in, 478–479
 liners in, 492
 materials and indications in, 441
 placing off, 452–454
 preparation of surface in, 442
 shaping the restoration, 446
 smoothing the restoration, 448
 Glossary of dental terms, 29–34
 Gloves in protective equipment, 639
 Glycopyrrrolate, 603

Goldman Fox scissors, 92
 Golfer's elbow, 650
 Gown in protective equipment, 640
 Gracey curettes, 80
 Green stones, 56
 Gross calculus removal, 186–204
 Guided tissue regeneration, 272, 274–275
 Gutta-percha, removal of, 399
 Gutta-Percha endodontic equipment, 110–111
 Guyon's Canal syndrome, 648

H

Haderup system, 6
 Halothane, 611
 Hand instrument(s)
 ergonomics in, 654
 holding techniques for, 196
 Hand washing at workplace, 638
 Handpiece station in dental operator, 660
 Handpiece(s)
 autoclave option with, 48
 burs, 62
 controls and ergonomics in, 654
 high-speed, 58
 low-speed, 48
 maintenance of, 46–47
 wrench less, 58
 Hard tissue formation, 353–355
 Hatchets, 112
 Hazards in workplace. *See* Safety in veterinary dentistry
 Headband-mounted lights, 662–663
 Headlamp light source, 68
 Health safety. *See* Safety in veterinary dentistry
 Heated gun/syringe techniques in obturation, 394–395
 Hedstrom files, 104
 Heidbrink root tip pick, 98
 Hemablock, 319
 Hemorrhage, 318
 of bone, 319
 High-rise syndrome, 592
 Histopathology in prophylaxis, 218–219
 History in dental records, 10
 Holmstrom pluggers and spreaders, 110
 Home care instructions in prophylaxis, 222–231
 Horizontal ramus, 560
 Hybrid composites, 435t
 Hybrid fillers, 432
 Hydrocolloid-alginate, 468
 Hydromorphone, 606, 624
 Hydroxyapatite liner/bases, 492t
 Hyperkeratotic lesions, 245
 Hyperthermia in anesthesia, 620
 Hypothermia in anesthesia, 618–620

I

Identification of dental radiographs, 139–140
 Identification systems for teeth, 4
 Impacted teeth in exodontics, 334–337
 Implant, 23
 Impression trays, 121–122
 Impressions
 in crown therapy, 466–469
 in orthodontics, 508–511
 Incisional biopsy, 218
 Incisor(s)
 extraction of, 298–301
 root canal preparation technique in, 369
 variations in endodontics, 400
 Inclined plane(s), 548–552
 India stones, 82

Indirect bonding of brackets, 521–522
 Indirect palatal acrylic appliance, 548–549
 Indirect restorations, 492–495
 Induction agent and drug combinations, 608–610
 Induction drugs, 607–608
 Inferior alveolar nerve block, 632
 Infrabony defect, 268
 Infraorbital nerve block, 630
 Inhalant anesthetic agents, 610–611
 Injection technique in obturation, 372–374
 Inlays, 493
 Instruments
 needed for practice, 40
 used in dentistry, 34
 Inter dental wiring, 576–581
 Inter fragmentary wiring, 582–583
 Interceptive orthodontics, 294, 530–531
 Internal bevel releasing flap surgery, 258–261
 Intraoral devices, 33–34
 Intraoral photography
 digital cameras in, 28
 film, 27
 lenses, 26–27
 lighting systems, 27
 mirrors in, 28
 range-finder cameras, 26
 single lens reflex (SLR) cameras, 26
 taking photographs, 28–29
 Intraoral splints, 570–575
 Intraosseous wiring, 582–583
 Intrusion in orthodontics, 506
 Intrusive luxation in periodontal trauma, 594
 Intubation in anesthesia and pain management, 610
 Inverted cone technique in obturation, 392
 Inverted-cone burs, 64
 Isoflurane, 611
 Ivy loop wiring, 578
 Iwanson spring caliper, 127

J

Jacquette 2Y-3Y Scaler, 78
 Jiffy tubes, 120–121

K

K-3 files, 368
 Kerr files, 104
 Ketamine, 607, 608, 609
 Kirkland knife, 90
 Kirschner-Ehmer apparatus, 584

L

La Grange scissors, 92
 Labial arch wires, 540
 Labial buccal pedicle flap technique, 334
 Lamina dura, 136
 Lamina lucida, 136
 Lance tooth, 504
 Laser use in periodontal surgery, 245–246
 Latch burs, 52
 Lateral and vertical condensation in obturation, 384
 Lateral epicondylitis, 650
 Lateral luxation, 594
 Lateral recumbency, 563
 Lenses in intraoral photography, 26–27
 Lentulo spiral fillers, 108
 Lesions, 168
 classification of, 416–421
 in endoperiodontal disease, 170
 in perioendodontic disease, 170
 resorptive, 172

- Level bite, 504
- Lidocaine, 626
- Light analysis tool, 116
- Light-cure gun, 114
 - accessories for, 114–116
- Light-cure restorative materials, 435t
- Light-cure technique, 436
- Lighting, 68–69
- Lighting systems in intraoral photography, 27
- Lingual approach to canine tooth extraction, 316
- Lingual surface flap technique, 256–257
- Lingual wire splinting technique, 278
- Liquids in dentifrices, 224
- Local anesthesia. *See* Anesthesia, local agents
- Luting or cementing glass ionomers, 440t
- Luxators, 96
- M**
- Macroretention, 422
- Magnetostriuctive with ferrite rod instrumentation, 190
- Magnification, 69–70
- Malocclusion, 294, 504
 - abbreviations for, 17t–18t
- Malpositioned tooth, 23
- Mandibular alveolar nerve block, 632
- Mandibular appliance for anterior crossbite, 554–555
- Mandibular brachygnathism, 504
- Mandibular canine(s)
 - lingual displacement in, 542
 - rostral displacement in, 534
 - tooth extraction in, 314
 - complications of, 316
- Mandibular fracture, 320
- Mandibular frenoplasty, 246–248
- Mandibular osteomyelitis, 256
- Mandibular third molars, extraction of, 298–301
- Mandibular tooth extractions, 293
- Mandibulectomy, 567
- Mandibulotomy, 336
- Mandrels, 56
- Manual film processing, 66
- Manual radiograph development, 154
- Margins in crown therapy, 464–465
- Maryland bridge, 553–554
 - splinting with, 280
- Mask or chamber induction, 611–612
- Material Safety Data Sheet (MSDS), 644
- Materials used in dentistry, 34
- Maxillary acrylic appliances, 542
- Maxillary appliance for anterior crossbite, 554
- Maxillary canine displacements, 534
- Maxillary fractures, 560
- Maxillary nerve block, 628
- Maxillary teeth
 - canine tooth extraction, 312–316
 - extractions generally, 293
 - first and second molar extraction, 306
 - fourth premolar extraction, 306
- Maxillofacial fractures
 - anatomy and biomechanics, 560
 - anesthetic management and positioning in, 562–563
 - caudal mandibular fractures, 588–590
 - external fixation of, 584–586
 - fractures of body of mandible, 568–570
 - initial management of, 560
 - interdental wiring, 576–581
 - intraoral splints, 570–575
 - intraosseous wiring, 582–583
 - management of periodontal trauma, 594–596
 - maxillomandibular fixation, 590–592
 - Maxillofacial fractures—cont'd
 - midline palatal fracture or separation, 592–594
 - miniplate and screws fixation, 586
 - principles of repair in, 560–562
 - symphyseal separation repair, 566–567
 - tape muzzles in, 564
 - Maxillomandibular fixation, 590–592
 - McSpadden method in obturation, 390
 - Mechanical devices in home care, 223
 - Mechanical honing set, 84–85
 - Medetomidine, 605, 609
 - Medial epicondylitis, 650
 - Median nerve problem(s). *See* Carpal tunnel syndrome
 - Medical film duplicating system, 162
 - Mental nerve block, 632–634
 - Meperidine, 606
 - Meperidine hydrochloride, 623
 - Mepivacaine, 626
 - Mesial mandibular excursion, 504
 - Mesiobuccal root access, 404
 - Metal appliance(s), 542
 - Microfil composites, 435t
 - Midazolam, 604, 609
 - Miniplate and screws fixation, 586
 - Minnesota retractor, 92
 - Mirrors
 - in dentistry, 28
 - in periodontics, 87
 - Mixing spatula and pads, 120
 - Mixing systems in orthodontics, 122
 - Mobile floor procedure lights, 662
 - Mobility, degree of, 20
 - Models in orthodontics, 512–515
 - Modified Triadan system, 4
 - Modified Widman flap surgery, 258–261
 - Molars
 - crown therapy in, 488–490
 - multirooted, extraction of, 302–306
 - Monitoring patients in anesthesia, 612–614
 - Morphine, 606, 607, 623
 - Morse 0-00 scaler, 78
 - Mouth survey, 141
 - Mueller bur, 54
 - Musculoskeletal disorders, 644
 - administrative factors in, 656
 - exercises to reduce, 656t–657t
 - major categories of, 645–651
 - personal factors in, 658
 - prevention/reduction of, 651–652
 - Mylar strip, 432, 436, 446
 - N**
 - National Institute for Occupational Safety and Health (NIOSH), 638
 - threshold standards for noise levels from, 640–641
 - Neodymium: yttrium-aluminum-garnet (Nd:YAG) laser, 245, 246
 - Neuroleptanalgesia, 606–607
 - Neutral body positions, 652
 - Nitrogen use in power equipment, 43–44
 - Noise levels in work place, 640–641
 - Notched probes, 86
 - Numerical order in tooth numbering, 5–6
 - Nylon as suture material, 102
 - O**
 - Obturation, 369–406
 - additional filling techniques in, 398
 - application of sealer alone, 370
 - application of solid filling material, 374

- Obturation—cont'd
 broken-instrument technique in, 390
 chloroform dip technique in, 386
 chloropercha-eucapercha technique in, 384
 cold lateral condensation in, 378
 continuous wave technique in, 384
 custom-point fill in, 388
 heated gun technique in, 394
 heated syringe technique in, 394–395
 injection technique in, 372–374
 inverted cone technique in, 392
 lateral and vertical condensation in, 384
 orthograde amalgam technique in, 392
 postoperative care in, 399
 single-cone technique in, 376
 spiral filling technique, 372
 thermafil in, 396–398
 thermomechanical condensation in, 390
 thermoplasticized gutta-percha in, 392
 vertical condensation in, 382–384
 warm lateral condensation in, 380
- Occlusal evaluation, 500–507
 classes of occlusion, 504–505
 orthodontic fundamentals, 506
- Occult margins, 464
- Occupational risk factors for carpal tunnel syndrome, 647t
- Occupational Safety and Health Administration (OSHA), 638
 threshold standards for noise levels, 640–641
- Ochsenbein Periosteal Chisel, 92
- Odontoblasts, 341
- Odontoclastic resorptive lesions, 448–450
- Oil, usage in compressors, 43
- Oil-level indicators, 44
- Omega wire, 546
- One-step rapid film processing, 66
- Onlays, 493–494
- Open flap curettage, 254–255
- Operating glasses-mounted lights, 662–663
- Operculectomy, 556
- Opioid agonists, 603
- Opioids, 606, 622–623
- Optic shields, 115
- Optical lenses, 69
- Oral diseases and conditions, 31–32
- Oral examination, 10–11
 equipment needed, 40
 in dental prophylaxis, 176–177
- Oral hygiene in dental records, 10–11
- Oral inflammatory disease, 11t
- Oral irrigation, 220–221
- Oral surgery, equipment needed, 40
- Orban knife, 90
- Oronasal fistula, 256, 320
 repair of, 329–334
- Orthodontic(s)
 abbreviations in, 17t–18t
 appliances
 acrylic, 526–530
 arch wires, 536–540
 direct orthodontics, 532–536
 expansion devices, 540–547
 gingival wedge, 552–553
 inclined plane(s), 548–552
 indirect bonding of brackets, 521–522
 Maryland bridge, 553–554
 consent form sample for, 506
 equipment and instruments in
 articulators in, 124
- Orthodontic(s)—cont'd
 bands in, 520
 impression trays, 121–122
 Iwanson spring caliper in, 127
 orthodontic wire, 524–526
 pliers in, 126
 rubber mixing bowls, 122
 separating endotracheal tubes, 128
 universal mixing/delivery system, 122
 vibrators in, 124
 welders in, 124
 wire cutters in, 126
 ethical veterinary practices in, 500
 extrusions in, 556
 fundamentals of, 506
 general techniques, 508–519
 direct bonding in, 516–519
 impressions in, 508–511
 model making in, 512–515
 interceptive, 530–531
 occlusal evaluation in, 500–507
- Orthograde amalgam technique in obturation, 392
- Oscillating prophyl angles, 48
- Oscillometric instruments, 614
- Ostectomy, 268
- Osteoplasty, 268, 270
- Overhead lighting, 68
- Overjet/overshot, 504
- Oximeter, 612–613
- Oxygene dentifrices, 225
- Oxymorphone, 606, 609, 624
- P**
- Packed blood cell volume (PCV), 603
- Pain management, 621–622
 postoperative and owner-administered, 622–624
- Palatal acrylic appliance(s), 548–549
- Palatal flap technique, 334
- Palatal fracture or separation, 592–594
- Palatal inverted flap technique, 332
- Palatal mucosal irritation, 552
- Palatal root amputation, 404
- Palatal surface flap technique, 256–257
- Palmer notation system, 5
- Panoramic film duplicator, 162
- Papillomas, 245
- Parallel technique in radiography, 141–143
- Partial coronal pulpectomy, 348
- Passive home care, 228–231
- Paste fillers, 56
- Paste injection system in obturation, 398
- Pastes in dentifrices, 224
- Patient positioning, in maxillofacial fractures, 562–563
- Pear-shaped burs, 64
- Pedicle graft, 264–265
- Peeso reamers, 54, 481
- Periapical pathology, 22
- Perioceutic treatment, 243
- Periodontal abbreviations, 18t
- Periodontal charting, 20–23
- Periodontal disease, 294
 autoimmune disease in, 184
 causes of, 178
 chronic ulceroproliferative faucitis, 184
 chronic ulceroproliferative stomatitis, 184
 dental resorptive lesions in, 184
 juvenile gingivitis or periodontitis, 184
 periodontal treatment planning in, 184–185
 radiographic diagnosis of, 167
 stages of, 178–183

- Periodontal dressings, 264
 Periodontal files, 80
 Periodontal infection and systemic disease, 234–236
 Periodontal ligament (PDL), 506
 Periodontal probing and exploring, 216–217
 Periodontal therapy, 234
 gingival curettage, 240–241
 objectives of, 236–237
 root planing, 237–239
 surgical options
 electrosurgery and radiosurgery, 244
 flap techniques, 254–264
 gingivectomy, 248–251, 252
 gingivoplasty, 252–253
 laser use in, 245–246
 management of defects in bone, 268–275
 mandibular frenoplasty, 246–248
 periosteal treatment, 243
 scalpel surgery, 244
 soft tissue grafting techniques, 264–267
 splinting, 275–289
 ultrasonic periodontal debridement, 242–243
 Periodontal trauma, management of, 594–596
 Periodontal-endodontic relationships, 412
 Periodontic equipment
 calculus removal forceps, 72
 curettes, 78–80
 dental claw, 74
 dental hoe (Chisel), 74
 dental mirrors in, 87
 explorers in, 86–87
 fine hand instruments, 74
 piezo electric scalers, 72
 probes in, 86
 sonic scalers, 70
 surgical instruments, 88–93
 ultrasonic scalers, 70
 Periodontitis, 180–183, 184
 Periodontium, 178. *See also* Periodontal disease
 Perioendodontic disease, 170
 Periosteal elevators, 92
 Personal protective equipment, 639–642
 Pharyngotomy, 562
 Phenothiazine derivatives, 604
 Phosphorus sensors, 166
 Photography in dentistry. *See* Intraoral photography
 Physical hazards in workplace, 638
 Piezo electric scalers, 72
 Piezoelectric instrumentation, 191
 Pin restoration, 460
 Pin stabilization splinting technique, 278
 Pit and fissure sealants, 425
 Pit fissure caries, 416
 Planned extracted tooth, 22
 Plaque. *See* Prophylaxis
 Plaque index, 20
 Plastic filling instruments, 120
 Pliers in orthodontic equipment, 126
 Pluggers in endodontic equipment, 108
 finger, 109
 Holmstrom, 110
 Poliglecaprone 25, 100
 Polishing in prophylaxis, 212–215
 Polydipsia, 343
 Polyglyconate, 100
 Polymerization of composites, 425
 Polypropylene as suture material, 102
 Polysulfide rubber, 466
 Porcelain-fused-to-metal (PFM) restoration, 464
 Positioning in dentistry, 31
 Posterior curettes, 79
 Posts, 23
 Posture in work place safety, 652
 Potassium pyrophosphate, 224
 Powders in dentifrices, 224
 Power equipment, 40–65
 air-driven (*See* Air-driven power equipment)
 electric motor handpieces in, 41
 features to consider in, 41
 Power instrumentation in prophylaxis, 188–190
 sonic, 191–195
 Pre-anesthetic procedures, 602–603
 Premolar(s)
 crown therapy in, 488–490
 first, extraction of, 298–301
 multirrooted, extraction of, 302–306
 root canal preparation technique in, 369
 Primary teeth extraction, 328–329
 Printer-proofer in film duplicating, 162–164
 Probes in periodontics, 86
 Procedure abbreviations, 16t–17t
 Procedure table(s), 659
 Prochlorpromazine, 604
 Prognathism, 504
 Prophyl angles, 48–50
 Prophylaxis, 185–186
 biopsy and histopathology in, 218–219
 closed subgingival plaque and calculus in, 204–209
 dental radiology in, 218
 detection of missed plaque and calculus in, 210–211
 equipment needed for, 40
 gross calculus removal, 186–204
 calculus-removing forceps in, 186–187
 scalers and curettes in, 196–203
 sonic power instrumentation in, 191–195
 ultrasonic instrumentation in, 190–191
 ultrasonic scalers in, 188–190
 home care instruction in, 222–231
 oral irrigation in, 220–221
 periodontal probing and exploring in, 216–217
 polishing in, 212–215
 Propofol, 608, 609, 610
 Protrusive mandible, 504
 Pulp capping
 direct, 348–352
 dental adhesives in, 352–353
 indirect, 345–347
 crown therapy, 348
 Pulp hemorrhage, 366–367
 Pulpitis, 518
 Pulse oximeter, 612–613
 Pulverization, 322–323
 Putty-wash technique, 467
 Pyogenic granulomas, 245
- Q**
- Quantec files, 368–369
- R**
- Radiation safety, 152
 Radiographic monitoring badges, 642
 Radiographic unit(s), 138–139
 in dental operator, 660–662
 Radiographs
 checklist for submitting, 174
 digital radiology, 164
 duplication of in dentistry, 160–166
 endodontic disease in, 168
 film, 139–140
 lesions in, 168–173

- Radiographs—cont'd
 - normal anatomy on, 134
 - periodontal disease in, 167
 - procedures for dentistry
 - bisecting angle technique, 144–148
 - complications in, 152
 - development of film, 154–159
 - extraoral use of intraoral film, 148–151
 - parallel technique, 141–143
 - radiation safety, 152
 - whole mouth survey, 141
 - reading of, 134
 - structures visible, 134–137
 - value of, 132t
 - Radiology equipment, 66–68
 - Radiosurgery, 244
 - Range-finder cameras, 26
 - Rawhide chewing products, 230
 - Raynaud syndrome, 648
 - Reading glasses for magnification, 69
 - Reamers, 102–104
 - Recapitulation, 362, 364
 - Records, 2–3, 10
 - anatomic charting, 12–13
 - anatomic identification system, 4–5
 - Federation dentaire internationale system, 8
 - Haderup system, 6
 - initial oral examination, 10–11
 - intraoral photography, 26–29
 - modified Triadan system, 4
 - numerical order in tooth numbering, 5–6
 - palmer notation system, 5
 - periodontal charting, 20–23
 - tooth identification systems, 4, 7
 - veterinary medical records, 8, 9
 - Zsigmondy system, 8
 - Regional anesthetic blocks, 626
 - Remote compressors, 42–43
 - Resin-based calcium hydroxide, 492
 - Resorptive lesions, 172, 184
 - Restoration, 22
 - Restorative agents, 432
 - Restorative dentistry, 416
 - bleaching of non vital teeth, 496
 - classification of lesions, 416–421
 - crown therapy in, 462–492
 - general techniques, 422
 - indirect restorations, 492–495
 - materials in, 422–459
 - amalgam, 454–458
 - composite resins, 424–439
 - glass ionomers, 440–454
 - pin restoration in, 460
 - Restorative equipment and instruments
 - amalgam (*See* Amalgam)
 - chisels, 112
 - curved-tip syringes, 121
 - excavators, 112
 - hatchets, 112
 - jiffy tubes, 120–121
 - light cure gun, 114
 - accessories for, 114–116
 - mixing spatula and pads, 120
 - plastic filling instruments, 120
 - Retained primary tooth, 22
 - Retained root, 22
 - Retention period, 506
 - Retrusive mandible, 504
 - Reverse bevel releasing flap surgery, 258–261
 - Ribbon splinting, 280
 - Rimadyl, 622
 - Risdon wiring, 580
 - Root canal therapy, 22
 - in restorative dentistry, 420
 - non surgical, 356–369
 - cleaning and shaping canal in, 358–366
 - coronal access in, 356–358
 - persistent pulp hemorrhage in, 366–367
 - preparation technique in, 369
 - rotary filing technique in, 368–369
 - obturation in, 369–406
 - surgical (*See* Endodontics)
 - Root caries, 416
 - Root planing, closed technique, 237–239
 - Root tip forceps, 100
 - Root tip fracture in exodontics, 318
 - Root-tip fragment extraction, 325–327
 - Rotary filing technique, 368–369
 - Rotation in orthodontics, 506
 - Rotator cuff tendinitis, 650
 - Rotopro bur, 64
 - Rubber based impression materials, 466–468
 - Rubber finger brush, 223
 - Ruffling, 238
- S**
- Safety glasses in protective equipment, 639
 - Safety in veterinary dentistry. *See also* Dental operator
 - design; Ergonomics
 - clinic equipment, 642–643
 - hazards, 638
 - personal protective equipment, 639–642
 - Saliva substitutes, 225
 - Salt and pepper technique, 528
 - Sanguinaria-based dentifrices, 225
 - Scalers, 70–72, 76–78
 - in gross calculus removal, 196–203
 - in subgingival therapy, 206–207
 - sharpening of, 83, 84
 - Scalpel blades, 88–90
 - Scalpel periodontal surgery, 244
 - Scanning in dental radiology, 166
 - Scissor bite, 504
 - Sealer application in root canals, 370
 - Secondary rest with scalers and curettes, 200
 - Sedatives, 604–606
 - Senn retractor, 92
 - Series 29 file, 103
 - Sevoflurane, 611
 - Sharpening stones, 82
 - Sharps container handling, 642–643
 - Shoulder joint margins, 464
 - Silk as suture material, 102
 - Siloxane polymers, 466
 - Single lens reflex (SLR) cameras, 26
 - Single-cone technique in obturation, 376
 - Single-film duplicator, 160–161
 - Single-step bonding agents, 430
 - Smooth surface caries, 416
 - Socket fracture in exodontics, 318
 - Sodium hexametaphosphate 1% acetic acid, 225
 - Sodium pyrophosphate, 224
 - Soft tissue grafting techniques, 264–267
 - Soft tissue hemorrhage, 318–319
 - Soldering techniques, 524
 - Sonic power instrumentation, 191–195
 - Sonic scalers, 70
 - Spear tooth, 504
 - Spiral filling technique in obturation, 372
 - Splinting, periodontal, 275–289

Sprays in dentifrices, 224
 Spreaders in endodontic equipment, 110
 Stabilized chlorine dioxide dentifrices, 225
 Stainless steel instruments, 75
 Standard of care, 342
 Stenosing tendinitis, 650
 Sternal recumbency, 563
 Stomatitis, 184
 Stout multiple-loop wiring technique, 576
 Subluxation in periodontal trauma, 594
 Surface preparation
 in composite resins, 426–429
 with glass ionomers, 442
 Surfaces in dentistry, 31
 Surgery and extraction abbreviations, 18t
 Surgical crown lengthening, 484
 Surgical dental elevators, 94–97
 Surgical extraction technique, 306–311
 Surgical knives, 89–90
 Suture material
 chromic gut, 100
 poliglecaprone 25, 100
 polyglyconate, 100
 silk, nylon and polypropylene, 102
 Symphyseal separation, 560
 repair of, 566–567
 Symphysis, 560
 Syringes
 curved-tip, 121
 high-pressure, 108
 Systemic disease and periodontal infection, 234–236

T

Table-side compressors, 43
 Tape muzzle in maxillofacial fractures, 564
 Tapered-fissure burs, 62
 Tartar control biscuits, 230
 Teeth, impacted, unerupted, or embedded, 334–337
 Temperature monitoring in anesthesia, 618–620
 Tennis elbow, 650
 Tenosynovitis, 648
 Terminology for dentistry, 29–34
 Tetracycline powder, 300
 Thermafil in obturation, 396–398
 Thermomechanical condensation, 390
 Thermoplasticized gutta-percha, 392
 Thiopental sodium, 607, 609, 610
 Thoracic outlet syndrome, 648
 Three-quarter crown preparation, 494
 Three-way syringes, 44
 Tight lip surgery in the Shar Pei dog, 282
 Tiletamine, 608
 Tipping in orthodontics, 506
 Tissue retractors, 92
 Tooth abbreviations, 17t
 Tooth identification systems, 4
 Toothbrushes in home care, 223
 Torbugesic, 623
 Total blood protein, 603
 Tranquilizers, 604–606
 Transcoronal approach in endodontics, 404
 Translation in orthodontics, 506
 Treatments in dentistry, 33
 Trigger finger(s), 650
 Trimeprazine, 604

Tubli-seal in obturation, 398
 Turbine cartridge replacement, 60

U

Ulnar nerve compression at elbow, 648
 Ulnar nerve entrapment at wrist, 648
 Ultrasonic instrumentation in prophylaxis, 190–191
 Ultrasonic periodontal debridement, 242–243
 Ultrasonic scalers, 70, 188–190
 ergonomics in, 654
 Underbite/underjet, 504
 Unerupted teeth in exodontics, 334–337
 Universal curettes, 79
 Universal tooth numbering system, 5–6
 Uremia, 343
 Urethane dimethacrylate (UDMA), 424
 Urine specific gravity, 603

V

Vagotonic drugs, 603
 Variable speed in dental equipment, 41
 Vertical condensation in obturation, 382–384
 Vestibule deepening, 282–284
 Veterinary medical records, 8, 9
 Veterinary medical units, 66
 Veterinary technicians safety. *See* Safety in veterinary dentistry
 Vibrators in orthodontic equipment, 124
 Vinyl polysiloxane polymers, 466
 Visualization of treatment field, 662–663
 Vital pulpotomy, 348–352
 in restorative dentistry, 420

W

W wire, 546
 Walking technique in bleaching, 496
 Warm lateral condensation in obturation, 380
 Water pick(s) in home care, 223–224
 Waterlase, 246
 Wedge biopsy, 219
 Welders in orthodontic equipment, 124
 Wheels, as equipment accessories, 56
 White stones, 56
 Winged elevators, 96
 Wiping technique, 228
 Wire cutters in orthodontic equipment, 126–127
 Work place issues. *See* Ergonomics; Safety in veterinary dentistry
 Working stroke, 238
 World Health Organization pressure probe, 86
 Wry bite, 504

X

Xylazine, 605

Y

Yohimbine, 605

Z

Zinc ascorbate, 225
 Zinc oxide-eugenol, 478
 Zinc phosphate cement, 478
 Zinc polycarboxylate, 478
 Zolazepam, 608
 Zsigmondy system, 8