



Hill's Atlas

of Veterinary

Clinical Anatomy

Contents

1 Introduction

Cardiovascular and Lymphatic Systems

- 2 Normal Heart
- 3 Chronic Valvular Disease
- 4 Normal Canine Heart
- 5 Heartworm Disease
- 6 Normal Canine Heart
- 7 Canine Dilated Cardiomyopathy
- 8 Normal Feline Heart
- 9 Feline Hypertrophic Cardiomyopathy
- 10 Normal Feline Heart
- 11 Feline Dilated Cardiomyopathy
- 12 Normal Lymph Node Architecture
- 13 Lymphosarcoma

Digestive System

- 14 Normal Feline Dentition
- 15 Periodontal Disease
- 16 Normal Canine Dentition
- 17 Carnassial Tooth Abscess
- 18 Normal Stomach
- 19 Hemorrhagic Gastritis with Ulcers
- 20 Normal Stomach
- 21 Gastric Dilatation with Volvulus
- 22 Normal Small Intestine
- 23 Foreign Bodies
- 24 Parvoviral Enteritis
- 25 Intussusception
- 26 Normal Canine Colon
- 27 Chronic Colitis

- 28 Normal Feline Colon
- 29 Constipation/Colonic Impaction

- 30 Normal Pancreas
- 31 Acute Pancreatitis
- 32 Normal Pancreas
- 33 Exocrine Pancreatic Insufficiency
- 34 Normal Liver
- 35 End-Stage Liver Disease
- 36 Normal Liver
- 37 Hepatic Neoplasia

Integumentary System

- 38 Normal Skin/Perineal Anatomy
- 39 Anal Sac Abscess
- 40 Skin Abscess
- 41 Flea-Allergy Dermatitis

Musculoskeletal System

- 42 Normal Vertebrate/Spinal Cord
- 43 Intervertebral Disk Disease
- 44 Normal Shoulder
- 45 Osteochondritis Dissecans
- 46 Normal Elbow
- 47 Ununited Anconeal Process/Panosteitis
- 48 Normal Hip Joint
- 49 Hip Dysplasia
- 50 Normal Rear Leg
- 51 Femoral Fracture

52 Normal Stifle
53 Ruptured Cranial Cruciate Ligament
54 Normal Stifle
55 Patellar Luxation

Respiratory System

56 Normal Mouth/Upper Airway
57 Tonsillitis
58 Normal Canine Thorax
59 Collapsing Trachea
60 Normal Feline Thorax
61 Pulmonary Edema

Urogenital System

62 Normal Canine Kidney
63 Chronic Renal Disease
64 Normal Canine Kidney
65 Acute Renal Failure
66 Normal Urinary Bladder
67 Bladder Stones
68 Normal Canine Lower Urinary System
69 Canine Urethral Obstruction
70 Normal Feline Lower Urinary System
71 Feline Lower Urinary Tract Disease
72 Normal Prostate Gland
73 Benign Prostatic Hyperplasia
74 Ovariohysterectomy
75 Pyometra
76 Canine Castration
77 Testicular Tumors

Special Senses

78 Normal Canine Eye
79 Nuclear Sclerosis/Cataracts
80 Normal Feline Eye
81 Glaucoma
82 Normal Feline Eye
83 Corneal Ulceration
84 Normal Hearing Apparatus
85 Otitis Externa/Media/Interna

Parasite Life Cycles

86 Heartworms
87 *Giardia*
88 Hookworms
89 Whipworms
90 Roundworms
91 Tapeworms (*Taenia*)
92 Tapeworms (*Dipylidium caninum*)
93 Fleas
94 Ticks
95 *Sarcoptes*
96 *Demodex*
97 *Cheyletiella*
98 Ear Mites
99 Bibliography

Introduction

At one time or another, all of us in clinical practice have explained to clients such things as the pathology of a failing heart or a prolapsed intervertebral disk. Oftentimes, we've used radiographs or hand drawings to communicate important points. Irrespective of our artistic skills, such drawings and explanations transfer information to clients not only about specific diagnoses but also about the rationale behind therapeutic plans.

Hill's Pet Nutrition thinks client communications is vital to the success of veterinary practice. In accord with that philosophy, Hill's is proud to present the Hill's Atlas of Veterinary Clinical Anatomy - PDF Version – a desktop version of our exam-room atlas to heighten client communications.

Each illustration in the Atlas has been drawn by professional medical illustrators. Generally, the even numbered page depicts normal anatomy, and the odd numbered page a pathologic presentation. A brief outline of diagnostic, therapeutic, and dietary plans is included on the odd numbered page.

This arrangement will allow you to show clients normal anatomy and the pathology affecting their pets while you describe how your therapeutic plan will, if possible, return their pets to health and normal anatomy.

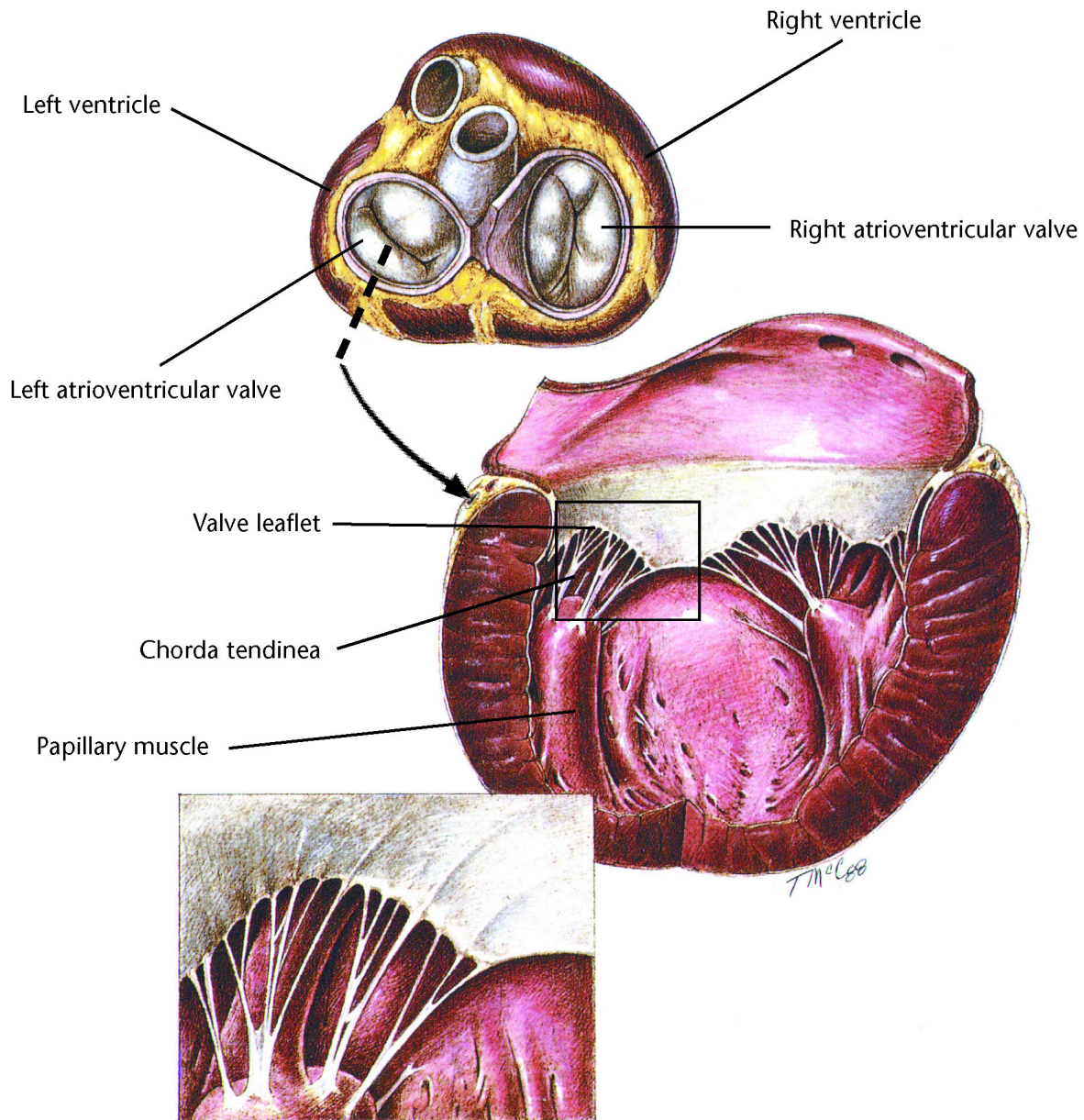
The Atlas contains eight sections- Refer to the contents pages for the page numbers and color assigned to each section. These blocks of color are placed around the page numbers at the top of each page. Each section has been assigned a different color for ease of use.

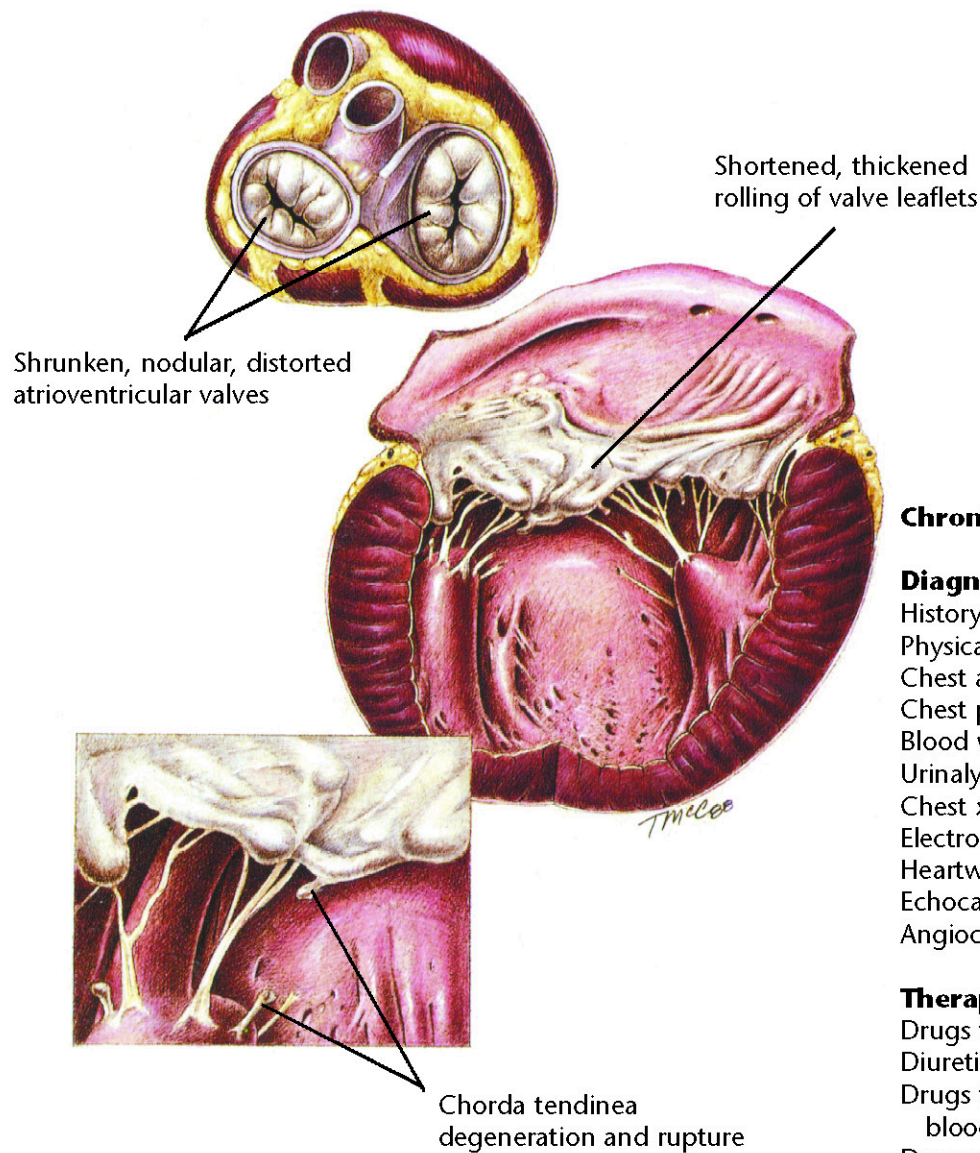
Every effort has been made to ensure the accuracy of the medical illustrations and the diagnostic, therapeutic, and nutritional plans in the Atlas. For example, each illustration has been reviewed by appropriate veterinary faculty at the College of Veterinary Medicine, Colorado State University. The Atlas is not intended to be an exhaustive review of anatomy, pathology, or medicine. For more information, consult the Bibliography, or call one of the Veterinary Consultation Service clinicians at Hills Pet Nutrition, Inc. (1-800-548-VETS).

This special PDF Version has been enhanced to make navigating the document as easy as possible. On the "Contents" pages simply click on the description for the atlas image you would like to see and you will immediately jump to that image. Click on the heading of each page or the Hill's Logo at the bottom of the page to return to the Table of Contents. Click on any image to see a full page view of that particular image. Of course the same navigation keys that typically work for other PDF files will work here as well.

We hope you enjoy this PDF enhanced version of the Hill's Atlas of Veterinary Clinical Anatomy. Feel free to print these images as client handouts or to aid in the education of your HealthCare Team.

Hill's Pet Nutrition, Inc.





Chronic Valvular Disease

Diagnostic Plan

History
Physical examination
Chest auscultation
Chest palpation
Blood work
Urinalysis
Chest x-rays
Electrocardiography
Heartworm check
Echocardiography
Angiocardiography

Therapeutic Plan

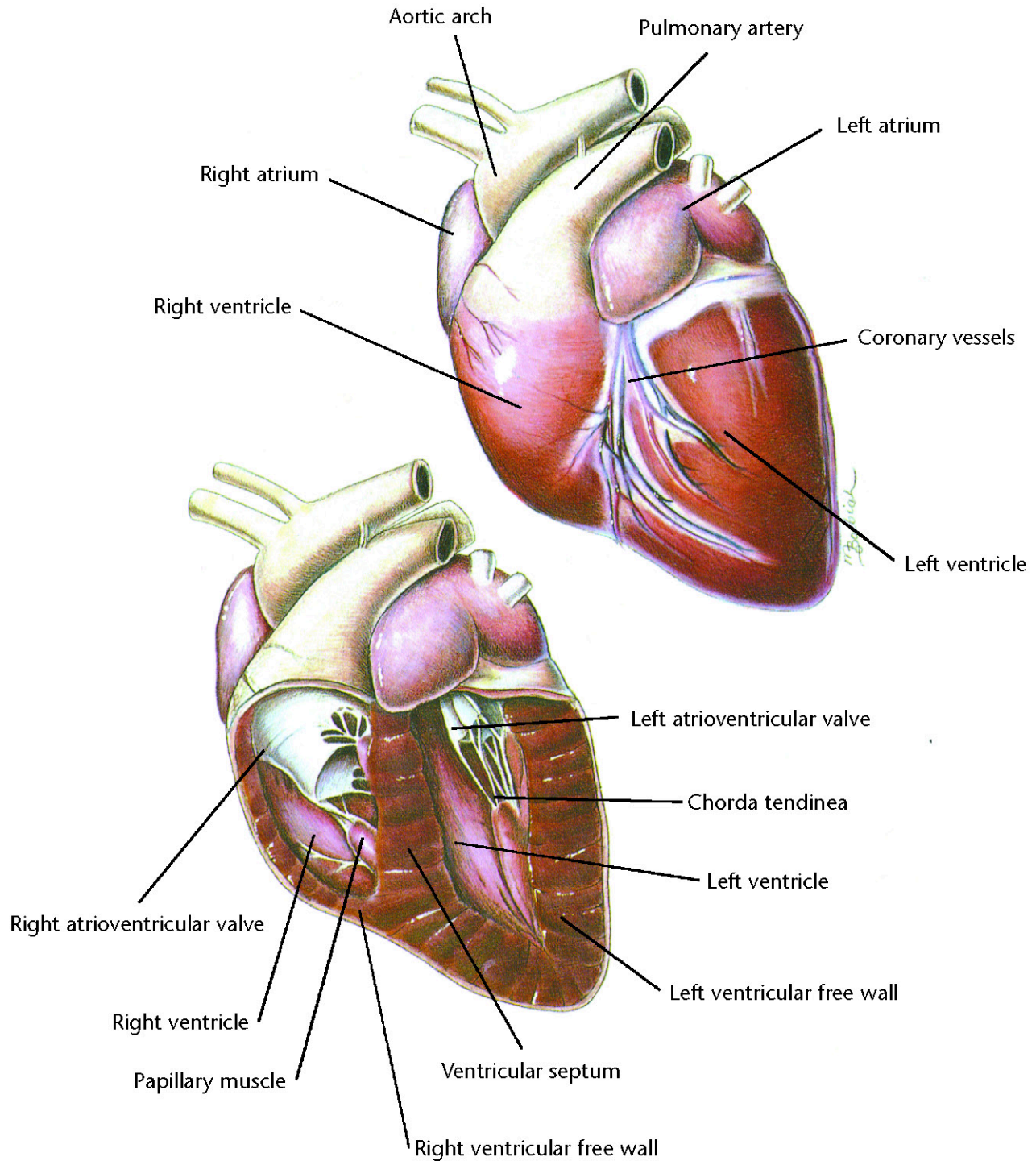
Drugs to strengthen the heart
Diuretics
Drugs that dilate blood vessels
Drugs that correct abnormal heart rhythms
Exercise restriction

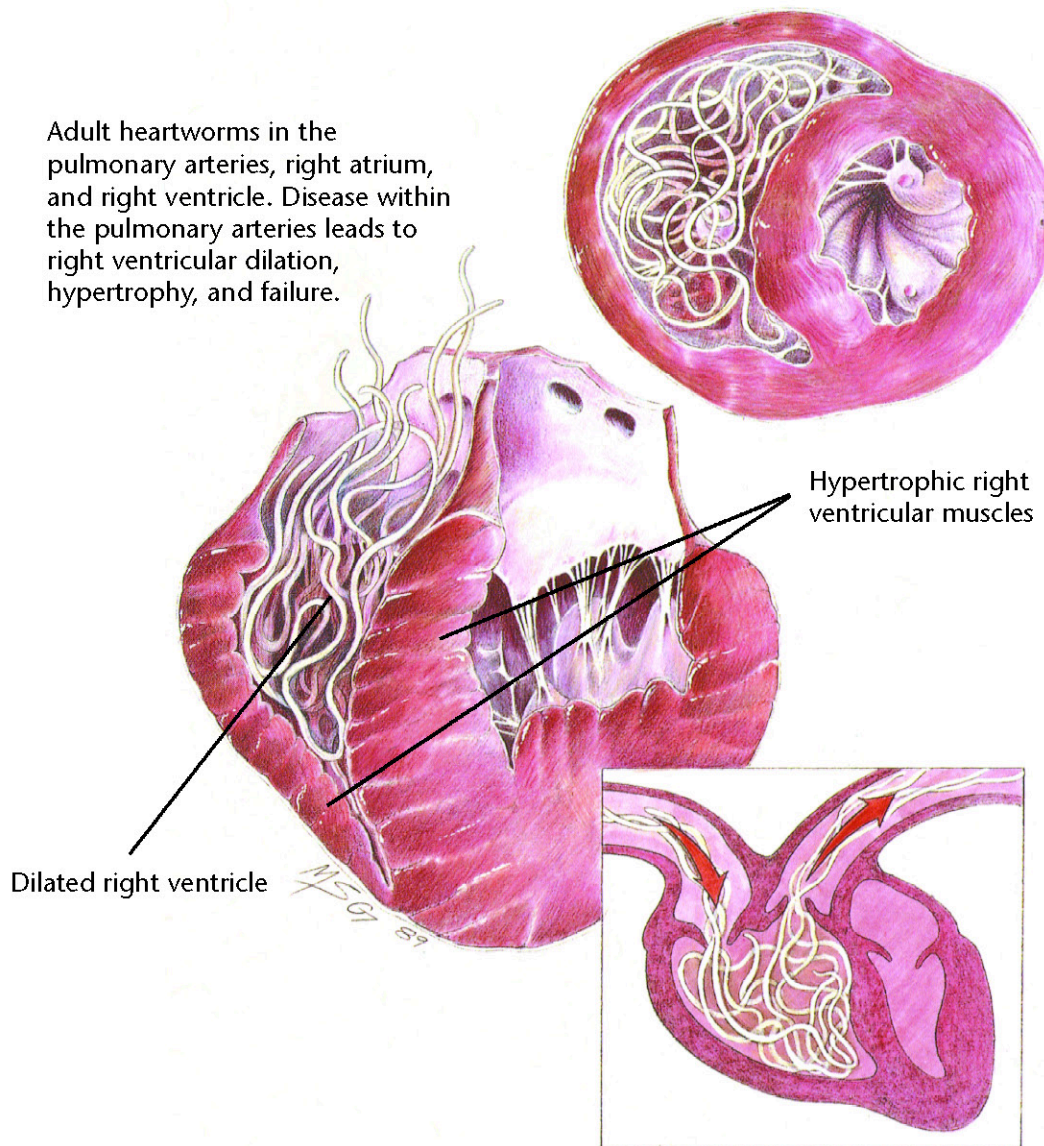
Dietary Plan

A mildly restricted sodium diet
or a moderately restricted sodium diet
If necessary, change to a severely restricted sodium diet

Hill's Atlas of Veterinary Clinical Anatomy

Normal Canine Heart





Heartworm Disease

Diagnostic Plan

History
Physical examination
Heartworm check
Blood work
Urinalysis
Chest x-rays
Electrocardiography
Echocardiography

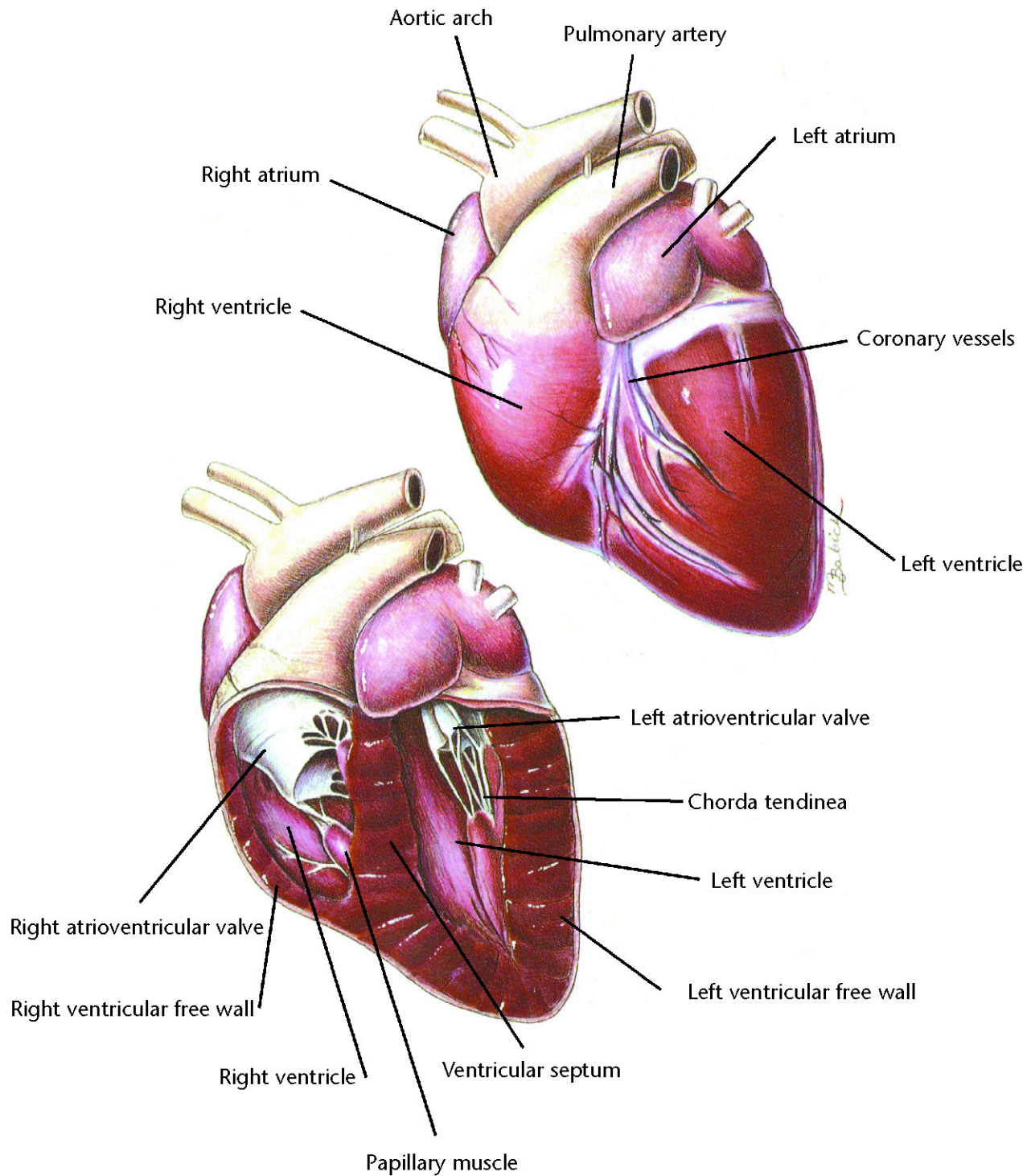
Therapeutic Plan

Drugs to kill adult worms
Restricted exercise
Aspirin
Corticosteroids
Drugs to kill larvae
in the bloodstream
Prevention
Surgery

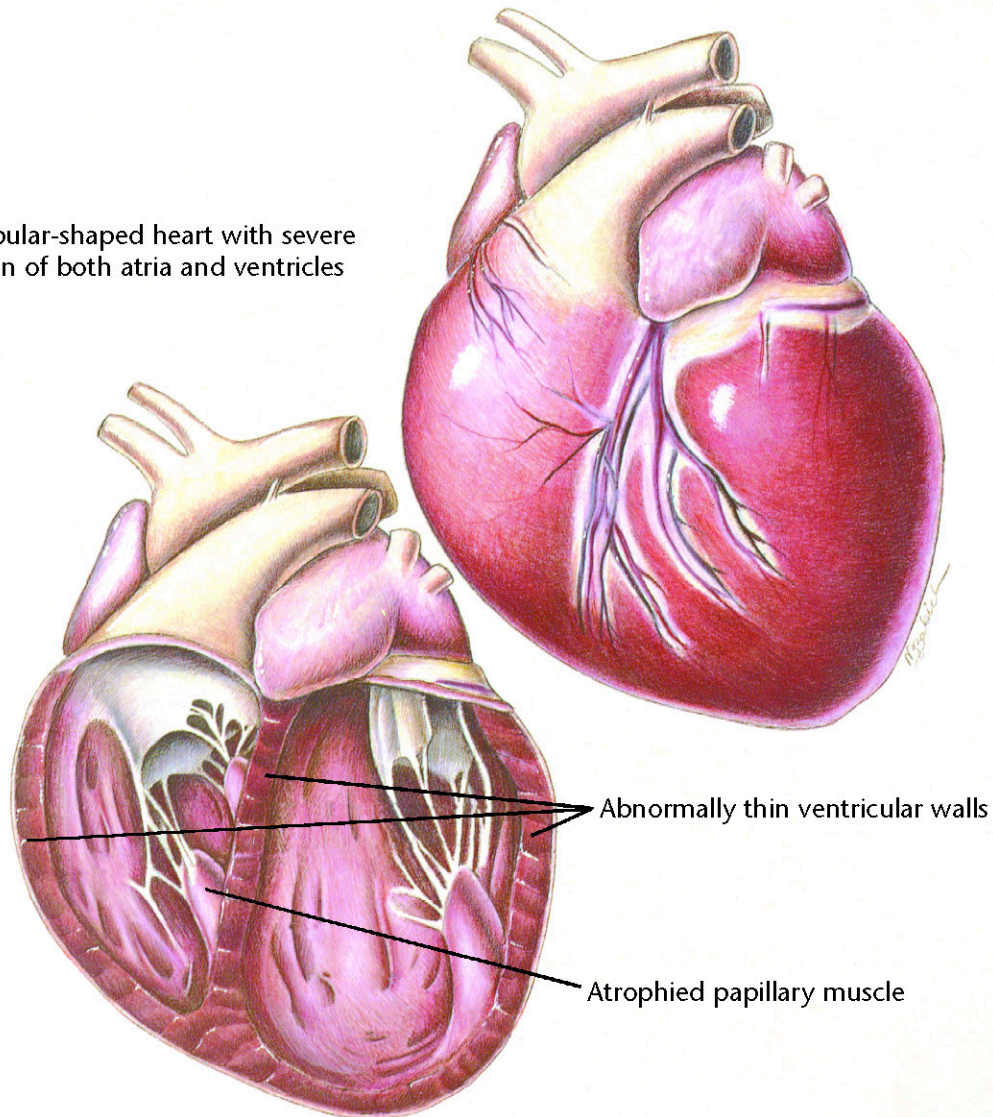
Dietary Plan

A diet with controlled levels of
protein, phosphorus and sodium
Consider body condition





A globular-shaped heart with severe dilation of both atria and ventricles



Canine Dilated Cardiomyopathy

Diagnostic Plan

History
Physical examination
Urinalysis
Blood work
Chest x-rays
Electrocardiography
Echocardiography
X-rays of the heart after dye injection

Therapeutic Plan

Enforced rest
Removal of fluid from the chest and abdomen
Diuretics
Drugs that strengthen the heart
Drugs that dilate blood vessels
Bronchodilators
Oxygen therapy

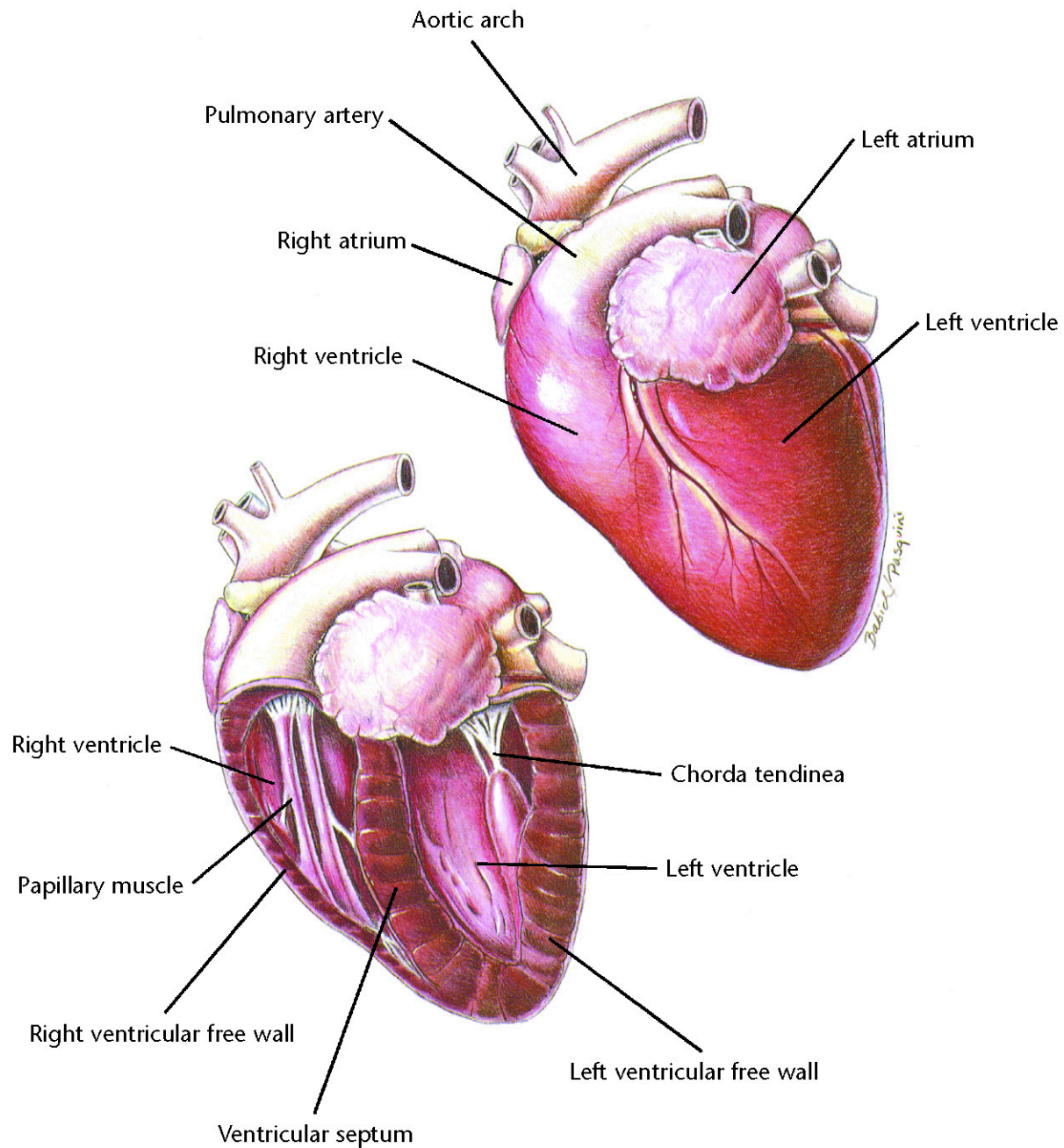
Dietary Plan

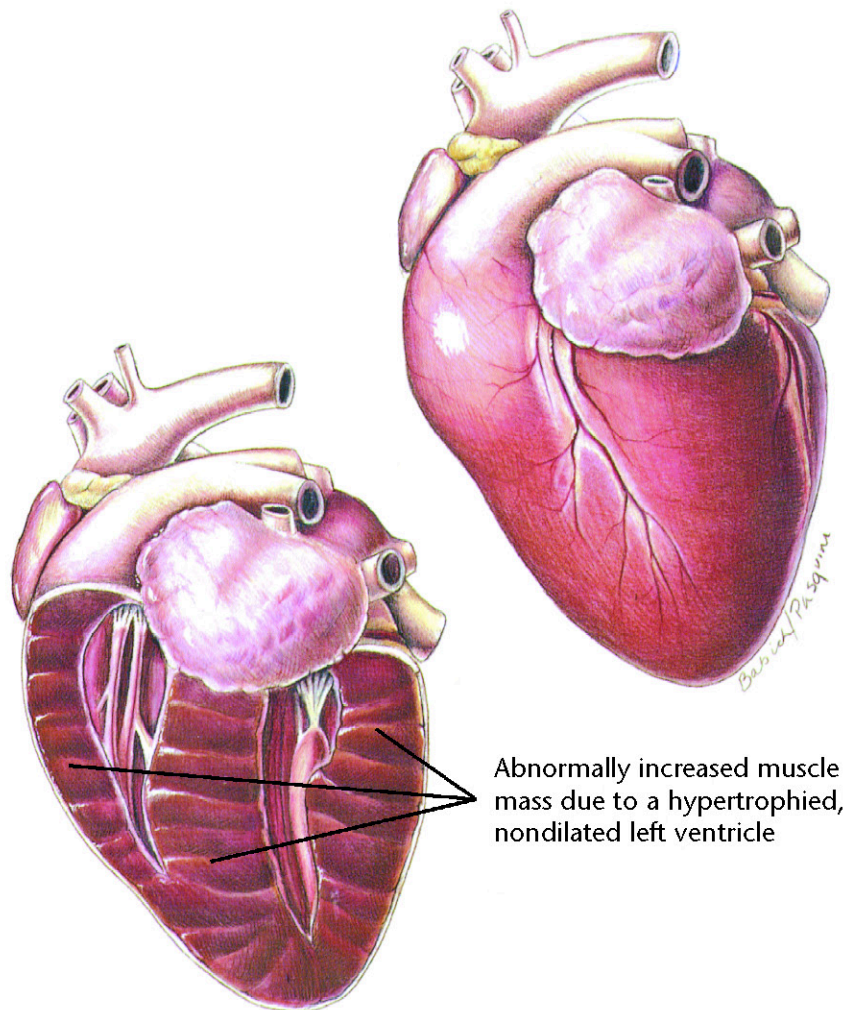
A diet that avoids excess levels of sodium



Hill's Atlas of Veterinary Clinical Anatomy

Normal Feline Heart





Feline Hypertrophic Cardiomyopathy

Diagnostic Plan

History
Physical examination
Chest auscultation
Palpation of femoral pulses
and hindlimb musculature
Blood work
Urinalysis
Electrocardiography
Chest x-rays
Echocardiography
X-rays of the heart and
abdominal blood vessels
after dye injection

Therapeutic Plan

Enforced rest
Bronchodilators
Oxygen therapy
Removal of fluid from
the chest and abdomen
Drugs that dilate blood vessels
Aspirin
Beta blockers
Heparin
Surgery

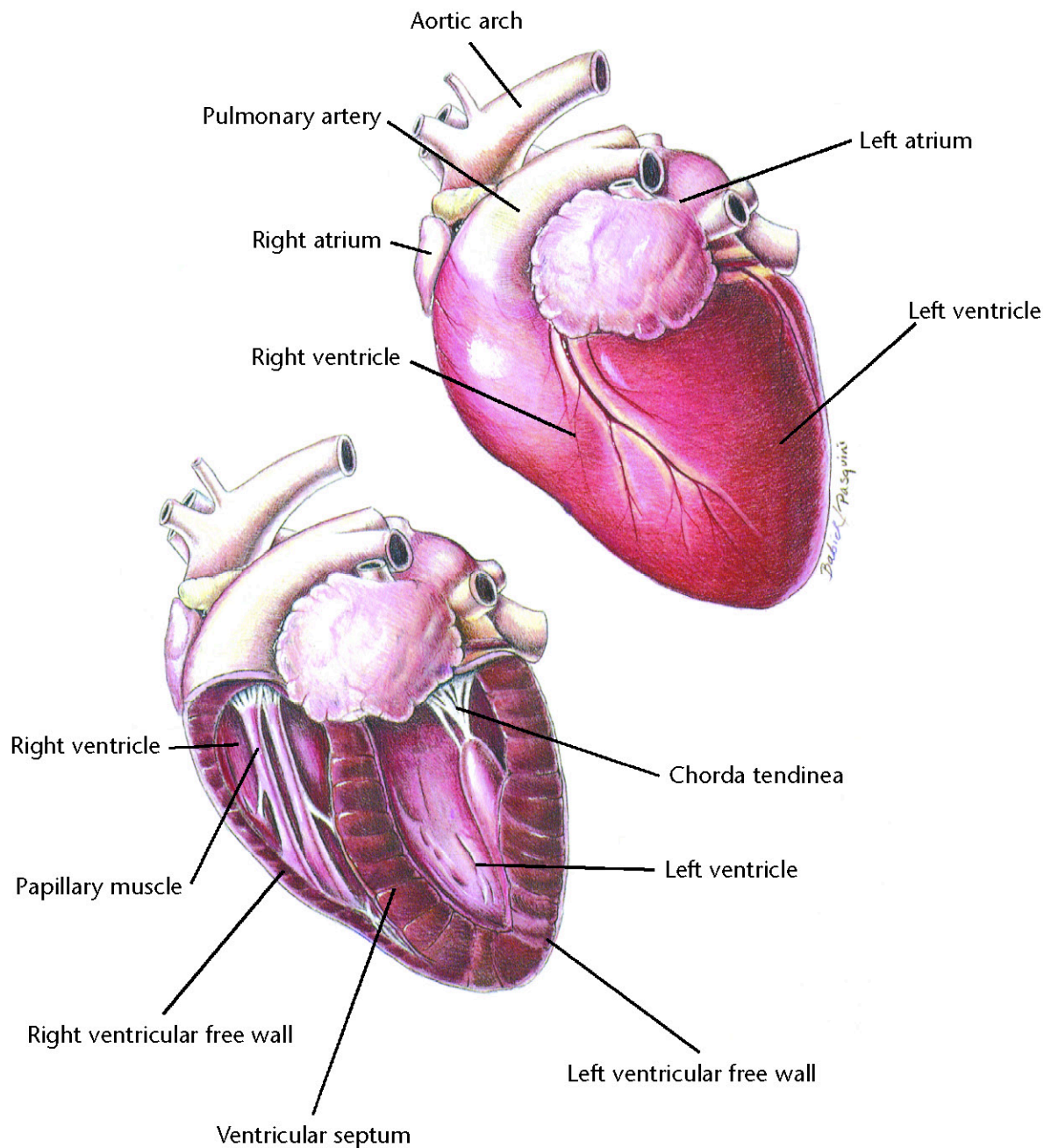
Dietary Plan

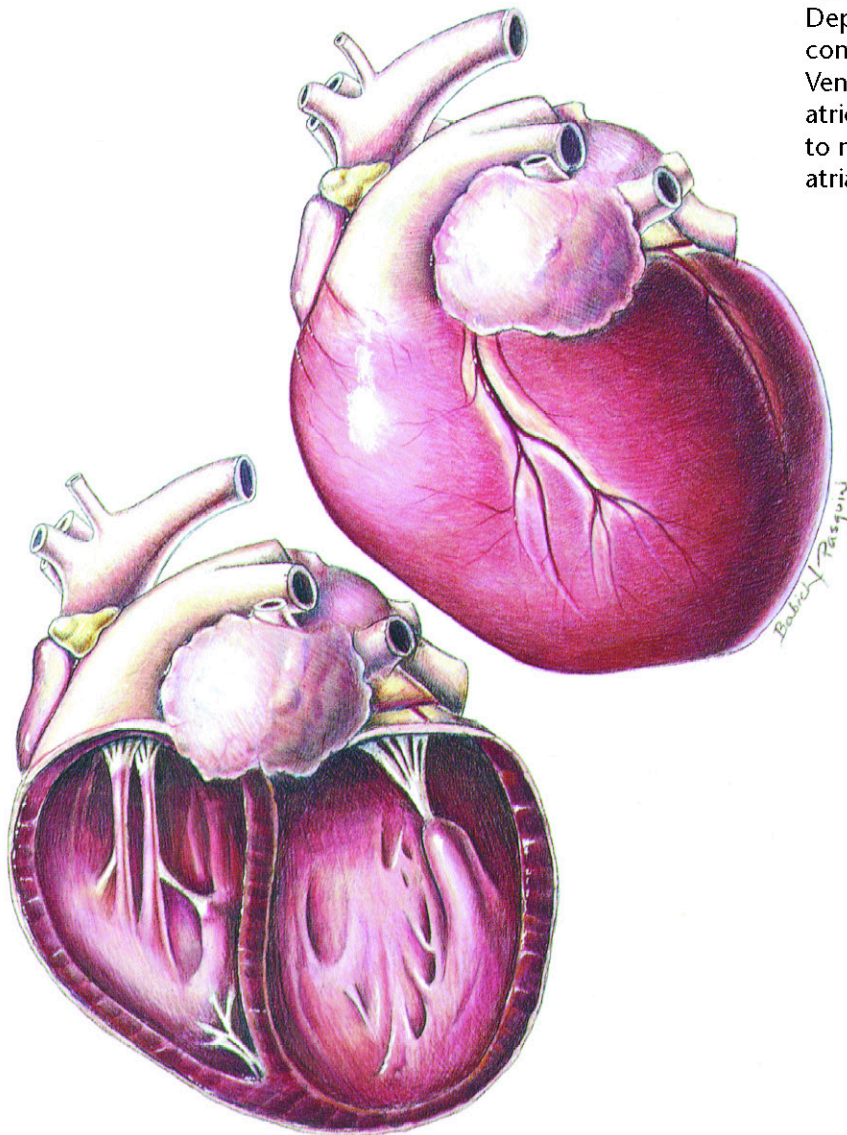
A diet that avoids excess
levels of sodium



Hill's Atlas of Veterinary Clinical Anatomy

Normal Feline Heart





A globular heart with severe dilation of the four chambers. Depressed ventricular contractile performance occurs. Ventricular dilation distorts the atrioventricular valves leading to mitral regurgitation and atrial enlargement.

Feline Dilated Cardiomyopathy

Diagnostic Plan

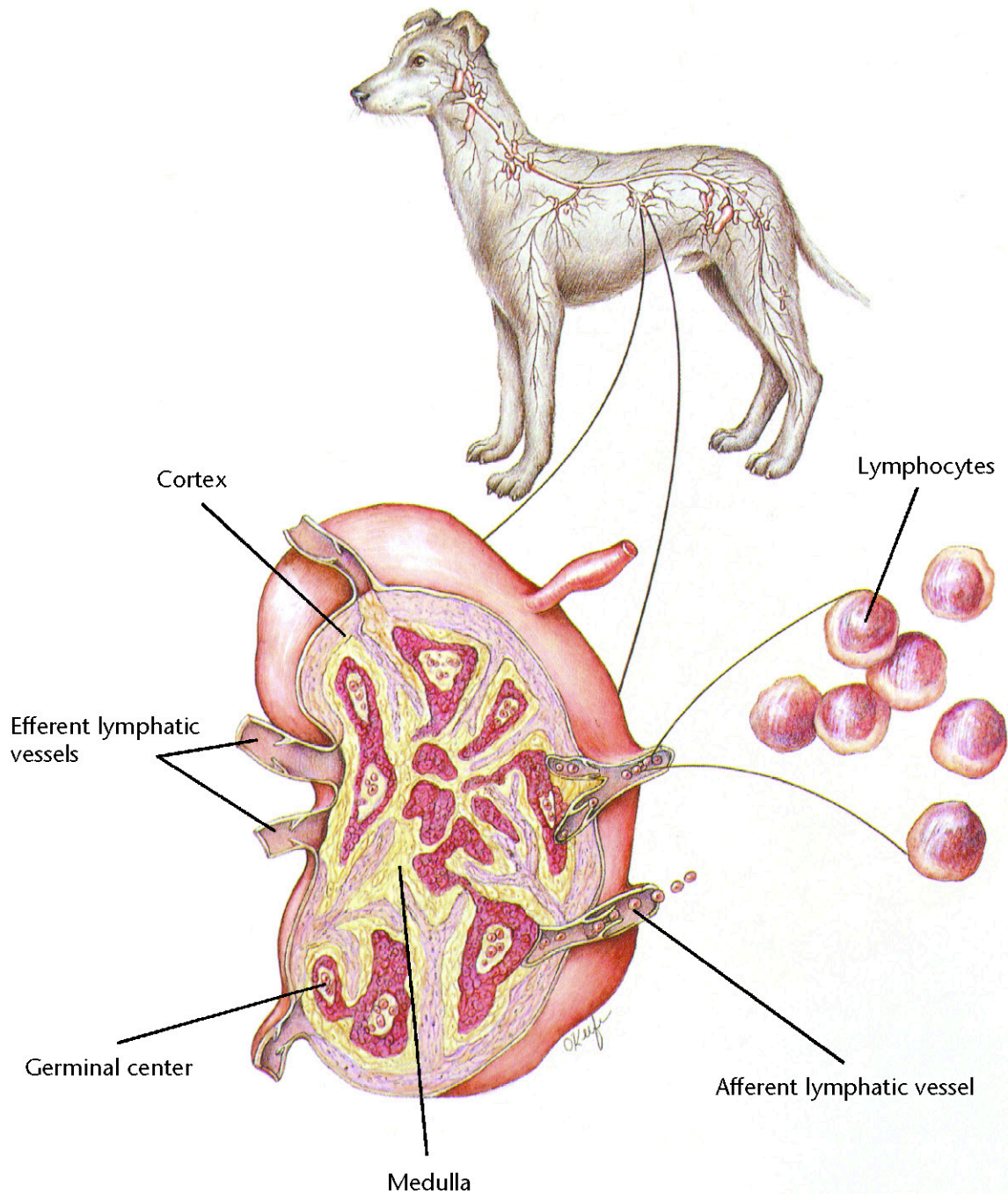
History
Physical examination
Chest auscultation
Palpation of femoral pulses and hindlimb musculature
Blood work
Urinalysis
Electrocardiography
Chest x-rays
Echocardiography
X-rays of the heart and abdominal blood vessels after dye injection
Plasma taurine analysis

Therapeutic Plan

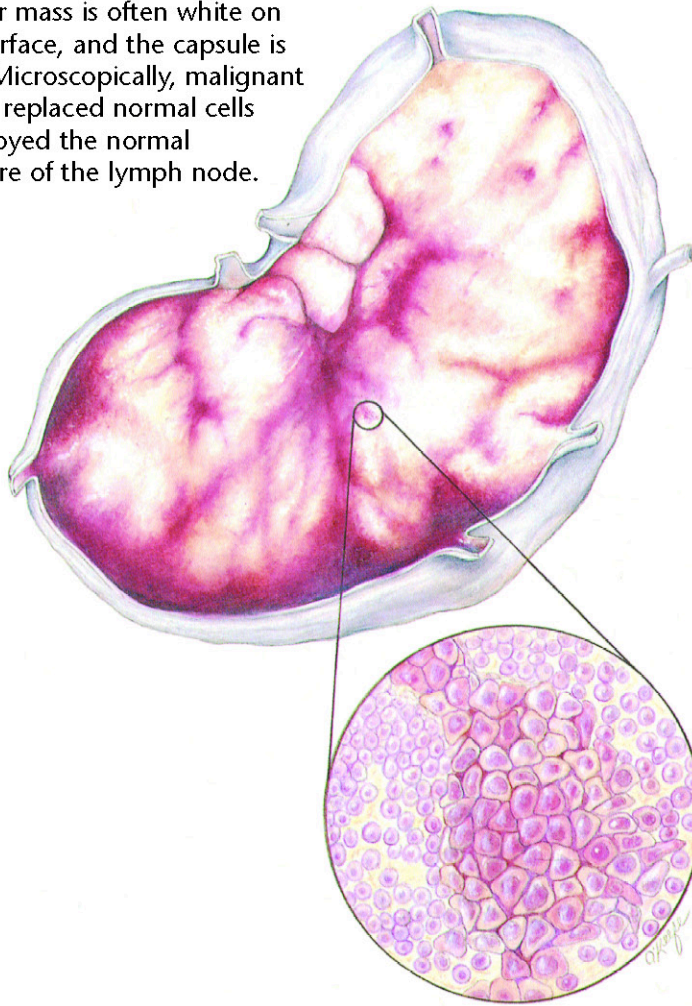
Enforced rest
Diuretics
Bronchodilators
Oxygen therapy
Removal of fluid from the chest and abdomen
Drugs that dilate blood vessels
Drugs that strengthen the heart
Heparin
Surgery

Dietary Plan

A diet that contains adequate levels of taurine and avoids excess levels of sodium



The tumor mass is often white on the cut surface, and the capsule is thinned. Microscopically, malignant cells have replaced normal cells and destroyed the normal architecture of the lymph node.



Lymphosarcoma

Diagnostic Plan

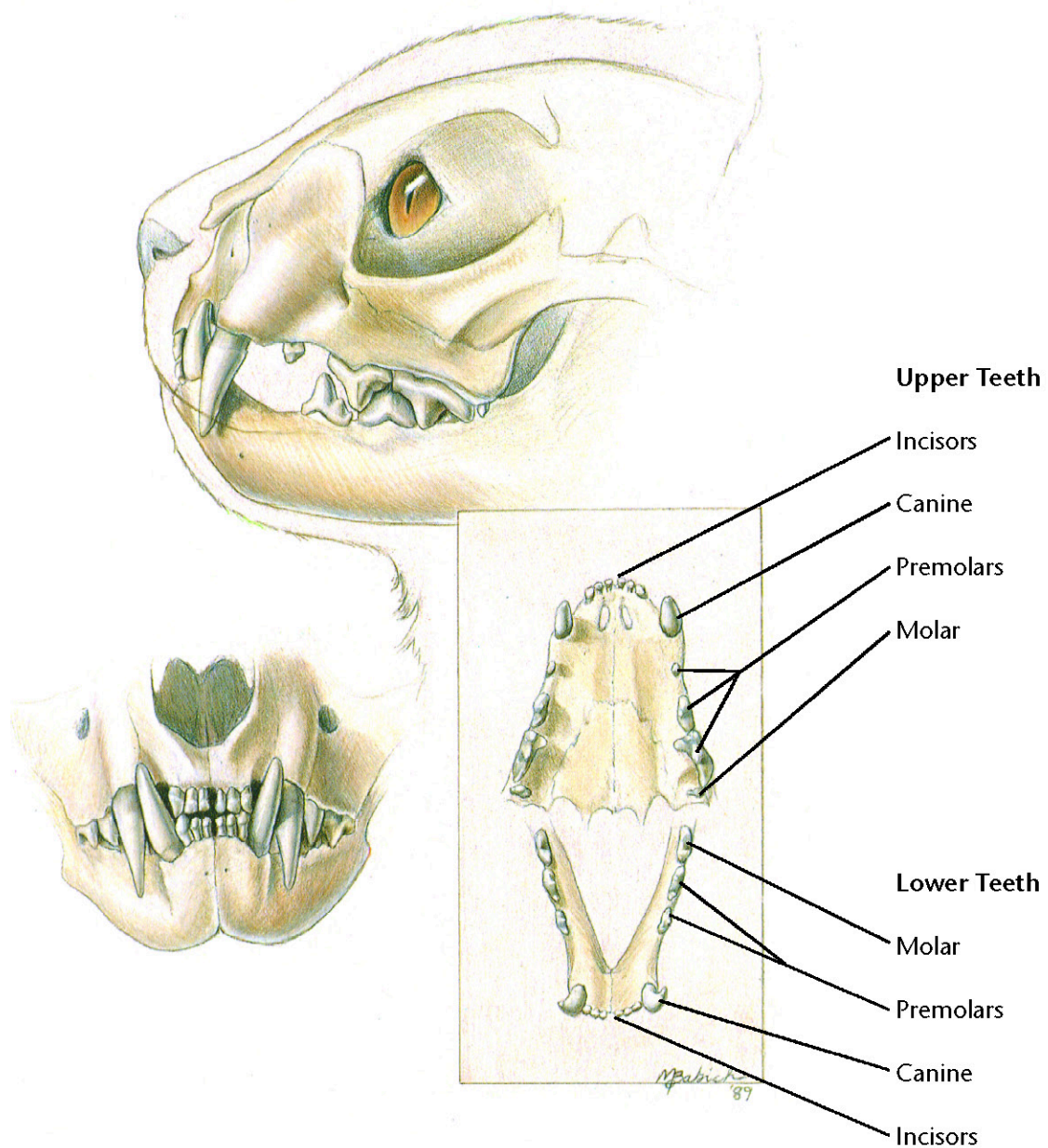
- History
- Physical examination
- Blood work
- FelV test (for cats)
- X-rays
- Urinalysis
- Biopsy of tissue
- Cell studies
- Endoscopy
- Exploratory surgery
- Examinations of chest and abdominal fluid
- Bone marrow biopsy
- Cerebral spine fluid examination

Therapeutic Plan

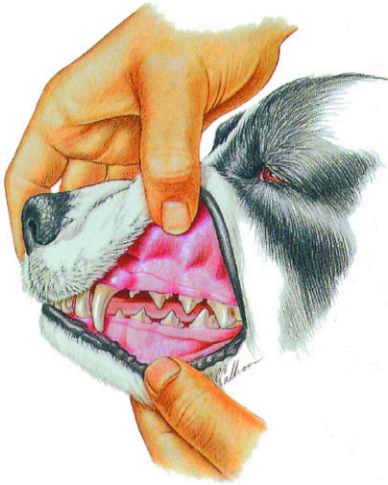- Supportive therapy
- Chemotherapy
- Surgical excision
- Radiation

Dietary Plan

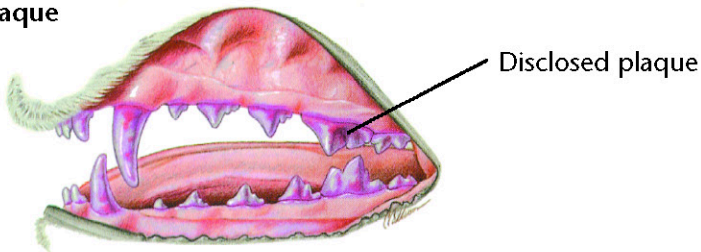
A diet based on individual patient evaluation including body condition and other organ system involvement or disease



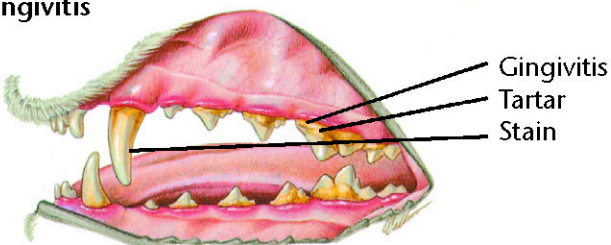
Normal Dental Examination



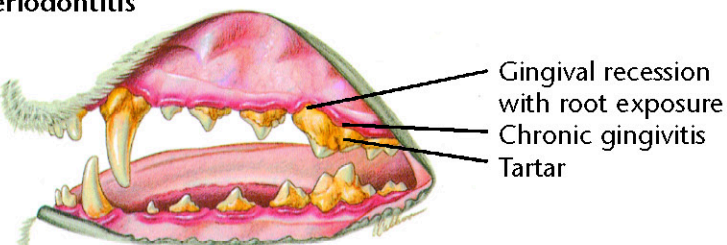
Plaque



Gingivitis



Periodontitis



Periodontal Disease

Diagnostic Plan

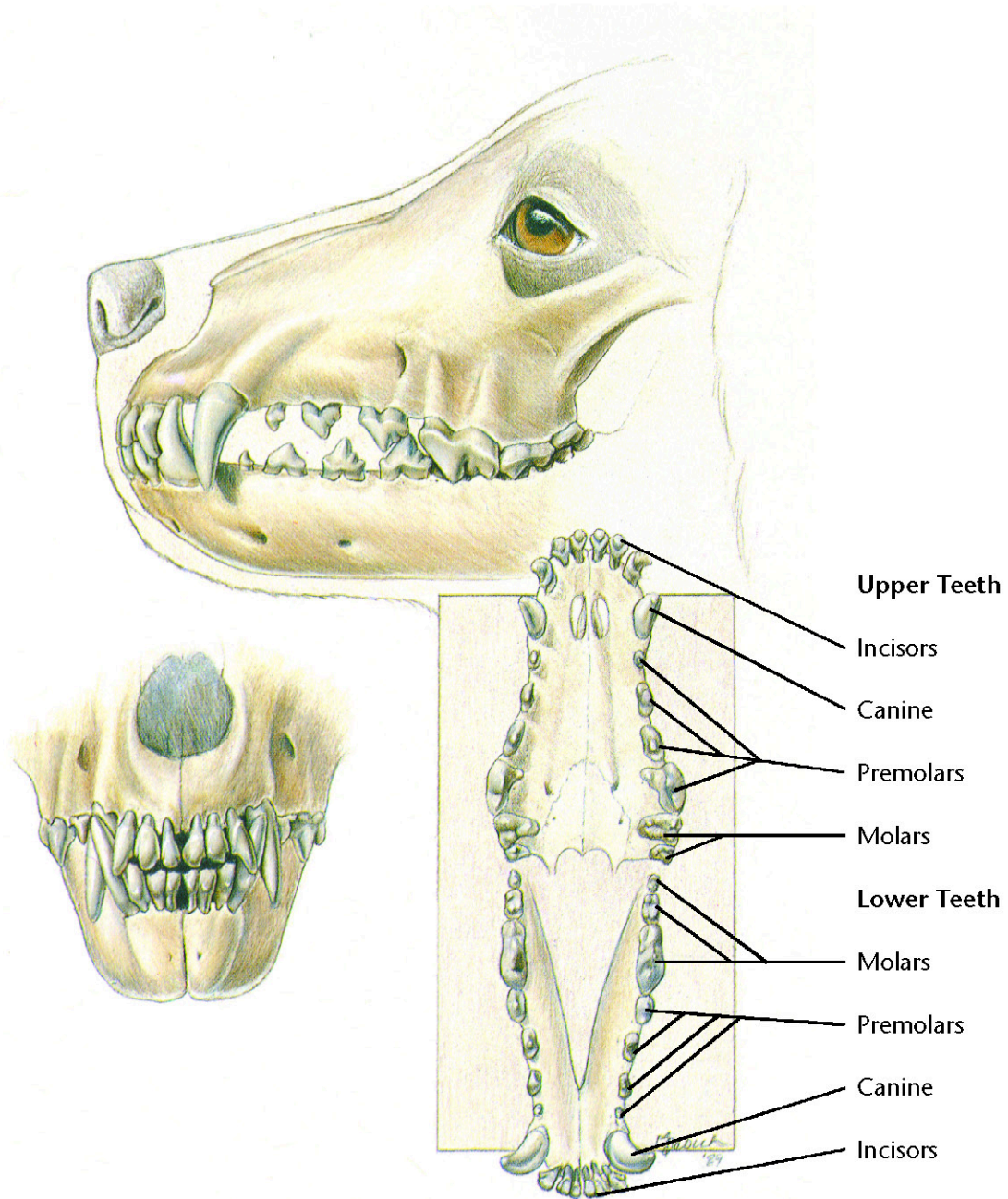
History
Physical examination
Oral examination
Dental x-rays

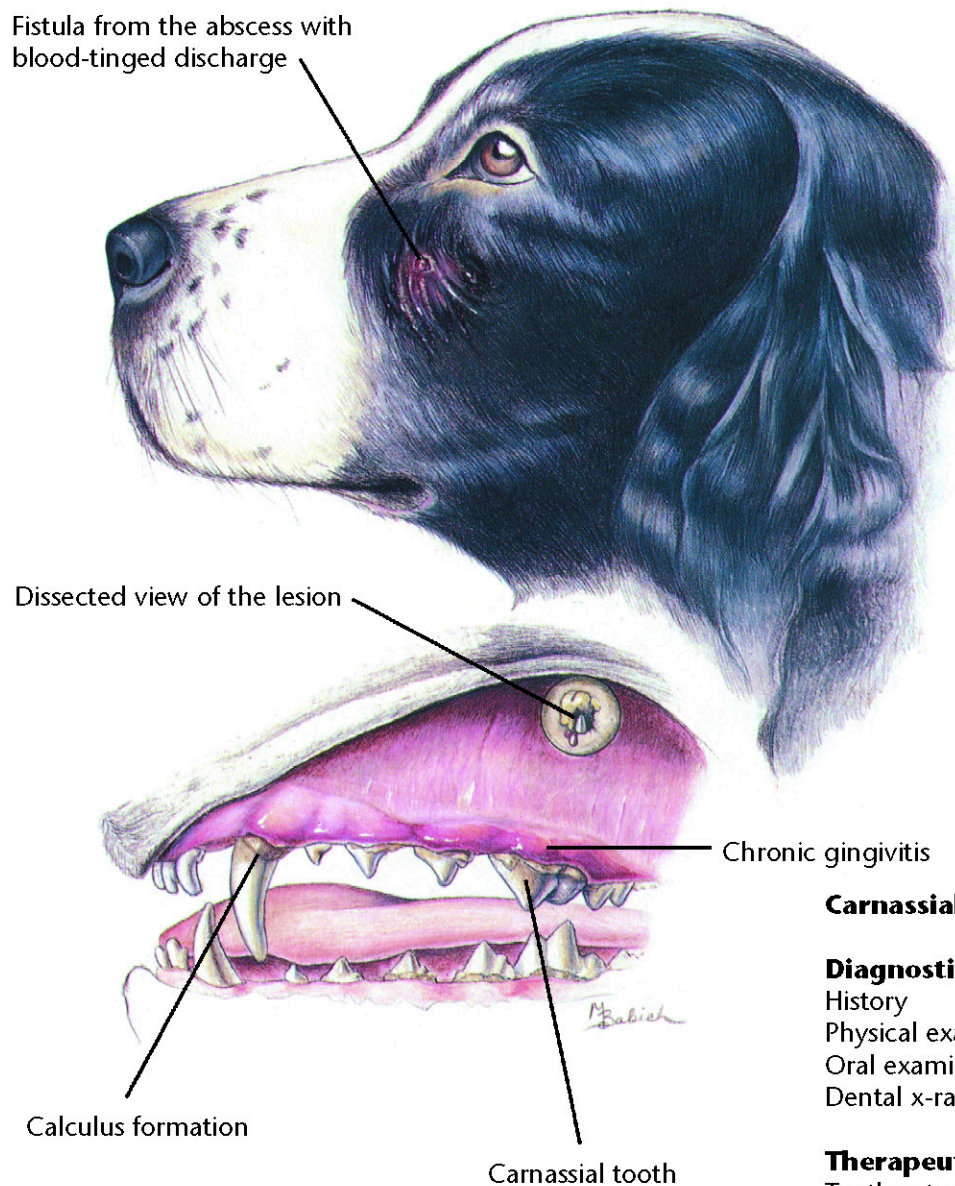
Therapeutic Plan

Tooth scaling above and below the gumline
Tooth polishing
Extraction
Surgery
Antibacterials
Tooth brushing

Dietary Plan

Postsurgery or extractions, a food with nutritional characteristics that support tissue repair. A soft food may minimize postprocedural discomfort. Long term, a food with formulation and texture that slows the accumulation of plaque and tartar.





Carnassial Tooth Abscess

Diagnostic Plan

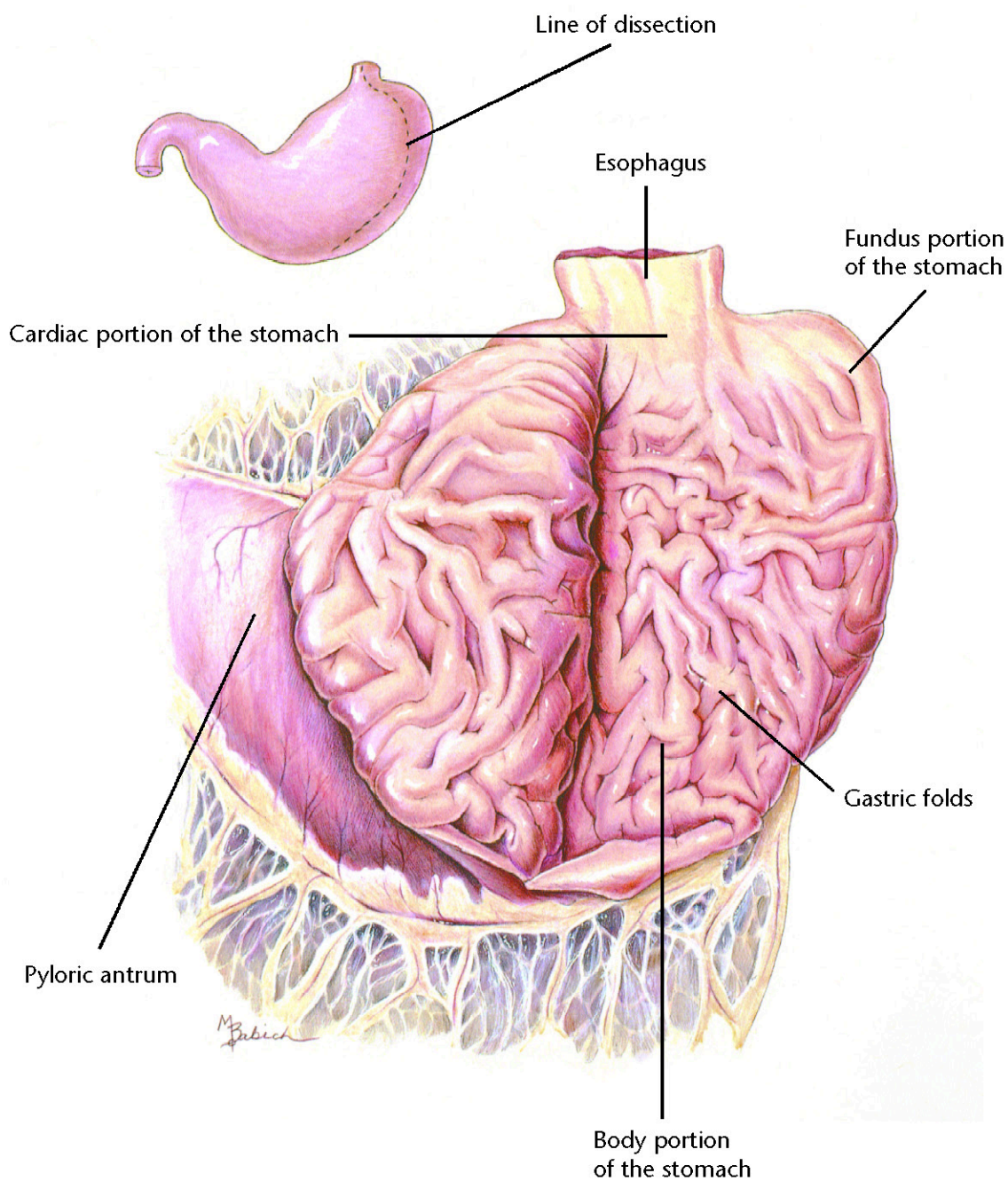
History
Physical examination
Oral examination
Dental x-rays

Therapeutic Plan

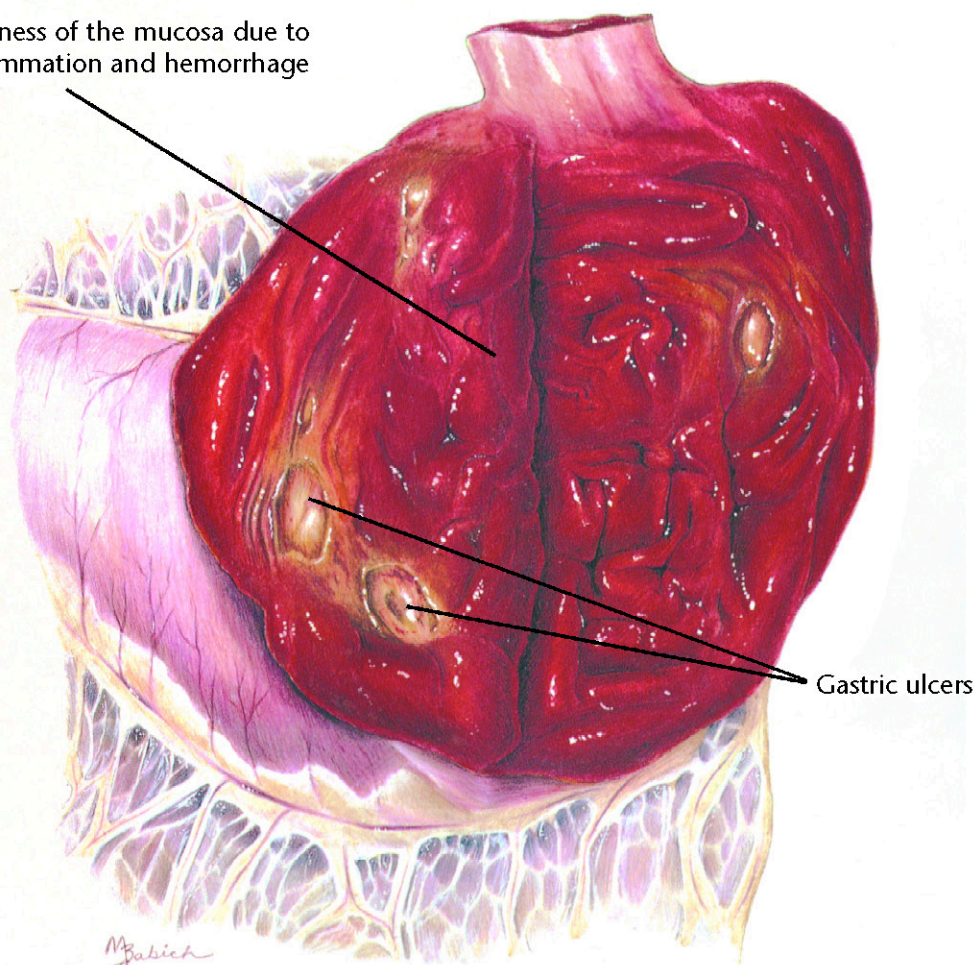
Tooth extraction
Root canals
Antibiotics

Dietary Plan

A diet based on overall patient evaluation including body condition and other organ system involvement
A soft diet may minimize postsurgical pain



Diffuse redness of the mucosa due to active inflammation and hemorrhage



Gastric ulcers

Hemorrhagic Gastritis with Ulcers

Diagnostic Plan

History
Physical examination
Blood work
Stool check for blood
Stool check for parasites
Urinalysis
X-rays of the stomach
Endoscopy
Gastric fluid analysis
Gastric biopsy

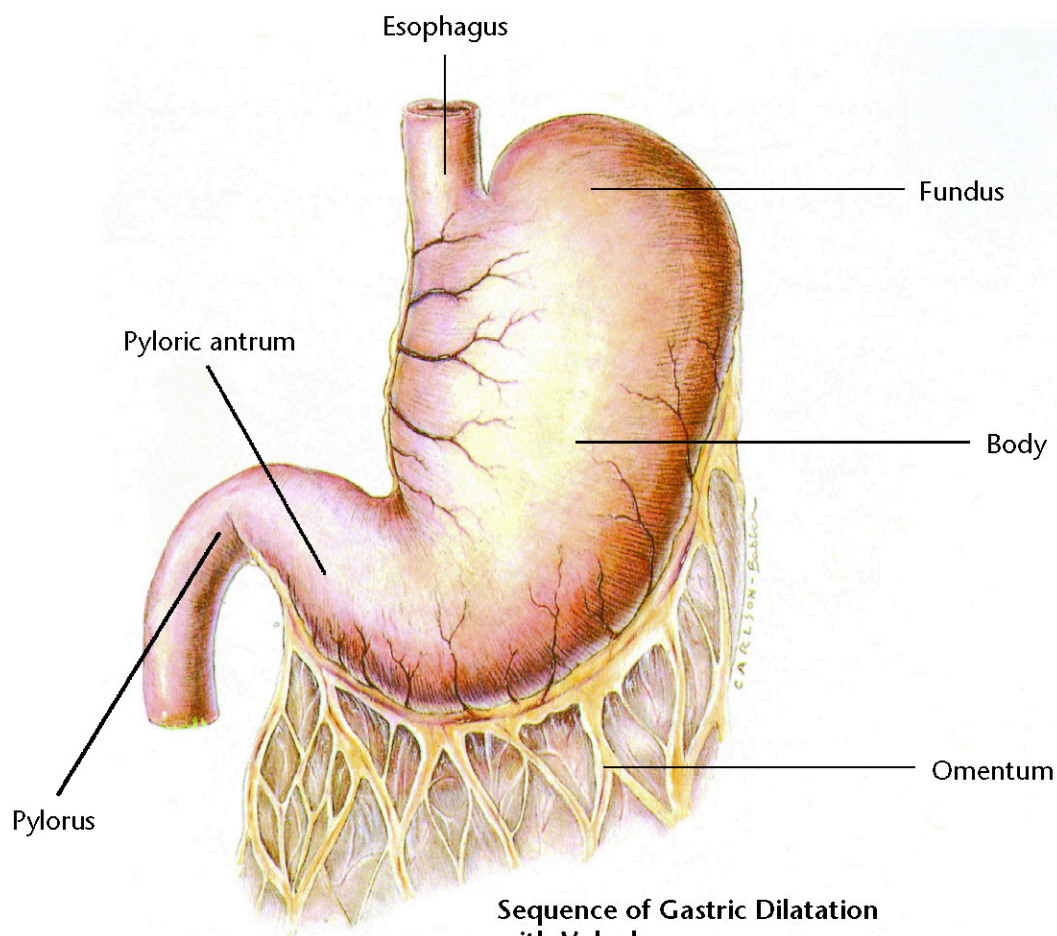
Therapeutic Plan

Nothing orally for 12 to 24 hours
Fluid therapy
Gastric lavage
Antiemetic drugs
Whole blood
Drugs to inhibit gastric acid secretion
Surgery

Dietary Plan

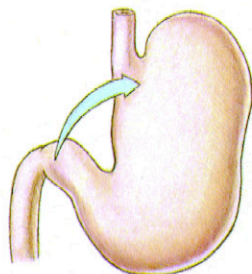
A diet based on overall patient evaluation including body condition and other organ systems
A diet with moderate protein and moderate to low levels of fat and fiber to minimize dietary-induced delays in gastric emptying
For pets with gastritis caused by food allergy, a hypoallergenic diet



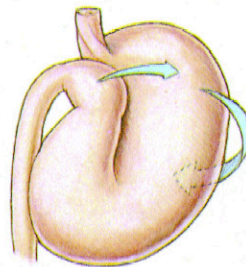


Sequence of Gastric Dilatation with Volvulus

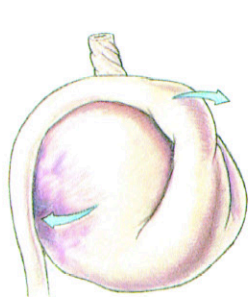
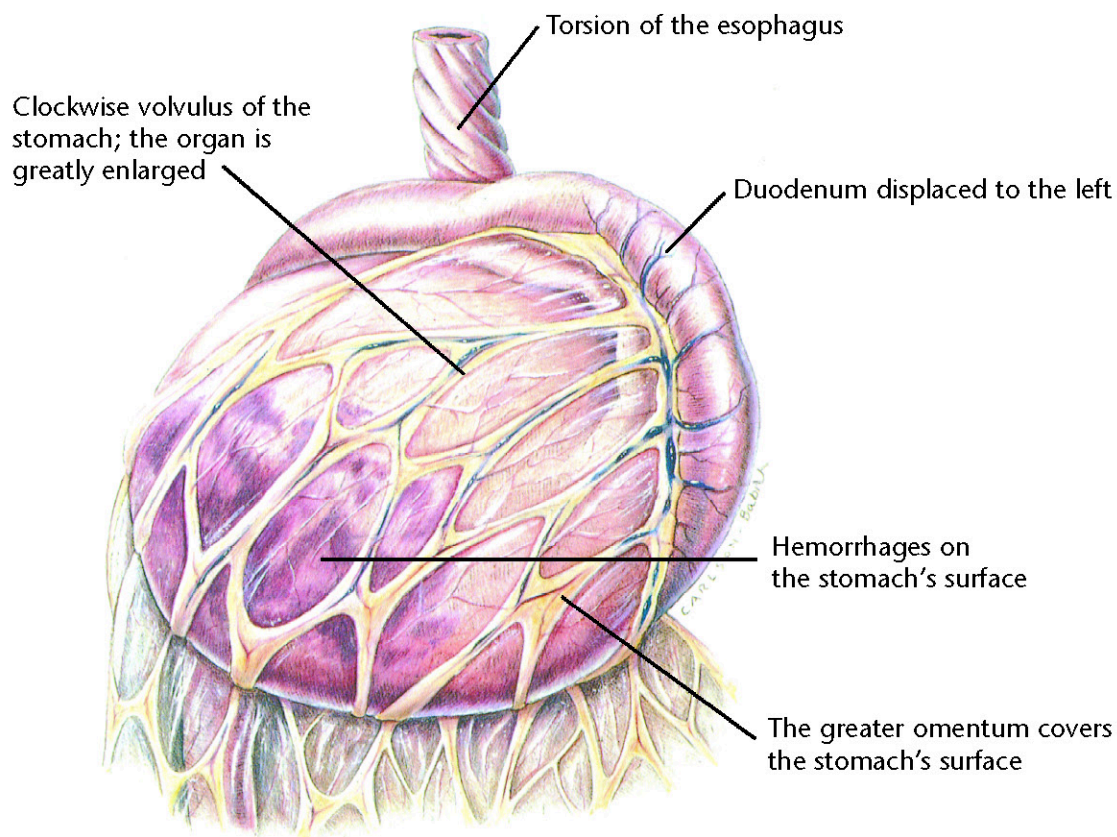
Clockwise rotation as viewed from a ventral position



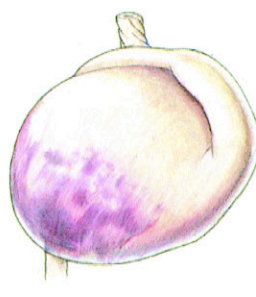The pyloric antrum is displaced downward.



The pylorus crosses the midline, passes underneath the distended proximal part of stomach, and moves upward along the left abdominal wall.



The gastric fundus moves ventrally and becomes located in the ventral abdomen.



The continuing gastric dilatation displaces the greater curvature ventrally.

Gastric Dilatation with Volvulus

Diagnostic Plan

History
Physical examination
X-ray of the stomach
Blood work

Therapeutic Plan

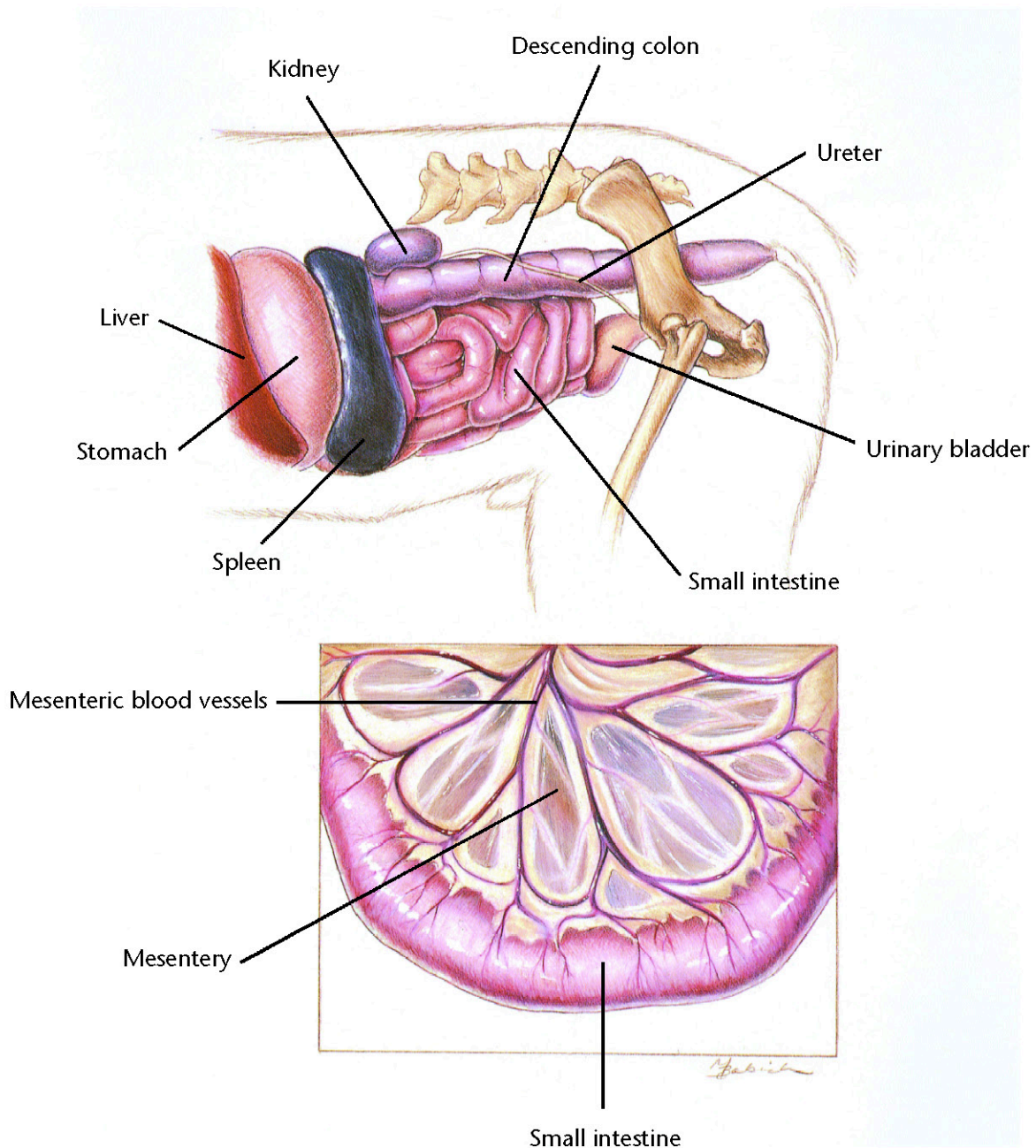
Stomach distention relief
Shock therapy
Surgery

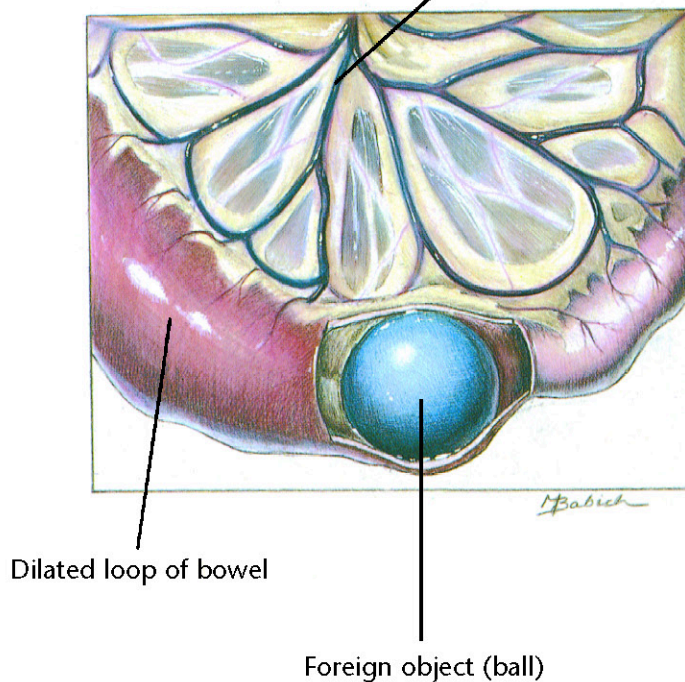
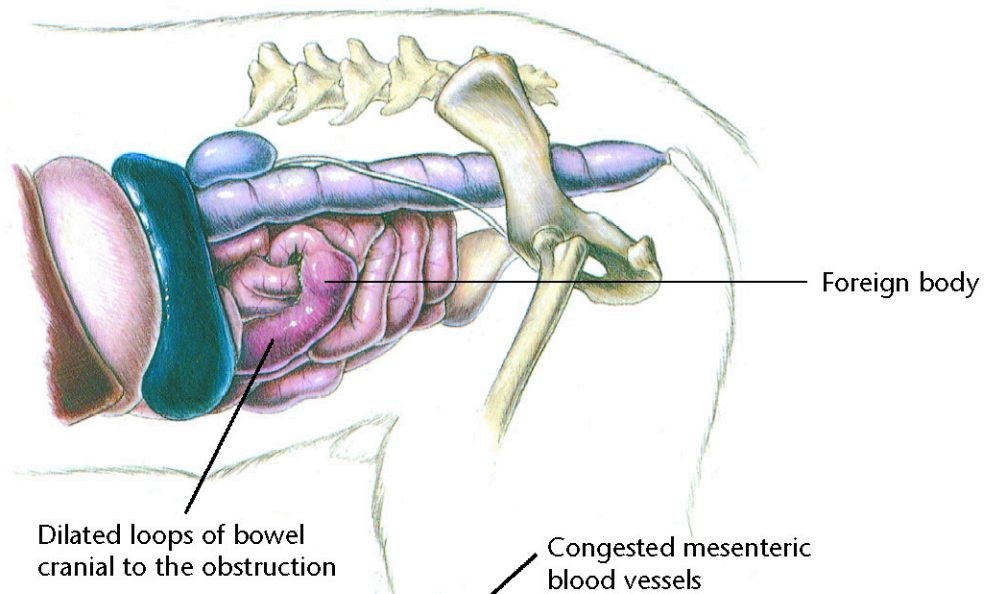
Dietary Plan

A low-residue diet, fed in small portions
Avoid excessive postprandial exercise

Hill's Atlas of Veterinary Clinical Anatomy

Normal Small Intestine





Foreign Bodies

Diagnostic Plan

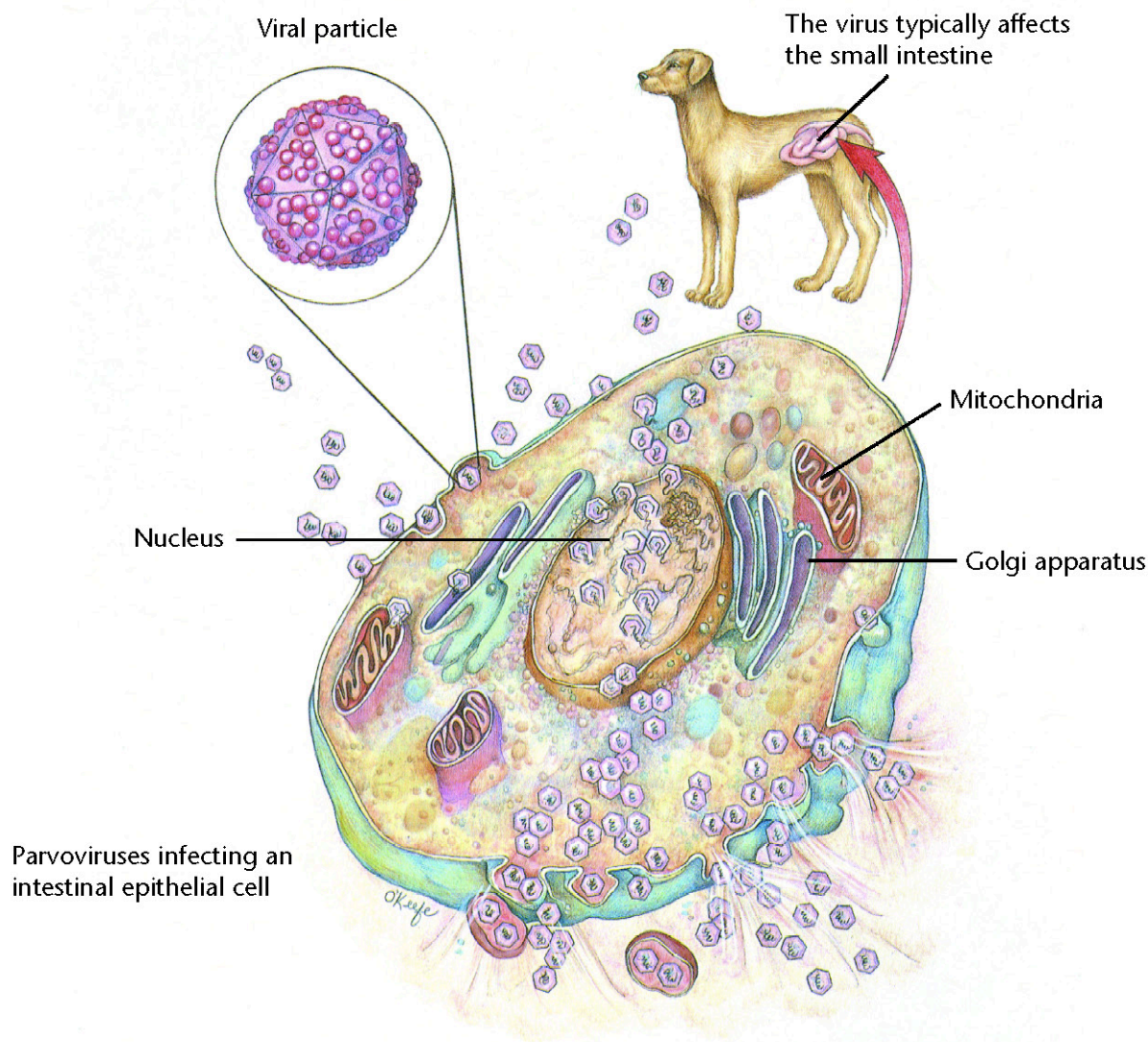
History
Physical examination
Abdominal palpation
Abdominal x-rays
Upper G.I. series
Stool analysis
Blood tests
Urinalysis
Endoscopy

Therapeutic Plan

Fluid therapy
Antibacterials
Surgery (to remove foreign bodies)
Nothing by mouth for 24-48 hours

Dietary Plan

Postsurgically, a low-residue diet fed in small portions
Consider overall patient condition when determining the protein level and caloric density of the diet



Parvoviral Enteritis

Diagnostic Plan

History
Physical examination
Stool analysis
Blood tests
Urinalysis
Abdominal x-rays
Upper G.I. series
Endoscopy with tissue biopsy

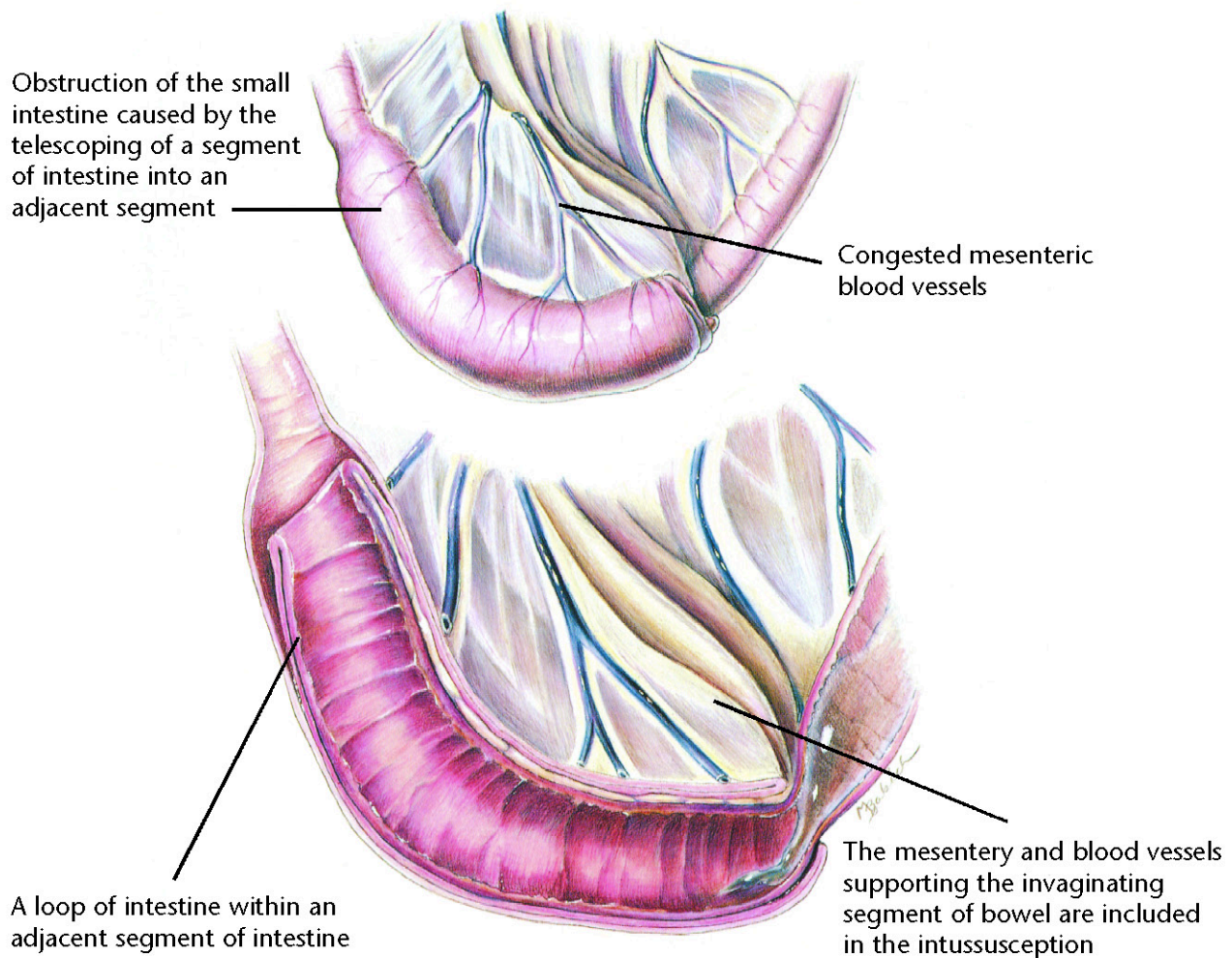
Therapeutic Plan

Nothing by mouth
Fluid therapy
Intestinal protectants
Antibacterials
Analgesics

Dietary Plan

A highly digestible diet
Consider overall patient condition when determining the protein level and caloric density of the diet





Intussusception

Diagnostic Plan

History
Physical examination
Abdominal palpation
Abdominal x-rays

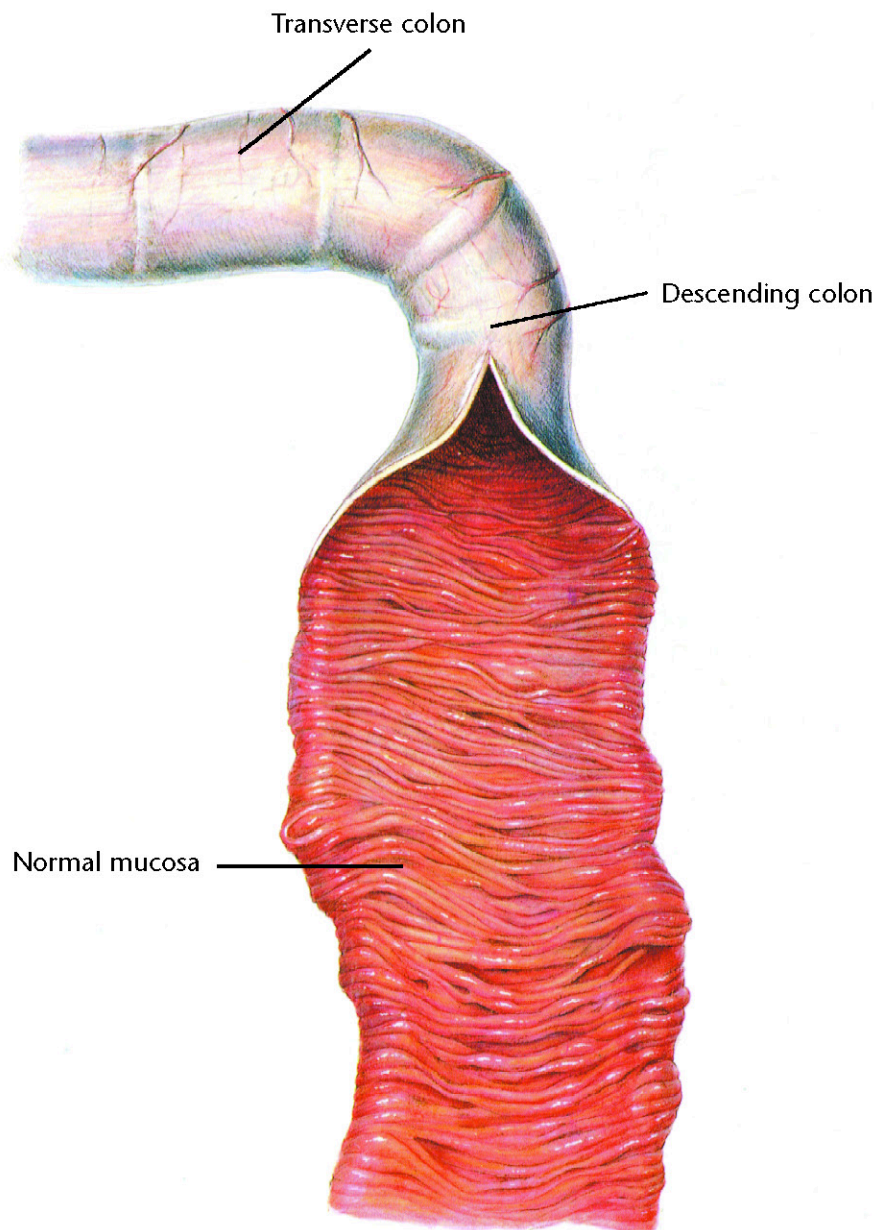
Therapeutic Plan

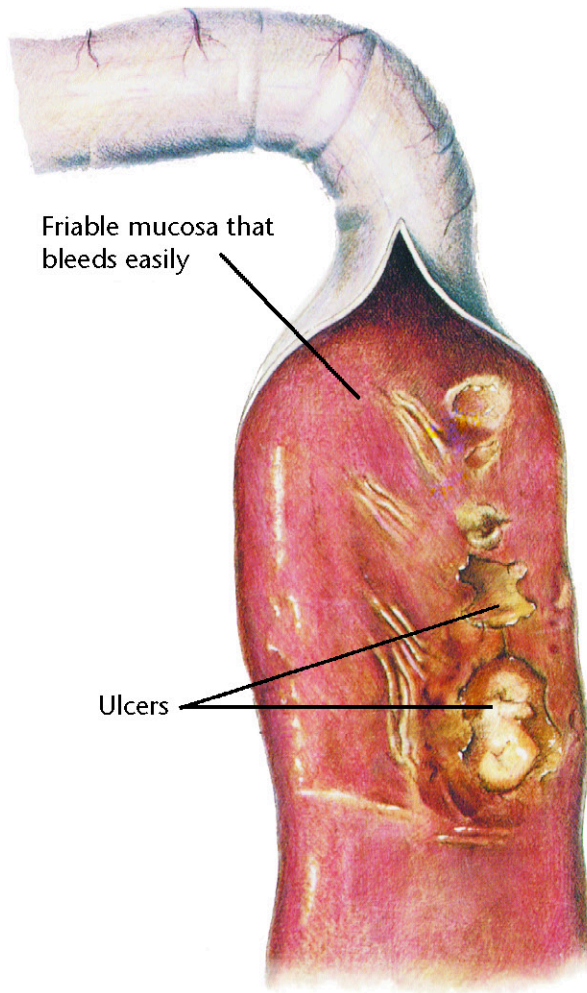
Fluid therapy
Surgery
Removal of the cause
Nothing by mouth

Dietary Plan

Postsurgically, a low-residue diet fed in small portions
Consider overall patient condition when determining the protein level and caloric density of the diet







Chronic Colitis

Diagnostic Plan

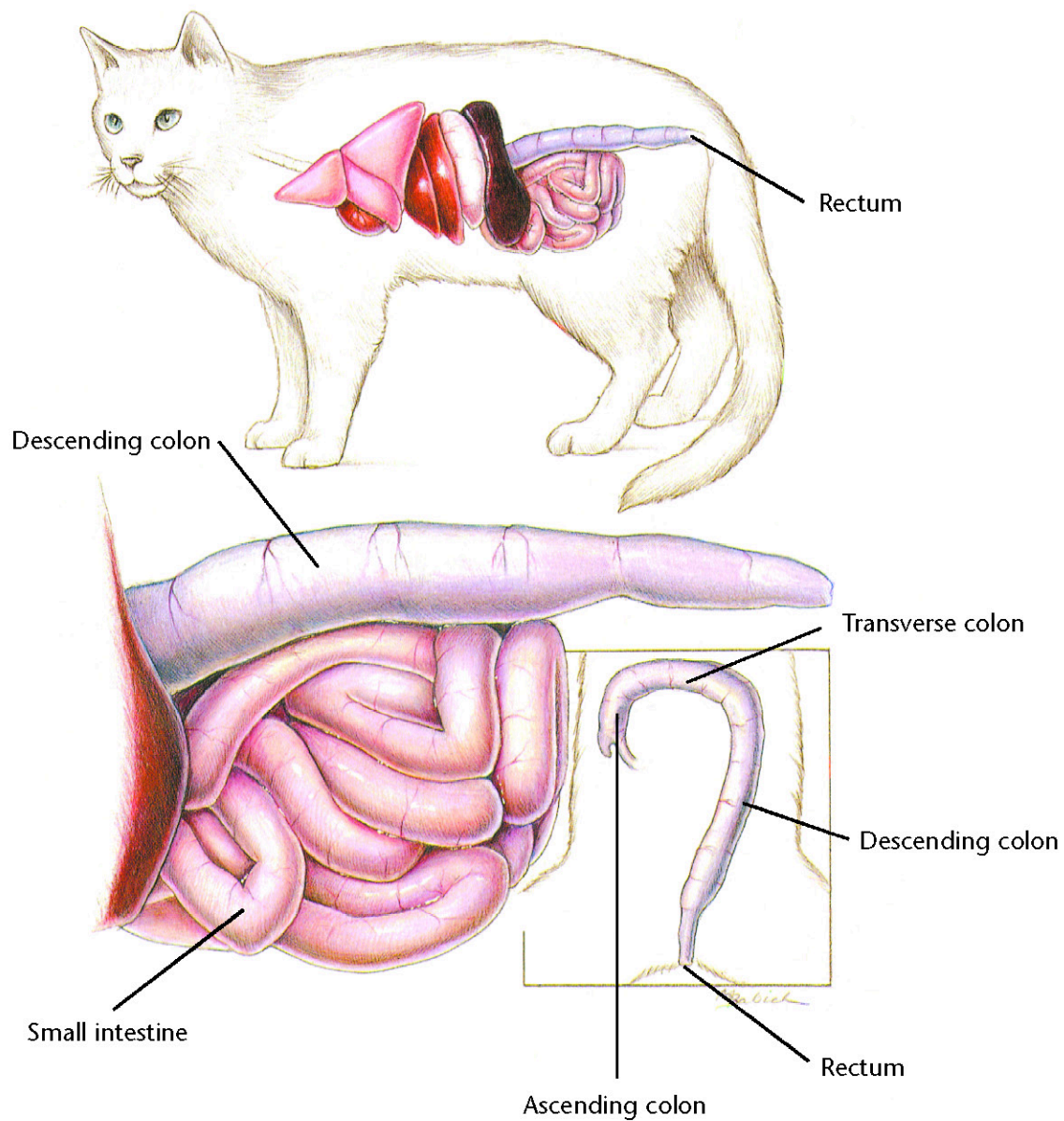
History
Physical examination
Stool analysis
Abdominal palpation
Rectal palpation
Stool culture
Blood work
Urinalysis
X-rays of the colon
Colonoscopy and biopsy

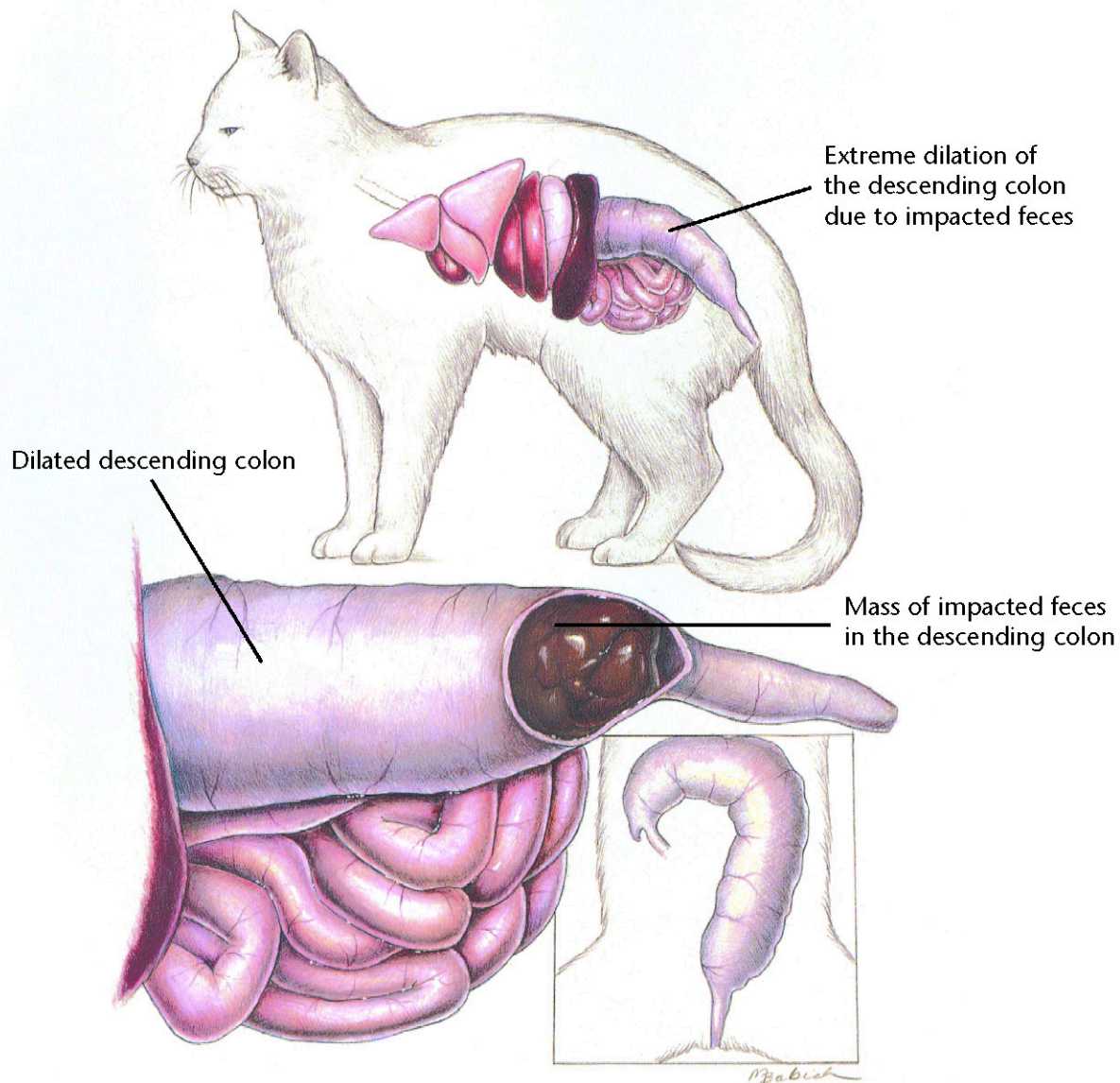
Therapeutic Plan

Antibacterials
Dewormers
Anti-inflammatory drugs

Dietary Plan

High-fiber diets benefit some cases of colitis
If a high-fiber diet is ineffective, a dietary trial using a low-residue diet is indicated
For a food-allergy-induced colitis, a hypoallergenic diet is indicated





Constipation/Colonic Impaction

Diagnostic Plan

History
Physical examination
Rectal palpation
Abdominal palpation
Abdominal x-rays

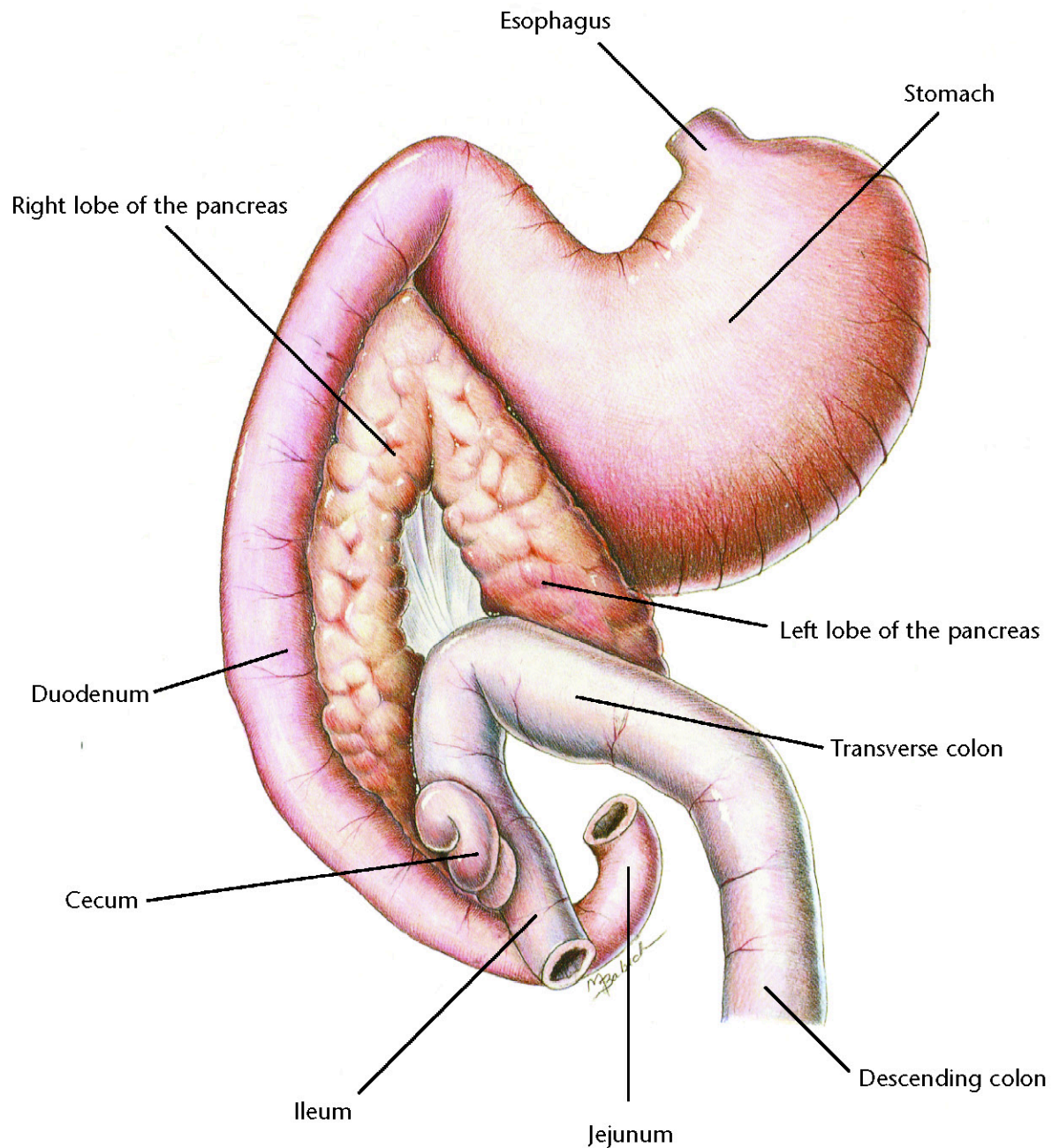
Therapeutic Plan

Fluid therapy
Laxatives
Enemas
Manual removal of impacted stool
Surgery
Treat primary cause, if possible
Stool softeners
Pro-motility medication

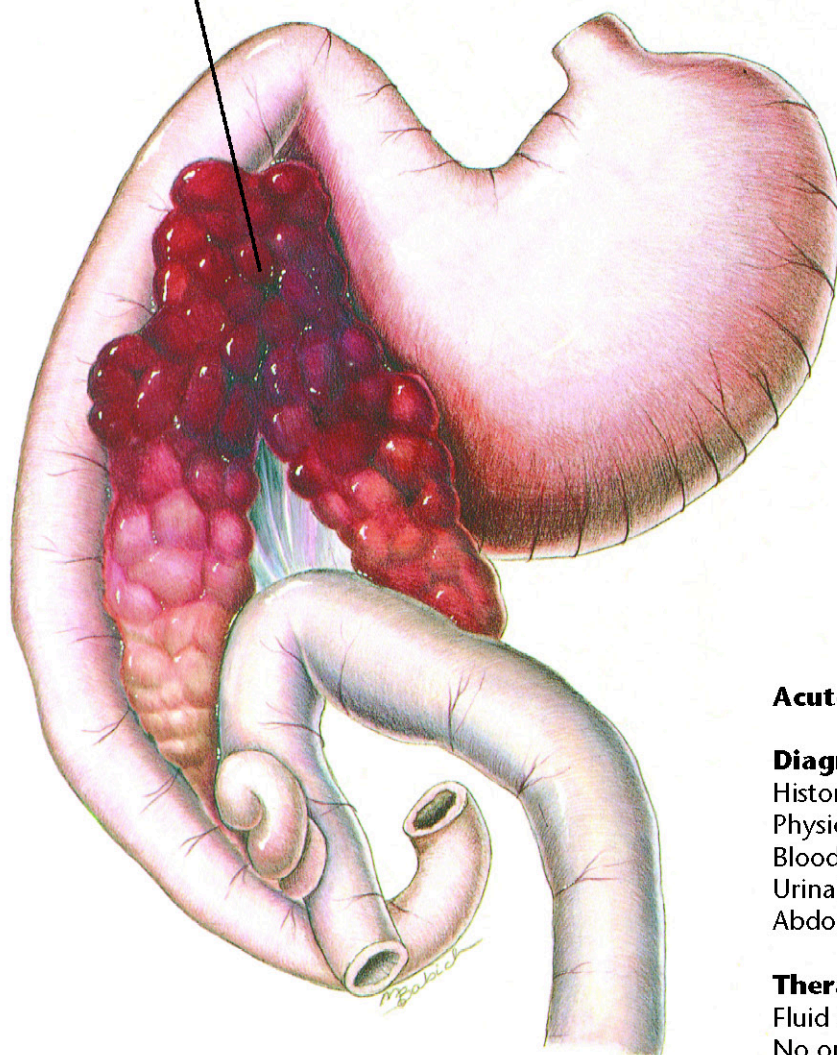
Dietary Plan

A moderate- to high-fiber diet if no neurologic or obstructive lesions; chronic cases may benefit from low residue food
Ensure adequate water intake





Swollen, inflamed pancreas with
areas of hemorrhage



Acute Pancreatitis

Diagnostic Plan

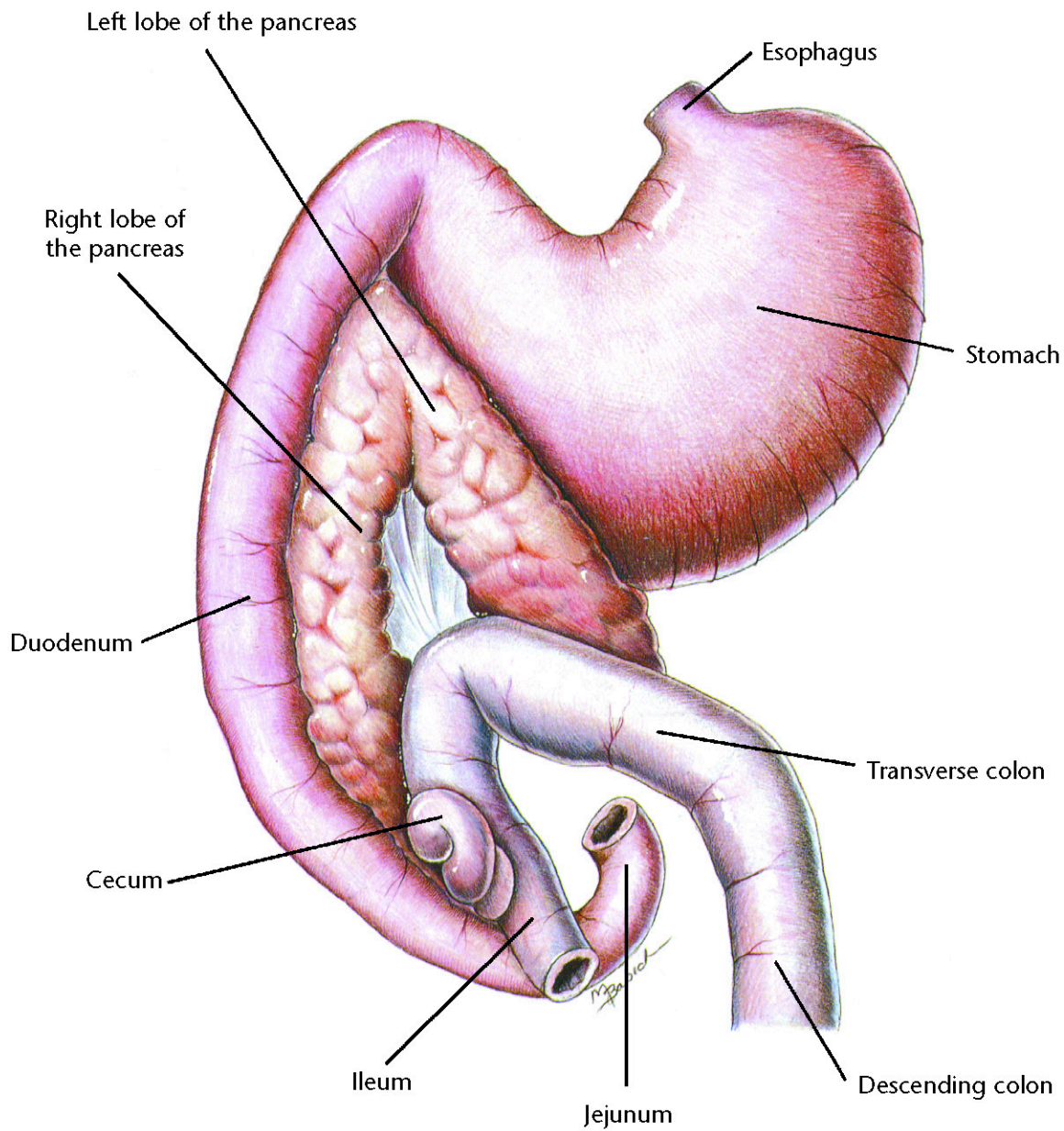
History
Physical examination
Blood work
Urinalysis
Abdominal x-rays

Therapeutic Plan

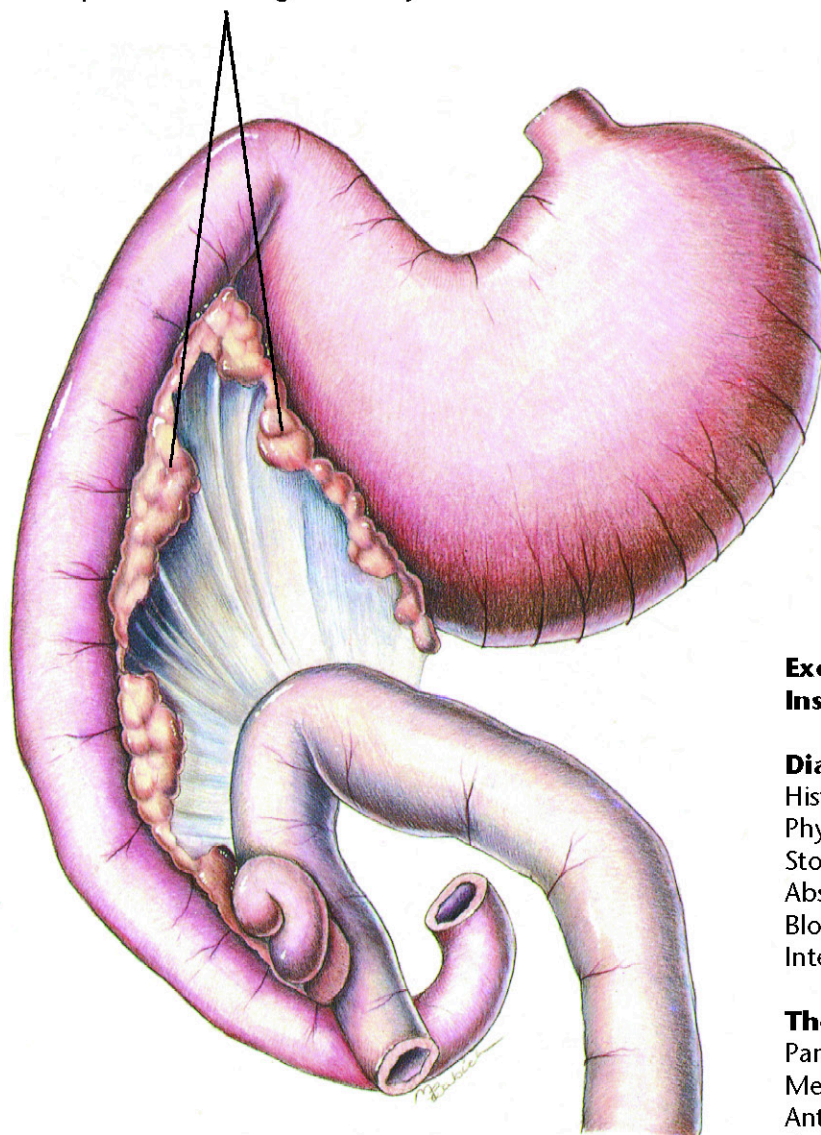
Fluid therapy
No oral medication or food
Antibacterials
Drugs to suppress vomiting
Analgesics

Dietary Plan

When resuming enteral nutrition,
small portions of a diet low in
fat and residue
After the initial episode, manage
hyperlipidemia, if necessary



Shrunken pancreatic lobes with
reduced production of digestive enzymes



Exocrine Pancreatic Insufficiency

Diagnostic Plan

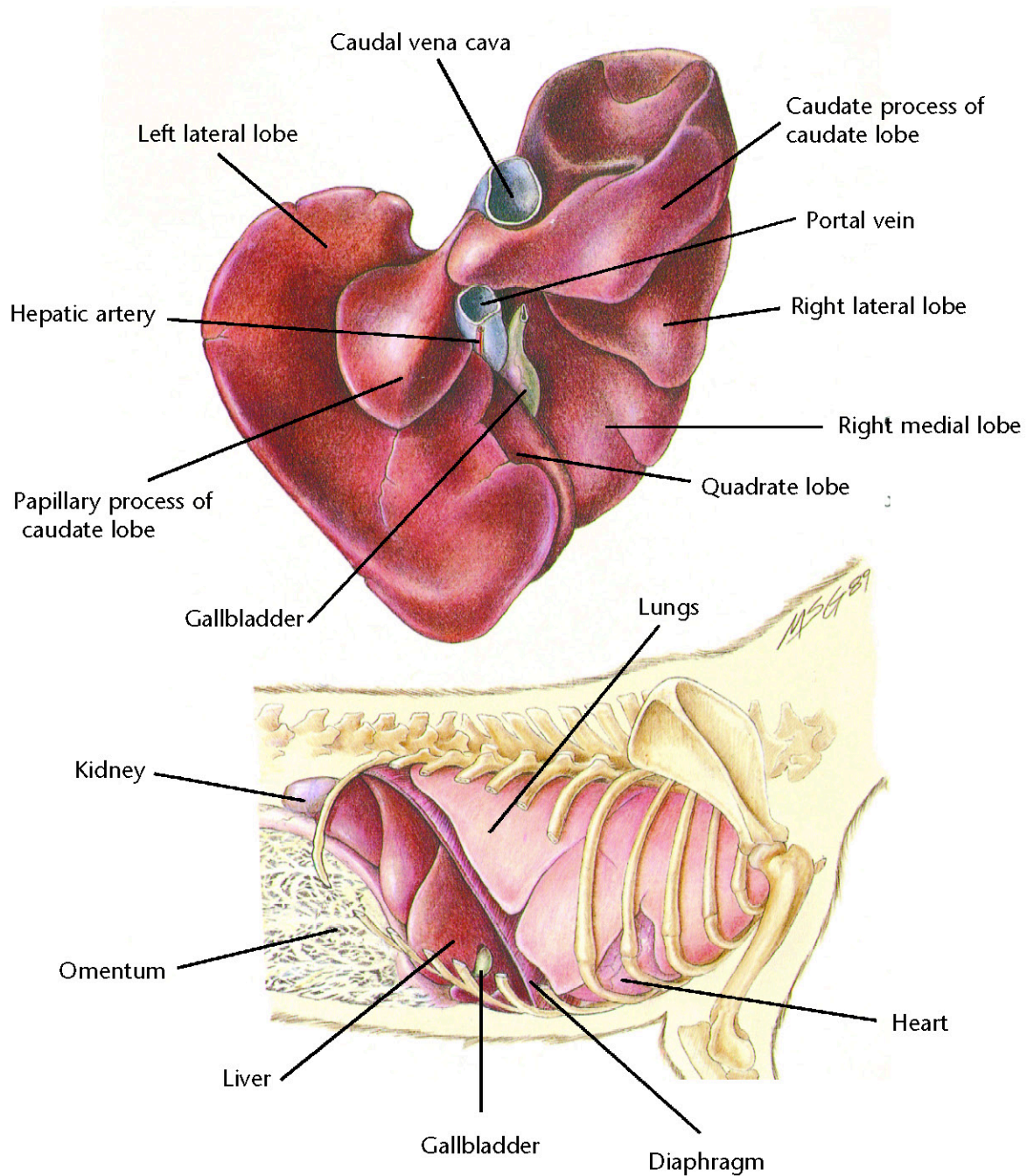
History
Physical examination
Stool analysis
Absorption tests
Blood work
Intestinal biopsy

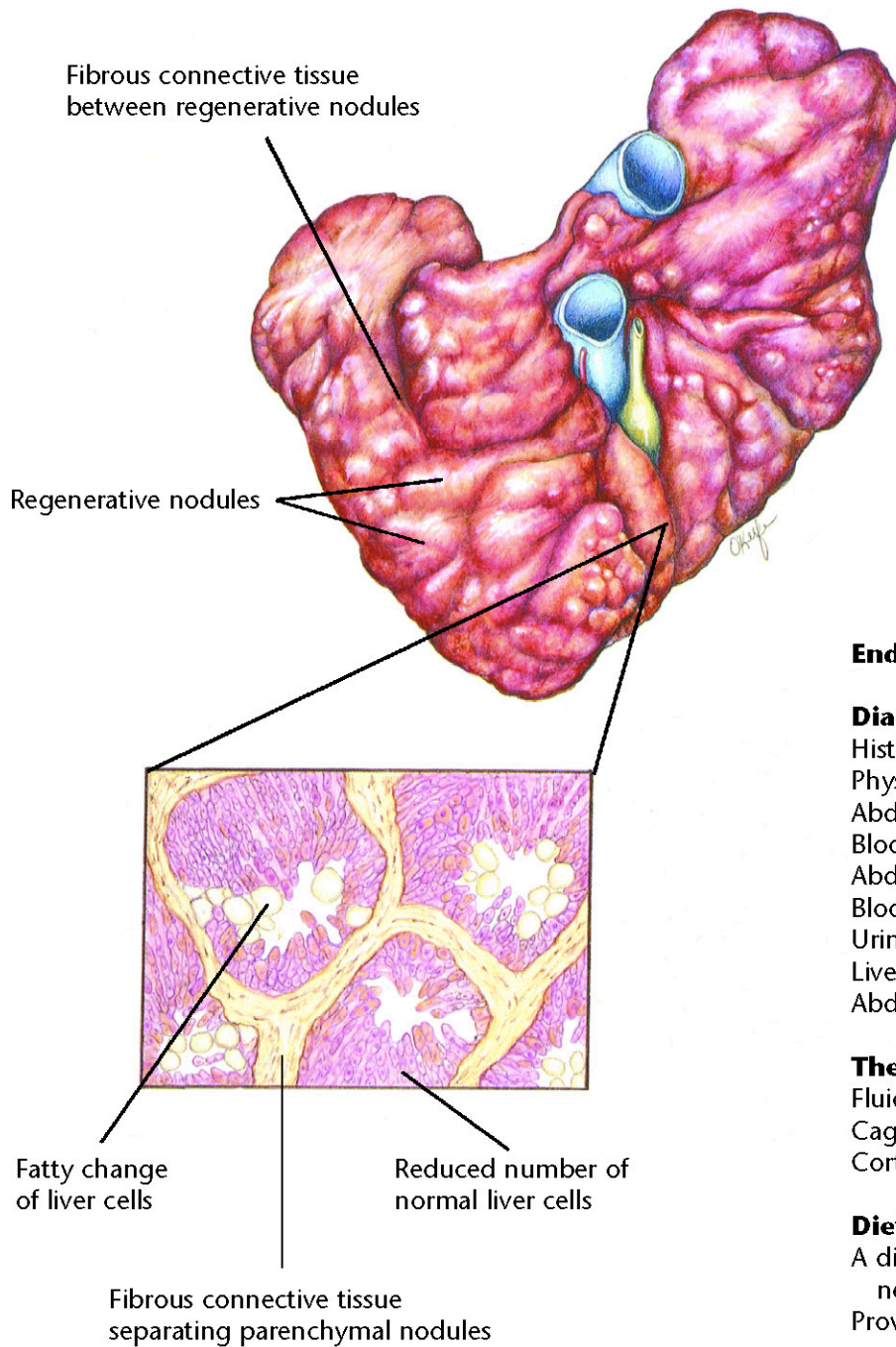
Therapeutic Plan

Pancreatic enzymes
Medium-chain fats
Antacids
Drugs that inhibit
acid secretion in the stomach

Dietary Plan

A highly digestible diet
Consider overall body condition
Feed quantities sufficient to
maintain normal body weight
Avoid excess fat





End-Stage Liver Disease

Diagnostic Plan

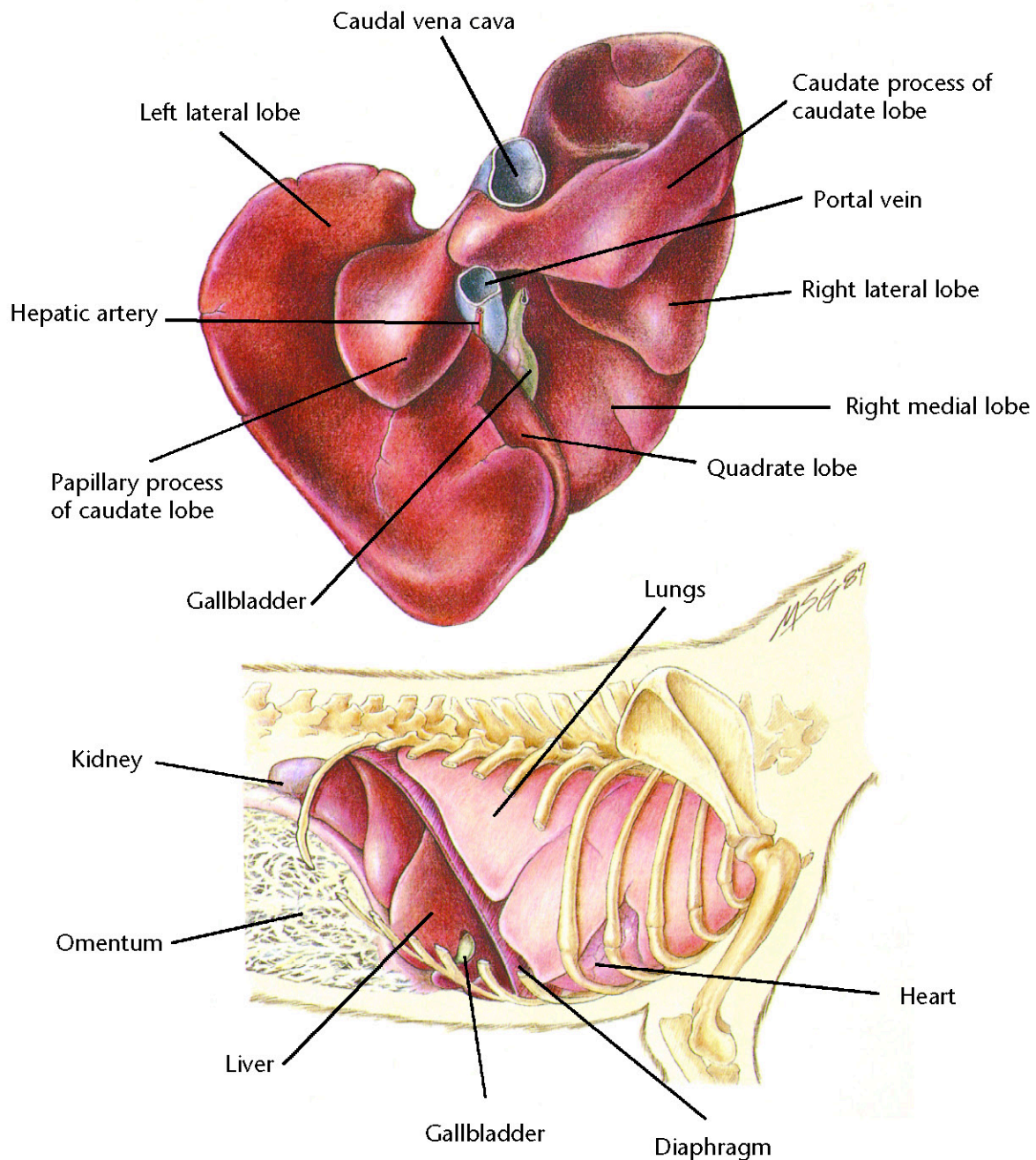
History
Physical examination
Abdominal palpation
Blood work
Abdominal x-rays
Blood clotting time
Urinalysis
Liver biopsy
Abdominal ultrasonography

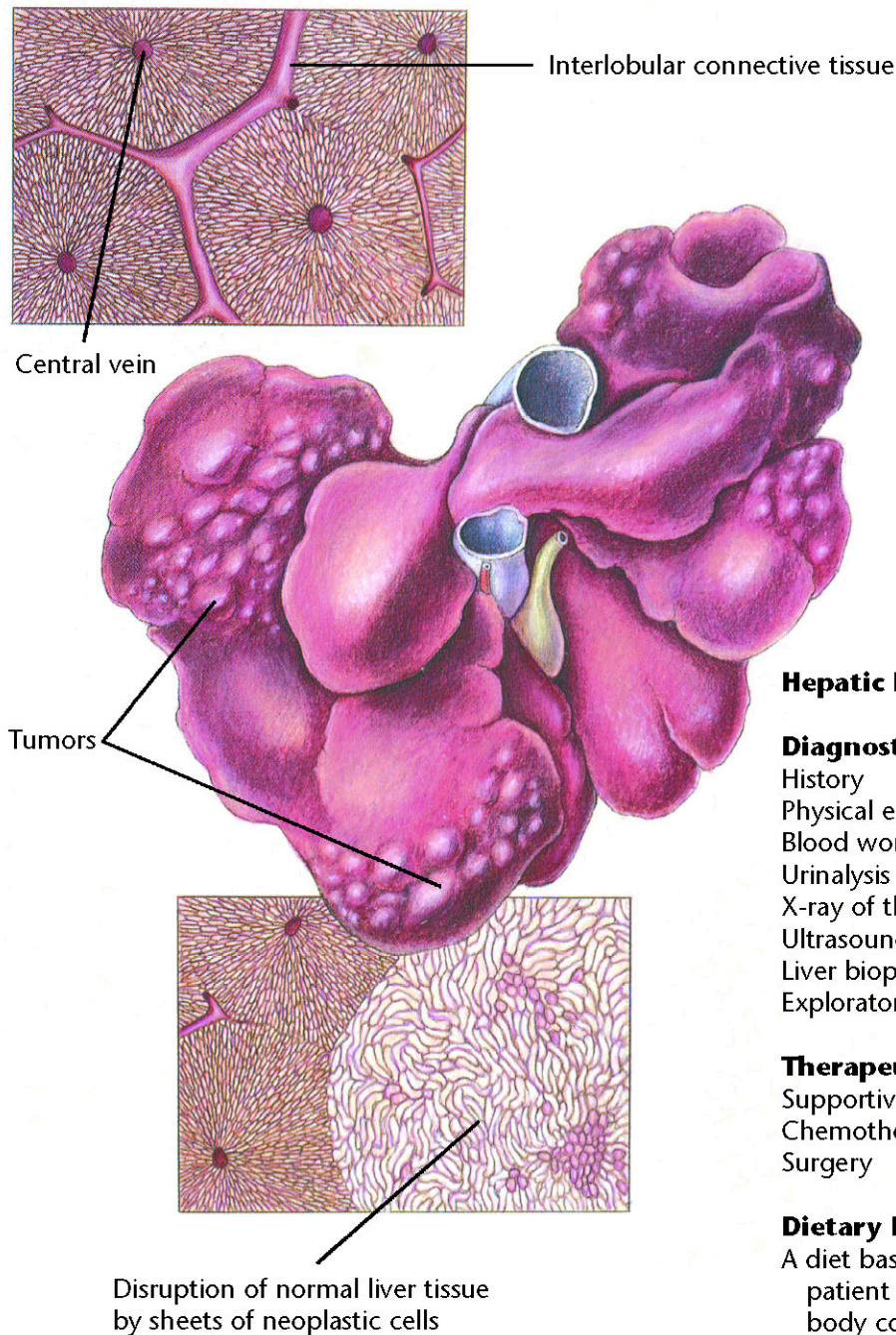
Therapeutic Plan

Fluid therapy
Cage rest
Corticosteroids

Dietary Plan

A diet that will reduce the need for certain liver functions
Provide adequate protein, but avoid excess
Consider possible need for controlled sodium intake





Hepatic Neoplasia

Diagnostic Plan

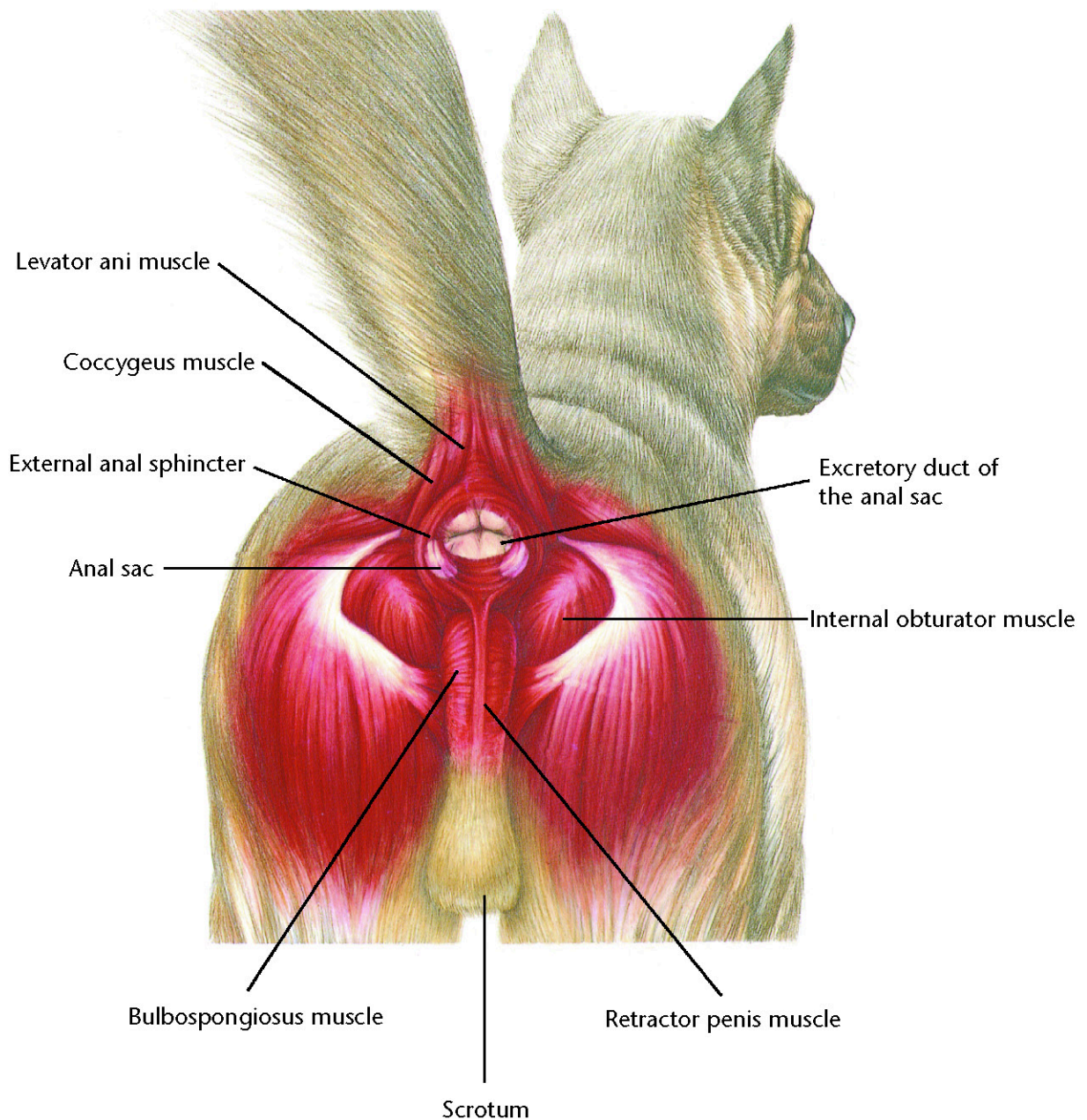
History
Physical examination
Blood work
Urinalysis
X-ray of the liver
Ultrasound
Liver biopsy
Exploratory surgery

Therapeutic Plan

Supportive care
Chemotherapy
Surgery

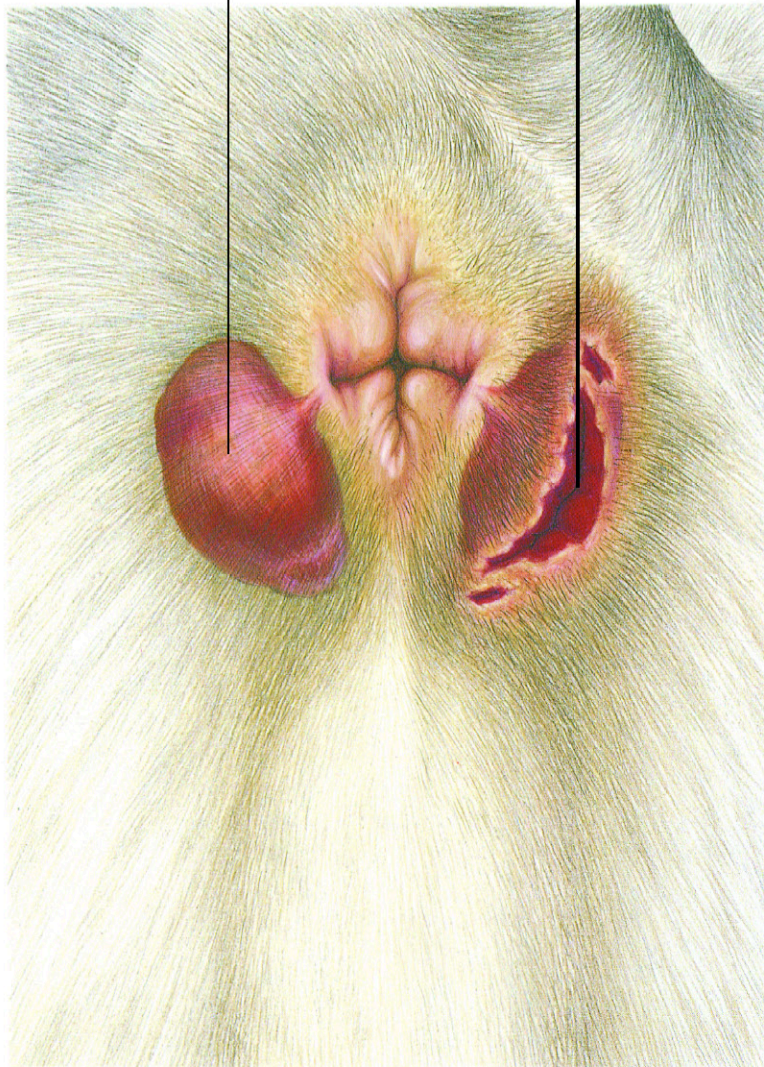
Dietary Plan

A diet based on individual patient evaluation including body condition and other organ system involvement. Special attention should be given to protein levels and amino-acid balance of the diet.



Enlarged, inflamed anal sac

Ruptured anal sac abscess



Anal Sac Abscess

Diagnostic Plan

History
Physical examination
Abscess culture

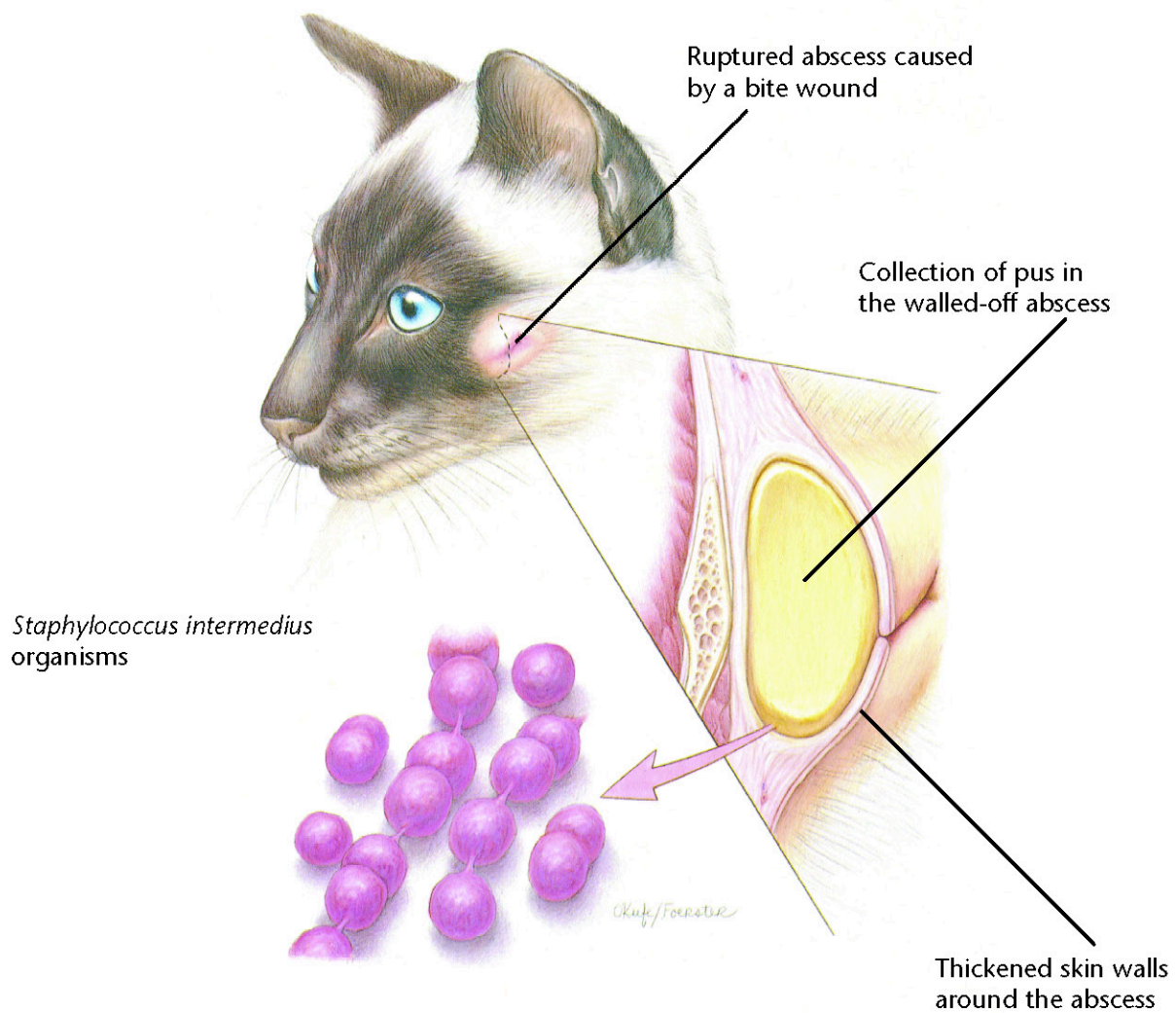
Therapeutic Plan

Lancing of the abscess
Anal sac expression
Hot soaks
Antiseptic solutions
Antibacterials
Anal sac removal

Dietary Plan

Postsurgically, a diet adequate for tissue repair



**Skin Abscess****Diagnostic Plan**

History
Physical examination
Abscess culture
X-rays

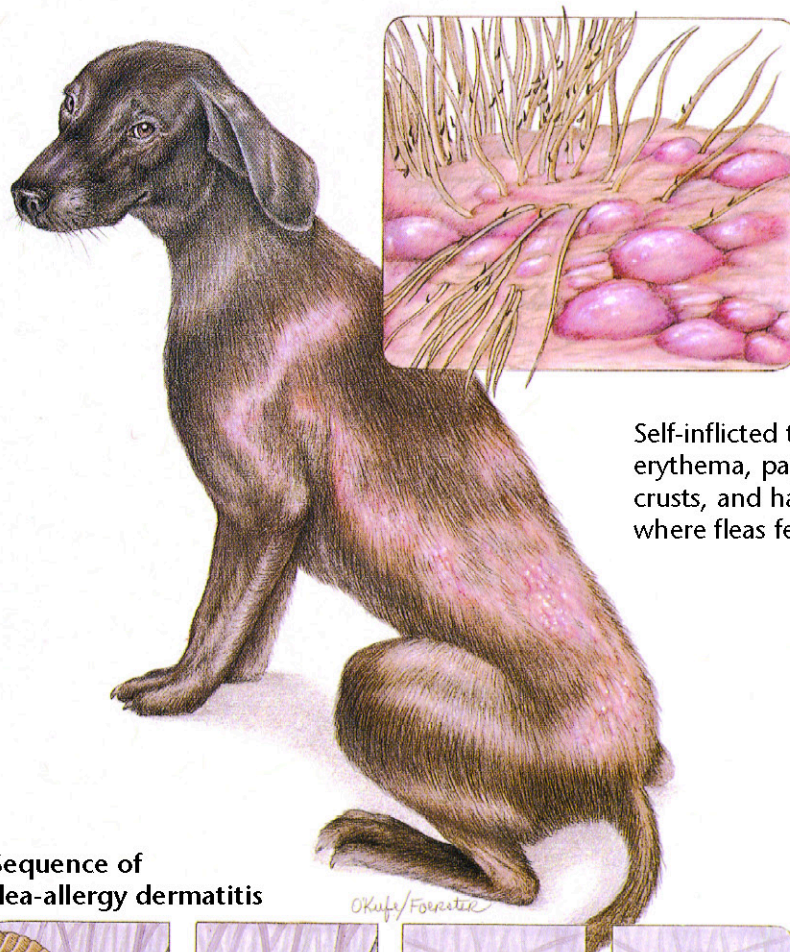
Therapeutic Plan

Hot compresses
Abscess drainage
Dead tissue removal
Antibacterial therapy
Surgery

Dietary Plan

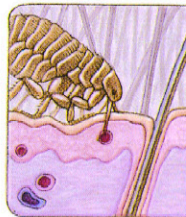A diet adequate for tissue repair



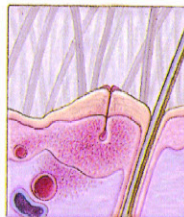

Self-inflicted trauma results in erythema, papules, pustules, crusts, and hair loss in areas where fleas feed.

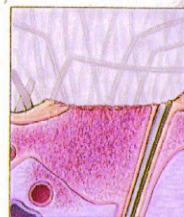Sequence of flea-allergy dermatitis



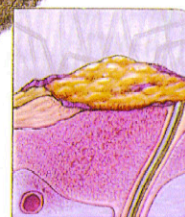Flea punctures skin to feed.



Flea saliva sets up an antigen-antibody reaction.



Excoriation and inflammation result from self-inflicted trauma.



Acute bacterial infection results.

Flea-Allergy Dermatitis

Diagnostic Plan

History
Physical examination
Detection of fleas, flea dirt, and tapeworm segments
Intradermal skin testing

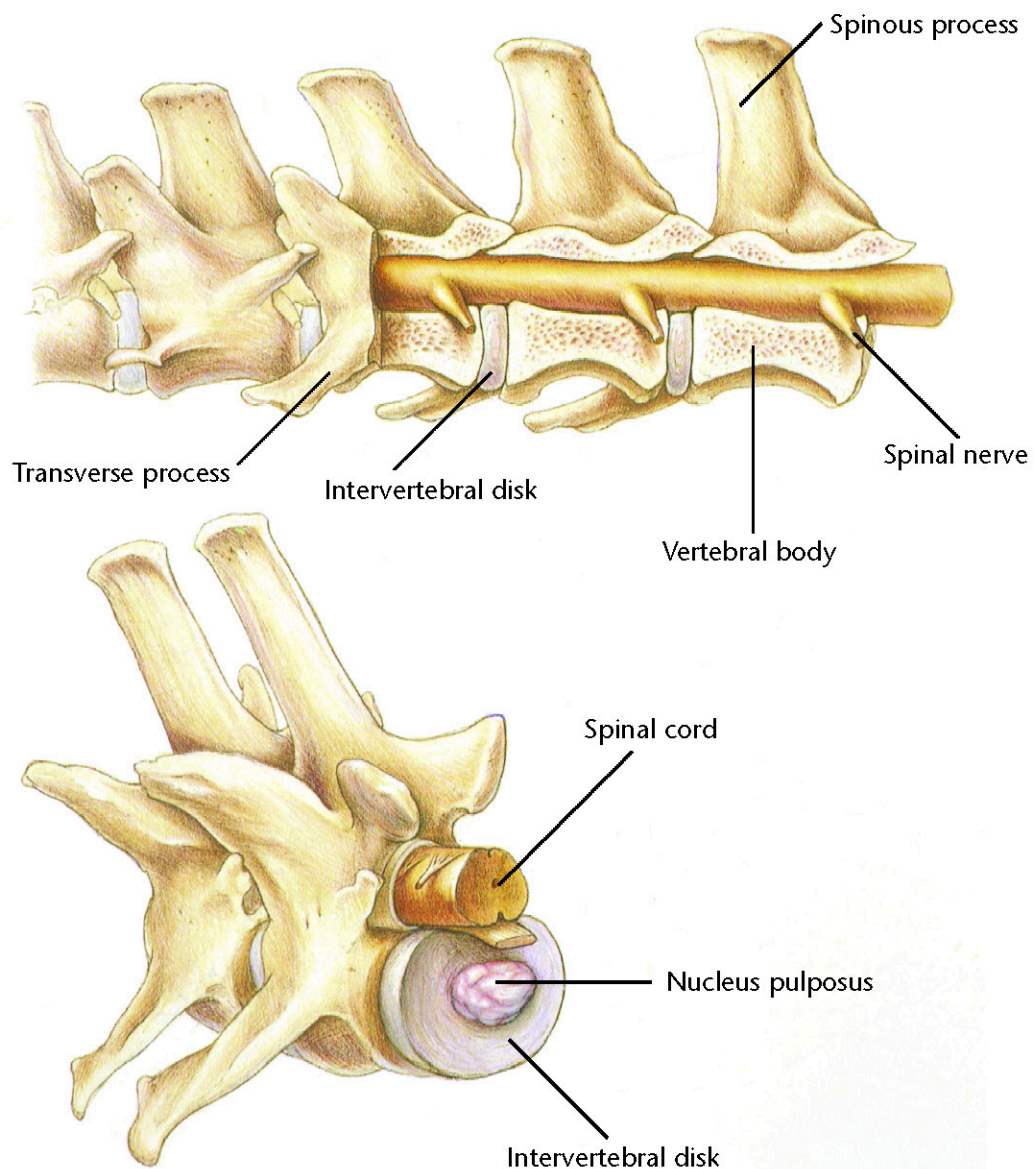
Therapeutic Plan

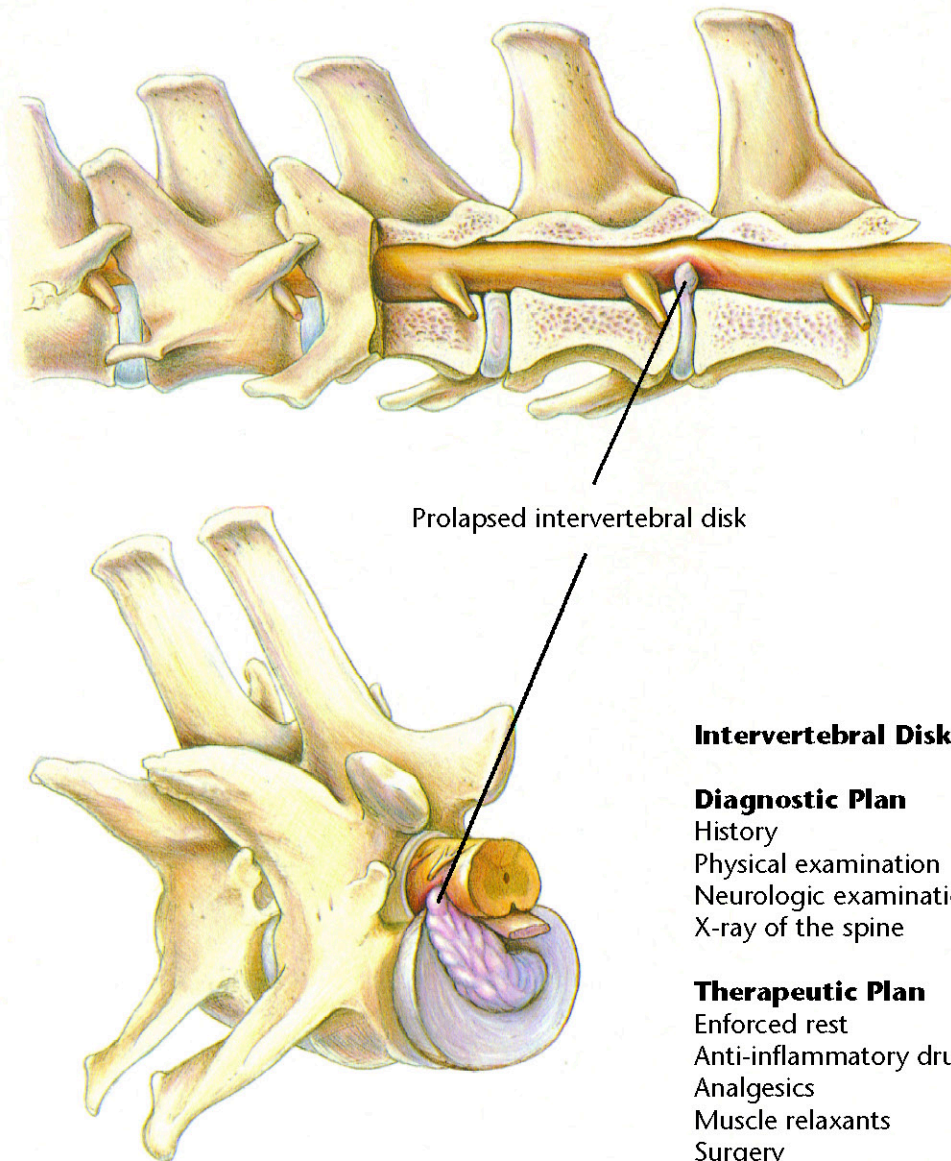
Flea control
Short-term corticosteroids

Dietary Plan

A diet adequate for tissue repair







Prolapsed intervertebral disk

Intervertebral Disk Disease

Diagnostic Plan

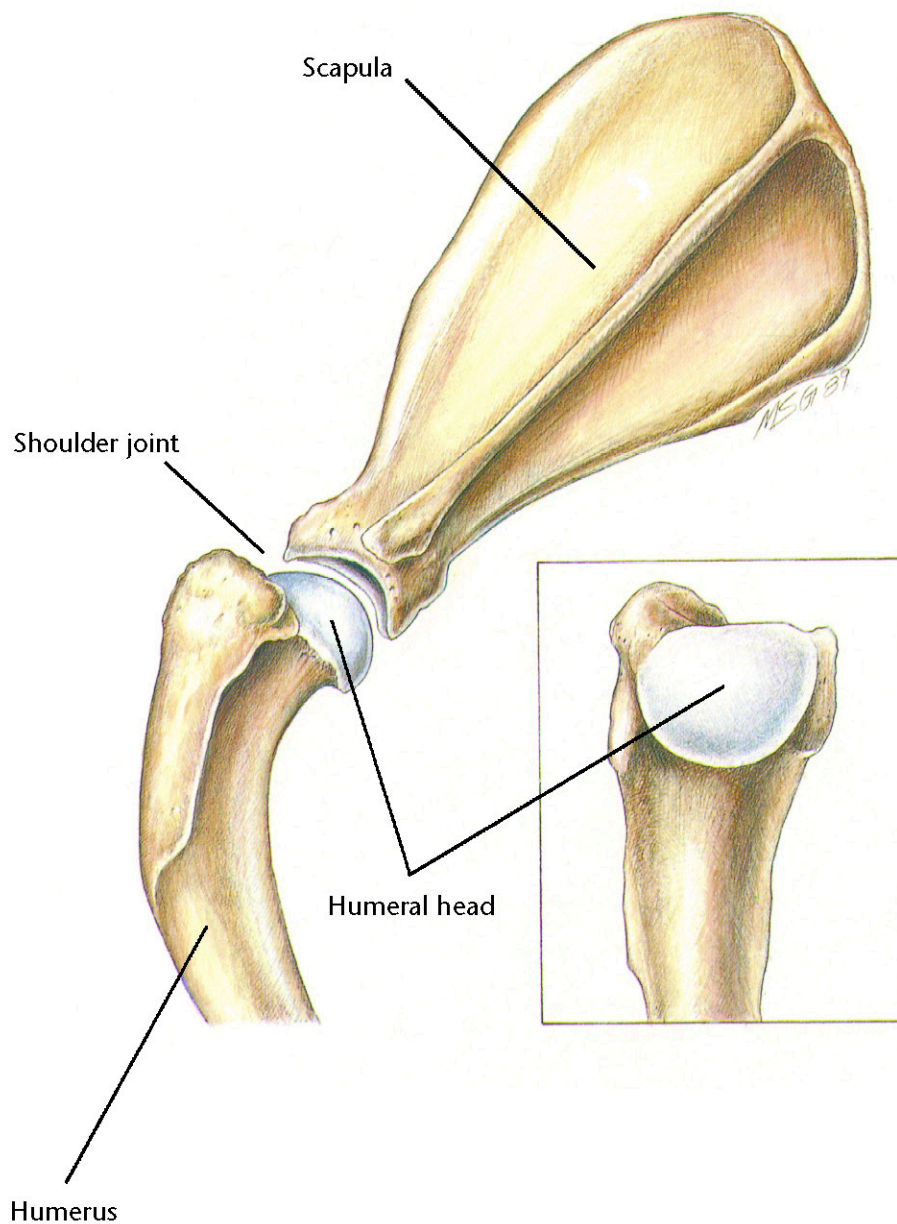
History
Physical examination
Neurologic examination
X-ray of the spine

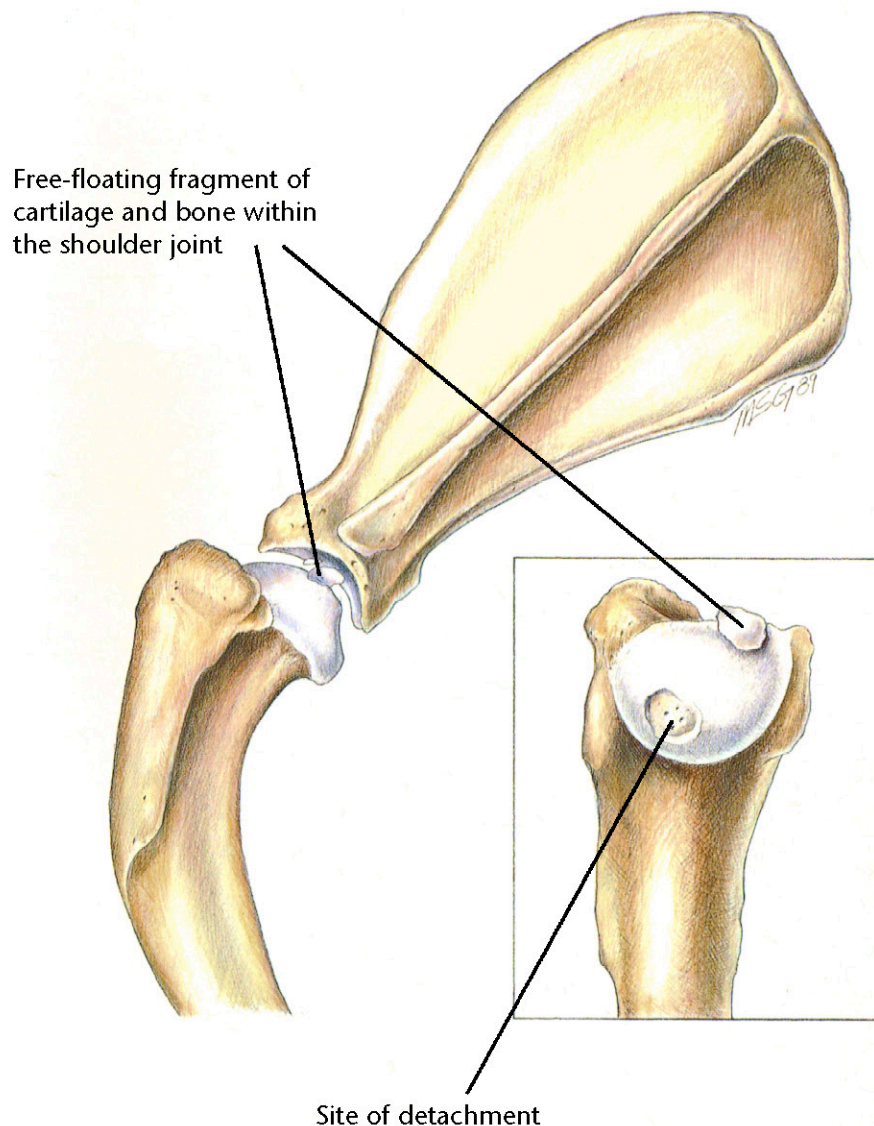
Therapeutic Plan

Enforced rest
Anti-inflammatory drugs
Analgesics
Muscle relaxants
Surgery
Physical therapy

Dietary Plan

Postsurgically, a diet adequate for tissue repair
If obesity is a complicating factor, restrict caloric intake so the patient reaches and maintains an ideal body weight





Osteochondritis Dissecans

Diagnostic Plan

History
Physical examination
X-rays

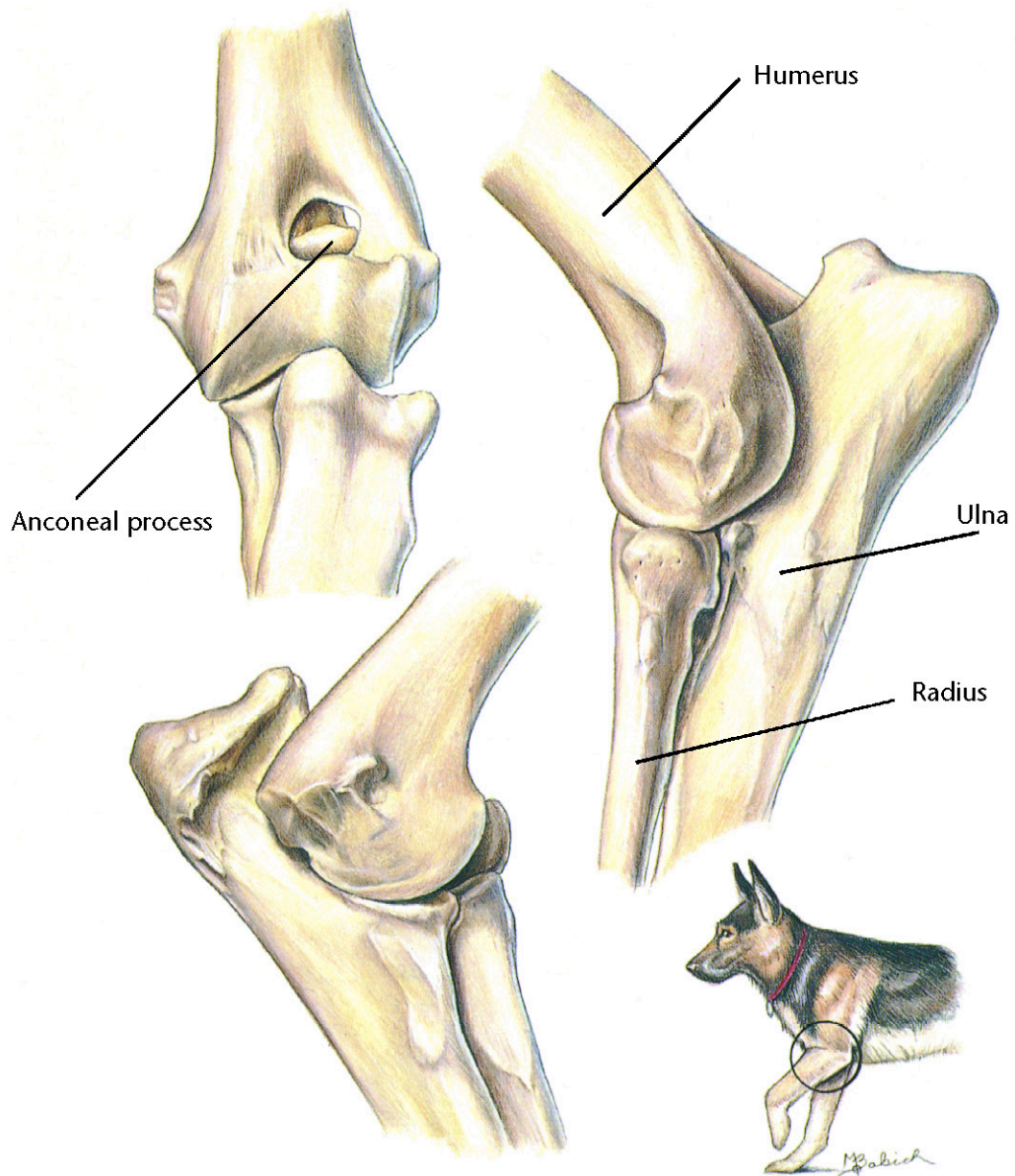
Therapeutic Plan

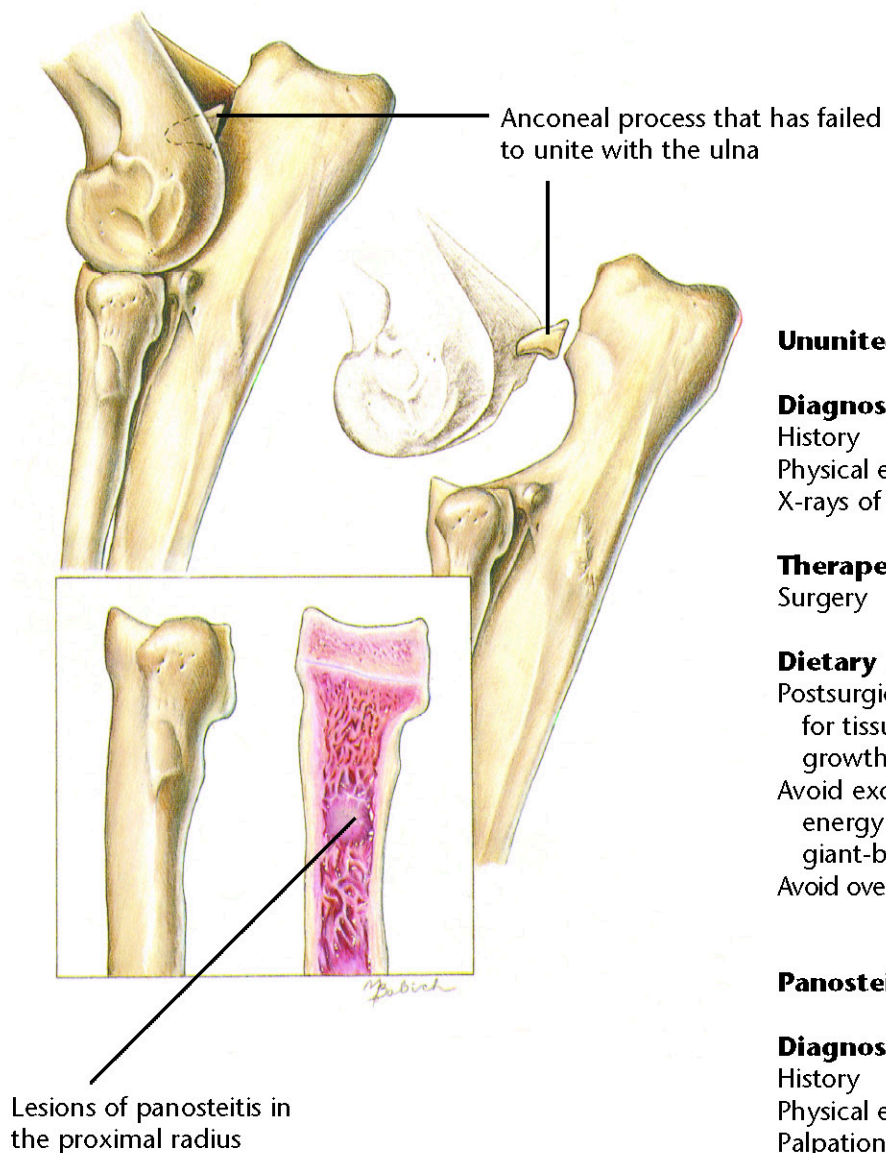
Surgery

Dietary Plan

Postsurgically, a diet adequate for tissue repair and patient growth
Avoid overfeeding throughout life
Avoid excess calcium and energy in growing large and giant-breed pups







Ununited Anconeal Process

Diagnostic Plan

History
Physical examination
X-rays of the elbow

Therapeutic Plan

Surgery

Dietary Plan

Postsurgically, a diet adequate for tissue repair and patient growth
Avoid excess calcium and energy in growing large and giant-breed pups
Avoid overfeeding throughout life

Panosteitis

Diagnostic Plan

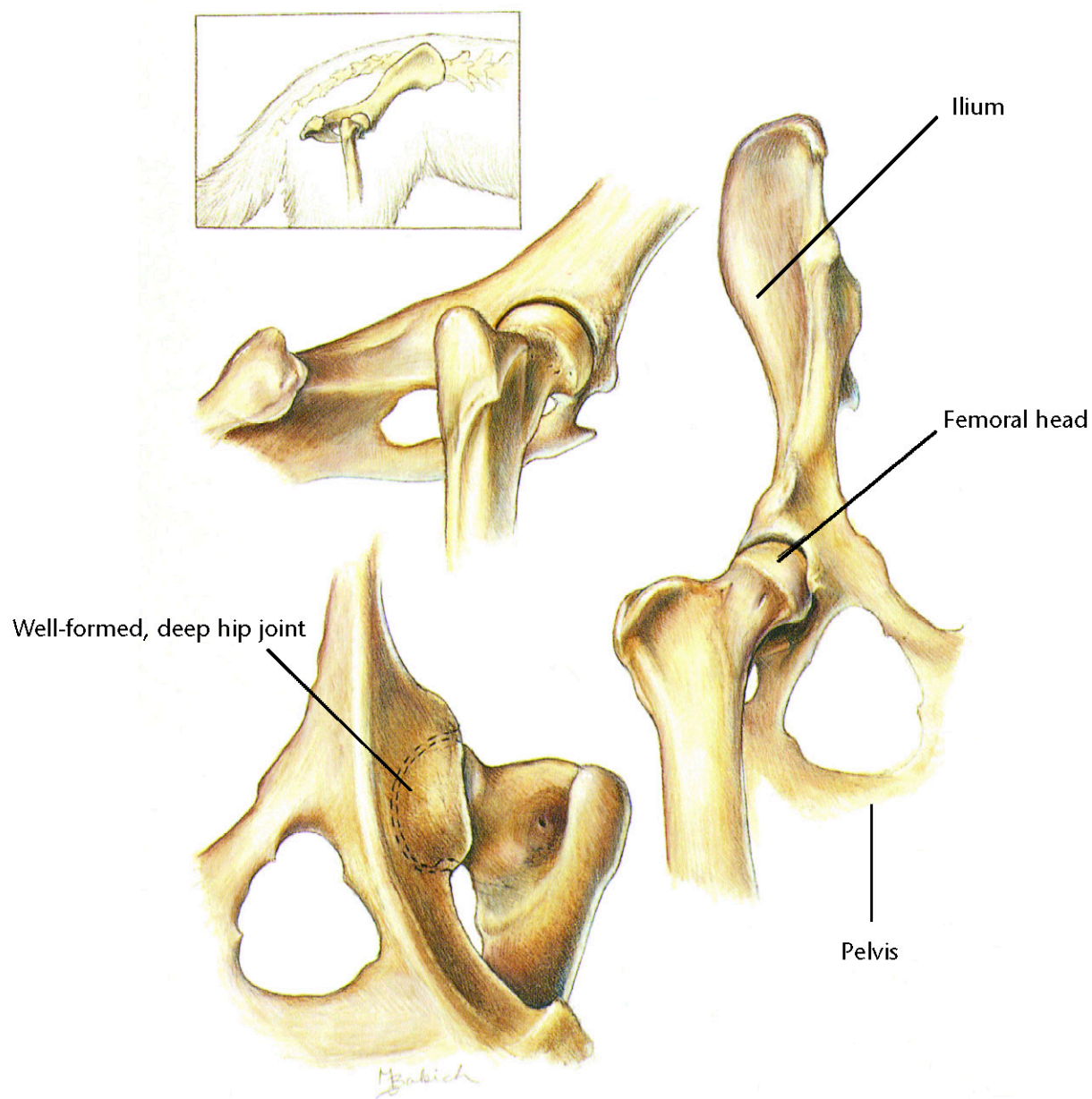
History
Physical examination
Palpation
X-rays

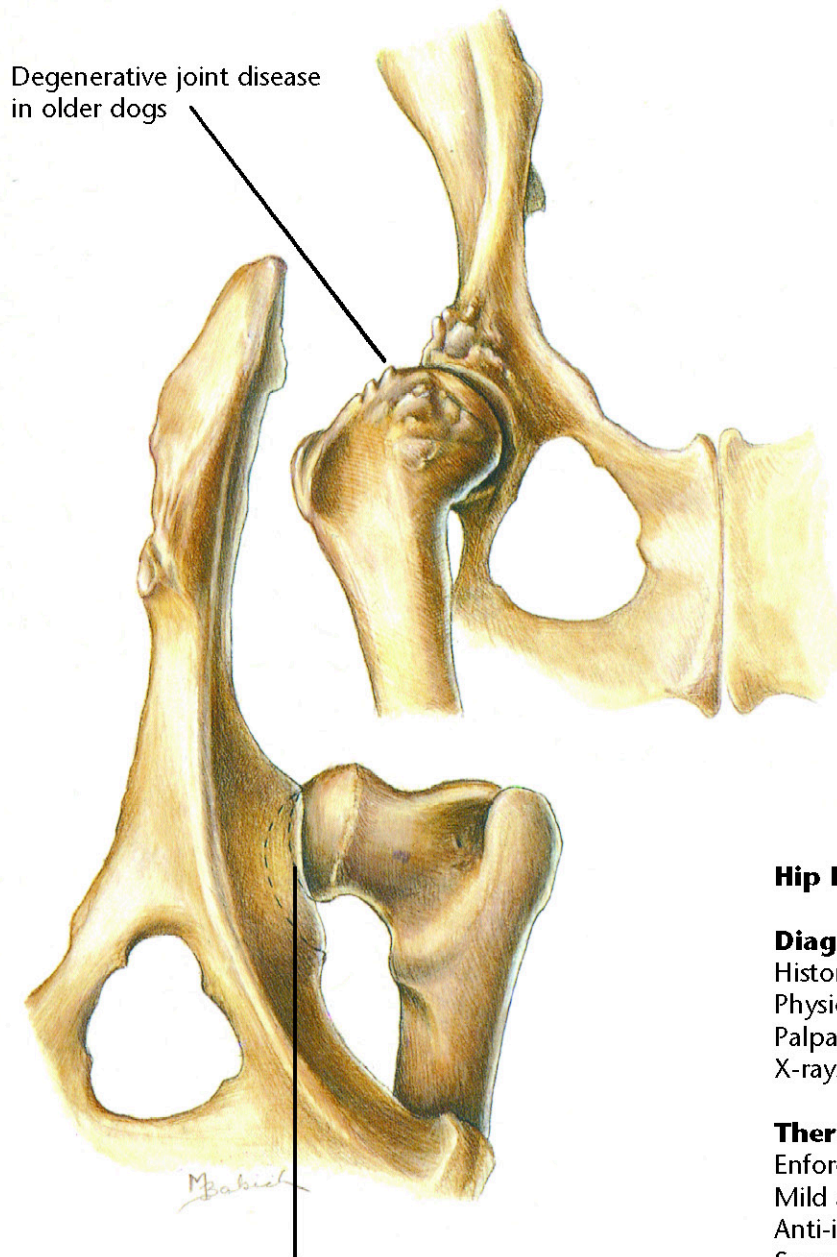
Therapeutic Plan

Analgesics

Dietary Plan

A diet adequate for growth
Avoid overfeeding throughout life





Degenerative joint disease
in older dogs

Shallow hip joint with
subluxated femoral head
in younger dogs

Hip Dysplasia

Diagnostic Plan

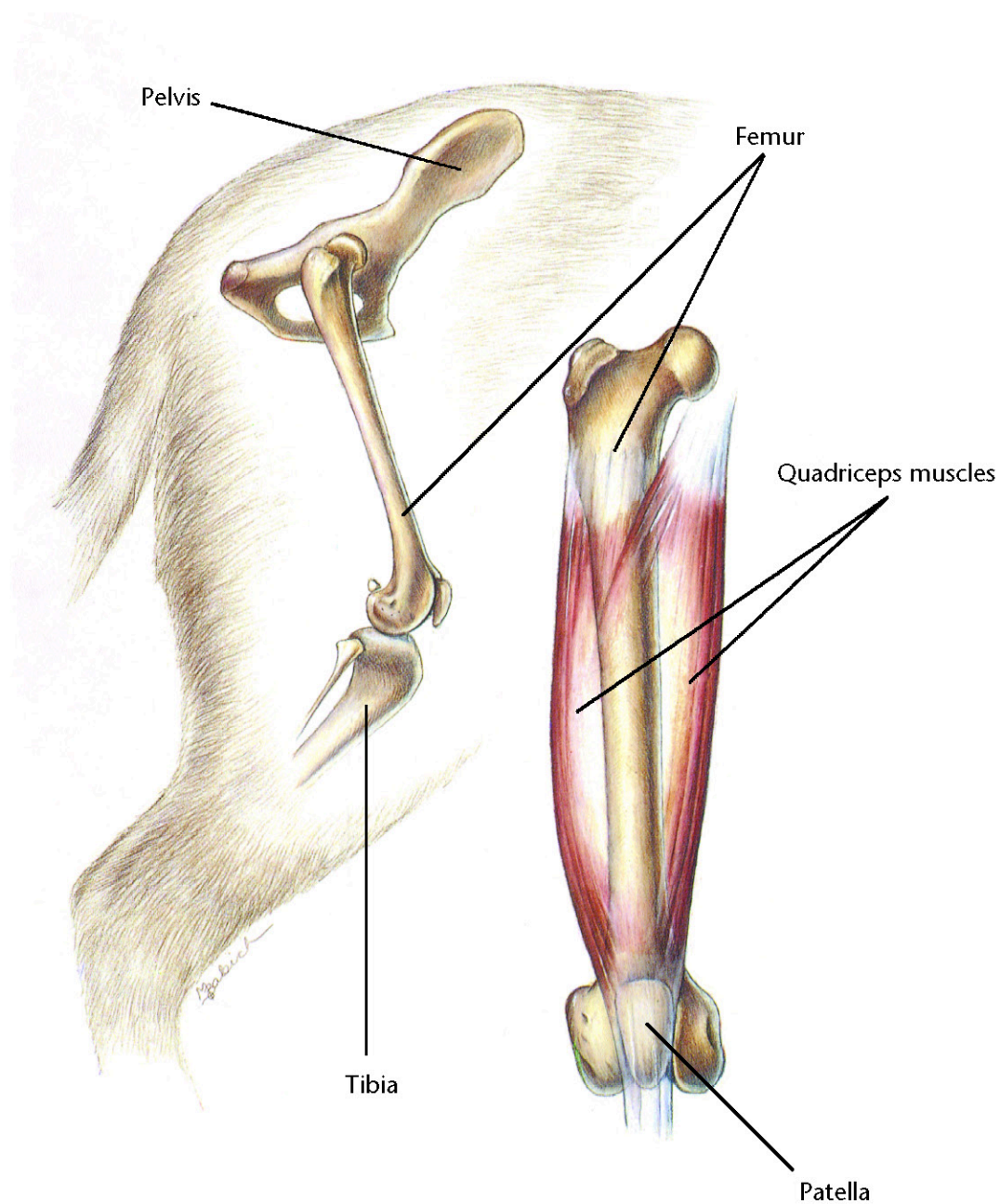
History
Physical examination
Palpation of the hips
X-rays of the hips

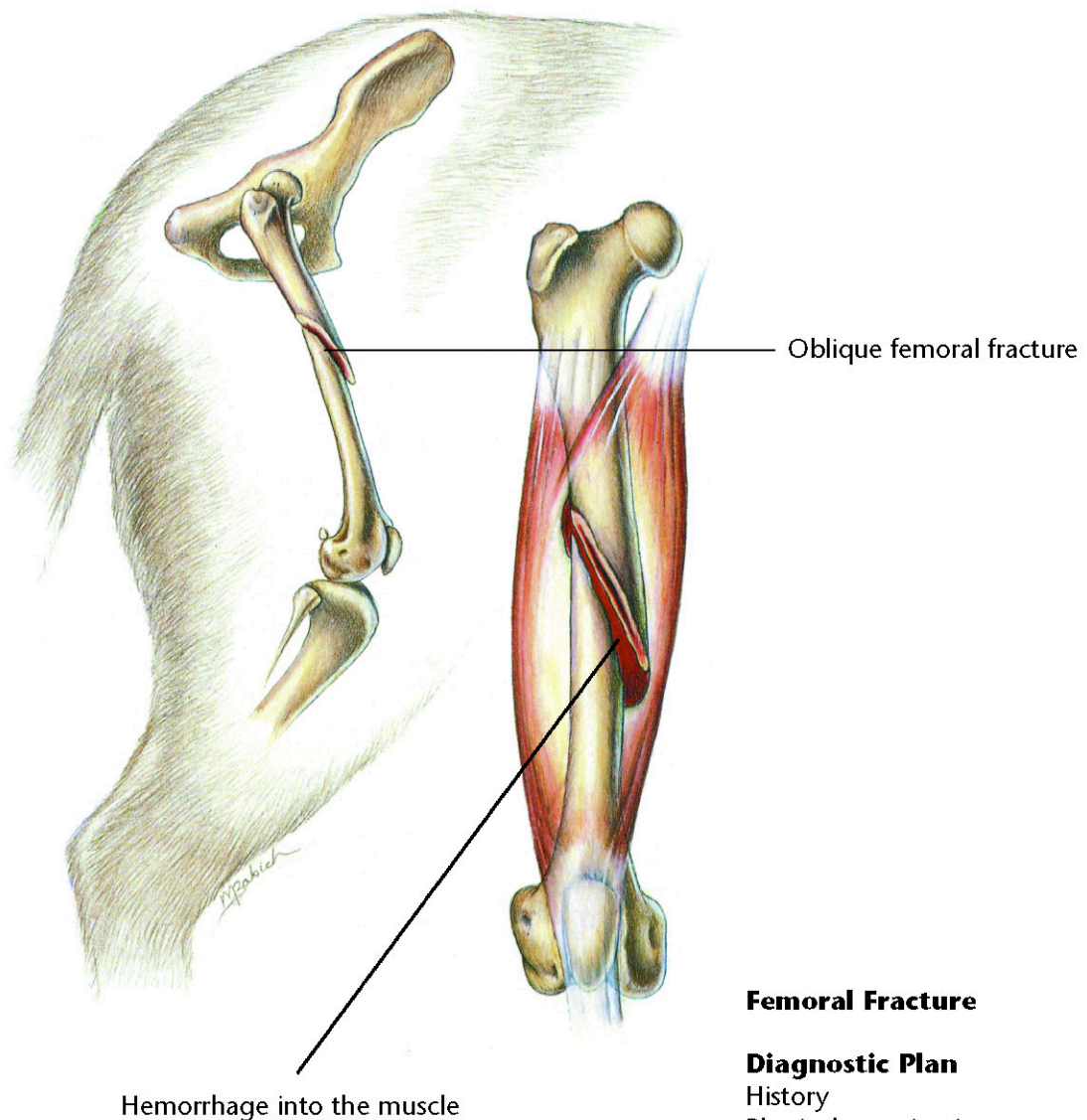
Therapeutic Plan

Enforced rest
Mild analgesics
Anti-inflammatory drugs
Surgery

Dietary Plan

Postsurgically, a diet adequate for
tissue repair
If obesity is a complicating factor,
restrict caloric intake so the
patient reaches and maintains an
ideal body weight





Femoral Fracture

Diagnostic Plan

History
Physical examination
Palpation of the femur
X-rays

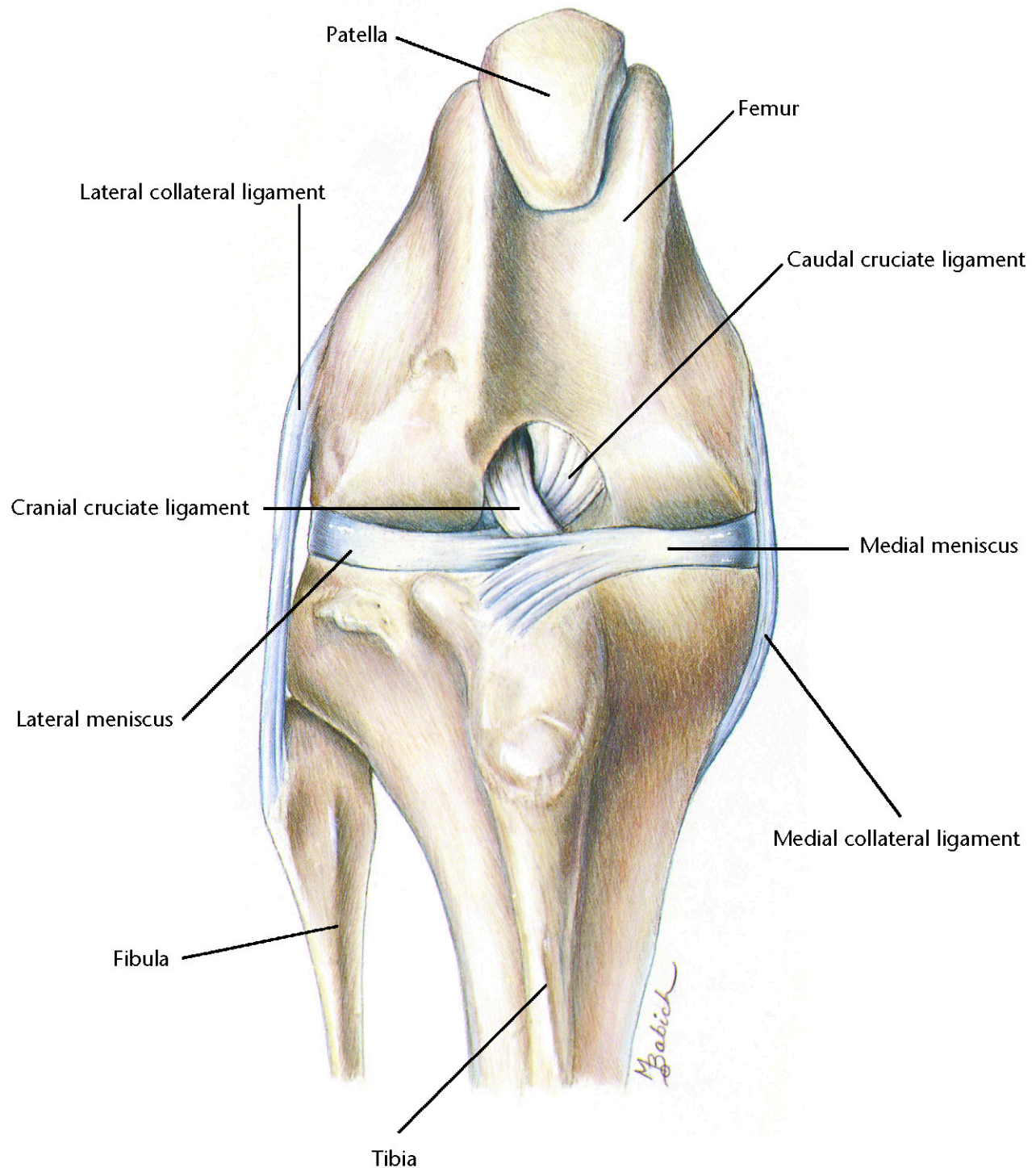
Therapeutic Plan

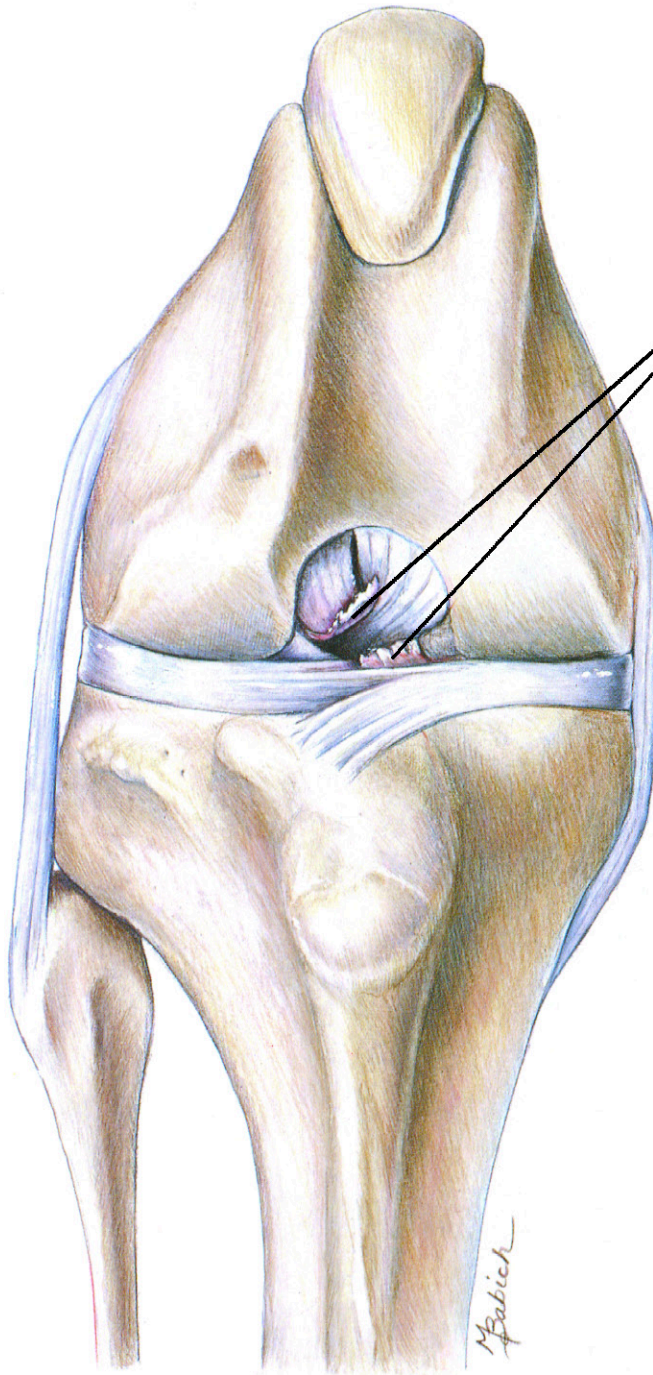
Surgery

Dietary Plan

A diet adequate for tissue repair







Ends of the ruptured cranial
cruciate ligament

Ruptured Cranial Cruciate Ligament

Diagnostic Plan

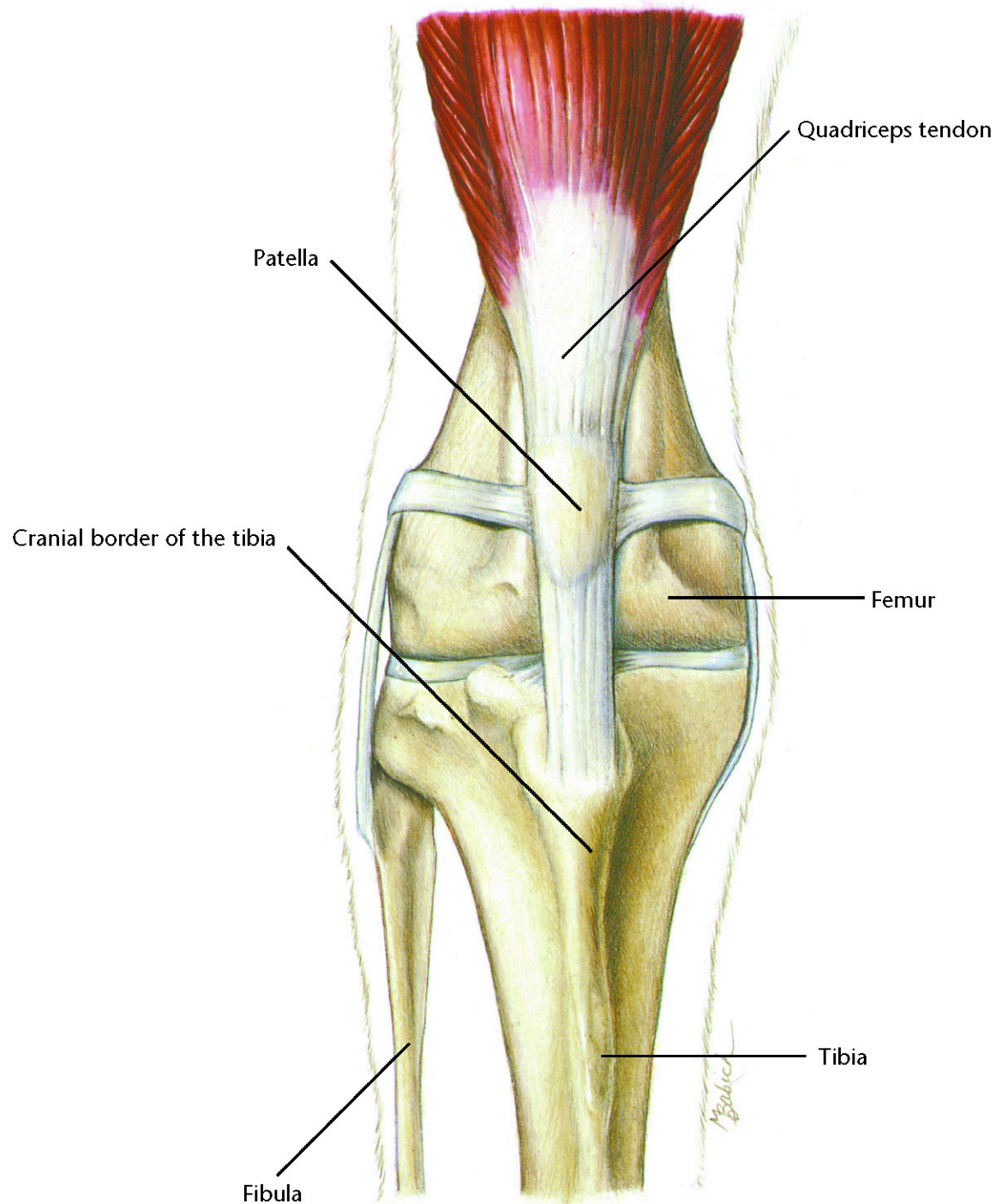
History
Physical examination
Palpation of the knee
X-rays of the knee

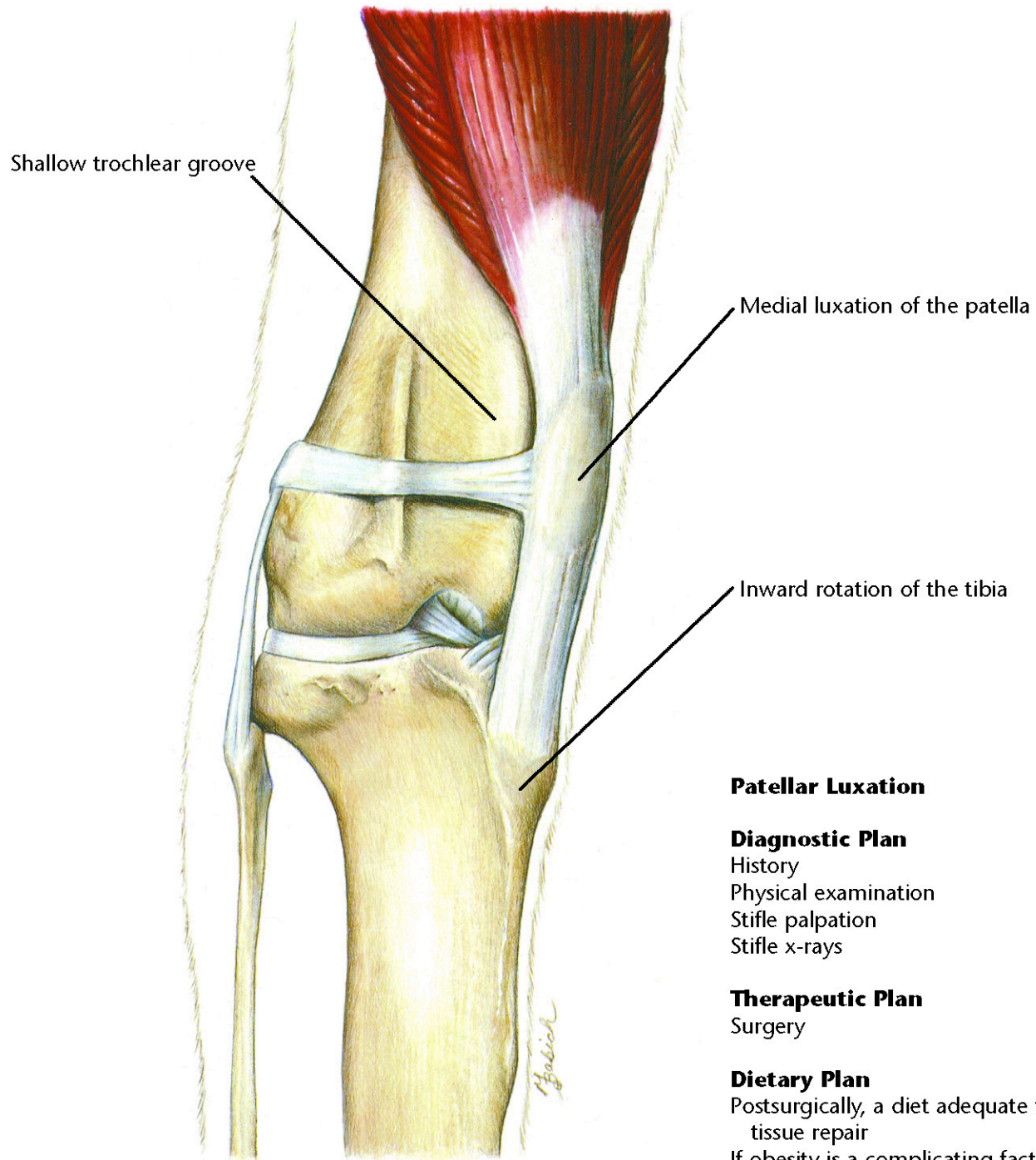
Therapeutic Plan

Enforced rest
Analgesics
Surgery

Dietary Plan

Postsurgically, a diet adequate for
tissue repair
If obesity is a complicating factor,
restrict caloric intake so the
patient reaches and maintains
an ideal body weight





Patellar Luxation

Diagnostic Plan

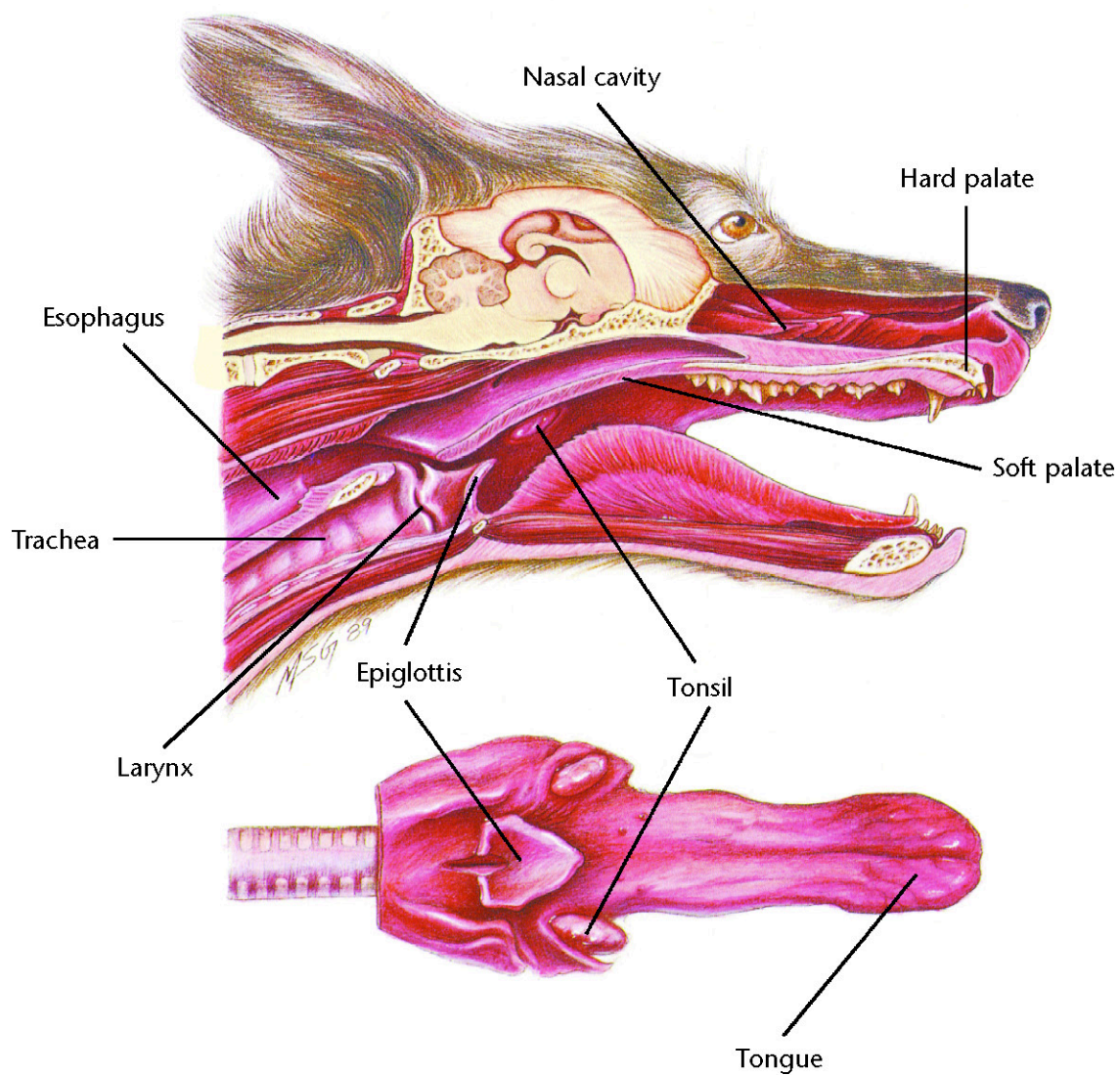
History
Physical examination
Stifle palpation
Stifle x-rays

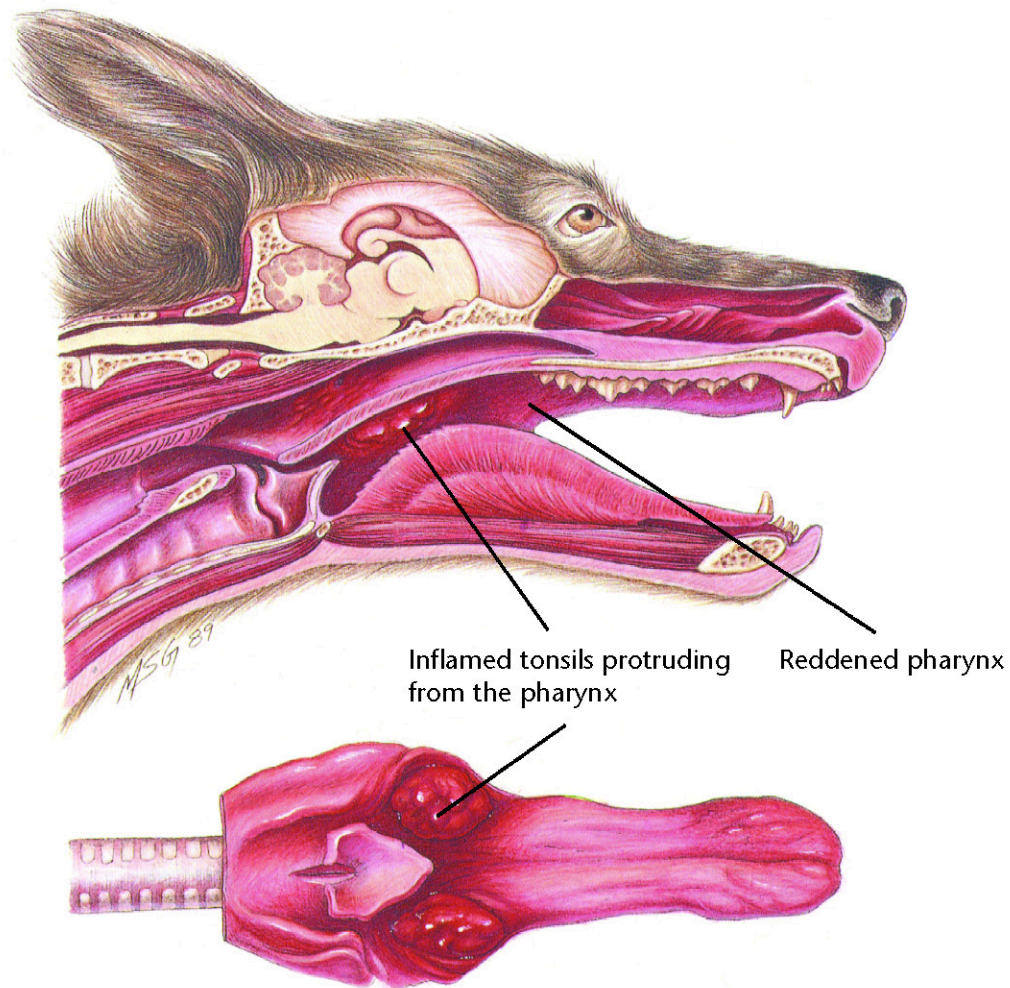
Therapeutic Plan

Surgery

Dietary Plan

Postsurgically, a diet adequate for tissue repair
If obesity is a complicating factor, restrict caloric intake so the patient reaches and maintains an ideal body weight





Tonsillitis

Diagnostic Plan

History
Physical examination
Examination of the tonsils
Culture of the tonsils
Cytologic study of tonsillar exudate
X-rays

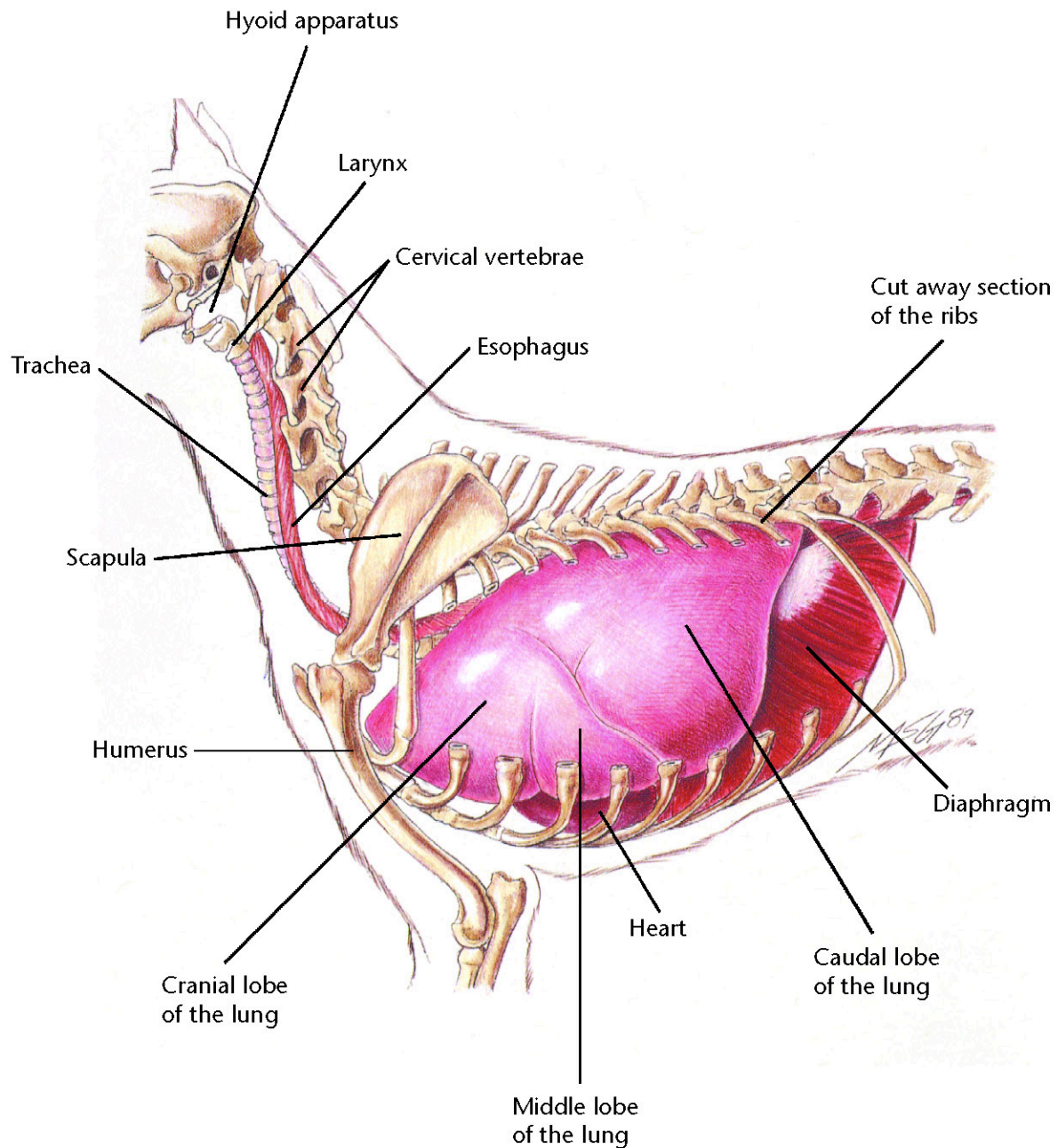
Therapeutic Plan

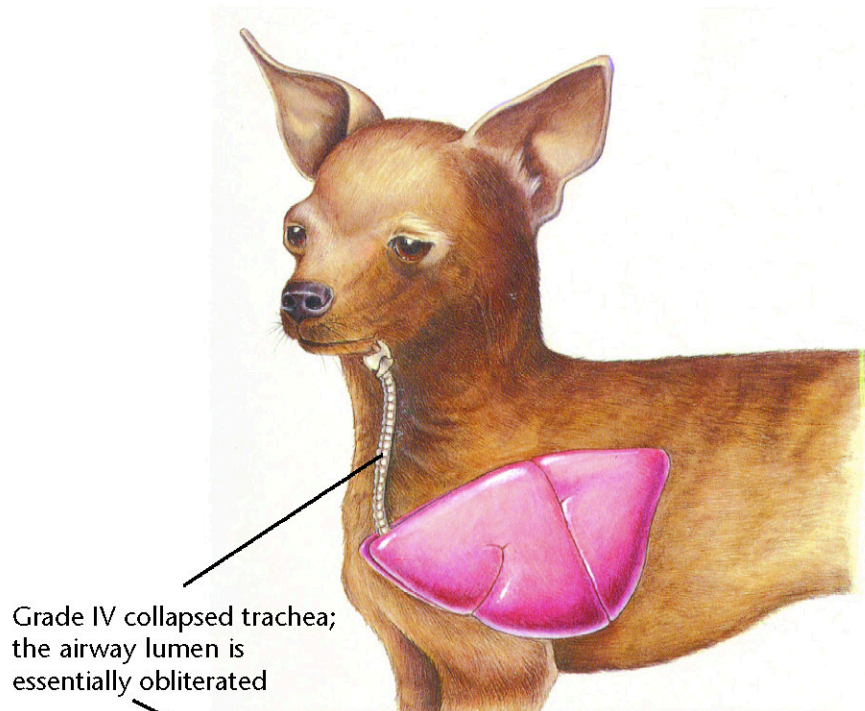
Elimination of the cause
Antibacterials
Tonsillectomy

Dietary Plan

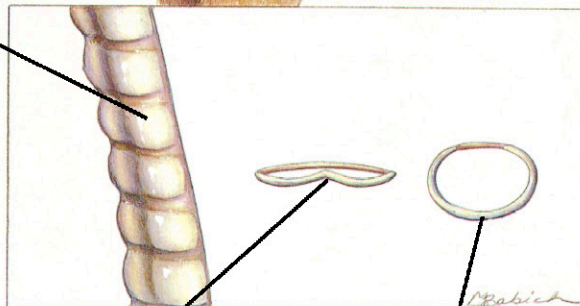
A diet based on overall patient evaluation including body condition and other organ system involvement
A soft diet may minimize postsurgical pain







Grade IV collapsed trachea;
the airway lumen is
essentially obliterated



The tracheal cartilage is
inverted dorsally and contacts
the tracheal membrane

Normal tracheal ring

Collapsing Trachea

Diagnostic Plan

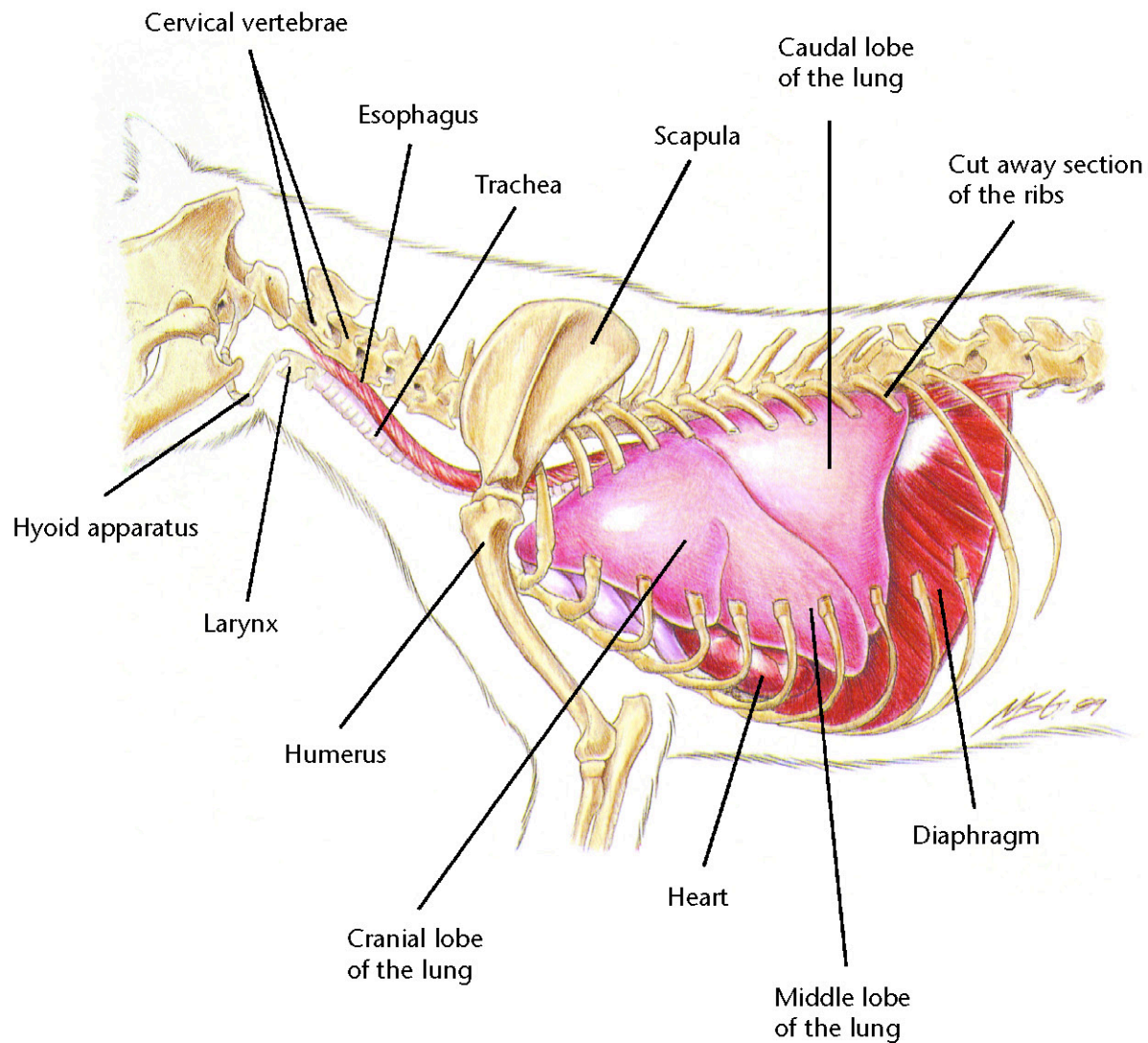
History
Physical examination
Tracheal palpation
Chest auscultation
Chest x-rays
Tracheoscopy
Cultures of tracheal wash fluid

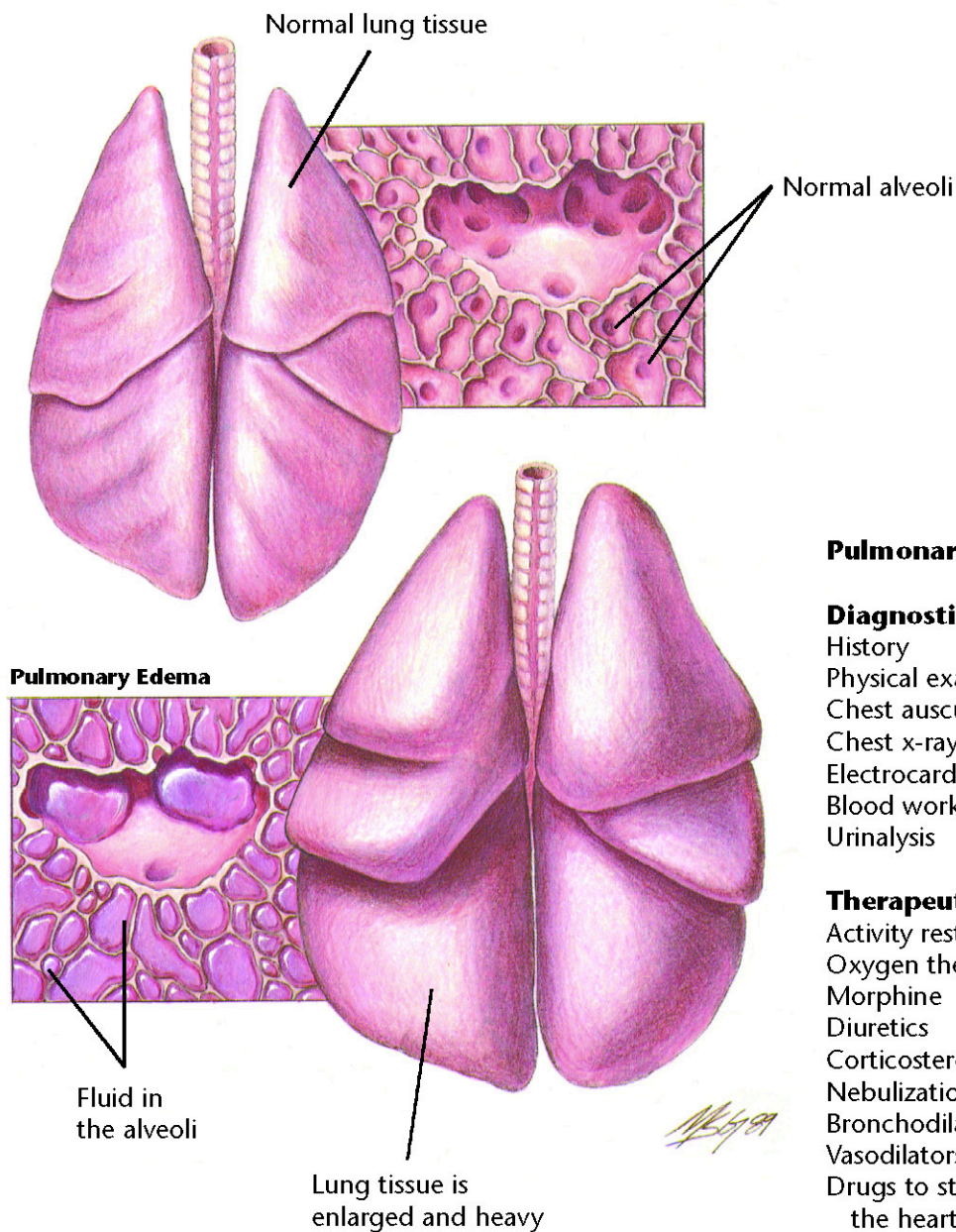
Therapeutic Plan

Activity restriction
Corticosteroids
Steam vaporization
Bronchodilators
Antitussives
Antibacterials
Surgery

Dietary Plan

If surgery is performed, a diet
adequate for tissue repair
If obesity is a complicating factor,
restrict caloric intake so the
patient reaches and maintains
an ideal body weight





Pulmonary Edema

Diagnostic Plan

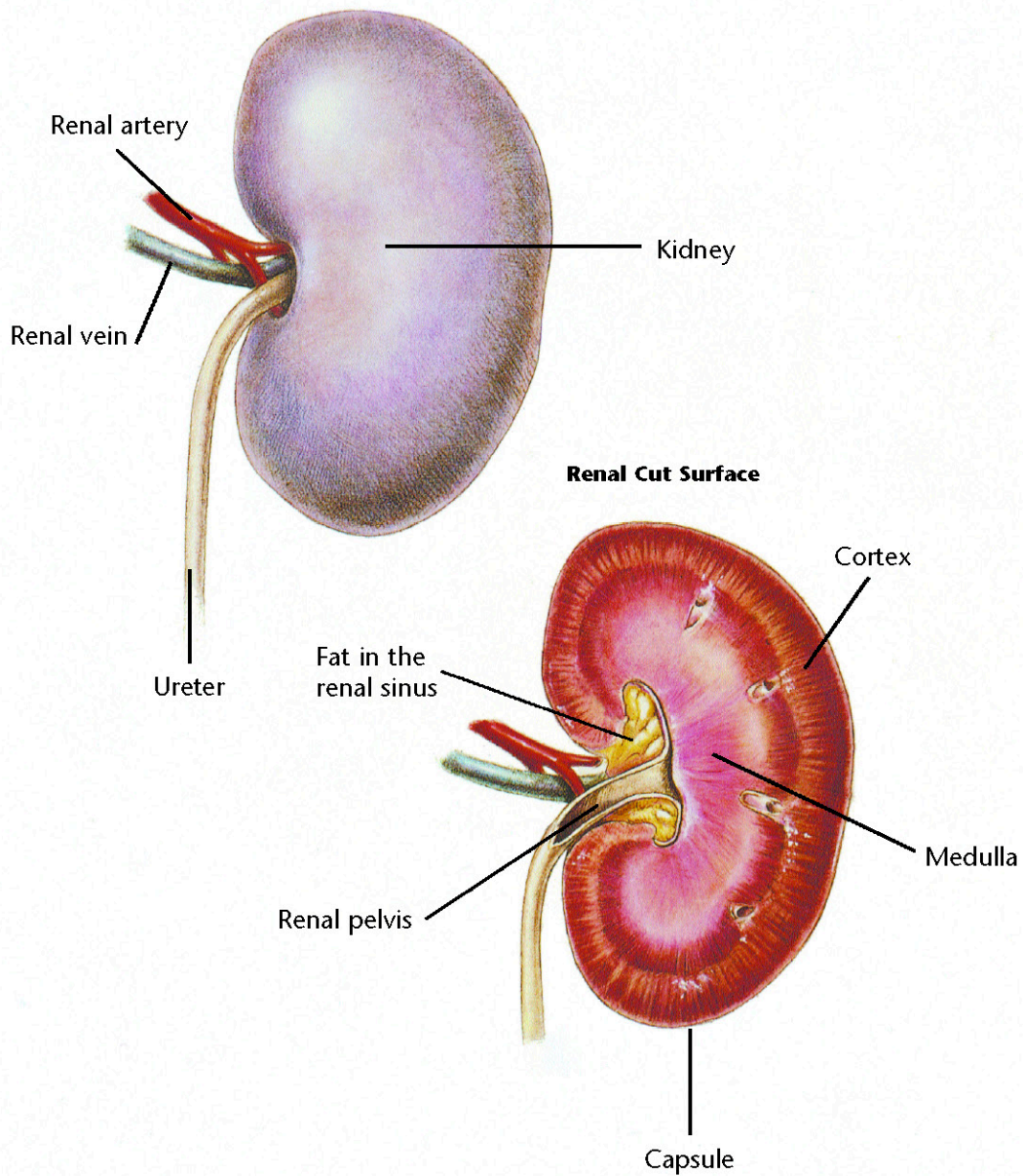
History
Physical examination
Chest auscultation
Chest x-rays
Electrocardiography
Blood work
Urinalysis

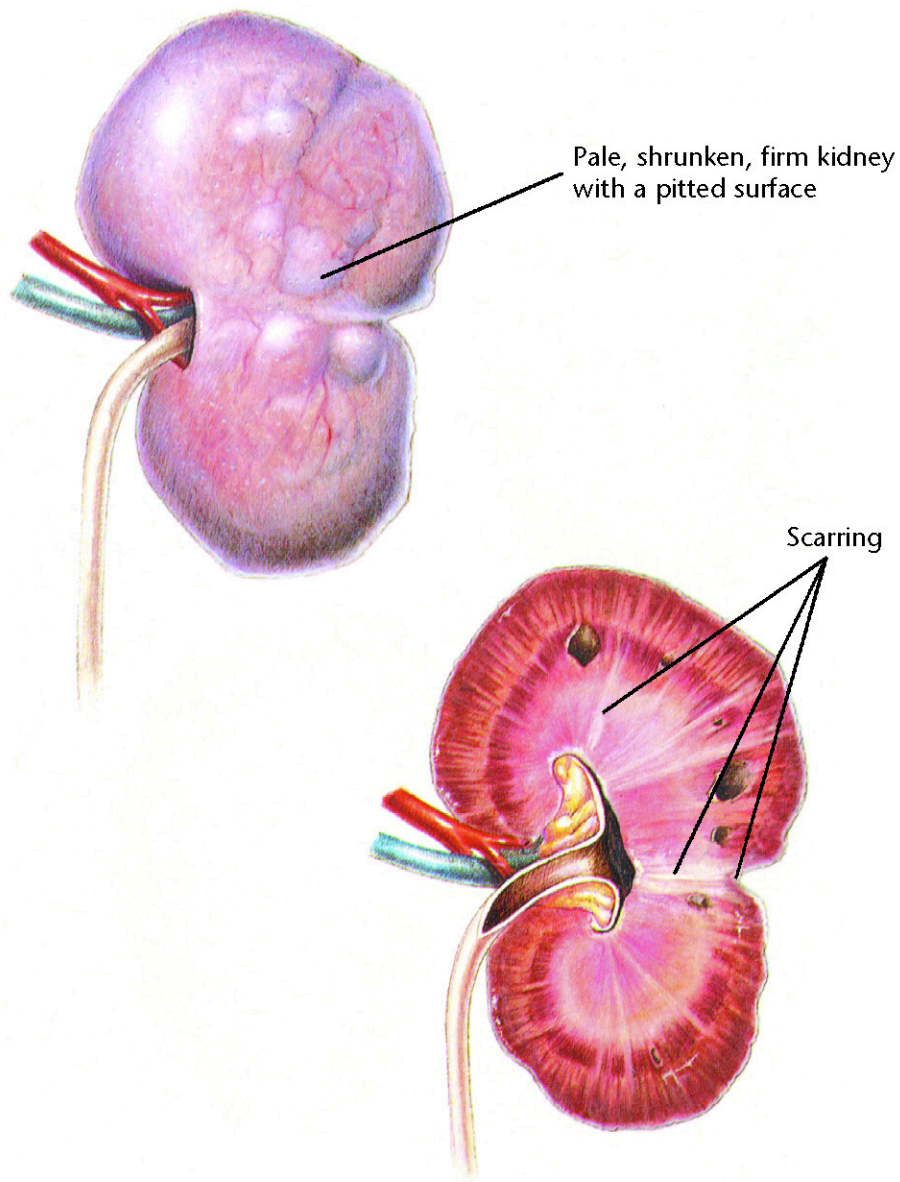
Therapeutic Plan

Activity restriction
Oxygen therapy
Morphine
Diuretics
Corticosteroids
Nebulization
Bronchodilators
Vasodilators
Drugs to strengthen the heart

Dietary Plan

A diet based on individual patient evaluation including body condition and other organ system involvement or disease
Avoid excess sodium





Chronic Renal Disease

Diagnostic Plan

History
Physical examination
Abdominal palpation
Urinalysis
Blood work
Blood pressure measurement
Abdominal x-rays
Kidney biopsy
Ultrasound

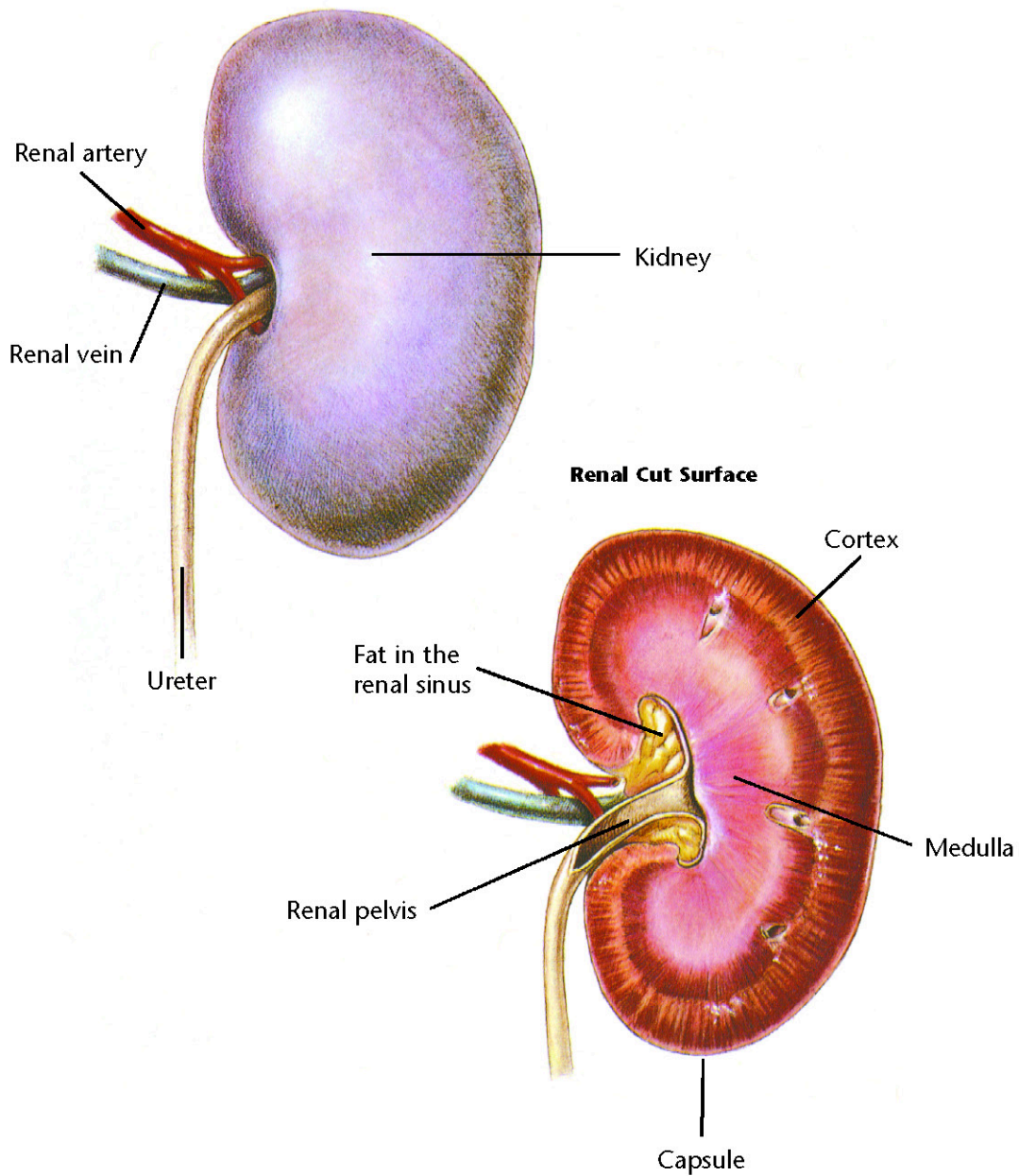
Therapeutic Plan

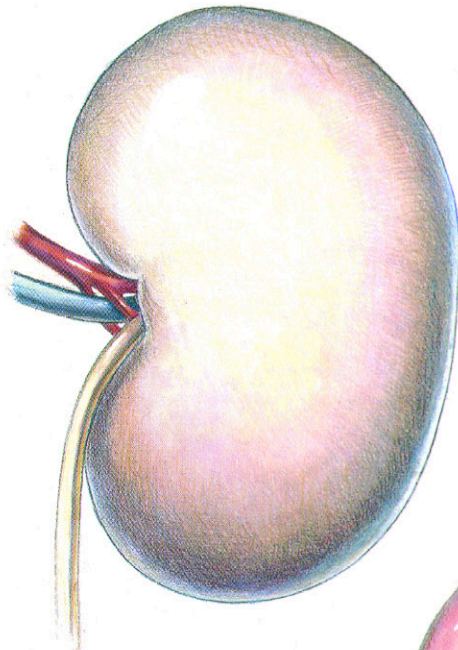
Fluid therapy
Sodium bicarbonate
Drugs to control stomach acidity
Phosphate binders
Blood transfusions
Anabolic steroids
Peritoneal dialysis

Dietary Plan

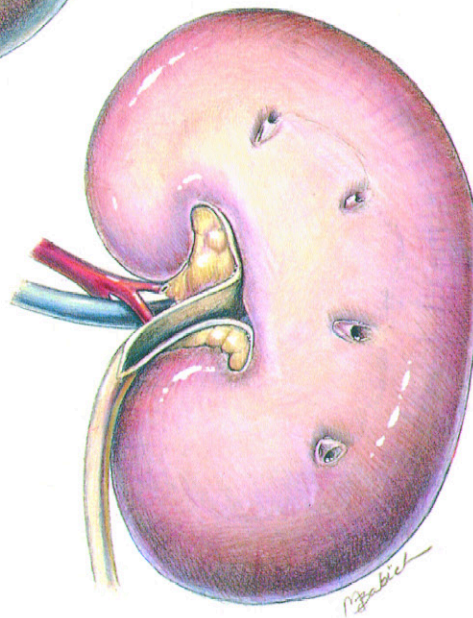
A diet with controlled and appropriate levels of protein, phosphorus, sodium, and calories







Pale, swollen kidney



Acute Renal Failure

Diagnostic Plan

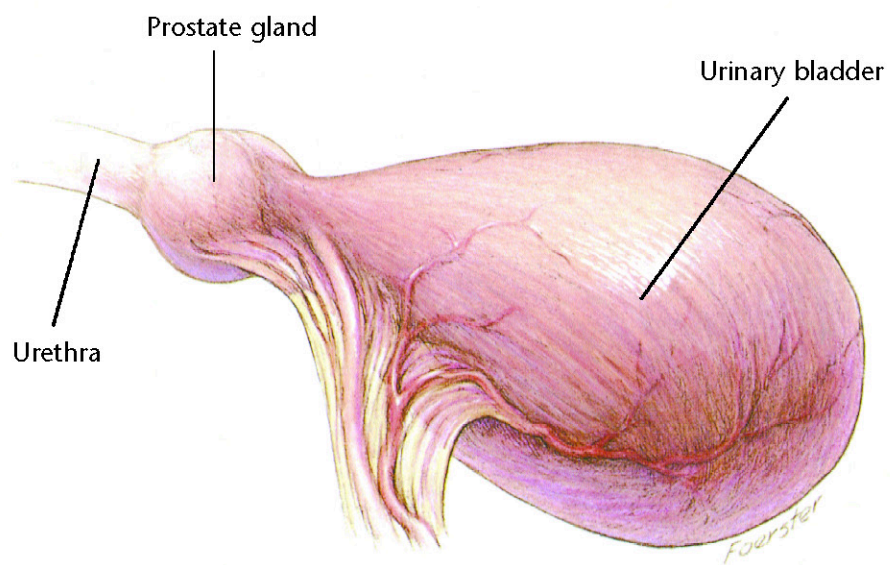
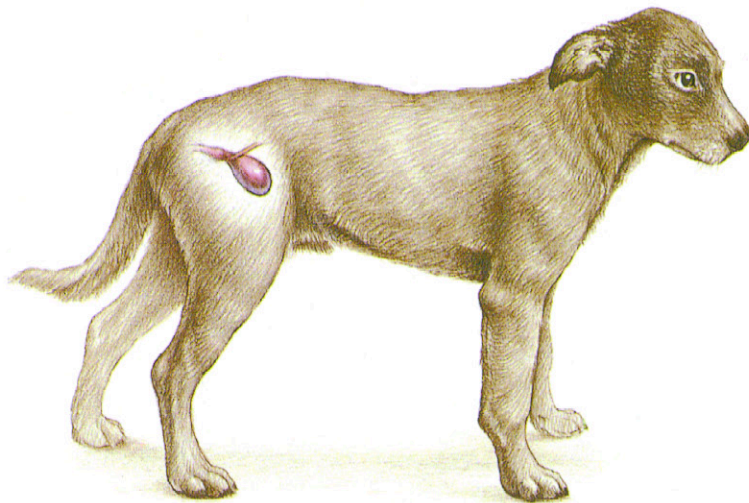
History
Physical examination
Abdominal palpation
Urinalysis
Blood work
Abdominal x-rays
Kidney biopsy
Ultrasound

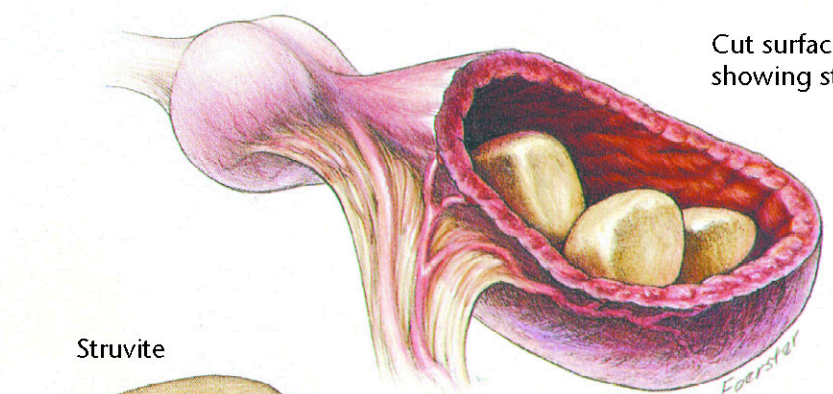
Therapeutic Plan

Fluid therapy
Diuretics
Phosphate binders
Sodium bicarbonate
Drugs to control
 stomach acidity
Peritoneal dialysis

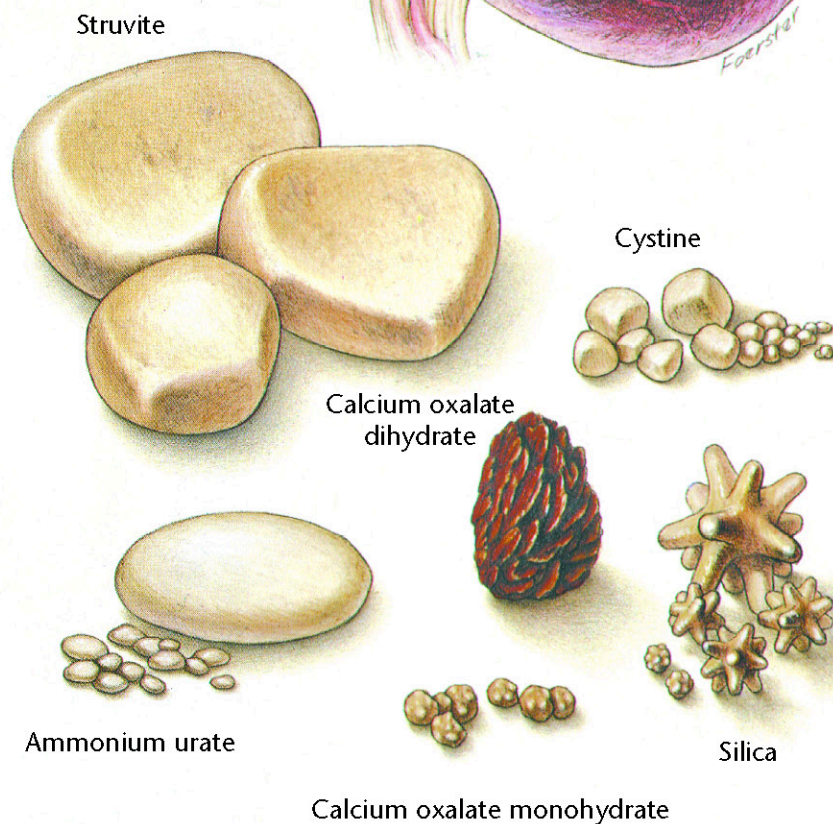
Dietary Plan

A diet with controlled and appropriate levels of protein, phosphorus, sodium, and calories





Cut surface of a bladder
showing struvite calculi



Bladder Stones

Diagnostic Plan

History
Physical examination
Palpation of the urethra
and urinary bladder
Urinalysis
Urine culture
Blood work
X-rays of the urinary tract
Quantitative analysis of
passed bladder stones

Therapeutic Plan*

Fluid therapy
Antibacterials
Urease inhibitors
Xanthine oxidase inhibitors
Urine alkalizers
Thiol-containing drugs
Surgery
Voiding urohydropropulsion

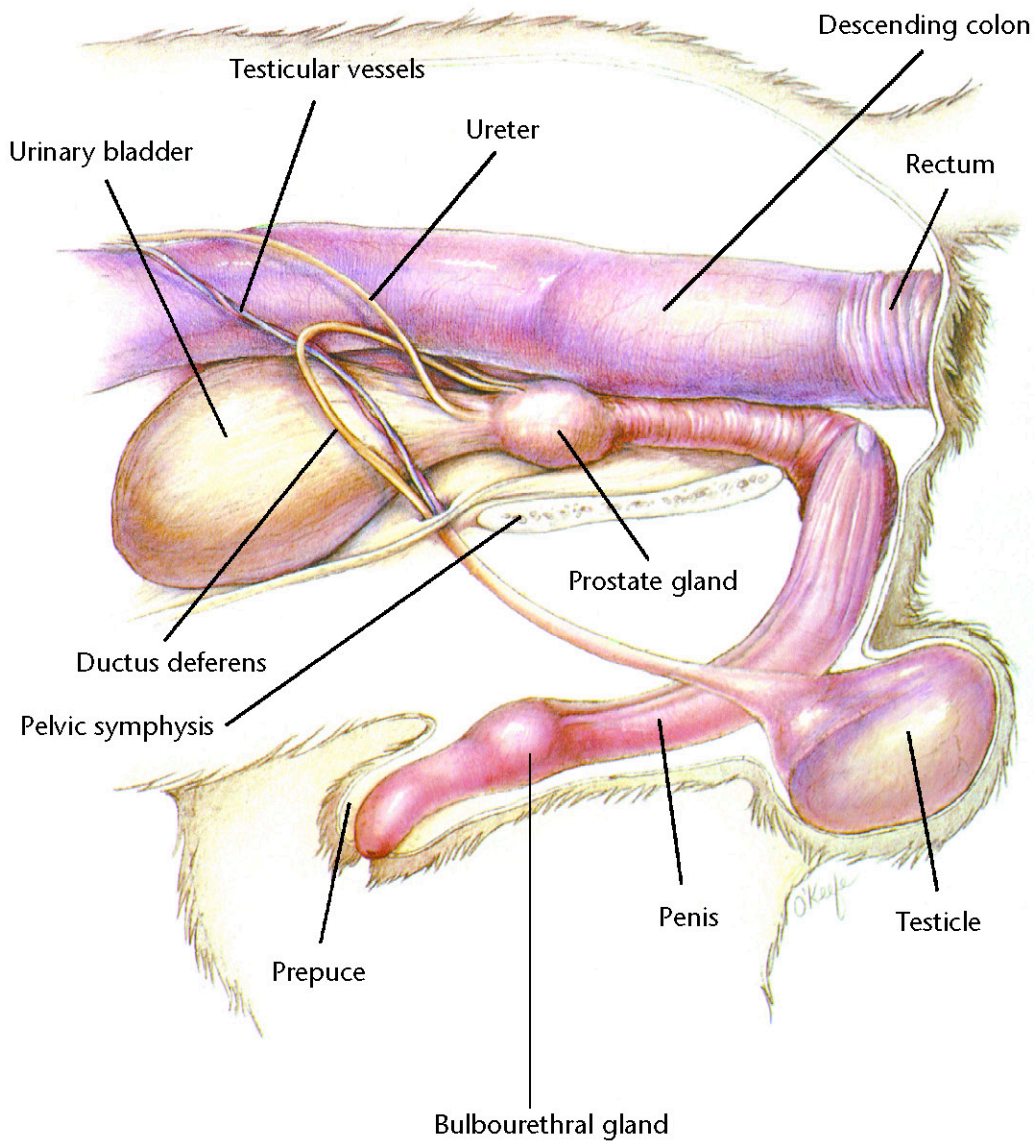
Dietary Plan*

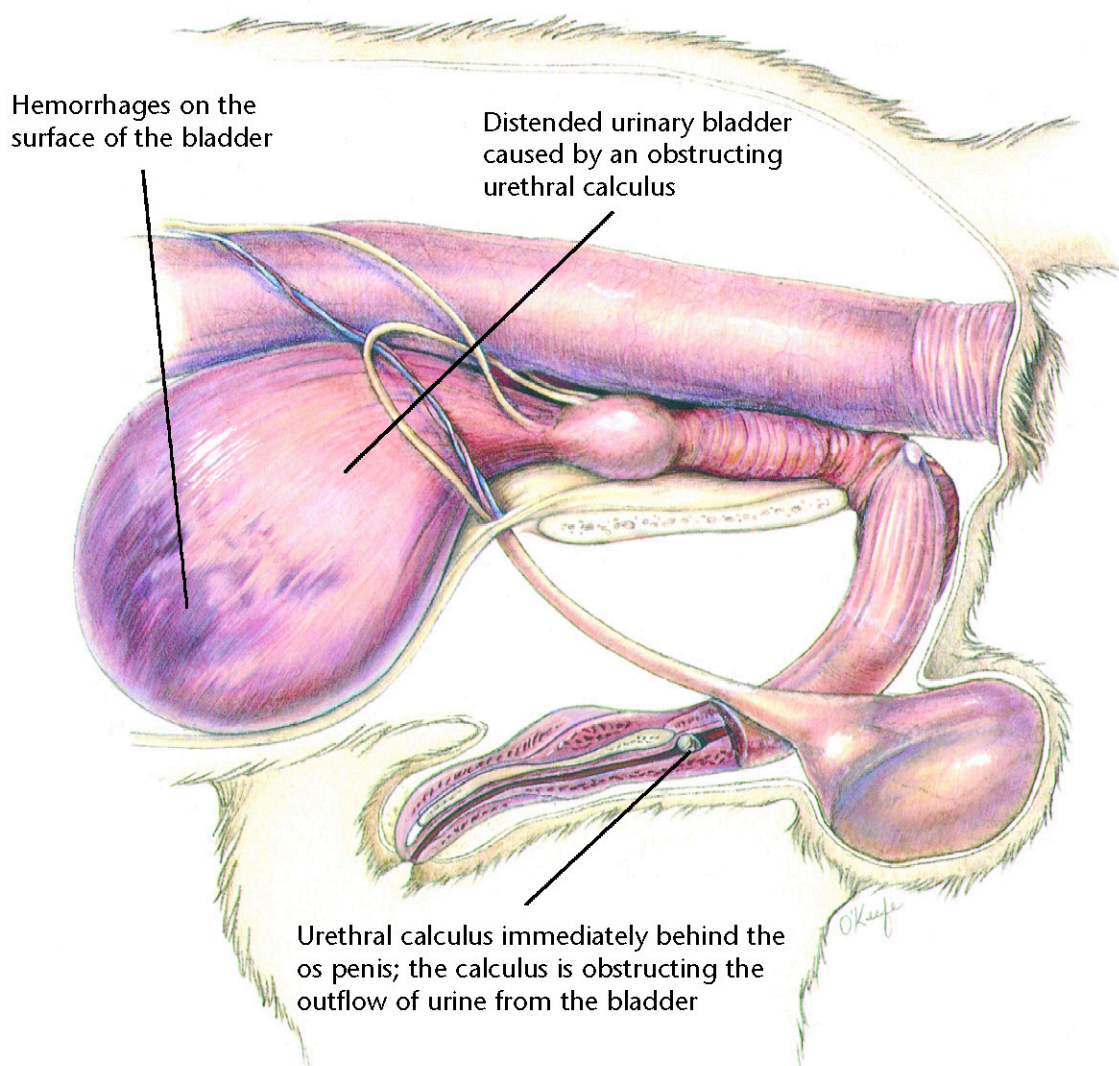
For dissolution, the proper
calculolytic diet
To aid in prevention or
recurrence, a diet that
allows the body to produce
the appropriate urine pH
and avoids excesses of the
urolith's precursors
If surgery is necessary, a diet
adequate for tissue repair

*Determined by stone type



Hill's Atlas of Veterinary Clinical Anatomy Normal Canine Lower Urinary System





Canine Urethral Obstruction

Diagnostic Plan

History
Physical examination
Urethral palpation
Abdominal palpation
X-rays of the urinary tract
Urinalysis
Urine culture
Blood work
Analysis of passed bladder stones

Therapeutic Plan

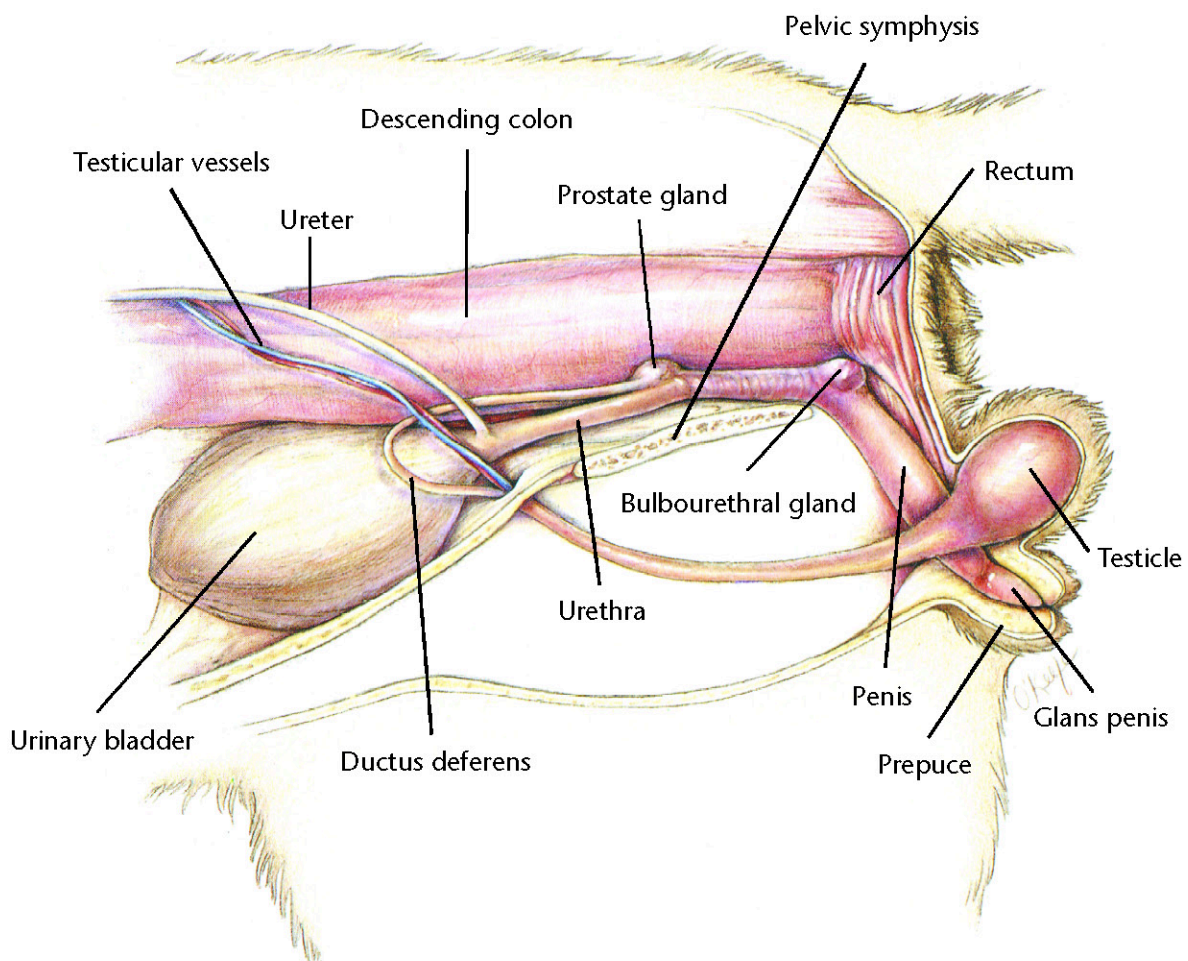
Emptying of the bladder
Fluid therapy
Flushing of the urethral calculi into the bladder
Surgery

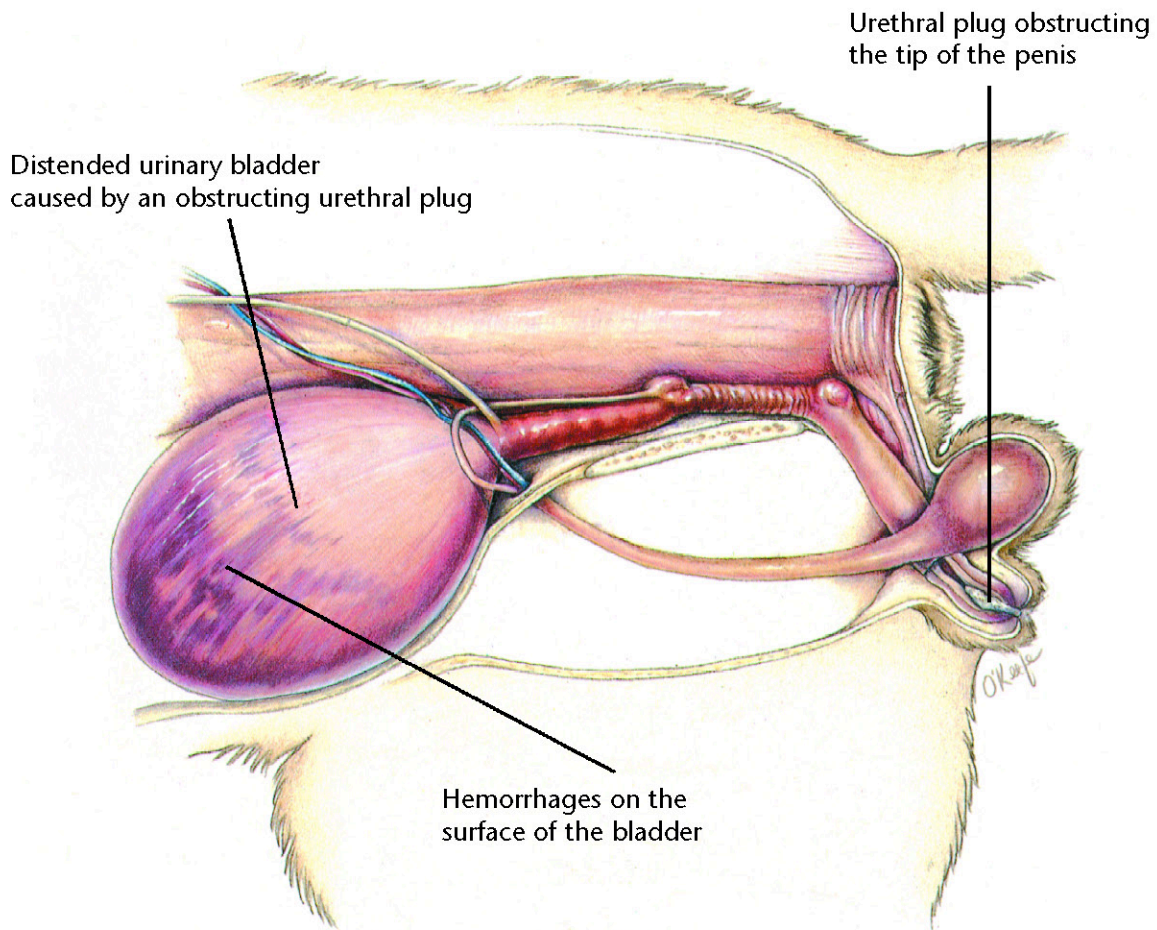
Dietary Plan

For dissolution, the proper calculolytic diet
To aid in prevention or recurrence, a diet that allows the body to produce the appropriate urine pH and avoids excesses of the urolith's precursors
If surgery is necessary, a diet adequate for tissue repair



Hill's Atlas of Veterinary Clinical Anatomy Normal Feline Lower Urinary System





Feline Urologic Syndrome

Diagnostic Plan

History
Physical examination
Abdominal palpation
Urethral palpation
Urinalysis
Urine culture
X-rays of the urinary tract
Blood work

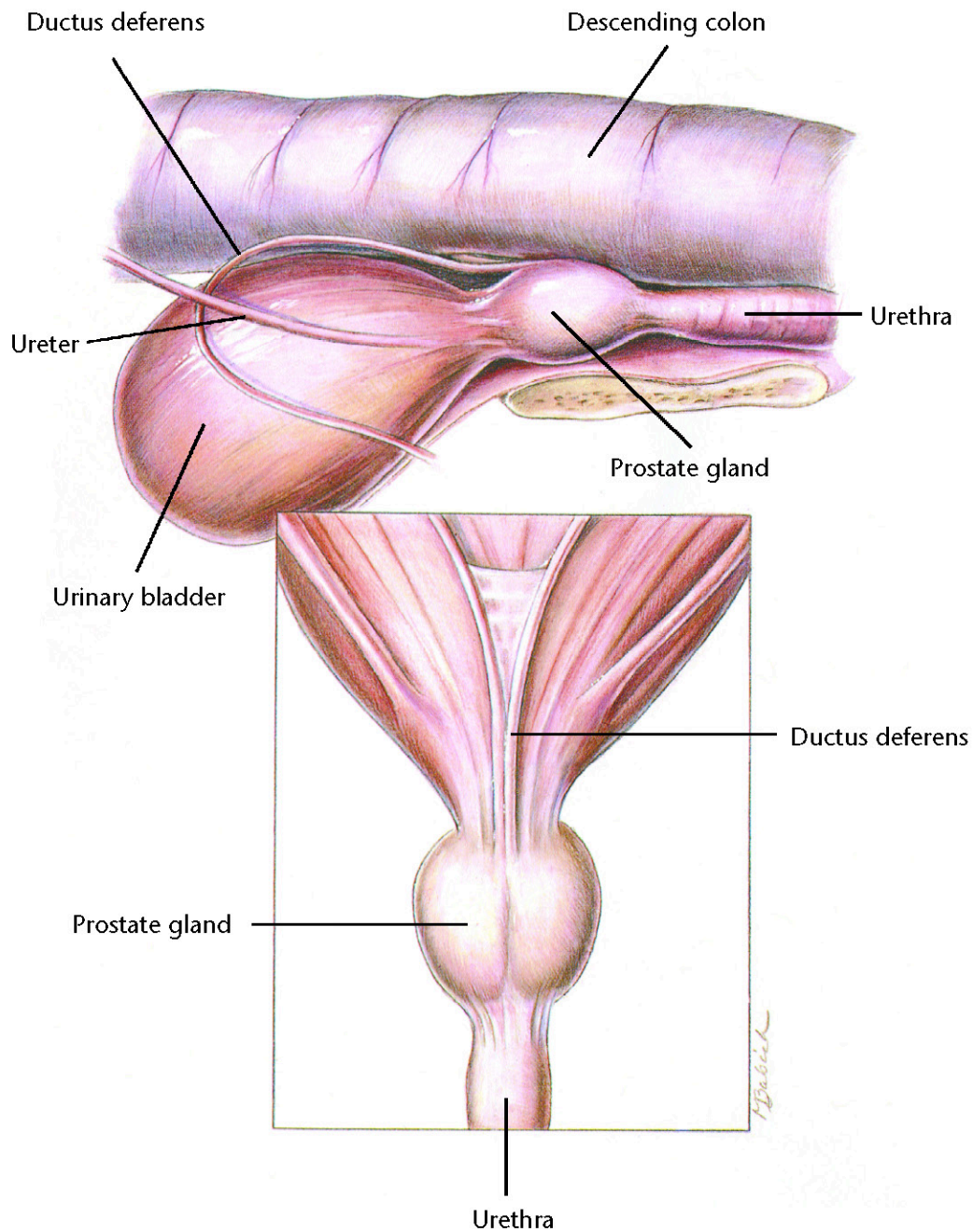
Therapeutic Plan

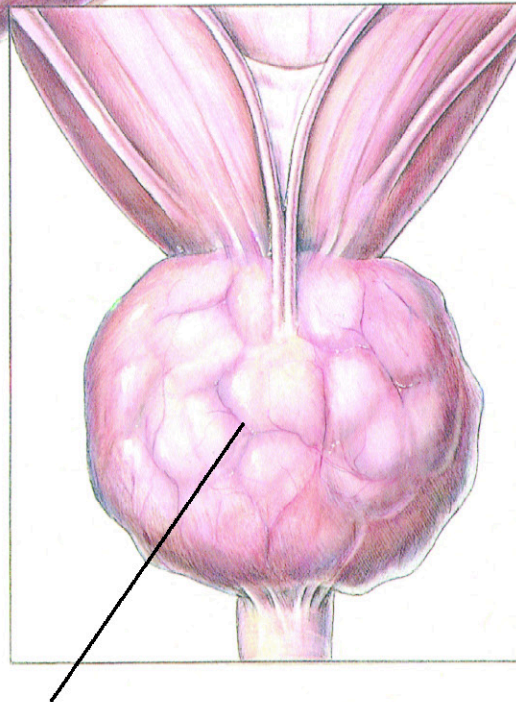
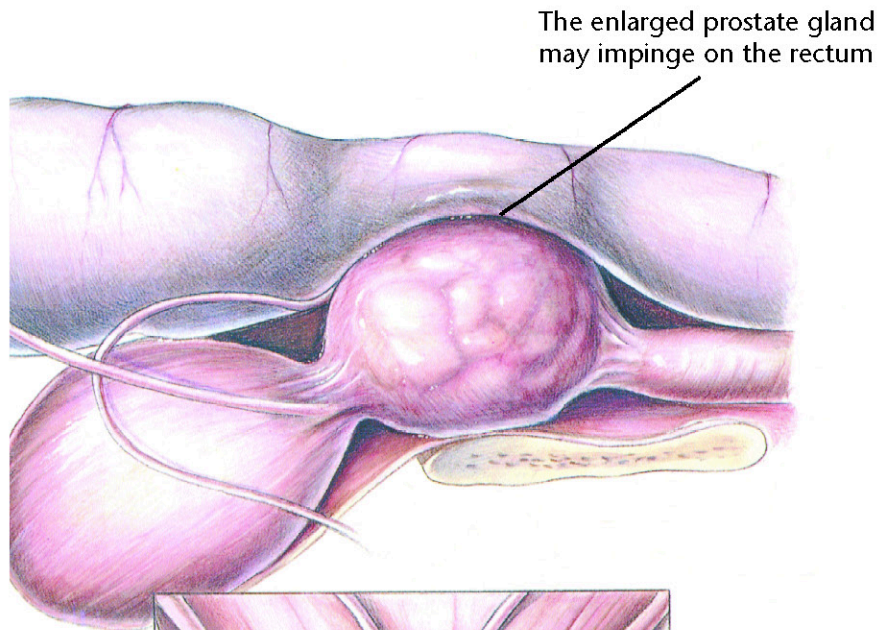
Emptying of the bladder
Fluid therapy
Removal of the
urinary obstruction

Dietary Plan

For dissolution, the proper
calculolytic diet
To aid in prevention or
recurrence, a diet that allows
the body to produce the
appropriate urine pH and
avoids excesses of the
urolith's precursors
If surgery is necessary, a diet
adequate for tissue repair







Benign Prostatic Hyperplasia

Diagnostic Plan

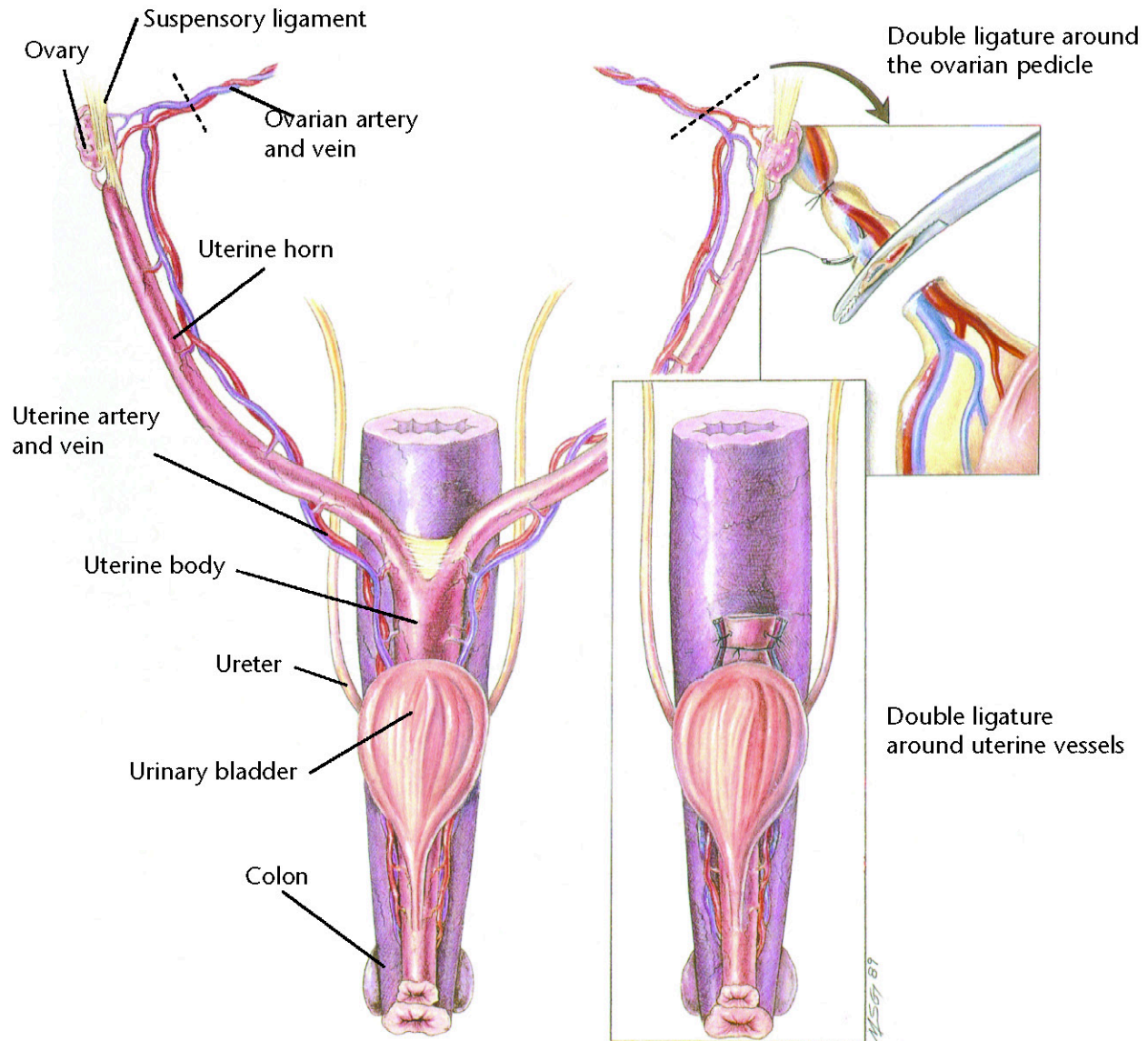
History
Physical examination
Rectal palpation
Abdominal palpation
X-rays
Ultrasound
Urinalysis
Urine culture
Blood work
Prostate biopsy

Therapeutic Plan

Emptying of the bladder
Enemas
Stool softeners
Castration
Medical therapy

Dietary Plan

If surgery is necessary, a diet
adequate for tissue repair
A low residue food



Ovariohysterectomy

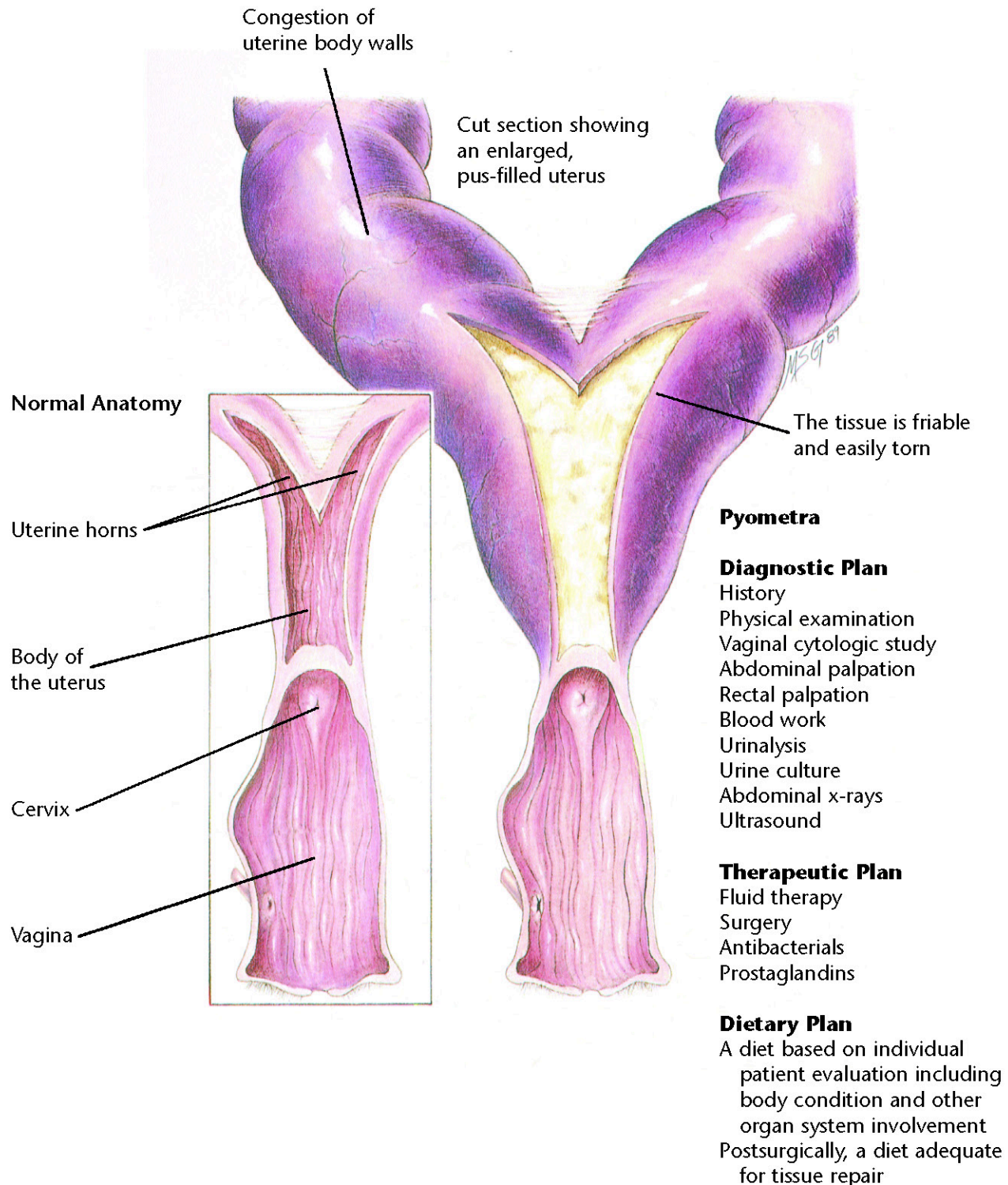
Indications

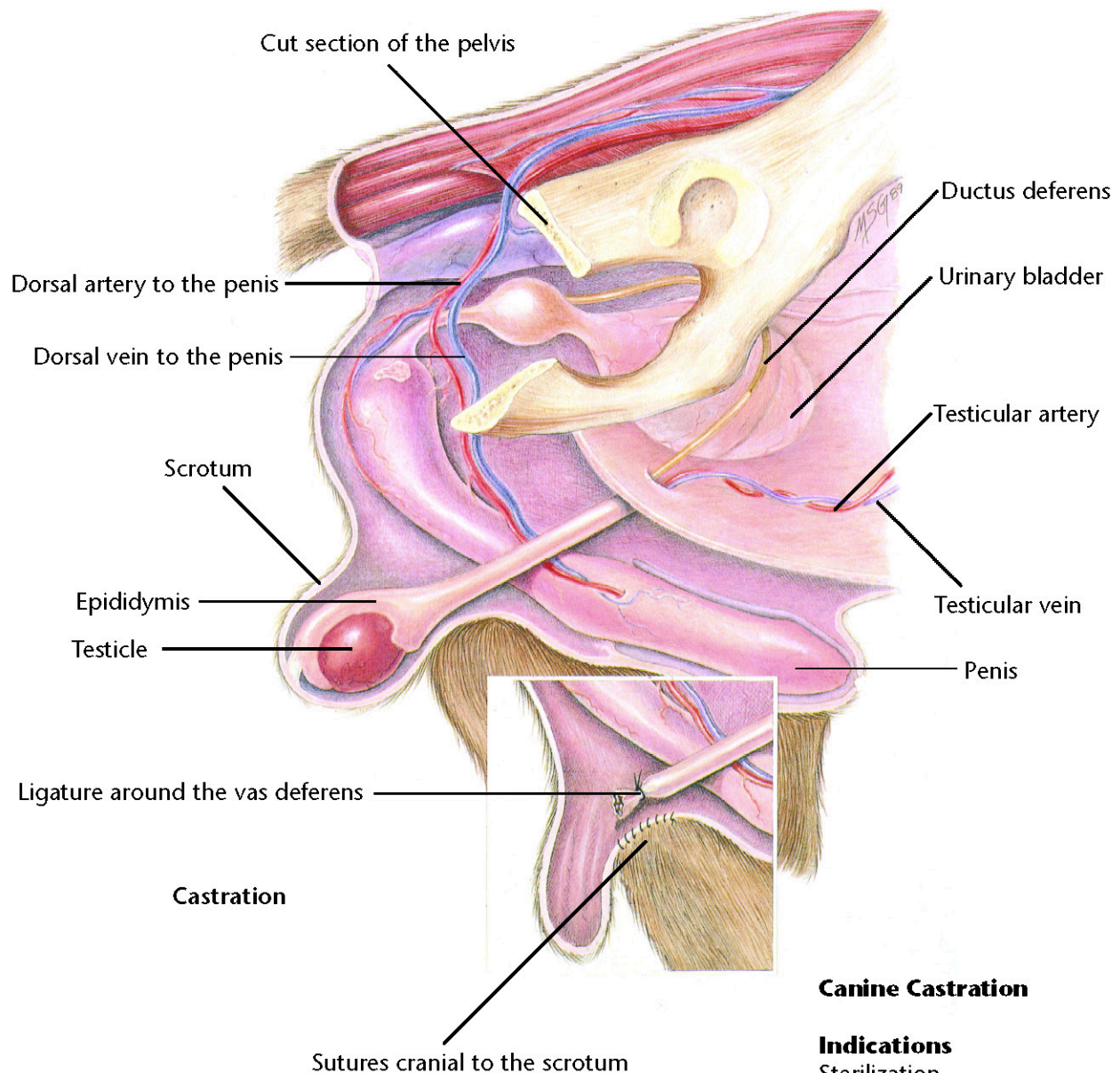
Sterilization
 Ovarian disease
 Uterine disease
 Behavioral problems
 Vaginal hyperplasia
 Diabetes
 Epilepsy
 Mammary tumor prevention

Dietary Plan

Postsurgically, a diet adequate for tissue repair







Canine Castration

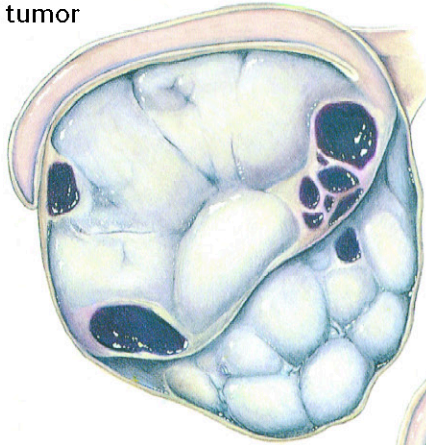
Indications

Sterilization
 Testicular disease
 Prostatic disease
 Behavioral problems
 Retained testicles

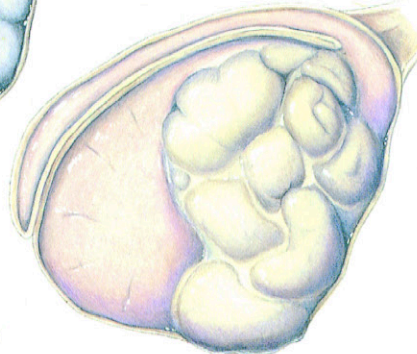
Dietary Plan

Postsurgically, a diet adequate for tissue repair

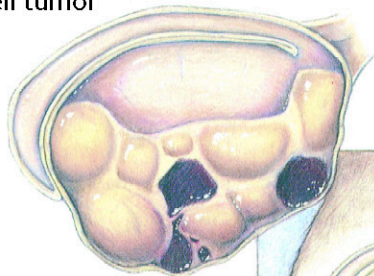
Sertoli-cell tumor



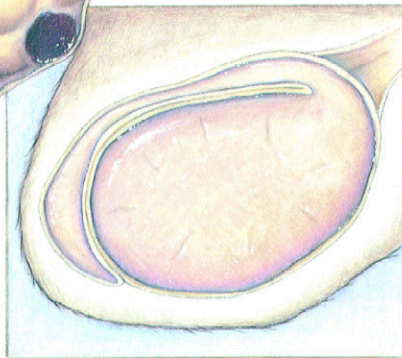
Seminoma



Leydig-cell tumor



Normal testis



Testicular Tumors

Diagnostic Plan


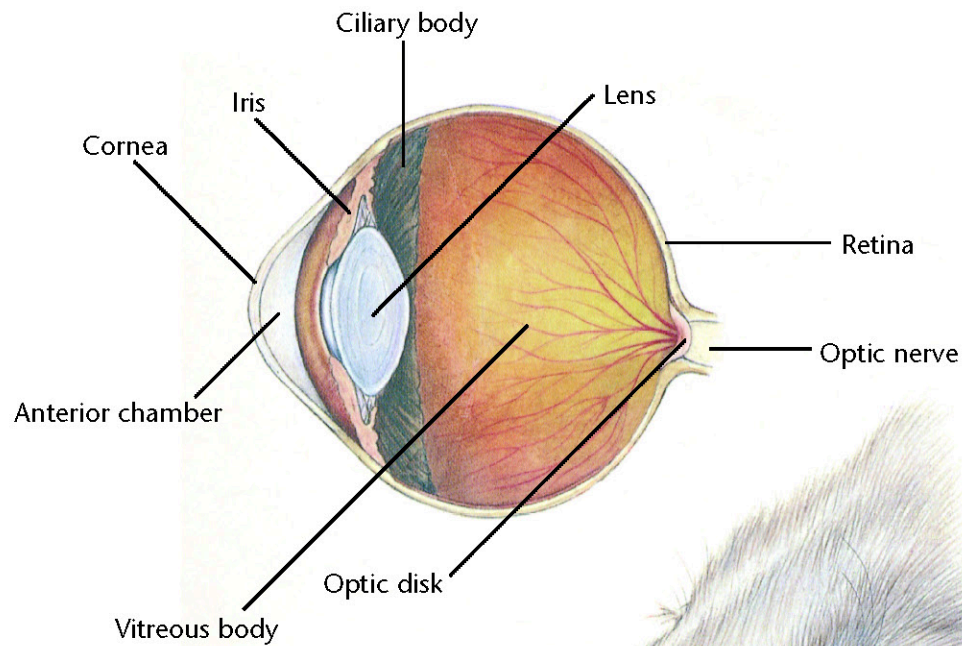
History
Physical examination
Testicular palpation
X-rays of the abdomen
Biopsy

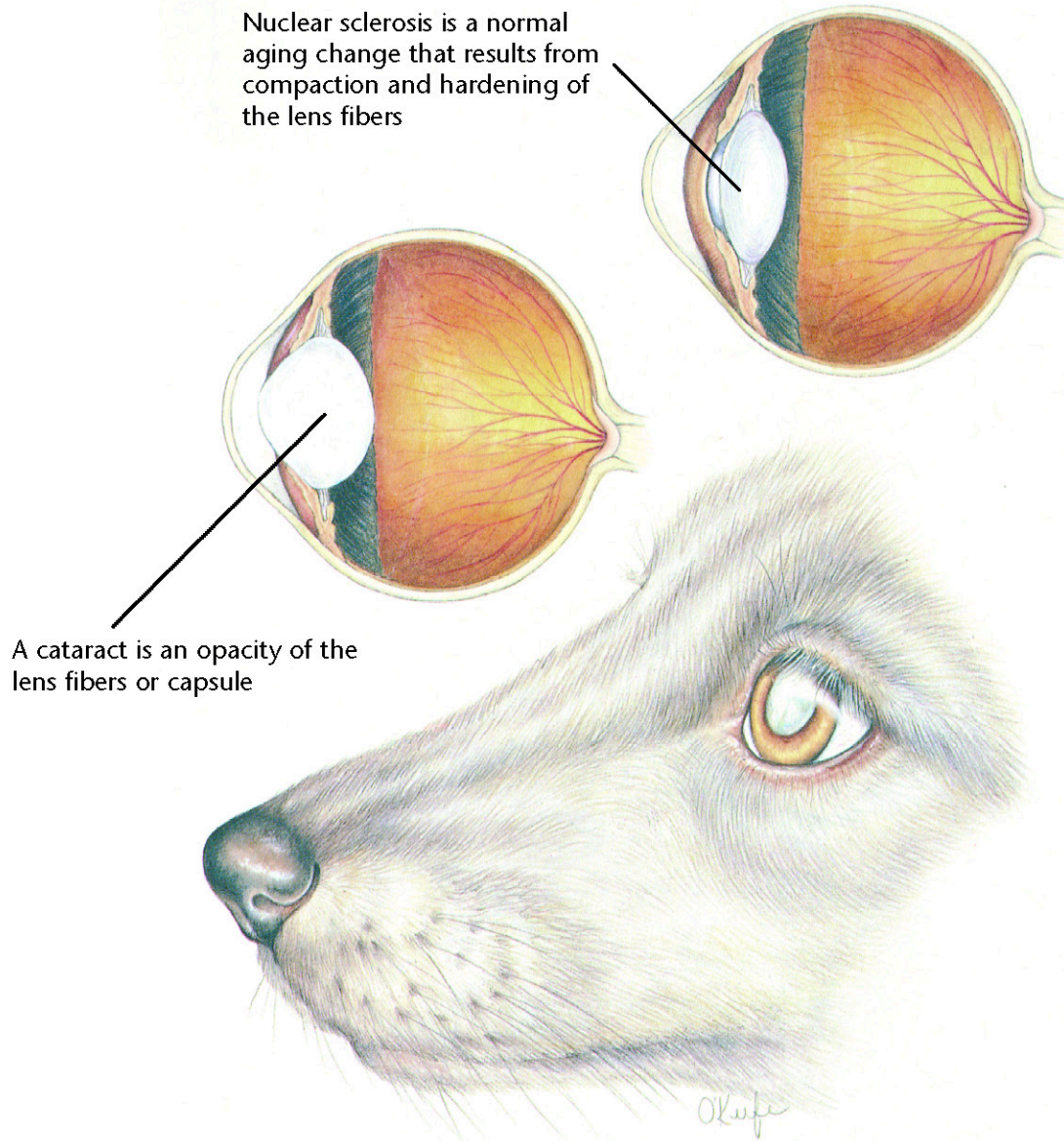
Therapeutic Plan

Surgery
Chemotherapy

Dietary Plan

Postsurgically, a diet
adequate for tissue repair
Consider body condition;
feed a diet appropriate
to maintain ideal
body weight





Nuclear Sclerosis/Cataracts

Diagnostic Plan

History
Physical examination
Ophthalmic examination
Blood tests
Urinalysis

Therapeutic Plan

Surgery
Therapy for any concurrent disease
No therapy is necessary for nuclear sclerosis

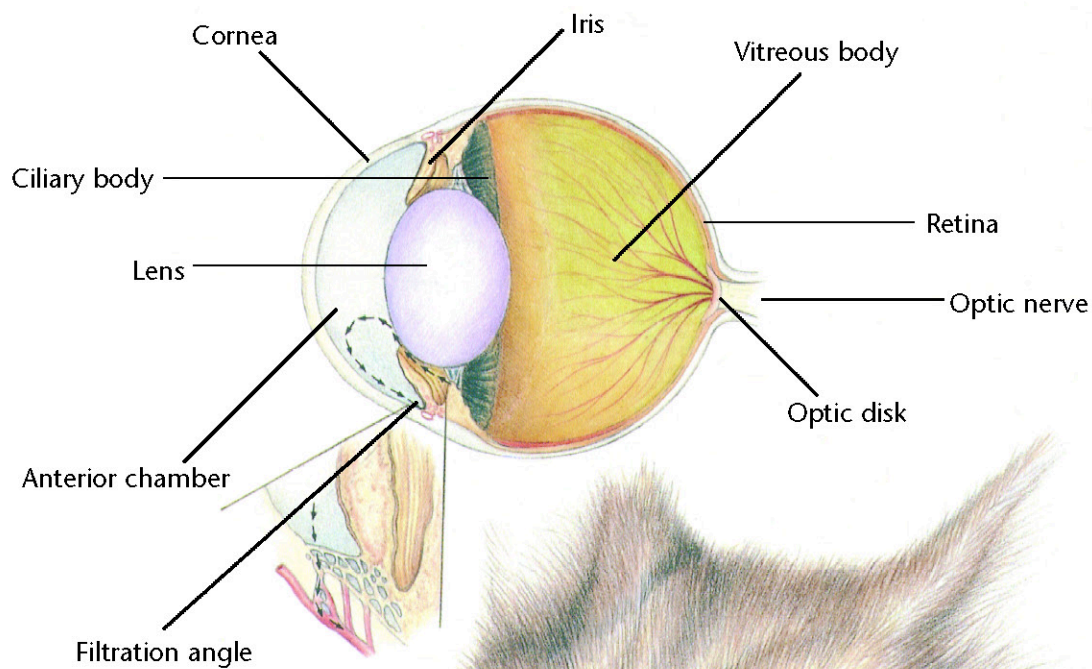
Dietary Plan

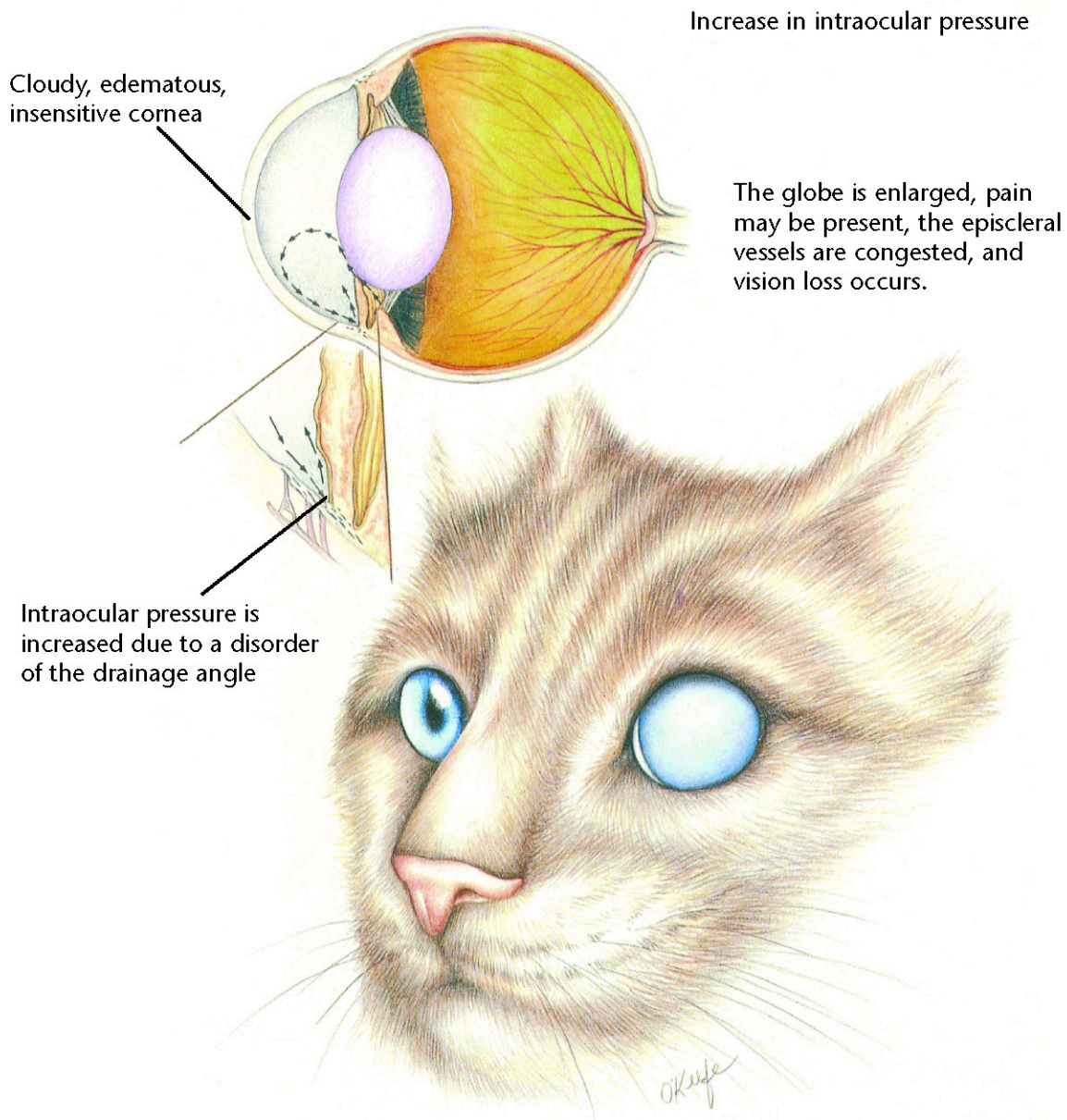
A diet based on individual patient evaluation including body condition and other organ system involvement or disease



Hill's Atlas of Veterinary Clinical Anatomy

Normal Feline Eye





Glaucoma

Diagnostic Plan

History
Physical examination
Ocular examination
Measurement of intraocular pressure

Therapeutic Plan

Drugs that relieve intraocular pressure
Surgery


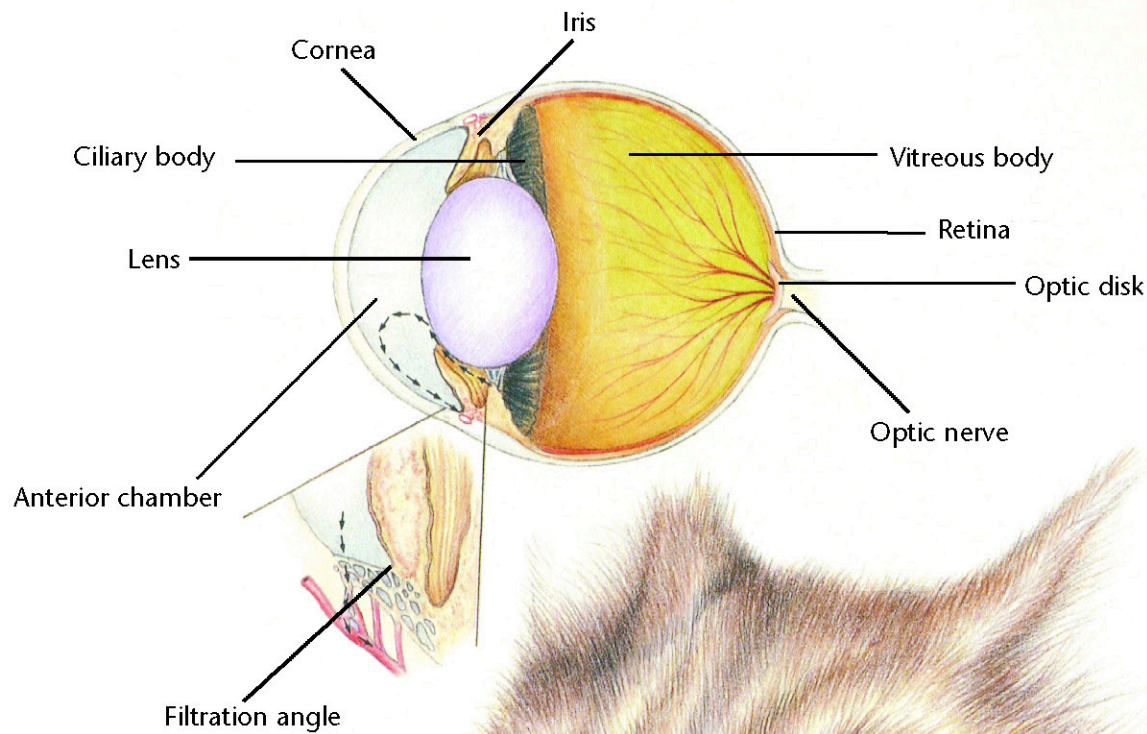
Dietary Plan

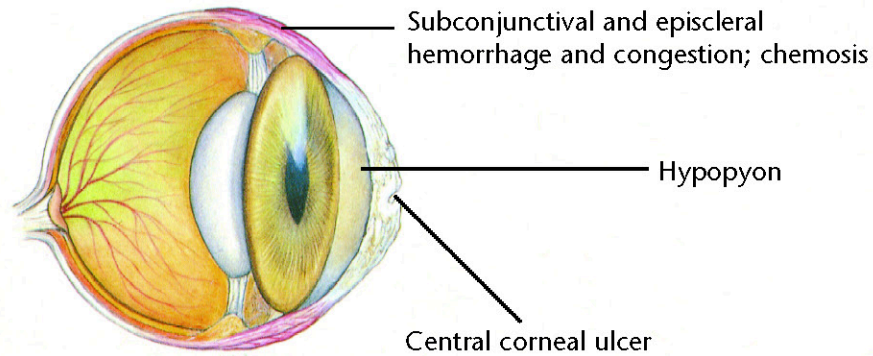
A diet based on individual patient evaluation including body condition and other organ system involvement or disease



Hill's Atlas of Veterinary Clinical Anatomy

Normal Feline Eye





Corneal Ulceration

Diagnostic Plan

History
Physical examination
Ocular examination
Fluorescein stain
Culture
Cytologic examination

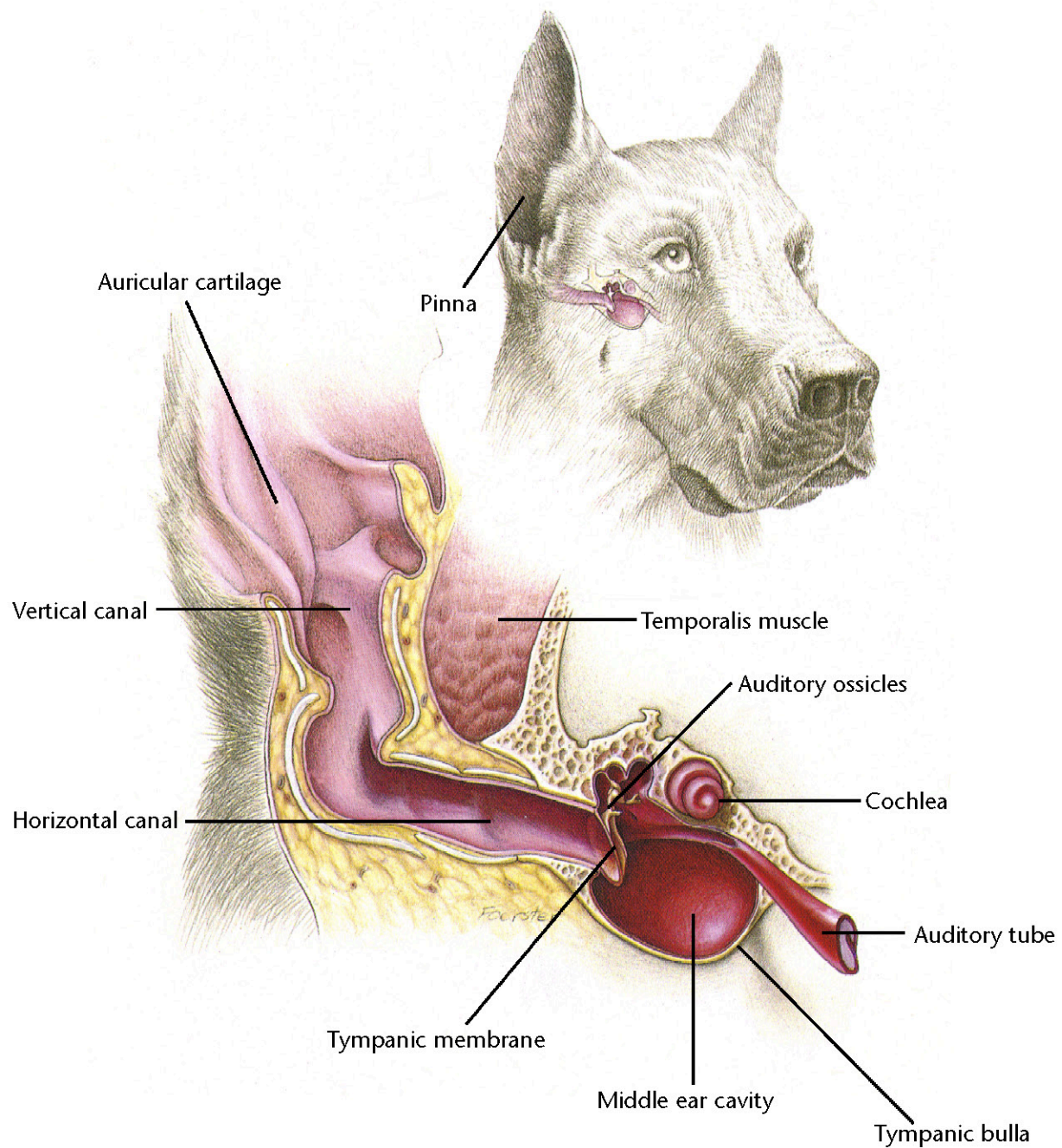
Therapeutic Plan

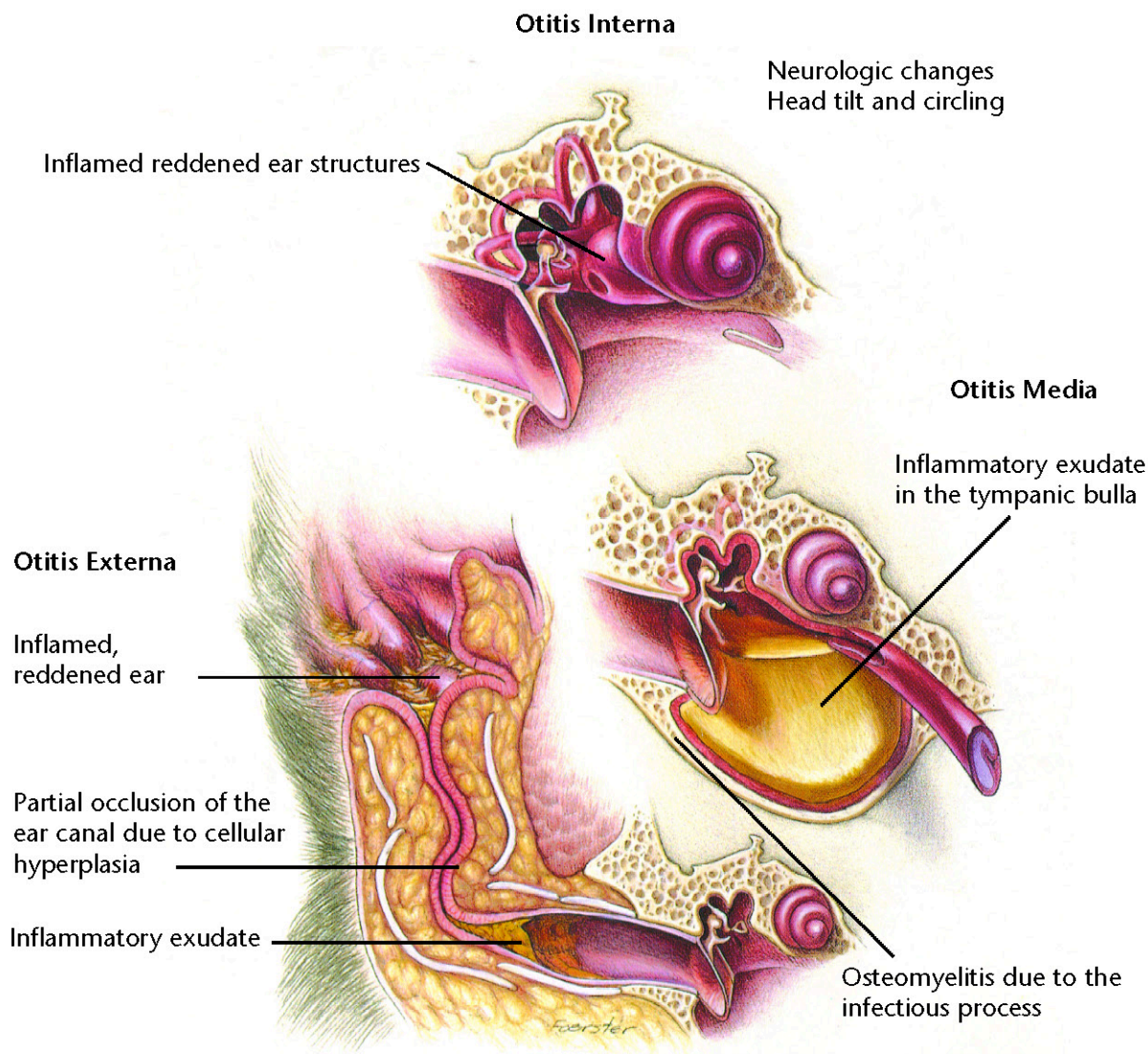
Antibacterial ointment and solutions
Drugs that dilate the pupil
Surgery
Drugs to lessen the risk of pigment formation in the cornea

Dietary Plan

A diet based on individual patient evaluation including body condition and other organ system involvement or disease







Otitis Externa, Media, Interna

Diagnostic Plan

History
Physical examination
Ear examination
Ear cultures
Thyroid hormone levels
Intradermal skin testing
X-rays
Therapeutic trials with insecticides
and hypoallergenic diets

Therapeutic Plan

Removal of ear canal hair
Ear cleaning
Topical application of
antibacterials/corticosteroids
Systemic antibacterials
Systemic corticosteroids
Surgery

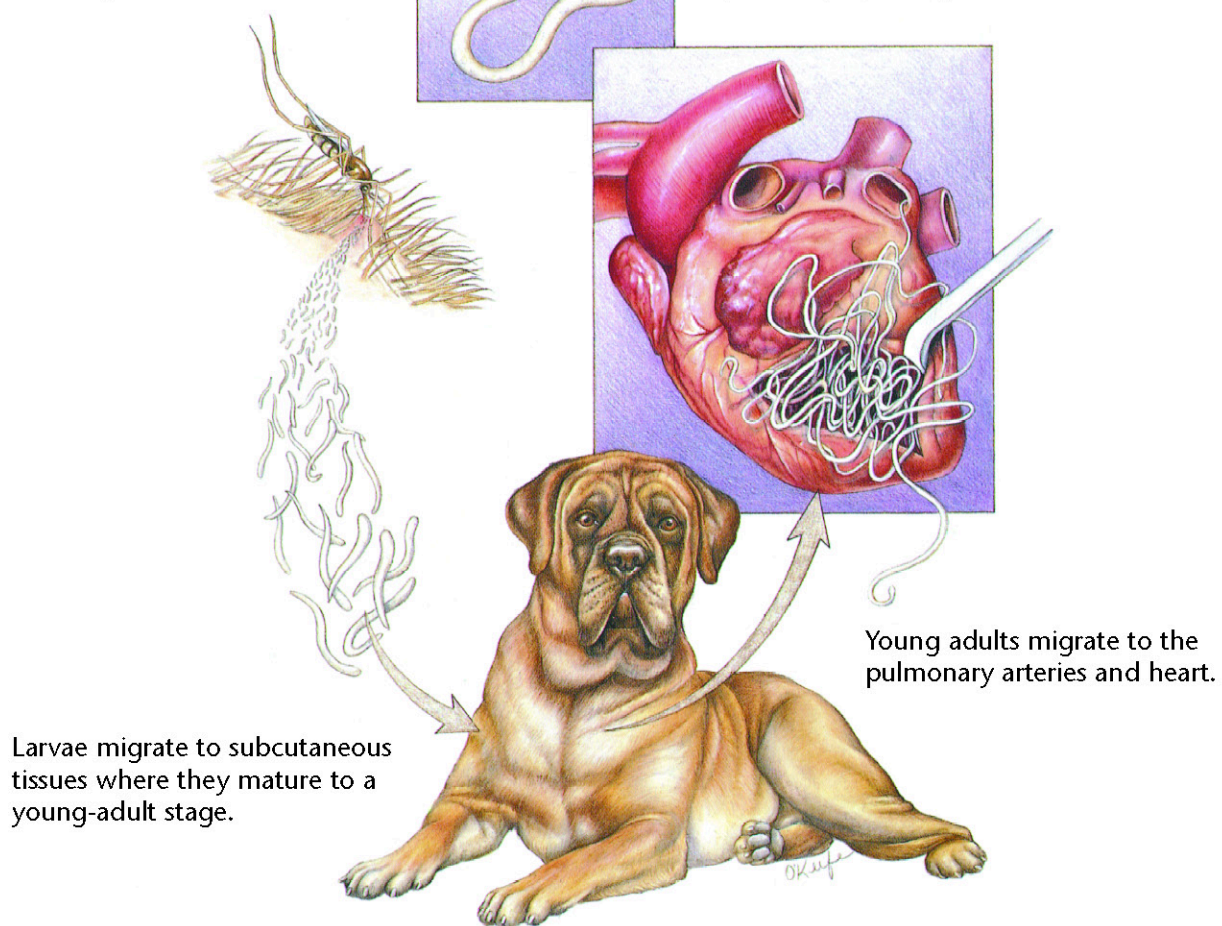
Dietary Plan

A diet based on individual
patient evaluation including
body condition and other
organ system involvement
or disease
Hypoallergenic diets



Infected mosquitoes deposit heartworm larvae into the animal's hemolymph by puncturing the animal's skin.

Mature females release microfilariae into the bloodstream where they are picked up by mosquitoes.



Heartworms

Diagnostic Plan

History
Physical examination
Heartworm check
Chest x-rays
Blood work
Urinalysis

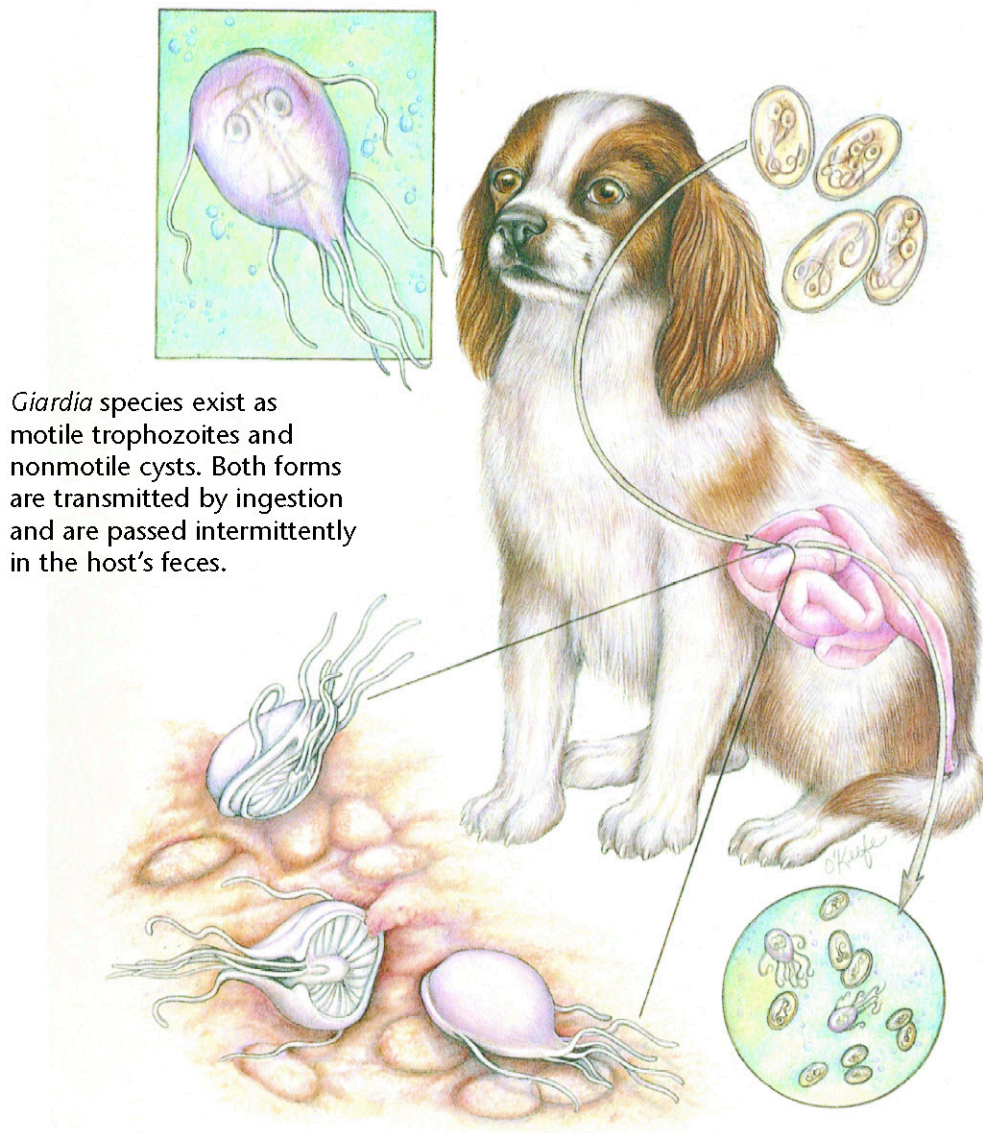
Therapeutic Plan

Drugs to kill adult worms
Aspirin
Corticosteroids
Restricted exercise
Drugs to kill larvae in the bloodstream
Prevention
Surgery

Dietary Plan

A diet with controlled levels of protein, phosphorus, and sodium
Consider body condition





Giardia species exist as motile trophozoites and nonmotile cysts. Both forms are transmitted by ingestion and are passed intermittently in the host's feces.

Giardia

Diagnostic Plan

History
Physical examination
Stool analysis
Analysis of intestinal scrapings
collected during endoscopy
Blood test
(Giardia antigen test)

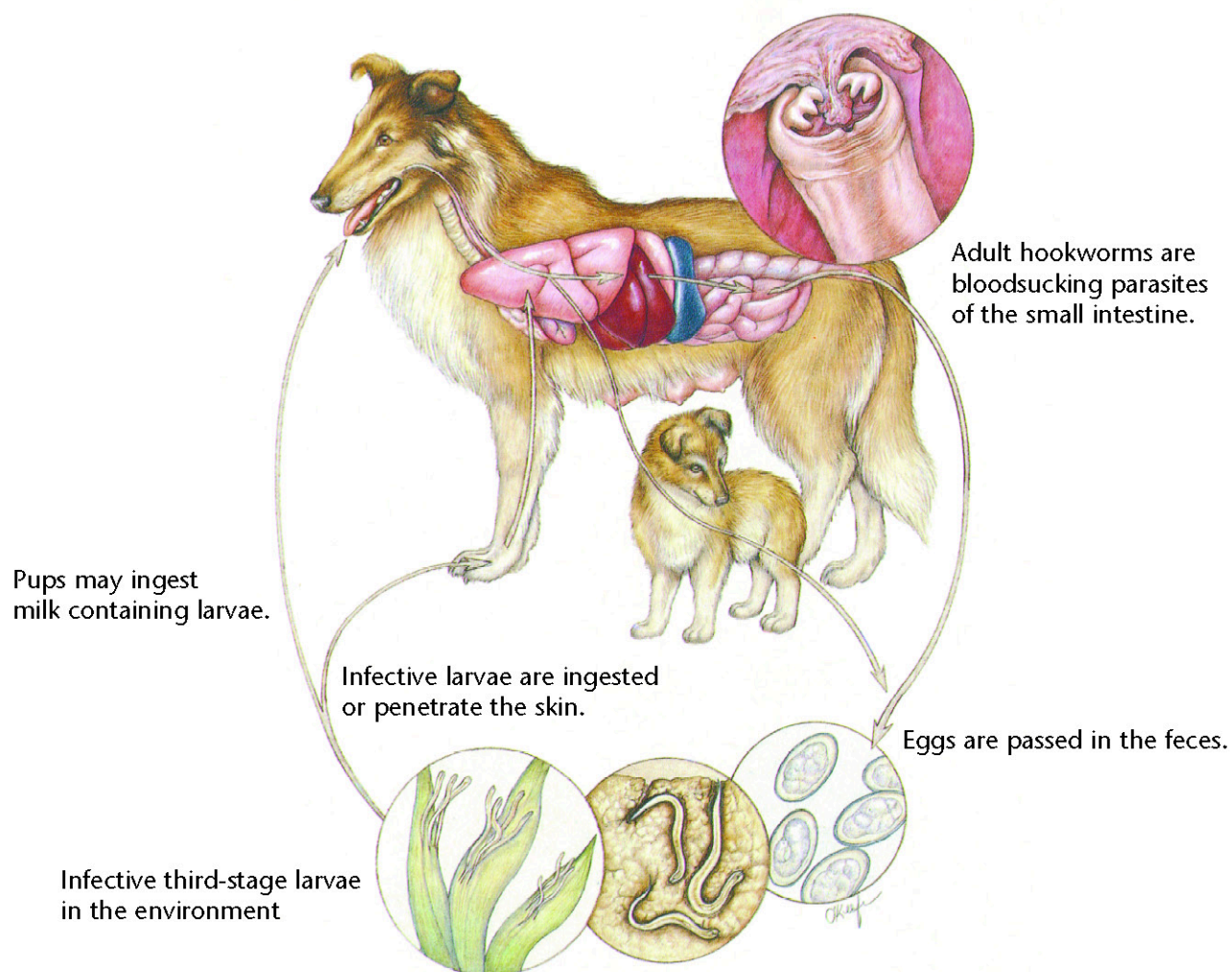
Therapeutic Plan

Drugs to kill the parasite

Dietary Plan

A diet based on individual patient evaluation including body condition and other organ system involvement or disease





Hookworms

Diagnostic Plan

History
Physical examination
Stool analysis
Blood work

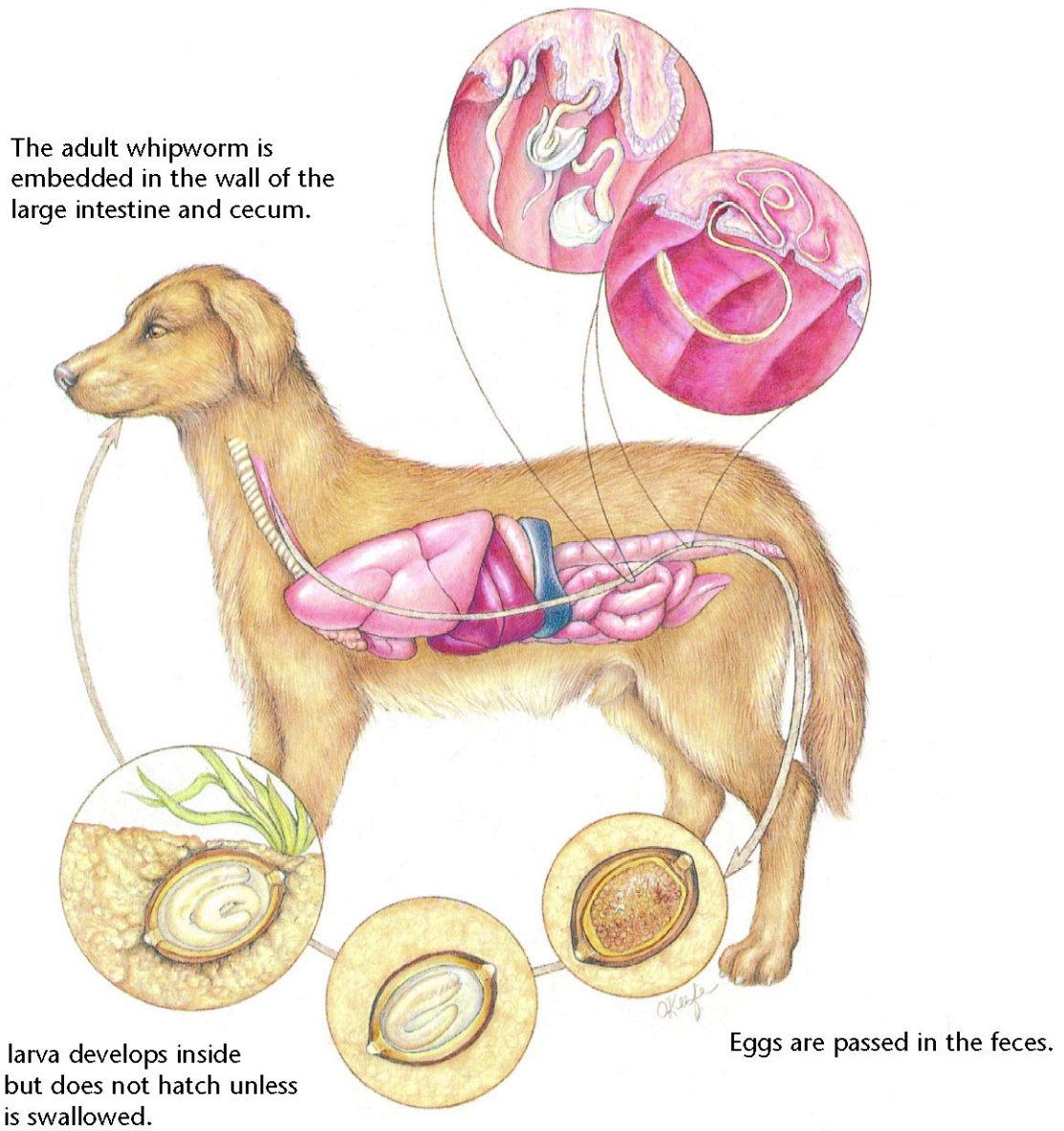
Therapeutic Plan

Dewormers
Blood transfusions
Supportive therapy

Dietary Plan

A diet based on individual patient evaluation including body condition and other organ system involvement or disease





Whipworms

Diagnostic Plan

History
Physical examination
Stool analysis
Colonoscopy
Therapeutic deworming

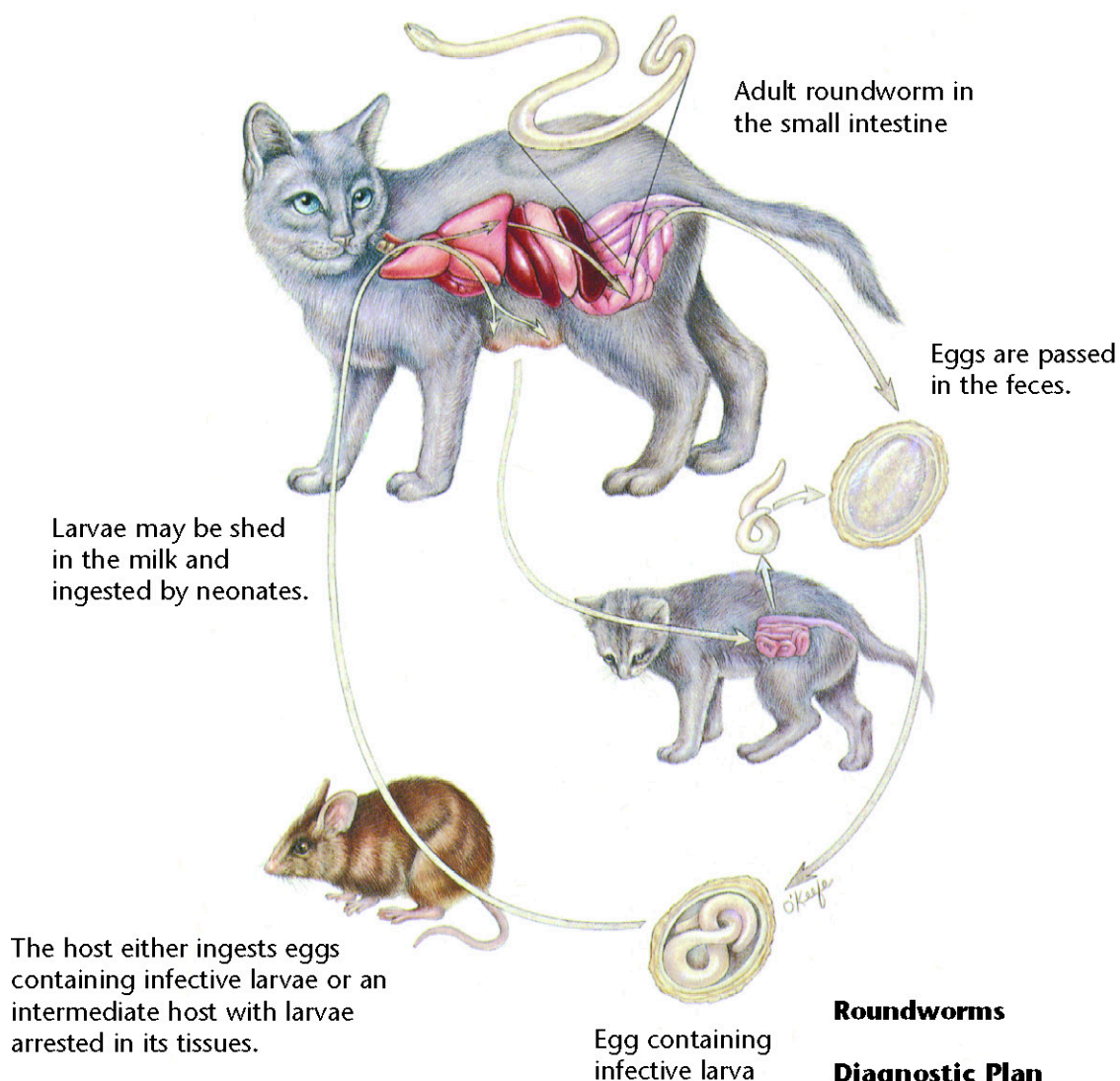
Therapeutic Plan

Dewormers
Supportive therapy

Dietary Plan

A diet based on individual patient evaluation including body condition and other organ system involvement or disease





Roundworms

Diagnostic Plan

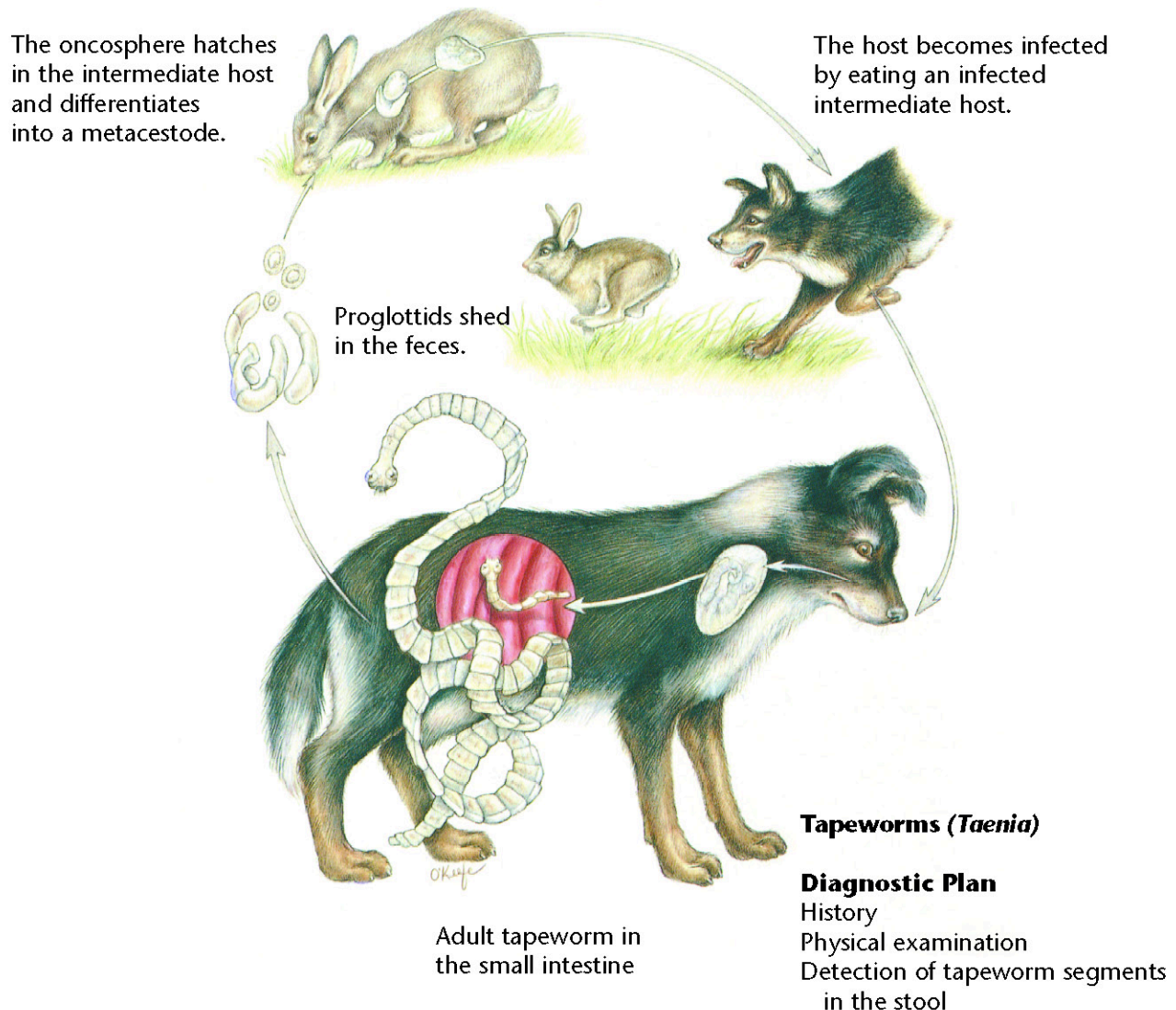
History
Physical examination
Stool analysis

Therapeutic Plan

Dewormers
Supportive therapy

Dietary Plan

A diet based on individual patient evaluation including body condition and other organ system involvement or disease



Tapeworms (*Taenia*)

Diagnostic Plan

History
Physical examination
Detection of tapeworm segments in the stool

Therapeutic Plan

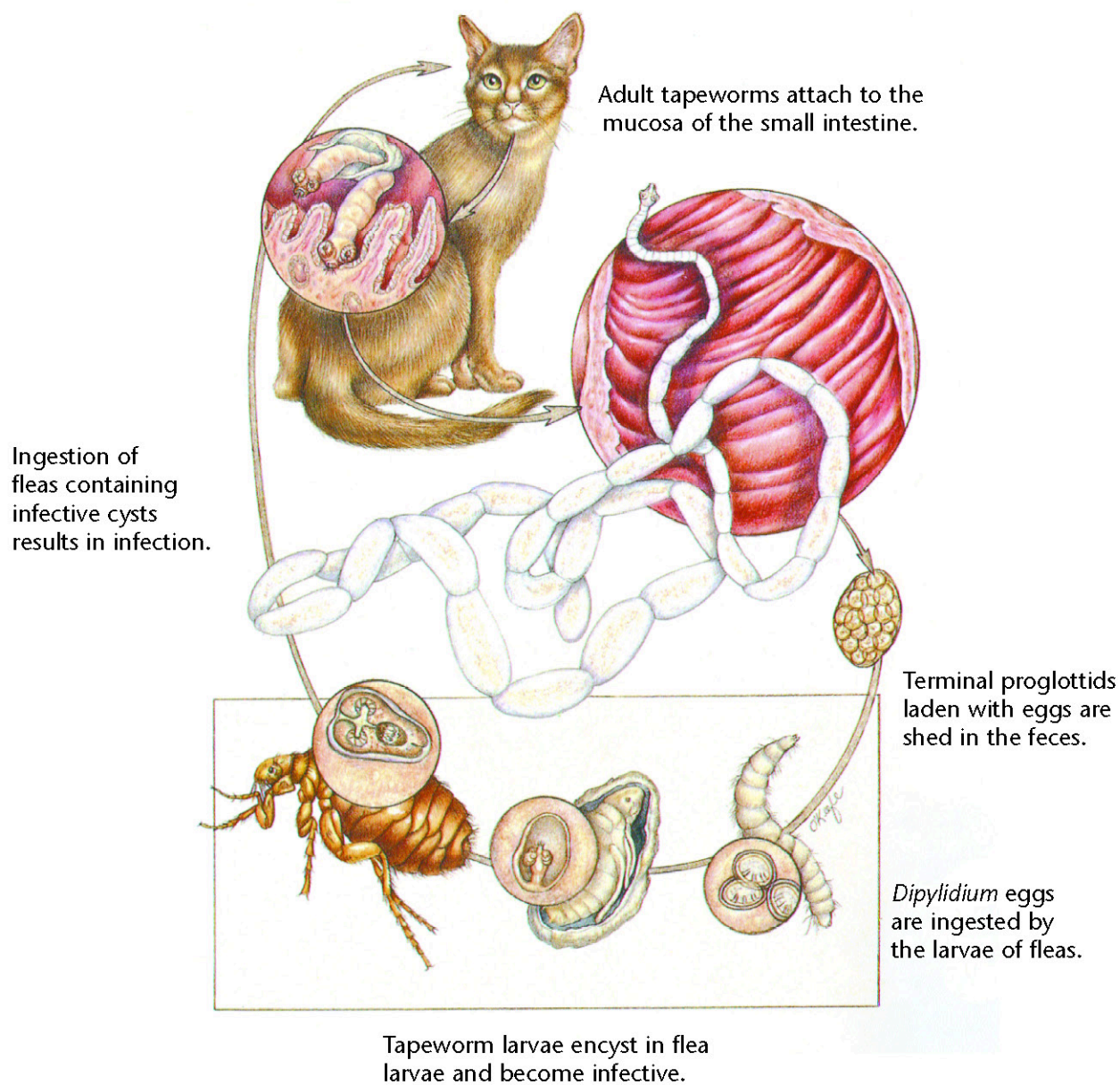
Dewormers
Control of patient's hunting and eating habits

Dietary Plan

A diet based on individual patient evaluation including body condition and other organ system involvement or disease

Hill's Atlas of Veterinary Clinical Anatomy

Tapeworms (*Dipylidium caninum*)



Tapeworms (*Dipylidium caninum*)

Diagnostic Plan

History
Physical examination
Detection of tapeworm segments in the stool
Detection of fleas or flea dirt

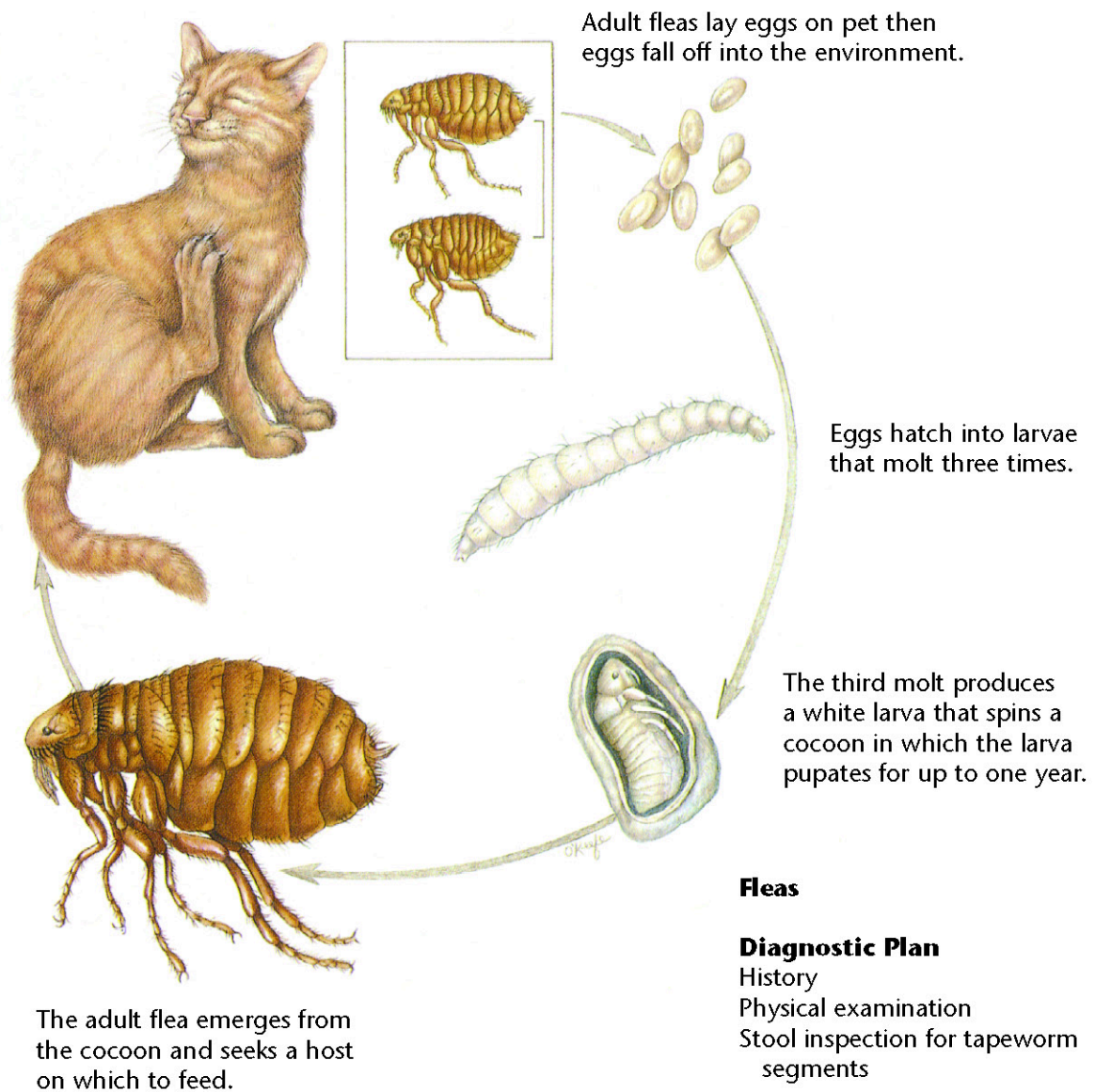
Therapeutic Plan

Dewormers
Flea control

Dietary Plan

A diet based on individual patient evaluation including body condition and other organ system involvement or disease





Fleas

Diagnostic Plan

History
Physical examination
Stool inspection for tapeworm segments

Therapeutic Plan

Flea control

Dietary Plan

A diet based on individual patient evaluation including body condition and other organ system involvement or disease

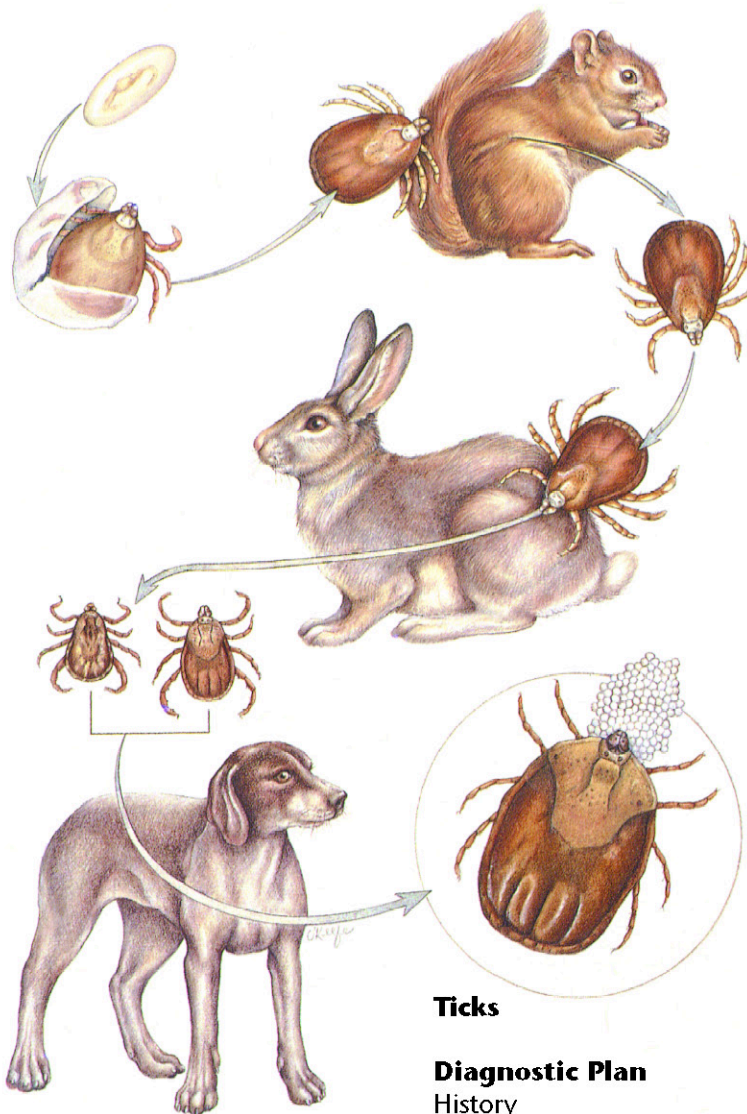
Adult ticks lay thousands of eggs, which undergo two molts: larva to nymph and nymph to adult.

Larvae, nymphs, and adults feed on blood and lymph.

Dermacentor variabilis larvae and nymphs feed on small mammals and drop off between molts.

Adults feed on pets.

Rhipicephalus sanguineus larvae, nymphs, and adults all feed on pets.



Ticks

Diagnostic Plan

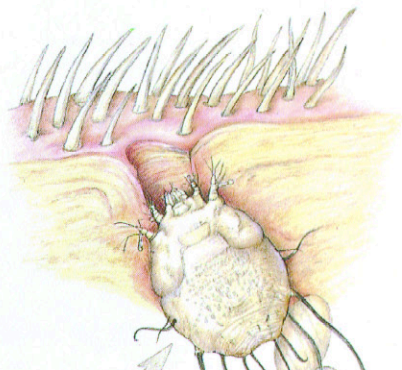
History
Physical examination

Therapeutic Plan

Tick removal
Insecticide baths or dips
Topical insecticide dips or baths

Dietary Plan

A diet based on individual patient evaluation including body condition and other organ system involvement or disease



Female mites burrow into the skin and lay eggs in the tunnels that they form.

Larvae and nymphs develop in these tunnels.

The patient response is often severe self-inflicted trauma.



Sarcoptes

Diagnostic Plan

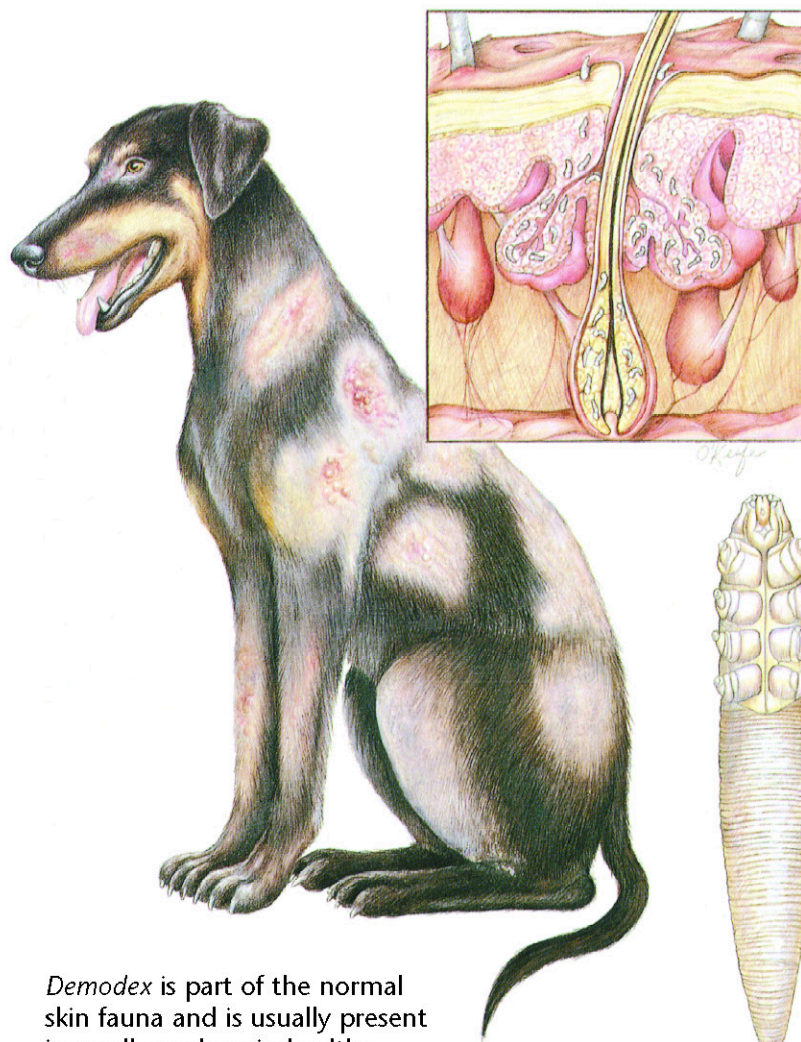
History
Physical examination
Skin scrapings
Skin biopsy
Therapeutic trial

Therapeutic Plan

Coat clipping
Parasitidal dips
Antibacterials

Dietary Plan

A diet based on individual patient evaluation including body condition and other organ system involvement or disease



Demodex is part of the normal skin fauna and is usually present in small numbers in healthy animals.

The entire life cycle is spent on the host in the hair follicles or sebaceous glands.



Adult *Demodex* mite

Demodex

Diagnostic Plan

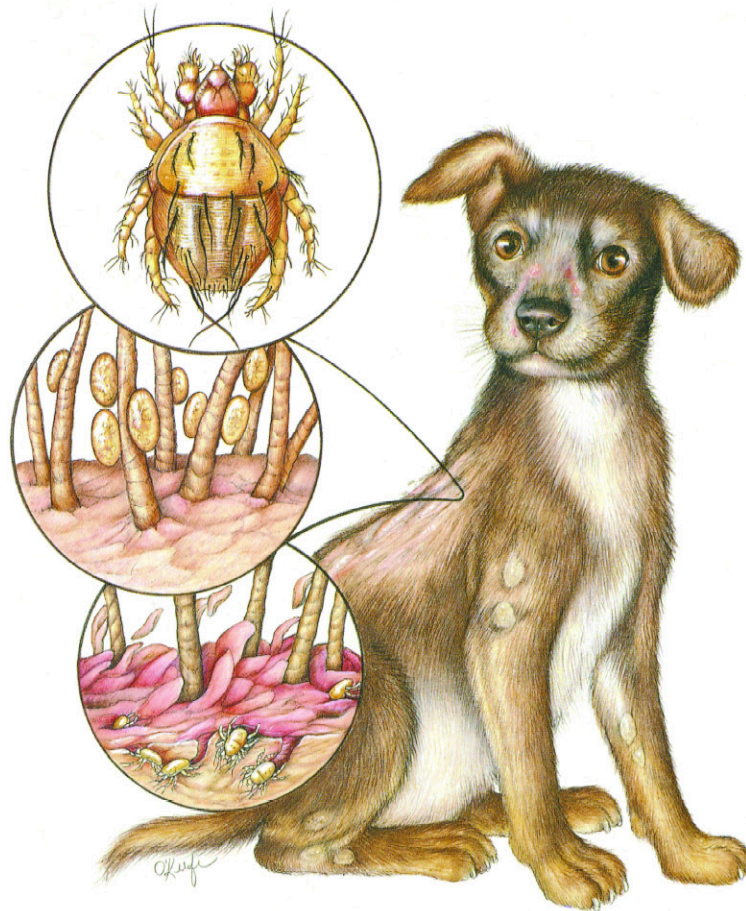
History
Physical examination
Skin scrapings
Skin biopsy
Skin culture

Therapeutic Plan

Topical keratolytic agents
Antibacterials
Topical drugs to kill the mite

Dietary Plan

A diet adequate for tissue repair
A diet based on individual patient evaluation including body condition and other organ system involvement or disease
Medication to kill the mite



These mites live in keratin on the skin's surface and feed on tissue fluids.

The entire life cycle is thought to occur on the host.

Cheyletiella

Diagnostic Plan

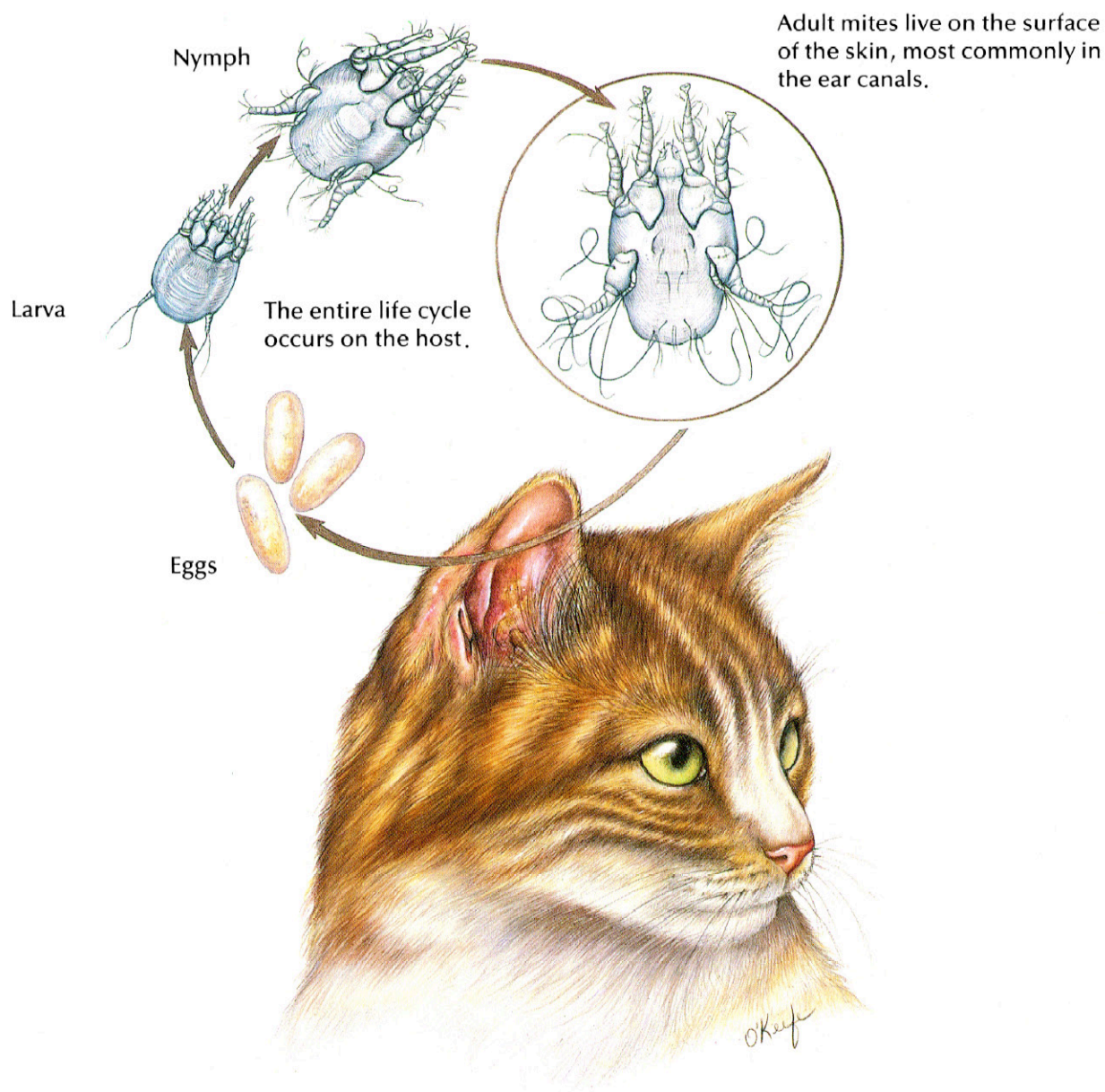
History
Physical examination
Skin scrapings
Skin biopsy
Acetate tape impressions
Direct visualization of the parasite

Therapeutic Plan

Parasitidal dips

Dietary Plan

A diet based on individual patient evaluation including body condition and other organ system involvement or disease



Ear Mites

Diagnostic Plan

History
Physical examination
Ear examination
Microscopic examination
of ear canal exudate

Therapeutic Plan

Ear canal cleaning
Drugs to kill the mites
Surgical repair of
aural hematomas
Antibacterials, if needed

Dietary Plan

A diet adequate for tissue repair
A diet based on individual patient
evaluation including body
condition and other organ
system involvement or disease



Bibliography

1. Evans, H.E.; Christensen, G.C.: *Miller's Anatomy of the Dog*, 2nd Ed. W.B. Saunders, Philadelphia, Pa., 1979.
2. Fox, P.R. (ed.): *Canine and Feline Cardiology*. Churchill Livingstone, New York, N.Y., 1988.
3. Georgi, J.R.: *Parasitology for Veterinarians*, 4th Ed. W.B. Saunders, Philadelphia, Pa., 1985.
4. Harvey, C.E.: *Veterinary Dentistry*. W.B. Saunders, Philadelphia, Pa., 1985.
5. Holzworth, J. (ed.): *Diseases of the Cat: Medicine & Surgery*. W.B. Saunders, Philadelphia, Pa., 1987.
6. Jones, B.D. (ed.): *Canine and Feline Gastroenterology*. W.B. Saunders, Philadelphia, Pa., 1986.
7. *Key to Dietary Management With Prescription Diet® Products*. Hill's Pet Products, Topeka, Kan.
8. Kirk, R.W.; Bistner, S.I.: *Veterinary Procedures & Emergency Treatment*, 4th Ed. W.B. Saunders, Philadelphia, Pa., 1985.
9. Kirk, R.W. (ed.): *Current Veterinary Therapy IX: Small Animal Practice*. W.B. Saunders, Philadelphia, Pa., 1986.
10. Lewis, L.D. et al: *Small Animal Clinical Nutrition III*. Mark Morris Associates, Topeka, Kan., 1987.
11. Magrane, W.G.: *Canine Ophthalmology*, 3rd Ed. Lea & Febiger, Philadelphia, Pa., 1977.
12. *Managing Canine and Feline Urolithiasis*. Veterinary Medicine Publishing, Lenexa, Kan., 1989.
13. *Managing Fiber-Responsive Diseases*. Veterinary Medicine Publishing, Lenexa, Kan., 1988.
14. Morgan, R.V. (ed.): *Handbook of Small Animal Practice*. Churchill Livingstone, New York, N.Y., 1987.
15. Muller, G.H.; Kirk, R.W.: *Small Animal Dermatology*, 2nd Ed. W.B. Saunders, Philadelphia, Pa., 1976.
16. *Proc. 5th Ann. Vet. Med. Forum*, ACVIM. San Diego, Calif., 1987.
17. *Proc. 6th Ann. Vet. Med. Forum*, ACVIM. Washington, D.C., 1988.
18. *Proc. 7th Ann. Vet. Med. Forum*, ACVIM. San Diego, Calif., 1989.
19. Rawlings, C.A.: *Heartworm Disease in Dogs and Cats*. W.B. Saunders, Philadelphia, Pa., 1986.
20. *Scientific Proceedings, 56th Ann. Mtg., AAHA*, St. Louis, Mo., 1989.
21. Sherding, R.G. (ed.): *Medical Emergencies*. Churchill Livingstone, New York, N.Y., 1985.
22. Sherding, R.G. (ed.): *The Cat: Diseases and Clinical Management*. Churchill Livingstone, New York, N.Y., 1989.
23. Slatter, D.H. (ed.): *Textbook of Small Animal Surgery*. W.B. Saunders, Philadelphia, Pa., 1985.
24. Soulsby, E.J.L.: *Helminths, Arthropods and Protozoa of Domesticated Animals*, 7th Ed. Lea & Febiger, Philadelphia, Pa., 1982.

