VE
Vet eBooks
VET-EBOOKS.COM

FREE · NO SIGN-UP

ANATOMY · ILLUSTRATED GUIDE

Anatomical Planes in Animals

Sections, Directions and How to Read a Vet Atlas

Animals are described using four planes — median, sagittal, transverse and dorsal — and a set of directional terms measured from them.

PAGES	SECTIONS	FIGURES	TABLES	SELF-TEST
13	11	5	6	16 questions

INSIDE THIS GUIDE

01 The four planes
02 Frontal or dorsal? The one renamed plane
03 The directional terms
04 The head plays by different rules
05 Limb terms and the carpus line
06 How to read a section plate
07 Terms combine, and that is the whole trick
08 How radiographic views are named
09 The mistakes that cost marks
10 Quiz: test yourself
11 Anatomical planes in animals — frequently asked questions

EDITION
November 2026

READ ONLINE
vet-ebooks.com/articles/anatomical-planes-in-animals

Contents

The 11 sections of this guide, in order.

01 The four planes

02 Frontal or dorsal? The one renamed plane

03 The directional terms

04 The head plays by different rules

05 Limb terms and the carpus line

06 How to read a section plate

07 Terms combine, and that is the whole trick

08 How radiographic views are named

09 The mistakes that cost marks

10 Quiz: test yourself

11 Anatomical planes in animals — frequently asked questions

Figures reproduced for educational reference from *Clinical Anatomy and Physiology for Veterinary Technicians*, *Anatomy and Physiology of Domestic Animals* and *Atlas of Topographical Anatomy of the Domestic Animals*; copyright remains with the original authors and publishers. Each figure is credited beneath it.

IN SHORT

Animals are described using **four planes** — median, sagittal, transverse and dorsal — and a set of directional terms measured from them. The traps are that **anterior and posterior belong to the head** in quadrupeds, that the plane your textbook calls **frontal** is properly the **dorsal** plane, and that below the carpus and tarsus **cranial becomes dorsal**. Get those three right and an atlas plate, a dissection and a radiograph request all start reading the same way.

KEY POINTS

1. There is exactly **one median plane**. Planes parallel to it are sagittal, and there are infinitely many.
2. **Transverse** is defined against the long axis of the body *or of the part* — which is why a transverse section of a cannon bone is at right angles to the bone.
3. The **dorsal plane** is what older texts call the frontal plane. Veterinary nomenclature renamed it because "frontal" refers to the plane of the human forehead.
4. In quadrupeds, **anterior, posterior, superior and inferior are restricted to certain structures of the head**. On the body use cranial, caudal, dorsal and ventral.
5. **Rostral** means toward the nose and is a head term only.
6. At the **carpus and tarsus** the surface terms change: cranial and caudal become **dorsal** and **palmar** or **plantar**.
7. On a section plate, which side of the page is the animal's left depends on **which cut face you are viewing** — the caption tells you.
8. Radiographic views are named by the beam's **point of entry, then point of exit**.

About the images

The plates are reproduced for educational reference from *Clinical Anatomy and Physiology for Veterinary Technicians* (Colville & Bassert, Elsevier), *Anatomy and Physiology of Domestic Animals* (Akers & Denbow, Wiley) and Popesko's *Atlas of Topographical Anatomy of the Domestic Animals* (Saunders). Each figure is credited beneath it; copyright remains with the original authors and publishers.

What you should be able to do after reading this

Name the four planes and say which one there is only one of · explain why a transverse section of a limb is not parallel to a transverse section of the trunk · give the correct veterinary term for any surface of any part of the body · say where on a limb the terminology changes and why · look at a cross-section plate and work out which side is the animal's left · and read a radiograph view name and know exactly how the animal was positioned.

Every atlas plate, every dissection instruction and every radiograph request is written in the same small vocabulary. It takes an afternoon to learn and it is assumed for the next five years, which is why a gap in it is so expensive: you can know exactly where the spleen sits and still lose the mark for putting it on the *anterior* aspect of the abdomen — a word veterinary anatomy reserves for a handful of structures of the head.

The short answer. Animals are sectioned along four planes — **median**, **sagittal**, **transverse** and **dorsal** — and located with directional terms measured from them: cranial, caudal, dorsal, ventral, medial, lateral, rostral, proximal, distal, palmar and plantar. This guide takes them one at a time, then does the part the term lists skip — using them to read a real section plate and a real radiograph view name.

Scope, before you start

The terms here are the veterinary nomenclature for **domestic mammals**, and they describe direction *relative to the animal's own body* — not to the ground, and not to how it happens to be lying. A structure is craniodorsal whether the animal is standing, in lateral recumbency or upside down. Birds are covered by a separate international nomenclature; for the anatomy that goes with it see avian anatomy.

01 The four planes

A plane is an imaginary flat surface passed through the body. Three of the four are defined relative to the midline, so the midline gets defined first.

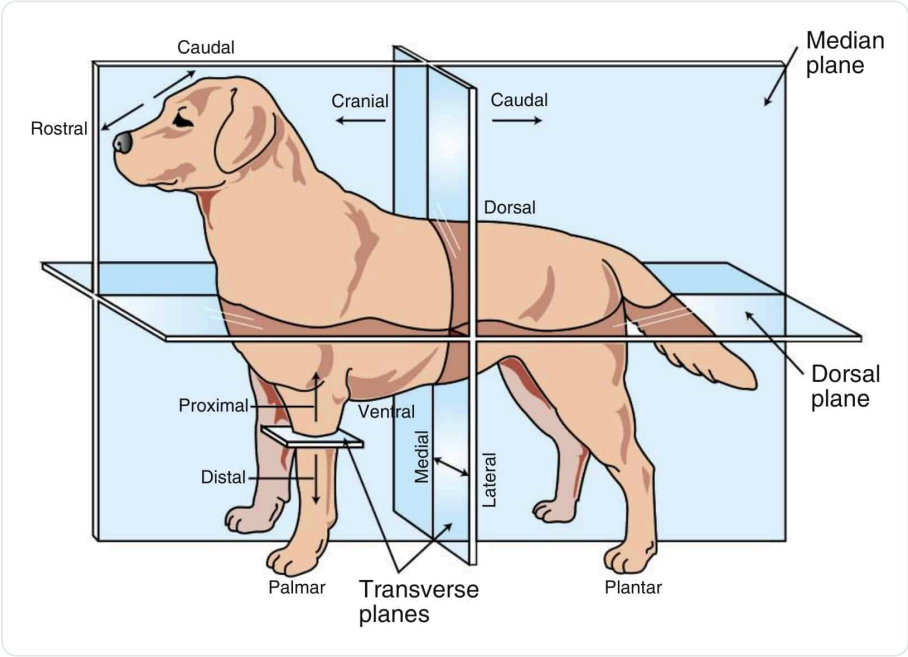

Fig 1 — The whole vocabulary on one dog. The **median plane** divides the animal into equal right and left halves; the **dorsal plane** runs parallel to the back and separates dorsal from ventral; the **transverse planes** cut across the long axis. Around them sit the directional terms: **rostral** toward the nose, **cranial** and **caudal** along the trunk, **dorsal** and **ventral**, **medial** and **lateral** measured from the median plane, and **proximal**, **distal**, **palmar** and **plantar** on the limbs. Note that this plate uses the correct veterinary name, *dorsal plane*.

Image — Colville T, Bassert JM. Clinical Anatomy and Physiology for Veterinary Technicians , 4th ed. Elsevier — Fig. 1.1. Reproduced for educational reference.

PLANE	WHERE IT RUNS	WHAT IT GIVES YOU
Median also called midsagittal · *planum medianum*	Straight down the midline, dividing the animal into **equal right and left halves**. There is only **one** median plane in any animal	The reference every side-to-side term is measured from. **Medial** means closer to it, **lateral** further from it
Sagittal *plana sagittalia*	Any plane **parallel to the median plane** — so off to one side of the midline. There are infinitely many	Lets you describe something as lying in a sagittal plane without claiming it is on the midline. A sagittal section of a limb, for instance
Transverse the section you meet most · *plana transversalia*	**Perpendicular to the long axis** of the body *or of the part* — that second half matters: a transverse section of the metacarpus is at right angles to the cannon bone, not to the whole animal	Cuts the body into cranial and caudal pieces, or a limb into proximal and distal pieces. This is the plane of a cross-section plate and of a CT slice
Dorsal the one your textbook may still call frontal · *plana dorsalia*	Parallel to the back, at right angles to both the median and the transverse planes	Divides the animal into dorsal and ventral parts. In a standing quadruped it runs roughly parallel to the ground

The one that catches people: transverse is relative

A transverse plane is at right angles to the long axis of *the body or of the part*. For the trunk that is a vertical slice like a loaf of bread. For the metacarpus it is at right angles to the cannon bone; since that bone stands nearly vertical in a weight-bearing limb, the plane cutting across it is nearly horizontal. Both are transverse sections, and they are not parallel to each other.

02 Frontal or dorsal? The one renamed plane

If you have read a human anatomy text, or an older veterinary one, you will have met the **frontal plane**. You will also meet it in books still in print. It is the same plane veterinary nomenclature now calls the **dorsal** plane, and the reason for the change is worth knowing rather than memorising.

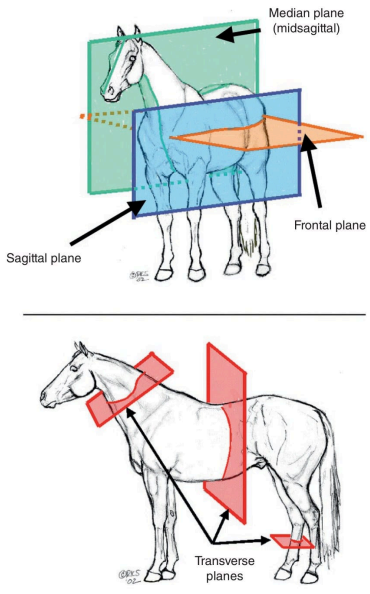

Fig 2 — The same planes on a horse, labelled the older way. This plate shows the **median (midsagittal)** plane in green, a **sagittal** plane in blue and **transverse** planes in red — and it labels the orange plane the **frontal plane**. Compare it with the dog above, which calls the same plane *dorsal*. Neither book is careless: "frontal" is the older name, retained from human anatomy, where it is the plane of the *forehead*. Because a quadruped's forehead faces forward rather than up, that name describes nothing useful in an animal, and the veterinary nomenclature replaced it with **dorsal plane**. Expect to see both; write dorsal.

Image — Akers RM, Denbow DM. Anatomy and Physiology of Domestic Animals , 3rd ed. Wiley — Fig. 1.7. Reproduced for educational reference.

03 The directional terms

These are the words that place one structure relative to another. They are defined against the planes above, which is why the planes come first.

TERM	WHAT IT MEANS	WHERE YOU MAY USE IT
Cranial / caudal	Toward the head / toward the tail	Neck, trunk, and the parts of the limb **proximal to the carpus and tarsus** — the carpus and tarsus themselves already belong to the manus and pes

TERM	WHAT IT MEANS	WHERE YOU MAY USE IT
Rostral	Toward the tip of the nose or the mouth opening	**The head only.** There is no rostral on a leg
Dorsal / ventral	Toward the back / toward the belly	Back and dorsum of neck, trunk and tail; the corresponding surface of the head. On a limb, **dorsal** switches meaning — see the next section
Medial / lateral	Closer to the median plane / further from it	Anywhere. Both are measured from the median plane, which is why that plane is defined first
Superficial / deep superficialis / profundus	Toward the surface / away from it	Anywhere
Internal / external	Inside / outside a cavity or organ	Anywhere
Dexter / sinister	Right / left — the animal's own right and left	Anywhere, and worth saying out loud: **left means the animal's left**, never yours

Anterior and posterior are head words

This is the single most common error in student writing, and the ranking search results teach it wrongly. In quadrupeds the veterinary nomenclature restricts **anterior**, **posterior**, **superior** and **inferior** to certain structures of the head — the anterior chamber of the eye, for example. The front of the tibia is its **cranial** surface, never its anterior surface. In humans the terms are fine, because a human is built vertically; borrow them for a dog and you have said something that does not resolve.

04 The head plays by different rules

On the head it is *cranial* that stops being useful — everything on the head is at the cranial end of the animal already. So the head gets its own forward term, while caudal carries on working normally.

Rostral means toward the tip of the nose, or toward the opening of the mouth. The eye is rostral to the ear; the incisors are rostral to the molars. Its opposite on the head is **caudal**, and **dorsal** and **ventral** work normally. There is no rostral anywhere else on the body — the term has no meaning off the head, and using it on a limb is a straightforward error. For the head in detail, see our guide to the canine skull and dental anatomy.

05 Limb terms and the carpus line

Proximal means toward the trunk and **distal** toward the free end. Those two are easy. The hard part is that at one specific point in each limb, the surface terms change — and the exact position of that line is worth being fussy about, because it is a favourite exam target.

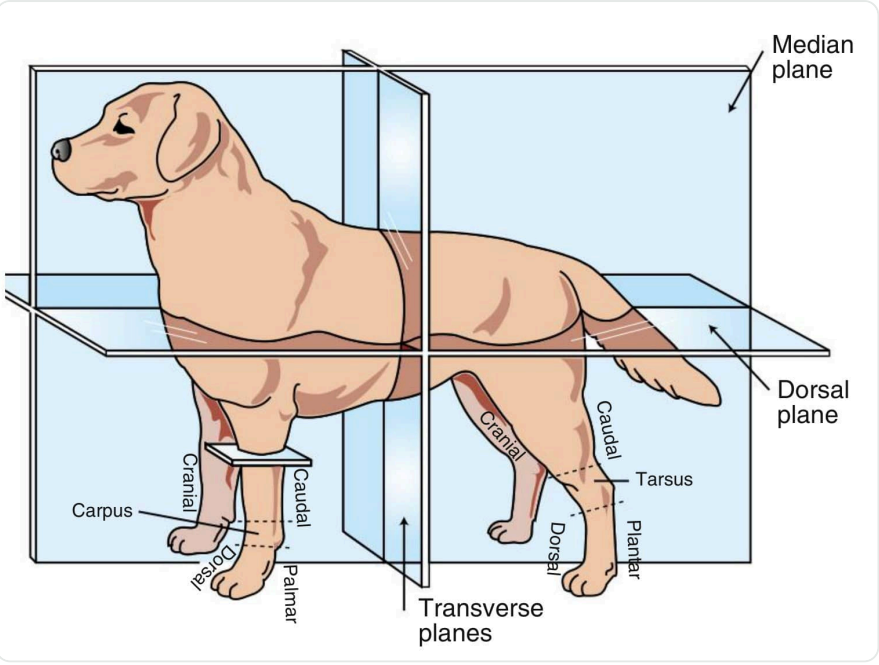

Fig 3 — Where the vocabulary changes: the carpus and the tarsus. Above the **carpus** in the forelimb and the **tarsus** in the hindlimb, the surfaces of the limb are **cranial** and **caudal**, like the trunk. From the proximal border of those joints onward — the carpus and tarsus included, because they are part of the manus and pes — they are renamed: the front becomes **dorsal**, and the back becomes **palmar** in the forelimb and **plantar** in the hindlimb. The dotted lines on this plate mark exactly where the change happens. This is why a hoof has a dorsal wall and not a cranial one, and why "palmar" on a hind leg is wrong rather than merely unusual.

Image — Colville T, Bassert JM. Clinical Anatomy and Physiology for Veterinary Technicians , 4th ed. Elsevier — Fig. 1.1. Reproduced for educational reference.

TERM	WHAT IT MEANS	THE CATCH
Proximal / distal	Toward the trunk / toward the free end of the limb	Chiefly on limbs and other appendages, where they mean nearer to or further from the point of attachment. The carpus is distal to the elbow and proximal to the fetlock
Dorsal (on a limb)	The **front** surface of the manus or pes	This is the trap. On the trunk dorsal means the back; on a foot it means the front. The word did not change — the reference did
Palmar	The back surface of the **manus** (front foot)	Forelimb only. The mirror term on the hindlimb is plantar
Plantar	The back surface of the **pes** (hind foot)	Hindlimb only. Saying "palmar" of a hindlimb is a marked error
Axial / abaxial	Closer to / further from the axis of the limb	Used on the **digits** of dog, cat, pig and ruminants. The cloven hoof is the case to hold onto: the **axial** surfaces are the two that *face each other*, the **abaxial** surfaces are the two facing outward — which is exactly how interdigital lesions get described

The reason is that the **manus** begins at the proximal border of the carpus and takes in the carpus, metacarpus and digits; the **pes** likewise takes in the tarsus, metatarsus and digits. A hand has a back and a palm, so the surfaces of the whole manus are dorsal and palmar — the carpal region included. Nomenclature puts it the other way round, which is the wording to memorise: cranial and caudal are used on the limb *proximal to* the carpus and tarsus. For the whole distal limb in a species where it matters most, see horse hoof anatomy, and for the muscles that move it, dog muscle anatomy.

06 How to read a section plate

This is where the vocabulary starts paying. A transverse section is a flat, unfamiliar picture, and the first question to ask of it is not what the structures are but **which way you are facing**.

Cut an animal across the trunk and you produce two cut faces: the **caudal surface** of the cranial piece, and the **cranial surface** of the caudal piece. They are mirror images. An atlas always tells you which one it has drawn.



Fig 4 — A transverse section, and how to orient yourself in it. A section of the ox at the **13th thoracic vertebra**, drawn as a **view of the caudal surface** — you are looking at the cut face from behind, and therefore looking toward the animal's head. That single fact fixes everything else: **the animal's left is on your left**. You can check it without trusting the caption. The huge grey organ filling the left of the picture is the **rumen**, which lies on the left in cattle; the **liver** (21) and the **omasum** (28) are on the right, where they belong. The atlas key confirms it in print: **7** is the *left* crus of the diaphragm and **8** the *right*, and 7 is drawn on the left of the image.

Image — Popesko P. Atlas of Topographical Anatomy of the Domestic Animals , Vol. II: Trunk, 6th ed. Saunders — Fig. 43. Reproduced for educational reference.

The rule, and how to check it in five seconds

A section drawn as a **caudal surface** view is seen looking cranially, so the animal's left falls on your left. A section drawn as a **cranial surface** view is seen looking caudally — like meeting the animal face to face — so left and right swap. Rather than memorise it, **find an organ whose side you already know**: the rumen is left, the liver is largely right, the apex of the heart points left. One known organ orients the whole plate.

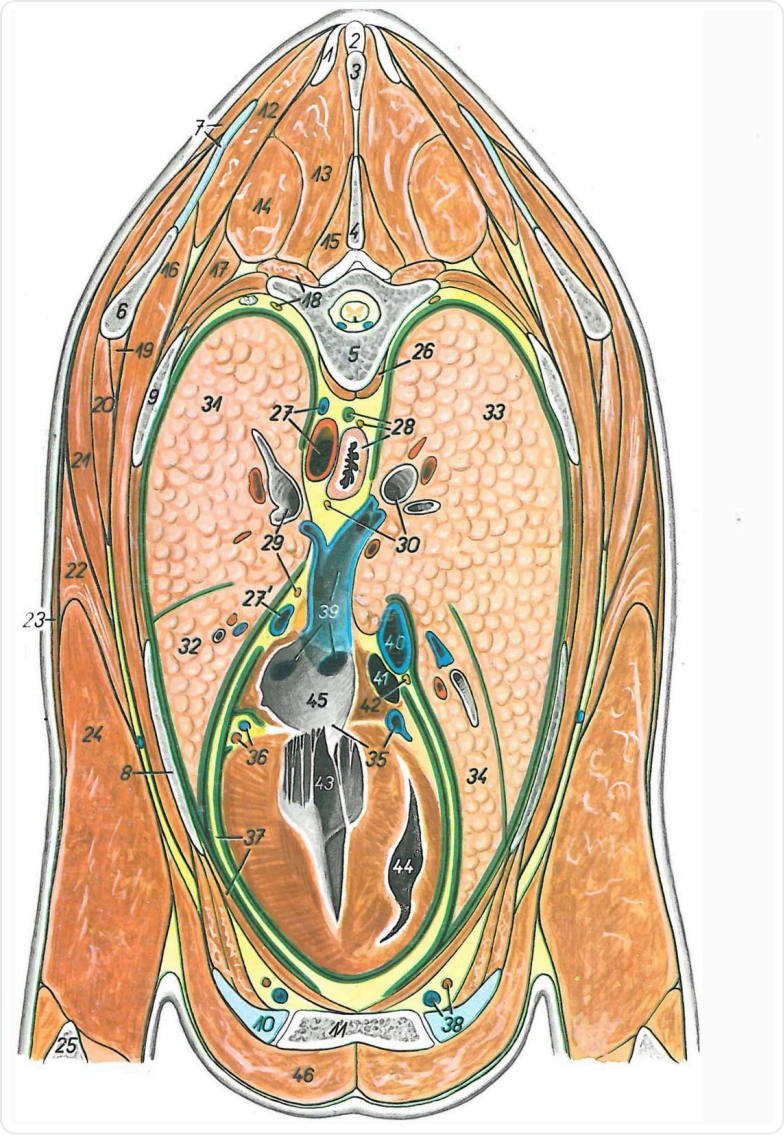

Fig 5 — The same animal, a different level. Move forward to the **5th thoracic vertebra** and the same section plane cuts a completely different picture: heart, lungs, oesophagus, aorta and the thoracic vertebra above them. This is why a section is always labelled with its level — without it the image cannot be placed. The left-on-your-left rule holds here too, and the key proves it again: **43** is the *left* ventricle and **44** the *right*; **31** and **32** are parts of the *left* lung and **33** of the *right*. Compare the two plates and you have the two skills a section demands: know the level, and know the direction of view.

Image — Popesko P. Atlas of Topographical Anatomy of the Domestic Animals , Vol. II: Trunk, 6th ed. Saunders — Fig. 20. Reproduced for educational reference.

Both plates come from a topographical atlas, which is the kind of book that becomes useful the moment you can orient yourself in it. The same discipline transfers directly to abdominal ultrasound, where you are generating the section yourself and the plane is whatever you have chosen to hold.

07 Terms combine, and that is the whole trick

Everything so far has been single words. In practice you will almost never read one on its own. Open the standard textbook at the pelvis and it calls the ilium *the craniodorsal part* of the hip bone — one word carrying two directions at once. Nobody tells you that word is allowed, or how it was built, and that is the gap this section closes.

The pattern: name the two directions, and the first takes an "-o-" combining form. Cranial + dorsal becomes **craniodorsal**. Caudal + ventral becomes **caudoventral**. Dorsal + medial becomes **dorsomedial**. Read one by splitting it back into its halves and applying both at once: a **craniodorsal** hip luxation is one in which the femoral head has moved *cranially and dorsally* relative to the acetabulum.

Two honest caveats. The combining order follows *accepted usage* rather than a rule you can derive — not every pairing is standard, and you will meet compounds of more than two parts. And for **radiographic projections** the order is not a convention at all but a defined one, which is what the next section is about.

COMPOUND	SPLIT IT BACK INTO	WHERE YOU MEET IT
Craniodorsal	cranial + dorsal — toward the head and toward the back	Craniodorsal hip luxation, the commonest direction a canine hip dislocates
Caudoventral	caudal + ventral — toward the tail and toward the belly	A typical rib runs caudoventrally from its vertebral end toward its ventral end

COMPOUND	SPLIT IT BACK INTO	WHERE YOU MEET IT
Dorsomedial / dorsolateral	dorsal + medial, or dorsal + lateral	Describing exactly where on a joint surface a lesion sits
Ventrolateral	ventral + lateral — toward the belly and away from the median plane	Approaches and incisions, where two directions are needed to be unambiguous
Craniomedial, **craniolateral**, **caudomedial**, **caudolateral**	all four cranial/caudal pairings with medial or lateral	Surgical approaches to the stifle and elbow
Dorsopalmar	dorsal + palmar — but here it is a *beam path*	Radiographic view names, where order means entry then exit — the next section

Why this makes the next section easy

A radiographic view name is this same rule applied to the path of the beam rather than to a position: **dorso** + **palmar** is a beam entering the dorsal surface and leaving the palmar one. So there is no separate list to memorise below — if you can build *craniodorsal*, you can already read *dorsopalmar*. The only extra thing the view names add is that the *order* carries meaning: entry first, exit second.

08 How radiographic views are named

Radiographic view names look like jargon and are in fact a sentence: they describe the path the beam took through the patient. **The point of entry is named first, the point of exit second.**

VIEW NAME	WHERE THE BEAM ENTERS AND LEAVES	WHAT YOU ARE LOOKING AT
Lateromedial	Enters the **lateral** side, leaves the **medial** side	A side-on view of a limb, shot from the outside in
Mediolateral	Enters medial, leaves lateral	The same limb shot from the inside out — a different view, and not interchangeable
Dorsopalmar	Enters the dorsal (front) surface, leaves the palmar surface	A front-to-back projection of the **manus** — the carpus, metacarpus and digits
Dorsoplantar	Enters dorsal, leaves plantar	The same projection of the **pes** — the tarsus, metatarsus and digits
Palmarodorsal / plantarodorsal	The reverse of the two above	Same anatomy, beam reversed — and the image is not the same, because what is nearest the plate is sharpest

Be precise about what the name does and does not tell you: a **projection** name gives the surface the central ray *enters* and the surface it *leaves*. It does not by itself tell you the animal's recumbency — the same entry-to-exit path can be achieved from more than one position, and side markers are separate information again. What the name does inherit is the anatomy: the manus has a *palmar* surface, so its front-to-back projection is **dorsopalmar**; the pes has a *plantar* surface, so the same projection there is **dorsoplantar**.

One thing to check rather than assume

Which side of a *radiograph or a CT slice* shows the patient's left is set by the display convention of the modality and the software, not by anatomy. Radiographs are marked with a physical L or R marker for exactly this reason. **Read the marker.** The caudal-surface rule above is a property of the atlas plate you are holding, and it is safe there; do not carry it across to a screen without checking.

Worked example: building a position statement

Exam questions rarely ask what a term means; they ask you to *use* the terms. Take "describe the position of the bovine spleen". Build it in the order the vocabulary is defined. **Which side?** Left — so start from the median plane: it lies *to the left of* it. **Where in the abdomen?** Forward and upward relative to the animal, which is the compound term *craniodorsal*. **Against what?** The left half of the diaphragm, and the craniodorsal part of the rumen. **Which surface faces where?** Use the proper surface names: the *parietal* surface faces the diaphragm and body wall, the *visceral* surface faces the rumen. Put together: *"The bovine spleen lies to the left of the median plane in the cranial abdomen, over the craniodorsal part of the rumen and against the left half of the diaphragm, with its parietal surface toward the diaphragm and its visceral surface toward the rumen."* Almost every word came from a table above — that is what the vocabulary is *for*. (Position after Dyce, Sack and Wensing.)

09 The mistakes that cost marks

Almost all of them are one of six things.

THE MISTAKE	WHY IT IS WRONG	WHAT TO WRITE INSTEAD
"The **anterior** surface of the tibia"	In quadrupeds anterior is reserved for some structures of the head. The tibia is not on the head	**Cranial** surface of the tibia
"The **frontal** plane"	It is the human forehead's plane, which is why veterinary nomenclature renamed it	**Dorsal** plane — and expect to see "frontal" in older texts
"The **cranial** surface of the hoof"	Below the carpus and tarsus, cranial and caudal are replaced	**Dorsal** surface of the hoof
"The **palmar** aspect of the hind fetlock"	Palmar belongs to the front foot only	**Plantar** aspect
"**Sagittal** section" when you mean the midline	Every median plane is sagittal, but most sagittal planes are not median	**Median** section, if it really is down the midline
"On the **left** of the image, so the left kidney"	Which side of the picture is the animal's left depends entirely on which face of the section you are looking at	Read the plate's own caption first, then decide

Checkpoint

Cover the tables and answer these three. Which plane is there only one of? Where on a forelimb does "cranial" stop being correct? In a lateromedial view, which side did the beam enter? If all three came easily, the quiz below is the useful next step; if not, the tables above are worth one more pass first.

10 Quiz: test yourself

Sixteen questions on the planes, the directional terms, the limb rule, sections and projections. Cover the answers first.

1. How many median planes does an animal have?**Answer: One.** The median plane is the single plane that divides the body into equal right and left halves. Planes parallel to it are **sagittal**, and there are infinitely many of those.2. What is the difference between a sagittal and a median plane?**Answer:** A median plane is a sagittal plane that happens to lie exactly on the midline. Every median plane is sagittal; almost no sagittal plane is median. If you mean the midline, say **median**.3. Your lecturer says dorsal plane and your textbook says frontal plane. Who is right?**Answer:** Both describe the same plane, but **dorsal** is the veterinary term. Veterinary nomenclature replaced "frontal" precisely because it refers to the plane of the *human* forehead, which is meaningless in an animal that walks on four legs.4. A transverse section of the cannon bone — perpendicular to what?**Answer:** To the **long axis of that part**, not of the whole animal. Transverse is defined against the axis of the body *or of the part being sectioned*, which is why a transverse section of a limb is at right angles to the limb.5. Why can you not say the anterior surface of the radius?**Answer:** Because in quadrupeds **anterior, posterior, superior and inferior** are restricted to certain structures of the head. On a limb above the carpus the correct term is **cranial**.6. Where exactly does cranial stop and dorsal start on a limb?**Answer:** At the **proximal border of the carpus** in the forelimb and of the **tarsus** in the hindlimb. Proximal to that border the surfaces are cranial and caudal; from that border distally — including the carpus or tarsus itself — they become **dorsal** and **palmar** (forelimb) or **plantar** (hindlimb).7. What does rostral mean, and where can you use it?**Answer:** Toward the tip of the nose or the opening of the mouth, and **only on the head**. The eye is rostral to the ear; nothing on a leg is rostral to anything.8. What do axial and abaxial mean?**Answer:** Closer to and further from the axis of the limb, used on the **digits** of dog, cat, pig and ruminants. In a cloven hoof the axial surfaces are the two that face each other.9. A

plate says “view of caudal surface of section”. Where is the animal’s left?**Answer:** On **your left**. You are looking at the cut surface from behind, i.e. looking toward the head, so the animal’s left side is on the same side as your own left hand. Check it against an organ you know: in the ox the rumen is on the left.10. In a lateromedial radiograph, which way did the beam travel?**Answer:** In through the **lateral** side and out through the **medial** side. The rule is simple: name the point of **entry** first and the point of **exit** second.11. Is a dorsopalmar view the same as a palmarodorsal one?**Answer:** The anatomy is the same; the image is not. The beam has been reversed, and the structures closest to the plate are the ones recorded most sharply.12. Why is dorsopalmar used for the front foot and dorsoplantar for the hind?**Answer:** Because palmar belongs to the manus and plantar to the pes. The view name inherits whichever surface term the limb actually has.13. What is the difference between medial and median?**Answer: Median** is the midline plane itself. **Medial** is a direction — closer to that plane. The mitral valve is medial to the left lung; it does not lie in the median plane.14. Deep and superficial, or internal and external?**Answer: Superficial and deep** describe distance from the surface. **Internal and external** describe being inside or outside a cavity or an organ wall. They are not synonyms.15. What does craniodorsal mean, and how would you build the opposite?**Answer:** Toward the head *and* toward the back at the same time. Compound terms name two directions, the first taking an “-o-”. The opposite pairs the other two members: **caudoventral**.16. Does left on an anatomical drawing mean the animal’s left?**Answer:** Only if the caption tells you which face you are viewing. **Left and right always belong to the animal**, never to the reader — but which side of the paper they land on depends on the direction of view.

11 Anatomical planes in animals — frequently asked questions

What are the anatomical planes in animals?

Four: the **median** plane down the midline, **sagittal** planes parallel to it, **transverse** planes at right angles to the long axis, and the **dorsal** plane running parallel to the back. Older books call the last one the frontal plane.

Why do veterinary anatomists avoid anterior and posterior?

In a quadruped they are ambiguous. Standard veterinary nomenclature restricts anterior, posterior, superior and inferior to certain structures of the head, and uses cranial, caudal, dorsal and ventral for the rest of the body.

What is the difference between dorsal on the back and dorsal on the foot?

The word is consistent; the reference body part changes. On the trunk, dorsal means toward the **dorsum** — the back. On a limb it means toward the dorsum *of the manus or pes*, which is the front of the foot. Neither definition depends on how the animal happens to be standing or lying. In practice the foot is the confusing case: on the trunk dorsal is the back, and on a foot it is the front. From the carpus and tarsus distally — those joints included — dorsal replaces cranial.

How do you know which side of a cross-section is the animal’s left?

From the caption. A section viewed from its **caudal** surface puts the animal’s left on your left; a section viewed from its cranial surface reverses that. If the caption is silent, find an asymmetric organ you can name.

How are radiographic views named in veterinary medicine?

By the path of the beam: **point of entry first, point of exit second**. Lateromedial enters laterally and exits medially. Dorsopalmar enters the front of a forefoot and exits the back.

Do I need to learn the Latin?

You need to recognise it. The Latin forms are the ones printed in atlases and in the international nomenclature, and they are what makes an atlas from any country readable.

Sources

1. Schaller O, Constantinescu GM (eds.). *Illustrated Veterinary Anatomical Nomenclature*, 4th ed. Thieme — the illustrated companion to the *Nomina Anatomica Veterinaria*, which is issued by the World Association of Veterinary Anatomists. Source of every definition in this article, including the restriction of anterior, posterior, superior and inferior to structures of the head, the use of cranial and caudal on the limb proximal to the carpus and tarsus, and the note that the dorsal plane replaces the former frontal plane.
2. Popesko P. *Atlas of Topographical Anatomy of the Domestic Animals*, Vol. II: Trunk, 6th ed. Saunders — the two bovine transverse sections and their numbered keys.
3. Colville T, Bassert JM. *Clinical Anatomy and Physiology for Veterinary Technicians*, 4th ed. Elsevier — the planes, directions and carpus/tarsus plates.
4. Akers RM, Denbow DM. *Anatomy and Physiology of Domestic Animals*, 3rd ed. Wiley — the equine planes figure.
5. Dyce KM, Sack WO, Wensing CJG. *Textbook of Veterinary Anatomy*, 5th ed. Elsevier — general anatomical terminology.
6. University of Pennsylvania, Large Animal Radiology — Nomenclature — open-access reference for the entry-to-exit rule for radiographic view names.

Vet-eBooks.com · free veterinary study guides · the full illustrated article, with every figure at full size, is at vet-ebooks.com/articles/anatomical-planes-in-animals/

Vet eBooks
VET-EBOOKS.COM

MORE FREE STUDY GUIDES · RESOURCES

More free veterinary study guides

This is one of a growing library of free veterinary study guides on vet-ebooks.com — written for practising vets and students, sourced from the standard veterinary texts, and every one free with a downloadable PDF and no sign-up.

3,400+
veterinary books

400+
drug profiles

Study guides
a free PDF with each

All free
no sign-up needed

www.vet-ebooks.com

For educational use. Always confirm doses and clinical decisions against current authoritative texts and your own clinical judgment. © vet-ebooks.com — share freely, do not modify.