

FRANCESCO ALBANESE

Canine and Feline Skin Cytology

A Comprehensive and
Illustrated Guide to the
Interpretation of Skin Lesions
via Cytological Examination

 Springer

Canine and Feline Skin Cytology

Francesco Albanese

Canine and Feline Skin Cytology

A Comprehensive and Illustrated Guide to the
Interpretation of Skin Lesions via Cytological
Examination

 Springer

Francesco Albanese
Arezzo
Italy

ISBN 978-3-319-41239-9 ISBN 978-3-319-41241-2 (eBook)
DOI 10.1007/978-3-319-41241-2

Library of Congress Control Number: 2016959559

© Springer International Publishing Switzerland 2017

This work is subject to copyright. All rights are reserved by the Publisher, whether the whole or part of the material is concerned, specifically the rights of translation, reprinting, reuse of illustrations, recitation, broadcasting, reproduction on microfilms or in any other physical way, and transmission or information storage and retrieval, electronic adaptation, computer software, or by similar or dissimilar methodology now known or hereafter developed.

The use of general descriptive names, registered names, trademarks, service marks, etc. in this publication does not imply, even in the absence of a specific statement, that such names are exempt from the relevant protective laws and regulations and therefore free for general use.

The publisher, the authors and the editors are safe to assume that the advice and information in this book are believed to be true and accurate at the date of publication. Neither the publisher nor the authors or the editors give a warranty, express or implied, with respect to the material contained herein or for any errors or omissions that may have been made.

Printed on acid-free paper

This Springer imprint is published by Springer Nature
The registered company is Springer International Publishing AG
The registered company address is: Gewerbestrasse 11, 6330 Cham, Switzerland

*I dedicate this book to my family,
To Chiara, my wife, whom I love as if it were
the first day
To my two jewels, Veronica and Emilio,
whose smiles remind me every day ... how
lucky I am.*

Foreword

This book is born with the aim of becoming a classic. Not only, obviously, because it was conceived and born in Tuscany, Italy, but mainly because of its features and outstanding quality. This is the first textbook focused exclusively on cutaneous cytology of the dog and cat, a subspecialty that has developed enormously in recent years. Medical and scientific textbooks constitute a mirror in which one can see the state of the art of a discipline. Reading one general textbook should provide a glimpse of the level of development of a specific scientific field. This book by Francesco Albanese is an unquestionable proof of the extraordinary progress that has experienced cutaneous cytology in recent decades; a technique that has become essential for the good practice of dermatology, due to its simplicity, speed, minimally invasive character and high diagnostic value. This book will certainly help to the expansion and proper use of cytology in veterinary dermatology in the years to come.

The content of this book may be defined as exhaustive. The reader will find in it all currently available knowledge on skin cytology of dog and cat, supported by an extensive list of very updated and carefully selected bibliographic references. In most cases, images and cytological features of a process are presented together with the clinical picture and the corresponding histopathology, so that the reader has a truly complete vision of the disease process and of the indications, use and limitations of cytology. Undoubtedly, the comprehensive training of the author, clinical dermatologist and also cytopathologist, has been instrumental in the design and development of this work.

The extensive content of this book allows defining this work as broad spectrum, suitable for all audiences. The student or the beginner in the science and art of cytology will find extremely useful Chaps. 1 and 2, devoted to the morphology and function of skin cells and to collecting, preparation and staining techniques. The more experienced reader will also find wealth of advanced information, especially in Chaps. 3, 4, and 5, devoted to the cytology of specific canine and feline skin diseases. Besides prevalent diseases, this book contains also the cytological characteristics of less common and so far poorly documented diseases such as botryomycosis, phaeohyphomycosis or cutaneous dirofilariasis, just to mention a few examples.

Chapter 5, for instance, contains absolutely novel information about cytology of cutaneous metastasis, including metastasis to the skin of uncommon internal neoplasia as prostatic, gastric or salivary carcinomas.

Books, despite stiff competition from the new digital formats, continue being objects of worship, full of charm and with an intangible value. The new e-books have many advantages, but printed Books can be touched and fondled; books have weight and give off specific odour and establish multiple links of various kinds with the reader, including emotional or sentimental. The accuracy of this work, the quality of the images and printing, makes this book a precious object, almost of artisanal value. During the reading of this book, leafing through its pages, it is easy to imagine all the effort and illusion that the author devoted to each image, to each single explanation or note. It is for sure that from now on we will see this book on the shelves of libraries and veterinary clinics, alongside other classics of our profession.

Lluís Ferrer, DVM, PhD, Dipl.ECVD
Department of Clinical Sciences
Cummings School of Veterinary Medicine
Tufts University
Medford
MA, USA

Curriculum Vitae

Francesco Albanese graduated in Veterinary Medicine at the University of Naples “Federico II” in 1993. Since 1994, he has been focusing his interest in veterinary dermatology by attending many congresses and courses in Italy and abroad. From 1996 to 1998, he attended the advanced course in dermatology at the European School for Advanced Veterinary Studies (ESAVS). In June 2000, he passed the first part of the exam for the European College of Veterinary Dermatology (ECVD). He decided to not continue the final part. He is a full member of both the European (ESVD) and the Italian (SIDEV) Society of Veterinary Dermatology. He has been an invited speaker in many national and international workshops on canine and feline skin cytology. He has published in both national and international journals, He has also written some books on feline and canine dermatology and skin cytology such as the *Atlas of Dermatological Cytology of Dogs and Cats* that has been translated into five languages. Dr. Albanese currently works as a freelancer on referred canine and feline dermatological cases. He is also a consultant of dermatology, skin cytology and histopathology for the private veterinary laboratory “La Vallonea”.

Preface

In this textbook, the main cytological findings of neoplastic and non-neoplastic (inflammatory) skin diseases of the dog and cat are discussed. The book is divided into five chapters.

The first chapter focuses on the morphology of the cells that normally make up the skin, knowledge of which is essential for interpreting pathological findings.

In the second chapter, diagnostic techniques that can be performed for the collection of cells from skin lesions are discussed. According to the clinical aspects of skin lesions, it provides readers with the correct guidance with regard to which technique to use to obtain a sample that is as indicative of its origin as possible.

The third and fourth chapters focus on non-neoplastic and neoplastic lesions respectively, especially those that are useful to investigate using cytology. To better interpret the cytological specimens, it is mandatory to know and distinguish the clinical aspects of the skin lesions from where the cells have been sampled; for this reason, in the chapter on inflammatory diseases, the author discusses the cytological findings, starting from clinical signs and not based on the cytological inflammatory patterns. This practical approach even allows veterinarians who are less confident in dermatology to interpret the cytological results in a more rational way, and to obtain critical information for interpretation.

The final chapter deals with the main metastatic neoplasms originating from non-skin primary neoplasia.

The book is accompanied by about 750 high-resolution colour images, including clinical, histological and cytological pictures, to exhaustively address all the clinico-pathological aspects of skin lesions of the dog and cat.

Arezzo, Italy

Francesco Albanese, DVM

Acknowledgements

When you get to write a book for Springer, one of the most important book publishers in the world, it means that there are many people to thank.

Throughout my professional life, I have met many people who, to a greater or lesser extent, have contributed to my professional training and to whom I extend my sincerest thanks.

- The first thanks are for to Prof. Lluís Ferrer (Dipl. ECVD), who has agreed to do the foreword of my book. Well, what to say, I am very honoured by the fact that the preface of this book is written by one of the most competent pathologists in the world. However Lluís, as well as a great teacher of veterinary medicine, is also a master of humility and humanity, as all the colleagues who work with him and all the students, who as a professor, were able to see. Thanks Lluís, your signature on this book makes me immensely proud; it is really a great gift!
- Thanks to Alessandro Fogliazza (Merial Italy), who gave me the opportunity to write a few years ago *Atlas of Dermatological Cytology of Dogs and Cats* that has been the springboard for the publication of this book.
- Thanks to Walter Bertazzolo (Dipl. ECVCP), who agreed to co-author the chapter regarding the cytology of cutaneous metastases, enriching it with his experience and great skills in general cytopathology. Thanks Walter for your continuous support and enthusiasm.
- Thanks to Professor Francesca Abramo who, besides being a dear friend, has been an essential professional reference from the beginning of my career.
- Thanks to Giovanni Tortorella, a great professional, a great person, always ready to smooth my vehement character, to give me comfort in times of crisis and to support me in the most complex histopathological diagnosis.
- Thanks to Guglielmo Giordano, the owner of the private veterinary laboratory “La Vallonea” for which I am proud to work. Thanks Guglielmo, for giving me the opportunity to read dermatopathology for your lab, which has allowed me to achieve a steady growth in this field.
- Thanks to Laura Marconato (dipl. ECVIM-CA Oncology) for her continued support about my questions on clinical oncology of dogs and cats.

- Thanks to Francesca Giordano, Martina Tarantino and particularly to Maria Massaro, the technicians of the laboratory at LaVallonea, who daily prepare cytological and histopathological slides with great love and professionalism and who have endured me over the years.
- Thanks to all the colleagues who have referred dermatological clinical cases during these 22 years in the profession, and who allowed me to gain immense clinical experience without which the interpretation of cytological and histopathological findings would be much more complex.
- Thanks to Cristiano Necci, from Kinaweb Graphic Studio, for the drawings of the skin lesions included in the Chap. 2.

Finally, I would like to thank the colleagues who have certified my credentials to the publisher; thanks to Monica Linek (Dipl. ECVD), Chiara Noli (Dipl. ECVD), Domenico Santoro (Dipl. ECVD and ACVD) and, in particular, to the late Didier Noel Carlotti (Dipl. ECVD), who has left a great void in people who have had the pleasure of knowing him. Thanks Didier, for the affection and openness that you have always shown me.

Francesco

Contents

1 Morphology and Function of Skin Cells	1
1.1 Introduction	1
1.2 The Cells of the Epidermis	1
1.2.1 Stratum Basale	2
1.2.2 Stratum Spinosum	2
1.2.3 Stratum Granulosum	4
1.2.4 Stratum Corneum	4
1.3 The Cells of the Dermis and Adnexa	8
1.4 The Subcutaneous Tissue or Hypodermis	18
1.5 The Cells of Inflammation	19
1.5.1 Red Blood Cells	19
1.5.2 Neutrophils	20
1.5.3 Eosinophils	25
1.5.4 Basophils	26
1.5.5 Lymphocytes	26
1.5.6 Plasma Cells	27
1.5.7 Macrophages	29
1.5.8 Mast Cells	33
1.6 The Inflammatory Patterns	34
1.6.1 Neutrophilic Inflammation	34
1.6.2 Neutrophilic and Macrophagic (Granulomatous/ Pyogranulomatous) Inflammation	35
1.6.3 Eosinophilic Inflammation	38
1.6.4 Lymphoplasmacellular Inflammation	39
2 Techniques of Sampling, Preparation and Staining of Cytological Specimens	41
2.1 Introduction	41
2.2 Sampling Techniques	41
2.2.1 Impression Smears	42

- 2.3 Fine Needle Biopsy (With or Without Aspiration) 57
 - 2.3.1 Cytological Sampling from *Nodules* and *Plaques* 57
- 2.4 Scraping 61
 - 2.4.1 Cytological Sampling from *Ulcers* 61
- 2.5 Preparation of Slides 63
- 2.6 Staining of Slides 66
 - 2.6.1 Romanowsky Stains (Wright’s, Giemsa) 66
 - 2.6.2 Periodic Acid–Schiff 68
 - 2.6.3 Grocott’s Methenamine Silver 68
 - 2.6.4 Ziehl–Neelsen 69
 - 2.6.5 Oil- Red-O 71
 - 2.6.6 Von Kossa 71
 - 2.6.7 Toluidine Blue 73
 - 2.6.8 Prussian Blue, or Perls’ Reaction. 73
 - 2.6.9 Congo Red 74
- References. 75
- 3 Cytology of Canine and Feline Non-neoplastic Skin Diseases 77**
 - 3.1 Introduction 77
 - 3.2 Papules 77
 - 3.2.1 Papular Diseases in Dogs 78
 - 3.2.2 Papular Diseases in Cats 80
 - 3.3 Nodular Papules 86
 - 3.3.1 Deep Pyoderma (Furunculosis) 86
 - 3.3.2 Facial Eosinophilic Furunculosis 96
 - 3.3.3 Papular–Nodular Canine Leishmaniasis 100
 - 3.3.4 Sterile Granuloma and Pyogranuloma Syndrome 104
 - 3.3.5 Calcinosis Cutis 108
 - 3.3.6 Xanthomatosis 116
 - 3.4 Pustules 122
 - 3.4.1 Pustular Diseases in Dogs 122
 - 3.4.2 Pustular Diseases in Cats 149
 - 3.5 Scales 155
 - 3.5.1 Scaling Diseases in Dogs and Cats 155
 - 3.6 Erosions 173
 - 3.6.1 Erosive Diseases in Dogs 173
 - 3.6.2 Erosive Diseases in Cats 176
 - 3.7 Ulcer. 176
 - 3.7.1 Ulcerative Diseases in Dogs 177
 - 3.7.2 Ulcerative Diseases in Cats 180
 - 3.8 Plaques and Nodules 191
 - 3.8.1 Infectious and Parasitic Causes 194
 - 3.8.2 Sterile Diseases 245

3.9	Juvenile Cellulitis.	266
3.9.1	Juvenile Sterile Granulomatous Dermatitis and Lymphadenitis (Juvenile Cellulitis)	266
3.9.2	Plasma Cell Pododermatitis.	271
	References.	275
4	Cytology of Skin Tumours	291
4.1	Introduction	291
4.2	Round Cell Tumours	292
4.2.1	Mast Cell Tumour	293
4.2.2	Lymphoma.	311
4.2.3	Plasma Cells Tumour.	321
4.2.4	Transmissible Venereal Tumour	328
4.2.5	Histiocytic Diseases.	335
4.3	Epithelial Tumours.	358
4.3.1	Squamous Cell Carcinoma.	358
4.3.2	Follicular Cysts and Follicular Tumours	372
4.3.3	Sebaceous Gland Tumours.	399
4.3.4	Sweat Gland Tumours (<i>Apocrine Gland Tumours</i>)	418
4.3.5	Fibroadnexal Hamartoma (Fibroadnexal Dysplasia).	430
4.4	Mesenchymal (Spindle) Cell Tumours	435
4.4.1	Fibroma and Fibrosarcoma	435
4.4.2	Myxoma and Myxosarcoma	445
4.4.3	Haemangioma and Haemangiosarcoma.	445
4.4.4	Perivascular Wall Tumours	450
4.4.5	Peripheral Nerve Sheath Tumour.	454
4.4.6	Lipoma and Liposarcoma	459
4.4.7	Anaplastic Soft-Tissue Sarcoma with Many Giant Cells	470
4.5	Melanocytic Tumours	473
	References.	482
5	Cutaneous Metastasis from Non-primary Skin Tumors	491
5.1	Introduction	491
5.2	Metastatic Pulmonary Carcinoma in Cats (Lung–Digit Syndrome).	492
5.3	Cutaneous Metastasis from Inflammatory Mammary Carcinoma	499
5.4	Cutaneous Metastasis from Internal Haemangiosarcoma	504
5.5	Others Rare Skin Metastasis	508
	References.	517
	Index.	521

Chapter 1

Morphology and Function of Skin Cells

1.1 Introduction

In this chapter, the morphology of the cells that make the skin is discussed. To better interpret the cytological specimens collected from skin lesions, it is mandatory to know the morphology of the cells that compose the epidermis, the dermis and the subcutaneous tissue, in addition to the cells that normally reside in the dermis and finally, those produced from bone marrow that reach the skin via the bloodstream during inflammatory processes.

Anatomically, the skin is made up of three main different anatomical parts: the *epidermis*, the *dermis* with the *follicular* and *glandular adnexa*, and the *hypodermis*, also known as the *subcutis*.

1.2 The Cells of the Epidermis

More than 90% of the *epidermis* consists of nucleated cells that mature to become anucleate and completely keratinised cells. The remaining cells comprise *melanocytes* and *Langerhans cells* (dendritic antigen-presenting cells), which are only detectable in the case of proliferative/neoplastic processes, which occur in *melanocytomas/melanomas* and in *cutaneous histiocytoma* respectively. As epidermal cells are mainly composed of keratin, they are named *keratinocytes*, which make up the four strata of the epidermis: *basale*, *spinosum*, *granulosum* and *corneum*; because the latter is completely keratinised, its cells are called *corneocytes* (Fig. 1.1).

Under normal conditions, it is possible to collect only a few corneocytes from healthy skin, as they are the only cells present on the surface of the epidermis as a result of the physiological keratinisation process.

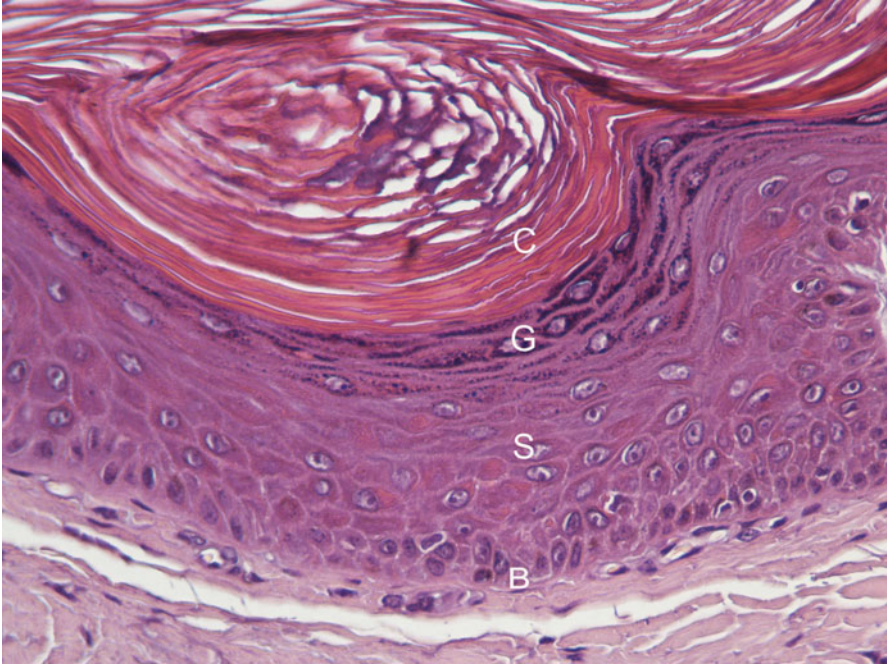


Fig. 1.1 Histology of the epidermis: hyperplastic epidermis, in which the different epidermal layers are well defined: *b* stratum basale, *s* stratum spinosum, *g* stratum granulosum and *c* stratum corneum

1.2.1 *Stratum Basale*

The cells of the basal layer are the smaller among the keratinocytes and are also those less frequently observed on cutaneous specimens. They are cuboidal in shape in the tissue, but appear roundish when observed on cytological specimens; they measure 8–10 μm , have round nuclei, sometimes with a single evident nucleolus, and a high nucleus–cytoplasm ratio (N/C ratio). The cytoplasm is sparse and deep blue in colour. Sometimes, it can be difficult to differentiate between a basal keratinocyte and a non-activated histiocytic cell. Two cytological characteristics of the basal keratinocytes that help the cytologist to recognise them are the presence of a thin clear halo that is interposed between the nucleus and cytoplasm and they are usually arranged in clusters (only rarely singularly; Fig. 1.2).

1.2.2 *Stratum Spinosum*

The cells of the *spinosum* layer are larger than basal ones, and are much more frequently observed as they are the most numerous nucleated cells of the epidermis. *Spinous keratinocytes* are large polygonal cells with angled borders and round to oval nuclei, usually central, with a lower N/C ratio than basal cells. The cytoplasm is large and of varying colours, which range from pale pink to sky blue and even dark blue (Fig. 1.3).

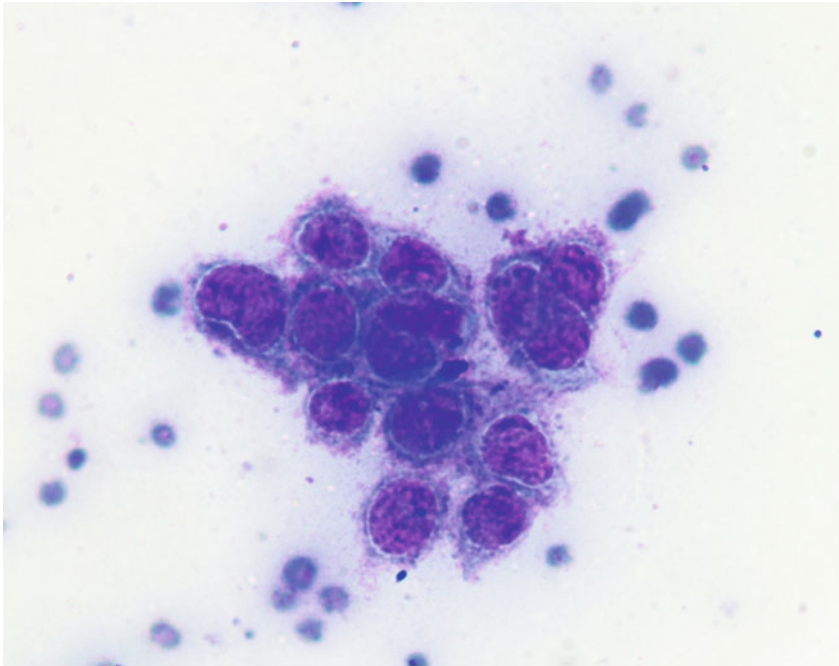


Fig. 1.2 Cytology of the stratum basale: a cluster of basal keratinocytes. Note the achromatic perinuclear halo

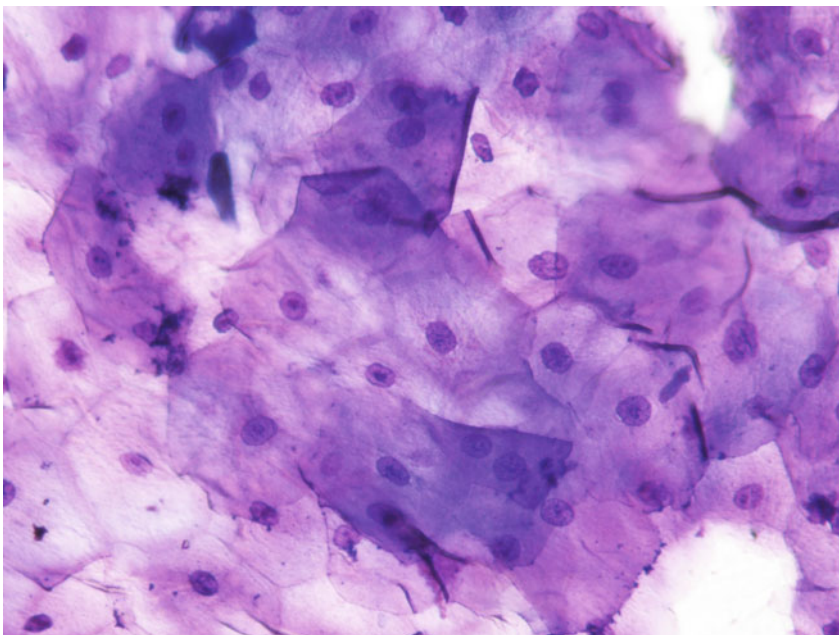


Fig. 1.3 Cytology of stratum spinosum: large polygonal spinous cells with angled borders and central oval nuclei with single evident nucleoli

1.2.3 *Stratum Granulosum*

The cells of the *granulosum layer* are so called because they contain intracytoplasmic *keratohyaline granules* of different sizes and round in shape. The granules take on an eosinophilic colour when stained with Romanowsky type dye. The pink colour of the granules makes them easily recognisable and cytologically distinguishable from any other type of granule, pigment or microorganism, which can be detected on the surface of keratinocytes. The size of the cells is variable, but they are voluminous with a polygonal shape and a low N/C ratio (Fig. 1.4).

1.2.4 *Stratum Corneum*

The normal epidermal keratinisation process results in the formation of the *stratum corneum*, which is composed of keratinocytes that have lost the nucleus to become completely keratinised. For this reason they are also called *corneocytes*. The morphology of the corneocytes is highly variable and ranges from large polygonal, flattened, anucleate cells with angled borders, to deeply blue-stained cells with a

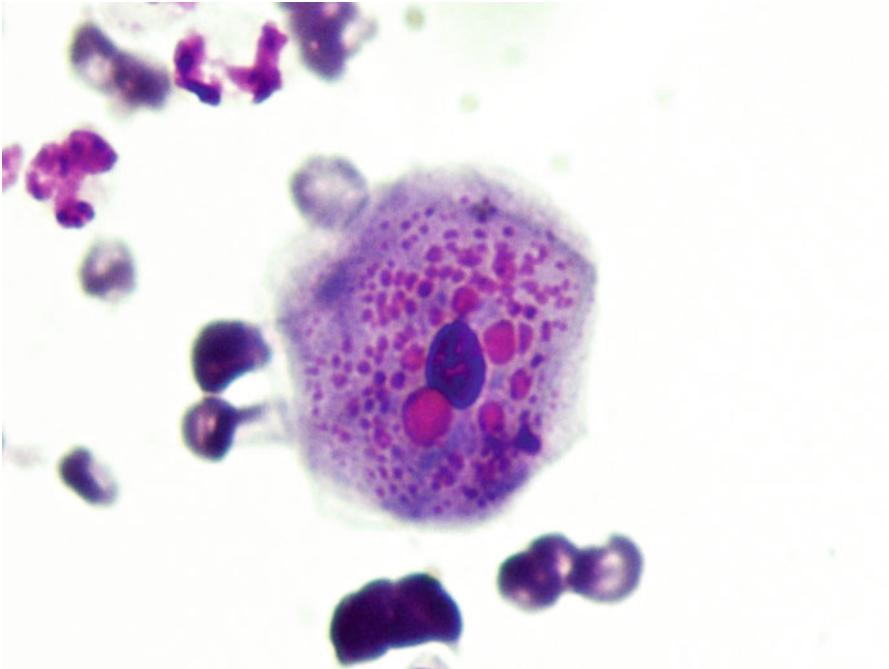


Fig. 1.4 Cytology of the stratum granulosum: large polygonal keratinocytes with cytoplasm filled with roundish and eosinophilic keratohyalin granules

lanceolate or *papyrus-like* appearance (Figs. 1.5 and 1.6). Colour differences in corneocytes range from completely unstained cells to cells that are coloured in various shades of pink, purple and blue. These differences depend not only on the amount of keratin present in the individual cells, but also on the failure to dissolve ceramides, sphingosine and cholesterol, the normal constituents of the lipid film forming the skin barrier that are still present on their surface. The excessive presence of lipids can, in fact, reduce or inhibit the penetration of stains into the cells.

The cytological recognition of keratinocytes is very important, because in many cases their identification provides very useful indications, as occurs in specimens collected from pustules of animals suffering from pemphigus foliaceus (acantholytic keratinocytes). It should be stressed that knowledge of the normal morphology of keratinocytes can be very useful so to make a better interpretation, in the context of an inflammatory lesion, of the *dysplastic* versus *neoplastic* changes in the epithelial cells that allow malignancy to be rapidly suspected and histology to be performed more quickly (Fig. 1.7).

Under normal conditions, only large sheets of corneocytes can be collected from the surface of the skin (Fig. 1.8). With transparent acetate tape, the collection of only nucleated keratinocytes from superficial desquamative crusty lesions, can indicate, in animals with peculiar clinical presentation, the presence of *parakeratotic hyperkeratosis* (Fig. 1.9). These cytological findings can be observed in some *primary keratinisation defects* such as superficial necrolytic dermatitis (hepato-cutaneous

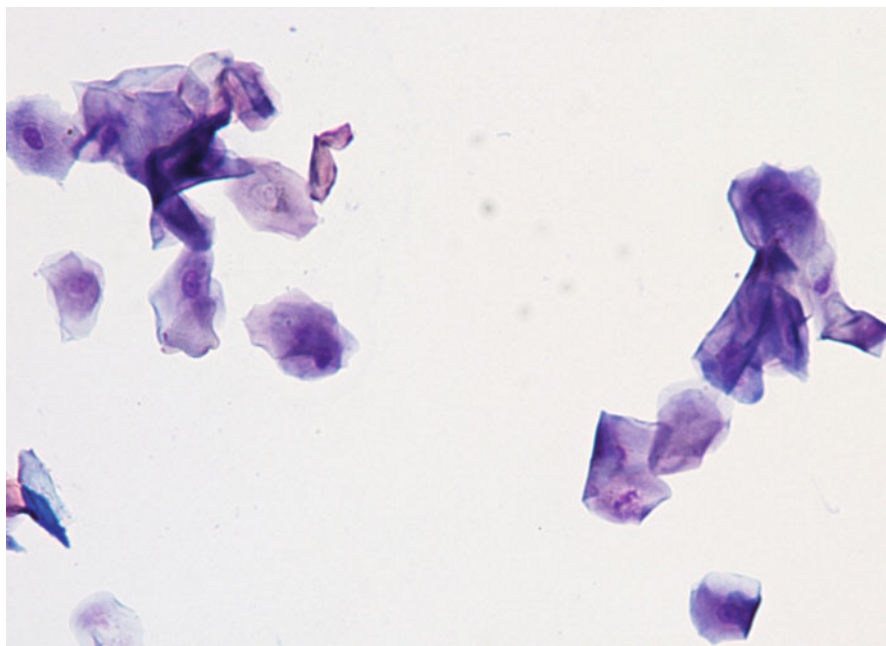


Fig. 1.5 Cytology of the stratum corneum: many anucleate keratinocytes (corneocytes) and few nucleated keratinocytes of the spinous layer

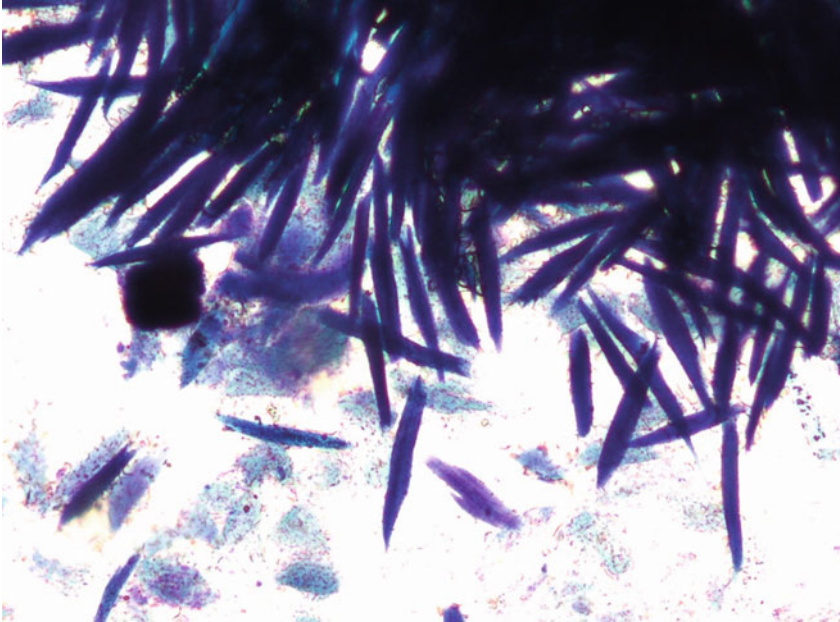


Fig. 1.6 Cytology of the stratum corneum: many lanceolate and deeply blue stained corneocytes

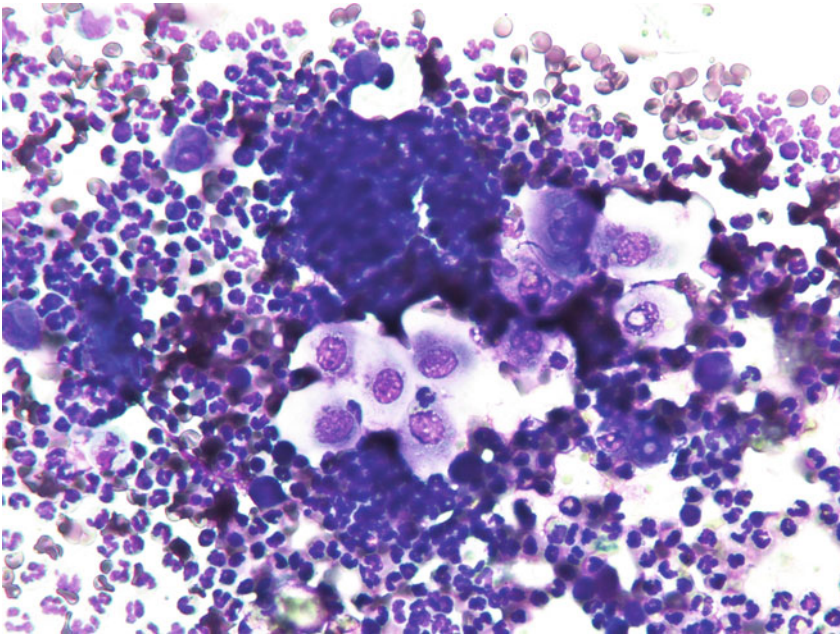


Fig. 1.7 Cytology of dysplastic keratinocytes: note the alterations represented by nuclei with irregular profiles and pseudo-vacuolation

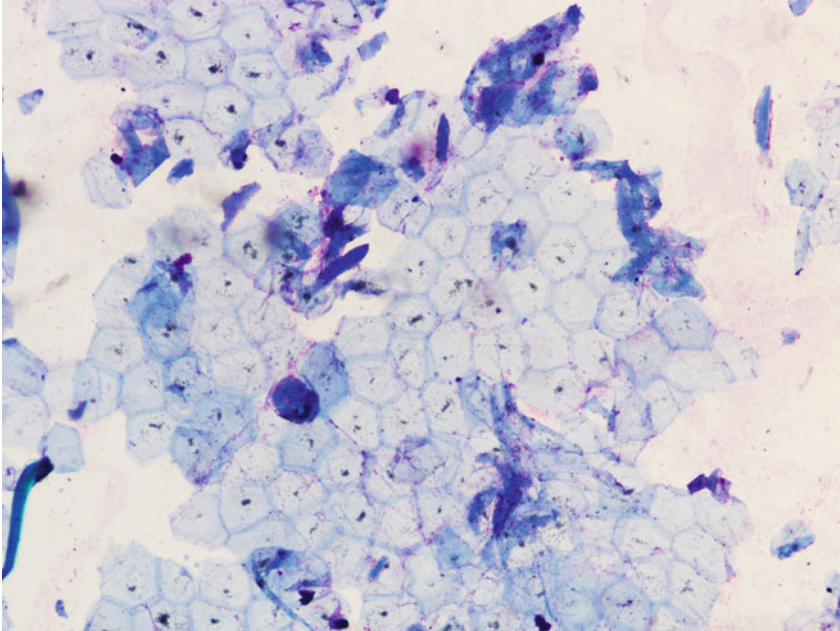


Fig. 1.8 Cytology of the normal skin surface: large sheet of corneocytes collected using the acetate tape technique

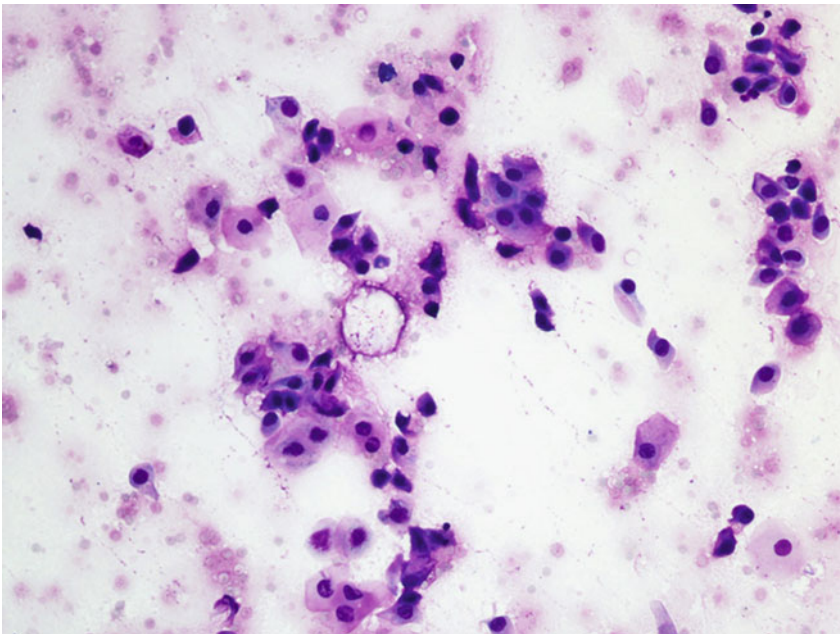


Fig. 1.9 Cytology collected from the nose of a Labrador retriever affected by idiopathic nasal parakeratosis. Note the presence of nuclei in all the keratinocytes sampled

syndrome), zinc-responsive dermatosis and idiopathic nasal parakeratosis of the Labrador retriever (Fig. 1.10). It must be pointed out that a small number of nucleated keratinocytes collected from the skin surface, together with corneocytes, is a common finding in canine and feline dermatology. Indeed, focal parakeratosis is an alteration in keratinisation alteration observed in many diseases and not necessarily linked to primary keratinisation defects; in these cases, the clinical presentation guides the clinician in the diagnostic procedures to follow.

1.3 The Cells of the Dermis and Adnexa

The *dermis* is the intermediate portion of the skin located between the *epidermis* and the *adipose tissue*. Anatomically, it is the most complex part of the skin because it is made up of the *connective tissue*, *vascular* and *nervous* networks, and by the adnexa represented by *hair follicles* and *sebaceous* and *sweat glands*.

The connective tissue is composed of *fibres*, *ground substance* and *cells*. The fibres are both insoluble as collagen and elastin and soluble such as proteoglycans and hyaluronan (hyaluronic acid). Most of the extracellular matrix is produced by fibroblasts, which also generate the ground substance (glycosaminoglycans or mucopolysaccharides).

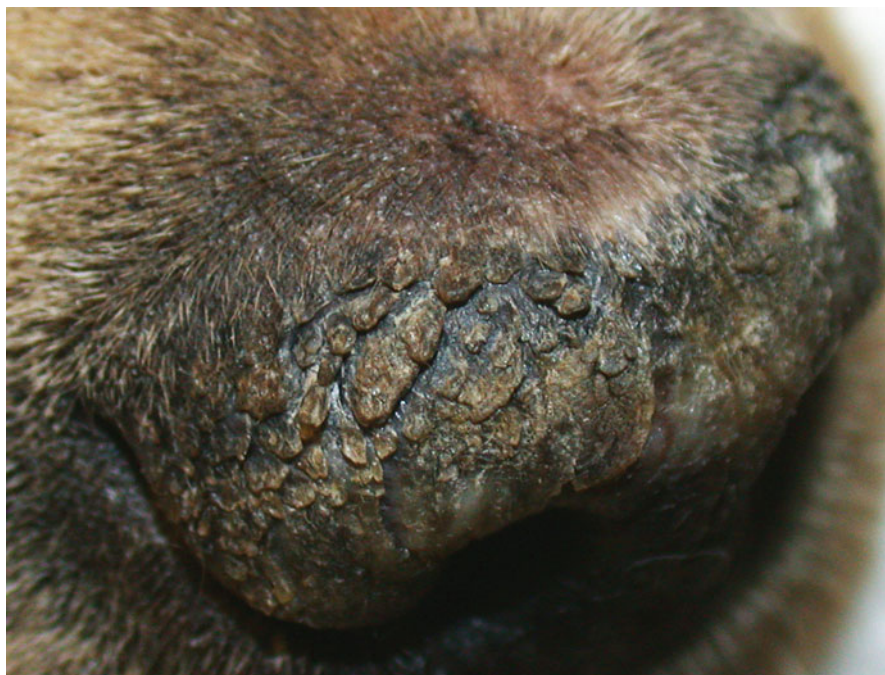

Fig. 1.10 Adherent scales on the nose of a Labrador retriever with idiopathic nasal parakeratosis

Without going into the complex world of the connective tissue, which is beyond the aim of this chapter, it can be deduced from the above that fibrocytes/fibroblasts are the most frequently detectable dermal resident cells on slides coming from inflammatory skin lesions.

Fibrocytes are inactive *fibroblasts*, with elliptical nuclei, slightly basophilic cytoplasm and with opposing thin tails that give the cells an elongated spindle shape (Fig. 1.11). *Fibroblasts* are also spindle cells that can take a star-like or tentacular appearance; the nuclei are round to oval and the cytoplasm is basophilic and often vacuolated. Sometimes, fibroblasts are found as pseudo-aggregates, in which they produce an extracellular matrix that holds the cells together; the latter is cytologically recognisable as an eosinophilic amorphous and fibrillar material (Fig. 1.12). *Fibroblasts* are usually found in specimens collected from the wound-healing process (granulation tissue) and in these cases, they must not be confused with mesenchymal neoplastic cells. Reactive fibroblasts may show severe morphological atypia, such as anisocytosis, double nuclei, prominent nucleoli and many mitosis, which resemble those observed in some spindle cell tumours (Fig. 1.13). When the biosynthetic activity of fibroblasts ends, they turn into fibrocytes; therefore, fibroblasts and fibrocytes represent two functional moments in the existence of the same cell. However, a small number of fibroblasts can be found in all chronic inflammatory processes in which they are inevitably stimulated to repair tissue damage.

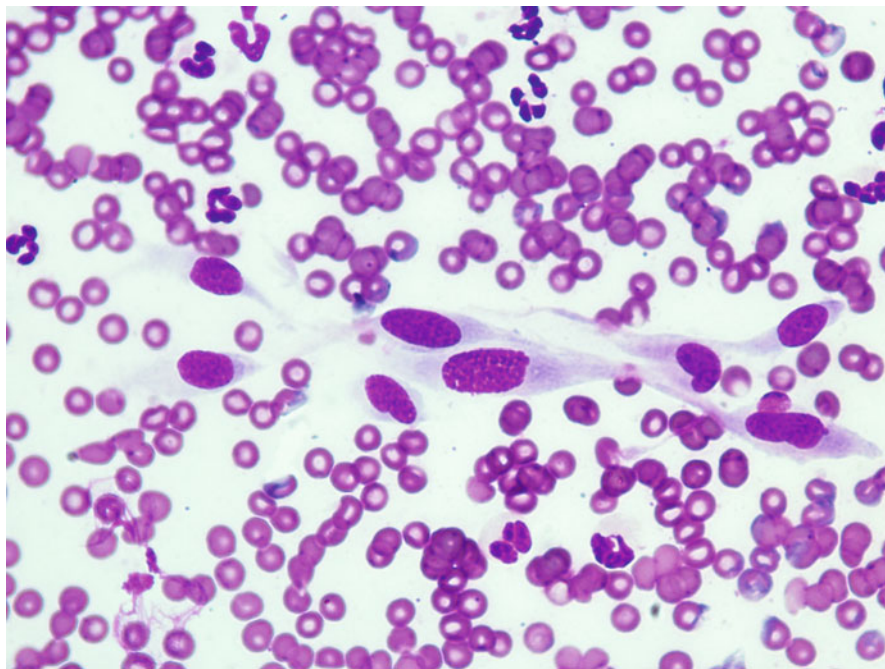


Fig. 1.11 Cytology of fibroblasts: spindle cells with elongated nuclei and tailed cytoplasm with ill-defined margins

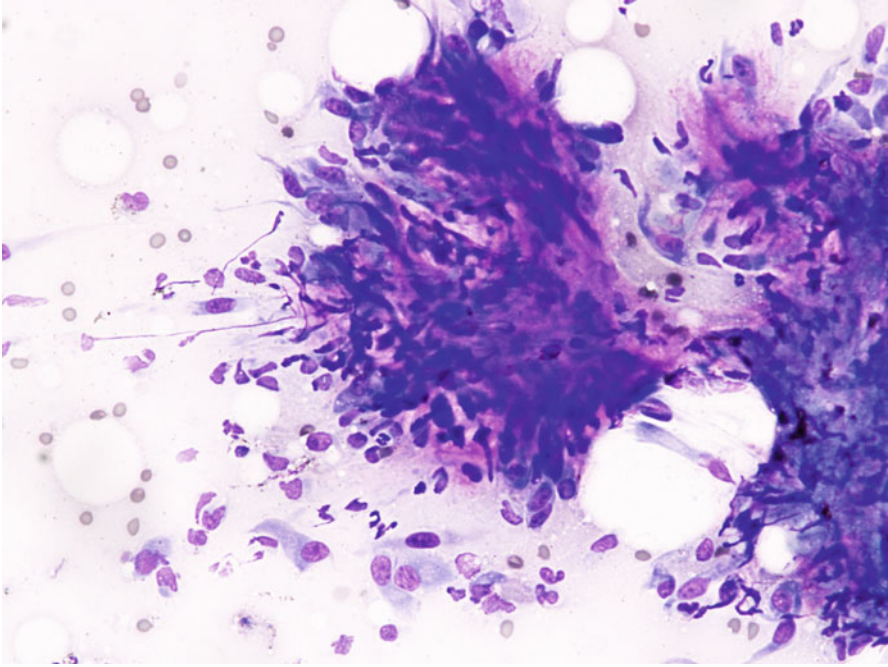


Fig. 1.12 Cytology of the extracellular matrix: bright eosinophilic material that holds together many reactive fibroblasts. This material represents the ground substance produced by fibroblasts

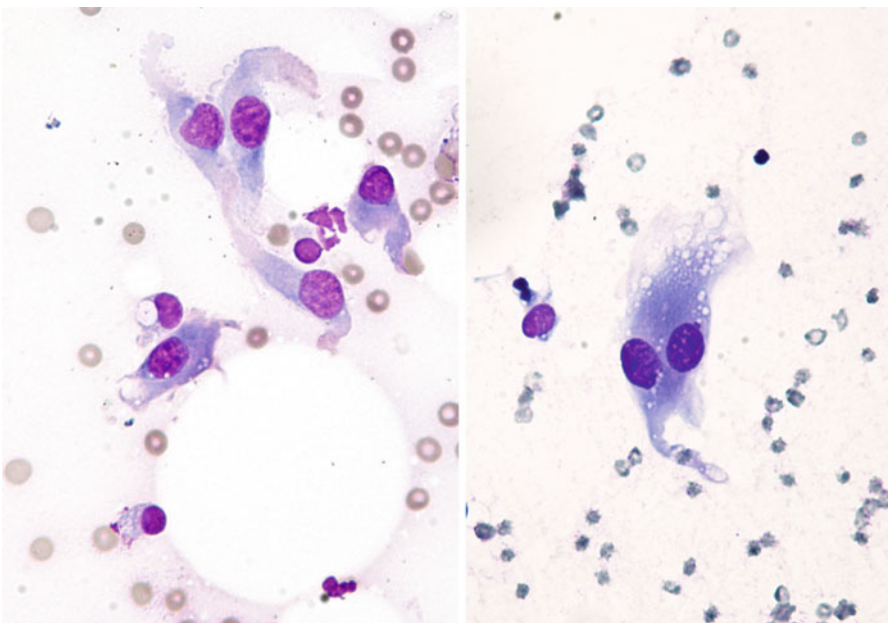


Fig. 1.13 Cytology of reactive fibroblasts: dysplastic fibroblasts with a spindle or starry appearance. Some cytological features can generate doubts with regard to a spindle cell neoplasia

Dendritic antigen-presenting cells (APCs) are also present in the dermis, although they are few and not distinguishable from other histiocytes on cytological specimens.

A reactive proliferation or a neoplastic transformation of dermal APCs gives origin to the so-called *histiocytic diseases*, such as cutaneous/systemic reactive histiocytosis and histiocytic sarcomas in dogs and feline progressive histiocytosis in cats, which are discussed in Chap. 4.

Finally *melanocytes*, around the vessels and hair follicles, particularly in dogs with black coats, are physiologically present; these cells are not visible in cytology until their neoplastic transformation occurs.

In some samples it is possible to find *blood capillaries*, represented by linear and sometimes branched structures, composed of endotheliocytes with elongated nucleus and indistinct cytoplasm that delimitate a thin central lumen in which some red blood cells (RBCs) may be still evident (Fig. 1.14).

Collagen fibres are proteic components of connective tissue produced by fibroblasts, which are cytologically recognisable as fibrillar linear or branched eosinophilic formations (Fig. 1.15).

The dermal *adnexa* are composed of *hair follicles* and *sebaceous* and *sweat glands*.

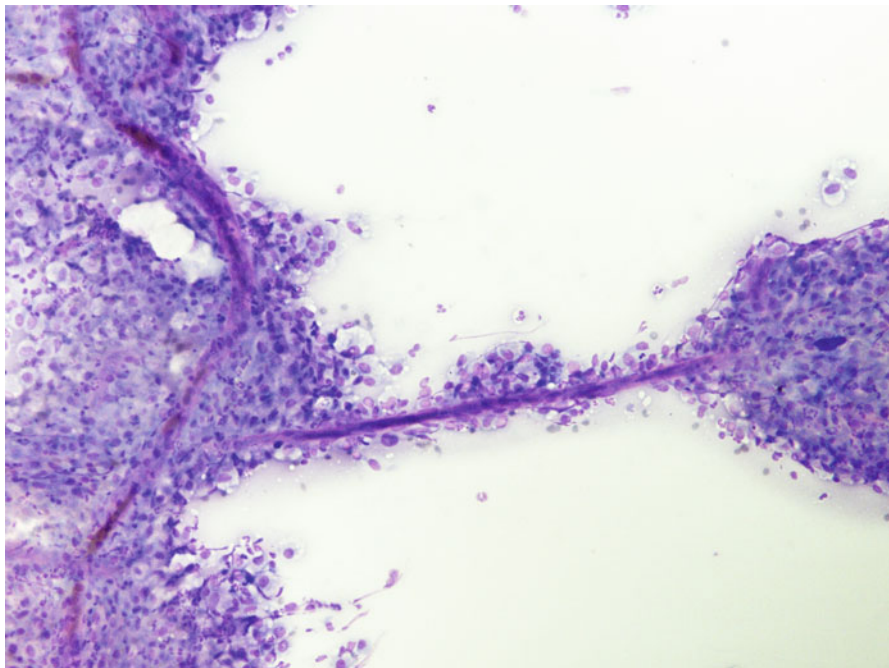


Fig. 1.14 Cytology of vessels: linear and branched hematic vessels surrounded by many inflammatory cells

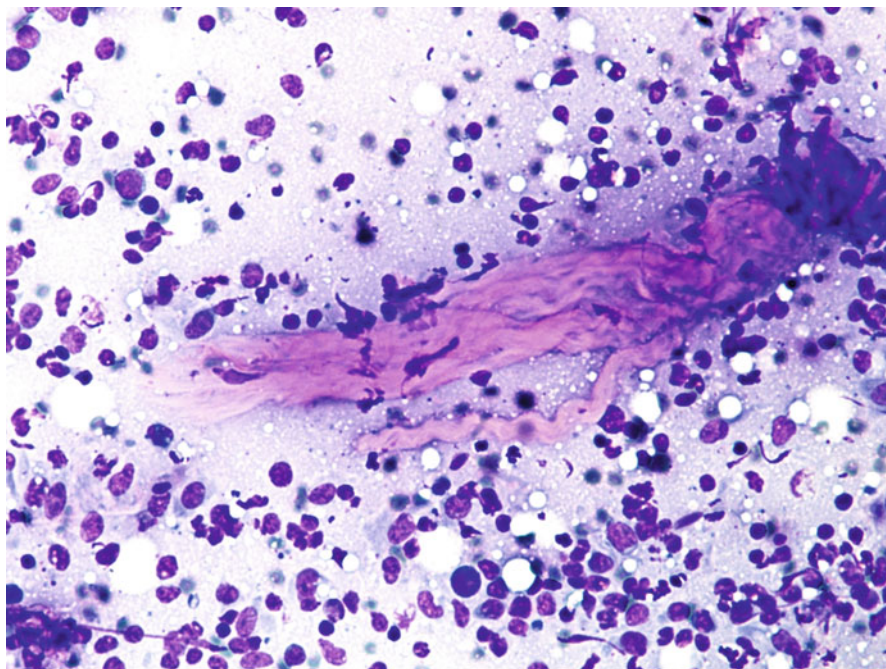


Fig. 1.15 Cytology of collagen fibres: linear wavy eosinophilic formations represent collagen fibres

The *follicles* are a continuation of the external epidermis, which direct downwards to form the follicular wall. Knowledge of the follicular cells and of the different types of keratins they produce is mandatory for the interpretation of cytology of follicular neoplasms. A more detailed description of the follicular morphology and of the different types of keratins are dealt with in the chapter regarding epithelial tumours (Chap. 4).

During inflammatory processes, epithelial aggregates of sebaceous and apocrine glandular tissue are commonly collected.

The sebaceous glands are associated with follicles forming the so-called *pilosebaceous unit*. Morphologically, they are characterised by round to elongated lobular aggregates of cells that contain many intracytoplasmic overlapping micro-vacuoles, filled with sebum, giving cells a characteristic *foamy* appearance. Lobules of mature sebocytes are bordered by a single line of *basaloid* cells, uniform in size and with small hyperbasophilic cytoplasm, representing immature *germinative cells* (reserve cells), which mature into sebocytes (Fig. 1.16). In cats, mature sebocytes are similar to those found in dogs, the difference being that the size of the cytoplasmic vacuoles is more uniform in cats. The secretory duct, named the *pilosebaceous canal*, is short, lined with squamous epithelium and ends directly in the follicular lumen, in which sebum is drained. Sebaceous glands have a holocrine way of secretion, in which the plasma membrane dissolves and the intracytoplasmic sebum is released into the lumen. In cytological specimens, immersed in the sebum, debris of the dead

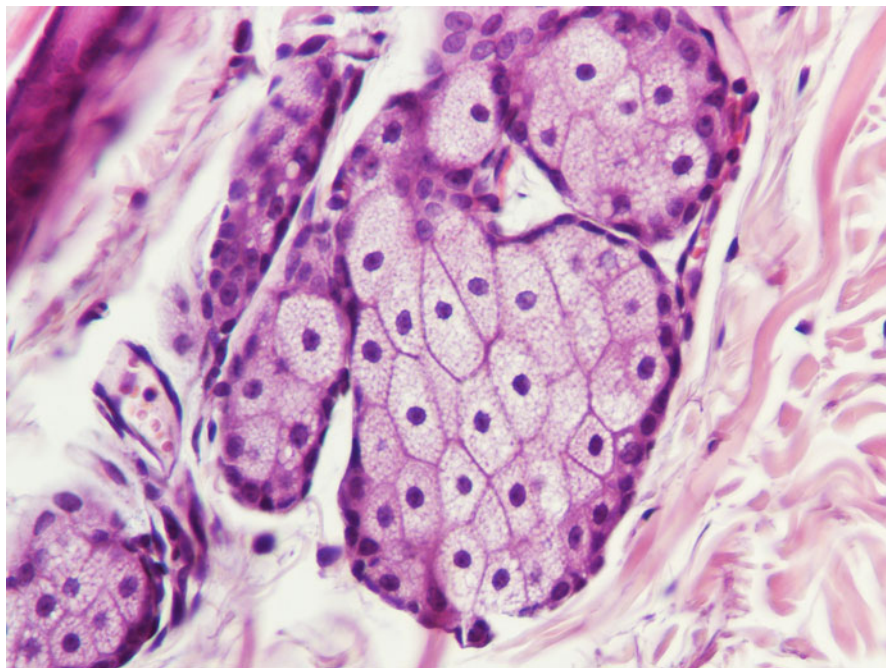


Fig. 1.16 Histology of normal sebaceous glands: lobules of micro-vacuolated sebaceous cells bordered with basaloid reserve cells

sebocytes and some keratinocytes coming from the ductal epithelium can be observed (Figs. 1.17, 1.18 and 1.19). Clusters of well-differentiated sebocytes are commonly observed in dogs with hyperplasia and neoplasia of the sebaceous glands. In some cases, aggregates of sebocytes of variable size can be collected during the sampling from inflammatory lesions (Fig. 1.20). In these cases, they must be interpreted as being *innocent bystanders*.

In the canine skin, some *modified* or *specialised* sebaceous glands are also present. Because of their slight microscopic similarity to hepatocytes, they are called *hepatoid glands* and have a secretory duct that opens into the follicular lumen. These glands are commonly affected by hyperplastic and neoplastic changes and, even if they are anatomically located in the perianal area and on the tail gland, they are rarely detected at other body sites. Hepatoid glands are not present in cats where the tail gland is composed only of sebocytic sebaceous glands that, in the case of sebum overproduction, are the cause of the clinical aspect “stud tail”. The cytological features of the hepatoid glands are exhaustively discussed in Chap. 4.

The other glands present in the dermis are the *sweat glands*, which can be morphologically divided into *epitrichials* and *atrichials*. The epitrichial glands, which use *apocrine* secretion, are characterised by the fact that their secretory ducts open into the follicular lumen. The *atrichial* glands are of *eccrine* or *merocrine* nature instead, and release sweat directly onto the skin surface; in pets, the atrichial glands

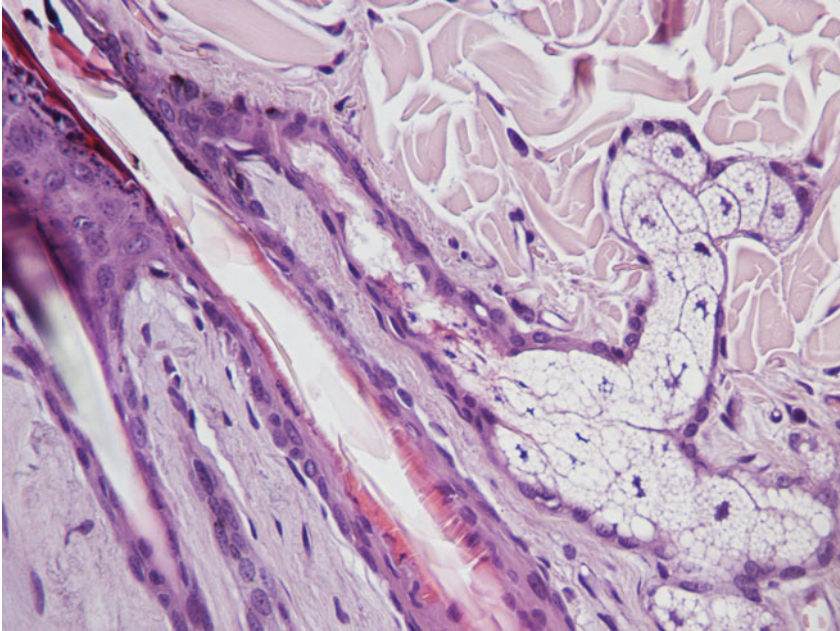


Fig. 1.17 Histology of normal sebaceous glands: pilosebaceous canal lined with squamous epithelium that ends directly in the follicular lumen

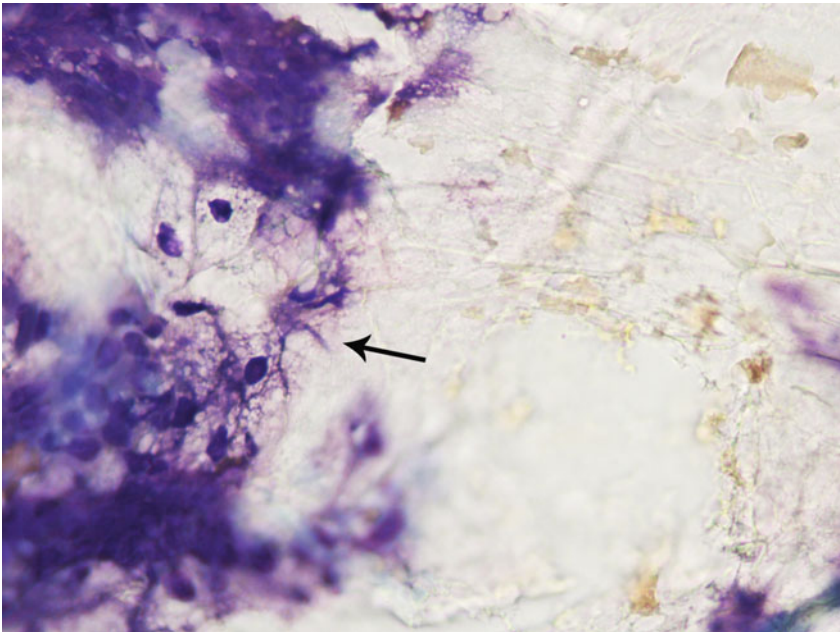


Fig. 1.18 Cytology of normal sebaceous glands: holocrine secretion in which the cytoplasm of sebocytes dissolves and gives origin to the sebum (*arrow*)

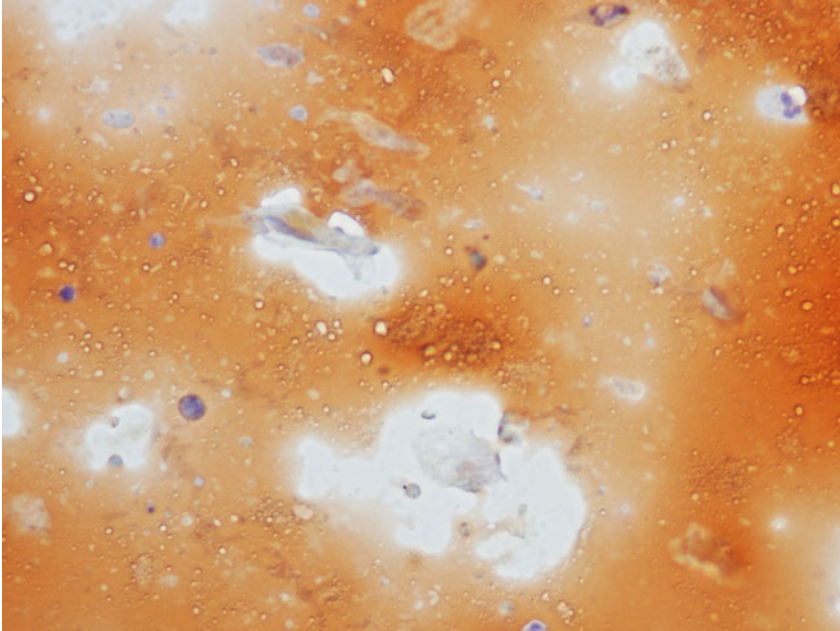


Fig. 1.19 Cytology of the sebum: with Oil-red-O staining, the sebum is coloured *red-orange*. Note the presence of some corneocytes that represent the inner cells of the sebaceous ducts

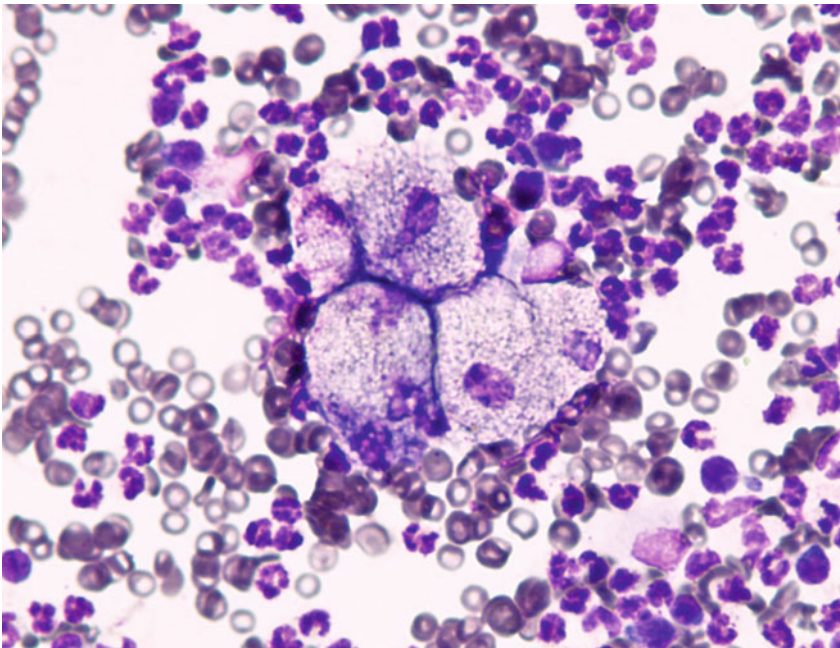


Fig. 1.20 Cytology of the sebaceous glands: a small cluster of mature sebocytes is immersed in an inflammatory population of cells

are exclusively present in the skin of the paw pads. As epitrithial glands account for almost all of the sweat glands in the skin, the term of *apocrine glands* is usually used to describe them when speaking about sweat glands. In pets, these glands have no thermoregulatory function.

On slides, apocrine glands are usually observed in the case of benign or malignant neoplasms. Rare apocrine aggregates can also be observed in specimens coming from hamartomas or inflammatory diseases. Cytologically, the sweat glands appear as small aggregates of cuboidal to cylindrical cells, of uniform size, arranged in short palisades or in cohesive clusters with microacinar architectures (Figs. 1.21 and 1.22). Nuclei are uniform in size and shape, round, central or basal in location and the cytoplasm is small to moderate in size, basophilic in colour and sometimes containing coarse dark blue secretory material representing sweat. Cytoplasmic *blebs* on the apical luminal surface of the secretory cells, representing the typical secretion via *cytoplasmic decapitation* of the apocrine glands, are also detectable (Fig. 1.23).

In dogs with deep pyoderma, small clusters of sweat glands and their secretion, the latter represented by deeply blue or violet amorphous material, can be collected together with inflammatory cells (Fig. 1.24).

In cases of lesions such, as hamartomas or neoplasms, the latter both benign and malignant, the apocrine cells can also be yielded as large sheets of cells.

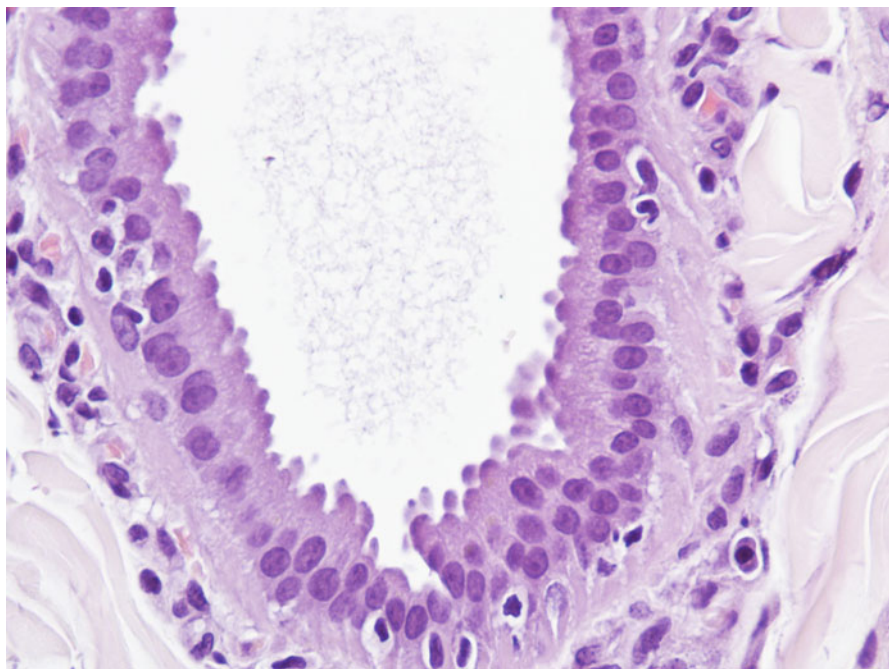


Fig. 1.21 Histology of the sweat glands: secretory portion of the apocrine gland composed of a double line of columnar cells. Note the secretion through *cytoplasmic decapitation* (blebs) and the scant basophilic reticular secretion present in the lumen

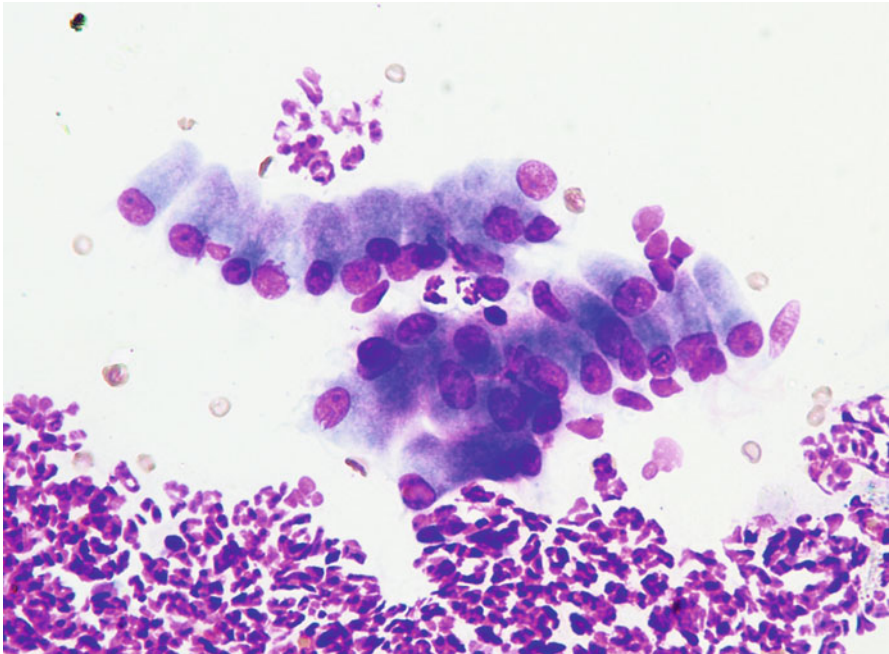


Fig. 1.22 Cytology of the sweat glands: a palisade of cylindrical apocrine cells immersed in an inflammatory population of cells

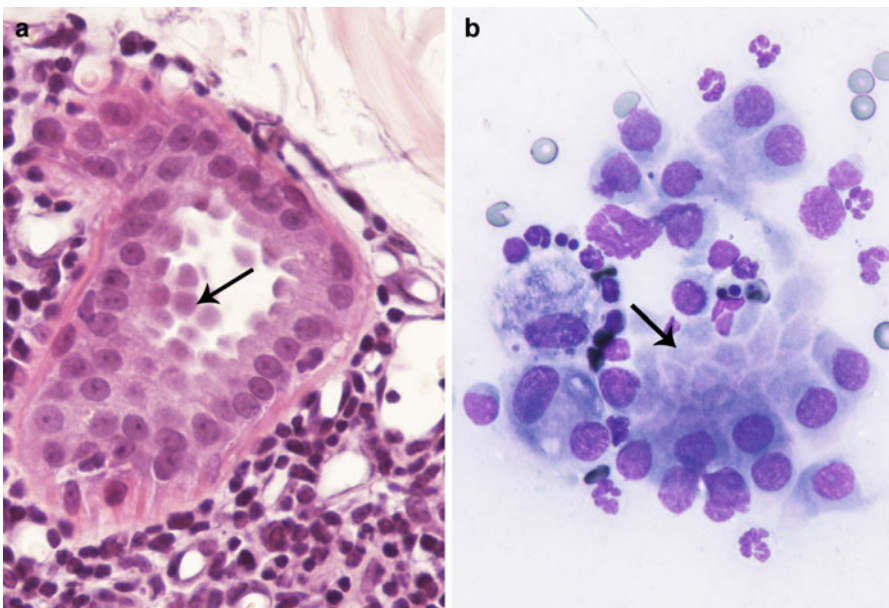


Fig. 1.23 Histology and cytology of the sweat glands: (a) blebs of cytoplasm are released in the ductal lumen (arrow); (b) identical cytological features can be seen in cytological specimens (arrow)

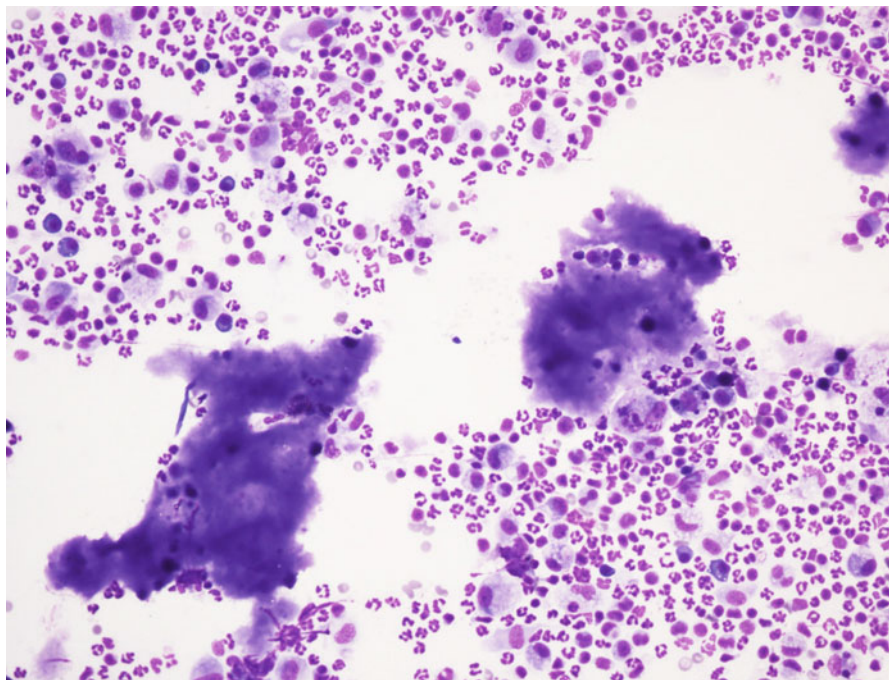


Fig. 1.24 Cytology of the deep pyoderma: sweat represented by amorphous and purple material is immersed in an inflammatory population of cells

Ceruminous glands are specialised apocrine glands located in the external ear canal, while *anal sac glands* consist of apocrine glands that cover the inner surface of the anal sacs from which very aggressive malignant tumours can originate. The cytological features of both are discussed with neoplastic lesions.

1.4 The Subcutaneous Tissue or Hypodermis

The *subcutis* is represented by the adipose tissue, composed of multiple layers of mature *adipocytes* of a different thickness according to the anatomical area of the body. Adipocytes can be released as single cells or in both small and large clusters.

When normal fat is collected through fine-needle aspiration biopsy (FNAB), as occurs in the attempt to sample a deep lesion, sheets of large, non-overlapping polygonal adipocytes with angled borders, are usually observed (Fig. 1.25). In the case of lipoma, voluminous and roundish clusters of usually overlapping cells, with optically empty cytoplasm, in which a single or multiple vacuoles filled with lipids characterise the adipocytes. The nuclei of the fat cells, when visible, are small, mainly hyperchromatic and oval in shape, of pyknotic aspect and often located at

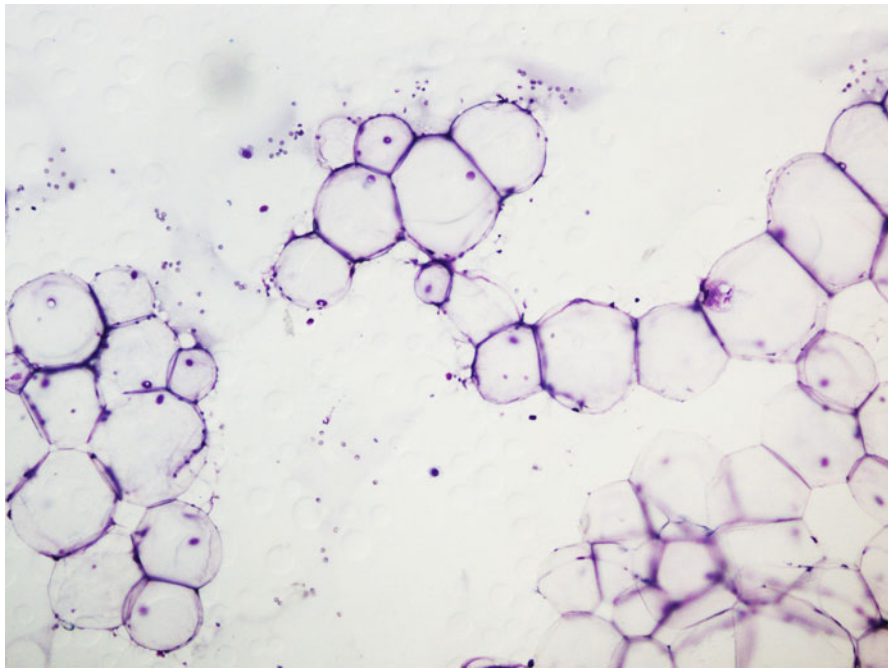


Fig. 1.25 Cytology of normal fat: polygonal to round large adipocytes

the periphery of the cells. On slides from inflammatory lesions, adipocytes can occasionally be observed, but their finding together with inflammatory cells does not authorise a diagnosis of primary panniculitis, as it is not possible to define, with cytology, if the fat is secondarily infiltrated by inflammatory cells coming from the dermis (innocent bystanders; Fig. 1.26).

1.5 The Cells of Inflammation

Cells of hematic origin and those residing in the dermis that can commonly be detected in a cutaneous inflammatory process are briefly described below.

1.5.1 Red Blood Cells

Red blood cells (RBCs) are commonly present in samples from skin lesions. In inflamed and reparative tissues, strong neo-vascularisation is often present and in ulcerated lesions, bleeding is frequently observed; moreover, because some sampling techniques such as scraping or FNAB can cause bleeding, it is easy to

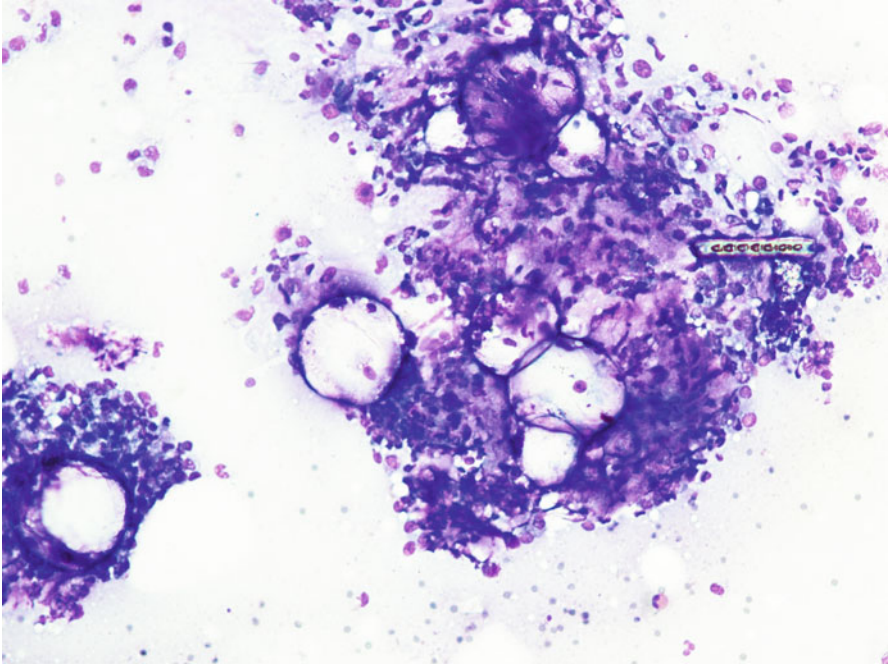


Fig. 1.26 Cytology of the deep pyoderma: single or small clusters of adipocytes are immersed in an inflammatory population of cells

imagine, in skin cytology, why blood contamination is commonly observed. The RBCs are anucleate round cells, measuring 6–7 μm , that are pale pink to deep violet in colour (Fig. 1.27). Their presence is rarely important in skin cytology, but allows us to define the depth of the lesions (the epidermis is not vascularised) and can be used as a *cytological meter* to compare the size of other cells.

1.5.2 Neutrophils

Neutrophils are the most frequently detected cells in cytological specimens coming from inflammatory skin lesions. Neutrophils leave the bloodstream and, together with other leukocytes, migrate into the dermis in response to chemotactic molecules released from the same cells of the skin or from micro-organisms, parasites, foreign bodies etc. The neutrophils are cells of the acute phase of inflammation, but in all chronic and persistent inflammatory processes, they are often still present. Morphologically they are characterized by nuclei with multiple lobes, whose number and aspect are strictly dependent from the age of the cells and the damage caused by environment or microorganisms. There are 3–5 nuclear lobes in healthy cells, connected to each other by thin chromatin striae that are not always detectable with

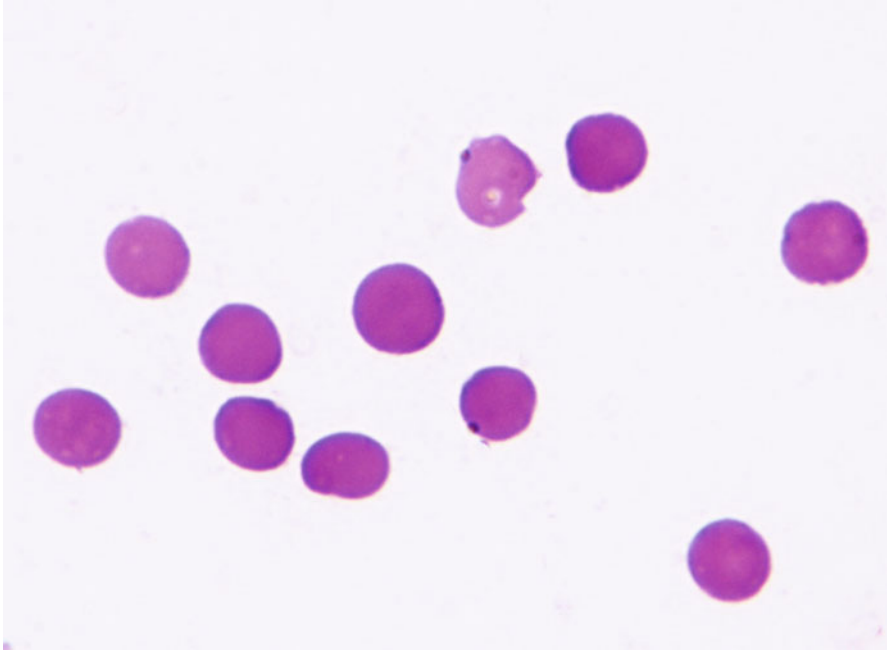


Fig. 1.27 Cytology of red blood cells (RBCs): small round anucleate cells cytologically characterise the red blood cells

cytology. Unlike eosinophils and basophils, the cytoplasm of neutrophils is apparently devoid of granules; the latter are not detectable with routine stainings and the cytoplasm takes on a scant grey–blue colour. In some cells, the plasmatic membrane is barely perceptible (Fig. 1.28).

The morphology of the nucleus can provide the cytopathologist with useful information about the possible pathogenesis of the lesions.

Healthy multilobulated granulocytes are called *segmented*, whereas those with fewer lobes showing degenerative changes are called *degenerate*. The three main morphological nuclear alterations in cytology are *karyolysis*, *karyopyknosis* (*pyknosis*) and *karyorrhexis*.

Karyolysis is the most common and diagnostic form of nuclear degeneration as it is indicative of severe cell damage usually caused by bacterial toxins.

Karyolytic nuclei undergo complete dissolution of the chromatin because of the enzymatic degradation by endonucleases. Nuclei appear swollen, hypochromatic, with a loss of the lobatures, owing to water penetration into the cells through damaged plasma membrane (Fig. 1.29).

Many short nuclear streaks, linked to the rupture of severely degenerated nuclei, are often present on the slides coming from pyoderma (Fig. 1.30). The presence of these nuclear features suggests to the cytopathologist to search for the presence of a bacterial microorganism, especially *Staphylococcus pseudintermedius*, the main

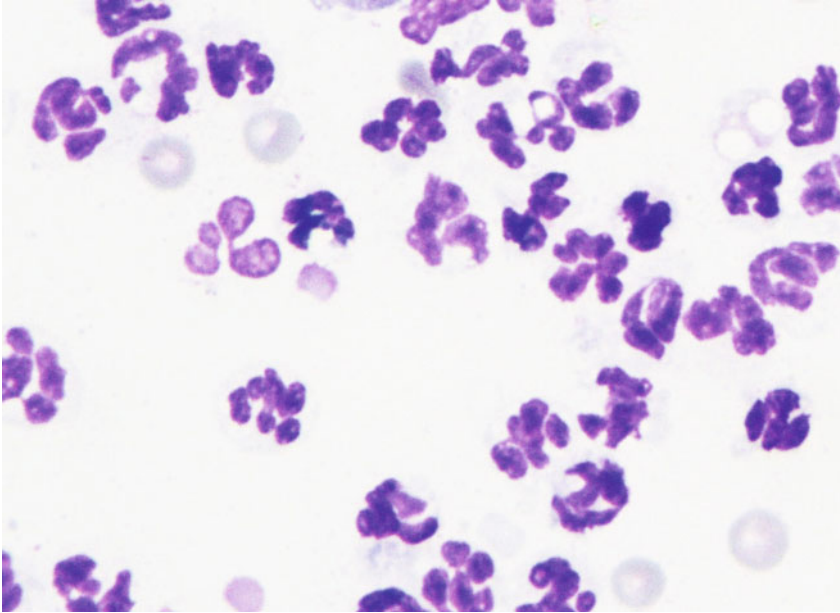


Fig. 1.28 Cytology of neutrophils: polymorphonucleated cells, with no evident granules and with barely perceptible plasmatic membrane

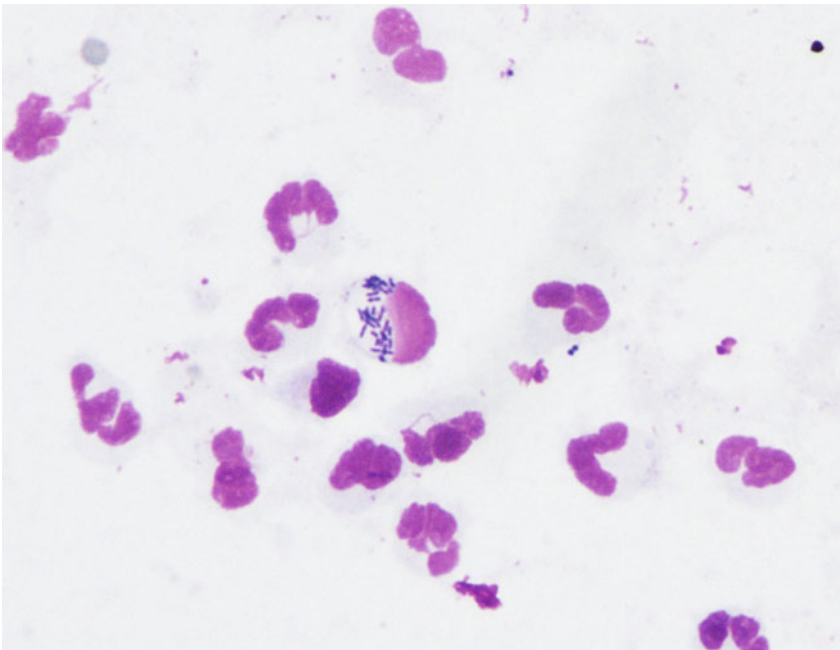


Fig. 1.29 Cytology of karyolytic neutrophils: pale and swollen nuclei characterise the nuclear degeneration termed *karyolysis*. Many cocci and rod-shaped bacteria justify the severe degenerative nuclear changes

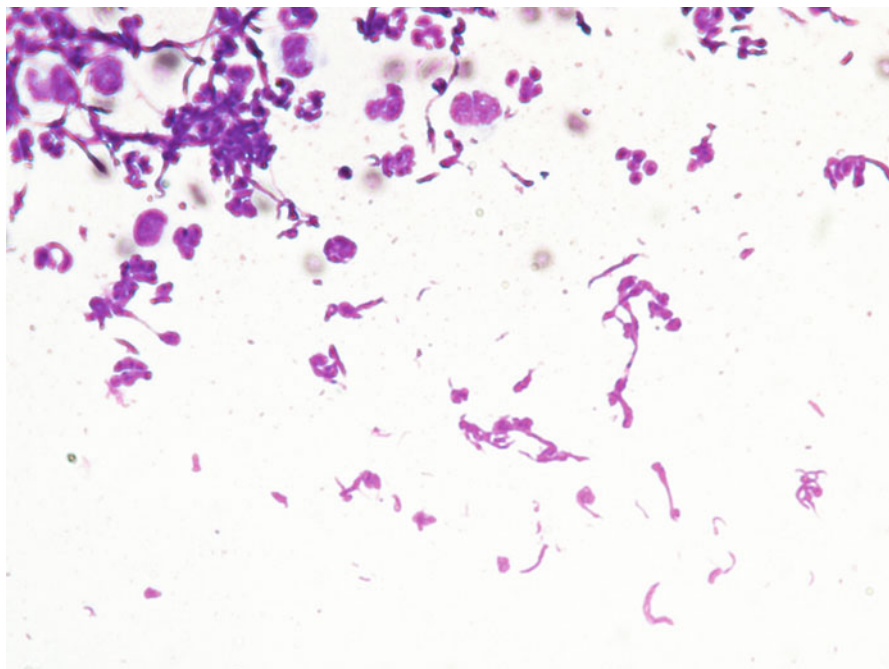


Fig. 1.30 Cytology of karyolytic neutrophils: short fragments of severely degenerated nuclei of neutrophils

cause of skin infection in dogs. The streaks observed in karyolytic neutrophils must be differentiated from longer and thinner ones caused by an excessive manoeuvre during preparation of the slides (Fig. 1.31).

Pyknosis is a less severe change of nuclear material. Unlike karyolysis, it is not linked to bacterial toxins, but can also be a cytological presentation of *apoptotic* cellular death. Pyknosis is indeed the result of the chromatin condensation and this is the most characteristic feature of apoptosis. The nuclear size progressively reduces as the chromatin condenses into single or multiple round and hyperchromatic formations (Fig. 1.32).

Karyorrhexis is the destructive fragmentation of the nucleus of a dying cell into many small round and hyperchromatic formations of different sizes, sometimes punctiform, much smaller than those observed in pyknosis. It is usually preceded by pyknosis and can occur as a result of apoptosis (programmed cell death), senescence or necrosis.

Pyknosis and karyorrhexis, but not karyolysis, are therefore most frequently seen in apoptotic cells.

Cytologically, it is not possible to define if pyknosis and karyorrhexis are secondary to apoptosis or may be part of the cytomorphological changes in the case of necrosis. Fortunately, their findings have no clinico-pathological meaning in inflammatory skin lesions.

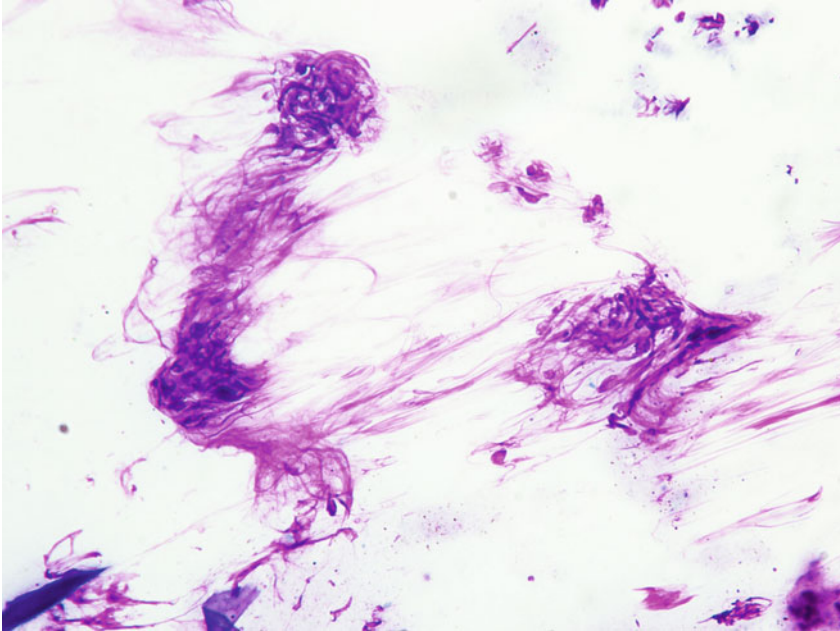


Fig. 1.31 Excessive manoeuvres during the slide preparation can be the cause of slender nuclear streaks

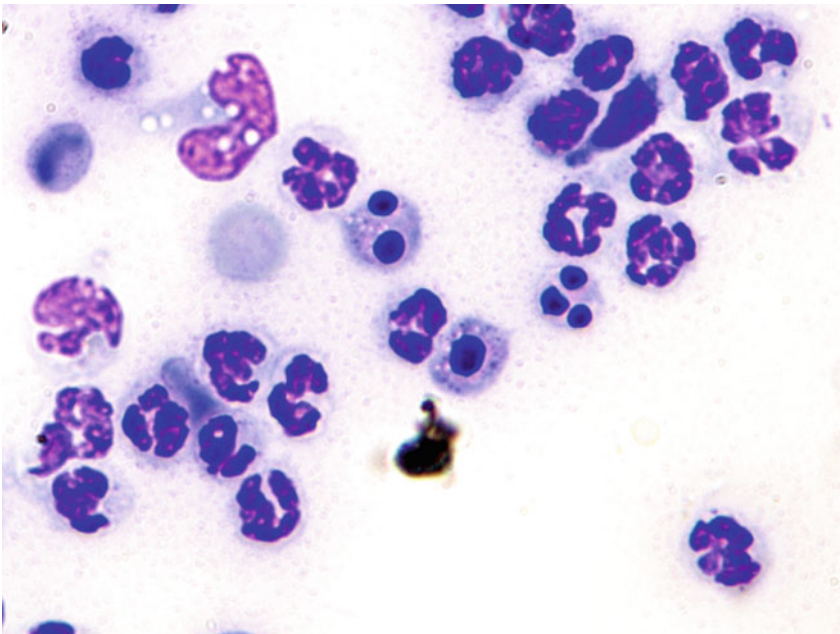


Fig. 1.32 Cytology of nuclear pyknosis: condensed chromatin causes the roundish and deeply blue nuclear material that characterises the pyknosis

The neutrophils are cells with phagocytic activity and therefore intracytoplasmic microorganisms such as bacteria, fungi and protozoa are commonly observed in many infectious diseases.

1.5.3 Eosinophils

Eosinophils are observed in many cutaneous inflammatory processes, especially in cats. Their presence is common in both acute and chronic lesions, even if the exact mechanisms by which infiltrates are plentiful in eosinophils, for example in *feline eosinophilic lesions*, is not yet clear. Although the presence of eosinophils is often associated with parasitic or hypersensitivity diseases, this is not the rule; in fact, parasitic diseases such as demodicosis and dirofilariasis do not usually stimulate eosinophilic inflammation. Moreover, many eosinophils are present in completely different diseases such as feline herpesvirus infection.

Eosinophils are morphologically similar to neutrophils, but are larger, with less evident nuclear lobes and with the presence of orange-pinkish cytoplasmic granules, which are *round* in dogs and *rod-shaped* in cats (Figs. 1.33 and 1.34). In cats, lobes of eosinophils are scarcely visible and, at low magnification, the granules are not always evident; in some cases, the eosinophils are in fact recognised for their

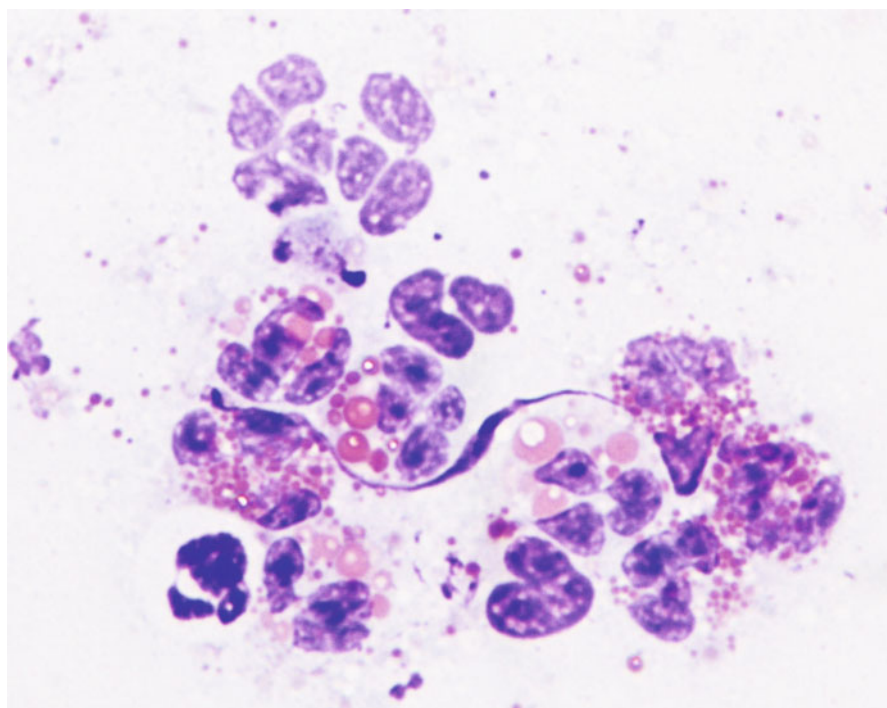


Fig. 1.33 Cytology of canine eosinophils: note the round pink–orange intracytoplasmic granules

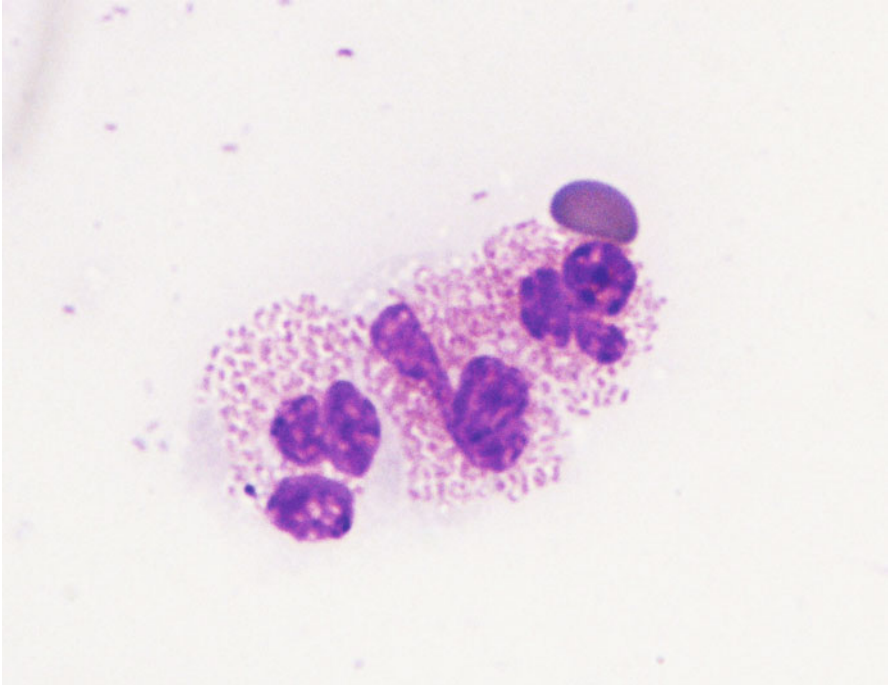


Fig. 1.34 Cytology of feline eosinophils: note the rod-shaped pink–orange granules that characterise the eosinophils of cats

diffuse intracytoplasmic orange-pinkish colour. During the preparation of slides, cells are frequently broken and the dispersion of eosinophilic granules in the background is a common finding. An inexperienced cytologist must not confuse rod-shaped granules with bacteria; with rapid Romanowsky-type stainings, the bacteria are always stained dark blue and never orange.

1.5.4 Basophils

Basophils are rarely observed in skin cytology. They are slightly larger than eosinophils and characterised by a polylobulated nucleus and a cytoplasm full of granules, which stain a very pale blue (Fig. 1.35). In cats affected by eosinophilic diseases, basophils are rarely found.

1.5.5 Lymphocytes

Lymphocytes are cells that play an important role in chronic inflammatory processes, particularly in those that are immune-mediated or when there is a chronic

antigenic stimulus, such as *granulomas*. Lymphocytes are discrete round cells, slightly larger than RBCs, with round, sometimes indented nuclei that occupy almost the entire cell and with chromatin distributed in hyperchromatic areas (heterochromatin) interspersed with lighter areas (euchromatin); the cytoplasm is scarce and confined to a small peripheral area that assumes an intense basophilic colour (Fig. 1.36).

1.5.6 Plasma Cells

Plasma cells come from B-lymphocytes and are specialised in the production of antibodies. Plasma cells have an oval silhouette, with round eccentric nuclei and an intensely basophilic cytoplasm, which is separated from the nucleus by a characteristic arc-shaped colourless area, the *Golgi apparatus* (Fig. 1.37). Some activated plasma cells, called *Mott cells*, contain numerous large intracytoplasmic vacuoles, the so-called *Russell bodies*, representing immunoglobulin and which give the cells a *foamy appearance* (Fig. 1.38).

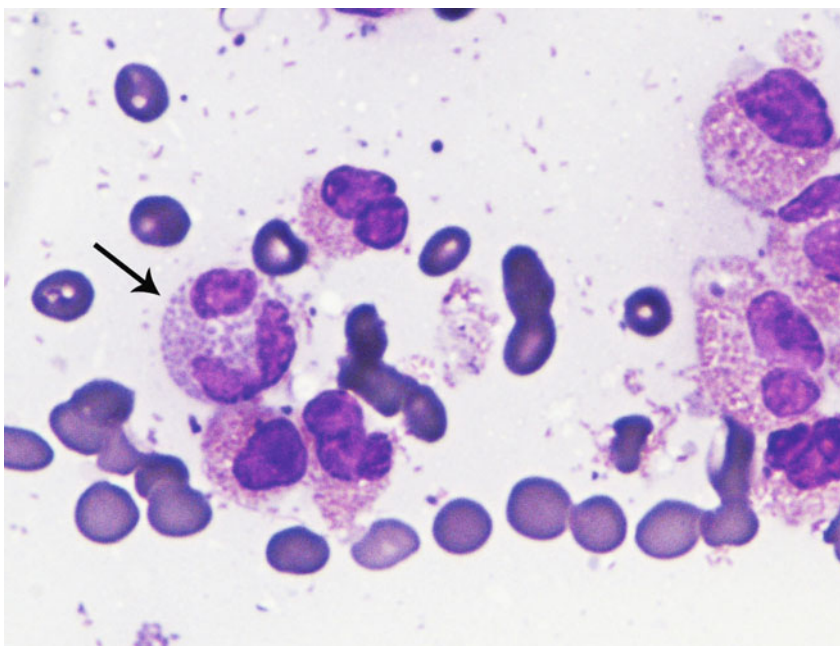


Fig. 1.35 Cytology of basophils: pale basophilic granules in the cytoplasm of a basophil granulocyte (arrow). Note the difference in colour (*bluish*) compared with those of eosinophils (*orange*)

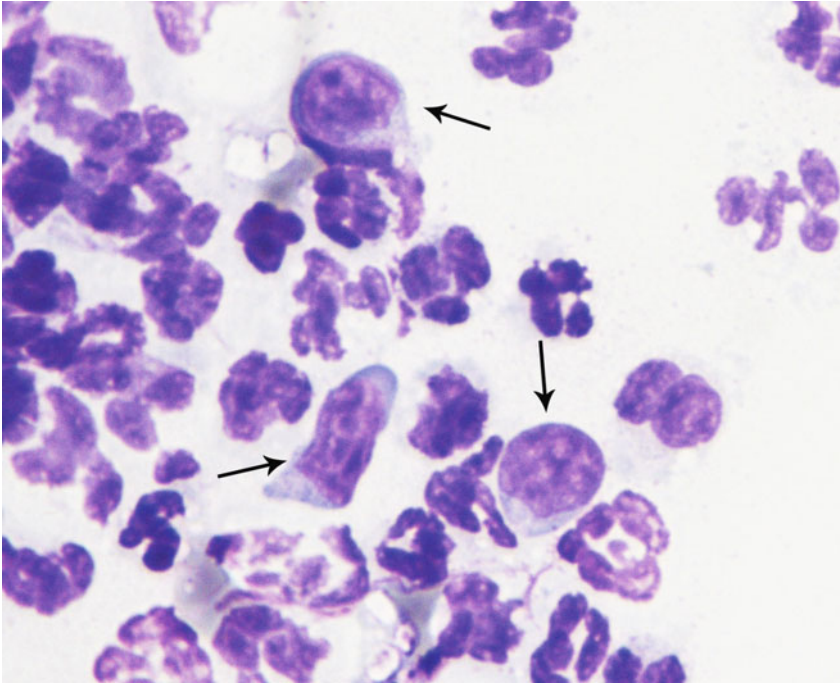


Fig. 1.36 Cytology of lymphocytes: lymphocytes are round cells with sparse, deeply blue cytoplasm and coarse chromatin (*arrows*)

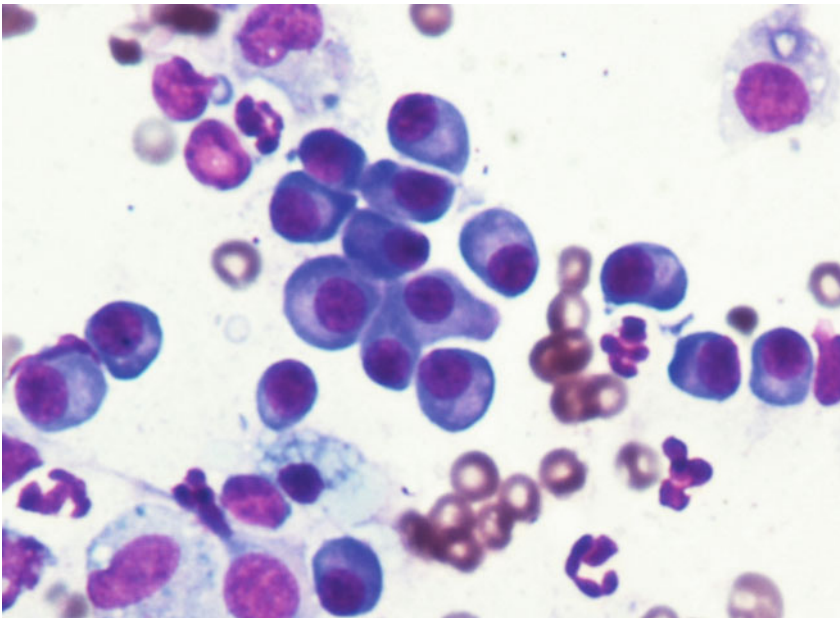


Fig. 1.37 Cytology of plasma cells: the cells are oval to roundish with eccentric nuclei, sparse, deeply blue cytoplasm and with a small achromatic area representing the Golgi apparatus

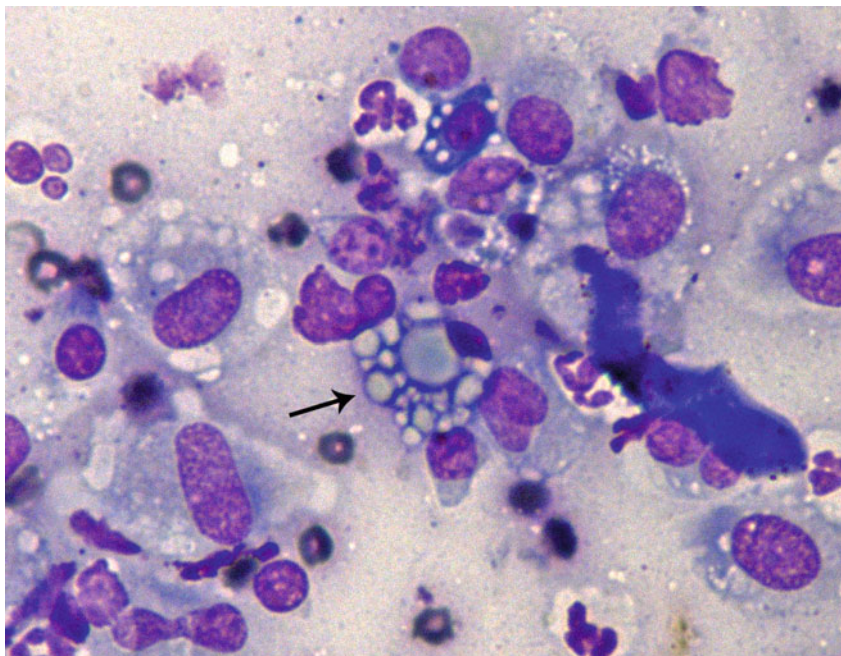


Fig. 1.38 Cytology of plasma cells: a Mott cell, filled with many Russell bodies, is immersed in a neutrophilic and macrophagic inflammation

1.5.7 Macrophages

Macrophages are histiocytic cells that represent the transformation in the tissue of circulating monocytes, which in turn, migrate into the dermis, to carry out their main function: *phagocytic activity*. Macrophages are the key cells of chronic inflammatory processes affecting various organs and systems, among them also the skin. The macrophages have an extremely variable morphology depending on the stage of activation: they are usually round, with a very high variability in size, with round-oval nuclei, centrally or eccentrically located, very often indented or with a characteristic kidney-shape and with regular chromatin and inconspicuous nucleoli. The cytoplasm may be scarce to very abundant, from pale grey to dark blue and, when activated, filled with vacuoles of different sizes (Fig. 1.39). As the main activity of the macrophages is the phagocytosis, cytoplasm can contain cellular debris, fragments of leukocytes, melanin pigment (melanophages), small foreign bodies and various infectious agents such as protozoa, fungi, mycobacteria etc. (Fig. 1.40). In the case of haematoma or haemorrhagic lesions, erythrophagocytosis is usually observed and the cytoplasm of macrophages can contain products of heme degradation such as *haemosiderin* and *haematoidin*; the first is a black material of granular appearance, the latter yellow-orange rhomboid crystals (Fig. 1.41).

In *granulomas* or when large microorganisms are present, in addition to the presence of voluminous foreign bodies that macrophages cannot eliminate, the latter can transform itself into larger round cells, with round to oval and often indented nucleus and basophilic cytoplasm. This particular morphology is similar to that of the epithelial

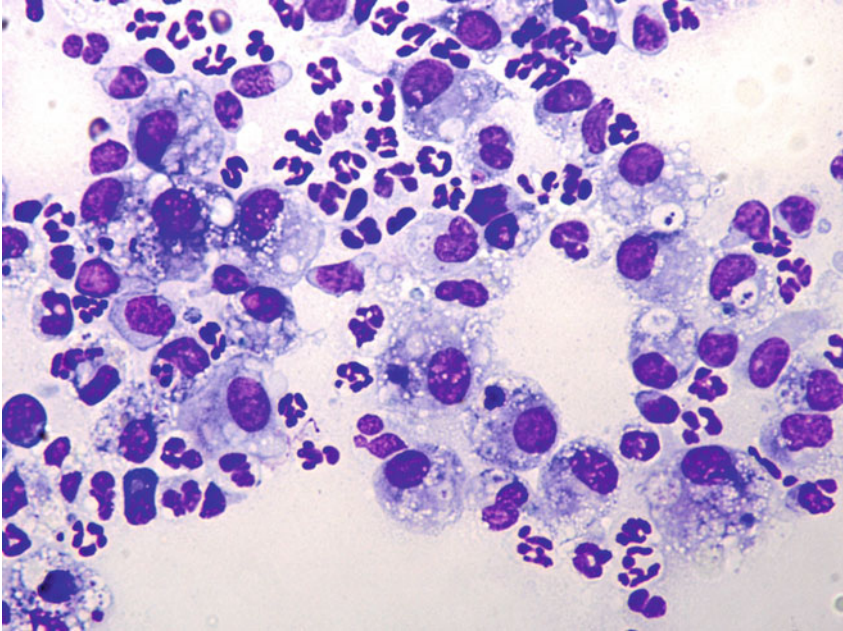


Fig. 1.39 Cytology of macrophages: many macrophages of different sizes and with strongly vacuolated cytoplasm

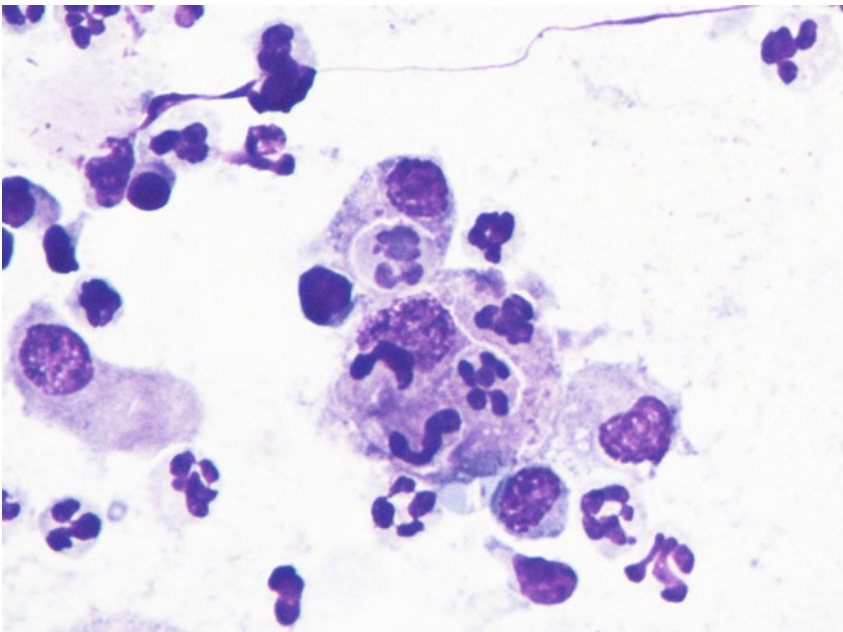


Fig. 1.40 Cytology of macrophages: macrophages with cytoplasm filled with neutrophils at different degrees of degeneration (leukophagocytosis)

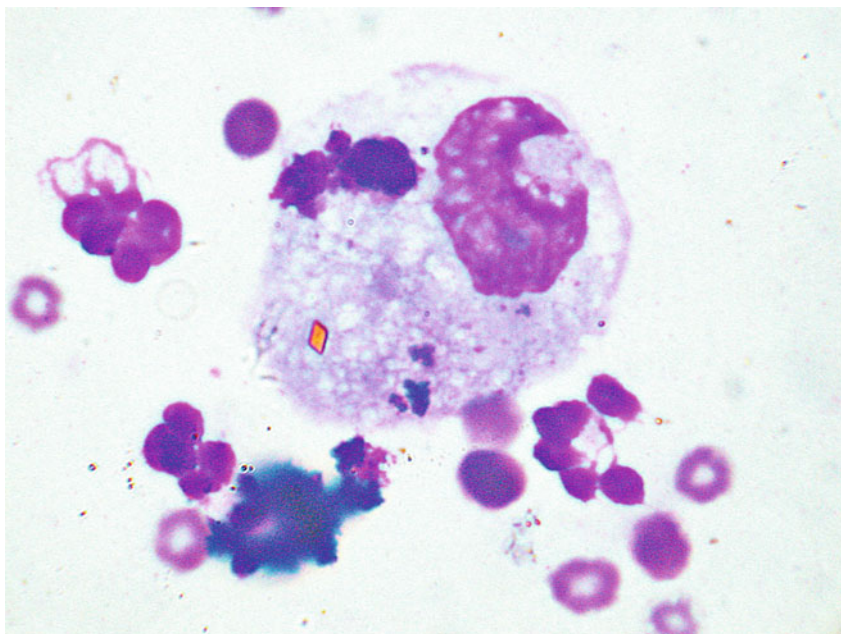


Fig. 1.41 Cytology of macrophages: a haematoidin crystal is clearly recognisable as a yellow–orange rhomboid formation

cells and, therefore, these macrophages are called *epithelioid cells*. In many cases, epithelioid cells can assume an unequivocal spindle shape, which must not be confused with spindle mesenchymal cells such as fibroblasts. These cells tend to be arranged both individually and in groups around large foreign bodies (e.g. corneocytes), forming epithelial-like arrangements, as is commonly observed in the case of furunculosis (Fig. 1.42). In association with epithelioid macrophages, some macrophages can transform into *multinucleated giant cells*. The mechanism underlying the formation of these cells, also called *foreign body cells*, is not entirely clear and two theories dominate this field: the first theory is that different cells fuse, the second one states that giant cells arise as a consequence of incomplete mitosis, in which occurs karyodieresis but not cytodieresis. The giant cells are very large and are characterised by a multiple number of nuclei ranging from three to over 50 (Fig. 1.43). As they have phagocytic activity, foreign substances (keratinocytes, hair shafts, mineral salts) and infectious microorganisms (especially fungi and protozoa) can be found in their cytoplasm.

The nuclei of giant cells can be haphazardly distributed in the centre of the cell or arranged at the periphery in a *horseshoe shape*. The former giant cells are named *foreign body cells* and are those most frequently observed in skin cytology when an exogenous material is present. The second type of giant cells, named *Langhans cells*, are rarer and typically observed in *immunological* diseases linked to fungal infection, mycobacteriosis or in all cases of a granulomatous reaction.

Many multinucleated reactive histiocytic cells are also stimulated from some malignant neoplasms such as in the case of anaplastic sarcomas. Care must be taken not to confuse these cells with those neoplastic cells observed in many anaplastic sarcomas

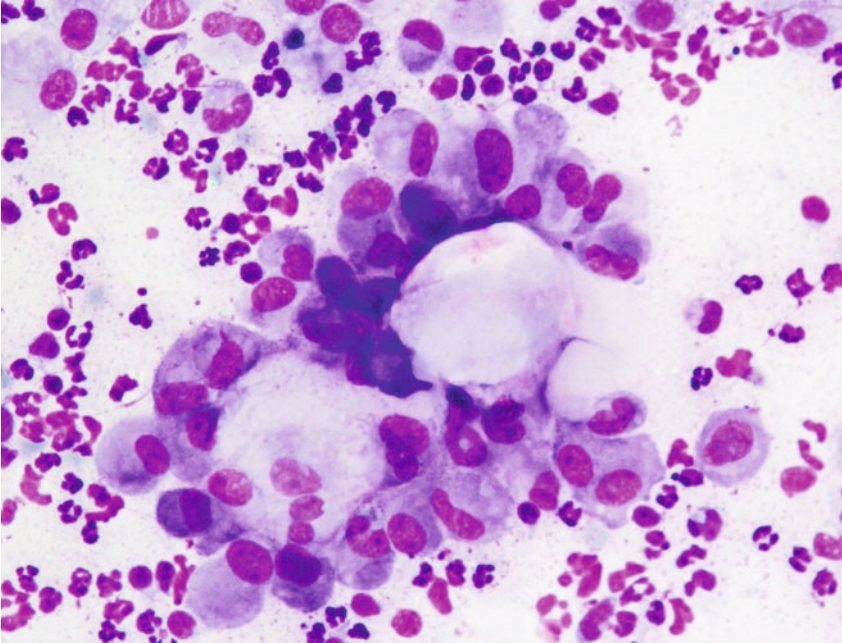


Fig. 1.42 Cytology of epithelioid macrophages: many epithelioid cells, arranged around keratinocytes

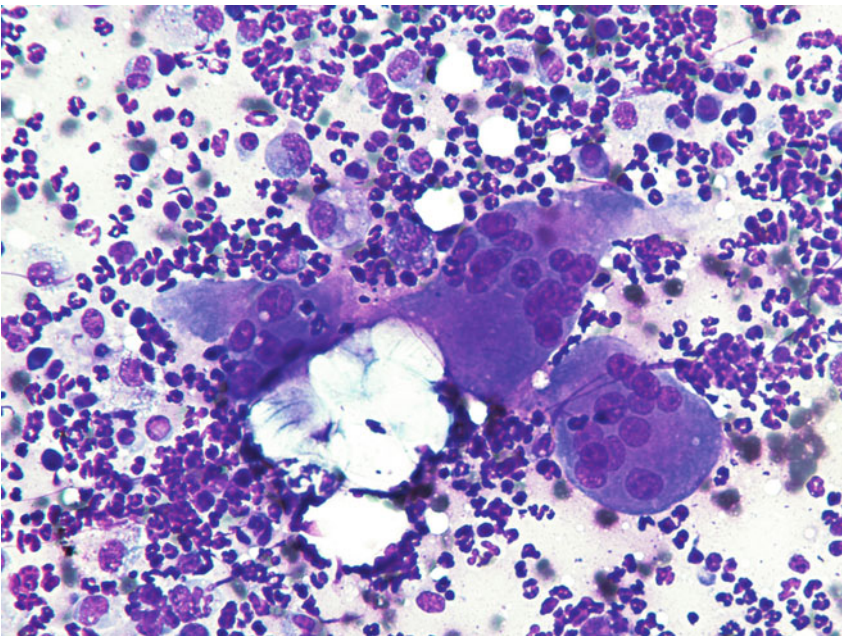


Fig. 1.43 Cytology of giant cells: many roundish and spindled histiocytic multinucleated cells (giant cells), in the attempt to eliminate a large foreign body represented by cluster of corneocytes

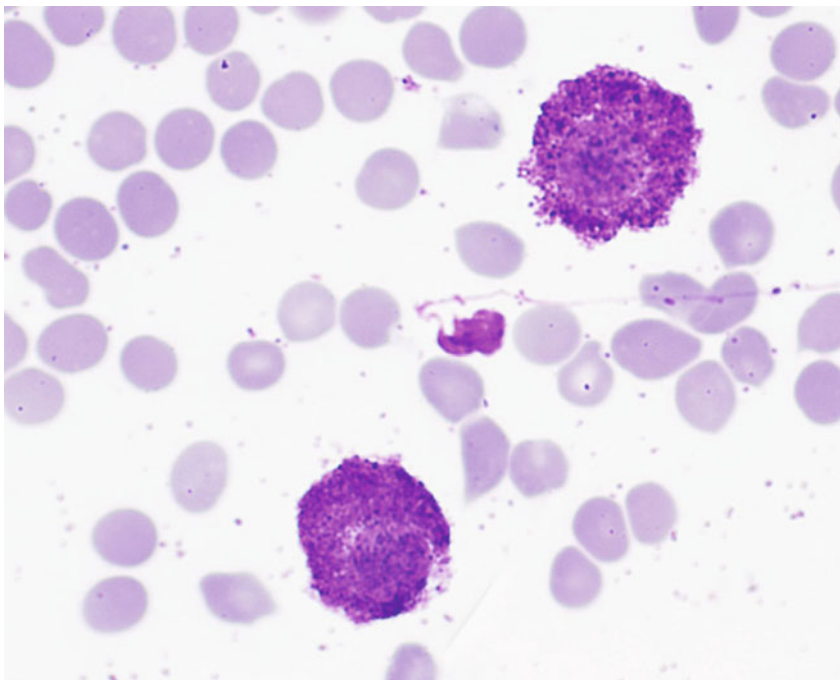


Fig. 1.44 Cytology of mast cells: numerous intracytoplasmic purple granules characterise the well-differentiated mast cells

with a large number of giant cells. An important cytological difference is that in neoplastic cells, the nuclei are often of different sizes and can show many atypia (irregular profile, macronucleoli, multiple nucleoli), whereas in histiocytic inflammatory giant cells the nuclear size is uniform, with regular chromatin and inconspicuous nucleoli. These differences are not always respected, as it is possible to observe inflammatory cells with different sized nuclei; therefore, the interpretation of such cells must be assessed based on the clinical signs and above all, on the coexisting cell population.

1.5.8 Mast Cells

Mast cells originate from the bone marrow precursors that migrate through the bloodstream and reach the dermis, where they turn into *mast cells* and become a resident cell of the connective tissue mainly located around vessels. Mast cells especially intervene in hypersensitivity diseases. Morphologically, they are discrete round cells, with central round nuclei, often completely obscured by the presence of numerous intracytoplasmic metachromatic granules that, with the rapid Romanowsky dyes, take on a distinctive purple colour (Fig. 1.44). The number of mast cells in inflammatory processes is always poor, although it is possible to find a high amount of cells in cytological samples taken from the skin of cats with eosinophilic diseases.

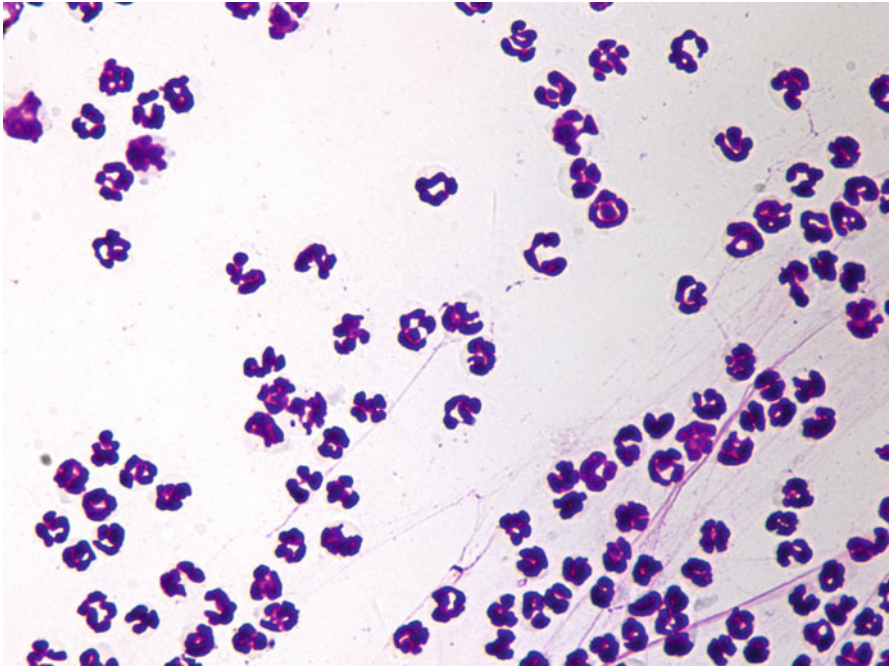


Fig. 1.45 Cytology of neutrophilic inflammation: the totality of the observed cells is composed of segmented neutrophils

1.6 The Inflammatory Patterns

The combination of the above-mentioned cell types gives rise to so-called *inflammatory patterns*, which allow, when interpreted in the light of the clinical lesions, a diagnosis of the disease to be obtained; if not diagnostic, the cytological findings can direct clinicians towards the selection of further tests to perform. A brief description of the four major inflammatory patterns observed in the skin cytology of dogs and cats is discussed below, and the inflammatory diseases of the skin are exhaustively discussed in the third chapter.

The four inflammatory patterns are: *neutrophilic*, *neutrophilic and macrophagic* (sometimes named *granulomatous* or *pyogranulomatous*), *eosinophilic* and *lymphoplasmacellular*.

1.6.1 Neutrophilic Inflammation

Neutrophilic inflammation is one of the most common patterns observed in skin cytology, in which the predominant cell is the *neutrophil*. The percentage of neutrophils is far higher than that of other cells present in the sample, even reaching more than 90% of the whole cell population (Fig. 1.45). This type of inflammation is also

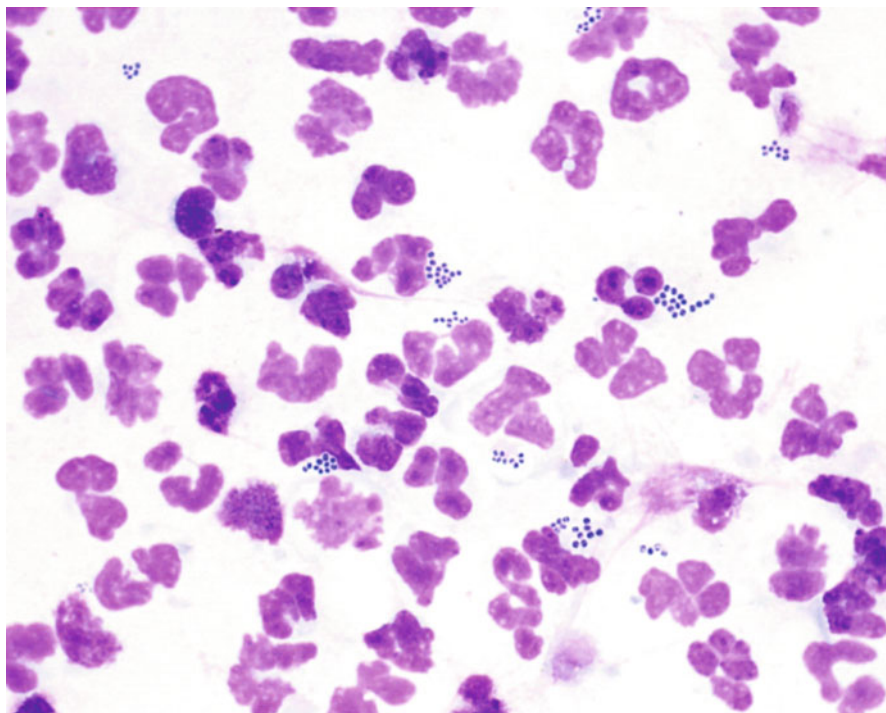


Fig. 1.46 Cytology of neutrophilic *suppurative* inflammation: severely karyolytic nuclei in the course of staphylococcal pyoderma

commonly defined as *purulent* or *suppurative*. There is confusion regarding the terms *purulent* and *suppurative*; for some, the terms are interchangeable, whereas others, including the author, believe that it would better to reserve the term *suppurative* for the septic inflammations composed of karyolytic neutrophils and bacteria (Fig. 1.46). Therefore, the term *purulent* does not necessarily indicate a bacterial aetiology, as a high presence of neutrophils (pus), can also be found in sterile processes such as some pustular immune-mediated/autoimmune diseases (pemphigus foliaceus or sub-corneal pustular dermatitis) or in rare pustular forms associated with canine leishmaniasis (Fig. 1.47).

1.6.2 Neutrophilic and Macrophagic (Granulomatous/Pyogranulomatous) Inflammation

Neutrophilic and macrophagic inflammation is characterised by the simultaneous presence of the two cell populations, which are present in variable percentages in specimens. In some cases, the histiocytic component is equal to or greater than the neutrophilic one, as occurs in some infectious diseases such as mycobacteriosis or some forms of deep mycosis. In some cases, in addition to macrophages, it is

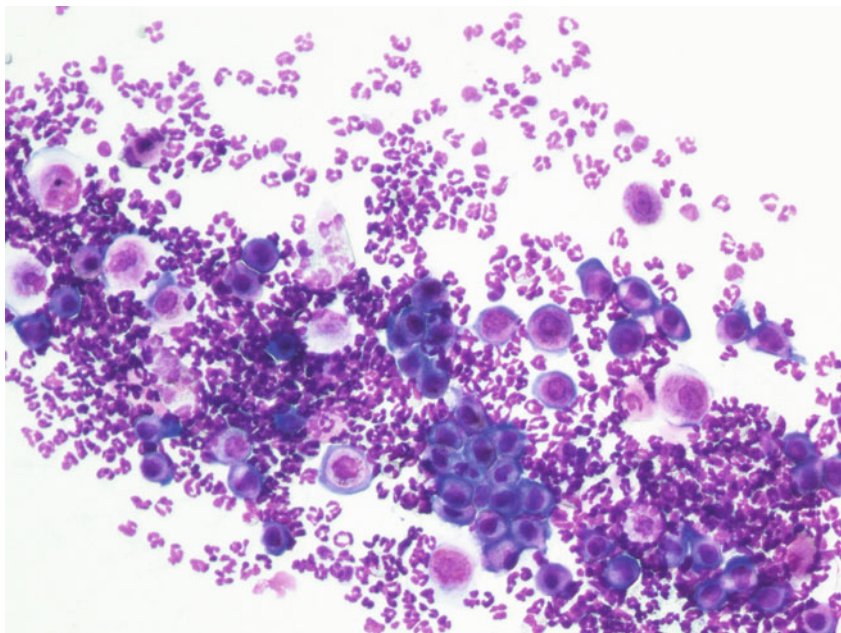


Fig. 1.47 Cytology of sterile neutrophilic inflammation in the course of pemphigus foliaceus: many segmented neutrophils with numerous acantholytic keratinocytes

common to find a variable number of *epithelioid macrophages* and *giant histiocytic cells*, which authorises the cytologist to adjectivise the inflammatory process with the term *pyogranulomatous inflammation*, as both cells are indicative of granuloma (Fig. 1.48). When speaking of terminology, it must be highlighted that the detection of only neutrophils and macrophages does not authorise us to define the inflammatory pattern as *pyogranulomatous*, because such cells can be distributed diffusely in the tissues and not necessarily organised as a granuloma (Fig. 1.49).

Granulomas are in fact always histologically characterised by the presence of *epithelioid macrophages*, with or without *giant cells* (foreign body giant cells or Langhans-type giant cells). In practice, the term *pyogranulomatous inflammation* should be reserved for cases in which epithelioid macrophages are detected. The term *naked granuloma* means a granuloma in which neutrophils are almost absent and, in these cases, the inflammatory process can be cytologically defined as *granulomatous*.

This inflammatory pattern, characterised by a variable percentage of neutrophils, macrophages, epithelioid macrophages and giant cells, can be caused by many different infectious and parasitic diseases, whose causes include bacteria (deep staphylococcal pyoderma and mycobacteriasis), fungi (dermatophytosis, phaeohyphomycosis and cryptococcosis), protozoa (leishmaniasis) and parasites (demodicosis); nevertheless, many sterile diseases, such as cellulitis or panniculitis (juvenile cellulite and sterile nodular panniculitis), reactions to foreign bodies (endofollicular keratin of hair shaft fragments) and accumulation of fat or of mineral salts in the

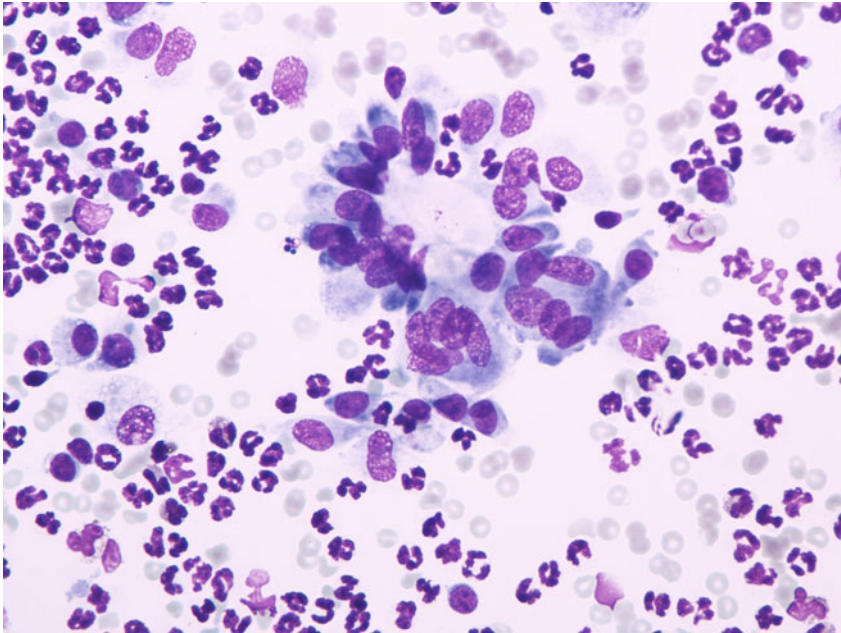


Fig. 1.48 Cytology of granulomatous inflammation: many epithelioid macrophages and giant cells, which attack a large aggregate of corneocytes, are indicative of a granulomatous lesion

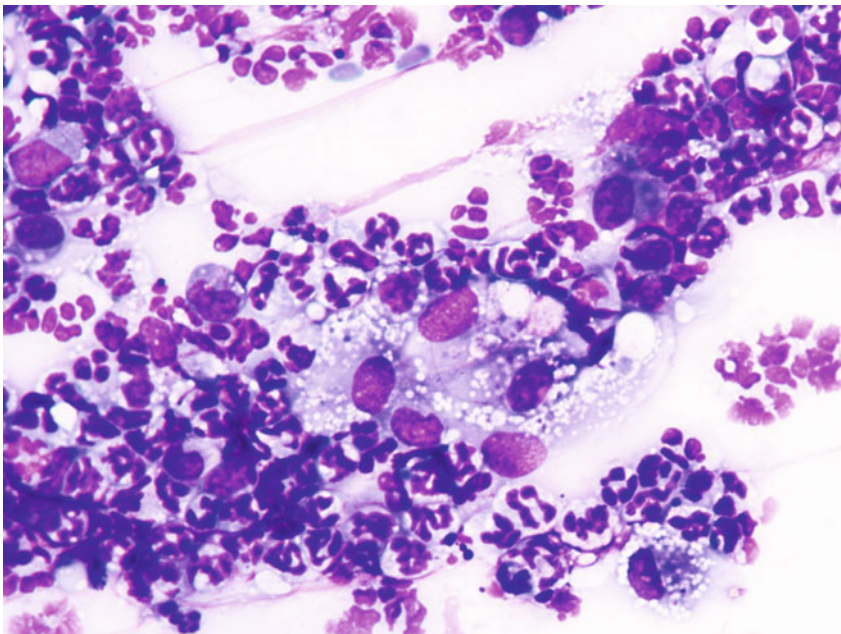


Fig. 1.49 Cytology of neutrophilic and macrophagic inflammation: segmented neutrophils and vacuolated macrophages collected from a sterile lesion

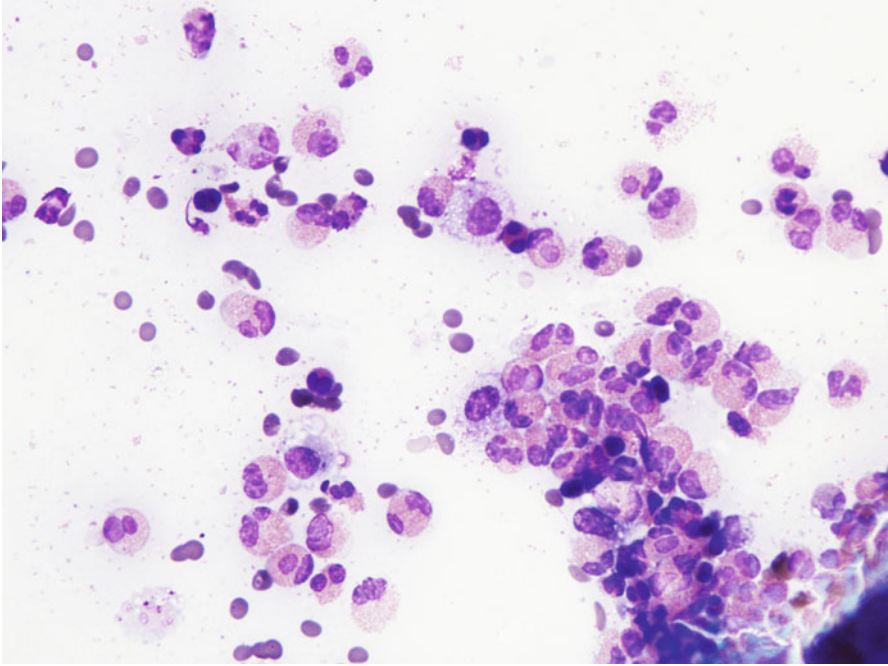


Fig. 1.50 Cytology of eosinophilic inflammation: many eosinophils with rod-shaped granules sampled from a feline eosinophilic disease

dermis (xanthomatosis and cutaneous calcinosis), are able to evoke pyogranulomatous inflammation.

1.6.3 Eosinophilic Inflammation

Eosinophils are present in a variable number in many inflammatory processes, usually in association with other different types of cells such as neutrophils, macrophages, lymphocytes and, especially in cats, mast cells. When the number of eosinophils is very high so as to exceed that of the other cells, the inflammatory process is defined as eosinophilic (Fig. 1.50). *Eosinophilic inflammation* is very common in cats, considering the frequency of so-called *feline eosinophilic diseases* (eosinophilic granuloma complex, miliary dermatitis, mosquito bite hypersensitivity), whereas it is much less common in dogs (eosinophilic granuloma and facial eosinophilic furunculosis).

Unlike to what was formerly believed, not only parasitic or allergic diseases are able to evoke the presence of eosinophils in the tissues; in fact, other diseases such as pemphigus foliaceus and skin localisation of feline herpesvirus can be characterised by a high amount of eosinophils.

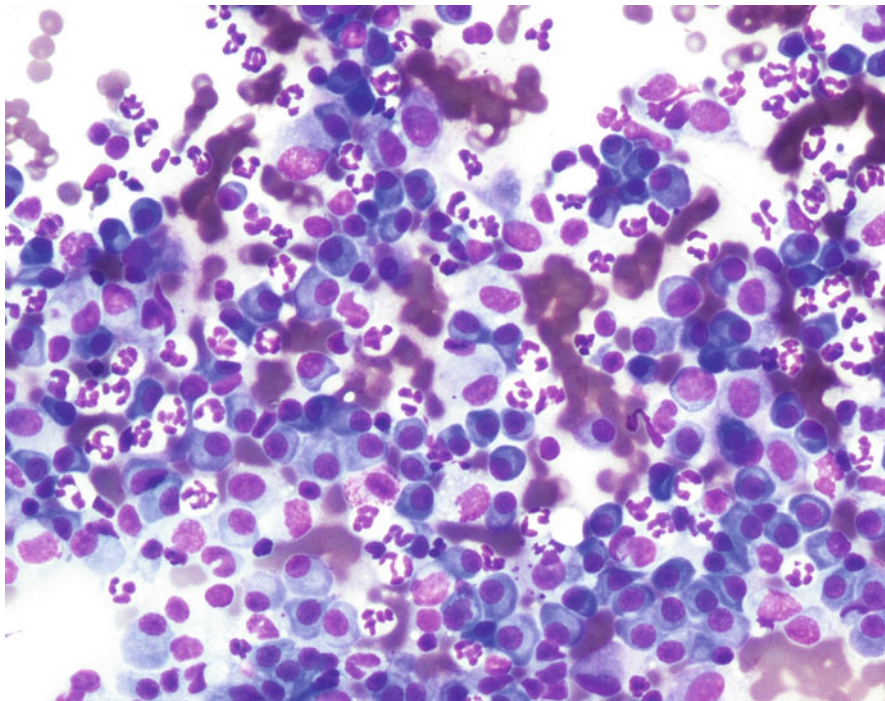


Fig. 1.51 Cytology of lymphoplasmacellular inflammation: many plasma cells and some histiocytic cells from a chronic inflammatory skin lesion

Finally, it should be stressed that eosinophils frequently infiltrate some mast cell tumours, especially in dogs. Their presence is of great help in suspecting a mastocytoma when neoplastic cells do not present the characteristic purple metachromatic granules, as happens in some undifferentiated tumours or, in the rare cases in which the granules do not stain with the rapid Romanowsky dye.

1.6.4 Lymphoplasmacellular Inflammation

Skin diseases characterised by pure *lymphocytic* and *plasma cells inflammation* are rare in dogs and cats; nevertheless, a relevant number of lymphocytes and plasma cells are commonly detected on slides sampled from chronic skin lesions (Fig. 1.51). Their presence is usually only indicative of a chronic, persistent, non-specific antigenic stimulus.

These cells characterise the feline *lympho-plasmacellular pododermatitis*, an immune-mediated disease that affects cats and is characterised by dermal inflammation rich in lymphocytes and plasma cells. A high number of these cells can also be observed in specimens collected from inflammatory lesions located at the mucocutaneous junctions. Many lymphocytes and plasma cells, in addition to many histiocytic cells, are very often observed in many cases of canine leishmaniasis. In these cases the inflammatory pattern can be defined *histio-lympho-plasmacellular*.

Chapter 2

Techniques of Sampling, Preparation and Staining of Cytological Specimens

2.1 Introduction

There are many skin lesions and they differ from one another morphologically. Papules, pustules, epidermal collarettes, scales, erosions, ulcers, plaques, nodules and swellings are clinically easy to recognise. Some of these lesions may be present simultaneously in the same patient, representing different stages of the same disease or clinical signs of different coexisting diseases.

Cytology is one of the fastest, most inexpensive and easy to perform of the diagnostic techniques available. As with all diagnostic tests, the quality of the specimens is basic for correct interpretation; even if more than one sampling technique can be performed from the same lesion, there is always one that is most suitable, offering more guarantees of obtaining a representative sample. This chapter discusses the sampling methods in canine and feline skin cytology. Starting from clinical lesions, the reader is provided with fundamental information for a correct preparation and staining of slides.

Based on the above, the execution of a correct cytological sampling cannot disregard three basic steps:

- (a) *The choice of the lesion to be sampled*
- (b) *The choice of the sampling method most suitable for that particular lesion*
- (c) *Proper preparation of the slide*

2.2 Sampling Techniques

In practice, the most commonly used sampling techniques include the *impression smear*, the *fine needle biopsy*, with or without aspiration, and the *scraping* (Raskin and Meyer 2015; Valenciano and Cowell 2014).

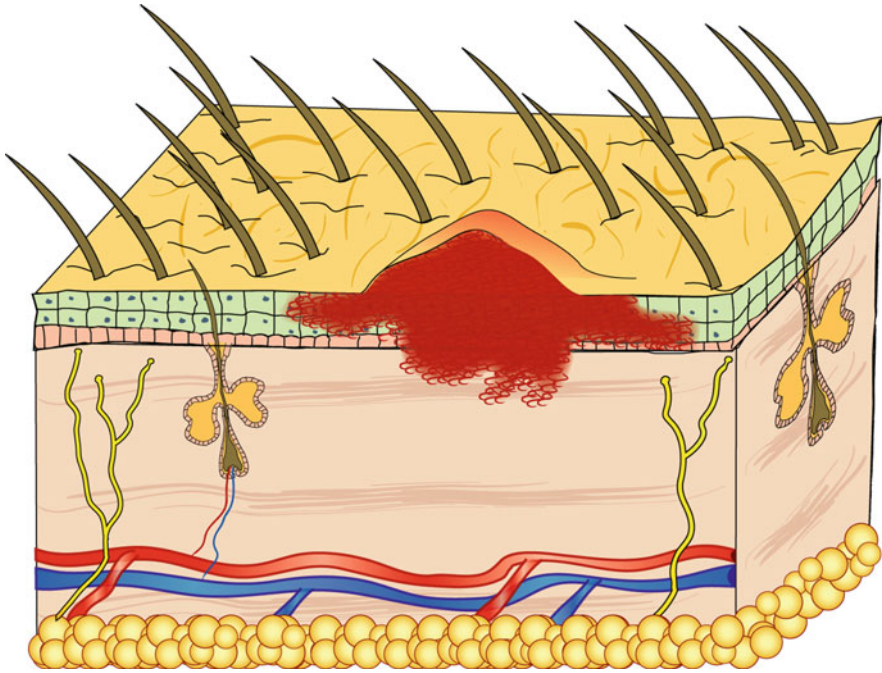


Fig. 2.1 Schematic representation of a papule

2.2.1 Impression Smears

The *impression smear* is the only executable method we can perform when cells must be sampled from non-raised, superficial “wet” (exudative) lesions. This technique is frequently used because with this method, it is possible to collect cells simply by placing a slide on the lesion. As the cells easily adhere to the slide, it is sufficient to gently place it on the lesion without exerting excessive pressure, which could alter the cell morphology. Nevertheless, there are some basic precautions that differ according to the lesion that must be investigated. The skin lesions from which cells can be obtained using the impression smears technique are numerous and are covered below.

2.2.1.1 Cytological Sampling from Papules

Papules are small, solid, raised and palpable primary lesions, usually erythematous, smaller than 1 cm (Figs. 2.1 and 2.2). Histopathologically, papules are composed of inflammatory or, exceptionally, neoplastic cells, located in the superficial dermis and usually cause a slight hyperplasia of the overlying epidermis. Intra-epidermal exocytosis of inflammatory cells or small ulceration of the epidermis, the latter

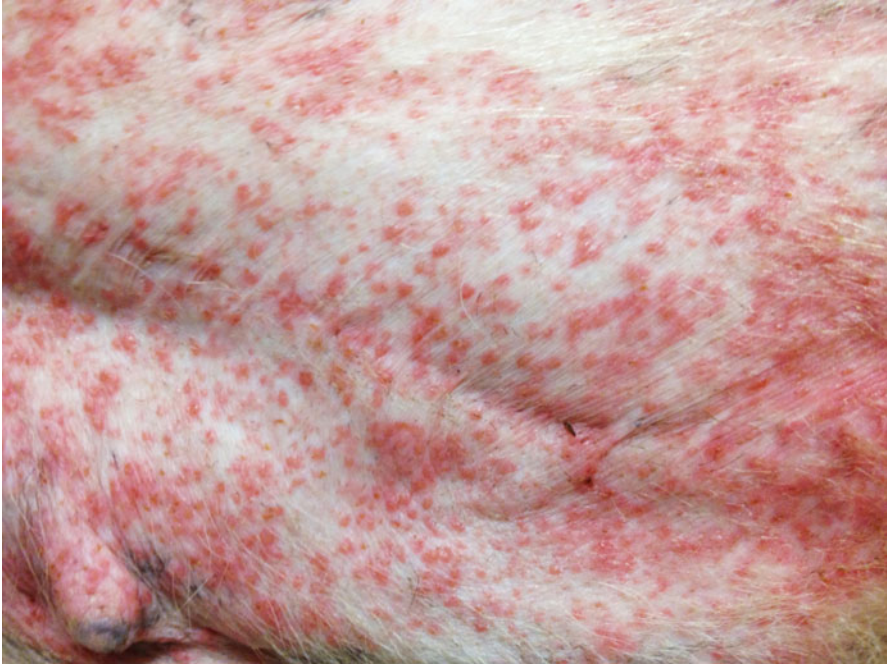

Fig. 2.2 Multiple erythematous papules on the abdomen of a dog with superficial pyoderma

often located on the top of the papule, cause discharge of a small amount of exudate that, once dehydrated, gives rise to a small crust (Fig. 2.3). These types of lesions are called *crusted papules* and are frequently observed in cats with miliary dermatitis and in dogs with scabies.

Papules with an intact surface are too small for FNB and cells cannot be collected using the imprint technique; therefore, only the papular crusted lesions permit the collection of a few cells using this method.

Some dermatologists use the term *nodular papule* to describe a lesion that is raised and round in shape, which is of intermediate size between a papule and a nodule. Nodular papules are less than 1 cm and even if they can sometimes slightly exceed this size, they do not appear large enough to justify the definition of nodules (Fig. 2.4). These lesions, compared with papules, provide more diagnostic specimens, because through FNB they can supply sufficient cells.

The author prefers to treat the cytological findings of papular nodular lesions separately from those of papules, as he believes that the former are characteristic of some skin diseases and for this reason, deserve a more detailed cytological description.

Sampling Technique

In general, *papules* do not yield many cells, but, in some cases, even the few cells collected may be useful in the interpretation of the lesions.

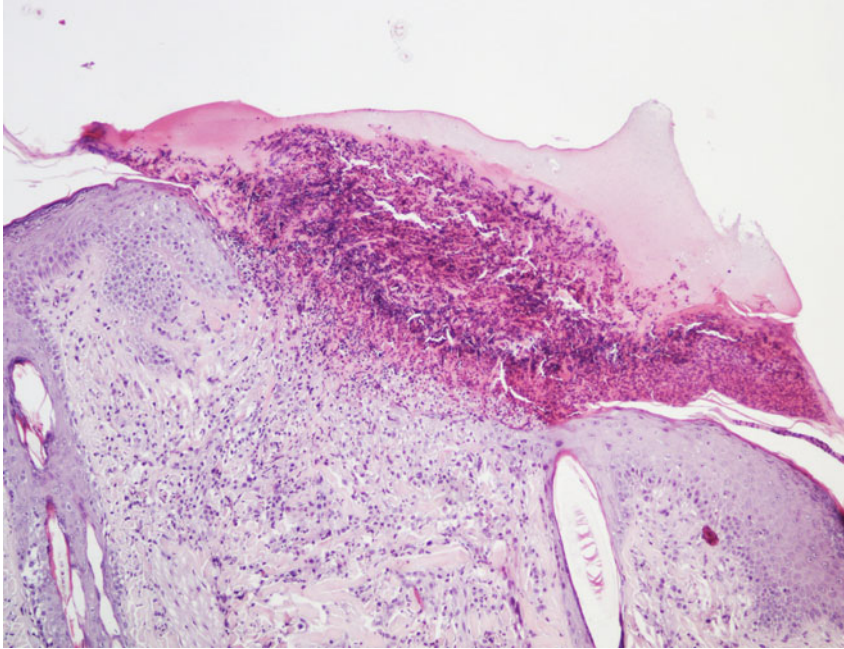


Fig. 2.3 Histology of a crusted papule: note the crust covering the ulcer

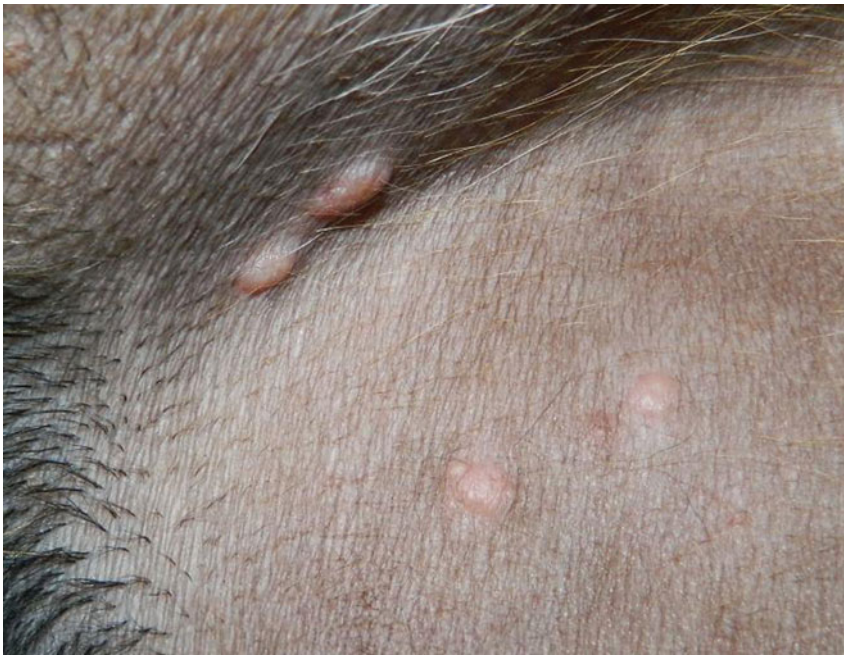

Fig. 2.4 Papular nodules in a dog with the papular form of leishmaniasis

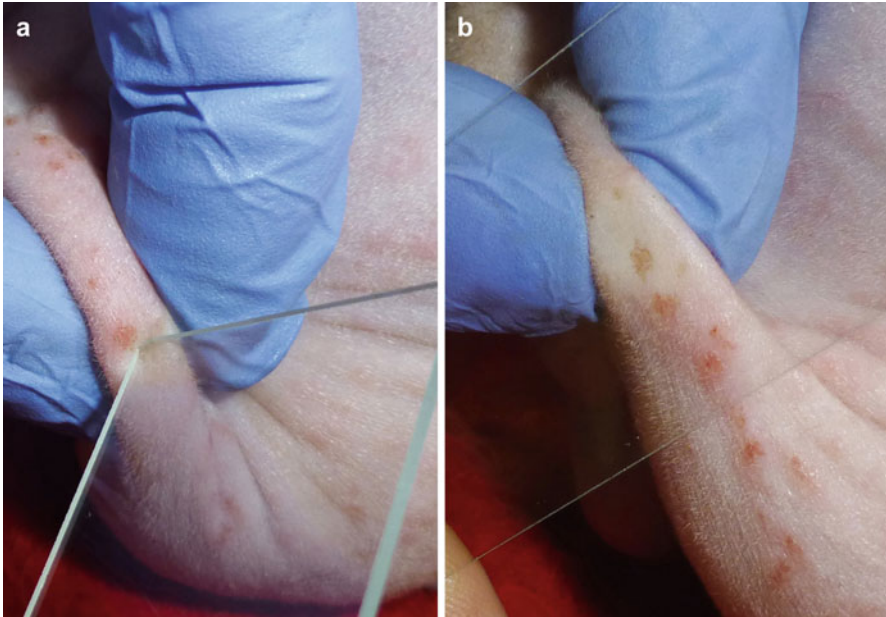


Fig. 2.5 (a) Removal of a crust with a slide, (b) placing the slide onto the exposed exudate

In the case of papules with an intact epidermis, the collection of cells is not possible using an impression smear. When the papules ulcerate or when spongiosis promotes the leukocytic exocytosis through the epidermis, it is possible to collect some cells by gently placing a slide on top. To collect cells from *crusted papules*, the superficial crust must be removed before placing the slide on the exposed exudate (Fig. 2.5). In the case of *nodular papules*, it is possible try collecting cells via FNB using a small needle (23 G), a technique that will be discussed later.

2.2.1.2 Cytological Sampling from *Pustules*

Pustules are raised, soft, yellowish, intra-epidermal or intra-follicular skin lesions. The yellowish colour of the pustules is closely related to their content of granulocytes, both neutrophils and eosinophils, which are the main cells that comprise the purulent exudate (Figs. 2.6 and 2.7).

By definition, pus is an inflammatory exudate composed of karyolytic neutrophils, necrotic debris and bacteria; according to this definition, the term pus should only be used to describe the content of pustules from pyoderma. As there are many diseases that produce a *sterile* purulent exudate, the term *pus* should refer only to its granulocytic composition, and should not imply a bacterial infection.

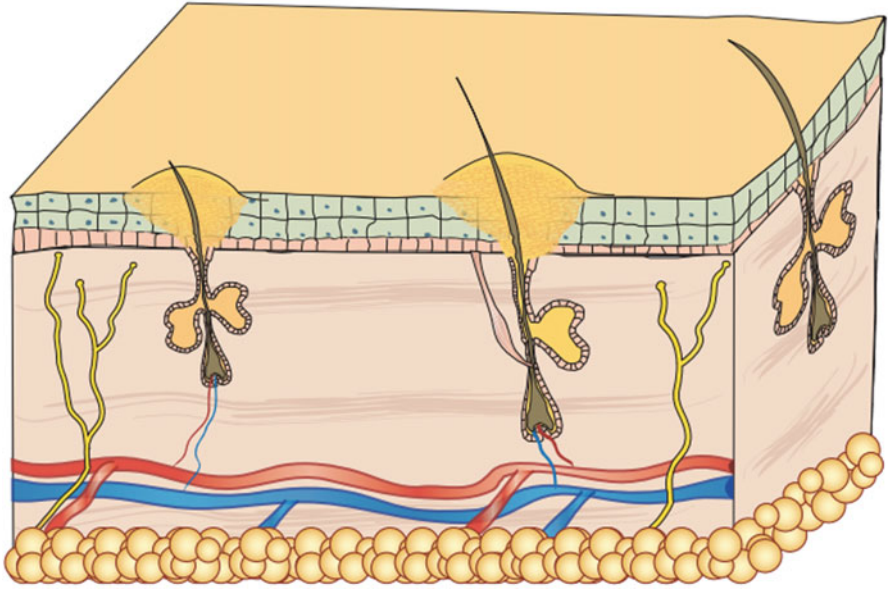


Fig. 2.6 Schematic representation of a follicular pustule

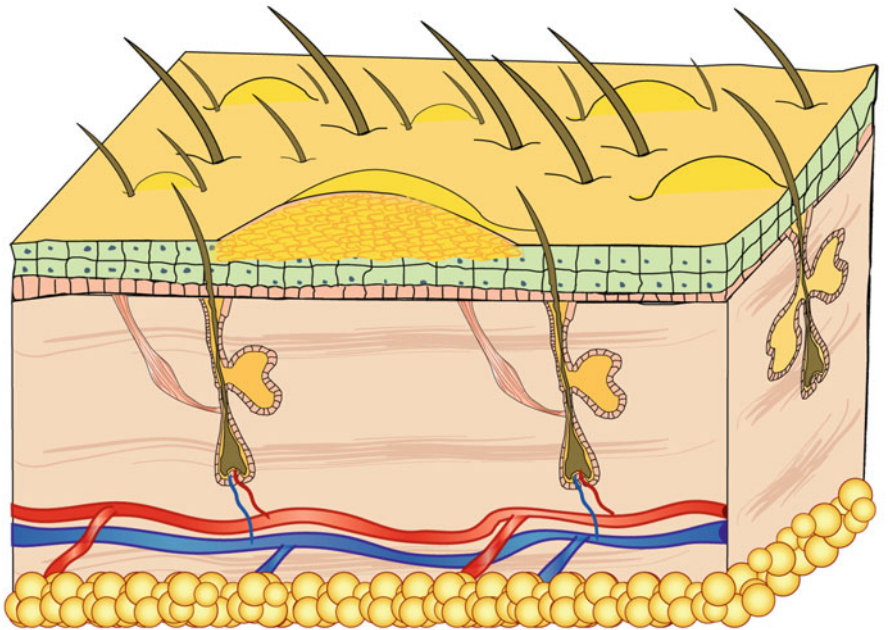


Fig. 2.7 Schematic representation of a non-follicular pustule

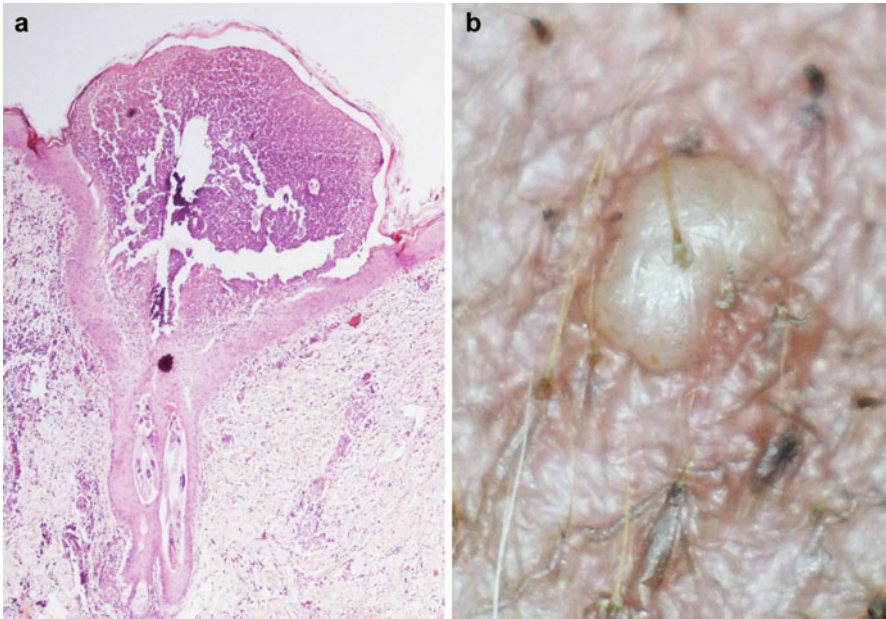


Fig. 2.8 (a) Histology of a follicular pustule: note how the pustule is located on the centre of the follicle; (b) clinical aspect of a follicular pustule: a hair shaft emerges from the centre of the pustule

In addition to granulocytes, pustules may contain other cell types (keratinocytes), microorganisms (bacteria), parasites (*Demodex* spp.) etc.. The detection of these components in cytological samples provides important diagnostic clues.

Clinically, pustules can be divided into *follicular* and *non-follicular*. *Follicular pustules* are characterised by pus located in the follicular lumen and are clinically recognisable by their small size and by a hair shaft protruding from its centre. As follicular pustules are very small, they are always round and less than 1 cm in size (Fig. 2.8). The term *follicular pustule* is also used in histopathology to describe an intramural follicular sterile pustule, sometimes observed in pemphigus foliaceus. In these cases, the pustules are so small that they are not clinically detectable; thus, when a hair emerges from a pustule, infectious folliculitis should be suspected (Fig. 2.9).

In *non-follicular pustules*, pus is not present in the follicular lumen, but it is intra-epidermal and more frequently intra-corneal (Fig. 2.10). Depending on their extent, non-follicular pustules can be of variable size, round or irregular in shape. They may be small and localised between follicles or so large that they inevitably encompass many hairs, ranging from a few millimetres to over 2 cm (Fig. 2.11). The clinical aspect and localisation of pustules not only has a descriptive meaning, it may also help the clinician to better interpret the cytological results.

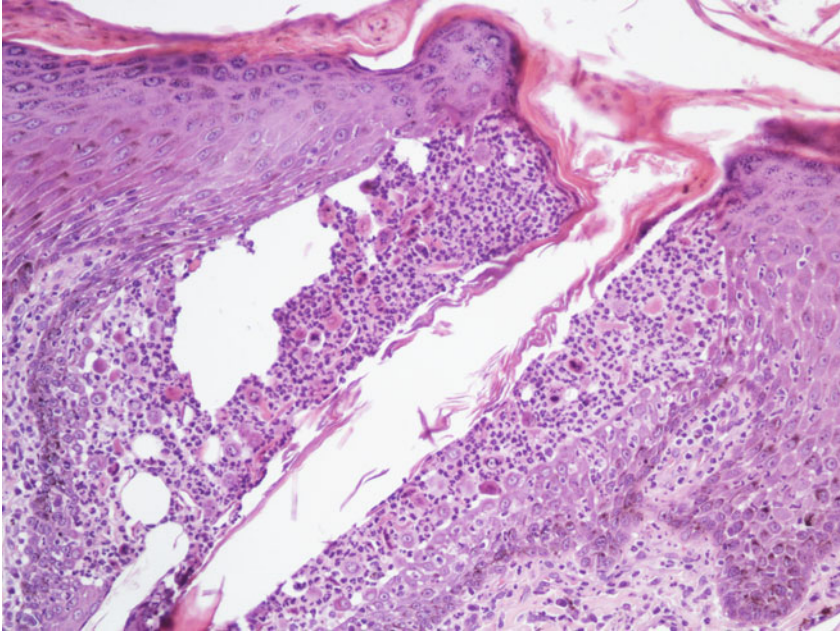


Fig. 2.9 Histology of two intramural acantholytic follicular pustules in course of pemphigus foliaceus. Note how the pustules are confined in the follicular wall and, as they do not emerge from the center of the follicle, they are not macroscopically evident

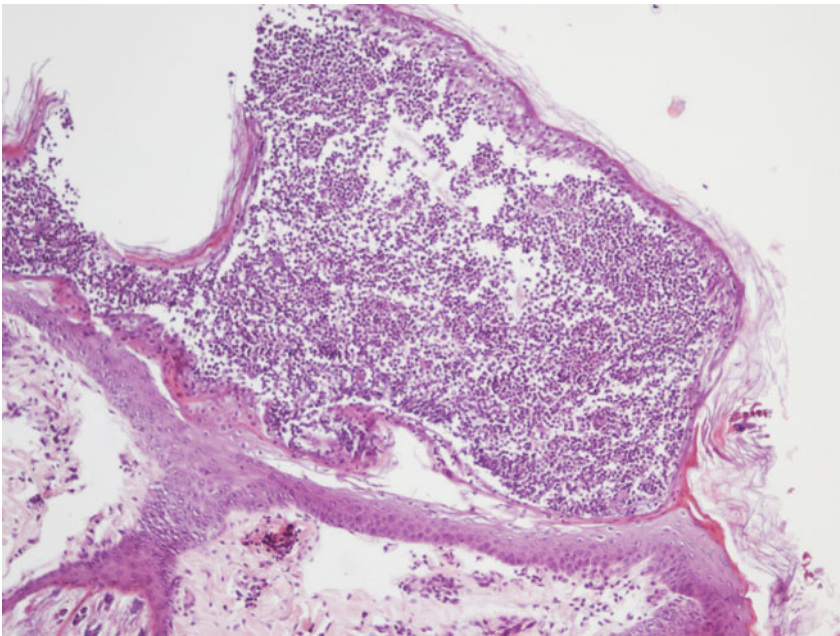


Fig. 2.10 Histology of a non-follicular pustule: note how the pustule does not involve the follicle

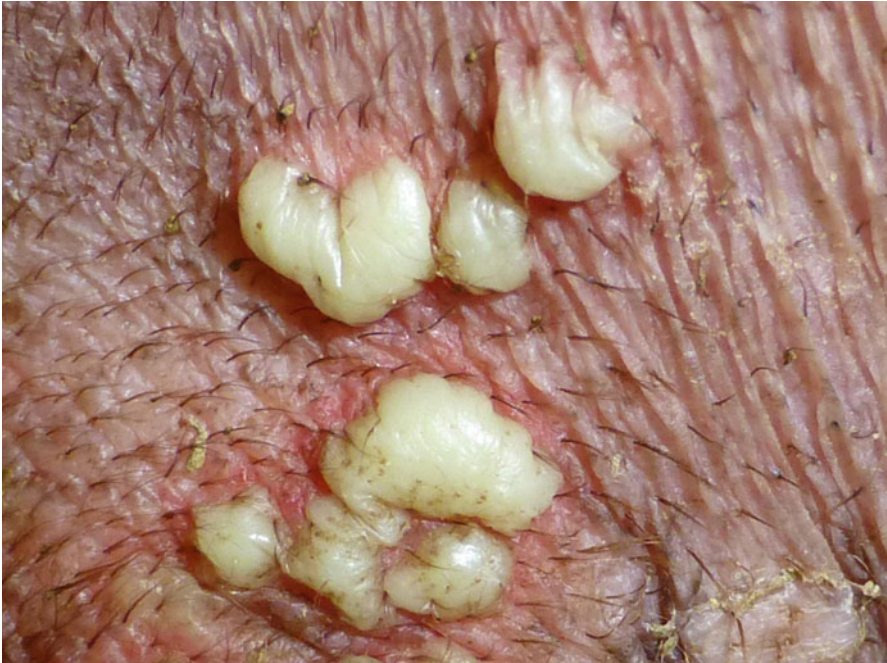

Fig. 2.11 Large and non-follicular pustules of irregular shapes in a dog with juvenile impetigo

Sampling Technique

Pustules may be the most important lesions in canine skin cytology, as they usually represent the direct action of a disease or a microorganism. In the case of large pustules, cells can be collected using the impression smear technique: breaking the base of the pustule with a fine needle and lifting the keratinocytes that form its “roof”. The pus is exposed and a sample can be taken by gently placing a slide. This method is a variant of the technique conceived by Dr. Arnault Tzanck, a French dermatologist who was a pioneer of diagnostic cytology in the early 20th century and for this reason, the technique is known as the *Tzanck test* (Fig. 2.12).

When pustules are very small, like follicular pustules, this method is very difficult to perform and the risk of penetrating the dermis with the needle and causing bleeding is very high. In these cases, the shorter part of the slide must be slightly and laterally pushed against the base of the pustule, allowing the pus to be transferred onto it (Fig. 2.13).

Once collected, the material must be gently smeared onto another slide and left to dry. Pustules tend to rapidly dehydrate and give rise to yellowish crusts or epidermal collarettes. In these cases, as described below, it is possible to obtain cytological specimens by collecting the exudate present below the crust at the edges of the collarettes.

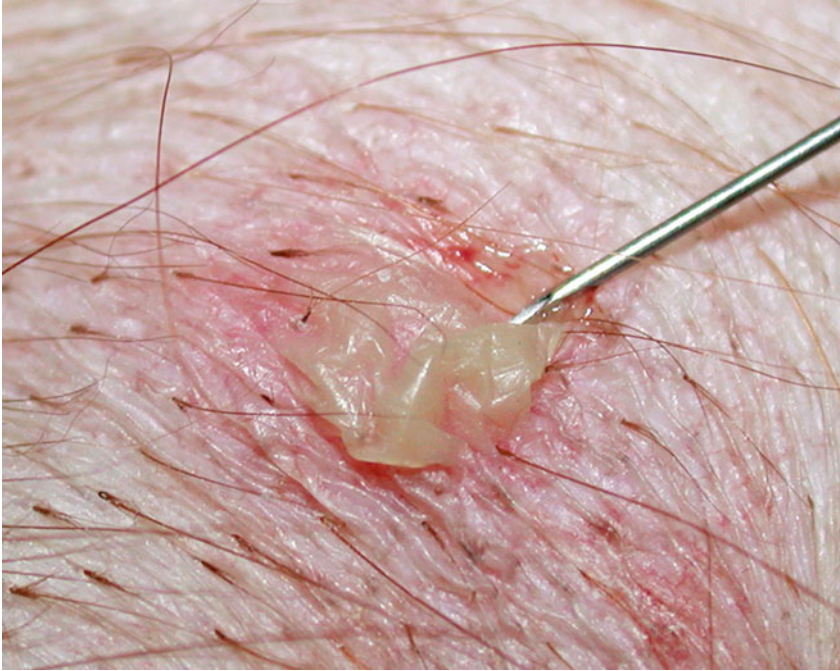

Fig. 2.12 The Tzanck test: rupture of a large pustule with a needle

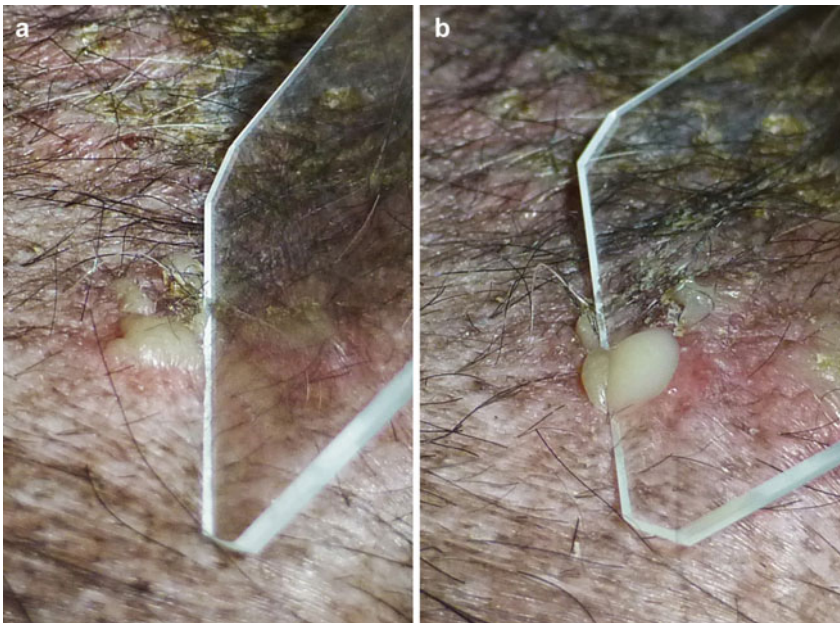


Fig. 2.13 (a) Lateral pressure placed on a small pustule with a slide; (b) the pus is transferred onto the slide

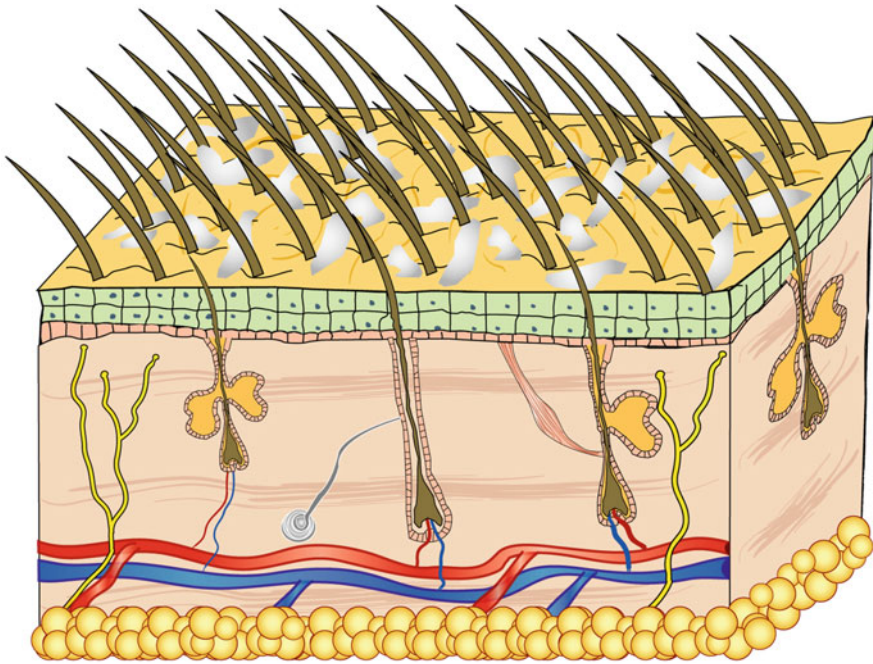


Fig. 2.14 Schematic representation of scales

2.2.1.3 Cytological Sampling from Intact Skin Covered with “Dry” or “Oily/Waxy” Scales

Scales are aggregates of corneocytes that represent the final product of the physiological keratinisation process of the epidermis and are continuously released into the environment, both singly and in small clusters (Fig. 2.14). When scales are visible to the naked eye, the clinical finding is described as *exfoliative* or *desquamative dermatitis*, which is observed in many canine and feline skin diseases. Scaling diseases recognise both *primary* and *secondary* causes; primary causes are usually linked to genetic or idiopathic disorders and in these cases, cytology has no diagnostic interest. Scales are also very common in secondary keratinisation defects, usually caused by infectious (leishmaniasis, dermatophytosis, pyoderma, *Malassezia* spp.), parasitic (demodicosis), and autoimmune diseases (pemphigus foliaceus), in addition to neoplasia (epitheliotropic lymphoma), whose cytology provides diagnostic information or can direct clinicians in selecting additional diagnostic tests.

Sampling Technique

Placing a slide onto an oily/waxy skin allows keratinocytes and different microorganisms present on their surface to be collected. In patients with dry scaly dermatitis, the impression smear technique does not permit the cells to adhere to the slide; in these cases, sampling requires the use of a piece of transparent acetate tape (Fig. 2.15). This method is very useful when searching for yeasts and dermatophytes,



Fig. 2.15 Many scales remain stuck to the adhesive acetate tape

but it can be used to collect any type of cell or parasite present on the skin surface, as will be discussed in the Chap. 3.

2.2.1.4 Cytological Sampling from *Erosions*

Erosions are superficial lesions characterised by the loss of the outer layers of the epidermis and do not involve the dermis (Fig. 2.16). Determining the integrity of the basement membrane is not always clinically possible, particularly when the erosion is deep and its base is composed only of the basal layer of the epidermis. Cytological examination confirms or rule outs an ulcer, based on the presence or absence of red blood cells respectively.

Epidermal collarettes are the most frequent erosive lesions observed in canine dermatology and are also more valuable for cytological examination. Collarettes are round erosion, with an erythematous or hyperpigmented central area and peripherally bordered by scales, in case of vesicles, or crusts in case of pustules (secondary lesions). As vesiculo-bullous lesions are extremely rare in pets and are mostly located at the dermal–epidermal junctions, rupturing them produces an ulcer; for this reason, almost all epidermal collarettes are secondary to dehydration and breakage of a pustule. Collarettes are very common in dogs because of the high frequency of superficial pyoderma in this species; indeed, these lesions are

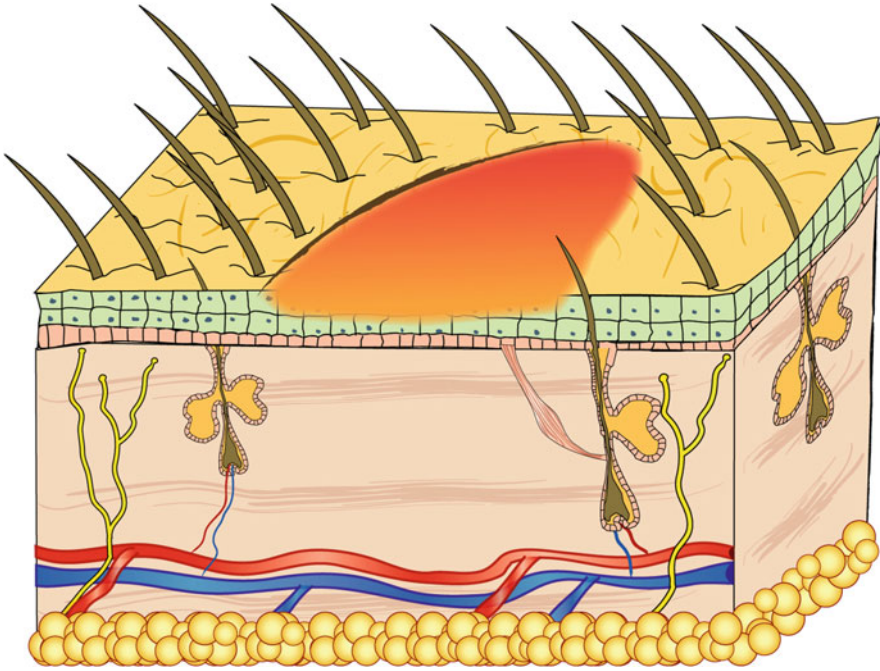


Fig. 2.16 Schematic representation of an erosion. Note how the lesion is located in the epidermis with no dermal involvement

frequently found in combination with papules and pustules. Rarely, epidermal collarettes are the only type of detectable lesion and, thus, the only lesion that can be sampled (Fig. 2.17).

In some dogs affected by so-called spreading pyoderma, the intra-corneal diffusion of the infection leads to the development of large and confluent, erosive, collarette-like lesions, which originate from a clinical presentation similar to exfoliative dermatitis. Less frequently, collarettes are observed in other pustular sterile diseases such as pemphigus foliaceus, in which cytology from collarettes could be very useful.

Sampling Technique

Because of their superficial location, erosions are flat and exudative lesions; therefore, placing a slide on their surface can provide the clinician with useful information. As for all lesions exposed to the external environment, cytological specimens obtained from collarettes using the impression smear technique must always be interpreted with caution. Clinicians must be aware of the ever-present possibility of the secondary contamination of specimens from both environmental bacteria and, in the case of excessive licking, the oral cavity (e.g. *Simonsiella* spp., rod-shaped and filamentous bacteria).

The collection of cells from epidermal collarettes is performed by lifting the crusts that delimit the lesion and placing a slide on the exposed fresh exudate.

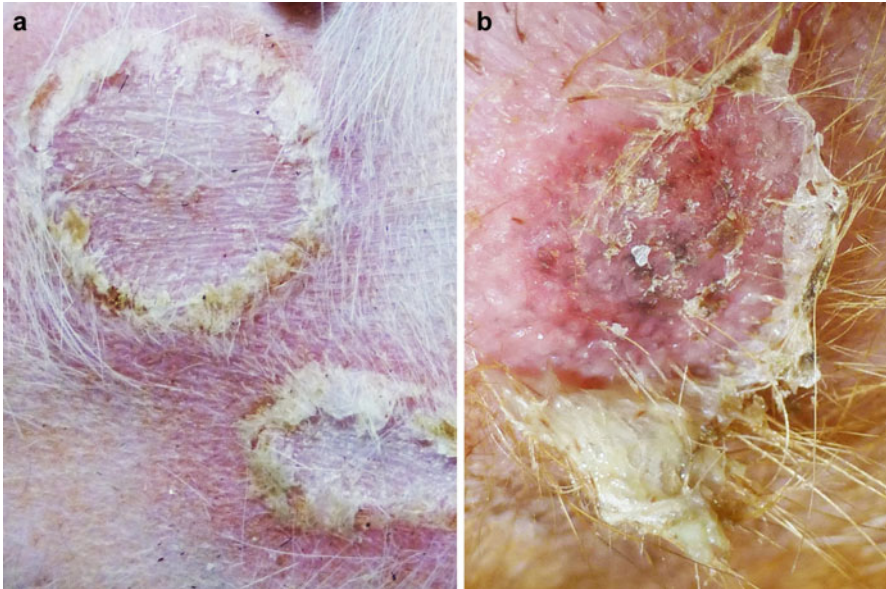


Fig. 2.17 (a) Epidermal collarettes with a dry central area; (b) purulent exudate is present under the peripheral crusts

2.2.1.5 Cytological Sampling from *Ulcers*

Ulcers are deep lesions that represent an excavation in the skin with a loss of all epidermal layers and part of the dermis (Fig. 2.18). Based on this definition, it is clear why it is common to find red blood cells in cytological specimens from ulcers (Fig. 2.19). Samples from ulcers are usually of poor quality and highly haemocontaminated; thus, only in rare cases do ulcerative diseases provide useful specimens. Most ulcerative diseases, such as cutaneous lupus, vesiculo-bullous, sub-epidermal diseases, erythema multiforme etc., can be diagnosed only by histopathology. Nevertheless, there are some ulcerative diseases for which cytology may provide an immediate diagnosis.

Sampling Technique

The method of sampling differs according to the depth of the ulcer. In deep ulcers with raised edges, the impression smear technique is not feasible because the slide cannot reach the bottom of the ulcer; in these cases, cells can be sampled by scraping (Fig. 2.20). In shallower ulcers with loss of only small portions of the dermis, the cells may be collected by placing the slide.

2.2.1.6 Cytological Sampling from *Crusts*

Crusts are secondary lesions, composed of inflammatory cells, keratinocytes, debris and, possibly, of hair shaft fragments, blood and microorganisms (Fig. 2.21).

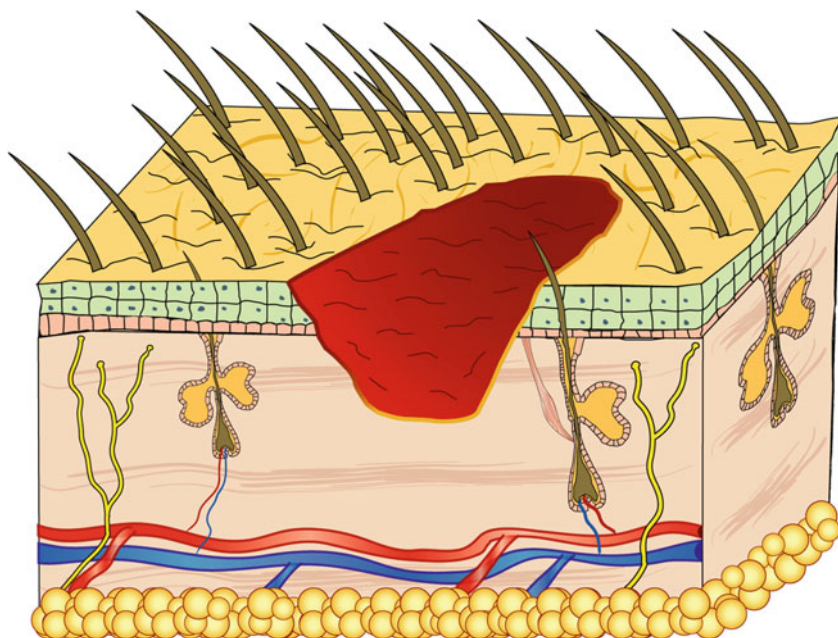


Fig. 2.18 Schematic representation of an ulcer. Note how the lesion is deep and involves the dermis

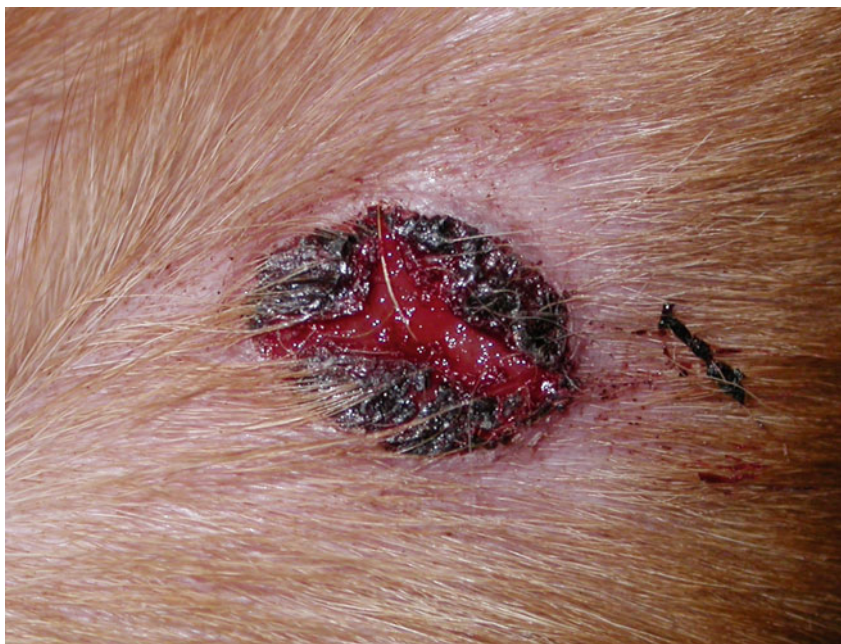

Fig. 2.19 Round ulcer covered with an haematic crust

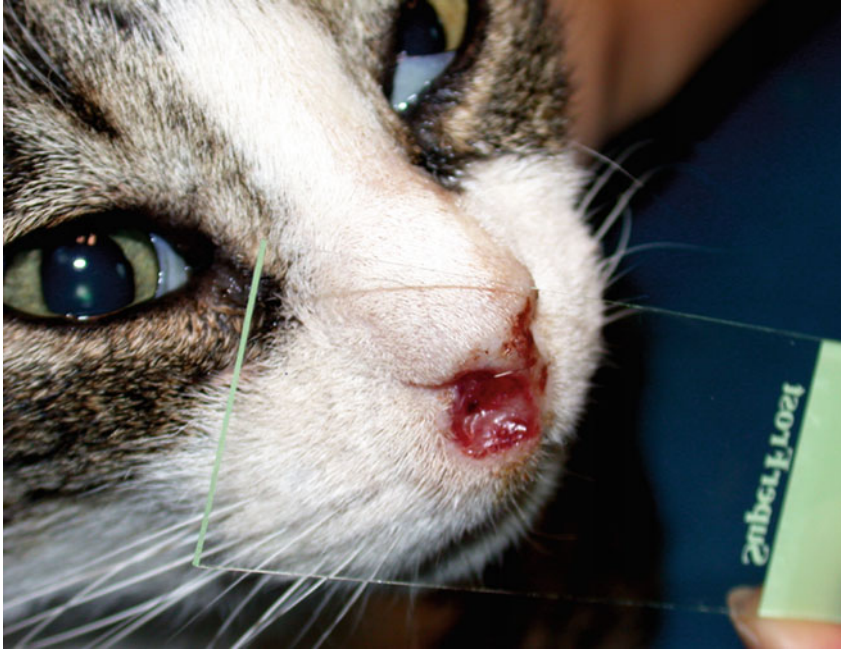

Fig. 2.20 In the case of deep ulcers, placing a slide does not permit the cells to be collected

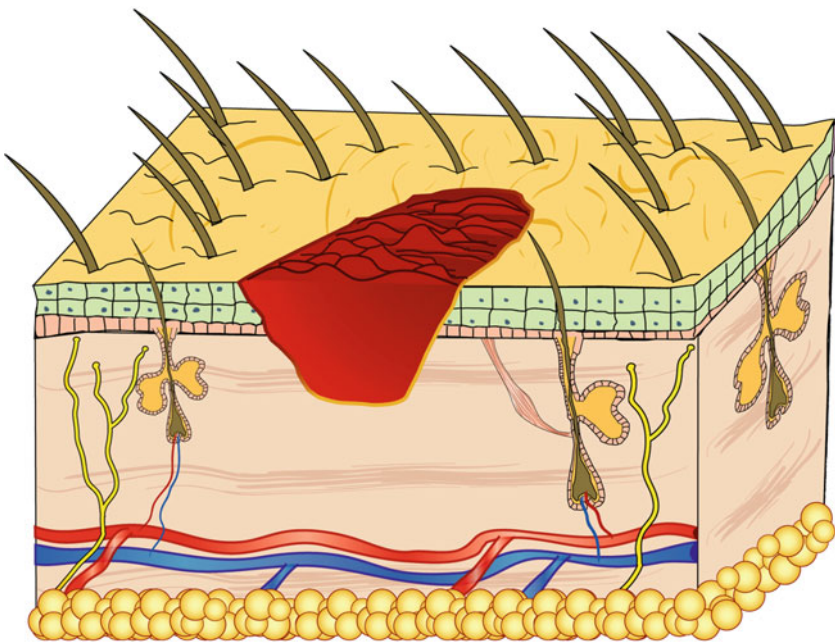


Fig. 2.21 Schematic representation of a haematic crust covering an ulcer

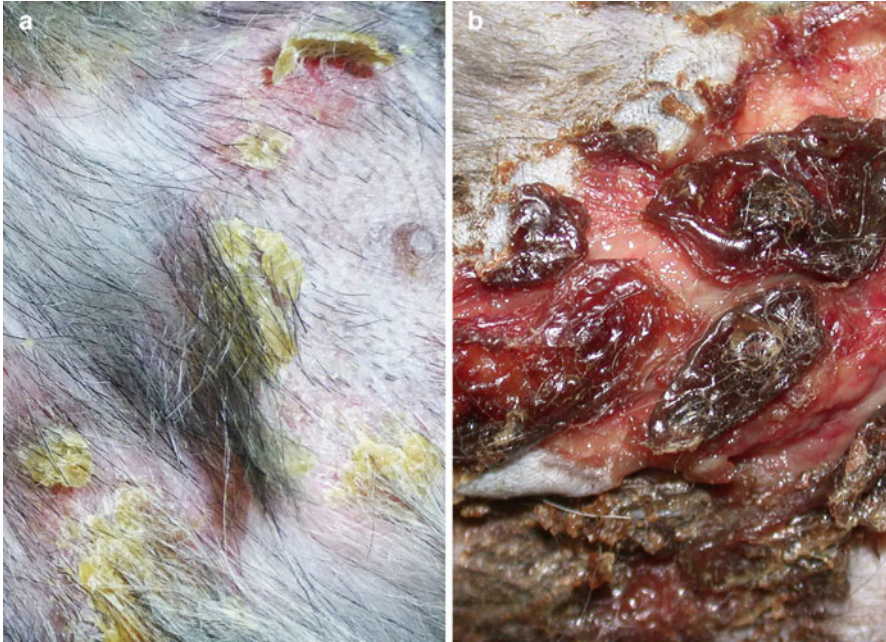


Fig. 2.22 (a) Yellowish superficial crust secondary to pustule dehydration; (b) dark red haematic crusts secondary to a deep lesion

Clinically, the crusts are classified as *superficial* and *deep*. The former are confined to the epidermis and therefore, as this portion of skin is not vascularised, they are not haematic, but usually characterised by a yellowish-brown colour; deep crusts are instead secondary to an ulcer and therefore, as they contain blood, appear dark, red-black in colour (Fig. 2.22). This clinically different appearance is easily recognised by visual examination and allows the clinician to obtain useful information regarding their aetiology. Cytologically, the superficial crusts are the most interesting, as they represent dehydrated pustules, whereas, in the case of haematic crusts, the specimens are more haemocontaminated and provide less useful results.

Sampling Technique

Sampling of cells from the crust is performed following its removal and by placing a slide on its inner surface or on the exposed pus (Fig. 2.23).

2.3 Fine Needle Biopsy (With or Without Aspiration)

2.3.1 Cytological Sampling from Nodules and Plaques

By definition, *nodules* are raised lesions, dermal or subcutaneous in location, greater than 1 cm in size and with a tendency to grow in height rather than in width (Figs. 2.24 and 2.25). The *plaques* are also raised lesions, but they tend to extend further in width

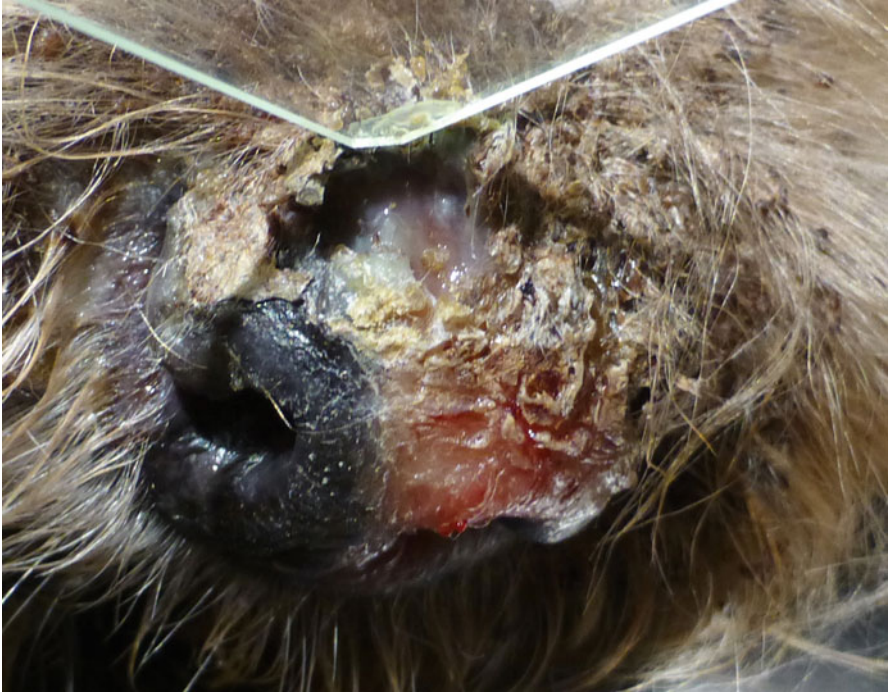

Fig. 2.23 Purulent exudate exposed after the crust has been removed

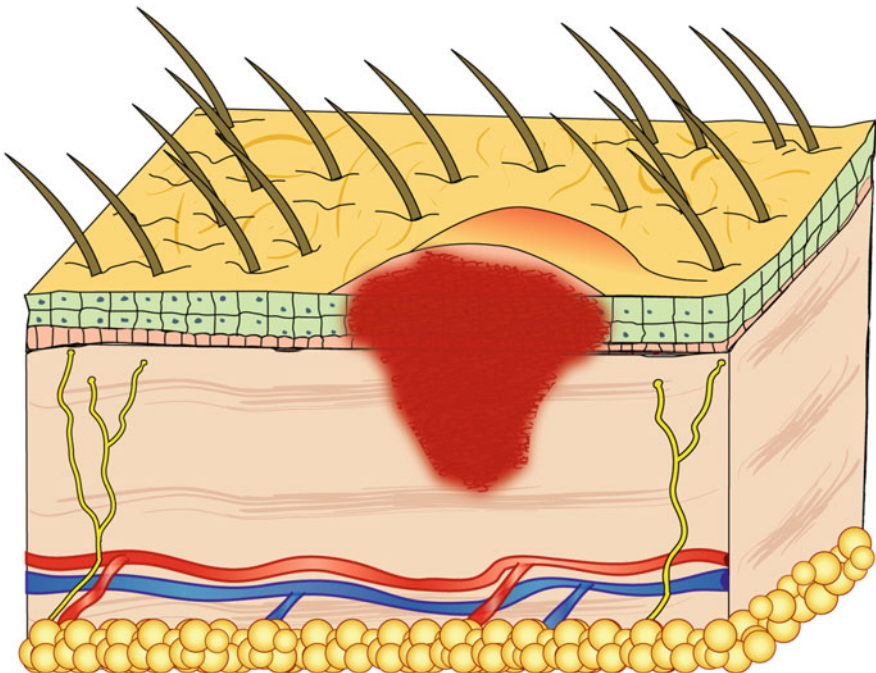


Fig. 2.24 Schematic representation of a nodule

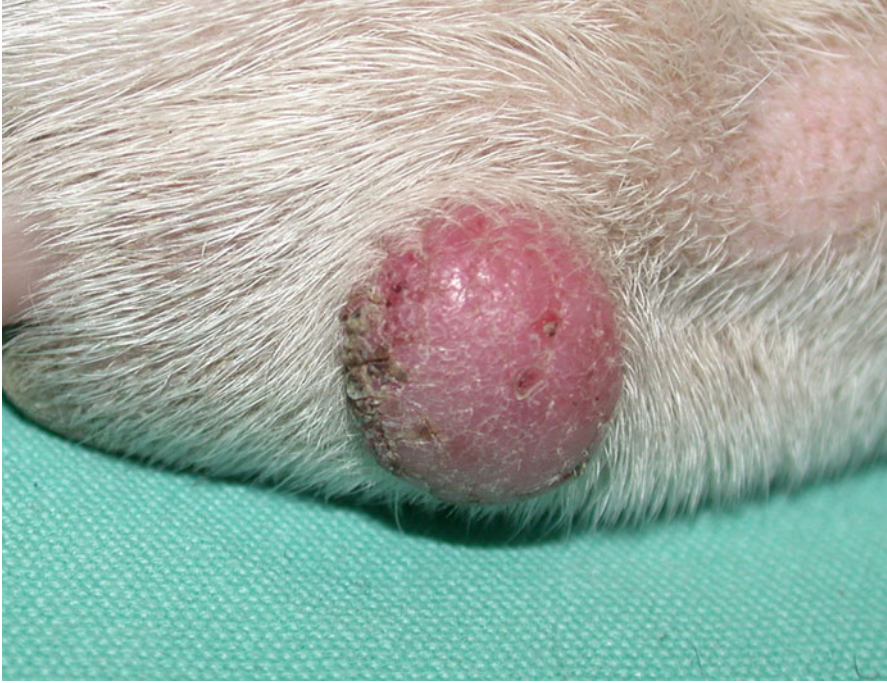

Fig. 2.25 Round, alopecic, nodular, benign, cutaneous histiocytoma in a dog

than in height (Fig. 2.26). Large nodules are defined *masses*. Nodules and plaques may be composed of both inflammatory and neoplastic cells, or can be caused by the accumulation of fat (xanthomatosis) or mineral salts (calcinosis) in the dermis.

All nodules and plaques can be investigated using FNB, which is the best method when very small nodules must be sampled, especially those located in delicate areas such as the eyelids or mucocutaneous junctions. When cells are few and not representative of the lesion, or if it is necessary to sample a large cutaneous mass, it is better to perform a forced aspiration with needles of higher gauges (fine needle aspiration biopsy [FNAB]).

Sampling Technique

In cases of plaques or nodules, the fine-needle biopsy (FNB) or the FNAB is the most appropriate technique (Fig. 2.27).

The FNB technique is based on the simple insertion of a needle into a nodule. In most cases, this is adequate for collecting a high number of cells. A needle with a small gauge (23–25 G) is usually adequate for sampling nodules and plaques. The author routinely uses small needles as they reduce the possibility of vessel rupture and secondary haemocontamination. The needle must be inserted into different areas of the lesion, taking care to perform continuous and repeated *rotational* and *back and forth* movements. These measures are mandatory because many nodules and plaques are not uniform and may have a mixed composition, be necrotic or have central or multifocal cystic areas. As many nodules and plaques are ulcerated, the impression smear technique can provide contaminated samples. In these cases, FNB must be always pre-

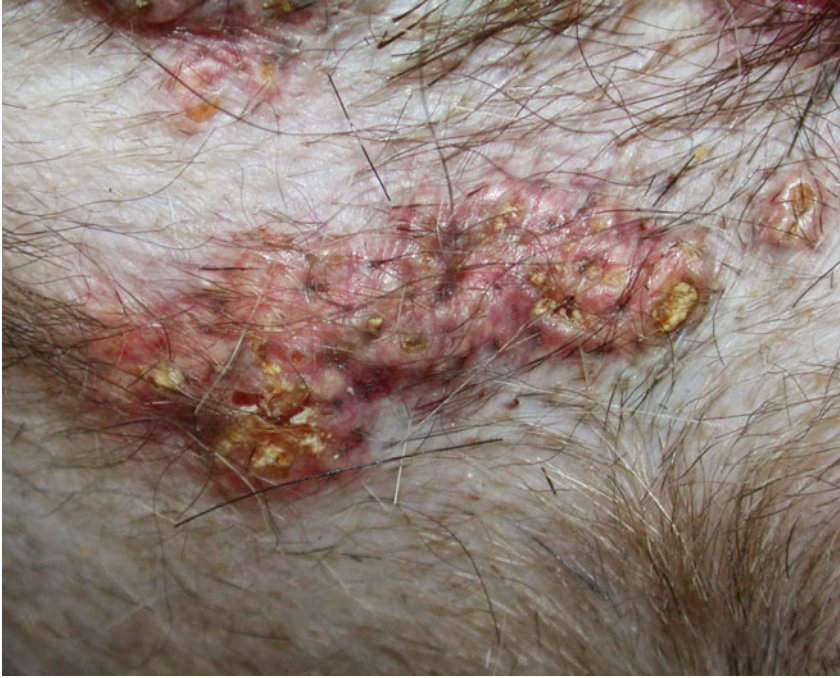

Fig. 2.26 Plaque in a dog affected by *calcinosis cutis*

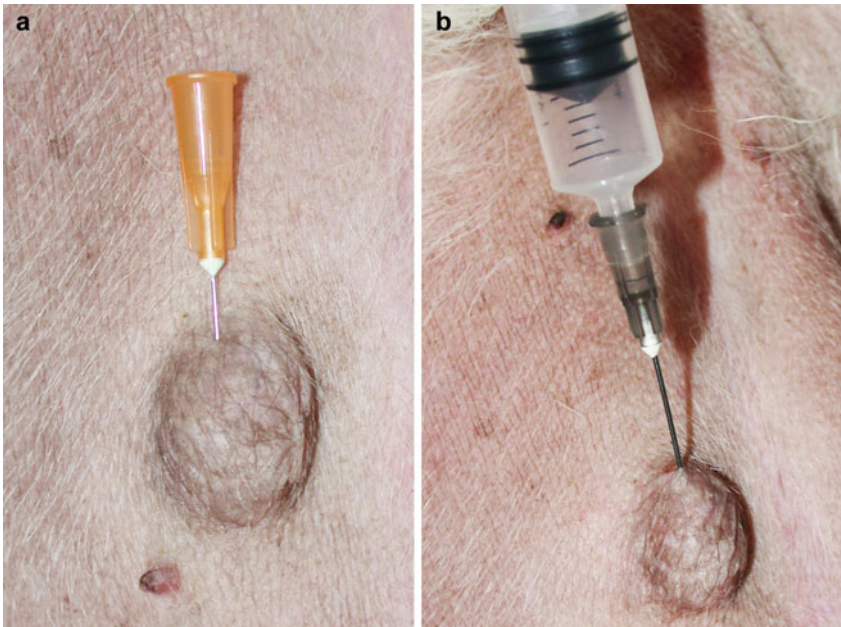


Fig. 2.27 (a) Fine needle biopsy; (b) fine needle aspiration biopsy

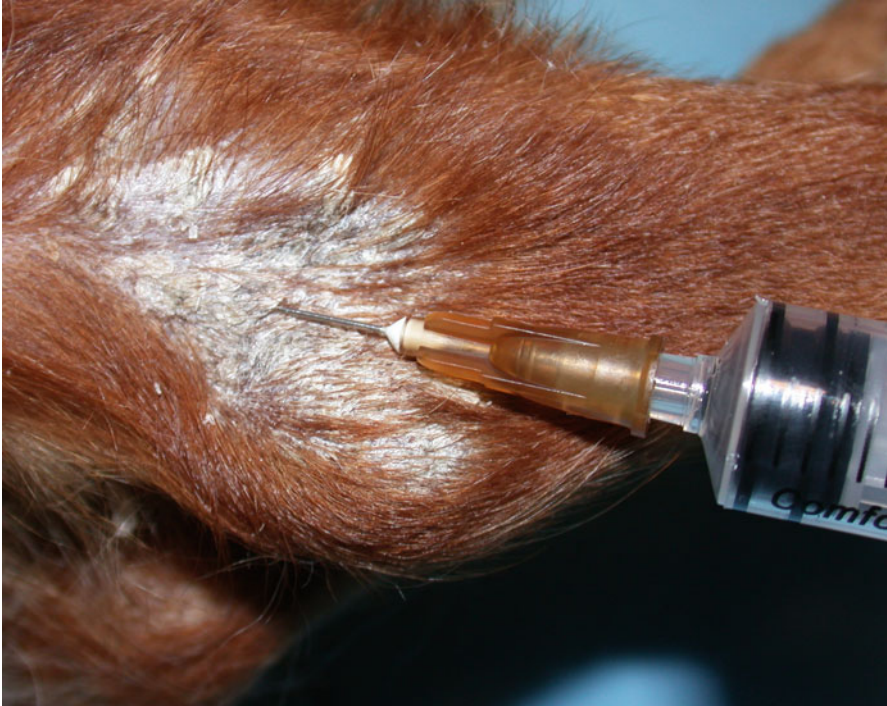

Fig. 2.28 Intradermal fine needle aspiration biopsy in a dog with leishmaniasis

ferred as it permits cells to be collected from deeper and uncontaminated areas of the same lesion, reducing the possibility of sampling unrepresentative inflammatory cells.

Cells from superficial dermis can also be obtained, in flattened lesions, by FNB or FNAB. In some non-nodular lesions, as in the course of desquamative lesions, where it is not possible to obtain the diagnosis by sampling superficial cells, it is possible to try to collect cells located just below the epidermis. A 23-gauge needle connected to a 5-ml syringe must be inserted into the sub-epidermal area and aspiration movements made. In this way, it is possible to collect cells that are indicative of the origin of the lesion.

In cases of exfoliative leishmaniasis, amastigotes are frequently localised in the subepidermal dermis; therefore in more lucky cases, they can be collected with this technique (Fig. 2.28).

2.4 Scraping

2.4.1 Cytological Sampling from Ulcers

As mentioned, samples collected from ulcers using the impression smear technique can produce non-diagnostic specimens, often comprising only contaminated specimens (Fig. 2.29).

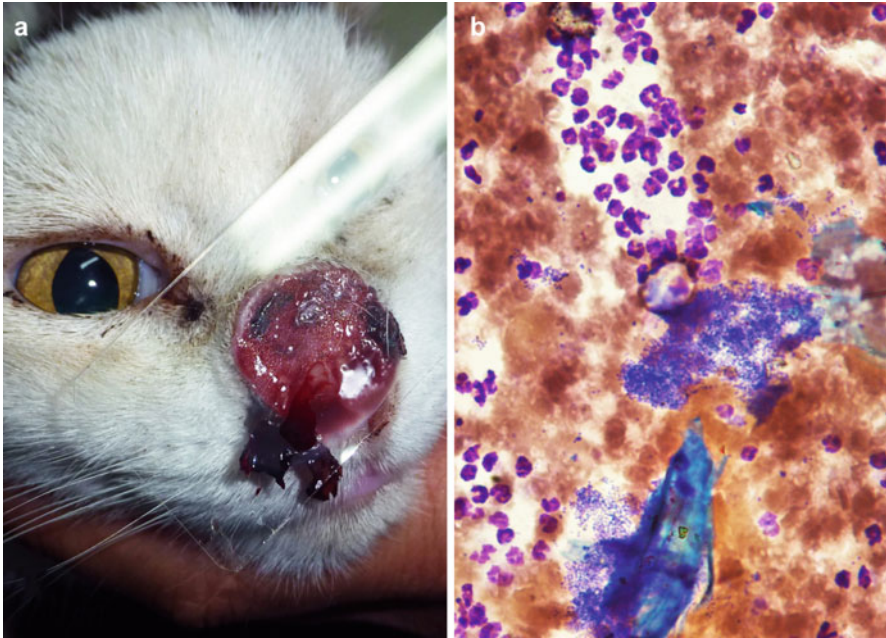


Fig. 2.29 (a) Impression smear technique used on the ulcerated nose of a cat with squamous cell carcinoma; (b) blood and many contaminant bacteria dispersed with arranged in large groups

Scraping is a traumatic method that allows numerous cells to be collected. The traumatic detachment of cells from the original tissue has the disadvantage of causing the vessels to break and of constantly providing haemocontaminated specimens. *Scraping* is therefore the most suitable technique for deep ulcers, because it enables the collection of cells from areas unreachable with other less invasive methods. A typical example is the *squamous cell carcinoma* in cats where the neoplastic keratinocytes deeply infiltrate the dermis, causing ulcerative lesions. In these cases, FNB is not a good method of sampling, whereas scraping provides more possibilities for obtaining diagnostic cells.

Sampling Technique

As ulcers are typically covered with a haematic crust containing inflammatory–necrotic cells or debris, sampling by scraping the upper material would be useless. According to the above, the first scrapes must be carried out to remove the superficial debris and after these, other scrapes must be gently performed to collect more representative specimens.

It is possible to use any sharp instrument, such as a scalpel blade or the edge of a glass slide; whichever tool is used, it is critical that multiple delicate scrapings must be repeated to gradually reach the bottom of the ulcer without excessive bleeding (Fig. 2.30).

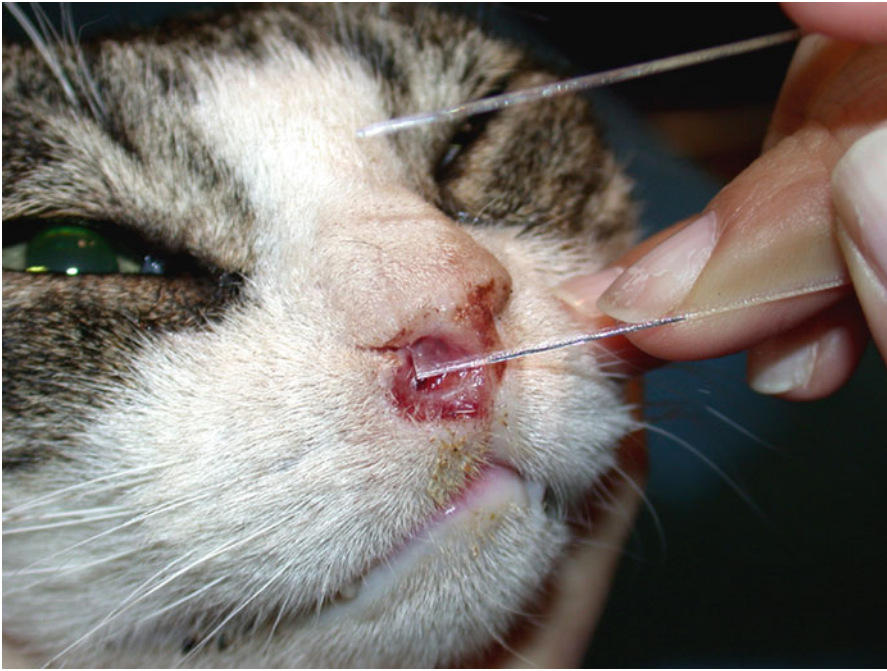


Fig. 2.30 Cells collected via scraping of an ulcerative lesion

2.5 Preparation of Slides

The reading of a cytological specimen requires the slides to be correctly prepared. As already mentioned, once the lesion and the sampling technique have been chosen, the success of good preparation also depends on the manual skill of the operator who, with experience, is able to prepare slides of high quality. When the *impression smear* technique is performed on wet and exudative skin, it is sufficient to place the slide onto the surface to determine the direct transfer of cells (Fig. 2.31). The clinician must take care to place the slide gently to minimise or avoid cell damage.

In the case of sampling by *needle*, either by *FNB* or by *FNAB*, the material collected must be transferred onto a slide. This step is very delicate and fundamental to obtaining good-quality samples. The collected material should not be sprayed too energetically onto a slide, but must be gently deposited to approximately 1 cm from the frosted area of the slide. In this way, all the cells are contained in the central part of the slide. To avoid exerting too much pressure on the cells, the use of a 1-ml syringe is usually sufficient, and only if a tiny amount of material escapes from the needle should a larger syringe, either 2.5 or 5 ml be used. When collecting a large amount of material, it is mandatory not to deposit all of it on a single slide. Distributing only a small amounts of material onto more

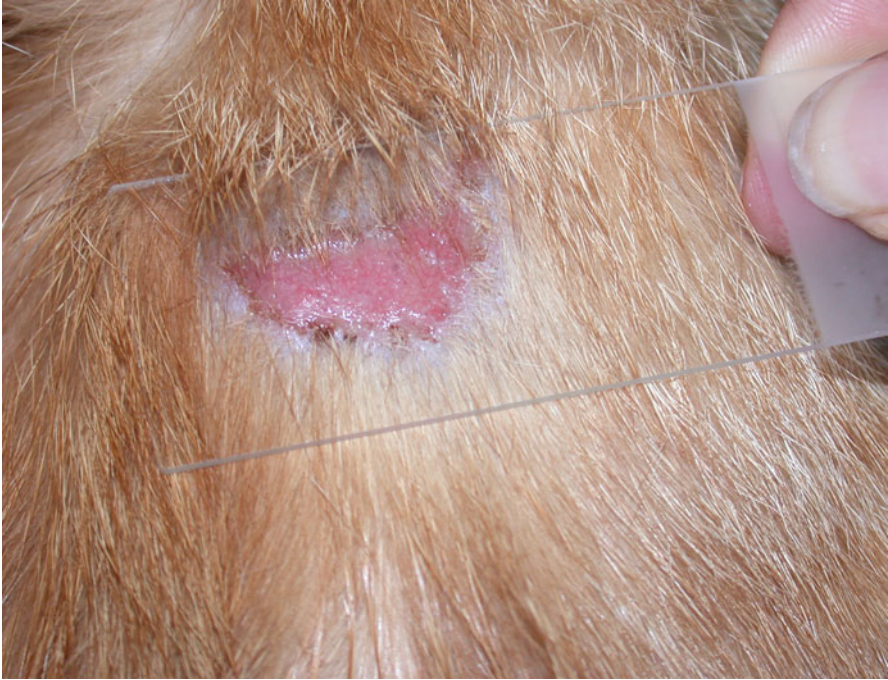

Fig. 2.31 Impression smear technique: a slide is placed on an exudative lesion

slides has two advantages: (a) obtaining a specimen distributed in a single layer that permits the rapid dyes (e.g. Romanowsky) to penetrate and stain the cells, (b) obtaining more slides, some of which can be used for special or immunocytochemical staining.

Once sufficient material has been deposited on the slide; this must be gently smeared using a second slide. The two slides, maintaining a constant pressure and speed, are gently slid in opposite directions (Figs. 2.32 and 2.33). It will be down to the experience of the operator to evaluate, case by case, the pressure to be exerted on the two slides to obtain a high-quality sample. On good-quality slides, all the material must be contained in the central area without reaching the edges, forming a sort of ellipse (Fig. 2.34).

In the case of fluids, such as that collected from apocrine cysts, the slides may stick together, making it difficult for one slide to slip onto the other. This phenomenon can cause marked cell damage, which can be avoided by preparing slides of liquid consistency with the same method as that used for blood smears.

Material collected by *scraping* must be transferred onto a slide. In general, because with this method a large number of cells is collected and because rapid stains fail to penetrate specimens that are too thick, it is necessary to exert a higher pressure on the slides. With experience, clinicians acquire the skill of producing excellent slides.



Fig. 2.32 Cytological material sprayed too energetically on a slide and not smeared

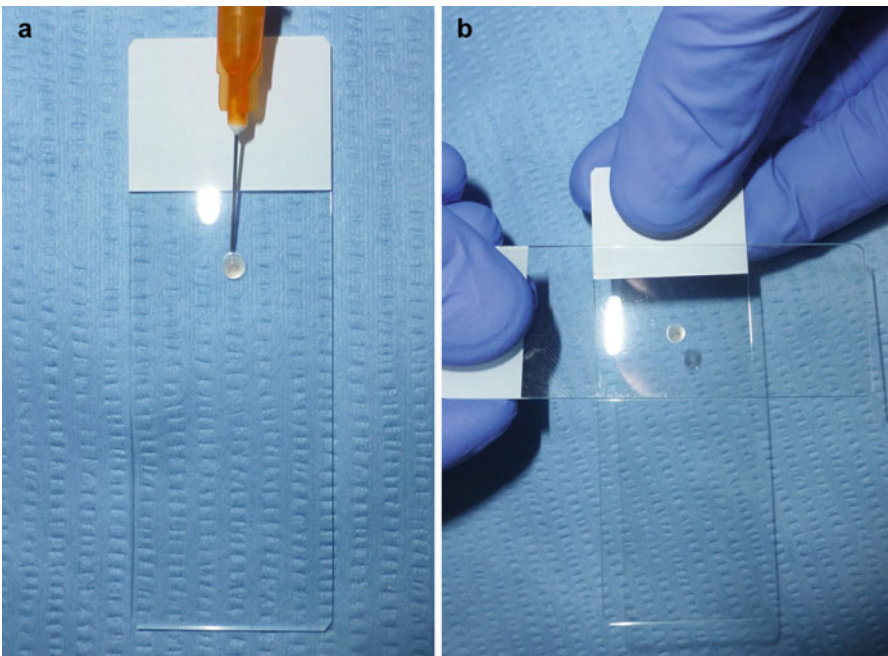


Fig. 2.33 (a) The collected material is gently transferred onto the slide; (b) smear technique: another slide is placed on the collected material and slipped onto it



Fig. 2.34 Ellipsoidal shape of the smeared material characterises a well-made slide

2.6 Staining of Slides

The last step before observation under the microscope is *staining*. In recent years, cytology has become a very common diagnostic method in veterinary practice; thus, many vets carry out staining of blood smears or cytological samples from skin lesions or internal organs on a daily basis.

The first rule that clinicians must respect before staining slides for microscopic evaluation is to avoid contact between unstained slides and the formalin vapours; indeed, formalin fumes do not permit the stains to penetrate the cells, which remain faintly coloured and have a *faded appearance* (Fig. 2.35).

2.6.1 Romanowsky Stains (Wright's, Giemsa)

Most veterinarians use rapid Romanowsky dye, a polychromatic stain originally composed of methylene blue and eosin. The staining method comprises a first dip in an alcoholic fixative (methyl alcohol) and two consecutive passages in two stains: the first is Azure B (N,N,N, -Trimethylamine), a basic dye that is a metabolite of methylene blue, and the second is Eosin Y (Tetrabromofluorescein), an acid dye. With this type of stain, it is necessary for slides to be air-dried before being dipped

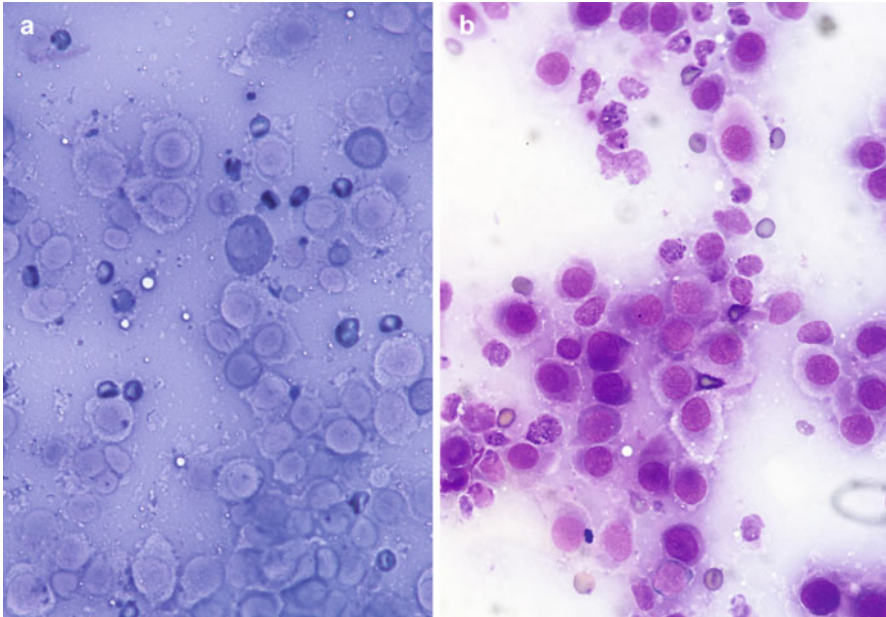


Fig. 2.35 Romanowsky dye: (a) unstained slides because of contact with the formalin vapours; (b) the same sample not exposed to formalin fumes

in the alcoholic fixative. Romanowsky-type staining was conceived for blood and bone marrow smears, but over time and with the expansion of cytopathology, it has found widespread use for staining any type of cytological sample.

Romanowsky is a panchromatic stain that allows the adequate display of nuclear characteristics and is excellent at highlighting cytoplasmic details, such as granules and most microorganisms. The nuclei take on a *purple* colour, whereas cytoplasm stain *azure blue*.

Beginners should be aware that when using this stain, cells must be distributed in a thin, single layer, as specimens that are too thick do not permit the dyes to properly penetrate into the cells.

The technique is very simple and rapid: the slide must be air-dried and immersed into the three aforementioned solutions. There is no predetermined number of dips or seconds to be met for each pass, as much depends on how the dyes are used and how often they are filtered or renewed. In general, the number of dips for each colour depends on how long it takes both the fixative and the dyes to permeate the cells. Three to four dips of 1–2 s each may be sufficient for good staining. In time, the operator acquires the expertise to perform efficient staining.

The Romanowsky method is also useful when transparent acetate tape must be stained. As some tapes are of poor quality, they may curl or become opaque once immersed in the fixative; it is possible to obtain good coloration using only the third dye (blue) or other stains such as blue lactophenol or crystal violet. It is sufficient to deposit only a few drops of the dye on a slide to which the lower surface of the

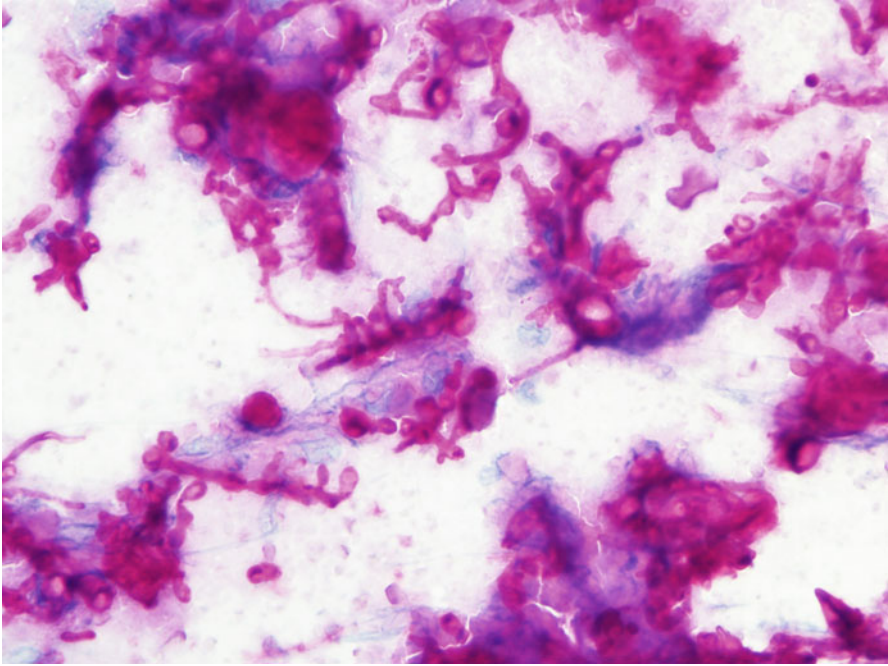


Fig. 2.36 Periodic acid–Schiff staining: fungal bodies stained magenta

adhesive tape where the cells are attached is placed. Before looking at the slides under the microscope, the excess dye, which would make it difficult to view the cellular details, is removed with a piece of absorbent paper.

2.6.2 *Periodic Acid–Schiff*

Periodic acid–Schiff (PAS) is a dye commonly used in histology to indicate molecules that contain a high percentage of carbohydrate, such as, glycogen, mucins and fungi. In skin cytology, it is most commonly used to highlight fungi that take on a characteristic *magenta* colour (Fig. 2.36). As it does stain different substances, slides can have a PAS-positive background and for this reason, in specimens composed of many inflammatory cells and only a few fungi, the latter are not always easily recognisable (Fig. 2.37).

2.6.3 *Grocott's Methenamine Silver*

Like PAS, *Grocott's* is also a dye that is used to better visualise fungal organisms. In most fungi, the cell wall is composed of chitin, a polymer of N-acetylglucosamine, which can be linked to polymers of D-glucose, D-mannose, proteins and lipids.

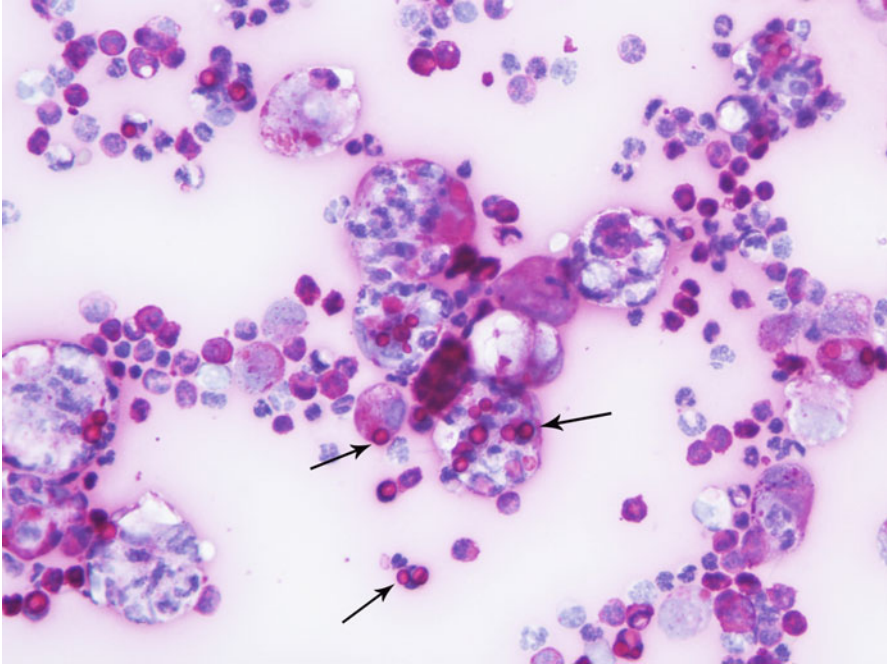


Fig. 2.37 Periodic acid–Schiff staining: in highly cellular specimens, fungi can be hardly detected. The fungal bodies are evident as round, deeply magenta-stained cells (*arrows*)

With use of Grocott's dye, the aldehydic groups that are produced by the oxidation of mucopolysaccharides present in the fungal wall reduce the silver chloride to metallic silver, permitting their visualisation. Fungi are coloured *black* and the rest of the cells and the background *green* (Fig. 2.38). In the author's experience, Grocott's dye is preferable to PAS, as the fungi are more easily detectable and it is particularly useful in cases of dermatophyte kerion, in which only a few arthroconidia are usually present (Fig. 2.39).

2.6.4 Ziehl–Neelsen

Ziehl–Neelsen (Z–N) staining is used to colour *mycobacteria*.

Acid resistance is a particular characteristic of the mycobacteria consisting of the ability of these micro-organisms, once stained with carbol fuchsin, to maintain their red colour, even when subjected to energetic bleaching treatment. The acid resistance is due to the characteristic composition of the cell wall of mycobacteria, which is very rich in lipids. With Z–N staining, mycobacteria are coloured *bright red*, whereas the nuclei take on a *blue* colour (Fig. 2.40).

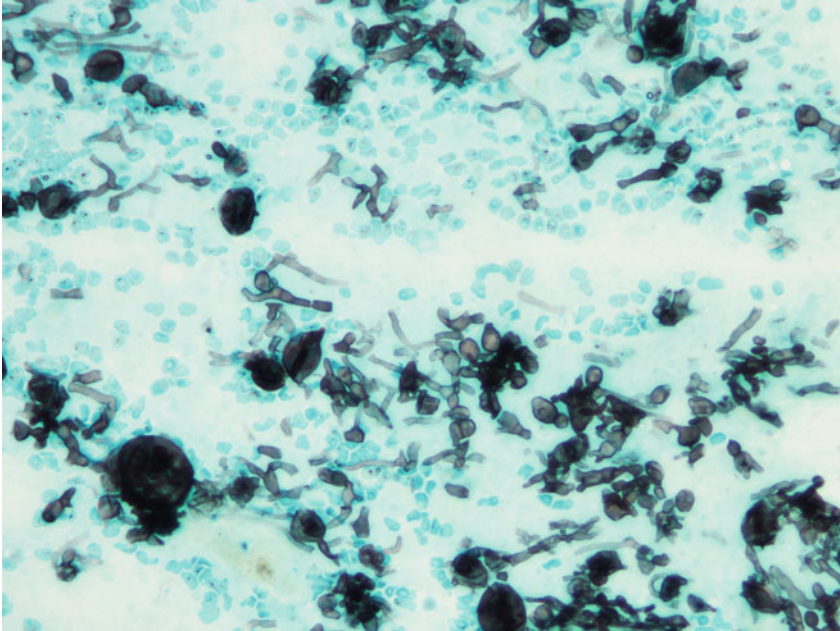


Fig. 2.38 Grocott's staining: many fungal bodies are easily detected because of their black colour against a green background

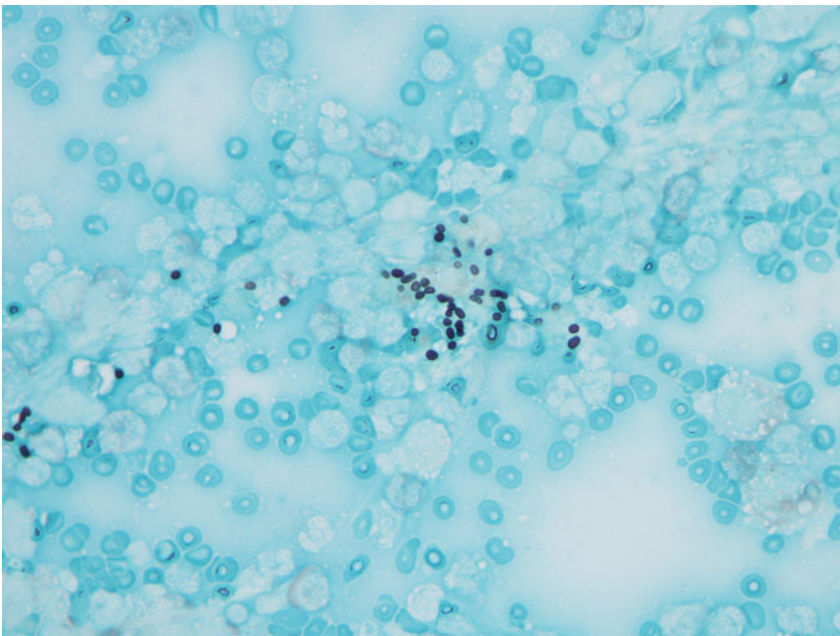


Fig. 2.39 Grocott's staining: small, round, black-stained arthroconidia are easily detectable against a green background

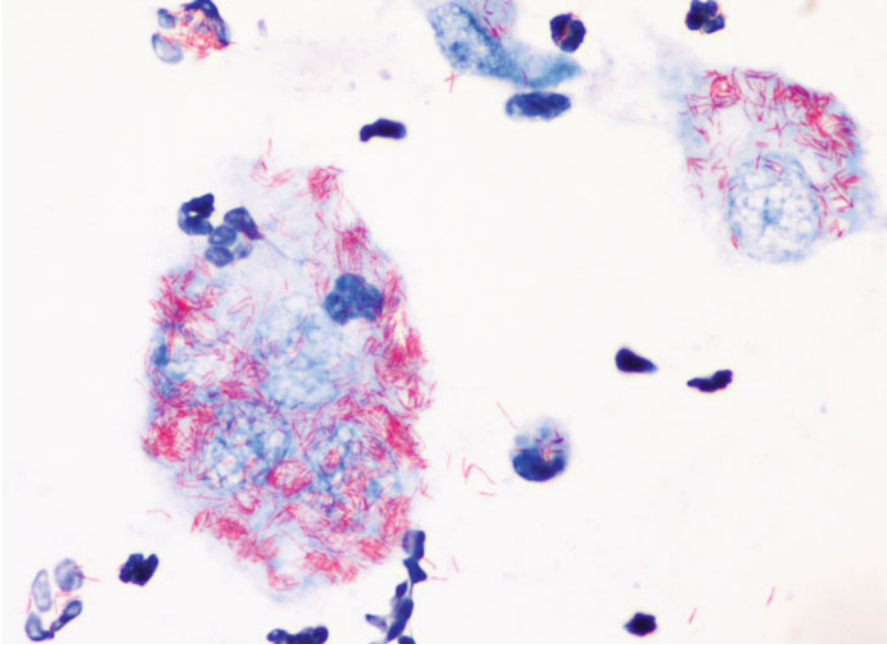


Fig. 2.40 Ziehl-Neelsen staining: mycobacteria are detected as bright red bacilli in the cytoplasm of macrophages

2.6.5 *Oil-Red-O*

The dye *Oil-red-O* is fat-soluble and therefore selectively binds to the lipid structures of cells. The staining can only be performed on fresh samples, as alcohol fixation removes most of the lipids; for this reason, slides must not be dipped in the alcoholic solution. *Oil-red-O* is used for staining fatty substances and in practice it is very useful to confirm the presence of fat in the vacuoles of macrophages and giant cells, as happens in cases of panniculitis and xanthomatosis, or when, in poorly differentiated liposarcomas, we want to detect intracellular lipid material. The lipids assume a *red-orange* colour (Fig. 2.41).

2.6.6 *Von Kossa*

Usually, *Von Kossa* staining is used to highlight *calcium* ions in histological sections. A substitution reaction is the basis of this stain. Cells are treated with a solution of silver nitrate that replaces the calcium salt. In specimens, the areas of *calcium* are coloured in *black*, while the nuclei stain *red* (Fig. 2.42). Such coloration may be useful for confirming the presence of *calcium* salts in specimens from dogs with

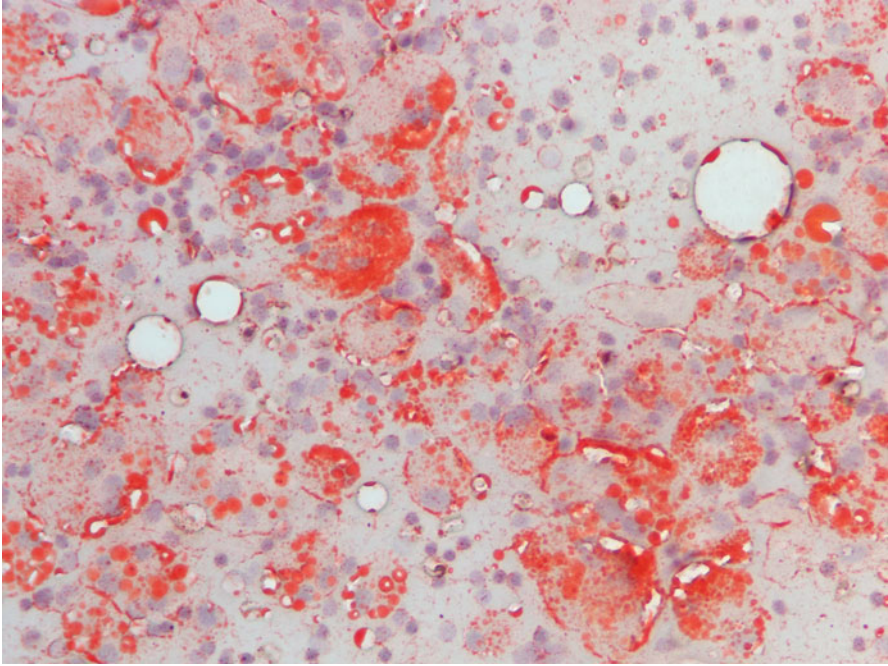


Fig. 2.41 Oil-red-O staining: bright red-stained lipids are evident in the cytoplasm of macrophages

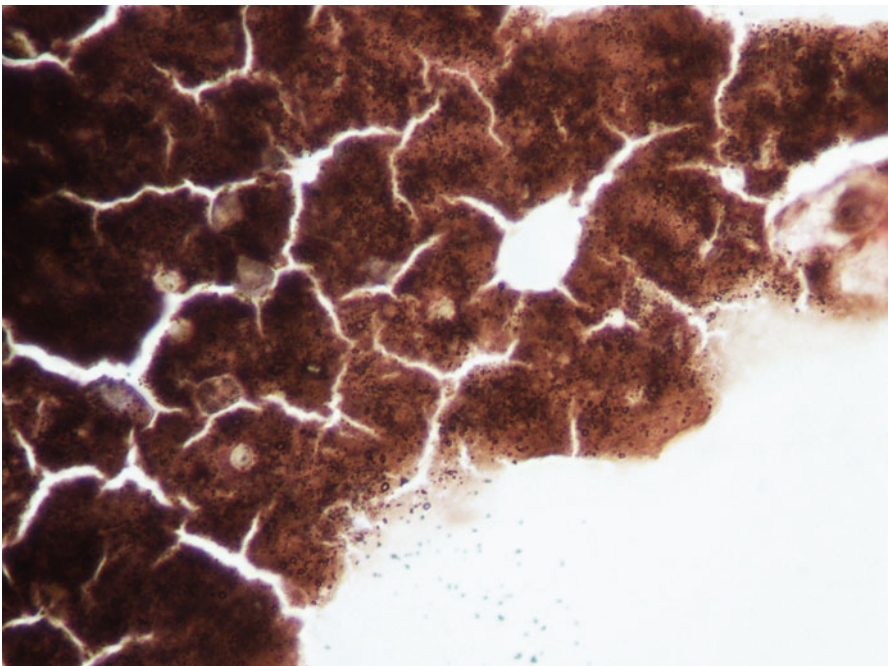


Fig. 2.42 Von Kossa dye: the area where *calcium* salts were present stains black

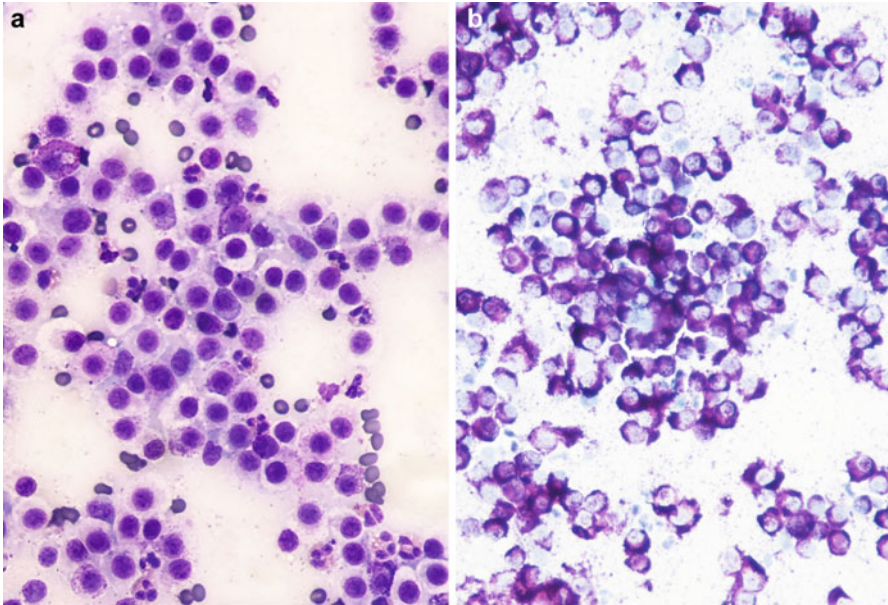


Fig. 2.43 (a) Romanowsky dye: mast cell tumour in which few purple granules are evident in the cytoplasm of neoplastic cells; (b) toluidine blue dye highlights many red-stained granules in the same specimen

cutaneous mineralisation, as in cases of *calcinosis cutis* or *calcinosis circumscripta*.

2.6.7 Toluidine Blue

Toluidine blue dye is used for the metachromatic staining of acidic substances. In practice, it is utilised in poor granular mast cell tumours, where the low number of granules make identification of the mast cells less obvious. The granules of the mast cells stain *red* (Fig. 2.43).

2.6.8 Prussian Blue, or Perls' Reaction

Prussian blue is a dye commonly used in histopathology to detect ferric iron and ferritin in the tissue.

It is a histochemical reaction rather than a true staining technique. Hydrochloric acid splits the protein, allowing the potassium ferrocyanide to combine with the ferric iron, forming ferric ferrocyanide or *Prussian blue*. In skin cytology, it can be

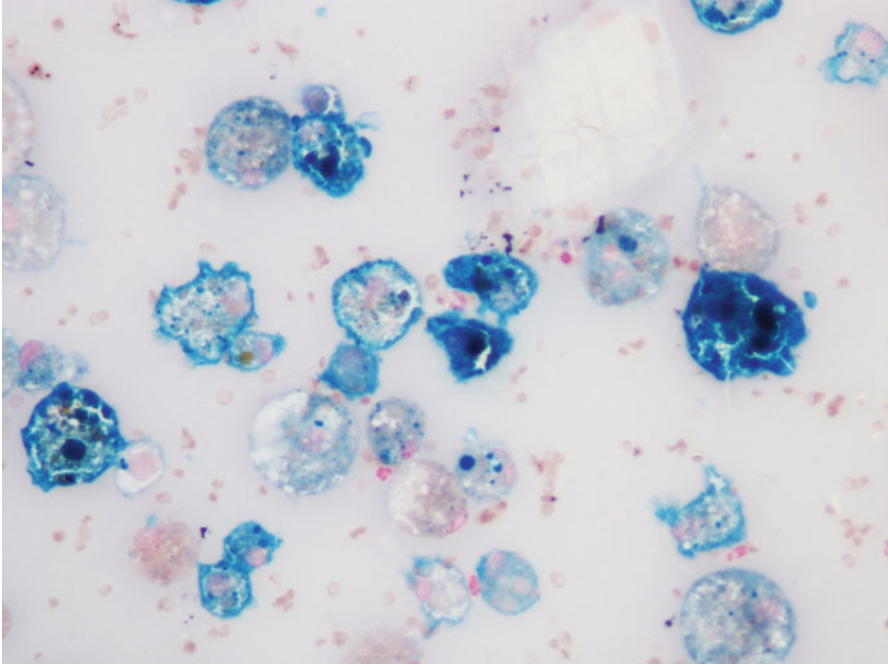


Fig. 2.44 Perl's reaction: with Prussian blue dye, the iron component of apocrine gland secretion is evident in the macrophages sampled from an apocrine cyst

used to confirm the presence of iron in the granular material observed in the cytoplasm of apocrine cells or when only macrophages filled with coarse dark blue material are collected from a cystic lesion suspected of being of apocrine origin. With Prussian blue staining, the ferric iron takes on an *azure blue* colour, whereas nuclei stain *red* (Fig. 2.44).

2.6.9 Congo Red

Amyloid is an acidophil and hyaline (glassy) substance stained by acid dyes. Amyloid is not definitively identified by routine haematoxylin and eosin staining and therefore, special stains are required. Among these, *Congo red* dye is most frequently used. It is an anionic dye that is capable of depositing in amyloid fibrils. With Romanowsky staining, the amyloid cytologically appears as a fibrillar to globular, bright pink extracellular matrix that cannot be differentiated from other substances. With Congo red staining, the amyloid takes on an *orange-red* colour (Fig. 2.45).

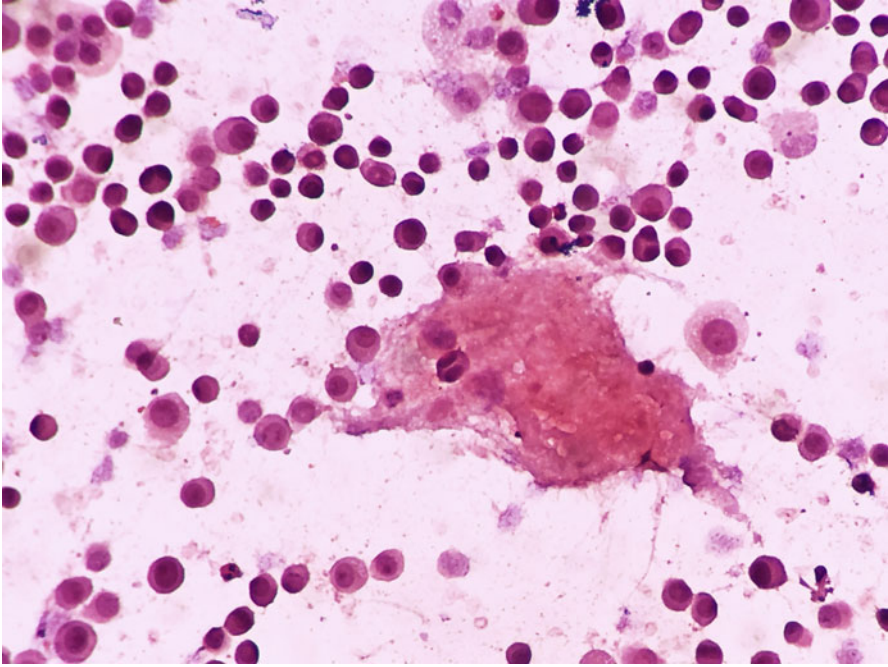


Fig. 2.45 Congo red staining: amyloids can be detected using Congo red. In the pictures, the amyloid is stained orange among many neoplastic plasma cells

References

- Raskin RE, Meyer DJ (2015) The acquisition and management of cytology specimens. In: Canine and feline cytology. A color atlas and interpretation guide. Saunders Elsevier, St. Louis, pp 1–15
- Valenciano AC, Cowell RL (2014) Sample collection and preparation. In: Cowell and Tyler's diagnostic cytology and hematology of the dog and cat, 4th edn. Mosby, Elsevier Inc, St. Louis, pp 1–19

Chapter 3

Cytology of Canine and Feline Non-neoplastic Skin Diseases

3.1 Introduction

In this chapter, cytopathological findings of the main *non-neoplastic* skin diseases are discussed. Unlike skin neoplasias, non-neoplastic skin diseases, which in this book are also named *inflammatory diseases*, are characterised by a wide clinical polymorphism.

Although the following classification is not useful for diagnostic purposes, skin lesions are usually classified as *primary*, which represent the damage of the disease on the skin, and *secondary*, the evolution of lesions over time or the outcome of self-trauma. Skin lesions that are observed on a dermatological patient are numerous and morphologically very varied, and although the macroscopic appearance makes them easily recognisable, cytological findings allow us to interpret them. Unfortunately, their nature may not always be able to be established through cytology; in these cases, other diagnostic techniques or a histopathological examination are necessary. In this chapter, only the skin lesions, in which a cytological investigation may be diagnostic or useful for diagnosis, are discussed. The author believes that to better interpret the cutaneous inflammatory cytology, it is mandatory to be able to distinguish clinical aspects of the skin lesions from where the cells have been sampled and, for this reason, he prefers to discuss the cytological findings starting from clinical signs. This more practical approach allows veterinarians, even those less confident with dermatology, to interpret cytological results in an easier and more rational way, and to gain from them all the information possible for their interpretation.

3.2 Papules

As mentioned in the chapter on sampling techniques, it is very unlikely to obtain a diagnosis through cytological examination from *papules*, as they usually result in poor cellular specimens.

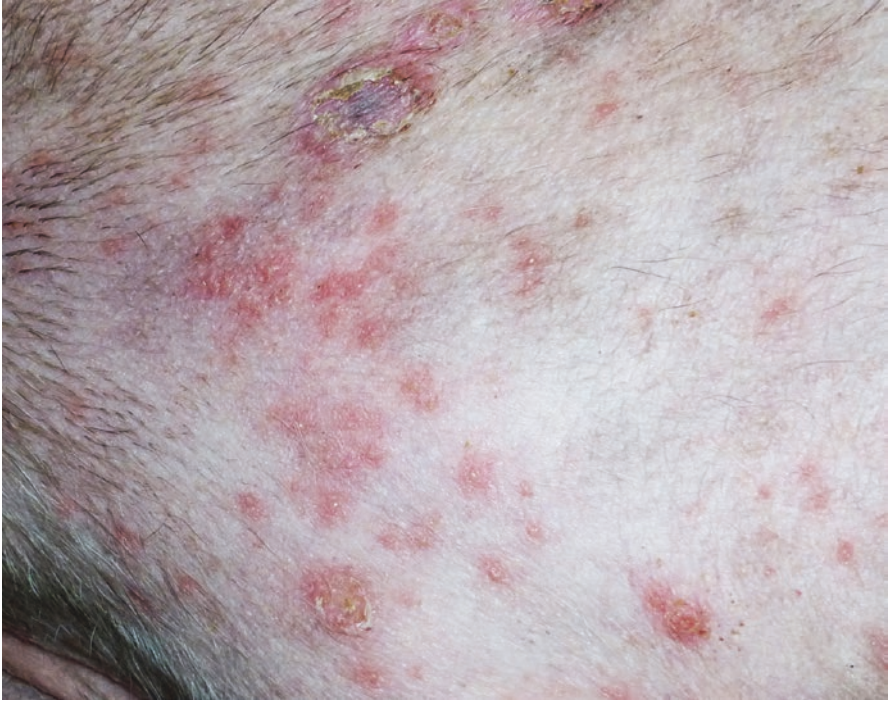

Fig. 3.1 Papules, pustules and epidermal collarettes on the abdomen of a dog with superficial pyoderma

Papules with an intact surface are too small for FNB and cells cannot be collected by the imprint technique; therefore, only crusted papules permit the collection of a few cells, which, even if they are not diagnostic, may guide the clinician in the choice of further diagnostic tests.

3.2.1 Papular Diseases in Dogs

3.2.1.1 Pyoderma

In dogs, *papules* are frequently observed during *superficial staphylococcal pyoderma* (Ihrke 1996; Miller et al. 2013). In this disease, papular lesions are very often associated with pustules and epidermal collarettes, which help the clinician to suspect the disease (Fig. 3.1). When present, pustules must always be preferred to papules for sampling cells, but when papules are the only lesions available, it is possible try to collect cells via the imprint technique.

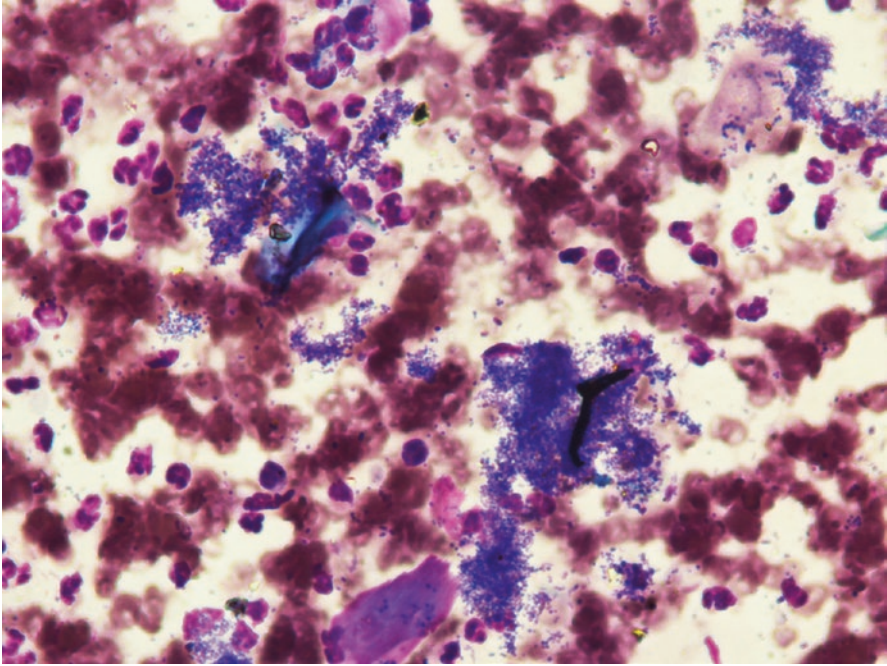


Fig. 3.2 Blood, rare neutrophils and multiple aggregates of bacteria indicative of environmental contamination

Cytological Findings

Slides from papular bacterial infection are sparsely cellular, usually haemocontaminated and have few moderately karyolytic neutrophils. In more exudative papules or in crusted papules, it is very rare to detect cocci phagocytosed by neutrophils. Usually, the superficial crusts that cover the papules entrap a large number of cocci, which are spread on the background of the slide; in these cases, grouped bacteria must not be interpreted as pathogenic, as they are simply indicative of environmental contamination (Fig. 3.2).

3.2.1.2 Scabies and Fleabite Allergic Dermatitis

Papules are very common in many canine parasitic and hypersensitivity diseases. Scabies and fleabite allergic dermatitis are characterised by papules and small crusted papules. In these diseases, it is not possible to obtain diagnosis through cytology, but the detection of many eosinophils, together with the history and the distribution of the lesions on the body, can help the clinician to suspect the disease.

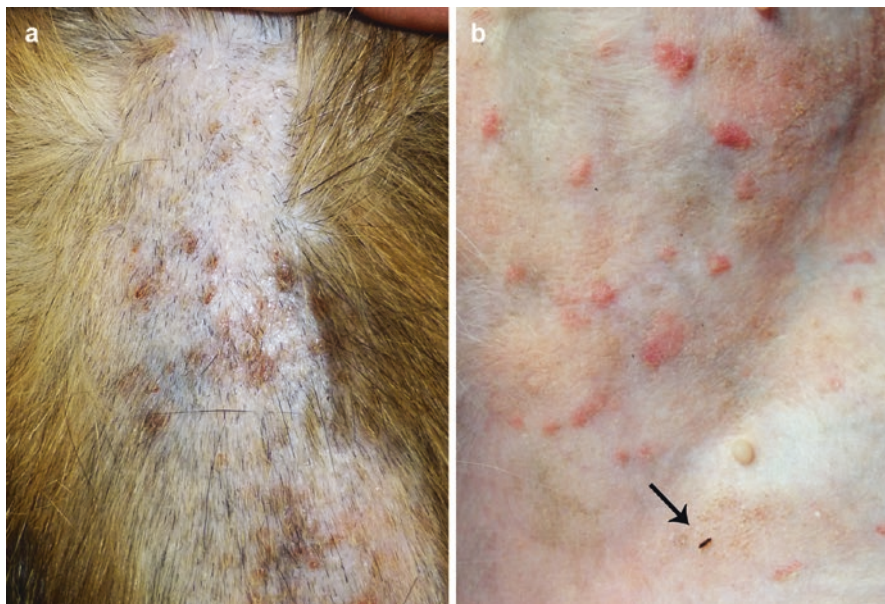


Fig. 3.3 (a) Crusted papules on the back of a cat with miliary dermatitis; (b) erythematous papules in a cat with fleabite dermatitis: note the adult flea (*arrow*)

3.2.2 Papular Diseases in Cats

Papular lesions in cats are observed in numerous diseases and are grouped under the umbrella of *miliary dermatitis*, so called because the papular lesions are the same size as millet seeds. Miliary dermatitis represents a very common and aspecific pattern of feline skin reaction, which occurs in many diseases with different causes, but they all share the presence of an eosinophilic infiltrate into the dermis. It is deduced, as in all these diseases, that the cytological specimens are similar.

As for dogs, the cytology of crusted papules does not permit a diagnosis, but may be helpful in confirming a clinical suspicion or aid the clinician in the selection of further tests to perform.

3.2.2.1 Hypersensitivity Diseases

Among the most common causes of miliary dermatitis in cats are *fleabite dermatitis* and *food or environmental allergy* (no-food and no-flea hypersensitivity) (Hobi et al. 2011; Favrot et al. 2011; Miller et al. 2013; Ravens et al. 2014).

Skin lesions are identical and for this reason do not allow clinical differentiation between them (Fig. 3.3).

Another disease characterised by papules, and less frequently by papular–nodular lesions, is *mosquito bite hypersensitivity* (Gross et al. 2005). The cause of this

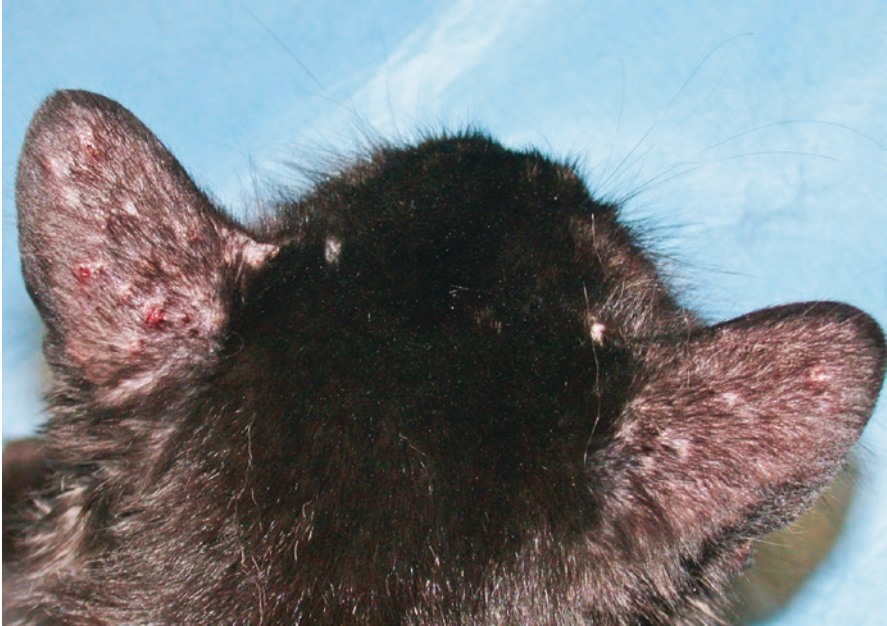


Fig. 3.4 Multiple ulcerated and crusted papules on the pinnae of a black -coated DSH cat with mosquito bite hypersensitivity

disease is an immune-mediated type I hypersensitivity reaction against antigens of mosquitoes. Clinically, it is characterised by crusted papules on the head and especially on the outer surface of the pinna, the bridge of the nose and on the nose (Figs. 3.4 and 3.5) (Nagata and Ishida 1997). Less frequently, lips, eyelids and paws are affected. It seems that black-coated domestic short-haired (DSH) cats are most predisposed to becoming hypersensitive, although the cause of this preference has never been investigated or demonstrated. Skin lesions are very pruritic and tend to ulcerate owing to self-trauma.

Cytological Findings

In all the hypersensitivity diseases characterised by *miliary dermatitis*, cytological specimens show a variable number of eosinophils. In some cases, in small crusted papules, the slides will be composed only of blood, with a basophilic proteic background, few eosinophils intermingled with neutrophils and rarely histiocytes can also be observed (Figs. 3.6 and 3.7). In larger ulcerated papules and in more successful samples, it is possible to obtain many more cellular specimens, rich in eosinophils and with a variable number of macrophages (Fig. 3.8).

Rarely, in some cases, it is possible to observe a few basophils, distinguishable from eosinophils by their larger size, and especially for characteristic intracytoplasmic basophilic granules, which stain pale blue (Fig. 3.9).

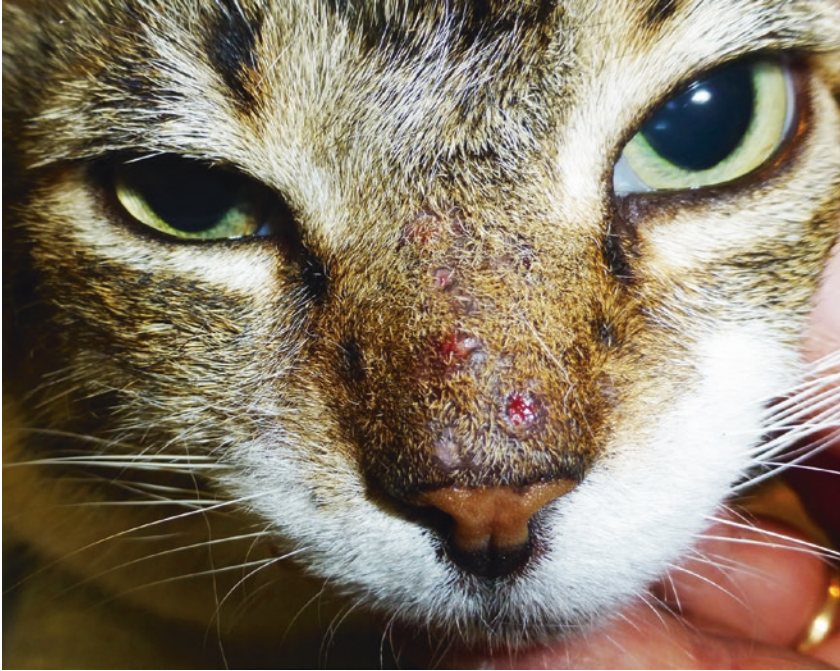

Fig. 3.5 Crusted papules on the nose of a cat with mosquito bite hypersensitivity

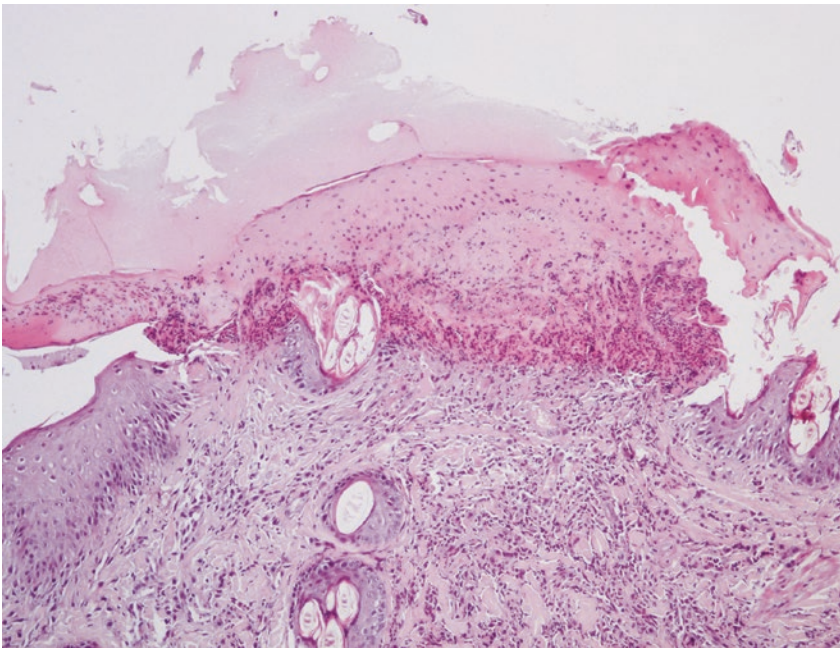


Fig. 3.6 Histopathology of a crusted papule: sero-neutrophilic crusts covering a small erythematous papule

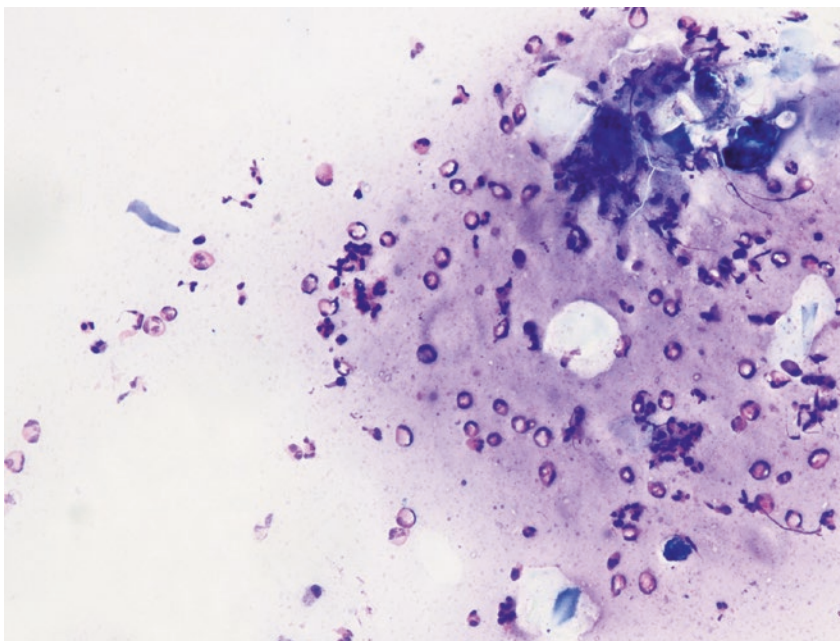


Fig. 3.7 Cytology of miliary dermatitis: many eosinophils and few corneocytes on a proteinaceous background

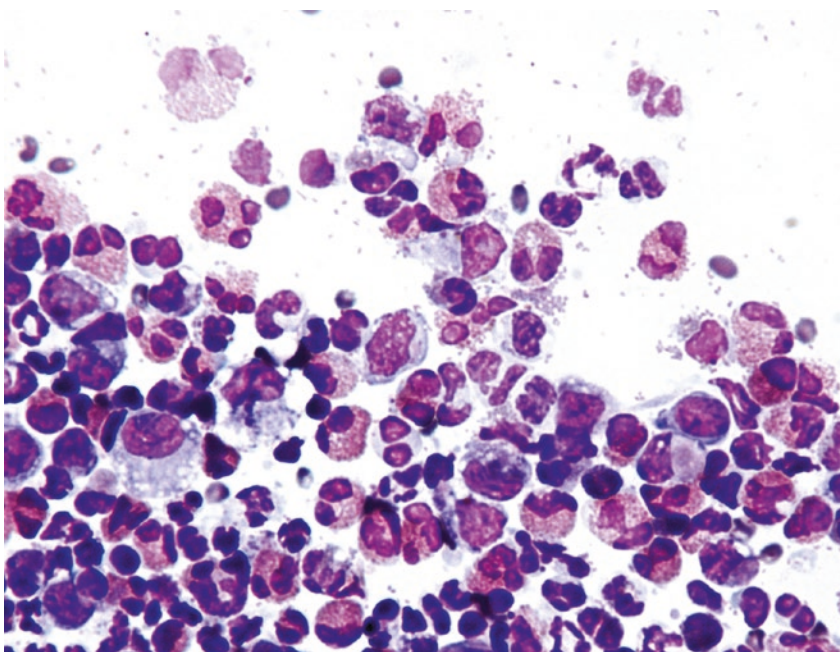


Fig. 3.8 Cytology of miliary dermatitis: many eosinophils intermingled with neutrophils and macrophages

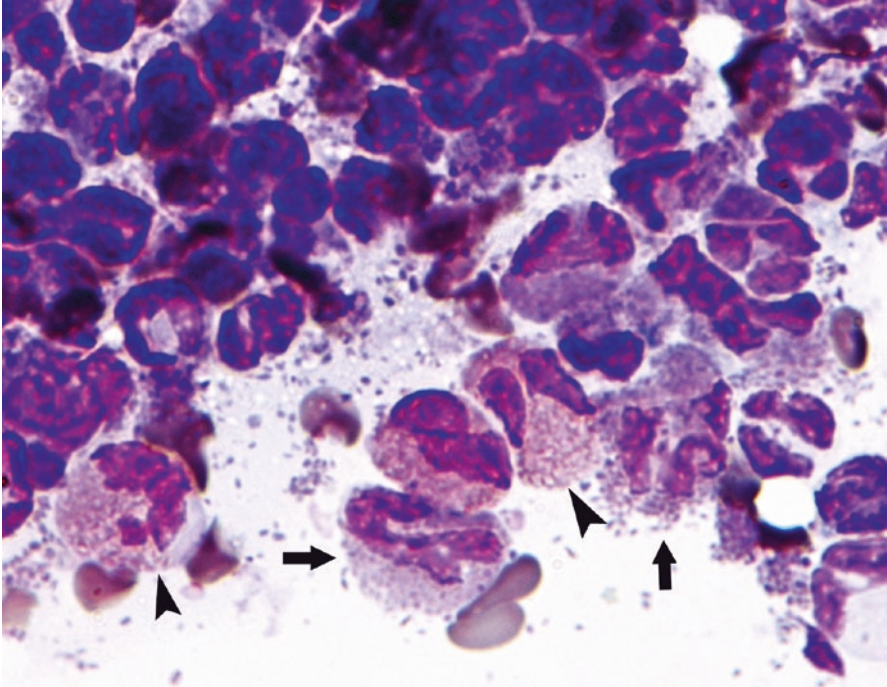


Fig. 3.9 Cytology of miliary dermatitis: basophils (*arrow*) and eosinophils (*head of arrow*)

3.2.2.2 Benign Papular Mastocytic Hyperplasia

In human medicine, urticaria pigmentosa is a form of cutaneous mastocytosis. An idiopathic papular disease, named *benign papular mastocytic hyperplasia*, and also defined as *urticaria pigmentosa-like* disease, has been reported in cats (Vitale et al. 1996; Noli et al. 2004). This disease has been reported in Sphynx and Devon rex cats as a clinical form of mastocytosis exclusively localised to the skin. The affected cats develop, in the early stages, many crusted papules (miliary dermatitis), which spread all over the body and with a linear configuration that is more evident on the ventral region of the abdomen (Fig. 3.10). Skin lesions often tend to coalesce, resulting in little plaques with thickened skin (Fig. 3.11). The cause of this disease is not known and as it is observed almost exclusively in these feline breeds, it is assumed that there may be a genetic cause. The healing of the lesions following immunomodulatory therapy and the non-specificity of the histopathological pattern make it impossible to differentiate from *feline hypersensitivity diseases*, which must always be ruled out. In rare cases, miliary dermatitis may be secondary to dermatophytic hypersensitivity. Some Devon rex cats affected by dermatophytosis and with clinical and histopathological lesions similar to urticaria pigmentosa-like disease, have been reported (Colombo et al. 2012).

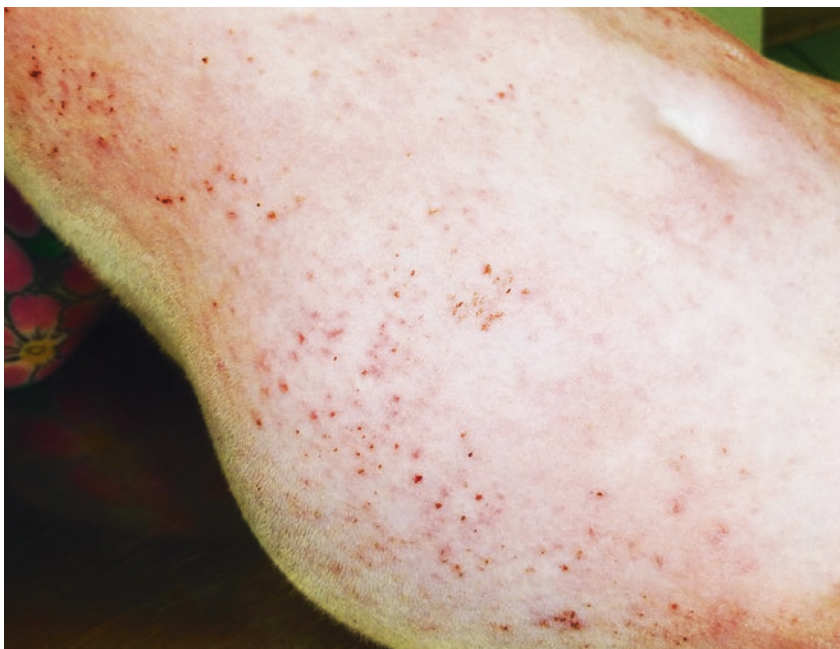

Fig. 3.10 Miliary dermatitis on the abdomen of a Sphynx cat affected by benign papular mastocytic hyperplasia

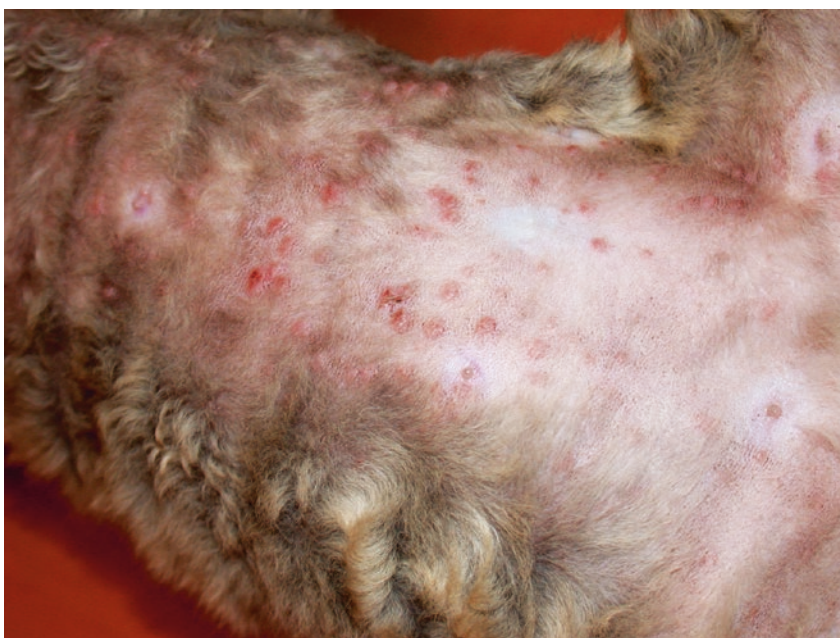

Fig. 3.11 Multiple papules and small plaques on the abdomen of a Devon rex with urticaria pigmentosa-like disease

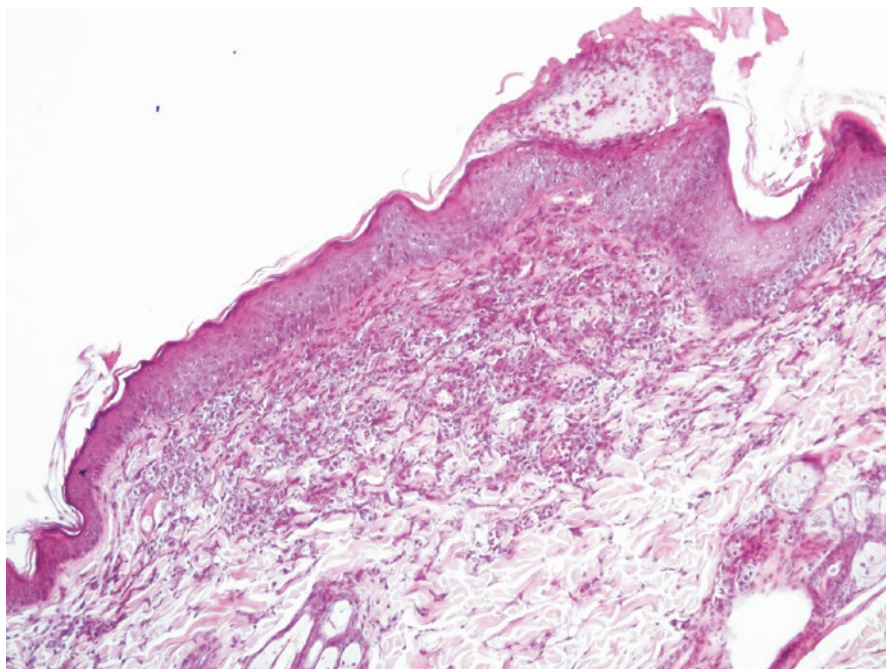


Fig. 3.12 Histopathology of benign papular mastocytic hyperplasia: superficial dermal infiltration of mast cells and eosinophils with mild hyperplasia of the epidermis

Cytological Findings

Histologically, the lesions are characterised by slight superficial perivascular dermatitis with a significant number of mast cells and few eosinophils (Fig. 3.12). Cytology obtained using the imprint technique, after removal of the crust that covers the top of crusted papules, is haemodiluted and usually characterised by neutrophils. Rarely, in more successful slides, specimens can show some well-differentiated mast cells and rare eosinophils, which do not authorise the diagnosis of *benign papular mastocytic hyperplasia*, but reinforce the suspicion of the disease, which must be confirmed with histopathology (Fig. 3.13).

3.3 Nodular Papules

Nodular papules provide more diagnostic specimens compared with papules, because their size permits more cells to be collected.

3.3.1 Deep Pyoderma (*Furunculosis*)

Histologically, rupture of the hair follicles following bacterial staphylococcal folliculitis creates small dermal pyogranulomas focused on corneocytes or on hair

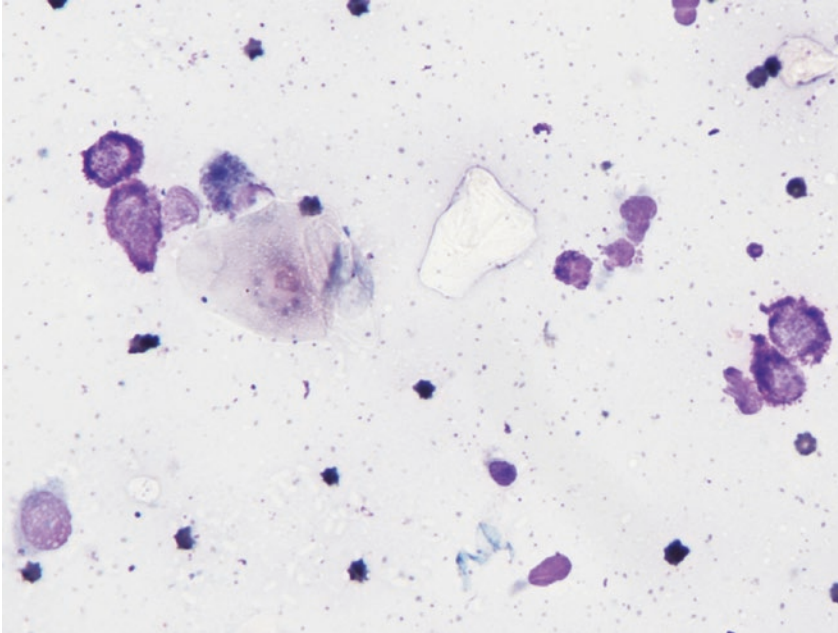


Fig. 3.13 Cytology of benign papular mastocytic hyperplasia: many well differentiated mast cells collected from papules

shaft fragments, both from follicular lumen (Figs. 3.14, 3.15, and 3.16) (Gross et al. 2005). Furunculosis in dogs with *deep pyoderma* is clinically characterised by papular–nodular lesions that are mostly detectable on the chin, on the limbs and among the interdigital areas, especially in shorthaired breeds (Figs. 3.17, 3.18, and 3.19) (Miller et al. 2013). Many nodular papules fistulise on the skin surface, where a purulent exudate is discharged; therefore, a large amount of cells can be collected for cytopathological examination via FNB of intact lesions or via an imprint on the exudate released from draining tracts.

Cytological Findings

Samples obtained by FNB are certainly of better quality and are usually composed of many inflammatory cells, mainly represented by numerous karyolytic and segmented neutrophils and macrophages. The latter are of variable size and morphology, with large and often vacuolated cytoplasm, and show phagocytosis of leukocytes, cellular debris, amorphous material and, sometimes, of melanin pigment (melanophages) in animals with pigmented skin or with post-inflammatory hyperpigmentation (Fig. 3.20). In dogs with furunculosis, keratin is spread in the dermis as lamellar corneocytes or as hair shaft fragments; because keratin is strongly antigenic and irritating, it attracts many inflammatory cells, but as keratinocytes are very large, normal macrophages are not able to eliminate them. For this reason, macrophages tend to transform into so-called *epithelioid macrophages*, larger cells with wide cytoplasm that resemble epithelial cells (hence the term “epithelioid”) and also give origin to *histiocytic multinucleate giant cells* (Gross et al. 2005).

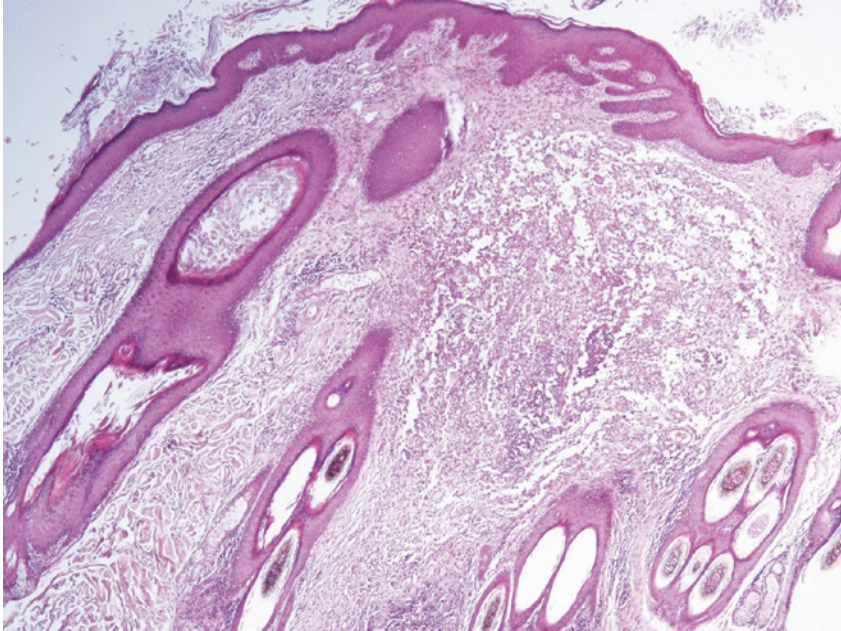


Fig. 3.14 Histopathology of deep pyoderma: large nodular pyogranulomatous inflammation replacing normal pilosebaceous units in a dog with deep pyoderma

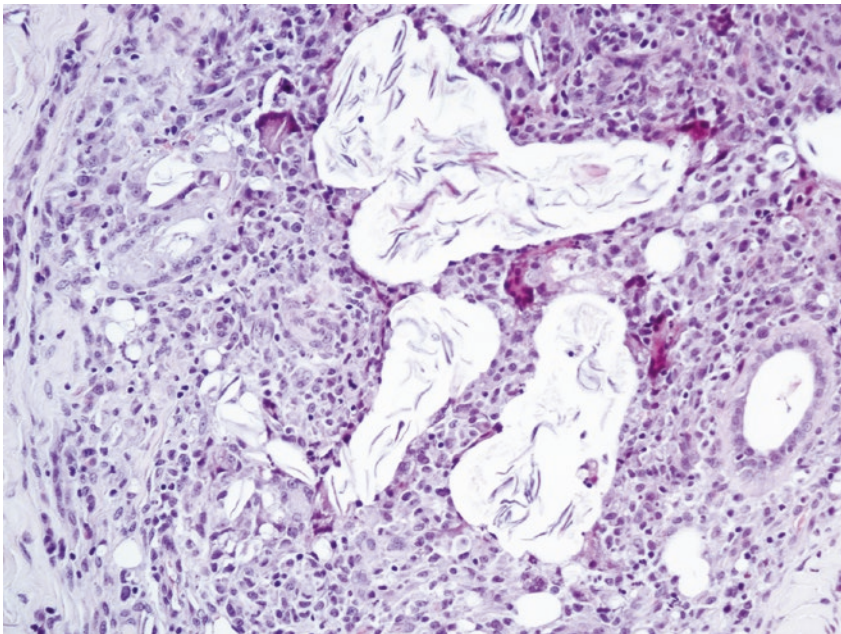


Fig. 3.15 Histopathology of deep pyoderma: granulomatous inflammation around lamellar corneocytes

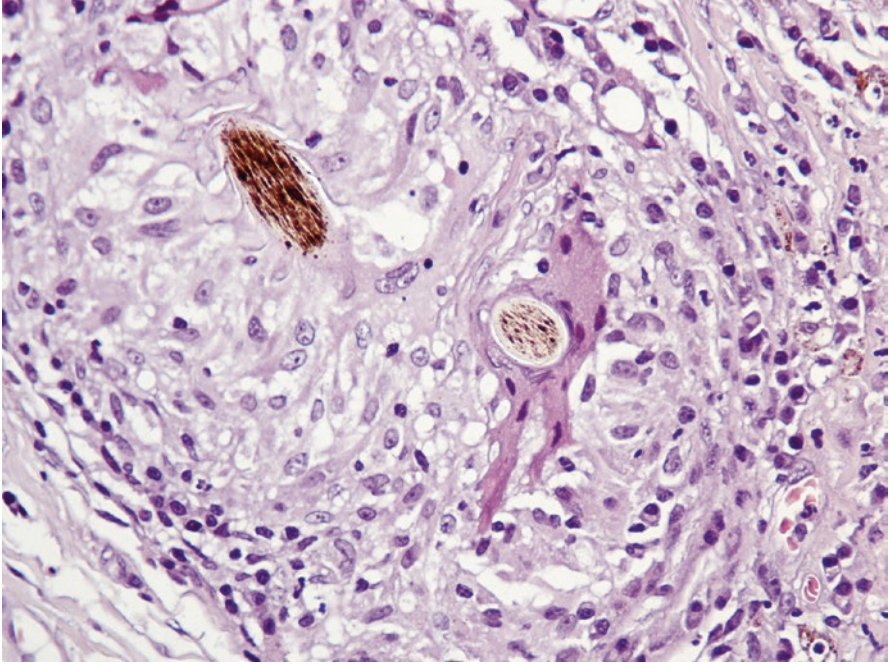


Fig. 3.16 Histopathology of deep pyoderma: epithelioid macrophages and a large giant cell; the latter is phagocytosing a hair shaft fragment

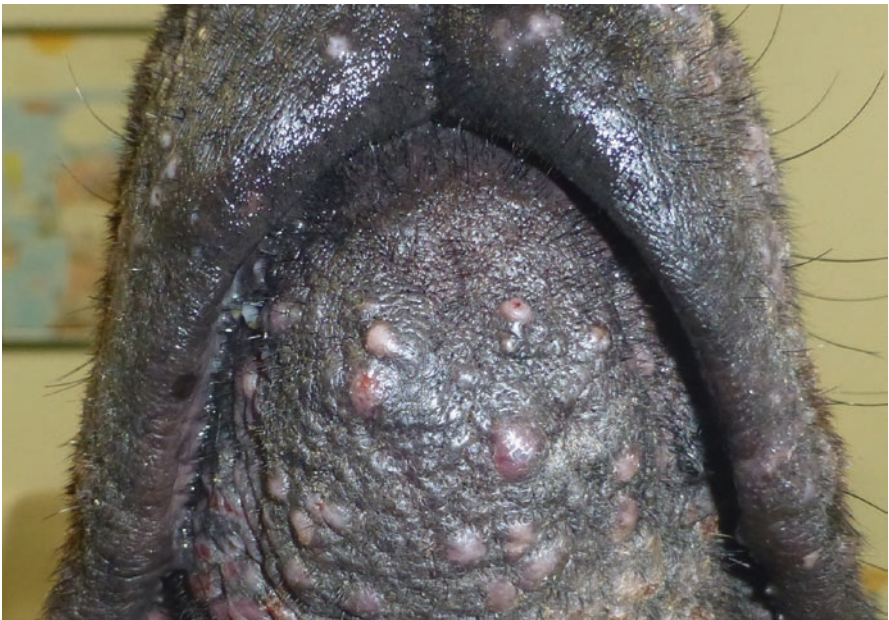

Fig. 3.17 Multiple nodular papules on the muzzle of a Doberman affected by deep pyoderma

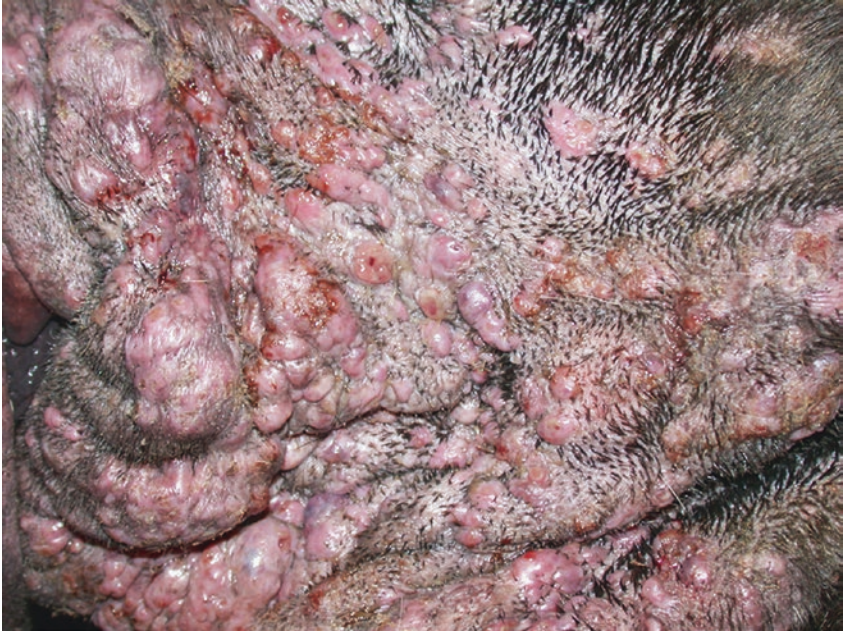

Fig. 3.18 Many single and confluent nodular papules on the muzzle and lips of a Neapolitan mastiff with deep pyoderma

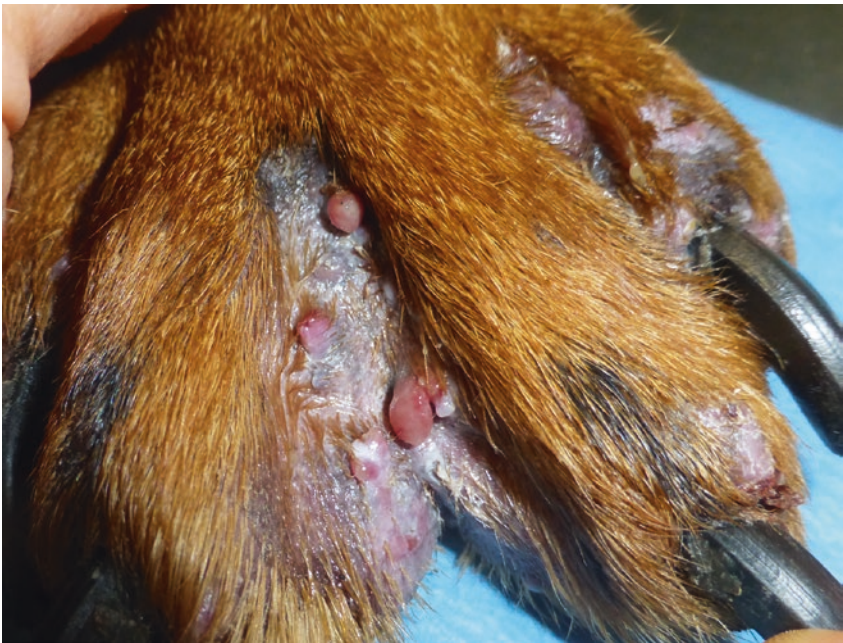

Fig. 3.19 Papular-nodular lesions in the interdigital spaces of a Doberman with pyoderma

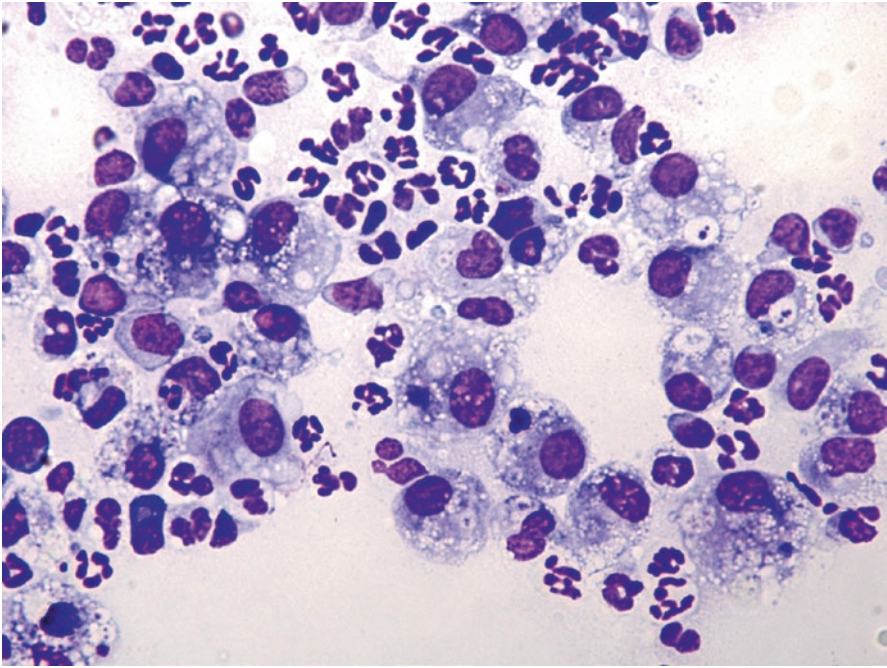


Fig. 3.20 Cytology of deep pyoderma: segmented neutrophils and many vacuolated macrophages showing leukophagocytosis

On cytological specimens, both cells are variably numerous and often arranged around single or rafts of corneocytes (Figs. 3.21, 3.22, and 3.23).

As the keratin acts as a true foreign body, the secondary impressive pyogranulomatous reaction observed in furunculosis is the reason why, in deep pyoderma, bacteria are not easily observed (Fig. 3.24). This cytological aspect is very important in canine skin cytology, because the failure to see bacteria in samples from deep pyogranulomatous lesions does not authorise us to rule out a pyoderma. In chronic lesions, cytological samples enriched with lymphocytes and plasma cells indicate continuous antigenic stimulation.

Similar clinical, cytological and histopathological findings are observed in dogs with furunculosis due to demodicosis (Figs. 3.25 and 3.26) (Gross et al. 2005; Mueller 2004; Mueller et al. 2012; Miller et al. 2013). The pathogenetic mechanism underlying the furunculosis is the same as deep pyoderma and although cytological examination is not the best technique for diagnosing demodicosis, it is sometimes possible, from FNB performed for papular–nodular lesions, to detect *Demodex canis* mites or their eggs, immersed in pyogranulomatous inflammation (Figs. 3.27, 3.28, and 3.29).

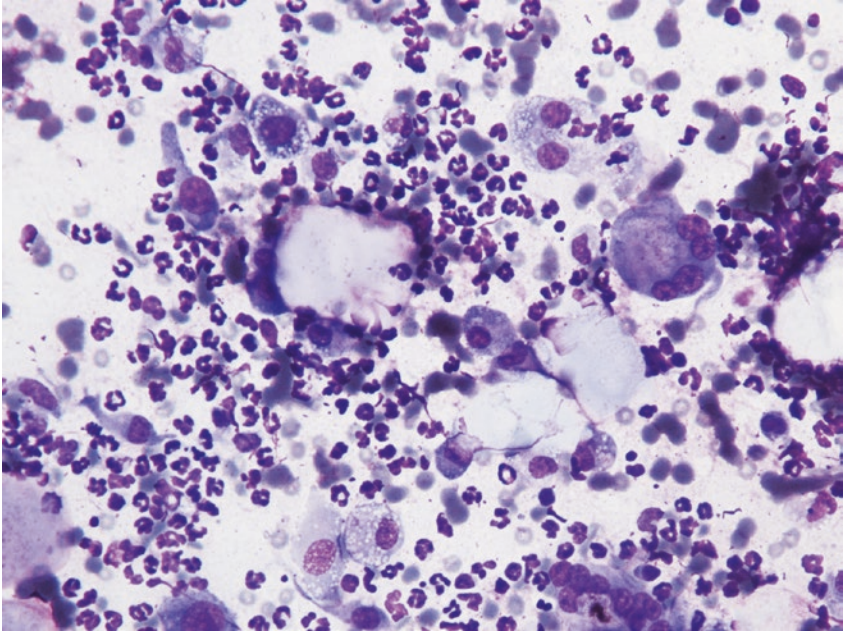


Fig. 3.21 Cytology of deep pyoderma: neutrophils, macrophages and multinucleated giant cells attacking keratinocytes

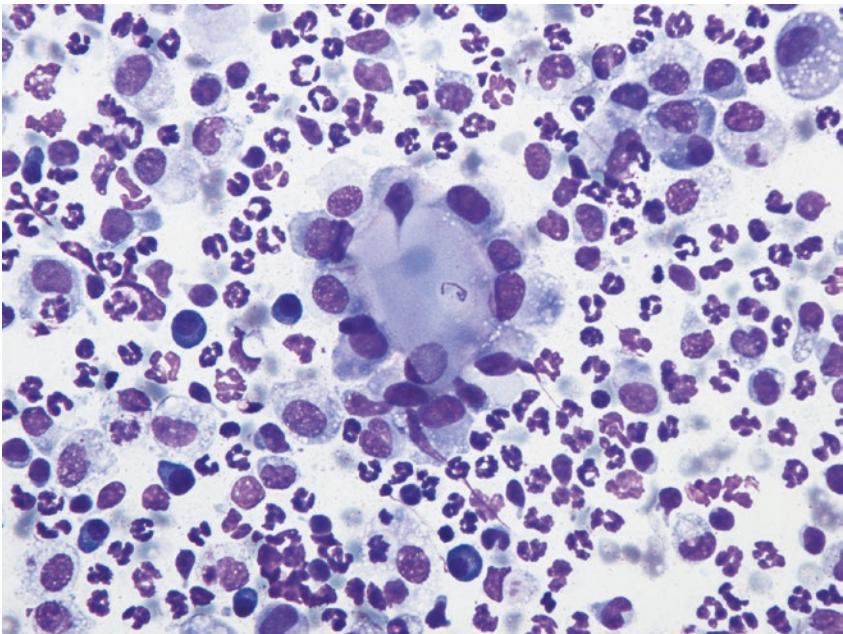


Fig. 3.22 Cytology of deep pyoderma: epithelioid macrophages surrounding a group of keratinocytes

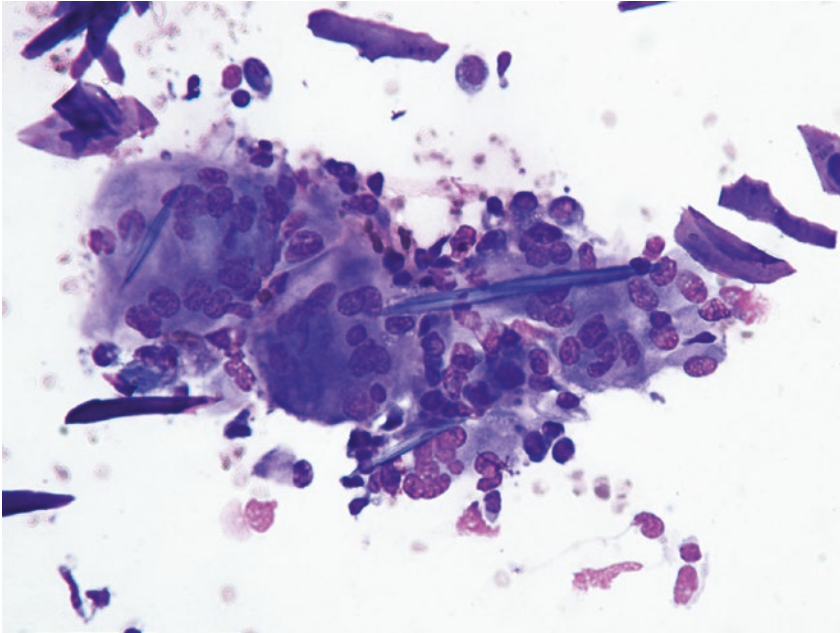


Fig. 3.23 Cytology of deep pyoderma: many giant cells are phagocytosing keratin fragments

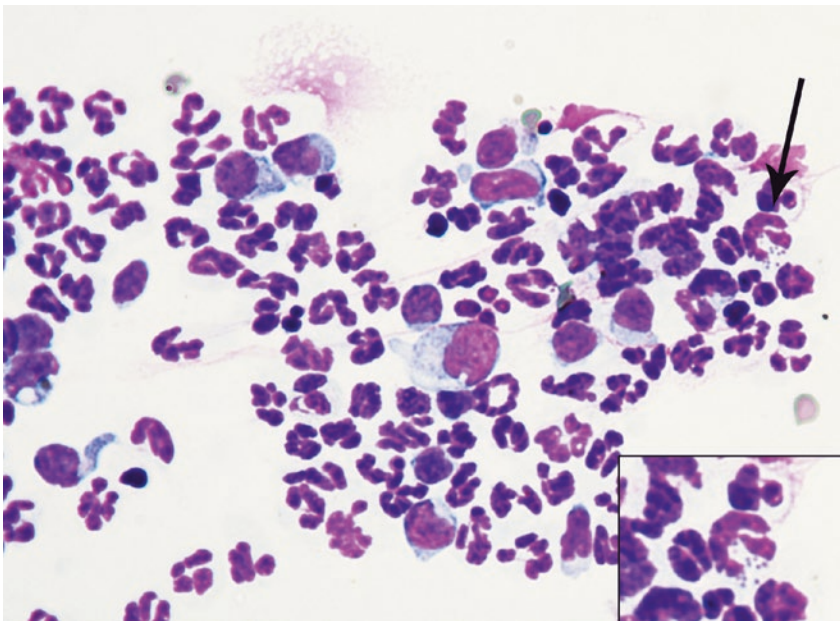


Fig. 3.24 Cytology of deep pyoderma: few macrophages and many karyolytic neutrophils with intracytoplasmic cocci (*arrow inset*)

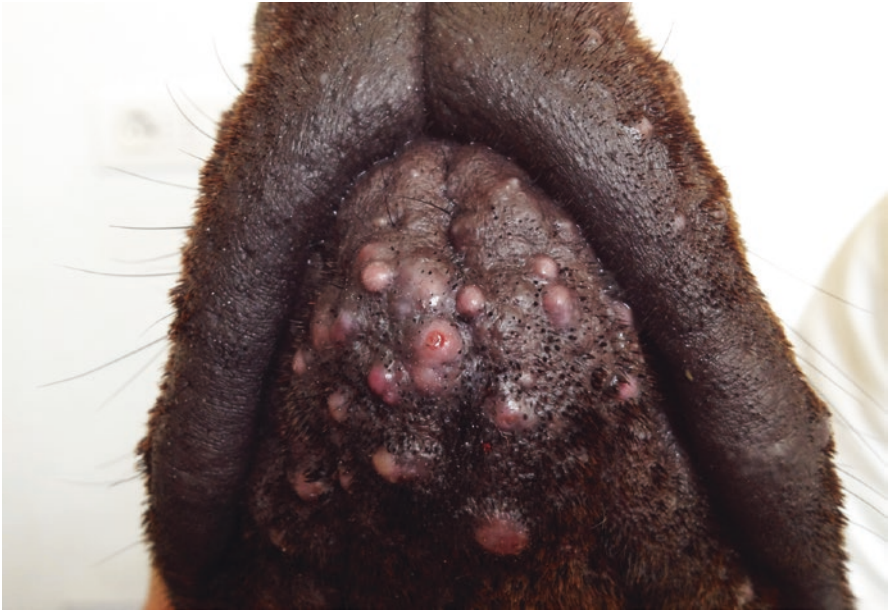

Fig. 3.25 Papular–nodular lesions with follicular plugs and comedones on the muzzle of a Dobermann with demodicosis

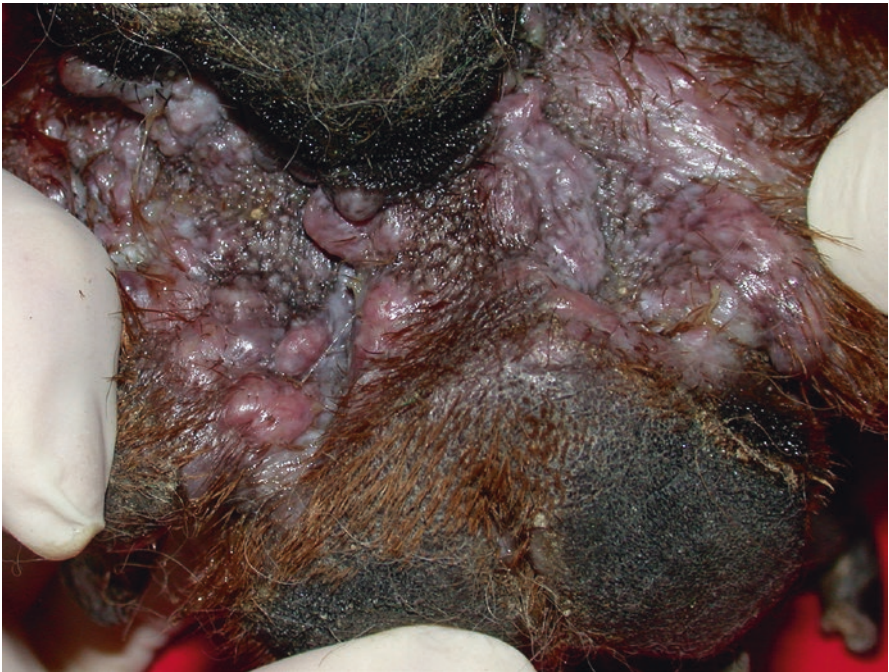

Fig. 3.26 Multiple confluent nodular papules on the interdigital area of a dog with demodicosis

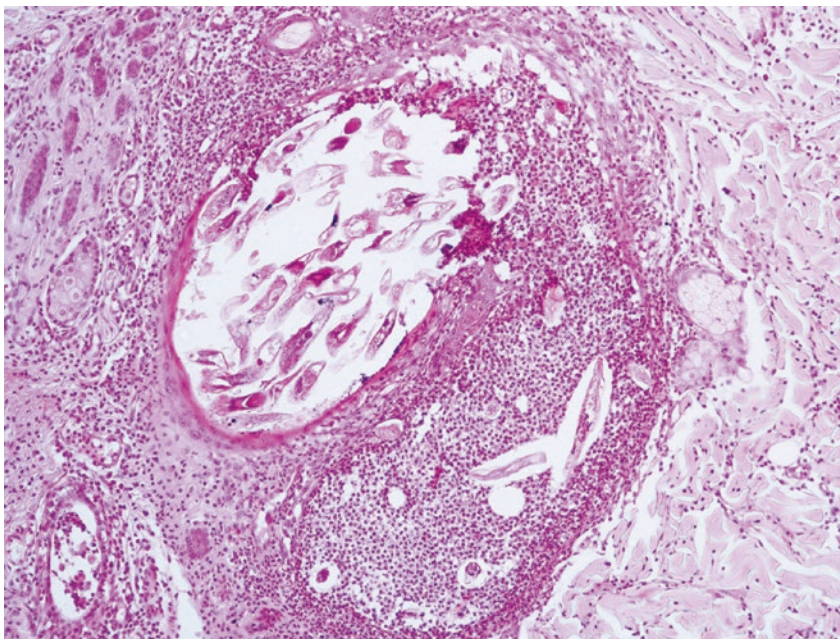


Fig. 3.27 Histopathology of demodicosis: many *Demodex canis* immersed in a pyogranulomatous exudate due to the rupture of an infested follicle

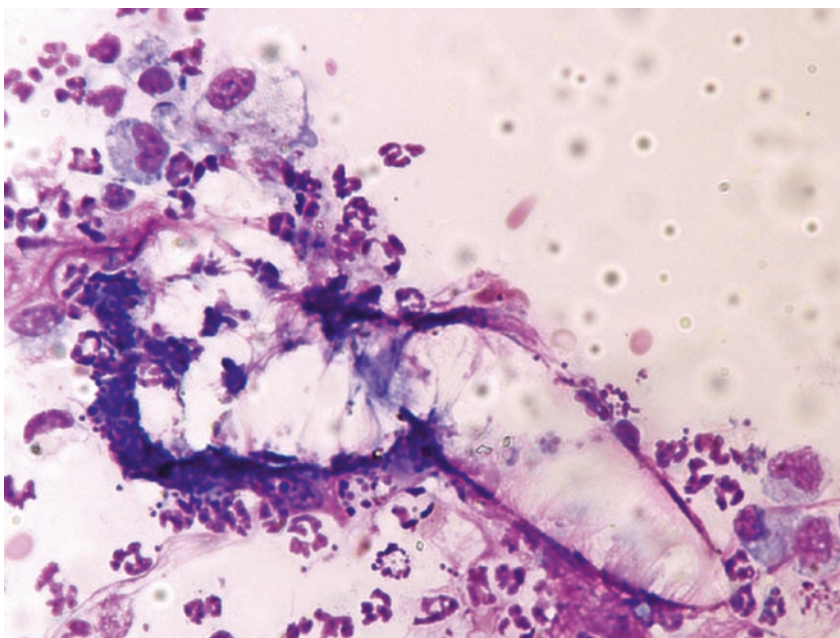


Fig. 3.28 Cytology of demodicosis: an adult *Demodex* surrounded by neutrophils and macrophages

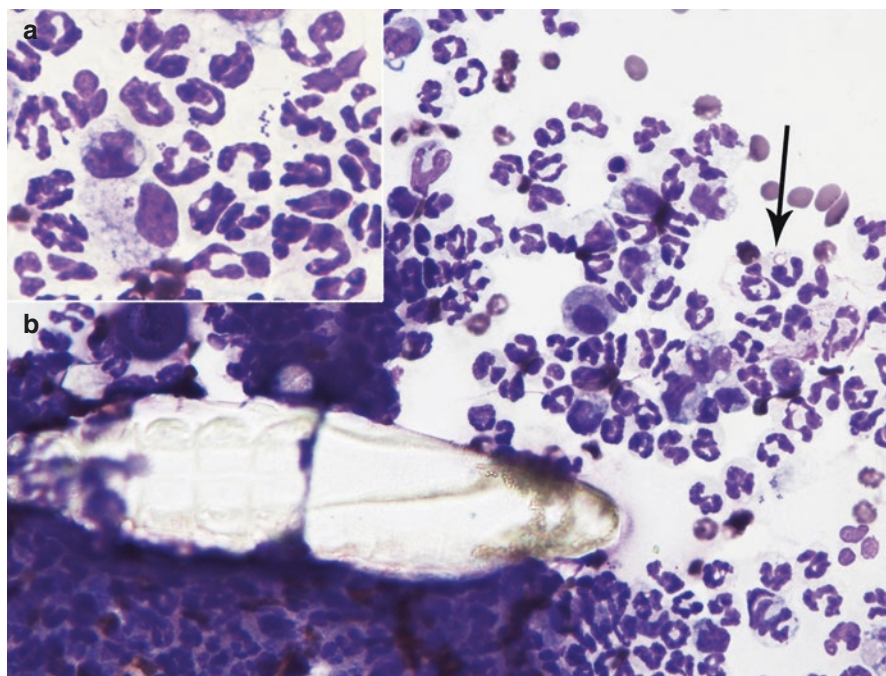


Fig. 3.29 Cytology of demodicosis: a *Demodex canis* mite surrounded by macrophages and neutrophils, the latter with many intracytoplasmic cocci (arrow); cocci are well recognizable into the cytoplasm of neutrophils and into a macrophage (inset)

3.3.2 Facial Eosinophilic Furunculosis

Eosinophilic furunculosis is a disease of dogs, characterised by the acute onset of papular–nodular lesions, mostly located on the face and less frequently on other parts of the body such as the pinna, neck, abdomen and limbs. Early lesions are represented by nodular papules, mainly spread over the bridge of the nose and muzzle (Fig. 3.30) (Curtis et al. 1995; Gross 1993; Guaguère et al. 1996). In a few hours, nodular papules tend to grow and merge with each other, giving rise to plaques and nodules, which tend to ulcerate and become infected (Fig. 3.31). Eosinophilic furunculosis is usually very pruritic and this is the reason why self-trauma can rapidly change the initial papular–nodular appearance (Fig. 3.32).

Cytological Findings

Although histologically the target of the inflammatory process are the follicles that cause furunculosis, the number of giant cells observed in cytological specimens is very low compared with what is usually seen in furunculosis from deep pyoderma (Fig. 3.33). The specimens of early and non-infected lesions are therefore characterised by a high number of eosinophils, macrophages and a variable number of neutrophils (Gross et al. 2005). Epithelioid macrophages and multinucleated cells are present in variable amounts (Figs. 3.34 and 3.35).

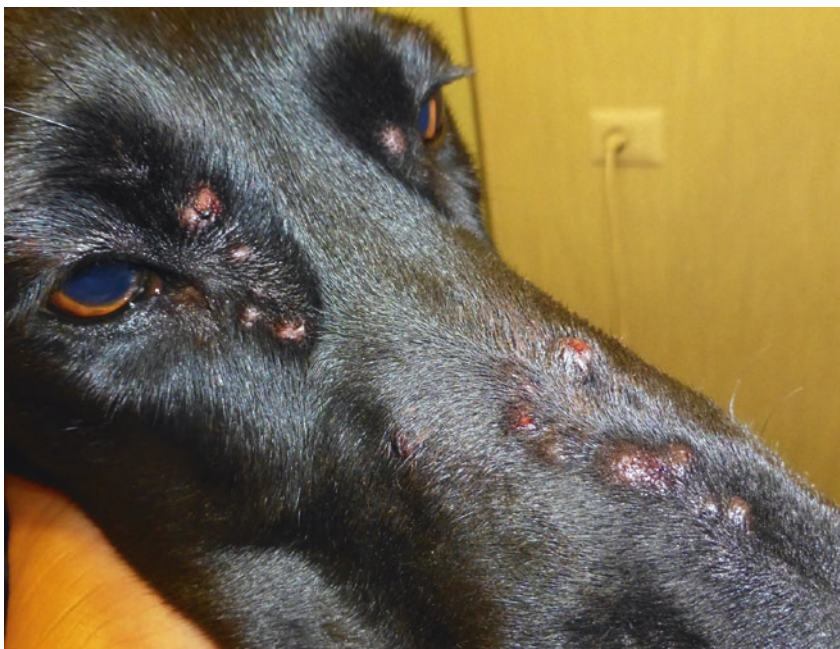

Fig. 3.30 Many small erythematous nodular papules on the bridge of the nose and eyelids of a dog with eosinophilic furunculosis

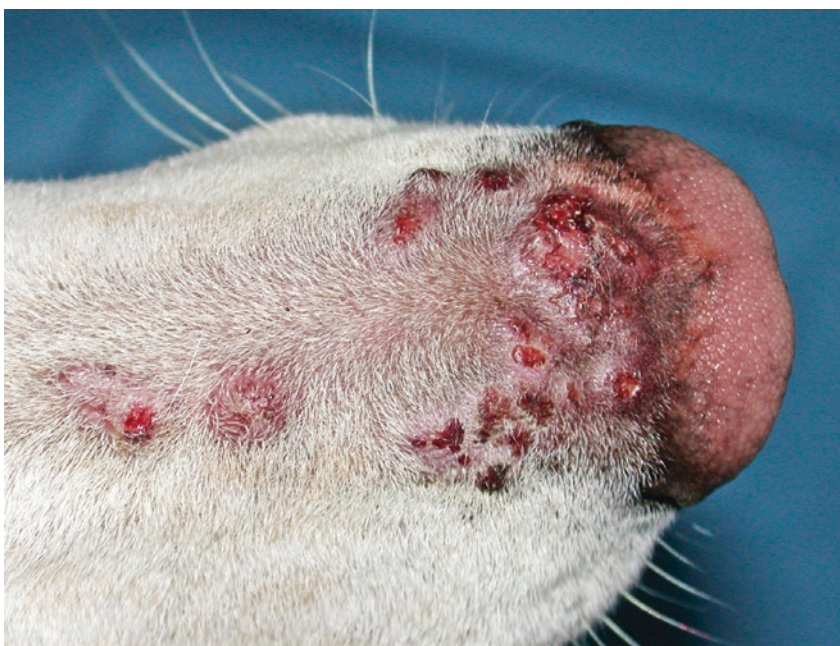

Fig. 3.31 Single and confluent papular nodular lesions on the nose of a dog with eosinophilic furunculosis

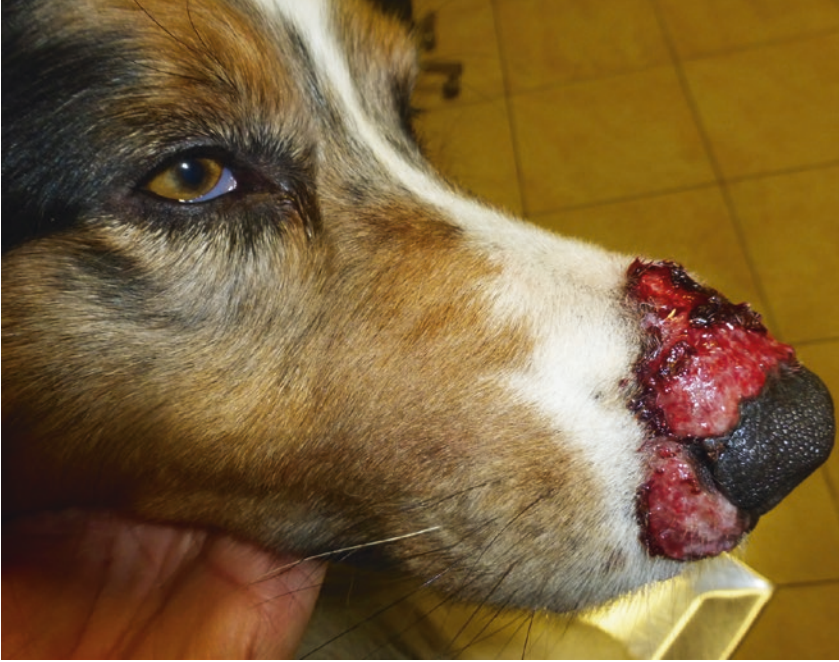

Fig. 3.32 Ulcerative lesions secondary to self-trauma in an Australian shepherd with eosinophilic furunculosis

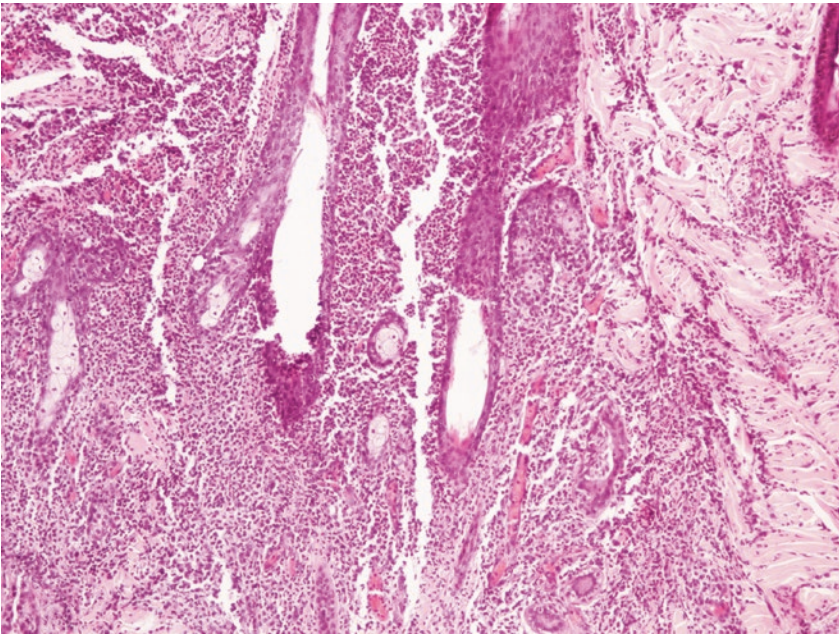


Fig. 3.33 Histopathology of eosinophilic furunculosis: note that the follicles are the target of the eosinophilic inflammation

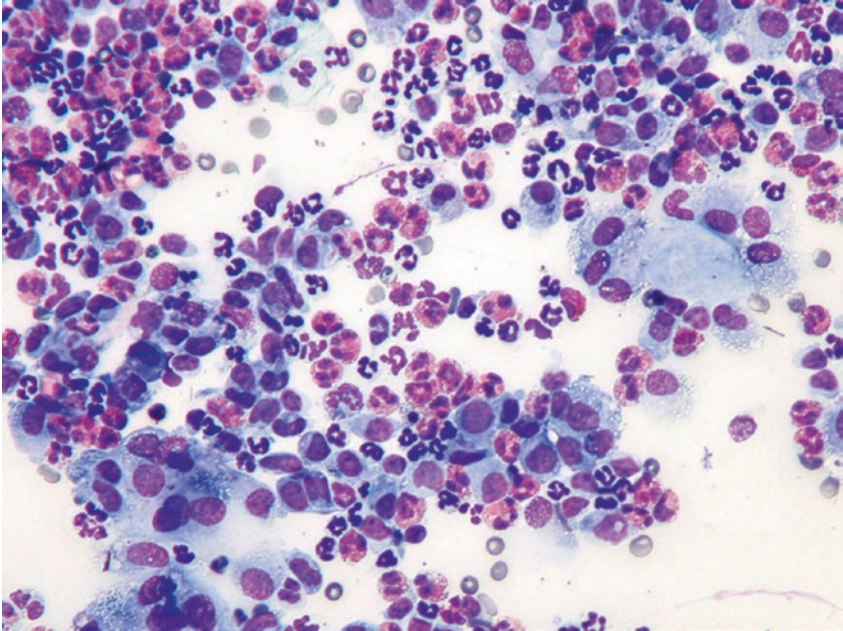


Fig. 3.34 Cytology of eosinophilic furunculosis: many eosinophils and macrophages. Note that the corneocytes are attacked by epithelioid macrophages

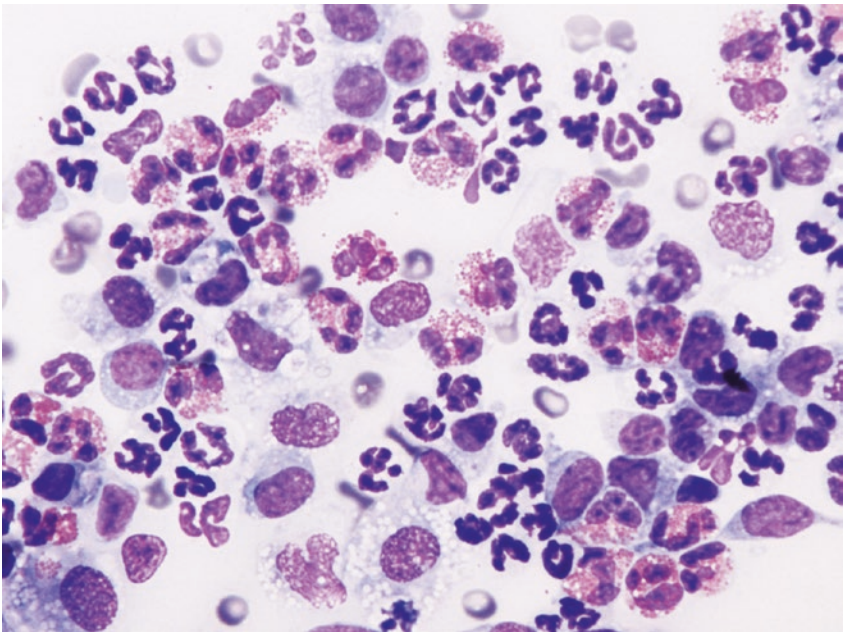


Fig. 3.35 Cytology of eosinophilic furunculosis: neutrophils, macrophages and many eosinophils

Karyolytic neutrophils with cocci, intermingled with eosinophils, are only observed in secondarily infected lesions. A low number of lymphocytes and plasma cells completes the cytological findings.

3.3.3 Papular–Nodular Canine Leishmaniasis

Canine leishmaniasis is a protozoan disease characterised by a wide clinical polymorphism, depending on the type of immune response developed by affected dogs. In the clinical classification of canine leishmaniasis, a form characterised only by *papular–nodular lesions*, mainly located on hairless areas of the face, the bridge of the nose, eyelids, the inner surface of the pinna, and less frequently on the hairless areas of the abdomen and thighs, has been reported (Ordeix et al. 2005; Bottero et al. 2006; Solano-Gallego et al. 2009, 2011; Lombardo et al. 2014). Lesions are alopecic, slightly erythematous and mostly characterised by an *umbilicated* shape with a central depression (Figs. 3.36, 3.37, and 3.38). Usually, these types of lesions are observed in young dogs with no other dermatological signs and systemic symptoms, with normal blood values and negative or very low anti-leishmanial antibody titres. Some authors speculate that such lesions might represent a local reaction to phlebotomus bites in immunocompetent animals (Ordeix et al. 2005).

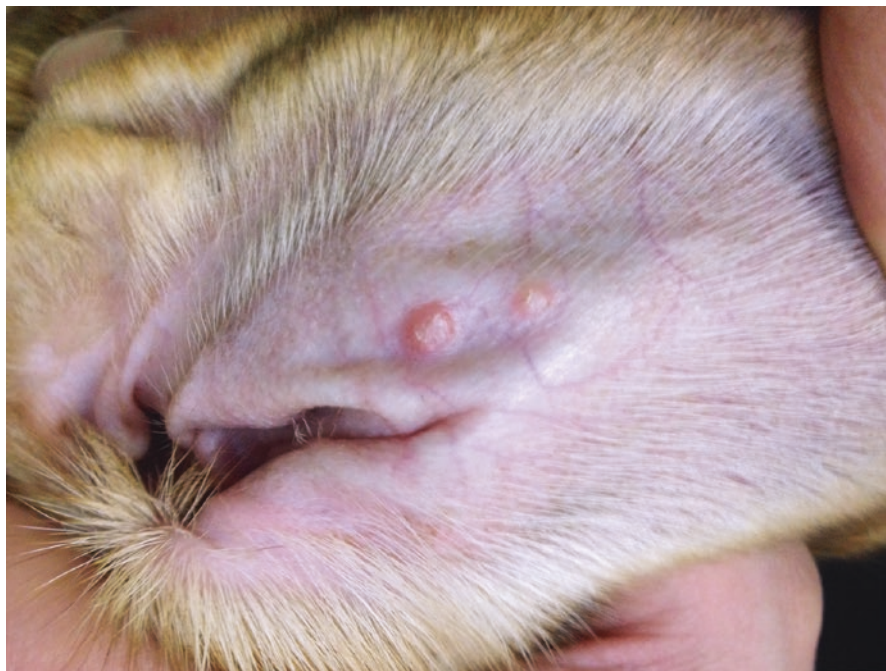

Fig. 3.36 Two nodular papules on the inner surface of the pinna of a leishmaniotic dog

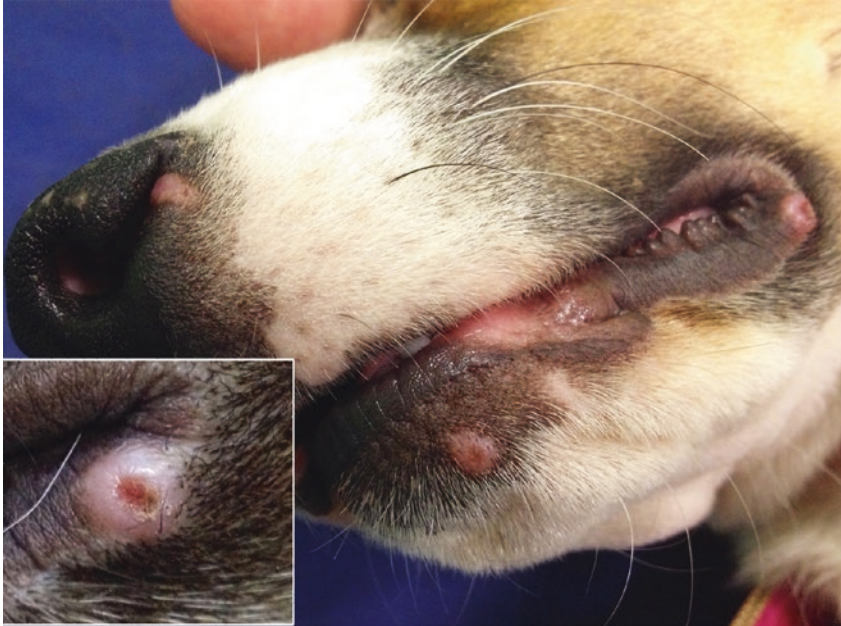

Fig. 3.37 Multiple papular–nodular lesions on the nose and lips of a young dog with canine leishmaniosis. *Inset:* typical umbilicated shape of a nodular papule

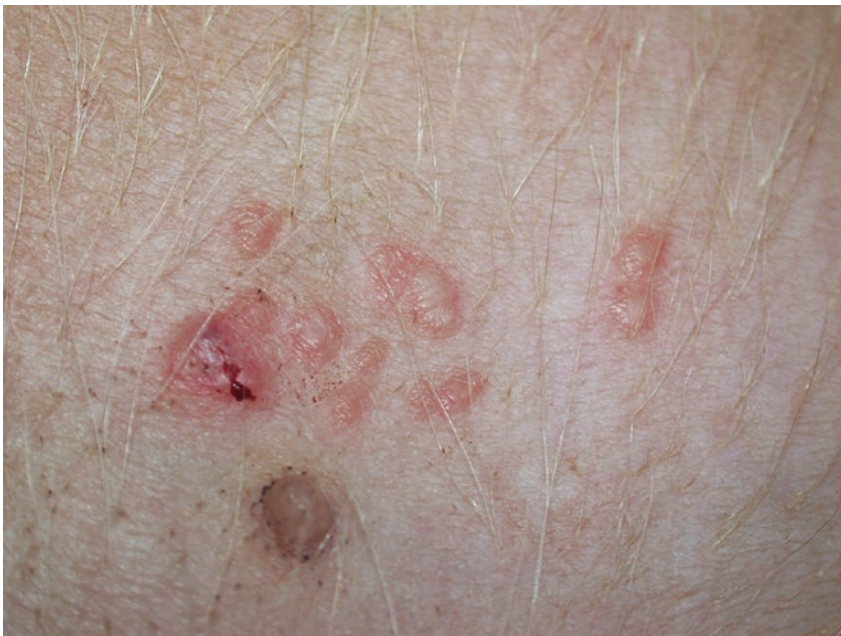

Fig. 3.38 Multiple nodular papules on the abdomen of a Dogue de Bordeaux with papular leishmaniasis

Cytological Findings

The *Leishmania infantum* amastigotes are recognisable by their characteristic oval shape, measuring approximately $1-2 \times 2-5 \mu\text{m}$, containing a rod-shaped hyperchromatic *kinetoplast*, from which the flagellum originates in the *promastigote* stage. Morphology of *Leishmania* spp. is easy to recognise when the kinetoplast is perpendicular to the nucleus, giving a T-shaped appearance (Fig. 3.39). Histopathological examinations of skin biopsies reveal a nodular or diffuse lympho-histio-plasmacellular dermatitis (Fig. 3.40) (Gross et al. 2005). Mixed inflammatory cells characterise slides, together with a variable number of amastigotes in the cytoplasm of macrophages (Fig. 3.41). In literature, there are discrepancies about the number of amastigotes that can be detected in cytological specimens from this lesions; some articles report a low number of parasites (Ordeix et al. 2005), whereas in other case reports, the number of amastigotes detected was consistently high (Bottero et al. 2006; Noli and Corneigliani 2006). Anecdotally, according to some of these authors, the number of amastigotes may be related to the chronicity of the lesions. Cytological specimens are mainly composed of macrophages and many lymphocytes and plasma cells, whereas the number of amastigotes can be so low that specimens must be carefully observed to detect few protozoa (Fig. 3.42). Sometimes, as reported, immunohistochemical staining is needed to confirm the presence of the parasites (Ordeix et al. 2005).

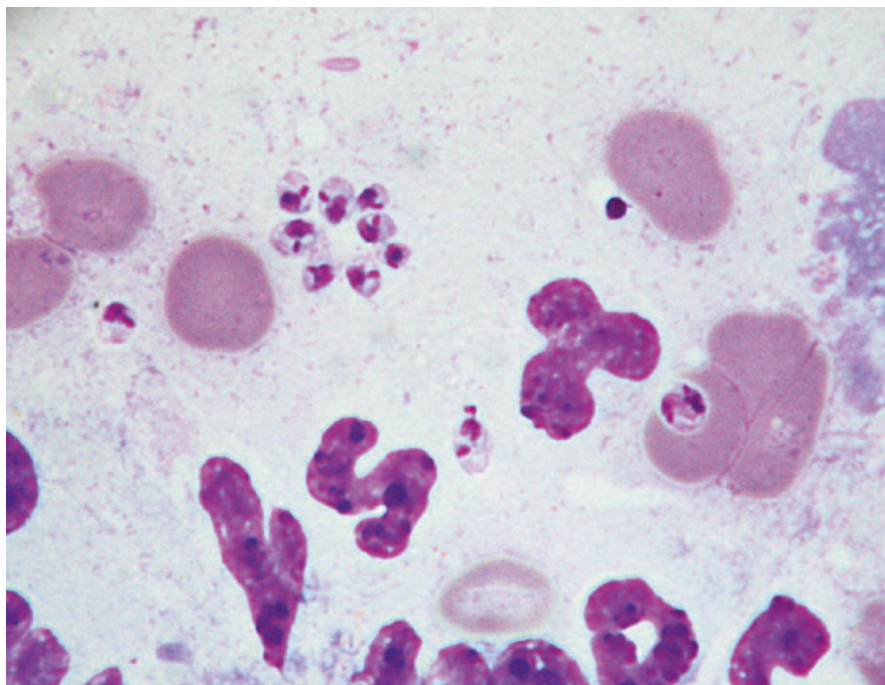


Fig. 3.39 Cytology of leishmaniasis: amastigotes of *Leishmania* spp. in which kinetoplast is easily recognisable as a rod-shaped structure

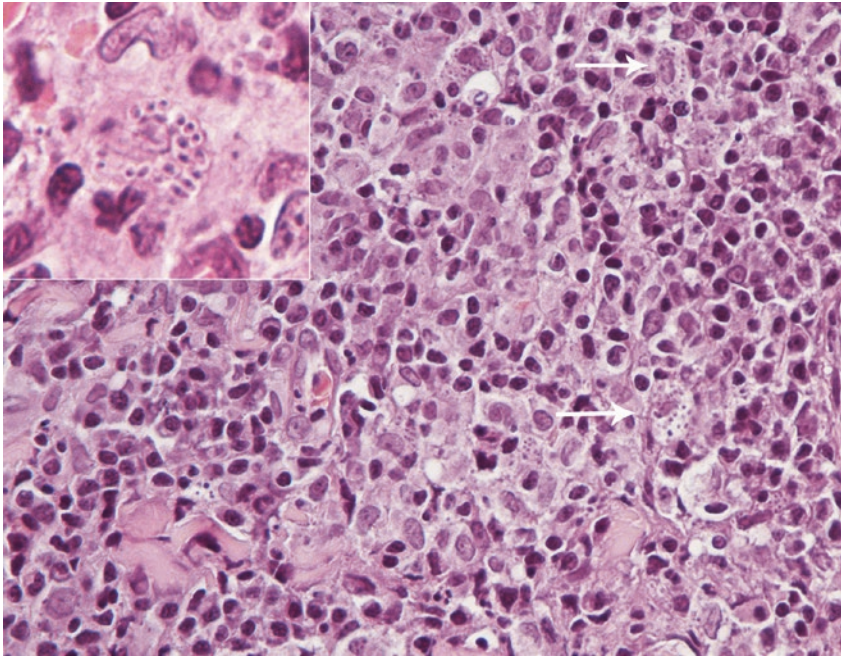


Fig. 3.40 Histopathology of leishmaniasis: diffuse dermatitis composed mostly of macrophages, lymphocytes and plasma cells. Many macrophages are filled with matigotes (*arrow, inset*)

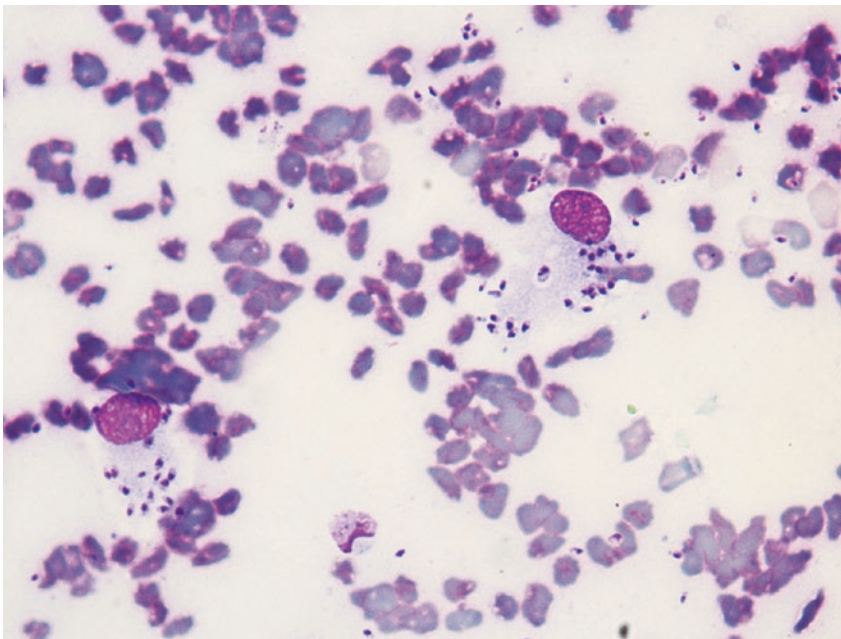


Fig. 3.41 Cytology of leishmaniasis: many amastigotes, both free and in the cytoplasm of macrophages

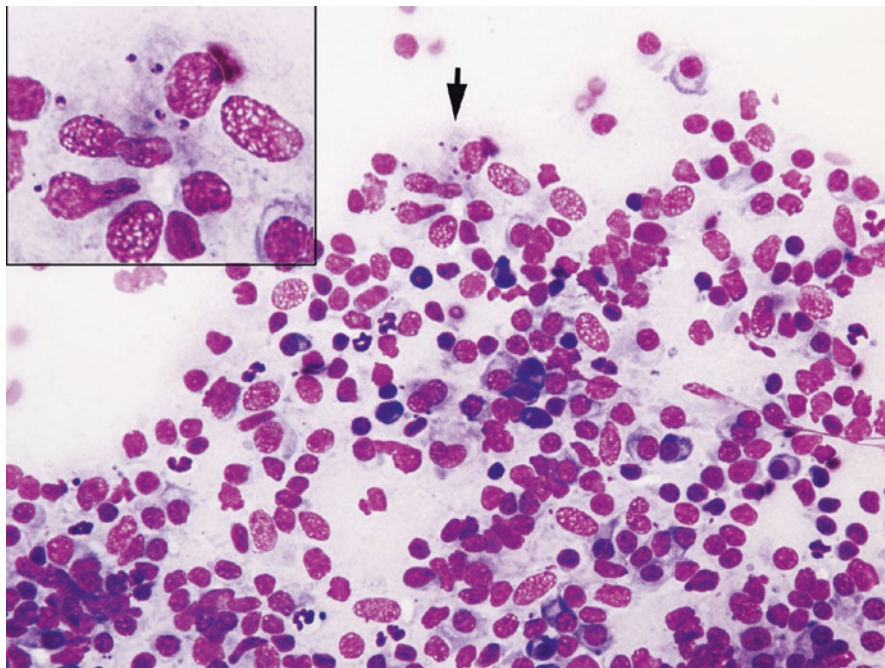


Fig. 3.42 Cytology leishmaniasis: many macrophages and plasma cells; few amastigotes are evident in the cytoplasm of macrophages (*arrow, inset*). Note that neutrophils are completely absent

3.3.4 Sterile Granuloma and Pyogranuloma Syndrome

Although *sterile granuloma and pyogranuloma syndrome* (SGPS) is commonly included under nodular dermatitis, because in the early phases the lesions appear as nodular papules, it is discussed in this chapter. SGPS is rare in dogs and extremely rare in cats. In dogs, lesions are mainly located on the face, eyelids, nose, bridge of the nose and pinna, and with regard to clinical aspect, size and location, they are very similar to those observed in papular–nodular leishmaniasis from which it must be always differentiated. In some dogs, the lesions may coalesce to form plaques or primarily arise as true nodules, which can be observed in different areas of the body (Figs. 3.43, 3.44, 3.45, and 3.46) (Scott et al. 1990; Panich et al. 1991; Miller et al. 2013).

The SGPS is a sterile idiopathic disease and, although some authors have suggested that an infectious antigen can cause an immunity dysfunction that results in an aberrant histiocytic immune response, its real pathogenesis is still unknown. The histological features and the good response to immunomodulatory drugs suggest the sterile nature of the lesions (Scott et al. 1990; Gross et al. 2005; Miller et al. 2013). In a study of 46 dogs with a histological diagnosis of SGPS, 21 were positive for *Leishmania* according to polymer chain reaction (PCR) and immunohistochemical staining (Corneigliani et al. 2005). The meaning of this positivity needs to be clarified because the detection of DNA fragments of amastigotes in the skin does not necessarily imply that they play a role in the development of the lesions.



Fig. 3.43 Papular nodules on the eyelids of a dog with sterile granuloma and pyogranuloma syndrome (SGPS)

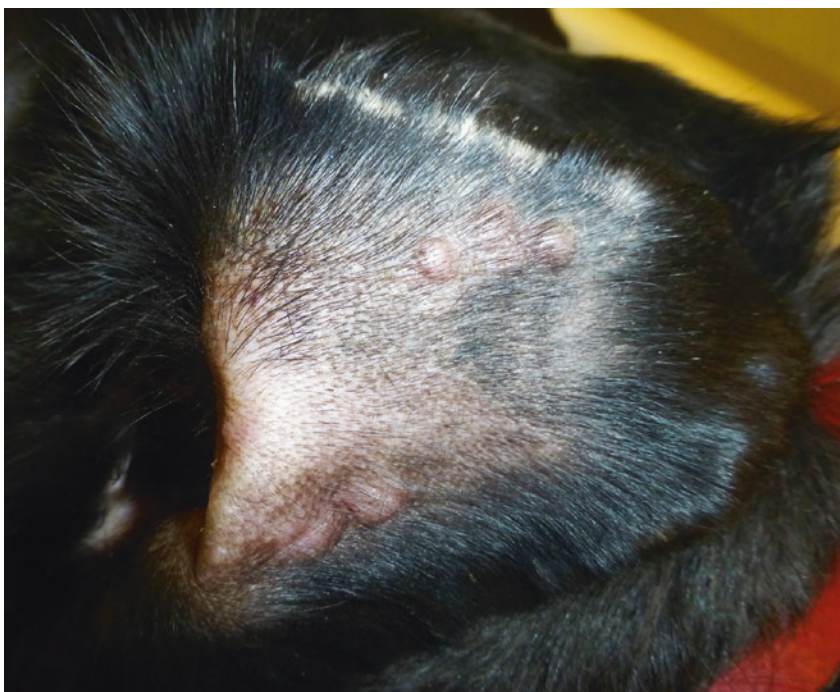

Fig. 3.44 Papular nodules on the inner surface of the pinna

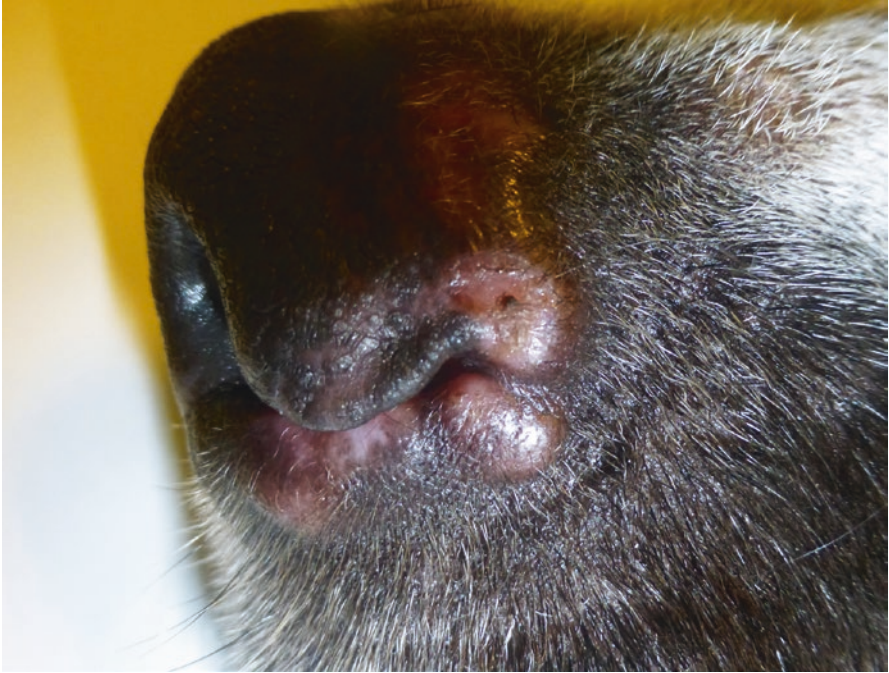

Fig. 3.45 Papular nodules on the mucocutaneous junction of the left nostril

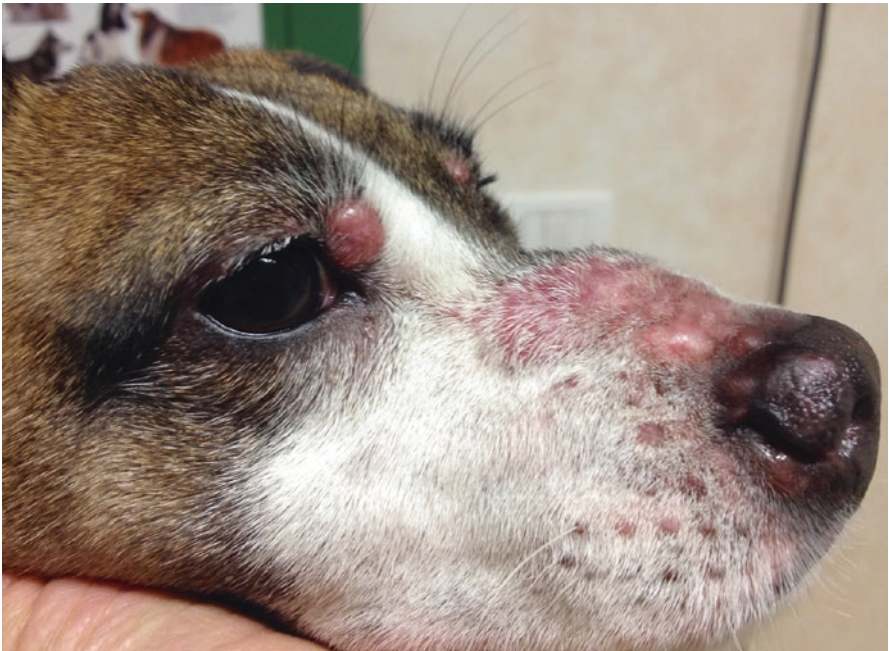


Fig. 3.46 Confluent papular nodules, which form plaques on the bridge of the nose of a Jack Russell terrier with SGPS

Regarding SGPS, the term *sterile* should only be attributed to cases where granulomatous/pyogranulomatous lesions with typical clinical and histopathological findings and those in which any microorganisms have been excluded by special stains, PCR, immunohistochemistry and bacterial culture.

Further studies are needed to determine the true sterile nature of the lesions included in the SGPS group or if the possibility of a triggering stimulus operated by infectious agents really exists.

Cytological Findings

A typical histopathological feature of SGPS is *perifollicular granulomas* with a characteristic *elongated* or *sausage-like* shape (Figs. 3.47 and 3.48).

In the early phase of the disease, as granulomas are small and scattered between follicles, it is not always easy to collect a large number of cells; indeed, in these cases, it is very difficult to centre the small granulomas with the needle. However, when granulomas merge and transform from nodular to diffuse dermatitis, it is easier to obtain more cellular samples. When this situation occurs, the typical histological aspect of SGPS is lost. Despite the term pyogranuloma, the number of neutrophils is usually poor and, when present, they are clearly segmented and located in the centre of the granulomas. Slides are therefore usually characterized by a high number of poorly vacuolated macrophages and epithelioid macrophages, the latter with oval to kidney-shaped nuclei and moderate to

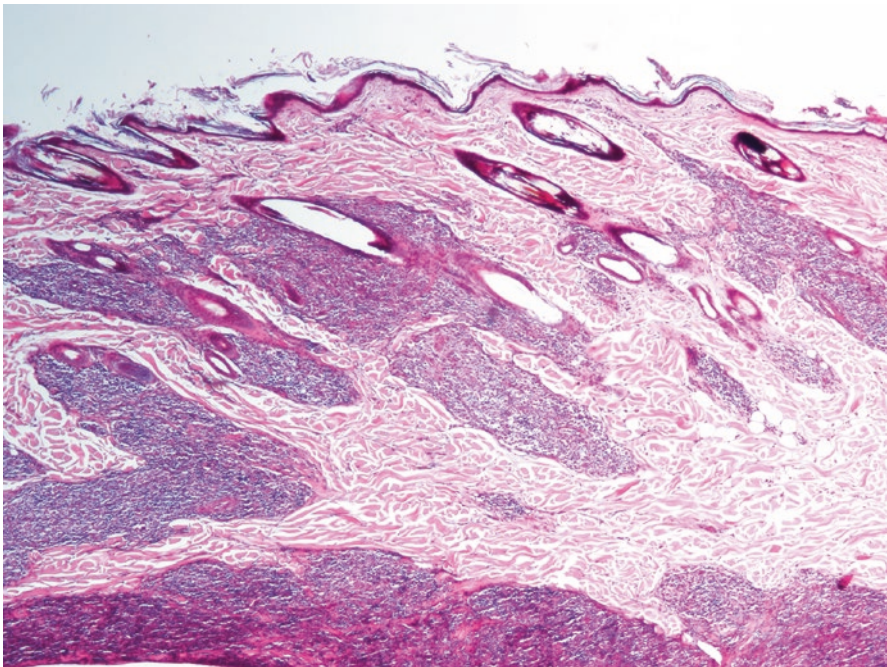


Fig. 3.47 Histopathology of SGPS: multiple elongated perifollicular nodules

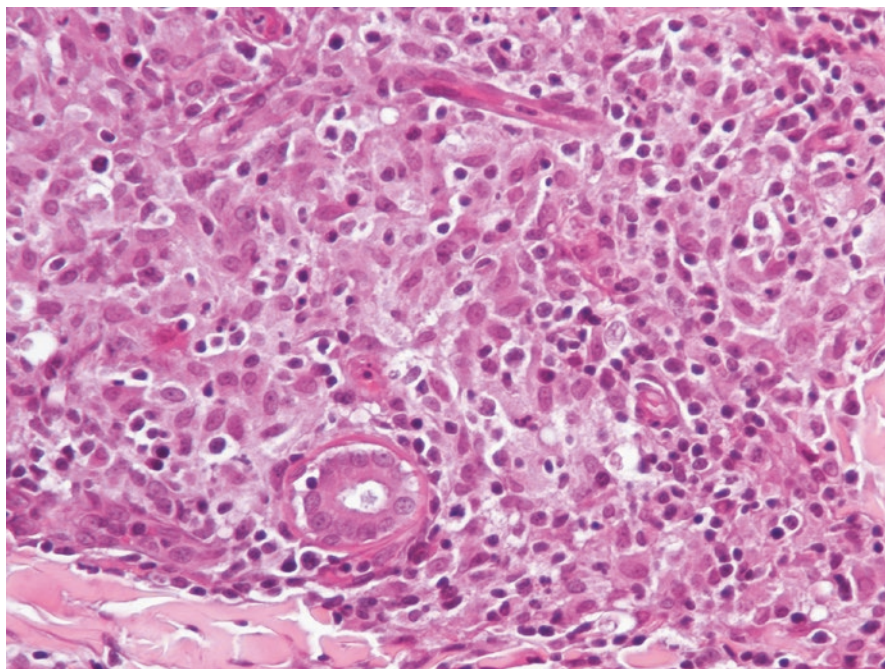


Fig. 3.48 Histopathology of SGPS: at high magnifications it is possible recognise many histiocytes and lymphocytes

large, slightly grey–blue cytoplasm. Many histiocytes are represented by bare nuclei, associated with a variable number of lymphocytes and a few plasma cells. The main clinical–cytological differential is with the papular–nodular form of canine leishmaniasis. In specimens in which amastigotes are not detected, it is in fact impossible to cytologically differentiate SGPS from canine leishmaniasis. The main cytological difference between these two diseases is probably the higher number of plasma cells observed in the latter (Figs. 3.49 and 3.50).

3.3.5 *Calcinosis Cutis*

Skin tissue mineralisation can occur through different pathogenetic mechanisms: dystrophic, metastatic, idiopathic and iatrogenic. *Calcinosis cutis* is a skin disease characterised by widespread mineralisation of the dermis (collagen fibres) and rarely of the epidermidis. The mineral salts deposited in the skin, are insoluble inorganic compounds mainly composed of a combination of *calcium*, *phosphate* and *carbonate* salts. Because the former are the most common, the term *calcinosis* is commonly used to describe the presence of mineral salts, even if their composition has not been investigated (Gross et al. 2005; Doerr et al. 2013).

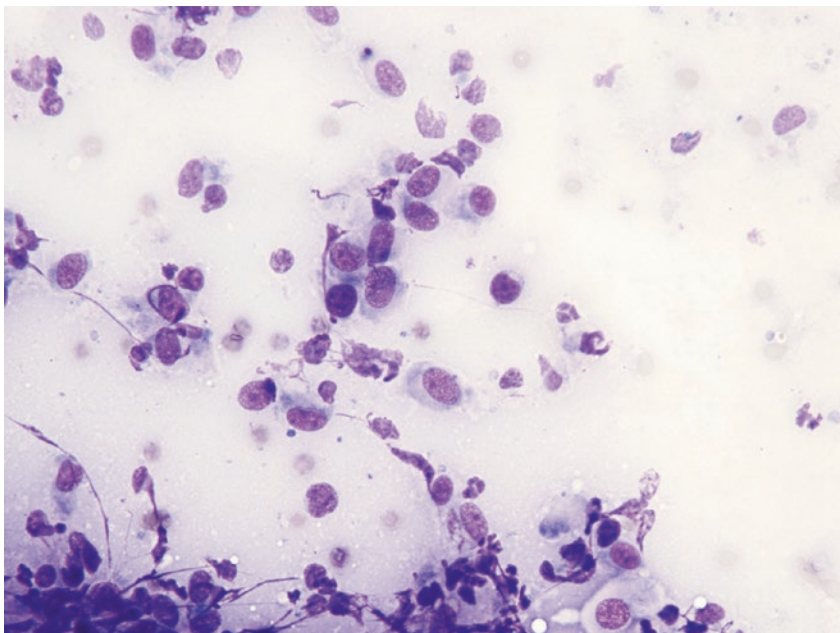


Fig. 3.49 Cytology of SGPS: histiocytes and rare lymphocytes

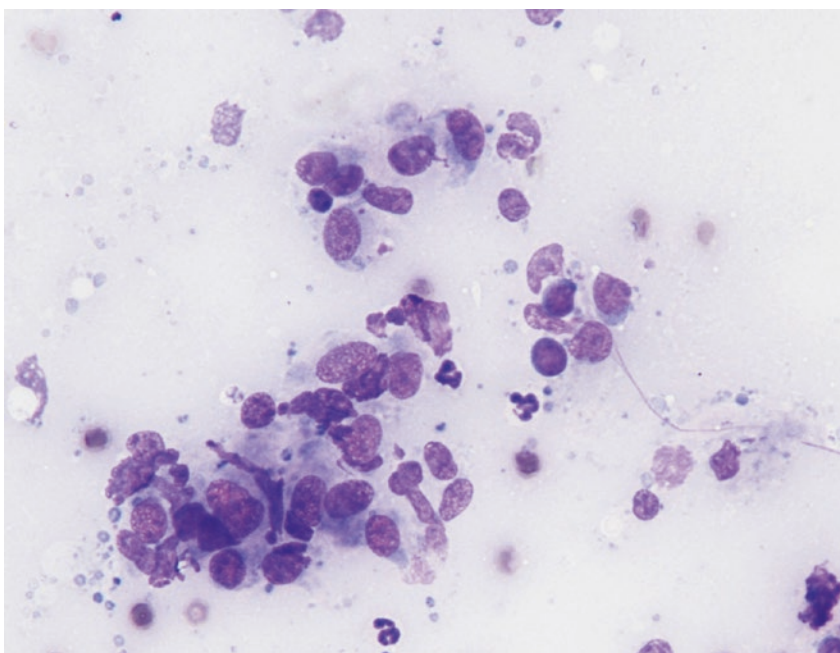


Fig. 3.50 Cytology of SGPS: histiocytes and rare lymphocytes. Note the presence of lymphoglandular bodies indicative of the rupture of many lymphocytes

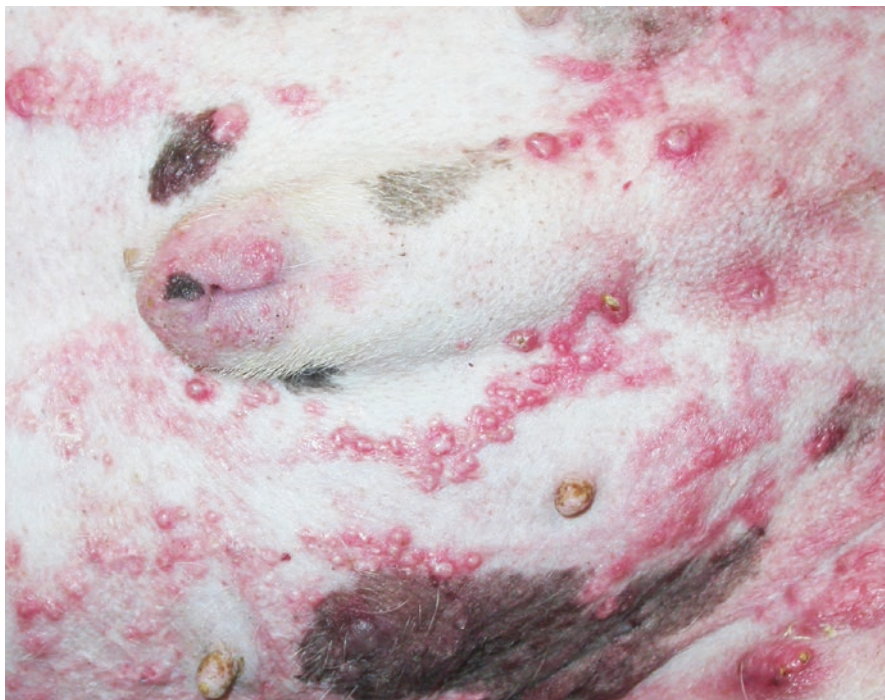

Fig. 3.51 Multiple erythematous nodular papules on the abdomen of a dog with calcinosis cutis secondary to iatrogenic hypercortisolism

In dogs, the most frequent cause of skin calcium salt deposits is spontaneous or iatrogenic hypercortisolism (Frazier et al. 1998). The reason why, in this disease, *calcium* salts are deposited in the dermis is not clear and the definition of dystrophic calcinosis used by many authors to describe *calcium* salt deposits in the course of hypercortisolism could be not correct at the time; the term dystrophic should in fact be associated with cases where structural damage to the tissue, which may lead to intra- or extracellular deposits of minerals, has been identified.

Clinical lesions are vary greatly, ranging from small papular–nodular lesions, often alopecic, erythematous and confluent, to form different sized plaques, often linear or serpiginous in shape (Figs. 3.51, 3.52, and 3.53) (White et al. 2013; Miller et al. 2013). Papular and nodular lesions are better visible in the hairless areas of the axilla, groin and abdomen. As the host tries to eliminate *calcium* salts through the epidermidis, lesions are often ulcerated and covered with crusts and pus as a result of a secondary bacterial infection (Fig. 3.54).

Cytological Findings

Cytological specimens are characterised by very different aspects, which differ based on the inflammatory reaction developed around the mineral salts and by the potential for secondary bacterial infections. In cases of lesions with an intact epidermidis, histopathology is characterised by multifocal deposits of mineral salts

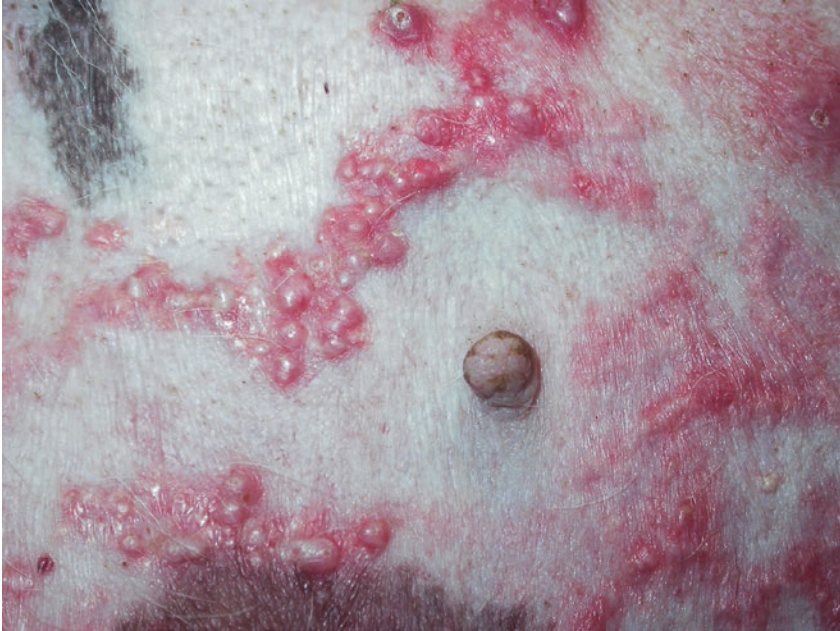

Fig. 3.52 Close up of the same lesions as in Fig. 3.51

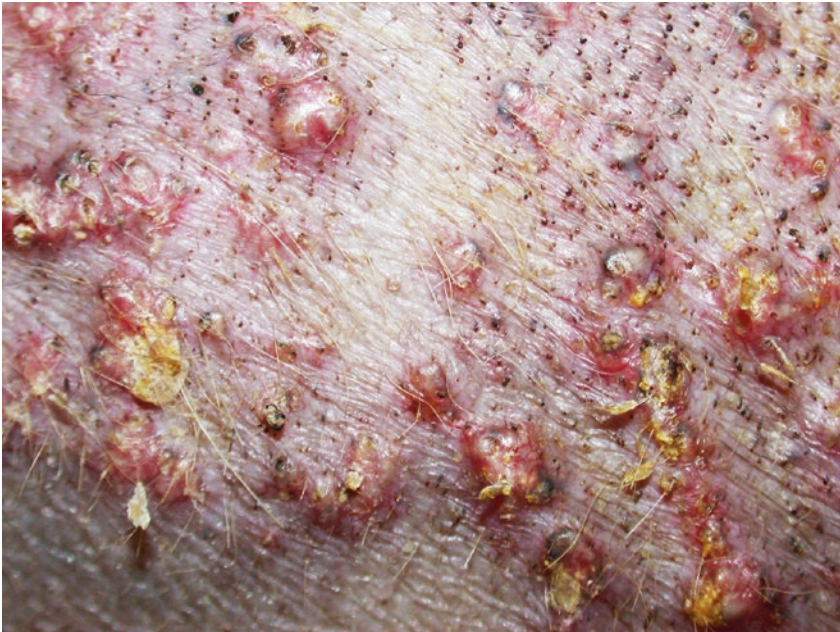

Fig. 3.53 *Calcinosis cutis*: multiple nodular papules, some of them confluent, which form small plaques in a dog with spontaneous pituitary-dependent hyperadrenocorticism. Note the presence of comedones

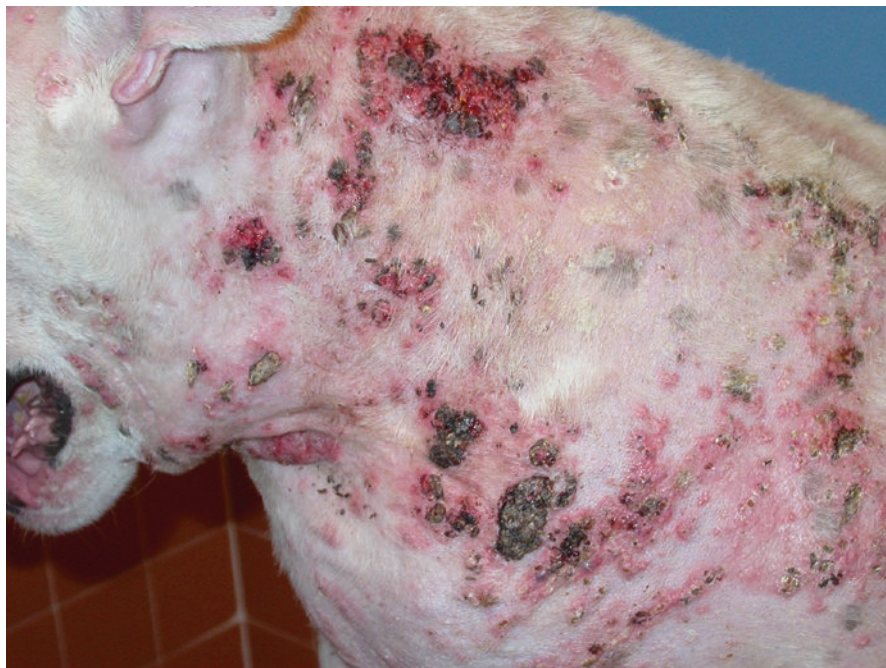

Fig. 3.54 *Calcinosis cutis*: multiple nodular papules, plaques and haematic crusts in a bull terrier with iatrogenic hypercortisolism

surrounded by a variable inflammatory response, usually composed of epithelioid macrophages and multinucleated giant cells (Figs. 3.55 and 3.56).

Cytology shows the same findings as those observed in histopathology, with many giant cells surrounding the *calcium salts*. In many cases, a severe fibroblastic reaction, cytologically represented by many spindle cells with some atypia, is detected. To an inexperienced cytologist, especially when mineral salts are not evident, this cytological appearance could be confused with an *anaplastic soft tissue sarcoma* with *giant cells*; fortunately, the clinical aspects of calcinosis cannot be confused with a malignant neoplasia (Figs. 3.57, 3.58, and 3.59).

When the lesions ulcerate, many neutrophils infiltrate the dermis. In these cases, slides show neutrophilic or pyogranulomatous inflammation (Fig. 3.60).

In cytology, the morphology of *calcium salts* can be very different, ranging from basophilic pointed or coarse granulations to more typical formations with an amorphous, glassy, transparent and sometimes *rhomboidal* or *needle-like* appearance.

In some cases, mineral salts may hardly be detectable in hypercellular inflammatory specimens; in such cases, to better demonstrate the *calcium salts*, it is possible to stain some slides with Von Kossa, which colours in black the area where *calcium salts* were present.

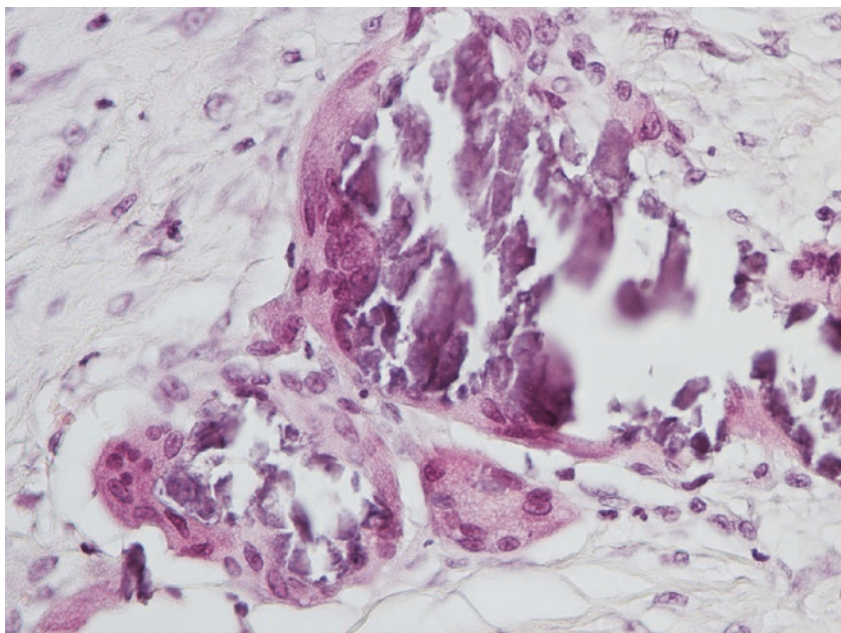


Fig. 3.55 Histopathology of *calcinosis cutis*: multifocal mineralisation of the dermis

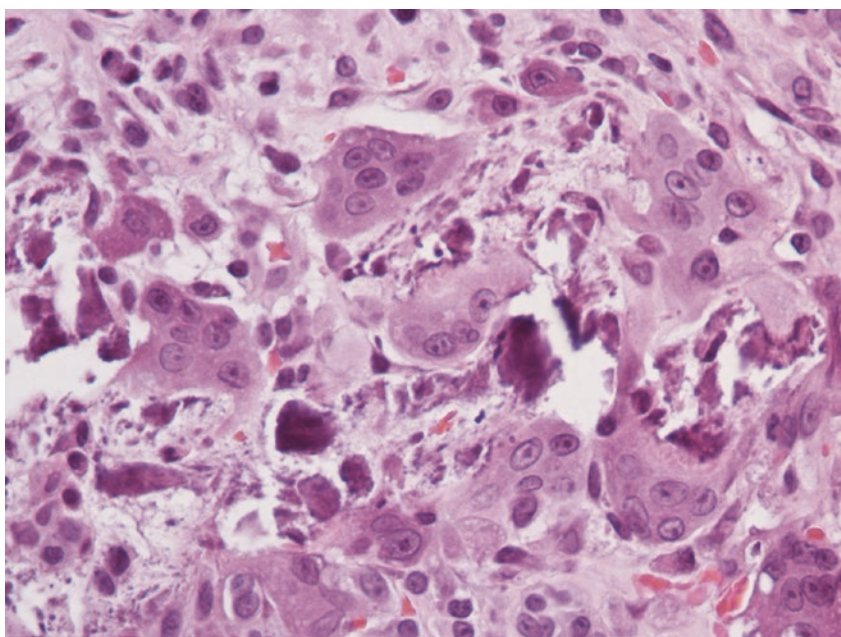


Fig. 3.56 Histopathology of *calcinosis cutis*: multinucleated giant cells and reactive fibroblasts surrounding mineral salts

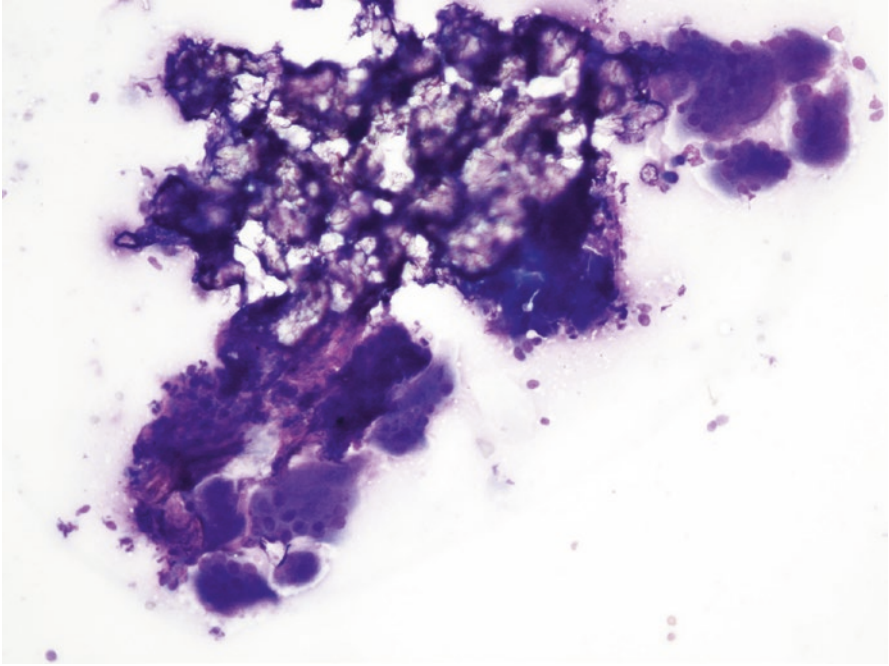


Fig. 3.57 Cytology of *calcinosis cutis*: many multinucleated giant cells surrounding mineral salts

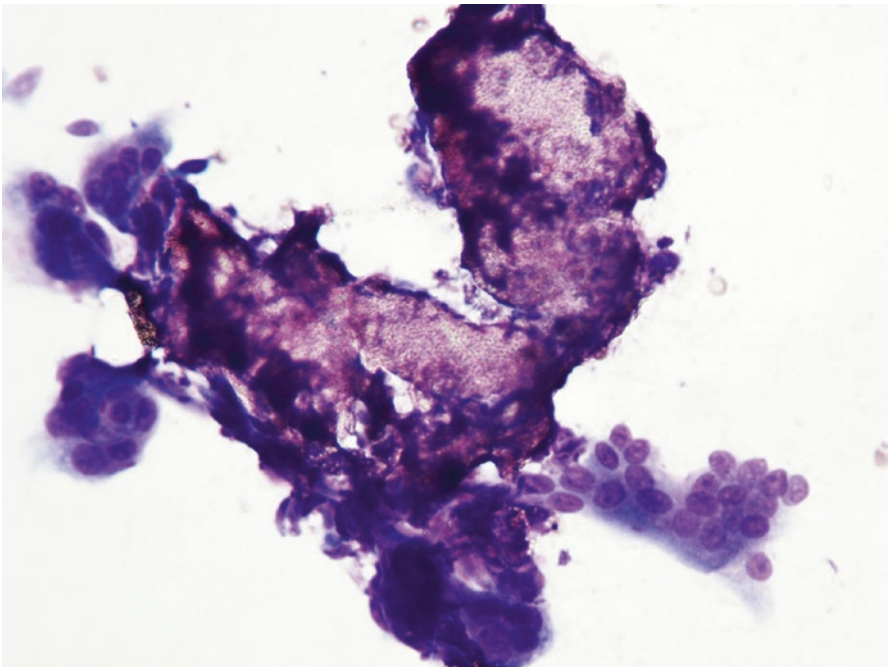


Fig. 3.58 Cytology of *calcinosis cutis*: many giant cells attacking calcium salts

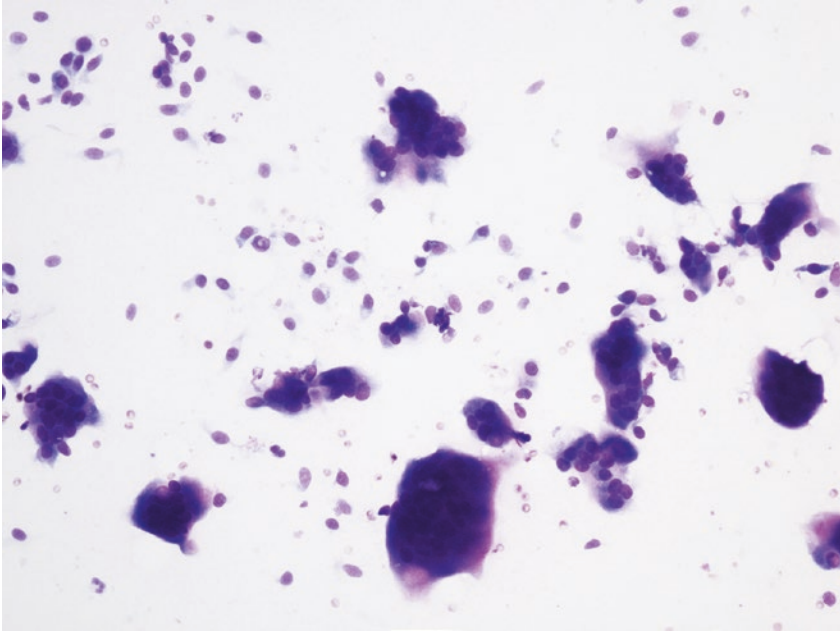


Fig. 3.59 Cytology of *calcinosis cutis*: many spindle fibroblasts and giant cells. Mineral salts are not present on this image

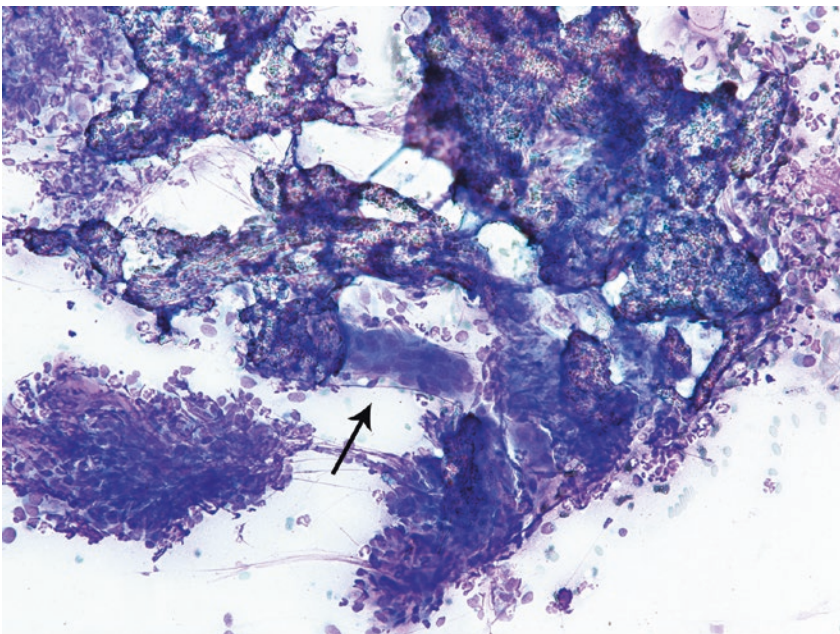


Fig. 3.60 Cytology of *calcinosis cutis*: inflammatory pyogranulomatous inflammation surrounding mineral salts. Note the giant cell (arrow)

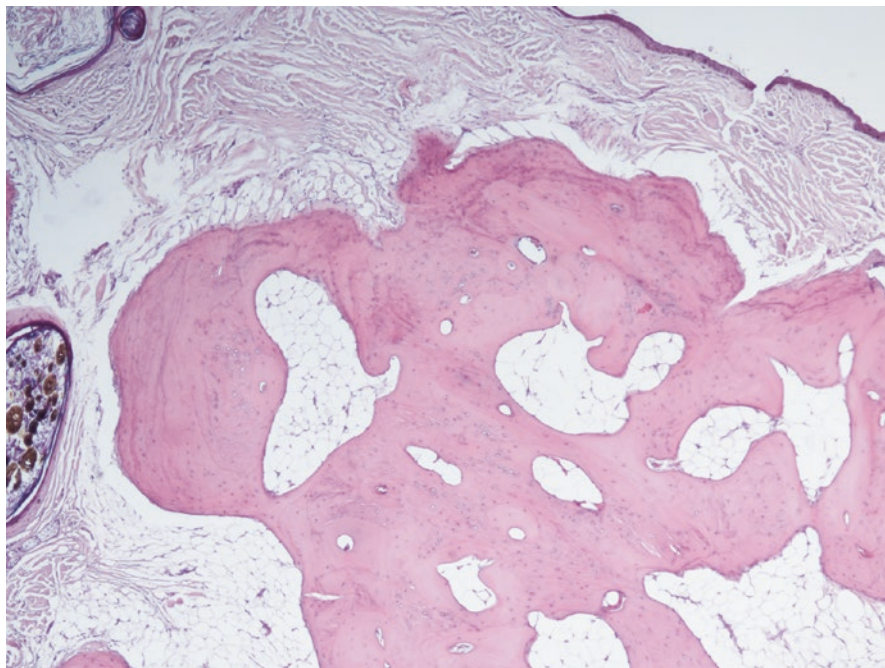


Fig. 3.61 Histopathology of *osteoma cutis*: osseous metaplasia secondary to chronic deposit of calcium salts in the dermis

When a needle is introduced into a mineralised lesion, it is possible to perceive a crunching sensation between the fingers, which helps to support the suspicion of the presence of mineral salts in the tissue. In chronic cases, calcium salts can transform into bone tissue (osseous metaplasia) and lesions turn from *calcinosis cutis* to *osteoma cutis*; in these cases, the suspicion may be generated when even large needles cannot penetrate the firm nodular papules (Frazier et al. 1998). Histology is the only examination that allows the diagnosis of *osteoma cutis*, as the clinical lesions cannot be differentiated from *calcinosis cutis* (Fig. 3.61).

3.3.6 Xanthomatosis

Cutaneous *xanthomatosis* is a rare skin disease of cats and dogs in which cholesterol, triglycerides and phospholipids accumulate in the dermis. In cats, xanthomas are mostly due to diabetes mellitus, both spontaneous and iatrogenic, the latter usually secondary to chronic corticosteroid therapy administered to manage pruritic diseases (especially allergic dermatitis). Less commonly, feline xanthomatosis develops in cats fed with a high-fat diet, in young patients suffering from idiopathic hyperlipidaemia or in patients with pancreatitis (Vitale et al. 1998; Chanut et al. 2005).

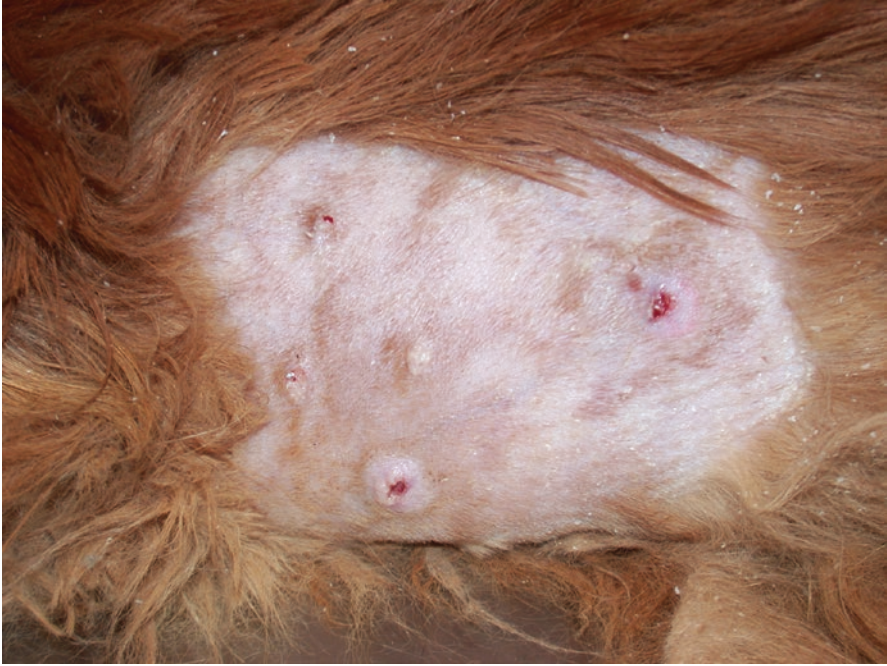

Fig. 3.62 Multiple ulcerated xanthomas on the chest of a cat with diabetes mellitus

In dogs, xanthomatosis can be idiopathic or, as in cats, secondary to an excessively fatty diet or to diabetes mellitus (Banajee et al. 2011). In any case, skin lesions are represented by papular nodules and little plaque and nodules, usually multiple and located in the dermis, alopecic and white–yellow in colour, from which greasy material is drained (Figs. 3.62, 3.63, 3.64, and 3.65) (Gross et al. 2005). Single nodular lesions are rarely reported both in normolipaemic dog and cats (Ravens et al. 2013).

Cytological Findings

Cytologically, xanthomatous nodules are composed almost exclusively of histiocytic cells represented by large macrophages with cytoplasm rich in vacuoles, containing lipids that give the cell a characteristic *foamy* appearance (Figs. 3.66, 3.67, and 3.68). Neutrophils are few or absent, whereas numerous giant cells, with haphazardly distributed nuclei, are commonly observed. The multinucleated cells with nuclei arranged in a crown shape, similar to the *Touton giant cells* reported in human xanthomatosis, are rarely observed in our pets. Some macrophages and giant cells can show a central homogeneous and eosinophilic cytoplasmic area, representing a pre-xanthomisation stage (Fig. 3.69). To better show the lipid content of the vacuoles, a *oil-red-O stain* can be performed; lipids stain bright red (Fig. 3.70).

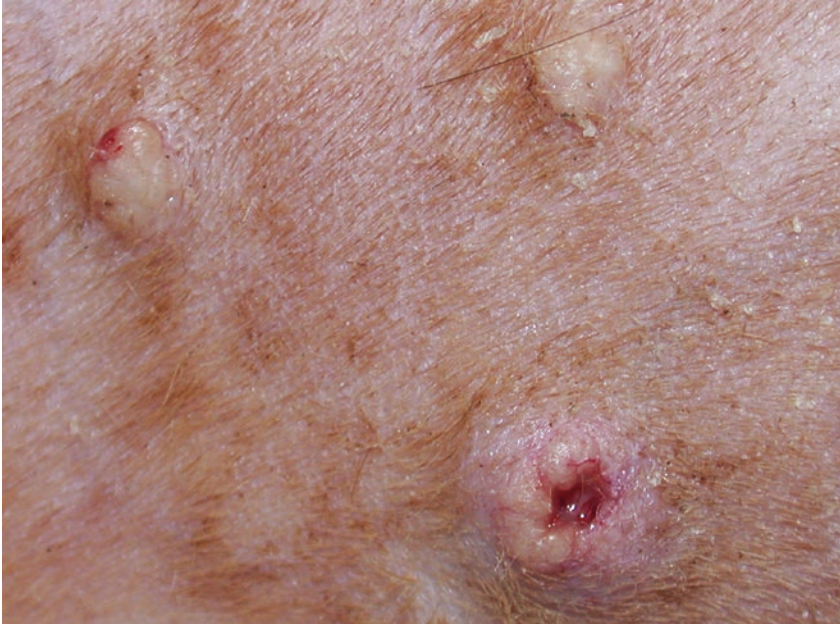

Fig. 3.63 Close-up of the lesions of the same cat as in Fig. 3.62

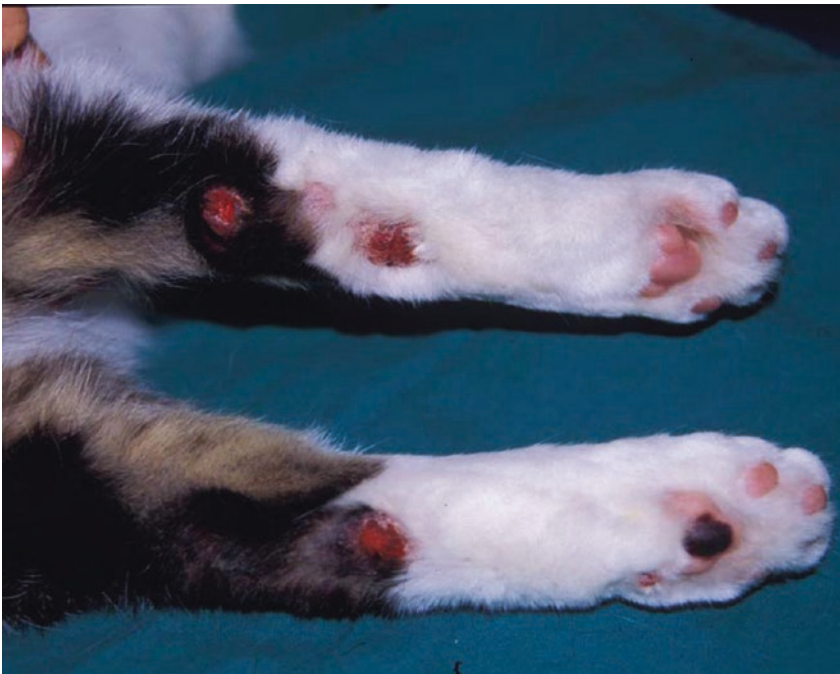

Fig. 3.64 Multiple and ulcerated nodules on the rear legs of a kitten affected by idiopathic hyperlipaemia (Courtesy of Dr. C. Noli, Italy)

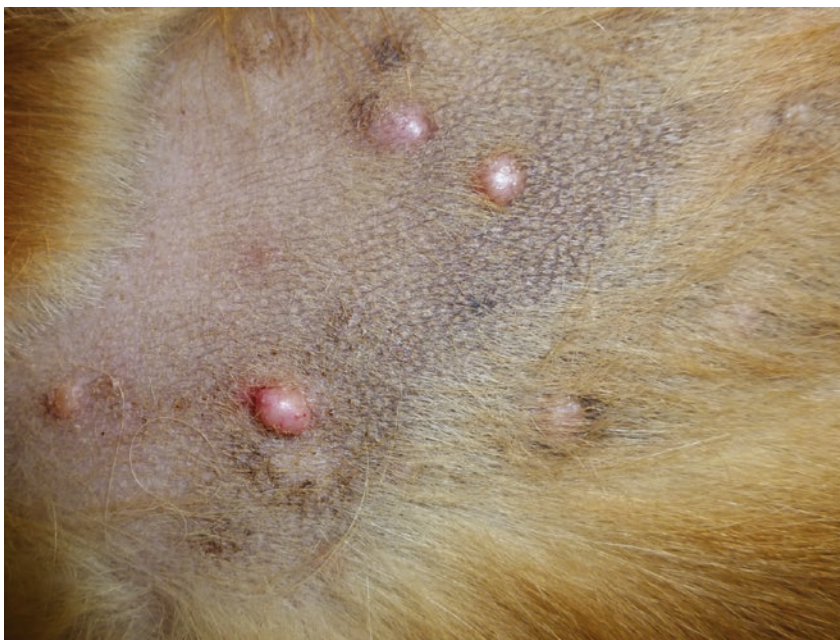

Fig. 3.65 Multiple papular nodules on the chest of a dog with idiopathic xanthomatosis

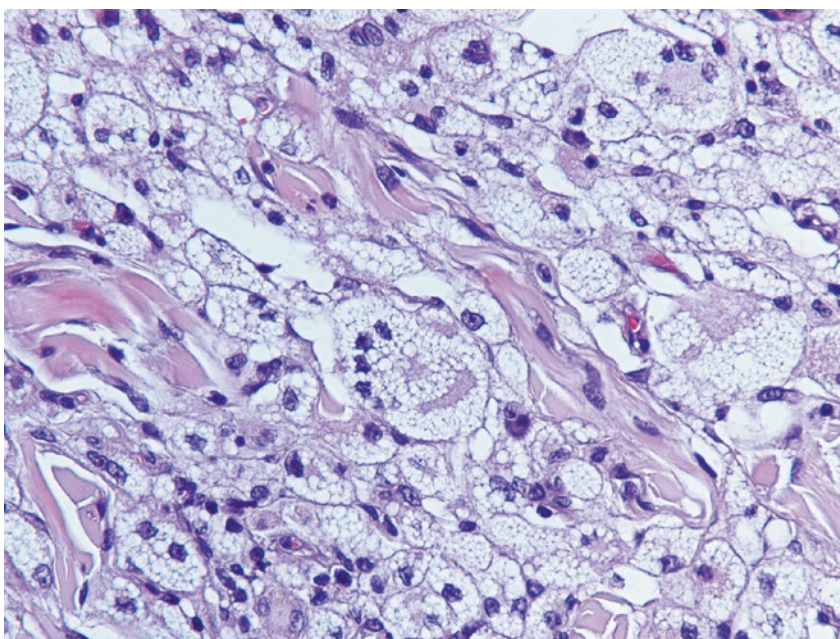


Fig. 3.66 Histopathology of xanthomatosis: many foamy macrophages and giant cells infiltrating the dermis

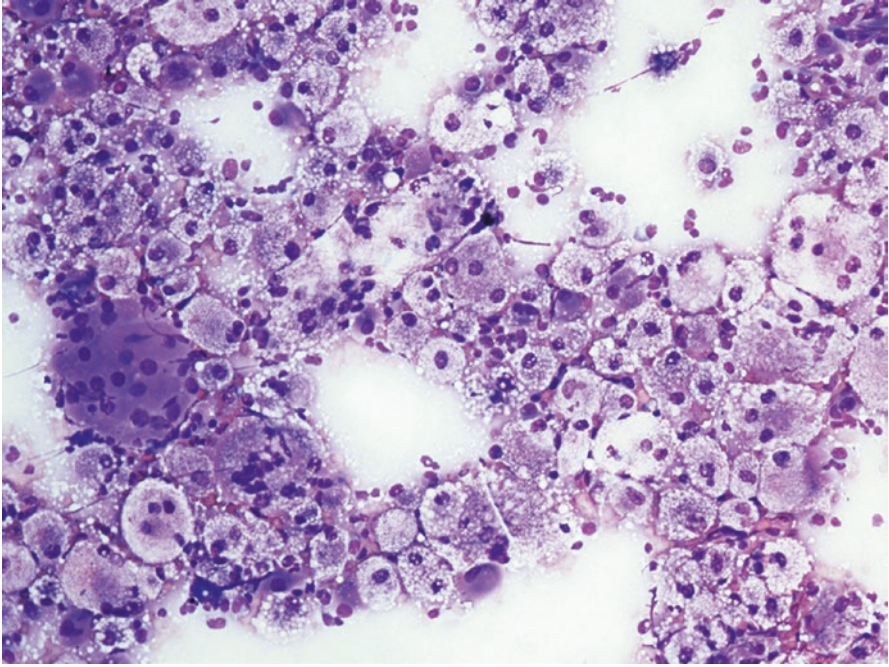


Fig. 3.67 Cytology of xanthomatosis: many foamy macrophages and giant cells

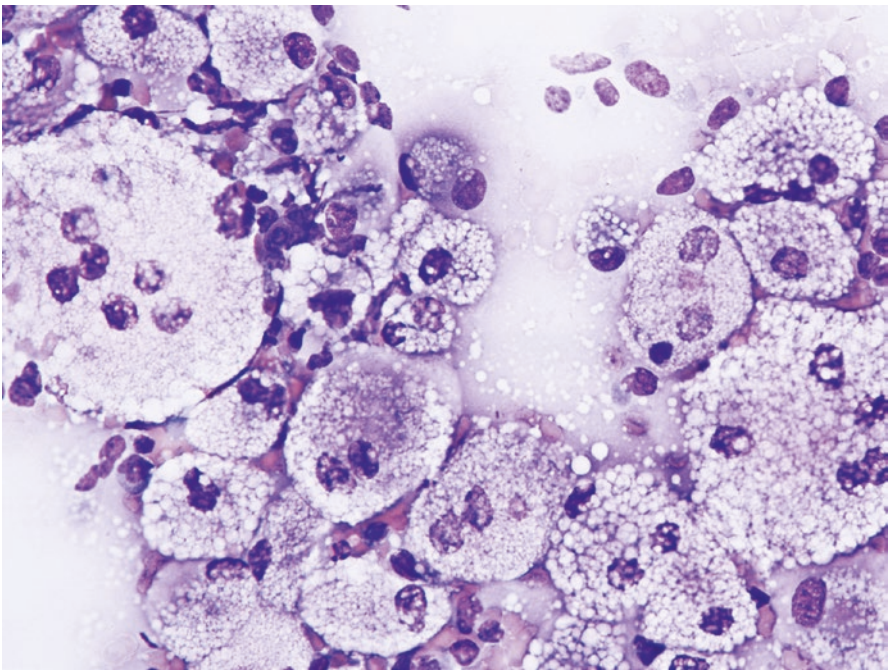


Fig. 3.68 Cytology of xanthomatosis: at high magnifications the foamy macrophages and giant cells are more evident

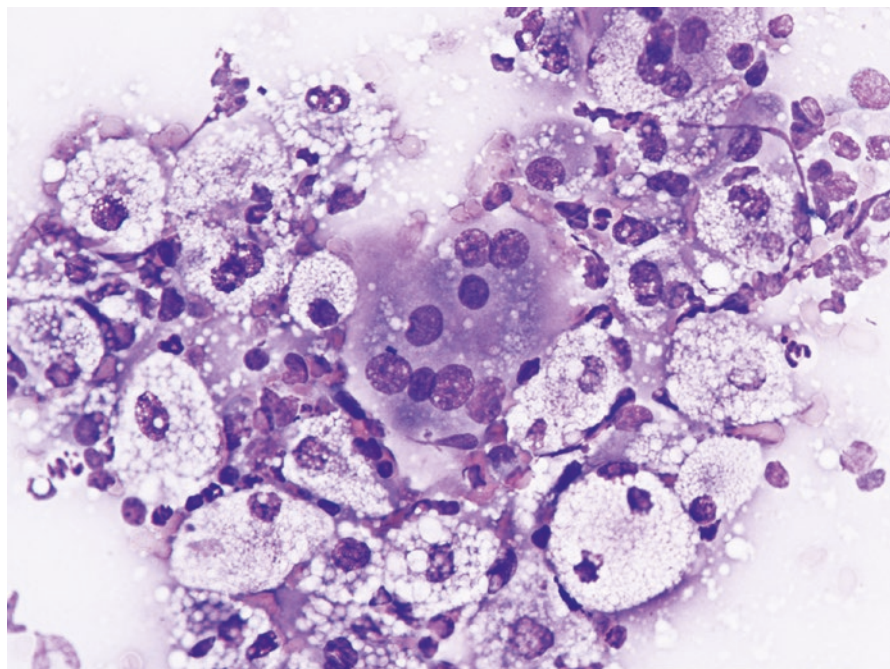


Fig. 3.69 Cytology of xanthomatosis: note the incompletely xanthomized giant cell

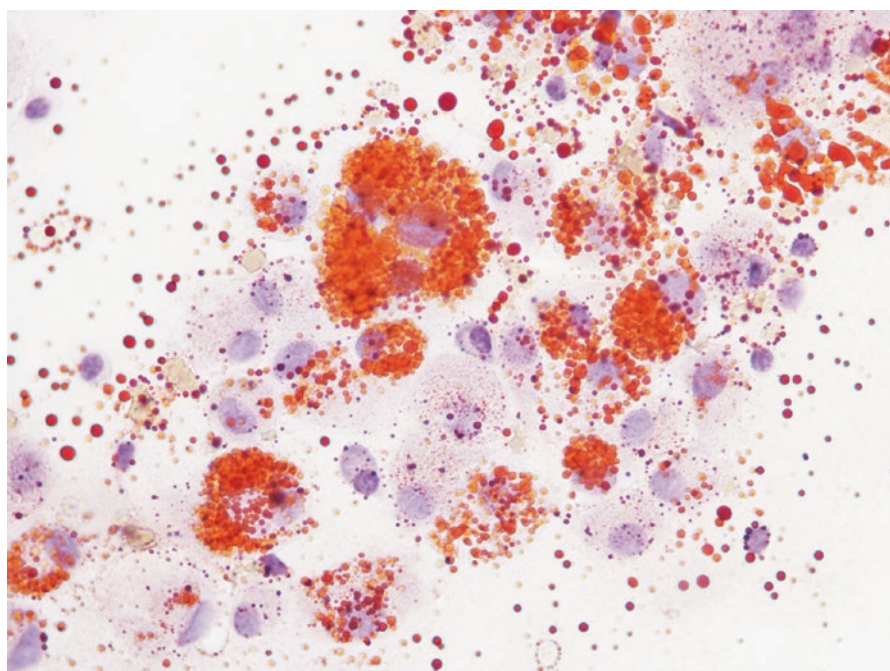


Fig. 3.70 Cytology of xanthomatosis: the lipid content of vacuoles is stained red with oil-red-O stain

3.4 Pustules

Specimens collected from pustules are always very useful and many often provide a diagnosis.

The gross recognition of follicular and non-follicular pustules is very useful in interpreting the origin of the lesions.

3.4.1 Pustular Diseases in Dogs

3.4.1.1 Diseases Characterised by Follicular Pustules

Follicular pustules indicate an infection localised in the follicular lumen and, when observed, an intrafollicular disease such as bacterial folliculitis, demodicosis or, exceptionally, dermatophytic folliculitis, must be suspected.

Bacterial Folliculitis

The most common cause of follicular pustules in dogs is *bacterial folliculitis*. Pyoderma is a very common disease in dogs and the predisposing causes are numerous and of different origin. Microorganisms, parasites, allergic diseases and endocrine disorders can frequently cause an injury to the skin barrier, allowing bacteria such as *Staphylococcus pseudintermedius* to cause infection (Miller et al. 2013).

Clinically, pustules are mainly follicular, but because they are delicate lesions, they rapidly dehydrate and form crusts and epidermal collarettes (Fig. 3.71) (Irhke 1996; Gross et al. 2005; Miller et al. 2013).

Cytological Findings

Slides from an intact pustule contain a large number of neutrophils characterised by nuclear degeneration represented by swollen and hypochromatic nuclei with a loss of the classical multilobed silhouette, due to severe cell membrane damage that permits water to penetrate into the cell. As mentioned in Chap. 1, this very common type of nuclear degeneration is known as *karyolysis*.

In the cytoplasm of neutrophils many coccus bacteria are usually present, arranged singly, in pairs or in tetrads. Many bacteria are also extracellular, but this is linked to the rupture of severely degenerated neutrophils that inevitably occurs during the preparation of the slides (Fig. 3.72).

Karyolytic neutrophils are very delicate and once broken give rise to streaks of nuclear material. Together with neutrophils, it is common to find a small number of corneocytes, which are the cells comprising the *roof* of the pustule that exfoliate into pus. Sometimes, in specimens sampled from bacterial pustules, it is possible to detect a few nucleated keratinocytes of the spinous or granular layers (acantholytic

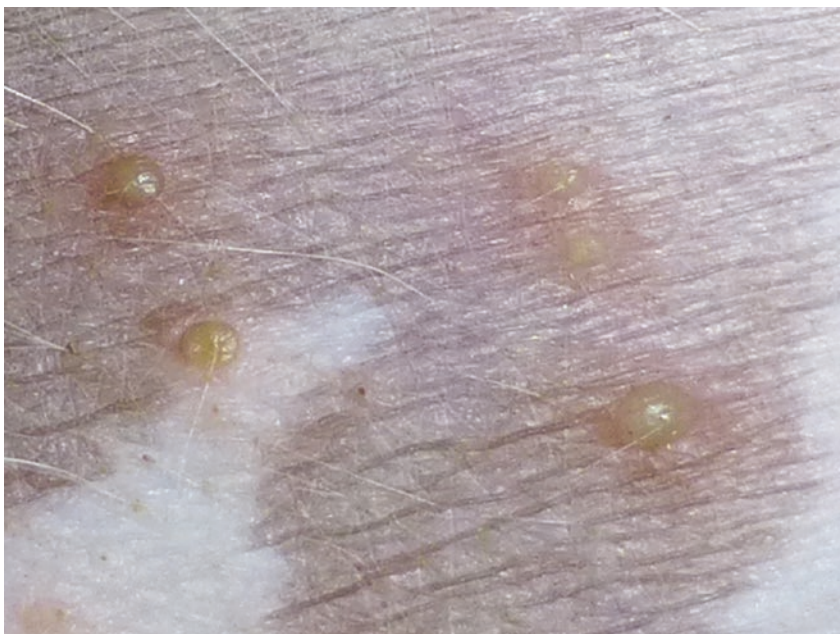


Fig. 3.71 Multiple follicular pustules: note that a hair emerges from the centre of the pustules

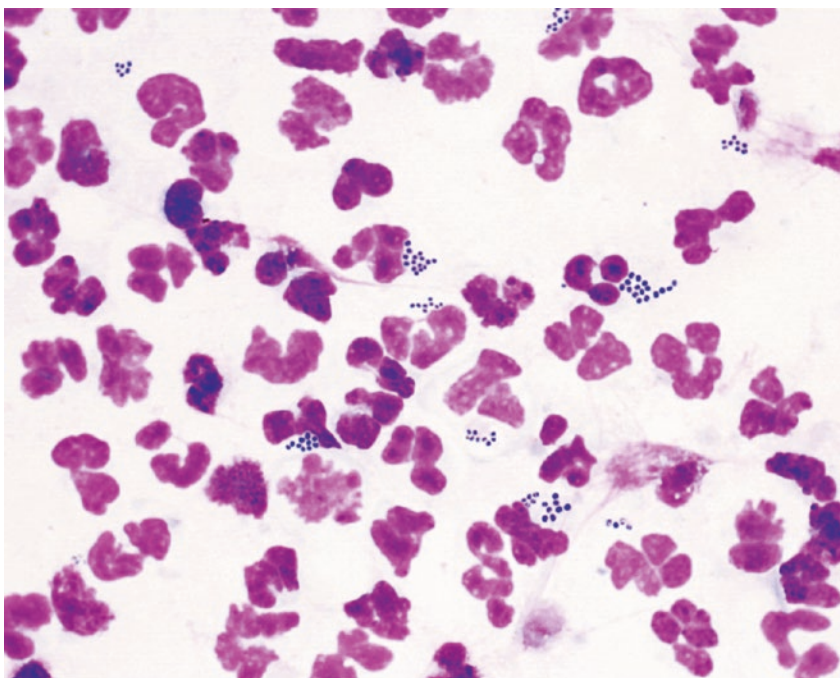


Fig. 3.72 Cytology of pyoderma: karyolytic neutrophils with many intracytoplasmic cocci

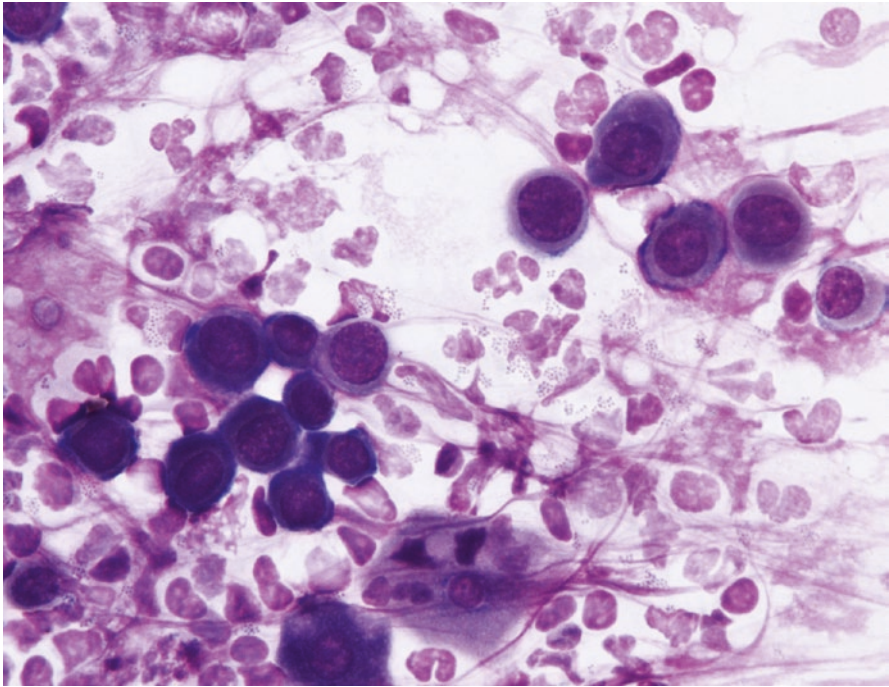


Fig. 3.73 Cytology of pyoderma: severe karyolysis of neutrophils with many cocci and acantholytic keratinocytes

cells); these epithelial cells separate from other keratinocytes because of the proteolytic enzymes released by bacteria (acantholysis). Rarely, in superficial pyoderma, there is a very high number of acantholytic keratinocytes (AKs) (Fig. 3.73).

Demodicosis

In dogs with *demodicosis* and secondary pyoderma, pustules are very common lesions and are usually associated with comedones, which contribute to the suspicion that the problem involves the follicles (Figs. 3.74 and 3.75) (Gross et al. 2005; Mueller et al. 2011; Miller et al. 2013).

Cytological Findings

Cytology specimens from pustules are similar to those described in pyoderma, because although the cause of the lesions is *Demodex* mites, pustules are caused by secondary bacterial intrafollicular infection (Figs. 3.76 and 3.77). In addition to karyolytic neutrophils that phagocytose cocci, a variable number of adult and immature mites and their eggs are usually observed (Figs. 3.78 and 3.79). As mentioned for pyoderma, it is also possible to observe a variable number of acantholytic cells.

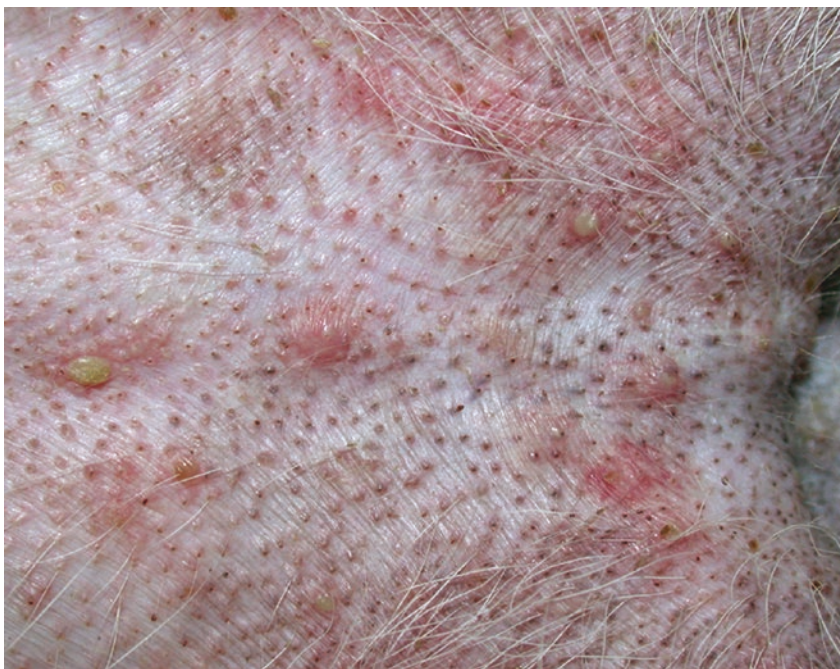

Fig. 3.74 Follicular pustules and comedones in a puppy with demodicosis

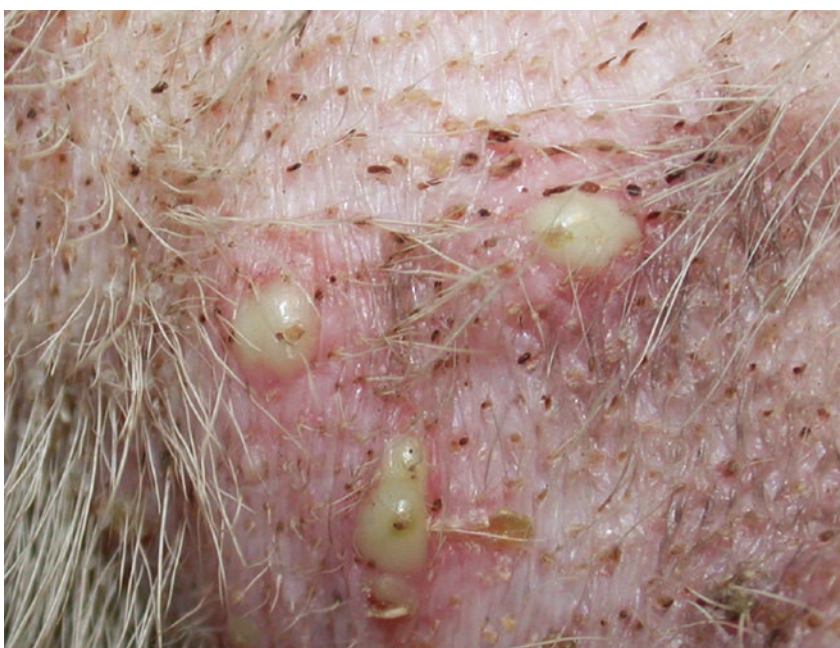

Fig. 3.75 Follicular pustules: note that a hair emerges from the centre of the pustule

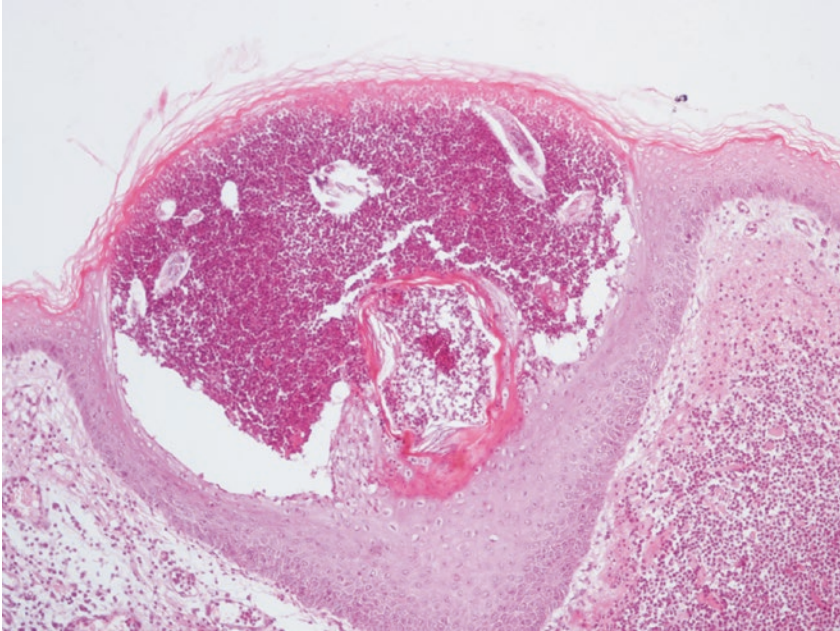


Fig. 3.76 Histology of pustular demodicosis: follicular pustule containing many *Demodex* mites

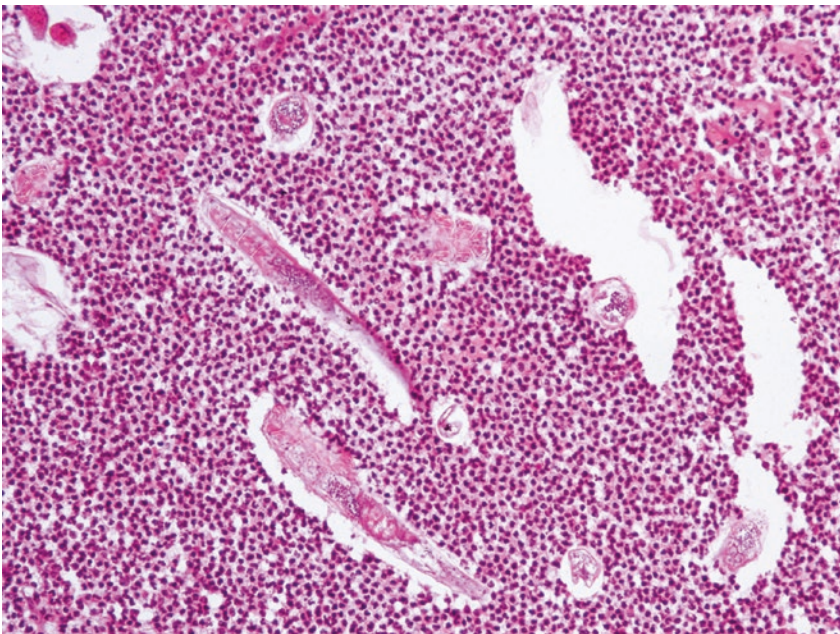


Fig. 3.77 Histology of pustular demodicosis: at high magnifications mites are clearly recognisable

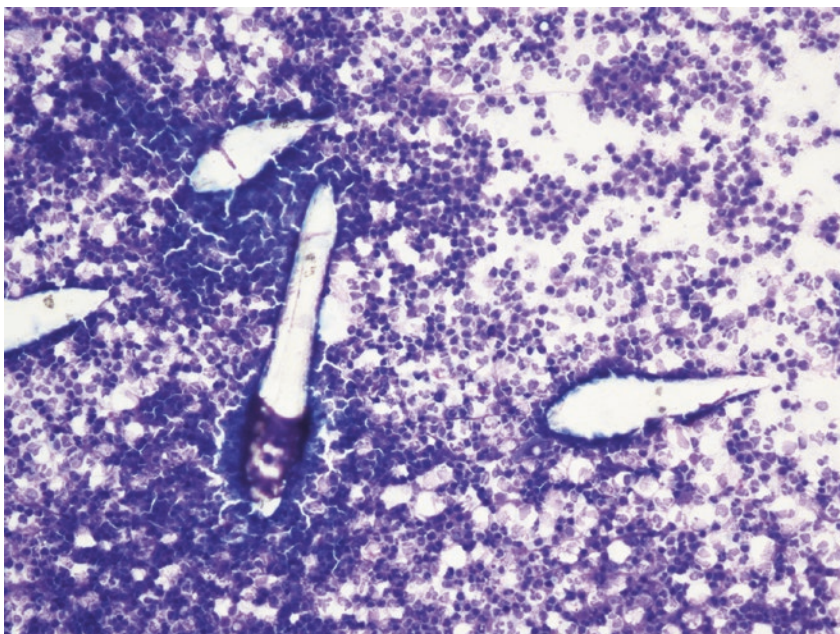


Fig. 3.78 Cytology of pustular demodicosis: many *Demodex canis* immersed in a neutrophilic exudate

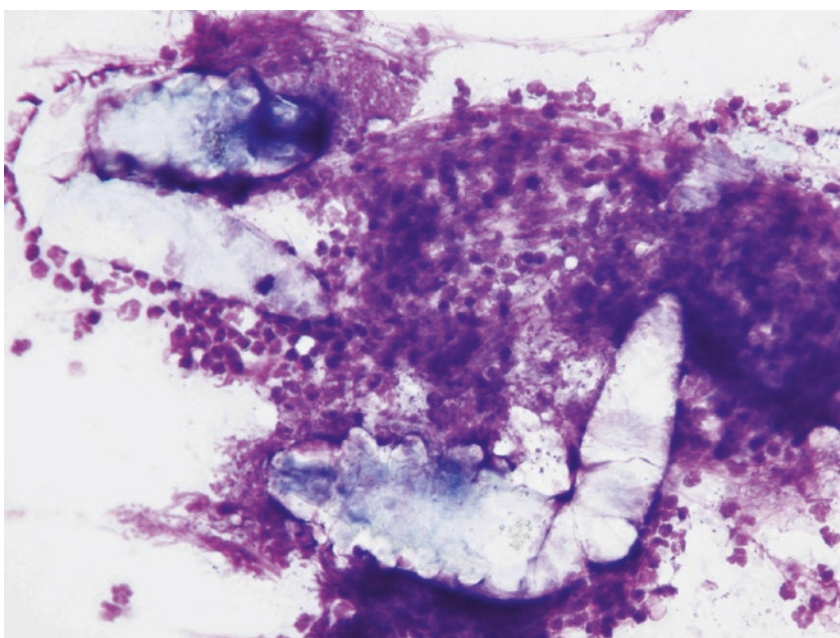


Fig. 3.79 Cytology of pustular demodicosis: two adult *Demodex canis* and karyolytic neutrophils, which phagocytose many cocci

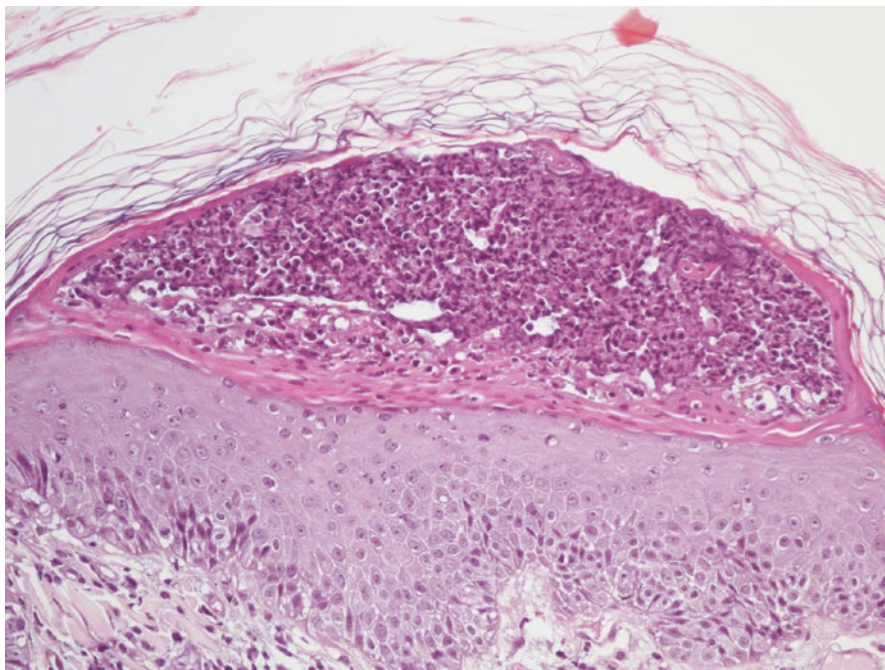


Fig. 3.80 Histology of impetigo: large non-follicular pustule

Pustular Dermatophytosis

In dogs with *dermatophytosis* intrafollicularly infected hair shafts is a common finding; nevertheless, it is less frequent for fungi to attract neutrophils in the follicular lumen in such quantities as to be grossly evident as follicular pustules.

3.4.1.2 Diseases Characterised by Non-follicular Pustules

Unlike from follicular pustules that are almost exclusively linked to bacterial infections, numerous infectious and sterile diseases cause *non-follicular pustules*. As mentioned, non-follicular pustules may vary in size according to their cause and extension into the epidermal layers.

Pustular Non-follicular Staphylococcal Infection (Impetigo)

In *superficial pyoderma* it is possible to observe intra-epidermal subcorneal pustules that are not localised in the follicular lumen (Fig. 3.80) (Gross et al. 2005). *Impetigo* is a form of surface pyoderma mostly reported in puppies and young dogs, mainly hunting breeds, clinically characterised by small to medium-sized *non-follicular pustules*, localised on the abdomen, groin and axilla (Ihrke 1996). Pustules

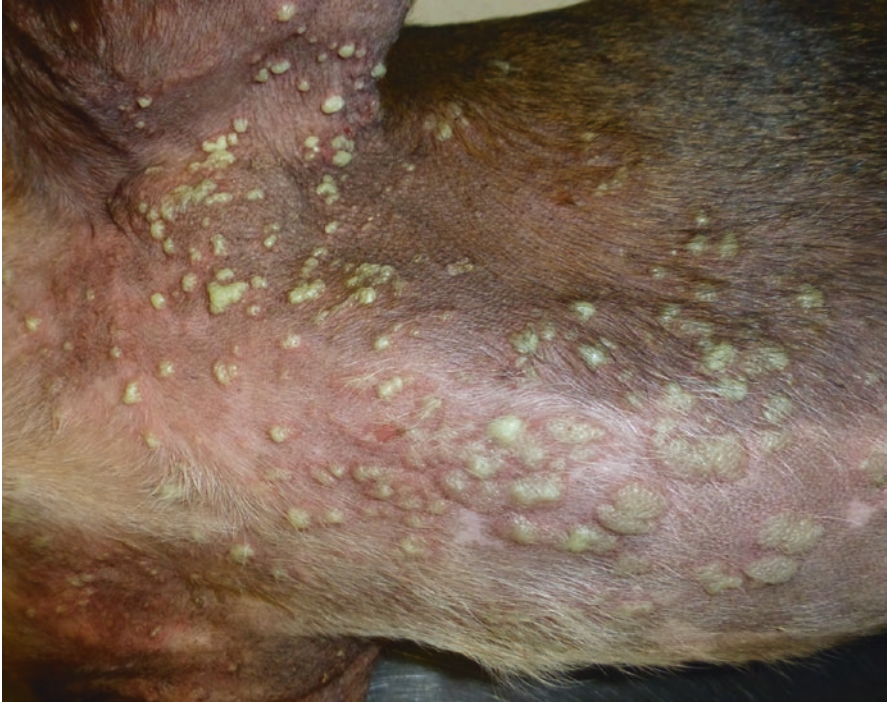


Fig. 3.81 Multiple large non-follicular pustules on the sternum and chest of a dog with juvenile impetigo

are of varying shapes, from round to irregular and with a tendency to merge (Figs. 3.81 and 3.82). The causes of bacterial infection are not always ascertained, but, because the lesions are observed in young animals and do not recur once recovered, stressful events or local trauma associated with poor hygiene have been speculated to be possible causes. Rarely, an infectious predisposing disease such as in puppies suffering from distemper can cause impetigo. In adults or old dogs affected by several immunosuppressive systemic diseases such as spontaneous or iatrogenic hypercortisolism, it is common to observe large and often coalescent non-follicular pustules. Because of their large size, this form of pyoderma is named *bullous impetigo* (Figs. 3.83 and 3.84). In this pustular pyoderma, exotoxins produced by *Staphylococcus pseudintermedius* bind to the extracellular portion of the desmoglein-1 (Dsg-1) and, in association with the development of proteolytic enzymes, are the cause of the keratinocytes splitting and of the consequent development of pustules (Terauchi et al. 2003; Nishifuji et al. 2008; Amagai 2009).

Cytological Findings

The cytology of an impetiginous pustule is very similar to that described for a follicular pustule. In many cases of impetigo, especially in the bullous variant, the karyolytic nuclear changes are so severe as to make it difficult for an inexperienced cytologist to recognise those cells as degenerated neutrophils (Fig. 3.85).

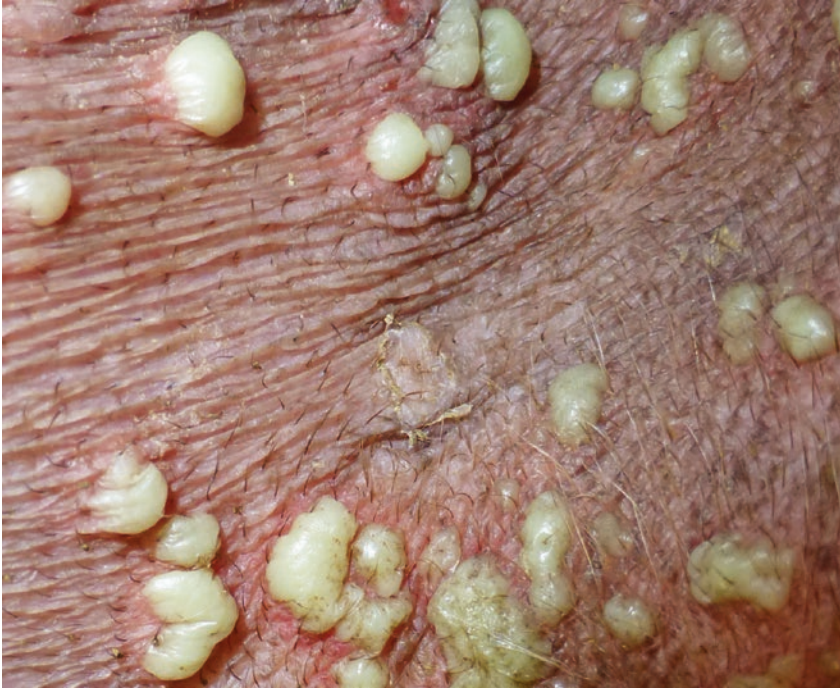

Fig. 3.82 Non-follicular pustules of different shapes and sizes in the same dog as in Fig. 3.81

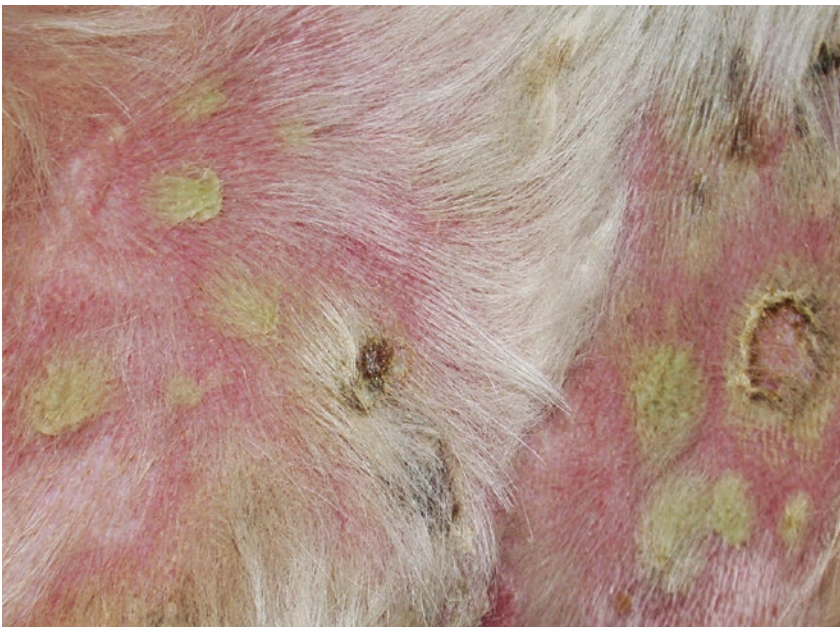


Fig. 3.83 Bullous impetigo: large non-follicular pustules in a dog treated for a long time with corticosteroids

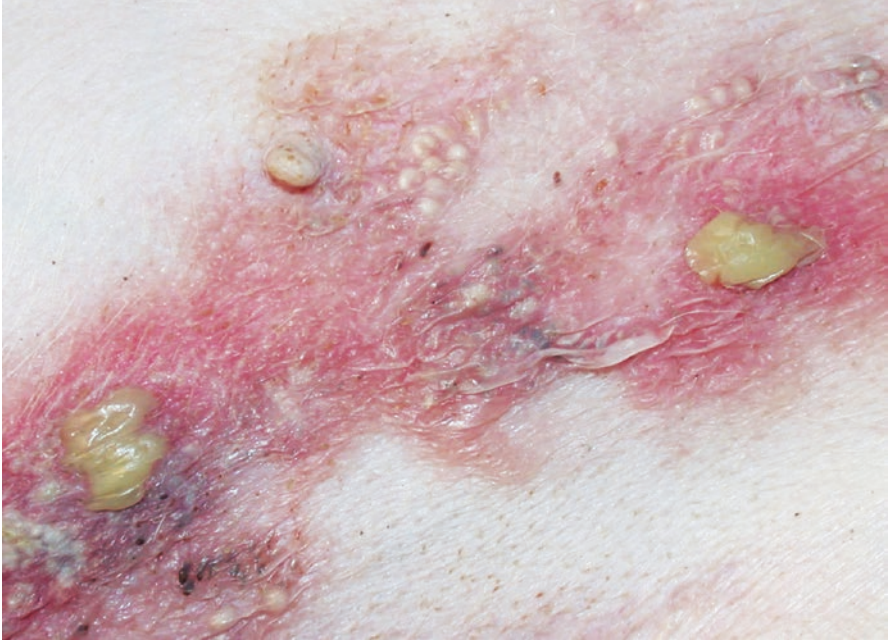

Fig. 3.84 Bullous impetigo: erythema, comedones, skin atrophy and multiple small follicular cysts in a dog with spontaneous hypercortisolism are present together with large non-follicular pustules

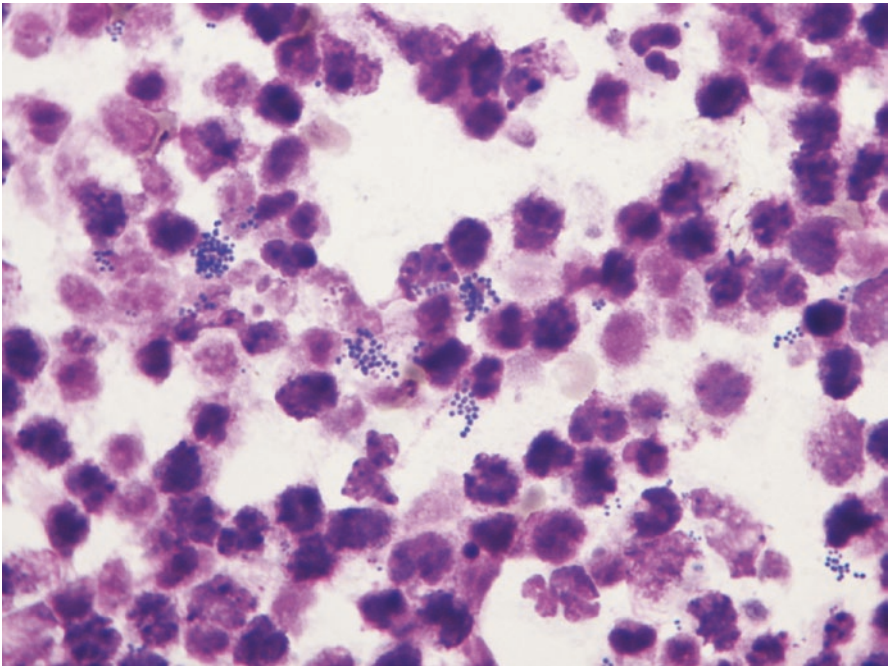


Fig. 3.85 Cytology of bullous impetigo: severe nuclear degeneration of neutrophils (karyolysis) characterised by unlobulated faded nuclei. Many cocci are immersed in the pus

Another characteristic is the high number of bacteria detected compared with those observed in typical follicular pustules. This difference could be explained because *bullous impetigo* is usually secondary to severe and systemic immunosuppressive diseases that can impair the phagocytic ability of neutrophils, allowing them to proliferate massively.

Pemphigus Foliaceus

Among the sterile diseases characterised by non-follicular pustules, *pemphigus foliaceus* (PF) is definitely the most common. PF is an autoimmune disease histologically characterised by intra-epidermal pustules, which can be localised in the spinous, granular or corneal layer (Gross et al. 2005; Vaughan et al. 2010). The pathogenic mechanism of the pustular formation is *acantholysis* during which the splitting of keratinocytes following the breakage of the intercellular junctions (*desmosomes*) occurs. Autoantibodies of the PF target the extracellular component of some cadherins (adhesion molecules) that make up *desmosomes* (desmocollin-1 and to a lesser extent desmoglein-1 and plakoglobin) (Olivry 2006; Olivry and Linder 2009). Following the attack to desmosomes operated by autoantibodies, neutrophils that fill the intra-epidermal cleft created by acantholysis are recruited and give origin to the pustules.

Pemphigus foliaceus is a pustular disease that is clinically characterised by large *non-follicular pustules* (Fig. 3.86). Pustules rapidly dehydrate, creating a yellowish crusty dermatitis, which involves mainly the skin of the abdomen, face, pinna, muzzle and bridge of the nose (Figs. 3.87 and 3.88). The nose often shows an inflammatory depigmentation with crusts over the surface (Fig. 3.89). Paws, scrotum and mucocutaneous junctions are other sites where pustules are often observed and, in generalised cases, lesions can be present all over the body (Figs. 3.90 and 3.91) (Gross et al. 2005; Olivry 2006; Miller et al. 2013).

Cytological Findings

As mentioned above, the histopathology of lesions in PF is characterised by intra-epidermal pustules that should contain many *AKs* (Fig. 3.92). Because PF is a sterile disease, samples obtained by intact pustules are typically characterised by many non-degenerated neutrophils with *segmented* nuclei in which nuclear lobes are recognisable. In intact pustules that have been present for several days, neutrophils can manifest morphological alterations indicative of cellular aging, such as poorly evident nuclear lobes and hyperchromatic nuclei. Together with neutrophils, a large number of keratinocytes characterised by a round/oval to polygonal shape and deep basophilic cytoplasm is observed. These cells represent the result of acantholysis and are thus named *acantholytic cells* or *AKs* (Figs. 3.93 and 3.94).

Acantholytic keratinocytes come from both the spinous and granular layers, depending on which part of the epidermis the acantholysis occurs. *AKs* have round or polygonal shape and the cytoplasm is often so dark (deep blue) that it can mask

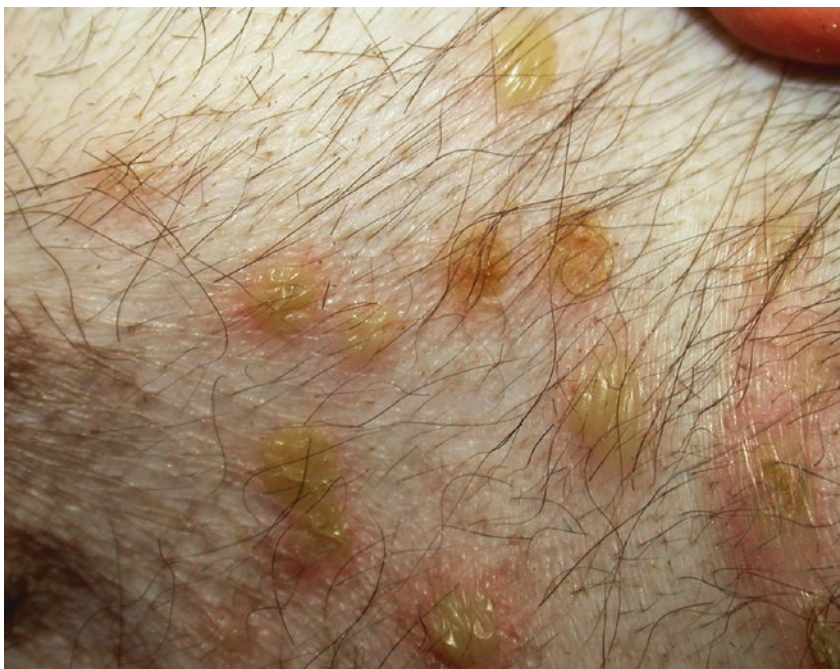

Fig. 3.86 Large non-follicular pustules in a dog affected by pemphigus foliaceus (PF)

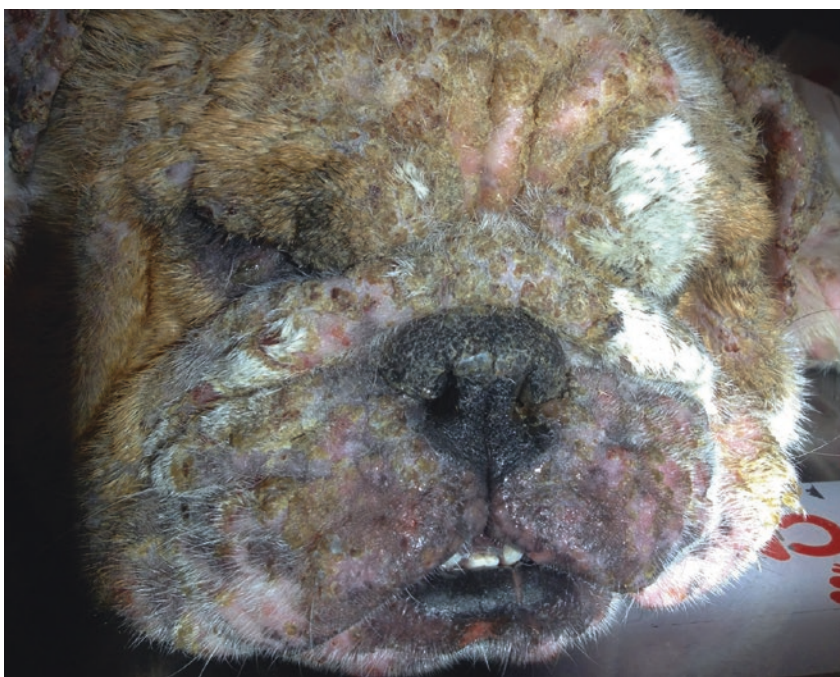

Fig. 3.87 Yellowish crusts spread all over the face of an English bulldog with PF

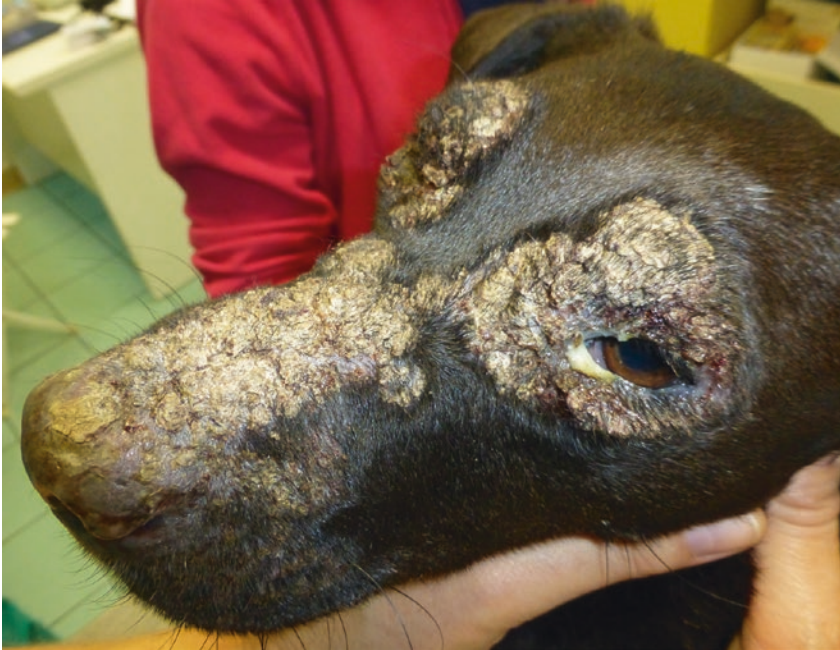

Fig. 3.88 Pemphigus foliaceus: symmetrical yellowish crusts on the bridge of the nose and on the periocular area

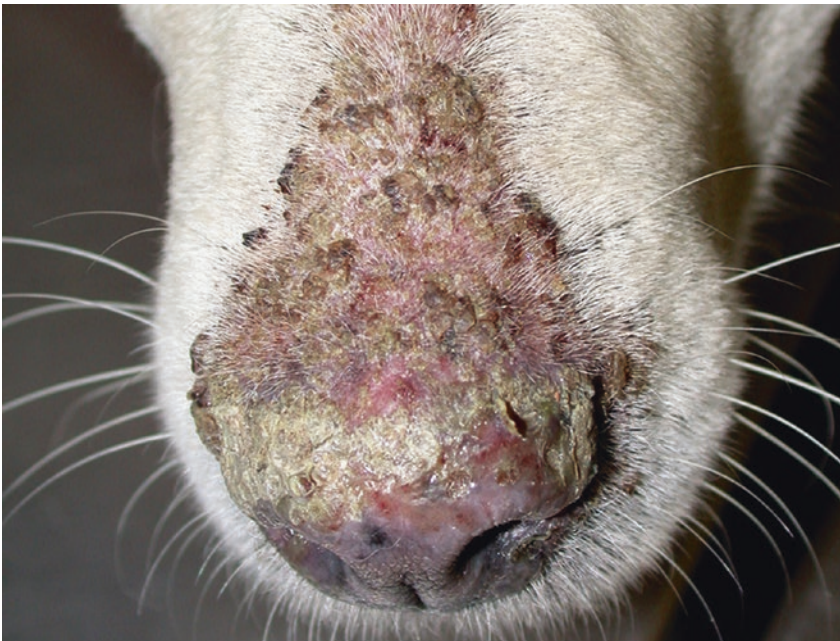

Fig. 3.89 Inflammatory depigmentation of the nose and yellowish crusts in a dog with PF

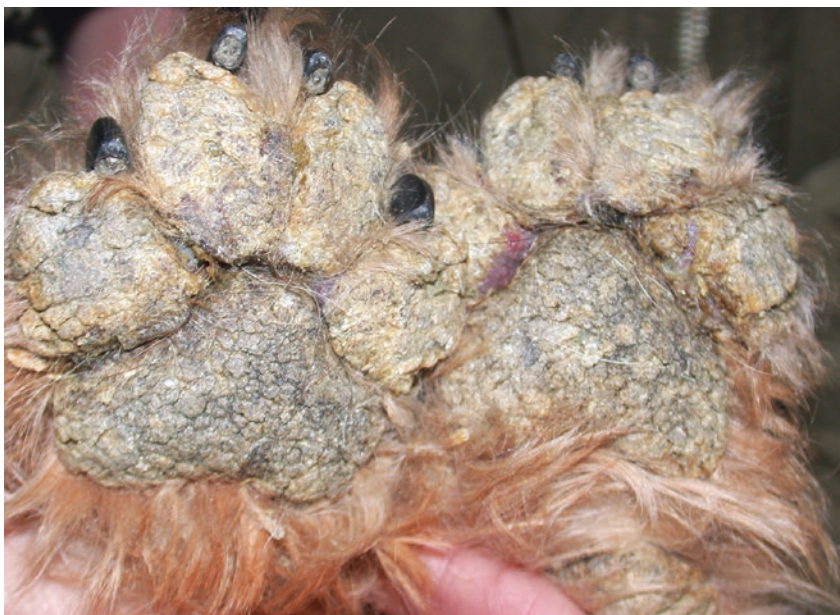

Fig. 3.90 Diffuse crusts on the paws of a dog affected by PF

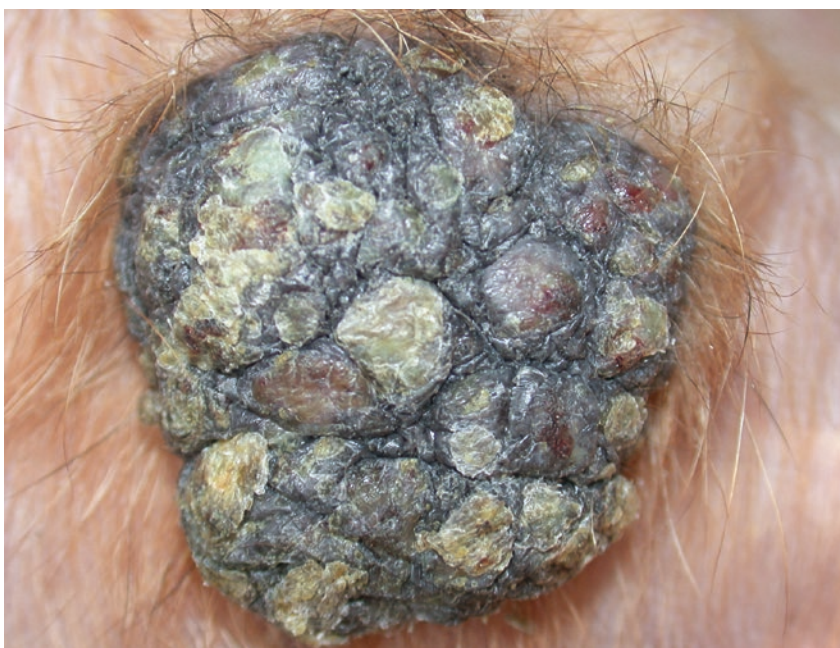

Fig. 3.91 Yellowish crusts on the scrotum of a dog with PF

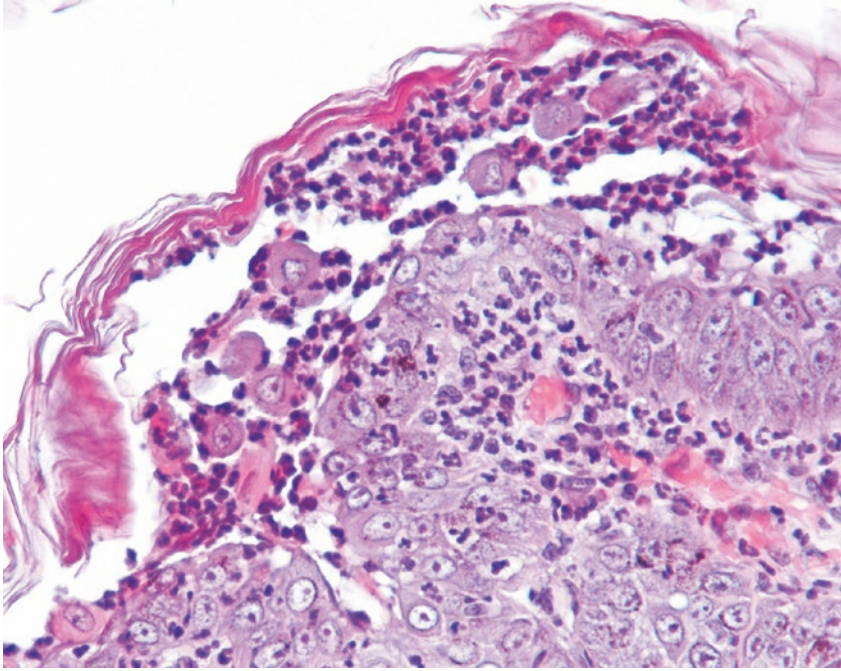


Fig. 3.92 Histology of PF: subcorneal non-follicular pustule filled with many acantholytic keratinocytes

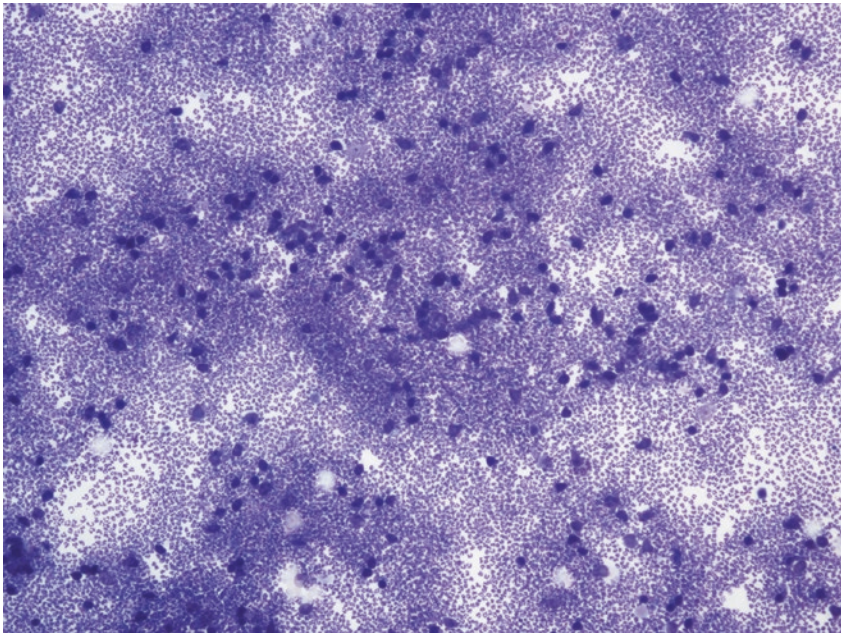


Fig. 3.93 Cytology of PF: at low magnifications acantholytic cells are not clearly recognisable

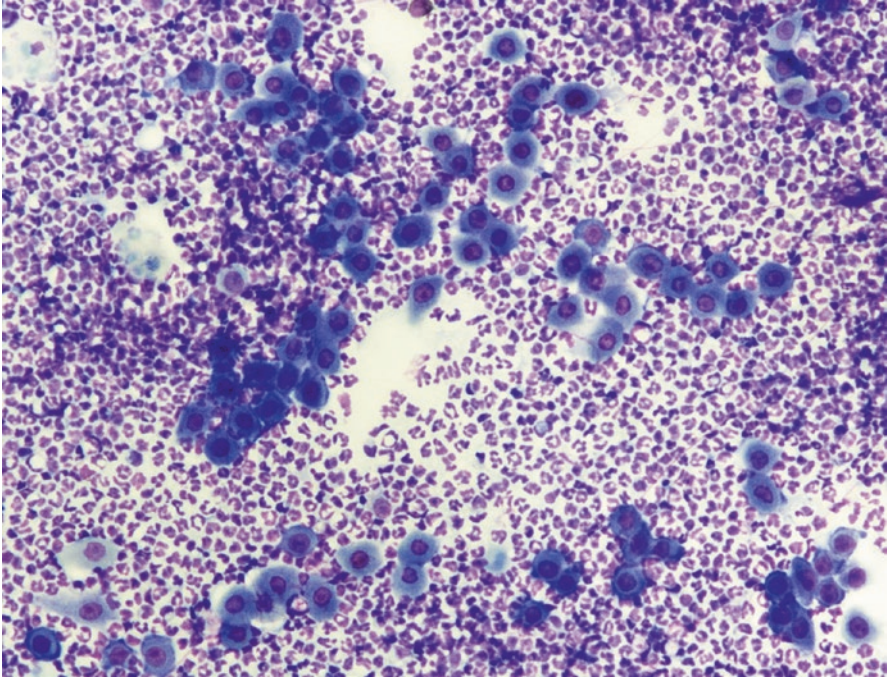


Fig. 3.94 Cytology of PF: many segmented neutrophils and acantholytic cells indicative of PF

the nuclear profile when viewing the slides at low magnifications (Fig. 3.95). The nucleus is round and central, with a single nucleolus often evident. AKs can be released into the pustules, both singly and in small clusters (Fig. 3.96).

Although they are the typical cells of PF, AKs are not pathognomonic of that disease, as it is possible to observe them in other infectious (bacteria and dermatophytes) and sterile pustular diseases as well. In any case, when many AKs are collected from an animal with typical clinical lesions, they are highly indicative of PF and histology must be performed to confirm this.

In many specimens it is possible to observe many single AKs surrounded by a single line of granulocytes arranged in a *wagon wheel* or *flower petal* arrangement; when AKs with these cytological findings are very numerous, PF should be suspected (Fig. 3.97). In about half of dogs with PF, cytology of pustules can show, along with neutrophils, a significant number of eosinophils, but the latter are rarely more numerous (Figs. 3.98 and 3.99) (Vaughan et al. 2010).

Dermatophytosis

Pustular dermatitis in dogs affected by *dermatophytes* belonging to the *Trichophyton mentagrophytes* complex, are rarely reported (Scott 1994; Parker and Yager 1997; Poisson et al. 1998).

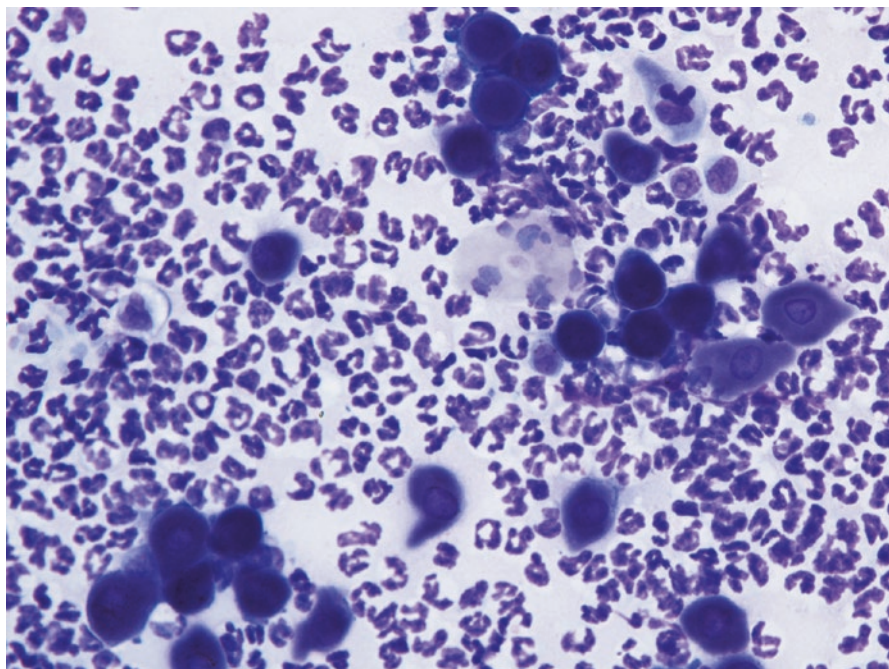


Fig. 3.95 Cytology of PF: deep blue round and polygonal acantholytic cells. Note that in many acantholytic keratinocytes the nucleus is not visible

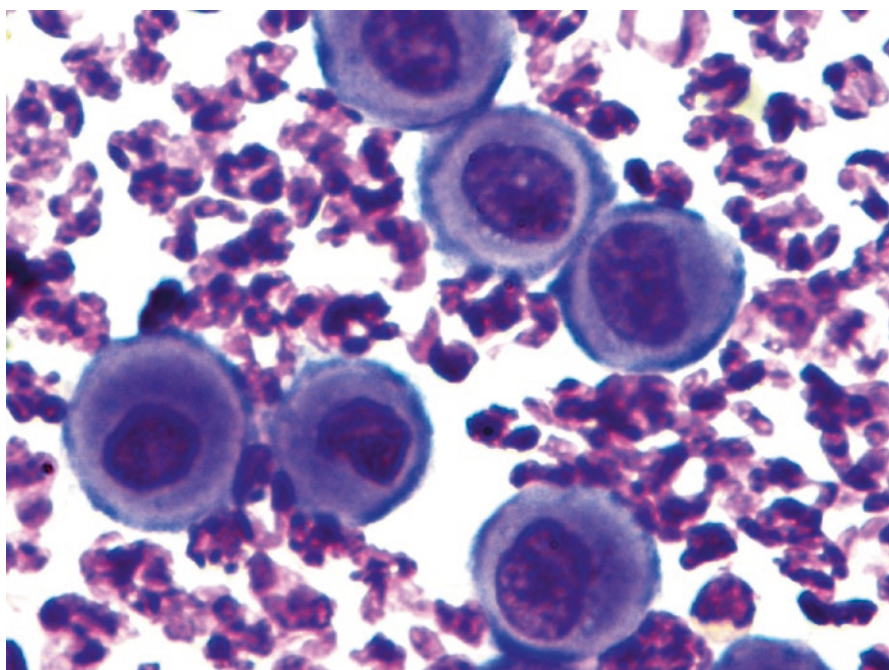


Fig. 3.96 Cytology of PF: round-shaped acantholytic keratinocytes

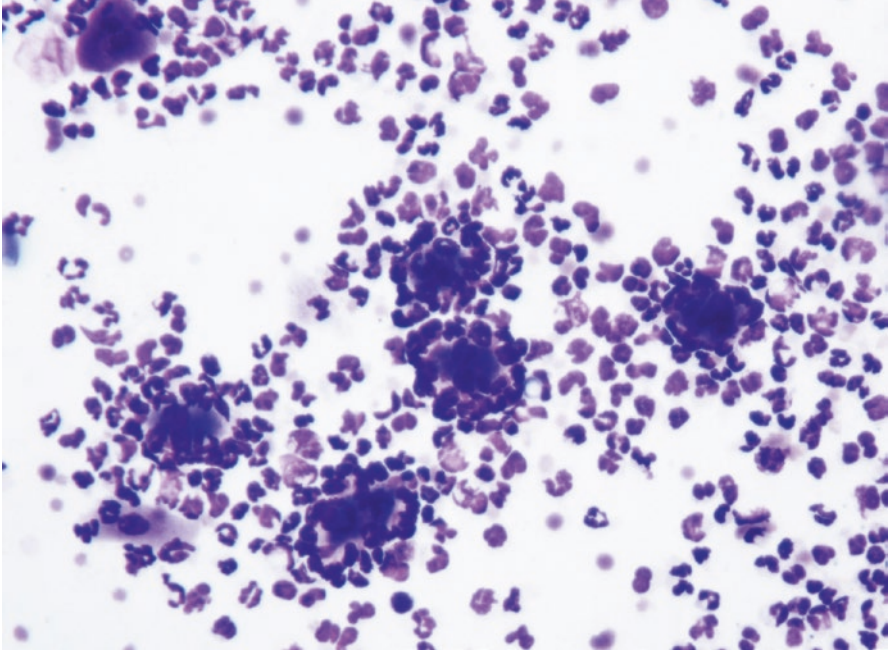


Fig. 3.97 Cytology of PF: many neutrophils arranged around single acantholytic cells

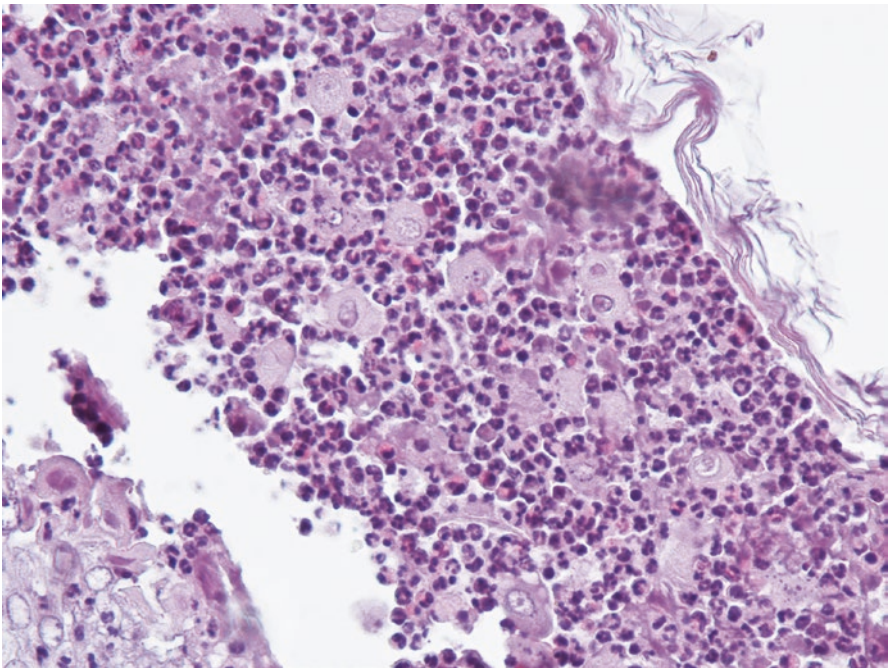


Fig. 3.98 Histology of PF: non-follicular pustule containing neutrophils, acantholytic cells and many eosinophils

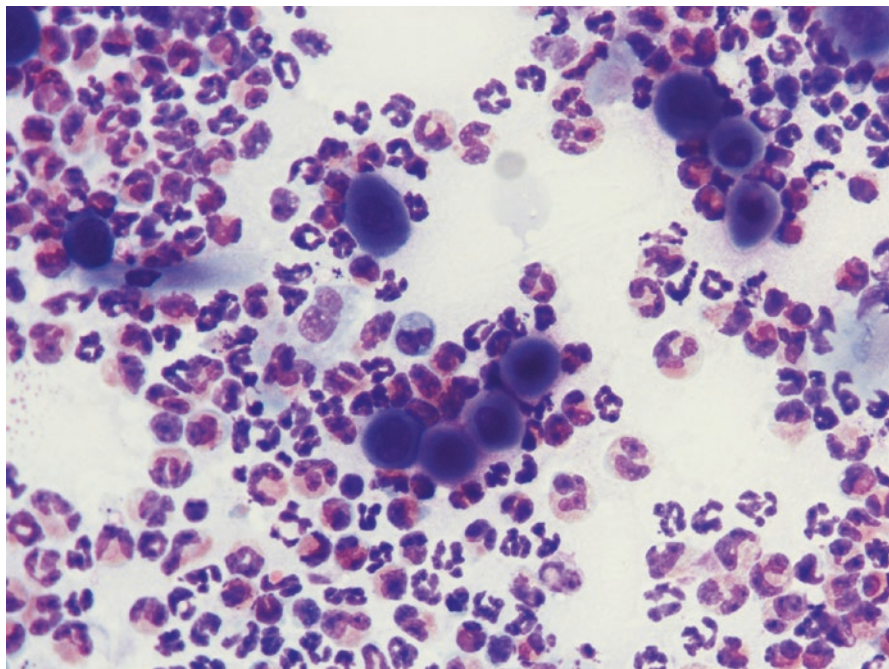


Fig. 3.99 Cytology PF: neutrophils, acantholytic cells and many eosinophils

This form of dermatophytosis is histopathologically characterised by superficial epidermal, *non-follicular pustules*. In some dogs, pustules may contain a variable number of AKs and histopathological findings can be very similar to those observed in PF (Fairley 2001; Gross et al. 2005; Peters et al. 2007). For a definitive diagnosis fungal hyphae should be discovered in the stratum corneum, sometimes detectable only using special stains such as PAS or Grocott's. The mechanisms by which dermatophytes cause acantholysis is still unknown, but presumably it occurs because of proteases secreted by the fungi (Poisson et al. 1998; Olivry and Linder 2009).

The clinical lesions are characterised by superficial pustules and yellowish crusts with a distribution resembling that of PF (Fig. 3.100).

Cytological Findings

As mentioned, cytological specimens from intact pustules may be very similar to those described in PF, with many AKs and segmented neutrophils. If there is the clinical suspicion of dermatophytic pustulosis, to detect fungi, the surface of the corneocytes dispersed on the specimens must be accurately checked. In more successful cases, septate hyphae are detected on the surface of the keratinocytes (Figs. 3.101 and 3.102). Special stains such as PAS or Grocott's can also be useful in identifying hyphae on cytological specimens.

Idiopathic and Drug-Related Sterile Pustular Diseases

Apart from PF, other immune-mediated sterile pustular diseases, such as *subcorneal pustular dermatosis with IgA deposits* (Kalahar and Scott 1990; Gross et al. 2005),

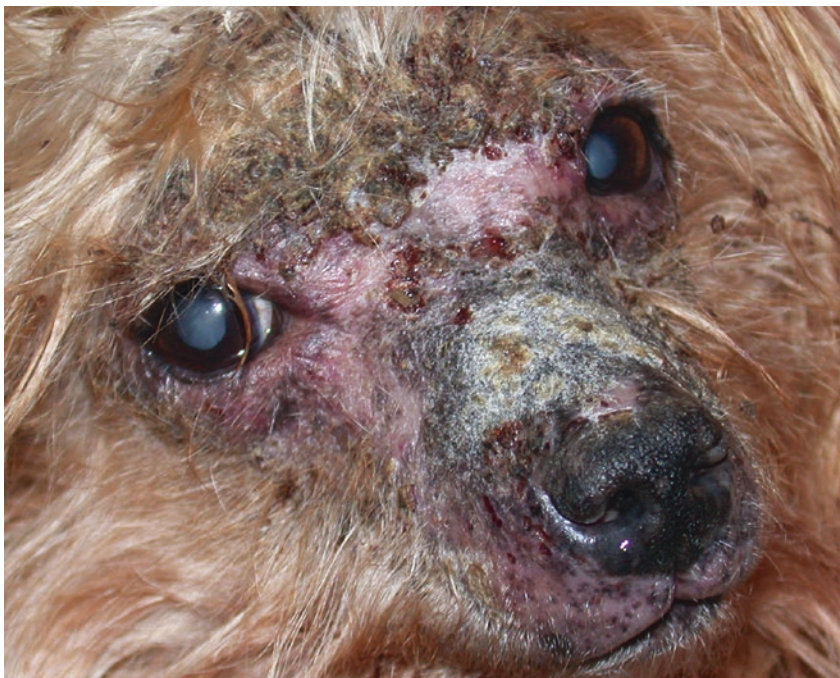

Fig. 3.100 Pustular dermatophytosis: yellowish crusts on the face and on the bridge of the nose (Courtesy of Dr. C. Caporali, Italy)

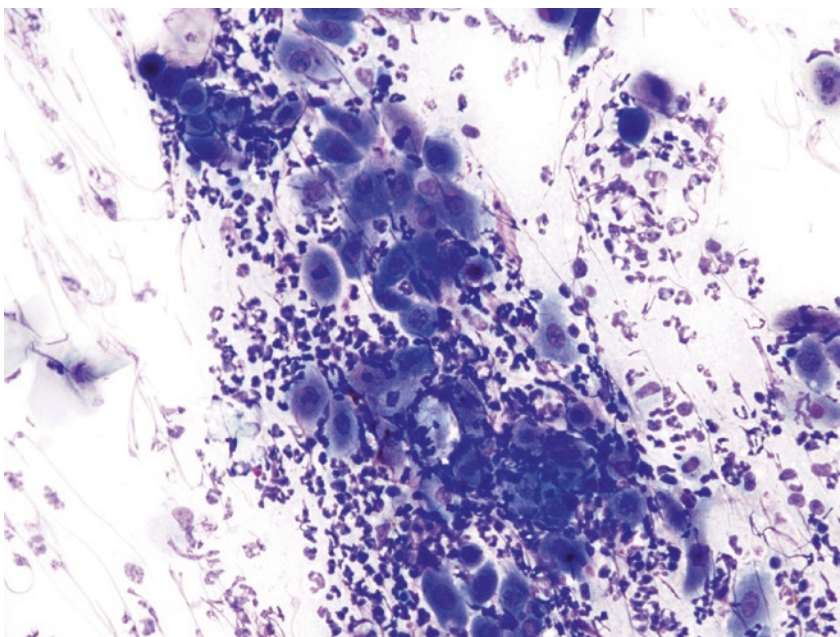


Fig. 3.101 Cytology of pustular dermatophytosis: segmented neutrophils and many acantholytic cells. Note that the cytological features are similar to those observed in PF

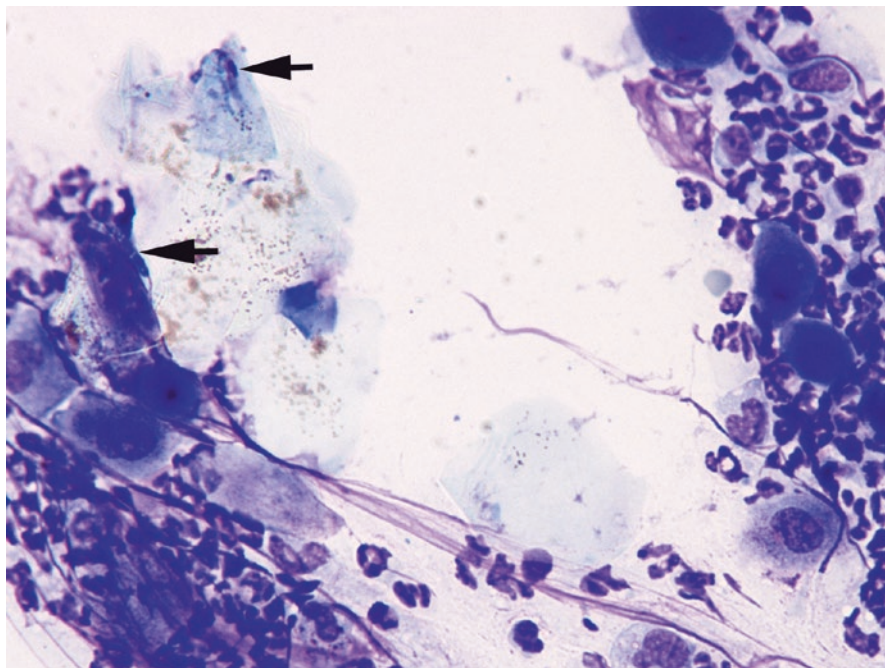


Fig. 3.102 Cytology of pustular dermatophytosis: some septate hyphae are detected on the surface of the corneocytes (arrows)

superficial acantholytic pustulosis due to a *drug reaction* (Oberkirchner et al. 2011; White et al. 2002; Bizikova et al. 2014, 2015) and *idiopathic pustular dermatitis*, are rarely reported in dogs. All these diseases are clinically characterised by non-follicular pustules spread all over the body (Figs. 3.103 and 3.104) (Miller et al. 2013).

Cytological Findings

Cytological specimens are not diagnostic, as they are composed of segmented neutrophils and a variable number, usually low number, of acantholytic cells (Fig. 3.105).

Non Follicular Pustulosis in Dogs With Canine Leishmaniasis

In veterinary literature, there are only a few articles describing neutrophilic pustular lesions in dogs affected by *leishmaniasis* in which superficial pustules are reported (Ferrer et al. 1988; Saridomichelakis and Koutinas 2014). Unfortunately, a clear description of the characteristics of pustules and their localisation is lacking. Histopathological examination describes subcorneal neutrophilic pustules with few or no AKs (Bardagi 2012).

In a recent paper, dogs suffering from visceral leishmaniasis associated with pustular dermatitis have been reported (Colombo et al. 2016). Cultures of the purulent exudate are negative and many dogs had not responded to previous systemic antibiotic therapy. The author has visited many leishmaniotic dogs with this clinical presentation that have not regressed with anti-protozoal therapy, but required

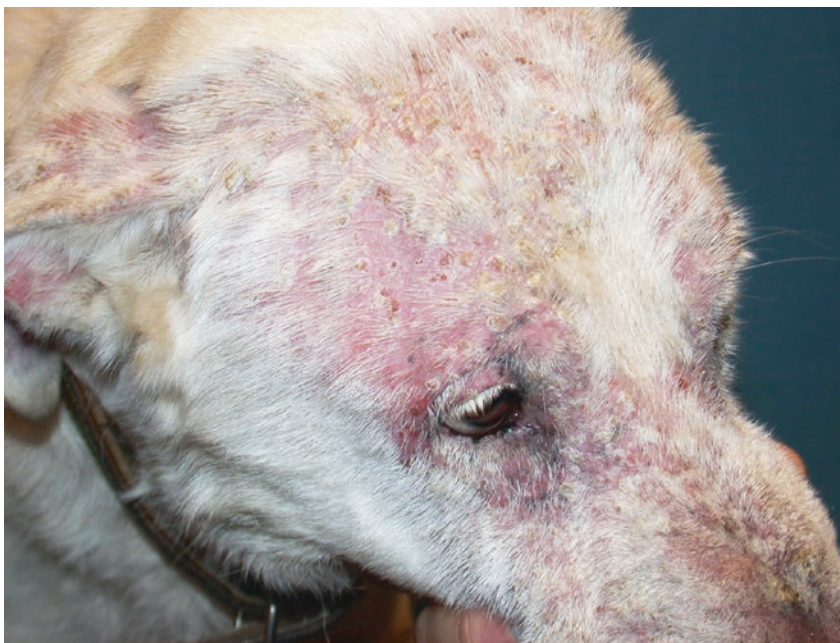

Fig. 3.103 Yellowish crusts secondary to pustule dehydration in a dog with sterile neutrophilic subcorneal pustulosis

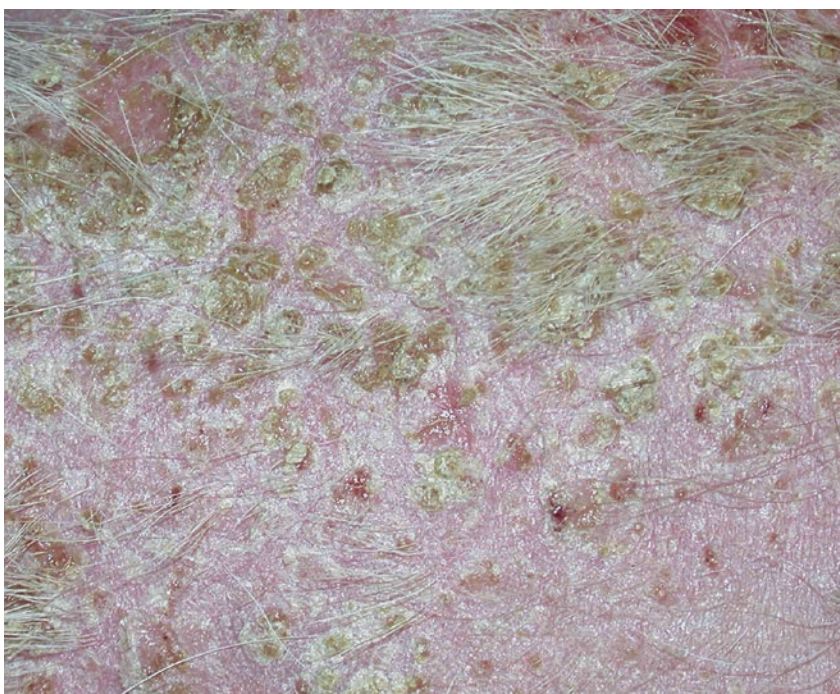


Fig. 3.104 Close-up of the same lesions as in Fig. 3.103

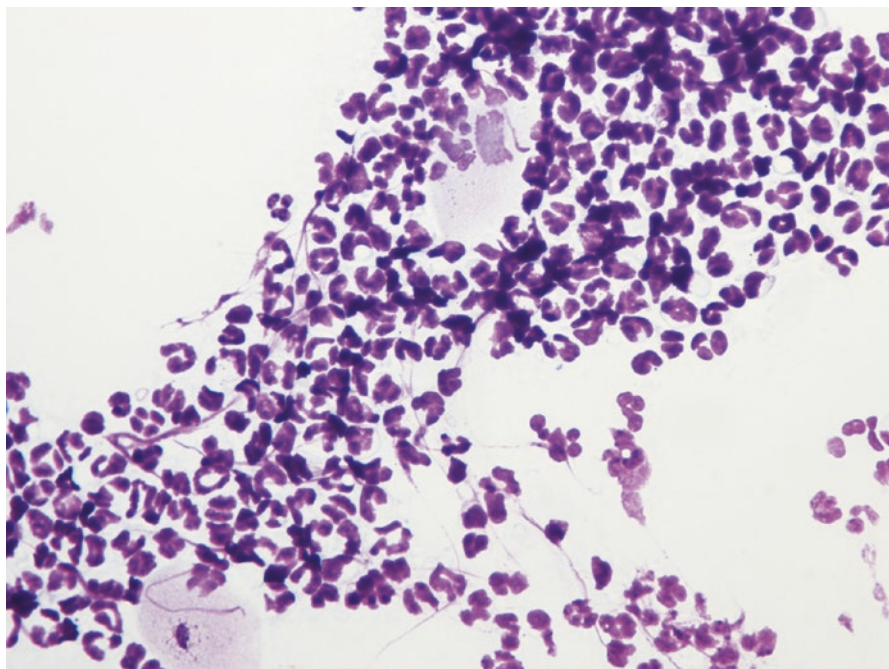


Fig. 3.105 Cytology of sterile subcorneal pustulosis: many segmented neutrophils and no acanthocytic cells

immunosuppressive drugs. The healing of the lesions with immunomodulatory drugs suggests that an immune-mediated mechanism, probably triggered by leishmaniasis, might have occurred.

As canine leishmaniasis is endemic in many countries, it is not possible to exclude the possibility that two different diseases might affect animals simultaneously. A small criticism of this evidence is that in practice sterile pustular diseases are very rare in dogs and it seems strange that most dogs with this clinical presentation are simultaneously affected by leishmaniasis. However, to date, it has not been possible to demonstrate the real role of *Leishmania* in the development of pustular eruptions. Pustules have an aspect and distribution similar to those described for PF, and as occurs in this autoimmune disease, systemic symptoms such as fever and malaise are sometimes observed (Figs. 3.106 and 3.107).

Cytological Findings

Cytological and histopathological findings are not compatible with PF and in most cases AKs are absent. When they are present, they are less numerous than in PF. Histopathologically, pustules are non-follicular and in many dogs, macrophages filled with amastigotes can be detected in the subepidermal dermis (Figs. 3.108 and 3.109). In some dogs, to detect a few amastigotes in the dermis, immunohistochemical staining must be performed (Fig. 3.110). Cytology of pustules is composed of segmented neutrophils, whereas AKs are usually scarce or totally absent (Fig. 3.111).

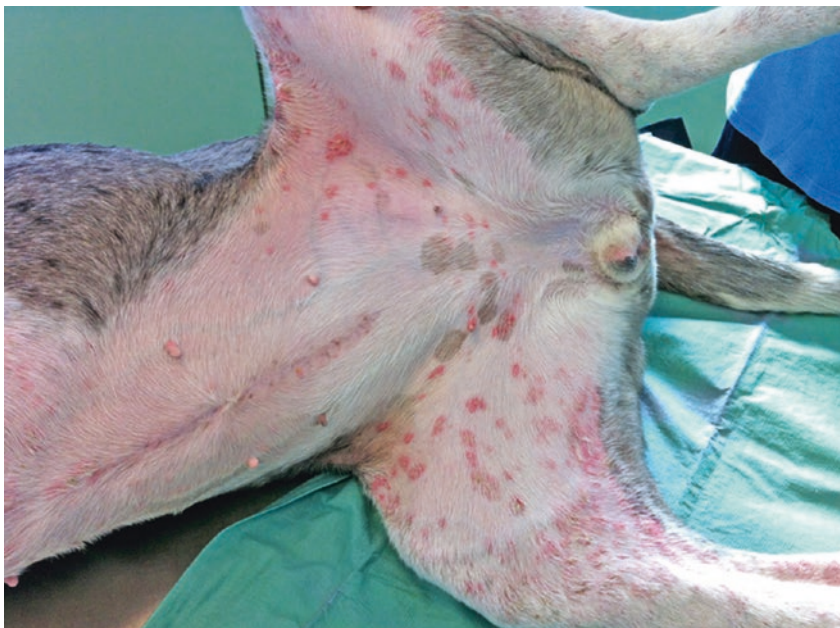

Fig. 3.106 Large non-follicular pustules with an erythematous halo in a dog affected by sterile pustulosis associated with leishmaniasis

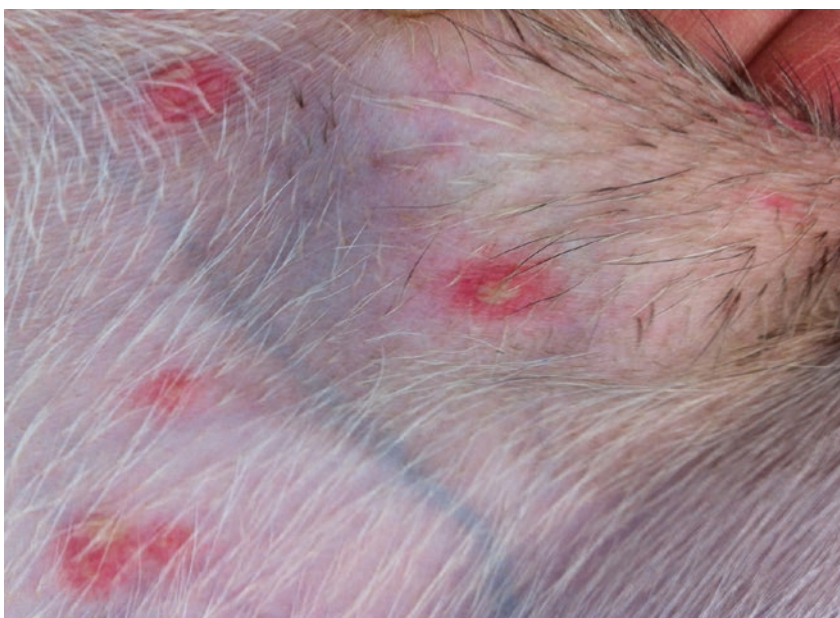

Fig. 3.107 Close-up of the same pustules as in Fig. 3.106

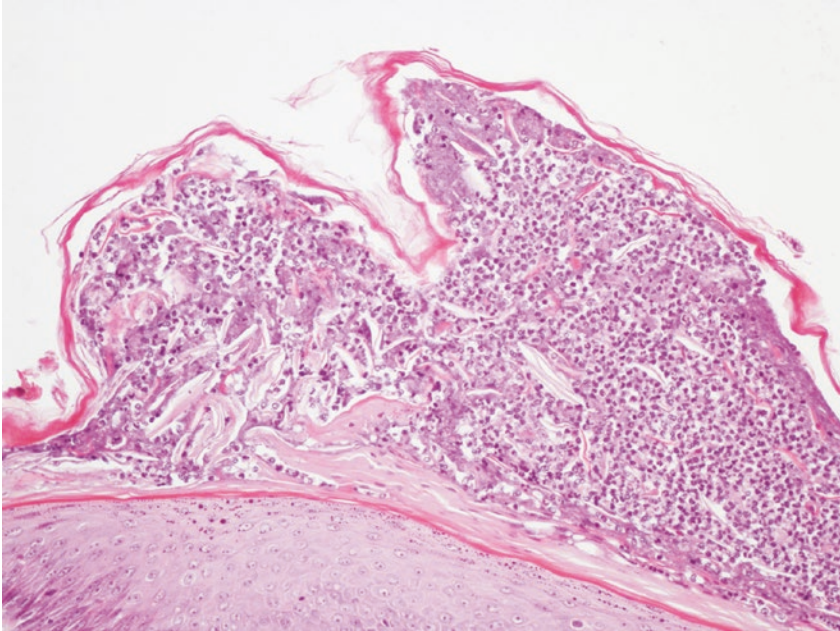


Fig. 3.108 Histology of sterile pustules in a leishmaniotic dog: very large subcorneal non-follicular pustule with no acantholytic keratinocytes

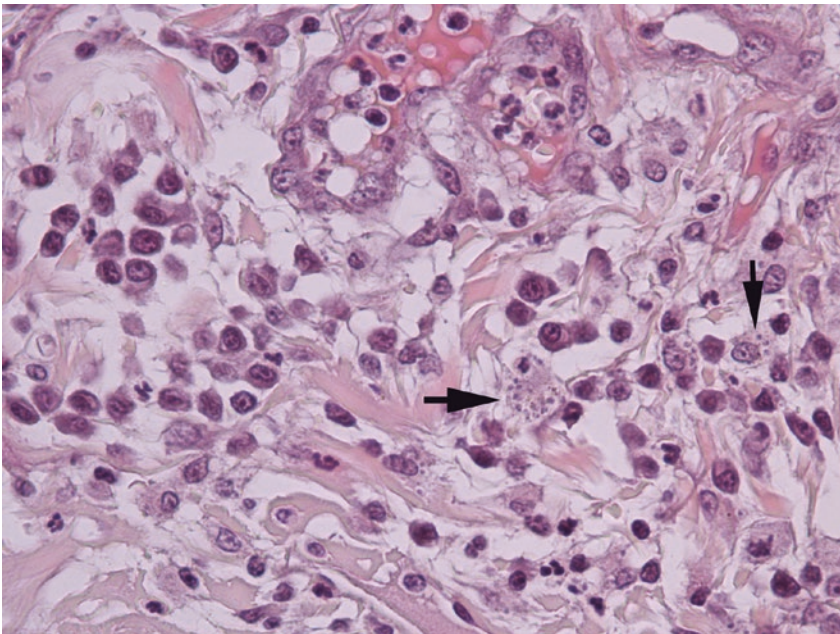


Fig. 3.109 Histology of leishmaniasis: many amastigotes of *leishmania infantum* in the cytoplasm of macrophages (arrows)

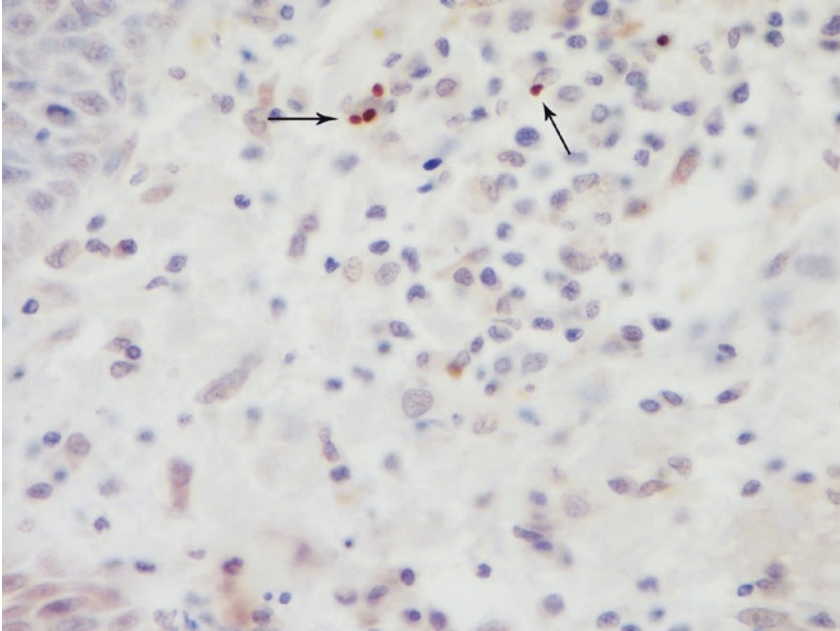


Fig. 3.110 Immunohistochemistry: few amastigotes of *leishmania infantum* are highlighted by immunohistochemical staining (*arrows*) (Courtesy of Prof. F. Abramo, Italy)

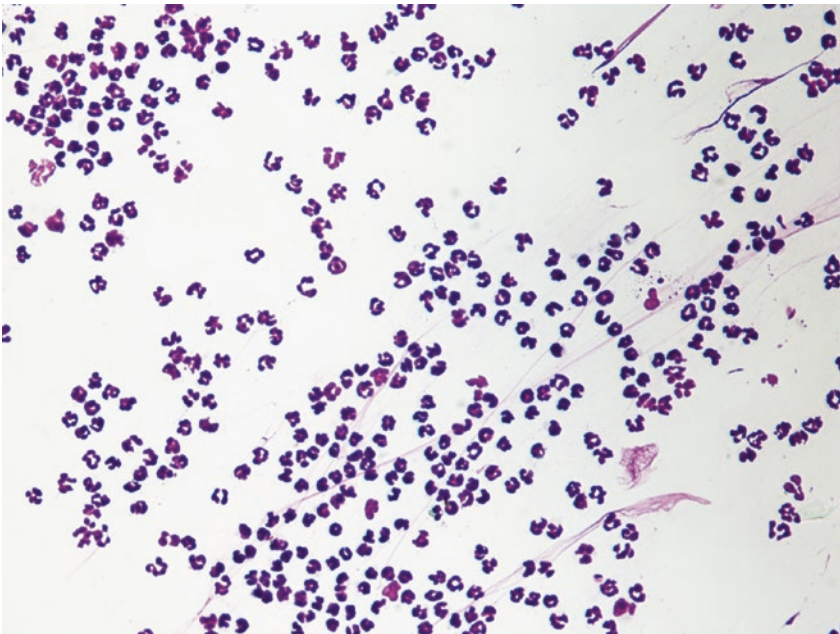


Fig. 3.111 Cytology of a sterile pustule in a dog with leishmaniasis: many segmented neutrophils and no acantholytic cells

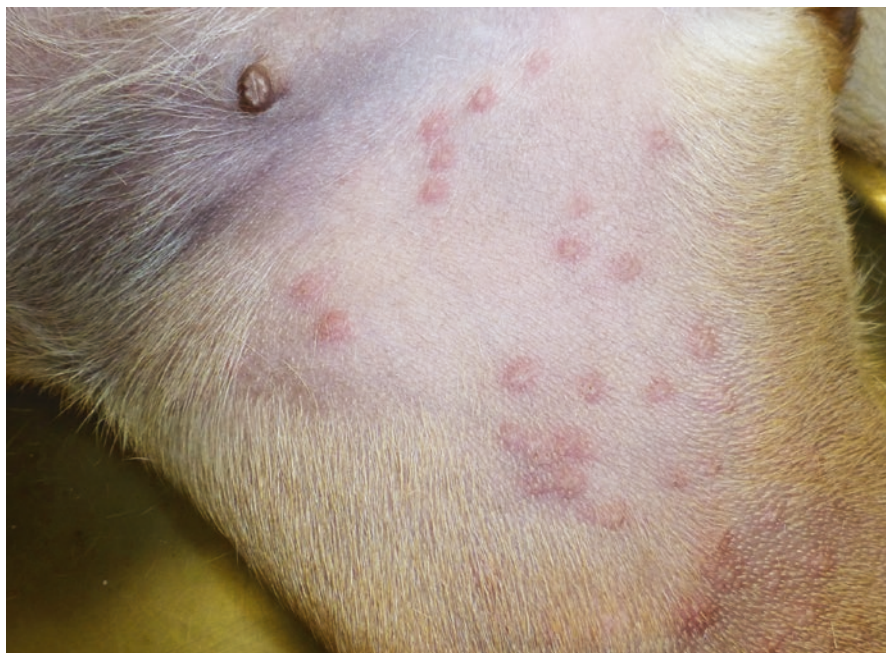

Fig. 3.112 Multiple small and non-follicular pustules on the inner surface of the legs in a dog with fleabite dermatitis

Eosinophilic Pustulosis

Sterile eosinophilic pustulosis is a rare idiopathic disease of dogs characterised by the development of intra-epidermal or subcorneal pustules, predominantly localised on the trunk and associated with systemic symptoms such as fever, malaise, lymphadenopathy and eosinophilia (Scott 1987; Carlotti et al. 1989; Gross et al. 2005). The cause of skin lesions is unknown, but the response to immunomodulatory drugs suggests an immune-mediated pathogenesis.

Intra-epidermal eosinophilic pustules are a common finding in histopathological samples from animals affected by *fleabite allergic dermatitis* (Gross et al. 2005). The pustules are microscopic and not clinically appreciable. Although the primary clinical lesions most commonly found in dogs with fleabite allergy are papules or crusted papules on the rump, backs of the thighs and abdomen, sometimes it is possible to observe small *non-follicular pustules* on the groins, abdomen and ventral area of the thighs (Fig. 3.112) (Miller et al. 2013). As these eosinophilic pustules are clinically indistinguishable from those observed in canine pyoderma, a cytological investigation could rapidly differentiate between them. The cytological findings and the concomitant presence of adult fleas on the skin, allow the cause of the pustules to be ascribed to fleabite hypersensitivity.

Cytological Findings

Cytology is characterised by numerous eosinophils, a variable number of neutrophils and rare or no AKs (Fig. 3.113).

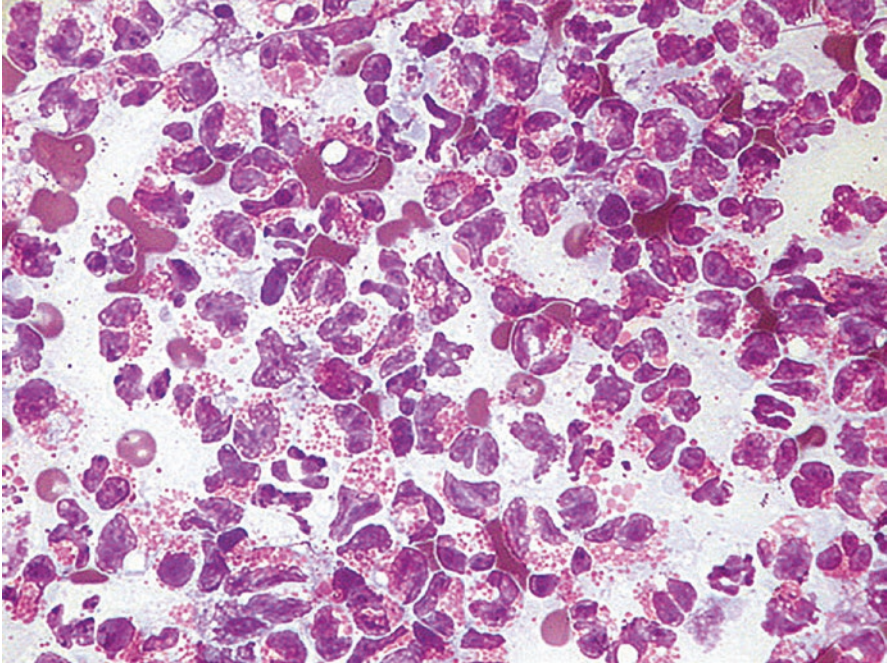


Fig. 3.113 Cytology of eosinophilic pustulosis: pure eosinophilic inflammation

3.4.2 Pustular Diseases in Cats

Pustular diseases are very rare in cats; thus, the chances of detecting intact pustules on the skin of cats are extremely low.

3.4.2.1 Bacterial Infection

Apart from *abscesses* and other rare bacterial infections (mycobacteriosis), pyoderma in cats is usually related to the complication of self-trauma in patients with pruritic diseases, and the pathogenic role of bacteria in these cases has not been proven. However, clinical presentations in cat pyoderma are very different from those seen in dogs.

An uncommon form of localised pyoderma that rarely shows *non-follicular pustules* is observed in *feline acne*. Feline acne is considered an idiopathic disease associated with a defect of follicular keratinisation. Skin lesions vary depending on the chronicity and the development of furunculosis; sometimes together with comedones, papules and papular–nodular lesions, a few non-follicular pustules can be observed (Fig. 3.114). Exceptionally, non-follicular pustules may be detected in cats with systemic diseases such as endocrine disorders (Fig. 3.115).

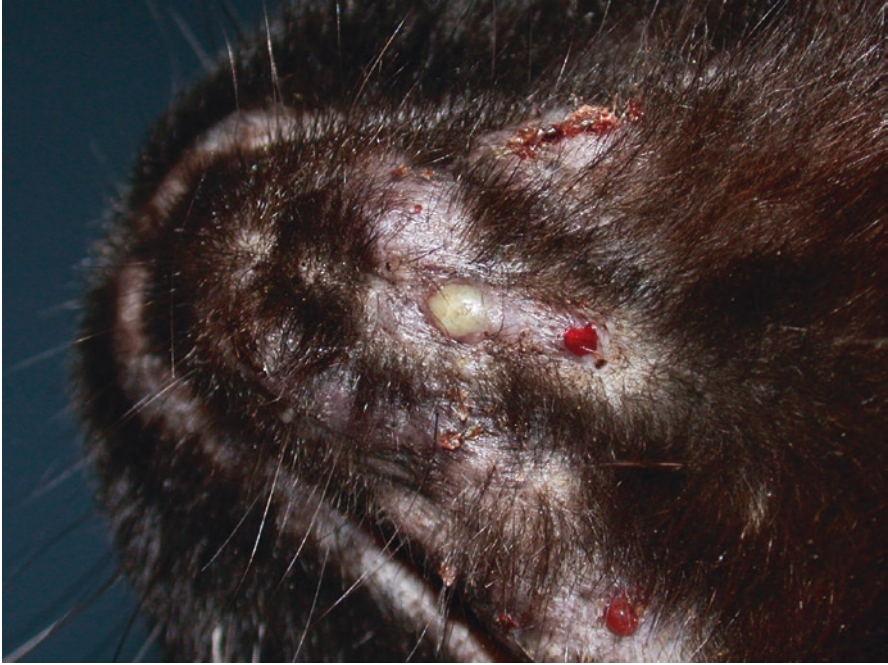

Fig. 3.114 Large non-follicular pustule on the chin of a cat with feline acne

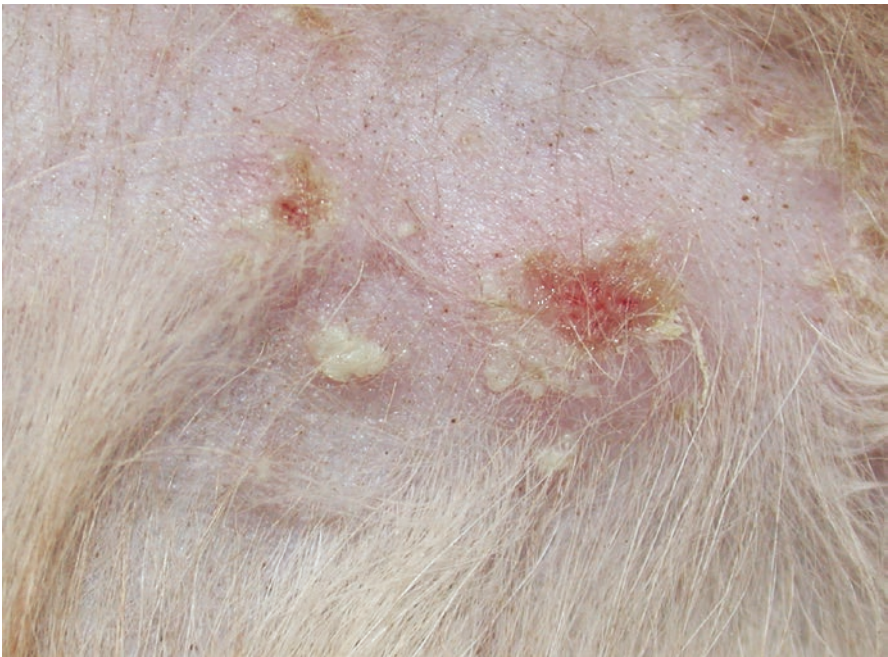

Fig. 3.115 Large non-follicular and confluent pustules on the abdomen of a cat affected by diabetes mellitus

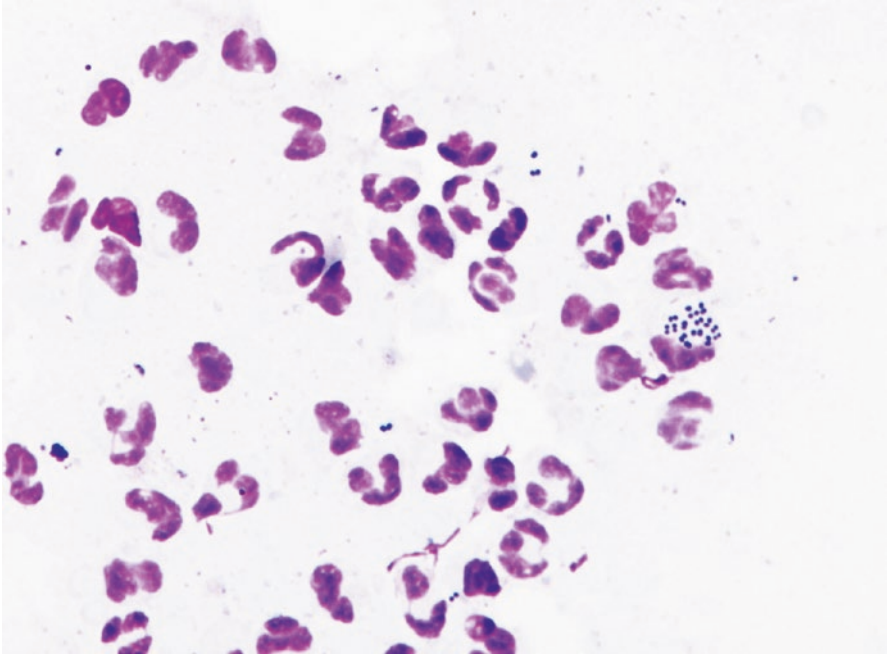


Fig. 3.116 Cytology of pyoderma: karyolytic neutrophils that phagocytose many cocci

Cytological Findings

As in dogs, cytology of bacterial pustules in cats consists of karyolytic neutrophils with intracytoplasmic cocci (Fig. 3.116).

3.4.2.2 Pemphigus Foliaceus

Even in cats, PF is a pustular disease. Unlike the dog, the skin of the cats is thinner and the possibility of finding intact pustules is very rare. Pustules rapidly dehydrate and give rise to yellowish crusts. Pustules or crusts located on the pinna, face, nose and around the nipples are highly indicative of feline PF. In association, multidigital paronychia with the nail fold covered by dehydrated pus with a characteristic *cheesy* appearance, is commonly present (Figs. 3.117, 3.118, and 3.119; Preziosi et al. 2003; Miller et al. 2013).

Cytological Findings

Histopathology and cytology of feline PF are similar to those for PF in dogs, with a population of segmented neutrophils and a high number of acantholytic cells (Fig. 3.120) (Gross et al. 2005). In most cats is very hard to find intact pustules; thus, cytological sampling must be performed from the inner surface of the crusts and histopathological diagnosis of PF is often based on the detection of AKs in the crusts (Figs. 3.121 and 3.122). Cytological examination of the pus sampled from the nail folds is rarely diagnostic because it is usually characterised by numerous karyolytic neutrophils, owing to the innumerable bacteria that infect the lesions. Furthermore, AKs are rare to absent in many specimens collected from nail folds.

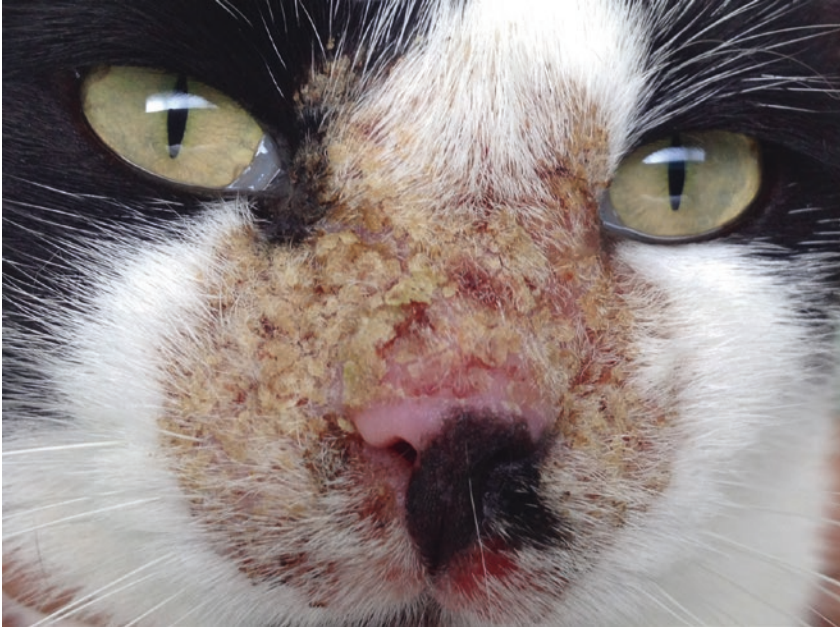

Fig. 3.117 Yellowish crusts around the nose of a cat with PF

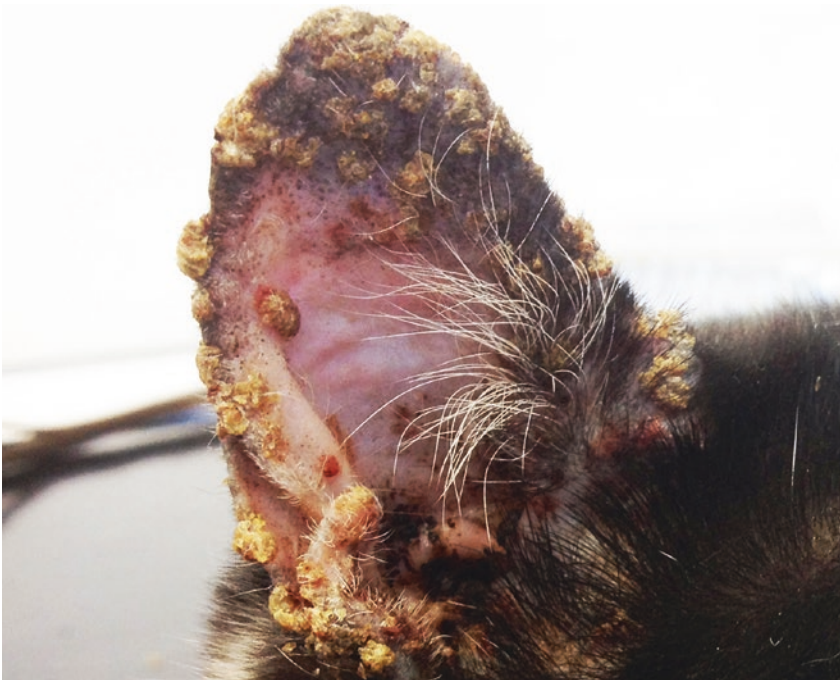


Fig. 3.118 Yellowish crusts from dehydrated pustules on the pinna of a cat with PF

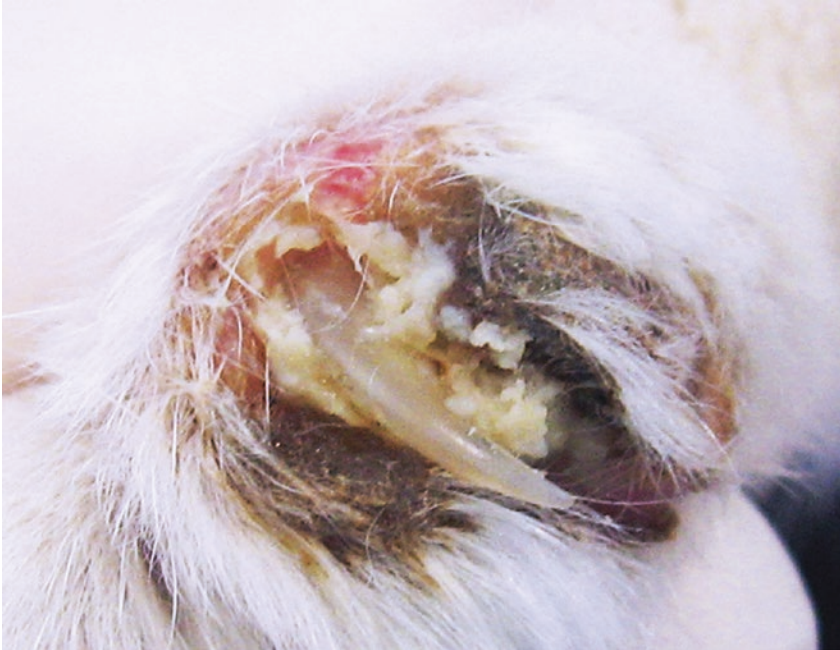

Fig. 3.119 Paronychia with dried pus with a *cheesy* appearance on the nail fold

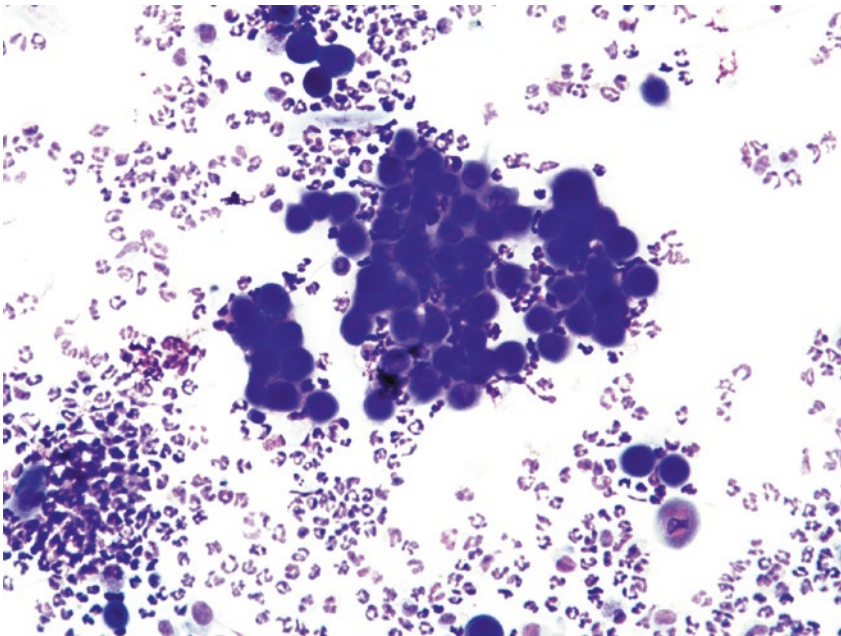


Fig. 3.120 Cytology of PF: segmented neutrophils and many acantholytic keratinocytes arranged both singly and in large clusters

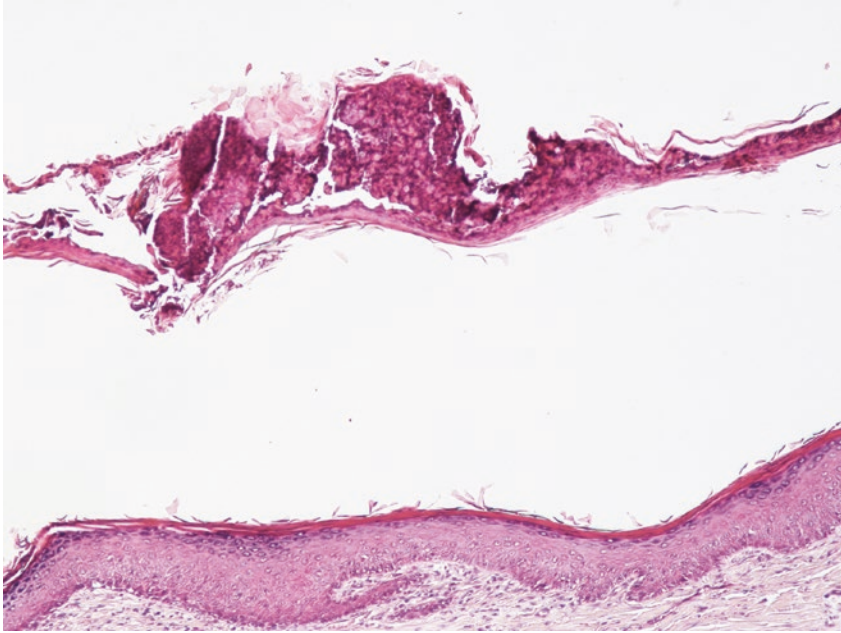


Fig. 3.121 Histology of PF: neutrophilic crust detached from the superficial epidermidis

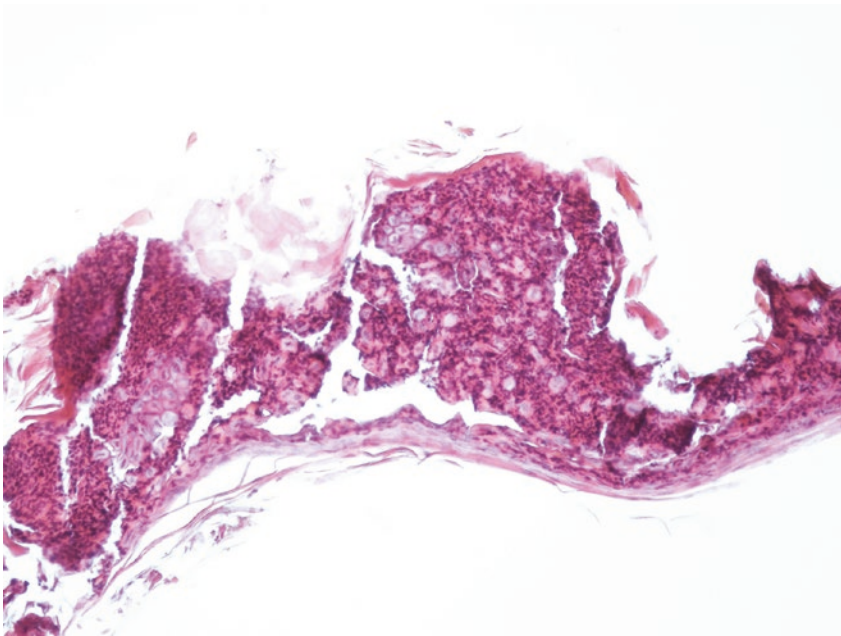


Fig. 3.122 Histology of PF: at high magnifications, many acantholytic keratinocytes are evident in the context of the crust

3.5 Scales

In many dogs and cats, collection using the impression smear technique from skin with an intact epidermal surface covered in dry or oily/waxy scales can provide useful diagnostic results.

3.5.1 *Scaling Diseases in Dogs and Cats*

3.5.1.1 Bacterial Overgrowth Syndrome

Bacterial overgrowth syndrome (BOGS) is a dermatological disorder observed in dogs characterised by an overgrowth of bacteria on the skin surface in the absence of true neutrophilic inflammation (Jasmin et al. 2001; Pin et al. 2006). An underlying disease usually affects dogs with BOGS, most frequently *atopic dermatitis*, as it causes injury to the cutaneous barrier and consequently impairs the defensive mechanisms favouring bacterial overgrowth and toxin overproduction. From the above, to resolve BOGS, the underlying predisposing disease must be diagnosed and treated. Skin lesions are characterised by erythema, pruritus, with skin usually covered in a shiny, sticky film and frequently associated with chronic lesions such as lichenification and hyperpigmentation, especially on the groin and axilla (Fig. 3.123).

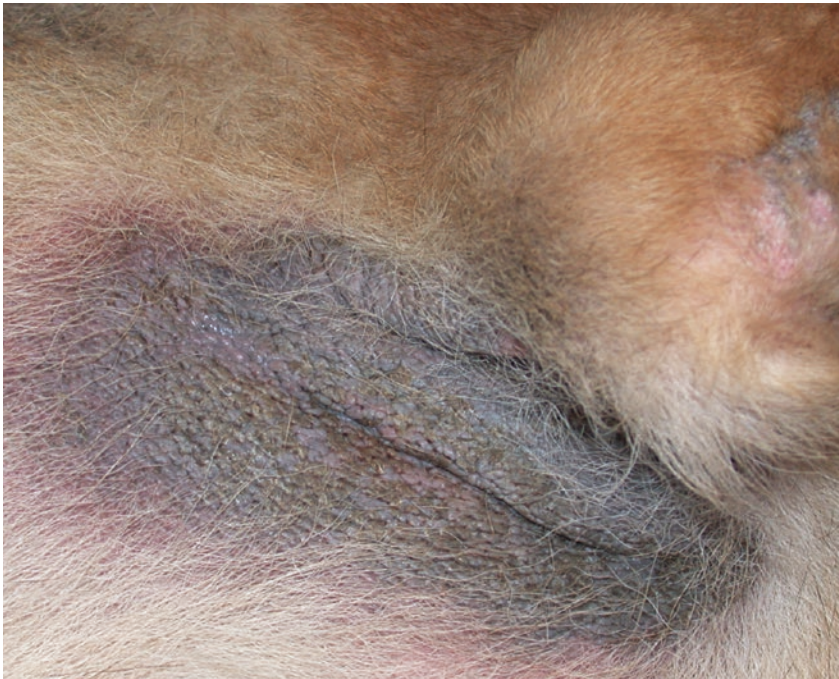


Fig. 3.123 Lichenification and skin hyperpigmentation of the axilla in a dog with bacterial overgrowth syndrome (BOGS)

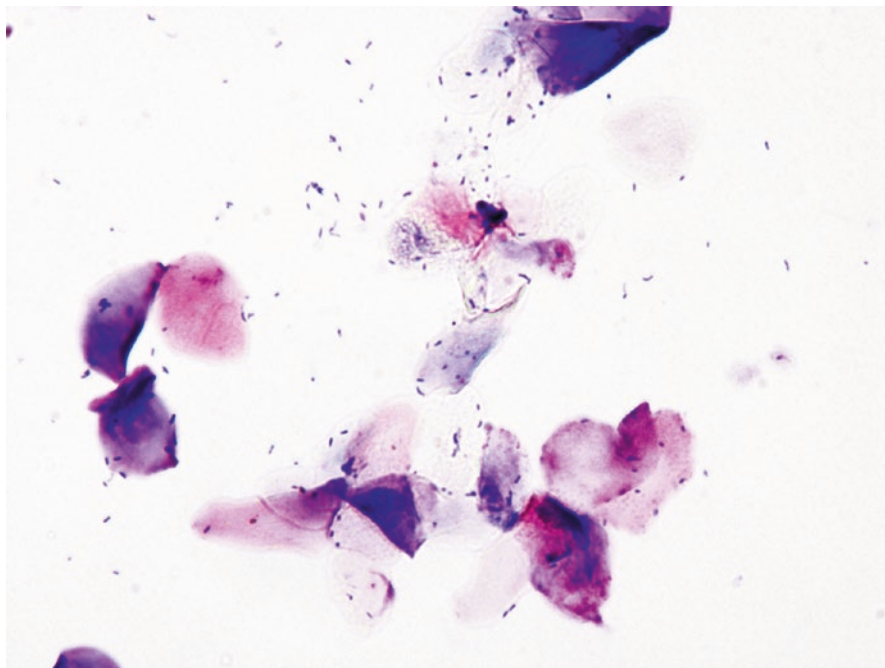


Fig. 3.124 Cytology of BOGS: polygonal corneocytes with many cocci and rod-shaped bacteria on their surface. Note the absence of neutrophils

Cytological Findings

Cytology is characterised by a large number of corneocytes with many cocci on their surface, but with no inflammatory cells. Anecdotally, although the number of bacteria is usually much higher, it is believed that to diagnose BOGS, more than five bacteria per immersion field ($\times 100$) must be detected (Fig. 3.124).

3.5.1.2 *Malassezia* Overgrowth

Malassezia pachydermatis is commensal on the skin and mucous membranes of dogs. As discussed for BOGS, there are factors that promote pathogenicity and allow *Malassezia* overgrowth, such as high temperatures and humidity, excessive secretion of lipids and underlying diseases, e.g. atopic dermatitis (Guaguère et al. 1996; Mauldin et al. 1997, 2002; Chen and Hill 2005; Gross et al. 2005). *Malassezia overgrowth* usually causes very pruritic dermatitis associated with scaling, erythema and a bad smell (Bond et al. 2004). Typology and topography of lesions are the same as described for BOGS, with which it is often associated.

Malassezia overgrowth/dermatitis is a frequent complication in dogs suffering from allergic diseases (especially atopic dermatitis), even though any disease that affects the skin surface ecosystem can cause excessive multiplication of yeasts. In dogs, clinical lesions are characterised by erythema, greasy scaling, often with a

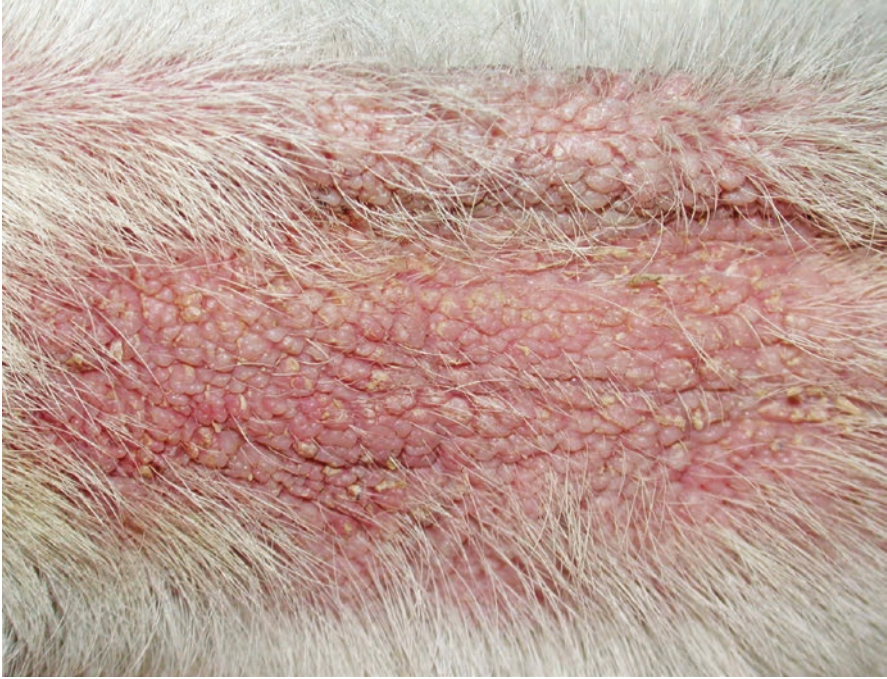

Fig. 3.125 Alopecia, lichenification and waxy scales in a dog with *Malassezia* overgrowth

waxy appearance, orange in colour, and with rancid smell, usually associated with lichenification and hyperpigmentation (Figs. 3.125 and 3.126). Such findings are mainly evident in more humid body areas such as the interdigital area, the nail fold, the ventral surface of the neck, axilla and groin, but in some individuals they may be present throughout the body.

Frequently, whether associated with other skin lesions or not, dogs present ceruminous otitis with a yeast overgrowth characterised by yellowish and smelly secretion.

In feline patients *Malassezia overgrowth* is rarer than in dogs (Miller et al. 2013). Usually, yeasts are observed in cats affected by hypersensitivity or immune-suppressive diseases, such as paraneoplastic alopecia associated with liver or pancreatic neoplasia and exfoliative dermatitis associated with thymoma (Forster-Van Hijfte et al. 1997; Godfrey 1998).

Cytological Findings

As mentioned, *Malassezia* spp. is a commensal yeast that lives on the skin surface and when there is overgrowth, a high number of yeasts are usually collected. *Malassezia* is an oval microorganism, measuring 3–8 μm , that assumes a characteristic bilobate appearance during the budding phase (*American peanut* shape; Fig. 3.127). The number of yeasts present on cytopathological preparations is variable and dependent on the type of injury, the sampling method and the breed. It has

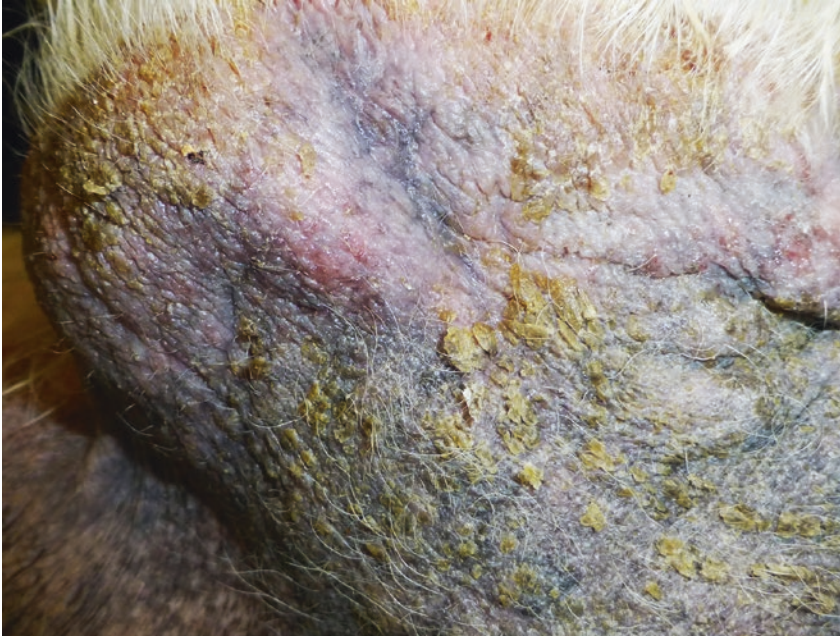

Fig. 3.126 Alopecia, erythema, lichenification and waxy scales in a dog with *Malassezia* dermatitis

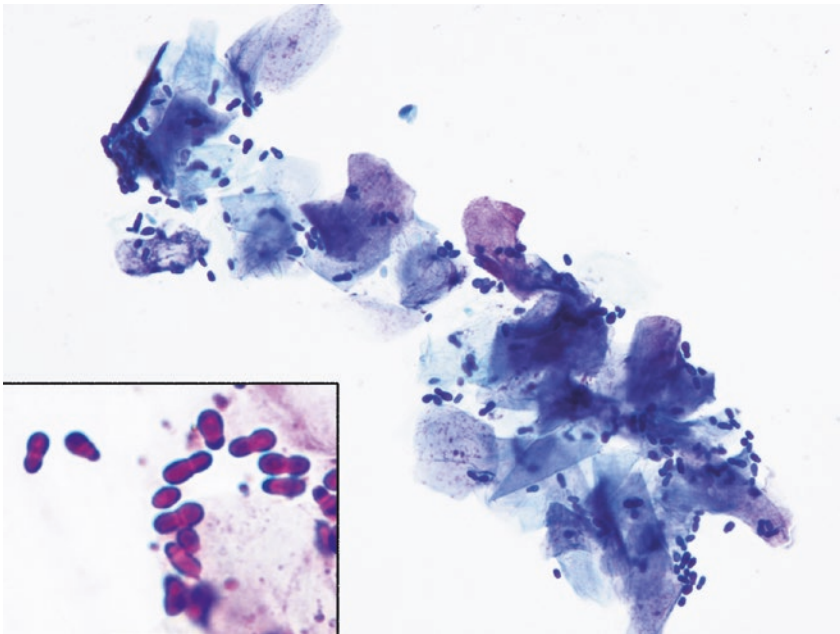


Fig. 3.127 Cytology of *Malassezia* overgrowth: many yeasts adhering to the surface of the corneocytes. *Inset:* at high magnifications, the characteristic peanut-shape of yeasts is easily recognisable

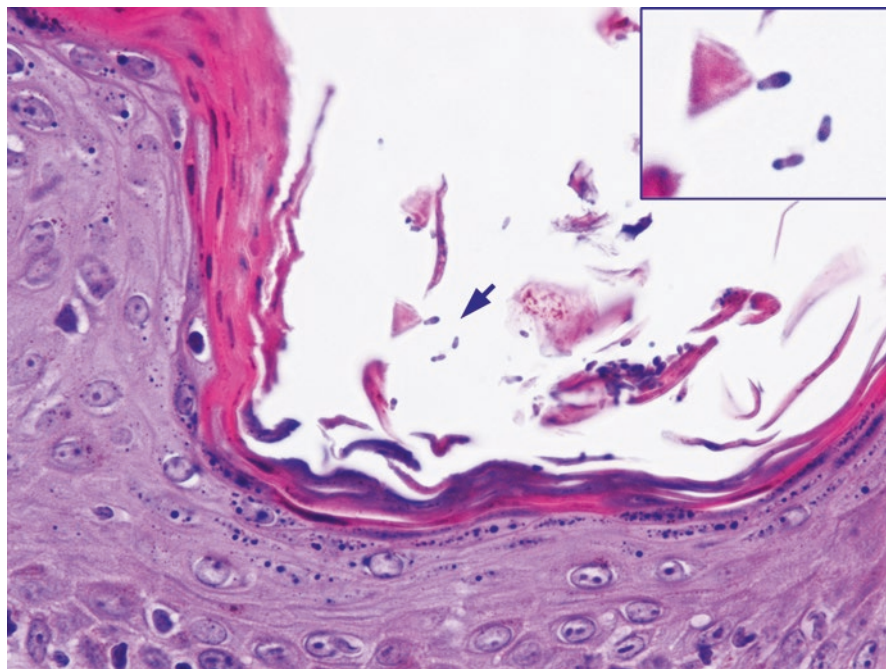


Fig. 3.128 Histology of *Malassezia* overgrowth: many yeasts in the stratum corneum (*arrow*). Note as the typical bilobed shape is well evident (*inset*)

been shown that in some feline breeds such as the Devon rex or in canine breeds such as the Basset hound, the number of yeasts on the skin is physiologically higher than in other breeds (Ahman et al. 2007). Anecdotally, it is believed that when diagnosing a *Malassezia* overgrowth more than two yeasts per immersion field ($\times 100$) need to be found. Although the number of yeasts usually found is greater than that considered relevant to diagnosing a *Malassezia* overgrowth, in some dogs with chronic lichenification, it is possible to obtain negative samples. This occurrence is because severe epidermal hyperplasia may not allow the sampling of yeasts *hidden* between the epidermal folds. To avoid this misdiagnosis it is advisable to carry out repeated sampling from the same area to try to collect more deeply located yeasts. In a severe infection, the number of yeasts is so high that many *Malassezia* spp. can be easily collected with a piece of transparent acetate tape (Figs. 3.128 and 3.129).

3.5.1.3 Cutaneous Candidiasis

Candida albicans is a commensal mycelial yeast that colonises the mucous membranes of dogs and cats. In addition to *C. albicans*, other yeasts such as *C. parapsilosis* and *C. guilliermondii* have been reported to cause dermatitis in dogs (Carlotti and Pinn 1999; Mueller et al. 2002; Gross et al. 2005). These yeasts can occasionally cause dermatitis, but when it happens they are usually opportunistic infections due to an underlying disease that impairs the immune system, such as metabolic diseases (superficial necrolytic dermatitis/hepatocutaneous syndrome), hormonal

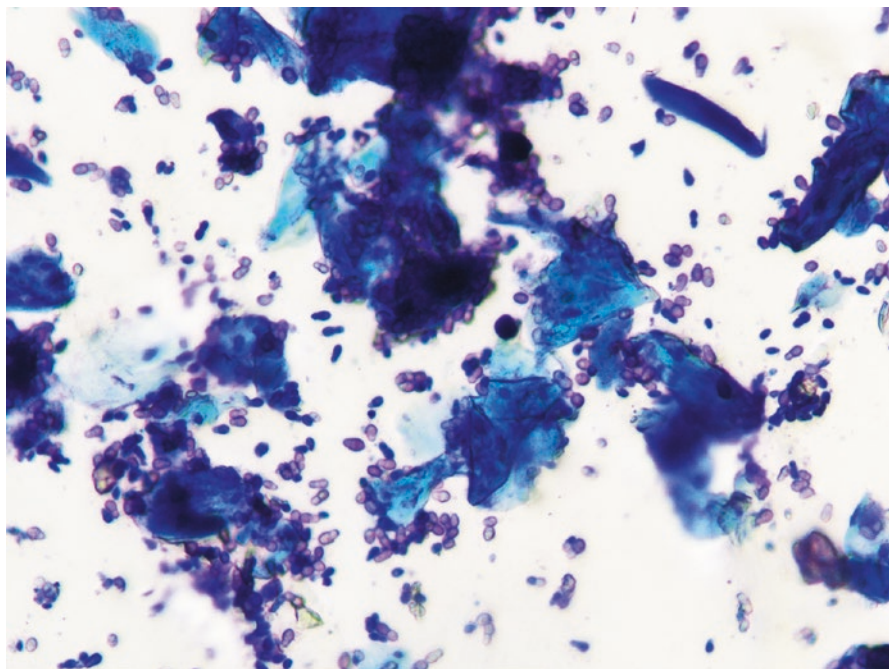


Fig. 3.129 Cytology of *Malassezia* dermatitis: numerous *Malassezia pachidermatis* collected from the same lesion as in Fig. 3.128

disorders (hypercortisolism and diabetes mellitus), visceral neoplasia etc. Usually, the more humid body areas such as mucocutaneous areas, interdigitals, and skin fold areas are more frequently affected and sometimes a smelly whitish film is observed on the skin surface (Figs. 3.130 and 3.131) (Carlotti and Pinn 1999; Greene 2012; Scott et al. 2001; Miller et al. 2013).

Like *Malassezia*, *Candida* may also be easily sampled using the imprint technique with a slide or a piece of transparent acetate tape.

Cytological Findings

Candida albicans yeasts live in the superficial layers of the epidermidis and for this reason they are usually observed together with a variable number of keratinocytes (Fig. 3.132). *Candida* is a dimorphic fungus and a normal inhabitant of the mucous membranes. Unlike *Malassezia*, it is a mycelial yeast and can be observed in the form of both roundish and oval spores, measuring 3–6 μm , and sometimes arranged in pseudo-mycelia or in chains or as branched hyphal filaments (bipolar or multipolar narrow based budding). Spores stain blue with the Romanowsky stain and have a thin, transparent, pericellular halo (Figs. 3.133 and 3.134).

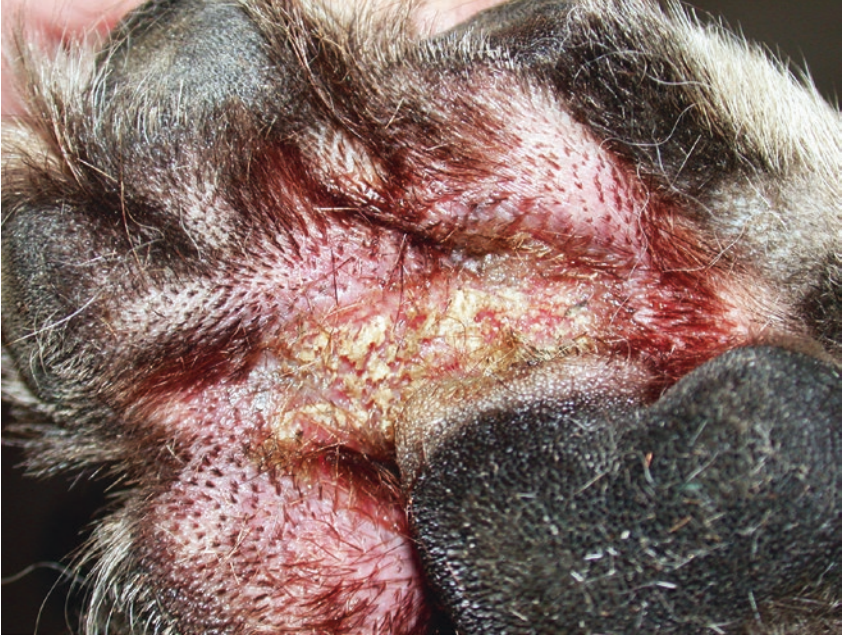

Fig. 3.130 Erythema and whitish patina in the interdigital area of a dog with pododermatitis due to *Candida albicans*

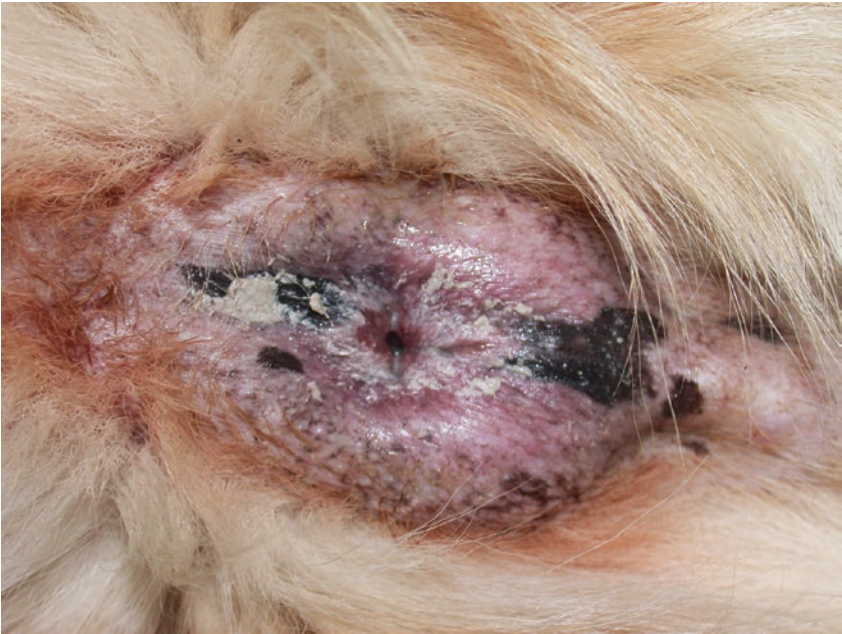

Fig. 3.131 Erythema and whitish patina on the anal mucocutaneous junction in a dog with cutaneous candidiasis

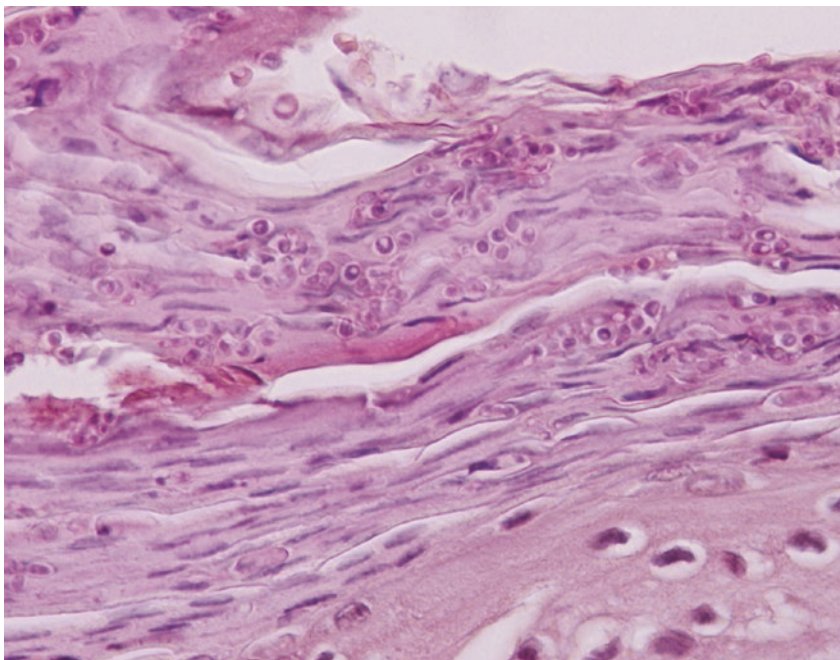


Fig. 3.132 Histology of cutaneous *candidiasis*: many round to oval yeasts in the stratum corneum

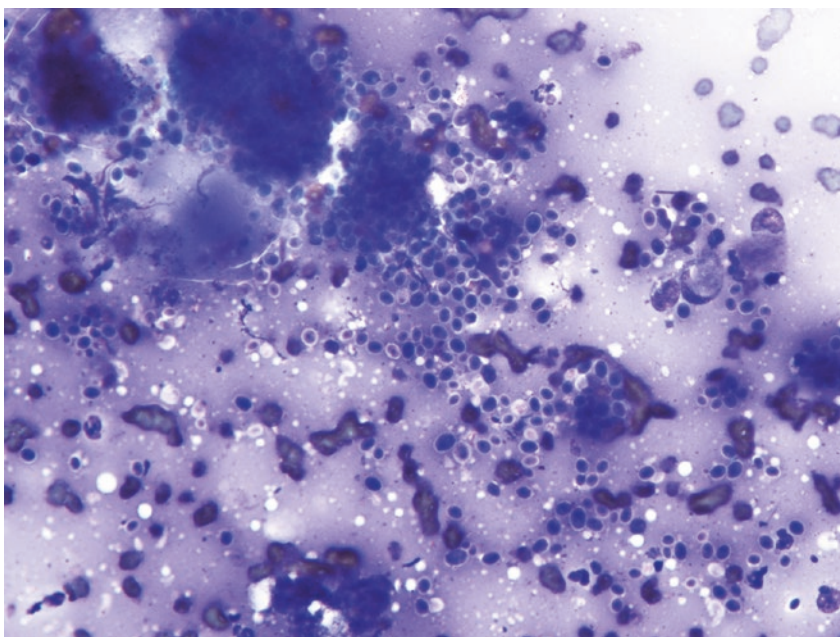


Fig. 3.133 Cytology of cutaneous *candidiasis*: many oval-shaped yeasts with a clear peripheral halo, which adhere to corneocytes

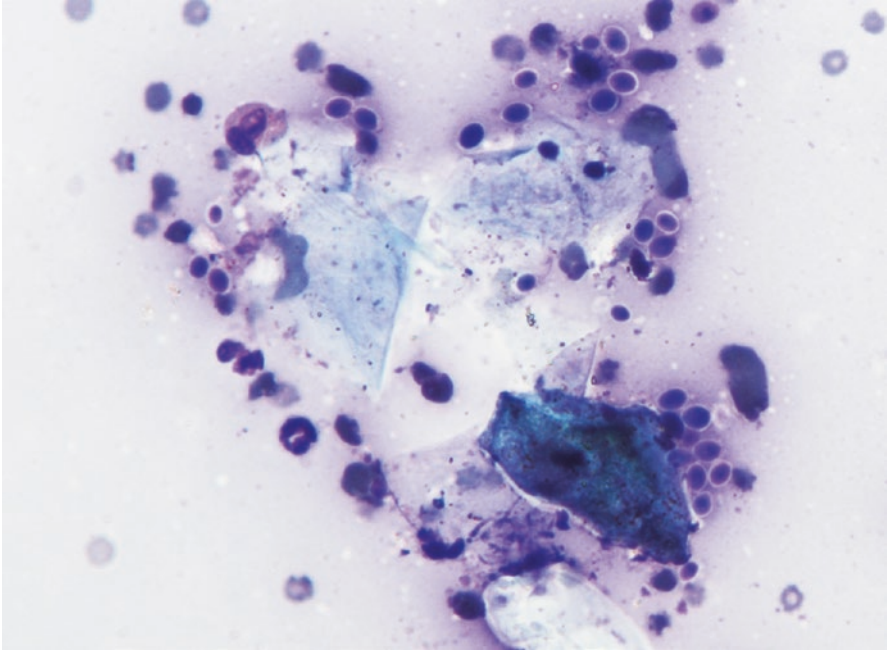


Fig. 3.134 Cytology of cutaneous *candidiasis*: many oval yeasts with a achromatic peripheral halo

3.5.1.4 Dermatophytosis

Dermatophytosis is a fungal disease caused by keratinophilic fungi, mostly represented by *Microsporum canis*, *Microsporum gypseum* or by fungi belonging to the *Trichophyton mentagrophytes* complex (Miller et al. 2013). As dermatophytes infest keratin, one of the most common clinical signs is exfoliative dermatitis with alopecia, scales, erythema and broken hairs (Figs. 3.135, 3.136, and 3.137). For this reason, it is not so uncommon to detect arthroconidia and/or hyphae on corneocytes, especially in cats (Gross et al. 2005). The best sampling method for collection is the imprint technique using a piece of transparent acetate tape.

In the case of infections caused by *Microsporum persicolor*, as this fungus is corneophylic, which means that it does not infect hairs, but only the keratin of keratinocytes, the sampling of scales is the only way to try to find fungi through cytology (Carlotti and Bensignor 1999).

Cytological Findings

The infectious outer layers of the stratum corneum permits the collection of fungal elements using the acetate tape test. The quantity of fungi is strictly linked to the severity of the infestation (Figs. 3.138 and 3.139). Spores (arthroconidia) are very small, rounded or oval, and are cytologically characterised by a pericellular clear halo, whereas hyphae are linear branched filaments, with multiple segmentations that give to fungi a *bamboo pole* appearance (Figs. 3.140 and 3.141). Hyphae are of several different lengths, whereas arthroconidia vary in size from 2 to 5 μm , smaller for *M. canis*, larger for *M. gypseum* and *T. mentagrophytes*, and assume a blue colour with rapid stains, magenta with PAS and black with Gomori staining (Fig. 3.142).

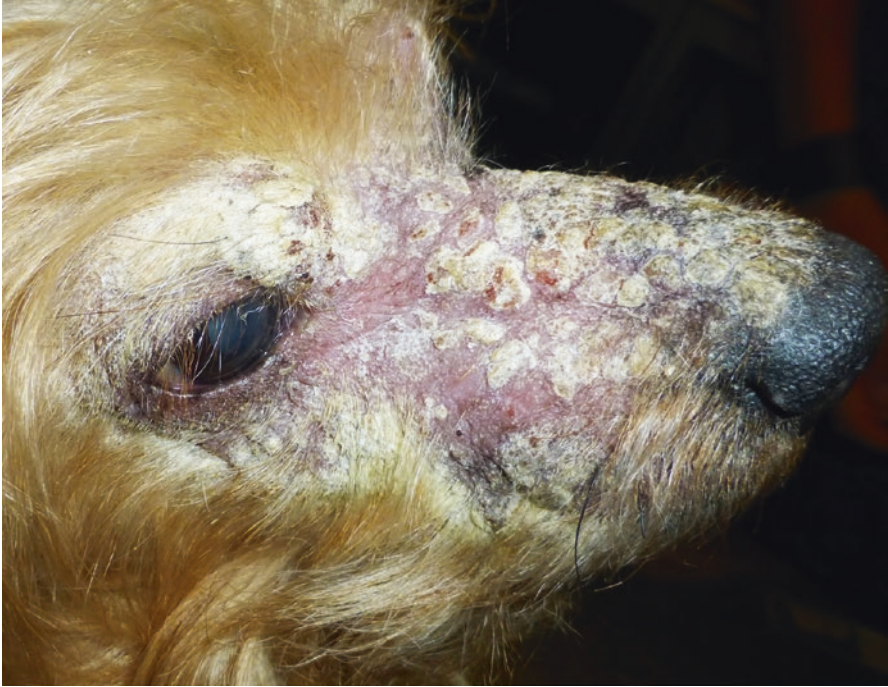

Fig. 3.135 Yellowish scales on the face of a Yorkshire terrier with generalised dermatophytosis

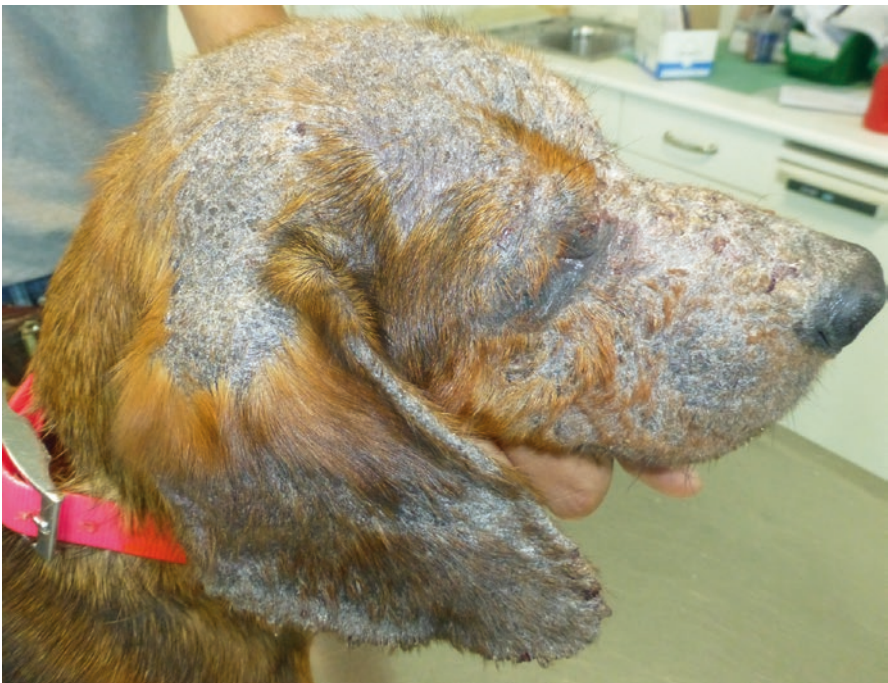

Fig. 3.136 Scales on the head and pinna of a dog with generalised dermatophytosis

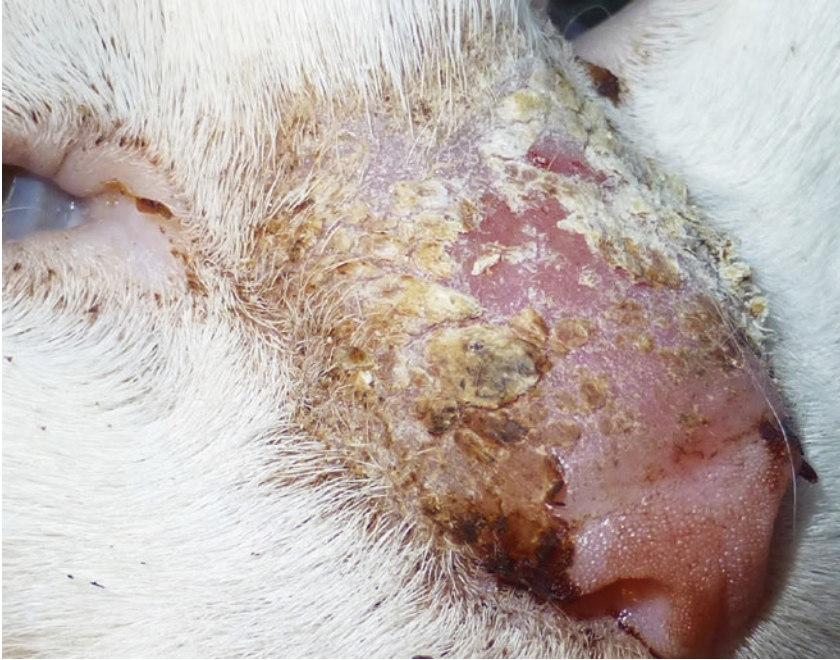

Fig. 3.137 Yellowish scales on the nose of a domestic short-haired (DSH) cat with dermatophytosis

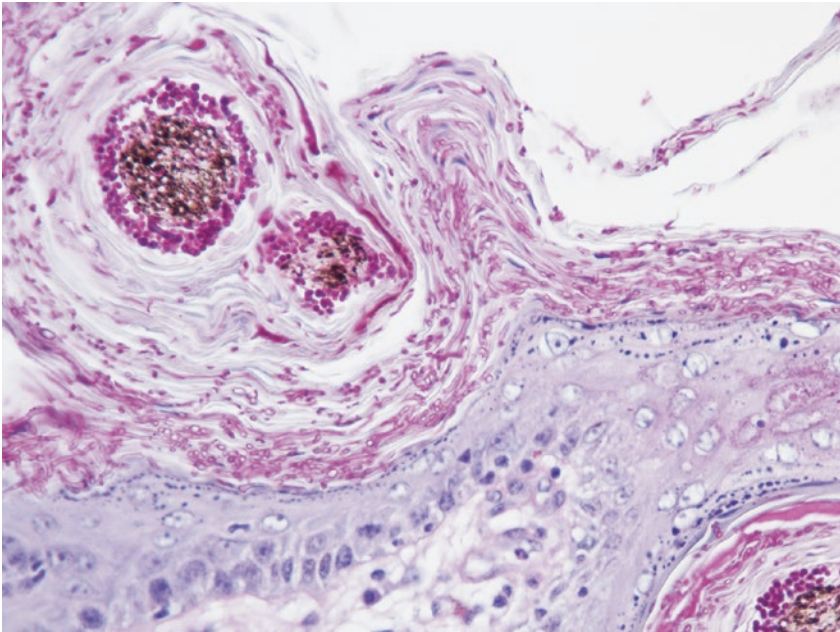


Fig. 3.138 Histology of dermatophytosis (PAS staining): many arthroconidia surround hair shafts and slender segmented hyphae in the stratum corneum

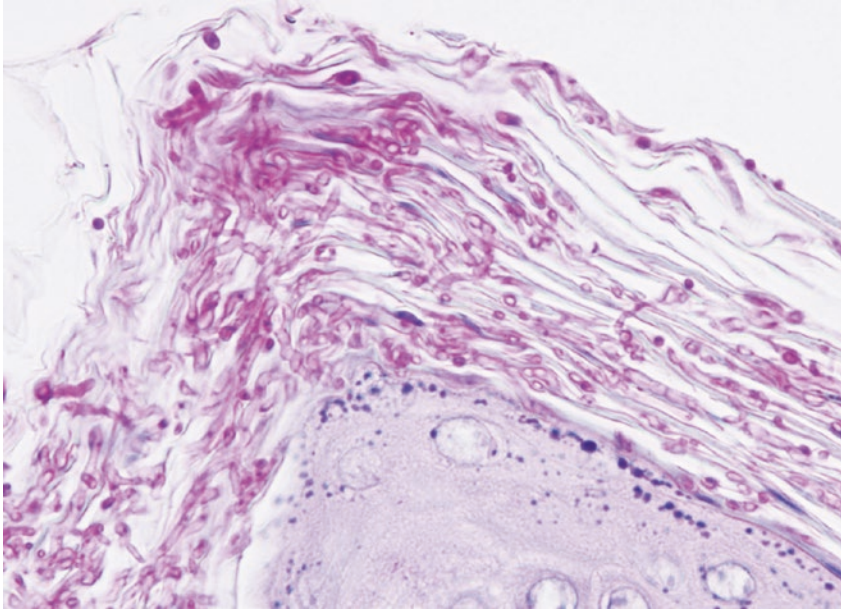


Fig. 3.139 Histology of dermatophytosis (PAS staining): numerous hyphae in the stratum corneum

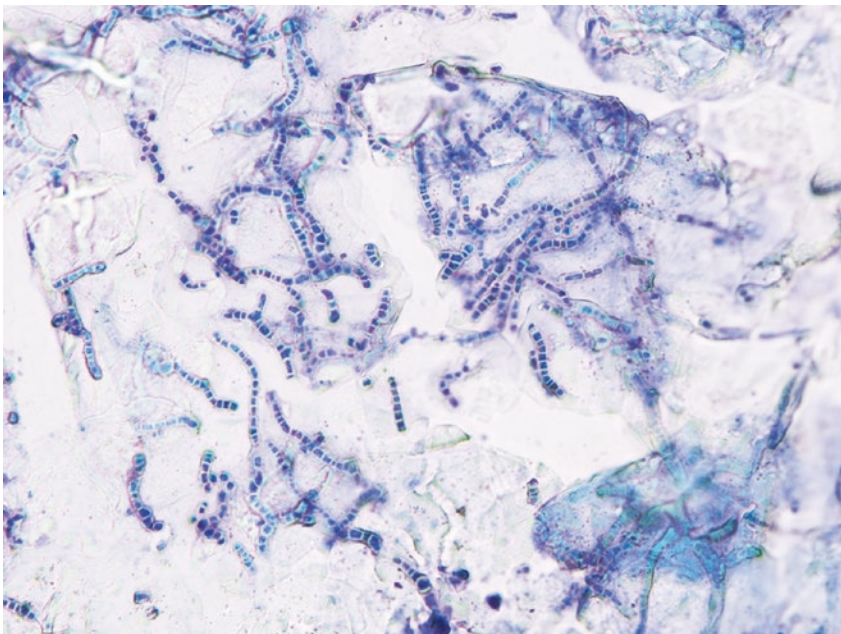


Fig. 3.140 Cytology of dermatophytosis: numerous elongated and septated hyphae on the surface of corneocytes

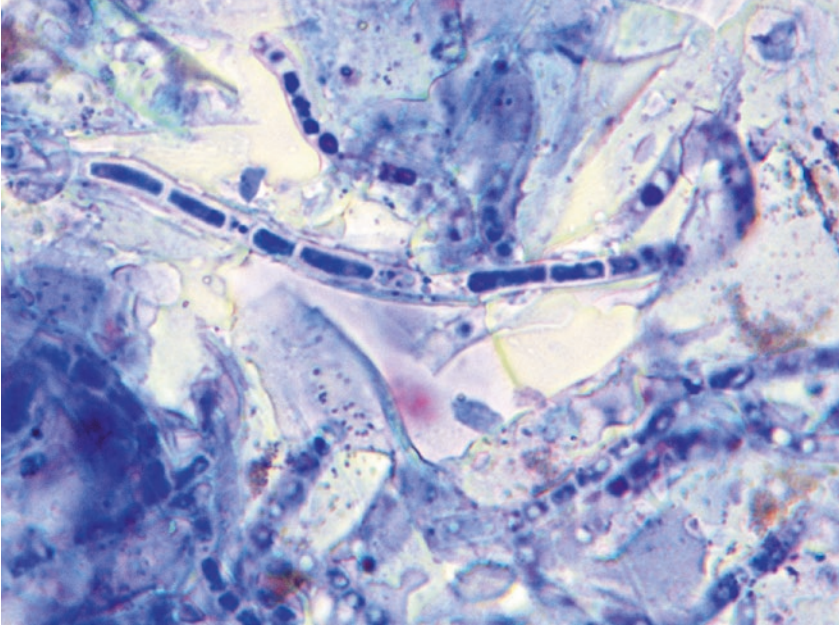


Fig. 3.141 Cytology of dermatophytosis: septated hyphae on the surface of corneocytes

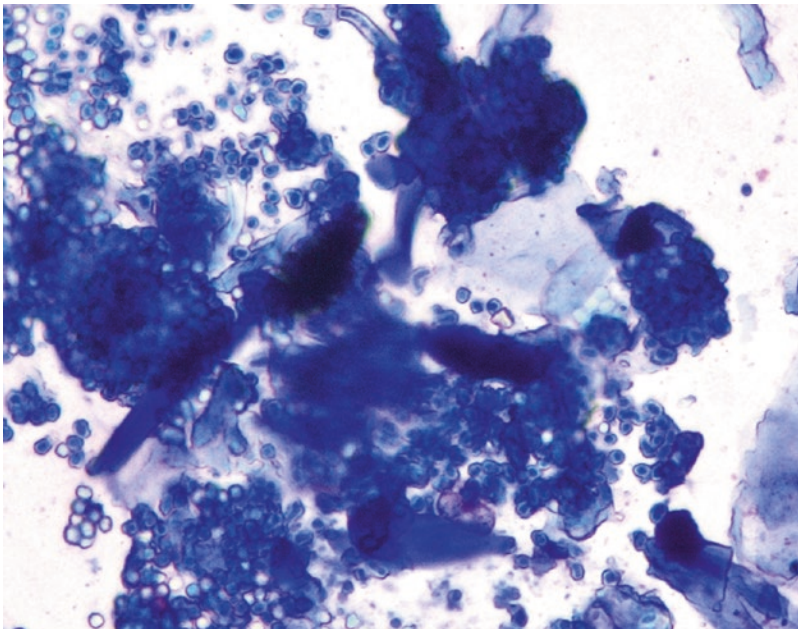


Fig. 3.142 Cytology of dermatophytosis: numerous arthroconidia on the surface of the corneocytes

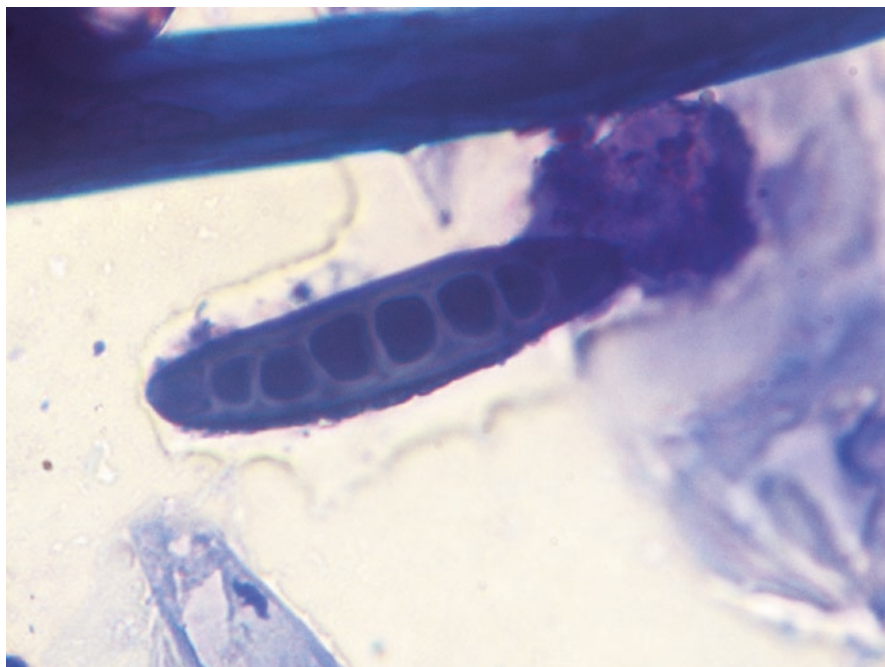

Fig. 3.143 Cytology: a non-dermatophytic fungal body that looks like pathogenic dermatophytic macroconidia

It should be remembered that any structure found on the slides resembling *macroconidia*, should not be confused with pathogenic fungi, as the macroconidia of dermatophytes grow exclusively on cultures and not on the skin (Fig. 3.143).

3.5.1.5 Demodicosis and Other Superficial Ectoparasites

Demodex mites are normal commensals of the skin of dogs and cats. Genetic predisposition and imbalances of the immune system predispose animals to develop an uncontrolled proliferation of mites. Diagnosis of demodicosis can be made using various methodologies; among them, the deep skin scraping technique is the more accurate (Miller et al. 2013; Mueller 2004). In dogs and cats different *Demodex* spp. are recognised, showing morphological differences. In both species mites with long and short bodies are distinguished; in dogs, a recent paper has demonstrated that the short body mite formerly named *Demodex cornei* is genotypically strictly related to *Demodex canis* and seems to be only a morphological variant of the latter (Sastre et al. 2012).

In many dogs affected by generalised demodicosis, especially with exfoliative dermatitis, numerous normal and short-body *D. canis* mites can be collected via the




Fig. 3.144 Scaly dermatitis in a West Highland white terrier with generalised demodicosis

transparent tape test (Fig. 3.144) (Mueller 2004; Mueller et al. 2012; Gross et al. 2005; Miller et al. 2013). Unlike dogs, the long and short variants of feline *Demodex*, named *D. cati* and *D. gatoi* respectively, have been recently demonstrated to indicate two different types of mites (Ferreira et al. 2015). In cats affected by exfoliative demodicosis, *D. gatoi* is frequently observed, especially in patients with an immune-suppressive disorder or following corticosteroid therapy. In these cases, it is very common to collect mites on the surface of the skin, as the stratum corneum seems to be the habitat of these mites (Fig. 3.145).

Cytological Findings

Although normal sized *D. canis* mites live in the follicles and sebaceous glands, they mate on the skin surface, after which the females go into the follicular lumen in which they lay eggs; for this reason, in many cases of generalised demodicosis, it is also possible to collect them with a piece of transparent tape (Figs. 3.146 and 3.147). In the case of secondary bacterial infection, karyolytic neutrophils with phagocytosed cocci can also be observed (Fig. 3.148).

In the rare cases of canine *crusty* or *Norwegian scabies*, unlike classic scabies infections, the number of mites is very high and they can easily be collected via the acetate tape test (Fig. 3.149). This evidence is normal in cats affected by notoedric mange, in which the chance of collecting mites via the scotch test is very high, because *Notoedres* mites are always numerous on the skin (Fig. 3.150).

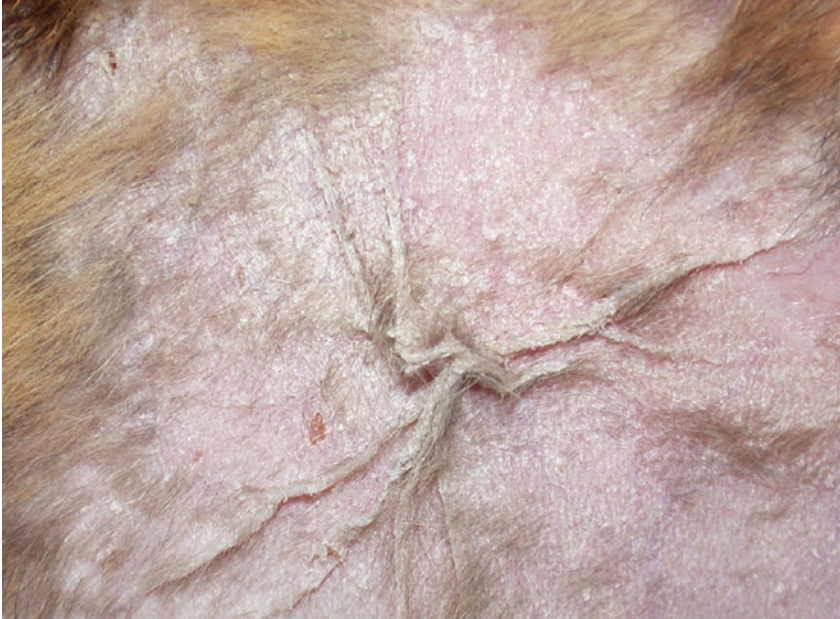

Fig. 3.145 Skin atrophy and scaly dermatitis due to iatrogenic administration of steroids with secondary *Demodex gatoii* infestation

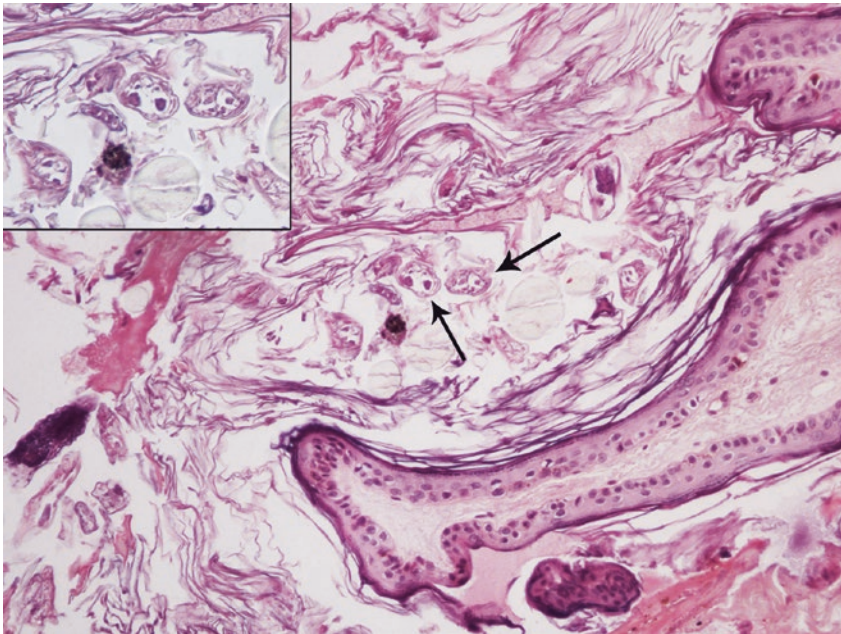


Fig. 3.146 Histology of demodicosis: many *Demodex canis* in the stratum corneum (arrows, inset)

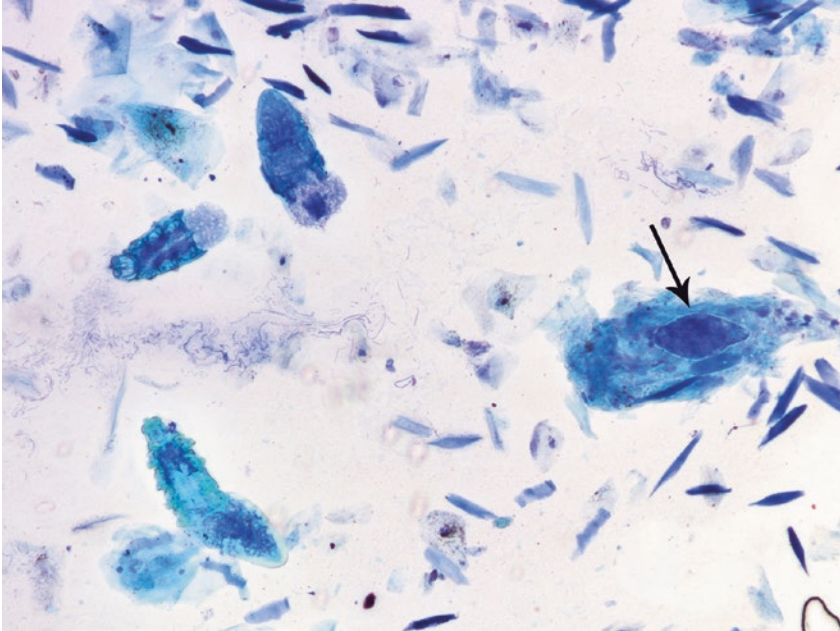


Fig. 3.147 Cytology of demodicosis: two adult *Demodex canis* short body and one egg (arrow)

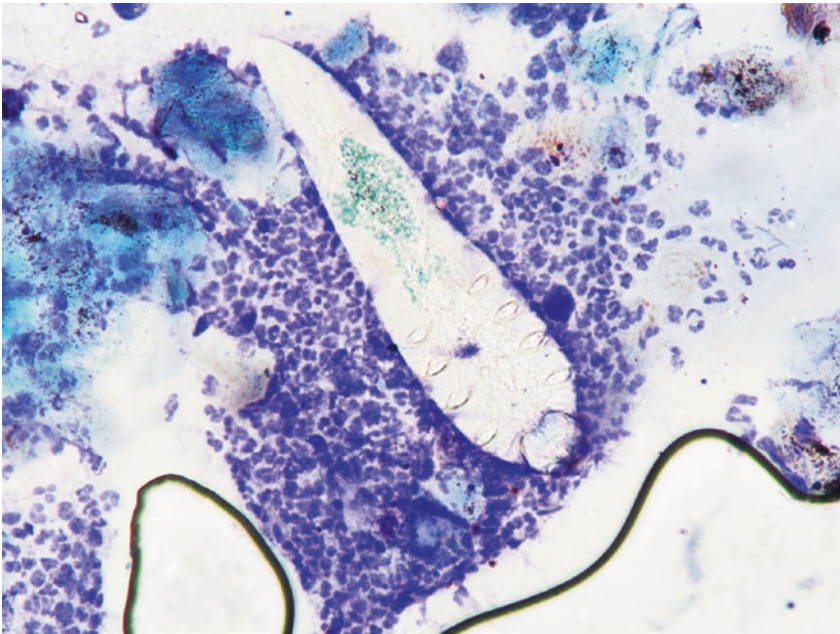


Fig. 3.148 Cytology of demodicosis: an adult *Demodex canis* immersed in a neutrophilic inflammatory background

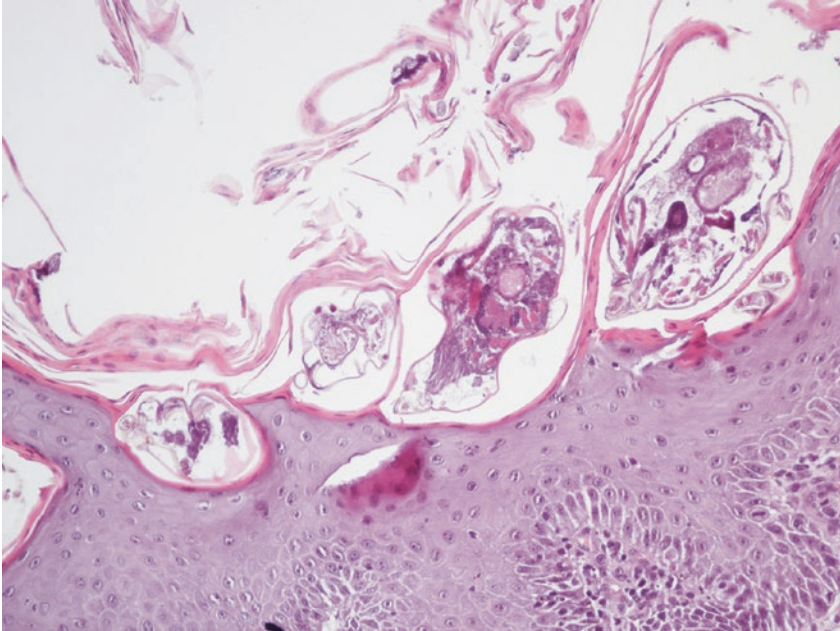


Fig. 3.149 Histology of scabies: many *Sarcoptes scabiei* var. *canis* on the skin surface

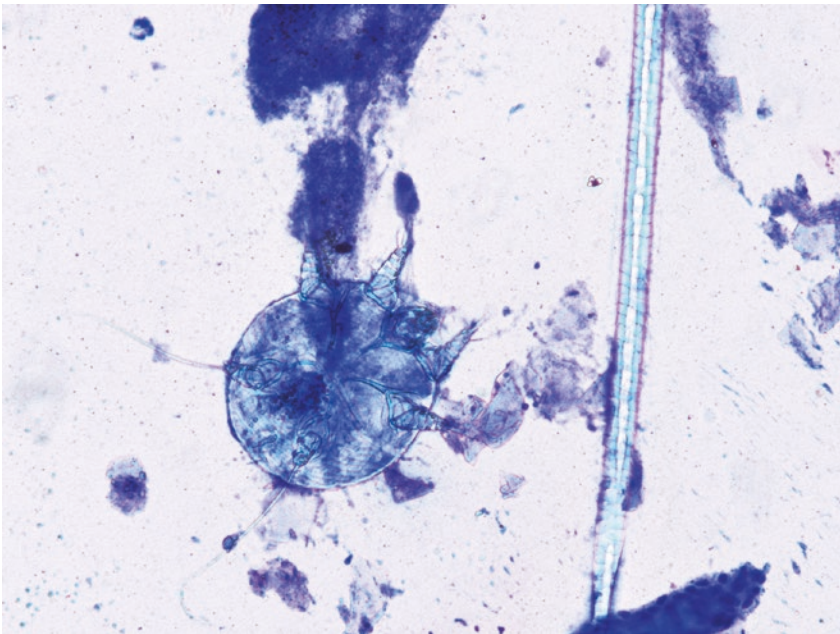


Fig. 3.150 Cytology: an adult *Notoedres cati* sampled via the acetate tape technique

3.6 Erosions

3.6.1 Erosive Diseases in Dogs

Epidermal collarettes are the most frequent erosive lesions observed in canine dermatology and are also more valuable for cytological examination. Collarettes are round secondary lesions with an erythematous or hyperpigmented central area, peripherally bordered by scales or crusts, which originate following the breakage of a pustule. Only in very rare cases is this secondary to the rupture of an intra-epidermal vesicle (Ihrke 1996; Gross et al. 2005; Miller et al. 2013). As mentioned in Chap. 2, as vesiculo-bullous lesions are extremely rare in dogs and cats and are mostly located at the dermal–epidermal junctions, in the case of vesiculo-bullous diseases, their rupture is the cause of the development of an ulcer. Accordingly, the possibility of detecting intra-epidermal vesicles from which collarettes may originate is extremely rare and limited to pemphigus vulgaris. For this reason, it is possible to assert that collarettes are almost always secondary to pustules, and therefore, cytology can often provide very useful results (Fig. 3.151).

Usually, in canine superficial pyoderma, collarettes are present in association with papules and intact pustules, but sometimes they are the only lesions present. Large and confluent lesions that resemble collarettes can be observed in *spreading pyoderma*, an exfoliative variant of superficial staphylococcal pyoderma (Fig. 3.152).

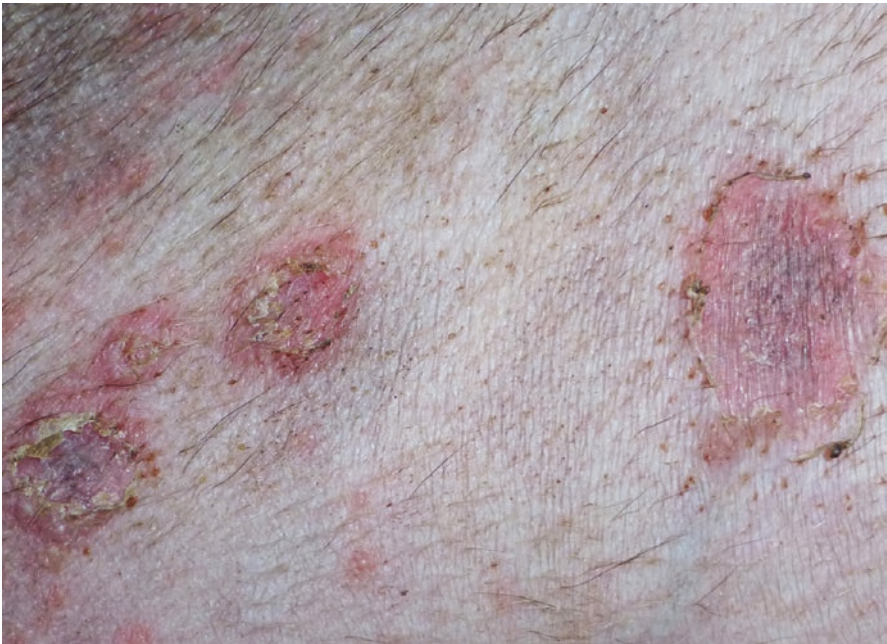

Fig. 3.151 Epidermal collarettes in a dog with superficial pyoderma

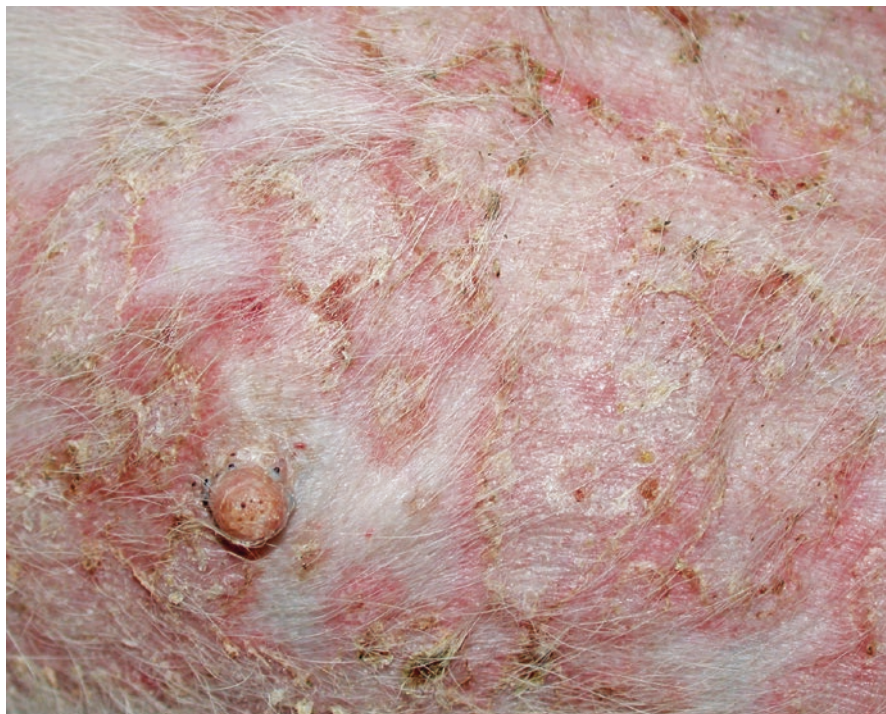

Fig. 3.152 Multiple and coalescent erosive and scaly lesions similar to collarettes in a dog with superficial spreading pyoderma

Although pyoderma is the most frequent cause of *collarette* formation, they can develop in all cases of *pustular dermatosis*. In dogs affected by pemphigus foliaceus, during the rest phase of pustular eruption, skin lesions may only be represented by yellowish crusts and epidermal collarettes and the clinical lesions may mimic those observed in superficial and spreading pyoderma (Figs. 3.153 and 3.154). In this case, cytology from collarettes can provide important indications for the diagnosis of autoimmune disease when many acantholytic cells are observed.

Cytological Findings

Cytology obtained from collarettes in dogs with pyoderma shows the same cytology as that observed in specimens from intact pustules.

Specimens are less cellular and composed of more corneocytes or nucleated keratinocytes, the latter from the spinous and granular layers, together with many entire or broken karyolytic neutrophils (nuclear streaks) and cocci, both phagocytosed and free on the slide's background (Fig. 3.155).

As mentioned, collarettes can be detected in all pustular diseases, regardless of the cause.

In pemphigus foliaceus, the cytological evidentiatio of segmented neutrophils and acantholytic keratinocytes can orientate the clinicians to perform a histopathological examination.

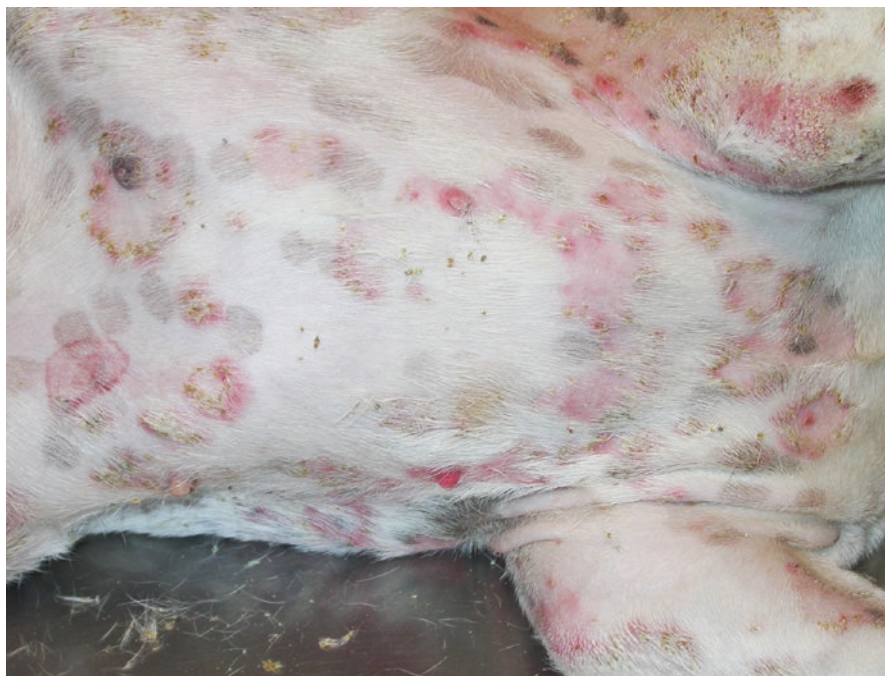

Fig. 3.153 Multiple and diffuse epidermal collarettes in an English bulldog with PF

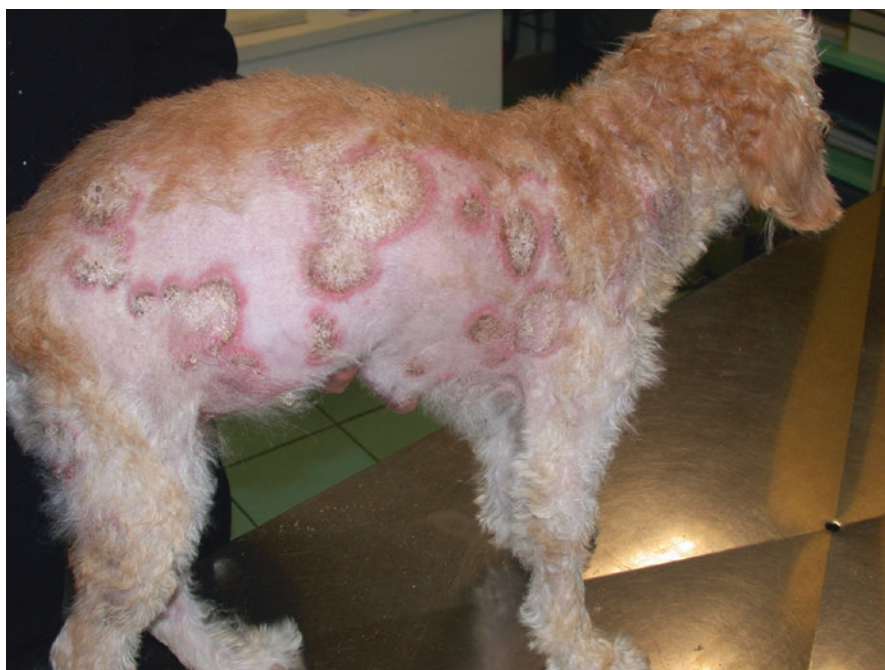

Fig. 3.154 Very large and coalescent epidermal collarettes in a dog with PF

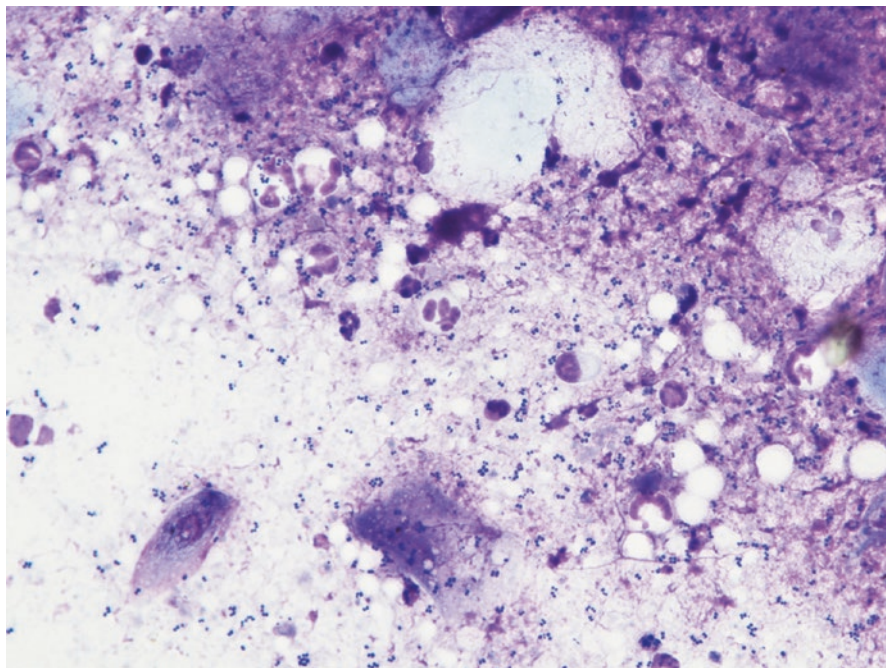


Fig. 3.155 Cytology collarettes: karyolytic neutrophils with many cocci both intracytoplasmic and on the bottom of the slide

When sampling erosions, it should be remembered that the visualisation of bacteria should be interpreted with more caution, as erosions are exposed to environmental and oral contaminants. The aspect of lesions, and the history orientate the clinicians towards a correct interpretation of the detected bacteria.

3.6.2 Erosive Diseases in Cats

Epidermal collarettes are extremely rare in cats since pustules are very rare lesions in this species. In pustular diseases such as PF, rather than collarettes, yellowish crusts indicative of the dehydration of pustules are more frequently observed. Round lesions with scaly borders similar to epidermal collarettes are often observed in cats affected by *dermatophytosis*, but are not secondary to pustules.

3.7 Ulcer

As mentioned in the chapter regarding the diagnostic techniques, samples from *ulcers* are usually of poor quality and highly haemocontaminated; for this reason, ulcerative diseases rarely supply useful specimens. Nevertheless, there are some ulcerative diseases for which cytology may provide an immediate diagnosis.

3.7.1 Ulcerative Diseases in Dogs

3.7.1.1 Deep Pyoderma

Ulcers can characterise *deep pyoderma* in dogs. Ulcer formation can be caused by self-trauma or following deep lesions such as in cases of bacterial cellulitis or furunculosis. Ulcers can be localised as in callus pyoderma or spread all over the body. In all these cases, ulcerative lesions are secondary and are usually not the direct expression of bacterial infection (Ihrke 1996; Miller et al. 2013). In dogs, the so-called *mucocutaneous pyoderma* is characterised by depigmentation and skin ulceration located at the mucocutaneous junctions of the lips, eyelids, nares and, less frequently, the anal and genital junctions (Figs. 3.156 and 3.157) (Bassett et al. 2004; Wiemelt et al. 2004). These particular variants of pyoderma are clinically indistinguishable from some autoimmune-mediated diseases such as mucocutaneous lupus and, in many cases, the histopathological findings are not sufficient for a definitive diagnosis either (Wiemelt et al. 2004; Olivry et al. 2015). Another form of deep pyoderma, characterised by ulcerative lesions, is the so-called *idiopathic recurrent pyoderma* of the German shepherd dog. The pathogenesis of this form of pyoderma is unclear and the role of bacteria in the development of the lesions is debated, because many forms are idiopathic. Furthermore, many dogs recover without the use of antibacterials, and dramatic improvement with therapies based on immunomodulators suggests an immune-mediated pathogenesis (Fig. 3.158) (Wisselink et al. 1990; Gross et al. 2005; Rosser 2006; Miller et al. 2013). As with erosions,

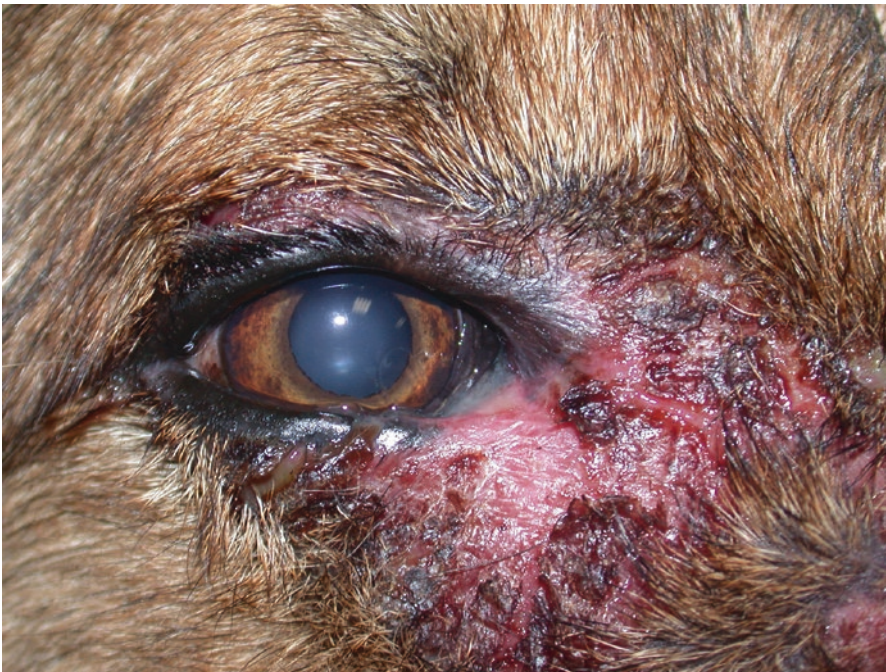

Fig. 3.156 Ulcerative blepharitis in a German shepherd with mucocutaneous pyoderma

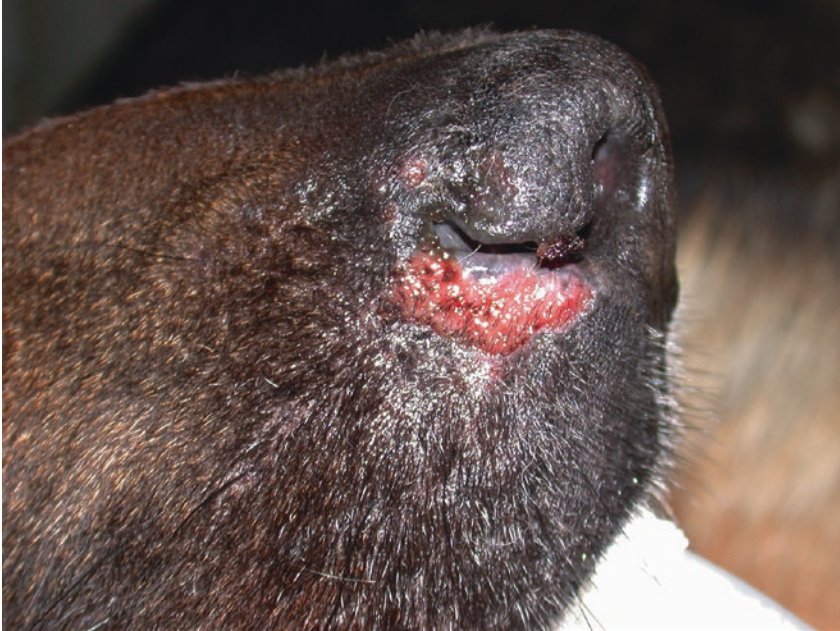

Fig. 3.157 Inflammatory depigmentation and ulcer of the mucocutaneous junction of a nostril of the same dog as in Fig. 3.156

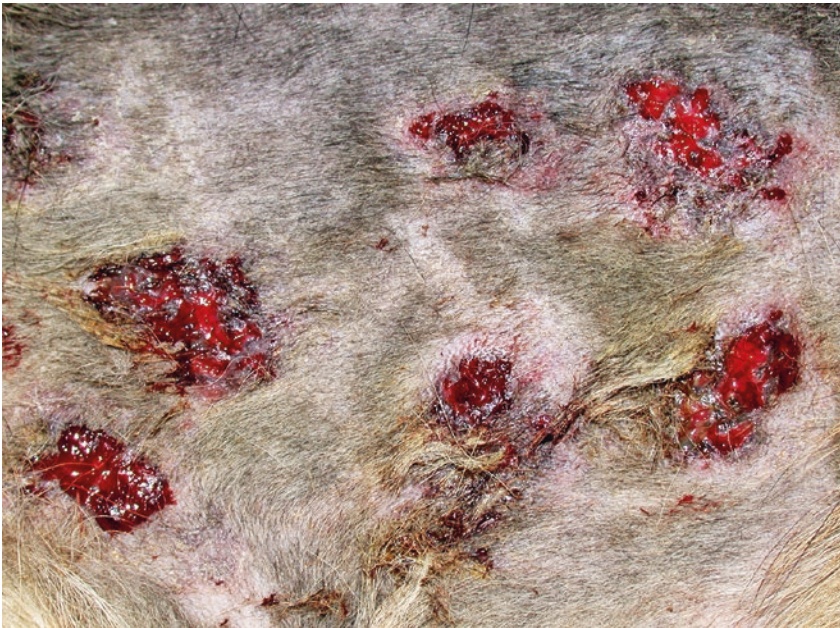

Fig. 3.158 Multiple bleeding ulcers on the trunk of a German shepherd with *idiopathic deep pyoderma*

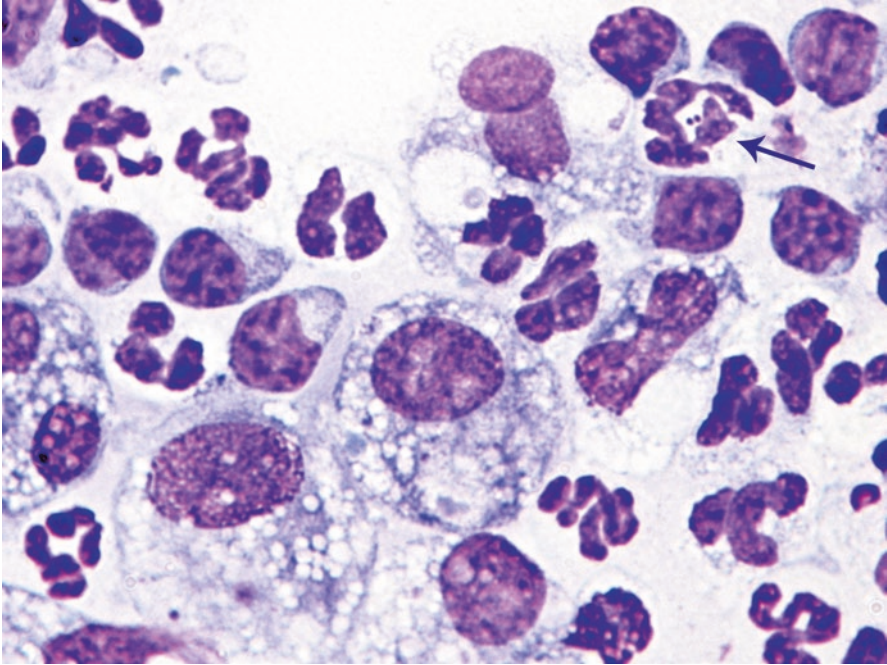


Fig. 3.159 Cytology of deep pyoderma: few coccoid bacteria are present in the cytoplasm of a neutrophil (*arrow*)

ulcers may be contaminated by non-pathogenic bacteria coming from the environment or, in cases of excessive licking, transferred onto the skin from the oral cavity. In such cases, clinicians must carefully interpret the presence of bacteria based on the clinical lesions from which cells are sampled.

Cytological Findings

Samples from *ulcerative pyoderma* are composed of blood, amorphous debris and a high number of neutrophils and macrophages, with a variable number of lymphocytes and plasma cells. Keratinocytes from different epidermal layers are always evident.

As mentioned, bacteria are the hallmark for a cytological diagnosis of pyoderma, but their presence must be interpreted with caution; large numbers of extracellular bacteria arranged in clusters and spread between the inflammatory cells must be interpreted as contaminants, whereas few intracytoplasmic bacteria have a definite pathological significance. It must be remembered that, as in deep pyoderma, especially when characterised by ulcerative lesions, the failure to visualise bacteria is a very frequent occurrence and does not allow the disease to be excluded (Fig. 3.159).

3.7.1.2 Leishmaniasis

Canine *leishmaniasis* is a disease clinically characterised by a large polymorphism and ulcers are very commonly observed in sick animals (Gross et al. 2005; Solano-Gallego et al. 2009). In endemic areas, the presence of bleeding ulcers on the tip of the tail and

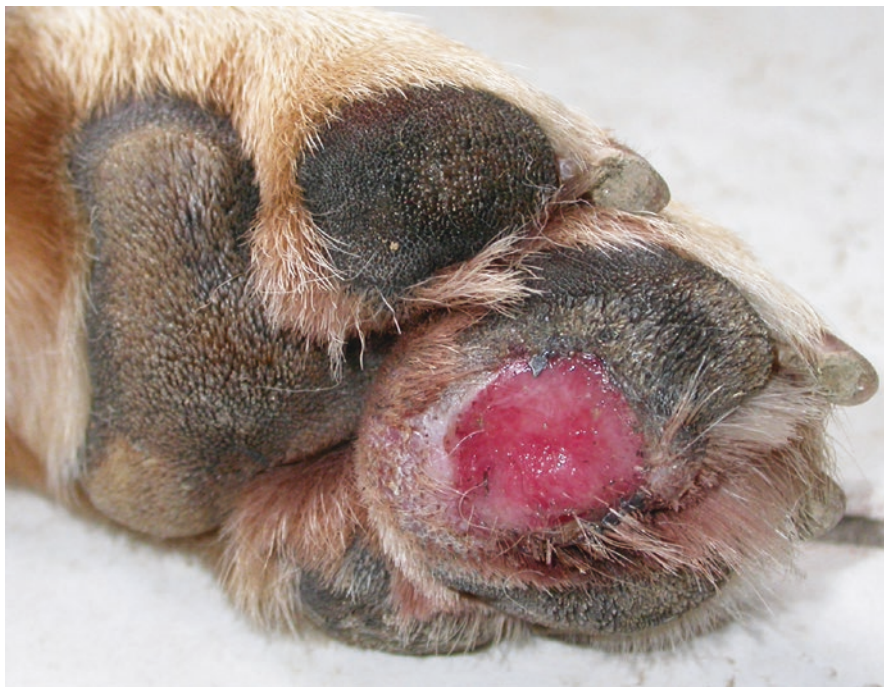

Fig. 3.160 Ulcer on the paw pad of a dog with leishmaniasis

pinna are very common in affected dogs; lesions on these body sites are usually interpreted as secondary to vasculitis, although in most cases, skin biopsies are not performed or if carried out, do not always exhibit the histopathological findings of vasculitis. Chronic ulcers that tend not to heal, usually with raised edges and commonly seen on the pressure points such as the hook, elbow and carpus, or on the mucous membranes, can sometimes provide diagnostic samples (Figs. 3.160 and 3.161).

Cytological Findings

As in other ulcerative diseases, cytological specimens from ulcerative lesions provide haemocontaminated samples together with many inflammatory cells. In samples from non-bleeding ulcers, a granulomatous/pyogranulomatous inflammation with a variable number of amastigotes, from low to very high, can be detected. Protozoa are usually localised in the cytoplasm of macrophages or are free on the background of the slides following cell rupture during the preparation of the specimens (Fig. 3.162).

3.7.2 Ulcerative Diseases in Cats

Ulcerative dermatitis is very common in cats and most cases are observed following self-trauma in pruritic allergic cats, with lesions mainly located on the head and neck. Other feline spontaneous inflammatory ulcerative lesions can be investigated through cytology.

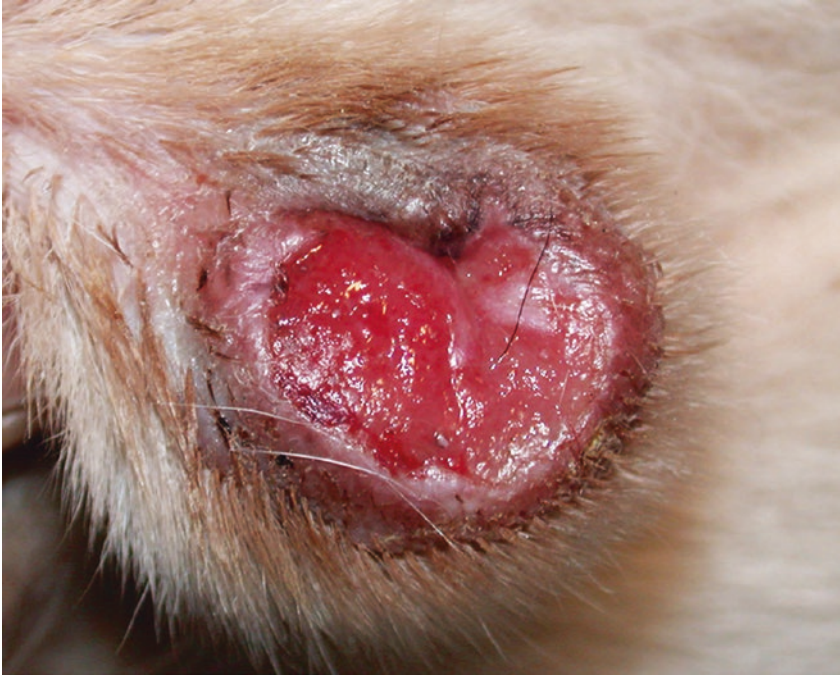

Fig. 3.161 Ulceration of the mucocutaneous junction of the penis in a dog affected by leishmaniasis

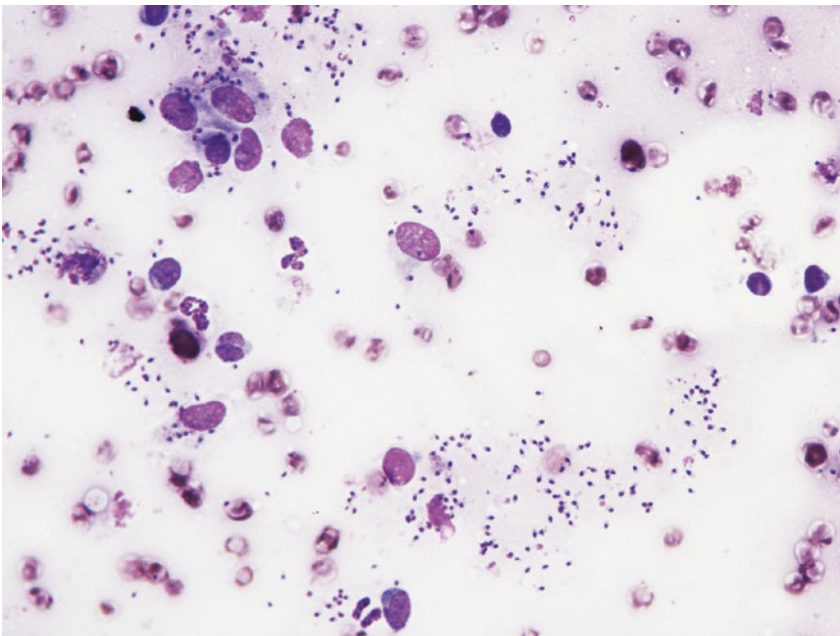


Fig. 3.162 Cytology of leishmaniasis: many amastigotes both intracytoplasmic and free on the background of the slide

3.7.2.1 Feline Indolent Ulcer

Feline indolent ulcer (IU) is a characteristic lesion localised to the lip and sometimes extending to the filter of the nose (Colombini et al. 2001; Miller et al. 2013). These are grouped into a so-called *eosinophilic granuloma complex* (EGC), a recognised entity in cats along with *eosinophilic granuloma* and *eosinophilic plaque*. The latter, although sometimes manifested as ulcers, are more frequently nodular and for this reason are discussed in detail with nodular lesions.

Indolent ulcer is a typical skin ulceration observed on the lips of cats. Clinically, they can be single or symmetrical on the upper lips; the lesions are not painful to palpation and characterised by a smooth, non-bleeding, yellowish-pink surface (Fig. 3.163).

The typical morphology and localisation of IU does not usually require confirmatory cytology. Some authors include as a main differential the squamous cell carcinoma (SCC), which in cats is usually ulcerative. Unlike IU, carcinomas do not have a smooth and dry surface, but are irregular in shape and have a tendency to bleed and be covered with a bloody crust; furthermore, SCCs are not symmetrical and rarely affects only the upper lips. The suspicion of an SCC may arise only when a severe SCC starting from the nasal planum involves the filter and upper lips; in these cases, cytological or histopathological investigations can be performed to differentiate between the two diseases (Fig. 3.164).

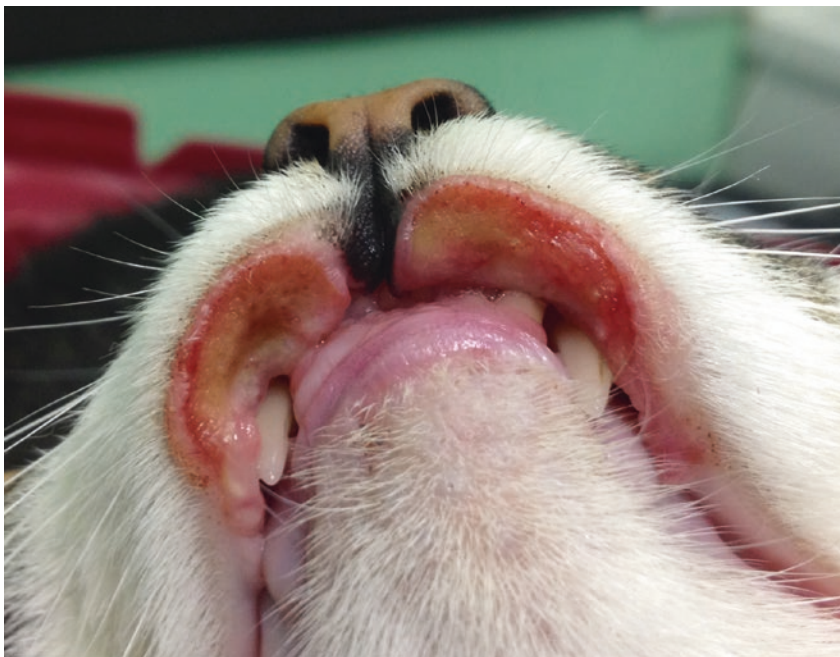


Fig. 3.163 Symmetrical and bilateral non-bleeding ulcer on the upper lips of a cat with an indolent ulcer

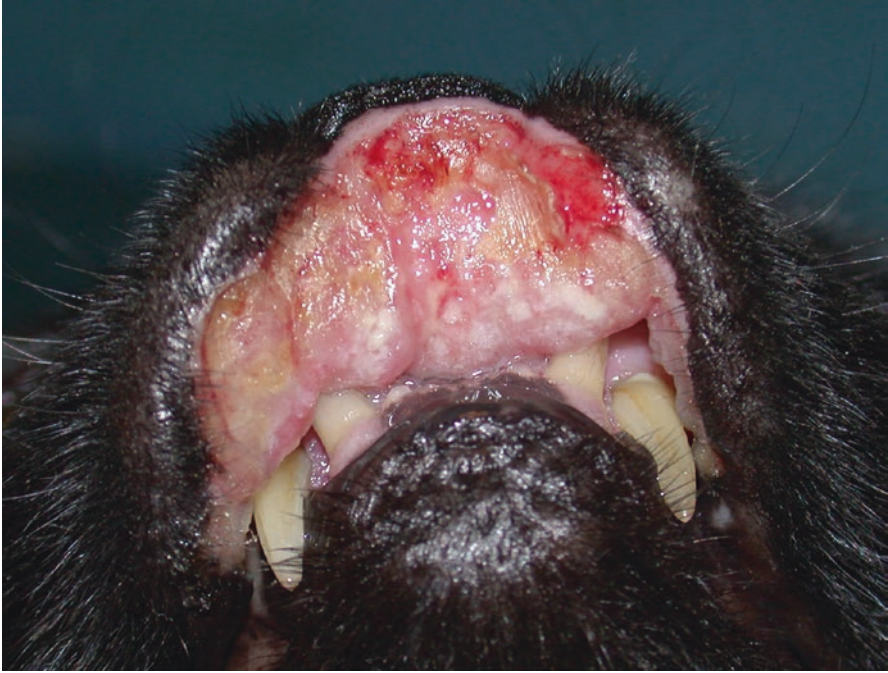

Fig. 3.164 Large indolent ulcers on the upper lips that mimic a squamous cell carcinoma

Cytological Findings

Although included in the EGC, the inflammatory infiltrate of IUs is not always characterised by eosinophils as might be expected. The histopathology of many IUs is characterised by a few or no eosinophils and this may also depend on the chronicity of the lesions (Gross et al. 2005). Another problem is linked to the characteristic IU surface, which, being dry and firm, could not provide any cells if sampled using the imprint technique. Finally, the mucocutaneous location inevitably leads to specimens contaminated by bacteria from the normal resident flora of the oral cavity (Fig. 3.165).

In the early phases of the disease, a sampling made by gentle surface scarification can help to remove the first superficial and contaminated layers and to collect a significant number of eosinophils (Fig. 3.166).

3.7.2.2 Eosinophilic Granuloma

As mentioned, the *eosinophilic granuloma* (EG) is a polymorphous lesion that ranges from nodules to ulcers (Fondati et al. 2001; Bardagi et al. 2003; Gross et al. 2005; Miller et al. 2013).

Ulcers are usually due to the strong dermal eosinophilic infiltrate, which leads to epidermal ulceration. Clinically, a typical ulcerative granulomatous lesion on the

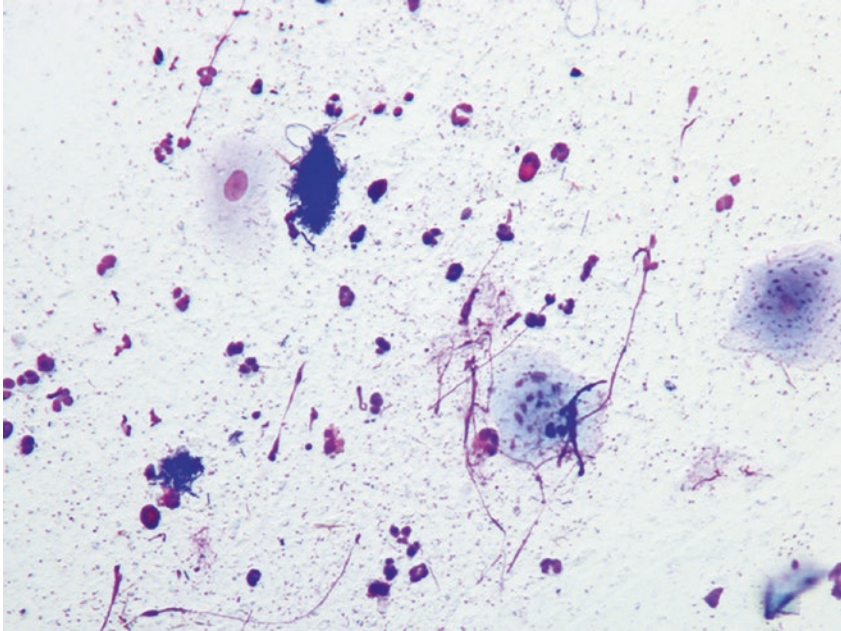


Fig. 3.165 Cytology of an indolent ulcer: eosinophils, nuclear stripes, aggregates of coccoid bacteria (oral cavity contamination) and debris collected from the surface of the ulcer

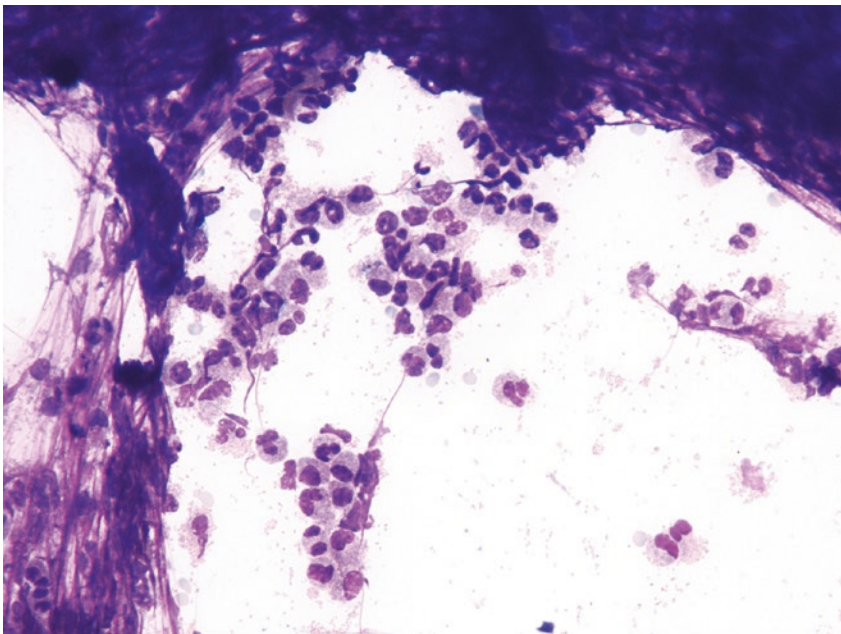


Fig. 3.166 Cytology of an indolent ulcer: many eosinophils

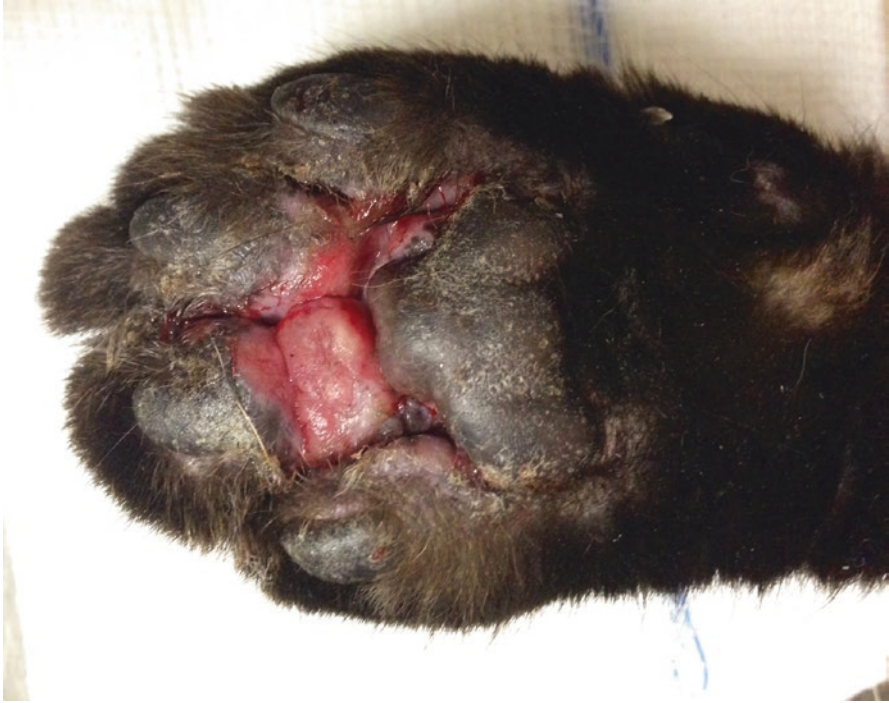

Fig. 3.167 Interdigital ulceration in a cat with eosinophilic granuloma

paws and in the interdigital spaces is observed in affected cats (Fig. 3.167). Ulcerated lesions belonging to the feline eosinophilic granuloma are localised in the oral cavity, where single or multiple ulcerated nodules and plaques can be detected (Fig. 3.168).

Cytological Findings

Cytology from interdigital EG lesions is not easy to perform and, like every ulcer, rarely provides specimens of good quality. Secondary pyoderma together with constant licking can further complicate the specimens. In some cases, diagnostic slides could be obtained via FNB that permit eosinophils to be collected directly from the dermis. A predominant population of eosinophils with many macrophages are the typical cytological findings; the amount of neutrophils depends on the sampling technique used and on secondary infections (Fig. 3.169).

3.7.2.3 Herpesvirus

Type 1 herpesvirus is the aetiological agent of *feline rhinotracheitis*, causing the well-known respiratory and ocular symptoms (Suchy et al. 2000; Sánchez et al. 2012).

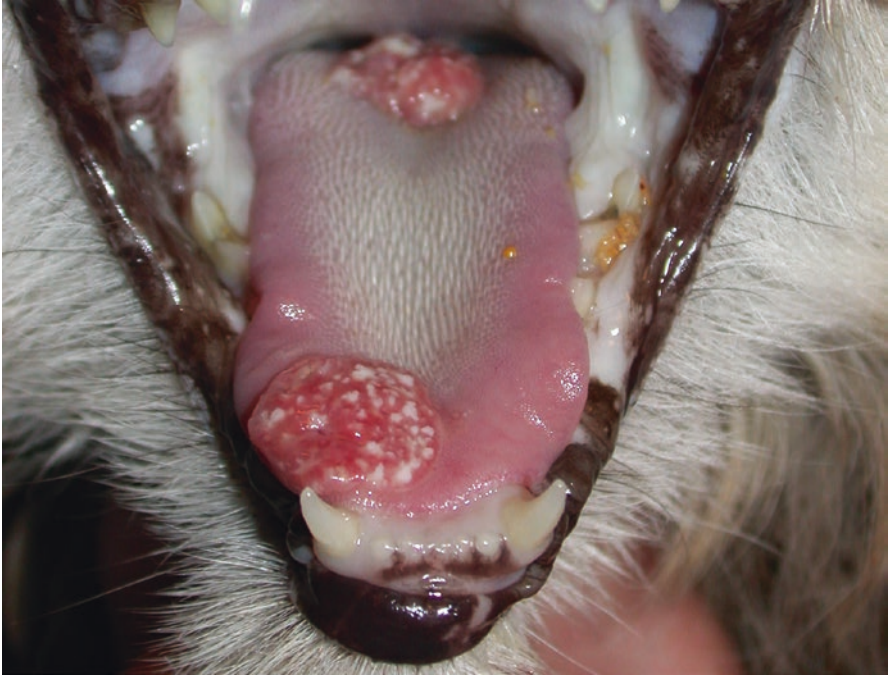

Fig. 3.168 Eosinophilic granuloma: ulcerated plaques on the tongue of a cat

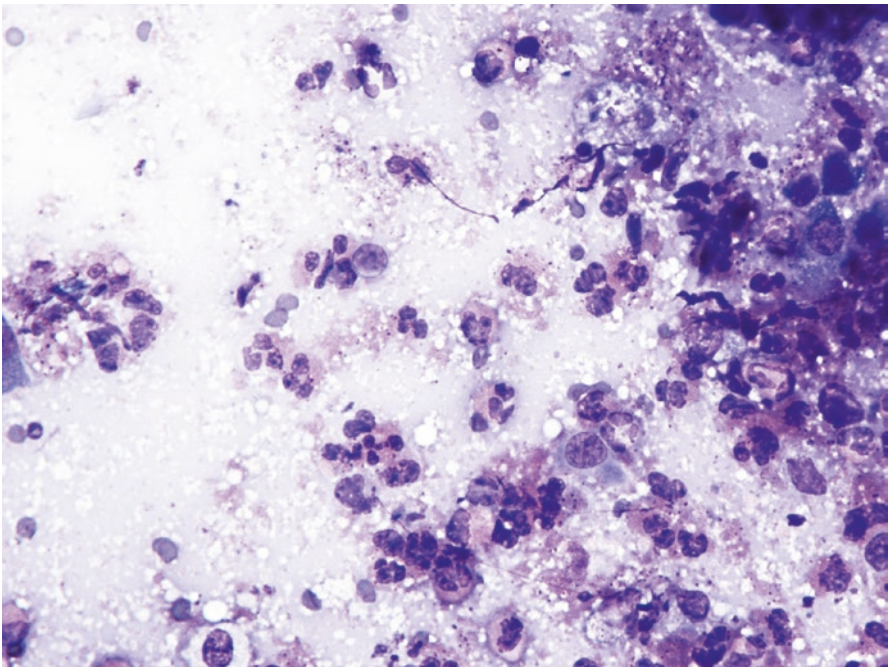


Fig. 3.169 Cytology of eosinophilic granuloma: many eosinophils and some macrophages

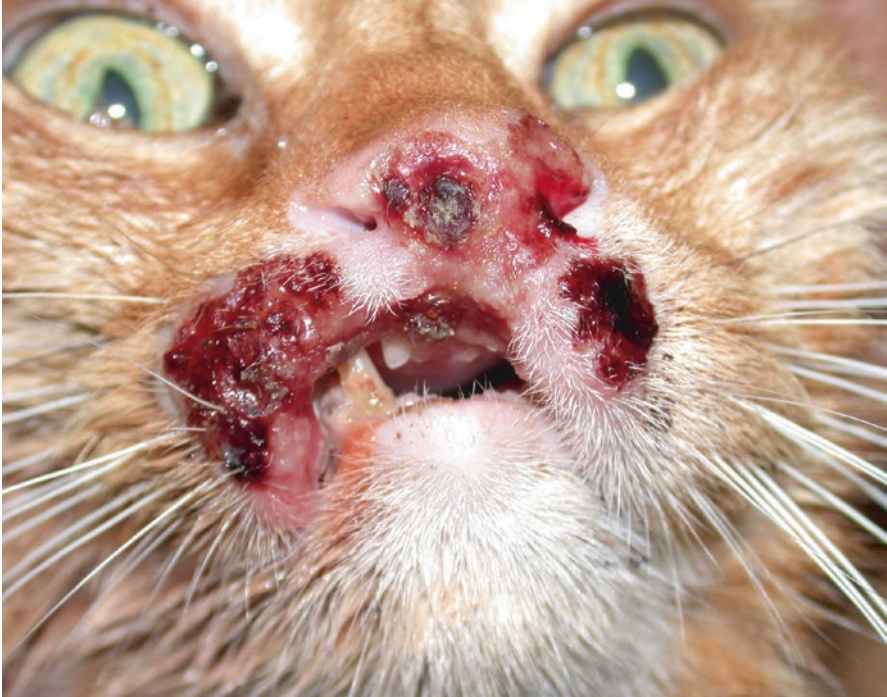

Fig. 3.170 Feline cutaneous herpesvirus ulcers and haematic crusts on the nose and lips (Courtesy of C. Caporali, Italy)

The viral tropism for keratinocytes rarely causes ulcerative lesions, and is usually confined to the facial skin with involvement of the nose, muzzle and eyelids. In some cases, the virus can be the cause of severe and extensive *necrotising facial dermatitis* (Figs. 3.170 and 3.171) (Flecknell et al. 1979; Hargis et al. 1999; Lee et al. 2010). Histopathologically, the herpesvirus lesions are characterised by a necrotic dermatitis involving the epidermis and the follicle wall (mural folliculitis) in association with strong eosinophilic and neutrophilic diffuse dermal inflammation (Gross et al. 2005). The diagnosis of herpesvirus is very difficult, but can be formulated if viral inclusion bodies in the nuclei of keratinocytes are detected by histology. Unfortunately, it is hard to find those viral inclusions in histological specimens and it is almost impossible to observe them through cytology (Fig. 3.172).

Cytological Findings

Slides obtained through impression smear from ulcers or from the lower surface of the crusts, are always haemocontaminated and characterised by an eosinophilic exudate mixed with a varying amount of neutrophils and macrophages (Fig. 3.173). As a large number of eosinophils are usually found on facial lesions of allergic cats, care must be taken to make a diagnosis of an allergy based only on eosinophils detection. Treatment with systemic steroids, commonly used for the management of many allergic diseases, may have serious consequences in cats with herpesvirus infection.

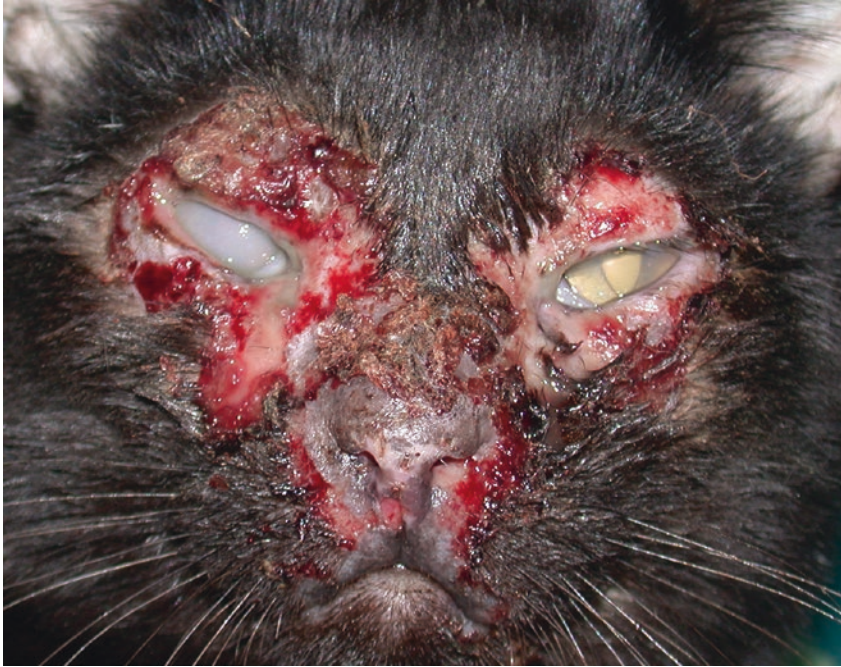

Fig. 3.171 Severe ulcerative facial dermatitis and corneal oedema in a cat with herpesvirus infection that has received a chronic steroid therapy

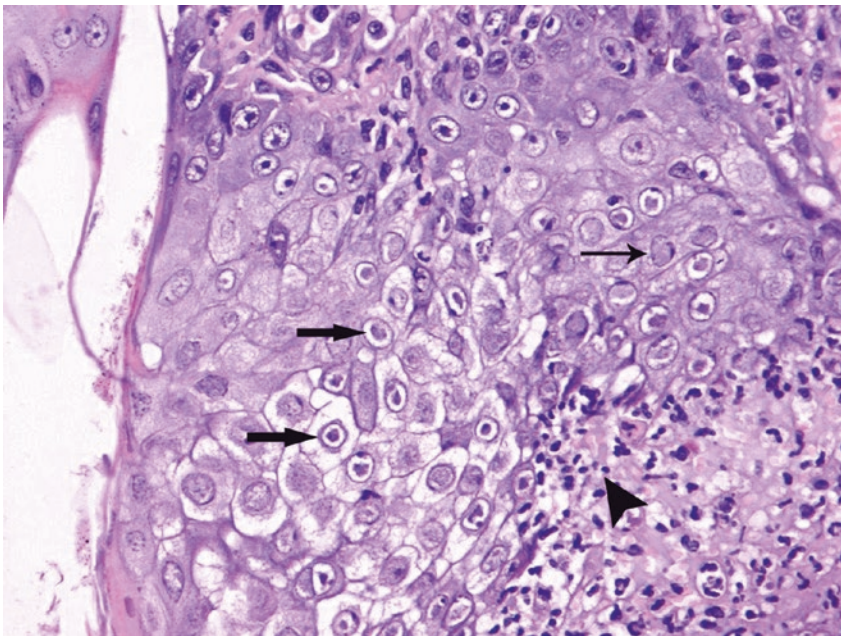


Fig. 3.172 Histology of herpesvirus: intranuclear viral inclusion (*arrows*), some of them amphiphilic (*thin arrow*); note the eosinophilic infiltrate in the superficial dermis (*head of arrow*) (Courtesy of Prof. F. Abramo, Italy)

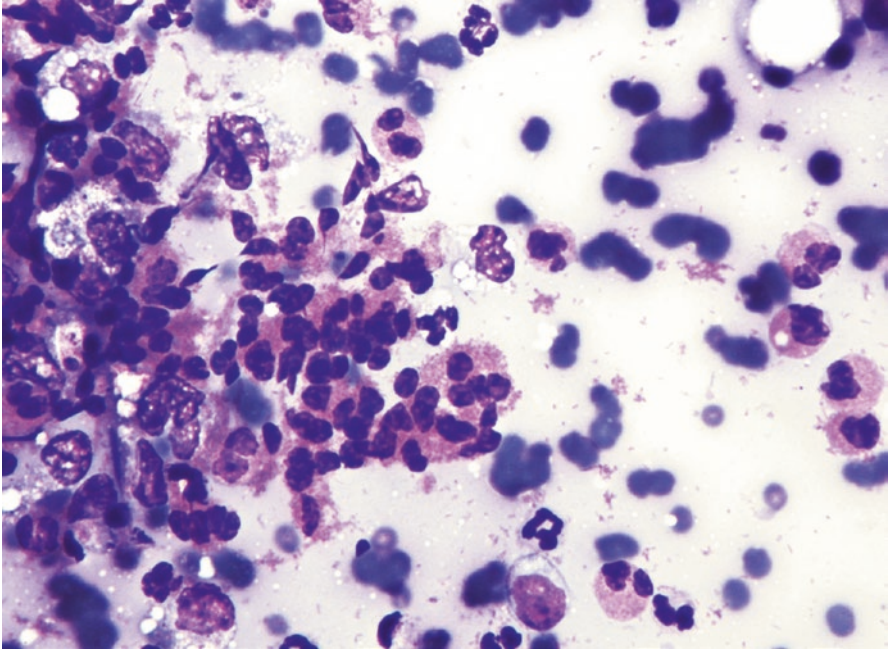


Fig. 3.173 Cytology of herpesvirus: many eosinophils and macrophages collected using the impression smear technique from the inner surface of a facial crust

Ulcers covered with haematic crusts, the lack of pruritus and the history of previous upper respiratory symptoms and conjunctivitis can direct clinicians to suspect a viral infection and perform a skin biopsy.

3.7.2.4 Sporotrichosis

Sporothrix schenckii is an ubiquitous dimorphic fungus that causes *sporotrichosis*, a cutaneous and subcutaneous fungal disease of cats and dogs. The disease is observed mainly in certain geographical areas, such as the USA, and in some areas of South America, such as Brazil (Dunstan et al. 1986; Fleury et al. 2001; Crothers et al. 2009; Madrid et al. 2012; Miller et al. 2013; Silva et al. 2015). As the disease is mostly observed in cats, and it is characterised by skin lesions on the extremities such as the head and legs, it has been speculated that *Sporothrix* might penetrate into the dermis through bites and scratches.

Clinically, three different forms of the diseases are recognised: a *localised* or *fixed cutaneous form* that seems more frequent in dogs, a *cutaneous lymphatic form*, and a *disseminated form*, the latter usually associated with the lymphatic form (Crothers et al. 2009). In cats, the cutaneous lymphatic form is most common, with skin lesions presenting with nodules and ulcers, and as the lymphatic vessel involvement creates mostly ulcerative lesions, the author prefers to discuss this fungal disease in the group of ulcerative lesions (Figs. 3.174, 3.175, and 3.176).

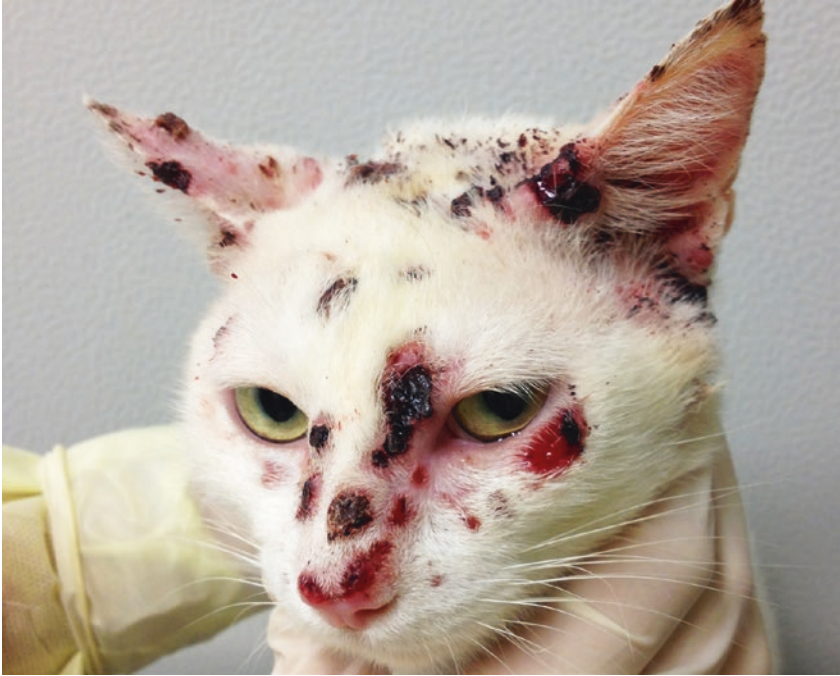

Fig. 3.174 Sporotrichosis: multiple ulcerative lesions on the face and on the pinna (Courtesy of Dr. A. Vieira Pereira, Brazil)

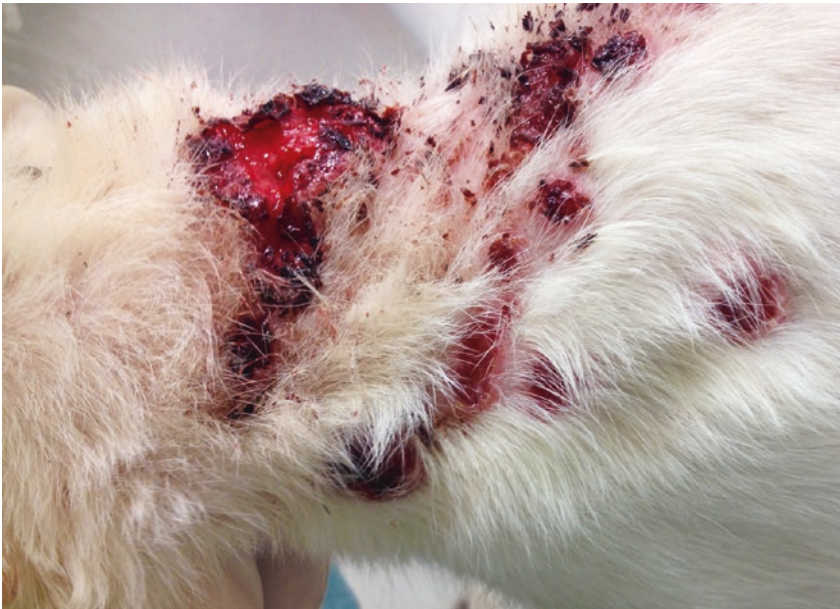

Fig. 3.175 Ulcers and crusts on the neck (same cat as in Fig. 3.174) (Courtesy of Dr. A. Vieira Pereira, Brazil)

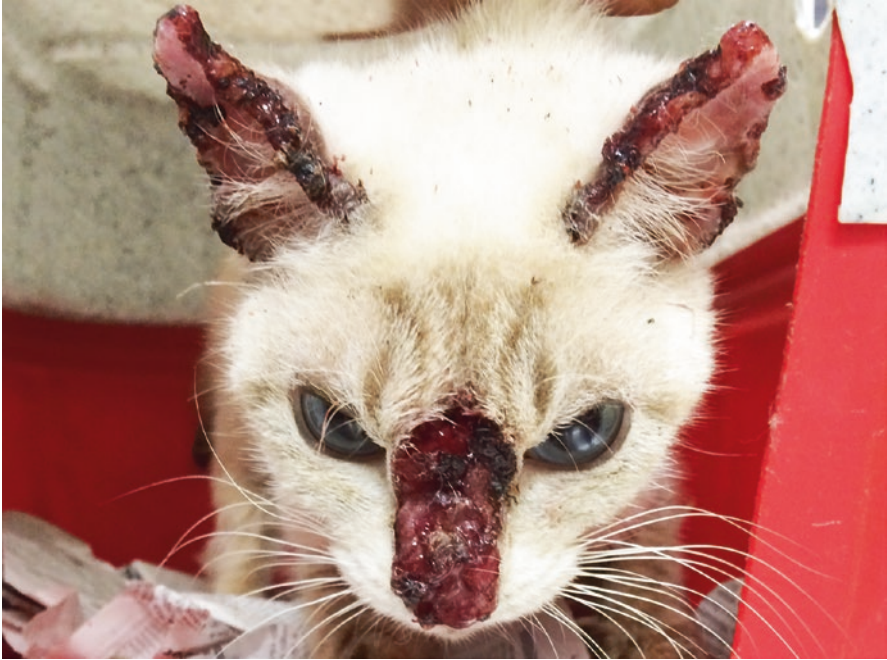

Fig. 3.176 Ulcerative dermatitis on the pinna and on the bridge of the nose in a cat affected by sporotrichosis (Courtesy of Dr. A. Vieira Pereira, Brazil)

Cytological Findings

Cytological specimens show many macrophages filled with fungal bodies; the latter usually seem to be less numerous in samples collected from dogs (Fig. 3.177). The fungal bodies can show double morphology, ranging from oval-shaped to a more characteristic *cigar* shape measuring 2.5–5 μm with a thin, peripheral, clear halo (Fig. 3.178). As mentioned, *Sporothrix* are easily observed, but in dogs and rarely in some cats, PAS or Grocott's staining can help to detect fungal bodies immersed in the inflammatory cells (Figs. 3.179 and 3.180).

3.8 Plaques and Nodules

In pets, many skin lesions grow as *nodules* or *plaques* and include numerous *neoplastic* and *non-neoplastic* (inflammatory) skin diseases.

Unfortunately, skin nodules are clinically not differentiable from each other; for this reason, to simplify the discussion about inflammatory diseases presenting with nodules and plaques, they have been divided on the basis of the presence or absence of infectious agents. Therefore, they are classified into two groups: *infectious* and *parasitic diseases*, in which a causative microorganism or a parasite is recognisable, and *sterile diseases*, in which the cause is not a microorganism.

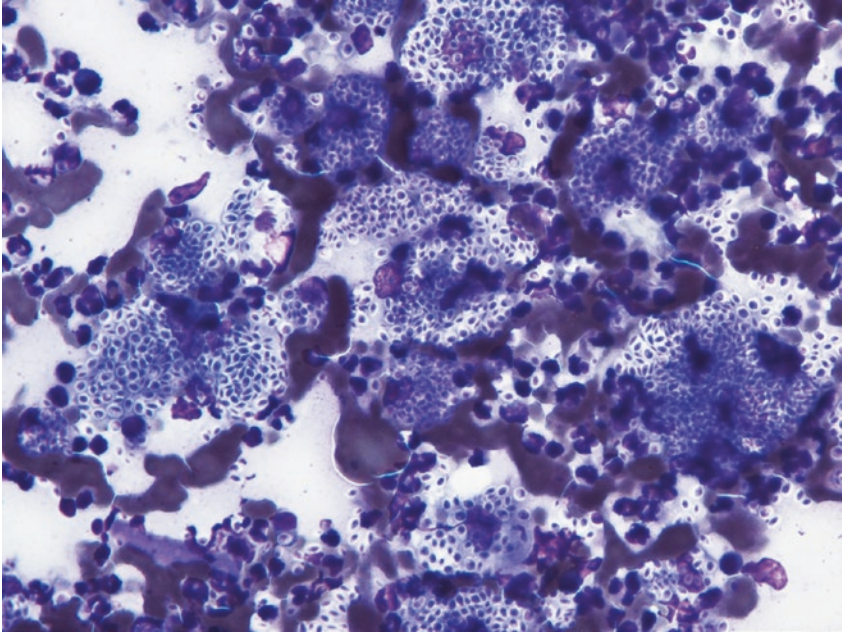


Fig. 3.177 Cytology of sporotrichosis: many *Sporothrix schenckii* in the cytoplasm of macrophages and multinucleated giant cells

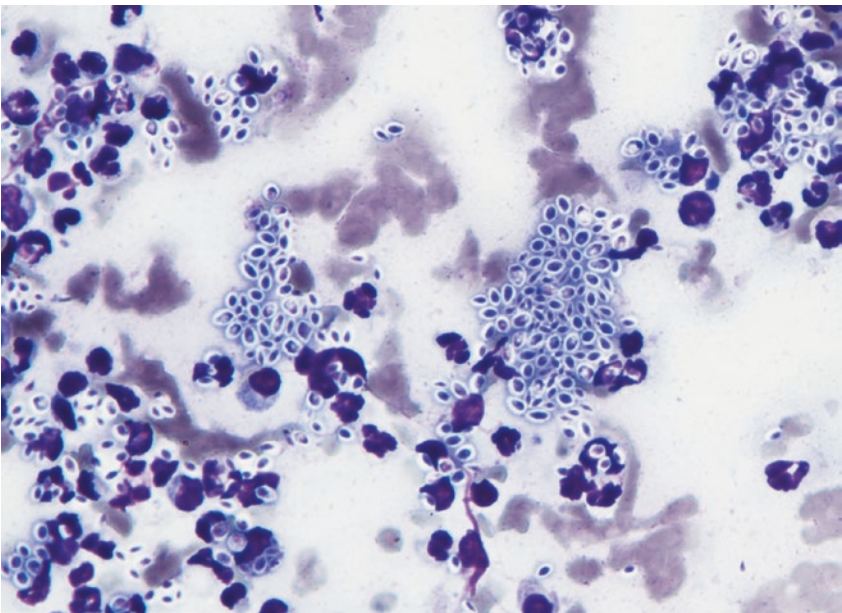


Fig. 3.178 Cytology of sporotrichosis: at high magnifications the double morphology of *Sporothrix schenckii*, round and cigar-shaped, is clearly evident

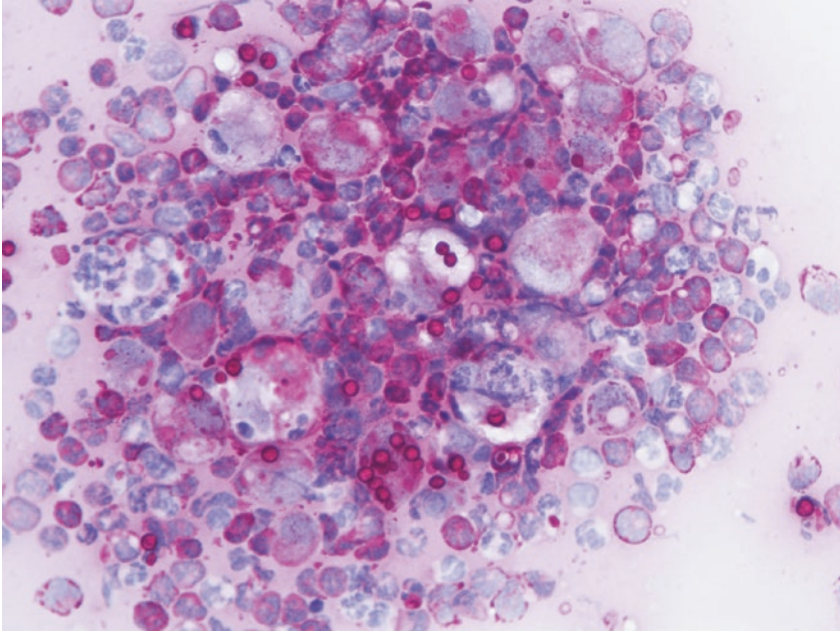


Fig. 3.179 Cytology of sporotrichosis (PAS staining): PAS-positive fungal bodies could not be easily recognisable in specimens composed of many inflammatory cells

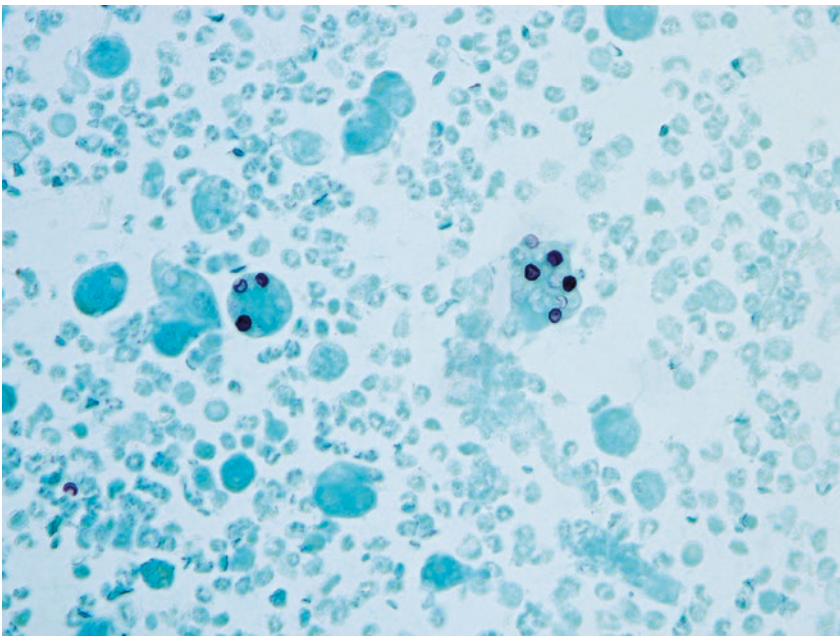


Fig. 3.180 Cytology of sporotrichosis (Grocott's staining): fungal bodies stain black on a green background

3.8.1 Infectious and Parasitic Causes

3.8.1.1 Bacteria

Bacterial Nodular Diseases in Dogs and Cats

Excluding papular–nodular lesions caused by *Staphylococci*, the development of nodules in dogs with pyoderma is due to the penetration of bacteria into the dermis or subcutis.

Nocardiosis and Actinomycosis

These nodular forms of deep pyoderma are caused by the deep penetration into the dermis and panniculus, of Gram-positive filamentous bacteria belonging to the Actinomycetaceae family.

Nocardia spp. are partially alcohol–acid-resistant bacteria among which the *N. asteroides* complex includes *N. brasiliensis* and *N. otitidiscaviarum*, whereas in cats, *N. nova* is most frequently involved (Malik et al. 2006; Siak and Burrows 2013).

Actinomycosis is caused by *Actinomyces*, alcohol–acid-resistant bacteria, mostly represented by *A. viscosus*, *A. hordeovulneris* and *A. odontolyticus* (Greene 2012).

The list of these groups of bacteria expands continuously with some change in their names. Although sharing the filamentous morphology, the two bacteria have completely different habitats; *Nocardia* lives as a saprophyte in the soil and penetrates the skin mostly via deep infected wounds, whereas *Actinomyces* is a commensal of the oral cavity and intestines of dogs and cats and penetrates the skin with bites, but also via infected vegetal foreign bodies (Kirpensteijn and Finland 1992; Gross et al. 2005; Greene 2012).

The skin lesions are characterised by single or multiple nodules that often tend to ulcerate or develop draining tracts, which discharge purulent and smelling exudate that may contain visible *white* or *brown grains* similar to those observed in true mycetoma (Fig. 3.181). In cats with actinomycosis, lesions are seen more frequently on the extremities, face and neck, which are the sites that are most prone to bites. In some cases, lesions are represented as swelling and poorly defined nodules, with panniculitis especially on the abdominal area; clinical findings resemble those observed in cats with opportunistic mycobacterial infections (Miller et al. 2013) (Fig. 3.182).

Cytological Findings

Cytologically, *filamentous* microorganisms are easily to recognise because of their characteristic silhouette. At low magnification, when present, *grains* are composed of extracellular clusters of bacteria and are represented as deep blue or reddish amorphous material immersed in a neutrophilic and macrophagic inflammation. Neutrophils are karyolytic and macrophages are vacuolated and show leukophagocytosis. At high magnification, elongated, slender, filamentous, often branched, linear or beaded bacteria are recognisable (Figs. 3.183 and 3.184).

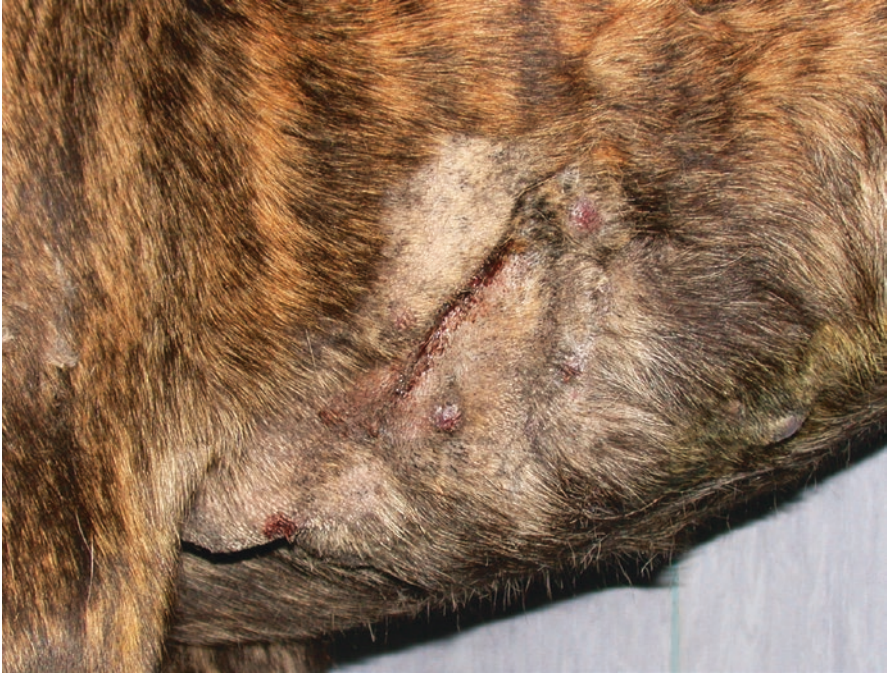

Fig. 3.181 Confluent nodules and draining tracts on the chest of a dog with *Nocardia asteroides* infection

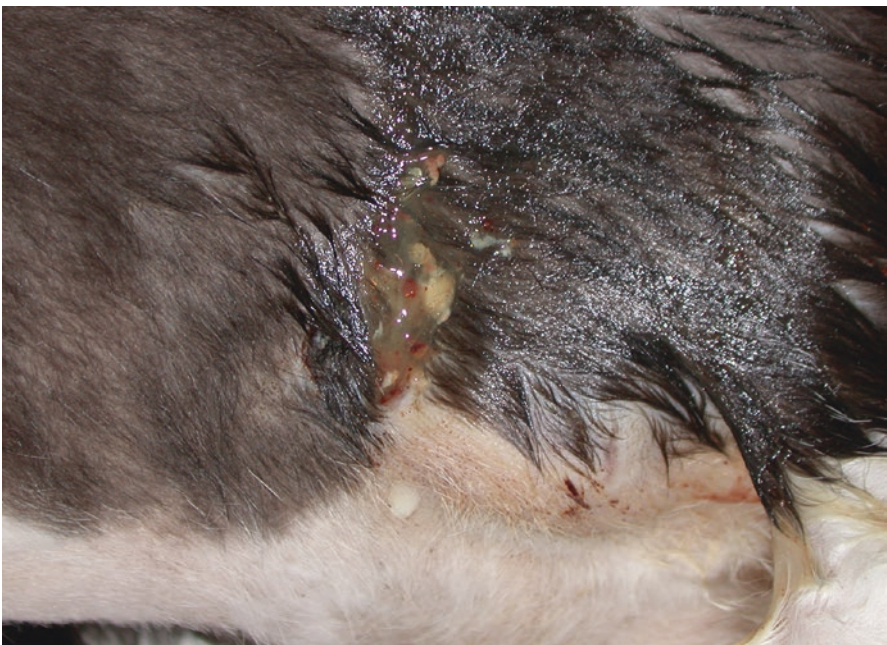

Fig. 3.182 Nocardiosis: draining tracts discharging grainy purulent exudate in a cat

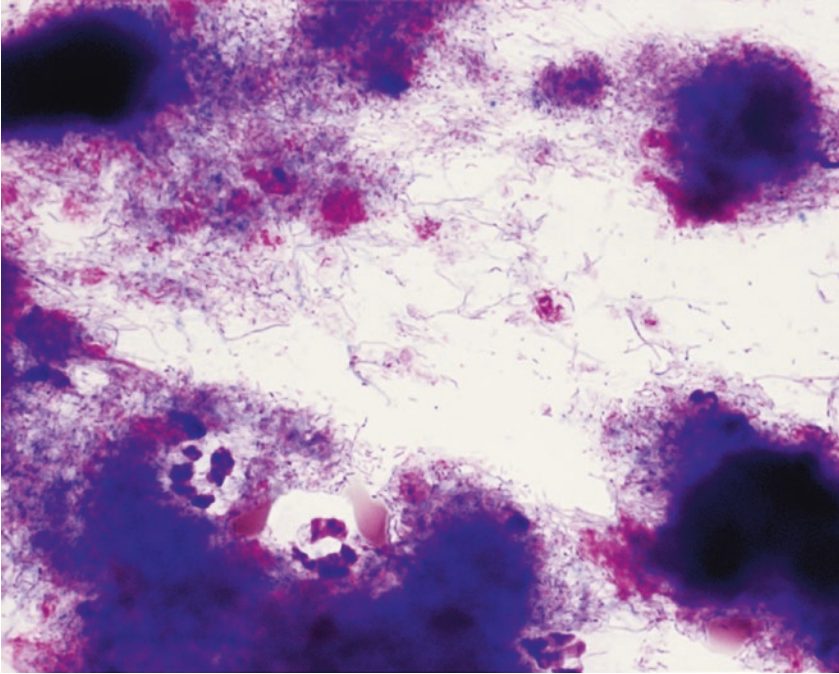


Fig. 3.183 Multiple dense cluster of bacteria (grains) with slender and filamentous *Nocardia asteroides*

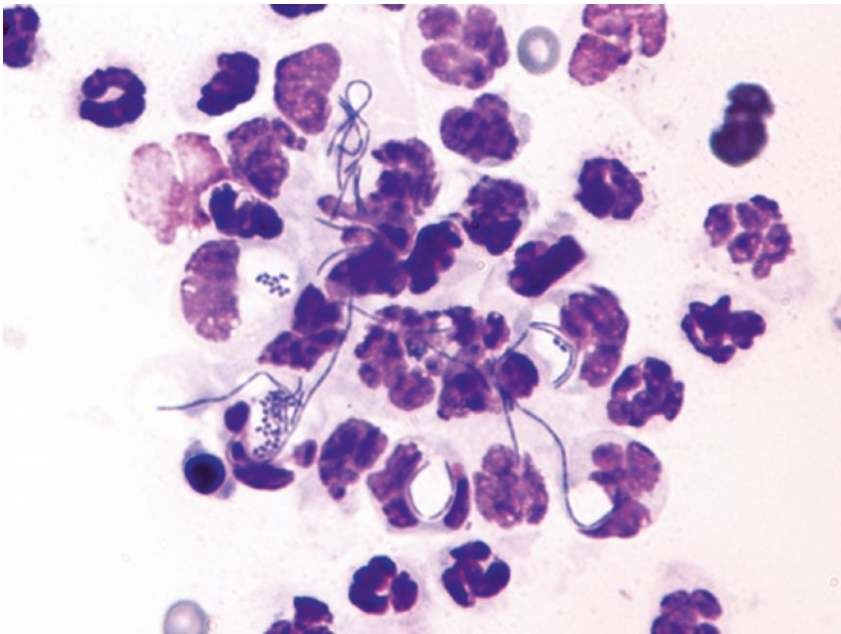


Fig. 3.184 Many cocci, some rods and filamentous bacteria belonging to *Actinomycetaceae* family phagocytosed by neutrophils

It is not possible to typify bacteria through cytology, with which we can only define the shape; for a final typing, an anaerobic culture or molecular tests such as PCR are mandatory.

Botryomycosis

In some cases, deep nodular pyoderma can be linked to dermal or the hypodermal localisation of *non-branching* and *non-filamentous* bacteria such as cocci and rod-shaped bacteria.

The deep infections not linked to filamentous bacteria are called *Botryomycosis*. As non-filamentous bacteria do not usually form grains, as normally some fungi do in true mycetomas, this form of deep granular bacterial infection is also defined by the confusing term of *bacterial pseudomycetoma* (Scott 2007; Miller et al. 2013).

The most frequently isolated bacteria include *P. aeruginosa*, *E. coli*, *Proteus* spp., *P. acne*, *S. marcescens*, *P. multocida* etc., which penetrate the skin through contaminated foreign bodies and tend to arrange themselves in large clusters surrounded and isolated by the inflammatory cells.

Clinically, single or multiple nodules, swellings and draining tracts can be observed and, in rare cases, lesions are represented by abdominal panniculitis resembling those observed in cats with opportunistic mycobacterial infections (Figs. 3.185

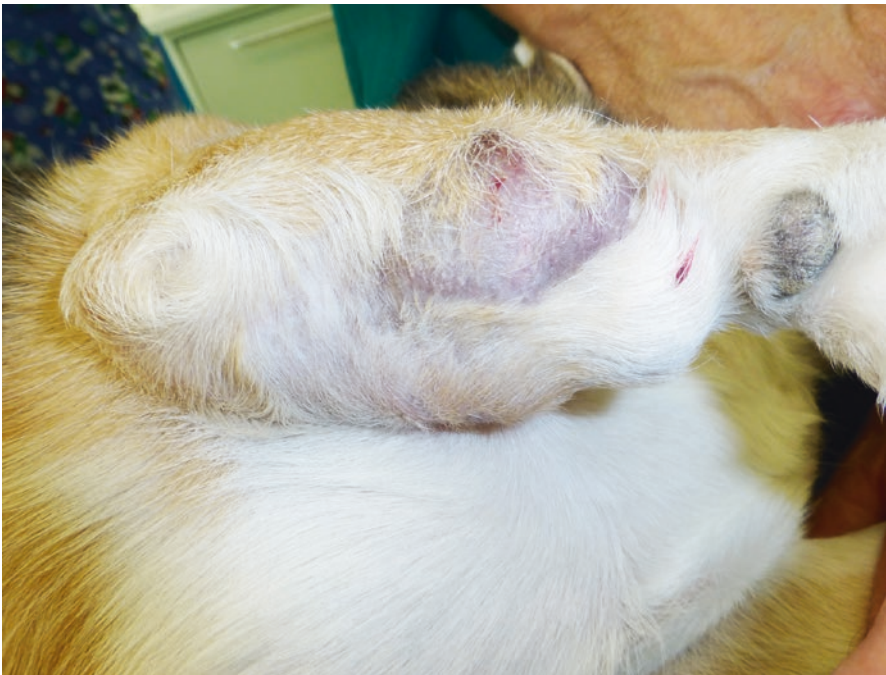


Fig. 3.185 Subcutaneous nodule on the leg of a dog with *botryomycosis*

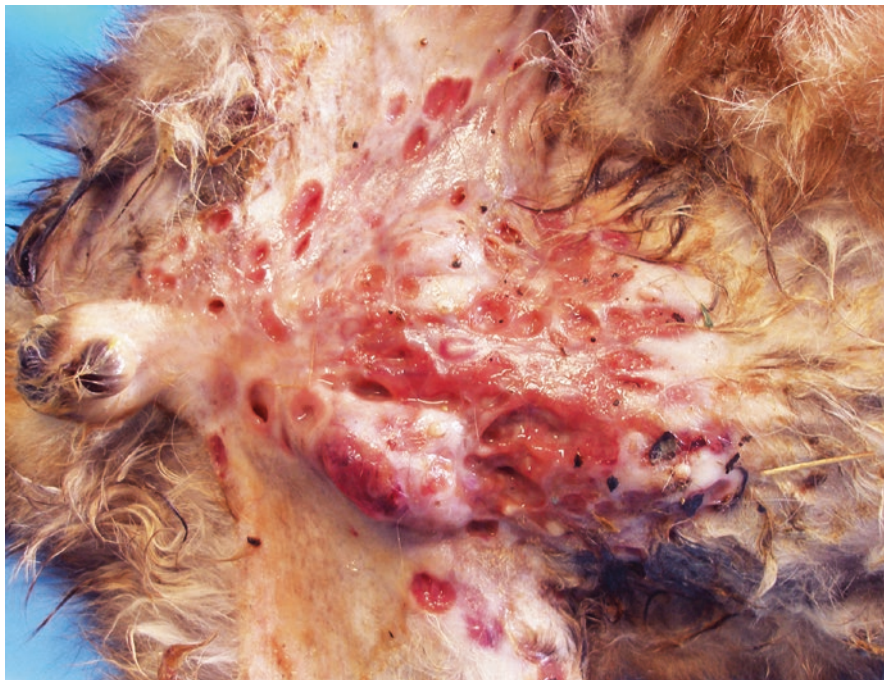

Fig. 3.186 Multiple subcutaneous nodules and draining tracts on the abdomen of a cat infected with *Rhodococcus equi* (Courtesy of Dr. C. Caporali, Italy)

and 3.186). Bacteria, together with a peripheral host reaction, comprise the *grains*, which are clinically recognisable as small granular formations immersed in purulent exudate (mycetoma-like). Histopathological specimens reveal a nodular-to-diffuse pyogranulomatous dermatitis and panniculitis with many grains that resemble a *bunch of grapes* (Figs. 3.187 and 3.188). At the periphery of the grains, an eosinophilic material composed of immunoglobulin and fibrin, named the *Splendore-Hoeppli reaction*, is observed. This reaction is not pathognomonic of botryomycosis as is always observed in the true mycetomas. It is sometimes detected in deep pyoderma because of filamentous bacteria (*Actinomycetaceae*), and in rare cases of deep localisation of *Microsporum canis* (dermatophytic pseudomycetoma) (Gross et al. 2005).

Cytological Findings

Cytologically, at low magnifications, the *grains* are recognisable as amorphous basophilic material immersed in neutrophilic and macrophagic inflammation (Figs. 3.189 and 3.190). At high magnifications, cocci and/or rod-shaped bacteria are recognisable, both free and phagocytosed by karyolytic neutrophils; many vacuolised leukophagocytic macrophages are evident, together with variable amounts of lymphocytes (Fig. 3.191).

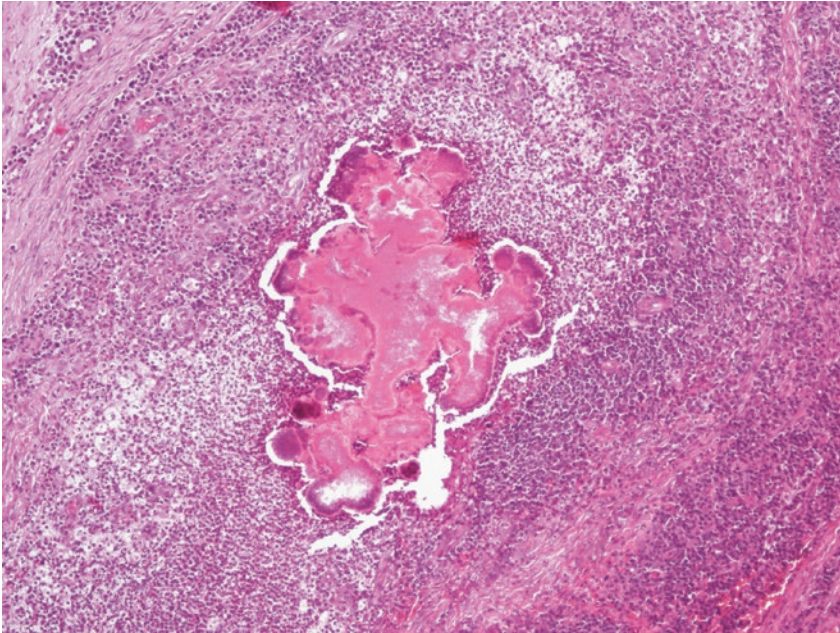


Fig. 3.187 Histology of *botryomycosis*: eosinophilic material (grain) composed of non-filamentous bacteria, immersed in a pyogranulomatous exudate

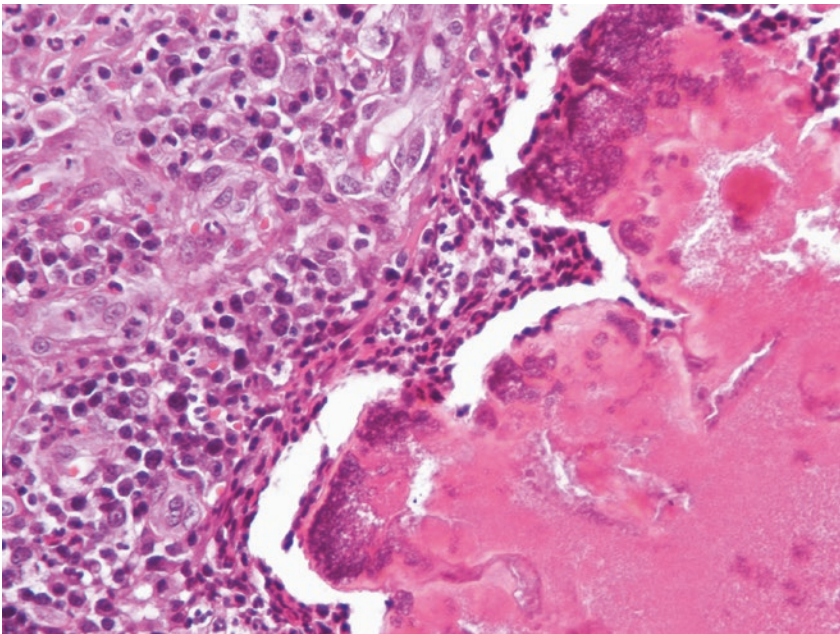


Fig. 3.188 Histology of *botryomycosis*: pyogranulomatous inflammation surrounding the cluster of bacteria

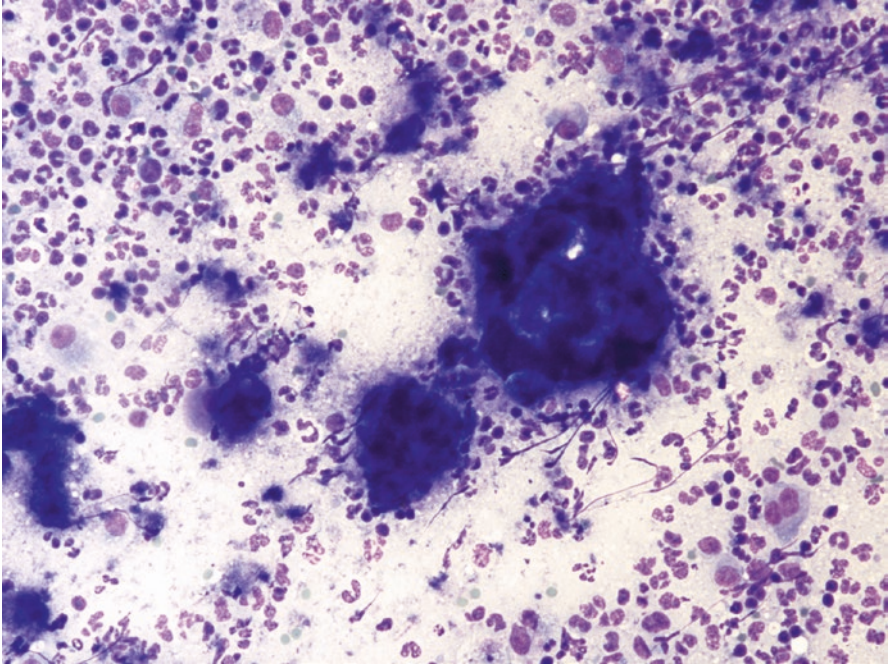


Fig. 3.189 Cytology of *botryomycosis*: cluster of bacteria immersed in pyogranulomatous inflammation

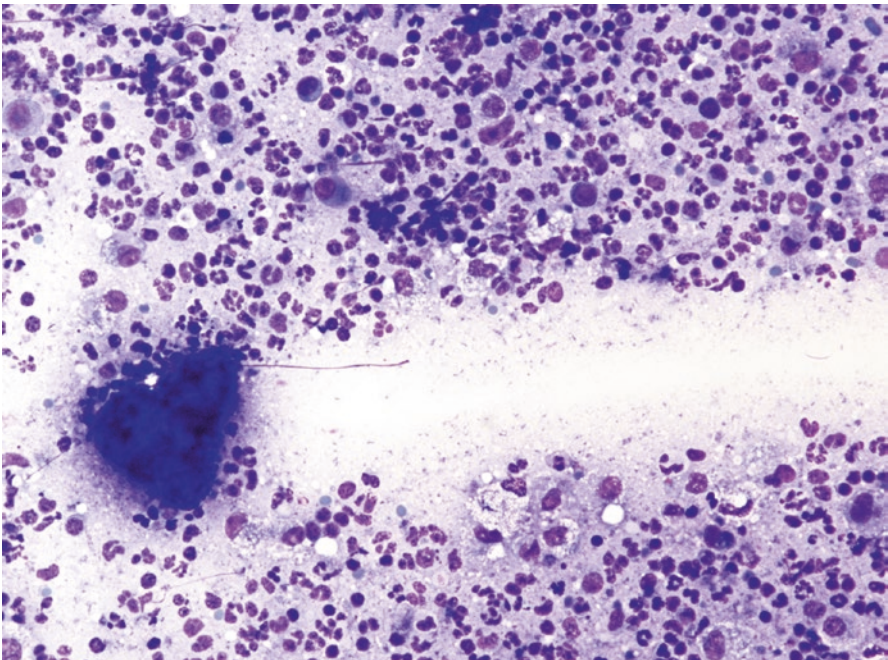


Fig. 3.190 Cytology of *botryomycosis*: cluster of bacteria (grain) smeared on the slides

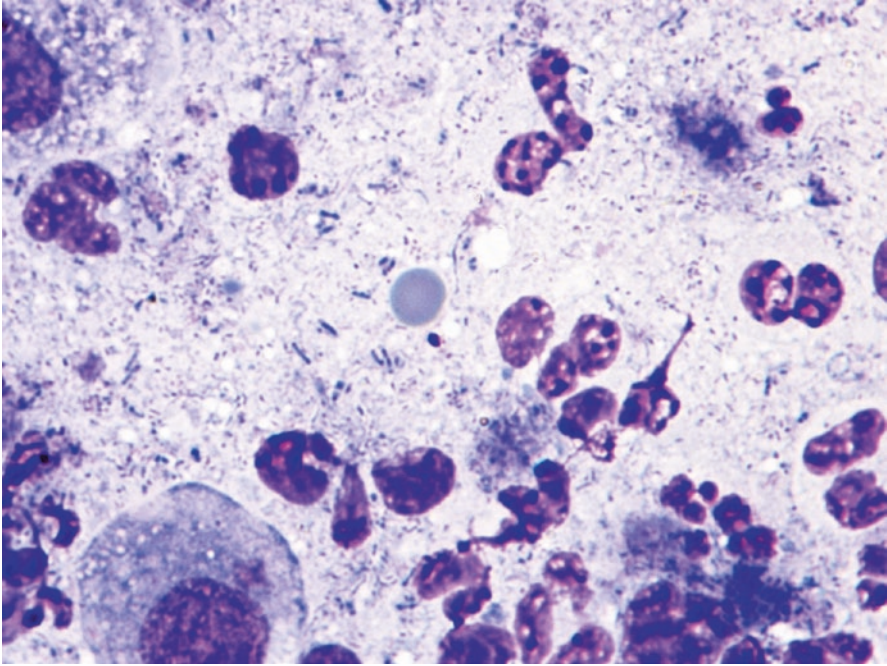


Fig. 3.191 Cytology *botryomycosis*: at high magnifications cocci and rod-shaped bacteria are evident, free or phagocytosed by neutrophils

Mycobacteriosis

Mycobacteria are a group of rod-shaped, alcohol–acid-resistant bacteria that can be classified into two main groups, namely: *obliged* and *facultative* pathogens, the latter also known by the terms *opportunistic* or *atypical mycobacteria* (Greene 2012; Laprie et al. 2013; Miller et al. 2013; Gunn-Moore 2014).

These microorganisms are causative of three different syndromes namely *Tuberculosis* (*M. tuberculosis* complex which comprises *M. tuberculosis*, *M. bovis* and *M. microti*), the *feline leprosy syndrome* (*M. lepraemurium* and *M. visibile* and a novel unnamed species) and facultative pathogenic opportunistic saprophytes (non-tuberculous mycobacteriosis) which represent a group of ubiquitous *mycobacteria* (*M. fortuitum*, *M. smegmatis*, *M. genavense* etc.) that live in soil and water and, through traumatic wounds or infected foreign bodies, can cause infections in immunodeficient cats and, less frequently, in dogs. Infections caused by the so-called *Mycobacterium avium complex* (MAC) also belong in the latter group, are also frequently reported (Malik et al. 2000, 2004, 2013; Greene 2012).

Clinical lesions are characterised by single or multiple nodules, often ulcerated and with draining tracts (Miller et al. 2013).

In cats affected by leprosy, *Mycobacteria* is inoculated subcutaneously via bites from infected rats. Depending on the modality of transmission, lesions are characterised by single or multiple nodules of different sizes, particularly located at the extremities and often ulcerated (Figs. 3.192 and 3.193).

In dogs, a self-limiting nodular form of mycobacteriosis named *canine leprosy syndrome* has been documented, particularly in Australia and Brazil, in which

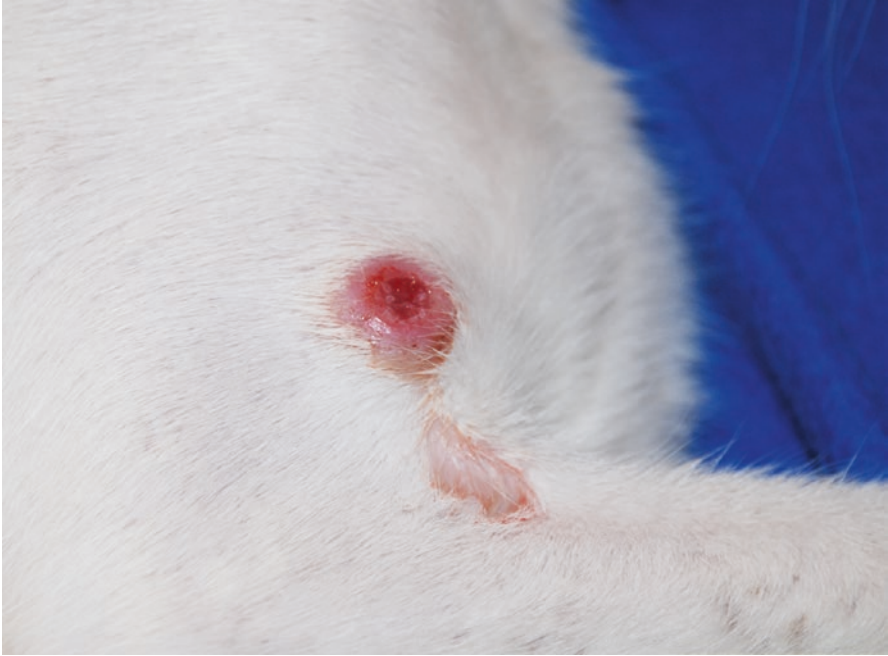


Fig. 3.192 Ulcerated nodule on the foreleg of a cat with feline leprosy (Courtesy of Dr. V. Imburgia, Italy)

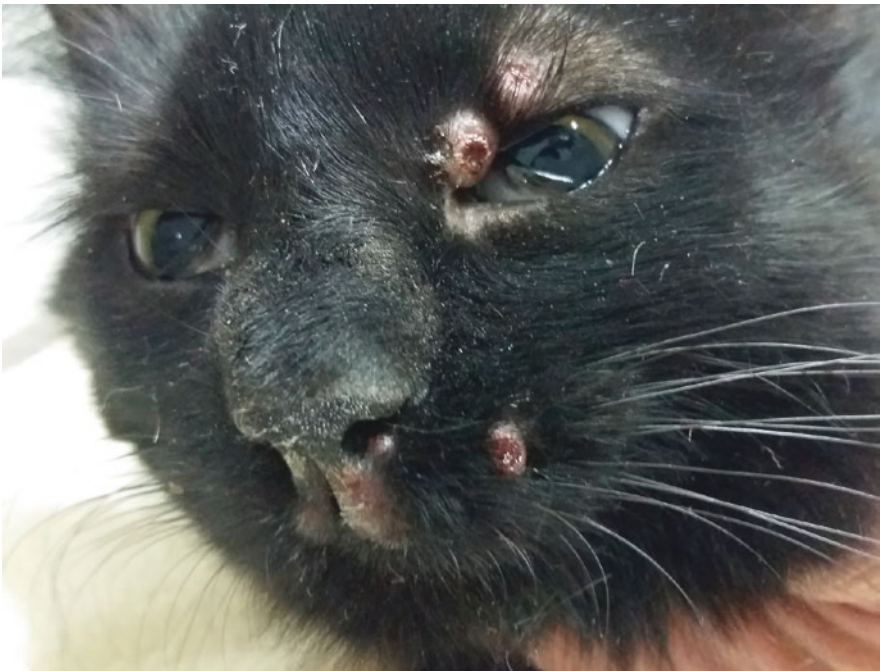

Fig. 3.193 Multiple erythematous papular nodular lesions on the face of a cat affected by mycobacteria belonging to *Mycobacterium avium* complex (MAC) (Courtesy of Vet Center Anacaprese, Italy)

multiple nodules on the ears and head are observed. Recently a case has been reported in Europe for the first time (Dedola et al. 2004). Boxer dogs are over-represented and the constant localisation of the lesions suggests that mycobacteria could be transmitted through insect bites (Smits et al. 2012) (Figs. 3.194 and 3.195).

In cats, characteristic abdominal panniculitis caused by opportunistic mycobacteria with lipidic tropism is well recognised. Lesions range from poorly defined nodules to fistulas, which drain a purulent exudate mixed with fat that, in chronic untreated cases, leads to the destruction of all the adipose abdominal tissue (Figs. 3.196 and 3.197).

Cytological Findings

Feline leprosy can be histologically divided into two forms: *lepromatous* and *tuberculoid*. In the former, cytological specimens are composed of neutrophils and many epithelioid and giant cells filled with intracytoplasmic mycobacteria, in the tuberculoid form, cytology seems instead characterised by fewer giant cells and mycobacteria and a higher number of lymphoid cells (Gross et al. 2005; Davies et al. 2006).

Cytological findings in the course of mycobacterial infections differ depending on the causative bacteria. In leprosy, slides show pyogranulomatous inflammation with many intracellular and extracellular, achromatic linear rod-shaped area representing unstained bacteria (negative images) (Figs. 3.198 and 3.199). *Mycobacteria* are covered by mycolic acid, which does not permit standard dyes (Romanowsky-type) to penetrate the microorganism; therefore, to detect *mycobacteria*, the

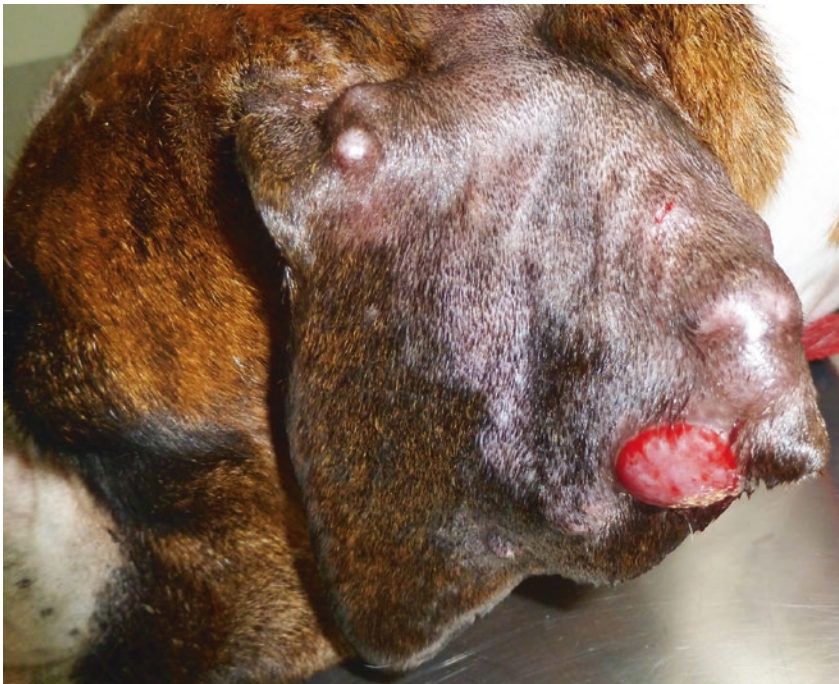

Fig. 3.194 Multiple ulcerated nodules on the pinna of a Boxer with canine leproid syndrome (Courtesy of Dr. L. Cotta, Brazil)

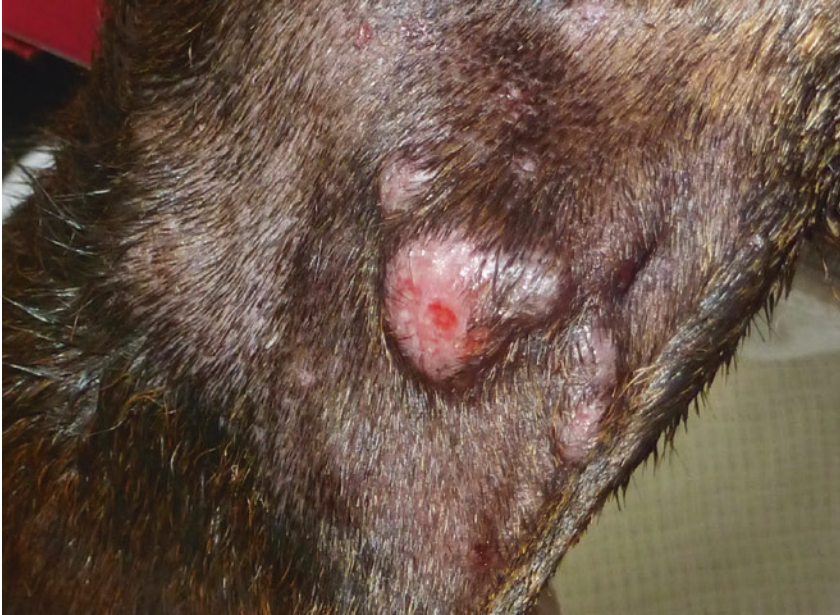

Fig. 3.195 Nodules of different sizes on the pinna of the same dog as in Fig. 3.194 (Courtesy of Dr. L. Cotta, Brazil)

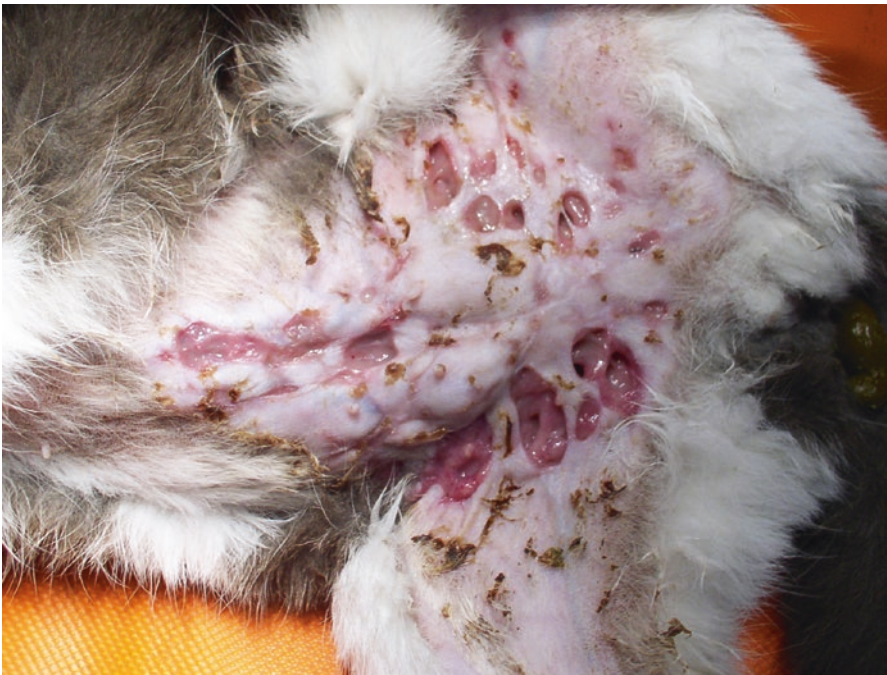


Fig. 3.196 Multiple ulcers and draining tracts in a cat with panniculitis caused by opportunistic *mycobacteria* (Courtesy of Dr. S. Fanfoni, Italy)

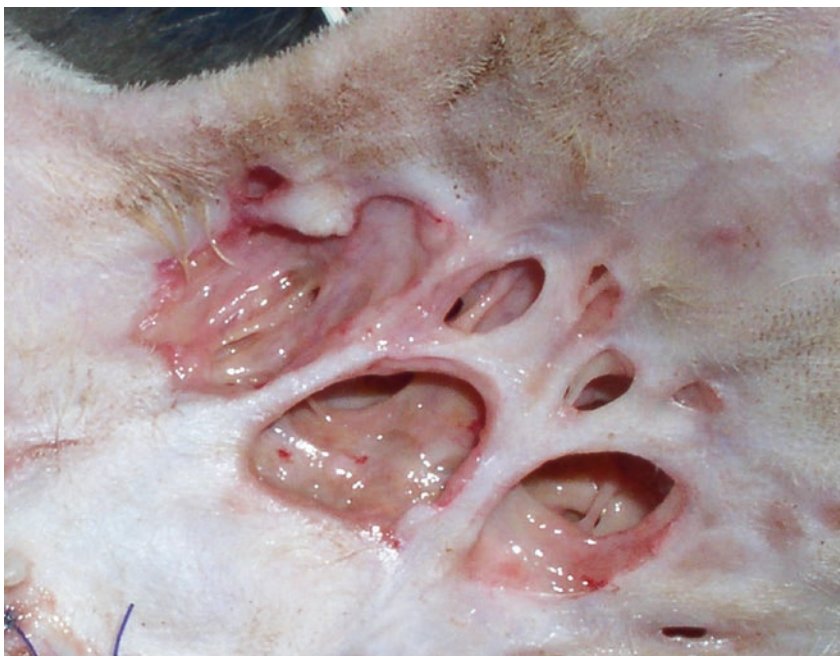

Fig. 3.197 Close-up of the lesions of the same cat as in Fig. 3.196 (Courtesy of Dr. S. Fanfoni, Italy)

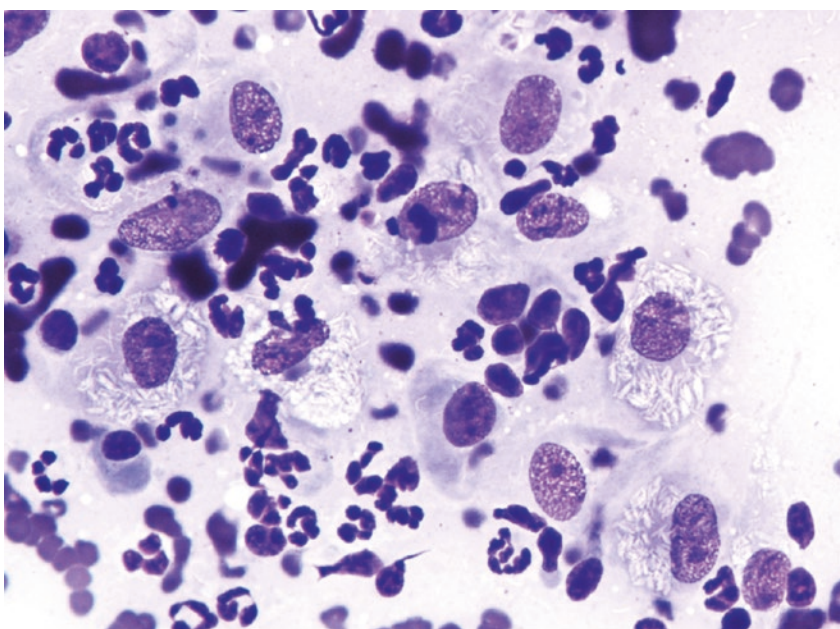


Fig. 3.198 Cytology of feline leprosy: many macrophages filled with linear achromatic spaces in the cytoplasm

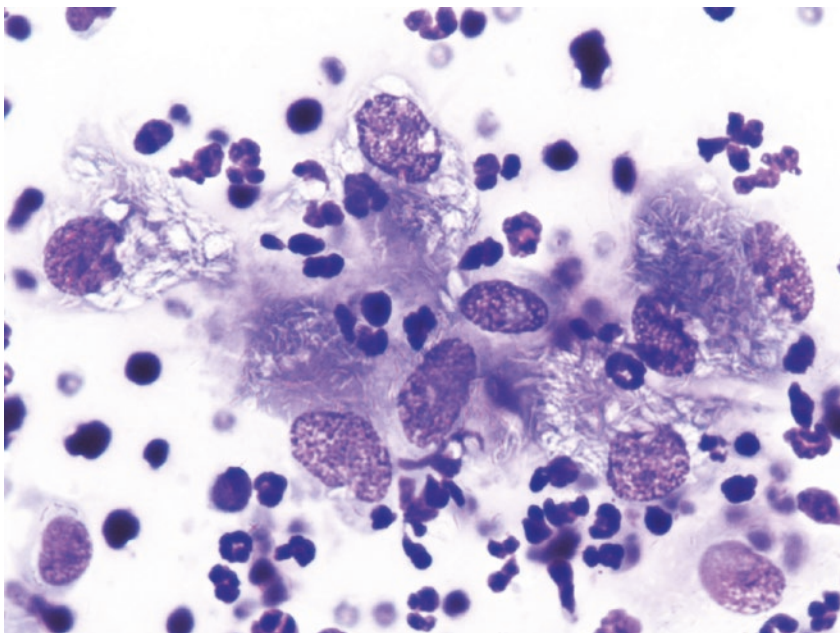


Fig. 3.199 Cytology of feline leprosy: many macrophages filled with linear achromatic spaces in the cytoplasm

Ziehl–Neelsen (Z–N) stain is required, with which bacteria take up the carbol fuchsin and typically stain *bright red* (Figs. 3.200 and 3.201).

In the atypical (opportunistic) mycobacteriosis, macrophages are present in varying numbers, but always high, whereas the number of giant cells seems irrelevant and inflammation is typically neutrophilic and macrophagic. Opportunistic mycobacteria have a lipidic tropism and for this reason they must be histologically checked in the lipid droplet surrounded by neutrophilic and macrophagic inflammation (Fig. 3.202). In many cases, mycobacteria are viewable only with the Z–N or Fite–Faraco stains (Figs. 3.203 and 3.204). In *opportunistic mycobacteria panniculitis*, cytology is similar to that observed in other forms of fat inflammation and it is also very difficult to see bacteria with Z–N staining too. Specimens are composed of segmented neutrophils together with normal or foamy lipophagocytic macrophages and may also contain some lymphocytes and plasma cells. With special stains, a few mycobacteria can be found in the fat, but not in the macrophages (Fig. 3.205).

Infection caused by mycobacteria belonging to the *Mycobacterium avium* complex (MAC) seems histologically characterised by a granulomatous/pyogranulomatous inflammation with a variable number of giant cells and, in some variants, with an impressive fibroblastic reaction that can cytologically mimic a soft-tissue sarcoma with giant cells.

In MAC with a poor fibroblastic reaction the number of microorganisms is nevertheless high. It must be stressed that it is not possible to typify mycobacteria through cytology, for which, culture examinations (often difficult to perform) or molecular biology tests (PCR) are mandatory.

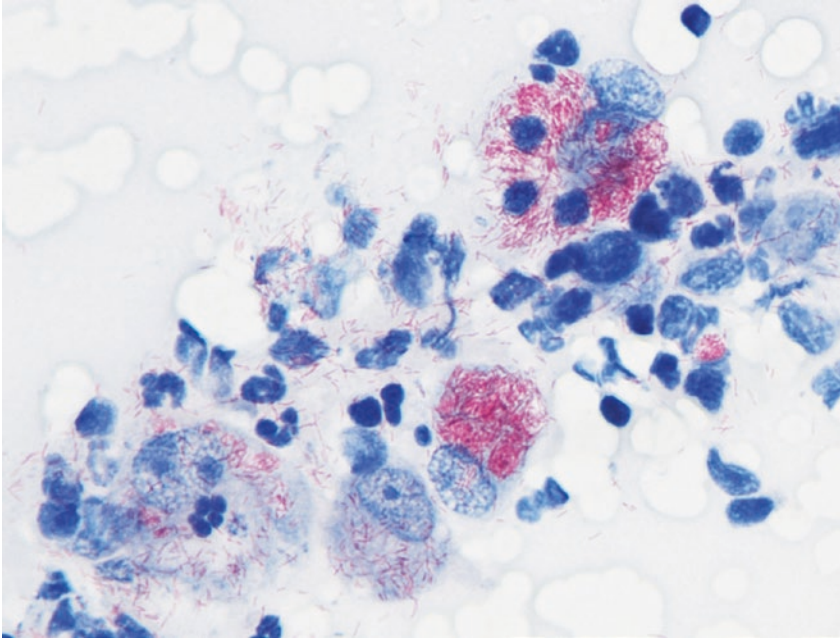


Fig. 3.200 Cytology of feline leprosy: many macrophages filled with linear bright red bacteria in the cytoplasm (Ziehl–Neelsen staining)

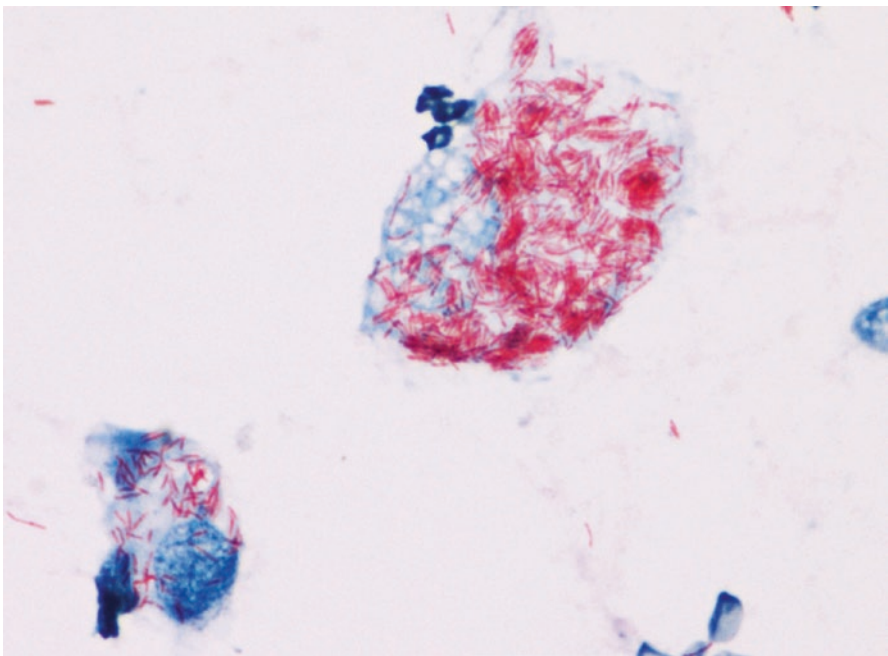


Fig. 3.201 Cytology of feline leprosy: at high magnifications red-stained mycobacteria are easily recognisable (Ziehl–Neelsen staining)

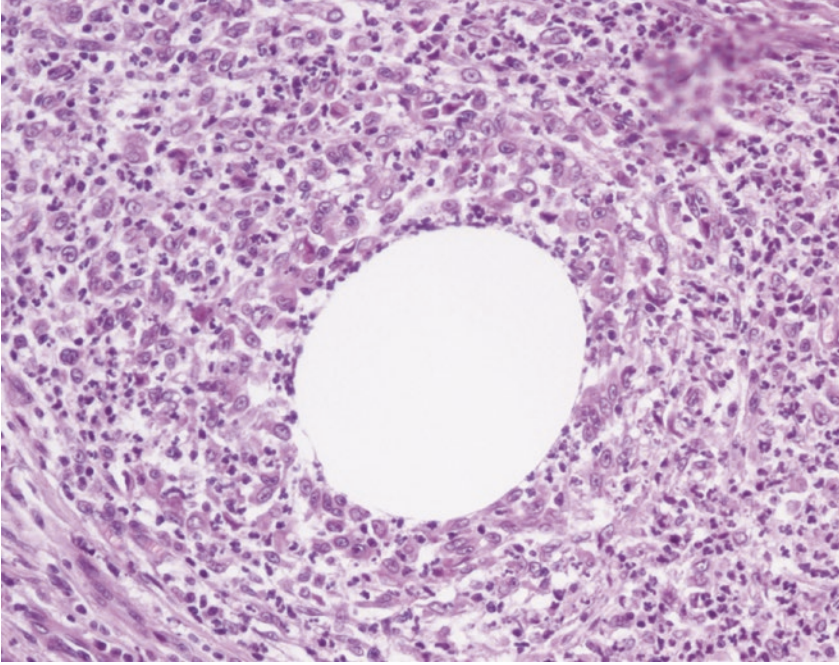


Fig. 3.202 Histology of opportunistic mycobacteriosis: granulomatous panniculitis with well-demarcated central lipid vacuoles in which bacteria are not evident with H-E staining

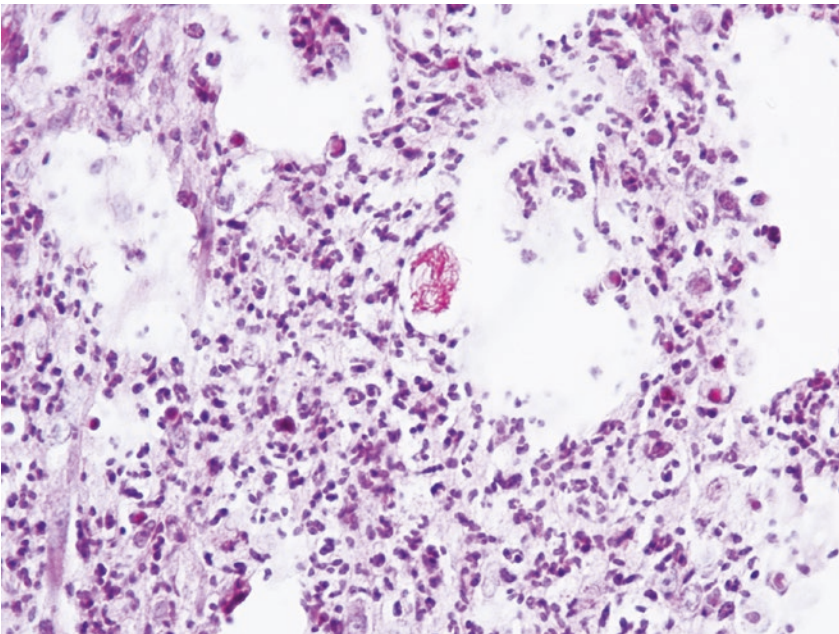


Fig. 3.203 Histology of opportunistic mycobacteriosis: many Z-N-positive bacteria in a lipid vacuole surrounded by pyogranulomatous inflammation

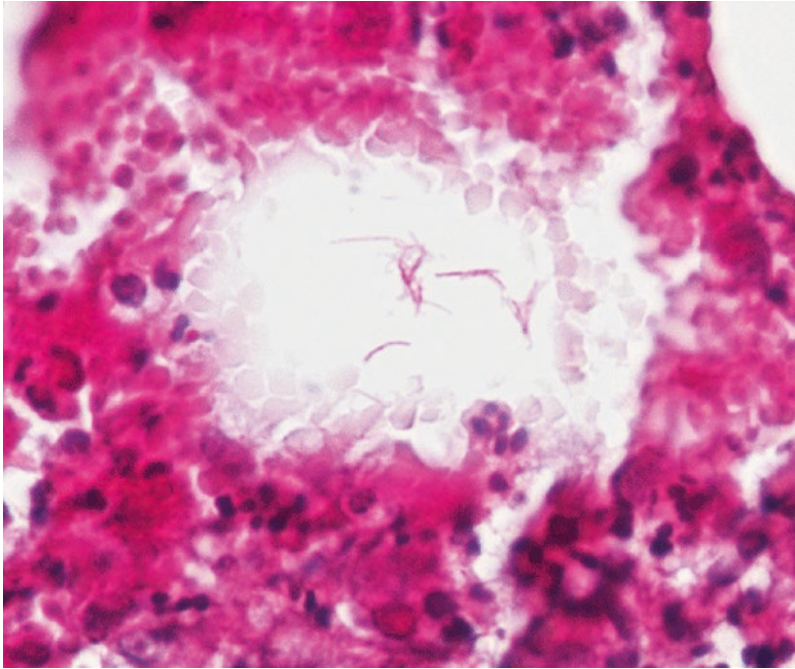


Fig. 3.204 Histology of opportunistic mycobacteriosis: at high magnifications Z-N-positive bacteria are well recognisable

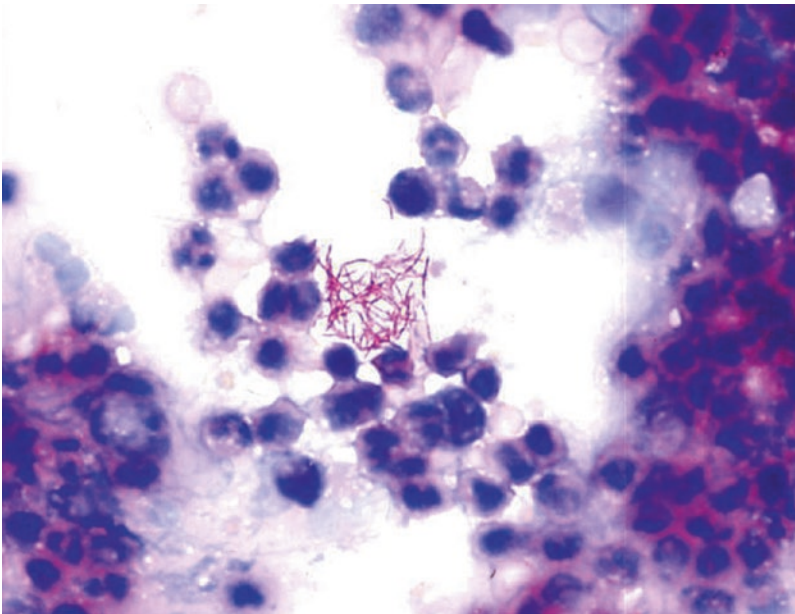


Fig. 3.205 Cytology of opportunistic mycobacteriosis: many Z-N-positive bacteria are present in lipidic material, but not in the cytoplasm of inflammatory cells (Courtesy of Dr. W. Bertazzolo, Italy)

3.8.1.2 Protozoa

Leishmaniasis

As already mentioned, skin lesions in canine leishmaniasis are very diverse, but nodular lesions are rarely reported. Apart from the papular–nodular form described above, which is considered a local reaction to sandfly bites in immunocompetent animals, dogs suffering from systemic leishmaniasis can develop both single and multiple cutaneous/subcutaneous nodules (Figs. 3.206 and 3.207) (Solano-Gallego et al. 2009). *Leishmaniasis* in cats is very rare, but even though the typology of skin lesions has not yet been characterised, it is known that cats seem to develop nodules and ulcerative lesions (Figs. 3.208 and 3.209) (Poli et al. 2002; Pennisi et al. 2013).

Cytological Findings

Unlike some papular lesions, in leishmaniotic animals, nodular lesions are usually rich in amastigotes. Inflammatory cells are represented by segmented neutrophils, macrophages and a variable number of epithelioid macrophages and giant cells; lymphocytes, and especially plasma cells, are usually numerous (Gross et al. 2005). Amastigotes are visible in the cytoplasm of both histiocytes and neutrophils and scattered on the slide background following the breakage of some of the cells during slide preparation (Figs. 3.210, 3.211, and 3.212).

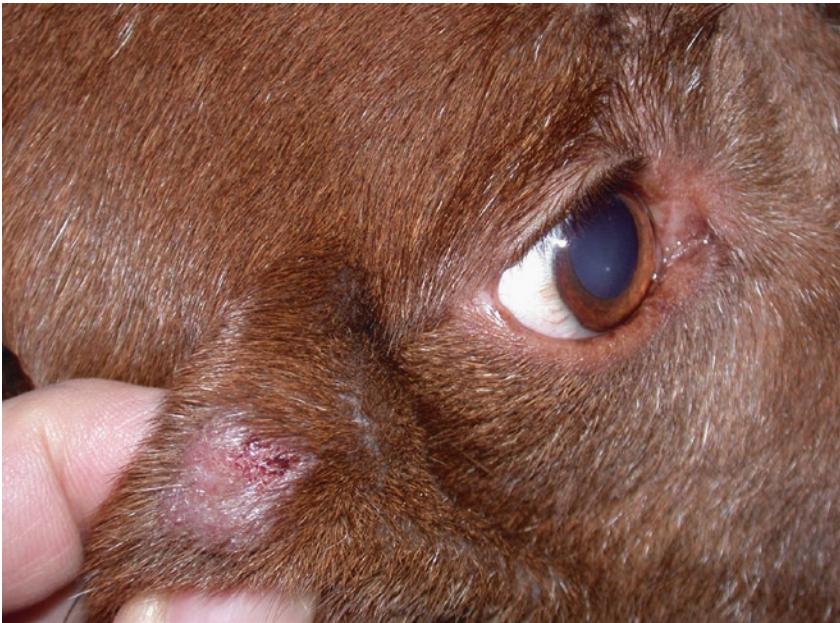


Fig. 3.206 Single alopecic nodule on the face of a dog with systemic leishmaniasis



Fig. 3.207 Multiple subcutaneous nodules in a Doberman with systemic leishmaniasis

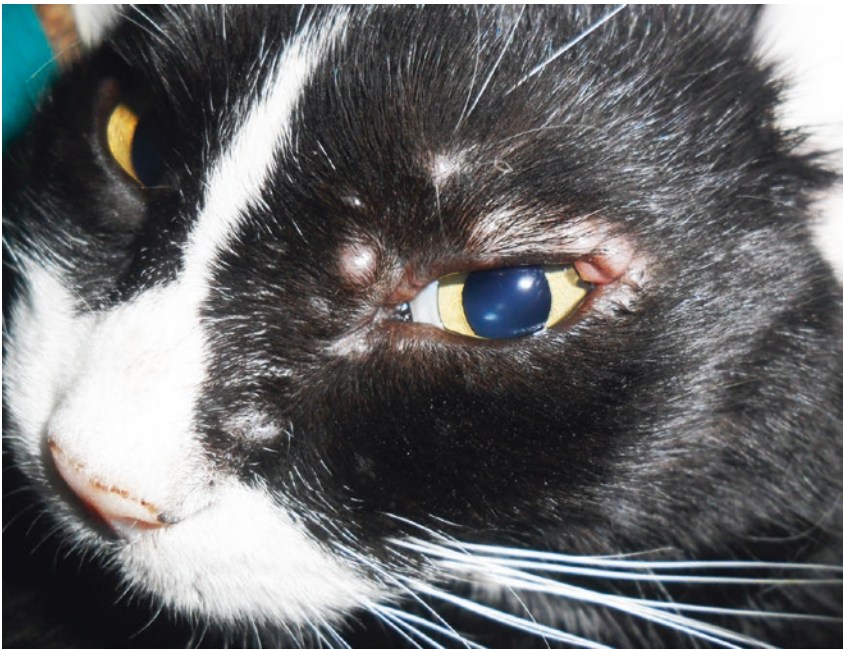

Fig. 3.208 Multiple cutaneous nodules on the eyelids of a cat with leishmaniasis (Courtesy of Dr. I. Fileccia, Italy)

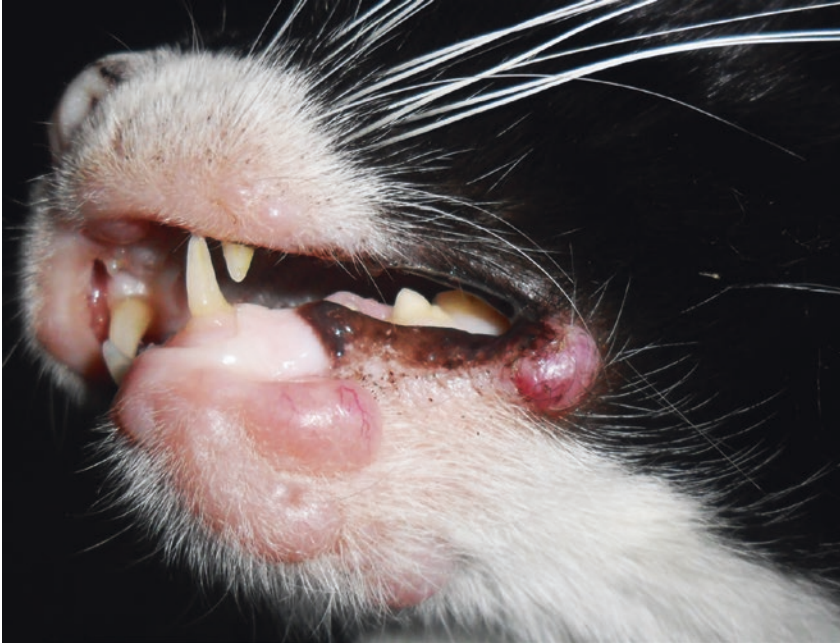

Fig. 3.209 Multiple cutaneous nodules on the lips of a cat with leishmaniasis (Courtesy of Dr. I. Fileccia, Italy)

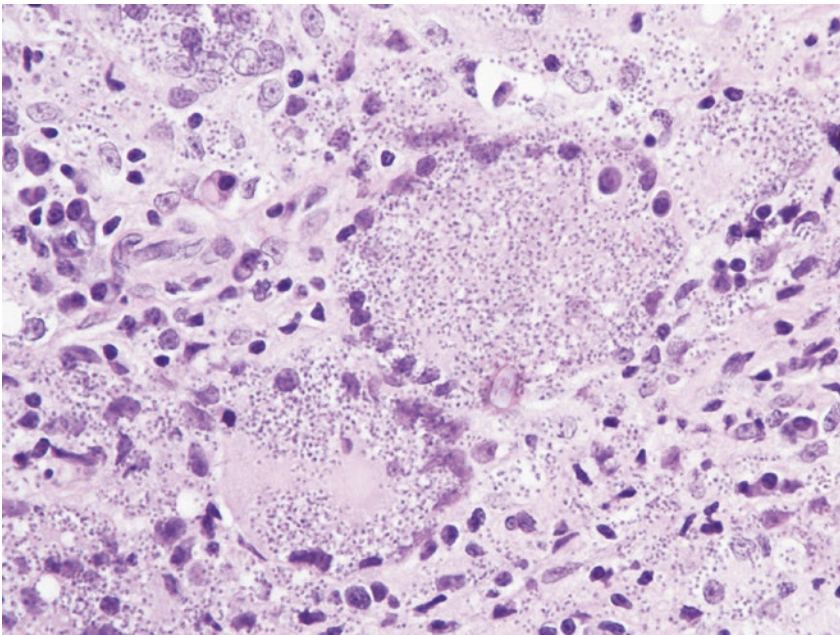


Fig. 3.210 Histology of feline leishmaniasis: pyogranulomatous inflammation with many amastigotes of *leishmania infantum* in the cytoplasm of both macrophages and giant cells

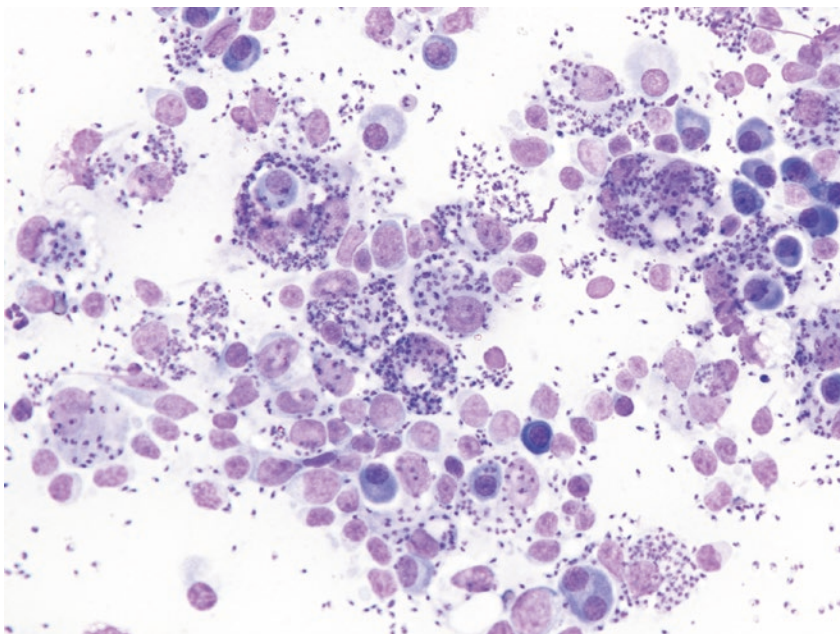


Fig. 3.211 Cytology of feline leishmaniasis: many amastigotes of *leishmania infantum*, both free and in the cytoplasm of macrophages and giant cells. Note the high number of plasma cells

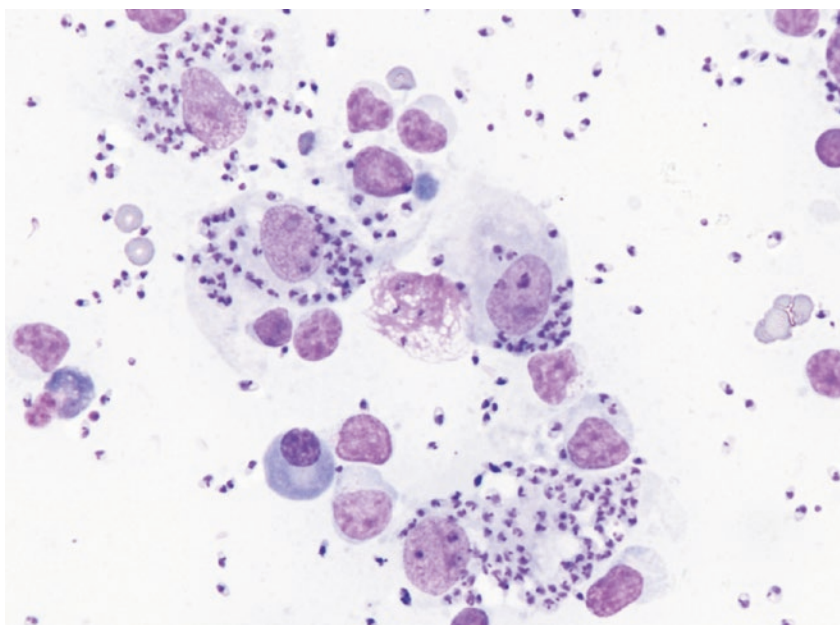


Fig. 3.212 Cytology of feline leishmaniasis: many amastigotes of *leishmania infantum*, both free and in the cytoplasm of macrophages and giant cells

Toxoplasmosis and Neosporosis

Toxoplasma gondii is a protozoa that infects all warm-blooded animals. Cats are the definitive hosts, whereas both felids and non-felids serve as intermediate hosts. Transmission of *Toxoplasma* can occur via ingestion of oocysts from feline faeces or ingested feeding infected intermediate animals. Systemic toxoplasmosis occurs in kittens or in immune-compromised adults such as feline immunodeficiency virus (FIV)- and/or feline leukaemia virus (FeLV)-positive cats. Rarely, a cutaneous localisation of the *T. gondii* tachyzoites has been reported in patients with systemic disease; skin lesions consisted of multiple cutaneous and subcutaneous nodules (Figs. 3.213 and 3.214) (Dubey and Carpenter 1993; Anfray et al. 2005; Little et al. 2005; Park et al. 2007; Kul et al. 2011; Greene 2012). Rarely, cutaneous localization of *Toxoplasma* has been reported in dogs (Hoffmann et al. 2012). *Neospora caninum* infection with cutaneous involvement has been reported in dogs (Dubey et al. 1995; La Perle et al. 2001; Perl et al. 1996; Ordeix et al. 2002; Greene 2012; Donahoe et al. 2015; Legnani et al. 2016; Mann et al. 2016). In most of these cases the lesions were secondary to immune-suppressive therapy with corticosteroids (Lloret et al. 2002). The skin lesions were mostly characterised by multiple nodules and draining tracts and with histological features of a pyogranulomatous dermatitis rich with tachyzoites (Fig. 3.215).

Cytological Findings

Cytologically, cutaneous localisation of both protozoa is characterised by neutrophilic and macrophagic inflammation with many phagocytosed tachyzoites.

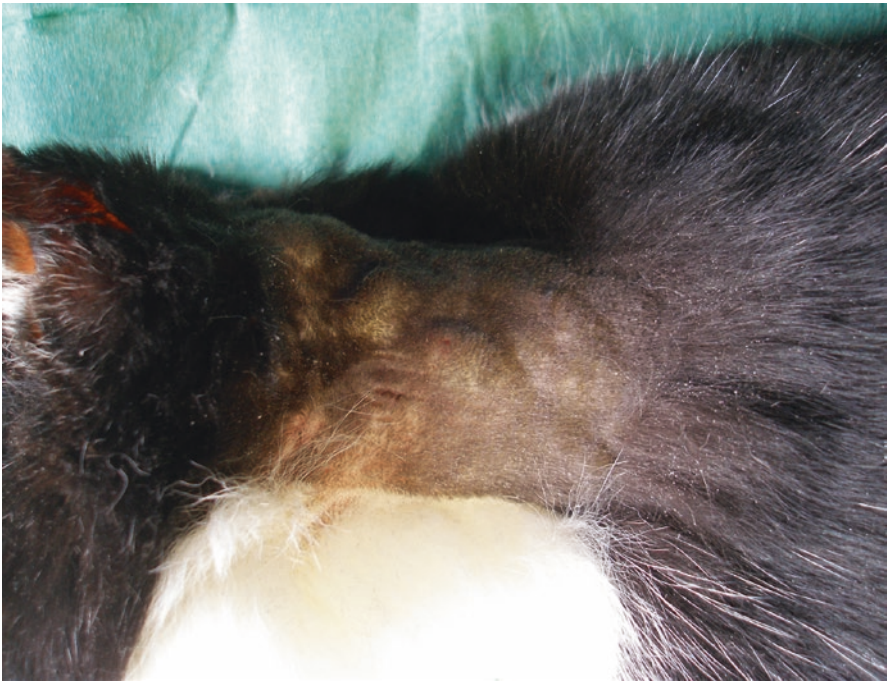


Fig. 3.213 Cutaneous toxoplasmosis: multiple subcutaneous nodules on the neck of a cat (Courtesy of Dr. C. Caporali, Italy)

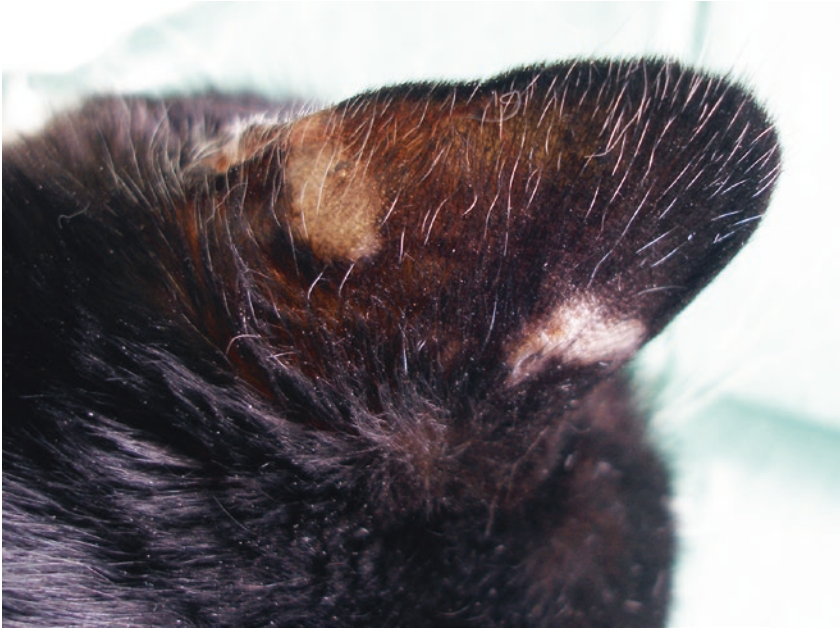


Fig. 3.214 Cutaneous toxoplasmosis: alopecic nodules on the pinna of the same cat as in Fig. 3.213 (Courtesy of Dr. C. Caporali, Italy)

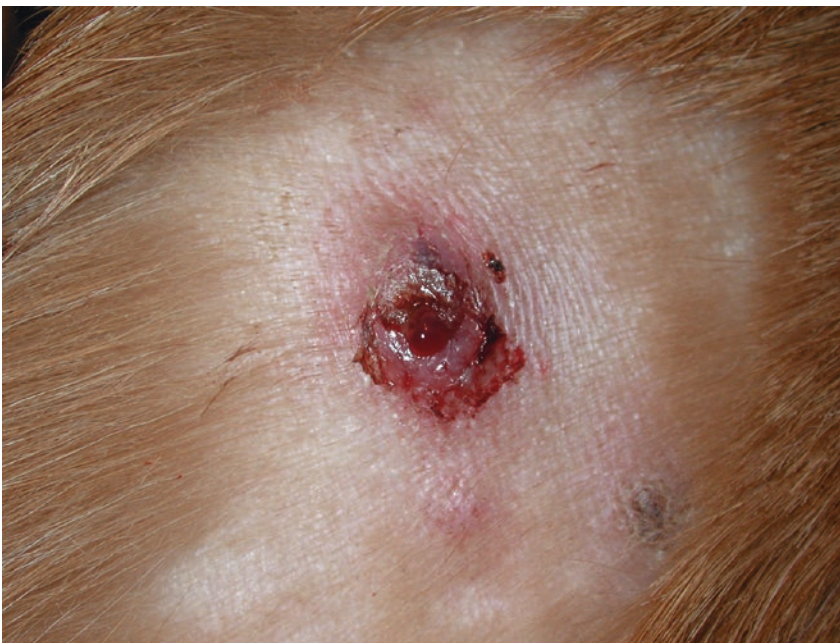

Fig. 3.215 Cutaneous neosporosis: ulcerated nodule in a dog (Courtesy of Dr. G. Zanna, Italy)

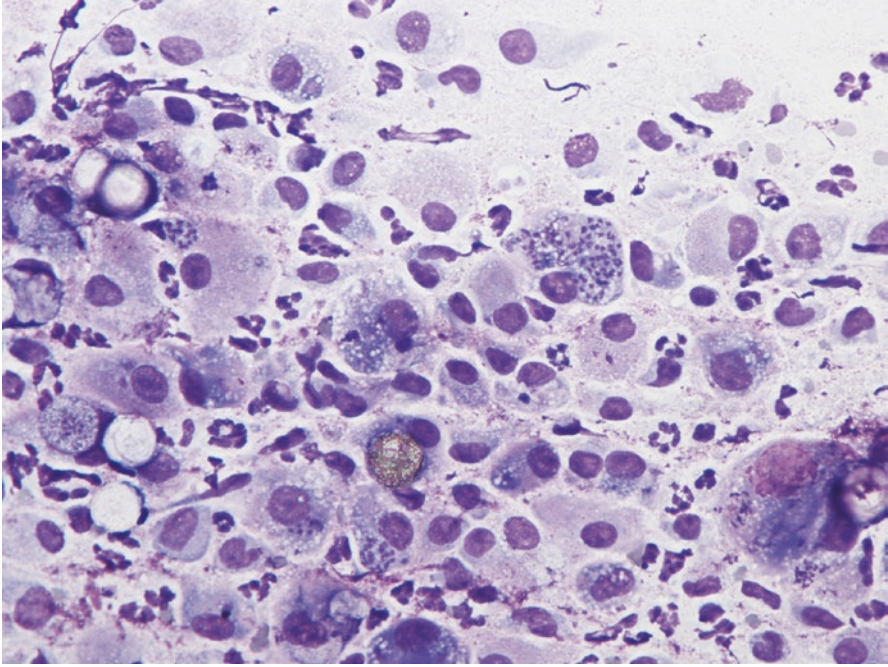


Fig. 3.216 Cytology of toxoplasmosis: pyogranulomatous inflammation. Note the presence of many protozoa in the cytoplasm of macrophages

When tachyzoites are intracytoplasmic, they are usually crowded and contained in a pseudo-cyst called a *parasitophorous vacuole*; in this phase, they can be confused with amastigotes of *Leishmania* spp. (Fig. 3.216). The characteristic silhouette of the protozoa is more recognisable when parasites are free on the background of the slides, rather than intracellular. Tachyzoites measure $6-7 \times 2-3 \mu\text{m}$, with oval nuclei and basophilic cytoplasm, and are easily identifiable when their crescent-shaped silhouette is clearly evident (Figs. 3.217, 3.218, and 3.219).

Toxoplasma gondii and *N. caninum* cannot be differentiated using cytology and should undergo serology, immunohistochemistry, electron microscopy or PCR for identification.

3.8.1.3 Worms

Dirofilariasis

Adult worms of *Dirofilaria repens* live in the subcutaneous tissues of dogs and cats, where the mature females release microfilariae (Larva 1) into the blood. Although *D. repens* seems to be responsible for a subclinical disease in dogs, a plethora of non-specific cutaneous findings (e.g. erythema, papules, nodules, alopecia and pruritus) have been reported (Hargis et al. 1999; Tarello 2002; Miller et al. 2013).

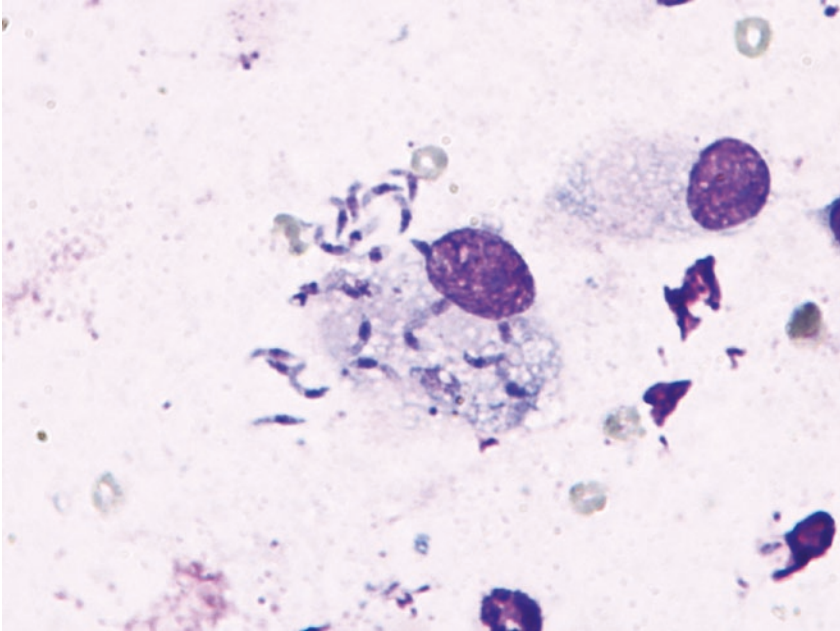


Fig. 3.217 Cytology of toxoplasmosis: many crescent-shaped *tachyzoites* of *T. gondii*, both free and in the cytoplasm of a macrophage

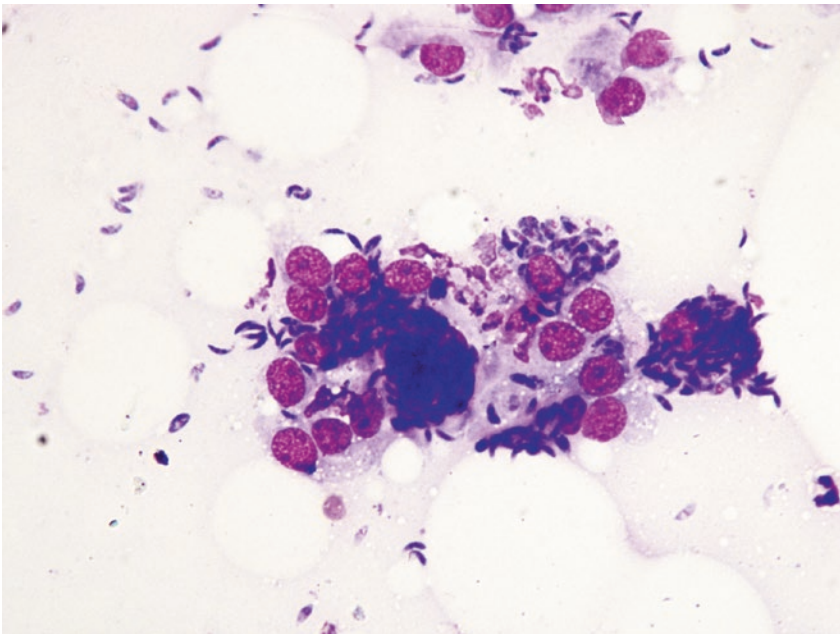


Fig. 3.218 Cytology of neosporosis: pyogranulomatous inflammation. Note the presence of many protozoa in the cytoplasm of macrophages and giant cells

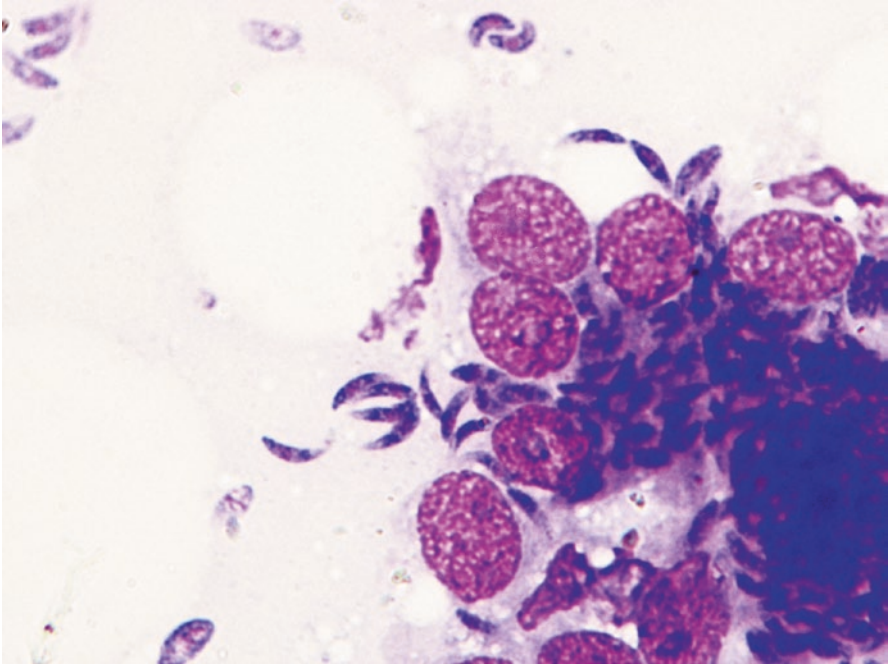


Fig. 3.219 Cytology of neosporosis: at high magnifications the typical crescent shape of *Neospora caninum* protozoa is clearly evident

However, in these reports, the presence of *D. repens* in skin lesions was not always ascertained; thus, the role of parasites in the development of lesions has only been presumed (Tarello 2002). In a recent study of 16 dogs, the only lesions observed were single or multiple subcutaneous nodules containing adult worms and microfilariae (Albanese et al. 2013). Nodules of cutaneous dirofilariasis may vary in size and are often barely perceptible on palpation as they are localised in the panniculus, the normal habitat of adult worms (Fig. 3.220).

Cytological Findings

Cytological findings vary depending upon whether the nodule is composed of only adult worms or if a secondary inflammatory reaction, following the release of larvae into the dermis, has occurred.

In the latter cases, slides are characterised by a variable amount of microfilariae immersed in an exudate composed of many slightly degenerated neutrophils and a variable number of vacuolated macrophages (Figs. 3.221 and 3.222). In some cases, few eosinophils are observed. When the adult worms entirely occupy the nodules and a secondary inflammatory reaction is not yet present, the body parts of some adult worms are inevitably collected via FNB. In these cases, small pieces of uterus containing numerous eggs and immature larvae can be observed on the slides (Figs. 3.223, 3.224, 3.225, 3.226, 3.227, and 3.228; Giori et al. 2010).

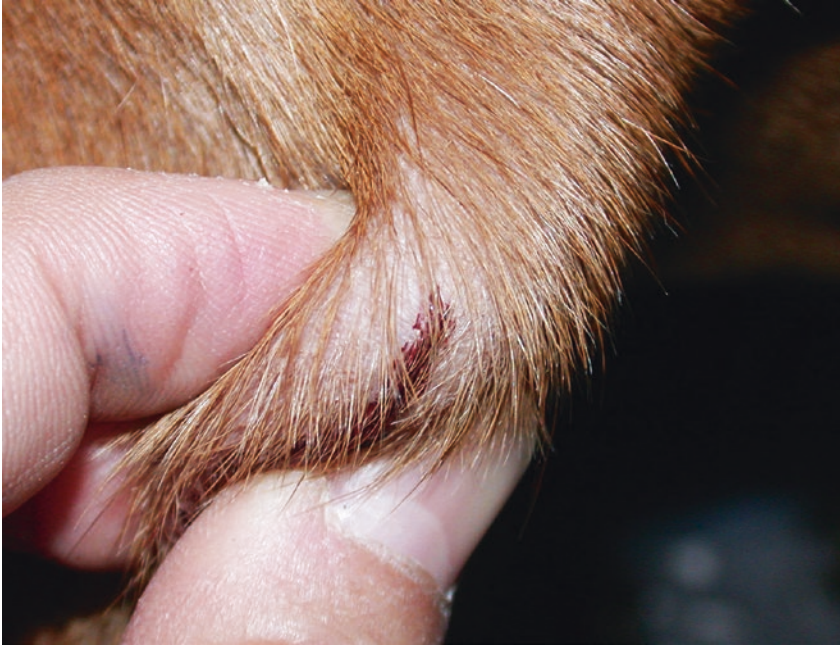

Fig. 3.220 Small subcutaneous nodule containing adult worms of *Dirofilaria repens*

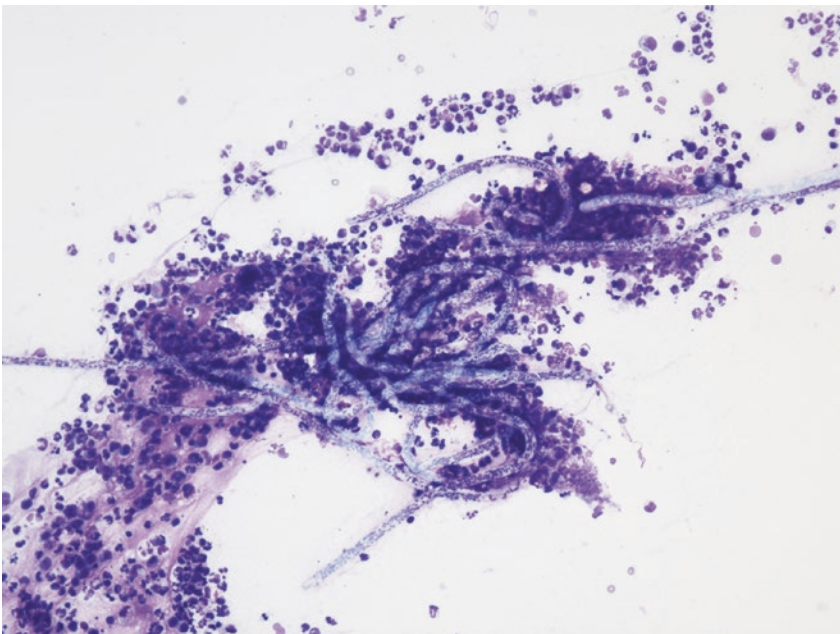


Fig. 3.221 Cytology of cutaneous dirofilariasis: many microfilariae immersed in a pyogranulomatous inflammation

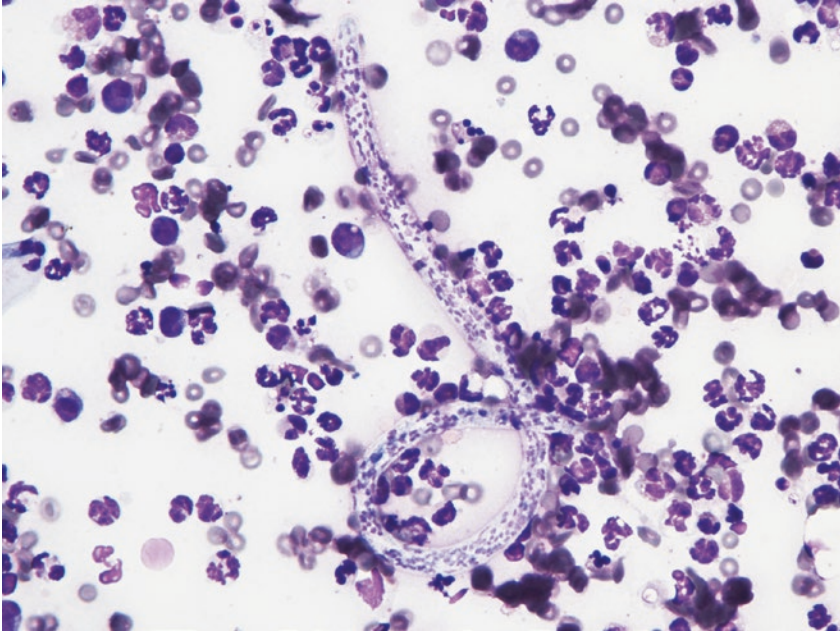


Fig. 3.222 Cytology of cutaneous dirofilariasis: immature larva of *Dirofilaria repens*

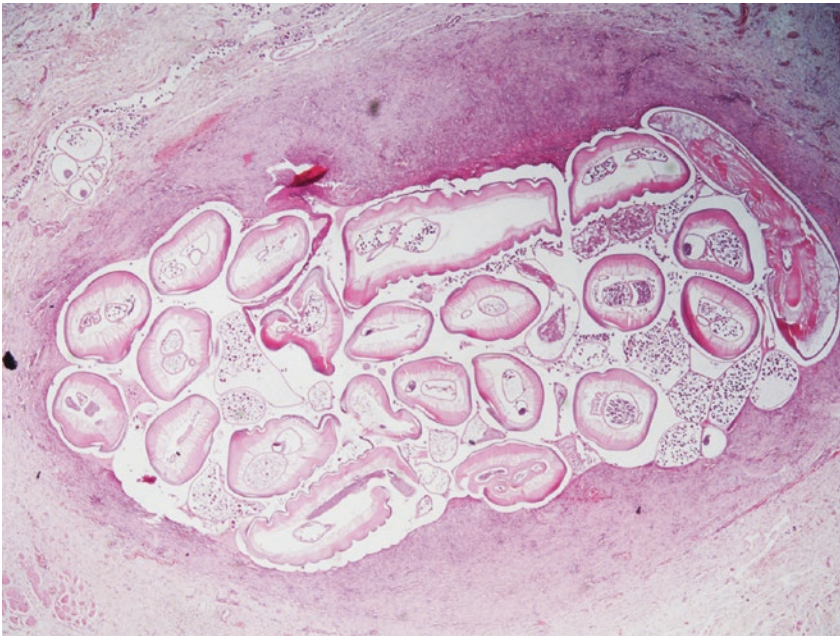

Fig. 3.223 Histology of dirofilariasis: female macrofilaria of *Dirofilaria repens* in the deep dermis, surrounded by mild inflammation

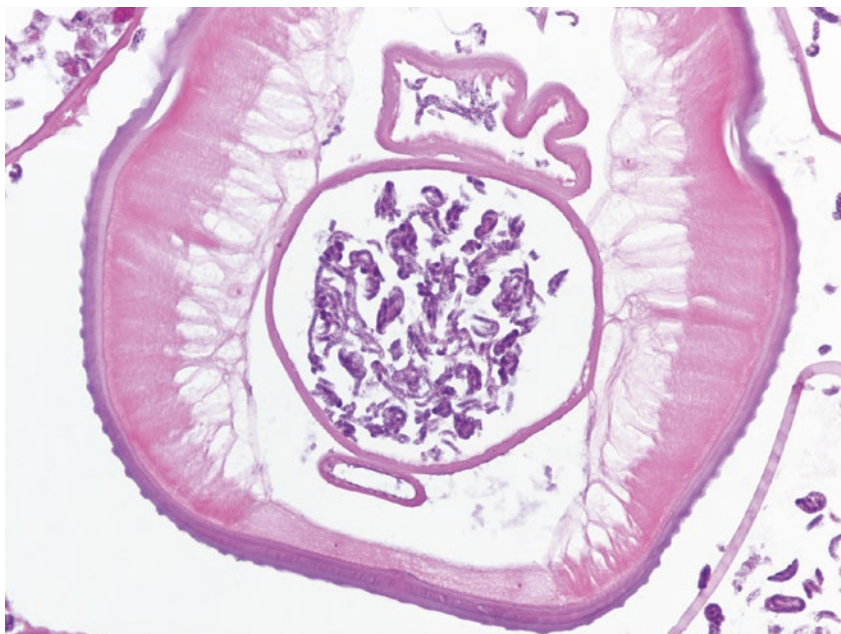


Fig. 3.224 Histology of dirofilariasis: section of a female adult worm in which the uterus, filled with immature microfilariae, is evident

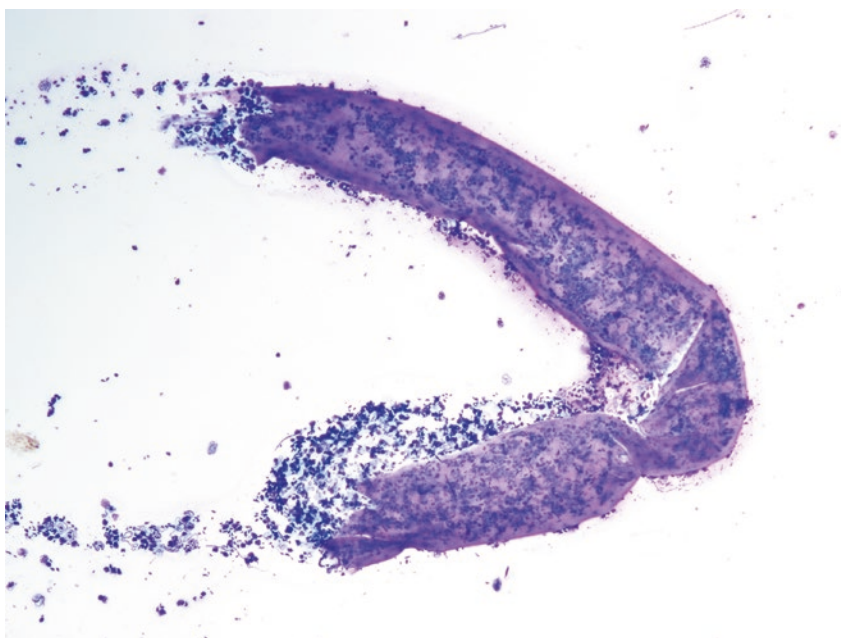


Fig. 3.225 Cytology of dirofilariasis: fragment of uterus filled with eggs and microfilariae

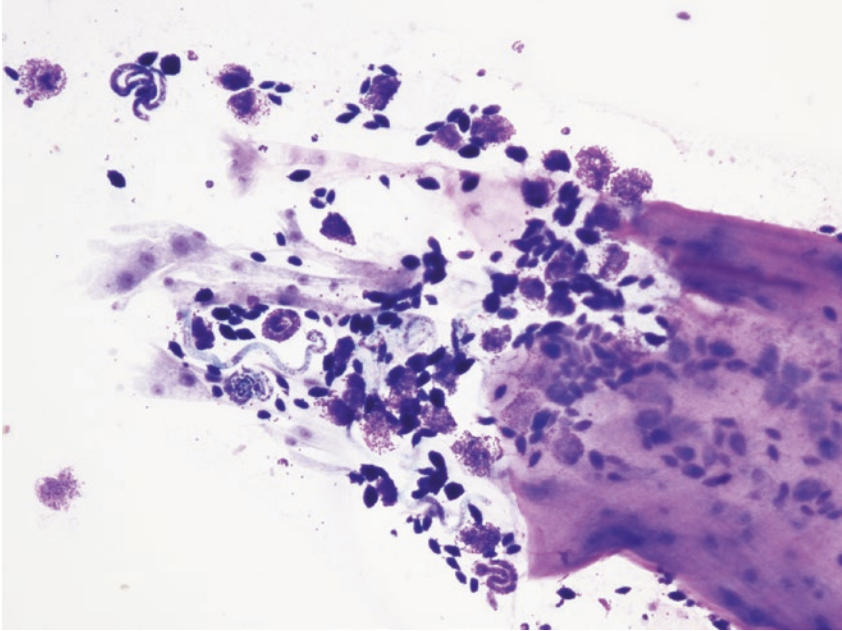


Fig. 3.226 Cytology of dirofilariasis: many eggs and larvae in the uterus

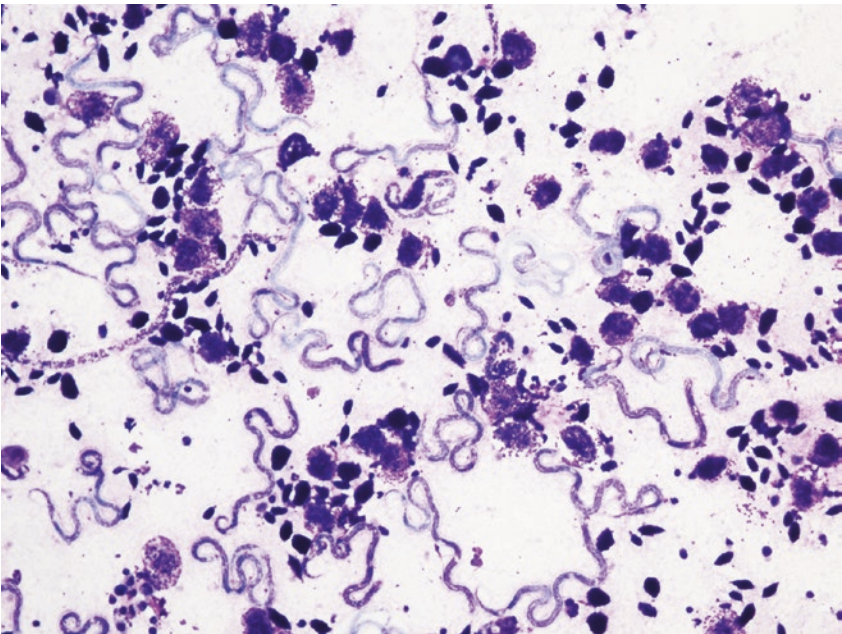


Fig. 3.227 Cytology of dirofilariasis: many immature larvae

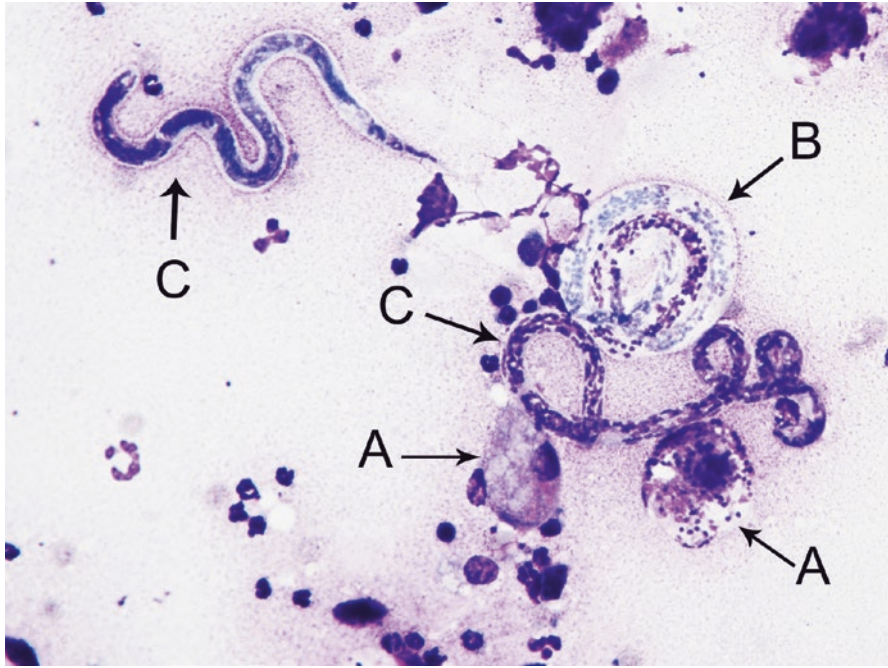


Fig. 3.228 Cytology of dirofilariasis: (A) eggs at different stages; (B) larva in to the eggshell; (C) free larvae at different stages

Clinicians should be aware that the sampling of microfilariae from a cutaneous nodule that yields a haemocontaminated specimen with no inflammatory cells must not be interpreted as a cutaneous localisation of worms; indeed, it may only indicate the presence of microfilaraemia.

3.8.1.4 Fungi

Dermatophytic Kerion

Dermatophytic kerion is a pyogranulomatous nodular disease due to the spread into the dermis of dermatophytes because of the rupture of the infected follicles. It is believed that it represents the outcome of an abnormal response of the immune system against dermatophytes, which infest hairs and, as a result of the rupture of the follicular wall, a reactive granulomatous inflammation occurs. *Kerions* are usually observed as single nodules, located mostly on the face, especially on the bridge of the nose and lips, but in many dogs they can be numerous and spread all over the body. In the early stage, the kerions are characterised by a round nodule, usually button-shaped, covered in hairs and crusted exudate, and in which multiple draining tracts that ooze purulent exudate can be present. In a few days it becomes alopecic,

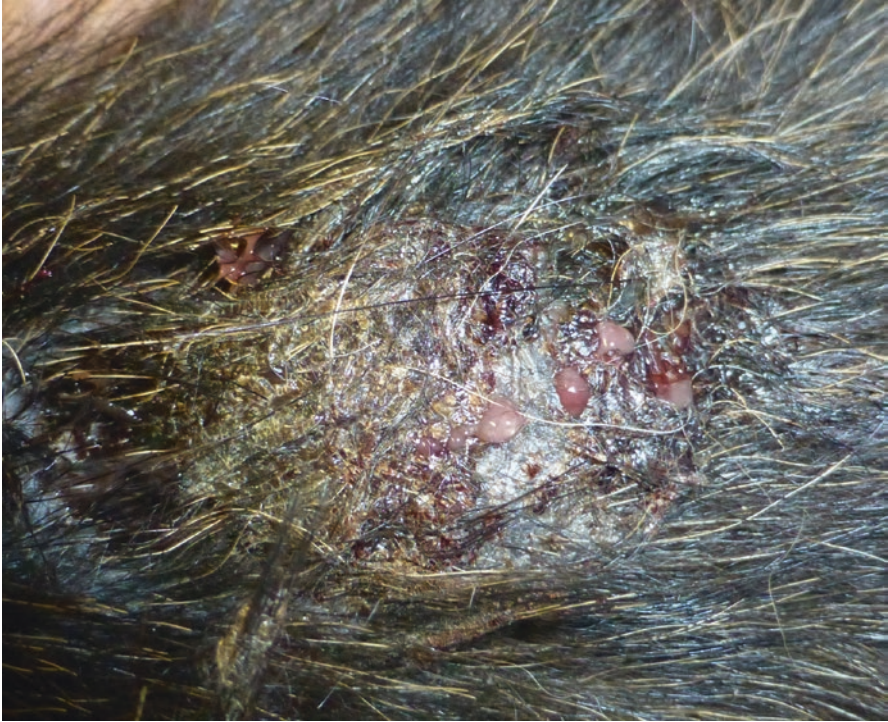

Fig. 3.229 Dermatophytic kerion: nodule covered by crusty purulent exudate discharged from fistulous tracts

with smooth to irregular surfaces on which many small draining tracts discharging a purulent exudate are often apparent (Figs. 3.229, 3.230, 3.231, and 3.232). Although some authors assert anecdotally that kerions are often caused by *M. gypsum* and *T. mentagrophytes* (Miller et al 2013), in some papers *M. canis* was the most frequently isolated dermatophyte (Koutinas et al 2003; Albanese and Caruso 2007; Cornegliani et al 2009).

Cytological Findings

The histopathology of a dermatophytic kerion is characterised by multiple pyogranulomas secondary to the breakage of the follicular wall and following the spread of infected hair shafts into the dermis (Fig. 3.233) (Gross et al 2005). Slides are usually composed of segmented neutrophils, macrophages and very few epithelioid macrophages and giant cells. In some cases a relevant number of eosinophils can be detected. In more successful specimens, it is possible to find, free or in the cytoplasm of neutrophils and macrophages, a variable number of fungal arthroconidia, which allow a rapid diagnosis of dermatophytosis. Round, oval to elongated basophilic bodies measuring 2–5 μm , surrounded by a thin clear halo, characterise the dermatophytic arthroconidia (Figs. 3.234 and 3.235). When fungal elements are scarce and not easily detectable, slides can be stained with special stains such as

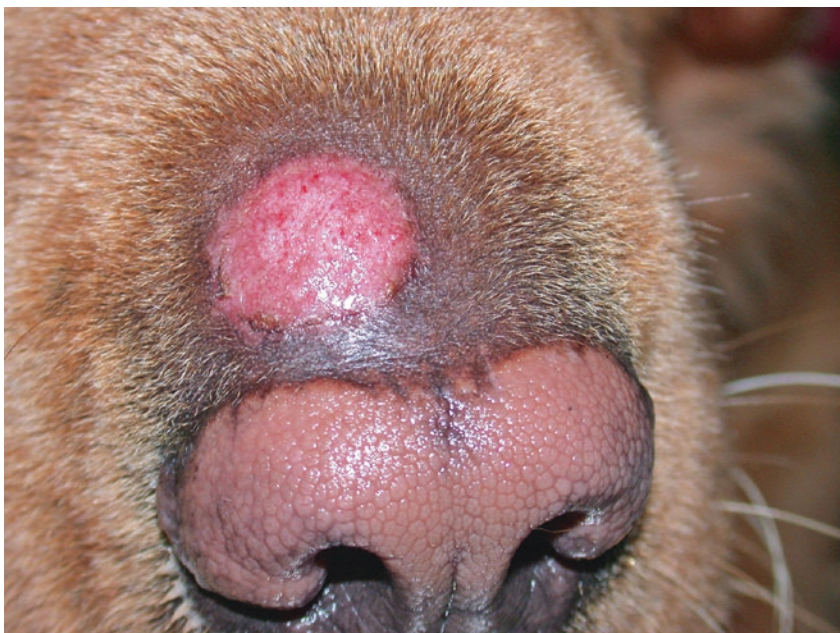

Fig. 3.230 Dermatophytic kerion: erythematous and alopecic nodule on the bridge of the nose in a dog

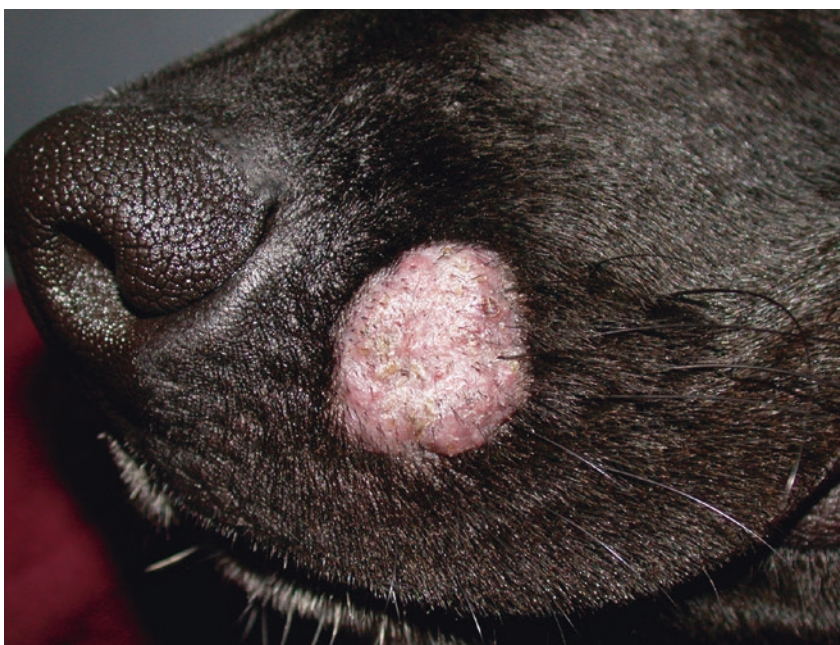


Fig. 3.231 Dermatophytic kerion: alopecic dermatophytic kerion on the muzzle

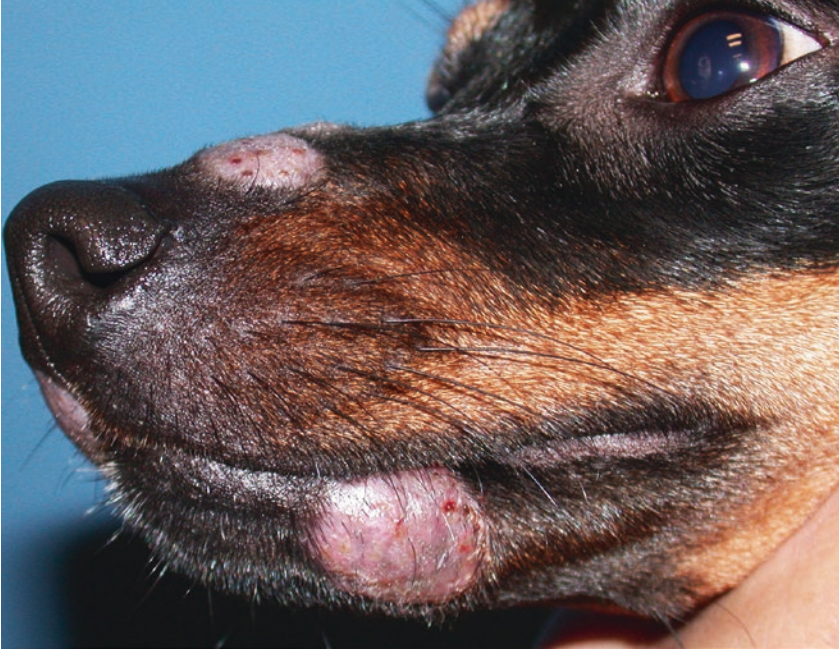

Fig. 3.232 Dermatophytic kerion: multiple alopecic nodules on the lips and eyelids of a Pinscher

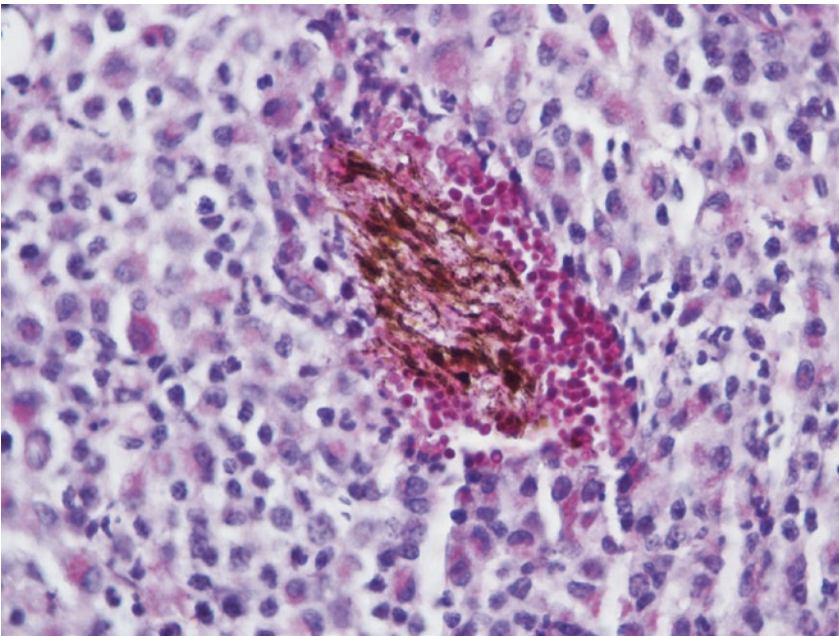


Fig. 3.233 Histology of a dermatophytic kerion: fragment of infested hair shaft surrounded by pyogranulomatous inflammation. Note the PAS-positive arthroconidia stained magenta

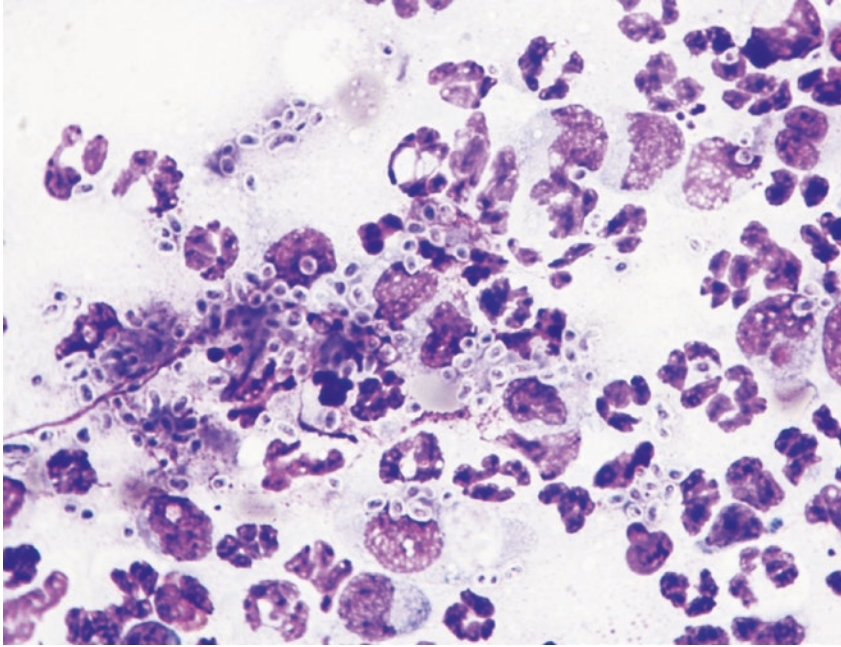


Fig. 3.234 Cytology of dermatophytic kerion: neutrophils, macrophages and many arthroconidia of *M. canis*

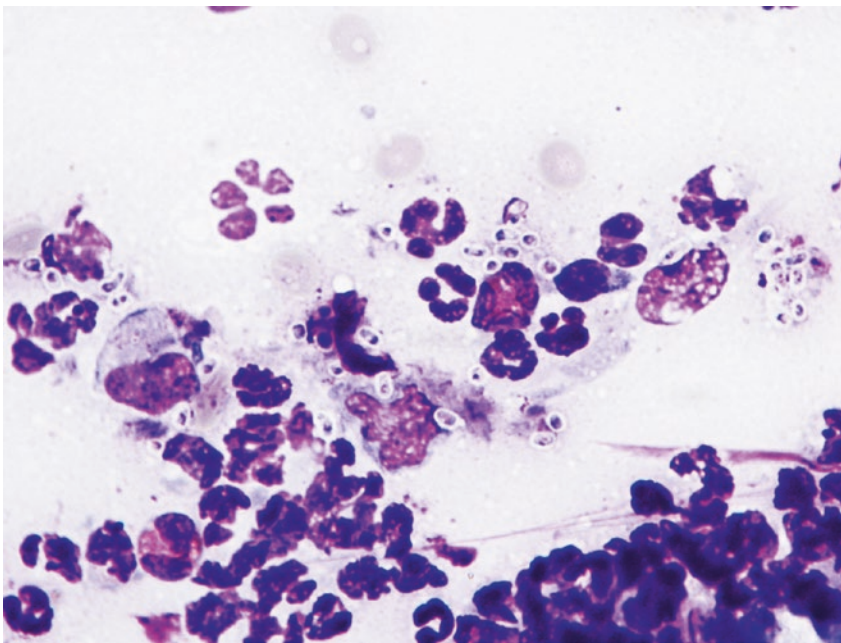


Fig. 3.235 Cytology of dermatophytic kerion: at high magnification spores are recognisable as round to oval bodies surrounded by a clear halo

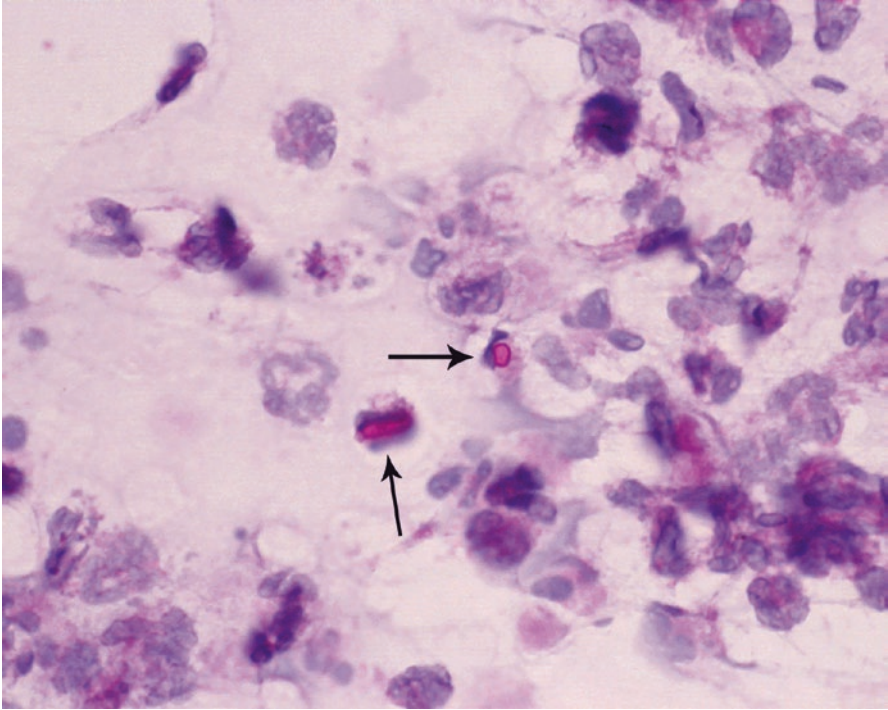


Fig. 3.236 Cytology of dermatophytic kerion (PAS staining): the magenta-stained bodies are arthroconidia of dermatophytes

PAS or Grocott's, which colour fungal bodies *magenta* or *black* respectively (Fig. 3.236). Unfortunately, PAS staining colours not only fungal bodies, but also intracytoplasmic material or those present in the background; therefore, if arthroconidia are few and dispersed in highly cellular inflammation, Grocott's staining is preferred (Fig. 3.237).

Dermatophytic Pseudomycetoma

Dermatophytic pseudomycetoma is a rare fungal nodular pyogranulomatous disease characterised by the atypical location of *Microsporium canis* in the dermis. As only true mycetomas are normally localised in the dermis and produce grains, the formation of grains in the course of dermatophytic infection is absolutely abnormal. For this reason, these deep nodular infections are defined as *dermatophytic pseudomycetoma*. To date, *M. canis* is the only species isolated in dermatophytic pseudomycetoma. They are mostly observed in cats, especially in long-haired breeds such as the Persian cat, although it has also been reported in DSH cats (Thian et al. 2008; Miller 2010; Chang et al. 2011); in contrast, it is only rarely reported in dogs (Abramo et al. 2001). Usually, as dermatophytes are keratinophilic fungi, they

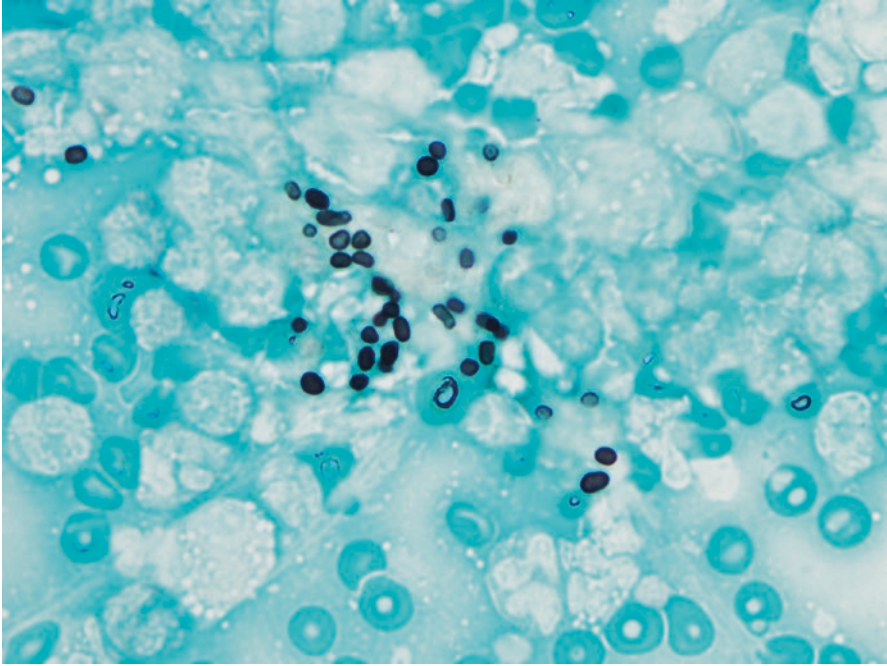


Fig. 3.237 Cytology of dermatophytic kerion (Grocott's staining): arthroconidia stained black on a green background

exclusively infect external keratin structures such as scales, hair and nails. For reasons that are still unknown, *M. canis* occasionally is localised deep in the dermis or the panniculus, causing single or multiple nodules especially on the head, trunk and tail (Fig. 3.238).

Nodules are often ulcerated and contain yellowish-white grains that represent a mixture of fungi and pyogranulomatous inflammation (Figs. 3.239 and 3.240). Histologically, lesions are characterised by a severe nodular pyogranulomatous inflammation around many fungal aggregates surrounded by a typical antigenic reaction (*Splendore–Hoeppli* reaction; Figs. 3.241, 3.242, and 3.243) (Gross et al. 2005).

Cytological Findings

Slides are characterised by a strong granulomatous inflammation with many neutrophils, macrophages, epithelioid cells and numerous giant cells arranged around grains; the latter are composed of an amorphous, from granular to coarse deep blue material that represents the *Splendore–Hoeppli* reaction observed on histopathology and that contains many fungal bodies (Figs. 3.244 and 3.245). This dark blue material, together with fungal bodies, is mainly phagocytosed from epithelioid macrophages and giant cells (Fig. 3.246). At high magnifications, it is possible to recognise, both at the periphery and inside the grains, many fungi as *short* and *distorted*

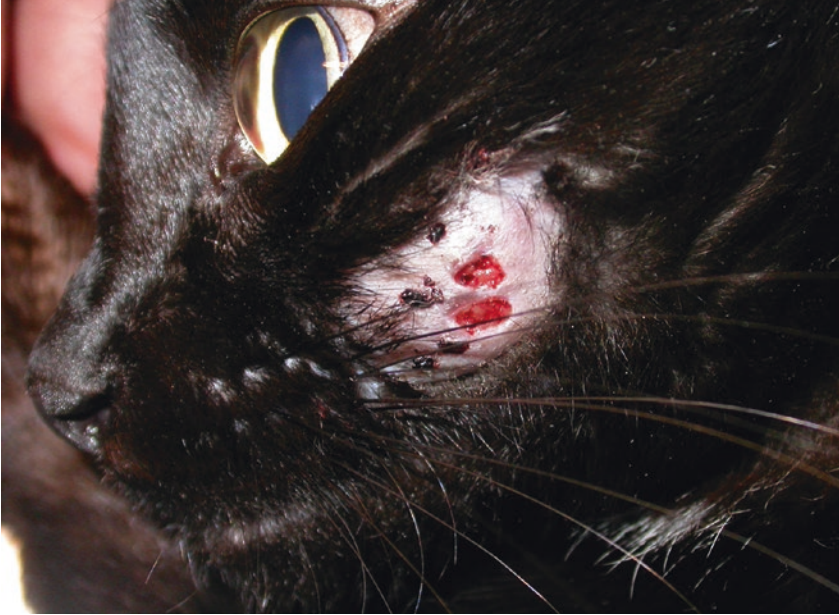

Fig. 3.238 Ulcerated plaque on the face of a cat with dermatophytic pseudomycetoma

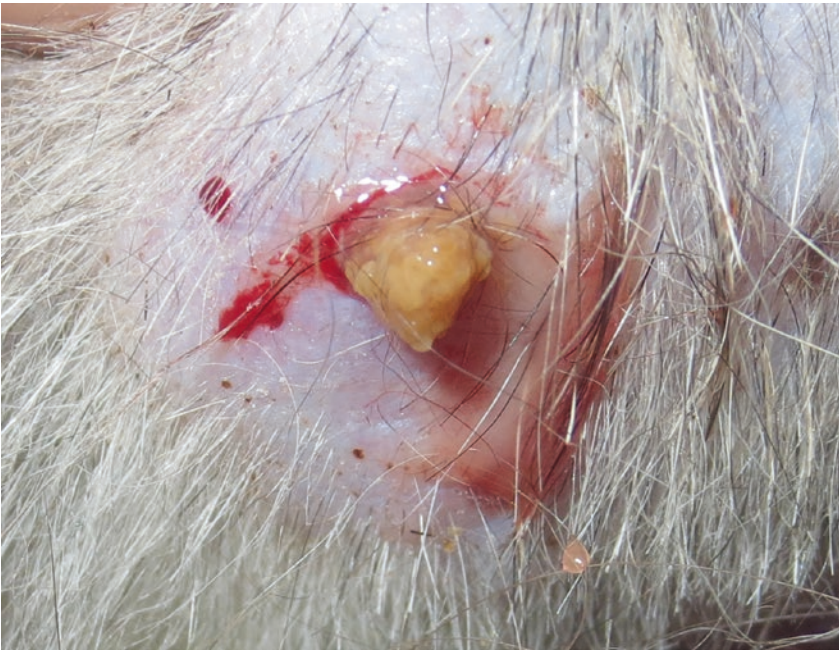

Fig. 3.239 Ulcerated nodule oozing a yellowish grainy exudate (Courtesy of Dr. F. Necci, Italy)

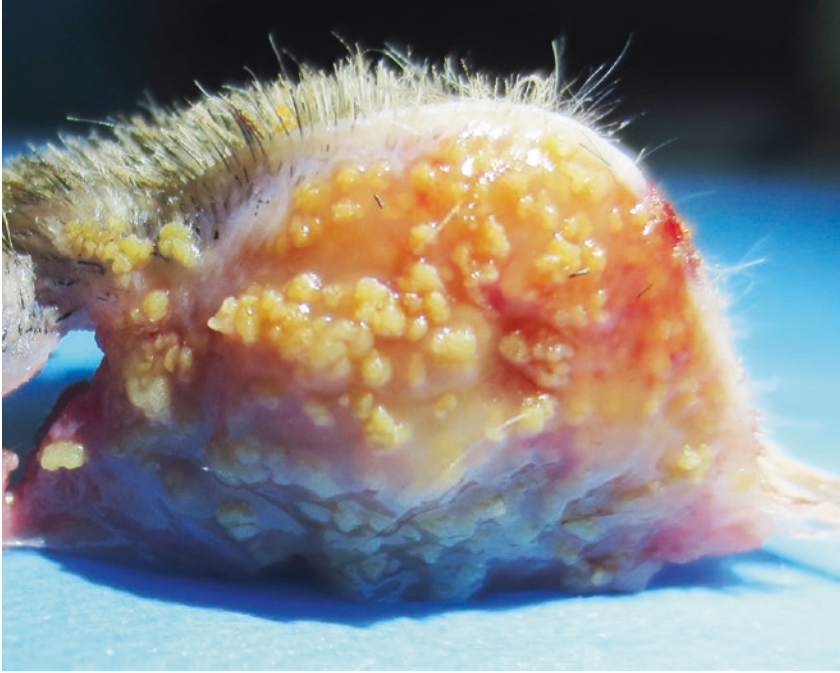


Fig. 3.240 Note the yellow grains that characterise the dermatophytic pseudomycetoma (Courtesy of Dr. F. Necci, Italy)

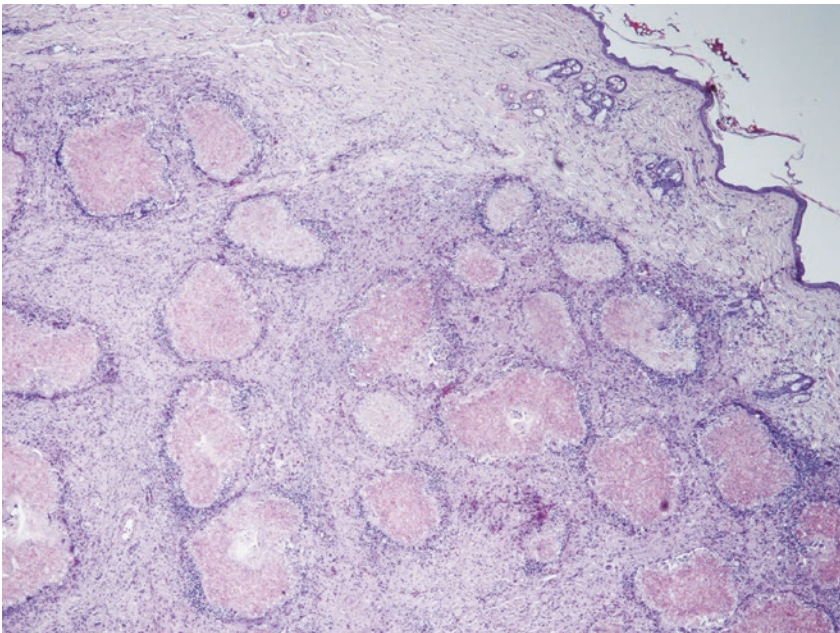


Fig. 3.241 Histology of dermatophytic pseudomycetoma: multiple granulomatous nodules

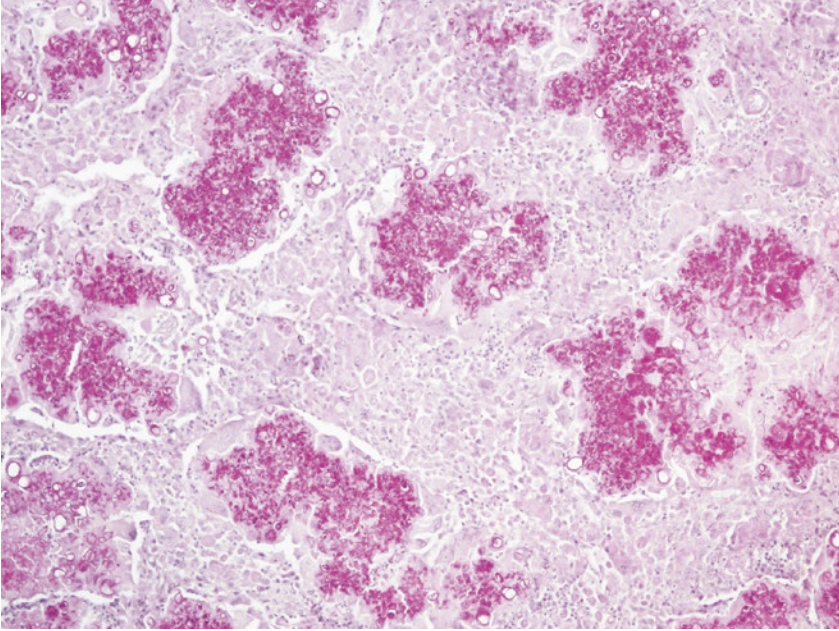


Fig. 3.242 Histology of dermatophytic pseudomycetoma (PAS staining): nodules are PAS-positive

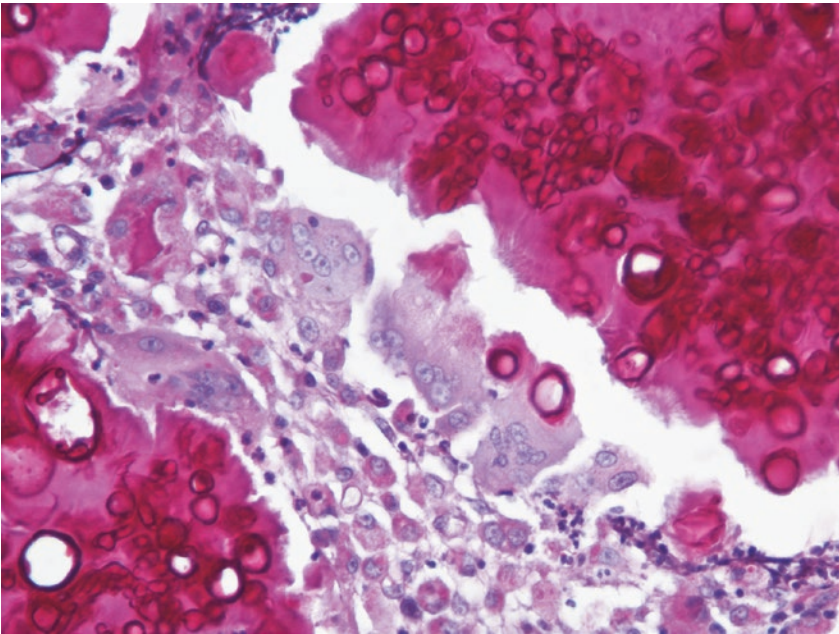


Fig. 3.243 Histology of dermatophytic pseudomycetoma: at high magnifications, the pyogranulomatous inflammation composed of numerous giant cells is clearly recognisable

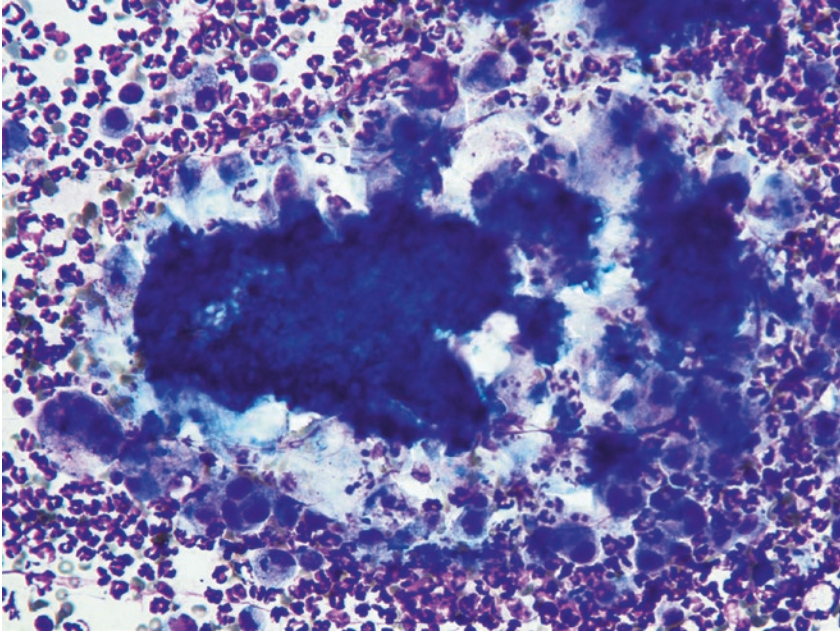


Fig. 3.244 Cytology of dermatophytic pseudomycetoma: large amorphous deeply basophilic material is surrounded by pyogranulomatous inflammation

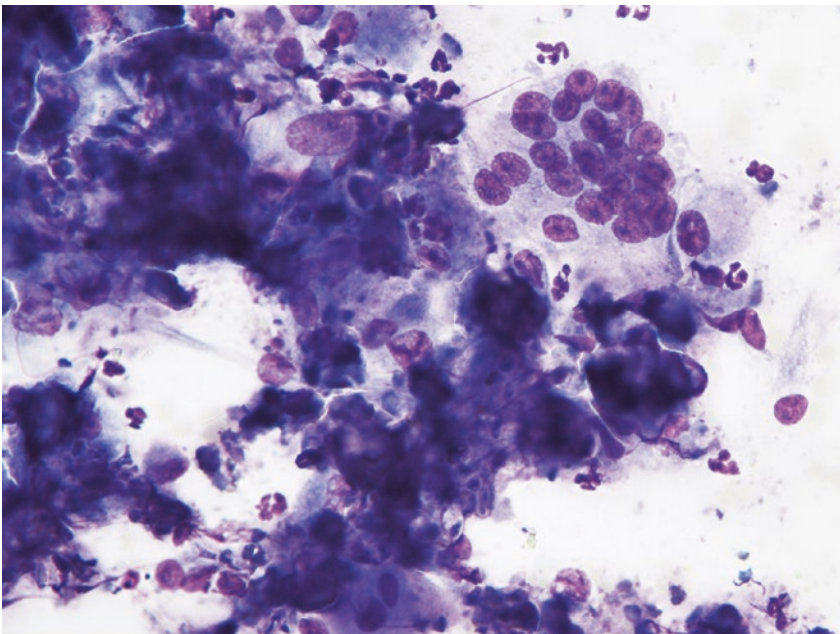


Fig. 3.245 Cytology of dermatophytic pseudomycetoma: macrophages and giant cells attacking the amorphous deep blue material

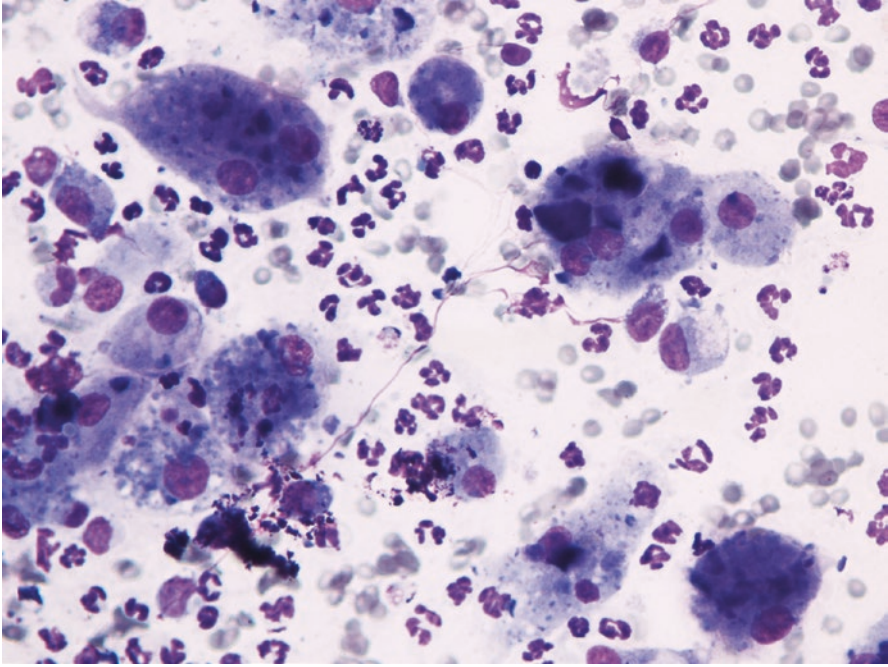


Fig. 3.246 Cytology of dermatophytic pseudomycetoma: macrophages and giant cells that phagocytose deeply basophilic acellular material

hyphae, often septated and with branches, and many *large* and *vesicular bodies*, round or oval in shape, with a thick wall morphologically similar to that of *chlamydozoospores* (Fig. 3.247). The grains must be carefully observed to detect fungi, which tend to be only partially stained using the standard rapid dyes. For better recognition of the microorganisms, PAS or Grocott's staining can be performed (Figs. 3.248 and 3.249).

Phaeohyphomycosis

Phaeohyphomycosis comprises a group of deep mycoses affecting both cats and dogs, in which fungi are localised in the dermis and/or panniculus (Gross et al. 2005; Greene 2012). This group of fungi includes many different saprophytic, free-living environmental moulds that, in poorly immunocompetent animals, can cause nodular lesions following implantation of contaminated foreign bodies (Greene 2012; Miller et al. 2013). Fungal isolates belong to different groups and the list of microorganisms that cause *phaeohyphomycosis* is increasing based on the literature; among these are reported *Alternaria alternata*, *Bipolar* spp., *Curvularis* spp., *Phialophora verrucosa*, *Fonsecaea* and many others (Fondati et al. 2001; Abramo et al. 2002; Beccati et al. 2005).

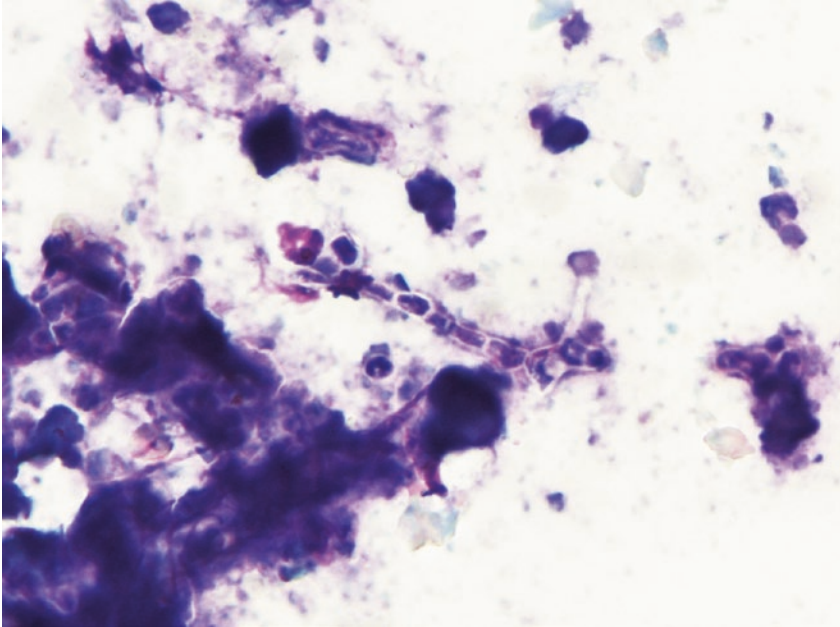


Fig. 3.247 Cytology of dermatophytic pseudomycetoma: septate hyphae are visible at the periphery of a grain

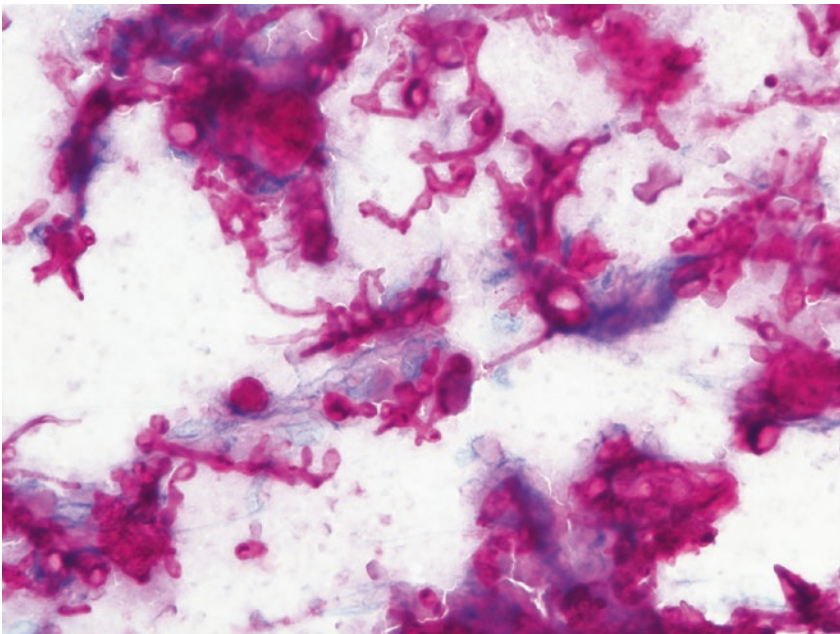


Fig. 3.248 Cytology of dermatophytic pseudomycetoma (PAS staining): septate hyphae at large round fungal bodies coloured magenta

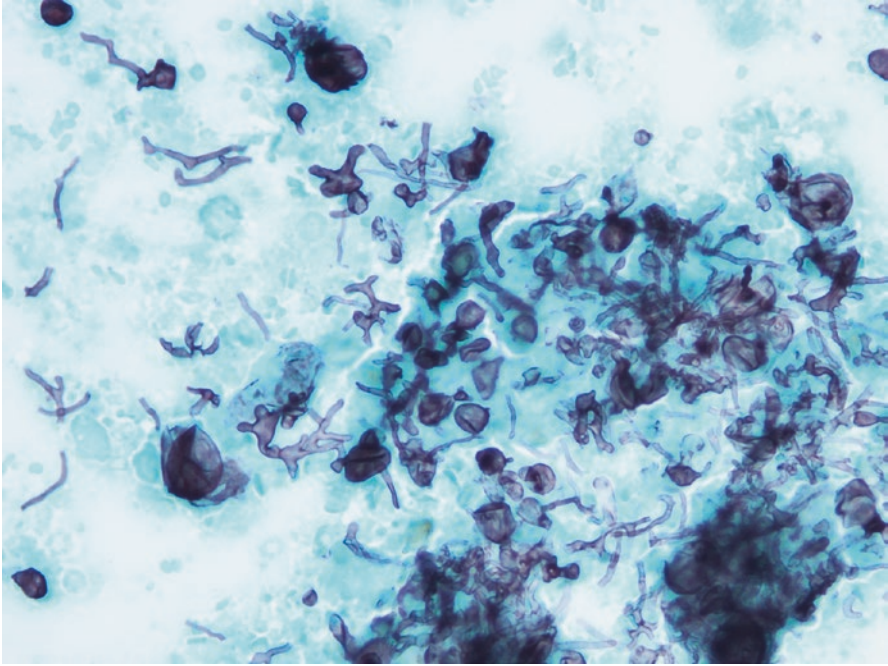


Fig. 3.249 Cytology of dermatophytic pseudomycetoma (Grocott's staining): septated hyphae and large round fungal bodies stained black

Single or multiple nodules, often ulcerated, usually located on the extremities and on the nose, rarely diffuse via lymphatics into adjacent areas without metastasis. Fungi included under the umbrella of *phaeohyphomycosis* are dematiaceous (dark) fungi, as they give rise, when cultured, to pigmented fungal colonies (Fig. 3.250). Some moulds can also be dark in nature and, in these cases, nodules on animals can have black pigmentation (Figs. 3.251 and 3.252).

Cytological Findings

Slides are characterised by a granulomatous inflammation with a high number of neutrophils, from segmented to moderately degenerate, accompanied by a variable number of epithelioid macrophages and many multinucleated giant cells; occasional lymphocytes and plasma cells can be found. Fungi are represented by septate and branched hyphae, of different lengths, together with yeast-like roundish bodies, of variable size and vesicular in appearance, with a distorted profile and a thick wall, that look similar to *chlamydo*spores. Fungi are often very numerous and large and are therefore unlikely to be observed in the cytoplasm of inflammatory cells. For this reason, many cytological samples are characterised by large fungal aggregates intermingled with inflammatory cells. In other cases, fungi are smaller in size and with short distorted hyphae (Figs. 3.253, 3.254, and 3.255). In cases in which fungi are pigmented in nature, dark fungal bodies can be also detected on cytological specimens (Fig. 3.256). In cytological specimens, fungi are usually numerous, but sometimes they are few; in these cases, special stains such as PAS and Grocott's permit their detection.

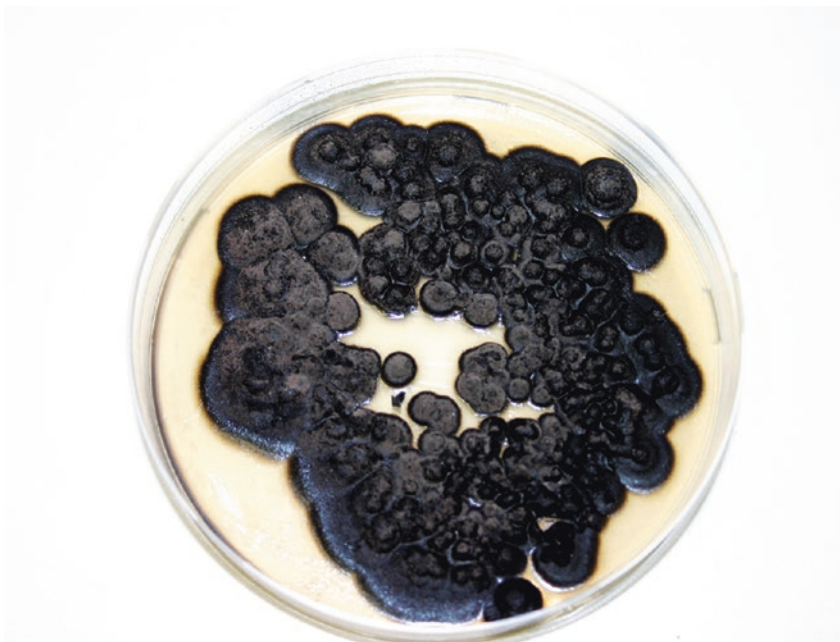

Fig. 3.250 Phaeohyphomycosis: pigmented colonies of *Phialophora verrucosa* (Courtesy of Prof. A. Peano, Italy)



Fig. 3.251 Phaeohyphomycosis: pigmented and ulcerated nodule on the nose of a cat (Courtesy of Dr. D.N. Carlotti, France)



Fig. 3.252 Pigmented neformation on the nose of a cat affected by phaeohyphomycosis (Courtesy of Dr. F. Bastelli, Italy)

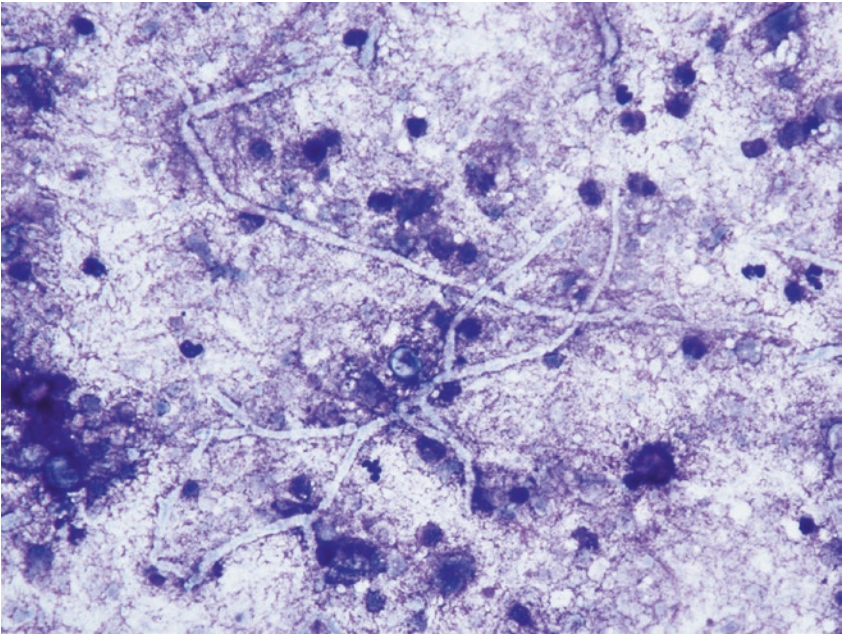


Fig. 3.253 Cytology of phaeohyphomycosis: non-pigmented, elongated and branched hyphae together with round fungal bodies are immersed in a necrotic background

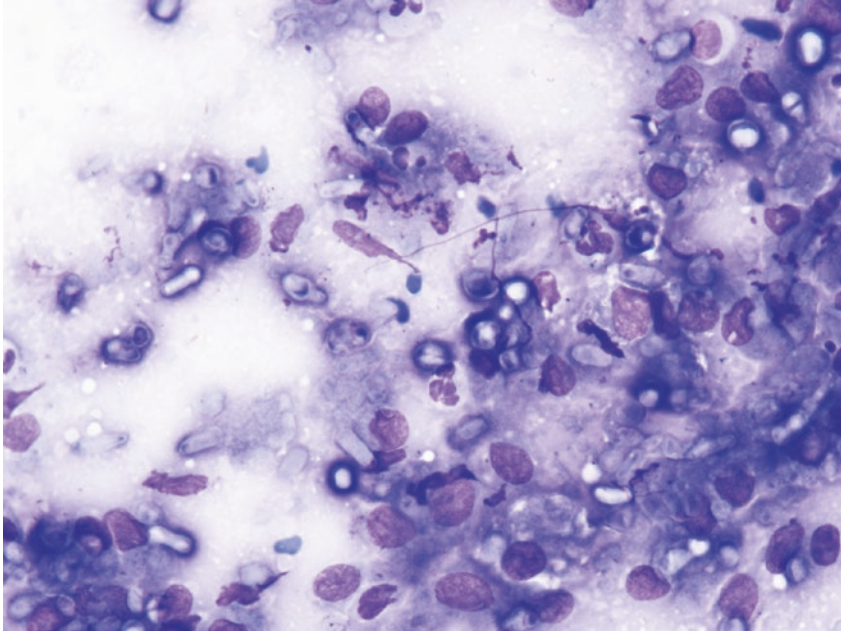


Fig. 3.254 Cytology of phaeohyphomycosis: unstained, small, roundish to oval fungal bodies are phagocytised by macrophages

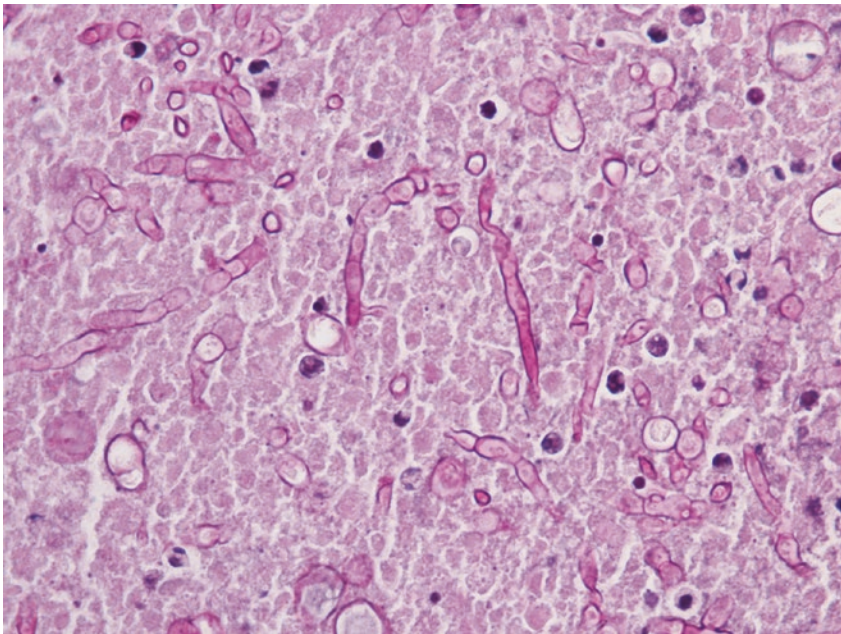


Fig. 3.255 Histology of phaeohyphomycosis (PAS staining): PAS-positive elongated and branched hyphae and round fungal bodies immersed in a necrotic background

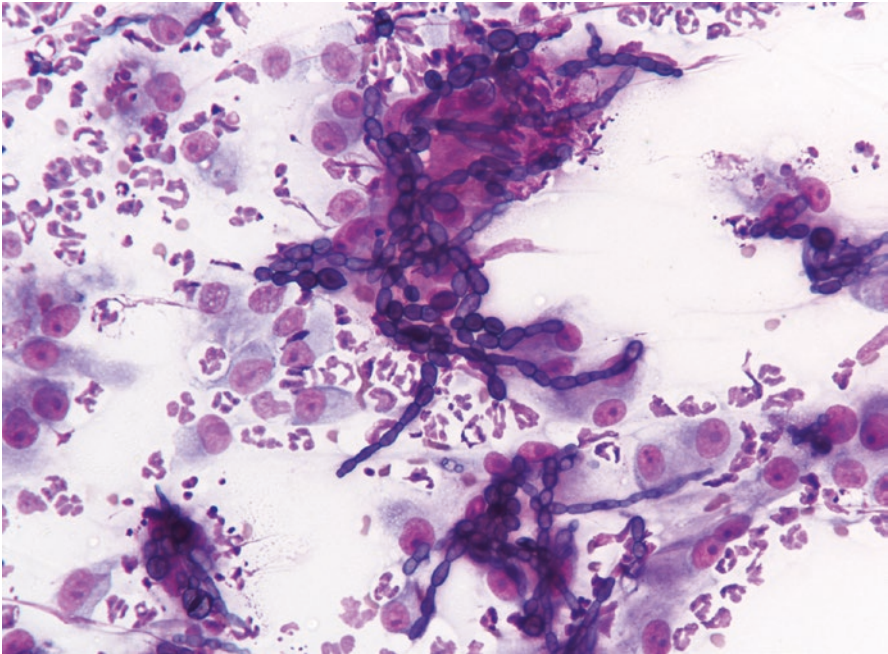


Fig. 3.256 Cytology of phaeohyphomycosis: pigmented, elongated and branched hyphae immersed in pyogranulomatous inflammation

Cryptococcosis

Cryptococcosis is the most frequently observed form of systemic mycosis in cats; the disease is rarely observed in dogs. *C. neoformans* and *C. gattii* are the most common reported species, which have different biological reservoirs that are mainly the pigeon stools for the former and the eucalypt plants for the *C. gattii*.

As *cryptococcosis* is a systemic disease, many affected patients can develop respiratory and neurological signs (Malik et al. 2001; Xiarong and Heitman 2006; Martins et al. 2011; Greene 2012; Miller et al. 2013).

In some animals, fungi can spread to the skin, causing nodular lesions that could be single or multiple, often ulcerated and located mainly on the face, head and extremities (Figs. 3.257, 3.258, and 3.259).

Cytological Findings

In cytopathological specimens fungal bodies are very numerous and usually associated with an inflammation composed mainly of macrophages and giant cells and of few neutrophils. Fungal bodies, are always very numerous and thus easily detectable in the cytoplasm of the inflammatory cells (Fig. 3.260) (Gross et al. 2005).

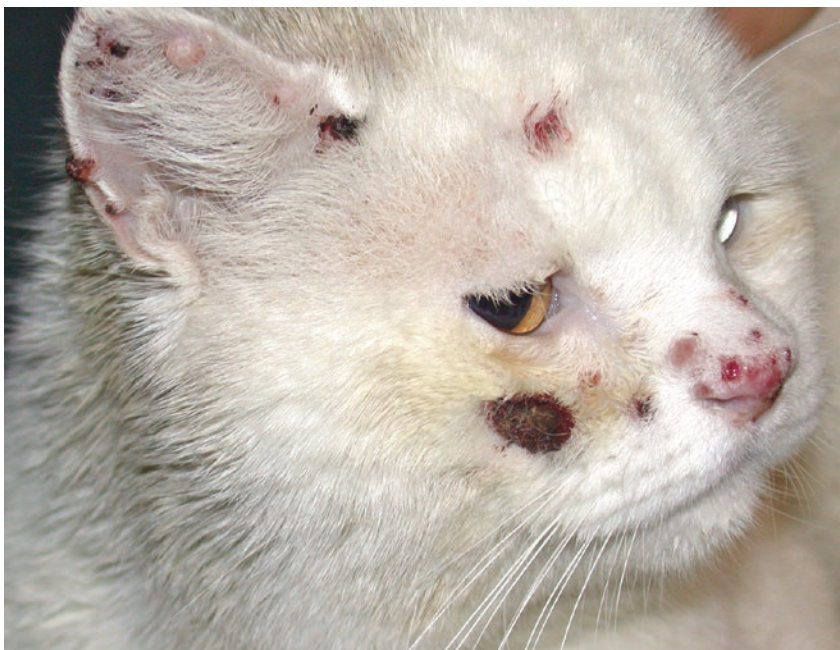

Fig. 3.257 Multiple nodules, some of them ulcerated, on the face and pinna of a cat with cutaneous localisation of cryptococcosis

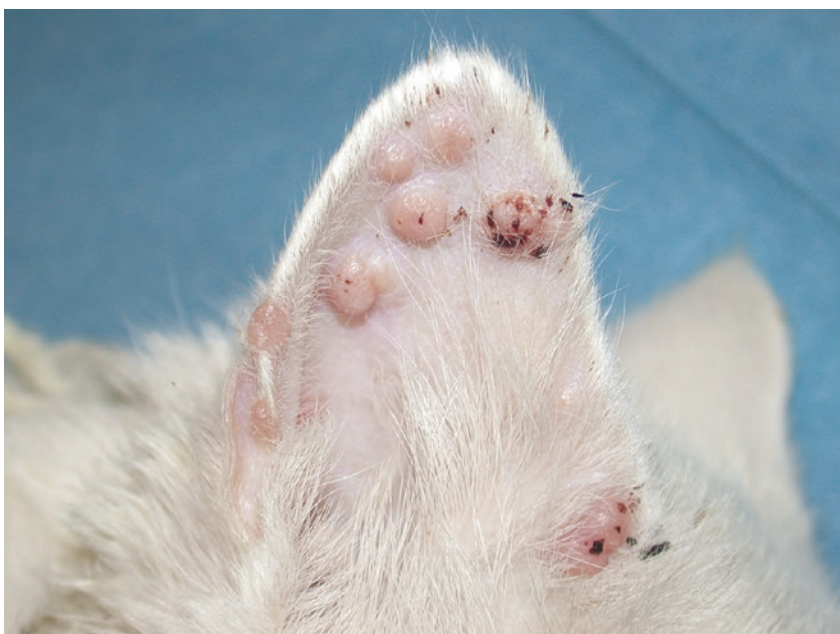

Fig. 3.258 Multiple nodules on the pinna of the same cat as in Fig. 3.257

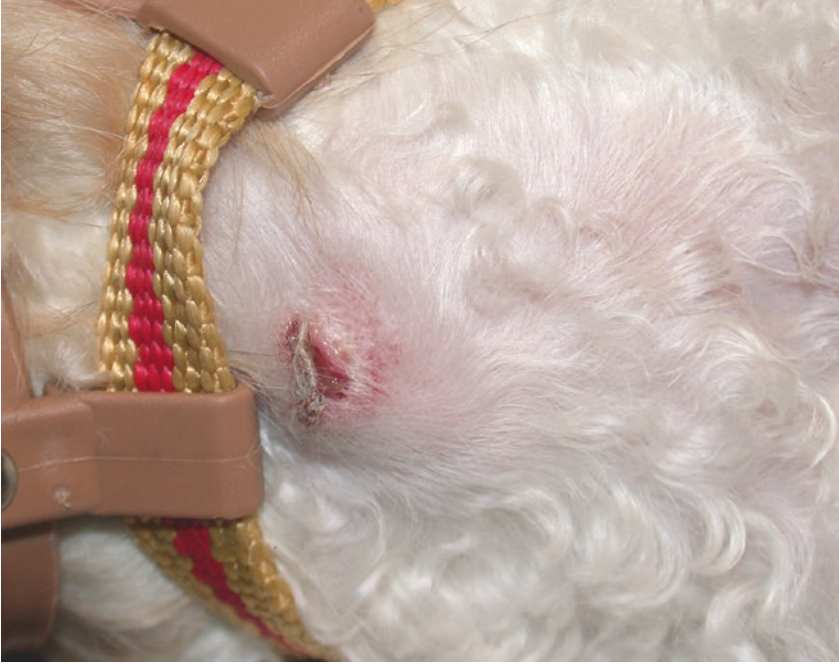

Fig. 3.259 Canine cryptococcosis: single ulcerated nodule on the neck of a Coton de Tulear

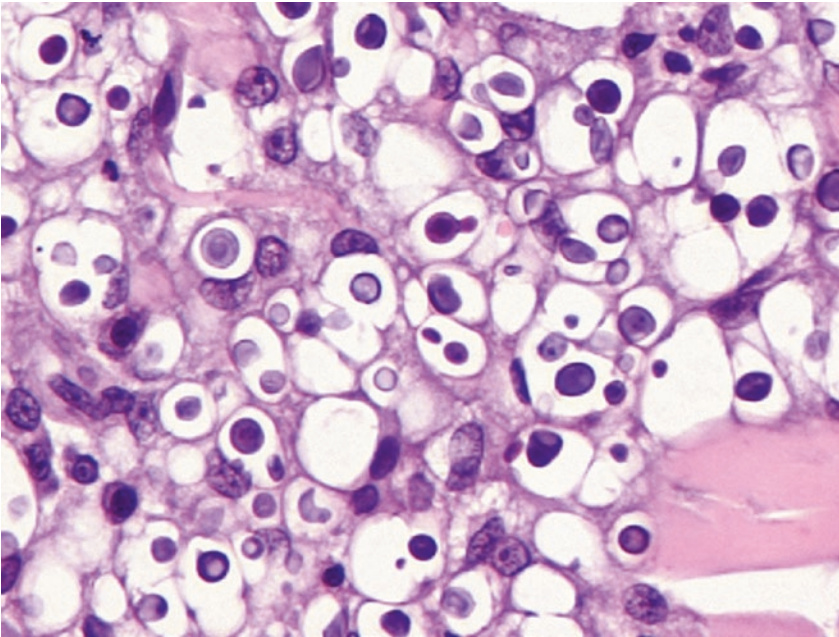


Fig. 3.260 Histology of cryptococcosis: the large achromatic capsule and the narrow-based budding characterises the cryptococcus fungus

Cryptococcus neoformans is a dimorphic fungus that assumes in the tissues a characteristic yeast-like morphology, round or oval, measuring 4–20 μm in diameter, with a round, oval or elliptical nucleus and a characteristic wide mucopolysaccharide capsule that does not stain with the common rapid Romanowsky-type dyes. This large achromatic pericellular area of variable size is a hallmark of cryptococcosis, together with typical narrow-based unipolar budding, which provides a characteristic *teardrop* appearance. Consecutive unipolar budding formations may give rise to more structures similar to short hyphae (pseudo-hyphae) (Figs. 3.261 and 3.262).

The large capsule and the typical narrow-based budding show better visibility when special stains for fungi are used, such as PAS and Grocott's (Fig. 3.263).

Another rapid staining that is very useful in highlighting the capsule is India ink. Putting some India ink drops on a just smeared specimen that is still wet obtains on a black background excellent visualisation of the unstained capsules as a large and clear halo (Fig. 3.264).

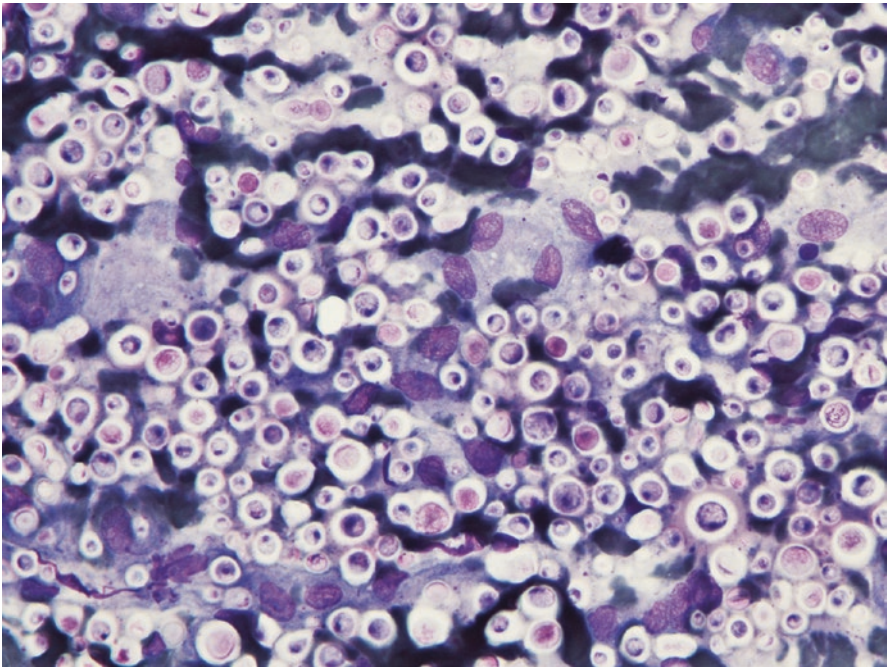


Fig. 3.261 Cytology of cryptococcosis: pyogranulomatous inflammation with many fungal bodies

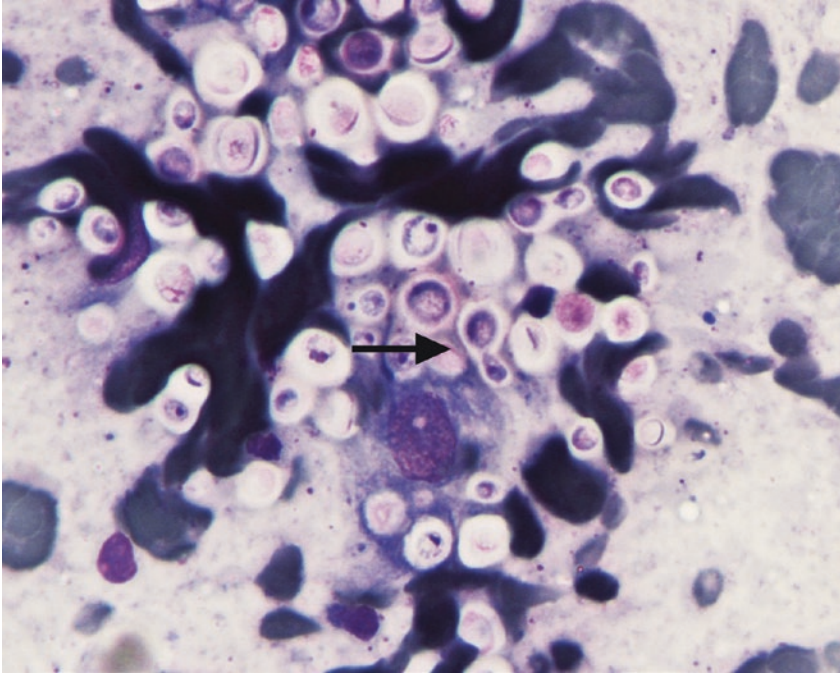


Fig. 3.262 Cytology of cryptococcosis: typical narrow-based budding (*arrow*)

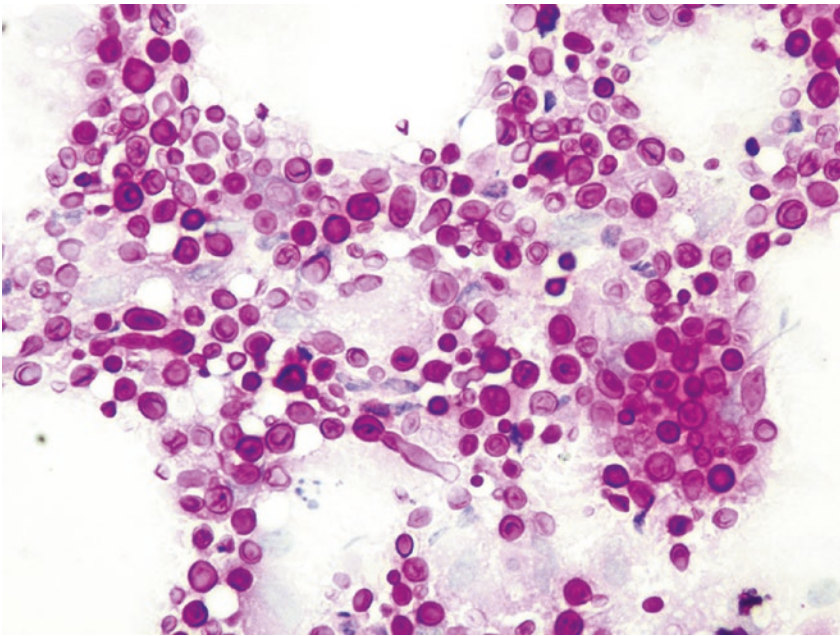


Fig. 3.263 Cytology of cryptococcosis (PAS staining): narrow-based unipolar budding and pseudo-hyphae are clearly recognisable

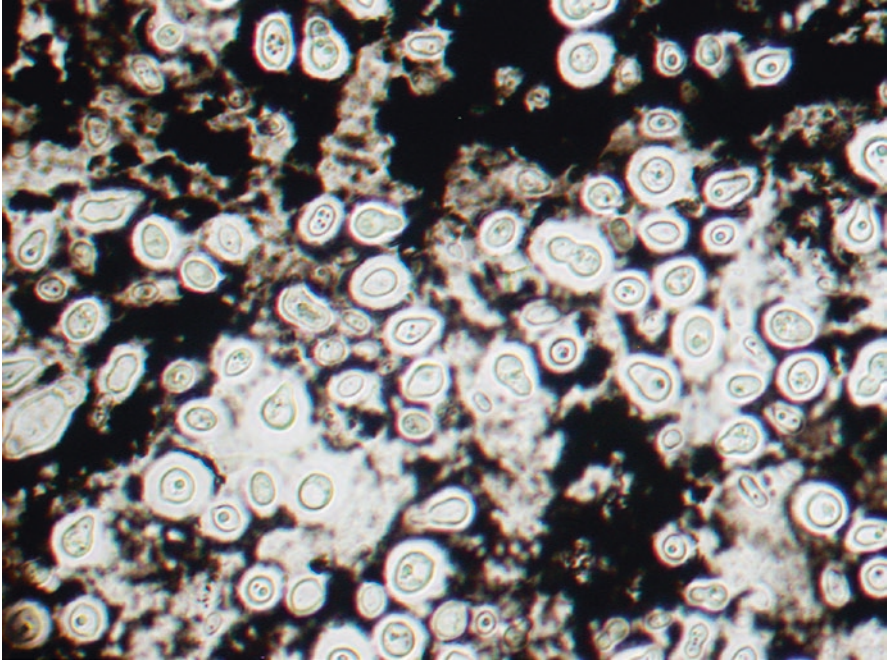


Fig. 3.264 Cytology of cryptococcosis (India ink): with India ink the capsule of *Cryptococcus* spp. is highlighted as an achromatic peripheral area

3.8.2 Sterile Diseases

This group of diseases include several disorders of different natures, which share the characteristic of not being caused by an infectious microorganism. For some diseases reported below, the pathogenesis is clear, whereas it is completely unknown for others.

Hypersensitivity diseases, immune-mediated disorders, metabolic diseases, skin deposits or accumulation of lipids or mineral salts and traumatic lesions may be the cause of the development of single or multiple nodular lesions observed in dogs and cats.

3.8.2.1 Cutaneous Mineralization

Skin mineralisation is characterised by deposits of *calcium salts* in the dermis, epidermis and rarely in the subcutaneous tissue (Scott and Buerger 1988; Gross et al. 2005; Tafti et al. 2015).

In addition to *calcinosis cutis* discussed in papular–nodular lesions and almost exclusively observed in dogs with spontaneous or iatrogenic hypercortisolism, there are other forms of mineralisation characterised by single or multiple skin nodules.

Metastatic calcinosis due to chronic kidney disease has been reported in cats, but rarely in dogs (Gross 1997). Affected animals develop hypercalcaemia by altering the Ca:P ratio, especially when the Ca:P product exceeds a value of 70. Lesions are

small, firm, irregular and often ulcerated nodules, localised to the paws and between the toes (Figs. 3.265 and 3.266) (Bertazzolo et al 2003). *Dystrophic calcinosis* follows traumatic causes in which the *calcium* deposit occurs in damaged tissue as is thought should happen in *calcinosis circumscripta*. Finally, in *idiopathic cutaneous calcinosis*, skin nodules are reported in patients with no history of trauma and no hypercalcaemia.

Calcinosis circumscripta is a form of calcinosis clinically characterised by a single nodule of varying size, mainly observed on the pressure points or digits, probably as these are skin areas more prone to trauma (Doerr et al. 2013; Gross et al. 2005). Young German shepherds and Rottweilers seem to be over-represented, but lesions can develop in any breed (Figs. 3.267 and 3.268).

A clinical feature that suggests the presence of mineral salts in a skin nodule is the characteristic crunching sensation that the operator can feel following the passage of the needle into the mineralised tissue during the sampling. Furthermore, another macroscopic indicator of the mineral composition of a nodule is the typical whitish and *chalk-like* aspect of the collected material when smeared onto a slide (Fig. 3.269).

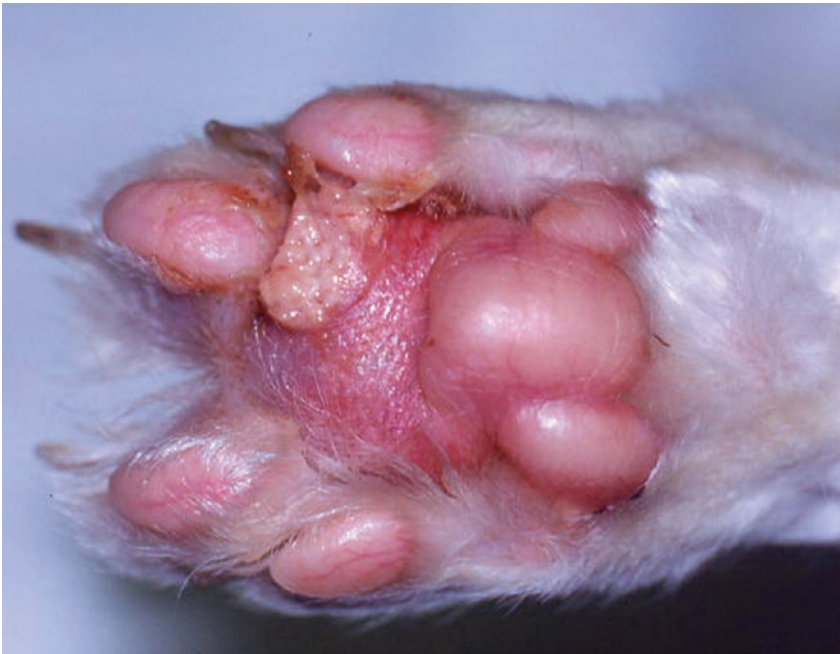

Fig. 3.265 Interdigital swelling with a calcified nodule in a cat with renal chronic disease (Courtesy of Dr. W. Bertazzolo, Italy)

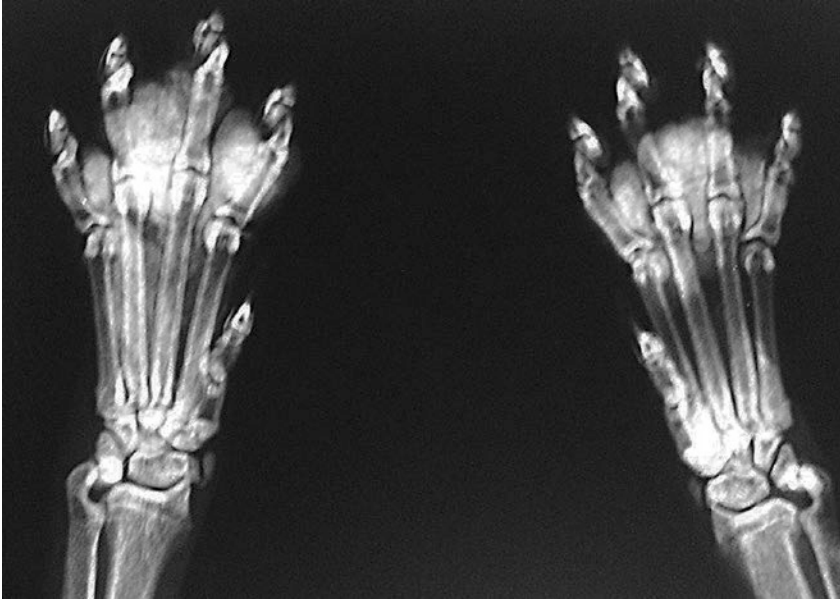

Fig. 3.266 Radiography of the paws in which multiple calcified interdigital areas are observed (Courtesy of Dr. E. Antoniazzi, Italy)

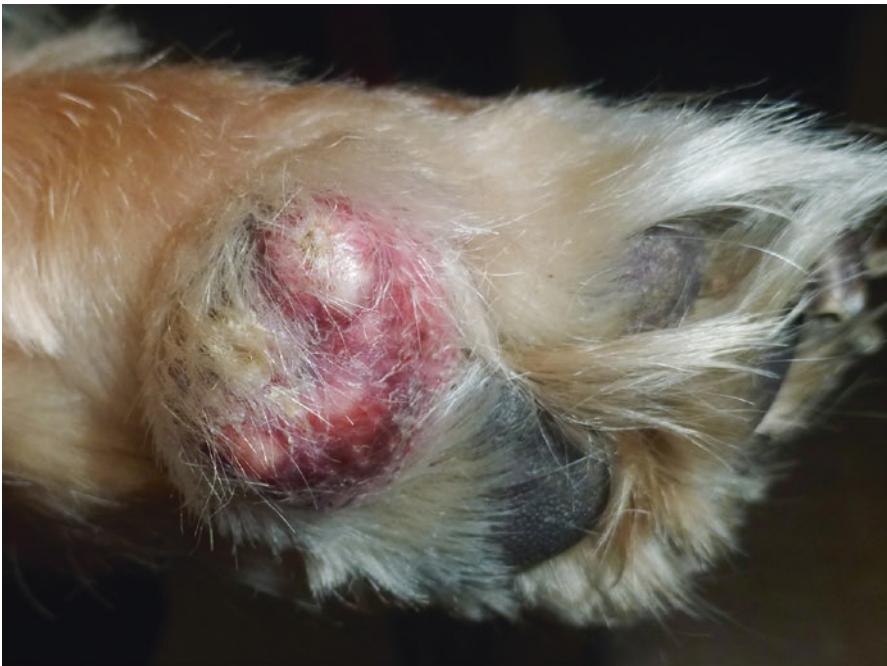

Fig. 3.267 Multiple nodules on the paw of a WHWT with *calcinosis circumscripta*

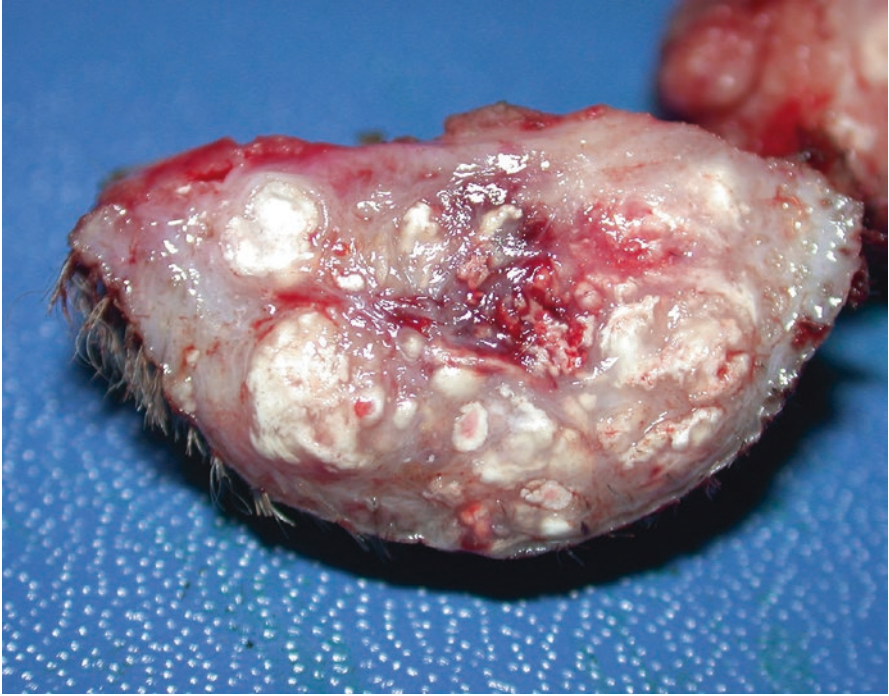

Fig. 3.268 *Calcinosis circumscripta*: multiple areas of mineralisation

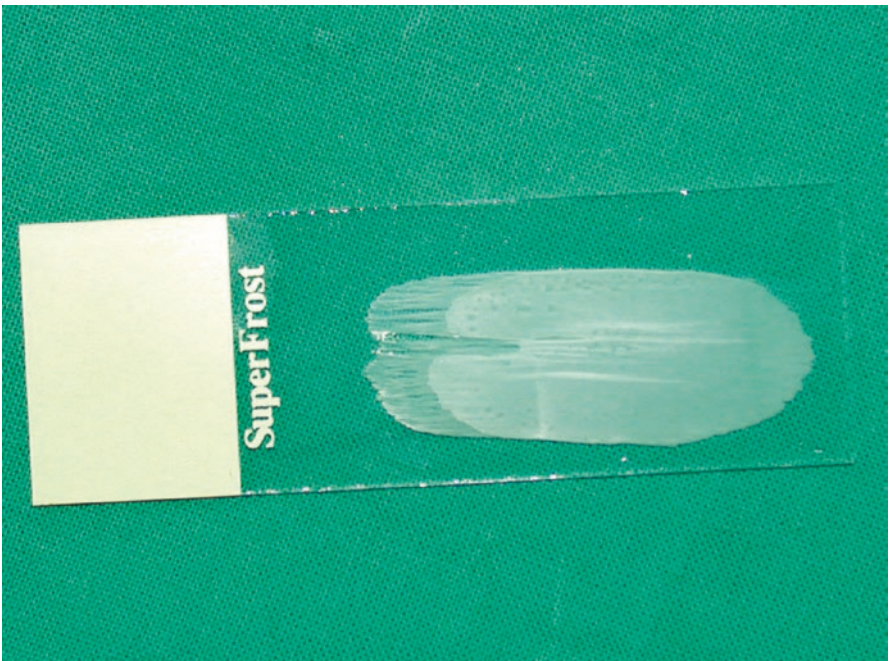


Fig. 3.269 Chalk-like aspect of the material collected from a mineralised nodule

Cytological Findings

Calcium salts are cytologically characterised by amorphous, punctiform, grainy, rhomboidal or needle-like acellular material, which stains violet to pale blue, even though, in many cases, it is transparent (Fig. 3.270). *Calcium* acts as a true foreign body; thus, slides from *calcinosis circumscripta* or from other calcified lesions can demonstrate pyogranulomatous inflammation with macrophages and multinucleated giant cells attacking fragments of mineral salts (Figs. 3.271, 3.272, and 3.273).

The composition of *calcium* in mineralised tissue can be identified using Von Kossa staining, which colours black the areas in which *calcium* salts were present (Fig. 3.274).

3.8.2.2 Eosinophilic Granuloma and Eosinophilic Plaque

In cats, *eosinophilic granuloma* (EG), *eosinophilic plaque* (EP) and *indolent ulcer* (IU) are grouped into the so-called *eosinophilic granuloma complex* (EGC). As these lesions show marked differences on clinical aspects and histopathological findings, the definition of CGE is widely considered obsolete and many dermatologists prefer to use the more generic term *feline eosinophilic dermatitis* (Fondati et al. 2001; Miller et al. 2013). The only aspect shared by these lesions is the presence of an eosinophilic infiltrate (Gross et al. 2005).

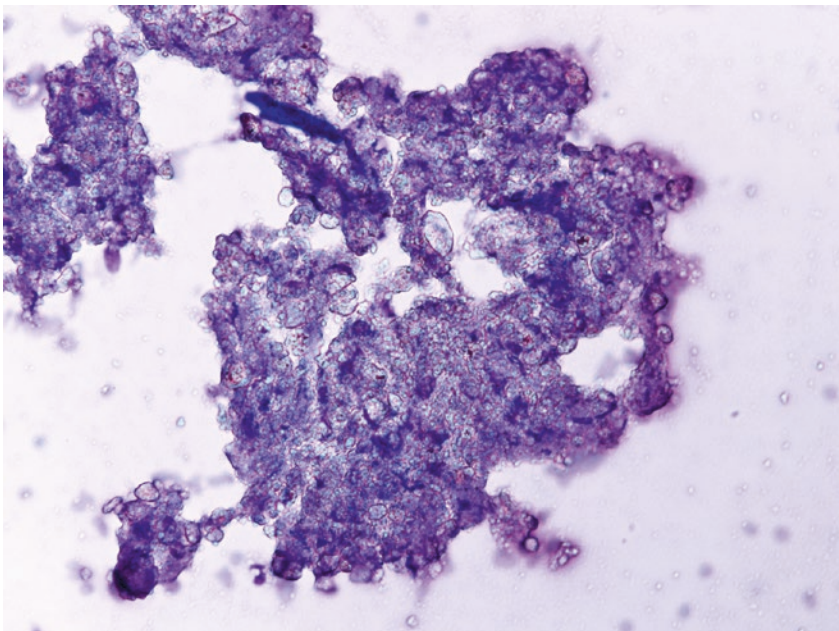


Fig. 3.270 Cytology of *calcinosis circumscripta*: amorphous, acellular and granular material representing *calcium* salts

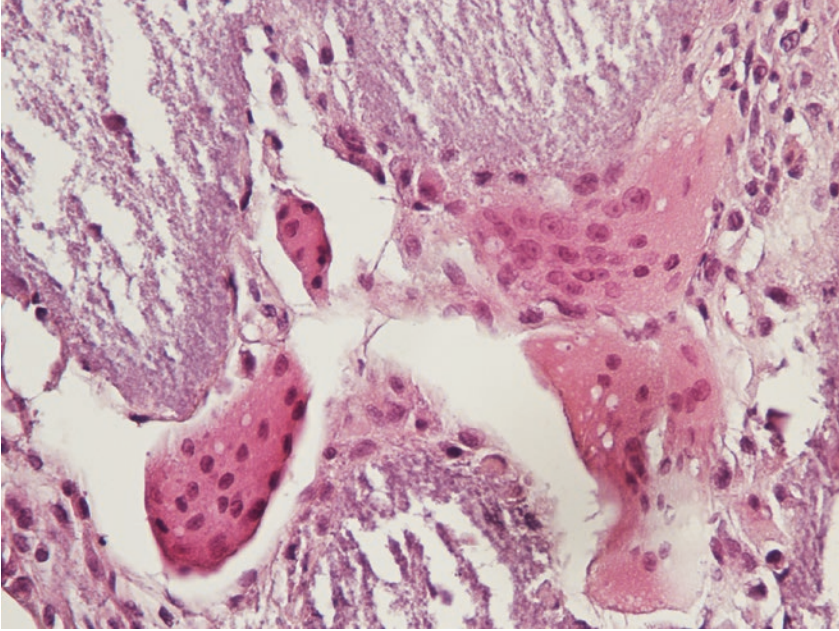


Fig. 3.271 Histology of *calcinosis circumscripta*: many giant cells that surround amorphous and granular calcium salts

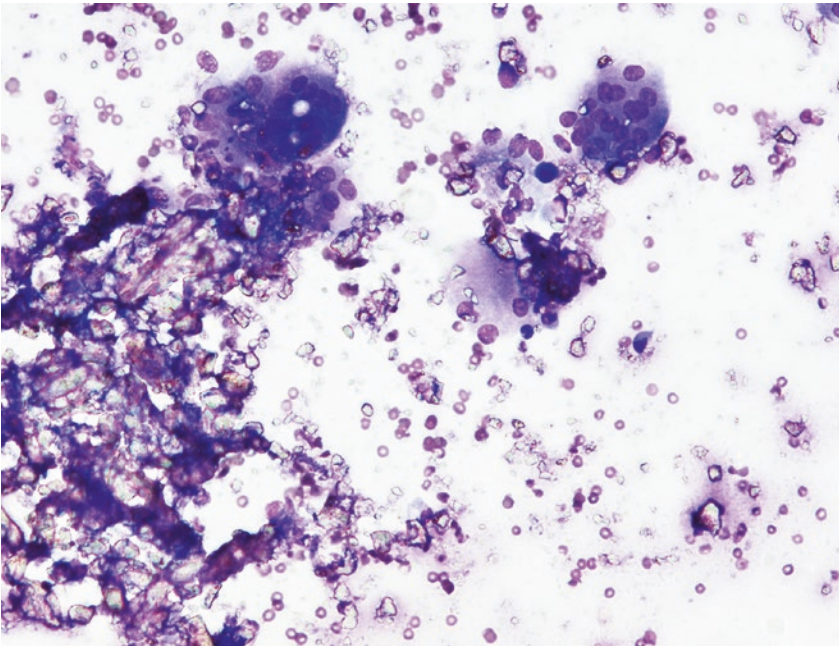


Fig. 3.272 Cytology of *calcinosis circumscripta*: many giant cells that surround amorphous, transparent calcium salts

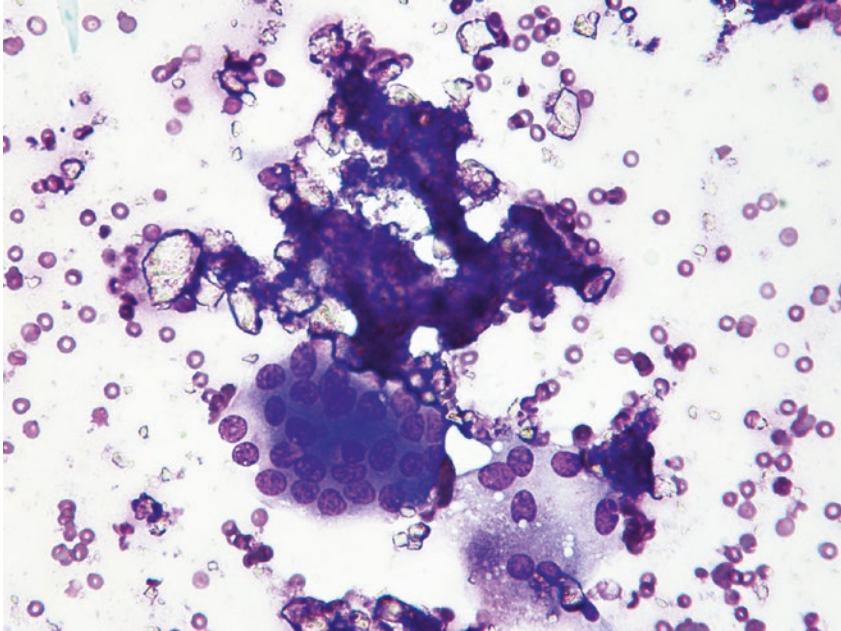


Fig. 3.273 Cytology *calcinosis circumscripta*: two giant cells surrounding amorphous, transparent calcium salts

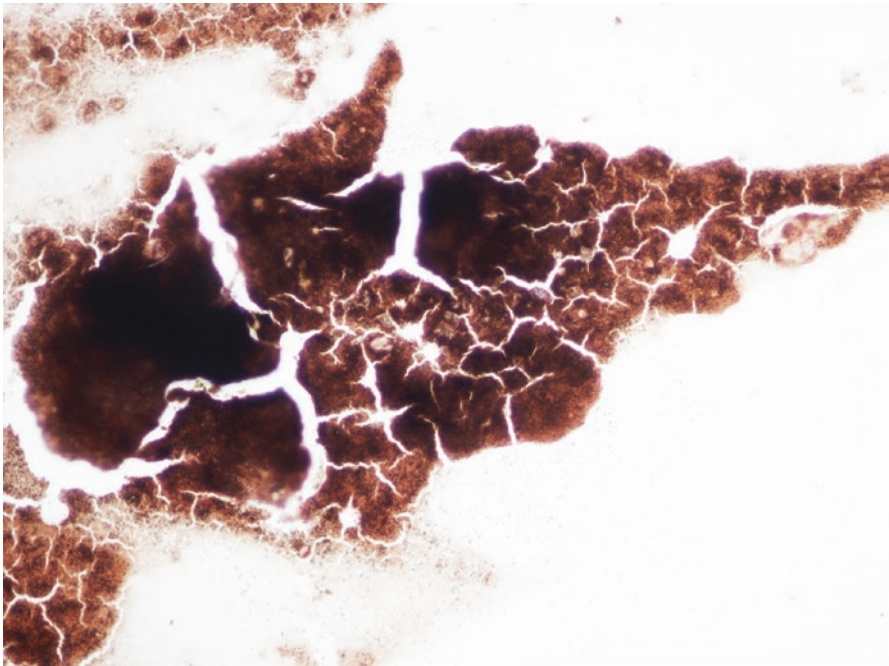


Fig. 3.274 Cytology of *calcinosis circumscripta* (Von Kossa staining): the area in which calcium salts were present is stained black with Von Kossa staining

Eosinophilic granuloma clinically manifests with different lesions, but in most cases the inflammatory cells lead to nodular lesions. EG is very common in cats and rare in dogs.

In cats, a single nodule on the chin, or more precisely, in the area between the lower lip and chin, can develop (Fig. 3.275). A linear, cord-like nodular lesion distributed along the rear profile of one or both thighs is well-known in cats; due to its configuration, this form of EG is named *linear eosinophilic granuloma*. (Fig. 3.276).

The surface of linear granuloma is often covered with scales and crusts, but on palpating the lesion the presence of small nodules is noticeable and in some cases also evident at a visual inspection.

Finally, it is not uncommon to observe nodules and plaques in the mouth, especially on the hard palate and tongue (Fig. 3.277). A macroscopic characteristic common to all forms of EG, which reinforces the clinical suspicion, is the yellowish–pinkish surface. The cause of most EGs is hypersensitivity disease, although idiopathic causes have been reported, especially in young cats.

Eosinophilic granuloma in dogs is very rare and observed mainly as ulcerated oral nodules and plaques, especially in the Siberian husky and Cavalier King Charles (Madewell et al. 1980; Joffe and Allen 1995; Gross et al. 2005). Occasionally, EG has been reported in other breeds (Fig. 3.278) (Vercelli and Cornegliani 2002).

The *eosinophilic plaque* is a common eosinophilic lesion observed in cats. EP is clinically characterised by an erythematous and exudative, single or coalescent, usually pruritic plaque, mainly localised on the abdomen and medial thighs (Figs. 3.279 and 3.280) (Gross et al. 2005). As for EG, hypersensitivity diseases are the most common causes in EPs as well (Miller et al. 2013).

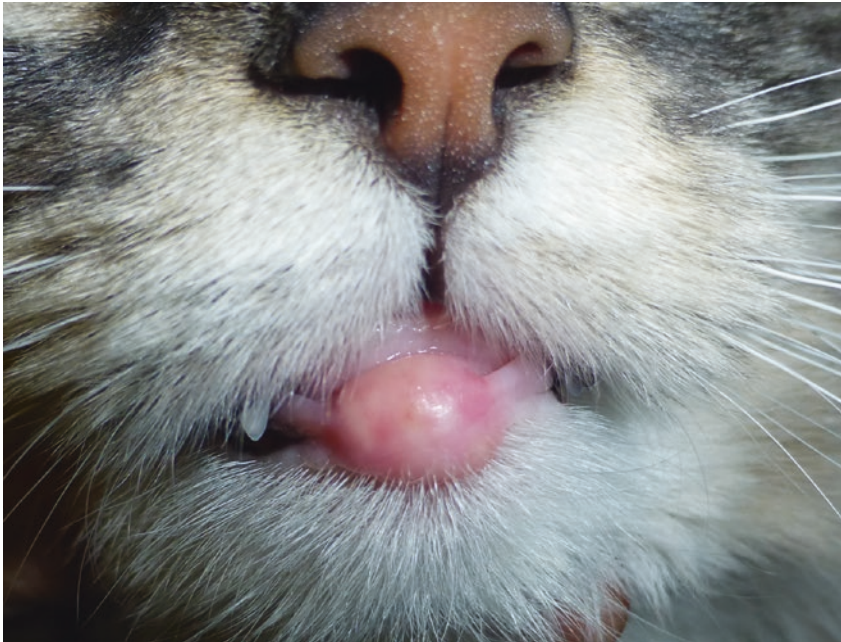

Fig. 3.275 Eosinophilic granuloma: nodule on the chin of a cat

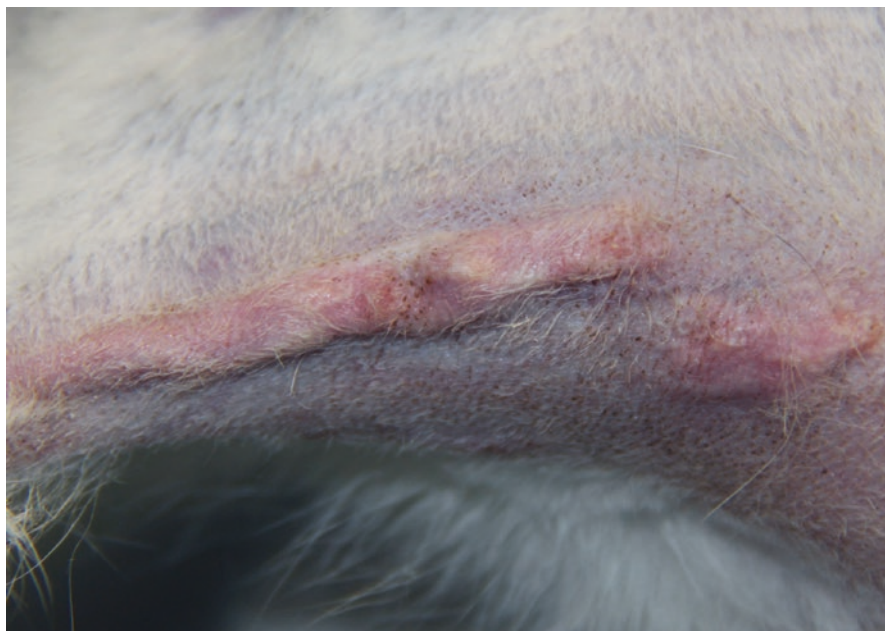


Fig. 3.276 Eosinophilic linear granuloma (EG): multiple nodules on the rear profile of the thigh

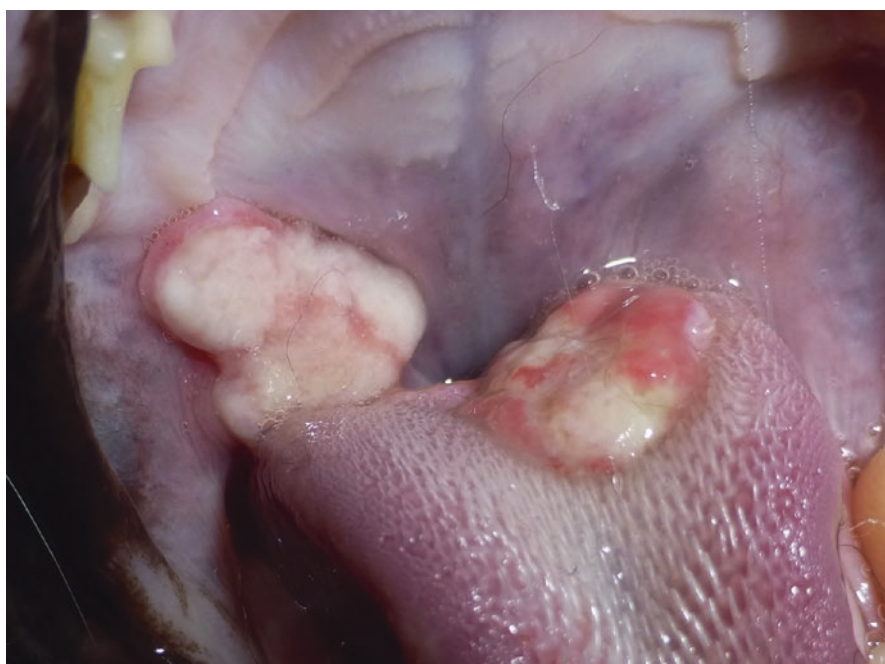

Fig. 3.277 Ulcerated plaques on the tongue and palate of a cat with EG

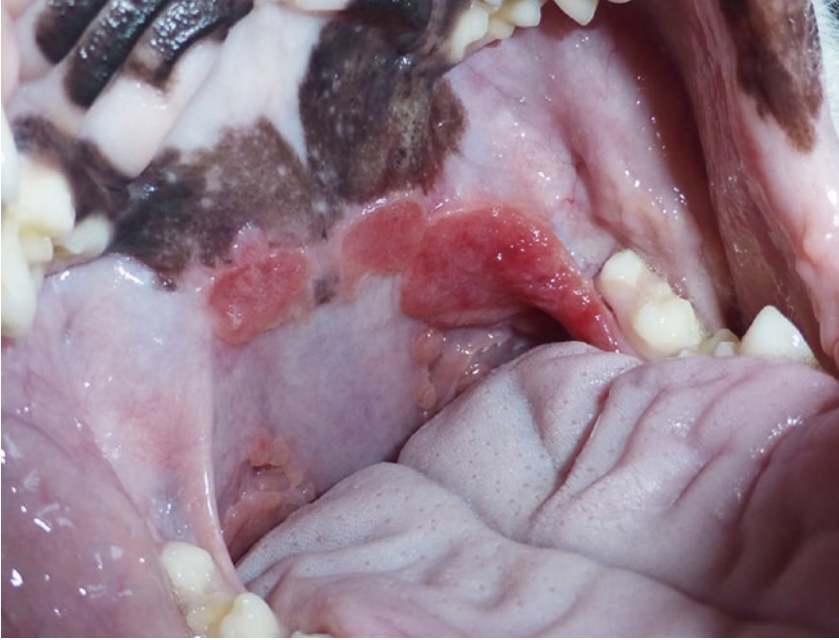

Fig. 3.278 Ulcerated plaques on the hard palate of a Cavalier king with oral EG

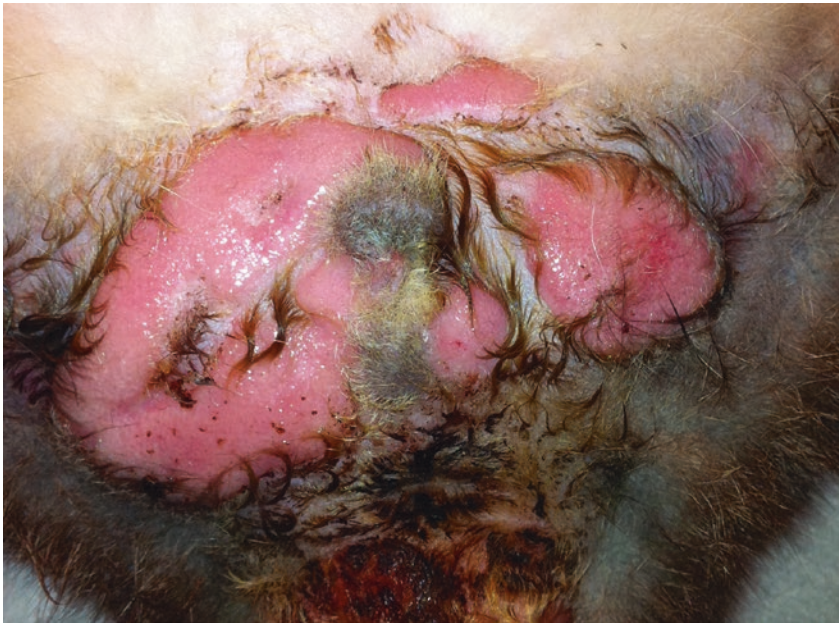

Fig. 3.279 Large and exudative eosinophilic plaque (EP) on the perigenital area of an allergic cat

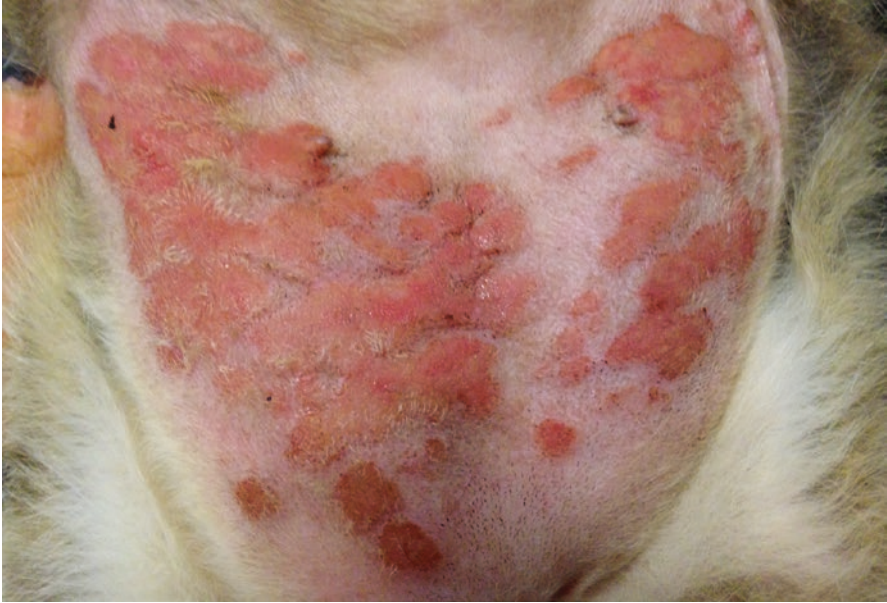

Fig. 3.280 Multiple confluent plaques on the abdomen of a cat with EP

Cytological Findings

Histopathological findings of EG in cats show diffuse eosinophilic dermatitis in which few to many *flame figures* are evident, multiple foci of collagen fibres trapped in the amorphous eosinophilic material, consisting of the fragmentation and degranulation of eosinophils (Figs. 3.281 and 3.282) (Fondati et al. 2001; Bardagi et al. 2003; Gross et al. 2005). Other formations observed and recently histopathologically defined are the so-called *necrotic foci*. These are composed of amorphous granular eosinophilic to lightly basophilic material, surrounded by fibroblasts, epithelioid cells and giant cells. Unlike flame figures, in necrotic foci, collagen fibres are not usually observed (Porcellato et al. 2014).

Specimens collected from EGs show a large number of eosinophils and a variable amount of neutrophils and macrophages (Fig. 3.283). In some cases, many histiocytic giant cells arranged around amorphous, acellular and intensely basophilic material, which represent the material that compose the flame figures observed in histology, are detected (Figs. 3.284 and 3.285) (Porcellato et al. 2014).

Eosinophilic plaque is histologically characterised by a diffuse dermal eosinophilic infiltrate with a smaller amount of histiocytes, mast cells and neutrophils, with the latter increased in chronic or ulcerated lesions (Fig. 3.286) (Fondati et al. 2001; Miller et al. 2013). The epidermis is frequently ulcerated and covered in a crust filled with blood, debris and many aggregates of contaminant bacteria (Figs. 3.287 and 3.288). Cytology obtained via FNB from uncomplicated plaques is composed almost completely of eosinophils and a variable number of mast cells (Fig. 3.289). In association with eosinophils, in specimens sampled using the

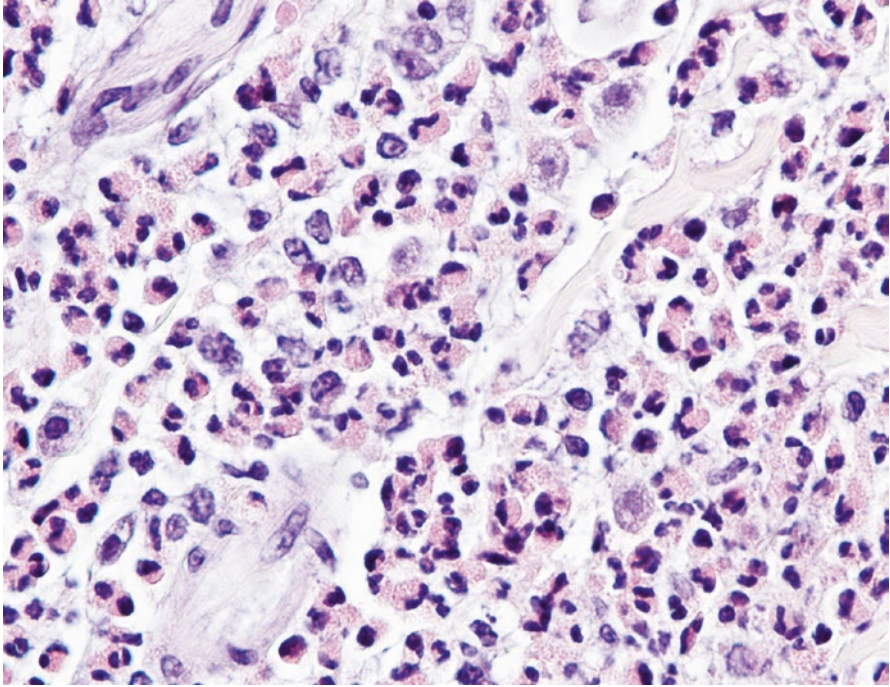


Fig. 3.281 Histology of EG: diffuse eosinophilic inflammation

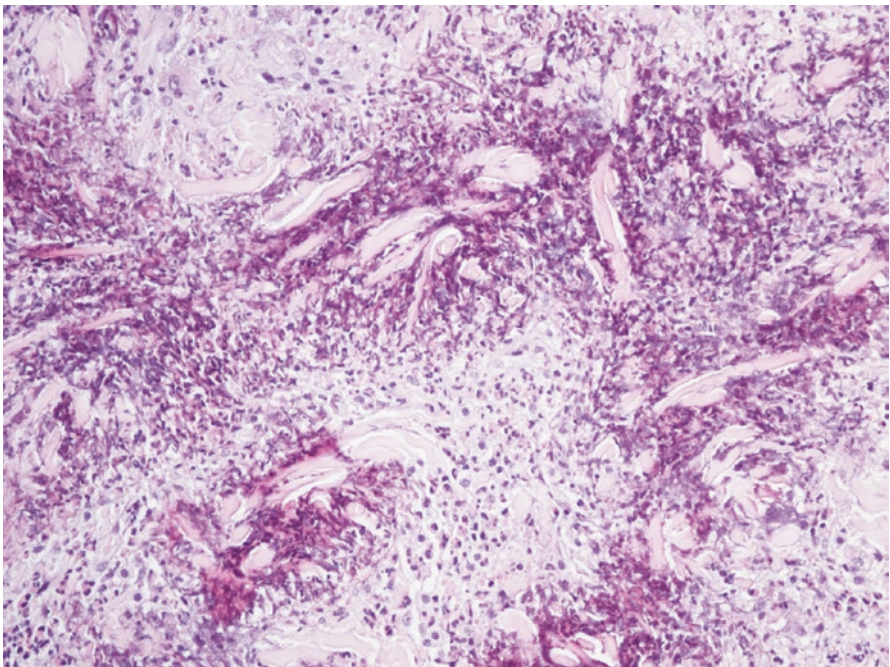


Fig. 3.282 Histology of EG: many *flame figures* immersed in eosinophilic inflammation

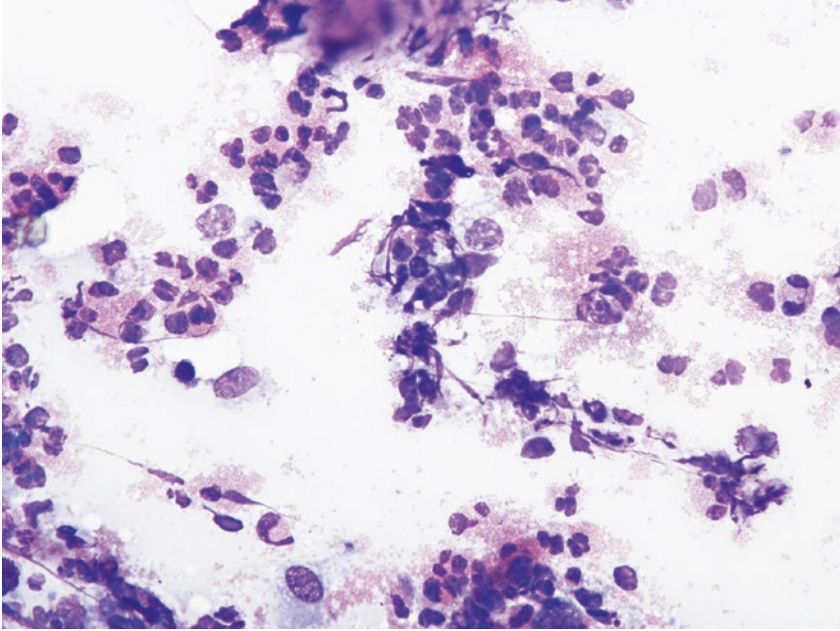


Fig. 3.283 Cytology of EG: many eosinophils and rare macrophages

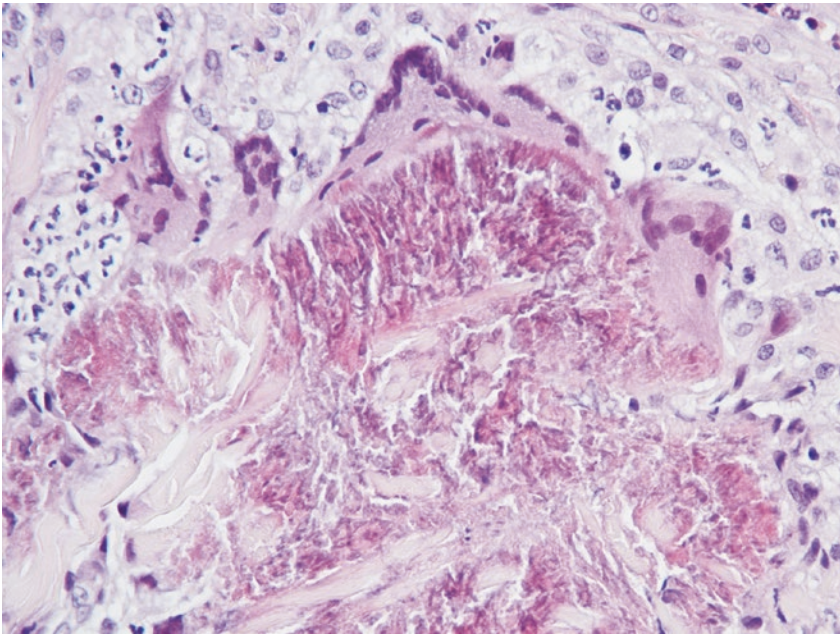


Fig. 3.284 Histology of EG: many giant cells surrounding an amorphous eosinophilic material, consisting of fragmentation and degranulation of eosinophils

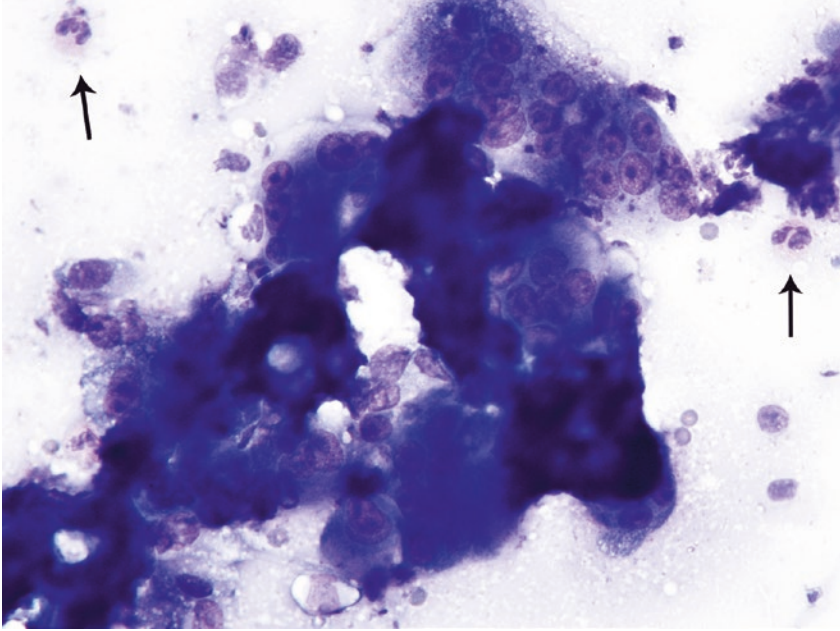


Fig. 3.285 Cytology of EG: the eosinophilic material observed in histology is cytologically recognisable as basophilic amorphous material surrounded by many giant cells. Note the presence of some eosinophils (*arrow*)

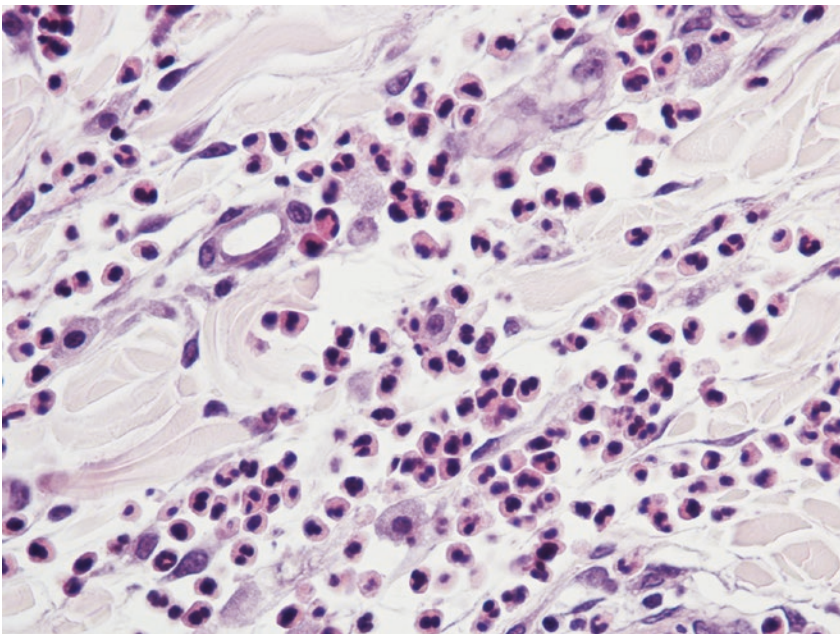


Fig. 3.286 Histology of EP: eosinophils and some mast cells infiltrate the dermis

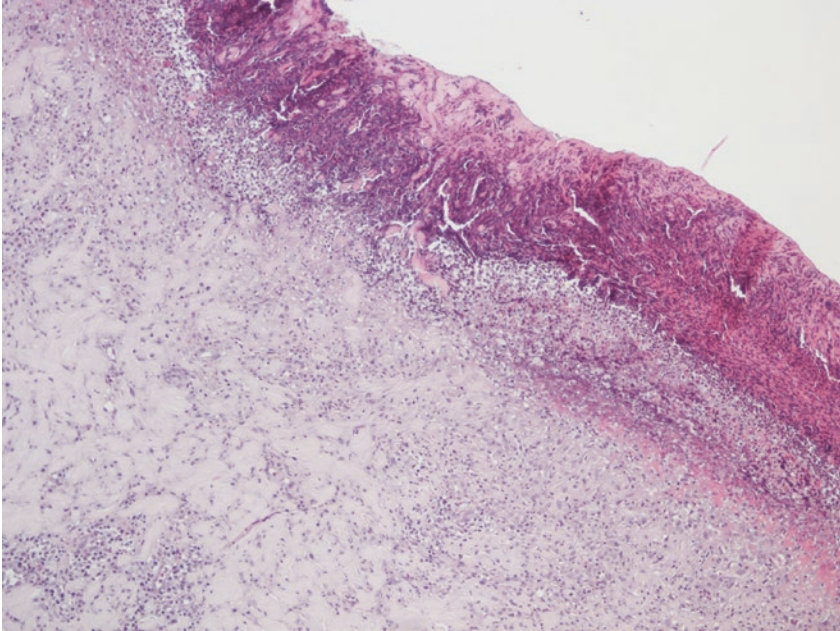


Fig. 3.287 Histology of EP: dermal eosinophilic infiltrate with an ulcerated surface

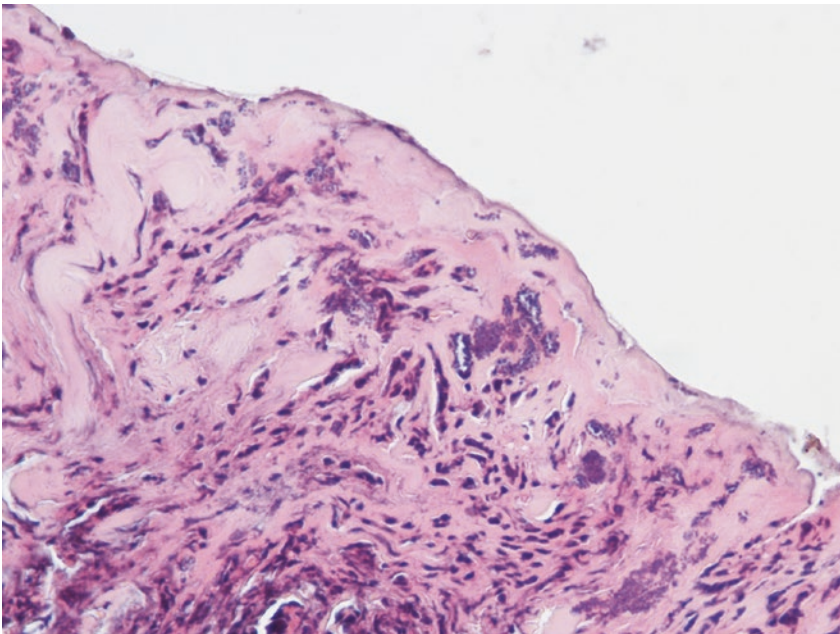


Fig. 3.288 Histology of EP: ulcerated epidermis covered by a crust, which entraps blood, debris and many aggregates of contaminant bacteria

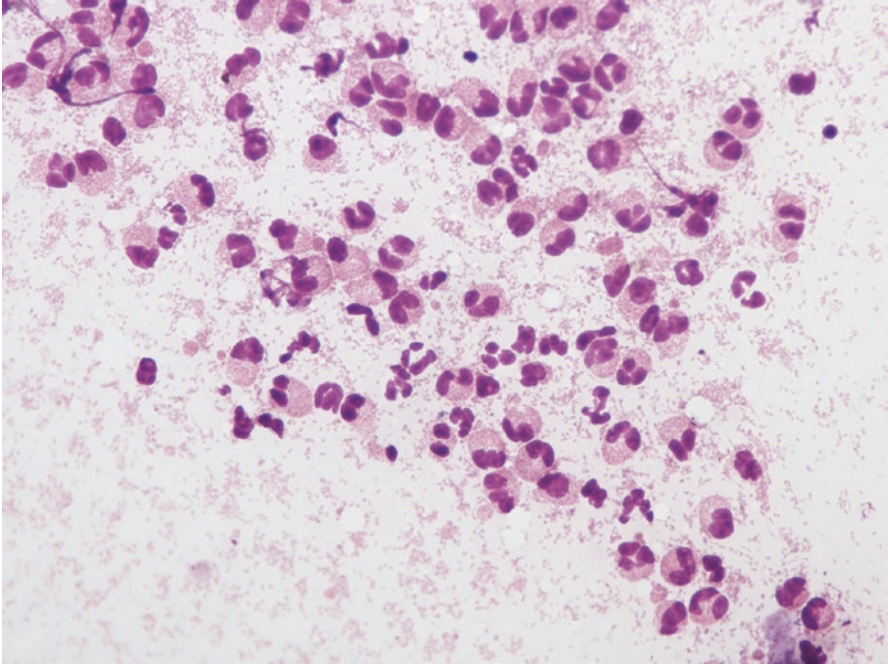


Fig. 3.289 Cytology of EP: pure eosinophilic inflammation

impression smear technique, neutrophils with intracytoplasmic cocci or rod-shaped bacteria also dispersed on the background of the slide, are commonly seen. This evidence indicates that a secondary infection from environmental or oral cavity bacteria has occurred, the latter due to excessive licking (Fig. 3.290).

In these cases, the typical clinical aspect of EP added to the presence of eosinophils helps the clinician to interpret pyoderma as secondary. However, there are situations in which a specimen should be exclusively composed of karyolytic neutrophils with bacterial phagocytosis without eosinophils. In these cases, even if there is a clinical suspicion, it is not possible to make a diagnosis of eosinophilic plaque with cytology. For this reason, in every raised skin lesion, the best technique for cell collection remains FNB.

It should be remembered that rarely, EP is associated with a variable amount of well-differentiated mast cells and when these cells are numerous, we should be careful not to formulate a diagnosis of cutaneous mast cells that can notoriously chemotactically recall a variable number of infiltrating eosinophils.

3.8.2.3 Panniculitis

Adipose tissue inflammation is called *panniculitis*. Panniculitis in dogs and cats can have various causes including aetiological agents (e.g. atypical *Mycobacteria*, *Leishmania infantum*), trauma (post-injecting, penetrating foreign bodies), metabolic (pancreatitis), drugs, vaccines, immune-mediated (rheumatoid arthritis,

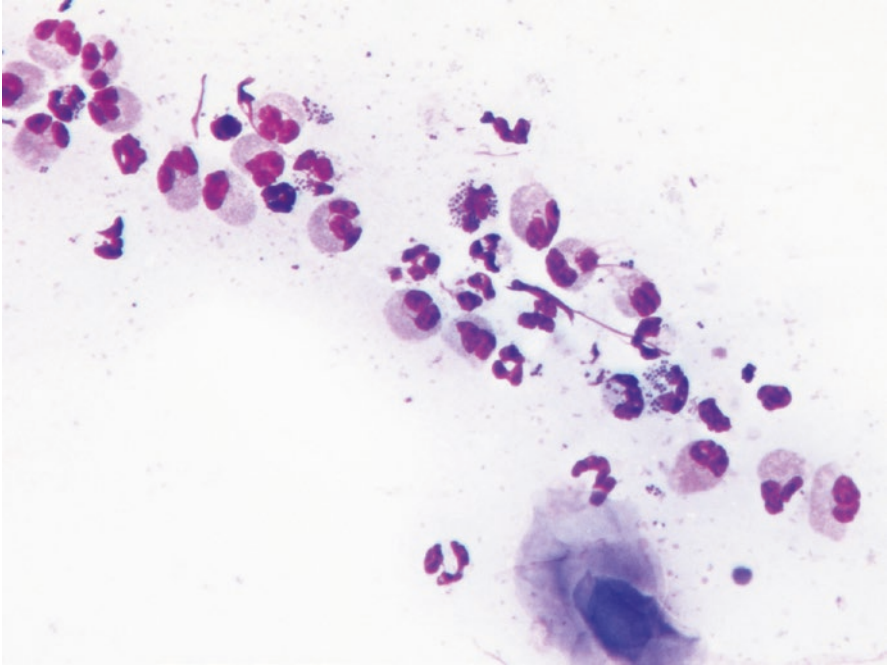


Fig. 3.290 Cytology of EP: mixed inflammation composed of eosinophils and some neutrophils which phagocytose many cocci

lymphoplasmacytic colitis) and sterile idiopathic diseases (Scott and Anderson 1988; German et al. 2003; Mellanby et al. 2003; O’Kell et al. 2010; Kim et al. 2011; Boynosky and Stokking 2014; Contreary et al. 2015).

Clinical signs are single or multiple nodules based on the pathogenesis, localised into the fat, usually painful and with draining tracts or an ulcerated surface. Single nodules are most commonly observed following drug injections such as antibiotics or vaccines, whereas in the case of multinodular panniculitis, *sterile nodular panniculitis* should be considered (Fig. 3.291). In this uncommon immune-mediated disease, multiple painful and mostly truncal subcutaneous nodules, are present; lesions tend to ulcerate rapidly and drain a lipid material mixed with blood (Figs. 3.292 and 3.293). In many cases, the healing of lesions results in the formation of permanent scars. Associated with skin lesions systemic symptoms such as malaise and hyperthermia are always present (Yamagishi et al. 2007).

In cats, characteristic panniculitis located at the injection site of rabies vaccine, has been well documented (Gross et al. 2005).

Cytological Findings

At low magnifications a lipidic background characterises panniculitis. Many achromatic, round, different-sized lipid droplets are constantly present. Immersed in this lipidic background, many inflammatory cells, usually represented by neutrophils, macrophages, lymphocytes and plasma cells, are detected; their typology and percentages are strictly dependent on the cause of panniculitis (Fig. 3.294) (Gross et al. 2005).

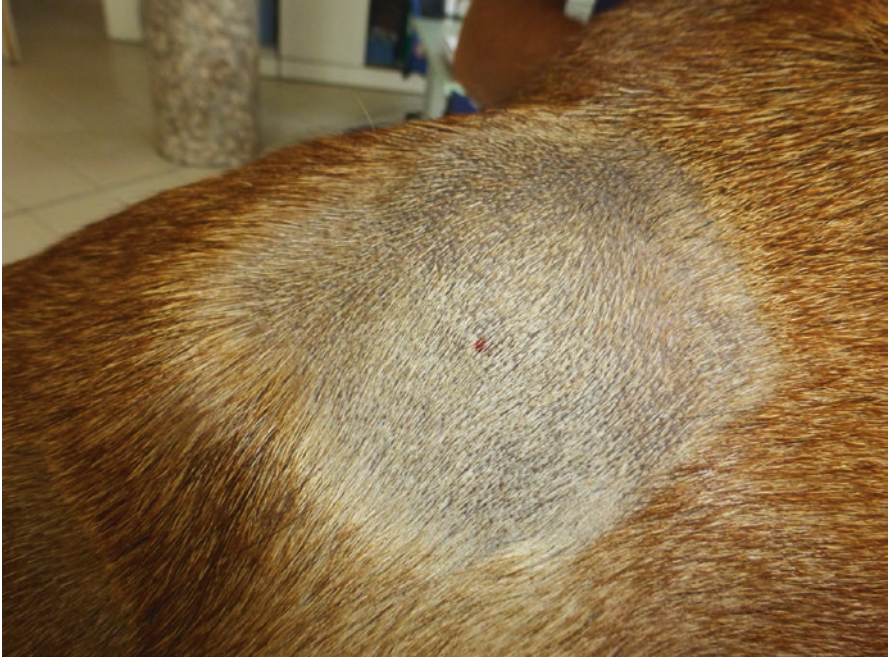

Fig. 3.291 Iatrogenic subcutaneous nodule in a dog (panniculitis) due to an antibiotic injection

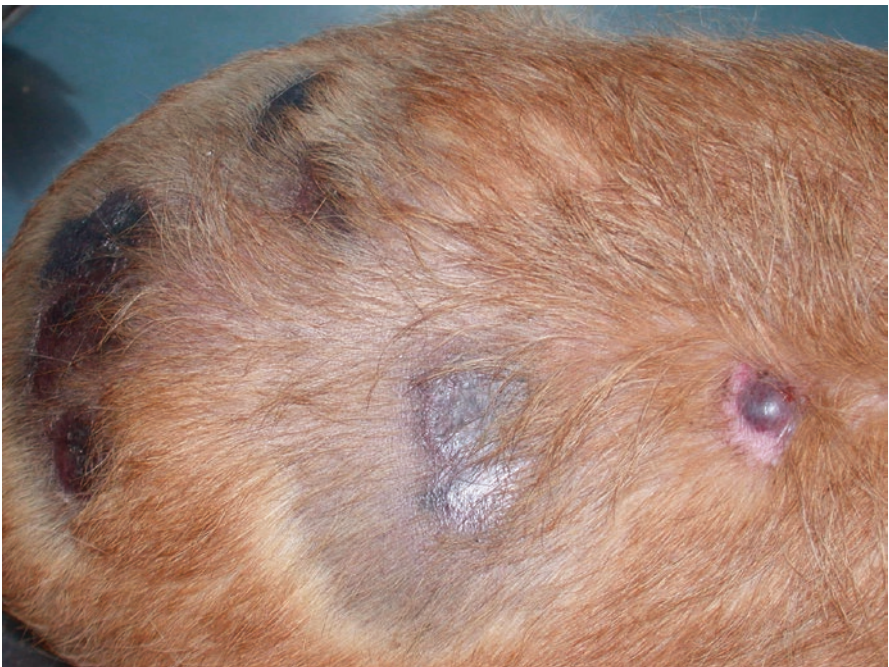

Fig. 3.292 Haemorrhagic nodule and multifocal scars secondary to sterile panniculitis

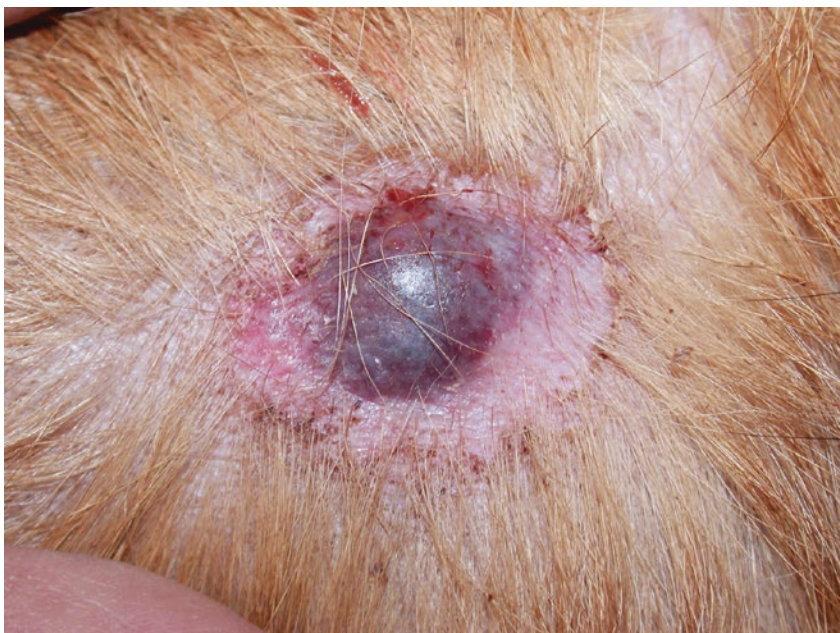

Fig. 3.293 Close-up of a nodule of panniculitis on the dorsum of the same dog as in Fig. 3.292

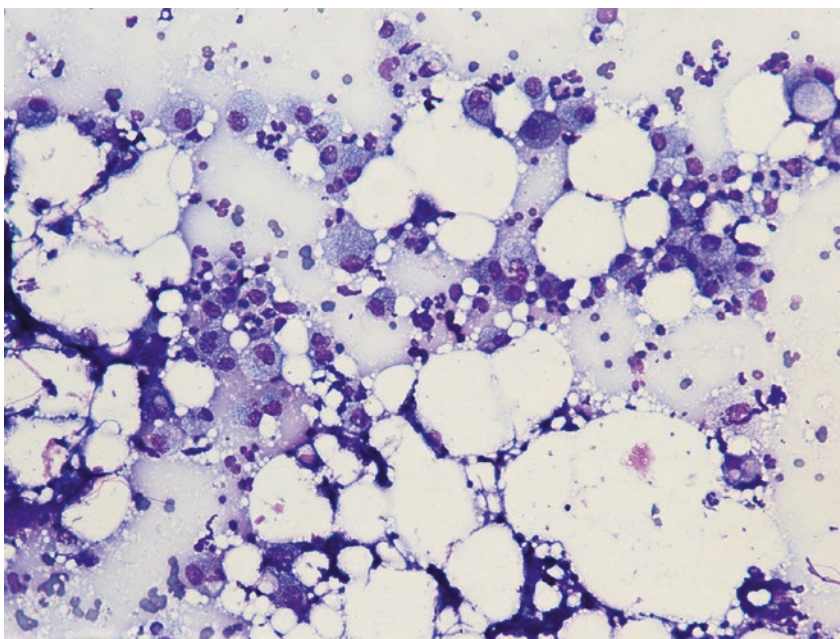


Fig. 3.294 Cytology of panniculitis: lipidic background, in which pyogranulomatous inflammation is clearly evident

In *sterile idiopathic nodular panniculitis*, macrophages and neutrophils are the main cells, while in *post-injection single panniculitis* the number of lymphocytes and plasma cells can be higher. Usually, macrophages have cytoplasm filled with microvacuoles rich with lipid that give cells a *foamy appearance* (Figs. 3.295 and 3.296). In panniculitis, secondary to drug injection, amorphous, foreign material, such as mineral salts, could be found both free and phagocytosed by neutrophils and macrophages. In the case of panniculitis secondary to rabies vaccination, a high amount of necrotic debris, surrounded by strong granulomatous inflammation rich in giant cells, is characteristically observed in cytology. If the needle has been inserted into the centre of the necrotic area, the lipidic material that characterises the cytological findings of all the types of panniculitis cannot be observed (Fig. 3.297). In these cases, the history of a previous anti-rabies vaccination can orientate the diagnosis.

In some chronic cases, severe fibroplasia can occur and many plump reactive fusiform cells (fibroblasts) may be intermingled with the inflammatory cells; some fibroblasts can be so dysplastic as to be cytologically not easy to differentiate from neoplastic mesenchymal spindle cells.

Many infectious agents can cause panniculitis, such as leishmania, opportunistic mycobacteria, fungi etc., thus, if they are not detected by cytology, before defining the panniculitis as sterile, microbiological culture, special stains and molecular biology tests must be performed. Finally, in animals with diffuse panniculitis, a careful check for metabolic disorders must be carried out.

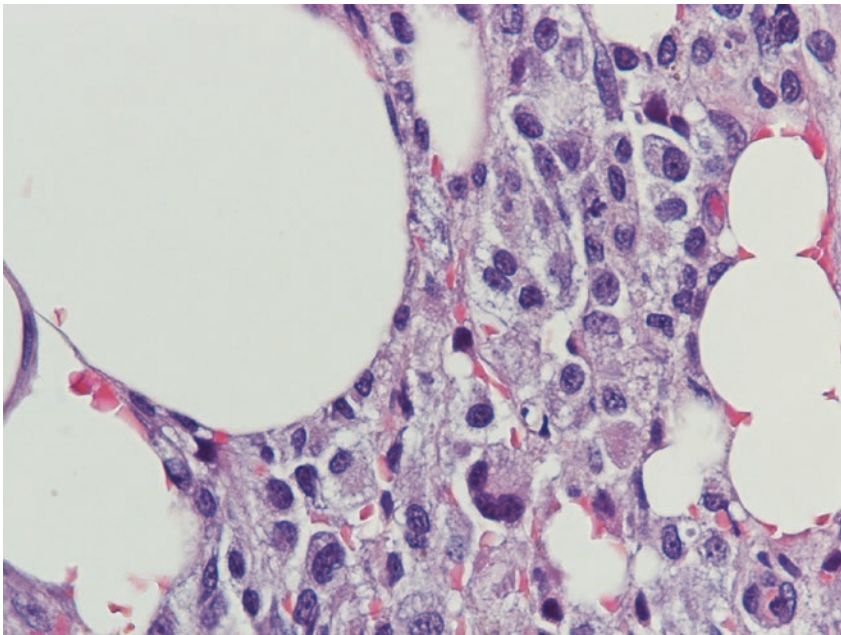


Fig. 3.295 Histology of panniculitis: *foamy* macrophages and giant cells in the panniculus

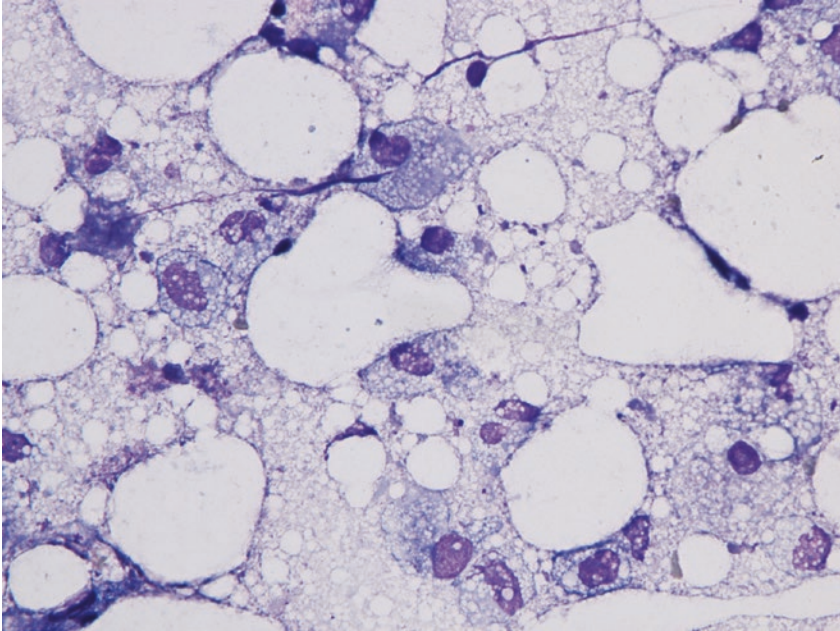


Fig. 3.296 Cytology panniculitis: foamy macrophages are characterised by many small and overlapping intracytoplasmic vacuoles, which indicate lipophagocytosis

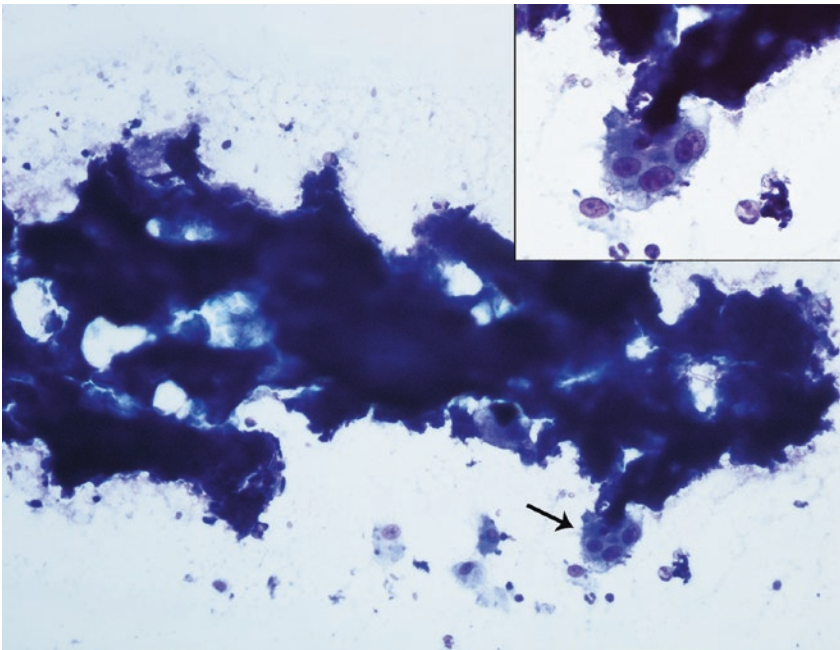


Fig. 3.297 Cytology post-rabies vaccination panniculitis: necrotic amorphous material surrounded by a granulomatous reaction represented mostly by giant cells (*arrow, inset*)

3.9 Juvenile Cellulitis

In this group two diseases have been included that, because of the typology of clinical lesions, are difficult to include in the groups dealt with above. Both diseases are clinically characterised, in the early stages, by swelling of the skin.

3.9.1 *Juvenile Sterile Granulomatous Dermatitis and Lymphadenitis (Juvenile Cellulitis)*

Juvenile cellulitis is a disease of unknown cause that affects young dogs from a few weeks of age and in rare cases adult dogs. Certain breeds such as Cocker spaniel, Dachshund and Setter Gordon, seem more frequently represented (Jeffers et al. 1995; Reimann et al. 1989; Scott and Miller 2007; Miller et al. 2013). Because the lesions are resolved following treatment with immunomodulatory drugs, an immune-mediated pathogenesis that could be triggered by vaccinations, viral infections etc., has been speculated. The early skin manifestations are swelling and exudation of the skin of the ears, eyelids, lips and dorsum of the nose, which rapidly tend to be covered with a purulent-like exudate (Figs. 3.298 and 3.299). Mucocutaneous junctions may also be swollen and exudative and some dogs may develop multiple nodules mainly distributed on the trunk (Fig. 3.300). During the

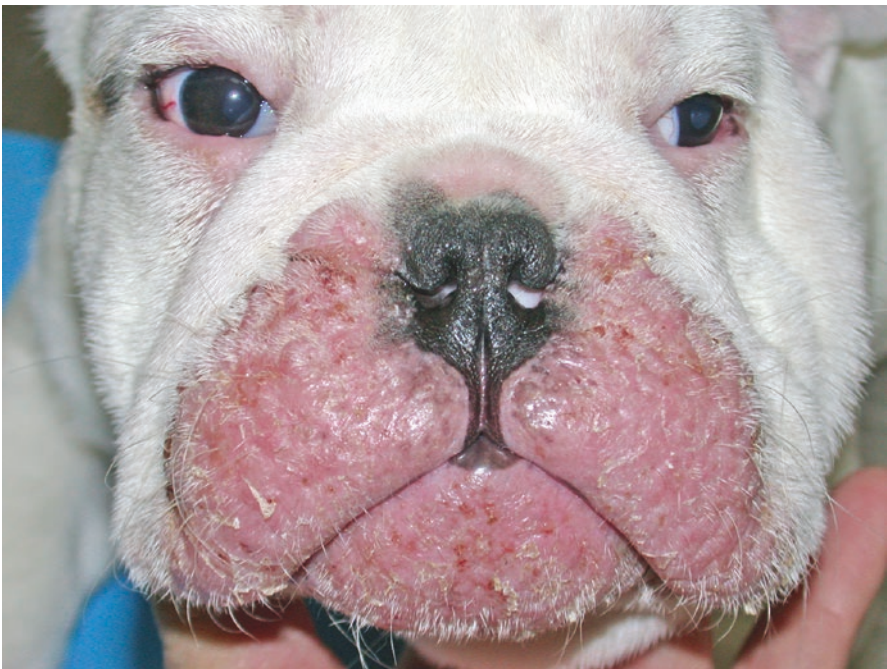

Fig. 3.298 Swelling of the muzzle in a bulldog puppy with juvenile cellulitis

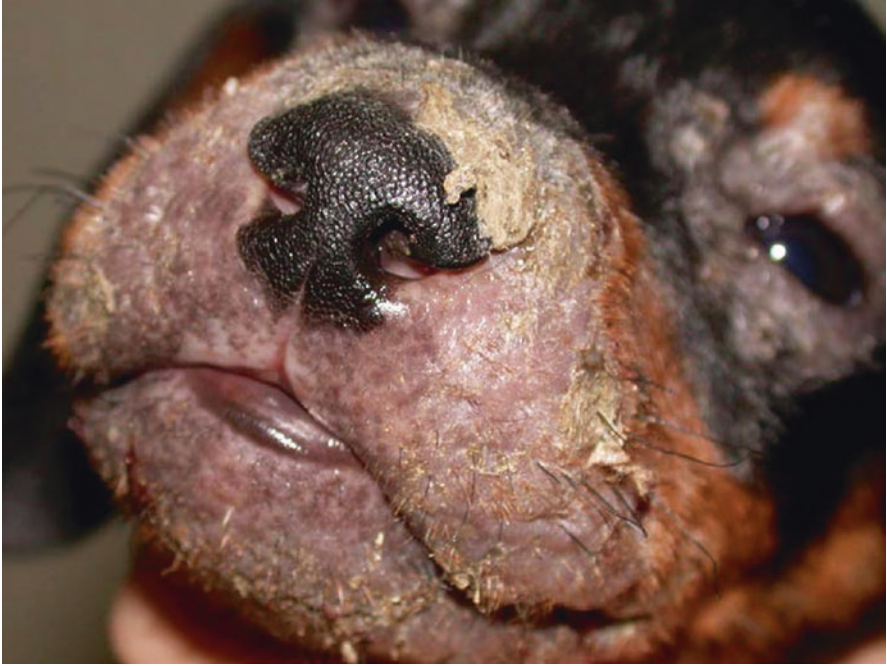

Fig. 3.299 Juvenile cellulitis: swelling and dried pus on the muzzle and eyelids of a Dachshund

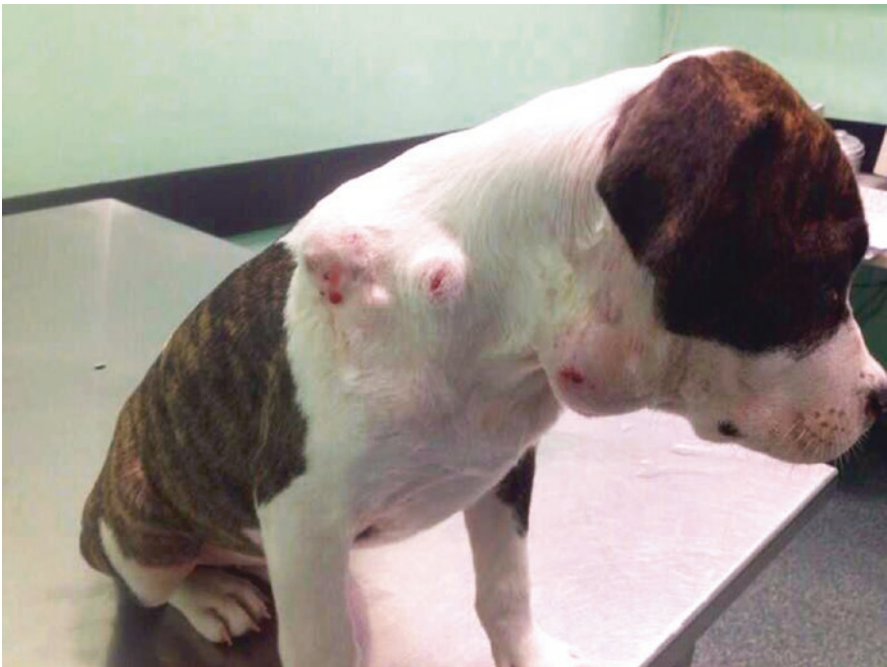

Fig. 3.300 Multiple cutaneous nodules in a young Pitt bull with juvenile cellulitis (Courtesy of Dr. A. Rauseo, Italy)

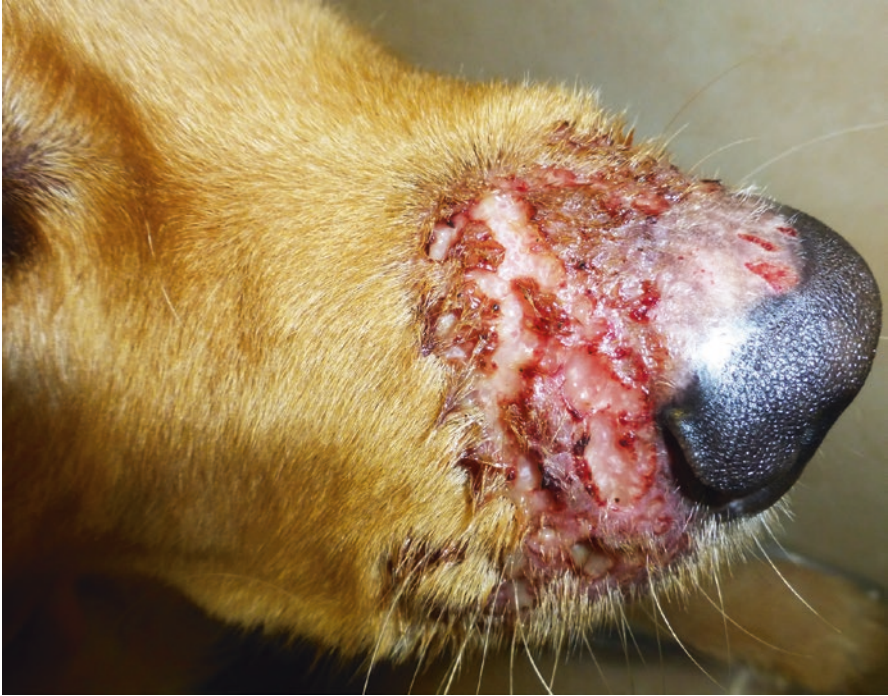

Fig. 3.301 Juvenile cellulitis: ulcerative dermatitis in a Golden retriever

advanced stage of the disease, deep ulcerations mostly located on the muzzle and secondary pyoderma can modify the initial clinical presentation (Fig. 3.301).

Skin lesions are associated with general malaise, fever, joint pain, enlarged and painful lymph nodes, and lead to loss of appetite and weakness.

Cytological Findings

Slides obtained from dogs with juvenile cellulitis may vary according to the sampling method and the stage of the disease.

Considering the type of skin lesions represented by draining tracts discharging a mixed haematic and purulent exudate often complicated by bacteria, sampling cells by imprinting is not the ideal technique. Histopathologically, juvenile cellulitis is characterised by large perifollicular sterile granulomas/pyogranulomas composed of macrophages and large epithelioid macrophages with a central core of neutrophils (Gross et al. 2005); therefore, in an attempt to collect cells that are as representative as possible of the disease, an FNB, inserting the needle directly into the sterile granulomas, is desirable (Figs. 3.302 and 3.303).

In good-quality specimens, cytological findings are very suggestive and if evaluated with clinical signs, the diagnosis of juvenile cellulitis could be made. Well-segmented neutrophils, macrophages with variable vacuolated cytoplasm and many epithelioid macrophages are the classical cells sampled from non-infected specimens. As the inflammatory process is perifollicular without involvement of the follicles, the possibility of finding giant cells is very low. When this occurs, secondary furunculosis must be suspected (Figs. 3.304 and 3.305).

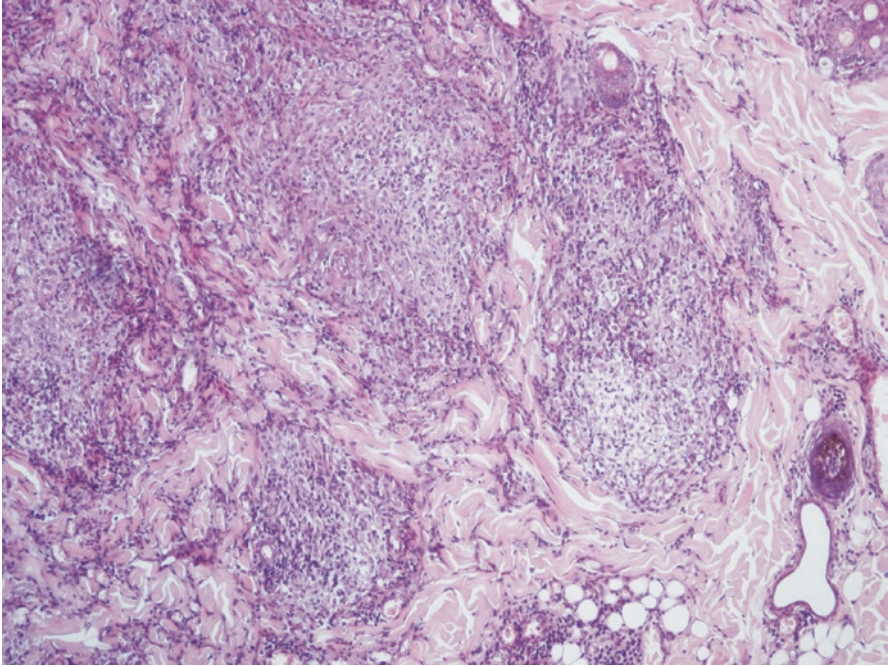


Fig. 3.302 Histology of juvenile cellulitis: multiple perifollicular granulomas

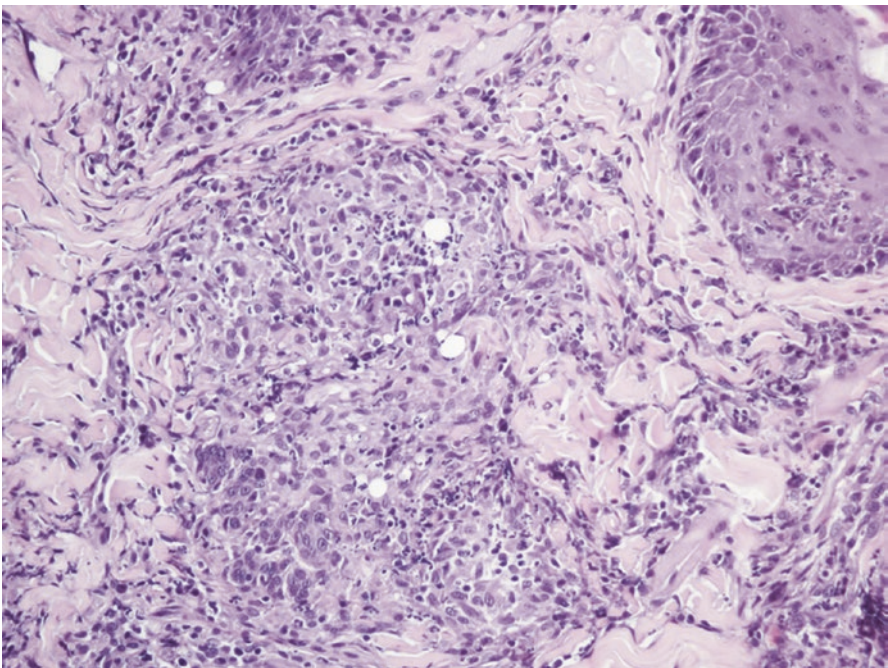


Fig. 3.303 Histology of juvenile cellulitis: at high magnifications, nodules are composed mostly of histiocytes and of a variable number of neutrophils

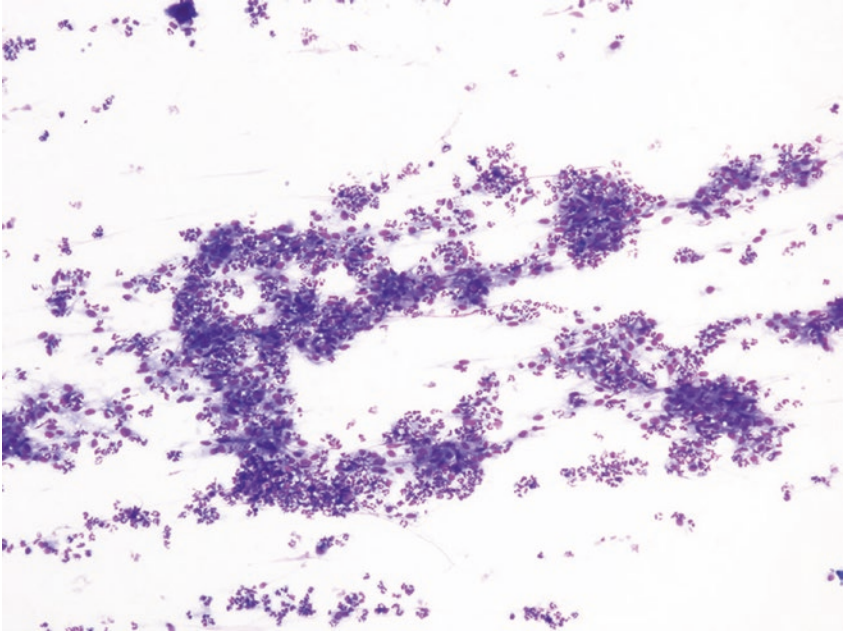


Fig. 3.304 Cytology of juvenile cellulitis: neutrophilic and macrophagic inflammation

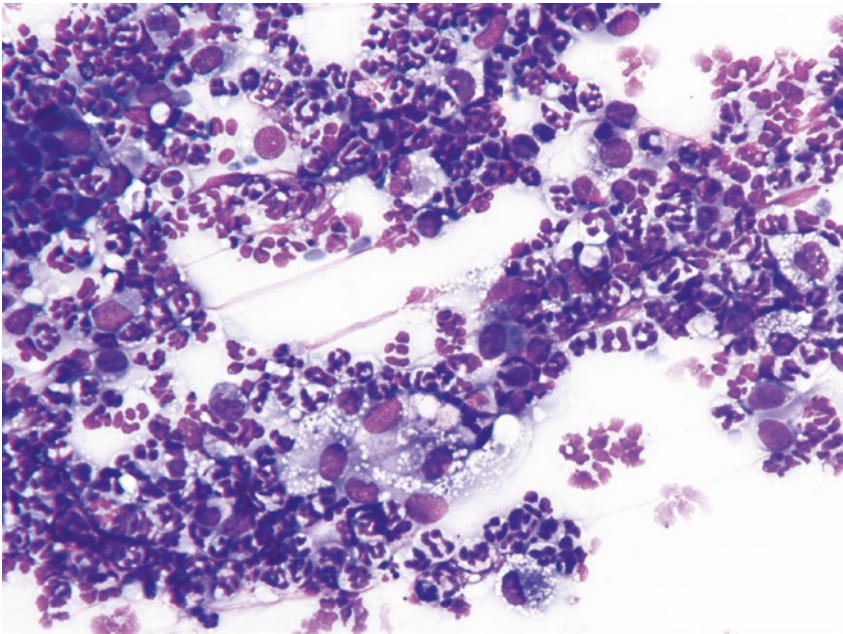


Fig. 3.305 Cytology of juvenile cellulitis: segmented neutrophils and vacuolated macrophages

Collection is very easy when intact nodules are present, from which a large amount of well-segmented neutrophils, macrophages and epithelioid macrophages can easily be sampled using FNB.

3.9.2 Plasma Cell Pododermatitis

Plasma cell pododermatitis is an inflammatory disease of unknown cause. Based on the type of cells characterising the disease and the good response to immunomodulating drugs, an immune-mediated pathogenesis has been suspected. This disease affects exclusively cats, in which clinical lesions are characterised by pododermatitis that usually affects all feet and is characterised by swelling and erythema of the paw pads (Gruffydd-Jones et al. 1980; Pereira and Faustino 2003; Miller et al. 2013). In early lesions, paws are swollen and some can develop a central ulcer from which erythematous and haemorrhagic tissue, with a *fleshy* appearance, can protrude (Figs. 3.306 and 3.307). Paws that remain intact and are not ulcerated seem deflated and lose elasticity. In some cats a swelling of the dorsum of the nose is also present and histopathologically characterised by a diffuse plasmacellular infiltrate in the dermis. This particular type of lesion has been observed along with pododermatitis or by itself (Fig. 3.308) (Declercq and De Bosschere 2010).

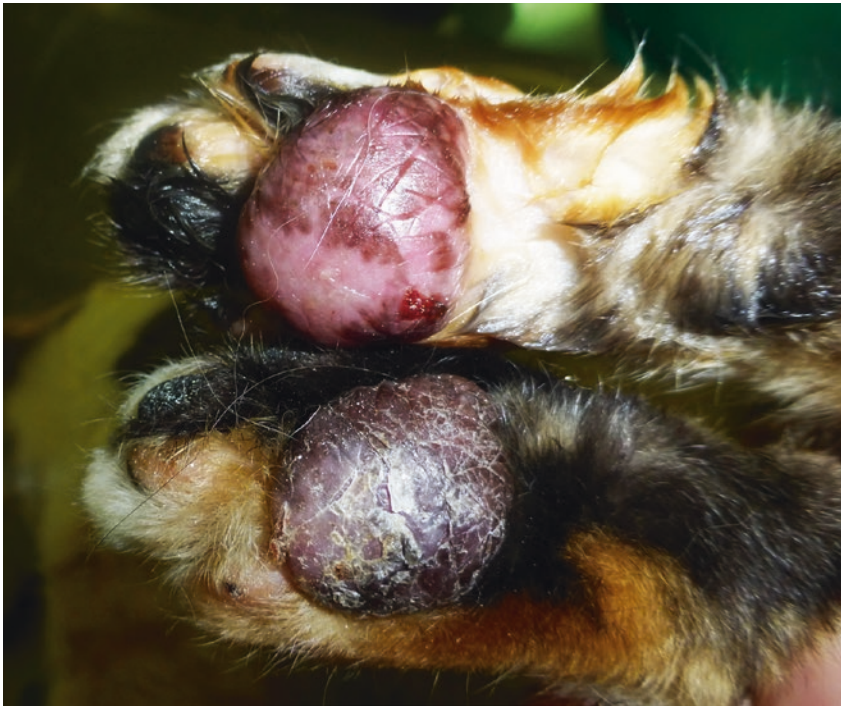

Fig. 3.306 Swelling of paws in a cat with plasma cell pododermatitis

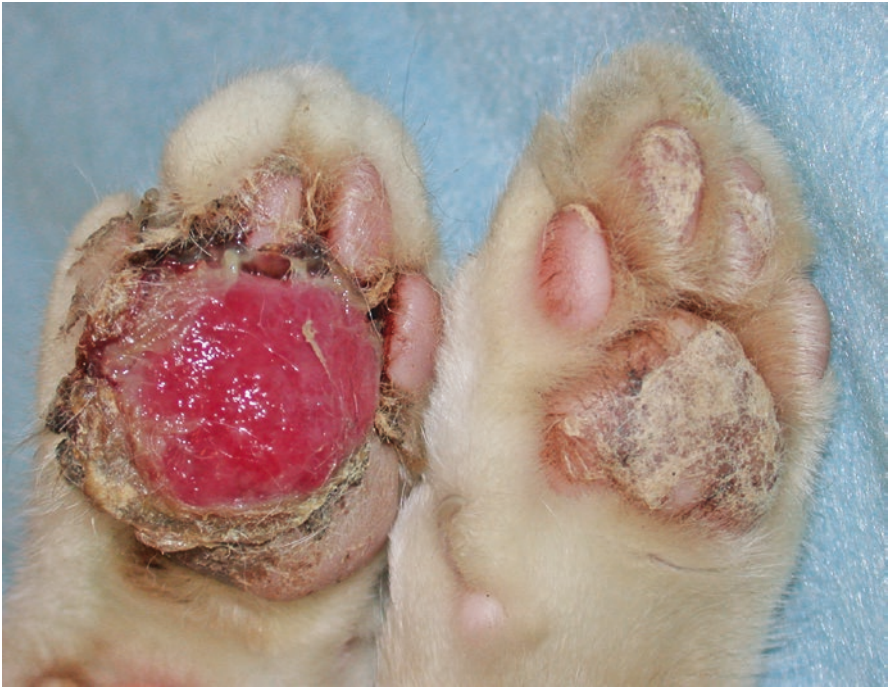

Fig. 3.307 Ulceration of a paws in a cat with plasma cell pododermatitis



Fig. 3.308 Swelling of the nose in a cat with concomitant plasma cell pododermatitis

Cytological Findings

Cytology obtained from early lesions should be the most representative and reflect the typical plasma cell inflammation that characterises the histopathological samples (Gross et al. 2005; Fig. 3.309). Unfortunately, slides are almost always poorly cellular and only in very successful specimens, mature lymphocytes and a variable amount of plasma cells can be collected (Figs. 3.310 and 3.311). In some cases, *Mott cells*, representing hyperproductive plasma cells, filled with large and irregular vacuoles named *Russell bodies*, are present on slides. Finally, specimens from ulcerated lesions can be infected and rich with neutrophils and macrophages.

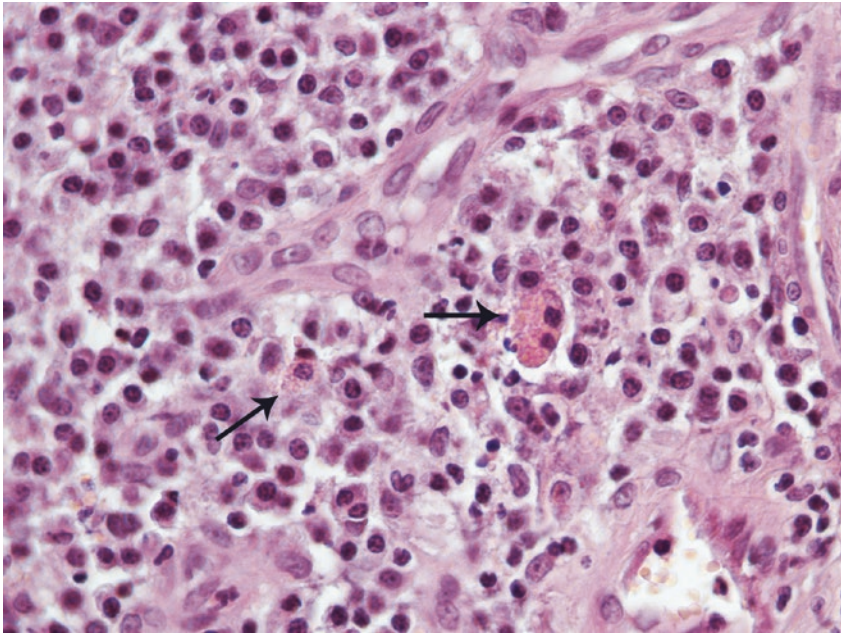


Fig. 3.309 Histology of plasma cell pododermatitis: diffuse plasma cells inflammation; note the two Mott cells, filled with Russell bodies, recognisable for the vacuolated eosinophilic cytoplasm (*arrows*)

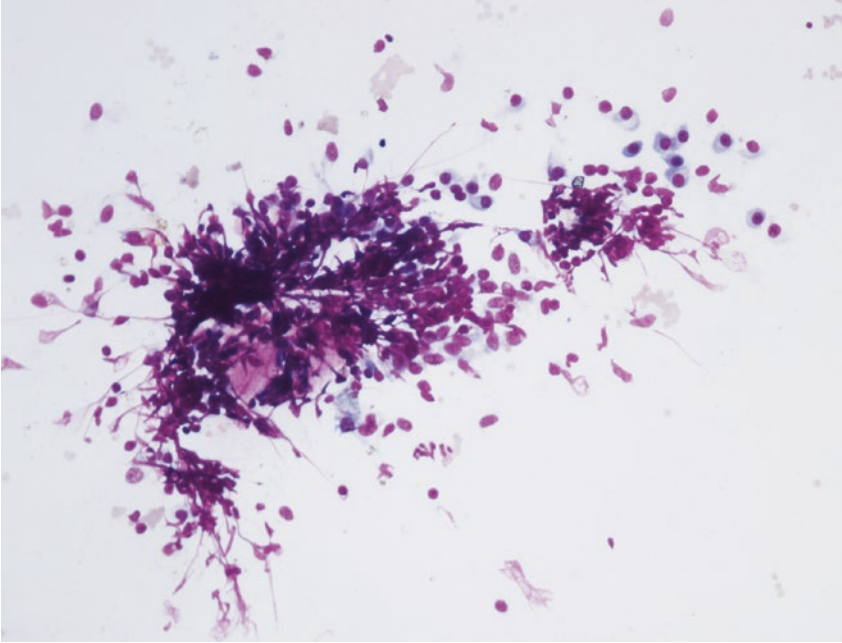


Fig. 3.310 Cytology of plasma cell pododermatitis: group of cells mostly composed of plasma cells

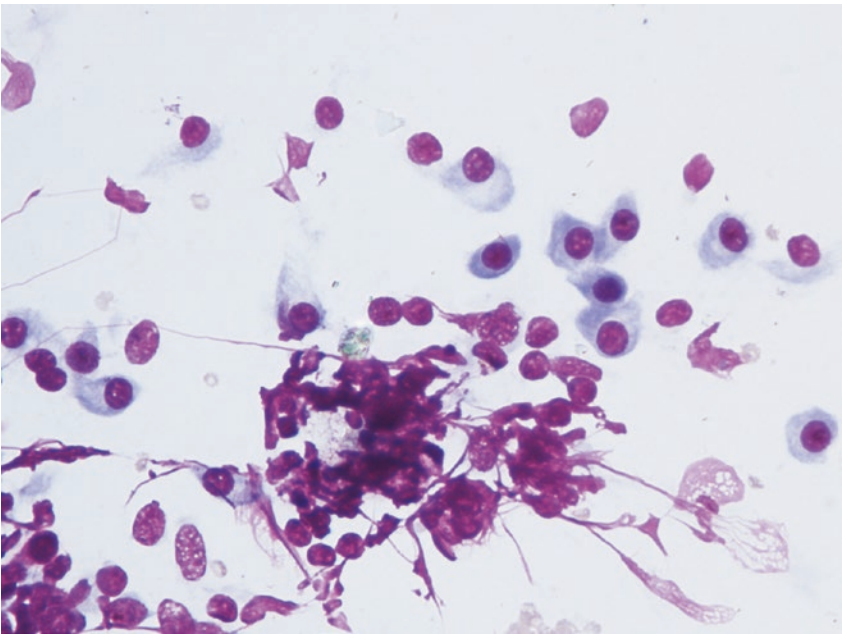


Fig. 3.311 Cytology plasma cell pododermatitis: at high magnifications, well-differentiated plasma cells are easily recognisable

References

Papular Diseases in Dogs

Pyoderma

- Ihrke PJ (1996) Bacterial skin disease in the dog: a guide to canine pyoderma. Veterinary Learning Systems, Trenton, pp 1–97
- Miller WH, Griffin CE, Campbell KL (2013) Superficial bacterial folliculitis. In: Muller & Kirk's- small animal dermatology, 7th edn. Elsevier, St. Louis, pp 194–195

Papular Diseases in Cats

Hypersensitivity Diseases

- Favrot C, Steffan J, Seewald W et al (2011) Establishment of diagnostic criteria for feline nonflea-induced hypersensitivity dermatitis. *Vet Dermatol* 23:45–51
- Gross TL, Ihrke PJ, Walder EJ et al (2005) Feline mosquito bite hypersensitivity. In: *Skin diseases of the dog and cat: clinical and histopathological diagnosis*, 2nd edn. Blackwell Science, Ames, pp 345–347
- Hobi S, Linek M, Marignac G (2011) Clinical characteristics and causes of pruritus in cats: a multicentre study on feline hypersensitivity-associated dermatoses. *Vet Dermatol* 22(5):406–413
- Nagata M, Ishida T (1997) Cutaneous reactivity to mosquito bites and its antigens in cats. *Vet Dermatol* 8(1):19–26
- Miller WH, Griffin CE, Campbell KL (2013) Feline mosquito hypersensitivity. In: Muller & Kirk's- small animal dermatology, 7th edn. Elsevier, St. Louis, pp 412–414
- Ravens PA, Xu BJ, Vogelnest LJ (2014) Feline atopic dermatitis: a retrospective study of 45 cases (2001–2012). *Vet Dermatol* 25:95–104

Benign Papular Mastocytic Hyperplasia

- Colombo S, Scarampella F, Ordeix L et al (2012) Dermatophytosis and papular eosinophilic/mastocytic dermatitis (urticaria pigmentosa-like dermatitis) in three Devon Rex cats. *J Feline Med Surg* 14(7):498–502
- Noli C, Colombo S, Abramo F et al (2004) Papular eosinophilic/mastocytic dermatitis (feline urticaria pigmentosa) in Devon Rex cats: a distinct disease entity or a histopathological reaction pattern? *Vet Dermatol* 15(4):253–259
- Vitale CB, Ihrke PJ, Olivry T et al (1996) Feline urticaria pigmentosa in three related Sphinx cats. *Vet Dermatol* 7(4):227–233

Papular-Nodular Diseases in Dogs

Deep Pyoderma (Furunculosis)

- Gross TL, Ihrke PJ, Walder EJ et al (2005) Pustular and nodular diseases with adnexal destruction. In: Skin diseases of the dog and cat: clinical and histopathological diagnosis, 2nd edn. Blackwell Science, Ames, pp 442–449
- Miller WH, Griffin CE, Campbell KL (2013) Deep folliculitis, furunculosis and cellulitis. In: Muller & Kirk's- small animal dermatology, 7th edn. Elsevier, St. Louis, pp 198–203 and 305–314
- Mueller RS (2004) Treatment protocols for demodicosis: an evidence-based review. *Vet Dermatol* 15(2):75–89
- Mueller RS, Bensignor E, Ferrer L et al (2012) Treatment of demodicosis in dogs: 2011 clinical practice guideline. *Vet Dermatol* 23(2):86–96, e20–e21

Facial Eosinophilic Furunculosis

- Curtis CF, Bond R, Blunden AS et al (1995) Canine eosinophilic folliculitis and furunculosis in three cases. *J Small Anim Pract* 36(3):119–123
- Gross TL (1993) Canine eosinophilic furunculosis of the face. In: Ihrke PJ et al (eds) *Advances in veterinary dermatology*, vol II. Pergamon Press, New York, p 239
- Gross TL, Ihrke PJ, Walder EJ et al (2005) Eosinophilic furunculosis of the face. In: Skin diseases of the dog and cat: clinical and histopathological diagnosis, 2nd edn. Blackwell Science, Ames, pp 450–453
- Guaguère E et al (1996) Furonculose éosinophilique chez le chien. *Prat Méd Chir Anim Comp* 31:413

Papular-Nodular Canine Leishmaniasis

- Bottero E, Poggi M, Viglione M (2006) Lesioni papulari indotte da *Leishmania* spp. in 8 cani giovani. *Veterinaria* 20:33–36
- Lombardo G, Pennisi MG, Lupo T et al (2014) Papular dermatitis due to *Leishmania infantum* infection in seventeen dogs: diagnostic features, extent of the infection and treatment outcome. *Parasit Vectors* 7:120
- Noli C, Cornegliani L (2006) Leishmaniosi bottoniforme. Descrizione di cinque casi italiani e confronto con la letteratura veterinaria. *Quaderni di dermatologia* 11(1):23–26
- Ordeix L, Solano-Gallego L, Fondevila D et al (2005) Papular dermatitis due to *Leishmania* spp. infection in dogs with parasite-specific cellular immune responses. *Vet Dermatol* 16:187–191
- Solano-Gallego L, Koutinas A, Miro G et al (2009) Directions for the diagnosis, clinical staging, treatment and prevention of canine leishmaniasis. *Vet Parasitol* 165:1–18
- Solano-Gallego L, Miro G, Koutinas A et al (2011) LeishVet guidelines for the practical management of canine leishmaniasis. *Parasit Vectors* 4:86

Sterile Granuloma and Pyogranuloma Syndrome

- Cornegliani L, Fondevilla D, Vercelli A et al (2005) PCR technique detection of *Leishmania* spp. but not *Mycobacterium* spp. in canine cutaneous 'sterile' pyogranuloma/granuloma syndrome. *Vet Dermatol* 16(4):233–238

- Gross TL, Ihrke PJ, Walder EJ et al (2005) Sterile granuloma and pyogranuloma syndrome. In: *Skin diseases of the dog and cat: clinical and histopathological diagnosis*, 2nd edn. Blackwell Science, Ames, pp 320–323
- Miller WH, Griffin CE, Campbell KL (2013) Sterile granuloma/pyogranuloma syndrome. In: *Muller & Kirk's- small animal dermatology*, 7th edn. Elsevier, St. Louis, pp 704–706
- Panich R, Scott DW, Miller WH (1991) Canine cutaneous sterile pyogranuloma/granuloma syndrome: a retrospective analysis of 29 cases (1976–1988). *J Am Anim Hosp Assoc* 27:519–528
- Scott DW, Bueger RG, Miller WH Jr (1990) Idiopathic sterile granulomatous and pyogranulomatous dermatitis in cats. *Vet Dermatol* 1(3):129–137

Calcinosis Cutis

- Doerr KA, Outerbridge CA, White DS et al. (2013) Calcinosis cutis in dogs: histopathological and clinical analysis of 46 cases. *Vet Dermatol* 24:355–e79
- Frazier KS, Hullinger GA, Liggett AD et al (1998) Multiple cutaneous metaplastic ossification associated with iatrogenic hyperglucocorticoidism. *J Vet Diagn Invest* 10:303–307
- Gross TL, Ihrke PJ, Walder EJ et al (2005) Calcinosis cutis. In: *Skin diseases of the dog and cat: clinical and histopathological diagnosis*, 2nd edn. Blackwell Science, Ames, pp 373–378
- Miller WH, Griffin CE, Campbell KL (2013) Calcinosis cutis In: *Muller & Kirk's- small animal dermatology*, 7th edn. Elsevier, St. Louis, pp 680–682, 831–832
- White SD, Kass PH, Shiraki R et al (2013) Calcinosis cutis in dogs: histopathological and clinical analysis of 46 cases. *Vet Dermatol* 24(3):355–361, e78–e79

Xanthomatosis

- Banajee KH, Orandle MS, Ratterree W et al (2011) Idiopathic solitary cutaneous xanthoma in a dog. *Vet Clin Path* 40(1):95–98
- Chanut F, Colle MA, Deschamps JY et al (2005) Systemic xanthomatosis associated with hyperchylomicronemia in a cat. *J Vet Med A Physiol Pathol Clin Med* 52(6):272–274
- Gross TL, Ihrke PJ, Walder EJ et al (2005) Cutaneous xanthoma. In: *Skin diseases of the dog and cat: clinical and histopathologic diagnosis*. Blackwell Publishing, Oxford, pp 330–333
- Ravens PA, Vogelnest LJ, Piripi SA (2013) Unique presentation of normolipaemic cutaneous xanthoma in a cat. *Aust Vet J* 91(11):460–463
- Vitale CB, Ihrke P, Gross TL (1998) Diet-induced alterations in lipid metabolism and associated cutaneous xanthoma formation in 5 cats. In: Kwochka KW, Willemse T, von Tscharner C (eds) *Advances in veterinary dermatology*, vol 3. Butterworth-Heinemann, Oxford, pp 243–249

Pustular Diseases in Dogs

Staphylococcal Folliculitis

- Gross TL, Ihrke PJ, Walder EJ et al (2005) Sterile granuloma and pyogranuloma syndrome. In: *Skin diseases of the dog and cat: clinical and histopathological diagnosis*, 2nd edn. Blackwell Science, Ames, pp 406–410
- Ihrke P (1996) Bacterial skin disease in the dog: a guide to canine pyoderma. *Veterinary Learning Systems*, Trenton, pp 1–97

Miller WH, Griffin CE, Campbell KL (2013) Superficial bacterial folliculitis. In: Muller & Kirk's-small animal dermatology, 7th edn. Elsevier, St. Louis, pp 194–195

Demodicosis

Gross TL, Ihrke PJ, Walder EJ et al (2005) Pustular and nodular diseases with adnexal destruction. In: Skin diseases of the dog and cat: clinical and histopathological diagnosis, 2nd edn. Blackwell Science, Ames, pp 442–449

Miller WH, Griffin CE, Campbell KL (2013) Demodicosis. In: Muller & Kirk's- small animal dermatology, 7th edn. Elsevier, St. Louis, pp 305–314

Mueller RS, Bensignor E, Ferrer L et al (2011) Treatment of demodicosis in dogs: clinical practice guideline. *Vet Dermatol* 23(2):86–96, e20–e21

Pustular Non-follicular Staphylococcal Infection (Impetigo)

Amagai M (2009) The molecular logic of pemphigus and impetigo: the desmoglein story. *Vet Derm* 20(5-6):308–312

Gross TL, Ihrke PJ, Walder EJ et al (2005) Pustular diseases of epidermis. In: Skin diseases of the dog and cat: clinical and histopathological diagnosis, 2nd edn. Blackwell Science, Ames, pp 4–9

Ihrke P (1996) Bacterial skin disease in the dog: a guide to canine pyoderma. Veterinary Learning Systems, Trenton, pp 1–97

Nishifuji K, Sugai M, Amagai M (2008) Staphylococcal exfoliative toxins: “molecular scissors” of bacteria that attack the cutaneous defense barrier in mammals. *J Dermatol Sci* 49:21–31

Terauchi R, Sato H, Hasegawa T et al (2003) Isolation of exfoliative toxin from *Staphylococcus intermedius* and its local toxicity in dogs. *Vet Microbiol* 94:19–29

Pemphigus Foliaceus

Gross TL, Ihrke PJ, Walder EJ et al (2005) Pemphigus foliaceus. In: Skin diseases of the dog and cat: clinical and histopathologic diagnosis. Blackwell Publishing, Oxford, pp 13–19

Miller WH, Griffin CE, Campbell KL (2013) Canine pemphigus foliaceus. In: Muller & Kirk's-small animal dermatology, 7th edn. Elsevier, St. Louis, pp 441–445

Olivry T (2006) A review of autoimmune skin diseases in domestic animals: I – superficial pemphigus. *Vet Dermatol* 17:291–305

Olivry T, Linder KE (2009) Dermatoses affecting desmosomes in animals: a mechanistic review of acantholytic blistering skin diseases. *Vet Dermatol* 20(5–6):313–326

Vaughan DF, Hodgins EC et al (2010) Clinical and histopathological features of pemphigus foliaceus with and without eosinophilic infiltrates: a retrospective evaluation of 40 dogs. *Vet Dermatol* 21(2):166–174

Dermatophytosis

- Fairley RA (2001) The histopathological lesions of *Trichophyton mentagrophytes* var. *erinacei* infection in dogs. *Vet Dermatol* 12:119–122
- Gross TL, Ihrke PJ, Walder EJ et al (2005) Superficial pustular dermatophytosis. In: *Skin diseases of the dog and cat: clinical and histopathologic diagnosis*. Blackwell Publishing, Oxford, pp 11–13
- Parker WM, Yager JA (1997) *Trichophyton* dermatophytosis – a disease easily confused with pemphigus erythematosis. *Can Vet J* 38:502–505
- Peters J, Scott DW, Erb HN et al (2007) Comparative analysis of canine dermatophytosis and superficial pemphigus for the prevalence of dermatophytes and acantholytic keratinocytes: a histopathological and clinical retrospective study. *Vet Dermatol* 18:234–240
- Poisson L, Olivry T, Lemons C (1998) Subcorneal neutrophilic acantholytic pustular dermatitis: an unusual manifestation of dermatophytosis resembling canine pemphigus foliaceus. In: Kwochka KW, Willemse T, von Tscharner C (eds) *Advances in veterinary dermatology*, vol 3. Butterworth-Heinemann, Oxford, pp 456–457
- Scott DW (1994) Marked acantholysis associated with dermatophytosis due to *Trichophyton equinum* in 2 horses. *Vet Dermatol* 5:105–110

Idiopathic and Drug Related Sterile Pustular Diseases

- Bizikova P, Linder KE, Olivry T (2014) Fipronil–amitraz–S-methoprene-triggered pemphigus foliaceus in 21 dogs: clinical, histological and immunological characteristics. *Vet Dermatol* 25(2):103–111
- Bizikova P, Moriello KA, Linder KA et al (2015) Dinotefuran/pyriproxyfen/permethrin pemphigus-like drug reaction in three dogs. *Vet Dermatol* 26(3):206–208, e45–e46
- Gross TL, Ihrke PJ, Walder EJ et al (2005) Subcorneal pustular dermatosis. In: *Skin diseases of the dog and cat: clinical and histopathologic diagnosis*. Blackwell Publishing, Oxford, pp 19–25
- Kalahar KM, Scott DW (1990) Subcorneal pustular dermatosis in dogs and in human being: comparative aspects. *J Am Acad Dermatol* 22:1023–1028
- Miller WH, Griffin CE, Campbell KL (2013) Subcorneal pustular dermatosis. In: *Muller & Kirk's-small animal dermatology*, 7th edn. Elsevier, St. Louis, pp 712–713
- Oberkirchner U, Linder KE, Dunston SM et al (2011) Metaflumizone–amitraz (Promeris)-associated pustular acantholytic dermatitis in 22 dogs: evidence suggests contact drug-triggered pemphigus foliaceus. *Vet Dermatol* 22:436–448
- White SD, Carlotti DN, Pin D et al (2002) Putative drug-related pemphigus foliaceus in four dogs. *Vet Dermatol* 13:195–202

Pustular Pemphigus-Like in Dogs with Canine Leishmaniasis

- Bardagi M (2012) Canine leishmaniasis: the challenge of histopathological diagnosis. In: *Proceedings of the International Society of Veterinary Dermatopathology (ISVD). Precongress Day of the 7th World Congress of Veterinary Dermatology*. Vancouver, pp 22–30
- Colombo S, Abramo F, Borio S, Albanese F et al (2016) Pustular dermatitis in dogs affected by leishmaniasis: 22 cases. *Vet Dermatol* 27(1):9–e4
- Ferrer L, Rabanal R, Fondevila D et al (1988) Skin lesions in canine leishmaniasis. *J Small Anim Pract* 29:381–388

Saridomichelakis MN, Koutinas AF (2014) Cutaneous involvement in canine leishmaniosis due to *Leishmania infantum* (syn. *L. chagasi*). *Vet Dermatol* 25:61–71, e22

Eosinophilic Pustulosis

Carlotti D, Prost C, Magnol J-P et al (1989) La maladie d'Ofugi (pustulose eosinophilique sterile). *Prat Méd Chir Anim Comp* 24:131–138

Gross TL, Ihrke PJ, Walder EJ et al (2005a) Sterile eosinophilic pustulosis. In: *Skin diseases of the dog and cat: clinical and histopathological diagnosis*, 2nd edn. Blackwell Science, Ames, pp 417–418

Gross TL, Ihrke PJ, Walder EJ et al (2005b) Canine flea allergy dermatitis. In: *Skin diseases of the dog and cat: clinical and histopathological diagnosis*, 2nd edn. Blackwell Science, Ames, pp 208–211

Miller WH, Griffin CE, Campbell KL (2013) Canine fleabite dermatitis. In: *Muller & Kirk's- small animal dermatology*, 7th edn. Elsevier, St. Louis, pp 405–410

Scott DW (1987) Sterile eosinophilic pustulosis in dog and man: comparative aspects. *J Am Acad Dermatol* 16:1022–1026

Pustular Diseases in Cats

Pemphigus Foliaceus

Gross TL, Ihrke PJ, Walder EJ et al (2005) Pemphigus foliaceus. In: *Skin diseases of the dog and cat: clinical and histopathologic diagnosis*. Blackwell Publishing, Oxford, pp 13–19

Miller WH, Griffin CE, Campbell KL (2013) Feline pemphigus foliaceus. In: *Muller & Kirk's- small animal dermatology*, 7th edn. Elsevier, St. Louis, pp 447–448

Preziosi DE, Goldschmidt MH, Greek JS et al (2003) Feline pemphigus foliaceus: a retrospective analysis of 57 cases. *Vet Dermatol* 14:313–321. Blackwell Publishing Ltd

Scaling Diseases in Dogs and Cat

Bacterial Overgrowth Syndrome (BOGS)

Jasmin P, Pin D, Carlotti DN (2001) Efficacy and interest of a systemic antibiotic treatment with cephalixin in dogs affected with bacterial overgrowth (BOG). In: *Proceedings of the 7th FECAVA and 47th Annual Congress of the FK-DVG, Berlin, October*, p 51

Pin D, Carlotti DN, Jasmin P et al (2006) Prospective study of bacterial overgrowth syndrome in eight dogs. *Vet Rec* 158(13):437–441

Malassezia Overgrowth

Ahman S, Perrins N, Bond R (2007) Carriage of *Malassezia* spp. yeasts in healthy and seborrhoeic Devon Rex cats. *Med Mycol* 45(5):449–455

- Bond R, Patterson-Kane JC, Lloyd DH (2004) Clinical, histopathological and immunological effects of exposure of canine skin to *Malassezia pachydermatis*. *Med Mycol* 42:165–175
- Chen T, Hill PB (2005) The biology of *Malassezia* organisms and their ability to induce immune responses and skin disease. *Vet Dermatol* 16(1):4–26
- Forster-Van Hijfte MA, Curtis CF, White RN (1997) Resolution of exfoliative dermatitis and *Malassezia pachydermatis* overgrowth in a cat after surgical thymoma resection. *J Small Anim Pract* 38:451–454
- Godfrey DR (1998) A case of feline paraneoplastic alopecia with secondary *Malassezia*-associated dermatitis. *J Small Anim Pract* 39:394–396
- Gross TL, Ihrke PJ, Walder EJ et al (2005) *Malassezia* dermatitis. In: *Skin diseases of the dog and cat: clinical and histopathologic diagnosis*. Blackwell Publishing, Oxford, pp 142–146
- Guaguère E, Prélard P (1996) Étude rétrospective de 54 cas de dermite à *Malassezia pachydermatis* chez le chien: résultats épidémiologiques, cliniques, cytologiques et histopathologiques. *Prat Méd Chir Anim Comp* 31:309–323
- Mauldin EA, Scott DW, Miller WH et al (1997) *Malassezia* dermatitis in the dog: a retrospective histopathological and immunopathological study of 86 cases (1990–95). *Vet Dermatol* 8:191–202
- Mauldin EA, Morris DO, Goldschmidt MH (2002) Retrospective study: the presence of *Malassezia* in feline skin biopsies. A clinicopathological study. *Vet Dermatol* 13:7–13
- Miller WH, Griffin CE, Campbell KL (2013) Feline *Malassezia* dermatitis. In: *Muller & Kirk's—small animal dermatology, 7th edn*. Elsevier, St. Louis, pp 243–249

Cutaneous Candidiasis

- Carlotti D, Pinn D (1999) *Candida* pododermatitis in the dog: a report of 5 cases. In: *Proceedings of the 15th AAVD/ACVD meeting, Maui*, pp 55–56
- Greene CE (2012) Algal and fungal diseases. In: *Infectious diseases of the dog and cat, 4th edn*. W.B. Saunders, Philadelphia, pp 666–671
- Gross TL, Ihrke PJ, Walder EJ et al (2005) Candidiasis. In: *Skin diseases of the dog and cat: clinical and histopathologic diagnosis*. Blackwell Publishing, Oxford, pp 9–11
- Miller WH, Griffin CE, Campbell KL (2013) Feline candidiasis. In: *Muller & Kirk's—small animal dermatology, 7th edn*. Elsevier, St. Louis, pp 267–268
- Mueller RS, Bettenay SV, Shipstone M (2002) Cutaneous candidiasis in a dog caused by *Candida guilliermondii*. *Vet Rec* 150(23):728–730
- Scott DW, Miller WH, Griffin CE (2001) *Muller & Kirk's small animal dermatology, 6th edn*. W.B. Saunders, Philadelphia, pp 361–363

Dermatophytosis

- Carlotti DN, Bensignor E (1999) Dermatophytosis due to *Microsporum persicolor* (13 cases) or *Microsporum gypseum* (20 cases) in the dog. *Vet Dermatol* 10:17–27
- Gross TL, Ihrke PJ, Walder EJ et al (2005) Feline and canine dermatophytosis. In: *Skin diseases of the dog and cat: clinical and histopathologic diagnosis*. Blackwell Publishing, Oxford, pp 410–415
- Miller WH, Griffin CE, Campbell KL (2013) Dermatophytosis. In: *Muller & Kirk's—small animal dermatology, 7th edn*. Elsevier, St. Louis, pp 231–243

Demodicosis and Other Superficial Ectoparasites

- Ferreira D, Sastre N, Ravera I et al (2015) Identification of a third feline Demodex species through partial sequencing of the 16S rDNA and frequency of Demodex species in 74 cats using a PCR assay. *Vet Dermatol* 26(4):239–e53
- Gross TL, Ihrke PJ, Walder EJ et al (2005) Pustular and nodular diseases with adnexal destruction. In: *Skin diseases of the dog and cat: clinical and histopathological diagnosis*, 2nd edn. Blackwell Science, Ames, pp 442–449
- Miller WH, Griffin CE, Campbell KL (2013) Demodicosis. In: *Muller & Kirk's- small animal dermatology*, 7th edn. Elsevier, St. Louis, pp 305–314
- Mueller RS (2004) Treatment protocols for demodicosis: an evidence-based review. *Vet Dermatol* 15(2):75–89
- Mueller RS, Bensignor E, Ferrer L et al (2012) Treatment of demodicosis in dogs: 2011 clinical practice guideline. *Vet Dermatol* 23(2):86–96, e20–e21
- Sastre N, Ravera I, Villanueva S et al (2012) Phylogenetic relationships in three species of canine Demodex mite based on partial sequences of mitochondrial 16S rDNA. *Vet Dermatol* 23(6):509–e101

Erosion in Dogs

- Gross TL, Ihrke PJ, Walder EJ et al (2005) Pustular diseases of epidermis. In: *Skin diseases of the dog and cat: clinical and histopathological diagnosis*, 2nd edn. Blackwell Science, Ames, pp 4–9
- Ihrke PJ (1996) Bacterial skin disease in the dog: a guide to canine pyoderma. *Veterinary Learning Systems*, Trenton, pp 1–97
- Miller WH, Griffin CE, Campbell KL (2013) Superficial bacterial folliculitis. In: *Muller & Kirk's- small animal dermatology*, 7th edn. Elsevier, St. Louis, pp 194–195

Ulcerative Diseases in Dogs

Deep Pyoderma

- Bassett RJ, Burton GG, Robson DC (2004) Antibiotic responsive ulcerative dermatoses in German Shepherd dogs with mucocutaneous pyoderma. *Aust Vet J* 82:485–489
- Gross TL, Ihrke PJ, Walder EJ et al (2005) Pyotraumatic dermatitis. In: *Skin diseases of the dog and cat: clinical and histopathological diagnosis*, 2nd edn. Blackwell Science, Ames, pp 116–118
- Ihrke PJ (1996) Bacterial skin disease in the dog: a guide to canine pyoderma. *Veterinary Learning Systems*, Trenton, pp 1–97
- Miller WH, Griffin CE, Campbell KL (2013) Bacterial skin diseases. In: *Muller & Kirk's- small animal dermatology*, 7th edn. Elsevier, St. Louis, pp 185–205
- Olivry T, Rossi MA, Banovic F (2015) Mucocutaneous lupus erythematosus in dogs (21 cases). *Vet Dermatol* 26:256–e55
- Rosser EJ Jr (2006) German shepherd dog pyoderma. *Vet Clin North Am Small Anim Pract* 36(1):203–211, viii. Review
- Wiemelt SP, Goldschmidt MH, Greek JS et al (2004) A retrospective study comparing the histopathological features and response to treatment in two canine nasal dermatoses, discoid lupus erythematosus and mucocutaneous pyoderma. *Vet Dermatol* 15:341–348

Wisselink MA, Koeman JP, Van den Ingh TS et al (1990) Investigations on the role of flea antigen in the pathogenesis of German shepherd dog pyoderma (GSP). *Vet Q* 12(1):21–28

Canine Leishmaniasis

Gross TL, Ihrke PJ, Walder EJ et al (2005) Cutaneous leishmaniasis. In: *Skin diseases of the dog and cat: clinical and histopathologic diagnosis*. Blackwell Publishing, Oxford, pp 312–316

Solano-Gallego L, Koutinas A, Miro G et al (2009) Directions for the diagnosis, clinical staging, treatment and prevention of canine leishmaniasis. *Vet Parasitol* 165:1–18

Ulcerative Diseases in Cats

Feline Indolent Ulcer

Colombini S, Hodgins EC, Foil CS et al (2001) Induction of feline flea allergy dermatitis and the incidence and histopathological characteristics of concurrent indolent lip ulcers. *Vet Dermatol* 12:155–161

Gross TL, Ihrke PJ, Walder EJ et al (2005) Feline indolent ulcer. In: *Skin diseases of the dog and cat: clinical and histopathological diagnosis*, 2nd edn. Blackwell Science, Ames, pp 128–130

Miller WH, Griffin CE, Campbell KL (2013) Indolent ulcer. In: *Muller & Kirk's- small animal dermatology*, 7th edn. Elsevier, St. Louis, pp 716–718

Eosinophilic Granuloma

Bardagi M, Fondati A, Fondevila D et al (2003) Ultrastructural study of cutaneous lesions in feline eosinophilic granuloma complex. *Vet Dermatol* 14:297–303

Fondati A, Fondevila D, Ferrer L (2001) Histopathological study of feline eosinophilic dermatoses. *Vet Dermatol* 12(6):333–338

Gross TL, Ihrke PJ, Walder EJ et al (2005) Feline indolent ulcer. In: *Skin diseases of the dog and cat: clinical and histopathological diagnosis*, 2nd edn. Blackwell Science, Ames, pp 128–130

Miller WH, Griffin CE, Campbell KL (2013) Feline eosinophilic granuloma. In: *Muller & Kirk's- small animal dermatology*, 7th edn. Elsevier, St. Louis, pp 714–715

Herpesvirus Ulcerative Dermatitis

Flecknell PA, Orr CM, Wright AI et al (1979) Skin ulceration associated with herpesvirus infection in cats. *Vet Rec* 104:313–315

Gross TL, Ihrke PJ, Walder EJ et al (2005) Feline herpesvirus ulcerative dermatitis. In: *Skin diseases of the dog and cat: clinical and histopathological diagnosis*, 2nd edn. Blackwell Science, Ames, pp 124–127

Hargis AM, Ginn PE, Mansell JEKL et al (1999) Ulcerative facial and nasal dermatitis and stomatitis in cats associated with feline herpesvirus 1. *Vet Dermatol* 10:267–274

- Lee M, Bosward KL, Norris JM (2010) Immunohistological evaluation of feline herpesvirus-1 infection in feline eosinophilic dermatoses or stomatitis. *J Feline Med Surg* 12:72–79
- Sánchez MD, Goldschmidt MH, Mauldin EA (2012) Herpesvirus dermatitis in two cats without facial lesions. *Vet Dermatol* 23(2):171–173, e35
- Suchy A, Bauder B, Gelbmann W et al (2000) Diagnosis of feline herpesvirus infection by immunohistochemistry, polymerase chain reaction, and *in situ* hybridization. *J Vet Diagn Invest* 12:186–191

Sporotrichosis

- Crothers SL, White SD, Ihrke PJ et al (2009) Sporotrichosis: a retrospective evaluation of 23 cases seen in northern California (1987–2007). *Vet Dermatol* 20(4):249–259
- Dunstan RW, Reimann KA, Langham RF (1986) Feline sporotrichosis. *J Am Vet Med Assoc* 189:880–883
- Fleury RN, Taborda PR, Gupta AK et al (2001) Zoonotic sporotrichosis. Transmission to humans by infected domestic cat scratching: report of four cases in Sao Paulo, Brazil. *Int J Dermatol* 40:318–322
- Gross TL, Ihrke PJ, Walder EJ et al (2005) Sporotrichosis. In: *Skin diseases of the dog and cat: clinical and histopathological diagnosis*, 2nd edn. Blackwell Science, Ames, pp 298–301
- Madrid IM, Mattei AS, Fernandes CG et al (2012) Epidemiological findings and laboratory evaluation of sporotrichosis: a description of 103 cases in cats and dogs in southern Brazil. *Mycopathologia* 173(4):265–273
- Miller WH, Griffin CE, Campbell KL (2013) Sporotrichosis. In: *Muller & Kirk's- small animal dermatology*, 7th edn. Elsevier, St. Louis, pp 249–252
- Silva JN, Passos RL, Menezes CR et al (2015) Diagnostic accuracy assessment of cytopathological examination of feline sporotrichosis. *Med Mycol* 53(8):880–884

Plaques and Nodules

Bacterial Nodular Diseases in Dogs and Cats

Nocardiosis and Actinomycosis

- Greene CE (2012) Actinomycosis and Nocardiosis. In: *Infectious diseases of the dog and cat*. 4th edn. W.B. Saunders, Philadelphia, pp 484–494
- Gross TL, Ihrke PJ, Walder EJ et al (2005) Actinomycosis and nocardiosis. In: *Skin diseases of the dog and cat: clinical and histopathological diagnosis*, 2nd edn. Blackwell Science, Ames, pp 272–275
- Kirpensteijn J, Fingland RB (1992) Cutaneous actinomycosis and nocardiosis in dogs: 48 cases (1980-1990). Department of Clinical Sciences, College of Veterinary Medicine, Kansas State University, Manhattan. *J Am Vet Med Assoc* 201(6):917–920
- Malik R, Krockenberger MB, O'Brien CR et al (2006) Nocardia infections in cats: a retrospective multi-institutional study of 17 cases. *Aust Vet J* 84(7):235–245
- Miller WH, Griffin CE, Campbell KL (2013) Bacterial diseases. In: *Muller & Kirk's- small animal dermatology*, 7th edn. Elsevier, St. Louis, pp 212–214
- Siak MK, Burrows AK (2013) Cutaneous nocardiosis in two dogs receiving ciclosporin therapy for the management of canine atopic dermatitis. *Vet Dermatol* 24:453–e103

Botryomycosis

- Gross TL, Ihrke PJ, Walder EJ et al (2005) Bacterial pseudomycetoma. In: Skin diseases of the dog and cat: clinical and histopathological diagnosis, 2nd edn. Blackwell Science, Ames, pp 275–276
- Miller WH, Griffin CE, Campbell KL (2013) Bacterial diseases. In: Muller & Kirk's- small animal dermatology, 7th edn. Elsevier, St. Louis, pp 212–214
- Scott DW (2007) Bacterial pseudomycetoma (Botryomycosis) in dogs: two new case reports and review of the literature. *Jpn J Vet Dermatol* 13(3):135–140

Mycobacteriosis

- Davies JL, Sibley JA, Myers S et al (2006) Histological and genotypical characterization of feline cutaneous mycobacteriosis: a retrospective study of formalin-fixed paraffin-embedded tissues. *Vet Dermatol* 17(3):155–162
- Dedola C, Zobba R, Pinna Parpaglia ML (2014) First report of canine leprosy in Europe: molecular and clinical traits. *Vet Rec* 1;174(5):120
- Greene CE (2012) Mycoplasmal and Bacterial diseases. In: Infectious diseases of the dog and cat. 4th edn. W.B. Saunders, Philadelphia, pp 495–521
- Gross TL, Ihrke PJ, Walder EJ et al (2005) Feline leprosy syndrome. In: Skin diseases of the dog and cat: clinical and histopathological diagnosis, 2nd edn. Blackwell Science, Ames, pp 276–288
- Gunn-Moore DA (2014) Feline mycobacterial infections. *Vet J* 201(2):230–238
- Laprie C, Duboy J, Malik R et al (2013) Feline cutaneous mycobacteriosis: a review of clinical, pathological and molecular characterization of one case of *Mycobacterium microti* skin infection and nine cases of feline leprosy syndrome from France and New Caledonia. *Vet Dermatol* 24(6):561–569, e133-4 Epub 2013 Sep 2
- Malik R, Wigney D, Dawson D et al (2000) Infection of the subcutis and skin of cats with rapidly growing mycobacteria: a review of microbiological and clinical findings. *J Feline Med Surg* 2(1):35–48
- Malik R, Shaw SE, Griffin C et al (2004) Infections of the subcutis and skin of dogs caused by rapidly growing mycobacteria. *J Small Anim Pract* 45(10):485–494
- Malik R, Smits B, Reppas G et al (2013) Ulcerated and nonulcerated nontuberculous cutaneous mycobacterial granulomas in cats and dogs. *Vet Dermatol* 24:146–153, e32–e33
- Miller WH, Griffin CE, Campbell KL (2013) Mycobacterial infections. In: Muller & Kirk's- small animal dermatology, 7th edn. Elsevier, St. Louis, pp 207–212
- Smits B, Willis R, Studdert V et al (2012) Case clusters of 'leproid granulomas' in foxhounds in New Zealand and Australia. *Vet Dermatol* 23:465–e88

Protozoa

Leishmaniasis

- Gross TL, Ihrke PJ, Walder EJ et al (2005) Cutaneous leishmaniasis. In: Skin diseases of the dog and cat: clinical and histopathologic diagnosis. Blackwell Publishing, Oxford, pp 312–316
- Pennisi MG, Hartmann K, Lloret A et al (2013) Leishmaniasis in cats: ABCD guidelines on prevention and management. *J Feline Med Surg* 15(7):638–642
- Poli A, Abramo F, Barsotti P et al (2002) Feline leishmaniasis due to *Leishmania infantum* in Italy. *Vet Parasitol* 106:181–191

Solano-Gallego L, Koutinas A, Miro G et al (2009) Directions for the diagnosis, clinical staging, treatment and prevention of canine leishmaniosis. *Vet Parasitol* 165:1–18

Toxoplasma and Neospora

- Anfray P, Bonetti C, Fabbri F et al (2005) Feline cutaneous toxoplasmosis: a case report. *Vet Dermatol* 16:131–136
- Donahoe SL, Lindsay SA, Krockenberger M et al (2015) A review of neosporosis and pathologic findings of *Neospora caninum* infection in wildlife. *Int J Parasitol Parasites Wildl* 4(2): 216–238
- Dubey JP, Carpenter JL (1993) Histologically confirmed clinical toxoplasmosis in cats: 100 cases (1952–1990). *J Am Vet Med Assoc* 203:1556–1566
- Dubey JP, Metzger FL Jr, Hattel AL et al (1995) Canine cutaneous neosporosis: clinical improvement with clindamycin. *Vet Dermatol* 6(1):37–43
- Greene CE (2012) Protozoal diseases. In: *Infectious diseases of the dog and cat*. 4th edn. W.B. Saunders, Philadelphia, pp 806–827
- Hoffmann AR, Cadieu J, Kiupel M et al (2012) Cutaneous toxoplasmosis in two dogs. *J Vet Diagn Invest* 24(3):636–640
- Kul O, Atmaca HT, Deniz A et al (2011) Clinicopathologic diagnosis of cutaneous toxoplasmosis in an Angora cat. *Berliner und Muncher Tierarzt Wochensh* 124:10–13
- La Perle KM, Del Piero F, Carr RF et al (2001) Cutaneous neosporosis in two adult dogs on chronic immunosuppressive therapy. *J Vet Diagn Invest* 13(3):252–255
- Legnani S, Pantchev N, Forlani A et al (2016) Emergence of cutaneous neosporosis in a dog receiving immunosuppressive therapy: molecular identification and management. *Vet Dermatol* 27(1):49–e14
- Little L, Shokek A, Dubey JP et al (2005) *Toxoplasma gondii*-like organisms in skin aspirates from a cat with disseminated protozoal infection. *Vet Clin Pathol* 34:156–160
- Lloret A, Fondevila D et al (2002) Cutaneous neosporosis during treatment of pemphigus foliaceus in a dog. *J Am Anim Hosp Assoc* 38(5):415–419
- Mann TR, Cadore GC, Camillo G et al (2016) Canine cutaneous neosporosis in Brazil. *Vet Dermatol* 27:195–197
- Ordeix L, Lloret A, Fondevila D et al. (2002) Cutaneous neosporosis during treatment of pemphigus foliaceus in a dog. *J Am Anim Hosp Assoc* 38(5):415–419
- Park CH, Ikadai H, Yoshida E et al (2007) Cutaneous toxoplasmosis in a female Japanese cat. *Vet Pathol* 44:683–687
- Perl S et al (1996) Pyogranulomatous dermatitis associated to *Neospora caninum* in a dog. *World Small Anim Vet Assoc* 21:417

Worms

Dirofilariasis

- Albanese F, Abramo F, Braglia C et al (2013) Nodular lesions due to infestation by *Dirofilaria repens* in dogs from Italy. *Vet Dermatol* 24:255–e56
- Giori L, Garbagnoli V, Venco L, et al (2010) What is your diagnosis? Fine-needle aspirate from a subcutaneous mass in a dog. Mixed neutrophilic-eosinophilic inflammation with *Dirofilaria* fragments. *Vet Clin Pathol* 39(2):255–256

- Hargis AM, Lewis TP, Duclos DD et al (1999) Dermatitis associated with microfilariae (Filarioidea) in 10 dogs. *Vet Dermatol* 10(2):95–107
- Miller WH, Griffin CE, Campbell KL (2013) *Dirofilariasis*. In: Muller & Kirk's- small animal dermatology, 7th edn. Elsevier, St. Louis, pp 292–293
- Tarello W (2002) Cutaneous lesions in dogs with *Dirofilaria* (Nochtiella) repens infestation and concurrent tick-borne transmitted diseases. *Vet Dermatol* 13:267–274

Fungi

Dermatophytic Kerion

- Albanese F, Caruso C (2007) Dermatophytic kerion: etiopathological, clinical, diagnostic and therapeutic aspects of 39 dogs. *Veterinaria* 21:9–18
- Cornegliani L, Persico P, Colombo S (2009) Canine nodular dermatophytosis (kerion): 23 cases. *Vet Dermatol* 20(3):185–190
- Gross TL, Ihrke PJ, Walder EJ et al (2005) Pustular and nodular diseases with adnexal destruction. In: *Skin diseases of the dog and cat. Clinical and histopathological diagnosis*, 2nd edn. Blackwell Science, Oxford, pp 420–459
- Koutinas AF, Saridomichelakis M, Lekkas S et al (2003) Clinical and histopathological aspects of dermatophyte kerion in the dog: a retrospective study of 20 spontaneous cases. *Vet Dermatol* 14:243 (Abstract)
- Miller WH, Griffin CE, Campbell KL (2013) *Dermatophytosis*. In: Muller & Kirk's- small animal dermatology, 7th edn. Elsevier, St. Louis, pp 231–241

Dermatophytic Pseudomycetoma

- Abramo F, Vercelli A, Mancianti F (2001) Two cases of dermatophytic pseudomycetoma in the dog: an immunohistochemical study. *Vet Dermatol* 12:203–207
- Chang SC, Liao JW, Shyu CL et al (2011) Dermatophytic pseudomycetomas in four cats. *Vet Dermatol* 22(2):181–187
- Gross TL, Ihrke PJ, Walder EJ et al (2005) *Dermatophytic pseudomycetoma*. In: *Skin diseases of the dog and cat. Clinical and histopathological diagnosis*, 2nd edn. Blackwell Science, Oxford, pp 288–291
- Miller RI (2010) Nodular granulomatous fungal skin diseases of cats in the United Kingdom: a retrospective review. *Vet Dermatol* 21(2):130–135
- Thian A, Woodgyer AJ, Holloway SA (2008) Dysgonic strain of *Microsporum canis* pseudomycetoma in a Domestic Long-hair cat. *Aust Vet J* 86(8):324–328

Phaeohiphomycosis

- Abramo F, Bastelli F, Nardoni S et al (2002) Feline cutaneous *phaeohiphomycosis* due to *Cladophialophora bantiana*. *J Feline Med Surg* 4:157–163
- Beccati M, Vercelli A, Peano A et al (2005) *Phaeohiphomycosis* by *Phialophora verrucosa*: first European case in a cat. *Vet Rec* 157(3):93–94
- Fondati A, Gallo MG, Romano E et al (2001) A case of feline *phaeohiphomycosis* due to *Fonsecaea pedrosoi*. *Vet Dermatol* 12:297–301
- Greene CE (2012) *Fungal and algal diseases*. In: *Infectious diseases of the dog and cat*. 4th edn. W.B. Saunders, Philadelphia, pp 685–688

- Gross TL, Ihrke PJ, Walder EJ et al (2005) Cutaneous infections of other opportunistic fungi. In: *Skin diseases of the dog and cat: clinical and histopathologic diagnosis*. Blackwell Publishing, Oxford, pp 301–312
- Miller WH, Griffin CE, Campbell KL (2013) Chromomycosis (phaeohyphomycosis and chromoblastomycosis). In: *Muller & Kirk's- small animal dermatology*, 7th edn. Elsevier, St. Louis, pp 253–255

Cryptococcosis

- Greene CE (2012) Fungal and algal diseases. In: *Infectious diseases of the dog and cat*. 4th edn. W.B. Saunders, Philadelphia, pp 621–633. section III
- Gross TL, Ihrke PJ, Walder EJ et al (2005) Cutaneous cryptococcosis. In: *Skin diseases of the dog and cat: clinical and histopathologic diagnosis*. Blackwell Publishing, Oxford, pp 295–298
- Malik R, Jacobs GJ, Love DN (2001) Cryptococcosis: new perspectives on etiology, pathogenesis, diagnosis, and clinical management. In: August JR, ed. *Consultations in Feline Medicine*. Philadelphia, PA: W.B. Saunders Co.: 39–50
- Martins DB, Zanette RA, França RT et al (2011) Massive cryptococcal disseminated infection in an immunocompetent cat. *Vet Derm* 22(2):232–234
- Miller WH, Griffin CE, Campbell KL (2013) Feline cryptococcosis (torulosis, european blastomycosis). In: *Muller & Kirk's- small animal dermatology*, 7th edn. Elsevier, St. Louis, pp 262–265
- Xiarong L, Heitman J (2006) The biology of the *Cryptococcus neoformans* species complex. *Annual Review of Microbiology* 60:69–105

Sterile Diseases

Cutaneous Mineralization

- Bertazzolo W, Toscani L, Calcaterra S et al (2003) Clinicopathological findings in five cats with paw calcifications. *J Feline Med Surg* 5:11–17
- Gross TL (1997) Calcinosis circumscripta and renal dysplasia in a dog. *Vet Dermatol* 8:27–32
- Gross TL, Ihrke PJ, Walder EJ et al (2005) Calcinosis circumscripta. In: *Skin diseases of the dog and cat: clinical and histopathological diagnosis*, 2nd edn. Blackwell Science, Ames, pp 378–380
- Scott DW, Buerger RG (1988) Idiopathic calcinosis circumscripta in the dog: a retrospective analysis of 130 cases. *J Am Anim Hosp Assoc* 24:651–658
- Tafti AK, Hanna P, Bourque AC (2005) Calcinosis circumscripta in the dog: a retrospective pathological study. *J Vet Med A Physiol Pathol Clin Med* 52(1):13–17
- Doerr KA, Outerbridge CA, White SD et al (2013) Calcinosis cutis in dogs: histopathological and clinical analysis of 46 cases. *Vet Dermatol* 24(3):355–361, e78–e79

Eosinophilic Granuloma and Eosinophilic Plaque

- Bardagi M, Fondati A, Fondevila D et al (2003) Ultrastructural study of cutaneous lesions in feline eosinophilic granuloma complex. *Vet Dermatol* 14:297–303
- Fondati A, Fondevila D, Ferrer L (2001) Histopathological study of feline eosinophilic dermatoses. *Vet Dermatol* 12(6):333–338

- Gross TL, Ihrke PJ, Walder EJ et al (2005a) Feline eosinophilic plaque. In: *Skin diseases of the dog and cat: clinical and histopathological diagnosis*, 2nd edn. Blackwell Science, Ames, pp 109–111
- Gross TL, Ihrke PJ, Walder EJ et al (2005b) Feline eosinophilic granuloma; canine eosinophilic granuloma. In: *Skin diseases of the dog and cat: clinical and histopathological diagnosis*, 2nd edn. Blackwell Science, Ames, pp 355–360
- Joffe DJ, Allen AL (1995) Ulcerative eosinophilic stomatitis in three Cavalier King Charles spaniels. *J Am Anim Hosp Assoc* 31:34–37
- Madewell BR, Stannard AA, Pulley LT et al (1980) Oral eosinophilic granuloma in Siberian Husky dogs. *J Am Vet Med Assoc* 177:701–703
- Miller WH, Griffin CE, Campbell KL (2013) Feline eosinophilic granuloma complex. In: *Muller & Kirk's - small animal dermatology*, 7th edn. Elsevier, St. Louis, pp 714–716
- Porcellato I, Giontella A, Mechelli L et al (2014) Feline eosinophilic dermatoses: a retrospective immunohistochemical and ultrastructural study of extracellular matrix remodelling. *Vet Dermatol* 25(2):86–94, e26
- Vercelli A, Corneigliani L (2002) Oral eosinophilic granuloma in two German Shepherd dogs. In: *Proceedings of the 18th ESVD/ECVD meeting, Nice*, p 243

Panniculitis

- Boynosky NA, Stokking LB (2014) Potassium-bromide associated panniculitis. *J Small Anim Pract* 55:640–642
- Contreary CL, Outerbridge CA, Affolter VK et al (2015) Canine sterile nodular panniculitis: a retrospective study of 39 dogs. *Vet Dermatol* 26:1–10
- German AJ, Foster AP, Holden D et al (2003) Sterile nodular panniculitis and pancreatitis in three weimaraners. *J Small Anim Pract* 44:449–455
- Gross TL, Ihrke PJ, Walder EJ et al (2005) Disease of the panniculus. In: *Skin diseases of the dog and cat: clinical and histopathological diagnosis*, 2nd edn. Blackwell Science, Ames, pp 538–560
- Kim HJ, Kang MH, Kim J-H et al (2011) Sterile panniculitis in dogs: new diagnostic findings and alternative treatments. *Vet Dermatol* 22:352–359
- Mellanby RJ, Stell A, Baines E et al (2003) Panniculitis associated with pancreatitis in a Cocker Spaniel. *J Small Anim Pract* 44:24–28
- O'Kell AL, Inteeworn N, Diaz SF et al (2010) Canine sterile nodular panniculitis: a retrospective study of 14 cases. *J Vet Intern Med* 24:278–284
- Scott DW, Anderson WI (1988) Panniculitis in dogs and cats: a retrospective analysis of 78 cases. *J Am Anim Hosp Assoc* 24:551–559
- Yamagishi C, Momoi Y, Kobayashi T et al (2007) A retrospective study and gene analysis of canine sterile panniculitis. *J Vet Med Sci* 69:915–924

Swelling

Juvenile Sterile Granulomatous Dermatitis and Lymphadenitis (Juvenile Cellulitis)

- Jeffers JG, Duclos DD, Goldschmidt MH (1995) A dermatosis resembling juvenile cellulitis in an adult dog. *J Am Anim Hosp Assoc* 31(3):204–208

- Gross TL, Ihrke PJ, Walder EJ et al (2005) Juvenile sterile granulomatous dermatitis and lymphadenitis. In: *Skin diseases of the dog and cat: clinical and histopathological diagnosis*, 2nd edn. Blackwell Science, Ames, pp 327–330
- Miller WH, Griffin CE, Campbell KL (2013) Juvenile cellulitis. In: *Muller & Kirk's- small animal dermatology*, 7th edn. Elsevier, St. Louis, pp 708–709
- Reimann KA, Evans MG, Chalifoux LV et al (1989) Clinicopathologic characterization of canine juvenile cellulitis. *Vet Pathol* 26:499–504
- Scott DW, Miller WH (2007) Juvenile cellulitis in dogs: a retrospective study of 18 cases (1976–2005). *Jpn J Vet Dermatol* 13(2):71–79

Plasma Cell Pododermatitis

- Declercq J, De Bosschere H (2010) Nasal swelling due to plasma cell infiltrate in a cat without plasma cell pododermatitis. *Vet Dermatol* 21(4):412–414
- Gross TL, Ihrke PJ, Walder EJ et al (2005) Plasma cell pododermatitis. In: *Skin diseases of the dog and cat: clinical and histopathological diagnosis*, 2nd edn. Blackwell Science, Ames, pp 363–364
- Gruffydd-Jones TJ, Orr CM, Lucke VM (1980) Foot pad swelling and ulceration in cats: a report of five cases. *J Small Anim Pract* 21:381–389
- Miller WH, Griffin CE, Campbell KL (2013) Plasma cell pododermatitis. In: *Muller & Kirk's- small animal dermatology*, 7th edn. Elsevier, St. Louis, pp 718–719
- Pereira PD, Faustino AMR (2003) Feline plasma cell pododermatitis: a study of 8 cases. *Vet Dermatol* 14(6):333–337

Chapter 4

Cytology of Skin Tumours

4.1 Introduction

The primary neoplasms of the skin are discussed in this chapter. Skin metastases originating from internal malignancies are not included in this wide group of neoplasia, as they will be briefly covered in the Chap. 5. With rare exceptions, such as ulcerative feline squamous cell carcinoma and exfoliative erythematous dermatitis in some cases of canine epitheliotropic lymphoma, almost all skin neoplasia are nodules or plaques. For this reason, an approach based on clinical signs, as used for inflammatory skin diseases, is not possible. Therefore, to discuss the cytology of skin neoplasms, a classification based on the cytological and histological morphology of the neoplastic cells must be used.

In the “WHO Histological Classification of Tumours of Domestic Animals” published in 1998, skin tumours are divided into *epithelial*, *melanocytic*, *mesenchymal* and *unclassifiable*; in addition to these four groups, *metastatic tumours* to the skin, *cysts*, *hamartomas* and *neoplastic-like lesions* are also included. This classification is obsolete as it does not include many skin tumours, which are now well documented in many articles and books on histopathology and clinical oncology of the skin (Gross et al. 2005; Withrow et al 2012).

In recent decades, the study of histopathology and the increased use of immunohistochemical stains, allowed a broader and more detailed classification of tumours of the skin of pets (Yager and Wilcock 1994; Gross et al. 2005). At the same time, veterinary neoplastic cytology has made great strides, which has led to the publication of many books focused on general and skin cytopathology (Baker and Lumsden 1999; Valenciano and Cowell 2014; Raskin and Meyer 2015). Furthermore, a number of articles supporting the accuracy of cytology in the diagnosis of skin cancer and its high correlation with histopathological findings have been published (Griffiths et al. 1984; Chalita et al. 2001; Cohen et al. 2003; Ghisleni et al. 2006). All these factors have led to the routine use of cytology as a mandatory step in the diagnosis of skin lesions; the results of the cytology may in fact define the nature of

a tumour and direct the veterinarian in selecting the right tests to be performed for proper pre-surgical staging of the tumour.

The textbooks on skin cytology and dermatology in dogs and cats use a “hybrid” cytological classification of skin cancers; indeed, although for certain cancers a definition based on the origin of the cells and/or their architectural arrangement (e.g. *epithelial* and *mesenchymal* tumours) is used, other tumours are grouped based exclusively on their morphology (e.g. *round cell* tumours). Tumours of melanocytic origin, such as *melanocytoma* and *melanoma*, can increase confusion in this classification, as the neoplastic melanocytes are characterised by a remarkable polymorphism; indeed, they can be round or spindle-shaped, or organised in an epithelioid arrangement. For this reason, they are included in a separate group under the heading *melanocytic tumours*. This cytological classification does not reflect that used in histopathology (Gross et al. 2005); moreover, a cytological approach focused on the morphology of the cells allows the veterinarians to follow a simplified algorithm aimed at more rapid achievement of the diagnosis. It should be stressed that regarding neoplastic cytology, the cells do not always respect the morphological rules on which the above classification is based, as is exhaustively discussed in this chapter.

In this textbook, the skin neoplasms are divided into four groups:

- *Round cell tumours*
- *Epithelial tumours*
- *Mesenchymal tumours*
- *Melanocytic tumours*

4.2 Round Cell Tumours

Round cell tumours, although originating from different cell lines, share some cytological characteristics: the high number of cells yielded, the roundish silhouette with well-defined cytoplasmic margins and the trait of being discrete, meaning that they do not aggregate with each other or to an extracellular matrix. Although the above characteristics are observed in the majority of cases, some exceptions are recognised. A typical example is the histiocytic sarcoma, which belongs to the round cell tumour group (histiocytic diseases); in the spindle cell subtype of this neoplasia, the cytological features that allow the cells to be defined as *round cells* are not observed. In contrast, there are other skin cancers such as liposarcomas, melanomas or some poorly cohesive anaplastic carcinomas, which, although they are not included in this group, may present as round cells. From the above, it is deduced that this cytological classification is not free from risks of interpretation and should only be used as a diagnostic orientation, and, if diagnosis has not been achieved through cytology, further histopathological and sometimes immunohistochemical investigations must be performed.

Tumours included in this group are *mast cell tumours*, *lymphomas*, *plasma cell tumours*, *transmissible venereal tumours* and the so-called *histiocytic diseases*.

4.2.1 Mast Cell Tumour

Mast cell tumours (MCTs) are very common in dogs while they are less frequent in cats (Goldschmidt and Hendrick 2002; Welle et al. 2008). MCTs originate from dermal mast cells. In dogs, mast cell tumours are the most common form of skin cancer and can appear as nodules or plaques of varying sizes, ranging from a few millimetres up to large masses. The nodules are usually single, but can be multiple, dermal or subcutaneous in location, dome- or button-shaped, pedunculated, alopecic, erythematous or hyperpigmented, firm, soft or gelatinous in consistency and sometimes ulcerated (Figs. 4.1, 4.2, 4.3, and 4.4). Adults and old dogs are most commonly affected, but rarely, single or multiple MCTs can also be observed in very young animals. Many canine breeds, such as Boxer, Shar-pei, Labrador, Golden retriever, Boston terrier etc., are strongly predisposed; in Shar-pei dogs, which have a high quantity of mucin in the dermis, the MCTs frequently present as swellings with undefined margins (Fig. 4.5) (Blackwood et al. 2012).

A transitory change in the size occurring after a slight trauma, such as a FNB, is commonly observed in many canine MCTs; this clinical behaviour is unique to MCTs, in which nodules tend to increase in size and then, after a few hours, return to the original size. This phenomenon is due to the degranulation of mast cells, causing

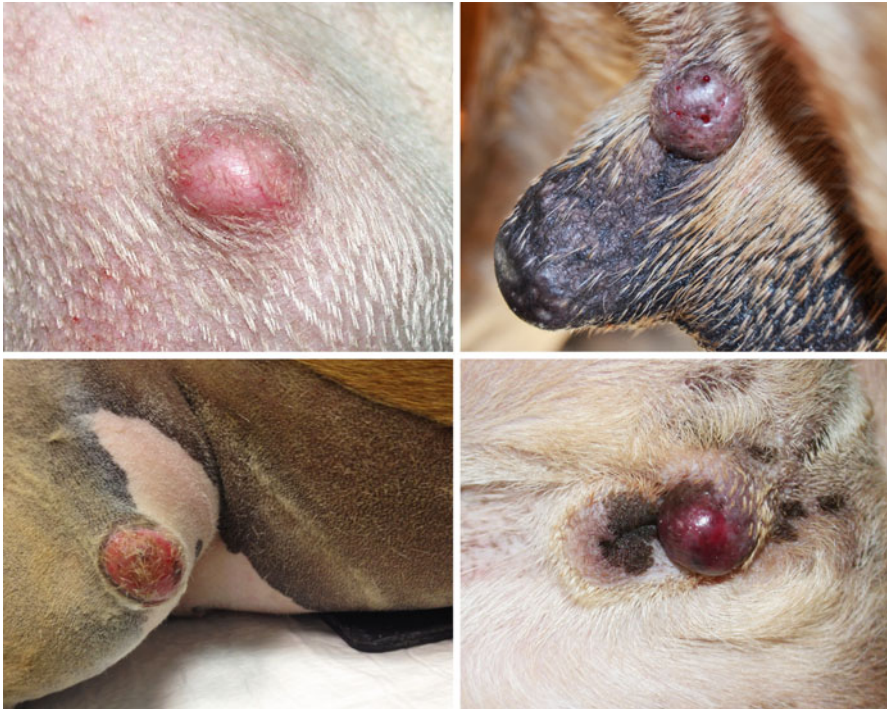

Fig. 4.1 Canine mast cell tumours (MCTs): single alopecic and erythematous nodules

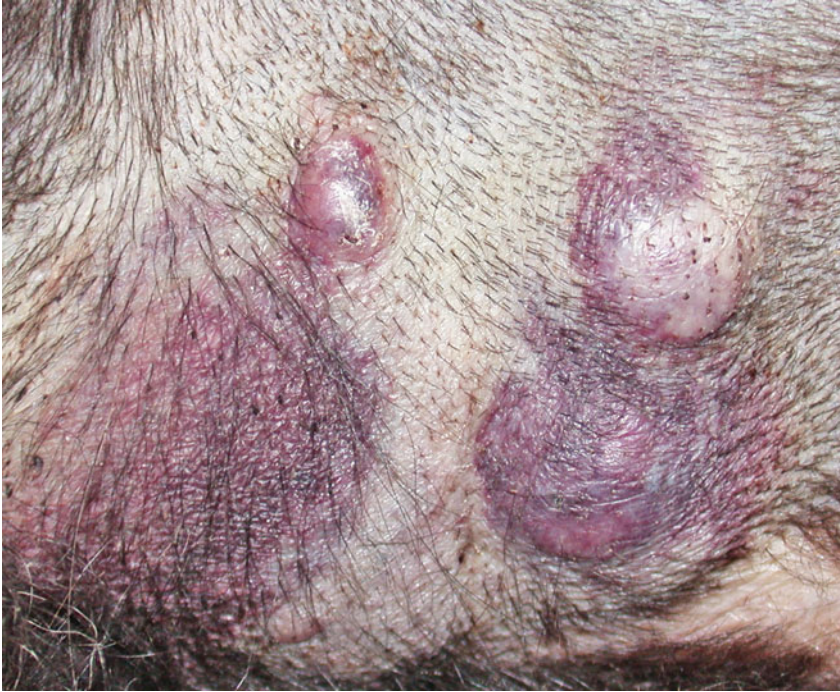

Fig. 4.2 Multiple MCTs on the chest of a dog

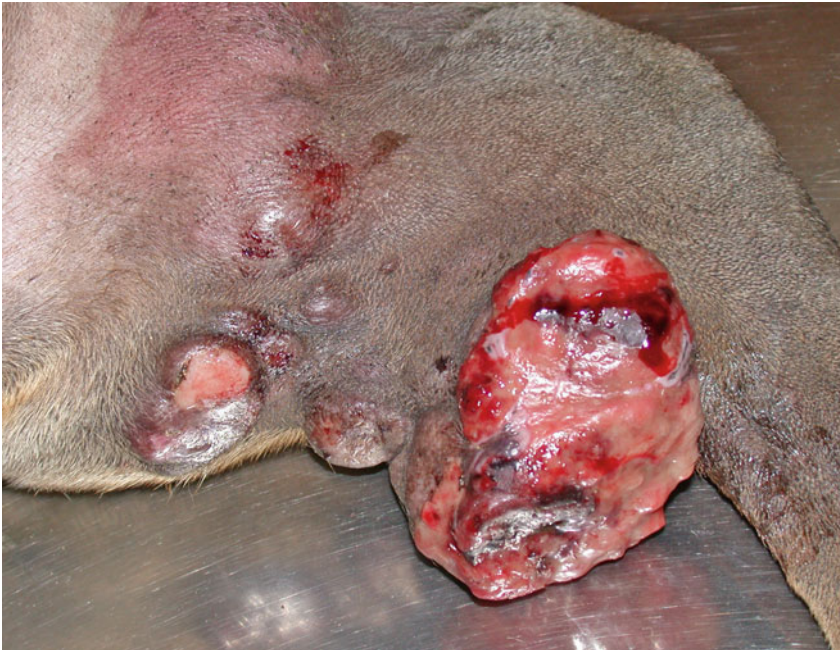

Fig. 4.3 Canine MCTs: multiple ulcerated masses on the leg of a Boxer

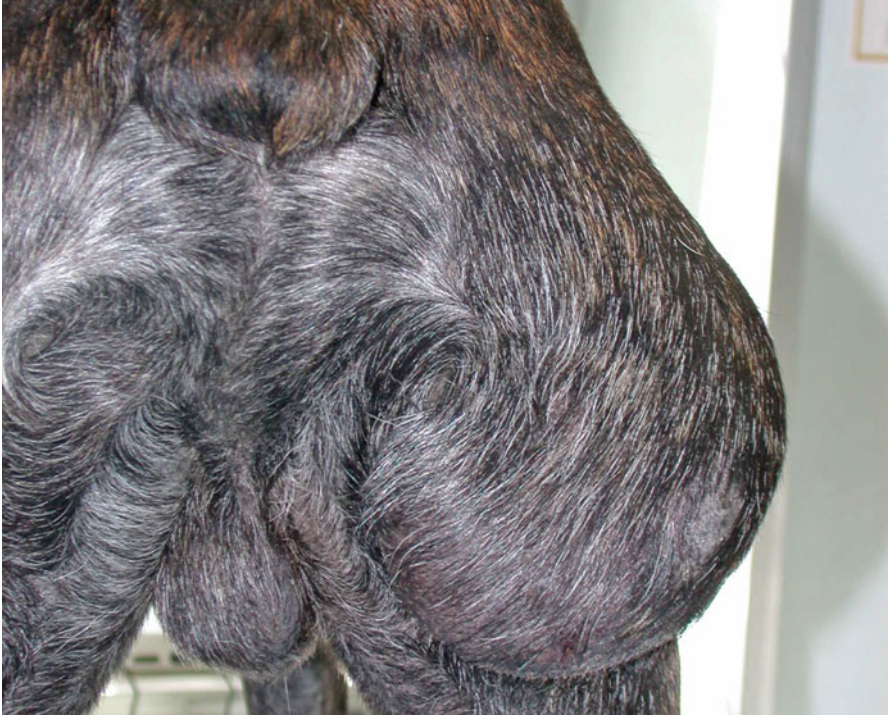

Fig. 4.4 Large mass, of pasty consistency, on right rump of a Boxer

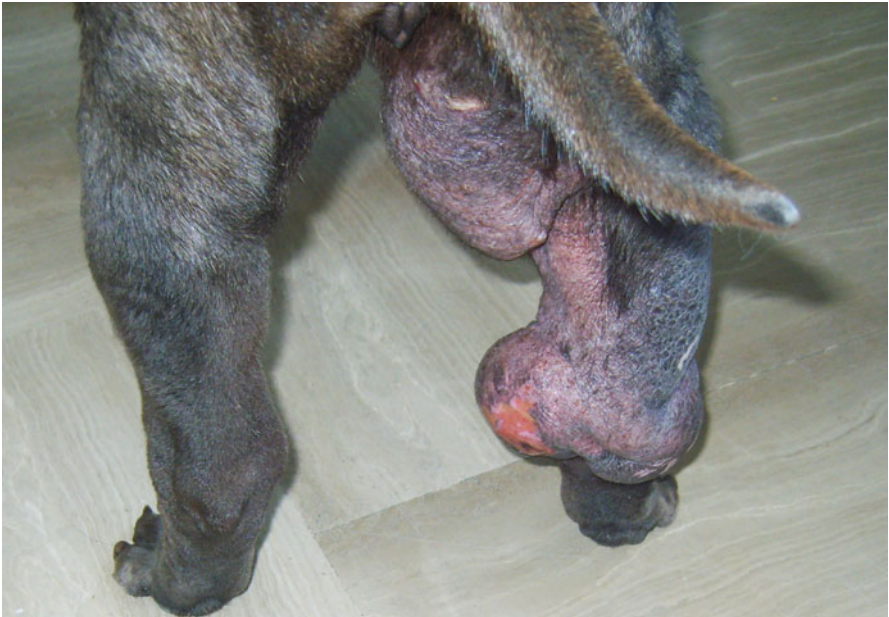

Fig. 4.5 Diffuse swelling with indistinct margins is a typical clinical presentation of MCTs in Shar-pei dogs

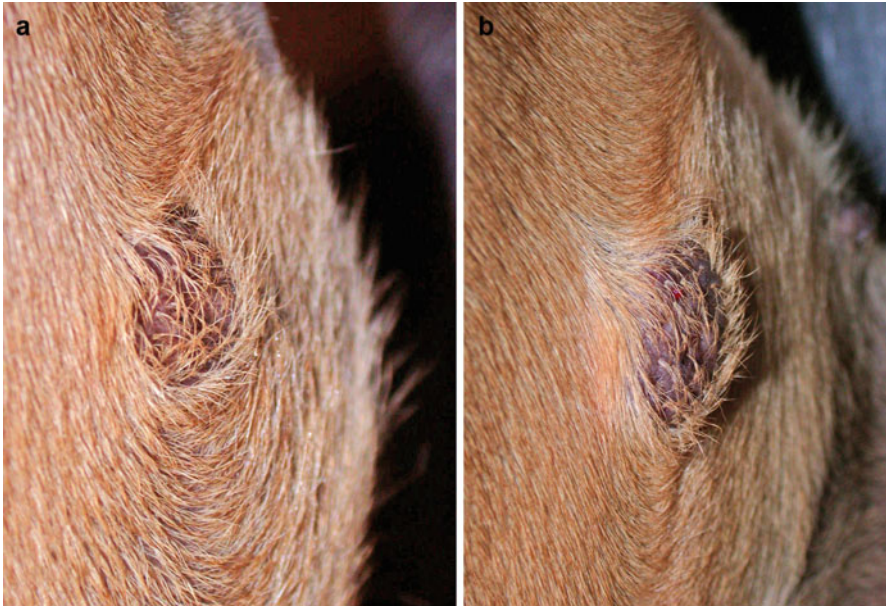

Fig. 4.6 Canine mastocytoma. Size modification during fine needle biopsy (FNB): (a) before and (b) after the sampling. Note how the nodule has increased in size

the release of intragranular vasoactive substances, which results in an intra- and peri-lesional oedema (Fig. 4.6). In some cases, as result of this degranulation, diffuse erythema of the skin covering the tumour can be observed (Darier's sign; Fig. 4.7).

Feline *MCT* usually occurs as a small, single, alopecic, pinkish or erythematous nodule, mostly located on the head, ears or extremities (Figs. 4.8 and 4.9). In some patients, multiple nodules or plaques with intact or ulcerated skin are present (Figs. 4.10 and 4.11) (Johnson et al. 2002; Blackwood et al. 2012; Henry and Herrera 2013). The single tumours are usually confined to the skin, whereas the multicentric lesions are often secondary to a metastasis from a primitive splenic or intestinal *MCT*. In any case, the discovery of a cutaneous *MCT* must always be followed by the search for a possible primary or metastatic visceral lesion. A clinical variant of *MCT* affecting young Siamese cats, from a few months to 4 years of age, has occasionally been reported. This subtype, called *atypical* or *poorly granulated MCT*, is clinically characterised by the spontaneous regression of the nodules (Figs. 4.12 and 4.13).

Cytological Findings

In well-differentiated *MCTs*, the cytological diagnosis is easy and immediate, especially when proper sampling is performed; slides are usually highly cellular and in 90% of cases the diagnosis can be made (Fig. 4.14) (Pedraza et al. 2011). In dogs, the *MCTs* are composed of round cells characterised by many intracytoplasmic granules, which assume a characteristic purple colour with the use of Romanowsky-type staining (Fig. 4.15). In many cells, the granules are so numerous as to

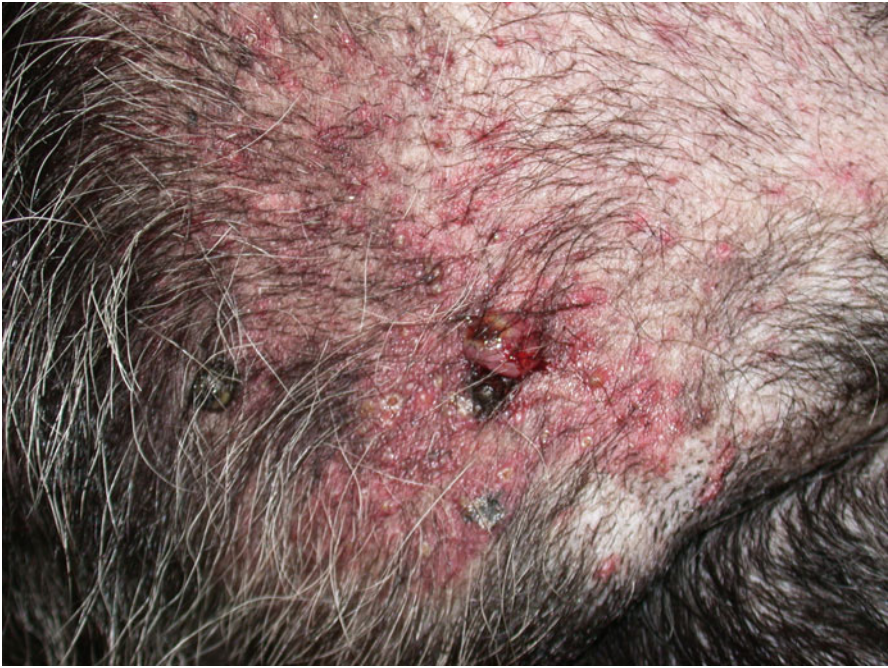

Fig. 4.7 Redness of the skin around an MCT characterises Darier's sign

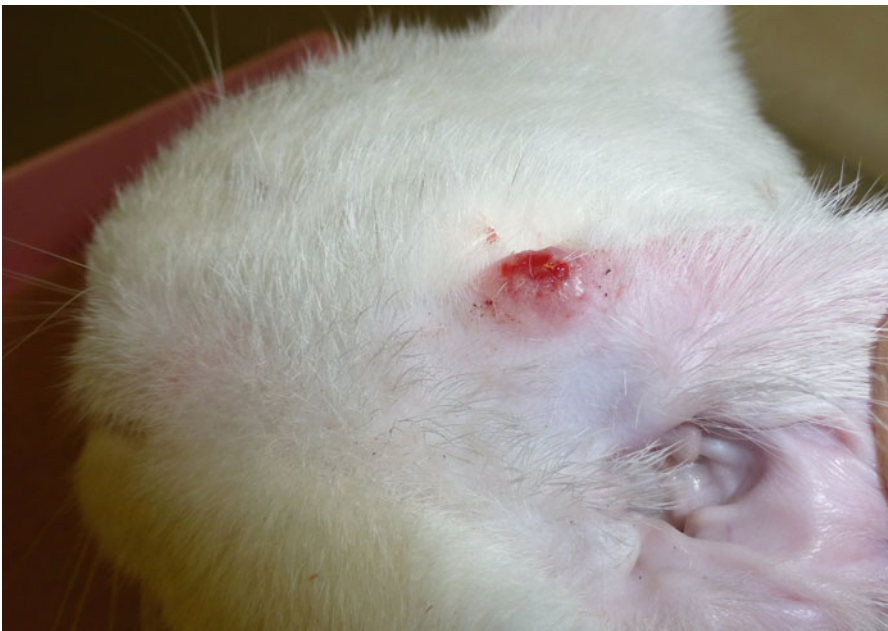

Fig. 4.8 Single and ulcerated MCT at the base of the pinna in a cat

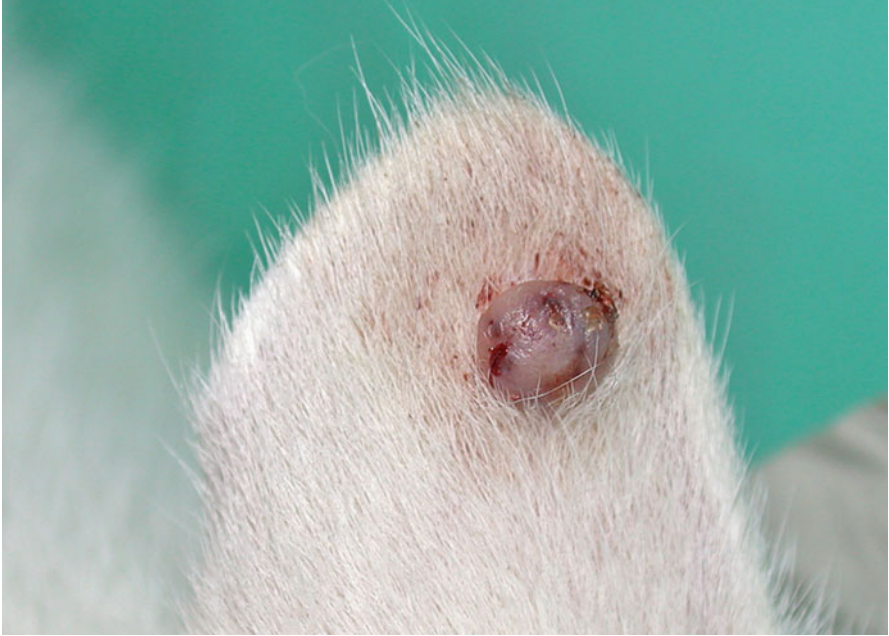

Fig. 4.9 A MCT in a cat: small and alopecic nodule on the pinna

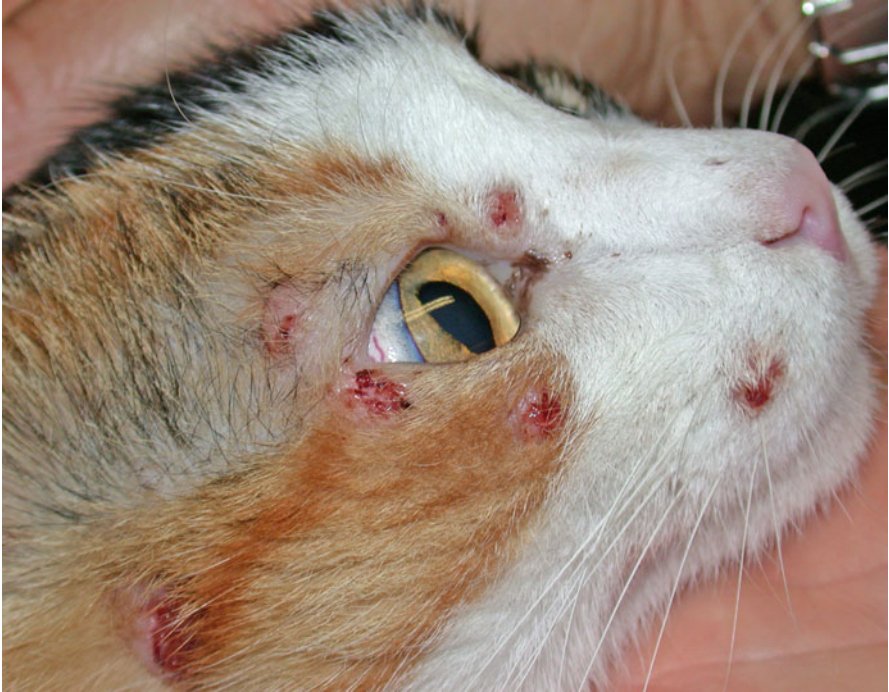

Fig. 4.10 Multiple nodules, some of them ulcerated, on the face of a cat with multicentric MCTs

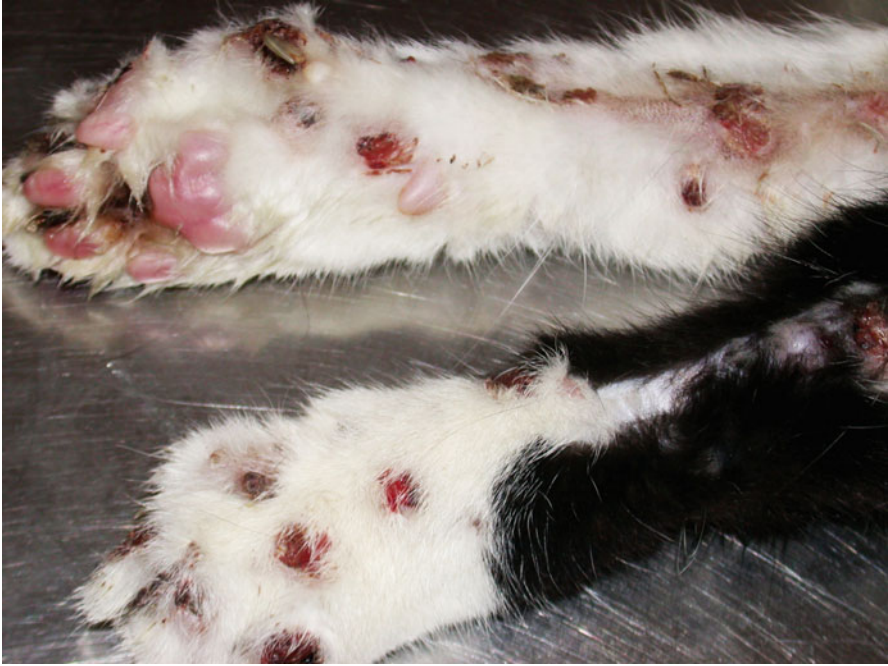

Fig. 4.11 Multiple metastatic MCTs. The primary neoplasm was located in the spleen

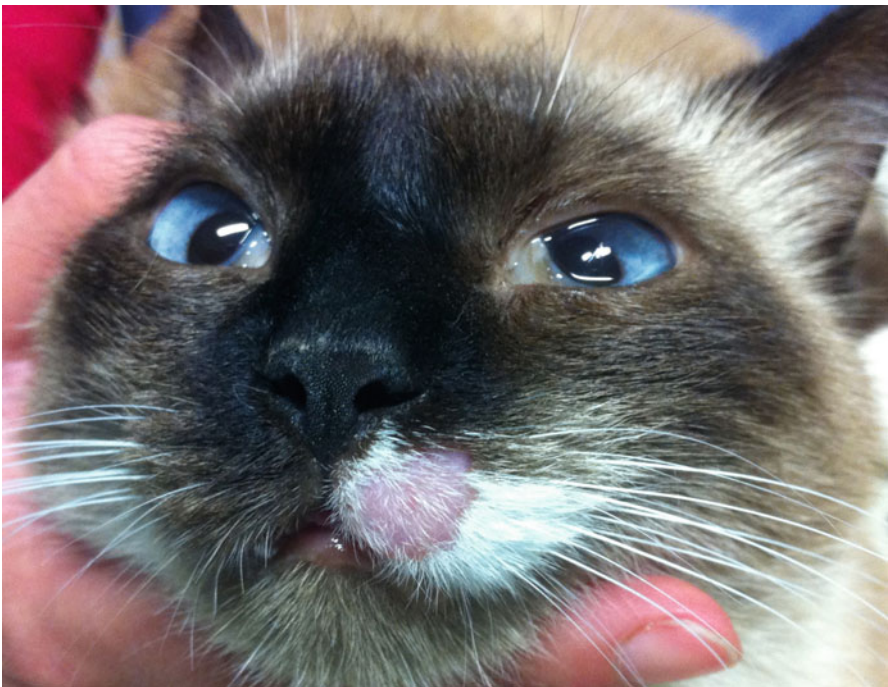

Fig. 4.12 Atypical MCT in a Siamese cat

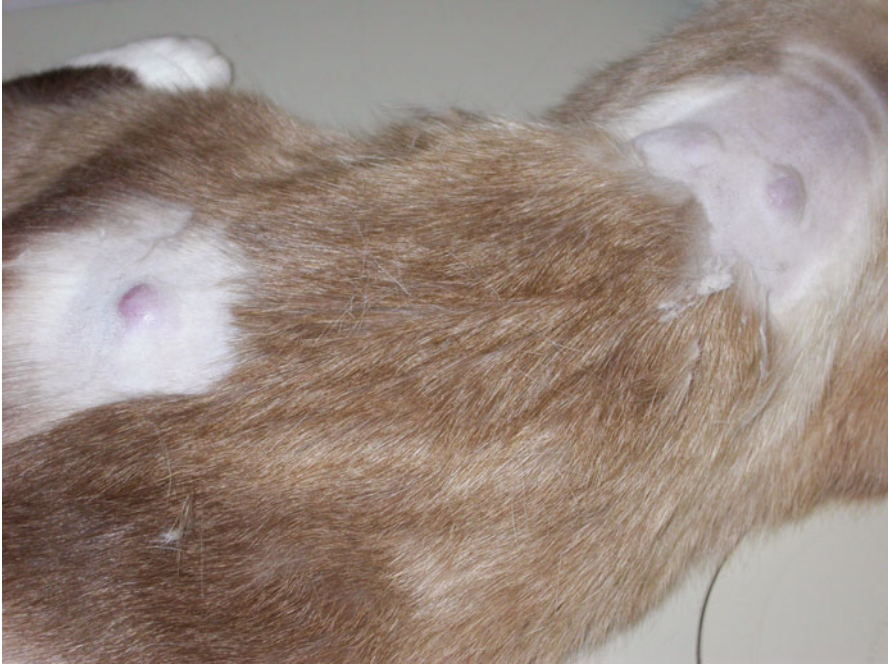


Fig. 4.13 Multiple MCTs on the same cat as in Fig. 4.12

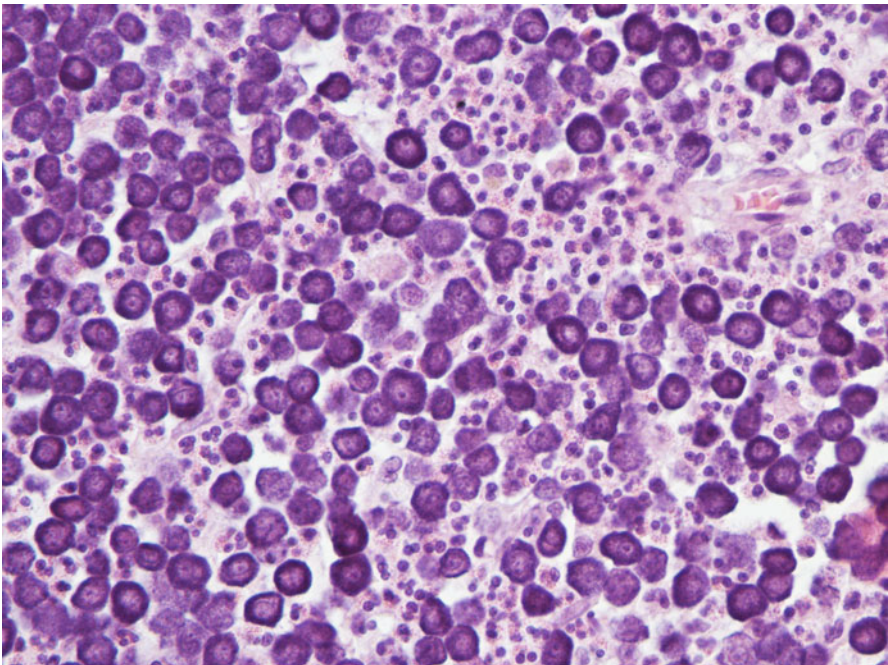


Fig. 4.14 Histopathology of a canine MCT: proliferation of well-differentiated neoplastic mast cells

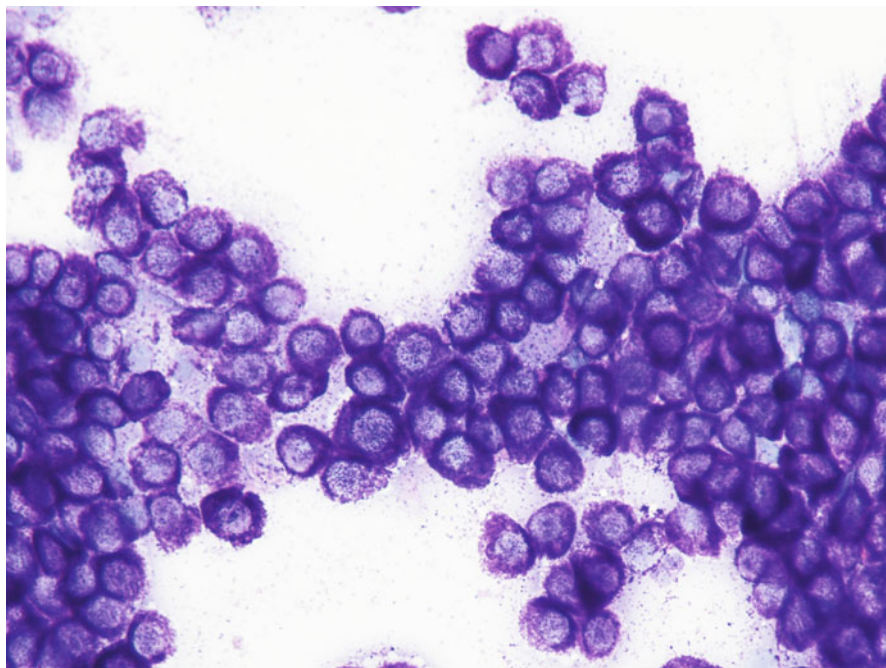


Fig. 4.15 Cytology of a canine MCT: many well-differentiated mast cells

completely obscure the nuclei; in other cases, the granules absorb most of the dye and the nuclei are barely noticeable in the centre of the cell as a faded and pale blue round area, surrounded by intensely stained granules (Fig. 4.16). In all the textbooks and papers relating to canine MCTs, the possibility that Romanowsky-type dye is not capable of staining granules is constantly reported. In practice, this phenomenon is a very rare occurrence and, in most cases, a careful observation of the slide allows the detection of intracytoplasmic granules in some cells. In cases where the granules are few or poorly visible, it is possible to highlight them with toluidine blue, which stains the granules red (Fig. 4.17).

In many tumours a variable number of *eosinophils*, from few to many, attracted by the eosinophilic substances contained in the granules, are usually observed; eosinophils are therefore of great help in suspecting undifferentiated or poorly granular mast cell tumours. In some tumours, the number of eosinophils is higher compared with the neoplastic cells. In this case, before formulating a diagnosis of eosinophilic inflammation, a histopathology examination of the lesion is mandatory. The number of eosinophils seems lower in anaplastic MCTs (Fig. 4.18).

Many *reactive fibroblasts* are also frequently detected, probably as a result of the release of intracytoplasmic substances that stimulate fibrosis, especially in well-differentiated canine MCTs (Fig. 4.19). Fibroblasts can exhibit cytological abnormalities such as anisokaryosis, double nuclei and prominent nucleoli, and in some samples they can be so numerous that, especially for an inexperienced cytologist, a misdiagnosis of mesenchymal neoplasm could be made. In well-differentiated

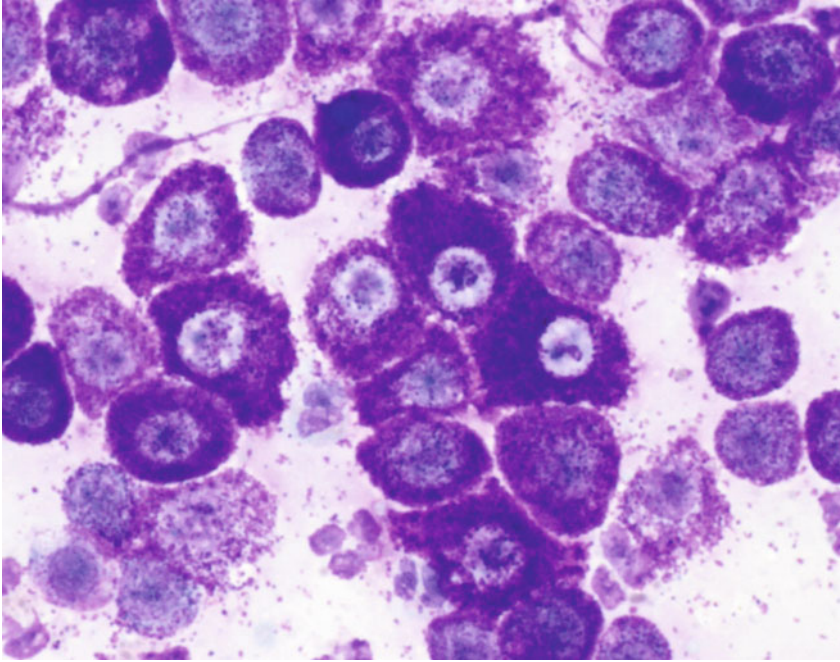


Fig. 4.16 Cytology of a canine MCT: note the pale, barely evident central nuclei and the intensely purple intracytoplasmic granules

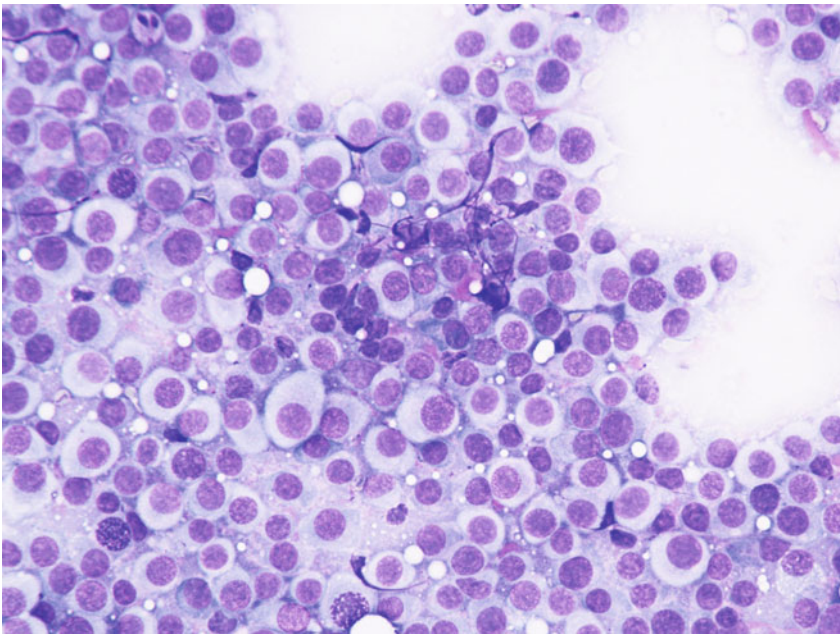


Fig. 4.17 Cytology of a canine MCT: Romanowsky staining. The characteristic purple intracytoplasmic granules have not taken the colour

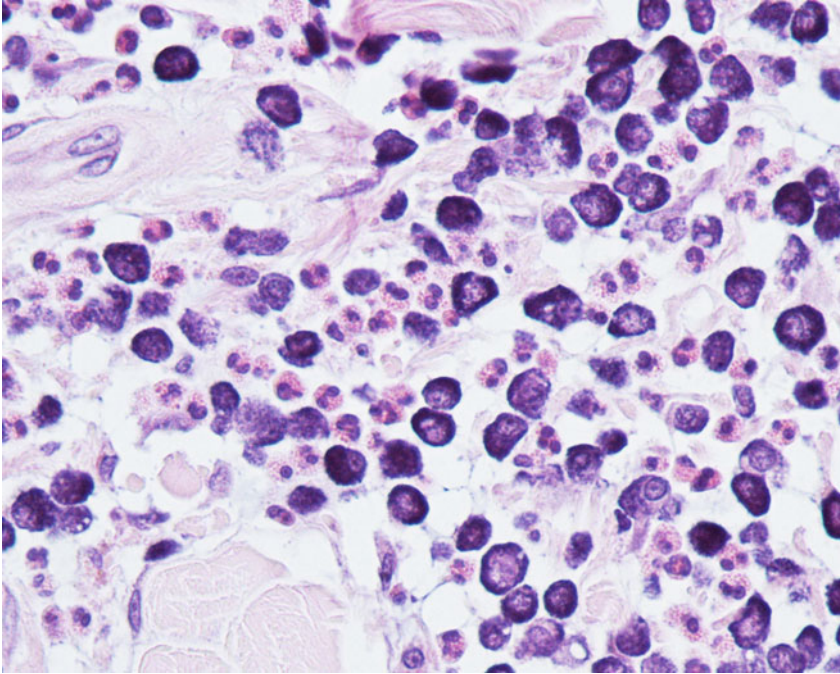


Fig. 4.18 Histopathology of a well-differentiated canine MCT: many eosinophils infiltrate the neoplastic cells

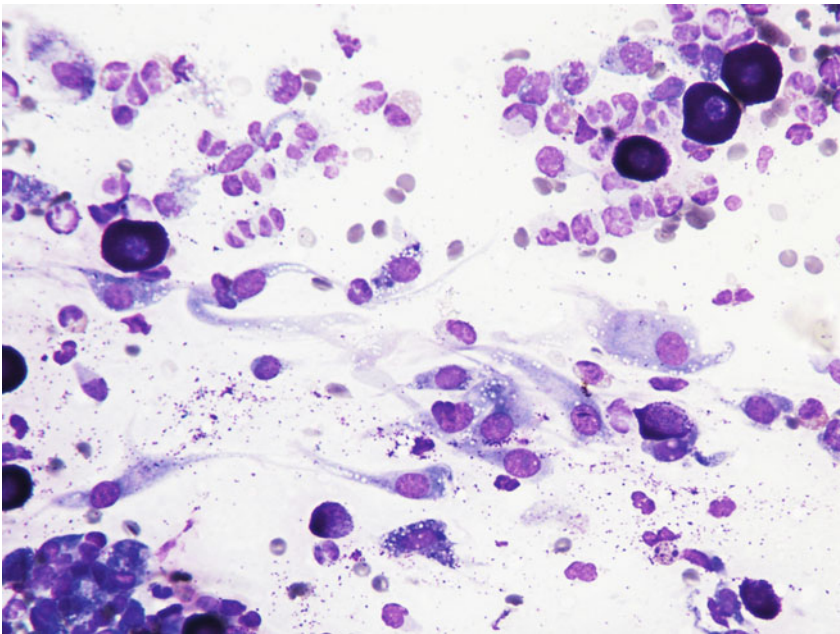


Fig. 4.19 Cytology of a canine MCT: many reactive fibroblasts together with few mast cells and eosinophils

MCTs, some eosinophilic *collagen fibres*, probably because of the increase in fibroblasts or following the collagenolytic action of certain substances contained in the cytoplasmic granules, are frequently observed (Figs. 4.20 and 4.21). In so-called *keloidal mast cell* tumours, the collagen fibres are numerous, thicker and pale pink in colour (Fig. 4.22).

In *poorly differentiated MCTs*, malignant aspects of cells are more evident: the nuclei show more atypia, such as anisokaryosis, can be multiple, with a bizarre shape and with prominent nucleoli (Fig. 4.23). In some cases, the granules are few or completely absent, and cytoplasm can contain multiple micro-vacuoles. The number of atypical mitoses increases. Sometimes in very anaplastic tumours the presence of eosinophils allows the cytologist to suspect an MCT (Figs. 4.24 and 4.25).

Although a cytological evaluation of cellular morphology may provide some indications regarding the degree of differentiation of the MCTs, the definition of the grading remains of exclusive pertinence to the histopathology (Patnaik et al. 1984; Kiupel et al. 2011). Cytologically, when slides show remarkable features of malignancy, a high-grade MCT can be diagnosed, whereas in cases in which MCTs are composed exclusively of well-differentiated mast cells, a low grade can only be hypothesised and histopathological confirmation is mandatory.

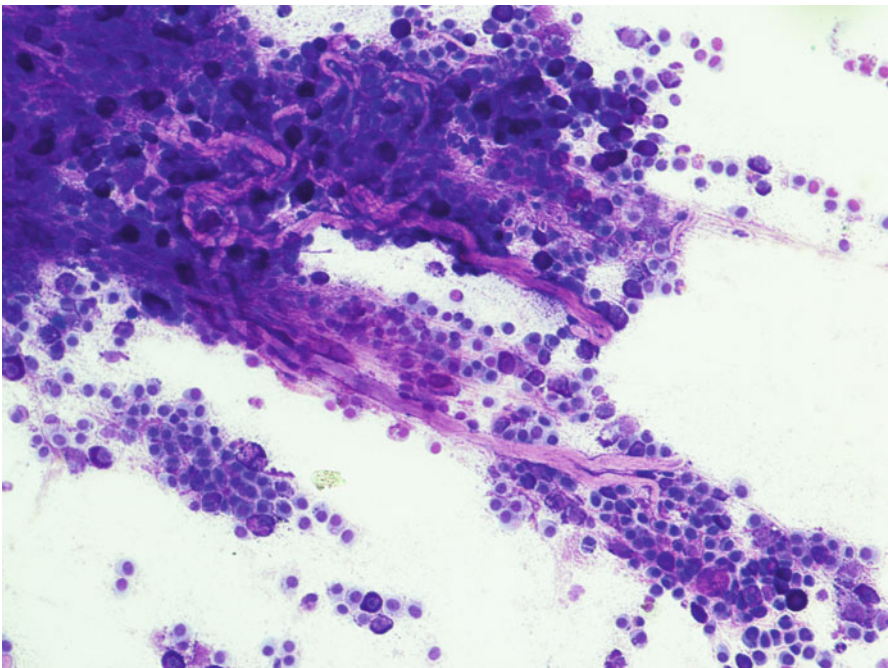


Fig. 4.20 Cytology of a canine MCT: the eosinophilic elongated formations represent collagen fibres. These fibres are very commonly observed in well-differentiated MCTs

The Patnaik histopathological system classifies MCTs into three grades, from I to III. The first two, more frequent grades, in which the cells have cytological aspects indicative of good (grade I) or moderate differentiation (grade II), up to grade III in which the cytological features of atypia increase. In addition to the morphological aspects, this classification is also based on the spread of the neoplastic cells, and for this reason, it is clear how it is not cytologically possible to differentiate between the first two grades of MCT.

In an interesting recent study, the possibility of making a cytological grading of MCTs based on quantitative morphological criteria (number of mitoses, bizarre nuclei, multiple karyomegalic nuclei), which form the basis of the Kiupel's histopathological classification, has been assessed.

The system attributed to Kiupel and co-authors classifies MCTs as low-grade and high-grade (Kiupel et al. 2011). In this cytological study, the accuracy of predicting the histological grade was 94 %, but it was found to be less reliable in predicting high-grade MCTs. The number of mitoses and the presence of bizarre nuclei are in fact two parameters that offer a high probability of an incorrect cytological evaluation, as the granules often do not allow correct visualisation of the nuclear silhouette. Furthermore, cells can be broken during an improper slide preparation,

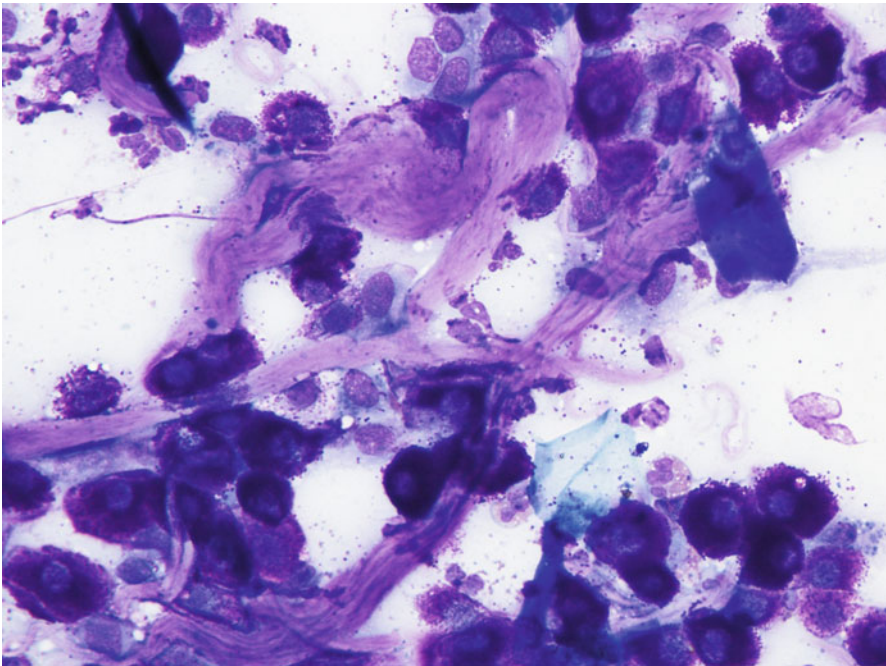


Fig. 4.21 Cytology of a canine MCT: at high magnification, the morphology of the collagen fibres is easily recognisable

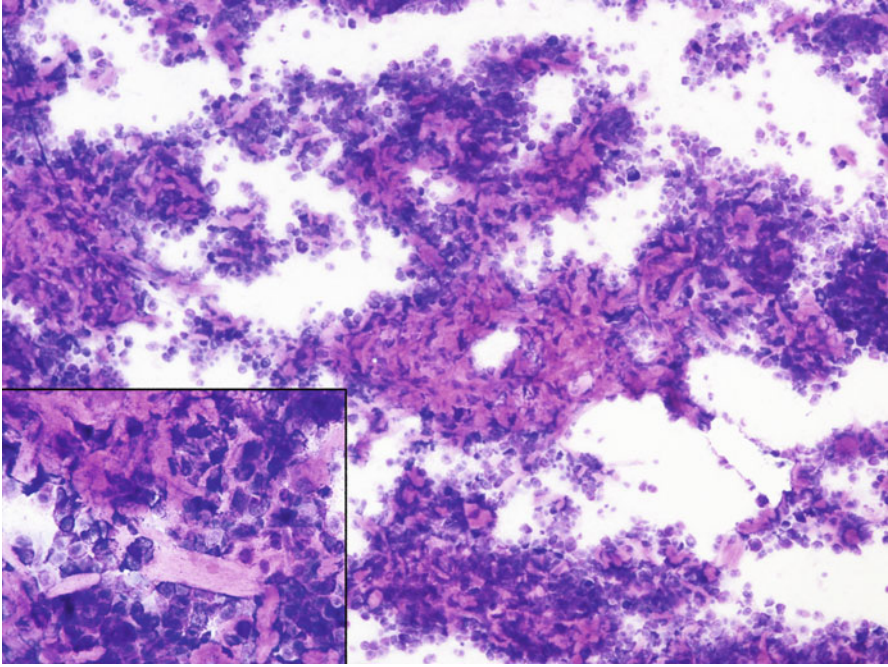


Fig. 4.22 Cytology of a keloidal canine MCT: many collagen fibres are intermingled within neoplastic mast cells. At high magnification, large and pale collagen fibres are easily recognisable (*inset*)

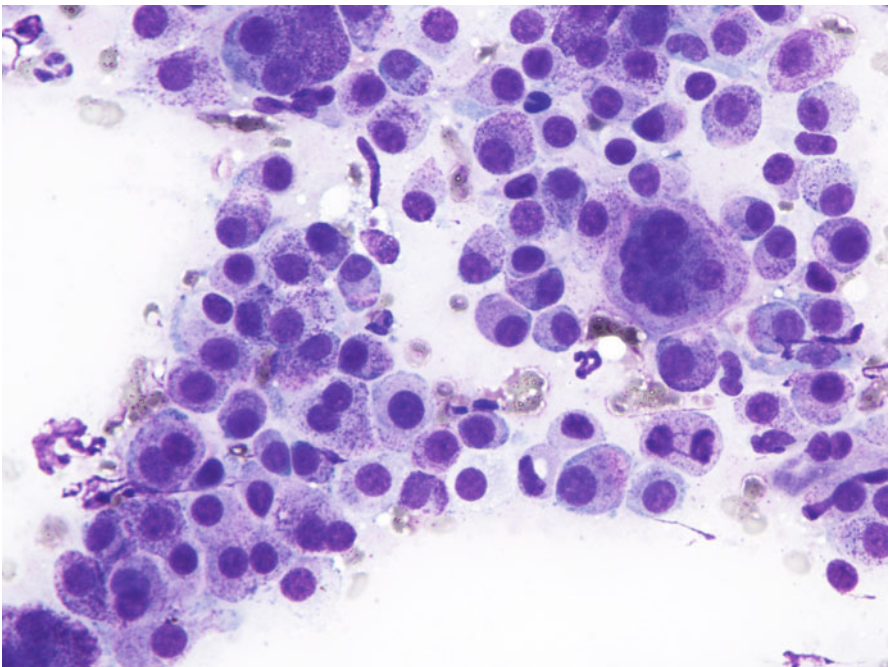


Fig. 4.23 Cytology of a poorly differentiated canine MCT: note the evident features of atypia, such as anisokaryosis, multiple nuclei and atypical mitosis

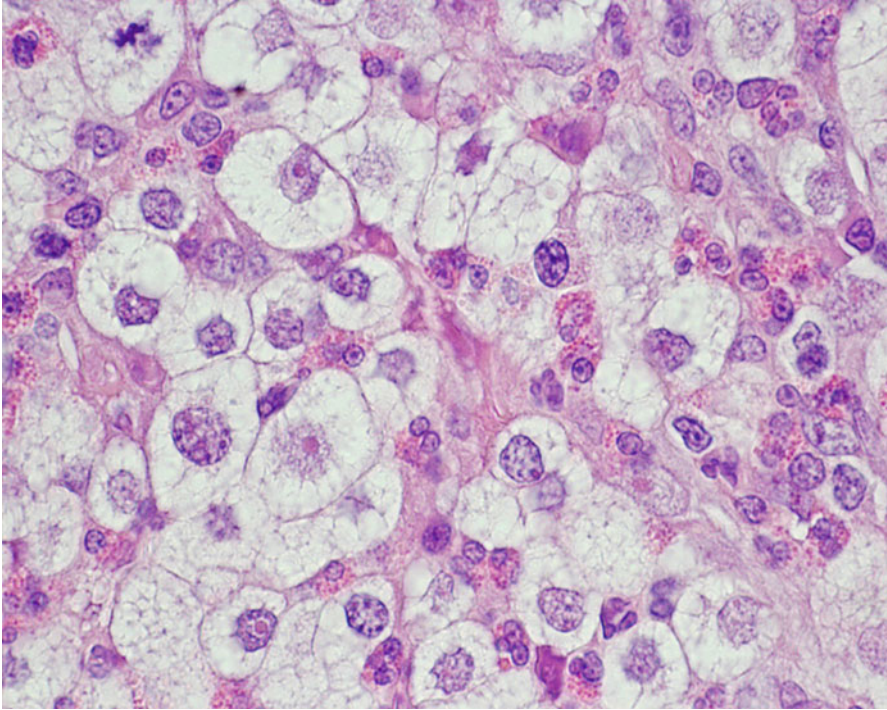


Fig. 4.24 Histopathology of a poorly differentiated canine MCT: severe cytological atypia. The high number of eosinophils aroused the suspicion of an MCT, which was confirmed by immunohistochemistry

making it impossible to make a correct assessment of the nuclear shape (bizarre nuclei) and karyomegaly, all parameters included in Kiupel's classification (Scarpa et al. 2014).

Furthermore, mitotic and multinucleated cells do not have a uniform distribution in the context of neoplastic proliferation and therefore the risk of not being sampled via FNB is very high, rendering the cytological grading less sensitive. Finally, as any MCTs must always be surgically removed and subjected to histopathological investigation, any attempt at grading MCTs through cytology has remained, until now, an unvalidated method. For this reason, cytology cannot substitute for histopathology, particularly because it may underestimate high-grade MCTs because of the very low cut-off of the parameters set by Kiupel's classification (at least 7 mitosis per 10 hpf; at least 3 multinucleated cells [with 3 or more nuclei] per 10 hpf; at least 3 bizarre nuclei per 10 hpf and karyomegaly) (Kiupel et al. 2011; Scarpa et al. 2014).

Feline MCTs are usually well differentiated and similar to those of the dog. As for the dog, the morphology of feline mast cells does not allow a histological correlation; moreover, in cats, a true grading of MCTs has not yet been validated. There

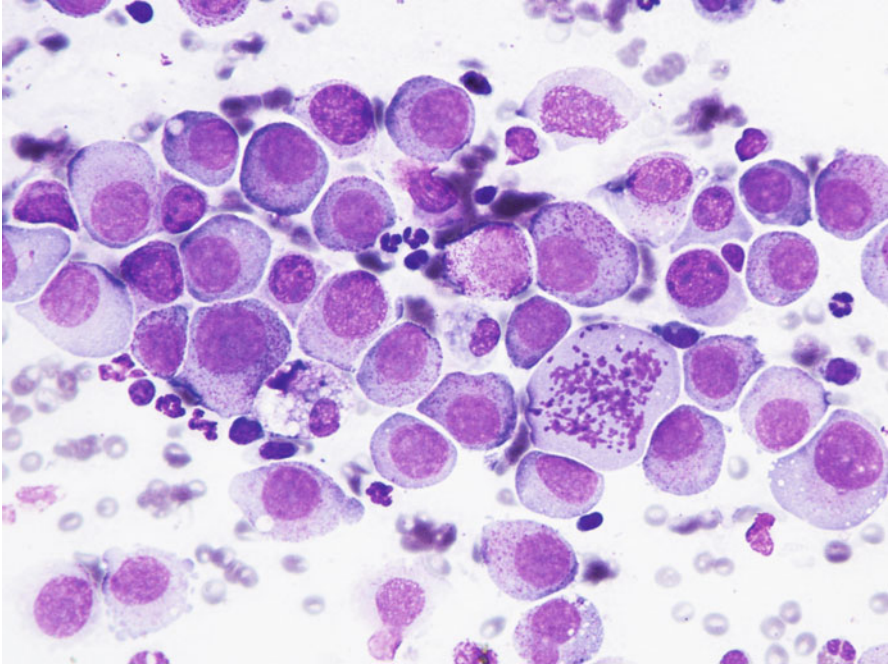


Fig. 4.25 Cytology of a poorly differentiated canine MCT: severe cytological atypia. Scattered purple granules are still detectable in the cytoplasm of some neoplastic cells

are currently three recognised histological types: *mastocytic well-differentiated MCT*, *mastocytic pleomorphic MCT* and the so-called *atypical MCT*, the latter formerly known by the term *histiocytic MCT* (Thamm and Vail 2007; Blackwood et al. 2012). To avoid confusion with the nomenclature of feline histiocytic disorders, some authors have therefore suggested abolishing the definition of *histiocytic MCT* and renaming this atypical subtype using the term *poorly granular mast cell tumour* (Melville et al. 2014).

The most common subtype in cats is the well-differentiated mastocytic subtype, usually clinically represented by a single nodule. Cells are round to polygonal in shape and usually adhere strongly to each other, giving a *pavement-like* appearance; the nuclei are usually central and granules are finer and less intensely stained, compared with those of dogs (Figs. 4.26 and 4.27). A variant of this form, considered a subgroup of the well-differentiated mastocytic subtype, is characterised by many *multinucleated mast cells*, in which the nuclei show a uniform size and the cytoplasm is heavily granulated (Figs. 4.28 and 4.29) (Melville et al. 2014). In poorly differentiated MCTs, the atypical aspects of cells increase and in some cases, a few mature lymphocytes dispersed onto slides can be observed (Gross et al. 2005; Melville et al. 2014; Sabbatini and Bettini 2010). In the cat, the *atypical* or *poorly granular* subtypes are characterised by cells that morphologically resemble histiocytes, with round or oval large nuclei, sometimes slightly indented, and a larger

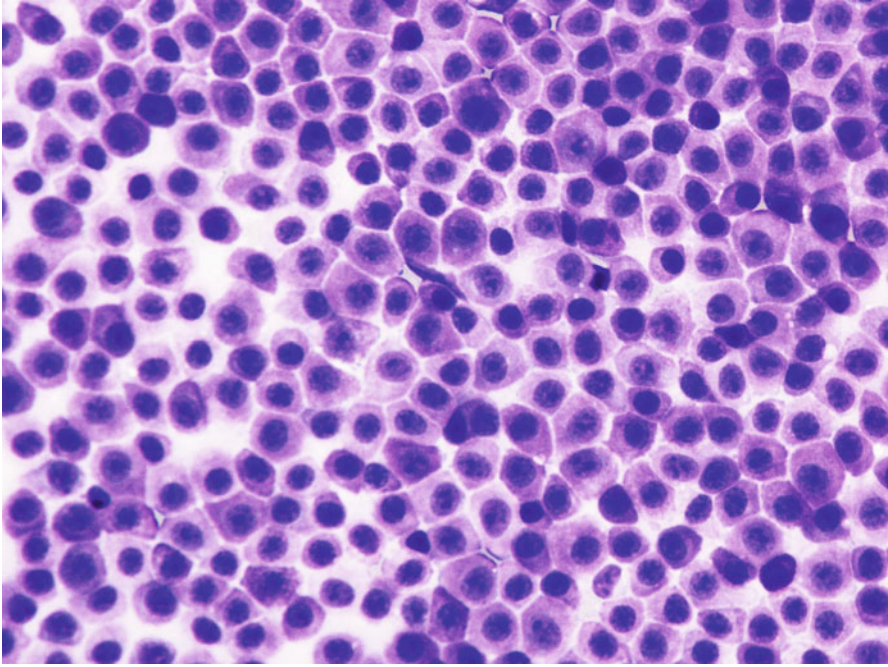


Fig. 4.26 Cytology of a feline mastocytic MCT: highly cellular sample. Note the polygonal silhouette of the feline mast cells

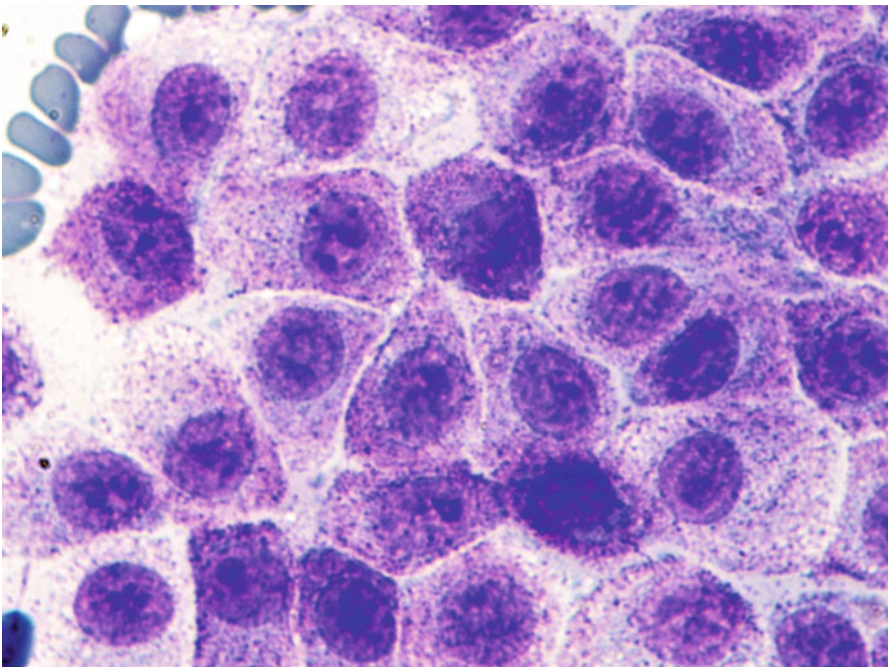


Fig. 4.27 Cytology of a feline mastocytic MCT: at high magnification, the fine purple intracytoplasmic granules are more evident

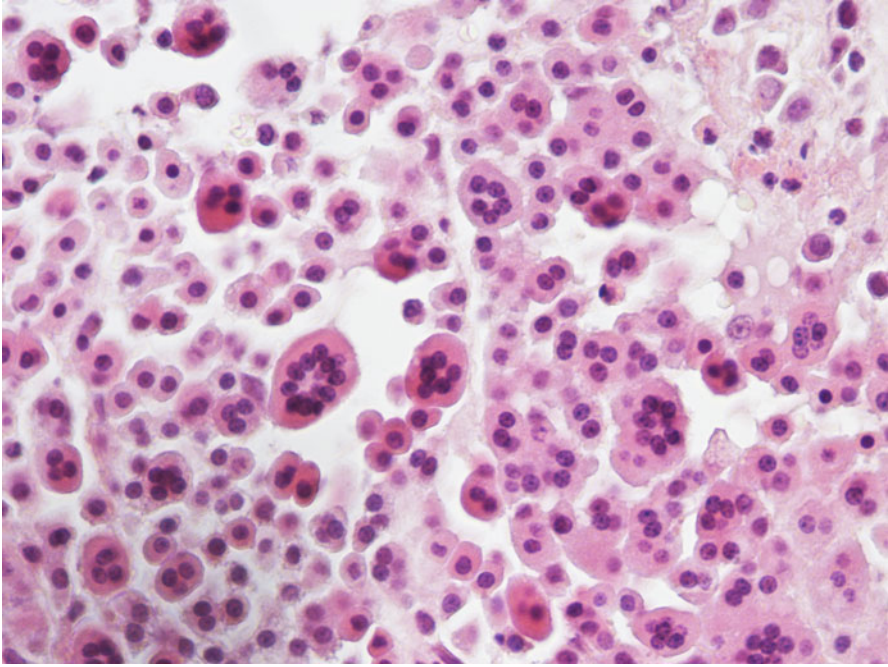


Fig. 4.28 Histopathology of a feline multinucleated mastocytic MCT: note the high number of multinucleated mast cells

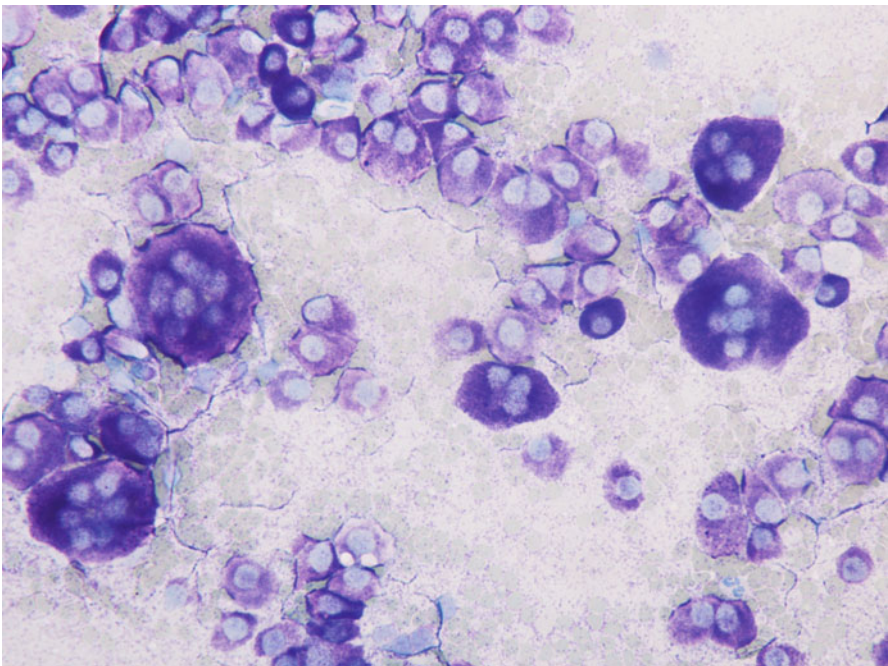


Fig. 4.29 Cytology of a feline multinucleated mastocytic MCT: many multinucleated mast cells

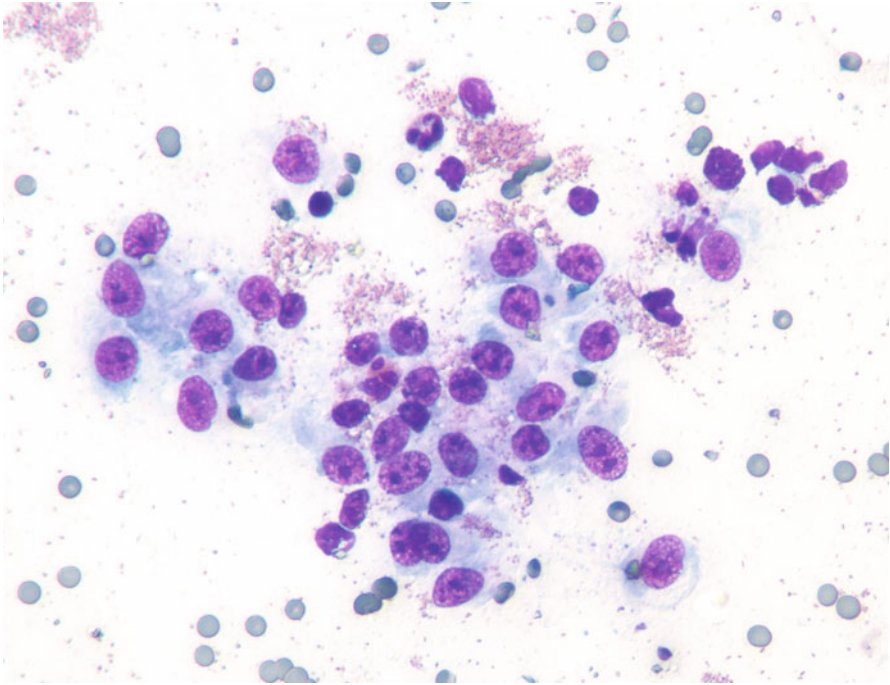


Fig. 4.30 Cytology of an atypical feline MCT: many single cells oval to spindle in shape, with slightly indented nuclei and a granular cytoplasm. Note the high number of eosinophilic granules in the background

cytoplasm that contains very few or no granules, and sometimes micro-vacuoles. In rare cases, toluidine blue can stain the rare granules. Some cells can have a spindle shape, which can cause them to be confused with a mesenchymal neoplasm or histiocytic disease. The number of eosinophils, usually scarce in most well-differentiated feline tumours, is often higher in the atypical subtype, and this could be very useful in suspecting a poorly granular MCT (Fig. 4.30).

4.2.2 Lymphoma

Cutaneous lymphomas are uncommon tumours in dogs and very rare in cats. Histologically, the cutaneous lymphomas are classified as either *epitheliotropic*, in which the neoplastic cells have a tropism for the epidermis, both external and follicular, or *non-epitheliotropic*, in which the neoplastic cells are localised in the dermis and can spread to the panniculus (Gross et al. 2005). The phenotype of epitheliotropic lymphoma is always T, whereas the phenotype can be both T and B in the non-epitheliotropic variant. In a recent case report, co-expression of T and B neoplastic cells in a dog with epitheliotropic lymphoma has been demonstrated (Brachelente et al. 2015).

In dogs, the macroscopic aspects of cutaneous lymphoma differ greatly depending on the location of the neoplastic cells.

Epitheliotropic lymphoma is a cancer of adult and old dogs in which different clinical presentations are recognised:

- (a) Diffuse erythema and desquamation (exfoliative erythroderma),
- (b) Plaques and nodules,
- (c) Depigmentation, erythema, erosions and ulcers of the mucocutaneous junctions and nose,
- (d) Erosions and ulcers localised exclusively to the oral cavity.

Such lesions may occur individually or simultaneously on the same animal (Figs. 4.31, 4.32, 4.33, and 4.34) (Moore et al. 2009; Affolter et al. 2009; Fontaine et al. 2009, 2010; Keller and Moore 2012; Miller et al. 2013).

In *non-epitheliotropic lymphoma*, lesions are characterized by multiple, dermal or subcutaneous in location, of different sizes, alopecic, erythematous and often ulcerated nodules and/or plaques (Moore et al. 2013). The more superficial nodules can sometimes assume a bizarre appearance characterised by a donut, arc or serpiginous shape (Figs. 4.35, 4.36, 4.37, and 4.38). This clinical presentation is highly suspicious, but not pathognomonic, for a non-epitheliotropic lymphoma, as it can also be observed in the course of other proliferative disorders such as cutaneous or systemic reactive histiocytosis.

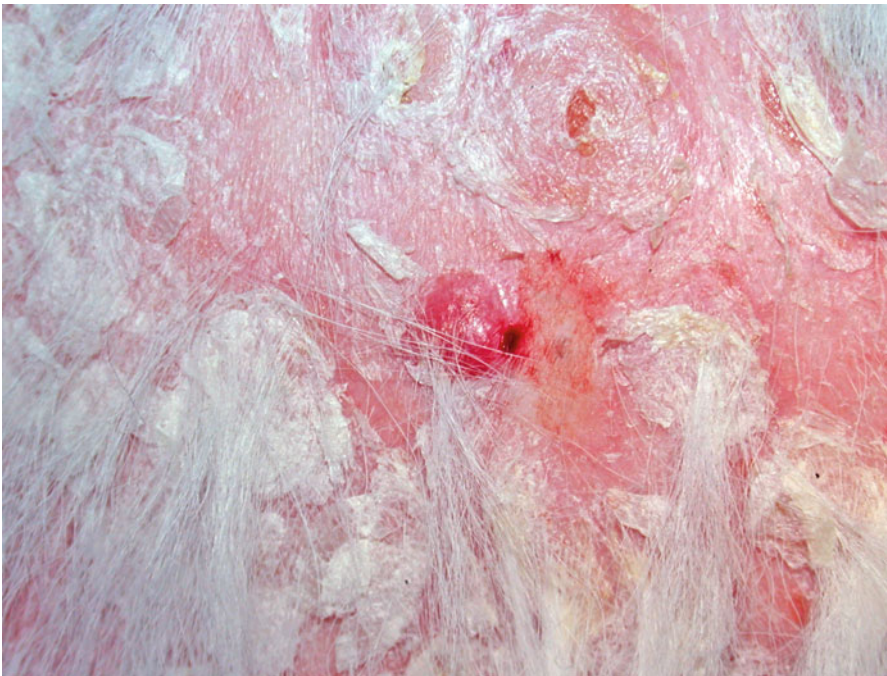

Fig. 4.31 Erythema with large scales in a dog with epitheliotropic lymphoma

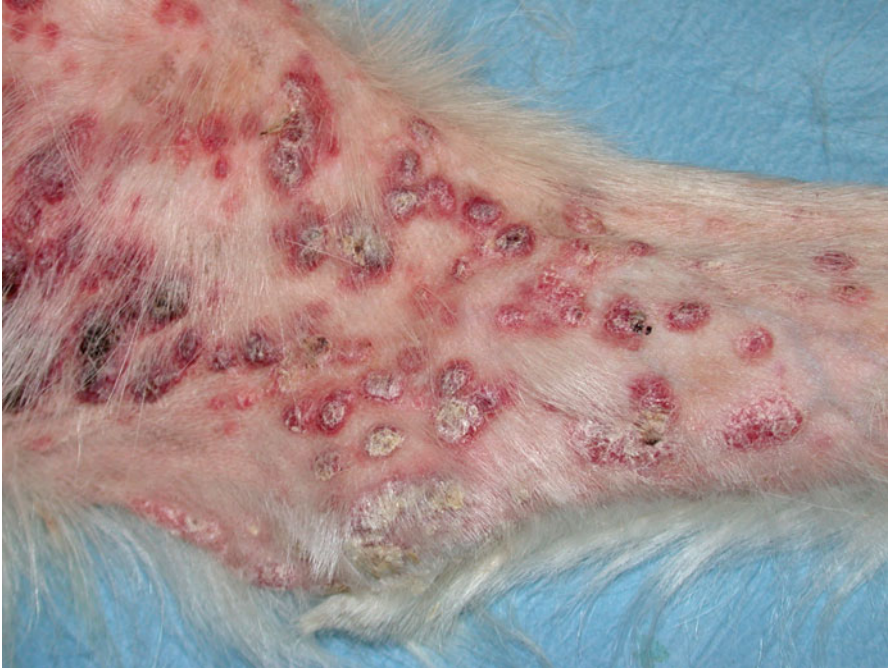

Fig. 4.32 Nodular canine epitheliotropic lymphoma: erythematous plaques and nodules on the axilla

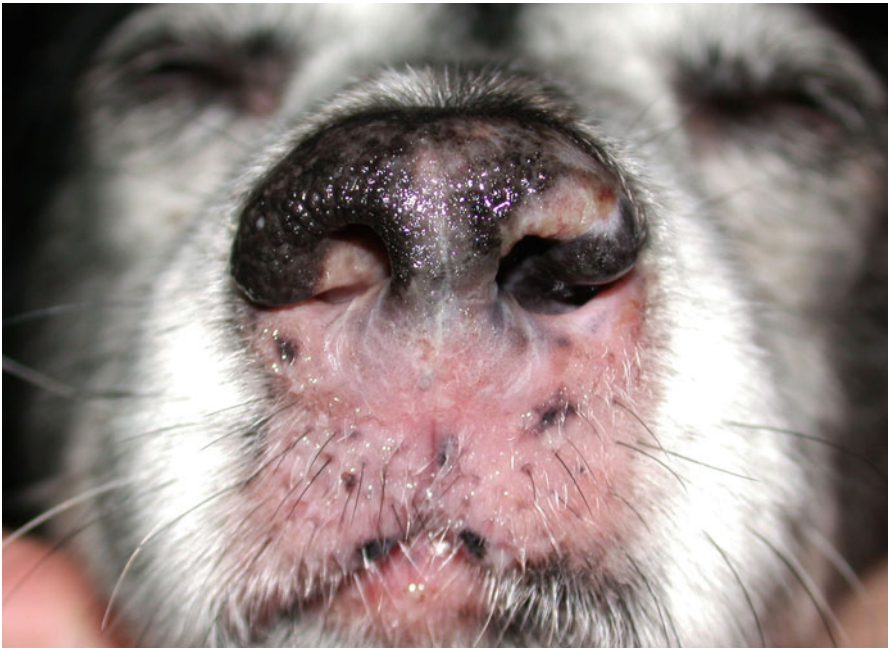

Fig. 4.33 Canine epitheliotropic lymphoma: inflammatory depigmentation of the nasal planum and lips

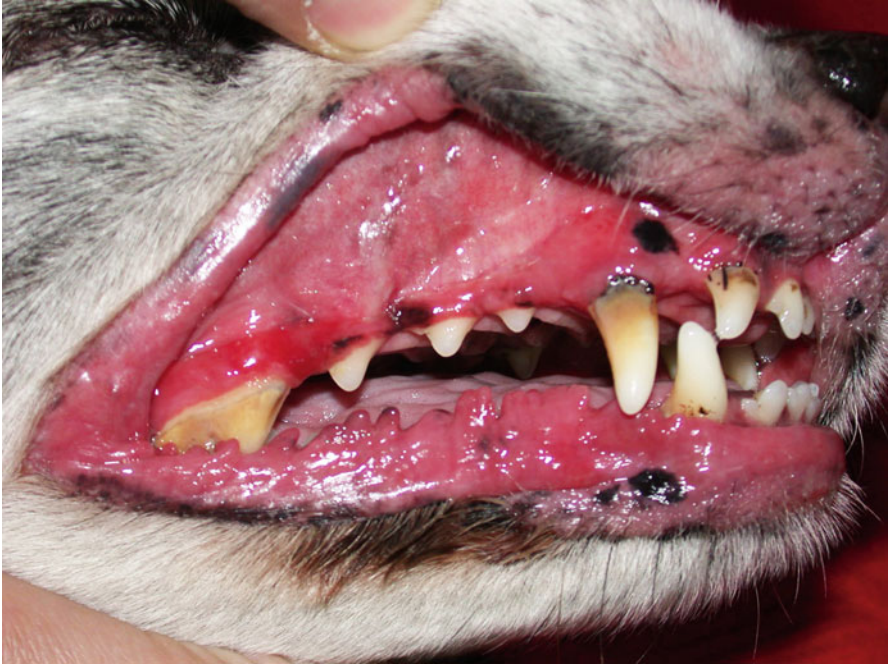

Fig. 4.34 Severe erythema and swelling of the oral mucosa and mucocutaneous junction in a dog affected by canine epitheliotropic lymphoma

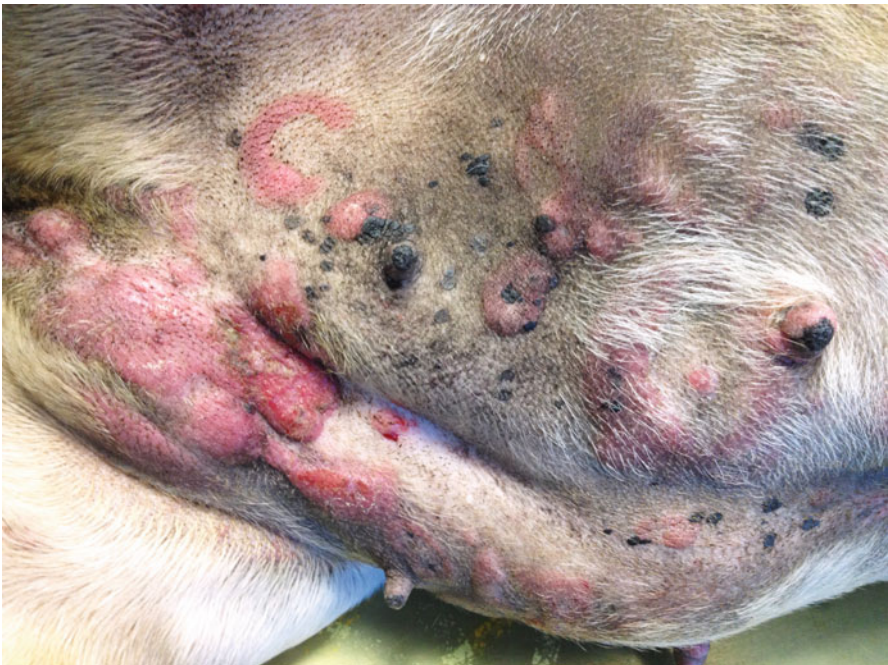

Fig. 4.35 Canine non-epitheliotropic lymphoma: nodules and serpiginous plaques. Note the C-shaped plaque

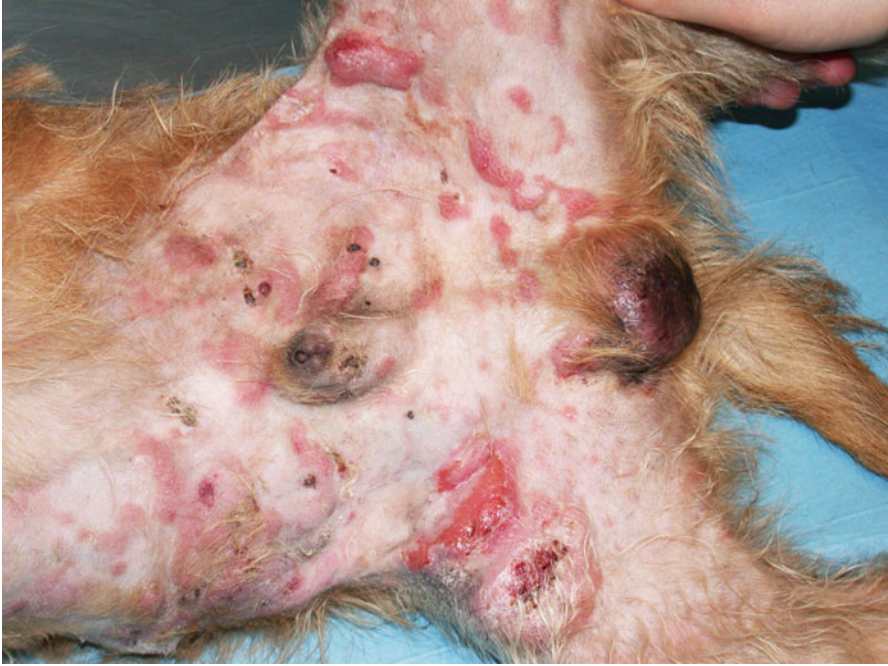

Fig. 4.36 Canine non-epitheliotropic lymphoma: nodules and serpiginous plaques on the abdomen and legs

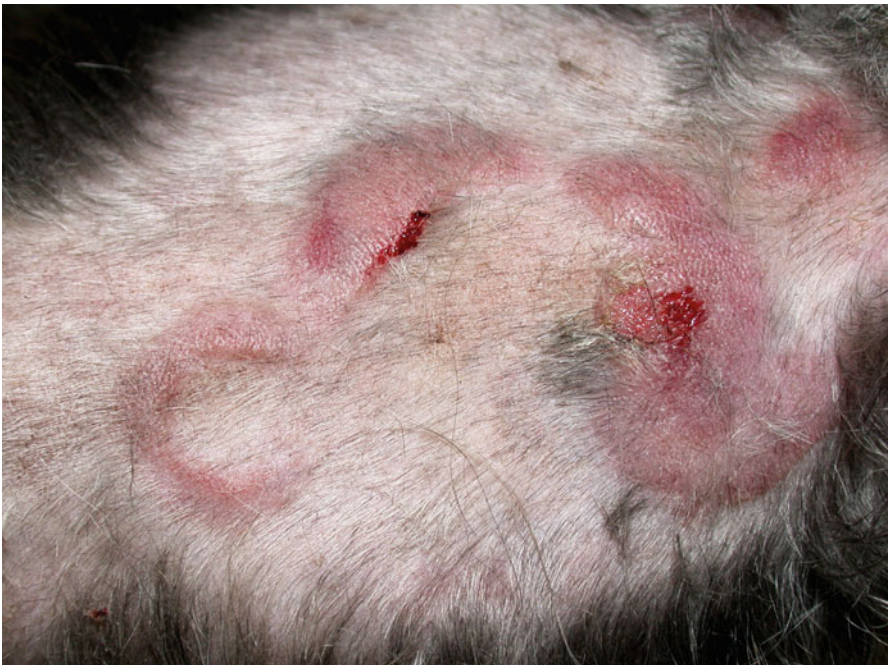

Fig. 4.37 Canine non-epitheliotropic lymphoma: at high magnification, the characteristic clinical lesions are more evident

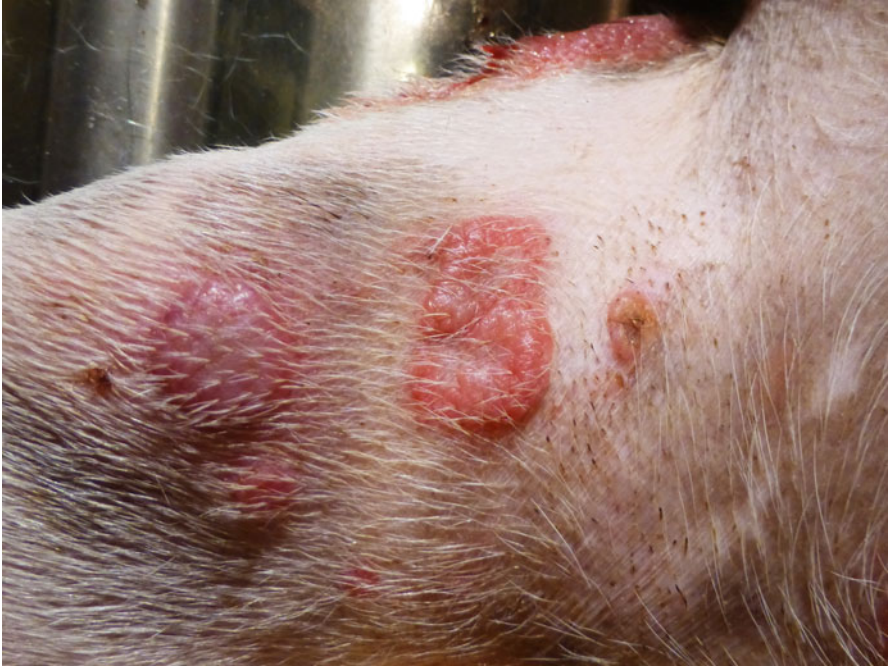

Fig. 4.38 Canine non-epitheliotropic lymphoma: bizarre S-shaped plaque

Feline epitheliotropic lymphoma is extremely rare and is usually grossly characterised by multifocal to generalised alopecia, erythema and desquamation, or by multiple, often ulcerated nodules and plaques of varying sizes; the latter are also typical in non-epitheliotropic lymphoma.

Cytological Findings

As occurs in other round cell tumours, apart from, those cases in which the epitheliotropic lymphoma does not occur as nodules (exfoliative erythroderma, depigmentation of the mucocutaneous junctions), cytopathological samples are usually rich in cells.

In the case of *epitheliotropic lymphoma*, the quantity of cells collected is strictly linked to the typology of the lesions and the technique of collection performed. The specimens containing the most cells are those sampled from nodular lesions, whereas the exfoliative lesions usually yield specimens with low numbers of cells. In the latter clinical form, cells can only be sampled by imprinting ulcerative lesions. Slides usually have low numbers of cells and, some inflammatory cells, mainly neutrophils, are often associated with the neoplastic cells. In these cases, because in many epitheliotropic lymphomas the cells do not show marked atypia, the coexistence with neutrophils can create mistaken interpretation (Figs. 4.39 and 4.40)

In the case of nodular lesions, slides are characterised by a homogeneous population of small to medium-sized roundish cells, characterised by round, often slightly indented and sometimes convoluted nuclei with an irregular profile. The nuclear

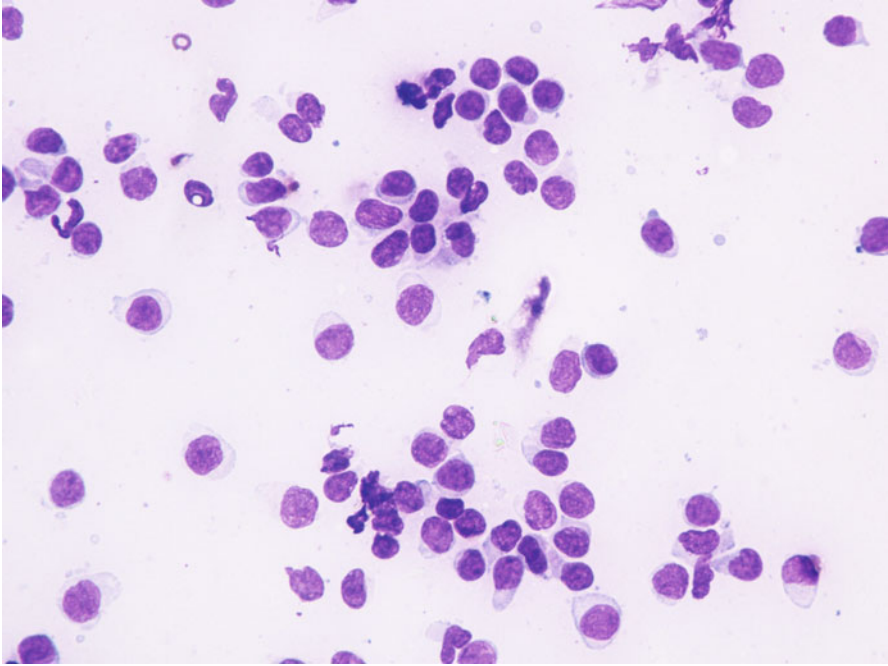


Fig. 4.39 Cytology of epitheliotropic lymphoma: neoplastic lymphocytes of uniform size and with only scarce atypia

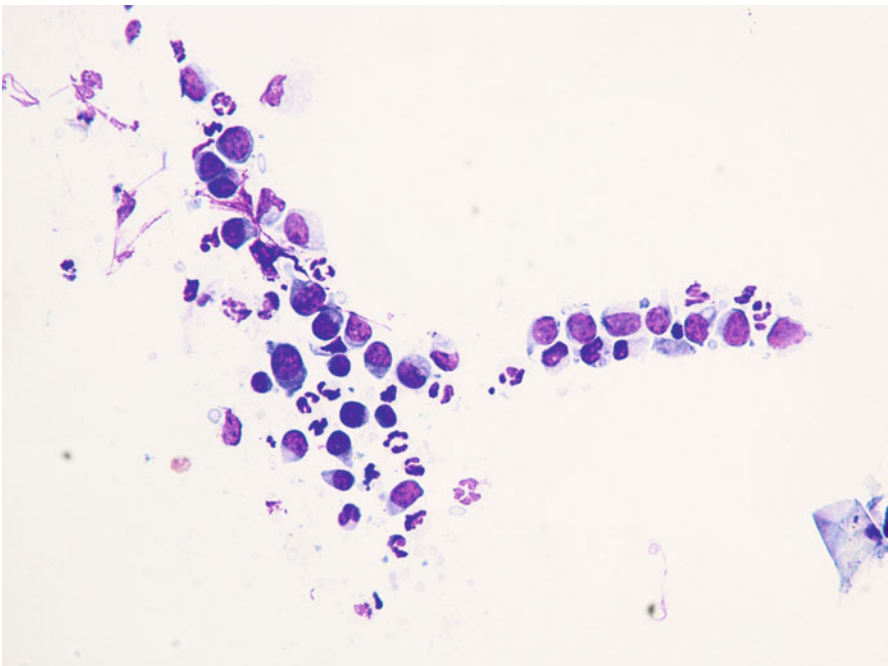


Fig. 4.40 Cytology of epitheliotropic lymphoma: neoplastic lymphoid cells associated with neutrophils. Note that the neoplastic cells do not show evident atypia

size is fairly uniform, with stippled chromatin, high nucleus/cytoplasm (N/C) ratio, and cytoplasm that shows varying shades of blue, from deep to pale. In *non-epitheliotropic lymphomas*, cells are usually larger and more pleomorphic (Fig. 4.41).

In some epitheliotropic lymphomas, cells can be less well-differentiated and anisokaryosis, voluminous nucleoli, multiple and bizarre chromatin patterns are more obvious. As most lymphomas originate from T lymphocytes, it is sometimes possible to observe nuclei with multiple and deep indentations that give the nuclei a *cerebriform* or *petal-like* appearance; cytoplasm is larger and paler and may contain basophilic granules (Fig. 4.42). These cytological characteristics can only suggest the T origin of neoplastic lymphocytes, but do not allow the differentiation between epitheliotropic and non-epitheliotropic lymphoma, for which a histopathological examination is mandatory.

As above mentioned, when lesions consist exclusively of exfoliative erythroderma, often associated with itching, lesions may be confused with other infectious or allergic diseases (dermatophytosis, leishmaniasis, atopic dermatitis). In these cases, it is possible to try to sample neoplastic cells using intradermal FNAB. This method, described in Chap. 2, does not always allow the collection of diagnostic cells, especially in the case of the *pagetoid* variant of epitheliotropic lymphoma, in which the neoplastic cells are exclusively located inside the epidermal and follicular

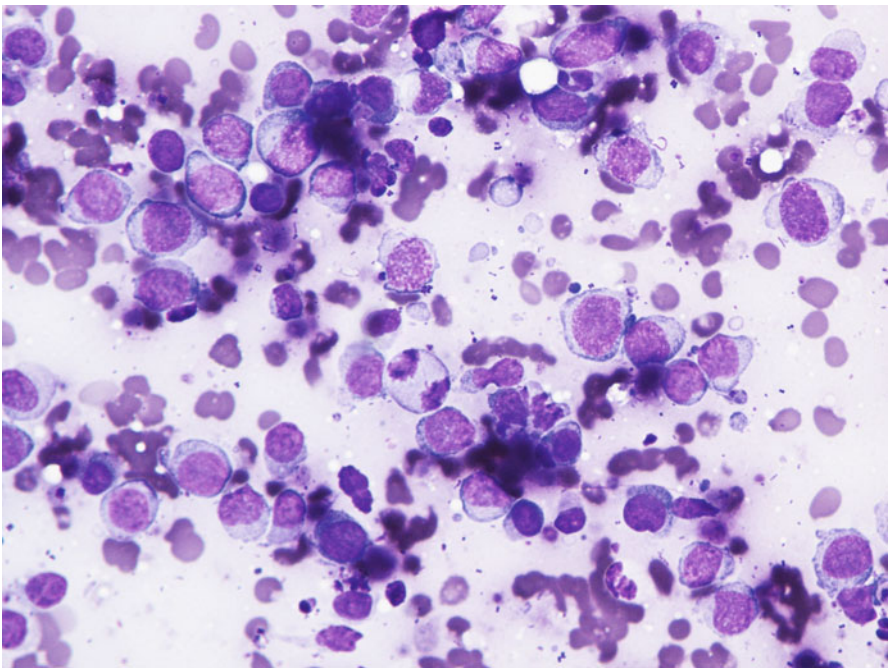


Fig. 4.41 Cytology of non-epitheliotropic lymphoma: large neoplastic lymphoblasts show many features of atypia

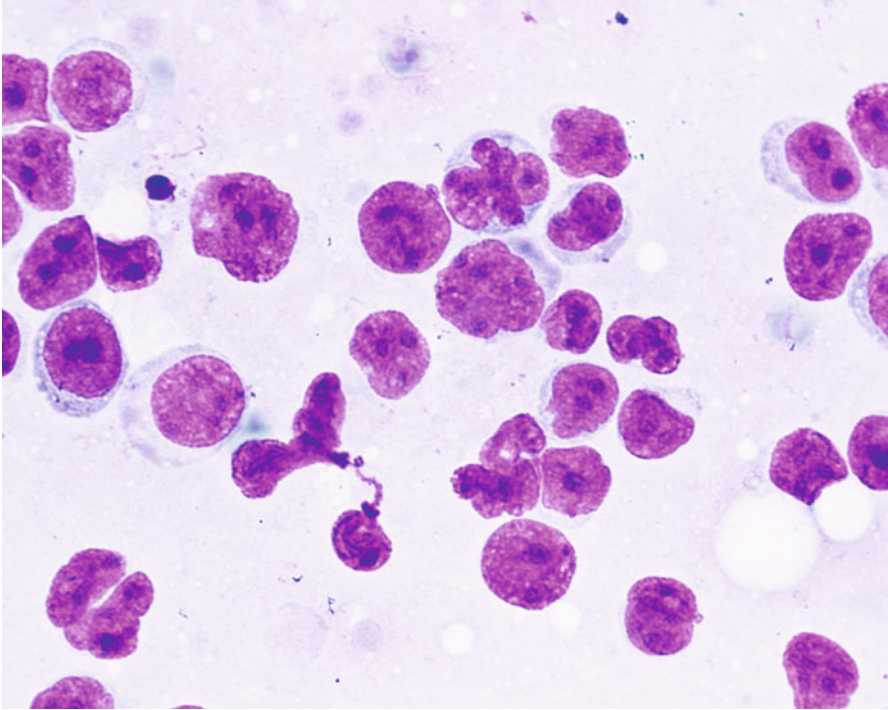


Fig. 4.42 Cytology of epitheliotropic lymphoma: the *cerebriform* or *petal* appearance of nuclei suggests their T origin

wall. Conversely, in the *tumoral* stages of the disease, when cells diffusely infiltrate the superficial and medium dermis, a variable number of neoplastic cells can be collected via FNAB (Figs. 4.43 and 4.44).

In the case of non-epitheliotropic lymphomas, histology is characterised by the presence of a diffuse neoplastic lymphoid infiltrating the dermis and the panniculus. When cells are mostly localised in the subcutis, many lipid droplets can be collected, together with a variable number of lymphoblasts. The latter often consist mostly of *bare* nuclei (without the cytoplasm) and only a small number of cells have the cytoplasm still intact. In these cases, it must be careful to not make a misdiagnosis of panniculitis. The usually high number of lympho-glandular bodies spread on the background helps to interpret the bare nuclei as being of lymphoid origin.

In the presence of a single skin nodule composed of lymphoid cells with neoplastic appearance, care must be taken before making a cytological diagnosis of lymphoma, because spontaneous regression of these lesions can occur (Fig. 4.45).

The clinical behaviour has allowed such lesions to be defined as *non-neoplastic lymphoid inflammatory reactions* of unknown cause that could be considered *pseudo-lymphomatous* lesions. From the above, based exclusively on cell morphology, many single nodules diagnosed as lymphoma only using histopathology could have been undefined non neoplastic lymphomatous proliferation. In these cases, to

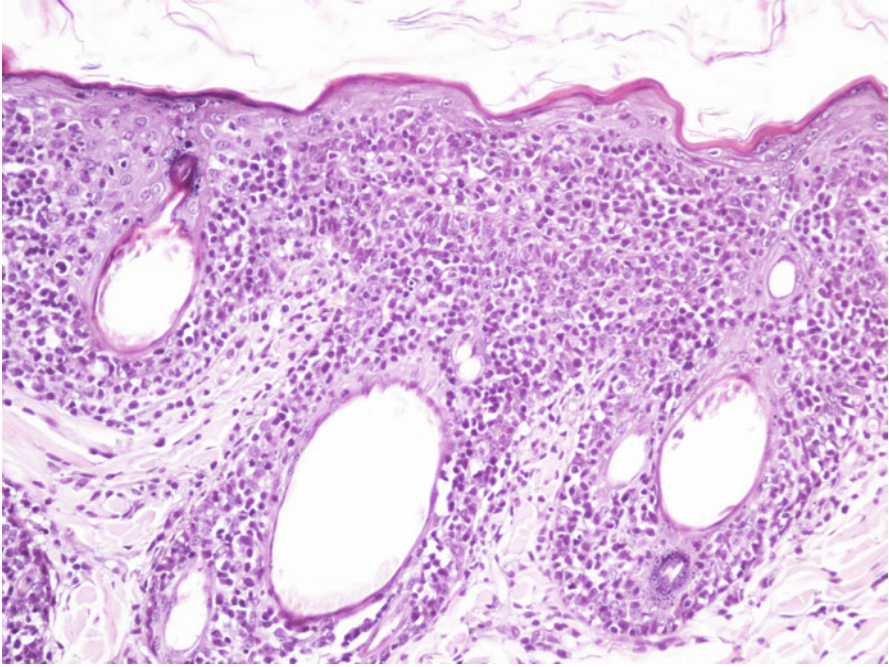


Fig. 4.43 Histopathology of epitheliotropic lymphoma: the neoplastic cells diffusely infiltrate both the external and follicular epidermis

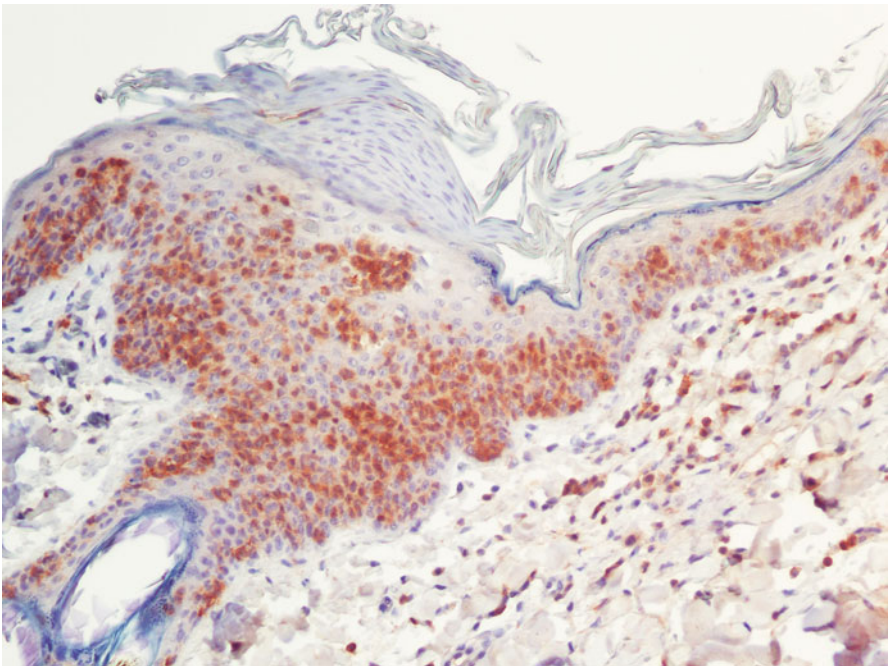


Fig. 4.44 CD3 immunostaining: strong positivity of intra-epidermal neoplastic cells

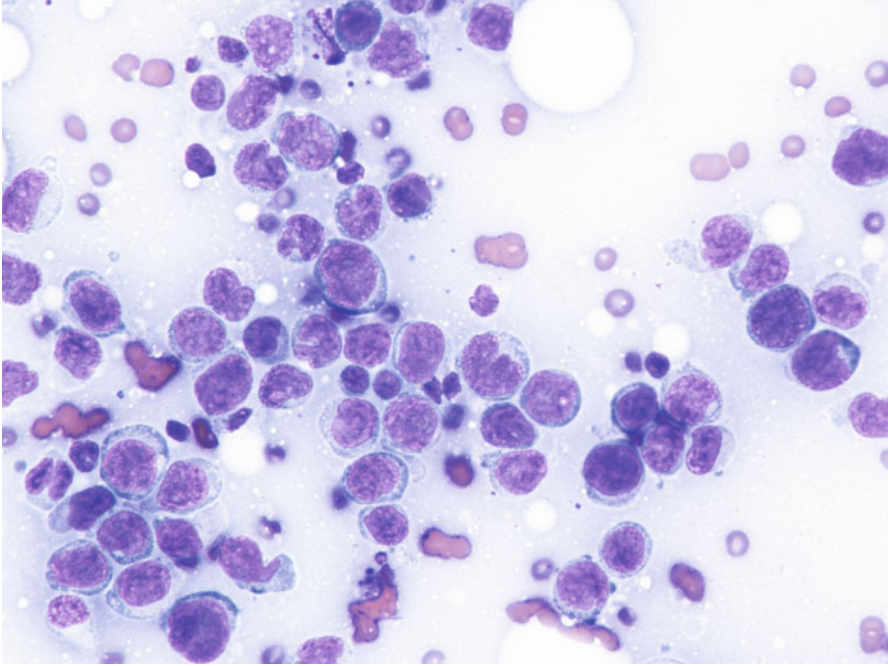


Fig. 4.45 Cytology of non-neoplastic lymphoid cells: note the high number of blasts and the scattered small lymphocytes

obtain the definitive diagnosis of lymphoma, the clonality of the cells, which should be monoclonal in neoplasia and polyclonal in reactive lesions, must be assessed. Therefore, the diagnosis of cutaneous lymphoma using cytology should always be made with caution, especially when only a single nodule is present.

4.2.3 Plasma Cells Tumour

Extra-medullary or cutaneous *plasma cell tumour* or *plasmacytoma* is an uncommon neoplasia in dogs and rare in cats. Canine cutaneous plasmacytoma usually develops as single and more rarely multiple alopecic nodules that are often pink-reddish in colour. Lesions are of varying sizes and shapes, located mainly on the toes, pads, pinna, nose, lips and in the mouth (Figs. 4.46, 4.47, 4.48, and 4.49). In cats, they are very rare tumours and are characterised by a single nodule, mostly reported on the legs, face and tail.

Cytological Findings

Canine *cutaneous plasmacytoma* is classified into five histological subtypes and therefore, the polymorphism of this tumour is remarkable. The five histotypes are: *hyaline*, *mature*, *cleaved*, *asynchronous* and *polymorphous-blastic* (Figs. 4.50 and 4.51) (Platz et al. 1999; Cangul et al. 2002; Gross et al. 2005). This detailed

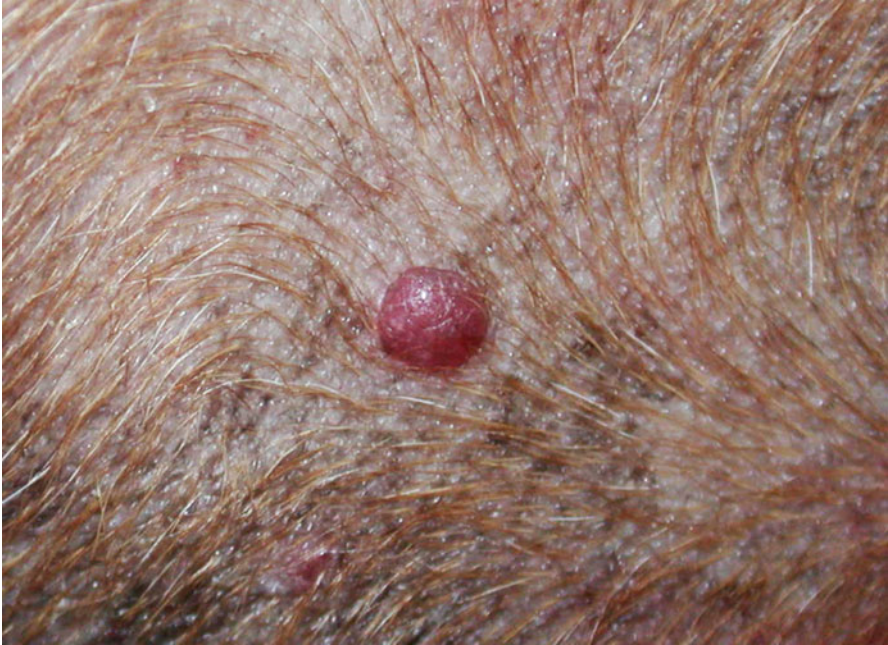

Fig. 4.46 Small erythematous cutaneous plasma cell tumours

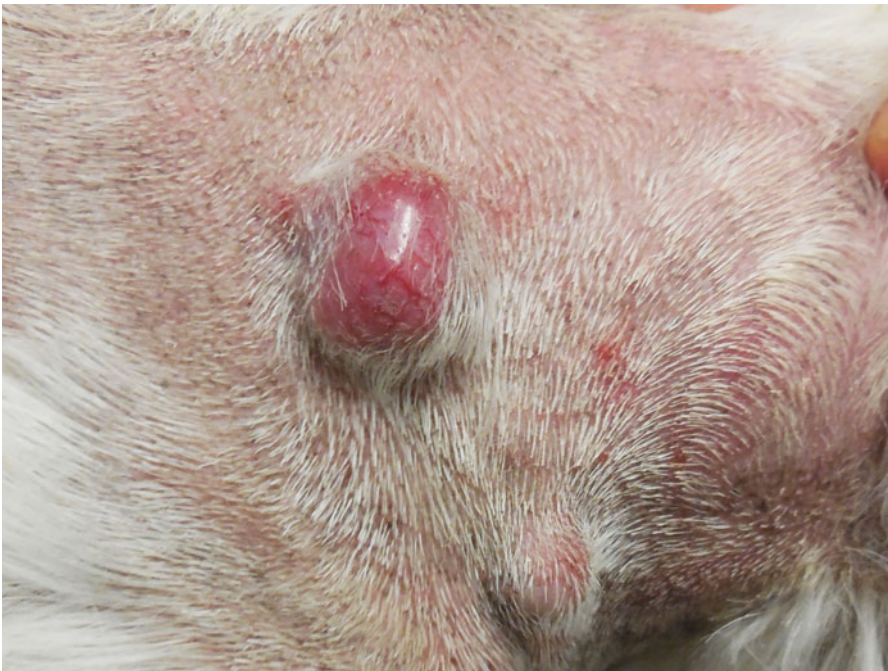

Fig. 4.47 Two cutaneous plasma cell tumours

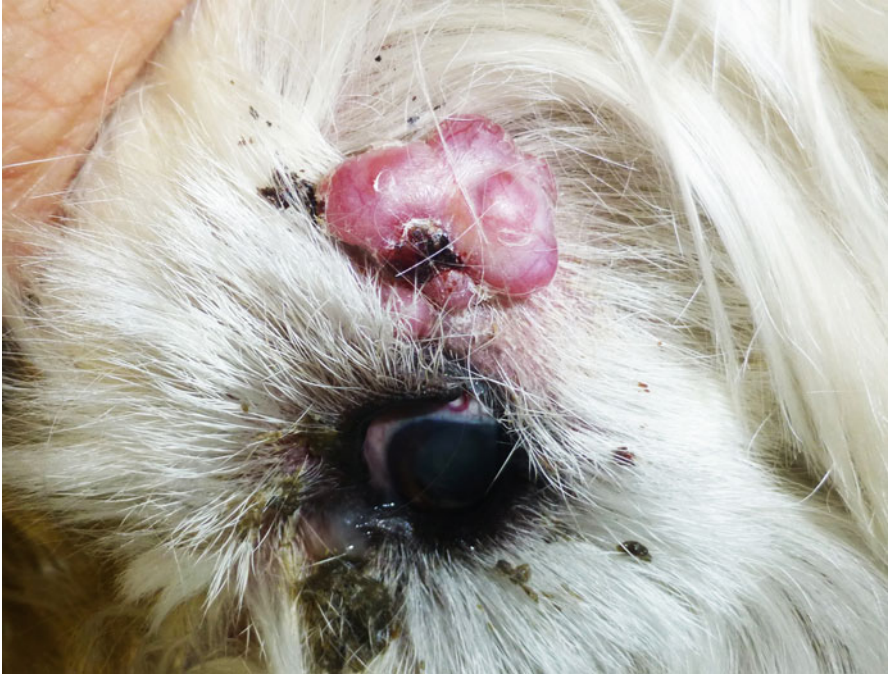

Fig. 4.48 Extramedullary plasma cell tumours with an irregular shape on the eyelid of a West Highland white terrier

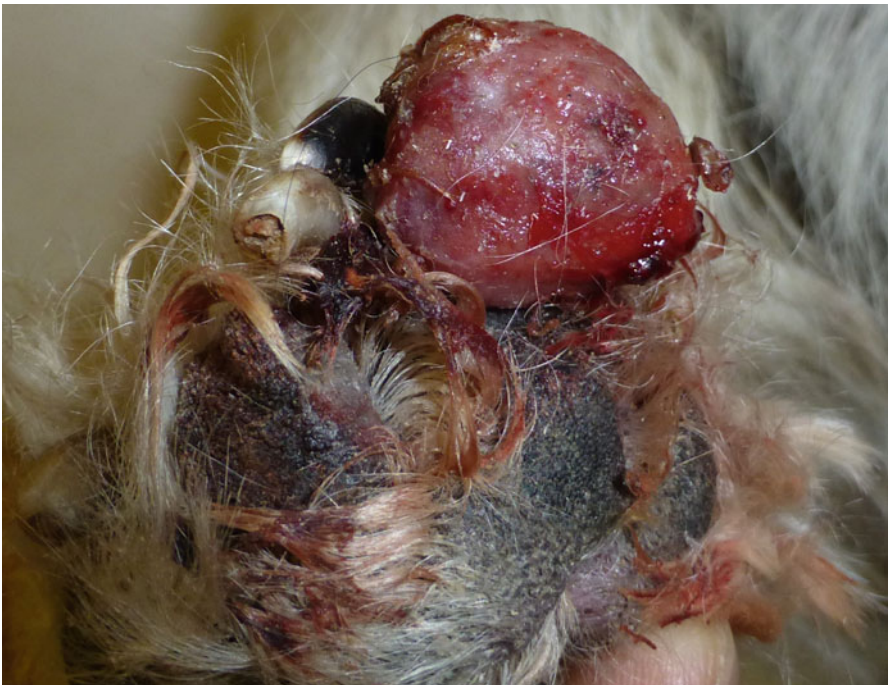

Fig. 4.49 Plasma cell tumours: large ulcerated and bleeding tumour on a digit

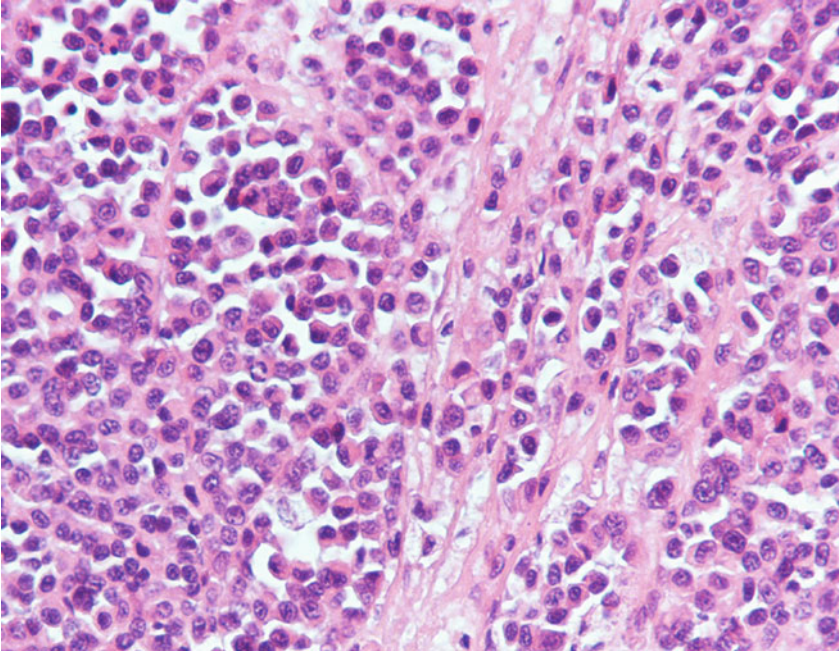


Fig. 4.50 Histopathology of well-differentiated plasmacytoma: small and uniform-sized neoplastic plasma cells, in which the silhouette resembles mature plasma cells

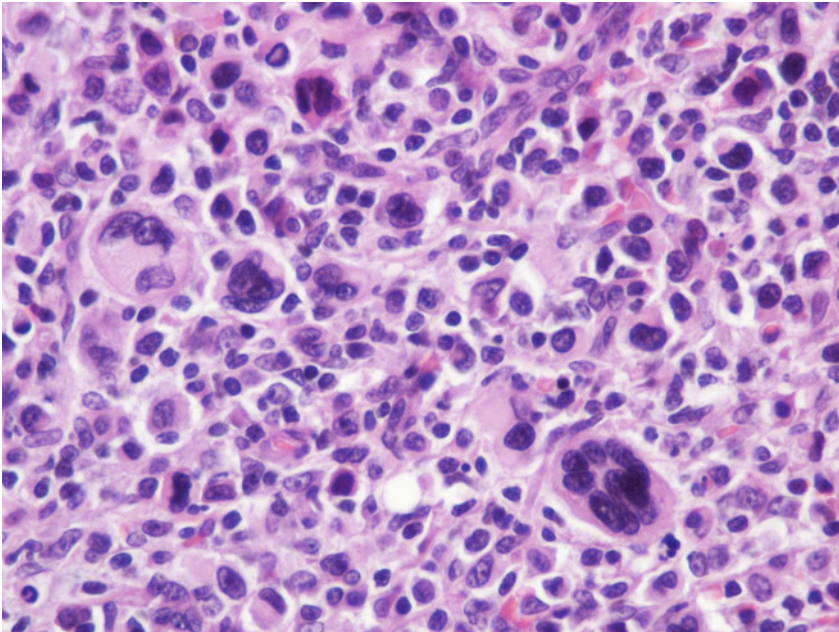


Fig. 4.51 Histopathology of pleomorphic plasma cell tumour: round and discrete neoplastic plasma cells with severe atypia

classification based on the cytological morphology does not seem to have any strong implications regarding the biological behaviour of the tumour. In cats, there appears to be four subtypes (Majzoub et al. 2003). Cytologically it is not always possible to recognise to which histotype the cells belong, also because in some cases, different histological types can coexist in the same tumour. Therefore, from a cytological point of view it is only possible to classify the grade of differentiation based on cell morphology, and define whether the neoplasia is well- or poorly differentiated or pleomorphic; the former are characterised by a monomorphous population of small cells, with roundish or oval eccentric or central nuclei, regular and sometimes stippled chromatin and, in some cells, an achromatic area between the nucleus and the cytoplasm is evident. This area represents the *Golgi complex* (Figs. 4.52 and 4.53). Some binucleated and a few multinucleated cells are a normal finding in well-differentiated plasma cell tumours (Fig. 4.54). These cytological features that permit the suspicion of a plasmacellular origin, are usually not evident in pleomorphic plasmacytomas, in which cells show varying degrees of anisocytosis, anisokaryosis, kidney-shaped or bizarre nuclei and a large number of multinucleated cells (Figs. 4.55 and 4.56). In these tumours, a small percentage of lymphocytes and eosinophils can be observed.

In less than 10 % of plasma cell tumours, it is possible to detect an amorphous fibrillary eosinophilic material interposed between the neoplastic cells. This represents the *amyloid* secreted by malignant plasma cells (Fig. 4.57) (Rowland et al. 1991). As the plasmacytoma is the only round cell tumour that produces

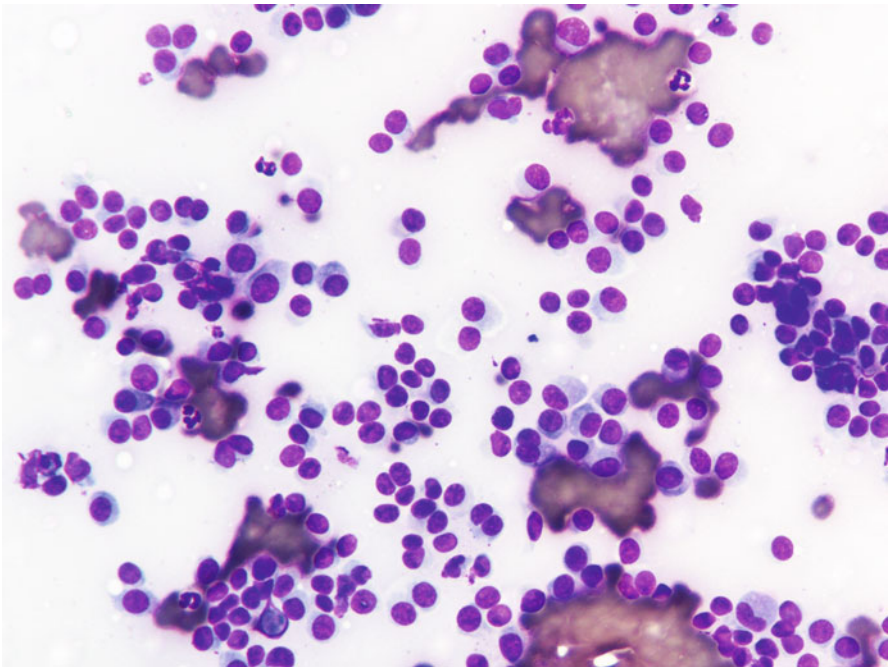


Fig. 4.52 Cytology of well-differentiated cutaneous plasma cell tumours: small, uniform-sized neoplastic plasma cells. Note that some cells preserve a recognisable plasma cellular morphology

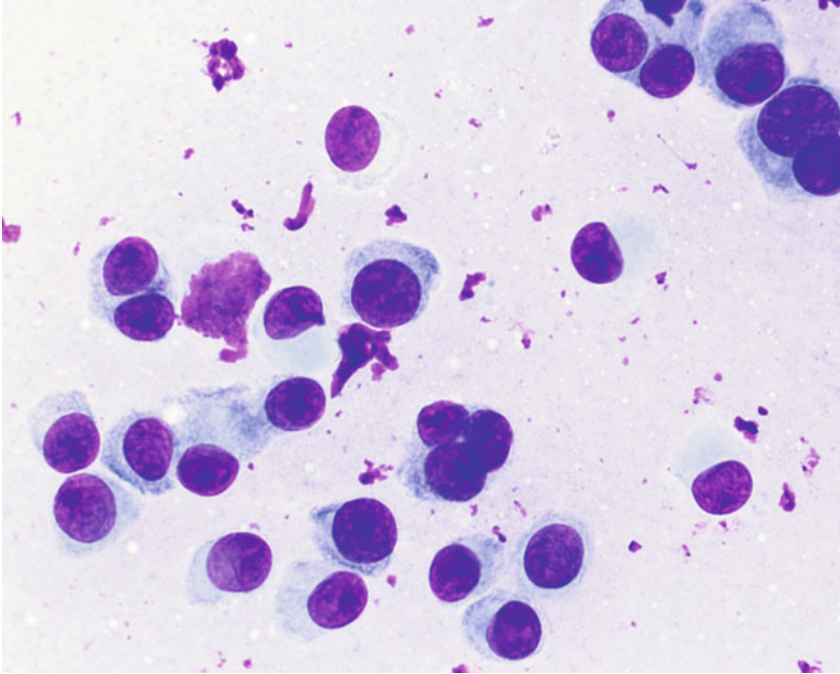


Fig. 4.53 Cytology of well-differentiated cutaneous plasma cell tumours: at high magnifications the plasma cellular morphology is more evident. Note that in some cytoplasm, the Golgi complex is still recognisable

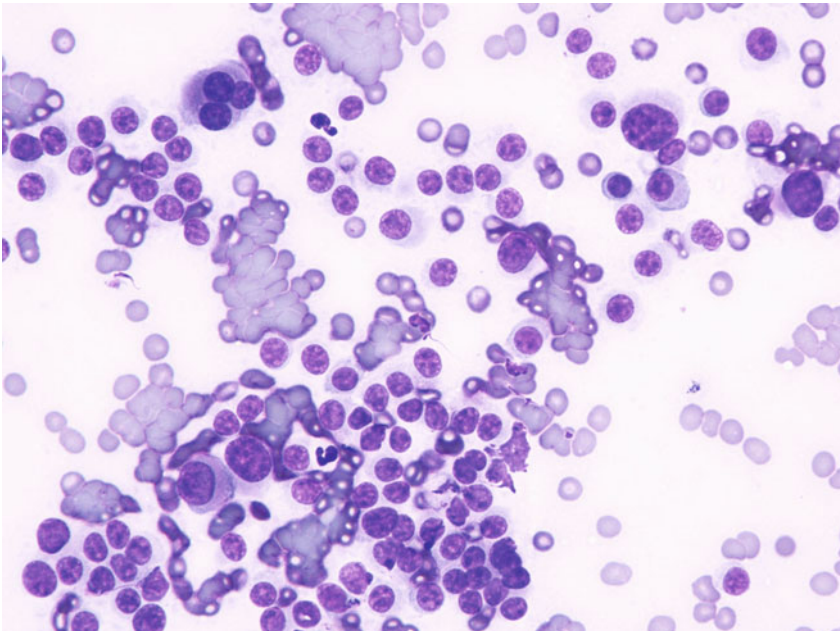


Fig. 4.54 Cytology of poorly differentiated cutaneous plasma cell tumours: anisocytosis, anisokaryosis and multinucleated cells. Only a few cells preserve a plasmacytoid appearance

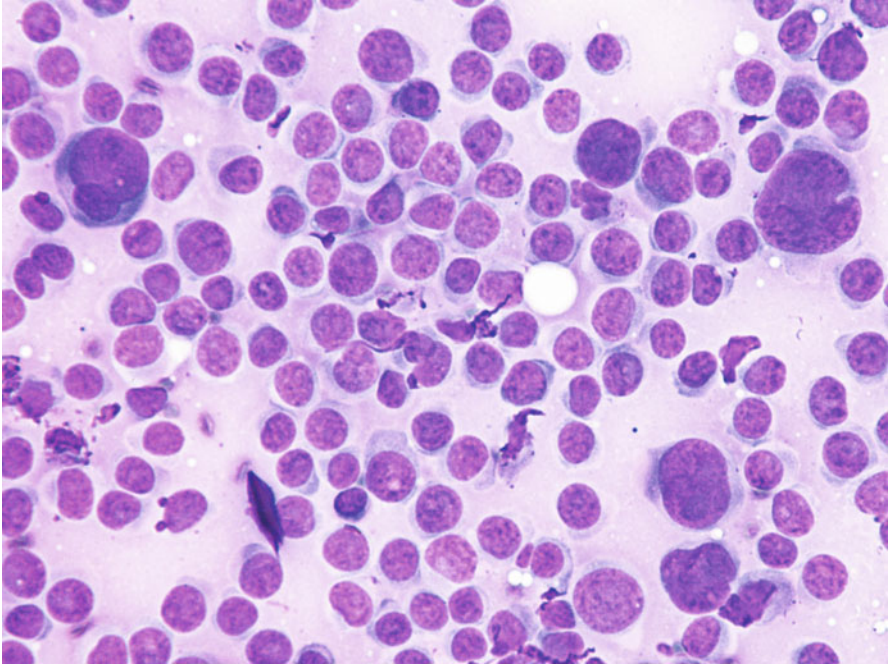


Fig. 4.55 Cytology of undifferentiated cutaneous plasma cell tumours: pleomorphic neoplastic cells with marked anisokaryosis

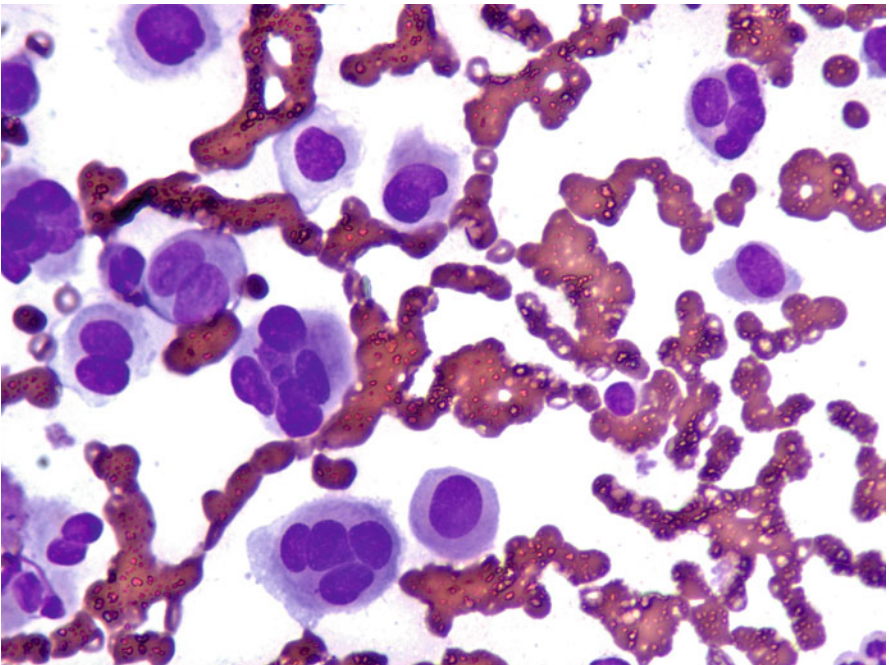


Fig. 4.56 Cytology of undifferentiated cutaneous plasma cell tumours: pleomorphic neoplastic cells, most are multinucleated. Note that the typical plasma cellular aspects are completely lost

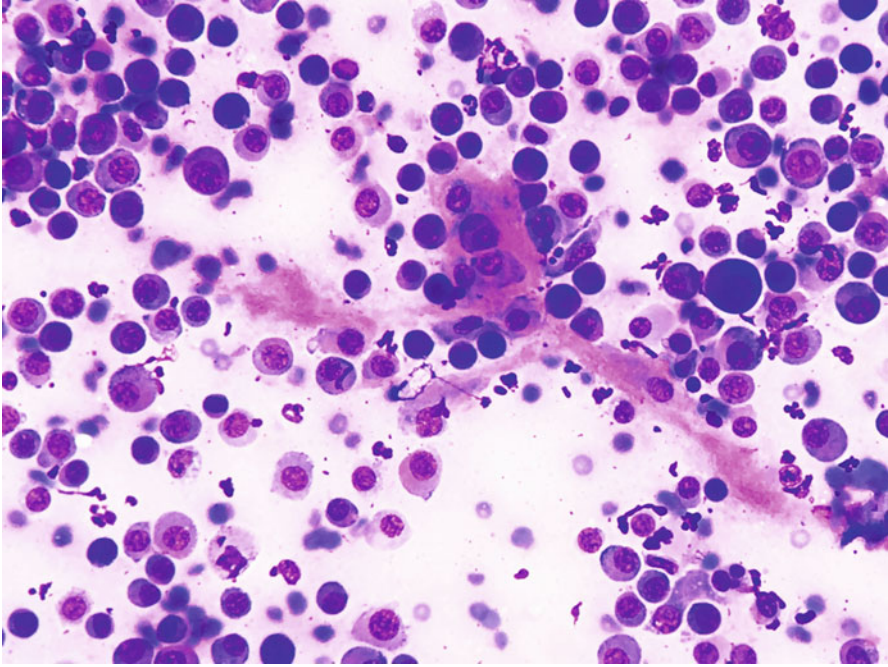


Fig. 4.57 Cytology of cutaneous plasma cell tumour: the eosinophilic amorphous material represents amyloid

amyloid, its presence allows the plasmacellular nature of the neoplastic tumour to be confirmed.

Although amyloid is usually produced by better differentiated plasma cells, its presence can be helpful in suspect plasmacytoma when typical cytological aspects of plasma cell origin are lacking. To detect amyloid, slides must be stained with *Congo red* dye, which colours the amyloid red–orange (Fig. 4.58). In rare cases, the production of amyloid is so strong that it stimulates a massive granulomatous inflammation with numerous giant cells; in these cases the diagnosis of plasmacytoma can be very difficult.

4.2.4 Transmissible Venereal Tumour

The canine *transmissible venereal tumour* (TVT) is a rare neoplasm of canidae, mostly reported in sub-tropical geographic areas (Das and Das 2000; Mukaratirwa and Gruys 2003). TVT cells have unique characteristics, showing a karyotype composed of only 59 chromosomes, very different from the 78 chromosomes of normal canine diploid cells. This tumour has the peculiarity of being transmitted from one dog to another, via the direct implantation of viable cells. It has been demonstrated

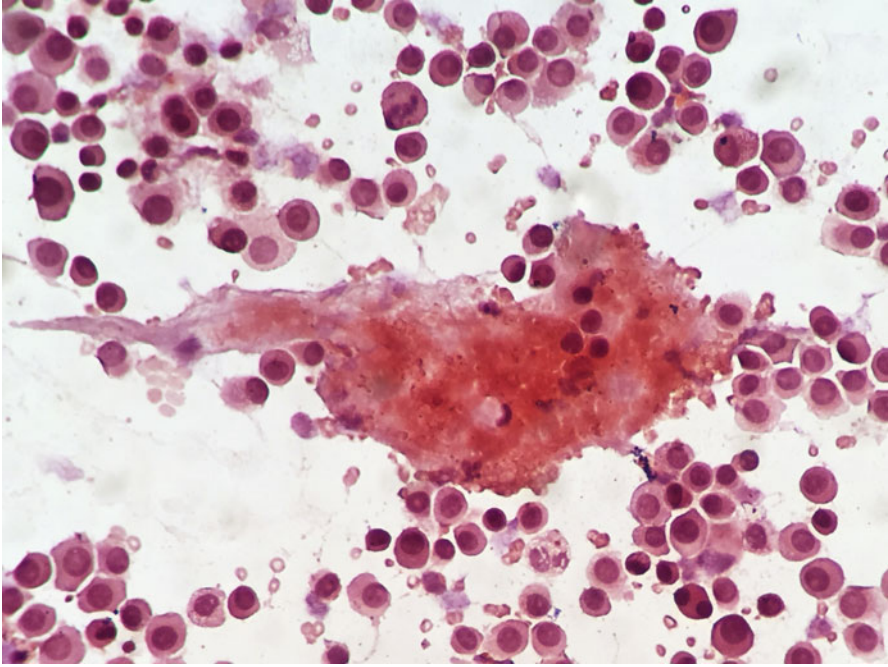


Fig. 4.58 Cytology of cutaneous plasma cell tumour: Congo red staining highlights the amyloid, as orange material intermingled between the neoplastic plasma cells

that the ancestral TVT cell has been propagated over time, passing from animal to animal until the present day; in practice, the neoplastic cell behaves like a parasite (Cohen 1985; Murgia et al. 2006; Murchison et al. 2014).

Social and sexual behaviour and fighting between stray dogs are the basis of the location of the lesions, which, as mentioned above, result from direct implant of neoplastic cells. The skin lesions are mostly seen in immune-compromised or in stray dogs living in a poor state of health.

Lesions are single and of various sizes, from small nodules to very large erythematous masses, with irregular surfaces and of friable consistency, often ulcerated and bleeding. The classical lesions of TVT are mainly observed on the external genitalia mucosa (Figs. 4.59 and 4.60). In some dogs skin nodules can be observed, in association or not with genital lesions, varying in size, located on any part of the skin and often ulcerated. In stray dogs with only cutaneous nodules, an implantation secondary to bites during the fighting has been hypothesised. In dogs with multiple lesions, TVT cells are spread via the bloodstream or via lymphatics and these two ways of transmission justifies the metastases reported in different internal organs (Park et al. 2006). In one case report, TVT cells were detected in the peripheral blood in a severely immune-compromised dog that had developed hundreds of TVT nodules spread all over the body (Figs. 4.61 and 4.62) (Albanese et al. 2006).

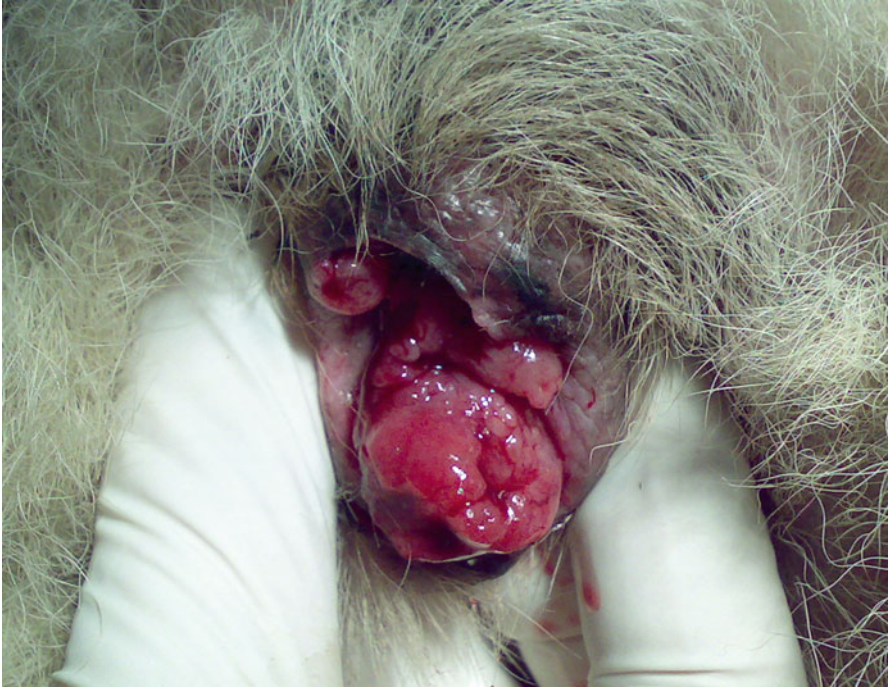

Fig. 4.59 Vulvar neof ormation in a bitch with transmissible venereal tumour (TVT)

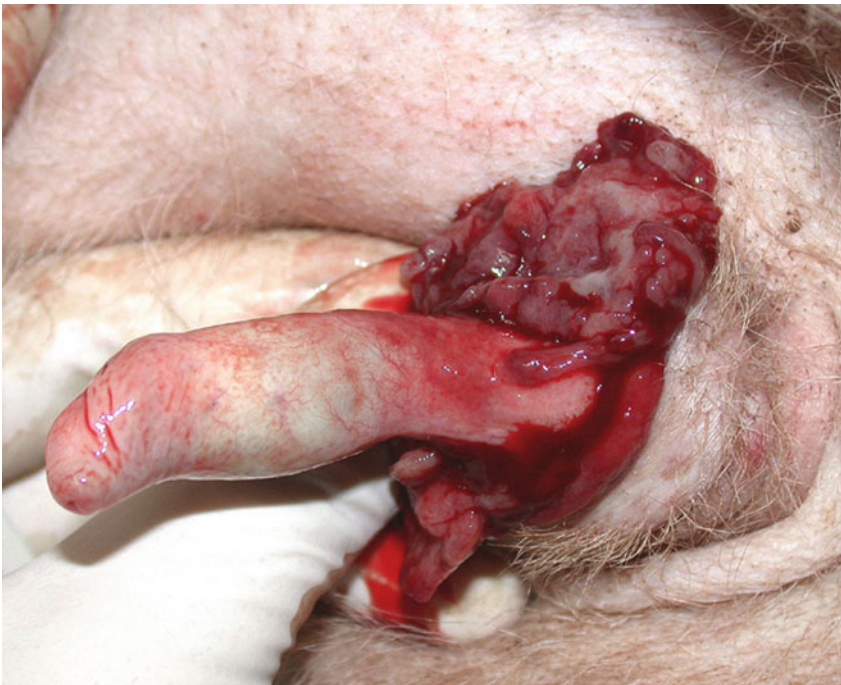

Fig. 4.60 Large, erythematous mass on the penis of a dog with TVT

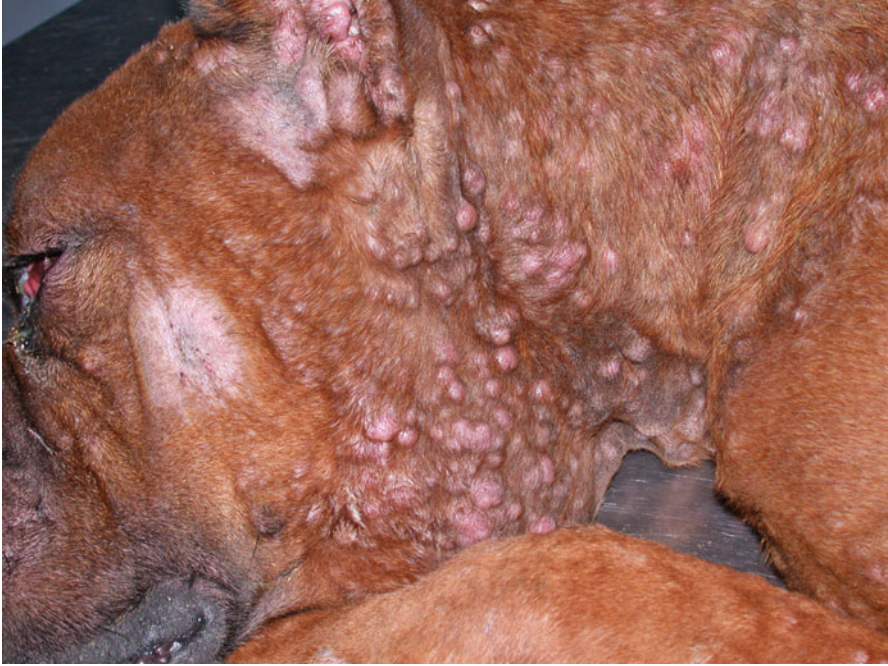

Fig. 4.61 Multiple and confluent TVT nodules in an immune-compromised Boxer

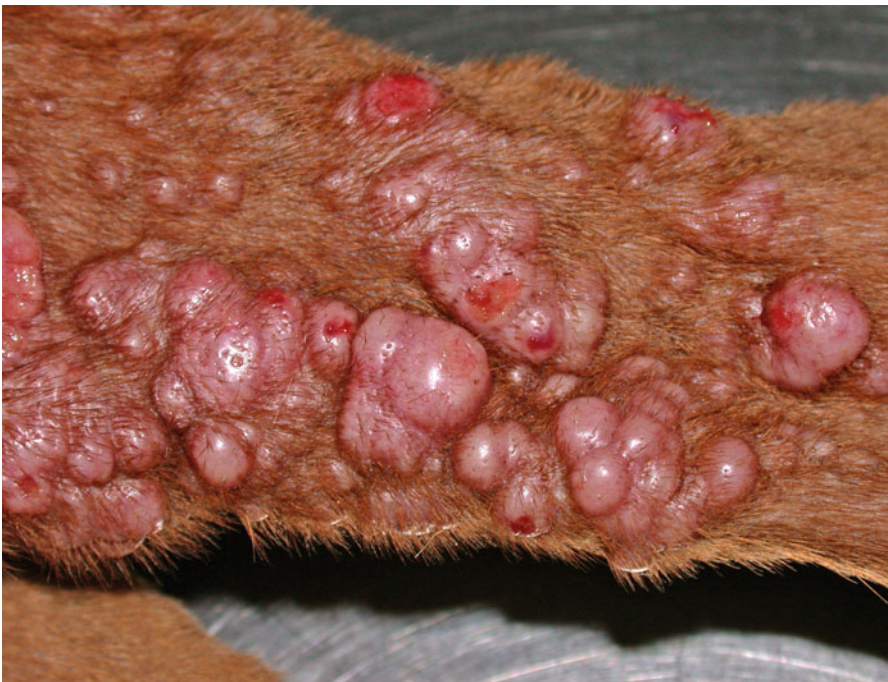

Fig. 4.62 A TVT. Multiple and overlapping nodules in the same dog as in Fig. 4.61

Cytological Findings

The nature of TVT cells has been debated for many years. The latest theories seem to agree on their histiocytic nature, based on the demonstration of their phagocytic activity and on the positivity of several immunohistochemical markers to histiocytes (Mozos et al. 1996; Marchal et al. 1997; Albanese et al. 2002; Mukaratirwa and Gruys 2003; Gross et al. 2005; Park et al. 2006).

The cytological samples collected from TVT lesions are characterised by very high cellularity, with densely packed cells, which are sometimes difficult to identify as discrete round cells at low magnifications (Figs. 4.63 and 4.64).

The nuclei are round, central or eccentric, with a regular chromatin pattern and a single nucleolus; the cytoplasm is large and pale and characterised by the presence of a variable number, usually high, of intracytoplasmic and non-overlapping vacuoles, of uniform size and with well-defined borders (Figs. 4.65 and 4.66). The anisocytosis is more obvious than in the other well-differentiated round cell tumours. Another characteristic histological feature of the TVT is the presence of a large number of *mitotic cells*, which must not be misinterpreted as an indicator of malignancy, as the TVT has a good prognosis owing to its excellent sensitivity to chemotherapy (Fig. 4.67). The TVT, although very rarely, can spontaneously

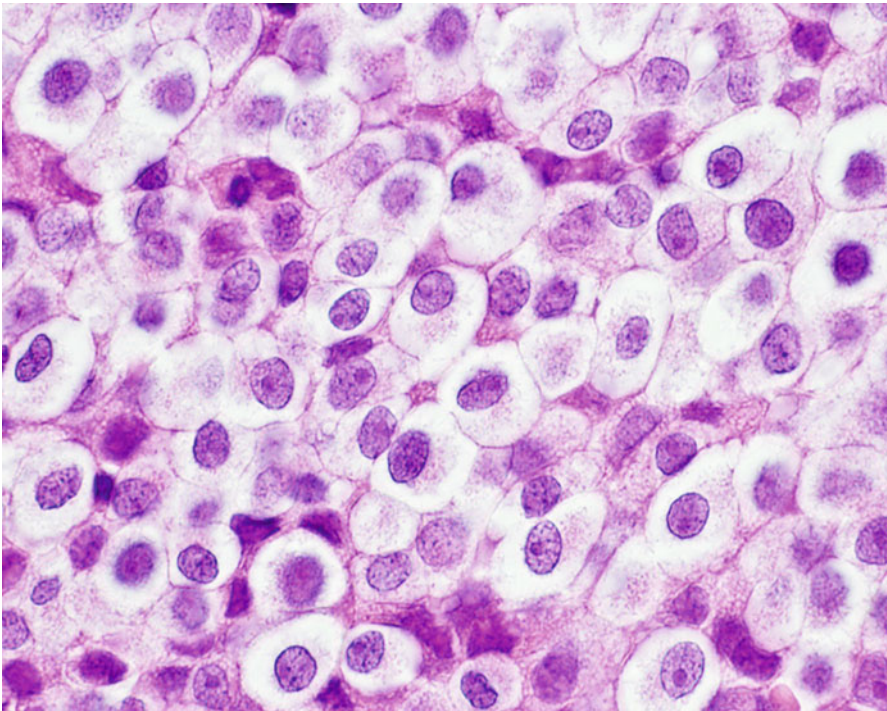


Fig. 4.63 Histology of TVT: discrete round cells with large cytoplasm. Note that with histology, the typical intracytoplasmic vacuoles are not as clearly evident as in cytological specimens

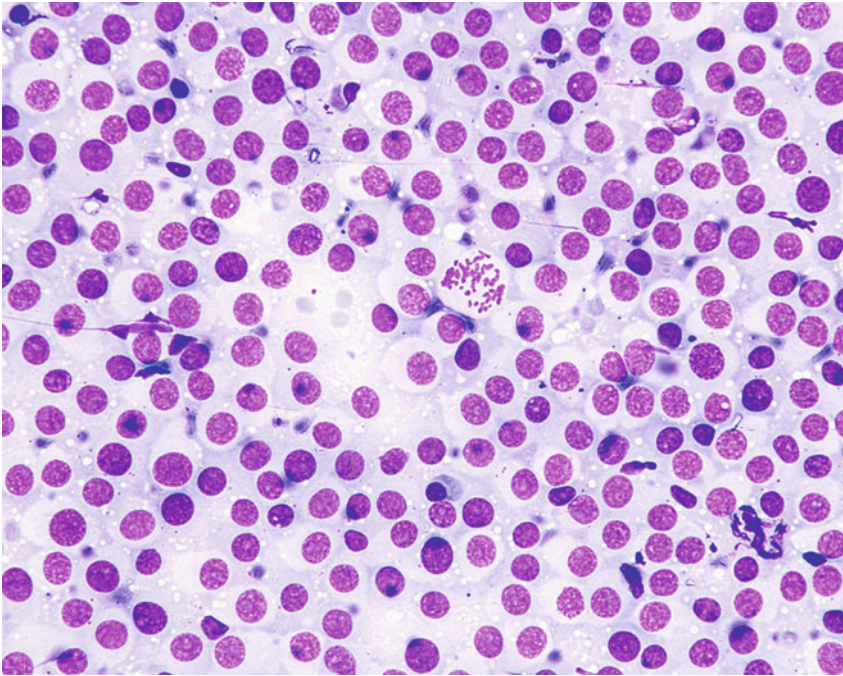


Fig. 4.64 Cytology of TVT: at low magnifications, the discrete arrangement of TVT cells is not easily recognisable

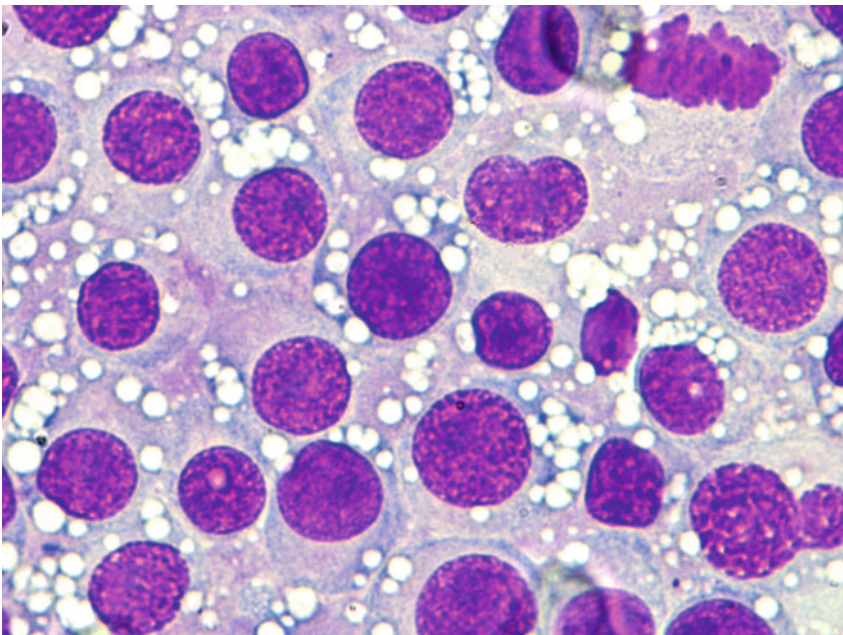


Fig. 4.65 Cytology of TVT: at medium magnifications, the round, well-delimited and non-overlapping vacuoles are clearly evident

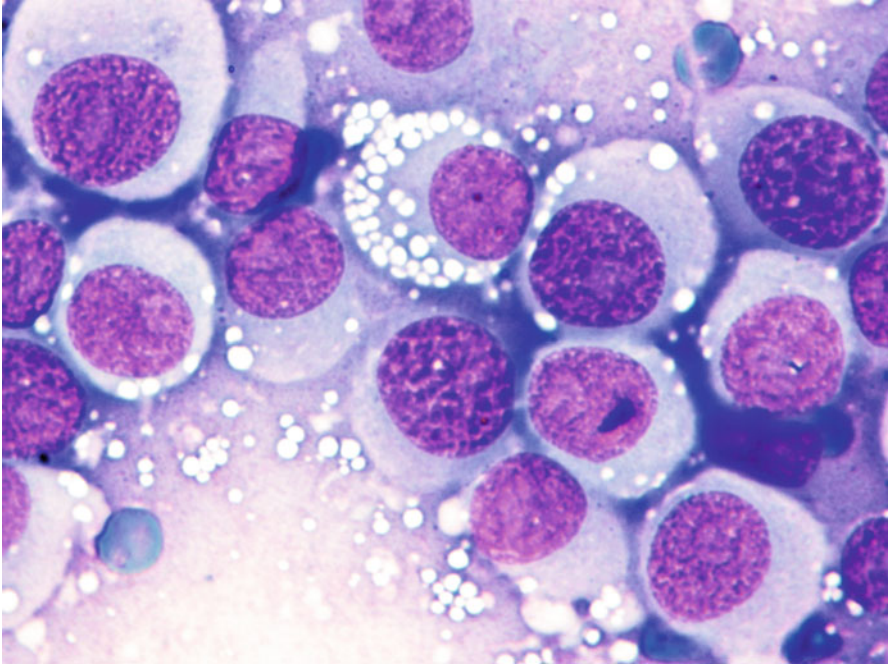


Fig. 4.66 Cytology of TVT: at high magnifications, the round silhouette of TVT cells is undoubted

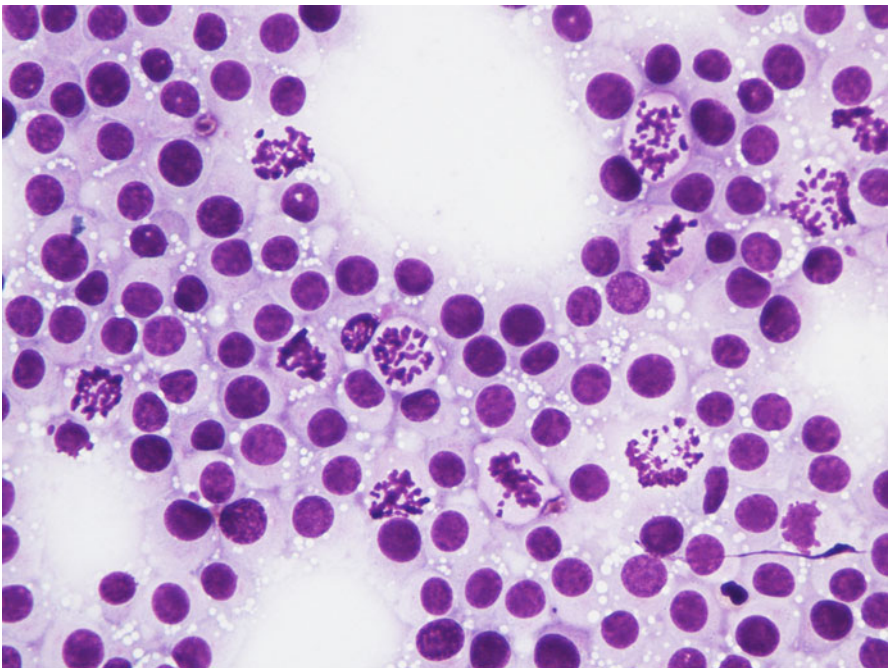


Fig. 4.67 Cytology of TVT: many mitotic cells characterise most TVT cytological slides

regress following an attack of cytotoxic T-lymphocytes; therefore, the detection of a high amount of mature lymphocytes must be interpreted as a positive prognostic index.

4.2.5 Histiocytic Diseases

Canine and feline *histiocytic diseases* encompass a complex group of reactive/neoplastic disorders, originating from dendritic cells, the so-called *antigen-presenting cells* (APCs), residing in the epidermis, dermis and subcutis.

This group includes the *benign cutaneous histiocytoma*, *Langerhans cell histiocytosis*, *reactive histiocytosis (cutaneous and systemic)* and the *histiocytic sarcoma complex (localised and disseminated)* (Moore 2014).

Some of the latter are not considered true neoplasms: *histiocytoma* is in fact a Langerhans cell proliferation that regresses spontaneously and *reactive cutaneous histiocytosis* is considered to be a reactive inflammatory response of interstitial dermal dendritic cells, based on the reported spontaneous regression of some cases and on the good response to several immune-modulatory drugs; for this reason, many authors prefer to group all these forms under the umbrella of *histiocytic disorders or diseases* and not as histiocytic neoplasia (Palmeiro et al. 2007; Moore 2014).

Although some of these disorders have some anamnestic, clinical and cytological peculiarities, differentiating them from other neoplastic and non-neoplastic diseases is not always easy.

A typical example is cutaneous reactive histiocytosis, which can be cytologically confused with other histiocytic diseases of macrophagic lineage, such as sterile granuloma syndrome or some nodular forms of leishmaniasis, in addition to the spindle variant of the histiocytic sarcoma, which cannot be cytologically differentiated from some anaplastic sarcomas of soft tissue with giant cells. In these cases, it is only possible to obtain a definitive diagnosis with the use of immunohistochemical investigations.

In cats, only the so-called *feline dendritic progressive histiocytosis* has been well documented as a true cutaneous histiocytic disorder; the few reported cases of *histiocytic sarcoma* in cats are mostly *haemophagocytic* (macrophagic lineage) and visceral in location (Affolter and Moore 2006).

4.2.5.1 Benign Cutaneous Histiocytoma

The canine cutaneous *histiocytoma* is a benign proliferation of Langerhans cells, the APCs residing in the epidermis (Moore 2014). It is common in young dogs (less than 3 years of age), although it can be observed in dogs of all ages. It usually appears as a single nodule, localised mainly on the limbs, head and pinna, but it can grow in any part of the body. The canine histiocytoma usually has a domed or button-like shape, it can be alopecic with an erythematous surface and grows rapidly (Figs. 4.68, 4.69, and 4.70). Less frequently, multiple nodules, especially in Shar-pei dogs, are reported (Fig. 4.71) (Maina et al. 2014).

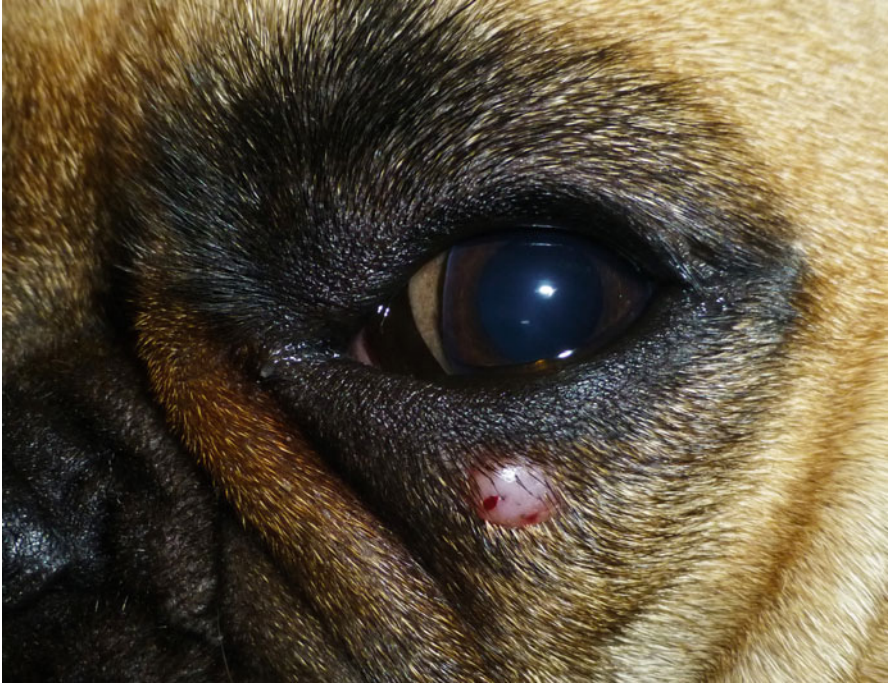

Fig. 4.68 Canine benign histiocytoma: small erythematous nodule on the eyelid of a French Bulldog

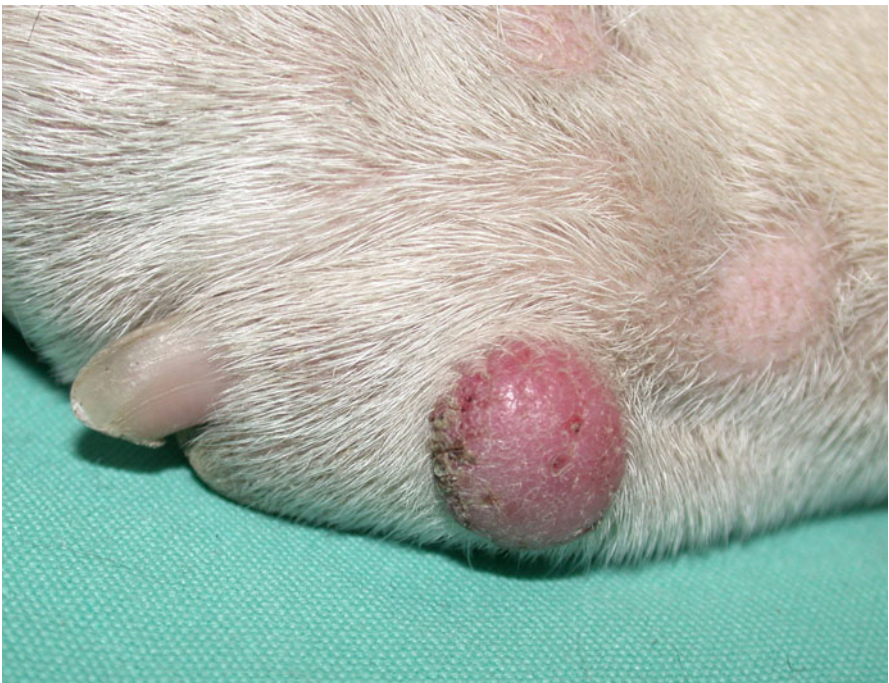

Fig. 4.69 Canine benign histiocytoma: erythematous and alopecic nodule on a digit of an English Bulldog

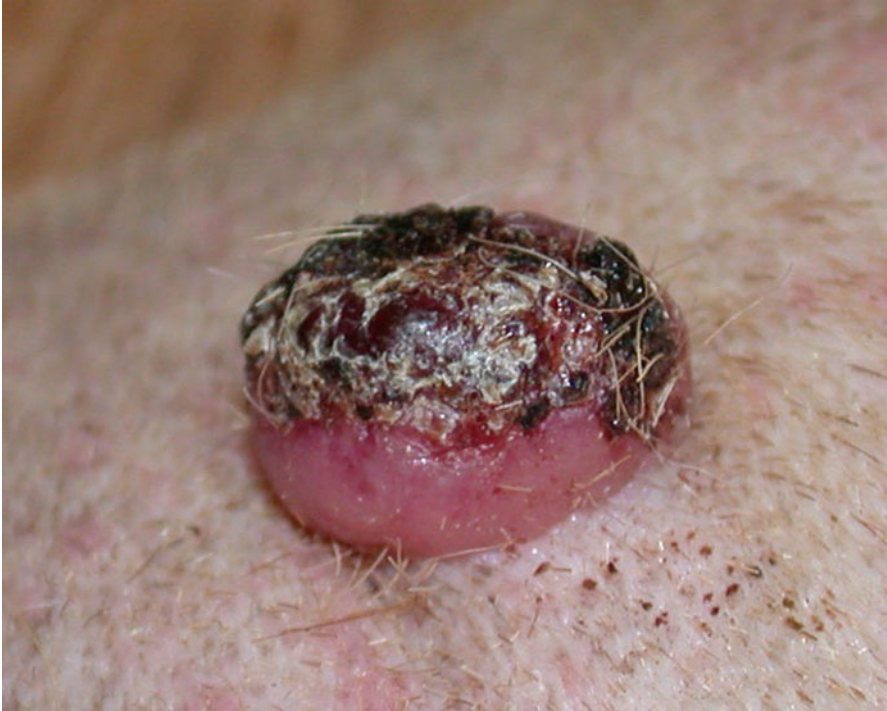

Fig. 4.70 Button-like alopecic, erythematous, ulcerated and crusty nodule, diagnosed as benign cutaneous histiocytoma

Although cutaneous *histiocytoma* displays clinical features that can alarm many owners, such as the rapid growth and tendency to ulcerate, it is characterised by a benign biological behaviour that results in spontaneous regression within a few months (Fig. 4.72). In rare cases, single or multiple histiocytomas do not spontaneously regress and can persist for a long time (*persistent cutaneous histiocytomas*; Figs. 4.73 and 4.74) (Maina et al. 2014). Some Langerhans cells can migrate to lymph nodes, causing a secondary enlargement; these forms also tend to regress spontaneously. The presence of multiple cutaneous histiocytomas with dissemination of Langerhans cells in the lymph nodes and internal organs, characterises *progressive Langerhans cell histiocytosis*, a disorder that is usually fatal in affected animals (Nagata et al. 2000).

Cytological Findings

Slides from *histiocytoma* are always highly cellular and are characterised by round discrete cells with slight anisocytosis and with a central or eccentric, round or oval nucleus, which often have a deep indentation that gives the nuclei a characteristic kidney shape; the chromatin is regular or stippled and the nucleolus, when visible, is small. The cytoplasm is from moderate to abundant and slightly basophilic or pale grey (Figs. 4.75, 4.76, and 4.77). In some cases, the cells are less characteristic and smaller, with scarce and more basophilic cytoplasm, creating difficulties in differentiating between lymphocytes and plasma cells (Fig. 4.78).

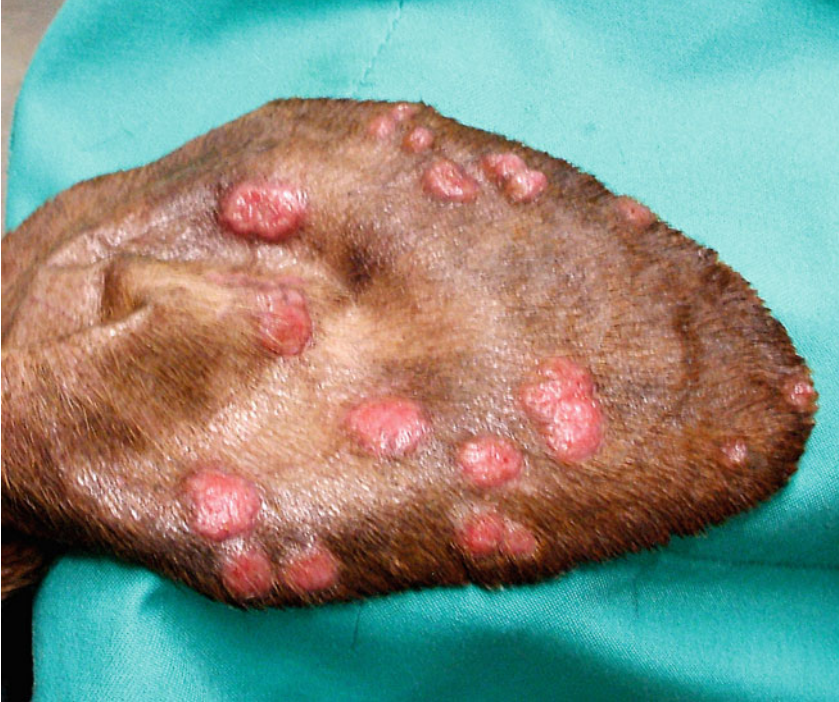

Fig. 4.71 Multiple cutaneous histiocytoma on the inner surface of the pinna of a dog (Courtesy of Dr. F. Leone, Italy)

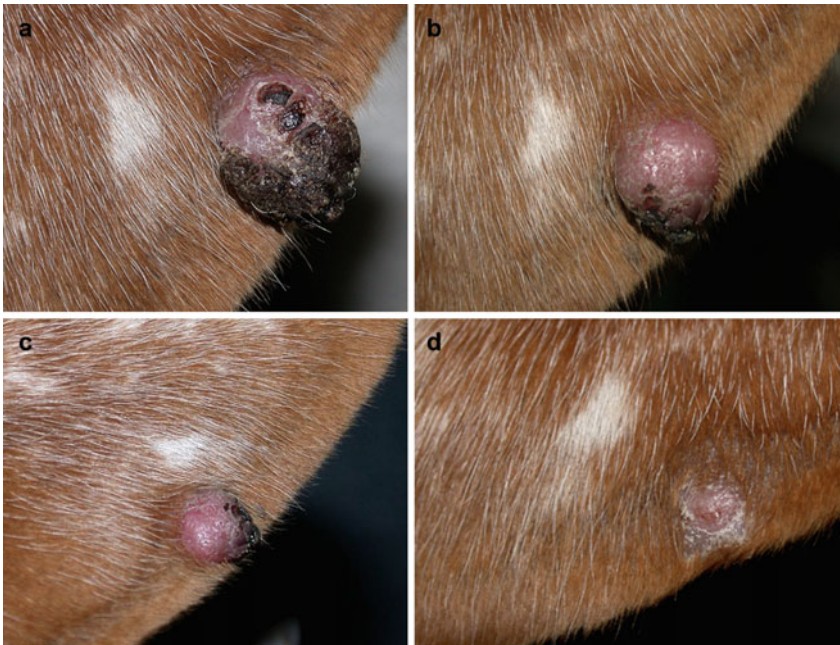


Fig. 4.72 Benign cutaneous histiocytoma. Regression phase: (a) day 0; (b) day 40; (c) day 60; (d) day 80

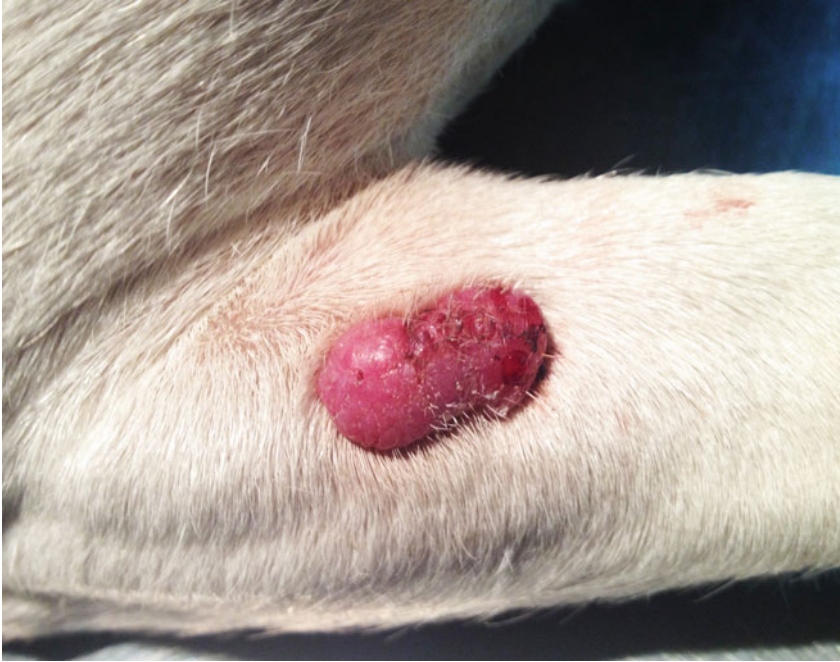

Fig. 4.73 Persistent cutaneous histiocytoma. The nodule was removed from the cytological diagnosis after 8 months. A histiocytoma was histopathologically confirmed

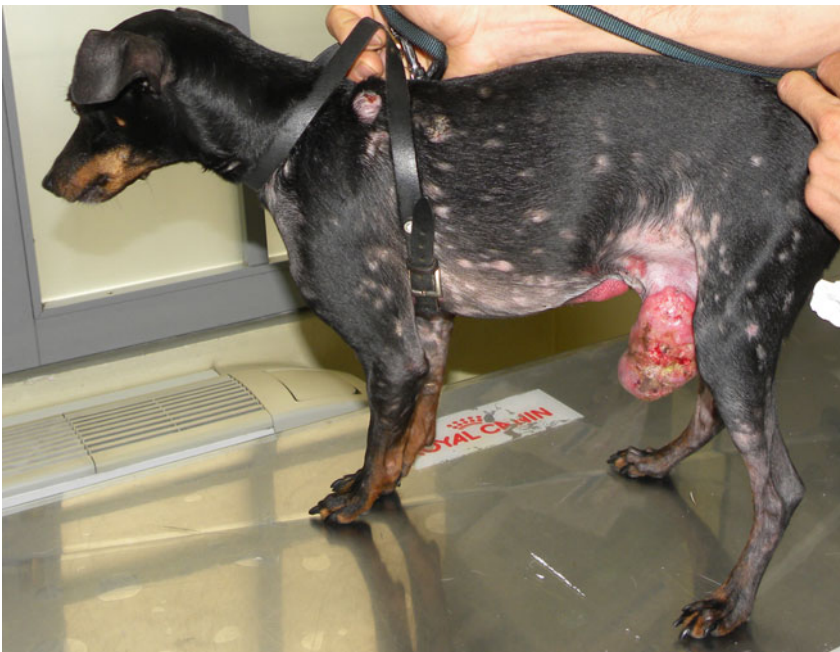

Fig. 4.74 Multiple nodules and masses spread all over the body of a Pinscher with multiple cutaneous histiocytomas (Courtesy of Dr. E. Maina, Italy)

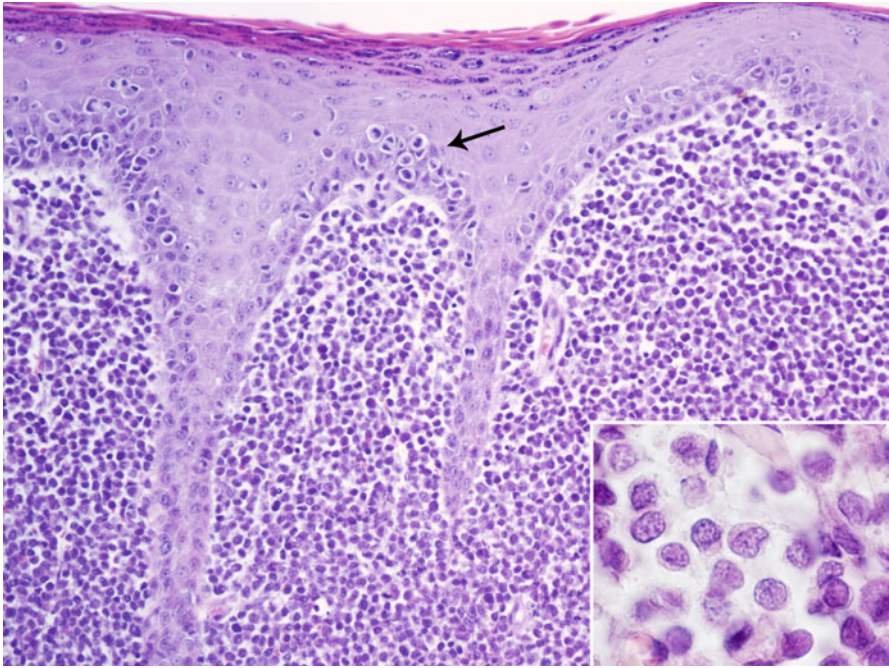


Fig. 4.75 Histopathology of cutaneous histiocytoma. Diffuse dermal proliferation of round and discrete cells. Note the epithelioidism of cells (*arrow*) and the deeply folded nuclei (*inset*)

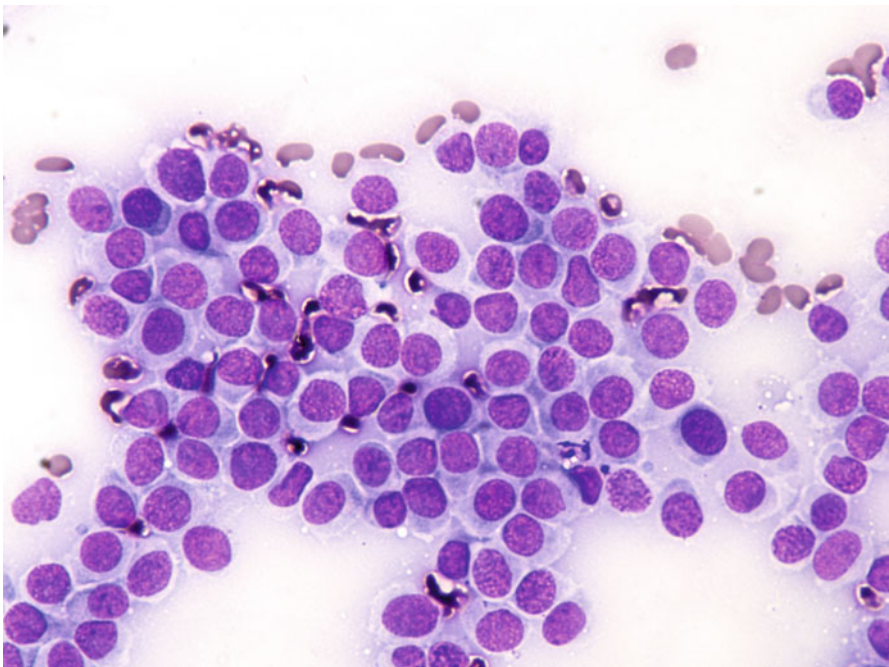


Fig. 4.76 Cytology of cutaneous histiocytoma. Many round cells with round and mostly central nuclei and with large pale blue cytoplasm

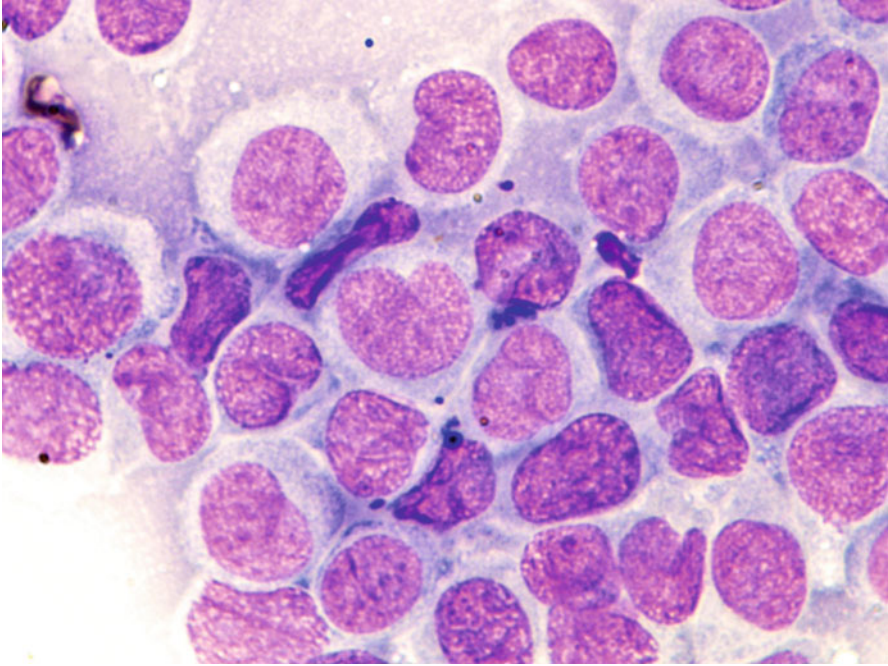


Fig. 4.77 Cytology of cutaneous histiocytoma. At high magnifications, the morphology of cells is more evident. Note the characteristic kidney-shaped nuclei

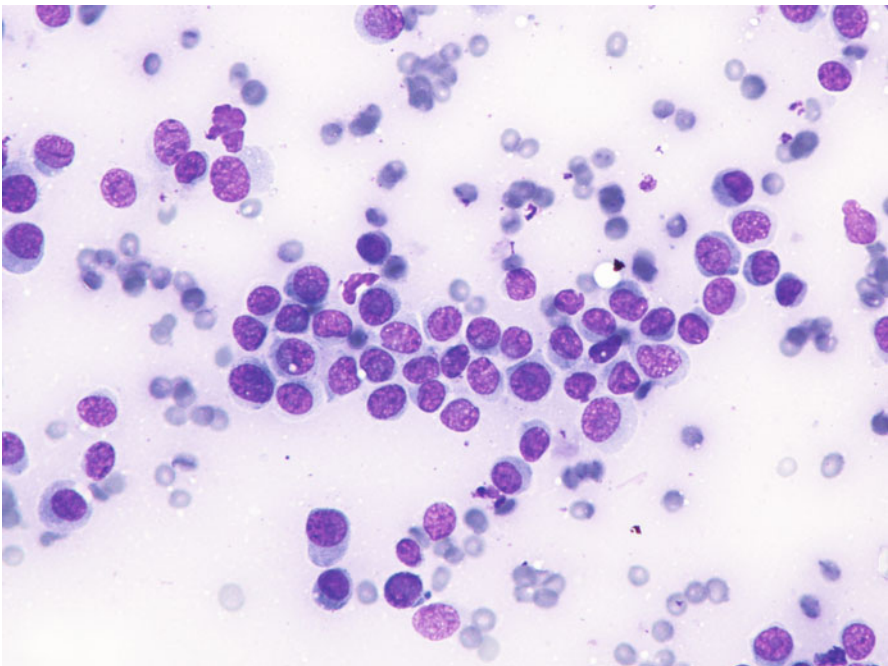


Fig. 4.78 Cytology of cutaneous histiocytoma. Small Langerhans cells with scarce cytoplasm can cause the misdiagnosis of plasma cell tumours

The cytoplasm may contain a low number of vacuoles even if, rarely, they can be numerous (Fig. 4.79). When specimens were collected in the regression phase, they are characterised by a variable number of small T-lymphocytes, which can be so numerous that they exceed the number of histiocytoma cells; the cytological sampling performed at this stage could make it difficult to diagnose the histiocytoma and may confuse the lesion for a chronic lympho-histiocytic inflammatory process (Figs. 4.80 and 4.81). In the advanced stages, together with lymphocytes, it is possible to find other histiocytic cells that are larger than those of a histiocytoma. These cells are characterised by a large cytoplasm and indented nuclei and represent infiltrating dendritic cells in the dermis. Finally, together with lymphocytes, a variable number of plasma cells can be observed. Some authors consider their presence a poor prognostic sign, which is observed in persistent histiocytomas. This biological behaviour linked to the presence of plasma cells does not seem to be based on any scientific evidence.

4.2.5.2 Cutaneous and Systemic Reactive Histiocytosis

Cutaneous reactive histiocytosis (CH) is an inflammatory lympho-histiocytic proliferation of the dendritic APCs residing in the dermis; a probable deregulation of the immune system of unknown origin, probably arising from the defective interaction

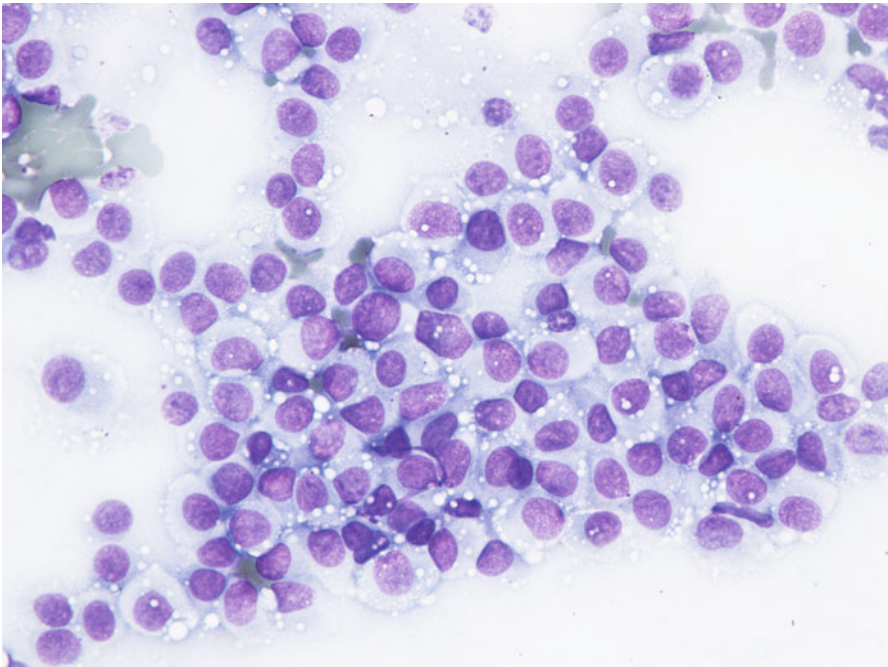


Fig. 4.79 Cytology of cutaneous histiocytoma. Many intracytoplasmic vacuoles are clearly evident. Note that the cells resemble TVT cells

of dendritic cells and T cells is suspected (Moore 2014). This pathogenic hypothesis is based on the spontaneous resolution of the lesions and the good response to several immune-modulatory drugs observed in many cases.

Two forms of reactive histiocytosis are reported: the *cutaneous*, in which lesions are confined to the skin, and another form characterised by the simultaneous involvement of skin and internal organs, named *reactive systemic histiocytosis* (SH) (Moore 1984, 2014; Affolter and Moore 2000). Not all cases of SH, however, have skin lesions. Skin lesions are represented by multiple nodules or plaques, dermal and subcutaneous in location, of variable size and appearance, sometimes showing a donut or an arc shape, which look very similar to the lesions observed in dogs with non-epitheliotropic lymphoma; the nodules are mostly localised on the head, face, trunk, scrotum, nose and extremities (Figs. 4.82, 4.83, 4.84, and 4.85). Many dogs simultaneously present involvement of the conjunctival and nasal mucosa. In the latter case, the nose can assume a so-called *clown nose* appearance (Gross et al. 2005). Sporadic cases exclusively localised to the nose are reported. In some cases, multiple nodules are arranged in a linear fashion to suggest distribution along the blood and lymphatic vessels (Fig. 4.86).

Cytological Findings

The cytological features depend on the stage of the disease. Histologically, reactive histiocytosis is characterised by peri-adnexal and often angiocentric granulomas,

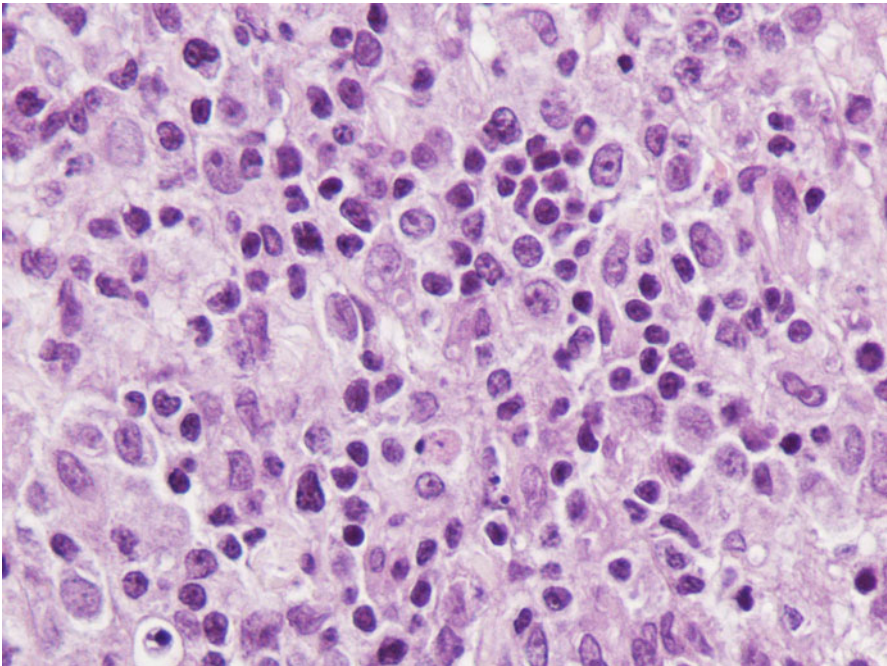


Fig. 4.80 Histopathology of cutaneous histiocytoma in regression stage. Many small infiltrating lymphocytes infiltrate the tumour

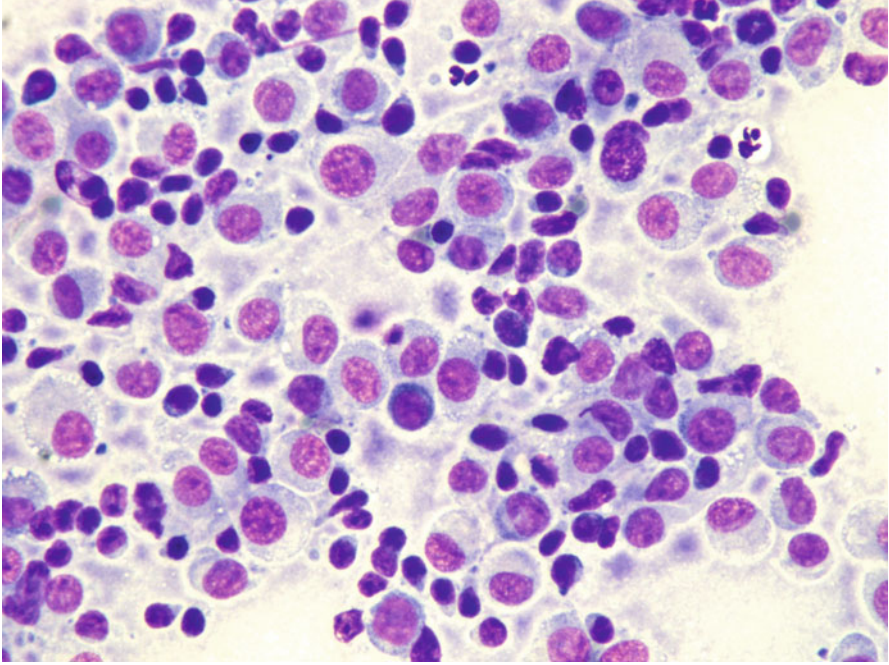


Fig. 4.81 Cytology of cutaneous histiocytoma in the regression phase. Many small lymphocytes are detectable between the dendritic cells of the histiocytoma

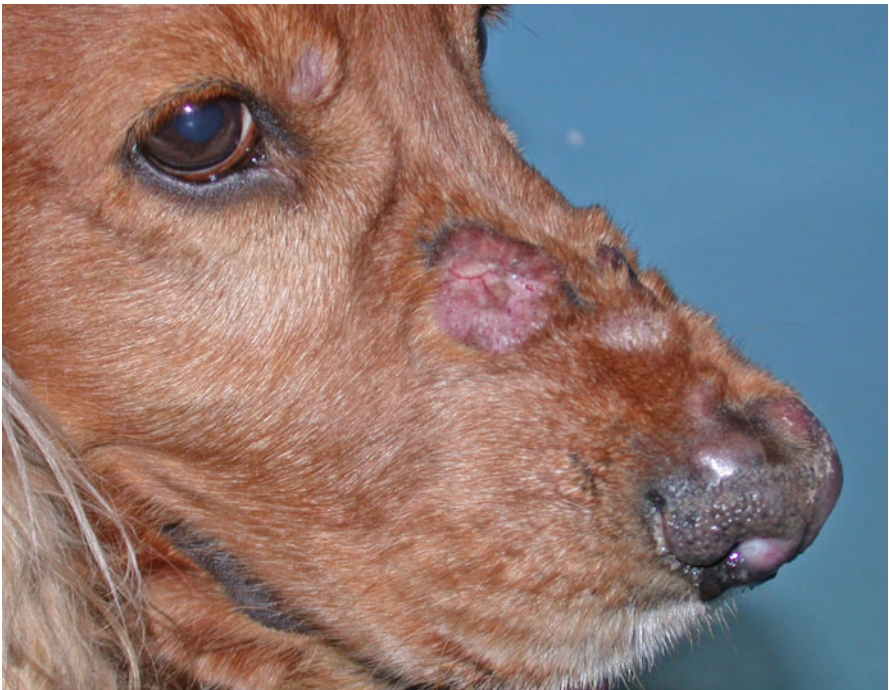

Fig. 4.82 Nodules and donut-shaped plaques in a Cocker with reactive cutaneous histiocytosis

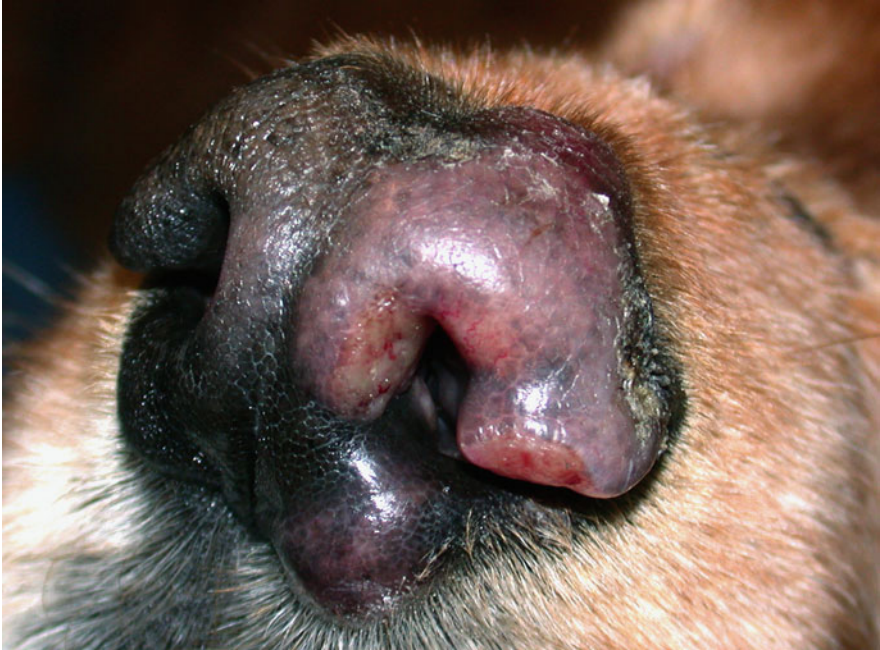

Fig. 4.83 Reactive cutaneous histiocytosis: nodule and swelling of the nose in the same dog as in Fig. 4.82

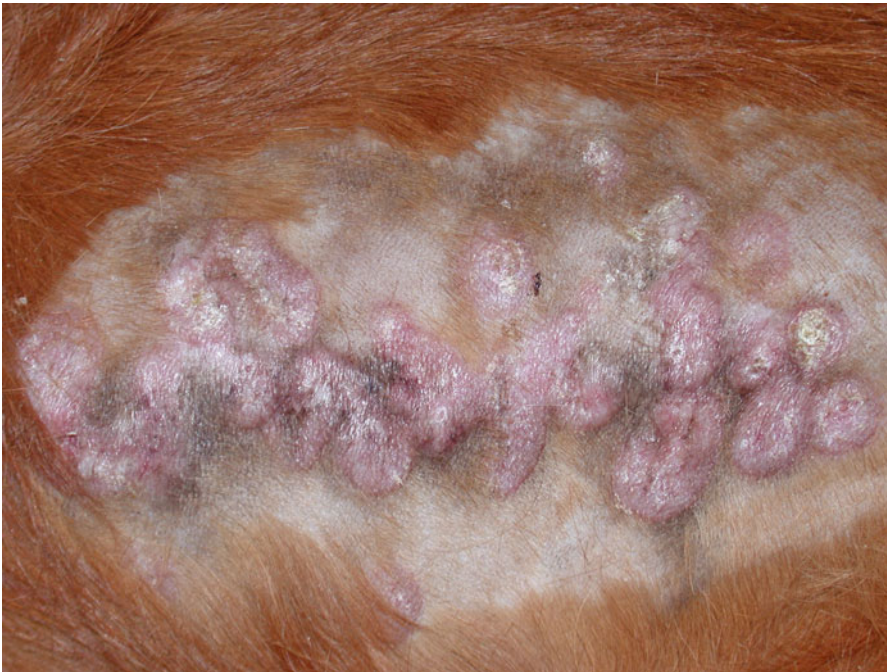

Fig. 4.84 Multiple and confluent donut-shaped plaque on the chest of a dog with reactive cutaneous histiocytosis




Fig. 4.85 Multiple erythematous nodules on the thorax of a Bernese Mountain dog with *cutaneous reactive histiocytosis*

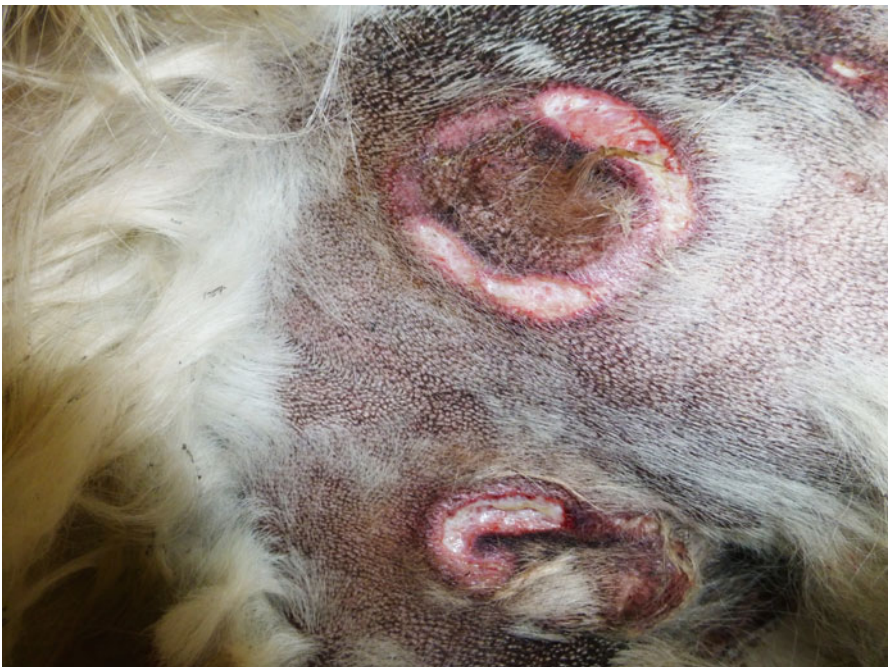

Fig. 4.86 Reactive cutaneous histiocytosis. Large annular ulcerated plaques on the sternal area of a Golden retriever

located in the deep dermis (bottom heavy) and infiltrating the panniculus (Figs. 4.87 and 4.88). In early stages, via FNB, the possibility of the needle penetrating the granulomas is very low; thus, samples usually contain few cells. In the advanced stages of the disease, granulomas can merge and the infiltrate changes from nodular to diffuse, allowing more successful collection of cells. In many cases, cells are yielded in a cohesive group and it is very hard to observe intact dendritic cells with a clear silhouette. More representative specimens are characterised by roundish histiocytes with oval, folded or kidney-shaped nuclei, regular chromatin, inconspicuous nucleoli and large and pale cytoplasm, sometimes with poorly defined margins and occasionally containing small vacuoles (Figs. 4.89 and 4.90). Many histiocytes are represented by bare nuclei with cytoplasm spread on the background. In association with histiocytic dendritic cells, a variable but usually high number of lymphocytes is constantly present; a few plasma cells and neutrophils are also detected. In most cases, cytological features are not differentiable from those observed in sterile granuloma syndrome or other granulomatous diseases, as the APCs can be cytologically similar to histiocytes of the macrophage lineage.

Definitive diagnosis, in cases where there is doubt, can only be achieved by histopathology and immunohistochemistry on frozen tissue, as on paraffin-embedded tissue, there is no one immunostain that can differentiate a dendritic histiocyte (APC) from a macrophage.

4.2.5.3 Histiocytic Sarcoma

Histiocytic sarcoma is a rare neoplasia in dogs and very rare in cats, and originates from interstitial dendritic cells present in many organs (Affolter and Moore 2002; Moore 2014). In the skin, the APCs from which the histiocytic sarcoma originates are present in the dermis and subcutaneous tissue.

The primarily cutaneous form is observed more frequently in certain breeds such as the Bernese mountain dog, the Rottweiler, the Golden and Flat-coated retriever (Moore and Rosin 1986; Constantino-Casas et al. 2011; Moore 2014) as single nodules of variable size, predominantly localised to the extremities, especially on the joints area, which are very often infiltrated (Fig. 4.91). The same neoplasia can metastasise to the internal organs or may originate primarily from a visceral organ such as the spleen. A clinical variant of histiocytic sarcoma that started as disseminated in multiple visceral organs and that can involve even the skin is well recognised (Figs. 4.92 and 4.93). All these forms with multicentric lesions are defined by the term *disseminated histiocytic sarcoma*, supplanting the old term *malignant histiocytosis*.

Cytological Findings

The cytological pattern of *histiocytic sarcoma* is pleomorphic and may vary depending on the area of the lesion that is sampled. It is possible to find two different types: a variant composed prevalently of *round cells* and another form with *spindle-shaped cells*. In any case, the malignant aspects of the neoplastic cells are always

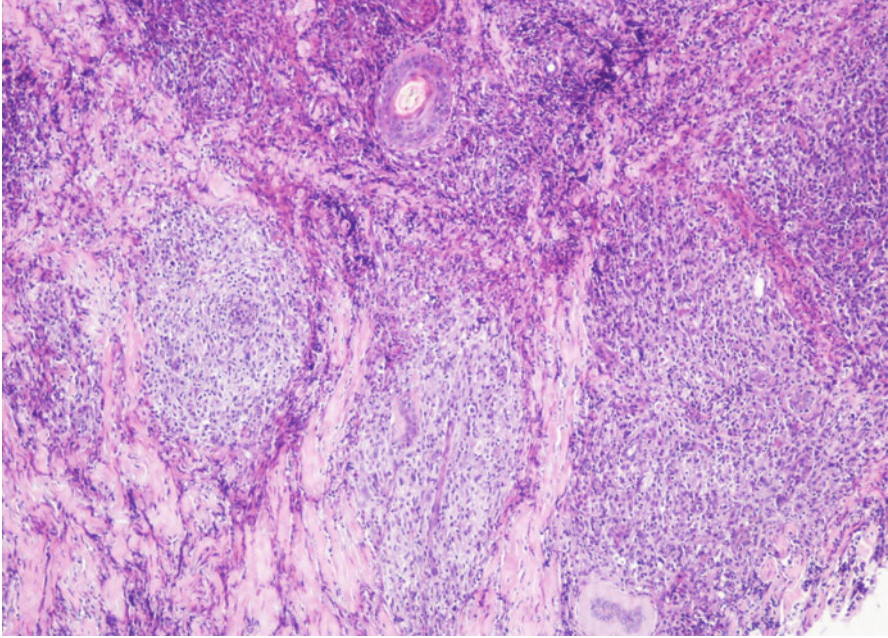


Fig. 4.87 Histopathology of reactive cutaneous histiocytosis: multiple deep and confluent dermal nodules

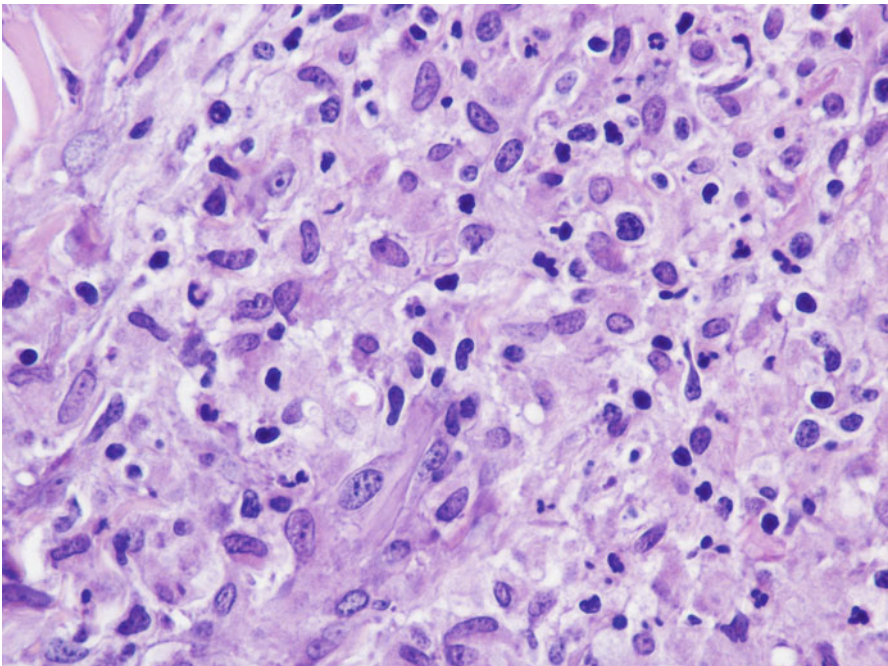


Fig. 4.88 Histopathology of reactive cutaneous histiocytosis: at high magnifications, large histiocytes and small lymphocytes are recognisable

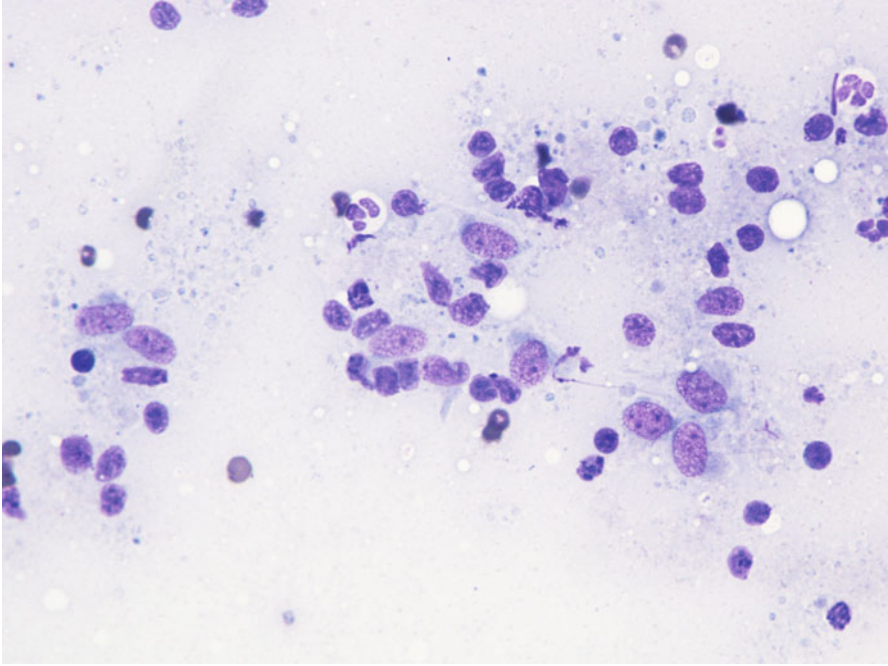


Fig. 4.89 Cytology of reactive cutaneous histiocytosis: histiocytes with oval and slightly indented nuclei. Many free bare nuclei and a few lymphocytes are also present

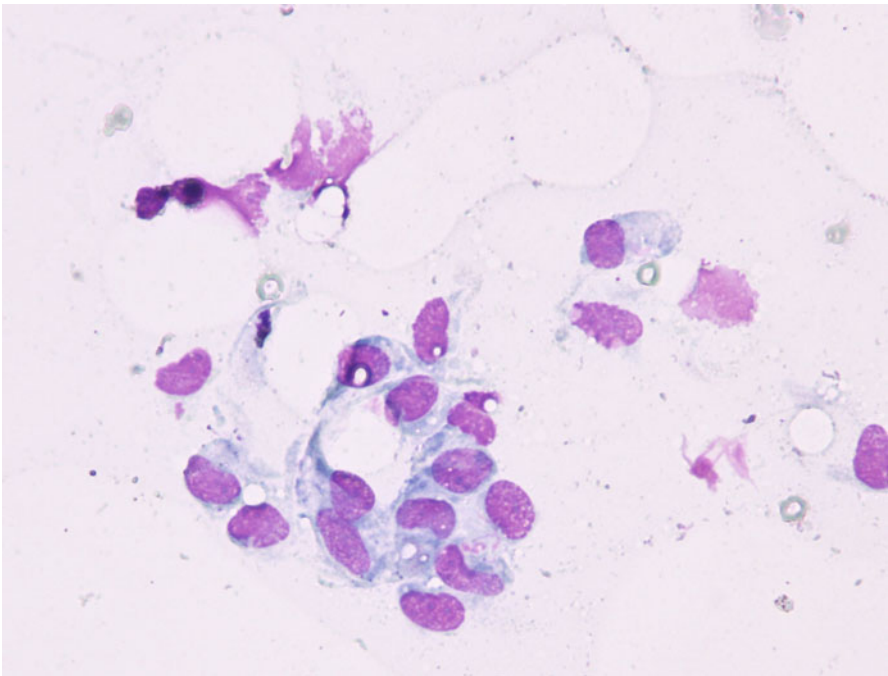


Fig. 4.90 Cytology of reactive cutaneous histiocytosis: histiocytes with oval and kidney-shaped nuclei, with poorly defined cytoplasmic margins

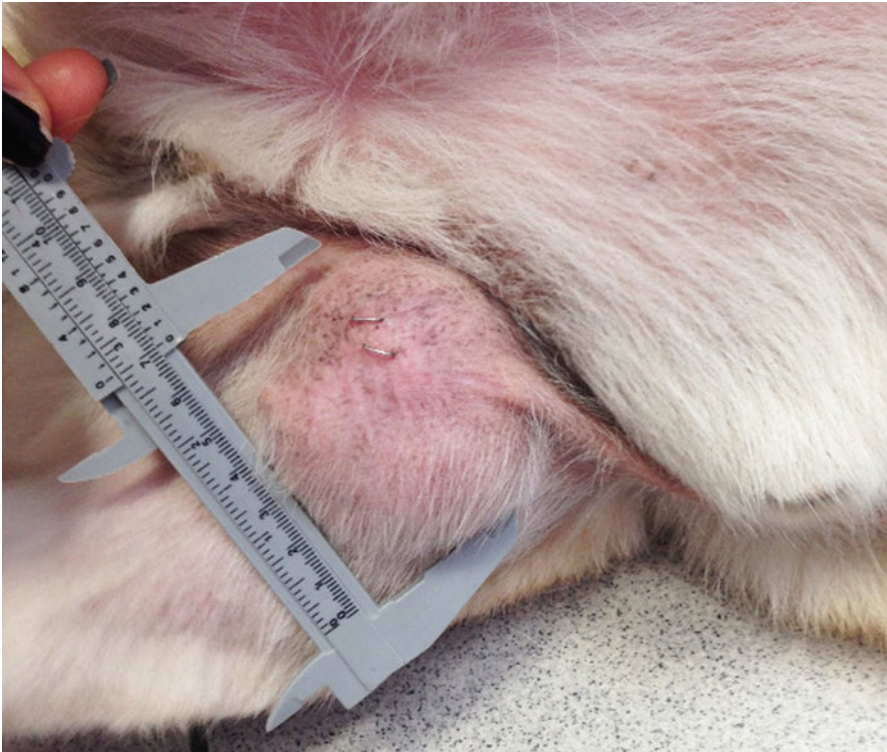

Fig. 4.91 Single mass on the leg of a dog with localised histiocytic sarcoma (Courtesy of Dr. L. Marconato, Italy)

remarkable. The round cells are characterised by marked anisocytosis, with very large, round or oval, often indented or kidney-shaped nuclei, with one or more bizarre nucleoli and large cytoplasm, slightly basophilic and usually micro-vacuolated (Figs. 4.94 and 4.95). The spindle cells have round to oval, often indented and distorted nuclei. In both variants, the cells exhibit severe aspects of atypia and in the spindle cell subtype, the presence of numerous multinucleated cells can create many diagnostic difficulties as the cytological features are very similar to those observed in some anaplastic sarcomas of the soft tissue with many giant cells (formerly named *malignant fibrous histiocytoma*; Figs. 4.96 and 4.97). In some samples it is also possible to find a variable number, often significant, of infiltrating leukocytes.

4.2.5.4 Feline Progressive Dendritic Histiocytosis

Feline progressive histiocytosis is a histiocytic disorder with involvement of the skin, observed in adult to old cats and originating from interstitial APCs (Moore 2014; Pinto da Cunha et al. 2014). In most reported cases, lesions are usually characterised by a single nodule on the limb that with time disseminates to other skin

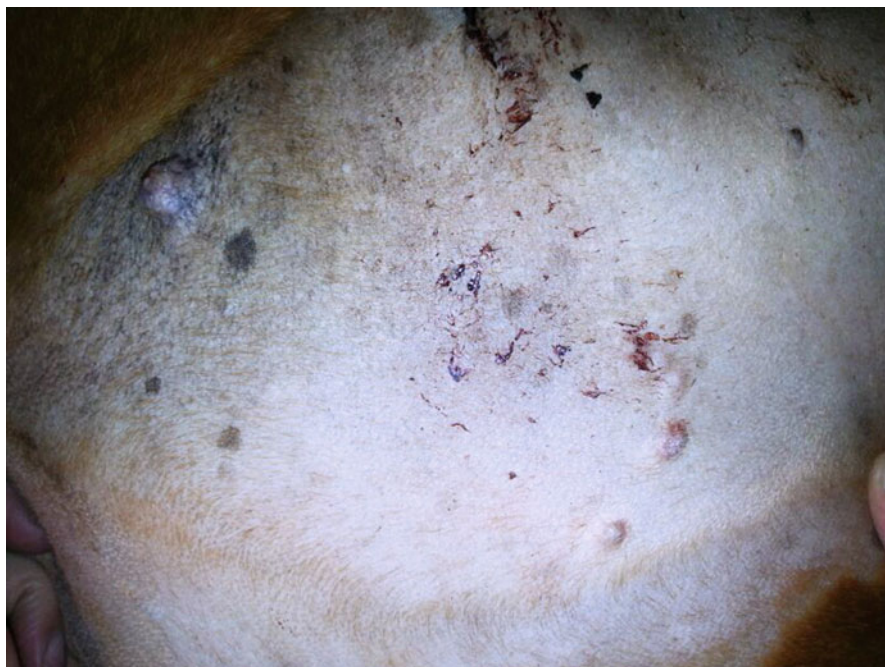

Fig. 4.92 Multiple small nodules in a boxer with disseminated histiocytic sarcoma

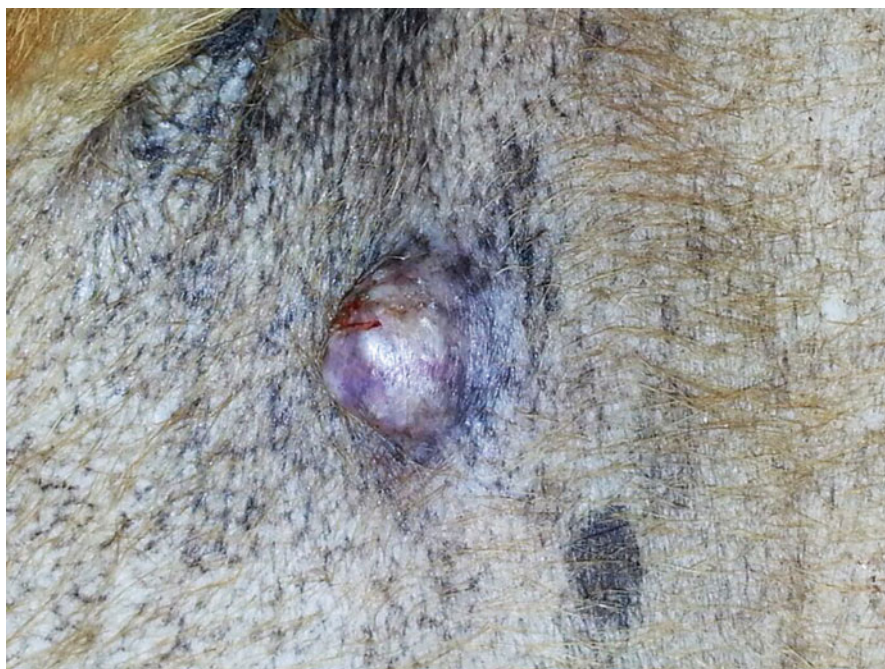

Fig. 4.93 Close-up of the same dog as in Fig. 4.92

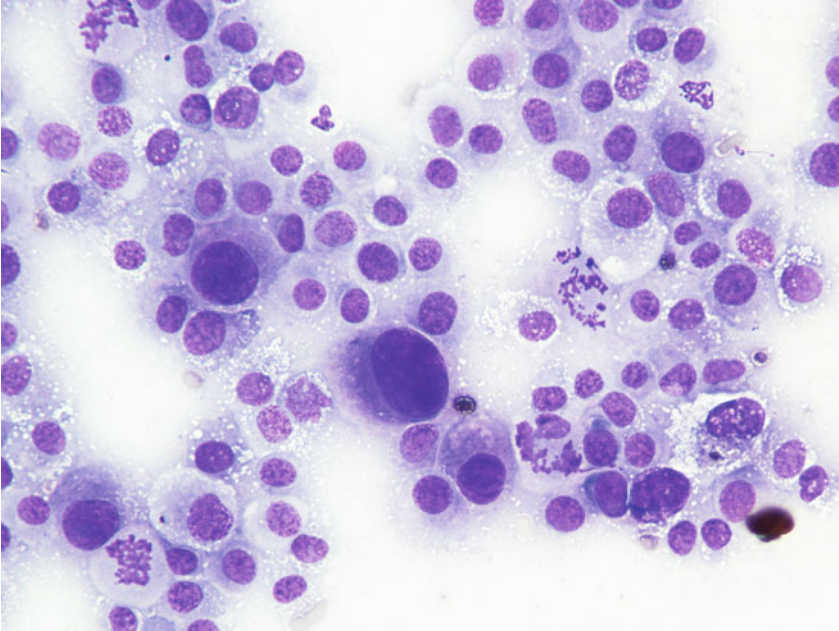


Fig. 4.94 Cytology of histiocytic sarcoma: round neoplastic dendritic cells, characterised by severe anisokaryosis and vacuolated cytoplasm

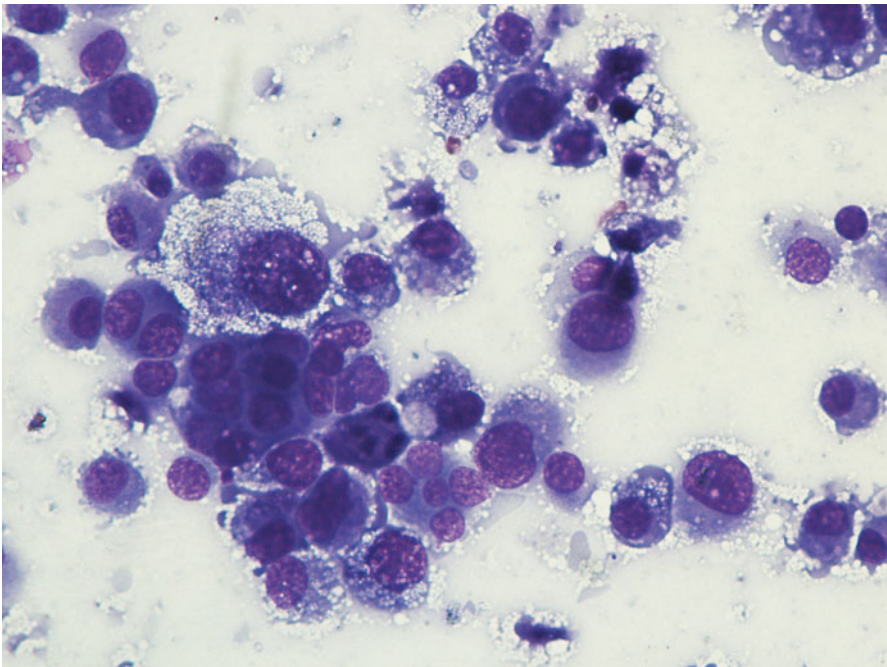


Fig. 4.95 Cytology of histiocytic sarcoma: round neoplastic dendritic cells, characterised by severe atypia and multinuclearity

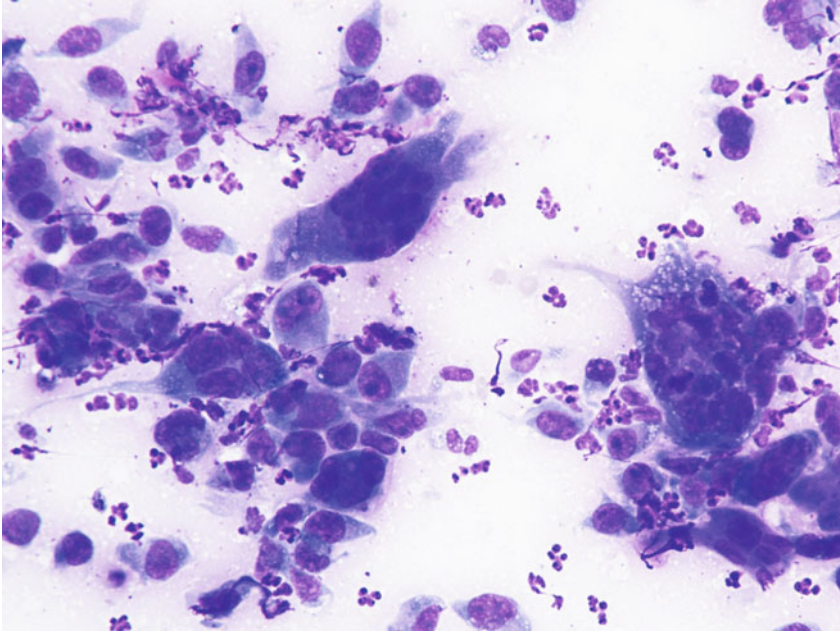


Fig. 4.96 Cytology of histiocytic sarcoma: spindle-shaped neoplastic dendritic cells. Marked atypia and multinuclearity characterise the cells. Note as they cannot be cytologically differentiated from a spindle-shaped anaplastic soft tissue sarcoma

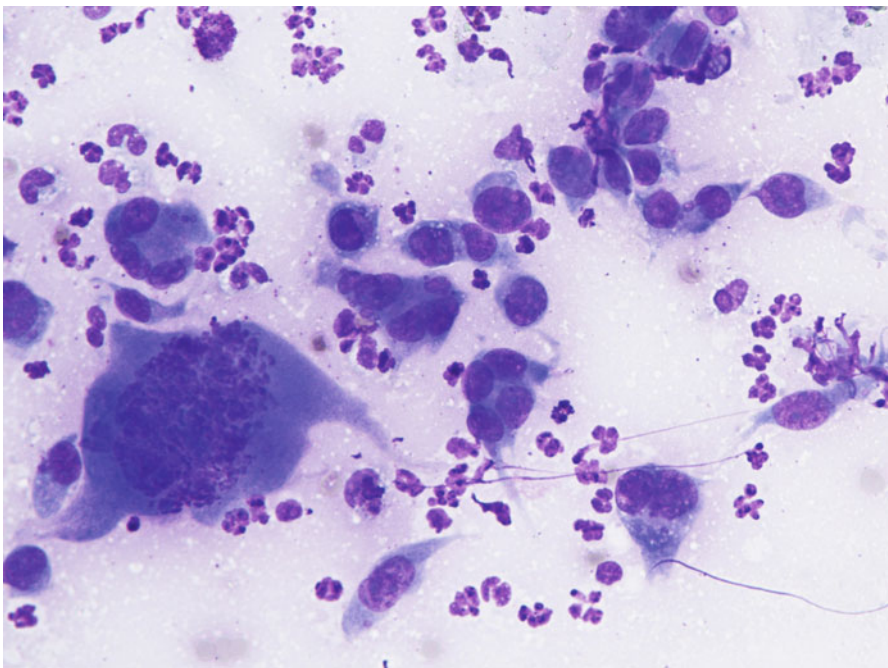


Fig. 4.97 Cytology of histiocytic sarcoma: note the severe atypical mitosis in the larger cell

sites (Figs. 4.98, 4.99, and 4.100). The spontaneous regression of some nodules is sometimes observed, but the disease always progresses and spreads to the skin or the internal organs. The cutaneous nodules vary in size, from small to very large and may coalesce in plaque formations mostly located on the head, limbs and trunk.

Cytological Findings

Slides from feline progressive histiocytosis are variable. In the initial stage, histiocytes vary from round to polygonal and less frequently spindle-shaped, with nuclei from round to indented, sometimes double and rarely multiple with scant cytoplasm stained pale blue (Figs. 4.101 and 4.102). In chronic cases the cytological atypia become much more evident until they become very pronounced (anisokaryosis, anisocytosis, bizarre nuclei, large and multiple macronucleoli) (Figs. 4.103 and 4.104). In chronic cases, a significant infiltration of lymphocytes and, less frequently of mast cells, is reported. Because of the difficulty of diagnosing the APCs in paraffin specimens that restrict the use of immunohistochemical markers, the possibility of using immunocytochemistry on frozen cytological specimens has recently been suggested in some works. The use of specific markers for the identification of various populations of dendritic histiocytes permits us to differentiate them not only from other dendritic cells, but also from histiocytic macrophages (Pinto da Cunha et al. 2014).

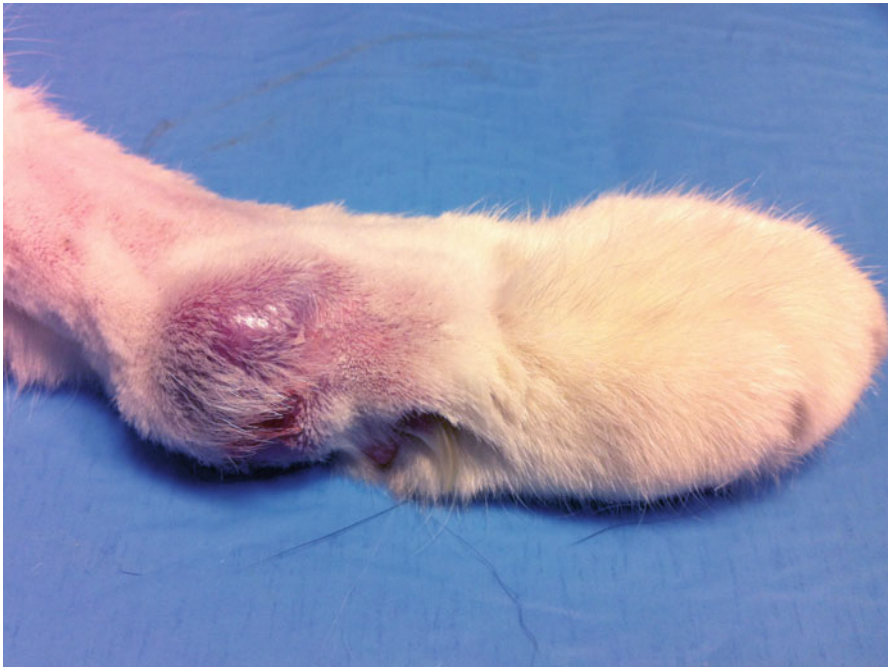


Fig. 4.98 Feline progressive histiocytosis. Single, alopecic and erythematous nodule on the leg

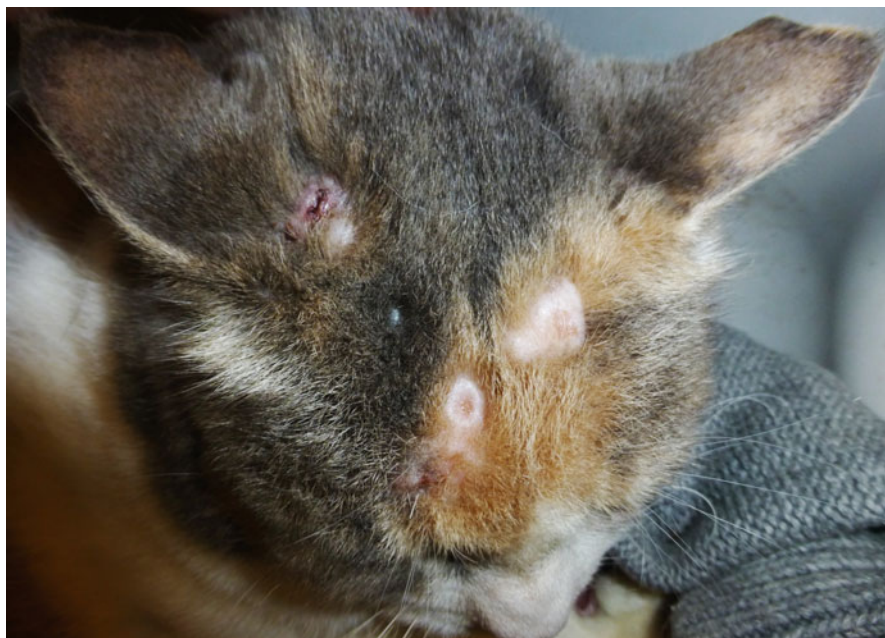

Fig. 4.99 Multiple alopecic nodules on the head of a cat with progressive histiocytosis

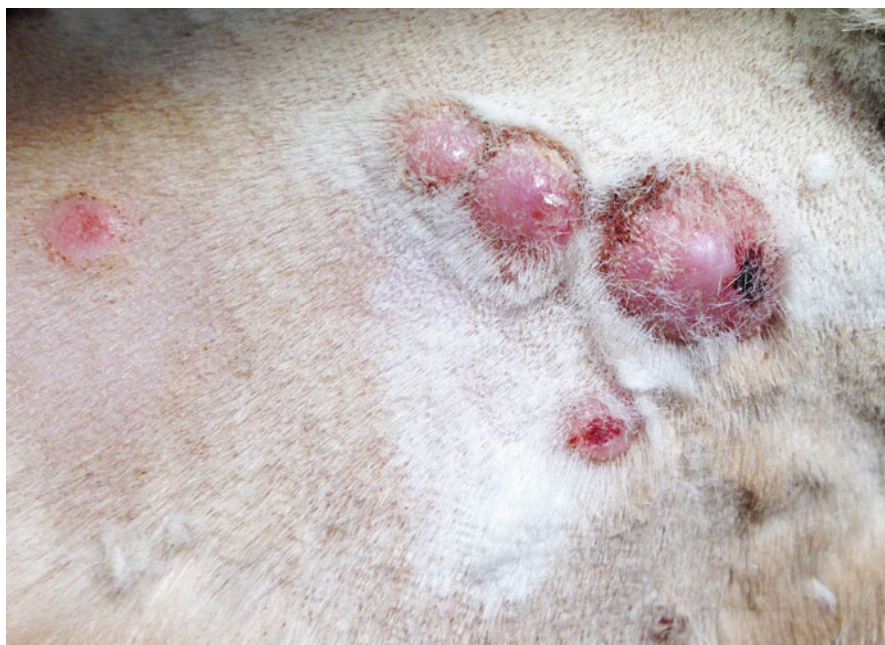


Fig. 4.100 Feline progressive histiocytosis. Close-up of multiple skin nodules on the chest of the same cat as in Fig. 4.99

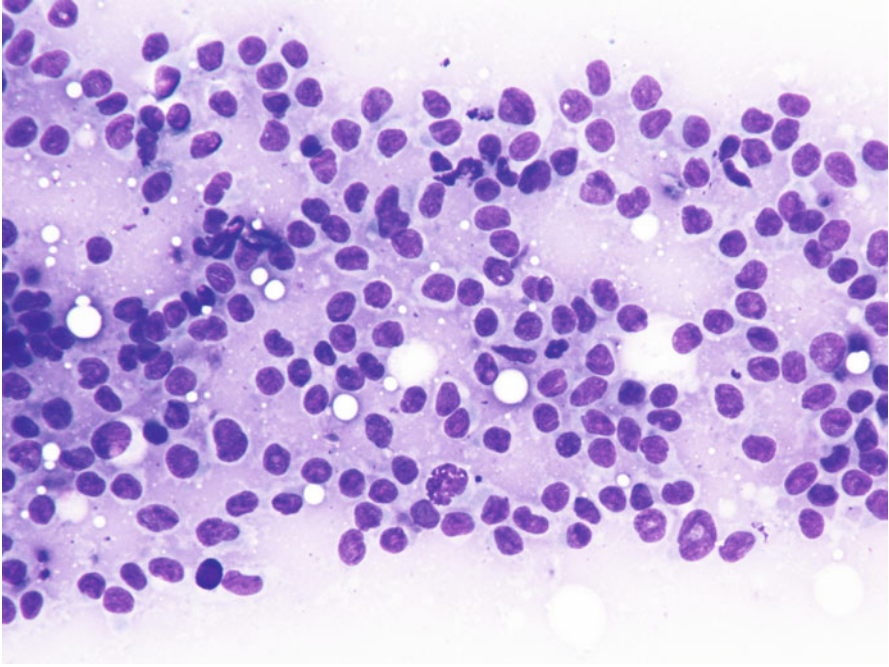


Fig. 4.101 Cytology of feline progressive histiocytosis. Discrete round dendritic antigen-presenting cells (APCs)

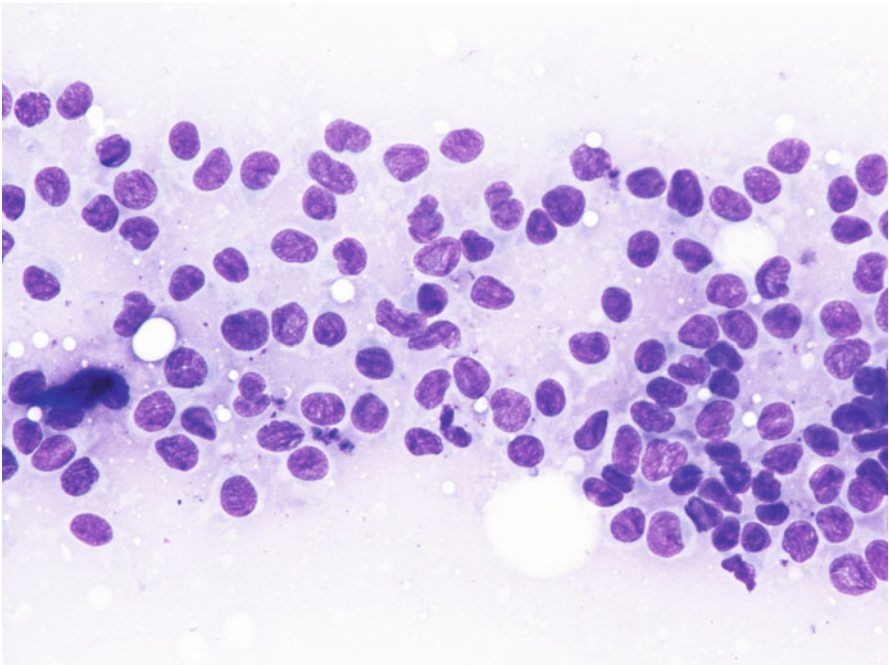


Fig. 4.102 Cytology of feline progressive histiocytosis. At high magnification, the histiocytic features are more evident. Note that many cells show indented nuclei

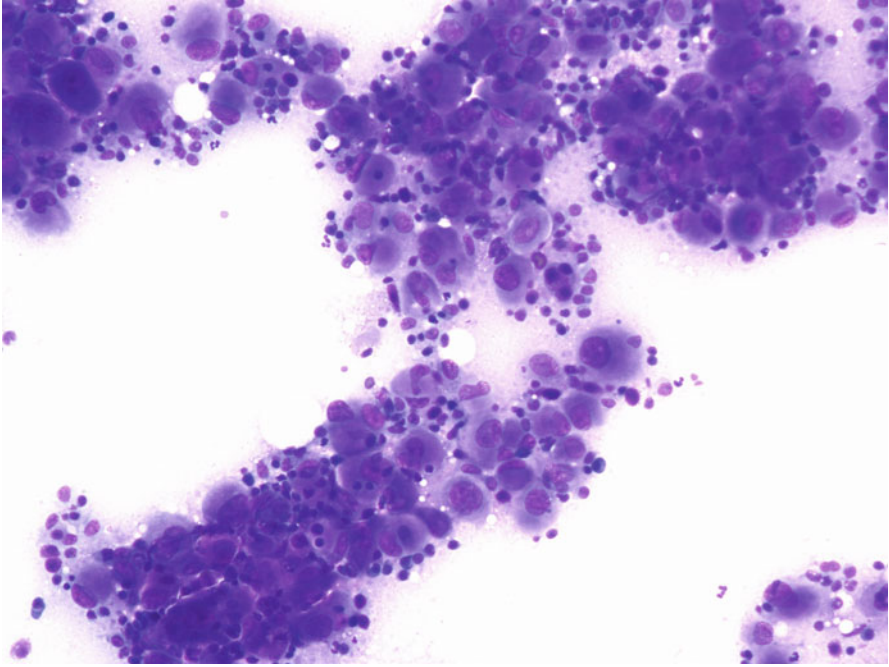


Fig. 4.103 Cytology of feline progressive histiocytosis. Highly cellular specimens composed of polymorphous round cells with severe malignant features

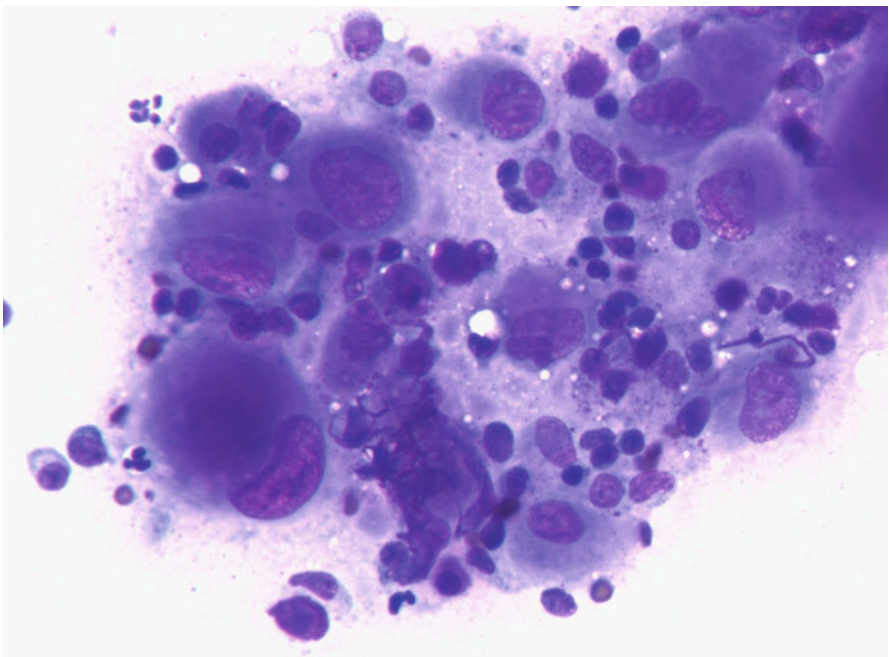


Fig. 4.104 Cytology of feline progressive histiocytosis. At high magnifications, large histiocytic dendritic cells of different sizes and some lymphocytes are evident

4.3 Epithelial Tumours

In this sub-group, tumours that originate from the epidermis and its adnexa are discussed.

Epithelial cells present in the skin, from where neoplasia can originate, are the *keratinocytes* from both external and follicular epidermis, and *sebaceous* and *apocrine* glands.

In addition to these tumours, neoplasms of specialised glands, which can be both apocrine (ceruminous and anal sac glands) and sebaceous (hepatoid glands) are also discussed.

The cytological features common to all epithelial tumours is that cells are yielded as cohesive clusters, as they are, by nature, strictly connected to each other by inter-cellular joints.

The epithelial tumours are composed of medium to large cells, with scarce to abundant cytoplasm and round to ovoid nuclei with chromatin ranging from fine to coarse. The presence of acinar, ductal and papillary cytoarchitecture, together with intracytoplasmic secretions, can cytologically identify the apocrine glandular origin of the tumour. Lobules of cohesive cells with foamy cytoplasm are instead indicative of their sebaceous origin.

In poorly differentiated tumours (anaplastic carcinomas), the above mentioned cytological features may be lost and the cells cannot be released as clusters, but singly and with severe cytological atypia. In these cases, the morphological aspects may make it difficult to include the tumour in the group of *epithelial tumours*. A classic epithelial tumour, in which the cells often appear singly, is the squamous cell carcinoma.

The epithelial neoplasms of the skin in dogs and cats are numerous and only the most important, or those for which the cytological examination is of great diagnostic aid, are described in detail in this chapter.

4.3.1 Squamous Cell Carcinoma

Squamous cell carcinoma (SCC) is a very common cancer in cats, but less common in dogs, and originates from the cells of the spinous layer of the epidermis (Gross et al. 2005; Webb et al. 2009; Hauck 2013; Murphy 2013). The main cause of SCC in pets is linked to chronic sun exposure and therefore SCCs are very frequent in animals with white skin, especially on glabrous or poorly haired areas and with thin skin.

The role of papillomavirus in the development of SCC has been widely documented in dogs and the ongoing discovery of new viral variants is a constant confirmation (Zaugg et al. 2005). In cats, the role of papillomavirus is limited to a few reports, although recent studies have shown that in many cases of SCC and *Bowenoid in situ carcinoma* (BISC), papillomavirus particles have been detected (Nespeca et al. 2006; Wilhelm et al. 2006; Favrot et al. 2009). Moreover, although BISC may

arise on feline viral plaques induced by papillomavirus (papillomavirus-induced feline viral plaque), some cases may also be associated with a non-viral cause (Wilhelm et al. 2006).

In dogs, the SCCs appear as nodules, plaques or exophytic masses with ill-defined margins and often with an ulcerated and bleeding surface. These tumours are mainly located on hairless and thin skin, such as the groin, abdomen and scrotum, especially in dogs with white skin, which is less protected from sunlight (Figs. 4.105 and 4.106). In many dogs, lesions are observed in association with actinic keratosis, which represents an *in situ* carcinoma that precedes the development of an infiltrating SCC (Fig. 4.107). Ulcerative SCCs are also observed on the nose, particularly in Labradors and Golden retrievers (Fig. 4.108) (Lascelles et al. 2000). Another area where SCC develops in dogs, considered highly malignant, is the nail bed; this location is most commonly observed in black-haired giant breeds such as in giant Schnauzers, Rottweilers and Labradors, where multiple toes of more than one leg can be simultaneously affected (Figs. 4.109 and 4.110). This must be stressed, as in the early stages of tumour development, lesions are characterised by the swelling of the digit and periungual area and cannot be clinically differentiated from inflammatory paronychia.

In cats, SCC is frequently observed on the nose, eyelids and on the pinna. Even in this species, the white coat is a strong predisposing factor. In the cat, the SCC

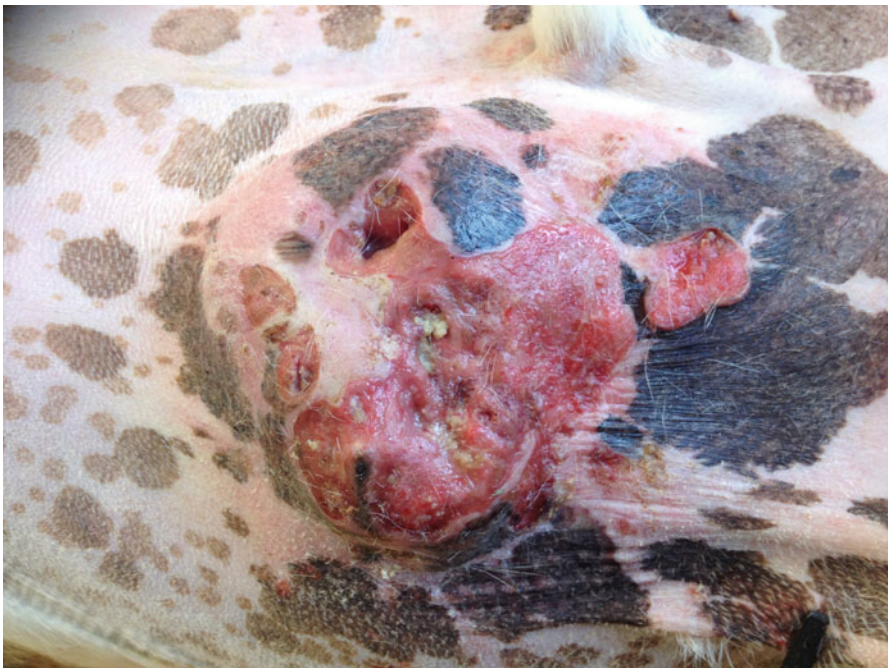

Fig. 4.105 Squamous cell carcinoma (SCC). Large and ulcerated mass on the abdomen of an Argentine dog

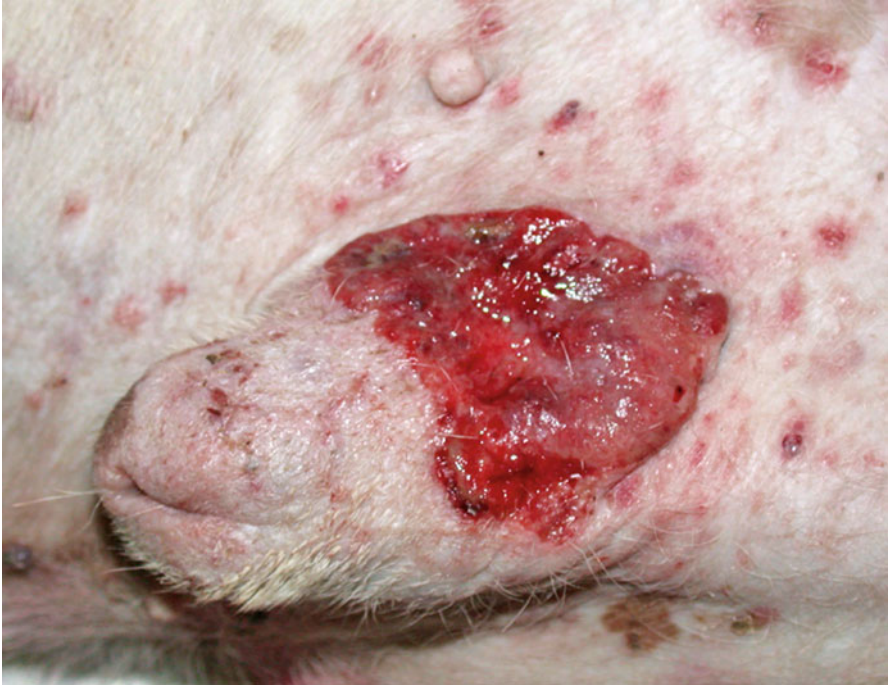

Fig. 4.106 Squamous cell carcinoma. Ulcerated SCC on the penis of a dog

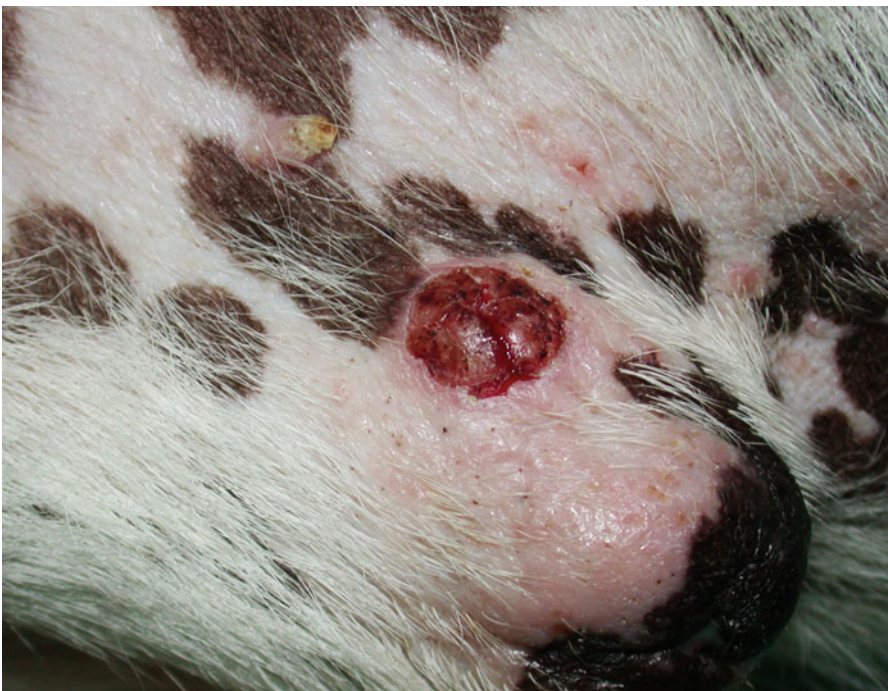

Fig. 4.107 An SCC and actinic keratosis on the penis of a white hair-coated dog

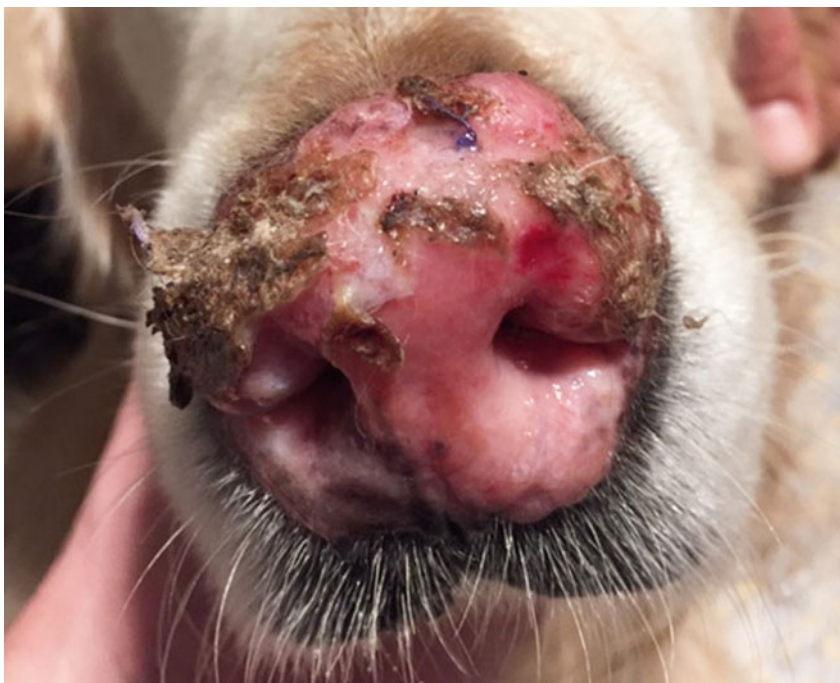

Fig. 4.108 An SCC of the nose in a Golden retriever (Courtesy of Dr. M. Annoni, Italy)

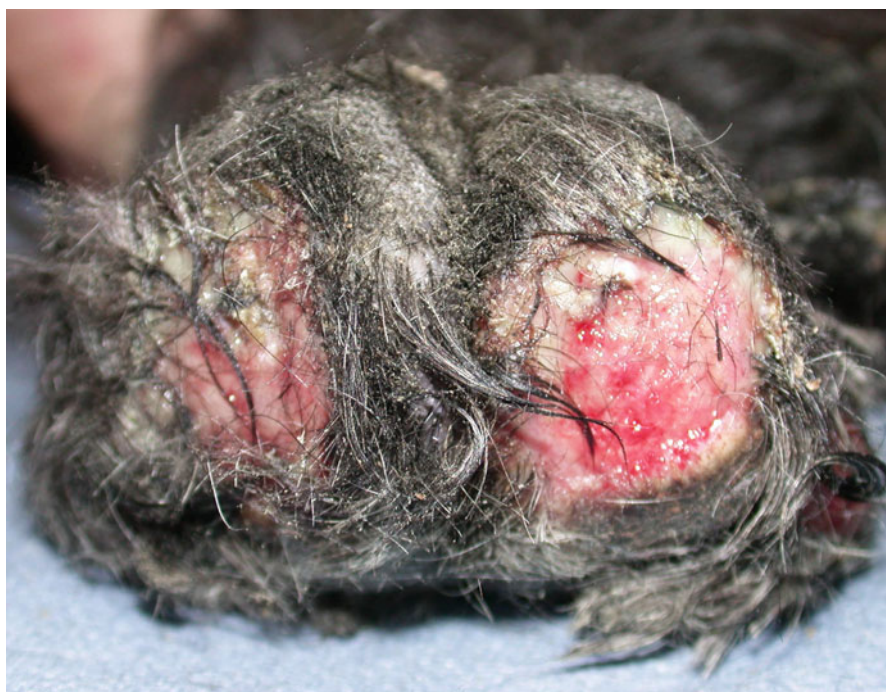

Fig. 4.109 Multidigital SCC of the nail bed in a Giant Schnauzer

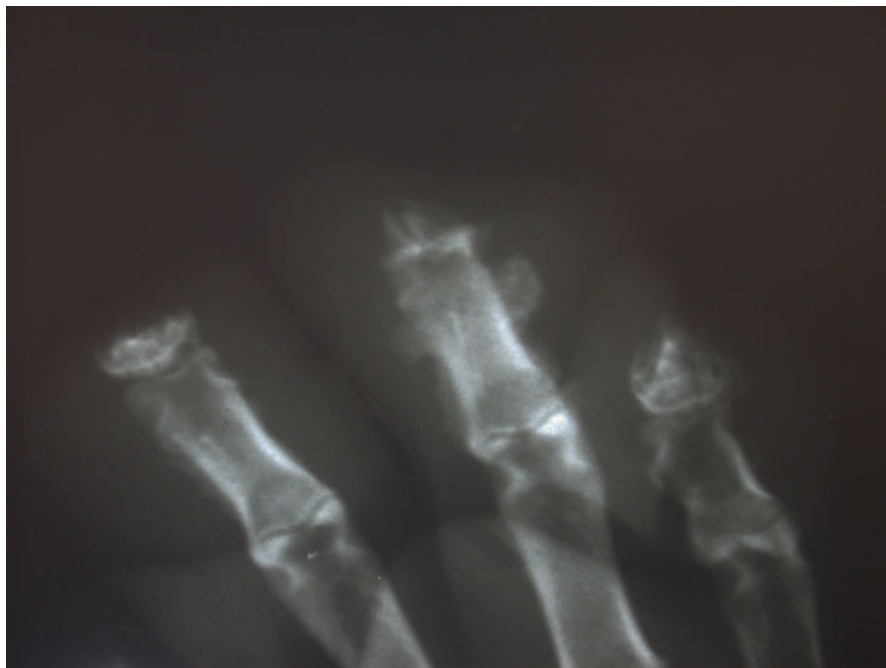

Fig. 4.110 Severe osteolysis of three adjacent digits of the same dog as in Fig. 4.109

occurs more frequently with ulcerative lesions that cause the loss of large portions of tissue disfiguring the affected areas (Figs. 4.111, 4.112, 4.113, and 4.114). Exophytic lesions are much less common than in dogs (Fig. 4.115).

Cases of non-sun-induced SCCs are usually observed, as single or multiple lesions, in cats with dark coats (BISC). In cats affected by BISC, skin lesions are usually characterised by multiple pigmented plaques, often covered with thick yellowish or brownish crusts, spread throughout the body and with frequent facial involvement. Clinically, they are often not suspected to be neoplasia, but are confused with non-tumoral lesions (Figs. 4.116, 4.117, and 4.118).

Cytological Findings

The cytological features of SCC is linked to its grade of differentiation and different aspects can coexist within the same neoplasia. Very pleomorphic features characterise the cytological specimens (Figs. 4.119 and 4.120). In most instances, the SCCs are well-differentiated and are cytologically characterised by small aggregates, more or less numerous, of epithelial cells in which evident aspects of squamous differentiation are present. Although the SCC is an epithelial neoplasia, the cells tend not to always maintain real cohesion and, for this reason, they are frequently yielded as single cells (Fig. 4.121).

The main cytological characteristic of SCC, already detectable at low magnifications, is the typical asynchronous maturation of different squamous cells and,

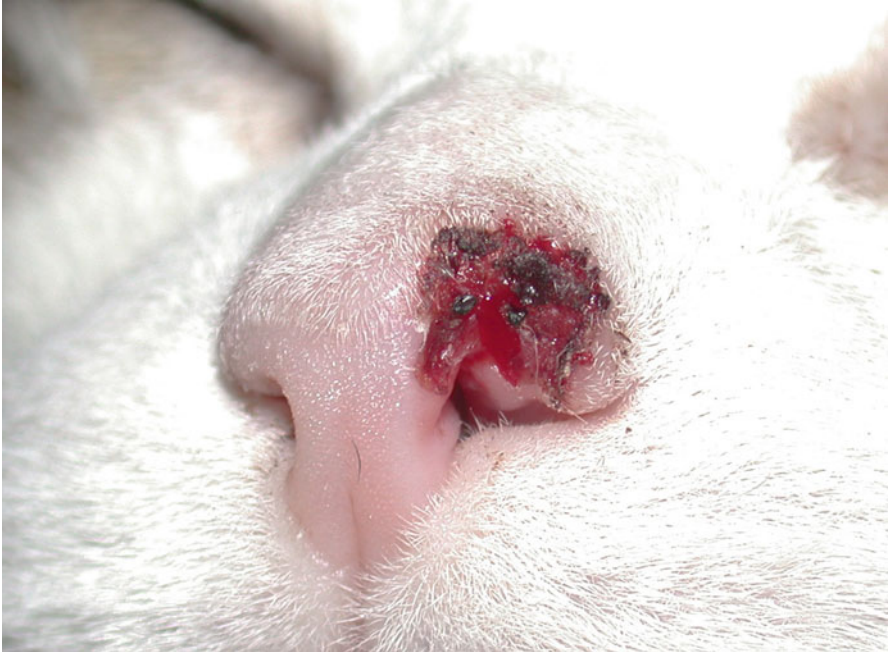

Fig. 4.111 An SCC in a cat. Ulcerated, bleeding and crusty lesion affects the nose

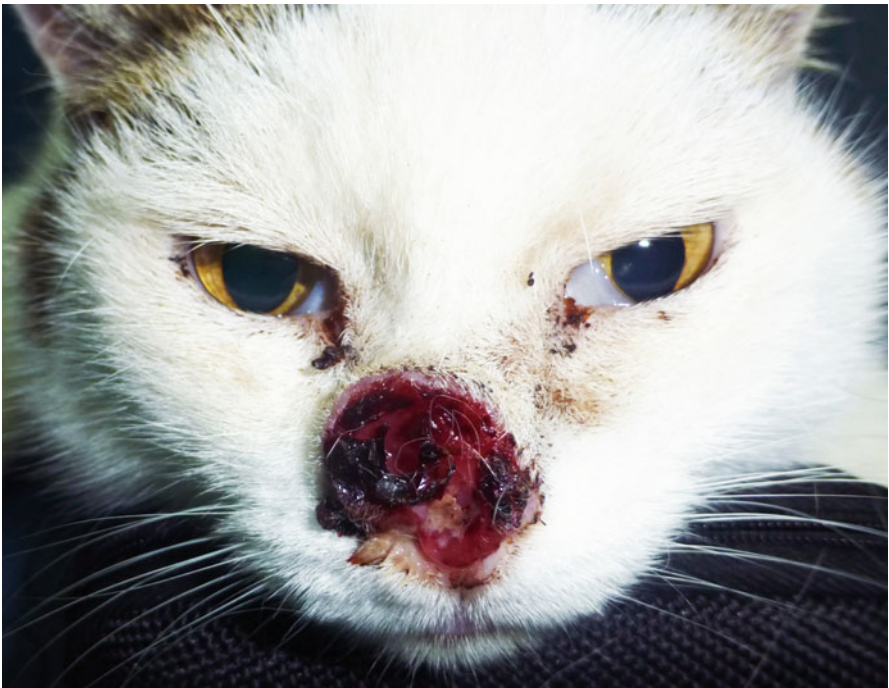

Fig. 4.112 White-haired cat with severe and deforming SCC of the nose

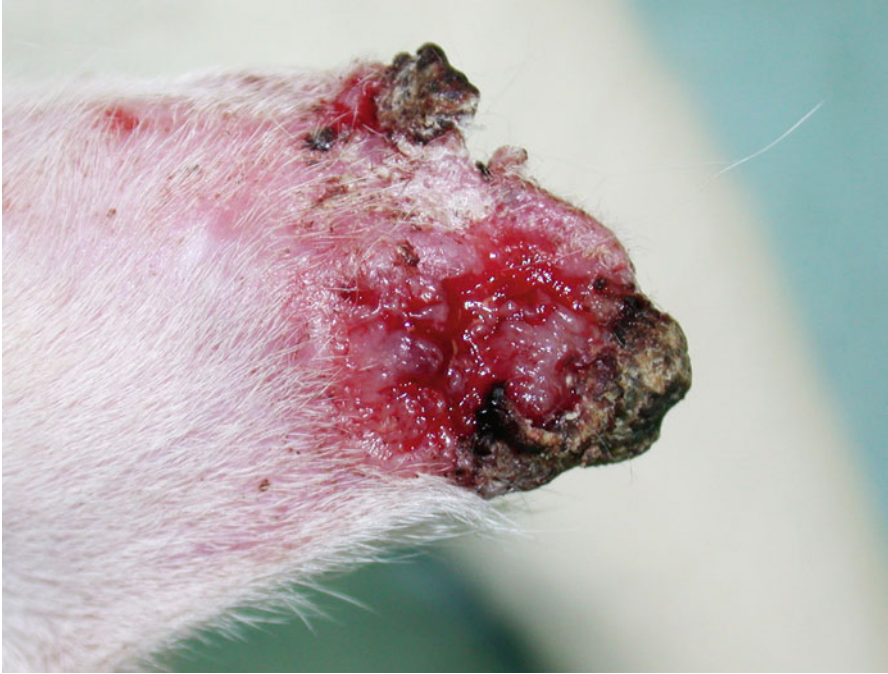

Fig. 4.113 Ulcerated SCC on the pinna of a white-haired cat

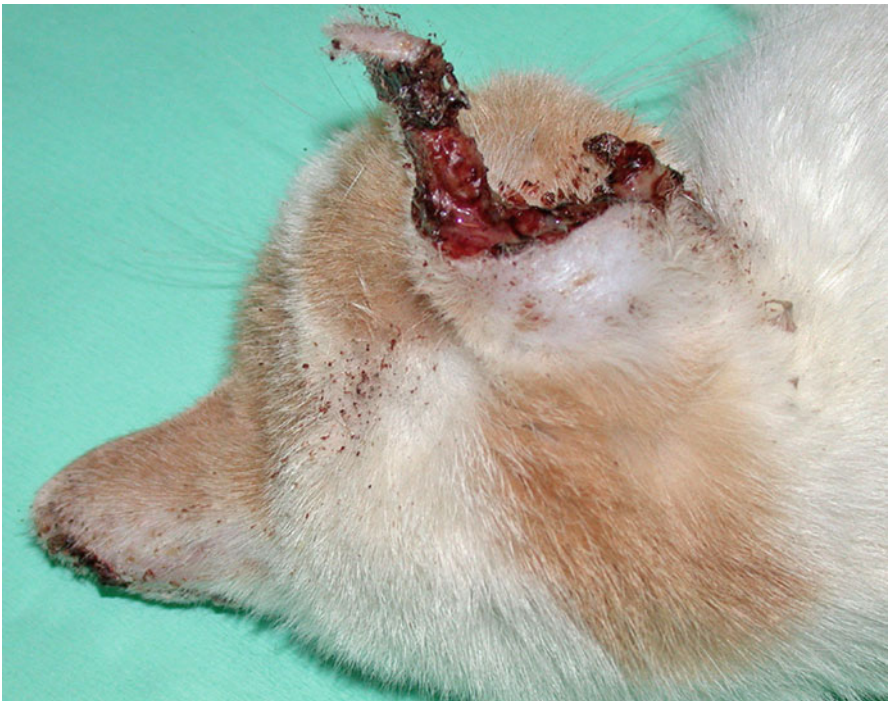

Fig. 4.114 Typical aspect of the SCC in a cat. Ulceration of both ear pinnas

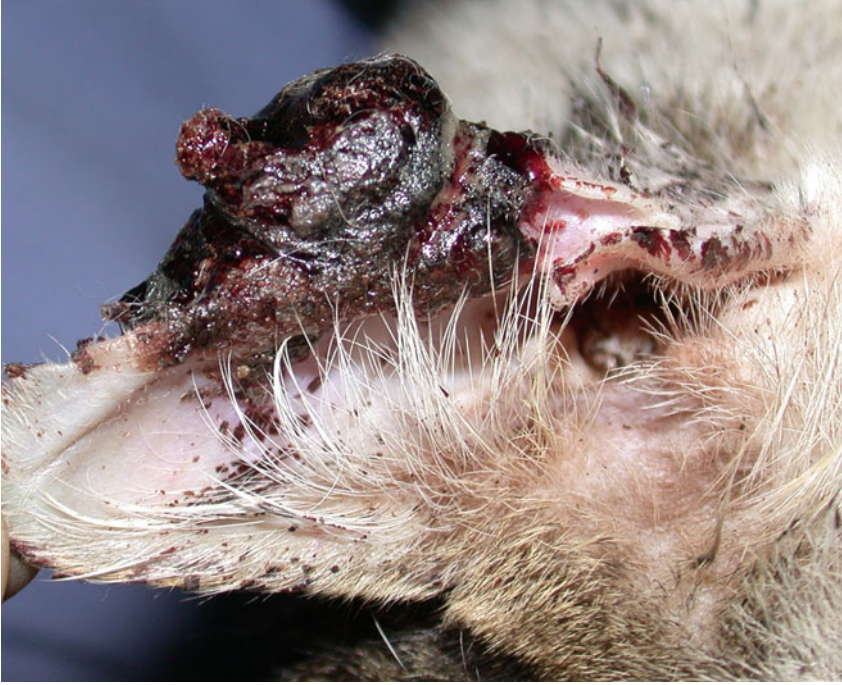

Fig. 4.115 Nodular SCC exophytic in growth on the pinna of a cat

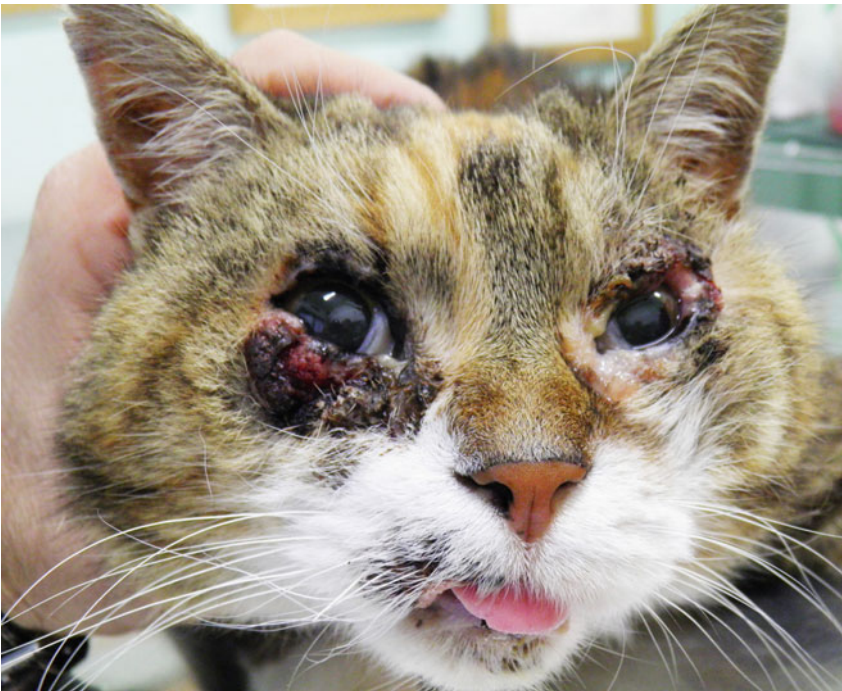

Fig. 4.116 *In situ* carcinoma on the eyelids of a cat

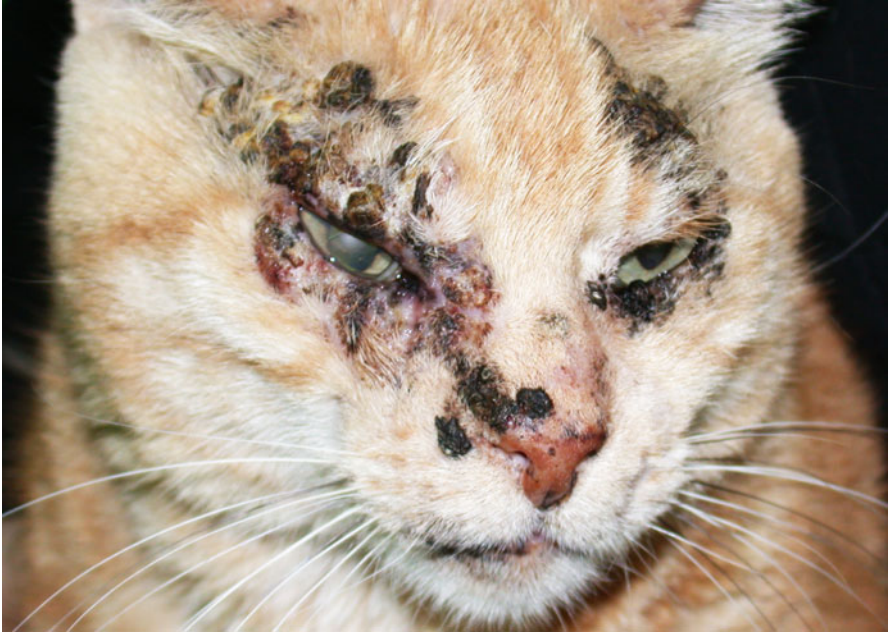

Fig. 4.117 *In situ* carcinoma presented as multiple dark crusty plaques on the face

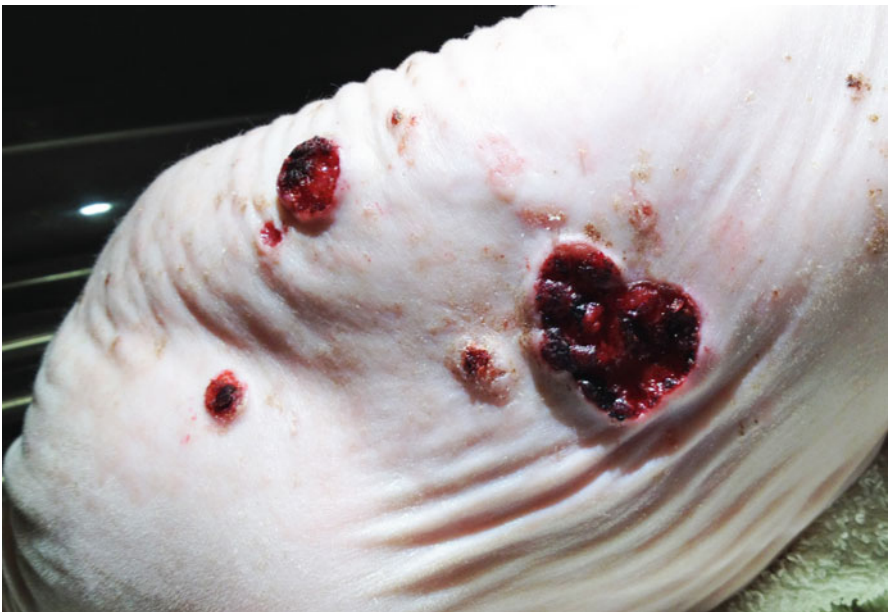

Fig. 4.118 Multiple lesions of both *in situ* carcinoma and SCC on the trunk of a Sphynx cat

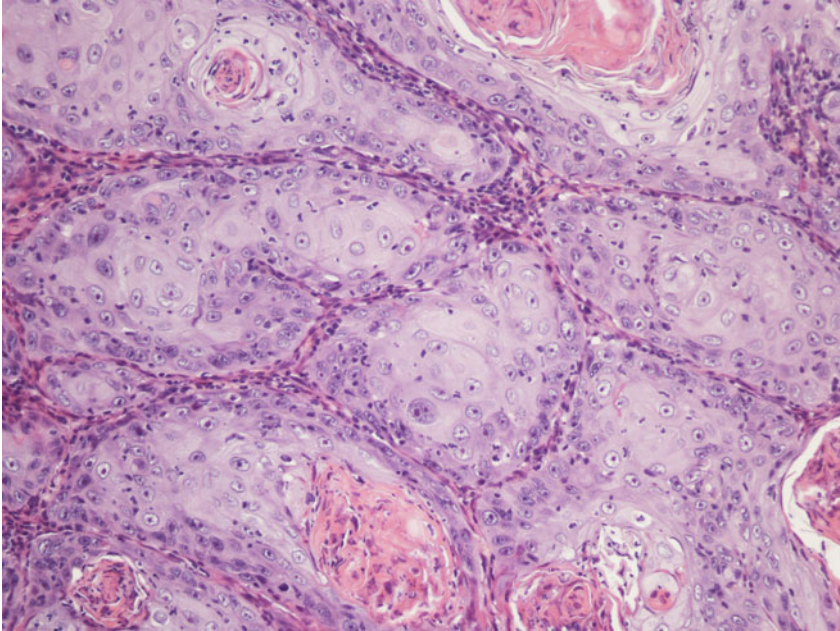


Fig. 4.119 Histopathology of SCC. Multiple nests of squamous neoplastic cells. Note the production of many keratin pearls

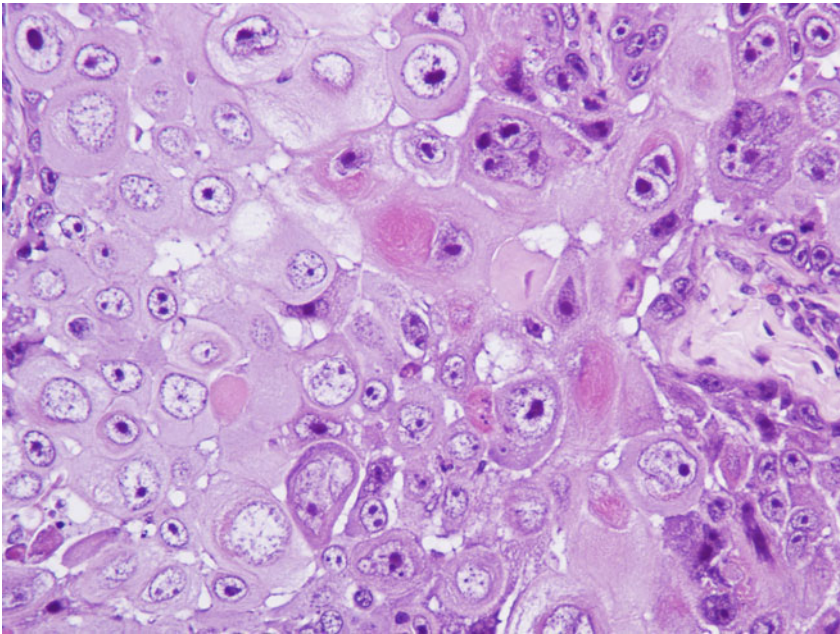


Fig. 4.120 Histopathology of SCC. Anisocytosis, anisokaryosis and macronucleoli represent the malignant aspects of the neoplastic keratinocytes

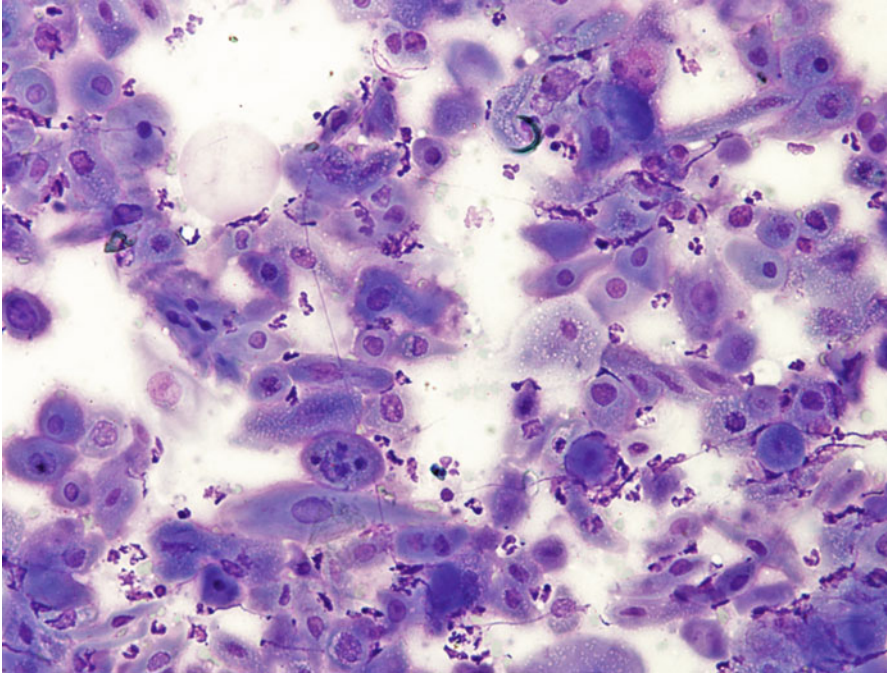


Fig. 4.121 Cytology of SCC. Marked asynchronous maturation of neoplastic keratinocytes

between the nucleus and the cytoplasm in the context of the same cell: a reduction of the size of the nucleus does not always follow a squamous differentiation of cytoplasm. Squamous differentiation manifests with the polygonal to roundish shape of the cells, with a large cytoplasm, which show very different colours, from light blue to greyish to pink (Fig. 4.122). In poorly differentiated SCCs, the diagnosis can be difficult, as very few cells exhibit squamous differentiation and slides may present more or poorly cohesive clusters of neoplastic keratinocytes with a high N/C ratio without any obvious squamous differentiation. However, some cells with squamous features are usually detected in most undifferentiated SCCs (Figs. 4.123 and 4.124).

The features of atypia are represented by anisokaryosis, with small to very large nuclei, sometimes double or multiple, coarse chromatin and large, multiple and bizarre nucleoli; small nuclear and perinuclear vacuolation and features of cannibalism can also be observed (Figs. 4.125 and 4.126). In some SCCs, spindle squamous cells with a *tadpole* appearance can be found (Fig. 4.127). In the spindle subtype of SCC, the high number of fusiform cells is the main feature and they should not be confused with mesenchymal cells.

In many SCCs keratinocytes tend focally to form keratin pearls; as keratin is highly antigenic and irritating, cytopathological samples from SCCs are often accompanied by a secondary predominantly neutrophilic inflammation. This phenomenon must be carefully considered when examining specimens from inflamed

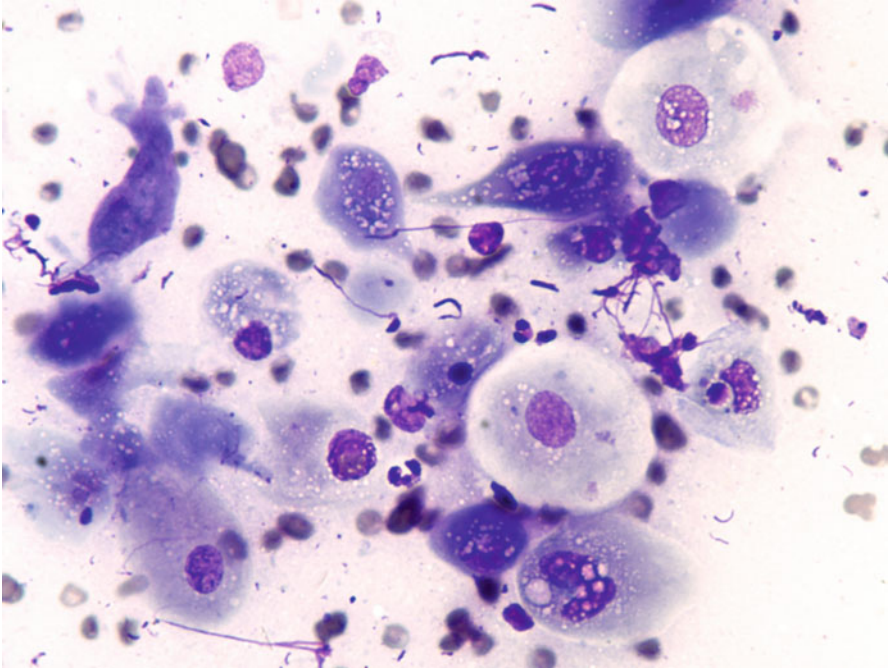


Fig. 4.122 Cytology of SCC. Round, polygonal and spindle squamous neoplastic cells

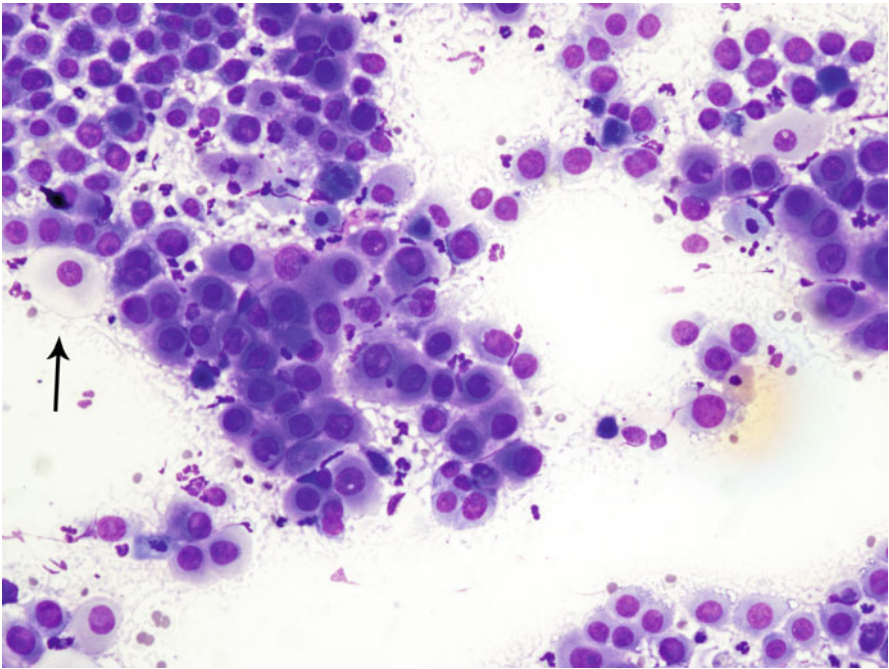


Fig. 4.123 Cytology of poorly differentiated SCC. Large and scarcely cohesive groups of poorly differentiated squamous neoplastic keratinocytes. Among them a cell with squamous differentiation is well evident (*arrow*)

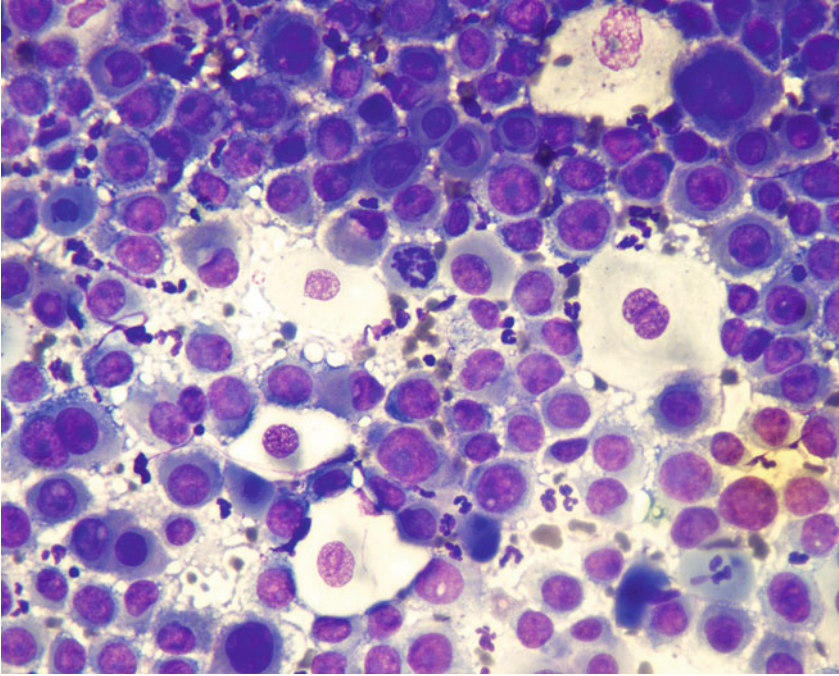


Fig. 4.124 Cytology of SCC. Among undifferentiated keratinocytes, some cells with squamous aspects are recognisable

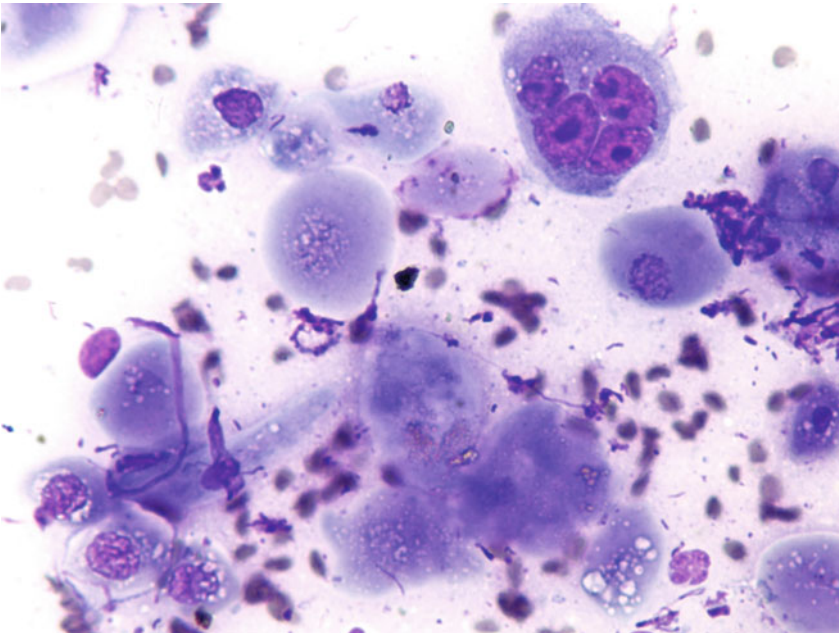


Fig. 4.125 Cytology of SCC. Note the highly malignant multinucleated cells

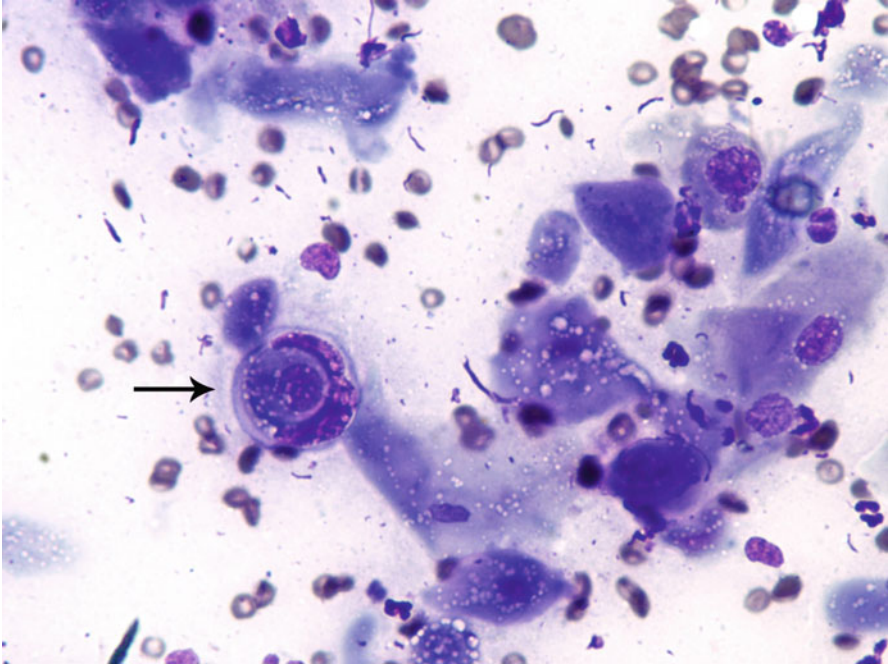


Fig. 4.126 Cytology of SCC. Note the cannibalism between two neoplastic cells (*arrow*)

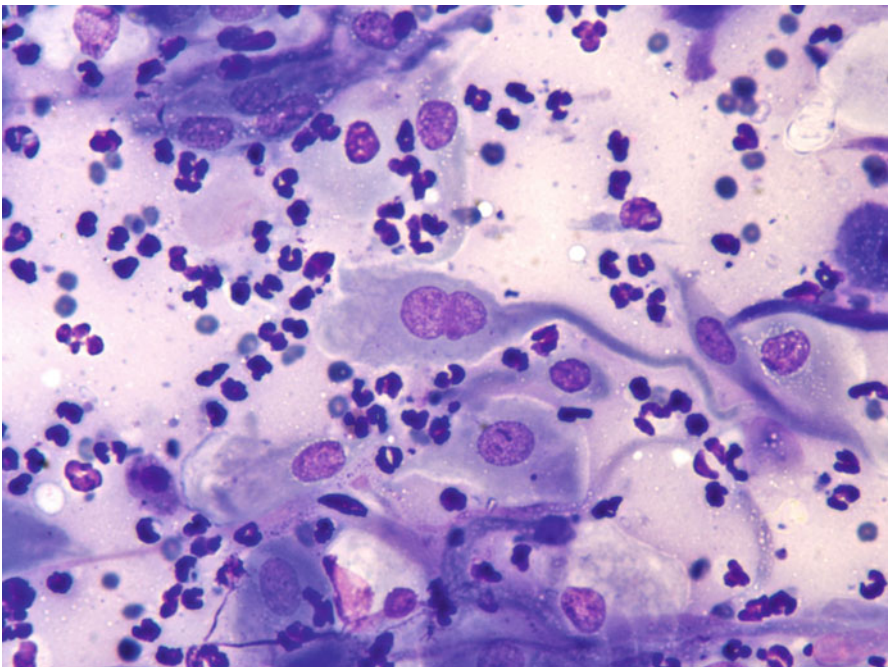


Fig. 4.127 Multiple spindle squamous neoplastic cells. The spindle or *tadpole* appearance of some neoplastic squamous cells should not be confused with mesenchymal cells

skin where keratinocytes may experience moderate to severe inflammation-induced dysplasia, which mimics the atypia observed in SCCs.

In the case of a single carcinoma *in situ* or BISC, cytology does not usually allow diagnostic cells to be collected; therefore, the definitive diagnosis needs histopathology.

In some cases, an attempt to sample neoplastic cells may be effected by insertion of a needle in the upper layers of the dermis (FNAB), with the hope of being able to collect neoplastic keratinocytes that, although still present in the epidermis (*in situ*), are directed downwards (Figs. 4.128 and 4.129).

4.3.2 Follicular Cysts and Follicular Tumours

The follicular lesions include *follicular cysts* and *follicular tumours*.

The cysts are divided into infundibular, isthmic, matrical and hybrid, the latter simultaneously showing different types of keratin production (Stannard and Pulley 1975; Scott and Anderson 1991; Abramo et al. 1999; Gross et al. 2005).

The group of follicular neoplasms is, however, very numerous and, among them, *infundibular keratinising acanthoma (IKA)*, which originates from the infundibulum and isthmus, *trichoblastoma*, from the follicular primitive germ, *pilomatrixoma*, from the matrix of the bulb, and *trichoepithelioma*, from all three parts of the follicle, deserve to be discussed in detail. With the exception of some rare cases of malignant pilomatrixomas and trichoepitheliomas, tumours of the hair follicle have a benign behaviour and a good prognosis.

As part of the same follicular neoplasia, several variants have been described (e.g. trabecular, ribbon and spindle cell trichoblastoma) and in the context of the same tumour different keratin differentiation (e.g. trichoepithelioma, hybrid infundibular/matrical cyst) or cystic areas, may be observed; therefore, the cytology of follicular tumours can only suggest a diagnosis, which must be confirmed by histopathology (Gross et al. 2005).

In most cases, single nodular lesions, mainly localised to the trunk and head, clinically represent follicular cysts (Figs. 4.129, 4.130, and 4.131). In some cases, and particularly in breeds such as German shepherd and Pekingese, they can be multiple (Figs. 4.132 and 4.133) (Park et al. 2010; White et al. 2013). Lesions usually measure a few centimetres, although rarely, they can grow to several centimetres. In dogs with hypercortisolism, in areas with thinner skin, such as the axilla and ventral abdomen, it is not uncommon to see a large number of small infundibular cysts. These multiple keratin cysts are probably secondary to excessive dilatation of comedones, which are very common lesions in dog affected by Cushing's syndrome (Fig. 4.134). The skin is usually intact, alopecic or with hair, and sometimes hyperpigmented. In many cases, the breaking of the wall of the cyst determines the spread of the keratin in the dermis, resulting in a severe pyogranulomatous reaction and discharging of grainy, yellowish to dark and of a creamy appearance, composed of keratinous material mixed with pus (Fig. 4.135). In other

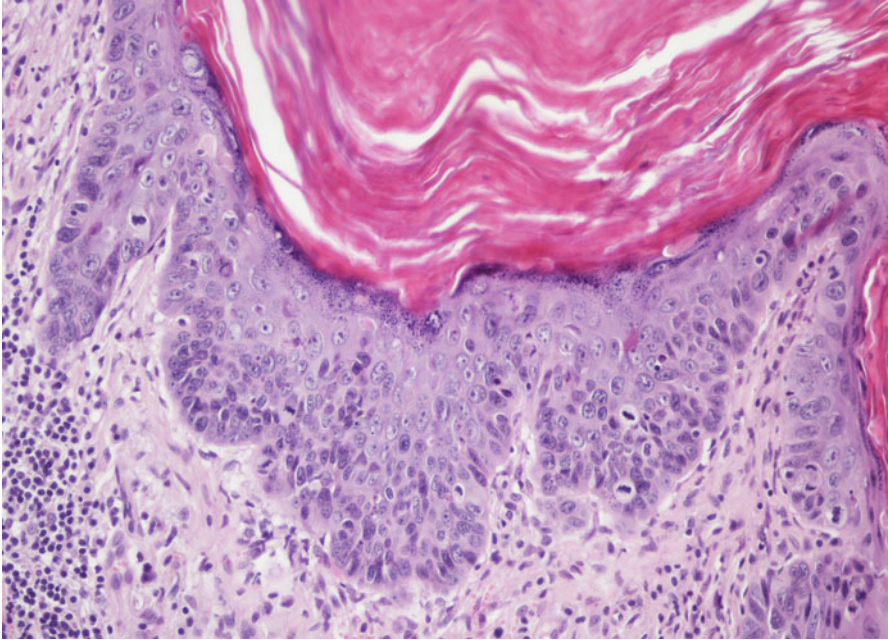


Fig. 4.128 Histology of in situ carcinoma. In the case of actinic keratosis, the neoplastic keratinocytes remain confined in the epidermis without breaking the basement membrane

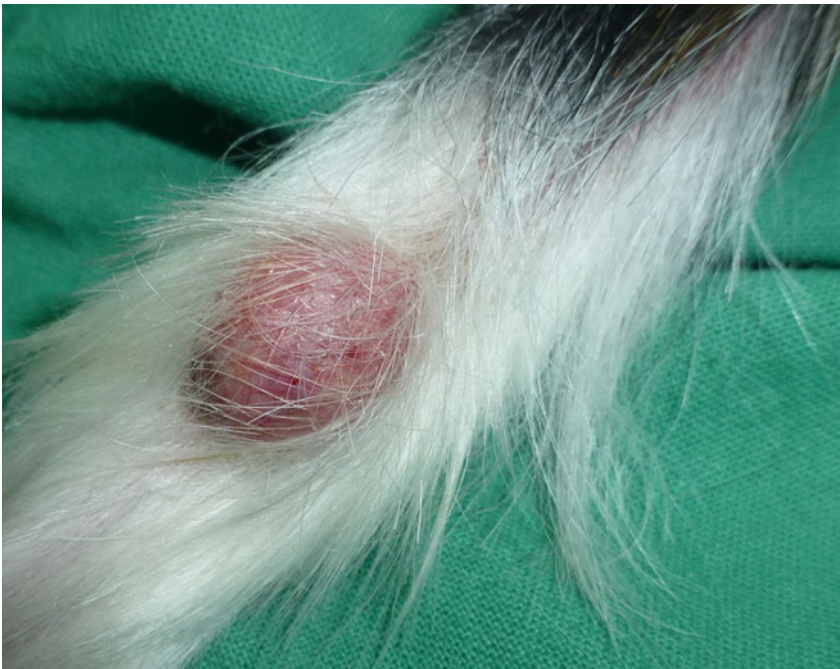

Fig. 4.129 Alopecic follicular keratin infundibular cyst on the tail of a Cavalier King Charles

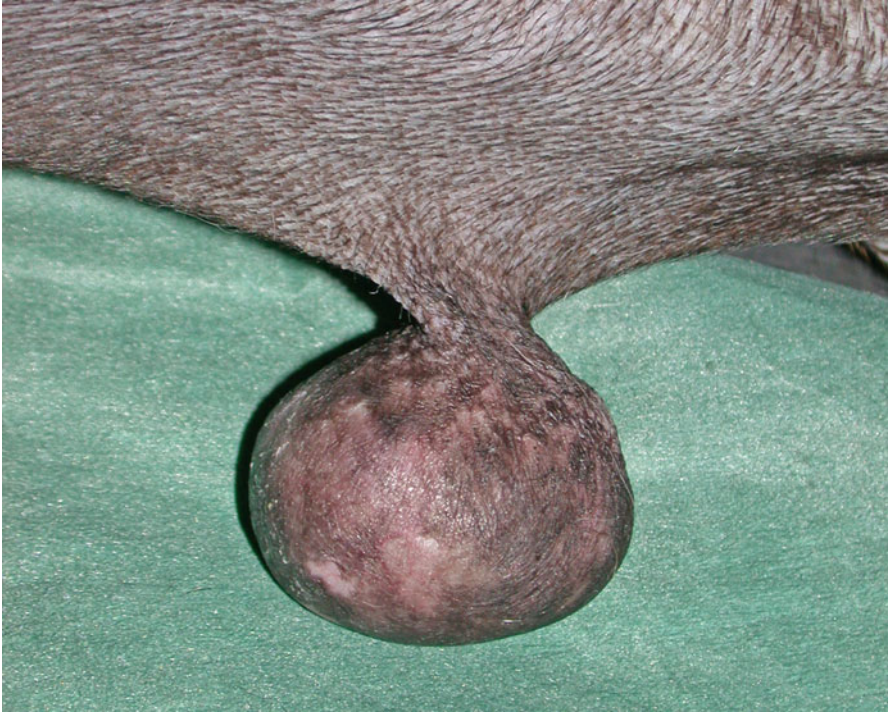

Fig. 4.130 Pedunculated follicular keratin infundibular cyst

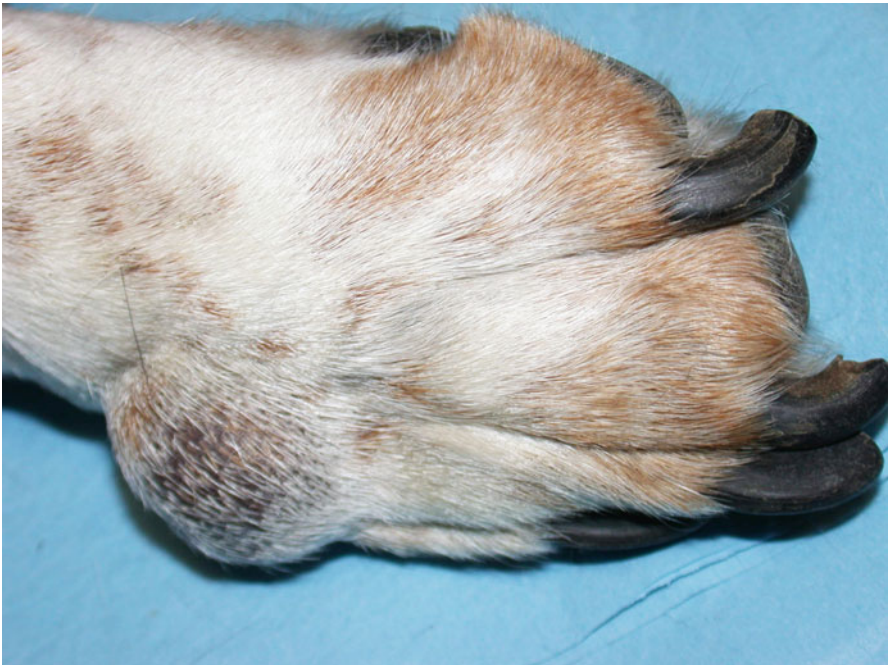

Fig. 4.131 Matrical cyst on the foot of a Basset hound

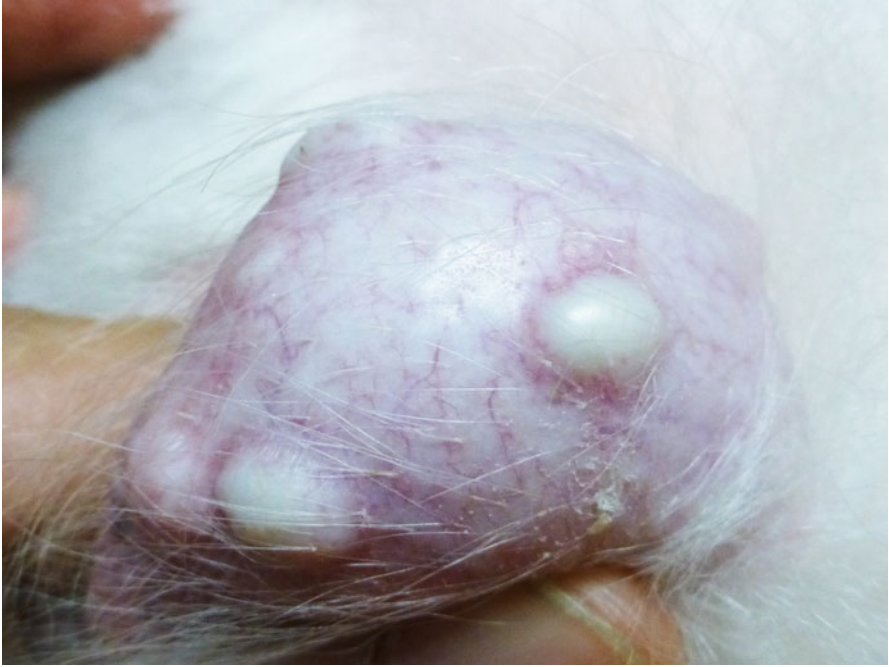

Fig. 4.132 Multiple infundibular cyst on the scrotum of a dog

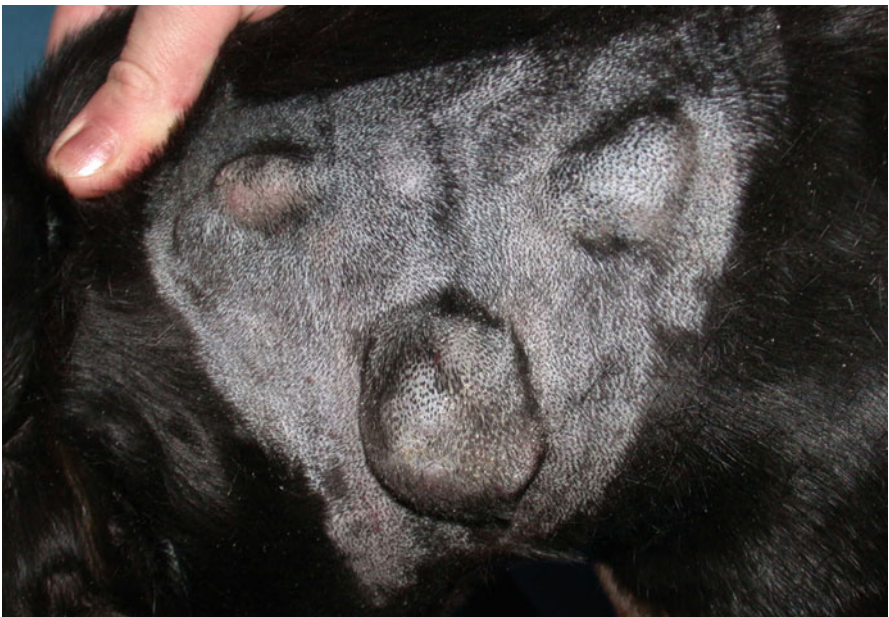

Fig. 4.133 Multiple infundibular cyst on the chest of a Doberman

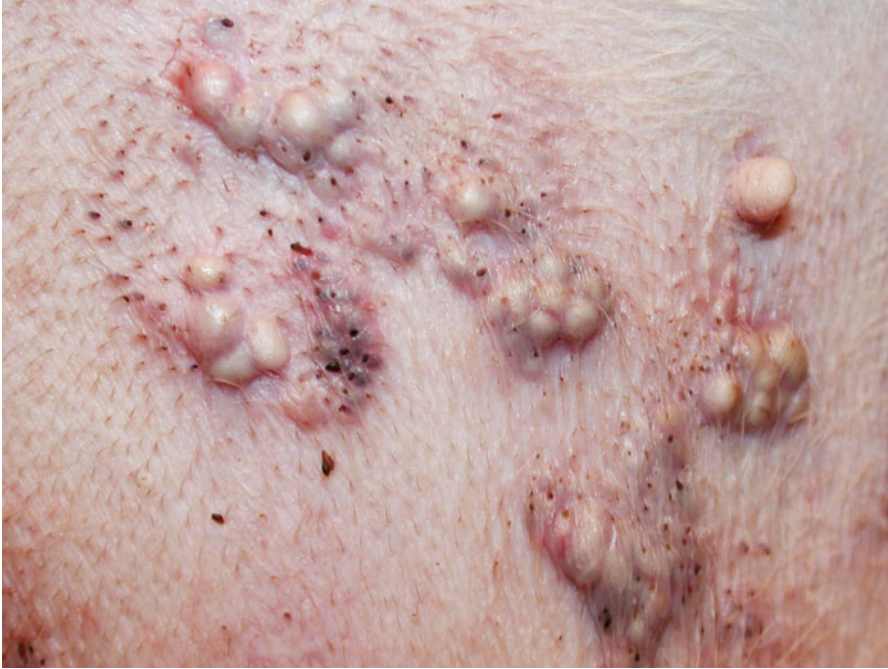

Fig. 4.134 Multiple small keratin infundibular cysts in a dog affected by spontaneous hypercortisolism

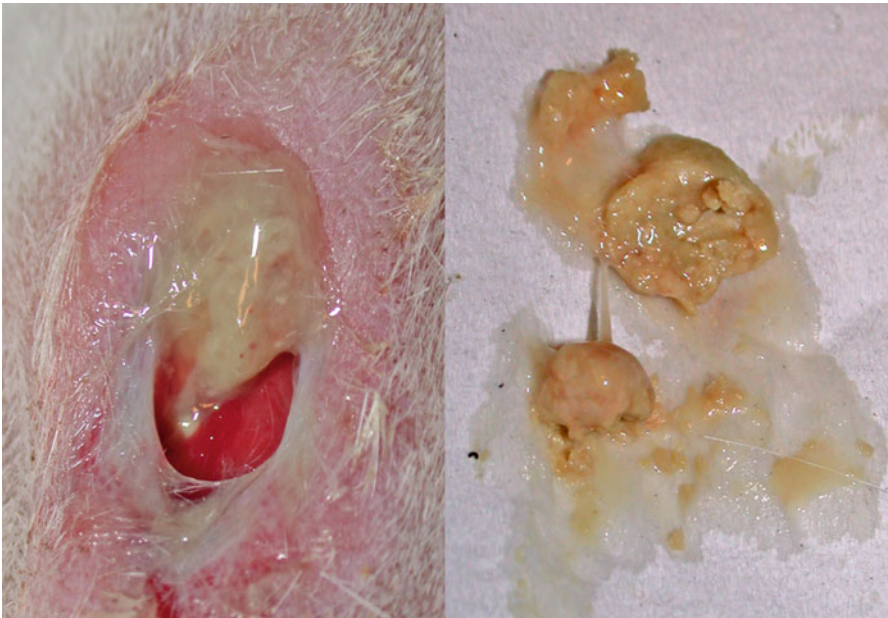


Fig. 4.135 Ulcerated follicular cyst. Note the dense and granular aspect of the keratin material contained in the cyst

cases, the cyst content can be dark and a more liquid consistency. These macroscopic aspects of keratin are also common in follicular neoplasms that produce keratin, and can therefore be used only to suspect the presence of a nodule containing keratin material. Another characteristic very indicative of the presence of keratin in a nodule is the difficulty encountered in depositing, onto the slide, the collected material, which, because it is very compact, obstructs the lumen of the needle. Strong pressure on the plunger of the syringe and the consecutive release of a plug of dense, grainy and greasy-looking material increases the suspicion of its keratin nature.

Even follicular neoplasms are clinically indistinguishable and are presented as individual nodules of variable size, from a few centimetres to over 10 cm, sometimes polypoid and pedunculated, often ulcerated and secondarily inflamed following the spread of the keratin in the dermis. Less commonly, follicular tumours can be multiple (Toma and Noli 2005; Campos et al. 2014). Sometimes the presence of some macroscopic characteristics can direct the clinician to suspected follicular neoplasia, such as when a small central crater from which keratin material protrudes suggests the presence of an IKA, especially in German shepherds and Lhasa-apso (Fig. 4.136) (Hauck 2013). The most frequent follicular tumours are certainly trichoblastoma, once defined as *basal cell* tumours, which are present with nodular lesions, usually alopecic and with a smooth surface, sometimes pigmented, of varying size, but usually of a few centimetres. Trichoblastoma is one of the most common skin tumours in cats, which is frequently observed on the head and neck. In dogs, it occurs frequently in the miniature Poodle where it is usually present on the neck and at the base of the pinna. Many follicular cysts and neoplasms are pigmented, because, as is well known, the keratinocytes may contain melanin (Figs. 4.137, 4.138, 4.139, 4.140, and 4.141).

Cytological Findings

In most cases, the cytology of follicular cysts and follicular tumours is not diagnostic and can only ascertain the follicular origin of the lesion. Furthermore, because both solid and cystic areas characterise many follicular neoplasms, cytology can provide very variable findings linked to the area of the lesions that have been collected.

For a better description of the cytological aspects of follicular lesions, they are discussed separately, highlighting the salient features of the most frequent neoplasms and those in which a cytological evaluation can be useful.

To better interpret the cytology coming from the cysts and from follicular neoplasms, a brief description of the anatomy of hair follicles and the different types of keratin produced by it is mandatory.

The hair follicle is a very complex structure that can be divided into three portions: the *infundibulum*, the *isthmus* and the *bulb*. These three different portions are characterised by keratinocytes and undergo very different processes of keratinisation. The *infundibulum* is the upper portion of the follicle: it is occupied from the external opening (follicular ostium) to the outlet of the sebaceous gland and it is characterised by the same type of keratinisation present on external epidermis, in

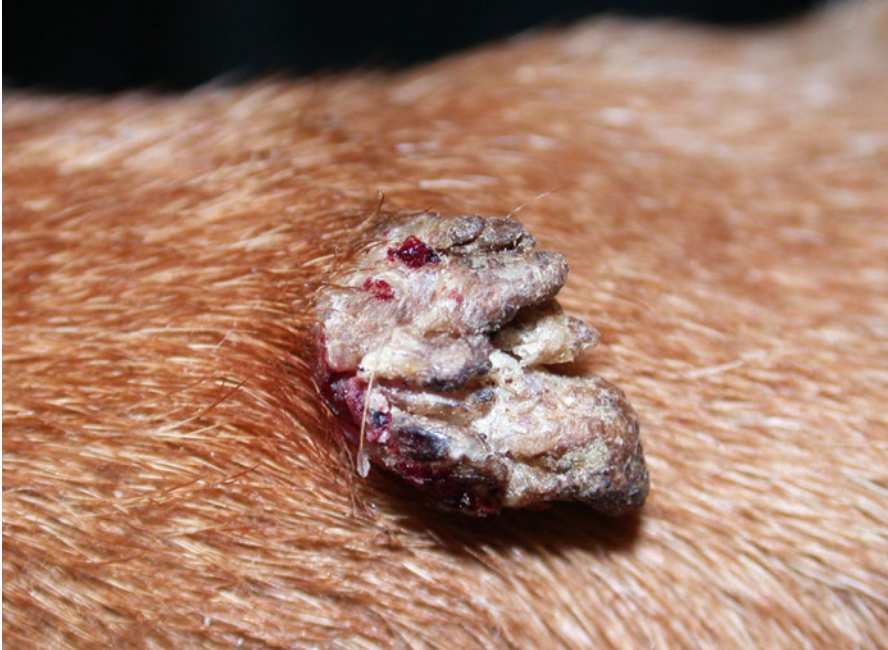

Fig. 4.136 Clinical aspect of an intact infundibular keratinising acanthoma (IKA) with keratin material, which protrudes from the central area

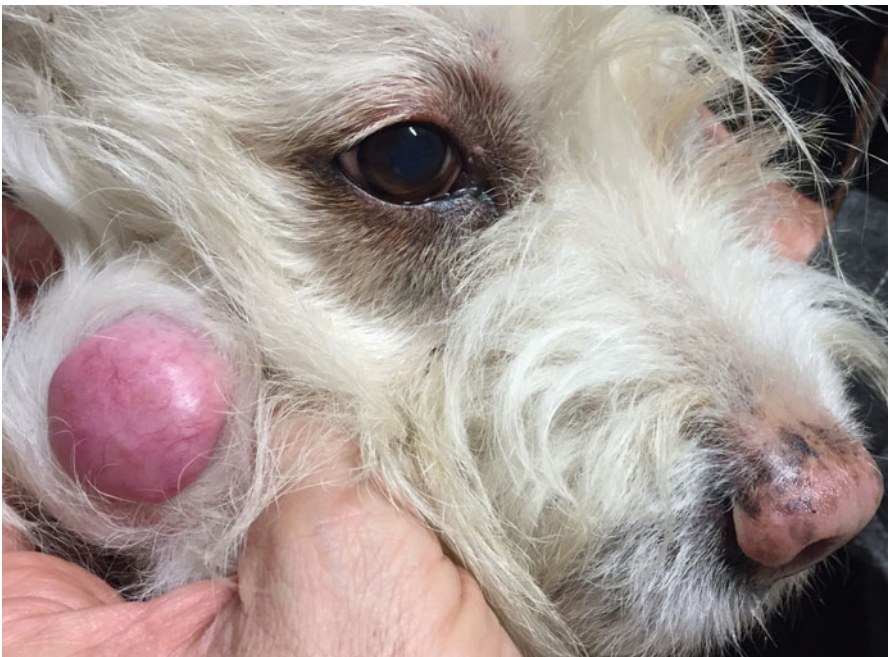

Fig. 4.137 Large and alopecic trichoblastoma on the face of a dog

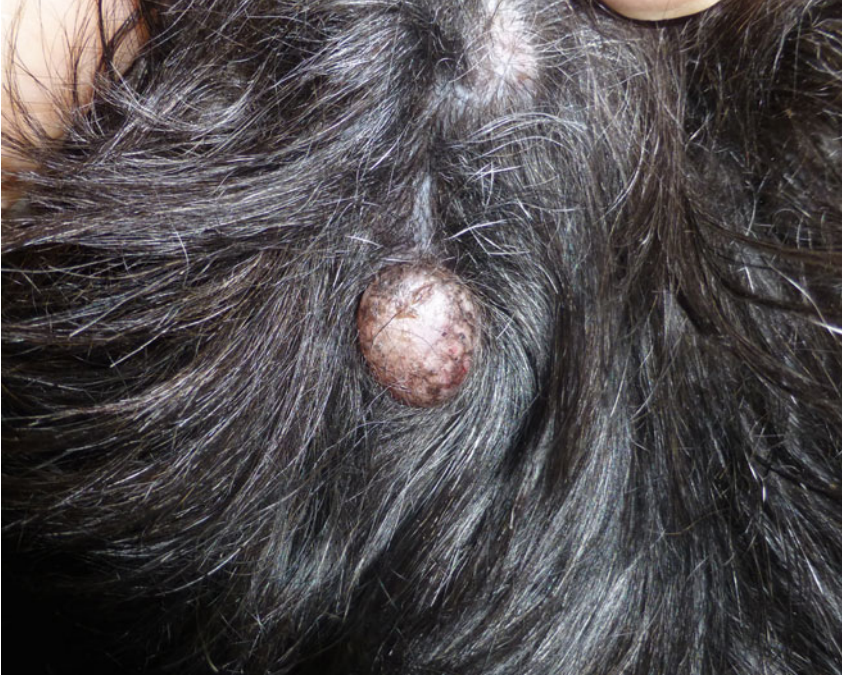

Fig. 4.138 Small and alopecic trichoblastoma on the head of a black hair-coated Poodle

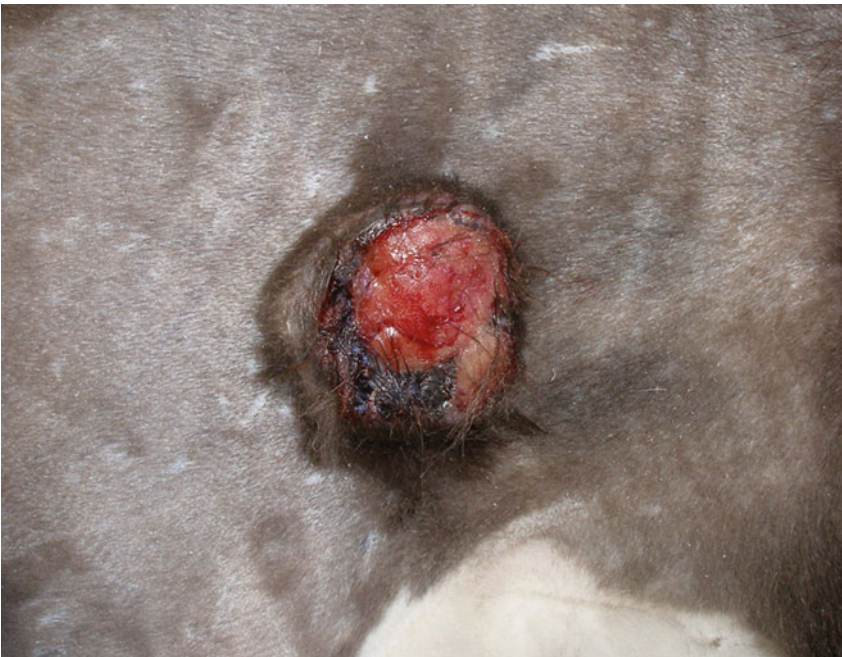

Fig. 4.139 Large and ulcerated trichoblastoma on the neck of a cat

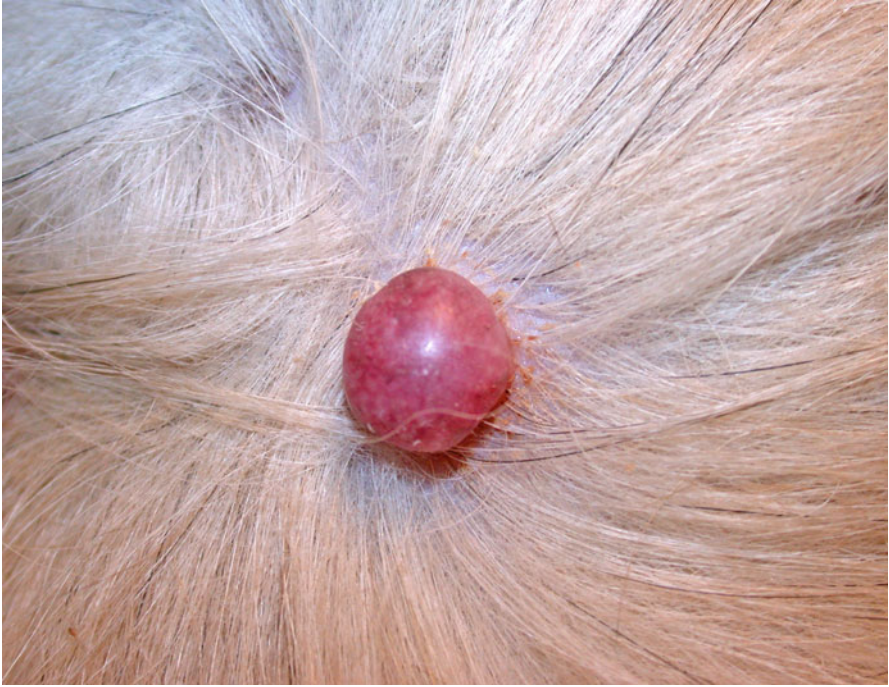

Fig. 4.140 Erythematous trichoepithelioma in a dog

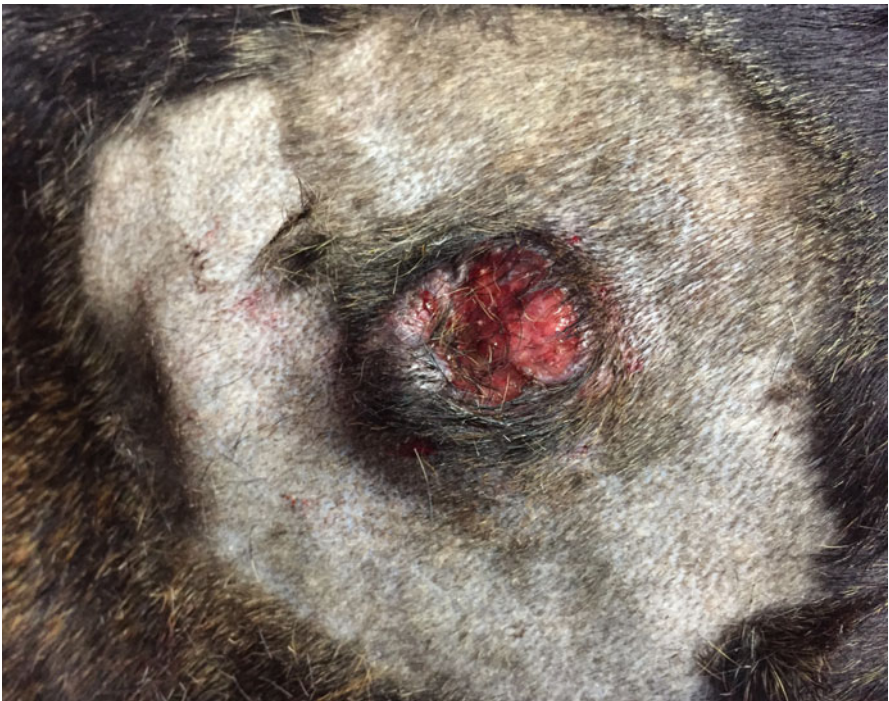

Fig. 4.141 Ulcerated malignant pilomatricoma on the chest of a Basset hound

which the production of lamellar keratin (scales) passes through the stratum granulosum rich with keratohyalin granules (Fig. 4.142). The *isthmus*, which is delimited at the top by the sebaceous glands outlet and at the bottom by the insertion of the arrector pili muscle, represents the middle portion. In this portion of the follicle, the epidermis is lacking the granular layer and therefore trichilemmal keratinisation is present; the keratin produced is amorphous and eosinophilic on routine histological stains (Fig. 4.143). The third and deeper follicular portion, which begins at the bottom of the insertion point of the arrector pili muscle is the *bulb*. In this follicular portion, the cells that reside in the matrix produce both the keratin of the hair and the cells of the inner root sheath (Fig. 4.144). The type of maturation that occurs in this location is called *matrical* and is characterised by the production of keratinised cells that still have an optically empty central area, representing the site where the nucleus was present; because of this cytological aspect these cells are defined as *ghost cells*.

4.3.2.1 Follicular Cysts

Infundibular Cysts

The cytology of *infundibular cysts* is characterised by lamellar corneocytes with a polygonal profile and by a varying tonality of colours; this different dyeing affinity is mainly linked to the presence of lipid material that normally surrounds the cells (lipid envelope) and that, if not properly dissolved by the fixative, can determine inadequate penetration of the stains into the cells (Figs. 4.145, 4.146, 4.147, and 4.148). The alcoholic fixing of slides can also cause the dissolution of the cholesterol present in the lipid envelope, with formation of crystals represented by transparent or rectangular formations (negative image), which are sometimes very numerous. Cysts that contain keratin of fluid consistency may cytologically show an amorphous and intensely basophilic proteinaceous background (Fig. 4.149).

Isthmic Cysts

Isthmic cysts originate from the outer root sheath and for this, they are characterised by trichilemmal keratinisation, abruptly produced from the isthmic portion of the follicle. The wall of the isthmic cyst does not exhibit the granular layer and therefore it presents as amorphous and paler and more homogeneous non-lamellar keratin (Figs. 4.150 and 4.151).

Matrical Cysts

Matrical cysts originate from the bulbar portion of the anagen follicle and are histologically composed of a single large cyst lined with basaloid matrical keratinocytes that abruptly transform into ghost cells (Figs. 4.152 and 4.153). The latter are

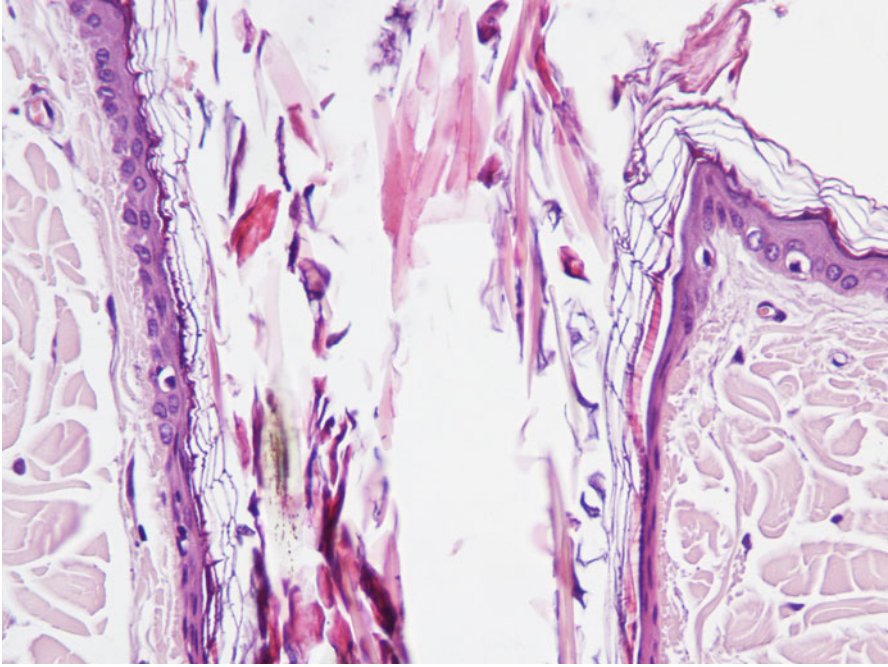


Fig. 4.142 Histology of an infundibulum. Note that the type of keratin produced is the same as in the external epidermis

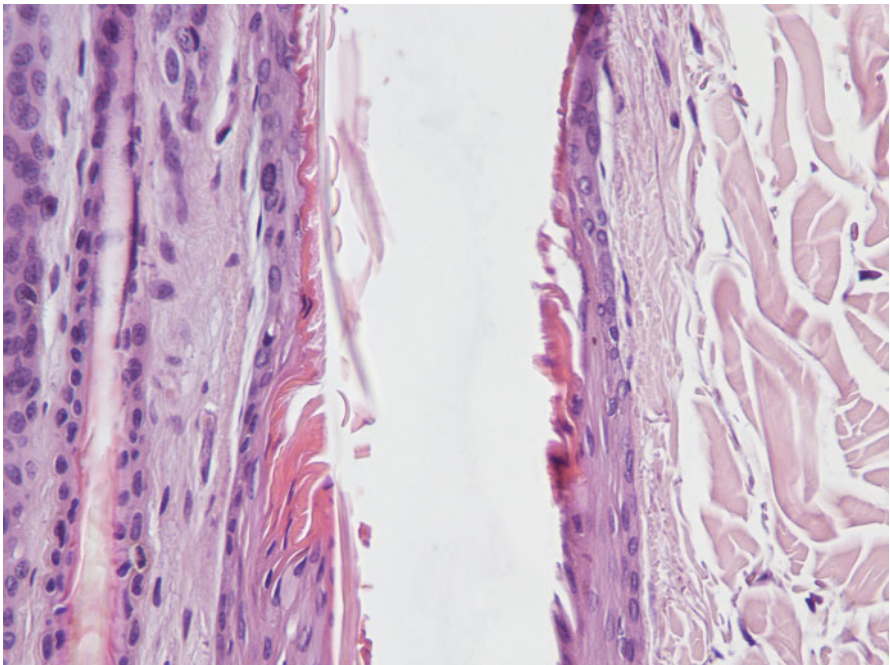


Fig. 4.143 Histology of the amorphous and eosinophilic trichilemmal keratin is produced in the isthmus of the follicle. Note the absence of the granular layer

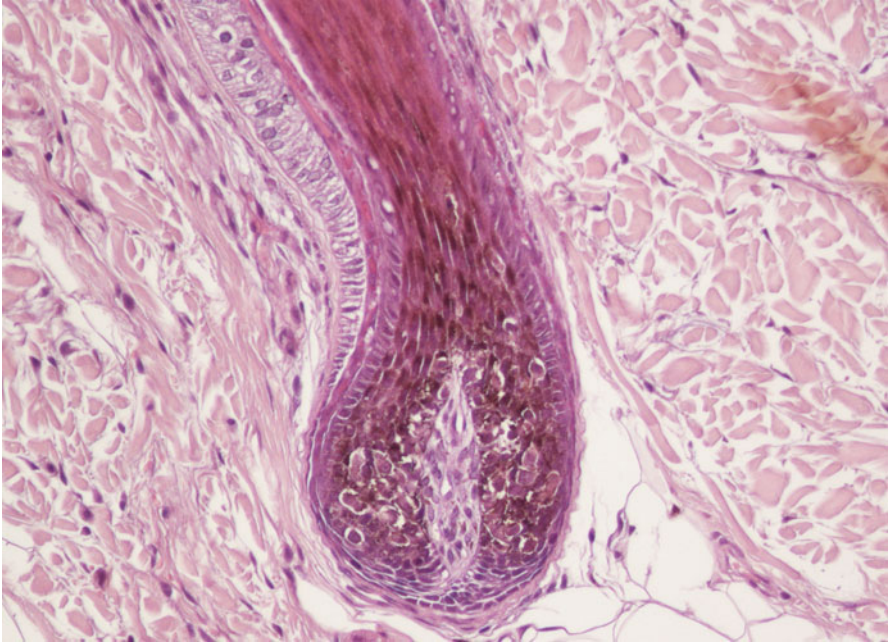


Fig. 4.144 Histology of the follicular bulb from where both the keratin of the hair and the cells of the inner root sheath are produced

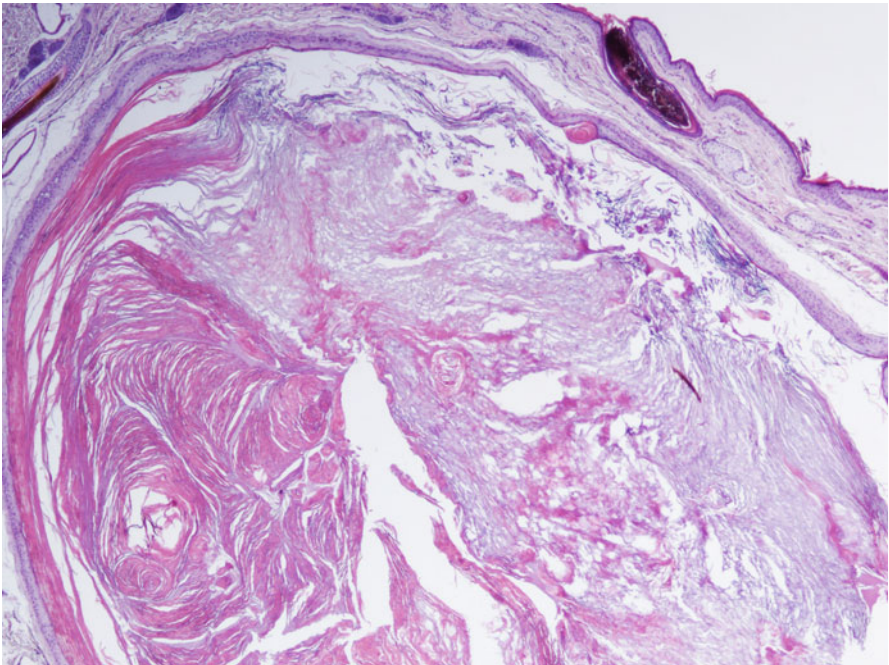


Fig. 4.145 Histopathology of an infundibular cyst. Large cyst filled with lamellar corneocytes

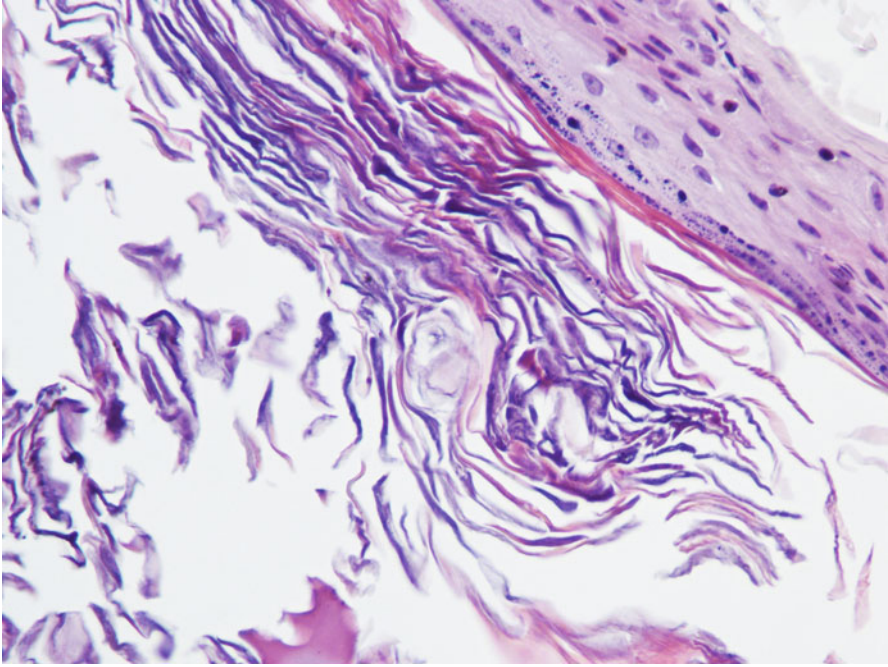


Fig. 4.146 Histopathology of an infundibular cyst. Note that the keratin is produced via the granular layer

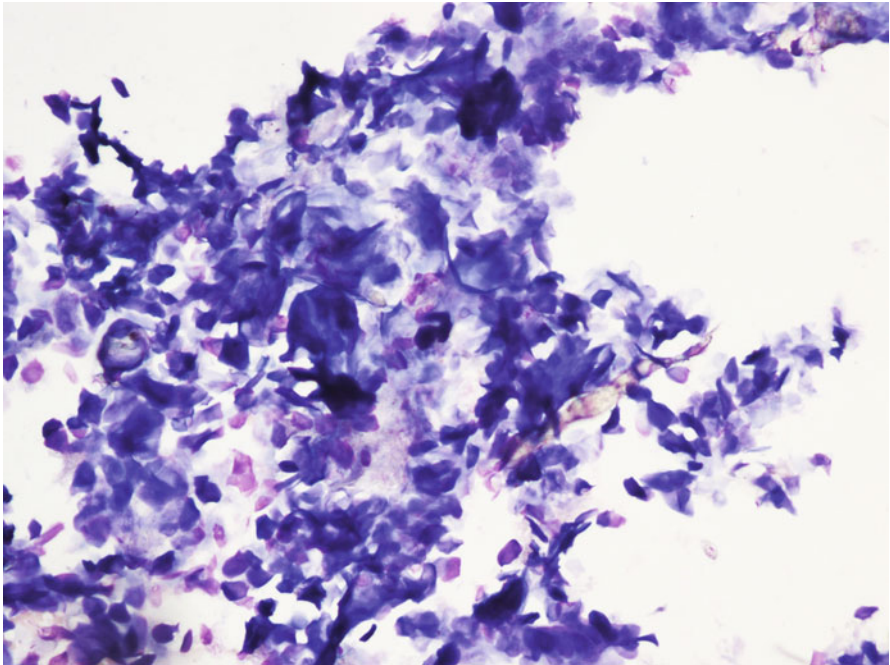


Fig. 4.147 Cytology of an infundibular cyst. Many polygonal anucleated keratinocytes

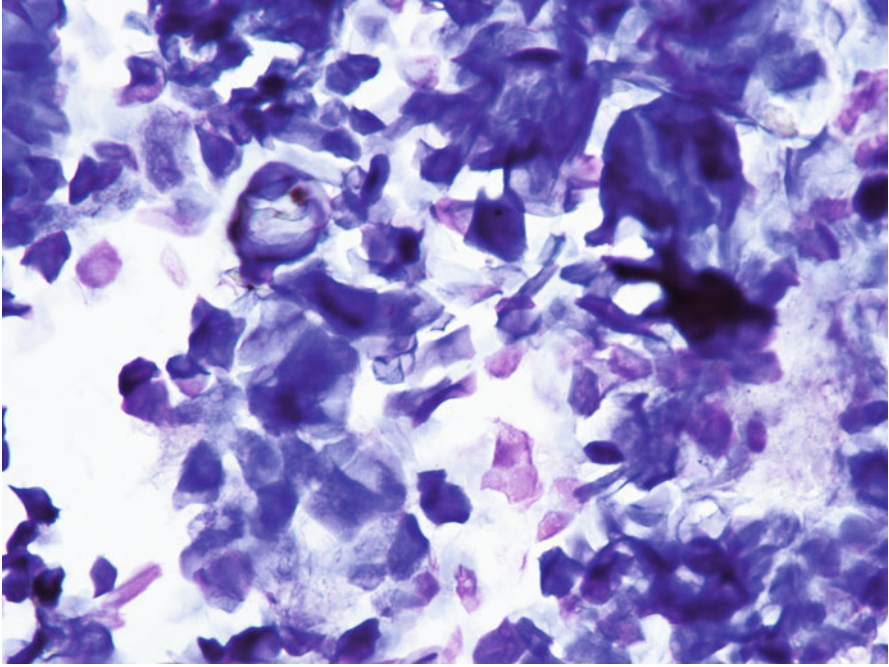


Fig. 4.148 Cytology of an infundibular cyst. Pink and blue polygonal corneocytes from the upper part of the follicle

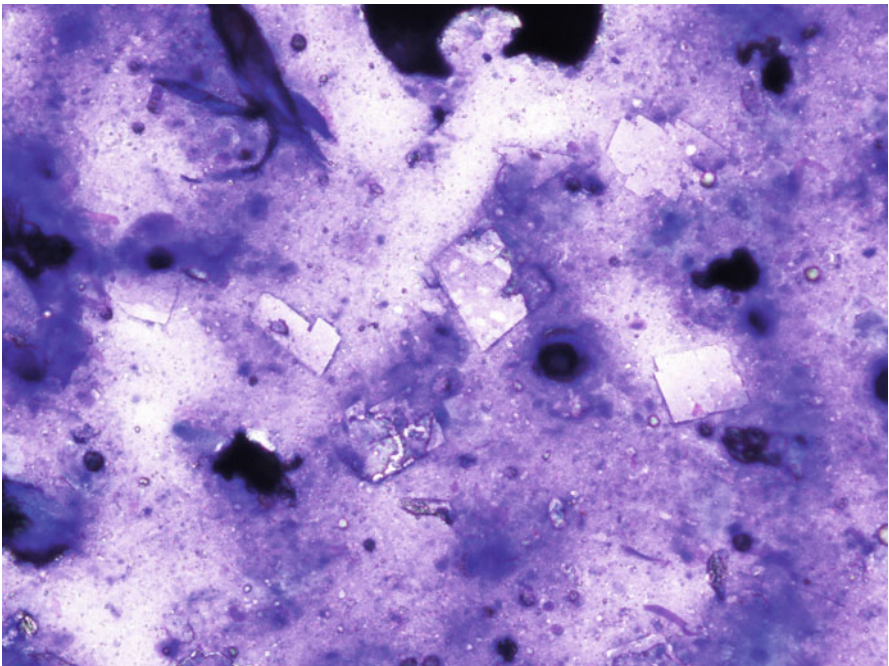


Fig. 4.149 Cytology of an infundibular cyst. More liquid keratin material in which some cholesterol crystals are recognisable as a negative formation with well-defined angular edges

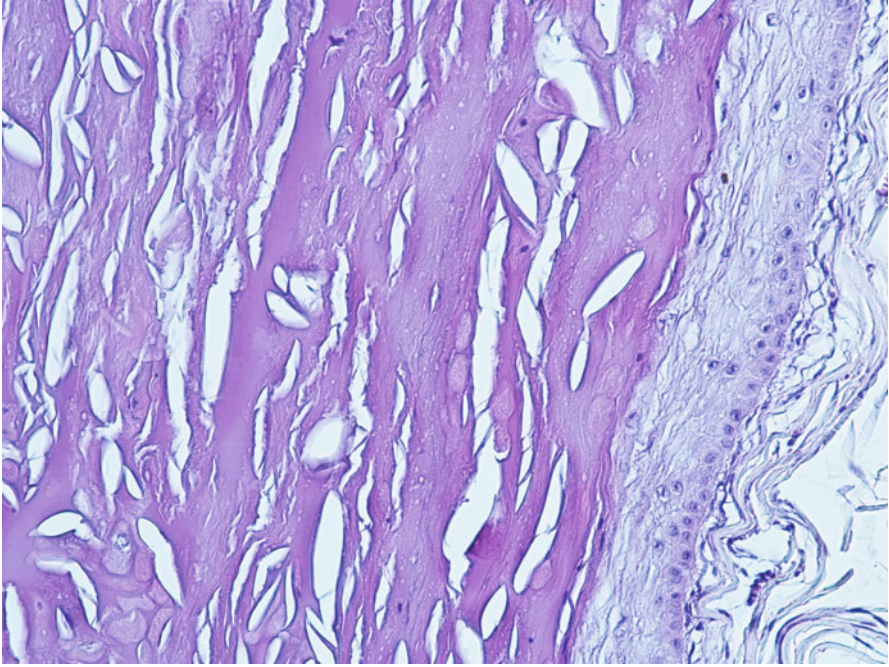


Fig. 4.150 Histopathology of an isthmic cyst. Amorphous keratin abruptly produced from the follicular wall. Note that the granular layer is not present

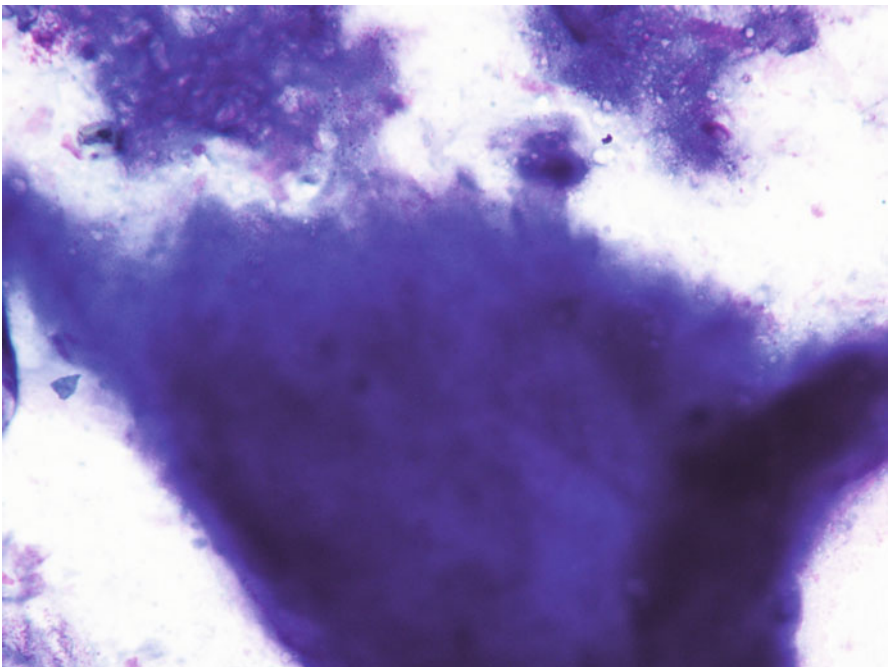


Fig. 4.151 Cytology of an isthmic cyst. Trichilemmal keratinisation is characterised by amorphous basophilic keratinous material

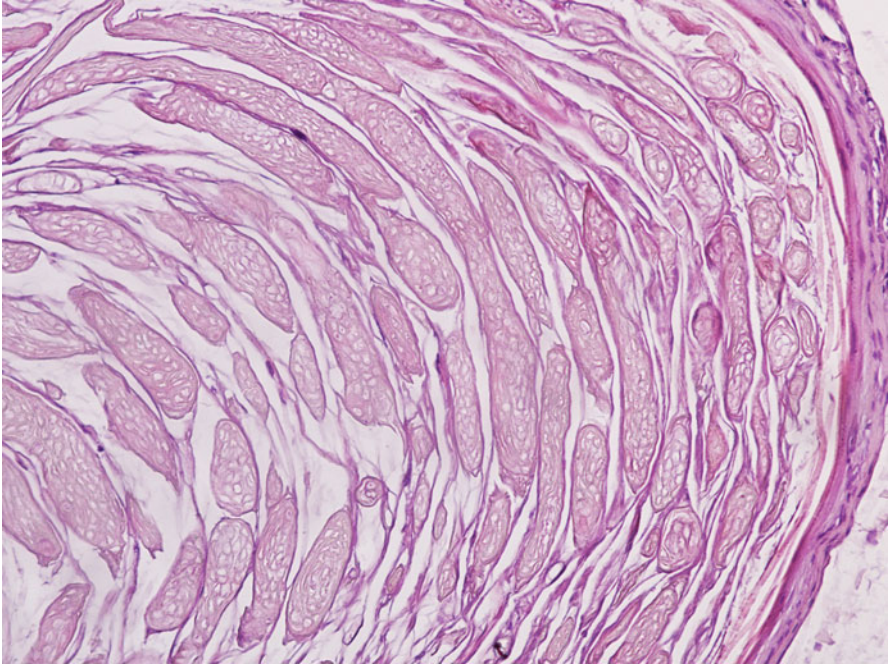


Fig. 4.152 Histopathology of a matrical cyst. Filled with multiple elongated clusters of ghost cells

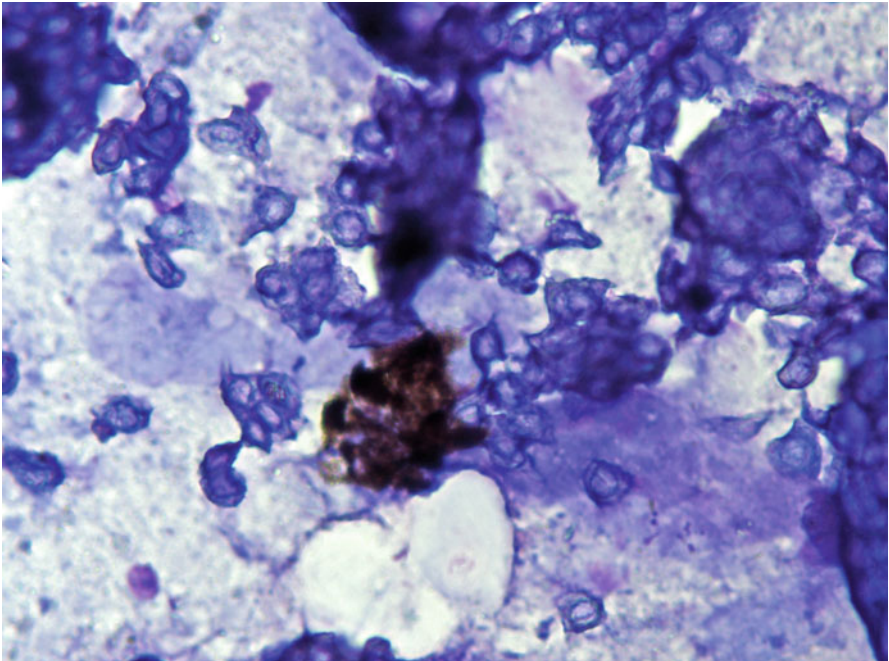


Fig. 4.153 Cytology of a matrical cyst. Ghost cells, both single and in large clusters

collected both singly and, more commonly, in highly cohesive aggregates forming oval or trabecular three-dimensional achromatic structures. The matrical cysts cannot be cytologically differentiated from a pilomatricoma, especially when in the latter, basaloid neoplastic cells are not present on the slide.

Hybrid Cysts

The *hybrid cysts* are composed of two or all three portions of the follicle and therefore, are characterised by cytological specimens composed of different types of keratin. A combination of lamellar corneocytes, trichilemmal keratin and ghost cells can be observed on cytological specimens from hybrid cysts (Figs. 4.154 and 4.155). This must be highlighted as, when lamellar corneocytes and ghost cells are simultaneously present on the same specimen, care must be taken in formulating a diagnosis of mixed infundibular–matrical cyst, because similar cytological features can be observed in trichoepitheliomas.

4.3.2.2 Follicular Neoplasms

Trichoblastoma

The *trichoblastoma* is a neoplasm arising from the cells of the hair germ, from which the follicle originates. This follicular neoplasia is more common in dogs than in cats.

Trichoblastoma is strongly suspected when in cytology, basaloid epithelial cells, characterised by round to oval nuclei, uniform in size, with scant cytoplasm, are detected. These basaloid cells are variably arranged in three-dimensional cohesive round or trabecular clusters, or in both linear and branched cord-like or ribbon-like formations or, especially in cats, in clusters of spindle cells. In many cases it is common to detect basaloid keratinocytes arranged in a double row, with nuclei orientated perpendicularly to their long axis, in a palisade-like arrangement (Stockhaus et al. 2001). These varying cell arrangements depend on the histological subtype of neoplasia; for example, different histological types such as *ribbon-type trichoblastoma*, with its three variants, *medusa-head*, *ribbon* and *garland*, which are more frequent in dogs, and the *trabecular trichoblastoma*, more frequent in cats, can yield different cytological findings (Figs. 4.156, 4.157, 4.158, 4.159, 4.160, 4.161, and 4.162). In cats, and occasionally in dogs, a spindle cell trichoblastoma, cytologically characterised by clusters of densely packed fusiform basaloid cells, is recognised (Figs. 4.163 and 4.164). The appearance of these spindle basaloid cells must not be confused with a mesenchymal neoplasm (Gross et al. 2005). Cytological differentiation of the various subtypes is not possible because many trichoblastomas may show different patterns in the context of the same tumour; furthermore, the exact identification of the histological subtype does not have any prognostic value, as all the tumours belonging to this group of neoplasia behave benignly. Often, the

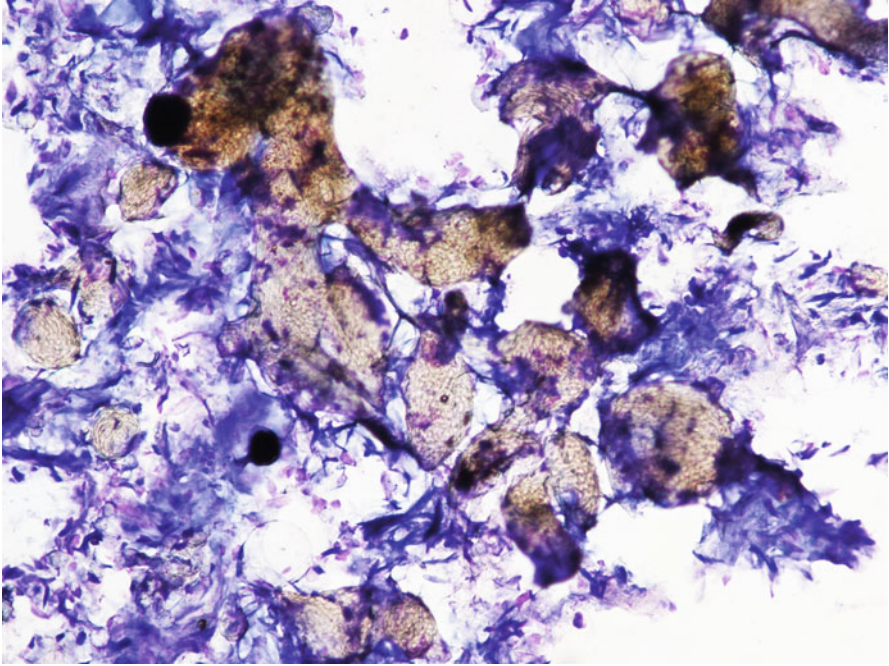


Fig. 4.154 Cytology of a hybrid cyst. Lamellar corneocytes together with multiple clusters of ghost cells

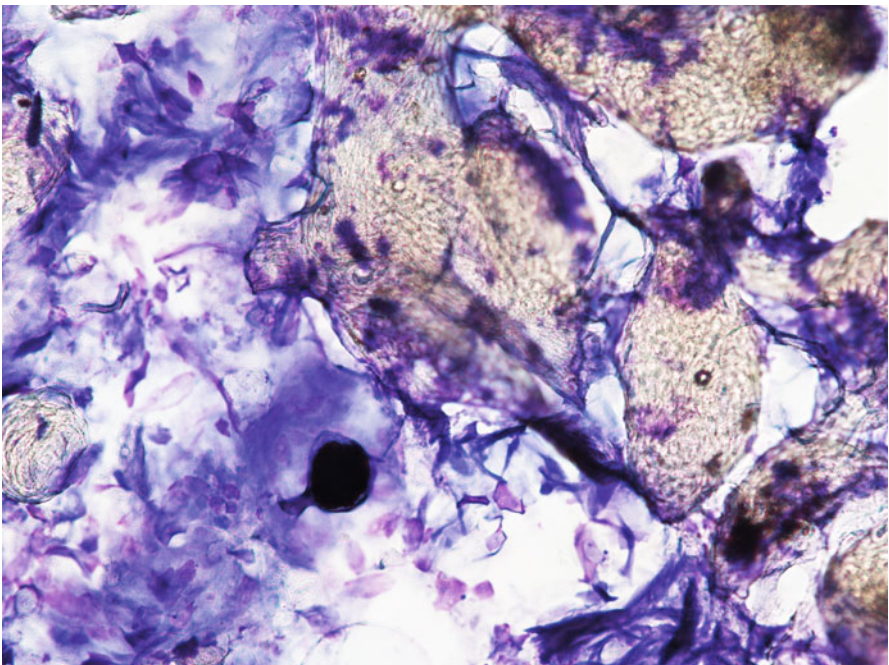


Fig. 4.155 Cytology of a hybrid cyst. At high magnifications the double keratin population is clearly evident

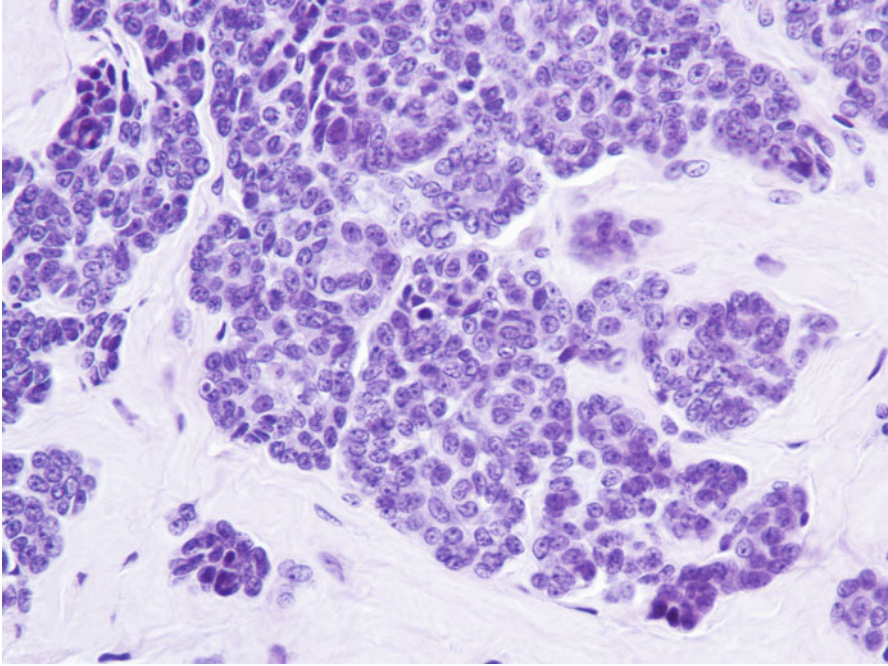


Fig. 4.156 Histopathology of a trichoblastoma: multiple nests of basaloid keratinocytes

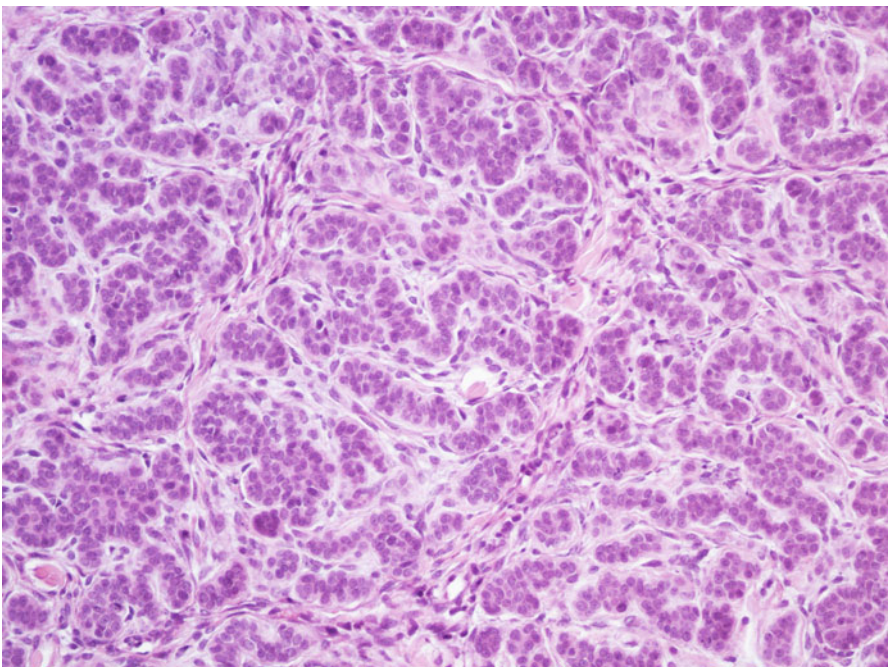


Fig. 4.157 Histopathology of a trichoblastoma: cords of basaloid cells

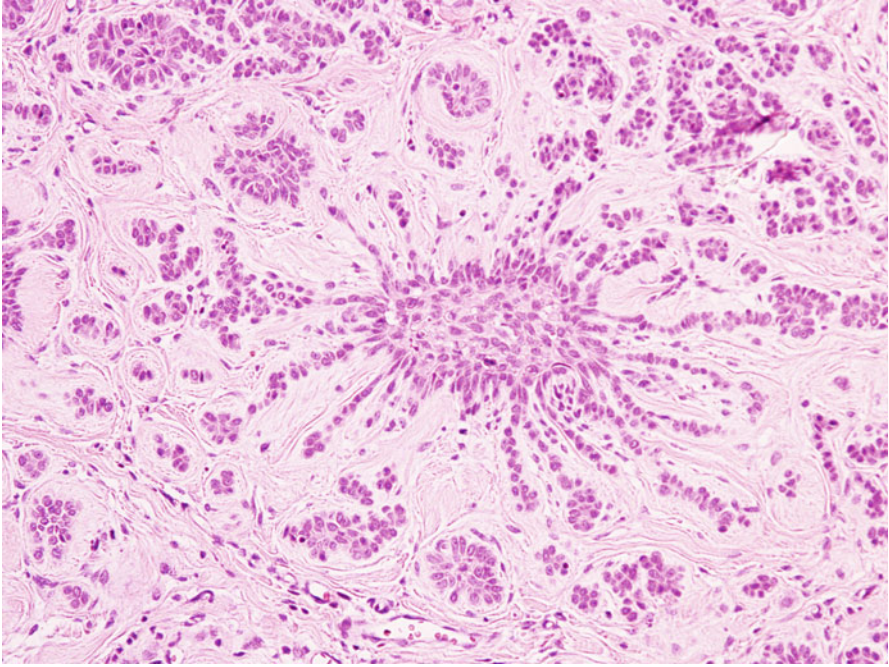


Fig. 4.158 Histopathology of a ribbon-type trichoblastoma (*medusa head* variant)

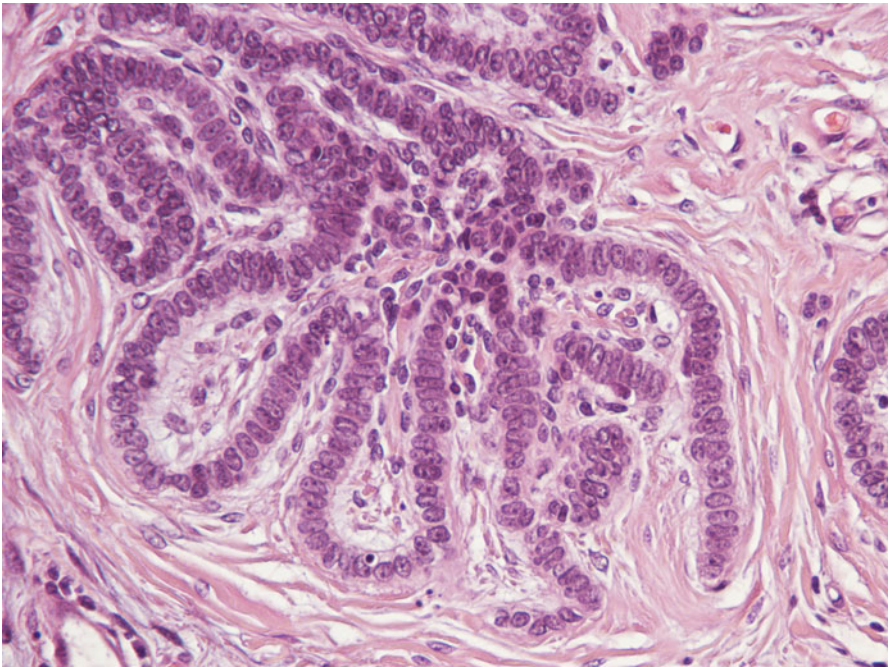


Fig. 4.159 Histopathology of a trichoblastoma: serpiginous rows of single or double basaloid keratinocytes arranged with nuclei orientated perpendicular to their long axis

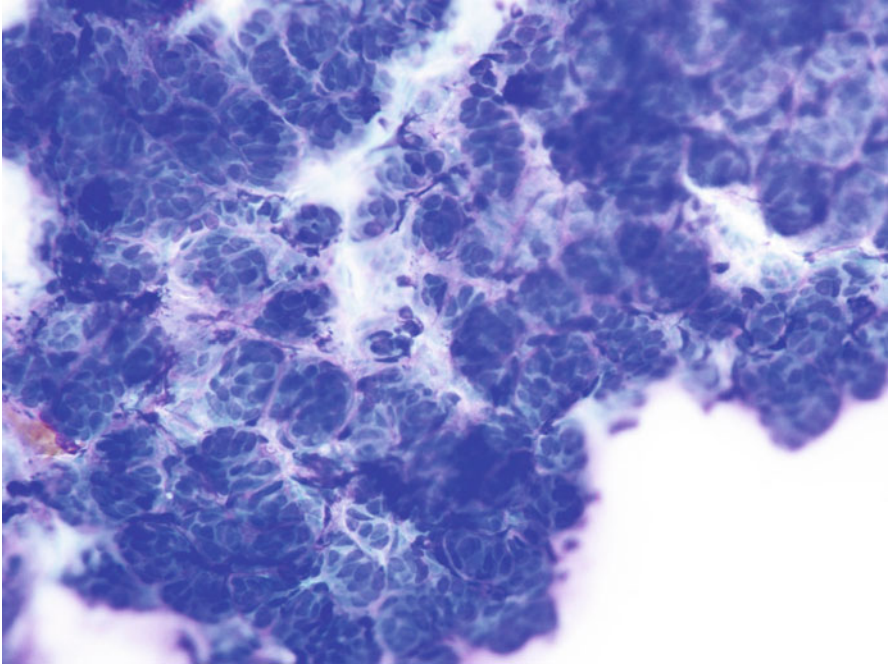


Fig. 4.160 Cytology of a trichoblastoma: multiple roundish clusters of basaloid cells

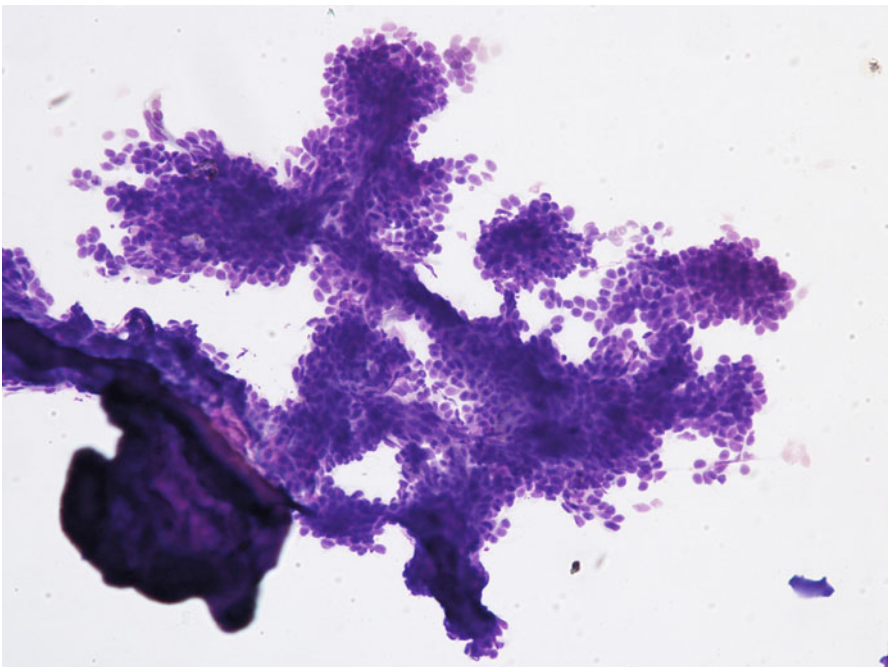


Fig. 4.161 Cytology of a trichoblastoma: multiple trabeculae of basaloid cells that start from a central axis

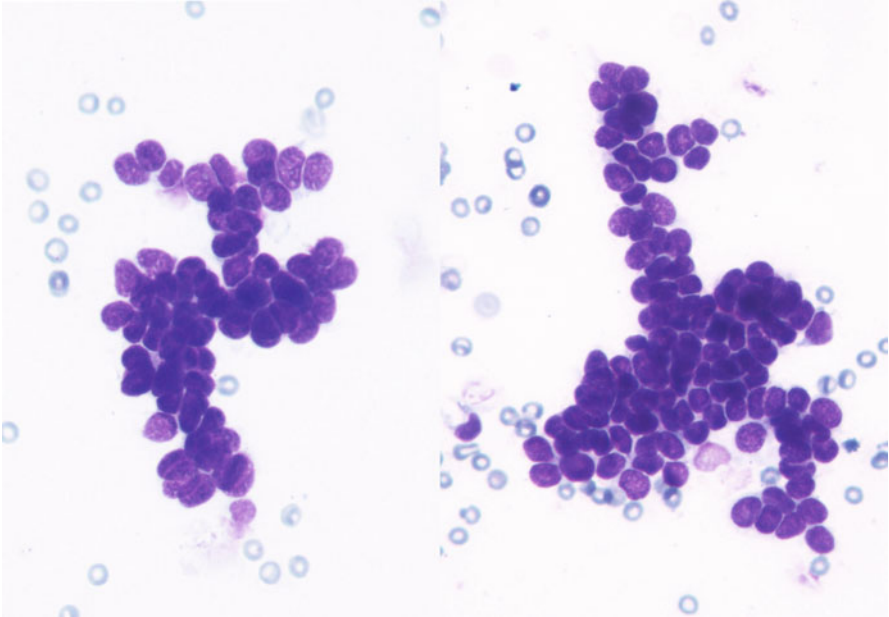


Fig. 4.162 Cytology of a trichoblastoma: typical rows of basaloid keratinocytes

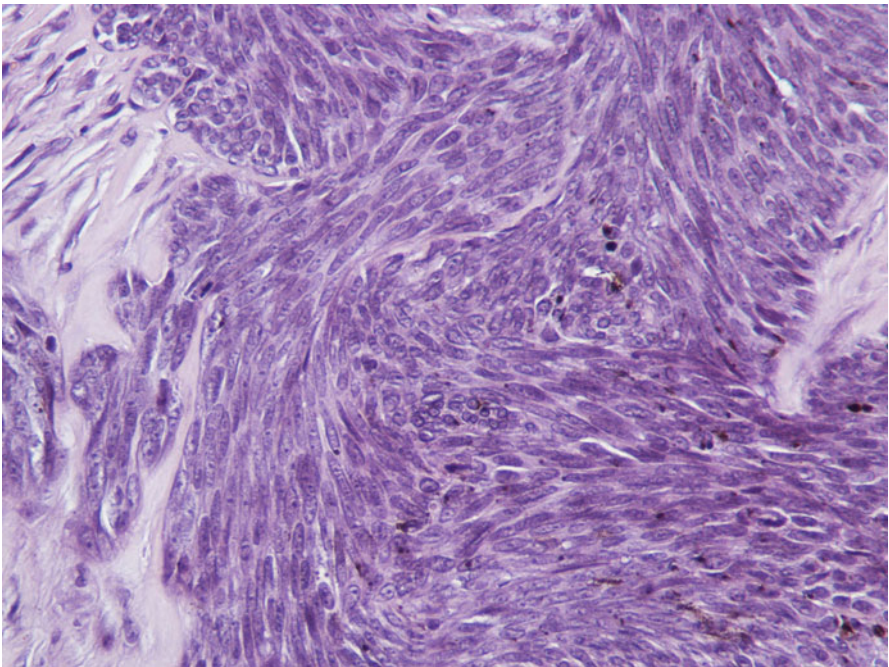


Fig. 4.163 Histopathology of a spindle trichoblastoma in a cat: many basaloid keratinocytes show a spindle shape

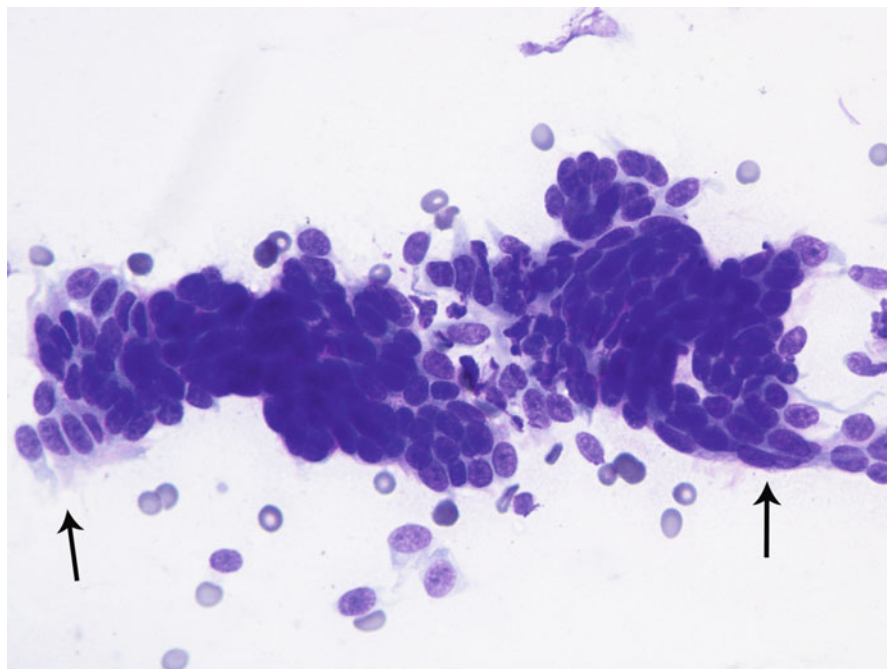


Fig. 4.164 Cytology of a spindle trichoblastoma: many basaloid cells show an evident spindle shape (arrows)

basaloid cells are heavily pigmented and other cytological specimens occasionally show a small amount of amorphous keratin (Fig. 4.165). Trichoblastomas, particularly in cats, may present with cystic areas containing colliquative fluid material; this must be taken into account when on the slides, clusters of basaloid cells, together with a large amount of amorphous debris, are collected (Figs. 4.166, 4.167, and 4.168). Macrophages in phagocytosis of necrotic material or melanin pigment, cholesterol crystals, are common cytological findings that are also observed in cystic neoplasms of different types, such as in the *apocrine solid cystic adenoma*, from which trichoblastoma is not always cytologically differentiable.

Infundibular Keratinising Acanthoma

Histologically, the *infundibular keratinising acanthoma* (IKA) is a benign follicular neoplasia characterised by the solid proliferation of epithelial cells forming a thick wall composed of nests and trabeculae of basaloid cells, which have undergone squamous differentiation, delimiting a large cavity filled with lamellar keratin (Fig. 4.169) (Stannard and Pulley 1975).

If the centre of the tumour is sampled, lamellar corneocytes and sometimes cholesterol crystals characterise the cytological specimens of IKAs. Unfortunately,

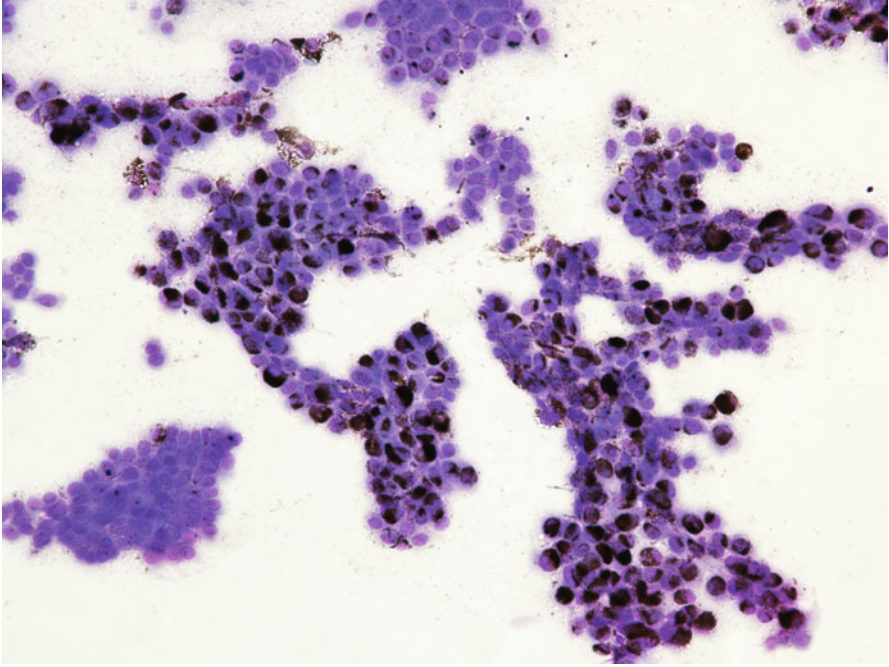


Fig. 4.165 Cytology of a trichoblastoma: many trabeculae of heavily pigmented basaloid cells

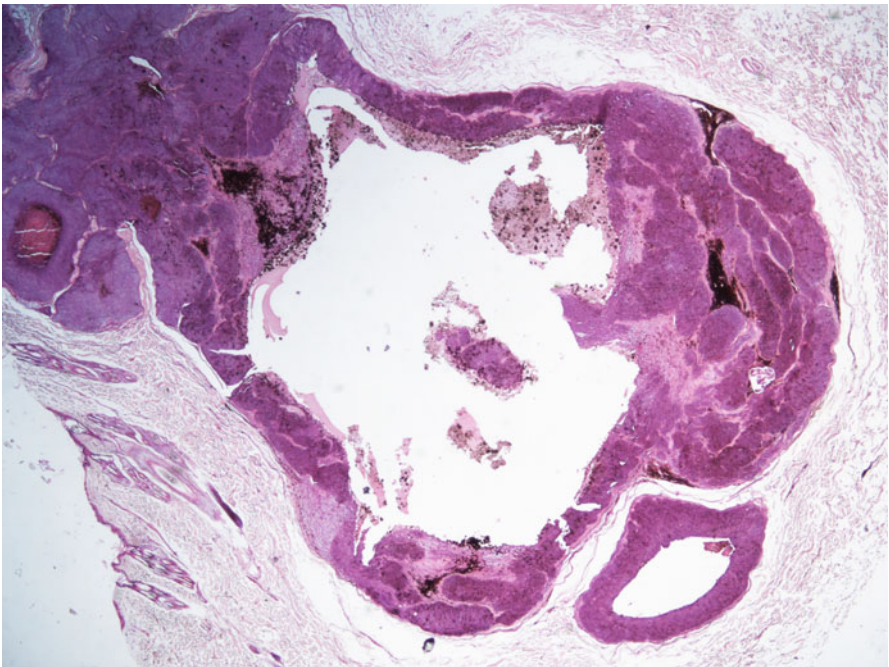


Fig. 4.166 Histopathology of a trichoblastoma: many basaloid keratinocytes with multiple cystic areas

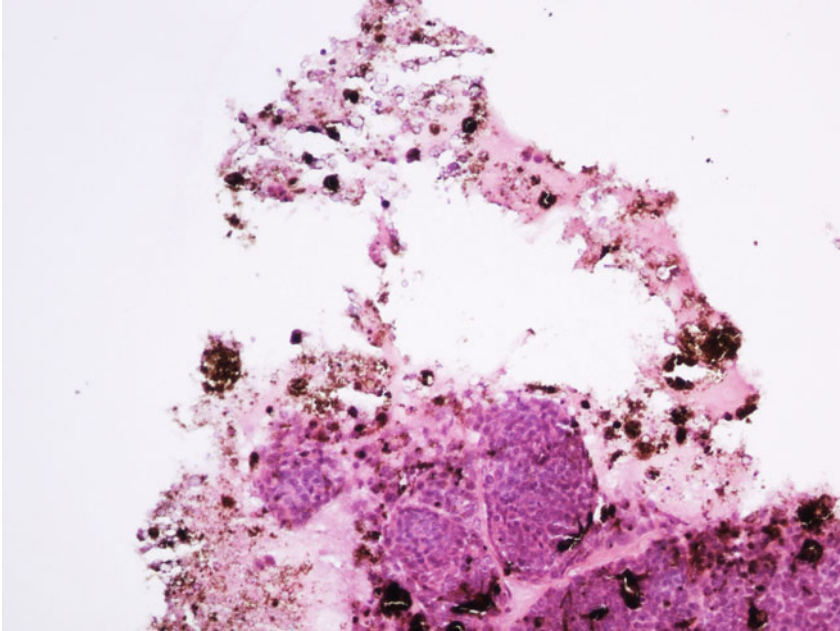


Fig. 4.167 Histopathology of a trichoblastoma: at high magnifications, many roundish aggregates of pigmented basaloid keratinocytes together with amorphous material and melanophages are evident

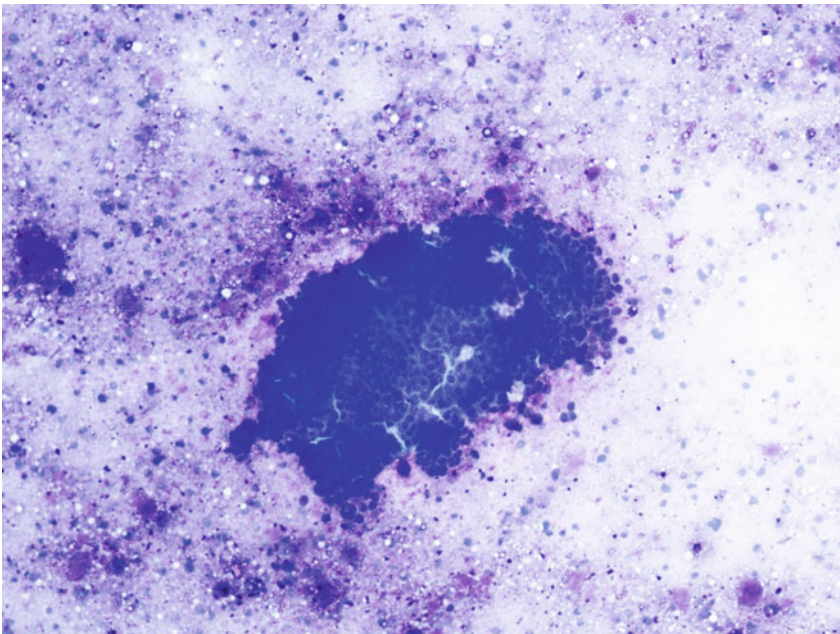


Fig. 4.168 Cytology of a trichoblastoma: a large sheet of basaloid keratinocytes is immersed in a background rich with amorphous debris and melanophages

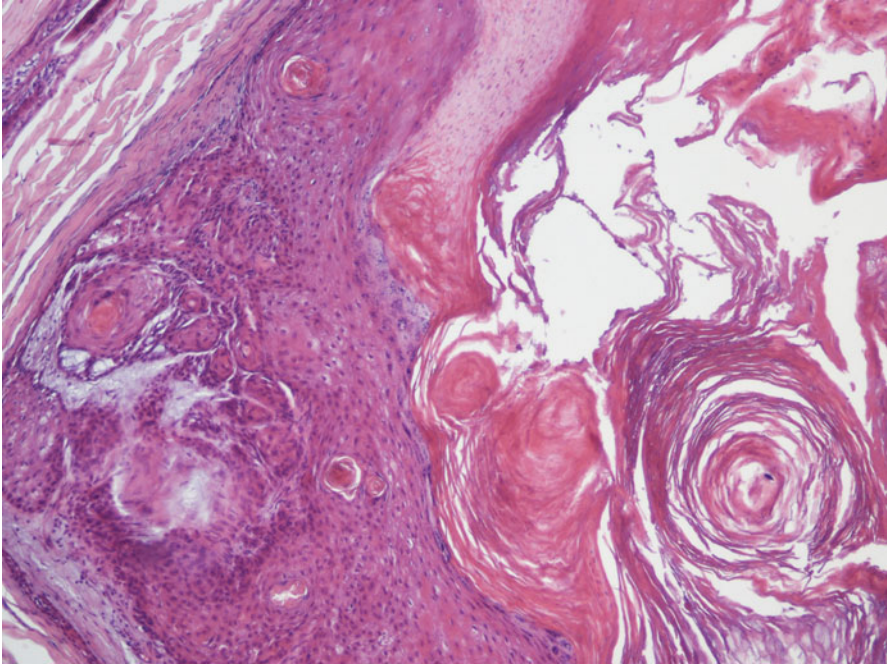


Fig. 4.169 Histopathology of an IKA: nests and trabeculae of basaloid and squamous keratinocytes delimiting a large cyst filled with lamellar keratin

these features are the same as those obtained from an infundibular cyst. In other cases, in addition to the lamellar keratin, small aggregates of basaloid and squamous cells can be sampled (Fig. 4.170).

Also in these cases, a cytological diagnosis of IKA is not possible, as the same cytology can be observed in some trichoepitheliomas in which the neoplastic cysts are mostly composed of the infundibular wall (production of lamellar corneocytes), rather than of the basal cells of the matrix (ghost keratin production). In the presence of a nodule that macroscopically shows a central pore from which keratin protrudes, the cytological features described could be very indicative of an IKA.

Trichoepithelioma

Trichoepitheliomas originate from all three components of the follicle and are histologically characterised by solid nests and, more frequently, multiple cysts of basaloid cells, uniform in size with ovoid nuclei. As the cells that compose the wall of the cysts come from all segments of the follicle, different types of keratin fill the lumens. In the area of matrical cells, abrupt keratinisation forming ghost cells is evident, whereas in follicular areas where epidermal keratinisation is present, lamellar keratin is produced via the granulosum layer (Fig. 4.171). As the walls of some

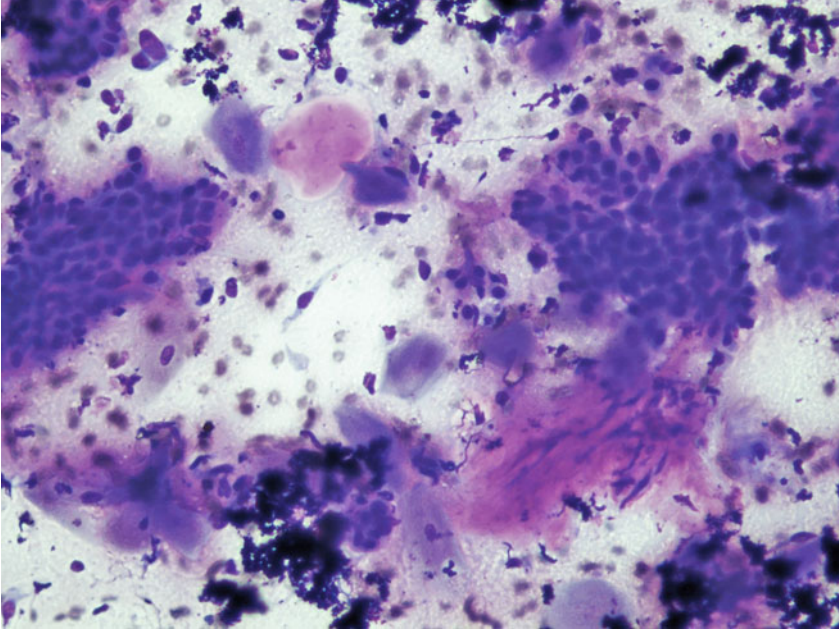


Fig. 4.170 Cytology of an IKA: large sheets of basaloid cells and scattered squamous cells are simultaneously present in association with corneocytes

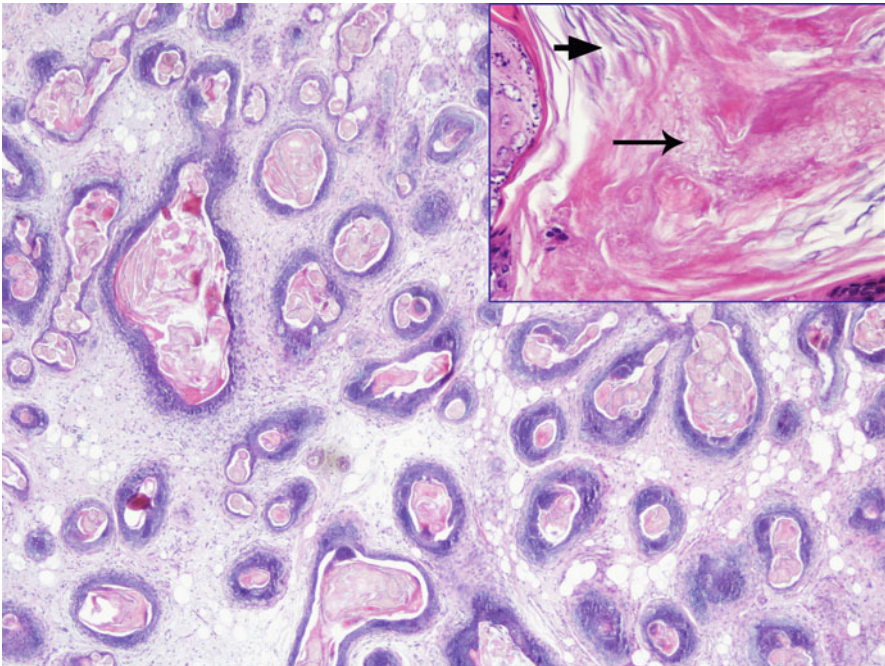


Fig. 4.171 Histopathology of a trichoepithelioma: multiple cysts are lined with keratinocytes from different parts of the follicle. Note as both lamellar (*short arrow*) and “ghost” matrical (*long arrow*) keratin are simultaneously present in the same cyst (*inset*)

cysts are composed of few layers of nucleated cells and because a large central cyst is usually present in these tumours, in addition to the different keratinised cells mentioned, the possibility of collecting nucleated basaloid cells is not so high. Cytological features of trichoepithelioma share many aspects that are similar to those observed in other follicular cysts and neoplasms. Indeed, when slides are only composed of lamellar and matrical keratin it is not possible to differentiate a trichoepithelioma from a hybrid cyst (infundibular–matrical), whereas the presence of basaloid cells and only lamellar keratin does not allow a trichoepithelioma to be differentiated from an IKA; finally, the simultaneous presence of basaloid and ghost cells does not permit us to cytologically differentiate a trichoepithelioma from a benign pilomatricoma (Figs. 4.172 and 4.173). Therefore, as for other follicular tumours, the definitive diagnosis requires histopathology. A histological variant of trichoepithelioma, with malignant biological behaviour, is occasionally reported (Goldschmidt and Hendrick 2002; Gross et al. 2005).

Pilomatricoma

Pilomatricoma are follicular tumours that originate from the germ cells of the hair matrix and are characterised by multiple cysts delimited by basaloid cells with large and ovoid nuclei that produce abruptly, keratinised ghost cells, as described above (Fig. 4.174). On more successful slides, basaloid matrical aggregates turning into ghost cells can be observed in cytological specimens (Masserdotti and Ubbiali 2002). In rare cases, the pilomatricomas undergo calcification and therefore, in cytological samples, it is possible to observe mineral salts and giant cells. It should be emphasised that the presence of large amounts of ghost cells is a common finding in cytological specimens obtained from a pure matrical or a matrical–hybrid cyst. In these two cases, the possibility of sampling basaloid cells is very low; therefore, when detected, a pilomatricoma is much more likely and must be confirmed by histopathological examination (Fig. 4.175).

Occasionally, pilomatricomas may be malignant and metastasise, although for some authors, the percentage of malignant variant is underestimated (Carroll et al. 2010).

4.3.3 Sebaceous Gland Tumours

Tumours of the sebaceous glands are very numerous and can originate from both mature *sebocytes* and *germinative* cells; the latter border peripherally the differentiated sebaceous cells and are named *basaloid reserve cells*. The reserve cells differentiate into lipidised sebocytes. Neoplasms of reserve cells include *sebaceous epithelioma* and its malignant counterpart, the *sebaceous epitheliomatous carcinoma*, whereas tumours arising from sebocytes comprise both benign and malignant tumours; the former are represented by *sebaceous hyperplasia* and *sebaceous*

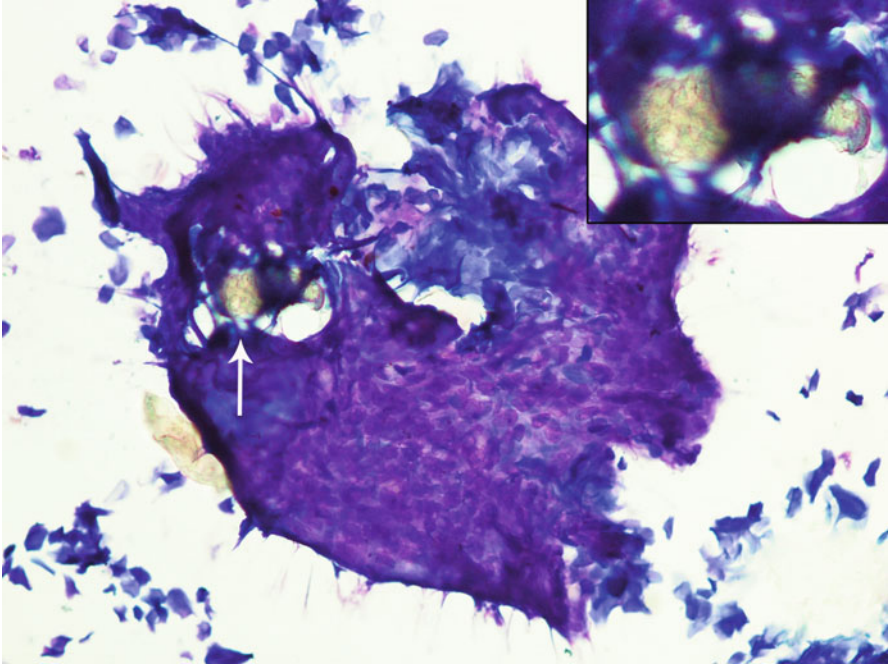


Fig. 4.172 Cytology of a trichoepithelioma: a large cluster of uniform basaloid cells, lamellar keratin and a small aggregate of matrical ghost cells (*arrow, inset*)

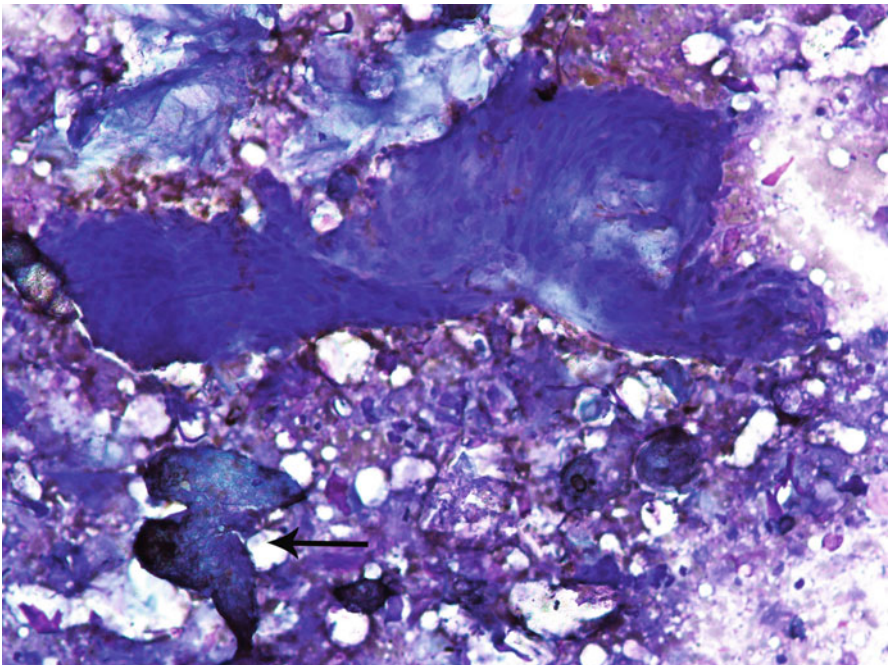


Fig. 4.173 Cytology of a trichoepithelioma: a large sheet of uniform basaloid cells, lamellar keratin and an aggregate of matrical ghost cells (*arrow*)

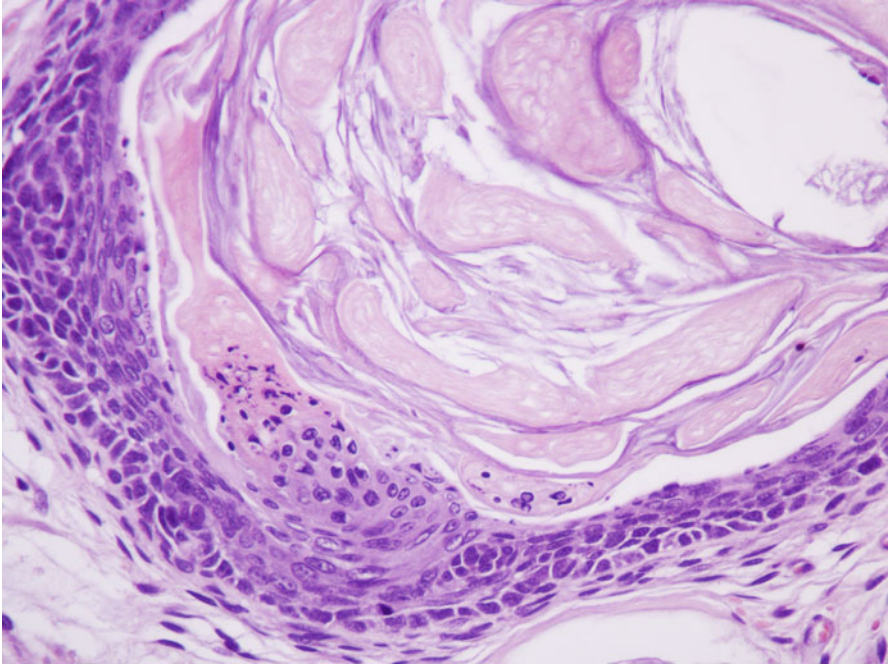


Fig. 4.174 Histopathology of a pilomatricoma: matrical cells undergo abrupt keratinisation, which gives origin to many ghost cells

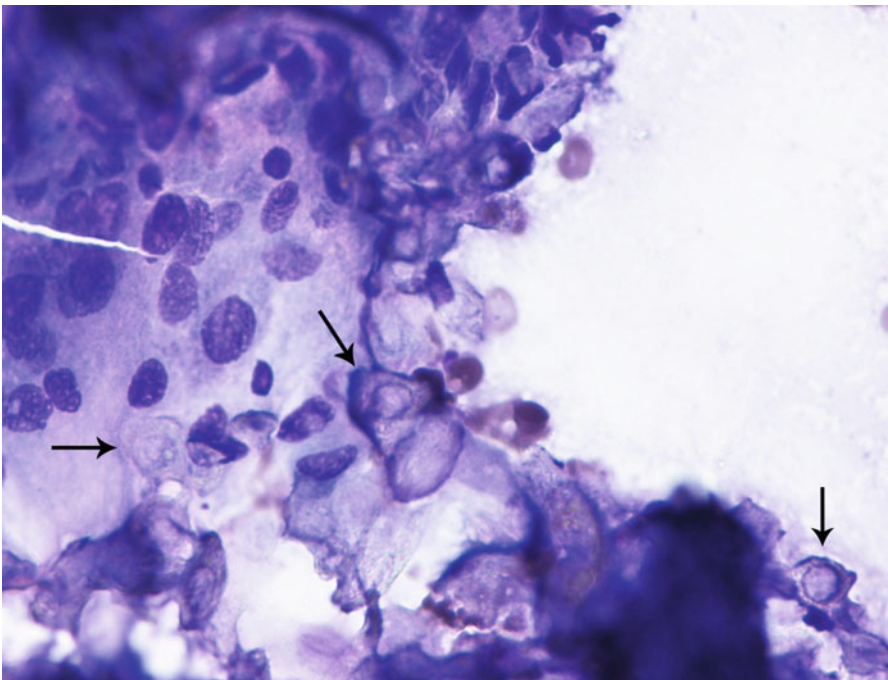


Fig. 4.175 Cytology of a benign pilomatricoma: abrupt production of matrical “ghost cells” is evident (*arrows*)

sebocytic adenoma, and the malignant variant is the *sebaceous sebocytic carcinoma* (Scott and Anderson 1990; Gross et al. 2005). The sebaceous tumours of the eyelids are called *Meibomian gland neoplasms*, mainly comprising adenomas and epitheliomas.

Another type of modified gland of sebaceous origin is present in the skin. These specialised glands, named *perianal glands* or, because of their histomorphological similarity to hepatocytes, *hepatoid glands*, are present only in dogs.

Benign hyperplasia of the sebaceous glands is the most frequent type of sebaceous tumour, especially in older dogs such as Cocker and Miniature Poodle, whereas it is rarer in cats (Scott and Anderson 1990). Grossly, lesions are characterised by nodules of various sizes, single or multiple, with a cauliflower or blackberry appearance, usually pink in colour or hyperpigmented. In many cases, a yellow–orange film of waxy sebum covers their surface (Figs. 4.176 and 4.177).

Sebaceous sebocytic adenoma and *sebaceous epithelioma* do not have a typical macroscopic aspect and usually occur as single and only rarely as multiple nodules, variable in size, of irregular shape, alopecic, erythematous and often ulcerated (Fig. 4.178). The sebaceous epithelioma, usually benign, is rarely reported as a potentially metastatic tumour (Bettini et al. 2009). In animals with multiple lesions, the simultaneous presence of hyperplasia, adenomas and epitheliomas on the same subject can be observed, which could indicate a different evolution of the hyperplastic nodules (Fig. 4.179). Carcinomas of the sebaceous glands are rarer and are usually characterised by a single nodule that is of varying size and often ulcerated.

The *hyperplasia* and *adenomas* of the *hepatoid glands* are very common in intact males and develop mainly in the perianal area, which is very rich in these glands. Less frequently, other body areas such as the tail, the prepuce, the back and thigh can be affected. The clinical appearance is variable. Nodules vary in size, and can be single or multiple, erythematous and ulcerated (Figs. 4.180, 4.181, 4.182, and 4.183).

Hepatoid glands are also physiologically present in the so-called *supracaudal organ* or *tail gland*, a group of sebaceous and hepatoid glands located in the dorsal portion of the tails of dogs, a few centimetres from the sacrum. As for the sebaceous glands, even from hepatoid glands, hyperplastic lesions, adenomas, epitheliomas and carcinomas may develop.

Cytological Findings

The cells of *sebaceous hyperplasia* and *sebaceous adenoma* do not differ morphologically from the normal sebocytes, nor can they be differentiated from each other using cytology. In these lesions, sebocytes are organised in small cohesive clusters, with round, uniform nuclei, mainly located in the centre of the cells, and with a micro-vacuolated cytoplasm filled with small overlapping lipid vacuoles that give cells a characteristic *foamy* appearance (Figs. 4.184 and 4.185). The vacuoles are different in size in dogs, whereas they are more uniform in cats (Fig. 4.186). Often, at the periphery of the aggregates of sebocytes, arranged in a single row, reserve cells characterised by small, round, hyperchromatic nuclei and scant cytoplasm are usually observed; as mentioned, these cells are immature cells that differentiate into sebocytes (Figs. 4.187, 4.188, and 4.189).

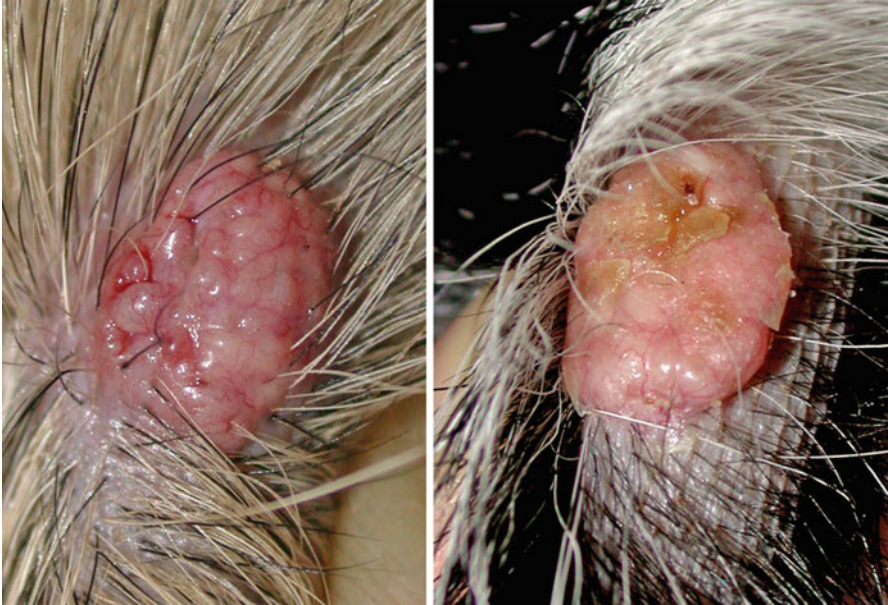

Fig. 4.176 Sebaceous hyperplasia. Typical clinical aspect of benign sebaceous hyperplasia. Note the orange waxy material that envelopes the surface of the right nodule

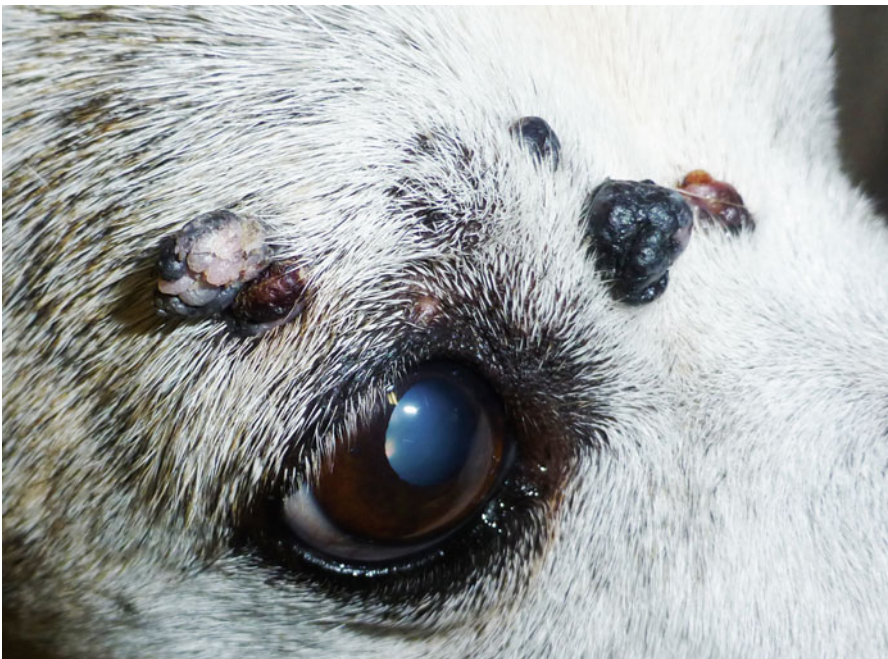

Fig. 4.177 Sebaceous hyperplasia. Multiple cauliflower-shaped and hyperpigmented nodules on the head of an old dog

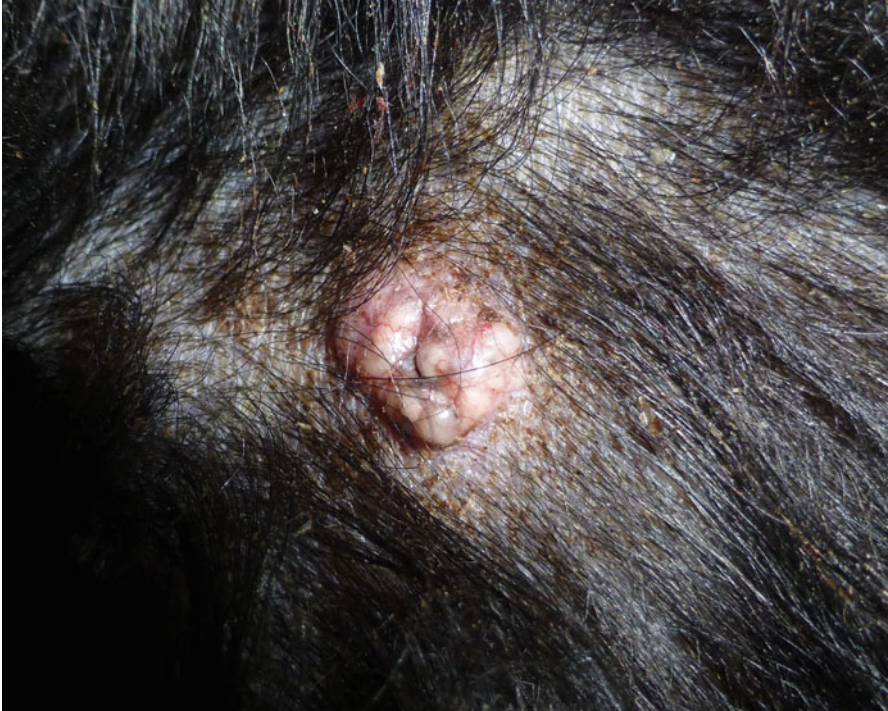

Fig. 4.178 Sebocytic sebaceous adenoma. Single nodule with irregularly multilobed surface

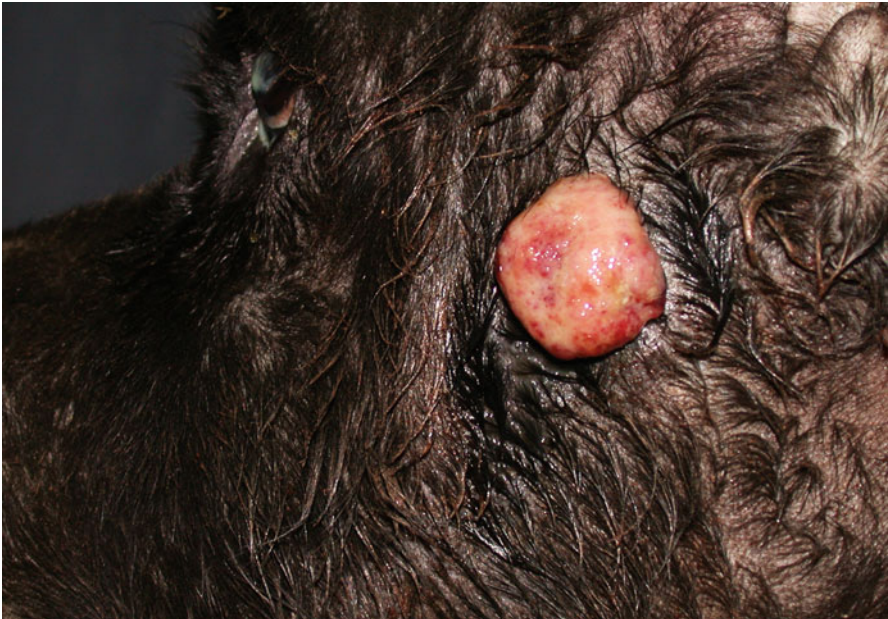

Fig. 4.179 Sebaceous epithelioma. Single ulcerated nodule on the face of a dog

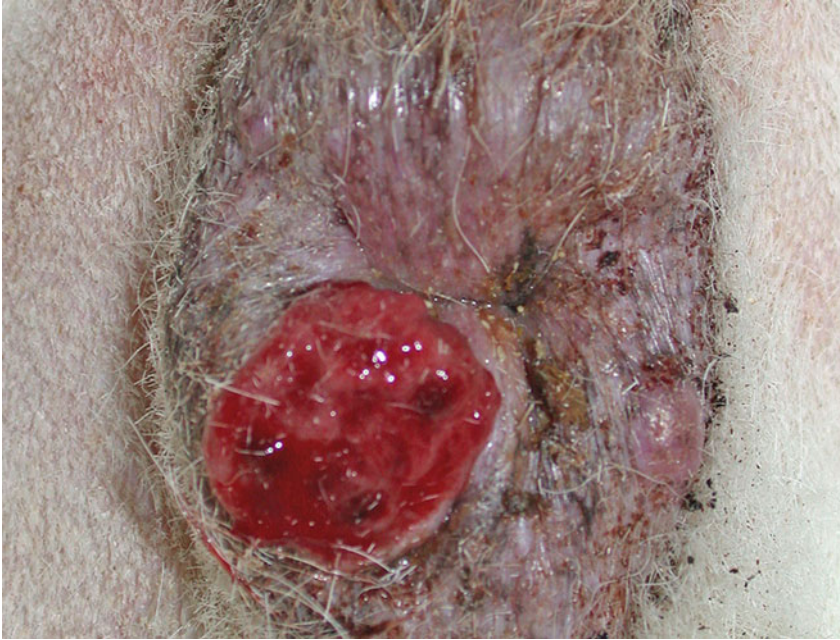

Fig. 4.180 Perianal hepatoid gland adenoma. Ulcerated nodule. Note the presence of a second smaller intact nodule on the right side of the anus. The latter was histologically diagnosed as nodular hyperplasia

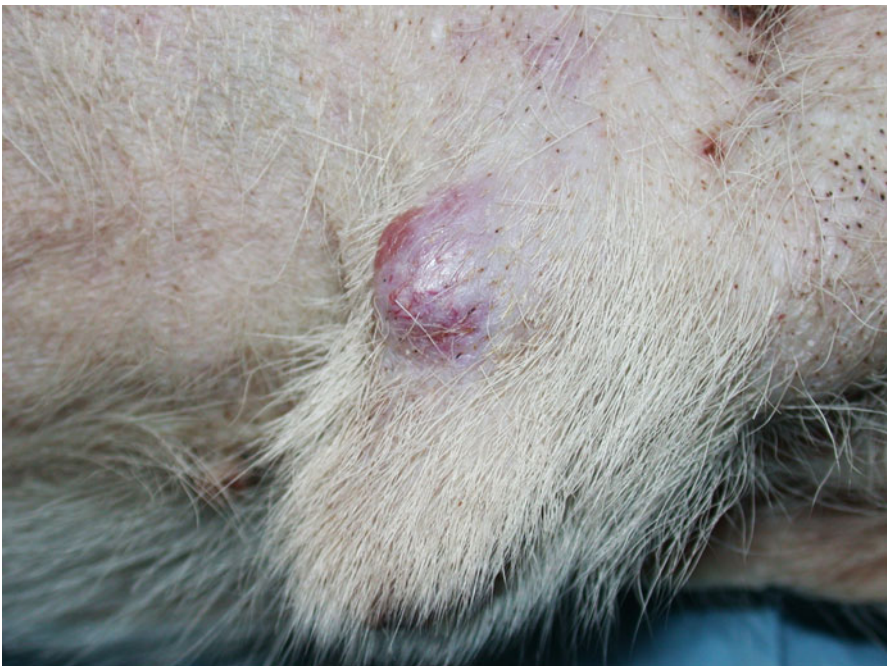

Fig. 4.181 Hepatoid gland adenoma in the preputial area

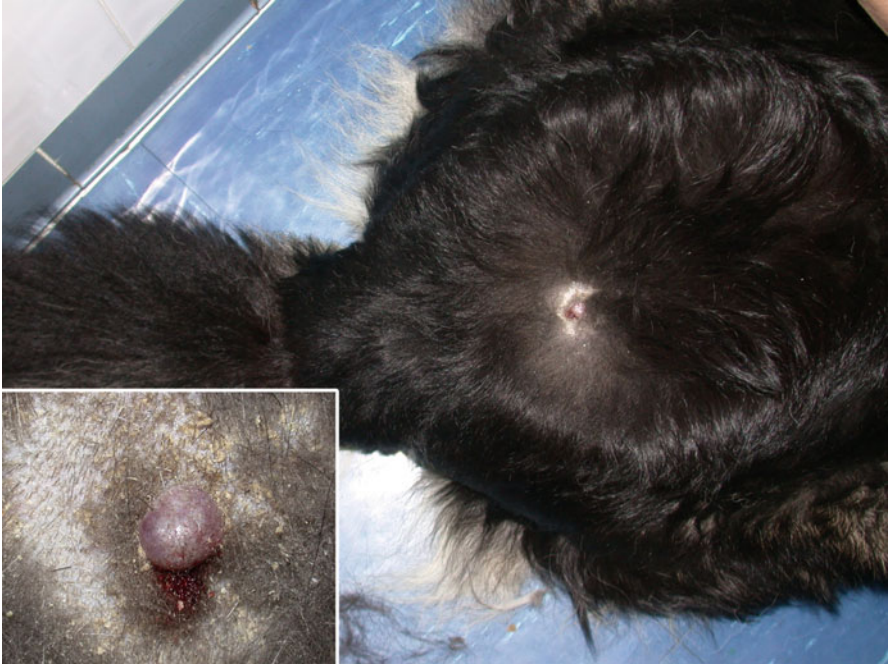

Fig. 4.182 Small alopecic hepatoid gland adenoma on the back of a mixed-breed dog. Close up of the neoplasia (inset)

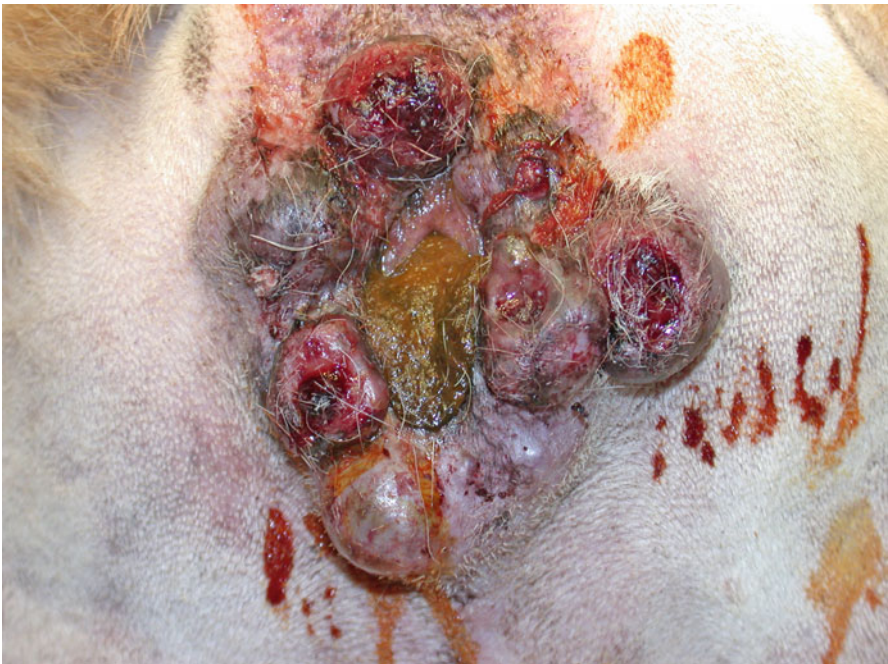

Fig. 4.183 Hepatoid gland carcinoma. Multiple ulcerated neof ormation on and around the anus

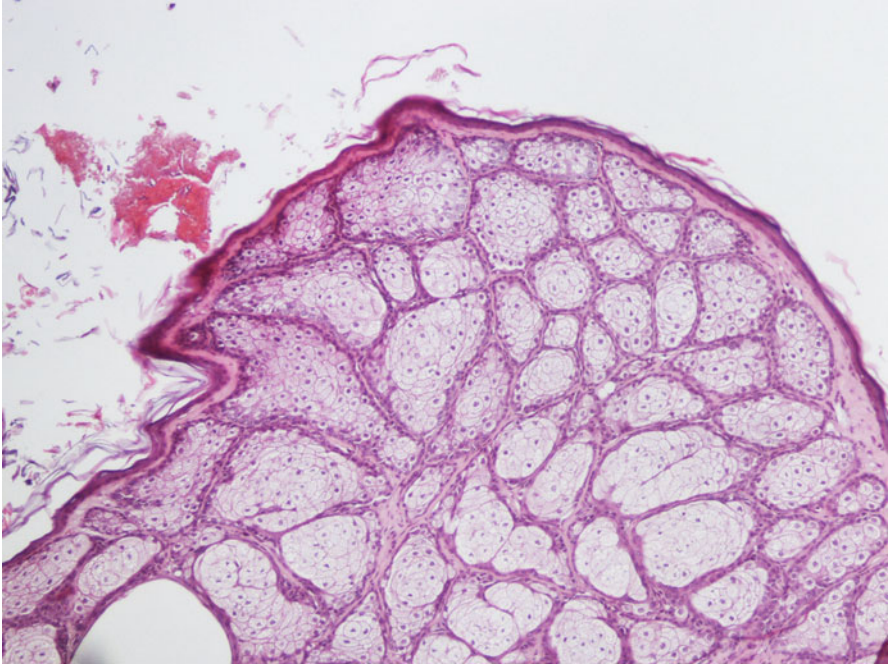


Fig. 4.184 Histopathology of sebaceous hyperplasia: regular and roundish lobules of uniform-sized sebocytes lined with a single layer of basaloid cells

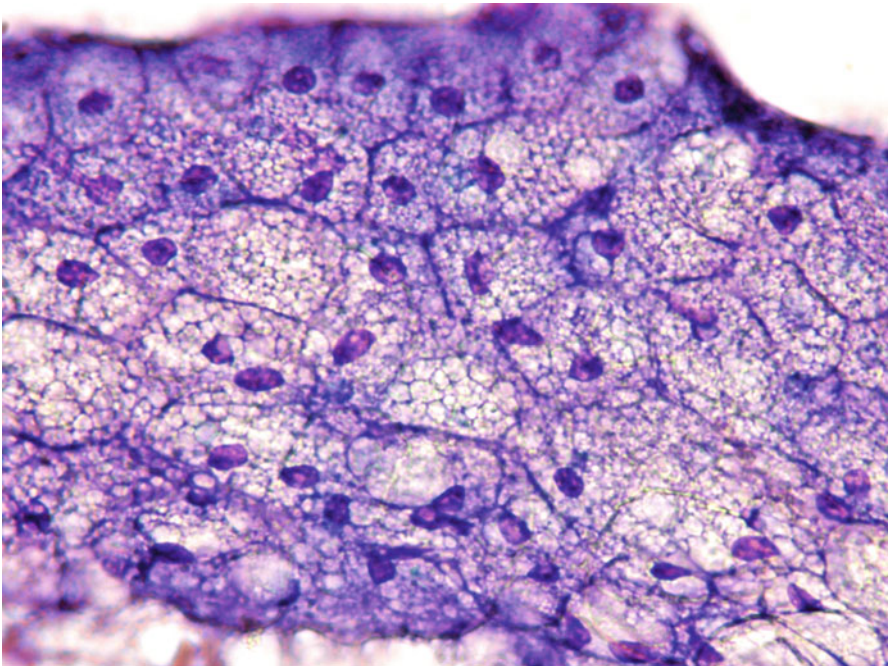


Fig. 4.185 Cytology of canine sebaceous hyperplasia: typical foamy appearance of sebocytes with intracytoplasmic vacuoles of different sizes

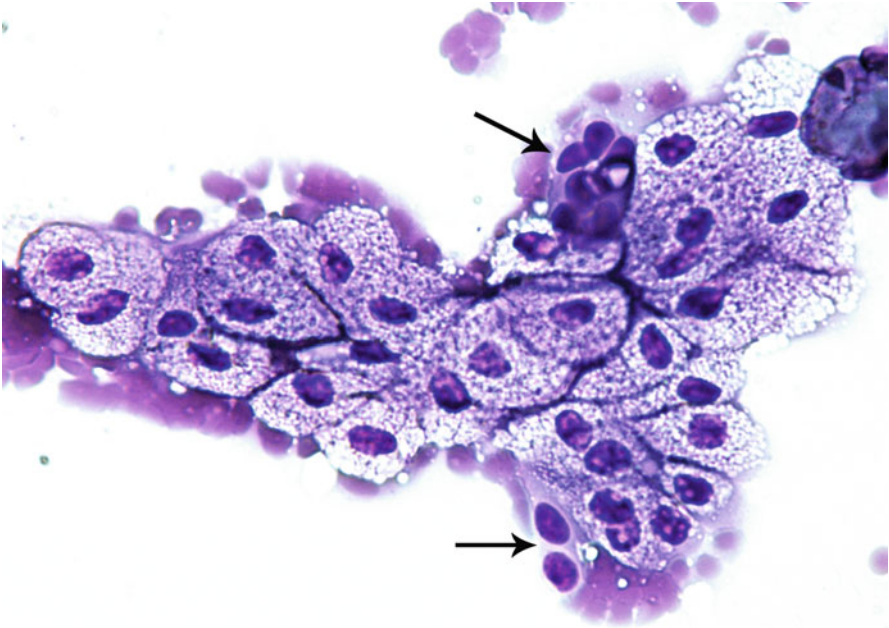


Fig. 4.186 Cytology of feline sebaceous hyperplasia: the intracytoplasmic vacuoles show a more uniform size compared with dogs. The *arrows* indicate small groups of reserve cells

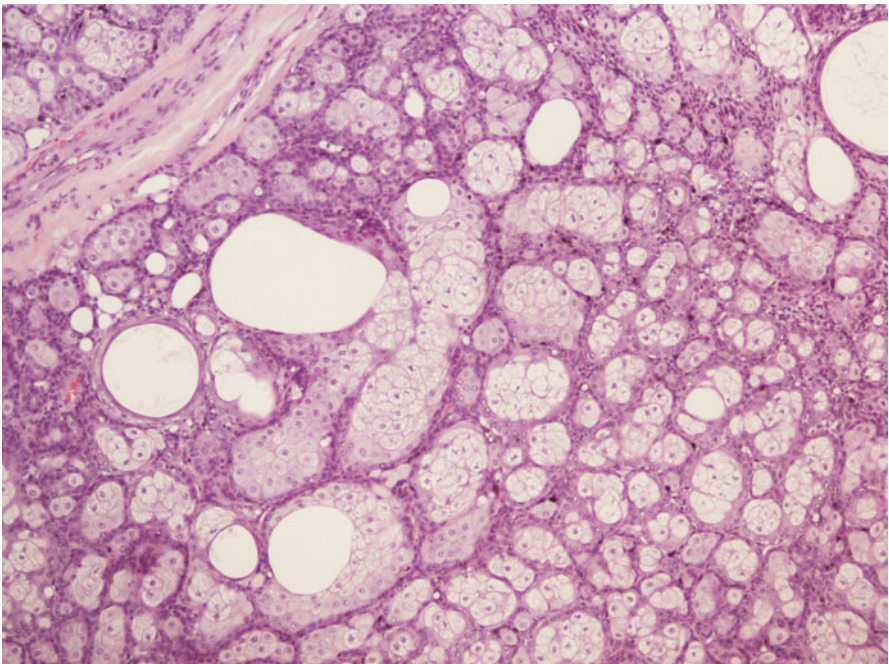


Fig. 4.187 Histopathology of a sebaceous gland adenoma: multiple layers of basaloid cells line irregular lobules and trabeculae of sebocytes. Some intra-neoplastic cysts and sebaceous ducts are also evident

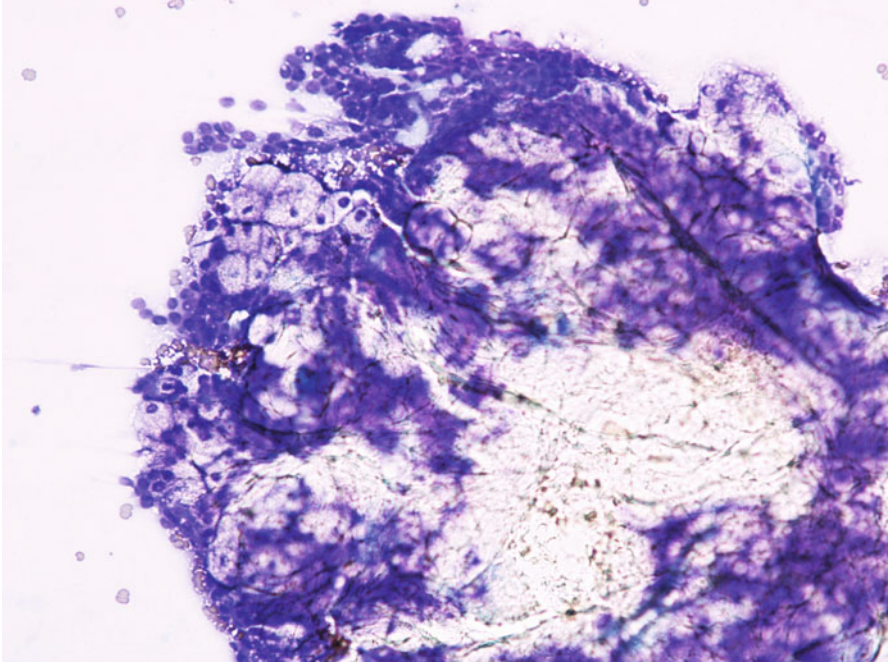


Fig. 4.188 Cytology of a sebaceous gland adenoma: a large aggregate of mature sebocytes lined with multiple layers of immature cells is evident. The achromatic central area represents a large cystic area in which sebum and lamellar keratin are contained

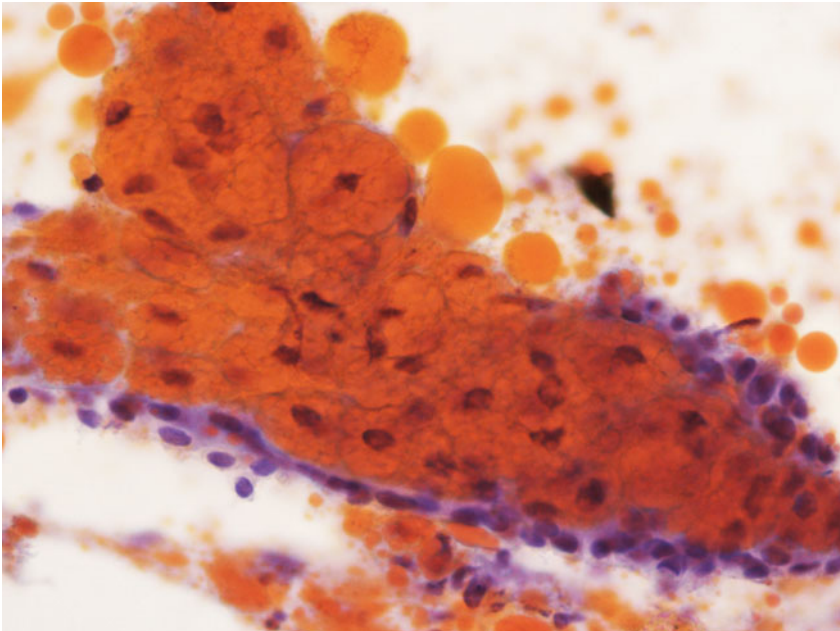


Fig. 4.189 Cytology of sebaceous gland hyperplasia: with oil-red-O staining, the fat is highlighted in red. Note that the peripheral reserve cells do not take the stain

In some cases, because the sebaceous glands are anatomically arranged around a large central cyst lined with a keratinised stratified epithelium, it is possible to sample large amounts of sebum mixed with a variable number of corneocytes (Fig. 4.190). Sebum is cytologically characterised by achromatic greasy material that does not take dye and in the context of which only a few corneocytes and rarely intact or necrotic sebocytes indicative of holocrine secretion are found (Fig. 4.191). This occurrence is more common in Meibomian gland neoplasias, often associated with secondary granulomatous inflammation and mainly represented by lipophagocytic macrophages. The cytological differentiation between benign sebaceous *hyperplasia* and *sebocytic adenoma*, as with two other benign sebaceous lesions, *sebaceous hamartoma* and *sebaceous nevus*, is not possible. It has been speculated that, if the specimens are composed of a higher number of reserve cells, with larger aggregates of less uniform sebocytes, an adenomatous lesion should be suspected. However, differentiation has no prognostic significance because of the benign behaviour of all these sebocytic sebaceous lesions.

Very rarely, both in hyperplasia and adenoma, a few elements with hepatoid differentiation can be observed. The *sebaceous epithelioma* is instead a neoplasm that originates from the reserve cells of the sebaceous glands (Fig. 4.192). Cytologically, large aggregates of uniform, single or clustered basaloid cells, in the context of which a very small number of mature sebocytes are observed (Figs. 4.193 and 4.194). The mature sebocytes usually have crenate, centrally located nuclei and typical micro-vacuolated foamy cytoplasm. In most cases it is not possible to cytologically distinguish a sebaceous epithelioma from a well-differentiated epitheliomatous sebaceous carcinoma, especially when in the latter, the cytological atypias are mild. In cases where very few mature sebocytes are present, they could be highlighted using the oil-red-O dye, which stains the intravacuolar lipids a red–orange colour (Fig. 4.195). In general, even if cytology is almost exclusively composed of basaloid cells, slides usually show many lipid droplets dispersed on the slide that help to interpret, as sebaceous, the basaloid reserve cells.

Sebocytic sebaceous carcinomas show cytological features that differ according to the grade of malignancy. Intracytoplasmic vacuoles are less numerous and larger in size (Fig. 4.196). In poorly differentiated carcinomas vacuoles may be absent and this makes it impossible to identify the sebaceous origin of the cells. Poorly cohesive clusters of cells characterise some cancers, whereas in other cases, many spindle-shaped cells can be observed; the latter must not be confused with mesenchymal cells (Fig. 4.197).

The cytology of *hyperplasia/adenoma of hepatoid glands* usually shows numerous and large aggregates of polygonal to round cells with round or oval nuclei, located centrally, usually with one or two clearly appreciable nucleoli and a large cytoplasm, pinkish in colour and of grainy appearance. At the periphery of the clusters, reserve cells usually arranged in a single layer are sometimes evident. The reserve cells are those from which the *perianal gland epithelioma* can arise (Figs. 4.198, 4.199, and 4.200). In many specimens, a variable number of bare

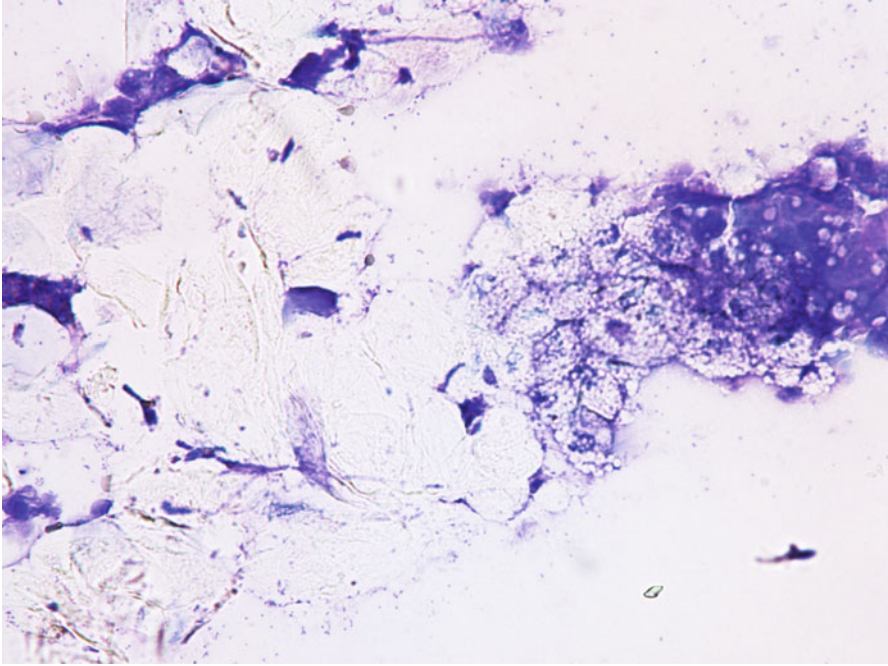


Fig. 4.190 Cytology of the sebaceous gland: holocrine secretion. The sebocytes dissolve, giving origin to the sebum in which many corneocytes from the sebaceous duct are often evident

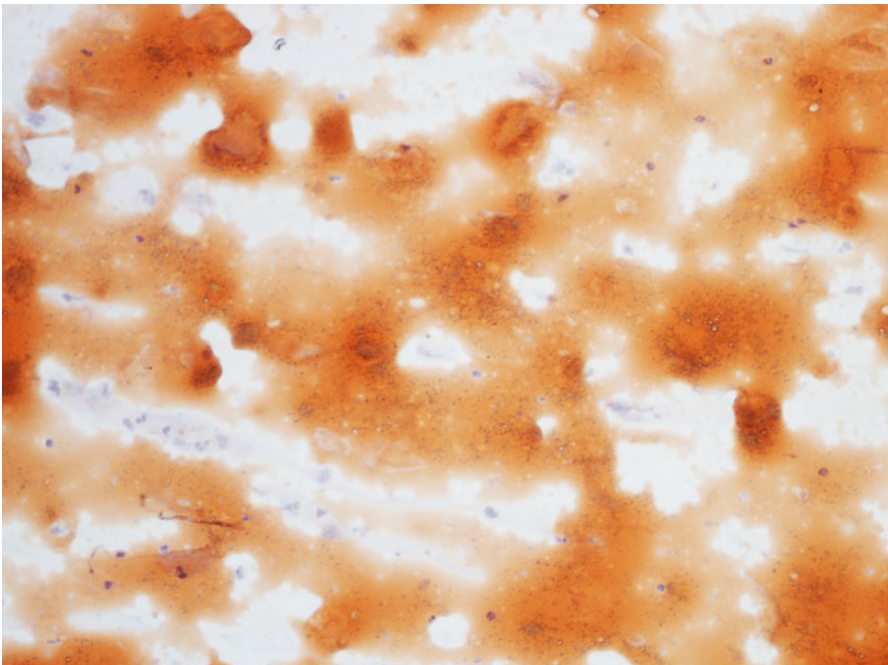


Fig. 4.191 Cytology of the sebaceous gland: with oil-red-O staining, the sebaceous secretion is diffusely stained red–orange owing to its lipid composition

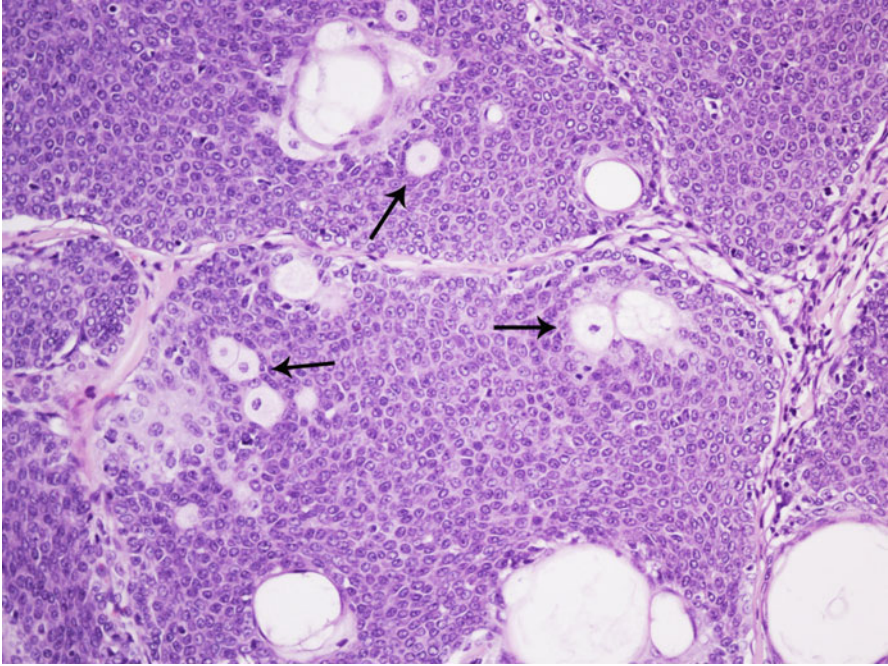


Fig. 4.192 Histopathology of a sebaceous epithelioma: large nests of basaloid germinative cells in which few single and small clusters of mature sebocytes are recognisable (*arrows*)

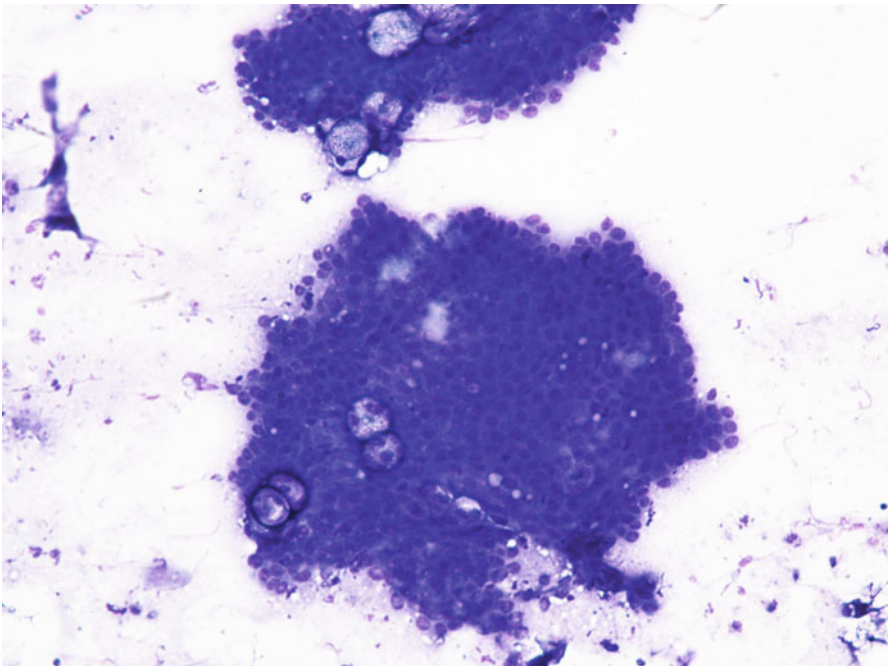


Fig. 4.193 Cytology of a sebaceous epithelioma: large sheets of basaloid cells in which scattered mature sebocytes are recognisable

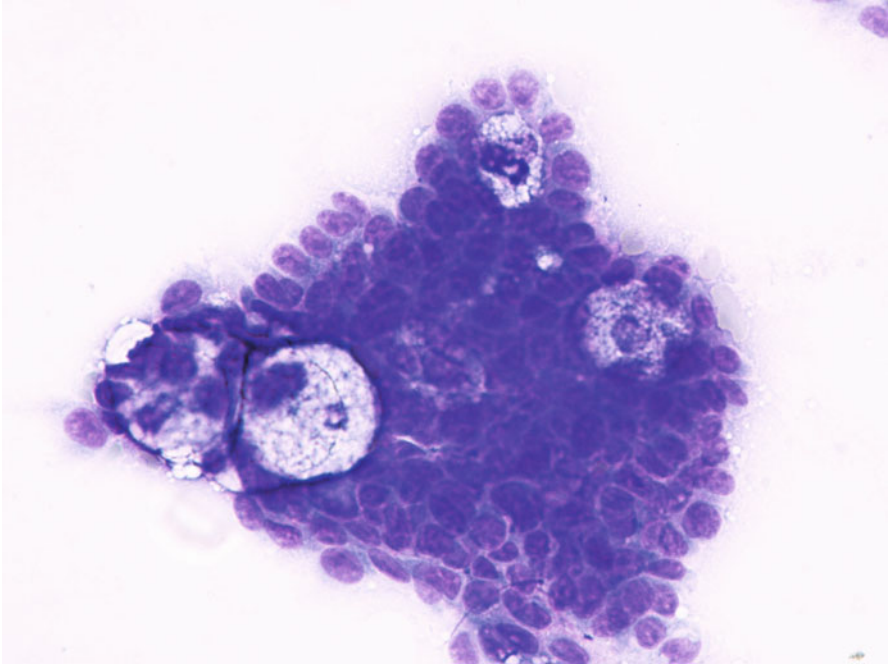


Fig. 4.194 Cytology of a sebaceous epithelioma: at high magnifications the foamy aspect of the mature sebocytes is more evident

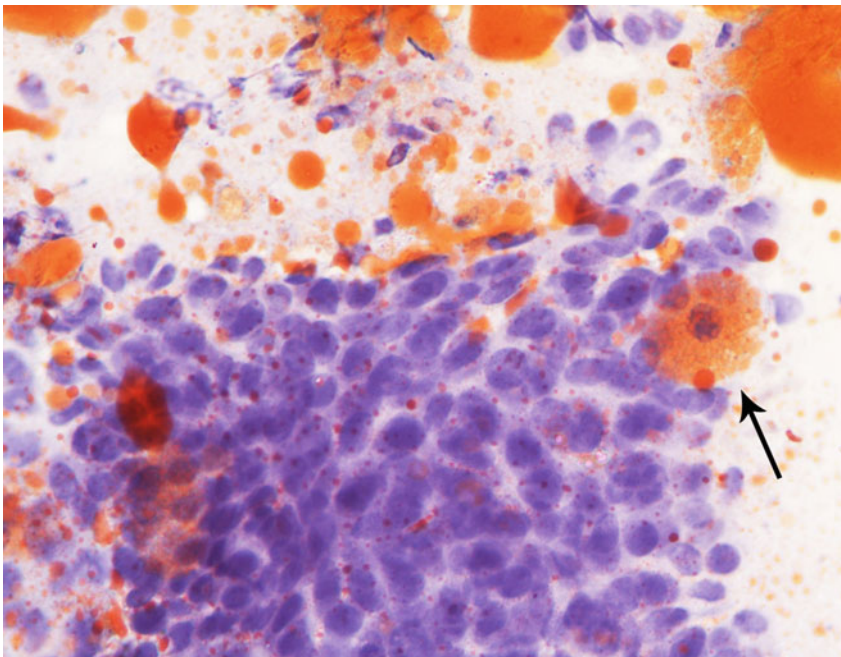


Fig. 4.195 Cytology of a sebaceous epithelioma: with oil-red-O staining a single well differentiated sebaceous cell can be highlighted between a large cluster of undifferentiated basaloid cells (*arrow*)

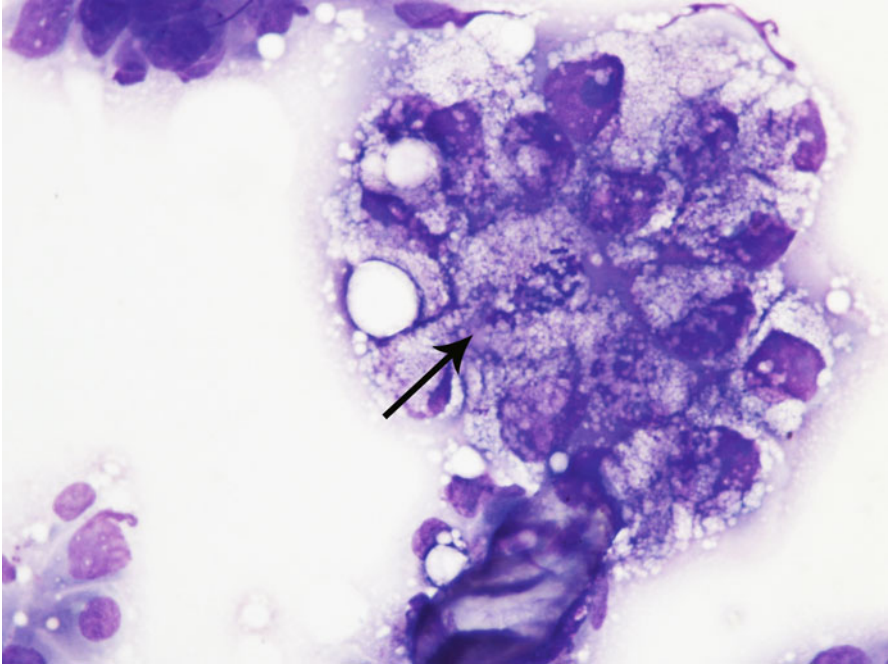


Fig. 4.196 Cytology of a sebaceous carcinoma: scarcely cohesive cluster of malignant sebocytes in which the foamy appearance of the cytoplasm is still recognisable. Note the atypical mitosis of a neoplastic cell (*arrow*)

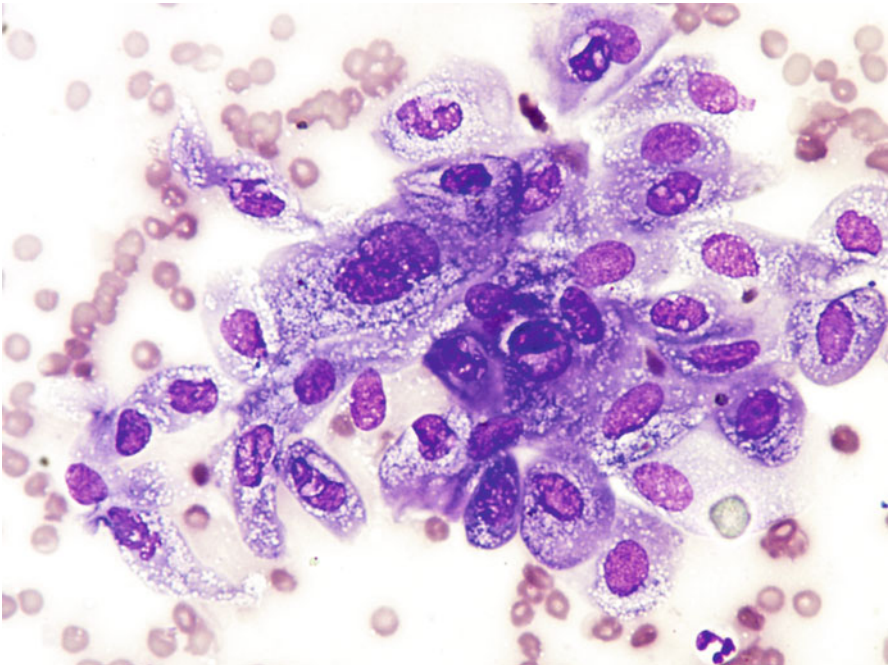


Fig. 4.197 Cytology of a sebaceous carcinoma: severe malignant atypia of sebaceous sebocytic cells. Note that some neoplastic cells assume a spindle shape

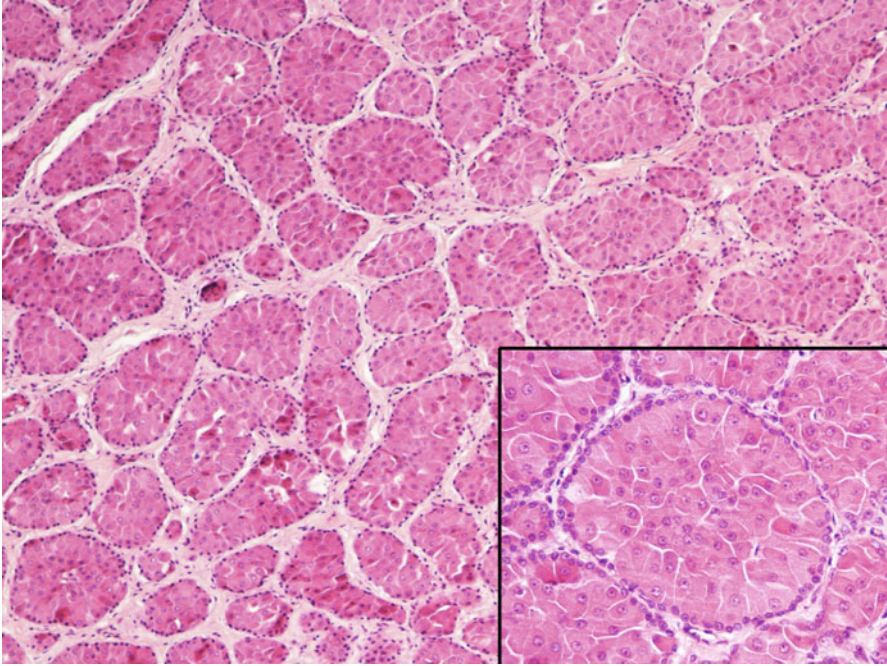


Fig. 4.198 Histopathology of hepatoid gland hyperplasia: multiple and regular, from round to oval lobules of hepatoid glands. A single layer of small basaloid cells, uniform in size and morphology, is evident (*inset*)

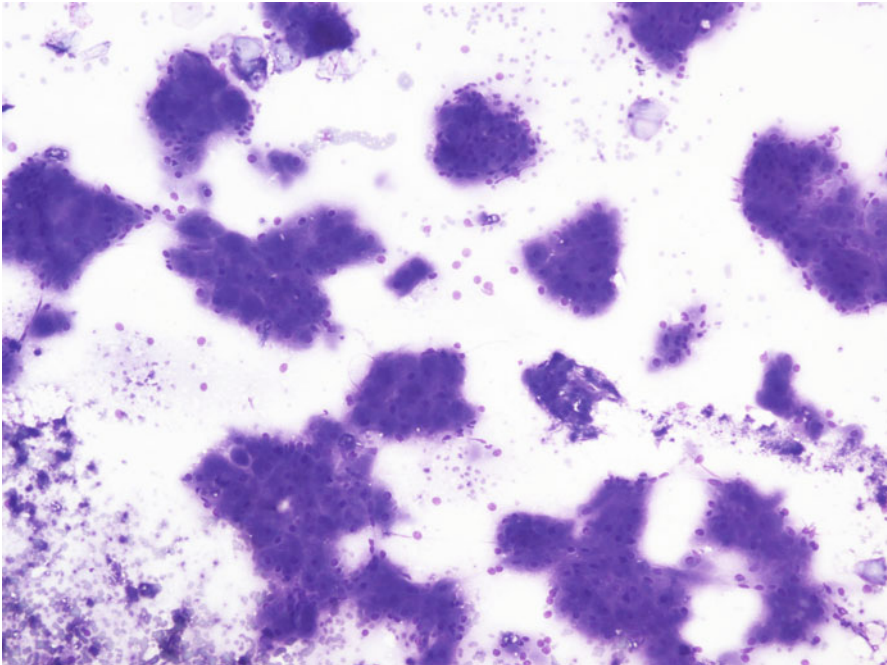


Fig. 4.199 Cytology of hepatoid gland hyperplasia: multiple and regular clusters of hepatoid glands

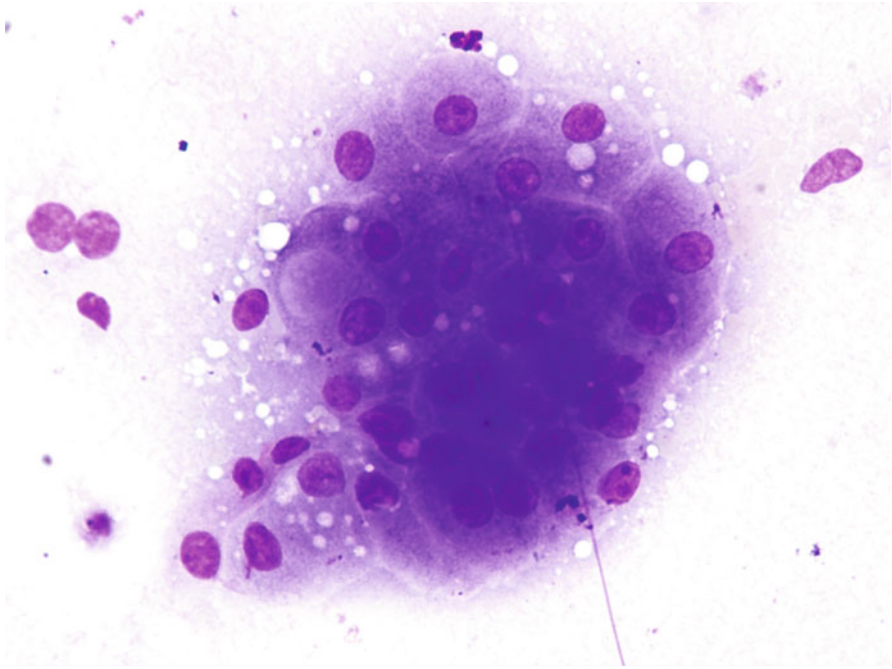


Fig. 4.200 Cytology of hepatoid gland hyperplasia: cluster of well-differentiated hepatoid cells with round nuclei and large cytoplasm of grainy appearance and violet in colour

nuclei due to the breakage of the cytoplasm during the preparation of slides is also frequently observed. Cytological differentiation between hyperplasia and adenoma is not simple and, based on histopathological knowledge, when irregular trabeculae of hepatoid cells are associated with numerous blood vessels, an adenoma must be suspected (Fig. 4.201). These cytological features are not usually evident in the case of hyperplasia, in which cells show a more regular, roundish arrangement, and in which the blood vessels are not usually present. However, these differences are not important for prognostic purposes. In some samples, cytological features indicative of squamous or sebaceous differentiation can be observed (Fig. 4.202).

Carcinomas of hepatoid glands are cytologically recognisable only when cell atypias are obvious. As some well-differentiated carcinomas do not show clear cytological signs of malignancy, a definitive diagnosis can only be obtained by histopathology. In addition, a common characteristic of hepatoid neoplasms is the simultaneous presence of carcinomatous areas in the context of a benign adenoma (Fig. 4.203). In these cases it is cytologically not possible to exclude a carcinoma if malignant cells are not present on the slides.

For this reason, cytology of hepatoid glands should be performed in any case, to identify their nature, but the definitive differentiation between the benign and malignant histotype is always based on histopathological results.

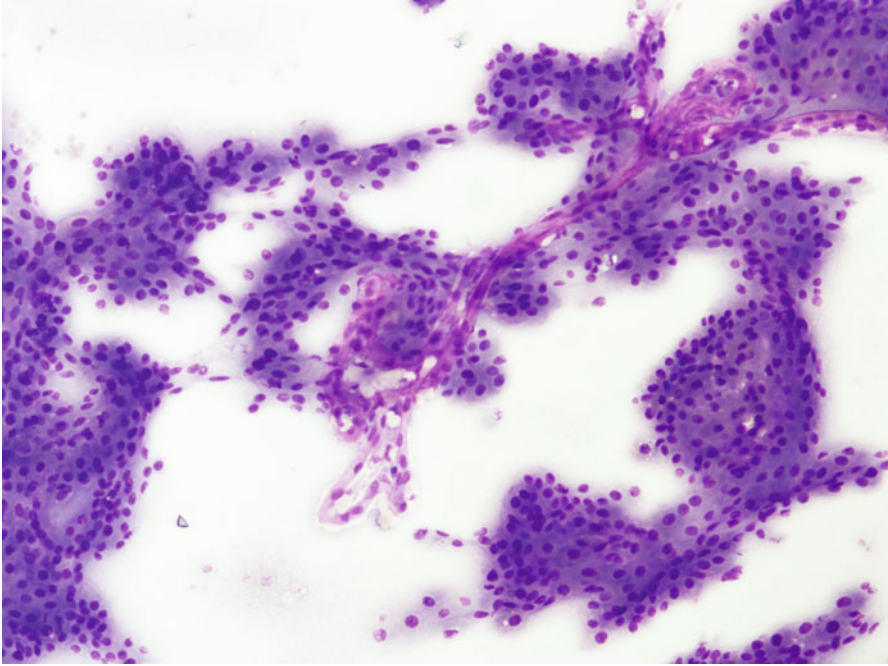


Fig. 4.201 Cytology of hepatoid gland adenoma: irregular cluster of well-differentiated hepatoid cells. Many haematic vessels are also present

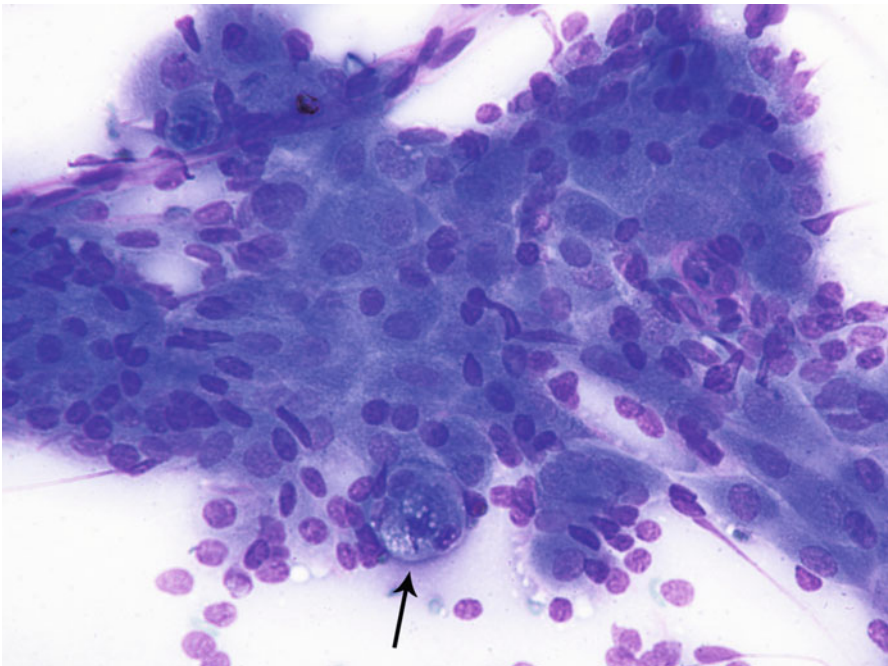


Fig. 4.202 Cytology of hepatoid gland adenoma: large sheet of hepatoid cells. Note the sebocytic differentiation (*arrow*)

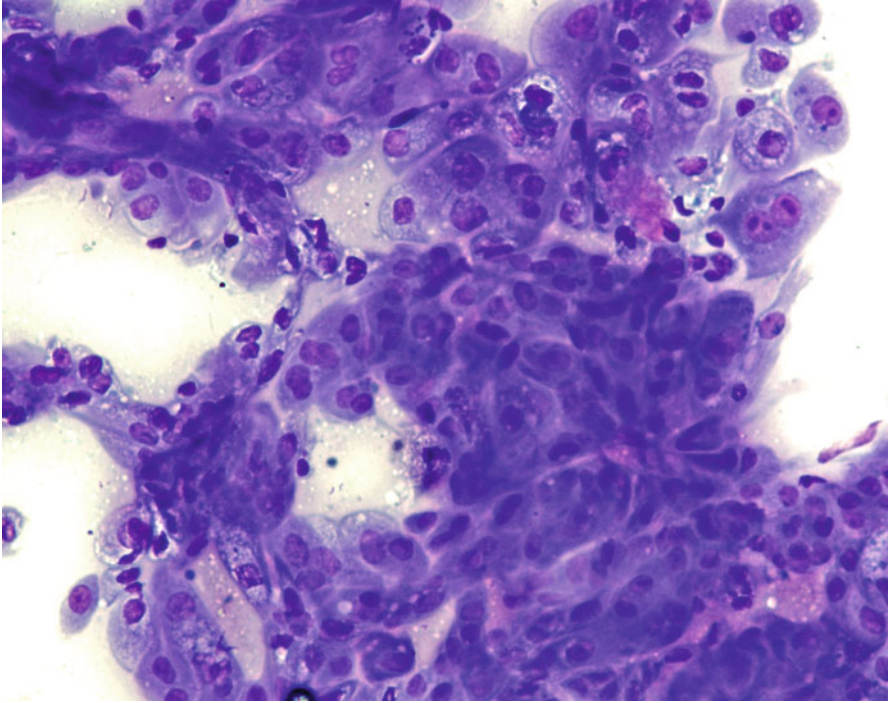


Fig. 4.203 Cytology of hepatoid gland carcinoma: cluster of malignant hepatoid gland cells

4.3.4 *Sweat Gland Tumours (Apocrine Gland Tumours)*

The classification of the *sweat gland tumour* has undergone considerable changes, as many tumours once diagnosed as basal cell tumours are, with the advent of immunohistochemical stains, reclassified as *apocrine*. Neoplasms that originate from sweat glands include many non-neoplastic and neoplastic lesions. Among the former, *single or multiple apocrine cysts* and *apocrine cystomatosis* are included, whereas the neoplasms include many variants related to different histomorphological features.

Among the tumours, the *apocrine cystadenoma*, with its *simple, ductal* and *complex* variants, the *apocrine adenoma*, the *solid cystic ductular apocrine adenoma* and malignant tumours such as the *apocrine secretory carcinoma*, which is in turn divided into *simple, complex* and *cystic* variants, the *ductular apocrine carcinoma*, the *solid cystic ductular apocrine carcinoma* and the *clear cell carcinoma* (Kalاهر et al. 1990; Simko et al. 2003; Gross et al. 2005).

Sweat gland tumours are quite common in dogs and cats, almost all of them originating from the *epitrichial* glands spread all over the body. They are *apocrine* and are characterised by secretion through *cytoplasmic decapitation*. *Atrichial* glands, which lead secretion directly on to the skin surface, are *eccrine* or *merocrine*,

and are only present in the skin of the paw pads. Tumours that originate from the eccrine glands are extremely rare and therefore not discussed in this book.

Two other glandular tissues originating from modified apocrine glands are known: the *ceruminous glands* and the *anal sac glands*, the latter covering the inner wall of the anal sacs.

Single or multiple (apocrine cystomatosis) *apocrine cysts*, are secondary to ductal obstruction and are presented as nodular formations of varying sizes, usually covered only by atrophic and alopecic skin as a result of the compression exerted by the liquid on the wall of the cyst. During FNAB, the sweat collected is usually colourless or, in chronic cases, dark. Once emptied of its contents, the thin atrophic wall is deflated and assumes the appearance of a vesicle, flabby in consistency, and no solid tissue can be palpated at its base (Fig. 4.204).

Apocrine feline cystomatosis shows multiple small cystic neoformations, dark bluish in colour, that are located on the face, the eyelids and the head and/or the inner surface of the pinna to the external ear canal (Figs. 4.205, 4.206, and 4.207). Persian and Himalayan cats seem to be predisposed to this condition (Chaitman et al. 1999; Marignac et al. 2002).

Adenomas and carcinomas of the apocrine glands do not have peculiar macroscopic aspects and can occur mainly on the head as nodules of variable size, alopecic and often ulcerated. One clinical feature that may suggest the apocrine origin of the tumour is the bluish colour of the nodules due to the dark bluish content of the cysts present in the context of almost all apocrine tumours. Apocrine tumours in cats are located mostly on the head (Fig. 4.208).

Neoplasms of *ceruminous glands* are found in the external ear canal or at its entrance and can be of variable size, alopecic, erythematous, ulcerated and often cystic. In cats, more than half are malignant (Fig. 4.209).

The *anal sac adenocarcinoma* is an uncommon tumour of dogs and cats. In older dogs it is rarely detected clinically; indeed, to appreciate it, because it is usually very small, digital exploration of the anal sacs must be performed (Williams et al. 2003; Shoieb and Hanshaw 2009). A severe paraneoplastic hypercalcaemia is often associated with these carcinomas and even if hypercalcaemia is secondary to other carcinomas and lymphomas, its detection should always suggest a careful exploration of the anal sacs (Fig. 4.210).

Cytological Findings

Cytology obtained from *apocrine lesions* does not allow the differentiation among the different neoplasms and indeed, in many cases where only a few basaloid cells are sampled, they are indistinguishable from those observed in trichoblastoma.

Slides obtained from *cystic lesions* contain only a clear liquid, which, in chronic stagnant lesions, can take on a darker colour. In some cases, rare vacuolated macrophages are observed.

In cats with *apocrine cystomatosis*, intracystic macrophages are filled with coarse deep blue material, which contains iron, and can be better highlighted with Prussia blue (Figs. 4.211 and 4.212). Crystal cholesterol may also be dispersed in the fluid and in calcified cases, transparent amorphous mineral salts may be present.

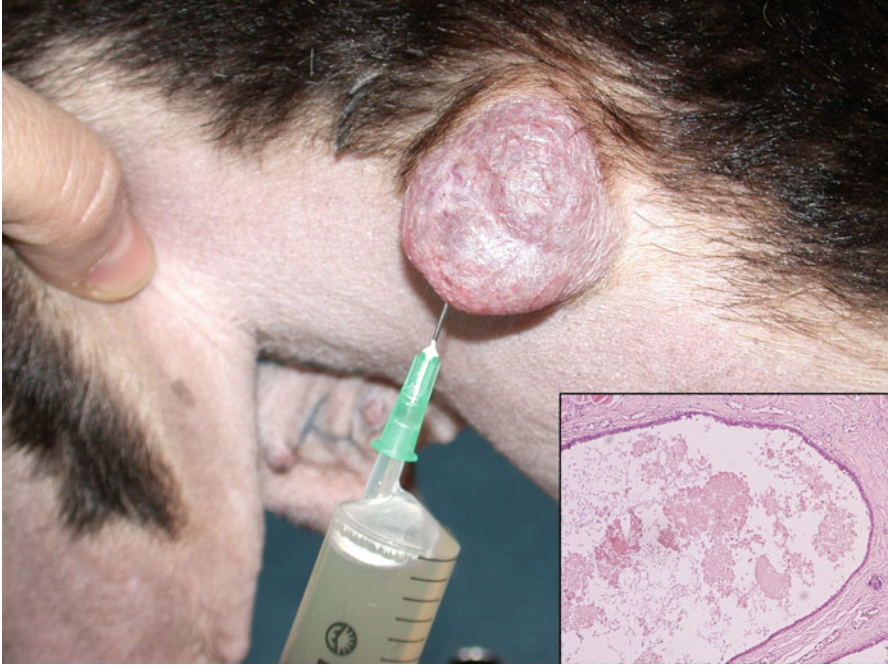

Fig. 4.204 Apocrine cysts in a dog: clear fluid collected by fine needle aspiration biopsy (FNAB). Histology: large cyst lined with a single layer of apocrine cells and filled with granular eosinophilic secretion (*inset*)

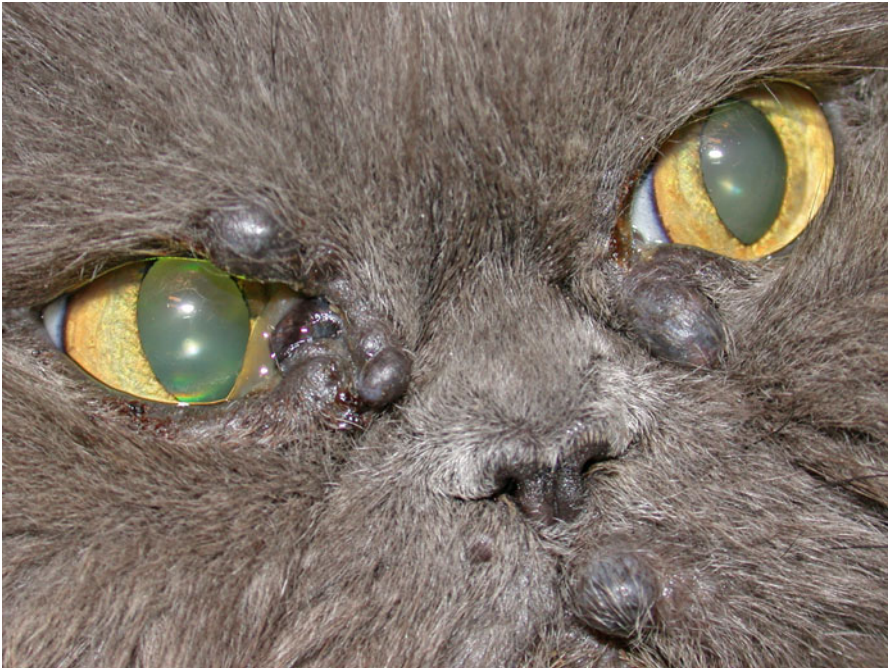


Fig. 4.205 Multiple dark cysts on the face of a Persian cat with feline apocrine cystomatosis

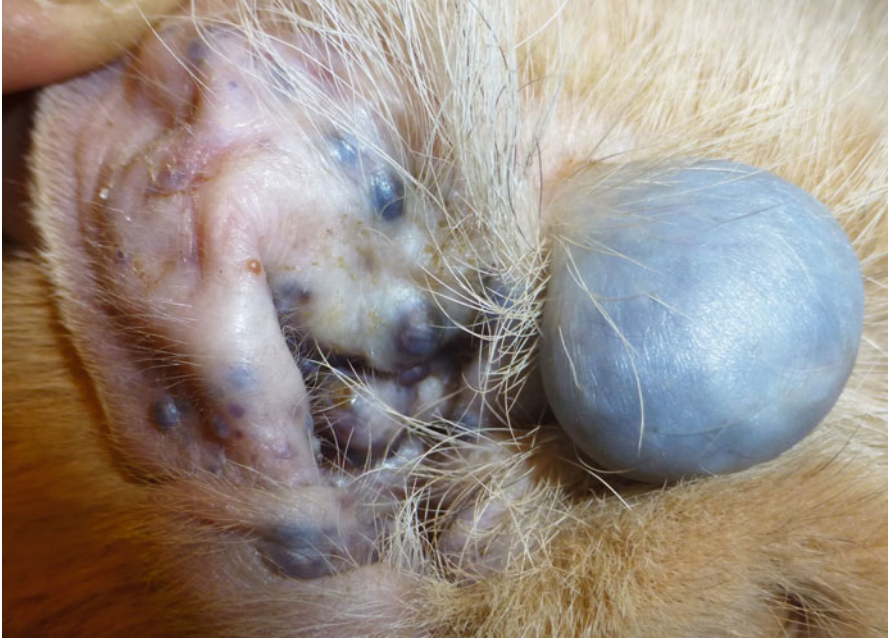

Fig. 4.206 Feline apocrine cystomatosis. Multiple small dark cysts are present on the pinna and in the ear canal of a domestic short-haired cat. Note the largest cyst in the temporal region

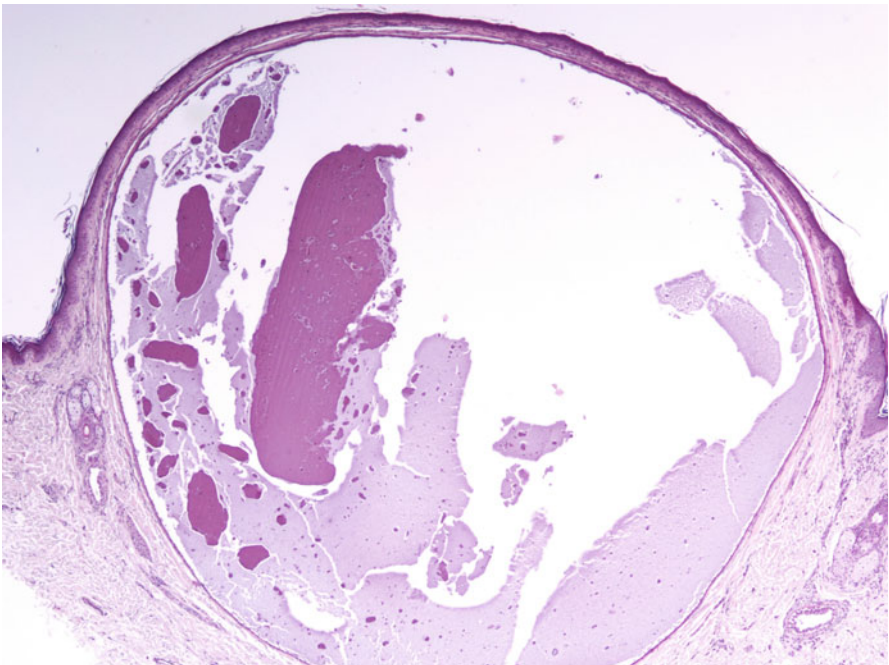


Fig. 4.207 Histopathology of feline apocrine cystomatosis. Large cysts filled with dark, amorphous secretion. Macrophages are not present in this case

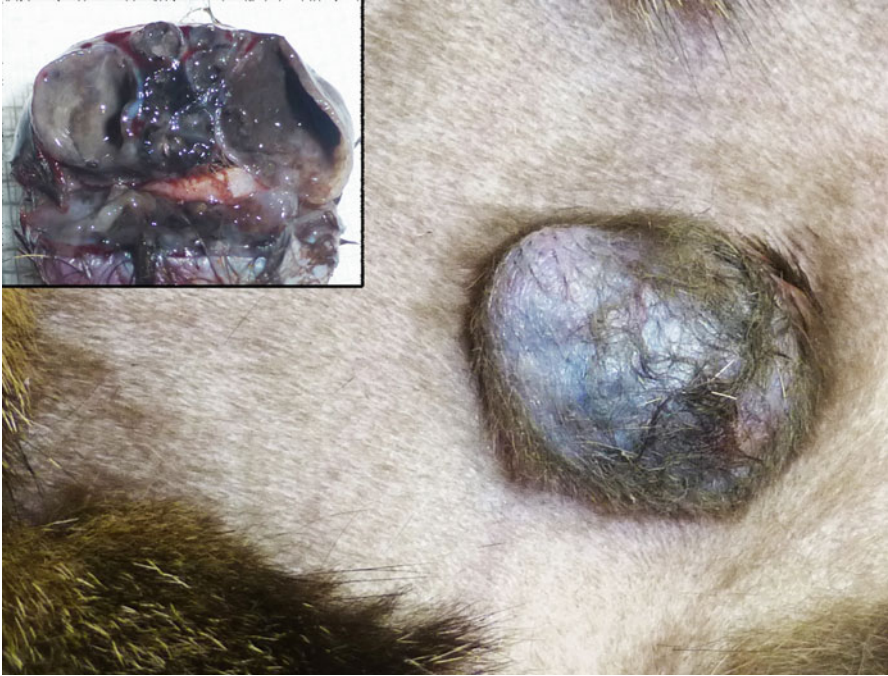

Fig. 4.208 Feline apocrine solid cystic adenoma. Single dark blue nodule on the neck of a cat. At the cut of the nodule, multiple large cysts are grossly recognisable (*inset*)

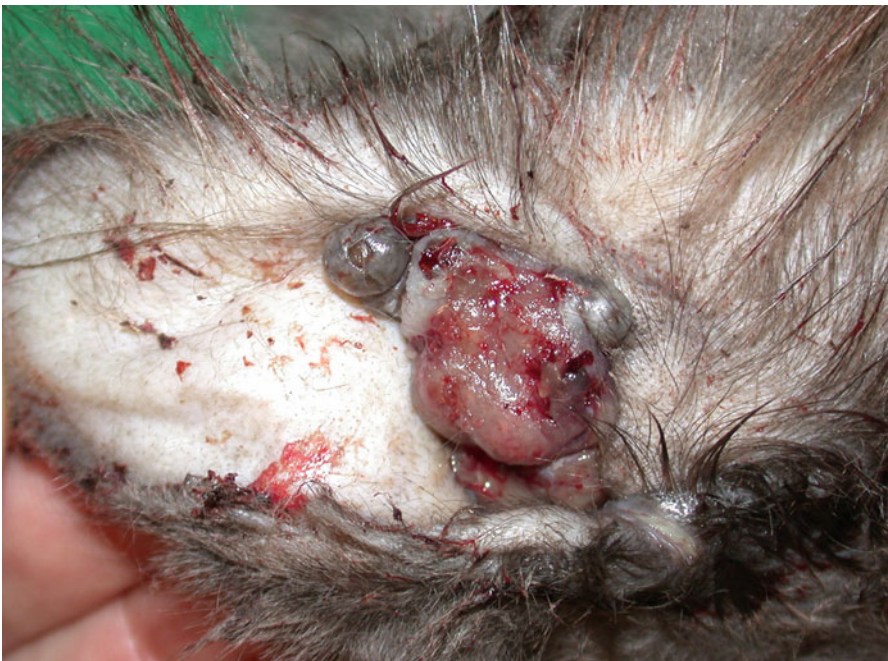

Fig. 4.209 Ceruminous gland carcinoma. Multiple confluent, dark blue or ulcerated nodules on the ear canal and pinna of a cat

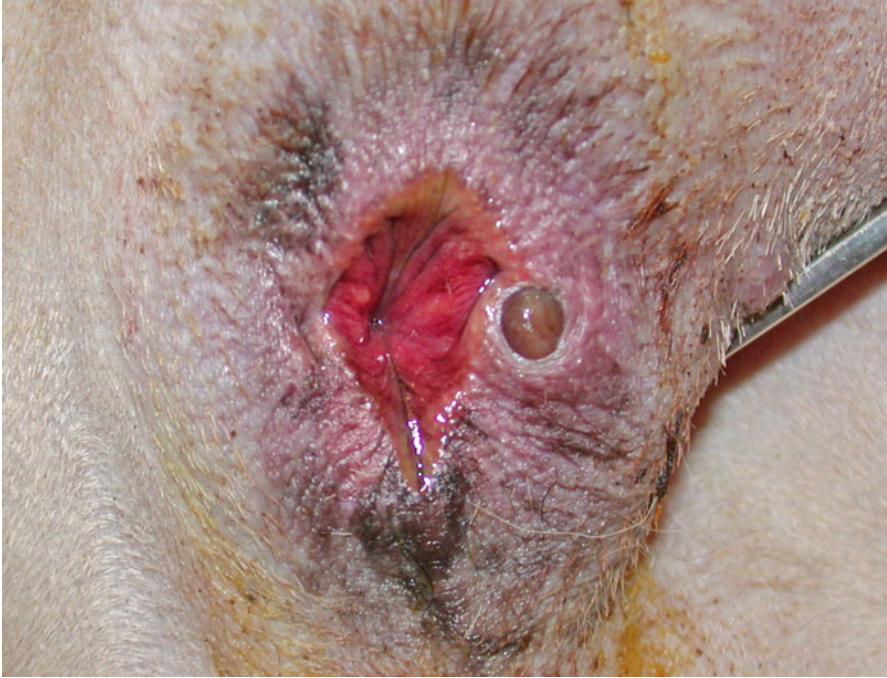

Fig. 4.210 Anal sac carcinoma. Small neof ormation that protrudes from the duct opening the right anal sac

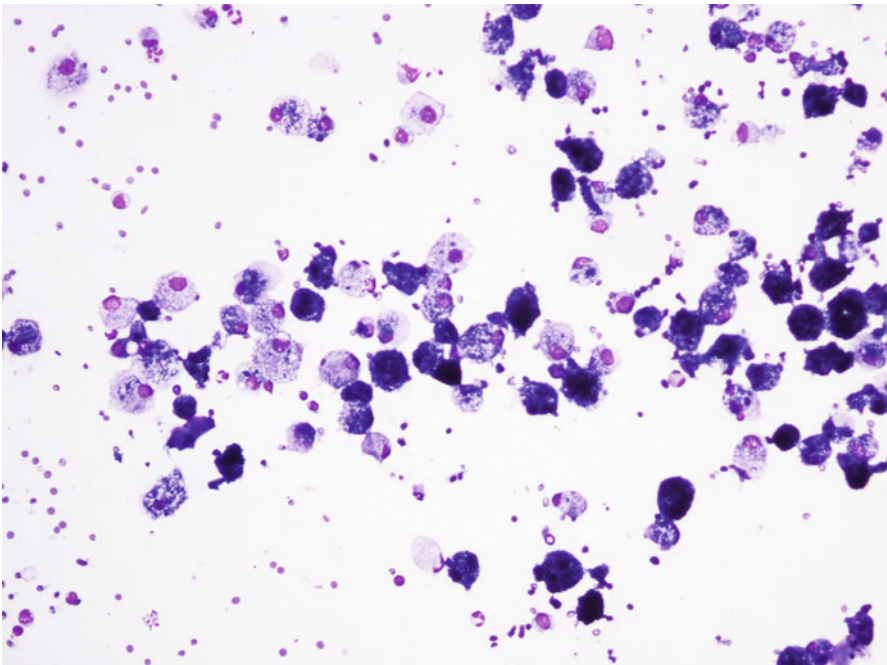


Fig. 4.211 Cytology of feline apocrine cystomatosis: many vacuolated macrophages filled with dark blue and coarse material

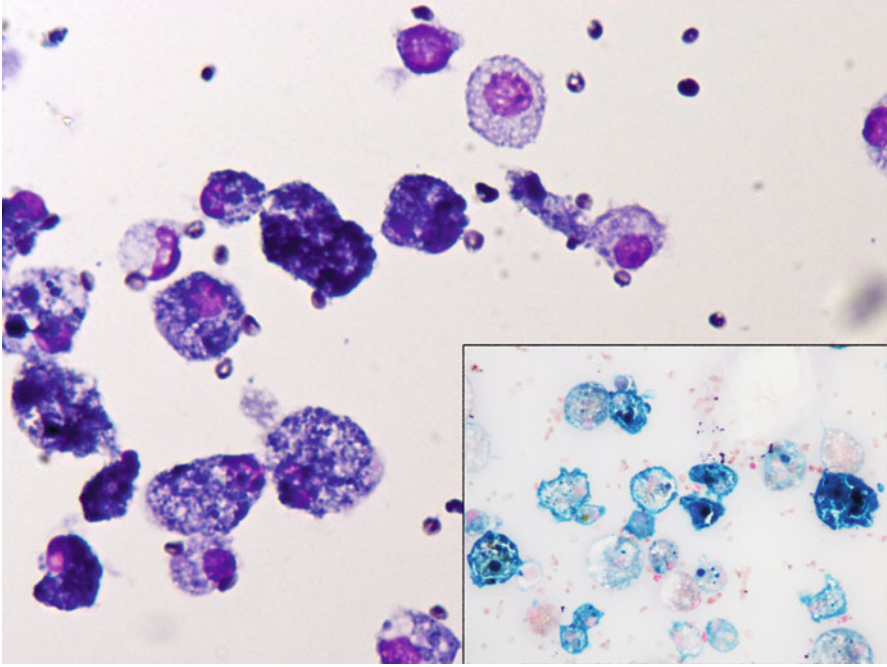


Fig. 4.212 Cytology of feline apocrine cystomatosis: at high magnification, the intracytoplasmic material is more evident. The Prussia blue staining highlights the iron contained in the secretion phagocytised by macrophages (*inset*)

Exceptionally, a few exfoliated ductal cells, cuboidal in shape and with basal nuclei are found on the slides.

Cytology of *apocrine adenomas* usually shows very cohesive clusters of uniform-sized basaloid cells with well-defined margins, round regular nuclei and scant cytoplasm. The cells can be yielded in sheets, sometimes with a pavement-like arrangement, or with acinar and ductal architectures, and are characterised by a cylindrical shape with basal nuclei and intracytoplasmic secretion. The presence of apical cytoplasmic blebs, indicative of secretion by cytoplasmic decapitation, may be evident in many well-differentiated adenomas (Figs. 4.213, 4.214, 4.215, and 4.216). Often, apocrine neoplasms are cystic and a variable amount of dark blue material is frequently observed, especially in the cytoplasm of intraductal macrophages (Figs. 4.217 and 4.218).

Carcinomas of the apocrine glands show cytological characteristics of varying severity, but in well-differentiated carcinomas, the cytological examination does not allow benign tumours to be differentiated from carcinomas (Figs. 4.219 and 4.220).

The cytology of *ceruminous gland* tumours follows the same features described for other apocrine tumours, and in the same way, the detection of large amounts of coarse basophilic intracytoplasmic secretions is very common. The same material is presented on the background of the slide and phagocytosed by macrophages (Figs. 4.221 and 4.222).

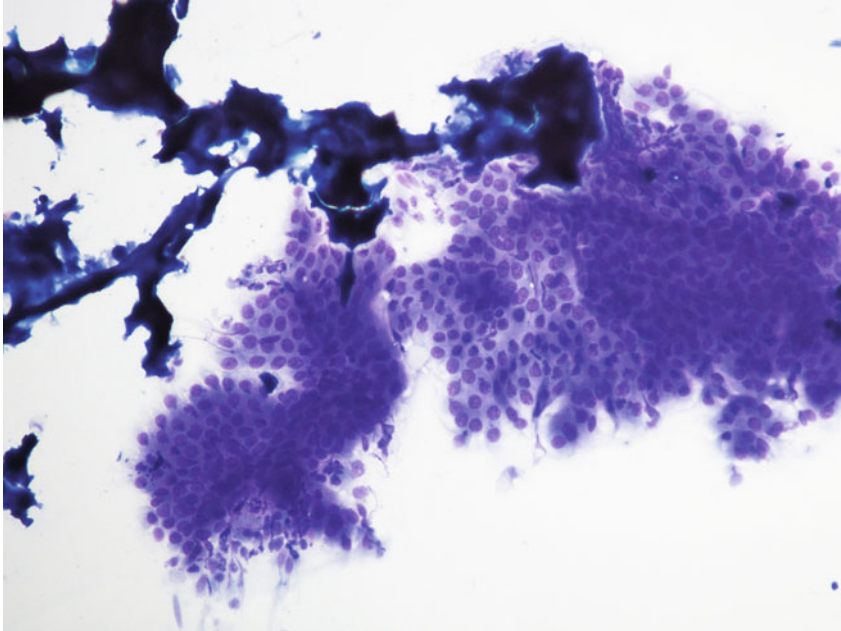


Fig. 4.213 Cytology of an apocrine adenoma: large clusters of apocrine glands. The deeply blue and acellular material represents sweat

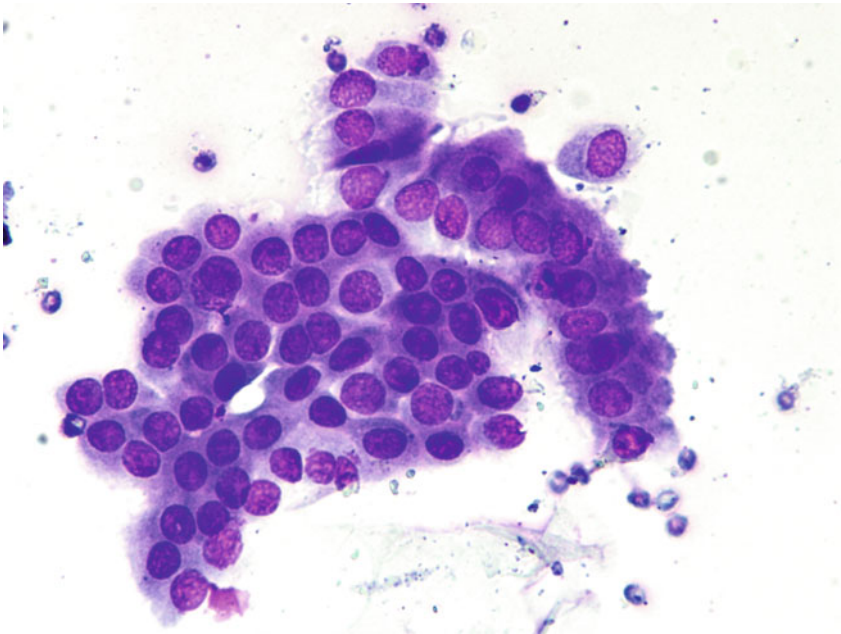


Fig. 4.214 Cytology of an apocrine adenoma: large clusters of apocrine glands. Note the columnar arrangement and the cytoplasmic apical blebs representing the secretion through cytoplasmic decapitation

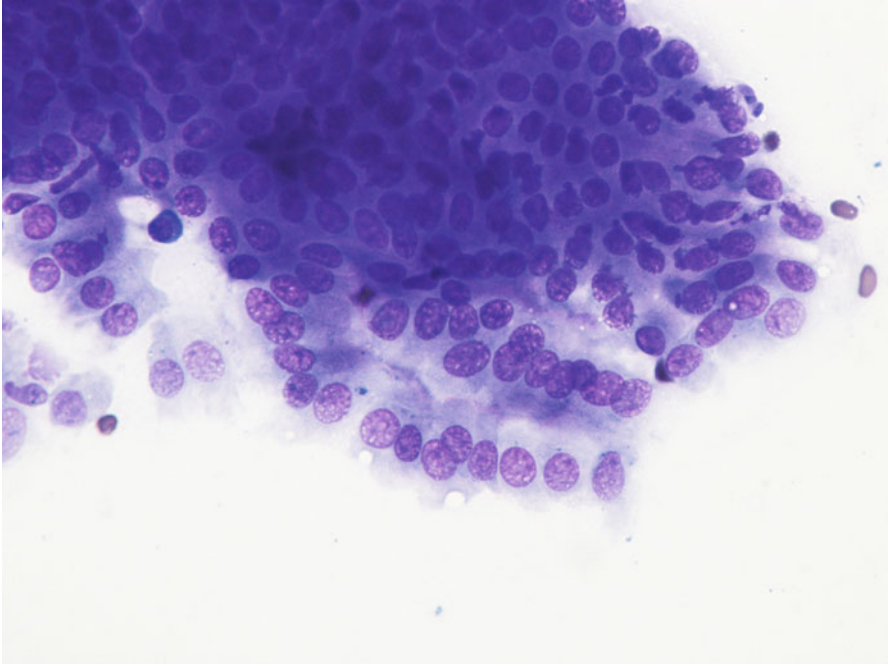


Fig. 4.215 Cytology of an apocrine adenoma: tubular arrangement of benign neoplastic apocrine cells

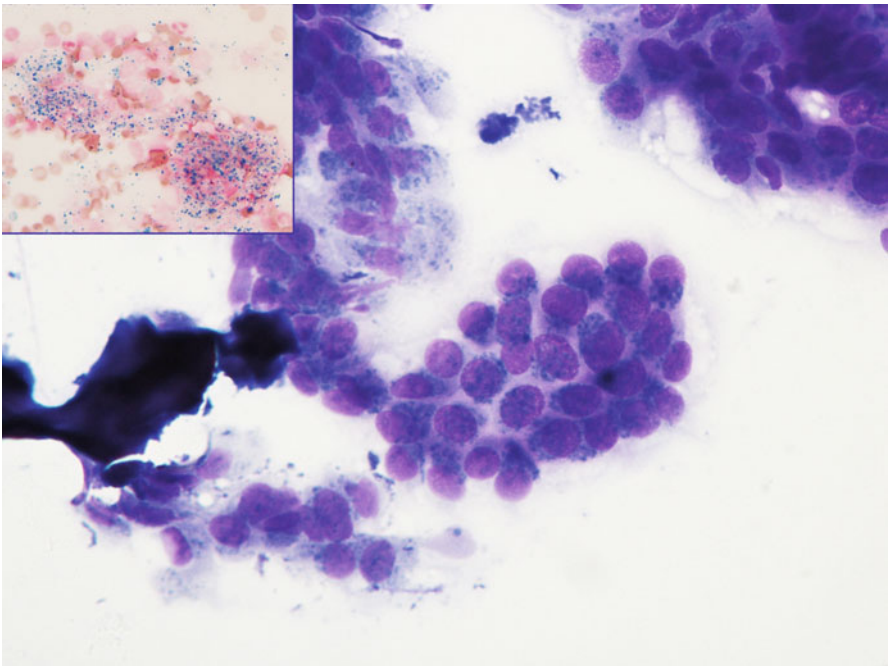


Fig. 4.216 Cytology of an apocrine adenoma: the granular blue material is evident in the cytoplasm of all the apocrine cells. The Prussia blue staining highlights its iron content (*inset*)

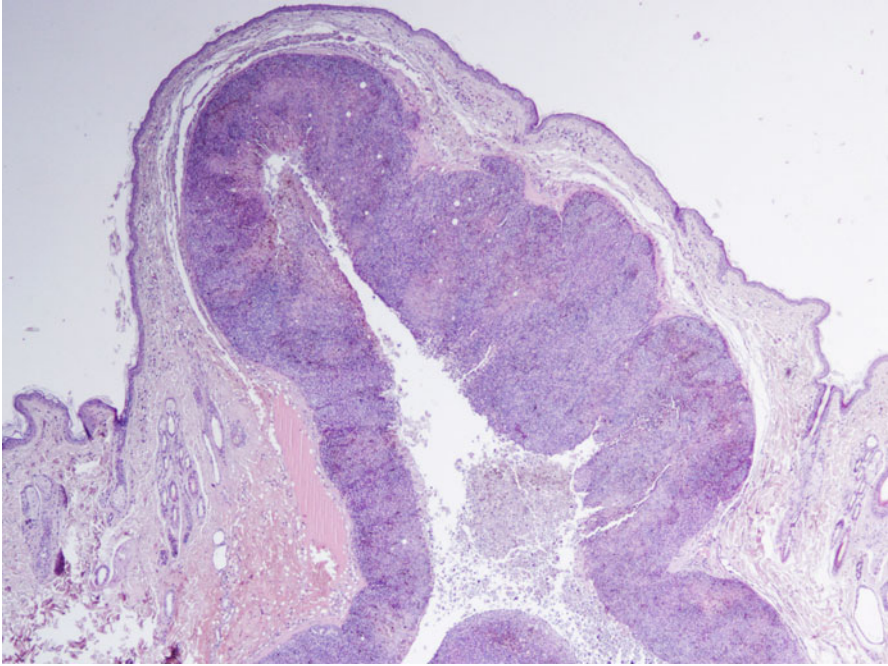


Fig. 4.217 Histopathology of a feline apocrine solid cystic adenoma. Large cyst bordered with multiple layers of uniform basaloid cells

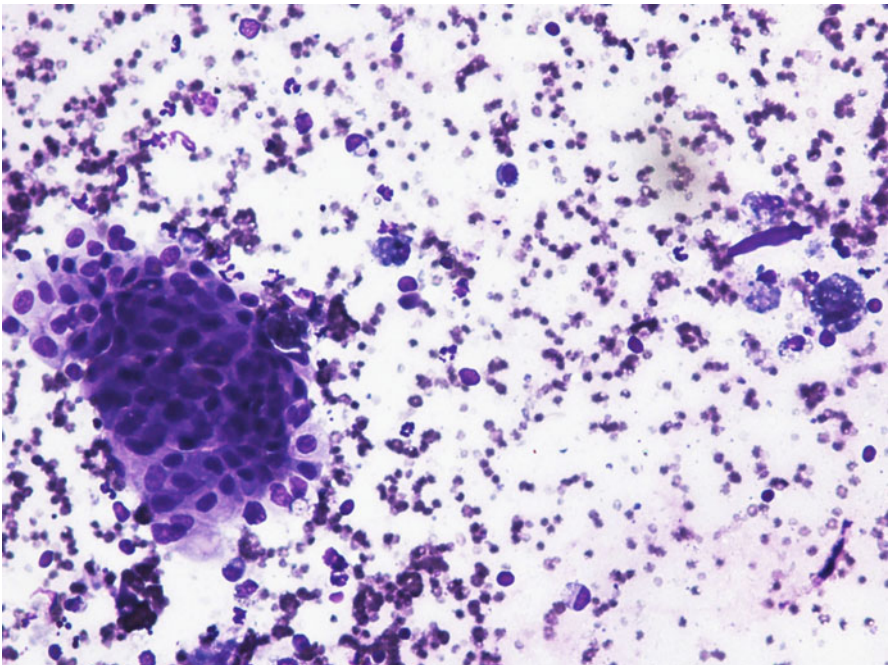


Fig. 4.218 Cytology of a feline apocrine solid cystic adenoma. Cluster of apocrine cells immersed in a background rich with macrophages with intracytoplasmic secretion products

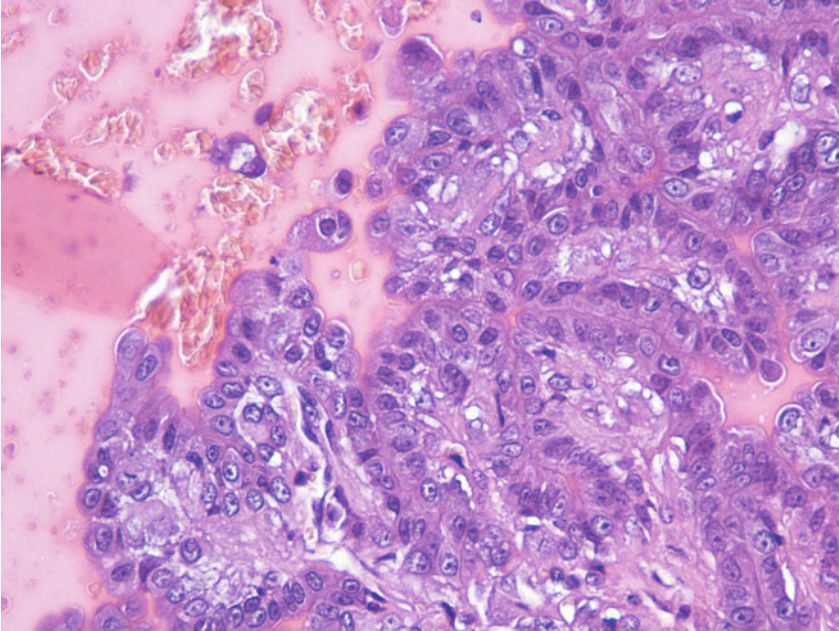


Fig. 4.219 Histology of an apocrine carcinoma. Tubular apocrine structures characterised by many malignant features (anisokaryosis, macronucleoli, cannibalism)

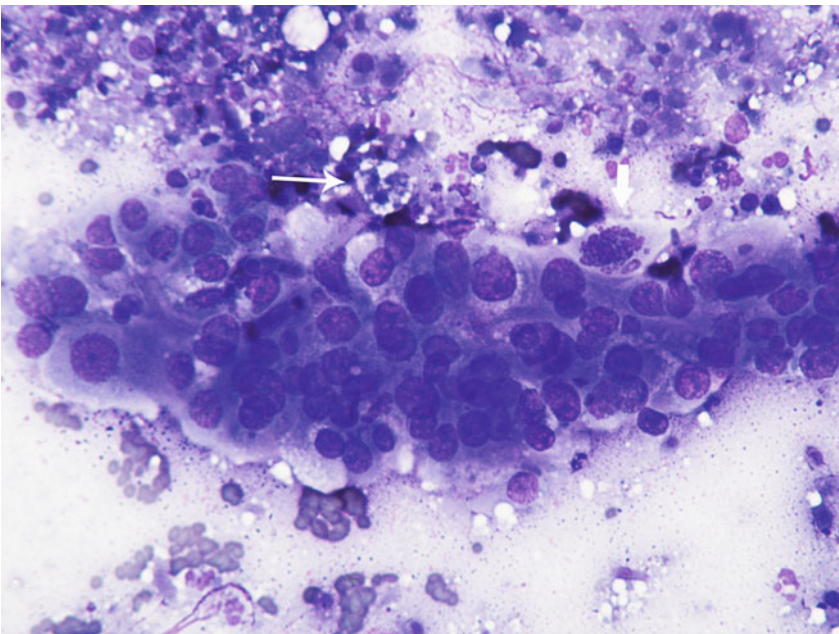


Fig. 4.220 Cytology of an apocrine carcinoma. Many malignant features are evident. Note the severe nuclear atypia (*short arrow*) and the presence of macrophages filled with the apocrine secretion (*long arrow*)

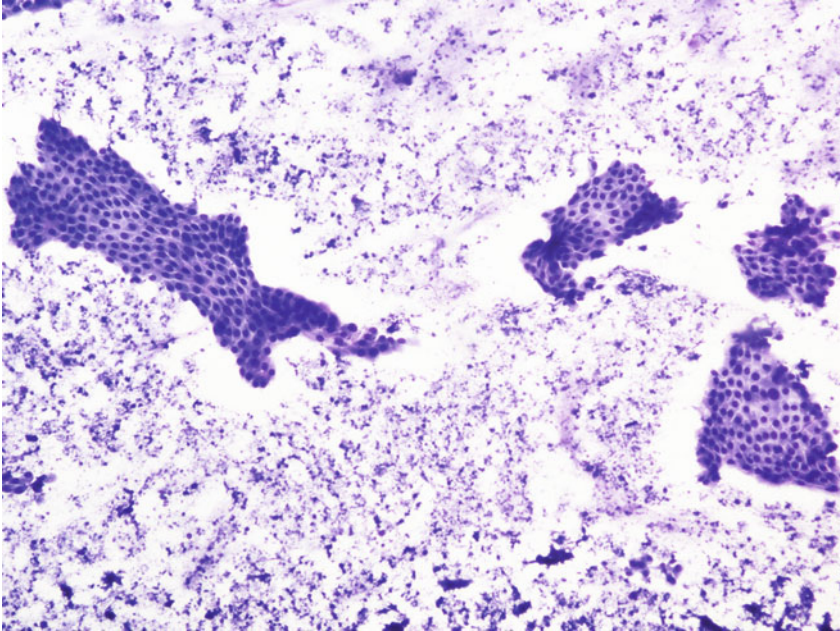


Fig. 4.221 Cytology of a ceruminous gland carcinoma. Large epithelial sheets are immersed in a background rich with amorphous debris

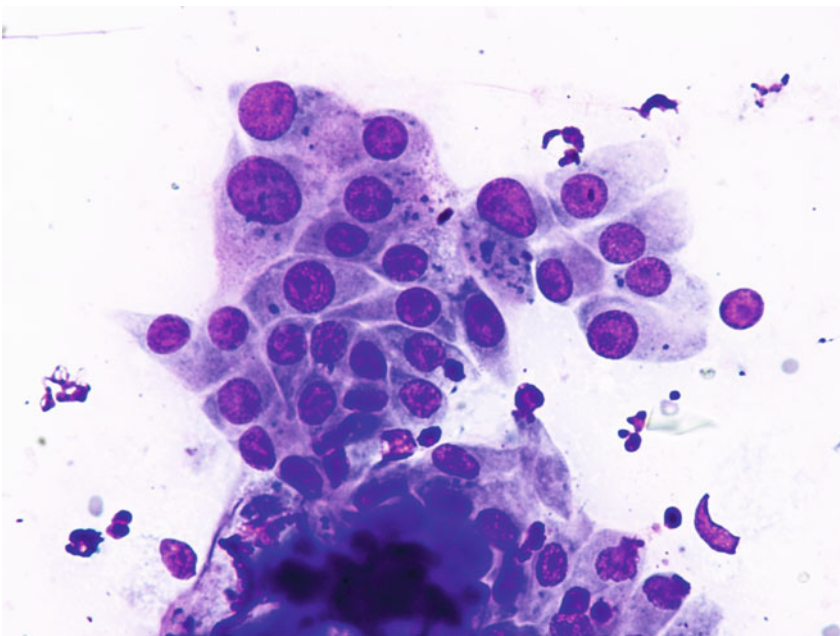


Fig. 4.222 Cytology of a ceruminous gland carcinoma. Many malignant features are evident. Note the presence of the typical coarse and deeply blue secretion that suggests the apocrine origin of the tumour

The cytology of *anal sac carcinomas* usually shows no obvious atypia, despite its very aggressive biological behaviour. Small, poorly cohesive clusters of cells with round nuclei, fine chromatin and clear cytoplasm with poorly defined margins are usually observed. Neoplastic cells are frequently represented by bare nuclei, with a background composed of the cytoplasmic material released following the breakage of the cells. Some cells show a tendency to be arranged in a papillary or acinar arrangement, in the central part of which it is possible to find secretion. These features allow the confirmation of the apocrine nature of the glands, although the location may eliminate any diagnostic doubts. In these tumours, the cytological atypias are usually scarce and, when present, they are represented by slight anisokaryosis (Figs. 4.223 and 4.224).

4.3.5 *Fibroadnexal Hamartoma (Fibroadnexal Dysplasia)*

The term *hamartoma* refers to a benign malformation of the skin appendages that can involve the connective tissue, the follicles, and the sebaceous and apocrine glands. Although the hamartomatous lesions indicate a congenital disorder, this is mainly acquired and, even if the pathogenesis remains controversial, it is thought that they might originate in areas where reactive fibroplasia has occurred, probably secondary to a traumatic event. Nevertheless, a primary defect of the pilosebaceous unit cannot be excluded.

Hamartomas usually occur as single, alopecic and sometimes hyperpigmented skin nodules, mainly located on the trunk and limbs (Figs. 4.225 and 4.226) (Kimura et al. 1991; Abramo et al. 2003).

In some cases, small multiple and often confluent nodular papules characterise cutaneous hamartomas (Fig. 4.227). Hamartomatous lesions can originate from follicles, collagen or from sebaceous glands, even though the coexistence of more adnexal structures is usually observed.

Cytological Findings

The cytological features of hamartomas are strictly linked to the adnexa involved. *Fibroadnexal dysplasia* is the most frequent hamartomatous lesion in dogs, in which a simultaneous presence of normal sebaceous glands, fibroblasts, collagen fibres and corneocytes is observed (Figs. 4.228 and 4.229). Because a wide hyperplasia of apocrine glands is often present around the dysplastic structures, a variable amount of clusters of sweat epithelia are present in the cytological samples (Fig. 4.230). Finally, in most cases, the follicle becomes very dilated and filled with lamellar keratin; following the breakage of the follicular wall and the spread of corneocytes into the dermis, highly pyogranulomatous inflammation is commonly observed and it can mask the real nature of the lesions.

In summary, when normal constituents of cutaneous adnexa are simultaneously present on the same specimen, a fibroadnexal hamartoma must be suspected.

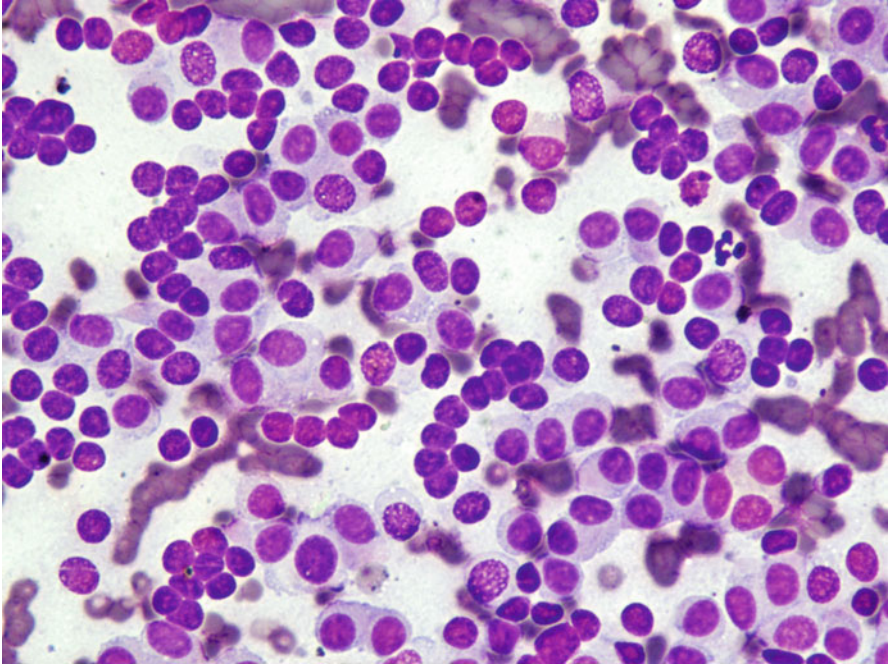


Fig. 4.223 Cytology of an anal sac carcinoma. Many bare nuclei arranged both singly and in short rows. Some cells have scant pale blue cytoplasm

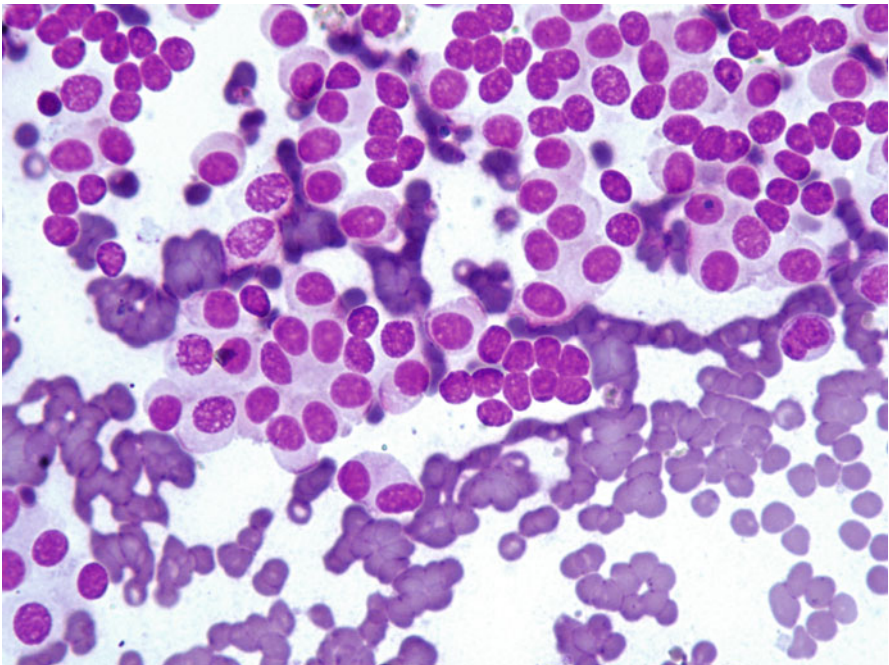


Fig. 4.224 Cytology of an apocrine carcinoma. An acinar pattern is clearly evident. Note that the cytological morphology of neoplastic cells does not show evident criteria of cellular malignancy

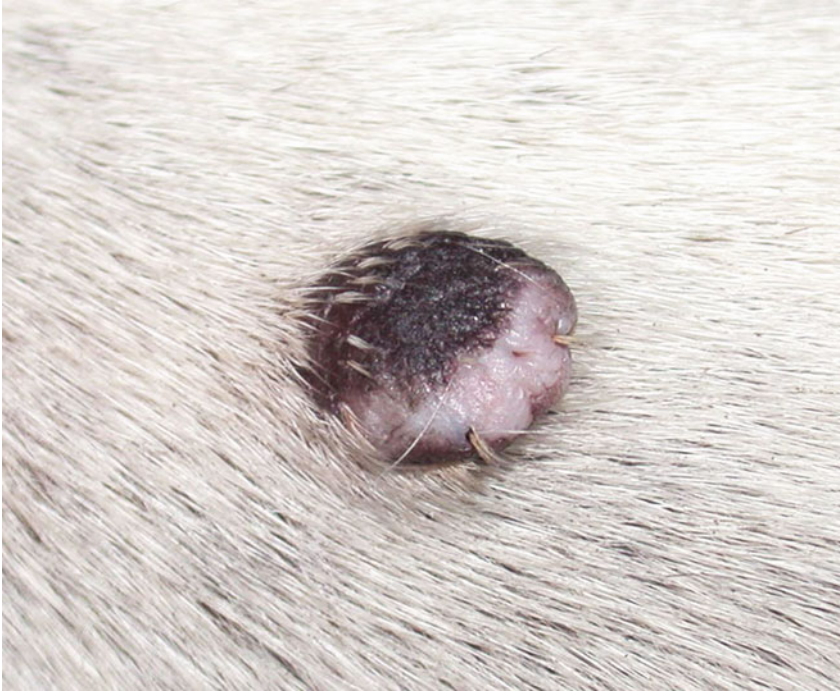

Fig. 4.225 Single and small fibroadnexal hamartoma

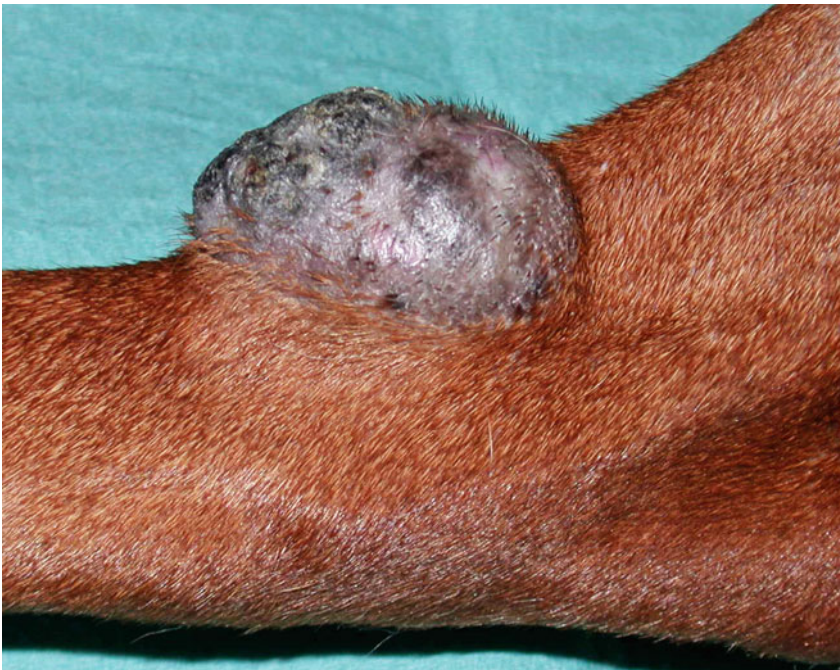

Fig. 4.226 Large and pigmented fibroadnexal hamartoma on a leg of a Rhodesian ridgeback

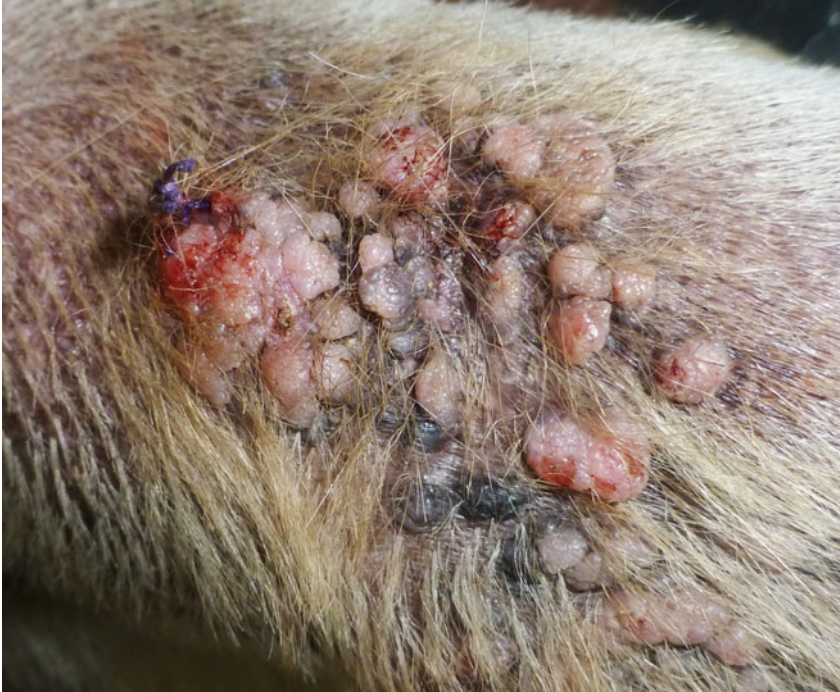

Fig. 4.227 Multiple and confluent fibroadnexal hamartomas on a leg of a Golden retriever

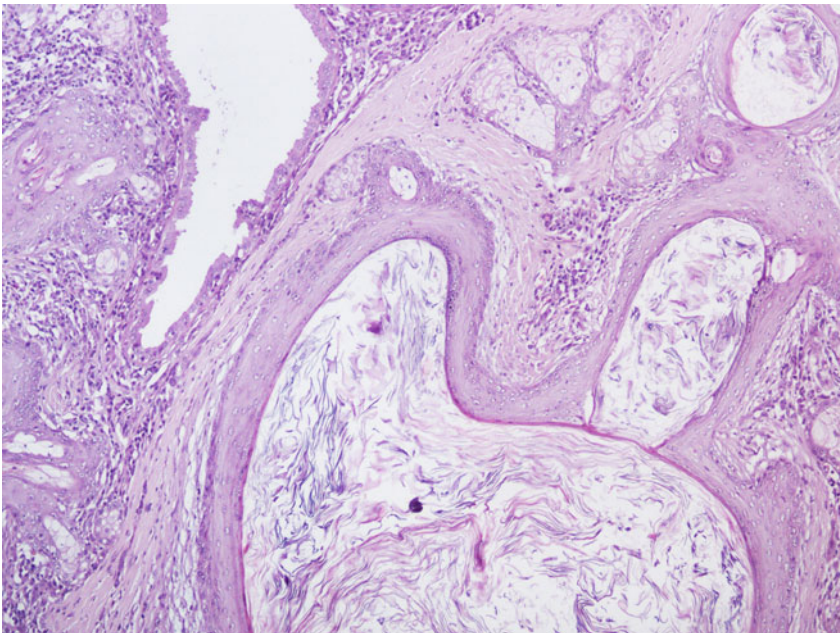


Fig. 4.228 Histology of a fibroadnexal hamartoma: simultaneous presence of dilated and malformed follicles and some orphan sebaceous glands. Note the dilated sweat gland

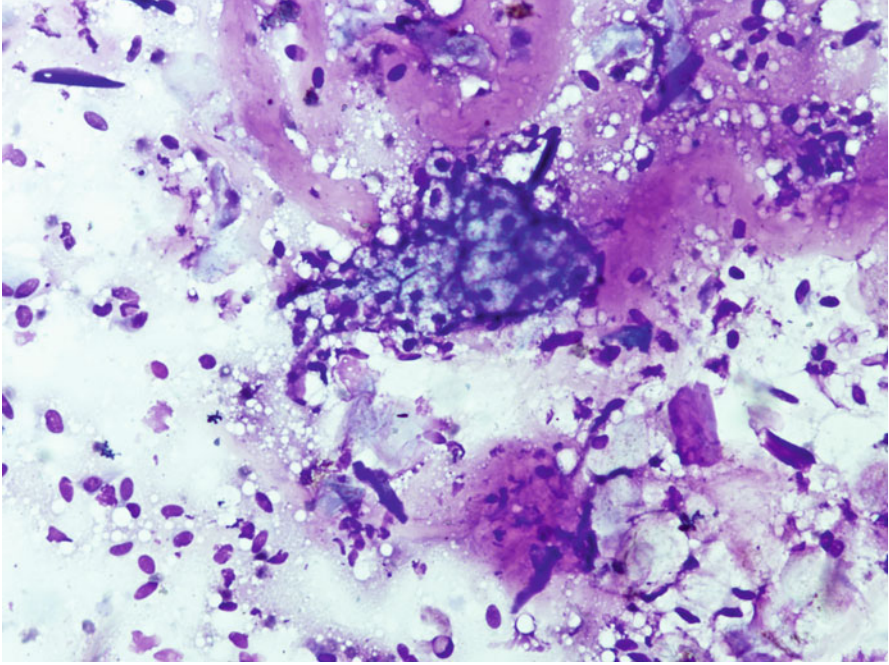


Fig. 4.229 Cytology of a fibroadnexal hamartoma: cluster of normal sebaceous glands and many fibroblasts, the latter mainly represented by bare oval nuclei, are simultaneously observed

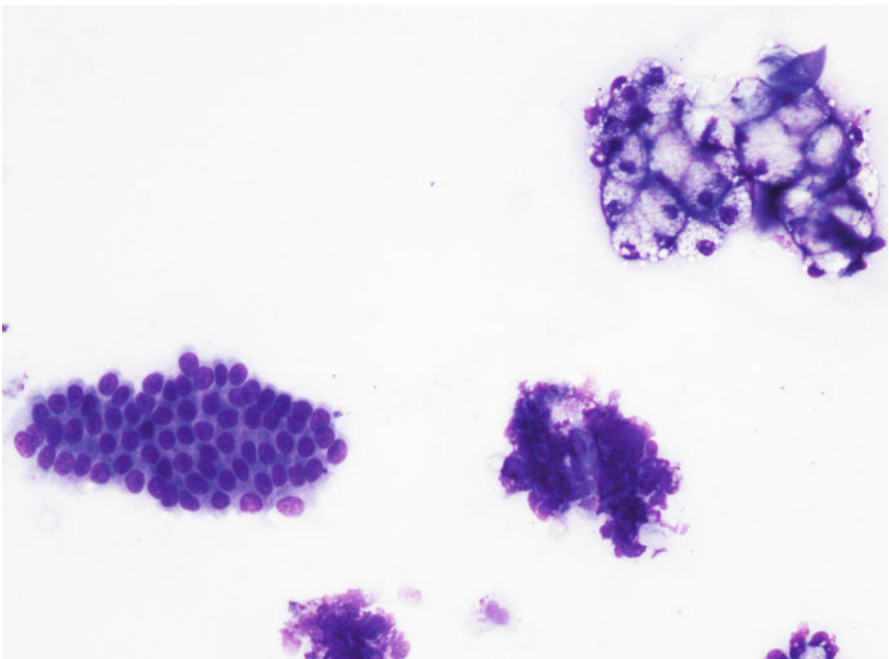


Fig. 4.230 Cytology of a fibroadnexal hamartoma: clusters of normal sebaceous and apocrine glands are simultaneously present

4.4 Mesenchymal (Spindle) Cell Tumours

The term *mesenchymal tumours* refers to a group of neoplasms arising from *support soft tissues* of the dermis and subcutis that are represented by the *connective tissue* (fibroblasts/fibrocytes), *blood* and *lymphatic vessels* (endothelial cells, smooth muscle, pericytes), *nerves* (Schwann cells), the erector *muscles* of the hair (smooth muscle) and *adipose tissue* (adipocytes).

Cytologically, the mesenchymal neoplasms share the morphological feature of being spindle-shaped, owing to the presence of single or multiple cytoplasmic tails; for this reason, some authors prefer to use the term *spindle cell tumours* to define them. The spindle-like appearance cannot, however, be considered a dogma, as some exceptions are recognised: tumours such as *lipomas* and some *undifferentiated round cell sarcomas* are typical examples. In contrast, spindle cells do not always indicate a mesenchymal neoplasia; indeed, as mentioned, some *melanomas*, *squamous cell carcinomas* and *histiocytic sarcomas* may be represented by spindle cells, even if they are not included in the group of spindle-cell tumours.

The cytoplasmic borders of mesenchymal cells are usually poorly defined with regard to those of the epithelial cells and nuclei can range from round to oval or elongated (elliptical) in shape.

As the stroma is made up of mesenchymal cells, the cytological slides generally contain few cells, and cells can be yielded both singly and arranged in pseudo-aggregates. In the latter case, the cells are held together by an *extracellular matrix* in which they are embedded, recognisable on cytology as an eosinophilic acellular substance, or by pre-existing stromal structures, such as the vessels (perivascular architecture). These features are observed in both benign and malignant neoplasms, but in the latter, they are associated with more richly cellular specimens. As for tumours belonging to other groups, the morphological aspects of cells cannot always be used to identify the tissue of origin and often the cytology of spindle cell tumours can only define their mesenchymal origin and describe the cytological features of malignancy. On the latter point, it should be emphasised that the evaluation of these aspects is not free from interpretative doubts; indeed, while some well-differentiated sarcomas show only a few cytological aspects of atypia, some cases of reactive fibroplasia are characterised by fibroblasts, which show obvious cytological atypia. In these cases, the history and the coexistence of inflammatory cells are fundamental for a correct diagnostic orientation, which often requires a histological investigation.

Mesenchymal neoplasms are very numerous and in this chapter, only the most important and those, for which cytology is most useful, are discussed.

4.4.1 Fibroma and Fibrosarcoma

Fibroma and *fibrosarcoma* are tumours that originate from dermal and subcutaneous fibrocytes/fibroblasts. *Fibromas*, which originate from fibrocytes, and *fibrosarcomas*, which originate from fibroblasts, develop mainly in elderly patients, usually presenting with single nodules, ranging in size and located mainly on the limbs, head and trunk.

Fibroma is uncommon in dogs and very rare in cats. It usually takes the form of a single cutaneous nodule or may exceptionally multiple nodules (Fig. 4.231).

In cats, the *fibrosarcoma* that arouses most interest is certainly the *injection-site sarcoma*, once defined as *vaccine-associated sarcoma*, for which various studies have shown that other injected substances, not linked to vaccination, such as long-acting glucocorticoids or antibiotics, may also determine a state of chronic inflammation that predisposes the neoplastic transformation of primitive mesenchymal cells (Hendrick et al. 1994; Hendrick 1998; Macy and Hendrick 1996; Madewell et al. 2001; Hauck 2003; Gross et al. 2005; Martano et al. 2011; Hartman et al. 2015). Because in cats injections are usually administered in the interscapular area, the development of post-injection sarcomas is frequently observed at this body site and is characterised by a single subcutaneous nodule of irregular shape and ranging in size from a few centimetres to a large, infiltrating and often ulcerated mass (Figs. 4.232 and 4.233). In the past, it was believed that all interscapular sarcomas originate from fibroblasts and therefore were classified as *fibrosarcomas*. Recent immunohistochemical and molecular studies have shown that these sarcomas can have a fibroblastic, myofibroblastic, myoblastic, osteoblastic, chondroblastic or an undifferentiated origin. Because without immunohistochemistry it is not possible to identify the exact histotype, and also because it is possible for two different histotypes to coexist in the same tumour, the generic term *injection-site sarcoma* is currently used.

In cats, another frequent cutaneous location in which fibrosarcoma is observed is the pinna. Animals can develop both nodular and ulcerative auricular lesions. The latter should not be confused with the more common squamous cell carcinoma (Figs. 4.234 and 4.235). In young feline leukaemia virus (FeLV)-positive cats, a form of *multicentric cutaneous fibrosarcoma* associated with the feline sarcoma virus (FeSV) is recognised (Hardy 1981; Harasen 1984).

Cytological Findings

The cytology of *fibroma* is usually characterised by a low to moderate number of single spindle-shaped cells. The nuclei are oval or elongated and uniform in size and shape, sometimes with a scarcely evident nucleolus and with tailed cytoplasm that usually has indistinct and slightly basophilic borders (Fig. 4.236). An amorphous eosinophilic proteinaceous background, which represents the collagen secreted by the fibroblasts, is often present; sometimes collagen fibres are also observed.

The *fibrosarcoma* is characterised by the increased cellularity compared with fibroma, even though the number of cells observed, as in all mesenchymal neoplasms, is linked to the amount of stromal collagen, detectable at the periphery of the individual cells or in the context of the pseudo-aggregates (stromal cytoarchitecture). For this reason, the neoplastic cells can be released singly or arranged in pseudo-aggregates containing varying amounts of cells (Figs. 4.237 and 4.238).

The cytological feature is polymorphic, from distinctly spindle-shaped to plump, with large round to oval, single or multiple nuclei, often multiple and prominent nucleoli and caudate cytoplasm with indistinct borders, basophilic in colour and

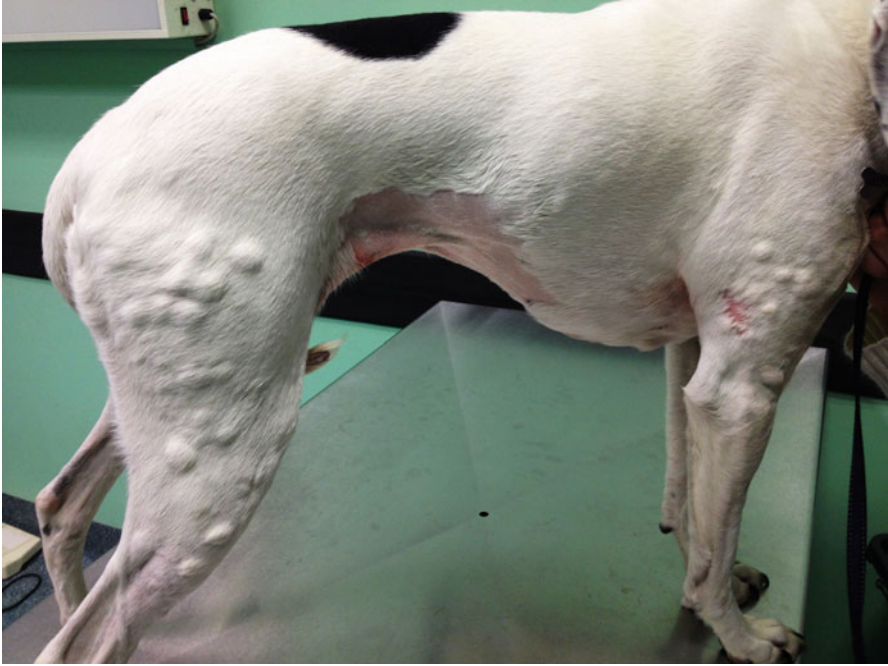

Fig. 4.231 Multiple fibromas are spread on the extremities and on the trunk of a mixed-breed dog

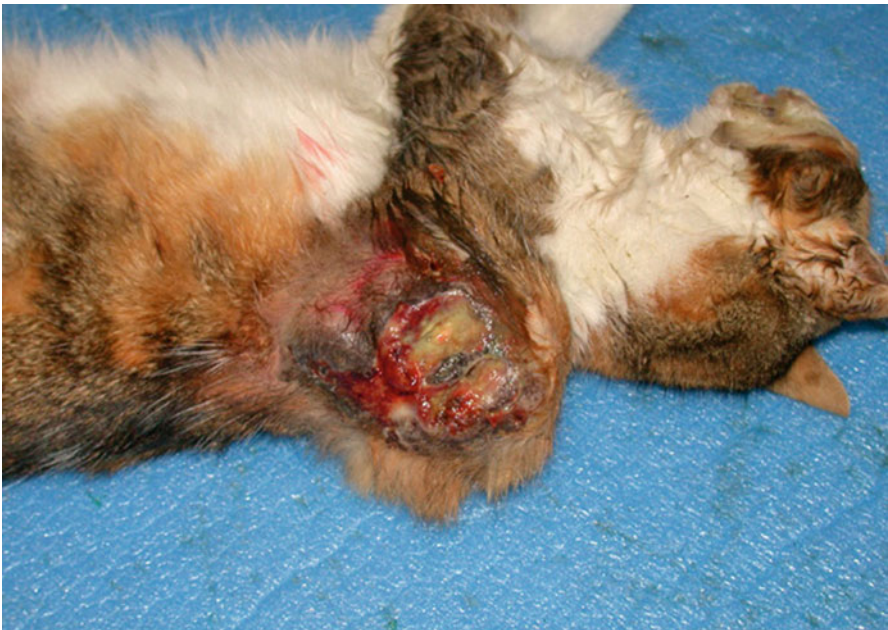

Fig. 4.232 Injection-site sarcoma. Ulcerated mass between the shoulders of an old cat

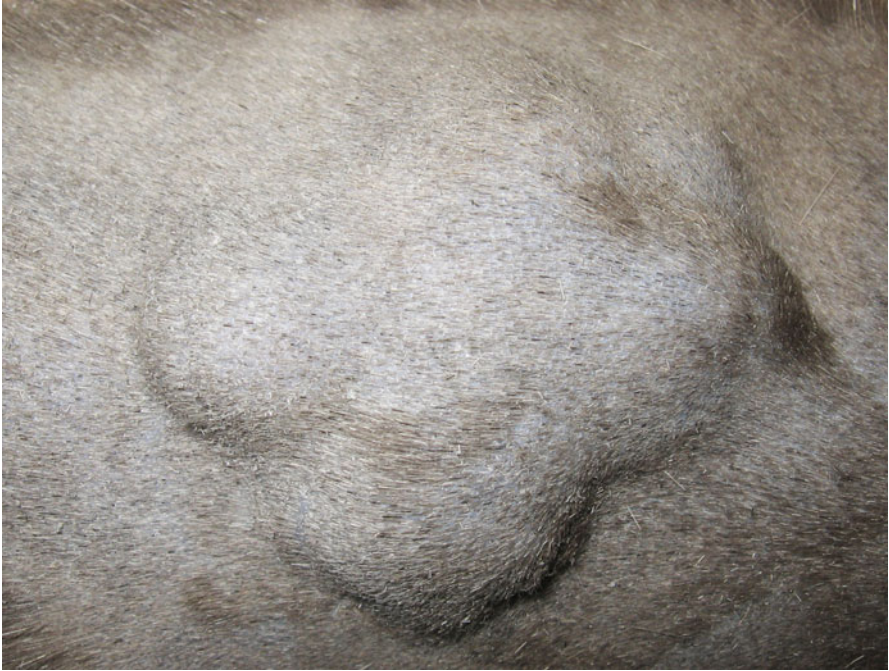

Fig. 4.233 Multilobulated injection-site sarcoma in a cat

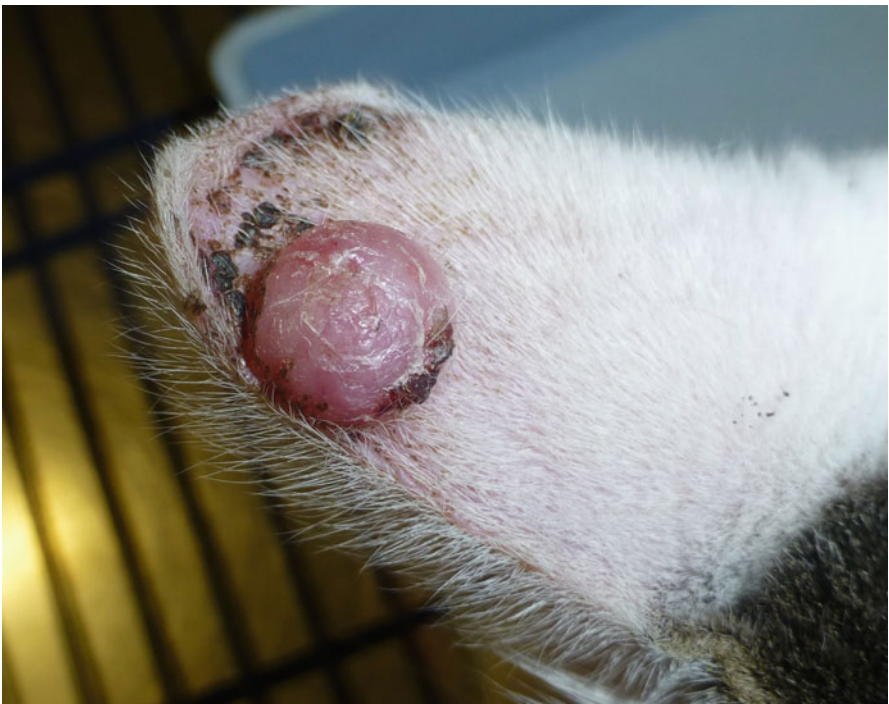

Fig. 4.234 Nodular fibrosarcoma on the pinna of cat

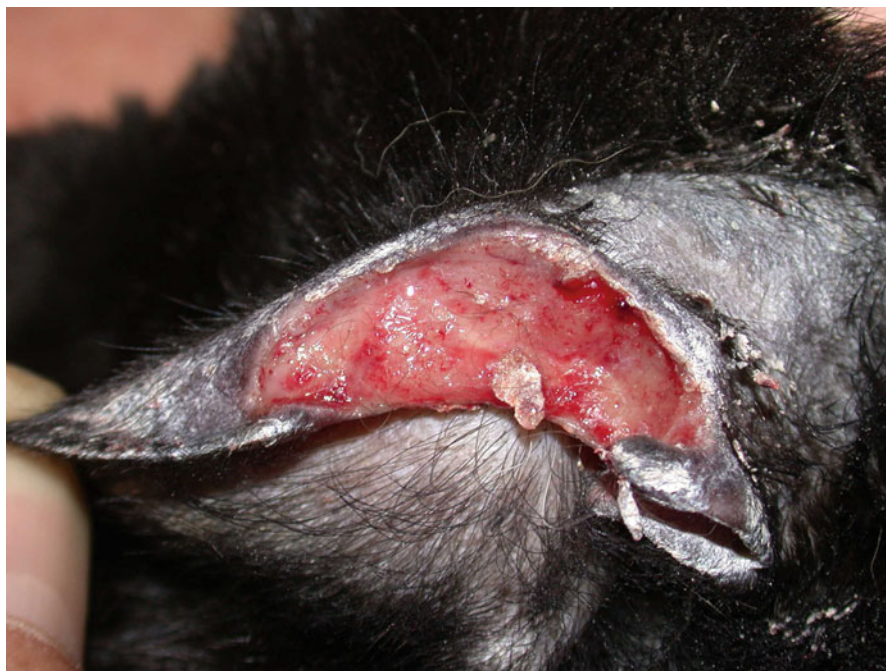

Fig. 4.235 Ulcerated fibrosarcoma on the pinna of a cat. This neoplasia must not be confused with an SCC, which is frequently ulcerated

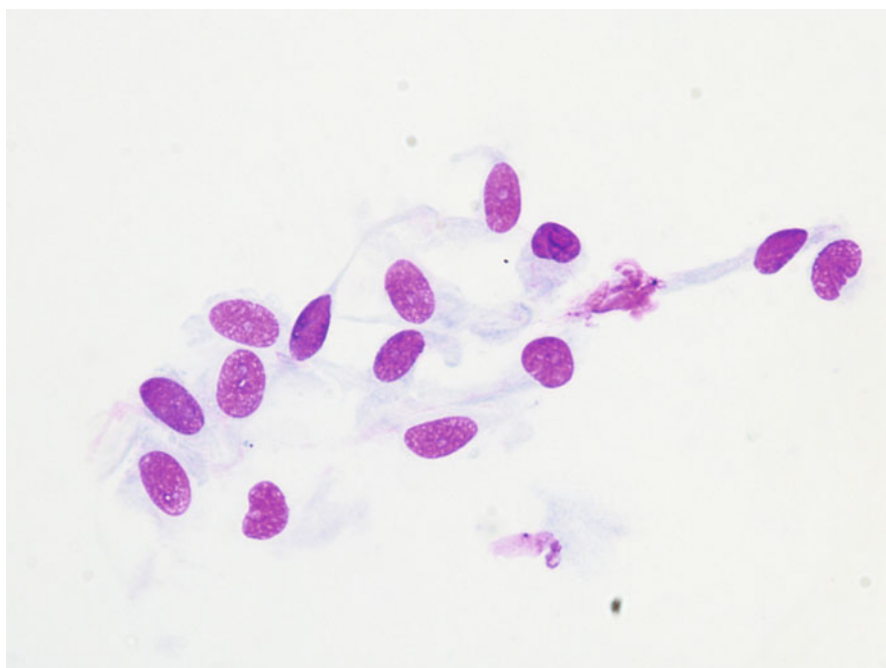


Fig. 4.236 Cytology of a fibroma. A group of benign fibrocytes without cytological atypia

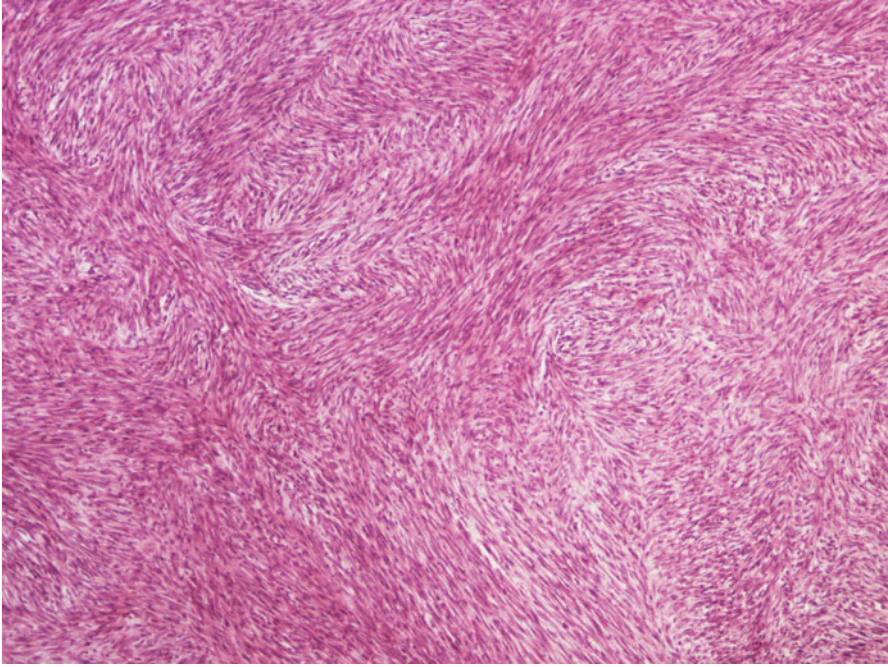


Fig. 4.237 Histopathology of a fibrosarcoma. Interlaced bundles of spindle cells, sometimes with a herringbone arrangement

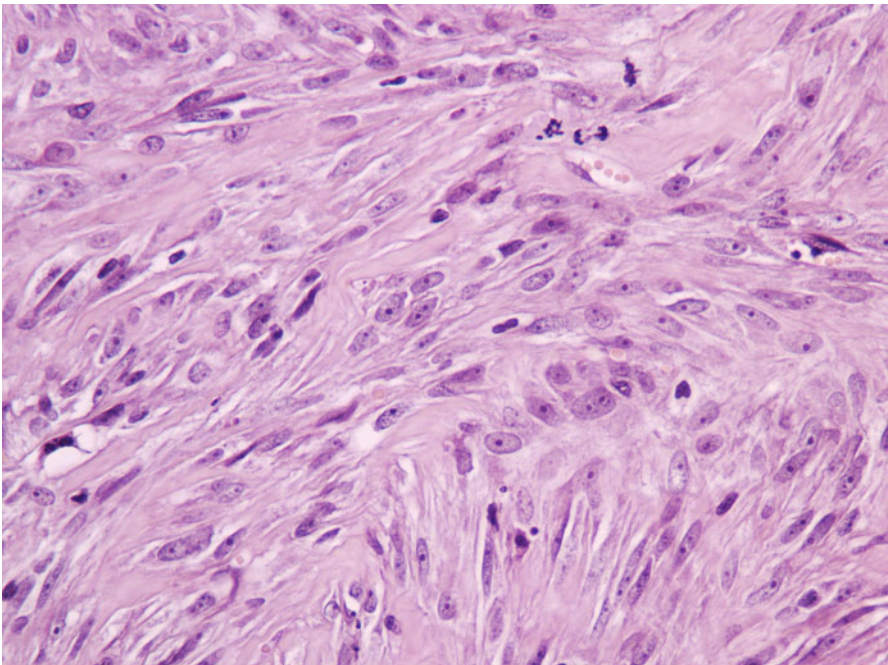


Fig. 4.238 Histopathology of a fibrosarcoma. At high magnifications, the cytological features of atypia, represented by anisokaryosis and a high number of mitoses, are easily detected

sometimes vacuolated. Some cells can show double or multiple tails that can give cells a star-like appearance (Figs. 4.239 and 4.240). Atypical mitoses are present in varying numbers. In some fibrosarcomas the cells can be yielded in large groups that still maintain their cytoarchitecture represented by small bundles of fusiform cells arranged in an orderly and sometimes wavy disposition (Fig. 4.241). These tumours usually contain a limited number of multinucleated cells, but they can be very numerous in more undifferentiated tumours, which are simultaneously observed together with spindle-shaped and round histiocyte-like cells. Feline fibrosarcomas usually show more giant cells than the canine counterparts.

In a large number of *soft tissue anaplastic sarcomas* with many *giant cells* (ASTSgcs), the multinucleated cells are not of neoplastic origin, but they are histiocytic (macrophagic giant cells), indicating a cell-mediated reaction from the immune system. To differentiate multinucleated cancer cells from the reactive histiocytic cells, immunohistochemical staining must be used. A cytological interpretation of their character can be attempted by evaluating the size of the nuclei, which are uniform and without atypia in the reactive giant cells. Moreover, they do not have a uniform size and there are obvious signs of abnormality in the cancer cells (Fig. 4.242).

The simultaneous presence of these three different cellular morphologies (spindle, histiocytoid and multinucleated), does not allow the differentiation between fibrosarcomas and other anaplastic soft-tissue sarcomas; the latter, once defined with the generic term *malignant fibrous histiocytoma*, are now included in a pleomorphic group of malignant undifferentiated sarcomas called ASTSgc (Daugaard 2004).

Finally, this triple morphology, especially in a dog with a single lesion on a limb, can also be observed in localised spindle-shaped histiocytic sarcoma, which, although belonging to the histiocytic diseases, can show cytological features indistinguishable from ASTSgc (Gross et al. 2005).

When *injection-site sarcoma* originates from neoplastic fibroblasts, the cells exhibit the same morphological aspects as described for the other fibrosarcomas. The cytological diagnosis of injection-site sarcoma, therefore, is not possible, but it is strongly suspected, when lesions are interscapular and when slides show the coexistence of small lymphocytes and necrotic debris, neutrophils and macrophages, the latter containing intracytoplasmic amorphous material representing the vaccine adjuvant or other injectable products.

The detection of inflammatory cells does not authorise a diagnosis of *injection-site sarcoma*; therefore, histopathological confirmation is needed. It should be pointed out that some fibrosarcomas are characterised by multiple intratumoral cystic areas, cytological samples can consist of only a proteinaceous background and few spindle cells, sometimes mainly represented by oval bare nuclei.

A subtype of *fibroma/fibrosarcoma*, named *keloidal fibroma/fibrosarcoma*, in which the neoplastic spindle-shaped cells are intermingled with a large number of thick eosinophilic collagen fibres, of hyaline or glassy appearance, is reported in dogs and cats (Figs. 4.243 and 4.244) (Mikaelian and Gross 2002; Little and Goldschmidt 2007; Gumber and Wakamatsu 2015). The nodules are usually small and subcutaneous and since a secondary infiltrate of mast cells can be present, care must be taken not to confuse these tumours with a keloidal mast cell tumour, which have already been described in the section on round cell tumours above.

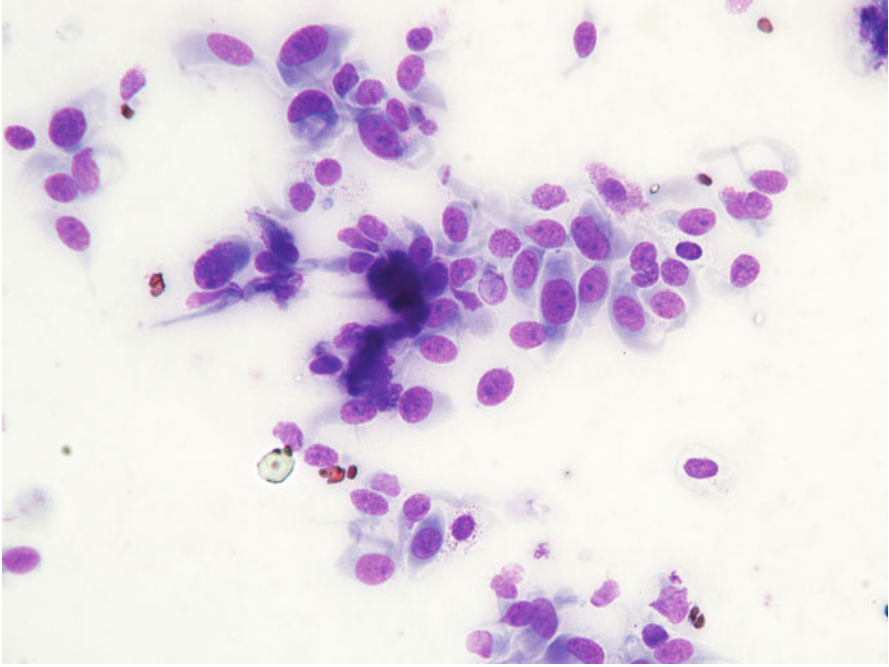


Fig. 4.239 Cytology of a fibrosarcoma. Many spindle-shaped neoplastic fibroblasts showing several malignant atypia

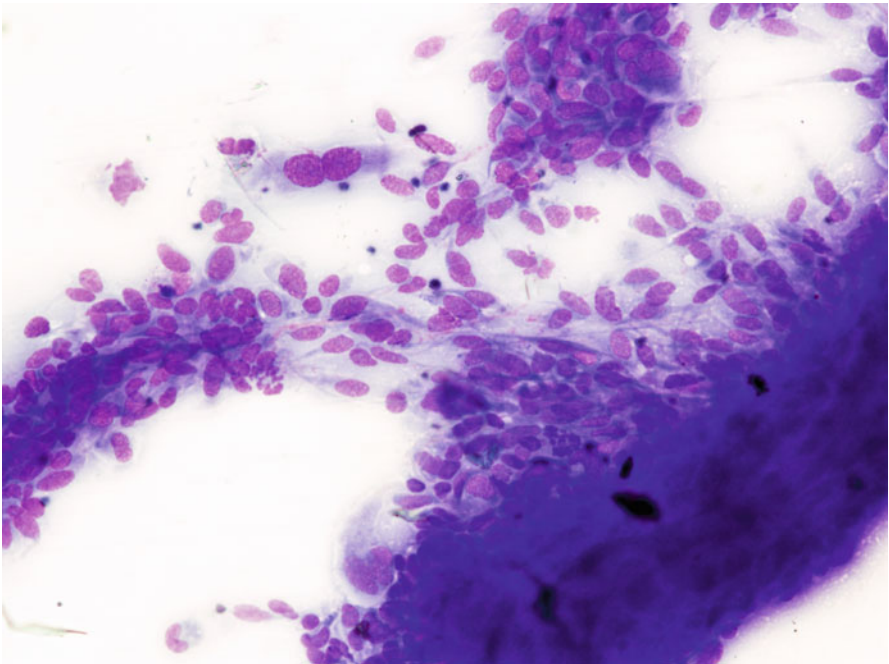


Fig. 4.240 Cytology of a fibrosarcoma. Spindle-shaped neoplastic fibroblasts arranged both in pseudo-aggregates and singly

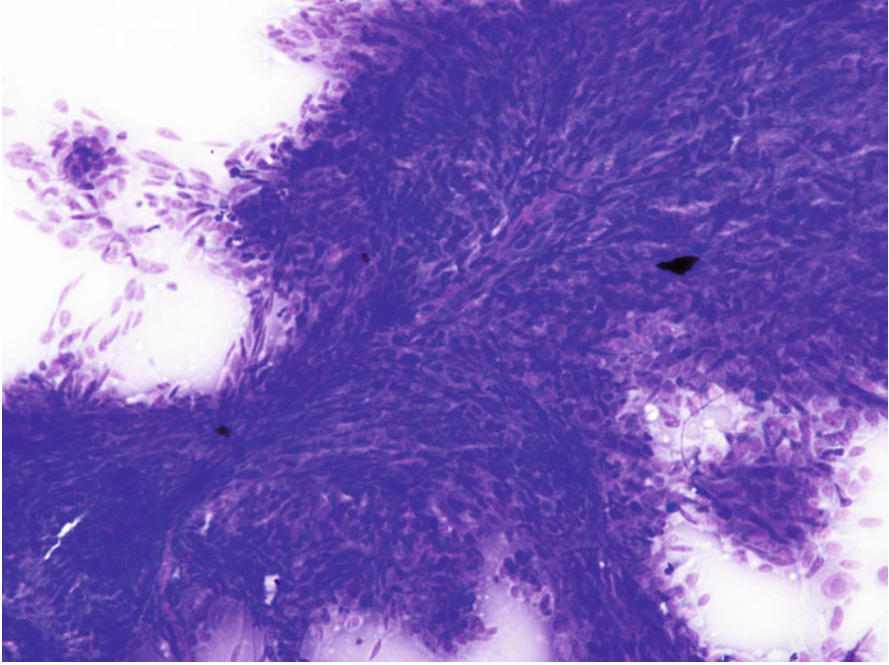


Fig. 4.241 Cytology of a fibrosarcoma. At low magnifications, the arrangement in interlaced bundles of the neoplastic cells is sometimes recognisable

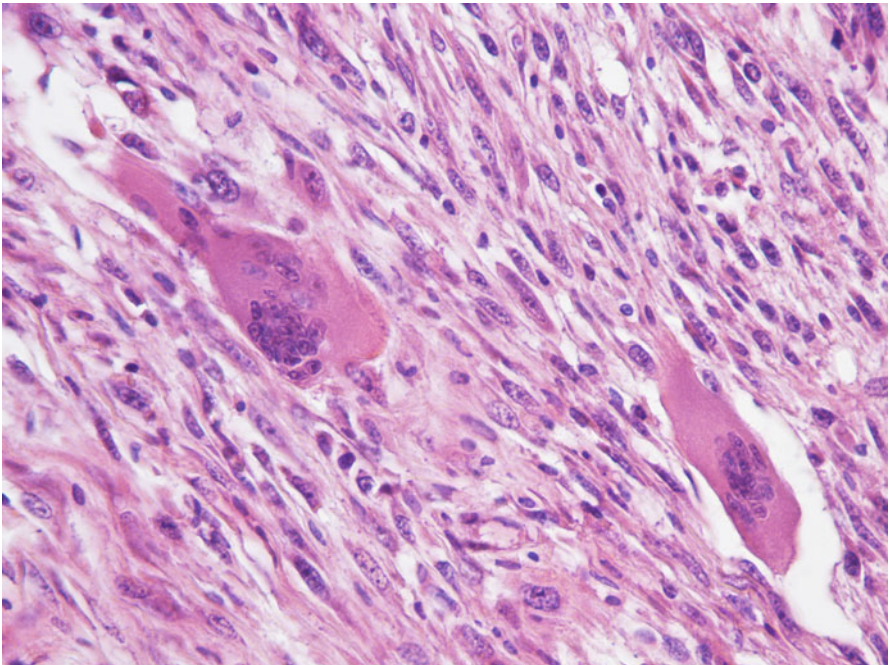


Fig. 4.242 Histopathology of a fibrosarcoma. Many giant cells are intermingled between neoplastic spindle fibroblasts

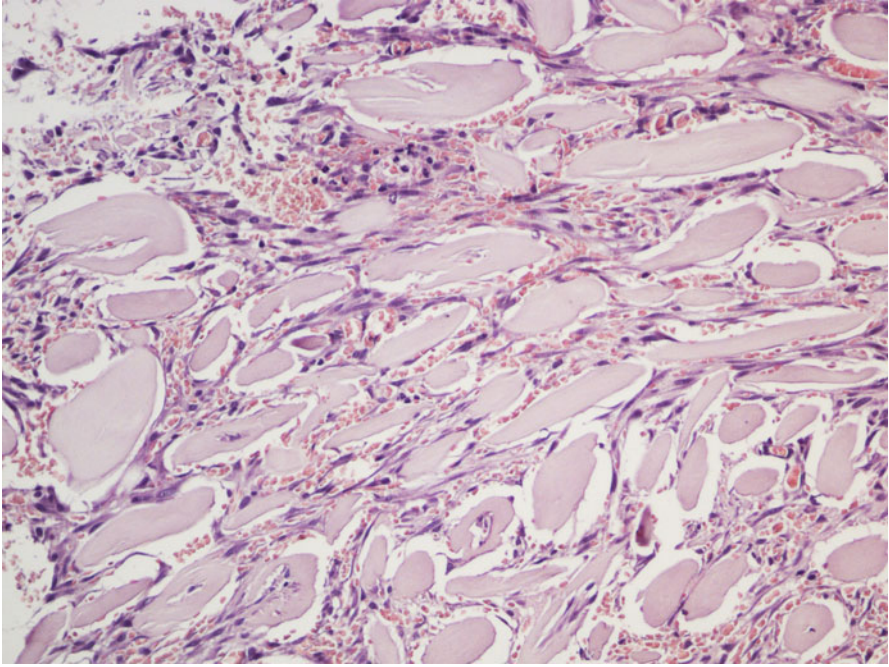


Fig. 4.243 Histopathology of a keloidal fibrosarcoma. Many neoplastic spindle-shaped cells are intermingled with a large amount of thicker and scantily eosinophilic collagen fibres

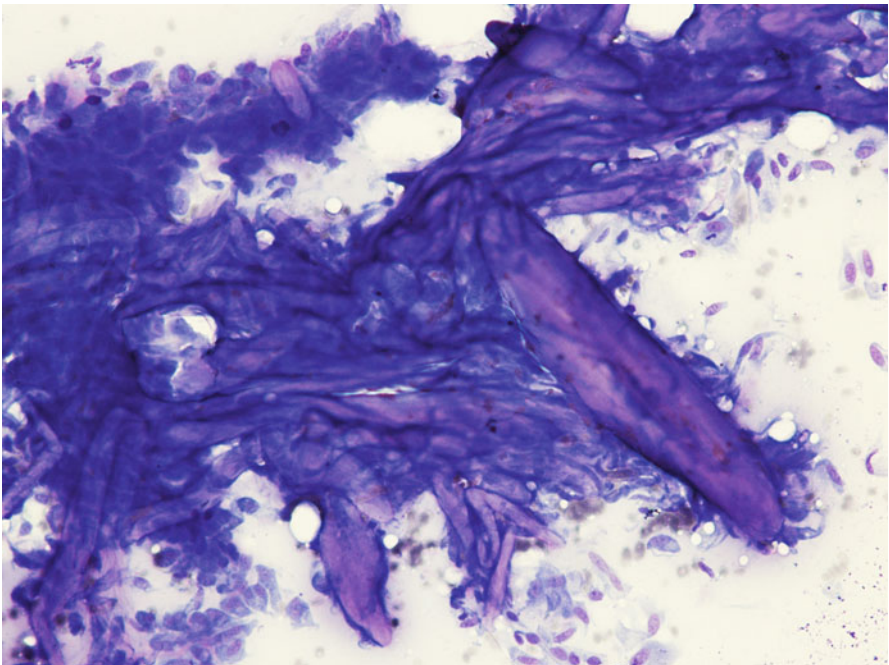


Fig. 4.244 Cytology of a keloidal fibrosarcoma. Spindle neoplastic cells and many thick collagen fibres characterise the cytology

4.4.2 *Myxoma and Myxosarcoma*

Myxoma and *myxosarcoma* are rare tumours originating from dermal or subcutaneous fibrocytes and rarely from other primitive mesenchymal cells that produce large amounts of mucin (Graadt van Roggen 1999; Gross et al. 2005). Macroscopically, they are characterised by barely delimited nodules of various sizes, soft in consistency and mainly localised to limbs and thorax, which can yield a clear and viscous fluid representing mucin (Figs. 4.245 and 4.246). In other cases, the lesions are characterised by large masses of a pasty consistency and with ill-defined margins.

Cytological Findings

The cytology of these tumours follows their histological features, highlighting a background composed of abundant intercellular matrix in the form of eosinophilic amorphous and finely granular material.

The cells from *myxoma* have oval or elongated nuclei with small nucleoli; cytoplasm is typically spindle-shaped or star-like, with scarcely evident borders, which often become lost within the intercellular matrix that they themselves produced (Fig. 4.247). The well-differentiated *myxosarcomas* are cytologically indistinguishable from *myxomas*, especially in specimens with few cells. Malignant *myxosarcomas* are instead characterised by many atypical and pleomorphic cells, from round to spindle or star-like in shape, with large nuclei, sometimes multiple, and by atypical mitosis. The cytoplasm is large and contains an eosinophilic material (mucin) that is also evident on the extra-cellular background (Figs. 4.248 and 4.249).

The abundant myxoid component, however, is not pathognomonic of myxomas and myxosarcomas; in fact, other sarcomas may produce mucin.

4.4.3 *Haemangioma and Haemangiosarcoma*

Haemangiomas (HA) and *haemangiosarcomas* (HSA) are benign and malignant tumours respectively that originate from endothelial cells of blood vessels of the dermis and subcutis (Carpenter et al. 1987; Gross et al. 2005).

A single nodule, macroscopically dark in colour when located in the dermis and covered with glabrous skin usually represents HA (Fig. 4.250). The cutaneous HSA is usually primitive and a single nodule of varying sizes, usually deeply red in colour and sometimes of a fleshy appearance, clinically characterises it (Figs. 4.251 and 4.252) (Brown et al. 1985; Hargis et al. 1992; Miller et al. 1992; Ward et al. 1994; McAbee et al. 2005; Johannes et al. 2007). In dogs, when multiple HSAs are present on the skin, they likely represent a metastatic spread from a primary splenic or heart auricle HSA, as discussed in Chap. 5 on skin metastases. In any case, when a cutaneous HSA has been diagnosed, staging of the neoplasia is mandatory. An exception, with benign behaviour, are the UVA-induced HSAs, which are observed on the glabrous skin of short-haired dogs with white skin, such as Argentine Dogo, American Staffordshire, Pit-bull, Dalmatian etc. The groin and the abdominal skin are the most frequently affected areas from solar-induced HSA.

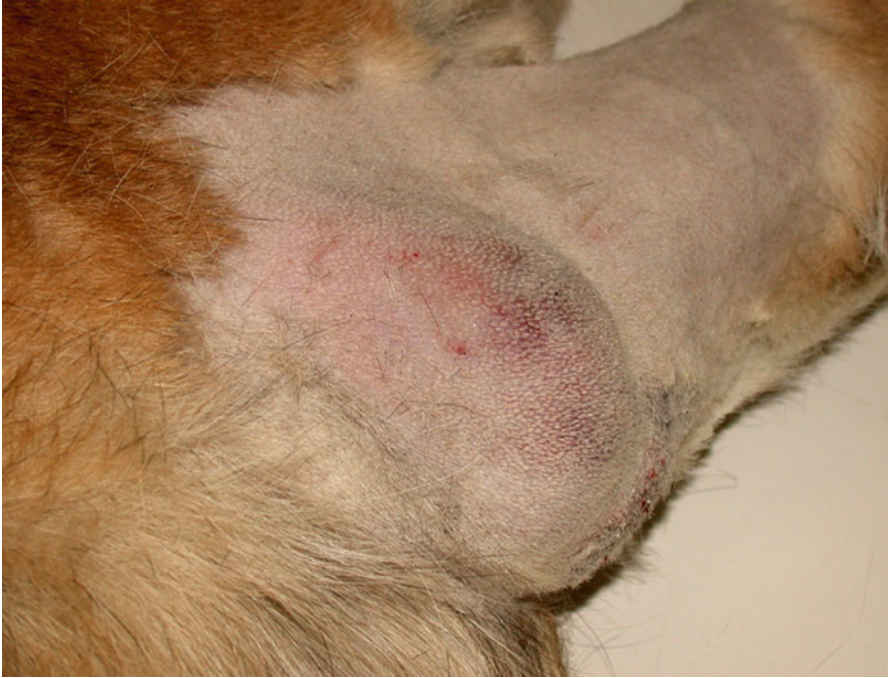

Fig. 4.245 Large myxosarcoma on the elbow of a German shepherd




Fig. 4.246 Viscous fluid collected from the lesion shown in Fig. 4.245

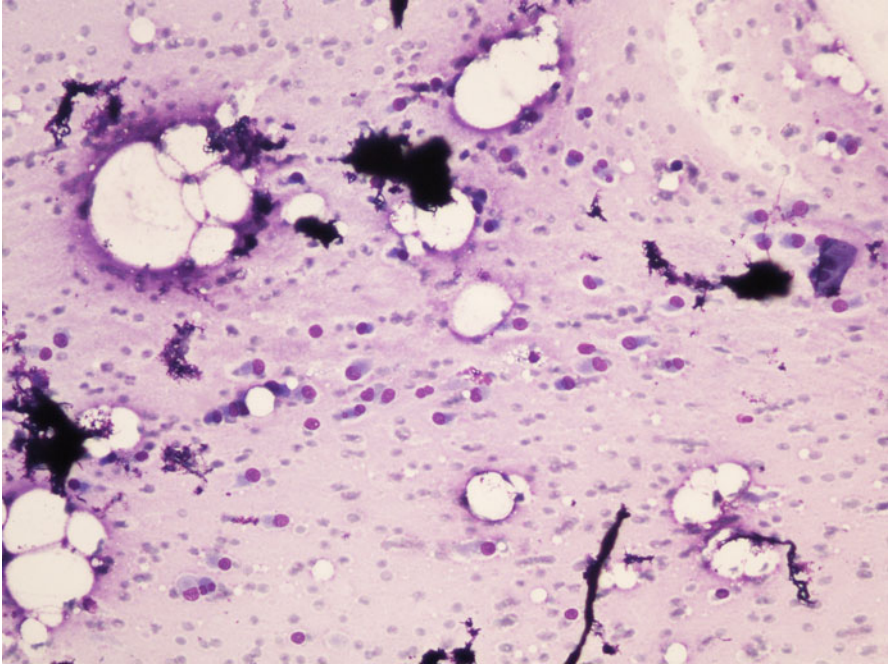


Fig. 4.247 Cytology of a myxoma. Many spindle fibrocytes are embedded in a dense proteinaceous material

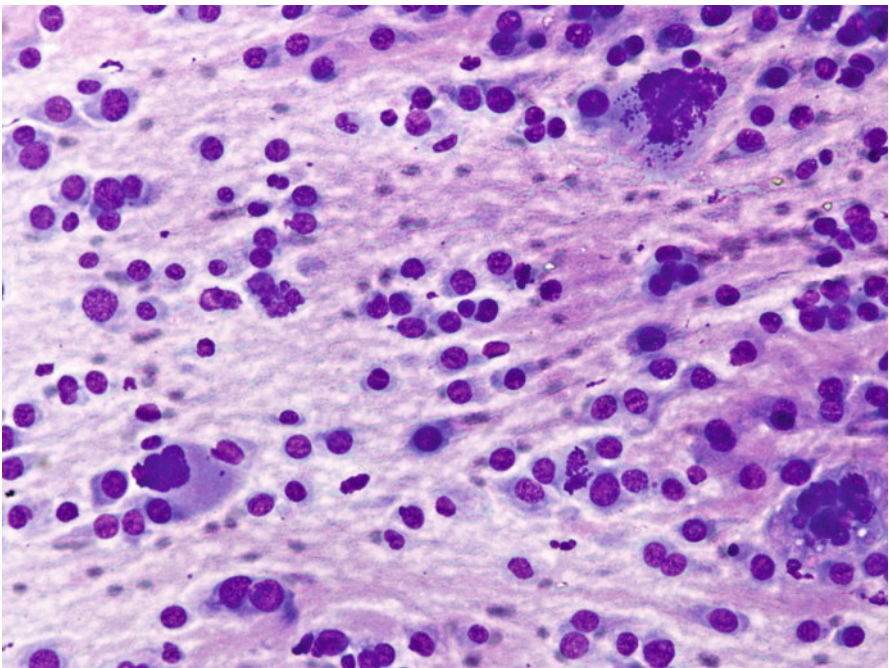


Fig. 4.248 Cytology of a myxosarcoma. Malignant spindle mesenchymal cells are immersed in a dense proteic and eosinophilic background representing mucin

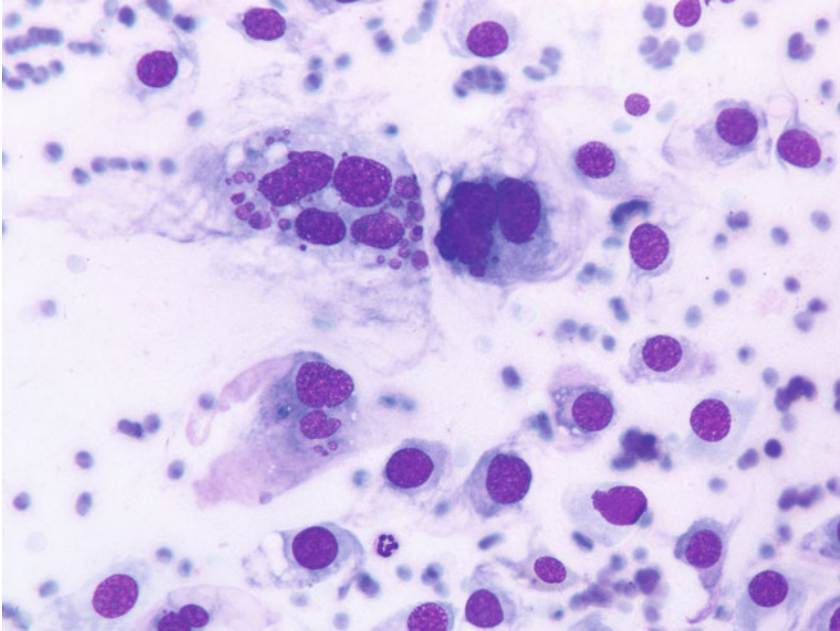


Fig. 4.249 Cytology of a myxosarcoma. Severe nuclear atypia of cells from a poorly differentiated mesenchymal tumour that secretes mucin. This neoplasia cannot be differentiated cytologically from other anaplastic soft-tissue sarcomas with many giant cells

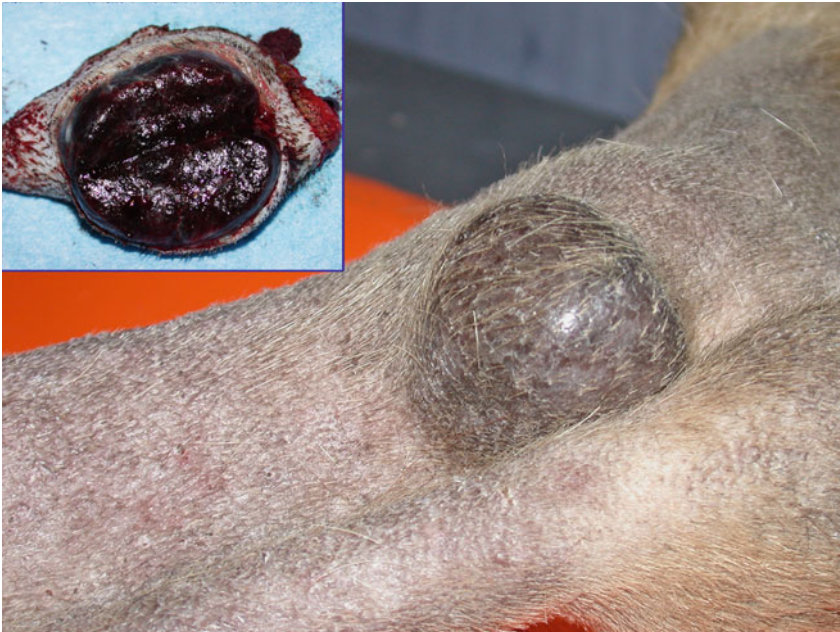

Fig. 4.250 Cavernous haemangioma. Pigmented nodule on the hock of a dog. Note the deep red cut surface (*inset*)

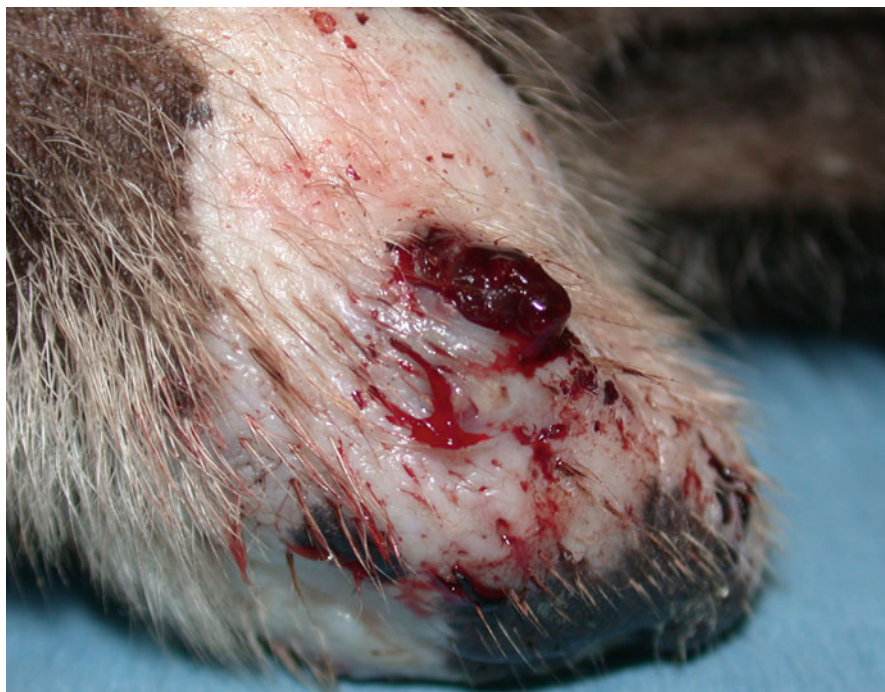

Fig. 4.251 Haemangiosarcoma on the penis of a Pit-bull

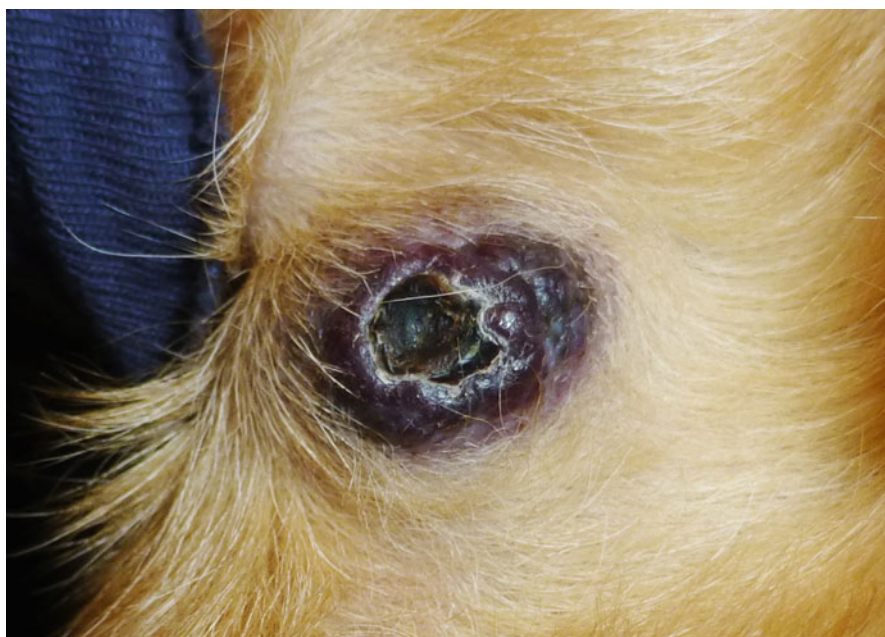

Fig. 4.252 Haemangiosarcoma. Deep purple, ulcerated and irregular shaped vascular neoplasia in a dog

Cytological Findings

Haemangioma is a vascular neoplasia and its most common form is the cavernous haemangioma. This histotype of HA is composed of multiple vascular lacunae filled with blood and lined with a monolayer of flattened endotheliocytes (Figs. 4.253 and 4.254). Cytology is in fact composed only of blood cells. For this reason, when after many fine needle biopsies, the nodule releases only blood, a vascular neoplasm should be suspected. The clinical appearance, the absence of traumatic history and the presence of platelets and erythrophagocytic macrophages, which contain metabolic degradation of haemoglobin products such as haemosiderin and haematoidin, allows us to differentiate a haemangioma from a haematoma.

A strong haematic background and a variable number of pleomorphic cells (spindle-shaped, star-like or epithelioid), characterised by atypical features that are related to the degree of malignancy of the tumour, characterise the cytological findings of HSA (Fig. 4.255). The cytoplasm is hyperbasophilic, may have indistinct borders and small punctate vacuoles are frequently observed (Figs. 4.256 and 4.257) (Bertazzolo et al. 2005). The cytology of HSA, as for most mesenchymal neoplasms, does not permit identification of their origin, for which histopathology is mandatory. A strong suspicion of HSA can be generated when angioformative features represented by small and irregular groups of neoplastic cells, sometimes with a whorl arrangement, set around a small central area containing a single or few red blood cells (RBCs), are observed (Fig. 4.258). This cytological finding is indicative of the presence of newly formed atypical vascular structures commonly observed on histological specimens from HSA. Another cytological aspect rarely observed in some cutaneous HSAs is the presence of haematopoietic precursors such as megakaryocytes and rubricytes.

4.4.4 Perivascular Wall Tumours

Perivascular wall tumours (PWTs) are mesenchymal neoplasms belonging to a group of neoplasms that originate from different cell lines surrounding the endothelial cells of the blood vessel walls, such as *pericytes*, *myopericytes*, *adventitial cells* and *myofibroblasts*. In veterinary medicine, a more detailed description of these tumours is relatively recent and evolving (Caniatti et al. 2001; Mentzel et al. 2006; Avallone et al. 2007, 2013; Stefanello et al. 2011; Palmieri et al. 2013). For a long period PWTs were diagnosed without ascertaining the exact line of the neoplastic cell, causing great confusion in their classification. New knowledge in veterinary pathology has shown that in the past, although they were histologically indistinguishable from other PWTs, many perivascular neoplasms were misdiagnosed as *haemangiopericytomas* (HPCs).

Recently, on the basis of the combination of the histological pattern and positivity to different immunohistochemical antibodies, different types of PWTs, originating from different lines of perivascular cells, have been demonstrated. As a result of these researches, many PWTs formerly diagnosed as HPCs, which originate from *pericytes* of the subendothelial space of the capillaries, were instead *myopericytomas* (MPCs), whose neoplastic cells are *myopericytes* that are located in the sub-endothelial cells of

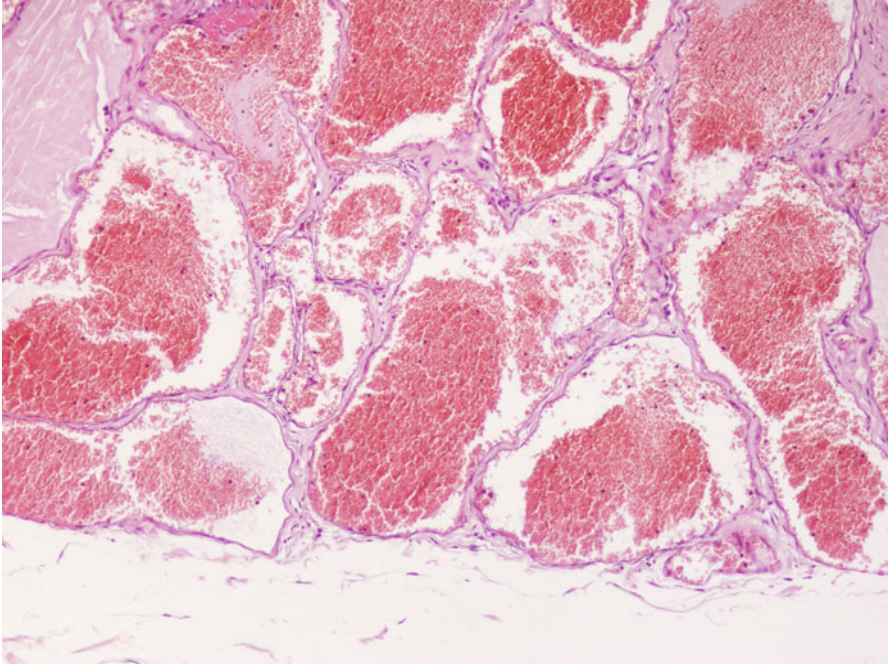


Fig. 4.253 Multiple vascular lacunae filled with blood, characterises the histopathology of the cavernous haemangioma

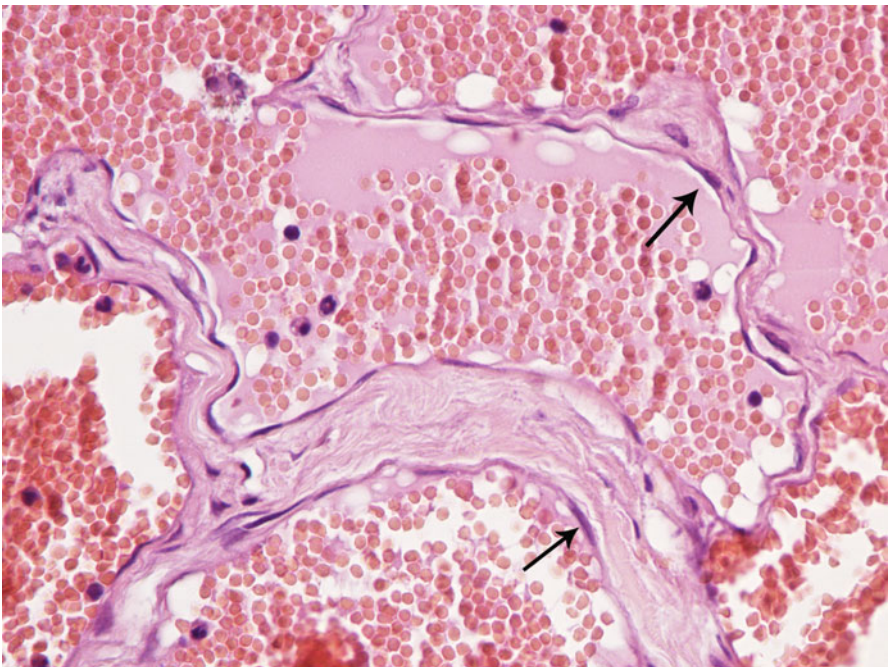


Fig. 4.254 Histology of a cavernous haemangioma. At high magnifications, a single layer of flattened uniform and spindle-shaped endotheliocytes lining the vascular lacunae is clearly evident (*arrows*)

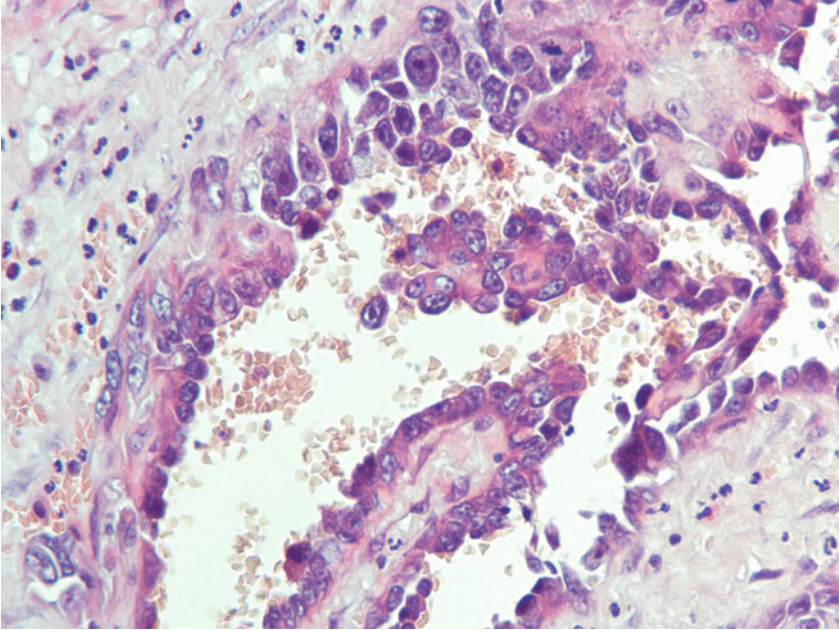


Fig. 4.255 Histology of a haemangiosarcoma. Highly malignant endotheliocytes delimit a vascular lacuna

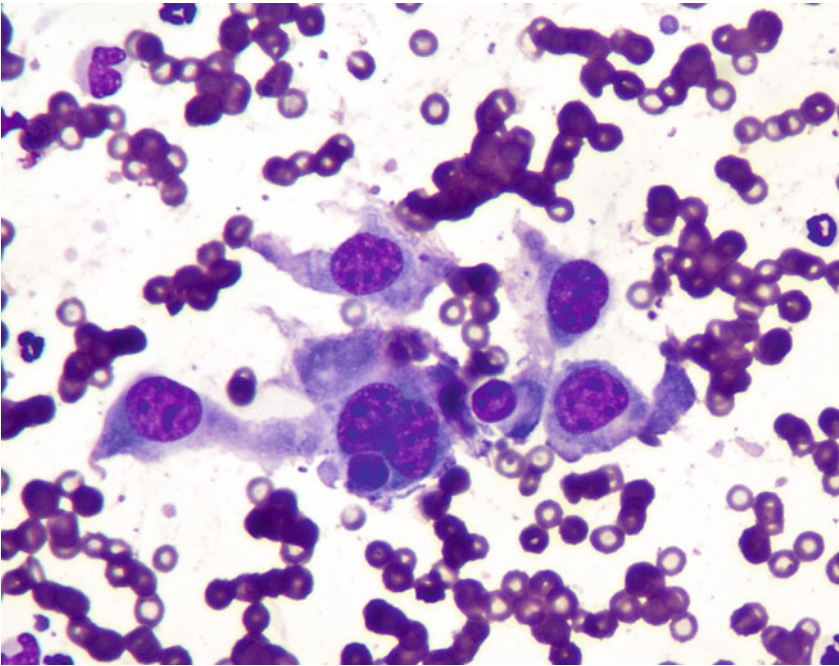


Fig. 4.256 Cytology of a haemangiosarcoma. Spindle and star-shaped neoplastic endotheliocytes show many cytological atypia

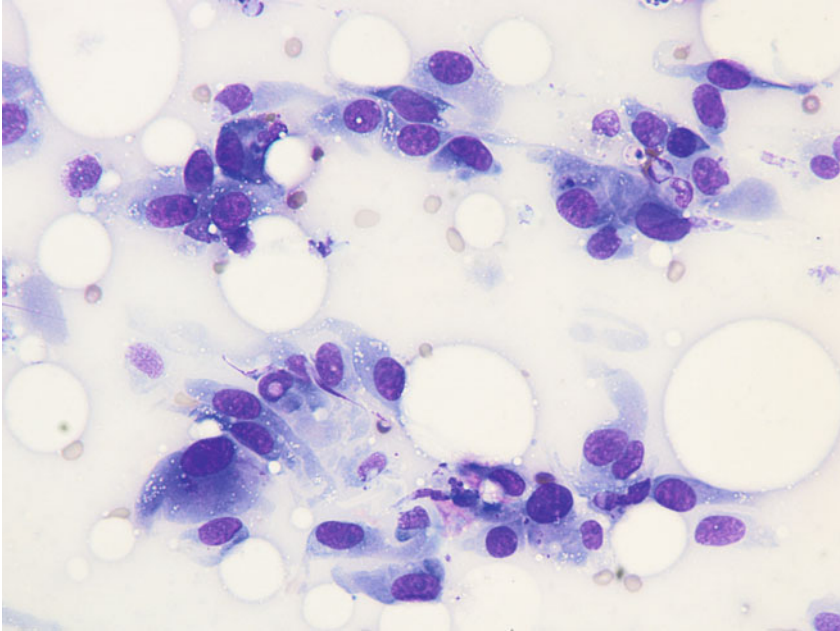


Fig. 4.257 Cytology of a haemangiosarcoma. Several cytological atypia are shown by neoplastic endothelial cells. Intracytoplasmic punctate vacuoles are also evident

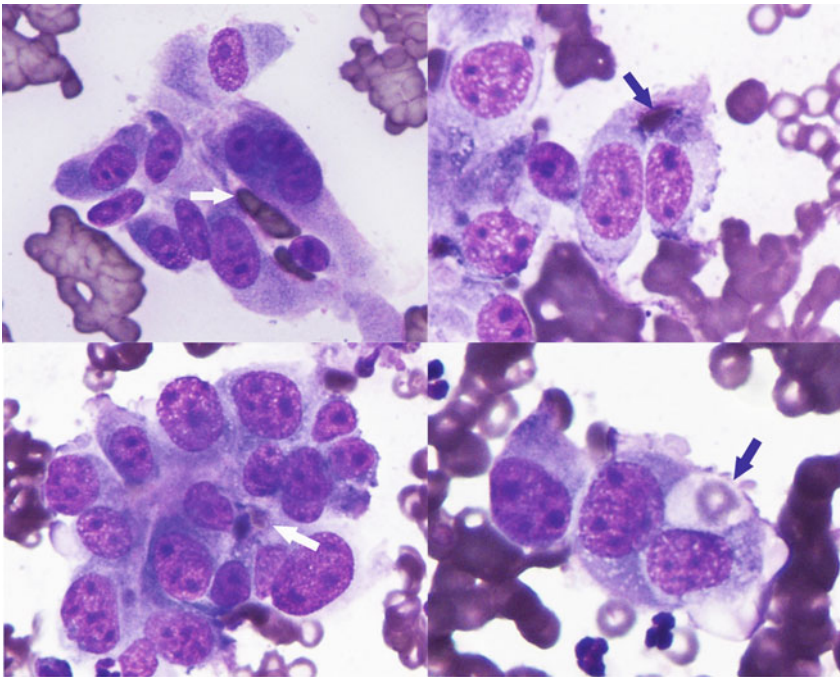


Fig. 4.258 Cytology of a haemangiosarcoma. Single or a few RBCs are contained between neoplastic cells (*arrows*). These cytological features are observed in many hypercellular haemangiosarcomas and could be interpreted as angioformative arrangements

medium-sized vessels (arterioles and venules). True HPCs exist in dogs, but they are much rarer than previously reported and, unlike the MPCs, seem to have a more aggressive biological behaviour (Avallone et al. 2007, 2013). Their differentiation, impossible with cytology, may therefore have a relevant prognostic value.

Other PWTs, including the *angioliomyoma/angioliomyosarcoma*, which originate from smooth muscle of the vascular wall, the *angiofibroma*, originating from cells of the vascular adventitia, the *angiomyofibroma* and *angiomyxoma*, originating from perivascular myofibroblasts, are rarely reported in veterinary medicine (Avallone et al. 2007).

Grossly, PWTs are present, with single nodules localised on the limbs, especially on the elbows and hocks and, less frequently on the abdomen and chest (Figs. 4.259 and 4.260). The size ranges from a few centimetres up to large masses measuring more than 15–20 cm. The MPCs tend to very rarely metastasise, but have a high index of local recurrence in that, because of their peculiar growth along the small vessels and the frequent localisation in areas with scarce subcutaneous tissue, surgical resection is often incomplete (Stefanello et al. 2011).

Cytological Findings

The morphology of PWTs has been well documented and when all the cytological features are present on the same specimen, they authorise the suspicion of the perivascular nature of the cells (Caniatti et al. 2001).

The slides range from poorly to highly cellular, depending on the amount of stroma in which tumour cells are immersed. With regard to its origin, the samples are always haemodiluted and the diagnosis is also strongly suggested when many pseudo-aggregates with a characteristic perivascular cytoarchitecture are detected (Figs. 4.261 and 4.262). The cells of PWTs are spindle-shaped and have thin cytoplasmic tails, which stain slightly basophilic, often with poorly defined borders and microvacuoles. The nuclei are plump or slightly oval, with regular chromatin, and the nucleoli are not obvious; nuclei can often be double and paired in an eccentric arrangement to give cells a so-called *insect head* appearance or can be multiple (five or more) arranged at the periphery of the cytoplasm giving origin to the so-called *crowns cells* (Figs. 4.263, 4.264, and 4.265) (Caniatti et al. 2001). Less frequently, in cases of PWTs histologically characterised by many whorled arrangements, it is possible to collect groups of perivascular cells that are arranged in cytoarchitecture reminiscent of the characteristic swirling pattern seen histologically (Figs. 4.266 and 4.267)

Since, to date, no other type of mesenchymal tumour has ever shown the cytological features mentioned, the cytology of PWTs has a very high predictive value.

4.4.5 *Peripheral Nerve Sheath Tumour*

The *peripheral nerve sheath tumours* (PNSTs), formerly known as *schwannomas*, are canine and feline tumours that originate from *Schwann cells* (nerve sheath) localised in the dermis and subcutis (Gross et al. 2005). They are classified into benign (BPNSTs) and malignant (MPNSTs) (Koestner and Higgins 2002). Clinically, they are usually single nodules that may arise anywhere, although they

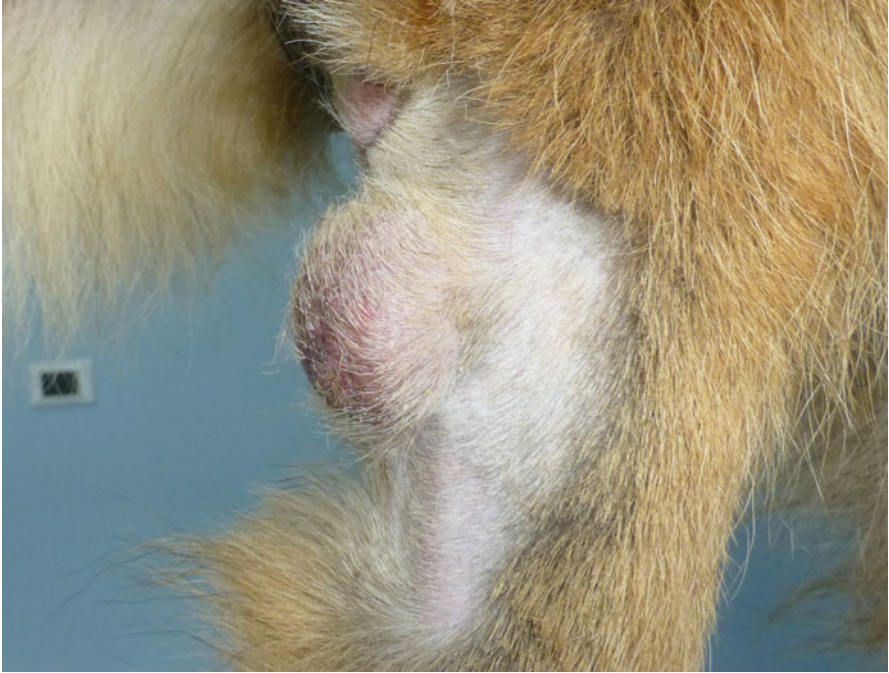

Fig. 4.259 Perivascular wall tumour (PWT) on the elbow of a German shepherd

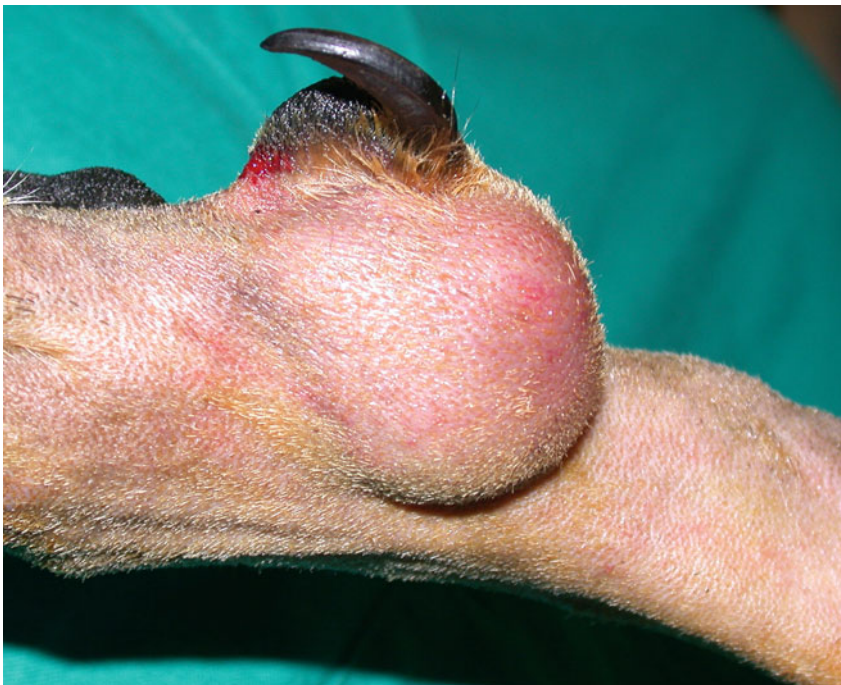

Fig. 4.260 A PWT on the leg of a dog

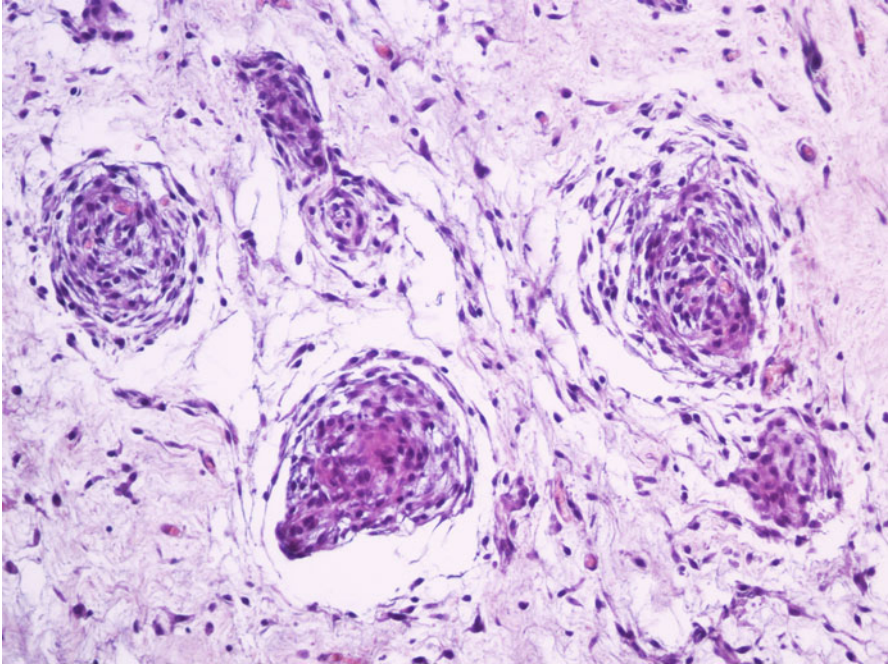


Fig. 4.261 Histology of a PWT: many whorl formations are arranged around small blood vessels

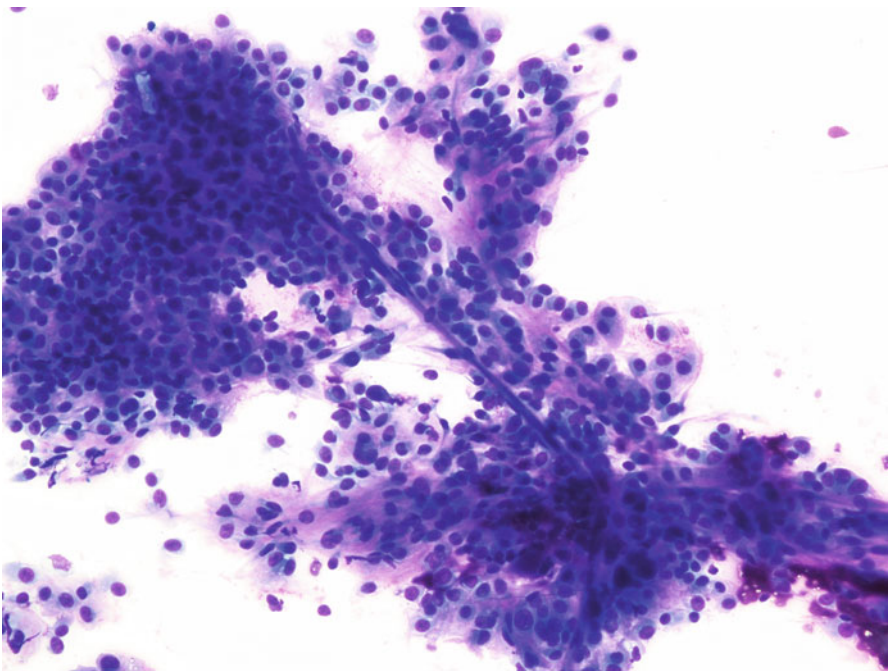


Fig. 4.262 Cytology of a PWT: perivascular arrangement of neoplastic cells

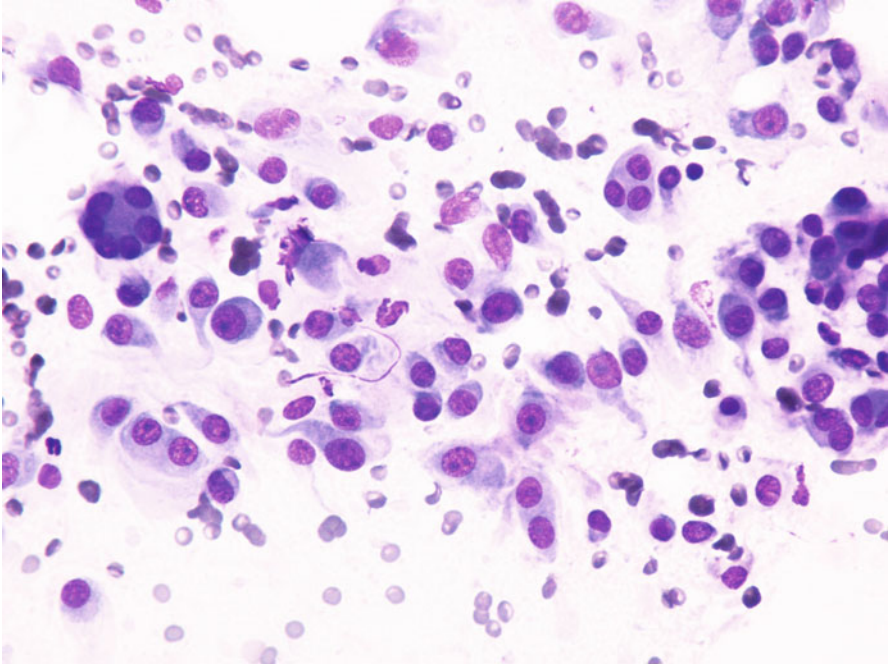


Fig. 4.263 Cytology of a PWT: many spindle-shaped and one multinucleated cell (crown cell)

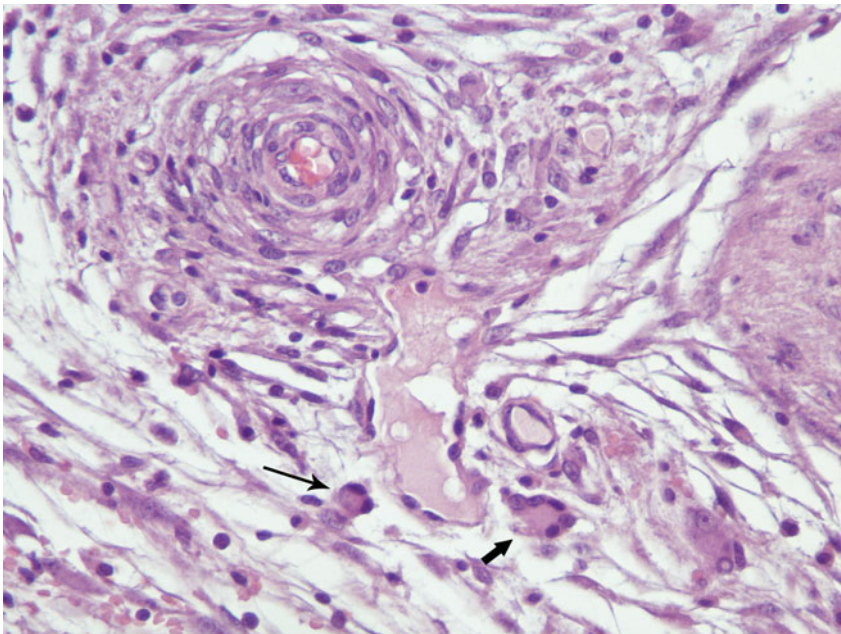


Fig. 4.264 Histology of a PWT: spindle neoplastic cells arranged to form a perivascular vortex. Note the presence of a multinucleated crown cell (*short arrow*) and of a binucleated insect-head cell (*long arrow*)

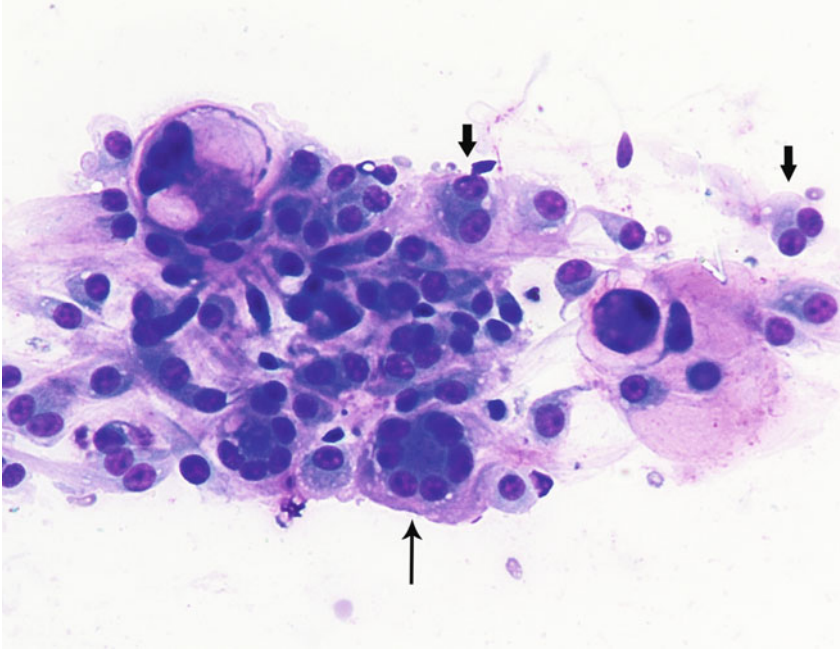


Fig. 4.265 Cytology of a PWT: characterised by multinucleated crown cells (*long arrow*) and binucleated insect-head cells (*short arrows*)

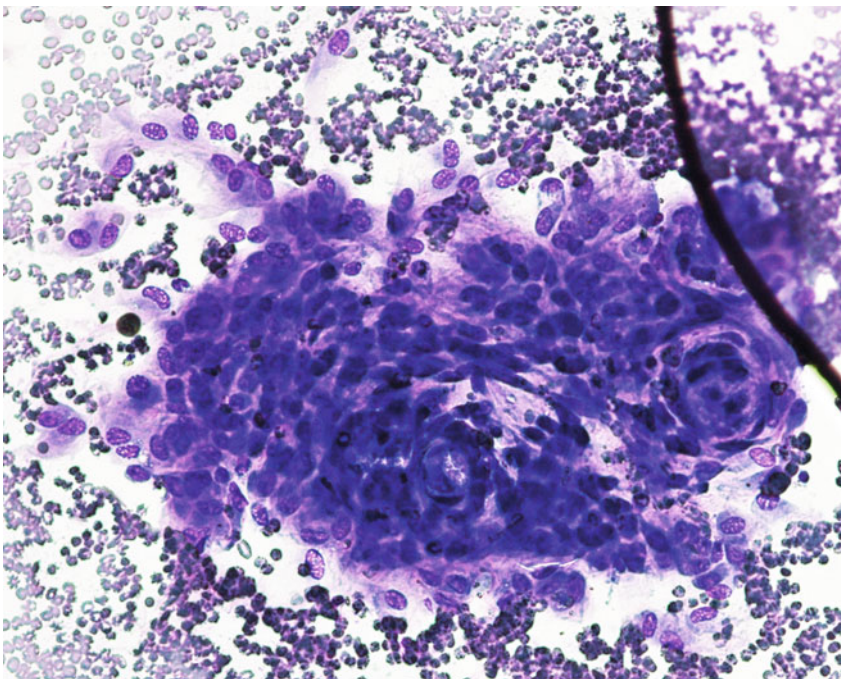


Fig. 4.266 Cytology of a PWT: spindle neoplastic cells arranged to form whorls

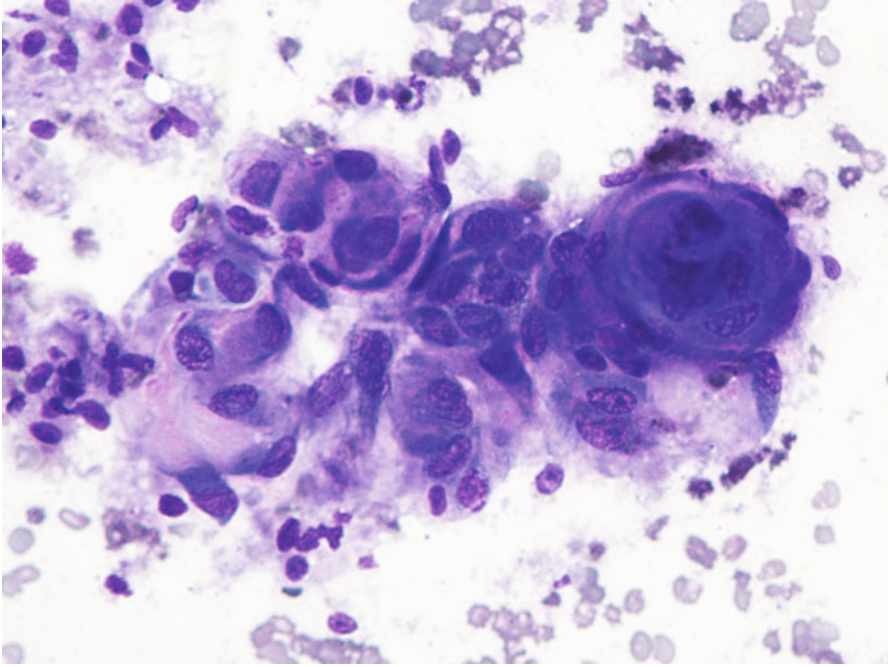


Fig. 4.267 Cytology of a PWT: at high magnifications, the whorls are more evident

are more frequently observed on the head, neck and limbs (Figs. 4.268, 4.269, and 4.270) (Gaitero et al. 2008; Schulman et al. 2009).

Cytological Findings

The *PNSTs* are spindle cell tumours that may have histopathological characteristics in common with other mesenchymal neoplasms and in particular with PWTs. To differentiate between them, especially in the absence of peculiar histological characteristics that are reminiscent of the nerve cell tumours, such as the so-called Antoni A and Antoni B patterns, definitive diagnosis requires immunohistochemistry (Chijiwa et al. 2004; Schulman et al. 2009; Suzuki et al. 2014) (Fig. 4.271). Cytology samples are from moderately to highly cellular and cells are spindle-shaped with oval or elongated nuclei and slender cytoplasmic tails. In specimens containing higher number of cells, bundles of variably arranged spindle cells can be collected (Figs. 4.272, 4.273, 4.274, and 4.275). The presence of spindle cells organized in a palisade arrangement which resembles an Antoni A pattern, it is very indicative of a neuronal origin of cells. Unfortunately these cytological findings are not common in dogs and cat. Hypercellularity and varying degrees. Varying degrees of cellular atypias confirm the malignancy of the tumour.

4.4.6 Lipoma and Liposarcoma

Lipoma is a benign tumour of the adipose tissue and is very common in dogs but rare in cats. *Liposarcomas* are less frequent than lipomas and are not derived from malignant transformation of the latter, but arise directly from malignant




Fig. 4.268 Small PNST on the upper lip of a cat

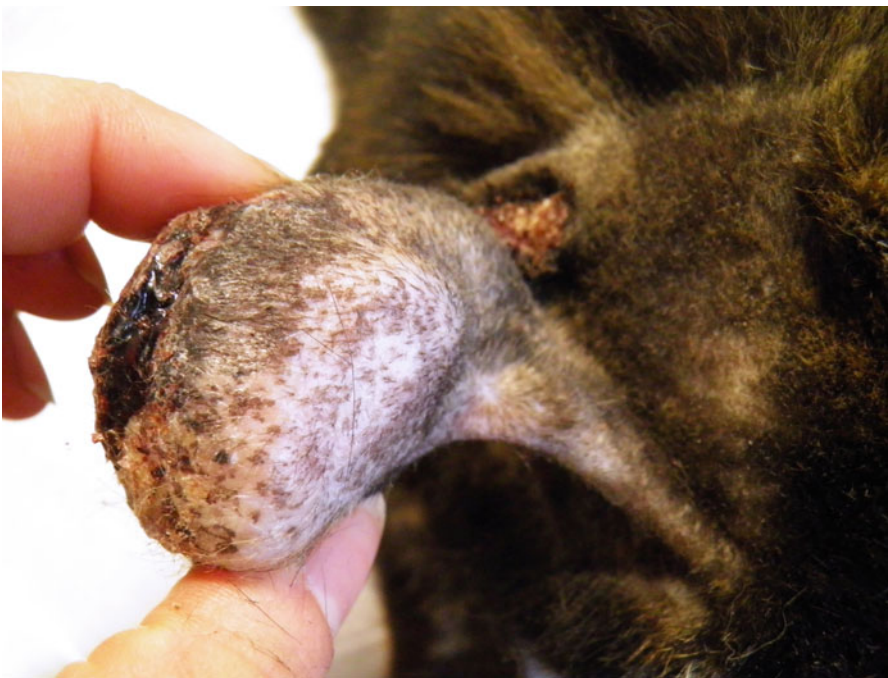


Fig. 4.269 Large and pedunculated peripheral nerve sheath tumour (PNST) on the face of a cat (Courtesy of Dr. C. Caporali, Italy)

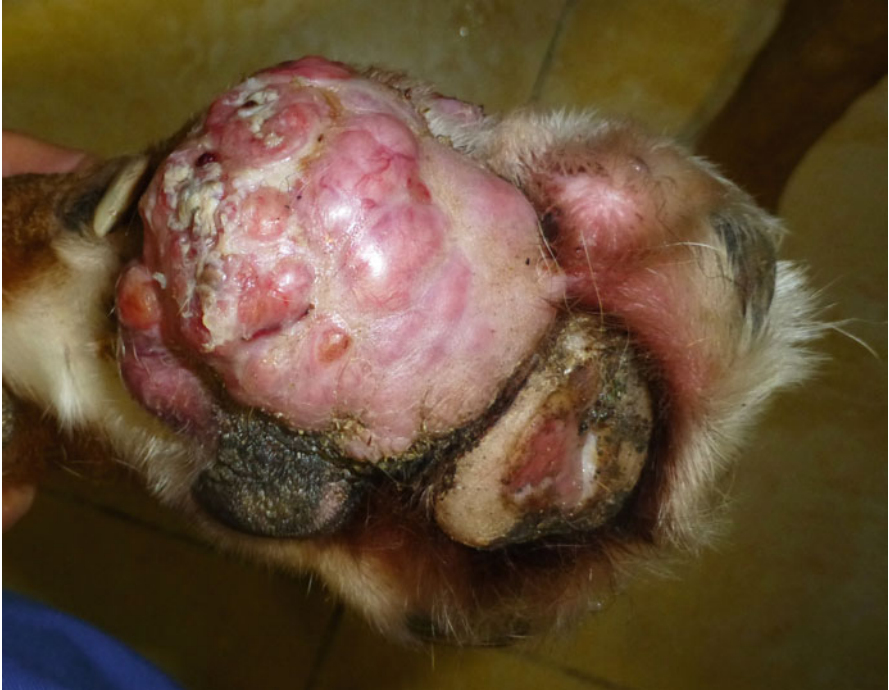

Fig. 4.270 Large and ulcerated malignant PNST on the paw of a dog

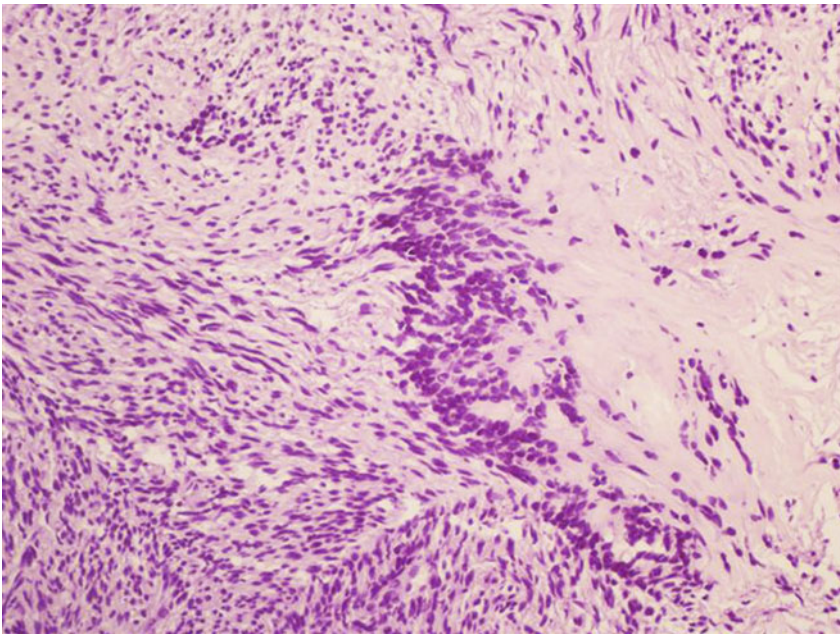


Fig. 4.271 Histology of a PNST: spindle cells are embedded in an eosinophilic matrix. A palisade arrangement of cells, which could resemble the Verocay bodies observed in human schwannomas, is evident (Courtesy of Prof. F. Abramo, Italy)

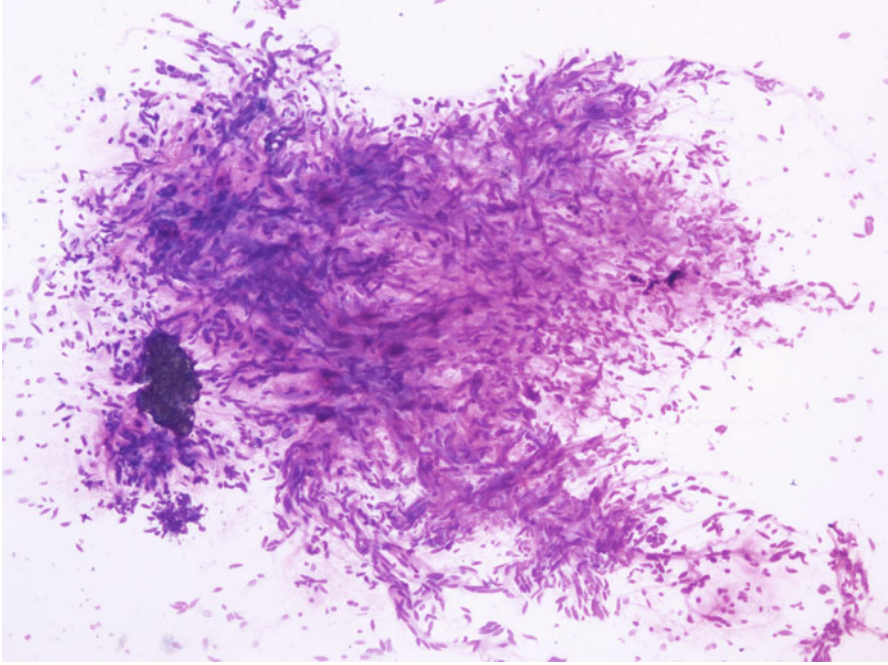


Fig. 4.272 Cytology of a PNST. Highly cellular sample, composed of disordered bundles of elongated spindle cells

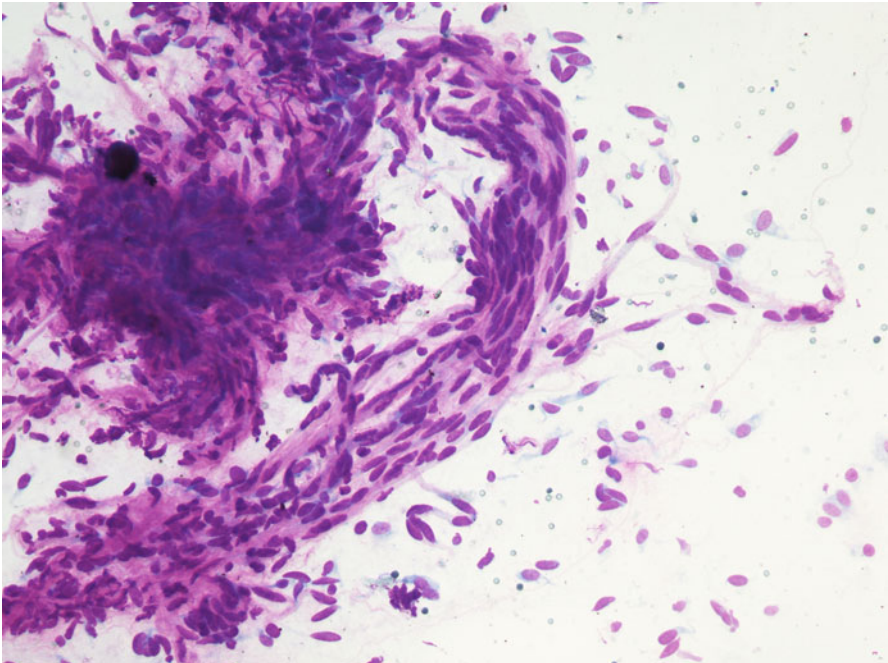


Fig. 4.273 Cytology of a PNST. At medium magnification, bundles of spindle cells are more evident

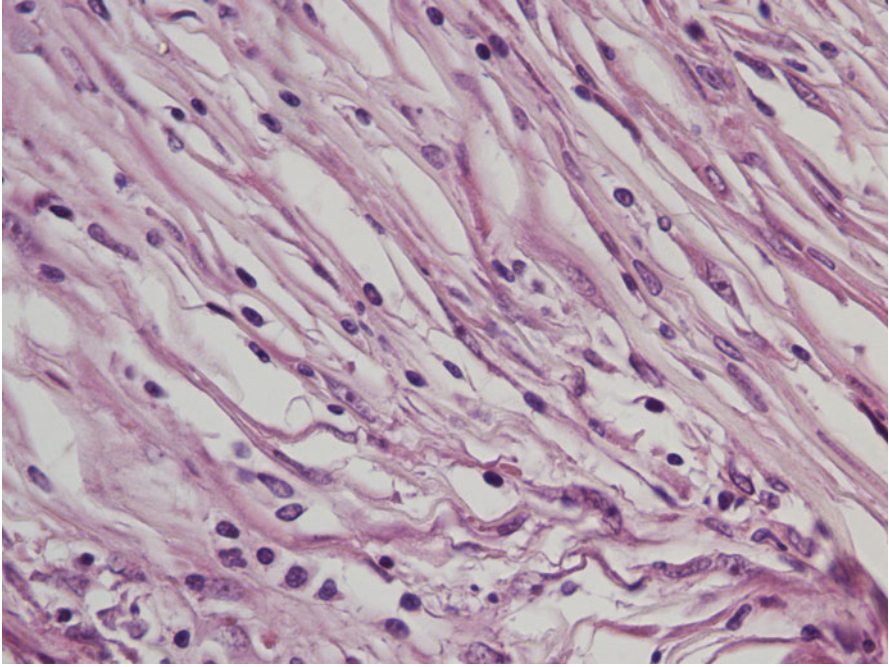


Fig. 4.274 Histology of a PNST. Slender undulating spindle cells, some of them with twisted nuclei

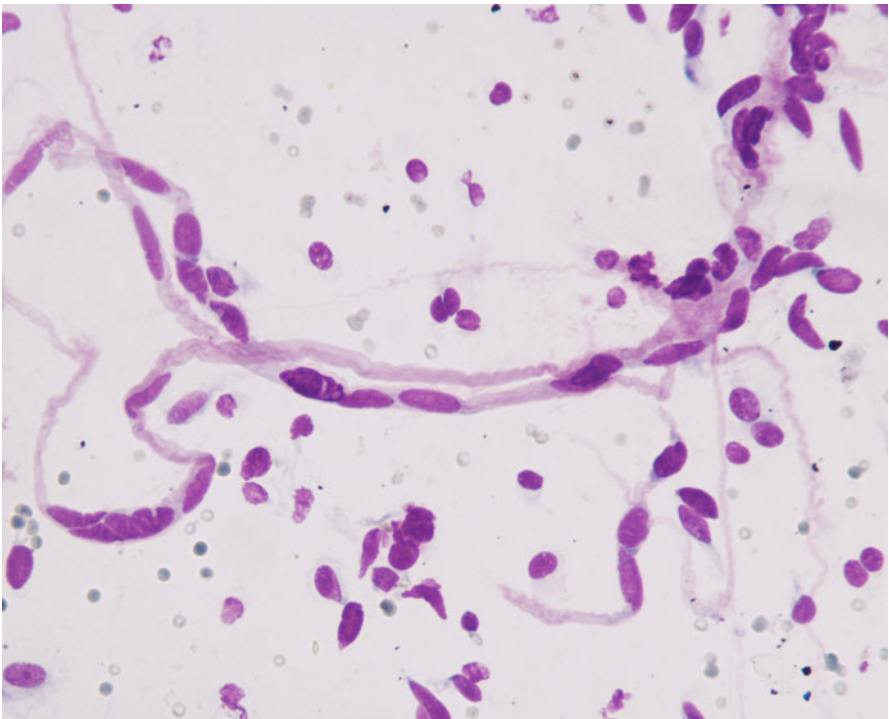


Fig. 4.275 Histology of a PNST. Slender undulating nervous spindle cells

subcutaneous lipoblasts (Baez et al. 2004; Gross et al. 2005). Lipoma occurs with single or multiple nodules, ranging in size from a few centimetres up to voluminous masses, soft-elastic in consistency, usually with well-defined and palpable margins. apart from the rarer cases of infiltrative lipoma, in which the fat infiltrates the underlying tissue. They are predominantly located on the trunk and on the proximal part of the limbs, especially in adult/elderly bitches and obese subjects (Figs. 4.276 and 4.277). The liposarcomas can be single or multiple and more firm on palpation than lipomas (Fig. 4.278). A first clue to the possible presence of a lipoma is provided by the macroscopic observation of colourless lipid droplets present on glass after collection; these droplets do not tend to dry and disappear once the slides are dipped into the alcoholic fixative (Fig. 4.279). This characteristic should not lead to a macroscopic diagnosis of lipoma.

Cytological Findings

It must be stressed that it is not possible to make a cytological diagnosis of *lipoma* as it is not possible to differentiate the normal adipocytes from the lipomatous tissue.

In any case, the cytology of lipoma is characterised by voluminous cells of different sizes, arranged singly or more often in clusters, with small, round or oval pyknotic and hyperchromatic nuclei. The latter are at the periphery of the cells, owing to the presence of intracellular fat, which gives the cytoplasm an optically empty appearance (Fig. 4.280).

In some cells, if the focus of the microscope is changed, it is possible to observe the presence of a single large vacuole filled with fat, whereas in others, multiple vacuoles are recognisable (Fig. 4.281).

Although the presence of capillary dispersed among adipocytes is more suggestive of lipoma, the diagnosis of lipoma through cytology is very hazardous, especially if the cytologist who read the slide has not personally collected the sample (Fig. 4.282). Therefore, the diagnosis of lipoma can only be made using histology.

There are also other histological variants of lipoma, including the *fibrolipoma*, the *angiolipoma*, the *angiofibrolipoma*, the *chondrolipoma* and the *spindle cell lipoma*, that are not identifiable with cytology and, for a definitive diagnosis, a histopathological examination is mandatory (Messick and Radin 1989; Liggett et al. 2002; Gross et al. 2005). Attention must be paid when making a diagnosis of sarcoma, when, together with adipocytes, many spindle cells are observed, as it is not cytologically possible to rule out that those fusiform cells come from a *spindle cell lipoma*.

Both round and spindle-shaped cells, usually arranged individually or in a perivascular arrangement, with central large round to oval nuclei and several atypia depending on the grade of differentiation, characterise the cytology of liposarcomas (Figs. 4.283, 4.284, and 4.285).

In samples from undifferentiated liposarcomas, in the absence of lipids in the intracytoplasmic vacuoles, cytological diagnosis is almost impossible. The nuclear and nucleolar atypias depend on the grade of malignancy and in the pleomorphic subtype, marked atypia and many multinucleated cells can be observed. In these cases it is not possible to differentiate a liposarcoma from other anaplastic soft-tissue sarcomas with many giant cells.

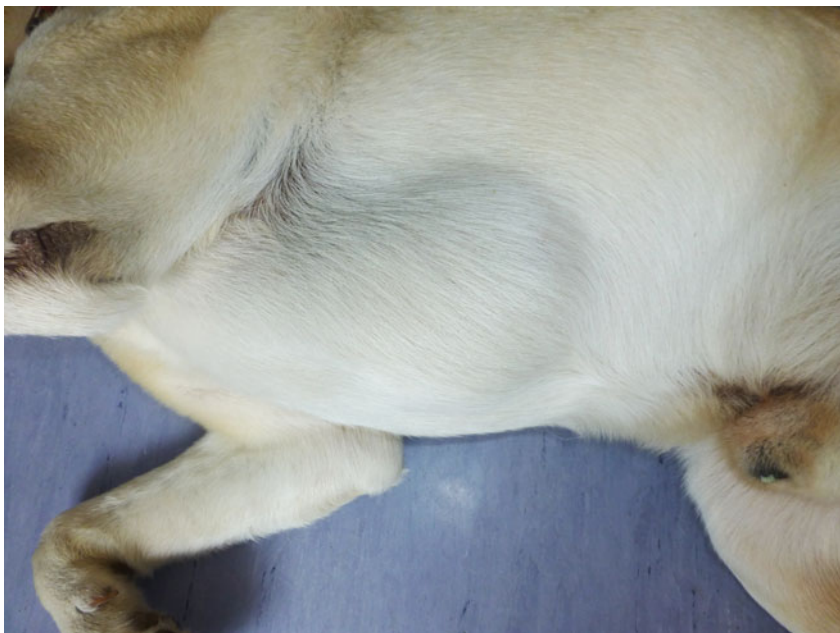

Fig. 4.276 Large lipoma on the sternal area of a Labrador retriever

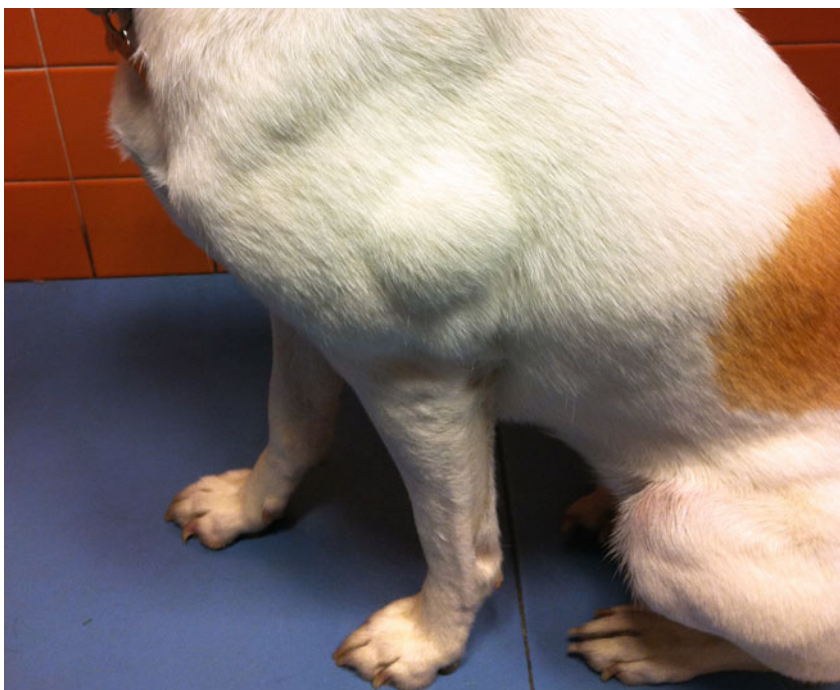

Fig. 4.277 Lipoma on the left shoulder of a mixed-breed dog

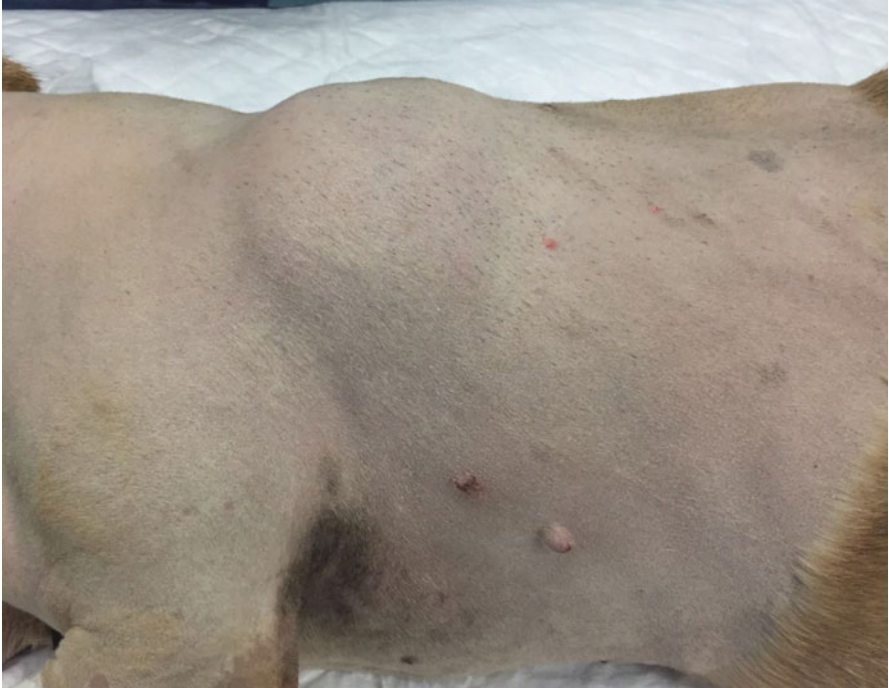

Fig. 4.278 Large liposarcoma on the chest of a dog (Courtesy of Dr. M. Annoni, Italy)



Fig. 4.279 Lipid drops on the slide

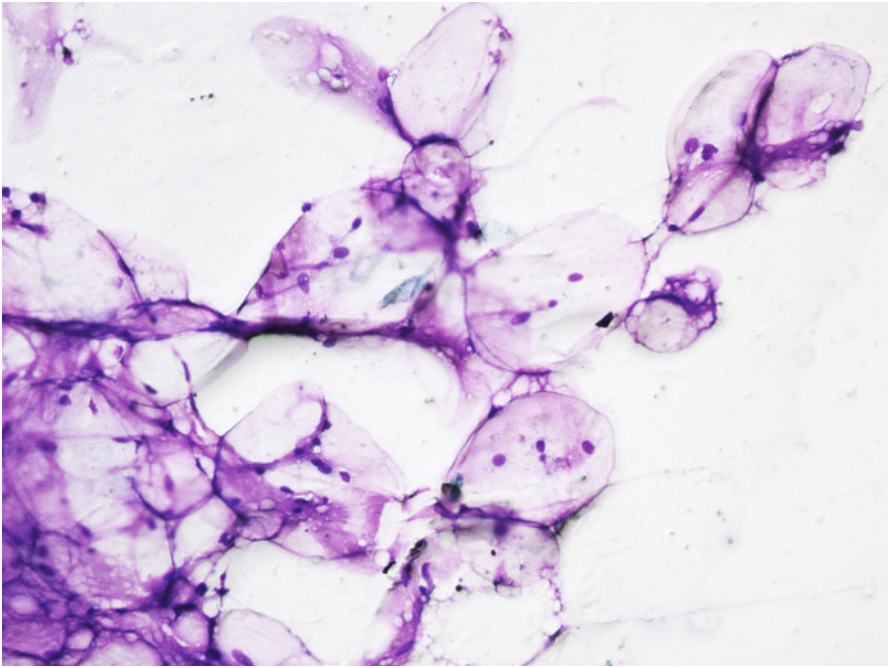


Fig. 4.280 Cytology of a lipoma. Large cluster of voluminous benign neoplastic adipocytes

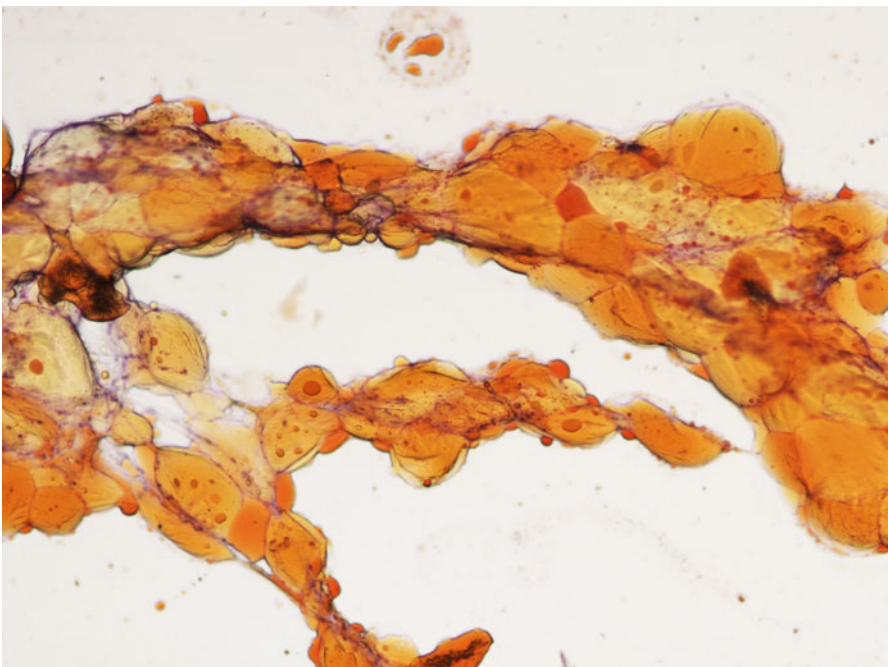


Fig. 4.281 Cytology of a lipoma. With oil-red-O staining, the lipid content of adipocytes is highlighted

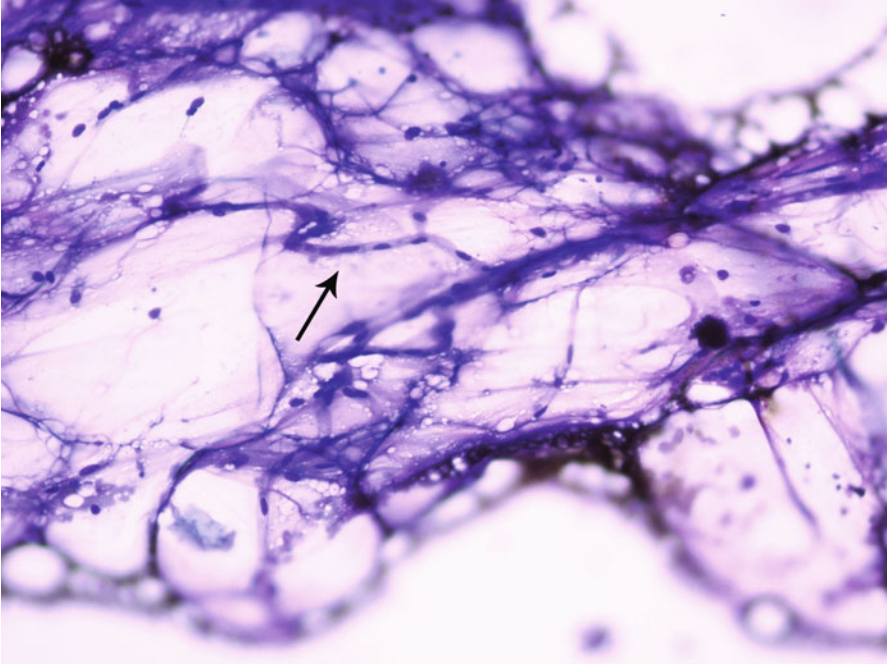


Fig. 4.282 Cytology of a lipoma. Note the blood vessels intermingled among the adipocytes (*arrow*)

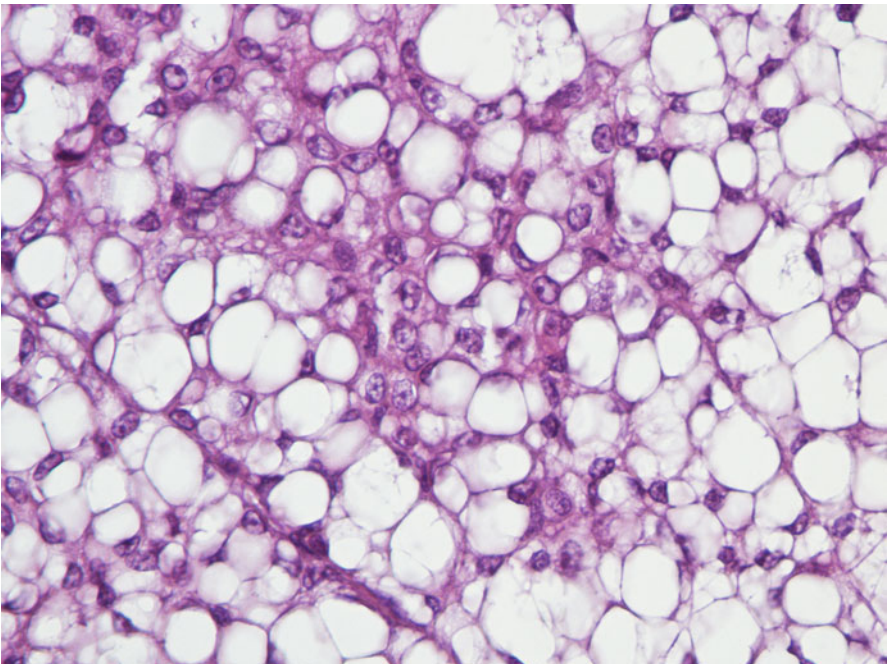


Fig. 4.283 Histology of a liposarcoma. Malignant fat cells in which large intracytoplasmic vacuoles are clearly recognisable

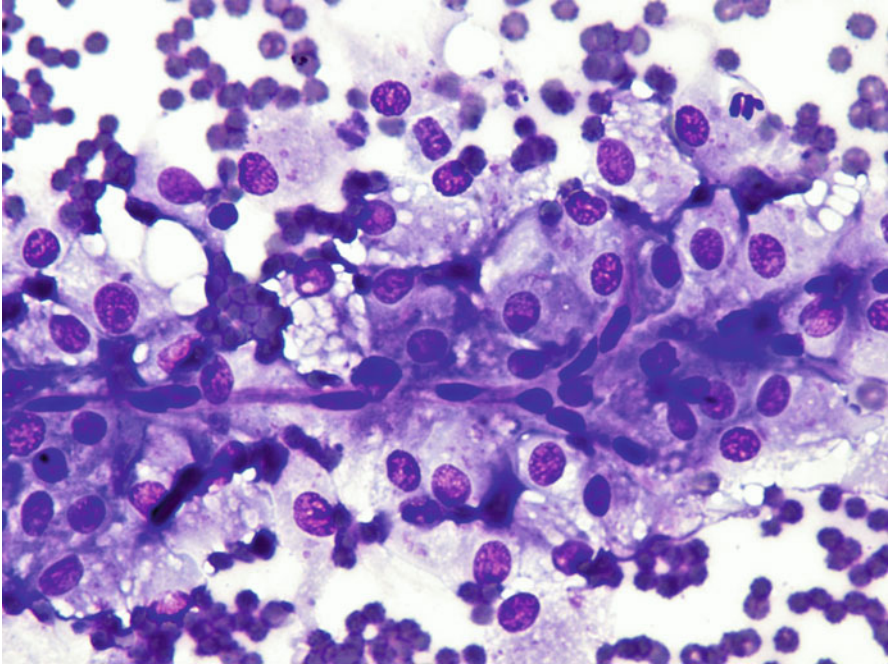


Fig. 4.284 Cytology of a liposarcoma. Perivascular arrangement of malignant adipocytes

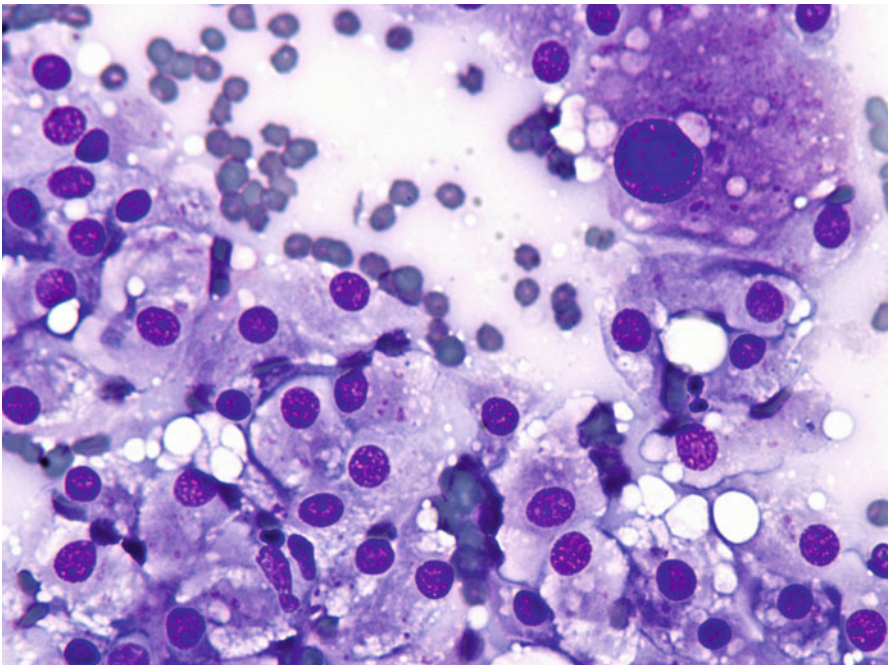


Fig. 4.285 Cytology of liposarcoma. Note the giant nucleated lipoblast of the larger cell with cytoplasm filled with large vacuoles

In poorly differentiated liposarcomas showing cytoplasmic vacuoles of uncertain origin, it is possible to demonstrate the lipid content of cytoplasm with the oil-red-O staining, which stains lipid red–orange (Masserdotti et al. 2006).

4.4.7 Anaplastic Soft-Tissue Sarcoma with Many Giant Cells

Many mesenchymal tumours are grouped under the umbrella of the ASTSgc, formerly classified as *malignant fibrous histiocytoma*. These tumours share the fact that they are composed of three different morphologies of cells: *spindle cells*, *plump roundish histiocytoid cells* and *multinucleated cells*; the latter may be either neoplastic or reactive (histiocytic giant cells).

The term *malignant fibrous histiocytoma* has been used over the years to describe a tumour cytologically characterised by a population consisting of the simultaneous presence of the above three different cellular morphologies. Many clinico-pathological, immunohistochemical and molecular biology studies, have shown that cancer is not histiocytic, but of mesenchymal origin; the term malignant fibrous histiocytoma is therefore only a descriptive morphological term and must be considered incorrect as it implies the existence of a fibrous histiocyte (Pace et al. 1994; Gross et al. 2005). For this reason, it is therefore more appropriate to use the generic term ASTSgc (Goldschmidt and Shofer 1992).

These tumours may originate from many different cell lineages and are cytologically indistinguishable from each other. Indeed, they could be an anaplastic variant of *fibrosarcoma*, *myofibroblastic fibrosarcoma*, *rhabdomyosarcoma*, *leiomyosarcoma*, *liposarcoma*, *synovial cell sarcoma* or another sarcoma.

It should be stressed that, because the *post-injection sarcoma* may present the same cytological findings, it can also be *morphologically* included in this group of neoplasms (Couto et al. 2002; Gross et al. 2005). Finally, it should be emphasised that the cytology of some spindle-cell subtypes of *histiocytic sarcomas* could show identical features to those described for ASTSgcs. In these cases, the only examination that allows the differentiation between ASTSgcs and histiocytic sarcomas is immunohistochemistry.

These neoplasms, uncommon in dogs and more frequent in cats, are clinically characterised by single and occasionally multiple nodules, of variable size and irregular in shape, mainly located on the trunk and limbs (Figs. 4.286 and 4.287).

Cytological Findings

As mentioned above, the cytology of this group of neoplasms is usually characterised by highly cellular specimens with a marked pleomorphism, represented mainly by spindle-shaped cells, by a variable number of round histiocyte-like cells, and by many multinucleated giant cells (Fig. 4.288).

The sarcomatous cells exhibit many traits of atypia, such as marked anisocytosis and anisokaryosis, irregular chromatin, multiple voluminous and bizarrely shaped nucleoli and atypical mitosis (Fig. 4.289). In many ASTSgcs, the giant cells are composed of a large number of nuclei, uniform in size and shape, that do not exhibit

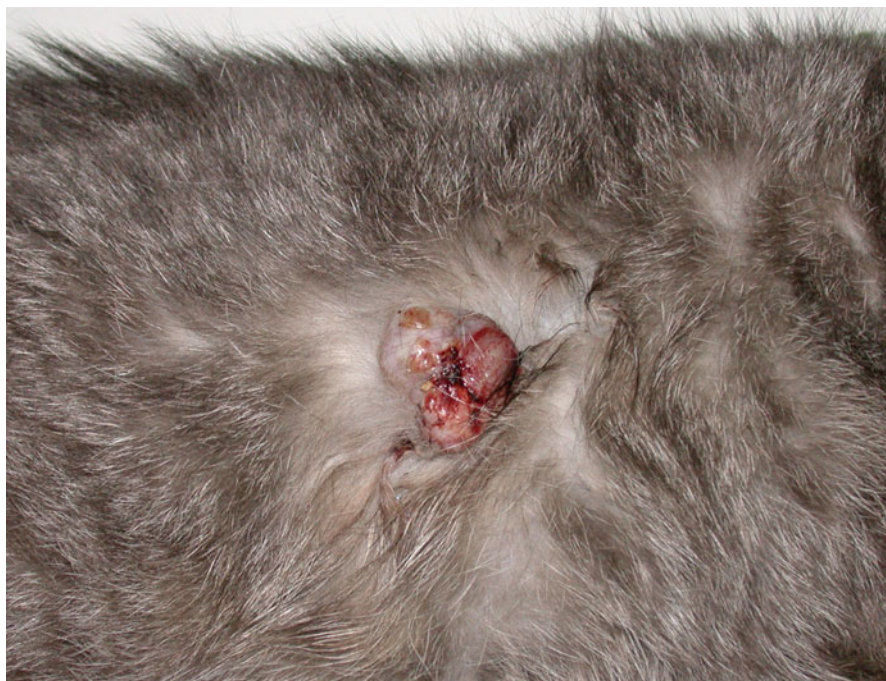

Fig. 4.286 Ulcerated anaplastic sarcoma with many giant cells (ASTSgc) on the chest of a cat

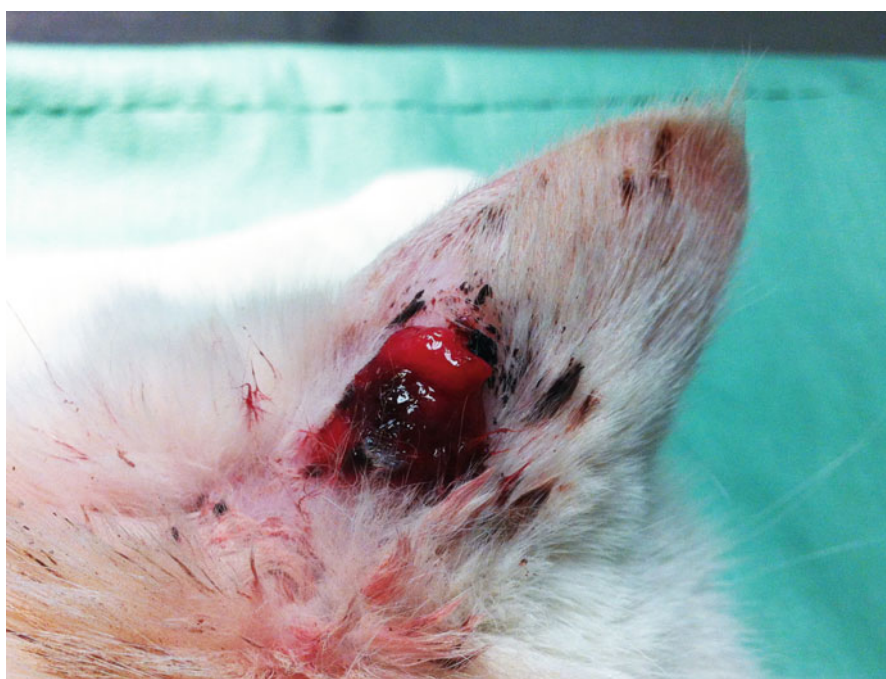


Fig. 4.287 Ulcerated ASTSgc on the pinna of a cat

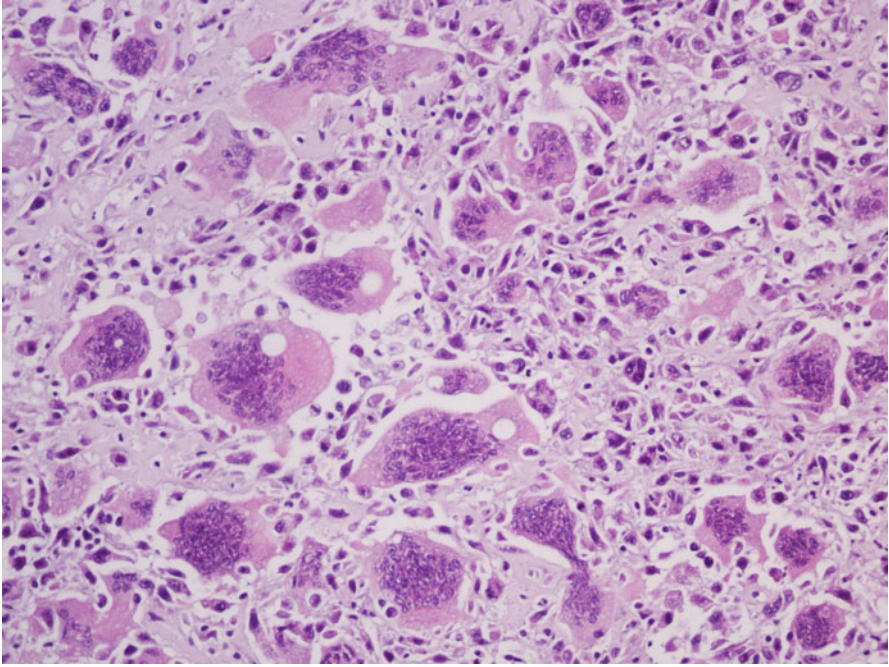


Fig. 4.288 Histology of an ASTSgc: numerous reactive histiocytic giant cells are interspersed within spindle mesenchymal cells

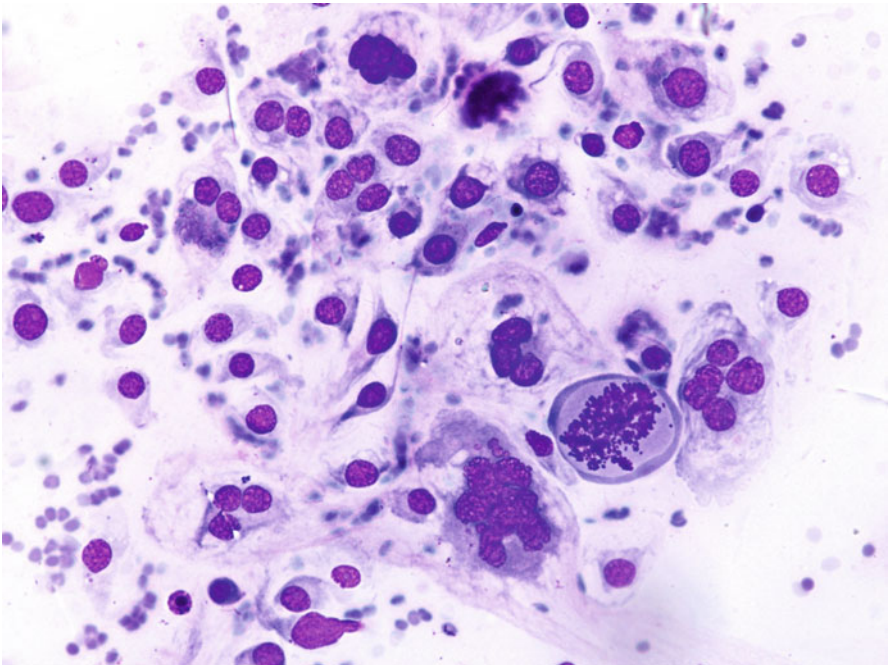


Fig. 4.289 Cytology of an ASTSgc: highly malignant mesenchymal cells. Note the giant mitotic cell

any cytological criteria of malignancy (Fig. 4.290). The benign appearance of these nuclei contrasts with the marked atypias observed in other cells, especially the spindle cells, and this difference allows the giant cells to be interpreted as reactive histiocytic cells that infiltrate the tumour; in human medicine, their presence is considered a positive prognostic indication.

4.5 Melanocytic Tumours

Melanocytic neoplasms can arise from epidermal, dermal and follicular melanocytes and are classified into two groups that differ on the basis of histological features: *melanocytoma* (benign melanoma) and *melanoma* (malignant melanoma). Melanocytic skin tumours are uncommon in dogs and rare in cats (Luna et al. 2000; Schultheiss 2006; Bergman et al. 2013). Single skin nodules, of variable size, alopecic and usually highly pigmented, grossly characterise melanocytomas, which are mainly located on the head, limbs and trunk (Fig. 4.291). Melanomas are larger than melanocytomas; they are single or multiple and not always pigmented, with an intact or ulcerated surface (Figs. 4.292 and 4.293). Over the years, many works have reported that oral and lip melanomas have a higher rate of malignancy compared with those arising at other body sites; recent studies have shown that, although melanomas grown in this area are very aggressive, the percentage of good prognoses is higher than previously reported (Smedley et al. 2011). In dogs, nail bed melanomas are very aggressive and are more frequently observed on large dogs with black fur (Smith et al. 2002; Gross et al. 2005).

Cytological Findings

The cytology of *melanocytic tumours* is strongly variable. As melanocytes are of neuro-ectodermal origin, neoplastic cells may exhibit, in the same tumour, cytological features of both mesenchymal and epithelial cells; therefore, when the melanin pigment is completely absent, the diagnosis is not possible, even for the most experienced cytologists. The neoplastic melanocytes collected from a melanocytoma are usually well differentiated and characterised by a moderate cytological polymorphism. Neoplastic cells can be round, with round to oval nuclei and moderate to large cytoplasm, filled with uniform rod- to round-shaped black or dark green granules; in some cases the granules may be so numerous that they completely obscure the nuclei (Figs. 4.294 and 4.295). As mentioned, neoplastic melanocytes can exhibit a round, spindle, epithelioid and balloon shape; the latter cells have clear and large cytoplasm containing small ovoid nuclei, whereas the epithelioid shape is very frequent and characterised by neoplastic cells that are arranged in pseudo-aggregates (Figs. 4.296, 4.297, 4.298, 4.299, and 4.300). These different morphologies are often present together in the same tumour. The cytological diagnosis of melanocytic neoplasia, whatever the cell morphology, is easy when the melanin pigment in the cytoplasm is evident.

A histological variant of melanoma, named the *signet-ring cell melanoma*, is recognised in dogs and cats (van der Linde-Sipman et al. 1997; Cangul et al. 2001). In this subtype of melanoma, cells have a plasmacytoid appearance, with eccentric nuclei, sometimes double, prominent nucleoli and eosinophilic cytoplasm containing

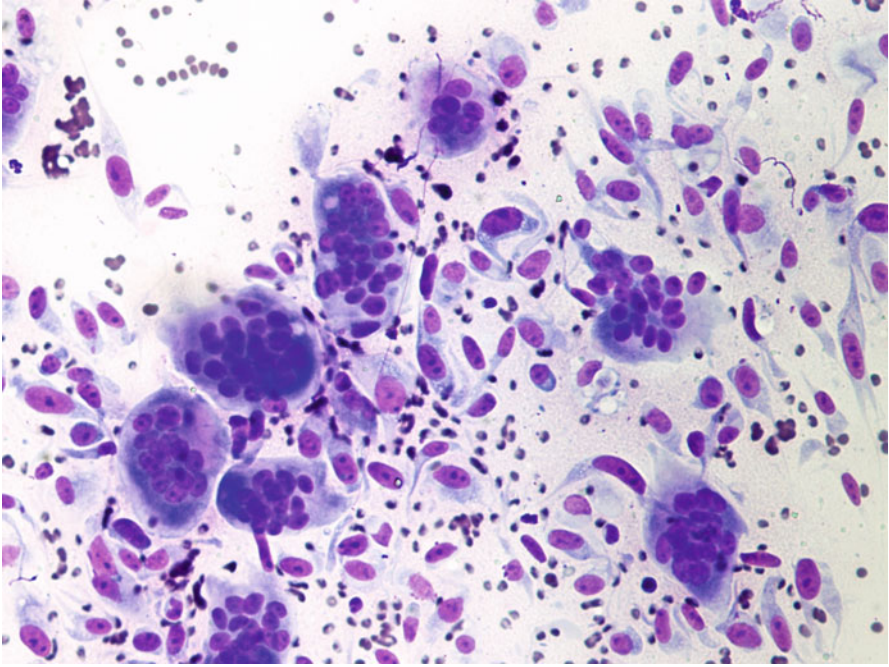


Fig. 4.290 Cytology of an ASTSgc: the coexistence of roundish, spindle and multinucleated cells characterise the mesenchymal neoplasms grouped under the ASTSgc umbrella

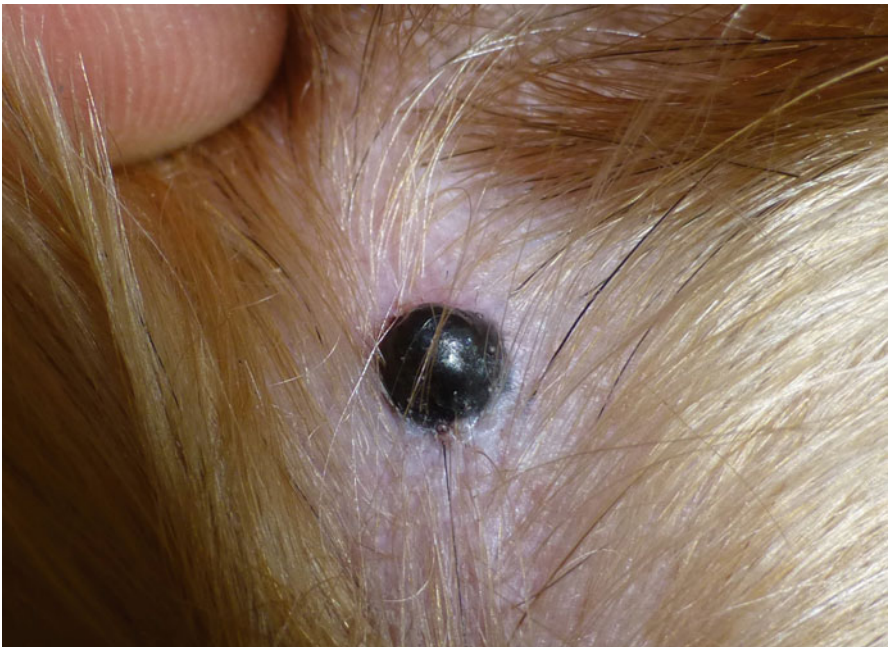

Fig. 4.291 Small pigmented melanocytoma

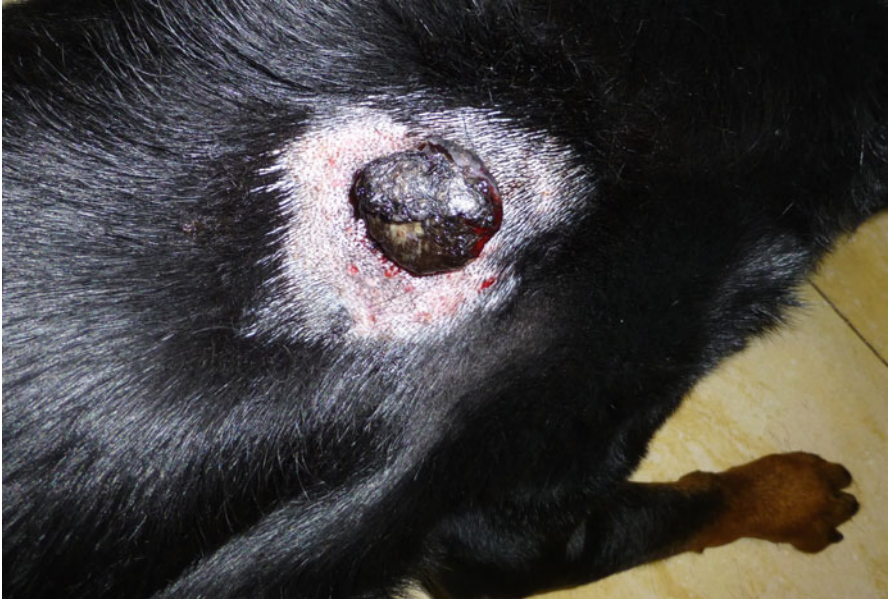


Fig. 4.292 Large ulcerated melanoma on the trunk of a Rottweiler

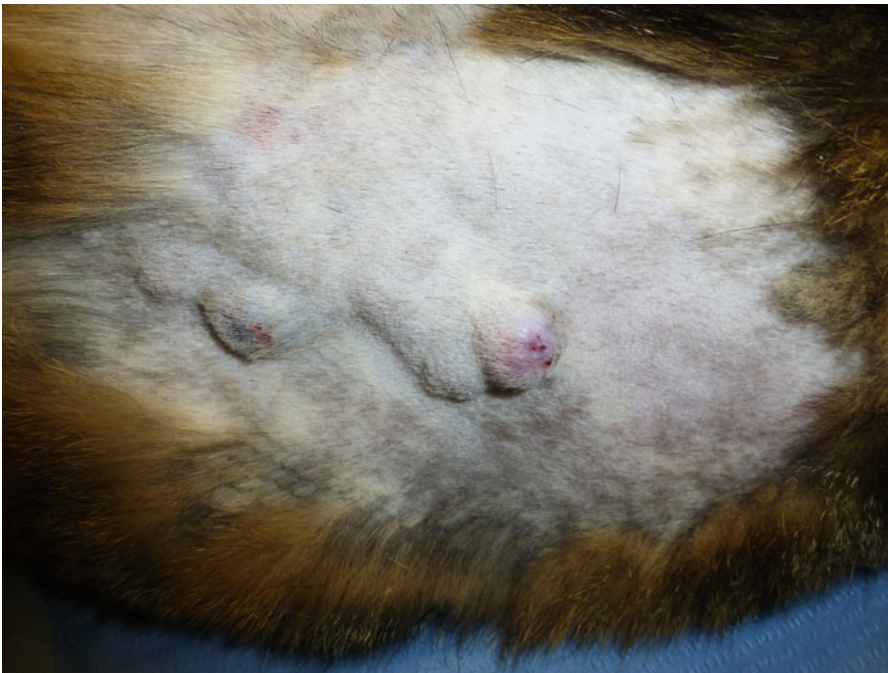


Fig. 4.293 Multiple and confluent nodules in a cat with *signet-ring* cell melanoma (Courtesy of Dr. C. Damiani, Italy)

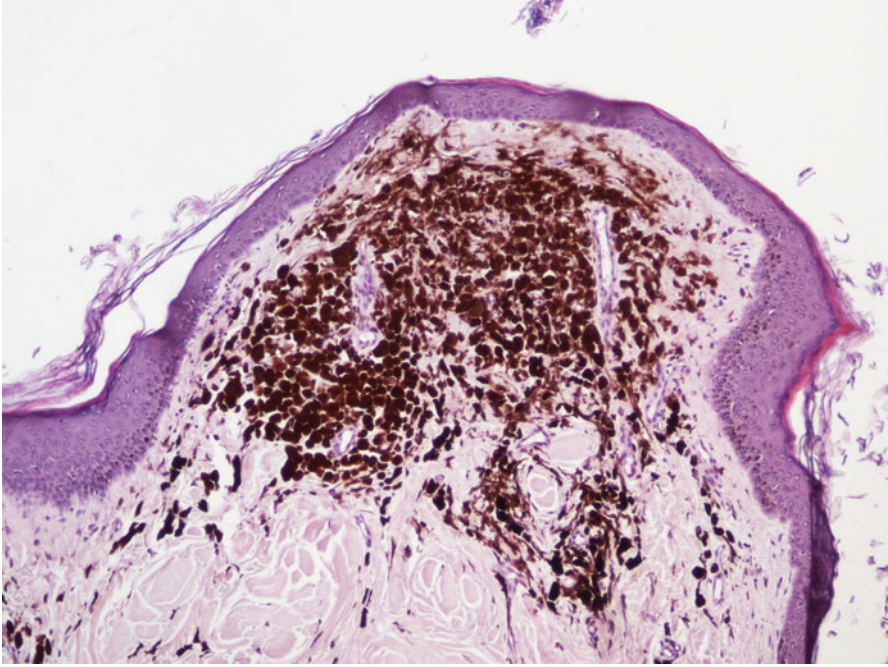


Fig. 4.294 Histology of a melanocytoma. Dermal proliferation of highly pigmented melanocytes

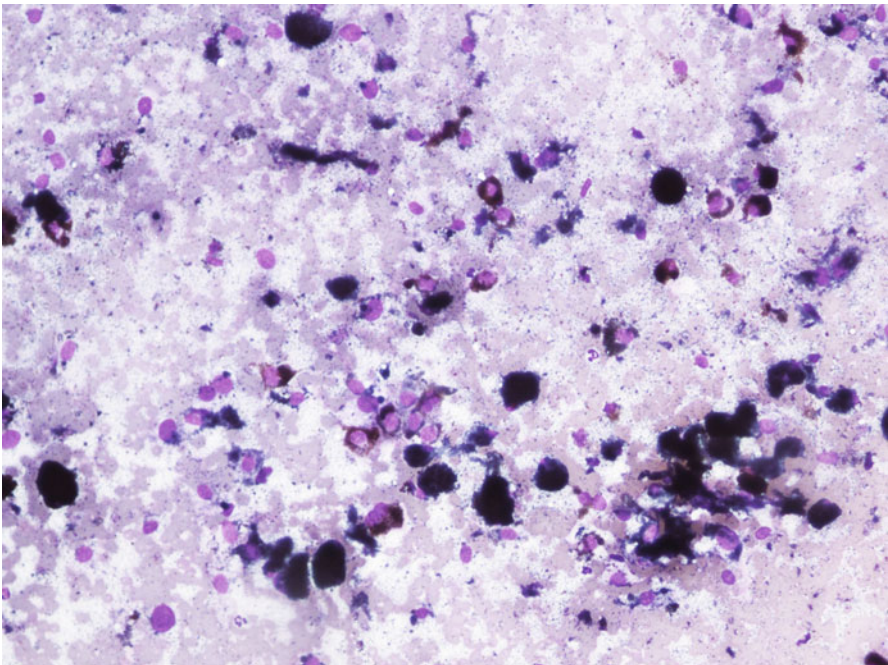


Fig. 4.295 Cytology of a melanocytoma. The nuclear characteristics of melanocytes are not clearly visible owing to the high amount of intracytoplasmic melanin

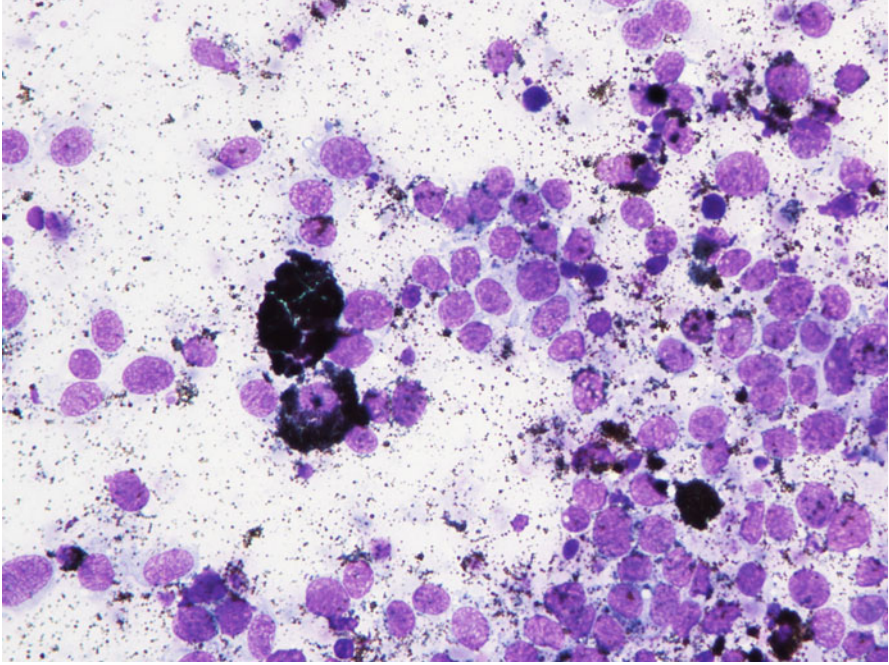


Fig. 4.296 Cytology of a melanoma. Round and pigmented neoplastic melanocytes

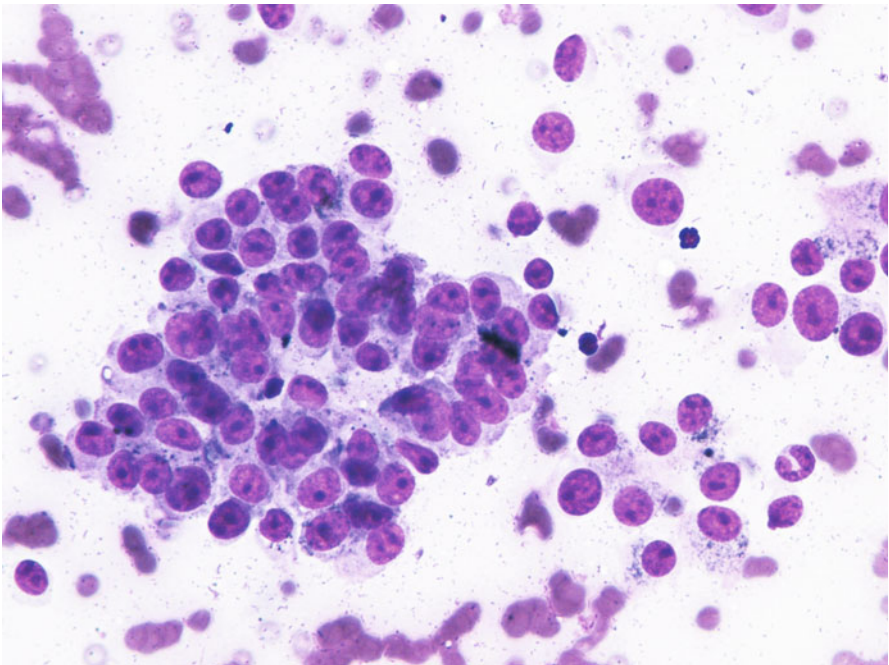


Fig. 4.297 Cytology of a melanoma. A large pseudo-aggregate of neoplastic melanocytes with epithelioid appearance

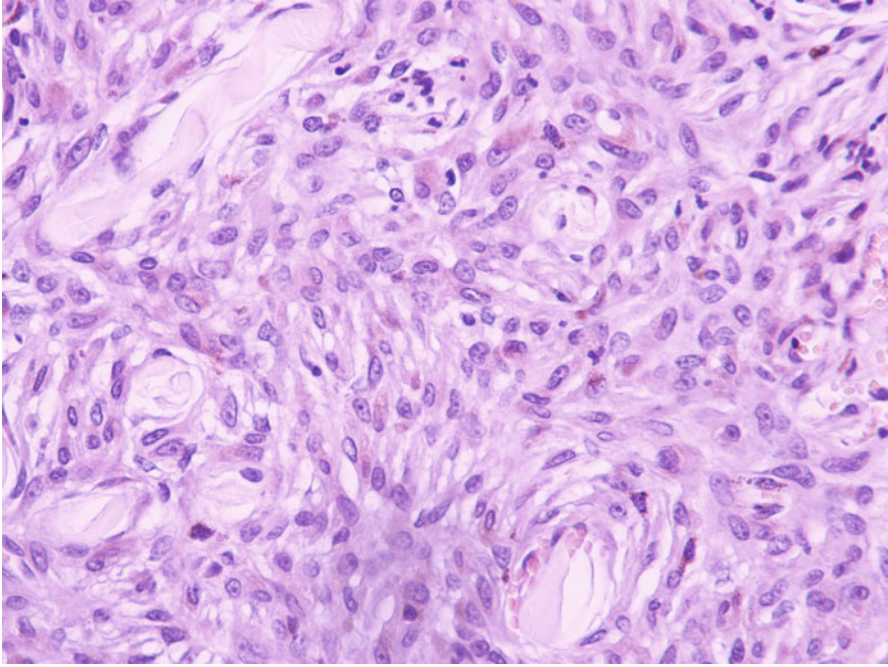


Fig. 4.298 Histology of a spindle cell melanoma. Note the melanin pigment in the cytoplasm of some spindle melanocytes

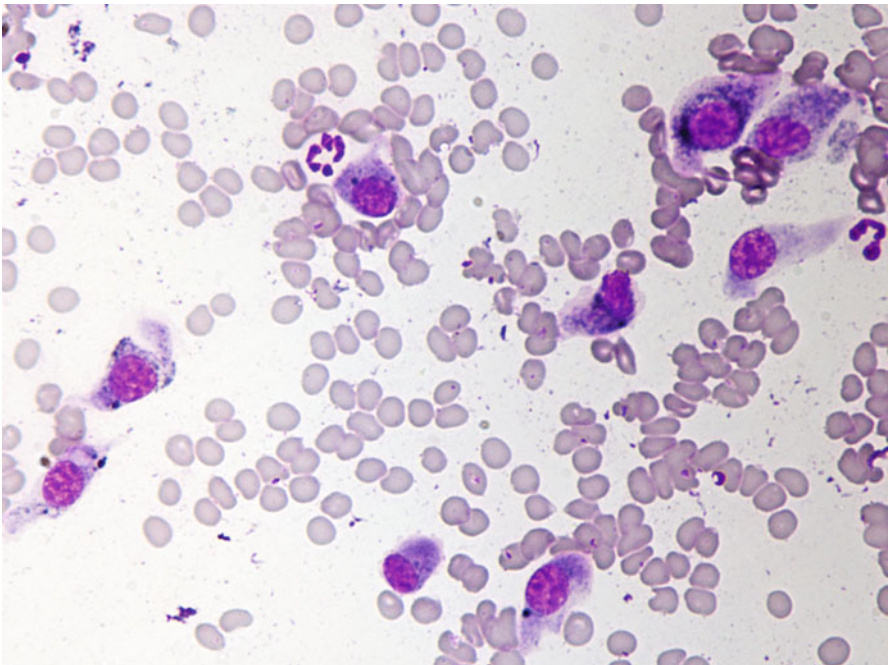


Fig. 4.299 Cytology of a spindle cell melanoma. Note that all the spindle cells contain melanin pigment, which confirms their melanocytic origin

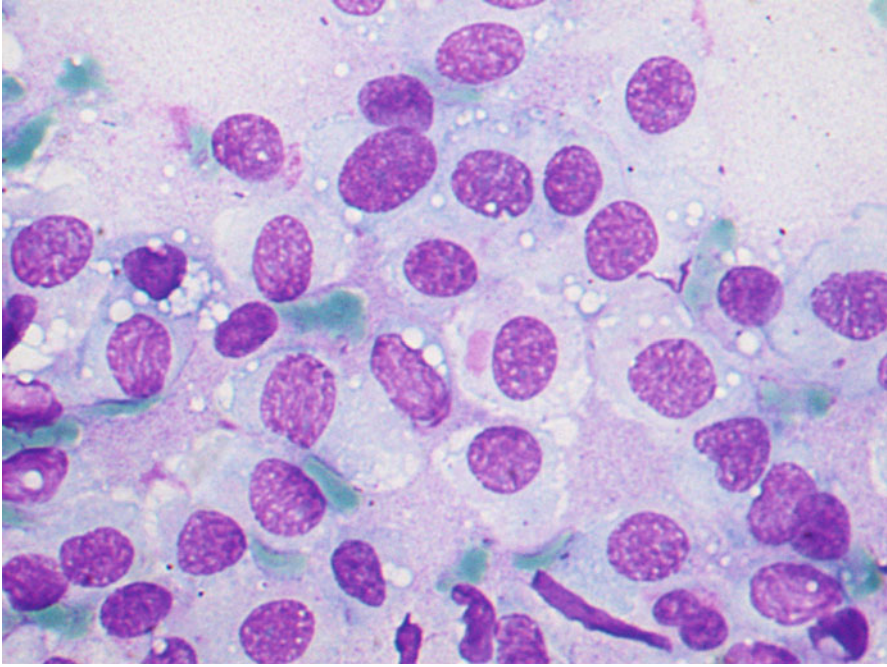


Fig. 4.300 Cytology of a balloon cell melanoma. Large melanocytic neoplastic cells characterised by uniform nuclear chromatin and large cytoplasm without pigmentation (Courtesy of Dr. L. Marconato, Italy)

inclusion-like globular bodies (Figs. 4.301, 4.302, and 4.303). In melanomas characterised by signet-ring cells, and in balloon cell melanomas, the pigment is usually scarce to totally absent (Wilkerson et al. 2003). In completely *amelanotic signet-ring melanomas*, differentiating them from a plasmacytoma is very difficult and requires histopathology to detect melanin pigment. Furthermore if the latter is not present, only immunohistochemical stains achieve diagnosis.

The cytological distinction between melanocytoma and well-differentiated melanoma can be complex, for which reason in many cases it is necessary to perform confirmatory histopathology. In poorly differentiated tumours, marked aspects of malignancy are observed; nuclei with large and often multiple and with bizarre-shaped macronucleoli are commonly detected. In very anaplastic amelanotic melanomas, especially when characterized by spindle and multinucleated cells, a cytological diagnosis is not possible. Similar cytological findings can be indeed observed in specimens coming from anaplastic soft tissue sarcoma or dendritic histiocytic sarcomas (Fig. 4.304; Choi and Kusewitt 2003). Fortunately, amelanotic melanoma are extremely rare on the skin, while are more common in oral cavity.

In amelanotic melanomas, the detection of melanophages increases the suspicion of a melanoma. The melanophages may be recognisable, and therefore differentiated from melanocytes, by the appearance of nuclear chromatin, the presence of cytoplasmic vacuoles and by a coarser intracytoplasmic melanin pigment (Fig. 4.305). This cytological differentiation is not always easy, particularly when the amount of pigment obscures the nucleus.

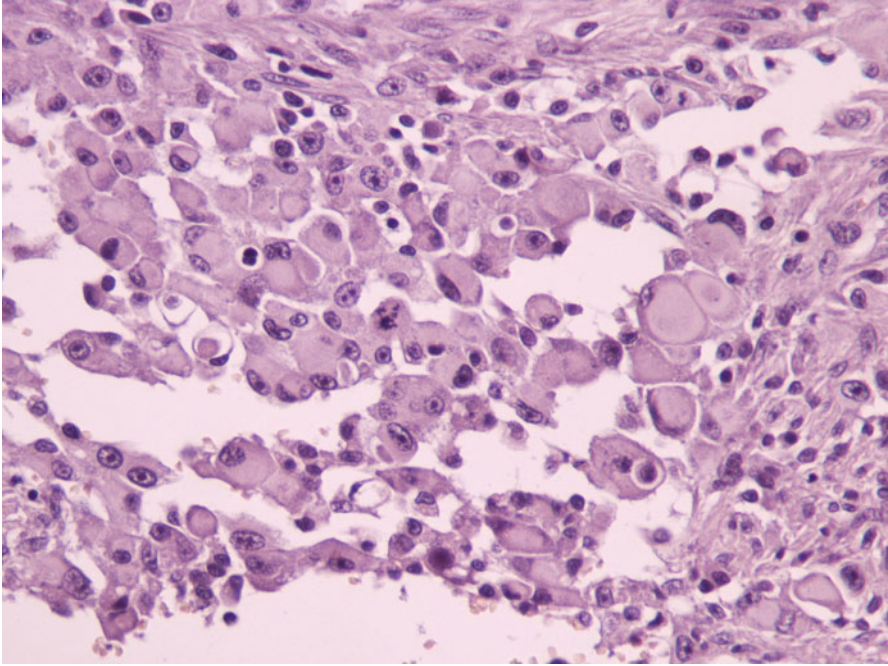


Fig. 4.301 Histology of a feline signet-ring cell melanoma. Cells with plasmacytoid appearance, with eosinophilic cytoplasm containing inclusion-like globular bodies

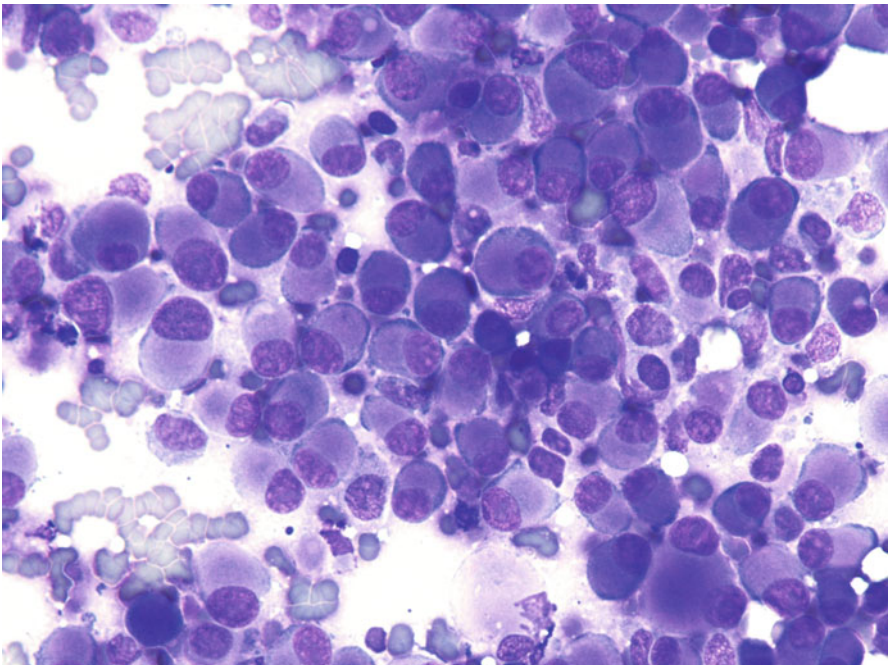


Fig. 4.302 Cytology of a signet-ring cell melanoma. Note the eccentric nuclei and the intracytoplasmic presence of an eosinophilic globular body

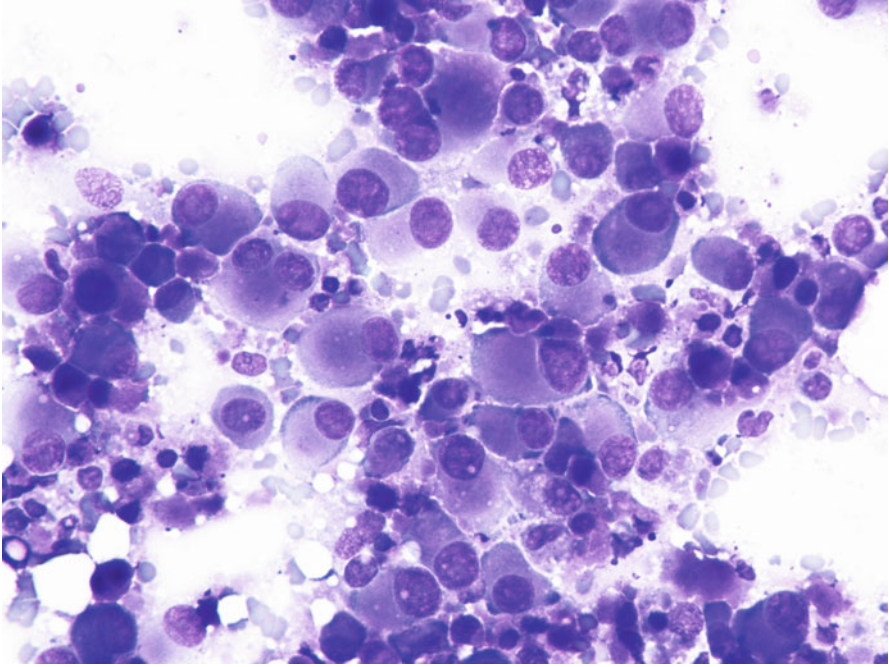


Fig. 4.303 Cytology of a signet-ring cell melanoma. At high magnifications the cytological features of this type of melanoma are evident

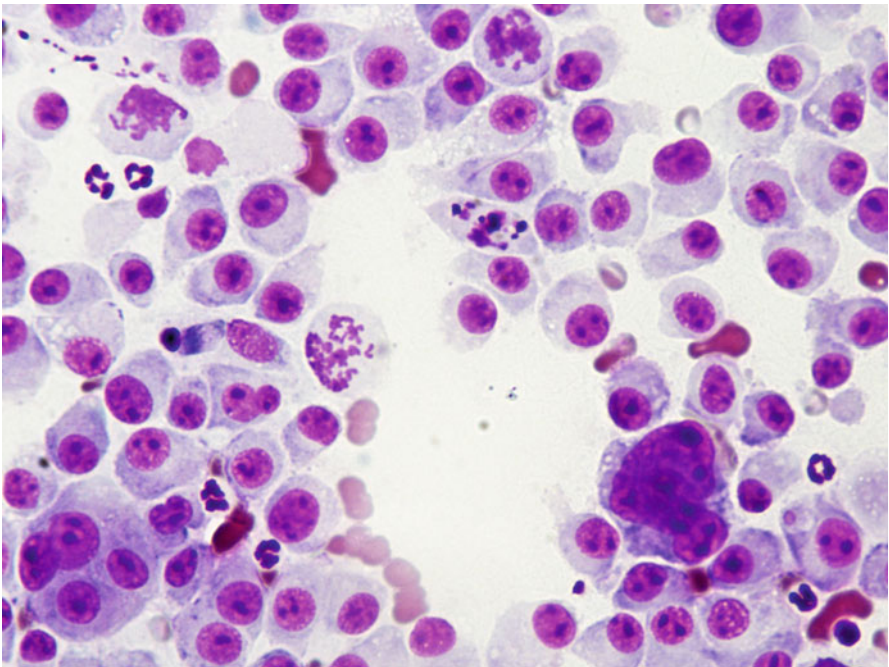


Fig. 4.304 Cytology of an undifferentiated amelanotic melanoma. Severe cytological features of malignancy are clearly evident

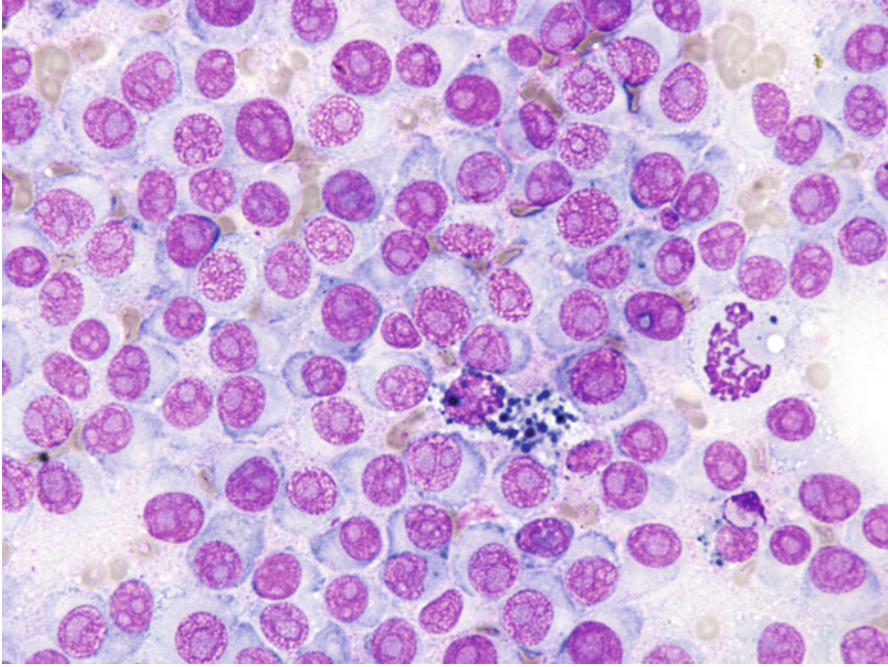


Fig. 4.305 Cytology of an undifferentiated amelanotic melanoma. A melanophage is evident among the neoplastic melanocytes. Melanin pigment is barely perceptible in the cytoplasm of few melanocytes

References

Introduction

- Baker R, Lumsden JH (1999) Colour atlas of cytology of the dog and cat. Mosby, St. Louis
- Chalita MC, Matera JM, Alves MT et al (2001) Nonaspiration fine needle cytology and its histologic correlation in canine skin and soft tissue tumors. *Anal Quant Cytol Histol* 23:395–399
- Cohen M, Bohling MW, Wright JC et al (2003) Evaluation of sensitivity and specificity of cytologic examination: 269 cases (1999–2000). *J Am Vet Med Assoc* 222:964–967
- Ghisleni G, Roccabianca P, Ceruti R et al (2006) Correlation between fine-needle aspiration cytology and histopathology in the evaluation of cutaneous and subcutaneous masses from dogs and cats. *Vet Clin Pathol* 35:24–30
- Griffiths GL, Lumsden JH, Valli VEO (1984) Fine needle aspiration cytology and histologic correlation in canine tumors. *Vet Clin Pathol* 13:13–17
- Gross TL, Ihrke PJ, Walder EJ et al (2005) Skin diseases of the dog and cat: clinical and histopathologic diagnosis, 2nd edn. Blackwell Science, Oxford
- Raskin RE, Meyer DJ (2015) Canine and feline cytology. In: A color atlas and interpretation guide, 3rd edn. WB Saunders Co, Philadelphia
- Valenciano AC, Cowell RL (2014) Cowell and Tyler's diagnostic cytology and hematology of the dog and cat, 4th edn. Elsevier/Masson, St. Louis
- Withrow SJ, Vail DM, Page R (2012) Withrow and MacEwen's small animal clinical oncology. Elsevier-Saunders, St. Louis

Yager JA, Wilcock BP (1994) *Dermatopathology and skin tumors, vol 1, Color atlas and text of surgical pathology of the dog and cat*. Mosby Inc, London

Round Cell Tumors

Mast Cell Tumors

- Blackwood L, Murphy S, Buracco P et al (2012) European consensus document on mast cell tumours in dogs and cats. *Vet Comp Oncol* 10:e1–e29
- Goldschmidt MH, Hendrick MJ (2002) Tumors of the skin and soft tissues. In: Meuten DJ (ed) *Tumors in domestic animals, 4th edn*. Iowa State Press/Blackwell, Ames, pp 45–117
- Gross TL, Ihrke PJ, Walder EJ et al (2005) *Skin diseases of the dog and cat: clinical and histopathologic diagnosis, 2nd edn*. Blackwell Science, Oxford, pp 853–865
- Henry C, Herrera C (2013) Mast cell tumors in cats: clinical update and possible new treatment avenues. *J Feline Med Surg* 15:41
- Johnson TO, Schulman FY, Lipscomb TP et al (2002) Histopathology and biologic behavior of pleomorphic cutaneous mast cell tumors in fifteen cats. *Vet Pathol* 39:452–457
- Kiupel M, Webster JD, Bailey KL et al (2011) Proposal of a 2-tier histologic grading system for canine cutaneous mast cell tumours to more accurately predict biological behaviour. *Vet Pathol* 48:147–155
- Melville K, Smith KC, Dobromylskyj MJ (2014) Feline cutaneous mast cell tumours: a UK-based study comparing signalment and histological features with long-term outcomes. *J Feline Med Surg* 17(6):486–493
- Patnaik AK, Ehler WJ, MacEwen EG (1984) Canine cutaneous mast cell tumor: morphologic grading and survival time in 83 dogs. *Vet Pathol* 21:469–474
- Pedraza F, Grandi F, Rocha NS (2011) The need for cytologic/histologic correlation studies to establish a cytologic grading system for canine mast cell tumors in veterinary medicine. *Vet Clin Pathol* 40:280–281
- Sabattini S, Bettini G (2010) Prognostic value of histologic and immunohistochemical features in feline cutaneous mast cell tumors. *Vet Pathol* 47:643–653
- Scarpa F, Sabattini S, Bettini G (2014) Cytological grading of canine cutaneous mast cell tumours. *Vet Comp Oncol*. 14(3):245–251
- Thamm DH, Vail DM (2007) Mast cell tumors. In: Withrow SJ, MacEwen EG (eds) *Withrow and MacEwen's small animal clinical oncology, 4th edn*. Saunders-Elsevier, St Louis, pp 402–424
- Welle MM, Rohrer Bley C, Howard J et al (2008) Canine mast cell tumours: a review of the pathogenesis, clinical features, pathology and treatment. *Vet Dermatol* 19:321–339

Cutaneous Lymphoma

- Affolter VK, Gross TL, Moore PF (2009) Indolent cutaneous T-cell lymphoma presenting as cutaneous lymphocytosis in dogs. *Vet Dermatol* 20(5–6):577–585
- Brachelente C, Affolter VK, Fondati A et al (2015) CD3 and CD20 coexpression in a case of canine cutaneous epitheliotropic T-cell lymphoma (mycosis fungoides). *Vet Pathol* 53(3):563–566
- Fontaine J, Bovens C, Bettenay S et al (2009) Canine cutaneous epitheliotropic T-cell lymphoma: a review. *Vet Comp Oncol* 7:1–14
- Fontaine J, Heimann M, Day MJ (2010) Canine cutaneous epitheliotropic T-cell lymphoma: a review of 30 cases. *Vet Dermatol* 21(3):267–275
- Gross TL, Ihrke PJ, Walder EJ et al (2005) *Skin diseases of the dog and cat – clinical and histopathologic diagnosis, 2nd edn*. Wiley-Blackwell, Oxford, pp 876–888

- Keller SM, Moore PF (2012) A novel clonality assay for the assessment of canine T cell proliferations. *Vet Immunol Immunopathol* 145(1–2):410–419
- Miller WH, Griffin CE, Campbell KL (2013) Tumors of lymphoid origin. In: Muller & Kirk's-small animal dermatology, 7th edn. Elsevier, St. Louis, pp 810–816
- Moore PF, Affolter VK, Graham PS et al (2009) Canine epitheliotropic cutaneous T-cell lymphoma: an investigation of T-cell receptor immunophenotype, lesion topography and molecular clonality. *Vet Dermatol* 20(5–6):569–576
- Moore PF, Affolter VK, Keller SM (2013) Canine inflamed nonepitheliotropic cutaneous T-cell lymphoma: a diagnostic conundrum. *Vet Dermatol* 24(1):204–211

Plasma Cell Tumors

- Cangul IT, Wijnen M, Van Garderen E et al (2002) Clinico-pathological aspects of canine cutaneous and mucocutaneous plasmacytomas. *J Vet Med A Physiol Pathol Clin Med* 49(6):307–312
- Gross TL, Ihrke PJ, Walder EJ et al (2005) Skin diseases of the dog and cat – clinical and histopathologic diagnosis, 2nd edn. Wiley-Blackwell, Oxford, pp 866–872
- Majzoub M, Breuer W, Platz SJ et al (2003) Histopathologic and immunophenotypic characterization of extramedullary plasmacytomas in nine cats. *Vet Pathol* 40:249–253
- Platz SJ, Breuer W, Pflieger S et al (1999) Prognostic value of histopathological grading in canine extramedullary plasmacytomas. *Vet Pathol* 36:23–27
- Rowland PH, Valentine BA, Stebbins KE et al (1991) Cutaneous plasmacytomas with amyloid in six dogs. *Vet Pathol* 28:125–130

Transmissible Venereal Tumor

- Albanese F, Marconato L, Salerni F (2006) Extragenital transmissible venereal tumour associated with circulating neoplastic cells in an immunologically compromised dog. *Vet Comp Oncol* 4(1):57–62(6)
- Albanese F, Poli A, Millanta F et al (2002) Primary cutaneous extragenital canine transmissible venereal tumor with Leishmania- laden macrophages: a further suggestion of histiocytic origin? *Vet Dermatol* 13:243–246
- Cohen D (1985) The canine transmissible venereal tumor: a unique result of tumor progression. *Adv Cancer Res* 43:75–112
- Das U, Das AK (2000) Review of canine transmissible venereal sarcoma. *Vet Res Commun* 24:545–556
- Gross TL, Ihrke PJ, Walder EJ, Affolter VK (2005) Transmissible Venereal tumor. In: Skin diseases of the dog and cat: clinical and histopathological diagnosis, 2nd edn. Blackwell Science, Ames, pp. 800–803
- Marchal T, Chabanne L, Kaplanski C et al (1997) Immunophenotype of the canine transmissible venereal tumour. *Vet Immunol Immunopathol* 57(1–2):1–11
- Mozos E, Mendez A, Gomez-Villamandos JC et al (1996) Immunohistochemical characterization of canine transmissible venereal tumor. *Vet Pathol* 33:257–263
- Mukaratirwa S, Gruys E (2003) Canine transmissible venereal tumour: cytogenetic origin, immunophenotype, and immunobiology. A review. *Vet Q* 25(3):101–111
- Murchison EP, Wedge DC, Alexandrov LB et al (2014) Transmissible dog cancer genome reveals the origin and history of an ancient cell lineage. *Science* 343(6169):437–440
- Murgia C, Pritchard JK, Kim SY et al (2006) Clonal origin and evolution of a transmissible cancer. *Cell* 126(3):477–487
- Park MS, Kim Y, Kang MS et al. (2006) Disseminated transmissible venereal tumor in a dog. *J Vet Diagn Invest* 18:130–133

Histiocytic Diseases

- Affolter VK, Moore PF (2000) Canine cutaneous and systemic histiocytosis: reactive histiocytosis of dermal dendritic cells. *Am J Dermatopathol* 22(1):40–48
- Affolter VK, Moore PF (2002) Localized and disseminated histiocytic sarcoma of dendritic cell origin in dogs. *Vet Pathol* 39(1):74–83
- Affolter VK, Moore PF (2006) Feline progressive histiocytosis. *Vet Pathol* 43:646–655
- Constantino-Casas F, Mayhew D, Hoather TM et al (2011) The clinical presentation and histopathologic-immunohistochemical classification of histiocytic sarcomas in the Flat Coated Retriever. *Vet Pathol* 48(3):764–771
- Gross TL, Ihrke PJ, Walder EJ, Affolter VK (2005) Reactive histiocytosis. In: *Skin diseases of the dog and cat: clinical and histopathological diagnosis*, 2nd edn. Blackwell Science, Ames, pp. 323–327
- Maina E, Colombo S, Stefanello D (2014) Multiple cutaneous histiocytomas treated with lomustine in a dog. *Vet Dermatol* 25:559–562, e98–e99
- Moore PF (1984) Systemic histiocytosis of Bernese mountain dogs. *Vet Pathol* 21(6):554–563
- Moore PF, Rosin A (1986) Malignant histiocytosis of Bernese mountain dogs. *Vet Pathol* 23(1):1–10
- Moore PF (2014) A review of histiocytic diseases of dogs and cats. *Vet Pathol* 51(1):167–184
- Nagata M, Hirata M, Ishida T et al (2000) Progressive Langerhans' cell histiocytosis in a puppy. *Vet Dermatol* 11(4):241–246
- Palmeiro BS, Morris DO, Goldschmidt MH et al (2007) Cutaneous reactive histiocytosis in dogs: a retrospective evaluation of 32 cases. *Vet Dermatol* 18(5):332–340
- Pinto da Cunha N, Ghisleni G, Scarpella F et al (2014) Cytologic and immunocytochemical characterization of feline progressive histiocytosis. *Vet Clin Pathol* 43(3):428–436

Epithelial Tumors

Squamous Cell Carcinoma

- Favrot C, Welle M, Heimann M et al (2009) Clinical, histologic, and immunohistochemical analyses of feline squamous cell carcinoma in situ. *Vet Pathol* 46(1):25–33
- Gross TL, Ihrke PJ, Walder EJ, Affolter VK (2005) Epidermal tumors. In: *Skin diseases of the dog and cat: clinical and histopathological diagnosis*, 2nd edn. Blackwell Science, Ames, pp 581–589
- Hauck ML (2013) Tumors of the skin and subcutaneous tissues. In: *Withrow and MacEwen's small animal clinical oncology*, 5th edn. Elsevier, St. Louis, pp 305–320
- Lascelles BD, Parry AT, Stidworthy MF et al (2000) Squamous cell carcinoma of the nasal planum in 17 dogs. *Vet Rec* 147(17):473–476
- Murphy S (2013) Cutaneous squamous cell carcinoma in the cat current understanding and treatment approaches. *J Feline Med Surg* 15(5):401–407
- Nespeca G, Grest P, Rosenkrantz WS et al (2006) Detection of novel papillomaviruslike sequences in paraffin-embedded specimens of invasive and in situ squamous cell carcinomas from cats. *Am J Vet Res* 67(12):2036–2041
- Webb JL, Burns RE, Brown HM et al (2009) Squamous cell carcinoma. *Compend Contin Educ Vet* 31(3):E9
- Wilhelm S, Degorce-Rubiales F, Godson D et al (2006) Clinical, histological and immunohistochemical study of feline viral plaques and bowenoid in situ carcinomas. *Vet Dermatol* 17(6):424–431
- Zaugg N, Nespeca G, Hauser B et al (2005) Detection of novel papillomaviruses in canine mucosal, cutaneous and in situ squamous cell carcinomas. *Vet Dermatol* 16:290–298

Follicular Cysts and Neoplasia

- Abramo F, Pratesi F, Cantile C et al (1999) Survey of canine and feline follicular tumours and tumour-like lesions in central Italy. *J Small Anim Pract* 40:479–481
- Campos AG, Cogliati B, Guerra JM et al (2014) Multiple trichoblastomas in a dog. *Vet Dermatol* 25(1):48–e19
- Carroll EE, Fossey SL, Mangus LM et al (2010) Malignant pilomatricoma in 3 dogs. *Vet Pathol* 47:937–943
- Goldschmidt MH, Hendrick MJ (2002) Tumors of the skin and soft tissues. In: Meuten DJ (ed) *Tumors in domestic animals*, 4th edn. Iowa State Press, Ames, p 60
- Gross TL, Ihrke PJ, Walder EJ, Affolter VK (2005) Follicular tumors. In: *Skin diseases of the dog and cat: clinical and histopathological diagnosis*, 2nd edn. Blackwell Science, Ames, pp 608–639
- Gross TL, Ihrke PJ, Walder EJ, Affolter VK (2005) Trichoblastoma. In: *Skin diseases of the dog and cat: clinical and histopathological diagnosis*, 2nd edn. Blackwell Science, Ames, pp. 625–634
- Gross TL, Ihrke PJ, Walder EJ, Affolter VK (2005) Trichoepithelioma. In: *Skin diseases of the dog and cat: clinical and histopathological diagnosis*, 2nd edn. Blackwell Science, Ames, pp. 616–619
- Masserdotti C, Ubbiali FA (2002) Fine needle aspiration cytology of pilomatricoma in three dogs. *Vet Clin Pathol* 31(1):22–25
- Park JK, Hong IH, Ki MR et al (2010) Multiple perianal infundibular follicular cysts in a dog. *Vet Dermatol* 21(3):303–306
- Scott DW, Anderson WI (1991) Canine hair follicle neoplasms: a retrospective analysis of 80 cases (1986–1987). *Vet Dermatol* 2:143–150
- Stannard AA, Pulley LT (1975) Intracutaneous cutaneous cornifying epithelioma (keratoacanthoma) in the dog: a retrospective of 25 cases. *J Am Vet Med Assoc* 167:385–388
- Stockhaus C, Teske E, Rudolph R et al (2001) Assessment of cytological criteria for diagnosing basal cell tumours in the dog and cat. *J Small Anim Pract* 42(12):582–586
- Toma S, Noli C (2005) Isotretinoin in the treatment of multiple benign pilomatrixomas in a mixed-breed dog. *Vet Dermatol* 16(5):346–350
- White A, Stern A, Campbell K et al (2013) Multiple (disseminated) follicular cysts in five dogs and one cat. *Vet Rec* 173(11):269

Sebaceous Gland Neoplasia

- Bettini G, Morini M, Mandrioli L et al (2009) CNS and lung metastasis of sebaceous epithelioma in a dog. *Vet Dermatol* 20:289–294
- Gross TL, Ihrke PJ, Walder EJ, Affolter VK (2005) Sebaceous tumors. In: *Skin diseases of the dog and cat: clinical and histopathological diagnosis*, 2nd edn. Blackwell Science, Ames, pp 641–664
- Scott DW, Anderson WI (1990) Canine sebaceous gland tumors: a retrospective analysis of 172 cases. *Canine Pract* 15:19–27

Sweat Gland Neoplasia

- Chaitman J, van der Woerd A, Bartick TE (1999) Multiple eyelid cysts resembling apocrine hydrocystomas in three Persian cats and one Himalayan cat. *Vet Pathol* 36:474–476
- Gross TL, Ihrke PJ, Walder EJ, Affolter VK (2005) Sweat gland tumors. In: *Skin diseases of the dog and cat: clinical and histopathological diagnosis*, 2nd edn. Blackwell Science, Ames, pp 665–689

- Kalahar KM, Anderson WI, Scott DW (1990) Neoplasms of the apocrine sweat glands in 44 dogs and 10 cats. *Vet Rec* 127:400–403
- Marignac G, Barlerin L, Meunier V et al (2002) Apocrine cystadenomatosis in three related Persian cats. In: *Proceedings of the ISVD meeting, Nice*, p 30
- Simko E, Wilcock BP, Yager JA (2003) A retrospective study of 44 canine apocrine sweat gland adenocarcinomas. *Can Vet J* 44:38–42
- Shoieb AM, Hanshaw DM (2009) Anal sac gland carcinoma in 64 cats in the United Kingdom (1995–2007). *Vet Pathol* 46(4):677–683
- Williams LE, Gliatto JM, Dodge RK et al (2003) Carcinoma of the apocrine glands of the anal sac in dogs: 113 cases (1985–1995). *J Am Vet Med Assoc* 223(6):825–831

Fibroadnexal Hamartoma (Fibroadnexal Dysplasia)

- Abramo F, Guido P, Davide L et al (2003) Canine fibroadnexal hamartoma (focal adnexal dysplasia): an epidemiological survey. In: *Proceedings of the 9th ESVD meeting, Tenerife*, p 154 (poster)
- Kimura T, Miyazawa H, Aoyagi T et al (1991) Folliculosebaceous cystic hamartoma: a distinctive malformation of the skin. *Am J Dermatopathol* 13:213–230

Mesenchymal (Spindle Cell) Neoplasia

Fibroma and Fibrosarcoma

- Daugaard S (2004) Current soft-tissue sarcoma classifications. *Eur J Cancer* 40:543–548
- Gross TL, Ihrke PJ, Walder EJ, Affolter VK (2005) *Fibroma and Fibrosarcoma*. In: *Skin diseases of the dog and cat: clinical and histopathological diagnosis*, 2nd edn. Blackwell Science, Ames, pp. 719–727
- Gumber S, Wakamatsu N (2015) Vaccine-associated fibrosarcoma with keloidal differentiation in a cat. *J Vet Diagn Invest* 23(5):1061–1064
- Harasen GL (1984) Multicentric fibrosarcoma in a cat and a review of the literature. *Can Vet J* 25(5):207–210
- Hardy WDJ (1981) The feline sarcoma virus. *J Am Anim Hosp Assoc* 17:981–997
- Hartman K, Day MJ, Thiry E et al (2015) Feline injection-site sarcoma ABCD guidelines on prevention and management. *J Feline Med Surg* 17:606–613
- Hauck M (2003) Feline injection site sarcomas. *Vet Clin North Am Small Anim Pract* 33(3):553–557
- Hendrick M (1998) Historical review and current knowledge of risk factors involved in feline vaccine-associated sarcomas. *J Am Vet Med Assoc* 213(10):1422–1423
- Hendrick MJ, Shofer FS, Goldschmidt MH et al (1994) Comparison of fibrosarcomas that developed at vaccination sites and at nonvaccination sites in cats: 239 cases (1991–1992). *J Am Vet Med Assoc* 205(10):1425–1429
- Little LK, Goldschmidt M (2007) Cytologic appearance of a keloidal fibrosarcoma in a dog. *Vet Clin Pathol* 36(4):364–367
- Macy DW, Hendrick MJ (1996) The potential role of inflammation in the development of postvaccinal sarcomas in cats. In: Rosenthal RC, Jeglum KA (eds) *Controversies in clinical oncology*, vol 26. W.B. Saunders, Philadelphia, pp 103–109
- Madewell BR, Griffey SM, McEntee MC et al (2001) Feline vaccine-associated fibrosarcoma: an ultrastructural study of 20 tumors (1996–1999). *Vet Pathol* 38(2):196–202
- Martano M, Morello E, Buracco P (2011) Feline injection-sarcoma: past, present and perspectives. *Vet J* 188:136–141

Mikaelian I, Gross TL (2002) Keloidal fibromas and fibrosarcomas in the dog. *Vet Pathol* 39(1):149–153

Myxoma and Myxosarcoma

Graadt van Roggen JF, Hogendoorn PC, Fletcher CD (1999) Myxoid tumours of soft tissue. *Histopathology* 35:291–312

Gross TL, Ihrke PJ, Walder EJ et al (2005) *Skin diseases of the dog and cat: clinical and histopathological diagnosis*, 2nd edn. Blackwell Science, Oxford, pp 727–730

Haemangioma and Haemangiosarcoma

Bertazzolo W, Dell’Orco M, Bonfanti U et al (2005) Canine angiosarcoma: cytologic, histologic, and immunohistochemical correlations. *Vet Clin Pathol* 34(1):28–34

Brown NO, Patnaik AK, MacEwen EG (1985) Canine hemangiosarcoma: retrospective analysis of 104 cases. *J Am Vet Med Assoc* 186:56–58

Carpenter JL, Andrew LK, Holzworth J (1987) Tumors and tumor-like lesions. In: Holzworth J (ed) *Diseases of the cat*. W.B. Saunders, Philadelphia, p 408, 479–80

Gross TL, Ihrke PJ, Walder EJ, Affolter VK (2005) Hemangioma and Hemangiosarcoma. In: *Skin diseases of the dog and cat: clinical and histopathological diagnosis*, 2nd edn. Blackwell Science, Ames, pp. 741–753

Hargis AM, Ihrke PJ, Spangler WL et al (1992) A retrospective clinicopathologic study of 212 dogs with cutaneous hemangiomas and hemangiosarcomas. *Vet Pathol* 29:316–328

Johannes CM, Henry CJ, Turnquist SE et al (2007) Hemangiosarcoma in cats: 53 cases (1992–2002). *J Am Vet Med Assoc* 231(12):1851–1856

McAbee KP, Ludwig LL, Bergman PJ, Newman SJ (2005) Feline cutaneous hemangiosarcoma: a retrospective study of 18 cases (1998–2003). *J Am Anim Hosp Assoc* 41(2):110–116

Miller MA, Ramos JA, Kreeger JM (1992) Cutaneous vascular neoplasia in 15 cats: clinical, morphological and immunohistochemical studies. *Vet Pathol* 29:329–336

Ward H, Fox LE, Calderwood-Mays MB et al (1994) Cutaneous hemangiosarcoma in 25 dogs: a retrospective study. *J Vet Intern Med* 8:345–348

Perivascular Wall Tumors

Avallone G, Boracchi P, Stefanello D et al (2013) Canine perivascular wall tumors: high prognostic impact of site, depth, and completeness of margins. *Vet Pathol* 51(4):713–721

Avallone G, Helmbold P, Caniatti M et al (2007) The spectrum of canine cutaneous perivascular wall tumors: morphologic, phenotypic and clinical characterization. *Vet Pathol* 44(5):607–620

Caniatti M, Ghisleni G, Ceruti R et al (2001) Cytological features of canine haemangiopericytoma in fine needle aspiration biopsy. *Vet Rec* 149:242–244

Mentzel T, Dei Tos AP, Sapi Z et al (2006) Myopericytoma of skin and soft tissues: clinicopathologic and immunohistochemical study of 54 cases. *Am J Surg Pathol* 30(1):104–113

- Palmieri C, Avallone G, Cimini M et al (2013) Use of electron microscopy to classify canine perivascular wall tumors. *Vet Pathol* 50(2):226–233
- Stefanello D, Avallone G, Ferrari R (2011) Canine cutaneous perivascular wall tumors at first presentation: clinical behavior and prognostic factors in 55 cases. *J Vet Intern Med* 25(6):1398–1405

Peripheral Nerve Sheath Tumors

- Chijiwa K, Uchida K, Tateyama S (2004) Immunohistochemical evaluation of canine peripheral nerve sheath tumors and other soft tissue sarcomas. *Vet Pathol* 41:307–318
- Gaitero L, Añor S, Fondevila D et al (2008) Canine cutaneous spindle cell tumours with features of peripheral nerve sheath tumours: a histopathological and immunohistochemical study. *J Comp Pathol* 139:16–23
- Gross TL, Ihrke PJ, Walder EJ, Affolter VK (2005) Peripheral nerve sheath tumor. In: *Skin diseases of the dog and cat: clinical and histopathological diagnosis*, 2nd edn. Blackwell Science, Ames, pp. 789–797
- Koestner A, Higgins RJ (2002) Tumours of the nervous system. In: Meuten DJ (ed) *Tumours in domestic animals*, 4th edn. Iowa State Press, Ames, p 697e738
- Schulman FY, Johnson TO, Facemire PR et al (2009) Feline peripheral nerve sheath tumors: histologic, immunohistochemical, and clinicopathologic correlation (59 tumors in 53 cats). *Vet Pathol* 46:1166–1180
- Suzuki S, Uchida K, Nakayama H (2014) The effects of tumor location on diagnostic criteria for canine malignant peripheral nerve sheath tumors (MPNSTs) and the markers for distinction between canine MPNSTs and canine perivascular wall tumors. *Vet Pathol* 51(4):722–736

Lipoma and Liposarcoma

- Baez JL, Hendrick MJ, Shofer FS et al (2004) Liposarcomas in dogs: 56 cases (1989–2000). *J Am Vet Med Assoc* 224:887–891
- Gross TL, Ihrke PJ, Walder EJ, Affolter VK (2005) Lipoma and Liposarcoma. In: *Skin diseases of the dog and cat: clinical and histopathological diagnosis*, 2nd edn. Blackwell Science, Ames, pp. 766–778
- Liggett AD, Frazier KS, Styer EL (2002) Angiolipomatous tumors in dogs and a cat. *Vet Pathol* 39:286–289
- Masserdotti C, Bonfanti U, De Lorenzi D et al (2006) Use of Oil Red O stain in the cytologic diagnosis of canine liposarcoma. *Vet Clin Pathol* 35(1):37–41
- Messick JB, Radin MJ (1989) Cytologic, histologic, and ultrastructural characteristics of a canine myxoid liposarcoma. *Vet Pathol* 26:520–522

Anaplastic Soft Tissue Sarcoma with Many Giant Cells

- Couto SS, Griffey SM, Duarte PC et al (2002) Feline vaccine-associated fibrosarcoma: morphologic distinctions. *Vet Pathol* 39:33–41
- Goldschmidt MH, Shofer FS (1992) *Skin tumors of the dog and cat*. Pergamon Press, Oxford, pp 2–3, 175–8
- Gross TL, Ihrke PJ, Walder EJ et al (2005) *Skin diseases of the dog and cat: clinical and histopathologic diagnosis*, 2nd edn. Blackwell Science, Oxford, pp 798–800
- Pace LW, Kreeger JM, Miller MA et al (1994) Immunohistochemical staining of feline malignant fibrous histiocytomas. *Vet Pathol* 31:168–172

Melanocytic Tumors

- Bergman PJ, Kent MS, Farese JP (2013) Melanoma. In: *Withrow & MacEwen's: small animal clinical oncology*, 5th edn. Elsevier, St. Louis, pp 321–333
- Cangul IT, van Garderen E, van der Linde-Sipman JS et al (2001) Canine balloon and signet-ring cell melanomas: a histological and immunohistochemical characterization. *J Comp Pathol* 125(2–3):166–173
- Choi C, Kusewitt DF (2003) Comparison of tyrosinase-related protein-2, S-100, and Melan A immunoreactivity in canine amelanotic melanomas. *Vet Pathol* 40(6):713–718
- Gross TL, Ihrke PJ, Walder EJ, Affolter VK (2005) Melanocytic tumors. In: *Skin diseases of the dog and cat: clinical and histopathological diagnosis*, 2nd edn. Blackwell Science, Ames, pp 608–639

Chapter 5

Cutaneous Metastasis from Non-primary Skin Tumors

In collaboration with Walter Bertazzolo (dipl. ECVCP)

5.1 Introduction

In this chapter, the cutaneous metastases of non-primary skin neoplasms, namely those originating from tumors of the internal organs, are discussed. Skin metastases of internal malignancies are, with some exceptions, very rare and only sporadic cases of metastases from *gastric*, *intestinal*, *prostatic* and *bronchial carcinomas*, from testicular *seminoma* and from some sarcomas such as *haemangiosarcomas* and *osteosarcomas*, have been reported in the veterinary literature. The spread of neoplastic cells occurs mainly via the bloodstream, and therefore, metastases can develop on any part of the skin. The most frequently observed cutaneous metastases are those linked to the bronchogenic carcinoma in cats, which characterise the so-called *lung–digit syndrome*. In this neoplastic disease, metastases are multicentric and mostly localised to the digits and muscles. Although mammary tissue is cutaneous adnexa, because of the importance and the enormity of the topic, mammary cancers are generally dealt with in textbooks exclusively dedicated to this subject. In dogs, as in human beings, a clinical variant of mammary neoplasia called *inflammatory mammary carcinoma* is well documented. This neoplasia, shows clinical signs very similar to other primary skin cancers or to nodular non-neoplastic skin diseases, and it is characterised by the lymphatic spread of neoplastic cells. For this reason, this variant of mammary carcinoma is discussed in this chapter. The metastasis of round cell tumors, such as mast cell tumours, lymphomas, histiocytic diseases and multiple myeloma, are not included in this chapter. In these haematopoietic tumours, the simultaneous presence of lesions in the internal organs and on the skin is considered a common occurrence. Furthermore, it is not always possible to define when the skin neoplasia is primary or metastatic. The neoplasms included in this group of tumors have been extensively covered in Chap. 4.

5.2 Metastatic Pulmonary Carcinoma in Cats (Lung–Digit Syndrome)

The term *lung–digit syndrome* (LDS) is used to describe a clinical syndrome characterised by skin metastases secondary to the diffusion, via the bloodstream, of a primary bronchogenic carcinoma (Estrada and Lagadic 1992; Gottfried et al. 2000; van der Linde-Sipman and van den Ingh 2000). Adult to old cats are more predisposed, although, in rare cases, LDS has been reported in very young patients. In most cases LDS is characterised by the development of multiple lesions, mainly located on several digits of different feet; the digits appear swollen, ulcerated, discharging purulent exudate mixed with blood, painful on palpation and with deviation of the axis of the nail and/or onychomadesis (Figs. 5.1 and 5.2). The neoplastic cells cause osteolysis and cats develop lameness.

In some cats, extra-digital cutaneous localisation, both as a single lesion and in combination with the digital lesions, are reported (Favrot and Degorce-Rubiales 2005; Petterino et al. 2005; van der Linde-Sipman and van den Ingh 2000) (Fig. 5.3). Some cases of extra-skin metastases, predominantly affecting skeletal muscles and bones, have also been reported (Goldfinch and Argyle 2012; Langlais et al. 2006). Thoracic radiographs usually show a primary lung cancer, mostly single and well circumscribed; in rare cases, it is possible to find multiple lesions, whereas in other

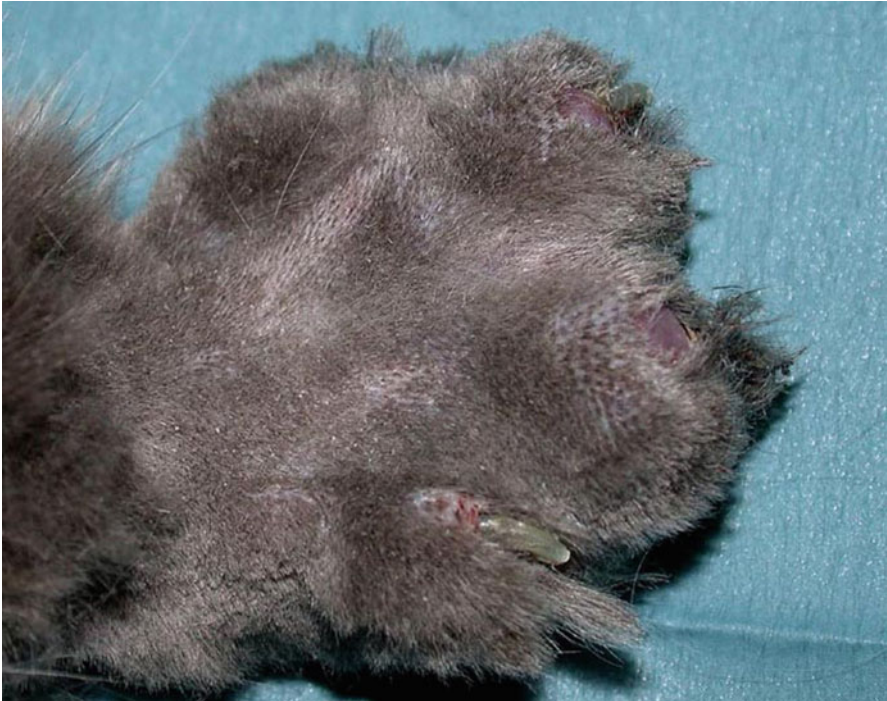

Fig. 5.1 Multiple digital swelling in a Persian cat with lung–digit syndrome (LDS)

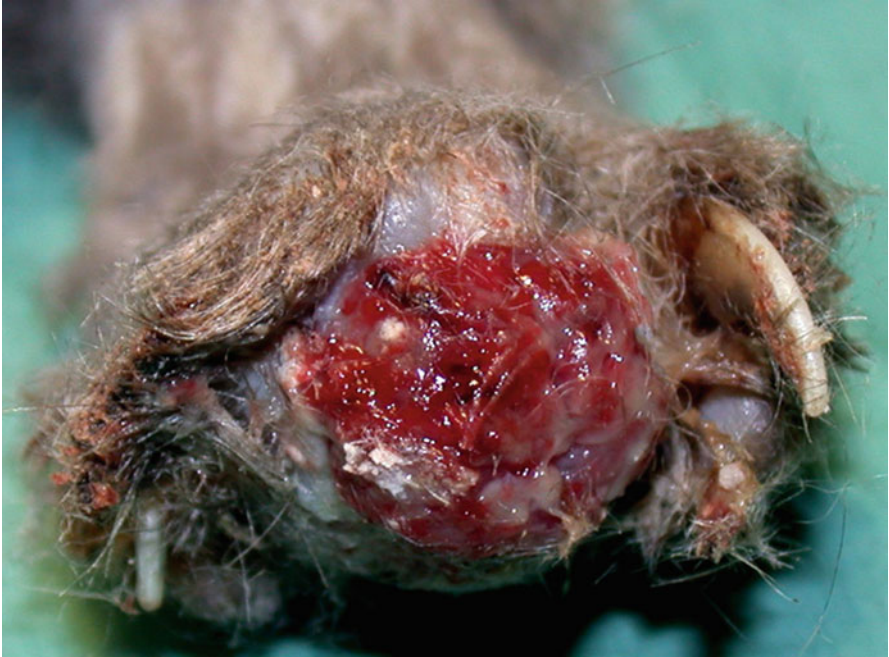

Fig. 5.2 Swelling, ulceration and onychomadesis of a digit of the same cat as in Fig. 5.1

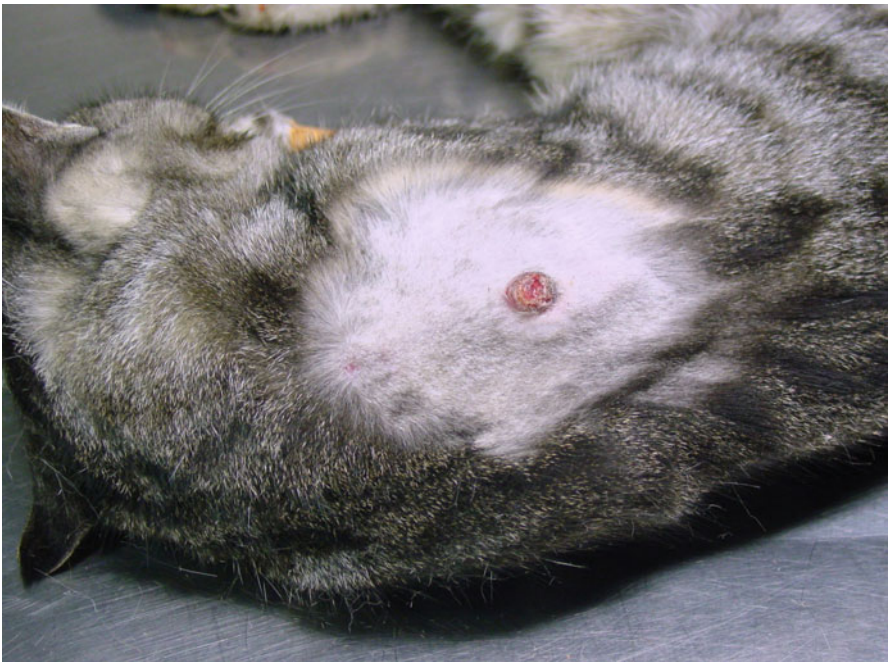


Fig. 5.3 Case of LDS: small and ulcerated cutaneous nodule on the chest of a cat. The primary neoplasm was confirmed as a bronchogenic carcinoma

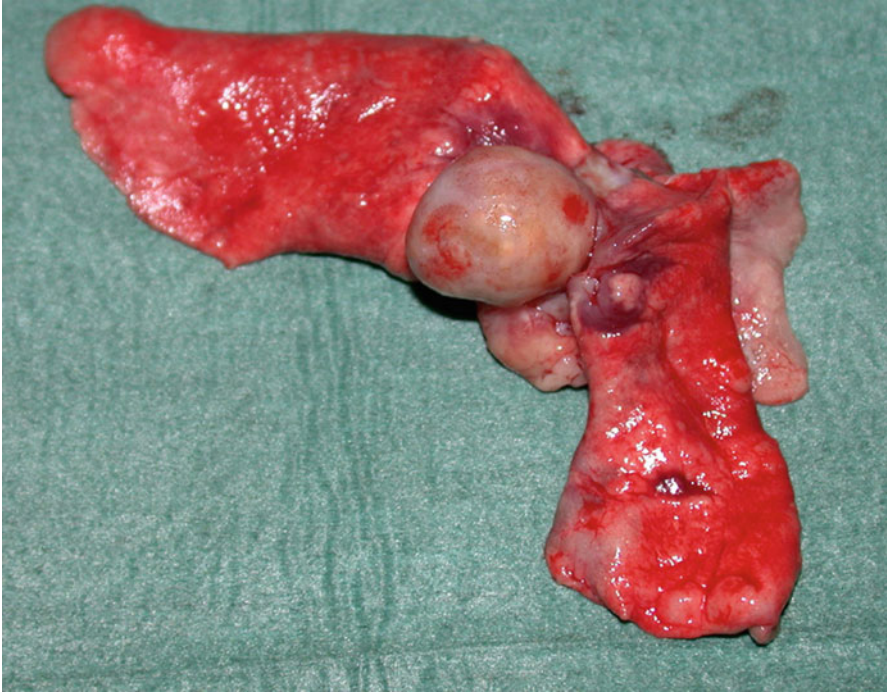


Fig. 5.4 Primary bronchial carcinoma. The small neoplasia was not evident to the radiographic investigation

patients, the cancer is not radiographically detectable, especially when the diaphragmatic lobe of the lung is affected (Fig. 5.4) (Barr et al. 1987). Most cats do not show respiratory symptoms (Moore and Middleton 1982). The angioinvasive power of this type of cancer, and the fact that cats have a high digital blood flow that permits better heat dissipation, are assumed to be the cause of the multiple digital metastases (Moore and Middleton 1982).

Cytological Findings

Three histological subtypes of bronchial carcinoma are recognised as causes of lung–digit syndrome: *adenosquamous* (mucoepidermoid) carcinoma, *squamous cell carcinoma* and *adenocarcinoma*. The first two seem to be the most frequent subtypes (Fig. 5.5) (Gross et al. 2005).

The cytology specimens are characterised by clusters of epithelial cells, more or less cohesive, from polygonal to columnar in shape, which show varying features of atypia such as anisocytosis, anisokaryosis, pleomorphic nuclei and prominent nucleoli. The presence of acinar or tubular arrangements allow identification of the glandular nature of the neoplasia, but the diagnosis of metastatic bronchial carcinoma can only be made when the *ciliated* and/or *goblet cells* (the mucin-secreting cells) are observed (Figs. 5.6, 5.7, and 5.8). The latter are recognisable by the

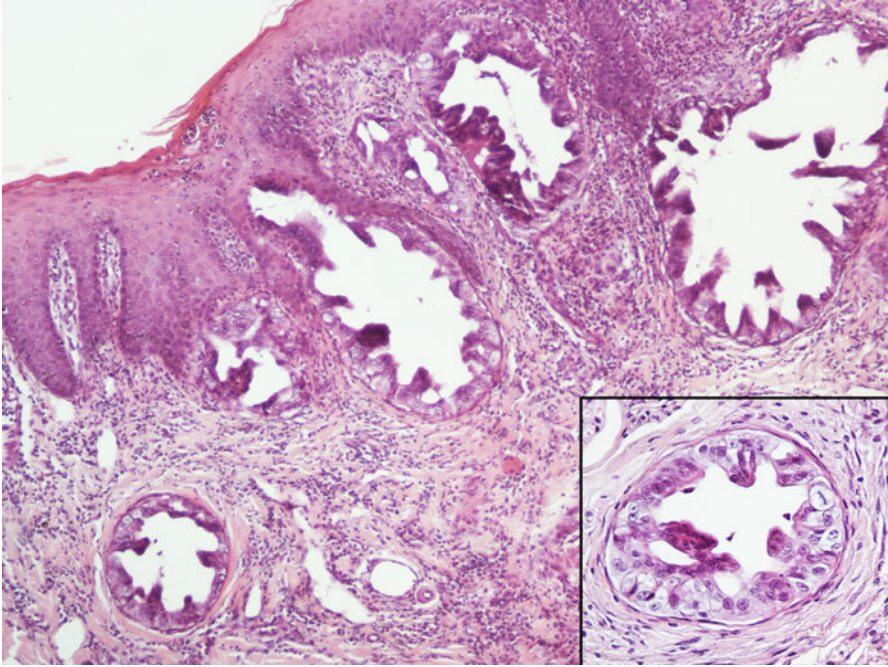


Fig. 5.5 Histopathology of the skin metastasis of a bronchogenic carcinoma: multiple cystic glandular formations composed of polygonal to columnar epithelial malignant cells. Neoplastic intravascular thrombus (*inset*)

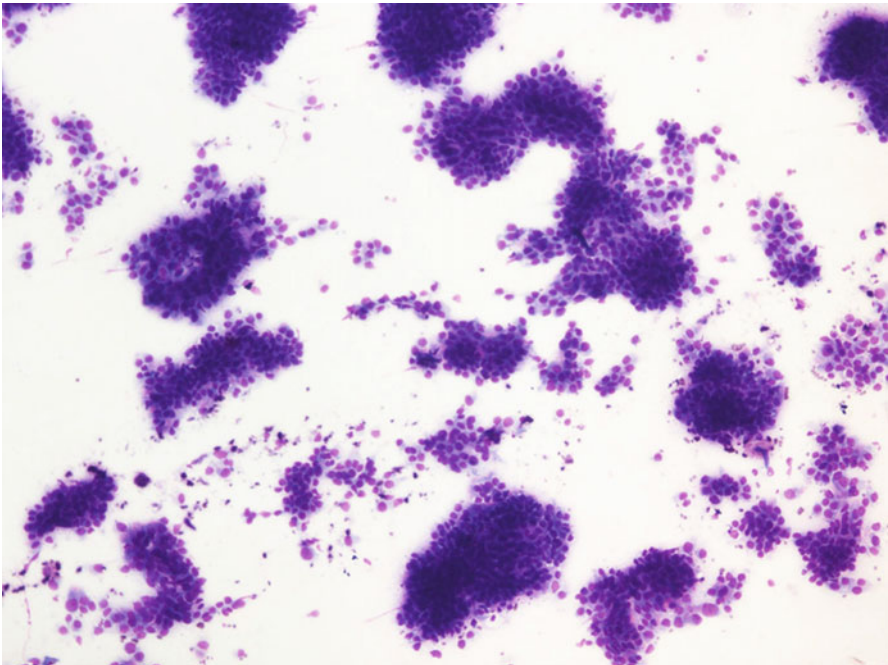


Fig. 5.6 Cytology of LDS: multiple cohesive clusters of epithelial carcinomatous cells

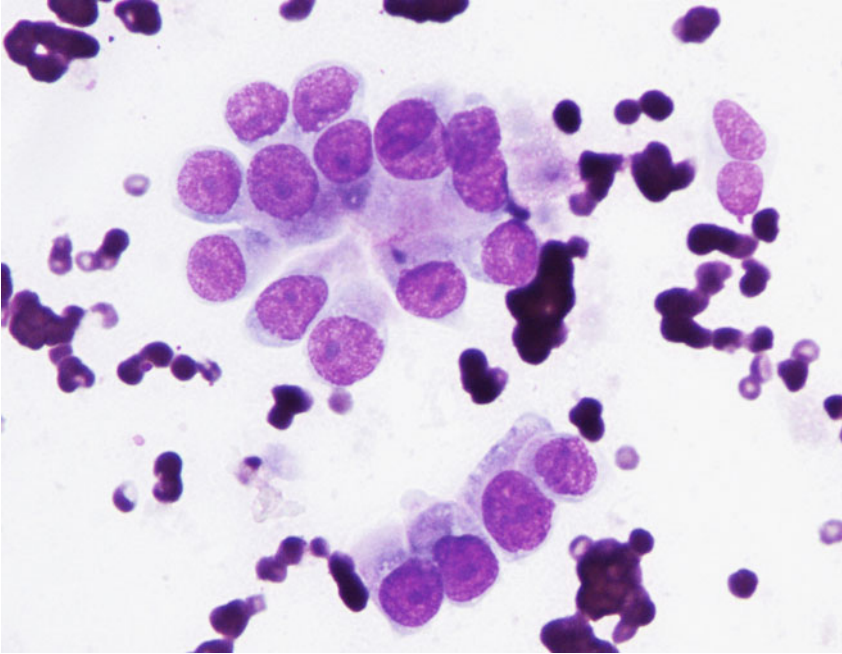


Fig. 5.7 Cytology of LDS: clusters of cuboidal bronchial cells showing acinar and palisading arrangements

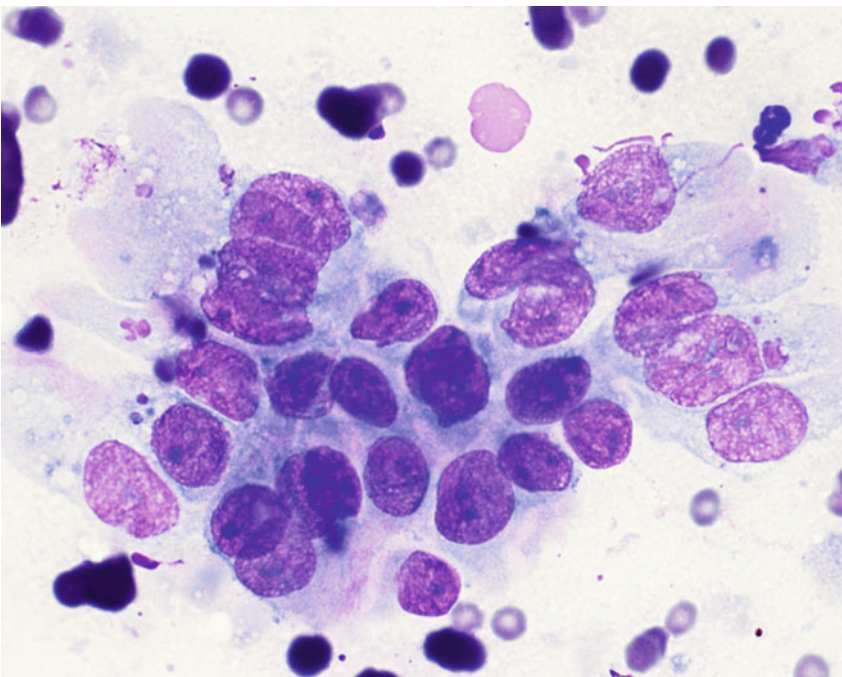


Fig. 5.8 Cytology of LDS: clusters of columnar bronchial cells showing acinar and palisading arrangements. The goblet cells show intracytoplasmic amorphous and coarse basophilic material

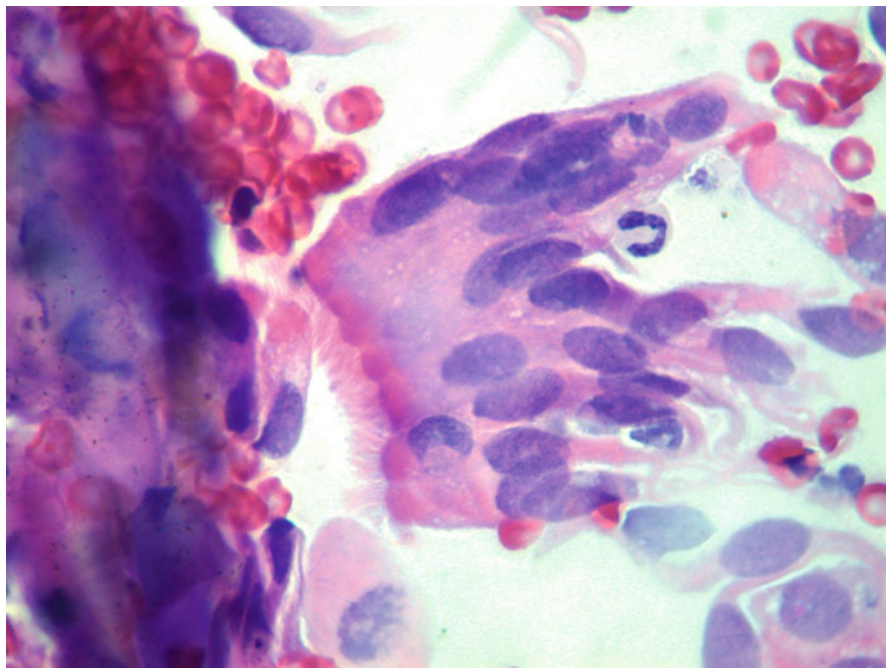


Fig. 5.9 Cytology of LDS: clusters of columnar bronchial cells. Cilia are clearly evident on the apical part of the cells (Courtesy of Dr. F. Carrani, Italy)

presence of vacuoles or of intracytoplasmic amorphous and coarse basophilic material, representing the mucous secretion (Fig. 5.9). These two cell types are more common in the adenocarcinomatous subtype, and, to a lesser extent, in the adenosquamous carcinoma variant. As the adenocarcinoma is the less frequent subtype of LDS, the detection of ciliated cells is not a constant finding; therefore, when they are not present on slides, the cytological diagnosis of metastatic bronchial carcinoma is not possible. In specimens collected from the adenosquamous subtype, it is possible to detect some epithelial cells showing squamous differentiation; the latter are the predominant cytological population in the histological SCC subtype (Figs. 5.10 and 5.11). For these reasons, cytological differentiation between a primary cutaneous SCC of the nail bed and digital metastasis from a bronchogenic SCC is very difficult and may be impossible. However, the detection of clusters with a glandular arrangement and the clinical aspect of multiple digital lesions lead to suspected LDS.

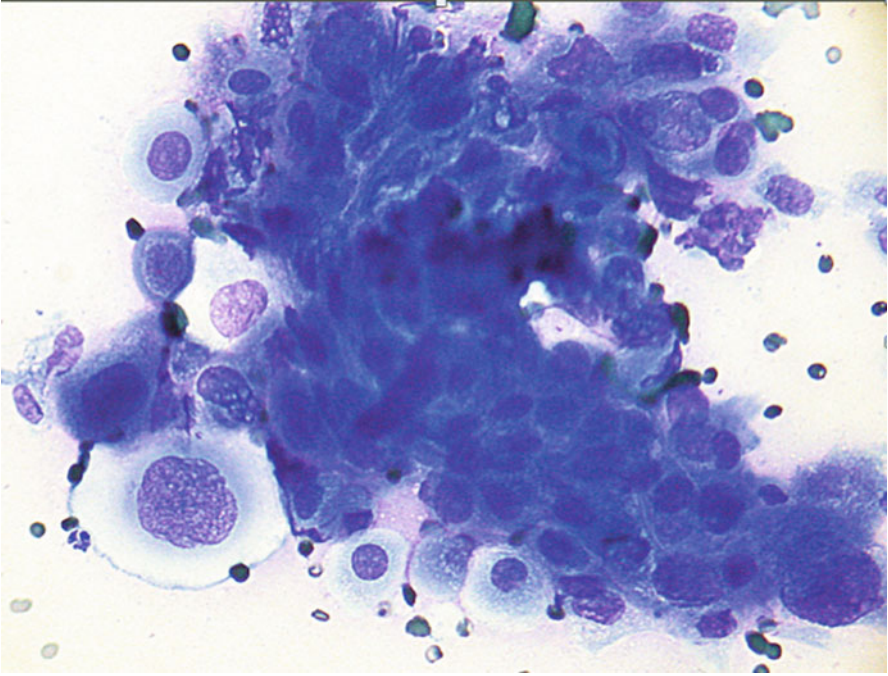


Fig. 5.10 Cytology of LDS: clusters of malignant bronchial cells showing squamous differentiation

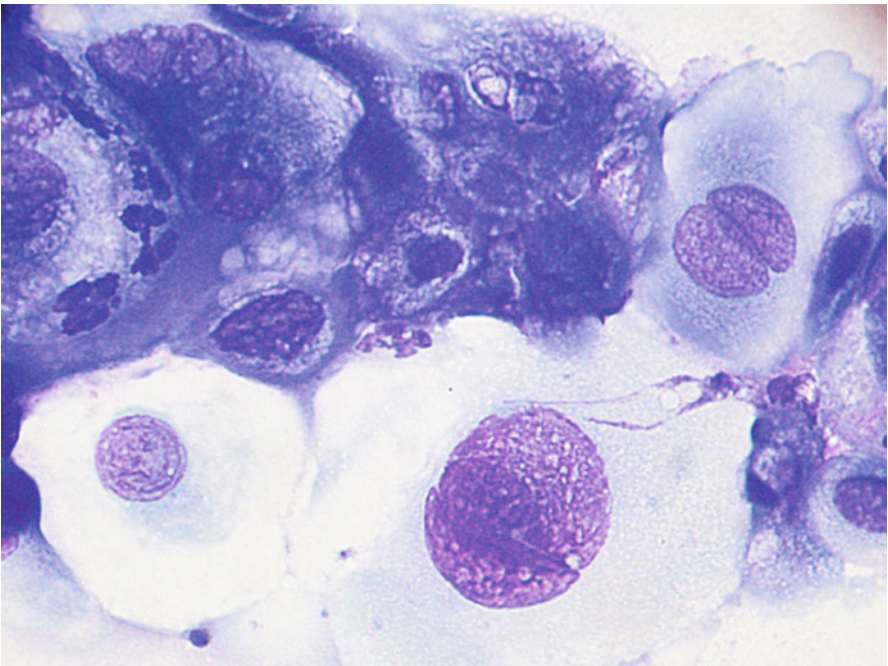


Fig. 5.11 Cytology of LDS: at high magnifications, squamous cells are more evident

5.3 Cutaneous Metastasis from Inflammatory Mammary Carcinoma

Inflammatory mammary carcinoma (IMC) is the most malignant, aggressive and lethal variant of mammary cancer in dogs and it is characterised by a clinical presentation that is completely different from that of other mammary carcinomas (Marconato et al. 2009; Perez Alenza et al. 2001). In human beings, studies on inflammatory breast cancer showed the high angiogenic and angioinvasive potential of the tumour, which contributes to its aggressive power (Kleer et al. 2000).

Although mammary carcinomas in dogs frequently metastasise to internal organs, the IMC is characterised by its ability to spread neoplastic cells through the cutaneous lymphatic vessels.

Grossly, the cutaneous metastatic lesions may appear as diffuse erythematous swelling of the skin, erosions and multiple, poorly defined and often confluent nodular–papular or nodular lesions (Figs. 5.12, 5.13, 5.14, and 5.15). The metastasis centrifugally expanded from a primary mammary neoplasm, but primary neoplasia is not always clinically evident and, in these cases, the IMC is suspected when the above-mentioned lesions are observed in the mammary area (Clemente et al. 2010). As the neoplasia rapidly metastasises via the lymphatics, in many dogs, the lesions can be observed far from the mammary area, such as the inner surface of the thighs and axilla and on the lateral area of the chest and shoulders. It must be pointed out

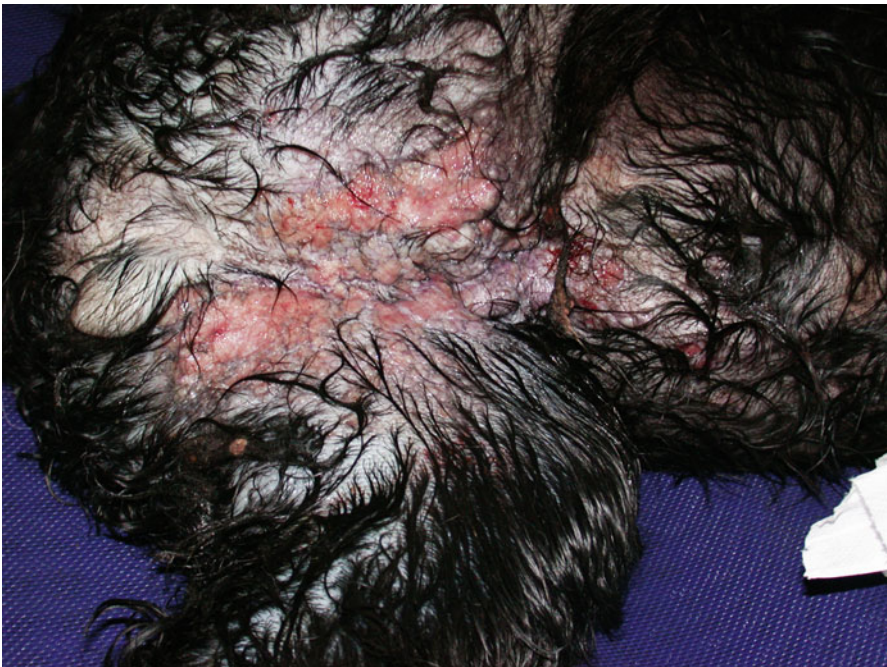

Fig. 5.12 Multiple, small, erythematous and ulcerated nodular papules and plaques, on the abdomen and inner thigh of a Cocker with an inflammatory mammary carcinoma (IMC). The wet hairs are due to excessive licking because of the strong pruritus

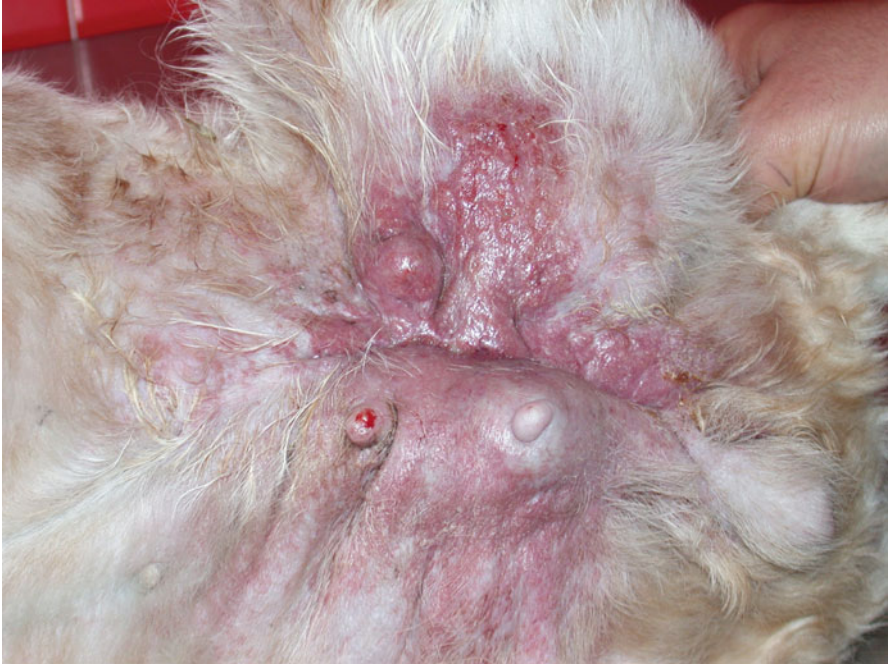

Fig. 5.13 Swelling and erythema of the skin covering a large mammary neoplasia. Note that the lesions are spread over the left thigh forming a large plaque

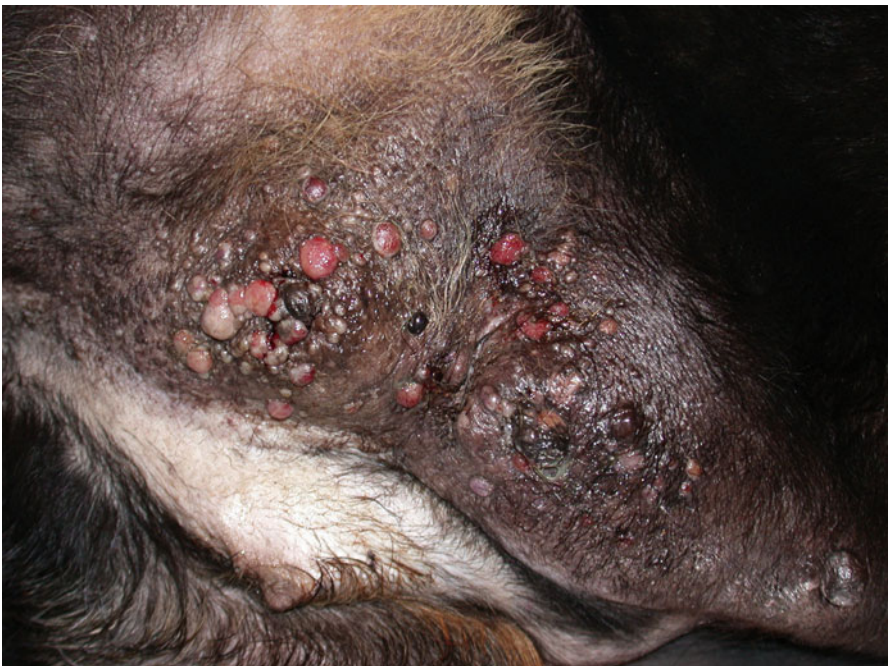

Fig. 5.14 Multiple neoplastic nodular papules and nodules on the abdomen and leg of a Rottweiler affected by an IMC

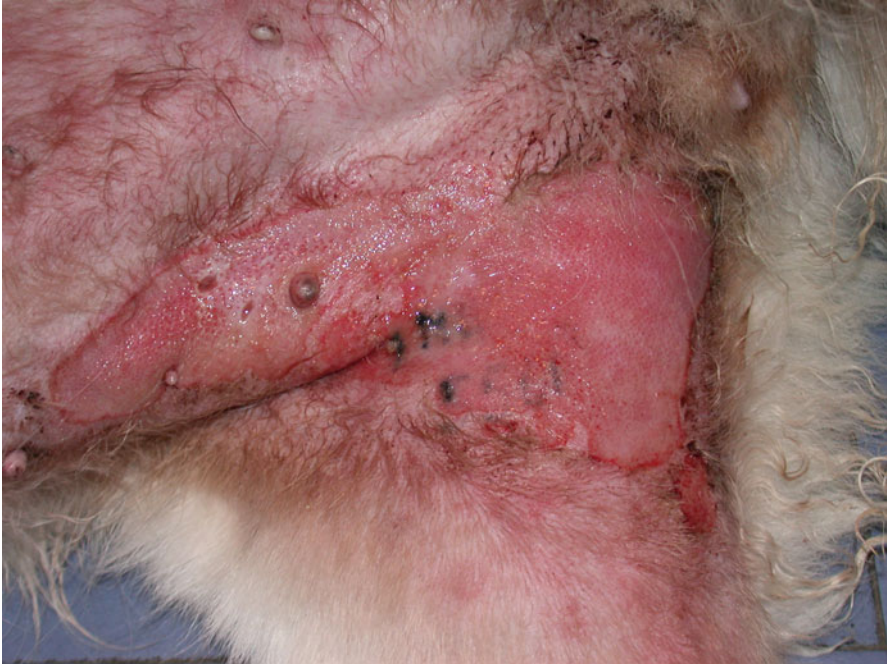

Fig. 5.15 Large erythematous skin ulceration on the right legs of a mixed-breed dog: unusual presentation of an IMC

that the clinical aspects of the skin lesions explain why the adjective *inflammatory* has been coined to define this variant of mammary cancer. The adjective is indeed related to the macroscopic characteristics of the cancer and it is absolutely not linked to the microscopic presence of inflammatory cells in the context of the neoplastic proliferation.

Cytological Findings

The microscopic feature of IMC is the spread of neoplastic cells through the lymphatic vessels, which can be easily diagnosed via histopathology (Figs. 5.16 and 5.17). This metastatic behaviour justifies why the neoplasia is also defined as *carcinomatous lymphangiectasia*. The cytological samples collected from papular–nodular lesions show highly cellular specimens usually characterised by a clean background, sometimes slightly haemocontaminated, with many clusters of malignant epithelial cells showing various features of malignancy, mostly anisocytosis, anisokaryosis, voluminous nuclei, macronucleoli, nuclear moulding, cannibalism and vacuolated cytoplasm of varying sizes that can contain granular secretion (Fig. 5.18). Many clusters of epithelial carcinomatous cells show a loss of cohesiveness; in these cases the intercellular spaces are more evident and sometimes, small clusters composed of a few cells or discrete neoplastic cells are observed (Fig. 5.19). The finding of acinar arrangements of the cells, especially in poorly differentiated carcinomas, helps to interpret the glandular origin of the neoplasia (Fig. 5.20). Single cells containing large secretory intracytoplasmic vacuoles that marginalise the nucleus, the so-called *signet ring cells*, are also often detected.

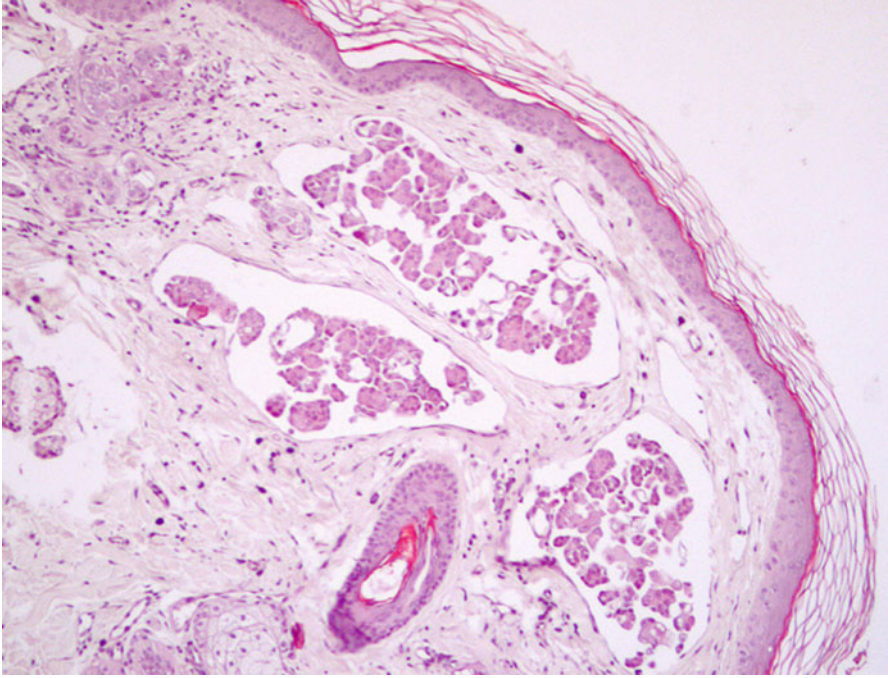


Fig. 5.16 Histopathology of an IMC: multiple neoplastic thrombi in lymphatic vessels

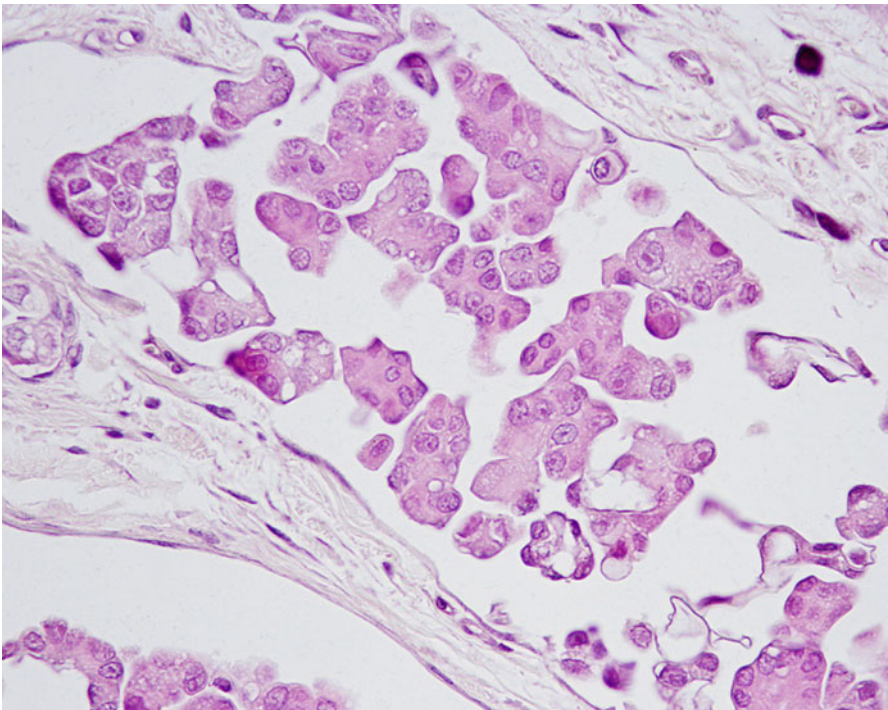


Fig. 5.17 Histopathology of an IMC: at high magnifications, the malignant features of the epithelial cells are well recognisable. Note that some cells have lost their cohesiveness

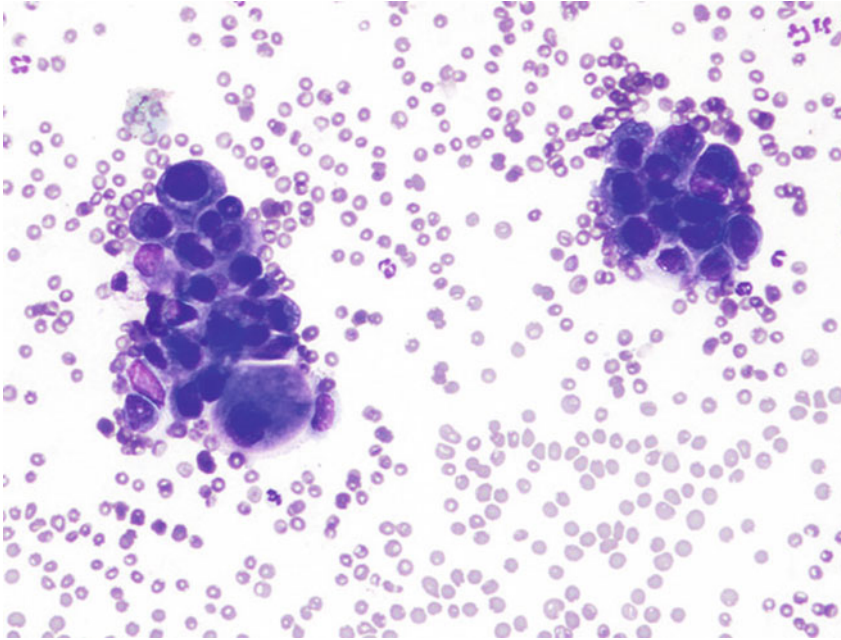


Fig. 5.18 Cytology of an IMC: cluster of carcinomatous mammary cells on a slightly haematic background

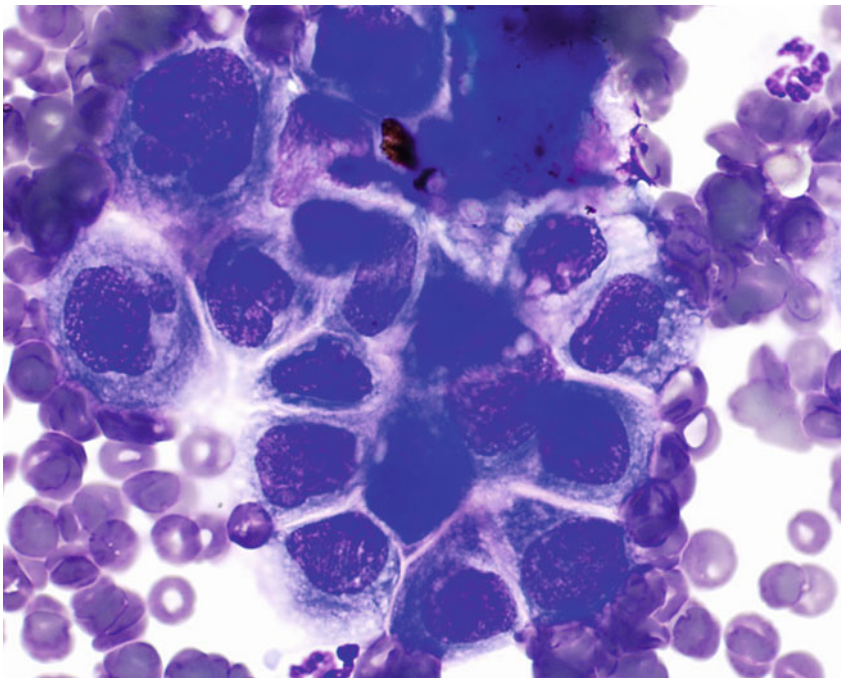


Fig. 5.19 Cytology of an IMC: at high magnifications the loss of cohesion and the nuclear atypia are well recognisable

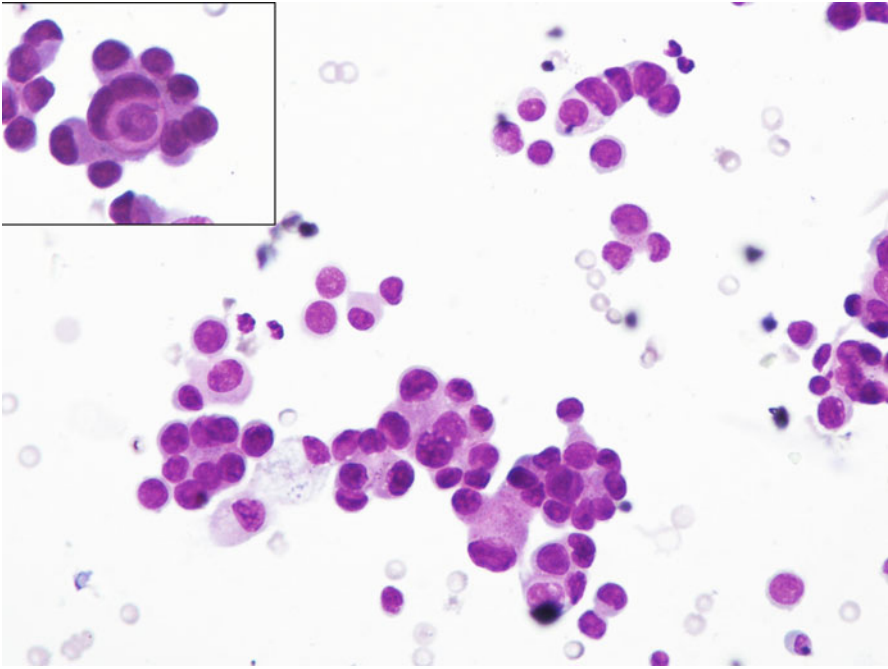


Fig. 5.20 Cytology of an IMC: neoplastic cells are isolated, in rows and in micro-papillary arrangements. Cells have a high N/C ratio, scant slightly basophilic cytoplasm and round nuclei. Note the cannibalised neoplastic cell (*inset*)

5.4 Cutaneous Metastasis from Internal Haemangiosarcoma

Visceral haemangiosarcoma (vHSA) has a highly metastatic potential and, occasionally, it can metastasise to the skin. The two main visceral locations of primary vHSA, from which metastases can start, are the spleen and cardiac auricle (Guaguère et al. 1994). In the case of multiple skin tumours and disseminated visceral metastases, it is difficult to define the primary site of origin (Hargis et al. 1992). Skin metastases from HSA usually appear as single or more frequently multiple cutaneous/subcutaneous nodules, with a red to purplish or dark blue colour (Fig. 5.21).

Cytological Findings

Cytological features are similar to those observed in HSA located at other sites: samples are always highly haematic and with moderate to low cellularity. Neoplastic cells may be spindle or pleomorphic, often arranged in loose pseudo-aggregates, with moderate to abundant basophilic cytoplasm, and often containing small, punctate, colourless vacuoles. Nuclei are round to oval, with prominent nucleoli and

malignant criteria are moderate to severe. An epithelioid variant of HSA has been described; in this uncommon histotype, round to polygonal cells are arranged in tight clusters that may resemble an epithelial tissue (Figs. 5.22 and 5.23) (Bertazzolo et al. 2005; Wilkerson et al. 2002). In many of these cases, a definitive diagnosis of endothelial origin requires immunohistochemical staining. A definitive diagnosis of HSA is achieved only by histology and by demonstrating positivity to endothelial markers by immunohistochemistry. An additional, less frequent cytological feature observed in HSA is the presence of apoptotic cells (most likely leukocytes), haemosiderophages, haematopoietic precursors and eosinophils, scattered among the neoplastic cells (Fig. 5.24). The cytological finding of megakaryocytes and rubricytes in samples obtained from a soft-tissue neof ormation should always raise concerns about a possible malignant vascular tumour, even if neoplastic cells are not present in the cytological sample. Finally, another feature that could help in supporting a cytological diagnosis of HSA is the presence of vasoformative features: cells may be arranged in pseudoacinar aggregates, in swirling structures surrounding erythrocytes, or occasionally, single cells may produce an intracytoplasmic vascular channel containing erythrocytes (Fig. 5.25) (Bertazzolo et al. 2005; Wilkerson et al. 2002).

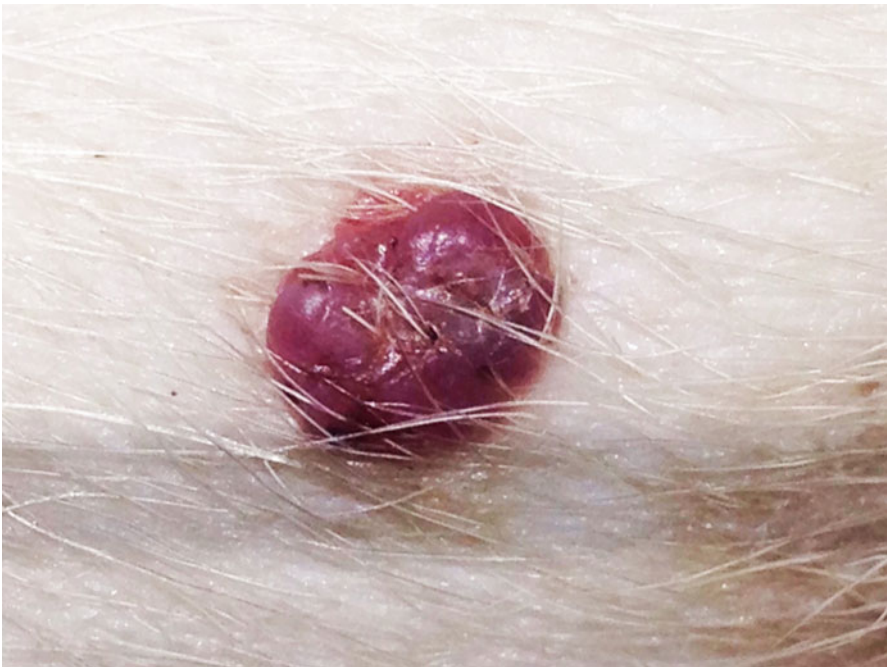

Fig. 5.21 Erythematous cutaneous haemangiosarcoma (HSA). Note the intense purple colour of the tumour, which is suggestive of haematic content

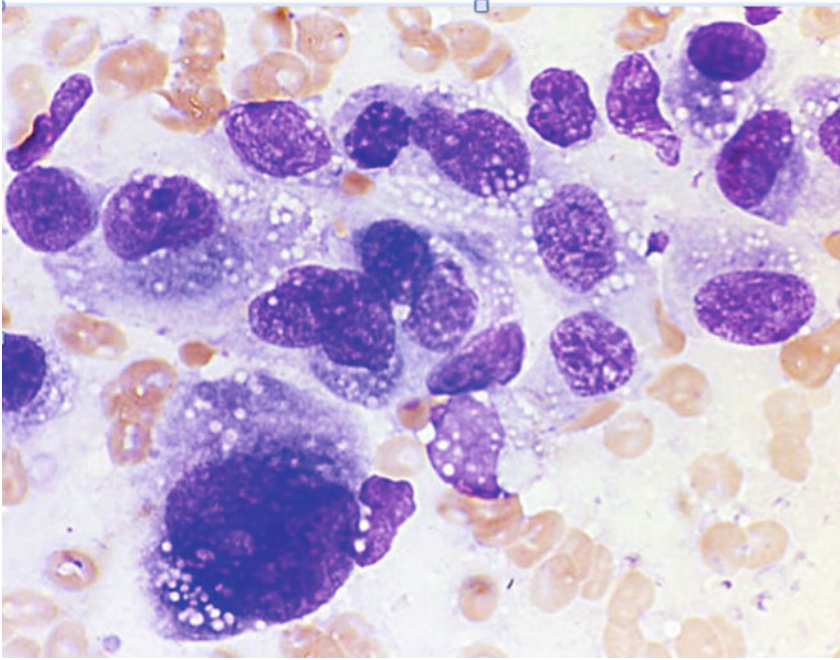


Fig. 5.22 Cytology of an HSA: a cluster of pleomorphic neoplastic cells. Despite their cohesiveness and epithelial-like appearance, they are endothelial neoplastic cells. Note the numerous punctate vacuoles

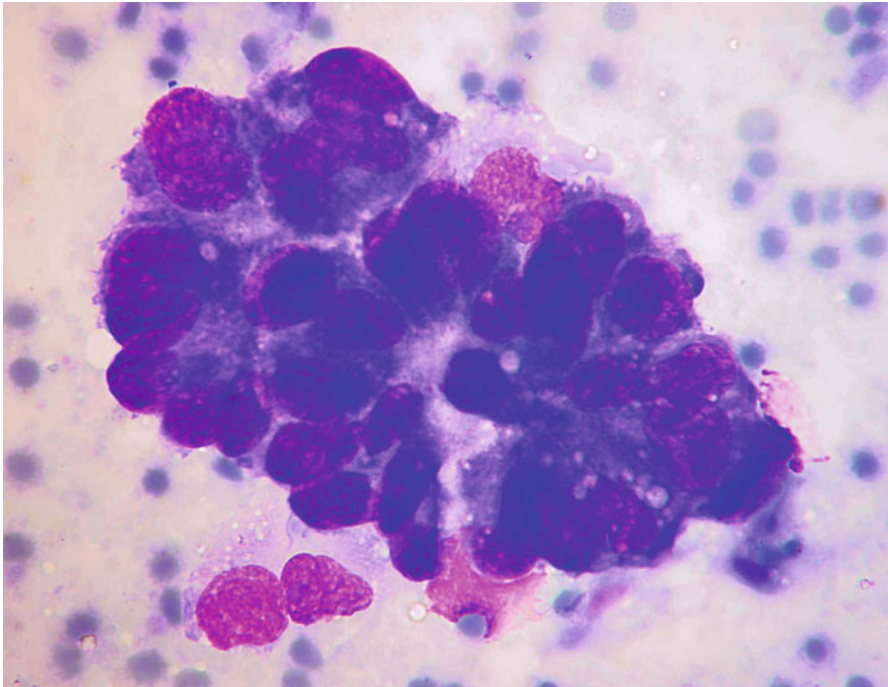


Fig. 5.23 Cytology of an HSA: epithelial-like appearance of endothelial neoplastic cells

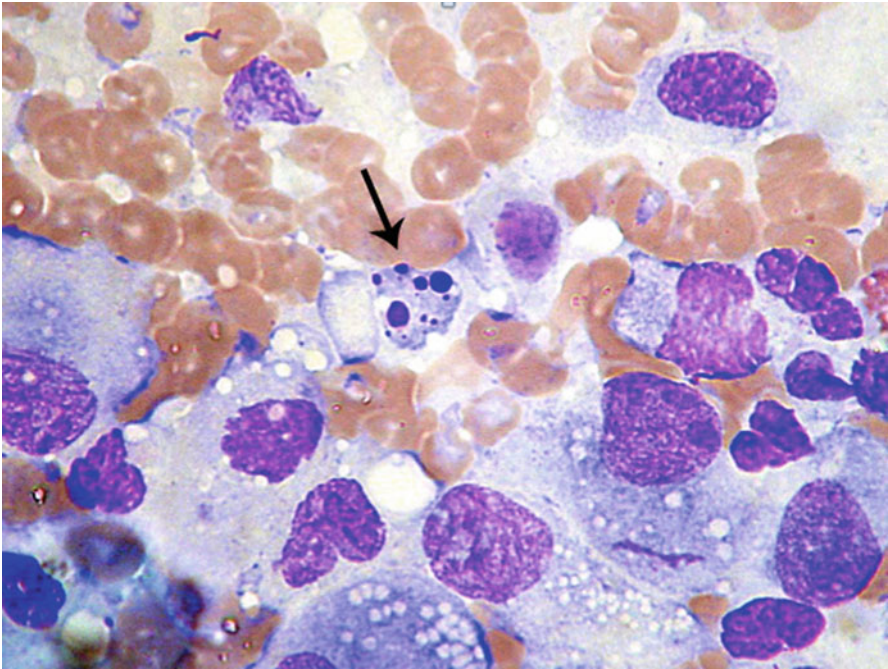


Fig. 5.24 Cytology of an HSA: a single apoptotic cell represented by a multiple fragmented roundish portion of the nucleus (*arrow*)

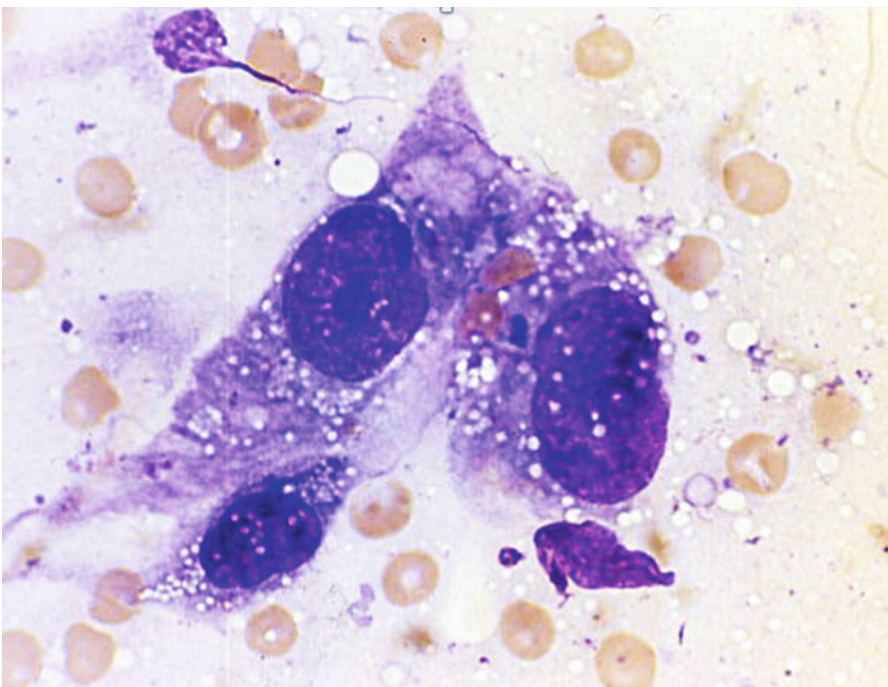


Fig. 5.25 Cytology of an HSA: malignant spindle endotheliocytes in a vasoformative arrangement

5.5 Others Rare Skin Metastasis

Other neoplasms have been reported to be responsible for skin metastases in dogs: a few case reports have been documented describing cases of skin metastases from *testicular seminoma* (Lucas et al. 2012; Spugnini et al. 2000; Takiguchi et al. 2001), *appendicular osteosarcoma* (Gorman et al. 2006), *duodenal carcinoma* (Juopperi et al. 2003), *transitional cell carcinoma* (Reed et al. 2013), *colonic adenocarcinoma* (Tomlinson et al. 1982), *gastric mucinous carcinoma* (Figs. 5.26, 5.27, 5.28, 5.29 and 5.30) (Dell'Orco et al. 2005), *nasal neuro-endocrine tumour* (Koehler et al. 2011) and a disseminated *alveolar rhabdomyosarcoma* (Otrocka-Domagala et al. 2015).

Other rare cutaneous metastases from internal malignancies have been observed by the authors (unpublished data). Two cases of cutaneous metastases of *prostatic carcinomas* have been diagnosed by one of the authors (WB). Multiple nodules, mainly located over the trunk, abdominal and inguinal areas, characterised the skin metastases (Fig. 5.31). Multiple internal organs were also involved.

Slides showed a unique population of pleomorphic cells, single to cohesive in small clusters, with moderate to abundant slightly basophilic cytoplasm, oval nuclei with evident nucleoli and other cytological atypias such as multiple nuclei, cannibalism and atypical mitosis, indicative of a high-grade malignancy (Figs. 5.32 and 5.33).

In some prostatic cancers, such as transitional cell carcinoma, carcinomatous spindle-shaped cells that may be erroneously attributed to a mesenchymal origin can be detected. It is assumed that a de-differentiation towards a mesenchymal type, including the co-expression of cytokeratins and vimentin, is considered an indicator of increased malignancy.

Multiple cutaneous and subcutaneous metastatic nodules from a primary *salivary gland carcinoma* have also been diagnosed by one of the authors (WB; Fig. 5.34). Cytology of nodules was characterised by a large amount of amorphous eosinophilic matrix embedding pleomorphic and poorly cohesive atypical neoplastic cells (Figs. 5.35, 5.36 and 5.37).

Finally, a 9-year-old mixed-breed dog with a cutaneous metastatic *pheochromocytoma* was diagnosed by both the authors (Fig. 5.38). A single subcutaneous metastasis was observed on the right side of lumbar area, whereas the primary neoplasm was present on the left adrenal gland. Cytological findings were consistent with a neuroendocrine tumour, exhibiting many different sized bare nuclei in rows or with an acinar arrangement (Fig. 5.39). When present, cytoplasm ranged from scarce to moderate and was slightly basophilic (Fig. 5.40). Some cytological features of malignancies were also observed. The confirmation of the neuroendocrine origin of the tumour was achieved with histopathology and with positivity to synaptophysin immune-staining (Figs. 5.41 and 5.42).

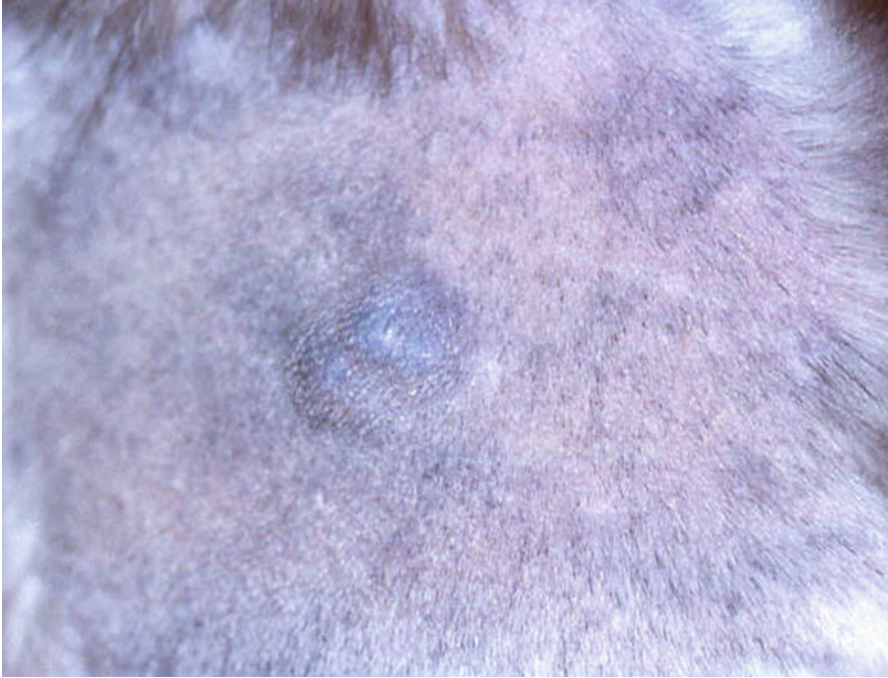


Fig. 5.26 Metastatic gastric adenocarcinoma presented as a small bluish cutaneous nodule

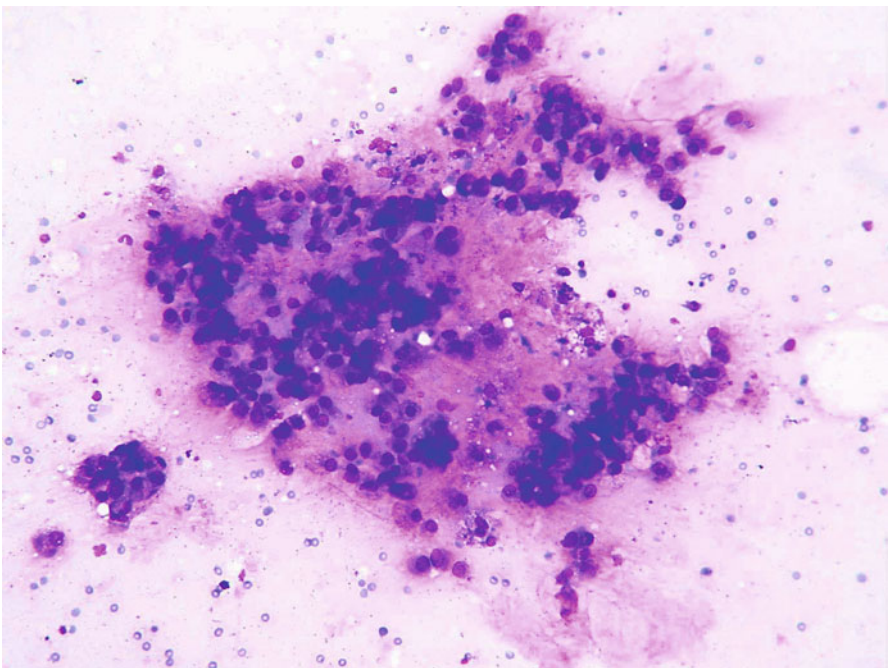


Fig. 5.27 Cytology of a gastric adenocarcinoma: at low magnifications, neoplastic cells are embedded in an abundant eosinophilic, muco-proteinaceous matrix

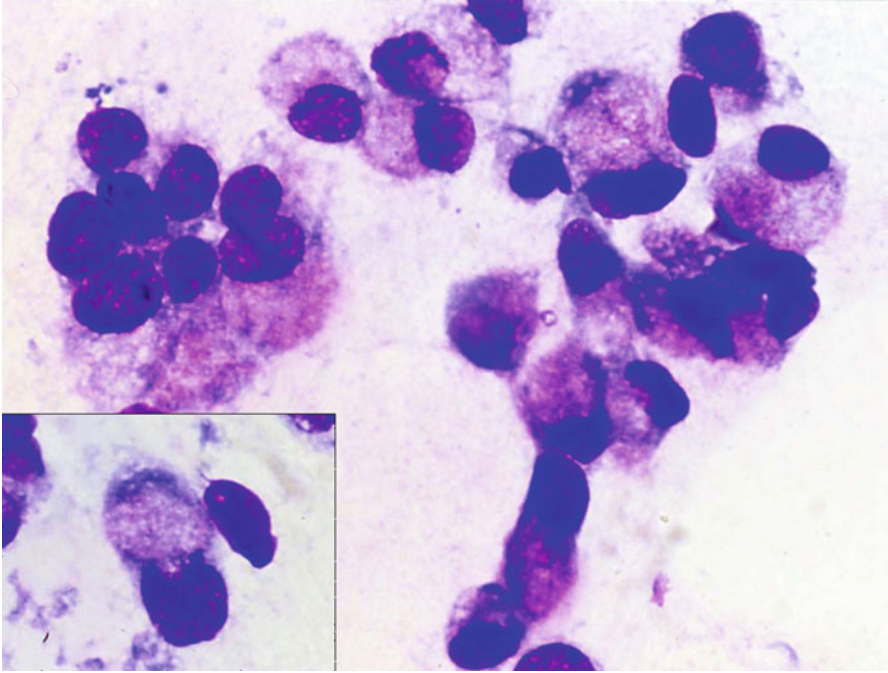


Fig. 5.28 Cytology of a gastric adenocarcinoma: at higher magnifications, neoplastic cells are arranged singly or as small clusters; the cytoplasm is large, eosinophilic and of granular appearance. Occasionally, cells look like goblet cells (*inset*)

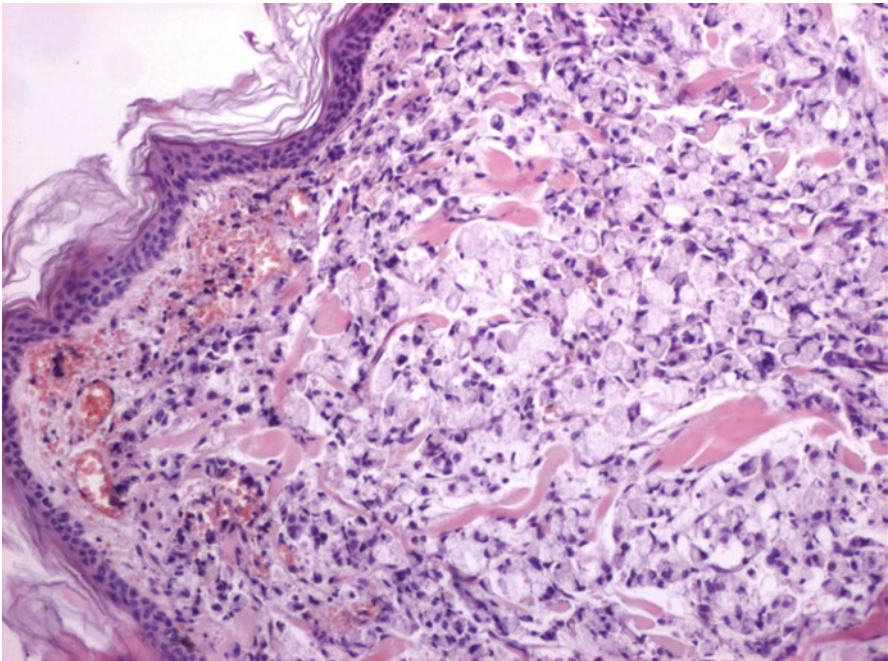


Fig. 5.29 Histology of skin metastasis from a gastric adenocarcinoma: neoplastic cells characterised diffusely infiltrate the dermis

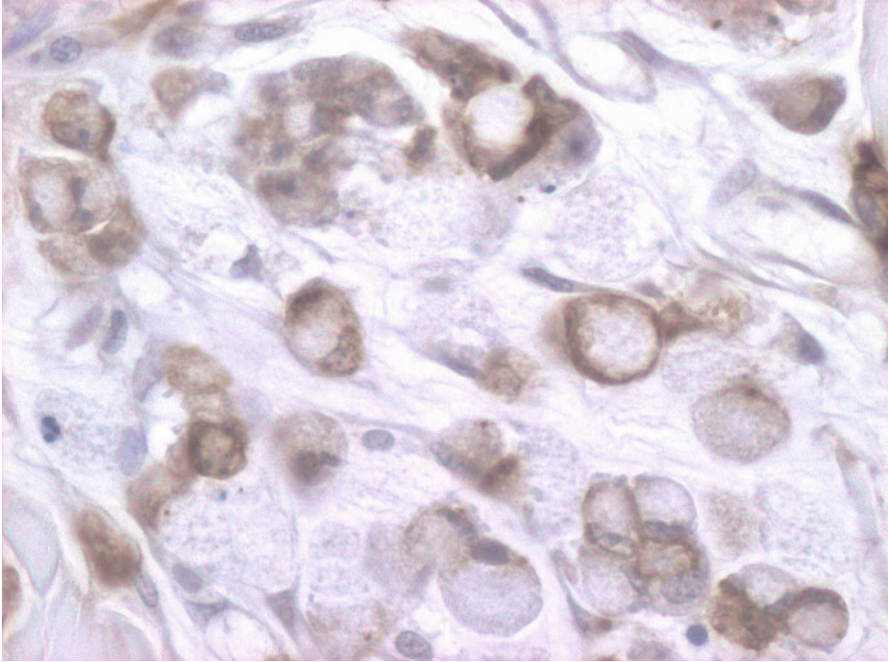


Fig. 5.30 Immunohistochemistry of a gastric adenocarcinoma: neoplastic cells show strong positivity to pan-cytokeratin immunostaining

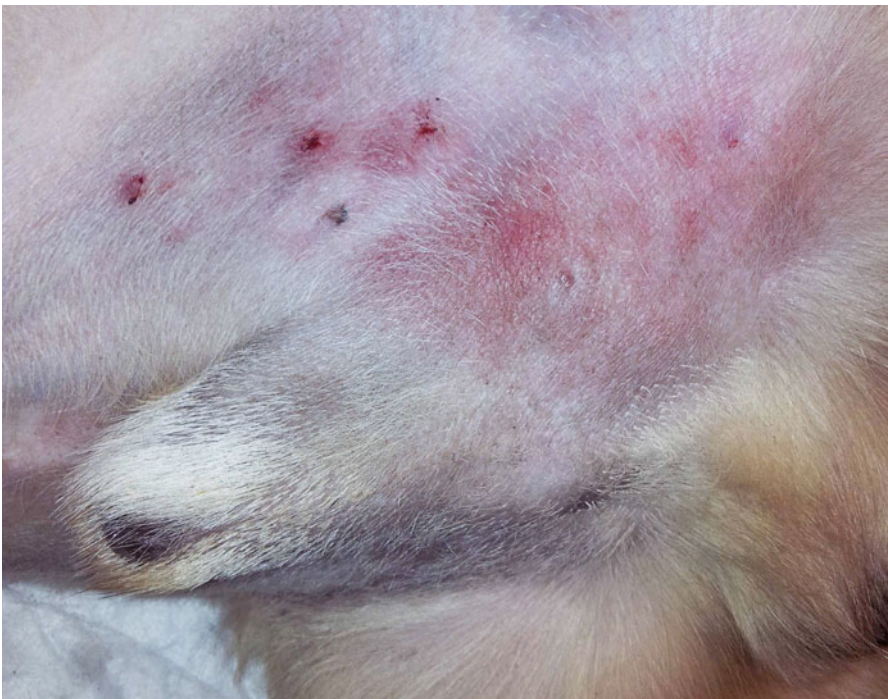

Fig. 5.31 Swelling and multiple small nodules on the abdomen of a dog. Histopathology allowed diagnosis of metastasis from a prostatic carcinoma (Courtesy of Dr. M. Annoni, Italy)

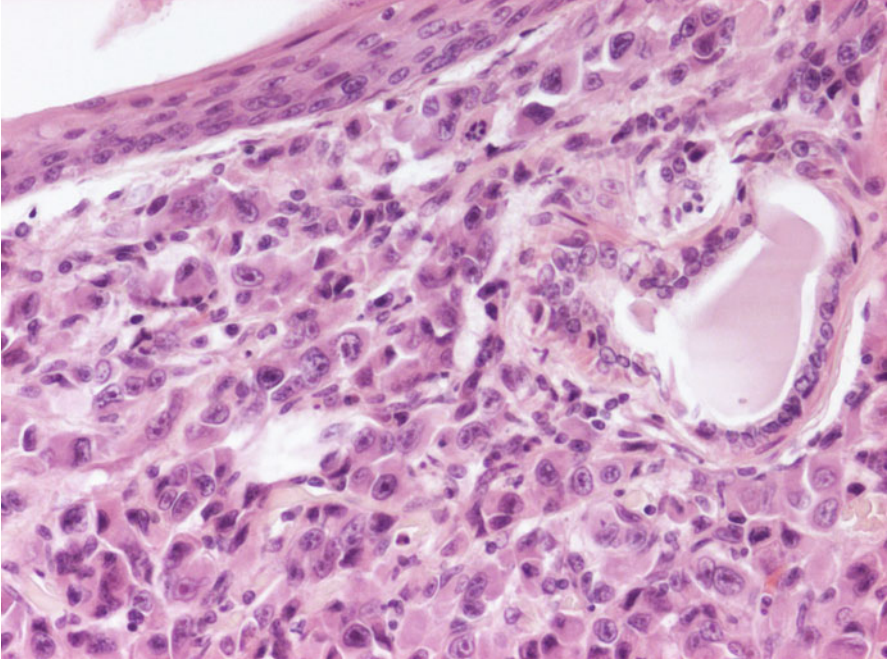


Fig. 5.32 Histology of skin metastasis from a prostatic carcinoma: superficial and diffuse dermal proliferation of malignant prostatic cells

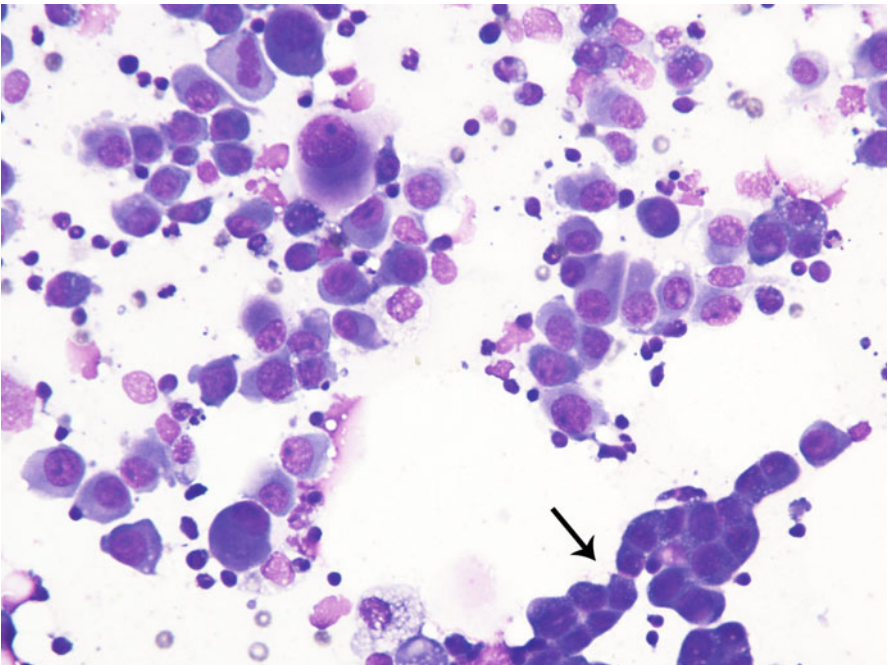


Fig. 5.33 Cytology of a prostatic carcinoma: monomorphous population of neoplastic round to polygonal cells. The epithelial nature of the cells is indicated by the presence of small aggregates with an intercellular junction (*arrow*)

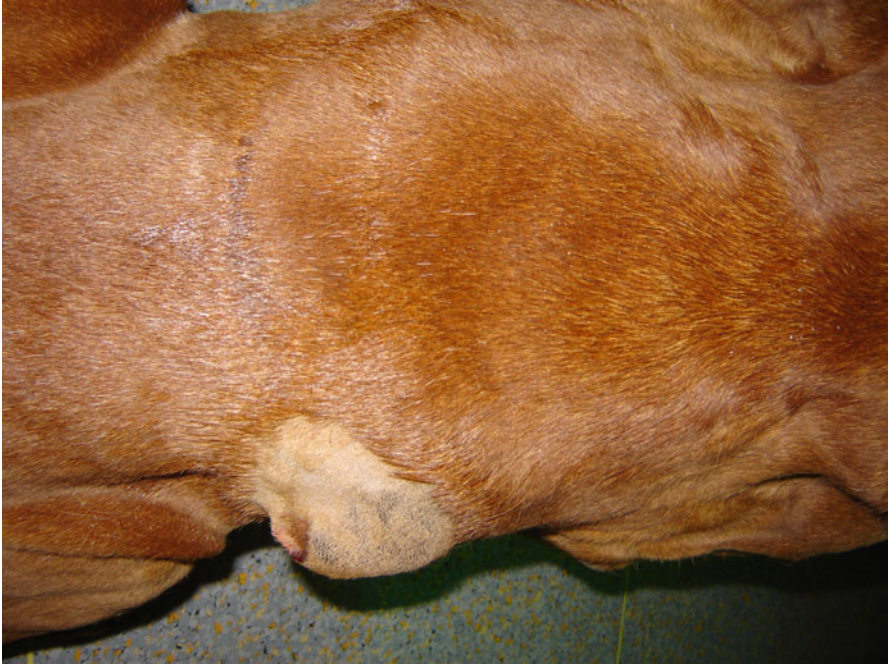

Fig. 5.34 Skin metastasis of a primary salivary carcinoma: large nodule on the right thorax of a Boxer

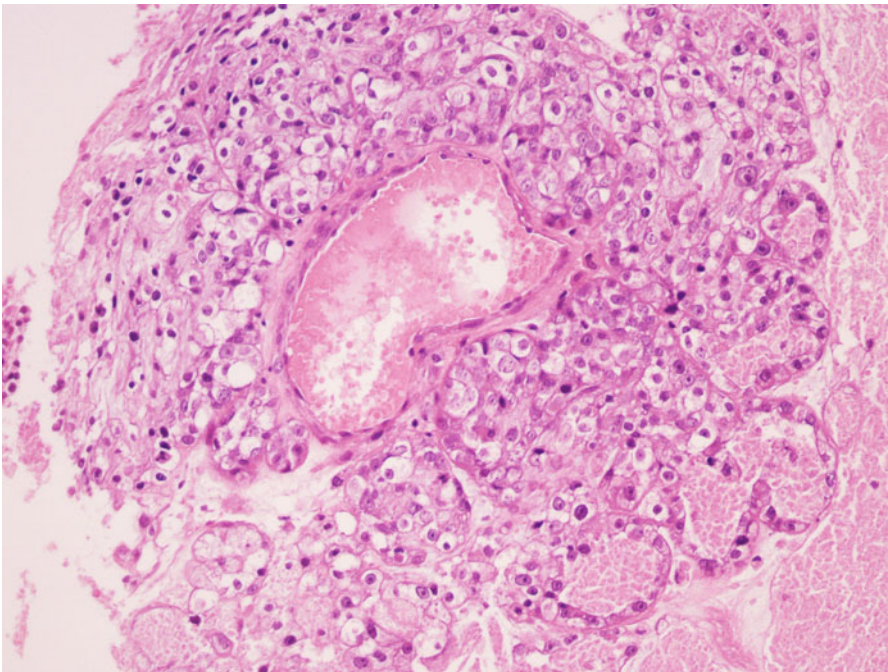


Fig. 5.35 Histology of skin metastasis from a salivary carcinoma: malignant neoplastic salivary cells show a disorganised arrangement. adenomera are still well recognisable

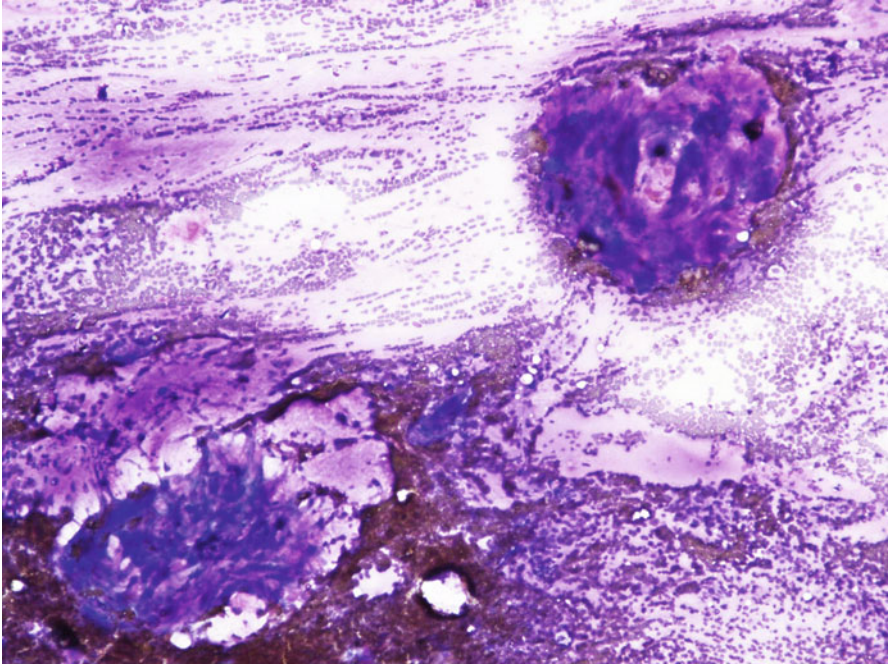


Fig. 5.36 Cytology of a salivary carcinoma. At low magnifications, an amorphous, eosinophilic, mucinous material embedding poorly defined cells is evident

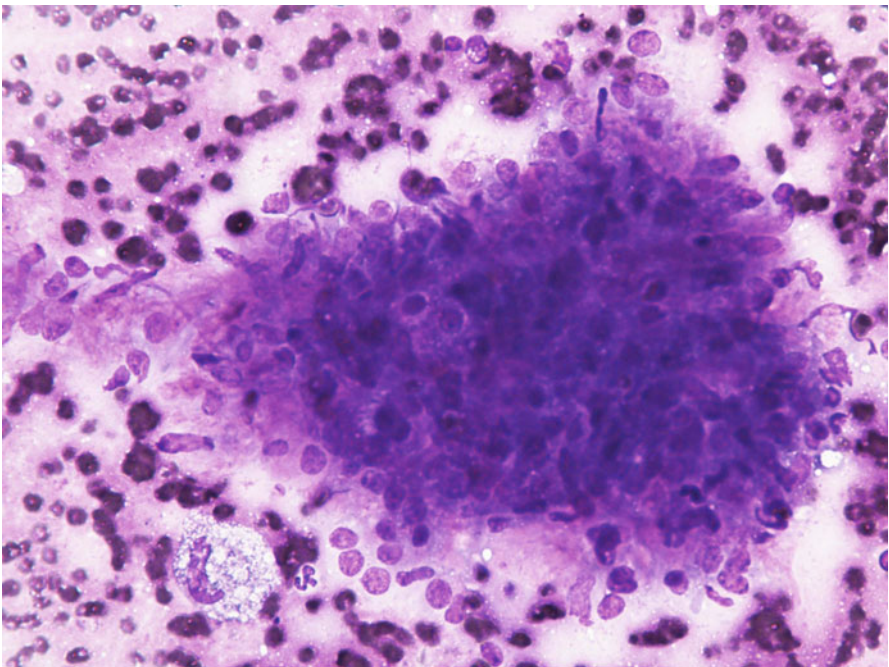


Fig. 5.37 Cytology of a salivary carcinoma. Loosely cohesive pleomorphic cells are embedded in an eosinophilic matrix. Cells show indistinct borders, moderate, slightly basophilic cytoplasm, monomorphic oval nuclei with coarse chromatin, and indistinct to prominent nucleoli

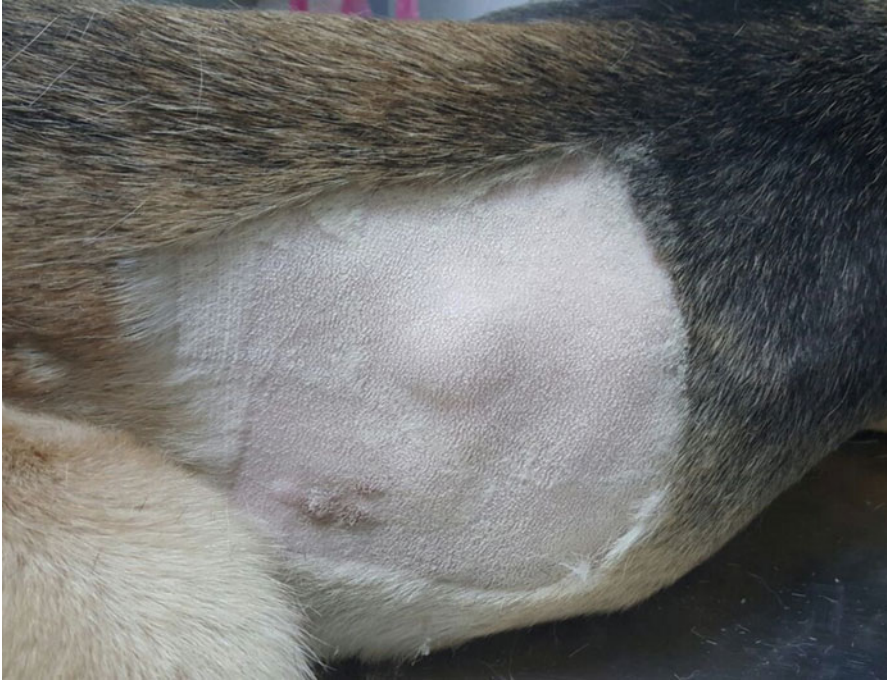

Fig. 5.38 Metastatic subcutaneous nodule from a primary adrenal pheochromocytoma (Courtesy of Dr. C. Damiani, Italy)

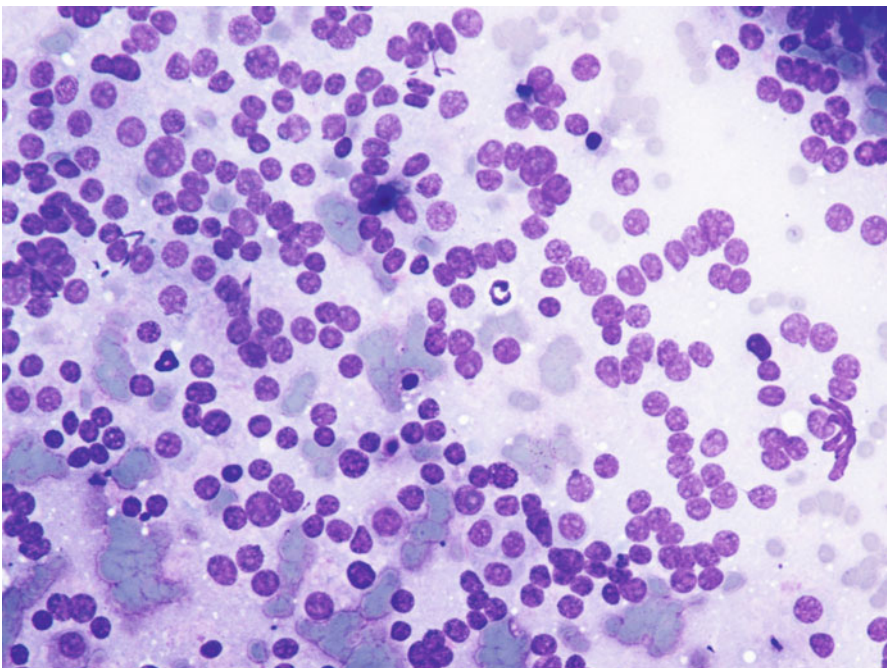


Fig. 5.39 Cytology of a metastatic pheochromocytoma: monomorphic population of round, bare nuclei, often arranged in rows and pseudo-acinar structures

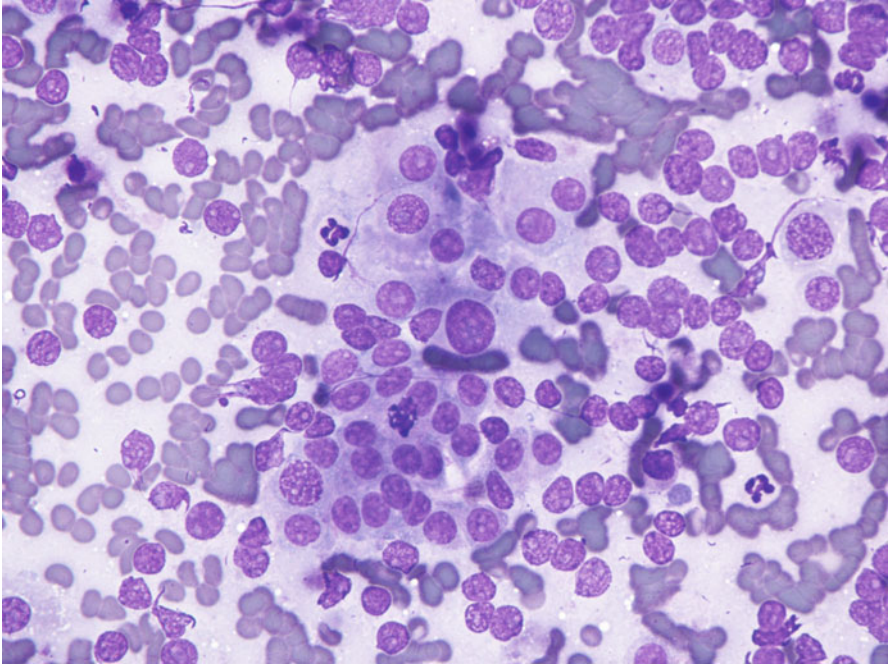


Fig. 5.40 Cytology of a metastatic pheochromocytoma: intact cells organised in cohesive clusters with a plasmacytoid appearance

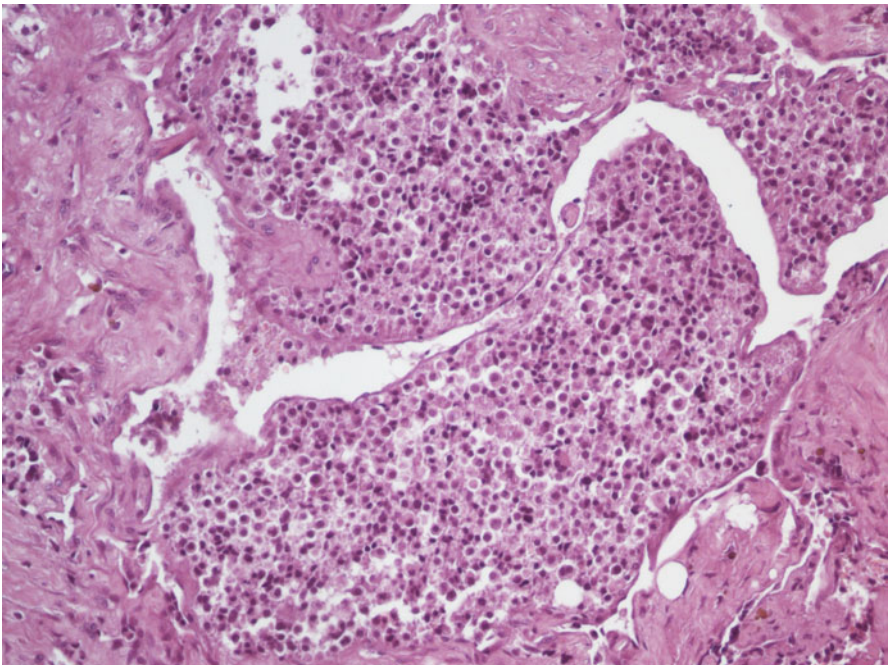


Fig. 5.41 Histology of skin metastasis from a pheochromocytoma: neoplastic cells are arranged in tight nests embedded in a fibrous, connective, stromal tissue

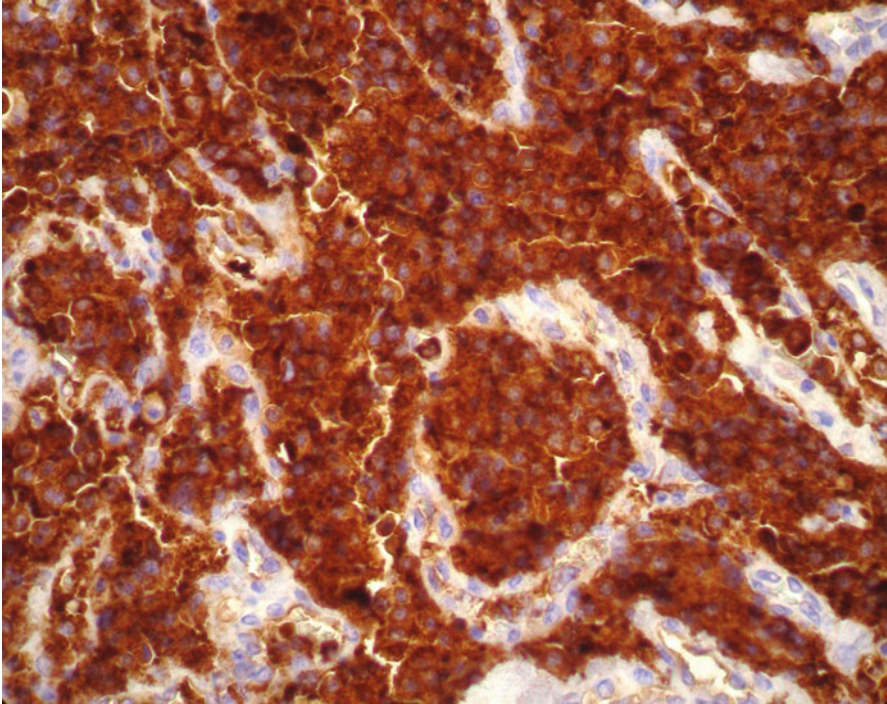


Fig. 5.42 Immunohistochemistry of metastatic pheochromocytoma: neoplastic cells show strong positivity to synaptophysin immunostaining

References

Lung–Digit Syndrome

- Barr F, Gruffydd-Jones TJ, Brown PJ et al (1987) Primary lung tumours in the cat. *J Small Anim Pract* 28:1115–1125
- Estrada M, Lagadic M (1992) Métastases digitales d'un carcinome pulmonaire asymptomatique chez le chat: Etude d'une série de 11 cas. *Prat Med Chir Anim Comp* 27:791–795
- Favrot C, Degorce-Rubiales F (2005) Cutaneous metastases of a bronchial adenocarcinoma in a cat. *Vet Dermatol* 16(3):183–186
- Goldfinch N, Argyle DJ (2012) Feline lung-digit syndrome: unusual metastatic patterns of primary lung tumours in cats. *J Feline Med Surg* 14(3):202–208
- Gottfried SD, Popovitch CA, Goldschmidt MH et al (2000) Metastatic digital carcinoma in the cat: a retrospective study of 36 cats (1992-1998). *J Am Anim Hosp Assoc* 36(6):501–509
- Gross TL, Ihrke PJ, Walder EJ, Affolter VK (2005) Metastatic pulmonary carcinoma in cats. In: *Skin diseases of the dog and cat: clinical and histopathological diagnosis*, 2nd edn. Blackwell Science, Oxford, pp 703–706
- Langlais LM, Gibson J, Taylor JA et al (2006) Pulmonary adenocarcinoma with metastasis to skeletal muscle in a cat. *Can Vet J* 47:1122–1123

- Moore AS, Middleton DJ (1982) Pulmonary adenocarcinoma in three cats with non-respiratory signs only. *J Small Anim Pract* 23:501–509
- Petterino C, Guazzi P, Ferro S et al (2005) Bronchogenic adenocarcinoma in a cat: an unusual case of metastasis to the skin. *Vet Clin Pathol* 34:401–404
- van der Linde-Sipman JS, van den Ingh TS (2000) Primary and metastatic carcinomas in the digits of cats. *Vet Q* 22:141–145

Inflammatory Mammary Carcinoma

- Clemente M, Pérez-Alenza MD, Peña L (2010) Metastasis of canine inflammatory versus non-inflammatory mammary tumours. *J Comp Pathol* 143(2–3):157–163
- Kleer CG, van Golen KL, Merajver SD (2000) Molecular biology of breast cancer metastasis. Inflammatory breast cancer: clinical syndrome and molecular determinants. *Breast Cancer Res* 2(6):423–429
- Marconato L, Romanelli G, Stefanello D et al (2009) Prognostic factors for dogs with mammary inflammatory carcinoma: 43 cases (2003–2008). *J Am Vet Med Assoc* 235(8):967–972
- Perez Alenza MD, Tabanera E, Peña L (2001) Inflammatory mammary carcinoma in dogs: 33 cases (1995–1999). *J Am Vet Med Assoc* 219:1110–1114

Cutaneous Metastasis from Internal Hemangiosarcoma

- Bertazzolo W, Dell’Orco M, Bonfanti U et al (2005) Canine angiosarcoma: cytologic, histologic, and immunohistochemical correlations. *Vet Clin Pathol* 34(1):28–34
- Guaguère E, Vanderkerckhove M, Mialot M (1994) Cutaneous metastases of a visceral haemangiosarcoma in a Brittany Spaniel. *Prat Med Chir Anim Comp* 29(5):479–480
- Hargis AM, Ihrke PJ, Spangler WL et al (1992) Retrospective clinicopathologic study of 212 dogs with cutaneous hemangiomas and hemangiosarcomas. *Vet Pathol* 29(4):316–328
- Wilkerson MJ, Chard-Bergstrom C, Andrews G et al (2002) Subcutaneous mass aspirate from a dog. *Vet Clin Pathol* 31(2):65–68

Other Rare Skin Metastasis

- Dell’Orco M, Bertazzolo W, Vergine M et al (2005) Gastric mucinous adenocarcinoma with cutaneous metastases in a dog: diagnosis by fine-needle aspiration cytology. *J Small Anim Pract* 46(9):449–453
- Gorman E, Barger AM, Wypij JM et al (2006) Cutaneous metastasis of primary appendicular osteosarcoma in a dog. *Vet Clin Pathol* 35(3):358–361
- Juopperi TA, Cesta M, Tomlinson L et al (2003) Extensive cutaneous metastases in a dog with duodenal adenocarcinoma. *Vet Clin Pathol* 32(2):88–91
- Koehler JW, Weiss RC, Aubry OA et al (2011) Nasal tumor with widespread cutaneous metastases in a Golden Retriever. *Vet Pathol* 49(5):870–875
- Lucas X, Rodenas C, Cuello C et al (2012) Unusual systemic metastases of malignant seminoma in a dog. *Reprod Domest Anim* 47(4):e59–e61

- Otrocka-Domagala I, Pazdzior-Czapula K, Gesek M et al (2015) Aggressive, solid variant of alveolar rhabdomyosarcoma with cutaneous involvement in a juvenile labrador retriever. *J Comp Pathol* 152(2–3):177–178
- Reed LT, Knapp DW, Miller MA (2013) Cutaneous metastasis of transitional cell carcinoma in 12 dogs. *Vet Pathol* 50(4):676–681
- Spugnini EP, Bartolazzi A, Ruslander D (2000) Seminoma with cutaneous metastases in a dog. *J Am Anim Hosp Assoc* 36(3):253–256
- Takiguchi M, Iida T, Kudo T et al (2001) Malignant seminoma with systemic metastases in a dog. *J Small Anim Pract* 42(7):360–362
- Tomlinson MJ, McKeever PJ, Nordine RA (1982) Colonic adenocarcinoma with cutaneous metastasis in a dog. *J Am Vet Med Assoc* 180(11):1344–1345

Index

A

- Acantholytic cells, 124, 132, 136–142, 144, 147, 151, 174
- Acantholytic keratinocytes, 5, 36, 48, 124, 132, 136, 138, 146, 153, 154, 174
- Actinomycosis, 194
- Anal sac adenocarcinoma, 419
- Anal sacs glands, 18, 358, 419
- Anaplastic soft tissue sarcoma with many giant cells, 470–473
- Apocrine feline cystomatosis, 419
- Apocrine gland tumors, 358, 418–430

B

- Bacterial folliculitis, 122–123
- Bacterial overgrowth syndrome (BOGS), 155–156
- Basophils, 21, 26, 28, 81, 84
- Benign cutaneous histiocytoma, 59, 335–342
- Benign papular mastocytic hyperplasia, 84–87
- Botryomycosis, 197–201

C

- Calcinosis circumscripta*, 73, 245, 247–252
- Calcinosis cutis*, 60, 73, 108–116, 245
- Candidiasis, 159–163
- Canine leishmaniasis, 35, 61, 100–104, 108, 142–144, 179, 209
- Ceruminous glands, 18, 419, 422, 424, 429
- Collagen fibres, 11, 12, 108, 249, 256, 304, 306, 430, 436, 441, 444
- Congo red, 74–75, 328, 329

- Corneocytes, 1, 4–8, 15, 32, 37, 51, 83, 86–88, 91, 92, 99, 123, 140, 142, 156, 158, 162, 163, 166, 167, 174, 381, 383, 385, 388, 389, 394, 397, 398, 410, 411, 430
- Crusted papules, 43–45, 79–82, 84, 86, 148
- Crusts, 43–45, 49, 52–58, 79, 82, 86, 110, 112, 123, 132–135, 140, 141, 143, 151, 152, 154, 173, 174, 176, 181, 187, 189, 190, 249, 256, 259, 362
- Cryptococcosis, 36, 240–245
- Cutaneous, 1, 2, 8, 11, 19, 25, 38, 54, 59, 73, 77, 84, 116, 155, 159–163, 187, 189, 209, 211, 212, 214, 216–220, 223, 241, 245, 261, 267, 296, 311, 312, 321, 322, 325–329, 335–349, 352–354, 430, 436, 445, 450, 493–535
- Cutaneous and systemic reactive histiocytosis, 342–347
- Cutaneous metastasis, 493–535

D

- Deep pyoderma, 16, 18, 20, 86–93, 96, 177–179, 194, 198
- Demodicosis, 25, 36, 51, 91, 94–96, 122, 124–127, 168–171
- Dendritic antigen presenting cells (APC), 1, 11, 335, 342, 347, 350, 356
- Dermatophytic kerion, 223–229
- Dermatophytic pseudomycetoma, 198, 228–236
- Dermatophytosis, 36, 51, 84, 128, 137–142, 160, 164–167, 176, 224

Dermis, 1, 8–20, 27, 33, 38, 42, 49, 52, 54, 55, 59, 61, 62, 80, 87, 108, 110, 112, 113, 116, 117, 119, 144, 185, 188, 189, 194, 218, 220, 223, 224, 228, 229, 234, 245, 258, 271, 277, 293, 311, 319, 335, 342, 347, 372, 430, 435, 445, 454, 522

Dirofilariasis, 25, 216–223

E

Eosinophilic granuloma (EG), 38, 181, 183–186, 249, 252–258, 283

Eosinophilic inflammation, 25, 38–39, 98, 149, 255, 256, 260, 301

Eosinophilic plaque, 181, 249, 254, 256, 261

Eosinophilic pustulosis, 148, 149

Eosinophils, 4, 9–12, 21, 25–26, 28, 33, 34, 38, 39, 45, 79–81, 83, 84, 86, 96–100, 117, 137, 139, 140, 148, 149, 181, 183–189, 198, 218, 224, 248–261, 273, 301, 303, 304, 307, 311, 325, 328, 381, 382, 420, 436, 444, 445, 447, 461, 479, 480, 500, 503, 520, 521

Epidermal collarettes, 41, 49, 52–54, 78, 123, 173–176

Epidermis, 1–8, 12, 20, 42, 45, 51–53, 57, 61, 132, 187, 245, 256, 311, 320, 335, 358, 372, 373, 377, 381, 382

Epithelial tumors, 12, 292, 358–435, 473, 495

Epithelioid cells, 27, 32, 229, 256

Epithelioid macrophages, 31, 32, 36, 37, 87, 89, 92, 96, 99, 112, 209, 224, 229, 236, 268

Epitheliotropic lymphoma, 51, 61, 291, 311–320, 343

Erosions, 41, 52–54, 173–177, 312, 497

F

Facial eosinophilic furunculosis, 38, 96–100

Feline indolent ulcer (IU), 181–183, 249

Feline progressive dendritic histiocytosis, 350–354

Fibroadnexal hamartoma, 430–434

Fibroblasts, 8–11, 27, 112, 113, 115, 207, 256, 265, 301, 303, 304, 430, 434–436, 442, 443, 450, 454, 470

Fibrocytes, 9, 435, 439, 445, 447

Fibroma, 435–437, 439, 441, 454

Fibrosarcoma, 435–444, 470

Fleabite allergic dermatitis, 79–80, 148

Follicular cysts, 131, 372–377, 381–394

Follicular neoplasms, 12, 372, 377, 388–394

Follicular pustules, 46–49, 122–129, 131

Follicular tumors, 372–377, 399

G

Grocott, 68–70, 140, 191, 193, 228, 229, 234, 236, 240, 243

H

Haemangioma, 445–451

Haemangiopericytomas, 450, 454

Haemangiosarcoma, 445, 448–453, 493, 499–501, 514

Hair follicles, 8, 11, 86, 372, 377

Hepatoid glands, 13, 358, 402, 405, 406, 410, 415–418

Herpesvirosis, 185–189

Histiocytic diseases, 11, 292, 335–342, 441, 493

Histiocytic multinucleate giant cells, 87

Histiocytic sarcoma, 11, 292, 335, 347–351, 435, 441, 470

Hybrid cysts, 388, 389, 399

Hyperplasia/adenoma of hepatoid glands, 410

Hypersensitivity diseases, 25, 33, 79–84, 245, 249

Hypodermis, 1, 18–19

I

Idiopathic pustular dermatitis, 142

Impetigo, 49, 128–132

Impression smears, 42, 45, 49, 51, 53, 54, 59, 61–64

Inflammatory mammary carcinoma, 493, 497–99, 505

Infundibular cysts, 372–376, 381, 383–385, 397

Infundibular keratinizing acanthoma, 394, 397

Isthmic cysts, 381, 386

J

Juvenile cellulitis, 61, 266–270

Juvenile sterile granulomatous dermatitis and lymphadenitis, 266–270

K

Karyolysis, 21–23, 123, 124, 132
 Karyorrhexis, 21, 23

L

Leishmaniasis, 35, 36, 44, 51, 61,
 100–104, 108, 142, 144–147,
 179–182, 209–212, 318, 335
 Lipoma, 18, 59, 435, 459–468
 Liposarcoma, 71, 292, 459, 464,
 466, 468–470
 Lung-digit syndrome, 493–497
 Lymphocytes, 26–28, 38, 39, 41, 108, 109,
 179, 198, 207, 209, 236, 261, 272,
 308, 317, 318, 321, 325, 335, 337,
 342–344, 347–349, 354, 357, 441
 Lymphoma,
 51, 61, 191, 291, 292, 311–321, 493
 Lymphoplasmacellular inflammation, 39

M

Macrophages, 02–27, 104–33, 35–38, 71,
 72, 74, 81, 83, 87, 89, 91–93, 95,
 96, 99, 107, 112, 117, 119, 120,
 144, 146, 179, 180, 185–187, 189,
 191, 192, 194, 198, 205–207, 209,
 212, 213, 216–218, 224, 227, 229,
 233, 234, 236, 239, 240, 247, 256,
 257, 261, 264, 268, 270, 272, 347,
 354, 394, 410, 419, 421, 423, 424,
 427, 428, 441, 450
 Malassezia, 51, 156–160
 Malignant fibrous histiocytoma,
 350, 353, 441, 470
 Mast cells, 33, 38, 39, 73, 86, 87, 256, 258,
 261, 292–311, 354, 441, 493
 Mast cell tumors (MCTs),
 293–301, 304–311
 Matrical cysts, 372, 374, 381–388
 Melanocytes,
 1, 11, 292, 473, 476–478, 482
 Melanocytic tumors, 473–482
 Melanocytoma, 1, 292, 473, 474, 476, 479
 Melanoma, 1, 292, 435, 473, 475, 477–482
 Mesenchymal (spindle) cell tumors, 265
 Multinucleated giant cells,
 31, 92, 112–114, 192, 236, 247, 470
 Mycobacteriosis,
 31, 149, 201–204, 207–210
 Myopericytomas, 450
 Myxoma, 445, 447, 454
 Myxosarcoma, 445–448

N

Neosporosis, 214, 215, 217, 218
 Neutrophilic and macrophagic
 (granulomatous/pyogranulomatous)
 inflammation, 29, 35–38, 194, 198,
 207, 214, 270
 Neutrophilic inflammation, 34–38, 155, 368
 Nocardiosis, 194, 195
 Nodular papule, 43, 45, 86–117, 430, 505, 507
 Nodules, 41, 43, 44, 57–59, 96, 104–107,
 117–119, 183, 185, 189, 191–269,
 291, 293, 296, 298, 308, 312–314,
 316, 318, 319, 321, 329–331, 335–337,
 339, 343–346, 348, 350, 351, 354, 377,
 397, 402–405, 419, 422, 430, 435, 436,
 441, 445, 448, 450, 454, 464, 473, 496,
 501, 503, 507, 519, 524, 527, 531
 Non-epitheliotropic lymphoma, 312, 314–316,
 318, 319, 343
 Non-follicular pustules, 46–49, 122, 128–133,
 136, 139, 140, 142, 145, 146, 148–150

O

Oil-Red-O, 15, 71, 72, 117, 121,
 409–411, 413, 467, 470

P

Panniculitis, 19, 36, 71, 194, 197, 198, 204,
 207, 208, 261–265
 Papules, 41–45, 53, 77–149, 173, 216, 430,
 505, 507
 Pemphigus foliaceus (PF),
 5, 35, 36, 38, 47, 51, 53, 131–141, 144,
 151–154, 174, 176
 Periodic acid–Schiff (PAS), 68, 69, 140, 163,
 165, 166, 191, 193, 226, 228, 232, 234,
 Peripheral nerve sheath tumor (PNST),
 454–463
 Perivascular wall tumors (PWT), 450–459
 Phaeohyphomycosis, 36, 234–240
 Pilomatricoma, 372, 380, 388, 399, 401
 Plaques, 41, 57, 59, 84, 85, 96, 104, 106,
 110–112, 117, 181, 185, 186, 191–263,
 291, 293, 296, 312–316, 343–346, 354,
 359, 362, 366, 505, 506
 Plasma cells, 27, 29, 39, 75, 91, 100, 102–104,
 108, 179, 209, 213, 236, 261, 271–274,
 292, 321–329, 337, 341, 342, 347
 pododermatitis, 271–274
 tumor, 27, 29, 39, 75, 91, 100, 102–04,
 108, 179, 207, 209, 213, 236, 261,
 272–274, 321–329, 337, 342, 347

Preparation of slides, 26, 63–66, 416
 Prussian blue or Perls' reaction, 73–74
 Pustular, 35, 53, 122, 126–129, 131, 132, 137,
 140–142, 144, 149, 151, 174, 176
 Pustules, 5, 41, 45–50, 52, 53, 57, 78,
 117–153, 173, 174, 176
 Pyknosis, 21, 23, 24
 Pyoderma, 372, 380, 383, 399, 401

R

Romanowsky-type, 4, 26, 33, 39, 64, 66–68,
 73, 74, 160, 204, 243, 296, 301, 302
 Round cell tumors, 493

S

Sampling techniques, 19, 41–57, 59, 61–63
 Scales, 8, 41, 51, 155–167, 173,
 229, 249, 312, 381
 Scraping, 19, 41, 54, 61–64, 168
 Sebaceous epithelioma,
 399, 402, 404, 410, 412, 413
 Sebaceous epitheliomatous carcinoma, 39
 Sebaceous gland tumors, 399–418
 Sebaceous hyperplasia,
 399, 402, 403, 407, 408, 410
 Sebaceous sebocytic adenoma, 402
 Sebaceous sebocytic carcinoma, 402
 Sporotrichosis, 189–193
 Squamous cell carcinoma (SCC),
 62, 181, 183, 291, 358–364,
 366–371, 435, 436, 439, 495–497
 Staining of slides, 41, 66–73
Staphylococcal pyoderma, 35, 36, 78, 173
 Sterile granuloma and pyogranuloma
 syndrome (SGPS), 104–109

Stratum basale, 2, 3
 Stratum corneum, 2, 4–8, 140, 159,
 162, 163, 165, 166, 169, 170
 Stratum granulosum, 2, 4, 381
 Stratum spinosum, 2–4
 Subcorneal pustular dermatosis, 140
 Subcutaneous tissue,
 1, 18–19, 216, 245, 347, 454
 Sweat glands, 8, 11, 13, 16, 17,
 418–430, 433
 tumors, 418–434

T

Toluidine blue, 73, 301, 311
 Toxoplasmosis, 214–217
 Transmissible venereal tumor, 292, 328–335
 Trichoblastoma, 372, 377–379, 389–396, 419
 Trichoepithelioma, 372, 380, 388, 397–400

U

Ulcer, 41, 44, 52, 54–57, 62, 173, 176–190,
 204, 249, 271, 312, 313

V

Visceral haemangiosarcoma (vHSA), 499
 Von Kossa, 71–73, 112, 249, 252

X

Xanthomatosis, 38, 59, 71, 116–117, 119–121

Z

Ziehl–Neelsen, 69, 71, 204, 206, 207