Roberto J. Estrada

Ultrasound-Guided Procedures in Equine Orthopedics and Surgery

MOREMEDIA

Springer

Ultrasound-Guided Procedures in Equine Orthopedics and Surgery

Roberto J. Estrada

Ultrasound-Guided Procedures in Equine Orthopedics and Surgery

Springer

Roberto J. Estrada
Large Animal Surgery Department
and Equine Hospital
Universidad Nacional
Heredia, Costa Rica

ISBN 978-3-031-17561-9 ISBN 978-3-031-17562-6 (eBook)
https://doi.org/10.1007/978-3-031-17562-6

This work contains media enhancements, which are displayed with a "play" icon. Material in the print book can be viewed on a mobile device by downloading the Springer Nature "More Media" app available in the major app stores. The media enhancements in the online version of the work can be accessed directly by authorized users.

© Springer Nature Switzerland AG 2024
This work is subject to copyright. All rights are reserved by the Publisher, whether the whole or part of the material is concerned, specifically the rights of translation, reprinting, reuse of illustrations, recitation, broadcasting, reproduction on microfilms or in any other physical way, and transmission or information storage and retrieval, electronic adaptation, computer software, or by similar or dissimilar methodology now known or hereafter developed.
The use of general descriptive names, registered names, trademarks, service marks, etc. in this publication does not imply, even in the absence of a specific statement, that such names are exempt from the relevant protective laws and regulations and therefore free for general use.
The publisher, the authors, and the editors are safe to assume that the advice and information in this book are believed to be true and accurate at the date of publication. Neither the publisher nor the authors or the editors give a warranty, expressed or implied, with respect to the material contained herein or for any errors or omissions that may have been made. The publisher remains neutral with regard to jurisdictional claims in published maps and institutional affiliations.

This Springer imprint is published by the registered company Springer Nature Switzerland AG
The registered company address is: Gewerbestrasse 11, 6330 Cham, Switzerland

Paper in this product is recyclable.

Adriana, Valentina, and Santiago, thank you for always being there for me, for your patience, and for being my motivation to always keep moving forward. I love you guys!!!

My parents, Manuel and Betty, who taught me to be humble, work hard, and never give up.

My patients, who have taught me so much and gave me so many joys during my professional life.

Last but not least, I would like to thank God for giving me health, strength, and wisdom to conclude this project.

Acknowledgments

I would like to extend my most sincere thanks to all the people who made this handbook possible. Colleague veterinarians, students, assistants, farriers, grooms, and owners were all of great help to make this dream come true.

I would also like to thank the team of the Equine Hospital, School of Veterinary Medicine, Universidad Nacional, for all the support during this process.

Roberto J. Estrada

Large Animal Surgery Department and
Equine Hospital, Universidad Nacional
Heredia, Costa Rica

Contents

1 Principles of the Ultrasound-Guided Procedures 1
1.1 Injection Site Selection 2
1.2 Transducer and Instrumentation Selection 2
1.3 Positioning, Immobilization, and Preparation 3
1.4 Image Quality 5
1.5 Transducer Marker vs Screen Marker 5
1.6 Transducer Alignment with the Needle 5
1.7 Target's Depth 6
References 7

2 Ultrasound-Guided Injections in Tendons, Ligaments, and Joints . . . 9
2.1 Tendons and Ligaments 9
2.1.1 Ultrasound-Guided Procedures to the Flexor Tendons and Accessory Ligament of the Deep Digital Flexor Tendon . . . 10
2.1.2 Ultrasound-Guided Injections to the Suspensory Ligament 12
2.1.3 Ultrasound-Guided Injections to the Collateral Ligament of the Distal Interphalangeal Joint 19
2.2 Cervical Facet Joints 23
2.2.1 Dorsal Approach to the Cervical Facet Joints 23
2.2.2 Dorsocranial Approach to the Cervical Facet Joints 24
2.3 Thoracolumbar Facet Joints 28
2.3.1 Medial Approach to the Thoracolumbar Facet Joints 28
2.3.2 Lateral Approach to the Thoracolumbar Facet Joints 31
2.4 Sacroiliac Region 32
2.4.1 Cranial Approach to the Sacroiliac Region 32
2.4.2 Caudal Approach to the Sacroiliac Region 35
2.5 Coxofemoral Joint 37
2.5.1 Cranioventral Approach 38
2.5.2 Craniodorsal Approach 40

2.6 Scapulohumeral Joint 42
2.6.1 Caudolateral Approach 42
2.6.2 Craniolateral Approach 43
2.7 Medial Femorotibial Joint 46
References 49

3 Ultrasound-Guided Injections in Bursae and Nerve Blocks 53
3.1 Navicular Bursa 53
3.1.1 Trancuneal Approach 54
3.1.2 Palmarodistal Digital Approach 56
3.1.3 Lateral Approach (Tendon-Sparing) 58
3.2 Bicipital Bursa 60
3.3 Infraspinatus Bursa 62
3.4 Tibial Nerve Block 66
3.5 Median Nerve Block 68
References 72

4 Ultrasound-Assisted Surgery 75
4.1 Intraoperative Ultrasound Marking 75
4.2 Intraoperative Ultrasound Guidance 77
4.2.1 Ultrasound-Guided Surgical Incision and Drainage 77
4.2.2 Dissection, Bone Curettage, Exostosis Resection, and Fragment Removal 80
4.2.3 Tendon and Ligament Surgery 85
4.2.4 Ultrasound Guidance During Synovial Endoscopy 97
4.2.5 Ultrasound Guidance for Implant Removal 99
References 100

5 Ultrasound-Guided Treatment of Cervical Nerve Radiculopathy . . . 103
5.1 Cervical Spinal Nerve Roots 104
References 108

Index 111

About the Author

Roberto J. Estrada is Associate Professor and Surgeon of the Equine Hospital, School of Veterinary Medicine, Universidad Nacional, Costa Rica. He combines the work in the university with his ambulatory private practice focused on equine orthopedics and medical imaging. Dr. Estrada worked for several years in the Equine Clinic, Freie Universität Berlin, Germany, where he did his specialized training in surgery and orthopedics and became a certified specialist in equine surgery (Dipl. ECVS-LA). After performing hundreds of US-guided injections and surgeries and being part of studies in the field, Dr. Estrada saw the necessity of compiling and sharing these techniques with his colleagues, convinced that learning about US-guided procedures has an extremely positive impact in daily equine practice.

List of Abbreviations

ALDDFT	Accessory ligament of the deep digital flexor tendon
CFJ	Coxofemoral joint
CSL	Collateral sesamoidean ligament
DDFT	Deep digital flexor tendon
DIPJ	Distal interphalangeal joint
FTJ	Femorotibial joint
MHz	MegaHertz
MRI	Magnetic resonance imaging
OCD	Osteochondrosis
P2	Second phalanx
SDFT	Superficial digital flexor tendon
SHJ	Scapulohumeral joint
SIJ	Sacroiliac joint
SL	Suspensory ligament
TIVA	Total IV anesthesia
UFP	Upper fixation of patella

Principles of the Ultrasound-Guided Procedures

1

Abstract

Ultrasound-guided procedures are used every day in equine practice around the world. Sadly, an important number of these procedures are not done properly because of the lack of understanding of the basic principles that are needed to perform injections and surgeries accurately. This chapter discusses the basic principles behind these techniques, allowing the reader to learn how to improve precision and decrease failure. This will not only have an important impact in the results obtained but also would potentially decrease the morbidity and mortality related to these procedures.

Keywords

Ultrasound-guided procedures · Ultrasound-guided injections · Principles · Basic

The main reason behind the use of ultrasonography for the guidance of injections and surgical procedures is to improve precision. Placing the needle exactly where one wants or reducing the size of the incision during surgery will positively affect the outcome of the patient. Therefore, there are several basic principles that have to be followed to allow the operator to be as accurate as possible.

It has been demonstrated that the learning curve of these procedures significantly varies from operator to operator and that to be proficient the operator must perform an important number of supervised procedures. Barrington et al. (2012) determined that novice operators become competent in localizing the needle at variable rates and estimated that they required approximately 28 trials before competency was achieved. Therefore, it is vital that the operator understands the basic principles of this kind of procedure and ideally practices the technique in phantoms or specimens before attempting it on a patient.

© Springer Nature Switzerland AG 2024

R. J. Estrada, *Ultrasound-Guided Procedures in Equine Orthopedics and Surgery*,
https://doi.org/10.1007/978-3-031-17562-6_1

1.1 Injection Site Selection

The injection site must be scanned prior to the injection to determine which approach is the more convenient (shallower, less risk of iatrogenic damage to vital structures, safer for the operator, etc.). During this scan, the distance between the skin and the target should be measured to determine the length of the needle needed for the procedure (Fig. 1.1).

Marking externally the injection site (clipping, staples, markers, white correction fluid, etc.) accelerates the injection process once the site is properly disinfected. The idea is to place the external marks at 90° angles, so that the extension of these lines intersects at the intended injection site.

1.2 Transducer and Instrumentation Selection

The selection of the transducer depends on the characteristics of the injection site and the depth of the target. Linear transducers with higher frequencies are usually used for superficial structures with a relatively flat surface, like flexor tendons and

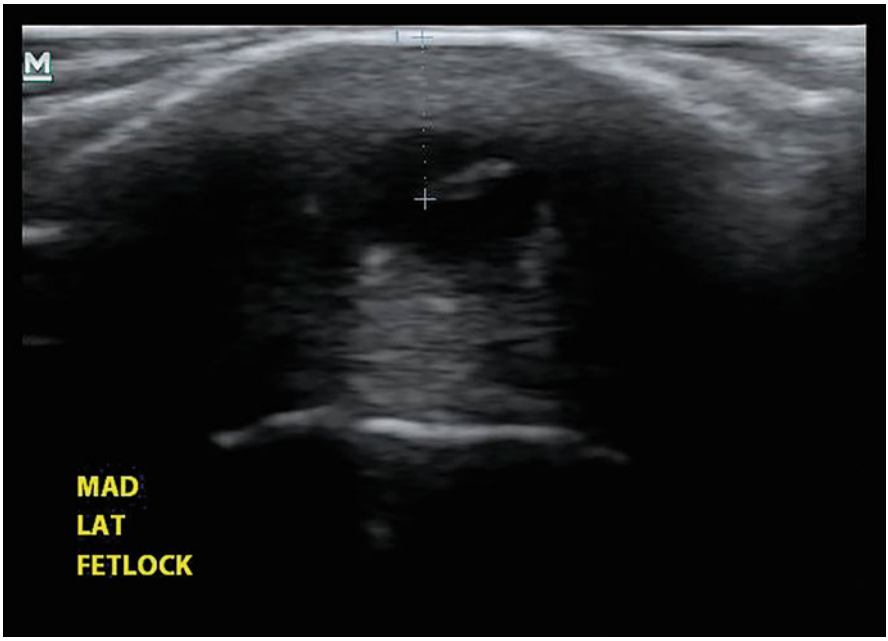

Fig. 1.1 Preliminary scan of the injection and/or surgery site allows us to measure the distance between the skin and the objective. In this case, the patient presents a hypoechogenic structure with a defined hyperechoic capsule (most likely an aseptic reaction, due to its chronicity, lack of signs of inflammation and drainage) around a suspected foreign body, just dorsal to the fetlock joint

ligaments of the metacarpal region. On the other hand, microconvex probes are convenient for locations that present a concave surface or where a larger footprint may affect the positioning of the needle, like bursa injections and cervical facet joints. Lastly, macroconvex probes are useful for deeper procedures that need a more panoramic view and that present a relatively flat deformable surface, like sacroiliac joints, thoracolumbar facet joints, or coxofemoral joints (Vaughan et al. 2009).

The needle selection is of paramount importance for a successful ultrasound-guided injection. The selection of the needle should be based on the depth of the target. In general, 20G 1.5 in. hypodermic needles are used to inject the SDFT, DDFT, and SL branches and the majority of the joints. For the SL origin and body, the bicipital bursa and the cervical and thoracolumbar facet joints are usually more convenient to use 18G 3–5 in. spinal needles. In the case of deeper structures, like the coxofemoral joint and sacroiliac joint (and some thoracolumbar facet joint in larger horses), a 18-20G 6-9 in. needle is usually required (Vaughan et al. 2009).

1.3 Positioning, Immobilization, and Preparation

The procedure should be ideally performed in an appropriate environment, silent, good footing, closed, and slightly dark. Nevertheless, this is usually not the case if the injections are performed under field conditions. It is important that both the operator and client understand and accept the risks and limitations of performing these procedures under suboptimal conditions. Regarding the immobilization of the patient, it is important to have someone with experience holding the head of the horse and at least another person that can pass things to the operator, move the ultrasound, and/or lift a limb if necessary. The horse should be sedated (xylazine 0.5–1 mg/kg or detomidine 0.01 mg/kg, with or without butorphanol 0.02 mg/kg) and might need a twitch in some cases. The area is usually clipped (not always allowed by the client), washed, and then aseptically prepared. To keep the sterility of the region, the probe should be covered with a sterile glove or a sterile sleeve. An assistant pours non-sterile ultrasound gel inside of the glove and then the probe is inserted into the glove by the assistant. The operator then manipulates the covered probe with sterile gloves on (Fig. 1.2). The contact with the skin is then achieved with alcohol (Vaughan et al. 2009). This is easy, is cheap, and takes basically no time. An infection of a musculoskeletal structure after an injection might have catastrophic consequences for the patient and legal consequences for the operator; therefore, it is of paramount importance to avoid it. Even though regional blocks have been recommended for performing this kind of procedure, in my experience, the majority of the cases react to the contact of the needle with the skin; therefore, I usually use a local anesthetic subcutaneous bleb at the site of the injection. This is easier and usually enough. If a bleb is going to be used, the operator should take into account that all the bubbles in the syringe should be eliminated to avoid artifacts.

Fig. 1.2 Sterile preparation of the transducer. (**a**) The operator puts on sterile gloves and then place a sterile glove over the transducer with the help of an assistant. (**b**) The assistant puts ultrasound gel on the footprint of the transducer, (**c**) the operator introduces the transducer inside of the glove, (**d**) the operator pulls the glove back to cover the complete transducer's head and neck. (**e**) Once the glove is in position, the operator can grasp the transducer head and start the ultrasound-guided procedure. (**f**) If desired, hold the cuff of the glove around the transducer-cord junction, pull the fingers of the glove back, and fixate them with the cuff of the glove using white tape or a thin strip of duct tape

1.4 Image Quality

It is of paramount importance to have a good image before attempting to perform an ultrasound-guided procedure. Having a clear target is the first step of achieving a successful injection or localizing a foreign body in the depth. A good quality image will not only allow the operator to see the target but also will help him or her to avoid structures that might cause complications when perforated by the needle or transected by the scalpel blade (arteries, nerves, intestine, etc.).

1.5 Transducer Marker vs Screen Marker

Ultrasound machines usually have a marker on the probes that correlates with a marker on the screen (Fig. 1.3). It is vital to know in advance where to expect the needle appearing on the screen; not knowing this will most likely end up in failure of the ultrasound guidance. Advancing the needle blindly might end up in a completely different location, having the potential to cause complications. Some ultrasound machines allow one to change the marker to the other side of the screen if needed or preferred by the operator.

1.6 Transducer Alignment with the Needle

To really guide the procedure with the ultrasound, the needle or scalpel must be perfectly aligned with the ultrasound beam. Ideally, the operator should never lose visualization of the tip of the needle and should be able to advance it until reaching the target. For this, the needle should always be aligned with the center of the transducers' footprint and the longitudinal axis of the probe. If the needle crosses in front of the ultrasound probe transversally, the ultrasound waves "cut" the needle

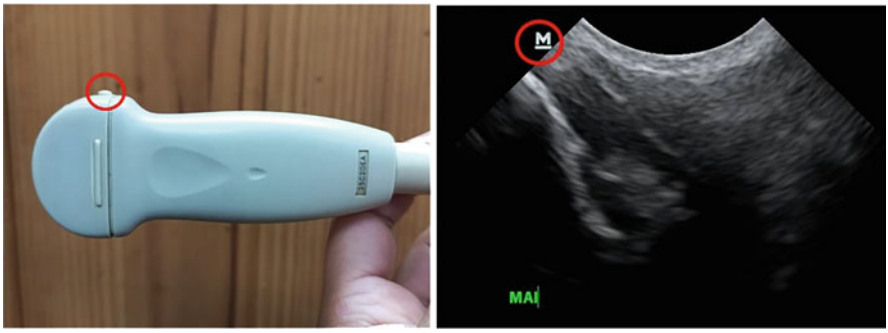

Fig. 1.3 Marker at the ultrasound screen correlates with marker at the transducer. Being aware of this it is vital to know where the needle is coming from in the screen while performing the injection. Failure to do so will most likely end up with failure to guide the needle accurately to the target



Fig. 1.4 The needle has to be aligned with the longitudinal axis of the probe to effectively guide the needle during its insertions (there are very few exceptions!!!). If the needle is crossing transversely the ultrasound waves, the image obtained would be an echogenic dot that has nothing to do with the tip of the needle. Moreover, if the needle is completely offset from the ultrasound beam, the needle is not going to be seen at all. (**a**) Needle aligned with the longitudinal axis of the probe (and the ultrasound beam). (**b**) Needle not aligned with the longitudinal axis (crossing transversely)

when it passes in front of the probe, creating a focal hyperechoic artifact that might look like the tip of the needle. When this happens, the real tip of the needle will end up elsewhere (Vaughan et al. 2009) (Fig. 1.4).

1.7 Target's Depth

Before attempting an ultrasound-guided injection, it is of paramount importance to determine the depth of the target. The depth of the target will determine the initial angulation of the needle. Deeper targets usually need flatter angulation of the needle with respect to the transducer, a convex or microconvex probe, and more distance between the probe and the needle (at the level of the skin). On the other hand, shallower targets need steeper needle angulation with respect to the transducer, a linear probe, and less distance between the transducer and the needle. This will dramatically improve the chances of efficiently guiding the needle to the desired target (Fig. 1.5).

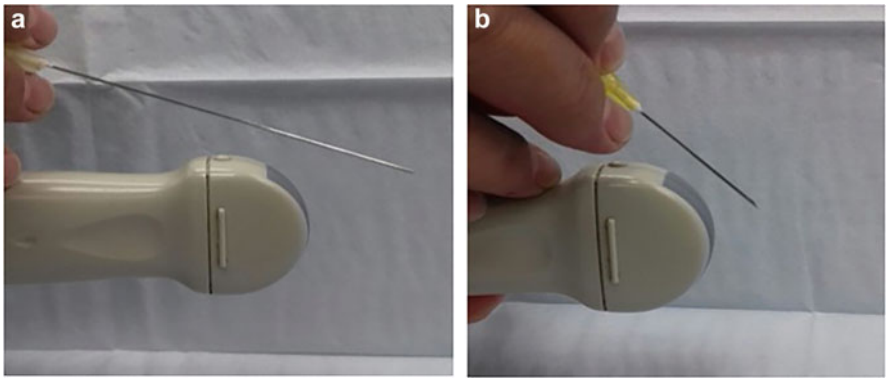

Fig. 1.5 Deeper structures need flatter angulation of the needle and shallower structures need steeper angulation of the needle when entering the skin. (**a**) Needle angulation for deeper structures. (**b**) Needle angulation for shallower structures

References

Barrington MJ, Wong DM, Slater B, Ivanusic JJ, Ovens M (2012) Ultrasound-guided regional anesthesia: how much practice do novices require before achieving competency in ultrasound needle visualization using a cadaver model. Reg Anesth Pain Med 37(3):334–339. https://doi.org/10.1097/AAP.0b013e3182475fba

Vaughan B, Whitcomb MB, Maher O (2009) How to improve accuracy of ultrasound-guided procedures. AAEP Proceedings, vol 55

Ultrasound-Guided Injections in Tendons, Ligaments, and Joints

2

Abstract

Probably one of the most common applications of ultrasound-guided procedures in equine practice are injections to tendons, ligaments, and joints. These techniques are used for diagnostic and therapeutic purposes in equine orthopedics. Accurate injection of medication inside of the joint or within a tendon or ligament lesion can completely change the response to a therapy and the outcome of a patient. On the other hand, precise injections will also decrease the risk of tissue trauma, complications, and poor responses. This chapter reviews the most common applications and the reported techniques in this field, always striving to help the clinician to select the most adequate technique based on the best evidence available. Injections to tendons and ligaments, cervical facet joints, thoracolumbar facet joints, sacroiliac joint, coxofemoral joint, scapulohumeral joint, and medial femorotibial joint will be discussed in depth.

Keywords

Ultrasound-guided injections · Tendon · Ligament · Joints

2.1 Tendons and Ligaments

Ultrasound-guided injections in tendon and ligament lesions are one of the first and still one of the most important applications of this type of procedure in equine orthopedics. Interestingly, even though these procedures have been performed for

Supplementary Information The online version contains supplementary material available at https://doi.org/10.1007/978-3-031-17562-6_2. The videos can be accessed individually by clicking the DOI link in the accompanying figure caption or by scanning this link with the SN More Media App.

© Springer Nature Switzerland AG 2024

R. J. Estrada, *Ultrasound-Guided Procedures in Equine Orthopedics and Surgery*,
https://doi.org/10.1007/978-3-031-17562-6_2

years, there are few detailed descriptions of how to perform these injections. The injection technique is similar, but depending on the structure there are several tips that will definitively facilitate an accurate injection. The objective of this chapter is to describe and illustrate the injection techniques in the most commonly affected tendons and ligaments.

2.1.1 Ultrasound-Guided Procedures to the Flexor Tendons and Accessory Ligament of the Deep Digital Flexor Tendon

The flexor tendons are commonly affected in race and sport horses (Gaschen and Burba 2012; Murray et al. 2006). Murray et al. reported a significant effect of the sport category and level on the diagnosis (Murray et al. 2006). Thoroughbred racehorses, polo ponies, and elite eventing and elite showjumping horses are commonly affected by lesions of the superficial digital flexor tendon (SDFT). On the other hand, distal deep digital flexor tendon (DDFT) lesions have been reported more frequently affecting showjumping elite horses. Warmbloods and ponies present more frequently lesions in the accessory ligament of the deep digital flexor tendon (ALDDFT). Nowadays, it is common practice to inject products in tendon and ligament lesions, aiming at improving the tissue quality and decreasing the healing time. To obtain the best out of these treatments it is of paramount importance to be as accurate as possible when injecting the products. Ultrasound-guided injections are the ideal tool for this purpose.

Equipment and Preparation
In an appropriate environment, the animal is sedated, the area of the injection is clipped and aseptically prepared, a regional block or subcutaneous bleb is performed, and the probe is covered with a sterile glove. A 20G 1.5 in. needle is used. Alcohol or sterile gel is used as an acoustic coupling agent.

Ultrasonographic Anatomy and Landmarks
The regional ultrasonographic anatomy of the flexor tendons has been previously reported (Rantanen et al. 2011). Even though there are shape and direction changes, the SDFT is always the most superficial structure in the metacarpal region. The DDFT is usually directly dorsal to the SDFT along the complete metacarpal region. The ALDDFT is located in the proximal aspect of the metacarpal region, dorsal and dorsolateral to the DDFT (Fig. 2.1).

Technique
In the case of the SDFT, with the animal bearing weight on the affected limb, an initial transverse ultrasound image is obtained to localize the lesion. The transducer is slowly rotated 90 degrees until acquiring a good longitudinal image of the lesion. The needle should enter the skin 0.5 cm proximal to the probe in an 80-degree angle with respect to the floor and is advanced in a proximopalmar-distodorsal direction

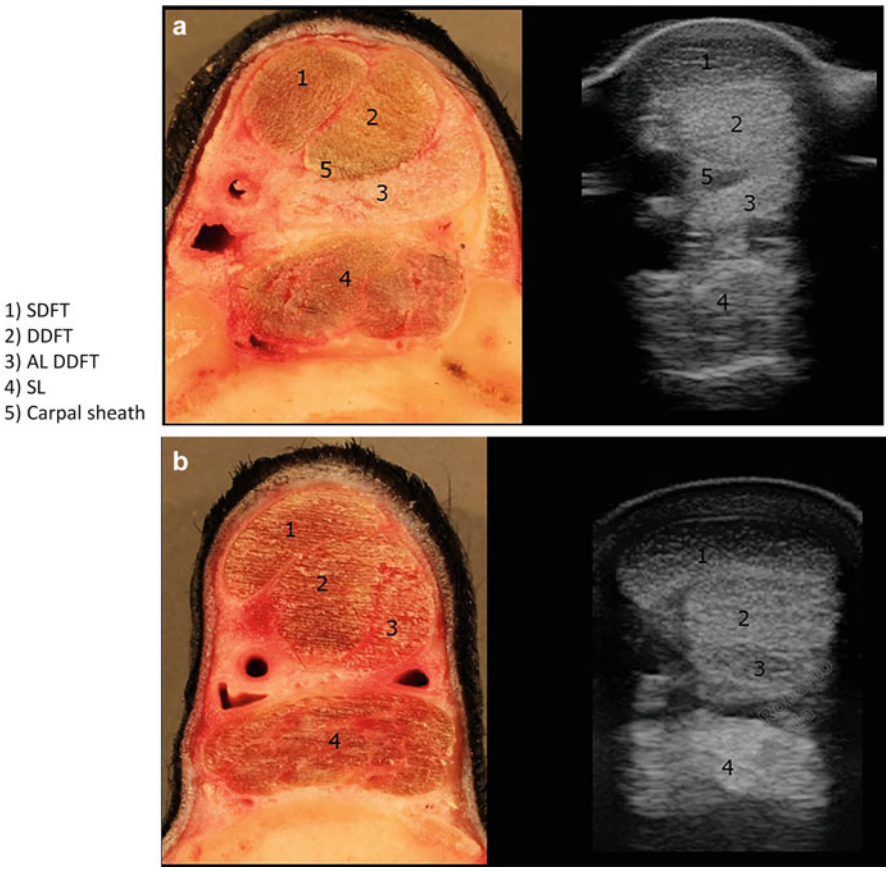

Fig. 2.1 Ultrasonographic anatomy of the proximal and mid sections of the cannon bone region in the horse. (**a**) Zone 1B, (**b**) Zone 2B

guiding it with the ultrasound until the tip reaches the lesion. Once in position the treatment is injected (Figs. 2.2 and 2.3).

For lesions of the DDFT or ALDDFT, the approach is similar to the SDFT. Nonetheless, the injection is usually performed at the proximolateral aspect of the cannon (proximolateral-distomedial direction). Some clinicians prefer to perform the injections using transverse views; nevertheless, in the author's experience it is more difficult to maintain the ultrasound probe in a steady position.

Afterward a sterile, non-adhesive wound dressing is applied together with a modified Robert Jones bandage.

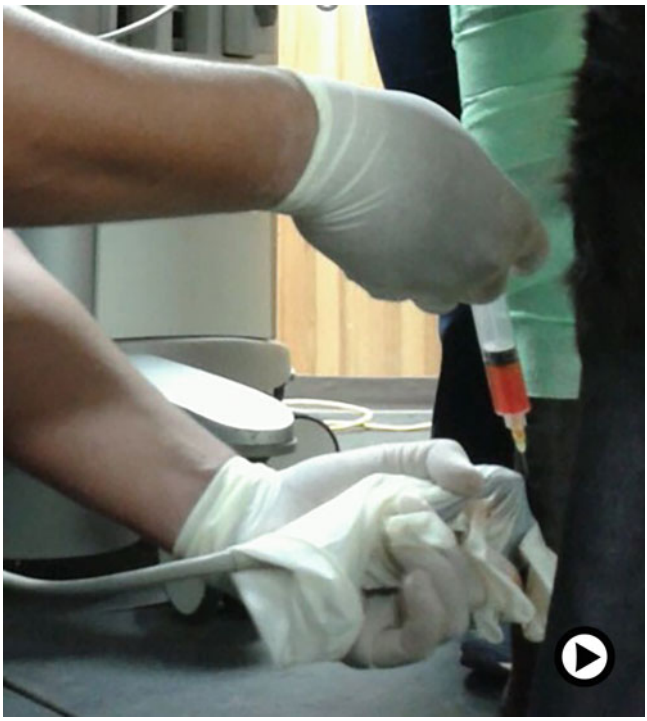

Fig. 2.2 Ultrasound-guided injection to the superficial digital flexor tendon. External needle position (▶ https://doi.org/10.1007/000-aw3)

2.1.2 Ultrasound-Guided Injections to the Suspensory Ligament

The suspensory ligament (SL) is one of the most commonly affected structures in race and sport horses (Gaschen and Burba 2012; Murray et al. 2006). Murray et al. reported that there is a significant effect of the sport category and level on the diagnosis (Murray et al. 2006). While dressage horses tend to suffer more of the origin of the suspensory ligament in the hindlimbs, other sport and racehorses also suffer lesions of the suspensory ligament but more commonly branches (usually unilateral) and origin of the forelimbs. Thoroughbreds and Standardbreds present more frequently lesions of the body of the SL. Peruvian, Costarrican Pasofino, and PRE are more commonly affected by suspensory ligament degeneration, which mainly affects the body and the branches (usually both). This pathology commonly affects old mares in the hindlimbs and it seems to be correlated to genetics.

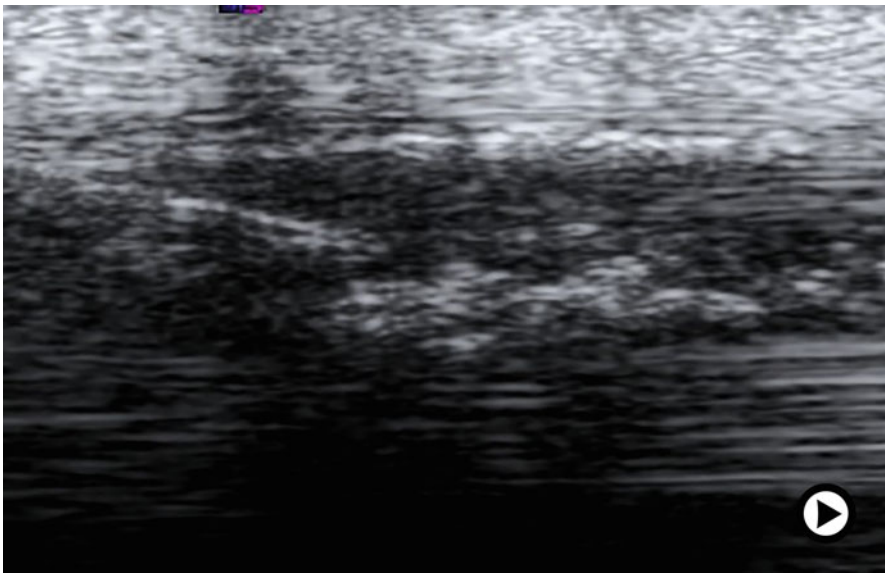

Fig. 2.3 Ultrasound-guided injection to the superficial digital flexor tendon. Ultrasound image (▶ https://doi.org/10.1007/000-av9)

2.1.2.1 Origin and Body of the Suspensory Ligament

Equipment and Preparation

In an appropriate environment, the animal is sedated, the area of the injection is clipped and aseptically prepared, a regional block or subcutaneous bleb is performed, and the probe is covered with a sterile glove. For the injection of the origin a 20G, 9-cm, spinal needle is used and for the body a 20G, 1.5 in., needle is used. Alcohol or sterile gel is used as an acoustic coupling agent.

Ultrasonographic Anatomy and Landmarks

The regional ultrasonographic anatomy of the suspensory ligament has been previously reported (Rantanen et al. 2011). The SL originates from the proximopalmar aspect of the metacarpal (metatarsal) bone and courses distally to form the body and the lastly the branches (Fig. 2.4).

Technique

For the origin of the SL the limb is elevated and semi-flexed by an assistant. A good quality transverse image of the injured ligament is obtained by placing a linear musculoskeletal probe at the palmaro(plantaro)-medial aspect of the limb. The needle is placed between the fourth metacarpal(metatarsal) bone and the flexor tendons (palmaro(plantaro)-lateral) and then advanced using US guidance until reaching the lesion. Afterwards a sterile, non-adhesive wound dressing is applied together with a modified Robert Jones bandage. The same technique can also be used for injecting the body of the SL. In the case of the origin of the suspensory ligament

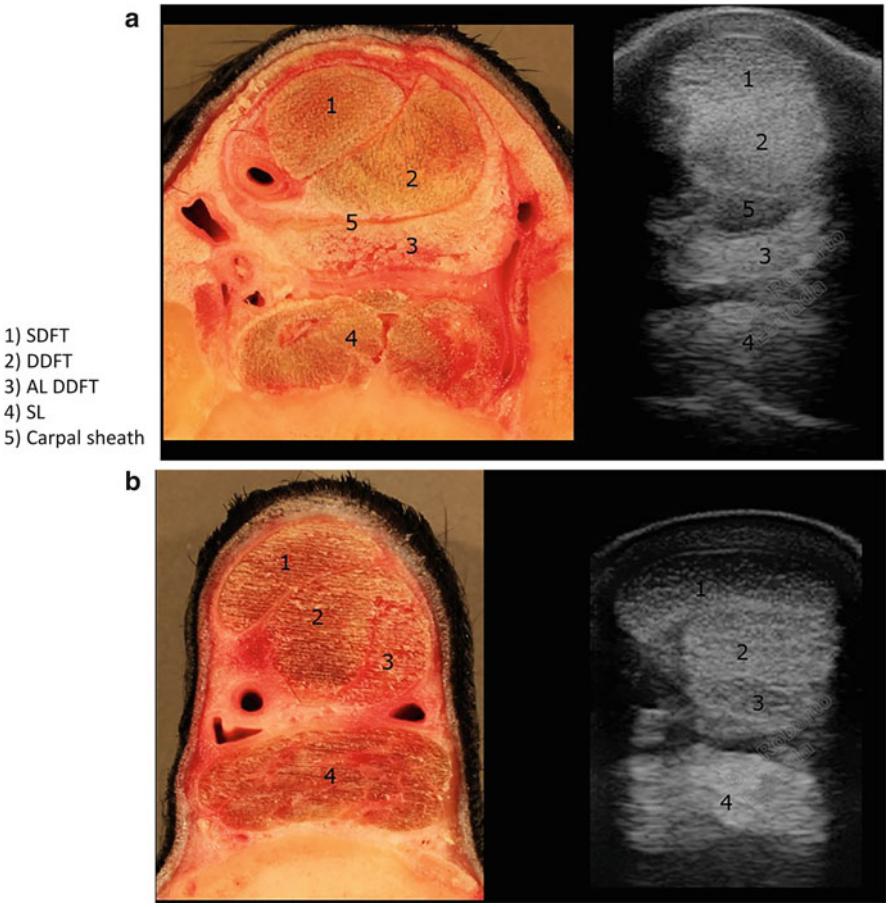

Fig. 2.4 Ultrasonographic anatomy of the origin and body of the suspensory ligament in the equine forelimb. (**a**) Origin of the suspensory ligament (Zone 1A). (**b**) Body of the suspensory ligament (Zone 1B)

at the hindlimb, the limb is lifted and pulled back, and the fetlock is flexed to relax the flexors. The probe is placed at the medial aspect of the proximal cannon, using the DDFT as a window to acquire an image of the origin of the SL. The needle is inserted in a plantarolateral-dorsomedial direction between the splint and the SDFT (Figs. 2.5, 2.6, 2.7, 2.8, 2.9, and 2.10).

▶ **Commentaries**

It is vital to perform this injection when the limb is elevated and semi-flexed. Attempts to inject under weight-bearing conditions will most likely result in trauma to the neurovascular bundle and the flexor tendons. Injections using longitudinal views at the origin and body of the SL are limited by the anatomy.

Fig. 2.5 Ultrasound-guided injection to the origin of the suspensory ligament at the forelimb. External needle position (▶ https://doi.org/10.1007/000-ava)

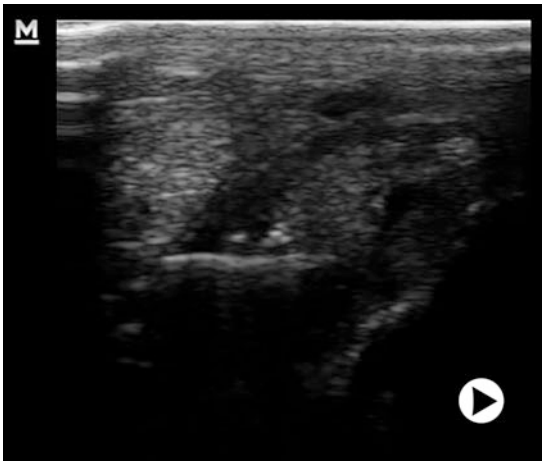

Fig. 2.6 Ultrasound-guided injection to the origin of the suspensory ligament at the forelimb. Ultrasound image (▶ https://doi.org/10.1007/000-avb)

2.1.2.2 Branches of the Suspensory Ligament

Equipment and Preparation

In an appropriate environment, the animal is sedated, the area of the injection is clipped and aseptically prepared, a regional block or subcutaneous bleb is performed, and the probe is covered with a sterile glove. A 20G 1,5 in. needle is used. Alcohol or sterile gel is used as an acoustic coupling agent.

Fig. 2.7 Body of the suspensory ligament. External needle position (▶ https://doi.org/10.1007/000-avc)

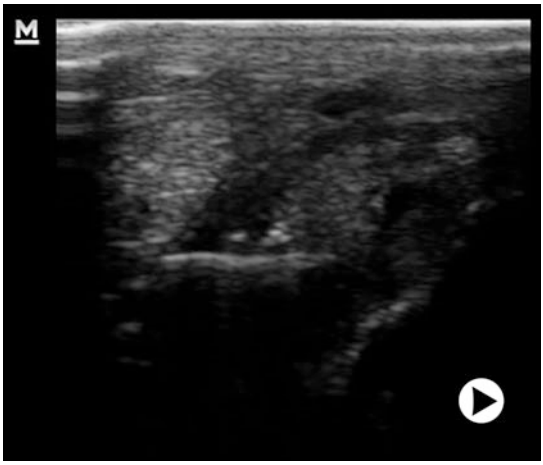

Fig. 2.8 Body of the suspensory ligament. Ultrasound image (▶ https://doi.org/10.1007/000-avd)

Ultrasonographic Anatomy and Landmarks

The regional ultrasonographic anatomy of the suspensory ligament has been previously reported (Rantanen et al. 2011). Two main branches originate from the body at the distal third of the metacarpal (metatarsal) region, inserting at the proximolateral aspect of the proximal sesamoid bones. The dorsal branches of the SL originate from

Fig. 2.9 Origin of the suspensory ligament at the hindlimb. External needle position (▶ https://doi.org/10.1007/000-ave)

the proximal sesamoid bones and course dorsodistally until inserting at the extensor tendon (Fig. 2.11).

Technique

Initially a transverse view of the affected branch is acquired. Once the lesion is located, the transducer is rotated 90 degrees slowly until obtaining a longitudinal image of the lesion. Once in position, the needle is inserted proximal to the transducer, in an 80-degree angle with respect to the floor and is advanced in a proximolateral-distomedial (lateral branch) or proximomedial-distolateral (medial branch) direction, guiding it with the ultrasound until the tip reaches the lesion. Once in position, the treatment is injected (Figs. 2.12 and 2.13).

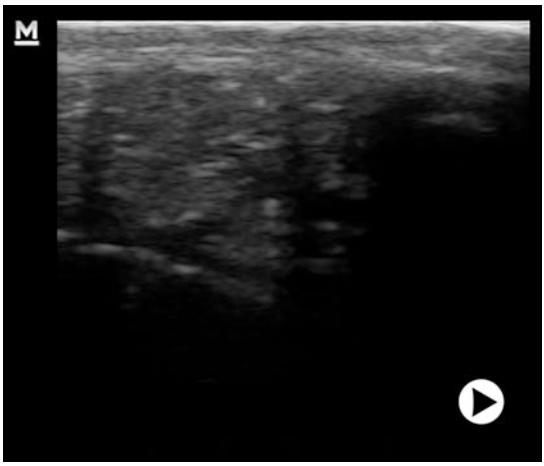

Fig. 2.10 Origin of the suspensory ligament at the hindlimb. Ultrasound image (▶ https://doi.org/10.1007/000-avf)

1) SDFT
2) DDFT
3) Manica Flexoria
4) DFTS
5) Palmar anular ligament
6) Intersesamoidal ligament / proximal scutum
7) Branch SL
8) Proximal sesamoid bones
9) Sagital crest MTCIII (caudal)

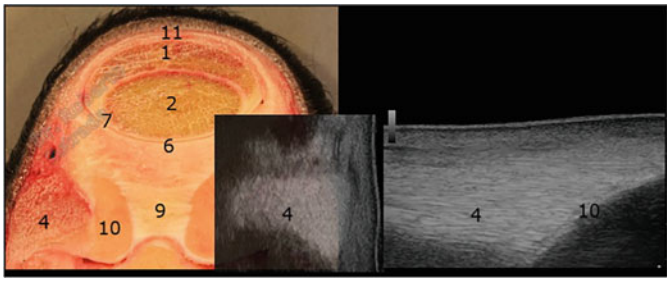

Fig. 2.11 Ultrasonographic anatomy of the branches of the suspensory ligament in the equine forelimb. (**a**) Regional anatomy, cross section, and longitudinal section of the branch of the suspensory ligament

▶ **Commentaries**

The lateral longitudinal approach is not only easier but also minimizes inadvertently puncturing the digital sheath or the proximolateral metacarpophalangeal joint recess when compared to the transverse technique. Due to the irregular surface of this location, to use the transverse injection technique one would also need a microconvex probe (the small footprint and convex shape adapts better to the concavity between the third metacarpal/metatarsal bone and the dorsal aspect of the suspensory ligament branch).

Another important consideration is the difficulty and risk of performing treatments on the medial branches. In this case, it is usually easier and safer to completely desensitize the limb with a regional block and also to perform the injection from the other side of the patient, simply placing the affected limb forward from the contralateral one. This usually creates enough space to work.

Fig. 2.12 Ultrasound-guided injection to the branch of the suspensory ligament. External needle position (▶ https://doi.org/10.1007/000-avg)

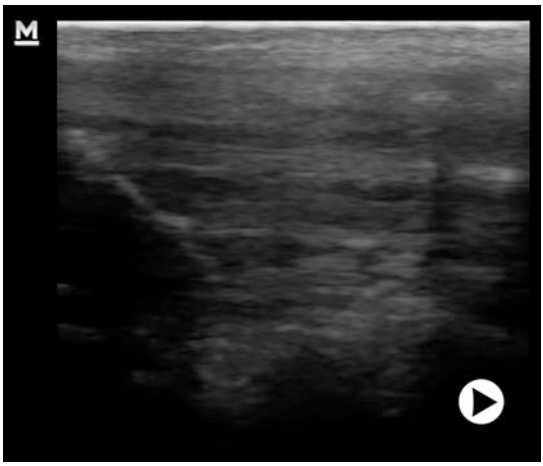

Fig. 2.13 Ultrasound-guided injection to the branch of the suspensory ligament. Ultrasound image (▶ https://doi.org/10.1007/000-avh)

2.1.3 Ultrasound-Guided Injections to the Collateral Ligament of the Distal Interphalangeal Joint

Equipment and Preparation

In an appropriate environment, the animal is sedated, the area of the injection is clipped and aseptically prepared, a regional block is performed, and a microconvex, 3.5–7.5 MHz probe is covered with a sterile glove. A 20G 1.5 in. needle is used. Alcohol or sterile gel is used as an acoustic coupling agent.

1) Second phalanx (collateral groove)
2) Collateral ligament distal Interphalangeal joint
3) Coronal cushion
4) Corium limbi and periople

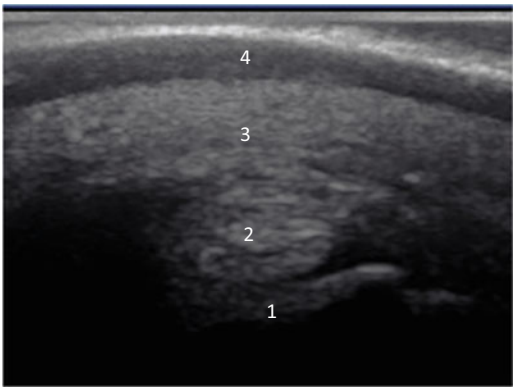

Fig. 2.14 Ultrasonographic anatomy of the collateral ligament of the distal interphalangeal joint. Transverse ultrasound section of the collateral ligament of the distal interphalangeal joint. 1: middle phalanx (collateral fossa); 2: collateral ligament of the distal interphalangeal joint; 3: coronal cushion; 4: corium limbi and periople. Note the heterogenous appearance of the ligament

Ultrasonographic Anatomy and Landmarks

The collateral ligament of the distal interphalangeal joint can be observed at the level of the coronary band dorsolateral and dorsomedial aspect of the hoof (at 11 and 2 o'clock). The observable portion of the collateral ligament (proximal aspect) lies at the smooth concave collateral insertion fossa of P2. The probe has to be oriented perpendicular to the skin. At this location, the observed structures are the medial and lateral collateral ligaments of the distal interphalangeal joint, the second phalanx (collateral insertion fossa), ungular cartilage, coronal vessels, coronal cushion, and corium limbi/periople (Denoix et al. 2011) (Fig. 2.14).

Technique

A transverse image of the collateral ligament is obtained. The needle is positioned 0.3 cm proximal to the probe (ca. 2 cm proximal to the coronary band), in an 85-degree angle to the floor and following a proximoabaxial-distoaxial direction. Once the needle is aligned with the middle of the ligament, the transducer is then rotated 90 degrees to further guide the needle into it (Figs. 2.15, 2.16, and 2.17). Once in position, the injection is performed (Smith et al. 2020). The injection site is protected using an impervious hoof bandage [synthetic cotton, latex gloves covering the hoof, cohesive bandage, and a sole with a more resistant tape (Ductape, Vetplast, etc.)]. The bandage is important to isolate the injection site (at least for some hours) from the heavily contaminated surface of the box.

▶ **Commentaries**

Ultrasound-guided injections to the collateral ligament of the coffin joint have been reported in the literature (Smith et al. 2020; Lewis et al. 2016). Both studies coincide that even though it is possible to inject these

ligaments using ultrasound guidance, in a high percentage of the attempts the DIPJ is injected inadvertently. In my opinion, this is usually not a clinical problem, since a proportion of these horses also present secondary inflammation of the DIPJ and infiltration of the joint might be beneficial.

It is important to take into account that higher accuracy rates have been reported for MRI-guided injections at this location (the problem is usually the cost and lack of practicability of performing these injections with MRI).

More than in the other intrasynovial injections, aseptic preparation of the injection site is of paramount importance, due to the proximity with the floor. As in the aforementioned techniques, clipping and proper disinfection with a combination of chlorhexidine and alcohol are recommended.

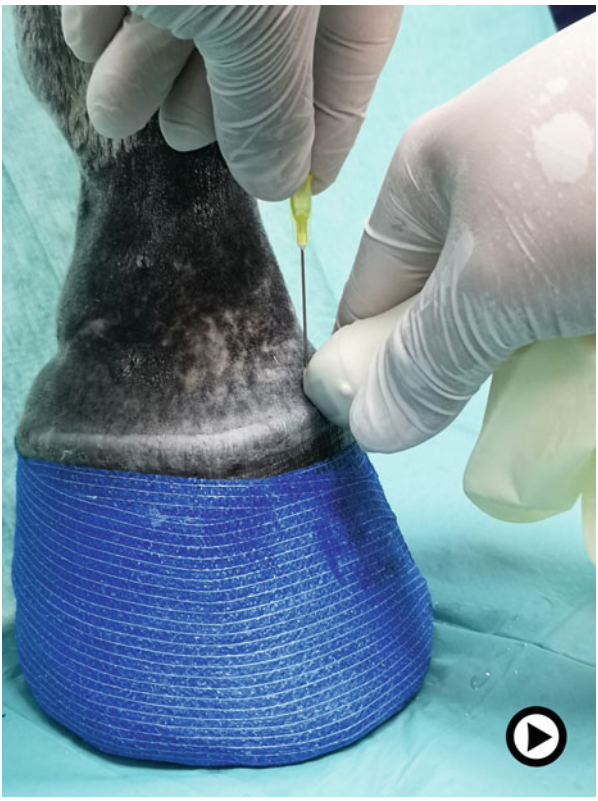

Fig. 2.15 Ultrasound-guided injection to the collateral ligament of the distal interphalangeal joint. External needle position (▶ https://doi.org/10.1007/000-avj)

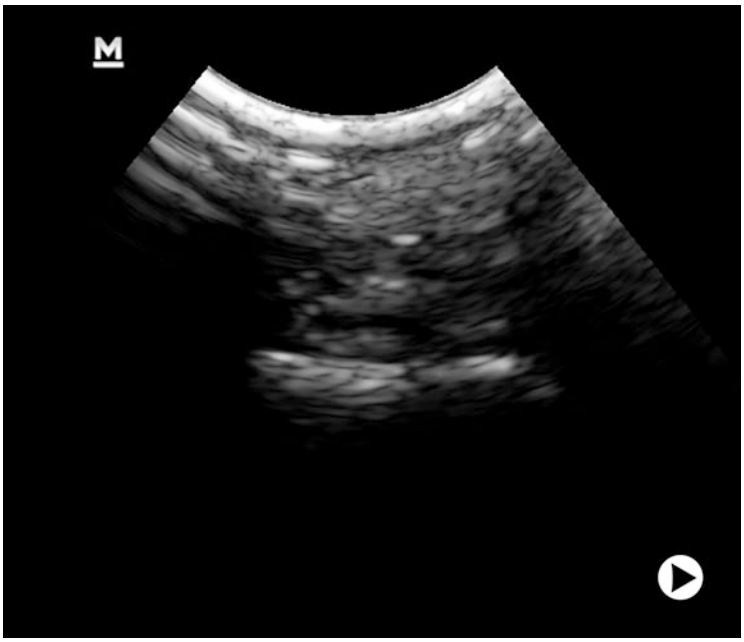

Fig. 2.16 Ultrasound-guided injection to the collateral ligament of the distal interphalangeal joint. Ultrasound transverse image (▶ https://doi.org/10.1007/000-avk)

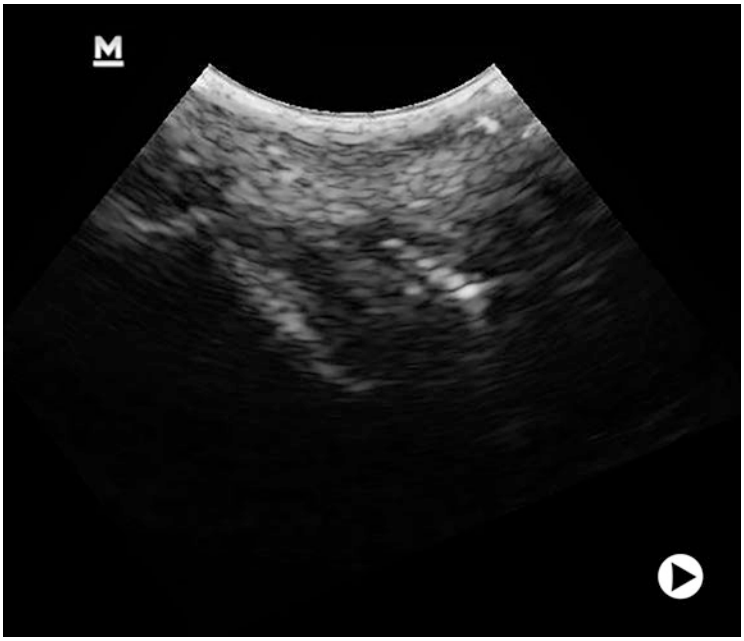

Fig. 2.17 Ultrasound-guided injection to the collateral ligament of the distal interphalangeal joint. Ultrasound longitudinal image (▶ https://doi.org/10.1007/000-avm)

2.2 Cervical Facet Joints

Osteoarthritis and/or synovitis of the cervical facet joints is recognized as a source of neck pain and stiffness in sport horses, causing poor performance and lameness (Dyson 2011a). In general, this diagnosis is made after a complete lameness workup to discard any other source of pain in the distal limb, clinical findings of neck pain, and medical imaging findings at the cervical facet joints. Since these joints are located in the depth of the neck musculature, accurate injections of these joints are only possible using ultrasound guidance.

2.2.1 Dorsal Approach to the Cervical Facet Joints

Equipment and Preparation
For the dorsal approach to the equine thoracolumbar facet joints, a microconvex, 5–7.5 MHz, probe covered with a sterile glove is recommended. The area is clipped and the injection site and transducer are aseptically prepared (for the transducer a sterile glove or sleeve is used). The patient is sedated. An 8–15 cm, 18G, spinal needle is recommended. Alcohol or sterile gel is used as an acoustic coupling agent (Nielsen et al. 2003).

Ultrasonographic Anatomy and Landmarks
For the dorsal approach, a transverse view of the cervical facet joints is acquired. The articular processes are the most dorsolateral bony structures in the neck. At this site, the cranial facet of the caudal cervical vertebra, the caudal facet of the cranial cervical vertebra, the joint space, and the joint capsule are observed. Depending on the selected injection site the regional musculature varies. In the case of the last three cervical vertebrae (the most commonly injected), the brachiocephalicus muscle, the serratus ventralis cervicii muscle, the longissimus cervicii muscle, the multifidus cervicii muscle, and the intertransversarii muscle are also observed. At more proximal locations the splenius muscle, longissimus capitis muscle, semispinalis capitis muscle, multifidus cervicii muscle, and the intertransversarii muscle are commonly seen (Berg et al. 2003) (Fig. 2.18).

Technique
A transverse view of the facet joint is obtained (at the widest joint space visible). Thereafter, the transducer is slightly tilted ventrally without losing the image of the joint, to allow the introduction of the needle dorsal to the probe. Once a good image is acquired, the spinal needle is introduced ca. 1 cm dorsal to the transducer in a relatively flat angulation (ca. 30 degree), aiming at the articular border of the joint. After contacting the bone (once the fibrous joint capsule is penetrated) the injection can be performed. Synovial fluid can be obtained in some patients; nonetheless, in the majority of the cases fluid and gas can be observed entering in the joint space while controlling the injection with the ultrasound (Nielsen et al. 2003) (Figs. 2.19 and 2.20).

1) Caudal facet of Cranial vert
2) Cr facet of cd vert
3)Joint space
4) Joint capsule
5) Multifidii cervicii
6) Longisimus cervicii
7) Intertransversarius Cervicii
8) Serratus ventralis c Cervicii
9)brachiocephalicus

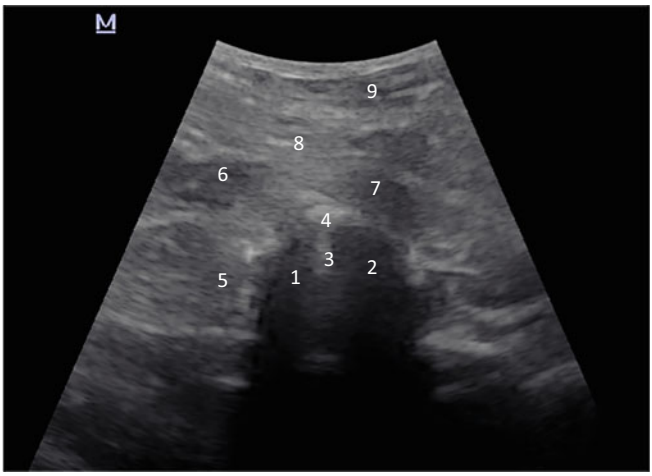

Fig. 2.18 Ultrasonographic anatomy of the transverse view of the caudal cervical region

Fig. 2.19 Ultrasound-guided injection to the cervical facet joint using the dorsal approach. External needle position (▶ https://doi.org/10.1007/000-avn)

2.2.2 Dorsocranial Approach to the Cervical Facet Joints

Equipment and Preparation

For this technique the equipment and preparation is exactly the same as that for the dorsal approach; the only difference is that this technique could be performed with a linear probe (which might be an advantage if one does not have a microconvex probe) (Mattoon et al. 2004).

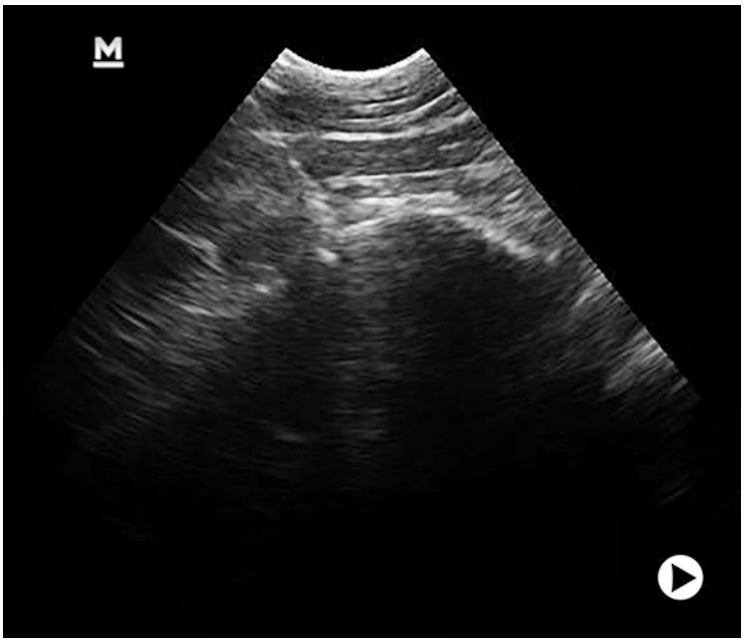

Fig. 2.20 Ultrasound-guided injection to the cervical facet joint using the dorsal approach. Ultrasound image (▶ https://doi.org/10.1007/000-avp)

Ultrasonographic Anatomy and Landmarks

First, acquire a transverse view of the joint as in the dorsal approach. Then turn the probe slowly until obtaining a longitudinal image of the cervical facet joint. Once in position, the cranial and caudal articular processes form a characteristic "S-shaped" hyperechoic interface. This is referred to as the "chair" sign, the cranial articular process forming the seat and the cranial margin of the caudal process forming the chair back (Mattoon et al. 2004). The muscle layers observed with this approach are the same as in the transverse view (but different orientation) and as in the dorsal approach the anatomy varies from joint to joint (Fig. 2.21).

Technique

Once the joint space is located, the needle is inserted using ultrasound guidance. The joint space is located at the junction of the cranial and caudal processes (between the back of the chair and the back of the chair), identified as an anechoic gap between the two articular processes. Turning the horse's head and neck away from the site of injection facilitates needle placement by tensing the overlying soft tissues and widening the articular process joint (Mattoon et al. 2004) (Figs. 2.22 and 2.23).

1) Caudal facet cr vert
2) Cr facet caudal vert
3) Joint space
4) Joint capsule
5) Vertebral body cr vert
6) Intertransversarius cervicii
7) Serratus ventralis cervicii
8) Brachiocepahlicus

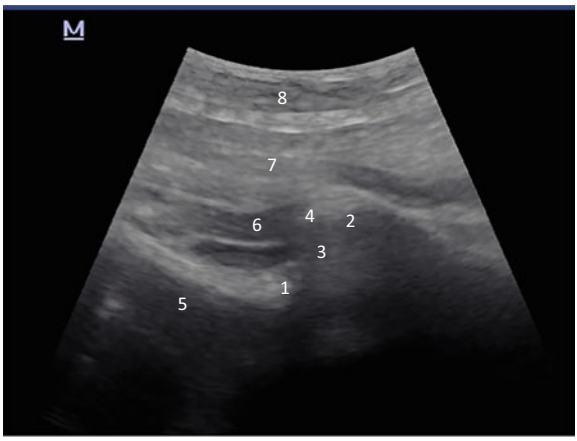

Fig. 2.21 Ultrasonographic anatomy of the longitudinal view of the caudal cervical region

Fig. 2.22 Ultrasound-guided injection to the cervical facet joint using the dorsomedial approach. External needle position (▶ https://doi.org/10.1007/000-avq)

- Sacroiliac caudal

1 Spinous process sacrum
2 Transverse process sacrum
3 Ileal wing
4 Sacroiliac joint
5 Sacrocaudalis dorsalis muscle
6 Gluteus medius muscle

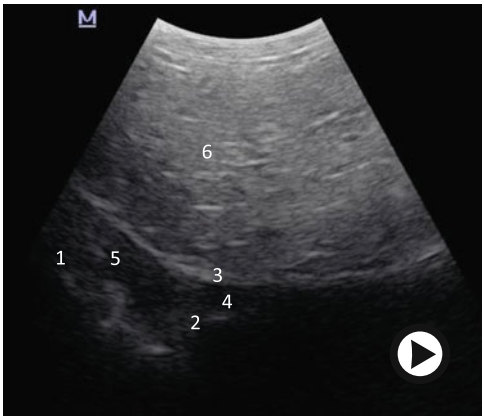

Fig. 2.23 Ultrasound-guided injection to the cervical facet joint using the dorsomedial approach. Ultrasound image (▶ https://doi.org/10.1007/000-avr)

GENERAL COMMENTARIES

Recently, the dorsocranial and dorsal approaches for ultrasound-guided injection to the cervical facet joints were compared. This study demonstrated that both techniques were highly accurate and that there was no significant difference regarding the accuracy of both techniques (Johnson et al. 2017).

For both techniques, external localization of the joints is useful to correlate ultrasonographic and radiographic findings and also to determine which is the joint to be treated, when the diagnosis was made radiologically. In an average size horse, there is a space of approximately one hand of an adult human between cervical joints. For example, on the left side of the horses' neck, the left wing of the atlas is located and the left hand of the operator is placed on top of the wing. The cranial aspect of the hand is placed on the cranial aspect of the wing, and the caudal aspect of the hand would be on the estimated position of the joint between C1 and C2. Thereafter, the right hand of the operator is placed directly behind the left hand. In this case, the joint of the C2-3 would be located caudal to the right hand. This can be continued caudally until all the estimated positions of the joints are identified. The joint location can be marked externally (marker, clipping, etc.) to facilitate the identification when performing the US-guided injection.

Flexing the neck toward the contralateral side of the injection might be helpful to open the joint space and facilitate intraarticular injections (Mattoon et al. 2004).

It is important to point out that some people use skin blebs with local anesthetic to avoid a reaction of the horse once the needle is introduced. Nevertheless, the usage of these local blocks is usually unnecessary once the

(continued)

animals are well sedated and restrained. One should also take into account that if the bleb is used, all the gas in the syringe should be removed. If this is not done, the gas in the tissue could dramatically affect the visibility of the joint and therefore affect the ability of the operator to guide the needle accurately.

2.3 Thoracolumbar Facet Joints

Back pain is a relatively common primary or secondary problem that has the potential to affect the athletic performance in the horse. Even though pain at the thoracolumbar region might be caused by different pathologies, studies suggest that osteoarthritis of the facet joint in the aforementioned region probably contributes to back pain (Girodroux et al. 2009; Denoix and Dyson 2011). Since these joints are located under the epiaxial muscles of the back, the only accurate and practical method to treat them is by means of ultrasound-guided injections.

2.3.1 Medial Approach to the Thoracolumbar Facet Joints

Equipment and Preparation
For the medial approach to the equine thoracolumbar facet joints, a macroconvex, 5 MHz, probe covered with a sterile glove is recommended. The area is clipped and the injection site and transducer are aseptically prepared (for the transducer a sterile glove or sleeve is used). The patient is sedated. An 8–15 cm, 18G, spinal needle is recommended. Alcohol or sterile gel is used as an acoustic coupling agent.

Ultrasonographic Anatomy and Landmarks
A transverse view of the facet joints is acquired. For this, the probe is placed over the longissimus dorsi muscle 3–4 cm paramedian from the spinous processes of the vertebrae. At this site, the transverse process of the lumbar vertebrae or ribs, the cranial facet, the caudal facet, the dorsal spinous process, the longissimus dorsi muscle, and the multifidus muscle are observed (Fig. 2.24).

Technique
Once the transverse view of the facet joints is obtained, the transducer is slightly tilted ventrally, to allow the introduction of the needle between it and the dorsal spinous processes of the vertebrae. The needle is introduced dorsal to the transducer, approximately 2.5 cm paramedian from the dorsal midline, directing the needle perpendicular to the skin, aiming toward the border of the "seat" formed by both facets, where the facet joint is located. In the case that the injection is performed in the thoracic facet joints, the needle should be aimed sagittal from the mamillary process to increase the chances of an intraarticular injection. After contacting the bone (once the fibrous joint capsule is penetrated), the injection can be performed (Figs. 2.25 and 2.26).

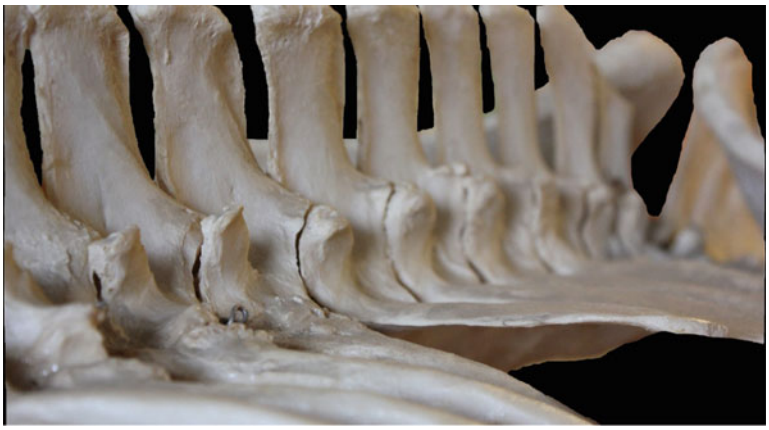

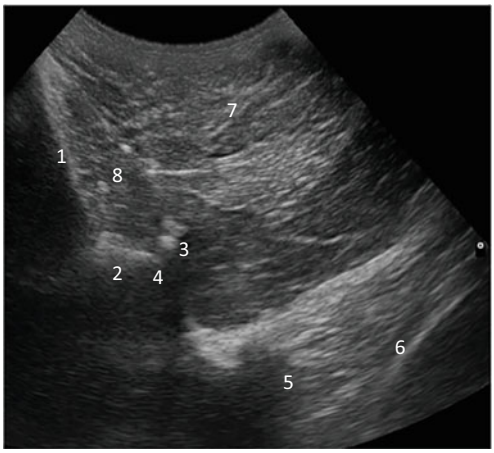

1) Spinous process of the vertebrae
2) Caudal facet of the cranial vertebra
3) Cranial facet of the caudal vertebra (mammilary process).
4) Facet Joint space
5) Costovertebral joint
6) Rib
7) Erector spinae muscle
8) Multifidus muscle

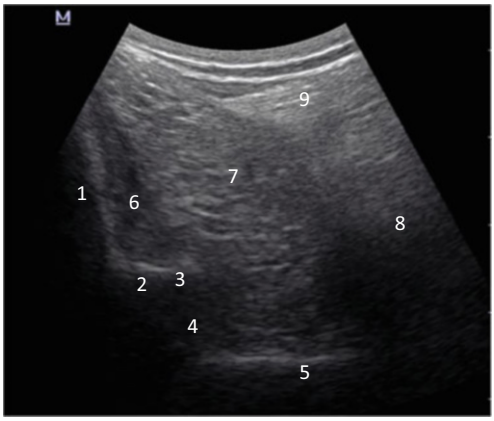

1) Spinous process
2) Caudal facet cr vert
3) Joint space
4) Cr facet of caudal vert
5) Transverse process
6) Multifidus muscle
7) Longisimus dorsi muscle
8) Ileocostalis muscle
9) Gluteus medius muscle (lumbar portion)

Fig. 2.24 Ultrasonographic anatomy of the transverse view of the thoracolumbar region in the horse. (I) External anatomy of the thoracolumbar facet joint, (II) thoracic facet joints, (III) lumbar facet joints

Fig. 2.25 Ultrasound-guided injection to the thoracolumbar facet joints using the medial approach. External needle position (▶ https://doi.org/10.1007/000-avs)

Fig. 2.26 Ultrasound-guided injection to the thoracolumbar facet joints using the medial approach. Ultrasound image (▶ https://doi.org/10.1007/000-avt)

2.3.2 Lateral Approach to the Thoracolumbar Facet Joints

The equipment, preparation, material, and technique of the lateral approach are quite similar to those of the medial approach; the difference is that the needle is inserted ventral (paramedian) to the probe and the probe is located more dorsal. Once an adequate image is obtained, the needle is guided to the facet joint in the same fashion as with the previous technique (Fig. 2.27).

► **Commentaries**

Two different groups investigated the ultrasound-guided injections at the thoracolumbar region (ex vivo) almost simultaneously. Both studies compared the accuracy rate of the lateral (parasagittal) and medial (sagittal) approaches to the facet joint, obtaining different results.

While Cousty et al. (2011) did not observe any difference in the accuracy rate between the lateral or medial approaches (86% were intraarticular and 96% were at or within 0.5 cm of an articular margin), Fuglbjerg et al. (2010), with a larger number of injections, demonstrated that 77% of the injections were intraarticular and that both medial approach and a 18G needle were significantly correlated with intraarticular injections at this site. Based on this data and the fact that with the medial approach usually the needles needed are shorter than with the lateral approach, I recommend using the medial approach for the injection of the thoracolumbar facet joints.

For these injections, as for the cervical facet joints, I usually do not use blebs at these injection sites. In my opinion, this has the potential to

Fig. 2.27 Ultrasound-guided injection to the thoracolumbar facet joints using the lateral approach. External needle position

affect the visualization when performing the injection and also stresses the horse with more injections. Usually good sedation and restraint (ideally in a stock) is more than enough to be able to perform this kind of injections.

2.4 Sacroiliac Region

Sacroiliac disease has been long associated with pain and poor performance in the horse (Goff et al. 2008). It has been reported that horses with the aforementioned issues usually present back muscle contractures, reduced flexibility of the thoracolumbar region, and low-grade hindlimb lameness with lack of impulsion. Moreover, affected animals usually show poor bit contact, poor canter quality, and bucking during canter (Barstow and Dyson 2015). Injections to the sacroiliac region have been traditionally used for diagnostic analgesia and/or treatment of this area (Barstow and Dyson 2015; Goff et al. 2008). Various different techniques have been reported to inject the aforementioned region (Dyson and Murray 2003; Engeli et al. 2004); nevertheless, a more accurate and controlled needle placement can be achieved using ultrasound guidance (Denoix and Jacquet 2008; Cousty et al. 2008). It is important to take into account that the majority of these approaches are very efficient reaching the periphery of the sacroiliac joint (SIJ), but in most of the cases the injections are not intraarticular (Denoix and Jacquet 2008; Cousty et al. 2008).

Even though several ultrasound-guided techniques are reported, the cranial and caudal approaches to the sacroiliac region are by far the most commonly used in the field.

2.4.1 Cranial Approach to the Sacroiliac Region

Equipment and Preparation

For the cranial approach to the equine sacroiliac area, a macroconvex, 5 MHz, probe covered with a sterile glove is recommended. Appropriate sedation, clipping, and aseptic preparation of the injection site and the transducer (using a sterile glove) are mandatory. For this injection, a 150 mm 20G spinal needle is used. Alcohol or sterile gel is used as an acoustic coupling agent.

Ultrasonographic Anatomy and Landmarks

For this, the ultrasound probe is located paramedian, 5–7 cm from the median plane (spinous processes of the last lumbar vertebrae), aligning the cranial border of the tuber coxae to the cranial border of the transducer. At this site the iliac crest, the iliac wing, the transverse processes of the fifth and sixth of the lumbar vertebra, the erector spinae muscle, and the gluteus medius muscle are observed (Fig. 2.28).

Fig. 2.28 Ultrasonographic anatomy of the lumbosacral region (landmarks for the cranial approach to the sacroiliac joint)

Technique

For this injection, a subcutaneous bleb with 1 ml mepivacaine is normally used to avoid reactions of the patients when introducing the needle. Once a good image is obtained, a 150 mm 20G spinal needle is inserted at a point 4–6 cm cranial to the probe and advanced carefully (slightly laterally) until observable at the ultrasound screen. Once the tip of the needle is located and it is confirmed that the direction is adequate, the needle is further guided between the iliac wing and the transverse process of the lumbar vertebra. Using this approach, the needle disappears under the acoustic shadow casted by the ilium. The needle is further advanced until contacting a bony surface, which is usually the dorsal aspect of the sacral wing, in the vicinity of the sacroiliac joint (Denoix and Jacquet 2008) (Figs. 2.29 and 2.30).

▶ **Commentaries**

Interestingly, Cousty et al. (2008), reported a very similar approach; nonetheless, a curved needle was used. This group reported that when using the cranial approach the mean distance from the latex to the SIJ was 1.7 cm (73% of the injections were at less than 2 cm away from the joint). Moreover, no injections contacted the regional neurovascular structures using this approach.

There are anecdotal reports of neurological complications after performing the cranial approach. During the necropsy, a hemorrhage

Fig. 2.29 Ultrasound-guided injection to the sacroiliac joint using the cranial approach. External needle position (▶ https://doi.org/10.1007/000-avv)

Fig. 2.30 Ultrasound-guided injection to the sacroiliac joint using the cranial approach. Ultrasound image (▶ https://doi.org/10.1007/000-avw)

was observed in the region apparently associated with the puncture of an artery. Therefore, it is important to take into account that the needle has to be directed slightly laterally to avoid these problems (Denoix 2022).

2.4.2 Caudal Approach to the Sacroiliac Region

Equipment and Preparation

The initial preparation is similar to the cranial approach. To perform this injection, a 90–150 mm (depending on the size of the horse), 20G, spinal needle and a 5 MHz convex probe covered with a sterile glove are needed. Alcohol or sterile gel is used as an acoustic coupling agent.

Ultrasonographic Anatomy and Landmarks

The scan is centered on the dorsal sacroiliac joint space, between the transverse process of the sacrum and the caudal margin of the iliac wing. Initially, the caudal aspect of the iliac wing is localized using a transverse view; from this point the probe is moved caudally until the sacrum is observed. Thereafter, the transducer is rotated in a craniodorsal-caudoventral direction until the sacrum and the ilium are contacting each other; the joint can be found between these two structures. It must be taken into account that if the transducer is placed some centimeters caudal to the aforementioned location, the sciatic nerve, the cranial gluteal artery, and the rectum can be observed. Inadvertent injection of these structures should be avoided at all costs (Fig. 2.31).

Technique

The probe is placed caudal to the ipsilateral sacral tuberosity, on a craniolateral-caudomedial oblique plane and separated 3–4 cm from the spinous process of the sacrum. The needle is inserted into the ultrasound beam, between the probe and the spinous of the sacrum, through the gluteus medius muscle, in a caudodorsal-cranioventral direction toward the sacroiliac joint space (Figs. 2.32 and 2.33).

► **Commentaries**

Even though it has been reported that caudal technique is more accurate at guiding the needle closer to the sacroiliac joint (88% of the injection were less than 2 cm away from the SIJ margin) (Cousty et al. 2008), more recent studies suggest that there is no significant difference when depositing injectate ≤2 cm from sacroiliac joint margins, when comparing the cranial vs the caudomedial approaches (Stack et al. 2016). It is important to mention that the caudomedial approach seems to be more risky than the cranial approach. It has been also demonstrated that in 18–57% of the cases (depending on modification to the caudal

Fig. 2.31 Ultrasonographic anatomy of the dorsal sacral region (caudal approach to the sacroiliac joint)

Fig. 2.32 Ultrasound-guided injection to the sacroiliac joint using the caudal approach. External needle position (▶ https://doi.org/10.1007/000-avx)

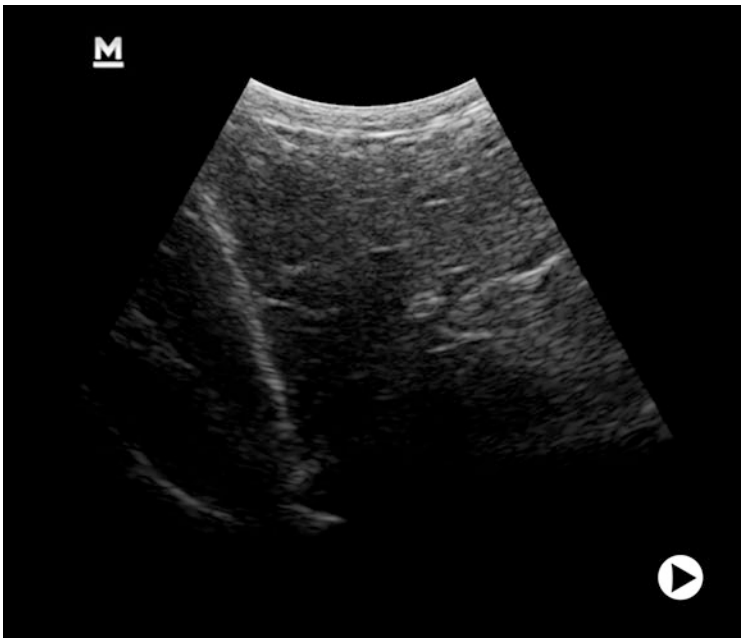

Fig. 2.33 Ultrasound-guided injection to the sacroiliac joint using the caudal approach. Ultrasound image (▶ https://doi.org/10.1007/000-avy)

technique), the needle contacted the neurovascular structures of the region (sciatic nerve and gluteal artery) (Cousty et al. 2008). Puncture of the aforementioned structures could end up causing temporary muscle paresis or paralysis or hematomas, respectively. Moreover, with the caudomedial approach there is also a risk of puncturing the rectum, which might lead to septic contamination (Denoix and Jacquet 2008). Using this technique is a viable option, but the correct identification of the ultrasonographic anatomy and a precise injection are of paramount importance.

2.5 Coxofemoral Joint

Coxofemoral joint (CFJ) pathologies are considered to be a rare cause of lameness in the horse (Dyson 2003; Hendrickson 2002). Even though a wide variety of lesions have been reported to affect this joint, pathologies at this anatomical location still represent a diagnostic challenge for the equine practitioners (David et al. 2007). Traditional injections techniques have been reported for this joint; nevertheless, these approaches have several limitations (difficulty to confirm intraarticular

positioning, difficulty to palpate trochanteric notch in some horses, and risk of paresis when inadvertently blocking the sciatic nerve due to extraarticular injections) (David et al. 2007). Based on this, it has been mentioned in the literature that the arthrocentesis of the coxofemoral joint in horses is one of the most challenging (Lewis 1996). On the other hand, a more recent study has demonstrated that ultrasound-guided injections technique of the equine CFJ is accurate, reliable, and safe, allowing real-time control of needle introduction (David et al. 2007). Vaughan et al. (2009) reported a modification of this technique inserting the needle from the dorsal aspect of the probe (craniodorsal approach). The same group also reported a cranioventral ultrasound-guided approach; nevertheless, it can only be used in animals with distension of the cranioventral recess of the CFJ, which represent approximately 10% of animals that underwent pelvic ultrasound at a referral center (Whitcomb et al. 2016). Nowadays, these techniques (or variations of them) are successfully used around the world for the diagnosis and management of coxofemoral pathologies.

2.5.1 Cranioventral Approach

Equipment and Preparation

The coxofemoral joint region is clipped and aseptically prepared. The patient is sedated. A macroconvex, 3.5 MHz, probe covered with a sterile glove and a 18G 15 cm spinal needle are used (David et al. 2007). Alcohol or sterile gel is used as an acoustic coupling agent.

Ultrasonographic Anatomy and Landmarks

Due to the inconsistency of the external landmarks, the ultrasound scan is initiated with a transverse view of the iliac wing (concave echogenic line). The transducer is moved distocaudally until the beginning of the iliac body is observed (convex echogenic line). At this point, the transducer is turned 90 degrees to obtain a longitudinal view of the iliac body. The probe is moved further caudally through the iliac body until reaching the coxofemoral joint. Then slide the transducer further caudodorsally until observing a clear image of the coxofemoral joint region (Whitcomb et al. 2018). Once in this position the femur trochanter, femoral neck, femoral head, joint space, and acetabulum should be identified (Whitcomb et al. 2018; David et al. 2007) (Fig. 2.34).

Technique

Once a good image of the coxofemoral region is acquired 1 ml of mepivacaine or lidocaine is injected subcutaneously at the caudal extremity of the transducer. The needle is also introduced at this site, ventral to the transducer and dorsal to the trochanter of the femur. The spinal needle is inserted through the muscular layers, using ultrasound guidance, until reaching the joint space (Figs. 2.35 and 2.36).

1) Ilium body
2) Acetabulum
3) Joint space
4) Femoral head
5) Femoral Neck
6) Gluteus medius muscle
7) Gluteus superficiales muscle
8) Gluteofemoralis muscle

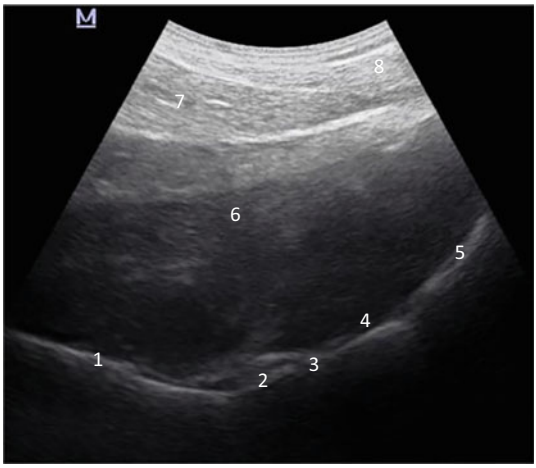

Fig. 2.34 Ultrasonographic anatomy of the coxofemoral region (landmarks for the cranioventral approach)

Fig. 2.35 Ultrasound-guided injection to the coxofemoral joint using the cranioventral approach. External needle position (▶ https://doi.org/10.1007/000-avz)

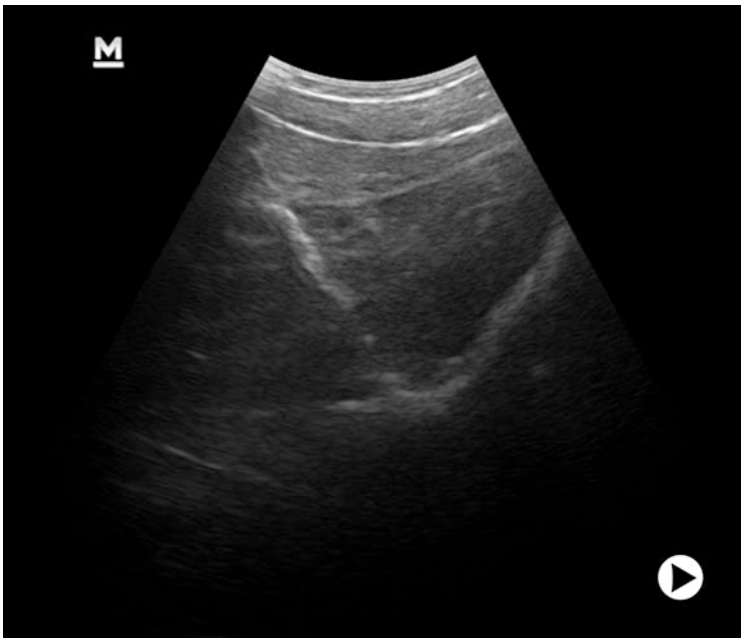

Fig. 2.36 Ultrasound-guided injection to the coxofemoral joint using the cranioventral approach. Ultrasound image (▶ https://doi.org/10.1007/000-aw0)

▶ **Commentaries**
David et al. (2007) reported a 100% accuracy injection rate using this technique. Contrast media was used to confirm the accuracy of the intraarticular injections.

2.5.2 Craniodorsal Approach

This approach was reported by Vaughan et al. (2009). For this particular technique, the equipment, preparation, and landmarks are the same (Fig. 2.37). The only difference is that the needle is inserted craniodorsally, dorsal to the cranial extremity of the transducer (Fig. 2.38).

▶ **Commentaries**
Even though there are no studies determining the accuracy rate of this technique, it is very likely that it is similar to what is reported for the caudoventral approach. One of the major advantages of this technique is that the cable of the transducer is not interfering with the injection and enables a better external visualization of needle placement (Vaughan et al. 2009).

1) Ilium body
2) Acetabulum
3) Joint space
4) Femoral head
5) Femoral Neck
6) Greater Trocanter
7) Gluteus medius muscle
8) Gluteus superficiales muscle
9) Gluteofemoralis muscle

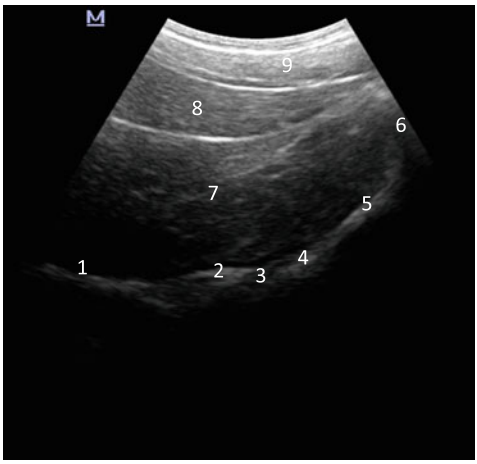

Fig. 2.37 Ultrasonographic anatomy of the coxofemoral region (landmarks for the craniodorsal approach)

Fig. 2.38 Ultrasound-guided injection to the coxofemoral joint using the craniodorsal approach. External needle position

2.6 Scapulohumeral Joint

Scapulohumeral joint (SHJ) pathologies in adult horses are comparatively rare, except after direct trauma to the shoulder region. In immature athletic horses, stress fracture of the scapula, humerus and radius, osseous cyst-like lesions, and osteochondrosis are relatively common (Dyson 2011b). Intraarticular injections of the SHJ are difficult to perform due to the small articular space and the thick layer of muscles covering this region (Carnicer et al. 2008). It has been demonstrated that using traditional "blind" injection techniques to this joint only 50% of the injections were intraarticular (Schneeweiss et al. 2012).

2.6.1 Caudolateral Approach

Equipment and Preparation
The SHJ region is clipped and aseptically prepared. The patient is sedated. A linear, 7.5 MHz or a microconvex 3.5–5 MHz probe covered with a sterile glove and a 20G 13 cm spinal needle are used (Schneeweiss et al. 2012). Alcohol or sterile gel is used as an acoustic coupling agent.

Ultrasonographic Anatomy and Landmarks
The greater tubercle of the humerus is located and the transducer is placed caudal and slightly proximal to it, in a proximodistal direction. Once in position, the probe is rotated 25 degree craniocaudally until observing the caudal aspect of the humeral head, the caudal rim of the glenoid cavity, the joint capsule, the joint space, and the triceps musculature (Schneeweiss et al. 2012) (Fig. 2.39).

1) Distal Scapula (Glenoid articualr margin)
2) Joint space
3) Humeral head
4) Joint Capsule
5) Supraspinatus muscle
6) Brachiocephalicus muscle

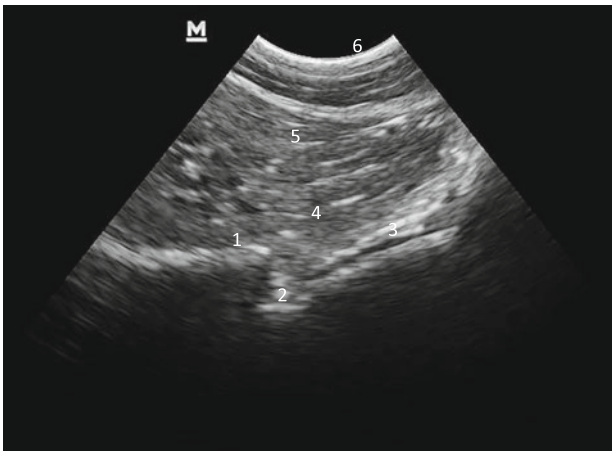

Fig. 2.39 Ultrasonographic anatomy of the scapulohumeral joint (caudolateral)

Fig. 2.40 Ultrasound-guided injection to the scapulohumeral joint using the caudolateral approach. External needle position

Technique

Once a good image of the caudal aspect of the scapulohumeral joint is acquired, the needle is introduced at this site in a caudodistal to cranioproximal direction, ventral to the transducer and proximal to the greater trochanter of the humerus. The spinal needle is inserted through the muscular layers, using ultrasound guidance, until reaching the joint space (Figs. 2.40 and 2.41).

► **Commentaries**

Ultrasound-guided injections to the shoulder joint have shown to be a practical option that has the potential of reducing complications associated with inadvertent trauma of surrounding structures (cartilage, vessels, and nerves) or inaccurate deposition of solutions (Schneeweiss et al. 2012; Carnicer et al. 2008). This technique proved to be highly reliable and accurate, achieving a 100% accuracy rate in one study (Schneeweiss et al. 2012).

2.6.2 Craniolateral Approach

Equipment and Preparation

The scapulohumeral joint region is clipped and aseptically prepared. The patient is sedated. A microconvex, 5–7.5 MHz, probe covered with a sterile glove and a 20G 5–9 cm spinal needle are used. Alcohol or sterile gel is used as an acoustic coupling agent. Local bleb at the needle entrance site might be useful in cases of sensitive animals (Carnicer et al. 2008).

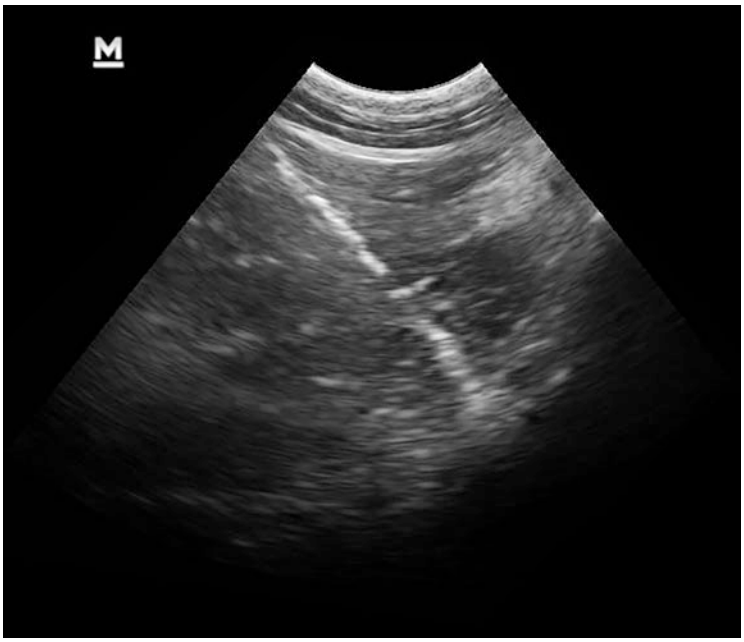

Fig. 2.41 Ultrasound-guided injection to the scapulohumeral joint using the caudolateral approach. Ultrasound image

Ultrasonographic Anatomy and Landmarks

The probe is placed vertically between the supraspinatus and infraspinatus tendons, proximal to the greater tubercle until observing the joint space, at the craniolateral aspect of the scapulohumeral joint. At this site, the humeral head, the caudal rim of the glenoid cavity, the joint capsule, the joint space, and the triceps musculature can be observed. Once in position, the probe is rotated 90 degrees to obtain a transverse image of the joint (omotransverse muscle, infraspinatus muscle, labrum glenoidae, capsule, and joint space) (Carnicer et al. 2008) (Fig. 2.42).

Technique

The needle is inserted cranially to the probe in a 45 angle with the median plane of the horse and in the ultrasound beam. The needle direction is controlled real time until reaching the joint space (Carnicer et al. 2008) (Figs. 2.43 and 2.44).

► **Commentaries**

Even though the authors of this technique claim to have performed many injections, the accuracy rate was not thoroughly tested. The craniolateral technique is another option to approach the scapulohumeral joint; nevertheless in light of the current evidence, I would recommend to use the caudolateral approach.

1) Scapula (Glenoid cranial articular border)
2) Joint Space
3) Humeral head
4) Joint capsule
5) Teres Minor Muscle
6) Deltoid Muscle

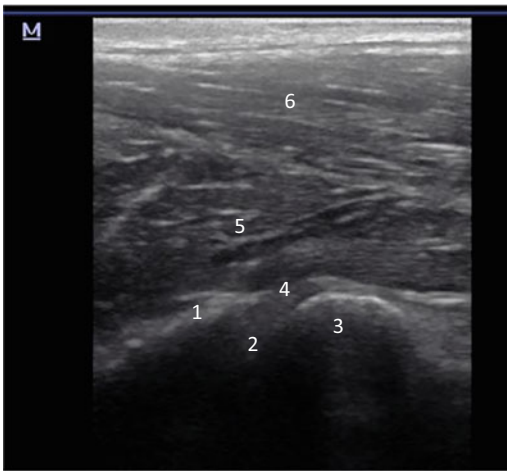

Fig. 2.42 Ultrasonographic anatomy of the scapulohumeral joint (craniolateral)

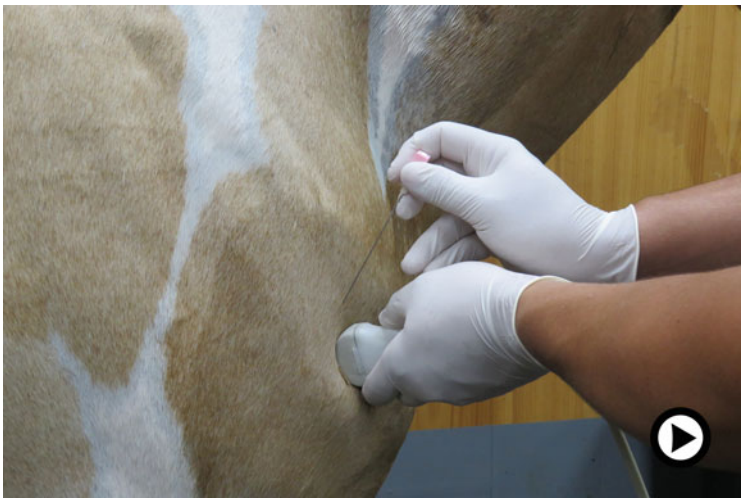

Fig. 2.43 Ultrasound-guided injection to the scapulohumeral joint using the craniolateral approach. External needle position (▶ https://doi.org/10.1007/000-aw1)

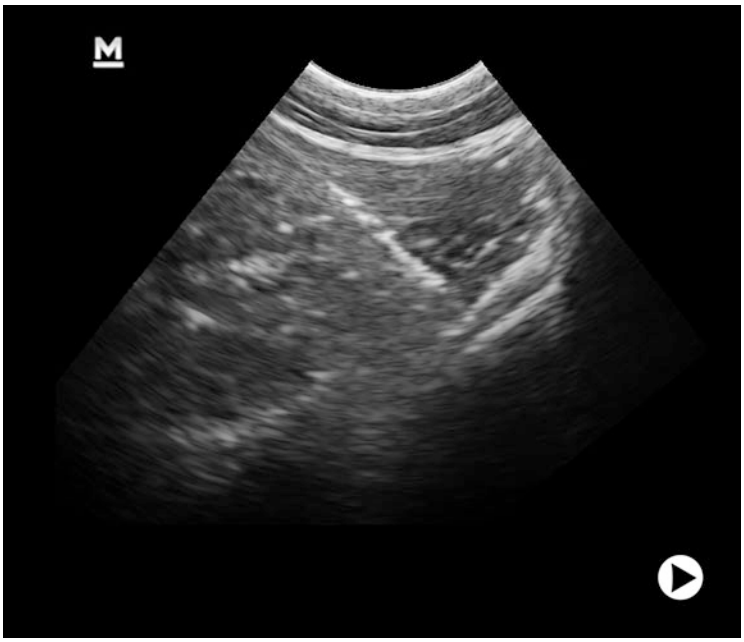

Fig. 2.44 Ultrasound-guided injection to the scapulohumeral joint using the craniolateral approach. Ultrasound image (▶ https://doi.org/10.1007/000-aw2)

2.7 Medial Femorotibial Joint

The stifle joint is the largest joint and more complex joint in the horse. The medial compartment of the femorotibial joint (FTJ) is an important source of pathologies that cause lameness in horses (Fowlie et al. 2012). Injection of this joint is indicated for the diagnosis and treatment of equine lameness. Several reasons support the use of ultrasound-guided injections to improve their accuracy at this site. Ultrasonographic examination has demonstrated that the size and shape of the recess of the medial femorotibial joint varies, synovial proliferation might obstruct the needle (confusing the operator even though it is intrasynovial), the needle could be placed subsynovial, and inadvertent injections of the femoropatellar joint are possible due to the proximity to the recess of the medial compartment of the FTJ (Kleider 2013).

Equipment and Preparation

The medial aspect of the stifle is clipped and aseptically prepared. The patient is sedated (food, twitch, or mild sedation are the best options when a block is attempted). A 1–2 ml bleb of local anesthetic is injected subcutaneously at the injection site (cranial to the probe). A linear, 7.5–10 MHz probe covered with a sterile glove and a 20G 1.5 in. hypodermic needle are used. When doing a solo

injection, the needle is attached from the start to the syringe. This facilitates the manipulation and allows the operator not to lose the correct position when trying to attach a syringe to the needle. Alcohol or sterile gel is used as an acoustic coupling agent (Kleider 2013).

Ultrasonographic Anatomy and Landmarks

In 2003, Denoix reported the ultrasonographic anatomy of the medial aspect of the equine joint. When performing a longitudinal scan of the stifle in this window, one can observe the recess of the medial femorotibial joint, the femoral fascia, the distomedial aspect of the femur, and the medial meniscus (Denoix 2003). Once in position, the probe is rotated 90 degrees without losing the recess in the ultrasound screen. At this site, the meniscus is no further observed, but the other structures are (Kleider 2013) (Fig. 2.45).

1 medial femorotibial joint recess
2 joint capsule
3 medial femorotibial joint space
4 medial meniscus
5 tibia

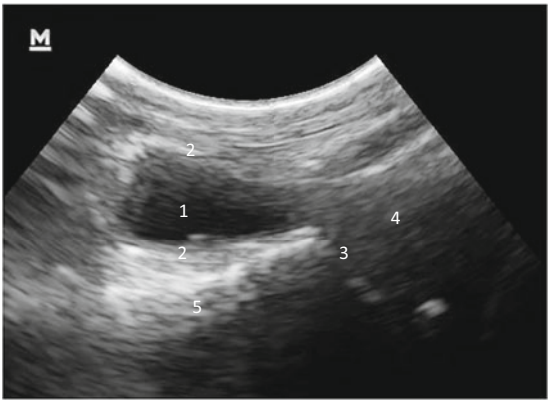

1 medial femorotibial joint recess
2 joint capsule
3 tibia

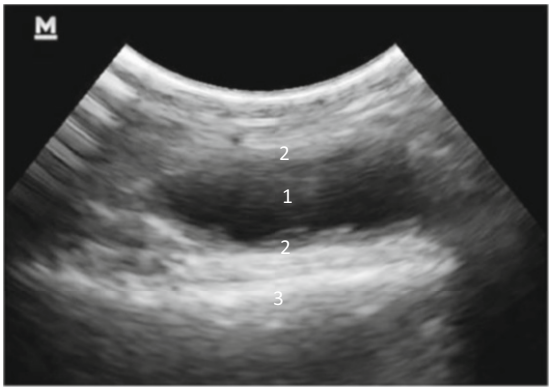

Fig. 2.45 Ultrasonographic anatomy of the medial femorotibial joint. (I) Initial longitudinal image of the medial femorotibial recess. (II) After turning the transducer 90°, the medial femorotibial joint recess looks more elongated and facilitates the view for the needle introduction

Technique

After the preparation, the ipsilateral forelimb is held in flexion by an assistant. The ultrasound probe is positioned at the medial aspect of the stifle (proximal to the tibial plateau, between the medial collateral ligament and the medial patellar ligament), and a longitudinal ultrasonographic view of the recess is acquired. Thereafter, the probe is rotated 90 degrees with the marker pointing cranially and without losing the recess in the screen. The needle is inserted just cranial to the probe using ultrasound guidance. Since the syringe is attached to the needle from the start of the procedure, as soon as the tip is in the recess, the fluid is injected and controlled real time. When injecting, gas, and/or a swirling movement of the fluid is observed (Kleider 2013) (Figs. 2.46 and 2.47).

► **Commentaries**

It has to be noted that blind technique reported for this recess has a pretty good accuracy rate reaching 93% when compared to other techniques (Kleider 2013). Nevertheless, the use of the US-guided technique allows us to perform more accurate injections to this recess (avoiding subsynovial injections). Lack of accuracy performing this injection with blind techniques might result in false-negative or poor therapeutic results.

Fig. 2.46 Ultrasound-guided injection to the medial femorotibial joint. External needle position (► https://doi.org/10.1007/000-av8)

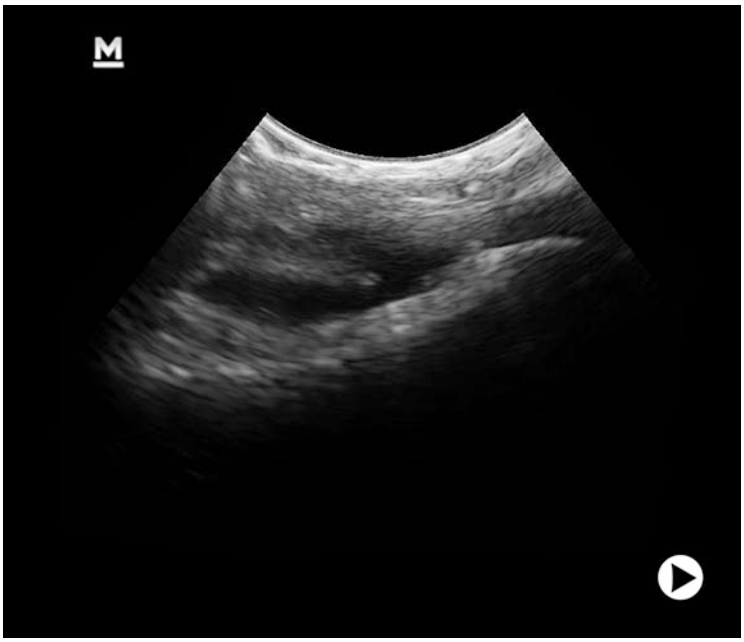

Fig. 2.47 Ultrasound-guided injection to the medial femorotibial joint. Ultrasound image (▶ https://doi.org/10.1007/000-aw4)

References

Barstow A, Dyson S (2015) Clinical features and diagnosis of sacroiliac joint region pain in 296 horses: 2004–2014. Equine Vet Educ 27(12):637–647

Berg LC, Nielsen JV, Thoefner MB, Thomsen PD (2003) Ultrasonography of the equine cervical region: a descriptive study in eight horses. Equine Vet J 35:647–655

Carnicer D, Coudry V, Denoix J (2008) Ultrasonographic guided injection of the scapulo humeral joint in horses. Equine Vet Educ 20(2):103–106. https://doi.org/10.2746/095777308X272102

Cousty M, Rossier Y, David F (2008) Ultrasound-guided periarticular injections of the sacroiliac region in horses: a cadaveric study. Equine Vet J 40(2):160–166. https://doi.org/10.2746/042516408X245252

Cousty M, Firidolfi C, Geffroy O, David F (2011) Comparison of medial and lateral ultrasound-guided approaches for periarticular injection of the thoracolumbar intervertebral facet joints in horses. Vet Surg 40(4):494–499. https://doi.org/10.1111/j.1532-950X.2011.00821.x. Epub 2011 Mar 21

David F, Rougier M, Alexander K, Morisset S (2007) Ultrasound-guided coxofemoral arthrocentesis in horses. Equine Vet J 39(1):79–83. https://doi.org/10.2746/042516407X153093

Denoix JM (2003) Ultrasonographic examination of the stifle in horses. In: Proceedings. Annual Meeting of the ACVS. p. 122

Denoix JM (2022) Módulo Dorso, Pelvis y Muslo. Asociación Latinoamericana de Patología e Imagenología Del Sistema Locomotor del Equino. Modalidad Virtual

Denoix JM, Dyson SJ (2011) Thoracolumbar spine. Diagnosis and Management of lameness in the horse, 2nd edn, pp 602–604. Chapter 52

Denoix JM, Jacquet S (2008) Ultrasound-guided injections of the sacroiliac area in horses 20(4): 203–207

Denoix JM, Bertoni L, Heitzmann AG, Werpy N, Audigié F (2011) Ultrasonographic examination of the collateral ligaments of the distal interphalangeal joint in horses: Part A: Technique and normal images. Equine Vet Educ

Dyson SJ (2003) Pelvic injuries in the non-racehorse. In: Ross M, Dyson S (eds) Diagnosis and management of lameness in the horse. W.B. Saunders, Philadelphia, pp 491–500

Dyson SJ (2011a) Lesions of the equine neck resulting in lameness or poor performance. Vet Clin North Am Equine Pract 27(3):417–437. https://doi.org/10.1016/j.cveq.2011.08.005

Dyson S (2011b) The elbow, brachium and shoulder. Chapter 40. Diagnosis and management of lameness in the horse, p 457

Dyson S, Murray R (2003) Pain associated with the sacroiliac joint region: a clinical study of 74 horses. Equine Vet J 35:240–245

Engeli E, Haussler KK, Erb HN (2004) Development and validation of a periarticular injection technique of the sacroiliac joint in horses. Equine Vet J 36:324–330

Fowlie JG, Stick JA, Nickels FA (2012) Chapter 99 – Stifle. In: Auer JA, Stick JA (eds) Equine surgery, 4th edn. W.B. Saunders, pp 1419–1442

Fuglbjerg V, Nielsen JV, Thomsen PD, Berg LC (2010) Accuracy of ultrasound-guided injections of thoracolumbar articular process joints in horses: a cadaveric study. Equine Vet J 42(1):18–22. https://doi.org/10.2746/042516409X454565

Gaschen L, Burba DJ (2012) Musculoskeletal injury in thoroughbred racehorses: correlation of findings using multiple imaging modalities. Vet Clin North Am Equine Pract 28(3):539–561. https://doi.org/10.1016/j.cveq.2012.09.005. Epub 2012 Oct 18. PMID: 23177131

Girodroux M, Dyson S, Murray R (2009) Osteoarthritis of the thoracolumbar synovial intervertebral articulations: clinical and radiographic features in 77 horses with poor performance and back pain. Equine Vet J 41(2):130–138. https://doi.org/10.2746/042516408x345099

Goff LM, Jeffcott LB, Jasiewicz J, McGowan CM (2008) Structural and biomechanical aspects of equine sacroiliac joint function and their relationship to clinical disease. Vet J. 176(3):281–293. https://doi.org/10.1016/j.tvjl.2007.03.005. Epub 2007 May 9

Hendrickson DA (2002) The coxofemoral joint. In: Stashak TS (ed) Adams' lameness in horses, 5th edn. Lippincott Williams & Wilkins, Philadelphia, pp 1037–1043

Johnson JP, Stack JD, Rowan C, Handel I, O'Leary JM (2017) Ultrasound-guided approach to the cervical articular process joints in horses: a validation of the technique in cadavers. Vet Comp Orthop Traumatol 30(3):165–171. https://doi.org/10.3415/VCOT-16-09-0139

Kleider N (2013) How to inject the medial femorotibial joint recess under ultrasound guidance. In: Proceedings. Annual Convention of the AAEP

Lewis RD (1996) Techniques for arthrocentesis of equine shoulder, elbow, stifle and hip joints. Proc Am Assoc Equine Practnrs 42:55–63

Lewis D, Scott M, Fischer CD, Bond SL, Léguillette R (2016) FEASIBILITY FOR ULTRASOUND-GUIDED INJECTION OF THE COLLATERAL LIGAMENTS OF THE DISTAL INTERPHALANGEAL JOINT IN HORSES. Vet Radiol Ultrasound 57(3): 299–305. https://doi.org/10.1111/vru.12341. Epub 2016 Jan 13

Mattoon JS, Drost WT, Grguric MR, Auld DM, Reed SM (2004) Technique for equine cervical articular process joint injection. Vet Radiol Ultrasound 45(3):238–240. https://doi.org/10.1111/j.1740-8261.2004.04042.x

Murray RC, Dyson SJ, Tranquille C, Adams V (2006) Association of type of sport and performance level with anatomical site of orthopaedic injury diagnosis. Equine Vet J Suppl 36:411–416. https://doi.org/10.1111/j.2042-3306.2006.tb05578.x

Nielsen JV, Berg LC, Thoefner MB, Thomsen PD (2003) Accuracy of ultrasound-guided intra-articular injection of cervical facet joints in horses: a cadaveric study. Equine Vet J 35(7): 657–661

Rantanen NW, Jorgensen JS, Genovese LR (2011) Ultrasonographic evaluation of the equine limb: technique. In: Ross M, Dyson S (eds) Diagnosis and management of lameness in the horse. W.B. Saunders, Philadelphia

Schneeweiss W, Puggioni A, David F (2012) Comparison of ultrasound-guided vs. 'blind' techniques for intra-synovial injections of the shoulder area in horses: scapulohumeral joint, bicipital and infraspinatus bursae. Equine Vet J 44(6):674–678. https://doi.org/10.1111/j.2042-3306.2011.00540.x. Epub 2012 Feb 15. PMID: 22332644

Smith R, Parsons J, Dixon J (2020) Risk of intra-articular injection with longitudinal ultrasound-guided injection of collateral ligaments of the equine distal interphalangeal joint. Vet Radiol Ultrasound 61(1):67–76. https://doi.org/10.1111/vru.12811. Epub 2019 Oct 1

Stack JD, Bergamino C, Sanders R, Fogarty U, Puggioni A, Kearney C, David F (2016) Comparison of two ultrasound-guided injection techniques targeting the sacroiliac joint region in equine cadavers. 29(5):386–393. https://doi.org/10.3415/VCOT-16-03-0041. Epub 2016 Jul 29

Vaughan B, Whitcomb MB, Maher O (2009) How to improve accuracy of ultrasound-guided procedures. 55AAEP Proceedings

Whitcomb MB, Vaughan B, Katzman S, Hersman J (2016) Ultrasound-guided injections in horses with cranioventral distension of the coxofemoral joint capsule: feasibility for a cranioventral approach. Vet Radiol Ultrasound 57(2):199–206

Whitcomb MB, Lamas LP, Head M (2018) Ultrasonography. Chapter 10. In: Henson FMD (ed) Equine neck and back pathology, 2nd edn

Ultrasound-Guided Injections in Bursae and Nerve Blocks

3

Abstract

Ultrasound-guided injections of bursae and nerves are commonly performed in equine practice. Bursae injections are used for diagnostic and therapeutic purposes, dramatically increasing the accuracy of the injections when compared to blind techniques. In the case of nerves, the perineural injections of anesthetic solutions are particularly useful to block large nerves like tibial and median nerves. This US-guided blocks significantly improve the repeatability of the response and decrease their onset time. This chapter reviews the most common applications and the reported techniques in this field, always striving to help the clinician to select the most adequate technique based on the best evidence available. Injections to the navicular bursa, bicipital bursa, infraspinatus bursa, tibial nerve block, and median nerve block will be discussed in depth.

Keywords

Ultrasound-guided injections · Bursae · Nerve blocks

3.1 Navicular Bursa

Pathologies of the podotrochlear apparatus are commonly diagnosed as the source of foot pain in the horse (Marsh et al. 2012; Dyson et al. 2005; Turner 1989). Injections to the navicular are routinely used for the diagnosis (Schramme et al. 2000; Schumacher et al. 2004; Dyson and Kidd 1993) and treatment (Schramme et al.

Supplementary Information The online version contains supplementary material available at https://doi.org/10.1007/978-3-031-17562-6_3. The videos can be accessed individually by clicking the DOI link in the accompanying figure caption or by scanning this link with the SN More Media App.

© Springer Nature Switzerland AG 2024

R. J. Estrada, *Ultrasound-Guided Procedures in Equine Orthopedics and Surgery*,
https://doi.org/10.1007/978-3-031-17562-6_3

2000; Gutierrez-Nibeyro et al. 2010; Bell et al. 2009; Dyson et al. 2005; Dabareiner et al. 2003) of horses with foot pain. Several ultrasound-guided injections to the aforementioned bursa have been proposed as an alternative to traditional blind or x-ray guided approaches (Nottrott et al. 2017; Estrada et al. 2015; Spriet et al. 2004).

3.1.1 Trancuneal Approach

Equipment and Preparation

The frog has to be trimmed (to provide a wide contact area and remove dry horn layer that causes ultrasound attenuation) (Spriet et al. 2004; Busoni and Denoix 2001). Soaking the foot in warm water for 15 min or placing a wet sponge at the frog after trimming facilitates obtaining a better quality image (Busoni and Denoix 2001). Alcohol or sterile gel is used as an acoustic coupling agent. The heel bulb region is clipped and aseptically prepared. The patient is sedated. A 1 ml bleb of local anesthetic is injected subcutaneously between the bulbs of the heels just above the coronary band. A linear, 7.5–10 MHz probe and a 20G 9 cm spinal needle are used (Spriet et al. 2004).

Ultrasonographic Anatomy and Landmarks

In 2001, Busoni and Denoix described the ultrasonographic anatomy of the bursa using the transcuneal window. When using this approach, the landmarks are the P3, navicular bone, DDFT (together with the distal digital annular ligament), the navicular bursa, impar distal ligament, distopalmar recess of the distal interphalangeal joint, digital cushion, and frog (Spriet et al. 2004; Busoni and Denoix 2001) (Fig. 3.1).

1 Third phalanx
2 Distal sesamoid (navicular)
3 Impar distalis ligament
4 Distal interphalangeal joint recess
5 Navicular bursa
6 Deep digital flexor tendon
7 Digital cushion
8 Distal digital annular ligament

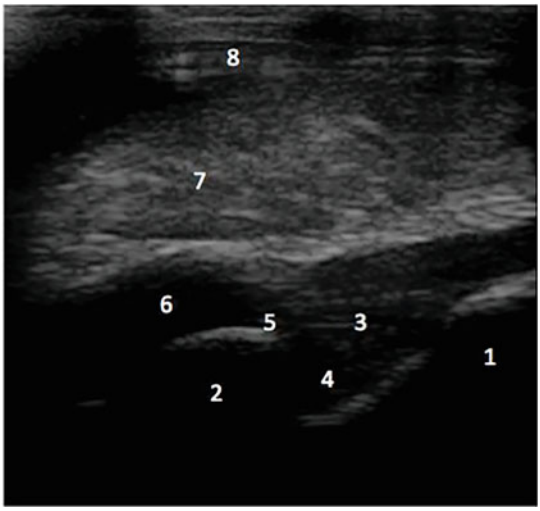

Fig. 3.1 Ultrasonographic anatomy of the podotrochlear region (transcuneal view)

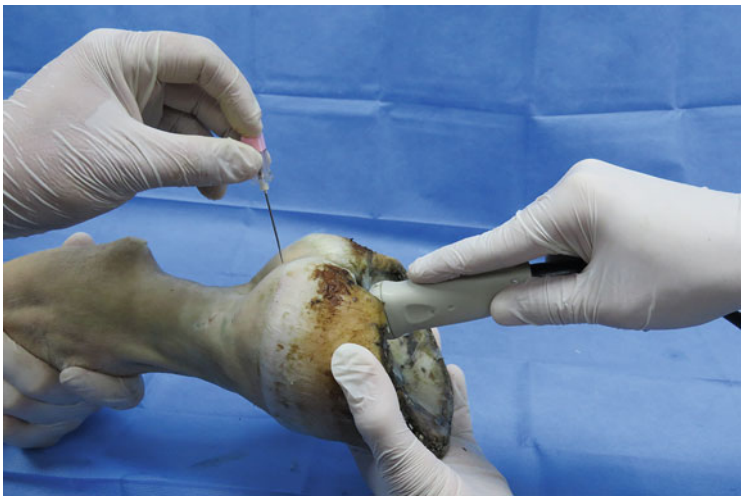

Fig. 3.2 Ultrasound-guided injection to the navicular bursa using the transcuneal approach. External image of positioning of the needle, the operator, and the assistants

Technique

The limb is held in flexion by the person performing the ultrasonographic examination and a second person (sterile) inserts the needle. The spinal needle is inserted between the heel bulbs, just proximal to the coronary band, directed in a sagittal plane, without ultrasound guidance, toward the "navicular position" as described by Verschooten et al. (1991). Once the needle is introduced, the ultrasound is used to assess the needle position (Spriet et al. 2004) (Fig. 3.2).

► **Commentaries**

Even though this technique is highly accurate in the hands of experienced operators, it is not very popular due to the extra time that it takes to prepare the hoof to achieve a good quality image (more if it is summer). The other issue is that this technique is not guiding the needle through the process; it is only controlling if the needle is in a good position. Since the needle is observed once the tendon is already penetrated, this technique has the potential of generating more trauma to the DDFT, in cases where repositionings are needed (occurring commonly in inexperienced operators). Even though there is no strong evidence that needle penetrations of this tendon are negative for the horse, it is ideal to minimize trauma as much as possible. In my opinion, this is another option to inject the bursa, but with the more modern approaches (palmarodistal digital and the lateral approaches), it does not make a lot of sense to use this technique nowadays.

3.1.2 Palmarodistal Digital Approach

Equipment and Preparation

The heel bulb region is clipped and aseptically prepared. The patient is sedated. A microconvex, 3–9 MHz, probe covered with a sterile glove and a 20G, 9 cm spinal needle are used. Alcohol or sterile gel is used as an acoustic coupling agent. A bleb of local anesthetic (0.5 ml mepivacaine) at the needle entrance site might be useful to avoid violent reactions to the needle in cases where intrasynovial anesthesia is performed (Estrada et al. 2015). In cases where the injections are performed to treat the bursa, an abaxial sesamoid block is better suited.

Ultrasonographic Anatomy and Landmarks

In 2007, Bolen et al. described the normal ultrasonographic anatomy of the palmarodistal aspect of the equine digit. When using this acoustic window, the landmarks are the P2, navicular bone, proximal ligament of the navicular bone, DIPJ, DFTS, DDFT, navicular bursa, distal digital annular ligament, and digital cushion (Estrada et al. 2015; Bolen et al. 2007) (Fig. 3.3).

Technique

The limb is held off the ground in extension by an assistant, who stood craniolaterally to the limb, with one hand holding the dorsal aspect of the third metacarpal bone and with the other pulling the toe. The probe is placed longitudinally between the heel bulbs, just proximal to the coronary band. Once a good quality image of the palmaroproximal aspect of the podotrochlear apparatus is acquired, the needle is directed through the digital cushion using ultrasound guidance, until contacting the palmaroproximal aspect of the navicular bone (Estrada et al. 2015) (Figs. 3.4 and 3.5).

1 Distal sesamoid (navicular)
2 Proximal ligament o fthe distal sesamoid (sagittal aspect colateral ligament)
3 Navicular bursa
4 Deep digital flexor tendon
5 Distal interphalangeal joint recess
6 Digital flexor tendon sheath
7 Second phalanx
8 Digital cushion

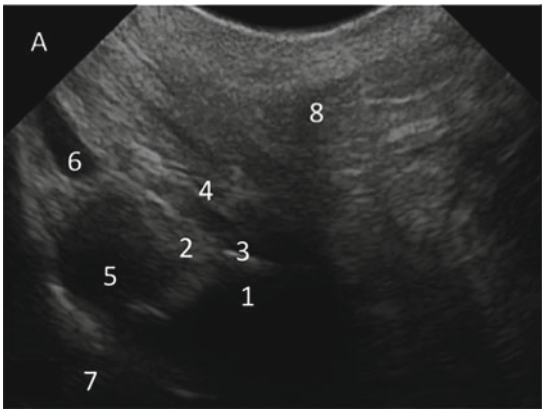

Fig. 3.3 Ultrasonographic anatomy of the podotrochlear region (palmarodistal sagittal view)

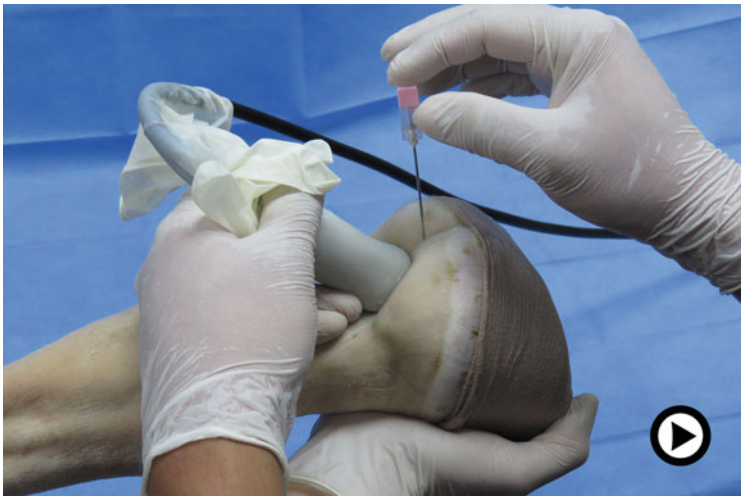

Fig. 3.4 Ultrasound-guided injection to the navicular bursa using the palmarodistal digital approach. External image (▶ https://doi.org/10.1007/000-awb)

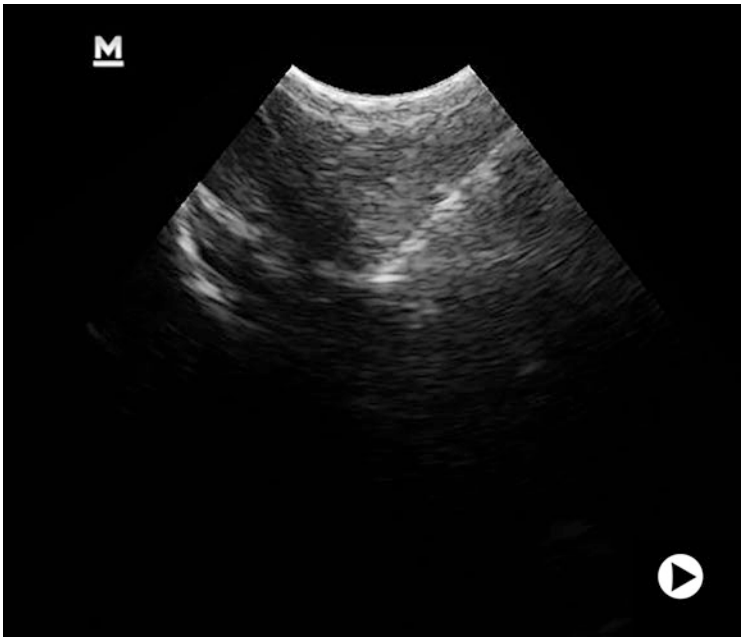

Fig. 3.5 Ultrasound-guided injection to the navicular bursa using the palmarodistal digital approach. Ultrasound image (▶ https://doi.org/10.1007/000-aw6)

Commentaries

This technique is highly accurate (92%) and can be performed with minimal preparation. Moreover, it has the advantage of being able to reposition the needle in the digital cushion without repeatedly perforating the DDFT. Even though this technique is not tendon-sparing, it minimizes the trauma to the DDFT. It is definitively important to select the patients for this technique, due to the fact that patients with optimal visibility of the landmarks present an accuracy rate as high as 100%. On the other hand, poor visibility of the landmarks can affect the accuracy rate dramatically (62.5%).

3.1.3 Lateral Approach (Tendon-Sparing)

Equipment and Preparation

The heel bulb region is clipped and aseptically prepared. The patient is sedated. A microconvex, 5–8 MHz, probe covered with a sterile glove and a 20G, 7.5–9 cm spinal needle are used. Alcohol or sterile gel is used as an acoustic coupling agent. Abaxial sesamoid block is usually recommended, but this can only be used for treatments and not for diagnostic anesthesia (Nottrott et al. 2017). A bleb of local anesthetic (0.5 ml mepivacaine) at the needle entrance site might be useful to avoid violent reactions to the needle in cases where intrasynovial anesthesia is performed.

Ultrasonographic Anatomy and Landmarks

Nottrott et al. reported the ultrasonographic anatomy of the oblique view of the navicular bursa. When using this acoustic window, the visualized landmarks are (1) navicular bone; (2) deep digital flexor tendon; (3) navicular bursa; (4) collateral sesamoidean ligament; (5) palmar digital artery, vein, and nerve bundle; (6) digital cushion; (7) middle phalanx; and (8) distal interphalangeal joint (Nottrott et al. 2017) (Fig. 3.6).

1 Navicular bursa (lateral recess) Distal sesamoid (navicular)
2 Deep digital flexor tendón (lateral lobe off beam)
3 proximal ligamen to fthe distal sesamoid
4 Distal interphalangeal joint recess
5 Secondphalanx

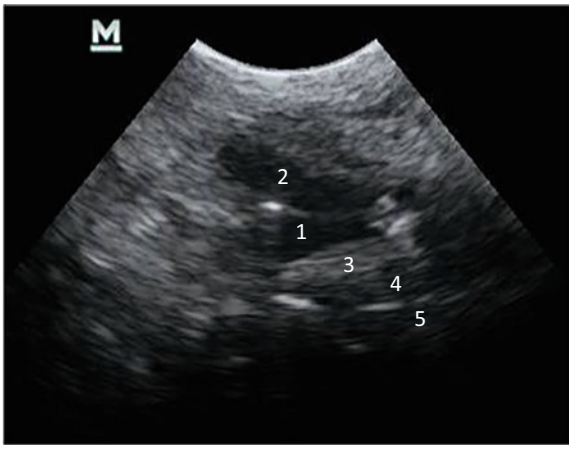

Fig. 3.6 Ultrasonographic anatomy of the podotrochlear region (palmarodistal oblique view)

Fig. 3.7 Ultrasound-guided injection to the navicular bursa using the tendon-sparing technique. External needle position (▶ https://doi.org/10.1007/000-aw7)

Technique

The foot is held in a flexed position on a standard 60 degree inclined radiographic navicular block by an assistant. The probe is placed longitudinally against the palmar aspect of the DDFT in the distal aspect of the pastern region (between the heel bulbs). The transducer is then rotated 45 degrees laterally, thereby causing it to lie obliquely, axial to the lateral ungular cartilage, with the center beam pointing dorsally (Nottrott et al. 2017).

A spinal needle is inserted directly proximal to the lateral ungular cartilage of the third phalanx, between the palmarolateral border of the middle phalanx and the dorsolateral border of the DDFT, palmar to the neurovascular bundle, at an angle of approximately 45 degrees to the solar plane of the foot in the frontal plane of the limb. The needle is advanced in a distomedial direction using real-time ultrasound guidance until reaching the palmar surface of the navicular bone, taking care to avoid penetration of the DDFT and the collateral sesamoid ligament (CSL) (Nottrott et al. 2017) (Figs. 3.7 and 3.8).

▶ **Commentaries**

Even though this technique is technically challenging, in the hands of experienced operators the accuracy rate can be as high as 94%. It is important to take into account that in 15% of the cases the injections resulted in presence of contrast media in both the navicular bursa and the DIPJ. This finding might be related to inadvertent puncture of the DIPJ and therefore might limit the use of this technique in cases where an infection of the navicular bursa is suspected. Another ultrasound-guided tendon sparing injection of the navicular bursa was also described by Perrin et al. 2016, nevertheless the success rate was quite poor (68%).

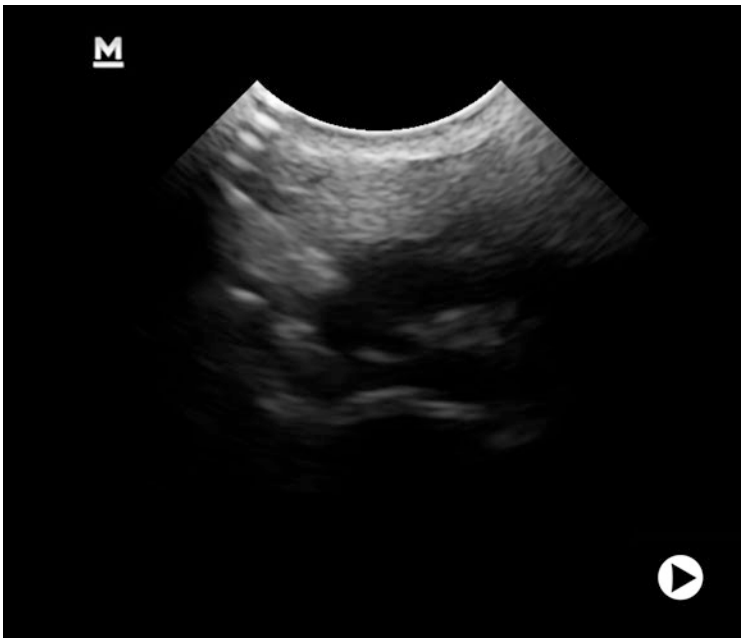

Fig. 3.8 Ultrasound-guided injection to the navicular bursa using the tendon-sparing technique. Ultrasound image (▶ https://doi.org/10.1007/000-aw8)

3.2 Bicipital Bursa

Lameness caused by disease associated with the bicipital bursa in horses is uncommon (Stashak 2002). Disorders of bicipital and infraspinatus apparatus such as osseous cyst-like lesions of the humeral tubercles, tendonitis, and septic or nonseptic bursitis have been described (Forresu et al. 2006; Dyson 1986; Vatistas et al. 1996). Diagnosis of these conditions remains difficult and technically challenging for equine practitioners (Schneeweiss et al. 2012). Ultrasound-guided injections to these synovial structures have been traditionally used for the diagnosis (intrasynovial anesthesia) and treatment of pathologies affecting these structures.

Equipment and Preparation

The cranial shoulder region is clipped and aseptically prepared. The patient is sedated. A linear musculoskeletal (7.5–13 MHz) or microconvex (5–8 MHz) probe covered with a sterile glove and a 20G, 13 cm spinal needle are used. Alcohol or sterile gel is used as an acoustic coupling agent (Schneeweiss et al. 2012). A bleb of local anesthetic (0.5 ml mepivacaine) at the needle entrance site might be useful to avoid violent reactions to the needle; nevertheless, with proper sedation it is usually enough.

1 Biceps tendon (lateral lobe)
2 Lateral branch of the supraspinous muscle
3 Major tubercle of the humerus
4 Intertubercular Groove of the humerus
5 Intermediate tubercle of the humerus
6 Biceps bursa
7 Biceps bursa capsule
8 Brachiocephalicus / omotrasnversarius muscle

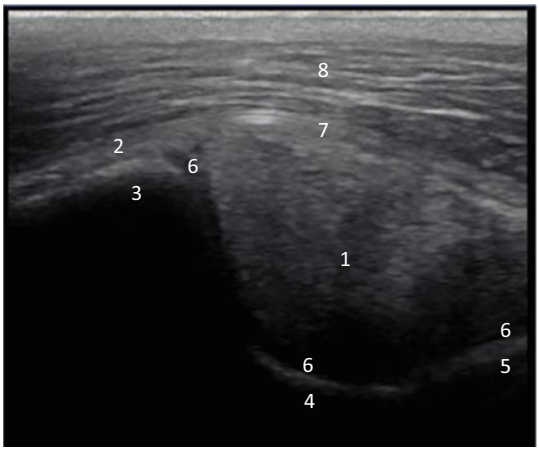

Fig. 3.9 Ultrasonographic anatomy of the bicipital bursa

Ultrasonographic Anatomy and Landmarks

Tnibar et al. reported the normal ultrasonographic anatomy of the bicipital bursa. In a transverse section of the cranial shoulder, the visualized landmarks are the bicipital tendon, bicipital bursa, cranial aspect of the lesser tubercle of the humerus, medial intertubercular groove of the humerus, intermediate tubercle of the humerus, lateral intertubercular groove of the humerus, cranial aspect of the greater tubercle of the humerus, the medial and lateral branches of the supraspinatus tendon, the brachiocephalicus muscle, and the subclavius muscle can be visualized (Tnibar et al. 1999) (Fig. 3.9).

Technique

Once a good quality transverse image of the cranial shoulder is acquired (to an area where the bicipital tendon is bilobed), the transducer is moved laterally until visualizing the lateral lobe of the bicipital tendon and the cranial eminence of the greater trochanter. The needle is inserted under ultrasound guidance between the aforementioned structures in a craniolateral to caudomedial direction (Schneeweiss et al. 2012) (Figs. 3.10, 3.11 and 3.12).

► **Commentaries**

It is important to mention that when compared to "blind" injection techniques to the bicipital bursa, the ultrasound-guided injections are significantly more accurate. Schneeweiss et al. (2012) demonstrated that only 62% of the "blind" injections were intrasynovial, when compared to 100% of the ultrasound-guided ones. It is possible to inject the distal recess of the bicipital bursa, distal to the tubercles of the humerus. Nonetheless, to the knowledge of the author, there is no study demostrating the accuracy of this technique.

Fig. 3.10 Ultrasound-guided injection to the bicipital bursa. External needle position: lateral view (▶ https://doi.org/10.1007/000-aw9)

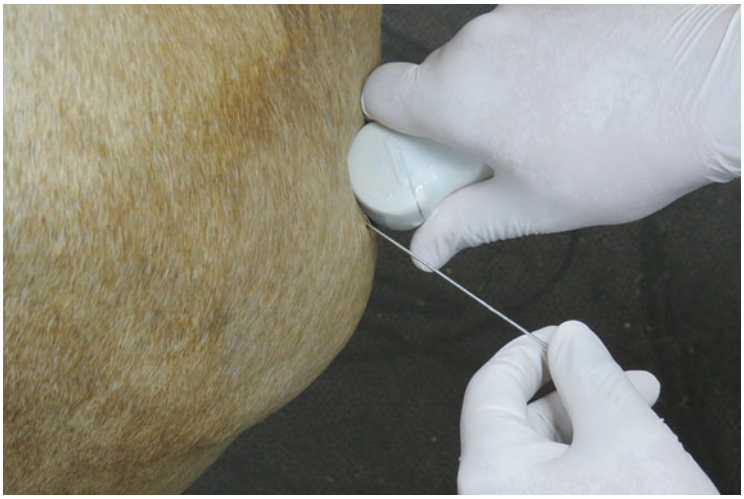

Fig. 3.11 Ultrasound-guided injection to the bicipital bursa. External needle position: dorsal view

3.3 Infraspinatus Bursa

Lameness caused by disease associated with the infraspinatus bursa in horses is uncommon (Stashak 2002). Disorders of bicipital and infraspinatus apparatus such as exostosis and/or osseous cyst-like lesions of the humeral tubercles, tendonitis, and septic or nonseptic bursitis have been described (Whitcomb et al. 2006; Forresu et al.

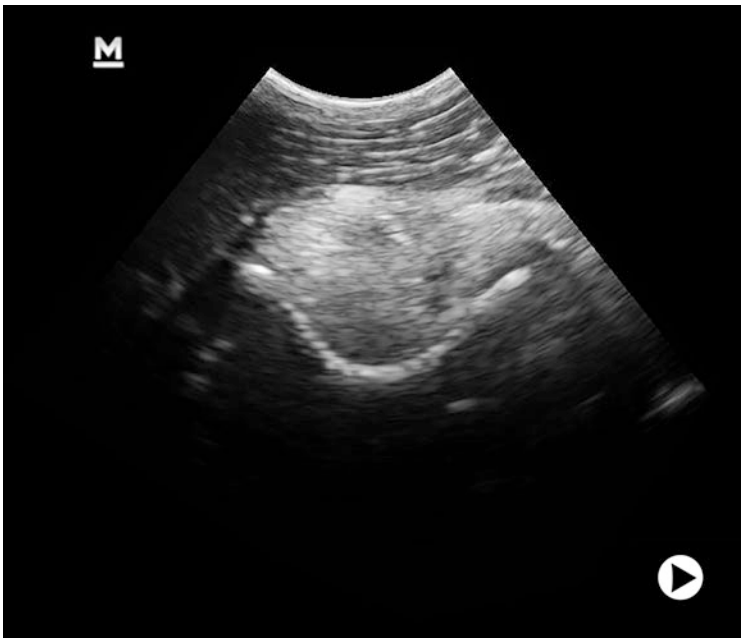

Fig. 3.12 Ultrasound-guided injection to the bicipital bursa. Ultrasound image (▶ https://doi.org/10.1007/000-awa)

2006; Dyson 1986; Vatistas et al. 1996). Diagnosis of these conditions remains difficult and technically challenging for equine practitioners (Schneeweiss et al. 2012). Ultrasound-guided injections to these synovial structures have been traditionally used for the diagnosis (intrasynovial anesthesia) and treatment of pathologies affecting these structures.

Equipment and Preparation

The lateral shoulder region is clipped and aseptically prepared. The patient is sedated. A linear musculoskeletal, (7.56–13 MHz) or microconvex, (5–8 MHz) probe covered with a sterile glove and a 20G, 13 cm spinal needle are used. Alcohol or sterile gel is used as an acoustic coupling agent (Schneeweiss et al. 2012). A bleb of local anesthetic (0.5 ml mepivacaine) at the needle entrance site might be useful to avoid violent reactions to the needle; nevertheless with proper sedation it is usually enough.

Ultrasonographic Anatomy and Landmarks

Tnibar et al. reported the normal ultrasonographic anatomy of the infraspinatus bursa. In a longitudinal section of the lateral shoulder, the visualized landmarks are omotransversarius muscle, the infraspinatus tendon, infraspinatus bursa, teres minor muscle, and caudal aspect of the greater tubercle of the humerus (Tnibar et al. 1999) (Fig. 3.13).

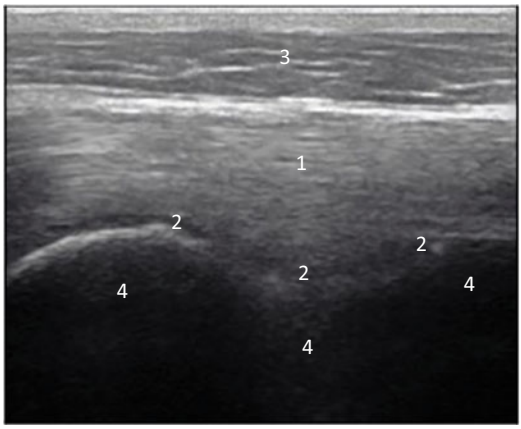

1 Infraspinatus tendon
2 Infraspinatus bursa
3 Brachiocephalicus / omotransversarius muscle
4 Major tubercle of the humerus

Fig. 3.13 Ultrasonographic anatomy of the infraspinatus bursa

Technique

First, in a transverse section, the infraspinatus muscle is identified caudal to the scapular spine. The probe is displaced distally until the musculotendinous junction is located. Then the probe is rotated 90 degrees and the infraspinatus tendon is then visualized gliding over the convexity of the caudal portion of the greater humeral tubercle in a longitudinal section. The spinal needle is inserted under ultrasound guidance through the tendon, in a distolateral to proximomedial direction, until reaching the underlying bone (Schneeweiss et al. 2012) (Figs. 3.14, 3.15 and 3.16).

Fig. 3.14 Ultrasound-guided injection to the infraspinatus bursa. External needle position: lateral view (▶ https://doi.org/10.1007/000-aw5)

Fig. 3.15 Ultrasound-guided injection to the infraspinatus bursa. External needle position: dorsal view

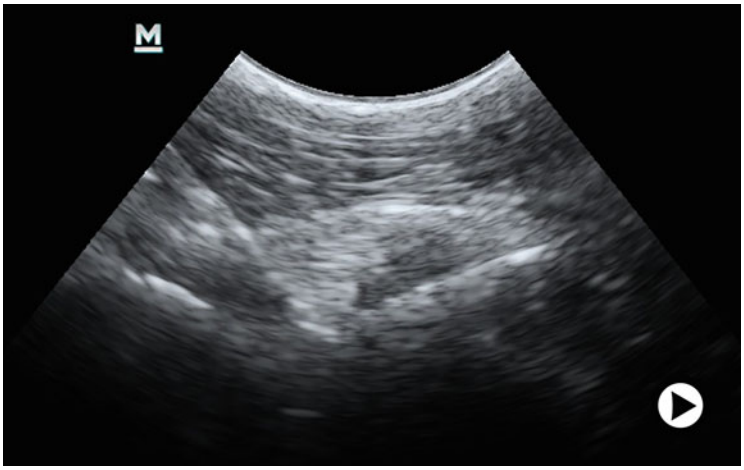

Fig. 3.16 Ultrasound-guided injection to the infraspinatus bursa. Ultrasound image (▶ https://doi.org/10.1007/000-awc)

▶ **Commentaries**
It is important to mention that when compared to "blind" injection techniques to the bicipital bursa, the ultrasound-guided injections are significantly more accurate. Schneeweiss et al. (2012) demonstrated that only 62% of the "blind" injections were intrasynovial, when compared to 100% of the ultrasound-guided ones.

3.4 Tibial Nerve Block

Local anesthesia of the tibial nerve in equines is usually indicated for diagnostic evaluation of hindlimb lameness. Moreover, this block is also used when performing standing procedures in the hindlimb (laceration repair, joint lavages, etc.). The tibial nerve lies at the superficial crural compartment, craniomedial to the Achilles tendon (tendo calcaneus communis). It is also in close relationship with the caudal root of the saphenous vein and the lateral digital flexor muscle body. Traditionally, blind techniques are used to inject this nerve; nevertheless, the effect is many times inconsistent. Ultrasound-guided injections of the tibial nerve allow accurate deposition of local anesthetic around the nerve, avoiding intramuscular and intravenous injection. This technique achieves fast (approximately 10–15 min vs. 30–60 min with blind techniques), effective, and reliable anesthesia (Denoix et al. 2020).

Equipment and Preparation
The caudomedial aspect of the crura is aseptically prepared. The patient is sedated. A microconvex, 6–8.5 MHz, probe covered with a sterile glove and a 20G, 1.5 in. hypodermic needle or a 20G, 15 mm, venipuncture set help to avoid reposition of the needle if the horse moves. Alcohol or sterile gel is used as an acoustic coupling agent.

Ultrasonographic Anatomy and Landmarks
Denoix et al. reported the normal ultrasonographic anatomy of the tibial nerve. The injection site is usually 10 cm proximal to the calcaneal tuberosity at the caudomedial aspect of the crura. In a cross section of these areas, the visualized landmarks are tibial nerve, caudal branch of the saphenous vein, body of the lateral digital flexor muscle, superficial crural fascia, deep crural fascia, SDFT, gastrocnemius tendon, and fat/lymphatic vessels (Denoix et al. 2020) (Fig. 3.17).

Technique
There are different options to perform this injection. When plenty of personnel are available, one person can image the nerve, another can perform the injection, and another assistant can hold the ipsilateral forelimb (Denoix et al. 2020). Even though this is ideal, it is not realistic in the majority of the cases when performing this block in ambulatory field practice. I usually ask an assistant to hold the hindlimb a bit

1 Tibial nerve
2 Caudal root of the saphenous vein
3 Deep caudal crural fascia
4 Superficial caudal crural fascia
5 lateral digital flexor muscle
6 Superficial digital flexor tendon
7 Gastrocnemius

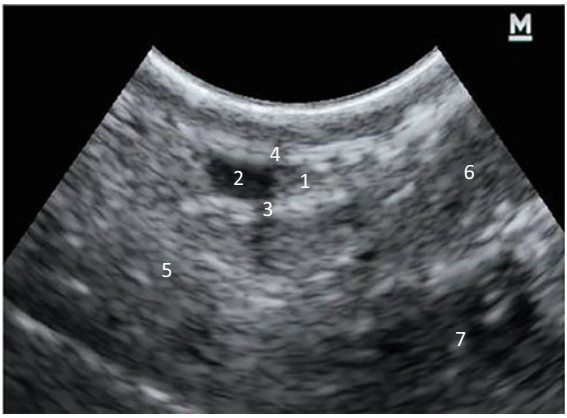

Fig. 3.17 Ultrasonographic anatomy of the tibial nerve

forward, grasping it from the cannon bone region. The operator injects passing both hands/arms under the horse's abdomen from the contralateral side. The image is acquired as previously described. The probe is tilted caudally and the needle is inserted directly cranial to the probe. Ultrasound guidance is used to control the perineural deposition of the local anesthetic. Thereafter, the probe is tilted cranially and the needle is inserted directly caudal to the probe, and another local anesthetic depo is injected. Using this technique, 10–15 ml of local anesthetic is injected in total (Figs. 3.18, 3.19 and 3.20).

Commentaries

Even though it seems that ultrasound-guided injections of the tibial nerve are significantly better at achieving consistent results, there are no studies comparing this technique with the traditional approach.

It is usually described in the literature that the tibial nerve block should be performed together with the fibular nerve. Nonetheless, performing the tibial nerve alone usually blocks the superficial and deep sensitivity of the majority of the tarsus, metatarsus (including bones and tendons), and distal limb (fetlock, pastern, and foot) (Denoix et al. 2020). Therefore, the fibular nerve block should be performed only when skin desensitization of the limb is needed for a particular procedure. The deep fibular branch can be easily blocked using ultrasound guidance, which helps to avoid the large cranial tibial veins.

Fig. 3.18 Ultrasound-guided injection to the tibial nerve. External needle position: cranial injection

3.5 Median Nerve Block

Regional anesthesia using the median nerve block is indicated for localizing pain in the carpal region when proximal metacarpal nerve blocks are negative or partially positive, suspicion of subchondral pain of the carpus, suspicion of carpal tunnel pain, exclusion of pain arising from the distal limb when proximal limb lameness is suspected, or surgery of the carpal region (Beaumont et al. 2021). The median nerve runs through the medial aspect of the antebrachium, caudal to the radius deep to the flexor carpi radialis muscle, closely associated with the median artery. Even though non ultrasound-guided techniques have been reported, accurate injection of deep nerves is a challenge for the equine practitioner. Ultrasound-guided perineural injection of the median nerve is a straightforward and safe option, enabling localization of the nerve, real-time positioning of the needle, and a correct distribution of the anesthetic around the nerve (Beaumont et al. 2021).

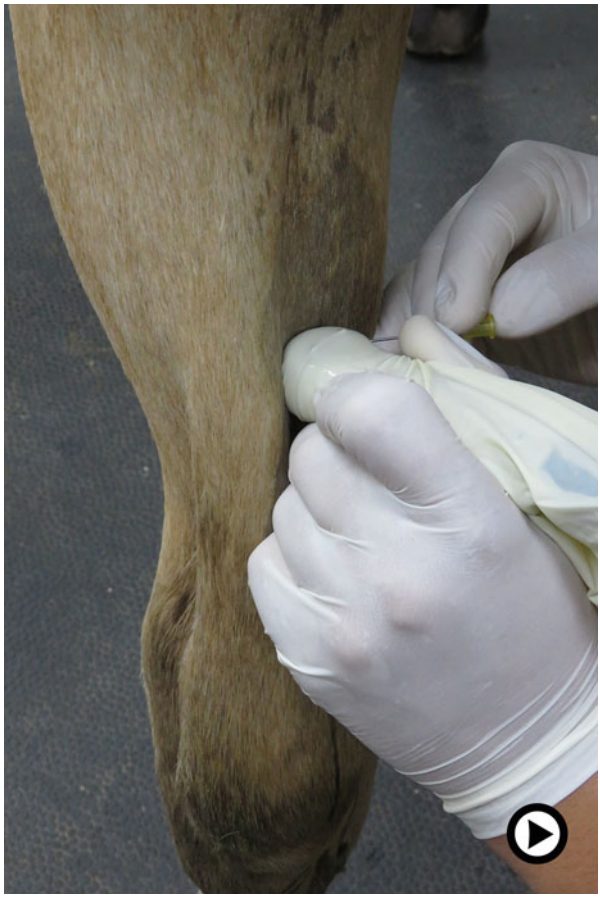

Fig. 3.19 Ultrasound-guided injection to the tibial nerve. External needle position: caudal injection (▶ https://doi.org/10.1007/000-awd)

Equipment and Preparation

The caudomedial aspect of the antebrachium is aseptically prepared. Clipping of the hair is not usually needed unless the horse has a long hair coat. The patient is sedated. A microconvex, 6–10 MHz, probe covered with a sterile glove and a 20G, 25 mm hypodermic needle are used. Alcohol or sterile gel is used as an acoustic coupling agent.

Ultrasonographic Anatomy and Landmarks

Alexander and Dobson (2003), reported the normal ultrasonographic anatomy of the median nerve. The injection site is usually 5–7 cm proximal to the chestnut at the medial aspect of the antebrachium. In a cross section of these area, the visualized landmarks are median nerve, the median artery, the median vein (collapsed), the

Fig. 3.20 Ultrasound-guided injection to the tibial nerve. Ultrasound image (▶ https://doi.org/10.1007/000-awe)

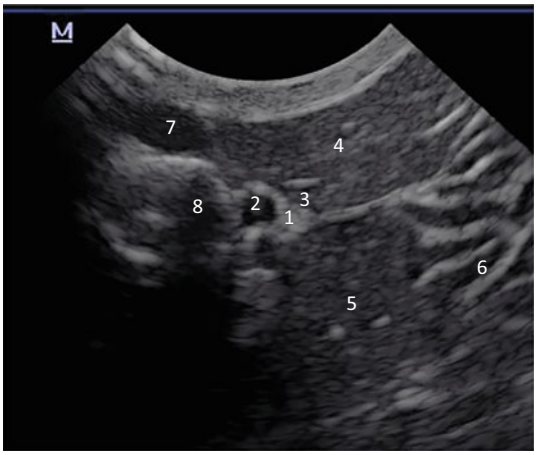

1 Median nerve
2 Median artery
3 Median vein collapsed
4 Flexor carpi radialis muscle
5 Radial head of the Deep digital flexor muscle
6 Humeral head of the Deep digital flexor muscle
7 Cephalic vein
8 Radius caudomedial aspect

Fig. 3.21 Ultrasonographic anatomy of the median nerve

flexor carpi ulnaris muscle, the deep digital flexor muscle, and the caudal aspect of the radius (Beaumont et al. 2021) (Fig. 3.21).

Technique

Caudal Approach

With the horse standing or the limb in elevation. A bleb of 1 ml of mepivacaine is used to desensitize the skin once the location of the needle entrance is defined. The probe is placed at the dorsomedial aspect to the belly of the flexor carpi radialis

Fig. 3.22 Ultrasound-guided injection to the median nerve. External needle position: caudal approach (▶ https://doi.org/10.1007/000-awf)

muscle until achieving a good image of the nerve. Once the median nerve is visualized, the needle is inserted under ultrasonographic guidance until locating it adjacent to the nerve. Ten ml of local anesthetic are injected around the nerve using ultrasonographic control. Even though a cranial approach has been reported, the needle can be relocated dorsomedial to the nerve using the caudal approach in cases where the anesthetic solution is not surrounding the nerve (Figs. 3.22 and 3.23).

▶ **Commentaries**

Direct injection of the median nerve should be avoided since the majority of the animals react violently to it. Therefore, it is important to perform a perineural injection using ultrasound control.

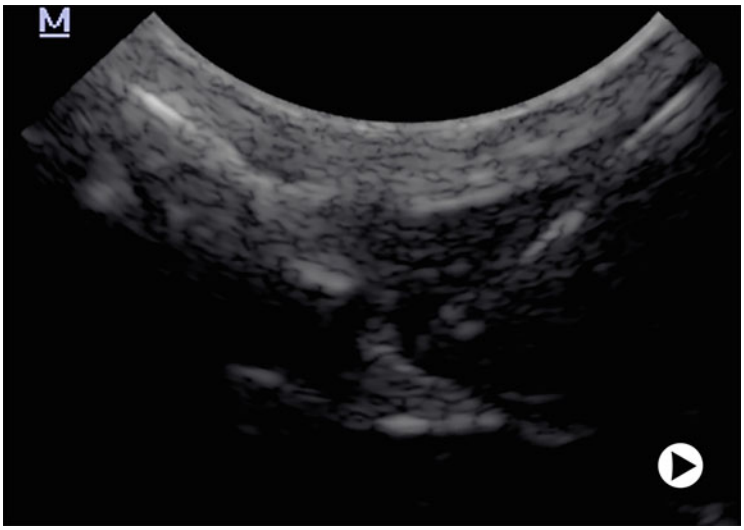

Fig. 3.23 Ultrasound-guided injection to the median nerve. Ultrasound image (▶ https://doi.org/10.1007/000-awg)

It is very important to take into account that to achieve a complete desensitization of the forelimb, blocking the ulnar nerve in conjunction with the median nerve is needed. The ulnar nerve is very superficial (3 mm from the skin) and can be located approximately 10 cm proximal to the accessory carpal bone, between the ulnaris lateralis muscle and the flexor carpi ulnaris muscle. Even though an ultrasound-guided technique can be used for the ulnar nerve, in general, blind techniques are usually effective.

References

Alexander K, Dobson H (2003) Ultrasonography of peripheral nerves in the normal adult horse. Vet Radiol Ultrasound 44:456–464

Beaumont A, Bertoni L, Denoix JM (2021) Ultrasound-guided block of the median nerve. Equine Vet Educ 33(4):208–214. https://doi.org/10.1111/eve.13287

Bell CD, Howard RD, Taylor DS, Voss ED, Werpy NM (2009) Outcomes of podotrochlear (navicular) bursa injections for signs of foot pain in horses evaluated via magnetic resonance imaging: 23 cases (2005-2007). J Am Vet Med Assoc 234:920–925

Bolen G, Busoni V, Jacqmot O, Snaps F (2007) Sonographic anatomy of the palmarodistal aspect of the equine digit. Vet Radiol Ultrasound 48:270–275

Busoni V, Denoix JM (2001 Nov–Dec) Ultrasonography of the podotrochlear apparatus in the horse using a transcuneal approach: technique and reference images. Vet Radiol Ultrasound 42(6):534–40. https://doi.org/10.1111/j.1740-8261.2001.tb00983.x. PMID: 11768522

Dabareiner RM, Carter GK, Honnas CM (2003) Injection of corticosteroids, hyaluronate, and amikacin into the navicular bursa in horses with signs of navicular area pain unresponsive to other treatments: 25 cases (1999-2002). J Am Vet Med Assoc 223:1469–1474

Denoix JM, Beaumont A, Bertoni L (2020) Ultrasound-guided block of the tibial nerve. Equine Vet Educ 32(7):372–377. https://doi.org/10.1111/eve.13020

Dyson S (1986) Shoulder lameness in horses: an analysis of 58 suspected cases. Equine Vet J 18: 29–36

Dyson SJ, Kidd L (1993) A comparison of responses to analgesia of the navicular bursa and intra-articular analgesia of the distal inter-phalangeal joint in 59 horses. Equine Vet J 25:93–98

Dyson SJ, Murray R, Schramme MC (2005) Lameness associated with foot pain: results of magnetic resonance imaging in 199 horses (January 2001-December 2003) and response to treatment. Equine Vet J 37:113–121

Estrada RJ, Pascual A, Lischer CJ (2015) Development and evaluation of ultrasound-guided navicular bursa injection using the palmarodistal digital approach in horses: an ex vivo study. J Equine Vet Sci 35:849–855

Forresu D, Lepage OM, Cauvin E (2006) Septic bicipital bursitis, tendonitis and arthritis of the scapulohumeral joint in a mare. Vet Rec 159:352–354

Gutierrez-Nibeyro SD, White NA, Werpy NM (2010) Outcome of medical treatment for horses with foot pain: 56 cases. Equine Vet J 42:680–685

Marsh CA, Schneider RK, Sampson SN, Roberts GD (2012) Response to injection of the navicular bursa with corticosteroid and hyaluronan following high-field magnetic resonance imaging in horses with signs of navicular syndrome: 101 cases (2000-2008). J Am Vet Med Assoc 241: 1353–1364

Nottrott K, De Guio C, Khairoun A, Schramme M (2017) An ultrasound-guided, tendon-sparing, lateral approach to injection of the navicular bursa. Equine Vet J 49(5):655–661. https://doi.org/10.1111/evj.12673. Epub 2017 Feb 28

Perrin R, Diguet AC, Cantet P, Bailly C, Brogniez L, Dugdale A, Nisolle JF, Vandeweerd JM (2016) Ex vivo assessment of an ultrasound-guided injection technique of the navicular bursa in the horse. Anat Histol Embryol 45(6):450–456. https://doi.org/10.1111/ahe.12220. Epub 2015 Dec 1

Schneeweiss W, Puggioni A, David F (2012) Comparison of ultrasound-guided vs. 'blind' techniques for intra-synovial injections of the shoulder area in horses: scapulohumeral joint, bicipital and infraspinatus bursae. Equine Vet J 44(6):674–678. https://doi.org/10.1111/j.2042-3306.2011.00540.x. Epub 2012 Feb 15. PMID: 22332644

Schramme MC, Boswell JC, Hamhougias K, Toulson K, Viitanen M (2000) An in vitro study to compare 5 different techniques for injection of the navicular bursa in the horse. Equine Vet J 32: 263–267

Schumacher J, Schumacher J, Schramme MC, DeGraves FJ, Smith R, Coker M (2004) Diagnostic analgesia of the equine forefoot. Equine Vet Educ 16:159–165

Spriet M, David F, Rossier Y (2004) Ultrasonographic control of navicular bursa injection. Equine Vet J 36:637–639

Stashak TS (2002) Inflammation of the intertubercular bursa (bicipital bursitis). In: Adams' lameness in horses, 5th edn. Lippincott Williams & Wilkins, Philadelphia, pp 905–908

Tnibar MA, Auer JA, Bakkali S (1999) Ultrasonography of the equine shoulder: technique and normal appearance. Vet Radiol Ultrasound 40(1):44–57. https://doi.org/10.1111/j.1740-8261.1999.tb01838.x. PMID: 10023995

Turner TA (1989) Diagnosis and treatment of the navicular syndrome in horses. Vet Clin North Am Equine Pract 5:131–144

Vatistas NJ, Pascoe JR, Wright IM, Dyson SJ, Mayhew IG (1996) Infection of the intertubercular bursa in horses: four cases (1978-1991). J Am Vet Med Assoc 208:1434–1437

Verschooten F, Desmet P, Peremans K, et al. (1991) Navicular disease in the horse: the effect of controlled intrabursal corticoid injection. J Equine Vet Sci 11:8.

Whitcomb MB, le Jeune SS, MacDonald MM, Galuppo LD, Judy CE (2006) Disorders of the infraspinatus tendon and bursa in three horses. J Am Vet Med Assoc 229(4):549–556. https://doi.org/10.2460/javma.229.4.549. PMID: 16910855

Ultrasound-Assisted Surgery

4

Abstract

Modern surgery always strives to decrease tissue trauma so that morbidity and mortality can be diminished. Using ultrasound guidance to perform surgical procedures has been demonstrated to be an extremely useful tool. Intraoperative ultrasound marking allows the clinician to precisely locate foreign bodies, abscesses, hematomas, and bone fragments in the depth, decreasing the incision size and therefore tissue trauma. Moreover, it avoids damaging delicate structures, that when injured, have the potential to cause complications in the patient. On the other hand, it has been also demonstrated that ultrasound guidance can be a great aid for open and endoscopic surgery. Learning about these techniques would definitively affect your daily practice and your patients positively.

Keywords

Ultrasound-guided procedures · Ultrasound-assisted surgery · Intraoperative ultrasound marking

4.1 Intraoperative Ultrasound Marking

Ultrasound guidance is also used to mark the site of the skin incision intraoperatively (Stack et al. 2016). The objective of this technique is to minimize tissue trauma by localizing the precise site of the incision and therefore diminishing the incision

Supplementary Information The online version contains supplementary material available at https://doi.org/10.1007/978-3-031-17562-6_4. The videos can be accessed individually by clicking the DOI link in the accompanying figure caption or by scanning this link with the SN More Media App.

© Springer Nature Switzerland AG 2024

R. J. Estrada, *Ultrasound-Guided Procedures in Equine Orthopedics and Surgery*,
https://doi.org/10.1007/978-3-031-17562-6_4

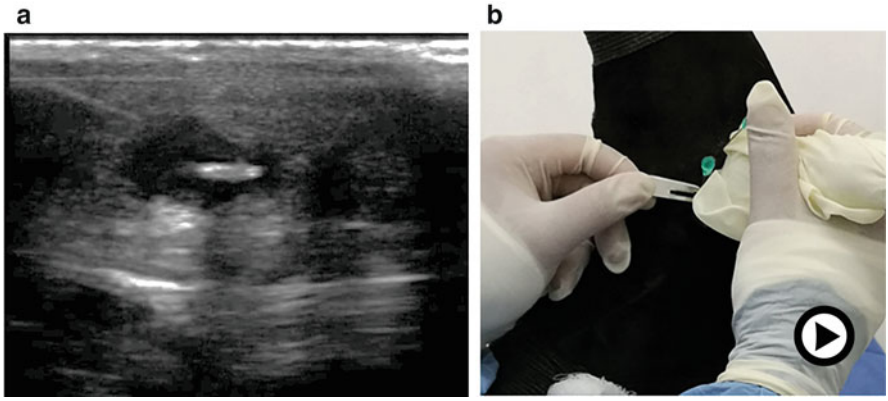

Fig. 4.1 Intraoperative ultrasound marking. Clip and prepare the surface aseptically; (**a**) Localize the target using a linear musculoskeletal probe (covered with a sterile glove), using alcohol as coupling agent; (**b**) introduce a sterilized metallic object (paper clip, blunt back of a 24 scalpel blade, stitch removal device, stainless steel ruler, etc.) between the skin and the probe, until the cone-down artifact is generated (▶ https://doi.org/10.1007/000-awq)

length and minimizing tissue dissection. This technique is particularly useful for the removal of foreign bodies, bone fragments, bone sequesters, implants, etc.

Equipment and preparation

The region of interest is clipped and aseptically prepared. The patient is anesthetized or a regional or local block is performed. The head of a linear musculoskeletal probe is covered with a sterile glove (with non-sterile gel inside) and the cable of the probe is protected with a sterile arthroscopic plastic sleeve. Alcohol or sterile gel is used as an acoustic coupling agent. A sterile stapler machine or needles are used to mark the skin. Finally, once the exact site is localized, basic surgery instruments are used (Stack et al. 2016). In cases where these procedures are performed under field conditions, only a sterile glove is used over the transducer, in a similar fashion to when performing an ultrasound-guided injection.

Technique

The approximate incision site is located with the ultrasound, locating the target (foreign body, bony fragment, implant) in the middle of the screen . A sterilized unfolded paper clip, a sterilized stainless steel ruler or the blunt side of a scalpel blade is slid between the transducer and the skin. A “cone-down” reverberation artifact is produced when the metallic object interacts with the ultrasound beam. The selected metallic object is moved between the probe and the skin until the cone-down artifact is aligned with a border of the target in the depth of the tissue. Once in position, a skin staple is placed at the site marked by the metallic object. Then the procedure is repeated for the other borders of the target (on longitudinal and transverse images), so that the desired incision site is demarcated. Using the ultrasound measuring tool, the depth from the skin to the area of interest can also be estimated (Figs. 4.1 and 4.2).

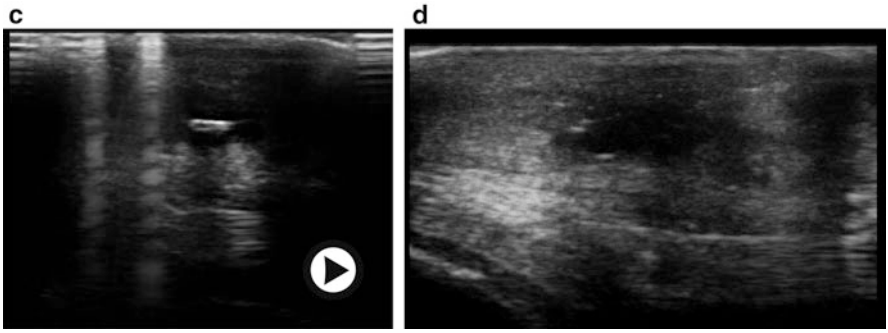

Fig. 4.2 Intraoperative ultrasound marking. (**c**) Slide the clip, stainless steel ruler or blunt side of the scalpel between the skin and the probe and use the cone-down artifact to mark the borders of the target in the depth and then place an external skin marker at this site (needles, staples, etc.). Depending on the size of the target, mark two (90° to each other) to four borders of the target. Videos of the cone-down artifact available. (**d**) Confirm that the target has been removed (▶ https://doi.org/10.1007/000-awj)

▶ **Commentaries**

As mentioned before, intraoperative ultrasound marking is extremely useful for many applications. Even though the technique has not been objectively validated, I concur with Stack et al. (2016) that it seems to be quite accurate.

4.2 Intraoperative Ultrasound Guidance

Intraoperative ultrasound guidance is a useful and powerful tool for the surgeons. In many situations, it allows finishing a surgery successfully. In general, this technique improves visualization, decreases surgery time, reduces tissue trauma, decreases complications, and decreases exposure to ionizing radiation (through minimizing the need of intraoperative radiographies) (Stack et al. 2016). Even though many ultrasound-guided techniques have been reported in the literature, some of them are not widely used. In this section, the most common, modern, applications of intraoperative ultrasound guidance will be discussed.

4.2.1 Ultrasound-Guided Surgical Incision and Drainage

In cases where the patients present abscesses, masses, hematomas, seromas, foreign bodies, etc., the combination of sharp and/or blunt dissection with intraoperative marking and guidance is extremely useful. The combination of these techniques allows the surgeon to minimize tissue trauma (usually the incisions are smaller) and decrease the risk of damaging or penetrating synovial structures, nerves, and vessels.

In general, the aforementioned techniques are used to dissect and remove the structures in toto or to drain its contents more efficiently.

Equipment and Preparation

Depending on the case (location, size, and horse temperament) the procedure can be performed standing (sedation and local blocks) or in general anesthesia (TIVA or inhalatory). The region of interest is clipped and aseptically prepared. The head of a linear musculoskeletal probe is covered with a sterile glove (with non-sterile gel inside) and the cable of the probe is protected with a sterile arthroscopic plastic sleeve. Alcohol or sterile gel is used as an acoustic coupling agent. A sterile stapler machine or needles are used to mark the skin.

Ultrasonographic Anatomy and Landmarks

Even though it is impossible to describe every single location and situation where these techniques can be used, it is of paramount importance to stress out the need of knowing the local anatomy before attempting to perform these procedures.

Technique

Surgical incision and drainage: This technique is particularly useful for draining abscesses, hematomas, or seromas that are located in the depth of muscular layers or that are close to synovial structures. In the case of fluid accumulations close to synovial structures, it is important to perform contrast studies before the drainage to rule out any communication. Stack et al. (2016) reported that ultrasound guidance was helpful in 100% of the cases where abscesses were drained and/or resected.

After the initial preparation, a scan of the region is performed to identify the anatomical structures and the fluid pocket. It is critical to identify the most distal aspect of the fluid accumulation since this would be the ideal location to create the new drainage. Failure to do so will most likely result in accumulation of fluid within the pocket and delay healing.

Once in position, an ultrasound-guided injection is performed using a 18G spinal needle (the length depends on the depth) until reaching the desired target. It is usually useful to withdraw some fluid to observe its characteristics and send it to pathology and/or bacteriology for further characterization. Thereafter, the needle is withdrawn and a number 3 scalpel with a number 11 scalpel blade is introduced through the tract of the needle until reaching the fluid pocket. Once the new drainage is achieved, the orifice of the drainage is enlarged on both sides carefully. If the structure is really fibrotic a number 20 scalpel blade or Mayo scissors are useful. After this, a curettage and lavage (sterile isotonic solution) of the pocket is performed. Polyhexanide gauze rolls (KERLIX) are helpful to pack the cavity and avoid further expansion of the infections or post-op infections in the case of seroma or hematomas (Figs. 4.3, 4.4, 4.5, 4.6, and 4.7).

Resection and Removal: In this case the surgical dissection is also combined with the intraoperative marking and guidance, the difference is that the ultrasound is used to locate the ideal place for the incision and guide the dissection. This technique is very helpful when a mass, abscess, or foreign body wants to be resected or removed.

Fig. 4.3 Ultrasound-guided surgical incision and drainage. External images: (**a**) Ultrasound-guided injection is performed to confirm the presence of fluid and/or accurately localize material that must be removed (foreign bodies, fragments, inspissated pus, espundia granules, etc.); a needle is introduced using ultrasound guidance to confirm the insertion site for the scalpel (▶ https://doi.org/10.1007/000-awk)

Real-time control of the dissection with the ultrasound helps to visualize the objective and the depth to be dissected, minimize tissue trauma, and avoid damage to vital structures (vessels, nerves, synovial structures). For this, once the incision is made, blunt and sharp dissection is used to approach the target. The progression of the dissection is controlled by introducing the transducer (covered with a sterile glove and sleeve) in the surgical wound. Once in position, the distance needed to reach the objective is measured. This is repeated as many times as needed by the surgeon. In case of removing an abscess in toto, this technique helps to approach the capsule carefully and decreases the risk of opening it in the wound. Also, the ultrasound scan helps to control that other structures are not damaged during the process. Stack et al. (2016) reported that intraoperative ultrasound guidance successfully aided dissection in more than 90% of the cases where it was used (Figs. 4.8 and 4.9).

Fig. 4.4 Ultrasound-guided surgical incision and drainage. External images: (**b**) A scalpel blade is introduced using ultrasound guidance into the fluid accumulations (abscess, seroma, hematoma, etc.) using ultrasound guidance; once the scalpel is in position it is rotated with the sharp side toward the skin to enlarge the incision; once the incision is enlarged it allows adequate debridement, lavage, and drainage (see Fig. 4.3 for video link)

4.2.2 Dissection, Bone Curettage, Exostosis Resection, and Fragment Removal

Bone sequesters, osteomyelitis, exostosis, and bone fragments are commonly found in equine practice. Ultrasound marking and guidance help to localize and remove them, minimizing incision size, tissue trauma, and damage to vital structures.

Equipment and Preparation

Depending on the case (location, size, and horse temperament) the procedure can be performed standing (sedation and local blocks) or in general anesthesia (TIVA or inhalatory). The region of interest is clipped and aseptically prepared. The head of a linear musculoskeletal probe is covered with a sterile glove (with non-sterile gel inside) and the cable of the probe is protected with a sterile arthroscopic plastic sleeve. Alcohol or sterile gel is used as an acoustic coupling agent. A sterile stapler machine or needles are used to mark the skin.

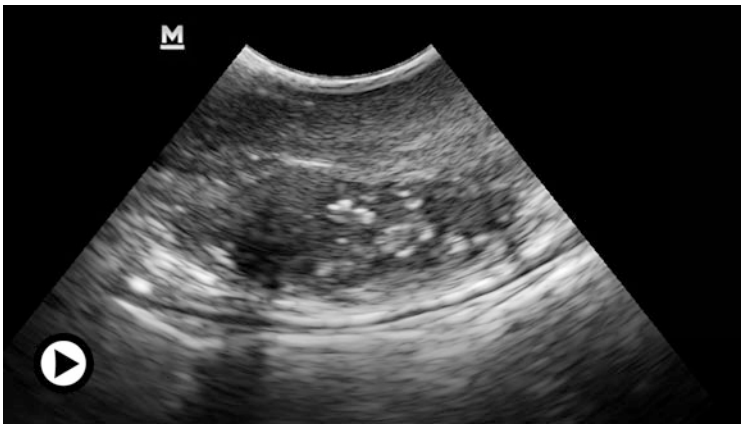

Fig. 4.5 Ultrasound-guided surgical incision and drainage. Ultrasound image: (**a**) The target is evaluated ultrasonographically to determine its margins and select a good incision site (▶ https://doi.org/10.1007/000-awm)

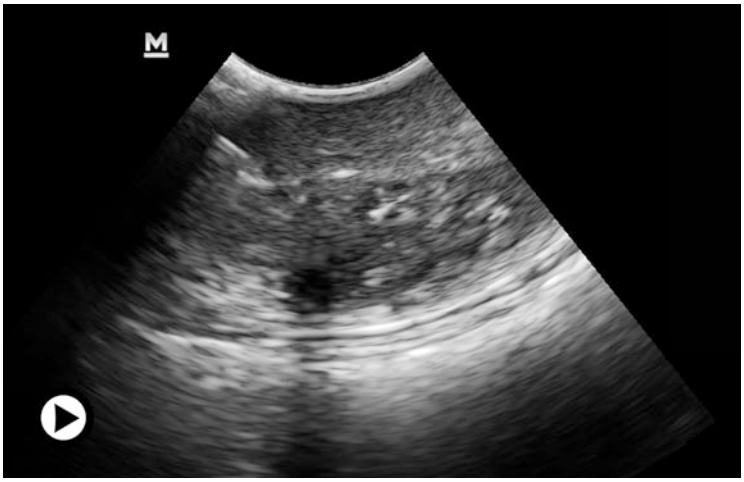

Fig. 4.6 Ultrasound-guided surgical incision and drainage. Ultrasound image: (**b**) To confirm the introduction site of the scalpel, a needle is inserted using ultrasound guidance (▶ https://doi.org/10.1007/000-awn)

Ultrasonographic Anatomy and Landmarks

Even though it is impossible to describe every single location and situation where these techniques can be used, it is of paramount importance to stress out the need of knowing the local anatomy before attempting to perform these procedures.

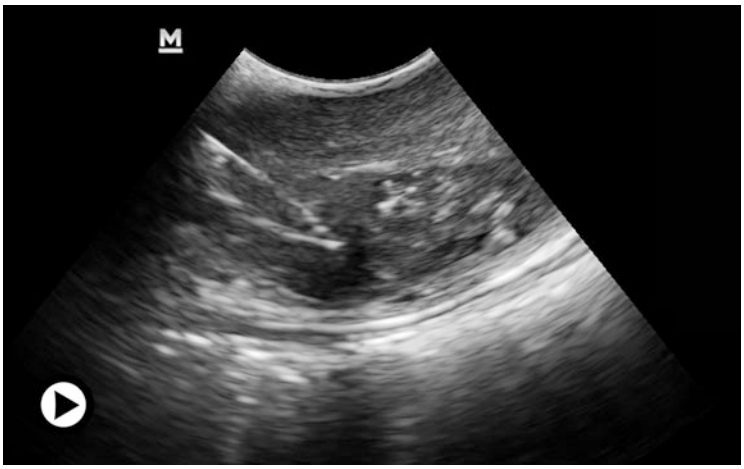

Fig. 4.7 Ultrasound-guided surgical incision and drainage. Ultrasound image: (**c**) Ultrasound-guided insertion of the scalpel until reaching the desired target. This procedure allows drainage of the contents, debridement, and lavage. These images are from an equine mare that presented an abdominal abscess with espundia granules caused by *Pythium insidiosum* (▶ https://doi.org/10.1007/000-awp)

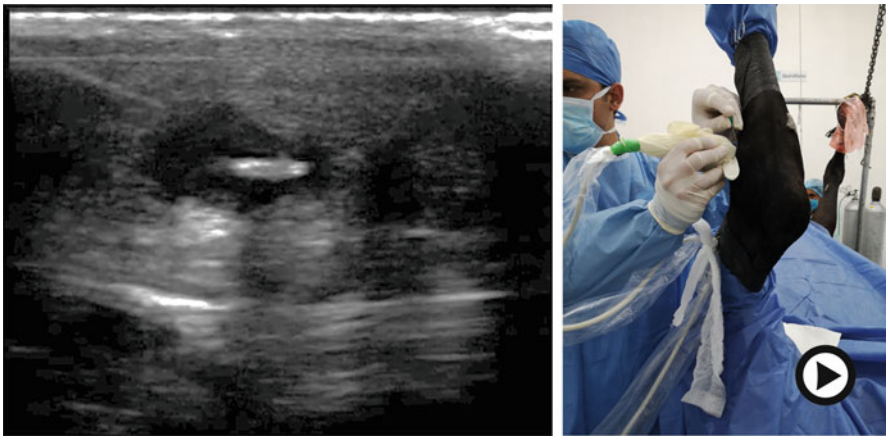

Fig. 4.8 Ultrasound-guided resection and removal. The patient is anesthetized, aseptically prepared, and draped. The probe is aseptically prepared with a sterile glove and sleeve. (I) The foreign body is localized using ultrasound and the depth between the skin and the artifact is measured. (II) An ultrasound-guided injection is performed to align the needle to the longitudinal axis of the foreign body, helping to determine the orientation of the incision (▶ https://doi.org/10.1007/000-awh)

Fig. 4.9 Ultrasound-guided resection and removal. (III) Once in position, the blunt back side of the scalpel blade or a sterilized metal clip is inserted between the skin and the transducer. (IV) This allows us to observe the cone-down artifact which helps to mark both ends of the foreign body with

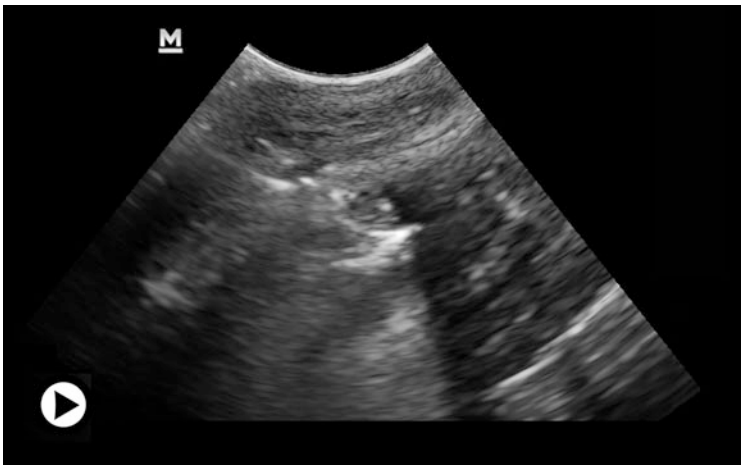

Fig. 4.10 Ultrasound-guided curettage. After opening a cavity using US guidance, ultrasound guidance of the curettage can be used to minimize the incision opening but ensuring that all the undesired materials (foreign bodies, inspissated pus, espundia granules, etc.) are removed properly. In the video, an espundia granule is localized ultrasonographically and curetted out of the tissue (▶ https://doi.org/10.1007/000-aws)

Technique

Curettage: In cases where a sequester, osteomyelitis, or a loose bone fragment is present, the target is initially located and ultrasound marking is performed as previously described. The skin incision and dissection are performed routinely until reaching the target. The sequester or bone fragments are removed and the bed of the fragment is curetted thoroughly. After this, a lavage with isotonic sterile fluids is made and the wound is left open to close by second intention. Further daily lavages are usually needed. Antibiotic therapy and/or packing of the wound must be implemented when needed. Stack et al. (2016) reported that ultrasound-guided surgery was useful in all horses presenting sequesters or osteomyelitis. In this study, the most commonly found sequesters were located at the limbs, head, tuber coxae, or spinous processes of the vertebrae. It was also mentioned that this technique was very useful to curettage perisynovial osteomyelitis since it allowed accurate cut-down to the infected area without breaching the synovial structures (Fig. 4.10).

Fig. 4.9 (continued) needles in the skin. (V) Once the length and orientation of the incision is marked, the incision is performed. (VI) Careful sharp and blunt dissection is used to reach the foreign body. When in doubt the ultrasound probe is introduced in the wound to control the depth of the incision. (VI) When the foreign body is reached, it is removed and the wound is debrided and lavaged. (VII) At the end of the procedure, the wound is checked with the ultrasound to confirm that the foreign body was completely removed (▶ https://doi.org/10.1007/000-awr)

Resection: Bone exostosis is commonly found in horses. In the majority of the cases, these bony growths are removed because of aesthetic or mechanical reasons (impingement of other structures). The exostosis is marked using ultrasound guidance. The incision and dissection is performed routinely, using ultrasound control when needed. The exostosis is removed using a chisel and a bone mallet. In cases of splint bone amputation, an oscillating saw can also be used. In the case of splint bone amputation, the usage of intraoperative ultrasound marking and guidance obviates the usage of intraoperative radiographs, reducing it to only the postoperative radiographs (Stack et al. 2016).

Fragment removal: Is not uncommon to have patients presenting intraarticular fragments that cannot be reached by endoscopic surgery, perisynovial fragments, or entheseal osseous fragments. Some of these fragments are not even clinically significant; nevertheless, they might affect the final price of the animals when a pre-purchase examination is performed. In these cases, a minimally invasive percutaneous approach is the best option. Intraoperative ultrasound marking facilitates the approach of these fragments, minimizing tissue trauma and therefore improving the outcome with less morbidity and faster recoveries. Primary closure of this wound is warranted since these are usually sterile surgeries and the fragments have a traumatic or developmental origin. It has been reported that the intraoperative marking aided the successful removal of the fragments, helping to avoid the joint capsule and the adjoining ligaments (Stack et al. 2016) (Fig. 4.11).

4.2.3 Tendon and Ligament Surgery

Ultrasound-guided procedures in tendon and ligaments are probably one of the first applications of these techniques in equine surgery. Intraoperative ultrasound guidance of these procedures helps to decrease the incision size, minimize tissue trauma, and avoid vital structures. Even though several of these approaches have been reported in the literature throughout the years, some of them never gained widespread popularity. Some of the reasons behind these are that several of these techniques are slower, have a relatively steep learning curve, and did not show significant benefits when compared to traditional methods. The objective of this section is to describe the most commonly used ultrasound-guided tendon and ligament techniques. Techniques for transection of the palmar anular ligaments in horses have been also described in literature (De Gasperi et al. 2023; Espinosa et al. 2017) , nonetheless they will not be described in this book since state of the art endoscopic tehcniques allow not only the transection of the ligament but also diagnosis and treatment of intrathecal tendinous lesions that are usually the primary cause of the problem.

4.2.3.1 Tendon and Ligament Splitting

Asheim was the first to report the tendon splitting as a treatment option for tendinopathies in horses (Asheim 1964). Initially, tendon splitting was recommended as treatment of choice for chronic tendon lesions, since it was

Fig. 4.11 Ultrasound-guided arthroscopic fragment removal. (I) A horse with a history of a chronic hock swelling after a suspected distortion was referred to the Equine Hospital, Universidad Nacional, Costa Rica. (II) Radiographically, the patient presented a radiopaque body at the dorsomedial recess of the tibiotarsal joint. (III) A hyperechoic body was also observed during ultrasonography, where it seemed to be embedded in the joint capsule. During arthroscopy, the fragment was not observable or palpable intraarticularly. (IV) Ultrasound guidance was used to locate the fragment externally and align the fragment with the arthroscope (external and internal view). (V) Thereafter, the borders of the fragments were located using ultrasound marking (cone-down artifact) and then marked with needles (20G hypodermic needles were passed through the joint capsule until observed with the arthroscope). Once positioned, the synovial resector was used to resect the capsule until reaching the fragment. (VI) After loosening from the capsule, regular arthroscopic technique was used to remove the fragment

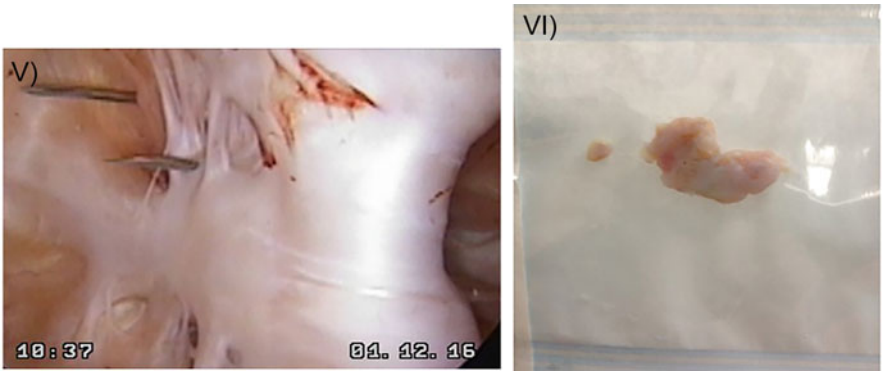

Fig. 4.11 (continued)

believed that it might improve the blood flow of the affected tendon. Nonetheless, this technique fell out of favor since subsequent research showed that splitting of chronic lesions caused extensive granulation tissue formation, increased trauma to the tendon, and caused persistent lameness post-treatment (Smith 2008). However, this technique is currently used for the treatment of large, acute, core tendon and ligament lesions (with ultrasonographic evidence of a hematoma or seroma). It is believed that the accumulation of fluid within the tendon causes a "compartment syndrome" affecting the perfusion of the area (Smith 2008; Tnibar 2007) and also increases the chances of causing expansion of the lesion (Smith 2008). Therefore, the objective of this procedure is to facilitate vascular ingrowth (Smith 2008; Tnibar 2007) and reduce proximo-distal expansion of the tendon lesion (Smith 2008). In a collagenase-induced experimental tendinitis model, tendon splitting resulted in a faster resolution of the core lesion, a quicker revascularization of the lesion, and an increased collagen deposition compared to controls (Henniger et al. 1992). Even though this procedure has been more commonly performed in flexor tendons, splitting of the suspensory ligament has also been reported (Tnibar 2007).

Equipment and Preparation

The procedure is usually performed standing (sedation and local blocks). When performing this procedure, a high 4-point block or a wheat block is recommended. The region of interest is clipped and aseptically prepared. The head of a microconvex, 5–8 MHz, probe is covered with a sterile glove (with non-sterile gel inside). Alcohol or sterile gel is used as an acoustic coupling agent. A # 11 scalpel blade is usually used to perform the stab incision.

Ultrasonographic Anatomy and Landmarks

Even though it is not practical to describe every single location where these techniques can be used, it is of paramount importance to stress out the need of knowing the local anatomy before attempting to perform these procedures. For this

particular technique, the ultrasonographic anatomy of the soft tissues of the cannon bone region is crucial to minimize the risk of complications.

Technique

Once the patient is prepared, a transverse view of the most distal aspect of the lesion is acquired. The transducer is then moved slightly medial without losing the image (palmaro-medial aspect of the tendon). The scalpel blade is introduced longitudinally (to minimize trauma), at the same level of the transducer, from the palmaro-lateral aspect of the tendon using real-time ultrasound guidance. The tip of the scalpel is observed as it enters the lesion, minimizing trauma to healthy fibers (Smith 2008; Tnibar 2007). Once the scalpel blade is inserted, it is "fanned" in a proximo-distal direction to enlarge the opening (Smith 2008). After performing the stab incision in acute lesions, it is common that fluid drains out of the tendon (Figs. 4.12 and 4.13). Even though some authors do not recommend suturing of the incision, I would definitely encourage suturing at least the skin. It is important to immobilize the limb with a modified Robert Jones bandage and box rest the horse for at least 2 weeks (Smith 2008; Tnibar 2007). This will help to stabilize the region, enhance healing of the stab incision in the tendon, and avoid further expansion of the lesion. In the case of the DDFT, the transducer is placed medial (transverse or longitudinal) and the scalpel blade is introduced from the lateral aspect of the tendon. The rest of the procedure is practically the same as in the SDFT.

In the case of the suspensory ligament, the branches and the body can be split, in a very similar fashion to the SDFT. In both cases, the transducer with a standoff pad is placed at the palmar/plantar aspect of the flexor tendons and the # 11 scalpel is

Fig. 4.12 Tendon splitting of the superficial digital flexor tendon (SDFT). External image (▶ https://doi.org/10.1007/000-awt)

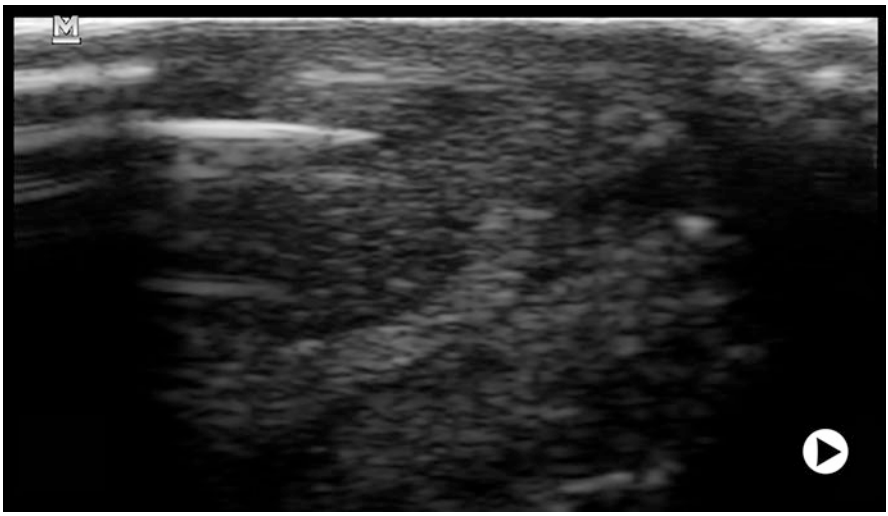

Fig. 4.13 Tendon splitting of the superficial digital flexor tendon (SDFT). Ultrasound image (▶ https://doi.org/10.1007/000-awv)

introduced from medial or lateral in the branches or from lateral in the body (Tnibar 2007). Even though it has been reported that ultrasound-guided splitting the origin of the suspensory ligament could aid ligament healing (Tnibar 2007), more recent experimental studies suggest that this technique did not improve several parameters when compared to sham-operated ones. Further studies are needed to determine the effect of this technique in clinical cases (Brokken et al. 2016). If splitting is to be attempted in the origin of the SL, general anesthesia is recommended, in an effort to be more accurate and avoid the nerves and vessels of the region (Tnibar 2007).

▶ **Commentaries**

It has to be noted that if the lesion does not present a significant hematoma or seroma, splitting might not be the best treatment option. Remember that when performing this technique no intralesional therapy can be instituted since the treatment will leak out of the lesion. In my opinion, in smaller, core, more subacute lesions, intralesional ultrasound-guided injections of platelet-rich plasma (PRP), stromal vascular fraction (SVF), or stem cells (MSC) are nowadays the treatment of choice.

4.2.3.2 Splitting (Desmoplasty) of the Medial Patellar Ligament

One of the most important features of the equine stay apparatus is the ability of the patella to rest on the medial trochlear ridge of the femur. Failure of the patella to disengage from the medial trochlear ridge is known as upward fixation of the patella (UFP). This pathology causes a typical hyperextension of the hindlimb; the locking in

extension of the stifle causes a simultaneous extension of the hock, due to the action of the reciprocal apparatus. The clinical signs are usually intermittent or permanent. Some patients present a mild form of UFP; in these cases, there is partial and intermittent locking of the patella manifested by instability of the patella and a palpable and sometimes audible click as the patella is released (Andersen and Tnibar 2016).

The majority of the animals affected by this condition respond to conservative therapy (controlled exercise, trimming, shoeing, etc.). However, surgery is the treatment of choice when the conservative approach is ineffective. Traditionally, the desmotomy of the medial patellar ligament was the treatment of choice for unresponsive cases. Nevertheless, this surgery has been related to persistent lameness caused by fragmentation of the distal aspect of the patella, fibrillation of articular cartilage, and patellar osteophyte formation (Andersen and Tnibar 2016).

Medial patellar ligament splitting was described by Tnibar 2002 as an alternative to the aforementioned technique. This procedure has shown to cause a significant thickening of the medial patellar ligament due to intraligamentous scar tissue. These changes positively affect the patellar function and in the large majority of the cases resolve the problem. A more recent, long-term, follow-up of 85 horses operated using this technique demonstrated that 97.5% of the patients had a complete resolution immediately after surgery or within a 2-week rehabilitation period. No short- or long-term complications were observed. No recurrency of the pathology was observed (Andersen and Tnibar 2016).

Equipment and Preparation

Depending on the horse's temperament, the procedure can be performed standing (sedation and local blocks) or in general anesthesia (TIVA or inhalatory). The stifle region is clipped and aseptically prepared. The head of a linear musculoskeletal probe is covered with a sterile glove (with non-sterile gel inside). In cases where the procedure is performed in the surgical room, the cable of the probe is protected with a sterile arthroscopic plastic sleeve. Alcohol or sterile gel is used as an acoustic coupling agent. A # 15 or # 11 scalpel blade (I prefer #11) is used to perform the stab incisions.

Ultrasonographic Anatomy and Landmarks

At the proximomedial aspect of the stifle, the medial patellar ligament is located between the medial collateral ligament and intermediate patellar ligament, medial to the medial trochlear ridge. At the surgical site (proximal third of the ligament), the medial patellar ligament, the joint recess, and the femur are usually identified. For this procedure, it is useful to identify the insertion of the patellar ligaments at the tibial tuberosity and identify the medial patellar ligament to follow it proximally (Fig. 4.14).

Technique

A transverse ultrasound scan of the cranial aspect of the stifle is performed. The insertion of the patellar ligaments is identified at the tibial tuberosity. The medial patellar ligament is followed proximally until reaching its proximal third. At this point, the transducer is rotated 90 degrees, until obtaining a longitudinal view of the

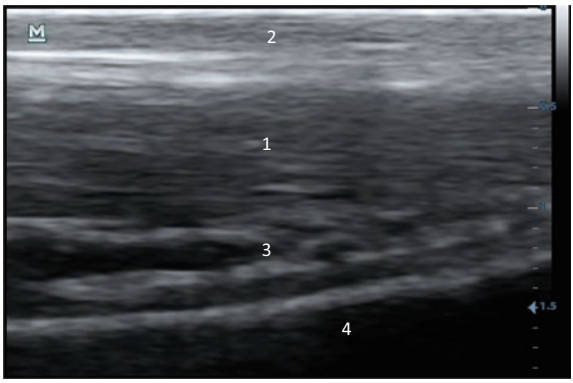

1 Medial patelar ligament
2 Subcutaneous tissue
3 Fat
4 Tibia

Fig. 4.14 Ultrasonographic anatomy of the medial patellar ligament

ligament. Since the transducer is directly over the medial aspect of the ligament, the scalpel blade is introduced longitudinally in a craniocaudal direction using ultrasound guidance to avoid the femoropatellar synovial recess and the articular cartilage of the trochlea. Once in position, the scalpel is fanned 45 degrees in a proximodistal direction and then in a mediolateral direction. The procedure is repeated in increments of 5 mm until the entire length of the proximal third of the patella has been split. The procedure is repeated several times (approx. 10 times). THIS IS AN EXCEPTION OF THE REGULAR US-GUIDED TECHNIQUE!, since the operator controls that the scalpel blade is in the ligament, but loses control of the tip of the blade. Splitting should be avoided at the fibrocartilage of the patella. The skin incisions are sutured routinely and a stent bandage is placed over the surgical site. Perioperative antibiotics are used for 3–5 days (Tnibar 2007) (Figs. 4.15 and 4.16).

► **Commentaries**
Even though it is possible to perform this procedure standing, when performed in fractious horses or stallions (the testicles are on the way), it is better to do it using a short-term TIVA. This will allow the surgeon to work faster and safer.

4.2.3.3 Ultrasound-Aided Desmotomy of the Accessory Ligament of the Deep Digital Flexor Tendon

Desmotomy of the ALDDFT is more commonly indicated for flexural deformities of the distal interphalangeal joint and the metacarpophalangeal joint and for the treatment of inferior check ligament refractory lesions (Tnibar 2007; Wagner et al. 1985; Blackwell 1980). The transection of this ligament elongates the musculotendinous unit and reduces strain on the DDFT and therefore the contracture. It has been reported that when this surgery is performed in animals less than 1 year old, 92% of the patients were used for its intended purpose. In horses treated after 1 year of age, the prognosis decreased to 78% (Wagner et al. 1985). A more recent study also

Fig. 4.15 Ultrasound-guided splitting (desmoplasty) of the medial patellar ligament. External image (▶ https://doi.org/10.1007/000-aww)

suggests that the result of desmotomy of the ALDFFT in adults is good, with 86% of the DIPJ contractures returning to the intended use (Yiannikouris et al. 2011). In 1995, White described an ultrasound-guided technique for the transection of the ALDFFT. This technique compares favorably with results obtained when using the open surgical approach. The ultrasound-guided desmotomy offers several advantages including reduced incision length, reduced morbidity, and improved cosmetic outcome. The minimally invasive approach may also be performed on the standing sedated horse (Tnibar 2010).

Equipment and Preparation

Depending on the horse temperament, the procedure can be performed standing (sedation and high 4-point or a wheat block) or in general anesthesia (TIVA or inhalatory). The metacarpal region is clipped and aseptically prepared. The linear musculoskeletal transducer is covered with a sterile glove (with non-sterile gel inside). In cases where the procedure is performed in the surgical room, the cable of the probe is protected with a sterile arthroscopic plastic sleeve. Alcohol or sterile

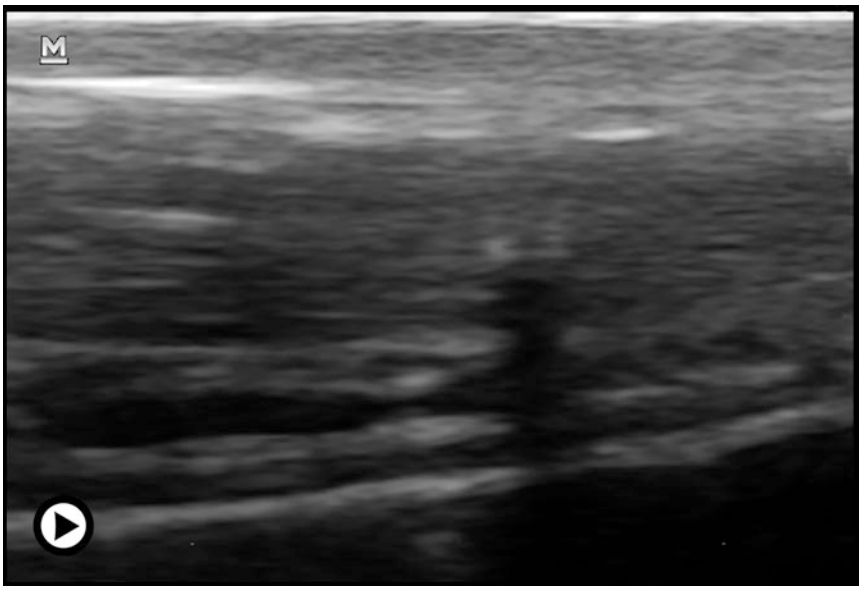

Fig. 4.16 Ultrasound-guided splitting (desmoplasty) of the medial patellar ligament. Ultrasound image (▶ https://doi.org/10.1007/000-awx)

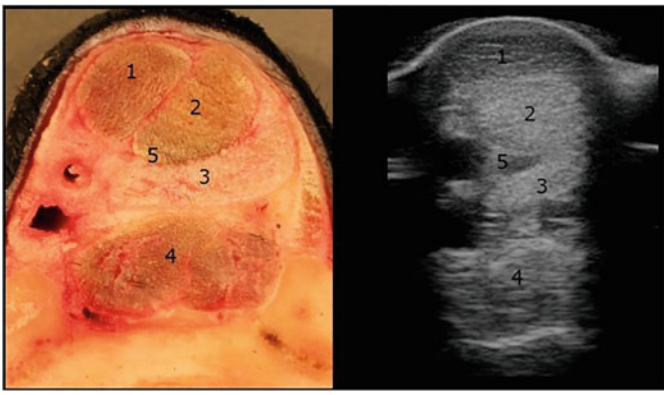

1) SDFT
2) DDFT
3) AL DDFT
4) SL
5) Carpal sheath

Fig. 4.17 Ultrasonographic anatomy of proximal cannon bone region in the equine forelimb

gel is used as an acoustic coupling agent. For the procedure, two curved mosquito forceps and a # 10 scalpel blade are needed.

Ultrasonographic Anatomy and Landmarks

At this site (zone 1B), the ALDDFT is located dorsal to the DDFT and palmar to the SL, slightly displaced laterally (Smith 2008). The major blood vessels and nerves are located medially (Tnibar 2007) (Fig. 4.17).

Technique

A 1.5 cm skin incision is created at level 1B (between the proximal and mid third of the cannon bone), where a separation between the ALDDFT and the DDFT is evident. Initially, curved mosquito forceps are inserted under ultrasound guidance between the dorsal aspect of the DDFT and the palmar aspect of the ALDDFT to separate the fascia between these two structures (with the curvature of the forceps following the curvature of the tendon). A second mosquito forceps is introduced between the dorsal aspect of the ALDDFT and the SL. The forceps that are located palmarly to the ALDDFT (first one) are then rotated and used to isolate the ligament with the help of the dorsal forceps. The ALDDFT is then retracted toward the skin incision and a Metzenbaum scissor is used to transect the ligament. Ultrasonography is used to control if all the structures were transected. It has to be taken into consideration that the air introduced into the wound might make this procedure difficult. The skin incision is suture routinely (Fig. 4.18). A modified Robert Jones bandage is recommended to protect the wound. Corrective shoeing is usually helpful to obtain better results (Tnibar 2007). Bandaging the limb for 3 weeks post-op (changing bandages every 4 days) helps to decrease the scar tissue formation and improves cosmetic appearance (Auer et al. 2019).

► **Commentaries**

It is of paramount importance to avoid trauma to the vasculature of the medial aspect of the limbs when retracting and transecting the ALDDFT. After the initial transection, it is important to check if there are fibers left that might need to be removed. Very young foals, ponies, or fractious horses should be performed under general anesthesia.

4.2.3.4 Ultrasound-Aided Tenotomy of the Deep Digital Flexor Tendon

Even though the tenotomy of the deep digital flexor tendon (DDFT) is a controversial procedure, it has been used as a salvage procedure for chronic refractory laminitis. The tenotomy in combination with derotation shoeing has proven to be an effective and viable option for chronic laminitis not responding to conservative therapy (Morrison 2011; Tnibar 2007). This technique is also indicated for the treatment of severe flexural deformities of the distal interphalangeal joint (stage II) (Fackelman GE et al. 1983).

Equipment and Preparation

Depending on the horse temperament, the procedure can be performed standing (sedation and high 4-point or a wheat block) or in general anesthesia (TIVA or inhalatory). The metacarpal region is clipped and aseptically prepared. The linear musculoskeletal transducer is covered with a sterile glove (with non-sterile gel inside). In cases where the procedure is performed in the surgical room, the cable of the probe is protected with a sterile arthroscopic plastic sleeve. Alcohol or sterile gel is used as an acoustic coupling agent. For the procedure, two curved mosquito forceps, a Metzenbaum, and a #10 scalpel blade are needed.

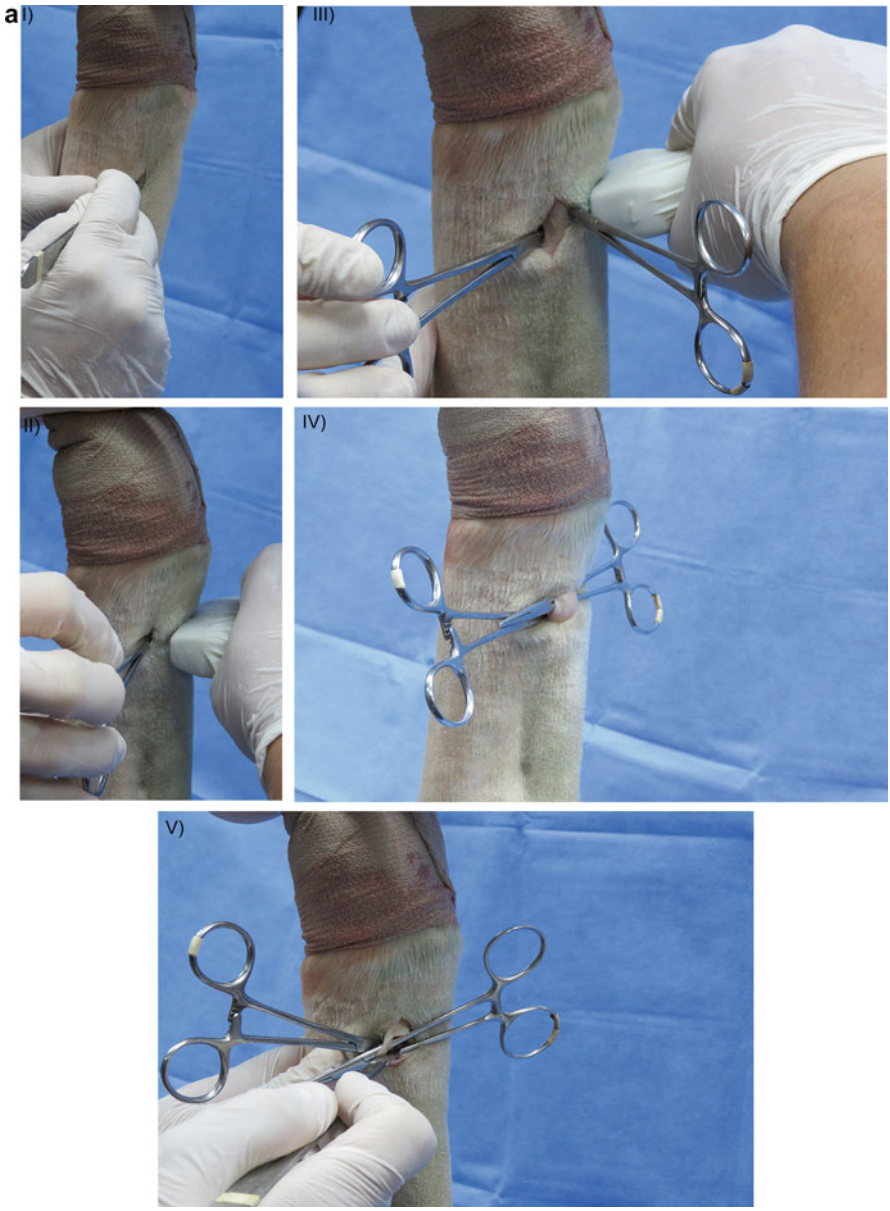

Fig. 4.18 Ultrasound-guided transection of the accessory ligament of the deep digital flexor tendon in the equine forelimb. (**a**) External images of the procedure: (I) Incision site, (II) US-guided introduction of the first forceps, (III) introduction of the second forceps, (IV) ALDDFT exteriorization, (V) transection of the ALDDFT. (**b**) Ultrasonographic image of the procedure: (I) US-guided introduction of the first forceps, (II) US-guided introduction of the second forceps

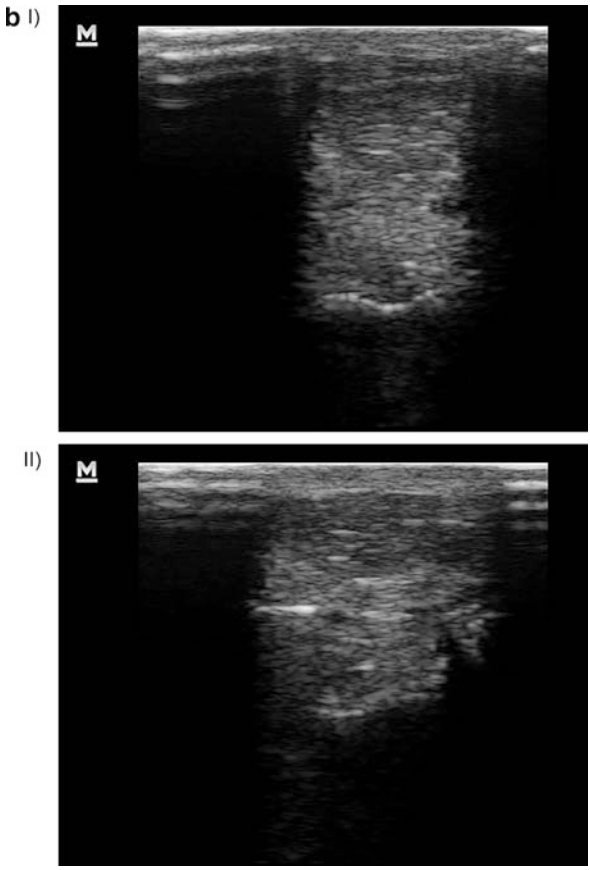

Fig. 4.18 (continued)

Ultrasonographic Anatomy and Landmarks

The surgery is performed at the mid cannon bone region (zone 2B). At this site, the DDFT is located dorsal to the SDFT and palmar to the SL and no ALDDFT is visible (Smith 2008) (Fig. 4.19).

Technique

Once the correct site is located, a 1–1.5 cm skin incision is performed over the lateral aspect of the DDFT. The DDFT is dissected free and then transected under real-time ultrasound guidance using Metzenbaum scissors. Care should be taken while transecting the medial aspect of the tendon near the median artery. The skin is sutured routinely. A sterile compressive bandage is applied over the limb (Tnibar 2007) (Fig. 4.20).

1) SDFT
2) DDFT
3) AL DDFT (inserted)
4) SL

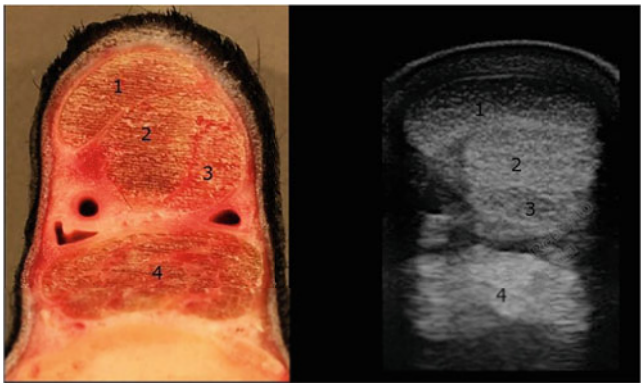

Fig. 4.19 Ultrasonographic anatomy of the equine mid cannon bone region in the horse

► **Commentaries**
Even though it has been reported that this technique is advantageous, the incision size and surgery time are not that different when compared to the traditional open tenotomy approach.

4.2.4 Ultrasound Guidance During Synovial Endoscopy

Intraoperative guidance of synovial endoscopic procedures has been claimed to be a useful aid during this type of surgeries. This combined technique has been mainly used for locating OCD fragments buried in the synovium. Other applications can be intrasynovial bone debridement and guidance of the portal placement in cases of septic synovial structures (where anatomic landmarks sometimes are not that clear) (Stack et al. 2016).

OCD Fragment Location
Even though the OCD fragments embedded in synovia might not be clinically significant, it is important to take into account that these fragments might affect the final price of the animal. In these cases, the use of intraoperative ultrasound guidance is extremely useful since these kinds of fragments are usually very difficult to identify with traditional arthroscopic techniques.

Just before starting the surgery (already scrubbed and draped), the external location of the OCD is identified using ultrasound marking. The site is marked using needles that penetrate into the joint capsule. The arthroscope is used to locate the needles intraarticularly. The correct position of the arthroscope is confirmed with the ultrasound. Once in position, the arthroscopic probe is used to identify the fragment; a synovial resector is used to detach the fragment from the capsule and synovial villi. If needed a beaver blade, side cutting arthroscopy knife or

Fig. 4.20 Ultrasound-guided transection of the deep digital flexor tendon in the horse. (**a**) External images of the procedure: (I) Incision site, (II) US-guided introduction of the first forceps, (III) introduction of the second forceps, (IV) transection of the DDFT. (**b**) Ultrasonographic image of the procedure: (I) US-guided introduction of the first forceps, (II) US-guided introduction of the second forceps

electrosurgery can be used to completely detach the fragment. Please refer to Figs. 4.8 and 4.9 where a case of an intrasynovial fragment is discussed.

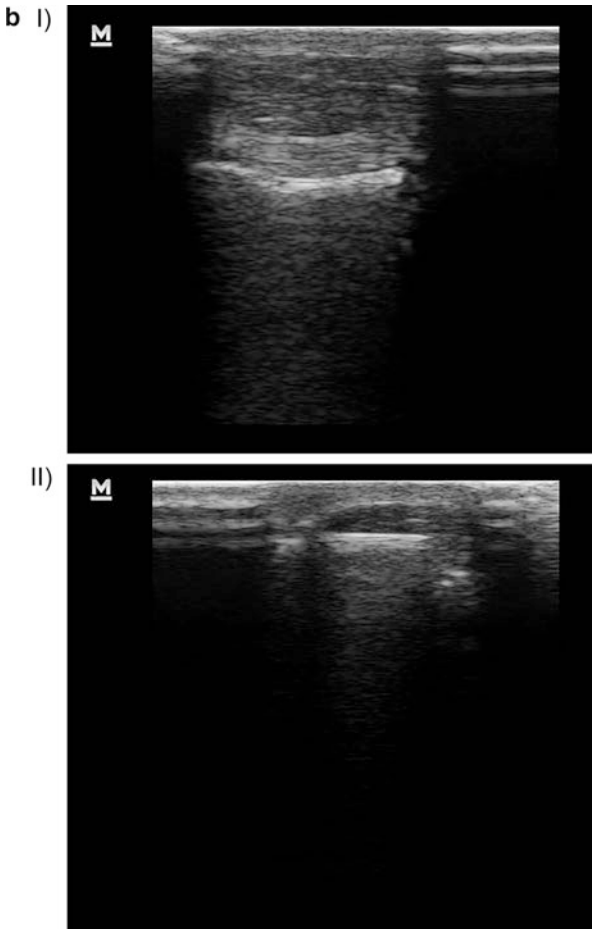

Fig. 4.20 (continued)

4.2.5 Ultrasound Guidance for Implant Removal

Intraoperative ultrasound marking is a very helpful tool to locate the implants accurately when they have to be removed and for some reason their margins are not readily identifiable (Stack et al. 2016). This technique minimizes tissue trauma, decreases surgical time, and avoids x-ray exposition. The orthopedic implants are hyperechogenic and cast a strong reverberation artifact, making them easy to identify (Fig. 4.21). After externally localizing and marking the implant location, standard surgery equipment is used to reach the implant and remove it. This technique has been reported useful for the removal of screws, transphyseal bridges, and plates (Stack et al. 2016).

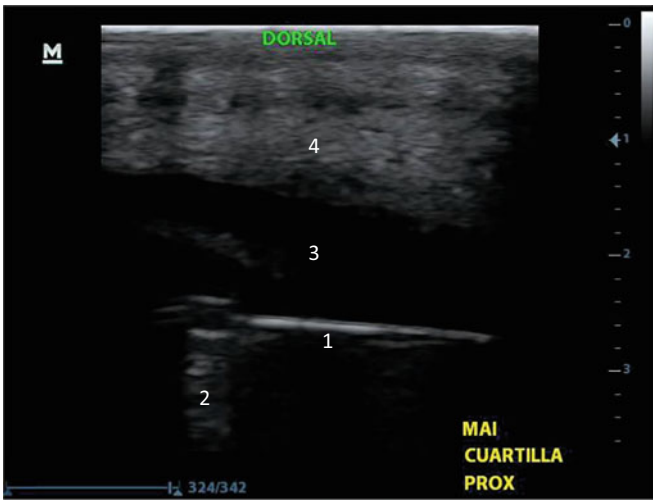

1) Plate
2) Screw
3) Fluid accumulation
4) Soft tissue dorsal

Pastern

Fig. 4.21 Ultrasonographic identification of the (**a**) bone plate and its margins and (**b**) screws and (**c**) fluid accumulation (hypoechoic region) around the implants associated with implant infection

References

Andersen C, Tnibar A (2016) Medial patellar ligament splitting in horses with upward fixation of the patella: a long-term follow-up. Equine Vet J 48(3):312–314. https://doi.org/10.1111/evj.12435. Epub 2015 May 26

Asheim A (1964) Surgical treatment of tendon injuries in the horse. J Am Vet Med Assoc 145:447–451

Auer J, Stick J, Kümmerle J, Prange T (2019) Equine surgery. Saunders

Blackwell RM (1980) Response of acquired flexural deformity of the metacarpophalangeal joint to desmotomy of the inferior check ligament. Proc Am Assoc Equine Pract 26:107–111

Brokken MT, Schneider RK, Roberts GD, Holmes SP, Gavin PR, Sampson SN, Farnsworth KD, Dahlgren LA (2016) Evaluation of a new surgical treatment for equine hind limb proximal suspensory desmitis. Vet Surg 45(7):868–878. https://doi.org/10.1111/vsu.12527. Epub 2016 Aug 22

De Gasperi D, Guo D, Guo D, Lu Y, Brounts SH (2023) Ex vivo evaluation of a percutaneous thread-transecting technique for desmotomy of normal palmar/plantar annular ligaments in horses. Vet Surg 52(3):388–394. https://doi.org/10.1111/vsu.13932. Epub 2023 Jan 10. PMID: 36625237

Espinosa P, Nieto JE, Snyder JR, Galuppo LD, Katzman SA (2017) A novel ultrasonographic assisted technique for desmotomy of the palmar/plantar annular ligament in horses. Vet Surg 46(5):611–620. https://doi.org/10.1111/vsu.12630. Epub 2017 Feb 10. PMID: 28186643

Fackelman GE, Auer JA, Orsini J, Von Salis B (1983) Surgical treatment of severe flexural deformity of the distal interphalangeal joint in young horses. J Am Vet Med Assoc 182:949–952

Henninger RW, Bramlage LR, Bailey M (1992) Effects of tendon splitting on experimentally-induced acute equine tendonitis. Vet Comp Orthop Traumatol 5:1

Morrison S (2011) Long-term prognosis using deep digital flexor tenotomy and realignment shoeing for treatment of chronic laminitis. J Equine Vet Sci 31(2):89–96

Smith RKW (2008) Tendon and ligament injury, vol 54. AAEP Proceedings

Stack JD, Cousty M, Sanders R, David F (2016) Techniques and indications for intraoperative ultrasound in horses. Vet Surg 45(7):936–942. https://doi.org/10.1111/vsu.12537. Epub 2016 Sep 13. PMID: 27623163

Tnibar MA (2002) Medial patellar ligament splitting for the treatment of upward fixation of the patella in 7 equids. Vet Surg 31(5):462–467. https://doi.org/10.1053/jvet.2002.34660

Tnibar A (2007) Ultrasound-aided tendon and ligament surgery in the horse. Equine Vet Educ 19(8):435–443. https://doi.org/10.2746/095777307X22947.1

Tnibar A (2010) Desmotomy of the accessory ligament of the deep digital flexor tendon in horses: an update. J Equine Vet Sci 30(12):715–719

Wagner PC, Grant BD, Kaneps AJ, Watrous BJ (1985) Long-term results of desmotomy of the accessory ligament of the deep digital flexor tendon (distal check ligament) in horses. J Am Vet Med Assoc 187(12):1351–1353

White NA III (1995) Ultrasound-guided transection of the accessory ligament of the deep digital flexor muscle (distal check ligament desmotomy) in horses. Vet Surg 24:373

Yiannikouris S, Schneider RK, Sampson SN, Roberts G (2011) Desmotomy of the accessory ligament of the deep digital flexor tendon in the forelimb of 24 horses 2 years and older. Vet Surg 40(3):272–276. https://doi.org/10.1111/j.1532-950X.2011.00815.x. Epub 2011 Mar 1. PMID: 21361994

Ultrasound-Guided Treatment of Cervical Nerve Radiculopathy

5

Abstract

The ventral branches of the caudal cervical nerve roots and first thoracic nerves form the brachial plexus, which then innervates the forelimb. Therefore, compression of these nerves can lead to forelimb lameness. Equine radiculopathy was usually a diagnosis of exclusion in patients with neck pain and forelimb lameness. Recently, nerve impingement has been diagnosed by combining the use of large bore computer tomography with myelography. It has been demonstrated that impingement and compression of the spinal cord, detected using CT myelography, can be as high as 85% of the horses with neck pain and stiffness, poor performance, forelimb lameness, and/or neurological deficits. In other species, cervical radiculopathy has been successfully treated with perineural corticosteroid injections. Even though larger clinical studies are needed to fully recommend this treatment in horses, anecdotal reports are promising. Significant improvement or complete resolution of clinical cases of cervical radiculopathy has been reported when treated with US-guided techniques.

Keywords

Ultrasound-guided injection · Perineural injection · Cervical nerve impingement · Cervical radiculopathy

Supplementary Information The online version contains supplementary material available at https://doi.org/10.1007/978-3-031-17562-6_5. The videos can be accessed individually by clicking the DOI link in the accompanying figure caption or by scanning this link with the SN More Media App.

© Springer Nature Switzerland AG 2024

R. J. Estrada, *Ultrasound-Guided Procedures in Equine Orthopedics and Surgery*, https://doi.org/10.1007/978-3-031-17562-6_5

5.1 Cervical Spinal Nerve Roots

The ventral branches of the caudal cervical nerve roots (6–8) and first thoracic nerves (T1-T2) form the brachial plexus, which then innervates the forelimb. Therefore, compression of C6–C8 nerves can lead to forelimb lameness (Fouquet et al. 2022). Cervical spinal nerve roots (CSNR) can be impinged by new bone formation at intervertebral foramina, resulting in cervical radiculopathy in humans (Woods and Hilibrand 2015; Corey and Comeau 2014). This syndrome has also been reported in dogs, with foraminal stenosis, lateralized disk herniation, and tumors being the most common causes (Eberhardt et al. 2019). Equine CSNR impingement had been poorly described in the literature due to previous limitations in medical imaging of their axial skeleton (Cruz-Sanabria et al. 2021). Equine radiculopathy was usually a diagnosis of exclusion in patients with neck pain and forelimb lameness (Fouquet et al. 2022). Recently, nerve impingement has been diagnosed using large bore computer tomography and myelography. Lindgren and others demonstrated that impingement and compression of the spinal cord, detected using CT myelography, can be as high as 85% of the horses with neck pain and stiffness, poor performance, forelimb lameness, and/or neurological deficits (125/147). These findings were more common in Warmbloods older than 4 years, the most common site was the C6-7 facet joint, and in 63% of the cases, the impingement was associated with osteoarthritis of the cervical facet joints (Lindgren et al. 2021). Lameness related to radiculopathy can be intermittent and have a short stride and the patients might keep the affected forelimb in semi-flexed position and be reluctant to bear weight (Fouquet et al. 2022; Touzot-Jourde et al. 2020). The patients might also show neck pain (Touzot-Jourde et al. 2020). In other species, cervical radiculopathy has been successfully treated with perineural corticosteroid injections (Giambuzzi et al. 2016; Woods and Hilibrand 2015). Even though larger clinical studies are needed to fully recommend this treatment in horses, anecdotal reports are promising. Johnson and others reported significant improvement or complete resolution of clinical cases of cervical radiculopathy treated with US-guided techniques (Johnson et al. 2021).

Equipment and Preparation

For the cervical spine nerve root injection, a microconvex or convex, 3.5–5 MHz, probe covered with a sterile glove is recommended. An ultrasound with color or power doppler is needed to detect the cervical vessels. The facet joints are located externally using manual palpation of the transverse process of C1 and counting segments of the width of the hand in a caudal direction (Mattoon et al. 2004). The area of interest is clipped and the injection site and transducer are aseptically prepared (for the transducer, a sterile glove or sleeve is used). The patient is sedated. An 8 cm, 20G, spinal needle is recommended. Alcohol or sterile gel is used as an acoustic coupling agent.

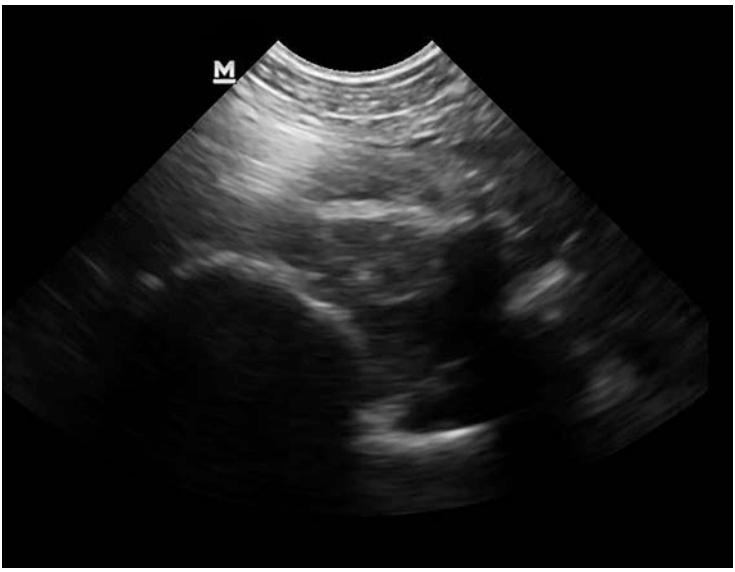

Fig. 5.1 Ultrasonographic anatomy of cervical spinal nerve root

Ultrasonographic Anatomy and Landmarks

The musculature covering the different facet joints varies depending on the injection site; therefore, the discussion will be focused on the bony, vascular, and neural structures that the operator needs to know to safely perform this injection. The probe is oriented perpendicularly to the vertebrae to obtain a reference image of the cervical facet joint (two articular processes and the joint space). Then to visualize a longitudinal section of the ramus ventralis (cervical spinal nerve root) and the cross section of the cervical vessels (using 2D and color Doppler mode), the transducer is glided ventro-caudally with an approximate 20° angle. The cervical root runs directly dorsal to the cervical vessels, and it is observed as a 2–5 mm hypo- to echogenic structure delineated by two hyperechoic borders (Fouquet et al. 2022; Touzot-Jourde et al. 2020) (Figs. 5.1 and 5.2).

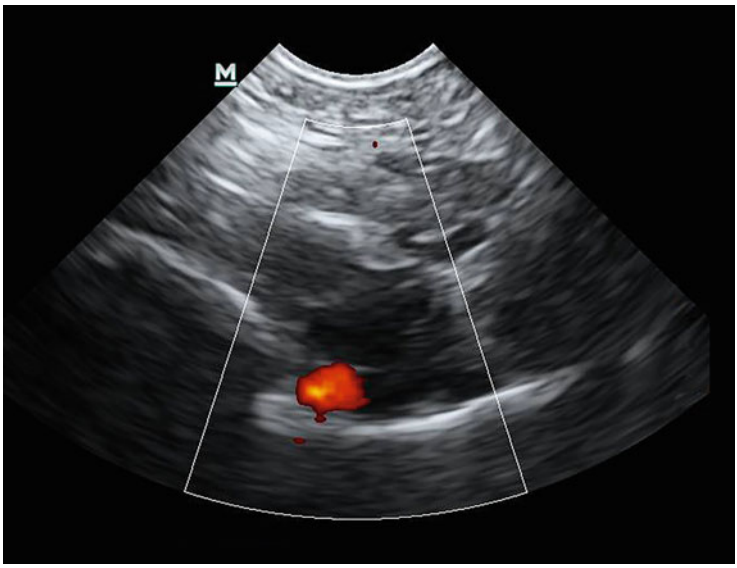

Fig. 5.2 Ultrasonographic anatomy of cervical spinal nerve root with power doppler

Technique

Once the cervical nerve root is located and an optimal image is acquired, the spinal needle is carefully introduced through the skin and musculature. The needle is inserted approximately 1–2 cm ventral to the transducer, to a position less than 5 mm away from the nerve surface, dorsal to the cervical vessels. Volumes of 7–14 ml have been successfully used to inject this nerve, but based on other reports it is likely that smaller volumes (3–5 ml) can effectively diffuse perineurally (Fouquet et al. 2022; Touzot-Jourde et al. 2020) (Figs. 5.3 and 5.4).

Fig. 5.3 Ultrasound-guided injection to the cervical nerve roots. External needle position (▸ https://doi.org/10.1007/000-awz)

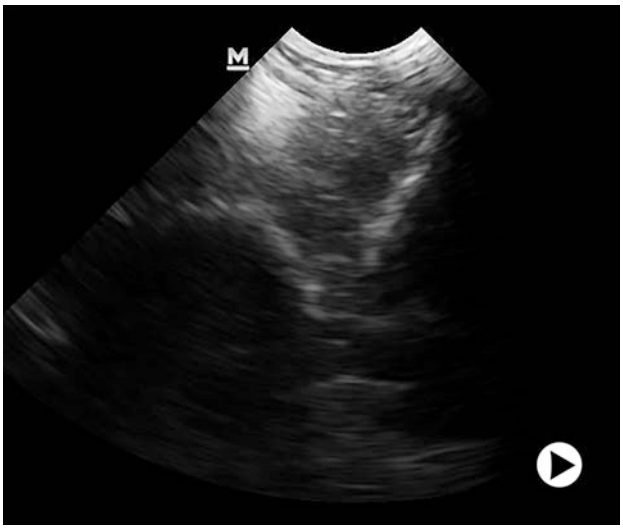

Fig. 5.4 Ultrasound-guided injection to the cervical nerve roots. Ultrasound image (▸ https://doi.org/10.1007/000-awy)

References

Corey DL, Comeau D (2014) Cervical radiculopathy. Med Clin North Am 98(4):791–799., xii. https://doi.org/10.1016/j.mcna.2014.04.001

Cruz-Sanabria JA, Gaschen L, Bragulla HH, Mitchell M, Leise BS (2021) A study of ultrasound-guided perineural injection of the caudal cervical spinal nerve roots in equine cadavers. Vet Anaesth Analg 48(4):603–611. https://doi.org/10.1016/j.vaa.2021.04.002. Epub 2021 May 5

Eberhardt L, Guevar J, Forterre F (2019) Das Nervenwurzelsyndrom beim Kleintier [The nerve root syndrome in small animals – A review focussing on pathophysiology and therapy in the dog]. Tierarztl Prax Ausg K Kleintiere Heimtiere 47(5):344–357. https://doi.org/10.1055/a-1010-0111. German. Epub 2019 Oct 18

Fouquet G, Abbas G, Johnson JP, Pompermayer E, Harel C, Aldous E, Puchalski S, David F (2022) Ultrasound-guided injection technique of the equine cervical nerve roots. Front Vet Sci 9: 992208. https://doi.org/10.3389/fvets.2022.992208. PMID: 36387391; PMCID: PMC9644134

Giambuzzi S, Pancotto T, Ruth J (2016) Perineural injection for treatment of root-signature signs associated with lateralized disk material in five dogs (2009-2013). Front Vet Sci 3:1. https://doi.org/10.3389/fvets.2016.00001

Johnson JP, Vinardell T, David F (2021) Ultrasound-guided injections of the equine head and neck: review and expert opinion. J Equine Sci 32(4):103–115. https://doi.org/10.1294/jes.32.103. Epub 2021 Dec 28. PMID: 35023988; PMCID: PMC8731684

Lindgren CM, Wright L, Kristoffersen M, Puchalski SM (2021) Computed tomography and myelography of the equine cervical spine: 180 cases (2013–2018). Equine Vet Educ 33(9): 475–483. https://doi.org/10.1111/eve.13350

Mattoon JS, Drost WT, Grguric MR, Auld DM, Reed SM (2004) Technique for equine cervical articular process joint injection. Vet Radiol Ultrasound 45:238–240. https://doi.org/10.1111/j.1740-8261.2004.04042.x

Touzot-Jourde G, Geffroy O, Tallaj A, Gauthier O, Denoix JM (2020) Ultrasonography-guided perineural injection of the *Ramus ventralis* of the 7 and 8th cervical nerves in horses: a cadaveric descriptive pilot study. Front Vet Sci 7:102. https://doi.org/10.3389/fvets.2020.00102. PMID: 32158773; PMCID: PMC7052177

Woods BI, Hilibrand AS (2015) Cervical radiculopathy: epidemiology, etiology, diagnosis, and treatment. J Spinal Disord Tech 28(5):E251–E259. https://doi.org/10.1097/BSD.0000000000000284

Index

B
Bicipital bursa, 3, 60–63, 66
Bone curettage, 80–85
Branches of the suspensory ligament, 15–19
Bursae
  bicipital bursa, 3, 60–63, 66
  infraspinatus bursa, 62–66
  navicular bursa
    lateral approach (tendon-sparing), 58–60
    palmarodistal digital approach, 56–58
    trancuneal approach, 54–55

C
Caudal approach to the sacroiliac region, 35–37
Caudolateral approach, 42–44
Cervical facet joints, 23–27
Coxofemoral joint (CFJ), 37–41
Cranial approach to the sacroiliac region, 32–35
Craniodorsal approach, 40–41
Craniolateral approach, 43–46
Cranioventral approach, 38–40

D
Deep digital flexor tendon
  desmotomy, 91
  tenotomy, 94–97
Desmoplasty
  deep digital flexor tendon, 91
Desmotomy, 90–94
Dissection, 76–85
Dissection, bone curettage, exostosis resection, and fragment removal, 80–85
Dorsal approach to the cervical facet joints, 23–25
Dorsocranial approach to the cervical facet joints, 24–27

E
Exostosis resection, 80–85

F
Fragment removal, 80–86

I
Image quality, 5
Immobilization, 3
Implant removal, 99
Infraspinatus bursa, 62–66
Injections
  in joints, 9–48
  in ligaments, 9–48
  in tendon, 9–48
Injection site
  selection, 2
Instrumentation selection, 2–3
Intraoperative ultrasound guidance, 77–99
Intraoperative ultrasound marking, 75–77, 85, 99

J
Joints
  cervical facet joints
    dorsal approach, 23, 24
    dorsocranial approach, 24
  coxofemoral joint
    craniodorsal approach, 38, 40–41
    cranioventral approach, 38–40
  distal interphalangeal joint, 19–21, 58, 91, 94
  medial femorotibial joint, 46–48
  scapulohumeral joint
    caudolateral approach, 42–44
    craniolateral approach, 43–46

© Springer Nature Switzerland AG 2024

R. J. Estrada, *Ultrasound-Guided Procedures in Equine Orthopedics and Surgery*,
https://doi.org/10.1007/978-3-031-17562-6

Joints (*cont.*)
thoracolumbar facet joints
lateral approach, 31–32
medial approach, 28–30

L
Lateral approach (Tendon-Sparing), 58–60
Lateral approach to the thoracolumbar facet joints, 31–32
Ligaments
injection in ligaments, 9–48
splitting, 85–90
surgery, 85–97
suspensory ligament
branches, 3, 15–19, 88
origin and body, 3, 13, 14

M
Marker
screen, 5
transducer, 5
Medial approach to the thoracolumbar facet joints, 28
Medial femorotibial joint, 46–49
Medial patellar ligament
splitting, 90–93
Median nerve block, 68–72

N
Navicular bursa, 53–60
Nerve blocks
median, 68
tibial, 66–68

O
Origin and body of the suspensory ligament, 13–16

P
Palmarodistal digital approach, 56–58
Positioning, 3, 37, 55, 68
Positioning, immobilization, and preparation, 3–4
Preparation, 3, 4, 10, 13, 15, 19, 21, 23, 24, 28, 31, 32, 35, 38, 40, 42, 43, 46, 48, 54, 56, 58, 60, 63, 66, 69, 76, 78, 80, 87, 90, 92, 94, 104
Principles, 1
Principles of the ultrasound-guided procedures, 1–7
Sacroiliac region, 32–37
caudal approach, 32, 35–37, 70
cranial approach, 32–34
Scapulohumeral joint (SHJ), 42–46
Selection
injection site, 2
instrumentation, 2–3
Sesamoidean ligament, 58
Splitting
medial patellar ligament, 90
tendon, 85–89
Splitting (Desmoplasty) of the medial patellar ligament, 89–91
Surgery
tendon and ligament, 85
Surgical drainage, 2, 77–79
Surgical incision, 77–82
Synovial endoscopy, 97–98

T
Target's depth, 2, 3, 6–7, 77
Tendon and ligament splitting, 85–89
Tendon and ligament surgery, 85–97
Tendons
deep digital flexor, 10, 58, 88, 91–95, 98
flexor, 2, 10, 13, 14, 87, 88
injections in, 9–48
splitting, 85–89
surgery, 85
Tendons and ligaments, 9–21
Tenotomy, 94–97
Thoracolumbar facet joints, 28–32
Tibial nerve block, 66–68
Trancuneal approach, 54–55
Transducer
alignment, 5–6
marker, 5
Transducer alignment with the needle, 5–6
Transducer and instrumentation selection, 2–3
Transducer marker *vs* screen marker, 5

U
Ultrasound-aided desmotomy of the accessory ligament of the deep digital flexor tendon, 91–94
Ultrasound-aided tenotomy of the deep digital flexor tendon, 94–97
Ultrasound-assisted surgery, 75–100

Ultrasound guidance during synovial endoscopy, 97–99
Ultrasound guidance for implant removal, 99–100
Ultrasound-guided injections in bursae and nerve blocks, 53–72
Ultrasound-guided injections in tendons, ligaments, and joints, 9–49
Ultrasound-guided injections to the collateral ligament, 19–22
Ultrasound-guided injections to the suspensory ligament, 12–19
Ultrasound-guided procedures to the flexor tendons and accessory ligament of the deep digital flexor tendon, 10–12
Ultrasound-guided surgical incision and drainage, 77–80