


# Avian Surgical Anatomy

## Thoracic and Pelvic Limbs

---

**Orosz ■ Ensley ■ Haynes**



# **Avian Surgical Anatomy**

## **Thoracic and Pelvic Limbs**

---



# Avian Surgical Anatomy

## Thoracic and Pelvic Limbs

---

**Susan E. Orosz, Ph.D., D.V.M.**

Department of Animal Science  
College of Veterinary Medicine  
University of Tennessee  
Knoxville, Tennessee

**Philip K. Ensley, D.V.M.**

Associate Veterinarian, San Diego Wild Animal Park  
Escondido, California

**Carol J. Haynes, M.S.**

Head, Art Department  
College of Veterinary Medicine  
University of Tennessee  
Knoxville, Tennessee

**St. Petersburg  
Junior College**



**W. B. Saunders Company**

Harcourt Brace Jovanovich, Inc.  
Philadelphia London Toronto Montreal Sydney Tokyo

**W. B. SAUNDERS COMPANY**  
Harcourt Brace Jovanovich, Inc.  
The Curtis Center  
Independence Square West  
Philadelphia, Pennsylvania 19106

Orosz, Susan E.  
Avian surgical anatomy: thoracic and pelvic limbs /  
Susan E. Orosz, Philip K. Ensley, Carol J. Haynes.  
p. cm.

ISBN 0-7216-3654-3

1. Birds—Surgery. 2. Birds—Anatomy. 3. Extremities  
(Anatomy)—Surgery. 4. Extremities (Anatomy)  
I. Ensley, Philip K. II. Haynes, Carol J. III. Title.  
SF994.076 1992  
636.5'0897—dc20 91-9867

*Editor:* Linda Mills

*Designers:* Julius Orosz, Michael Gurtzweiler, Sharon Brink, and  
the W. B. Saunders Staff

*Production Manager:* Peter Faber

*Manuscript Editor:* Judith Redding

*Mechanical Artist:* Risa Clow

*Illustration Coordinator:* Brett MacNaughton

*Page Layout Artist:* Megan Costello-Connell

*Indexer:* Kathleen Cole

*Cover Designers:* Carol J. Haynes and W. B. Saunders Staff

*Cover Illustration by:* Carol J. Haynes

Avian Surgical Anatomy:

Thoracic and Pelvic Limbs

ISBN 0-7216-3654-3

Copyright © 1992 by W. B. Saunders Company

All rights reserved. No part of this publication may be repro-  
duced or transmitted in any form or by any means, electronic or  
mechanical, including photocopy, recording, or any information  
storage and retrieval system, without permission in writing from  
the publisher.

Printed in the United States of America.

Last digit is the print number:

9 8 7 6 5 4 3 2 1

## DEDICATION

Sheldon Campbell

September 8, 1919—December 16, 1985

From 1983 until his death, Sheldon Campbell served  
as president of the Zoological Society of San Diego.  
During these years, as always, he brought his pas-  
sion for conservation and his abundant enthusiasm  
for the Zoo to the San Diego community and be-  
yond.

Sheldon Campbell did not covet the secrets of the  
Zoo. Instead, he shared them with others, enriching  
their lives and broadening their perspective of the  
Zoo and the animal world.

After viewing this anatomical and surgical study,  
Mr. Campbell encouraged the authors and called for  
its publication. We hope this book reflects the  
bountiful interest in wildlife which he demonst-  
rated. His early encouragement was instrumental in  
the development of this text.



Dr. Hiram Kitchen

September 24, 1932—February 8, 1990

Dr. Hiram Kitchen served as dean of the University  
of Tennessee's College of Veterinary Medicine from  
1980 until his death. Under his leadership, the Col-  
lege developed an active research program and es-  
tablished the Center of Excellence in Livestock Dis-  
eases and Human Health.

He championed the teaching of veterinary medical  
ethics and instilled a strong appreciation for the  
human-animal bond. Dr. Kitchen showed a strong  
commitment to the development of faculty, staff,  
and students. He also served as vice-chairman of  
the Board of Directors for the Knoxville Zoological  
Gardens.

Without his encouragement and support, this text  
would not be possible.







Avian medicine and surgery is a rapidly expanding area in the veterinary field. This is the result of an increasing interest in bird ownership, as well as in raptor and songbird rehabilitation.

The success of aviculturists in the captive breeding of psittacines and other species has also contributed to this growth.

Medical and surgical information on a variety of bird species has expanded correspondingly. Yet, published material on avian anatomy and surgical approaches are only sprinkled throughout the veterinary literature. Approaches to the long bones have been illustrated sparingly. Most clinicians realize, however, that proper orthopedic exposure of the long bones decreases trauma and enhances surgical success.

This atlas helps to fill this void by providing information on avian anatomy, surgical approaches, and basic

orthopedic principles for veterinary clinicians and students, aviculturalists, and others interested in bird care. It is unique in providing this variety of information under one cover.



The atlas evolved from a study funded, in part, by a grant from the Zoological Society of San Diego. The major emphasis for this project was to produce full-scale drawings depicting the anatomy of the limbs of the California condor as an aid in repairing long bone fractures. Surgical approaches previously published by Drs. Patrick T. Redig and James C. Roush were adapted to the California condor, and the anatomy associated with each of the exposures was illustrated.

The turkey vulture was used as an anatomical model in the above study because its anatomy most closely resembles that of the California condor. Radiographs from turkey vultures and an Andean condor, as well



as a skeleton of a California condor, were used to produce life-size drawings. From this work emerged the concept of an atlas that would provide avian drawings and anatomical information to the veterinary community. To make the book more useful to its veterinary and aviculture audience, additional anatomical illustrations were produced to help explain significant variations in the hawk, owl, and psittacine species. Studies on these additional species were funded through a grant from the Department of Animal Science, College of Veterinary Medicine, the University of Tennessee.



The turkey vulture and the California condor proved to be effective models for smaller avian species. Having established the skeletal and muscular relationships in the larger avians, as well as the locations of vessels and nerves, the anatomy could be more readily identified in small psittacines and other species, in which

dissections were difficult and the structures more minute.

A variety of avian species were dissected, including turkey vulture (*Cathartes aura*); barn owl (*Tyto alba*); Eastern screech-owl (*Otus asio*); red-tailed hawk (*Buteo jamaicensis*); red-shouldered hawk (*Buteo lineatus*); great horned owl (*Bubo virginianus*); double yellow-headed parrot (*Amazona ochrocephalus tressmariae*); cockatiel (*Nymphicus hollandicus*); and Senegal parrot (*Poicephalus senegalus*).

Though the study represents a small number of species, major variations in muscles appear only with the lateral femur. For example, psittacine musculature in this region is similar to hawk and owl musculature. A skeletal difference in psittacines is found in the fourth digit, which points cranially rather than caudally, and in a shorter tibiotarsus than in other species dissected. Variations such as these are important in a surgical context and are described from



either this study's dissections or from studies referenced from the literature.

This atlas concentrates on the anatomy of the thoracic and pelvic limbs, with an emphasis on surgical considerations. For this reason, the drawings and text have a regional rather than a systems approach. The atlas facilitates quick and easy access to each region of the limbs, as well as to the appropriate surgical approaches. The drawings, representing a variety of species, were made from dissections to provide the accurate and lifelike illustrations important for surgical detail. The illustrations in this book provide a plan for repairing long bone fractures in various avian species.



The first part of the book (Sections I and II) describes the anatomy of and surgical approaches to the wing. The second part of the book (Sections III and IV) describes the anatomy of and surgical approaches to the leg. Anatomical illustrations are provided with accompanying notes that briefly describe the muscles, bones, blood vessels, and nerves in each region. Surgical approaches are formatted from proximal to distal on the limb. For each approach, the surgical indications are briefly presented before the procedure is described. The description of procedure provides anatomical infor-

mation important for interpreting the surgical exposure and its accompanying illustrations. Information on wound closure, technique, and postoperative care is included. Basic orthopedic principles common to the care of all birds are presented in the third part (Section V). The radiographs in the body of the text are enlarged for greater detail in the appendix.




The anatomical terminology used in this atlas comes from a variety of sources. The principal terminology used is that of the *Nomina Anatomica Avium* (NAA), the recognized standard in the field. Additional terminology is provided to ease the process of cross-referencing other vocabularies. These terms, in many cases, have been adapted from those used in small animal anatomy. These quick-reference terms are intended not to imply homology but to orient the veterinary surgeon. Sources for these include *Sisson and Grossman's Anatomy of the Domestic Animal*, fifth edition, edited by Robert Getty; and H. F. Fisher's 1946 monograph on New World vultures that was published in the *American Midland Naturalist*. In the body of text, the NAA name for a structure appears first; quick-reference terms are shown in parentheses. A table at the end of this atlas provides a complete cross-referencing of NAA and quick-reference terms for identified structures.

## ACKNOWLEDGMENTS

The authors and medical illustrator would like to acknowledge the constructive criticisms of the manuscript and illustrations given by Drs. Robert Henry, Patrick Morris, Robert Paddleford, and Joseph Weigel from the College of Veterinary Medicine, University of Tennessee (UT-CVM); Dr. Scott Citino, Miami Metro Zoo; and Eric Bergman. We would also like to acknowledge the guidance on the production of the radiographs from Drs. Michael Walker and James Hoskinson while in the Radiology service at UT-CVM and from Kreis Weigel, Medical Photography, UT-CVM; the assistance of Ms. Wanda Aycok for the index and manuscript preparation; and UT-CVM, its department of Animal Science, and the Zoological Society of San Diego for their financial support. In addition, we would like to acknowledge the advice and support of Dr. Kurt Benirschke, Dr. Arthur Risser, Dr. Werner Heuschle, and William Toone; the assistance from the Photo Lab at the San Diego Zoo; the help from the staffs of the veterinary hospitals at the Zoo and Wild Animal Park; the members of the Research, Health and Conservation committee; the Board of Trustees of the Zoological Society of San Diego; Donoran McIntire for the use of some of the vulture anatomy sketches he originally prepared and Dave McClendenon for the condor photograph.

Lastly, we would like to thank those responsible for the original concept of this atlas and for its present design: Julius Orosz, art director; Michael Gurtzweiler, comprehensive design; and Sharon Brink, composition; and the staff at W.B. Saunders Co. with special thanks to Brett MacNaughton, Karen O'Keefe, and Risa Clow.





CONTENTS

**Part I      Anatomy of and Surgical Approaches to the Wing ..... 3**

**Section I:**    Anatomy of the Thoracic Girdle and Limb ..... 3

                 Lateral Axial Skeleton ..... 4

                 Dorsal Humerus ..... 6

                 Dorsal Distal Skeleton..... 14

                 Distal Thoracic Limb..... 18

                 Medial Proximal Skeleton..... 24

                 Ventral Humerus..... 26

                 Ventral Distal Skeleton ..... 32

                 Ventral Thoracic Limb ..... 36

**Section II:**    Surgical Approaches to the Thoracic Girdle and Limb ..... 41

                 Coracoid and Clavicle ..... 42

                 Proximal Humerus..... 44

                 Distal Humerus..... 46

                 Proximal Radius and Ulna..... 50

                 Distal Radius and Ulna ..... 52

                 Radius..... 54

                 Metacarpus ..... 56

**Part II      Anatomy of and Surgical Approaches to the Leg..... 59**

**Section III:**    Anatomy of the Pelvic Girdle and Limb ..... 59

                 Pelvic Girdle, Thigh, Leg, and Pes..... 60

                 Lateral Thigh and Leg ..... 62

                 Lateral Thigh ..... 74

                 Cranial Pelvic Limb Skeleton ..... 78

                 Medial Pelvic Limb Skeleton..... 80

                 Medial Thigh ..... 82

                 Cranial Leg and Digits..... 90

                 Caudal Leg and Digits..... 94

**Section IV:**    Surgical Approaches to the Pelvic Limb ..... 99

                 Coxofemoral Joint..... 100

                 Femur..... 102

                 Tibiotarsus..... 106

                 Tarsometatarsus and Phalanges ..... 108

**Part III      Considerations for Avian Surgery ..... 111**

**Section V:**    Initial Examination and Care of the Traumatized Patient..... 111

**Appendix..... 121**

**References ..... 129**

**Table of Homologous Terms ..... 131**

**Index ..... 137**

# **Avian Surgical Anatomy**

## **Thoracic and Pelvic Limbs**

---





# **Anatomy of and Surgical Approaches to the Wing**

## **Section I Anatomy of the Thoracic Girdle and Limb**

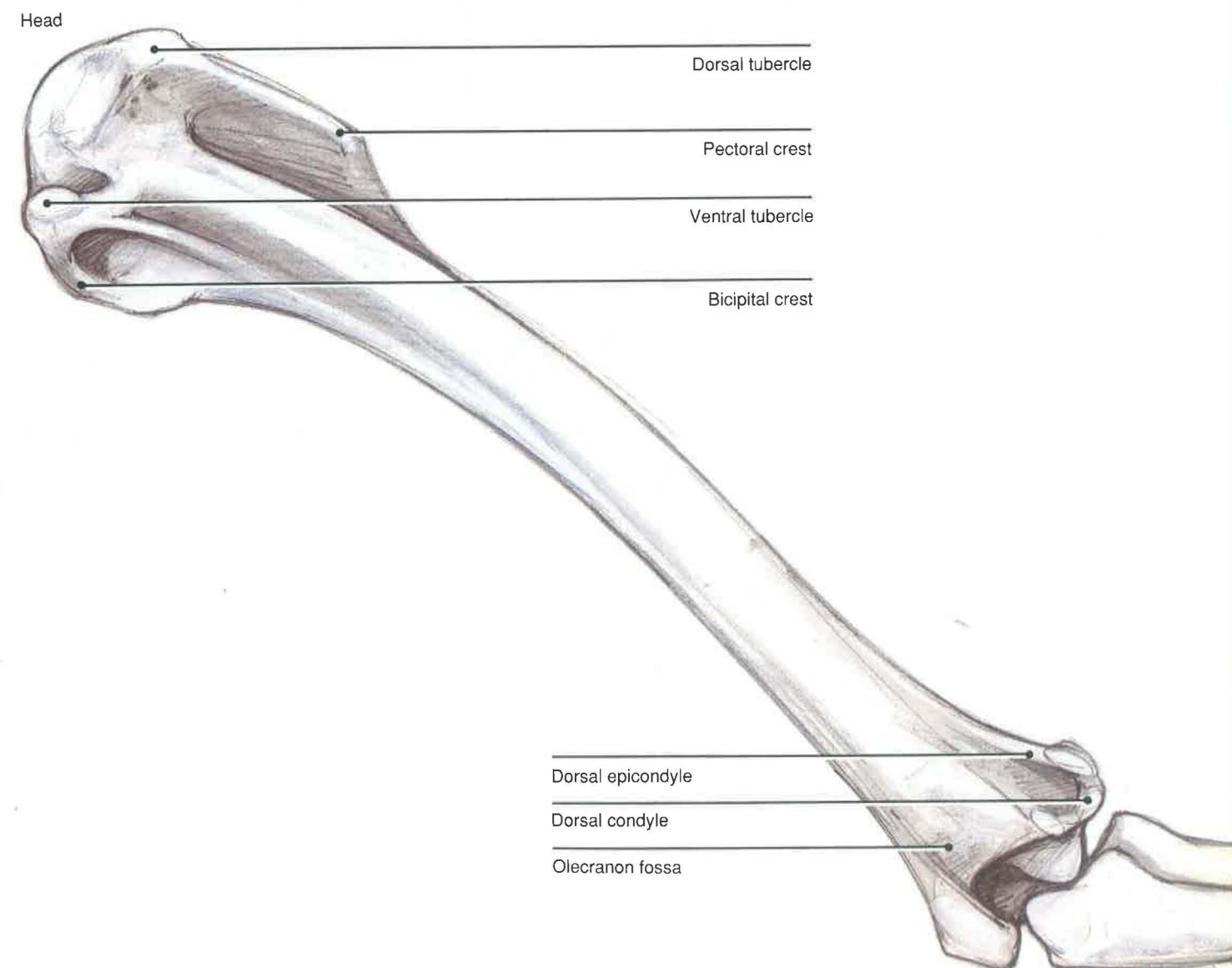
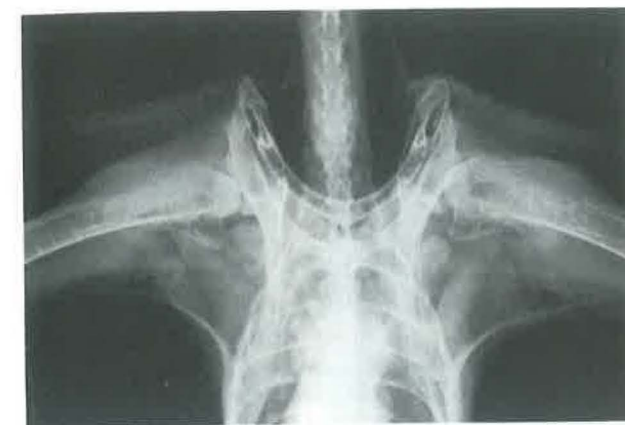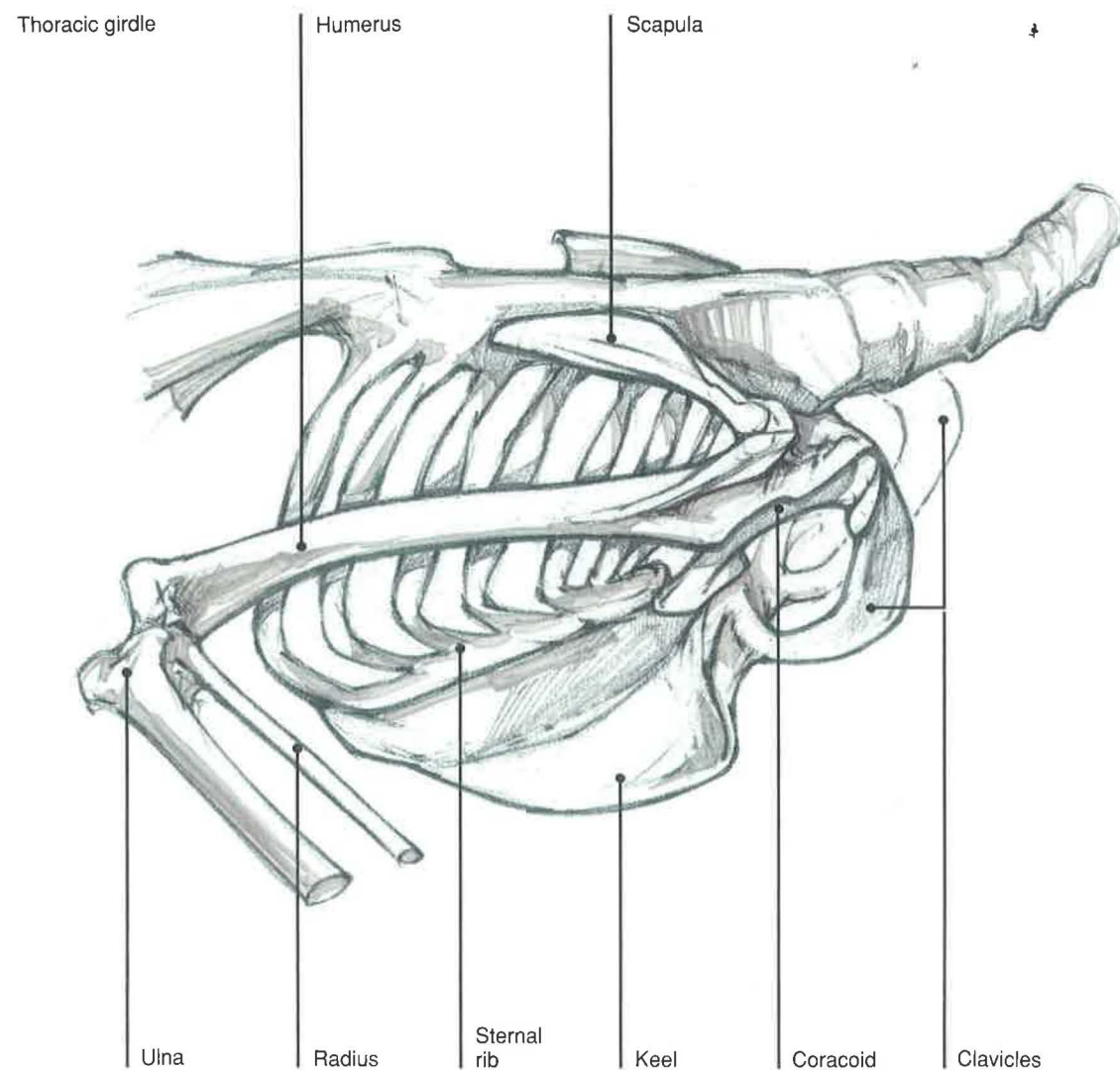


## Lateral Axial Skeleton

**Thoracic girdle**—The thoracic girdle is represented by the coracoid and the scapular bones, as well as by the fused clavicles. The two clavicles, or furunculae, are fused medially at the hypocleidium. This bony plate is connected to the sternum by the hypocleidial ligament. The coracoid bones act as supporting struts for the pectoral limbs by connecting them to the sternum. Each scapula lies against the ribs and articulates with the coracoid and clavicle cranially. The triosseal canal [*canalis triosseus*], or foramen triosseum, is formed by the articulation of the coracoid, scapula, and clavicle. In some species, the canal is bounded by only two bones, the coracoid and scapula.<sup>3</sup>

**Humerus**—The humerus is the largest bone of the pectoral limb. Its length in relation to wing length is fairly constant, but pneumaticity varies among species.

Cathartids have the greatest pneumaticity, while accipiters have the least.<sup>2</sup> The head of the humerus articulates with the glenoid cavity of the scapula. There is a long, cranially directed pectoral crest [ *crista pectoralis* ] or deltoid crest. Between the crest and the head of the humerus is a small protuberance, the dorsal tubercle (major tubercle in small animals). The ventral or minor tubercle is bounded by a fossa on the dorsal caudal surface of the humerus and the bicipital crest. Distally, the dorsal and ventral condyles articulate with the radius and ulna. The dorsal condyle is homologous to the lateral condyle in domestic animals, and the ventral condyle is homologous to the medial condyle. The extrathoracic portion of the clavicular air sac has extensions into the medullary cavity of the humerus, as well as into the coracoid, scapula, and clavicle.





## Dorsal Humerus

### SUPERFICIAL VIEW

**The propatagialis complex** [*tensor propatagialis*]<sup>1</sup>—The muscles that compose this mass over the cranial margin of the shoulder have various degrees of fusion; it is therefore convenient to describe them as the propatagialis complex. This muscle mass and its tendons of insertion are closely associated with the propatagial ([propatagium] or patagial) skin fold. There are two primary tendons of insertion: the pars brevis tendon, which inserts onto the tendon of origin of the extensor metacarpi radialis, as well as onto a fascial attachment running dorsally on the ulna; and the pars longus tendon, which inserts onto the extensor process of the metacarpus. The dermatensor patagii (similar to a slip of muscle from the cucullaris of reptiles)<sup>3</sup> inserts onto the humeral feather tract. In some vultures<sup>2</sup> and psittacines<sup>3</sup> it becomes continuous with the pars longus tendon. The propatagialis complex is rather large in psittacines. It helps extend the metacarpus and digits while flexing the elbow. The complex can also tense the propatagium, an important factor in controlling the angle of the wing for lift.<sup>2</sup>

**Deltoideus major**—The major deltoid originates from the scapula and inserts along the shaft of the humerus from the pectoral crest distally. The muscle pulls the wing caudally and dorsally, and it is therefore important for flapping flight.<sup>2</sup>

**Triceps brachii**—In cathartids the triceps is composed of three muscle bellies, one of which originates from the scapula. In many species, it has two heads: one from the scapula and another from the humerus.<sup>3</sup> The scapular (long) head acts to

draw the humerus caudally when the wing is extended and helps to maintain the semiflexed position important for flex gliding.<sup>2</sup>

**Latissimus dorsi**—This thin and flattened muscle is usually divided into two independent heads, the cranialis and caudalis. The cranial head arises from a number of caudal cervical and cranial thoracic spinous processes; the caudal head arises from caudal thoracic vertebrae down to and sometimes including the synsacrum. The cranialis inserts on the head of the humerus between two of the bellies of the triceps. The caudalis may be lacking in some birds (pigeons and finches) or may have a variable site of insertion.<sup>4</sup>

In raptors, the muscle is closely associated with two cutaneous bands of muscle that insert onto the area of the scapular coverts, namely the cutaneous costohumeralis. These muscular slips arise from the ribs ventral to the uncinat processes and swing dorsally. They correlate with the cutaneous trunci of mammals.

**Blood supply and innervation**—Branches of the subscapular artery and vein appear between muscle fascicles of the rhomboideus to provide muscular branches to the propatagialis complex and deltoideus muscles. The axillary nerve [*n. axillaris*] is found between the deltoideus major and minor. After supplying these muscles, it continues dorsally to innervate the propatagialis complex. Commonly, the radial nerve [*n. radialis*] emerges between the distal end of the deltoideus major and the triceps brachii.



Propatagialis complex

Rhomboideus superficialis

Subscapular artery

Tensor propatagialis,  
pars longus tendon

Deltoidaeus major

Latissimus dorsi, cranial head

Triceps brachii

Latissimus dorsi, caudal head

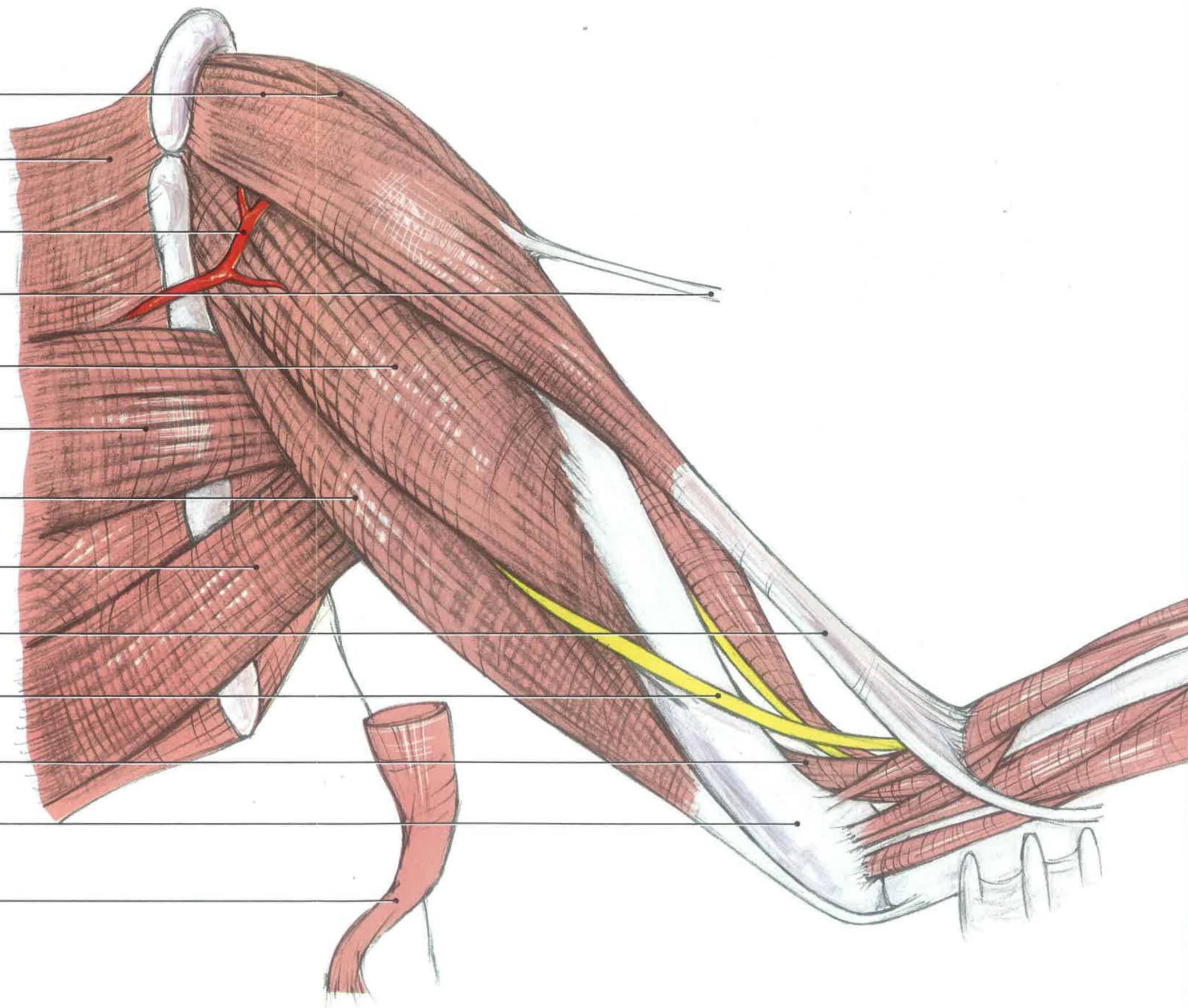
Tensor propatagialis,  
pars brevis tendon

Radial nerve

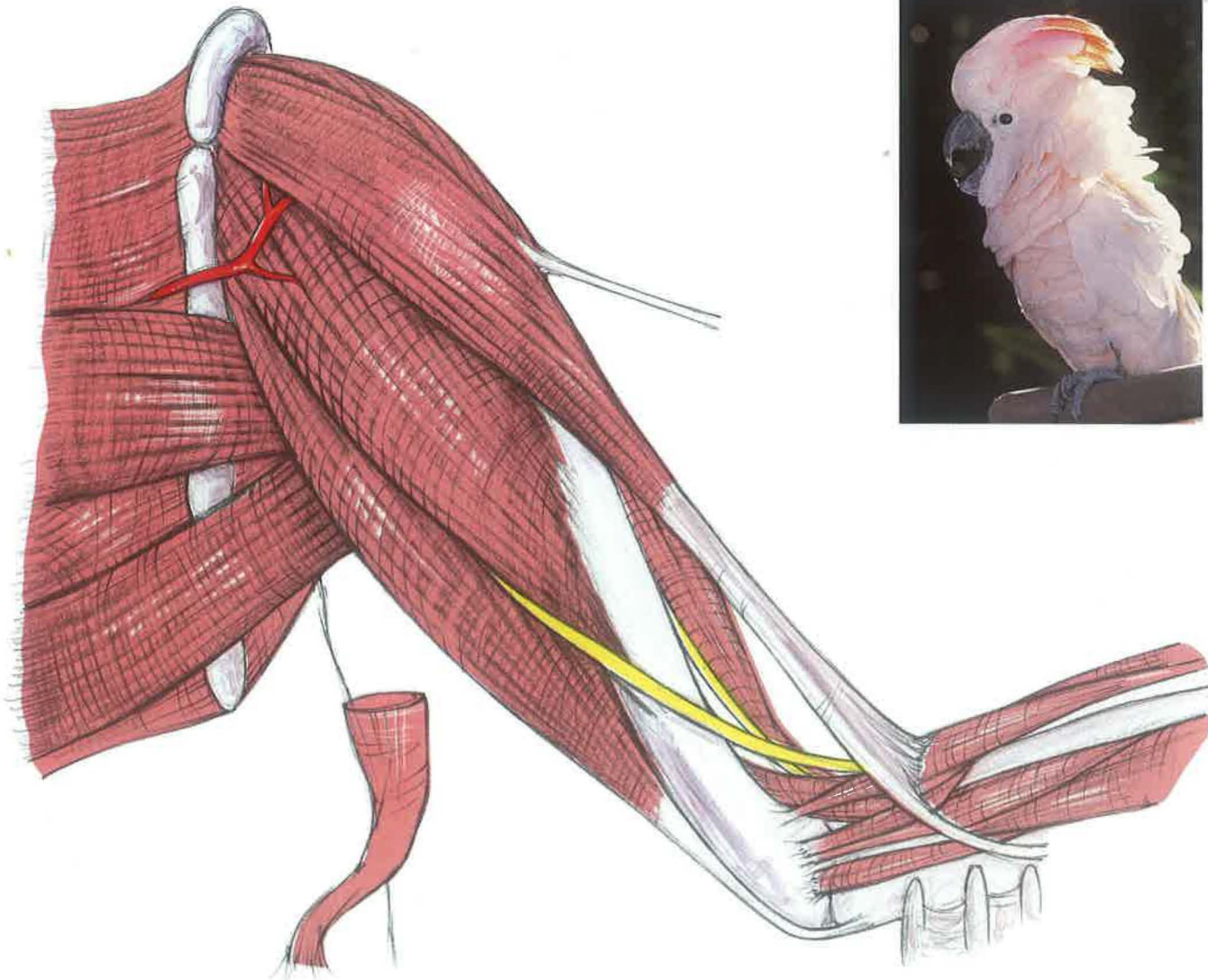
Brachialis

Humerus

Cutaneus costohumeralis







## Dorsal Humerus

### DEEP LAYERS

(Propatagialis complex removed)

**Deltoideus minor**—This muscle is found deep to the propatagialis complex and proximal to the deltoideus major. It originates from both the scapula and clavicle and inserts on the proximal humerus, thereby lifting the humerus and pulling it cranially. This may be important in the recovery stroke of the wing in flight.<sup>2</sup>

**Biceps brachii**—This muscle, a strong flexor of the forearm, originates on the cranial border of the proximal humerus. The tendon of the biceps divides, with the proximal, larger tendon inserting on the proximal radius. The other tendon inserts on the ulna and may include a small slip of fibers that forms part of the pars brevis tendon of insertion.<sup>3</sup>

**Brachialis**—This small muscle is found between the humerus and radius in the flexor space. It inserts on the ventral surface of the proximal ulna. Although the brachialis flexes the elbow, it is thought to maintain the forearm in a horizontal position in flight during gusts of wind.<sup>2</sup>

## Dorsal Humerus

### DETAIL OF SHOULDER

(Deltoid minor removed)

**Coracobrachialis cranialis** [*coracobrachialis dorsalis*]—This triangular muscle fills part of the space between the coracoid and the head of the humerus dorsally. As the name implies, it takes origin from the head of the coracoid bone, but it inserts on the ventral side of the humeral head. During the initial phase of the downstroke, it may function to pull the wing cranially.<sup>2</sup>



Clavicle

Coracoid

Coracobrachialis cranialis

Axillary nerve, branch

Deltoides minor

Subscapular artery

Rhomboideus superficialis

Scapula

Deltoides major

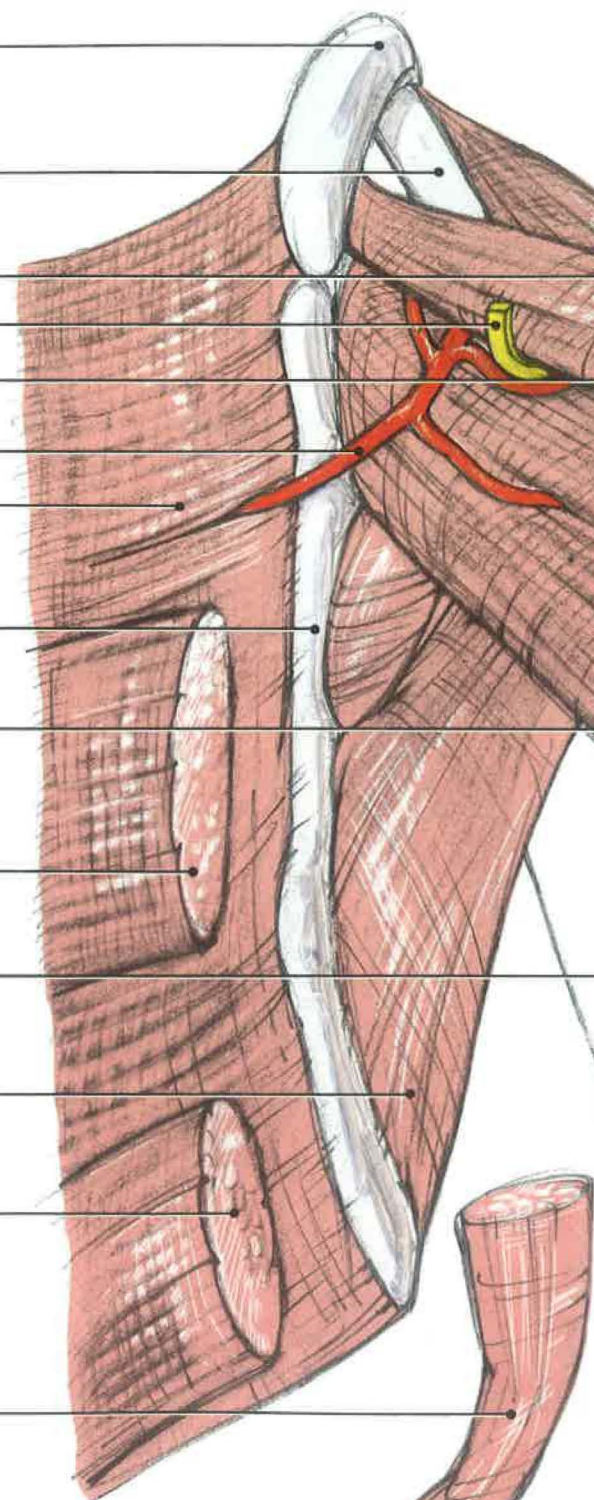
Latissimus dorsi, cranial head

Humeral shaft

Serratus ventralis

Latissimus dorsi, caudal head

Cutaneus costohumeralis



Clavicle

Coracoid

Triosseal canal

Coracobrachialis cranialis

Supracoracoideus

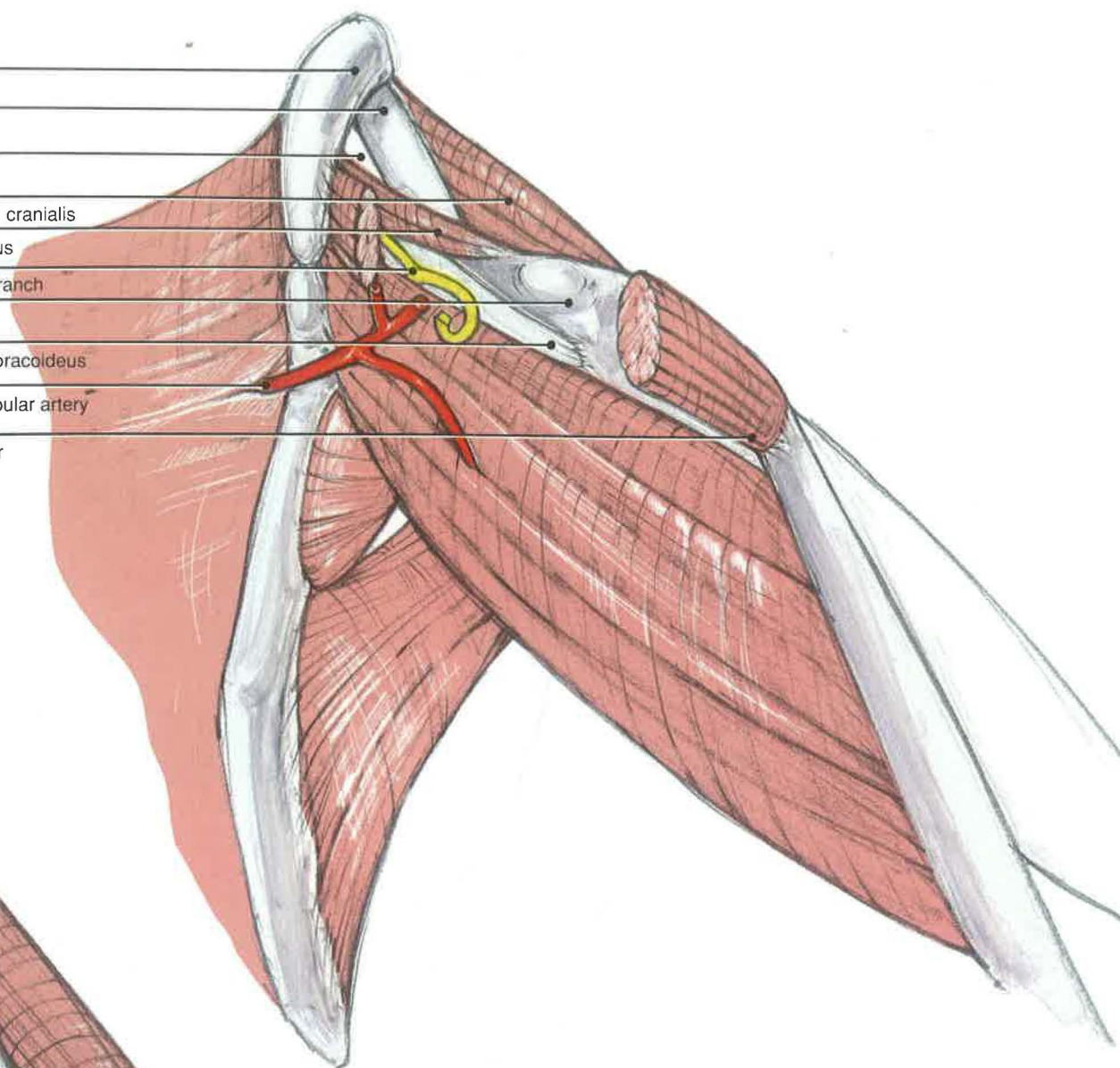
Axillary nerve, branch

Humeral head

Tendon, supracoracoideus

Branch, subscapular artery

Deltoides minor



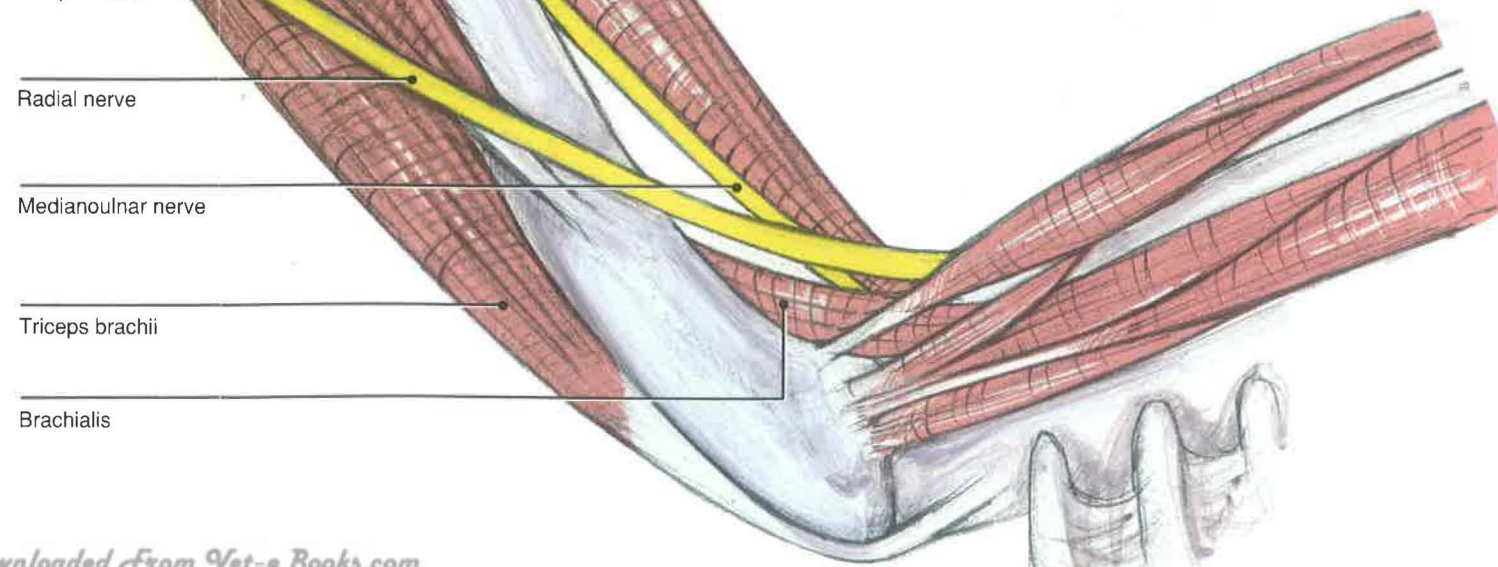
Biceps brachii

Radial nerve

Medianoulnar nerve

Triceps brachii

Brachialis





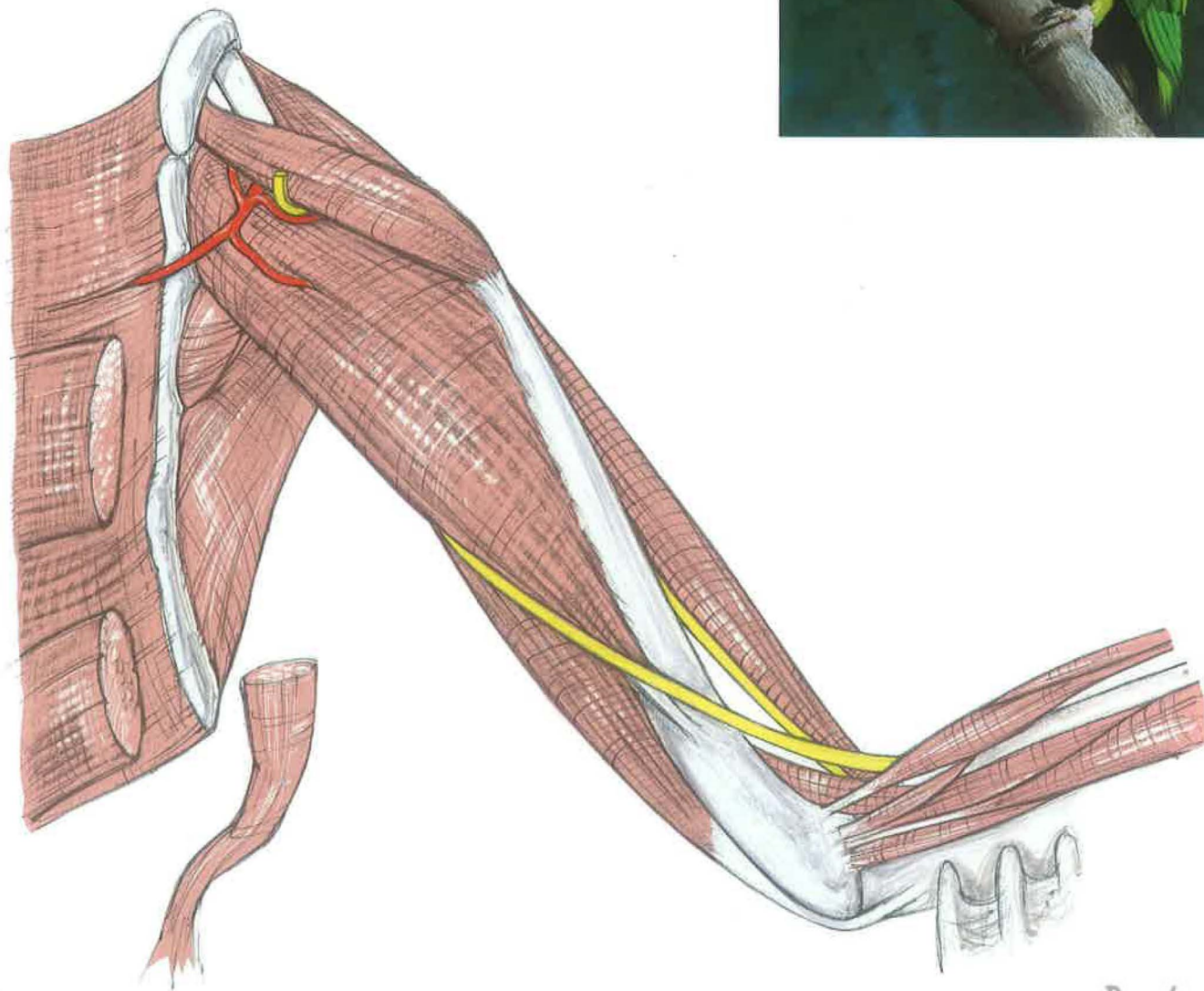
## Dorsal Distal Skeleton

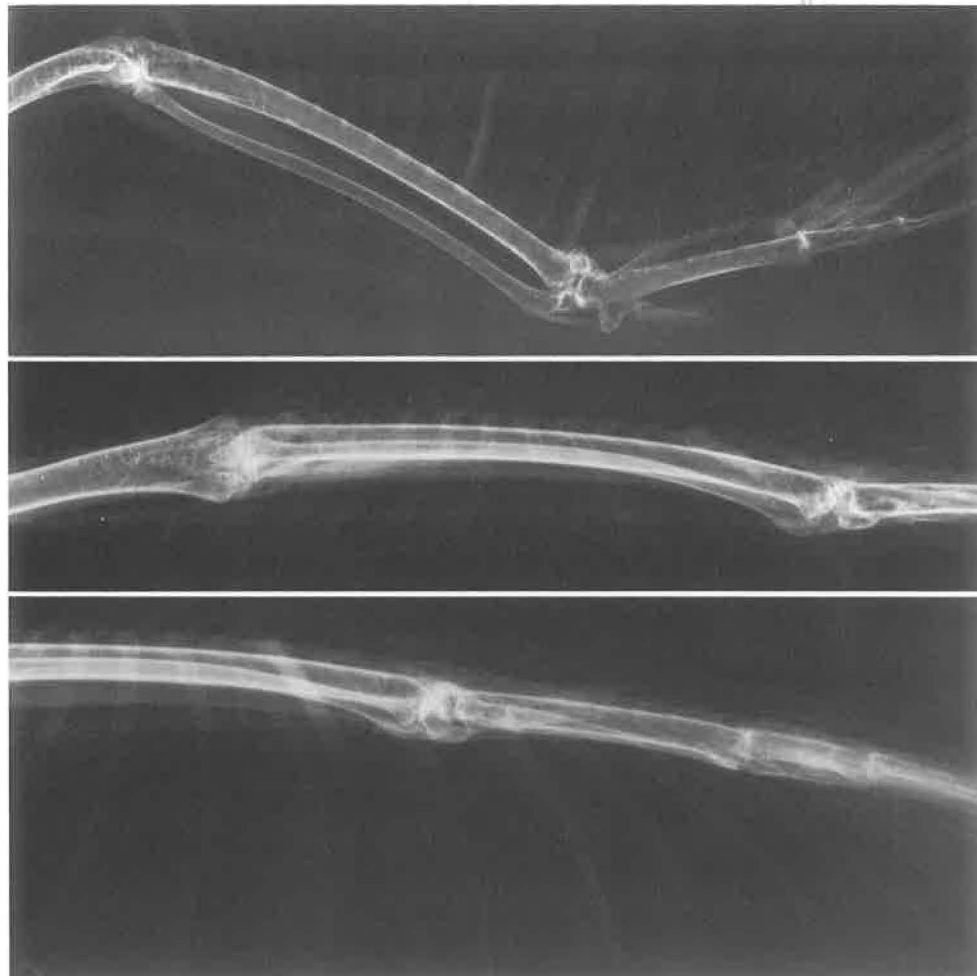
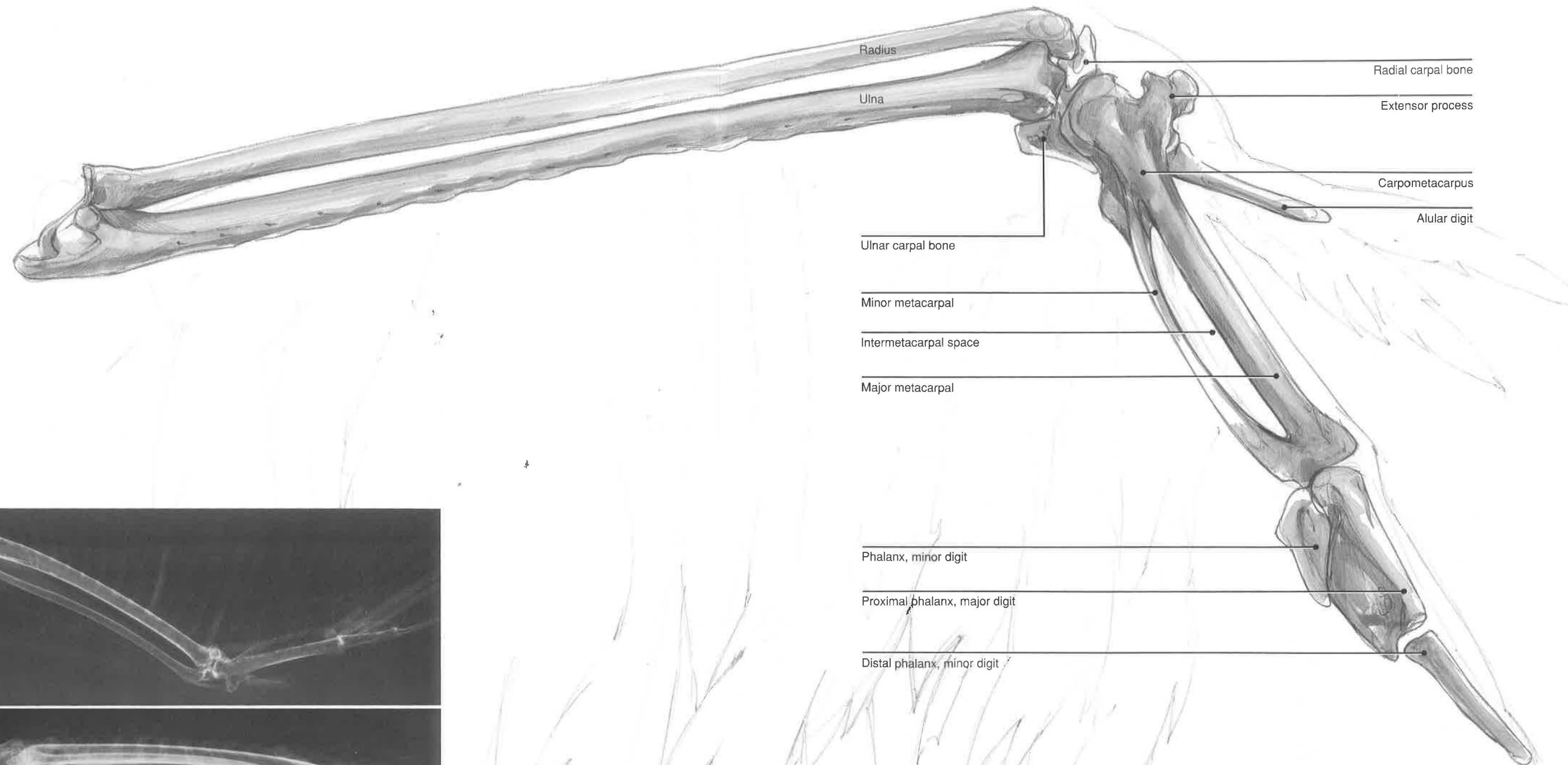
**Radius and ulna**—The bones of the forearm are the radius and ulna. They are of comparable length, with their distal ends curved caudally. The degree of curvature varies with the species. Unlike in mammals, the ulna in birds has a small olecranon for articulation with the humeral condyle, which is more pronounced in accipiters.<sup>2</sup> The radius and ulna act in concert to extend or flex the manus or hand in relation to the forearm. Flexion of the forearm results in flexion of the manus. When the forearm is extended, the ulna slides distally and pushes on the metacarpus, thereby extending it. This reciprocal mechanism is dependent on the ligamentous attachments from the carpus to the radius and ulna.<sup>1</sup>

**Carpus, metacarpus**—The carpus consists of two bones: the radial and ulnar carpal bones. The radial carpal bone is cranial, and the ulnar carpal bone is

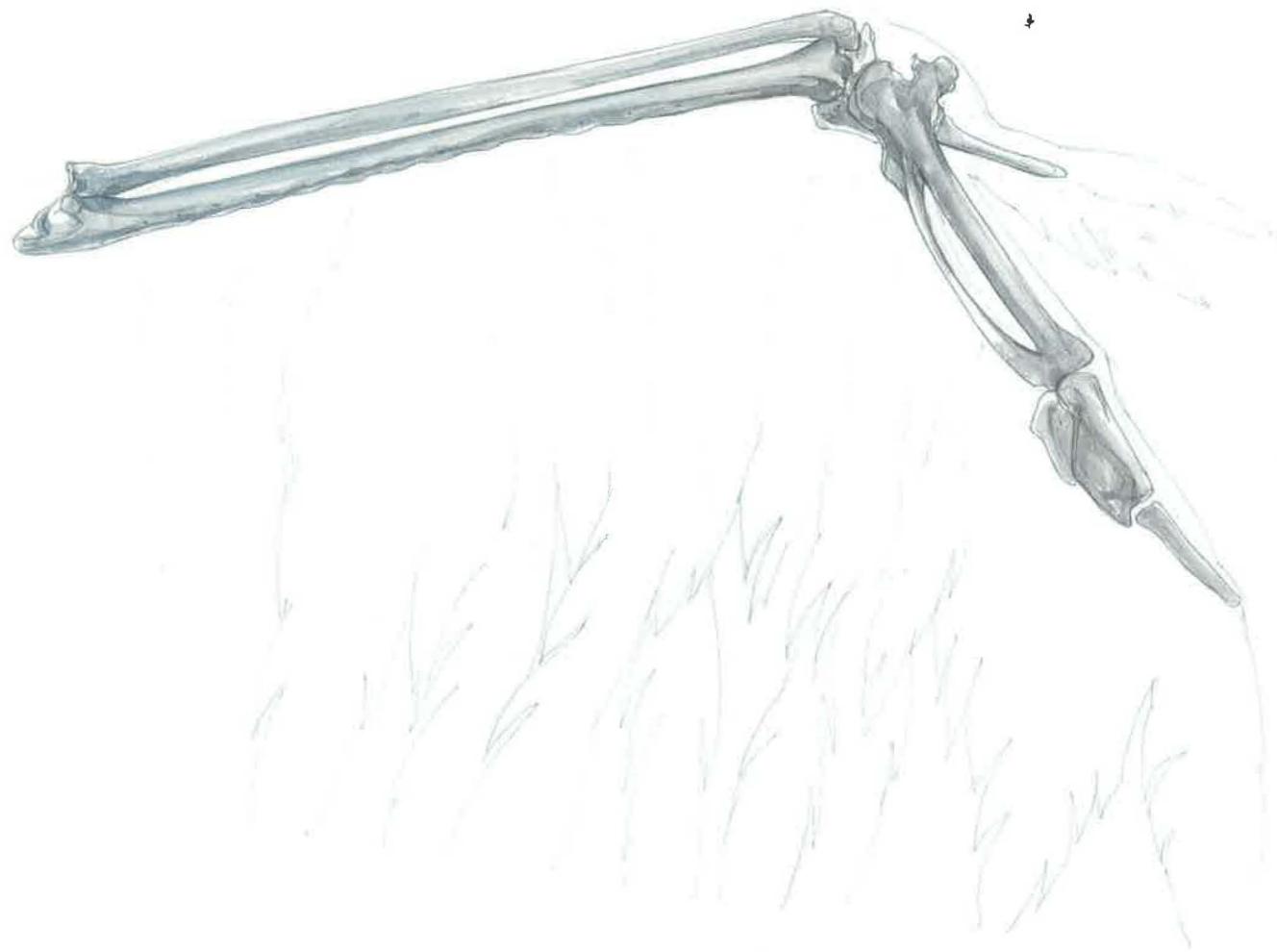
caudal. The carpometacarpus is composed of partially fused metacarpal bones.

Metacarpal I is represented as a small, cranially directed protuberance—the extensor process [*processus extensorius*]. The major metacarpal [*osmetacarpale majus*] and minor metacarpal [*osmetacarpale minus*] are fused both proximally and distally, forming an intermetacarpal space [*spatium intermetacarpale*] or interosseous space. Flat, articular surfaces for the phalanges are an adaptation for greater manipulation. The alular digit [*phalanx digiti alulae*] is important for lift.<sup>2</sup> It usually has one phalanx, *phalanx digiti alulae*. The major digit normally has two phalanges, *phalanx proximalis digiti majoris* and *phalanx distalis digiti majoris*. The minor digit normally has one phalanx, *phalanx digiti minoris*.









## Distal Thoracic Limb

### SUPERFICIAL VIEW

**Extensor metacarpi radialis**—This muscle is composed of two heads that insert as a common tendon onto the extensor process of the first metacarpal bone. Because it acts to extend the carpus and metacarpus, a portion of this tendon may be removed for pinioning. Owing to its origin on the epicondyle of the humerus, it also flexes the elbow.

**Extensor digitorum communis** [*common digital extensor*]—The origin of this muscle is the same as that for the other muscles of the dorsal forearm—the epicondyle of the humerus. The muscle has a short tendon that inserts on the base of the alular digit [*phalanx digiti alulae*], while the major tendon inserts onto the base of the proximal phalanx of the major digit [*phalanx proximalis digiti majoris*]. Although it extends the manus, it may flatten the alula against the metacarpus to decrease, lift, or stabilize the position of the alula.<sup>2,3</sup>

**Supinator**—The supinator usually takes origin with the extensor digitorum communis on the epicondyle of the humerus. It is involved in flexing the elbow. Most importantly, it elevates the cranial edge of the wing.<sup>2</sup>

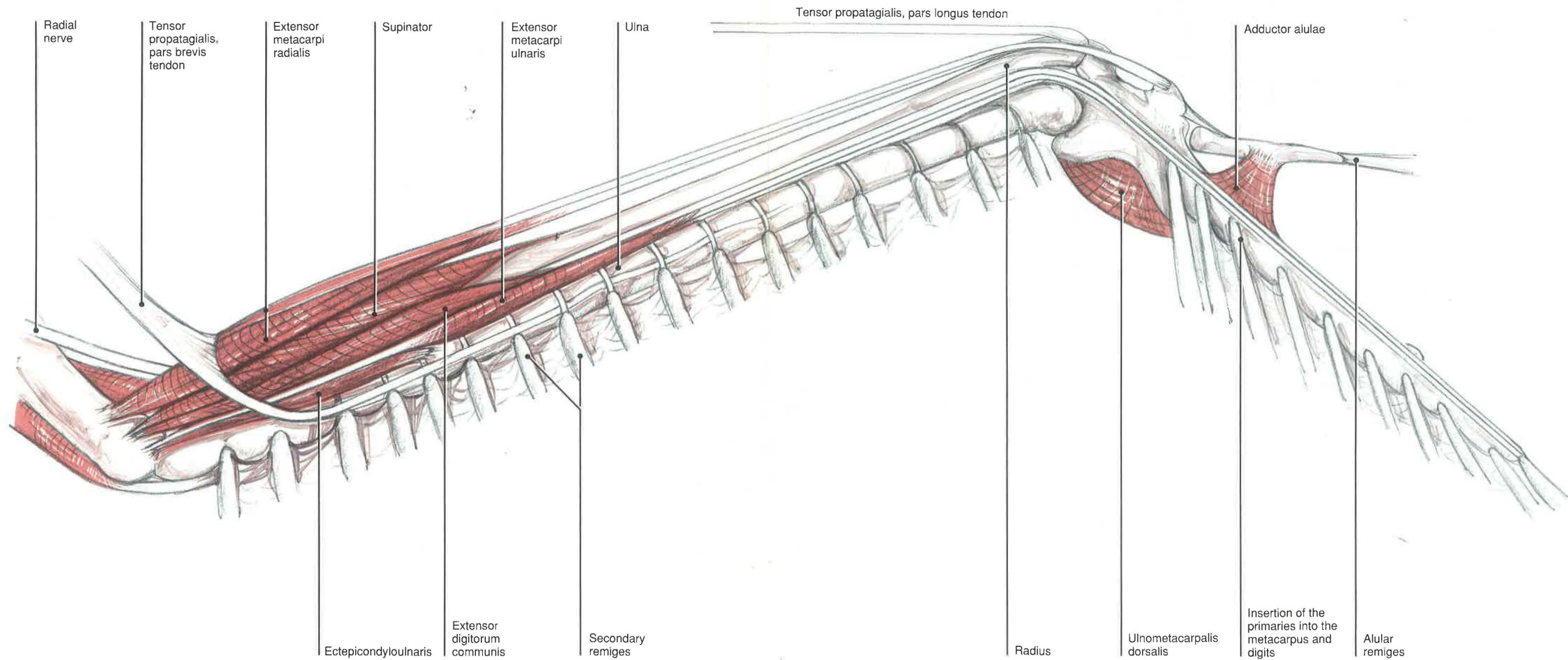
**Extensor metacarpi ulnaris** [*ulnaris lateralis*]—The tendinous origin of extensor metacarpi ulnaris muscle is in common with the ectepicondylo-ulnaris or anconeus on the dorsal epicondyle of the

humerus. This muscle flexes both the forearm and the manus.<sup>3</sup>

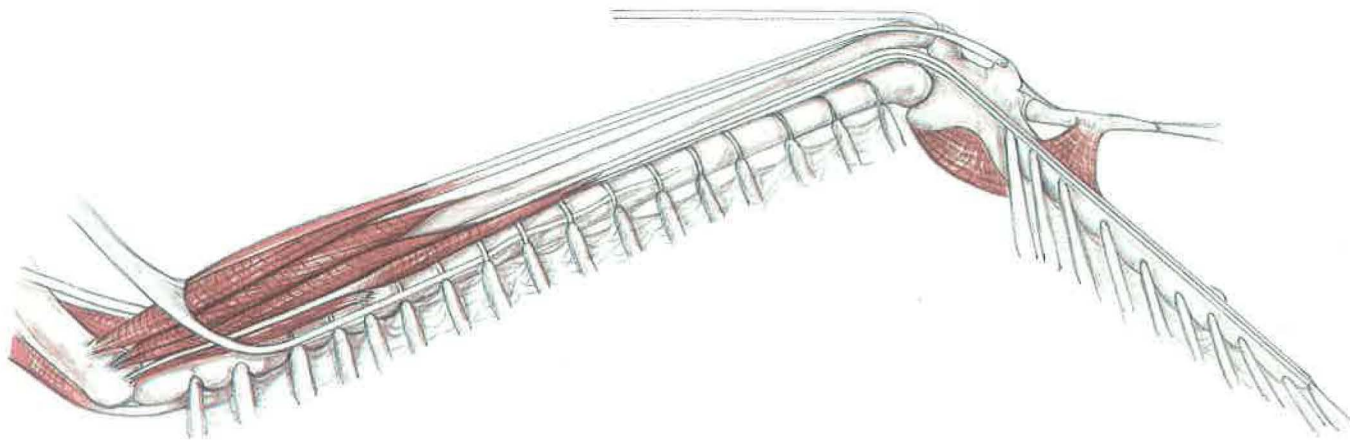
**Ulnometacarpi dorsalis** [*flexor metacarpi caudalis*]—This small muscle fills in the flexor space between the ulna and metacarpus. It inserts onto the minor metacarpal bone and onto the base of the primaries by tendinous slips. Just distal to this muscle is the flexor digiti minoris, which inserts onto the minor digit. The ulnometacarpalis dorsalis pulls the primaries medially or proximally to decrease the gap with the secondaries.<sup>2</sup>

**Muscles of the manus**—Soaring and gliding flight is associated with a number of small muscles of the carpus, metacarpus, and digits for fine motor control. The extensor brevis alulae extends the alular digit. The extensor longus alulae is a small muscle found on the caudal border of the distal radius, and it inserts on the extensor process of the metacarpus. It extends the manus, not the alula. The tendon of the extensor longus digiti majoris is found in a dorsal location at the carpus. Associated with its tendon of insertion is a small muscle, the extensor brevis digiti majoris (see detail).

**Ectepicondylo-ulnaris** [*anconeus*]—The origin of this muscle may be in common with the extensor metacarpi ulnaris. It inserts along the proximal cranial surface of the ulna to flex the forearm, as well as elevate it slightly.<sup>2</sup>

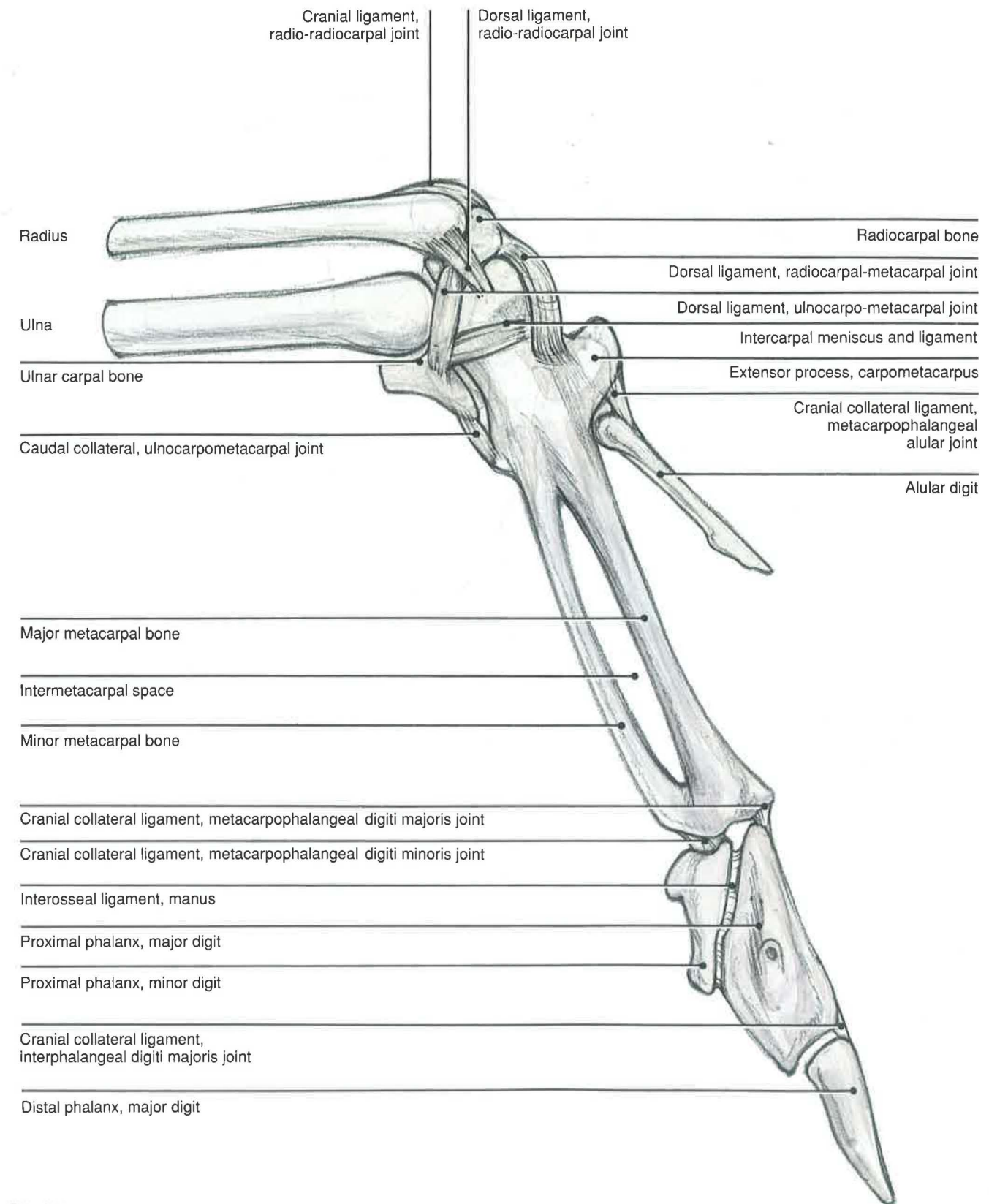






## Distal Thoracic Limb CARPOMETACARPUS AND DIGITS

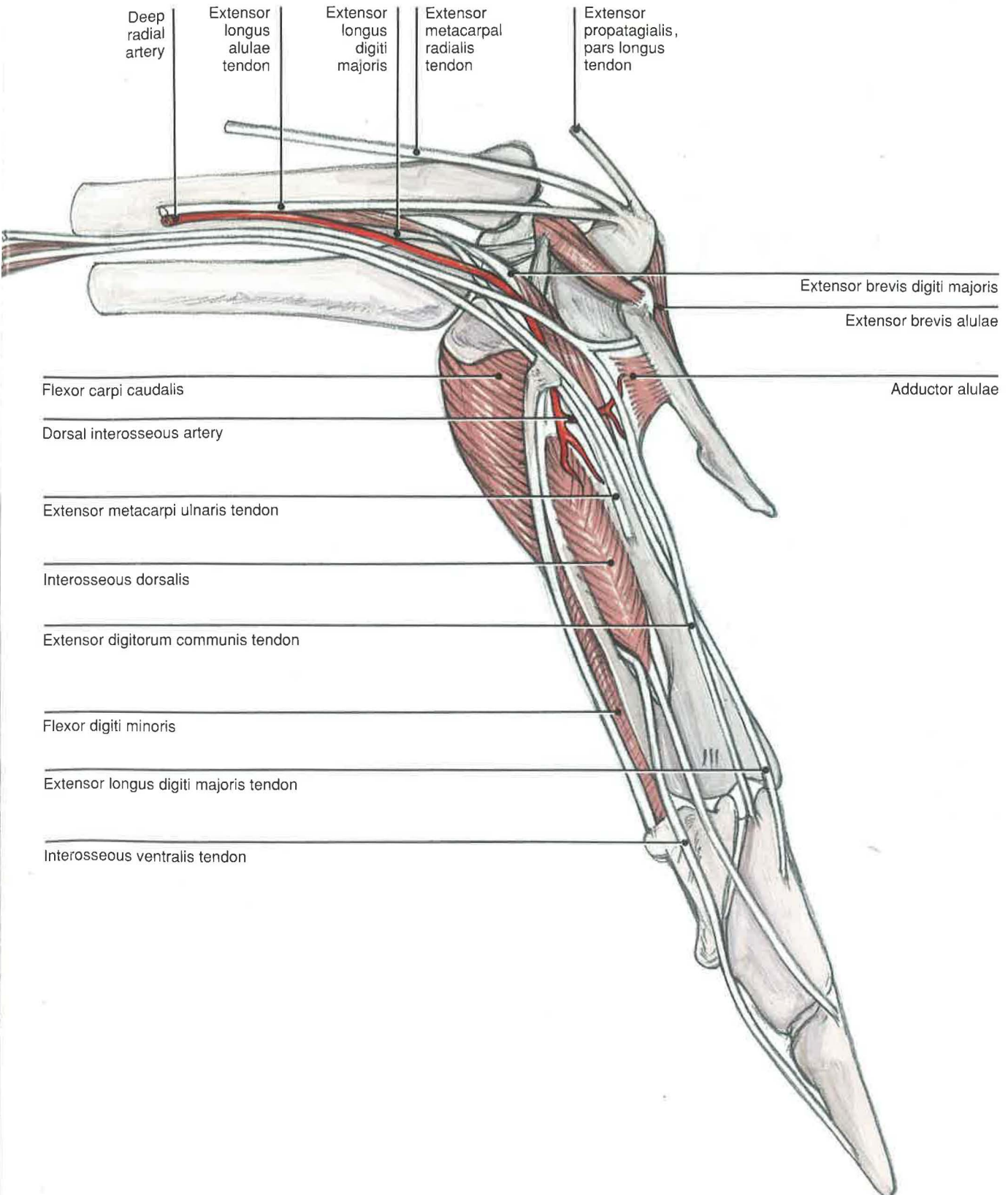
### *Dorsal Skeleton*



# Distal Thoracic Limb

## CARPOMETACARPUS AND DIGITS •

### Joint Detail



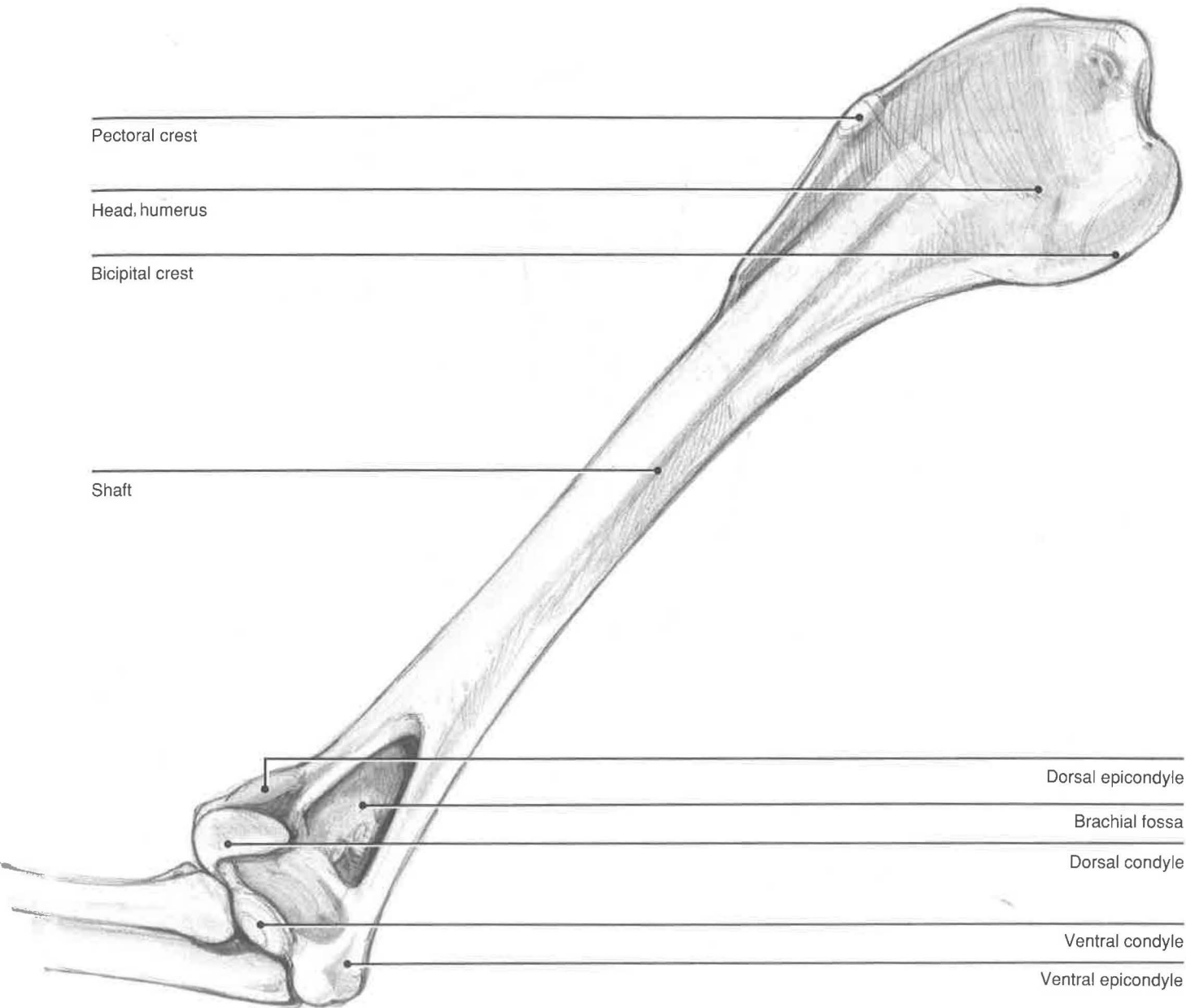
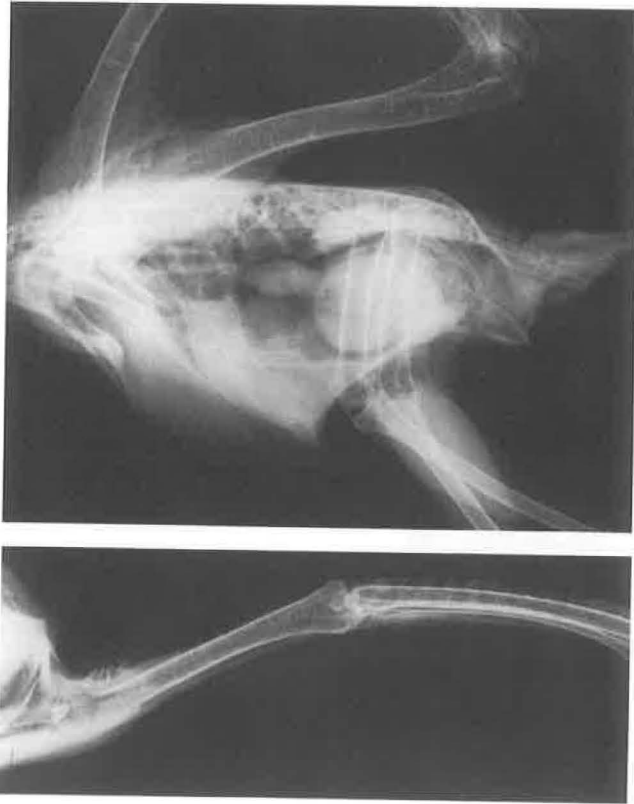

Medial Proximal Skeleton

**Sternum**—The breast bone of birds covers a large surface of the ventral thorax. In most birds, there is a central keel or carina for attachment of the powerful pectoral muscles and supracoracoideus. Some of the flightless birds do not have this ventral projection and have been designated ratities (*raft* in Latin). These include ostriches, cassowaries, emus, rheas, and kiwis.<sup>3</sup> The ventral segment of each of

the sternal ribs articulates with the sternocostal processes of the sternum.

**Humerus**—The dorsal and ventral condyles are more evident on the ventral surface of the humerus. Proximal to the condyles is a triangular depression, the brachial fossa.



## Ventral Humerus

### SUPERFICIAL VIEW

**Superficial pectoral muscle** [*pectoralis*]  
—There is considerable variation in the pectoral muscle mass among species of birds. Descriptions of these muscles also vary. For veterinary purposes, it is easier to describe two muscles, one superficial and the other deep. The superficial muscle is closely associated with the propatagial complex of muscles. Vanden Berge, in *Sisson and Grossman's Anatomy of the Domestic Animals*,<sup>3</sup> refers to a portion of the superficial pectoral muscle that inserts into the propatagium as the *pars propatagialis*. The superficial pectoral muscle covers the ventral surface of the sternum and represents the majority of the muscle mass that is palpated in a physical examination. Most of the muscle originates from the keel and inserts along the pectoral crest and the proximal humerus. Psittacines and raptors appear to have a single, large muscle mass without the superficial and deep divisions found in vultures. The large, powerful superficial pectoral muscle is very important in flapping flight. It is responsible for the downstroke, as well as for depressing the leading edge of the wing to reduce turbulence across the wing.<sup>2</sup>

**Biceps brachii**—This muscle originates on the cranial border of the proximal humerus. The tendon of the biceps divides, with the proximal, larger tendon inserting on the proximal cranial radius. The other tendon inserts on the ventral ulna. It is a strong flexor of the elbow.

**Blood supply**—Proximally between the biceps and triceps brachii are the major vessels and nerves to the thoracic limb. The most superficial vessel is a cutaneous vein often used for venipunctures: the basilic vein [*v. basilica*] or cutaneous ulnar vein. It provides the major drainage of venous blood from the wing to the axillary vein. The brachial artery divides into the ulnar and radial arteries in the proximal arm. These arteries course along the caudal margin of the biceps brachii, with the ulnar artery superficial and cranial to the radial. The radial artery runs with the medianoulnar nerve. Several small veins, the brachial veins, run with these arteries. Venous anastomoses are found between the basilic and brachial veins at the elbow and the proximal humerus. In addition, there are anastomoses between the basilic vein and the ulnar artery, the *venae comitantes*. These structures may play a role in counter-current thermoregulation.

**Innervation**—The brachial vessels surround the large medianoulnar nerve [*n. medianoulnaris*]. After supplying the muscles and propatagium in that region, the nerve divides into the median nerve [*n. medianus*] cranially and the ulnar nerve [*n. ulnaris*] caudally.



Clavicle

Tensor propatagialis, pars  
longus tendon

Superficial pectoral

Biceps brachii

Tensor propatagialis, pars  
brevis tendon

Extensor metacarpi  
radialis

Pronator superficialis

Superficial ulnar artery

Deep radial artery

Brachialis

Median nerve

Ulnar  
nerve

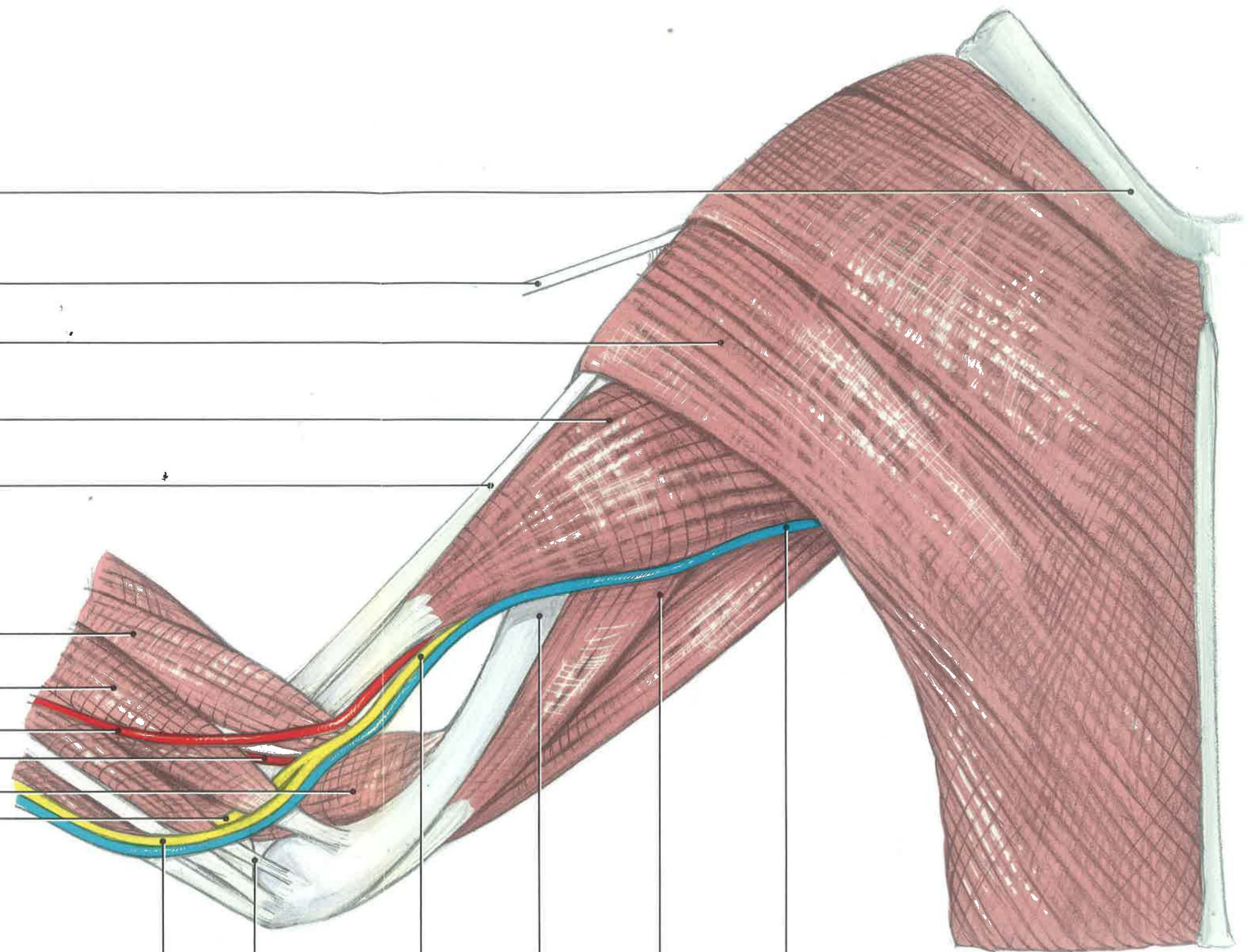
Pronator  
profundus  
tendon

Medianoulnar  
nerve

Humerus

Triceps  
brachii

Basilic vein



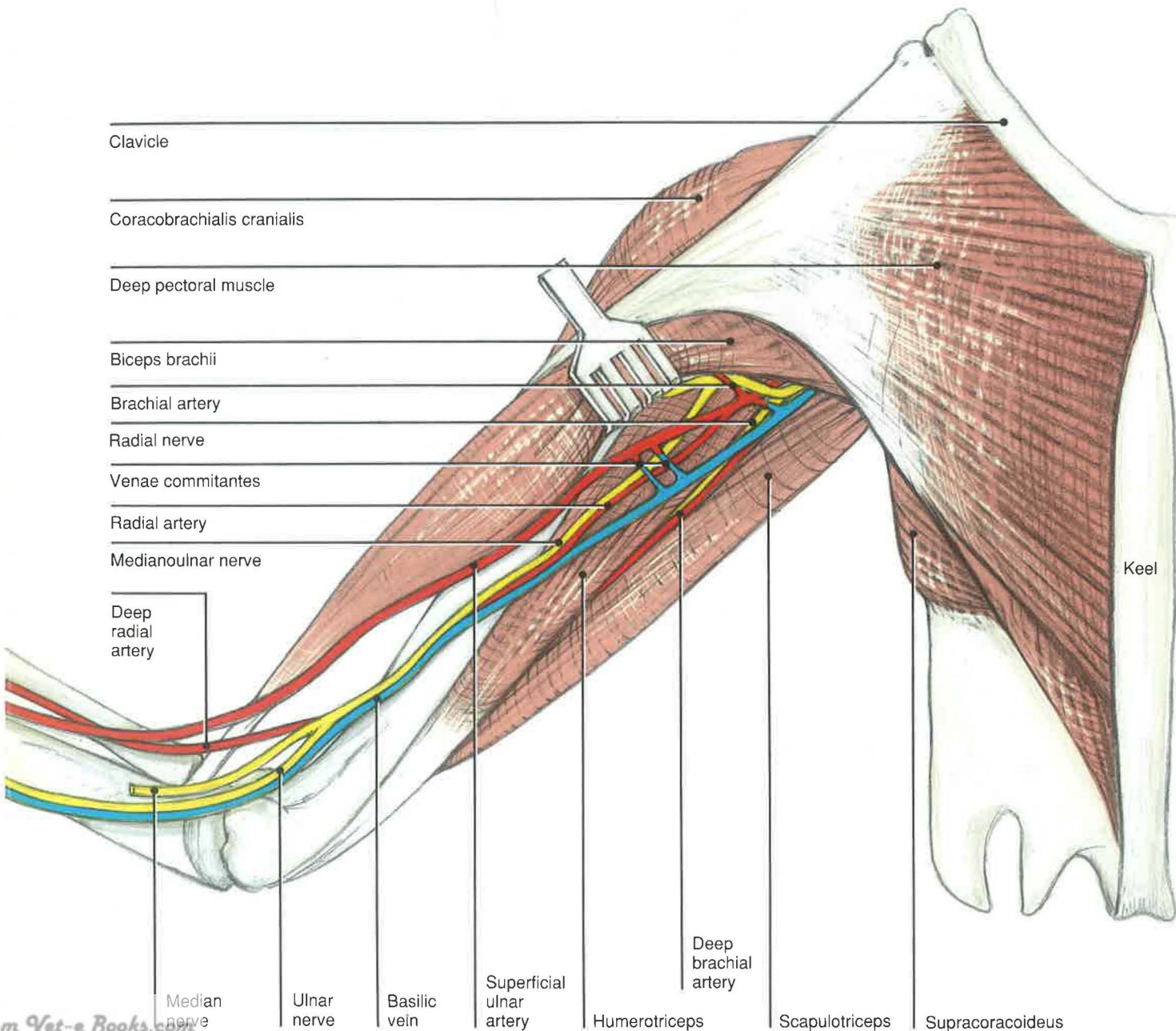
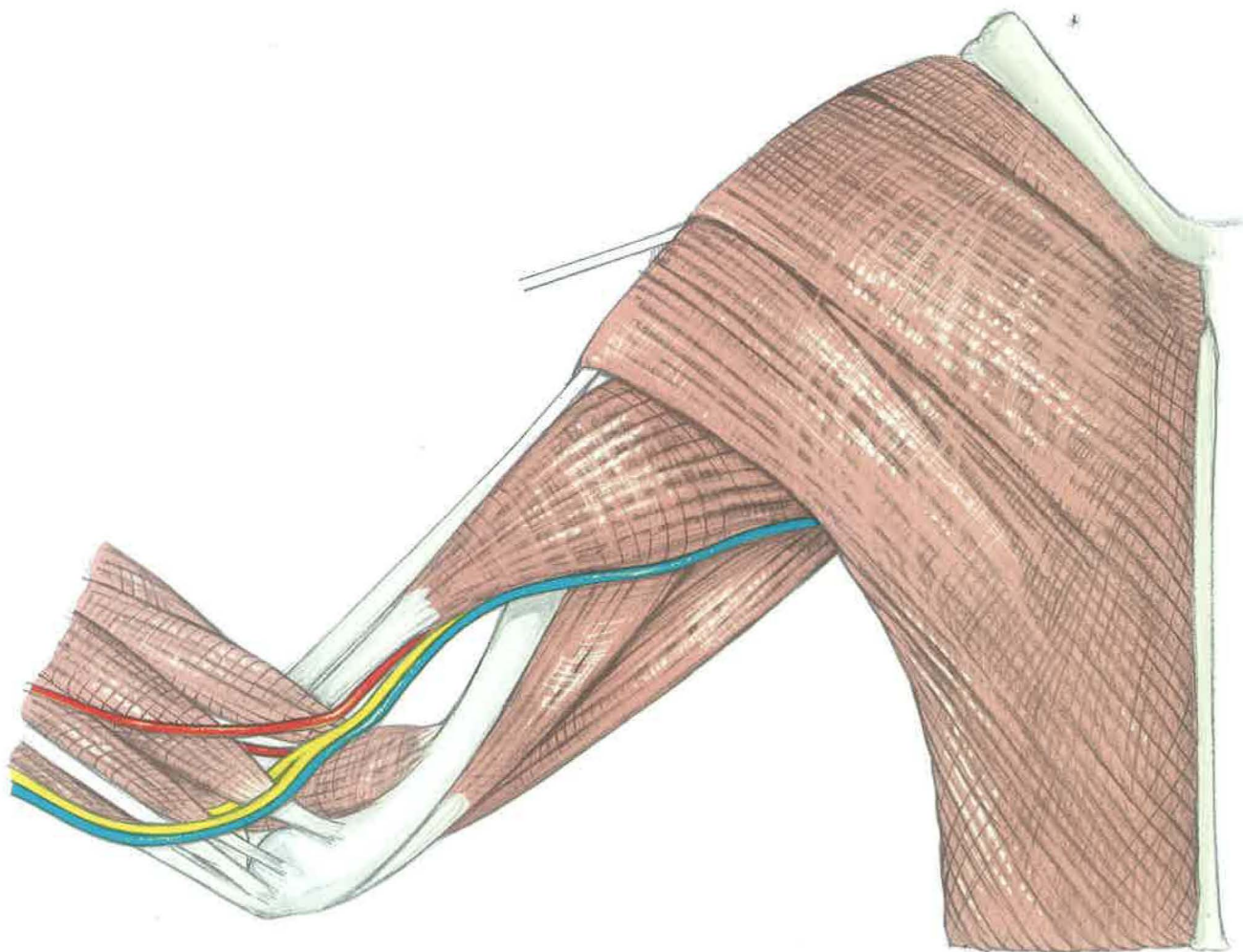



**Ventral Humerus**  
**MIDDLE LAYER**

**Deep pectoral muscle**—The deep pectoral muscle is found in vultures. The muscle originates from the keel and the clavicle, deep to the origin of the superficial pectoral muscle. Although its origin is fleshy, its insertion along the ventral side of the pectoral crest is tendinous. In these birds, the tendon of insertion does not go through the triosseal canal, as described for poultry. Instead, it continues ventrally to the proximal humerus. It is thought that this muscle is responsible for the

forward motion of the wing immediately prior to the downstroke. Psittacines, hawks, and owls do not have a well-defined deep pectoral muscle.

**Blood supply**—The brachial artery gives off the deep brachial artery before dividing into the ulnar and radial arteries. The deep brachial artery runs along the caudal surface of the scapular (long) head of the triceps with the radial nerve.





## Ventral Humerus

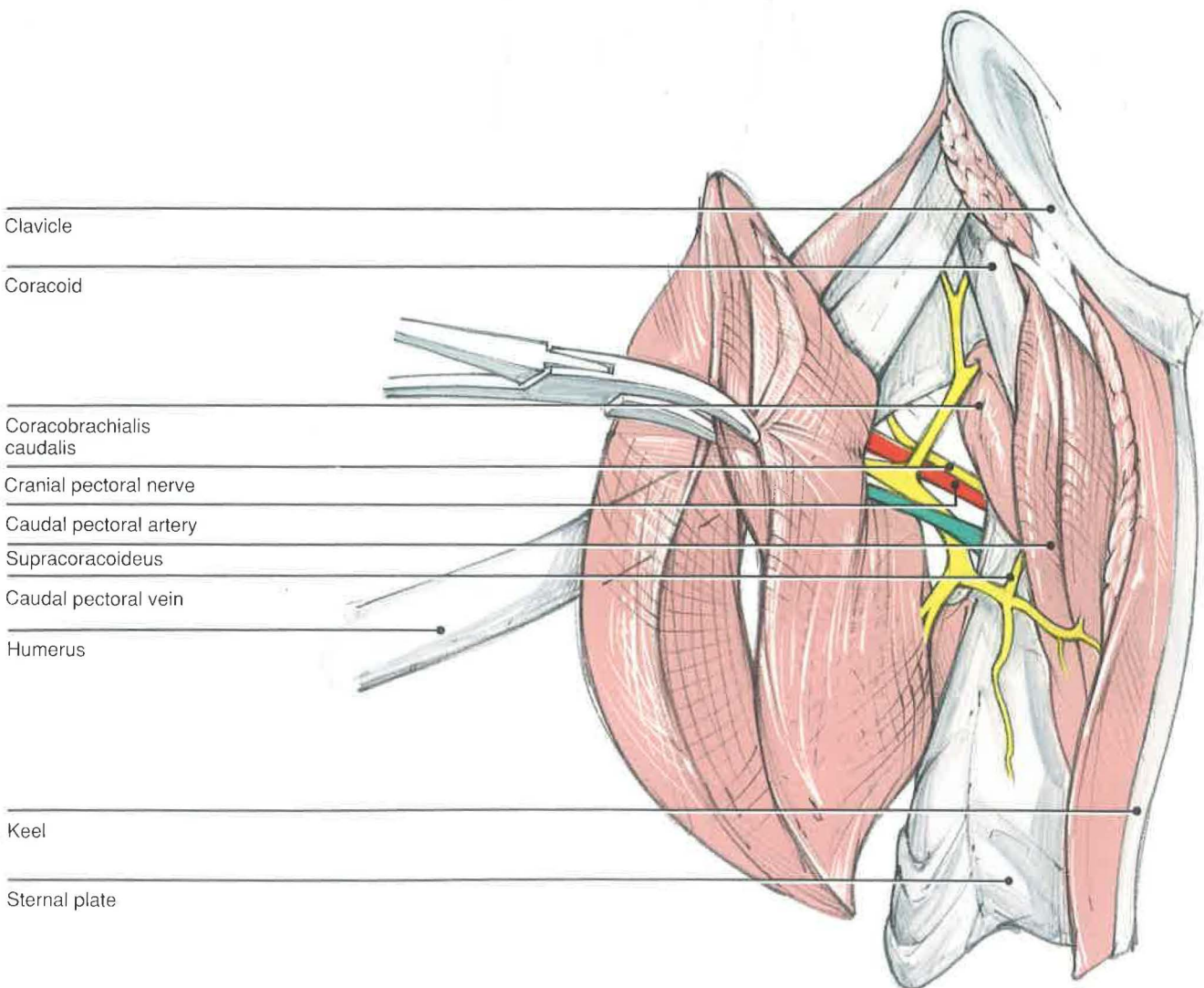
### DEEP LAYER

**Supracoracoideus**—A muscular slip and its accompanying tendon travel through the triosseal canal in a synovial sheath to insert on the dorsal tubercle of the humerus. This muscle is extensive in psittacines, because it covers a large area of the keel. By traversing the triosseal canal, the supracoracoideus produces a pulley effect that raises the wing during the upstroke.

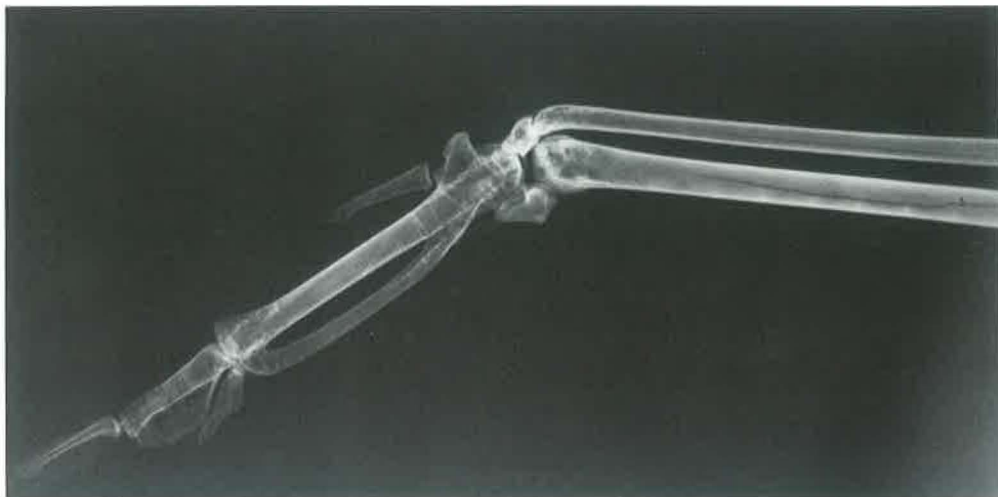**Coracobrachialis caudalis** [*coracobrachialis ventralis*]—This short, thick muscle covers the ventrolateral surface of the coracoid and inserts on

the ventral tubercle of the humerus. Although it may help to depress the wing, its mechanism of action remains controversial.<sup>2,3</sup>

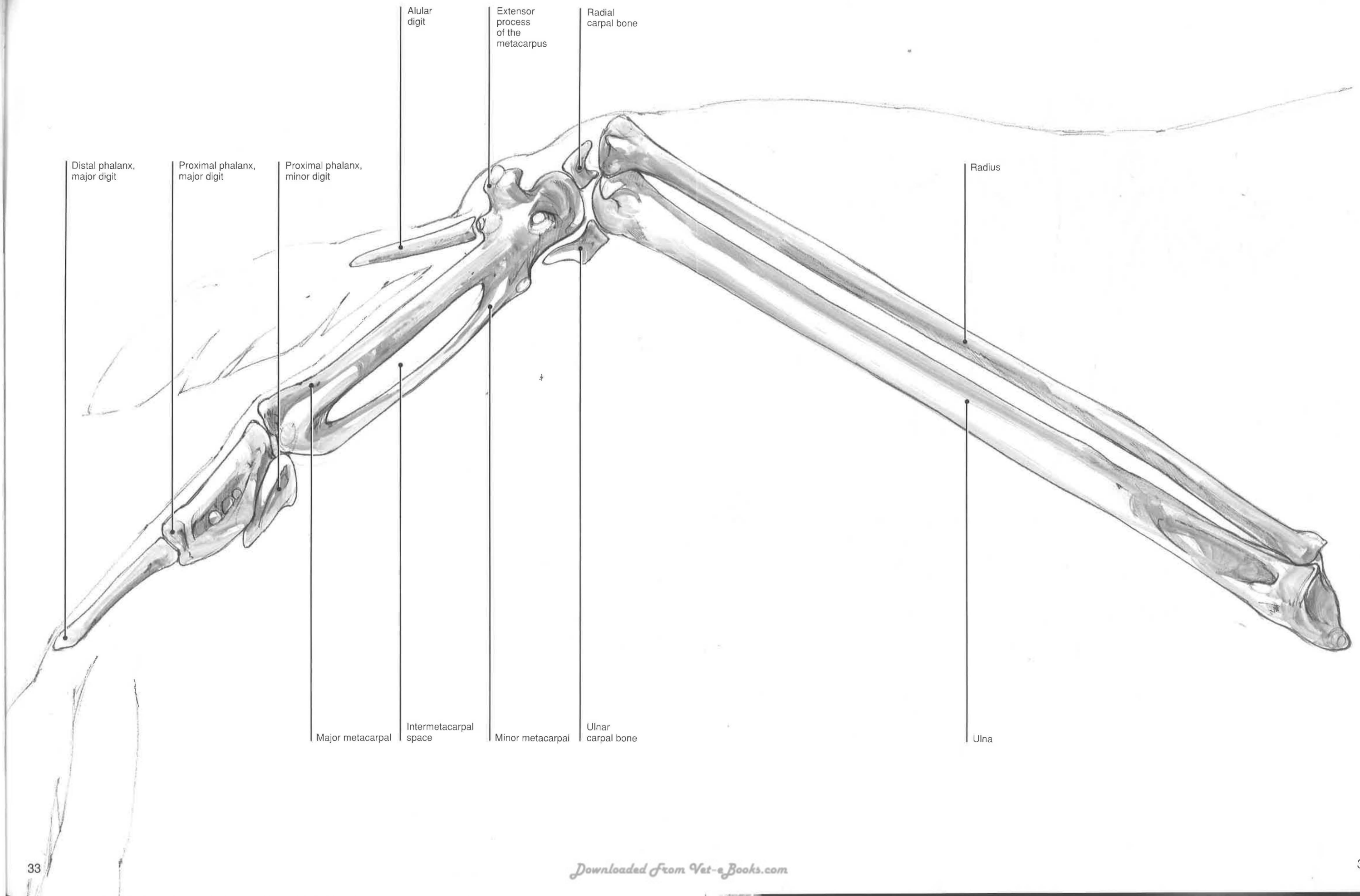
**Blood supply and innervation**—The vessels shown in this dissection represent muscular branches to the pectorals from the subclavian artery and vein. They are divided into pectoralis cranialis, medialis, and caudalis in the *Nomina Anatomica Avium*.<sup>4</sup> The muscular branches of the pectoral nerves [*n. pectoralis cranialis* and *caudalis*] arise from the brachial plexus.



## Ventral Distal Skeleton







## Ventral Thoracic Limb

### SUPERFICIAL LAYER

**Pronator superficialis and profundus** [*pronator brevis and longus*]  
—These muscles originate on the ventral epicondyle [*epicondylus ventralis*] of the humerus and insert onto the radius. By pronating the wing, they depress the cranial edge.<sup>2</sup>

**Flexor carpi ulnaris**—The flexor carpi ulnaris has been described as having three<sup>2</sup> or two<sup>3,4</sup> muscle bellies. It is probably more convenient to describe this muscle as having two muscle bellies that insert onto the ulnar carpal bone. It functions to flex the elbow and carpal joints.<sup>2</sup>

**Flexor digitorum superficialis**—The muscle and tendon cranial to the flexor carpi ulnaris collectively form the flexor digitorum superficialis. It crosses the carpus to insert onto the base of the distal phalanx of the major digit. When the wing is in full extension, the muscle may flex the distal end of the wing ventrally.<sup>3</sup> However, it may act to extend the wing.<sup>2</sup>

**Flexor digitorum profundus**—This flexor originates from the palmar surface of the ulna and inserts onto the distal phalanx of the major digit. The muscle flexes the metacarpus and may also depress and extend the major digit. These actions are important for flex gliding.<sup>2</sup>

**Extensor longus digiti majoris**—This muscle originates on the ventral side of the radius but crosses the carpus to insert dorsally on the distal phalanx of the major digit. Associated with the tendon of insertion is a small muscle, the extensor brevis digiti majoris, on the dorsum of the metacarpus. The combined muscle and tendon extend the major digit and the carpus.<sup>2</sup>

**Abductor digiti majoris**—This muscle lies between the tendons of the flexor digitorum profundus and the superficialis. It is a small muscle on the palmar side of the metacarpus that inserts on the base of the major digit. The abductor depresses the major digit ventrally and extends it.<sup>2</sup>

**Abductor alulae**—This tiny muscle is the most cranial muscle on the palmar side of the carpus. It originates from the inserting tendon of the extensor metacarpi radialis and extends the alula.<sup>3</sup>

**Flexor alulae**—The muscle lies next to the abductor. It is important in keeping the alula against the metacarpus, as well as in flexing the digit.<sup>2</sup>

**Interosseous dorsalis and ventralis**—These two muscles lie in the intermetacarpal space. The dorsal muscle extends the major digit owing to its insertion onto the cranial surface of the bone. The caudal insertion of the ventralis results in an opposing action for this digit.

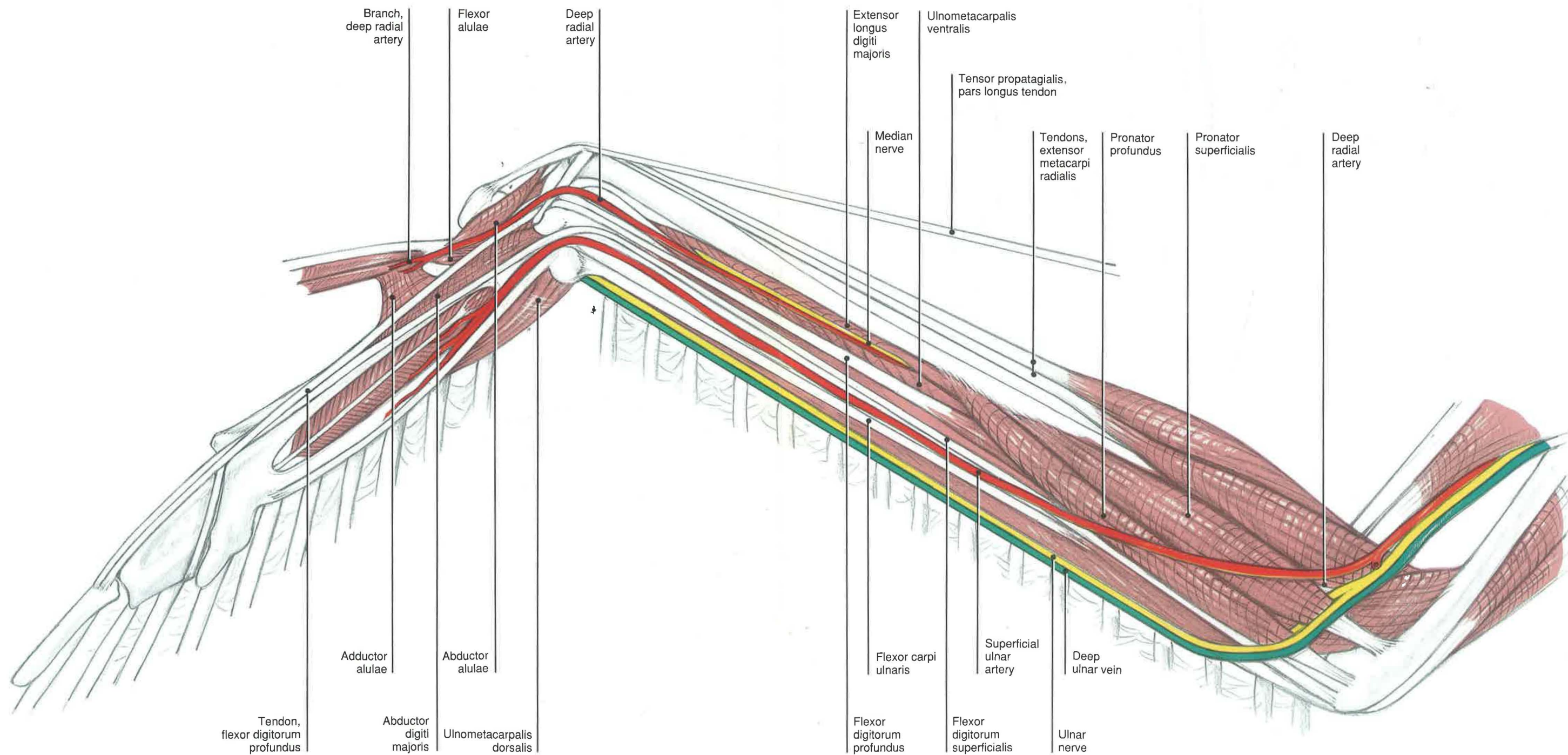
**Blood supply**—In the elbow region, the recurrent ulnar artery [*a. recurrens ulnaris*] branches from the ulnar artery. The recurrent ulnar artery continues distally between the cranial and caudal parts of the flexor carpi ulnaris as the deep ulnar artery [*a. ulnaris profundus*]. The ulnar artery continues as the superficial ulnar artery [*a. ulnaris superficialis*], which provides most of the vascular supply to the manus. The artery that runs along the caudal, palmar surface of the radius is the deep radial artery.

Usually several veins are associated with a small, deep ulnar artery. These provide the majority of the venous drainage to the manus and antebrachium. Several small venous branches accompany the superficial ulnar artery.

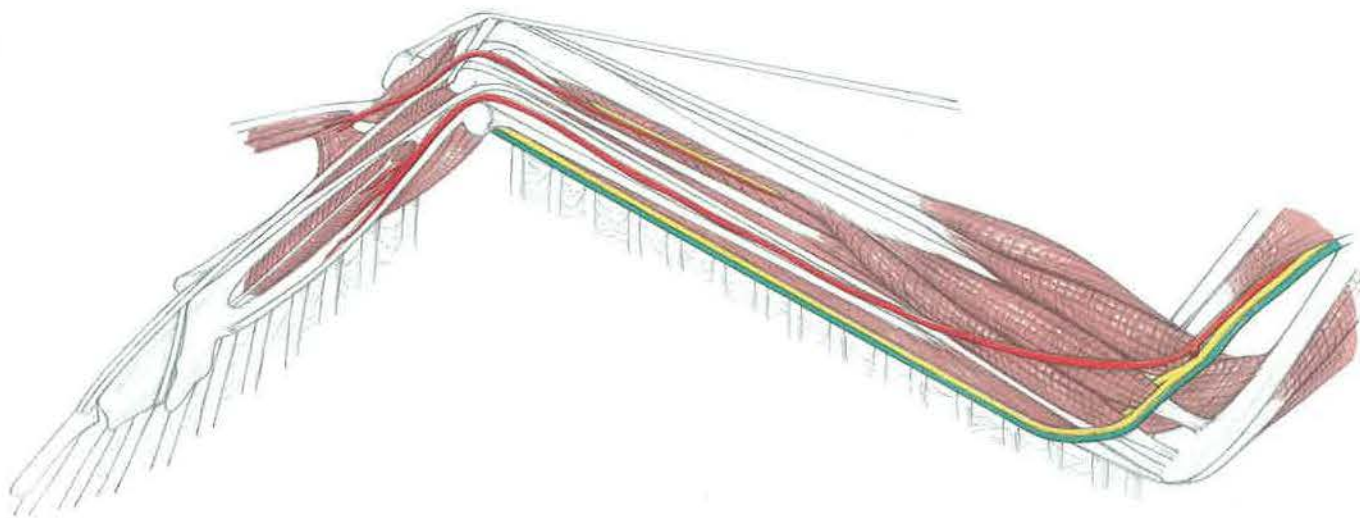
The superficial ulnar artery crosses the carpus and divides into several branches. One of these dives deep to the interosseous ventralis along the cranial border of the minor metacarpal bone. However, its location may vary among species. The arterial supply to the alula comes from the deep radial artery.













## **Section II**

### **Surgical Approaches to the Thoracic Girdle and Limb**

**Coracoid and Clavicle**  
**VENTRAL APPROACH**

**Indications**

The ventral approach is used for the open reduction and internal fixation of fractures of the coracoid and clavicular bones. The clavicle is more superficial than the coracoid and therefore is easier to approach surgically. Most commonly, cerclage wires are used to limit axial rotation.

**Procedure**

A) The bird is placed in sternal recumbency and the feathers are plucked over the ventral keel to reveal the proximal humerus and the area proximal to the clavicle on the neck.

B) The skin is incised just lateral to the clavicle and keel. In this drawing, the skin is reflected liberally for illustrative purposes.

C) The incision line is continued through the superficial pectoral muscle for its reflection from these bones. This reveals the more medial deep pectoral muscle that is found in cathartidae. Hawks, owls, and psittacines have a large pectoral mass that is not subdivided. Cranial and caudal pectoral vessels and nerves will be seen coursing between the superficial and deep pectoral muscles.

D) The incision line should be continued through the origin of the deep pectoral muscle. Reflection of this muscle provides a more complete exposure of the clavicle. At this point, the muscles surrounding

the coracoid bone are visible. The larger muscle, which takes its origin from the sternal plate, is the supracoracoideus. This muscle has a tendon that travels through the triosseal canal. The deeper, smaller muscle is the coracobrachialis caudalis. An incision between these two muscles with their reflection can increase the exposure of the coracoid bone. The pectoral vessels and nerves are found deep to the coracobrachialis caudalis, where they arise from the external thoracic artery and brachial plexus more medially. The head of the humerus will be deep to the coracoid bone.

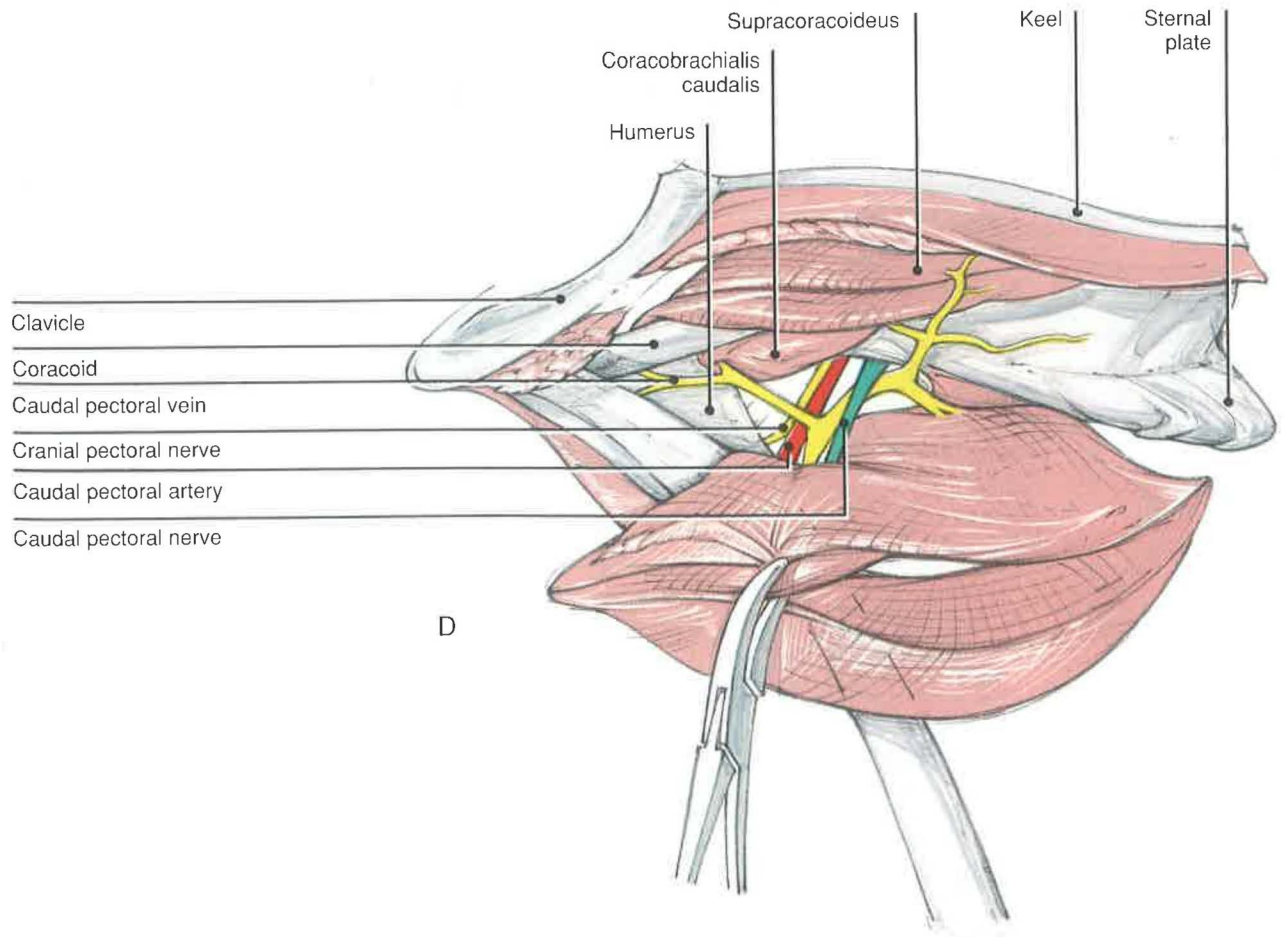
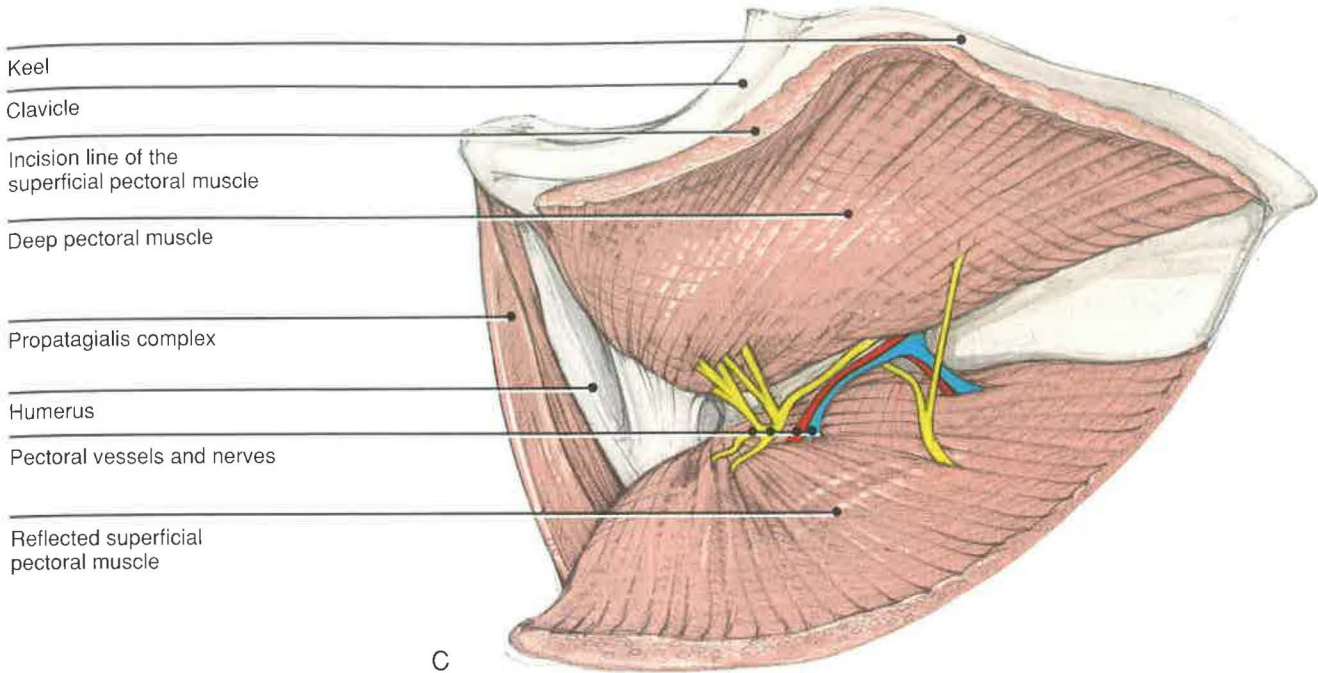
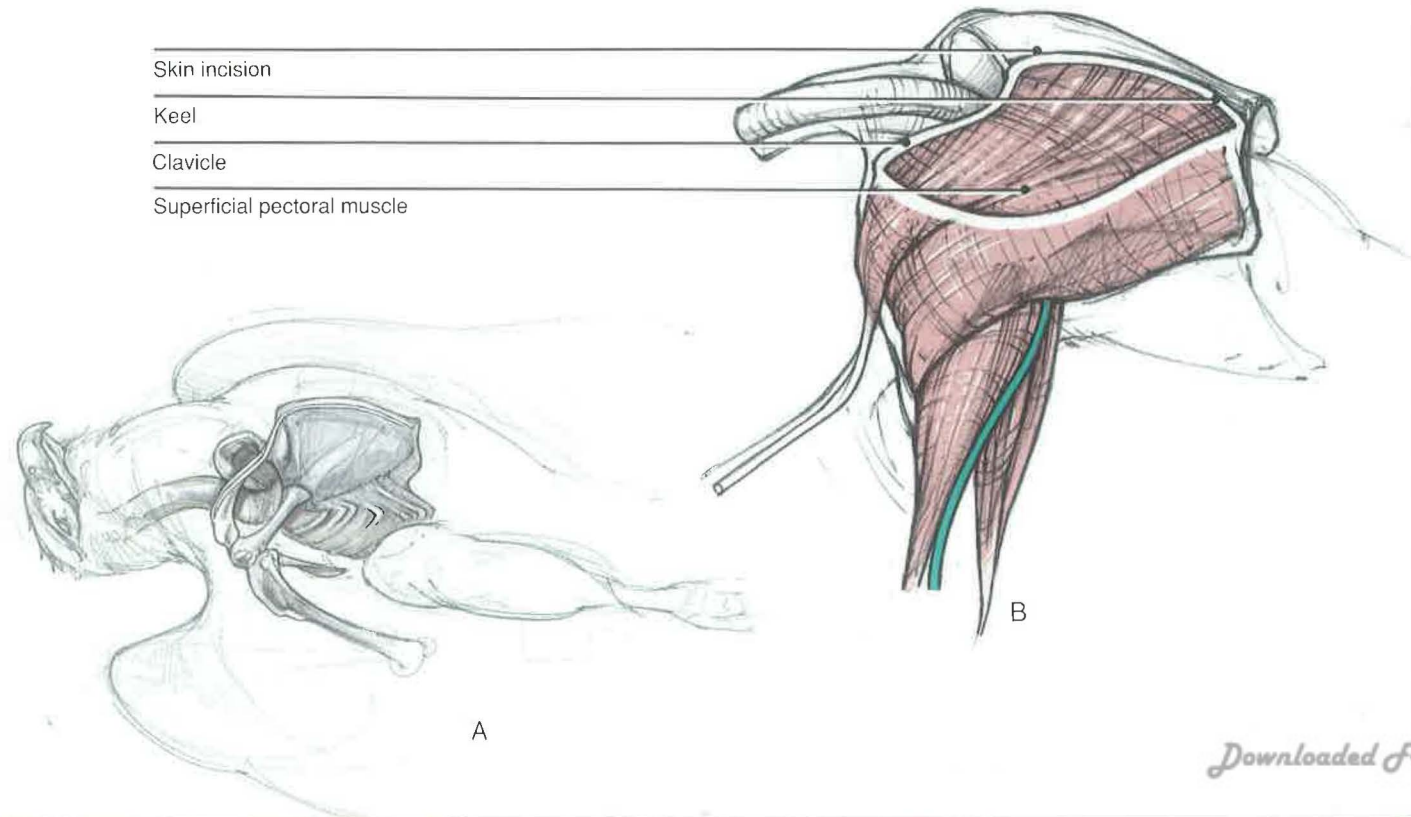
**Closure**

The supracoracoideus and coracobrachialis caudalis muscles should be sutured together if reflected. The deep and superficial pectoral muscles are sutured to their fascia of origin or periosteum as separate layers. The skin is closed separately.

**Comments**

If the species is known to feather pick, the bird should be bandaged postoperatively. Bandages should be changed as necessary.

The central area of the keel can be used as a site for graft material. Harvesting requires the reflection of the superficial and deep pectoral muscles from both sides of the sternum. The supracoracoideus must also be reflected from its origin from the sternum.





## Proximal Humerus

### DORSAL APPROACH

#### Indications

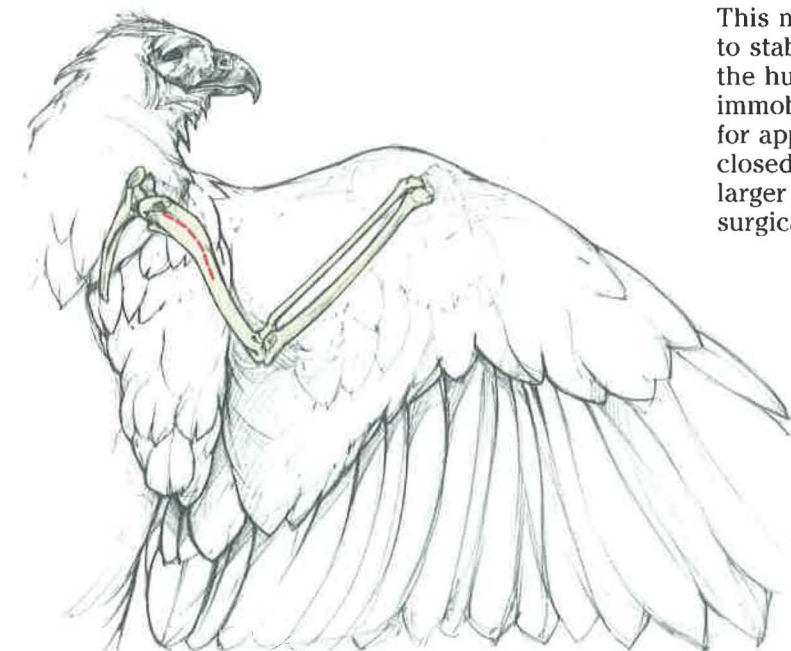The dorsal approach is used for the open reduction and internal fixation of the proximal one third of the humerus. Stacked pins are retrograded out the pectoral crest and normograded into the cortex of the ventral humeral condyle.

#### Procedure

A) The bird is placed in sternal recumbency with the wing in extension. The surgical site is prepared by plucking the proximal humerus. If intramedullary pins are used, the ventral or medial humerus should be plucked as well. The remainder of the wing should be wrapped in a stockinette.

In large birds of prey, the scapular coverts insert into a well-defined fascia that is a continuation of cutaneous costohumeralis. This complex of feathers, fascia, and muscle should be maintained, if possible, because it may be involved in some critical aspects of flight.

B) An incision is made along the shaft of the proximal humerus. In smaller birds of prey, Redig and Roush<sup>11</sup> describe a curvilinear incision that extends from the dorsal tubercle of the humerus down the shaft, as needed, for exposure. However, the propatagialis complex is much more pronounced in larger birds and psittacines, thereby making the exposure of the bone more difficult. The axillary nerve [*n. axillaris*] is found deep to the propatagialis complex in the proximal one third. A



branch of the subscapular artery lies medial and cranial to the nerve. The radial nerve crosses the bone approximately two thirds of the way down the shaft of the humerus, usually near the site of the distal insertion of the deltoideus major.

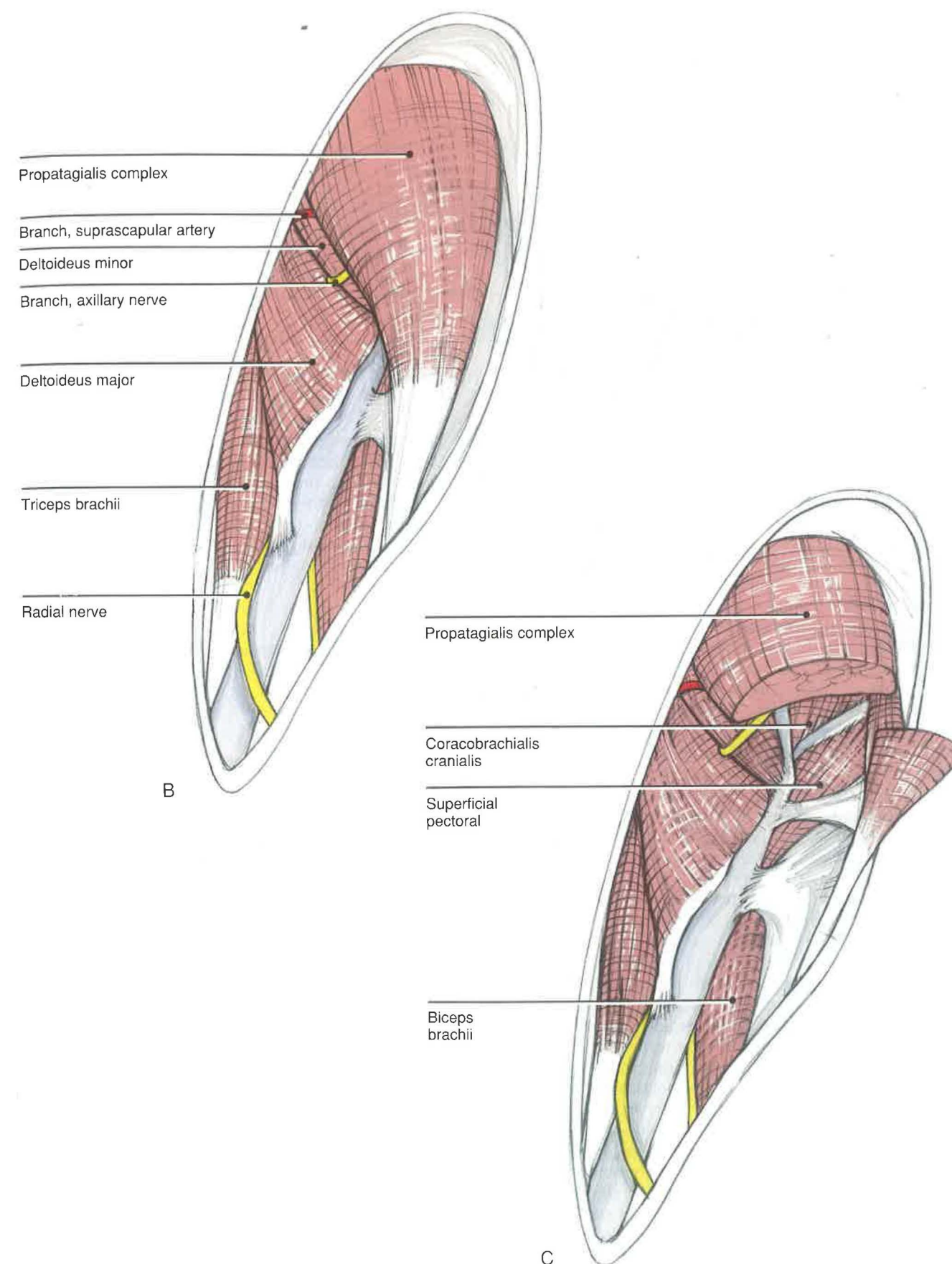
C) The exposure can be increased by transecting the propatagialis muscle in its distal one third and reflecting the stumps proximally and distally. However, care should be taken to avoid cutting the muscular branch of the axillary nerve. Another technique to expose the proximal end of the bone is to split or bluntly dissect through the propatagialis complex in the direction of the fibers. The deltoideus muscles may be retracted proximally after subperiosteal elevation, if necessary.

#### Closure

If the deltoideus muscles are elevated, a hole should be drilled through the humerus to reattach these muscles to the bone. The cut ends of the propatagialis muscle should be sutured together. Redig and Roush<sup>11</sup> suggest that the caudal edge of the deltoideus major be sutured to the triceps muscle; the position of the radial nerve may make this difficult. The skin is then closed as a separate layer. The wing is bandaged postoperatively in flexion, then taped to the body wall for approximately 3 to 4 weeks.<sup>10</sup>

#### Comments

The dorsal approach is much more difficult than the ventral approach, due to the propatagialis complex. This muscle mass may be sufficient, in some birds, to stabilize a fracture in the proximal one third of the humerus. In these cases, the wing is immobilized in flexion and taped to the body wall for approximately 3 to 4 weeks. The prognosis for closed fractures is good.<sup>9</sup> Open fractures in birds larger than budgerigars should be stabilized surgically with intramedullary or stacked pins.<sup>9,10</sup>





**Distal Humerus**  
**DORSAL APPROACH**

**Indications**

The dorsal approach is used for the open reduction and internal fixation of mid-shaft or distal humeral fractures. The mid-shaft or distal humerus may be approached using either a dorsal or a ventral incision. Pins should be individually stacked by retrograding them out of the pectoral crest and normograting them into the humeral condyle.

**Procedure**

A) The bird should be placed in sternal recumbency and the wing extended. Feathers should be plucked along the shaft of the humerus from the pectoral crest to at least the condyle. The proximal radius and ulna may be plucked, as needed.

For mid-shaft fractures, the incision should be made along the bone from the distal end of the proximal third to just proximal to the olecranon fossa (see B). With distal fractures, the incision should extend caudally toward the ventral epicondyle (see C). Directing the incision caudally will prevent ligating the origins of several muscles of the antebrachium and ligating the portion of the tendon of the tensor propatagialis, pars brevis muscle that inserts on the dorsal ulna (see anatomical drawing above the surgical approach drawings). With either mid-shaft or distal incisions, extreme caution is necessary in order to avoid the radial nerve. The nerve should be palpated to determine its location prior to making the skin incision. It crosses the shaft of the bone at the distal insertion of the deltoideus major muscle. Normally, this will be found in the middle third or in the proximal portion of the distal third of the humeral shaft, depending on the species.

B) After reflecting the skin, the distal end of the tendon of the tensor propatagialis, pars brevis muscle and the biceps brachii muscle are found cranial to the humerus. The wide, muscular insertions of the deltoideus major and the triceps brachii muscles are found along the caudal surface of the shaft. The radial nerve emerges between the distal margin of insertion of the deltoideus major and the triceps brachii as it runs along the caudal border of the humerus. The radial nerve must be handled carefully and kept moist with sterile saline.

C) To expose the distal end of the humerus, the incision should be extended caudally toward the ventral epicondyle. Reflection of the skin reveals three tendons originating from muscles of the antebrachium. The cranialmost tendon is from the extensor metacarpi radialis muscle. The second

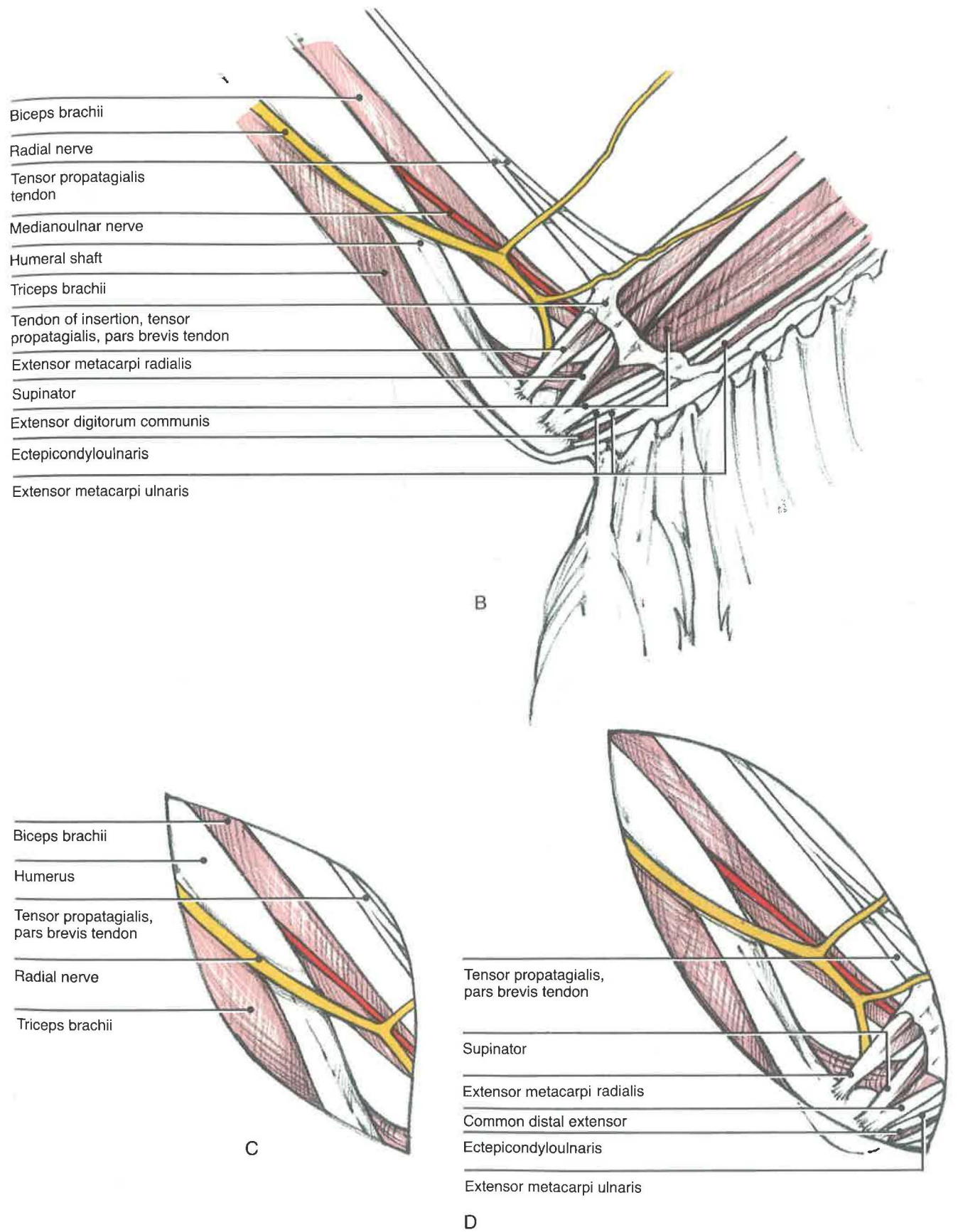
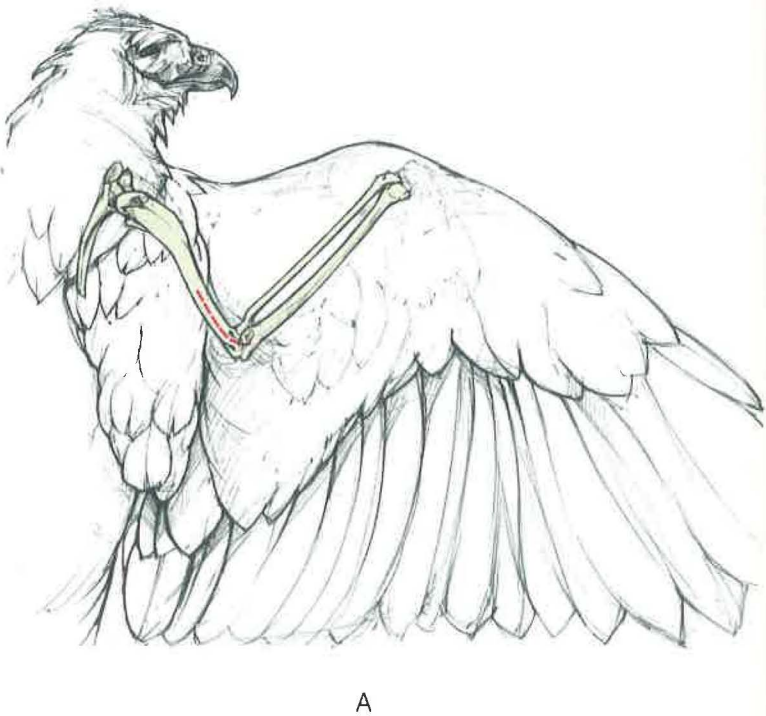
tendon of origin actually represents tendons from the supinator and the extensor digitorum communis or common digital extensor muscles. The caudalmost tendon of origin represents the tendon from the extensor metacarpi ulnaris or ulnaris lateralis muscle and the muscular slips from the ectepicondyloulnaris or anconeus. Slightly more distal on the antebrachium are the tendinous insertions of the tensor propatagialis, pars brevis muscle.

**Closure**

The skin, with its tightly applied superficial fascia, is closed as a single layer. Care should be taken to avoid damage to the radial nerve. The wing should be bandaged in flexion using a figure-of-eight technique and then taped to the body wall (see Section V). Once there is evidence of stability, the bandage holding the wing to the body wall may be removed. Figure-of-eight bandage changes and evaluation of joint mobility should be done at least weekly, particularly when full flight potential is a goal.

**Comments**

Distal humeral fractures that are distracted require surgical repair (see Distal Humerus, Ventral Approach).





## Distal Humerus

### VENTRAL APPROACH

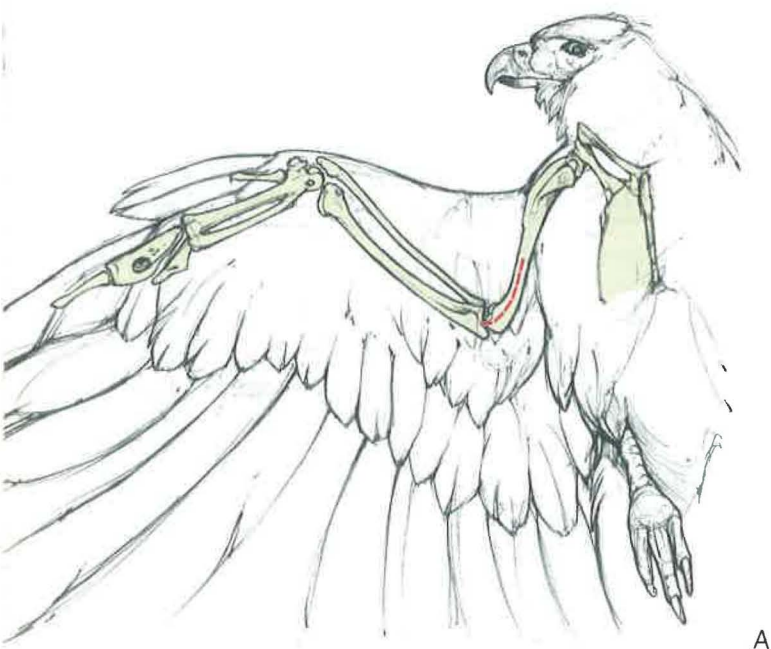#### Indications

The ventral approach is used for the open reduction and internal fixation of the humerus when fractured in the distal two thirds. Stacked pins are retrograded out the middle of the pectoral crest of the humerus and normograded into the ventral humeral condyle. Cerclage wires may be used to stabilize spiral fractures. This approach may be useful for the open reduction of elbow dislocations and proximal ulnar fractures.

#### Procedure<sup>1</sup>

A) The bird is placed in dorsal recumbency and the feathers are plucked over the distal two thirds of the ventral humerus and over the pectoral crest dorsally and cranially. The remainder of the wing is placed in a stockinette. The skin incision should follow along the shaft of the bone, with careful regard to the structures described in B, below.

B) The biceps brachii should be palpated cranial to the shaft of the humerus. The ulnar and radial vessels and medianoulnar nerve course deep to or on the caudal edge of this muscle. A superficial vein, the basilic vein, runs along the shaft of the bone caudal to these structures. (This vein often is used for blood collection.) To avoid these structures, the skin incision should be made along the belly of the biceps brachii or the shaft of the



A

humerus caudal to the vein. For internal fixation, it is best to continue the incision to the elbow.

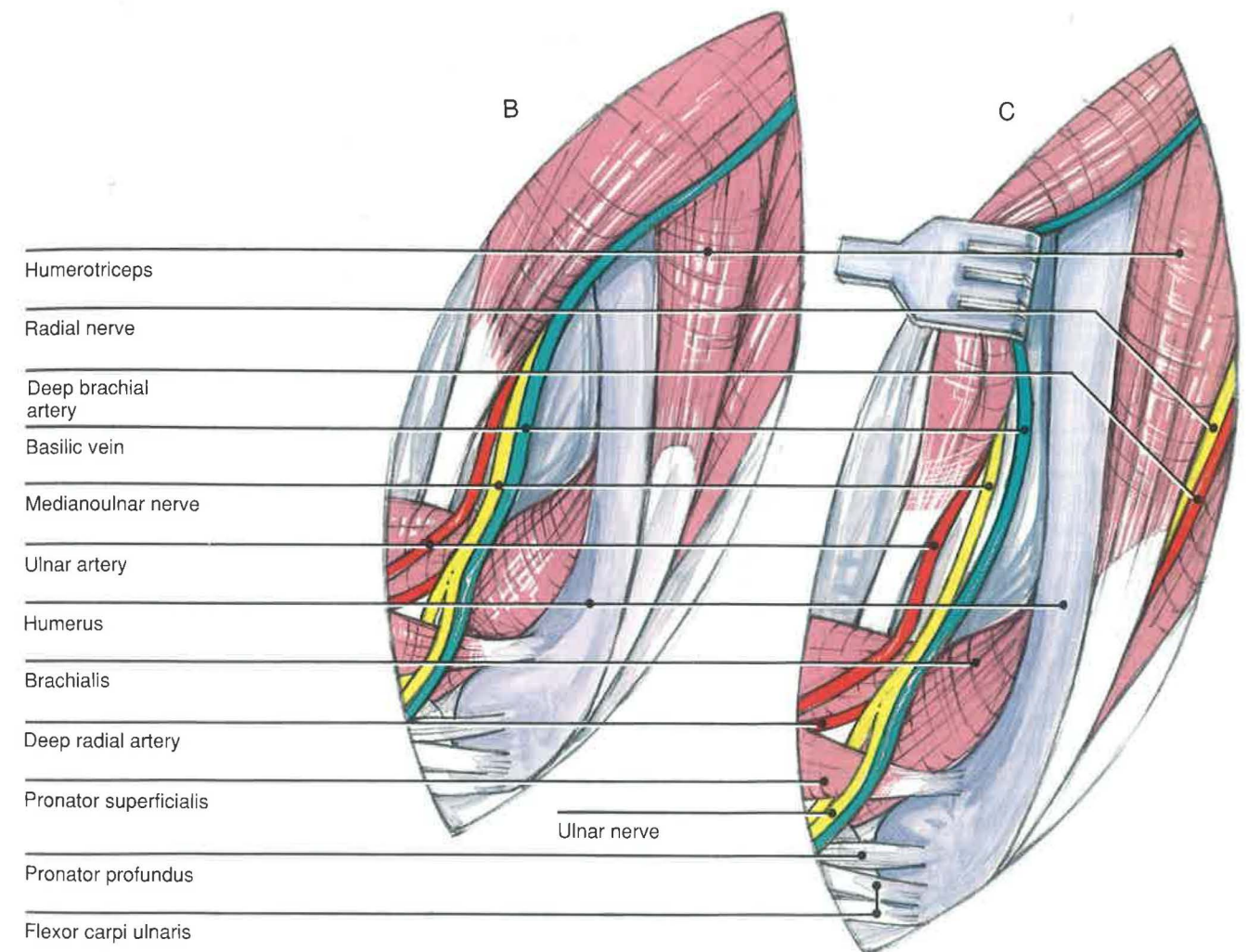
C) The humeral shaft is exposed more completely by elevating and retracting the biceps brachii with the medianoulnar nerve and brachial vessels. The triceps can be retracted caudally for a better exposure. Because of the branching of the vessels and nerves near the elbow, exposure of the joint may prove difficult.

#### Closure

The superficial fascia and skin are closed as a single layer. Following surgery, the wing should be bandaged in flexion with a figure-of-eight dressing and then taped to the body wall (see Section V). The bandage to the body wall should be removed as soon as there is evidence of fracture stability. The figure-of-eight bandage should be removed 1 to 2 weeks thereafter.<sup>9</sup>

#### Comments

Fractures of the humerus usually require surgical intervention because of the instability created by the pull of the powerful pectoral muscles. Mid-shaft fractures are often spiral, with the proximal fragment projecting dorsally and the distal fragment ventrally through the skin. The flexors of the thoracic girdle and elbow joint probably contribute to the distracted fragments and open fracture. Distal humeral fractures are usually flexed due to the pull from the biceps brachii. Stabilization and proper alignment of the humeral fragments are necessary in birds larger than budgerigars. The pin should fill as much of the medullary cavity as possible<sup>9,10</sup>; the curved humeral shaft may make this difficult. Comminuted fractures that are open have a poor to grave prognosis.<sup>9</sup>





## Proximal Radius and Ulna

### DORSAL APPROACH

#### Indications

The dorsal approach is used for fractures of the proximal radius and ulna and for dislocations of the elbow.

#### Procedure

A) The bird is placed in ventral recumbency and the feathers are plucked from the distal humerus to the middle of the antebrachium dorsally.

B) A curvilinear incision should be made over the distal end of the humerus, extending distally between the radius and ulna, as needed for exposure. Care should be taken to avoid cutting branches of the radial nerve or the insertion of the tensor propatagialis, pars brevis tendon, because it inserts on the ulna dorsally (also note the anatomical drawing above B and C).

C) In order to expose the proximal radius, the supinator muscle will need to be retracted cranially and the extensor digitorum communis or common digital extensor muscle caudally. However, for complete exposure of the proximal radius, the tendon of insertion of the tensor propatagialis, pars brevis muscle will need to be transected between the radius and ulna. The small size of the supinator makes it difficult to separate its muscle fibers for exposure of the head of the radius. Therefore, if the head of the radius must be visualized, the supinator muscle should be transected in its distal third. Before transecting this muscle, the deep radial nerve and its muscular branches to the antebrachium must be identified. They emerge over the neck of the radius, deep to the tendon of origin of the extensor metacarpi radialis and supinator muscles. The nerve continues distally along the caudal border of the radius. Two ligaments are associated with the head of the radius dorsally. The more proximal ligament lies over the meniscus radioulnaris. The ligamentum transversum radioulnare or transverse radioulnar ligament can be found slightly more distal.

D) Exposure of the proximal ulna is less difficult than that of the radius. An incision should be made between the retinaculum of the extensor metacarpi ulnaris (also known as the ulnaris lateralis) and the muscle itself. Because the portion of the tendon of the tensor propatagialis, pars brevis muscle that goes to the dorsal ulna inserts onto this retinaculum, it may be severed if exposure of the ulna is continued to or beyond that point. Care should be taken to avoid a branch of the deep radial nerve and interosseous dorsalis artery and vein, if possible. This neurovascular bundle emerges

along the caudal border of the extensor metacarpi ulnaris muscle and divides into two branches that run along the caudal surface of the ulna. The tendon of the triceps brachii muscle inserts onto the head of the ulna and should be identified. The ulnar bone can be exposed by retracting the extensor metacarpi ulnaris muscle cranially and its retinaculum caudally. The feather follicles may be cut and elevated subperiosteally for greater exposure of the bone. However, this should be performed only when necessary.

#### Closure

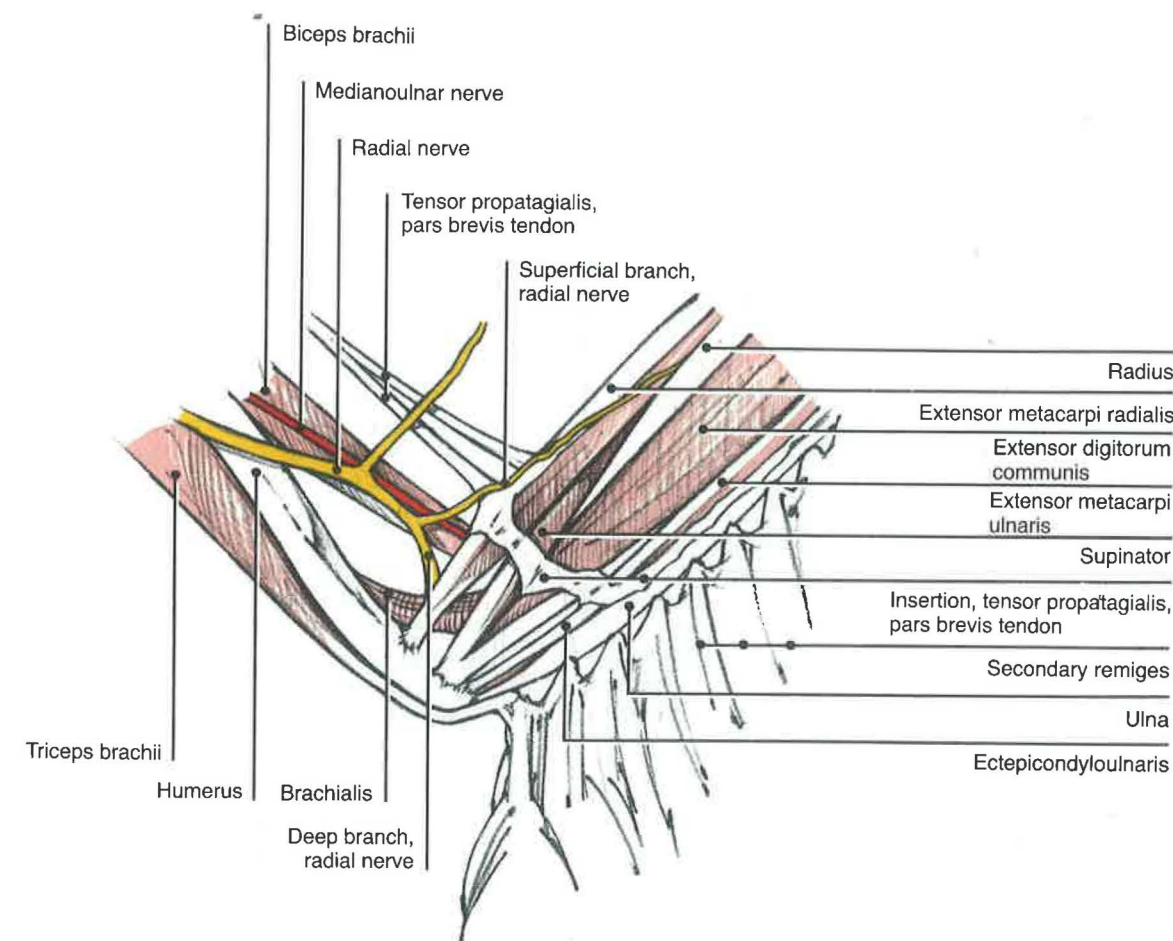
If the supinator muscle has been transected, it should be re-apposed. The retinaculum of the extensor metacarpi ulnaris may be sutured to its respective muscle, if it was incised. The cut ends of the tensor propatagialis tendon should be sutured. The wing should be bandaged in flexion and, if necessary, taped to the body wall (see Section V).

#### Comments

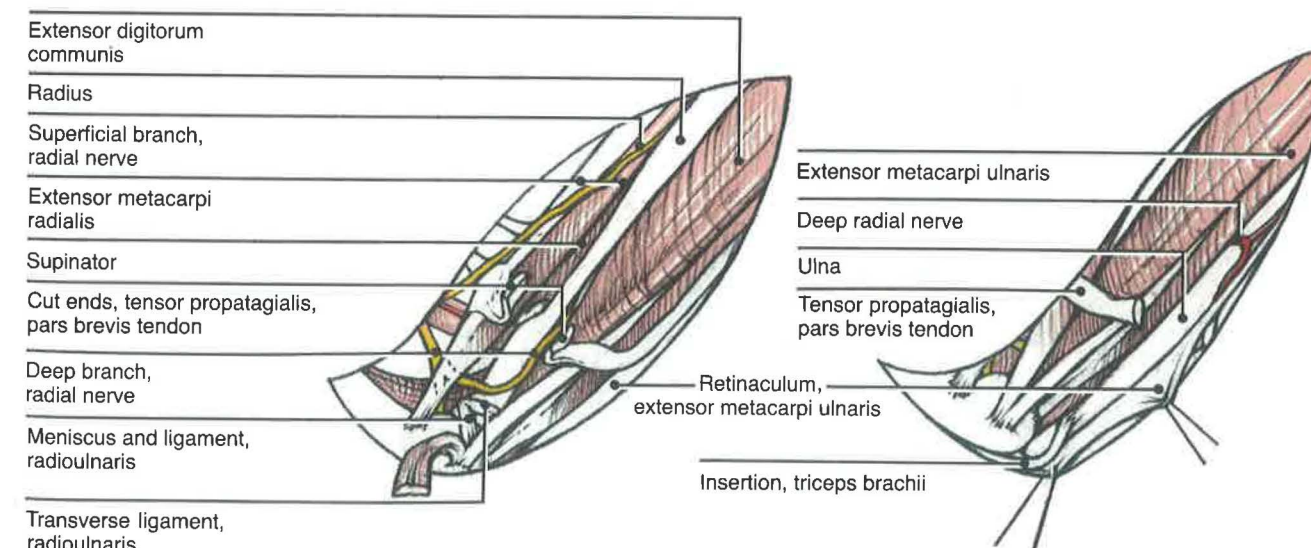
The dorsal approach avoids the various nerves, arteries, and veins that cross and branch at the elbow joint ventrally.



A



B



C

D



## Distal Radius and Ulna

### DORSAL APPROACH

#### Indications

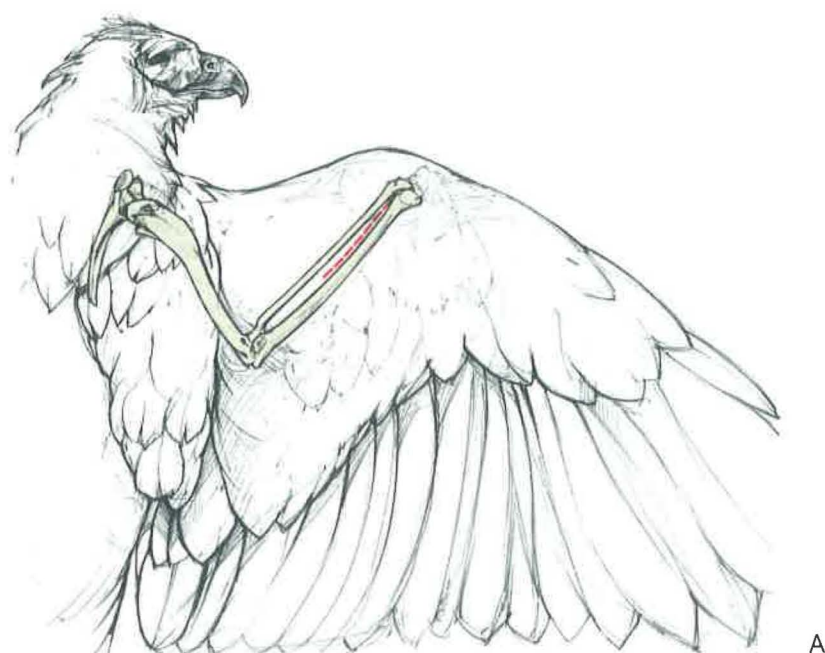
The dorsal approach is used for the open reduction of fractures of the radius and ulna and dislocations of these bones. The degree of curvature of the distal radius and ulna should be kept in mind when deciding on the orthopedic technique to be used.

#### Procedure

A) The bird is placed in sternal recumbency. The feathers are plucked along the length of the bone, leaving the secondaries intact. The skin incision should be made between the radius and ulna, because a deep branch and a superficial branch of the radial nerve run along the caudal margin of the radius and along the cranial margin of the ulna, respectively.

B) The extensor metacarpi radialis runs along the cranial surface of the radius and can be retracted if necessary. The muscle and tendon of the extensor metacarpi ulnaris are found on the dorsal surface of the ulna and also can be retracted, if necessary.

C) In order to repair the ulna, it may be necessary to remove the secondary remiges. In these instances, Redig and Roush suggest cutting the calamus at the base between the bone and the skin to avoid damage to the follicle.<sup>11</sup>



A

#### Closure

The skin should be closed as a single layer. The wing is gently folded and wrapped in a flexed position. It is taped to the body wall for approximately 2 to 3 weeks, with bandage changes as necessary.

#### Comments

If only one of the bones has been fractured, the remaining intact bone can act as a stabilizing brace. The prognosis usually is good for these cases, except when the fracture occurs close to a joint. The wing is wrapped in flexion as described above.

An intramedullary pin or modified Kirschner-Ehmer (K-E) apparatus (see Section V) is required when both the radius and ulna have been fractured. However, introduction of an intramedullary pin will commonly invade either the elbow or carpal joints. For this reason, Redig prefers a modified K-E apparatus, except with severe comminution.<sup>10</sup> A shuttled polyethylene pin cross-pinned with K-E wires can be used for stabilization, to avoid damaging joints. These wires are stabilized by orthopedic tape or resin polymer after the wing is gently folded against the body wall (see Section V). The wing should be bandaged postoperatively for 10 days and then maintained for the remainder of the healing period with the external fixation device.<sup>8,10,11</sup>

Cutting secondary feather follicles at the base of the ulna

Retraction of the extensor metacarpi radialis tendon

B

Extensor metacarpi radialis  
Extensor metacarpi ulnaris  
Supinator  
Extensor digitorum communis  
Ectepicondyloulnaris  
Tensor propatagialis, pars brevis tendon

C



## Radius

### VENTRAL APPROACH

#### Indications

The ventral approach is used for internal fixation of radial fractures. Fractures of the proximal radius or ulna and elbow dislocations may best be approached dorsally (see Proximal Radius and Ulna, Dorsal Approach).

#### Procedure

A) The bird is placed in dorsal recumbency and the feathers are plucked along the ventral antebrachium. The superficial ulnar artery should be palpated distal to the elbow joint.

B) The incision should begin just distal to this vessel and continue along the caudal border of the radius, extending distally along the shaft as needed for exposure.

C) Reflection of the skin will reveal a number of important structures. The pronator superficialis and profundus muscles insert along the caudal border of the proximal radius. The extensor longus digiti majoris muscle, its accompanying tendon, and the ulnometacarpalis ventralis muscle run along the caudal border of the radius. The median nerve and deep radial artery run on the cranial surface of the former muscle. The tendons of the deep and superficial digital flexor muscles are found caudal to the ulnometacarpalis ventralis muscle, with the superficial tendons most caudal. The muscle bellies and tendons of the flexor carpi ulnaris cover the ulnar surface ventrally, making it difficult to approach this bone surgically from this direction.

Proximally, a number of nerves, arteries, and veins must be identified when working in this area. The medianoulnar nerve divides into median and ulnar nerves distally along the shaft of the humerus ventrally. The median nerve courses between the extensor metacarpi radialis and pronator

superficialis muscles, while the ulnar nerve crosses the elbow joint more distally, where it runs along the caudal border of the ulna. The superficial ulnar artery may give off a deep radial branch before continuing between the radius and ulna. In some birds (gallinaceous birds and cathartidae), the vessel remains superficial, while in various hawks the vessel dives deep to the flexor tendons and emerges cranial to these structures at the carpus. The basilic vein runs medial to the medianoulnar and ulnar nerves.

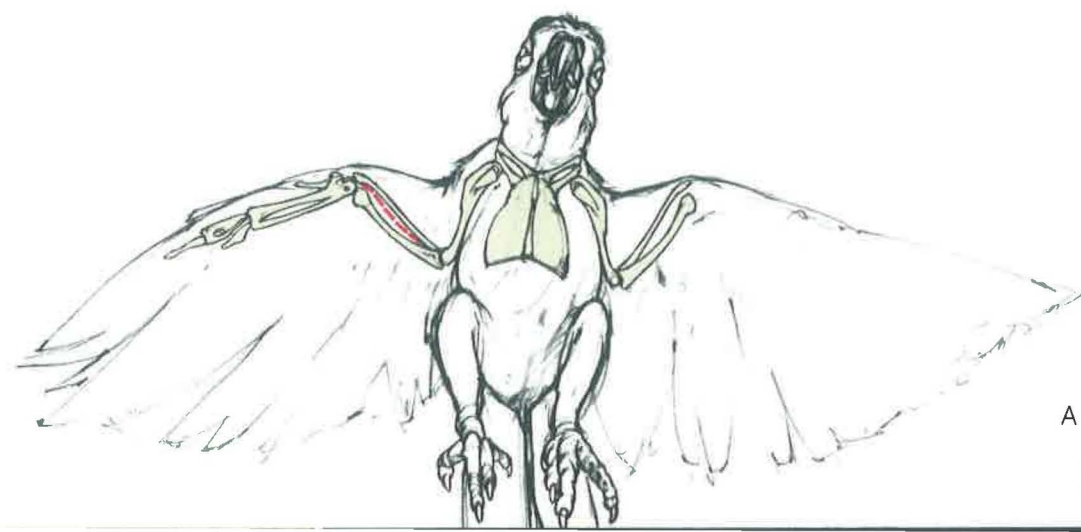
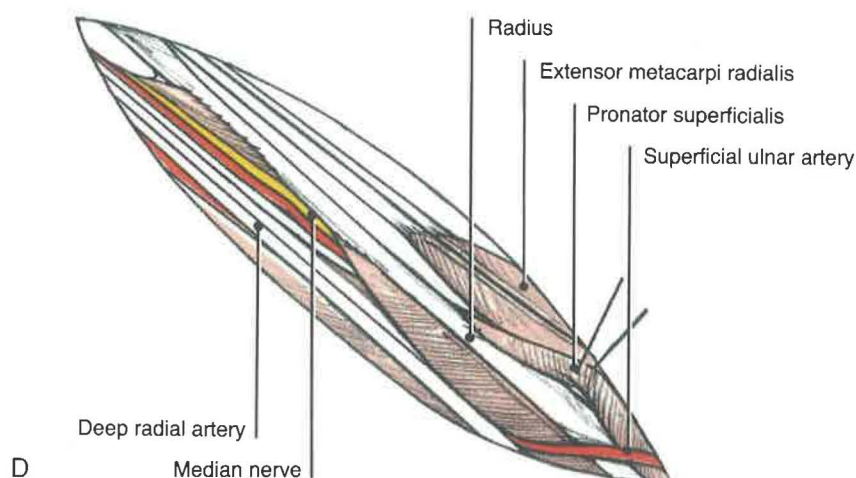
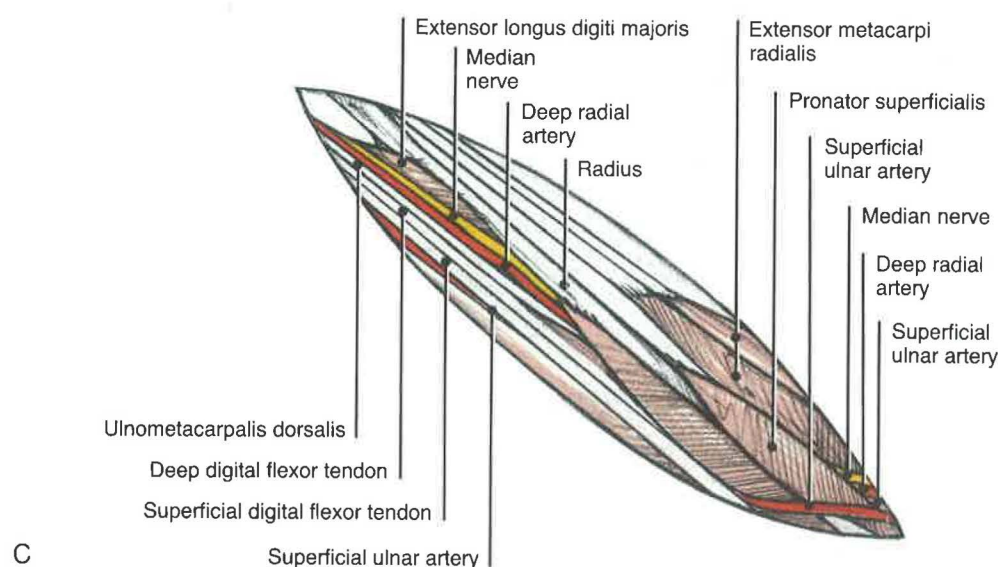
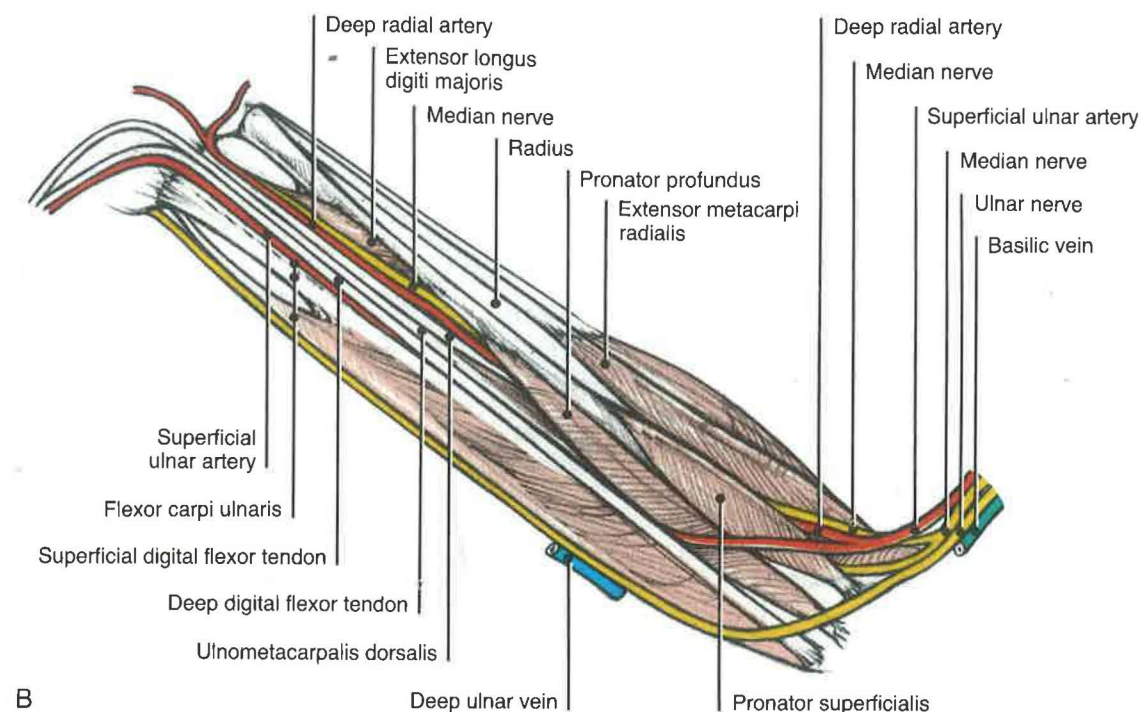
D) In order to expose the proximal shaft of the radius, the belly of the pronator superficialis must be reflected cranially away from the pronator profundus. The superficial ulnar artery must be avoided, because it crosses the radius proximally. Care should also be taken to avoid the deep radial artery, which dives between the extensor metacarpi radialis and pronator superficialis muscles. When one works on the distal end of the bone, the median nerve and deep radial artery on its caudal surface should not be compromised.

#### Closure

The pronator superficialis may be re-attached to the pronator profundus muscle. The skin and superficial fascia should then be closed as a single layer. The wing should be bandaged in flexion using a figure-of-eight technique (see Section V). The wing should be taped to the body wall for several weeks or until evidence of healing is determined radiographically. Bandages should be changed as needed; they should also be loosened periodically to prevent ankylosis of the immobilized joint.

#### Comments

See pages 50 and 52 See dorsal approaches to the proximal and distal radius and ulna





## Metacarpus

### VENTRAL APPROACH

#### Indications

The ventral approach is used for the open reduction of metacarpal fractures in large birds and for carpal dislocations. (Nonunions are more likely with these types of fractures.) Intramedullary pins or modified K-E devices may be used for fracture repair but may also lead to a nonunion.

#### Procedure

A) A ventral approach is preferred, due to the insertion of the primaries on the dorsal surface of the metacarpal bone. The bird is placed in dorsal recumbency and the feathers are plucked on the ventral surface of the metacarpal bones.

B) The incision line should be made carefully between the two metacarpal bones.

C) Two major tendons lie on the palmar surface of the partially fused metacarpal bones. The most cranial is the flexor digitorum profundus, while the flexor digitorum superficialis is caudal and runs diagonally. The abductor digiti majoris muscle lies between these two tendons. The ventral interosseous muscle is found in the intermetacarpal space. The ventral metacarpal artery and vein are sandwiched between this muscle and the dorsal interosseous muscle. The vessels usually run along the cranial border of the minor metacarpal bone but may vary. The continuation of the deep radial

artery and median nerve runs across the metacarpus to gain a position cranial to the major metacarpal bone.

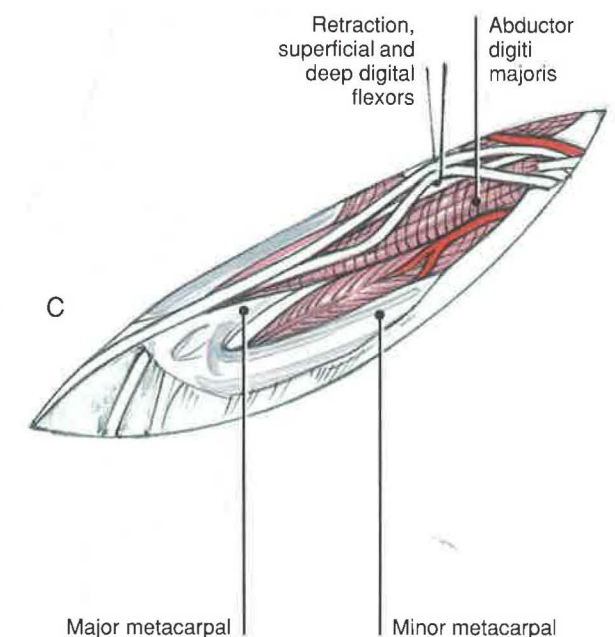
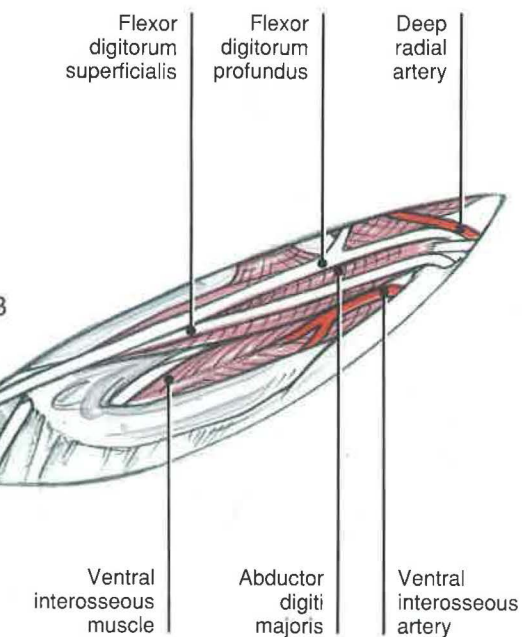
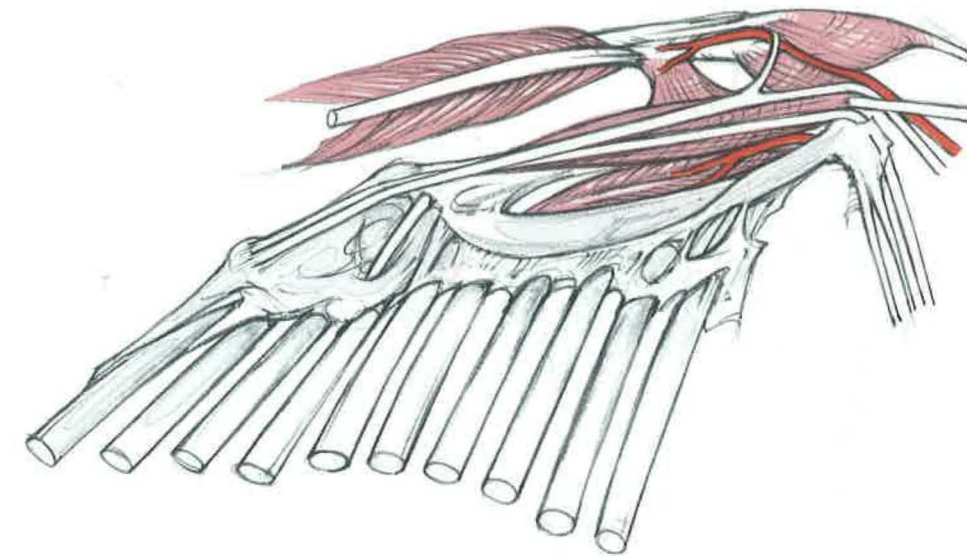
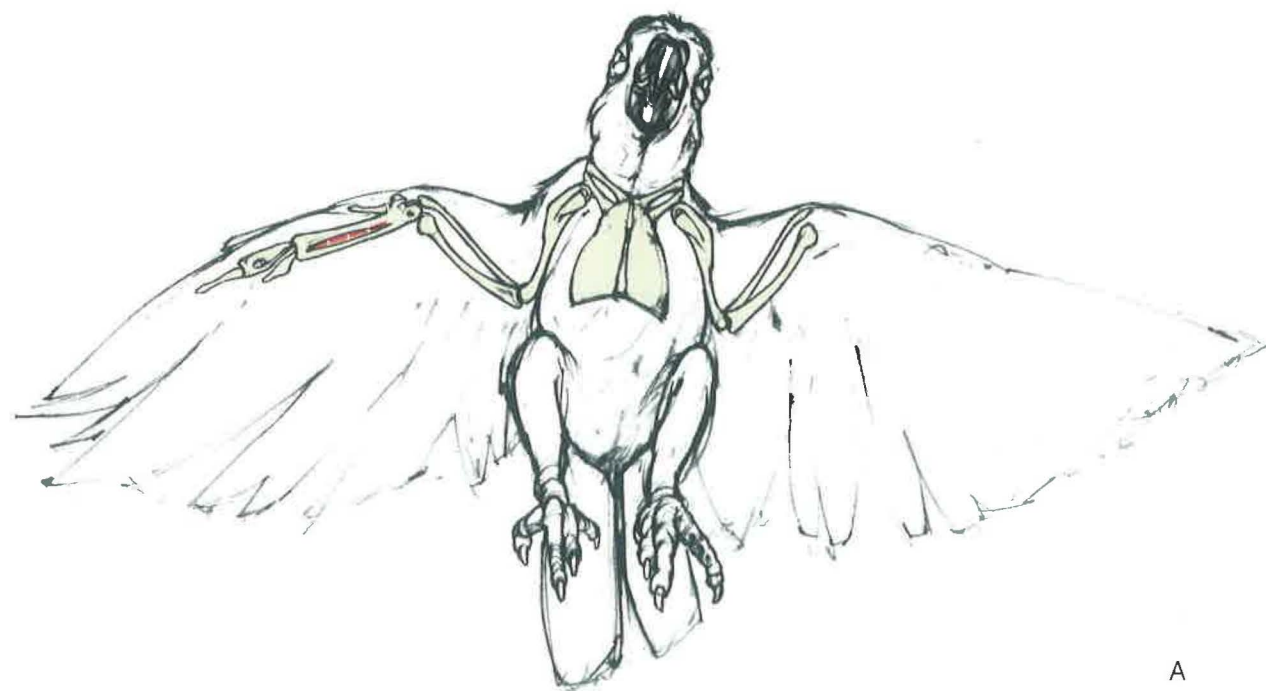
D) To approach the proximal major metacarpal bone, the two tendons of the digital flexors are retracted cranially. The abductor digiti majoris may be transected and then reflected for greater visualization of the bone, if necessary. Exposure of the minor metacarpal bone does not require any additional manipulation. The ulnometacarpalis dorsalis muscle or the flexor metacarpi caudalis is found caudal to the minor metacarpal bone.

#### Closure

The belly of the abductor digiti majoris is sutured transected. The skin is closed as a single layer. The wing should be wrapped in flexion until healed.

#### Comments

Fractures of the metacarpus are very difficult to treat, due to the lack of soft tissue and the tenuous blood supply to the region. Fractures may be managed nonsurgically by a figure-of-eight bandage applied longer than 3 to 4 months.<sup>8</sup> Prognosis is further worsened if the wound is open or comminuted. Nonunions can also occur with closed fractures. In either case, an intramedullary pin or K-E apparatus may be used to increase stabilization, with or without a bone graft.<sup>8</sup>



A





## **Anatomy of and Surgical Approaches to the Leg**

### **Section III Anatomy of the Pelvic Girdle and Limb**



**Pelvic Girdle, Thigh, Leg, and Pes**  
**LATERAL SKELETON**

Three bones form the pelvic girdle—the ilium, the ischium, and the pubis. These bones are partially fused to each other, as well as to the synsacrum. The synsacrum represents a fusion of a number of sacral, lumbar, and caudal vertebrae. Most of the bony pelvis is derived from the ilium cranially and the ischium caudally. The acetabulum lies between the two and contains a central acetabular foramen [*foramen acetabuli*]. Caudal to the acetabulum is an ilioischiatric foramen [*foramen ilioischiatricum*], with an obturator foramen [*foramen obturatum*] ventrally. The two slender pubic bones attach to the ischia cranially, but curve caudally and ventrally.

The femur in birds may be curved cranially on a lateral view (in gallus) or may be fairly straight (in cathartes and gymnogyps). Adaptation to terrestrial locomotion requires a displacement of the condyles or rotation of the femur to direct the lower leg under the body. Dislocation of the knee and tendons is reduced by deep grooves and ridges over the joint surface. These factors aid in locomotion and dexterity.<sup>2</sup>

At the proximal end of the femur is a prominent trochanter [*trochanter femoris*] for insertion of the iliopsochanteric muscles. There is an intercondylar sulcus [*sulcus intercondylaris*] between the lateral and medial condyles. It is continuous proximally with the patellar sulcus for the patella to slide.

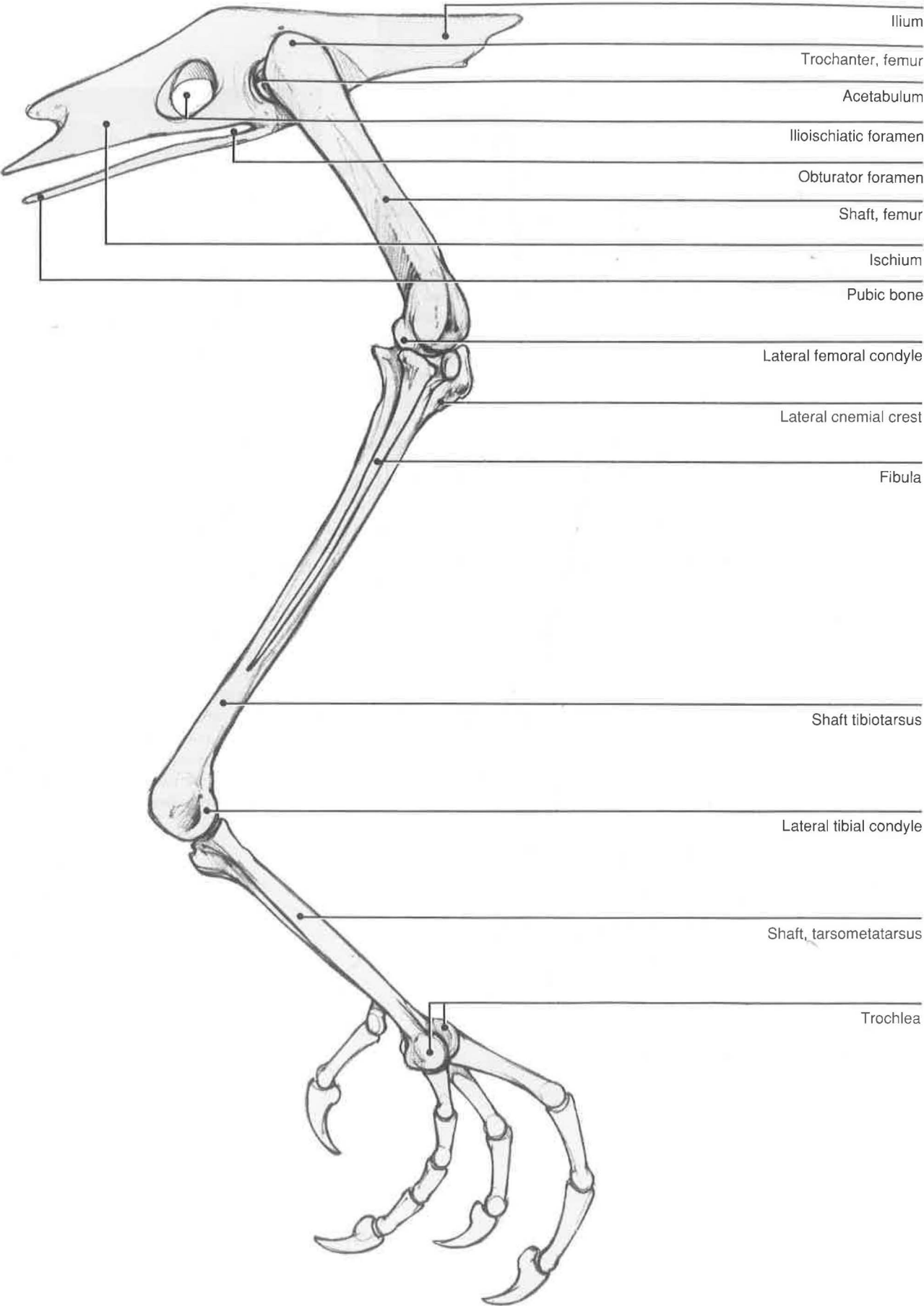
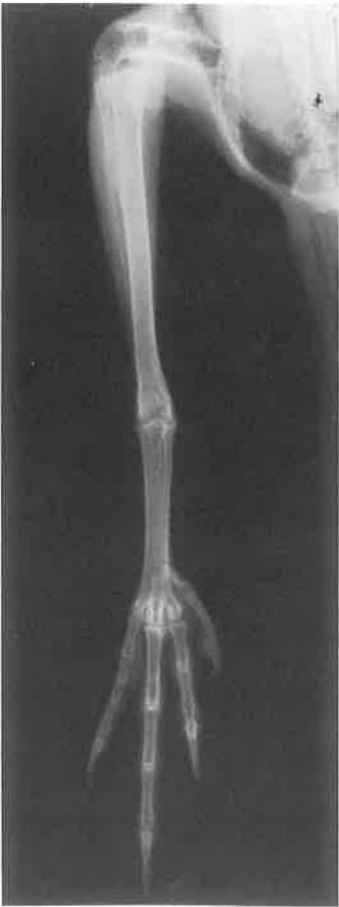On the proximal end of the tibiotarsus and fibula is an articular surface for the femoral condyles. Additionally, there are the cranial and lateral cnemial crests for the origins of some of the extensor muscles of the hock and digits. At the distal end of the bone on the cranial side is an extensor canal for the extensor digitorum longus. The medial and lateral condyles at the distal end of the bone articulate with the tarsometatarsus.

It is thought that during embryogenesis some of the proximal tarsal bones fuse with the tibia; hence, the term tibiotarsus. The tarsometatarsus is thought to include some of the distal tarsal bones with three metatarsal bones. Metatarsals II, III, and IV are fused in the adult,<sup>3</sup> with metatarsal I remaining separate.

The proximal tarsometatarsus has a medial and a lateral surface for articulation with the tibiotarsus.

At its distal end are three trochlea for articulation with digits II, III, and IV. There is an interosseous canal [*canalis interosseus tendineus*] for the tendon of the extensor of digit IV between the trochlea for digits III and IV. On the medial side of the tarsometatarsus is a fossa [*fossa metatarsi I*] for the first metatarsal.

Digits II, III, and IV usually have three, four, and five phalanges, respectively. Digit I, the hallux, usually has two phalanges. Digit IV may be directed cranially or caudally, depending on the species. The last phalanx of each digit is claw shaped.



## Lateral Thigh and Leg

### SUPERFICIAL LAYER

#### *Cathartidae and Galliformes*

**Iliotibialis cranialis** [*sartorius*]  
—This strap-like muscle is comparable to the sartorius of mammals, although it is not a direct homologue. It originates on the craniodorsal surface of the ilium and inserts on the craniomedial patella. Some fibers may insert on the cranial cnemial crest of the tibia. The iliotibialis cranialis extends the stifle while flexing the hip.<sup>2,3</sup>

**Iliotibialis lateralis**—In cathartidae, galliformes, and charadriiformes, this muscle is large, with a central aponeurotic zone. It partially covers the iliofibularis muscle.<sup>4</sup> It arises from the crest of the ilium to insert on the lateral cnemial crest and by a fascial attachment to the iliotibialis cranialis or sartorius as a part of the patellar tendon.<sup>2</sup> This muscle is commonly fused to the underlying femorotibialis externus and medius. It may be further subdivided anatomically into three heads;<sup>3</sup> however, in this text, it will be described as a single muscle.

**Fibularis longus** [*peroneus longus*]  
—The fibularis or peroneus longus muscle is the most cranial muscle of the crus. However, there is considerable variation among species. It may be absent in some (owls and ospreys), small (pigeons and parakeets), or large (fowl and vultures).<sup>2,3</sup> In hawks, it is found deep to the tibialis cranialis. The muscle arises from the lateral side of the tibia along the cnemial crests. There are two insertions—one of the tibial cartilage [*cartilago tibialis*], and a second on the tendon of the flexor perforatus digiti III. The two

points of insertion reflect two different actions. Its insertion on the tibial cartilage allows the muscle to extend and abduct the hock. It also helps to flex digit III.<sup>2</sup>

**Gastrocnemius**—The muscle can be divided into two or three muscle groups. If there are three heads, two heads usually arise from the femur and one arises from the tibia.<sup>3</sup> This drawing illustrates two muscular heads with the intermediate head (*pars intermedia*) fused to the medial head (*pars medialis*). The muscle is a strong extensor of the hock and flexor of the digits due to its numerous aponeurotic attachments to the digital flexors.<sup>2</sup>

**Flexor perforans et perforatus digiti III**—The tendon of this muscle (*flexor p. et p. digiti III*) moves from a lateral position on the tibia to one beneath the gastrocnemius tendon at the tarsus. It gives off a branch to the tendon of the flexor perforatus digiti III, before continuing down the metatarsus, where it passes over the trochlea of the third digit deep to the tendon of the perforatus. It passes through the split tendon of insertion of the flexor perforatus digiti III at the first phalanx before inserting on the ventral surface of the third phalanx of digit III. At its insertion, it is perforated by the deep flexor tendon, which inserts onto the base of the claw. The flexor perforans et perforatus digiti III perforates and is perforated by two separate flexors. It extends the hock, but mainly flexes the distal end of the third digit.



Iliotibialis cranialis

Iliotibialis lateralis

Iliofibularis

Flexor cruris lateralis

Flexor cruris medialis

Gastrocnemius,  
medial head

Gastrocnemius,  
lateral head

Fibularis longus

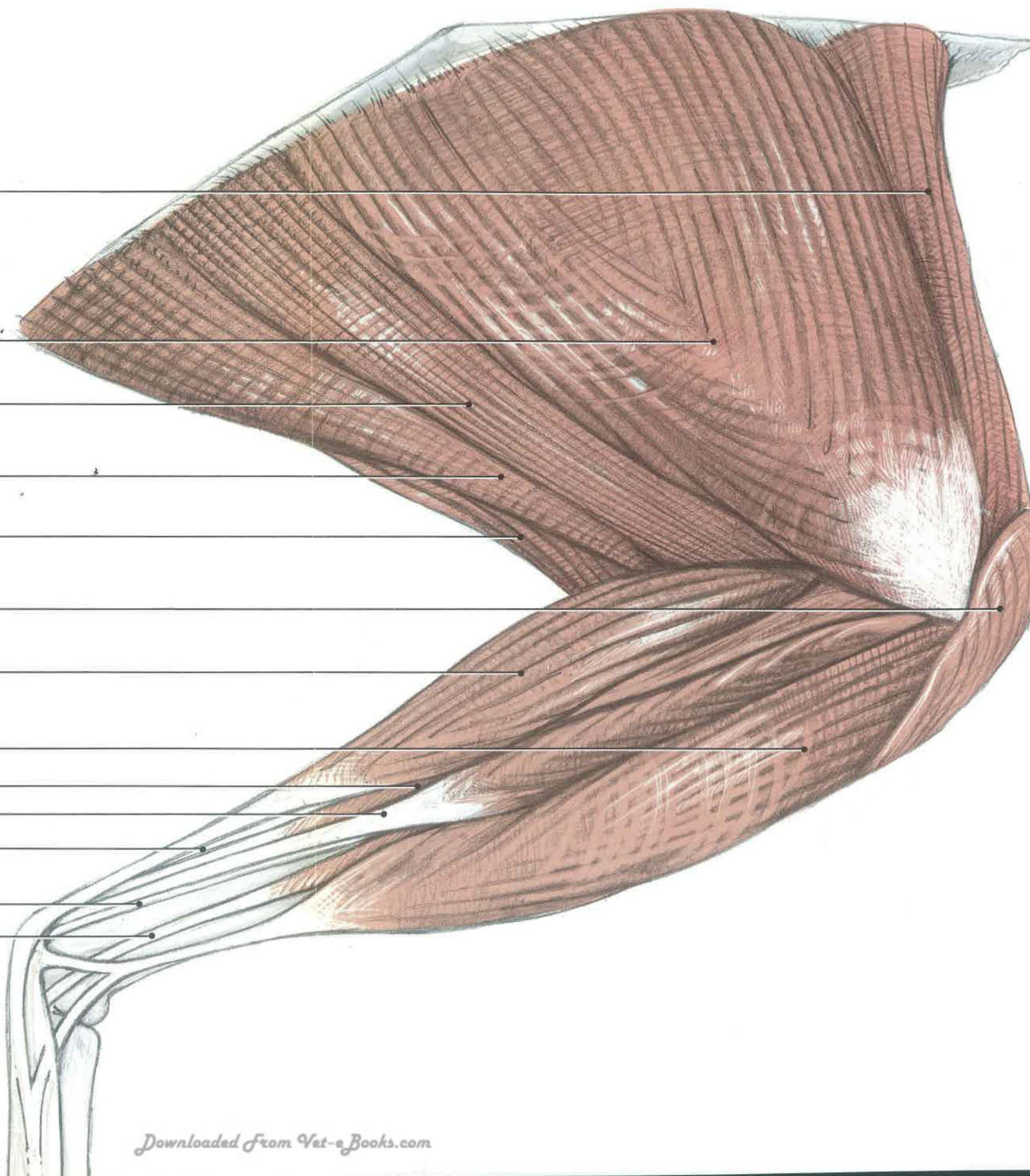
Flexor perforans et perforatus digiti II

Flexor perforans et perforatus digiti III

Flexor perforatus digiti III

Flexor perforatus digiti IV

Fibularis brevis





## Lateral Thigh and Leg

### MIDDLE LAYER

#### *Cathartidae and Galliformes*



**Femorotibialis externus**—The femorotibialis externus and medius are often partially fused to the overlying iliotibialis lateralis, particularly over its aponeurotic portion. The externus muscle covers the femoral shaft before inserting on the cnemial crests of the tibia. This muscle, along with the femorotibialis medius and internus, represents the quadriceps femoris of mammals. These three muscles form the patellar tendon in birds. The femorotibialis medius crosses over to the medial side of the femur.

**Ilioibularis**—This triangular muscle, similar to the biceps femoris of mammals, is distinguished by its retinaculum, which surrounds its tendon of insertion caudolaterally on the fibula. The fibular nerve and popliteal vein also course through this tendinous loop.

**Flexor cruris lateralis** [*semitendinosus*]—This muscle, along with the medialis, represents the hamstring muscles in mammals. The major portion of this muscle inserts onto the medial head of the gastrocnemius and the flexor cruris lateralis. There may be an accessory head that originates from the main tendon of insertion and courses perpendicular to the principal fibers. The muscle is absent in hawks and owls; swimming birds do not have an accessory head.<sup>3</sup> The flexor cruris lateralis extends the hip and flexes the stifle.

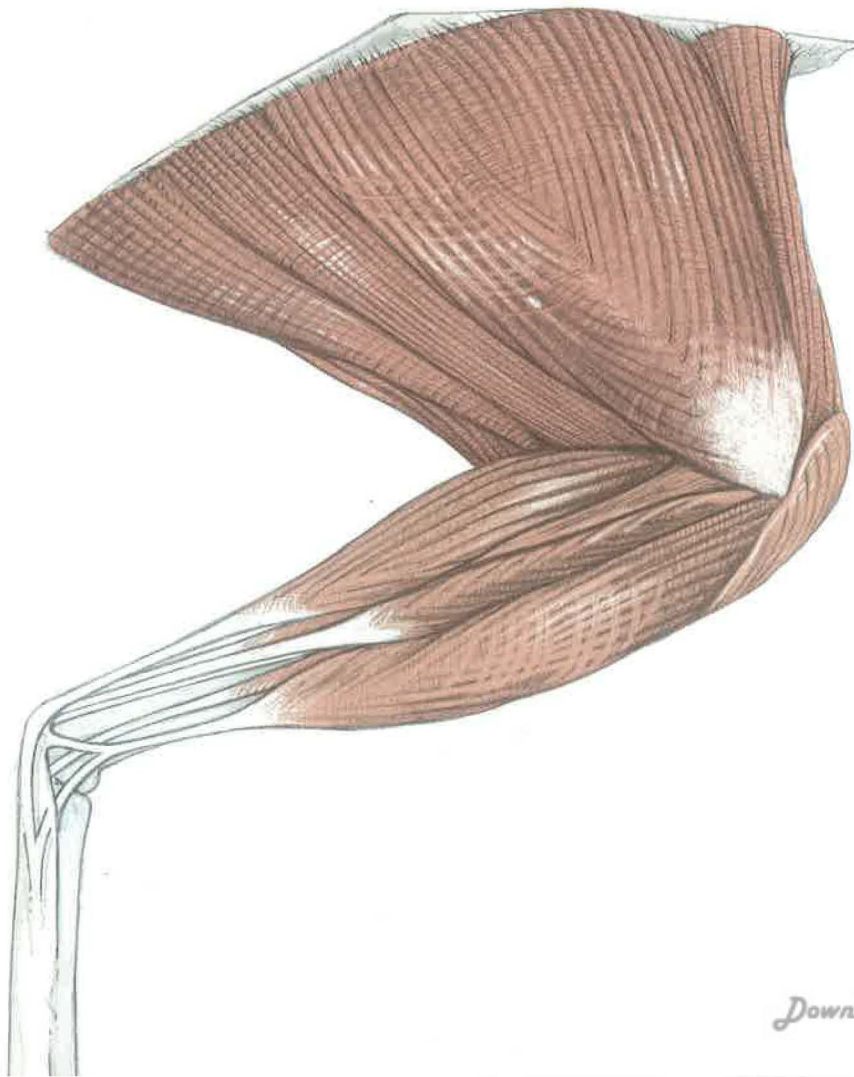
**Flexor cruris medialis** [*semimembranosus*]—This flat muscle originates at the ventral ilium and

inserts on the proximal medial tibia in common with the flexor cruris lateralis. Like the flexor cruris lateralis, the medialis extends the hip while flexing the stifle. It also adducts the limb.<sup>2</sup>

**Tibialis cranialis**—This muscle is covered by the fibularis longus. It is an important flexor of the hock (see page 90).

**Flexor perforans et perforatus digiti II**—Flexor perforans et perforatus digiti II lies caudal to the flexor perforans et perforatus digiti III. Its tendon courses along with flexor p. et p. digiti III to the hock, where it goes through a separate cartilaginous canal. It continues medially to perforate through the tendon of insertion of flexor perforatus digiti II. Flexor p. et p. digiti II continues down digit II to split at its insertion onto the base of its distal phalanx. At this point, it is perforated by the deep flexor tendon. The muscle flexes digit II while extending the hock.<sup>2</sup>

**Flexor perforatus digiti IV**—This perforatus originates caudal to the flexor perforans et perforatus digiti II. The tendon crosses over the distal end of the tibiotarsus and hock to gain a lateral position on the metatarsus. When it passes over the trochlea for digit IV, it divides into three parts. The inner tendon inserts on the medial, proximal end of phalanx 1, while the lateral one inserts on the distal lateral end of phalanx 1. The central tendon is perforated at its insertion site on phalanx 2 by the deep digital flexor tendon.<sup>2</sup>





Iliofemoralis externus

Iliotrochantericus caudalis

Head, femur

Iliotrochantericus  
cranialis

Femorotibialis medius

Femorotibialis externus

Iliofibularis

Flexor cruris lateralis

Flexor cruris medialis

Tibial nerve

Flexor perforatus  
digiti IV

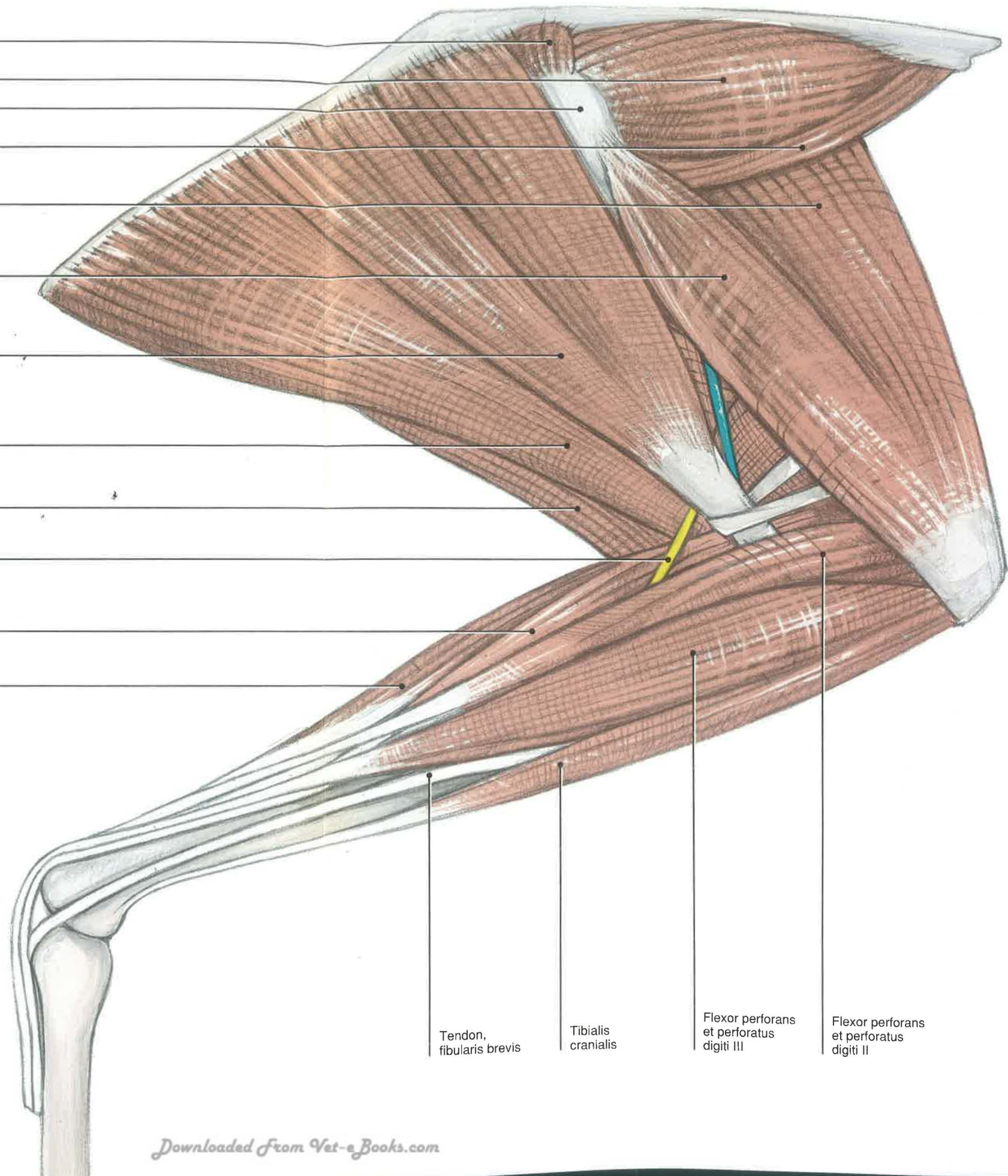
Flexor perforatus  
digiti III

Tendon,  
fibularis brevis

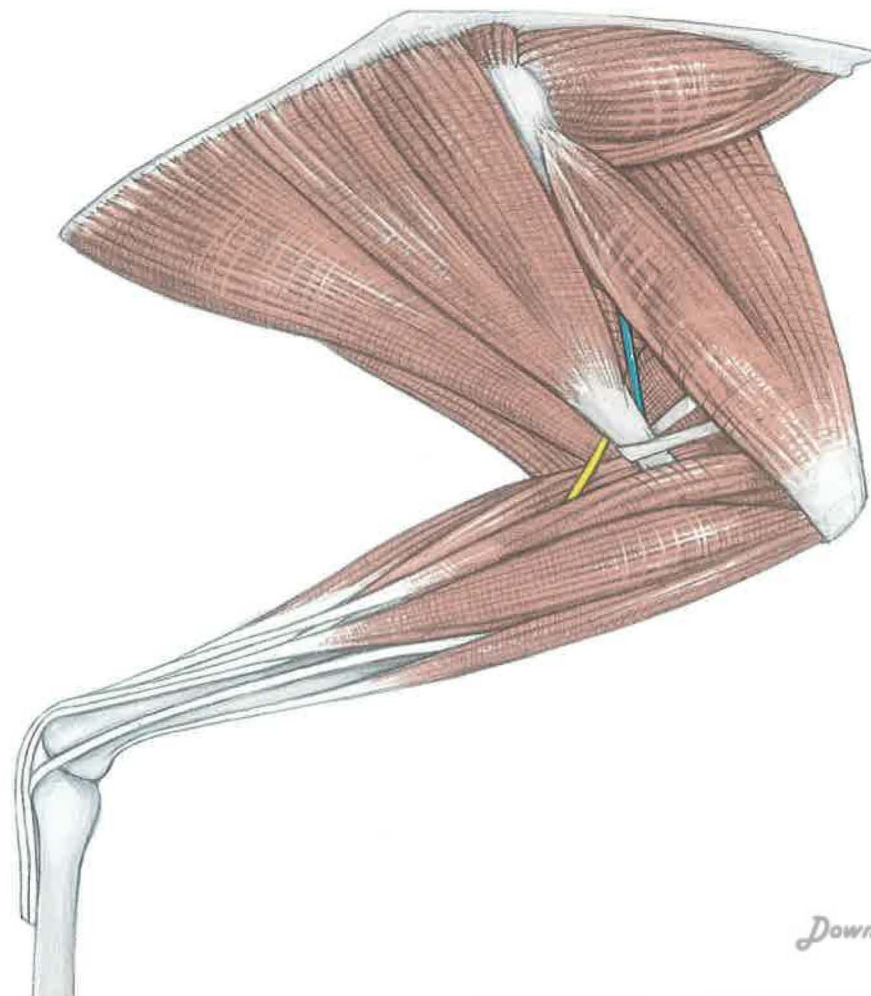
Tibialis  
cranialis

Flexor perforans  
et perforatus  
digiti III

Flexor perforans  
et perforatus  
digiti II







## Lateral Thigh and Leg

### DEEP LAYER

#### *Cathartidae and Galliformes*

**Iliotrochantericus cranialis and caudalis** [*gluteus profundus and medius*]*—*The iliopsoas cranialis (*gluteus profundus*) is a thin muscle that courses along the lateral ilium ventral to the iliopsoas caudalis. The muscle inserts on the lateral femur along the trochanter and its distal continuation, the iliopsoas impression. Both muscles serve to rotate the leg and flex the hip.<sup>2</sup>

**Iliopsoas externus** [*piriformis*]*—*The iliopsoas externus is comparable to the piriformis of mammals. It is a small triangular muscle that lies over the dorsolateral hip joint. Due to its small size, it probably has limited abilities for abduction.

**Ischiofemoralis** [*obturator externus*]*—*This muscle is on the external surface of the ischium and inserts on the trochanter of the femur. It acts to externally rotate the leg and extend the hip.<sup>2</sup>

**Caudofemoralis***—*This strap-like muscle runs from the pygostyle of the tail to the caudolateral shaft of the femur. Although it pulls the femur caudally, its major function may be to pull the tail laterally and ventrally. It is absent in some of the vultures and the California condor.<sup>2</sup>

**Flexor perforatus digiti III***—*Depending on the species of bird, this perforatus may have an accessory head. Near the hock, the major tendon is joined by a branch of the fibularis longus tendon. It divides at the trochlea to insert on the distal end of phalanx 1 of digit III. It is perforated by the flexor perforans et perforatus digiti III and the deep digital flexor.

**Flexor hallucis longus***—*The flexor hallucis longus may have attachments to the flexor digitorum

longus. Although these two tendons attach in a fibrous retinaculum or vinculum in birds of prey, gallinaceous birds, and parrots, they continue distally as separate tendons. In finches and canaries, there are two separate tendons with no attachments to each other. Ducks have only a small tendon that travels to digit I, with the major supply going to the three remaining digits.<sup>3</sup> Although this muscle flexes digit I or the hallux, it also helps to flex the other digits by way of its retinaculum.

**Flexor digitorum longus***—*The flexor digitorum longus lies against the caudolateral tibia with its tendon of insertion deep to the flexor hallucis longus. This deep digital flexor inserts on the base of each of the distal processes of digits II, III, and IV. Each of these tendons perforates the superficial [*flexores perforatus digiti II, III, and IV*] and intermediate tendons [*flexores perforans et perforatus digiti II and III*] before inserting at its distal attachment.

**Blood supply and innervation***—*The major blood and nerve supply to the leg is found at this deep layer. The ischiatic nerve [*n. ischiadicus*] travels through the ilioischiatic foramen [*foramen ilioischiadicum*] to enter the lateral leg just caudal to the shaft of the femur. The ischiatic artery [*a. ischiadica*] accompanies the nerve. The vein [*v. ischiadica*] enters the lateral leg just proximal to the insertion of the caudofemoralis and is the closest neurovascular structure to the femoral shaft.

At the distal end of the femur, the ischiatic nerve divides into the fibular nerve [*n. fibularis*] cranially and the tibial nerve [*n. tibialis*] caudally. In this region, the vascular supply changes names to the popliteal artery and vein [*a. and v. poplitea*] and the sural artery and vein [*a. and v. suralis*].

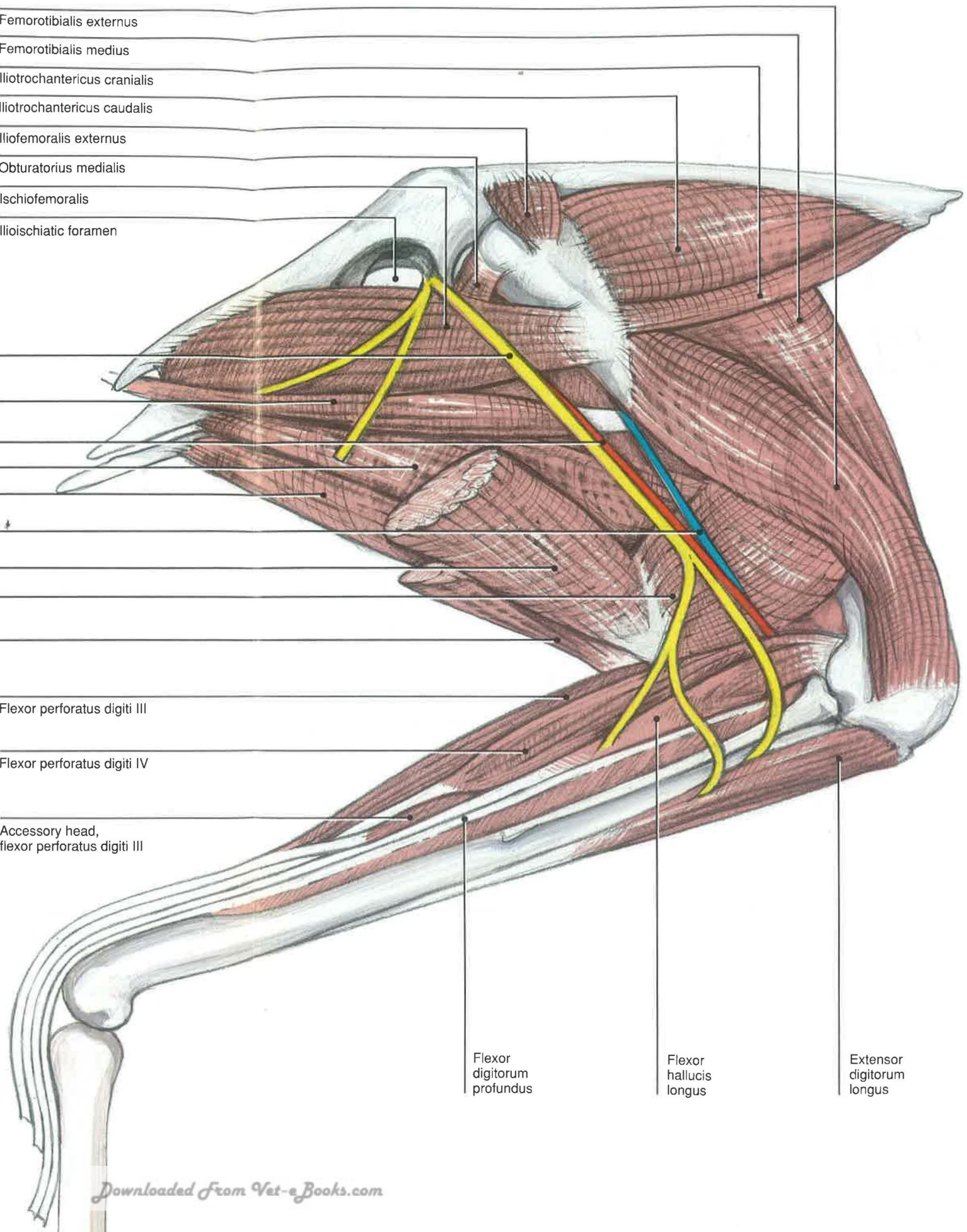


Ischiatic nerve  
 Caudofemoralis  
 Ischiatic artery  
 Pubo-ischio-femoralis, pars lateralis  
 Pubo-ischio-femoralis, pars medialis  
 Ischiatic vein  
 Flexor cruris lateralis  
 Accessory head, flexor cruris lateralis  
 Flexor cruris medialis

Femorotibialis externus  
 Femorotibialis medius  
 Iliotrochantericus cranialis  
 Iliotrochantericus caudalis  
 Iliofemoralis externus  
 Obturatorius medialis  
 Ischiofemoralis  
 Ilioischiatric foramen

Flexor perforatus digiti III  
 Flexor perforatus digiti IV  
 Accessory head, flexor perforatus digiti III

Flexor digitorum profundus  
 Flexor hallucis longus  
 Extensor digitorum longus





## Lateral Thigh SUPERFICIAL LAYER

### *Accipitridae, Strigiformes, and Psittaciformes*

**Iliotibialis lateralis**—This muscle is fused to the underlying femorotibialis externus in a number of avians, including hawks and owls. The lateralis muscle is similar to the tensor fascia lata of mammals. In these birds, the muscle is smaller than in vultures and gallinaceous birds, making it easier to visualize the femoral shaft.

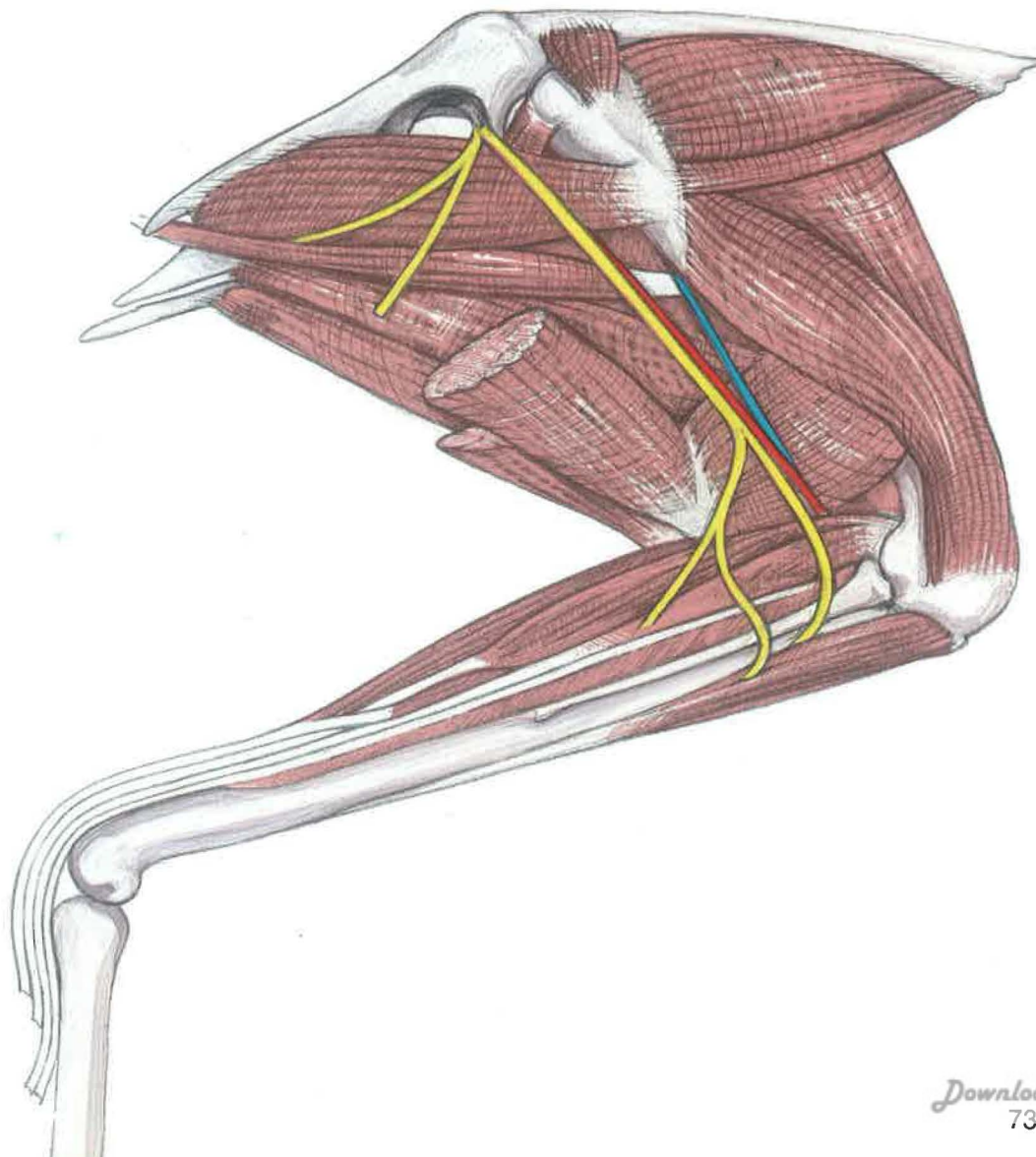
**Ilioibularis**—The ilioibularis muscle can be distinguished from the surrounding muscles by the retinaculum that surrounds its tendon of insertion on the caudal fibula. In the above species, it appears more prominent than the iliotibialis lateralis.

**Flexor cruris medialis**—This broad but thin muscle arises from the caudal end of the ischium to insert on the medial surface of the proximal tibiotarsus. A flexor cruris lateralis muscle comparable to vultures and gallinaceous birds is

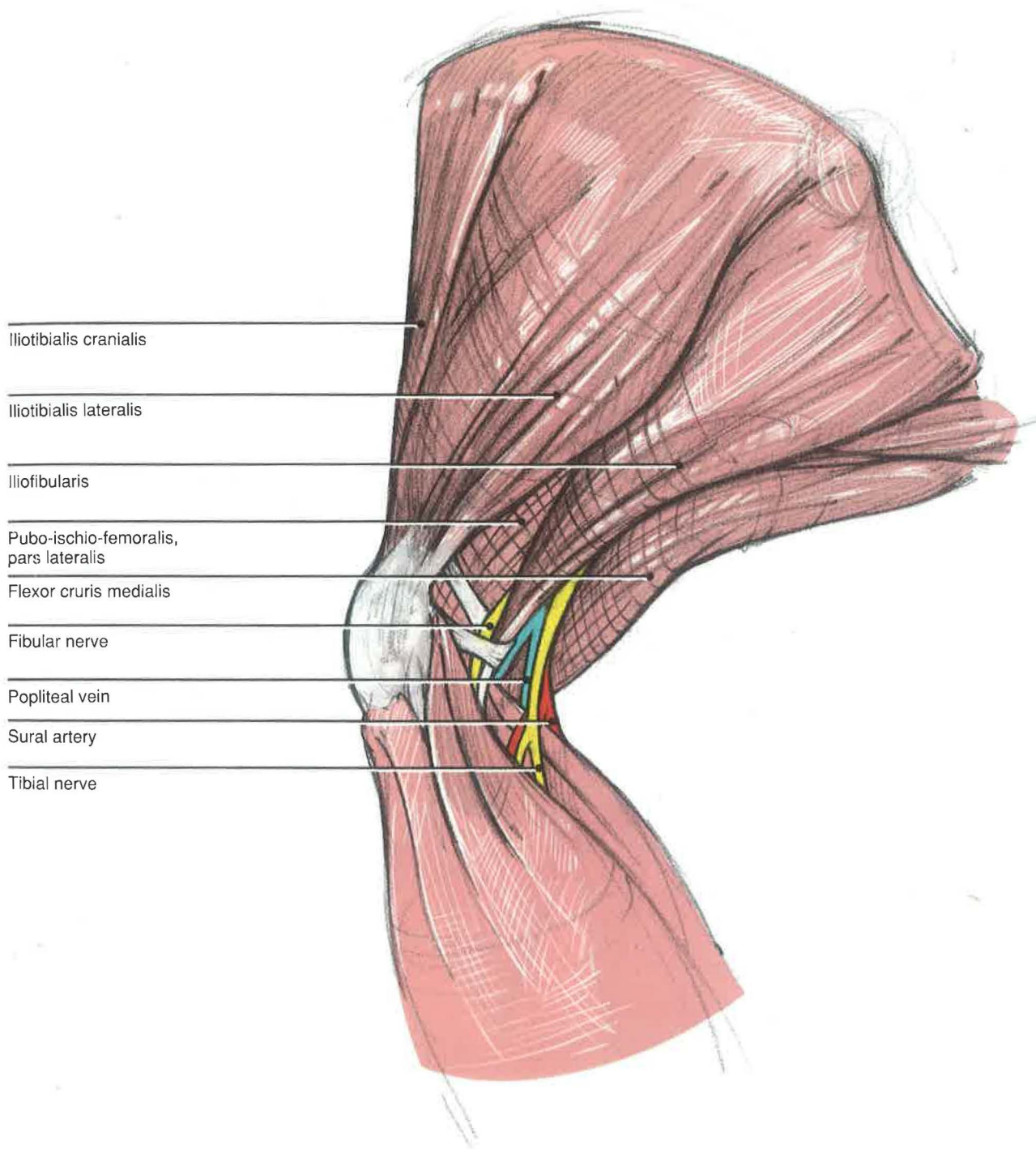
not present in common species of hawks, owls, and psittacines.

**Fibularis longus** [*peroneus longus*]—This muscle is found deep to the tibialis cranialis in hawks and psittacines and is absent in owls and osprey.<sup>3</sup> It can be distinguished from the tibialis cranialis by its point of insertion; the tibialis cranialis is associated with an extensor retinaculum as it crosses the hock to insert in a bony canal on the proximal dorsal tarsometatarsus. The fibularis muscle goes caudally across the lateral hock to insert on the tibial cartilage and the tendon of the flexor perforatus digiti III.

**Flexor perforatus digiti IV**—In psittacines this muscle has two muscle bellies that form a single tendon of insertion. Due to the change in direction of the fourth digit, this muscle acts to extend rather than flex the fourth digit.









## Lateral Thigh

### DEEP LAYER

#### *Accipitridae, Strigiformes, and Psittaciformes*

**Caudofemoralis**—The caudofemoralis is a strap-like muscle that depresses and moves the tail fan laterally when the leg is advanced.

**Iliotrochantericus caudalis** [*gluteus medius*]*—*This muscle inserts on the lateral head of the femur just distal to the trochanter. The iliotrochantericus may rotate the femur medially while flexing it, and it is thought to resist overextension during landing.<sup>3</sup>

**The ischiatic nerve** [*n. ischiadicus*]*—*This nerve runs laterally from cranial to caudal along the shaft of the femur. At its distal end, the nerve divides into the fibular nerve [*n. fibularis*] or peroneal nerve and the tibial nerve [*n. tibialis*]. The fibular nerve courses through the retinaculum of the iliofibularis to innervate the muscles of the craniolateral leg. These muscles are mainly involved in flexion of the hock and extension of the digits. In addition, the nerve has a superficial branch, which innervates the craniolateral tibiotarsus and hock. The larger tibial nerve innervates the extensions of the hock and the flexors of the digits.

**Blood supply**—The terminal ends of the abdominal aorta are the paired ischiatic arteries. They course between the middle and caudal divisions of the kidney before exiting through the ilioischiatic foramen to the pelvic limbs. Each artery gives branches to the hips and the muscles of the flexor compartment before dividing distally into the sural and popliteal arteries. The ischiatic vein [*v. ischiadica*] is the major venous channel for the leg. As it ascends the lateral thigh, it dives deep to the caudofemoralis. The majority of the blood from the ischiatic vein is diverted to the femoral vein [*v. femoralis*] through a communicating vein. The femoral vein continues as the external iliac vein [*v. iliaca externa*] before going through a renal portal valve [*valva portalis renalis*]. Blood from the leg must traverse the renal portal system before entering the general systemic circulation. The cranial femoral artery and vein are terminal branches of the femoral artery and vein. The cranial cutaneous femoral nerve [*n. cutaneus femoralis cranialis*] arises from the femoral nerve, a branch of the lumbar plexus.<sup>3,4</sup>

Iliotrochantericus caudalis

Iliotrochantericus cranialis

Obturatorius medialis

Ischiofemoralis

Ilioibularis

Femorotibialis externus

Caudofemoralis

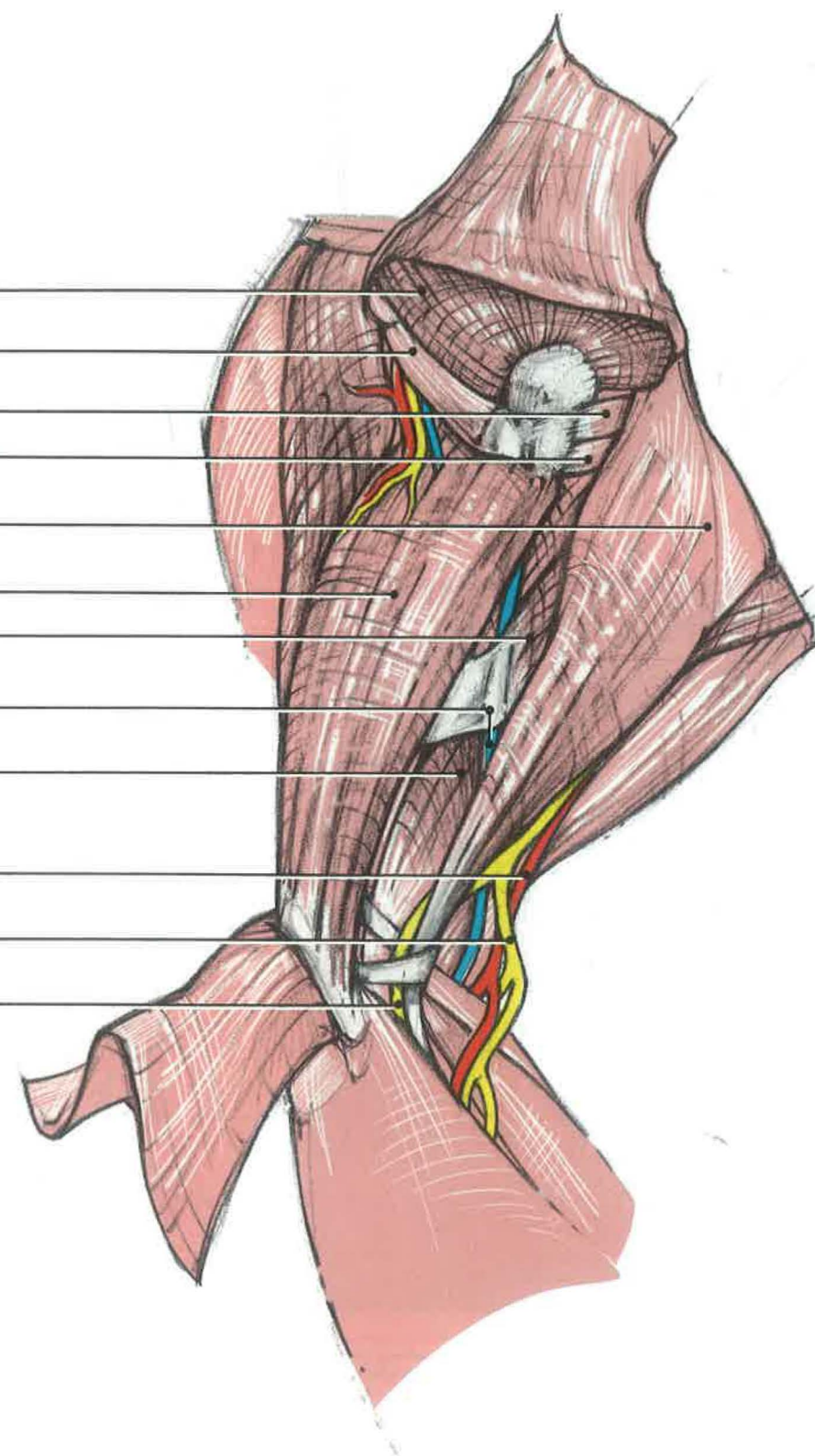
Ischiatic vein

Pubo-ischio-femoralis,  
pars lateralis

Ischiatic artery

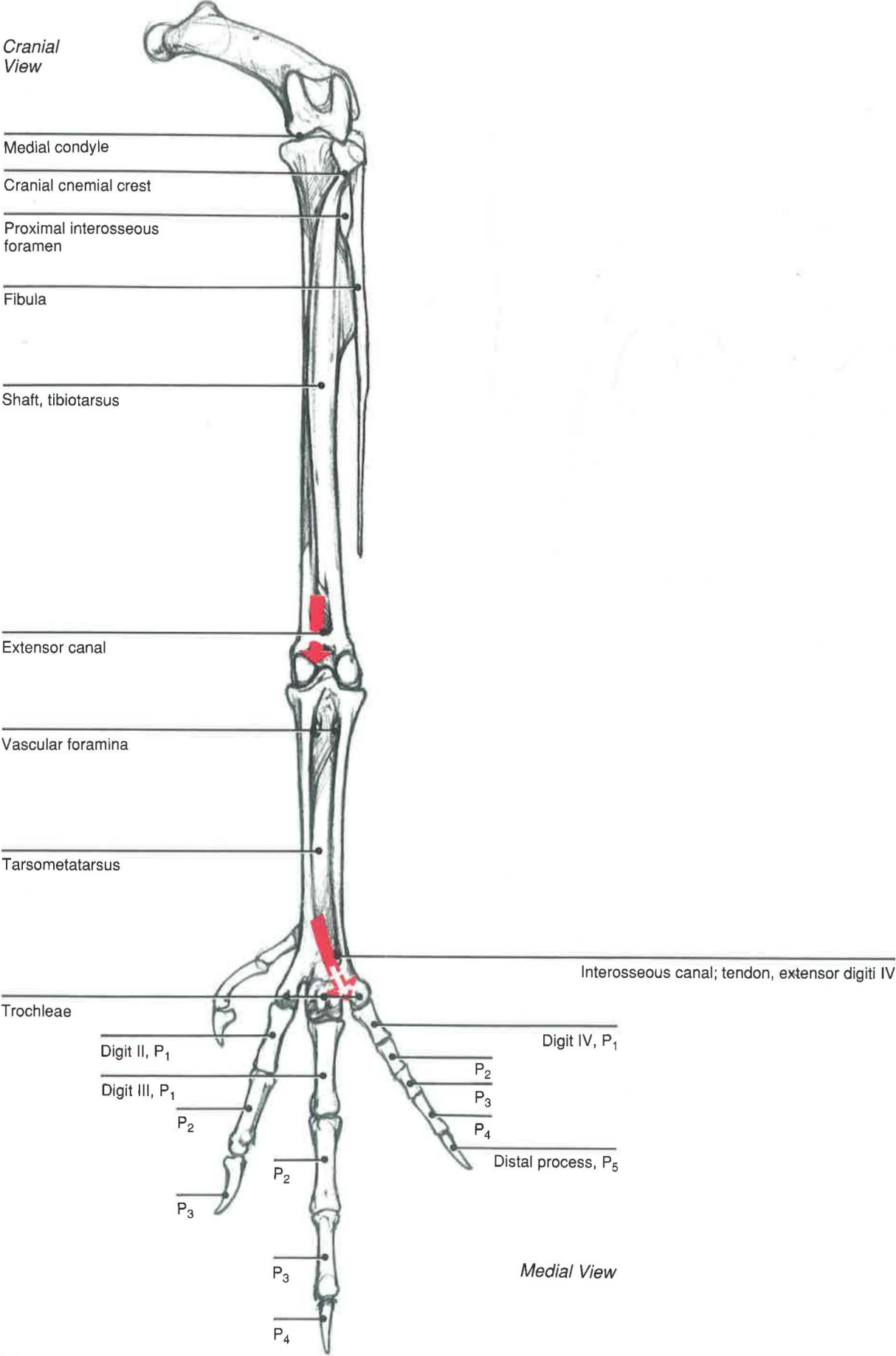
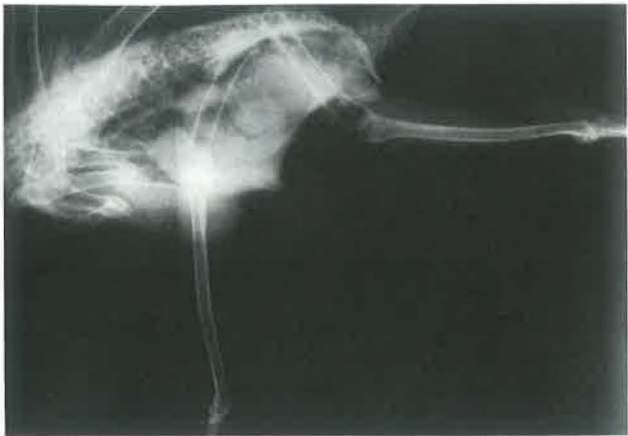Tibial nerve

Fibular nerve



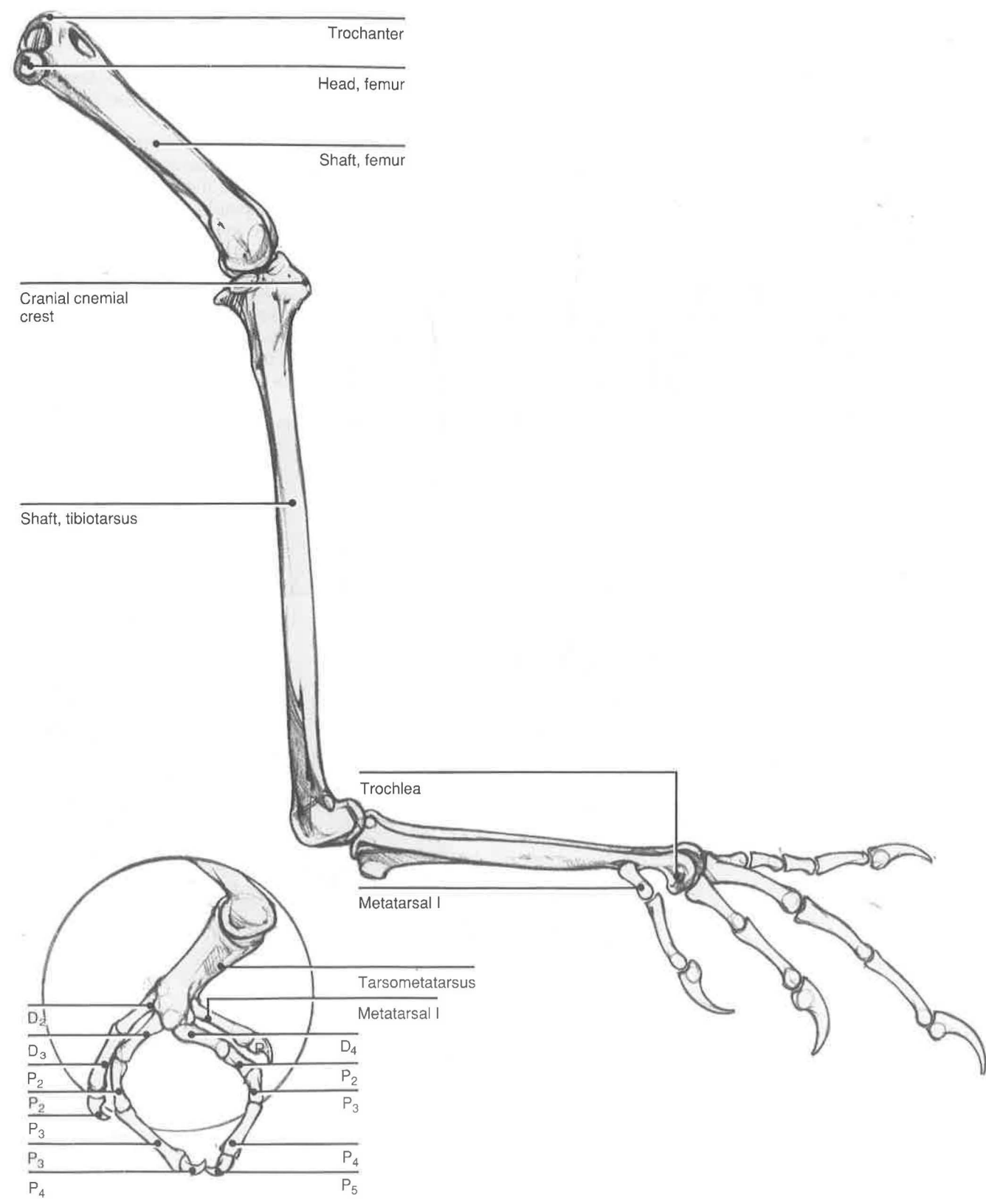
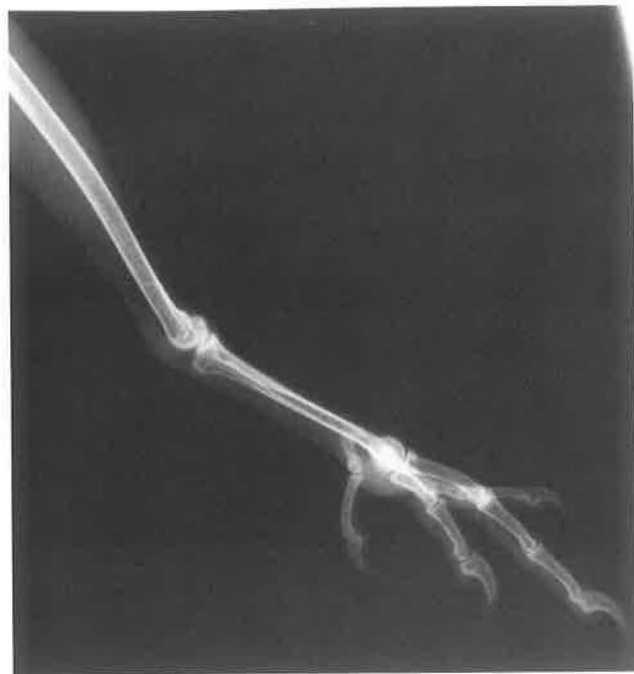

Cranial Pelvic Limb Skeleton





Medial Pelvic Limb Skeleton





## Medial Thigh

### SUPERFICIAL LAYER

**Flexor cruris medialis**—This muscle, comparable to the semimembranosus of mammals, originates mainly on the ischium. It inserts between the medial and intermediate heads of the gastrocnemius onto the caudal tibiotarsus. Its tendon may insert in common with the flexor cruris lateralis or semitendinosus, if the latter is present. The medialis muscle is a strong flexor of the hip and abductor of the thigh.<sup>2</sup>

**Pubo-ischio-femoralis, pars medialis** [*adductor magnus et brevis*]—This muscle may be closely adhered to the underlying pubo-ischio-femoralis, pars lateralis muscle. The pars medialis muscle is comparable to the adductor magnus et brevis of mammals, based on its medial location. Both muscles insert on the caudal surface of the femur,

including the medial femoral condyle and popliteal fossa. They adduct the femur and extend the hip.

**Ambiens** [*pectineus*]—The avian ambiens is homologous to the pectineus of mammals. Its muscle belly originates from the ilium and narrows to a tendon that crosses the patella. From there, it inserts onto the heads of the long flexors of the digits. It may not go beyond the patella in some species, and it may be absent in others (finches, canaries, and other passerines; some species of psittacines, pigeons, and doves).<sup>3</sup> The ambiens or pectineus has been described as the “perching muscle,” because it helps to flex the toes for grasping when the hock is flexed.<sup>3</sup>

4

Iliotibialis cranialis

Cranial femoral artery

Femorotibialis medius

Ambiens

Medial femoral vein

Pubo-ischio-femoralis,  
pars medialis

Pubo-ischio-femoralis, pars lateralis

Flexor cruris lateralis

Femorotibialis internus

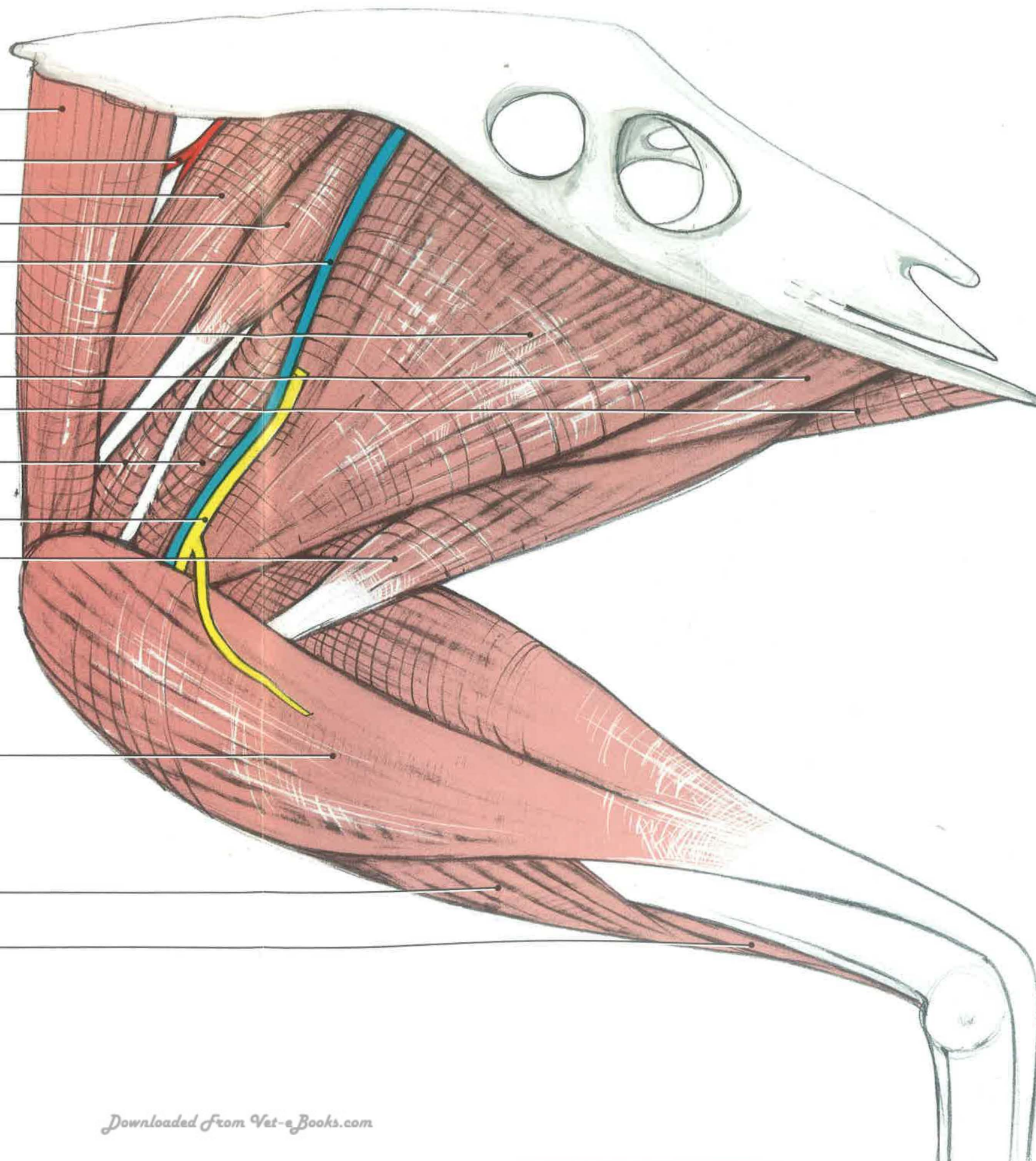
Medial femoral  
cutaneous nerve

Flexor cruris medialis

Gastrocnemius,  
medial head

Fibularis longus

Tibialis cranialis





## Medial Thigh

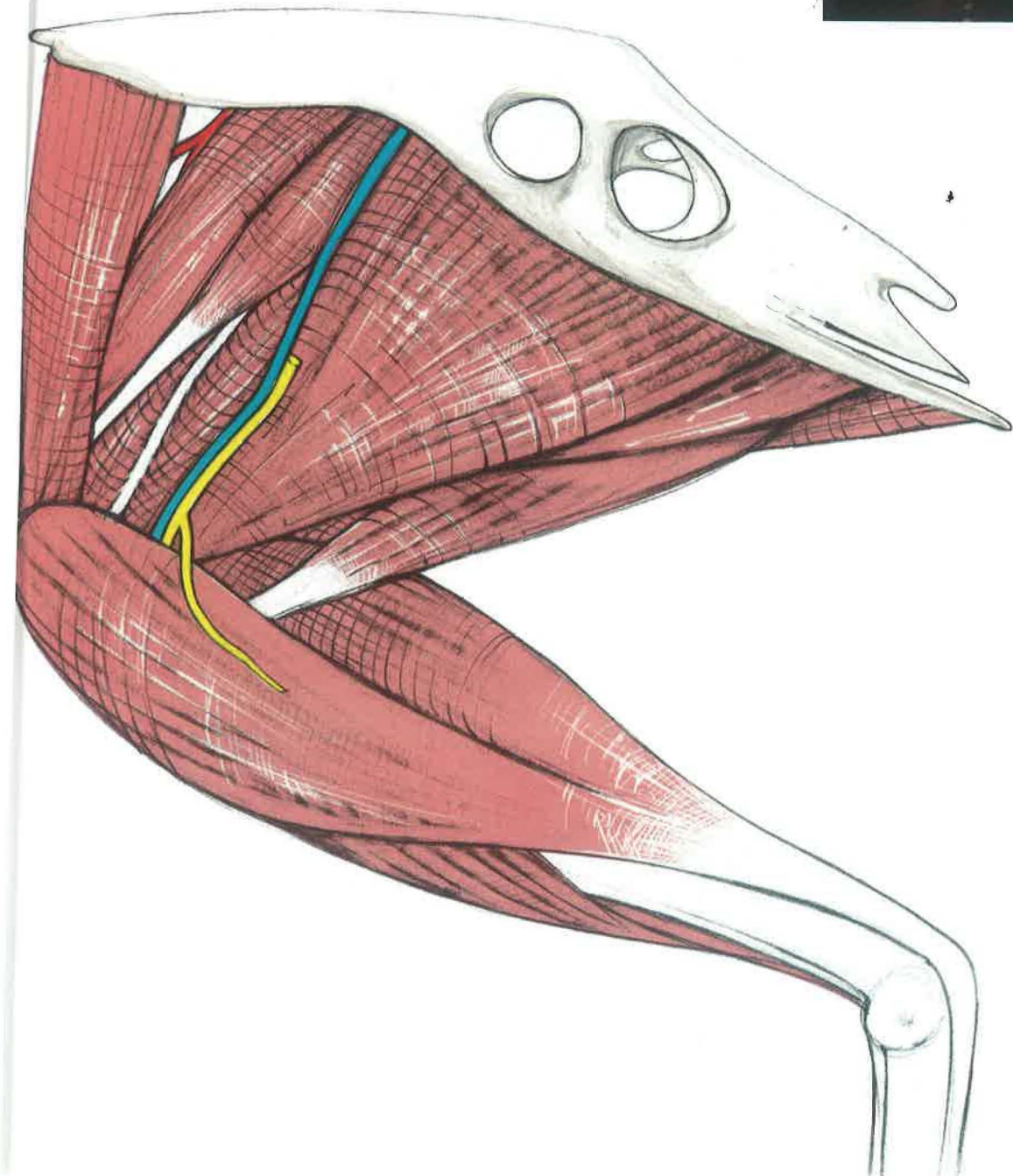
### DEEP LAYER



**Femorotibialis internus** [*vastus medialis*]*—*This muscle is one of the three muscles in birds that composes the quadriceps femoris in mammals. It is the most medial muscle of this group, and it is caudal to the ambiens muscle and cranial to both the pubo-ischio-femoralis, pars medialis muscle and the pubo ischio femoralis, pars lateralis muscle.

**Femorotibialis medius** [*femorotibialis medius*]*—*This muscle, combined with the rectus femoris, is considered in birds to represent one of the four heads of the quadriceps femoris. However, the rectus femoris originates on the femur, not the ilium, as in mammals. This muscle is continuous with the femorotibialis externus (also called the vastus lateralis), which is deep. The medius muscle inserts on the cnemial crest of the tibia as part of the patellar tendon to extend the stifle.

**Blood supply***—*The medial femoral artery [*a. femoralis medialis*] can be seen running with the medial femoral vein [*v. femoralis medialis*], between the pubo-ischio-femoralis, pars medialis or the adductor magnus et brevis and the femorotibialis internus. This artery is a branch of the femoral artery, which is the extra-abdominal continuation of the external iliac. It anastomoses distally with the medial tibial artery, a branch of the popliteal artery. The medial femoral vein ascends the thigh to drain into the femoral vein. The medial femoral cutaneous nerve [*n. cutaneus femoralis*] is found running with the artery and vein.<sup>3,4</sup>



Cranial femoral  
artery

Femorotibialis medius

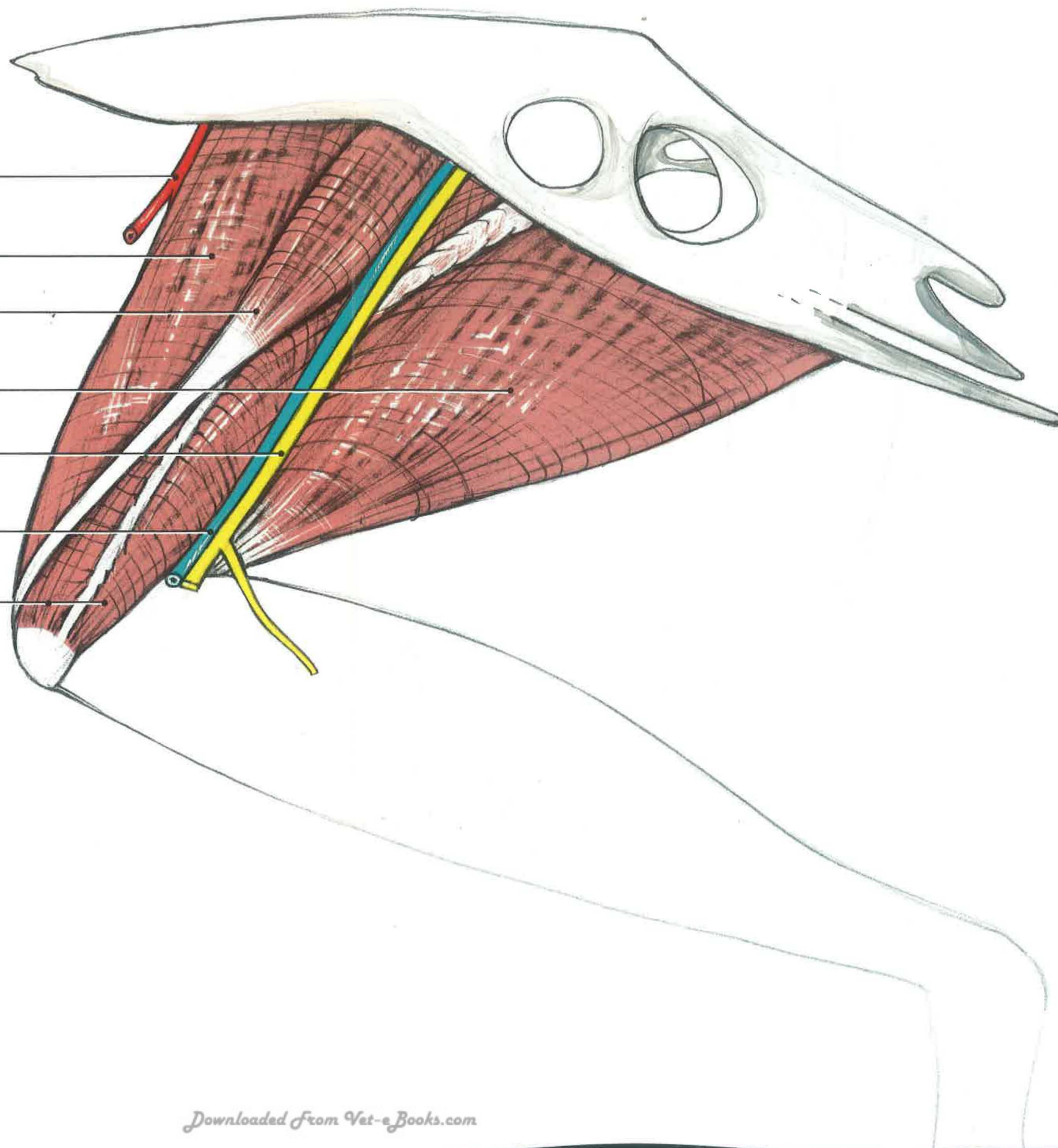
Ambiens

Pubo-ischio-femoralis,  
pars lateralis

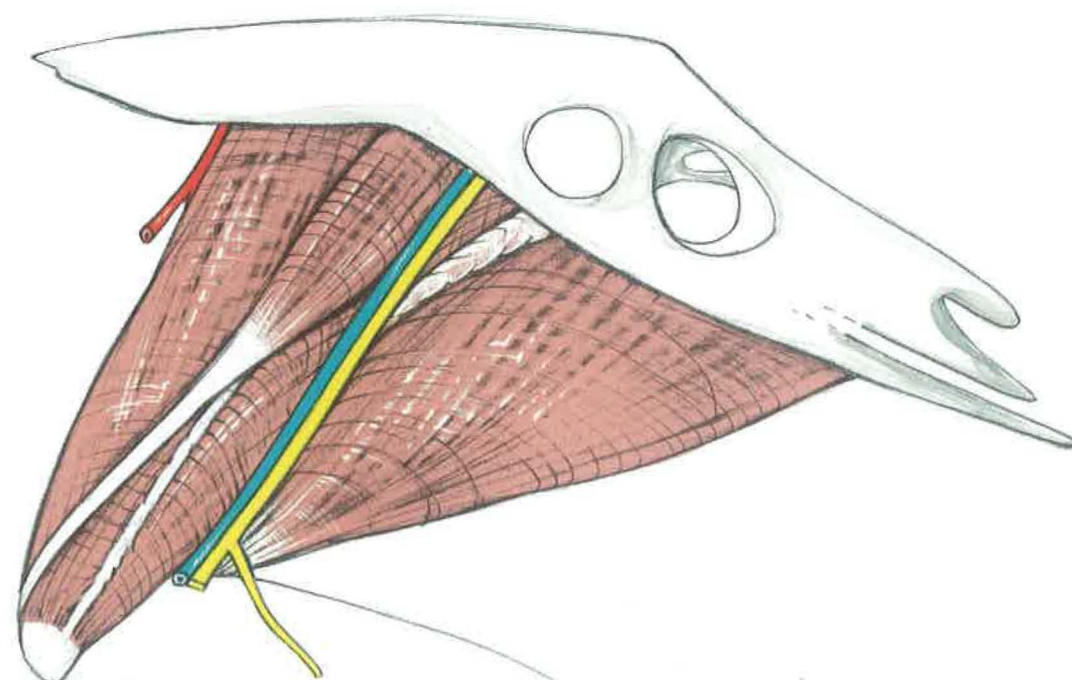
Medial femoral  
nerve

Medial femoral  
vein

Femorotibialis internus







## Cranial Leg and Digits

### SUPERFICIAL LAYER

#### *Accipitridae, Strigiformes, and Psittaciformes*

**Fibularis longus** [*peroneus longus*]  
—The fibularis longus of birds is comparable to the peroneus longus of mammals. This muscle is superficial in vultures and gallinaceous birds, as shown in the illustration page 91.

**Tibialis cranialis**—Located deep to the fibularis longus in most birds except psittacines and hawks, the tibialis cranialis is an important flexor of the hock. It has two heads—one on the lateral femoral condyle, and another on the lateral cnemial crest. These muscle bellies fuse to form a tendon that inserts in a groove on the dorsal metatarsus.

Gastrocnemius, medial head

Tibialis cranialis

Fibularis longus

Medial metatarsal vein

Extensor retinaculum

Cranial tibial artery

Extensor hallucis longus muscle

Dorsal metatarsal artery

Extensor hallucis longus tendon

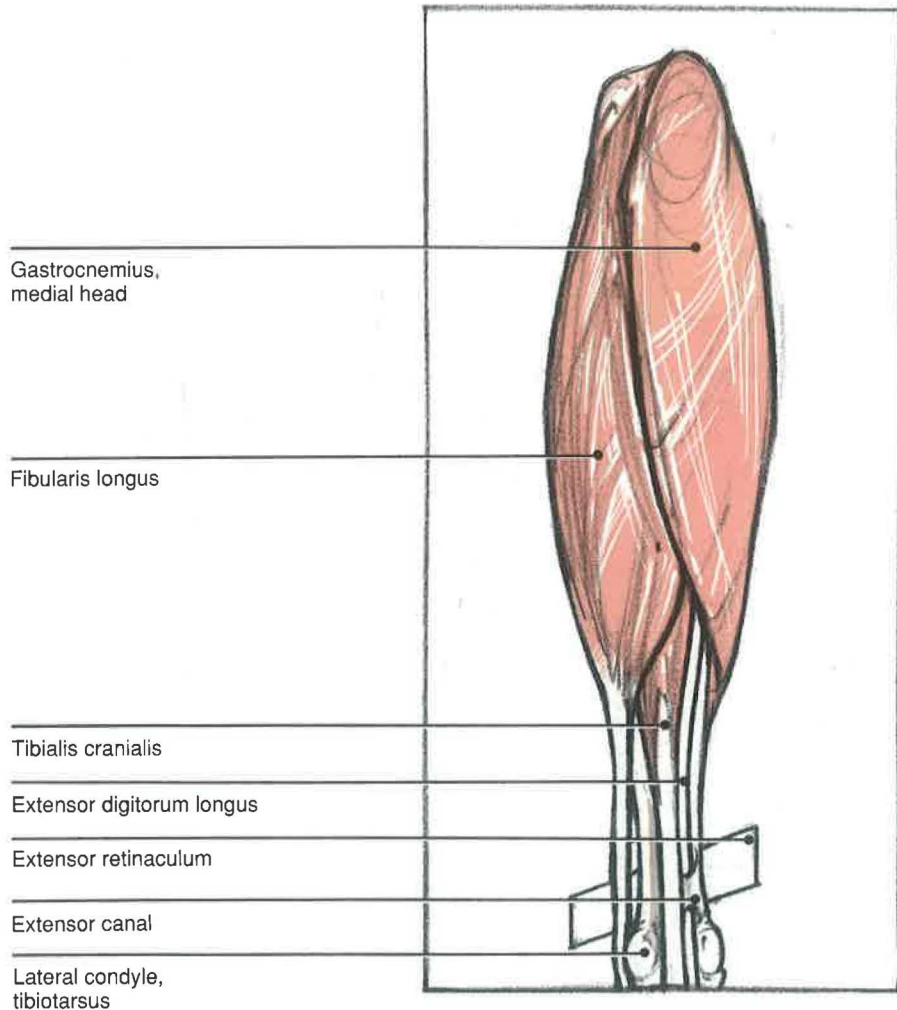
Extensor digitorum longus tendon

Abductor digiti II

## Cranial Leg and Digits

### SUPERFICIAL LAYER

#### *Cathartidae and Galliformes*



**Fibularis brevis** [*peroneus brevis*]**—**The fibularis or peroneus brevis muscle is located distally on the lateral shaft of the tibiotarsus and fibula. Its size is significant in vultures, falcons, and some psittacines, but it is absent or smaller in storks and flamingoes.<sup>3</sup> The tendon inserts on the proximal lateral tarsometatarsus.

**Extensor digitorum longus****—**This muscle is the extensor of digits II, III, and IV (except psittacines) and flexor of the tarsometatarsus. It originates on the cranial tibiotarsus and passes through the bony extensor canal to emerge deep to the extensor retinaculum. It divides into three tendons that insert on each of the distal processes.

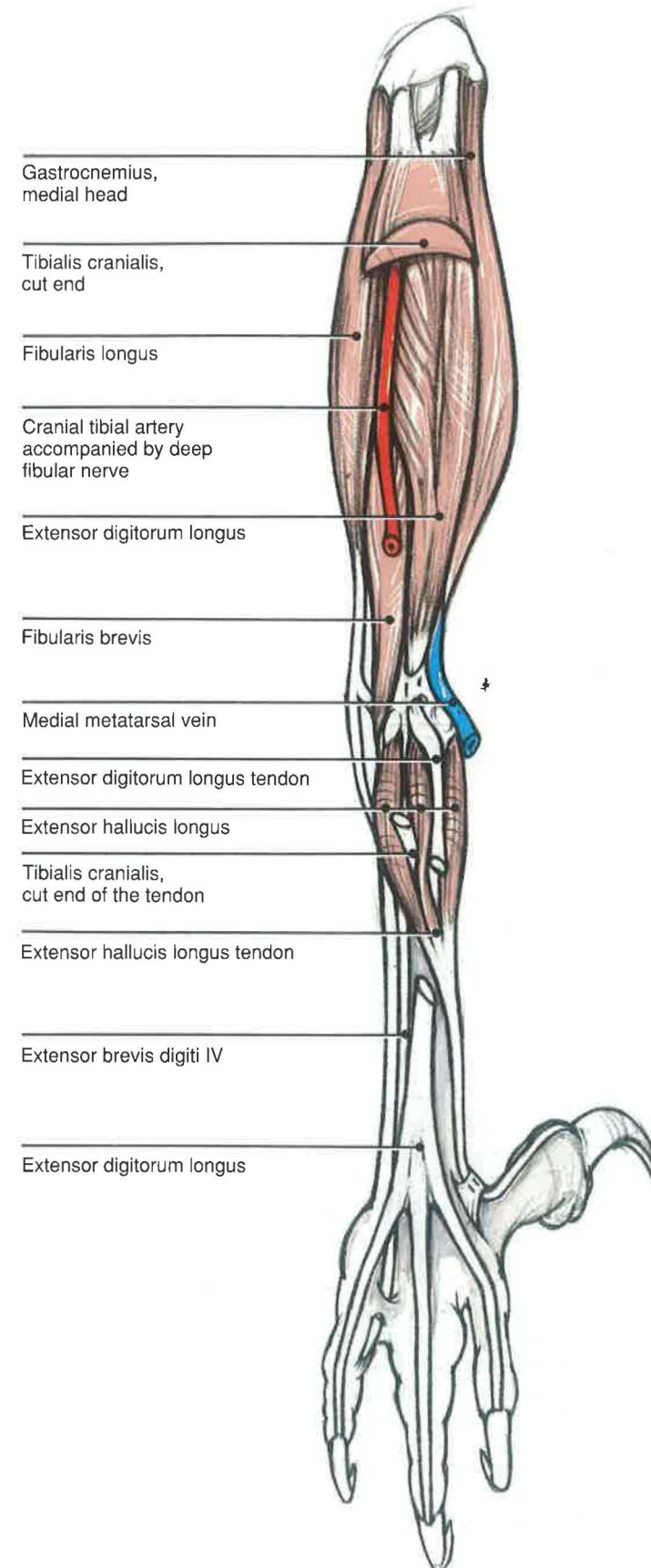
**Extensor brevis digiti III****—**This muscle takes origin on the distal end of the dorsal tarsometatarsus and inserts on the base of the proximal phalanx of digit III.

**Extensor hallucis longus****—**This muscle is the major extensor of the hallux or digit I. It originates on the dorsomedial surface of the tarsometatarsus and inserts on the distal process of digit I. Accessory heads may be found in some species.<sup>3</sup>

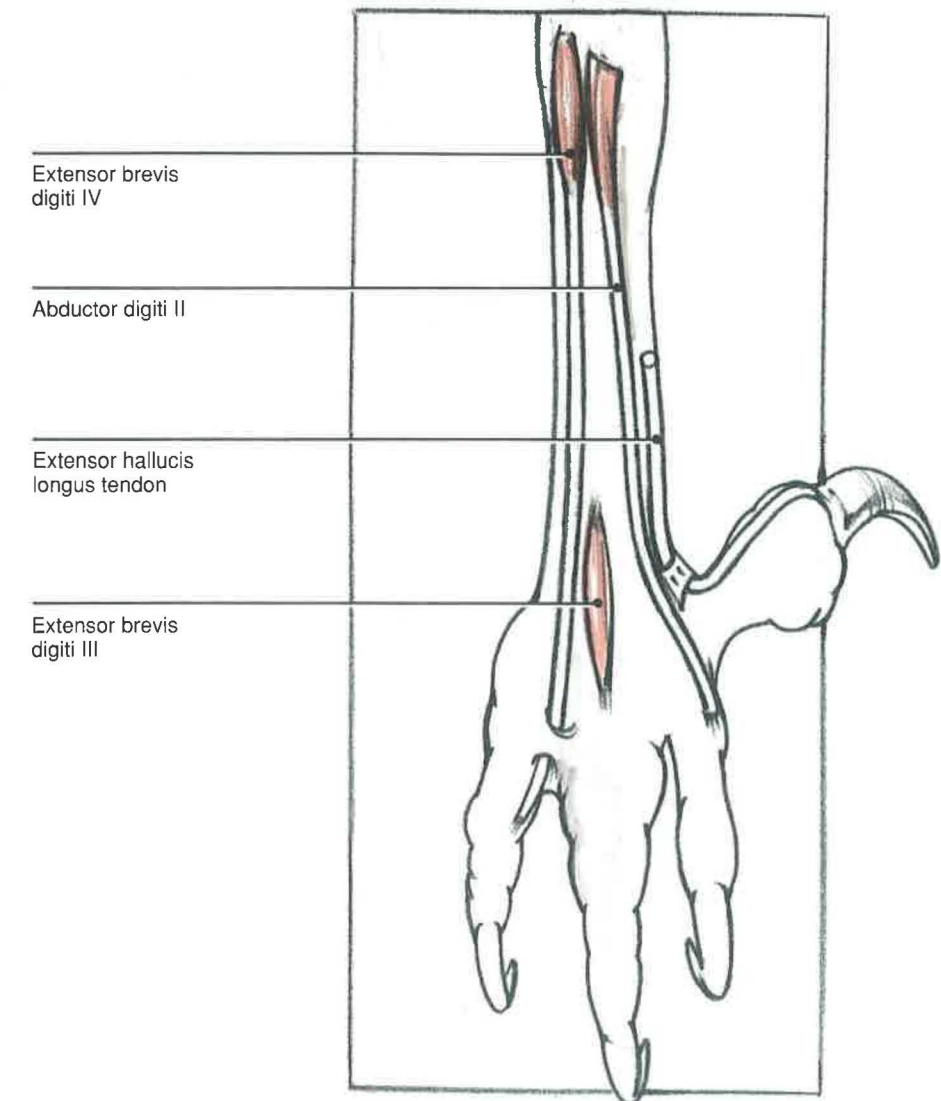
**Blood supply and innervation****—**The tendon of the tibialis cranialis courses through a ligamentous loop. It is accompanied by the deep fibular nerve [*n. fibularis profundus*] and the cranial tibial artery and vein [*a. and v. tibialis cranialis*]. The cranial tibial artery is the major vascular supply to the lower leg and digits. However, the major venous drainage is via the caudal tibial vein. After the artery and vein cross the hock, they are designated the dorsal metatarsal artery and vein. [*a. and v. metatarsales dorsales*]. The dorsal metatarsal nerves [*n. metatarsales dorsales*] are derived from branches of both the superficial and deep fibular nerves.



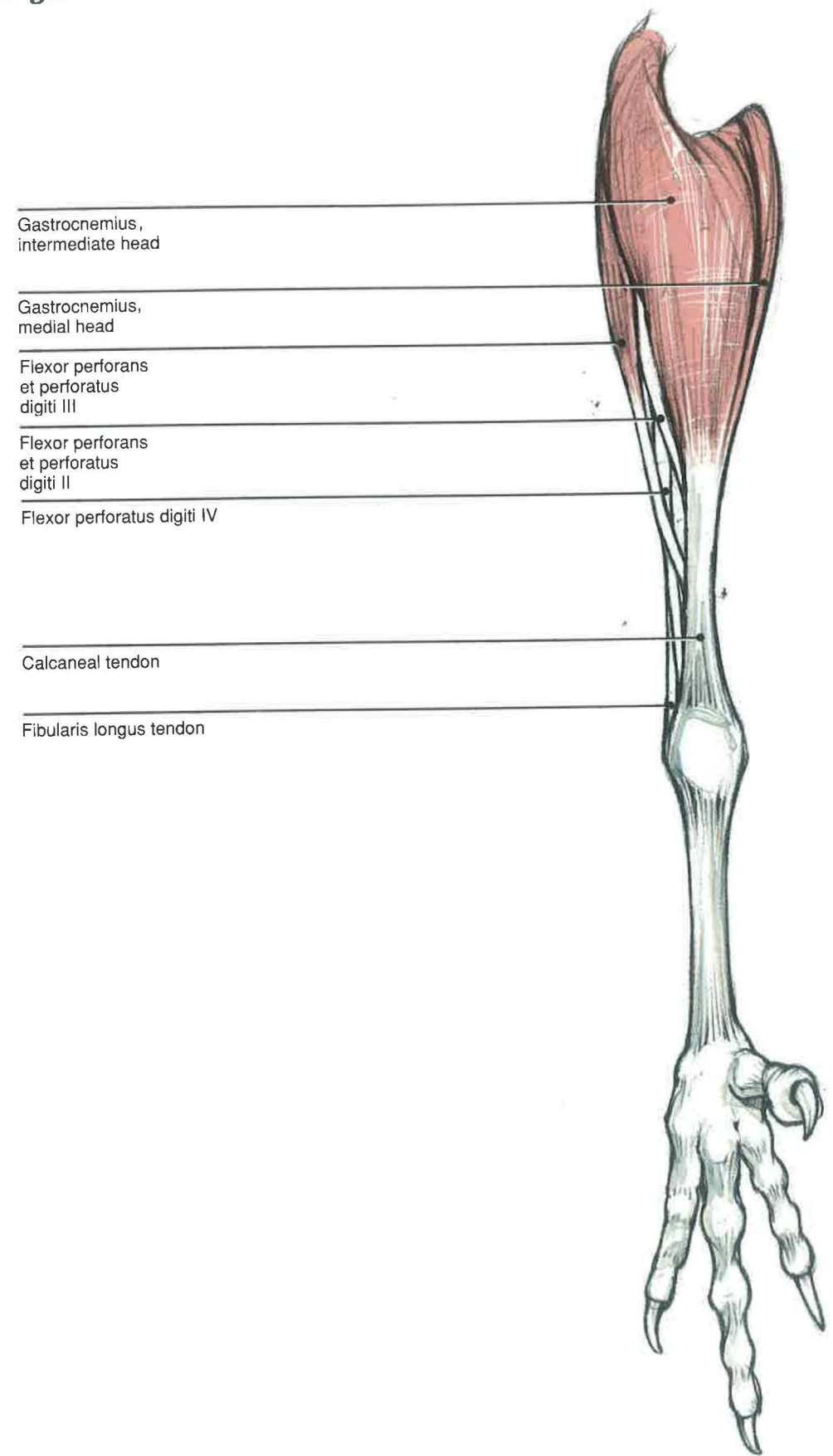
# **Cranial Leg and Digits** **MIDDLE LAYER** *Most Species*



# **Cranial Leg and Digits** **DEEP LAYER** *Most Species*

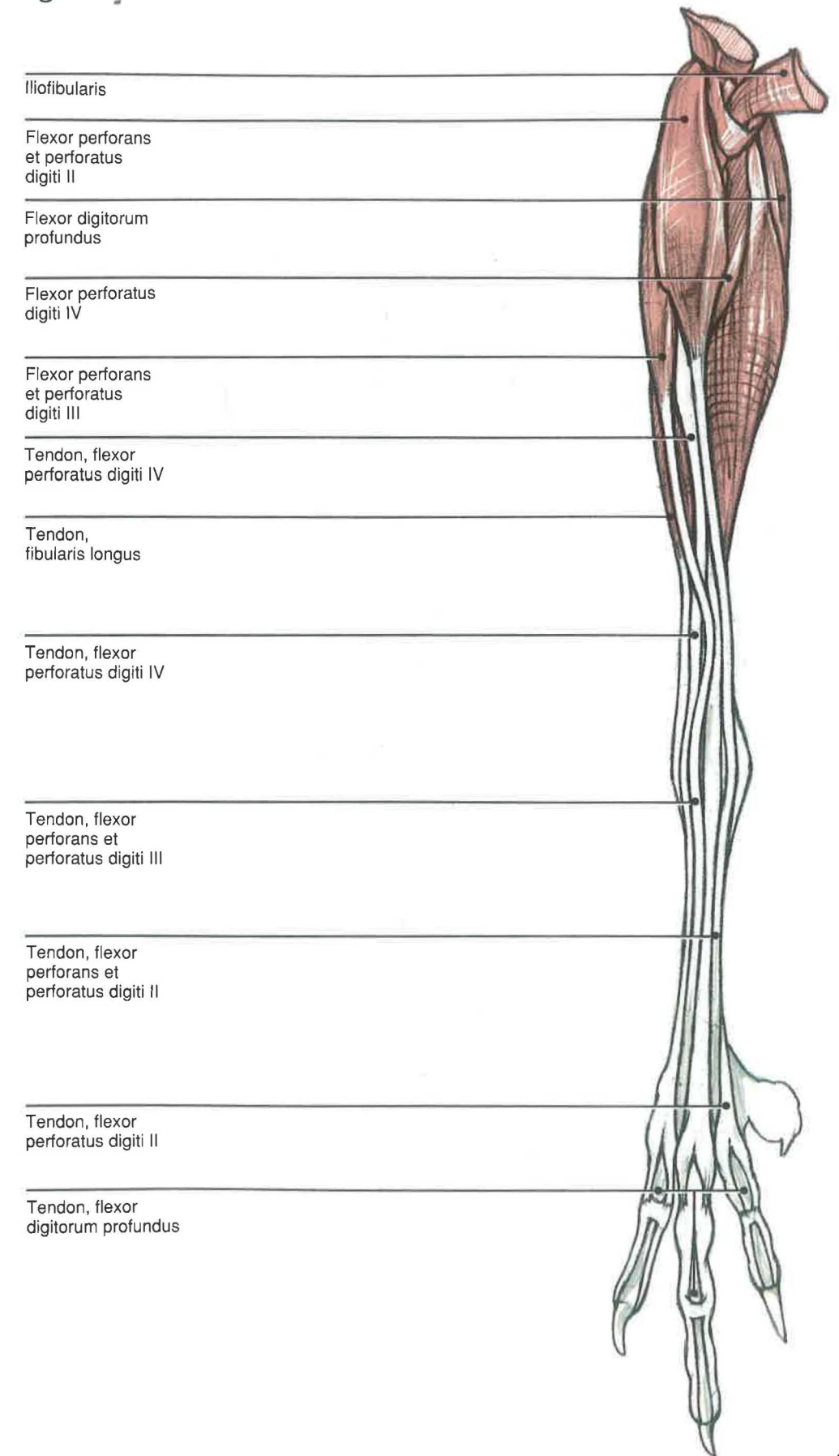


**Caudal Leg and Digits**  
**SUPERFICIAL LAYER**



- Gastrocnemius, intermediate head
- Gastrocnemius, medial head
- Flexor perforans et perforatus digiti III
- Flexor perforans et perforatus digiti II
- Flexor perforatus digiti IV
- Calcaneal tendon
- Fibularis longus tendon

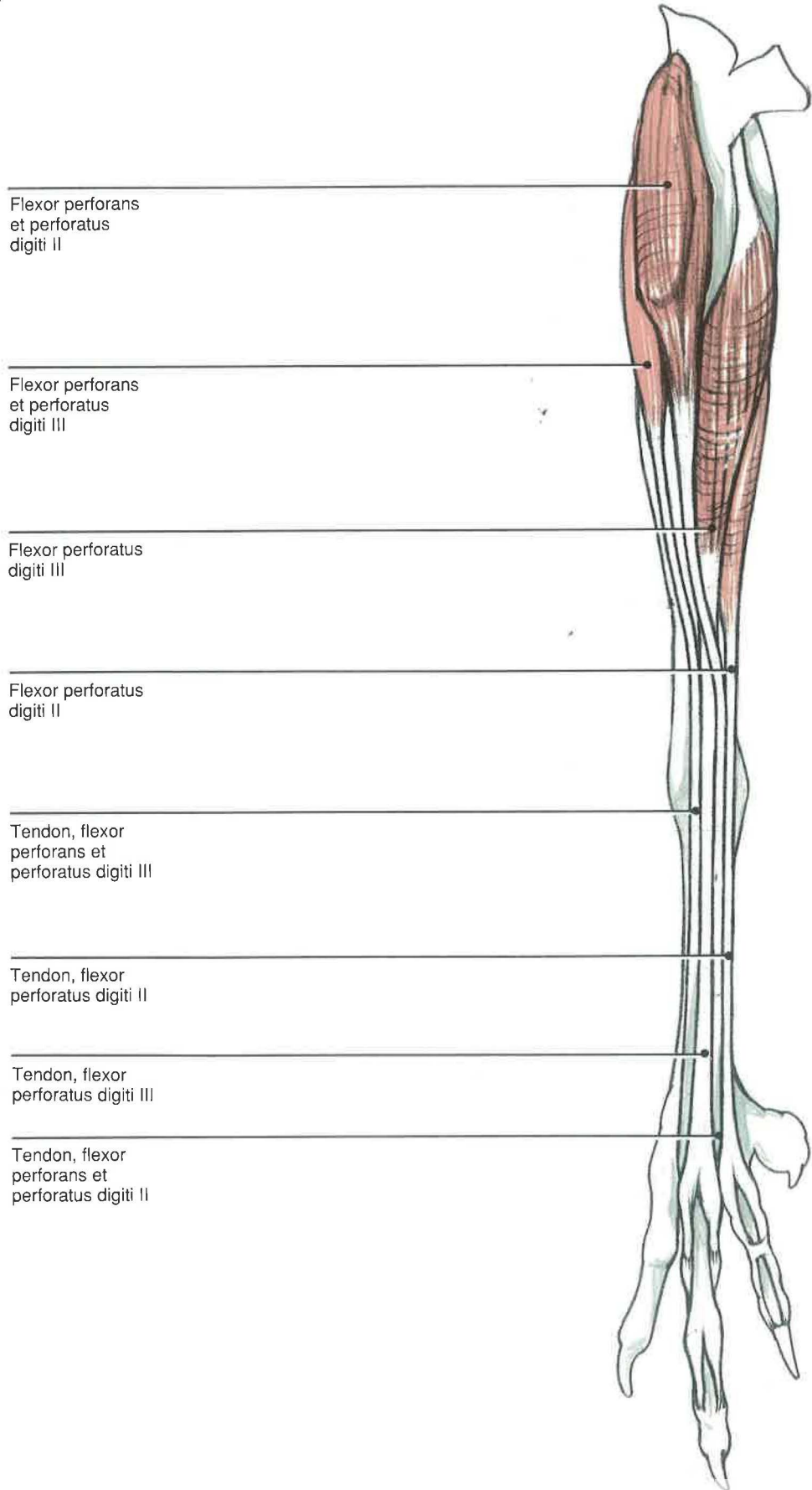
**Caudal Leg and Digits**  
**SECOND LAYER**



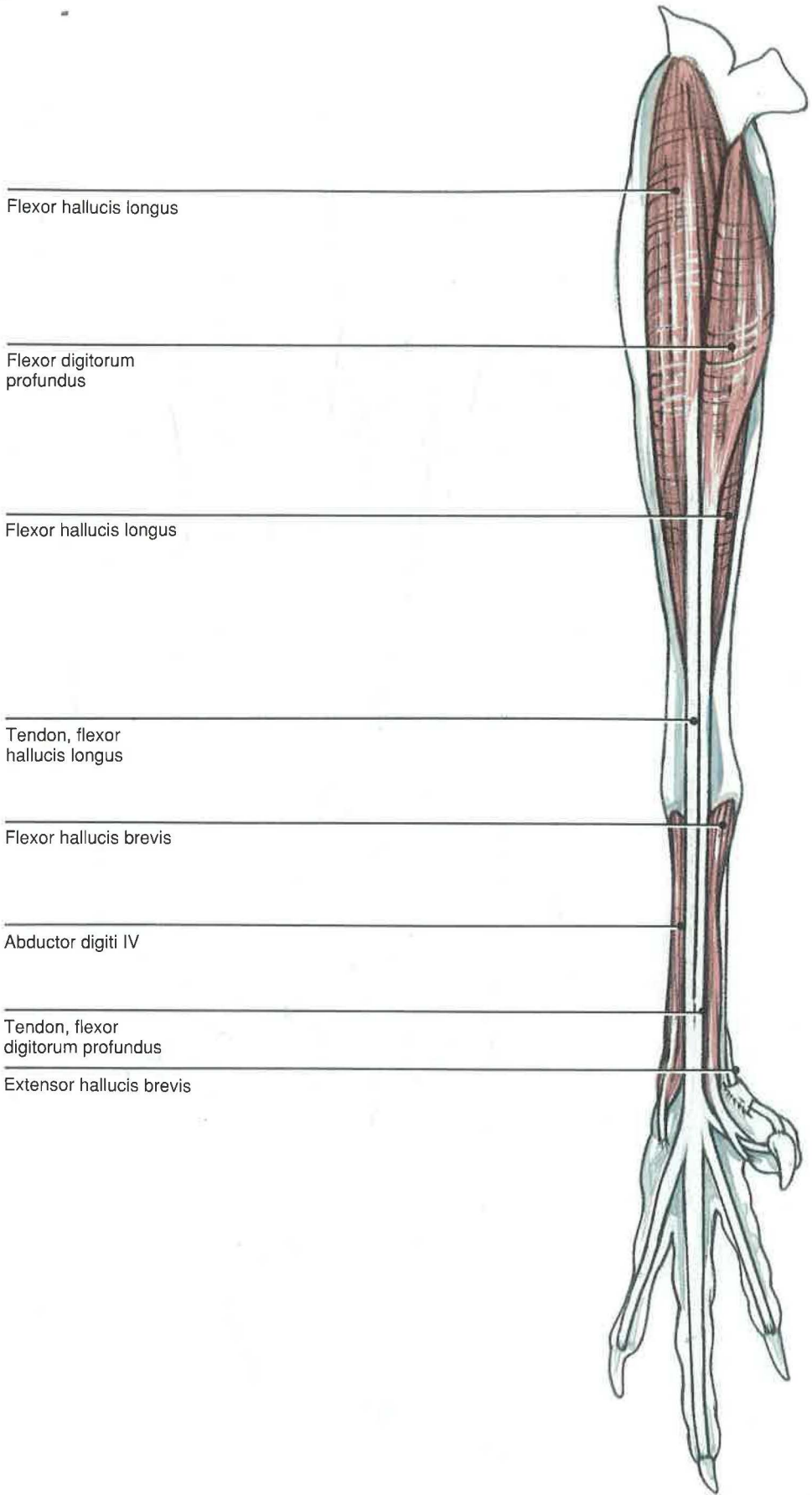
- Ilioibularis
- Flexor perforans et perforatus digiti II
- Flexor digitorum profundus
- Flexor perforatus digiti IV
- Flexor perforans et perforatus digiti III
- Tendon, flexor perforatus digiti IV
- Tendon, fibularis longus
- Tendon, flexor perforatus digiti IV
- Tendon, flexor perforans et perforatus digiti III
- Tendon, flexor perforans et perforatus digiti II
- Tendon, flexor perforatus digiti II
- Tendon, flexor digitorum profundus



**Caudal Leg and Digits**  
**THIRD LAYER**



**Caudal Leg and Digits**  
**DEEP LAYER**







**Section IV**  
**Surgical Approaches to**  
**the Pelvic Limb**



## Coxofemoral Joint

### LATERAL APPROACH

#### Indications

The lateral approach is used for the open reduction and stabilization of the coxofemoral joint or for excision arthroplasty of the femoral head.

#### Procedure<sup>6</sup>

A) The bird is placed in lateral recumbency with the wings tucked out of the surgical field. The feathers should be plucked from the dorsolateral femur and pelvic areas, and the site prepared for surgery. The incision should begin over the dorsolateral crest of the ilium and extend over the femoral trochanter, down the caudolateral side of the shaft, as needed, for exposure.

B) Reflection of the skin will reveal the iliotibialis lateralis muscle cranially and the iliofibularis caudally. These two muscles should be separated from distal to proximal. The incision should follow this line of separation to the dorsolateral iliac crest. This will require cutting the common aponeurotic tendon of origin of these two muscles as they insert onto this iliac crest.

Once the skin is reflected, a number of structures can be visualized. The iliofemoralis externus (piriformis) muscle inserts dorsally onto the femoral trochanter. The iliotrochantericus caudalis (gluteus medius) inserts just cranial to the iliofemoralis externus, while the iliotrochantericus cranialis (gluteus profundus) inserts onto the cranioventral margin of the trochanter. The combined obturatorius tendons insert with the ischiofemoralis tendons along the caudal border of the proximal femur.

An incision should be made through the musculotendinous insertion of the iliotrochantericus caudalis and the iliofemoralis externus, leaving enough tissue for re-attachment.

C) Once these muscles are reflected, a thin, transparent membrane that is superficial to the femoral neck is revealed. It may represent a protrusion of the caudal abdominal air sac. However, the bird will need to be turned 180° in order to visualize the neck of the femur. The arrow in this diagram represents the orientation for D.

D) A small blood vessel lies on the cranial margin of this transparent membrane and originates from the more deeply located femoral artery. The femoral nerve and vein are found running with the femoral artery at this location, but they were not included here to simplify the illustration. The joint capsule

runs from the medial margin of the trochanter to the dorsal rim of the antitrochanter and the acetabulum cranially.

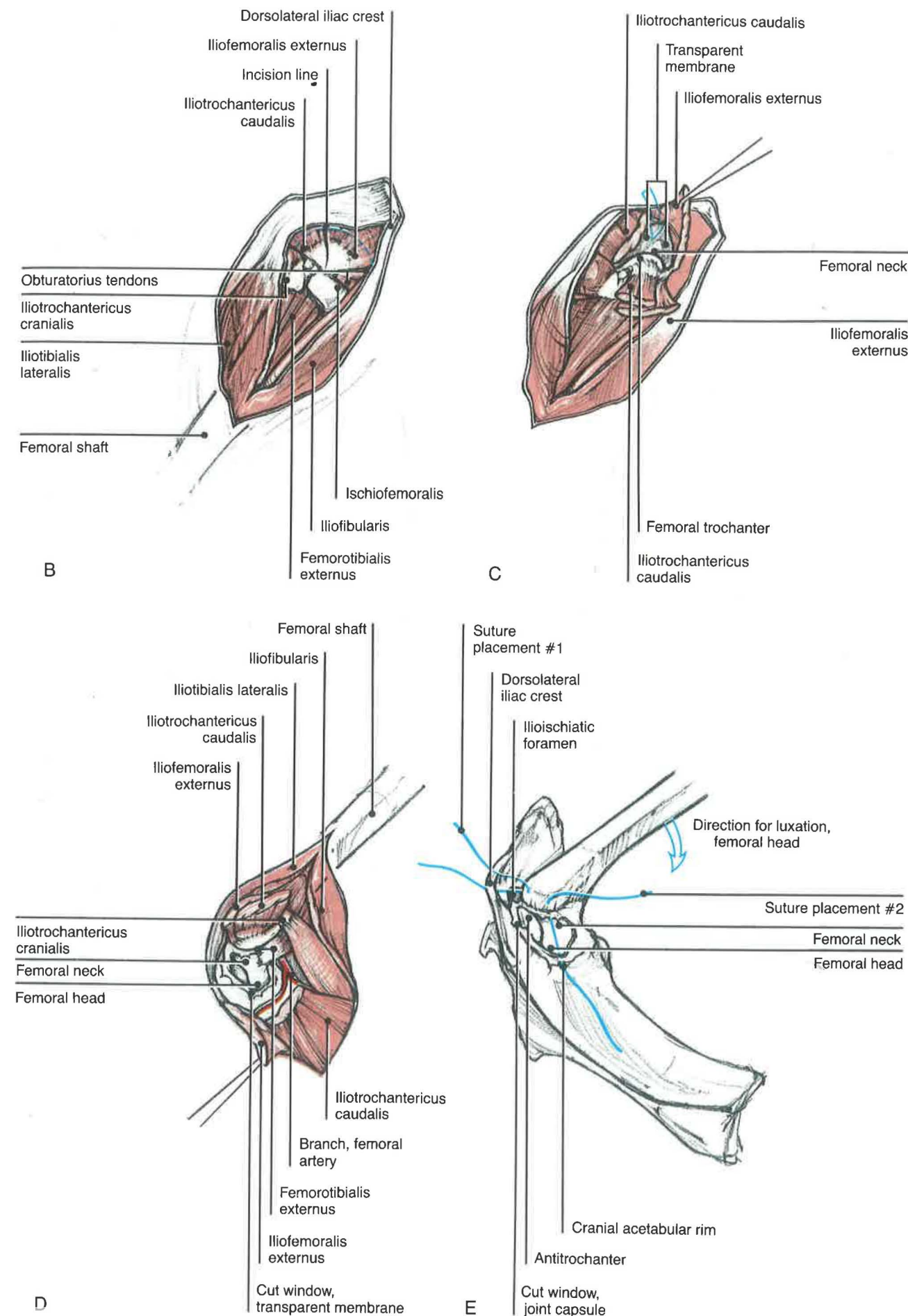
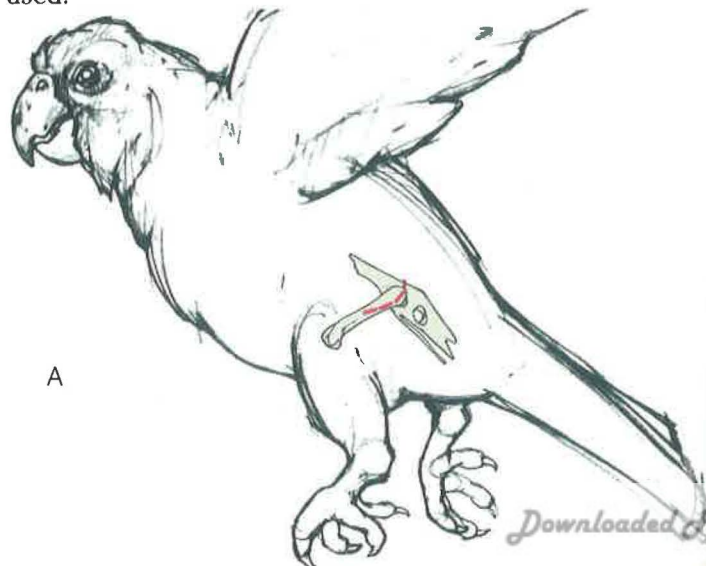
E) This diagram illustrates the relationship of the femoral head and neck and joint capsule to the pelvis. There are several thickenings in the joint capsule cranially and caudoventrally. The femoral head is maintained within the acetabulum by the ligament to the head of the femur. Traction of the limb will partially luxate the femoral head out of the acetabulum. Luxations of the femoral head can be reduced by placing nonabsorbable sutures through the trochanter of the femur and the dorsolateral iliac crest, caudal to the central axis of the femur (see suture placement #1). Another suture is then placed through the trochanter and the cranial acetabular rim (see suture placement #2). Both sutures should be tied off using a surgeon's knot.

#### Closure

The joint capsule may be closed using a simple interrupted pattern. The cut ends of the iliotrochantericus caudalis and the iliofemoralis externus muscles should be re-attached with a simple, continuous pattern. This same pattern can be used to suture the aponeurotic tendon of origin of the iliotibialis lateralis and the iliofibularis. A spica-type splint and bandage may be used to protect and support the limb for several weeks. The splint should be placed over the body dorsally and continue down the leg past the stifle joint.

#### Comments

Birds usually luxate their femoral heads craniodorsal to the acetabulum, although a cranioventral luxation may occur. If a closed reduction is not possible, an open reduction may be used.



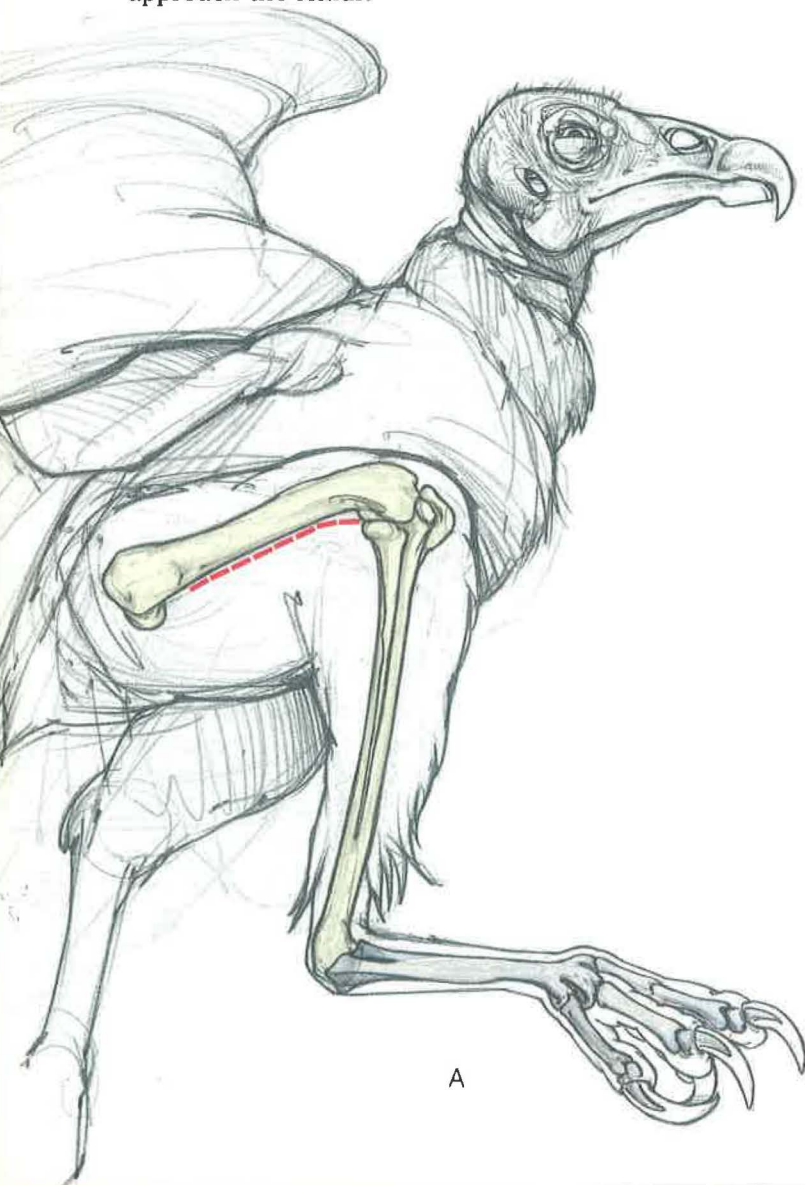

**Femur****LATERAL APPROACH*****Cathartidae and Gallinaceous Birds*****Indications**

The lateral approach is used for the open reduction of the femur for internal fixation. Owing to the close proximity of the body wall to the femur, external fixation is difficult at best. Stacked pins may be used to provide longitudinal stability; if the pins fill the marrow cavity, rotational stability is also afforded. Each pin should be retrograded out the trochanter and normograded into the condyles.

**Procedure**

A) This procedure is designed for birds that have a large superficial muscle mass that covers the underlying muscles and femur. Vultures,<sup>2</sup> various gallinaceous birds,<sup>3</sup> and cranes<sup>7</sup> have a large head of the iliotibialis lateralis that must be divided to approach the femur.



A

The bird is placed in partial sternal or lateral recumbency with the wing tucked under the leg being approached; the object is to keep the wing out of the surgical field. The feathers are plucked from the dorsal ilium to the proximal tibia before the surgical site is prepared. Palpation of the femoral shaft is important for determining the location of the skin incision. It should be made over the femoral shaft to avoid injuring underlying vessels.

B) The iliotibialis lateralis can be visualized on reflecting the skin. This muscle should be separated bluntly along the femoral shaft. Care should be taken, especially if the separation of the muscle is caudal, for the ischiatic vein is found just deep to the iliofibularis.

C) Retraction of iliotibialis lateralis reveals a number of important structures. Cranially, the femorotibialis externus covers the femoral shaft. The iliofibularis lies caudal to the femorotibialis externus.

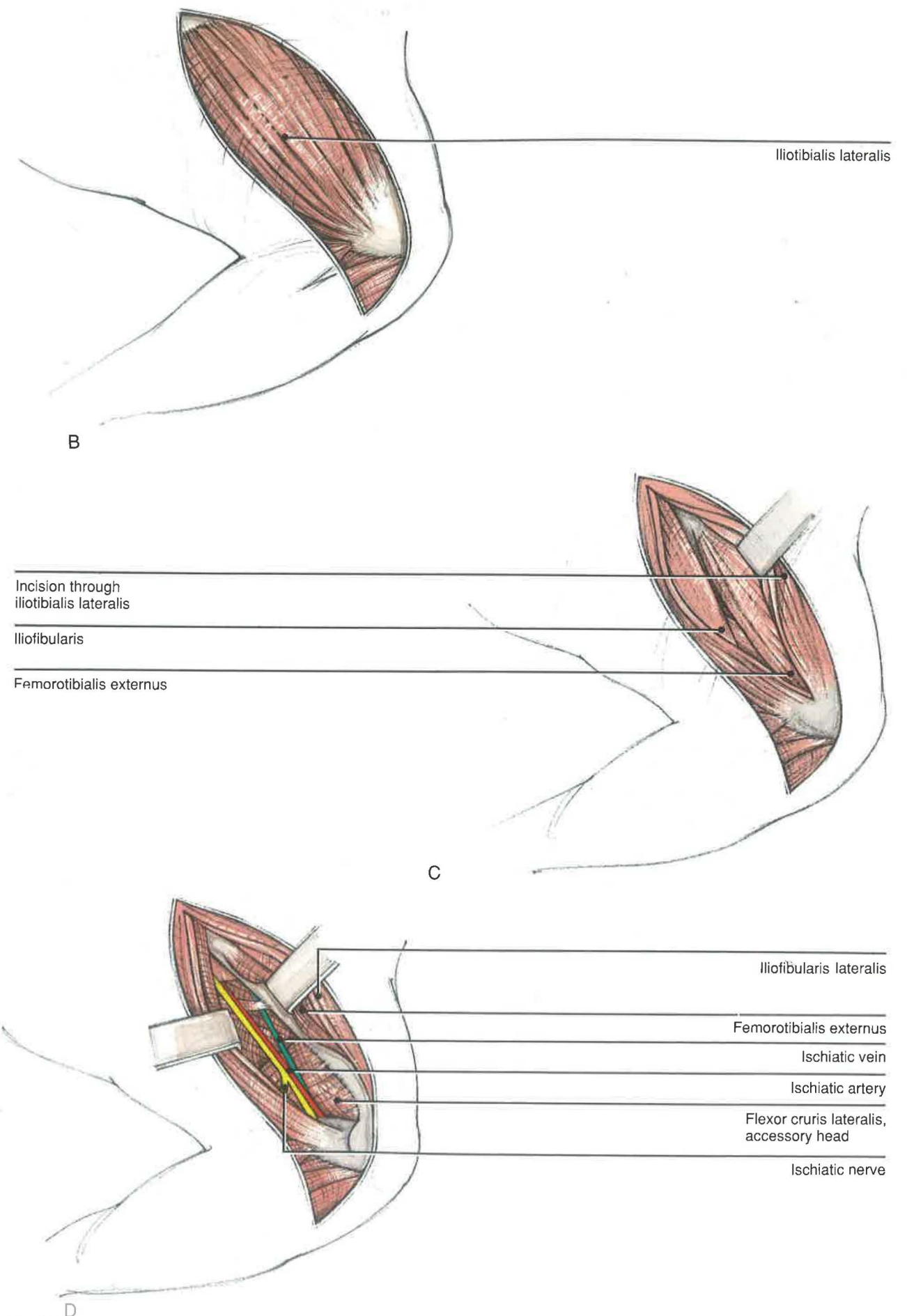
D) The accessory head of the flexor cruris lateralis or the semitendinosus is caudal but deep to the iliofibularis. The femorotibialis externus can then be retracted cranially to expose the femoral shaft. Greater exposure may be obtained by subperiosteal elevation of this muscle. The ischiatic vein, artery, and nerve lie caudal to the shaft, in that order.

**Closure**

If the periosteum has been incised to elevate the femorotibialis externus, several sutures may be required to re-attach it to the bone. The iliotibialis lateralis may need to be sutured to re-appose the edges properly before closing the skin as a single layer. Although difficult to apply in this location, a protective wrap may be applied until the skin has healed.

**Comments**

The pull from the muscles of the femur will commonly result in an overriding of fragments. Due to the size of these birds, surgical alignment and stabilization are required. Because the degree of curvature of the femoral shaft varies among species,<sup>2</sup> the distal fragment of the femur should be aligned with the tibia at surgery. Postoperatively, the bird should be cage-rested for approximately 3 weeks to reduce possible complications.<sup>8-10</sup>





**Femur**  
**LATERAL APPROACH**

*Accipitridae, Strigiformes  
and Psittaciformes*

**Indications**  
The lateral approach is used for the open reduction and internal fixation of the femur. (See additional details in the approach for cathartids and gallinaceous birds.)

**Procedure**  
A) The bird is placed in lateral recumbency with the wing positioned out of the surgical field. Feathers are plucked from the dorsal hip to the proximal tibia on the lateral side. The remainder of the leg is placed in a stockinette, and the site is prepared for surgery.

B) An incision is made in the skin along the shaft of the femur from the femoral trochanter to the lateral condyle. This exposes the iliotibialis lateralis and iliofibularis muscles. The iliotibialis lateralis in hawks, owls, and psittacines is thin and adheres tightly to the underlying femorotibialis externus. The ischiatic vessels and nerve are deep to the iliofibularis, with the vein cranial to the artery. At the distal end of the iliofibularis, there is a retinaculum, or ligamentous loop, for its tendon of insertion. The fibular or peroneal nerve also courses through this retinaculum.

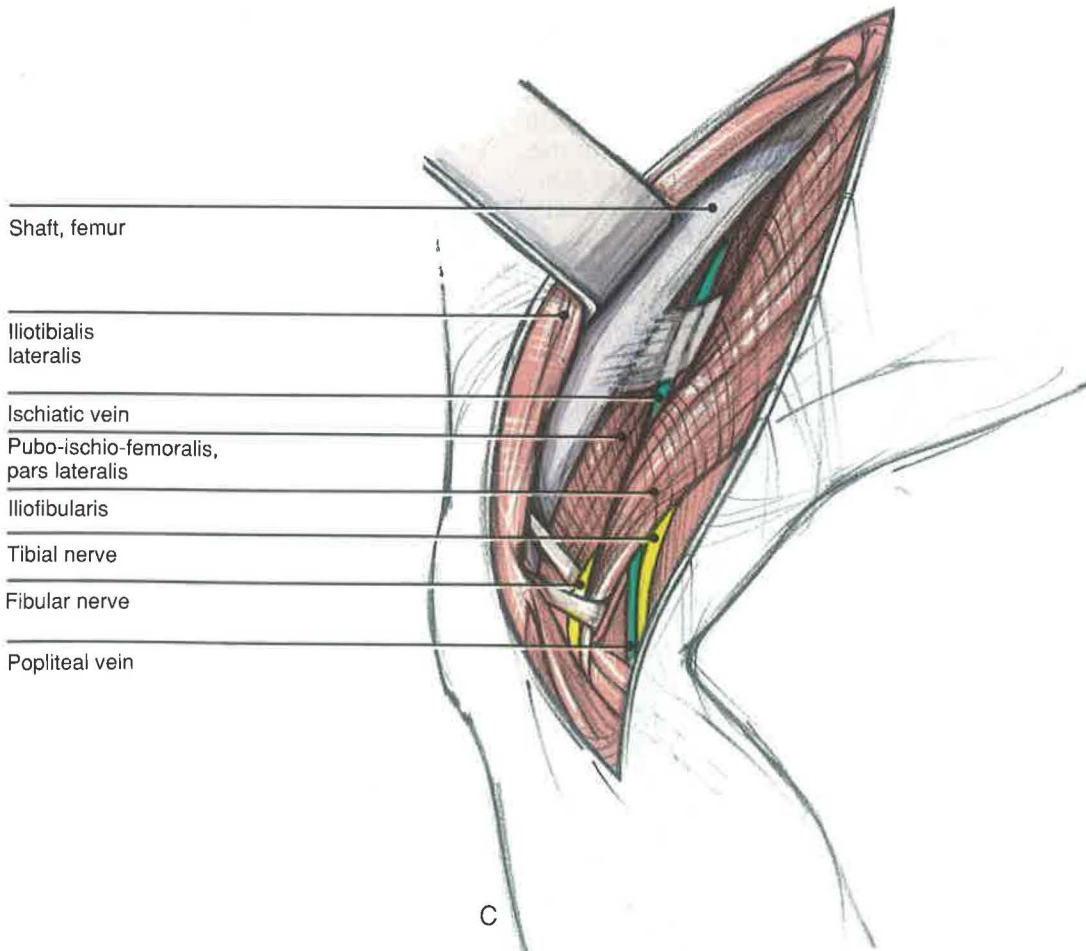
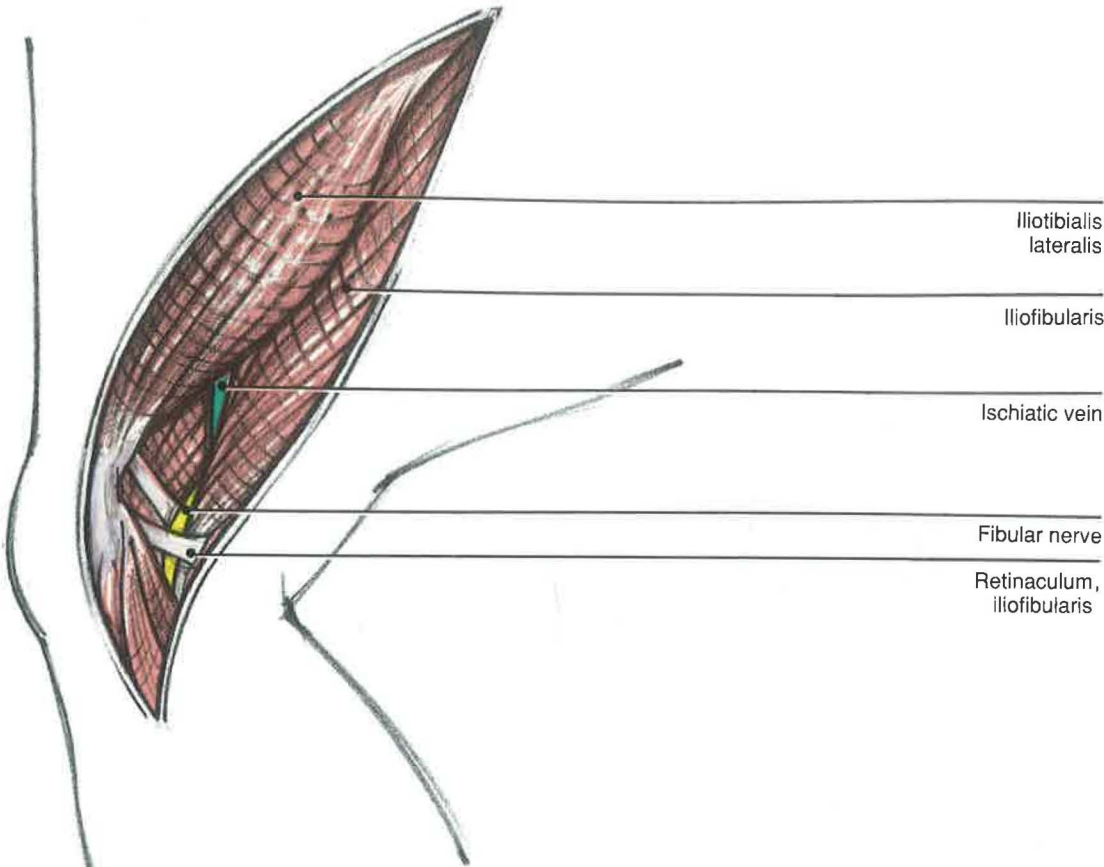
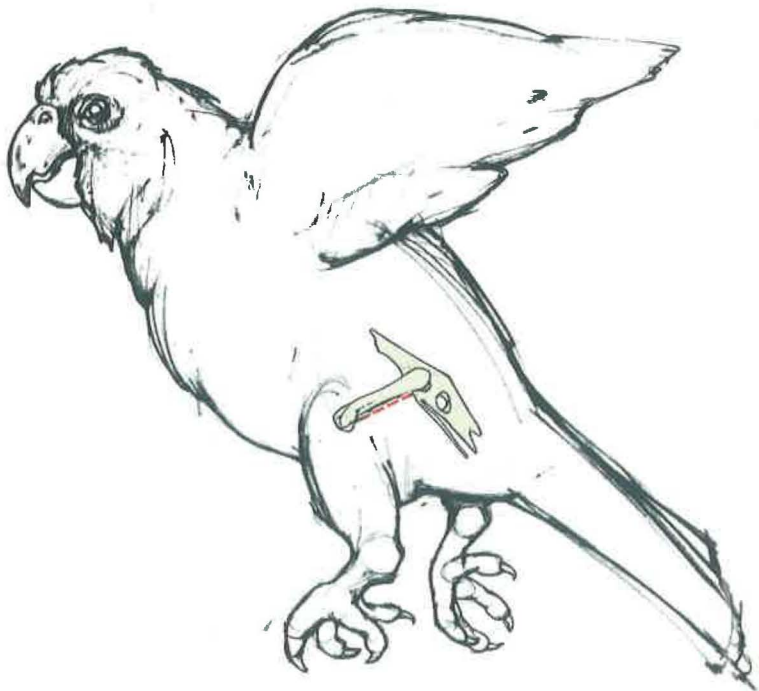
C) To expose the shaft of the femur, the iliotibialis lateralis and femorotibialis externus are retracted cranially as a single mass. Periosteal elevation of the femorotibialis externus may be used for greater exposure. The ischiatic vein runs just caudal to the femur in its middle third and should be avoided. The ischiatic artery and nerve are caudal to the ischiatic vein and deep to the iliofibularis.

**Closure**  
The skin and underlying subcutaneous tissue are closed as a single layer. A bandage should be applied for protection.

**Comments**  
Small birds and waterfowl that have a closed fracture of the femur may be cage-rested for at least 3 weeks.<sup>9</sup> Bandages or splints mostly are ineffective. Overriding of fragments may result in a shortening of the shaft or possible improper alignment with the tibia. This alters posture and function of the lower leg.

Once the femoral shaft is visualized, pins should be stacked in the medullary cavity by retrograding each pin out the trochanter and normograting it into the femoral condyles.<sup>10</sup> Although Redig and Roush<sup>11</sup> suggest suturing the iliotibialis lateralis to the iliofibularis, it probably is not necessary.

The prognosis for these fractures is good but is poorer if they are comminuted. Healing of comminuted fractures may be best if the fracture is left alone and the bird is cage-rested. Distal fractures of the femur may be stabilized with a modified K-E apparatus (see Section V).<sup>8,10</sup> Bumblefoot is a common sequela when raptors maintain most of their body weight on one leg.





**Tibiotarsus**  
**MEDIAL APPROACH**

**Indications**

The medial approach is used for the open reduction of the tibiotarsus. Intramedullary pins are retrograded out the hock and normograded into the stifle. Modified K-E devices may also be applied.

**Procedure**

A) Due to the large muscle mass on the lateral leg, a medial approach to the tibiotarsus is preferable to a lateral one. The bird is placed in lateral recumbency with the normal leg pulled caudally out of the surgical field. The feathers are plucked along the medial tibiotarsus to include the medial femoral condyle and the proximal tarsometatarsus.

B) Various structures should be noted before making the initial skin incision. The medial metatarsal vein courses over the hock joint, gains a caudal location, then ascends in the flexor compartment as the caudal tibial vein. The fibularis longus and cranial tibial are located cranial to the medial head of the gastrocnemius. The position of the fibularis longus varies in different species: in vultures, it is superficial to the cranial tibial muscle; in hawks and psittacines, it is deep.

After the noted structures are located, the skin incision should be made along the shaft of the tibiotarsus. It should begin just cranial to the medial metatarsal vein and proceed proximally between the fibularis longus and the medial head of the gastrocnemius to the medial femoral condyle.

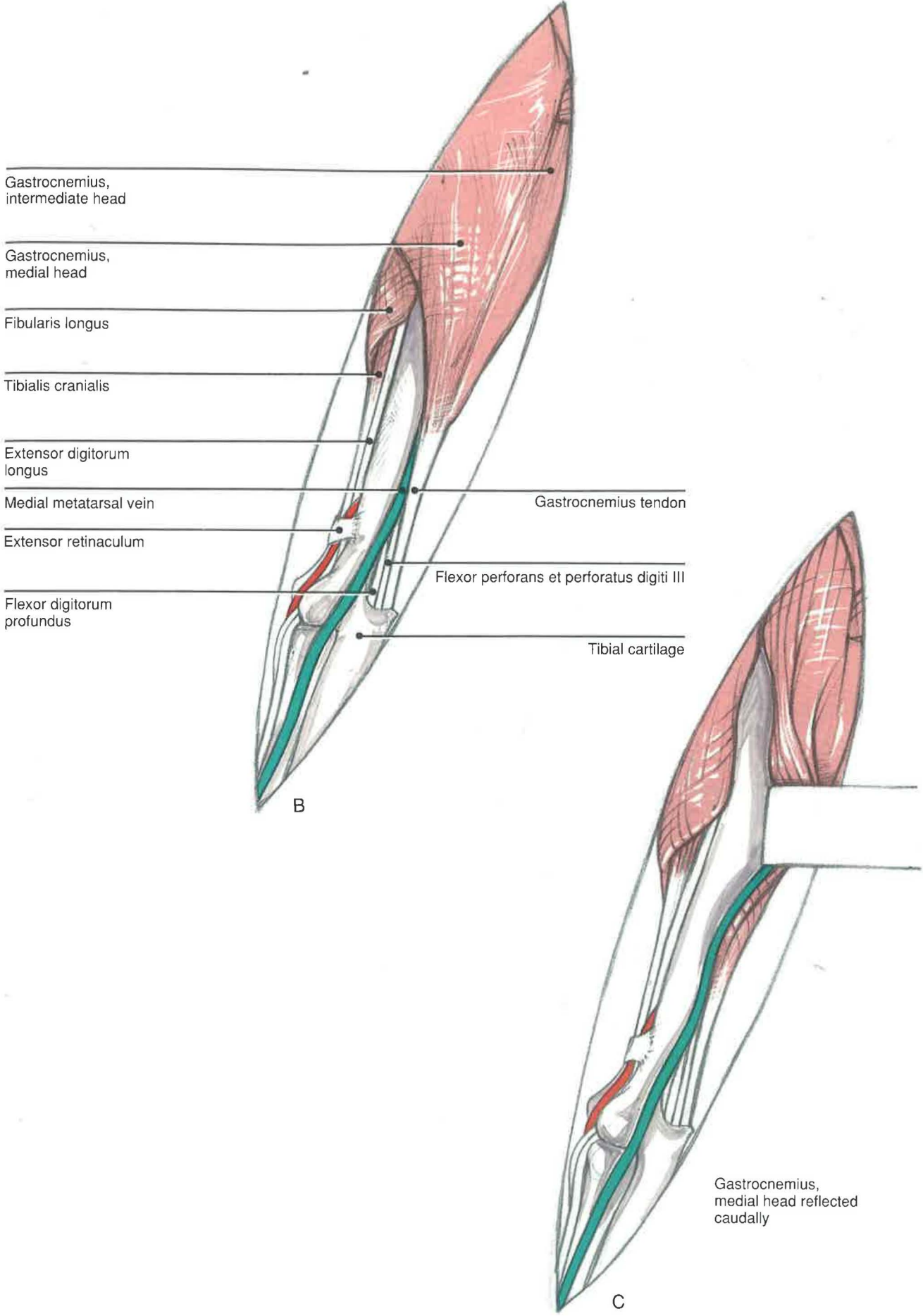
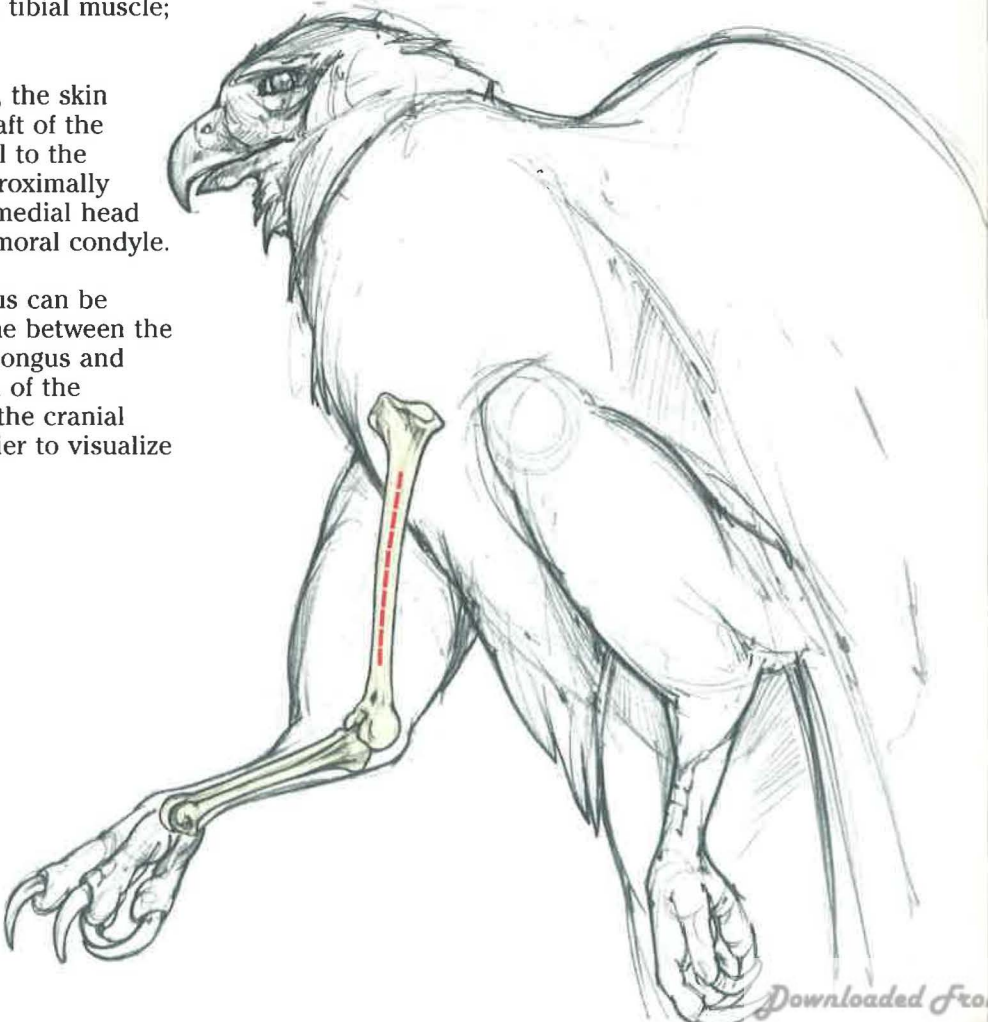
C) The proximal shaft of the tibiotarsus can be exposed by separating the fascial plane between the cranial complex of muscles (fibularis longus and tibialis cranialis) and the medial head of the gastrocnemius. The division between the cranial muscles and the gastrocnemius is easier to visualize in birds of prey than in psittacines.

**Closure**

The muscle bellies of the fibularis longus (or cranial tibial) and medial head of the gastrocnemius are sutured to each other before the skin is closed as a separate layer.

**Comments**

In birds that have a simple fracture, a single intramedullary pin may be placed in the intramedullary cavity to provide stability. The leg can then be bandaged with a Redig-modified Schroeder-Thomas splint<sup>9</sup> or a comparable coaptation device to prevent axial rotation. Results of this type of fixation are good to excellent and allow the bird to bear at least some weight postoperatively.<sup>8,9</sup> A comminuted fracture of the tibiotarsus has a greater chance of healing without a nonunion if stabilized by external support only. A tape splint of Altman (illustrated by Redig) can be used successfully for external fixation in birds weighing less than 150 g.<sup>9</sup>





**Tarsometatarsus and Phalanges**  
**LATERAL APPROACH**

**Indications**

The lateral approach is used for the open reduction and internal fixation of the tarsometatarsus or phalanges. A modified K-E apparatus can also be used to repair a fracture along the shaft of the tarsometatarsus.

**Procedure**

A) The bird is placed in lateral recumbency with the lateral side of the tarsometatarsus facing dorsally and the normal leg directed caudally out of the surgical field. The feathers are plucked along the lateral surface of the shaft of the bone from the hock to the digits.

B) The skin incision should be made along the shaft of the bone. The extensor tendons and blood vessels will be lying along the cranial margin of the bone, while the flexor tendons will be caudal. At the proximal end of the shaft are a small extensor of the fourth digit (extensor brevis digiti IV) that is located cranially and an abductor (abductor digiti IV) located caudally. When placing K-E wires

through the bone, keep in mind that the medial metatarsal vein is found along the medial end of the bone just cranial to the flexor tendons.

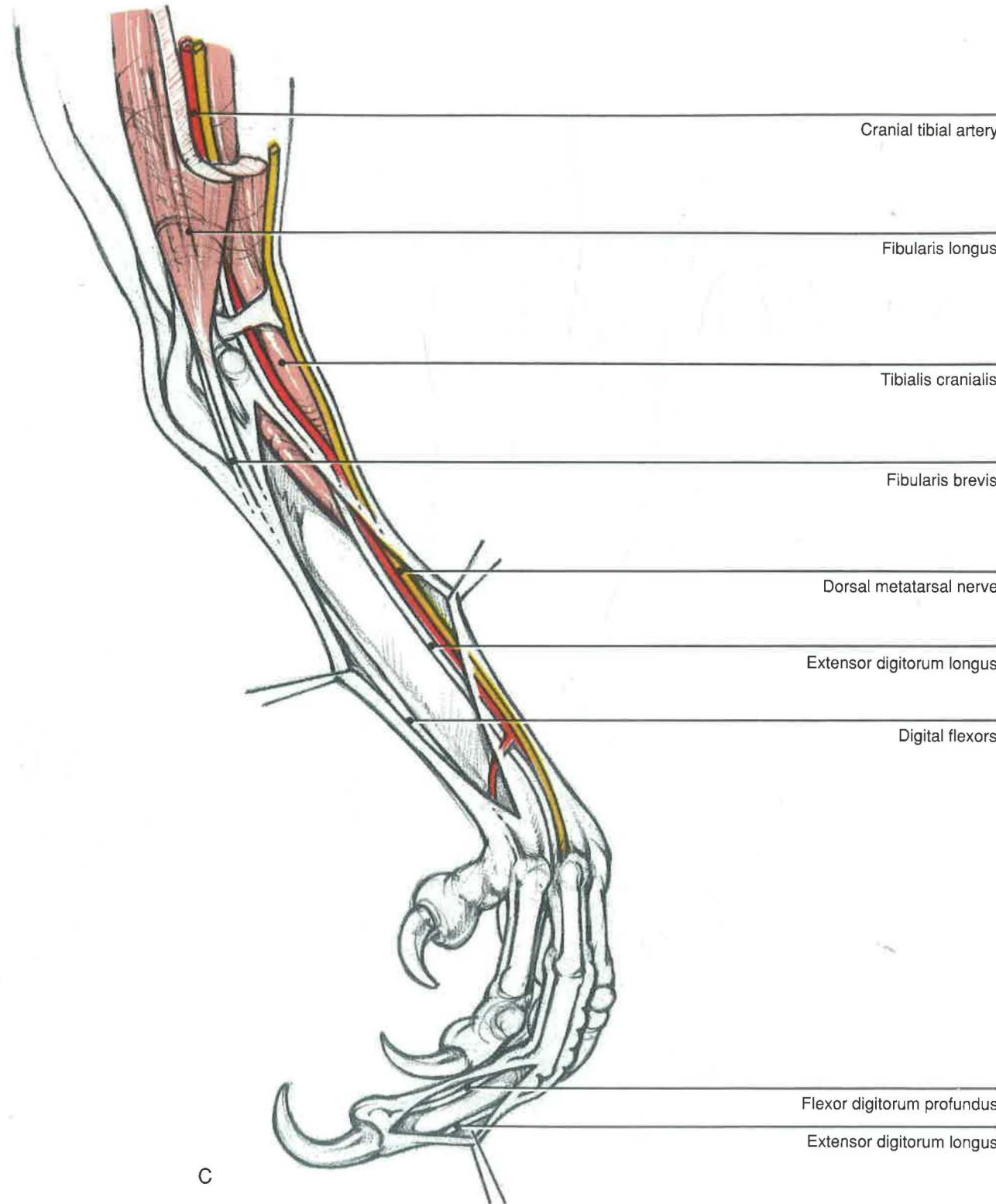
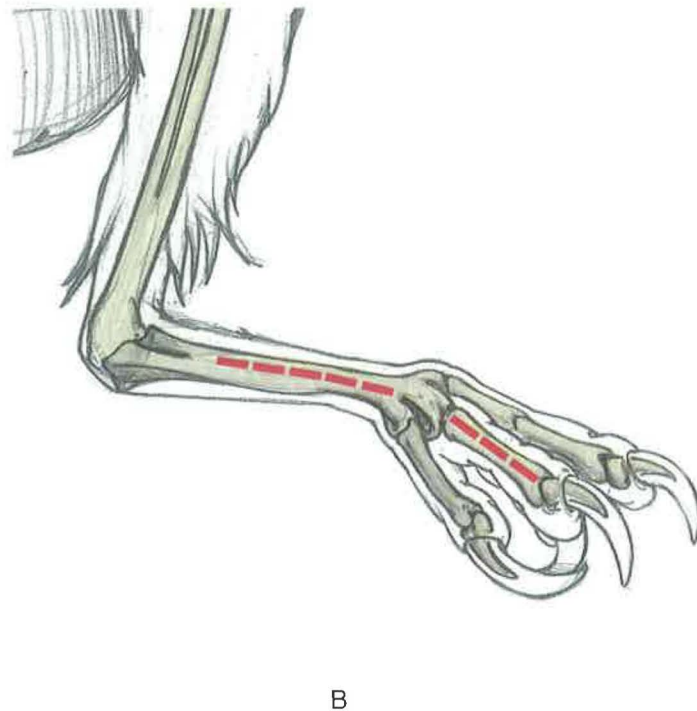
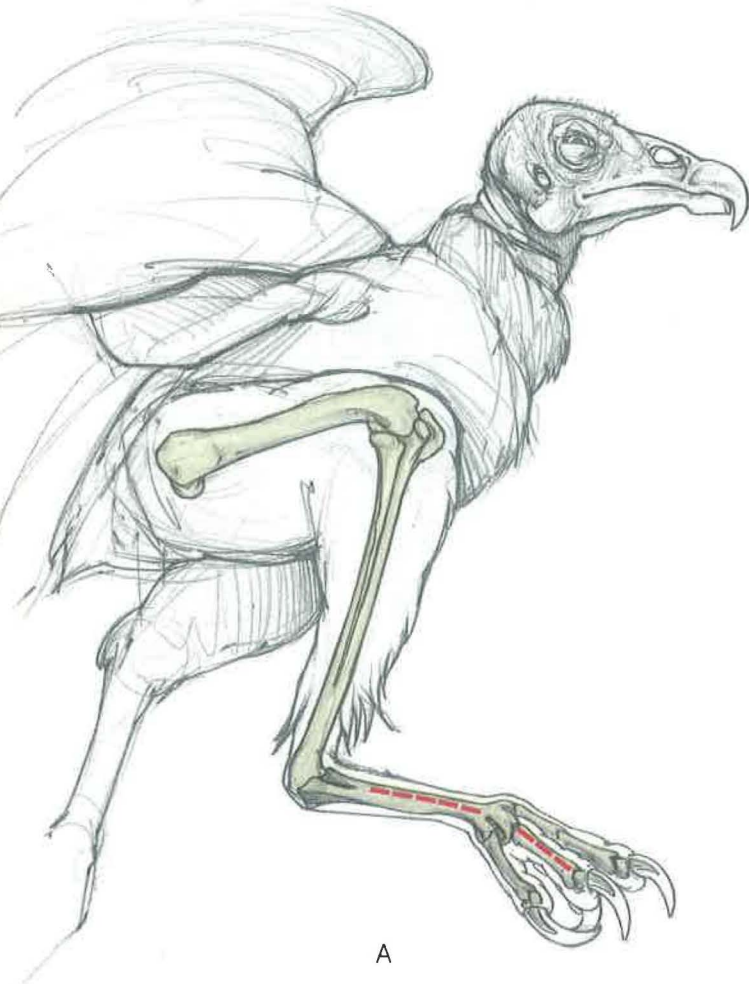C) The arrangement of the cranially directed extensor tendons and the caudally directed flexors requires a lateral or medial approach to the phalanges for fixation with intramedullary pins. After a skin incision is made along the lateral side of the bone, an intramedullary pin may be retrograded out the proximal condyle and seated into the distal one.

**Closure**

The skin incision should be closed as a single layer and bandaged with a protective wrap. The bandage should be changed as needed.

**Comment**

For fractures of the phalanges, a ball bandage that tapes the toes with at least some degree of extension may be adequate for fixation.





## **Considerations for Avian Surgery**

### **Section V Initial Examination and Care of the Traumatized Patient**







The initial examination of the avian patient should determine the location and severity of any injuries and the physical condition of the bird. For purposes of this discussion, the patient is assumed to have sustained a long bone fracture, which may be complicated with associated injuries to other structures. These potential injuries should be considered thoroughly during the examination. The nerve and blood supply to the fractured limb may be compromised beyond repair. Fractures may also be accompanied by injuries to the thoracic and abdominal cavities or to the head. Birds injured from lead shot often harbor additional lead pellets in the body and head, complicating therapy.<sup>20</sup> The severity of the fracture and associated injuries, as well as the general state of the bird, will influence treatment and prognosis.<sup>8,9,15</sup>

Avian species should not be handled excessively. Raptors and most large birds in good general condition can tolerate continued physical restraint during the initial examination, radiographic imaging, handling, and the application of dressings and medical treatment. However, weak raptors, debilitated parrots, many galliformes, and delicate passerines will not tolerate prolonged handling. For those patients and for birds that are weak or recumbent, it is important to provide warmth,

rehydration by cleisis or intravenous fluid therapy, and a quiet, dark environment. If possible, culture open wounds before starting antibiotic therapy.

The choice of therapy will be influenced by the type and location of injury, the condition of the bird, the species of bird, the prognosis, and the cost of treatment. Hence, each case must be evaluated individually. The location and severity of the injury may preclude complete or even partial restoration of function. For wild birds requiring near-normal function, this is a serious limitation; domesticated birds may not be so affected. Some birds will need surgical treatment, while others may need to be managed conservatively.

Fractures should be bandaged as a conservative procedure, preoperatively or postoperatively. A figure-of-eight bandage secured to the body wall (see pages 114-116) is used for support of fractures to the wing. Birds with femoral fractures are often cage-rested if surgical intervention is not undertaken. However, fractures of the tibiotarsus and tarsometatarsus can be splinted at least temporarily with a modified Schroeder-Thomas splint in birds over 400 g or with tape in smaller birds.<sup>9</sup>

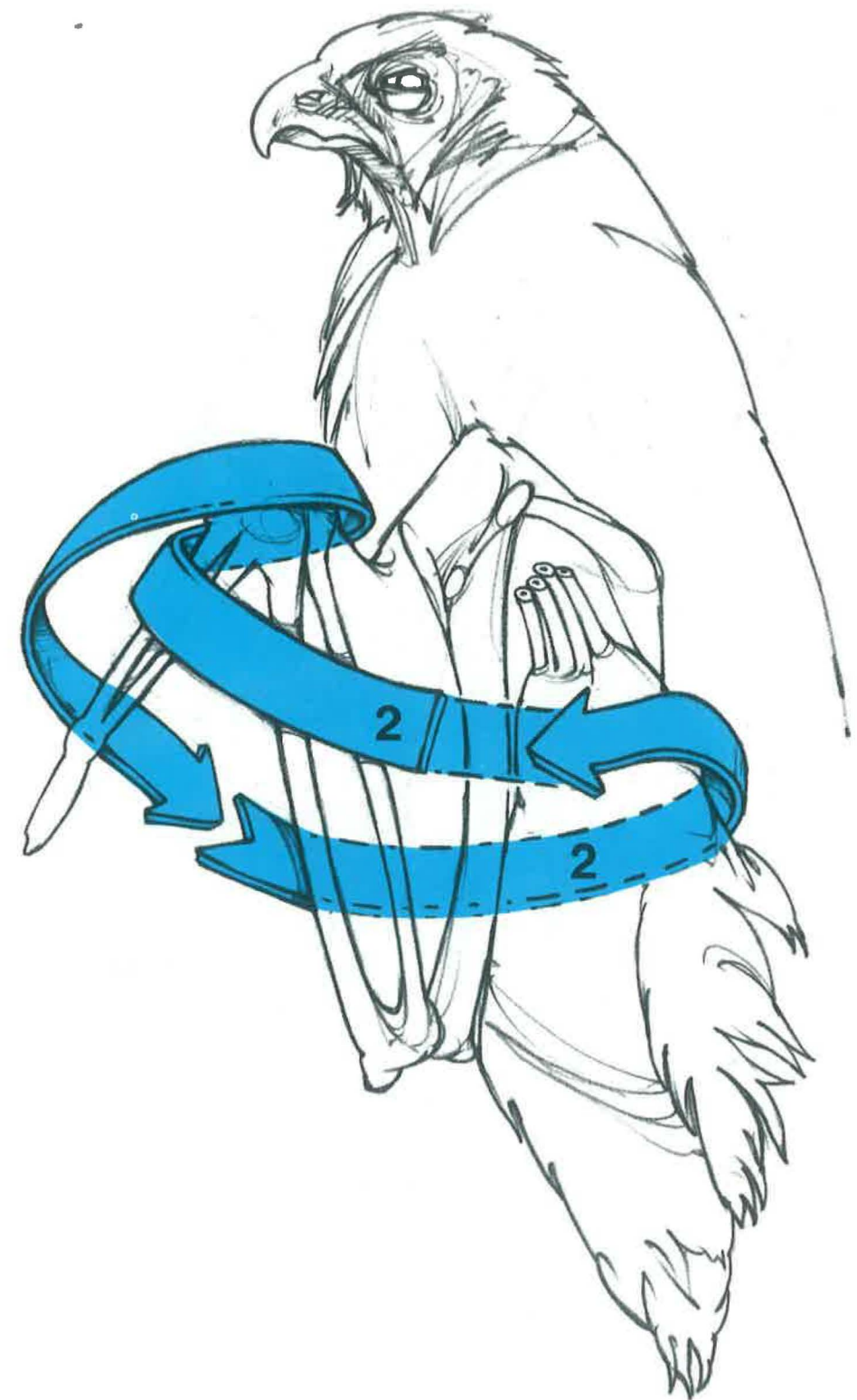
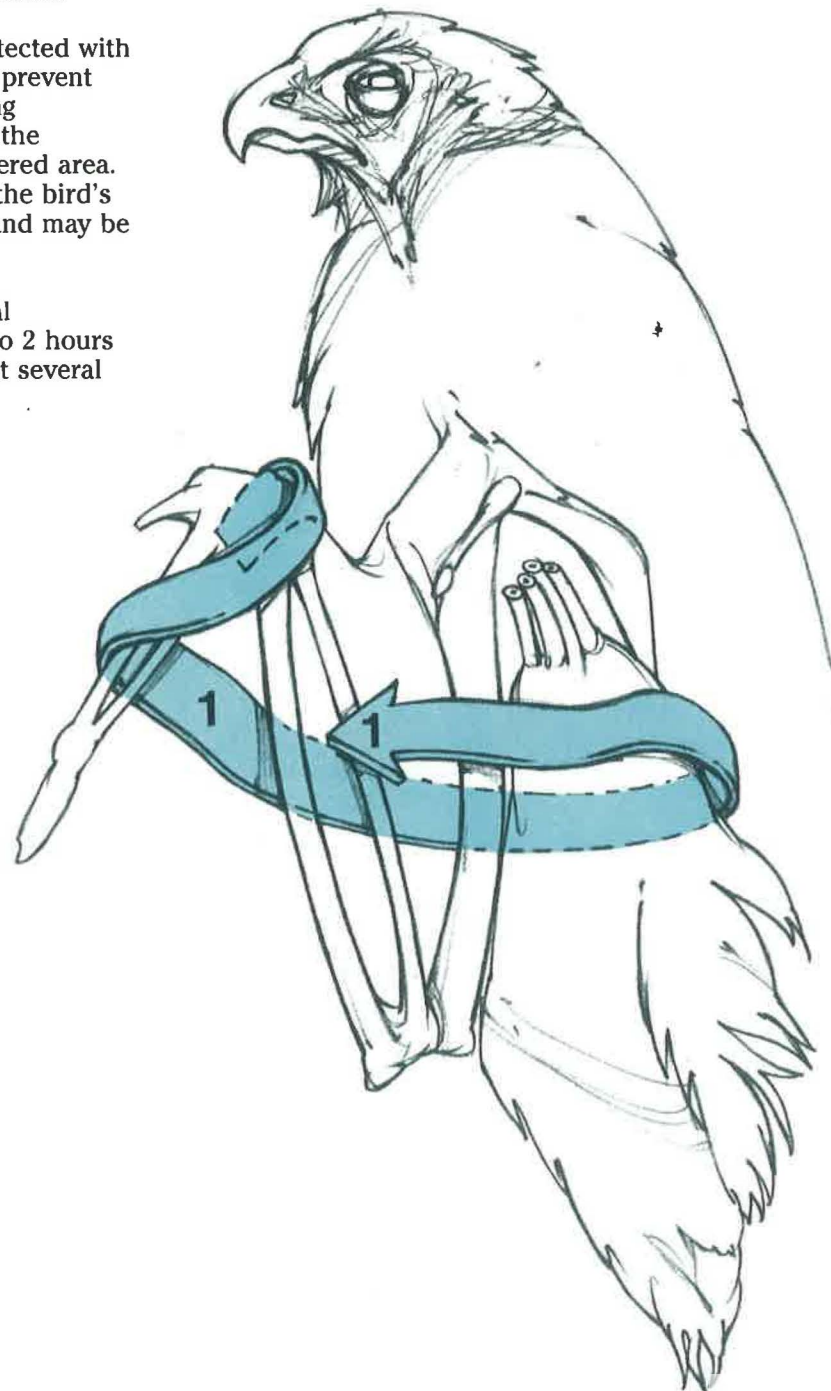


**Control of Sepsis**

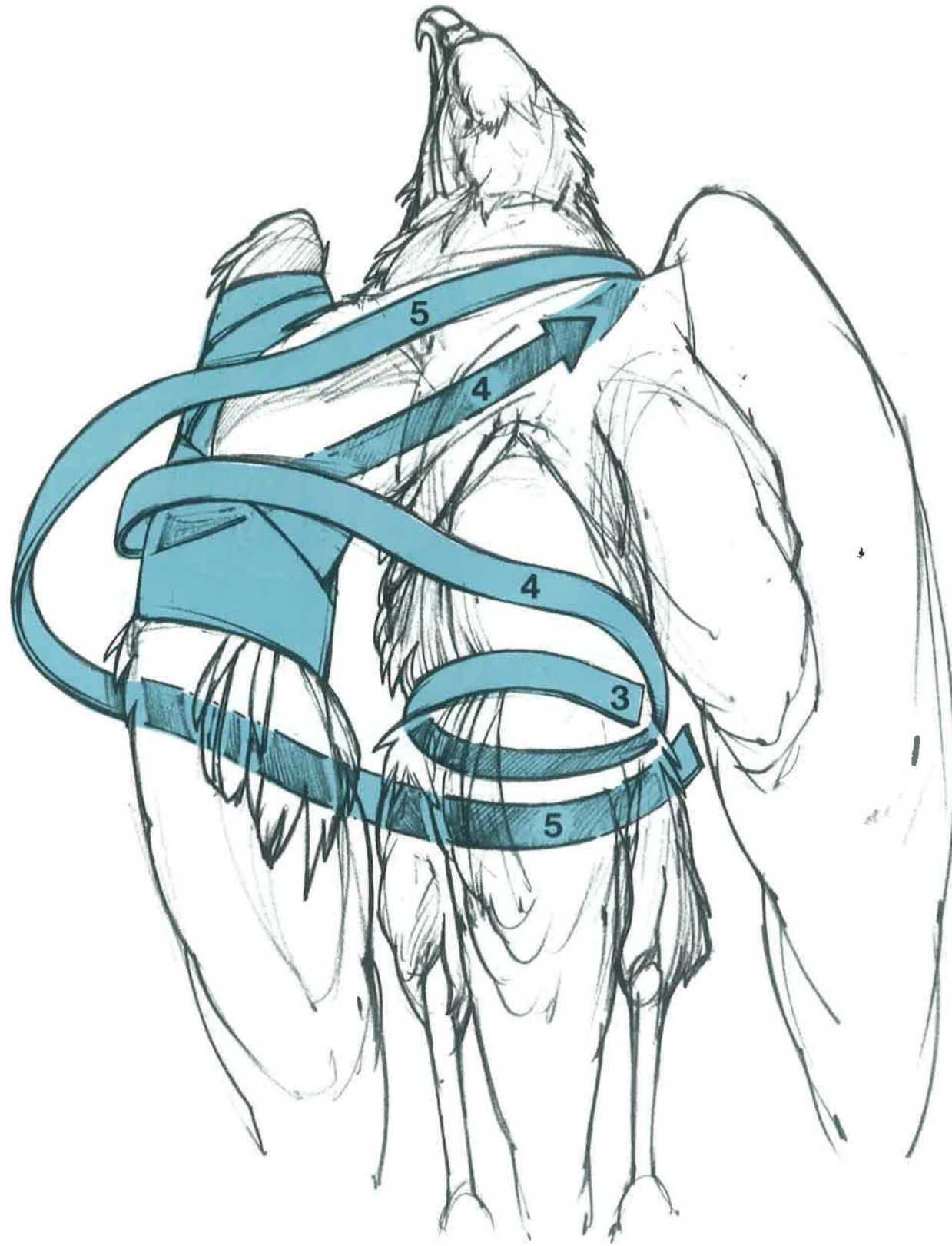
Open wounds on avian patients should be cultured, cleaned, and debrided. The control of sepsis will require individual treatment, depending on the extent of the trauma and the patient's physical condition. Avian patients presenting with open wounds should be placed on parenteral antibiotics. Choice of antibiotics will be based on culture and sensitivity results and clinical impressions.

Initial wound management should include local cleaning with an organic iodine preparation and irrigation with a sterile saline solution. Open wounds are most easily cleaned, lightly debrided, and dressed with the patient under anesthesia. Wounds that cannot be closed or are too contaminated to be closed should be protected with an ointment or powder and a dressing to prevent drying of exposed soft tissues. When using ointments, care should be taken to apply the oil-based preparation only to the unfeathered area. Excessive oil on the feathers will reduce the bird's ability to maintain its body temperature and may be aspirated when the patient preens.

If an avian patient is considered a surgical candidate, antibiotics should be given 1 to 2 hours prior to surgery and continued for at least several days postoperatively.





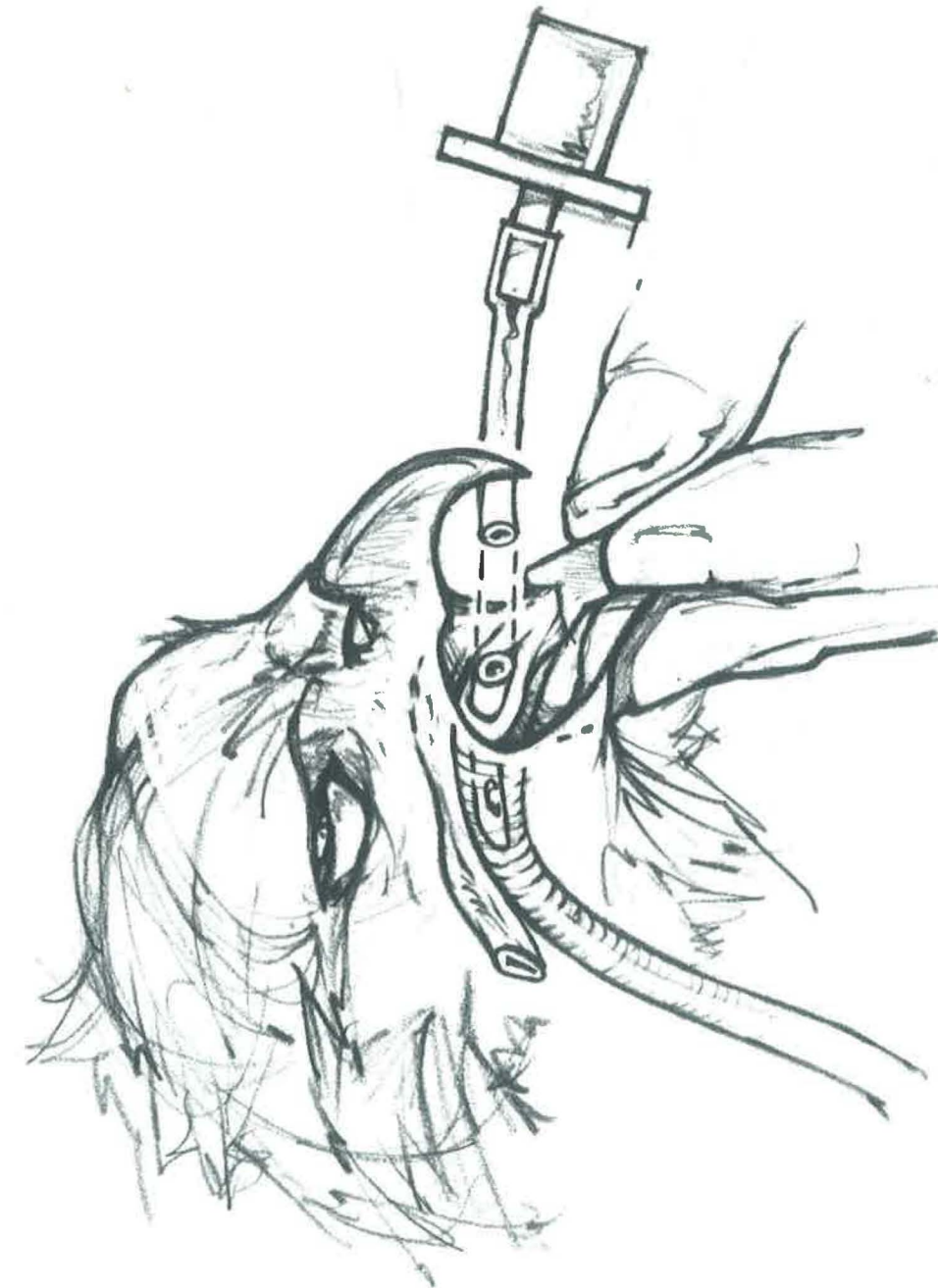


### Anesthesia

General anesthesia facilitates radiographic examination, wound care, coaptation procedures, and surgery. However, most buteos and large owls can be gently positioned for radiographic examination without general anesthesia. Falconiformes and other birds (including parrots) that often cause injury to themselves or to others should be anesthetized for radiography. Various parameters appropriate to the individual case should be assessed to determine the risk to the patient and may include a packed cell volume, total protein, or a more extensive serum chemistry panel; a hemogram; and a fecal or choanal Gram stain.<sup>14,15</sup>

Tests should be selected carefully to minimize trauma or stress to the patient.

The size of the crop or dilated esophagus should be evaluated prior to administration of anesthesia. Fasting the patient will reduce crop volume to prevent aspiration, regurgitation, or abnormal respiration associated with a large abdominal viscus. The use and duration of a fast varies among clinicians. Birds may be fasted for brief periods, but not as long as mammals. In preanesthetic fasts, small birds may be fasted briefly or not at all, while raptors may be fasted for several hours.





Ketamine is commonly used for short procedures; however, once given, the level of anesthesia cannot be controlled. Ketamine by itself may not provide sufficient relaxation unless combined with xylazine, diazepam, or gas anesthetic agents. The most common parenteral combination is ketamine (10–30 mg/kg) and xylazine (2–5 mg/kg), usually delivered by the same syringe. This combination has proven effective in a variety of avian species.<sup>13,18</sup> The route of administration and dosage is dependent on the length and type of procedure to be undertaken, as well as the recovery time. Usually the intravenous dose is one third to one half the recommended intramuscular dose. Xylazine may be reversed with yohimbine (0.5–5.0 mg/kg) administered intravenously.

The recovery period can be prolonged and violent with ketamine. Birds with long, thin pelvic limbs such as the gruiformes and ciconiiformes should be monitored closely during the recovery period. Recovery can be difficult in great horned owls and snowy owls anesthetized with ketamine<sup>21</sup> and, therefore, ketamine is not recommended as the sole anesthetic agent in these species.

Inhalation anesthesia is preferable to parenteral anesthesia, especially for long procedures. Halothane and isoflurane are the most commonly used gas anesthetic agents. Isoflurane has recently become popular due to its wide margin of safety.<sup>13</sup> During face mask induction, birds should be held quietly in a comfortable, upright position to prevent struggling. Induction chambers are useful for species such as parrots, in which hand restraint may produce violent struggling.

Anesthesia may be induced by an inhalant with a face mask or with an intravenous injection of a parenteral anesthetic. Once the bird is anesthetized, the beak is opened and the tongue is brought forward to visualize the opening of the larynx (aditus laryngus). A finger under the gular area will greatly facilitate elevation of the glottis for

intubation. Unlike mammals, birds do not have an epiglottis that covers this opening (see illustration on page 117). Intubation may seem unnecessary during brief periods (10–15 min.) of inhalation anesthesia or may prove difficult due to the size of the bird and the tubes available. However, intubation reduces the chance for aspiration of refluxed material, maintains a patent airway during an anesthetic emergency, and reduces contamination of the environment with escaped gases. Intubation is preferred for longer surgical procedures.

For procedures lasting up to 1 hour, it is desirable to give fluids before surgery—fluids can be administered by either subcutaneous or intravenous routes. Larger birds with accessible veins can be maintained on a slow drip of intravenous fluids such as lactated Ringer solution throughout anesthesia<sup>17</sup> or with small boluses of intravenous fluids given intraoperatively.

Maintenance of body temperature is critical during anesthesia and the recovery period. A temperature probe may be inserted into the crop of small birds or the cloaca of larger ones. The bird's temperature should be maintained above 97°F by using water-jacketed heating pads.

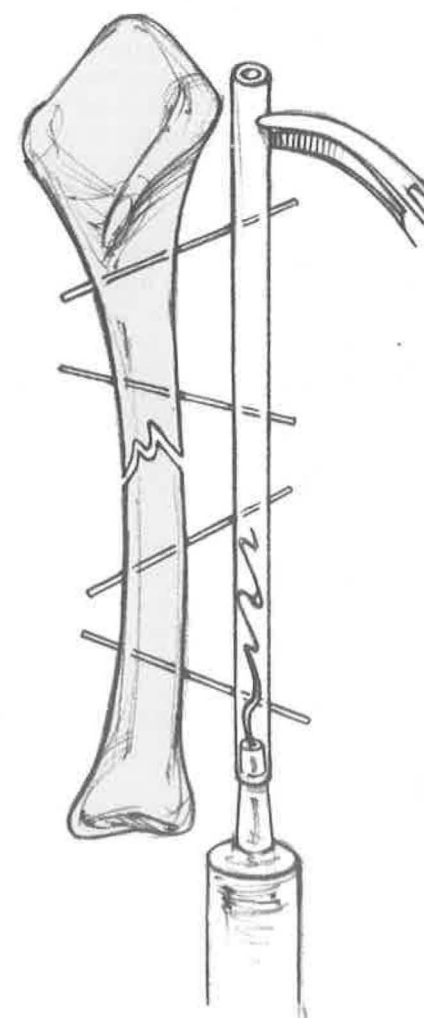
The depth of anesthesia is monitored by observing the rate and depth of respiration. Birds, like mammals, should have a slow, smooth, and rhythmic rate to their ventilatory pattern. A reflex response to palpebral or corneal stimulation is associated with a light plane of anesthesia. A slight toe pinch and withdrawal and cloacal sphincter reflex are still observed in birds in a surgical anesthetic plane. Birds should be bagged throughout the anesthetic period to reduce the potential for hypoxia. Care should be taken to not overinflate the lungs and air sac system. The use of an electrocardiogram may be useful in monitoring the bird. Myocardial hypoxia may be detected by an alteration in the bird's QRS complex or in its heart rate.

### Surgical Principles

The goal of surgical intervention is to achieve fixation with the maximum restoration of function while causing the least amount of trauma. The basic principles of orthopedics—stability of the fixation and preservation of vascularity and soft tissue—are basically no different from those of mammals, with the following exceptions:

- Surgical site preparation and limb manipulation are hindered by the presence of feathers.
- The avian integument in medium- and small-sized birds is especially thin and tears easily.
- The cortices of bone are relatively thin and brittle.<sup>12</sup>
- Some bones are directly related to respiration.

The surgical site is prepared after the approach has been selected and the patient positioned for surgery. Feathers should be removed from the surgical site by plucking or cutting them close to the skin. Feathers that are plucked will regrow,



while feathers that are cut must be molted before a bird is capable of successful flight. Care should be taken when removing primary or secondary remiges, because they aid in the alignment of the limb to the body wall for coaptation.<sup>11,22</sup>

Aseptic technique is as critical in avian bone repair as it is in mammals. The surgical site should be scrubbed lightly to avoid bruising and tearing of the skin. Organic iodine solutions are commonly used for surgical preparations. Open fractures should be lavaged cautiously to prevent further damage to the soft tissues. Once the surgical site has been prepared, a sterile solution is sprayed and left to dry on the skin. The feet are difficult to disinfect and should be covered with a sterile stockinette or gauze wrap. Surgical drapes should not be heavy or prevent observation of the patient's reflexes or respirations; plastic see-through drapes are preferable, especially for small avians.

There are several common techniques used to repair fractures in avians. Intramedullary pins may be used singly or stacked with or without cerclage wires. A metal pin may be replaced by a plastic pin that is shuttled into position. When a plastic pin is used, it is often combined with a modified K-E apparatus. This modification, along with others, has been developed to reduce the weight of the fixator. One version reduces or eliminates the heavy longitudinal bars and clamps by substituting several layers of orthopedic tape folded over the crosspins.<sup>10</sup> Another accomplishes this with resin or hoof acrylic polymerized in a plastic tubing that is pushed into the crosspins.<sup>23</sup> Steinmann pins may be replaced by Kirschner wires to further reduce weight. They are driven through the proximal and distal fragments at angles comparable to techniques designed for mammals, without regard to the longitudinal alignment of the bone. Then the fracture is reduced and one of the above materials—orthopedic tape or hoof acrylic polymerized in plastic tubing—is used to keep the Kirschner wires in place (see illustration on left).



Another repair technique for avians that reduces weight while stabilizing the fracture uses an intramedullary polypropylene pin in conjunction with a modified K-E device. The plastic pin is shuttled into position by pulling a thin-gauge wire run through the pin at an appropriate distance in order to seat it between the two fragments. Kirschner wires are then driven through the bone and the polypropylene pin as described above. This technique is thought to provide greater longitudinal and rotational stability than the others described.<sup>10,16</sup>

Irrigation with a sterile solution of saline is used to prevent drying of soft tissues during surgery and as a technique to reduce heat during the polymerization of these various plastics.

**Postoperative Care**

Anesthesia should be maintained postoperatively to permit the gentle positioning for wound dressing, external coaptation, and radiographs. Elizabethan collars may be applied to psittacines that pick at their bandages. With these birds, however, layers of adhesive tape may hamper them sufficiently from chewing their bandages. Body temperature must be maintained during this period as well; this can be accomplished by placing the bird in a warmed incubator during the initial postoperative period.

Recovery from anesthesia is enhanced by wrapping the bird in a towel and placing it in a dark, confined space. Long-legged birds may require monitoring and careful restraint of the support during the recovery period to reduce the potential of trauma. Birds that need to be cage-rested for at least a week should have their tail feathers (rectrices) protected by a wrap.

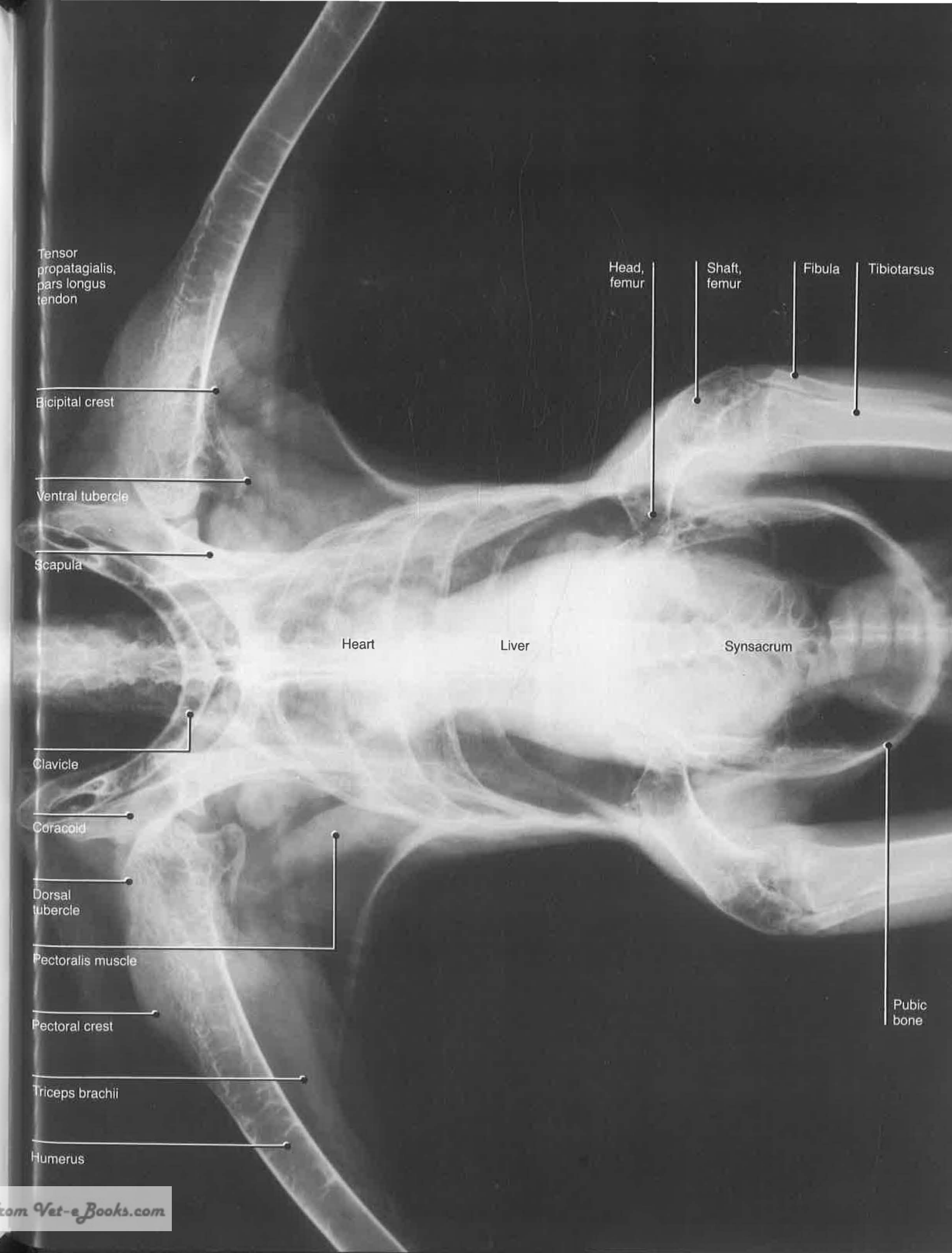
The first few days postoperatively are the most critical. During this period, external fixation devices or dressings should be monitored for comfort and complications. Open wounds may need to have dressing changes every few days or as needed. External stimulation should be kept to a minimum in order for the bird to feel comfortable in its cage. The bird may require a warmed cage for 1 to 2 days after surgery. Its appetite should be watched carefully and supplemented by tube feeding or force feeding if the bird is losing weight or not eating. Parrots, who use their feet while eating, may have difficulty if an external coaptation device is applied to one of their legs.

Talons should be blunted to prevent self-taloning if the bird is to be kept in captivity for a period of time or is unable to perch with the digits spread appropriately for the type of bird. Commonly, birds are cage-rested 3 weeks postoperatively. Perch sizes should be appropriate for the size and shape of the foot of the particular species. Padding or wrapping of the perch may reduce the possibility of bumblefoot during the postoperative period.<sup>19</sup> Parrots with a leg injury should have a low perch above a padded surface in order to let them hang the injured leg below their normal foot. If the bird will be handled frequently, the cage should be designed to permit easy access to limit struggling.

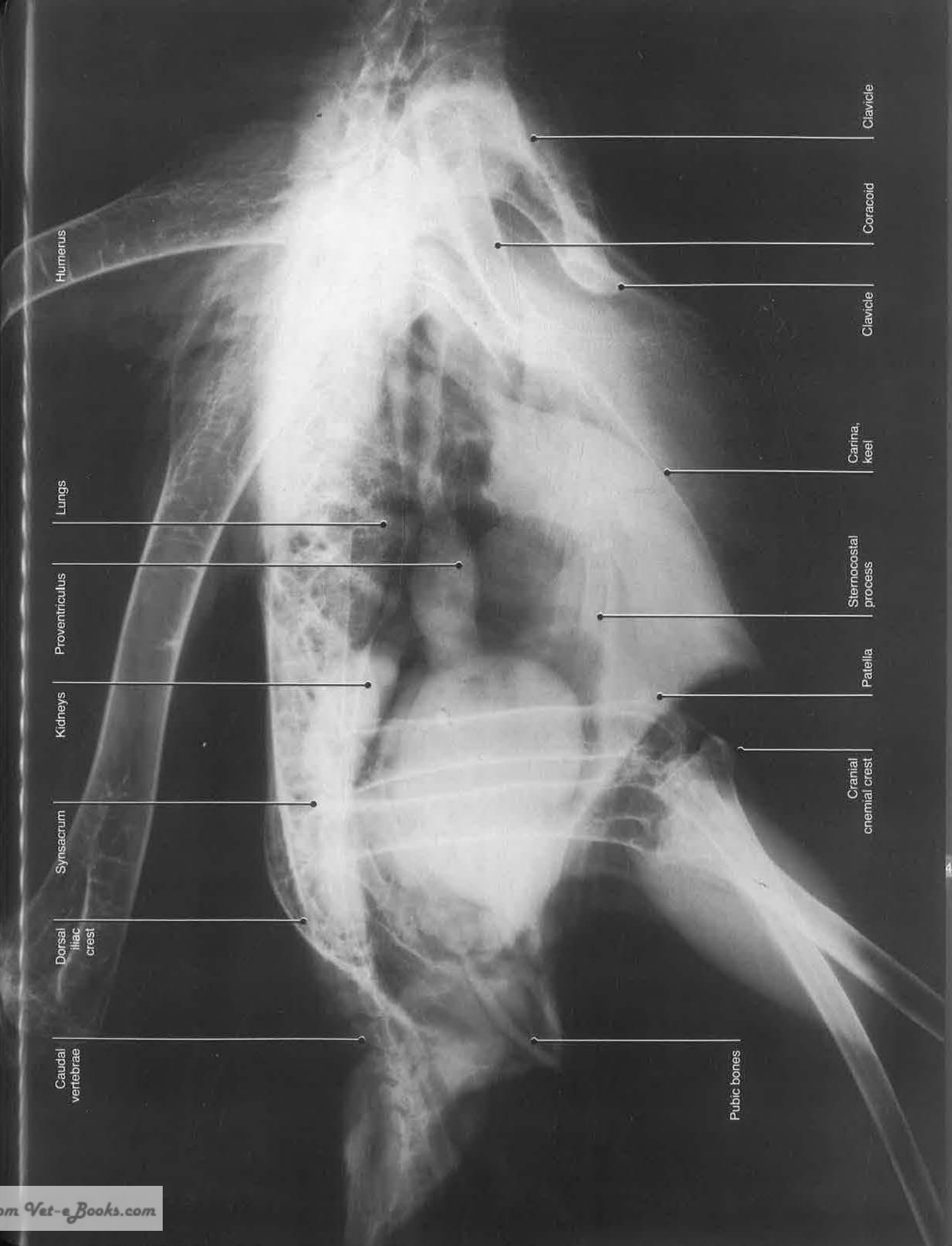
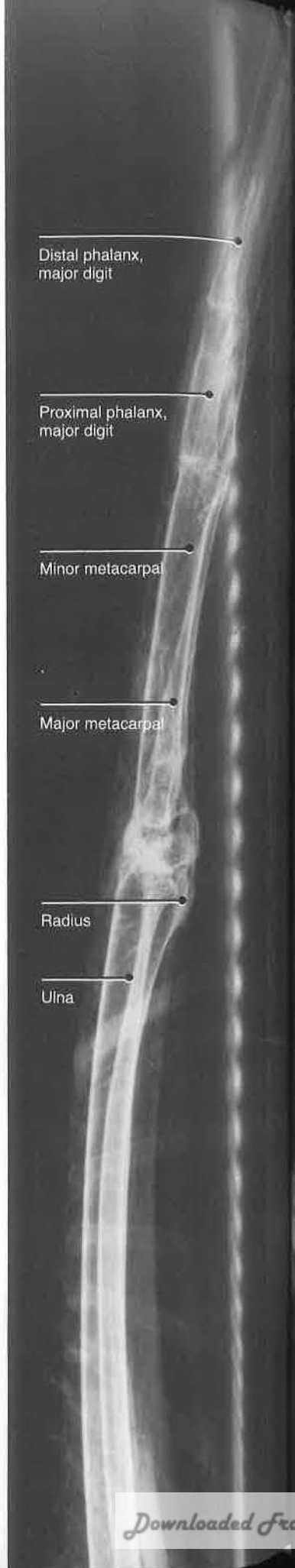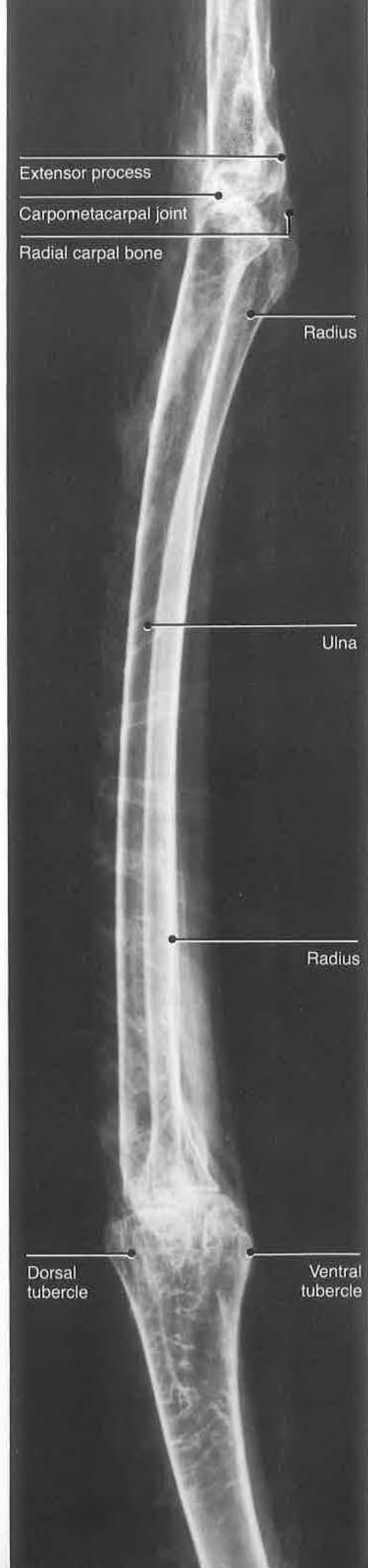
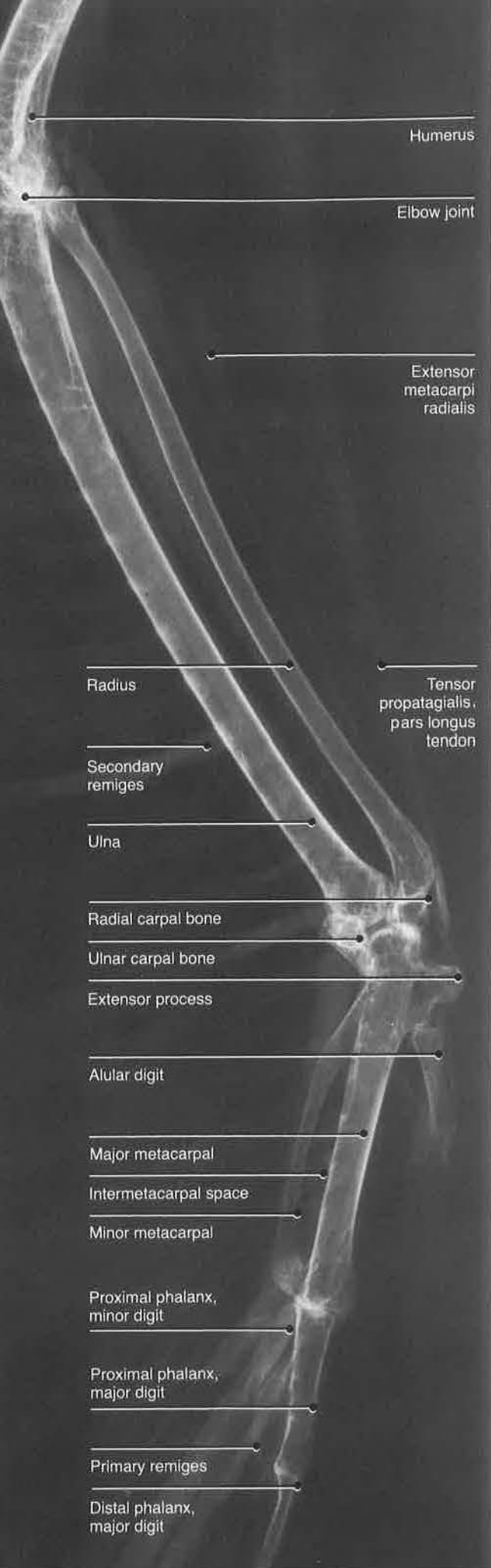
Return to normal mobility is dependent on a variety of factors, one of which is the range of motion permitted postoperatively. When bandaging is the sole external coaptation device or means of providing supplemental support, the joints near the fracture site are immobilized. Although this technique will enhance the healing process at the fracture site, it will also reduce joint mobility. This reduced range of motion can be permanent or may improve with physical therapy, depending on the individual situation. In some cases, the fixation device will allow for limited mobility almost immediately postoperatively. To reduce this loss in mobility associated with bandaging or the fixation required, the coaptation dressing may be relaxed at various times during the convalescent period. However, this should be evaluated carefully with special regard to movement and healing at the fracture site.

Radiographic examinations to evaluate the healing process should be made on an individual basis. However, radiographs should be taken under anesthesia immediately and 1 week postoperatively to check alignment and make modifications as needed.<sup>9</sup> These should be repeated as often as necessary. Intramedullary pins or a K-E apparatus are usually removed at 5 to 6 weeks, followed by 1 week of cage-rest. No implant should be removed until a bony union is present.

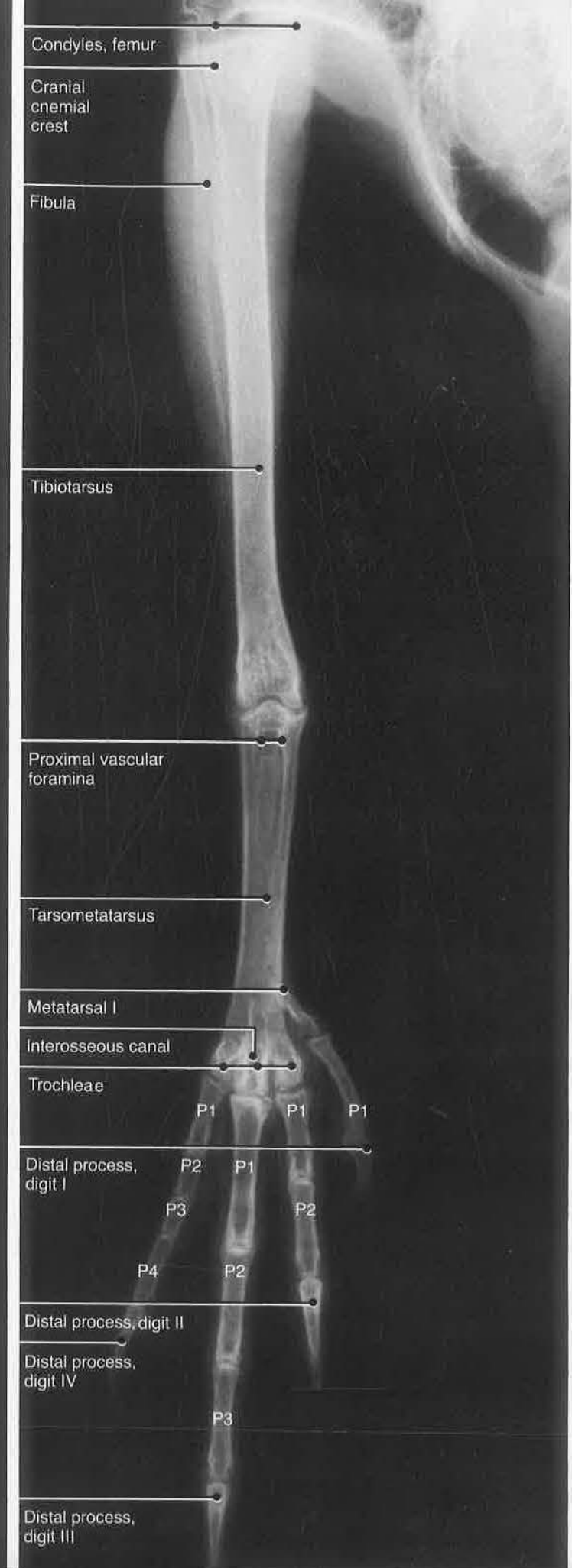
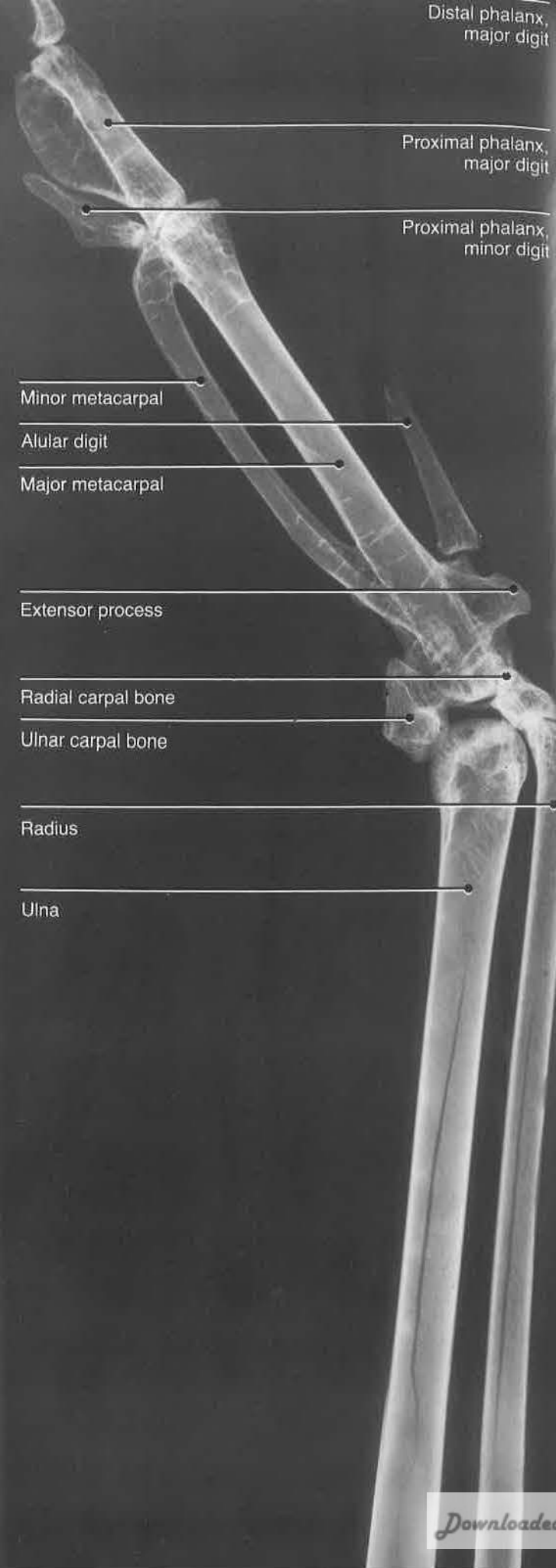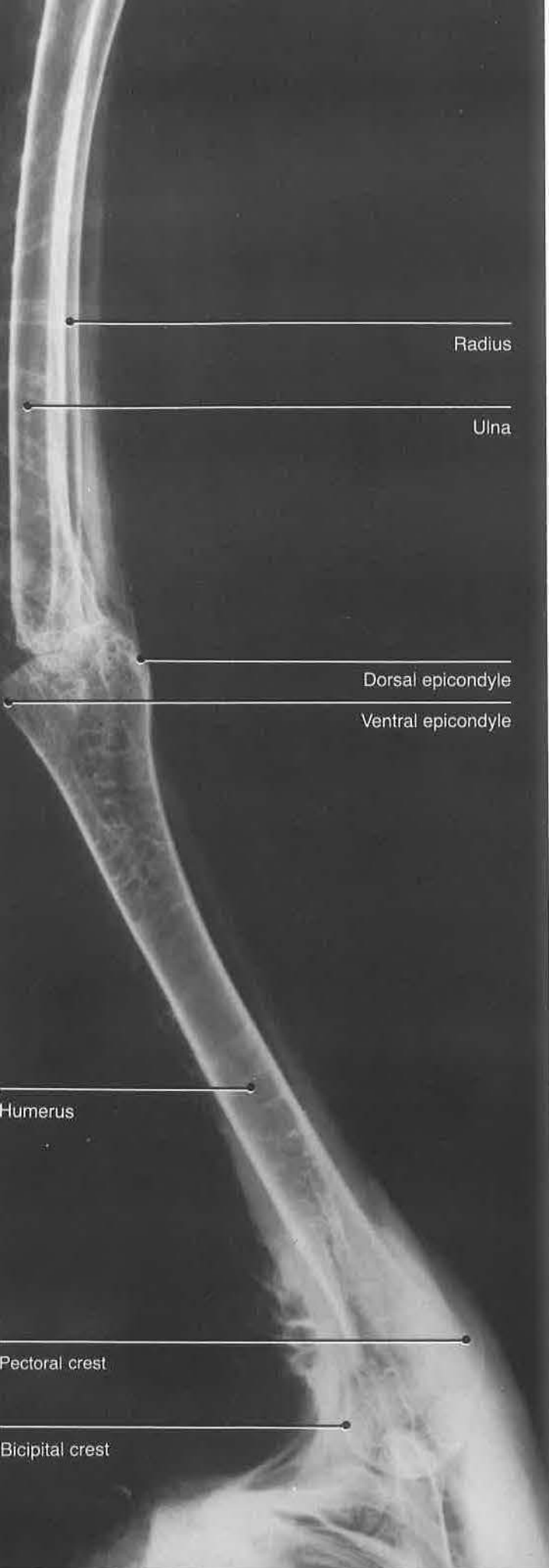Postoperative complications will ultimately affect the bird's ability to return to normal function. These complications are not different from those of mammals and include collapse at the fracture site around the intramedullary pin; joint ankylosis; extensive fibrocallous, incorporating surrounding soft tissues; bone sequestrum; nonunion of fractures; and osteomyelitis.



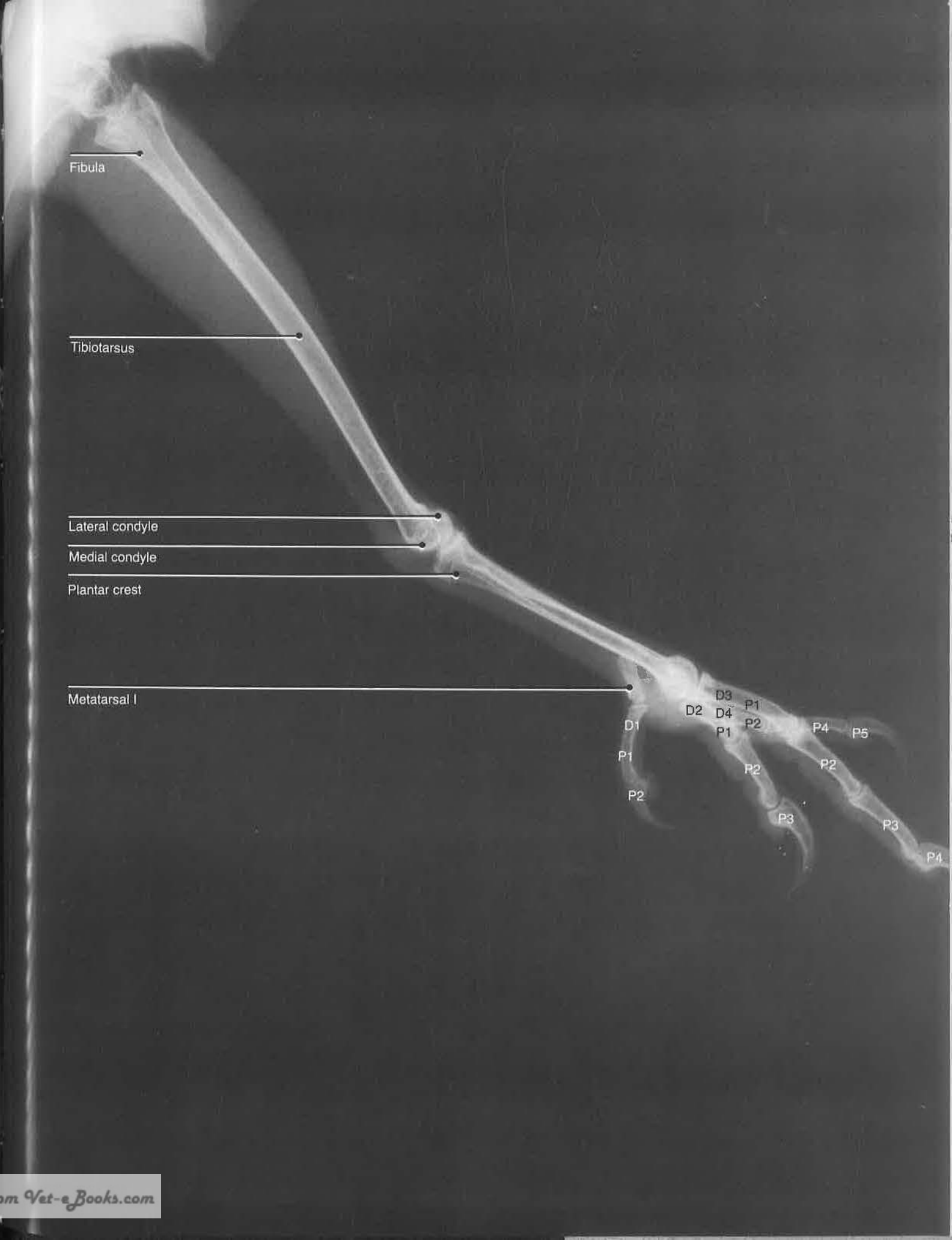
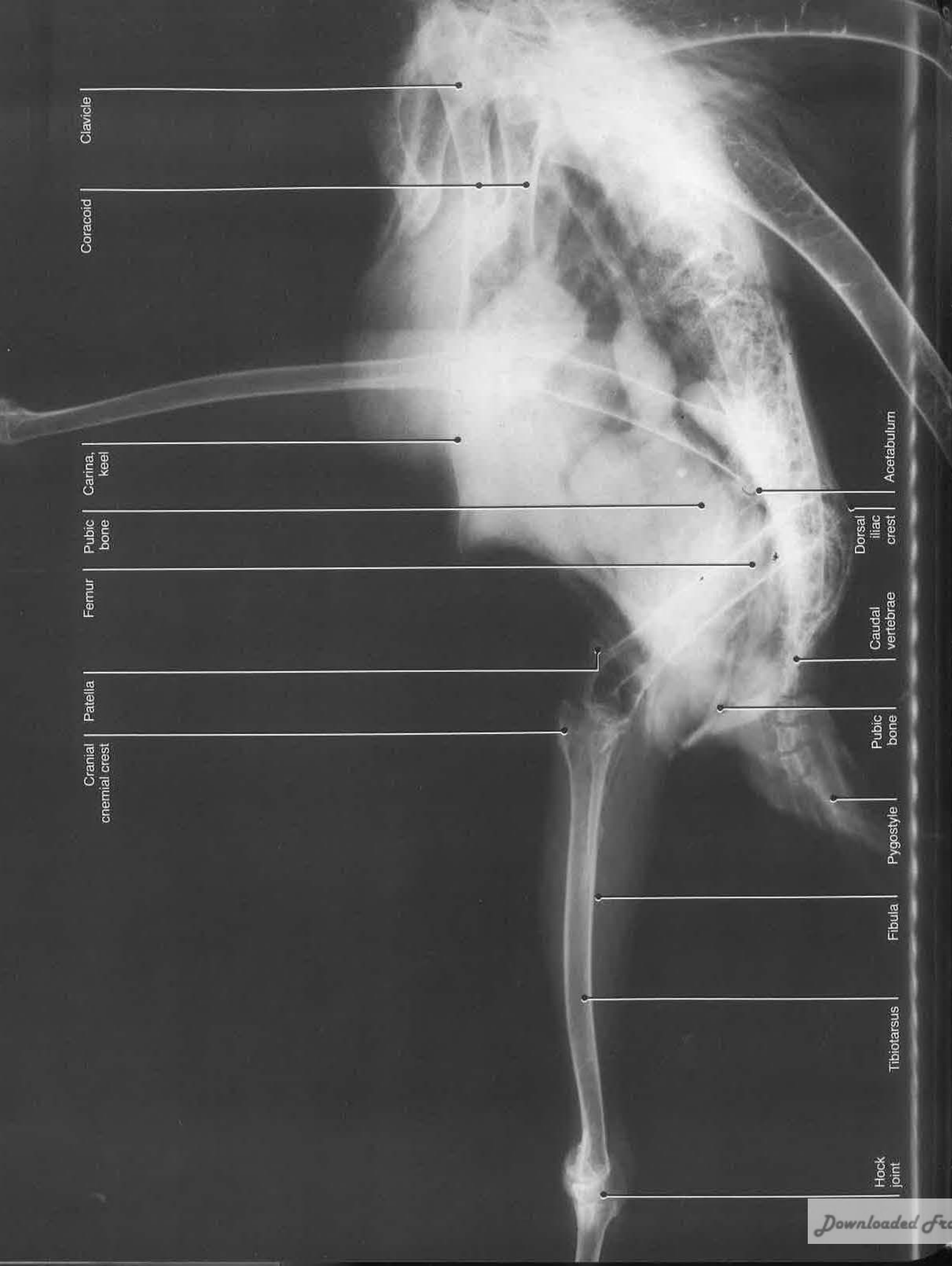
















## References

1. Baumel, J. (1983): Functional Anatomy of the Avian Thoracic Limb: Selected Topics. Proceedings Association of Avian Veterinarians (AAV), San Diego, CA, pp 67-70
2. Fisher, H.I. (1946): Adaptations and comparative anatomy of the locomotor apparatus of new world vultures. *Am. Midland Naturalist* 35:545-727
3. Getty, R. (1975): *Sisson and Grossman's Anatomy of the Domestic Animals*, ed 5, vol 2: Porcine, Carnivores, Aves. Philadelphia, WB Saunders
4. International Committee on Avian Anatomical Nomenclature (1979): *Nomina Anatomica Avium*, ed 1. London, World Association of Veterinary Anatomists
5. MacCoy, D.M. (1987): Techniques of fracture treatment in birds and their indications, external and internal fixation. *In Proceedings, First International Conference on Zoological and Avian Medicine*, Oahu, Hawaii, pp 549-563
6. Martin, H.D., Kabler, R., and Sealing, L. (1987): The avian coxofemoral joint: A review of regional anatomy and report of an open-reduction technique for repair of a coxofemoral luxation. *J. Assoc. Avian Vets.* 3:22-30
7. Redig, P.T. (1984): Personal communication
8. Redig, P.T. (1986): A clinical review of orthopedic techniques used in the rehabilitation of raptors. *In Fowler, M. (ed): Zoo and Wild Animal Medicine*, ed 2. Philadelphia, WB Saunders, pp 388-401
9. Redig, P.T. (1986): Evaluation and nonsurgical management of fractures. *In Harrison, G.J. and Harrison, L.R. (eds): Clinical Avian Medicine*. Philadelphia, WB Saunders, pp 380-394
10. Redig, P.T. (1986): Basic orthopedic surgical techniques. *In Harrison, G.J., and Harrison, L.R. (eds): Clinical Avian Medicine*. Philadelphia, WB Saunders, pp 596-598
11. Redig, P.T., and Roush, J.C. (1978): Surgical approaches to the long bones of raptors. *In Fowler, M. (ed): Zoo and Wild Animal Medicine*, ed 2. Philadelphia, WB Saunders, pp 246-253
12. Fowler, M.E. (1981): Ossification of long bones in raptors. *In Cooper, J.E., and Greenwood, A.G. (eds): Recent Advances in the Study of Raptor Diseases*. Keighley, England, Chiron Publishers, pp 75-82
13. Harrison, G.J. (1986): Anesthesiology. *In Harrison, G.J., and Harrison, L.R. (eds): Clinical Avian Medicine and Surgery*. Philadelphia, WB Saunders, pp 549-559
14. Harrison, G.J. (1986): Evaluation and support of the surgical patient. *In Harrison, G.J., and Harrison, L.R. (eds): Clinical Avian Medicine*. Philadelphia, WB Saunders, pp 543-548
15. Harrison, G.J., Harrison, L.R., and Fudge, A.M. (1986): Preliminary evaluation of a case. *In Harrison, G.J., and Harrison, L.R. (eds): Clinical Avian Medicine*. Philadelphia, WB Saunders, pp 101-114
16. MacCoy, D.M. (1983): High density polymer rods as an intramedullary fixation device in birds. *J. Am. Hosp. Assoc.* 19:767-772
17. Martin, H.D., Palmore, P., and Kollias, G. (1987): Studies of parameters used to monitor hydration status in avian patients. *In Proceedings, First International Conference on Zoological and Avian Medicine*, Oahu, Hawaii, pp 403-405
18. Redig, P.T. (1982): An overview of avian anesthesia. *In Proceedings, Annual Meeting, Association of Avian Veterinarians*, Atlanta, GA, pp 127-139
19. Redig, P.T. (1987): Treatment of bumblefoot and management of aspergillosis and various other problems seen in raptors. *In Proceedings, First International Conference on Zoological and Avian Medicine*, Oahu, Hawaii, pp 309-322
20. Redig, P.T., Degernes, L., Martell, N., and Dunnette, J. (1987): The diagnosis and treatment of lead poisoning in bald eagles and trumpeter swans. *In Proceedings, First International Conference on Zoological and Avian Medicine*, Oahu, Hawaii, pp 401-402
21. Redig, P.T., Larson, A.A., and Duke, G.E. (1984): Response of great horned owls given the optical isomers of ketamine. *Am. J. Vet. Res.* 45:125-127
22. Roush, J.C. (1980): Avian orthopedics. *In Kirk, R.W. (ed): Current Veterinary Therapy VIII*. Philadelphia, WB Saunders, pp 662-673
23. Satterfield, W., and O'Rourke, K.J. (1981): External skeletal fixation in avian orthopedics using a modified through-and-through Kirschner-Ehmer splint technique (the Boston technique). *J. Am. An. Hosp. Assoc.* 17:635-637



## Homologous Terms





Thoracic Limb

| Easy Reference Terms           | Fisher <sup>2</sup>                  | NAA <sup>4</sup>               | Getty <sup>3</sup>             |
|--------------------------------|--------------------------------------|--------------------------------|--------------------------------|
| Abductor alulae                | Abductor pollicis                    | Abductor alulae                | Abductor alulae                |
| Abductor digiti majoris        | Abductor indicis majoris             | Abductor digiti majoris        | Abductor digiti majoris        |
| Adductor alulae                | Adductor pollicis                    | Adductor alulae                | Adductor alulae                |
| Anconeus                       | Anconeus                             | Ectepicondylo-ulnaris          | Ectepicondylo-ulnaris          |
| Biceps brachii                 | Biceps                               | Biceps                         | Biceps brachii                 |
| Brachialis                     | Brachialis                           | Brachialis                     | Brachialis                     |
| Common digital extensor        | Extensor digitorum communis          | Extensor digitorum communis    | Extensor digitorum communis    |
| Coracobrachialis caudalis      | Coracobrachialis caudalis            | Coracobrachialis caudalis      | Coracobrachialis               |
| Coracobrachialis dorsalis      | Coracobrachialis anterior            | Coracobrachialis cranialis     | Coracobrachialis cranialis     |
| Deep pectoral                  | Pectoralis superficialis, deep layer | —                              | —                              |
| Deltoideus major               | Deltoideus major                     | Deltoideus major               | Deltoideus major               |
| Deltoideus minor               | Deltoideus minor                     | Deltoideus minor               | Deltoideus minor               |
| Dermotensor patagii            | Dermotensor patagii                  | Dermotensor patagii            | Dermotensor patagii            |
| Extensor brevis alulae         | Extensor pollicis alula              | Extensor brevis alulae         | Extensor brevis alulae         |
| Extensor brevis digiti majoris | Flexor metacarpi brevis              | Extensor brevis digiti majoris | Extensor brevis digiti majoris |
| Extensor longus digiti majoris | Extensor indicis longus              | Extensor longus digiti majoris | Extensor longus digiti majoris |
| Extensor longus alulae         | Extensor pollicis longus             | Extensor longus alulae         | Extensor longus alulae         |
| Extensor metacarpi radialis    | Extensor metacarpi radialis          | Extensor metacarpi radialis    | Extensor metacarpi radialis    |
| Flexor alulae                  | Flexor pollicis                      | Flexor alulae                  | Flexor alulae                  |

| Easy Reference Terms                            | Fisher <sup>2</sup>                                | NAA <sup>4</sup>                                | Getty <sup>3</sup>                          |
|---|--|---|---|
| Flexor carpi ulnaris                            | Flexor carpi ulnaris, posterior part               | Flexor carpi ulnaris                            | Flexor carpi ulnaris                        |
| Flexor digiti minoris                           | Flexor digiti III                                  | Flexor digiti minoris                           | Flexor digiti minoris                       |
| Flexor digitorum profundus                      | Flexor digitorum profundus                         | Flexor digitorum profundus                      | Flexor digitorum profundus                  |
| Flexor digitorum superficialis                  | Flexor carpi ulnaris, anterior part                | Flexor digitorum superficialis                  | Flexor digitorum superficialis              |
| Flexor metacarpi caudalis                       | Flexor metacarpi pollicis                          | Ulnometacarpalis dorsalis                       | Ulnometacarpalis dorsalis                   |
| Interosseous dorsalis                           | Interosseous dorsalis                              | Interosseous dorsalis                           | Interosseous dorsalis                       |
| Interosseous ventralis                          | Interosseous palmaris                              | Interosseous ventralis                          | Interosseous ventralis                      |
| Latissimus dorsi, pars cranialis; pars caudalis | Latissimus dorsi, pars anterior and pars posterior | Latissimus dorsi; pars cranialis; pars caudalis | Latissimus dorsi cranialis and caudalis     |
| Pronator brevis                                 | Pronator brevis                                    | Pronator superficialis                          | Pronator superficialis                      |
| Pronator longus                                 | Pronator longus                                    | Pronator profundus                              | Pronator profundus                          |
| Superficial pectoral                            | Pectoralis superficialis, superficial layer        | Pectoralis                                      | Pectoralis, pars thoracicus                 |
| Supinator                                       | Supinator brevis                                   | Supinator                                       | Supinator                                   |
| Supracoracoideus                                | Supracoracoideus                                   | Supracoracoideus                                | Supracoracoideus                            |
| Tensor propatagialis pars brevis and longus     | Tensor patagii brevis and longus                   | Tensor propatagialis pars brevis and longus     | Tensor propatagialis pars brevis and longus |
| Triceps brachii                                 | Triceps  | Triceps brachii                                 | Triceps brachii                             |
| Ulnaris lateralis                               | Flexor metacarpi radialis                          | Extensor metacarpi ulnaris                      | Extensor metacarpi ulnaris                  |
| Ulnometacarpalis ventralis                      | Flexor metacarpi posterior                         | Ulnometacarpalis ventralis                      | Ulnometacarpalis ventralis                  |

Thigh and Leg

| Easy Reference Terms                             | Fisher <sup>2</sup>                              | NAA <sup>4</sup>                                 | Getty <sup>3</sup>                               |
|--|--|--|--|
| <i>Abductor digiti II</i>                        | <i>Abductor digiti II</i>                        | <i>Abductor digiti II</i>                        | <i>Abductor digiti II</i>                        |
| <i>Abductor digiti IV</i>                        | <i>Abductor digiti IV</i>                        | <i>Abductor digiti IV</i>                        | <i>Abductor digiti IV</i>                        |
| <i>Adductor</i>                                  | <i>Adductor superficialis</i>                    | <i>Pubo-ischio-femoralis pars lateralis</i>      | <i>Pubischiofemoralis, pars lateralis</i>        |
| <i>Adductor digiti II</i>                        | <i>Adductor digiti II</i>                        | <i>Adductor digiti II</i>                        | <i>Adductor digiti II</i>                        |
| <i>Adductor magnus et brevis</i>                 | <i>Adductor profundus</i>                        | <i>Pubo-ischio-femoralis, pars medialis</i>      | <i>Pubischiofemoralis, pars medialis</i>         |
| <i>Biceps femoris, cranial head</i>              | <i>Extensor iliotibialis lateralis</i>           | <i>Iliotibialis lateralis</i>                    | <i>Iliotibialis lateralis</i>                    |
| <i>Biceps femoris, caudal head</i>               | <i>Extensor iliofibularis</i>                    | <i>Iliofibularis</i>                             | <i>Iliofibularis</i>                             |
| <i>Caudofemoralis</i>                            | <i>Caudofemoralis</i>                            | <i>Caudo-ilio-femoralis, caudofemoralis</i>      | <i>Caudiliofemoralis, pars caudofemoralis</i>    |
| <i>Extensor brevis digiti III</i>                | <i>Extensor brevis digiti III</i>                | <i>Extensor brevis digiti III</i>                | <i>Extensor brevis digiti III</i>                |
| <i>Extensor brevis digiti IV</i>                 | <i>Extensor brevis digiti IV</i>                 | <i>Extensor brevis digiti IV</i>                 | <i>Extensor brevis digiti IV</i>                 |
| <i>Extensor digitorum longus</i>                 | <i>Extensor digitorum longus</i>                 | <i>Extensor digitorum longus</i>                 | <i>Extensor digitorum longus</i>                 |
| <i>Extensor hallucis longus</i>                  | <i>Extensor hallucis longus</i>                  | <i>Extensor hallucis longus</i>                  | <i>Extensor hallucis longus</i>                  |
| <i>Flexor digitorum longus</i>                   | <i>Flexor digitorum longus</i>                   | <i>Flexor digitorum longus</i>                   | <i>Flexor digitorum longus</i>                   |
| <i>Flexor hallucis brevis</i>                    | <i>Flexor hallucis brevis</i>                    | <i>Flexor hallucis brevis</i>                    | <i>Flexor hallucis brevis</i>                    |
| <i>Flexor hallucis longus</i>                    | <i>Flexor hallucis longus</i>                    | <i>Flexor hallucis longus</i>                    | <i>Flexor hallucis longus</i>                    |
| <i>Flexor perforans et perforatus digiti II</i>  | <i>Flexor perforans et perforatus digiti II</i>  | <i>Flexor perforans et perforatus digiti II</i>  | <i>Flexor perforans et perforatus digiti II</i>  |
| <i>Flexor perforans et perforatus digiti III</i> | <i>Flexor perforans et perforatus digiti III</i> | <i>Flexor perforans et perforatus digiti III</i> | <i>Flexor perforans et perforatus digiti III</i> |
| <i>Flexor perforatus digiti II</i>               | <i>Flexor perforatus digiti II</i>               | <i>Flexor perforatus digiti II</i>               | <i>Flexor perforatus digiti II</i>               |
| <i>Flexor perforatus digiti III</i>              | <i>Flexor perforatus digiti III</i>              | <i>Flexor perforatus digiti III</i>              | <i>Flexor perforatus digiti III</i>              |

| Easy Reference Terms                  | Fisher <sup>2</sup>                           | NAA <sup>4</sup>                                | Getty <sup>3</sup>                   |
|---------------------------------------|---|---|--------------------------------------|
| <i>Flexor perforatus digiti IV</i>    | <i>Flexor perforatus digiti IV</i>            | <i>Flexor perforatus digiti IV</i>              | <i>Flexor perforatus digiti IV</i>   |
| <i>Gastrocnemius lateral head</i>     | <i>Gastrocnemius pars externa</i>             | <i>Gastrocnemius pars lateralis [externa]</i>   | <i>Gastrocnemius pars externa</i>    |
| <i>intermediate head</i>              | <i>pars media</i>                             | <i>pars intermedia</i>                          | <i>pars media</i>                    |
| <i>medial head</i>                    | <i>pars interna</i>                           | <i>pars medialis [interna]</i>                  | <i>pars interna</i>                  |
| <i>Gluteus medius</i>                 | <i>Gluteus profundus</i>                      | <i>Iliotrochantericus caudalis</i>              | <i>Iliotrochantericus caudalis</i>   |
| <i>Gluteus profundus</i>              | <i>Iliacus</i>                                | <i>Iliotrochantericus cranialis</i>             | <i>Iliotrochantericus cranialis</i>  |
| <i>Obturator externus</i>             | <i>Flexor ischiofemoralis</i>                 | <i>Ischiofemoralis</i>                          | <i>Ischiofemoralis</i>               |
| <i>Obturator internus</i>             | <i>Obturator internus</i>                     | <i>Obturatorius medialis</i>                    | —                                    |
| <i>Peroneus brevis</i>                | <i>Peroneus brevis</i>                        | <i>Fibularis brevis</i>                         | <i>Fibularis (peroneus) brevis</i>   |
| <i>Peroneus longus</i>                | <i>Peroneus longus</i>                        | <i>Fibularis longus</i>                         | <i>Fibularis (peroneus) longus</i>   |
| <i>Piriformis</i>                     | <i>Piriformis</i>                             | <i>Iliofemoralis externus</i>                   | <i>Iliotrochantericus externus</i>   |
| <i>Sartorius</i>                      | <i>Extensor iliotibialis anterior</i>         | <i>Iliotibialis cranialis</i>                   | <i>Iliotibialis cranialis</i>        |
| <i>Semimembranosus</i>                | <i>Flexor cruris medialis</i>                 | <i>Flexor cruris medialis</i>                   | <i>Flexor cruris medialis</i>        |
| <i>Semitendinosus</i>                 | <i>Flexor cruris lateralis</i>                | <i>Flexor cruris lateralis, pars pelvica</i>    | <i>Flexor cruris lateralis</i>       |
| <i>Semitendinosus, accessory head</i> | <i>Flexor cruris lateralis accessory head</i> | <i>Flexor cruris lateralis, pars accessoria</i> | <i>Flexor cruris lateralis</i>       |
| <i>Tibialis cranialis</i>             | <i>Tibialis anterior</i>                      | <i>Tibialis cranialis</i>                       | <i>Tibialis cranialis</i>            |
| <i>Vastus intermedius</i>             | <i>Vastus medialis</i>                        | <i>Femorotibialis medius</i>                    | <i>Femorotibialis pars medius</i>    |
| <i>Vastus lateralis</i>               | <i>Vastus lateralis</i>                       | <i>Femorotibialis externus</i>                  | <i>Femorotibialis, pars externus</i> |
| <i>Vastus medialis</i>                | <i>Femorotibialis internus</i>                | <i>Femorotibialis internus</i>                  | <i>Femorotibialis pars internus</i>  |



INDEX

A

Accipiters, 4  
Accipitridae, 76-77, 90, 104-105  
Acetabular rim, cranial, 101  
Anesthesia, 117-118  
    postoperative, 120  
Antitrochanter, 101  
Apparatus, Kirschner-Ehmer (K-E), 52, 56, 108, 119-120  
Artery, brachial, 26, 30  
    deep, 30, 49  
    caudal pectoral, 31, 43  
    cranial femoral, 83, 87  
    cranial tibial, 90, 91, 92, 109  
    dorsal interosseous, 23, 50  
    dorsal metatarsal, 90, 91  
    femoral, 100, 101  
    ischiatric, 70, 71-72, 77, 103, 104  
    medial femoral, 86  
    popliteal, 70  
    radial, 26, 30  
        deep, 23, 27, 30, 36, 37, 38, 49, 54, 55, 57  
    subscapular, 6, 7-8, 11, 12, 44, 45  
    sural, 70, 75  
    ulnar, 26, 30, 49  
        deep, 36  
        recurrent, 36  
        superficial, 27, 30, 36, 38, 54, 55  
    ventral metacarpal, 56

B

Blood supply, 6, 26, 30, 31, 36, 70, 76, 86, 91  
Bone. *See* Osteology.  
Buteos, 117

C

Canal, extensor, 79, 81  
    interosseous, 60, 79  
    triosseal, 12  
Cartilage, tibial, 62, 107  
Cassowaries, 24  
Cathartidae, 4, 42, 91, 102  
    lateral thigh and leg of, 62-73  
        deep layer of, 70-73  
        middle layer of, 66-69  
        superficial layer of, 62-65  
Condyle(s), 102  
    dorsal, 4, 5, 25  
    humeral, 46  
    lateral, 91  
        femoral, 61  
        tibial, 61  
    medial, 79  
        femoral, 106  
    proximal, 108  
    ventral, 4, 25  
Coxofemoral joint, 100-101  
Cranes, 102  
Crest, bicipital, 5, 25  
    cranial cnemial, 79, 81  
    deltoid, 4  
    iliac, dorsolateral, 100, 101  
    lateral cnemial, 61  
    pectoral, 4, 5, 6, 25, 30, 44, 46, 48

E

Emus, 24  
Epicondyle, dorsal, 5, 225  
    ventral, 25, 46  
Examination, initial, 113

F

Falconiformes, 117  
Finches, 6  
Foramen, ilioischiatric, 60, 61, 70, 71-72, 101  
    obturator, 60, 61  
    proximal interosseous, 79  
    vascular, 79  
Fossa, 60  
    brachial, 24, 25  
    olecranon, 5  
Fowl, 62  
Fractures, care of, 113  
    femoral, 102-105  
    humeral, reduction of, 46, 48  
    metacarpal, 56-57  
    phalangeal, 108-109  
    radial, 50-55  
    tarsometatarsal, 108-109  
    ulnar, 50-54

G

Galliformes, 91, 102  
    lateral thigh and leg of, 62-63  
        deep layer of, 70-73  
        middle layer of, 66-69  
        superficial layer of, 62-65  
Girdle, pelvic, 60  
    thoracic, 4

H

Halothane, for anesthesia, 118  
Hawks, 30, 42, 54, 66, 74  
Humerus, 25, 28, 31, 43, 44, 47, 49, 51, 224  
    distal, 6-13, 46-49  
        deep layers of, 10  
        superficial view of, 6-9  
    muscles of, 6  
        brachialis, 7-8, 10, 11-12, 27, 49, 51  
        deltoideus minor, 6, 10, 11, 12, 45  
        dermotensor patagii, 6  
        latissimus dorsi, 6  
    proximal, 44-45  
    ventral, 26-31  
        deep layer of, 31  
        middle layer of, 30  
        superficial view of, 26-29

I

Inhalation anesthesia, 118  
Isoflurane, for anesthesia, 118

J

Joint, coxofemoral, 100-101

K

Keel, 4, 30, 31, 42, 43  
Ketamine, for anesthesia, 118  
Kirschner wires, 119, 120  
Kirschner-Ehmer (K-E) apparatus, 52, 56, 108, 119-120  
Kiwis, 24

L

Lead, trauma from, 113  
Leg. *See also* Limb.  
    homologous terms for, 134-135  
        Ligaments, collateral, caudal, ulnocarpometacarpal joint, 22  
        cranial, interphalangeal digiti majoris joint, 22  
        metacarpophalangeal digiti majoris joint, 22  
        metacarpophalangeal digiti minoris joint, 22  
        metacarpophalangeal joint, 22  
    cranial, radio-radiocarpal joint, 22  
    dorsal, radiocarpal-metacarpal joint, 22  
    ulnocarpometacarpal joint, 22  
intercarpal, 22  
interosseal, manus, 22  
radioulnaris, 51  
transverse radioulnar, 50, 51  
Limb, distal thoracic, 18-23  
    dorsal skeleton of, 18-22  
    joint detail of, 23  
    superficial view of, 18-21  
pelvic, cranial, skeleton of, 78-79  
    medial, skeleton of, 80-81  
thoracic, homologous terms for, 132-133

M

Manus, 18, 22  
Meniscus, intercarpal, 22  
    radioulnaris, 51  
Muscles, abductor alulae, 36, 37, 132  
    abductor digiti II, 90, 93, 134  
    abductor digiti IV, 97, 108, 134  
    abductor digiti majoris, 36, 37, 56, 57, 132  
    abductor indicis majoris, 132  
    abductor pollicis, 132  
    adductor, 134  
    adductor alulae, 20, 22, 37, 132  
    adductor digiti II, 134  
    adductor magnus et brevis, 134  
    adductor pollicis, 132  
    adductor profundus, 134  
    adductor superficialis, 134  
    ambiens, 82, 83-84, 87  
    anconeus, 132  
    biceps, 132  
    biceps brachii, 10, 11-12, 27, 30, 45, 46, 47, 48, 51, 132  
    biceps femoris, caudal head, 134  
        cranial head, 134  
    brachialis, 132  
    caudo-ilio-femoralis, 134  
    caudofemoralis, 70, 71-72, 76, 77, 134  
    common digital extensor, 47, 132  
    coracobrachialis, 132  
    coracobrachialis anterior, 132  
    coracobrachialis caudalis, 31, 43, 132  
    coracobrachialis cranialis, 10, 11, 12, 30, 31, 45, 132  
    coracobrachialis dorsalis, 10, 132  
    cranial, 106  
    cutaneus costohumeralis, 7-8, 11  
    deep pectoral, 132







This one-of-a-kind color atlas gives you practice-applicable information on the anatomy, surgical approaches, and basic orthopedic principles of various avian species and shows you how to properly expose the thoracic and pelvic limbs, decrease trauma, and enhance your surgical success.

AVIAN SURGICAL ANATOMY first provides anatomical illustrations with notes that briefly describe the muscles, bones, vascular supply, and nerves of each region ... then reviews related surgical approaches. Closure of the wound, comments on technique, and post-operative care are also discussed to help you progress confidently from evaluation to close.

Brilliant layer-by-layer surgical drawings made from dissections and twelve fold-out illustrations of bird anatomy give you full-color, unobstructed, virtually life-sized perspectives of the patients you are likely to encounter.

**W. B. SAUNDERS COMPANY**

Harcourt Brace Jovanovich, Inc.



*Carol Haynes*



ISBN 0-7216-3001-3