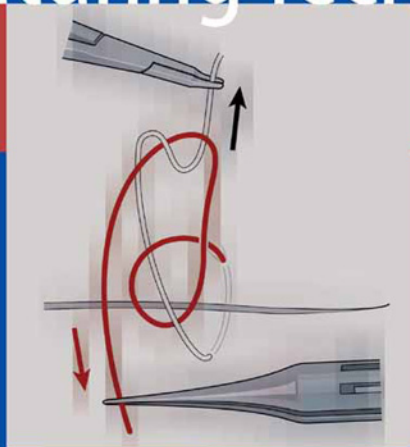


Marian S. Macsai  
*Editor*

# Ophthalmic Microsurgical Suturing Techniques



DVD-VIDEO



INCLUDED

 Springer

Marian S. Macsai (Ed.)

---

## **Ophthalmic Microsurgical Suturing Techniques**

Marian S. Macsai (Ed.)

---

# Ophthalmic Microsurgical Suturing Techniques

With 289 Figures, mostly in Color

This eBook does not include ancillary media that was packaged with the printed version of the book.

Marian S. Macsai, MD  
Professor and Vice Chair Ophthalmology  
Northwestern University  
Chief, Division of Ophtho  
Evanston Northwestern Healthcare  
2050 Pfingsten Rd.  
Glenview, IL 60025  
USA

ISBN-10 3-540-28069-3 Springer Berlin Heidelberg New York  
ISBN-13 978-3-540-28069-9 Springer Berlin Heidelberg New York

Library of Congress Control Number: 2006935423

This work is subject to copyright. All rights are reserved, whether the whole or part of the material is concerned, specifically the rights of translation, reprinting, reuse of illustrations, recitation, broadcasting, reproduction on microfilms or in any other way, and storage in data banks. Duplication of this publication or parts thereof is permitted only under the provisions of the German Copyright Law of September 9th, 1965, in its current version, and permission for use must always be obtained from Springer-Verlag. Violations are liable for prosecution under German Copyright Law.

Springer is part of Springer Science+Business Media.

Springer.com

© Springer-Verlag Berlin Heidelberg 2007

The use of general descriptive names, registered names, trademarks, etc. in this publication does not imply, even in the absence of a specific statement, that such names are exempt from relevant protective laws and regulations and therefore free general use.

Product liability: The publishers cannot guarantee the accuracy of any information about dosage and application contained in this book. In every individual case the user must check such information by consulting the relevant literature.

Editor: Marion Philipp, Heidelberg, Germany  
Desk Editor: Martina Himberger, Heidelberg, Germany  
Production: LE-T<sub>E</sub>X Jelonek, Schmidt & Vöckler GbR, Leipzig, Germany  
Illustrations: Albert R. Gattung + Regine Gattung-Petith, Edingen-Neckarhausen, Germany  
Typesetting: Arnold & Domnick, Leipzig, Germany  
Cover Design: Frido Steinen-Broo, EStudio Calamar, Spain

Printed on acid-free paper

24/3100/YL

5 4 3 2 1 0

## Dedication

For my husband, Jack,  
and his never ending support and love.  
For Ezra, Max and Emma,  
my continued sources of  
inspiration and joy.  
For my parents who taught me  
to learn, to teach and to enjoy life.

## Preface

In any surgical field, the importance of suturing is self-evident. In eye surgery, due to the lack of elasticity of the tissues and the influence of sutures on the visual outcome, proper microsurgical suturing technique is paramount. Inappropriate or careless suture placement and knot tying can impact visual function. If wound construction and closure are not astigmatically neutral, the visual outcome will be altered and further surgical intervention may be required. Wound related complications are more severe in the eye than in the skin. The close proximity of tissues allows for rapid spread of infection and the limited blood supply inhibits treatment. The same limited blood supply alters wound healing.

The translation of hand tying techniques, introduced in every medical school curriculum, to microsurgical instrument tying is not obvious. Essential differences exist in all aspects of ophthalmic microsurgical suturing techniques, from the use of the microscope itself to the instrumentation, tissue tactics, suture material and knot construction. The experienced surgeon shares the challenges that face surgeons in training, as they attempt to master new skills and handle more complicated cases. The role of wound closure and suturing techniques are basic building blocks for every ophthalmic surgical procedure. Breaking down the

complexity of microsurgical suturing to each of the numerous components required for tissue apposition that does not alter the function of the eye or impair the surgical outcome is the goal of this text.

Expert surgeons from different specialties have contributed their time and knowledge to the creation of this text. The uniform layout with key points identified at the beginning of each chapter allows the reader to quickly locate a particular technique. The authors have made great efforts to describe each technique in a step-by-step fashion, so that the reader can reproduce the technique on their own. Accompanying digital video clips of surgical footage clarify and demonstrate the different techniques. Mastery of basic and advanced ophthalmic microsurgical suturing techniques will facilitate expansion of any surgeon's armamentarium.

As ophthalmic surgery advances, a variety of skills are needed for the surgeon to stay current. This text offers the reader ophthalmic microsurgical suturing techniques that decrease the risk of postoperative infection and result in astigmatically neutral wound closure. Equipped with the knowledge of alternative techniques, when complications arise, the reader can decrease the need for further surgical intervention and improve their surgical outcomes.

## Acknowledgements

A text of this diversity is not possible without the input and help of many authors. I thank each of the authors who have freely contributed their expertise on an extremely tight schedule. Each was patient with the continuous revisions, illustrations, and video issues. Your continued help and support made this idea a reality. I could not have assembled all this material without Peggy Dow, who kept me organized and on track. A special thanks goes to all the people at Springer who gave so much to this project, especially Marion Philipp and Martina Himberger. I thank Renee Gattung for her expert illustrations, and Patrick Waltemate at LE-Tex for his patience.

# Contents

<b>1</b>	<b>The Physics of Wound Closure, Including Tissue Tactics .....</b>	<b>1</b>		
	Larry Benjamin			
<b>2</b>	<b>Needles, Sutures, and Instruments .....</b>	<b>9</b>		
	Jennifer H. Smith and Marian S. Macsai			
<b>3</b>	<b>Knot-Tying Principles and Techniques .....</b>	<b>21</b>		
	Anthony J. Johnson and R. Doyle Stulting			
<b>4</b>	<b>Microsurgical Suturing Techniques: Closure of the Cataract Wound .....</b>	<b>29</b>		
	Scott A. Uttley and Steven S. Lane			
<b>5</b>	<b>Suturing an Intraocular Lens .....</b>	<b>37</b>		
	Julie H. Tsai and Edward J. Holland			
<b>6</b>	<b>Corneal Suturing Techniques .....</b>	<b>49</b>		
	W. Barry Lee and Mark J. Mannis			
<b>7</b>	<b>Trauma Suturing Techniques .....</b>	<b>61</b>		
	Marian S. Macsai and Bruno Machado Fontes			
<b>8</b>	<b>Iris Reconstruction .....</b>	<b>71</b>		
	Steven P. Dunn and Lori Stec			
<b>9</b>	<b>Sclera and Retina Suturing Techniques .....</b>	<b>85</b>		
	Kirk H. Packo and Sohail J. Hasan			
<b>10</b>	<b>Glaucoma Surgery Suturing Techniques .....</b>	<b>101</b>		
	Joanna D. Lumba and Anne L. Coleman			
<b>11</b>	<b>Amniotic Membrane Suturing Techniques ...</b>	<b>107</b>		
	Scheffer C. G. Tseng, Antonio Elizondo, and Victoria Casas			
<b>12</b>	<b>Strabismus .....</b>	<b>117</b>		
	Mark J. Greenwald			
<b>13</b>	<b>Refractive Surgery Suturing Techniques .....</b>	<b>129</b>		
	Gaston O. Lacayo III and Parag A. Majmudar			
<b>14</b>	<b>Pterygium, Tissue Glue, and the Future of Wound Closure .....</b>	<b>135</b>		
	Sadeer B. Hannush			
	<b>Subject Index .....</b>	<b>141</b>		



## List of Contributors

### Larry Benjamin

Department of Ophthalmology  
Stoke Mandeville Hospital  
Mandeville Road  
Aylesbury, Bucks HP21 8AL, UK  
E-mail: larry.benjamin@bopenworld.com

### Victoria Casas

Ocular Surface Center, P.A.  
7000 SW 97th Ave., Ste. 213  
Miami, FL 33173-1492, USA  
E-mail: vcasas@ocularsurface.com

### Anne L. Coleman

Jules Stein Eye Institute  
100 Stein Plaza, #2118  
Los Angeles, CA 90095-7065, USA  
E-mail: colemana@ucla.edu

### Steven P. Dunn

Michigan Cornea Consultants  
29201 Telegraph Rd., Ste. 101  
Southfield, MI 48034-7630, USA  
E-mail: StevenPDunn@ameritech.net

### Antonio Elizondo

Ocular Surface Center, P.A.  
7000 SW 97th Ave., Ste. 213  
Miami, FL 33173-1492, USA

### Bruno Machado Fontes

Av. des Americas 2300 / B, cs 27  
Rio de Janeiro, RJ, Brazil 22640-101  
E-mail: brunofontes@openlink.com.br;  
brunofontes@oftalmo.epm.br

### Mark J. Greenwald

Department of Ophthalmology and Visual Science  
University of Chicago  
5841 S. Maryland Avenue, M/C 2114  
Chicago, IL 60637, USA  
E-mail: mgreenwa@uchicago.edu

### Sadeer B. Hannush

Cornea Service, Wills Eye Hospital  
Jefferson Medical College, Philadelphia, PA  
Correspondence:  
400 Middletown Blvd. Suite 110  
Langhorne, PA 19047, USA  
E-mail: SBHannush@comcast.net

### Sohail J. Hasan

Ingalls Hospital Professional Bldg.  
71 West 156th St., Ste. 400  
Harvey, IL 60426, USA

### Edward J. Holland

CEI-NKY  
580 South Loop Rd., Ste. 200  
Edgewood, KY 41017, USA  
E-mail: eholland@fuse.net

### Anthony Johnson

Cornea/Refractive Surgery  
SAUSHEC Ophthalmology  
3851 Roger Brooke Drive  
Fort Sam Houston, Tx 78234, USA  
E-Mail: Anthony.Johnson2@amedd.army.mil

### Gaston O. Lacayo III

Rush University Medical Center  
Department of Ophthalmology  
1725 W. Harrison St., Ste. 928  
Chicago, IL 60612, USA  
E-mail: Gaston\_O\_Lacayo@rush.edu

### Stephen S. Lane

280 N. Smith Ave., Ste. 840  
St. Paul, MN 55102, USA  
E-mail: sslane@associatedeyecare.com

### W. Barry Lee

Eye Consultants of Atlanta  
95 Collier Rd., Ste. 3000  
Atlanta, GA 30309, USA  
E-mail: Lee0003@aol.com

**Joanna Lumba**

1101 Welch Road, Suite B2  
Palo Alto, CA 94304, USA  
E-mail: lumbajo@yahoo.com

**Marian S. Macsai**

Professor and Vice Chair Ophthalmology  
Northwestern University  
Chief, Division of Ophtho  
Evanston Northwestern Healthcare  
2050 Pfingsten Rd.  
Glenview, IL 60025, USA

**Parag A. Majmudar**

Rush University Medical Center  
Department of Ophthalmology  
1725 W. Harrison St., Ste. 928  
Chicago, IL 60612, USA  
E-mail: pamajmudar@chicagocornea.com

**Mark J. Mannis**

Department of Ophthalmology  
University of California  
4860 Y St., Suite 2400  
Sacramento, CA 95817, USA

**Kirk H. Packo**

Rush University Medical Center  
Department of Ophthalmology  
1725 W. Harrison St., Ste. 945  
Chicago, IL 60612, USA  
E-mail: kirk\_packo@rush.edu

**Jennifer Hasenyager Smith**

2032 Valor Ct.  
Glenview, IL 60026, USA  
E-mail: Jhsmith2020@yahoo.com

**Lori Stec**

Beaumont Eye Institute  
3601 W. Thirteen Mile Road  
Royal Oak, Michigan 48073, USA

**R. Doyle Stulting**

Emory Vision  
875 Johnson Ferry Road  
Atlanta, GA 30342, USA  
E-mail: ophtrds@emory.edu

**Julie H. Tsai**

University of South Carolina School of Medicine  
Dept of Ophthalmology  
Four Medical Park, Suite 300  
Columbia, SC 29203, USA  
E-mail: tsaij3@gmail.com

**Scheffer C. G. Tseng**

Ocular Surface Center, P.A.  
7000 SW 97th Ave., Ste. 213  
Miami, FL 33173-1492, USA  
E-mail: stseng@ocularsurface.com

**Scott A. Uttley**

St. Paul Eye Clinic  
2080 Woodwinds Dr.  
Woodbury, MN 55125-2523, USA  
E-mail: uttle001@tc.umn.edu

# The Physics of Wound Closure, Including Tissue Tactics

1

Larry Benjamin

## Key Points

- Principles of wound closure vary, depending on whether the wound is extraocular or involves opening the pressurized globe and subsequent closure. Preparation, avoidance of infection, and maintaining wound integrity are vital in good wound management.
- When suturing, the tissue should be well controlled to stabilize the area through which the needle passes. Desired results are best achieved when this is done.
- Closure of the skin of the eyelid is comparable to skin closure elsewhere. Differences exist in the structure detail(s) included in the closure. There are a number of techniques for working with the lid, conjunctiva, and cornea and sclera.
- Because of the inflexible nature of the cornea and sclera, tissue suturing here requires precise suture placement.
- Successful ophthalmic wound closure results from proper technique modification and suture tension.

## 1.1

### Introduction

The closure of wounds in surgery relies on apposing surfaces and planes of tissue so that they can heal in an appropriate fashion. Knowledge of the biology of wound healing is important, as is being able to modify the processes involved to achieve the desired wound architecture in an appropriate time. When considering wound construction or repair in the cornea, wound anatomy and healing can both have a dramatic effect on visual outcome after the surgery because of the effect of surgically induced astigmatism on the corneal surfaces. Similarly, poor wound repair on the eyelid margins can have a long-term effect on the ocular environment by affecting lid closure and tear flow. This chapter addresses the forces and vectors involved in wound closure, the tactics used to achieve the desired effects, and how these relate to clinical principles.

## 1.2

### Wound Architecture

#### 1.2.1

#### Principles of Wound Closure

The principles of wound closure vary, depending on whether the wound is extraocular or involves opening the pressurized globe and subsequent closure. Paramount in the sequence of good wound management is preparation. This means adequate cleaning of surgical surfaces, excellent aseptic technique, as well as thorough postoperative care.

Avoiding infection is the best way to ensure wound integrity and healing in a timely fashion. In the eyelids, infection after surgery is uncommon, as there is a plentiful blood supply, but in the cornea and cavities of the globe, infection will last longer, cause more devastation, and be more difficult to eradicate.

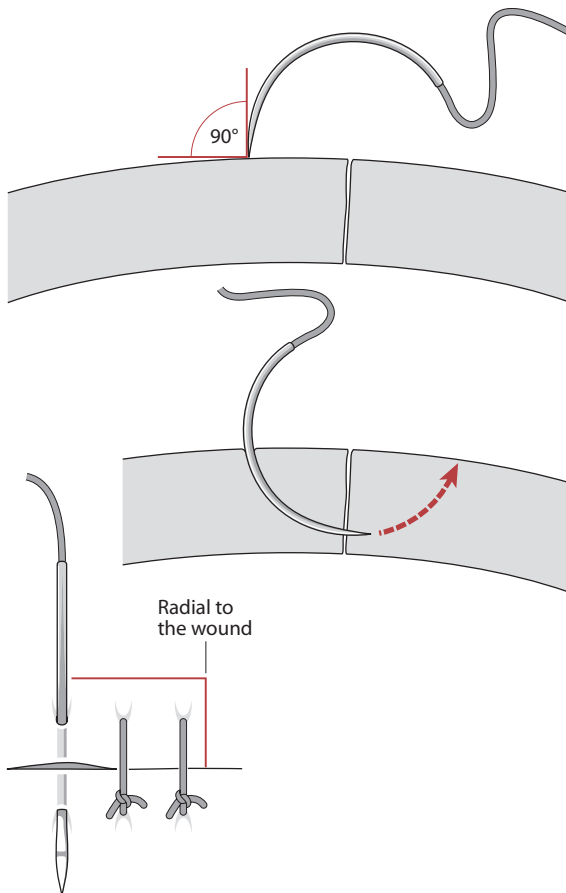
One of the overriding principles of wound closure is to keep the integrity of the body cavities intact and prevent ingress of infectious agents. In addition, when suturing the optical surfaces of the eye (any part that affects corneal curvature), care must be taken to avoid excessive astigmatic change while maintaining the integrity of the globe.

Choice of instrumentation is important, as some instrument tips may damage the delicate corneal tissues more than others. Toothed forceps will grasp tissue well but will puncture it. Notched forceps are more gentle and may be preferred, but under some circumstances where the tissue is edematous (such as after trauma), multiple attempts to grasp the tissue with notched forceps may result in further maceration and swelling, whereas a single sure grasp with toothed forceps may be preferable.

Microsurgery is distinctly different from general surgery. The operating microscope forces the surgeon to assume a particular posture that often must be maintained for several hours; the surgeon should sit in a natural position, leaning slightly forward, with a straight back and relaxed shoulders. Both feet should be flat on the floor. The visual field is restricted, as is the space for manipulation between the microscope

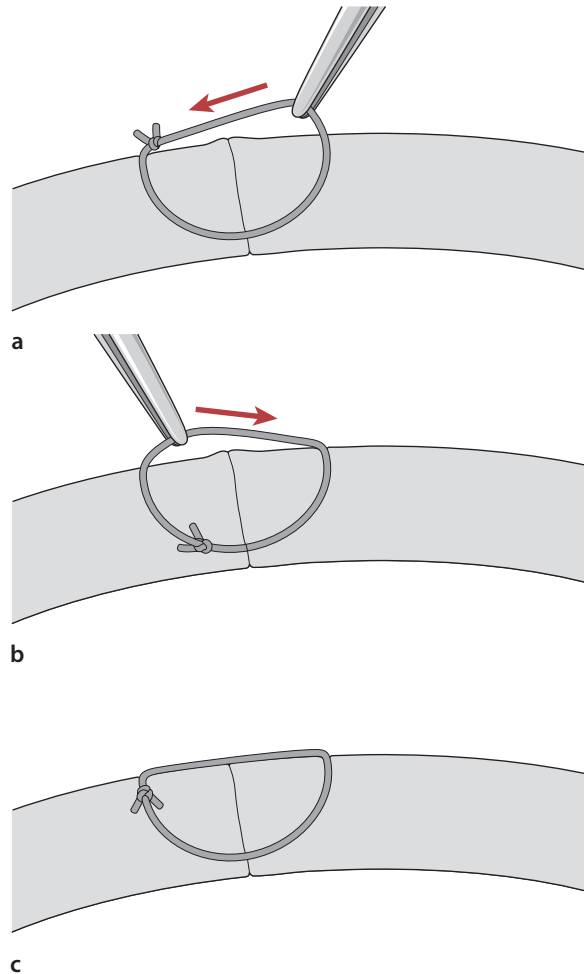
and the operative field. The operating microscope consists of the following elements: oculars, beam splitter, magnification system, and objective. Both focus and magnification should be adjustable with a remote foot control. The entire surgical field can be surveyed simply by dropping one's gaze to the operative field.

The function of sutures is to maintain apposition of wound edges artificially until scar tissue has attained sufficient strength. The ideal suture must appose the incised tissue edges in their normal anatomic position and provide adequate compression and minimal space for the scar tissue to bridge. Until formation of scar tissue is complete, the suture must maintain this apposition when external forces are applied. Simple interrupted suture presses the wound margins together and tends to assume a circular shape when tightened. When overtightened or overcompressed, the posterior aspect of the wound may gape, creating a fistula. Over-compression may cause the surgeon to place numerous unnecessary sutures to keep the wound watertight.



**Fig. 1.1** The needle is passed perpendicular to the surface of the tissue and exists equidistant from the point of entry when viewed from the anterior perspective of the laceration

Simple interrupted sutures produce inversion of the wound edges as the suture assumes a circular shape. Interrupted mattress sutures may produce inversion or eversion of the wound edges, depending on their placement and the degree of tightening. Continuous sutures flatten a convex wound and tend to straighten out curved incisions. The continuous suture will deform the surface when the suture bites are placed irregularly. Irregular sutures result from unequal suture depth placement, unequal length of suture passes and nonradial suture placement.



**Fig. 1.2** **a** After the knot is tied and the ends are cut short, the suture is grasped with smooth forceps and rotated into the tissue; care must be taken to avoid a twisting motion that may torque the tension on the suture and result in a shearing force that tears the tied suture. **b** The knot is then grabbed and rotated in the reverse direction. **c** The suture knot is now just beneath the surface of the tissue, and the ends extend away from the wound. This placement of the knot will facilitate removal as long as the knot is pulled out in a manner that does not require the knot to traverse the wound interface

### 1.3 Suture Placement

Tissue must be properly held in order to stabilize the area of tissue the needle is driven through. If this maneuver of passing the needle through the wound edge is controlled, the desired results are achieved (Figs. 1.1 and 1.2). Using 0.12 mm forceps, the tissue should be held with the two-teeth side of the forceps on the same side of the tissue through which the needle is being driven.

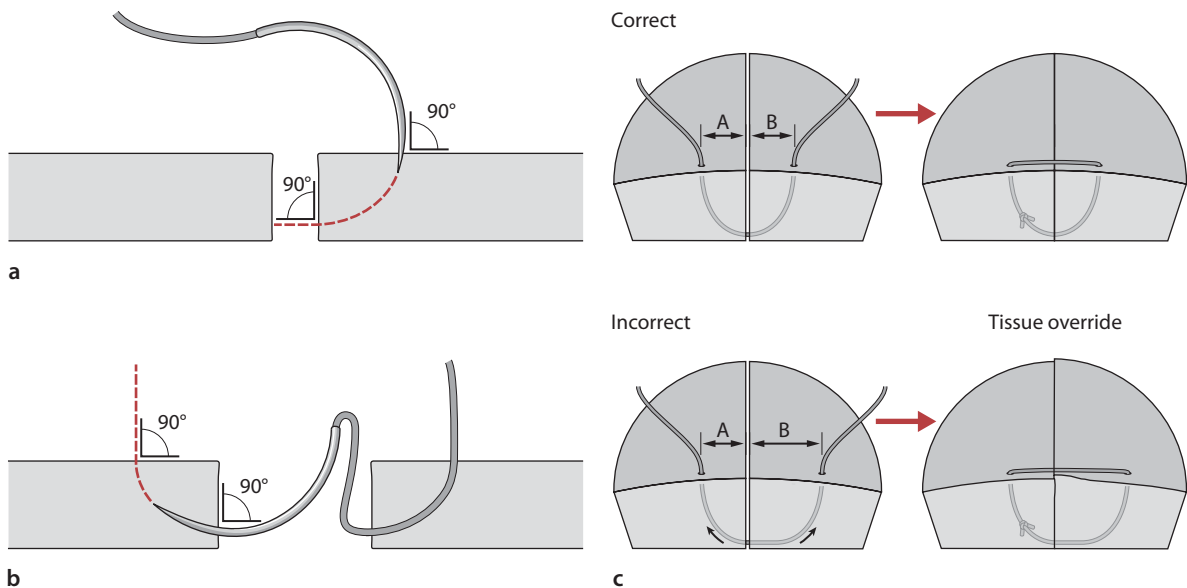
The needle should be two thirds of the way from the point of the surgical needle and held at a 90° angle from the needle holder. The needle must be parallel to the tissue plane (deviation will lead to tissue laceration with a side cutting spatulated needle), and slip (if not over tightend) or surgeon's knots may be used when tissue is under tension. After the wound is closed, the initial sutures may be replaced with astigmatically neutral sutures, surgeon's knots (2:1:1), at the desired tension, to avoid over compression of tissue, which can easily happen with slip knots that are tied to tightly.

#### 1.3.1 Suture Technique

The suture passes should be of equal depth in the tissue on either side of the wound and of equal length. In this way, the wound will appose correctly without wound override or inducement of astigmatism. The greatest

accuracy is achieved when the needle is inserted perpendicular to the tissue surface and emerges perpendicular to the wound surface (Fig. 1.3). This placement causes minimal shift of the wound surface when the suture is tied. The needle can be passed in two steps. First, it is inserted perpendicular to the tissue surface, and it emerges perpendicular to the wound surface. The needle should be brought out through the wound surface perpendicular to the wound surface such that it exits perpendicular to the tissue surface. When using this technique, it is sometimes difficult for the surgeon to determine the proper insertion site in the opposing wound surface. Furthermore, it is important for the surgeon to consider that the depth at which the exiting needle exits should be the same depth as when the needle enters the opposing wound surface. If the surgeon inadvertently changes the direction of the needle when entering the opposing wound surface or exits and enters at differing depths, the resultant torque on the tissue will displace the entire wound. Easier passage of the needle tip through the tissue at 90 degrees can be accomplished by everting the distal lip of the wound so the depth of the wound can be accurately ascertained. This allows a flatter trajectory of the needle through the tissue and enables the surgeon to see the depth of both sides of the wound and accurately position the needle into the second half of the wound.

The incised tissue is fixated with fixation forceps, and the needle position must be adjusted according to the amount of tissue deformation caused by the for-



**Fig. 1.3** A needle is passed in two steps. a The needle is rotated posteriorly, and it enters the tissue surface in a perpendicular fashion (90° angle) and emerges perpendicular to the wound surface. b The same angle of penetration is followed when the apposing tissue is entered perpendicularly and the

needle again emerges at a 90° angle to the tissue surface. This method causes minimal shift of the wound surface when the suture is tied. c This equal spacing of the suture results in correct wound apposition; unequal suture passes or bites can result in wound override and irregular astigmatism

ceps. The tissue should be fixated at the position where the suture is to be placed, not adjacent to this position. The needle shaft must be inclined posteriorly to allow the tip of the needle to pierce the tissue at a right angle. A deep semicircular stitch produces a large compression zone, which limits the number of interrupted sutures needed to close a wound. Care must be taken not to overtighten the sutures. Overtightening of sutures can shorten the suture track and deform the surrounding tissue, which interferes with wound closure. A single overcompressed suture can disrupt the closure of the full length of the wound. It is better to remove an overcompressed suture than to place numerous corrective sutures to provide countertension. These corrective sutures may make the wound watertight, but the result increases astigmatism.

### 1.3.2

#### Force Vectors of Sutures

All sutures produce vector forces that act in various directions as the suture is tightened. The vector forces extend in three different directions: perpendicular to the wound surface, parallel to the wound margin, and perpendicular to the tissue surface. If a suture is placed perpendicular to the wound surface, the force vectors cause compression in a line where the suture plane intersects with the wound surface. However, if the suture is placed obliquely, the compression vector force is an area on the wound surface; therefore, a lateral shift of the wound is produced. This shift is also the result of the vector force that is parallel to the wound margin. This force is not generated when the interrupted sutures are placed perpendicular to the wound. In continuous sutures, the shifting vectors of the bridging segments of the suture can serve to neutralize the shifting forces generated by each suture bite. The third vector component, perpendicular to the tissue surface, results in two forces in opposite direction in the simple interrupted suture. The first component results in eversion of the wound edge, and the second portion of the suture generates a force resulting in inversion of the wound edge. In the simple interrupted suture, these

forces cancel each other out, and they are in opposite directions. Continuous sutures produce both inverting and everting forces that are cancelled out if the loops are placed very close together; otherwise, significant irregularities of the tissue surface result. An example of the continuous suture can be found in Chap. 6.

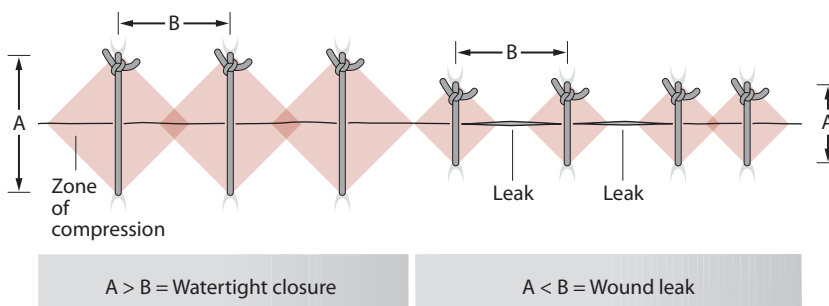
The effects of compressing vectors are maximal in the suture plane and diminish farther away from the suture. Each interrupted suture generates a zone of compression. The compressive effect is maximal in the plane between the point of suture entry and suture exit and falls off laterally. The action of the suture can be described in terms of force triangles extending laterally from the suture. The width of these compression zones depends on the length of the suture bites and the degree of suture tension after the suture is tightened. Adequate wound closure is achieved when the zones of compression of each interrupted suture overlap (Fig. 1.4).

### 1.4

#### Lid Wound Closure

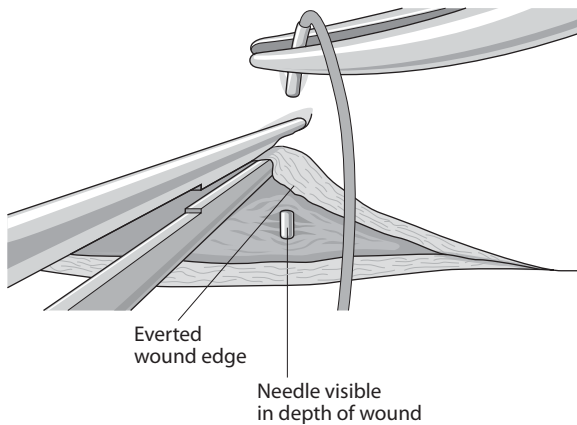
Closure of the skin of the eyelid is similar to skin closure elsewhere, although differences may exist in the detail of what structures are included in that closure. For example, incorporating the tarsal plate into the skin suture after a ptosis repair will cause a skin crease to form in the appropriate place. Essentially, lid skin closure is performed by placing a central suture, dividing the wound in half, and then dividing each half in half again. Deciding how many sutures to use depends on their length and tension. An adequate number of sutures have been used when the zone of compression of each suture overlap. Figure 1.4 shows the zone of compression for a single suture, which is the effective zone of closure that a suture exerts when tied at its particular tension. These zones should overlap slightly to ensure that the wound will not open between the sutures, and the closer the sutures are together, the more the adjacent compression zones overlap and the more secure will be the wound.

Decisions about suture placement are important in relation to their spacing, depth, tension, and length.

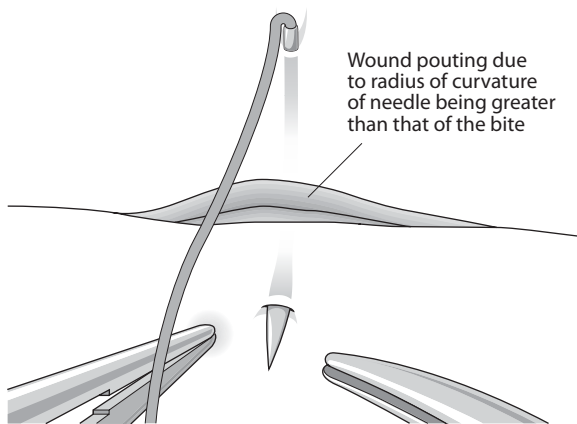


**Fig. 1.4** Zones of compression. Different lengths of suture bites result in different zones of compression. When the zones of compression overlap, adequate wound closure is achieved (arrows)





**Fig. 1.5** Everting the wound edge



**Fig. 1.6** Pouting of the wound

Usually, a suture should be symmetrical across a wound with equal depth and length across the wound. Suture bites are made with the needle at  $90^\circ$  to the tissue surface. Everting the wound edge is sometimes necessary to be able to see the placement of the needle tip as it enters the tissue (Fig. 1.5).

This also allows a view into the depth of the wound to ensure that the needle engages the opposite wound edge at the same depth. The suture track will sometimes be longer than the radius of curvature of the needle, which will make the wound pout when the needle is in both sides of the wound (Fig. 1.6).

The length of the suture track may be important in skin wounds, because if placed too close to the wound edge and made too tight, then avascular necrosis of the skin edge can occur. Skin sutures are usually tied slightly overtight to evert the edges together so that as healing progresses and subdermal involution of tissue occurs, the wound edges will end up flat.

## 1.5 Lid Margin Repair

There are a number of different techniques available for repairing lid margins, but the principles are the same. It is important to accurately align the three surfaces of the lid (skin, gray line, and conjunctiva) for an adequate time for healing to occur.

If a tarsal plate suture is used then additional skin sutures can be removed early (1 week), but if gray line and skin sutures are used without a cardinal tarsal suture, then they must be left in for 2 to 3 weeks to allow proper healing, especially if the wound is under tension such as when a proportion of the lid length has been removed in tumor removal or entropion repair. A cardinal tarsal suture should be placed horizontally parallel to the lid margin about 1 mm from its surface and should be within the lid substance entirely. In other words, the suture should not protrude through either skin at the front of the lid or conjunctiva at the back. A well-placed tarsal suture will provide the necessary strength and tension for the lid margin to heal with no notching, and will allow early removal of supplementary skin and lid margin sutures.

## 1.6 Conjunctiva Wound Repair

When suturing the conjunctiva, the surgeon must recognize the inherent tendency of the tissue to curl. When the conjunctival tissue curls, there is some retraction of the conjunctival epithelium. The retraction can be offset by countertraction on the subepithelial tissue. The epithelial layer can be recognized by its distinctive vascular pattern. Application of balanced salt solution to the cut margin of the conjunctival tissue makes this distinction easier because Tenon's capsule will appear white when the fibers are hydrated with the solution. Care must be taken to recognize the margin of the surgical dissection when suturing conjunctiva. When countertraction is applied, toothed forceps, such as 0.12-mm forceps, may be necessary to determine the margin of the surgical dissection and apply countertraction. If countertraction is not applied properly, inadvertent suturing of epithelial tissue in a subepithelial space can result in the post-operative formation of an epithelial inclusion cyst. Conjunctival tissue is extremely compliant, and postoperative adherence is accomplished rapidly because of the vascular substrate. Frequently, a rapidly absorbable suture, such as 8-0 collagen or 8-0, Vicryl is used to secure the conjunctival tissue in place.

## 1.7

### Corneal Wounds and Repair

Because of the unyielding nature of the cornea and sclera, suturing of these tissues requires extremely precise placement of sutures. The needle track must cut through the lamellae of the tissue. Surgical wounds can be placed to facilitate closure, whereas traumatic wounds often require thinking on one's feet at the time of repair because of their unpredictable architecture. Sometimes a surgical wound becomes difficult to close predictably, for example, overenlarging a phacoemulsification tunnel to insert an implant may destabilize a supposedly self-sealing wound and necessitate suturing. Examples of wound architecture and closure techniques for cataract wounds are detailed in Chap. 4. In order for a wound to be self-sealing, it must create a valve-like effect.

#### 1.7.1

##### Closing the Large Limbal Wound

This can be done with interrupted sutures or a continuous one. The theoretical advantage of a continuous suture is the more even distribution of tension along the length of the wound and thus, hopefully less astigmatism. However, a tight continuous suture can cause just as much astigmatism as interrupted ones, and also have the disadvantage of being less flexible in terms of astigmatism control. If it breaks or loosens, the whole thing must be removed and possibly replaced, whereas selective removal of individual sutures can be useful to adjust astigmatism.

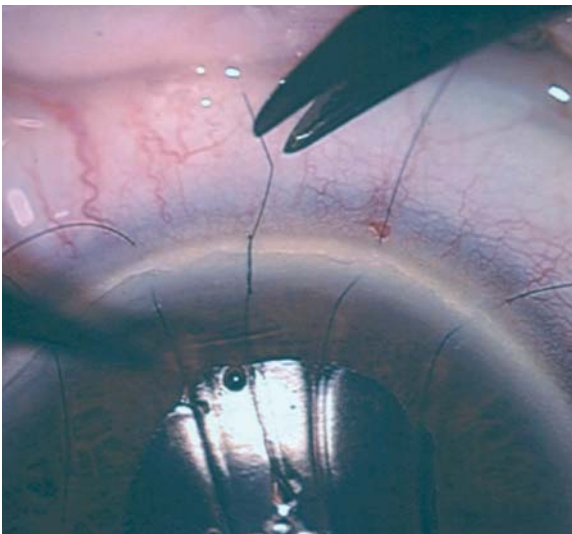
Assuming that the wound has been made 1 mm from the limbus and is beveled, then placement of the first 10-0 nylon suture is made centrally. The principle of this stitch is that it is used to stop the wound from opening, as opposed to keeping it closed. In principle, the wound will, if well constructed, keep itself closed and should heal with no astigmatism if left undisturbed. Clearly, patients cannot be asked to keep still for several weeks while the wound is healing, and so sutures are placed to keep the wound from opening. If this suture does not equally divide the wound, it will need to be replaced once sutures are placed on either side of the initial wound.

A 2-1-1 configuration of square knot (surgeon's knot) is used, and the first two throws can be laid down on the corneal surface at exactly the right tension to stop the wound opening, as shown in Fig. 1.7.

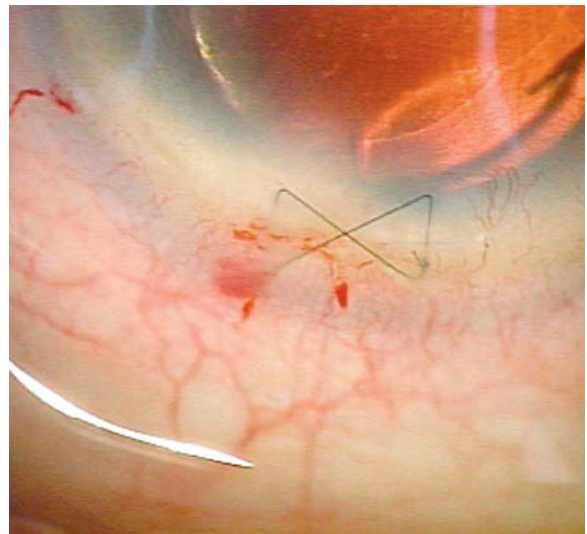
Subsequent throws are made to lock the knot at this tension, and it is imperative that proper square knots are made so that the tension in the first turns of the knot is not disturbed. Tying a square knot will ensure that it locks at the predetermined tension, whereas if a slipknot is inadvertently tied, the tension will increase as the knot slips rather than locks.

Further sutures are then placed either side of the first with equal spacing, length, depth, and tension and for wound of 140° in length, five sutures are usually adequate.

Overtightening a corneal suture will steepen the central curvature of the cornea and induce steepening in that meridian (causing a myopic shift in that meridian). Leaving them very loose may allow the corneal wound to "slip" (open slightly) and flatten the merid-



**Fig. 1.7** A 3-1-1 configuration of square knot (surgeon's knot) is used, and the first three throws can be laid down on the corneal surface at exactly the right tension to stop the wound opening



**Fig. 1.8** A simple butterfly or cross-stitch is all that is needed to close the wound, which will then effectively self seal as intraocular pressure is restored



ian concerned. It is therefore very important to make the wound self-sealing and tension the sutures to stop the wound from opening.

### 1.8

#### Suture Placement to Close a Phacoemulsification Wound

Occasionally a phacoemulsification wound is extended too far and becomes unstable. A simple butterfly or cross-stitch is all that is needed to close the wound, which will then effectively self-seal as intraocular pressure is restored, and the suture can be removed at a week (Fig. 1.8). A mattress suture is a good alternative to closing the wound, without inducing astigmatism.

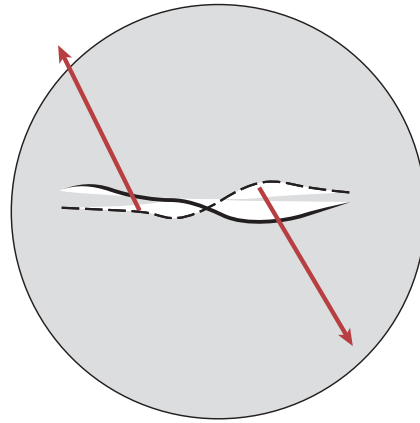


Fig. 1.9 A typical shelved wound

### 1.9

#### Corneal Transplant Suturing

All transplant surgeons know that it is not possible to produce astigmatism-free wounds reliably. The principles of suturing these wounds include the need for a watertight wound, with sutures that are placed equally deep in both host and donor tissue. Full thickness sutures should be avoided (endothelial damage and a potential track for infection into the anterior chamber). A running suture should have even tension for 360°, and all knots should be buried. A continuous suture provides relatively even tension and is quicker to perform. Interrupted sutures should be used when infection or inflammation is present, as they can be selectively removed if necessary. The torque induced by a continuous suture can be counteracted by an opposite running suture and some surgeons will use a mixture of 10-0 nylon and 11-0 nylon to provide this torque and counter torque.

overriding of the wound edge may occur. An easy way to ensure that equal depth is achieved is to keep the length of the deep portion of the suture equal and the epithelial portion unequal.

### 1.11

#### Conclusion

Closure of some ophthalmic wounds is similar to other areas of surgical practice. However, specific differences exist in wounds relating to the globe and the effect that suturing can have on vision by dramatically disturbing optical surface curvature resulting in astigmatism. Modification of technique and suture tension is critical if satisfactory functional as well as anatomical results are to be obtained.

### 1.10

#### Wound Closure in Trauma

The unpredictable nature of traumatic wounds means that closure requires careful thought. Wounds may shelf in different directions from one end to the other, and reliable watertight closure requires various suturing techniques during the procedure. A typical shelved wound is shown in Fig. 1.9, and it makes sense to place the first suture in the most unstable portion of the wound. In this case, centrally, to make the wound more stable, which makes subsequent closure easier.

Chapter 7 demonstrates the approach that is needed with a shelved wound to ensure accurate wound edge apposition. The critical point is to make the depth of the suture equal in the deep part of the wound, or else

# Needles, Sutures, and Instruments

# 2

Jennifer Hasenyager Smith and Marian S. Macsai

## Key Points

- Needle material, diameter, curvature, and point style all contribute to needle function and should be considered relative to the goal of suturing and tissue type when selecting a needle.
- Suture material and diameter determine strength, handling, adsorbability, knot security, and tissue reactivity. Together with the tissue type and goal of suturing, these characteristics should be considered when selecting suture material.
- Instruments used for microsuturing should be of the appropriate size and style to facilitate safe, effective suturing in light of the specific needle, suture, and tissue involved.
- New technology in suturing instrumentation includes suture swaged to needles of the same or smaller diameter, suture coated with bioactive glass and antibacterials, and microincision instruments for intraanterior chamber suturing.

## 2.1 Introduction

Information about suture materials and needles is important, as inappropriate use of a material or needle type can lead to wound breakdown or tissue injury. For example, following trauma, the use of an absorbable suture to repair a scleral rupture can lead to wound dehiscence a few weeks after the repair, and the use of a cutting or reverse-cutting needle on the sclera can lead to choroidal or retinal injury at the time of repair. The surgeon faces several decisions when closing a wound. These decisions include choice of suture and needle, placement of sutures, and type of knot.

## 2.2 Needles

Prior to 1959, eyed needles were commonly used in the United States for ocular suturing [48, 61]. These needles worked in a similar fashion to the common clothes sewing needles in current use. The use of an eyed needle threaded with suture resulted in a double thickness of suture being pulled through the needle tract; however, only a single-thickness of suture was left tied in the incision. This was problematic in that the needle tract was resultantly larger in diameter than the suture and was prone to leakage. The needle swage, or permanent attachment of the suture to the needle at the time of manufacture, which was patented in 1914 [35], eventually came into popular use and allowed for improved techniques in ocular suturing (Tables 2.1 and 2.2).

## 2.3 Needle Characteristics and Selection

(See Table 2.1.)

Although the performance of a needle is determined by its shape and its composition, needles are typically described in manufacturers' catalogs by shape but not by metallurgical composition. The characteristics that define a specific needle type include curvature (1/4, 3/8, or 1/2 circle), chord length, and radius (Fig. 2.1); linear needle length, wire diameter, and point cutting edge (Fig. 2.2).

There are two basic styles of needle swage (attachment of suture to needle end) in use for the small needles used in microsuturing, laser drilling, or channel fixation. Laser drilling forms a hole in the trailing end of the needle into which the suture is secured. Channel fixation involves the use of a tool that forms a planed cut that is half the thickness of the needle wire along the trailing end of the needle. The cut is approximately four times the length of a laser-bored hole, and the suture is fixed to a depression in the cut area. The process results in a groove and an unevenly rounded surface at the needle end. A disadvantage of the channel-fixed needle is that the suture can be loosened or the swage

**Table 1.** Basic surgical needle types and their characteristics. References [29, 32, 40, 42, 59]

Needle Type	Bite	Cross section	Side cutting Y/N	Tissue tract	Procedure(s)	Comment
1/4, 3/8 circle	Large/shallow					
1/2 circle	Short/deep					
Spatula		trapezoid	Y	Intralamellar plane	Lamellar keratoplasty, cataract incisions, strabismus surgery, etc	
Standard cutting		Triangle, point up	Y	Tracks superficially	Scleral grafts, corneal sutures, etc	Tough tissues, full-thickness bites. Sharper than reverse cutting.
Reverse cutting		Triangle, point down	Y	Tracks deeply	Scleral grafts, corneal sutures, etc	Tough tissues, full-thickness bites
Standard cutting/beveled edge		Triangle, point up	Y	Tracks superficially	Scleral grafts, corneal sutures, etc.	Tough tissues, full-thickness bites. Sharper than standard cutting or reverse cutting. More bending than non-beveled.
Taper-point		circle	N	Smaller than trailing suture	Trabeculectomy, iris suturing	Not good for tough tissues
Tapercut		Tip: triangle; Body: round	Y	Smaller than trailing suture	Trabeculectomy	Combination of reverse-cutting and taper point. Penetrates tissues more easily but still watertight.

**Table 2.2.** Common microsurgical needle characteristics

Model	Circle	Needle Type	Wire (mm)	Length (mm)
CIF-4	¼	Taper Point	0.20	13.34
PC-7	¼	Taper Point	0.23	13.34
BV 100-4	3/8	Taper Point	0.10	5.11
STC-6	Straight	Spatula	0.15	16.00
SC-5	Straight	Spatula	0.15	16.15
CTC-6	¼	Spatula	0.15	11.99
CTC-6L	¼	Spatula	0.15	14.00
CS160-6	3/8	Spatula	0.15	5.33

can be deformed when grasped by a needle holder at the swaged area. Laser-drilled swages have less wire bulk removed during manufacture and have a smoother trailing needle end. They are therefore less easily deformed when grasped near the trailing end [53]. The relative biomechanical performance of channel-style and laser-drilled needles was compared in two Ethicon needles in a standardized grading system [3]. It was shown that laser-drilled needles were both easier to pass through a test membrane and less likely to deform or break than channel-style needles. The authors of that study recommended laser drilling for all needles.

The properties of an ideal surgical needle have been summarized as: (1) sufficiently rigid so that it does not bend; (2) long enough so that it can be grasped by the needle holder for passage and then be retrieved without damage to its point; (3) of sufficient diameter to permit a slim-point geometry and a sharp cutting edge, resulting in a tract large enough to allow the knot

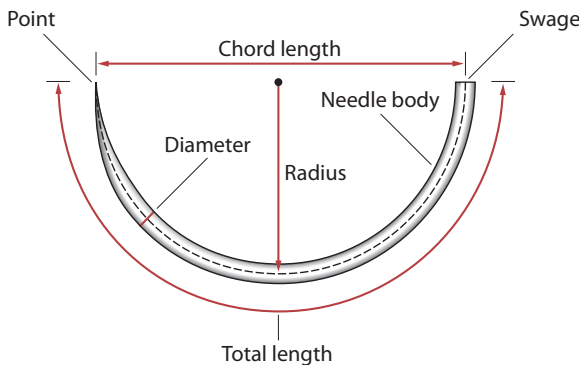
to be buried; and (4) as nontraumatic as possible [43]. Optimal surgical needles should also be composed of materials that resist dulling and permanent deformation during passage through tissue. At the same time, the material should not be so rigid that it is brittle and likely to fracture easily if stressed.

Needles can additionally be evaluated in terms of resistance to bending and ductility. A needle's resistance to bending can be objectively measured with a standardized procedure that generates a graph of force required to reversibly and irreversibly bend a needle [2, 14]. Factors affecting the resistance to bending of a needle include needle diameter, needle material, and the manufacturer. Needle ductility refers to the amount of deformation that a needle can withstand without breaking [18]. Superior ductility grading was seen in needles made from American Society for Testing and Materials (ASTM) 45500 alloy and finished with the electrohoning process [1, 14].

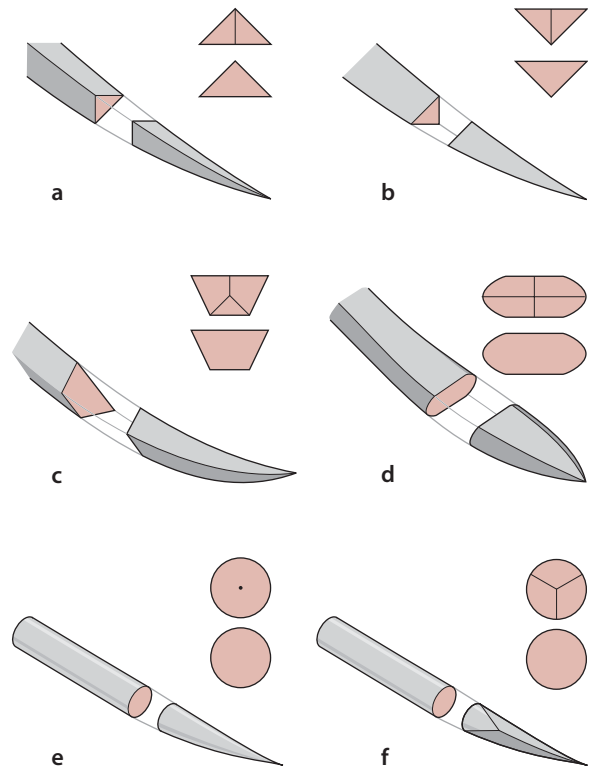
In studies of sharpness, needles with longer, more narrow cutting edges and needles made from ASTM alloy 45500 were the sharpest [14, 57]. The standard cutting edge and reverse-cutting edge needles both have triangular cross sections, with two lateral cutting edges that can influence needle sharpness [9]. The third cutting edge of a standard cutting needle is located on the concave surface (also referred to as the inner, or top, surface) of the curved needle. The reverse-cutting needle has its third cutting edge on the convex surface (outer, or bottom, surface) of the needle (Fig. 2.2). In standardized sharpness comparisons, the standard cutting needle was found to be sharper than the reverse-cutting needle [59], and a modified standard cutting edge needle with beveled edges and correspondingly narrower cutting edges (Fig. 2.3) was found to have further enhanced sharpness both in vitro through a synthetic membrane and in vivo for suturing skin lacerations in the emergency room [29]. The narrower cutting

angle along the concave surface facilitates tissue penetration [32]. However, it has also been recently shown that in comparison with triangular and diamond-shaped tips, a bevel tip causes more bending and is more easily affected by tissue density variations [40].

Taper-point needles (cardiovascular or BV needles) are frequently used to close conjunctiva when a watertight suture line is desired, such as in trabeculectomy [27]. Taper-point needles with two combined radii of curvature are also available and provide greater accuracy to a controlled depth and length of bite than does a curved needle with a single radius of curvature [15]. A modification of the taper-point needle, the Tapercut (Fig. 2.2F), combines a short reverse-cutting tip with a taper-point body. The resulting needle is sharper and initially penetrates tissue more easily than a taper point, and is still able to create tighter needle tracts with more watertight closures than would a reverse cutting needle. In order to create the smallest possible ratio of needle-to-suture diameter, polypropylene suture material can be extruded to create a tapered swage end of significantly smaller diameter than the remainder of the suture, allowing a channel swage to a needle of minimal diameter ([60]; Fig. 2.4).



**Fig. 2.1** Specifications terminology for surgical needles. (Reprinted from Steinert RF. *Cataract Surgery, Techniques, Complications, and Management*, 2nd Edition, p 53. © 2004, with permission from Elsevier)

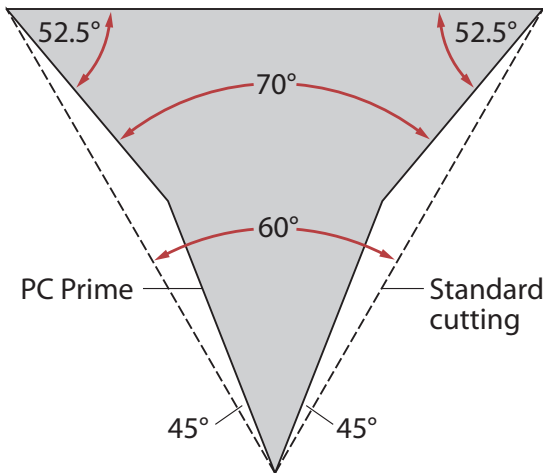


**Fig. 2.2** Schematic illustrations of surgical needle types. **a** Conventional cutting needle, **b** reverse cutting, **c**, **d** Spatula needles, **e** Taper-point needle, **f** Tapercut needle. (Reprinted from Steinert RF. *Cataract Surgery, Techniques, Complications, and Management*, 2nd Edition, p 52. ©2004, with permission from Elsevier)

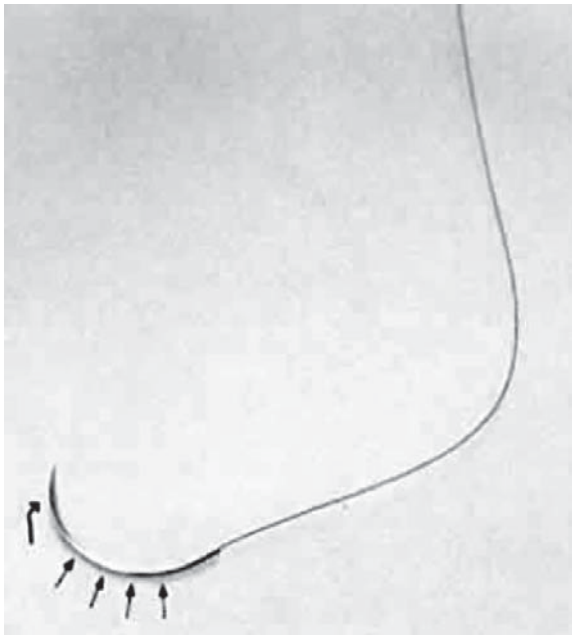
## 2.4

### Sutures

In the history of general surgery, many materials have been used as sutures, including horsehair, linen, silver wire, and twine. Early improvements in suture technology included the development of catgut and silk



**Fig. 2.3** Standard cutting needle (dotted outline) and PC prime needle (solid outline). (Reprinted from Steinert RE. *Cataract Surgery, Techniques, Complications, and Management*, 2nd Edition, p 53. ©2004, with permission from Elsevier)



**Fig. 2.4** Suture and needle used for ophthalmic microsurgery. The head of the needle (curved arrow) determines the tract through which the suture passes. The handle or shaft (straight arrows) is the area by which the needle is held. The most posterior aspect of the suture is the area of the swage. Grasping the needle in this area can result in loosening of the suture

sutures [18, 19]. Refinements continued, including sterilization of silk sutures and treatment of catgut with chromic and carbolic acids to increase the duration of the suture holding strength in tissue from a few days to weeks [21]. Synthetic materials such as nylon and polyester became available in the 1940s. More recently, additional synthetic materials such as polyglycolic acid, polybutester, polyglactin, and polydioxanone have been used to make suture.

Suture material is classified either as adsorbable or nonabsorbable. Absorbable suture is defined as suture that loses most of its tensile strength within 2 months. The time it takes for a suture to be degraded in tissue varies by type of material. Absorbable sutures include polyglactin (Vicryl), collagen, gut, chromic gut, and polyglycolic acid (Dexon) materials. Polyglactin (Vicryl) has a duration of about 2 to 3 weeks. Although it has a high tensile strength, this tensile strength decreases as the suture mass is absorbed. Polyglactin is available in braided or monofilament varieties. Collagen suture has a shorter duration and a lower tensile strength than does polyglactin. Gut has duration of approximately 1 week, with an increased amount of tissue reactivity. Because gut is composed of sheep or beef intestines, an allergic reaction is possible. Chromic gut differs from plain gut in that it has a longer duration of action, typically 2 to 3 weeks. It has less tissue reactivity than plain gut.

A nonabsorbable material such as nylon is much more slowly broken down over many months, and polypropylene, and other modern synthetics are much more inert. Nonabsorbable sutures include nylon, polyester (Mersilene), polypropylene (Prolene), silk, and steel materials. Nylon suture has high tensile strength, but loses between 10 and 15% of the tensile strength every year. It is a relatively elastic material and causes minimal tissue inflammation. Both polyester and polypropylene sutures are thought to be permanent, have high tensile strength, and similarly do not cause much tissue reaction. Unlike these sutures, silk has a duration that is less permanent, about 3 to 6 months. Silk is often associated with a greater amount of tissue inflammation as well. The advantage of silk suture, however, lies in the fact that it is very easy to tie and handle, as well as that it is well tolerated by patients in terms of comfort. Finally, steel sutures are used for permanent placement. Their advantages include high tensile strength and inability to act as a nidus for infection. (See Table 2.3 for a summary of commonly used suture materials and their characteristics.)

**Table 2.3** Commonly used surgical sutures and their characteristics

Material	Trade name example	Absorbable (Y/N)	Retains tensile strength	Inflammation	Handles well (+/-)	Comment
Gut	–	Y	4–5 days	+	+	
Chromic gut	–	Y	14–21 days	++	–	Very stiff
Polyglactic acid	Vicryl	Y	14–21 days	+	+/-	Less tensile strength than Dexon
Polyglycolic acid-braided	Dexon	Y	14–21 days	+	–	Maintains strength longer than gut or Vicryl, stiff
Polyglycolic acid-coated	Coated Vicryl	Y	14–21 days	+	+	Better knots and passage than braided
Polydioxanone	PDS	Y	6+ weeks	+/-	–	Minimal inflammation, very stiff
Polytri-methylene carbonate	Maxon	Y	6+ weeks	+/-	+	Stronger than PDS, better knot tying than Vicryl
Nylon	Ethilon	N	90% strength at 1 year	–	+/-	Occasional inflammatory response, inherent memory requires additional knot throws for security
Silk: virgin	–	N	3–4 months	+/-	+	Low tensile strength, variable inflammatory responses
Silk: braided	–	N	3–4 months	+/-	+	Less inflammatory than virgin silk
Polypropylene	Prolene	N	Years	–	+/-	Slippery—requires extra throws on knots
Braided polyester	Mersilene, Dacron	N	Years	–	+	Less slippery, equal strength to mono filaments
Coated polyester	Ethibond	N	Years	–	+	Less tissue drag
Polybutester	Novafil	N	Years	–	+	Elasticity accommodates edema of tissues, lasts longer than nylon

References: [5, 7, 8, 11, 13, 16, 17, 23–26, 28, 30, 33, 36, 37, 44–47, 49–51, 55, 56, 62, 65]

## 2.5 Suture Characteristics and Selection

Ideal characteristics for suture material in ophthalmic microsuturing vary depending on the tissue being sutured and the purpose for the suture. The avascular nature of the cornea and sclera presents a unique circumstance for suturing in that the lack of blood flow, and therefore the lack of cellular components required for wound healing, leads to prolonged wound healing times and diminished tissue strength at the incision site [20, 64]. Therefore, a strong and long-lasting suture that does not incite chronic inflammation is re-

quired for suturing cornea or sclera. Nylon (10-0) has become the most commonly used ophthalmic suture for closing limbal and corneal wounds. Nylon biodegrades and loses its tensile strength beginning at 12 to 18 months. When a more permanent suture is needed, as with suturing of the iris or transscleral fixation of an intraocular lens (IOL), 10-0 Prolene is used frequently. Prolene is difficult to work with, somewhat difficult to tie because of its memory, and has been shown to erode through both sclera flaps and conjunctiva. The iris is vascular; however, it typically does not show any healing response, is extremely delicate, and can generate little force or tension on a suture. The optimal suture



for the iris is therefore a material that is inert so as to last indefinitely and cause no intraocular inflammation, but also easily manipulated in the challenging intraocular space. The conjunctiva is very thin and very vascular and may exhibit a too-vigorous healing response, resulting in scar formation that can be both functionally and cosmetically unacceptable. It is therefore useful to use quickly degraded adsorbable suture or inert non absorbable suture for conjunctiva. For example, conjunctiva that is not under tension usually can be closed with a collagen (8-0) suture. However, when the conjunctiva is under tension, an 8-0 Vicryl suture would be more appropriate because of the longer duration of action of the Vicryl suture.

The purpose for which the suture is needed is also an important aspect of suture selection. For example, when closing incisions or lacerations, the purpose of the suture is to maintain tissue apposition and structural integrity until the healing and scarring response of the tissue has restored the tissue to a suitable degree of strength and stability. In ocular suturing, issues of watertightness are often important as well. Alternatively, when securing a device such as an IOL or a scleral buckle, the purpose of the suture is to permanently maintain the device in the desired location with minimum tissue reaction and maximum stability. Suture characteristics such as tensile strength, tissue reaction, handling (ease of knot tying, tendency to kink, pliability, etc.), adsorbability, and size (diameter of suture) are among the considerations when choosing a suture for a given application [17, 38, 39].

## 2.6 New Technology

Ongoing materials research has resulted in new materials and manufacturing processes such as melt spinning of a block copolymer to create a monofilament fiber that is comparable in strength to monofilament suture materials in current clinical use but is less costly to produce [6]. Other new bioabsorbable suture materials include self-reinforced poly-L-lactide (SR-PLLA), which has been found to have longer retention of tensile strength as compared with polyglyconate and polydioxanone in vitro [31] and lactide-epsilon-caprolactone copolymer (P[LA/CL]), whose degradation is not affected by changes in pH [58].

Recent advances in suture technology include coating of polyglactin sutures with both bioactive glass and antibacterials. Polyglactin suture with bioactive glass coating has been shown to develop bonelike hydroxyapatite crystal formation around the suture when immersed in simulated body fluid [10, 12]. The hydroxyapatite layer can become part of a 3-D scaffold for further tissue engineering applications [10, 12, 52]. Silver im-

pregnation of the bioactive glass coating can impart antibacterial properties to the suture as can coating of the suture with triclosan [10, 54]. Recent investigations of silk fiber, which is far more inert than previously believed [41], have revealed that it, too, has potential for tissue engineering by addition of growth or adhesion factors to silk's multitude of different side chains [4].

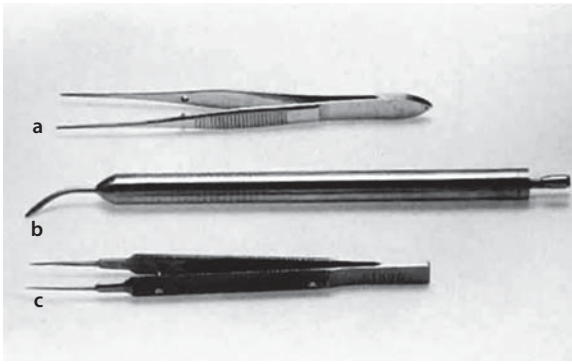
## 2.7 Suture Size

An integral aspect of suturing is knot construction. The suture material, suture gauge, and tying style all influence the ultimate size, strength, and stability of a knot. In ophthalmic microsuturing, it is desirable to minimize knot size while maximizing knot strength and stability. Large knots on the ocular surface are irritating to the patient and can cause inflammatory reactions [63]. Large knots are also difficult to bury and may distort incisions or adjacent tissues, resulting in induction of astigmatism or other adverse effects. It has been shown that suture gauge more greatly influences final knot size than the number of throws does. For example, adding two additional single throws to a suture knot of a given gauge increases knot mass by a factor of 1.5, whereas doubling the suture gauge increases knot volume by a factor of 4 to 6 [63].

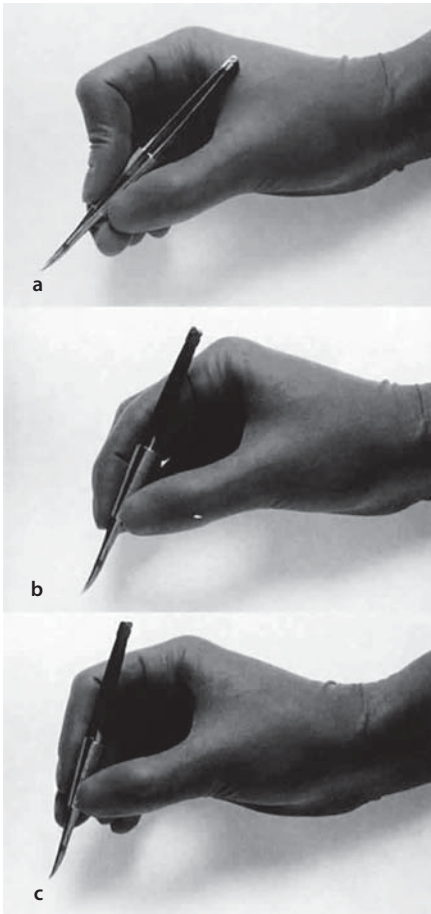
## 2.8 Instruments

Microsurgery requires fine control of instruments with minimal tendency for instrument slippage. Some microsurgical instruments have a serrated flat handle, others have a rounded knurled handle, and still others have a round serrated handle (Fig. 2.5). The serrated or knurled areas allow a firmer grasp and tighter control of the surgical instrument. An instrument with a round, knurled handle may be rotated in the fingertips, allowing greater flexibility during some procedures while maintaining a firm grasp with little tendency to slip.

No surgical instruments should be grasped like a pencil, resting in the crotch between the thumb and forefinger (Fig. 2.6). In ophthalmic microsurgery, longer instruments are rested against the first metacarpophalangeal joint, with the thumb and first two fingers encircling the handle. Stability is achieved by resting the side of the fifth finger on the periorbital facial structures. This method of holding surgical instruments allows rotation of the instrument between the fingertips, by flexing the fingers or by rotating the wrist. Great mobility is necessary when using a needle holder (needle driver) to pass a needle through tissue. When the surgeon en-



**Fig. 2.5** Three surgical instruments with three handle styles. **a** Flat serrated handle. **b** Round serrated handle. **c** Round knurled handle



**Fig. 2.6** **a** Surgical instrument held like a pencil, resting in the croch between the thumb and forefinger. No surgical instruments should be held in this manner. **b** Longer surgical instrument held resting against the first metacarpophalangeal joint of the first finger, with the thumb and the first finger encircling the handle. This position allows rotation of the instrument between the fingertips and flexion of the fingers or wrist. **c** The surgical instrument is held between the thumb and fingertips of the second and third digits. It is not resting on the first metacarpophalangeal joint. This position allows for a perpendicular positioning of the instrument on the eye

counters resistance from the tissue, it is usually necessary for the surgeon to twist the wrist or apply counter pressure on the tissue at the exit site of the needle.

Holding surgical instruments correctly provides the surgeon with increased flexibility and mobility. The serrations on the handle, regardless of style, allow the surgeon to hold the instrument lightly but firmly. With the level of precision of currently available instruments, it is never necessary to grasp an instrument tightly. The tendency to grasp instruments tightly must be avoided because it decreases flexibility and increases fatigue of the hand and forearm muscles.

The instruments required for microsuturing vary depending on the specific surgical circumstances. In general, suturing requires the use of a needle holder, tissue forceps, and suture scissors. Suture-tying forceps are often helpful as well, but may not be necessary if the tissue forceps have a tying platform.

## 2.9

### Needle Holders

Needle holders vary in size, shape, and mechanism. When suturing under the microscope, very small sutures and needles are employed, and therefore, a correspondingly small needle holder should be used. If the needle holder is too large in relation to the needle, the jaws of the needle holder may deform the needle in its grasp, or the needle may be difficult to grasp and pass through tissue.

A non-locking needle holder should be used when suturing under the microscope so that the locking and unlocking action does not cause uncontrolled movement of the needle holder tip, which is undesirable in the microscopic field.

The jaws of the needle holder should be flat on the inner surface rather than toothed or grooved so that the delicate shafts of the small needles are not inadvertently deformed or twisted when grasped. Needle holder tips may or may not be tapered and can be straight or curved. However, tapered and curved jaws facilitate grasping of suture ends if the needle holder is used for tying (Fig. 2.7).

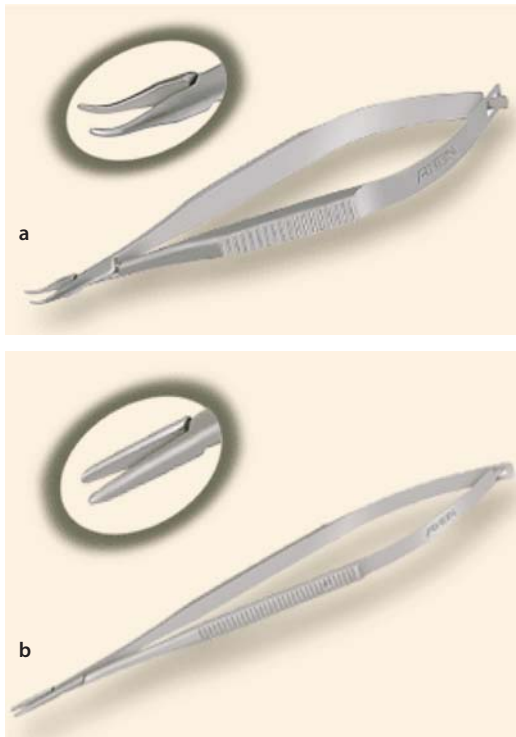
When grasping a needle with a needle holder, the needle should be gripped approximately one third of the way forward from the swage end. One should avoid gripping the needle close to the swage end because the suture can be inadvertently detached from the needle swage. Additionally, the cross section of any needle is round in the area of the swage, and the flat jaws of the needle holder will not be able to stably grip the needle—allowing for uncontrolled rotation of the needle during passage through the tissue. A firm but gentle grip of the needle well forward of the swage will allow for optimal control.



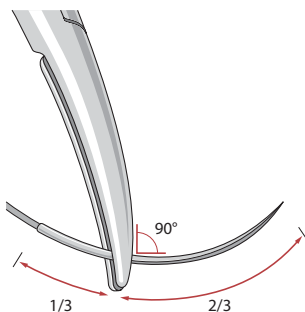
The needle itself should be held in the jaws of the needle holder perpendicular to the long axis of the needle holder and approximately one third to one half of the way back between the tips and the jaws of the needle holder (Fig. 2.8). Curved needle holders should be used with jaws curving upward.

## 2.10 Tissue Forceps

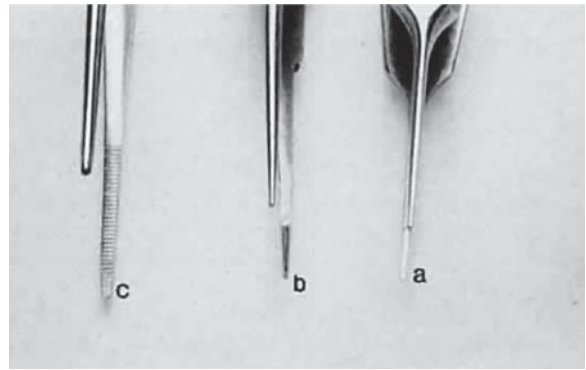
Before using forceps to grasp tissue, the surgeon must have a clear understanding of the mechanism by which the instrument holds tissue and the extent of damage caused by the instrument. In ophthalmic suturing, two different instruments are used to grasp tissue, smooth and toothed forceps.



**Fig. 2.7** Nonlocking needle holders. **a** Curved (Rhein). **b** Straight (Rhein)



**Fig. 2.8** Needle holder is shown grasping a surgical needle approximately two thirds of the way from the head of the needle to the suture. The needle is seated properly in the needle holder at a 90° angle



**Fig. 2.9** Three different smooth forceps. On the right are absolutely smooth forceps (a). In the middle are grooved forceps (b). On the left is an instrument with a serrated platform (c). The instrument on the right is used to grasp fine suture, whereas the instrument on the left is more commonly used to handle conjunctiva or thin tissue that can conform to the ridges of the serration

Smooth forceps (i. e., forceps without teeth) should be used when handling delicate tissues (Fig. 2.9). For example, smooth forceps are necessary when working with tissue that must not be punctured or damaged, such as the conjunctiva during a trabeculectomy. Serration of the grasping surface provides increased friction without damaging the tissue. It is effective in handling the conjunctiva because the conjunctival surface can conform to the ridges of the serration. Crisscross serrations permit traction in all directions, resulting in minimal tissue slippage.

Tissue forceps for ocular microsutures must be small at the tips, have teeth for a firm hold, and have a tying platform proximal to the toothed ends for handling of suture. There are multiple variations on the shape of the handles, length of the forceps, and configuration of the tips. All small-toothed forceps with tying platforms can be used for both tissue fixation and suture manipulation during suturing and tying.

Toothed forceps can have teeth at a 90° angle (surgical forceps) or angled teeth (mouse-tooth forceps, see Fig. 2.10). An example of a surgical toothed forceps is 0.12-mm forceps; an example of a forceps with angled teeth is the O'Brien forceps. Microscopic examination of the instrument from the side determines tooth design. Toothed forceps are needed for tough tissue, such as the cornea or sclera, whereas soft tissues, such as the iris or conjunctiva, are better handled with smooth forceps (see Fig. 2.10). Surgical toothed forceps damage delicate tissue. However, these forceps exert a high degree of resistance, which is necessary for manipulating tougher tissues. Forceps with angled teeth seize tissue lying in front of the end of the blades. This forceps grasps a minimal amount of tissue and produces minimal surface deformation, frequently without penetrating the tissue. The angle-tooth forceps can be useful

for grasping the cornea during suture placement. If the teeth are dull or bent, the forceps are ineffective.

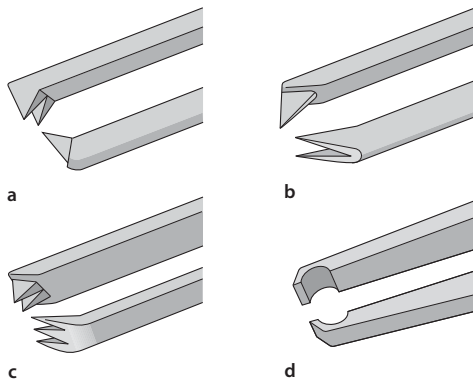
The number and orientation of the teeth on a forceps affect the stability of fixation and tissue damage. Teeth angled at  $90^\circ$  provide good fixation, but greater tissue damage than teeth angled at  $45^\circ$  (mouse-tooth forceps). Increasing the number of teeth also increases the degree of tissue fixation. One example is the Thorpe corneal fixation forceps, in which the  $90^\circ$  teeth are in a  $2 \times 3$  configuration. The Thorpe corneal fixation forceps have been modified with  $45^\circ$ -angled, 0.12-mm teeth in a  $2 \times 3$  configuration, thus allowing for increased stability of tissue fixation, with limited tissue damage. When driving or passing a needle through tissue that is fixed with toothed forceps, the forceps should be held such that the needle enters the tissue on the side of the forceps with the greatest number of teeth. In other words, when Thorpe corneal fixation forceps are used, the needle should pass through the tissue on the edge that is secured by three teeth. This maneuver limits the twisting of the tissue as the needle

is advanced through the tissue. Finally, an alternative is the Pierse-type forceps, which have no teeth but have a small hollow area immediately posterior to the tip. This hollow area allows for tissue displacement instead of the tearing of tissue that occurs with sharp-toothed forceps. A widely used microsuturing tissue forceps are the 0.12-mm Castroviejo toothed forceps (Fig. 2.11). If one attempts to use a serrated forceps on rigid material, such as the sclera, only the tips of the serration will hold the tissue, reducing the contact area and the effectiveness of the forceps. Therefore, toothed forceps must be used to grasp the sclera effectively (Fig. 2.12).


Toothed grasping forceps should never be used to directly handle a needle, because the fine teeth of the forceps may be damaged by the steel needle. The forceps may be used to indirectly handle the needle by grasping the suture near the needle swage. Additionally, toothed grasping forceps should be used with care when handling suture—if the suture is grasped with the teeth rather than by the tying platform, the suture can be inadvertently cut.

## 2.11 Tying Forceps

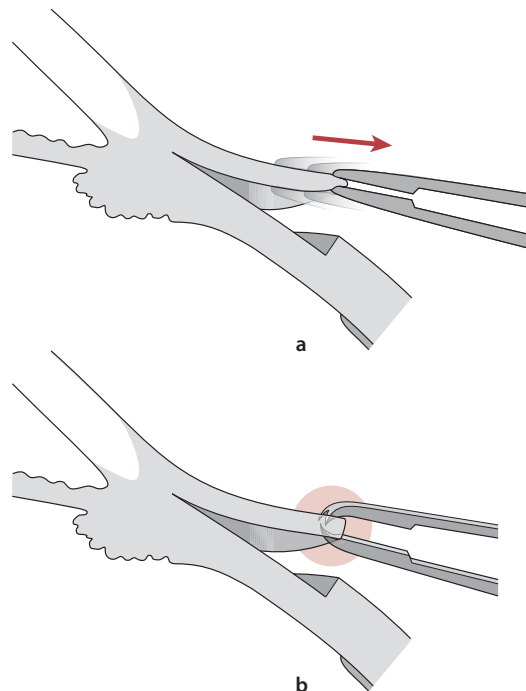
In contrast to tissue forceps, tying forceps should have no teeth and have smooth tips (no ridges or serrations) that are thin and tapered. The forceps tips should close



**Fig. 2.10** Tooth forceps may be identified by the angle of insertion of the teeth. **a** Forceps with teeth at a  $90^\circ$  angle. **b** Mouse-tooth forceps with angled teeth. **c** Thorpe corneal fixation forceps with  $45^\circ$  angled, 0.12-mm teeth in a  $2 \times 3$  configuration. **d** Pierse-type forceps with no teeth but with a small hollow area immediately posterior to the tip



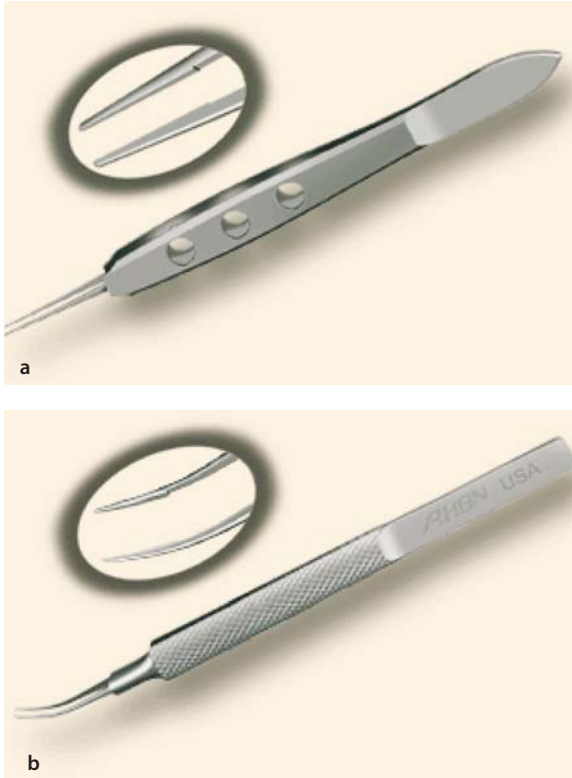
**Fig. 2.11** **a** Castroviejo 0.12-mm tissue forceps (Asico). **b** Detail of grasping toothed tips (Asico)



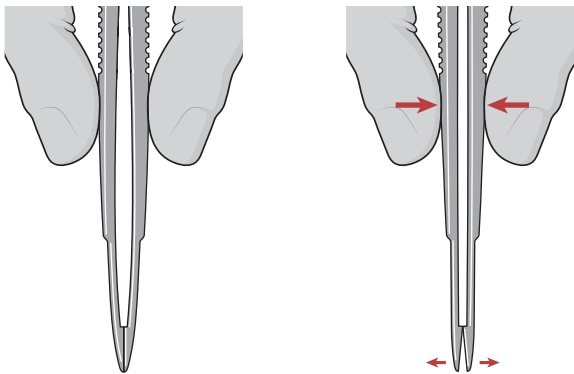
**Fig. 2.12** When smooth forceps are used to grasp rigid sclera, the forceps slip. **b** Toothed forceps are more effective to grasp rigid tissue such as the sclera or cornea

very precisely in order to securely but gently grasp small-gauge (e. g., 10-0) suture material (Fig. 2.13). The tips may be curved, angled, or straight, and the handle may be of varying length and shape.

Tying forceps are used for suture tying, suture rotation, and various other handling of suture. Overcompression of the forceps will cause the tips to gape (Fig. 2.14). When rotating sutures, it is critical to use only tying forceps with smooth jaws, because any forceps with teeth will likely cut the newly placed suture. Be-



**Fig. 2.13** Tying forceps (Rhein). **a** Jaffee straight tying forceps. **b** Tenant curved tying forceps (Rhein)



**Fig. 2.14** When a proper degree of force is applied to the instrument, the tips will align properly. However, if greater forces are applied, the instrument bends and the jaws do not appose correctly

cause of their delicate tips and smooth jaws, tying forceps are ineffective for handling ocular tissues and should not be used in place of toothed tissue forceps.

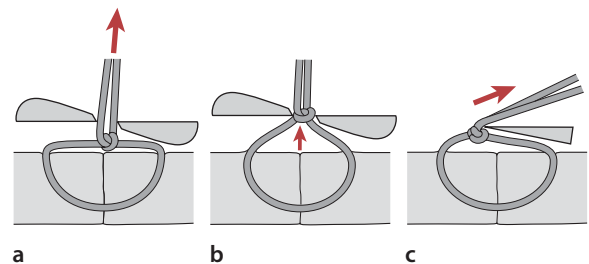
## 2.12 Scissors

Scissors for microsuturing should be of the squeeze-handle style rather than the larger, ring-handle style. The spring mechanism of the squeeze-handle scissors allows for much greater control of the scissor tips when cutting suture under the microscope. Scissor tips may be sharp or rounded. Smaller size tips are more easily used for trimming small gauge suture knots.

Scissors with curved tips should be used with the tips curving upward to facilitate visualization of suture knots and other surrounding material that the surgeon wishes to leave intact. The ends of the suture should be cut short, and the knot should be buried in the tissue to avoid excessive irritation and an increase in vascularization (Fig. 2.15).

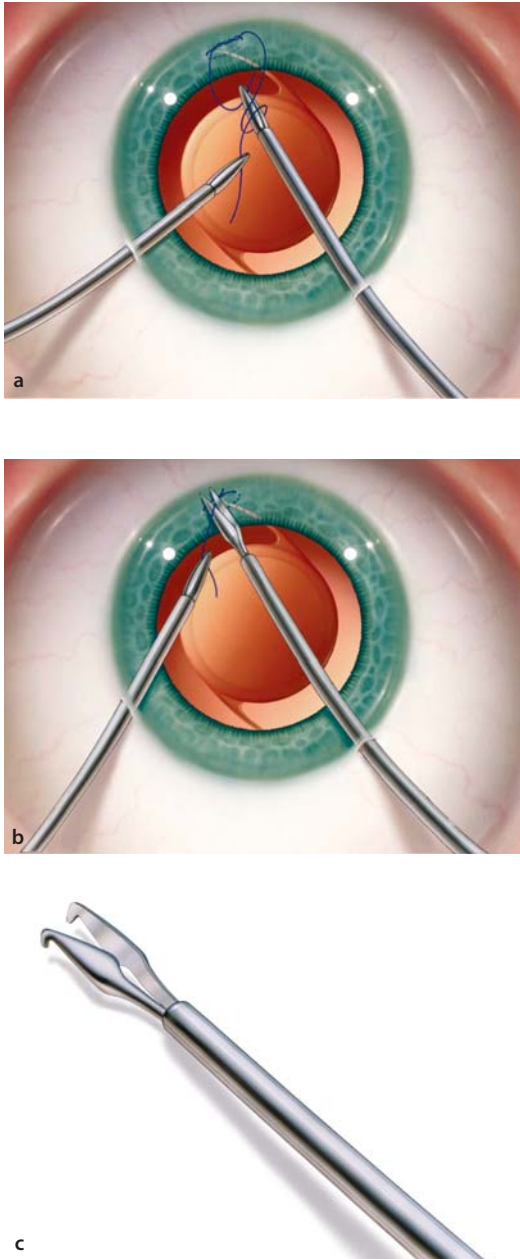
## 2.13 New Technology

With recent adoption by some surgeons of microincision (<2 mm) anterior chamber surgery, there are now available intraocular microsuturing instruments including tying forceps, tissue grasping forceps, and scissors that facilitate suturing of the iris, IOLs, and various other intraocular tissues and devices entirely within the eye (Fig. 2.16). Many of these instruments can be passed through a 2.0-mm paracentesis incision, which allows the surgeon to maintain a very stable anterior chamber while working entirely inside the eye. Multiple 1.0-mm paracenteses can be made around



**Fig. 2.15** **a** To cut the suture ends, the suture ends should be pulled up from the tissue plane, allowing the assistant to view the knot, but leaving the knot on the tissue plane. **b** If the knot is inadvertently pulled up from the tissue plane, it is more likely that the suture will be cut on the knot. **c** If the suture ends are cut with a single blade, it is best to apply tension to the thread that is being cut so that the knot is pulled up against the cutting edge of the blade. The blade should be held stationary so that the knot can be visualized

the periphery of the clear cornea to facilitate access to 360° of the anterior chamber, with use of multiple instruments and both hands. As microincision techniques continue to gain popularity with both surgeons and patients, it will become increasingly relevant for ophthalmic surgeons to incorporate the use of these effective new microinstruments into their surgical repertoire.



**Fig. 2.16** Intraocular suturing instruments (MicroSurgical Technology). **a** Tying a suture inside the anterior chamber with two tying forceps. **b** Cutting a suture inside the anterior chamber with tying forceps and scissors. **c** Detail of grasping force tip

## References

1. Abidin MR, Towler MA et al (1989) A new quantitative measurement for surgical needle ductility. *Ann Emerg Med*, 18(1):64–68
2. Abidin MR, Towler MA et al (1989) Biomechanics of curved surgical needle bending. *J Biomed Mater Res*, 23(A1 Suppl):129–143
3. Ahn LC, Towler MA et al (1992) Biomechanical performance of laser-drilled and channel taper point needles. *J Emerg Med*, 10:601–606
4. Altman GH, Diaz F et al (2003) Silk-based biomaterials. *Biomaterials*, 24(3):401–416
5. Aronson SB, Moore TE Jr (1969) Suture reaction in the rabbit cornea. *Arch Ophthalmol*, 82(4):531–536
6. Baimark Y, Molloy R et al (2005) Synthesis, characterization and melt spinning of a block copolymer of L-lactide and epsilon-caprolactone for potential use as an absorbable monofilament surgical suture. *J Mater Sci Mater Med*, 16(8):699–707
7. Balyeat HD, Davis RM et al (1988) Nylon suture toxicity after cataract surgery. *Ophthalmology*, 95(11):1509–1514
8. Bennett RG (1988) Selection of wound closure materials. *J Am Acad Dermatol*, 18(4 Pt 1):619–637
9. Bernstein G (1985) Needle basics. *J Dermatol Surg Oncol*, 11:1177–1178
10. Blaker JJ, Nazhat SN et al (2004) Development and characterization of silver-doped bioactive glass coated sutures for tissue engineering and wound healing applications. *Biomaterials*, 25(7–8):1319–1329
11. Blomstedt B, Jacobsson SI (1977) Experiences with polyglactin 910 (Vicryl) in general surgery. *Acta Chir Scand*, 143(5):259–63
12. Boccaccini AR, Stamboulis AG et al (2003) Composite surgical sutures with bioactive glass coating. *J Biomed Mater Res B Appl Biomater*, 67(1):618–26
13. Craig PH, Williams JA, Davis KW (1975) A biologic comparison of polyglactin 910 and polyglycolic acid synthetic absorbable sutures. *Surg Gynecol Obstet*, 141(1):1–10
14. Edlich RF, Towler MA et al (1990) Scientific basis for selecting surgical needles and needle holders for wound closure. *Clin Plast Surg*, 17:583–602
15. Edlich RF, Zimmer CA et al (1991) A new compound-curved needle for microvascular surgery. *Ann Plast Surg*, 27(4):339–344
16. Ethicon (1985) Wound closure manual. Ethicon, Somerville New Jersey, pp 1–101
17. Forrester JC (1972) Suture materials and their use. *Br J Hosp Med*, 578–592
18. Gibson T (1990) Evolution of catgut ligatures: the endeavours and success of Joseph Lister and William Macewen. *Br J Surg* 77:824–825
19. Goldenberg I (1959) Catgut, silk, and silver—the story of surgical sutures. *Surgery* 46:908–912
20. Gosset AR, Dohlman CH (1968) The tensile strength of corneal wounds. *Arch Ophthalmol*, 79:595–602
21. Halsted W (1913) Ligature and suture material. *JAMA*, 60:1119–1126
22. Herrmann JB (1971) Tensile strength and knot security of surgical suture materials. *Am Surg*, 37(4):209–217
23. Hartman LA (1977) Intradermal sutures in facial lacerations. Comparative study of clear monofilament nylon and polyglycolic acid. *Arch Otolaryngol*, 103(9):542–5433
24. Herrmann JB, Kelly RJ (1970) Polyglycolic acid sutures. Laboratory and clinical evaluation of a new absorbable suture material. *Arch Surg*, 100(4):486–490
25. Holmlund DE (1974) Knot properties of surgical suture materials. A model study. *Acta Chir Scand*, 140(5):355–62



26. Jongebloed WL, Figueras MJ (1986) Mechanical and biochemical effects of man-made fibres and metals in the human eye, a SEM-study. *Doc Ophthalmol*, 61(3-4):303-312
27. Katz LJ, Costa VP et al (1996) Filtration surgery. In: *The glaucomas, part three glaucoma therapy*. Mosby-Yearbook, Saint Louis, pp 1661-1702
28. Katz AR, Mukherjee DP et al (1985) A new synthetic monofilament absorbable suture made from polytrimethylene carbonate. *Surg Gynecol Obstet*, 161(3):213-222
29. Kaulbach HC, Towler MA et al (1990) A beveled, conventional cutting edge surgical needle: a new innovation in wound closure. *J Emerg Med*, 8:253-63
30. Macht SD, Krizek TJ (1978) Sutures and suturing—current concepts. *J Oral Surg*, 36(9):710-712
31. Makela P, Pohjonen T et al (2002) Strength retention properties of self-reinforced poly-L-lactide (SR-PLLA) sutures compared with polyglyconate (Maxon) and polydioxanone (PDS) sutures. An in vitro study. *Biomaterials*, 23(12):2587-2592
32. Masseria V (1981) Heat treating. In: *Metals handbook*, vol 4, edn. 9. American Society for Metals, Metals Park, Ohio, pp 621-649
33. McClellan KA, Billson FA (1991) Long-term comparison of Novafil and nylon in corneoscleral sections. *Ophthalmic Surg*, 22(2):74-77
34. McClelland WA, Towler MA et al (1990) Biomechanical performance of cardiovascular needles. *Am Surg*, 56:632-8
35. Minahan PR (1914) Eyeless needle, US Patent Office, No. 1,106,667, Aug 11
36. Morgan MN (1969) New synthetic absorbable suture material. *Br Med J*, 2(652):308-313
37. Moy RL, Kaufman AJ (1991) Clinical comparison of polyglactin acid (Vicryl) and polytrimethylene carbonate (Maxon) suture material. *J Dermatol Surg Oncol*, 17(8):667-9
38. Moy RL, Lee A et al (1991) Commonly used suture materials in skin surgery. *Am Fam Physician*, 44(6):2123-2128
39. Moy RL, Waldman B et al (1992) A review of sutures and suturing techniques. *J Dermatol Surg Oncol*, 18(9):785-795
40. Okamura AM, Simone C et al (2004) Force modeling for needle insertion into soft tissue. *IEEE Trans Biomed Eng*, 51(10):1707-1716
41. Panilaitis B, Altman GH et al (2003) Macrophage responses to silk. *Biomaterials*, 24(18):3079-3085
42. Polack FM, *Microsurgical instrumentation and sutures*. In: (1977) *Corneal transplantation*. Grune & Stratton, New York
43. Polack FM, Sanchez J, Eve FR (1974) Microsurgical sutures. I. Evaluation of various types of needles and sutures for anterior segment surgery. *Can J Ophthalmol*, 9:42-47
44. Postlethwait RW (1970) Long-term comparative study of nonabsorbable sutures. *Ann Surg*, 171(6):892-8
45. Postlethwait RW (1970) Polyglycolic acid surgical suture. *Arch Surg*, 101(4):489-494
46. Postlethwait RW, Willigan DA et al (1975) Human tissue reaction to sutures. *Ann Surg*, 181(2):144-150
47. Ray JA, Doddi N et al (1981) Polydioxanone (PDS), a novel monofilament synthetic absorbable suture. *Surg Gynecol Obstet*, 153(4):497-507
48. Rizutti AB (1968) Clinical evaluation of suture material and needles in surgery of the cornea and lens. *Ethicon*, Somerville, N.J.
49. Rodeheaver GT, Nesbit WS et al (1986) Novafil. A dynamic suture for wound closure. *Ann Surg*, 204(2):193-199
50. Schechter RJ (1990) Nylon suture toxicity after vitrectomy surgery. *Ann Ophthalmol*, 22(9):352-353
51. Soong HK, Kenyon KR (1984) Adverse reactions to virgin silk sutures in cataract surgery. *Ophthalmology*, 91(5):479-483
52. Stamboulis A, Hench LL et al (2002) Mechanical properties of biodegradable polymer sutures coated with bioactive glass. *J Mater Sci Mater Med*, 13(9):843-848
53. Steinert R, (2004) *Cataract surgery*. Saunders, Philadelphia, p 52
54. Storch M, Scalzo H et al (2002) Physical and functional comparison of Coated VICRYL\* Plus Antibacterial Suture (coated polyglactin 910 suture with triclosan) with Coated VICRYL\* Suture (coated polyglactin 910 suture). *Surg Infect (Larchmt)*, 3 Suppl 1:S65-77
55. Stroumstos D (1978) *Perspectives on sutures*. Davis and Geck, Pearl River, New York, pp 1-90
56. Swanson N, Tromovitch T (1982) Suture materials, 1980s: properties, uses, and abuses. *Int J Dermatol*, 21:373-378
57. Thacker JG, Rodeheaver GT et al (1989) Surgical needle sharpness. *Am J Surg*, 157:334-339
58. Tomihata K, Suzuki M et al (2001) The pH dependence of monofilament sutures on hydrolytic degradation. *J Biomed Mater Res*, 58(5):511-518
59. Towler MA, McGregor W et al (1988) Influence of cutting edge configuration on surgical needle penetration forces. *J Emerg Med*, 6:475-81
60. Towler MA, Tribble CG et al (1993) Biomechanical performance of new vascular sutures and needles for use in polytetrafluoroethylene grafts. *J Appl Biomater*, 4(1):87-95
61. Trier WC (1979) Considerations in the choice of surgical needles. *Surg Gynecol Obstet*, 149:84-94
62. *United States Pharmacopeia*, edn. 20 (1980) Washington, D.C.
63. van Rijssel EJC, Brand R et al (1989) Tissue reaction and surgical knots: the effect of suture size, knot configuration, and knot volume. *Obstet Gynecol*, 74:64-68
64. Yanoff M, Fine BS (1982) Surgical and non-surgical trauma. In: *Ocular pathology*. Harper and Row, Philadelphia, pp 132-138
65. Yu GV, Cavaliere R (1983) Suture materials: properties and uses. *J Am Podiatry Assoc*, 73(2):57-64

# Knot-Tying Principles and Techniques

# 3

Anthony J. Johnson and R. Doyle Stulting

## Key Points:

- The suture should be tied so that the position of the wound edges is apposed in the normal anatomic position.
- The first knotting loop, called the approximation loop, performs the actual suturing function: It apposes and fixes the wound edges in the desired position. All additional loops serve only to secure the approximating loop.
- Attention to surgical technique is very important; the position of the approximation loop is the direct result of the placement of each bite of the suture.
- Square knots and slipknots can both be tied from the same initial loop arrangement. The direction of traction on the suture arms may be the only factor that determines which knot is created.
- There is no substitute for good quality instrumentation and suture.

## 3.1 Introduction

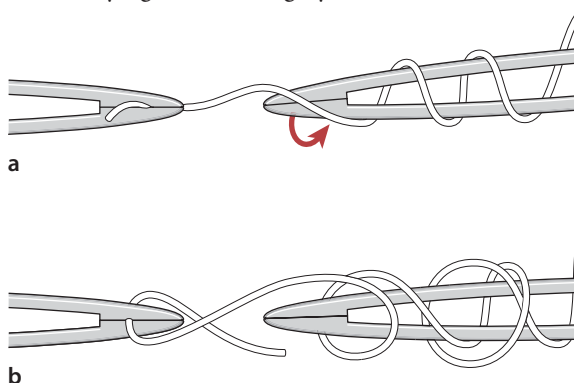
The tying of knots has played an important role in the everyday life of people since the earliest days of recorded history and rose to an art form within the 15th and 16th century sailing community, where complicated knots were explained under a pledge of secrecy. In modern medicine, the proper application of the appropriately placed knot is as much a science as it is an art form, which must be painstakingly mastered by all surgeons.

The correct application of a tying technique in ocular surgery can make complicated procedures easier, facilitate wound healing, and minimize scar formation. Conversely, failure to use the proper technique can result in knot failure, with potentially devastating results. Wounds may leak, leading to endophthalmitis and loss of vision. Massive bleeding may occur when the suture loop around a vessel prematurely unties. Throughout the scientific literature, one can find many

different tying techniques for specific surgical applications. Presented here are a few microsurgical knot tying techniques that can be applied to a variety of situations, and should be a part of the armamentarium of any ophthalmic surgeon.

## 3.2 Principles of Knot Tying

Basic microsurgical knot tying requires manipulation of sutures with tying forceps under the operating microscope. Proper handling of the forceps is essential to successful knot tying. The tip of the tying platform should be used to pick up the suture. If the suture material cannot be grasped, the tying platform should be inspected for incomplete closure because of damage to the platform or incarceration of foreign matter. Over-compression or tight squeezing of the handle may cause the tying platform to gape. If the suture is loaded into the tying forceps longitudinally so that the suture becomes an extension of the forceps, it is easier to wrap the suture around the second instrument to secure the tissue (Fig. 3.1). Mastery of handling the suture material within the tying forceps is a crucial step to successful knot tying in microsurgery.



**Fig. 3.1** **a** Suture is loaded into tying forceps longitudinally on the top so that the suture becomes an extension of the forceps. This positioning increases the ease with which the surgeon wraps the suture around the tying platform. **b** The suture is loaded obliquely in the tying platform. This placement frequently makes wrapping the suture around another tying forceps more difficult, and with less control

When a suture is tied, the wound edges should be apposed. Ideally, the globe should be pressurized. Various different knots may be used to accomplish this goal. The friction produced by the suture itself may determine which type of knot is used to secure the suture. Rough threads make poor slipknots. Smooth sutures, such as nylon, are easily tied into slipknots (see Chap. 2). The basic principles of ophthalmic microsurgical knot tying include:

1. The suture should be tied so that the wound edges are properly approximated.
2. The first knotting loop, called the approximation loop, performs the actual suturing function: It apposes and fixes the wound edges in the desired position. All additional loops serve only to secure the approximating loop.
3. The securing loops should be tightened at right angles to the suture plane so that they will not affect the established suture tension.
4. The approximation loop should not be tied too tightly, as this will contribute to tissue distortion or strangulation.
5. Extra throws do not add strength to a properly tied knot and only contribute to its bulk. A bulky knot can be difficult to bury.
6. The holding strength of a knot depends largely on the friction created within the tightened loops (hence, the quality of the suture material plays an important role in knot construction):
  - a. Rough suture material favors square knots because of their high friction.
  - b. Smooth suture materials favor slipknots because the approximating loop tends to loosen before the approximation loop is tied.
7. Attention to knot-tying technique is very important. Square knots and slipknots can be tied from the same initial loop arrangement. Only the direction of traction on the knots will determine which knot is created (Fig. 3.2).
8. Care must be taken to avoid damage to the suture material when handling it. Avoid excessive manipulation of the suture with surgical instruments. Excessive handling or twisting of the suture within the instrument may contribute to premature suture failure.
9. Knots left on tissue surfaces are a source of irritation, thus knots must be as small as possible, and if the material is sufficiently tissue compatible, they should be buried within the tissue.

Although there are thousands of knots that can be used to secure wounds, only a few fulfill the requirement of being practical, strong, and reliable. The most commonly used knots are discussed below.

### 3.3

#### Square Knot (Reef) versus Granny Knot

The square knot is the primary knot used by most surgeons. It is strong and sturdy, without the tendency to jam or slip, and should not be confused with its close relative, the granny knot. Although the differences between them are subtle, the misapplication of the square knot can result in a granny knot, so attention to detail is important in performing this knot.

#### 3.3.1

##### Surgical Technique

The square knot is performed in a similar fashion to shoe tying: a right-over-left wrap, followed by a left-over-right wrap. For instrument ties, the square knot is easily accomplished if the surgeon ensures that the tying forceps stay inside the loop being created (Fig. 3.9). The approximating loop is tied in its definitive position with the appropriate amount of tension. To obtain additional friction, two or three throws can be added to the approximating loop (see Sect. 3.5). After the approximating loop is completed, the suture should lie flat across the wound surface, held in place by the suture friction, with enough tension to just bring the wound edges together (Fig. 3.3).

The second loop is thrown in the opposite direction, keeping the needle driver between the suture ends (Figs. 3.4 and 3.5). The securing loop is tightened at right angles to the suture plane to avoid affecting the established tension of the approximating loop.

The final securing loop is again thrown in the original direction, and tightened at right angles to the suture plane (Fig. 3.6).

The granny knot is mistakenly performed if one completes two identical half knots (i. e., right over left followed by right over left). With instrument ties a granny knot will be created, if the initial suture is performed with the needle driver between the suture ends (Figs. 3.7 and 3.8) and the subsequent throw the needle drive is placed external to the suture ends (Fig. 3.9 and 3.10).

#### 3.3.2

##### Complications

Improper tying of this knot can result in the construction of the granny knot. The granny knot is significantly less stable and is prone to slip under tension. Additionally, placing adjacent square knots next to each other of different tensions can result in inappropriate tissue deformation and can lead to watertight wound failure.

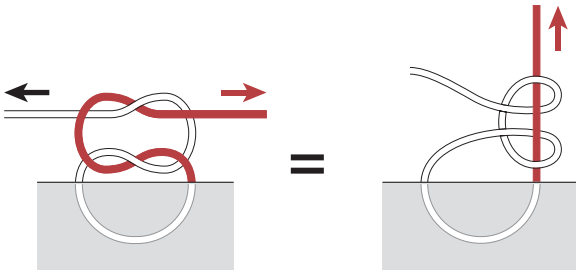


Fig. 3.2

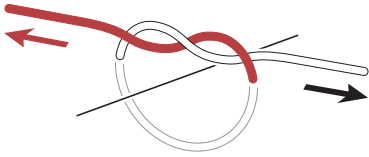


Fig. 3.3

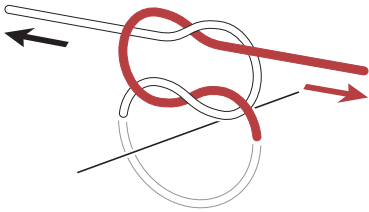


Fig. 3.4

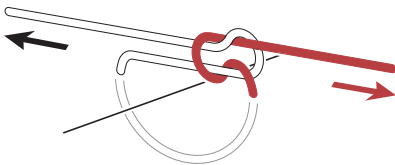


Fig. 3.5

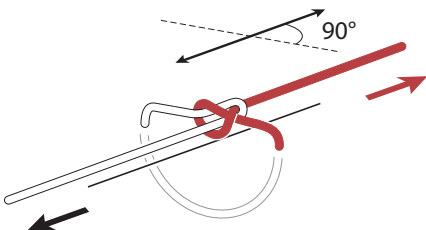


Fig. 3.6

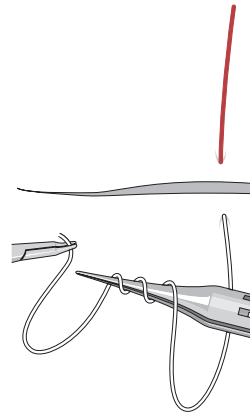


Fig. 3.7

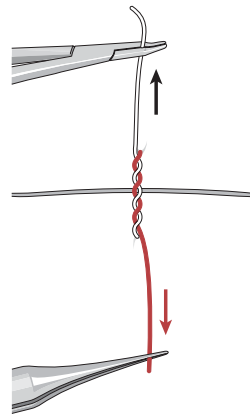


Fig. 3.8

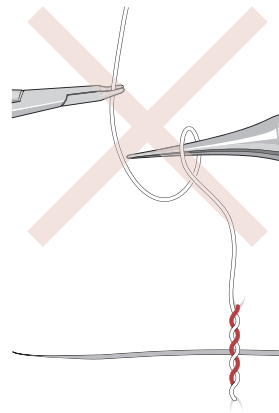


Fig. 3.9

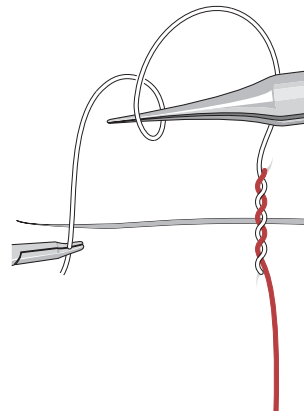


Fig. 3.10



### 3.5

#### Surgeon's or Ligature Knot (3-2-1, 3-1-1)

##### 3.5.1

##### Surgical Indications

This knot is the primary knot of most anterior segment surgeons. It can be used when securing any anterior segment wound and is especially helpful when the corneal wounds are under tension, with the additional approximating loop giving the knot additional friction to reduce slipping prior to the first securing loop placement.

The ligature knot, surgeon's knot or the 3-1-1 knot, is a square knot with an additional half knot placed in the approximating loop. Although the additional half knot adds bulk to the knot, the additional half knot in the approximating loop ensures that the approximating loop will not slip before the first securing loop can be placed.

##### 3.5.2

##### Surgical Technique

The technique of performing the knot is identical to that for the square knot outlined above, with the first approximating loop consisting of three throws. When using elastic suture with a lot of memory (such as Prolene suture), a reinforcing knot with two throws in the second tie (3-2-1) is preferred to keep the knot from reopening (Fig. 3.11).

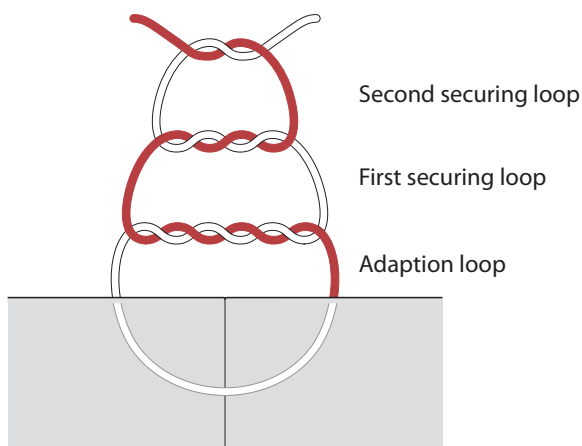


Fig. 3.11

### 3.6

#### Slipknot (1-1, 1-1)

##### 3.6.1

##### Surgical Indications

This knot is most applicable for closure of clear corneal wounds near the visual axis, or wounds in which minimizing tension or induced astigmatism is the primary concern. The adjustable slipknot provides both proprioceptive and visual control of the suture tension. If the suture is too tight, as evidenced by striae in the tissue, the suture can be loosened to obtain the desired tension.

##### 3.6.2

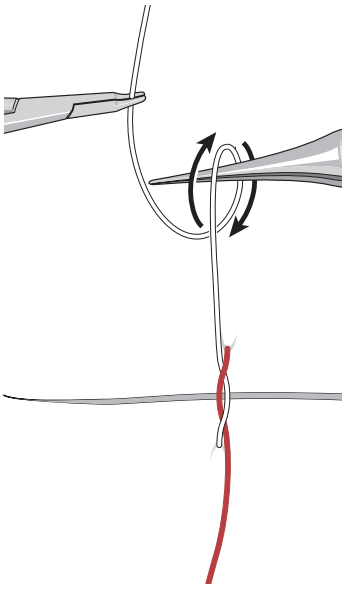
##### Surgical Technique

The first throw, or approximating loop of the adjustable slipknot, is a standard single or double throw. The double throw is somewhat less adjustable, but maintains its initial tension better than does the single throw.

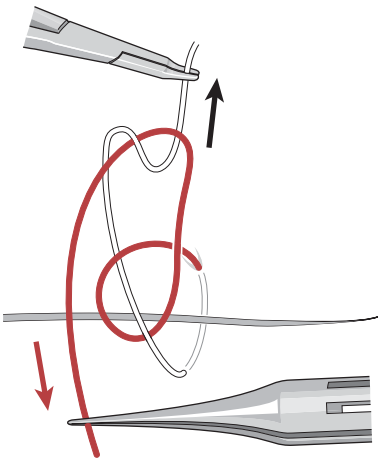
The second throw is wrapped in the same direction to create a granny knot. The tying forceps are placed under the proximal (needle) end of the suture. An overhand wrap is performed (Fig. 3.12). Then, the tying forceps are brought across the wound to grasp the free end of the suture (Fig. 3.13). Once the free end is grasped, the suture is pulled in the same direction as the first throw. The hands do not alternate positions; so, the needle remains on the same side of the wound when both the first and the second throw are secured. The slipknot is now created (Fig. 3.14). The suture is tightened by traction on the opposite ends of the suture. Holding the free end slightly elevated facilitates tightening of the knot.

If loosening of the suture is desired, placing an instrument under the suture loop and elevating it will loosen the loop.

After the desired tension is completed, then one or two single-throw securing loops in the opposite direction are thrown and tightened at right angles to the original wound edge. The securing throws are performed in the fashion of a properly performed square knot, with the tying forceps over the wound between the suture ends.



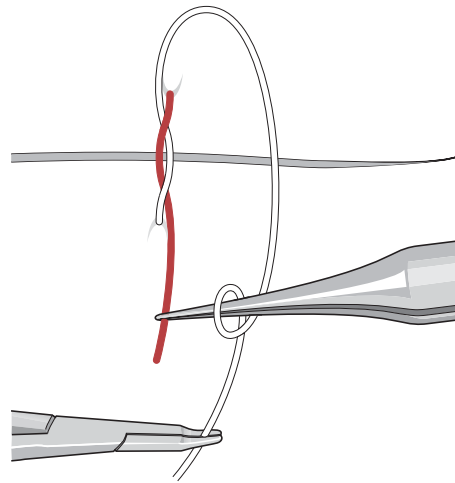
**Fig. 3.12** A granny knot is created by placing forceps external to proximal suture



**Fig. 3.14** The slipknot is created by not alternating hands

### 3.6.3 Complications

Failure to throw the second loop in the same direction as the approximating loop will result in the knot locking prematurely with inadequate tension on the wound, requiring that suture to be removed. Failing to secure the final knot with securing loops could result in this knot slipping or releasing under tension, resulting in poor wound closure.



**Fig. 3.13** The free suture end is grabbed and pulled through the loop

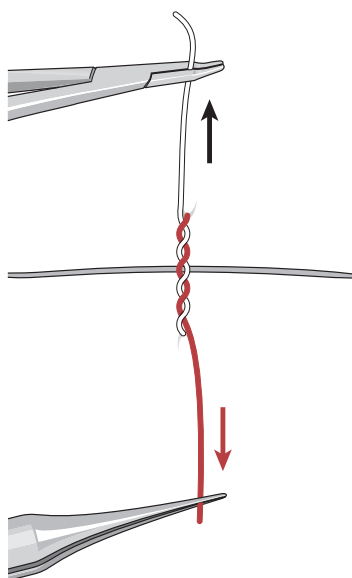
## 3.7 Locking Suture Bite

### 3.7.1 Surgical Indications

An alternative to the adjustable suture, and one of the most useful knot-tying techniques, is the locking bite. This technique is helpful when closing corneal wounds or any wound under tension, and allows the surgeon to ensure the tension on the wound is sufficient to close the wound without committing to tying a knot.

### 3.7.2 Surgical Technique

With this technique, the surgeon makes the three-throw approximating loop, as in the ligature knot described above (Fig. 3.15). The suture is then laid on the wound surface with the appropriate amount of tension, using the friction of the suture to hold the suture in place. With constant tension at the appropriate amount to hold the wound edges in position, the free end of the suture is pulled lightly to the same side of the wound as the proximal suture end while maintaining control of the proximal end with a forceps (Fig. 3.16). This compresses the three approximating loops between the suture and the wound, locking the suture tension in place. If the suture is too tight or too loose, the free end is grasped and brought back to the opposite side of the wound, and the approximating loops are laid down for another try. When the tension is cor-



**Fig. 3.15** Three-throw approximating loop (as in a surgeon's knot)

rect, the knot is completed with two single-throw securing loops in opposite directions, as in a standard square knot. The knot is then buried.

### 3.7.3

#### Complications

Failure to check the wound tension prior to securing this knot will result in a knot that is too tight or too loose, with the potential for excess wound compression, resulting in astigmatism or wound leak. Additionally, if the securing loops are not thrown carefully and the lock slips during suturing, the final knot will be too loose and the suture will have to be replaced.

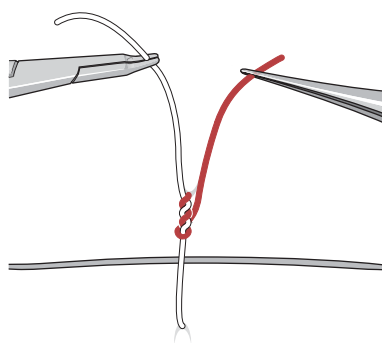
## 3.8

### The Bend (Securing Two Suture Ends)

#### 3.8.1

##### Surgical Indication

The bend is the knot used to splice two suture ends together. Although not often used, it is a very practical knot to learn and is helpful when the running cornea suture prematurely breaks and suture ends need to be spliced together. Although there are many different techniques for performing a bend, two different techniques are illustrated below. The type of suture used and the available amount of suture left to tie with will determine which technique is optimal.



**Fig. 3.16** Suture ends are brought to same side of wound compressing approximating loop and locking it in place

#### 3.8.2

##### Surgical Technique

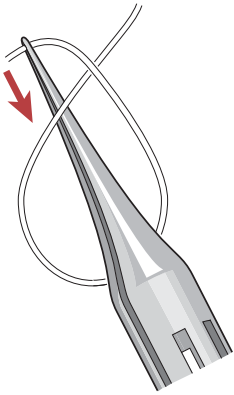
The technique involves tying the broken suture end into a simple loop with the fractured end on the top. The tying forceps are inserted through the loop under the suture, and then the end is grabbed and pulled through the loop (Figs. 3.17 and 3.18)

Using a tying forceps, the new suture is inserted through the loop, the above step is repeated, with the new suture to create two intertwining loops (Fig. 3.19). The free and proximal ends of each suture are pulled together to create the knot.

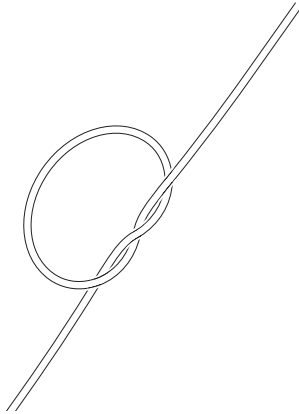
The knot is further secured by tying the two free ends of the new knot together (Fig. 3.20). This results in a nice bend that will allow continued suturing.

After the bend is created, the bend is pulled backward through the surgical wound until the bend exits from the initial wound entry point; the bend is then cut off, so there will be one continuous suture without any bends or splices.

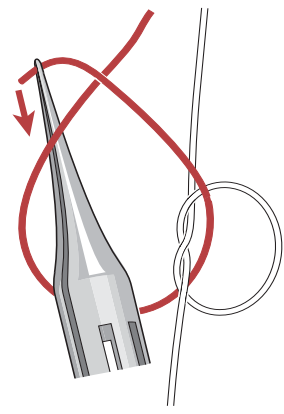
The final technique, also known as a carrick bend or sailor's knot, creates a knot that has a smaller profile and will not slip, and according to Ashley, is the perfect bend. This bend facilitates backing the knot through corneal wounds (i. e., when the continuous running suture breaks and the goal is a running suture with only one knot in the cornea). To perform this bend, a simple underhand loop is placed in the first suture, with the fractured end on the bottom (Fig. 3.21). The second suture is placed under the loop (Fig. 3.22). The suture is then threaded over the nonfractured portion and under the fractured end of the suture. The final step is to weave this suture over the first loop, under itself, and over the first loop. It is then tightened by pulling the new suture ends in the opposite direction of the old suture ends (Fig. 3.23). The free end of each suture is cut short, and the knot can be passed through the wound or buried in the tissue.



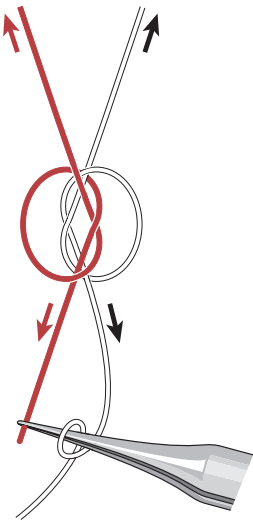
**Fig. 3.17** Forceps are inserted down through the loop to grasp the fractured end of the suture




**Fig. 3.18** The fractured end is pulled through the loop



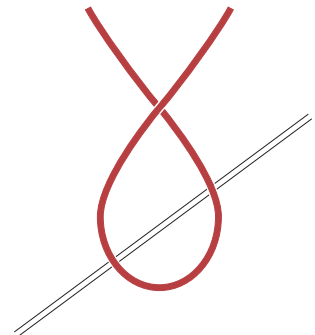
**Fig. 3.19** The new suture is threaded through loop, and the first step is repeated



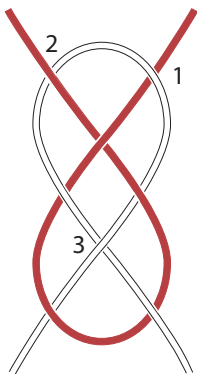
**Fig. 3.20** The ends of both sutures are pulled to tighten, and then a securing knot is thrown



**Fig. 3.21** A simple loop is formed with the fractured portion under the main portion of the suture



**Fig. 3.22** A new suture is placed under the first loop



**Fig. 3.23** The suture is woven over the main suture (1), under the fractured end (2), over the loop and under itself (3), and tightened

### 3.8.3 Complications

An improperly performed bend can result in the sutures detaching prior to completion of the running suture, resulting in the need to reconstruct the bend and decreased operative efficiency. If a cornea wound is completed with two knots, one of which is an improperly performed bend, the suture can slip under tension, and wound dehiscence may occur. An exposed suture can result with secondary infection, an immune reaction, or secondary corneal vascularization.

### **Suggested Reading**

Ashley CW (1944) The Ashley book of knots. Bantam Doubleday, New York  
Dangle ME, Keates RH (1980) The adjustable slip knot—an alternate technique. Ophthalmic Surg 11:843–846  
Eisner G (1980) Eye surgery, an introduction to operative technique, 2nd edn. Springer, Berlin Heidelberg New York

Ethicon Products (1994) Wound closure manual. Ethicon Products, Cincinnati  
Harris DJ Jr, Waring GO III (1992) A granny style slip knot for use in eye surgery. Refract Corneal Surg 8:396–398  
Rabkin SS, Troutman RC (1981) A clinical application of the slip knot tie in corneal surgery. Ophthalmic Surg 12:571–573

# Microsurgical Suturing Techniques: Closure of the Cataract Wound

# 4

Scott A. Uttley and Stephen S. Lane

## Key Points

### Surgical Indications

- The placement of a suture in a cataract wound should be considered if there is any concern about:
  - The integrity of the wound
  - Inadequate wound closure
  - A larger incision
  - Thermal wound burn

### Instrumentation

- Microtipped needle holder
- 0.12-mm forceps
- Vannas-style scissors
- Micro-tying forceps
- 10-0 monofilament nylon suture

### Surgical Technique

- Radial interrupted suture
- X-stitch
- Fine's infinity suture
- Shepherd's horizontal mattress suture
- Running suture
- Shoelace suture

### Complications

- Induced astigmatism
- Wound leak
- Full thickness suture with wound leak

## 4.1 Introduction

Historically, one of the most common microsurgical challenges that the ophthalmologist would face was closure of the cataract wound. Prior to phacoemulsification, most cataract surgeries were performed using an intracapsular or extracapsular technique that would utilize a large limbal incision beneath a conjunctival flap [1]. These long incisions would require multiple and varied suturing techniques to ensure adequate wound closure, and allowed ophthalmic surgeons to become very proficient and adept at their suturing skills. With the advent of phacoemulsification and foldable intraocular lenses, cataract wounds evolved and dramatically decreased in

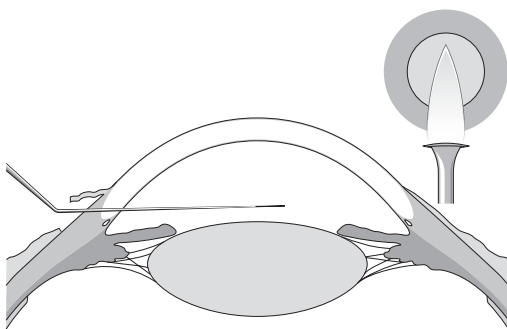
size [1, 2]. Large limbal wounds were first replaced by smaller scleral tunnel incisions, which in turn were replaced by even smaller clear corneal incisions. With each advancement, the role of suture placement in the closure of the cataract wound was greatly diminished. Indeed, with modern cataract extraction, it is now considered routine to see small, self-sealing, clear corneal incisions that do not require any suture placement.

Unfortunately, as the role of suturing has diminished in modern cataract surgery, so have the suturing skills for many ophthalmologists. It is not uncommon to speak with eye surgeons finishing their training who still have difficulty with proper suturing technique despite having performed a large number of cataract extractions. The purpose of this chapter is to review the basic principles involved with closure of the cataract wound, specific suturing techniques that can be utilized to close the cataract wound, and to discuss suturing options when faced with the intraoperative complication of thermal wound burn.

## 4.2 Surgical Indications

### 4.2.1 The Cataract Incision

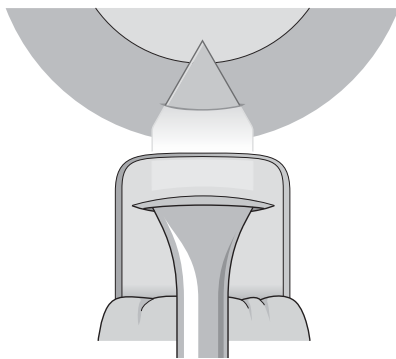
To understand the closure of the cataract wound, one must first familiarize oneself with the different types of cataract incisions that are employed in modern cataract surgery. The cataract wound can be divided into three major categories: limbal, scleral tunnel, and clear corneal [4]. The limbal incision has traditionally been used with an intracapsular or extracapsular cataract extraction. The technique usually involves the creation of a conjunctival flap exposing underlying bare sclera. A uniplanar incision is created using a razor knife at the gray area of the limbus to enter the anterior chamber (Fig. 4.1; [4]). The incision is then enlarged with corneoscleral scissors to the right and left, creating a large incision to facilitate removal of the lens nucleus (Fig 4.2). Although initially described with a uniplanar incision, some surgeons advocate a more shelved mul-



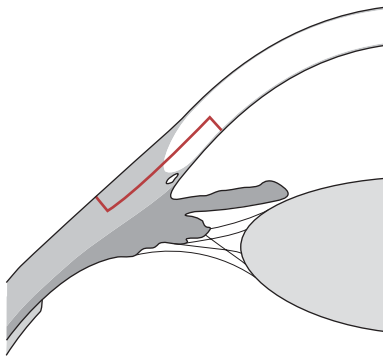
**Fig. 4.1** Limbal cataract incision showing entry into the anterior chamber at the gray line of the limbus using a razor knife



**Fig. 4.2** Limbal extracapsular cataract incision



**Fig. 4.3** Scleral tunnel incision



**Fig. 4.4** Scleral tunnel triplanar incision

tiplanar incision, which can minimize iris prolapse and help to facilitate wound closure [5].

The scleral tunnel incision was created in response to the rapid advancements in phacoemulsification, and offered cataract surgeons the option of a surgical entry site that was more astigmatically neutral and self-sealing [5, 6]. The incision is created under a fornix-based conjunctival flap exposing underlying sclera. A half-depth vertical groove incision is first created posterior to the limbus. Using a crescent blade, the incision is then tunneled forward into clear cornea so that the leading edge of the dissection is just beyond the limbal edge of the dissection. At this point, a paracentesis is created, the anterior chamber filled with a viscoelastic, and a keratome is used to enter the anterior chamber (Fig. 4.3). Using this technique, the scleral tunnel incision has a triplanar configuration that provides for a self-sealing incision up to 6 mm in length (Fig. 4.4; [8]).

The most common incision used in modern phacoemulsification is the clear corneal incision. The clear corneal incision is started immediately anterior to the limbal arcades, and a shelved incision is created until the anterior chamber is entered. The incision can be created in a uniplanar, biplanar, or triplanar incision; the formation is dependent on the creation of an initial groove (Fig. 4.5). The triplanar incision is preferred as it provides a self-sealing capacity with incisions up to 4 mm in length. Another advantage of a clear corneal incision is that it spares conjunctiva in patients with previous glaucoma surgeries or conjunctival disease. Because of the incisions close proximity to the central cornea, the major disadvantage is induced astigmatism, especially if the wound requires suturing [9].

Whereas suturing cataract wounds has been employed since the inception of modern cataract surgery, there remains some question as to when a cataract wound requires suture placement. It is important to remember that with any surgical wound, the primary role of sutures is to facilitate wound healing by holding the edges of a wound in apposition. In cataract surgery, sutures also help to minimize wound leaks and subsequent hypotony, prevent epithelial ingrowth, and help to decrease the risk of endophthalmitis. With this in mind, the placement of a suture in a cataract wound should be considered if there is any concern about the integrity of the wound, inadequate wound closure, a larger incision, or the presence of a thermal wound burn. The simple placement of a suture can help to avoid serious postoperative complications, and if a surgeon suspects a wound may need to be sutured, he or she probably should.



### 4.3 Instrumentation

Closure of a cataract wound requires minimal basic instrumentation including:

1. A fine-tipped microneedle holder appropriate for holding a small needle
2. Small, fine-toothed forceps to stabilize and not macerate the tissue, such as a 0.12-mm forceps
3. A fine monofilament suture with high tensile strength on a spatulated cutting needle
4. Small, sharp scissors to cut the suture, such as a Vannas-style scissors
5. Micro-tying forceps to cut and bury the suture

When properly used, it is possible to tie the suture utilizing the tying platform on the 0.12-mm forceps and the needle holder. The needle holder can also be used to bury the suture knot if the suture is grasped without creating a torque or twisting motion. Using this technique, the need for tying forceps is eliminated. However, it is important to avoid grasping the suture with the teeth of the 0.12-mm forceps, as these can also cause suture breakage.

### 4.4 Surgical Technique

A complete discussion as to proper microsurgical technique goes beyond the scope of this chapter and is covered more fully elsewhere in this volume; however, it does bear repeating that when approaching the suturing of a cataract wound, proper microsurgical techniques must be observed as to ensure a quality surgical outcome. These include [12]:

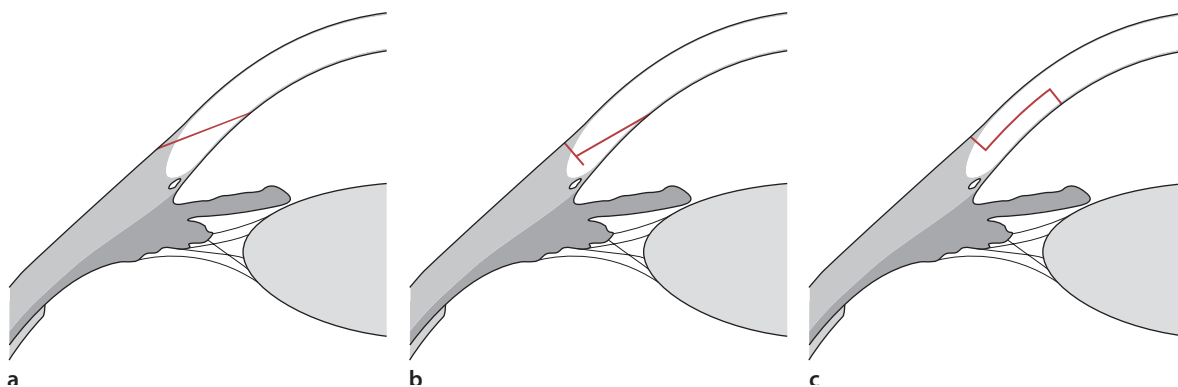
1. Grasping the needle two thirds of the way from the point of the needle
2. Holding the needle at a 90° angle from the needle holder
3. Avoiding excessive tissue manipulation or tissue laceration when placing sutures

When suturing a cataract wound, the major goals are to create a watertight wound and to minimize any astigmatic effect from the placement of the sutures. In order to achieve a watertight incision, one must achieve adequate tissue compression with the suture. This area was described as a “zone of compression,” which was equal to the length between the entry and exit sites of the suture [11, 13]. Long sutures would create a larger area of compression as compared with smaller sutures. Therefore, when closing longer incisions that require multiple sutures, a slight overlap of these compression zones must exist to assure adequate closer (see Chap. 4). In addition, one must be aware that sutures will flatten tissue immediately beneath the suture, but usually steepen the tissue nearer the visual axis [9, 13]. This effect will be more pronounced when the placement of the suture is closer to the visual axis [9, 13]. This is especially problematic when closing clear corneal incisions; large levels of astigmatism may be induced from a tightly placed suture.

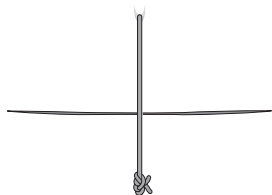
Throughout the evolution of cataract surgery, there have been many described techniques to close the cataract wound. The following examples are not meant to be an all-inclusive summary of the varied suturing techniques, but rather a set of effective methods to allow closure of the majority of cataract wounds. In a simplified form, most suturing techniques are classified into three major categories: interrupted, running, or a combination of the two [14]. All suturing techniques are completed using a standard 3-1-1 surgeon's knot or slipknot with the suture being trimmed flush with the knot using a sharp blade [12].

### 4.5 Interrupted Sutures

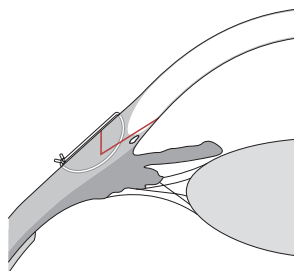
The simplest and most common form of wound closure is achieved with a single interrupted suture. The suture is usually placed in a radial fashion perpendicular to the cataract wound (Fig. 4.6). While allowing for



**Fig. 4.5** Uniplanar (a), biplanar (b), and triplanar (c) clear corneal incisions

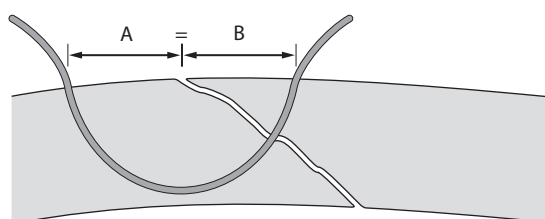


**Fig. 4.6** Single interrupted radial suture

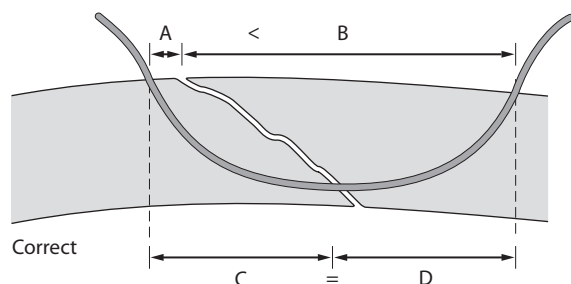
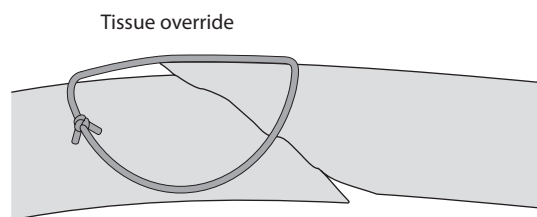


**Fig. 4.7** Proper closure should include the floor of a tunnel incision

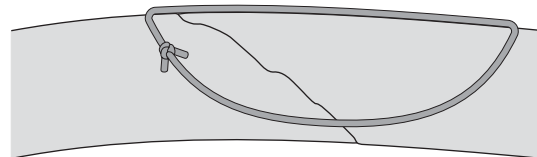
adequate closure of today's small incision cataract wounds, the major disadvantage of this suture is the risk of inducing large amounts of astigmatism given its perpendicular orientation to the wound. When placing an interrupted suture in a tunnel incision, care should be taken to ensure that the floor of the incision is incorporated into the suture pass to help stabilize the wound (Fig. 4.7; [15]). Likewise, it is important not to pass through the full thickness of the tissue, as this could result in a suture track wound leak. Placement of the suture should not distort tissue, but provide enough compression to produce a watertight closure, not tissue override. Tissue override can also be avoided if the suture is placed in a way to evenly distribute the deeper tissues of the cataract wound rather than the superficial layers (Fig. 4.8; [11, 13]). If the surgeon chooses to tie the suture outside of the wound, the knot should



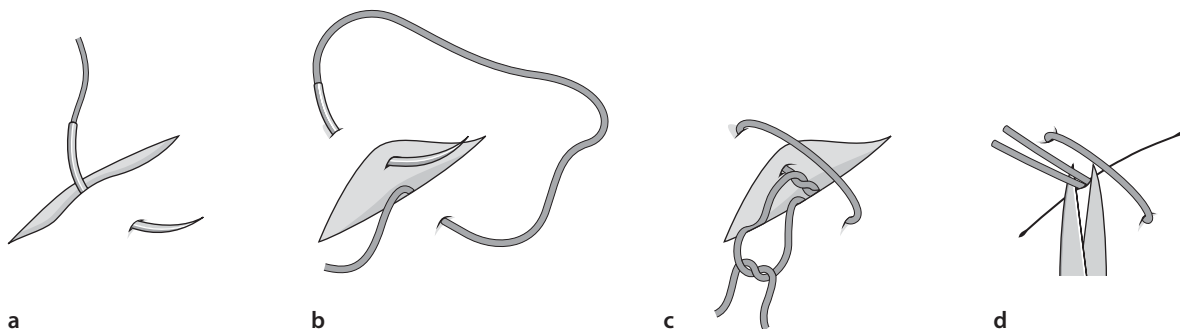
Incorrect



Correct

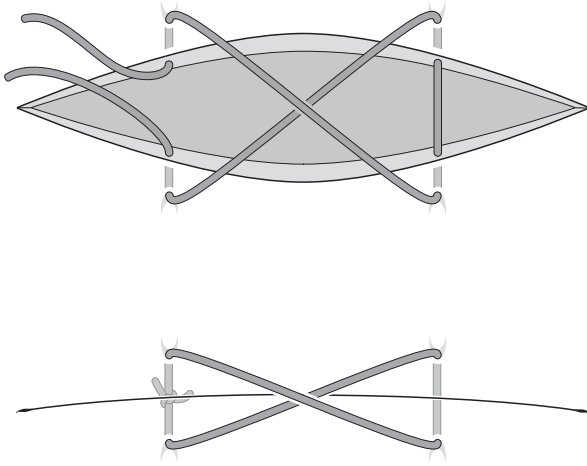


**Fig. 4.8** Even tissue distribution of the deeper layers of a shelved incision results in less tissue override and better wound closure

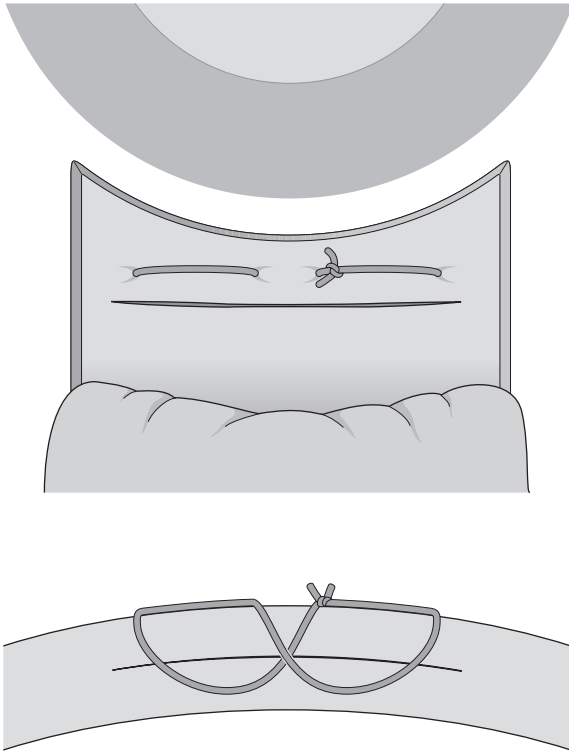


**Fig. 4.9** **a** The suture is initially started with a pass from the cut edge, or the initial pass is placed in the wound. **b** The second pass is from the surface toward the wound. Care must be taken that the passes are of equal depth on both sides of


the wound to avoid tissue override. **c** The ends are tied so that the wound is apposed, and the knot is formed in the wound. **d** The ends are pulled taut, and they are cut short so that the knot falls into the wound and the tissue is apposed



**Fig. 4.10** X-stitch



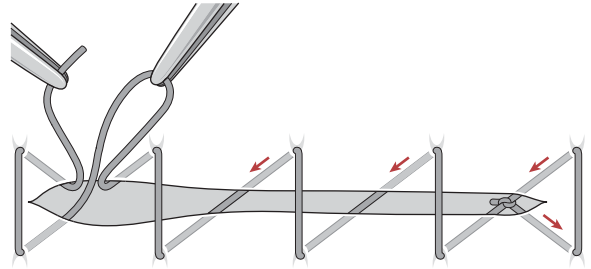
**Fig. 4.11** Infinity suture



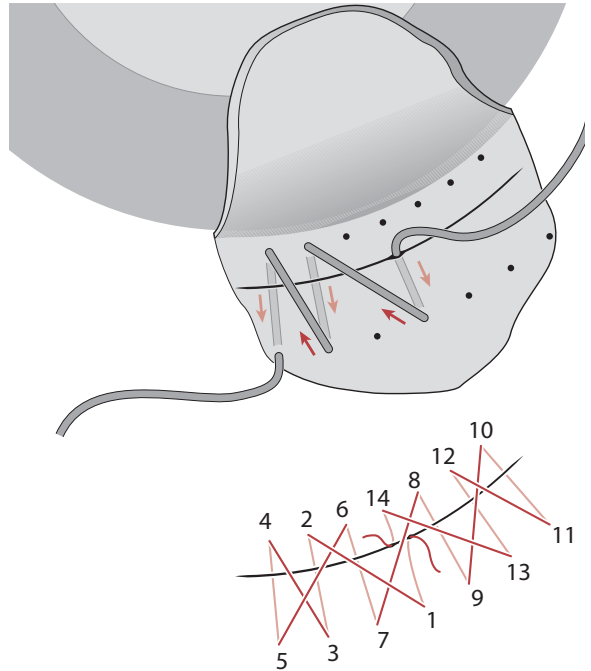
**Fig. 4.12** Horizontal mattress suture

be trimmed and rotated into the underlying tissue; otherwise, the suture can be placed so that the knot can be buried within the wound to help minimize patient discomfort (Fig. 4.9).

Other interrupted types of sutures include the X-stitch, Fine's infinity suture, and Shepherd's horizontal mattress suture [1, 10]. The X-stitch could be considered as an interrupted or mini-running suture with two passes. In using two passes, the radial forces are spread over a larger area, but the risk of induced astigmatism still exists (Fig. 4.10). The infinity suture (Fig. 4.11) and horizontal mattress technique (Fig. 4.12) each use suture placement in a horizontal fashion to provide wound apposition and theoretically less induced astigmatism.



**Fig. 4.13** Simple running suture



**Fig. 4.14** Shoelace suture (numbers indicate suture placement). The first and last pass are within the wound to facilitate burying the knot

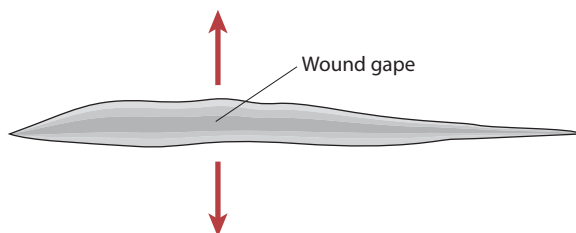
## 4.6 Running Sutures

The running suture is most commonly used with large cataract incisions, as seen in intracapsular or extracapsular cataract extractions. These incisions are rarely seen in phacoemulsification, but there remains the occasional need for the closure of a large cataract wound, and the running suture is ideal for this situation. In most situations the running suture can be placed so as to bury the knot within the cataract wound (Fig. 4.13; [11]).

Perhaps the most complicated suturing technique is the shoelace suture (Fig. 4.14). Intended for use with large cataract incisions, it is a running suture in a cross-stitch pattern. The first pass is made within the wound with each subsequent pass, as illustrated in Fig. 4.14. The final pass exits within the wound to allow the knot to be buried in the wound [14, 15].

One of the most frustrating intraoperative complications that the ophthalmologist can face is thermal wound injury, or wound burn. Thermal wound injury results when excess heat is generated during the phacoemulsification process, causing thermal damage to the surrounding cataract wound and contraction of the adjacent tissues [16]. Several factors have been reported as an etiology of thermal wound injury [3, 16, 17]. The most common is some type of interruption in the delivery of balance salt solution to the anterior chamber. This may occur from an equipment malfunction or a tight wound that causes compression on the outer sleeve of the phacoemulsification hand piece. Other causes can include blockage of the infusion ports with a viscoelastic agent, the delivery of excessive amounts of ultrasound energy during the phacoemulsification process, or the inappropriate use of thermal cautery to the wound edge. Regardless the cause, the result is the same: a gaping cataract wound that is often difficult to appose (Fig. 4.15).

When faced with this challenge, the first inclination of the inexperienced surgeon is to simply place a radial interrupted suture across the incision to appose the anterior and posterior edges of the wound. Unfortunately, because the contraction of tissue, closure of the wound usually requires a great deal of tension to be



**Fig. 4.15** Thermal wound injury resulting in wound gape

placed upon this radial suture, almost guaranteeing an extremely high level of induced astigmatism. Osher has proposed that a horizontal suture be used to appose the anterior edge of the wound to the bed of the wound rather than the posterior edge [18]. By doing so, closure of the wound is achieved without inducing high levels of astigmatism. To the surgeon, this technique may be unsettling, as the internal aspect of the wound is secured, but the posterior or external aspect of the wound may appear to gape at the end of the case. In severe cases of thermal wound injury, a patch graft may need to be used.

Postoperatively, the sutures must be removed unless they are covered by conjunctiva as in a scleral wound. The timing of suture removal is at the discretion of the individual surgeon. However, removal too early can induce the risk of wound dehiscence. In the case of new inflammation of the surrounding tissues or loosening of the suture, removal is not elective. Placement of one drop of povidone iodine or antibiotic solution prior to removal is recommended. Postremoval antibiotic drops may be indicated, depending on the trauma to the tissue created at the time of removal. Removal of a slipknot is easier than a surgeon's knot. After cutting the suture with a needle at the split lamp, the exposed suture end is grasped and pulled from the wound; as always, the knot should not be pulled across the wound to minimize the risk of wound dehiscence, should this occur, immediate resuturing is required.

## 4.7 Complications

The complications most frequently encountered in closure of the cataract wound are wound leakage, induced astigmatism, and rarely, a suture abscess. Each can have significant, devastating results, compromising an otherwise-flawless surgery. A wound leak may be the result of failure to overlap the zones of compression of each suture, nonradial placement, inadvertent full thickness passage of the suture through the cornea, or failure to recognize a thermal injury to the tissue. In each case, removal and replacement of the suture is indicated. In the case of a thermal injury, a horizontal suture may be required. Avoidance of induced astigmatism can be achieved by attention to suture placement initially. However, the induced astigmatism may not be recognized until the postoperative period. In the vast majority of cases, removal of the offending suture will incite regression of the induced astigmatism as the wound relaxes. If the astigmatism persists, correction may require spectacles, contact lenses, or refractive surgery including limbal relaxing incisions or laser reshaping procedures. A suture abscess may be sterile or infectious. In the noninfectious case, the sur-

rounding tissue reaction to the foreign substance (the nylon suture) is the usual cause. Regardless of the etiology, removal of the suture is required. Treatment with topical antibiotics is indicated immediately before and after suture removal. In the case of an abscess formation, culturing of the wound is required, with the intense use of topical antibiotics in the same manner as a corneal ulcer is treated.

Suturing of the cataract wound is much less common in modern phacoemulsification, but is still an important microsurgical skill for the ophthalmologist. While less frequent, there remain definite clinical situations in which suturing of the cataract wound is indicated. Familiarity with the wound, proper microsurgical skills, and knowledge of the different types of suturing techniques will help the ophthalmologist close most types of cataract wounds without difficulty ensuring a quality surgical result.

## References

1. Fine IH (2004) Incision construction. In: Steinart RF (ed) *Cataract surgery: technique, complications & management*. Saunders, Philadelphia
2. Kelman CD (1994) The history and development of phacoemulsification. *Int Ophthalmol Clin* 34:1–12
3. Karp CL (1999) Principles and techniques of cataract surgery phacoemulsification: methodology and complications. In: Albert DM (ed) *Ophthalmic surgery: principles and techniques vol. I*. Blackwell, Malden, Mass.
4. Emery JM, Little JH (1979) *Phacoemulsification and aspiration of cataracts*. Mosby, St. Louis
5. Emery J (1995) Extracapsular cataract surgery. In: Steinart RF (ed) *Cataract surgery: technique, complications & management*. Saunders, Philadelphia
6. Steinert RF et al (1991) Astigmatism after small incision cataract surgery: a prospective, randomized, multicenter comparison of 4- and 6.5-mm incisions. *Ophthalmology* 98:417–424
7. Shepherd JR (1989) Induced astigmatism in small-incision cataract surgery. *J Cataract Refract Surg* 15:85–88
8. Fine HI (1991) Architecture and constructions of a self-sealing incision for cataract surgery. *J Cataract Refract Surg* 17(Suppl):672–676
9. Rowsey JJ (1983) Ten caveats in keratorefractive surgery. *Ophthalmology* 90:148–155
10. Jaffe NS (1997) *Cataract surgery and its complications*, 6th edn. Mosby, St. Louis
11. Eisner G (1990) *Eye surgery*, 2nd edn. Springer, Berlin Heidelberg New York
12. Macsai MS (2002) Principle and basic techniques for ocular microsurgery. In: Tasman W (ed) *Duane's clinical ophthalmology*, vol. 6. Lippincott, Williams and Wilkins, Philadelphia
13. Rowsey JJ (1991) Corneal laceration repair: topographic considerations and suturing techniques. In: Shingleton BJ (ed) *Eye trauma*. Mosby, St. Louis
14. Maloney WF, Grindle L (1991) *Textbook of phacoemulsification*. Lasenda, Fallbrook, Calif.
15. Devine TM, Banko W (1991) *Phacoemulsification surgery*. Pergamon, New York
16. Sipple KC et al (2002) Phacoemulsification and thermal wound injury. *Semin Ophthalmol* 17:102–109
17. Majid MA, Sharma MK, Harding SP (1998) Corneal scleral burn during phacoemulsification surgery. *J Cataract Refract Surg* 24:1413–1415
18. Osher R (1999) Complications during phacoemulsification, part I. Continuing ophthalmic video education. Foundation of the American Academy of Ophthalmology, San Francisco

# Suturing an Intraocular Lens

# 5

Julie H. Tsai and Edward J. Holland

## Key Points

- The most common indication for intraocular lens (IOL) exchange with concurrent penetrating keratoplasty is corneal edema secondary to pseudophakic bullous keratopathy.
- Basic considerations of posterior chamber IOL (PCIOL) placement include anatomical and mechanical advantages over the anterior chamber lenses.
- Newer, small-incision techniques have made peripheral iris fixated IOLs more accessible for the anterior segment surgeon.
- An extensive vitrectomy is required to ensure that there is no vitreous incarceration during IOL fixation.
- Proper implantation of the transscleral-sutured PCIOL reduces lens-iris contact and thus reduces the risk of iris chafe and atrophy, pigment dispersion, iritis, and cystoid macular edema.
- The most common postoperative complication with secondary IOLs is persistent cystoid macular edema.

## 5.1 Introduction

Several alternatives exist for the placement of a secondary intraocular lens (IOL). In the presence of capsular support, a posterior chamber IOL (PCIOL) can be placed in the ciliary sulcus or the capsular bag. However, in the absence of such support, the surgeon must decide whether to place an anterior chamber intraocular lens (ACIOL), an iris clip IOL, an iris-sutured PCIOL, or a transscleral-sutured PCIOL. The new anterior chamber lenses with flexible, open-loop designs can often be placed judiciously in patients with normal anterior angles and iris configurations.

Suture-fixated IOLs offer new options for patients who require secondary IOL placement. As the PCIOL can offer distinct advantages over ACIOLs (Table 5.1), selection of these techniques can be advantageous for the

patient. For instance, peripheral fixation of the IOL to the posterior surface of the iris using polypropylene sutures has been shown to maintain satisfactory results, both anatomically and optically. Transscleral suturing of the IOL haptics into the ciliary sulcus has also been shown to be a viable option. This chapter introduces the basic techniques for fixation of a PCIOL, and the common complications that may arise from these procedures.

## 5.2 Indications

Clinical indications for the implantation of a secondary IOL are listed in Table 2. Several different reasons exist for the implantation of a posterior chamber lens. The most common indication for IOL exchange—with concurrent penetrating keratoplasty—is corneal edema secondary to pseudophakic bullous keratopathy (PBK) [1, 2]. Other etiologies for secondary IOL implantation include aphakic bullous keratopathy, aphakia, and IOL complications. The latter includes malpositioned or dislocated IOLs, uveitis-glaucoma-hyphema (UGH) syndrome, incorrect IOL power calculation, and complications during planned extracapsular cataract extraction [3].

Basic considerations of PCIOL placement include anatomical and mechanical advantages over the anterior chamber lenses. Implantation of the lens in the ciliary sulcus is closer to the natural position of the crystalline lens, which implies this position may offer the advantages of a capsule-stabilized lens. The anatomical location of a PCIOL may be preferable for patients with concurrent ocular conditions such as glaucoma, diabetes, compromised endothelial function, peripheral anterior synechiae, or cystoid macular edema (CME). Furthermore, a posterior chamber lens may provide a barrier against anterior movement of the vitreous and posterior diffusion of vasoactive mediators that may be responsible for such processes as corneal endothelial cell loss, CME, and retinal detachment. Lastly, posterior chamber lenses are associated with lower reported rates of pupillary block, UGH syndrome, and CME, as compared with ACIOLs [4].

It is important to realize that implantation of PCIOLs is not without risk. Intraocular surgery can result



**Table 5.1** Comparison of properties of posterior chamber intraocular lenses (PCIOLs) and anterior chamber intraocular lenses (ACIOLs)

PCIOLs Advantages	Disadvantages	ACIOLs Advantages	Disadvantages
<b>Non-sutured, standard:</b>		<b>Flexible, open-loop:</b>	
<ul style="list-style-type: none"> <li>• Low incidence of CME, UGH, PBK</li> <li>• Less endothelial cell loss</li> <li>• Positioned at nodal point of eye</li> <li>• Mechanical barrier diffusion/movement of vasoactive substances in posterior segment leading to CME/RD</li> <li>• Does not affect TM</li> </ul>	<ul style="list-style-type: none"> <li>• Requires intact posterior capsule and zonules</li> <li>• Increased risk of dislocation</li> </ul>	<ul style="list-style-type: none"> <li>• Easier insertion</li> <li>• Less operating time</li> </ul>	<ul style="list-style-type: none"> <li>• Difficulty with insertion</li> <li>• Iris tuck/ pupillary entrapment</li> <li>• Risk of uveitis, glaucoma, hyphema, CME, PBK</li> <li>• Pupillary block</li> </ul>
<b>Scleral-sutured standard:</b>		<b>Rigid, closed-loop:</b>	
<ul style="list-style-type: none"> <li>• Used with limbal wound or PK</li> <li>• Less pseudophakodonesis</li> <li>• Not dependent on presence of iris</li> <li>• Minimal uveal contact</li> </ul>	<ul style="list-style-type: none"> <li>• Difficulty with insertion (techniques)</li> <li>• Increased operating time</li> <li>• Extensive vitrectomy</li> <li>• Suture-related endophthalmitis</li> <li>• Risk of RD from vitrectomy/manipulation of vitreous base</li> <li>• Risk of hemorrhage from passage through CB</li> <li>• Suture-erosion</li> <li>• Haptic erosion of CB</li> </ul>	<ul style="list-style-type: none"> <li>• Similar to flexible, open loop ACIOL</li> </ul>	<ul style="list-style-type: none"> <li>• Damage to TM</li> <li>• Prolonged inflammation with or without CME</li> <li>• Corneal decompensation</li> </ul>
<b>Iris-sutured:</b>			
<ul style="list-style-type: none"> <li>• Similar advantages of nonsutured PCIOLs</li> </ul>	<ul style="list-style-type: none"> <li>• CME from uveal irritation</li> <li>• Pigment dispersion</li> <li>• Difficult insertion technique</li> <li>• Limited papillary excursion</li> <li>• Requires sufficient iris tissue</li> <li>• pseudophakodonesis</li> </ul>		

CME cystoid macular edema, UGH uveitis-glaucoma-hyphema syndrome, PBK pseudophakic bullous keratopathy, RD retinal detachment, TM trabecular meshwork, PK penetrating keratoplasty, CB ciliary body

in expulsive hemorrhages, one of the most devastating complications of ophthalmic surgery. This risk, which is generally low for small-incision cataract surgery, is reportedly 0.45% for routine penetrating keratoplasty [5]. The additional time and effort in suturing a secondary IOL increases the risk of choroidal hemorrhage, ranging from 0 to 2.2% [6–9]. Increased surgical time and intraocular manipulation, as well as concurrent medical disease (e. g., hypertension, older age, vascular disease, prior ocular surgery) are all factors that can affect the incidence of suprachoroidal hemorrhage.

## 5.3 Surgical Technique

### 5.3.1 Vitrectomy

Both techniques for PCIOL implantation require a generous anterior vitrectomy around the surgical site to prevent vitreous prolapse, vitreous–implant contact, CME, and subsequent tractional tears and detachment of the retina. A careful pars plana approach is recom-

**Table 5.2** Indications for implantation of secondary IOLs or IOL exchange

Corneal Edema
• Pseudophakic bullous keratopathy (ACIOLs, all styles)
• Aphakic bullous keratopathy
Aphakia
• CL intolerance
• Prior ICCE
• Trauma
Complications during planned ECCE
Cystoid macular edema
Decreased endothelial cell counts
Malpositioned IOL (decentered, lens tilt)
UGH syndrome
Pain
IOL power error

CL contact lens, ICCE, intracapsular cataract extraction, ECCE extracapsular cataract extraction

mended for removal of the anterior one third of the vitreous, as anterior vitrectomy through a limbal approach may not completely remove the anterior vitreous, leaving a significant amount which can become incarcerated around the sutured IOL. Identification of vitreous strands may be facilitated with the additional use of an endoscopic light source; failure to illuminate the vitreous will inevitably result in traction, incarceration, or prolapse with serious potential complications [10]. Pars plana vitrectomy may be completed by a modified pars plana approach utilizing only one pars plana port and an anterior infusion and light source. Alternatively, the pars plana vitrectomy may be completed in conjunction with a vitreoretinal surgeon to reduce the risk of vitreous hemorrhage, peripheral retinal tears, and ciliary body detachment.

With the open-sky approach, the vitrectomy can be easily completed through the corneal opening. Initial attention should be directed at prolapsed vitreous at the pupil as well as the vitreous located posterior to the iris. For the transscleral-sutured technique, the anterior vitreous skirt should also be thoroughly cleaned so that passage of the needles through this area is unencumbered.

## 5.4

### Peripheral Iris Suture Fixation

Initially described by Malcolm McCannel, this suture technique was used to stabilize an IOL that had dislocated postoperatively. The basic maneuver that McCannel described involved the use of long needles to pass suture through iris tissue and around the haptics

of the IOL. Today, suture fixation of a PCIOL to the iris offers some distinct advantages over transscleral suturing of a posterior chamber lens. Peripheral iris fixation can be employed in the setting of outpatient phacoemulsification procedures with inadequate capsular support. The use of topical and intracameral anesthetics are often adequate for the procedures, whereas the creation of conjunctival and sclera flaps would require longer-acting anesthetics delivered in a peribulbar or retrobulbar location.

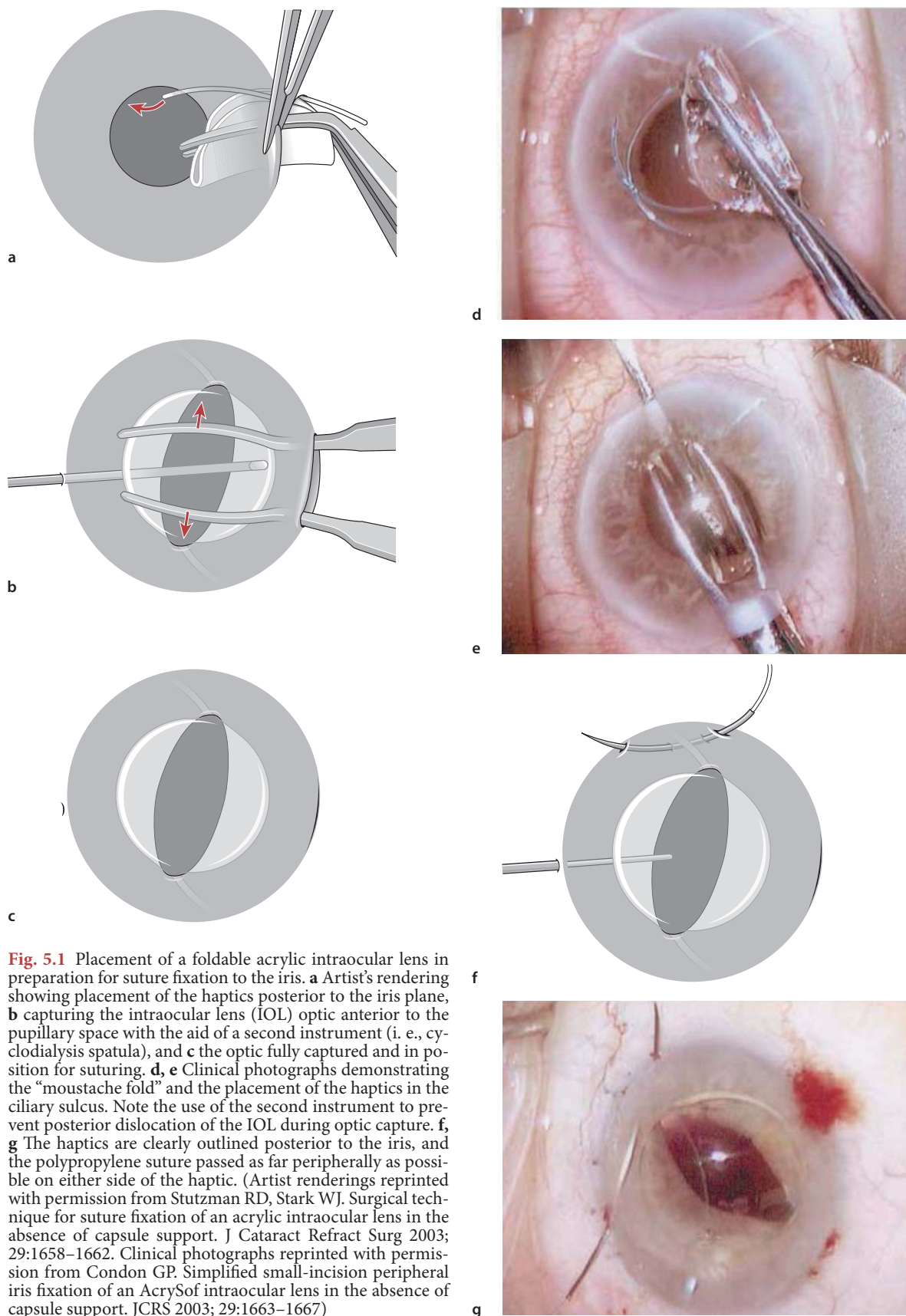
Second, preservation of conjunctiva for future glaucoma procedures can be accomplished by suturing the IOL elements to the iris. The presence of a functional filtering bleb is no longer a deterrent in the preoperative decision-making process. Most importantly, the surgical time required for the procedure can be significantly reduced, thereby reducing the risk of expulsive hemorrhage. The technique is more straightforward with the open-sky approach during penetrating keratoplasty, and much simpler to implement as compared with a limbal approach. Newer, small-incision techniques have made peripheral iris-fixed IOLs more accessible for the anterior segment surgeon.

The disadvantages of iris fixation involve the delicate and vascular nature of the iris itself; thus, some may deem this structure as suboptimal for anchoring a posterior chamber lens. Iris chafing and atrophy from the suture or haptics, pigmentary dispersion, and chronic uveal irritation can lead to uveitis and CME. Pupillary excursion is also restricted and may hinder posterior segment examination.

### 5.4.1

#### Open-Sky Approach

Two different scenarios exist that make this approach useful; both are combined with a penetrating keratoplasty. They include repositioning of a dislocated IOL during penetrating keratoplasty, or insertion of a secondary IOL during penetrating keratoplasty and anchoring the haptics to the iris if there is inadequate posterior capsular support. The initial steps of this technique involve constriction of the pupil once the IOL optic is captured. This ensures that the PCIOL optic can be adequately stabilized anterior to the iris plane. The haptics remain in the posterior chamber. In order to maintain a round, central pupil, the iris suture pass should be kept as short as possible, and as far peripheral as possible. A 10-0 polypropylene (Prolene®) suture on a CTC-6 needle (Ethicon) is passed through the iris tissue, capturing the PCIOL haptic, and then back through the iris. The suture is then tied and cut short. Some surgeons may advocate two-point fixation (one suture on each haptic in the periphery), whereas others advocate four-point fixation, with two sutures on each haptic. Once the PCI-



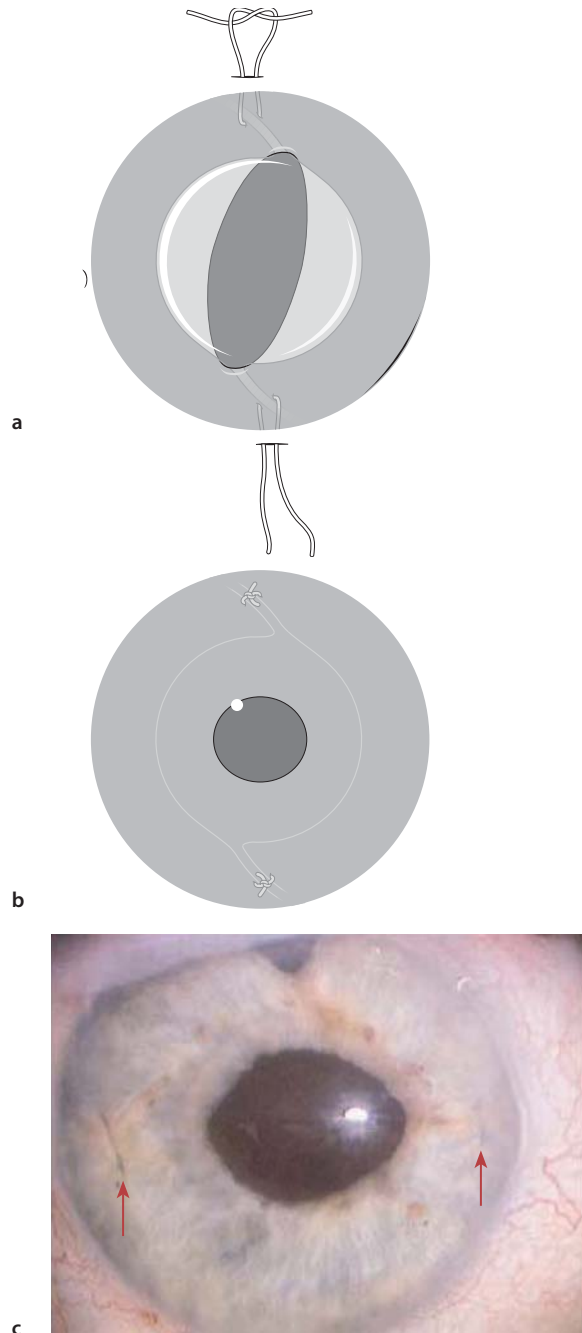
OL haptics are secured, the optic of the IOL is gently prolapsed into the posterior segment. The remainder of the corneal transplant can then proceed as planned.

#### 5.4.2 Limbal Approach

The initial steps of the procedure involve constriction of the pupil preoperatively in order to facilitate pupillary capture of the optic. The small-incision approach makes use of foldable IOL technology. A 3-mm incision is made at the limbus or in clear cornea. The PCIOL is then guided or injected into the anterior segment [11]. The haptics are prolapsed into the ciliary sulcus while the optic of the lens remains above the iris plane (Fig. 5.1). Use of an ophthalmic viscosurgical device (OVD) with a high molecular weight (e. g., Healon 5, Advanced Medical Optics, Santa Ana, Calif.) can facilitate the visualization of the haptics posterior to the iris. A peripheral paracentesis can be created to allow passage of the suture into the anterior chamber. A 10-0 polypropylene (Prolene®) suture on a CTC-6 needle (Ethicon) is passed through the paracentesis and under the haptic, so as close to the periphery as soon as possible and with as short a suture as possible. The needle can then be passed through clear cornea on the opposite side, or a paracentesis can be created at that location and the needle passed through the paracentesis (Fig. 5.1f, g).

Once the suture has been passed beneath the haptic, there are several approaches to tying the knot. The most basic techniques involve tying the suture in the anterior chamber, using the technique developed by McCannel [12]. However, this procedure involves suturing and manipulating the suture within the anterior chamber, thereby risking deformation of the chamber during the procedure. Several other suturing techniques have been developed to facilitate iris suture fixation. Stutzman and Stark [13] illustrate a small-incision suturing technique where the peripheral incision is created at the limbus over the haptic. Once the suture has been passed beneath the haptic, the two ends are pulled out through this incision, and then the suture is tied with two throws to prevent slippage of the suture (Fig. 5.2).

Another method of fixation involves the use of the Siepser technique [14]. Developed by Steven Siepser, the novel approach was initially developed to minimize intraocular manipulation and distortion of uveal tissue. This slipknot technique allows the surgeon to accomplish difficult iris reconstruction via the small-incision surgical technique. For suturing haptics posterior to the iris, the surgeon begins by creating two peripheral paracenteses. The placement of the paracentesis is determined by drawing an imaginary line

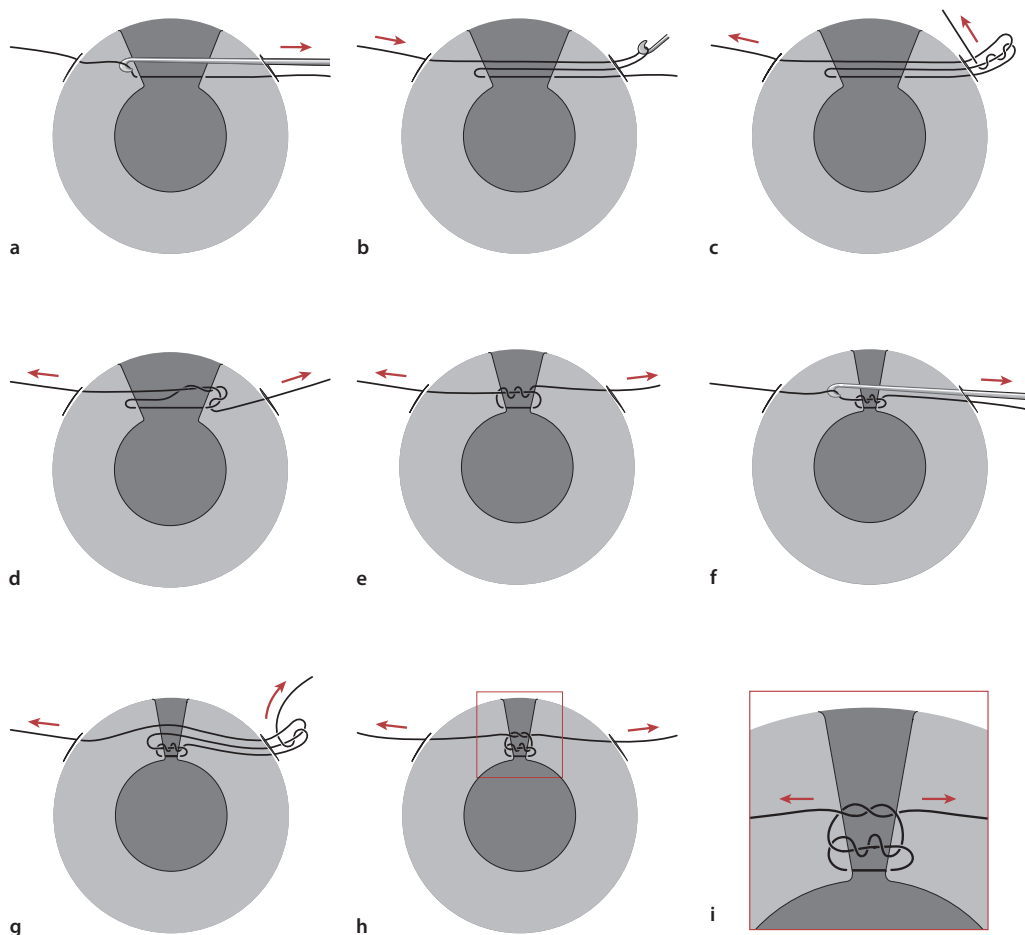


**Fig. 5.2** Suture-fixation of the haptics to the iris. **a, b** The two ends of the suture are then retrieved through a paracentesis created at the limbus overlying the haptic. The suture is then tied and trimmed intraocularly. **c** Postoperative appearance of a sutured posterior chamber lens. Note the blue polypropylene sutures at 3 and 9 o'clock in the midperipheral iris. The pupil is fairly rounded, with minimal distortion. (Artist renderings reprinted with permission from Stutzman RD, Stark WJ. Surgical technique for suture fixation of an acrylic intraocular lens in the absence of capsule support. *J Cataract Refract Surg* 2003; 29:1658–1662. Clinical photographs reprinted with permission from Condon GP. Simplified small-incision peripheral iris fixation of an AcrySof intraocular lens in the absence of capsule support. *JCRS* 2003; 29:1663–1667)

along the suture tract. The stab incisions are then placed at the points where the line crosses the limbus. One paracentesis is created at the entry point, and the other at the exit. The CIF4 needle on a 10-0 polypropylene suture is then introduced into the anterior chamber through the paracentesis. A 25-gauge cannula is introduced into the second paracentesis opening. This cannula not only provides a means of “docking” the needle tip, but also acts as countertraction to help guide the needle through the uveal tissue. The needle is then passed through iris tissue on both sides of the IOL haptic and subsequently, through the second paracentesis. The length of suture within the eye is manipulated to create a large loop, which is drawn out of the anterior chamber through the use of a small hook (e. g., Sinskey hook or Bonds microhook). Care must be taken to make sure that the end of the suture

exiting the eye does not get retracted into the anterior chamber. The end of the suture is grasped with smooth-tipped forceps and tied to the exposed loop. The suture ends are then grasped, and the slipknot cinched gently but securely within the anterior chamber. The steps are then repeated to create a square knot (Fig. 5.3).

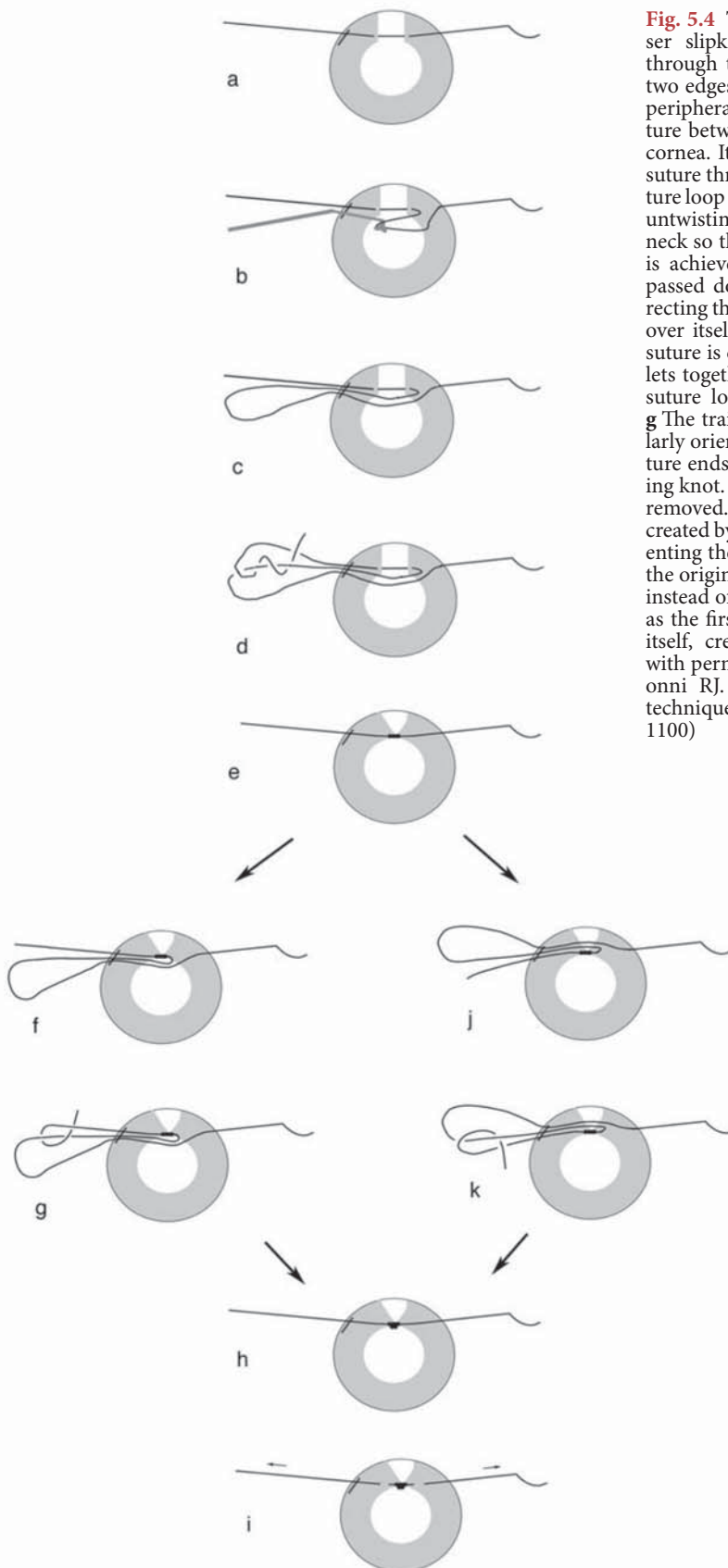
Most recently, a modification to the original Siepser technique was developed [15]. This new approach—developed by Osher, Snyder, and Cionni—involves the use of a locking knot in the Siepser slipknot technique (Fig. 5.4). A beveled stab incision is made just inside the corneolimbal junction. This entry point is determined in a similar fashion to that noted in the aforementioned technique. A 9-0 or 10-0 polypropylene (Prolene®) suture on a long needle (CIF-4 or CTC-6L, Ethicon) is passed through the stab incision, engaging first the proximal side of the iris, and then passing



**Fig. 5.3** The Siepser slipknot technique for suturing in a “closed” chamber. Figure a: Two paracentesis tracks are made in line with the proposed suture tract. The 9.0 Prolene suture is passed through the iris pillars. Figure b: A Bonds hook is introduced through the paracentesis and the distal suture drawn out through the wound. Figure c: A simple double throw slip knot is placed externally. Figure d: Drawn down over the suture site. Figure e: The Bonds hook is rein-

troduced. Figure f: The distal suture, once again, is drawn out of the paracentesis. Figure g: A single throw is then placed externally. Figure h: This is drawn down over the first tie and locks the knot. Figure i: A Grieshaber retinal siccors is then introduced to cut the suture at the knot site. (Reproduced with permission from: Siepser SB. The closed chamber slipping suture technique for iris repair. *Ann Ophthalmol* 1994; 26:71–72)





**Fig. 5.4** The Cincinnati modification of the Siepser slipknot method. The needle is passed through the stab incision, and then through the two edges of the iris leaflet then exiting the distal peripheral cornea. **b** A microhook engages the suture between the distal iris and where it exits the cornea. It is then withdrawn, retrieving a loop of suture through the incision. **c** The externalized suture loop is oriented adjacent to the original strand, untwisting any polypropylene within the incision neck so that the parallel orientation of the sutures is achieved. **d** The trailing end of the suture is passed down through the loop twice, always directing the passes back toward the cornea and then over itself. **e** Each free end of the polypropylene suture is cinched gently, drawing the two iris leaflets together with the initial slipknot. **f** The distal suture loop is again retrieved and externalized. **g** The trailing end is passed up through the similarly oriented loop and under itself. **h** The free suture ends are cinched gently completing the locking knot. **i** The ends of the suture are trimmed and removed. **j** Alternatively, the locking throw can be created by retrieving the distal suture loop, but orienting the loop and strand in the mirror image to the original; in this drawing the loop is now above instead of below. **k** The trailing end is then passed as the first end, down through the loop and over itself, creating the locking throw. (Reproduced with permission from: Osher RH, Snyder ME, Cionni RJ. Modification of the Siepser slip-knot technique. *J Cataract Refract Surg* 2005; 31:1098–1100)



through the distal iris margin. The needle is then directed through the distal peripheral cornea. A loop of suture is retracted through the stab incision and carefully draped over the conjunctiva just to side of the original suture. The first slipknot is created by passing the trailing end down through the loop from above and around the strand that emanates from the iris. Two throws are passed around this adjacent arm of the suture loop. Next, each suture end is grasped, and the slipknot is cinched securely, creating the initial slipknot inside the eye. The difference between the original Siesper technique and the Cincinnati modification is as follows. The knot is locked by duplicating the exact same maneuver by grasping the free end of the suture with a forceps, but this time entering the loop from below, in contrast to the first path. The two ends are grasped and the knot is locked and cinched securely inside the anterior chamber. This modified technique provides a highly satisfactory outcome for suturing in a “closed” anterior chamber, without the possible sequelae associated with extensive intraocular manipulation.

## 5.5 Transscleral Fixation

Fixation of a posterior chamber lens through scleral fixation offers several advantages over iris-sutured lenses. Proper implantation of the PCIOL reduces lens–iris contact and thus reduces the risk of iris chafe and atrophy, pigment dispersion, iritis, and CME [17]. The sutures are also more securely anchored, which eliminates pseudophacodonesis and limitation of pupillary function [6]. However, transscleral-sutured PCIOLs may require much more manipulation and time, and thus increase the risk of intraocular hemorrhage and infection. Also, the technique is more difficult since it often involves blindly placing the sutures through the ciliary sulcus. This may result in the passage of the needle through the iris root or the ciliary body, which can result in significant hemorrhage in the anterior and posterior segment [16]. Finally, late erosion and exposure of the polypropylene sutures through the conjunctiva has been reported [6, 7].

Several different approaches have been described in the literature for placement of transscleral-sutured PCIOLs. Placement of the sutures can vary from a vertical orientation to an oblique orientation. Horizontal placement of the sutures at 3 and 9 o'clock is not advised because of the danger of suturing through the long ciliary arteries and nerves found in these locations.

The aim of transscleral fixation of the PCIOL is to place the haptics of the lens in the ciliary sulcus. Anatomic studies have shown that the ciliary sulcus is

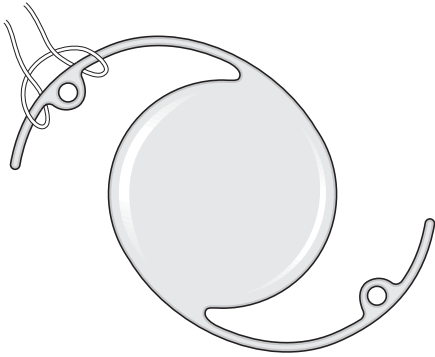0.8–0.9 mm posterior to the limbus in the vertical meridian, and 0.46 mm in the horizontal meridian [16, 17]. Duffey et al. showed that needles passed perpendicularly through the sclera at points 1, 2, and 3 mm posterior to the limbus exited internally at the ciliary sulcus, pars plicata, and the pars plana, respectively. It is important to note that these landmarks were identified by strictly placing the needles perpendicularly to the scleral wall. Tangential or oblique needle passes angled toward the iris plane will pass through the scleral wall, with the internal point far more anterior than expected. The surgeon must take care and anticipate that the external point of entry will need to be more posterior for the needle tip to exit at the level of the ciliary sulcus.

### 5.5.1 Technique

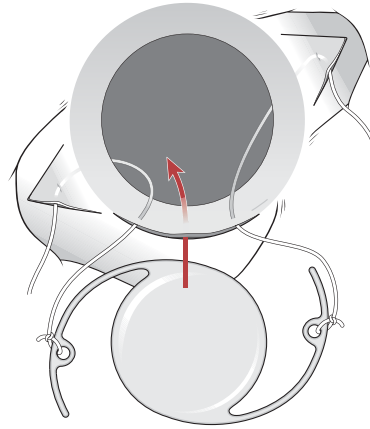
The IOL should have an optic diameter of at least 6.0 mm, and the overall haptic length should be between 12.5 and 13.5 mm such that it will extend and fit into the ciliary sulcus easily. Currently, this involves the implantation of a single-piece polymethylmethacrylate (PMMA) IOL with modified C-shaped haptics with eyelets through which the IOL is fixated. The suture may be passed through the eyelet itself for two point fixation, or a girth hitch (Fig. 5.5) may be used to secure the haptic and provide four-point fixation. A limited conjunctival peritomy is created over the areas where the haptics are secured. A scleral flap can be created at these locations, or the Lewis modification (to avoid the creation of scleral flaps) can be employed.

### 5.5.2 Ab Interno Approach

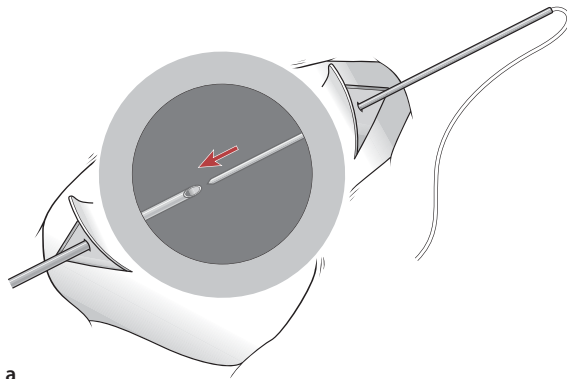
The ab interno (inside to outside) technique is more straightforward and likely faster than the ab externo (outside to outside). It is also more commonly used with an open-sky approach, as in penetrating keratoplasty. A long needle (e. g., CTC-6L, STC-6, or CIF-4; Ethicon) is required for the pass across the anterior chamber. The needles are passed under the iris into the ciliary sulcus. The surgeon can use the indentation of the iris with the needle from behind in order to ensure correct placement in the ciliary sulcus. The technique can be further adapted for use with foldable IOLs and thus take advantage of small, self-sealing incisions [18]. The disadvantage of the approach is the blind pass of the needle under the iris. Poor visualization can often lead to needle passes either too far anterior or posterior to the ciliary sulcus, resulting in intraocular hemorrhage and damage to the peripheral retina.



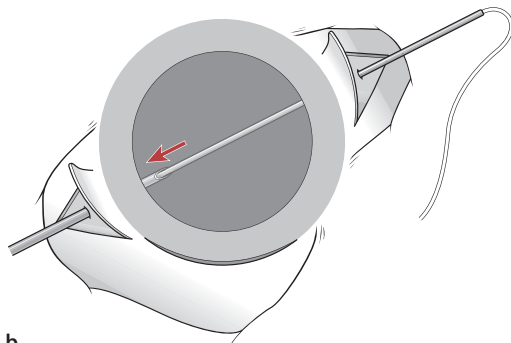
**Fig. 5.5** Girth hitch for fixation of the IOL haptic. (Reproduced with permission from: Steinert RF, Arkin MS. "Secondary Intraocular Lenses" in: *Cataract Surgery: Technique, Complications and Management*, 2nd Edition. Elsevier-Health Sciences Division, New York, 2003)



**Fig. 5.7** Technique for fixation of the suture to the IOL haptic in an ab externo technique employing partial thickness scleral flaps. (Reproduced with permission from: Steinert RF, Arkin MS. "Secondary Intraocular Lenses" in: *Cataract Surgery: Technique, Complications and Management*, 2nd Edition. Elsevier-Health Sciences Division, New York, 2003)

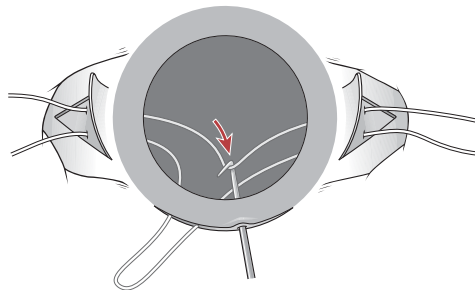
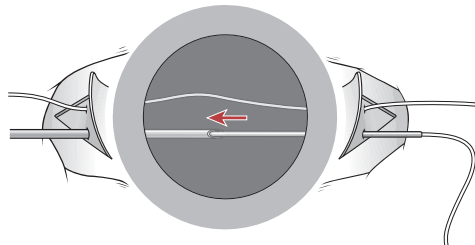
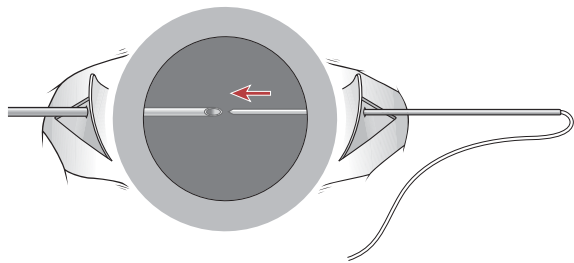


**a**



**b**

**Fig. 5.6** Ab externo technique. **a** Passage of the polypropylene suture into the anterior chamber via the ciliary sulcus. Partial thickness scleral flaps have been created. **b** "Docking" the suture needle in a hollow bore needle to facilitate exit of the suture from the prepared scleral bed. (Reproduced with permission from: Steinert RF, Arkin MS. "Secondary Intraocular Lenses" in: *Cataract Surgery: Technique, Complications and Management*, 2nd Edition. Elsevier-Health Sciences Division, New York, 2003)

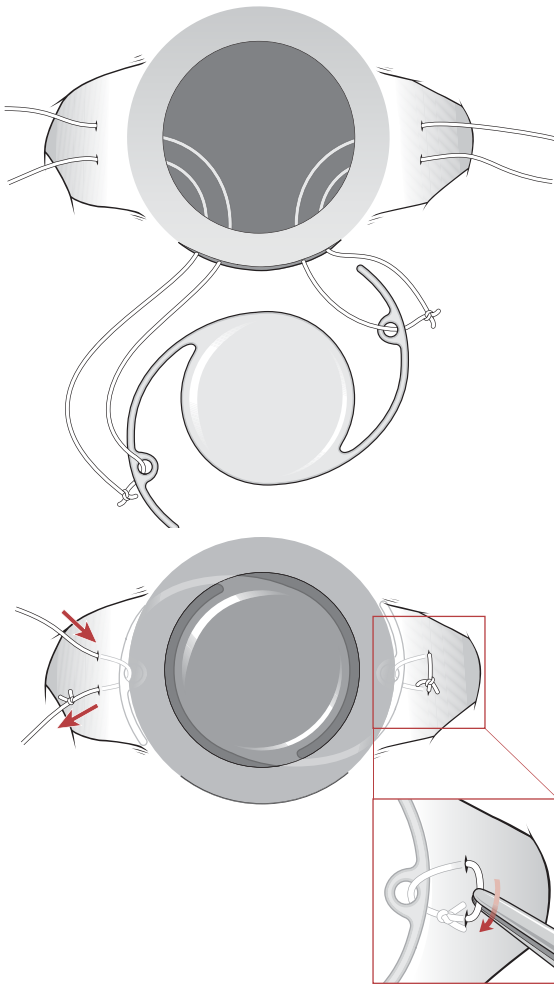


**Fig. 5.8** Variation of the ab externo technique employing two sutures. (Reproduced with permission from: Steinert RF, Arkin MS. "Secondary Intraocular Lenses" in: *Cataract Surgery: Technique, Complications and Management*, 2nd Edition. Elsevier-Health Sciences Division, New York, 2003)

### 5.5.3

#### Ab Externo Technique

The ab externo (outside to inside) technique was first described by Lewis [19]. This method uses 10-0 polypropylene sutures on a straight needle (e. g., Ethicon STC-6), which is passed perpendicularly through the sclera under partial thickness scleral flaps 0.75 mm posterior to the limbus. The needle should enter the ciliary sulcus (based on prior anatomical and histological studies). A second, hollow-bore needle (e. g., 25, 27, or 28 gauge) is passed through the ciliary sulcus on the opposite side, also with the ab externo technique. The tip of the 10-0 needle is then “docked” inside the tip of the hollow needle, and then the hollow needle is withdrawn with the solid needle still inside of it (Fig. 5.6) The polypropylene suture is thus drawn



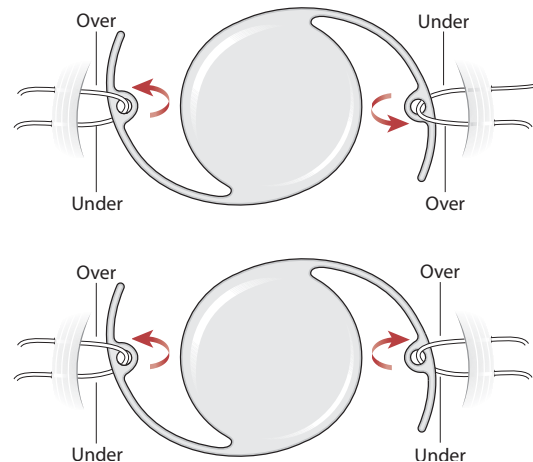
**Fig. 5.9** Variation on the scleral fixation technique illustrating the use of a rotated knot without the creation of an overlying scleral flap. (Reproduced with permission from: Steinert RF, Arkin MS. “Secondary Intraocular Lenses” in: *Cataract Surgery: Technique, Complications and Management*, 2nd Edition. Elsevier–Health Sciences Division, New York, 2003)

across the eye. A hook can then be used to pull the suture through a corneal or limbal wound. The suture can then be cut and each end affixed to one haptic of the IOL (Fig. 5.7). Once the lens is centered, the scleral sutures can then be tied to themselves to create a solid knot, which is buried under scleral flaps.

Alternatively, the Lewis ab externo technique can be modified to be used with two polypropylene sutures. The second suture is passed parallel to the first, usually 1 to 1.5 mm apart. The same technique is used to dock the suture needle in a second, hollow-bore needle, and the suture passed across the anterior chamber. At this point, the hook is then used to draw both sutures through a superior limbal incision. The sutures can then be cut and tied to the individual haptics of the IOL (Fig. 5.8).

A second variation on the Lewis ab externo technique involves the use of a loop of suture where the knot can be rotated to be buried in the sclera and thus avoid the necessity of creating a scleral flap [19, 20]. The main difference in this technique lies in the use of two polypropylene sutures and tying them securely to each other once they are looped around the haptic or through the haptic eyelet. Prior to positioning the IOL, the knot is rotated externally and then cut off, leaving two free suture ends. These ends are then tied and trimmed, and then gently rotated until the knot is beneath the surface of the sclera. The end result is similar to that shown in Fig. 5.9. Note that if this technique is chosen, the sutures must be tied such that easy rotation of the knot can be achieved.

One drawback to the use of the ab externo technique is the lengthy amount of time required to perform the procedure. However, the ab externo technique can give greater assurance of the location of



**Fig. 5.10** Suggested IOL fixation techniques to reduce lens tilt. (Reproduced with permission from: Steinert RF, Arkin MS. “Secondary Intraocular Lenses” in: *Cataract Surgery: Technique, Complications and Management*, 2nd Edition. Elsevier–Health Sciences Division, New York, 2003)

internal penetration with the needle tip. With careful and precise measurements, one can avoid the highly vascularized pars plicata. This in turn may minimize the risk of hemorrhage associated with scleral-fixated PCIOLs. Also, as the procedure is completed in a closed anterior chamber, it decreases the risk of ocular hypotony and its sequelae. This approach is not applicable for penetrating keratoplasties, as an *ab interno* technique is much faster and more easily visualized.

## 5.6 Complications

The most common postoperative complication with secondary IOLs is persistent CME, ranging from 6 to 36% in patients with scleral-fixated lenses [4, 7, 22, 23]. All IOLs are associated with acute CME in the postoperative period; some have stronger associations than others [24]. Whether this is because of intraoperative manipulation of the vitreous or the degree of uveal contact with the intraocular lens components, it is the persistent findings of angiographic and clinically evident CME that ultimately limit the visual outcome. Whereas anterior chamber lenses traditionally have the strongest association with postoperative CME, the rates of persistent CME appear to be similar when longer follow-ups are obtained. Hassan et al. report a rate of 36.4% for patients with ACIOL placement, which they note is similar to the incidence of clinically significant postoperative CME in the patients with both iris- and scleral-sutured PCIOLs. The authors also note that preoperative CME may be underreported, given the difficulty of diagnosis in eyes with corneal edema [25]. A study conducted by Schein et al. shows that macular edema may be reduced with use of iris-sutured IOLs [9]; however, a larger, randomized study has yet to determine if this difference is clinically significant. Other authors have noted a decrease in postoperative CME and improvement in acuity in patients that have had an ACIOL exchange for a sutured PCIOL. Several studies have confirmed postoperative visual acuities of 20/40 or better with penetrating keratoplasty and an iris-fixated or scleral-fixated PCIOL. Schein et al. noted a greater overall rate of complications with scleral-fixated lenses as compared with modern ACIOLs and iris-sutured lenses [9]. This can be attributed to poor visualization of the ciliary sulcus, as well as natural variations of the anatomy of the sulcus. However, Heidemann and Dunn reported comparable rates of complications for scleral-fixated IOLs as compared with both iris-sutured and modern ACIOLs. It is difficult to determine if these differences are secondary to preoperative factors such as preexisting disorders, or surgical technique [21]. It would appear that sutured PCIOLs have a slight advantage over ACIOLs,

but this has yet to be determined in a large case series focusing on outcome comparison between the new, flexible-loop ACIOLs and the sutured PCIOLs [26, 27].

The second most common complication with secondary IOL implantation is the development of new cases of glaucoma, or the exacerbation of preexisting disease. ACIOLs are strongly associated with postoperative glaucoma, whereas there is only a mild association with scleral- and iris-sutured lenses [3]. Regardless of type of implant, the mechanism is likely to be of mixed variety, considering the fact that keratoplasty alone is associated with 5–65% incidence of new onset glaucoma. Holland et al. noted the incidence of glaucoma in their patient population to be 30.3%. They also noted that 39 patients in the study had preexisting glaucoma. Heidemann and Dunn noted that 59% of the patients undergoing penetrating keratoplasty and a scleral-fixated IOL required additional glaucoma medications in the postoperative period. Though scleral-fixated IOLs are not commonly thought to affect the incidence of glaucoma, these early studies show that the incidence and prevalence of glaucoma may be higher than just with transplant alone. However, the latest results of 208 eyes with scleral-fixated PCIOLs showed that increases in IOP occurred in 18% of eyes [23]. It would seem that preoperative factors, disease predisposition, and perhaps surgical technique play a role.

Erosion of the sutures through the conjunctiva has prompted surgeons to place these knots under scleral flaps, or to develop new methods of burying the suture knot. Solomon et al. found that polypropylene suture erosion was the most common complication of scleral-fixated PCIOLs [7]. Despite the use of scleral flaps, up to 17% of patients have sutures that erode through the conjunctiva, as compared with 23.8% without the use of scleral flaps. Holland et al. found the highest rate of erosion in those cases merely covered by conjunctiva, and no cases of erosion in cases where a lamellar corneal graft was used to cover the suture. In the event of exposed sutures, it is recommended that all suture ends be covered with either lamellar corneal grafts or free scleral grafts. Alternatively, the ends can also be cauterized. All of these techniques are directed at reducing the rate of suture-related endophthalmitis. The newer trend of using polytetrafluoroethylene (PTFE) Gore-Tex® sutures may change the rates of suture erosions.

Finally, lens tilt and decentration can be found in as many as 10% of patients after scleral-sutured PCIOL implantation [22, 28]. However, with the current use of lenses with larger optics, the degree of decentration is not usually clinically evident. Placement of the suture as well as tension on the sutures can affect the amount of decentration and tilt. Figure 9 shows the various techniques of fixating the polypropylene suture to the IOL haptic to prevent tilting of the lens postoperatively.



## 5.7

### Future Challenges

The placement of a secondary IOL has now become an accepted standard of care for the treatment of aphakia. The standard posterior chamber lens is no doubt the preferred choice in cases where there is sufficient capsular support. However, in those cases without capsular support, sutured intraocular lenses remain an alternative technique. It is important to take into account preoperative history as well as ocular history in determining which technique to employ.

The visual results for patients in all three groups (modern ACIOL, iris-sutured PCIOL, or scleral-sutured PCIOL) are comparable. However, technical difficulty and some increased risk of serious complications with scleral-fixated PCIOLs should be considered on an individual basis for each patient. Those with significant risk factors for the development of choroidal hemorrhage, retinal detachment, glaucoma, and persistent CME may benefit from ACIOL placement or suture fixation of the lens to the iris. On the other hand, for those patients in which contraindications for ACIOL placement or iris fixation exist may benefit from scleral fixation of a posterior chamber lens.

The long-term effects of sutured lenses on endothelial cell density have yet to be addressed. Although the anatomical and theoretical benefits of a suture-fixated PCIOL exist, there are currently no available studies with enough statistical power or population to determine long-term outcomes of endothelial cell loss for patients randomized between modern ACIOLs and sutured PCIOLs. However, the progression of innovative materials and techniques, and the current body of research continue to show promising results.

### References

1. Cosar CB, Sridhar MS, Cohen EJ et al (2002) Indications for penetrating keratoplasty and associated procedures, 1996–2000. *Cornea* 21:148–151
2. Dobbins KRB, Price FW, Whitson WE (2000) Trends in the indications for penetrating keratoplasty in the Midwestern United States. *Cornea* 19:813–816
3. Steinert RF, Arkin MS, Secondary Intraocular Lenses. In: Steinert RF (2003) *Cataract Surgery: Technique, Complications and Management*, 2nd Edition. Elsevier—Health Sciences Division, New York, pp. 429–441
4. Soong HK, Meyer RF, Sugar A (1989) Techniques of posterior chamber lens implantation without capsular support during penetrating keratoplasty: a review. *Refract Corneal Surg* 5:249–255
5. Price FW, Whitson WE, Ahad KA, Tavakkoli H (1994) Suprachoroidal hemorrhage in penetrating keratoplasty. *Ophthalmic Surg* 25:521–555
6. Holland EJ, Daya SM, Evangelista BA et al (1992) Penetrating keratoplasty and transscleral fixation of posterior chamber lens. *Am J Ophthalmol* 114:182–187
7. Solomon K, Gussler JR, Gussler C, Van Meter WS (1993) Incidence and management of complications of transsclerally sutured posterior chamber lenses. *J Cataract Refract Surg* 19: 488–493
8. Walter KA, Wood TD, Ford JG et al (1998) Retrospective analysis of a novel method of transscleral suture fixation for posterior-chamber intraocular lens implantation in the absence of capsular support. *Cornea* 17:262–266
9. Schein OD, Kenyon KR, Steinert RF et al (1994) A randomized trial of intraocular lens fixation techniques with penetrating keratoplasty. *Ophthalmology* 1993; 100:1437–1443. With comment in: *Ophthalmology* 101:797–800
10. Probst LE, Holland EJ (1997) Anterior subtotal vitrectomy with fibre-optic illumination. *Can J Ophthalmol* 32:254–255
11. Condon GP (2003) Simplified small-incision peripheral iris fixation of an AcrySof intraocular lens in the absence of capsule support. *J Cataract Refract Surg* 29:1663–1667
12. McCannel MA (1976) A retrievable suture idea for anterior uveal problems. *Ophthalmic Surg* 7:98–103
13. Stutzman RD, Stark WJ (2003) Surgical technique for suture fixation of an acrylic intraocular lens in the absence of capsule support. *J Cataract Refract Surg* 29:1658–1662
14. Siepser SB (1994) The closed chamber slipping suture technique for iris repair. *Ann Ophthalmol* 26:71–72
15. Osher RH, Snyder ME, Cionni RJ (2005) Modification of the Siepser slip-knot technique. *J Cataract Refract Surg* 31:1098–1100
16. Duffey RJ, Holland EJ, Agapitos PJ, Lindstrom RL (1989) Anatomic study of transsclerally sutured intraocular lens implantation. *Am J Ophthalmol* 108:300–309
17. Davis RM, Campbell DM, Jacoby BG (1991) Ciliary sulcus anatomical dimensions. *Cornea* 10:244–248
18. Oshima Y, Oida H, Emi K (1998) Transscleral fixation of acrylic intraocular lenses in the absence of capsular support through 3.5 mm self-sealing incisions. *J Cataract Refract Surg* 24:1223–1229
19. Lewis JS (1993) Sulcus fixation without flaps. *Ophthalmology* 100:1346–1350
20. Lane SS, Lubiniewski AJ, Holland EJ (1992) Transsclerally sutured posterior chamber lenses: improved lens designs and techniques to maximize lens stability and minimize suture erosion. *Semin Ophthalmol* 7:245–252
21. Heidemann DG, Dunn SP (1992) Transsclerally sutured intraocular lenses in penetrating keratoplasty. *Am J Ophthalmol* 113:619–625
22. Althaus C, Sundmacher R (1993) Intraoperative intraocular endoscopy in transscleral suture fixation of posterior chamber lenses: consequences for suture technique, implantation procedure, and choice of PCL design. *Refract Corneal Surg* 9:333–339
23. Hannush SB (2000) Sutured posterior chamber intraocular lenses: indications and procedure. *Curr Opin Ophthalmol* 11:233–240
24. Rossetti L, Autelitano A (2000) Cystoid macular edema following cataract surgery. *Curr Opin Ophthalmol* 11:65–72
25. Hassan TS, Soong HK, Sugar A, Meyer RF (1991) Implantation of Kelman-style open-loop anterior chamber lenses during keratoplasty for aphakic and pseudophakic bullous keratopathy. *Ophthalmology* 98:875–880
26. Price FW, Whitson WE (1989) Visual results of suture-fixated posterior chamber lenses during penetrating keratoplasty. *Ophthalmology* 96:1234–1240
27. Hayashi K, Hayashi H, Nakao F et al (1999) Intraocular lens tilt and decentration, anterior chamber depth, and refractive error after trans-scleral suture fixation surgery. *Ophthalmology* 106:878–882
28. Guell JL, Barrera A, Manero F (2004) A review of suturing techniques for posterior chamber lenses. *Curr Opin Ophthalmol* 15:44–50

# Corneal Suturing Techniques

# 6

W. Barry Lee and Mark J. Mannis

## Key Points

### Surgical Indications

- Congenital corneal disorders
- Corneal dystrophies
- Corneal degenerations
- Corneal scarring/opacification
  - Infection
  - Inflammation
  - Trauma
- Graft failure
- Corneal decompensation
  - Pseudophakic
  - Aphakic
  - Iatrogenic
  - Dystrophic
  - Traumatic

### Surgical Instrumentation

- Operating microscope
- Microsuturing instruments
  - Fine-toothed 0.12-mm forceps
  - Fine-tip needle holder
  - Tying forceps
  - 10-0 or 11-0 monofilament suture
- Trephination device
- Preserved corneal tissue

### Surgical Technique

- Appropriate tissue fixation with forceps
  - Avoid compression or tissue maceration
  - Avoid donor endothelium
- Appropriate suture placement
  - Equal suture length on donor and host tissue
  - Radial placement
  - Appropriate depth
  - Adequate knot tension
- Interrupted suture placement at four cardinal positions
- Avoid donor–host mismatch
- Second suture is critical for placement
- Look for diamond-shaped striae
- Suture pattern
  - Interrupted technique
  - Combined interrupted and continuous technique

- Single continuous technique
- Double continuous technique

### Complications

- Intraoperative
  - Iris, lens, or vitreous prolapse
  - Iris trauma/iris incarceration with suture
  - Traumatic cataract
  - Suprachoroidal hemorrhage
  - Donor–recipient mismatch
- Postoperative
  - Astigmatism
  - Infection (suture abscess, graft ulcer, endophthalmitis)
  - Wound leak (flat or narrow chamber)
  - Traumatic cataract
  - Iris trauma (hyphema, peripheral synechiae, iris suture entrapment)

## 6.1

## Introduction

Suturing technique remains one of the most vital skills in the art of contemporary corneal surgery. Although the main purpose of suture placement remains adequate wound apposition and closure, meticulous attention to appropriate suture placement cannot only minimize postoperative astigmatism, but also may facilitate more rapid visual recovery and lead to a more stable wound long term. A variety of factors remain critical for suture placement, including avoidance of mismatch between radial and nonradial suture bite placement, appropriate donor and recipient bite lengths, appropriate bite depth, and symmetrical and adequately dispersed suture tension in each quadrant of the cornea, with special care to prevent excessive tightening. The evolution of corneal suturing techniques from overlay sutures to direct appositional suture closure, along with the discovery of small, monofilament suture material has revolutionized suturing techniques and postoperative success.

This chapter focuses on the suturing techniques in penetrating keratoplasty, including indications, instrumentation, various surgical techniques, complications,



and future considerations. Corneal suturing in settings other than keratoplasty is discussed elsewhere in this book.

## 6.2 Surgical Indications

The indications for keratoplasty encompass a diverse group of corneal disorders. The underlying pathologic mechanisms lead to the development of corneal edema, opacification, scarring, vascularization, and/or distortion creating an unacceptable level of vision. The broad range of corneal abnormalities include congenital disorders, hereditary dystrophic conditions, degenerative conditions, infections, inflammatory disorders, trauma, stem cell dysfunction, graft failure, and iatrogenic causes whether surgical or medication-induced.

The most common indications for corneal transplantation include pseudophakic bullous keratopathy, Fuchs' endothelial dystrophy, keratoconus, and previous graft rejection. Less common indications include aphakic bullous keratopathy, corneal scarring, other corneal dystrophies, chemical burns, congenital corneal opacities, and corneal sequelae from infections such as *Herpes simplex*, *Herpes zoster*, bacteria, and fungi [9, 12, 16, 29].

## 6.3 Instrumentation and Equipment

Corneal surgery requires an operating microscope, highly specialized microsurgical tools including fine-toothed forceps, fine corneal scissors, tying forceps, needle holders, and precision-cutting circular corneal trephines. Essential adjuncts to the microsurgical instruments include 10-0 or 11-0 monofilament suture, ophthalmic viscosurgical agents, and pharmacological agents such as miotics, corticosteroids, and topical and subconjunctival antibiotics.

The forceps in corneal surgery must have fine teeth that enable appropriate stabilization of corneal tissue while a fine-tip needle holder is used to pass suture. Single-point fixation forceps, typically 0.12-mm forceps, are used for tissue stabilization with care to avoid excessive grabbing or compression that may lead to tissue maceration. These forceps have a tying platform that can be used to hold one suture end during tying of the knot. The fine-tip needle holder can be used to hold the other suture end during tying of the knot. Alternatively, tying forceps can be used for suture tying once a suture has been adequately placed.

Corneal incisions during keratoplasty are typically constructed using vacuum-based or handheld trephine blades. A variety of vacuum systems are available but

all consist of a centration device, vacuum-suction tubing, multiple-sized trephination blades, and a turning platform to allow for controlled cutting of the host cornea. A cutting platform is typically used on a side table to make appropriately sized cuts into the donor tissue with the trephination blade size of choice.

Additional components of keratoplasty procedures include acquisition of donor tissue from eye banking establishments. The combination of improved methods of corneal tissue procurement by eye banks as well as tissue preservation, storage media, and advanced microsurgical instrumentation has contributed to the modern day success of keratoplasty surgery.

## 6.4 Surgical Technique

Surgical corneal procedures require meticulous suture technique for appropriate wound closure. The purpose of the suture is to hold the wound in stable apposition until the natural healing process is complete, rendering the suture unnecessary.

After appropriate trephination and sizing of the donor tissue and diseased host cornea, an ophthalmic viscoelastic is placed in the anterior chamber and angle. The donor corneal button is grasped with fine-toothed forceps, taking care to avoid compression of the donor endothelial cells. This maneuver is best performed with two-point fixation, toothed forceps (e. g., Polack forceps) for the initial suture placement. However, single fixation, toothed forceps are adequate as long as torque of the donor tissue can be avoided. The forceps should hold the anterior one third of the corneal tissue edge with the anterior fixation point contacting the donor epithelium and the posterior fixation point contacting the trephined edge of the corneal stroma. Torque can be avoided by grasping the tissue in this manner, allowing for the forceps tips to meet in direct opposition, without excessive squeezing of the tissue. The donor cornea is placed over the eye on the bed of viscoelastic, and the initial cardinal suture is placed at 12 o'clock. Previously placed radial ink marks from a radial keratotomy (RK) marker can aid appropriate radial suture placement. For suture placement, the point of the needle should enter the anterior graft surface approximately 0.75 mm from the wound edge and is passed at 95% depth through the donor cornea immediately behind the point of forceps fixation. The proper depth of suture placement should fall just anterior to Descemet's membrane. The suture is then passed through the recipient tissue with an equal amount of tissue purchase. The length of suture placement on the donor and recipient tissue should approximate 0.75 mm on each side of the wound. In some instances, a longer recipient bite is required such as a

thin recipient bed or a large tectonic graft procedure. The four “cardinal” sutures are passed at the 12 and 6 o'clock positions, followed by the 3 and 9 o'clock positions. Though controversial, some corneal surgeons intentionally place the four cardinal sutures completely through both the donor and the recipient, resulting in full-thickness sutures. It is thought this technique may result in better tissue apposition. Controversy exists as to whether the suture can act as a wick to allow ingress of bacteria from the tear film into the anterior chamber with the resultant risk of endophthalmitis.

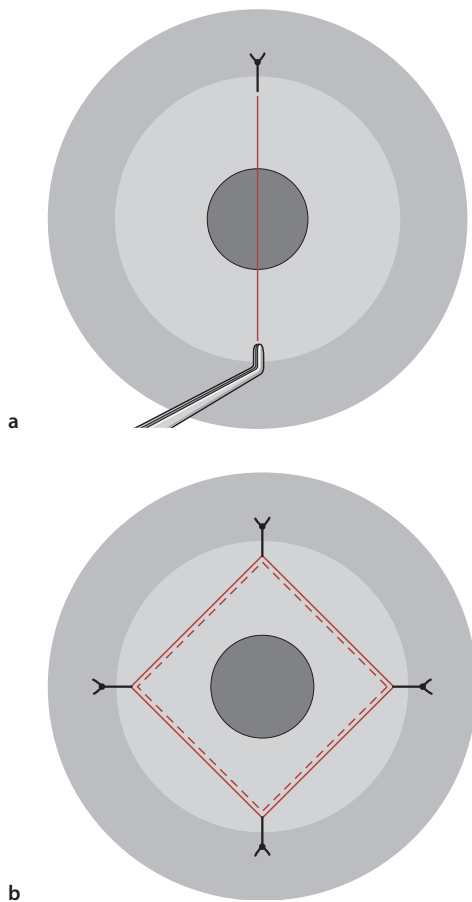
The second cardinal suture is considered the most important suture in keratoplasty, because it is crucial in determining lateral wound apposition, proper donor/recipient edge alignment, and corneal astigmatism. This suture is placed at the 6 o'clock position precisely 180° from the first cardinal suture. After placement of this suture, donor/recipient apposition should be equal at the 3 and 9 o'clock positions, with neither gap nor overlap and a tension line from 12 to 6 o'clock should bisect the donor tissue in two equal

halves (Fig. 6.1a). After placement of the second suture, the third and fourth sutures are placed at 3 and 9 o'clock, equidistant from the previous two sutures. After completion of the four cardinal sutures, equal tension lines form a diamond-shaped pattern within the donor cornea (Fig. 6.1b). Once the cardinal sutures are completed, the wound architecture and configuration of the donor/recipient junction has been determined, regardless of the placement of future sutures. Cardinal suture placement largely determines final corneal sphericity and subsequent corneal astigmatism. Once the cardinal sutures are in place, a variety of suturing techniques can then be implemented.

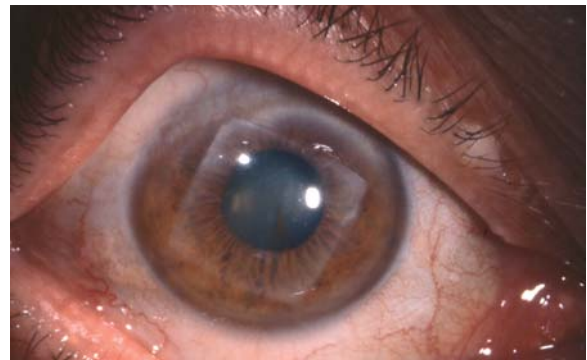
A variety of suture fixation patterns can be implemented for appropriate tissue alignment and wound closure. Interrupted sutures are the oldest technique of the modern keratoplasty era. Surgeons such as Castroviejo, Troutman, and Fine popularized the use of direct appositional interrupted sutures, which are now typically performed with 12, 16, or 24 interrupted equidistant 10-0 nylon sutures ([23, 24, 30, 46–49]; Fig. 6.2). An alternative pattern of corneal suture fixation employs interrupted sutures in combination with a continuous running suture. Finally, a single continuous running suture (SCS) or double continuous running suture (DCS) may also be used for corneal wound apposition with nylon, polypropylene, or Merseline suture.

#### 6.4.1 Single Interrupted Suture Technique

The single interrupted corneal suturing technique represents the oldest of the various suture techniques performed today, and it is the gold standard of wound closure and adequate wound apposition in corneal surgery. Regardless of the surgeon's preferred suturing technique, interrupted suture placement must be perfected by all surgeons, especially in keratoplasty, as certain cases mandate interrupted suture methods



**Fig. 6.1** **a** Schematic diagram of cardinal suture placement in keratoplasty demonstrating the typical appearance of vertical striae, with appropriate placement of the second cardinal suture. **b** The typical pattern of diamond-shape striae seen with appropriate placement of all four cardinal sutures.



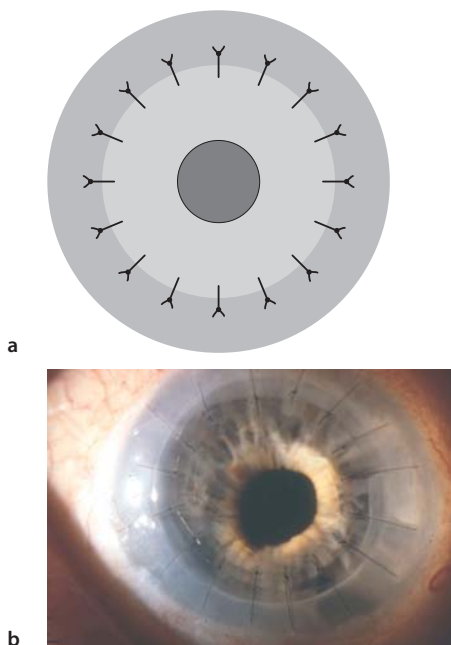
**Fig. 6.2** A square graft performed by Castroviejo with best-corrected vision of 20/20 almost 40 years after penetrating keratoplasty for keratoconus. (Courtesy of Bruce Varnum)

rather than continuous running methods. The interrupted suture technique should be performed in all cases of pediatric keratoplasty, traumatic or spontaneous graft dehiscence repair, tectonic keratoplasty, and cases in which corneal graft vascularization may occur, e. g., eccentric grafts, multiple prior rejection episodes, prior corneal inflammatory conditions, and host corneal vascularization or ulceration. The interrupted suture technique requires a minimum of eight sutures to maintain watertight wound closure; however, most surgeons perform 16 equidistant sutures for routine cases. Some surgeons advocate use of 24 rather than 16 interrupted equidistant sutures. Proper, equidistant spacing of the sutures can be facilitated by previously applied radial ink marks, using an RK marker. Pediatric grafts may include the use of varying numbers of interrupted sutures with 8, 12, 16, or 24 individual equidistant sutures depending on surgeon preference.

The interrupted suturing technique generally employs 10-0 monofilament nylon suture with a 160° single-curve 5.5-mm needle at the four cardinal positions in the order of 12, 6, 3, and 9 o'clock, as described earlier. Sutures can be tied with a variety of different techniques. A common method includes a 3-1-1 closure, with adjustment of tension before the second throw is made and the knot secured. The authors prefer a slipknot technique, with four single throws and adjustment of suture tension after the second throw. The third and fourth throws are square knots and ensure permanent suture tension. The slipknot technique

allows for easier adjustment of suture tension while retaining the ability to change undesirable suture tension easily before the third throw is completed. Regardless of the method of suture fixation, meticulous attention to appropriate suture tension with avoidance of loose or tight knots is essential for minimizing postoperative corneal astigmatism. Sutures should be replaced if tension is not adequate. Once all sutures have been placed with adequate knot tension and watertight wound closure, the ends are trimmed with a microsurgical blade or Vannas scissors, and all knots are buried (Fig. 6.3). Some surgeons prefer to bury the knots on the recipient side to reduce tension on the graft–host junction at time of suture removal, making risk of wound dehiscence less likely [34]. Other surgeons prefer to bury the sutures near the donor side, increasing the distance between the knot and the limbal vessels in order to reduce the risk of suture vascularization and inflammation [34].

Astigmatism adjustment with the interrupted technique is performed by removing the suture at the steep meridian as indicated by keratometry, photokeratocopy, or computerized corneal topography. Each suture creates tangential vector forces, creating adjacent flattening with central steepening along the meridian of suture placement. Interrupted sutures can be removed in a well-constructed corneal graft as early as 6 weeks postoperatively if a suture is felt to be too tight, contributing to abnormal corneal topography and high amounts of astigmatism, or if suture vascularization or infiltration occurs. While adjacent sutures should typically not be removed until 6 months postoperatively, earlier removal may be indicated at the surgeon's discretion if stable wound integrity exists, limiting the risk of wound dehiscence after removal, or if a running suture is in place. Circumstances for earlier suture removal may include severe visual compromise as a result of high amounts of astigmatism or suture vascularization in the setting of a stable corneal wound. Sutures can be left in place indefinitely but should be removed if they break, loosen, become inflamed, infected, or vascularized, or if removal will clearly improve the topographical profile and subsequent visual acuity. Typically a drop of antibiotic or povidone iodine solution is placed in the eye prior to removal, and the suture is cut with a needle and removed with typing forceps. Prior to cutting the suture, the knot location should be identified. The suture should be cut in a manner that allows removal without dragging the knot across the graft–host wound junction, as pulling the knot across the wound may result in a wound dehiscence. A quick, jerk-like motion is best used for interrupted suture removal rather than a slow movement. A topical antibiotic drop should be placed following suture removal, and topical antibiotics are used for several days following suture removal



**Fig. 6.3** **a** Schematic diagram and **b** immediate postoperative photograph demonstrating the interrupted suture technique with 16 individual 10-0 nylon sutures.

**Table 6.1** Comparison of final mean keratometric astigmatism in various suture techniques

Author(s)	No. of eyes	Suture technique	Final average keratometric astigmatism (D)
Murta et al. [35]	61	IS	2.77±1.34
Busin et al. [8]	15	IS	4.89±3.16
Troutman et al. [50]	74	IS/CICS	4.4–5.1
Heidemann et al. [26]	156	IS	6.36
Binder [4]	204	CICS	2.6
Karabatsas et al. [27]	51	CICS	2.66±1.70
Gross et al. [25]	63 (group 1)	CICS	2.94
	103 (group 2)	CICS	3.27
Van Meter et al. [53]	31	CICS	3.2±1.9
Binder [6]	188	CICS	3.5
Filatov et al. [22]	20	CICS	3.9±2.5
Assil et al. [2]	19	CICS	4.07
Dursun et al. [18]	92	CICS	4.19±2.94
Van Meter et al. [53]	26	SCS	1.5±1.1
Serdarevic et al. [43]	25	SCS	1.75±1.04
Filatov et al. [22]	18	SCS	2.7±2.2
Ramirez et al. [39]	44	SCS	3.00±2.20
Karabatsas et al. [27]	44	SCS	3.12±2.62
Murta et al. [35]	14	SCS	3.90±1.70
Van Meter [51]	43	SCS	4.4±2.5
Assil et al. [2]	14	DCS	1.54
Clinch et al. [11]	30	DCS	2.66±0.24
Heidemann et al. [26]	57	DCS	3.75
Dolorico et al. [17]	91	DCS	3.98
Busin et al. [8]	22	DCS	3.98±3.69
Ramirez et al. [39]	48	DCS	4.2±2.1
Davison et al. [14]	33	DCS	4.5
Wiffen et al. [54]	313	DCS	4.6

IS interrupted suture technique, CICS combined interrupted and continuous suture technique, SCS single continuous suture technique, DCS double continuous suture technique, D Diopter

to lower subsequent risk of infection. In order to minimize discomfort and promote re-epithelialization, overnight patching with antibiotic ointment can be administered when many sutures are removed at once.

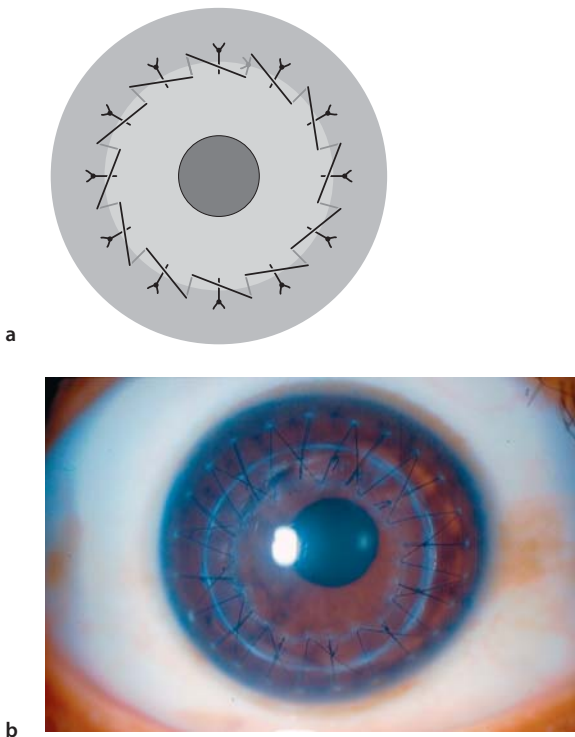
The interrupted suture technique has been associated with a wide range of postoperative astigmatism.

This technique can be associated with a high degree of astigmatism early in the postoperative course prior to selective suture removal. However, long-term keratometric astigmatism is quite acceptable, as reported in various clinical studies (Table 6.1).

### 6.4.2

#### Combined Interrupted and Single Continuous Suture

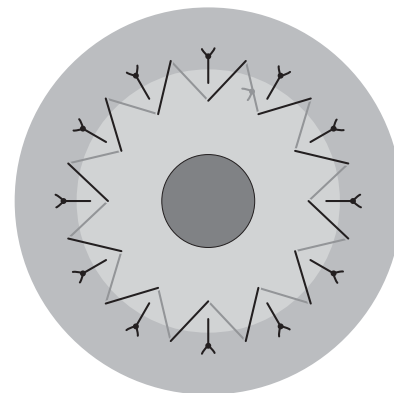
A combination of interrupted sutures and a continuous running suture (CICS) may be used to provide appropriate wound apposition and closure [2, 4–6, 25, 45]. One of the most commonly utilized suture patterns includes 12 interrupted sutures and a 12-bite continuous running suture (CS), although eight interrupted sutures and a 16-bite continuous running suture is also commonly employed (Fig. 6.4a, b). After placement of the four cardinal interrupted sutures, eight additional interrupted sutures are placed with 10-0 nylon suture. After the sutures are trimmed and the knots are buried, the CS is completed. Some surgeons employ qualitative keratotomy to adjust or replace interrupted sutures before placement of the CS component. These surgeons generally repeat keratotomy after CS placement as well. The CS is typically completed in a clockwise fashion, using 10-0 or 11-0 nylon suture, with the first bite midway between the 12 and 1 o'clock interrupted sutures. The CICS technique can be performed with radial bites equidistant between each of the interrupted sutures or by using an anti-



**Fig. 6.4** **a** Schematic diagram demonstrating appropriate suture placement using the combined interrupted and single continuous running keratoplasty technique with 12 interrupted sutures and a 12-bite running suture. **b** A slit-lamp photograph of the combined interrupted and continuous 12-bite running suture.

torque technique in which the apex of each bite in the donor cornea forms an isosceles triangle with each interrupted suture (Fig. 6.5). Several authors have suggested that the antitorque CR reduces the torquing effects and pressure distortion induced from each bite compared with radial running bites which may cause pressure distortion and torque when the running portion overlies the radial interrupted sutures [3, 19, 41, 47–49]. The CS depth is generally more superficial than are the deeper interrupted sutures, creating better approximation of Bowman's layer. The CS is run the entire 360°, with placement of a temporary knot at 12 o'clock. Additional slack is removed along the entire length of the CS to square the apical points within the corneal graft, and the suture is tied permanently at 12 o'clock with a 3-1-1 tying technique. The CS is then rotated with two tying forceps, and the knot is buried. Alternatively, the continuous running suture can be started within the wound, and finished at the same clock hour within the wound. A slipknot can be used to secure the suture and adjusted after the slack is relieved. Once tied permanently, the knot can be left in place after the ends are trimmed, and further manipulation of the CS to bury the knot is unnecessary.

The combination of interrupted and continuous running sutures allows for earlier removal of interrupted sutures to reduce postoperative astigmatism. If astigmatism is acceptable (generally less than 3 diopters [D]), sutures may be left alone until breakage, loosening, scarring, or vascularization develops, though the patient must be warned to call immediately if they develop a foreign-body sensation. Interrupted sutures can be removed as early as 4 weeks postoperatively to reduce corneal distortion and astigmatism as measured by keratometry, photokeratotomy, or computerized corneal topography. Selective interrupted suture removal can be performed until only the running suture is left in place. The CS can be left in place



**Fig. 6.5** Schematic diagram of the combined interrupted and single continuous running pattern using an antitorque running technique.



indefinitely, but is generally removed 12–18 months following surgery. Astigmatism with this technique varies from 2.16 to 4.19 D, with selective removal of interrupted sutures followed by removal of the CS (Table 6.1; [6, 18, 20, 27, 42]). If significant astigmatism exists following removal of all interrupted sutures, corneal astigmatism correction with surgical methods will need to wait until the wound is stable enough to have the continuous running suture removed. This technique should not be performed in pediatric keratoplasty, tectonic keratoplasty, vascularized host corneas from previous inflammation or infection, multiple graft rejections, or conditions in which a risk of melting is present such as in autoimmune conditions like rheumatoid arthritis.

### 6.4.3

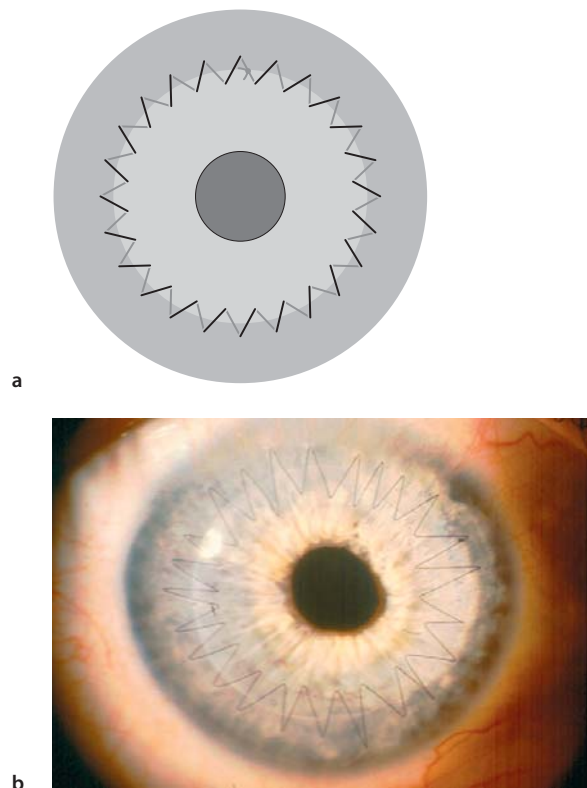
#### Single CRS Technique

The single continuous running suture technique was first described by Roper-Hall and popularized by McNeill in the United States [33, 40]. This technique carries the advantages of faster surgical time, one-time suture removal, and potential for suture adjustment intraoperatively and postoperatively. The disadvantages of this technique include increased technical difficulty, the increased risk of needle dullness, impaired wound integrity with only one improper bite, and difficulties of suture manipulation if the continuous suture breaks intraoperatively. The technique is typically performed with a 24-bite SCS of 10-0 nylon, although some surgeons have performed this with a 16-bite SCS. After the four cardinal sutures are placed as described above, the surgeon starts the SCS between 12 and 1 o'clock, and the suture is run clockwise until it is temporarily secured at 12 o'clock after completion. The surgeon places six bites per quadrant. The four cardinal sutures are removed, and the anterior chamber is filled to physiologic level before permanently tightening the knot to avoid a topographically flat donor cornea. Tightening of the is achieved by using tying forceps to release excess tension from each bite in a clockwise manner until the desired tension is achieved. Any excess tension from the lid speculum or a scleral fixation ring, if used, should be alleviated before the knot is tied permanently. Once the suture is tied permanently, it is trimmed to the knot, and the knot is buried. However, if the SCS is initiated within the wound, once tied and cut flush, the knot will be buried without further manipulation. The SCS can then be adjusted for appropriate sphericity with typing forceps using intraoperative qualitative keratotomy (Fig. 6.6a, b).

When using the SCS technique, the surgeon should pay careful attention to care of the needle point, place-

ment of continuous suture bites in a radial orientation, placement of evenly spaced, symmetrical bites at 95% depth, and prevention of suture breakage. If the SCS does inadvertently break, it should be removed if the pattern is in the first quadrant and restarted to prevent time delays. If the suture is broken in the final quadrants, a new suture can be spliced to proximal end with continuation, using the new needle (see Chap. 3 for suture-splicing technique description). The first spliced knot can be buried at the end of suturing, and the SCS can be tightened from the buried knot toward the suture completion at 12 o'clock. In some situations, if the initial suture end was left long, the SCS can be advanced to beyond the 12 o'clock position, and the spliced section can subsequently be removed, leaving only one knot to tie, as described earlier. When two knots are buried after splicing, suture adjustment should be performed in two separate portions to minimize astigmatism, but without exposure of either knot or repeat breakage.

While the SCS technique represents an efficient and effective method for keratoplasty wound closure, it can be problematic, as early suture removal may result in wound instability and unacceptably high astigmatism. Several clinical studies evaluating the single continu-



**Fig. 6.6** **a** Schematic diagram of the single continuous running keratoplasty suturing technique using 24 bites with 10-0 nylon suture. **b** A slit-lamp photograph of the single continuous running suture (CS) technique.

ous running suture describe low levels of astigmatism and more rapid visual recovery as compared with other suturing techniques when early postoperative suture adjustment techniques are implemented [22, 33, 42, 43, 45, 51–53]). Van Meter and colleagues compared the SCS, and CICS techniques and found that the former was associated with significantly less astigmatism ( $1.5 \pm 1.1$  D as compared with  $3.2 \pm 1.9$  D), fewer postoperative suture adjustments (0.9 as compared with 3.8), and earlier refractive stability (7 months earlier) (see Table 6.1 [53]). Patients undergoing intraoperative suture adjustment are reported to have significantly decreased astigmatism, more regular corneas, and better spectacle-corrected visual acuity until the running suture is eventually removed [42, 43, 51]. These data must be weighed against a 7.2% risk of spontaneous wound dehiscence following suture removal associated with this technique [1].

The ideal time for postoperative suture adjustment is 3–6 weeks following keratoplasty, since this provides adequate time for graft re-epithelialization and adequate measurement of astigmatism with corneal topography or keratometry. This timeframe also allows for easier manipulation of the SCS, with microsurgical instruments reducing risk of suture breakage, a risk that increases with later postoperative suture adjustments after more complete wound healing. SCS adjustment is performed with sterile tying forceps at the slit-lamp, following administration of a drop of topical antibiotic or topical povidone iodine and topical anesthetic. Keratometry, photokeratometry, or corneal topography should be reviewed prior to suture adjustment in order to establish the proper adjustment plan. Prior to suture adjustment, one tip of the tying forceps is placed through the epithelium and Bowman's layer along the graft-host junction at the steep meridian. After severing these anterior layers, the tip of the forceps is used to lift the suture, which is carefully advanced along the suture direction. This maneuver is performed at the steep meridian to serve as a relaxing incision in conjunction with suture adjustment. Once the suture moves, it is advanced loop by loop from the area of the flattest meridian and distributed to the area of the steepest meridian as measured by topography or keratometry until the tension has been evenly dispersed around the entire circumference of the wound. If a suture is too tight, adjustment plans should be aborted since attempting to adjust a very tight suture may lead to breakage. Avoidance of twisting the suture over the tips of the tying forceps and careful advancement of the suture along the line of suture placement can reduce the risk of the SCS breaking during adjustment. After completion of suture adjustment, the keratometric astigmatism should be measured after stabilization has occurred (typically in 2–3 weeks) to determine the effectiveness of the adjustment. Several

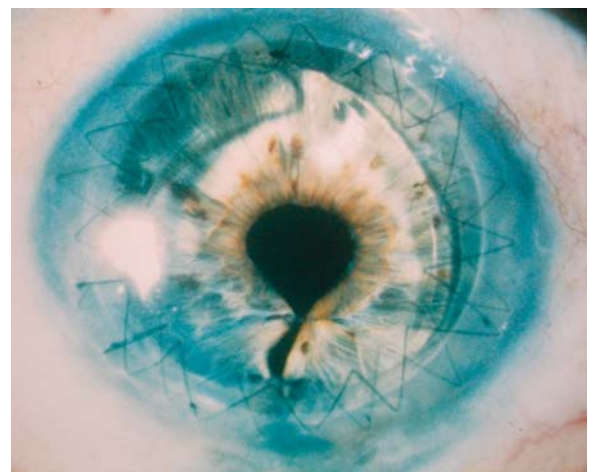
adjustments may be required to arrive at an acceptable level of keratometric astigmatism and subsequent visual acuity.

#### 6.4.4

#### Double Continuous Suture Technique

The double continuous running suture technique was first described in 1977 [32]. The DCS can be performed with two 10-0 nylon sutures, a 10-0 nylon suture and 11-0 nylon suture, or a 10-0 nylon suture and an 11-0 Mersilene suture. This technique provides the benefits of a SCS, with the added safety and security of a second SCS.

After placement of the four cardinal interrupted sutures, a 12-bite running 10-0 nylon CRS is placed. The CRS is run clockwise for  $360^\circ$  and tied temporarily at 12 o'clock. Each suture pass should be placed at 80% of the depth of the donor cornea and recipient cornea. The slack is removed and the knot is tied permanently at 12 o'clock and buried. The four cardinal sutures are removed. A second suture (10-0 or 11-0 nylon or 11-0 Mersilene) is placed between each of the previous bites and run clockwise for  $360^\circ$ . The second CRS is placed at 50–60% of the corneal depth to approximate Bowman's layer on both sides of the wound. The knot is tied temporarily at 12 o'clock, and the slack is removed, with a permanent tie completed at 12 o'clock (Fig. 6.7). The tension of the second suture should allow for only enough tension to take up slack in the suture. The second running suture permits early removal of the first CRS in 2–3 months, depending of the level of astigmatism. The second CRS may be left indefinitely, depending on the level of astigmatism, or it may be removed at 12–18 months.



**Fig. 6.7** Slit-lamp photograph depicting the double running suture technique. (Photo courtesy of Woodford Van Meter, M.D.)



The disadvantage of this technique is the time required to perform two continuous running sutures and requirement of significant expertise. This technique can potentially cause premature breakage or severing of the first suture with an improper pass of the second continuous running suture. In addition, care must be taken to avoid bending the needle during each pass or dulling the tips of the needle with each instrument grasp. Also, each suture bite must be regular and symmetrical in order to close the wound in an adequate fashion. Any irregular or improperly placed bite can lead to wound instability and inappropriate wound healing.

Several studies report excellent long-term stability with an acceptable range of postoperative astigmatism, and some authors consider it the most stable and secure suture technique [7, 14, 17, 32]. Rapid visual recovery and low levels of final astigmatism occur with early postoperative adjustment of the 10-0 nylon deep [11, 14, 32]. Marked variability exists in the literature regarding the effect of vision and postoperative astigmatism following suture removal with this technique, since some studies have shown an increase in astigmatism, whereas others have found no change or a decrease in the amount of astigmatism [7, 17, 32, 36, 46, 47, 50]. The deep 10-0 nylon CRS is typically removed first, followed by removal of the more anterior suture at 12–24 months. A retrospective study of 91 patients undergoing the DCS technique found an average postoperative keratometric astigmatism of 3.73 D after sutures were removed at an average follow-up of 13.7 months with 94% having best-correctable vision of 20/60 or better [17]. Average sutures-out keratometric astigmatism with this technique can vary widely as with all suture patterns in keratoplasty (see Table 6.1; [36, 54]).

## 6.5 Pediatric Keratoplasty

Pediatric keratoplasty deserves special mention, as these cases present a variety of challenges that are not routinely encountered in adult cases. Challenges in pediatric keratoplasty include smaller working space, decreased corneal dimensions, smaller ocular structures and shallow anterior chambers, more significant posterior pressure, and more scleral and corneal tissue elasticity. These factors provide heightened risks for intraoperative and postoperative complications, with a greater potential for iris prolapse or expulsion of ocular contents. A scleral fixation ring should be placed, with fixation to the episclera during the initial stages of the case to provide better globe stabilization and assist with management of increased posterior pressure and tissue elasticity.

In regard to suture placement, children have more elastic recipient corneas as compared with adults, more posterior pressure, more elastic donor corneas due to younger donor tissue, and a tendency for suture loosening sooner than adults, all of which account for greater suture pattern variability. This variability makes the single interrupted suture technique the ideal technique in pediatric cases, because it provides for better wound apposition and a more stable wound as sutures began to loosen over time. Continuous suture patterns are not recommended for pediatric cases. In pediatric keratoplasty, suture removal is often initiated as early as 2 weeks postoperatively, depending on the state of corneal healing. Frequent examinations under anesthesia are commonly encountered in pediatric cases for suture removal and adequate viewing of corneal grafts in cases where children are too young to cooperate with a slit-lamp examination. A team approach is often needed in these cases, with coordination of care between a pediatric ophthalmologist, a glaucoma specialist, and the corneal surgeon as amblyopia, glaucoma, and graft failure are very common occurrences in pediatric keratoplasty cases.

## 6.6 Suture-Related Complications

Complications from corneal suturing techniques in keratoplasty can be divided into intraoperative and postoperative complications. Intraoperative complications may include forward movement of the lens–iris diaphragm, disrupting suturing by iris prolapse and creating a potential for lens damage or expulsion. The most dreaded complication creating this forward shift is a suprachoroidal hemorrhage, a complication that can progress to an expulsive choroidal hemorrhage with expulsion of intraocular contents. Other intraoperative complications may include violation of, or contact with, the anterior lens capsule, leading to a traumatic cataract; inadvertent iridectomy when excising the diseased cornea; and damage to the donor endothelium from tissue manipulation or poor handling techniques. Improper suture placement can lead to iris incarceration, lens violation, and a higher risk of suture abscess or endophthalmitis in the postoperative course. Improper suture tension can create undesirable astigmatism or donor–recipient mismatch, which can lead to difficulty in creating a watertight wound once suturing is completed, as well as significant astigmatic refractive error postoperatively.

While intraoperative complications for an experienced corneal surgeon typically remain limited, postoperative complications are numerous and are commonly encountered. Postoperative complications following suture techniques in keratoplasty include

wound leak with a flat anterior chamber, hyphema, traumatic cataract, iris prolapse and peripheral iris synechiae to the graft–host junction, secondary glaucoma, and retrocorneal membranes [15]. Loose sutures in the immediate or late postoperative course can lead to suture vascularization or wound dehiscence [10]. In particular, late postoperative wound dehiscence has been reported in one study with the 24-bite SCS in 7.2% of patients, with the majority of cases occurring within 2 weeks of suture removal [1]. While wound dehiscence typically occurs soon after removal of sutures, late postoperative wound dehiscence has also been reported 10–19 years after suture removal [38]. Infections such as endophthalmitis, suture abscesses, and graft ulceration may also occur in association with loose sutures. Postkeratoplasty surface keratopathy is one of the most common postoperative complications after astigmatism. It can present in many forms including hurricane keratopathy, filamentary keratitis, keratitis medicamentosa, persistent epithelial defects, and superficial hypertrophic dendri-form epitheliopathy (SHDE) [19, 28]. These surface complications can indirectly affect sutures and require observation for potential suture melting or infiltration when present.

Astigmatism is the most common postoperative suture-related complication in keratoplasty. Factors felt to increase the risk of high amounts of astigmatism include increased external pressure exerted on the globe such as a tight lid speculum or improperly sutured scleral fixation ring. Other factors related to astigmatism include inappropriate trephination procedures, donor–recipient mismatch, sutures with inappropriate tension, inconsistent suture depth, lack of suture radiality, asymmetrical suture placement, and/or malpositioned cardinal sutures.

## 6.7

### Future Challenges

Despite the many advances made in corneal surgery over the last decade, the ideal suturing technique remains to be identified. Regardless of the various advances in instrumentation, surgical technique, and our knowledge of immunobiology, perfect and reproducible results in corneal surgery and keratoplasty in particular do not exist. Although the success of penetrating keratoplasty is commonly over 90% in routine cases, intraoperative and postoperative complications will always remain a risk with corneal surgery [7]. Despite the increased success of contemporary keratoplasty, suture-related complications continue to exist. Regardless of these inherent risks, postoperative complications such as astigmatism, wound dehiscence, and suture-related infections can be diminished with care-

ful attention to appropriate suture technique and careful and close follow-up of patients after corneal surgery techniques. Nonetheless, the fundamentals of corneal wound closure and appropriate tissue apposition represent the core foundation of knowledge for the corneal surgeon.

## References

1. Abou-Jaoude ES, Brooks M, Katz DG et al (2002) Spontaneous wound dehiscence after removal of single continuous penetrating keratoplasty suture. *Ophthalmology* 109:1291–1296
2. Assil KK, Zarnegar SR, Schanzlin DJ (1992) Visual outcome after penetrating keratoplasty with double continuous or combined interrupted and continuous suture wound closure. *Am J Ophthalmol* 114:63–71
3. Au Y-K, Mahjoub SB, Hart JC (1990) Suture patterns and corneal graft rotation in the cadaver eye. *Ophthalmic Surg* 21:472–474
4. Binder PS (1985) Reduction of postkeratoplasty astigmatism by selective suture removal. *Dev Ophthalmol* 11:86–90
5. Binder PS (1985) Selective suture removal can reduce postkeratoplasty astigmatism. *Ophthalmology* 92:1412–1416
6. Binder PS (1988) The effect of suture removal on postkeratoplasty astigmatism. *Am J Ophthalmol* 105:637–645
7. Bourne WM (1981) Current techniques for improved visual results after penetrating keratoplasty. *Ophthalmic Surg* 12:321–327
8. Busin M, Monks T, Al-Nawaiseh I (1998) Different suturing techniques variously affect the regularity of postkeratoplasty astigmatism. *Ophthalmology* 105:1200–1205
9. Brady SE, Rapuano CJ, Arensten JJ et al (1989) Clinical indications for and procedures associated with penetrating keratoplasty 108:118–122
10. Christo CG, Rooij J, Geerards AJM et al (2001) Suture-related complications following keratoplasty. *Cornea* 20:816–819
11. Clinch TE, Thompson HW, Gardner BP et al (1993) An adjustable double running suture technique for keratoplasty. *Am J Ophthalmol* 116:201–206
12. Cosar CB, Sridhar MS, Cohen EJ (2002) Indications for penetrating keratoplasty and associated procedures, 1996–2000. *Cornea* 21:148–151
13. Cottingham AJ (1980) Residual astigmatism following keratoplasty. *Ophthalmology* 87(S):113
14. Davison J, Bourne WM (1980) Results of penetrating keratoplasty using a double running suture technique. *Arch Ophthalmol* 99:1591–1595
15. Dhanda RP, Kalevar V (1972) Corneal surgery. *Int Ophthalmol Clin* 12:3–420
16. Dobbins KRB, Price FW, Whitson WE (2000) Trends in the indications for penetrating keratoplasty in the Midwestern United States. *Cornea* 19:813–816
17. Dolorico AMT, Tayyari, Ong HV et al (2003) Shortterm and longterm visual and astigmatic results of an opposing 10-0 nylon double running suture technique for penetrating keratoplasty. *J Am Coll Surg* 197:991–999
18. Durson D, Forster RK, Feuer WJ (2002) Suturing technique for control of postkeratoplasty astigmatism and myopia. *Trans Am Ophthalmol* 100:51–60
19. Eisner G (1980) *Eye Surgery: An Introduction to Operative Technique*. Springer, Berlin Heidelberg New York, pp38–40

20. Eliason JA, McCulley JP (1990) A comparison between interrupted and continuous suturing techniques in keratoplasty. *Cornea* 9:10–16
21. Feiz V, Mannis MJ, Kandavel G et al (2001) Surface keratopathy after penetrating keratoplasty. *Trans Am Ophthalmol Soc* 99:159–168
22. Filatov V, Steinert RF, Talamo JH (1993) Postkeratoplasty astigmatism with single running suture or interrupted sutures. *Am J Ophthalmol* 115:715–721
23. Fine M (1962) Technique of penetrating keratoplasty. Symposium on the Cornea. Trans New Orleans Acad Ophthalmol. Mosby, St. Louis, pp 132–142
24. Fine M (1970) Techniques of keratoplasty. *Int Ophthalmol Clin* 10:271–296
25. Gross RH, Poulsen EJ, Davitt S et al (1997) Comparison of astigmatism after penetrating keratoplasty by experienced cornea surgeons and cornea fellows. *Am J Ophthalmol* 123:636–643
26. Heidemann DG, Sugar A, Meyer RF et al (1985) Over-sized donor grafts in penetrating keratoplasty. *Arch Ophthalmol* 103:1807–1811
27. Karabatsas CH, Cook SD, Figueiredo FC et al (1998) Combined interrupted and continuous versus single continuous adjustable suturing in penetrating keratoplasty. *Ophthalmology* 105:1991–1998
28. Lee WB, Mannis MJ, Mehra N et al (2005) Superficial hypertrophic dendriform epitheliopathy: A follow-up series. *Cornea* 25:273–276
29. Lois N, Kowal VO, Cohen EJ et al (1997) Indications for penetrating keratoplasty and associated procedures, 1989–1995 16:623–629
30. Mannis MJ, Tran L, A Panorama, 1789–1999 (1999) In: Mannis MJ, Mannis AA (eds) *Corneal transplantation: a history in profile*. Wayenborgh, Belgium
31. Mannis MJ, Krachmer JH (1981) Keratoplasty: a historical perspective. *Surv Ophthalmol* 25:333–338
32. McNeill JI, Kaufman HE (1977) A double running suture technique for keratoplasty: earlier visual rehabilitation. *Ophthalmic Surg* 8:58–61
33. McNeill JI, Wessels F (1989) Adjustment of single continuous suture to control astigmatism after penetrating keratoplasty. *Refract Corneal Surg* 5:216–223
34. Melles GRH, Binder PS (1990) A comparison of wound healing in sutured and unsutured corneal wounds. *Arch Ophthalmol* 108:546–548
35. Murta JN, Amaro L, Tavares C et al (1994) Astigmatism after penetrating keratoplasty. *Doc Ophthalmol* 87:331–336
36. Musch DC, Meyer RF, Sugar A (1988) The effect of removing running sutures on astigmatism after penetrating keratoplasty. *Arch Ophthalmol* 106:488–492
37. Olson RJ (1988) Prevention of astigmatism in corneal transplant surgery. *Int Ophthalmol Clin* 28:37–45
38. Pettinelli DJ, Starr CE, Stark WJ (2005) Late traumatic corneal wound dehiscence after penetrating keratoplasty. *Arch Ophthalmol* 123:853–856
39. Ramirez M, Hodge DO, Bourne WM (2001) Keratometric results during the first year after keratoplasty: Adjustable single running suture technique versus double running technique. *Ophthalmic Surg Lasers* 32:370–374
40. Roper-Hall M (1985) Control of postoperative astigmatism. *Br J Ophthalmol* 69:348–351
41. Rowsey JJ (1987) Prevention and correction of corneal transplant astigmatism. Trans New Orleans Acad Ophthalmol 35:35–51
42. Serdarevic ON (1994) Refractive corneal transplantation: control of astigmatism and ametropia during penetrating keratoplasty. *Int Ophthalmol Clin* 34:13–33
43. Sedarevic ON, Rneard GJ, Pouliquen Y (1995) Randomized clinical trial of penetrating keratoplasty. *Ophthalmology* 102:1497–1503
44. Stainer GA, Perl T, Binder PS (1982) Controlled reduction of postkeratoplasty astigmatism. *Ophthalmology* 89:668–676
45. Temnycky GO, Lindahl KJ, Aquavella JV (1991) Early visual rehabilitation following keratoplasty using a single continuous adjustable suture technique. *Ophthalmic Surg* 22:208–212
46. Troutman RC (1974) *Microsurgery of the anterior segment of the eye*, vol. 1. Mosby, St. Louis, pp 187–195
47. Troutman RC (1977) *Microsurgery of the anterior segment of the eye*, vol. 2. Mosby, St. Louis, pp 40–41
48. Troutman RC, Willard DE (1965) Management of the aphakic patient. Symposium on cataracts. Trans New Orleans Academy of Ophthalmology. Mosby, St. Louis, pp 261–279
49. Troutman RC, Meltzer M (1972) Astigmatism and myopia in keratoconus. *Trans Am Ophthalmol Soc* 70:265–277
50. Troutman RC, Gaster RN (1980) Surgical advances and results of keratoconus. *Ophthalmology* 90:131–136
51. Van Meter W (1996) The efficacy of a single continuous nylon suture for control of post keratoplasty astigmatism. *Tr Am Ophth Soc* 44:1157–1180
52. Van Meter W, Katz DG (2004) Keratoplasty suturing techniques. In: Krachmer JH, Mannis MJ, Holland EJ (eds) *Cornea*, 2nd edn. Mosby, St. Louis
53. Van Meter WS, Gussler JR, Solomon KD et al (1991) Postkeratoplasty astigmatism control. *Ophthalmology* 98:177–183
54. Wiffen SJ, Maguire LJ, Bourne WM (1997) Keratometric results of penetrating keratoplasty with the Hessburg-Barron and Hanna trephine systems using a standard double-running suture technique. *Cornea* 16:306–313

# Trauma Suturing Techniques

# 7

Marian S. Macsai and Bruno Machado Fontes

## Key Points

- Assess the presence of life-threatening injuries.
- Vision at the time of presentation and the presence or absence of afferent pupillary defect are important prognostic factors in the Ocular Trauma Classification System [1].
- Surgical goals include:
  - Watertight wound closure
  - Restoration of normal anatomic relationships
  - Restoration of optimal visual function
  - Prevention of possible future complications
- Surgical indications:
  - Any perforating injury
  - Any wound with tissue loss
  - Any clinical suspicion of globe rupture requires exploration and possible repair
- Instrumentation:
  - Complete ophthalmic microsurgical tray
  - Phacoemulsification, vitrectomy and irrigation and aspiration machines
  - Variety of microsurgical sutures
- Surgical techniques:
  - Self-sealing wounds or lacerations <2 mm may not require surgical repair.
  - Close perpendicular aspect of the wound first, the oblique aspect second.
  - Avoid wound override.
  - In the zigzag laceration a mattress suture may be needed.
  - In a stellate laceration a purse string may suffice.
  - Extruded vitreous is a strong risk factor for retinal detachment.
- An ideal initial surgical repair may eliminate the need for future reconstruction.
- Monitor patient for postoperative complications.
- Long-term follow up indicated.

## 7.1

### Introduction

Ocular trauma is an important cause of unilateral vision loss worldwide, especially in young people, and surgical repair is almost always challenging [1–7]. A patient with an eye injury may need immediate intervention, and all ophthalmologists who cover emergency patients must have the knowledge and skills to deal with difficult and complex surgeries, as these initial actions and interventions may be determinants for the final visual prognosis [7–15]. One must keep in the mind that the result of the first surgery will determine the need for future reconstruction.

The epidemiology of ocular trauma varies according to the region studied. In the World Trade Center disaster, ocular trauma was found to be the second most common type of injury among survivors [16]. The most common causes of eye injuries include automotive, domestic, and occupational accidents, together with violence. Risk factors most commonly described for eye injuries are male gender (approximately 80% of open-globe injuries), race (Hispanics and African-Americans have higher risk), professional activity (e. g., military personnel), younger age (third decade), low education, contact sports, and failure to comply with safety devices and equipment [1–3, 5, 6, 9, 16–19]. Anterior corneoscleral lacerations, in sites of previous ocular surgery, and posterior ruptures are more common in the elderly as a result of frequent falls.

Any potentially life-threatening injury takes precedence over ocular injuries. The patient should undergo a careful evaluation by qualified emergency medical personnel and severe pain or nausea should be treated to decrease lid squeezing and Valsalva maneuver effects [4, 20–23]. The initial ophthalmologic evaluation is critical. Trauma mechanism and injury characteristics according to the Ocular Trauma Classification System [1, 7] can predict the prognosis and final visual outcomes (Fig. 7.1).

The evaluation of initial visual function is the most important measurement by the initial as visual function is directly related to visual prognosis, and is also important from a medicolegal perspective. The examiner should assess visual acuity with whatever equip-



ment is available and this information must be documented in the patient's chart. In addition, the examiner should assess the pupillary reflex with attention to the presence or absence of an afferent defect. A slit-lamp assessment of the extent of the injury should determine if the cornea is lacerated and whether the lens is clear or opacified. Any opacification may indicate rupture of the lens capsule. Visualization of the posterior pole should be attempted, as the first examiner may be the only one able to obtain a clear view of the posterior segment and their findings must be documented.

**THE OCULAR TRAUMA CLASSIFICATION SYSTEM<sup>1</sup> FOR OPEN-GLOBE INJURIES**

Type	Grade
A Rupture	Visual acuity *
B Penetrating	1. ≥ 20/40
C Intraocular foreign body	2. 20/50 to 20/100
D Perforating	3. 19/100 to 5/200
E Mixed	4. 4/200 to light perception
	5. No light perception†
Pupil	Zone
Positive: relative afferent pupillary defect present in affected eye	I. Isolated to cornea (including the corneoscleral limbus)
Negative: relative afferent pupillary defect absent in affected eye	II. Corneoscleral limbus to 5 mm posterior to the sclera
	III. Posterior to the anterior 5 mm of sclera

\* Measured at distance (20 ft, 6m) using Snellen chart or Rosenbaum near card, with correction and pinhole when appropriate.

† Confirmed with bright light source and fellow eye well occluded.

Fig. 7.1 Ocular Trauma Classification System

**7.2**  
**Surgical Indications**

Surgery is indicated when there is a risk of loss of normal anatomic structure or function of the eye. Indications include partial and/or full-thickness lacerations with aqueous leakage and intraocular tissue extrusion or prolapse. Surgery may be delayed by the patient's medical condition, but is best performed as soon as possible to reduce the risk of complications (such as endophthalmitis, tissue necrosis, and expulsive hemorrhage). A rigid shield is indicated to protect the globe from external pressure in all patients with open-globe

injuries. Topical ocular medications should be avoided because of the risk of intraocular toxicity, and systemic antibiotic prophylaxis should be started immediately. If indicated, tetanus prophylaxis must be updated.

Simple self-sealing wounds or short lacerations (<2 mm) with good tissue approximation, minimal gape, no evidence of intraocular penetration, and no sign of infection or necrosis can be managed with a bandage contact lens and/or tissue adhesive (Fig. 7.2), in addition to topical broad-spectrum antibiotics, cycloplegic, and hypotensive drugs. With this approach the need for sutures is diminished, but patients must be closely followed. An eye shield must be placed, and the patient must refrain from any activity that results in a Valsalva maneuver. This is not a reasonable approach for children and mentally disabled patients.

As a general principle, a surgical plan should be made before surgery, including tissue conservation and iatrogenic damage minimization. However, unexpected intraoperative situations can require a broad spectrum of surgical techniques. To avoid delays during the surgical procedure, the need for special equipment, such as a vitrectomy and/or phacoemulsification machine, should be determined previously. General anesthesia is preferred, as retrobulbar or peribulbar anesthesia may increase the intraocular pressure (IOP) and risk extrusion of intraocular contents. Surgical closure should proceed in a timely manner to decrease the risk of endophthalmitis, avoid tissue necrosis and decrease patient discomfort [23].

Overall surgical goals in ocular lacerations include (1) watertight wound closure, (2) restoration of normal anatomic relationships, (3) restoration of optimal visual function, and (4) prevention of possible future complications (e. g., glaucoma).

The overall goal is to restore the native corneal contour with minimal scarring. Corneal tissue should be conserved as much as possible to avoid wound distortion or misalignment resulting in irregular astigmatism.

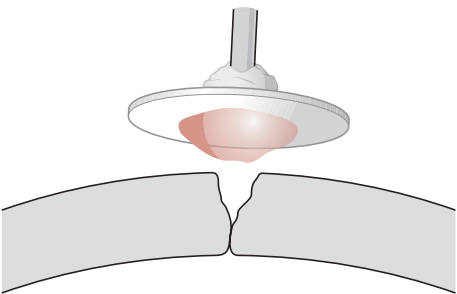


Fig. 7.2 Technique to apply tissue adhesive to small lacerations. A broken wooden applicator with a small cuff of ointment is adherent to a small polyethylene disk. The tissue glue is on the opposite side of the polyethylene disk and is applied to the area of the laceration. The wound must be dry and free of epithelium for the adhesive to stick. Tissue glue will not adhere to a wet or epithelialized surface

tism. If an avulsed piece of viable corneal tissue is present, it should be sutured back into place. Any anatomic landmark (such as pigmentation lines, scars, laceration edges, or the limbus) can help the surgeon identify and restore the eye's normal anatomy. Lacerations should be carefully explored to identify and remove any foreign materials. Infection should be assumed, and the wound and any intraocular samples should be submitted for culture and sensitivity.

### 7.3 Instrumentation and Equipment

- Lid speculum
- Microsurgical 0.12-mm forceps
- Microsurgical tying forceps (two)
- Nonlocking needle holder
- Vannas scissors
- Iris hooks
- Cyclodialysis spatula
- Muscle retractors
- Viscoelastic
- Cellulose sponges
- Tissue glue (when applicable)
- Phacoemulsification, irrigation, and aspiration, and automated vitrectomy units should be immediately available

### 7.4 Surgical Technique

For proper healing, the wound edges should be exactly apposed. Regardless of design, sutures seek (when tightened) their most stable geometric configuration. Therefore, correct passage of a suture is necessary to achieve good wound apposition.

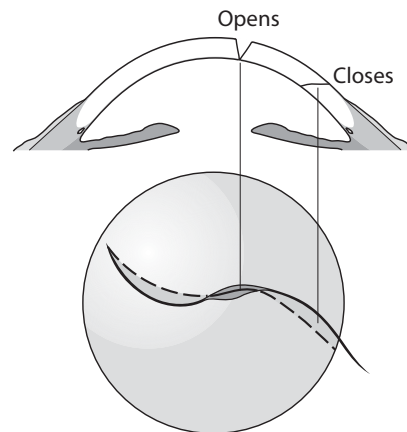
Perpendicular parts of the wound will open under normal IOP, so initial closure of these areas will enhance anterior chamber formation as the shelved areas of the incision are often self-sealing (Fig. 7.3). Temporary sutures may be needed to obtain a watertight closure, and once the shelved areas are closed, the initial sutures may be replaced with more astigmatically neutral sutures. If at all possible, suture bites through the visual axis should be avoided.

Management of prolapsed tissue is one of the initial step as the wound is closed, it is imperative that intraocular contents not be incarcerated in the wound or sutures. Extruded vitreous or lens fragments should be excised at the eye's surface. Retinal and uveal tissue should be gently repositioned if the tissue shows no sign of infection or necrosis. This can be done with a viscoelastic and smooth instruments to avoid additional damage.

#### 7.4.1 Suturing the Cornea

A monofilament suture (nylon or polypropylene) works well in the cornea, because of its low tissue reactivity. Spatulated needles are preferred for maintenance of suture depth in partial-thickness lacerations. The most stable configuration of interrupted sutures is a planar loop, so the tissue contained within the suture can be warped and distorted with inadequate suture tension. For proper placement, the tip of the needle placed perpendicular to the corneal surface, and the needle is rotated through the wound along its curve, exiting perpendicular to the cut surface. Corneal sutures should be 90% deep in the stroma and of equal depth on both sides of the wound. Full-thickness sutures may allow the suture material to act as a conduit for microbial invasion. Suture passes should be approximately 1.5 to 2.0 mm in total length, and the needle pass through the opposite side should mirror the initial needle pass in depth and length. This can be difficult in macerated and edematous tissue, and one must keep in mind the need to incorporate healthy tissue in each suture pass, or else the sutures will pull through the tissue when tied.

Sutures result in wound apposition by compressing the tissues within the loop. Interrupted sutures generate a plane of compression in the tissue contained within the suture loop and a zone of compression extending away from the suture itself. The compression zones have a roughly triangular configuration extending approximately one half the suture total length in either direction along the wound. Wound closure is achieved when compression zones abut. Wound leakage occurs when there is insufficient overlap of compression zones so as to permit wound gape and leakage (see Chap. 1).



**Fig. 7.3** The drawing illustrates the relationship between the perpendicular areas of the laceration and the shelved areas. If the perpendicular areas are closed initially, then the shelved areas are self-sealing and require fewer sutures under less tension



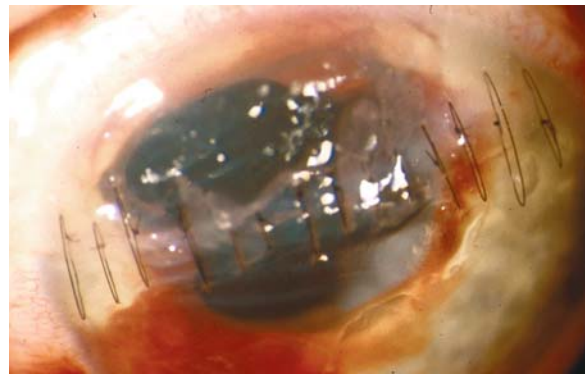
All knots should be trimmed short and superficially buried in the tissue, on the side away from the visual axis [23]. The ends of the buried knot should be directed away from the surface to facilitate subsequent removal. The suture should be tied using the smallest possible knot to facilitate burying of the surgical knot in the tissue. A granny-style slipknot allows for controlled closure of the wound and is small enough to be buried easily [23] (see Chap. 3).

Tissue compression leads to flattening of the overlying surface, and this fact is most important when suturing the cornea. The goal of cornea suturing is to make the wound watertight with minimal scarring and astigmatism. The Rowsey-Hays technique (Fig. 7.4) was developed with this aim [24] as the normal cornea flattens over any vertical or sutured incision, but steepens adjacent to tight limbal sutures. Therefore, corneal lacerations be closed with long, tight sutures in the corneal periphery, and shorter, minimally compressive sutures in corneal center (thus causing peripheral flattening and central steepening) (Fig. 7.5). Long suture bites allow a greater distance between sutures, and smaller bites require more closely spaced sutures, to overlap the zones of compression. But excessive overlap of compression zones can lead to excessive scarring and tissue flattening [20].

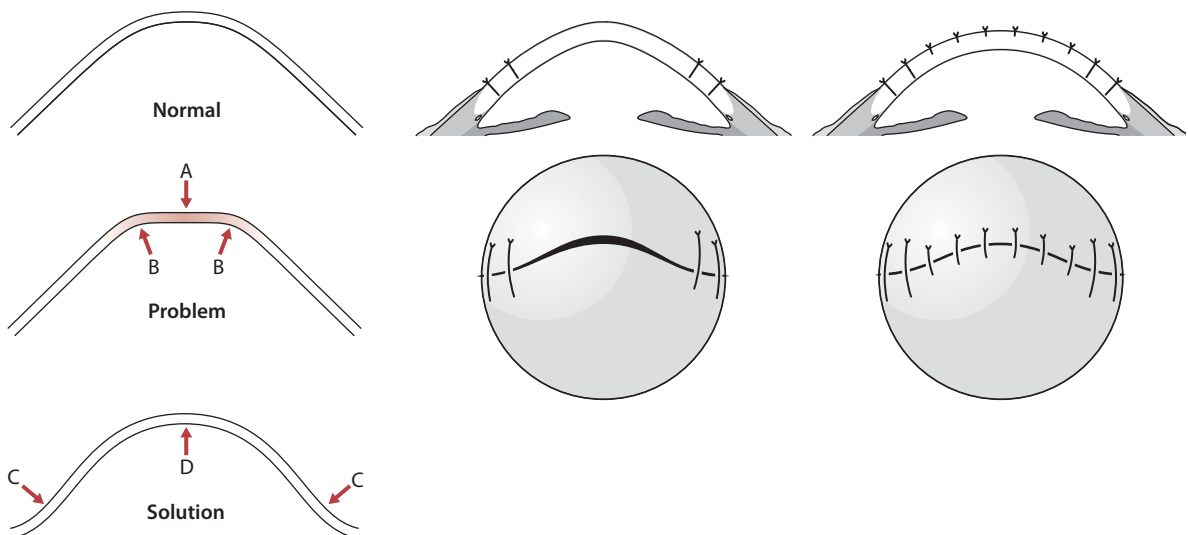
To avoid wound override (Fig. 7.6), the entry and exit of suture bites must be of equal tissue depth. Also, the bites on either side of the perpendicular laceration must be of equal depth from the anterior perspective, and the passage of the suture of equal lengths as gauged from the posterior aspect of the shelved wound not from the anterior view. As a result, the suture place-

ment in a perpendicular laceration will appear very different from the suture placement in a shelved incision. Suture placement is critical to avoid tissue override and the inducement of irregular astigmatism.

Running sutures have more complex effects on contained tissue: a single running suture will cause horizontal wound slippage equal to approximately one half the average suture bite. Running sutures tend to flatten the overlying corneal surface throughout the length of the suture and to straighten curvilinear wounds because of the continuous nature of the compressive effects of running sutures. In addition, closure with running sutures places the integrity of the entire wound on a single suture, which may pose a safety risk. For these reasons, running sutures avoided in traumatic corneal wounds.



**Fig. 7.5** Photograph of an astigmatically neutral closure of a large corneal laceration. The patient recovered 20/40 vision after suture removal



**Fig. 7.4** (A) Small, short bites will flatten the central cornea and create a bend (B) in the paracentral cornea. Placing larger bites in the periphery will steepen the peripheral cornea

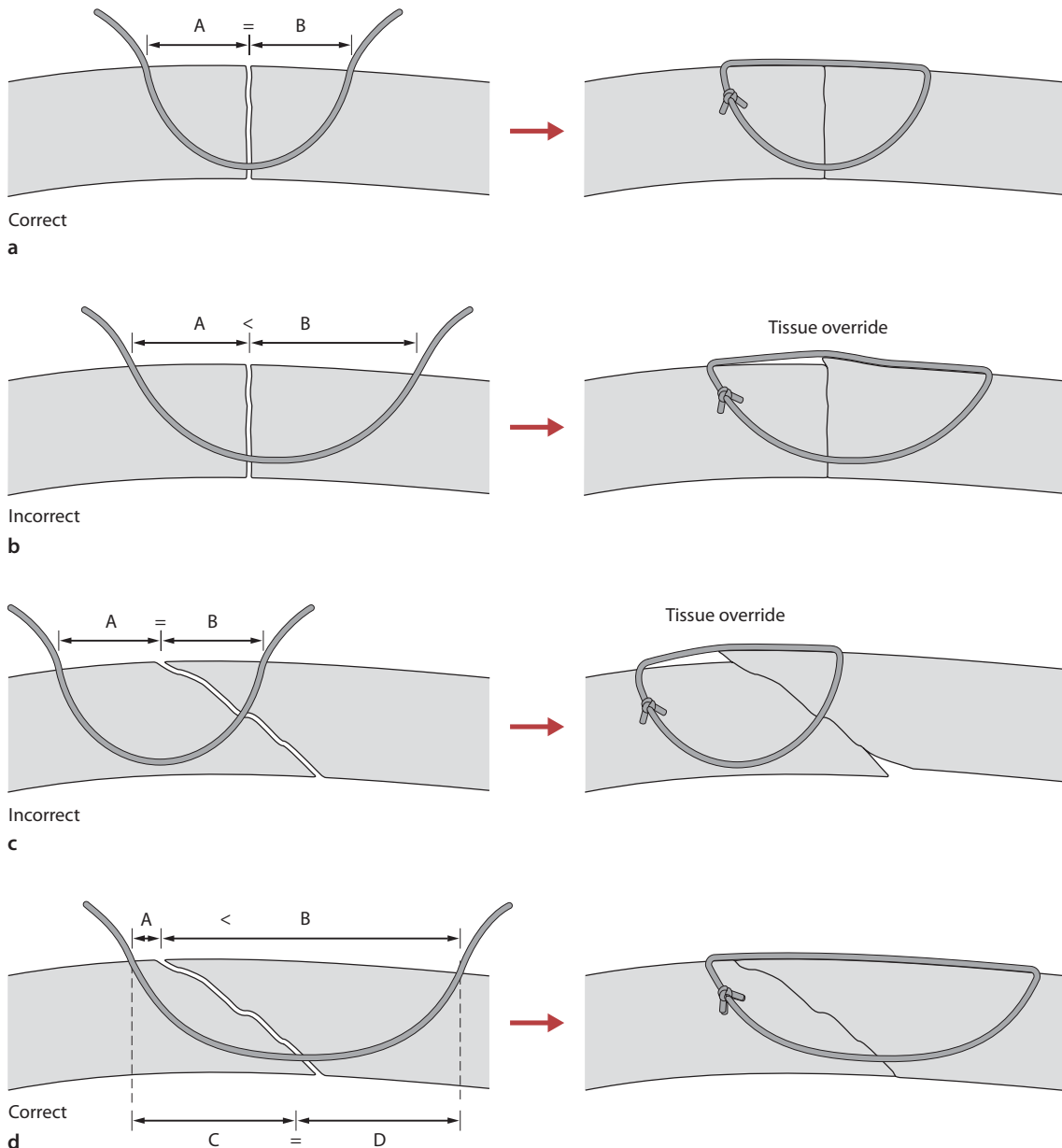
(C), while the small central short bites flatten the central cornea (D), resulting in a more normal cornea curvature.

### 7.4.2

#### Suturing the Zigzag Incision

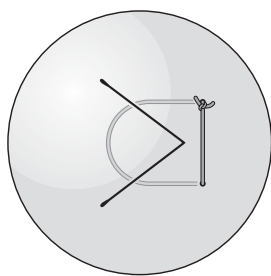
Each linear aspect of the incision should be closed individually to allow self-sealing of the wound apices and avoiding additional trauma. In repairing these lacerations,

the use of slipknots is helpful. The straight aspects of the zigzag incision are closed first with interrupted sutures. The apical portion of the incision may then self-seal (Fig. 7.7). If the apical portions require suture closure, a mattress suture technique [21, 25] (Fig. 7.8) may be useful.

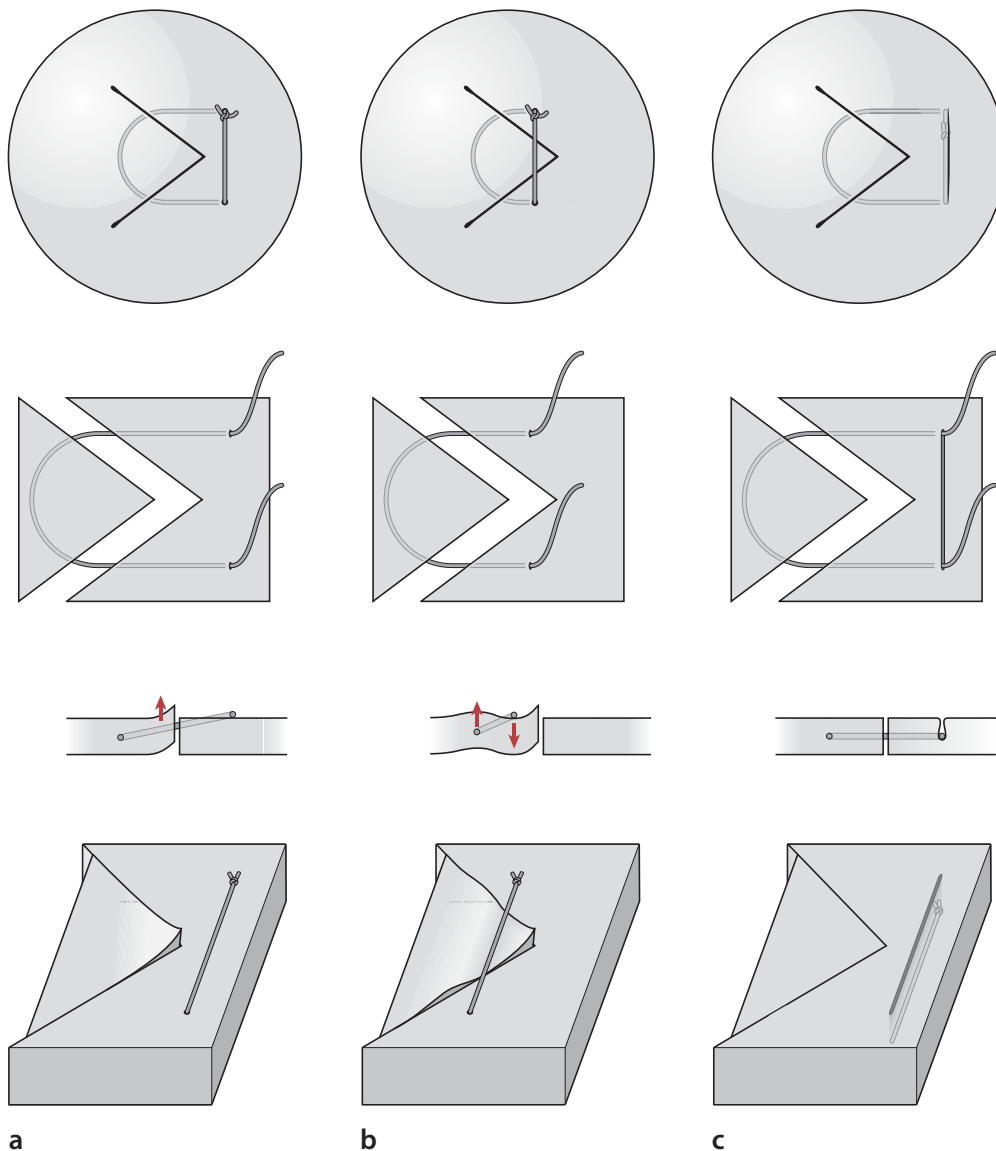


**Fig. 7.6** **a** Correct closure of perpendicular incision. The distance from the point of entry of the suture to the wound (A) is equal to the distance from the wound to the point of exit (B), and the sutures are passed at equal depths. **b** Incorrect closure of a perpendicular wound. The distance from the point of entry to the wound (A) is not equal to the distance from the wound to the point of exit (B). This results in wound override. **c** Incorrect closure of an oblique wound. If the same technique is followed for an oblique wound as is fol-

lowed for a perpendicular wound ( $A = B$ ), tissue override will result. **d** Correct closure of an oblique wound to ensure proper tissue apposition. In this technique, the distance from the point of entry of the suture to the point of exit through the wound (C) should be measured from the posterior aspect of the cornea, and should be equal to the distance from the wound to the point of exit (D) as measured from the posterior aspect of the cornea. As a result,  $C = D$  and  $A \neq B$  as they are measured from the anterior aspect of the cornea



**Fig. 7.7** The linear aspects of the zigzag laceration are closed initially, as the apical portions may be shelved and self sealing



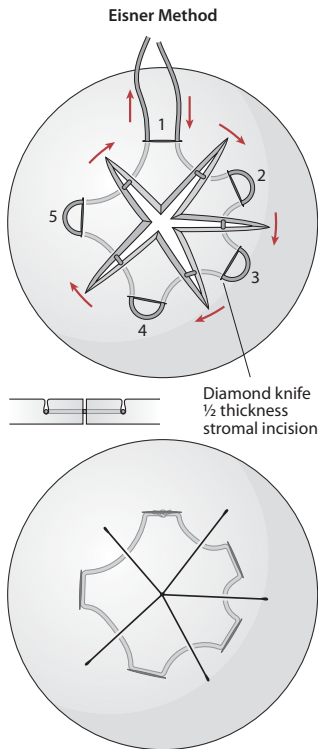
**Fig. 7.8** a A trephine is used to mark the area around the ulcerated area. Trephination is not performed, as the intraocular contents may extrude from the external pressure. b An exceptionally sharp blade is used to cut down to a 50–60% depth. c A lamellar dissection is performed to remove the necrotic tissue. The trephine is then moved to another peripheral area of the same cornea and used to trephine a

50% depth in the healthy peripheral corneal tissue. Lamellar dissection is used to harvest this donor lenticule. d The donor lenticule is secured in position with interrupted 10-0 nylon sutures to close the perforated area. The exposed stroma where the donor lenticule was harvested is allowed to heal by secondary intention, with either patching or a bandage contact lens

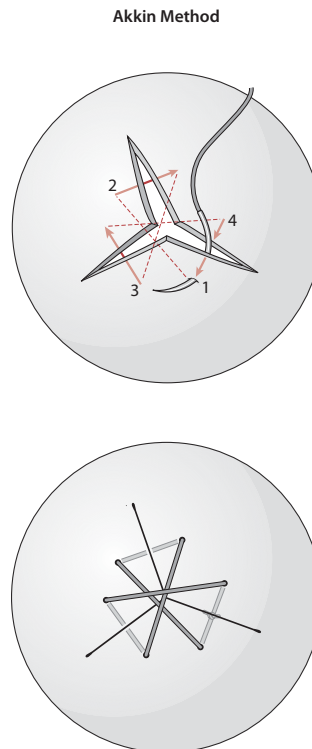
### 7.4.3

#### Stellate Laceration Closure

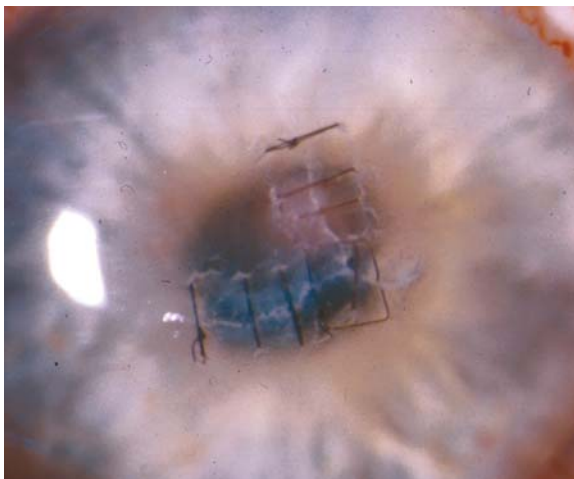
In the stellate laceration, the straight arms of the laceration are closed initially with interrupted sutures. The stellate portion is closed last. Two different techniques may be used including the Eisner method purse string (Fig. 7.9 and 7.10) [25] or the Akkin method (Fig. 7.11) [26].



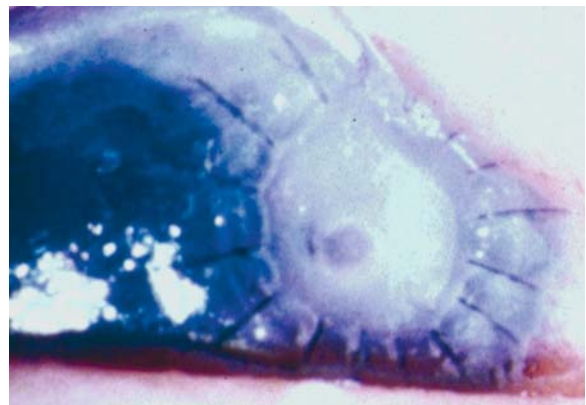
**Fig. 7.9** In the Eisner method, a partial thickness incision is made between the arms of the laceration and a purse-string suture is passed through these grooves and tightened to approximate the apices of the wound. Overtightening of the purse-string suture will result in forward displacement of the apices and wound leakage. The suture is buried when it is tied, and it is left in place indefinitely



**Fig. 7.11** With the Akkin method, no partial thickness groove is made. The suture is passed through the tissue and over the apices of the wound to appose the tissue



**Fig. 7.10** Photograph of an Eisner-style purse-string suture. (Photography courtesy of Dr. Steve Koenig)



**Fig. 7.12** The area around the wound is marked with a trephine, and a partial thickness bed is created with lamellar dissection. An autologous same-size lamellar piece of tissue is harvested from a separate area of the same eye and secured into position with interrupted sutures

tissue loss and donor tissue is not available, and autologous tissue patch graft can be used. A partial thickness trephination is performed over the area of tissue loss to create a bed for the autologous patch graft. A second partial thickness trephination is performed in an area separate from the area of tissue loss and out of the visual axis. Lamellar dissection of the autologous graft is performed, and the tissue is moved to the area of tissue loss and secured into position with interrupted 10-0 nylon sutures. The knots are buried, and the area of tissue loss is sealed. The donor site of the lamellar dissection heals by primary intention.

#### 7.4.4

#### Suturing the Sclera

Scleral lacerations are a special problem as the complete extension of the laceration is not always visible, and careful exploration of the wound is advised. Headlamps and loupes are useful in some situations as the sclera curves away from the horizontal plane and using the microscope is extremely difficult. If possible, the limbus is reapproximated first to restore normal anatomic relationships, using 8-0 or 9-0 nylon interrupted sutures.

To prevent prolapse of intraocular contents, the sclera should be closed in a step-wise fashion—with a limited anterior/posterior dissection and exposure of a small portion of the defect. Closure should be performed at the exposed site with repositioning of the intraocular contents, before further posterior dissection (hand-over-hand technique) is performed.

When dealing with separated edges, closure is facilitated by regrasping the needle after passage through the proximal wound edge. Extruded intraocular contents may be repositioned by the assistant with a spatula while the surgeon regrasps the needle and passes it through the distal wound edge. As the suture is tied, the intraocular contents are held in place by the assistant with the use of a blunt spatula. If the wound intersects a muscle insertion, the muscle may be disinserted to continue closure of the defect and reattached once the wound is closed. A small malleable retractor can be used to improve visibility.

Scleral lacerations are best repaired with polyglactin (Vicryl) sutures. Uveal tissue must be handled with extra care, and every effort made to preserve it. Prolapsed vitreous should be excised to minimize traction to the vitreous base and retina. In one study [3], extruded vitreous from scleral lacerations was found to be a strong risk factor for retinal detachment. These patients need close postoperative serial peripheral fundus examinations to rule out tractional detachments.

Injuries with tissue loss sometimes require replacement with either fresh or preserved donor scleral tissue. It is necessary to excise necrotic or infected tissue be-

fore graft placement to achieve success. The same technique can be used as described for the autologous corneal patch graft; however, donor sclera should be used.

Scleral lacerations that extend far posteriorly (near the optic nerve) are best managed by observation, as the surgical approach may increase tissue prolapse and cause additional damage. The orbital soft tissue serves to tamponade the wound as it heals. The prognosis in these cases is guarded.

## 7.5

### Complications

#### 7.5.1

#### Iris Damage

Iris wounds can lead to several complications, such as excess light scatter (leading to refractive issues), synechiae formation, secondary glaucoma, cystoid macular edema, prolonged inflammation, bleeding, and an undesirable cosmetic appearance. Prolapsed iris should be repositioned and the wound freed of incarcerated iris strands. Viscodissection may facilitate iris repositioning and future reconstruction of the iris diaphragm.

There is no “magical” time at which iris can safely be repositioned, but general recommendations indicate that 24 to 36 h is the maximal safe period. Necrotic, infected, and/or macerated iris tissue should be excised during surgery, no matter how long the tissue has been extruded from the eye. Signs of surface epithelialization indicate the need for excision.

Pharmacologic manipulation of the iris (dilating or myotic agents) may be useful, as well as indirect pressure with viscodissection in the anterior chamber to cause further deepening. If direct mechanical (surgical instruments) manipulation of the iris is needed, one must try to work from the center toward the periphery in order to minimize tension on iris root, thereby reducing the risk of bleeding (major arterial circle of the iris) and iridodialysis. Grasping the iris with a fixation forceps produces force in two directions, one tractional force moves toward the iris root, and the other extends to the pupil margin [27].

When excision is necessary, the iris tissue must be carefully inspected to ensure that the ciliary body is not involved. Trauma to the ciliary body can lead to serious bleeding. A surgical peripheral iridectomy in the area in which peripheral iris incarceration was relieved may minimize the risk of peripheral anterior synechiae formation [20]. The location of the surgical iridectomy should be considered. If created superiorly, the lid may cover the iridectomy and eliminate any resultant glare however, in the inferior aspect of the eye a surgical iridectomy may result in visually significant glare.



Reconstructive iris surgery can be accomplished either primarily or secondarily. In most cases excessive iris manipulation should be avoided at the initial repair. This helps prevent vigorous inflammation and other complications. Iris repair can be performed once the eye is less inflamed as a separate surgery.

Cataract formation either at the time of the initial trauma or postoperatively is a common complication, and its treatment will depend on several factors including: presence of intraocular foreign body, anterior and/or posterior synechiae, vitreous in the anterior chamber, retinal and/or vitreous involvement, corneal clarity, zonular integrity, and others. Every case should be independently assessed, but as a general rule, lens material in the anterior chamber must be removed. If the lens capsule is not ruptured, cataract surgery should be delayed until the initial trauma related inflammation has subsided.

## 7.5.2

### Wound Leak

Wound leak is a common post operative complication in ocular trauma. It is related to the quality of the first surgery repair, tissue necrosis, edema, infection, or an increase in IOP. The best course of action depends on each individual case: resuturing, topical and/or systemic medications, bandage contact lens, tissue glue, IOP lowering medications, and/or observation. With every technique, there is always a risk of fistula formation.

## 7.5.3

### Other Complications

#### 7.5.3.1

##### Endophthalmitis

Posttraumatic endophthalmitis is a sight-threatening condition, occurring in approximately 4 to 8% of open-globe injuries [29]. It can be a devastating complication following open-globe injuries, and the visual prognosis is related to the setting of injury (rural settings have a worse prognosis) rupture of the crystalline lens, presence of foreign bodies (type and size), time between trauma and surgery, positive intraocular cultures, and the virulence of the microorganism [8, 29].

#### 7.5.3.2

##### Necrosis

Necrosis of ocular and/or intraocular contents is directly related to delayed primary closure and infection of the tissues. The surgeon must assess the viability of

ocular tissues and decide to maintain or excise tissues during the surgery.

#### 7.5.3.3

##### Expulsive Hemorrhage

This catastrophic complication can occur during surgical repair, and the patient must be informed of this risk. Fortunately, this is a rare occurrence. Causative factors include the open-sky surgery and systemic hemodynamic factors.

#### 7.5.3.4

##### Glaucoma

Posttraumatic glaucoma can occur due to several mechanisms, including cyclodialysis, retinal hemorrhage, vitreous loss, intense inflammation, hyphema, infection, and others. IOP should be assessed (after globe reconstruction) at every visit, and prompt treatment initiated when necessary.

#### 7.5.3.5

##### Retinal Detachment

This is a serious complication after open-globe injuries, related to foreign bodies, infection, vitreoretinal proliferation, and direct retinal injury. Serial fundus evaluations should be performed, when possible, by a retinal specialist.

#### 7.5.3.6

##### Epithelial Downgrowth

This rare complication can occur relative to delayed primary wound closure and several anterior segment surgeries. It induces an almost untreatable glaucoma with a guarded visual prognosis.

#### 7.5.3.7

##### Amblyopia

Amblyopia can occur in children with open-globe trauma. Treatment is often difficult, and family support is critical. When possible, comanagement with a pediatric ophthalmologist is preferable.

#### 7.5.3.8

##### Hyphema

The most common finding after open-globe trauma that requires treatment is a hyphema [28]. It is associated with both blunt and open-globe trauma. It can induce elevated IOP and glaucoma and should be promptly treated with cycloplegics, hypotensive drugs, and topical steroids. Surgery is necessary in selected cases.



### 7.5.3.9

#### Irregular Astigmatism

Irregular astigmatism occurs relative to the type of laceration, as well as with the surgical technique used in the primary repair. Diagnosis is confirmed by clinical evaluation and corneal topographic maps. Treatment is achieved with specacles, a contact lens and/or corneal surgery.

### 7.5.3.10

#### Blindness

Despite all efforts, some patients evolve to blindness.

## 7.6

### Future Challenges

Despite marked improvement in medical training, advanced microsurgical techniques and access to the newest generation of equipment and technologies, open-globe injuries continue to be a leading cause of severe visual loss. General safety precautions, behavior modification, and consistent use of eye protection devices (e. g., use of safety glasses) could prevent much of the morbidity associated with eye injuries.

All medical records, including history, physical examination, and operative reports, should be recorded meticulously. In complex cases, the primary goal is to save the eye, and restoration of vision is a secondary objective.

To avoid frustration, the attending physician should discuss the severity of the injuries and the visual prognosis with the patient and family members (Ocular Trauma Classification System [1]). Several surgeries and long-term follow-up may be needed in order to achieve the best anatomical and optical results. However, careful attention to wound repair and microsurgical suturing techniques during the primary repair may negate the need for future surgical intervention.

## References

1. Pieramici DJ, Sternberg P, Jr., Aaberg TM, Sr., et al. A system for classifying mechanical injuries of the eye (globe). The Ocular Trauma Classification Group. *Am J Ophthalmol* 1997;123:820–831.
2. Andreotti G, Lange JL, Brundage JF. The nature, incidence, and impact of eye injuries among US military personnel: implications for prevention. *Arch Ophthalmol* 2001;119:1693–1697.
3. Fontes BM, Principe AH, Mitne S, Pwa HWT, Moraes NSB. Seguimento ambulatorial de pacientes vitimas de trauma ocular aberto. *Rev Bras Oftalmol* 2003;62:632–629.
4. Harlan JB, Jr., Pieramici DJ. Evaluation of patients with ocular trauma. *Ophthalmol Clin North Am* 2002;15:153–161.
5. Kuhn F, Morris R, Mester V, Witherspoon CD, Mann L, Maisiak R. Epidemiology and socioeconomic. *Ophthalmol Clin North Am* 2002;15:145–151.
6. May DR, Kuhn FP, Morris RE, et al. The epidemiology of serious eye injuries from the United States Eye Injury Registry. *Graefes Arch Clin Exp Ophthalmol* 2000;238:153–157.
7. Pieramici DJ, Au Eong KG, Sternberg P, Jr., Marsh MJ. The prognostic significance of a system for classifying mechanical injuries of the eye (globe) in open-globe injuries. *J Trauma* 2003;54:750–754.
8. Jonas JB, Knorr HL, Budde WM. Prognostic factors in ocular injuries caused by intraocular or retrobulbar foreign bodies. *Ophthalmology* 2000;107:823–828.
9. Kuhn F. Strategic thinking in eye trauma management. *Ophthalmol Clin North Am* 2002;15:171–177.
10. Kuhn F, Maisiak R, Mann L, Mester V, Morris R, Witherspoon CD. The Ocular Trauma Score (OTS). *Ophthalmol Clin North Am* 2002;15:163–165, vi.
11. Kuhn F, Morris R. The terminology of eye injuries. *Ophthalmologica* 2001;215:138.
12. Kuhn F, Morris R, Witherspoon CD, Heimann K, Jeffers JB, Treister G. A standardized classification of ocular trauma. *Graefes Arch Clin Exp Ophthalmol* 1996;234:399–403.
13. Kuhn F, Morris R, Witherspoon CD, Heimann K, Jeffers JB, Treister G. A standardized classification of ocular trauma. *Ophthalmology* 1996;103:240–243.
14. Kuhn F, Morris R, Witherspoon CD, Mester V. The Birmingham Eye Trauma Terminology system (BETT). *J Fr Ophthalmol* 2004;27:206–210.
15. Kuhn F, Slezak Z. Damage control surgery in ocular traumatology. *Injury* 2004;35:690–696.
16. Sobaci G, Akyn T, Mutlu FM, Karagul S, Bayraktar MZ. Terror-related open-globe injuries: a 10-year review. *Am J Ophthalmol* 2005;139:937–939.
17. Kuhn F, Collins P, Morris R, Witherspoon CD. Epidemiology of motor vehicle crash-related serious eye injuries. *Accid Anal Prev* 1994;26:385–390.
18. Kuhn FC, Morris RC, Witherspoon DC, et al. Serious fireworks-related eye injuries. *Ophthalmic Epidemiol* 2000;7:139–148.
19. Sobaci G, Mutlu FM, Bayer A, Karagul S, Yildirim E. Deadly weapon-related open-globe injuries: outcome assessment by the ocular trauma classification system. *Am J Ophthalmol* 2000;129:47–53.
20. Brent GJ, Meisler DM. Corneal and Scleral Lacerations, 3rd ed. In: Brightbill FS, editor. *Corneal surgery: theory, technique and tissue*. St. Louis: Mosby, 1999:553–563.
21. Brightbill FS. Corneal surgery: theory, technique and tissue, 3rd ed. St. Louis: Mosby, 1999:xxii, 942 s.
22. Krachmer JH, Mannis MJ, Holland EJ. *Cornea*. St. Louis: Elsevier–Mosby, 2005.
23. Macsai MS. Surgical Management and Rehabilitation of Anterior Segment Trauma, 2nd ed. In: Krachmer JH, Mannis MJ, Holland EJ, editors. *Cornea*. St. Louis: Elsevier–Mosby, 2005:1829–1854.
24. Rowsey JJ, Hays JC. Refractive reconstruction for acute eye injuries. *Ophthalmic Surg* 1984;15:569–574.
25. Eisner G. Eye surgery: an introduction to operative technique, 2nd, fully rev. and expanded ed. Berlin Heidelberg New York: Springer, 1990:xiv, 317 p.
26. Akkin C, Kayikcioglu O, Erakgun T. A novel suture technique in stellate corneal lacerations. *Ophthalmic Surg Lasers* 2001;32:436–437.
27. Macsai MS. Iris Surgery, 3rd ed. In: Brightbill FS, editor. *Corneal surgery: theory, technique and tissue*. St. Louis: Mosby, 1999:563–570.
28. Kuhn F, Mester V. Anterior chamber abnormalities and cataract. *Ophthalmol Clin North Am* 2002;15:195–203.
29. Lieb DE, Scott IU, Flynn HW, Jr., Miller D, Feuer WJ. Open globe injuries with positive intraocular cultures: factors influencing final visual acuity outcomes. *Ophthalmology* 2003;110:1560–1566.

# Iris Reconstruction

# 8

Steven P. Dunn and Lori Stec

## Key Points

### Surgical Indications

- Decreased visual acuity
- Incapacitating glare
- Photophobia
- Diplopia
- Cosmesis

### Instrumentation

- Contact lens
- Argon laser
- Polymethyl methacrylate (PMMA) pupil ring
- Intraocular iris prosthesis
- Polypropylene suture

### Surgical Technique

- Laser iridoplasty
- Suture iridopexy
- Pupil shaping with PMMA dilating ring
- Insertion of single-piece prosthetic iris with intraocular lens (IOL)
- Insertion of multipiece prosthetic iris

### Complications

- Glaucoma
- Iritis
- Subluxation of IOL
- Decreased vision
- Intraocular hemorrhage

scope and microsurgical instrumentation, were not readily available. Drops, sutures, various lasers, tattoo pigments, and tinted intraocular lenses are some of the approaches available today. This chapter discusses the surgical anatomy and healing response of the iris as well as a variety of approaches for use when reconstruction is necessary.

## 8.2

### Iris Anatomy and Wound Healing

The unique characteristics of the iris, its structure, and response to disease and injury make an appreciation of iris anatomy and wound healing of particular importance when contemplating iris repair.

The structure of the normal human iris consists of two parts, the anterior stroma and the posterior double-layered pigmented epithelium. Between these layers are sandwiched the iris dilator and sphincter muscles (Fig. 8.1). The stroma, in contrast to other ocular structures, has a very loose, discontinuous architecture. The anterior surface is made up of stromal cells, fibrocytes, and melanocytes. These cells have no defined linkage to one another and are separated by very large intercellular spaces. The intercellular space contains a few collagen fibrils, ground substance, and aqueous humor. Within the stroma is a loosely organized mix of melanocytes and iris blood vessels. The only continuous cell layer is found at the posterior surface of the iris, and it is formed by the sphincter muscle ring, the dilator myofibrils, and the pigment epithelium. The muscle cells of the iris sphincter form a dense mass adjacent to the pupil. The dilator muscle originates and is thickest near the iris root and thins as it extends toward the pupillary edge (Table 8.1).

Clinical and pathologic studies indicate that traumatic and surgical iris wounds do not heal spontaneously. When a gap occurs in the iris (i. e., iridotomy), and no bridging scaffold exists for stromal cells, pigment cells, or fibroblasts to migrate across, scarring between the margins of the defect does not occur. Clinical observations have raised the question of whether true wound healing occurs or whether a mechanical apposition of the wound margins is all that

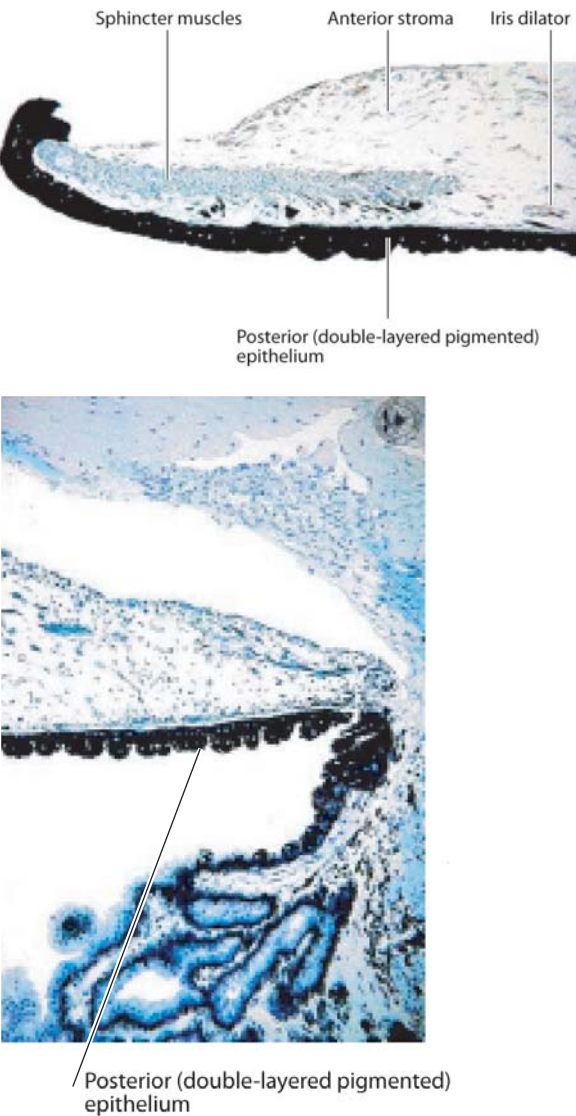
## 8.1

### Introduction

The function of the iris as a light-limiting diaphragm has been recognized for several thousand years. Initial attempts to modify the iris and pupil were pharmacologic in character. The concept of surgically modifying or repairing the iris did not receive much attention until 1917, when Key first wrote about his efforts at repairing an iridodialysis by suturing the iris edge to the sclera. Iris-to-iris repair was first described by Emmertich in 1957. Neither of these contributions attracted significant attention when initially published. In large part this was because suitable equipment to facilitate surgical reconstruction, namely the operating micro-

**Table 8.1** Standard measurements of the iris

Diameter	12 mm
Circumference	37.5 mm
Thickness: region of the iris root	0.2 mm
Thickness: region of the collarette	1.0 mm
Pupillary diameter	1.2–9.0 mm
Width of the sphincter muscle	0.6–0.9 mm
Thickness of the pigment epithelium: miosis	12 $\mu$ m
Thickness of the pigment epithelium: mydriasis	50–60 $\mu$ m



**Fig. 8.1** Histologic cross section of pupillary and peripheral portions of the iris.

takes place. Research in primates and human pathologic specimens indicates that iris wounds do not show any healing tendency or formation of scar tissue except in the area immediately surrounding an iris suture. At the site of the iris suture, there is a faint scar with activated fibroblasts, a few plasma cells and macrophages, but very little collagen deposition. Long-term apposition of an iris wound thus appears to be wholly dependent on the presence of sutures. If a significant fibrinoid reaction occurs, a cyclitic membrane may form, leading to “closure” of an iris defect. This, however, does not lead to the reestablishment of normal iris architecture or to the formation of a collagenous scar, and can result in further pathology.

### 8.3 Nonsurgical Approaches

This chapter is devoted to the surgical management of iris defects; however, it is worth emphasizing that many iris problems require no treatment or can be managed nonsurgically. Nonsurgical approaches to iris repair include the use of miotics and contact lenses. Miotics such as pilocarpine have minimal effect on the peripheral iris. Pupillary margin defects and traumatic paralytic mydriasis also respond poorly or not at all to strong miotics. For the sphincter muscle to constrict the pupillary opening, it must be able to pull against another structure. Under normal circumstances, it pulls against itself; however, when it is transected or a portion is missing, there is nothing against which the muscle can work. Alpha-2 agonists such as brimonidine have been used to temporarily induce miosis (without significant myopia or brow ache) in post-refractive surgery patients suffering from halos associated with enlarged pupils.

Long before contact lenses became a consumer commodity, custom labs were manufacturing them in various materials for therapeutic purposes. They were initially designed with a black pupillary zone and tinted periphery to hide corneal scars. Subsequent designs with a clear pupillary zone and opaque periphery became available for use in patients with aniridia and partial iris loss. Design parameters for these custom lenses are infinite. In many cases, the pupil diameter can be custom-designed to produce a near-pinhole effect if glare is significant. The need for the peripheral opaque portion of the lens to extend to the limbus often necessitates the use of soft and rigid gas-permeable contact lenses with large diameters. The greater gas permeability of today’s lens materials has had a major affect on the success of these lenses. Whereas most lenses have a paint/tint schema that is concentric in nature, focal painting/tinting can be done using truncated lenses.

## 8.4

### Surgical Indications

Many iris abnormalities, both congenital (albinism, aniridia, and coloboma) and acquired (traumatic mydriasis, aniridia, and iridodialysis) benefit from surgical intervention after nonsurgical options have been exhausted.

Modification or repair of the iris is indicated in three clinical settings. The first of these, and by far the most common, is associated with functional difficulties such as glare, photophobia, and/or diplopia. These optical symptoms are caused by an enlarged pupillary opening secondary to trauma, surgery or a congenital defect. An intact and functioning iris diaphragm decreases aberrations arising from the periphery of the lens. Traumatic or congenital aniridia is the ultimate example of pupil enlargement. A symptomatic paracentral or peripheral iridotomy or iridectomy would constitute the opposite extreme. The functional difficulties that these anatomic distortions present can often be confirmed by occlusion with the lid, the strategic obstruction of an iridotomy or sector iridectomy with a cotton applicator or the use of an opaque contact lens with a small, clear pupillary zone.

The second indication for repair is restoration of the iris diaphragm as part of a multifaceted surgical reconstruction. A large iris defect might require closure to support an anterior chamber intraocular lens. If a posterior chamber lens is implanted, the edges of an iris defect might be drawn together in an effort to reduce postoperative glare or diplopia (either because of the enlarged pupillary opening itself or as a result of light striking the lens edge). The removal of an iris lesion might be combined with iris reconstruction if enough iris is left to facilitate a primary repair. Corneal transplant surgeons will surgically tighten a loose, floppy iris diaphragm during penetrating keratoplasty to reduce the risk of the iris shifting forward, adhering to the endothelial surface and producing broad peripheral anterior synechiae and secondary glaucoma.

The third clinical situation, and by far the rarest, is repair of an iris defect for cosmetic purposes. The risks of surgery, the uncertainty of the final operative appearance, and the availability of excellent cosmetic contact lenses make this an uncommon surgical indication.

## 8.5

### Surgical Technique: General Considerations

The surgical management of an iris defect may involve alterations to the cornea, reconstruction or manipulation of the iris, or insertion of an opaque barrier in the lenticular plane. The decision as to which approach may be most beneficial depends on a variety of factors,

the first of which is a detailed history of the condition causing the iris defect and the various treatments, medical and surgical, that have produced the present picture.

Factors that should be determined preoperatively include the amount of iris that is missing, the amount of iris that remains, and the specific portion of iris that remains (i. e., collarette versus midperipheral). The character of the iris tissue is important to assess. Are multiple transillumination defects present? Is there schisis or delamination of the iris? Is there fraying of the surface or iris edge? Is rubeosis or abnormal vascularization present? The presence or absence of peripheral anterior synechia (PAS), lens capsule, iridocapsular adhesions, or iris or vitreous incarceration in old surgical or traumatic wounds must to be determined preoperatively.

Evaluation of the lens should determine if a cataract is present. If aphakic, it is important to look for a capsular ring with maximal dilation. If an intraocular lens is present, the type, placement, and stability of the intraocular lens should be assessed. When the results of slit-lamp examination are inconclusive, the angle, iris thickness, and posterior chamber can be evaluated by high frequency ultrasound biomicroscopy (UBM) or anterior chamber optical coherence tomography (OCT).

The overall integrity of the corneal surface, including surface staining, corneal sensation, and Schirmer testing, should be determined. The clarity of the cornea, the presence or absence of corneal edema or guttata, and an endothelial cell count are important factors to measure when planning a surgical approach. The central and peripheral corneal thickness should be evaluated by slit-lamp examination and measured ultrasonically if thinning or thickening is present.

The information resulting from these investigations will often illuminate other issues that affect the choices available for effective surgical management. A thickened cornea with guttata and signs of epithelial or stromal edema, or a low endothelial cell count suggest future corneal decompensation and the possible need for a corneal transplant. A low-grade, chronic uveitis may not only be the source of some of the patient's complaints, but may reduce the intraocular options for the patient and require treatment in advance.

Iris surgery, despite the most thorough preparation, is not always successful. At times one's best efforts may result in a tattered and frayed iris. Even when initially successful, the suture may gradually erode through the iris, resulting in reopening of the defect in part or full. Close attention to the anatomy of the iris (thickest at the collarette), the preoperative documentation of atrophic areas and areas of transillumination, careful full-thickness placement of sutures, and awareness of the amount of tension that the iris tissue is being subjected to is paramount.



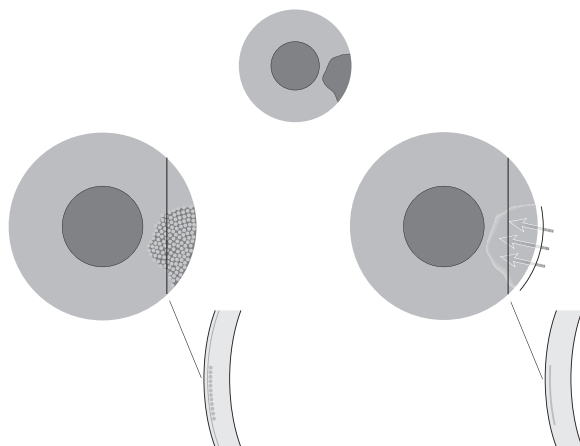
## 8.6

### Surgical Technique: Instrumentation

Monofilament polypropylene is now considered to be the best suture material for iris surgery. It has a smooth, snag-resistant finish; limited memory; and resists degradation. The particular reconstructive technique used will dictate the length, shape, and type of needle point to be used. A needle with a cutting tip and a tapered body (taper cut) is the least destructive as it passes through the iris (a BV needle). The tapered body does not cause further side cutting of the tissue as the needle passes through. Distortion of the iris should be avoided even when a tapered needle is used, since it will often lead to stretching or tearing of the suture tract (see Table 2.2, Chap. 2). A paracentesis, full-entry wound, or partial-thickness scleral flap is necessary with this needle because of the large amount of force necessary to push these needles through the sclera. Side-cutting spatula tip needles are necessary for piercing the cornea or sclera, but are prone to creating a larger slit rather than a small puncture as they pass through the iris.

In many situations, traditional tying techniques can be used to appose the iris. Closed-system repairs, however, often necessitate the use of alternative tying techniques that involve slipknots, such as that proposed by Siepser (see Sect. 8.7.5) or intraocular knot manipulation using long fine forceps or intraocular lens (IOL) manipulators.

Care must be exercised when handling the iris. The less iris tissue manipulation with forceps, the better. Flat, toothless forceps should be used and then only by grasping the full-thickness iris wound edge. Forceps with teeth are likely to tear the iris. Similarly, grasping the iris on its anterior surface may lead to shredding of the surface because of the loose linkage of stromal cells with one another.



**Fig. 8.2** Corneal tattooing: micropuncture and lamellar technique

Goniosynechiolysis with a flat, blunt-tipped spatula may free iris that has been trapped by PAS or captured within a prior wound. Care (and patience) needs to be exercised when lysing synechiae, as the instrument tip is not visible and can easily tear the iris, create a cyclo-dialysis, or trigger significant bleeding. An intraoperative goniolens for closed-system work or a small-diameter dental mirror for open-system work is extremely helpful. Goniosynechiolysis is best utilized when limited areas of PAS exist and the iris is not “floppy” in character. Large areas of PAS can be lysed; however, the exposed surfaces often re-adhere like two pieces of flypaper.

Vitreous on the anterior or posterior surface of the iris, pupil or angle must be removed before surgical reconstruction is attempted. Mechanical vitrectomy must carefully and completely remove the vitreous from the iris. Incarceration of vitreous into sutures or the wound may result in traction and possible retinal tears, detachment or macular edema in the post operative period.

Viscoelastic dissection should be used to deepen the anterior chamber and to help separate the iris from the underlying lens, capsule, or pseudophakos. The direction of instillation is important in that the viscoelastic can be used to the surgeon’s advantage to unfurl the iris (or, inadvertently, twist it further if one is not paying close attention).

## 8.7

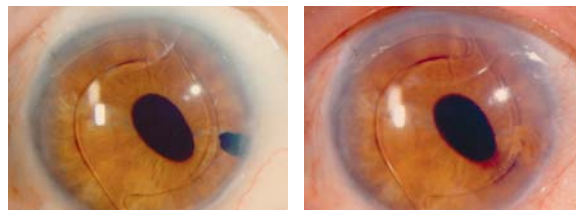
### Surgical Approaches

#### 8.7.1

##### Corneal Tattooing

Corneal tattooing has been used for centuries to treat cosmetically objectionable corneal leukomas.

The original technique involved imbedding India ink or carbon particles in the anterior and midstroma by a process similar to corneal stromal puncture (Fig. 8.2). Often the procedure had to be repeated in order to achieve the desired distribution and density of pigment. Over time the pigment tended to migrate from the puncture wounds, and the procedure needed re-



**Fig. 8.3** Corneal tattooing before (left) and after (right) the procedure. (Photo courtesy of Mark Mannis, M.D.)

peating. Given these problems, an alternative method was developed involving the creation of a lamellar pocket or flap into/under which pigment is instilled. This technique is easily adapted to almost any type, size, and shape of iris defect. The density and color distribution of the pigment can be varied according to the demands of the case.

One drawback of corneal tattooing is that the pigment (particularly when a densely pigmented, discretely edged tattoo is applied) often appears to be “stuck on” the surface of the cornea. This lack of depth is not a major problem when functional issues are the primary concern, but may be significant when cosmetic issues are paramount (Fig. 8.3).

### 8.7.2 Laser Iridoplasty

Since its introduction in 1958, the argon laser has been used to treat a variety of ocular diseases and disorders. Cleasby was one of the first to describe how the argon laser could be used effectively to alter the size, shape, and position of the pupil in cases of miosis, up-drawn pupil, or cyclitic membrane [1]. Most techniques advocate the application of laser spots at the pupillary margin or overlying the region of the collarette, causing destruction to the sphincter either physically or functionally (through denervation) [2].

Laser iris sphincterotomy by linear incision was promoted by Wise in 1985 to permanently alter the size, shape, and location of the pupil. Less of the iris required treatment, and as a consequence, less energy was required as compared with earlier techniques. The argon laser (0.02-s exposure, 50- $\mu$ m spot size, 800–1,500 mW) can be used to cut across the iris sphincter fibers in a radial line. Laser spots should be confined to the stroma, allowing the deep pigment epithelium to be pulled apart by iris tension. Treatment of the deeper stromal layers with a reduced exposure time of 0.01 s can minimize damage to the lens. The radial pull of the dilator muscle fibers are normally countered by the contracted sphincter muscles. Linear cuts with the laser across the sphincter leave the dilator fibers unopposed, facilitating pupillary mydriasis [3].

### 8.7.3 Intraoperative Pupil Dilators and Maintainers

The miotic pupil that fails to respond to mydriatics preoperatively creates a number of significant technical difficulties for the ophthalmic surgeon planning cataract or vitreoretinal surgery. An increased incidence of intraoperative complications is associated with this problem. The three-pronged Beehler pupil

dilator as well as bimanual stretching of the pupil using a push-pull technique provides temporary intraoperative enlargement of a miotic pupil. Mechanical pupil dilatation is often required when the above measures are ineffective, a very large papillary opening is required, or a prolonged procedure is anticipated. Multiple iris-retraction hooks can be rapidly and easily placed providing adequate exposure and pupil stability for lengthy operative procedures. The Morcher polymethyl methacrylate (PMMA) pupil-dilator ring or the Greather 2000 pupil expander can enlarge an otherwise-small pupil to 7.5 mm by acting as a “collar,” maintaining a fixed pupillary opening throughout the case ([4]; Fig. 8.4).

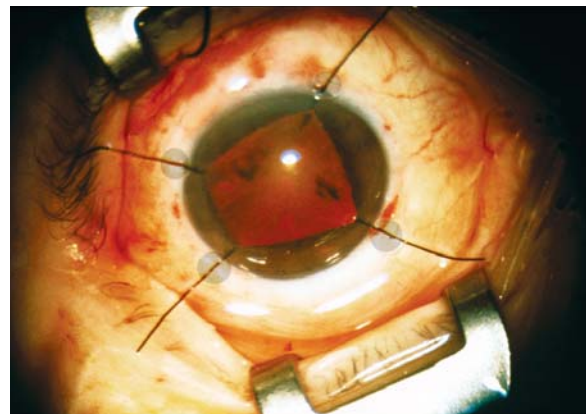
The pupil dilator ring and iris hooks are both temporary in nature. Perhaps, some variation of one or both of these will find clinical use as a permanent means of mechanically enlarging a miotic pupil in the future.

### 8.7.4 Iridoplexy for Coloboma Repair

Suture closure of iris defects can be handled in a number of ways.

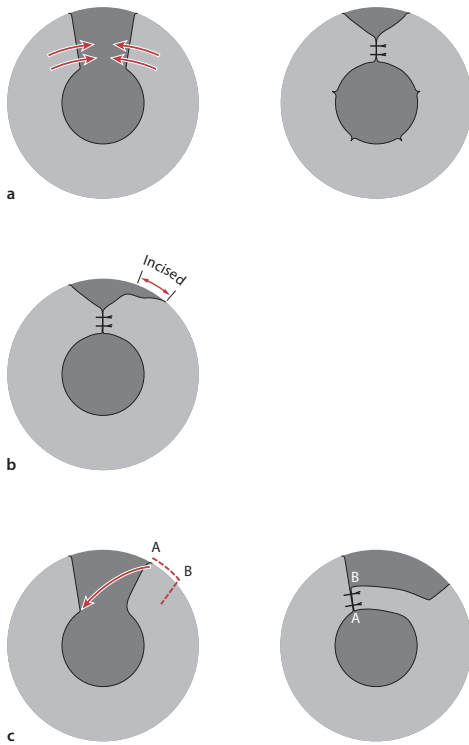
A small coloboma, as might occur following removal of a 1- to 2-mm lesion at the pupillary margin, can usually be drawn together with either one or two full-thickness sutures placed through the iris sphincter. One suture should be placed close to the edge to limit the amount of nicking that might develop postoperatively, the other suture within the sphincter itself. If the coloboma extends toward the iris root, then additional sutures may be required (Fig. 8.5a).

The management of a larger coloboma that extends to the iris root is much more difficult. A sector iridectomy may be closable at the pupil margin by one or two carefully placed sutures. It is rare, however, that the more peripheral portions can be pulled together com-

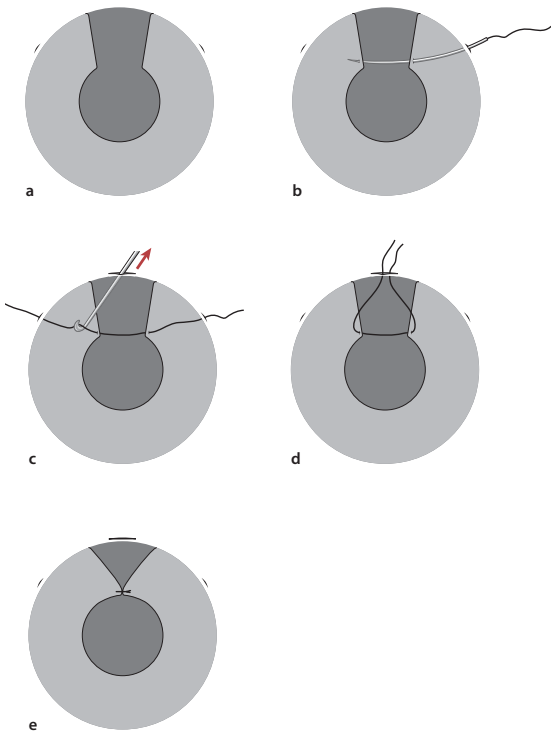


**Fig. 8.4** Intraoperative pupil enlargement. Iris hooks (*top*), Morcher pupil expander (*bottom*)





**Fig. 8.5** Iridopexy techniques: **a** Basic closure technique, **b** circumferential incision technique, and **c** rotating segment technique



**Fig. 8.6** An iridopexy technique: closed-system, single-armed, peripheral approach (McCannel technique)

pletely. If there is too much tension at the pupillary border, multiple small sphincterotomies evenly placed along the inner circumference of the pupil may be needed. Ignoring excess iris tension will usually lead to cheese-wiring of the suture and the production of a secondary iris defect. A circumferential incision at the root of the iris, to either side of the coloboma, will help to mobilize the iris (Fig. 8.5b). The pupillary edges of the coloboma may then be brought together, leaving a basal, eyebrow-shaped coloboma in the periphery. A rotational flap of iris tissue can also be used to help bridge a large coloboma (Fig. 8.5c). Thickened capsular remnants can sometimes be used to bridge a gap or simply as a backing material to give the reconstruction more stability. As yet, there is no artificial iris material that can be used for this purpose.

Various open- and closed-system suturing techniques can be adapted for repairing a large coloboma if adequate tissue is present. Wound tension (and indirectly the presence of sufficient tissue) is often the critical issue affecting one's ability to surgically repair an iris defect.

#### 8.7.4.1

##### Closed-System, Single-Armed, Peripheral Approach

A popular closed-system approach (McCannel technique) involves the creation of two paracenteses at the limbus at either end of a projected line that is perpendicular to the edge of the iris defect. A long, thin needle with a 10-0 polypropylene suture is then introduced through the entry site (Fig. 8.6a). The anterior chamber is filled with hyaluronic acid or viscoelastic introduced through the other paracentesis. If the hyaluronate is injected posterior to the iris edge, the uveal tissue can be “nudged” toward the tip of the needle. The needle is then passed through the iris edge on both sides of the wound, assisted by gentle counterpressure from the blunt tip of the hyaluronic acid cannula (Fig. 8.6b). The tip of the needle may be lodged in the open bore of the cannula—using it as a guide to both penetrate the iris and remove the needle via the opposite paracentesis. A full-thickness stab incision is made through the peripheral portion of the cornea between the paracenteses sites. A small hook is introduced through this incision, and both ends of the suture are brought out, tied together, cut flush, and then repositioned (Fig. 8.6c–e). This can be repeated as many times as needed to properly close an iris defect [9].

Shin modified McCannel's technique using a 1.6-cm 25-gauge hypodermic needle attached to a tuberculin syringe instead of a long thin needle. The hypodermic needle tip should pierce the proximal iris wound margin from anterior to posterior, and the distal wound edge from posterior to anterior before exiting through the opposite limbus (Fig. 8.7a). A 10-0 polypropylene suture can be threaded into the lumen

of the 25-gauge needle and passed through to its bevel (Fig. 8.7b). The 25-gauge needle is then removed, leaving the polypropylene suture in place. Retrieval of the suture with hooks and closure of the iris coloboma through a third incision is similar to the standard McCannel technique [10].

Siepsier further modified McCannel's technique by using only two paracentesis and a slipknot (see Fig. 5.3, Chap. 5). The 10-0 polypropylene suture is passed according to the technique described above. A large loop of suture is left externally at either end. A Bonds or similar microhook is then introduced; a loop of suture is taken from the opposite side of the anterior chamber and brought out through the entry paracentesis. A double-throw slipknot is then placed, and both suture ends are pulled outwards, drawing the knot back into the eye and apposing the iris edges. A second knot is made in a similar fashion to lock the first knot in place. The suture ends are trimmed with fine intraocular scissors [11]. This procedure can be repeated along the length of the iris defect if necessary.

#### 8.7.4.2

##### Closed-System, Double-Armed, Peripheral Approach

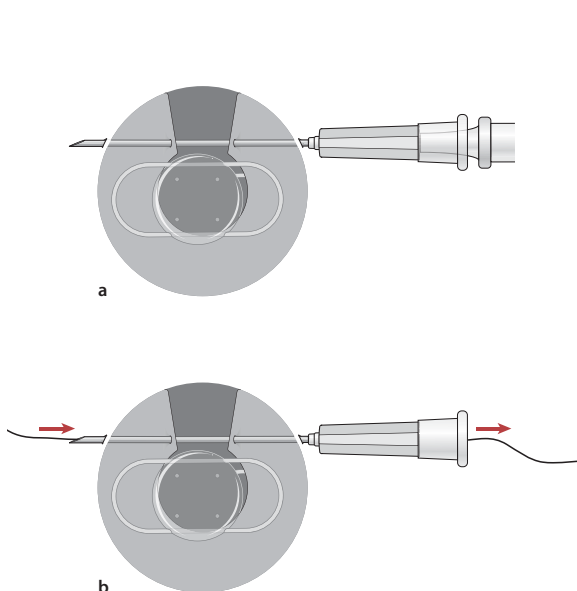
An iris coloboma can be closed via a single limbal incision, using a double-armed suture technique. Pallin described an approach in which a stab incision is made in the clear cornea peripheral to, but overlying, an iris defect. Each needle of a double-armed 10-0 polypropylene suture is passed through the corneal stab incision and then through opposite edges of the sector iris defect at the pupillary border (Fig. 8.8a, b). Each needle

end is then passed through clear limbal cornea adjacent to the iris base. A long needle with a moderate curve to it (such as the CIF-4 or bent straight needle) is needed to accomplish this without excessive distortion of the cornea. A paracentesis and cannula or a needle with open bore can greatly assist in the passage of the needle through the peripheral cornea. Retrieval of the suture with hooks and closure of the iris coloboma through the corneal incision is similar to the standard McCannel technique (Fig. 8.8c). This procedure can be repeated as needed distal to the pupillary border for complete closure of the iris defect [13].

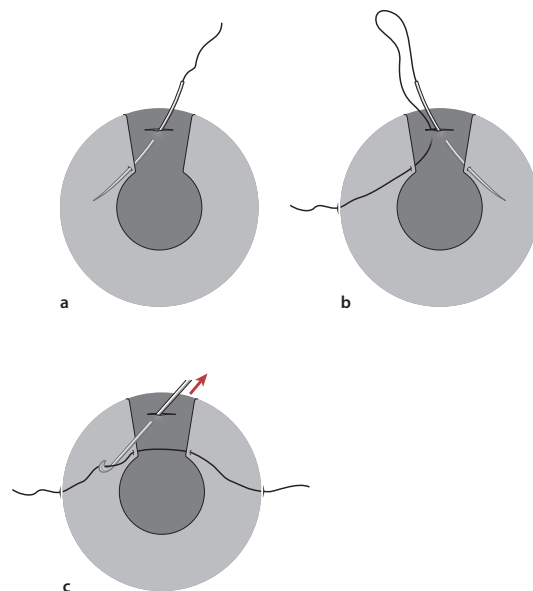
#### 8.7.4.3

##### Lasso Technique

This last technique is a lasso suture with three entry/manipulation "ports" and can be used for postoperative atonic pupils or traumatic mydriasis. Three 1.0-mm limbal or clear corneal stab incisions are made at 9, 5, and 1 o'clock (termed nos. 9, 5, and 1). After filling the anterior chamber with viscoelastic, a PC-7 needle (or similar) with a 10-0 polypropylene suture is inserted through no. 9. Forceps usually used for epiretinal membrane peeling are inserted through no. 1. The iris is grasped with the forceps at 10 o'clock and pulled centrally. The first bite is placed peripheral to the pupillary edge. This is repeated, making a continuous row of three to four suture bites in the lower part of the iris toward no. 5 (Fig. 8.9a, b). The forceps are withdrawn, and a blunt cannula is inserted into the anterior chamber at no. 5 to act as a guide to smoothly withdraw the needle tip from the anterior chamber. The



**Fig. 8.7** An iridopexy technique: closed-system, single-armed, peripheral approach (Shin modification)

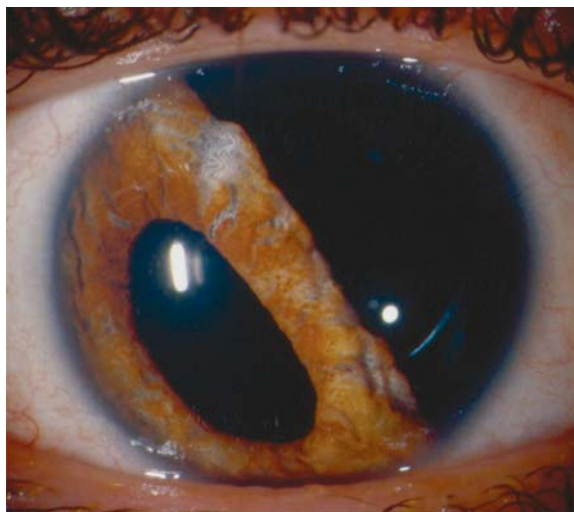

**Fig. 8.8** An iridopexy technique: closed-system, double-armed, peripheral approach (Pallin technique)

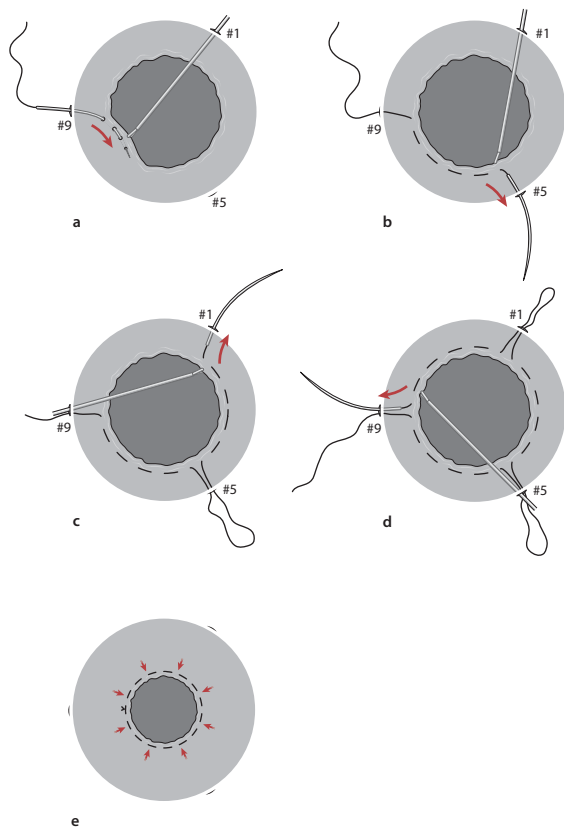
above steps are repeated to make a continuous loop from no. 5 to 1 and then from no. 1 to 9 (Fig. 8.9c, d). At the conclusion of these maneuvers, the ends of the suture will be coming out of no. 9. The suture tension can be adjusted for the desired pupil size prior to tying the final knot (Fig. 8.9e; [14]).

A special situation exists in keratoplasty cases where the free edge of a coloboma or a floppy, atonic iris may become adherent to the posterior edge of the graft–host junction. Peripheral anterior synechiae in the keratoplasty patient may become broader and “zipper” the angle, causing secondary glaucoma. Although the mechanism for this problem is not fully understood, progressive PAS is a rare finding when the iris diaphragm is intact, underscoring the importance of repairing iris colobomas in this group of patients.

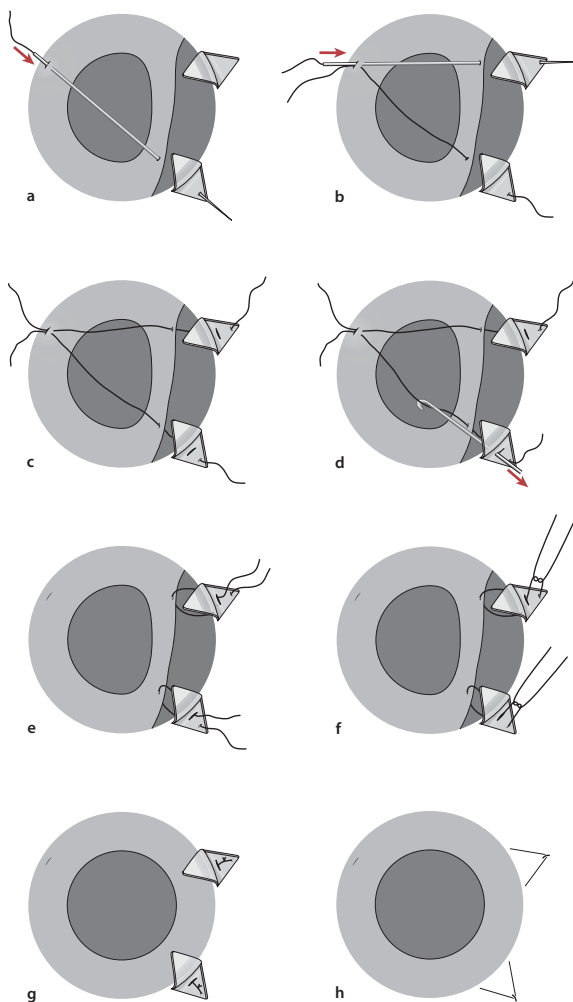
The techniques described above are easily adapted to an open-sky approach. In addition, iris flaps hinged at the collarette can be fashioned from the edge of the coloboma and used to bridge the gap. The end result should be a tight iris diaphragm with little anterior–posterior movement. One cautionary remark: If mobilization of the iris requires dissecting the iris off the endothelial surface peripherally or goniosynechialysis, then the raw



**Fig. 8.10** Large iridodialysis



**Fig. 8.9** Lasso technique



**Fig. 8.11** An iridodialysis technique: closed-system, single-armed, cross-pupil approach

surfaces produced have a tendency to act like two adhesive surfaces—attracting one another and re-apposing themselves, often with even more extensive adhesions.

### 8.7.5

#### Iridopexy for Iridodialysis Repair

Small iridodialyses rarely require repair unless they occur in the horizontal meridian and cause disabling glare or diplopia. When surgery is required, a single suture is often adequate to reduce symptoms. More than one suture, however, may be required to ensure full closure. Larger iridodialyses are frequently repaired for cosmetic as well as optical reasons. In these cases, refixation of the iris at two or more peripherally points is necessary. The presence of vitreous in the anterior chamber or in the vicinity of the iris defect must be recognized preoperatively and removed prior to suture placement.

Numerous techniques have been proposed to correct large iridodialyses (Fig. 8.10). Many are slight variations of one another. Techniques vary according to whether they are closed chamber in character and

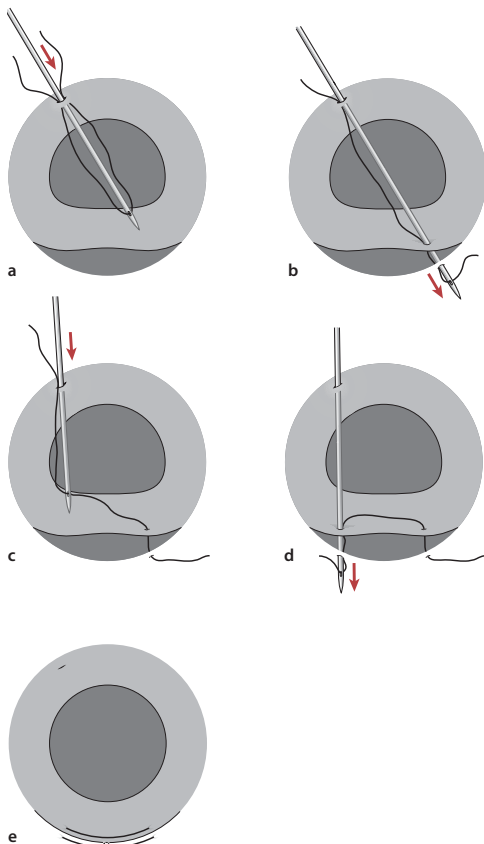
whether the needle crosses the pupil. While simple in concept, they often turn out to be more challenging than thought at first glance. This may relate as much to where the iridodialysis is (i. e., inferior or nasal) or to difficulties “spearing” the iris or suture tear-out (pulling through the iris tissue). A bimanual approach is often necessary in order to stabilize the iris enough for the needle to pass through it. A floppy iris edge has a tendency to “run away” from the needle point. One must keep in mind that the anatomy of these eyes may be altered as a consequence of the process (often traumatic) that led to the iridodialysis.

The following are a summary of some of the surgical approaches used to repair an iridodialysis.

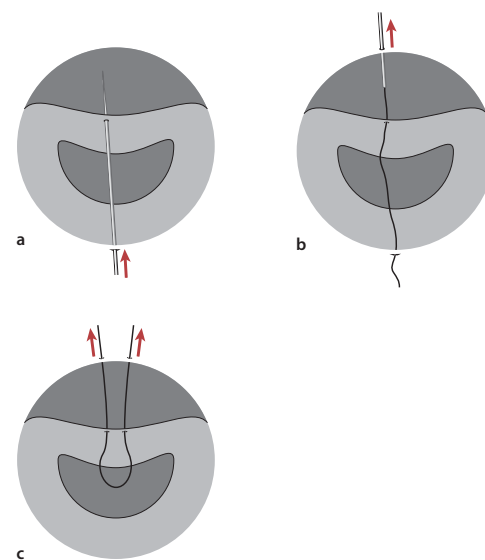
#### 8.7.5.1

##### Closed-System, Single-Armed, Cross-Pupil Approach

A 17-mm single-armed straight needle with 10-0 polypropylene suture is passed through a paracentesis site located 180° away from the iridodialysis. The needle is passed across the chamber, through the torn iris edge, and out through the sclera at the point of normal iris insertion. The needle exits beneath a large preplaced scleral flap (Fig. 8.11a, b). A second paracentesis site is then created just above the suture exit site (beneath the flap). An iris hook is then passed through this second entry site and used to retrieve the other end of the polypropylene suture (Fig. 8.11c–g). The suture is tied, buried, and the flap re-apposed (Fig. 8.11h). Additional flaps and exit–entry sites need to be created if additional sutures are to be placed [5]. This technique has more incisions than other techniques; however, it does



**Fig. 8.12** An iridodialysis technique: closed-system, thread-needle, cross-pupil approach (Bardak technique)



**Fig. 8.13** An iridodialysis technique: closed-system, double-armed, cross-pupil approach

allow for a bimanual approach if counter pressure is needed to spear the iris edge. As with the double-armed suture approach discussed below, a needle has to be passed over the unprotected pupil.

Bardak describes a modification of this technique using a 22.0-mm, 26-gauge hypodermic needle through which a 9-0 or 10-0 suture can be thread after it has been passed through the iris edge and out beneath the opposite scleral flap. (Fig. 8.12a-e; [6]). An MVR blade modified with a 0.4- to 0.6-mm hole at the tip can also function similarly [7].

### 8.7.5.2

#### Closed-System, Double-Armed, Cross-Pupil Approach

This technique involves performance of a peritomy in the area of the iridodialysis and a paracentesis 180° away. A 17-mm double-armed straight needle with 10-0 polypropylene suture is used. One needle is passed through the paracentesis, engaging the peripheral, torn iris root before exiting the sclera at a distance of 1.0- to 1.25-mm peripheral to the surgical limbus (Fig. 8.13a, b). The other needle of this double-armed suture engages the iris 1.0- to 1.5-mm lateral to the first suture and exits the globe in the same plane as the first, but 1.5- to 2.0-mm laterally (Fig. 8.13c). The two sutures are tied, and the knots are rotated into the needle tract. Alternatively, the needles may be brought out in the base of a previously made groove, and the knots cut short [8]. The principal risks/difficulties of this approach relate to the need for good control of the needle when passing the tip of the needle across the pupil.

### 8.7.5.3

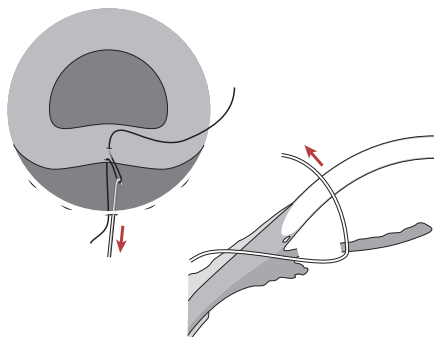
#### Closed-System, Single-Armed, Peripheral Approach

A second closed-system approach (McCannel technique) involves the creation of a peritomy in the quadrant of the iridodialysis. A number of full-thickness incisions measuring 1.0-mm wide are placed equidistant along the length of the iridodialysis, 1.0 mm be-

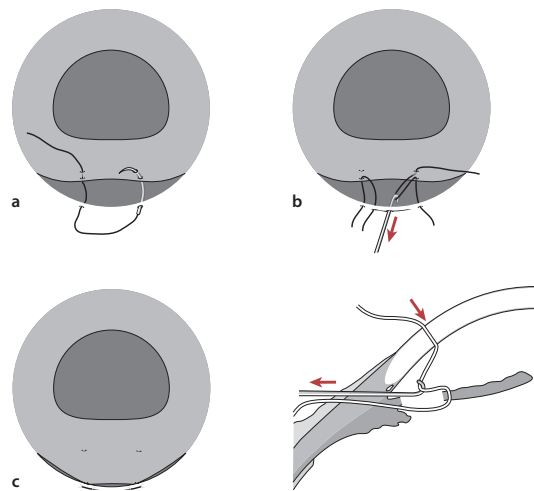
hind the limbus. A long, thin needle with 10-0 polypropylene is passed through a scleral incision, catching the edge of the incision as one enters the eye. The iris edge is then caught with the point of the suture, and the needle is then passed out of the eye through the cornea or a second scleral incision (Fig. 8.14). An iris hook is then passed through the first incision, and the suture caught and drawn out. The suture is tied to itself after drawing the iris edge to the posterior scleral edge. This can be repeated as many times as needed to properly reposition the iris [9]. A variation of this using a double armed suture has also been described (Fig. 8.15).

A variation of the above technique is worth considering if the peripheral iris edge has not retracted very far centrally. After entering the eye with a MVR blade and creating a 1.0- to 1.5-mm opening, viscoelastic is instilled on either side of the iris. An iris hook or fine retinal forceps are carefully advanced beneath the iris, catching the iris edge and drawing it out through the opening. A 10-polypropylene suture is then passed through the edge of the scleral incision, through the iris, and then through the opposite scleral edge. The iris is then repositioned in the anterior chamber and the wound closed. Care should be taken not to incarcerate the iris in the wound in order to avoid formation of a fistula tract in the postoperative period. Grasping the iris and drawing it into the paracentesis site may be more difficult than one might expect.

A second variation involves the creation of one large or multiple small scleral flaps in the region of the iridodialysis. A 30-gauge straight needle threaded with a 10-0 polypropylene is passed through the bed of the scleral flap and through the peripheral edge of the iris. Twenty-five-gauge retinal forceps entering from a more lateral paracentesis can be used to unfurl the iris and assist in passage of the needle through the iris (Fig.



**Fig. 8.14** An iridodialysis technique: closed-system, single-armed, peripheral approach (McCannel technique)



**Fig. 8.15** An iridodialysis technique: closed-system, double-armed, peripheral approach



8.16a). Once the suture is through the iris, the forceps grasp the suture, allowing the needle to be withdrawn. A second 25-gauge forceps or iris hook is then advanced through a paracentesis adjacent to the initial entry site, and the suture is withdrawn. The suture is then tied and the knot buried beneath the scleral flap (Fig. 8.16b). This approach can be repeated as many times as necessary to properly reposition the iris [10]. One advantage of this approach is that the needle is not passed over the pupil/lens. A disadvantage is that the surgeon needs to reach into the eye with forceps or an iris hook to grasp the suture, iris edge, or both.

#### 8.7.5.4

##### Open-System, Peripheral Approach

The final approach is an open-system approach in which a full-thickness scleral incision is made in the quadrant of the iridodialysis. Forceps or an iris hook is then used to grasp or “snag” the iris edge and draw it to the wound edge to be sutured to the sclera. The principal disadvantage of this approach is the large wound that is necessary (often 90–180°), the greater risks associated with an open eye, longer wound healing, wound instability, and increased astigmatism postoperatively.

#### 8.7.6

##### Intraocular Prostheses

The concept of implanting an anterior chamber lens with an optic surrounded by a colored diaphragm was first described in 1959 by Choyce [15]. Since then, Sundmacher (in cooperation with Morcher GmbH of Germany) has developed a series of posterior chamber

black diaphragm lenses specifically for use in patients with congenital or acquired aniridia (partial or complete), traumatic mydriasis and albinism [16]. These pseudophakic lenses have gone through a number of modifications and are available in different aperture (3.5, 4, and 5 mm) and optic diameters (7 × 10-mm elliptical, 8, 9.64, and 10 mm). The lenses can be capsular supported or sewn in, using haptic loops provided for this purpose (Fig. 8.17a–c).

Morcher black diaphragm lenses have not been Food and Drug Administration (FDA)-approved; however, they are available from Morcher on a case-by-case basis with approval of an investigational review board. There are several case series in the literature with long-term follow-up [17–19].

Ophtec BV is currently doing FDA trials with a similar lens. This is a single piece, non-foldable posterior chamber aniridic lens with a brown, blue, or green peripheral diaphragm [20, 21]. Ophtec is also evaluating a multipiece iris prosthetic system with components that can be inserted through a small incision and assembled inside the eye.

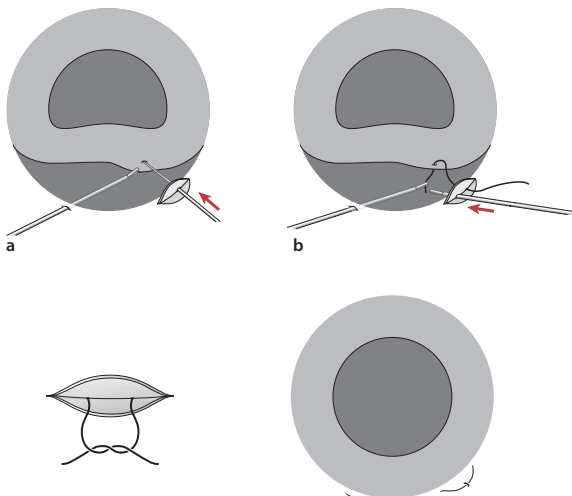
These lenses have significantly reduced postoperative glare dysfunction in aniridic patients and, as a consequence, have been associated with improvement in visual function. Low-grade intraocular inflammation and glaucoma are problems that have been reported with these lenses. It is unclear, however, if these problems are related to the lens, or to the underlying conditions and circumstances that have lead to the need for these specialized intraocular lenses.

A segmented opaque capsular tension ring is also available from Morcher and can be used to selectively block peripheral iris defects (areas of atrophy or an old peripheral iridectomy/iridotomy) (Fig. 8.18). These rings can be implanted into the capsular bag at the time of cataract extraction, or into the sulcus in an eye already containing a posterior chamber intraocular lens. The rings come in different configurations and can be combined to achieve even greater effect: Two rings can be rotated against one another to form a complete peripheral ring if required. Osher described six cases of cataract surgery combined with implantation of a variety of Morcher aniridia devices. Black iris diaphragm rings or iris segments were inserted through a small incision and assembled inside the capsule along with a posterior chamber intraocular lens [22].

#### 8.8

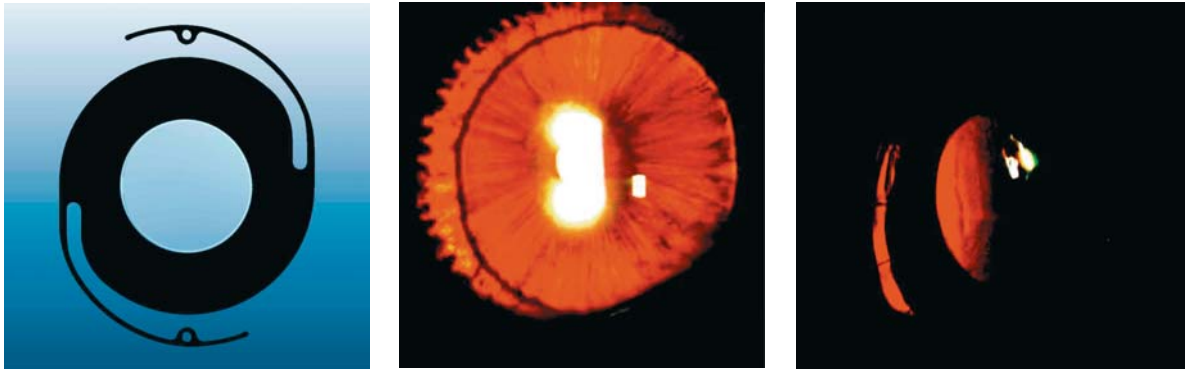
##### Complications

Surgical complications during or following suture iridoplasty are not distinctly different from those of other types of intraocular surgery. Hemorrhage, though, is a frequent complication. All patients should stop aspi-


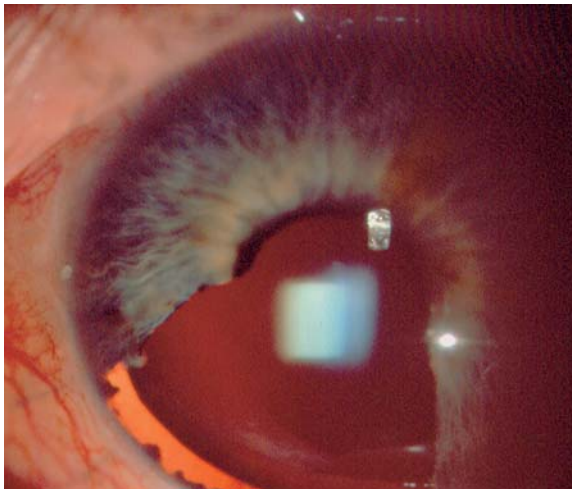


**Fig. 8.16** An iridodialysis techniques: closed-system, single-armed, peripheral approach





**Fig. 8.17** Aniridic intraocular lenses (IOLs) (Morcher GmbH) Preoperative photo of an aniridic eye prior to placement of the IOL. Postoperative photo of the same aniridic after placement of the IOL



**Fig. 8.18** Iris occlusive segments for correction of sector iris defects at or following cataract surgery.

rin, nonsteroidal antiinflammatory drugs (NSAIDs) and other anticoagulants at least 7 days prior to surgery. The peripheral iris (fortunately) does not contain many large blood vessels; however, the iris root and ciliary body are quite vascular and prone to bleeding. A fine-tip intraocular cautery is very helpful when increasing the intraocular pressure (with air, saline, or viscoelastics) fails to halt the bleeding. Epinephrine in the irrigating solution may be of some benefit. Supra-

choroidal hemorrhages may occur. Hyphemas and vitreous hemorrhage may develop within the first 24–48 h after surgery, even when bleeding was minimal (or easily brought under control) at the time of surgery.

Cyclodialysis clefts may be present as a result of the original problem and should be looked for preoperatively. Excessive traction on the iris or efforts at releasing PAS may result in the formation of a cyclodialysis cleft at the time of surgery. This often occurs in an area 180° away from the original iridodialysis.

Failure to recognize the presence of vitreous in the area requiring reconstruction can have devastating consequences. Intraoperatively, vitreous may interfere with suture passage and knot tying. Postoperatively, the resultant vitreous traction may result in chronic intraocular inflammation, or retinal detachment.

The vast majority of patients who require iris reconstruction have either a congenital abnormality of the iris or have sustained some form of surgical or traumatic injury to their eye. These eyes are abnormal in both obvious and not-so-obvious ways. Contact lenses may induce old blood vessels to recanalize. The tissue overlying peripheral tattooing may break down or become vascularized; the pigment may gradually diminish in density. A good understanding of the diaphanous nature of the tissue, the full extent of the injury, and the limitations that these impose on reconstruction is paramount to successful surgery. Complications associate with specific techniques are discussed in the various sections above. As emphasized in the surgical techniques section, the surgeon who is unprepared is likely to be extremely frustrated during surgery and disappointed with the result. It is not unusual for even the well-prepared surgeon to have to modify his or her plans in the middle of surgery. A clear and detailed discussion between the surgeon and patient is very important in this group of patients where surgical objectives may not always be achieved and the potential for operative and postoperative problems are high.

## 8.9

### Future Challenges

Advances in contact lens and intraocular lens technology will certainly affect the development of lenses for use in the area of iris repair and reconstruction. It is conceivable that these lenses may contain threshold triggered, photoreactive pigments that vary the size of the pupil according to the amount and intensity of available light. The development of a biocompatible iris replacement material and rapid acting, long-lasting adhesives for use within the eye will lead to greater flexibility and surgical innovation at the time of iris reconstruction. A rapidly polymerizing material might be injected into the eye to create a spider web-like scaffold over which fibroblasts and pigment cells might be stimulated to grow. Similarly a fine, folded mesh containing a tissue-specific growth factor might be inserted into the anterior chamber, unfolded, and clipped to iris remnants or other ocular structures. Iris repair and reconstruction is an area rife for innovation. The increased number of articles on this subject over the past few years suggests many new approaches will be available to assist us in the future.

### References

1. Cleasby, G.W., Photocoagulation coreplasty. *Archives of Ophthalmology*, 1970. 83(2): p. 145–151
2. L'Esperance, F.A.J., James, W.A., Jr., Argon laser photocoagulation of iris abnormalities. *Transactions of the American Academy of Ophthalmology and Otolaryngology*, 1975. 79(2): p. 321–339
3. Wise, J.B., Iris sphincterotomy, iridotomy, and synechiotomy by linear incision with the argon laser. *Ophthalmology*, 1985. 92: p. 641–645
4. Akman, A., Yilmaz, G., Oto, S., et al., Comparison of various pupil dilatation methods for phacoemulsification in eyes with a small pupil secondary to pseudoexfoliation. *Ophthalmology*, 2004. 111: p. 1693–1698
5. Nunziata, B., Repair of iridodialysis using a 17-millimeter straight needle. *Ophthalmic Surgery*, 1993. 24: p. 627–629
6. Bardak, Y., Ozerturk, Y., Durmus, M., et al., Closed chamber iridodialysis repair using a needle with a distal hole. *Journal of Cataract and Refractive Surgery*, 2000. 26: p. 173–176
7. Erakgun, T., Kayikcioglu, O., Akkin, C., MVR knife with a hole at the tip for secondary IOL implantation. *Journal of Cataract and Refractive Surgery*, 2000. 26: p. 1700–1701
8. Wachler, B., Krueger, R., Double-armed McCannell suture repair of traumatic iridodialysis. *American Journal of Ophthalmology*, 1996. 122(1): p. 109–110
9. McCannell, M., A retrievable suture idea for anterior uveal problems. *Ophthalmic Surgery*, 1976. 7: p. 98–103
10. Chang, S., Coll, G., Surgical techniques for repositioning a dislocated intraocular lens, repair of iridodialysis, and secondary intraocular lens implantation using innovating 25-gauge forceps. *American Journal of Ophthalmology*, 1995. 119: p. 165–174
11. Siepser, S.B., The closed chamber slipping suture technique for iris repair. *Annals of Ophthalmology*, 1994. 26: p. 71–72
12. Shin, D.H., Repair of sector iris coloboma. *Archives of Ophthalmology*, 1982. 100: p. 460–461
13. Pallin, S.L., Closed chamber iridoplasty. *Ophthalmic Surgery*, 1981. 12: p. 213–214
14. Behndig, A., Small incision single-suture-loop pupilloplasty for postoperative atonic pupil. *Journal of Cataract and Refractive Surgery*, 1998. 24: p. 1429–1431
15. Choyce, P., Intraocular lenses and implants. 1964, London: HK Lewis. 27–32, 162–178
16. Sundmacher, R., Reinhard, T., Althaus, C., Black-diaphragm intraocular lens for correction of aniridia. *Ophthalmic Surgery*, 1994. 24(3): p. 180–185
17. Reinhard, T., Engelhardt, S., Sundmacher, R., Black diaphragm aniridia intraocular lens for congenital aniridia: long-term follow-up. *Journal of Cataract and Refractive Surgery*, 2000. 26: p. 375–381
18. Thompson, C.G., Fawzy, K., Bryce, I.A., et al., Implantation of a black diaphragm intraocular lens for traumatic aniridia. *Journal of Cataract and Refractive Surgery*, 1999. 25: p. 808–813
19. Burk, S.E., DaMata, A.P., Snyder, M.E., et al., Prosthetic iris implantation for congenital, traumatic, or functional iris deficiencies. *Journal of Cataract and Refractive Surgery*, 2001. 27: p. 1732–1740
20. Esquenazi, S., Amador, S., Bilateral cataract surgery combined with implantation of a brown diaphragm intraocular lens after trabeculectomy for congenital aniridia. *Ophthalmic Surgery & Lasers*, 2002. 33(6): p. 514–517
21. Price, M., Price, F.W. Jr., Chang, D.F., et al., Ophtec iris reconstruction lens United States clinical trial phase I. *Ophthalmology*, 2004. 111: p. 1847–1852
22. Osher, R.H., Burk, S.E., Cataract surgery combined with implantation of an artificial iris. *Journal of Cataract and Refractive Surgery*, 1999. 25: p. 1540–1547

# Sclera and Retina Suturing Techniques

# 9

Kirk H. Packo and Sohail J. Hasan

## Key Points

### Surgical Indications

- Vitrectomy
  - Infusion line
  - Sclerotomies
  - Conjunctival closure
  - Ancillary techniques
- Scleral buckles
  - Encircling bands
  - Meridional elements

### Instrumentation

- Vitrectomy
  - Instruments
  - Sutures
- Scleral buckles
  - Instruments
  - Sutures

### Surgical Technique

- Vitrectomy
  - Suturing the infusion line in place
  - Closing sclerotomies
- Scleral buckles
  - Rectus muscle fixation sutures
  - Suturing encircling elements to the sclera
  - Suturing meridional elements to the sclera
  - Closing sclerotomy drainage sites
- Closure of the conjunctiva

### Complications

- General complications
  - Break in sterile technique with suture needles
  - Breaking sutures
  - Inappropriate knot creation
- Vitrectomy
  - Complications associated with sclerotomy closure
    - Intraoperative
    - Postoperative
- Scleral buckles
  - Complications associated with suturing to the sclera
  - Complications associated with suturing conjunctiva

### Future advances and alternatives to sutures

- Vitrectomy
- Scleral buckles

## 9.1

### Introduction

Discussion of ophthalmic microsurgical suturing techniques as they apply to retinal surgery warrants attention to two main categories of operations: vitrectomy and scleral buckling. This chapter reviews the surgical indications, basic instrumentation, surgical techniques, and complications associated with suturing techniques in vitrectomy and scleral buckle surgery. A brief discussion of future advances in retinal surgery appears at the end of this chapter.

## 9.2

### Surgical Indications

#### 9.2.1

#### Vitrectomy

Typically, there are three indications for suturing during vitrectomy surgery: placement of the infusion cannula, closure of sclerotomy, and the conjunctival closure. A variety of ancillary suturing techniques may be employed during vitrectomy, including the external securing of a lens ring for contact lens visualization, placement of transconjunctival or scleral fixation sutures to manipulate the eye, and transscleral suturing of dislocated intraocular lenses. Some suturing techniques such as iris dilation sutures and transretinal sutures in giant tear repairs have now been replaced with other non-suturing techniques, such as the use of perfluorocarbon liquids.

#### 9.2.2

#### Scleral Buckles

Suturing during scleral buckle surgery involves placement of rectus muscle fixation sutures, securing encircling elements, securing meridional elements, tying the ends of encircling elements, closing sclerotomy drainage sites, and closing the conjunctiva.

## 9.3 Instrumentation

### 9.3.1 Vitrectomy

Instrumentation required for suturing during vitrectomy includes caliper, forceps, needle holder, suture, and scissors. Calipers can be in a wide variety of styles. We have found a fixed caliper of 4.0 and 3.5 mm at alternate ends to be the most useful for vitrectomy. The two tissues involved with suturing during vitrectomy are the conjunctiva and sclera. The fixation forceps chosen to handle each tissue are by surgeon preference. We prefer to use a non-toothed ring forceps (ASICO, Chicago, Ill.) to manipulate conjunctiva. The ring tip provides an excellent grasp of the conjunctiva while minimizing bleeding. For scleral fixation, either 0.12-, 0.3-, or 0.5-mm toothed forceps, or 0.1-mm Maumenee-Colibri forceps can be used to grasp the sclera. The larger toothed forceps are useful for general scleral fixation, whereas the smaller-toothed varieties are useful for grasping the cut edge of sclera as in sclerotomy closure. We find that Maumenee-Colibri forceps are particularly useful because of their angle and small tooth size, which provides an excellent grasp of the cut scleral edges. Needle holders are chosen by surgeon preference. Design choices include platform size, locking versus non-locking, and straight versus curved. Because running and figure-of-eight sutures are common, we have found straight locking holders to be the most useful.

Suture choices also vary by surgeon preference. The spatula-tipped needle was first introduced by Lincoff in the 1960s and was a great advance for scleral suturing. The side cutting design allows the needle to pass within the scleral lamellae rather than across them, making tissue depth more constant throughout the pass. Several options exist for the infusion line cannula retention suture. A 5-0 Mersilene polyester fiber suture with a spatula needle can be used to temporarily fix the cannula, and is later removed completely at the end of the case. Alternatively, a 7-0 Vicryl suture can be placed in a figure-of-eight fashion (see Sect. 9.4 below) to secure the infusion cannula. If temporarily tied, this same suture can be loosened and used to close the sclerotomy site at the end of the case. Another option for sclerotomy site closure is to use a 9-0 or 10-0 synthetic monofilament suture, such as nylon or Prolene. Monofilament nylon sutures are elastic, and close wounds that have opened as a result of undue pressure on the globe [2]. For this reason, completely sutures (such as silk) should not be used. In a survey of 398 retinal surgeons by the American Society of Retina Specialist in 1999, 86% of surgeons prefer to close sclerotomies

with Vicryl, 9.3% close with a synthetic monofilament, 0.5% close with plain gut, and 1.3% close with another suture type [17]. Conjunctival sutures are most commonly plain gut, and may have either spatula or taper-tip styles. Some surgeons conserve resources by using the same suture to close the sclerotomies as the conjunctiva. The scissors chosen to cut the stitches are either the Westcott scissors typically used for the conjunctival opening or a separate dedicated sharp-tip stitch scissor. Cutting large sutures such as a 5-0 Mersilene should be done with larger tips, and more delicate scissors such as Vannas style should be avoided.

### 9.3.2 Scleral Buckles

The surgical instruments required for suturing during scleral buckle surgery include caliper, forceps, scissors, muscle hooks, needle holders, sutures, and retractors. The same fixation forceps and needle holders described for vitreous surgery have utility in scleral buckling. The suture choice to fix an episcleral implant varies, again, by surgeon preference and training. A spatula needle is universally chosen to ensure more depth control within scleral lamellae. The two most commonly utilized suture materials are either a 5-0 nonabsorbable nylon suture or a 5-0 nonabsorbable soft suture such as polyester Mersilene. The advantage of nylon is that its stiff memory holds the knot between throws and does not loosen as easily as does Mersilene. In addition, studies have shown less inflammatory reaction to nylon than to synthetic braided sutures, following chronic implantations in infected experimental wounds [24]. A Schepens-style orbital forked retractor or the de Juan retractor works very well to help visualize sclera for suturing [3]. A custom-designed illuminated orbital retractor is useful in visualizing the scleral surface in deep or tight orbits. The ends of an encircling band can be secured with a clove hitch nonabsorbable suture [1], tantalum clip [7], or silicone sleeve [25].

## 9.4 Surgical Technique

Retinal surgeons should exercise basic surgical principles that are universal to all ophthalmic suturing techniques. These include:

1. Always manipulate needles with instruments and never with the gloved hand. Holding needles with the finger tips is quick and often tempting, but runs the risk of accidental perforation of the glove tip. This perforation is often unrecognized and breaks sterile technique.

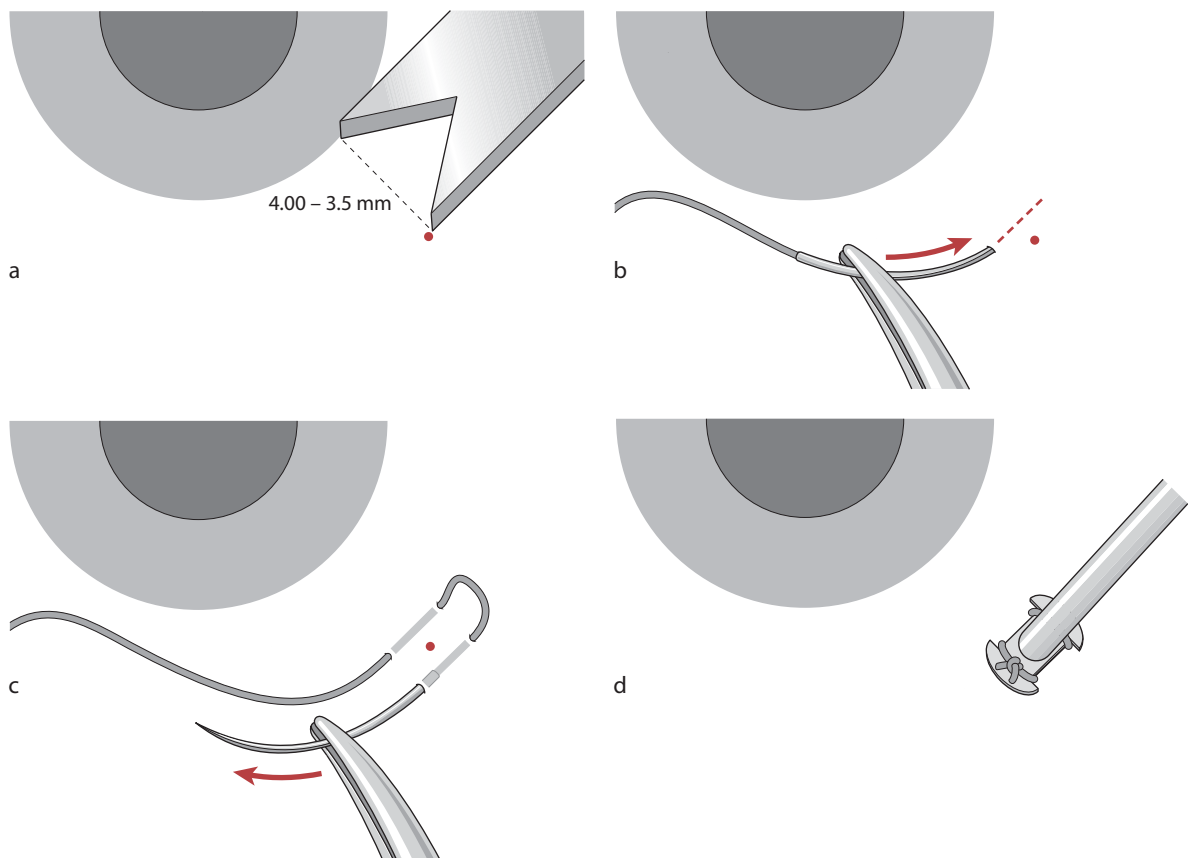
2. Never grasp a needle tip with the pick-up forceps. Needles should be grasped and held only with needle holders. When repositioning the needle on the holder, it should be done by holding the suture rather than the needle with the pick-up forceps near where the suture is swaged into the needle. This technique protects the fine teeth of the forceps.
3. Always match the needle holder platform size with the needle, and match the size of the scissors to the size of the suture being cut. For example, cutting 2-0 silk traction sutures with fine Vannas scissors will damage the scissor tips. Holding a large needle with too fine a needle holder allows less control and may also damage the holder.
4. Always unlock a locking needle holder prior to entering the tissue with the needle pass. This allows a simple open release at the completion of the pass, and obviates the squeeze to release the lock while the needle is embedded into the tissue, possibly contributing to tissue tearing or inadvertent penetration.
5. Always keep spatula needles flat to the tissue surface to avoid cheese-wiring of the suture, or improper depth of pass.
6. Bury all conjunctival knots.

### 9.4.1

#### Vitrectomy: Suturing of the Infusion Line

Using a caliper, a mark is placed in the inferotemporal quadrant 4 mm from the limbus in phakic eyes or 3.5 mm from the limbus in pseudophakic eyes below the horizontal, avoiding placement that would injure the long ciliary artery and nerve at the direct horizontal (Fig. 9.1a). The eye should be fixated immediately adjacent to where the suture will be passed using fine-toothed forceps. Fixating on the opposite side of the globe allows “scissoring” of the eye as the needle is passed and loss of control.

The suture passes should be parallel to the limbus at least one half to three quarters of scleral depth and should straddle the caliper mark. For a right-handed surgeon, the first pass should be to the right of the caliper mark regardless of the eye being operated on. The first pass for a left-handed surgeon should be to the left of the mark. This orientation is useful, allowing the surgeon to simply part his or her hands on the delivery of the first knot rather than crossing them. The first pass is placed in a backhanded fashion, traveling away from the surgeon (Fig. 9.1b). The second pass of the same needle is spaced to accommodate the base of



**Fig. 9.1** Vitrectomy: suturing of the infusion line



the infusion cannula and travels toward the surgeon. This creates a horizontal mattress suture parallel to the limbus (Fig. 9.1c). The suture slack is pulled, allowing a 0.5-cm diameter loop to remain on the inferior end of the suture passes. After penetrating the sclera with a micro-vitreoretinal blade, the cannula is twisted into position in an oscillatory fashion to ensure passage through the ciliary epithelium. The suture is then tied firmly in a 3-1-1 fashion (Fig. 9.1d). The ends of the suture should be trimmed close to the flange of the cannula. The cannula tip is then confirmed to be within the vitreous cavity by direct inspection to prevent inadvertent suprachoroidal or subretinal infusion.

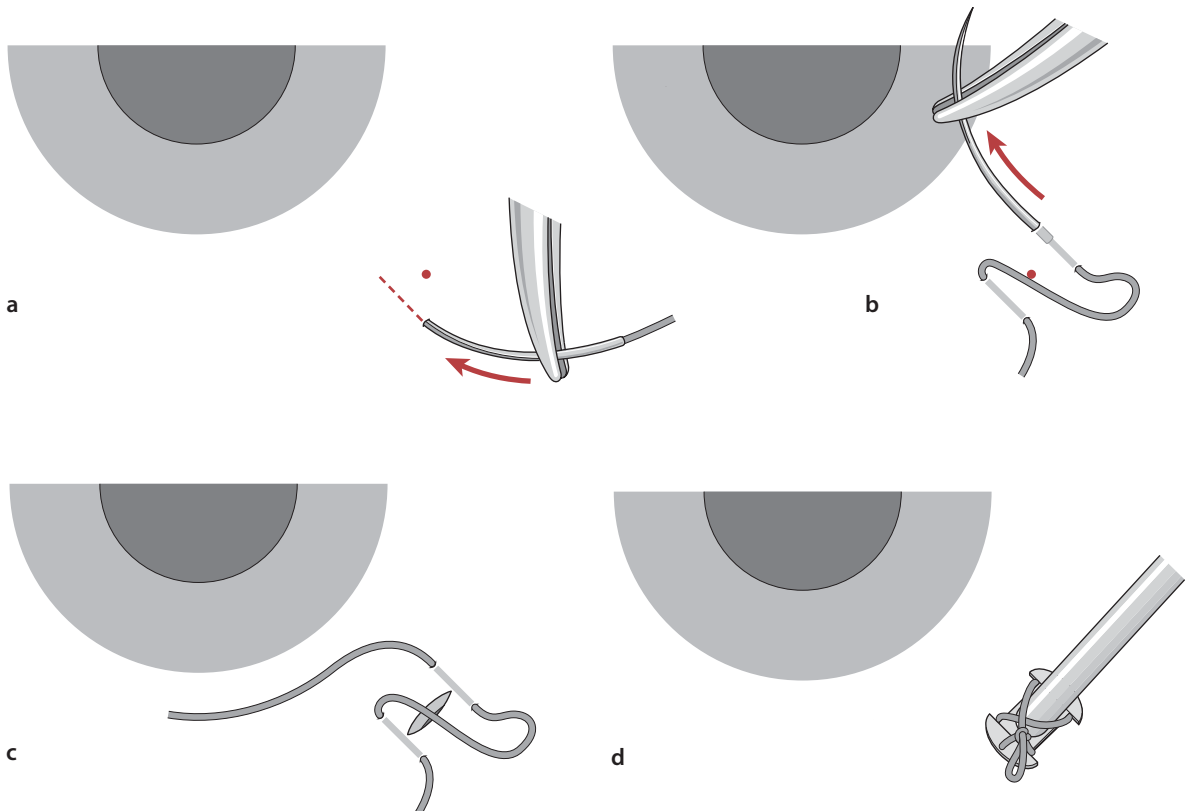
An alternative method of infusion line fixation allows for the same suture to be used for sclerotomy site closure at the end of the case. The caliper mark and eye is fixation is as described above. Two suture passes using a 7-0 Vicryl suture are made perpendicular to the limbus, with both passes placed toward the limbus. The first pass should be superior to the caliper mark (Fig. 9.2a). The second pass should again be spaced to accommodate the base of the infusion cannula. The second pass is made in the same direction as the first pass (toward the limbus), creating a figure-of-eight X across the sclerotomy (Fig. 9.2b). The middle pass of the suture is pulled, allowing a 0.5-cm diameter loop

to remain. The sclerotomy site is created with the MVR blade, taking care not to inadvertently cut the pre-placed suture (Fig. 9.2c). The cannula is twisted into position as above, the preplaced suture loops are pulled over the cannula wings, and the suture is tied in a 3-1-1 fashion, leaving a temporary loop on the final throw to allow subsequent loosening of the suture (Fig. 9.2d). The ends of the suture are then trimmed, leaving a generous length of suture to allow subsequent closure at the end of the case. At the end of the case, following closure of the superior sclerotomy sites, the final throw is simply released. The suture is loosened with fine forceps, and the cannula is removed and the suture is tied in a 3-1-1 fashion.

#### 9.4.2

##### Vitrectomy: Sclerotomy Site Closure

Unless a special shelved construction of a 20-gauge sclerotomy is created, a sclerotomy of this size must be sutured at the completion of the surgery. Although 20-gauge instruments are approximately 1 mm in diameter, the sclerotomy created by a 20-gauge MVR blade is approximately 1.4 mm long. This incision can be closed with a variety of techniques. A survey of 380



**Fig. 9.2** Alternative method of infusion line fixation allows for the same suture to be used for sclerotomy site closure at the end of the case

surgeons by the American Society of Retina Specialists in 2003 showed that 72% of surgeons close with a single figure-of-eight stitch, 14% use a figure-of-eight with one or more additional passes, and 11% use a single interrupted pass [7].

The closure is begun by stabilizing the eye with fine-toothed forceps (we prefer 0.1-mm Maumenee-Colibri forceps). The cut edge of the sclerotomy itself is grasped for maximum control, and a 7-0 Vicryl suture is used for closure. When closing with a single interrupted pass, the suture is passed perpendicularly through the center of the incision. Unlike monofilament sutures, braided Vicryl holds the tension of the knot relatively well with a single or double throw, and a triple throw is not required. Thus, the knot is best created with a 2-1-1 sequence rather than 3-1-1. This minimizes the bulk of the knot, decreasing postoperative inflammation slightly. For optimal security against wound leaks, we recommend more than just a single interrupted closure. A second pass in the same direction will create a standard figure-of-eight X-type closure (Fig. 9.3a). In this case, the first pass should be made through the very end of sclerotomy and the second through the opposite end. Some surgeons prefer to make one or two more additional passes creating either an X-plus-1 closure or a double-X figure-of-eight (Fig. 9.3b). A total of four throws are required to create a closure with two independent Xs. The first pass is made through the distal edge of the incision, the second through the center, the third through the proximal edge, and the final pass is made again through the center of the incision (Fig. 9.3c). This incision is particularly useful in closing incisions in ectatic sclera, in reoperations that have already thinned sclera, or in sclerotomies that have enlarged beyond 1.4 mm. All sutures are tied in a 2-1-1 fashion.

### 9.4.3

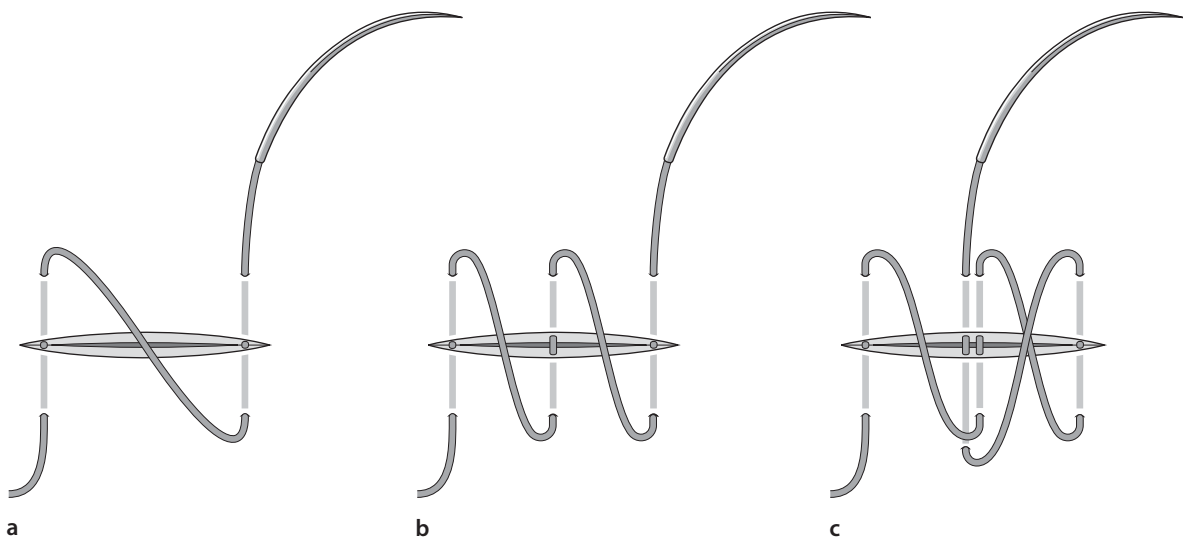
#### Vitrectomy: Ancillary Suturing Techniques

Over the past decade, the use of a non-contact wide field imaging system has replaced the use of contact lenses and fixation rings. However, some surgeons use an irrigating contact lens held over the eye by the assistant. Some lens rings are made of a soft silicone and will adhere to the eye surface without sutures. If a lens ring is secured, it is most commonly held in place by two 7-0 Vicryl sutures placed through the conjunctiva at the horizontal limbus. The sutures are only loosely tightened over the ring fixation tabs. A loose placement allows the ring to be temporarily removed if needed, while leaving the suture loops still in place for later replacement of the ring. Some surgeons will secure the ring with a larger diameter suture, such as a 4-0 silk, and leave the ring fixation suture long. The silk lens ring fixation suture can then be used for eye manipulation. Other ancillary suture techniques such as transscleral suture fixation of intraocular lenses and McCannel suturing of iris defects are described elsewhere in this book.

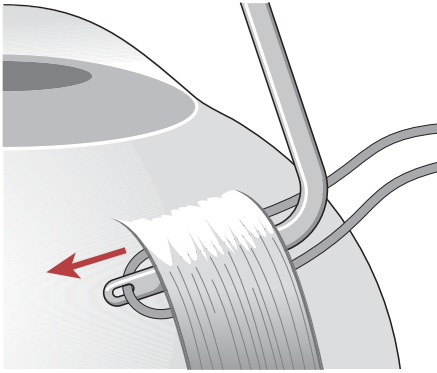
### 9.4.4

#### Scleral Buckles: Muscle Traction Sutures

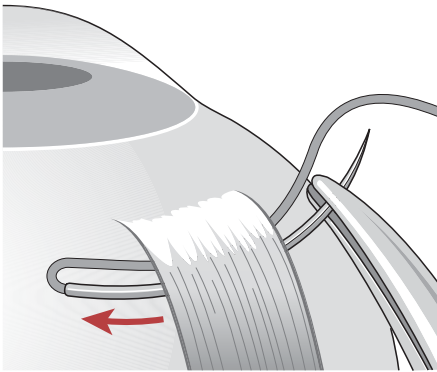
The first suturing requirement during scleral buckle surgery is the placement of the muscle traction sutures. Passing sutures beneath the rectus muscle insertions can be accomplished with a needleless tie or a suture with a curved needle (Fig. 9.4). When passing a needleless tie, the suture can be passed beneath the insertion with forceps or a curved hemostat. We prefer to use a



**Fig. 9.3** Vitrectomy: sclerotomy site closure

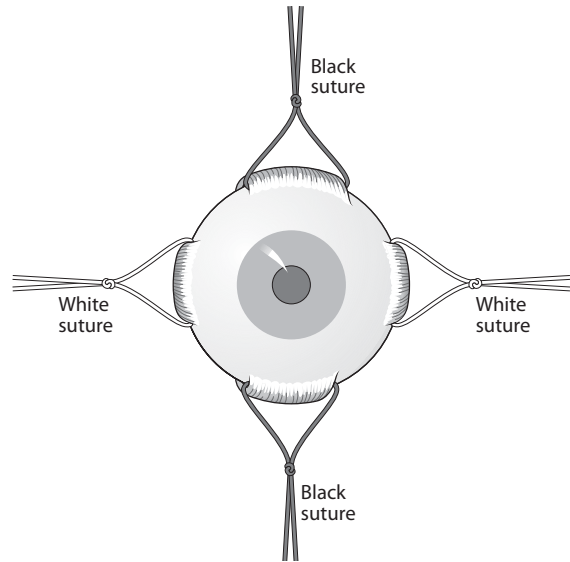


**Fig. 9.4** Gass muscle hook. When passing a needleless tie, the suture can be passed beneath the insertion with forceps or a hemostat. The suture is preloaded within the hook and then passed beneath the muscle, allowing the muscle insertion to be isolated at the same time the suture is passed. Typically, a large suture such as a 2-0 or a 4-0 silk tie is chosen.



**Fig. 9.6** Passing the Gass hook from the nasal side of the superior rectus avoids hooking the superior oblique tendon

Gass muscle hook containing an eyelet at its tip. The suture is preloaded within the hook, and then passed beneath the muscle, allowing the muscle insertion to be isolated at the same time the suture is passed. Typically, a large suture such as a 2-0 or 4-0 silk tie is chosen. We prefer to use 2-0 black silk beneath the horizontal rectus muscles, and 2-0 white cotton beneath the vertical muscles (Fig. 9.5). Color coding the opposite muscles in this way helps greatly in maintaining proper orientation and facilitating communication between the surgeon and assistant. It is better to pass the Gass hook from the nasal side of the superior rectus to avoid hooking the superior oblique tendon (Fig. 9.6).



**Fig. 9.5** Utilizing suture colors differently on the horizontal and the vertical rectus muscles helps to maintain orientation during surgery.

#### 9.4.5

#### Scleral Buckles: Encircling Elements

Following identification and localization of retinal breaks, an appropriate explant is selected. In 2003, a survey of 384 surgeons by the American Society of Retina Specialists showed that 82% of surgeons usually place an encircling element for most buckles, whereas 18% place either a meridional or circumferential segmental elements alone [17]. The vast majority of buckles are currently placed as explants. Regardless of technique, proper placement of the element requires accurate and effective suturing technique. Encircling expolant bands can be secured to the sclera with sutureless partial thickness scleral “belt-loop” tunnels or with scleral sutures. Larger encircling elements (sponges and tires) as well as meridional and segmental elements require sutures.

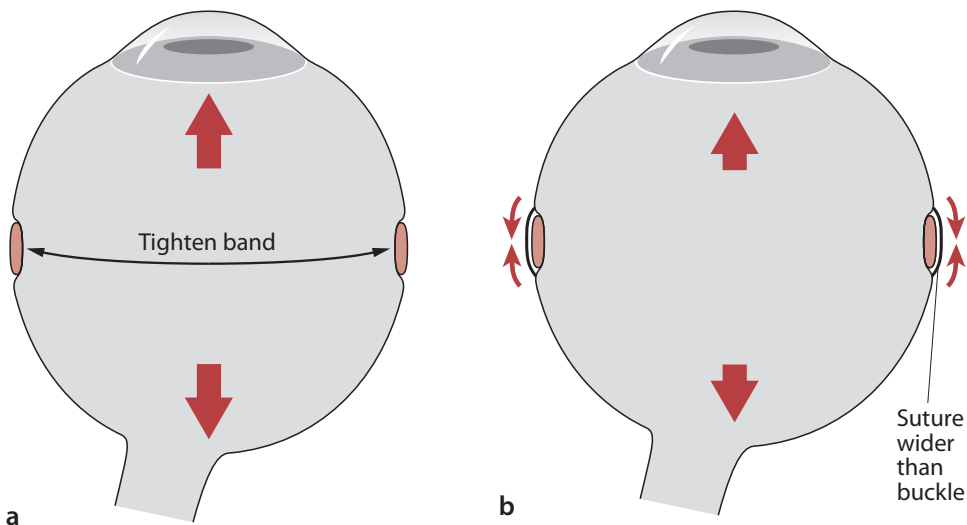
The buckle's goal of creating scleral indentation, thereby decreasing internal vitreous traction, can be accomplished in two ways: (1) tightening the encircling element, ultimately decreasing the total circumference of the eye, or (2) placing fixation sutures wider than the element, thereby imbricating the element and driving it internally. If the indentation effect is created primarily by tightening the encircling element, the eye is elongated and increased myopia results (Fig. 9.7a). Relying on the sutures to create the indentation more than tightening the element is preferred, as this minimizes the elongation and secondary myopia (Fig. 9.7b). Properly placed sutures on a 360° element can actually result in very little additional myopia. Sutures

should be placed in the sclera a minimum of 2 mm wider than the width of the encircling element. This technique can actually decrease axial length [9]. When silicone bands are secured only with scleral belt loops, the indentation effect can only be created with tightening of the element and a significant amount of postoperative myopia can occur.

When placing episcleral sutures, it is vital that the globe be firmly fixated to avoid inadvertent penetration into the eye by the needle. The eye can be fixated by the surgeon with toothed forceps, or the eye can be held steady by the assistant. Since the maximum scleral indentation is achieved directly below an episcleral suture, it is desirable to locate the suture in the same

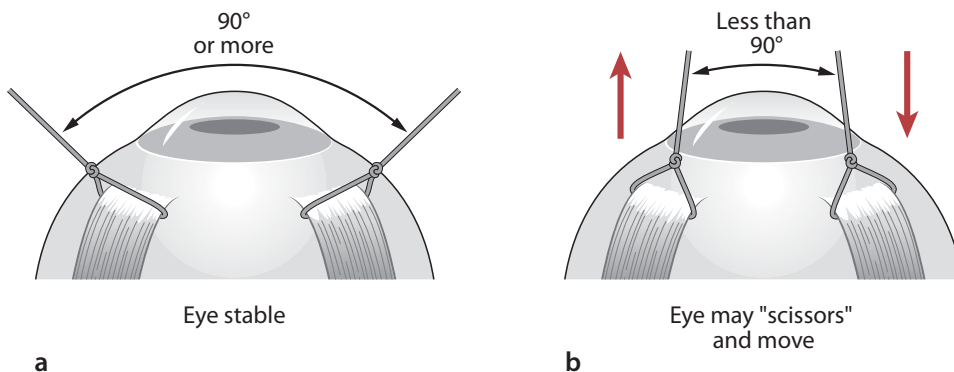
location and meridian as the retinal tear. Ideally, each tear is marked on the sclera externally with an ink dot prior to the suture placements. A caliper is used to create a scleral indentation mark on either side of the retinal tear location spot. As noted above, the width of the planned suture pass should be 2 to 3 mm wider than the element to be secured.

The assistant must follow several important principles in holding the eye steady. First, it is vital to always hold the traction sutures at least  $90^\circ$  or more apart to maximize the stability (Fig. 9.8a). Holding the sutures at less than a  $90^\circ$  angle may allow the eye to scissor, causing inadvertent eye motion during the suture pass (Fig. 9.8b). Secondly, the eye should be rotated by the



**Fig. 9.7** The buckle's goal of creating scleral indentation, thereby decreasing internal vitreous traction, is accomplished by (1) tightening the encircling element, ultimately decreasing the total circumference of the eye, or (2) placing fixation sutures wider than the element, thereby imbricating the element and driving it internally. If the indentation effect

is created primarily by tightening the encircling element, the eye is elongated and increased myopia results (a). Relying on the sutures to create the indentation more than tightening the element is preferred, as this minimizes the elongation and secondary myopia (b).

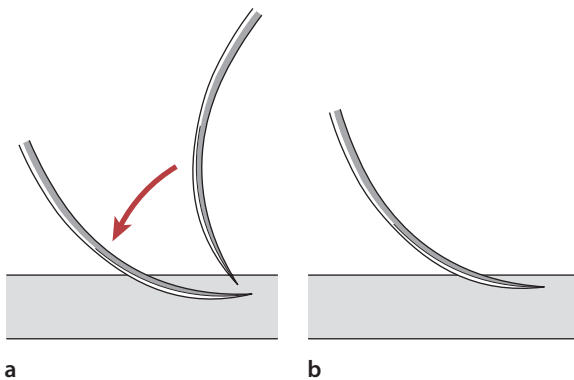


**Fig. 9.8** When placing episcleral sutures, the assistant must follow several important principles in holding the eye steady. First, it is vital to always hold the traction sutures at least  $90^\circ$

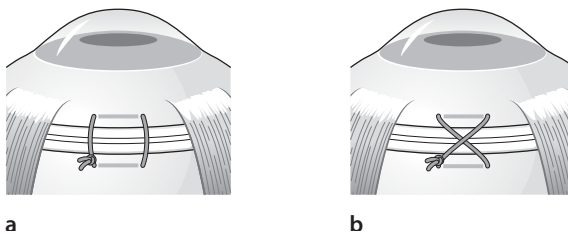
or more apart to maximize the stability (a). Holding the sutures at less than a  $90^\circ$  angle may allow the eye to scissor, causing inadvertent eye motion during the suture pass (b).

assistant to move the exposed quadrant toward the canthus. This maximizes exposure for the surgeon. Third, the assistant should pull quite firmly on the sutures to rotate the equator up out of the orbit, further improving exposure. Finally, the assistant should never move once the surgeon begins the suture pass. An assistant may have the urge to lean forward to watch the surgeon, and if this is done during the suture pass, the eye may move slightly creating potential problems. The surgeon's use of magnification loupes can also facilitate safe suture placement.

A single-armed spatula needle with a 5-0 nonabsorbable suture (we prefer nylon) is passed through the sclera at one-half to three-fourths depth over a distance of 3 to 5 mm parallel to the long axis of the encircling element. Care should be taken to pass the needle at an even depth to decrease the likelihood of scleral perforation. Adequate depth and length are essential for maximum suture strength [14]. For safest passage through sclera, the needle should be grasped half of the way



**Fig. 9.9** The best needle depth is achieved by actually beginning the needle pass more perpendicular to the sclera, passing directly into the sclera, and then quickly flattening the needle tangentially once the sclera has been engaged



**Fig. 9.10** The anterior second pass is made in the opposite direction of the first for a simple vertical mattress suture across the element. If the second pass is made in the same direction as the first to form a cross X-mattress suture across the element (a). A simple vertical mattress suture allows more imbrication than a cross X-mattress suture. As each suture is placed, it is grasped temporarily with a serrefine clamp to help keep the numerous suture ends from tangling (b). After all sutures are placed, the buckle is then passed beneath each mattress suture and muscle insertion as necessary

along the curve of the needle. If the needle holder is of the locking type, it should always be unlocked prior to passage of the needle. We prefer to pass the most posterior pass first, saving the anterior pass for last.

As the curve of the globe and the curve of the needle are in opposite directions, it is important to engage the sclera deep enough at the start of the pass in order to avoid too shallow a placement. The use of a spatula needle helps to keep the needle within the same scleral lamella during the pass; however, the needle still needs to be placed deep enough to avoid cheese-wiring. There is a natural tendency, especially among inexperienced surgeons, to avoid too deep a passage by beginning the suture pass with the needle held very tangential to the eye at the start. The best needle depth is achieved by actually beginning the needle pass more perpendicular to the sclera, passing directly into the sclera, and then quickly flattening the needle tangentially once the sclera has been engaged (Fig. 9.9). Surgeons should take care to modify this technique and to begin more tangentially in highly myopic eyes or when obvious scleral thinning or dehiscences are visible. Additionally, it is most important to begin the needle pass with the flat of the spatula held perfectly flat to the eye. If the needle is tilted such that one of the cutting edges is higher than the other, the suture is more likely to cheese-wire through the sclera after tying.

After the needle has been passed through the sclera and the tip brought out, care should be taken to complete the passage, following the curve of the needle. This will help to avoid unnecessary posterior pressure on the base of the needle, which lead to scleral perforation.

A second suture pass with the same needle is then made on the opposite side of the encircling element. Alternatively, a double-armed suture can be used, and the opposite needle is passed for the anterior bite. One popular technique is to make the anterior pass at the muscle insertion line, ensuring that the encircling element creates a buckle effect to the ora serrata internally. The anterior second pass is made in the opposite direction of the first for a simple vertical mattress suture across the element. If the second pass is made in the same direction as the first to form a cross X-mattress suture across the element (Fig. 9.10a). A simple vertical mattress suture allows more imbrication than a cross X-mattress suture. As each suture is placed, it is grasped temporarily with a serrefine clamp to help keep the numerous suture ends from tangling (Fig. 9.10b). After all sutures are placed, the buckle is then passed beneath each mattress suture and muscle insertion as necessary.

When making the suture permanent, it is tied in a 3-1-1 fashion. The memory nature of monofilament sutures tends to hold the tension of the initial triple throw nicely. If a soft braided suture such as Dacron or



Merseline is used, the assistant will often need to grasp the initial triple throw knot to prevent its loosening as the surgeon creates the next throw. The proper tension of the first triple throw is the most important to achieve the appropriate degree of imbrication. Tightening the suture is the easiest when the eye is soft prior to the attempt. Thus, draining the subretinal fluid prior to the suture tightening is desirable. If the surgeon expects to tap the anterior chamber to soften the eye in non-drainage techniques, it is desirable to perform the tap prior to tightening the buckle sutures. In non-drainage techniques, the eye will be firm, and tightening and judging the indentation effect are more difficult. Judging the indentation effect of the sutures is more difficult in non-drainage cases, as the indentation effect will increase postoperatively as the eye pressure later drops to normal. Once the knot has been completed and cut flush, it should be rotated to the posterior edge of the buckle to prevent later erosion through the conjunctiva. This is easily accomplished by pulling anteriorly on one arm of the mattress with one tying instrument while pulling posteriorly at the same time on the opposite arm with a second instrument.

Some variations in suture placement may be required based on the individual anatomy or pathology involved. When the posterior suture location is marked, it is not uncommon to need to place the pass of the suture at or near the exit of a scleral vortex vein. To avoid injury to the vein, it may be necessary to straddle the vein by taking a short bite on either side of the vein as it exits the sclera (Fig. 9.11). Sometimes long suture passes are not possible through thin sclera. In this case, it may be necessary to take several short bites in areas of thicker sclera.

Once the encircling silicone tire or sponge is sutured to the episclera, the surgeon then addresses how the ends of the encircling element are secured. When a silicone tire is placed either 360° or segmentally, an overlying encircling silicone band is usually used. The ends of the silicone band can be closed with a silicone sleeve (Watzke sleeve), tantalum clip, or suture. A silicone sleeve allows easy adjustment of band tension. When closing with a suture, the most common stitch is a clove hitch knot. Soft multifilament sutures work better than stiffer monofilament sutures for this closure, but both are adequate. This knot consists of two half hitches lying in opposite directions around the band. Unlike a square knot, a clove hitch is liable to slip. It requires a load in each direction in order to be effective, and this is typically achieved since the band will want to loosen in both directions under the knot. To tie a clove hitch, a loop is first placed around both bands, with the working end of the suture on top. The working end of the suture is passed around the bands once more until the place meeting where the sutures cross, and then the working end is passed under the cross. The hitch knot is pulled

tight to exert some tension on the bands. The surgeon then adjusts the tension on the band as necessary, and when finalized, the clove hitch is tightened more. The creation of a small nick with scissors in the edge of the silicone band on either side of the suture will prevent the band from loosening, since the suture will catch the nick as the band slides open, preventing further loosening (Fig. 9.12).

#### 9.4.6

#### Scleral Buckles: Meridional Elements

Some surgeons prefer to use meridional sponge elements, based on the configuration of the detachment and tear location. Many of the techniques of suture placement described for encircling elements above apply to the placement of meridional buckles. Again, sutures are generally placed 2 mm beyond the width of the sponge to allow for appropriate imbrication. Usually, at least two horizontal mattress sutures are placed. Unlike the placement of mattress sutures with encircling elements, the mattress suture for meridional elements are placed perpendicular to the limbus. They can be simple mattress or crossed X-type mattress su-

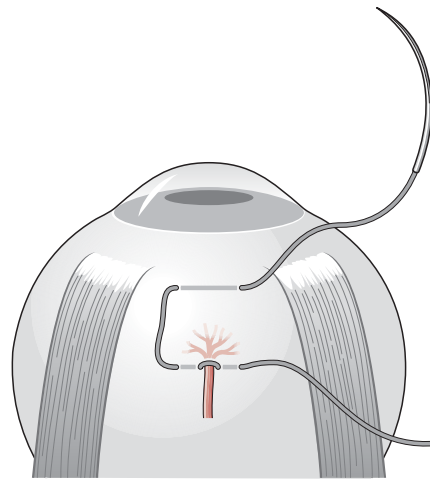


Fig. 9.11 The vortex vein is straddled with a suture

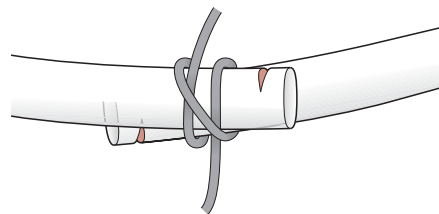


Fig. 9.12 Clove hitch knot. Note the notch in the silicone band to prevent loosening past suture

tures; however, the crossed mattress does not provide as much imbrication as a simple mattress suture; it is less effective. We have found that passing the suture from anterior to posterior is easier and more controlled than the reverse. For this reason, we use a double-armed suture (Fig. 9.13a). As with encircling buckles, the tying of the suture is much easier to accomplish in a soft eye, and so the eye should be tapped or subretinal fluid drained prior to attempting the suture tightening. The rotation of the final knot to the side of the sponge can be done but is usually not necessary (Fig. 9.13b).

#### 9.4.7

##### Closure of Sclerotomy Drainage Sites

In a 2005 survey by the American Society of Retina Specialists, 88% of surgeons prefer to routinely drain subretinal fluid during scleral buckle surgery [18]. When an external scleral cutdown is created, it may be placed under the planned buckle location or outside the buckle. If the sclerotomy is placed beneath the buckle, it may be left open allowing the overlying buckle to close the opening once the buckle is secured. Some surgeons prefer to routinely close the sclerotomy even when located beneath the buckle, and any sclerotomy outside the buckle must be sutured closed.

It is desirable to preplace the suture into the edges of the sclerotomy prior to penetrating the choroid into the subretinal space. In this way the suture need only be pulled up and closed at the end of the drainage, preventing additional scleral manipulation or retinal incarceration. A single interrupted, horizontal mattress or figure-of-eight preplaced suture can all be used, but the latter provides the best closure. After the scleral incision is made, typically the edges of the scleral are shrunk slightly with hot cautery or diathermy. Com-

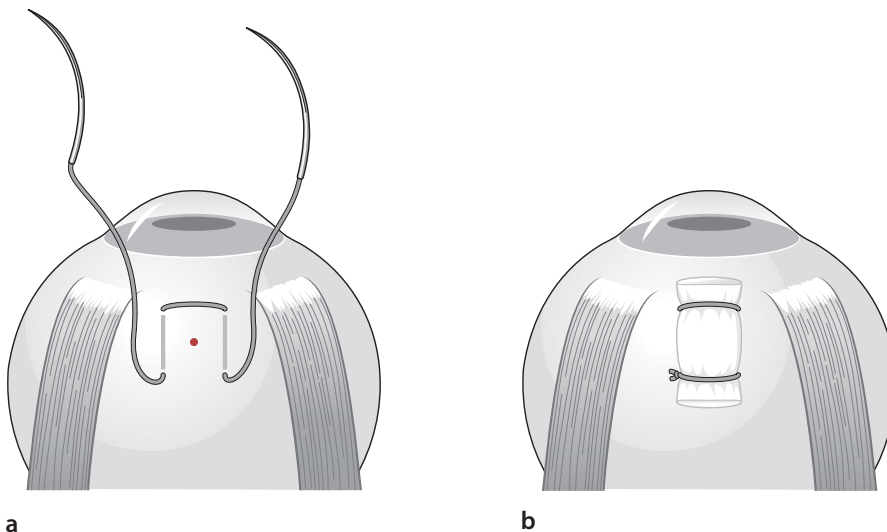
monly, a small knuckle of choroidal tissue will prolapse into the center of the sclerotomy. This prolapsed choroid is also commonly shrunk slightly with diathermy in an attempt to avoid penetration into the subretinal space at this stage. The suture is then carefully preplaced into the edges of the sclerotomy. We prefer to place this preplaced suture by wearing the ophthalmoscope and utilizing the light of the scope through a 20-diopter lens acting as a magnifying loop. It is necessary to move the buckle and orbital tissues out of the way during the suture placement. Once the suture is preplaced, it is carefully looped out of the way. We prefer to use the same monofilament nylon to close the drainage site as was used to secure the buckle. Since nylon easily melts, it is important to avoid injuring the preplaced stitch when diathermizing the prolapsed choroid. Once the drainage of the subretinal fluid is accomplished the suture is closed with a standard 3-1-1 knot and cut flush.

#### 9.4.8

##### Closure of the Conjunctiva

Closure of the conjunctiva should be done with care for both vitrectomy and scleral buckle surgery. Improper conjunctival closure from retinal surgery can contribute greatly to many postoperative complications outlined below. Taking time and extra care during the conjunctival closure can significantly add to the patient's short- and long-term comfort and should not be rushed.

The surgeon may wish to irrigate Tenon's capsule and the globe with antibiotic and retrobulbar anesthetic solution prior to closure. This acts to clean the surgical field and reduce postoperative pain, following either general or local anesthesia [4]. Additionally, this



**Fig. 9.13** Passing the suture from anterior to posterior is easier and more controlled than is the reverse. For this reason, a double-armed suture can be used (a). As with encircling buckles, the tying of the suture is much easier to accomplish in a soft eye, and so the eye should be tapped or subretinal fluid drained prior to attempting the suture tightening. The rotation of the final knot to the side of the sponge can be done but is usually not necessary (b)

irrigation serves to whiten the appearance of the Tenon's fascia as compared with the more pearl-colored conjunctiva assisting in proper tissue closure.

The conjunctiva can be closed alone or a layered approach can be used to first close Tenon's capsule prior to closure of the conjunctiva. We prefer a layered closure over radial sponge elements in order to minimize the possibility of element extrusion. A layered closure also acts to remove tension on the conjunctiva; this can be especially useful when the conjunctiva is thin and easily torn. Tenon's capsule is identified in all four quadrants. This is an essential step regardless of the type of closure. In order to identify Tenon's capsule, the anterior edge of conjunctiva is first held with forceps. A second set of forceps is then used to reach deep into the conjunctival fornix and grasp Tenon's capsule. The capsule can then be attached to the edge of each muscle insertion by using two sutures in the quadrant of the radial element or by using two sutures per quadrant in all four quadrants. We prefer to use 6-0 plain gut suture, single-armed, with a spatula needle for this purpose. Other suture options for Tenon's capsule and conjunctival closure include 7-0 Vicryl and 8-0 collagen. The main advantages of 6-0 plain gut include minimal knot slippage while tying, minimal suture reaction, and rapid dissolution.

Conjunctival closure varies with the type of opening [12, 16]. We routinely use a 360° incision 2 mm posterior to the limbus for scleral buckle surgery. Making the incision 2 mm posterior to the limbus (rather than right at the limbus) also allows less disruption of limbal stem cells and creates less perilimbal conjunctival irregularity. Such irregularity may contribute to postoperative dellen formation, and make subsequent contact lens wear more difficult.

When a 360° peritomy is created, we prefer a 360° running suture for closure of conjunctiva around a scleral buckle encircling element. Alternatively, two or more interrupted sutures can be used at the limbus to tack the peritomy back in place. If a non-running closure is used, care should be taken to avoid "hooding" the conjunctiva on to the cornea. Although overhanging conjunctiva will usually later retract, it may not if the corneal epithelium was also removed during the procedure, leading to a poor cosmetic result. The relaxing incision(s) can also be closed using the same running suture. Care should be taken to evert the edges of the incision to decrease the possibility of conjunctival cyst formation.

We prefer "ring" forceps for manipulation of the conjunctiva during closure. A buried knot is first placed at the anterior edge of the temporal relaxing incision, pulling the temporal portion of the conjunctiva back into position first. The short end of the suture is cut, and the remaining long end is then used to run the closure 360°. A straight locking needle holder has the

greatest utility for running closures. As always, the locking mechanism should be released prior to passing the needle into the tissue with each pass. We also find it easier to direct each pass from the conjunctival flap anteriorly into the collar of conjunctiva at the limbus rather than vice versa. Coming up through the collar from the posterior cut edge in this way allows a more controlled depth and accuracy, minimizing cheese-wiring of the needle. For efficiency, it is desirable to finish each pass by re-grasping the needle ready to proceed with the next pass rather than adjusting the needle manually between passes. When the needle is passed up through the tissue, it is pulled forward until the back swedge of the needle is just barely embedded into the tissue. The needle holder can then be used to grasp the visible forward part of the needle at its mid-portion, allowing it to be ready for the next pass. Although most passes are run smoothly without locking, an occasional pass can be locked to lessen the degree of slippage. Care must be taken to prevent bunching of the conjunctiva (particularly at the horizontal meridian nasally). Care should also be taken nasally to displace the caruncle, which creates a poor cosmetic result. After reaching the starting point temporally, the suture is run down the radial relaxing incision. Here, the suture can be tied to the short end of the original buried knot in a 2-1-1 fashion.

For patient comfort, it is always desirable to bury the knots during conjunctival closure. This is the easiest during interrupted suture placement of when placing the first knot of a running closure. The first pass begins in the wound, and the needle is passed upwards to the surface of the conjunctiva. The suture is then carried across the conjunctival opening, through the surface of the conjunctiva, ending within the wound. Tying the ends thus places the knot beneath the conjunctival surface. Burying the end of a running suture is more difficult, but still possible. At the end of the running suture, the surgeon makes the final pass by allowing the suture to be looped out of the conjunctival opening. The last pass of the suture is placed as a mattress pass back into the wound on the same side as the final pass. In this way, both the loop and the end of the suture containing the needle exit through the wound and not through the conjunctival surface. The final knot is then tied in a 2-1-1 fashion, but only the loop is cut away, leaving the end with the needle still in place. One final pass is then made into the wound adjacent to the knot, bringing the needle out through the undersurface of the conjunctiva. The slack on the stitch is pulled tight, pulling the knot deep under the conjunctiva. The suture is then cut away flush to the conjunctiva, allowing the trailing suture end to retract back beneath the surface.

Closure of the conjunctival openings from vitreous surgery is accomplished using the same techniques

outlined above, attempting to again always bury the knots and to completely cover the sclerotomy sites. During reoperations, the conjunctiva may be scarred and difficult to pull back over the sclerotomies completely. This can be facilitated by dissecting the conjunctiva free more deeply into the orbit, freeing the conjunctival tension assisting in the closure. Occasionally, the conjunctiva is so scarred or disrupted that the sclerotomies cannot be covered, and must be left bare.

## 9.5 Complications

### 9.5.1 General Suture-Related Complications

#### 9.5.1.1 Vitreotomy: Complications Associated with Sclerotomy Site Closure

The complications associated with sclerotomy site closure can be divided into intraoperative and postoperative complications. Intraoperative complications include ciliary body laceration and vitreous base incarceration in the wound [23]. Ciliary body laceration can lead to vitreous hemorrhage, which, if sufficiently small, is usually self-limited and spontaneously resolving. This complication can be avoided, of course, by taking only partial thickness bites through sclera and by staying in close proximity to the sclerotomy site with the suture pass. Vitreous base incarceration can be avoided by properly preparing the wound prior to closure. The vitrectomy probe can be used to clear the wound until a steady stream of fluid passes through an unobstructed sclerotomy site. Care should be taken to avoid damaging the sclerotomy site with the vitreous cutter. Alternatively, a cellulose sponge together with Vannas scissors can be used to trim vitreous from the sclerotomy site. The sponge should be introduced into the wound in an attempt to engage vitreous. The sponge should then be gently lifted a short distance from the sclera while vitreous is trimmed at the scleral surface using scissors. This sequence should be repeated until it is no longer possible to engage vitreous through the wound using the sponge.

Postoperative complications associated with sclerotomy site closure include wound leak, astigmatism, neovascular ingrowth, and external symptoms from polyester (Dacron) or polyglycolic acid (Dexon) suture [23]. Risk factors for wound leaks include reoperations, high myopia with thin sclera, and systemic diseases leading to scleral thinning. A number of options for closure are available should the sclerotomy site continue to leak. If the wound is leaking after the initial closure attempt, ad-

ditional suture can be passed over the first. This creates more bulk to the suture contributing to more postoperative inflammation, and it is often desirable to cut away the first stitch and place a new primary closure with deeper or more numerous passes. If the wound is extremely ectatic, more complex solutions may be needed, including using a synthetic or donor scleral patch graft, using a fibrin sealant like Tisseel or Hemacure or by using cyanoacrylate glue.

Astigmatism is the result of corneal distortion secondary to deformation of the adjacent sclera by the sutures. Although astigmatism is often minimal and temporary because of the use of dissolvable sutures typically 3.5 to 4 mm behind the limbus, significant astigmatism can occasionally result. This side effect can be lessened by ensuring that the sclerotomy sites are made the correct distance from the limbus (3.5 mm in pseudophakic patients and 4.0 mm in phakic patients). Sutures should be tied firmly but not overtightened. Of course, scleral deformation can also be lessened by eliminating the need for scleral sutures through the use of a sutureless 25-gauge vitrectomy system (see below).

Neovascular ingrowth (especially in diabetics) can be lessened by ensuring that the wound is as free of vitreous as possible prior to closure (see above for technique). If neovascularization should occur, treatment with photocoagulation or cryotherapy may induce resolution. In difficult cases resulting in repeated postoperative hemorrhages, reoperations may be necessary.

Finally, external symptoms such as injection and irritation can be caused by polyester or polyglycolic acid suture. It is for this reason that we prefer to use 7-0 polyglactin (Vicryl) suture for sclerotomy site closure. Vicryl can still insight a postoperative scleritis in some patients that can be quite painful. Symptoms of Vicryl scleritis include marked injection, induration, and point tenderness over each sclerotomy closure. This can be minimized by attempting to minimize the bulk of the Vicryl suture with fewer passes and suture throws per closure. Some surgeons choose to avoid this scleritis altogether by using a nonabsorbable monofilament suture rather than Vicryl. When significant scleritis occurs in select patients, we have found the use on parenteral nonsteroidal medications such as ibuprofen or indomethacin to be the most helpful. Topical steroids or nonsteroidal drops are less effective in relieving symptoms.

#### 9.5.1.2 Scleral Buckles: Complications Associated with Suturing to Sclera

The complications associated with suturing encircling and meridional elements to the sclera include scleral perforation and its sequelae, suture erosion, and suture failure. Significant risk factors for scleral perforation



during retinal detachment surgery include reoperation after failed retinal detachment surgery and preexisting scleral pathologic conditions such as senile scleral dehiscence or scleral thinning in high myopia. Although this complication may be compatible with a good visual outcome in some patients, a high incidence of persistent or recurrent retinal detachment with proliferative vitreoretinopathy worsens the visual outcome for most patients with this complication [22].

Scleral perforation can be detected during suture placement in a number of ways. The needle may suddenly give way as scleral resistance is no longer felt. Pigment, subretinal fluid, or a combination thereof may present through the suture tract. Should a perforation occur, the needle should be withdrawn slowly, and the retina should be inspected immediately with an indirect ophthalmoscope. In the absence of bleeding, retinal perforation, or continued subretinal fluid drainage, nothing further need be done in the area of the needle pass, and another suture should be placed in a new area of sclera. If subretinal fluid drainage continues, drainage is allowed to proceed while maintaining constant intraocular pressure (to help avoid retinal incarceration) with the use of cotton swabs externally applied to the eye. When drainage stops, the retina should be inspected using an indirect ophthalmoscope. Any remaining sutures can then be placed and the buckle positioned appropriately. If the perforation creates a retinal break, it should be treated immediately with cryopexy or laser retinopexy. The break should be supported by the encircling element or with the use of an additional radial element. If scleral perforation results in a subretinal hemorrhage, immediate pressure should be applied to the eye over the perforation site. The eye should be positioned to help avoid accumulation of blood beneath the fovea. If a massive subretinal hemorrhage occurs, one should consider immediate vitrectomy with internal drainage of subretinal fluid and blood [20]. Choroidal hemorrhage is perhaps the most disastrous complication of scleral perforation. It may present with dark-red bleeding at the site of perforation. The site of perforation should be closed immediately with a suture or with the scleral buckle itself. The intraocular pressure should be elevated above the systolic perfusion pressure. The eye should be positioned so that the perforation site is as inferior as possible to avoid subfoveal blood (as above). After the perforation site is closed, the pressure elevated, and the eye positioned, the extent of hemorrhage should be assessed using the indirect ophthalmoscope.

Retinal incarceration may also develop as a result of scleral perforation, or within a planned drainage site. Retinal incarceration can be identified when the retina is inspected with the indirect ophthalmoscope. The retina has a characteristic dimpled appearance in the

area of incarceration. If the incarceration occurs within a drainage sclerotomy that was initially planned to be left open beneath a buckle element, it is best to quickly place a suture to close the sclerotomy even when it is beneath the buckle. Small amounts of incarceration need not be treated. Large amounts of incarceration, however, should be supported with the buckle or by the addition of a radial element. Controversial is whether or not an incarceration site need also to be treated with cryotherapy. Most often we choose not to induce additional inflammation by cryotherapy to the incarceration site, but treat the area only by support with the buckle [26].

Other postoperative complications of scleral perforation include subretinal choroidal neovascularization [11] and endophthalmitis. Just as for sclerotomy site neovascularization, treatment with photocoagulation or cryotherapy may induce resolution of the neovascularization. Inadvertent entry into the eye with a suture needle also increases the risk of endophthalmitis. Treatment should be initiated as it would be for any other case of postoperative endophthalmitis.

### 9.5.1.3

#### Complications Associated with Suturing Conjunctiva

The complications associated with conjunctival closure include dehiscence, exposure of Tenon's capsule, suture granuloma, conjunctival cyst, and dellen formation. Long-term complications, particularly in poorly closed conjunctiva, include tear film disruption with the resultant signs and symptoms of dry eye. Risk factors for conjunctival dehiscence include a thin, friable conjunctiva, with or without excessive tension on the conjunctiva. Use of atraumatic ring forceps will allow gentler manipulation of the conjunctiva and lessen the possibility of conjunctival tearing and hole formation during closure. This will, in turn, decrease the likelihood of conjunctival dehiscence. In addition, prior closure of Tenon's capsule can remove tension on the conjunctival closure, thereby lessening the chance of dehiscence. Exposure of Tenon's capsule can result from conjunctival dehiscence or from inadvertent suturing of conjunctiva to Tenon's capsule during closure creating a poor cosmetic result. Running closure of the radial relaxing conjunctival incision(s) will also reduce the risk of subsequent exposure of Tenon's capsule and symblepharon formation. Granulomas can form at the site of suture knots. Larger knots are more prone to granuloma formation, as are more reactive nonabsorbable sutures such as Dacron or Merseline. Tying 6-0 plain gut in a 2-1-1 square knot fashion will result in a compact knot that is less likely to form a granuloma than is a knot with too many throws. It is important to evert the edges of the incision during conjunctival closure in order to diminish the chance of conjunctival



inclusion cyst formation. Should a cyst occur, the cyst can be observed, drained, or excised. Apart from the cosmetic appearance, conjunctival inclusion cysts are usually harmless unless close to the limbus where they can promote dellen formation. Many large cysts will ultimately flatten without therapy if left untreated. In many cases, the cyst may need to be excised. Unfortunately, simple drainage is usually only a temporary solution, with a high recurrence of cyst formation. If excised, the entire cyst and its lining should be removed to decrease the possibility of recurrence.

Corneal dellen can form as a result of a large suture knot, conjunctival inclusion cyst, or otherwise-elevated conjunctiva at the limbus. Dellen formation is particularly problematic in the diabetic patient because of poor corneal basement membrane and the higher likelihood of continued epithelial breakdown. Compact buried knots and care to evert the conjunctival incision during closure can help to avoid granulomas, inclusion cysts, and subsequent dellen formation. Use of a 360° running closure (as opposed to cardinal sutures) can help to ensure a more level conjunctival closure that is less likely to promote dellen formation. It is for this reason that care should be taken to avoid bunching of the conjunctiva (particularly at the horizontal meridian nasally) during the closure. Should a dellen form, the treatment consists of aggressive topical lubrication and removal of the inciting cause.

Finally, dry eye can result from disruption of the tear film secondary to conjunctival goblet cell destruction. Limbal stem cells can also incur damage because of disruption of the conjunctiva at the time of surgery. A 360° incision made 1 mm posterior to the limbus, which is subsequently closed using a 360° running suture, can help minimize limbal stem cell and goblet cell destruction.

## 9.6

### Future Advances and Alternatives to Sutures

#### 9.6.1

##### Vitrectomy

The advent of 25-gauge [8] and 23-gauge [5] transconjunctival sutureless vitrectomy instrumentation has reduced the need for sutures during vitrectomy altogether. Lakhanpal et al. [13] have recently reported that 25-gauge instrumentation may hasten postoperative recovery by decreasing overall surgical time and postoperative inflammation. Procedures requiring minimal intraocular manipulation may be better suited for this surgical modality. If a leaking sclerotomy is identified at the end of a small gauge vitrectomy, it is still desir-

able to close the leaking sclerotomy to prevent postoperative hypotony and its secondary complications [10, 15]. We prefer to close these leaking sclerotomies with a single transconjunctival Vicryl suture. This prevents the need to open the conjunctiva, rapidly dissolves and falls away, and still maximizes patient comfort.

#### 9.6.2

##### Scleral Buckles

Alternatives to sutures do exist for scleral buckle surgery. For example, in eyes with very thin sclera, polymethylmethacrylate belt loops can be fixed to the sclera with cyanoacrylate adhesive to allow 360° scleral buckling without sutures [21]. However, this may not spell an end to sutures entirely. For example, the use of cyanoacrylate adhesive such as Histoacryl to support suture bites in thin sclera has also been described [6]. The use of Histoacryl tissue adhesive has been described in some types of retinal detachment surgery [19]. Preserved human scleral graft and Histoacryl-blue tissue adhesive were used in four cases of retinal detachment surgery to obtain scleral buckling effect and to protect staphylomatous or necrotic scleral areas. The use of Histoacryl produced a strong and resistant adhesion between the host and the preserved scleral patch. The postoperative inflammatory reaction was mild and disappeared within 1 week.

## 9.7

### Conclusion

The materials and techniques for retinal surgery have undergone continued refinement over the past 40 years. This has resulted in a relatively high rate of retinal reattachment. Further understanding of the pathophysiology of retinal detachment together with pharmacologic and instrument advances should contribute to even further success in the future, with even less patient morbidity. Recently, advances in sutureless primary vitrectomy have been introduced. Although these techniques clearly have some advantages, they are unlikely to completely eliminate the need for sutures and excellent suturing technique.

## References

1. Aaberg TM, Wiznia RA (1976) The use of solid soft silicone rubber explants in retinal detachment surgery. *Ophthalmic Surg* 7:98–105
2. Charles S (2001) Principles and techniques of vitreous surgery. In: Ryan S, Wilkinson C P (eds) *Retina*. Mosby, St. Louis, pp 2121–2141
3. de Juan E Jr, Hickingbotham D, Allf B (1987) A conjunctival retractor for retinal surgery. *Arch Ophthalmol* 105:614

4. Duker JS, Nielsen J, Vander JF, Rosenstein R, Benson WE (1991) Retrobulbar bupivacaine irrigation for post-operative pain after scleral buckling: a prospective study. *Ophthalmology* 98:514–518
5. Eckardt C (2005) Transconjunctival sutureless 23-gauge vitrectomy. *Retina* 25(2):208–211
6. Folk JC, Dreyer RF (1986) Cyanoacrylate adhesive in retinal detachment surgery. *Am J Ophthalmol* 101:486–487
7. Friedman MW (1966) Clip for encircling procedures. *Am J Ophthalmol* 62:151–153
8. Fujii GY, de Juan E Jr, Humayun MS, Pieramici DJ, Chang TS, Awh C, Ng E, Barnes A, Sommerville DN (2002) A new 25-gauge instrument system for transconjunctival sutureless vitrectomy surgery. *Ophthalmology* 109(10):1807–1812
9. Harris MJ, Blumenkranz MS, Wittpen J, Levada A, Brown R, Frazier-Byrne S (1987) Geometric alterations produced by encircling scleral buckles: biometric and clinical considerations. *Retina* 7:14–19
10. Hilton GF (1985) A sutureless self-retaining infusion cannula for pars plana vitrectomy. *Am J Ophthalmol* 99(5):612
11. Holland PM (1985) Postoperative subretinal neovascular membrane at the drain site of a scleral buckle. *Ophthalmic Surg* 16:174–177
12. King LM Jr, Schepens CL (1974) Limbal peritomy in retinal detachment surgery. *Arch Ophthalmol* 91:295–298
13. Lakhanpal RR, Humayun MS, de Juan E Jr, Lim JJ, Chong LP, Chang TS, Javaheri M, Fujii GY, Barnes AC, Alexandrou TJ (2005) Outcomes of 140 consecutive cases of 25-gauge transconjunctival surgery for posterior segment disease. *Ophthalmology* 112(5):817–824
14. Lum DMB, Thompson JT (1988) The tensile strength of sclera in the placement of sutures for scleral exoplasms. *Invest Ophthalmol Vis Sci* 29(suppl):303
15. Mason G, Sullivan JM, Olk RJ (1990) A sutureless self-retaining infusion cannula for pars plana vitrectomy. *Am J Ophthalmol* 110(5):577–578
16. O'Connor (1976) External buckling without drainage. *Int Ophthalmol Clin* 16:107–126
17. Pollack JS and Packo KH, Preferences and Trends (PAT) Annual Survey, American Society of Retina Specialists, 1999, 2003
18. Mittra R, Preferences and Trends (PAT) Annual Survey, American Society of Retina Specialists, 2005
19. Regenbogen L, Romano A, Zuckerman M, Stein R (1976) Histoacryl tissue adhesive in some types of retinal detachment surgery. *British Journal of Ophthalmology* 60:561–564
20. Rubsamen PE, Flynn HW Jr, Civantos JM, Smiddy WE, Murray TG, Nicholson DH, Blumenkranz MS (1994) Treatment of massive subretinal hemorrhage from complications of scleral buckling procedures. *Am J Ophthalmol* 118:299–303
21. Sternberg P Jr, Tiedeman J, Prensky JG (1988) Sutureless scleral buckle for retinal detachment with thin sclera. *Retina* 8:247–249
22. Tabandeh H, Flaxel C, Sullivan PM, Leaver PK, Flynn HW Jr, Schiffman J (2000) Scleral rupture during retinal detachment surgery: risk factors, management options, and outcomes. *Ophthalmology* 107(5):848–852
23. Tardiff YM, Schepens CL, Tolentino FI (1977) Vitreous surgery. XIV. Complications from sclerotomy in 89 consecutive cases. *Arch Ophthalmol* 95(2):229–234
24. Varma S, Lumb WV, Johnson LW, Ferguson HL (1981) Further studies with polyglycolic acid (Dexon) and other sutures in infected experimental wounds. *Am J Vet Res* 42(4):571–574
25. Watzke RC (1963) An encircling element connection for scleral buckling procedures. *Am J Ophthalmol* 56:989–991
26. Weinberger D, Lichter H, Gaton DD, Kremer I, Axer-Siegel R, Yassur Y (1995) Intraocular intrusion of sutures after retinal detachment buckling surgery. *Retina* 15(5):417–421

# Glaucoma Surgery Suturing Techniques

# 10

Joanna D. Lumba and Anne L. Coleman

## Key Points

### Surgical Indications

- Trabeculectomy and drainage devices
- Progressive glaucomatous optic nerve damage and uncontrolled intraocular pressure

### Instrumentation

- Colibri forceps
- French forceps (dressing forceps)
- Straight and curved tying forceps
- Fine needle holder
- Westcott and Vannas scissors
- 10-0 Nylon suture 9001 G needle
- 7-0 Prolene suture
- 8-0 Vicryl J547 needle
- 9-0 Vicryl BV100 needle

### Surgical Technique

- Careful, delicate handling of the conjunctiva
- Partial-thickness suture passes through sclera

### Complications

- Buttonholing of conjunctiva
- Piercing sclera full-thickness on passing sutures

## 10.1 Introduction

This chapter introduces the beginning surgeon and refreshes the experienced surgeon on suturing techniques used in glaucoma surgeries, including trabeculectomies and drainage devices. A key tenet of glaucoma surgery is careful and delicate handling of the conjunctiva in all procedures. The following pages present descriptions of techniques used in closing the conjunctiva in both trabeculectomy and drainage device implantation. Suturing the trabeculectomy flap, the drainage device, and pericardial tissue/donor sclera is also covered in this chapter.

## 10.2 Surgical Indications

Glaucoma surgery is indicated in cases of progressive glaucomatous optic nerve damage and uncontrolled intraocular pressure despite medical management [1]. Trabeculectomy is the preferred surgical procedure to obtain the lowest achievable intraocular pressure. However, implantation of a drainage device may be chosen in cases of glaucoma secondary to neovascularization of the anterior chamber angle, uveitic processes, prior penetrating/lamellar keratoplasty, prior failed trabeculectomy, or aphakia [2].

## 10.3 Instrumentation and Equipment

As mentioned, careful handling of the conjunctiva is of utmost importance in successful glaucoma surgery. Use of proper instrumentation facilitates every step of surgery. Nontoothed forceps, such as French forceps, are preferred when handling conjunctiva, as they limit the risk of perforation of the delicate tissue by the forceps teeth [3]. Toothed forceps, such as Colibri forceps, are designed to grasp and steady tissue and may be used to assist in stabilizing the trabeculectomy flap when passing sutures.

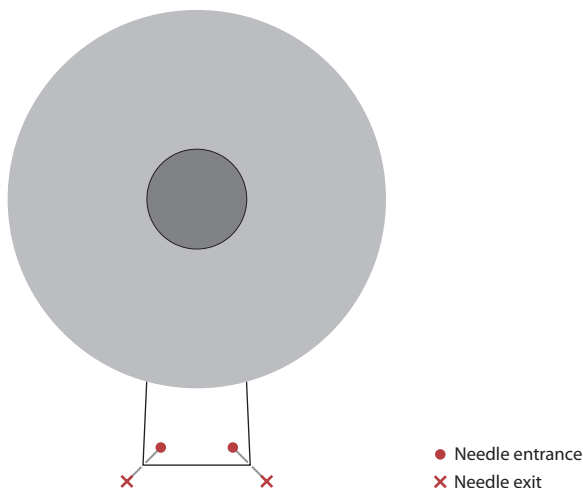
## 10.4 Surgical Techniques

### 10.4.1 Suturing the Trabeculectomy Flap (the Partial-Thickness Scleral Flap that Overlies the Trabeculectomy Site)

Suturing the flap may be performed in different manners. A standard 3-1-1 knot or a slipknot may be used at the apices of a rectangular trabeculectomy flap. Alternatively, a releasable suture may be placed instead of locking sutures. As shown in Fig. 10.1, suturing the trabeculectomy flap requires first passing a half-thickness

scleral bite at each apex of the trabeculectomy flap with a 10-0 nylon suture. Colibri forceps may be used to grasp the flap and stabilize the tissue as the needle is passed through the flap. The goal of suture placement and tying is to allow the flap to sit in its dissected scleral bed, without distortion of the wound edges. Each suture should be placed symmetrically and equidistant from each corner of the flap. Prior to tying the knots used to secure the trabeculectomy flap, the intraocular pressure should approximate normal physiologic pressure by refilling the anterior chamber with balanced salt solution. Tying sutures on a trabeculectomy flap in a hypotonous eye may cause the suture tension to be too tight. This may result in a trabeculectomy flap that prohibits adequate filtration from the trabeculectomy site, corneal astigmatism and/or wound distortion. If the sutures are too tight and there is inadequate aqueous filtration, early suture lysis can be used to improve filtration through the site. If filtration is appropriate for the eye, despite the tight sutures, the resulting corneal astigmatism and/or wound distortion.

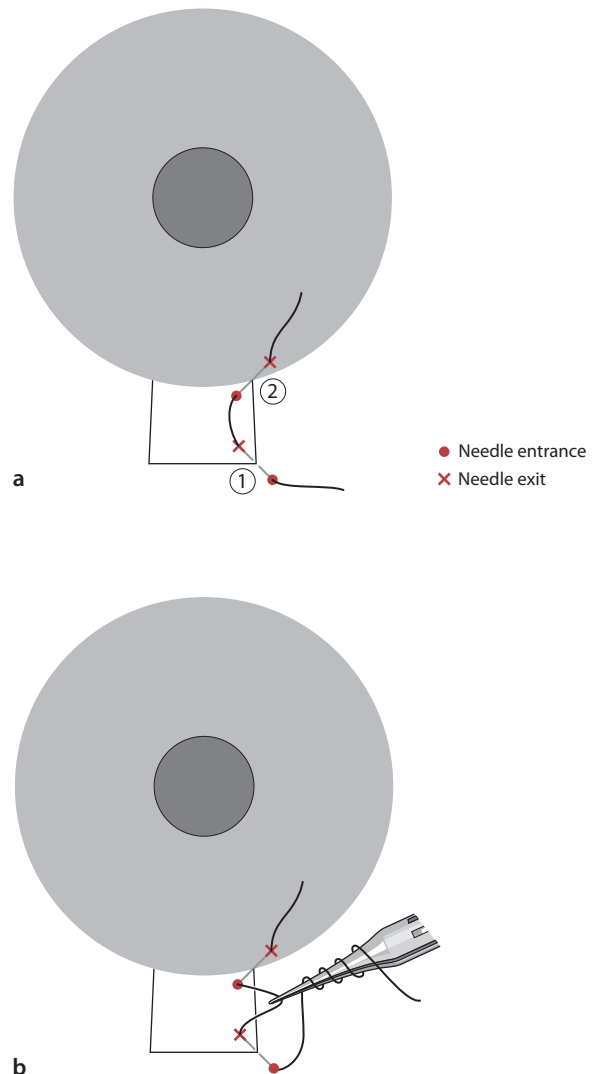
The flap should be sutured at each corner, with equal tension to allow adequate flow of aqueous from under the flap. Using straight tying forceps to grasp one end of the suture, three loops of suture are thrown over the curved tying forceps. The curved tying forceps are then used to pull the trailing end of suture through the triple loop. This first throw of suture should then be pulled to the appropriate tension, positioning the trabeculectomy flap so the knot lies flush against the sclera. To place the second throw, the straight tying forceps are used to throw one loop over the curved tying forceps, and the knot is pulled in the opposite direction of the first triple-thrown suture



**Fig. 10.1** Placement of trabeculectomy flap sutures using 10-0 nylon. Each suture is passed at a 50% depth of the sclera. The suture may be tied with a 3-1-1 knot or a slip knot. • Needle entrance, × needle entrance

pass. The second throw will determine the final tension of the suture knot, and should be thrown taking care not to disrupt the tension of the first triple-thrown suture or to lift the first triple-thrown suture off the sclera and thereby loosen the tension. The third throw of the suture is placed in the same manner as the second throw but pulled in the opposite direction to form a square knot and lock the suture knot in place.

An alternative way to suture the trabeculectomy flap, which may facilitate achieving equal tension at each corner of the trabeculectomy flap, is the slipknot, described by Dangel and Keates [4]. Using the straight



**Fig. 10.2** **a** Placement of a releasable suture using 10-0 nylon. Each pass of the suture is at approximately a 50% depth of the sclera or cornea. **b** Tying the releasable suture. Four throws of suture are thrown over the tying forceps prior to grasping the loop to pull through the four throws. The loop is then laid on top of the trabeculectomy flap. • Needle entrance, × needle entrance

tying forceps to grasp one end of the suture, one loop of suture is thrown over the curved tying forceps. The single loop is then pulled to the appropriate tension to lie flush against the sclera. Without releasing the hold on the end of the suture with the straight tying forceps, another single loop is thrown over the curved tying forceps in the same direction as the previous loop. The curved tying forceps are then used to grasp the trailing end of the suture. The ends are then pulled in the same direction as the first throw. This creates a slipknot that can move to adjust the tension of the knot and adjust the position of the trabeculectomy flap. The third locking throw will be held in reserve until the other sutures in the trabeculectomy flap have been preplaced as slipknots, and both loops of suture have been thrown. After the sutures have been tied with two loops of suture in the same direction, the tension of each suture may be adjusted, loosened or tightened, prior to throwing one more throw to lock the slipknot. In this technique, the tension on the trabeculectomy flap and the position of the tissue can be meticulously adjusted.

An alternative technique for suturing the trabeculectomy flap is a releasable suture, described by Cohen and Osher [5]. The releasable suture may be removed using jeweler's forceps at the slit lamp. A releasable suture is ideal in eyes where difficulty in finding the sutures postoperatively is expected, such as eyes with heavily pigmented conjunctiva, thick Tenon's tissue, or a large amount of subconjunctival hemorrhage intraoperatively.

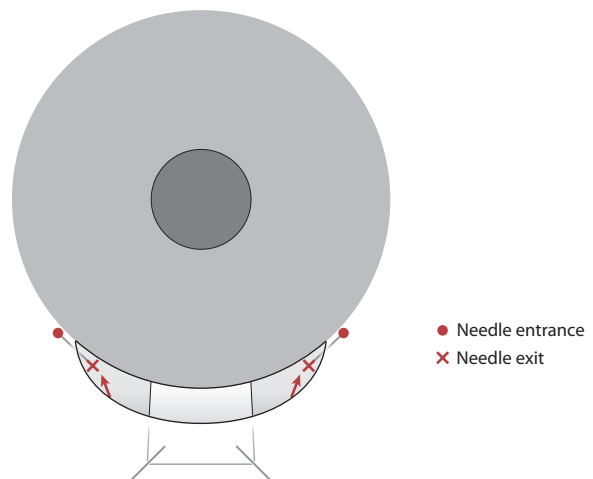
As seen in Fig. 10.2a, the needle of a 10-0 nylon suture is passed first into the sclera just posterior to the apex of the scleral flap and then through the flap. The needle is then passed through the base of the scleral flap near the limbus, and finally through the peripheral cornea. The releasable suture is then tied with a quadruple-throw slipknot (Fig. 10.2b). A rectangular flap can be closed with two releasable sutures at the apices, whereas a triangular flap can be closed with two releasable sutures on the sides and one permanent suture at the apex. A second pass of the needle is made into the peripheral cornea. The end of the suture is cut flush to the corneal suture. The portion of the suture in the peripheral cornea may be grasped to remove the suture, typically 1 to 10 days postoperatively.

#### 10.4.2

#### Suturing the Conjunctiva in a Fornix-Based Trabeculectomy

The conjunctiva can be reapproximated at the limbus with a 9-0 or 10-0 Vicryl or nylon wing suture at each end of the peritomy. One end of the conjunctiva is grasped using nontoothed forceps and pulled to its original position at the limbus. The suture is then

passed in a forehanded fashion, partial-thickness through the sclera to create a 1-mm purchase of sclera that anchors the suture. The needle then exits immediately adjacent to the conjunctival incision. The conjunctiva is then draped over the needle (Fig. 10.3). The suture is then tied with a 3-1-1 locking knot, as the tissue is under tension and a slipknot would not be appropriate when the tissue is under tension. The other side of the conjunctiva is then reapproximated at the limbus, ensuring that it is pulled taut against the superior limbus. The needle is then passed through the sclera in a similar manner as the first wing suture, and then conjunctiva is passed over the needle, pulled taut against the superior limbus and tied in a locking 3-1-1 knot. Occasionally, if the conjunctiva remains retracted after the placement of the two wing sutures, a mattress suture may be placed at the center of the retracted conjunctiva at the limbus, to ensure proper closure of the conjunctiva. Alternatively, a running mattress closure may be performed with a noncutting 9-0 Vicryl suture (BV 100 needle), as described by Lerner and Parrish [3]. A BV 100 needle is a vascular needle that creates a hole the same diameter as the suture, unlike cutting or tapered needles, which create holes that are larger than the suture. The advantage of the vascular needle is that the risk of leakage of aqueous at the suture hole is minimized (Fig. 10.4). The needle is passed forehand through the anterior Tenon's capsule and conjunctiva at one end of the conjunctival flap. It is then directed in a backhand pass through the conjunctiva and Tenon's capsule to enter the limbus and exit through the peripheral cornea. The needle is then passed from the peripheral cornea into the limbus near



**Fig. 10.3** Placement of the winged sutures used to close the conjunctival flap in a fornix-based trabeculectomy using either 10-0 Vicryl or 10-0 nylon sutures. The needle should exit immediately adjacent to the conjunctival incision. A 3-1-1 knot is used to secure the wound. • Needle entrance, × needle exit



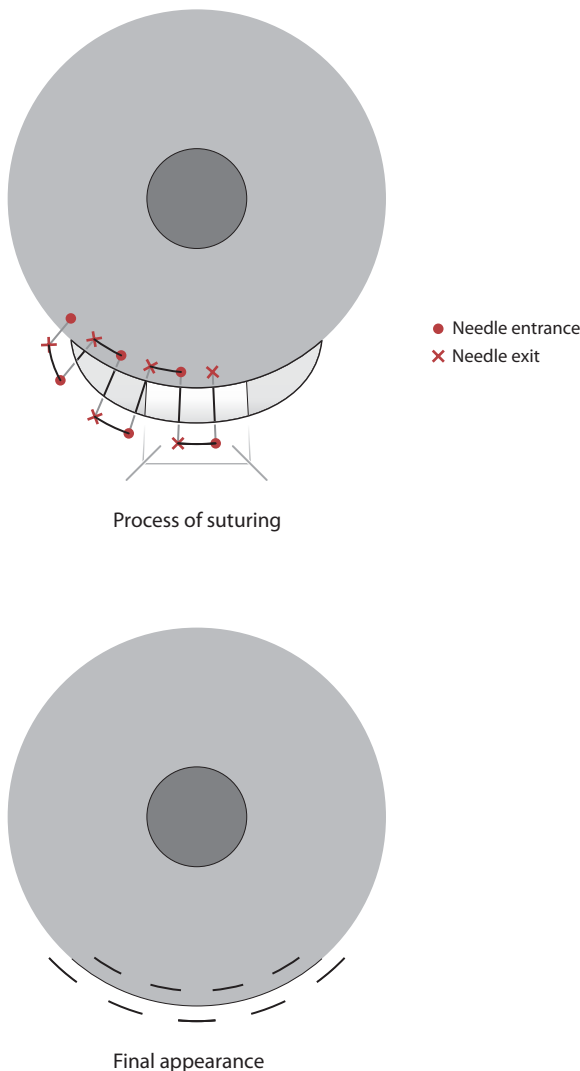
the original suture site, and this pattern is then repeated across the conjunctival flap. Alternatively the mattress suture is tied and additional mattress sutures are placed in a similar fashion across the length of the conjunctival flap to achieve watertight closure.

### 10.4.3

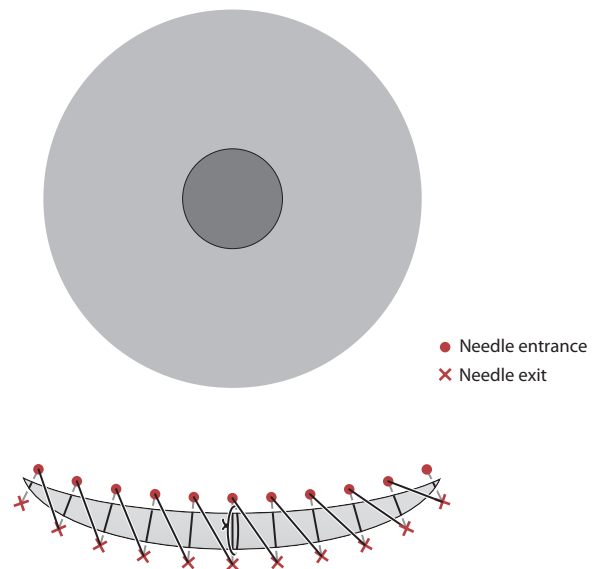
#### Suturing the Conjunctiva in a Limbus-Based Trabeculectomy

A running 9-0 Vicryl suture is used to close the conjunctiva at the fornix. A cutting or tapered needle can be used because each bite includes Tenon's capsule, and the risk of leakage at the suture hole is less if Ten-

on's capsule is present at the wound. When tension on the conjunctiva makes closure more difficult with a simple running suture, a single interrupted suture may be placed through the conjunctiva in the middle of the wound edges to be closed. This does not require an episcleral bite. A running suture may then be started at one end of the wound edge with 9-0 Vicryl (preferably on a BV needle) using the same suture, incorporating Tenon's capsule with each purchase of conjunctiva (Fig. 10.5). No episcleral bite is required at the start of the running suture. A 3-1-1 knot is thrown to start the running suture, one end of which is cut short while the other end is used to create a running closure. Alternatively, the Tenon's capsule layer may be closed separately, prior to closing the conjunctiva. Each pass of the running suture through the conjunctiva should be equally spaced, approximately 1 mm between each bite. The needle may be passed through the tissue, or the tissue may be carefully draped over the needle that is stabilized by the needle driver. Another alternative is to lock every other bite or every bite. To lock the suture, the suture is passed through both edges of the wound and then passed under the suture loop that is created prior to tightening the suture. The long suture end is then pulled and the bite is locked.



**Fig. 10.4.** Placement of a horizontal mattress suture to close the conjunctival flap in a fornix-based trabeculectomy using either 9-0 or 10-0 Vicryl or 10-0 nylon sutures. • Needle entrance, × needle entrance



**Fig. 10.5.** Placement of a running suture to close the conjunctival flap in a limbus-based trabeculectomy using a 9-0 Vicryl suture. A single interrupted 9-0 Vicryl suture may be placed in the middle of the conjunctival flap prior to the running suture if excessive tension of the conjunctiva makes closure difficult. • Needle entrance, × needle entrance

#### 10.4.4 Suturing the Drainage Device

After the drainage device is positioned approximately 8 mm from the limbus, it is sutured to the sclera. A nonabsorbable suture is used, such as 7-0 Prolene, 8-0 nylon, or 5-0 Mersilene. The nonabsorbable suture ensures that the plate will not move anteriorly, posteriorly, nasally, or temporally. The formation of fibrous tissue through the eyelets of the drainage device requires for the implant to be immobile for at least 2 weeks. If the plate were to move anteriorly from its intended position, it could cause the tube to touch the lens, causing a cataract, or touch the cornea, causing corneal endothelial damage. An anteriorly located plate also causes erosion of the overlying conjunctiva, which could predispose the eye to infection. If the plate were to move posteriorly, the plate could injure the optic nerve. Finally, if the plate were to move either nasally or temporally, it could cause scarring of the adjacent extraocular muscles, resulting in strabismus. The needle should pass partial thickness through the sclera, being careful not to penetrate the sclera. A retinal tear/detachment could result from a full-thickness pass of the needle. After the partial-thickness scleral passes are made, the needle is then passed through the eyelets of the drainage device, and a 3-1-1 knot is used to secure the device in place.

#### 10.4.5 Suturing Pericardial Tissue/Donor Sclera over the Tube

The pericardial tissue should be cut to the appropriate dimensions to cover the tube completely, with approximately a 1-mm margin to overlay the tube. The pericardial tissue may be secured to the sclera with two to four Vicryl sutures according to the surgeon's preference. The 8-0 or 9-0 Vicryl suture may be placed at two or four corners of the pericardial tissue/donor sclera, passing partial-thickness bites of sclera and tying with 3-1-1 locking suture knots. Less than four sutures may be needed to secure the patch graft because it has fibrous adhesions to the episclera within 2 weeks.

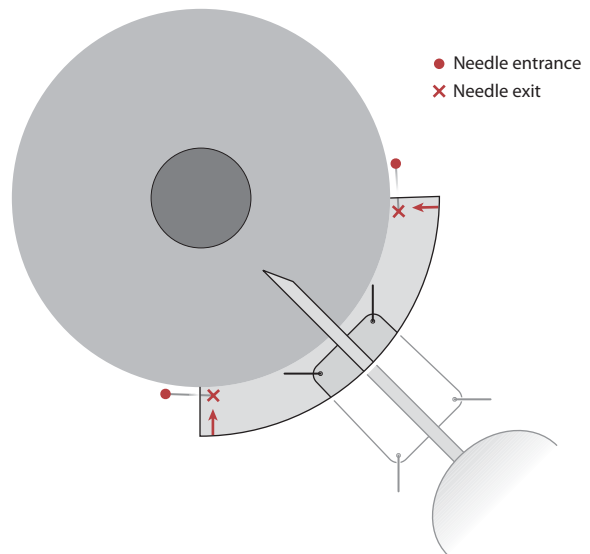
#### 10.4.6 Closing the Conjunctiva after Placement of a Drainage Device

Two French forceps (or other nontoothed forceps) should be used to grasp the conjunctiva and reapproximate it at the limbus. Two wing sutures may be used to close the conjunctiva at the limbus in the same manner as described in fornix-based trabeculectomy surgery

(Fig. 10.6). As much of the pericardial tissue should be covered as possible; this limits the amount of exposed pericardial tissue that needs to be re-epithelialized postoperatively. If needed, the Tutoplast may be trimmed at the limbus. Additional interrupted sutures may be placed to close the conjunctival peritomy if a radial extension of the conjunctiva has developed.

### 10.5 Complications and Future Challenges

Complications may arise with rough manipulation of the conjunctiva. If toothed forceps are used to grasp the conjunctiva, a buttonhole or tear may be created, which could cause a leak postoperatively. It is essential to use nontoothed forceps and to handle the conjunctiva in a delicate manner in all cases, especially in eyes with minimal Tenon's capsule. If there is a buttonhole in the conjunctiva, this hole can be closed with a 9-0 Vicryl suture on a BV needle or a 10-0 nylon suture on a tapered needle. Care should be taken to handle the conjunctival tissues gingerly. The hole may be closed with a mattress suture or a cross-stitch. The cross-stitch is done where the first pass of the suture is parallel to the edge of the wound. The second pass of the suture is parallel to the other edge of the wound in the same direction. A 3-1-1 locking knot secures the suture. Buttonholes should always be closed if detected intraoperatively, especially when doing a trabeculectomy. Not closing a buttonhole can result in a persistent leak and ocular hypotony.



**Fig. 10.6.** Closure of the conjunctival flap after placement of a drainage device with 9-0 or 10-0 Vicryl. Radial conjunctival incisions may be closed with interrupted 9-0 Vicryl sutures. • Needle entrance, × needle entrance

Partial-thickness scleral passes can be difficult for the beginning surgeon. The needle should be passed at approximately 50% depth through the sclera to obtain a strong purchase of tissue. Bites that are too shallow may not hold a drainage device in place and could lead to anterior migration of the plate postoperatively. Bites that are too deep can penetrate the sclera and lead to retinal tears and/or detachments. You should be able to see the faint outline of the needle under the scleral tissue. If the needle tip appears with a blob of vitreous or pigment on it, there is a very strong possibility of a scleral perforation. Indirect ophthalmoscopy and scleral depression should be done.

## 10.6 Conclusions

For both the expert and novice surgeons, glaucoma surgery can be a challenge because of the variability in the tissue quality of individual eyes. This variability requires the surgeon to be able to use suturing techniques in tissues that are so fragile that they easily tear if the surgeon does not treat them with great respect. In this chapter, we have covered in detail many of those surgical techniques. We stress that the surgeon who does glaucoma surgery must learn to be gentle, careful, and meticulous especially when handling the conjunctiva.

## References

1. Kolker, A, Filtration surgery. In: Morrison JC, Pollack IP (2003) Glaucoma. Thieme New York.
2. Sidoti, PA, Aqueous shunts. In Morrison JC, Pollack IP (2003) Glaucoma. Thieme. New York.
3. Lerner, SF, Parrish RK, Standard trabeculectomy. In: Lerner, SF, Parrish RK (2003) Glaucoma surgery, Lippincott Williams & Wilkins, Philadelphia.
4. Dangel, ME, Keates RH, The adjustable slide knot-an alternate Technique. Ophthalmic Surgery, December 1980, Vol. 11, No.12.
5. Cohen JS, Osher RH. Releasable scleral flap suture. Ophthalmol Clin North Am. 1988;1:187–197.

# Amniotic Membrane Suturing Techniques

# 11

Scheffer C. G. Tseng, Antonio Elizondo, and Victoria Casas

## Key Points

### Surgical Indications

- To promote epithelial healing and reduce inflammation, scarring, and unwanted blood vessels on the ocular surface
- Used as a biological bandage to suppress inflammation or as a graft to replace missing basement membrane for reconstructing both the cornea and conjunctiva in a number of ocular surface diseases

### Instrumentation

- Preferred instruments include 0.12-mm forceps, 10-0 nylon and 8-0 Vicryl sutures with a spatula sharp needle, and sharp Wescott scissors.

### Surgical Technique

- Interrupted or running 10-0 nylon or 8-0 Vicryl sutures
- Can be performed in conjunction with other surgical procedures or as a graft
- Can also be applied without sutures by using fibrin glue
- PROKERA™ can be inserted as an overlaid therapeutic graft without sutures.

### Complications/Contraindications

- Dissolves rapidly in the event of severe inflammation and exposure (dryness)
- Amniotic membrane alone is not sufficient to restore the ocular surface that has a substantial loss or metaplasia of epithelial stem cells.

served AM as a graft for ocular surface reconstruction was reported by Kim and Tseng in 1995 [2].

When appropriately procured, processed, and preserved based on good tissue practices (GTP) set forth by the Food and Drug Administration (FDA), cryopreserved AM has been successfully used for ocular surface reconstruction, since 1997. A number of studies have shown that preserved amnion graft transplantation (AMT) is effective in facilitating epithelial wound healing and in reducing stromal inflammation, scarring, and unwanted new blood vessel formation [1, 3–8]. The plausible mechanisms explaining how preserved amnion graft exerts antiinflammatory and antiscarring actions have recently been reviewed [9].

The aforementioned cryopreserved method kills allogenic amniotic cells in AMNIOGRAFT® [10], thus eliminating the need for immunosuppression while maintaining the integrity of its cytokine-rich extracellular matrix. In addition, cryopreservation kills the epithelial cell layer; therefore, the cryopreserved amnion graft transplantation does not supply epithelial cells to the surface on which it is transplanted.

Clinical uses of preserved amnion graft for ocular surface reconstruction can be categorized as a graft (for host cells to grow over or into the membrane) or as for host cells to grow underneath the membrane. In the former situation, the membrane is used to fill in the tissue defect of the cornea or the conjunctiva so that it will be integrated into the host tissue. In the latter situation, the membrane is applied as if it were a bandage lens to cover both the healthy host tissue and the site of interest so that epithelial healing is completed underneath the preserved amnion graft. Therefore, the transplanted membrane is invariably dissolved or removed. In either of these two modes of preserved amnion graft transplantation, the membrane can be secured in the patient's eye by surgical sutures. In this chapter, we describe the traditional suturing techniques to secure AM to the ocular surface. As detailed below, securing preserved preserved amnion graft to the ocular surface without sutures can shorten the surgical time and eliminates suture-induced inflammation. In this chapter, we also describe how such new emerging “sutureless” surgical approach may be practiced through the use of PROKERA™ as a

## 11.1

### Introduction

The amniotic membrane (AM), or amnion, is the innermost layer of the placental membrane and consists of a simple epithelium, a prominent basement membrane, and an avascular stroma (ca. average 75  $\mu$ m). Historically, AM prepared by different methods had been used mostly as a “dressing” in several surgical specialties, including ophthalmology, starting from the early 20th century [1]. The more recent use of pre-

an overlaid graft and through the use of fibrin glue for preserved amnion graft.

## 11.2 Surgical Indications

### 11.2.1 AM as an Overlaid Graft

When preserved amnion graft is used as an overlaid graft, it is intended to suppress inflammation on the ocular surface incited by various diseases and insults. As shown in Table 11.1, the clinical disease indications include intense ocular surface inflammation and epithelial erosion caused by acute chemical and thermal burns [11–14], and acute inflammatory and ulcerative stage of Stevens-Johnson syndrome (SJS) with or without toxic epidermal necrolysis (TEN) [15, 16]. For these devastating clinical emergencies, cryopreserved amnion graft effectively reduces inflammation and facilitates epithelial wound healing.

If an overlaid graft is used in the form of PRO-KERA™ (see below), besides the aforementioned clinical effects, its polymethyl methacrylate (PMMA) conformer ring can be used by oculoplastic surgeons as a symblepharon ring and together may help reduce conjunctival inflammation/swelling following reconstruction in the orbit/socket, lids, or the fornix.

**Table 11.1** Surgical indications for temporary overlaid grafts.\*

#### In human patients:

- Acute chemical/thermal burns
- Acute Stevens-Johnson syndrome with or without toxic epidermal necrolysis
- Chronic recalcitrant keratitis caused by HZO, HSV, or vernal keratitis
- Persistent or recurrent epithelial defect (erosion)
- High-risk corneal grafts (to reduce inflammation)
- In conjunction with socket or fornix reconstruction (to prevent lid/lash rubbing)

#### In experimental animals:

- Excimer laser ablation (PRK/PTK) (to prevent haze)
- Implantation of keratoprosthesis

### 11.2.2 AM as a Graft

When preserved amnion graft is used as a permanent graft, it is intended to replace the deficient or destroyed ocular surface tissue caused by diseases or surgeries,

and to promote regeneration rather than repair of the ocular surface. The basement membrane side of cryo-preserved amnion graft helps rapid epithelialization of the ocular surface, whereas the stromal side of cryo-preserved amnion graft exerts antiinflammatory, antiscarring, and antiangiogenic effects to help the newly reconstructed ocular surface heal with less inflammation and scarring.

Contrary to conventional corneal or conjunctival transplantation in which donor epithelial and mesenchymal cells are transplanted, AMNIOGRAFT® or any preserved AM does not contain live cells, and hence depends on migrating host cells to heal. Therefore, the surrounding host tissue must retain healthy epithelial stem cells, and if the surrounding host stroma does not manifest persistent inflammation, scarring, or ischemia, preserved amnion graft may successfully be used in the corneal and conjunctival diseases listed in Table 11.2 [7].

**Table 11.2** Surgical indications for preserved amnion graft

#### I. Corneal diseases:

- Persistent epithelial defects with stromal ulceration
- Corneal ulcers (central or peripheral)
- Descemetocoele or perforation
- Neurotrophic keratitis
- Bullous keratopathy
- Band keratopathy

#### II. Conjunctival diseases:

- Primary and recurrent pterygia
- Pingueculae
- Tumors
- Conjunctivochalasis
- Superior limbic keratoconjunctivitis
- Scars and symblepharon
- Chemical burns, Stevens-Johnson syndrome and pemphigoid
- Leaking Blebs

#### III. Other diseases:

- Limbal stem cell deficiency
- Scleral melt/ischemia
- Fornix reconstruction
- Socket reconstruction

### 11.2.3 Preserved amnion graft in Conjunction with Other Measures or Procedures

Preserved amnion grafts can also be performed in conjunction with other measures or procedures to augment the therapeutic effects. In the event of persistent inflammation or scarring in the stroma threaten-



ing the benefit of AM used as a permanent graft, intraoperative application of a long-acting steroid [17] or 0.04% mitomycin C [18–20] can be considered. It is worth noting that restoration of a noninflamed deep fornix and effective ocular surface defense, e. g., normal lid closure and blinking and no lid- or lash-related mechanical microtrauma, is a prerequisite for successful transplantation of autologous and allogeneic limbal epithelial stem cells [19, 21–3].

### 11.3

#### Instrumentation and Equipment

Cryopreserved amnion graft transplantation with sutures requires standard surgical instruments and microsurgical equipment. The authors prefer the use of toothed forceps such as 0.12 mm because the cryopreserved amnion graft is quite resilient to tears. However the surrounding tissues may not be resilient to tears, therefore a smooth forceps may be needed in addition to a 0.12 mm forceps. For corneal, limbal, and bulbar conjunctiva, 10-0 nylon sutures are preferred to secure the membrane with a scleral bite, and the knots are buried when used as a graft, but are left with a long end without burying the knots if used as a temporary graft. For the fornix area, 8-0 Vicryl sutures are preferred to

secure the membrane with episcleral bites and placed parallel to the border of the membrane so that each suture can seal a large area of the conjunctival defect. The knots are left unburied and removed in 3 weeks.

In the operating room, the surgeon retrieves the nitrocellulose paper, to which the membrane is attached to one side, yielding a slightly semitransparent appearance. The membrane can be easily peeled off from the paper by two forceps grabbing the two corners while the assistant peels the paper away (Fig. 11.1a). Once detached from the paper, the two sides of the cryopreserved amnion graft can be discerned by touching it with the tip of a dry MicroSponge™ (Alcon Surgical, Fort Worth, Tex.); the stromal side is sticky while the epithelial side is not (Fig. 11.1b). In general, the cryopreserved amnion graft is placed with the stromal (sticky) side on the recipient bed. AMNIOGRAFT® is available in four sizes; Table 11.3 shows the recommended size for different indications. AmnioGraft® is always manufactured with the stromal (sticky) side adherent to the white paper and the epithelial (nonsticky) side facing away from it.

### 11.4

#### Surgical Techniques

##### 11.4.1

##### Conventional Suturing Techniques

To secure preserved amnion graft onto the ocular surface using sutures, preserved amnion graft transplantation is performed under local or general anesthesia depending on the complexity of the disease.

##### 11.4.1.1

##### Preserved Amnion Graft as an Overlaid Graft

To cover the corneal surface as an overlaid graft for the indications shown in Table 11.1, cryopreserved amnion graft (2.5 × 2.0-cm size) is secured by a 10-0 nylon suture at 2 to 3 mm parallel to the limbus in a purse-string running fashion for a total of eight to ten episcleral bites (Fig. 11.2). To secure AM as an overlaid graft over both corneal and conjunctival surfaces, especially for acute chemical/thermal burns or acute SJS with or without toxic epidermal necrolysis, two large pieces of cryopreserved amnion graft (3.5 × 3.5-cm size) are recommended. One piece is laid on the palpebral surface recipient bed, with the stromal surface of the cryopreserved amnion graft facing the palpebral bed and secured to the skin surface of the upper lid margin by a 10-0 nylon suture placed in an interrupted or running manner. The cryopreserved amnion graft is then tugged into the upper fornix with a muscle

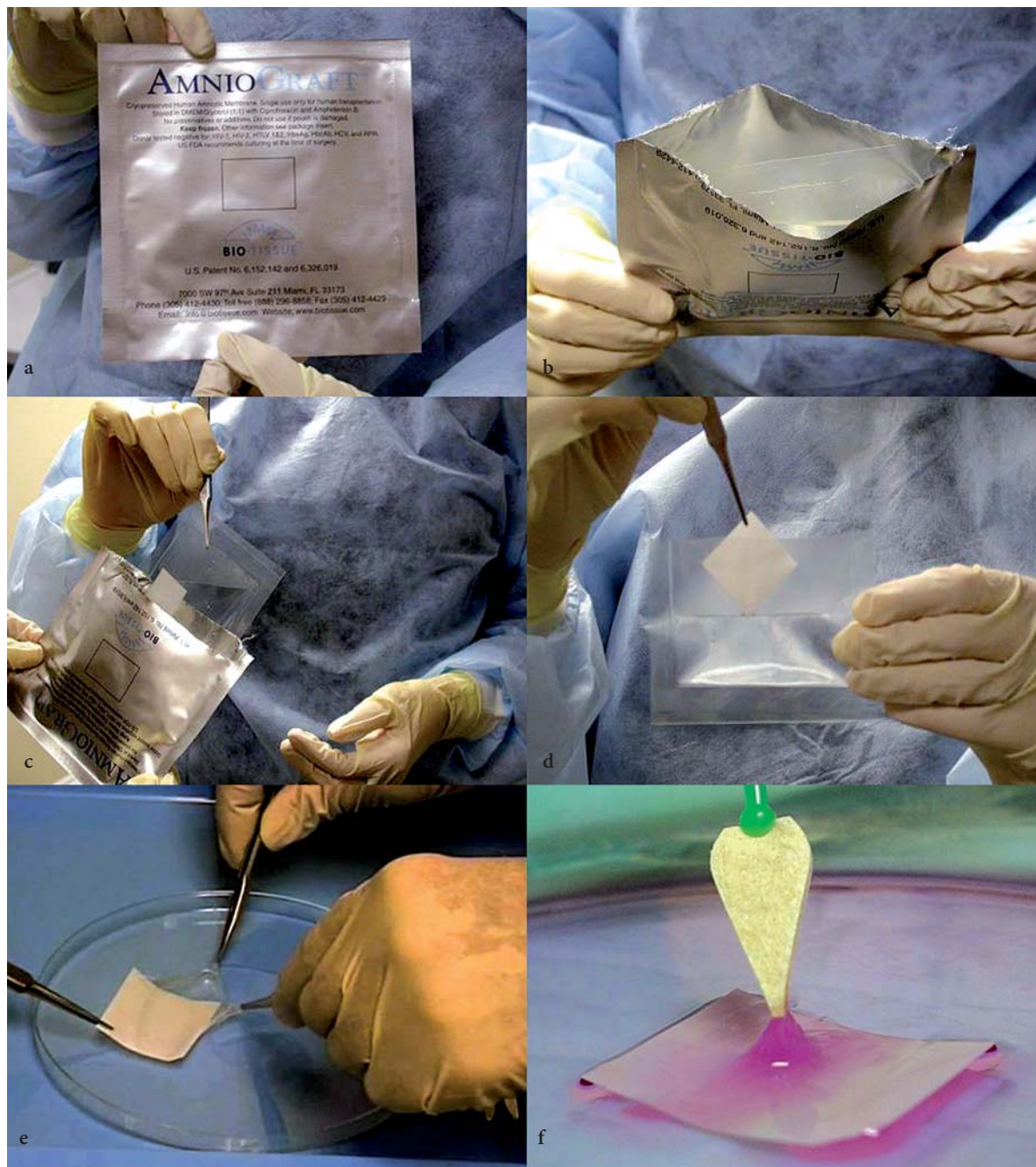
**Table 11.3** Recommended sizes of AMNIOGRAFT® for common indications

Indication	Recommended size <sup>a</sup>
Acute chemical burn	Two-size AG-3535
Band keratopathy	Size AG-2520
Bullous keratopathy	Size AG-2520
Conjunctivochalasis: focal	Size AG-2015
Conjunctivochalasis: inferior bulbar	Size AG-2520
Conjunctivochalasis: 360	Size AG-3535
Corneal descemetocele	Size AG-2520
Corneal epithelial defect	Size AG-2520
Corneal ulcer	Size AG-2520
Pterygium: primary	Size AG-2520
Pterygium: recurrent	Size AG-2520 or AG-3535
Symblepharon: focal	Size AG-2520
Symblepharon: both lids	Two-size AG-3535
Symblepharon: single lid	Size AG-3535

Note AG-1510 = 1.5 × 1.0 cm, AG-2015 = 2.0 × 1.5 cm, AG-2520 = 2.5 × 2.0 cm, and AG-3535 = 3.5 × 3.5 cm

hook and secured in the superior fornix by passing a double-armed 4-0 black silk in a mattress fashion through the lid to the skin surface, and tied over a bolster made of either cotton or 25-gauge i.v. tubing (Fig. 11.3). The remaining cryopreserved amnion graft is spread to cover the upper bulbar conjunctiva and a

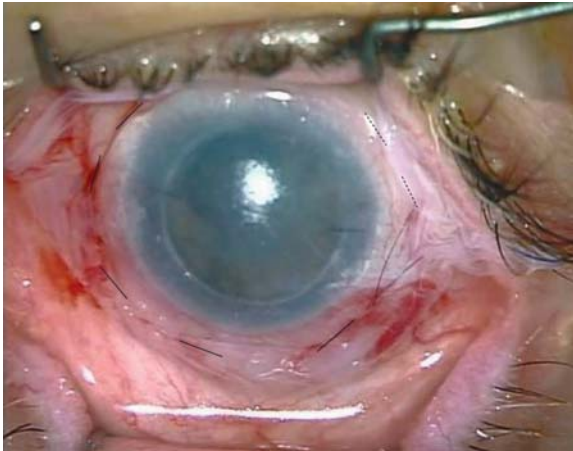
part of the upper corneal surface. The second piece of cryopreserved amnion graft is secured to the lower lid margin and the lower fornix in a similar fashion. The loose edge is tucked under the first cryopreserved amnion graft on the corneal surface, and secured by a running 10-0 nylon suture placed around the limbus



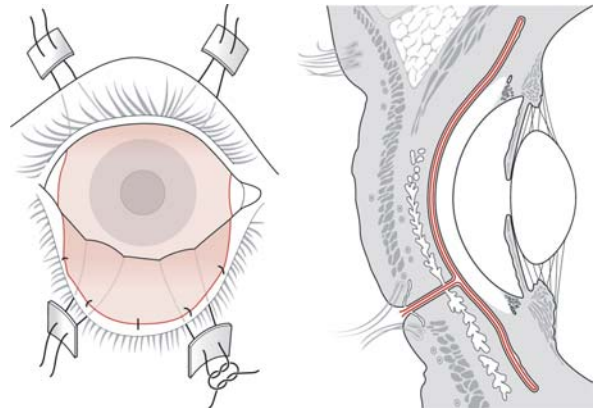
**Fig. 11.1** Cryopreserved AMNIOGRAFT® is stored and shipped in an aluminum foil (a). Upon thawing, one end of the foil is torn to reveal the sterile inside, which contains a transparent pouch bag (b). Using a sterile technique, this bag is retrieved (c), and the white filter paper is then removed with smooth forceps after the bag is cut open from one end

(d). Under the microscope, the membrane is peeled off from the filter paper by using two-toothed forceps to grab its two corners while the assistant removes the filter paper with another forceps (e). The basement membrane surface is not sticky, but the stromal surface (facing the filter paper before [e]) is sticky when touched with a dry Weckcel (f)

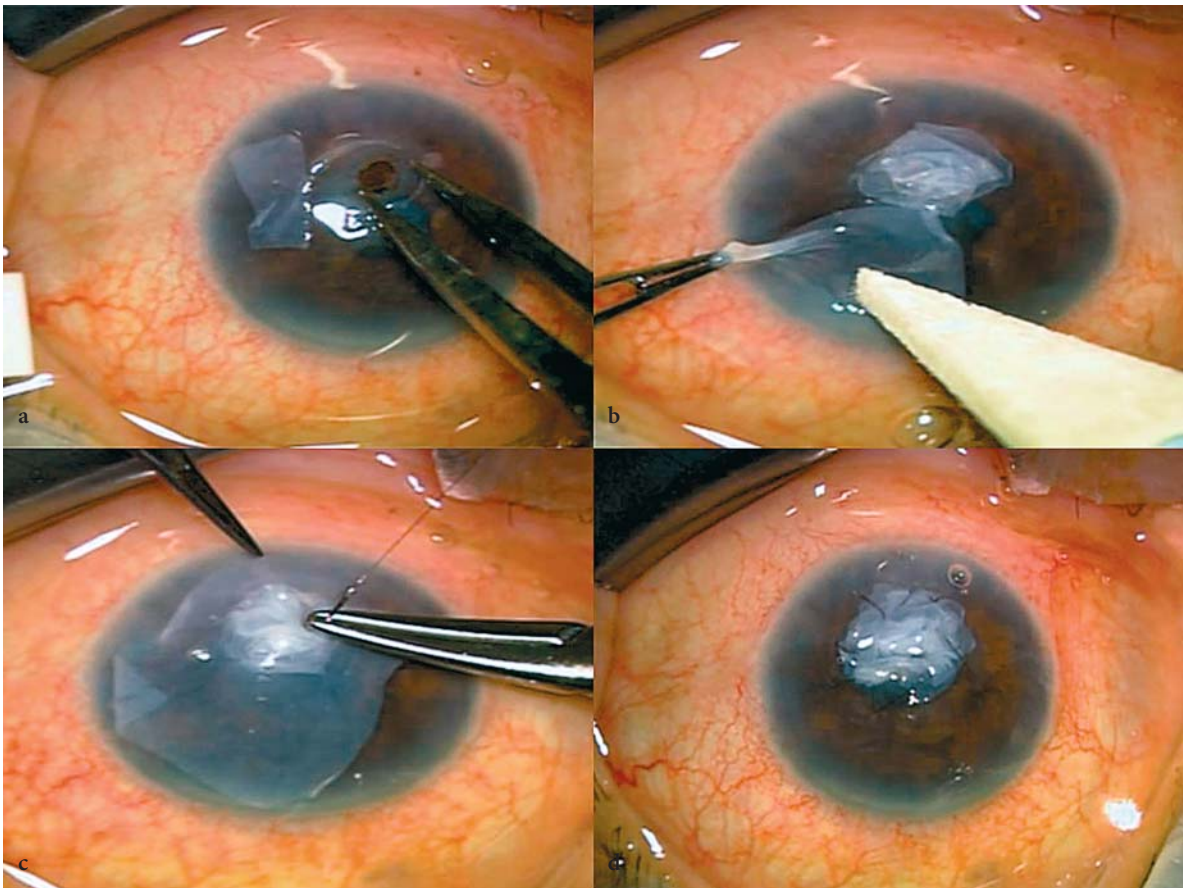




**Fig. 11.2** Surgical depiction of AMNIOGRAFT® used as a temporary graft to cover the corneal surface by anchoring it to the perilimbal sclera by a 10-0 nylon running suture



**Fig. 11.3** The scheme depiction of how AMNIOGRAFT® is used as a temporary graft to cover the entire ocular surface with interrupted or running 10-0 Vicryl suture to the lid margin and double armed 4-0 silk sutures to the skin secured by a bolster



**Fig. 11.4** Surgical steps of using AMNIOGRAFT® and PROKERA™ for corneal perforation. The perforation is around 2 mm in diameter (a). After deepening the chamber by Healon V, fibrin glue is used to attach on layer of AMNIOGRAFT® to the base, and then several layers of AMNIO-

GRAFT® are overlaid (b). A larger layer of AMNIOGRAFT® is then overlaid to cover both the perforation and the healthy tissue, and then secured by a running 10-0 nylon suture (c, d). In the end, a PROKERA™ is inserted and protected by a small temporal sutured tarsorrhaphy

in a purse-string fashion as shown in Fig. 11.2. In the end, a temporary tarsorrhaphy may be used to minimize the lid fissure if there is an exposure concern because of large scleral show or infrequent blinking as a result of a neurotrophic state.

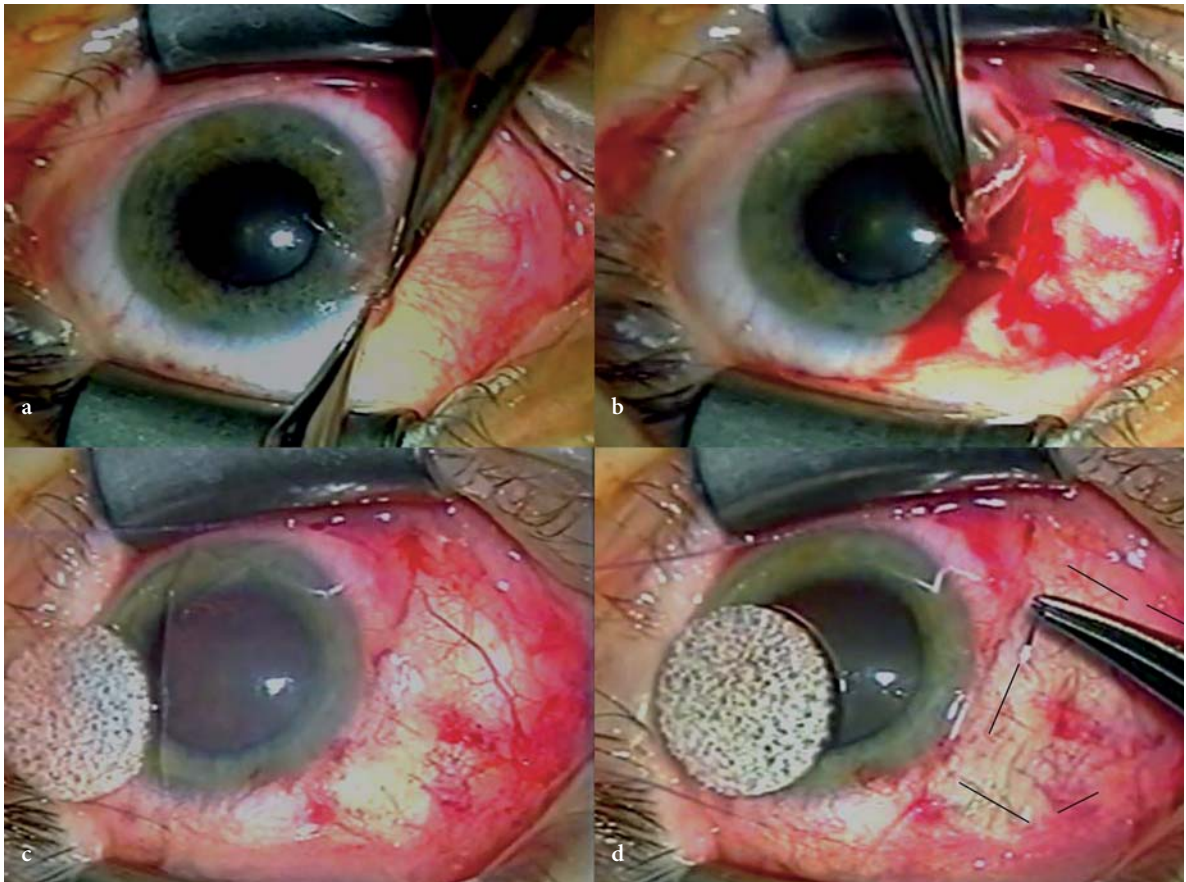
#### 11.4.1.2

##### Preserved Amnion Graft as a Graft

For the corneal indications listed in Table 11.2, preserved amnion graft ( $2.5 \times 2.0$ -cm or  $2.0 \times 1.5$ -cm size) can be used as a single layer or multiple layers to fill in the stromal defect created by an ulcer (once sterile) or following superficial keratectomy, depending on the depth of the stromal loss (Fig. 11.4). The orientation of the bottom layers does not matter (Fig. 11.4a), whereas the top layer meant for epithelialization is best placed with the stromal side down (Fig. 11.4b) and secured tightly to the corneal surface with 10-0 nylon sutures, either interrupted or running (Fig. 11.4c, d). To ensure that epithelialization will take place above, but not un-

derneath, the membrane, a lamellar pocket can be prepared with a crescent blade to allow insertion of the membrane edge, e. g., for bullous keratopathy.

For the conjunctival indications listed in Table 11.2, AM (size depending on the area of the defect to be covered; see also Table 11.3) can be used to substitute the conjunctival tissue (Fig. 11.5). Following the excision of a large conjunctival lesion, e. g., primary pterygium head and body (Fig. 11.5a, b, respectively), the membrane is placed with the stromal side facing the sclera (Fig. 11.5c) and secured by 10-0 nylon sutures for perilimbal bulbar regions and by interrupted 8-0 Vicryl for forniceal regions (Fig. 11.5d). For small scleral defects layers of AM can also be used to fill in the scleral defect (melt) in the same manner as shown for the corneal stromal defect in Fig. 11.4. When used in conjunction with tenonplasty, preserved amnion graft is placed both under and above the Tenon's tissue. When used in conjunction with conjunctival autograft, limbal conjunctival autograft or allograft, or kerato-limbal allograft, AM is placed below these grafts.



**Fig. 11.5** Surgical steps of using AMNIOGRAFT® for conjunctival reconstruction after removal of primary pterygium with sutures. The pterygium head and body are removed in the conventional manner (a, b). AMNIOGRAFT® is laid on

the corneal surface (c), transferred to the denuded sclera, and secured by interrupted 10-0 nylon sutures as outlined, and 8-0 Vicryl suture in the fornix and caruncle area (d)



### 11.4.2 Sutureless Techniques

Topical anesthesia with 0.5% proparacaine hydrochloride, 0.5% tetracaine hydrochloride, or 2% xylocaine jelly is needed if AMT is performed without sutures.

#### 11.4.2.1 PROKERA™ as an Overlaid Graft

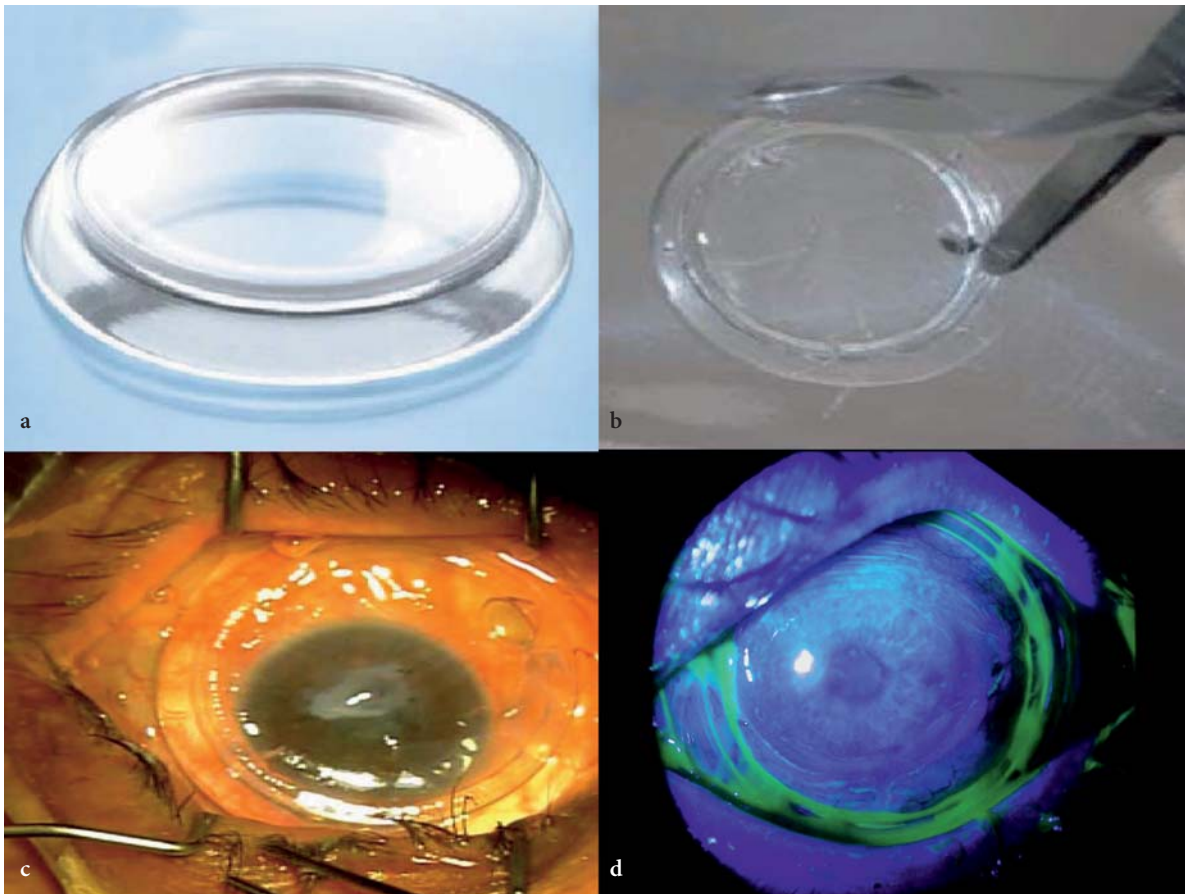
PROKERA™ is a class II medical device that contains a circular piece of AMNIOGRAFT® clipped into a concave dual ring system that conforms to the cornea like a contact lens, and can be used to deliver an overlaid graft onto the corneal surface without sutures (Fig. 11.6a). PROKERA™ is retrieved from the package using sterile technique (Fig. 11.6b), and is available in two sizes, i. e., 15- and 16-mm cryopreserved amnion graft inner diameter. PROKERA™ can be easily inserted without sutures in the office, and at the bedside or in the emergency room, the intensive care unit, or the

burn unit, where it may not be amenable to bring the patient to the operating room due to medical reasons.

PROKERA™ is inserted with the aid of a lid speculum (Fig. 11.6c). The size of PROKERA™ is chosen to ensure that the PMMA ring is behind the tarsal conjunctiva by judging the lid fissure (in millimeters) when the eye is maximally open so as to avoid dislodging or discomfort. While wearing PROKERA™ as an overlaid graft, corneal epithelialization can be assessed by fluorescein staining [24], and the intraocular pressure can be monitored by Tonopen [25] without removing PROKERA™ (Fig. 11.6d). Upon complete healing, e. g., 1–2 weeks, PROKERA™ can be easily removed from the ocular surface under topical anesthesia with forceps.

#### 11.4.2.2 Fibrin glue and Preserved Amnion Graft

Fibrin glue may be used to secure preserved amnion grafts to the corneal or conjunctival surface without sutures (Fig. 11.7). Currently, fibrin glue uses in oph-



**Fig. 11.6** The cartoon depiction of PROKERA™ (a), which consists of a polymethyl methacrylate (PMMA) symblepharon ring fastened with semitransparent cryopreserved AMNIOGRAFT® (b). It can be inserted at the time of surgery

behind the speculum (c), or in the office or the bedside. After insertion, the status of epithelial healing can still be assessed by fluorescein staining without its removal (d)

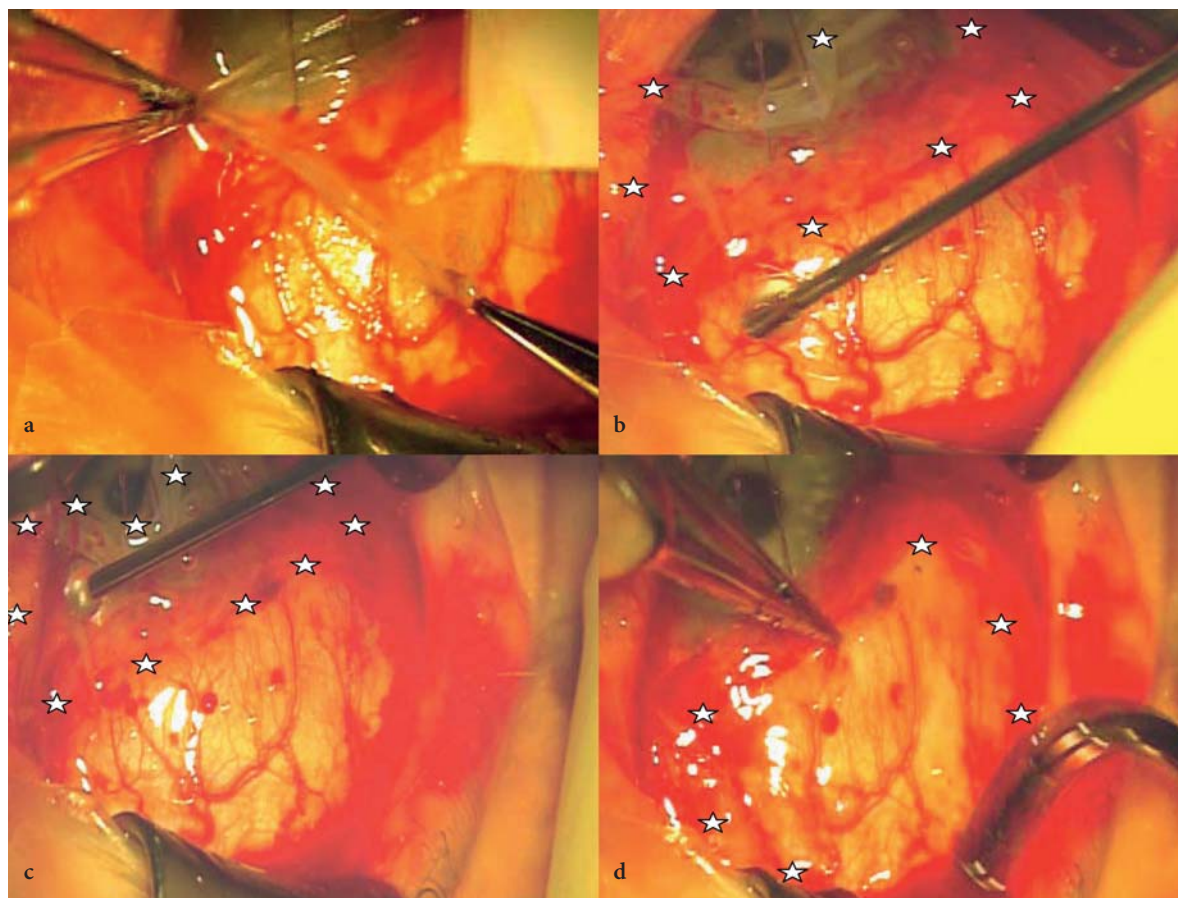


thalmology are considered off-label (i. e., not approved by the FDA), although they have been applied to conjunctival autograft [26, 27] and AM (28, 29). There are two commercially available fibrin glues, Tisseel® and CoSeal® (Baxter Biologics, Inc.). The former requires prewarming in a thermal/stirrer provided by the manufacturer; the latter is ready for use without warming. Both come with two components, thrombin and fibrinogen. After the excision of a large conjunctival lesion, e. g., conjunctivochalasis, AM is laid with the stromal surface up (Fig. 11.7a). Although the two components can be delivered simultaneously via a provided dual injection syringe, it is more convenient and easier to control the time of polymerization of fibrin by applying the thinner, clear thrombin solution on the recipient bed and the thicker (Fig. 11.7b), fibrinogen solution on the stromal side of the preserved amnion graft (Fig. 11.7c). A muscle hook is used to flatten and attach the membrane onto the ocular surface with ease within 15–20 s (Fig. 11.7d; AM is marked by stars). For

fornix reconstruction, the membrane is attached to the bulbar sclera first before being affixed to the fornix and the palpebral conjunctiva with fibrin glue.

## 11.5 Complications and Future Challenges

As aforementioned, because preserved amnion graft tissue does not contain live cells, the ultimate healing is dependent on the surrounding host tissue if used as an overlaid graft. Therefore, in such cicatricial diseases as recurrent pterygium, ocular cicatricial pemphigoid, SJS, chemical burns and trachoma, where there is still active inflammation, scarring, or ischemia in the stroma, preserved amnion graft tissue alone may not achieve a satisfactory success. To restore an aesthetic appearance, other adjunctive measures such as intraoperative injection of long lasting steroids, intraoperative application of mitomycin C and tenonplasty may



**Fig. 11.7** Surgical steps of using AMNIOGRAFT® for conjunctival surface reconstruction after removal of conjunctivochalasis without sutures. AMNIOGRAFT® is retrieved from the filter paper to be laid down on the corneal surface with the stromal surface facing up (a). The thrombin solu-

tion is applied on the denuded sclera (b), while the fibrinogen solution is applied on the stromal surface of the amniotic membrane (c, marked by stars). The membrane is attached to the denuded sclera by flipping and smoothing by a muscle hook (d)

be necessary. If the surrounding conjunctival epithelial tissue is intrinsically abnormal, e. g., severe squamous metaplasia with frank keratinization, the healing of AM-covered area may not be normal unless AMT is performed in conjunction with conjunctival autograft. If there is total limbal stem cell deficiency, AMT alone is not sufficient to heal the persistent corneal epithelial defect unless combined with transplantation of limbal epithelial stem cells [12, 30].

When AMT or PROKERA™ is used as graft, it may require more than one application to suppress severe inflammation. Furthermore, if the membrane dissolves within 1 week, it usually signifies that the corneal surface is excessively exposed, i. e., the tear film cannot be effectively maintained. This concern can be addressed by application of bandage contact lens [31] or simply by placing a small temporary tarsorrhaphy. In a severe dry eye, preserved amnion grafts may fail. Correction of these deficits by other methods helps the success of preserved amnion grafts.

## Acknowledgments

The development of sutureless PROKERA™ is supported by SBIR phase I grant (R43 EY014768-01) from National Institute of Health, National Eye Institute. Other works described here was supported in part by a research grant (RO1 EY06819) from National Institute of Health, National Eye Institute, and in part by research funding from TissueTech, Inc., and by a fellowship grant from Ocular Surface Research & Education Foundation, Miami, Fla.

## Proprietary Disclosure

SCGT holds more than 5% shareholders of TissueTech, Inc., which owns US Patents on the method of preparation and clinical uses of cryopreserved human AM registered under the name of AMNIOGRAFT®, which is currently distributed by Bio-Tissue, Inc., an affiliated entity of TissueTech, Inc. Other authors do not have any proprietary interest.

## References

1. Dua HS, Gomes JA, King AJ, Maharajan VS. The amniotic membrane in ophthalmology. *Surv Ophthalmol.* 2004;49:51–77.
2. Kim JC, Tseng SCG. Transplantation of preserved human amniotic membrane for surface reconstruction in severely damaged rabbit corneas. *Cornea.* 1995;14:473–484.
3. Kruse FE, Volcker HE, Rohrschneider K. Transplantation of amniotic membrane for reconstruction of the eye surface. *Ophthalmology.* 1998;95:114–119.
4. Dua HS, Azuara-Blanco A. Amniotic membrane transplantation. *Br J Ophthalmol.* 1999;83:748–752.
5. Sippel KC, Ma JJK, Foster CS. Amniotic membrane surgery. *Curr Opin Ophthalmol.* 2001;12:269–281.
6. Tseng SCG. Amniotic membrane transplantation for ocular surface reconstruction. *Bioscience Rep.* 2002;21:481–489.
7. Bouchard CS, John T. Amniotic Membrane Transplantation in the Management of Severe Ocular Surface Disease: Indications and Outcomes. *The Ocular Surface.* 2004;2:201–211.
8. Kenyon KR. Amniotic membrane: mother's own remedy for ocular surface disease. *Cornea.* 2005;24:639–642.
9. Tseng SCG, Espana EM, Kawakita T, Di Pascuale MA, Wei Z-G, He H, Liu TS, Cho TH, Gao YY, Yeh LK, Liu C-Y. How does amniotic membrane work? *The Ocular Surface.* 2004;2:177–187.
10. Kruse FE, Jousens AM, Rohrschneider K, You L, Sinn B, Baumann J, Volcker HE. Cryopreserved human amniotic membrane for ocular surface reconstruction. *Graefes Arch Clin Exp Ophthalmol.* 2000;238:68–75.
11. Kim JS, Kim JC, Na BK, Jeong JM, Song CY. Amniotic membrane patching promotes healing and inhibits protease activity on wound healing following acute corneal alkali burns. *Exp Eye Res.* 1998;70:329–337.
12. Meller D, Pires RTE, Mack RJS, Figueiredo F, Heiligenhaus A, Park WC, Prabhasawat P, John T, McLeod SD, Steuhl KP, Tseng SCG. Amniotic membrane transplantation for acute chemical or thermal burns. *Ophthalmology.* 2000;107:980–990.
13. Sridhar MS, Bansal AK, Sangwan VS, Rao GN. Amniotic membrane transplantation in acute chemical and thermal injury. *Am J Ophthalmol.* 2000;130:134–137.
14. Kobayashi A, Shirao Y, Yoshita T, Yagami K, Segawa Y, Kawasaki K, Shozu M, Tseng SCG. Temporary amniotic membrane patching for acute chemical burns. *Eye.* 2003;17:149–158.
15. John T, Foulks GN, John ME, Cheng K, Hu D. Amniotic membrane in the surgical management of acute toxic epidermal necrolysis. *Ophthalmology.* 2002;109:351–360.
16. Di Pascuale MA, Espana EM, Liu DT, Kawakita T, Li W, Gao YY, Baradaran-Rafii A, Elizondo A, Raju VK, Tseng SC. Correlation of corneal complications with eyelid cicatricial pathologies in patients with Stevens-Johnson syndrome and toxic epidermal necrolysis syndrome. *Ophthalmology.* 2005;112:904–912.
17. Solomon A, Pires RTE, Tseng SCG. Amniotic membrane transplantation after extensive removal of primary and recurrent pterygia. *Ophthalmology.* 2001;108:449–460.
18. Inoue T, Hirata A, Kimura A, Sonoda S, Tanihara H. Mitomycin C trabeculectomy in an eye with cicatricial conjunctiva following amniotic membrane transplantation. *Acta Ophthalmol Scand.* 2003;81:673–674.
19. Sangwan VS, Murthy SI, Bansal AK, Rao GN. Surgical treatment of chronically recurring pterygium. *Cornea.* 2003;22:63–65.
20. Tseng SCG, Di Pascuale MA, Liu D-Z, GAO Y-Y, Baradaran-Rafii A. Intraoperative mitomycin C and amniotic membrane transplantation for fornix reconstruction in severe cicatricial ocular surface diseases. *Ophthalmology.* 2005;112:896–903.
21. Espana EM, Di Pascuale M, Grueterich M, Solomon A, Tseng SC. Keratolimbal allograft in corneal reconstruction. *Eye.* 2004;18:406–417.
22. Meallet MA, Espana EM, Grueterich M, Ti SE, Goto E, Tseng SC. Amniotic membrane transplantation with conjunctival limbal autograft for total limbal stem cell deficiency. *Ophthalmology.* 2003;110:1585–1592.
23. Tseng SCG, Prabhasawat P, Barton K, Gray T, Meller D. Amniotic membrane transplantation with or without limbal allografts for corneal surface reconstruction in patients with limbal stem cell deficiency. *Arch Ophthalmol.* 1998;116:431–441.

24. Kobayashi A, Ijiri S, Sugiyama K, Di Pascuale MA, Tseng SC. Detection of corneal epithelial defect through amniotic membrane patch by fluorescein. *Cornea*. 2005;24:359–360.
25. Yoshita T, Kobayashi A, Takahashi M, Sugiyama K. Reliability of intraocular pressure by Tono-Pen XL over amniotic membrane patch in human. *J Glaucoma*. 2004;13:413–416.
26. Koranyi G, Seregard S, Kopp ED. The cut-and-paste method for primary pterygium surgery: long-term follow-up. *Acta Ophthalmol Scand*. 2005;83:298–301.
27. Uy HS, Reyes JM, Flores JD, Lim-Bon-Siong R. Comparison of fibrin glue and sutures for attaching conjunctival autografts after pterygium excision. *Ophthalmology*. 2005;112:667–671.
28. Duchesne B, Tahi H, Galand A. Use of human fibrin glue and amniotic membrane transplant in corneal perforation. *Cornea*. 2001;20:230–232.
29. Hick S, Demers PE, Brunette I, La C, Mabon M, Duchesne B. Amniotic membrane transplantation and fibrin glue in the management of corneal ulcers and perforations: a review of 33 cases. *Cornea*. 2005;24:369–377.
30. Anderson DF, Ellies P, Pires RT, Tseng SC. Amniotic membrane transplantation for partial limbal stem cell deficiency. *Br J Ophthalmol*. 2001;85:567–575.
31. Gris O, Campo Z, Wolley-Dod C, Guell JL, Bruix A, Calatayud M, Adan A. Amniotic membrane implantation as a therapeutic contact lens for the treatment of epithelial disorders. *Cornea*. 2002;21:22–27.

# Strabismus

# 12

Mark J. Greenwald

## Key Points

### Surgical Indications

- Limbal conjunctival incision is preferable for most reoperations, recess/resect procedures, and in older adult patients.
- Adjustable suture technique is advantageous with recession of a previously operated lateral rectus muscle in an amblyopic eye undergoing recess/resect surgery for large angle consecutive exotropia.

### Instrumentation

- Use spatulated needles for all scleral suturing.
- Use nonabsorbable braided polyester sutures for large “hangback” recession of the superior rectus, posterior fixation, and plication procedures.

### Surgical Technique

- Create a secure locking bite knot by pulling the suture needle through the loop from the correct side.
- Enter sclera with the needle tip parallel to the surface of the globe.

### Complications

- Suspect scleral perforation if resistance to needle passage abruptly diminishes or if pigment emerges from sclera with the suture.

signs for Vision, Inc., make them a sound investment, even for the beginning surgeon.

Some strabismus surgeons employ an operating microscope, particularly in teaching and learning situations. Advantages include greater confidence in determining the depth of scleral needle passes, consistency with other operative approaches, and the relative ease with which video recording of cases can be done. Microscope magnification is also helpful when preservation of anterior ciliary vessels is attempted. Magnification should generally be kept low to maximize field of view and depth of focus, zooming to higher magnification, if desired, when passing needles through sclera.

If a microscope is not used, careful attention must be paid to illumination of the operative field. At least two overhead lights should be positioned to minimize shadows. Some surgeons use a fiber optic headlamp, particularly for procedures that require working on the posterior half of the globe.

This chapter emphasizes techniques used in performing recession and resection of previously unoperated horizontal rectus muscles. Procedures on cyclovertical muscles and reoperations involve maneuvers that are often quite similar.

## 12.1 Introduction

Eye muscle surgery differs from the other topics addressed in this volume in that it is not routinely done using a microscope. Flawless muscle operations can in fact be performed absent any magnifying device, especially if the surgeon is not yet presbyopic. However, there is unquestionably an advantage to operating on muscles with, at a minimum,  $\times 1.75$  to  $\times 2.5$  magnification provided by spectacle-mounted telescopes (loupes). Simple and inexpensive but highly serviceable Telesight loupes are available from numerous vendors. The excellent optical quality and durability of high-end surgical telescopes such as those from De-

## 12.2 Indications

Planning muscle surgery involves making numerous decisions and choices. Foremost among these are whether surgery is in fact the most appropriate therapeutic option in a particular case at a particular time, and which muscle(s), which procedure(s), and what quantification are likely to yield the best outcome in all gaze positions. Consideration of these issues is beyond the scope of this discussion, but their importance cannot be overemphasized [6, 7, 15].

Having made a choice of muscles and procedures, the surgeon must decide which conjunctival incision to employ. Since the 1960s, nearly all muscle surgery in North America has been done using either a limbal approach, following the example of Gunter von Noorden [16], or a fornix approach, as developed and taught by Marshall Parks [13, 14]. Limbal incisions make for



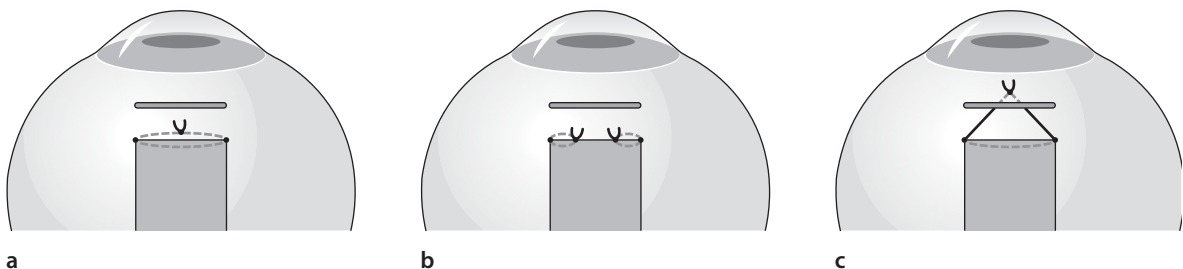
greater ease of locating and isolating rectus muscle insertions, particularly helpful if the eye has previously undergone surgery, and provide the opportunity to resect or recess conjunctiva. Fornix incisions are indispensable for procedures involving oblique muscles. The principal advantages of this approach for rectus muscle surgery are reduced operating time and greater early postoperative comfort for the patient. For horizontal muscles, inferior fornix incisions are usually preferred, but use of the superior fornix is desirable when supraplacement of the muscle (for A or V pattern, or reduction of a small vertical deviation) is planned.

Prior to the advent in the 1970s of synthetic polymer absorbable sutures, 5-0 catgut was used for most muscle surgery. The relatively frequent breakage of this material made it essential to secure each muscle with two separate sutures. The superior quality of sutures currently available [12] has fostered the development of one-suture reattachment approaches that are now widely preferred. Nevertheless, use of two sutures per muscle (representing the two parts of a two-needle double-armed suture cut in half) still offers a number of advantages. With two sutures and two knots, excellent scleral apposition and ease of tying can be achieved without the requirement of long scleral tunnels, reducing the risk of perforation. Because the unsupported central span is substantially shorter with two-suture than with one-suture reattachment (absent incorporation of tissue into the knot at the time of tying), there is actually less tendency for a doubly sutured muscle to sag despite the fact the midportion of the tendon is “out of the loop” (Fig. 12.1a, b). Using two sutures and securing one end of the tendon at a time makes it considerably easier to achieve muscle–scleral apposition with a tight muscle, especially valuable for resection and advancement procedures. Finally, two-suture technique is better suited to instrument tying, an advantage for the surgeon who finds hand tying distasteful. Muscle reattachment with two sutures was the

original choice of von Noorden for use with limbal incisions, and remains particularly well matched with that approach.

Prior to the 1980's strabismus surgeons believed that muscles needed to be tightly apposed to sclera when reattached. The popularization of adjustable sutures by Arthur Jampolsky in the 1980s [9] called this belief into serious question, leading many practitioners to begin using adjustable-inspired “hangback” suturing for most recession procedures (Fig. 12.1c). In this approach, scleral support is at the original insertion, and postoperative attachment site is determined by the length of suture left between scleral and muscle anchor points and tension in the muscle. The hangback technique provides acceptable results and is relatively easy to perform. Nevertheless, many surgeons use conventional suturing in most circumstances. During hangback reattachment using absorbable suture material, it is important (especially with the medial rectus) that the muscle not be recessed for more than the length of the scleral “arc of contact,” because a muscle that is suspended off the scleral surface cannot be relied upon to form an adequate connection to the globe. Hangback suturing is useful for large (10 mm or more) recessions of the superior rectus muscles in dissociated vertical deviation. A nonabsorbable suture should always be used because recession exceeds the arc of contact and the interposed superior oblique tendon complicates the rectus–scleral healing process.

Adjustable sutures remain somewhat controversial even after decades of widespread experience, with some surgeons using the approach for nearly all possible applications in adults and even children [4], while others continue to reject the technique altogether. No convincing clinical trial has established the superiority of adjustable suture technique for any category of strabismus [1]. The adjustable suture technique adds to the patient's postoperative stress and discomfort, yet the “second chance to get it right” provided by adjustment has an undeniable appeal.



**Fig. 12.1** **a** Conventional one-suture muscle reattachment. **b** Conventional two-suture muscle reattachment. Note that, in contrast to **a**, the muscle is supported at four points across its width. **c** “Hangback” muscle reattachment. Suture ends

may also be anchored in sclera in the same manner as conventional one-suture reattachment, entering at the two poles of the original insertion



### 12.3

#### Sutures and Instruments

The great majority of muscle surgery is done using braided synthetic absorbable suture materials, of which polyglactin (Vicryl, Ethicon) is by far the most popular. Most surgeons prefer 6-0, though 5-0 is also suitable. Dusting with fine particles of the same polymer (coating) in the manufacturing process reduces the tendency for such sutures to adhere to fascial tissue against which they brush.

Spatulated needles, flat on the upper and lower surfaces, are essential to minimize the risks of scleral perforation and pull-through (Fig. 12.2). The S-29 needle (Ethicon) has a small cross-sectional area that ensures a desirable degree of friction between the suture and the scleral tunnel and helps keep recessed muscles from sliding posteriorly during tying. S-14 and S-24 needles also work well, especially with 5-0 suture. The S-28 needle has a tighter curve that is useful for suture placement in closely confined situations.

Sutures of nonabsorbable material such as braided polyester (Mersilene, Ethicon) equipped with similar needles should be available for applications in which formation of a bond between muscle or tendon and sclera may be problematic, such as large hangback recessions (especially involving the superior rectus), posterior fixation, and plications.

The Barraquer needle holder (Storz/Bausch & Lomb E3843) is advantageous because its hemicylindrical handles facilitate holding the needle in a variety of orientations, without adjustment of overall hand position. It also works well as a tying instrument.

It is desirable to have both right- and left-handed scissors available for muscle disinsertion, so that the lower scissor blade can be placed beneath the tendon regardless of the direction from which the instrument is advanced. The author's preferred instruments for this purpose are the Aebli corneal section scissors (Storz/Bausch & Lomb, right E3289, left E3290). If only standard right-handed Westcott scissors are available, the maneuver can still be performed optimally if the tips are advanced in the proper direction (e. g., from below the right medial rectus and above the left medial rectus) when engaging the tendon.

Table 12.1 lists a complete set of instruments useful in performing the maneuvers described below.

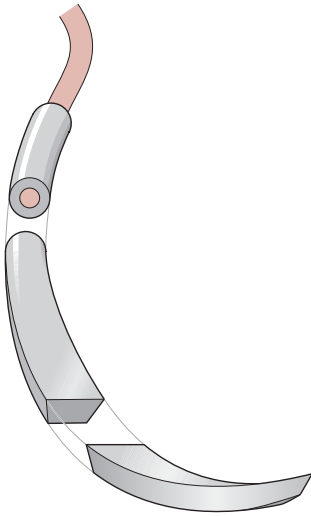
**Table 12.1** Instruments for eye muscle surgery

No. of items per tray	Item	Storz/Bausch & Lomb catalog nos.
2	Stevens tenotomy hooks	E0600
2	Green strabismus hooks	E0588
1	von Graefe strabismus hook	E0593
1	Lester fixation forceps	E1656
2	Bishop-Harmon tissue forceps	E1500
3	0.5-mm locking Castroviejo forceps	E1798S
2	Storz tying forceps	E1887
1	Westcott utility scissors	E3322
1	Westcott stitch scissors	E3221
1	Aebli corneal section scissors, right	E3289
1	Aebli corneal section scissors, left	E3290
2	Barraquer curved locking needle holder	E3843
1	Castroviejo caliper	E2404
1	Hartman straight mosquito hemostat	E3915
2	Storz serrefine clamps	E3900
1	Iris spatula	E0700
1	Desmarres retractor, 11 mm	E0980
1	Desmarres retractor, 13 mm	E0981
1	Cook eye speculum, pediatric	E4082
1	McKinney eye speculum	E4086

### 12.4

#### Technique

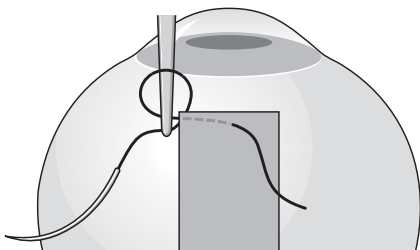
Suture placement and tying involve similar maneuvers for recession and resection of rectus muscles, differing mainly in location. The following description will cover both procedures, with consideration of one-suture and two-suture approaches, using conventional, hangback, and adjustable technique, and performed through fornix and limbal incisions [3, 4].



**Fig. 12.2** A spatulated needle. Note the difference in cross section between the cutting portion and the swaged portion

#### 12.4.1 Muscle Suturing

For initial passage of suture through tendon (in recession) or muscle (in resection), the needle should be grasped as far from the tip as possible without placing the needle holder jaws on the circular cross-sectional portion into which the suture is swaged (Fig. 12.2). A key point of reference in making this pass is the site of exit from tissue, which should be as close as possible to the sclera for recession and at the appropriate measured distance from the insertion for resection. The needle is introduced into tissue with the tip parallel to the muscle plane and directed toward the exit point, entering either in the middle of the tendon when using a single double-armed suture, or one quarter the muscle's width from the edge when using one of two sutures. The exact entry site and path prior to exit are not critical, and it is even acceptable if the suture emerges from the tissue for a portion of its course. When mak-



**Fig. 12.3** Path of suture through tendon. Passage of the needle holder from anterior to posterior through the suture loop before grasping the needle end ensures creation of a true knot, if the second pass through tissue was more anterior (closer to the insertion) than was the first

ing half-width passes in a one-suture recession, starting 1 to 2 mm from sclera makes it easier to guide the curved needle to its exit (at the muscle insertion). The needle point should emerge precisely through the tendon or muscle edge, not from the posterior or anterior surface, creating slight outward bowing of the capsule as it does so.

When regrasping the needle to withdraw it from tissue in preparation for placement of the locking bite, the needle holder should be applied with the convex side of the curved jaws oriented toward the needle tip. The suture is pulled in the same direction it took passing through the tissue (following the curve) until about half the length of the suture is beyond the muscle.

Completion of tendon or muscle anchoring with a locking bite should create a true knot that encircles and tightly engages about 1 mm of tissue [10]. To achieve this goal, careful attention to needle placement is required (Fig. 12.3). The needle should be passed full thickness through the tendon or muscle, perpendicular to the tissue plane as close as possible and immediately anterior to the first tissue pass for recession, and immediately posterior to the first pass for resection. The needle is released, and the empty needle holder tip is passed through the loop of suture between the exit point of the first tissue pass and the entry point of the second pass for a recession on the anterior side of the first pass, the needle holder needs to enter the loop heading away from the insertion (Fig. 12.3); with the second pass for a resection on the posterior side of the first, the needle holder must enter the loop heading toward the insertion. Failure to execute this maneuver properly will result in a less secure spiral rather than a true knot. The locking bite should finally be tightened by grasping and pulling the two sutures (not the needles) against each other in a continuous straight line. This entire process is then repeated on the opposite side of the muscle with the other end of the intact double-armed suture in one-suture technique, or with the other half of the divided suture in two-suture technique. The locking bite may be the weakest link in the muscle's reattachment. If for any reason the surgeon doubts its adequacy, a second locking bite should be placed in the same location, using the same technique described above.

#### 12.4.2 Disinsertion

Separation of the muscle from the globe is performed with blunt-tipped scissors. For both recession and resection, cleavage should be as close as possible to the sclera. With recession, this is necessary to minimize the risk of cutting the preplaced suture that is very close to the sclera, and to avoid an unsightly ridge that

will be visible through conjunctiva after healing. With resection there is no need to leave a muscle stump because reattachment sutures should be anchored in sclera, not muscle or tendon tissue. The blade of the scissors that is internal to the muscle should be the blade that is closer to sclera; having available both right and left configured scissors aids in achieving this. At the beginning of disinsertion, traction on the muscle hook should be great, and scissors tips should be firmly pressed against sclera. As the process is completed, traction on the hook should be relaxed and scleral pressure reduced or eliminated; otherwise, force transmitted through the narrow remaining attachment will tent up sclera and create a risk of perforation.

During disinsertion the sutures need to be kept under tension and away from the advancing scissors blades. With one-suture technique, the author prefers to hold the suture ends with the same hand that holds the muscle hook, grasping the hook between the curved third and fourth fingers while controlling the suture with the thumb and forefinger (Fig. 12.4). This permits tension in the muscle and the suture to be adjusted independently. With two-suture technique, applying serrefine (bulldog) clamps to the sutures and draping them off to the side from which the muscle originates works well.

Gentle traction on the suture ends after disinsertion should confirm that the locking bite knots are secure. If this proves not to be the case (typically evidenced with one-suture technique by one edge of the muscle sliding toward the other), the nonsecure corner is grasped with a locking forceps and held a full muscle width away from the other corner, which is supported by the suture. A new locking bite is created by passing the nonsecure corner's needle perpendicularly through the full thickness of tissue immediately adjacent to the forceps, and then proceeding to complete the knot as described above.

It may also be discovered at this point in a one-suture recession that the suture has been accidentally severed between the two locking bite knots during disinsertion, either because the suture dipped slightly into sclera in the course of passage through the tendon or because scissors tips were insufficiently close to sclera at disinsertion. This should be suspected if the two edges of the tendon can be pulled further from each other than the original muscle width, and is confirmed by identifying the cut ends in the tendon. Released from tension by the resulting discontinuity in the suture loop, the lock bite knots can loosen and lose their grip on tissue; therefore, the entire suture must be replaced. Locking forceps are immediately applied to both corners of the tendon, and a new double-armed suture is passed and anchored as close as possible to the original, with separation between the new locking bite knots equal to the tendon's original width. When

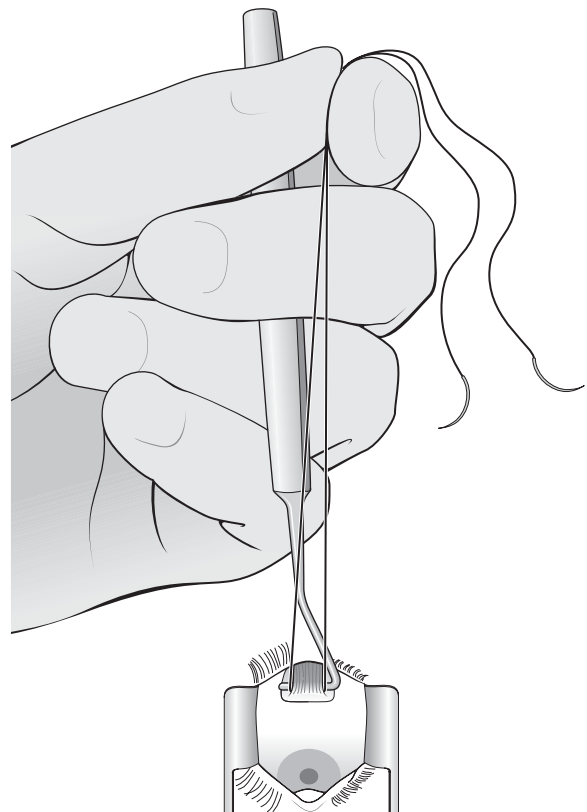
the new suture is securely in place, the original suture's emerging ends are trimmed (being careful not to confuse them with the new ends). The original locking bite knots and their extensions into tissue can be left in place.

In resection, before disinsertion a clamp is firmly applied across the full width of the muscle just in front of the sutures, taking care not to crush the sutures themselves, and the posterior muscle hook is withdrawn. The clamp is removed after excising the tissue anterior to it, with either sharp-tipped scissors or a blade.

### 12.4.3

#### Scleral Anchoring

Preparation for needle passage through sclera, the most critical element in muscle suturing, begins with application of Castroviejo 0.5-mm locking forceps to stabilize and position the globe, usually at the two ends of the original insertion site. No matter how close the disinsertion has been, the line of former tendon attachment can be identified by noting the abrupt change in scleral thickness that is seen there, supplemented if



**Fig. 12.4** Hand position that permits independent control of tension in the muscle and in the suture during disinsertion

necessary by palpating with a hook the step-up that occurs when sliding from behind to in front of the line. Achieving an adequate grasp with the forceps can be tricky. It is helpful to start by lodging the single-tooth forceps arm against the scleral step-up, directed toward the limbus, and then dragging the double-tooth arm over the anterior scleral surface to engage tissue just before locking. Pressing too firmly tends to stretch the sclera, making the process more difficult. With gentle force, a slight fold can be created that facilitates engagement. If repeated attempts fail to gain an effective tissue grip, it may help to reverse the arms of the forceps. When supraplacement or infraplacement is planned, the first forceps are applied at the center of the insertion site and the second at a point along the line of the insertion whose distance from the center equals the width of the original insertion. The same maneuvers can be performed here despite the lack of a scleral step-up, if the single-tooth arm is deliberately engaged in tissue at first.

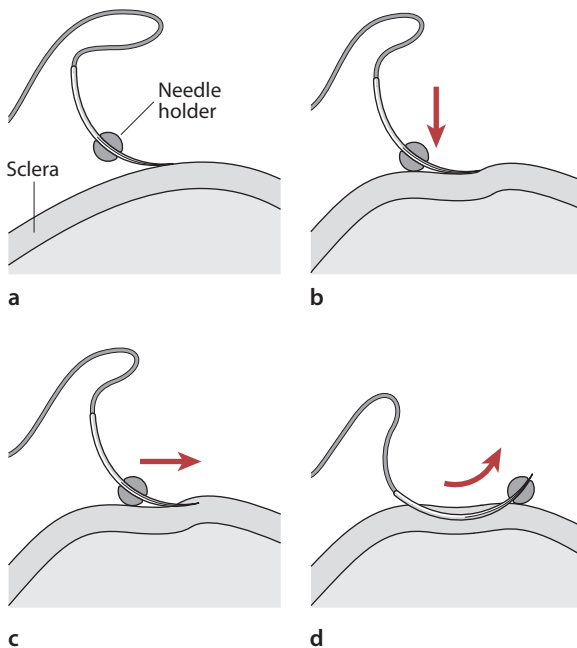
Positioning the globe for scleral suturing is accomplished by holding both locking forceps in one supinated hand and applying force so as to rotate the globe as far as possible toward the side opposite the muscle's field of action, lifting it slightly from the orbit, and displacing the insertion upward or downward as necessary to provide optimal access to the scleral target of the needle while maintaining the line of insertion in

vertical (head to foot) orientation. The needle should be positioned between the needle holder jaws, close to their tips, and locked in place. To maintain adequate control during scleral passage, it is important that the needle be grasped closer to its tip than to the suture-swaged end (Fig. 12.5a). The tip of the needle is brought to rest on the scleral surface, with its direction parallel to the original insertion and pointing toward the center of the new insertion, its location exactly at the marked entry site, and its convex flat side exactly tangent to the scleral surface (Fig. 12.5a).

Immediately before entering sclera, the needle holder lock is released by gently squeezing. With pressure directed toward the center of the globe, the needle is used to create an indentation in sclera (Fig. 12.5b), and while maintaining this pressure, the needle tip is moved slowly but steadily forward to enter and advance through scleral tissue in approximately its midplane (Fig. 12.5c). At this point, the surgeon must consciously resist the temptation to let up on the indenting pressure, which will result in loss of appropriate depth. (If the proper plane is not reached quickly after entry, the suture will pull through the outer wall of the initial portion of the tunnel during tying and undesirably shorten the new attachment). The tip of the needle should be visible through overlying tissue throughout the scleral passage. If it becomes hard to see, stroking over it with the tip of a small muscle hook may be helpful.

When two sutures are used for recession, the total length of the scleral tunnel should match the length of the suture's passage through tendon, about one quarter of the insertion width or 2 to 3 mm. A passage of this length can usually be achieved without regripping the needle while the tip is within tissue. When the appropriate exit point has been reached, the needle holder is rotated slightly so as to direct the needle tip toward the surface, and the tip is advanced out of tissue. The trailing end is then pushed to advance the needle until it can be pulled the rest of the way through by grasping the tip, taking care to follow the needle's arc and not apply force against the thin inner wall of the tunnel (Fig. 12.5d). Both ends of the suture are again placed in a serrefine clamp, and draped to the side opposite the muscle's origin. The second suture is anchored in a similar manner.

For a one-suture procedure, the needle must be advanced further through sclera by repeatedly regripping and pushing, slightly rotating the needle holder each time to keep the tip directed parallel to the sclera it is entering. When the tip of the first needle has traversed a distance (about 5 mm) equal to half the separation between the locking forceps, it is directed toward the surface by rotating the needle holder slightly, and then advanced to expose 2 to 3 mm at the tip, without being withdrawn from sclera. The second needle is passed similarly from its marked entry point,



**Fig. 12.5** Scleral needle placement, with jaws of the needle holder shown in cross section. **a** Needle tip resting flat on sclera. **b** Sclera indented by needle tip. **c** Needle engages sclera, advancing parallel to a plane tangent to the sclera. **d** Withdrawal from sclera along arc of needle

along the same line as the first but in the opposite direction. Its tip remains within sclera until it has reached or gone slightly beyond the exit point of its mate (directed slightly to one side if it collides with the first needle), and is then guided to the surface where the two needles create a so-called crossed-swords effect. In placing these needles, it is desirable to avoid leaving even a tiny separation between exit points as a result of tunneling for too short a distance. Such a gap makes it difficult to avoid slack in the suture loop when tying. There is no problem if long tunnels extend a bit beyond each other's end.

Scleral anchoring for a resection, a hangback, or an adjustable recession is done at the original insertion site. In turn, each needle is placed against sclera just behind the step-up, tangent to the surface and angled about 45° toward the center of the insertion. Under minimal pressure toward the center of the globe, the needle is moved forward into the step-up, emerging from the surface about 2 to 3 mm anteriorly and centrally. For resection, the entry sites are at the ends of the original insertion; for a hangback or an adjustable, they straddle the center, separated from each other by about 3 mm, with the needles emerging as nearly as possible at the same point in crossed swords configuration.

#### 12.4.4

##### Knot Formation

In preparation for tying, the muscle is drawn forward to bring the knots into apposition with the scleral entry sites. The entry site must be watched carefully as suture passes into it, and if it is noted that adherent fascia is being pulled toward the tunnel, traction should be released until the tissue is freed.

Hand tying the final knot offers considerable advantage in terms of speed and control with one-suture recession. Alternatively, instrument tying may be performed as discussed in Chap. 3. Regardless of the technique, a double throw followed by two single throws is used to secure the suture. Friction between the suture and the long scleral tunnels is usually sufficient to keep the slackened muscle from retracting, so maintaining tension is unnecessary during the process of knot formation. The suture ends should be held as far as possible from the globe for hand tying, close to the needles, which have not been trimmed. When tightening the knot, force should build simultaneously in both suture ends, which are stretched in a continuous straight line tangent to the globe. This is best achieved by pulling horizontally across the bridge of the nose and the lateral canthus. After tightening the first throw, it is important to avoid jarring the knot until it has been stabilized by the second throw. Successive throws (first one double followed by two or three single) should be

formed with practiced alternating hand movements to ensure that they go down square and flat. The suture ends are finally trimmed to a length of 2 to 3 mm.

Two-suture reattachments are best done with instrument tying, forming a 2-1-1 knot. Either needle holders or broad tying forceps can be used, one for each suture end. The end that has passed through sclera (pulling end) should be trimmed of its needle to a 3- to 4-cm length, and the other (looping) end to about 10 cm or more. Especially when tension in the muscle is increased, as is typical with resection, force applied along the line of scleral passage must be maintained on the pulling end. The looping end should be deliberately kept slack, and suture contact with tissue scrupulously avoided, until the knot is formed and rests on sclera. With the initial double throw, it may be necessary to jiggle the looping end repeatedly to overcome snags, while steadfastly maintaining tension in the pulling end. As suture length emerges from the diminishing loop, the looping end should be repeatedly regripped to keep the tying instrument close to the knot. The knot is tightened by pulling both ends in a horizontal straight line tangent to the globe. After the knot has been stabilized by the second throw, one or two more throws are added in standard overhand fashion, taking care to make them square and flat, before trimming the ends to 2 to 3 mm.

#### 12.4.5

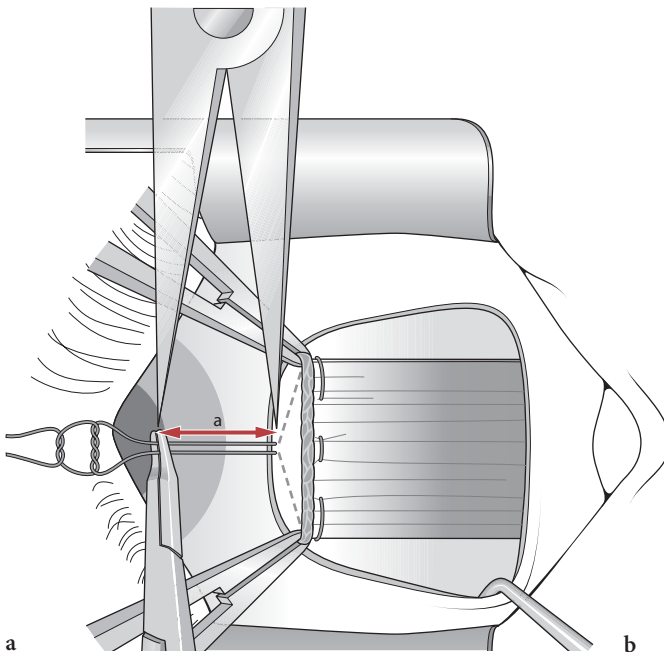
##### Hangback Suture

The ends of a double-armed suture used for hangback recession without adjustment must be tied to each other to leave a measured length of slack. This is accomplished by first pulling the muscle forward until the locking bite knots are tight against sclera at their respective tunnel entry sites, bringing the cut tendon back up to its original line of attachment. Using a caliper, the planned recession distance is measured anteriorly from the tunnels' scleral exit site, and a locking needle holder is applied across the two contiguous sutures, with the anterior surface of its jaws at the point indicated by the caliper (Fig. 12.6). The emerging sutures are tied together to make a 2-1-1 surgeon's knot in contact with the needle holder, which is released after trimming the ends. When the muscle retracts and pulls this knot back until it is stopped by the scleral tunnel exits, the locking bite knots move back the same distance from the entrances to establish the measured recession.



### 12.4.6 Adjustable Suture

To form an adjustable knot, a loop is formed with a single overhand throw in the middle of a 15- to 20-cm length of 6-0 Vicryl (which may be trimmed from one of the muscle suture ends emerging from sclera). The loop is slipped over the two muscle suture ends and cinched as tightly as possible around them before adding two more single throws. The resulting knot should slide along the muscle sutures with moderate resistance. To facilitate identification and manipulation for postoperative adjustment, the ends of the sliding knot suture are tied to each other (over an instrument such as a closed Westcott scissors) to make a 4- to 5-mm loop, and then trimmed short. The knot is positioned (in the manner described above for a hangback suture) to allow recession of the desired amount. The muscle suture ends are trimmed to a length of about 5 cm and tucked into the inferior cul-de-sac. To aid in adjustment, a “handle” for the globe is created by anchoring an additional suture (which may be 6-0 silk or nylon) in sclera just posterior to the limbus directly in front of the recessed muscle, tying it on itself to make another 4- to 5-mm loop. (The adjustment process is described at the end of this section.)

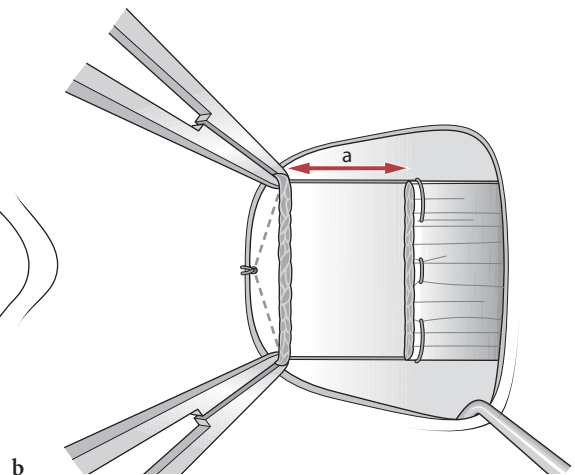


**Fig. 12.6** Tying a hangback suture. Length of suture *a* that extends beyond the scleral exit site when the muscle is pulled

### 12.4.7 Finishing Touches

After tying, the muscle should be closely inspected to make sure both locking bite knots are tightly apposed to their respective scleral tunnel entrances, and the center of the anterior tendon or muscle edge does not sag excessively (more than 1 to 2 mm) behind the line joining the entry sites. Suture slack behind a tunnel entrance can be remedied as follows. The needle attached to one of the leftover 6-0 Vicryl suture ends should be passed once through muscle or tendon just behind the sagged locking bite, and then into sclera at a distance from the entry site of the previously placed suture equal to the distance the locking bite has pulled back, measured away from the muscle along the line passing through the two entry sites (Fig. 12.7a). When the suture is tied on itself, the former sag will be converted into increased width of scleral contact along the appropriate line.

Central sagging with one-suture reattachment in recession is a common occurrence that can usually but not always be prevented by making sure the two scleral entry sites are separated from each other by a distance equal to the full width of the muscle, and that the tunnels reach full depth as soon after scleral entry as possible. Fortunately this problem is easily eliminated in the course of completing the final knot by bringing the needle attached to either suture end up through the center of the tendon 1 to 2 mm behind the cut edge



up to the original insertion (a) converts to an equal amount of recession when the muscle is allowed to pull back (b)

(just posterior to the span of suture) after the second or third throw, and then finishing with two to three additional throws (Fig. 12.7b).

Central sagging with two-suture reattachment is infrequent with recession but typical with resection. It is nicely dealt with by passing the two ends of an 8-0 double-armed Vicryl suture through the muscle, from external to internal, each at a distance of 1 to 2 mm from the center and from the anterior edge, and then anchoring each in sclera just anterior to the muscle for 1 to 2 mm, with emergence in a crossed swords configuration, followed by hand or instrument tying (Fig. 12.7c).

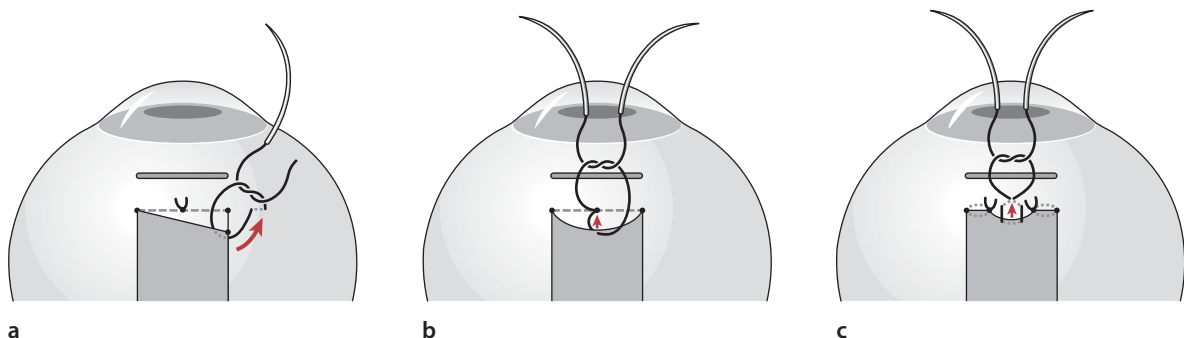
#### 12.4.8 Conjunctiva Closure

With a fornix incision, particularly for the medial rectus muscle, conjunctival reapposition can often be accomplished effectively without suturing. After completion of muscle reattachment, a small hook is used to gently separate Tenon's fascia from sclera between the limbus and the incision, and to massage conjunctiva in a posterior direction until the incision returns to its original position. If Tenon's fascia is bulging between the wound edges, it is excised as necessary to permit relaxed apposition. (Removing the lid speculum may be necessary to determine if apposition is adequate.) Persistent gaping is eliminated by placement of one or more sutures. Although it is tempting to use an end of the 6-0 Vicryl trimmed from the muscle for this purpose, the resulting knot may be a source of significant postoperative discomfort. A softer material such as fast-absorbing 6-0 gut is preferable.

Limbal incisions may be closed at the limbus, or with the anterior edge recessed several millimeters (usually to the original line of muscle attachment) after recession. Conjunctival epithelium grows quickly to cover exposed anterior sclera, with no adverse effect

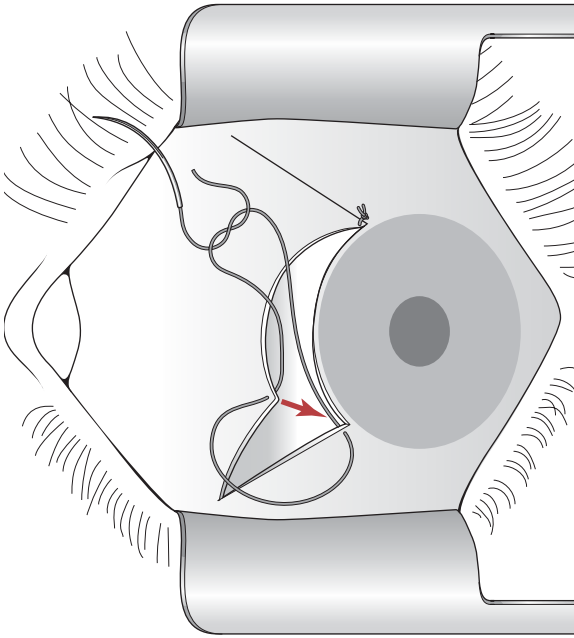
on postoperative comfort or appearance. Excision of a 2- to 3-mm strip of tissue (conjunctiva and Tenon's fascia) from the anterior edge is an option following resection or advancement. Recession of conjunctiva is indicated if the tissue is abnormally tight or thickened from prior surgery or inflammation. In the author's experience, both recession and resection of conjunctiva are valuable adjuncts to most combined recession-resection procedures, promoting flat and smooth healing of the ocular surface in addition to possibly enhancing the surgical effect in such cases, and making limbal incisions particularly well suited to them.

Conjunctiva and Tenon's layer tend to retract and coil during limbal incision surgery on the underlying muscles, and need to be gently unfurled and stretched forward prior to closure. (When closing a nasal limbal incision, it is critical to identify the semilunar fold and to ensure that it is not mistakenly sutured as the anterior edge.) The author prefers to close at the limbus with 8-0 Vicryl, which is passed first through the fixed side of the upper radial portion of the incision, either as close as possible to the limbus or at the desired recession distance posteriorly, coming from beneath to the surface of tissues stabilized by the limbus while stretched from a distance with tissue forceps. The needle is then passed through the mobile tissues of the flap (grasped with forceps exactly at the point of desired needle placement) from external to internal, so that the knot will be buried when tied, taking care to emerge anterior to the bridging portion of the suture so as to avoid a figure-eight configuration (Fig. 12.8). It is not mandatory to suture at the original "corners" of the flap, and in fact there may be advantage in shifting placement to achieve desired positioning when completing closure with a second suture on the lower side of the flap. Tenon's tissue protruding at the limbus or along the radial incision lines should be trimmed. Additional sutures may be placed along the radial lines but are seldom necessary. If stretched conjunctiva



**Fig. 12.7** Elimination of muscle sagging. **a** Sag at pole, corrected by placing an additional single-armed suture of 6-0 Vicryl to convert posterior displacement to lateral displacement. **b** Central sag with one suture, corrected by engaging

center with one arm of previously tied 6-0 Vicryl suture, and then tying again. **c** Central sag with two sutures, corrected by placing a double-armed 8-0 Vicryl suture in mattress fashion



**Fig. 12.8** Suture placement to close conjunctiva at the limbus with a buried knot

overlies the cornea to an undesired degree, the situation can be remedied by making a short radial nick in the center of the anterior conjunctival edge with scissors.

Most surgeons apply a topical antibiotic–corticosteroid combination, in drop or ointment form, at the conclusion of surgery. Subsequent suture adjustment may be facilitated by injecting corticosteroid subconjunctivally and avoiding topical ointment. Patching the eye is not routinely indicated, but it may enhance patient comfort after unilateral surgery, and is necessary to protect unsecured adjustable sutures. The author uses two oval cotton pads, the deeper of which has been moistened with saline solution, securing them in place with two 6-cm Tegaderm squares (3M Health Care), which provide better adherence and comfort than tape and are less painful to remove.

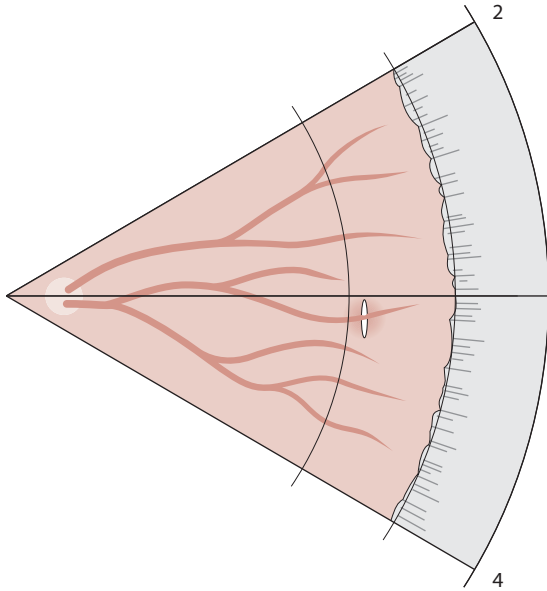
#### 12.4.9 Suture Adjustment

Suture adjustment is best performed a few hours after surgery, but can be deferred for up to about 24 h. The patient should be fully alert, sitting upright in a setting that allows the head to be lowered if syncope threatens, and with an emesis basin in hand. Topical anesthetic is applied liberally. Loupes are helpful. The emerging muscle suture ends are first retrieved from the cul-de-sac and cleared of accumulated mucus by sliding a needle holder or tying forceps from the knot to the

tips. Alignment is measured and binocular function assessed. If reduction or increase in the amount of recession is indicated, the muscle is advanced slightly by pulling forward on the suture ends while rotating the globe toward the muscle with tissue forceps applied to the handle loop anchored in sclera. The sliding knot is moved posteriorly or anteriorly as appropriate by 1 to 2 mm, and the muscle repositioned by having the patient look into its field of action against countertraction on the handle loop. The process is repeated as necessary to achieve desired alignment and/or binocular status, at which point the two muscle suture ends are tied to each other with three additional throws. These ends and the loop of the sliding knot are finally trimmed away and the handle suture is removed.

### 12.5 Complications

Scleral perforation during needle passage can be avoided by taking care to keep the needle tip parallel to the scleral surface and visible through the thin overlying tissue layer at all times. Signs that perforation may have occurred include tactile recognition of an abrupt decrease in tissue resistance as the needle is advanced and observation of dark pigment clinging to the suture as it emerges from sclera. If perforation is suspected, the fundus should be examined by indirect ophthalmoscopy, using a sterile viewing lens and a small muscle hook for scleral indentation. (If 2.5% phenylephrine drops have been administered before starting surgery to blanch conjunctival vessels, the pupil will usually be dilated adequately for this purpose.) Perforation is recognizable as a small round or short circumferential linear loss of fundus pigmentation with sharp borders (Fig. 12.9). Sometimes suture fibers can actually be seen within the pigmentary defect. There may be a small amount of subretinal or retinal hemorrhage. Management of scleral needle perforation remains controversial [4, 8]. Because this relatively common occurrence very seldom leads to significant consequences, and there is concern that overly vigorous application of cryopexy may lead to significant retinal damage, many surgeons choose not to treat the complication in the absence of retinal detachment. It is the author's practice to inject a subconjunctival antibiotic if perforation is documented, and to apply light cryopexy under direct visualization if a retinal hole is recognized.



**Fig. 12.9** A needle track lesion in the fundus caused by a deeply placed suture securing the recessed right medial rectus muscle to sclera

## 12.6 Future Challenges

The recent pace of change in muscle surgery has been slow as compared with other areas in ophthalmology. Most of the techniques described in this chapter have been in use for decades and seem unlikely to be radically modified in the foreseeable future. As with other areas covered by this volume, there has been preliminary investigation of tissue adhesive as a substitute for suturing in muscle surgery [1, 11].

A fundamental limitation of all current surgical approaches to strabismus is that we work on the agents of disordered ocular motility, not its sources. Break-through advances are not likely to occur in this field until we succeed in determining the underlying causes of the most common forms of surgically treated strabismus.

## References

1. Bloom JN, Duffy MT, Davis JB, McNally-Heintzelman KM (2003) A light-activated surgical adhesive technique for sutureless ophthalmic surgery. *Arch Ophthalmol* 121:1591–1595
2. Bishop F, Doran RM (2004) Adjustable and non-adjustable strabismus surgery: a retrospective case-matched study. *Strabismus* 12:3–11
3. Calhoun JH, Nelson LB, Harley RD (1987) *Atlas of pediatric ophthalmic surgery*. Saunders, Philadelphia
4. Del Monte MA, Archer SM (1993) *Atlas of pediatric ophthalmology and strabismus surgery*. Churchill Livingstone, New York
5. Engel JM, Roust ST (2004) Adjustable sutures in children using a modified technique. *J AAPOS* 8:243–248
6. Greenwald MJ (1992) Surgical management of essential esotropia. In: Nelson LB, Lavrich JB (eds) *Strabismus surgery*. Saunders, Philadelphia. *Ophthalmology Clinics of North America* 5(1):9–23
7. Greenwald MJ (1993) Paretic strabismus. In: Cibis GW, Tongue AC, Stass-Isern ML (eds) *Decision making in pediatric ophthalmology*. Mosby, Saint Louis, pp 230–233
8. Greenwald MJ, Lasky JB (1999) Extraocular muscle surgery. In: Krupin T, Kolker AE, Rosenberg LF (eds) *Complications in ophthalmic surgery*. Mosby, Saint Louis, pp 195–216
9. Jampolsky A (1979) Current techniques of adjustable strabismus surgery. *Am J Ophthalmol* 88:406–418
10. Mims JL 3rd (1992) Forming and teaching true knots for strabismus surgery. *Ophthalmic Surg* 23:477–481
11. Mulet ME, Alio JL, Mahiques MM, Martin JM (2006) Adal-1 bioadhesive for sutureless recession muscle surgery: a clinical trial. *Br J Ophthalmol* 90:208–212
12. Neumann D, Neumann R, Isenberg SJ (1999) A comparison of sutures for adjustable strabismus surgery. *J AAPOS* 3:91–93
13. Parks MM (1968) Fornix incision for horizontal rectus muscle surgery. *Am J Ophthalmol* 65:907–915
14. Parks MM, Parker JE (1983) *Atlas of strabismus surgery*. Harper Row, Philadelphia
15. Plager DA, Buckley EG, Repka MX, Wilson ME, Parks MM, von Noorden GK (2004) *Strabismus Surgery: basic and advanced strategies*. Oxford University Press, Oxford New York
16. von Noorden GK (1968) The limbal approach to surgery of the rectus muscles. *Arch Ophthalmol* 80:94–97

# Refractive Surgery Suturing Techniques

# 13

Gaston O. Lacayo III and Parag A. Majmudar

## Key Points

### Surgical Indications

- Hyperopia following radial keratotomy
- Visually significant flap striae following laser in situ keratomileusis (LASIK)
- Visually significant epithelial ingrowth following LASIK

### Surgical Technique

- Grene lasso technique
- Lindstrom “over-and-under” technique
- Flap suturing for flap striae
- Flap suturing and epithelial debridement for epithelial ingrowth

### Instrumentation

- Proparacaine 0.5%
- 25-Gauge needle on syringe
- No. 64 blade
- Merocel sponges
- Balanced salt solution
- Eight-incision radial marker
- 7-mm optical zone marker
- 10-0 nylon suture
- Soft contact lens
- Polymethylmethacrylate (PMMA) contact lens

### Complications and Future Challenges

- Decreased predictability
- Difficulty in titrating refractive error correction
- Over time, the steepening effect may be lost
- Potential for suture erosion
- Diffuse lamellar keratitis, infection and temporary induced astigmatism
- Striae or epithelial ingrowth may recur

In the 1970s, the development of microsurgical suturing spurred ophthalmic surgery perhaps more than any other invention, with the exception of the operating microscope. However, in the field of refractive surgery, sutures and suturing technique play a lesser role than do excimer lasers and microkeratomes. Nonetheless, there are several indications for suturing to aid in visual correction following refractive surgery.

## 13.1

### Management of Hyperopia after Radial Keratotomy

#### 13.1.1

#### Introduction

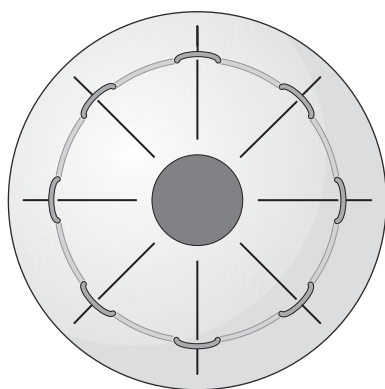
Radial keratotomy (RK) was one of the earliest forms of refractive surgery. Although it is effective in reducing myopia, unfortunately it is plagued by vagaries of the corneal wound healing response. The conversion of a myopic to a hyperopic refractive error is one of the most frequent and significant complications of RK [1]. The clinical manifestations of hyperopia after RK can be seen either in the immediate postoperative setting or years after the initial surgery. Hyperopia in the immediate post-RK period can be because of corneal edema and wound gape, leading to greater flattening of the central cornea, and it often resolves spontaneously. The more common manifestation of hyperopia after RK is a gradual onset in the late postoperative period. This slow flattening of the cornea resulting in progressive hyperopia is referred to as the “hyperopic shift.” Other patients experience continued diurnal fluctuations in their vision. In the Prospective Evaluation of Radial Keratotomy (PERK) study, 43% of patients demonstrated a hyperopic shift of +1.00 D or more over a 10-year follow-up period. The greatest rate of change occurred between 6 months and 2 years postoperatively at a rate of +0.21 D per year, with a smaller rate of change of 0.06 D per year between years 2 and 10 [2]. The degree of hyperopic shift is closely correlated to higher degrees of preoperative myopia. Other factors contributing to progressive hyperopia after RK include radial incisions that extend to the limbus, multiple enhancement procedures, peripheral redeepening procedures, use of a metal rather than diamond blade [3], lack of preoperative cycloplegia with undiscovered latent hyperopia, postoperative contact wear, and postoperative ocular massage [2]. In addition, it has been found that travel to a high altitude can induce a hyperopic shift [4]. Although RK has fallen out of favor since the introduction of laser in situ keratomileusis (LASIK), over 1.2 million RK procedures have



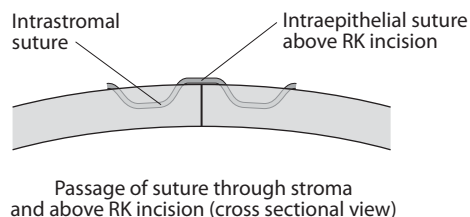
been performed worldwide since 1970, and it is estimated that 20 to 30% of these patients may now be hyperopic [5].

### 13.1.2 Surgical Indications

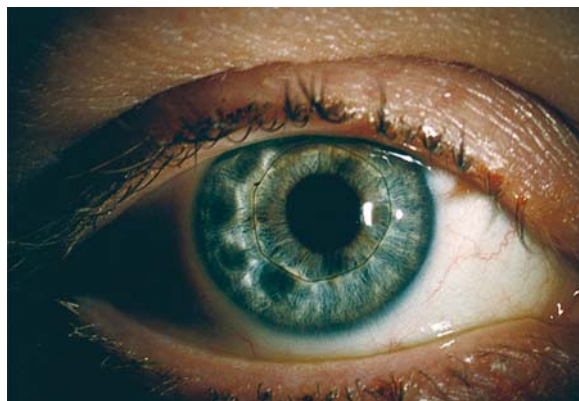Hyperopia following radial keratotomy may be treated surgically in a number of ways [6]. For the purposes of this discussion, only the techniques that involve suturing are discussed.



Cornea with »lasso« suture (frontal view)



**Fig. 13.1** Technique of Grene lasso placement (Am J Ophthalmol 1998; 126:825–827)



**Fig. 13.2** Appearance of completed lasso procedure (Am J Ophthalmol 1998; 126:825–827)

### 13.1.3 Instrumentation and Equipment

- Fluorescein
- Polymethylmethacrylate (PMMA) contact lens
- 7-mm optical zone marker
- 10-0 nylon suture on compound J-curve needle (Ethicon)

### 13.1.4 Surgical Technique

The objective in suturing a post-RK cornea is to reestablish a steeper central curvature and thereby decrease the level of hyperopic shift. Compression sutures are particularly useful in patients with diurnal fluctuation in vision. The surgeon may opt for single interrupted sutures, especially in the setting of asymmetric incisions. When placing single interrupted sutures, one must choose an optical zone for suture placement. A 7-mm optical zone appears to be optimal, as sutures placed in smaller optical zones can induce higher amounts of astigmatism. A disadvantage to the interrupted suture technique is the loss of effect (by up to 70%) over time [7].

Lasso, or continuous “purse-string” sutures are best for symmetrical incisions. Hofman reported the use of a single continuous suture of Merseline as a management for overcorrection in 1987 [8]. The Grene lasso was developed to better address wound gape by forcing the corneal “knee” posteriorly [9]. It was first described in 1994 and refined in subsequent years for management of post-RK hyperopia [7]. This procedure involves anesthetizing the cornea with proparacaine 0.5% and placing a PMMA contact lens with a base curve 1.00 D greater than the preoperative keratometry, followed by a drop of fluorescein on the cornea. The amount of steepening needed is titrated by observing the fluorescein pattern beneath the contact lens, with the end point being the initial disappearance of the bubble. The technique of the Grene lasso utilizes 10-0 nylon suture on a compound J-curve needle (Ethicon CS-B-6, Johnson and Johnson, Somerville, N.J.) with a “steep-and-deep” suture path. Each suture bite enters and exits adjacent to a radial incision to a depth of 70 to 80% (Fig. 13.1). The suture is superficial over the RK incisions and deep within the stroma between the RK incisions. This is in contrast to traditional continuous suturing where the superficial portion of the suture is over the intervening stroma, and the suture is passed through the cornea adjacent and beneath the RK incision. When the lasso is completed, the knot is triple-tied and buried as deeply as possible (Fig. 13.2). The Grene lasso addresses three factors that contribute to hyperopia: wound gape, micro-irregular astigmatism

tism, and overcorrection [9]. Lindstrom modified the Grene lasso into the over-and-under technique instead of the steep-and-deep technique as described by Grene. In an eight-cut RK, the first bite goes under or through an incision, and the next goes over an incision, alternating under and over four times [9, 10]. With either technique, the effect can be titrated quantitatively with a surgical keratometer. Lindstrom recommends steepening the cornea by twice the amount of the consecutive hyperopia. For example, if the patient is +2.00 D with a mean keratometry reading of 40.00 D, the cornea should be steepened 4 to 44.00 D. This induces mild myopia, which slowly drifts toward plano over time. In the over-and-under technique, there is a possibility of loosening of the sutures, which can lead to irritation. Multiple lasso sutures may also be placed at various optical zones to titrate the effect [11].

### 13.1.5

#### Complications and Future Challenges

Nylon is the preferred suture material over Merseline or Prolene. Approximately half of patients receiving the Merseline sutures developed inflammatory keratitis, and Prolene tended to stretch, resulting in less effective compression. Nylon is less inflammatory but, may still cheese-wire through the cornea or dissolve with time. In general, intrastromal circular sutures (lasso sutures) are not highly predictable. Risks with this procedure are decreased predictability and difficulty in titrating the refractive correction. Over time, the steepening effect may be lost, and there is also the potential for suture erosion.

### 13.2

#### Management of Recalcitrant Striae or Recurrent Epithelial Ingrowth after LASIK Surgery

#### 13.2.1

##### Introduction

Visually significant flap striae and epithelial ingrowth can occur following uncomplicated LASIK surgery ([12,13]; Figs. 13.3 and 13.4) Risk factors for striae include overhydration of the flap, delayed management of primary misalignment, or high refractive error requiring a deep ablation, causing flap-bed mismatch (microstriae). Risk factors associated with epithelial ingrowth include intraoperative epithelial defects (which reduce the oncotic pressure of the endothelial pump, and result in microscopic flap elevation), primary flap misalignment, enhancement surgeries, and trauma. If untreated and progressive, significant astig-

matism and melting of the overlying flap because of expression of collagenases from the epithelial cells may result, with an associated loss in best-corrected visual acuity (BCVA). Whereas simple techniques such as debridement of epithelial cells, or lifting and mechanical flap stretching to eliminate striae often correct such problems [14, 15], infrequently they may persist, leading to loss of BCVA. In the presence of striae and/or epithelial ingrowth, flap suturing offers a safe and effective treatment for this troublesome complication.

Suturing as a treatment for flap striae following LASIK was originally described by Lam et al [13] and more recently by Jackson et al. for treatment of recalcitrant macrostriae [16]. Flap suturing for epithelial ingrowth was first reported by Lim et al. [14]. The authors described interface epithelial growth beneath the hinge, which required surgical removal of the flap prior to epithelial removal. The corneal lenticule was then sutured back the bed, and no recurrence was observed. Spanggord et al. recently described flap suturing with proparacaine for recurrent epithelial ingrowth after LASIK. The authors were able to show effective reduction of recurrent epithelial ingrowth, in previously debrided corneas, with the use of flap suturing and topical proparacaine [19].

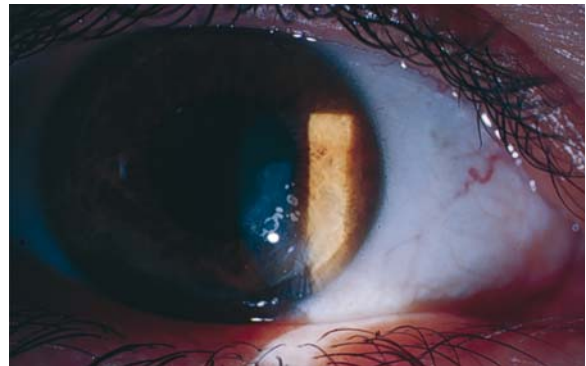


Fig. 13.3 Epithelial ingrowth

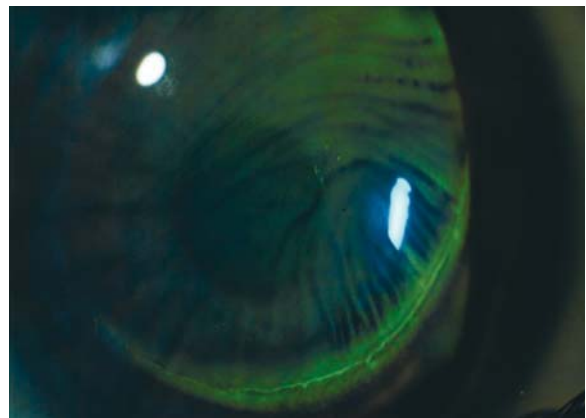
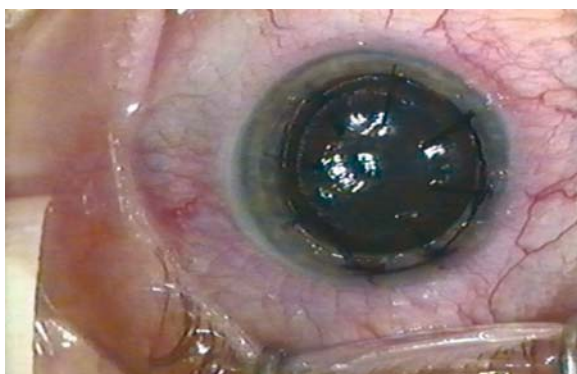
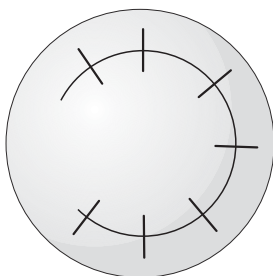


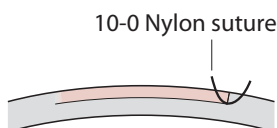
Fig. 13.4 Flap striae



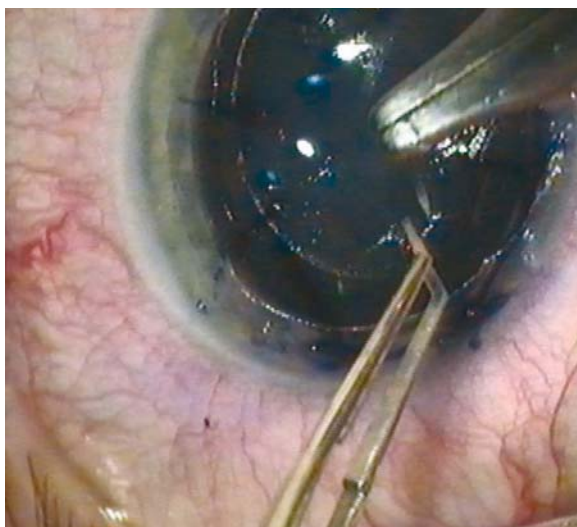
**Fig. 13.5** Eight-incision radial marker to the surface of the flap, making sure the radial marks cross the interface in numerous locations



**Fig. 13.6** Seven interrupted radial sutures are placed along premarked locations



**Fig. 13.7** Flap suturing technique



**Fig. 13.8** Five to seven interrupted 10-0 nylon sutures are placed full thickness through the edge of the flap and partial thickness into the base of the adjacent corneal surface

### 13.2.2

#### Surgical Indications

Treatment of recalcitrant flap striae or epithelial ingrowth, affecting quality of vision, following LASIK.

### 13.2.3

#### Instrumentation and Equipment

- Proparacaine 0.5%
- 25-Gauge needle on syringe
- No. 64 blade
- Merocel sponges
- Balanced salt solution
- Eight-incision radial marker
- 10-0 nylon suture
- Soft contact lens

### 13.2.4

#### Technique

Patients may be sedated with 10 to 20 mg of oral diazepam 30 min before the procedure. The eye is prepped with povidone iodine swabs, following the instillation of two sets of proparacaine hydrochloride 0.5% eye drops, 5 min apart. The flap margin is then identified at the slit lamp. Using a sterile 25-gauge needle attached to a syringe, the flap edge is identified. A Sinskey hook is used to undermine the edge of the flap for two to three clock hours. The patient is then placed under an operating microscope, a lid speculum is applied, and the flap is lifted from the stromal bed using forceps and Merocel sponge applied to the undersurface of the flap.

Epithelial ingrowth, if present, is removed from both the stromal side and the underside of the flap with a gentle scraping with a no. 64 blade. Proparacaine 0.5% drops are placed on both surfaces for 30 s in an attempt to exploit the known epithelial toxicity of this agent [17, 18]. The flap undersurface and stromal bed are irrigated with balanced salt solution injected through a cannula. It is advisable to recess 1 mm of epithelium around the entire flap edge (excluding the area occupied by the hinge) with a Merocel sponge or blade to minimize the potential for recurrent fistula formation before replacing the flap.

Once the flap is replaced, irrigation with balanced salt solution is used in the interface. The interface is then dried and stretched with two dry Merocel sponges. An inked eight-incision radial marker is applied to the surface of the flap, making sure the radial marks cross the interface in numerous locations (Figs. 13.5 and 13.6). Five to seven interrupted 10-0 nylon sutures are placed full thickness through the edge of the flap and partial thickness into the base of the adjacent cor-



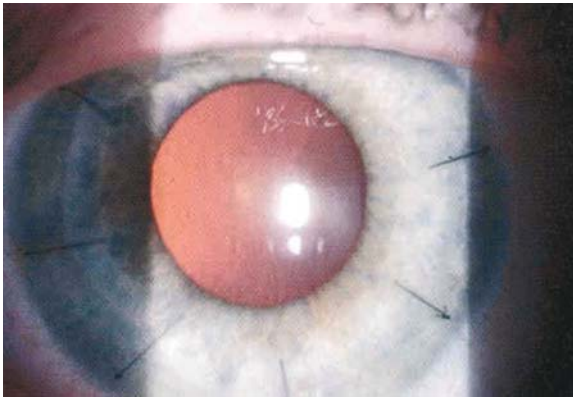
neal surface (Figs. 13.7 and 13.8). The number of sutures is determined by the size of the hinge, because no sutures are placed along the hinge. The knots are rotated on the host, or external side, of the interface to minimize the potential of flap dislocation with later suture removal (Fig. 13.9).

A soft contact lens (Bausch and Lomb Soflens-66, flat/medium) should be palced for 72 h and the patient instructed to use antibiotic (gatifloxacin 0.3% or moxifloxacin 0.5%) and a steroid (loteprednol etabonate 0.5% or prednisolone acetate 1%) for the eye four times a day for 1 week. Suture removal is performed between 6 days and 6 weeks posttreatment, depending on duration of striae or ingrowth (Table 13.1), unless loosening occurs before this time (in which case sutures are removed immediately).

### 13.2.5

#### Complications and Future Challenges

Diffuse lamellar keratitis, infection, and temporary induced astigmatism may arise after suture placement. Recurrent striae or epithelial ingrowth may recur, but is not common following this technique.



**Fig. 13.9** Postoperative picture with six interrupted radial sutures

**Table 13.1** Postoperative management of suture removal

Duration of striae or epithelial ingrowth	Duration of sutures
0 to 1 week	1 week
1 to 4 weeks	2 weeks
1 to 6 months	4 weeks
> 6 months	6 weeks

### 13.3

#### Conclusions

The management of refractive surgery complications remains very challenging. The number of refractive surgery procedures continues to grow steadily with new advancements in technology. Whereas the majority of surgeries are uneventful, the refractive surgeon needs to remain aware of surgical techniques that may improve visual outcomes. The use of suturing in refractive surgery complications for both RK and LASIK procedures offer a safe and effective method to help patients improve their overall level of visual function as well as quality of life.

#### References

1. Arrowsmith PN, Marks RG: Visual, refractive and keratometric results of radial keratotomy: a two-year follow up. *Arch Ophthalmol* 1987; 105:76–80
2. Waring GO III, Lynn MJ, McDonnell PJ. Results of the Prospective Evaluation of Radial Keratotomy (PERK) Study 10 years after surgery. *Arch Ophthalmol* 1994; 112:1298–1308
3. Deitz MR, Sanders DR, Raanan MG. Progressive hyperopia in radial keratotomy. Long-term follow-up of the diamond-knife and metal-blade series. *Ophthalmology* 1986; 93(10):1284–1289
4. Mader TH, Blanton CL, Gilbert BN et al. Refractive changes during 72-hour exposure to high altitude after refractive surgery. *Ophthalmology* 1996; 104:1188–1195
5. Hardten, DR. Correction of progressive hyperopia after radial keratotomy. refractive surgery subspecialty day. American Academy of Ophthalmology 2002
6. Muller LT, Majmudar PA. Management of Hyperopia after Radial Keratotomy, In: Sher N (2003) *Surgery for Hyperopia*. Slack
7. Lindquist TD, Williams PA, Lindstrom RL. Surgical treatment of overcorrection following radial keratotomy: evaluation of clinical effectiveness. *Ophthalmic Surg.* 1991; 22:12–15
8. Hoffman RF. Reoperations after radial keratotomy and astigmatic keratotomy. *J Refract Surg* 1987; 3:119–128
9. Grene RB. Use of the Grene lasso following radial keratotomy. *Rev Ophthalmol* 1996; 11:31–42
10. Miyashiro MJ, Yee RW, Patel G et al. Lasso procedure to revise overcorrection with radial keratotomy. *Am J Ophthalmol* 1998; 126:825–827
11. Miyashiro MJ, Yee RW, Patel G, Karas Y, Grene RB. Lasso procedure to revise overcorrection with radial keratotomy *Am J Ophthalmol* 1998; 126(6):825–827
12. Frah SG, Azar DT et al. Laser in situ keratomileusis: literature review of developing technique. *J Cataract Refract Surg* 1998; 24:989–1006
13. Lam DSC, Leung ATS et al. Management of severe flap wrinkling or dislodgement after laser in situ keratomileusis. *J Cataract Refract Surg* 1999; 25:1441–1447
14. Lim JS, Kim Ek et. A simple method for the removal of epithelial growth beneath the hinge after LASIK. *Yonsei Med J* 1998; 39(3):236–239
15. Probst LE, Machat J, Removal of flap striae following laser in situ keratomileusis. *J Cataract Refract Surg* 1998; 24(2):153–155

16. Jackson DW, Hamill MB, Koch DD. Laser in situ keratomileusis flap suturing to treat recalcitrant flap striae. *J Cataract Refract Surg* 2003; 29:264–269
17. Haw WW, Manche EE. Treatment of progressive or recurrent epithelial ingrowth with ethanol following laser in situ keratomileusis. *J Cataract Refract Surg* 2001; 17(1):63–68
18. Wang MY, Maloney RK. Epithelial ingrowth after laser in situ keratomileusis. *Am J Ophthalmol* 2000; 129(6):746–751
19. Spangord HM, Epstein RJ, Lane HA et al. Flap Suturing with proparacaine for recurrent epithelial ingrowth following laser in situ keratomileusis surgery. *J Cataract Refract Surg* 2005; 31:916–921



# Pterygium, Tissue Glue, and the Future of Wound Closure

14

Sadeer B. Hannush

## Key Points

### Surgical Indications

- Pterygium and other surface surgery with conjunctival or amniotic membrane grafting

### Instrumentation

- Fibrin sealant

### Surgical Technique

- Excision of pterygium
- Harvesting of conjunctival graft
- Securing graft (or amniotic membrane) in position with fibrin sealant

### Complications

- Rapid setting of fibrin sealant
- Conjunctival graft retraction

## 14.1

### Introduction

Pterygium represents fibroelastic degeneration of the conjunctiva with encroachment onto the cornea, causing chronic inflammation and frequently interfering with vision. It usually occurs nasally but can occur elsewhere. It is more common in hot, dry, windy environments with increased exposure to ultraviolet radiation [1]. Some have speculated damage to limbal epithelial stem cells as an etiology, though this has not been proven. A hereditary component has been considered as an etiology as well [2].

When chronic inflammation is present, significant corneal astigmatism is induced, or vision is threatened, surgical removal of the pterygium is indicated. More than a hundred techniques have been described over the past several centuries because of concern over recurrence.

Cornea specialists favor one of two approaches for surgical removal, simple excision with primary closure after controlled application of mitomycin C intraoperatively [3] or excision followed by free conjunctival autograft or amniotic membrane transplantation (with or without mitomycin C application). The conjunctival or amniotic membrane grafts are traditionally secured in position with 10-0 monofilament nylon or 7-0 to

10-0 absorbable Vicryl™ suture [3–6]. Suturing adds significantly to operative time and contributes to post-operative inflammation and discomfort.

## 14.2

### Surgical Indications

The historical indications for pterygium surgery have included (1) visual disturbance either through encroachment over the pupillary aperture or by significantly affecting corneal toricity and inducing corneal astigmatism, (2) documented enlargement over time in the direction of the center of the cornea, (3) chronic symptomatic inflammation, (4) motility disturbance limiting abduction (more common with recurrent pterygium), and (5) cosmesis.

Recurrence is the major complication of pterygium surgery, therefore various techniques have been advocated, including the use of  $\beta$ -radiation, 5-fluorouracil, thiotepa, and mitomycin C. The technique favored by many cornea specialists includes intraoperative application of mitomycin C, as well as conjunctival or amniotic membrane transplantation after simple excision. Recent concerns over potential long-term effects of mitomycin use have increased the popularity of conjunctival or amniotic membrane transplantation.

## 14.3

### Instrumentation and Equipment

The use of an operating microscope is all but mandatory in pterygium surgery, in addition to standard microsurgical instruments and fibrin sealant or tissue glue (Tisseel). Standard microsurgical instruments required include calipers, 0.12-mm forceps, smooth conjunctival forceps, Wescott scissors, cautery, microneedle driver (when sutures are used), nylon or Vicryl™ suture material, no. 64 beaver blade, diamond dusted burr, and amniotic membrane if a conjunctival autograft is not used.

Historically, a free conjunctival autograft or amniotic membrane has been secured in place with either 10-0 monofilament nylon or with 7-0 to 10-0 absorb-

able Vicryl™ sutures. Suture placement may add significantly to the operative time. Sutures are usually associated with significant postoperative discomfort and inflammation. Nylon sutures have to be removed, whereas Vicryl™, although absorbable, may last several weeks and may be associated with increased postoperative inflammation.

At this time there are limited choices for tissue closure with a fibrin sealant or tissue adhesive. Tisseel VH fibrin sealant (Baxter, Vienna, Austria) is a two-component tissue adhesive, which mimics natural fibrin formation by utilizing the last step of the blood coagulation cascade, where fibrinogen is converted by thrombin to form a solid-phase fibrin clot. Fibrin sealants have been used over the past two decades in general surgery for repair of hepatic and splenic ruptures as well as for bowel anastomoses, in orthopedic and gynecologic surgery, as well as in dermatologic surgery for skin grafts in burn patients [7, 8]. In ophthalmology, fibrin sealants have found applications in oculoplastic and cosmetic surgery, for conjunctival closure in strabismus surgery [9–11], for repair of bleb leaks after glaucoma filtering surgery [12–16], and for repair of conjunctival lacerations and corneal perforations [17–20]. Recent reports have advocated the use of fibrin sealants for lamellar keratoplasty [21, 22] and for management of recurrent epithelial ingrowth after LASIK [23]. A recent application of fibrin sealants is the fixation of conjunctival autografts at the time of pterygium surgery [24–28]. However, at the time of this writing ocular use of Tisseel fibrin sealant remains an off label use as Food and Drug Administration (FDA) approval has not been obtained for this indication.

The source of the thrombin and fibrinogen in Tisseel VH fibrin sealant is pooled human sera. Donors are tested, and retested after a three-month interval, for viral infections including hepatitis B and C, HIV, and human parvovirus. The source of the aprotinin in Tisseel is bovine, from closed herds in areas of the world with no history of bovine spongiform encephalitis (BSE or mad cow disease). Vapor heating adds another measure of safety to the product. In more than 10 million uses of Tisseel, there have been no reports of infection with hepatitis, HIV, or BSE, and only two reports (more with other fibrin glues [29]) of transmission of human parvovirus B19 (HPV B19) before 1999, when polymerase chain reaction testing was instituted for HPV.

## 14.4 Surgical Technique

Under topical, subconjunctival, or peribulbar anesthesia, the pterygium is excised with the individual surgeon's preferred technique (Fig. 14.1). Removal of a

limited amount of adjacent conjunctiva and Tenon's capsule is recommended. Depending on the severity of the pterygium, excision of surrounding subconjunctival Tenon's capsule may be indicated if excessive scarring is present. Limited cautery is applied as necessary. A diamond-dusted burr on a high-speed drill or a no. 64 beaver blade is used to smooth the peripheral cornea and limbus [27]. The excised specimen is submitted for pathologic examination to confirm the diagnosis. Placement of the specimen flat on filter paper allows the pathologist the ability to examine the lesion in the clinical orientation, without excessive curling or folding of the tissue. An appropriately sized conjunctival graft (equal or slightly larger than the conjunctival defect), with or without adjacent limbal epithelium (surgeon's preference) is harvested in the usual manner from the superotemporal quadrant (if the pterygium is nasal) and slid nasally, keeping the limbal edge facing the limbus, to cover the exposed scleral bed created by the pterygium excision. If tissue adhesive is not available, the conjunctival graft is secured into position with sutures. The limbal aspect of the conjunctival graft is secured with two interrupted 10-0 nylon sutures at the limbus. Each interrupted suture includes episcleral tissue and is tied with a slipknot. The ends are cut short, and the knots are buried in the cornea. These sutures are removed 2 to 6 weeks postoperatively. The remaining conjunctival graft is secured with 9-0 Vicryl™ sutures. Interrupted sutures may be used with inclusion of episcleral tissue to stabilize the graft, or a running suture of the same material may be used. Either way the corners of the graft need to be anchored to the episcleral tissue to prevent dislocation or slippage of the graft during the healing process. The Vicryl™ suture is secured with a surgeon's knot and the ends are cut short. The knots are not buried, as they quickly soften and cause little irritation.

Tissue adhesive allows a more rapid closure of the conjunctival graft without the issue of discomfort and inflammation that may result from sutures. In this technique, the surgical assistant prepares the two components of the Tisseel VH fibrin sealant using the manufacturer's instructions while the surgeon removes the pterygium. The product may be delivered to the ocular surface in either of two ways to form the fibrin clot. The first technique involves application through the Duploject syringe supplied in the Tisseel VH kit: after combining the two components in the Y-connector, ten drops are wasted before injecting one drop under the conjunctival graft. The graft is then rapidly positioned by smoothing out (pasting) the graft over the scleral bed with a smooth instrument. The coagulum (fibrin clot) starts forming in 5 to 7 s, achieves 70% of its final tensile strength in 10 min, and full strength in 2 h. The second technique is a more controlled joining of the two components and may be achieved by flip-

ping the conjunctival autograft epithelial side down onto the cornea adjacent to its final resting place ([25]; Fig. 14.2). One drop of the thrombin solution is placed on the scleral bed and one drop of the protein solution on the underside of the conjunctival graft (now facing up) (Fig. 14.3) before the graft is flipped over and glued into position (Fig. 14.4). The graft is smoothed into position. Any excess product that comes out from under the graft may be trimmed after it clots, with a pair of 0.12-mm forceps and Wescott scissors. The product does not adhere to epithelialized conjunctival or corneal surfaces. After 2 to 3 min of observation, the speculum is removed, and a spontaneous or forced-blink test is performed (depending on the type of anesthetic) to confirm that the graft is securely in place. An antibiotic–steroid ointment is applied over the ocular surface, and the case terminated. Postoperative antibiotics and steroids are used per the surgeon's preference.

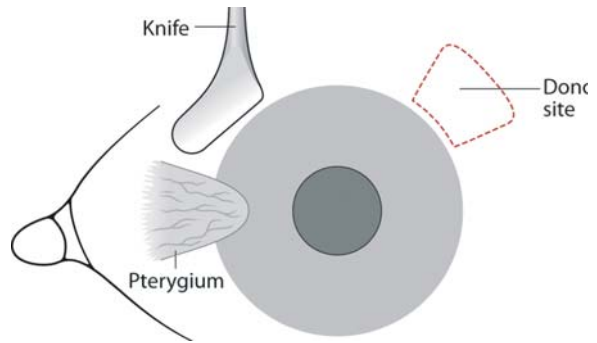
The above procedure using tissue adhesive may be completed in significantly less time than if sutures are utilized. Moreover, postoperative discomfort is decidedly less than with any type of suture. Of course, suture removal is obviated. The eyes appear quieter after Tisseel VH fibrin sealant is used than with sutures (Fig. 14.5). This may be explained by the absence of the irritating sutures themselves, the potential antiinflammatory properties of Tisseel, or the prevention of peripheral fibroblast migration under the graft. The rate of recurrence of pterygium with this technique appears equal or less [26] than with suture placement.

For those surgeons who prefer to use amniotic membrane (AmnioGraft™ or AmbioDry™) instead of conjunctiva for the graft to cover the area exposed after the pterygium is removed, the exact same technique may be utilized. Care must be taken to keep the basement membrane side of the amnion up. Also, amnion may be a little more difficult to manipulate than conjunctiva. Should the dried version of amnion (AmbioDry™) be used, we suggest gluing it in position before hydration.

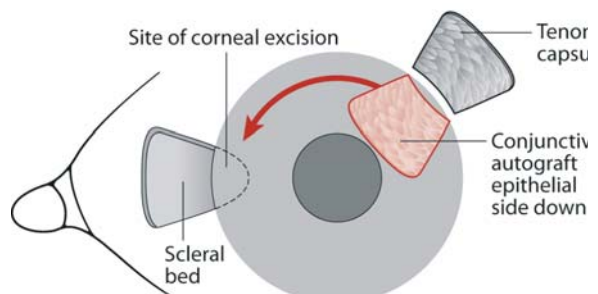
The same technique may be adopted for more extensive ocular surface surgery with amniotic membrane transplantation.

## 14.5 Complications and Future Challenges

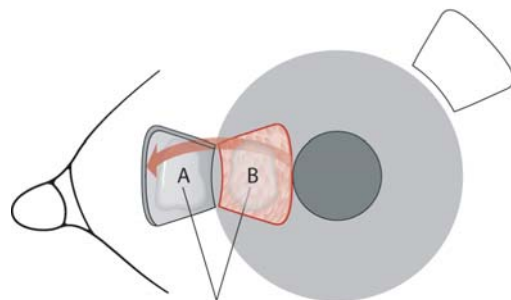
As with any surgical procedure, there is a learning curve involved with the use of Tisseel VH fibrin sealant for pterygium surgery. Complications arise from using too much product (rarely, too little) and not squeezegeeing excess product out from under the graft, which may then be trimmed with scissors once the coagulum forms. If the product is not distributed evenly under the graft, the graft may have an edematous ap-



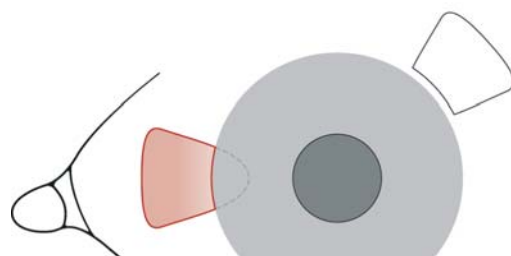
**Fig. 14.1** Pterygium is excised using surgeon's technique of choice. Conjunctival autograft is harvested with or without limbal epithelium



**Fig. 14.2** The conjunctival autograft is prepared and flipped over, epithelial side down on the cornea in preparation for transfer nasally



**Fig. 14.3** The conjunctival autograft is positioned nasally epithelial side down onto the cornea, limbal side facing the limbus. A drop of thrombin solution (A) is placed on the scleral bed, and a drop of fibrinogen/protein (B) on the autograft



**Fig. 14.4** The conjunctival autograft is flipped over and pasted onto the scleral bed

pearance in the early postoperative period. Any parts of the underlying sclera not receiving Tisseel will lead to poor adherence and retraction of the graft. The surgeon should pay close attention to the edges of the graft as he or she lays it flat on the scleral bed avoiding rolling-in of the edges or incomplete coverage of the defect.

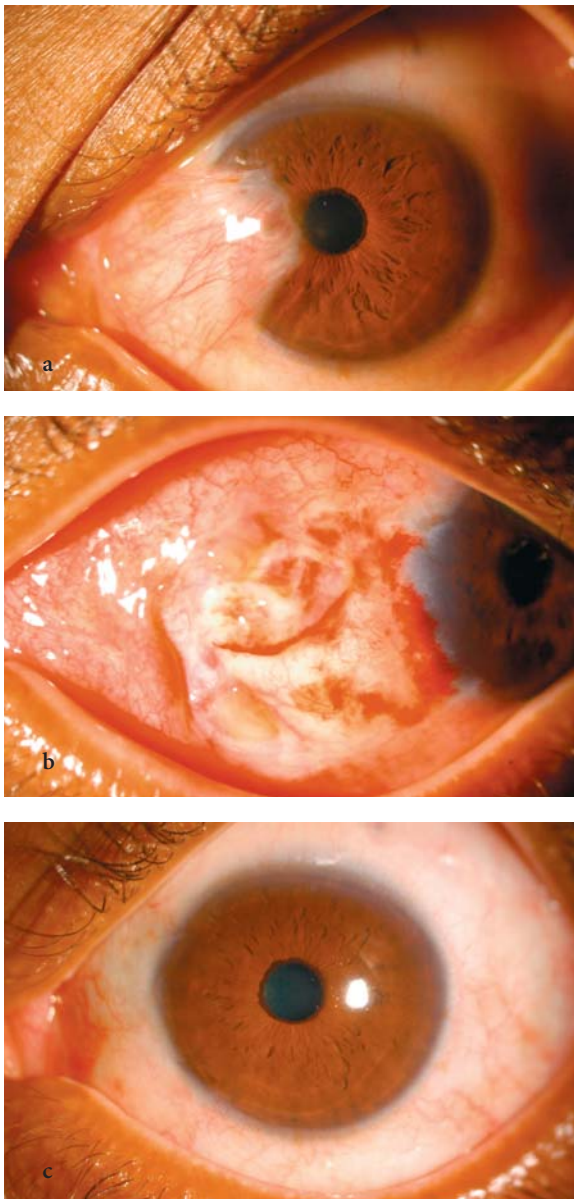
Some surgeons have complained that the rapid formation of the fibrin clot does not allow adequate time for controlled placement of the graft in the desired manner at the desired location. This may be easily ad-

ressed by diluting the thrombin component (500 IU/ml, original concentration after constitution, intended for rapid clot formation in other types of surgery) with stock CaCl<sub>2</sub> in a 1:100 concentration, resulting in a thrombin concentration of 5 IU/ml [30]. At this concentration, the time required for fibrin clot formation may be 30 to 60 s, allowing ample time of proper manipulation of the graft by the surgeon. Some have even advocated doing away altogether with the thrombin component and allowing the patient's own blood to form the clot with only one Tisseel component (fibrinogen/protein).

Of note, Tisseel VH fibrin sealant is used elsewhere in the body at sites subjected to higher shearing forces than the ocular surface, where the only forces are those of the blinking lid or inadvertent eye rubbing. Future challenges include the ability to determine whether Tisseel VH fibrin sealant or other tissue glues (chemical, biodendrimers [31, 32], etc.) may be able to replace suture for other types of ocular wound closure, especially those subjected to higher shearing forces.

As exciting as this technology is for decreasing surgical time and postoperative discomfort, a few things are worth mentioning. First, despite the impeccable track record of Tisseel VH fibrin sealant, anytime the product source is pooled human sera and bovine protein, the possibility exists, at least in principle, for transmission of viral [27] and prion disease. Secondly, the cost of a 1-ml vial of Tisseel is three to four times that of one pack of nylon or Vicryl™ suture. However, one vial of Tisseel may be used for four to five cases on the same day if this can be arranged, since only a few drops are needed for each case. This makes the use of Tisseel less expensive than suture, even before taking into consideration the amount of savings incurred in reduced operating room time.

In conclusion, Tisseel VH fibrin sealant may be an alternative to suture for securing a conjunctival or amniotic membrane graft during pterygium surgery. It shortens surgical time, may lead to faster surface rehabilitation, and is more comfortable for the patient.



**Fig. 14.5** **a** Pterygium: preoperative appearance. **b** First day post-conjunctival autograft with Tisseel fibrin sealant. **c** Six weeks post-conjunctival autograft with Tisseel fibrin sealant

## References

1. Moran DJ, Hollows FC. Pterygium and ultraviolet radiation: a positive correlation. *Br J Ophthalmol* 1984; 68: 343–6
2. Booth F. Heredity in one hundred patients admitted for excision of pterygia. *Aust N Z J Ophthalmol* 1985; 13: 59–61
3. Chen PP, Ariyasu RG, Kaza V, et al. A randomized trial comparing mitomycin C and conjunctival autograft after excision of primary pterygium (see comments). *Am J Ophthalmol* 1995; 120: 151–160
4. Kenyon KR, Wagoner MD, Heltinger ME. Conjunctival autograft transplantation for advanced and recurrent pterygium. *Ophthalmology* 1985; 92: 1461–1470
5. Frau E, Labetoulle M, Lautier-Frau M, Hutchinson S,



- Offret H. Corneo-conjunctival autograft transplantation for pterygium surgery. *Acta Ophthalmol Scand* 2004, 82(1):59–63
6. Prabhasawat P, Barton K, Burkett G, et al. Comparison of conjunctival autografts, amniotic membrane grafts, and primary closure for pterygium excision. *Ophthalmology* 1997, 104: 974–985
  7. Redl H, Schlag G. Fibrin sealant and its modes of application. In: Schlag G, Redl H, eds. *Fibrin sealant in operative medicine*, vol. 2. Ophthalmology, neurosurgery. Berlin Heidelberg New York: Springer, 1986: pp. 13–25
  8. Jackson MR. Fibrin sealants in surgical practice: an overview. *Am J Surg* 2001, 182: 1S–7S
  9. Biedner B, Rosenthal G. Conjunctival closure in strabismus surgery: Vicryl versus fibrin glue. *Ophthalmic Surg Lasers* 1996, 27(11):967
  10. Mohan K, Malhi RK, Sharma A, Kumar S. Fibrin glue for conjunctival closure in strabismus surgery. *J Pediatr Ophthalmol Strabismus* 2003, 40(3): 158–160
  11. Dadeya S, Ms K. Strabismus surgery: fibrin glue versus Vicryl for conjunctival closure. *Acta Ophthalmol Scand* 2001, 79(5):515–517
  12. Kajiwaru K. Repair of a leaking bleb with fibrin glue. *Am J Ophthalmol* 1990, 109(5):599–601
  13. Asrani SG, Wilensky JT. Management of bleb leaks after glaucoma filtering surgery. Use of autologous fibrin tissue glue as an alternative. *Ophthalmology* 1996, 103(2): 294–298
  14. O'Sullivan F, Dalton R, Rostron CK. Fibrin glue: an alternative method of wound closure in glaucoma surgery. *J Glaucoma* 1996, 5(6):367–370
  15. Gammon RR, Prum BE Jr, Avery N, Mintz PD. Rapid preparation of small-volume autologous fibrinogen concentrate and its same day use in bleb leaks after glaucoma filtration surgery. *Ophthalmic Surg Lasers* 1998, 29(12):1010–1012
  16. Seligsohn A, Moster MR, Steinmann W, Fontanarosa J. Use of Tisseel fibrin sealant to manage bleb leaks and hypotony: case series. *J Glaucoma* 2004, 13(3): 227
  17. Khadem JJ, Dana MR. Photodynamic biologic tissue glue in perforating rabbit corneal wounds. *J Clin Laser Med Surg* 2000, 18(3):125–129
  18. Duchesne B, Tahi H, Galand A. Use of human fibrin glue and amniotic membrane transplant in corneal perforation. *Cornea* 2001, 20(2):230–232
  19. Sharma A, Kaur R, Kumar S, Gupta P, Pandav S, Patnaik B, Gupta A. Fibrin glue versus N-butyl-2-cyanoacrylate in corneal perforations. *Ophthalmology* 2003, 110(2): 291–298
  20. Hick S, Demers PE, et al. Amniotic membrane transplantation and fibrin glue in the management of corneal ulcers and perforations. *Cornea* 2005, 24 (4):369–377
  21. Kim MS, Kim JH. Effects of tissue adhesive (Tisseel) on corneal wound healing in lamellar keratoplasty in rabbits. *Korean J Ophthalmol* 1989, 3(1):14–21
  22. Ibrahim-Elzembely HA. Human fibrin tissue glue for corneal lamellar adhesion in rabbits: a preliminary study. *Cornea* 2003, 22(8): 735–739
  23. Anderson NJ, Hardten DR. Fibrin glue for the prevention of epithelial ingrowth after laser in situ keratomileusis. *J Cataract Refract Surg* 2003, 29(7): 1425–1429
  24. Cohen RA, McDonald MB. Fixation of conjunctival autografts with an organic tissue adhesive (letter). *Arch Ophthalmol* 1993, 111: 1167–8
  25. Koranyi G, Seregard S, Kopp ED. Cut and paste: a no suture, small incision approach to pterygium surgery. *Br J Ophthalmol* 2004, 88(7):911–914
  26. Koranyi G, Seregard S, Kopp ED. The cut-and-paste method for primary pterygium surgery: long-term follow-up. *Acta Ophthalmol Scand* 2005, 83: 298–301
  27. Hannush SB. Sutureless Conjunctival autograft. Paper presented at the American Academy of Ophthalmology 108th Annual Meeting on 24 October 2004
  28. Panday V, Hannush SB. Sutureless conjunctival autograft [ARVO abstract]. *Invest Ophthalmol Vis Sci* 2004 B577. Abstract no. 2942
  29. Kawamura M. Frequency of transmission of human parvovirus B19 infection by fibrin sealant used during thoracic surgery. *Ann Thorac Surg* 2002, 73(4): 1098–1100
  30. Goessl A, Redl H. Optimized thrombin dilution protocol for a slowly setting fibrin sealant in surgery. *Eur Surg* 37(1): 43–51
  31. Goins KM, Khadem J, Majmudar PA, Ernest JT. Photodynamic biologic tissue glue to enhance corneal wound healing after radial keratotomy. *J Cataract Refract Surg* 1997, 23(9):1331–1338
  32. Goins KM, Khadem J, Majmudar PA. Relative strength of photodynamic biologic tissue glue in penetrating keratoplasty in cadaver eyes. *J Cataract Refract Surg* 1998, 24(12):1566–1570



# Subject Index

## A

ab externo technique 45, 46  
abscess formation 35  
absorbable suture 5, 9, 12, 14, 118, 119  
Acute chemical burn 109  
adjustable knot 124  
adjustable recession 123  
adjustable suture 25, 117, 118, 124, 126  
afferent pupillary defect 61, 62  
akkin method 67  
albinism 73, 81  
Alpha-2 agonists 72  
AM as a temporary graft 109  
AmbioDry™ 137  
Amblyopia 70  
American Society for Testing and Materials (ASTM) 11  
AMNIOGRAFT 107–113, 115, 137  
amniotic membrane 107, 114, 135, 137  
amniotic membrane graft 135, 138  
amniotic membrane transplantation 135, 137  
AMT 107, 113, 115  
angle-tooth forceps 17  
aniridia 72, 73, 81  
anterior chamber intraocular lens 38, 73  
anterior chamber intraocular lens (ACIOL) 37  
antibacterials 9, 14  
antitorque 54  
aphakia 37, 39, 48, 101  
aphakic 37, 39, 49, 50  
aphakic bullous keratopathy 37, 39, 50  
appose 2, 18, 34, 67, 74  
argon laser 71, 75  
astigmatically neutral 3, 30, 63, 64  
astigmatism 3, 4, 6, 7, 14, 26, 31, 32, 49, 54, 55, 56, 58, 64, 96, 131  
astigmatism adjustment 52

## B

bandage contact lens 62, 69, 115  
Bardak technique 79  
Beehler pupil dilator 75  
bioactive glass 9, 14  
bleb leaks 136  
Blindness 70  
Bonds hook 42  
Bowmans layer 54, 56  
broken suture 26  
bullous keratopathy 108, 109, 112  
buttonhole 105  
Buttonholing of conjunctiva 101  
BV needle 11, 74, 104, 105

## C

C-shaped haptics 44  
capsular bag 37, 81  
capsular support 37, 39, 48  
cardinal sutures 51, 55, 56, 58, 98  
Castroviejo 17, 51, 119, 122  
Castroviejo toothed forceps 17  
cataract 11, 29, 69  
cataract incision 10, 29, 30, 31, 34  
cataract surgery 12, 29, 30, 31, 38, 69, 81, 82  
cataract wound 6, 29, 30, 31, 32, 34, 35  
– biplanar 30, 31  
– clear corneal 29  
– epithelial ingrowth 30  
– gaping 34  
– hypotony 30  
– integrity 30  
– limbal 29  
– limbal incision 29  
– scleral tunnel 29  
– self-sealing 30  
– sutures 30  
– thermal wound burn 30  
– triplanar 30, 31  
– uniplanar 30, 31  
– wound closure 30  
– wound leaks 30  
cheese-wiring 76, 87, 92, 95  
choroidal hemorrhage 38, 48, 57, 97  
Choyce 81  
ciliary body laceration 96  
ciliary sulcus 37, 41, 44, 45, 46, 47  
ciliary vessels 117  
Cincinnati modification 43, 44  
clear corneal incision 29, 30, 31  
CL intolerance 39  
closed-system 74, 76, 77, 79, 80  
closed-system approach 76, 80  
closing the conjunctiva 85, 101, 104, 105  
clove hitch 86, 93  
CME 37, 38, 39, 44, 47, 48  
coloboma 73, 75, 76, 78  
Coloboma Repair 75  
Color coding 90  
Compression sutures 130  
computerized corneal topography 52, 54  
conjunctiva 11, 13, 14, 16, 34, 86, 89, 93–98, 103, 104  
Conjunctiva Closure 125  
conjunctival autograft 112, 135–138  
conjunctival closure 85, 94, 95, 97, 136  
conjunctival cyst 95, 97  
Conjunctival diseases 108  
conjunctival graft 135, 136, 137  
conjunctival incision 97, 98, 103, 117  
conjunctival reconstruction 112  
conjunctival surface reconstruction 114

conjunctival transplantation 108  
 conjunctivochalasis 108, 109, 114  
 contact lens 34, 39, 66, 70–73, 82, 83, 89, 129, 130, 133  
 continuous suture 2, 4, 6, 7, 26, 54, 55, 57, 130  
 continuous suture technique 53  
 cornea 1, 6, 13, 16, 17, 19, 26, 27, 30, 34, 41, 44, 49, 50,  
 62–66, 73–77, 80, 103, 105, 107, 113, 129, 130, 131, 135,  
 136, 137  
 corneal astigmatism 51, 52, 102, 135  
 corneal contour 63  
 corneal decompensation 38, 49, 73  
 Corneal dellen 98  
 Corneal diseases 108  
 corneal disorders 50  
 corneal edema 37, 39, 47, 50, 73, 129  
 corneal epithelial defect 109, 115  
 corneal graft 47, 52, 54, 57  
 corneal lacerations 64  
 corneal perforations 136  
 corneal scissors 50  
 corneal sphericity 51  
 corneal stromal puncture 74  
 corneal surgery 49, 50, 51, 58  
 – astigmatism 52, 57  
 – cardinal suture 50, 51  
 – continuous running 51  
 – eccentric grafts 52  
 – forceps fixation 50  
 – full-thickness sutures 51  
 – graft-host wound 52  
 – graft dehiscence 52  
 – interrupted suture 51  
 – keratometric astigmatism 57  
 – Merseline 51  
 – nylon 51, 57  
 – nylon suture 52  
 – pediatric keratoplasty 52  
 – polypropylene 51  
 – postoperative astigmatism 57  
 – radial ink marks 50  
 – recipient bite 50  
 – rejection 52  
 – RK marker 52  
 – single 53  
 – single throws 52  
 – slipknot 52  
 – suture placement 50  
 – suture technique 51, 57  
 – tectonic keratoplasty 52  
 – tension 51, 52  
 – tissue apposition 51  
 – toothed forceps 50  
 – Torque 50  
 – trephination 50  
 – ulceration 52  
 – vascularization 52  
 – vector forces 52  
 – watertight 52  
 – wound apposition 51  
 – wound closure 50, 52  
 – wound dehiscence 52  
 – wound integrity 52  
 corneal suture 6, 10, 51, 63, 103  
 corneal tattooing 74, 75  
 corneal tissue 1, 49, 50, 57, 63, 66, 67  
 corneal topography 52, 54, 56  
 corneal transplant 7, 41, 73  
 corneal ulcer 35, 109  
 corneal wounds 13, 24, 25, 26, 65  
 Corneal Wounds and Repair 6  
 cornea suturing 64

corneoscleral lacerations 61  
 corneoscleral scissors 29  
 cryopreserved amnion graft 107–110, 113  
 crystalline lens 37, 69  
 cystoid macular edema 37, 39, 68

## D

decentration 47  
 dellen formation 95, 97, 98  
 Descemet's membrane 50  
 diamond-dusted burr 136  
 Diffuse lamellar keratitis 129, 133  
 dilator muscle 71, 75  
 diplopia 71, 73, 79  
 disinsertion 119, 121, 122  
 dislocated IOLs 37  
 diurnal fluctuation 129, 130  
 donor 7, 49, 50, 51, 66  
 donor-recipient 49  
 donor/recipient 51  
 donor cornea 50, 51, 54, 55, 56  
 donor corneal 50  
 donor corneas 57, 67  
 donor sclera 68, 101, 105  
 donor tissue 50, 51, 57, 67  
 double-armed 77, 79, 80, 92, 94, 109, 118, 120, 121,  
 123, 125  
 double-throw slipknot 77  
 double continuous suture technique 53, 56  
 drainage device 101, 105, 106  
 dry eye 97, 98, 115  
 Duploject syringe 136

## E

Eisner method 67  
 encircling silicone tire 93  
 endophthalmitis 21, 30, 38, 47, 49, 51, 58, 62, 69, 97  
 endophthalmitis 69  
 endothelial cell count 39, 73  
 entropion 5  
 entry site 30, 76, 79, 80, 81, 120, 122, 123, 124  
 episcleral tissue 136  
 epithelial debridement 129  
 epithelial downgrowth 70  
 epithelial ingrowth 129, 131, 132, 133, 136  
 epithelialization 68, 108, 112, 113  
 erosion of the overlying conjunctiva 105  
 etc 10  
 explants 90  
 expulsive hemorrhage 37, 39, 62, 70  
 extracapsular 29, 30, 34, 37, 39  
 eye banking 50  
 eye injuries 61, 70  
 eyelid 1, 4  
 eye muscle surgery 117, 119

**F**

fibrin glue 107, 108, 111, 113, 114, 136  
 fibrin sealant 96, 135–138  
 fibrocytes 71  
 fine-toothed forceps 31, 50, 87, 89  
 Fines infinity suture 29, 33  
 fistula formation 69  
 fixation sutures 85, 90, 91  
 flap dislocation 133  
 flap striae 129, 131, 132  
 Flap suturing for flap striae 129  
 Flap suturing technique 132  
 flat 1, 5, 14, 15, 22, 49, 55, 74, 87, 92, 119, 122, 123, 125, 136, 138  
 foldable IOL 41, 44  
 forceps 1, 3, 16, 17, 18, 21, 25, 29, 31, 42, 44, 49, 50, 52, 55, 56, 63, 68, 74, 77, 80, 81, 86–90, 95, 97, 101, 102, 103, 107, 109, 110, 113, 119, 121, 122, 123, 125  
 Fornix-Based Trabeculectomy 103  
 fornix approach 117  
 fornix incisions 118  
 fornix reconstruction 108, 114  
 French forceps 101, 105  
 Fuchs endothelial dystrophy 50  
 full-thickness lacerations 62  
 Full thickness suture 7, 29

**G**

general anesthesia 62, 109  
 girth hitch 44, 45  
 glare 69, 72, 73, 79  
 glare dysfunction 81  
 glaucoma 37, 38, 39, 47, 48, 57, 70, 71, 73, 78, 81, 101, 106, 136  
 goniosynechialysis 74, 79  
 goniosynechiolysis 74  
 Gore-Tex 47  
 graft-host junction 56  
 graft failure 49, 50  
 granny knot 22, 24, 25  
 granuloma 97, 98  
 Greather 2000 pupil expander 75  
 Grene lasso technique 129  
 Gunter von Noorden 117

**H**

hand tying 118, 123  
 hangback 118, 119, 123, 124  
 hangback recessions 119  
 hangback suture 123, 124  
 haptic 39, 40, 41, 44, 46, 81  
 Haptic erosion 38  
 healing 1, 5, 14, 50, 57, 63, 71, 72, 136  
 horizontal mattress 33, 88, 93, 94  
 horizontal mattress suture 33  
 hyperopia 129, 130  
 hyperopic shift 129, 130  
 hyphema 38, 70  
 hypotony 47, 98, 105

**I**

imbrication 92, 93, 94  
 increased astigmatism 81  
 induced astigmatism 1, 24, 29, 30, 33, 34, 129, 133  
 infection 1, 7, 12, 27, 44, 49, 50, 52, 55, 58, 62, 63, 69, 70, 105, 129, 133, 136  
 inflammation 7, 12, 13, 14, 34, 49, 52, 55, 68, 69, 70, 81, 89, 96, 97, 98, 107, 108, 115, 135  
 intraplacement 122  
 infusion line 85, 86, 87, 88  
 insertion site 3, 122, 123  
 instruments 9, 14, 15, 16, 18, 19, 50, 63, 85, 86, 88, 119, 135  
 instrument ties 22  
 instrument tying 118, 123, 125  
 interrupted 2, 4, 6, 7, 29, 32, 33, 34, 49, 51–54, 63, 66, 67, 68, 89, 95, 105, 107, 109, 130, 132, 136  
 interrupted radial sutures 132, 133  
 interrupted suture 2, 4, 49, 51, 54, 55, 130, 136  
 interrupted suture technique 51, 52, 53, 130  
 interrupted suturing technique 52  
 intracapsular 29, 34, 39  
 Intralamellar 10  
 intraocular hemorrhage 44, 71  
 intraocular lens 13, 29, 37, 40, 41, 45, 47, 48, 71, 73, 74, 81, 82, 83, 85, 89  
 intraocular lens (IOL) exchange 37  
 IOL fixation techniques 46  
 IOL haptic 37, 42, 45, 47  
 iridectomy 68, 69, 73, 81  
 iridodialysis 68, 71, 73, 78–82  
 Iridodialysis Repair 79  
 iridopexy 75, 76, 79  
 iridopexy technique 76, 77  
 iris 13, 14, 18, 37, 39, 41, 42, 44, 48, 49  
 iris-retraction hooks 75  
 iris-sutured 37, 38, 44, 47, 48  
 iris-sutured IOLs 47  
 iris-sutured lenses 47  
 iris abnormalities 73  
 iris anatomy 71  
 iris chafe 37, 44  
 Iris chafing 39  
 iris clip IOL 37  
 iris coloboma 77, 78  
 iris defect 72, 73, 75, 76, 77, 79, 82, 89  
 iris dilation 85  
 iris fixation 39, 40, 48  
 iris prolapse 30, 57  
 iris prosthetic system 81  
 iris repair 69, 71, 72, 83  
 iris root 44, 68, 71, 72, 75, 76, 80, 82  
 iris wound 68, 71, 72, 74, 77  
 iritis 37, 44, 71  
 irregular astigmatism 3, 63, 64, 70

**J**

Jaffee straight tying forceps 18

**K**

keratome 30  
 keratometric astigmatism 53, 56, 57  
 keratoplasty 50, 51, 54, 55, 57, 58, 78, 101  
 keratoplasty complications  
 – astigmatism 58  
 – cardinal sutures 58

- donor-recipient mismatch 57, 58
- endophthalmitis 57
- epithelial defects 58
- expulsive choroidal hemorrhage 57
- filamentary keratitis 58
- flat anterior chamber 57
- glaucoma 57
- hurricane keratopathy 58
- hyphema 57
- improper suture placement 57
- improper suture tension 57
- inappropriate trephination 58
- iridectomy 57
- iris incarceration 57
- iris prolapse 57
- lens damage 57
- lens violation 57
- medicamentosa 58
- refractive error 57
- retrocorneal membranes 57
- superficial hypertrophic dendriform epitheliopathy 58
- suprachoroidal hemorrhage 57
- surface keratopathy 58
- suture depth 58
- suture placement 58
- suture vascularization 57
- traumatic cataract 57
- wound leak 57
- keratotomy 54, 55, 56
- knot 10, 32, 34, 50, 52, 54, 55, 56, 64, 86, 87, 89, 93, 94, 95, 97, 98, 101, 102, 103, 117, 118, 120, 121, 123–126, 130
  - adverse effects 14
  - bury 14
  - distort 14
  - induction of astigmatism 14
  - mass 14
  - size 14
  - strength 14
- knot construction 14
- Knot Formation 123
- knot tension 49
- knot tying 13, 14, 21, 22, 82

## L

- lamellar dissection 68
- lamellar keratoplasty 10, 101, 136
- lamellar pocket 75, 112
- Laser iridoplasty 71, 75
- LASIK 129, 131, 132, 133, 136
- LASIK complications
  - debridement 131
  - deep ablation 131
  - enhancement surgeries 131
  - epithelial ingrowth 131, 132
  - epithelial toxicity 132
  - fistula formation 132
  - flap-bed mismatch 131
  - flap misalignment 131
  - flap suturing 131
  - high refractive error 131
  - lifting 131
  - mechanical flap stretching 131
  - Merocel sponge 132
  - recalcitrant macrostriae 131
  - recurrent epithelial ingrowth 131
  - Risk factors for striae 131
  - trauma 131
- lasso 78, 130, 131

- lasso suture 77, 131
- lens 49, 72, 73, 81
- lens-iris contact 37, 44
- lens tilt 39, 46, 47
- Lewis ab externo technique 46
- Lid Margin Repair 5
- Lid Wound Closure 4
- ligature knot 24, 25
- limbal approach 39, 117
- Limbal cataract incision 30
- limbal incisions 117, 118, 119, 125
- limbal wound 6, 29, 38, 46
- limbus 6, 29, 30, 41, 42, 44, 46, 63, 68, 72, 76, 77, 80, 87, 88, 89, 93, 95, 96, 98, 103, 109, 122, 124, 125, 126, 136
- limbus-based trabeculectomy 104
- Lindstrom {over-and-under} technique 129
- locking bite 117, 120, 121, 124
- locking bite knots 121, 124

## M

- magnification loupes 92
- Marshall Parks 117
- mattress suture 2, 7, 61, 66, 92, 94, 103, 104, 105
- McCannel 39, 41, 76, 77, 89
- McCannel technique 76, 77, 80
- medicolegal perspective 61
- melanocytes 71
- meridional sponge 93
- Merocel sponge 129, 132
- Merseline 93, 97, 130, 131
- Mersilene 56, 86, 119
- microincision instruments 9
- microincision techniques 19
- microkeratomes 129
- miotic pupil 75
- mitomycin C 109, 115, 135
- Monofilament polypropylene 74
- monofilament suture 14, 31, 49, 50, 63, 86, 89, 92, 93, 96
- Morcher 75, 81, 82
- Morcher polymethyl methacrylate (PMMA) pupil-dilator ring 75
- mouse-tooth forceps 16, 17
- muscle-scleral apposition 118
- muscle anchoring 120
- muscle hooks 86
- muscle insertion 68, 90, 92, 95, 120
- muscle reattachment 118, 125
- muscle surgery 117, 118, 119, 127
- muscle suturing 120, 122
- muscle traction sutures 89
- MVR blade 80, 88

## N

- needle 1, 3, 5, 6, 9, 10, 11, 12, 17, 129, 130, 132
  - bending 11
  - beveled edge 10
  - beveled edges 11
  - biomechanical performance 10
  - Bite 10
  - BV 11
  - cardiovascular 11
  - channel swage 12
  - characteristics 9
  - chord length 9
  - circle 10
  - composition 9

- Cross section 10
- curvature 9
- curved needle 11
- cutting 9
- cutting edge 11
- diameter 9, 10, 11
- diamond-shaped 11
- ductility 11
- ductility grading 11
- dulling 11
- edge 9
- grading system 10
- Grasping 12
- handle 12
- head 12
- length 9
- material 9, 11
- metallurgical composition 9
- passage 11
- point cutting 9
- point style 9
- properties 10
- radius 9
- radius of curvature 11
- reverse-cutting 9
- reverse-cutting edge 11
- Reverse cutting 10
- shaft 12
- shape 9
- sharp cutting 10
- sharpness 11
- sharpness comparisons 11
- Side cutting 10
- slim-point geometry 10
- Spatula 10
- spatulated cutting needle 31
- Standard cutting 10
- swage 9, 12
- taper-point 10, 11
- Tapercut 10, 11
- tapered swage 11
- triangular 11
- Type 10
- wire diameter 9
- needle depth 92
- needle holder 3, 10, 14, 15, 16, 29, 31, 49, 50, 86, 87, 92, 95, 101, 119, 120, 122, 123, 124, 126
  - control 16
  - curved 15, 16
  - grasping 15
  - jaws 15, 16
  - Nonlocking 16
  - passage 15
  - rotation 15
  - straight 15
- needle swage 9, 15, 17
  - channel-style 10
  - channel fixation 9
  - laser-bored hole 9
  - laser-drilled 10
  - laser drilling 9
- needle tract 9, 80
- neovascular ingrowth 96
- non-locking needle holder 15
- nonabsorbable suture 12, 86, 92, 97, 105, 118
- nontoothed forceps 101, 103, 105
- nylon 6, 7, 12, 13, 22, 29, 35, 51, 54–57, 86, 92, 94, 101–105, 107, 109, 110, 111, 112, 124, 129, 130, 132, 135, 136, 138

## O

- oblique muscles 118
- O'Brien forceps 16
- ocular injuries 61
- ocular lacerations 62
- ocular surface 107, 108, 109, 111, 113, 115, 125, 136, 137
- ocular trauma 61, 69, 70
- Ocular Trauma Classification System 61, 62
- one-suture procedure 123
- one-suture technique 120, 121
- open-globe injuries 61, 62, 69, 70
- open-sky 39, 44
- open-sky approach 78
- operating microscope 1, 2, 21, 49, 50, 71, 117, 129, 132, 135
- optical coherence tomography 73
- optical symptoms 73
- optical zone 130, 131
- optical zone marker 129
- overlaid graft 108, 113
- Overtightening 4, 6, 67

## P

- Pallin 77
- Pallin technique 77
  - paracentesis 19, 30, 41, 42, 74, 76, 77, 79, 80, 81
  - pars plana 38, 39, 44
  - PAS 73, 74, 78, 82
  - patch graft 34, 67, 68, 96, 105
  - PBK 37, 38
  - pediatric keratoplasty 55, 57
  - amblyopia 57
  - glaucoma 57
  - graft failure 57
  - suture pattern 57
  - suture placement 57
  - suture removal 57
  - wound apposition 57
- penetrating keratoplasty 37, 38, 39, 44, 47, 51, 58, 73
- perforation 86, 97, 101, 118, 121, 126, 139
- pericardial tissue 101, 105
- peripheral iris 37, 39, 41, 57, 68, 80, 81, 82
- peritomy 44, 80, 95, 103, 105
- phacoemulsification 6, 29, 30, 34, 35, 39, 61, 62
- phacoemulsification wound 7
- photoreactive pigments 83
- Pierse-type forceps 17
- pigmentary dispersion 39
- pigment dispersion 37, 38, 44
- pilocarpine 72
- placement of sutures 6, 9, 73
- plane of compression 63
- polypropylene 11, 12, 37, 39–47, 63, 71, 74, 76, 77, 79, 80
- polytetrafluoroethylene 47
- posterior chamber intraocular lenses 38
- posterior chamber IOL (PCIOL) 37
- posterior chamber lens 37, 39, 44, 48, 73
- posterior ruptures 61
- postoperative discomfort 125, 136, 137, 138
- preserved amnion graft 107, 108, 109, 112–115
- PROKERA 107, 108, 111, 113, 115
- Prolapsed iris 68
- prolapsed vitreous 39, 68
- Prolene 12, 13, 24, 39, 41, 42, 86, 101, 105
- Prospective Evaluation of Radial Keratotomy (PERK) study 129
- prosthetic iris 71
- pseudophakic 49, 81, 87, 96



pseudophakic bullous keratopathy 37, 38, 39, 50  
 pterygium 109, 112, 135, 136, 137  
   – 5-fluorouracil 135  
   – abduction 135  
   – amniotic membrane transplantation 135  
   – corneal astigmatism 135  
   – corneal toricity 135  
   – cosmesis 135  
   – inflammation 135  
   – mitomycin C 135  
   – motility disturbance 135  
   –  $\beta$ -radiation 135  
 pterygium excision 136  
 pterygium surgery 135, 136, 137, 138  
   – conjunctival autograft 135  
   – fibrin sealant 135, 136  
   – Nylon 136  
   – nylon 135  
   – operative time 136  
   – Suture placement 136  
   – Tisseel 135, 136  
   – tissue adhesive 136  
   – tissue glue 135  
   – Vicryl 135, 136  
 pupil 39, 41, 62, 68, 71–76, 78, 79, 80, 83, 126  
 pupil/lens 81  
 pupillary block 37, 38  
 Pupil shaping 71  
 purse-string 67, 110, 130  
 purse-string running 109

## R

radial 33, 34, 49, 52, 54, 55, 95, 97, 105  
 radial interrupted suture 29, 54  
 radial keratotomy 50, 129, 130  
 radial keratotomy complications  
   – astigmatism 130  
   – contact lens 130  
   – corneal “knee” 130  
   – Grene lasso 130  
   – hyperopia 130  
   – Merseline 131  
   – Multiple lasso sutures 131  
   – Nylon 131  
   – nylon suture 130  
   – over-and-under technique 131  
   – overcorrection 131  
   – plano 131  
   – Prolene 131  
   – steep-and-deep suture path 130  
   – surgical keratometer 131  
   – suture bite 130  
   – wound gape 130  
 radial marker 129, 132  
 reattachment sutures 121  
 recalcitrant flap striae 132  
 Recalcitrant Striae 131  
 recession 117,–121, 123, 124, 125  
 recipient cornea 56, 57  
 rectus muscle 85, 89, 90, 117, 118, 119, 125  
 refractive surgery 129, 133  
 regression 34  
 relaxing incision 34, 56, 95  
 releasable suture 101, 102, 103  
 resection 117–121, 123, 125  
 response 13, 14, 30, 67, 71, 129  
 retina 9, 44, 85  
 retinal detachment 37, 38, 61, 68, 70, 82, 97, 98, 126  
 retinal incarceration 94, 97

retinal perforation 97  
 retractors 86  
 rounded knurled handle 14  
 round serrated handle 14, 15  
 running mattress closure 103  
 running suture 7, 26, 27, 29, 33, 34, 51, 52, 54, 55, 56, 64, 65, 95, 98, 104, 111, 136

## S

scar formation 14, 21  
 scar tissue 2, 72  
 scissors 18, 19, 29, 31, 52, 63, 77, 86, 87, 93, 96, 101, 107, 119, 121, 124, 126, 135, 137  
   – curved tips 18  
   – ring-handle 18  
   – squeeze-handle 18  
   – tips 18  
   – Vannas-style scissors 31  
 sclera 6, 13, 16, 17, 68, 71, 74, 79, 80, 81, 85, 86, 88, 89, 90–93, 96, 97, 98, 102, 114, 117, 119–125, 138  
 scleral 85, 97  
 scleral-fixated IOLs 47  
 scleral-fixated PCIOLs 48  
 scleral anchoring 122, 123  
 scleral buckle 85, 86, 89, 93–98  
 Scleral Buckles: Encircling Elements 90  
 scleral buckling 85, 86, 98  
 scleral contact 124  
 scleral fixation 44, 46, 48, 85, 86  
 scleral fixation ring 55, 57, 58  
 scleral flap 44, 45, 46, 47, 80  
 Scleral grafts 10  
 scleral lacerations 68  
 scleral passage 122, 123  
 scleral perforation 92, 97, 117, 119, 126  
 scleral step-up 122  
 scleral tunnel 119, 122, 124  
 scleral tunnel incision 29, 30  
 scleral vortex vein 93  
 sclerotomy 85, 86, 88, 89, 94, 96, 97, 98  
 sclerotomy site 86, 88, 96, 97  
 secondary IOL 37, 38, 39, 47, 48  
 sector iridectomy 73, 76  
 self-sealing 6, 7, 29, 30, 44, 63  
 self-sealing incision 30  
 self-sealing wounds 61, 62  
 serrated flat handle 14  
 shelved incision 30, 32, 64  
 shelved wound 7, 64  
 Shepherds horizontal mattress suture 29, 33  
 Shin 76  
 shoelace suture 29, 33, 34  
 Side-cutting spatula tip needles 74  
 Siepser 41, 42, 74, 77  
 Siepser slipknot method 43  
 Siepser technique 41, 42, 44  
 silicone band 93  
 silicone sleeve 86, 93  
 simple running suture 33, 104  
 single-piece polymethylmethacrylate (PMMA) IOL 44  
 Single CRS Technique 55  
 single interrupted suture 31, 32, 51, 57, 104  
 Sinskey hook 42, 132  
 slipknot 6, 21, 22, 24, 25, 31, 34, 41–44, 52, 54, 64, 66, 74, 77, 101, 102, 103, 136  
 small needle 15, 31  
 smooth-tipped forceps 42  
 smooth forceps 16, 109, 110  
 spatulated needle 3, 119, 120

- sphincter muscles 71, 75
- splice 26
- spliced knot 55
- square knot 6, 21, 22, 24, 26, 42, 52, 93, 97, 102
- standard cutting 10, 11, 12
- steepening 6, 52, 64, 129, 130, 131
- stellate laceration 61, 67
- strabismus 10, 105, 117, 118, 127, 136
- stromal cells 71, 74
- subretinal fluid 93, 94, 97
- suprachoroidal hemorrhage 38, 49
- supraplacement 118, 122
- surgeon 1, 2, 3, 5, 15, 16, 18, 19, 21, 22, 25, 29, 30, 32, 34, 37, 39, 41, 52, 55, 57, 58, 63, 67, 68, 69, 75, 81, 82, 86, 87, 88, 90–95, 108, 109, 117, 118, 120, 122, 130, 133, 136, 138
- surgeon's knot 3, 6, 24, 26, 31, 34, 123, 136
- surgical dissection 5
- surgical indication 24, 25, 29, 49, 50, 61, 62, 71, 73, 85, 101, 107, 108, 117, 129, 130, 132, 135
- surgical instrument 14, 15, 68, 86, 109
  - counter pressure 15
  - fatigue 15
  - firmer grasp 14
  - flexibility 14, 15
  - grasp 14, 15
  - handle 15
  - method of holding 14
  - mobility 14, 15
  - resistance 15
  - slip 14
  - tighter control 14
- surgical technique 21, 22, 24, 25, 26, 29, 31, 38, 41, 47, 49, 50, 58, 63, 70, 71, 73, 74, 85, 86, 101, 107, 117, 129, 130, 135, 136
- suture 2, 9, 11, 12, 14, 15, 16, 17, 18, 19, 21, 26, 27, 32, 39, 65
  - Absorbable 13
  - Absorbable suture 12
  - actide-epsilon-caprolactone copolymer (P[LA/CL]) 14
  - adsorbability 9
  - adsorbable 14
  - antibacterials 14
  - braided 12
  - carbolic acids 12
  - catgut 12
  - characteristics 12, 13
  - chromic 12
  - Chromic gut 13
  - chromic gut 12
  - Coated Vicryl 13
  - coating 14
  - collagen 12, 14
  - Dexon 12, 13
  - diameter 9
  - erode 13
  - Ethibond 13
  - Ethilon 13
  - Gut 13
  - handling 9
  - horsehair 12
  - inert 14
  - Inflammation 13
  - issue reactivity 12
  - linen 12
  - mass 12
  - material 9, 13
  - Maxon 13
  - memory 13
  - Mersilene 12
  - Mersilene, Dacron 13
  - monofilament 12
  - nonabsorbable 12, 14
  - Novafil 13
  - Nylon 13
  - nylon 12
  - optimal 13
  - PDS 13
  - permanent 12, 13
  - Polybutester 12, 13
  - polydioxanone 12, 13, 14
  - polyester 12
  - Polyglactic acid 13
  - polyglactin 12
  - polyglycolic acid 12
  - polyglyconate 14
  - Polypropylene 13
  - Polytrimethylene carbonate 13
  - Prolene 13
  - selection 14
  - silk 12, 13
  - silver wire 12
  - steel 12
  - strength 9
  - tensile strength 12, 13
  - tension 13
  - tissue inflammation 12
  - Trade name 13
  - triclosan 14
  - twine 12
  - Vicryl 12, 13, 14
- Suture-tying forceps 15
- suture abscess 34, 49, 57, 58
- suture adjustment 55, 56, 126
- suture bite 4, 49, 57, 65
- suture breakage 31, 55, 56
- suture characteristics 13, 14
  - adsorbability 14
  - bioabsorbable 14
  - degradation 14
  - handling 14
  - monofilament 14
  - self-reinforced poly-L-lactide (SR-PLLA) 14
  - size 14
  - tensile strength 14, 31
  - tissue reaction 14
- suture erosion 47, 97, 129, 131
- suture failure 22, 97
- suture fixation 39, 40, 41, 48, 51, 52, 89
- suture gauge 14
- Suture iridopexy 71
- suture length 49, 123
- sutureless vitrectomy 98
- suture material 9, 11–14, 21, 22, 63, 74, 86, 119, 131, 135
- suture placement 1, 2, 3, 4, 17, 29, 30, 33, 34, 49, 50, 51, 52, 56, 79, 92, 93, 94, 97, 102, 119, 126, 130, 133, 137
- suture removal 34, 35, 52, 53, 55, 56, 57, 58, 133, 137
- suture scissors 15
- suture technique 3, 53
  - astigmatism 53
- suture tension 7, 24, 52
- suturing technique 29, 31, 34, 41, 49, 51, 52, 55, 57, 58, 70, 76, 85, 86, 90, 98, 101, 106, 107, 109, 129
  - astigmatism 34
  - combination 31
  - full thickness 32
  - horizontal suture 34
  - induced astigmatism 34
  - interrupted 31, 32
  - perpendicular 31, 32
  - radial 31, 32
  - radial interrupted suture 34
  - running 31

- tissue override 32
- watertight closure 32
- wound gape 34
- suturing the conjunctiva 5, 103, 104
- suturing the cornea 63, 64
- swage 9, 15, 16
- symblepharon 97, 108, 109

## T

- tapered needle 74, 104, 105
- tarsal suture 5
- tectonic 55
- tectonic graft 50
- Tenant curved tying forceps 18
- tendon attachment 122
- tenonplasty 112, 115
- tenons capsule 5, 94, 95, 97, 136
- Tenons layer 125
- tensons capsule 137
- thermal wound injury 34
- Thorpe corneal fixation forceps 17
- Tisseel 96, 114, 136, 137, 138
- tissue 1, 3, 4, 9, 11–17, 21, 22, 24, 26, 31, 32, 34, 35, 118–123, 125, 126
- tissue adhesive 62, 98, 127, 136, 137
- tissue apposition 14, 58, 65
- tissue compression 31, 64
- tissue conservation 62
- tissue deformation 3, 22
- tissue displacement 17
- tissue fixation 17, 49
- tissue forceps 15–18, 125, 126
  - angled teeth 16
  - damage 16
  - fixation 17
  - friction 16
  - handles 16
  - length 16
  - mechanism 16
  - resistance 16
  - serrations 16
  - smooth 16
  - suture manipulation 16
  - suturing 16
  - teeth 17
  - tips 16
  - tissue damage 17
  - tissue fixation 16
  - tying 16
- tissue grasping forceps 18
- tissue laceration 3, 31
- tissue override 32, 64, 65, 66
- tissue penetration 11
- tissue prolapse 68
- tissue strength 13
- Tissue tract 10
- toothed forceps 1, 5, 16, 17, 50, 86, 91, 101, 105, 109, 110
- toothless forceps 74
- topographical profile 52
- torque 3, 7, 31, 50, 54
- trabeculectomy 10, 11, 16, 101, 102, 105
- trabeculectomy flap 101, 102, 103
- traction sutures 87, 91
- transscleral-sutured PCIOL 37
- transscleral-sutured technique 39
- transscleral fixation 13, 44
- transscleral fixation of the PCIOL 44
- trauma 1, 7, 39, 49, 50, 61, 66, 68, 69, 70
- traumatic mydriasis 73, 77, 81

- traumatic wounds 6, 7, 73
- trephine 50, 67
- tunnel incision 32
- two-suture reattachments 123
- two-suture technique 118, 120, 121
- tying 16, 17, 118, 119, 122, 123, 124
- tying forceps 18, 19, 21, 22, 24, 26, 31, 50, 54, 55, 56, 101, 102, 103, 123, 126
  - angled 18
  - curved 18
  - grasp 18
  - length 18
  - Micro-tying forceps 31
  - rotating sutures 18
  - shape 18
  - smooth jaws 18
  - straight 18
  - suture material 18
  - tips 18
  - toothed 18
- tying platform 15, 21, 31, 50

## U

- UGH syndrome 37, 39
- ultrasound biomicroscopy 73
- uniplanar incision 29
- uveitis 38, 39, 73
- uveitis-glaucoma-hyphema (UGH) syndrome 37

## V

- Vannas-style scissors 29
- vector forces 4
- vertical deviation 118
- Vicryl 5, 13, 14, 68, 86, 88, 89, 95, 96, 98, 101, 103, 104, 105, 107, 109, 112, 119, 124, 125, 135, 136, 138
- viscoelastic 30, 34, 50, 63, 74, 76, 77, 80, 82
- visual prognosis 61, 69, 70
- vitrectomy 37, 38, 39, 61, 62, 63, 74, 85, 86, 87, 89, 96, 97, 98
- vitreous base incarceration 96
- vitreous prolapse 38, 49
- vitreous traction 82, 90, 91
- vortex vein 93

## W

- watertight closures 11
- watertight wound 7, 31, 52, 57, 61, 62
- wing sutures 103, 105
- wound 32, 65
- wound apposition 3, 33, 49, 51, 54, 63
- wound architecture 1, 6, 51
- wound burn 29, 30, 34
- wound closure 1, 4, 25, 29–32, 51, 52, 55, 58, 61, 62, 64, 70, 135, 138
- wound compression 26
- wound dehiscence 9, 27, 34, 52, 56, 57, 58
- wound edge 2, 4, 5, 7, 21, 22, 24, 25, 34, 50, 63, 68, 77, 81, 102, 104, 125
- wound gape 34, 64, 129, 130
- wound healing 1, 13, 21, 30, 56, 57, 71, 81, 107, 108, 129
- wound instability 55, 57, 81
- wound leak 26, 29, 32, 34, 49, 67, 69, 89, 96
- wound leakage 34, 64
- wound management 1

wound override 3, 61, 64  
wound repair 1, 5, 70  
wound surface 3, 4, 22, 25

## **X**

X-stitch 29, 33

## **Z**

zigzag incision 65, 66  
zigzag laceration 61, 66  
zone of compression 4, 31, 34, 64