Systemic Pathology of Fish



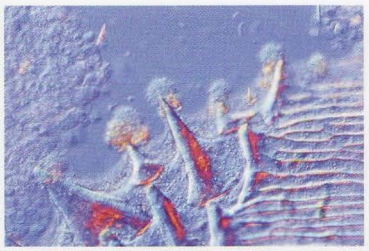

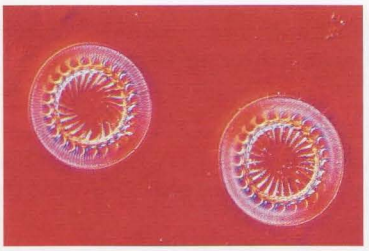



SCOTIAN PRESS

Systemic Pathology of Fish

A Text and Atlas of Normal Tissues in Teleosts and their Responses in Disease



Second Edition

Edited by
Hugh W. Ferguson, BVM&S, PhD, DipACVP, MRCVS, FRCPath

Contributors

Ellen Bjerkås DVM, PhD, Diplomate ECVO, Professor,
Department of Companion Animal Clinical Sciences, Norwegian School of Veterinary Science,
P.O. Box 8146 Dep N-0033 Oslo, Norway.
ellen.bjerkas@veths.no

Øystein Evensen DVM, PhD, Professor,
Department of Basic Sciences and Aquatic Medicine,
Norwegian School of Veterinary Science, P.O. Box 8146 Dep N-0033 Oslo, Norway.
oystein.evensen@veths.no

Hugh W. Ferguson BVM&S, PhD, Diplomate ACVP, MRCVS, FRCPath, Professor,
Institute of Aquaculture, University of Stirling, Scotland FK9 4LA, UK.
h.w.ferguson@stir.ac.uk

Salvatore Frasca Jr. VMD, PhD, Diplomate ACVP, Associate Professor of Pathobiology and Veterinary Science,
Department of Pathobiology and Veterinary Science,
University of Connecticut, U-3089, 61 North Eagleville Road, Storrs, CT 06269-3089, USA.
salvatore.frasca@uconn.edu

Erling Olaf Koppang VMD, dr.med.vet, Associate Professor, Section of Anatomy and Pathology,
Department of Basic Sciences and Aquatic Medicine,
Norwegian School of Veterinary Science,
P.O. Box 8146 Dep N-0033 Oslo, Norway.
erling.o.koppang@veths.no

John F. Leatherland BSc, PhD, Professor, Department of Biomedical Sciences,
Ontario Veterinary College, University of Guelph, Ontario N1G 2W1, Canada.
jleather@ovc.uoguelph.ca

John S. Lumsden BSc, DVM, MSc, PhD, MACVSc, Diplomate ACVP, Associate Professor,
Department of Pathobiology, Ontario Veterinary College, University of Guelph,
Ontario N1G 2W1, Canada.
jslumsde@uoguelph.ca

Daniel Martineau DMV, MSc, PhD, Diplomate ACVP, Département de Pathologie et Microbiologie,
Faculté de Médecine Vétérinaire, Université de Montréal, 3200 Sicotte, Saint-Hyacinthe, Québec J2S 7C5, Canada.
daniel.martineau@umontreal.ca

Edward J. Noga MS, DVM, Professor of Aquatic Medicine,
Department of Clinical Sciences, College of Veterinary Medicine,
North Carolina State University, 4700 Hillsborough Street, Raleigh, NC 27606 USA.
ed_noga@ncsu.edu

Trygve T. Poppe DVM, Dr. Scient, Professor, Department of Basic Sciences and Aquatic Medicine,
Norwegian School of Veterinary Science, P.O. Box 8146, Dep., 0033 Oslo, Norway.
trygve.poppe@veths.no

Mark Powell BSc., MSc, PhD, Senior Lecturer, School of Aquaculture,
Tasmanian Aquaculture and Fisheries Institute, University of Tasmania, Locked Bag 1370,
Launceston, Tasmania 7250 Australia.
Mark.Powell@utas.edu.au

Renate Reimschuessel VMD, PhD, Senior Research Biologist,
Center For Veterinary Medicine, FDA, 8401 Muirkirk Road, Laurel, MD 20708, USA.
rreimsch@cvm.fda.gov

David J. Speare DVM, DVSc, Professor of Fish Pathology,
Department of Pathology & Microbiology, Atlantic Veterinary College,
University of Prince Edward Island, 550 University Ave., Charlottetown, Prince Edward Island C1A 4P3 Canada.
speare@upei.ca

James Turnbull BVM&S, MSc, PhD, MRCVS, Senior Lecturer, Institute of Aquaculture,
University of Stirling, Scotland FK9 4LA, UK.
j.f.turnbull@stir.ac.uk

To our families.



Hugh W. Ferguson is a professor of veterinary pathology, and holds the Chair of Diagnostic Pathology and Microbiology in the Institute of Aquaculture, University of Stirling, Scotland, where he is responsible for co-ordinating the delivery of veterinary diagnostic services. He is a Member of the Royal College of Veterinary Surgeons, a Diplomate of the American College of Veterinary Pathologists, and a Fellow of the Royal College of Pathologists.

SCOTIAN PRESS

© Published by Scotian Press 2006
Dalton House, 60 Windsor Avenue, London SW19 2RR, UK
www.scotianpress.com

Systemic Pathology of Fish: a text and atlas of normal tissues in teleosts and their responses in disease.

ISBN : 0-9553037-0-2
978-0-9553037-0-8

First published 1989,
Iowa State University Press, Ames, Iowa 50010, USA.
Reprinted Taiwan edition, 1990.
Second Edition, revised and expanded 2006.

British Library Cataloguing in Publication Data.
A catalogue record for this book is available from the British Library.

Copyright @ Scotian Press, 2006. All rights reserved. No part of this publication may be reproduced, photocopied, stored in a retrieval system, or transmitted in any form or by any means electronic, mechanical, recording or otherwise, except as permitted under the UK Copyright, Designs and Patents Act 1988, without prior permission from the publisher. This book was printed in the United Kingdom.

Design: kennethkerr2@blueyonder.co.uk
Photography: dunedinstudios@blueyonder.co.uk

Printed and bound by CPI-Bath Press Ltd.

CONTENTS:



Preface

Acknowledgements

1 Introduction **10**

2 Gills and Pseudobranchs **24**

3 Skin **64**

4 Kidney **90**

5 Spleen, Thymus, Reticulo-Endothelial System, Blood **120**

6 Cardiovascular System **140**

7 Gastrointestinal Tract, Swimbladder, Pancreas and Peritoneum **168**

8 Liver **200**

9 Nervous System **218**

10 The Eye **244**

11 Endocrine and Reproductive Systems **266**

12 Musculoskeletal System **288**

13 Neoplasia **321**

14 Physiological and Clinical Pathology **336**

Index **356**



Preface

This set of notes was originally intended as an aid to graduate students coming from a comparative pathology background, and who therefore already had a fairly good grasp of the basic principles and jargon appropriate to the subject. They were meant to illustrate some of the ways in which teleost fish respond in a range of disease situations, and to compare and contrast these responses to those in mammals. They were never intended to be an exhaustive list of aetiologies, but were aimed primarily at the diagnostic pathologist faced with a section of fish tissues, possibly for the first time. The first edition seemed to appeal to a far wider audience than was originally intended, and it sold out rapidly, as did the second printing. The publishers were understandably keen to see a second edition, but after only five years I did not feel that our understanding of disease processes had progressed significantly to justify the effort. However, it is now seventeen years since the first printing, and the book is long overdue for a rewrite, even though I still question whether my own level of understanding has advanced markedly!

Despite virtual stagnation in most forms of traditional animal production, aquaculture has continued to grow substantially in the intervening years, as have our interest in and awareness of the importance of the aquatic environment. Mirroring this, private and public aquaria have flourished, enabling the study of disease in individual animals, as opposed to the more usual group approach. Fish have also become one of the major tools for genetic research, and in some countries their use in laboratories has outpaced the more conventional rodents to become numerically the most important species. Inevitably these factors have conspired to produce a parallel increase in the numbers of samples requiring diagnosis.

There is no denying that conventional morphological pathology takes a lot of effort to achieve a decent degree of competency, and that many students seem reluctant to put in the work required, turning instead to newer and "sexier" areas of endeavour. During this time of expanded and sometimes pressing diagnostic need, we have seen a parallel growth in the exciting field of molecular biology, and many of the newer techniques now in routine use in most diagnostic laboratories are based in this discipline.

Finding a way of harnessing the power intrinsic to molecular approaches and applying them to conventional pathology remains a worthy goal, especially considering the extremely valuable archives of paraffin wax blocks found in most diagnostic laboratories. By their very nature, however, many molecular techniques in the fish world are aetiologically driven. Understanding disease processes, and the impact that pathogens have upon their hosts, have regrettably taken a back seat, and even finding money for training students in the discipline of pathology has become extremely hard to find. How can we possibly hope to control disease in a rational manner if we do not properly understand its sequential pathology and pathophysiology?

One of the major attractions for prospective students contemplating entering the field of fish pathology is the chance to work with a brand new disease entity. In few other areas would this be possible. When constantly faced with new diseases and new pathogens, in a wonderful but sometimes bewildering variety of different species of fish, there is no substitute for morphological pathology as the initial approach.

As last time, therefore, I have attempted to set out each chapter in a similar fashion. An overview of normal is followed by the general response of each tissue to disease, and then a few specific diseases. Inevitably the diseases chosen to illustrate these processes are in large part a reflection of the interests of the writer(s) as well as of the commercially important fish species. Mostly they are taken from routine diagnostic material. I have tried hard to integrate the text into a readable whole, cross-referencing chapters to each other, and leaving as few gaps as possible. Once again, the text assumes a reasonable working knowledge of pathology and the jargon appropriate to the subject.

Hugh W. Ferguson, Stirling, 2006



Acknowledgements

Towards the end of my undergraduate programme I wrote to Dr Ron Roberts congratulating him on his recent Nuffield Foundation award that helped create the Unit of Aquatic Pathobiology in the University of Stirling, and telling him how glad I was that the veterinary profession was starting to look beyond the confines of its more traditional roles. Ron's response was to invite me on a diagnostic visit to a fish farm and on the way back he offered me the chance to do a PhD. His enthusiasm and self-evident vision were enough, and I was hooked! So for more than 30 years I have been able to indulge what started off essentially as a hobby, but rooted in a conviction that this was an important area. How could one want for more out of a working life?

Along the way I have had the rare privilege of working with some wonderful colleagues and inspiring comparative pathologists: Angus Stuart in the Medical School, Edinburgh; Charlie Dow and Geoff Pearson in Stormont, Belfast; and Joan Budd, Ted Valli, Ole Nielsen, Tony Hayes, Ian Barker, Rob Jacobs, Peter Little, Brian Wilcock, Ric Miller, Dean Percy, Dick Julian, Tom Hulland, Joe Geraci and Nigel Palmer in Ontario Veterinary College, Guelph. I hesitate to name my graduate students, because some of them are contributors to this book! Once again, however, it was a genuine privilege to have had the chance to learn from all of them; I was nearly always well out of my depth when they were trying to explain something, but they tolerated me, and over the years many have become something akin to family.

They say you should never retrace your steps, but here I am back in Stirling, recruited eight years ago by Randolph Richards! My present position allows me to continue to indulge my passion for diagnostic pathology of fish, encouraged by the hard-working environment, the team of dedicated researchers here, and supported by a great professional and technical staff including Mags Crumlish, Debbie, Fiona, Gillian, Jacquie, Maureen and Linton. We are able to access material from all round the world, and pursue diagnoses using the full suite of tools presently available. Such luxury!

My thanks go to the contributors to this book. They tolerated with great equanimity and good grace my "encouragements" for their contributions. Many have been very generous with illustrations, Brent Whitaker and Juan Morales, but especially Trygve Poppe, whose artistic inclinations can be seen scattered throughout. George Ferguson was responsible for most of the unbelievably high quality images that have been used to separate chapters. Many people provided help, good comments and valuable suggestions on organizational structure, including Gerry Johnson and Steve Smith. Kenneth Kerr was responsible for the design and layout of the book, and for refusing to accept anything less than the highest possible standards in reproduction and printing quality. He successfully scotched the suggestions about a pop-up or a scratch-and-sniff edition, made by some of my less serious friends! His tolerance, encouragement, friendship and sheer professionalism along the way have been invaluable.

Several journals are thanked for permission to reproduce pictures. They include Canadian Journal of Zoology (Fig 4.2B), Journal of Fish Diseases (Figs 2.2B, 2.4A&D, 2.15D&F, 2.10D&E, 3.2, 3.6A&B, 3.17A&B, 4.25D&E, 12.18B), Journal of Comparative Pathology (Figs 1.2C, 5.2C, 6.4C), Diseases of Aquatic Organisms (Fig 1.2F), The Veterinary Record (Figs 6.19E & 8.14B), Veterinary Pathology (Fig 4.9) and Canadian Veterinary Journal (Figs 2.13D&E).

I know that work should never be allowed to stand in the way of family obligations and commitments, but inevitably this happens, so I can only hope that our families forgive us, and feel that it was all worthwhile.







Introduction

CHAPTER 1

by Hugh W. Ferguson

Post-mortem techniques

Sample submission and processing

Unlike mammals which tend to cool down after death, thereby slowing autolysis, fish out of water often warm up. Tissues must, therefore, be placed into fixative as quickly as possible or artifacts can start to hinder interpretation. We have found this to be especially true with gills, and a time lag of even five minutes (not long if one is doing a necropsy!) may produce lamellar epithelial swelling and lifting from the basement membrane, partly due to the lack of compensatory water pressure within the branchial cavity. Sick but live fish are probably the most useful samples to receive for diagnostic purposes, therefore, followed by freshly dead animals, kept cool, but not frozen. Keeping marine species cool by placing them directly on top of a bed of freshwater ice inevitably leads to osmotic destruction of skin and most associated pathogens.

Ten per cent neutral buffered formalin is the fixative of choice for most situations and 24 hours on a shaker is the optimum, prior to trimming. If keen to get tissues into the processor overnight so that slides can be read the next day, even 3-4 hours fixation can be sufficient in an emergency. Using seawater instead of saline is also a good substitute, as it is quite well buffered. Use of unbuffered formalin often leads to oxidation of haem and the presence of haematin in sections, presenting as an annoying brown pigment. Bouin's fixative is especially useful for eyes and gills, or for skin, or small fish, where its demineralizing properties minimize distortion and tearing artifacts from scales and other bony structures, and in the case of small fish, permits whole-body sections without the need to dissect out (and often destroy!) the various organs. Fixation for 24-48 hours, followed by storage in 70% alcohol until processing, is usually adequate. *Decal* is also used as a routine, as is decalcification of the block face (hard tissues) for an hour immediately prior to section cutting. One of the many advantages of working with fish over mammals is the ability to get a section of the entire animal on a single slide; the relative proportions and inter-relationships of the organs are thereby easily examined (***Fig 1.1A***).

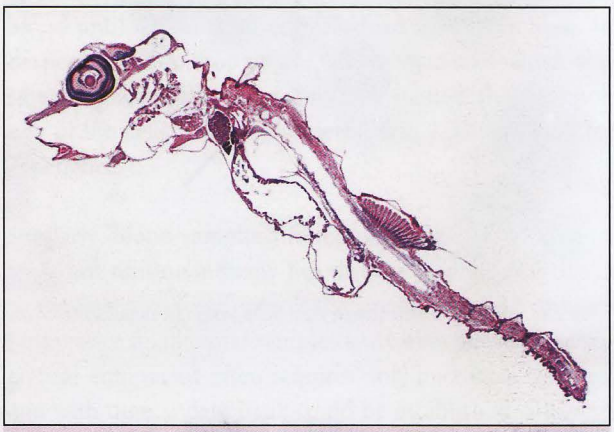

Fig 1.1A. Saggital section through young seahorse

For ultrastructural work, 2-2.5% glutaraldehyde in a cacodylate or phosphate buffer with a total osmolality of roughly 320 mOsm, and pH 7.2 has been found acceptable for primary fixation under most circumstances. This is usually followed by secondary fixation with 1 per cent osmium tetroxide in a phosphate buffer, and then dehydration in graded ethanols prior to resin embedding. So much of our diagnostic material is mailed to us, however, that when we feel the need for some ultrastructural work, we usually have nothing except formalin fixed tissues with which to work, and getting new material appropriately fixed is either not possible, or it would take too long. Accordingly, we use a post-formalin fixation strategy of 30 minutes in glutaraldehyde, followed by buffer rinse and then osmium staining. The results are more than acceptable for diagnostic purposes. The routine processing and staining methods used in any pathology laboratory are employed for the preparation of paraffin wax sections from fish tissues.

Any discussion of fixative at this stage is possibly premature because the importance cannot be over-emphasized of routinely employing tissue scrapes, smears and squashes from live and anaesthetized, or freshly dead fish. This is especially true for skin and gill diseases and where protozoan or other parasitic diseases are suspect: some of the protozoa do not survive processing very well, and there is little substitute for seeing the cell move when trying to decide if it is of host origin or not! And even then, you

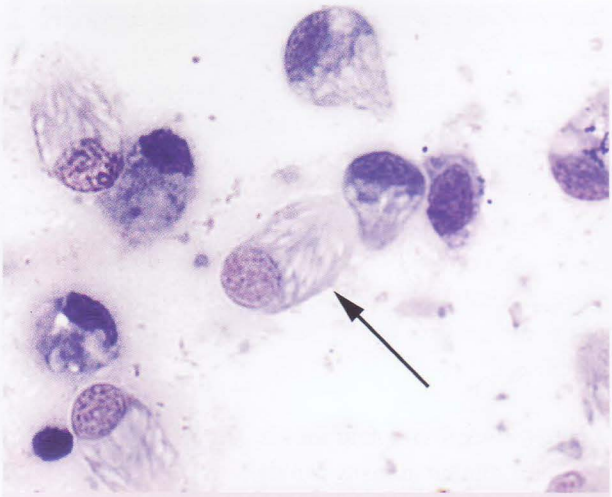

Fig 1.1B. Giemsa stained scrape from head lesion in angelfish to show rodlet cells (arrow).

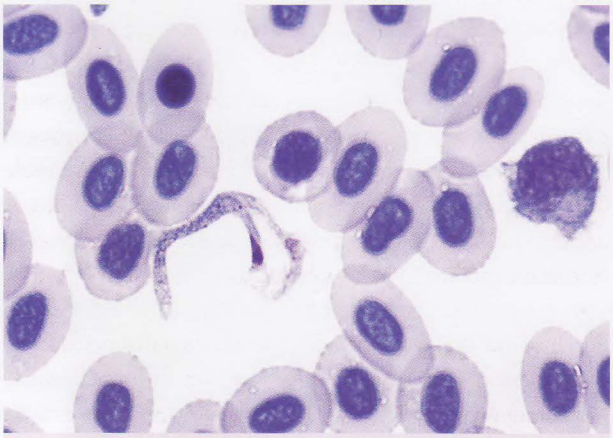

Fig 1.2A. Blood smear from white sucker showing the presence of a *Cryptobia* flagellate.



Fig 1.2B. Blood smear from turbot showing the apicomplexan sporozoan *Haemogregarina* within white blood cell.



Fig 1.2C. TEM of buffy coat from turbot showing the apicomplexan sporozoan *Haemogregarina* within white blood cell.

need to be aware of some of the unusual cell types seen in teleosts *e.g.* rodlet cells can look rather like protozoa, and yet they are almost certainly host cells **(*Fig 1.1B*)**. When mounting skin or gill smears from freshwater fish in the hunt for pathogens, do NOT use 10% saline; once again, osmotic forces would destroy many organisms.

Blood sampling and euthanasia

Blood smears often provide diagnostic clues, but generally speaking they are not as useful as in mammalian work. Nevertheless, "more is missed by not looking than not knowing", so we keep looking, and there are occasional successes **(*Fig 1.2*)**. Blood smears and tissue imprints can be stained by hand using Giemsa stain or with an automatic slide stainer using a polychrome methylene blue stain, and they give good results for most purposes.

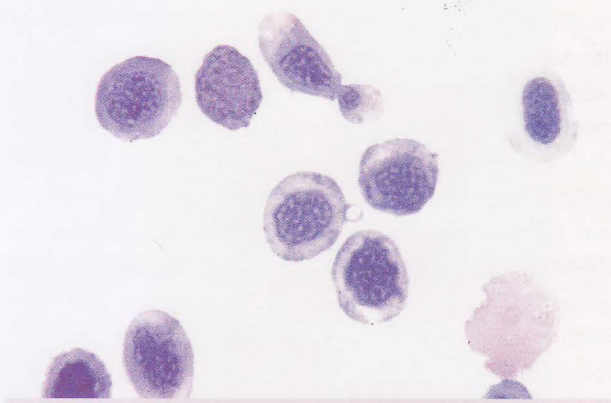

Fig 1.2D. Blood smear from rainbow trout with lipoid liver disease showing large number of immature erythrocytes. Although a responsive anaemia, the consumption of vitamin E seen in this disease inhibits proper maturation of erythocytes.

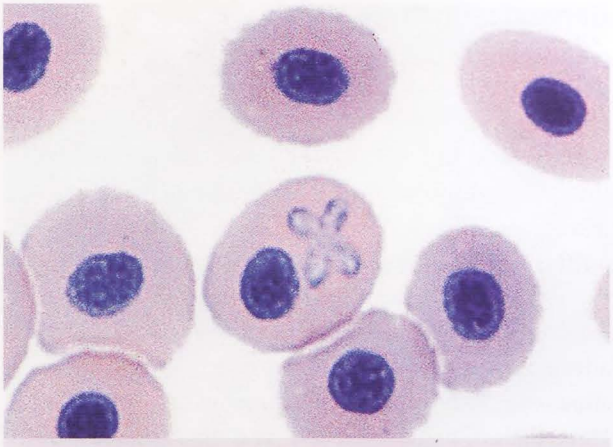

Fig 1.2E. Babesioma mariae within erythrocyte of this cichlid.

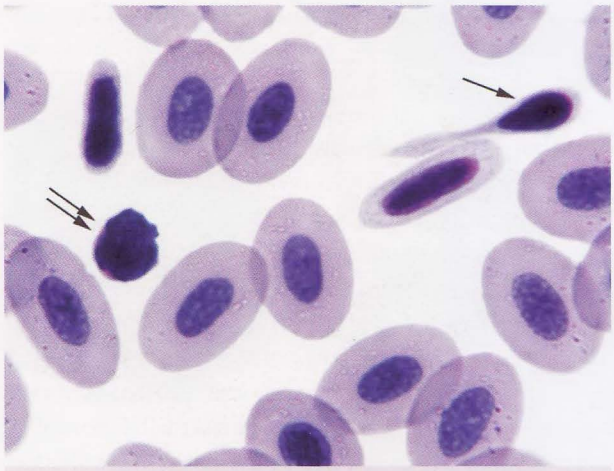

Fig 1.3A. Blood smear from rainbow trout showing thrombocyte with tail (arrow) and lymphocyte (double arrow).

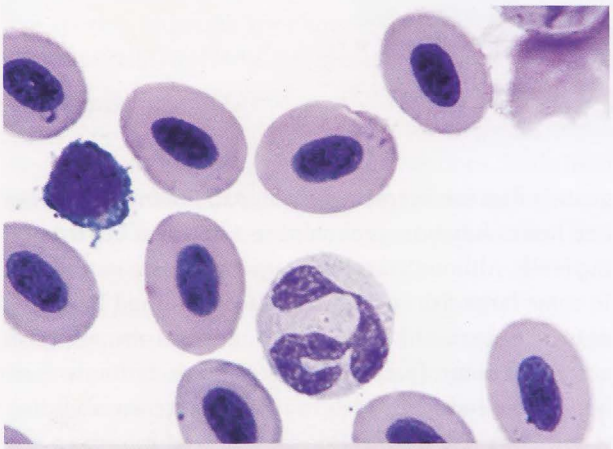

Fig 1.3B. Rainbow trout blood smear showing lymphocyte and segmented neutrophil. A "smudge" cell can be seen at the top right.

Despite many years of practice, and trying all usual techniques, I still have great difficulty in getting a really good smear, with perfectly preserved cells; far too many "ghost" or "smudge" cells are almost invariably present. The very best smears are made by undergraduates often trying the technique for the first time, and who have forgotten to take blood until the animal has been dead for half an hour. In desperation they chop off the tail, wring out the fluid, and smear it thickly all over a slide! Once stained, the morphology of the cells is often wonderful **(*Fig 1.3*)**. So much for experience!

Similarly, blood sampling for serology or clinical chemistry is not routine in many fish disease laboratories: this is sometimes a consequence of the small size of the animals (and hence small blood samples available), but modern analytical equipment often requires only microlitre samples, and with time, a data bank could be established, allowing useful comparisons to be made. We are really only just starting to investigate fish disease using clinical chemical approaches **(*see Chapter 14*)**. Caudal vein is the preferred sampling site where possible, because cardiac puncture may damage an organ sometimes crucial to a diagnosis. The dorsal aorta, running along the roof of the mouth, is another possible sampling site, but again, its use is limited to certain species, notably salmonids.

For euthanasia, severance of the spinal cord just behind the opercula is preferred to a sharp blow on the head, owing to problems of intra-cranial haemorrhage and brain trauma with the latter method! Even spinal severance is not without problems, however, as the frequency of branchial lamellar aneurysms is greatly increased. Aqueous anaesthesia, therefore, is the most commonly employed method of euthanasia in this laboratory. Anaesthetics employed include benzocaine or tricaine methane sulphonate or MS-222 (1 in 1000 is lethal within a few minutes for most species).

Necropsy procedure

As with mammals there are a great many suitable approaches to performing a necropsy on a fish, and as has been said so often, probably the most important aspect is consistency, thereby allowing comparisons to be made from one animal to the next. Small fish up to about 4 cm may be fixed and processed whole: it is important in these cases only to remove an operculum and incise the abdominal cavity to allow proper penetration of fixative. If the fish are bigger however, the following technique may be useful:

a) In this laboratory, fish lie on their right side (except flat-fish which are approached from the top) on a non-absorbent surface. Similarly, avoid the use of paper towels or any other absorbent material designed to reduce slipperiness, because pathogens are easily removed, as is the superficial epidermis. Any external lesions are then examined, and skin scrapings made.

b) An incision is made just anterior to the pelvic girdle as this reduces to a minimum the chances of inadvertently incising the gut. In salmonids, the organ closest to this location is the spleen, but a bit of blunt dissection to gain access to the peritoneal cavity usually avoids all damage.

c) A mid-line incision progressing anteriorly to the ramus of the mandible and posteriorly to the anus is the next step, and in some fish, especially old ones, a very stout pair of clippers is needed to get through the pelvic girdle.

d) Remove the uppermost abdominal body wall to expose viscera, as well as the operculum, paying particular attention to pseudobranch, thymus and thyroid (being diffuse, the thyroid cannot easily be seen in the normal state). Examine gills and prepare gill scrapings and whole mounts. Remove arches for histopathology: unless there are obvious lesions, we routinely sample the second and fourth. *If gill disease is suspected from the history, fix the arches as soon as possible after euthanasia.*

e) Reflect viscera and swimbladder. Remove spleen for microbiological culture if required. Perform any microbiological procedures on kidney at this stage.

f) Examine and remove samples from heart, liver, kidney and gastrointestinal tract making sure to open stomach (if present) to check for the presence of food.

g) Remove the eye and cut off the head just behind the opercula.

h) Place the head, cut face down, on the chopping board and remove the cranium by slicing vertically downwards with a strong knife to expose the brain.

i) Remove a block of skin and muscle - several if the history suggests it. We routinely remove one from immediately anterior to the dorsal fin, and a second from the lateral line of the still uppermost (left side) body of the fish.

General pathology of fish

By comparison with mammals, fish do not under most circumstances appear to mount an especially pronounced acute cellular inflammatory response despite possessing the cells and probably most of the systems to do so, at least as determined from paraffin sections. The reasons for this are not fully understood, although it must be remembered that the acute inflammatory response exists to localize, destroy, or *dilute* the inciting agent, and inhabitants of the aquatic environment should, at least in some situations, have little trouble accomplishing the latter! Nevertheless, fish do respond, and the cardinal signs of acute inflammation, namely heat, pain, redness, swelling and loss of function, probably are all present but to varying levels. Although there is a degree of thermoregulation in some large fish such as tuna, accomplished by means of counter-current heat-exchange mechanisms, most fish are ectothermic (poikilothermic) and accordingly their body temperature is determined by the surrounding water. Thus, the justification for *heat* remaining as a cardinal sign of acute inflammation may be questionable. Behavioural fever, however, has been shown to occur in

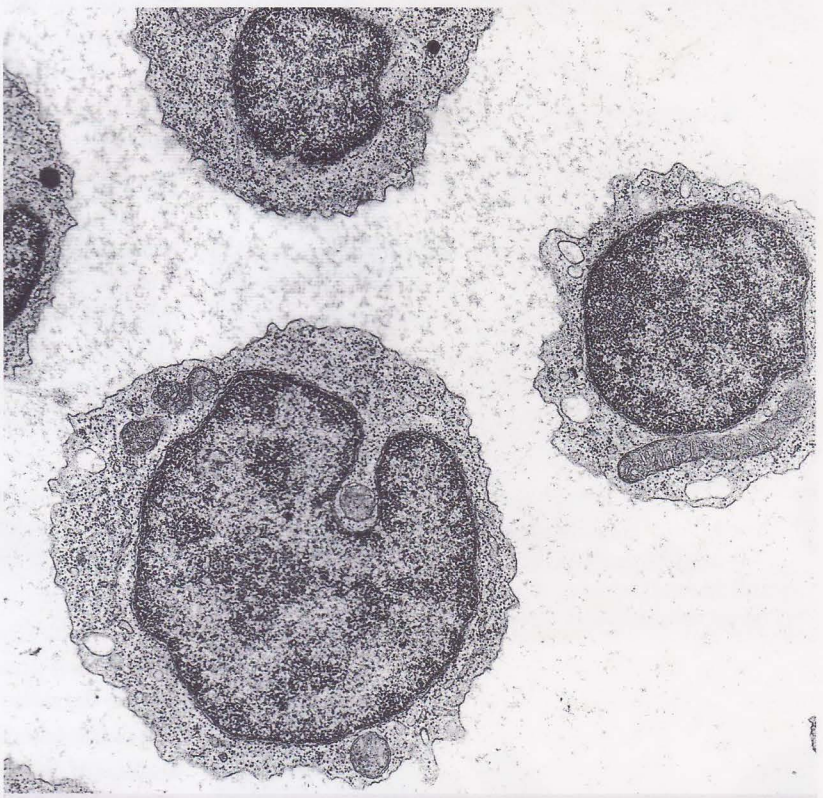

Fig 1.4A. TEM of buffy coat from plaice showing several lymphocytes with scant cytoplasm and prominent mitochondria.

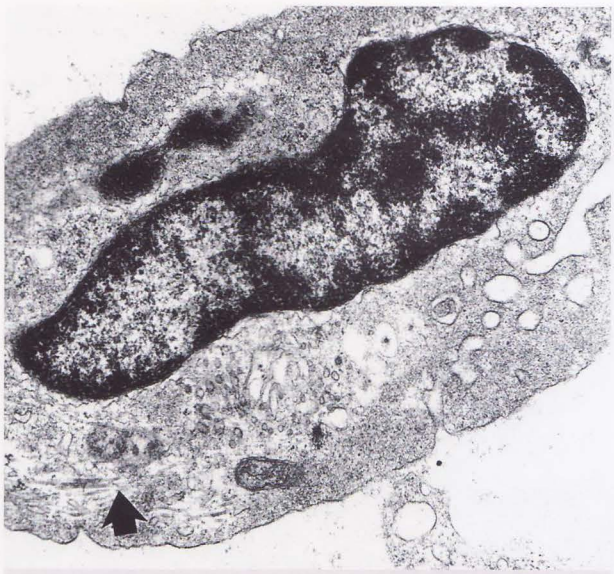

Fig 1.4B. TEM of buffy coat from plaice showing thrombocyte with peripheral microtubules (arrow). Note too the prominent cross-hatching of the chromatin.

fish injected with pyrogens, whereby they selected water at a higher than normal temperature. There are however, some contradictory studies that failed, using endotoxin and prostaglandin E1, to confirm these observations. Endogenous mediators, including complement (both classical and alternative pathways), are present in fish, and fragments are chemotactic. Alternative pathway activity is very high in fish serum compared to mammals, especially in bacterial diseases, suggesting that it is important, and notably at low water temperatures.

Fish possess neutrophils and other granulocytes, plus monocytes, lymphocytes and thrombocytes; these are found in different proportions in the blood depending on the species, although lymphocytes are usually the most common cell ***(Fig 1.4A)***. A well-made smear will show the tail and typical cross-hatched chromatin pattern of the thrombocyte, but these cells can be very difficult to distinguish from lymphocytes in paraffin sections. Aside from their role in clotting, the involvement of the thrombocyte in immune functions such as antigen presentation and regulation, is slowly becoming clear.

Phagocytosis is the ancient animal defense mechanism and many of the inducible mechanisms involved in phagocytosis in mammals, such as the respiratory burst and nitric oxide production, have been demonstrated in fish. Neutrophils are found in acute inflammation particularly where there is tissue destruction ***(Fig 1.5)***; one of the best examples of this is found in diatom-induced branchitis, in which the sharp silica shells and spines seem to cause local damage and foreign-body type reactions *(see Fig 2.13 C&D)*. Often, however, they are not especially prominent, possibly reflecting their relatively low (compared to mammals) numbers in the peripheral circulation. In only some species is their nucleus multi-lobed (notably

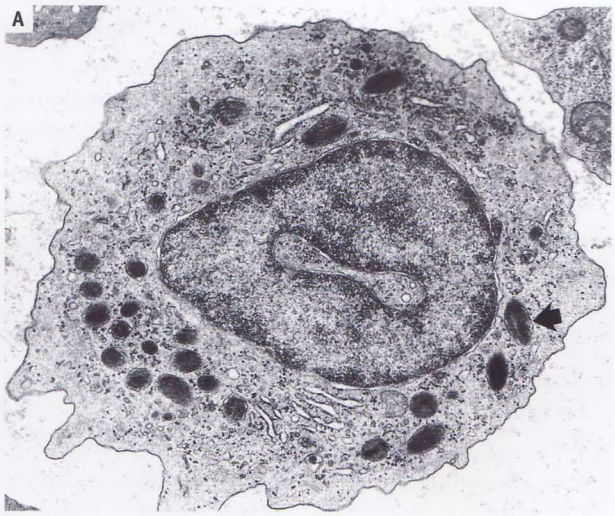



Fig 1.5 A&B. Low and high power TEM of buffy coat from a teleost showing typical neutrophil appearance; note the fibrillar nature of the granules (arrows).

present in salmonids) and their distinction from macrophages in paraffin sections can therefore be difficult. Despite their evident involvement in acute inflammation, and their possession of efficient killing mechanisms, the neutrophils of many species of fish are, at best, only poorly phagocytic under normal circumstances, although

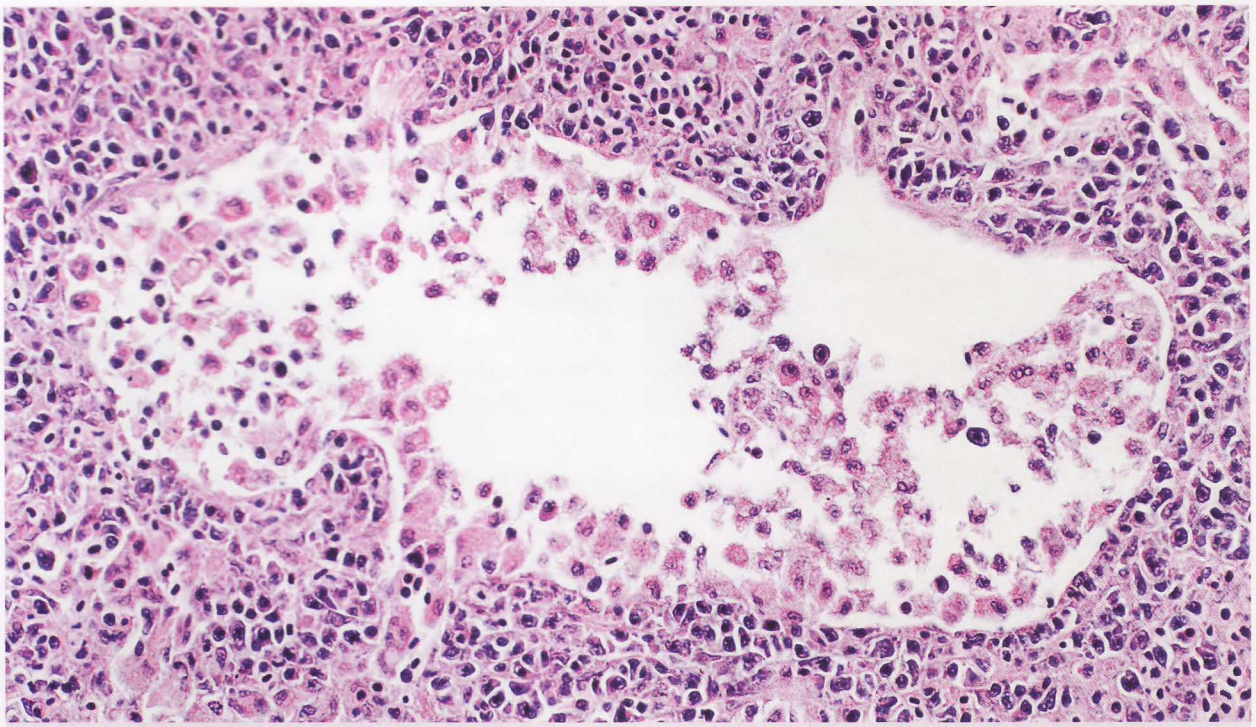

Fig 1.5C. Subacute bacterial disease in trout showing large numbers of neutrophils pouring into the sinusoids.

uptake does vary with the particle involved, the immune status of the individual animal, and the route of exposure. For example, Afonso and co-workers have elegantly demonstrated conclusively that neutrophils within the previously stimulated peritoneal cavity can be phagocytic for *Yersinia*. In naturally-occurring disease, however, they can remain remarkably inactive, and this is especially obvious when compared with macrophages, which in the same piece of tissue may be virtually obliterated by the quantity of ingested material, whether antigenic or inert *(see Fig 4.23 D&E)*. Neutrophils may have a more important role to play in extracellular killing accomplished by secreting enzymes and other anti-microbial substances into the immediate vicinity of the invading particle. It has certainly been shown that there are classes of neutrophils with differing abilities that are recruited to sites of inflammation, and this may help explain these different observations. From a comparative standpoint, it is interesting to consider that the neutrophil's *primary* role may have been directed more towards enzyme production and transport rather than phagocytosis, and that this latter facility has been "fine tuned" only at a later stage

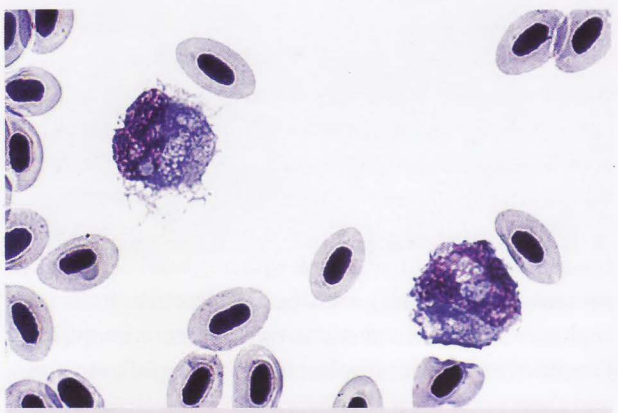

Fig 1.5D. Peripheral blood smear from Atlantic salmon with *Pasteurella skyensis* bacteraemia. Note the toxic appearance of the neutrophils.

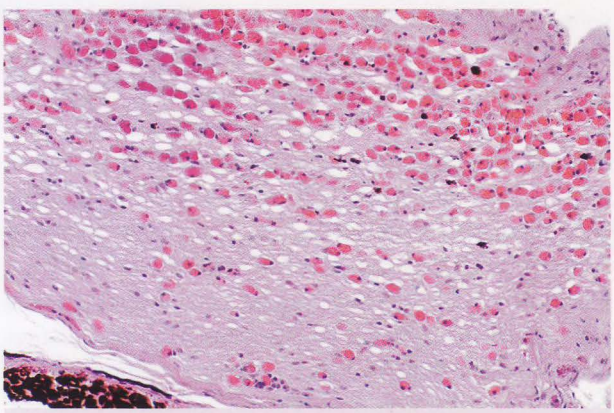

Fig 1.5E. Eosinophilic granular cells within optic nerve of apparently normal cichlid.

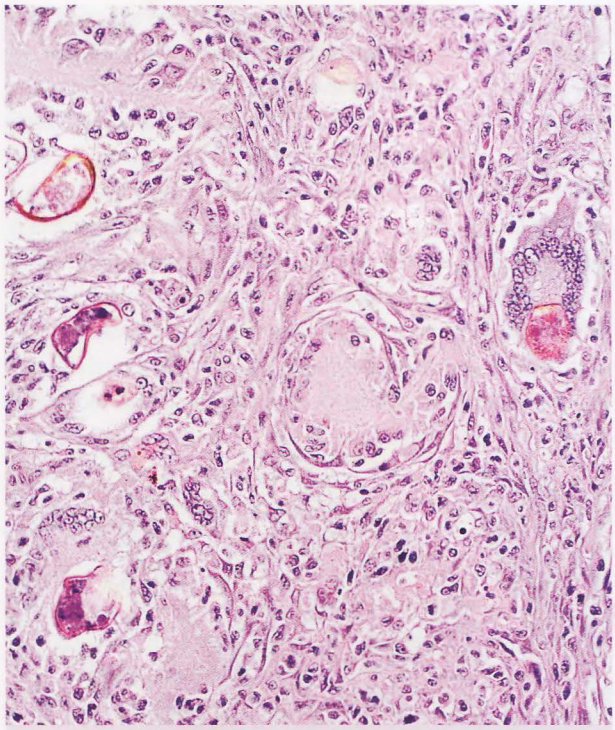

Fig 1.6A. Giant cell response to metazoan parasite eggs in the bile duct of this rainbow trout.

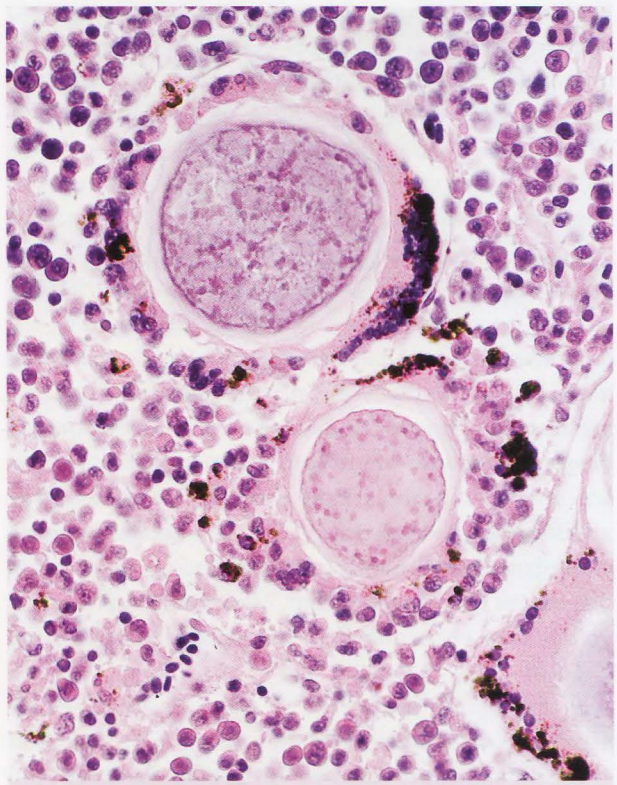

Fig 1.6B. Rainbow trout kidney showing melanomacrophage giant cell response to *Ichthyophonus*.

in phylogeny. Elucidating the precise role of the fish neutrophil in inflammation under all circumstances, therefore, remains a worthy challenge.

The formation of frank pus is not a feature of teleost inflammation, although focally intense aggregates of neutrophils are sometimes seen **(see Fig 3.11)**. Fibrinous exudates, however, are regularly encountered, often with neutrophilic invasion, suggesting that as in mammals, fish fibrin or its degradation products is chemotactic. Eosinophilic granular cells (EGC's) are seen in many species within tissues such as gills, CNS (including optic nerve), and submucosa of gastro-intestinal tract **(Fig 1.5E)**. Their precise identity(ies) and complete range of functions are unknown, although they have many similarities to mammalian mast cells (see Reite, 1997). Certainly, numbers increase in particular types of disease, notably parasitic ones in gills.

While fish often fail to mount acute inflammatory responses as impressive as those seen in mammals under similar circumstances, there should be no disappointment among pathologists over chronic, especially granulomatous, inflammation. Many species of bacteria, notably *Mycobacterium* spp., elicit such a response, and the extent of granulomata formation may be so extensive as to virtually obliterate the involved organ, often the reticuloendothelial (and haematopoietic) tissues of spleen and kidney, but also heart and other viscera. Macrophages, epithelioid cells, lymphocytes, plasma cells and fibroblasts all participate in the response. Giant cells are also found, particularly in fungal and metazoan parasitic infections; in the latter, chitin is at least one component that seems to stimulate their formation **(Fig 1.6)**. They are also very common in response to some oil adjuvants used in vaccines; in some situations, the peritoneal response can be massive and debilitating. Giant cells are not common in chronic *bacterial* diseases, however, although they are encountered occasionally in diseases such as bacterial kidney disease and *Edwardsiella* infection. Both foreign-body and Langhans type giant cells are found, although the latter are rarely described from other than experimental situations. Splendore-Hoeppli type reactions are sometimes seen, notably in *Pasteurella skyensis* infections in Atlantic salmon and also in adjuvant vaccine responses **(Fig 1.7)**.

A prominent feature of chronic inflammatory responses is the presence of melanin or other pigment-containing

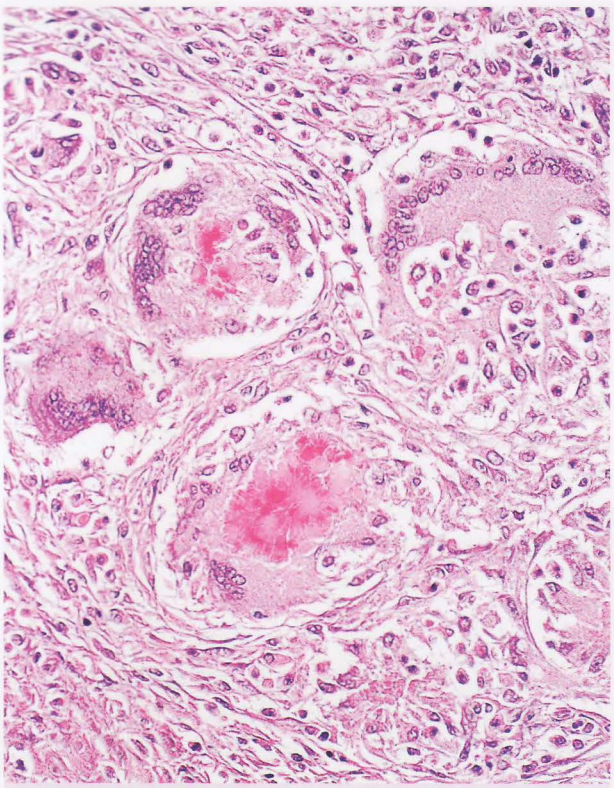

Fig 1.6C. Severe granulomatous peritonitis in this Atlantic salmon, a response to vaccine adjuvant.

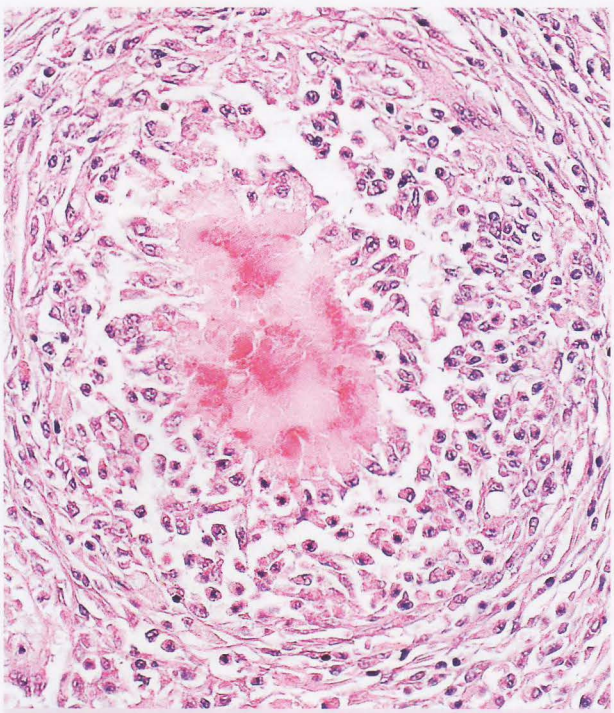

Fig 1.7 Splendore-Hoeppli-like reaction to oil adjuvant in vaccine in the peritoneal cavity of this Atlantic salmon. These sorts of responses indicate immune hypersensitivity.

macrophages, "melanomacrophages". These cells not only form discrete aggregates (melanomacrophage centres or MMC) in spleen, kidney and often liver, to which particulate material is sequestered, but they may also be found within the encapsulating response to many foreign bodies or parasites (and may themselves sometimes form giant cells). This response may be so extensive as to render the aggregate grossly black; hence the metacercariae of many digenetic trematodes encysted within muscle or skin achieve the popular name "black spot" *(see Fig 3.32)*. The reason for this affinity is unclear but it is felt that the melanin may function to scavenge free radicles produced by the

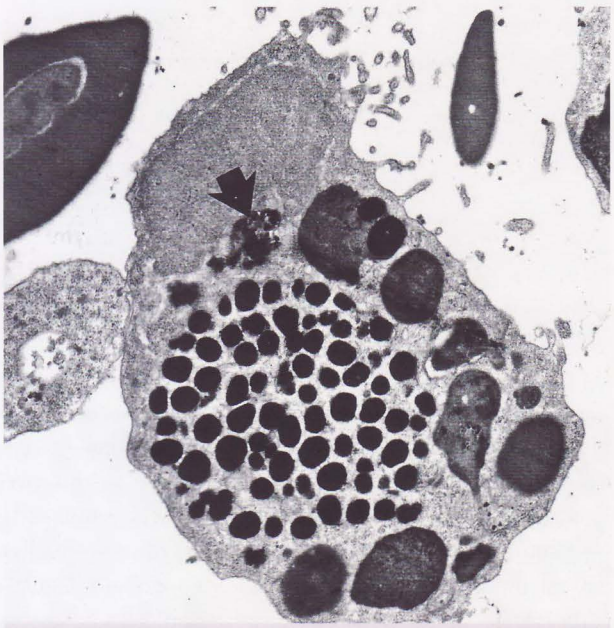

Fig 1.8. Melanomacrophage in the circulation of a fish injected with colloidal carbon, some of which may be seen within the cytoplasm of the cell (arrow).

invader, and may thereby protect surrounding host tissues from further damage. In acute viraemic situations, melanomacrophages can be seen to be mobilizing, as they move into the sinusoids. Similarly, their disppearance in other diseases like the systemic myxozoan-caused proliferative kidney disease (PKD) can herald the onset of the granulomatous response, even before the parasites themselves can be recognized. Melanomacrophages are occasionally encountered in the peripheral circulation *(Fig 1.8)*.

An overriding consideration when questioning the speed of the inflammatory response is the effect of water (and hence body) temperature. Different species have preferred water temperatures, and therefore one tempera-

ture may be considered too low for one, but acceptable for another. For example, from an immunological perspective, 4°C is considered "non-permissive" for salmonids, but it is as high as 22°C for catfish. A drop of 10°C will roughly halve the metabolic rate of a fish, and while it has been shown experimentally that this will decrease the rate of clearance of bacteria from the bloodstream, whether or not this particular aspect has any biological importance is less clear; despite operating at low temperatures, efficiency is still very high. Fish do, however, succumb rapidly to disease, especially bacterial ones, with rapidly varying water temperatures. Disseminated intravascular coagulation (DIC) is sometimes seen in fish, a consequence usually of severe bacteraemic disease, but whether DIC is related to temperature is unknown.

One of the major effects of temperature is on the specific immune responsiveness, and while a discussion on this whole aspect is considered to be well outside the scope of these notes, suffice it to say that the lymphocyte subpopulations with B and T-like properties would seem to have different temperature sensitivities. Possibly the greatest impact of low water temperatures is on T-helper cells, mediated through loss of fluidity of lymphocyte plasma membranes and/or their carbohydrate receptors. By contrast, some aspects of the *non-specific* defences are less impacted, including the alternative complement pathway, and non-specific cytotoxic cells (the mammalian equivalent of natural killer NK cells) which show enhanced killing ability. Phagocyte respiratory burst activity is also enhanced at low temperatures. The ability to respond, therefore, may depend on the interaction between the replicative or enzymatic powers of the pathogen (in the case of a micro-organism) and the speed of recognition, co-operation, and synthesis within the immune system. The undoubted importance of stressors (handling, crowding and fright to name a few) and the influence of corticosteroids on immune responsiveness are still not completely understood, but it has been shown experimentally that the administration of physiological doses of cortisol (probably the single most important final common pathway for stress) results in a marked lymphocytopoenia.

Hyperplastic responses are well developed in fish, as is neoplasia. Classification of fish tumours is largely based on mammalian criteria, and while many exhibit histopathological evidence of malignancy and may show local invasion, with the exception of hepatic carcinomas (notably those induced by aflatoxins), relatively few appear to metastasize, compared to their mammalian counterparts. The reasons for this fundamental biological difference from mammals are surely worth investigating. Could it be a reflection of lower immunological or other selection pressures exerted on the altered cells, or some basic enzymatic deficiency? Or maybe it is something simple like the relatively low intra-vascular pressure, or even lower awareness? Repair and regenerative mechanisms in fish are also very efficient, and even very severe lesions often heal with little gross evidence of scarring. It is surely interesting that tissues such as myocardium and the central nervous system, including retina, are all capable of *regeneration*. Once again, however, the process is a temperature dependent one, and abnormalities outside of the preferred range are not uncommon.



References

Afonso, A., Lousanda, S., Silva, J., Ellis, A., and Silva, M. (1998) Neutrophil and macrophage responses to inflammation in the peritoneal cavity of rainbow trout *Onchorhynchus mykiss*. A light and electron microscopic cytochemical study. *Diseases of Aquatic Organisms* 34:27-37.
Agius, C. (1979) The role of melano-macrophage centres in iron storage in normal and diseased fish. *Journal of Fish Diseases* 2:337-343.
Agius, C. and Agbede, S.A. (1984) An electron microscopical study on the genesis of lipofuscin, melanin and haemosiderin in the haemopoietic tissues of fish. *Journal of Fish Biology* 24:471-488.
Ambrosius, H. and Hadge, D. (1983) Phylogeny of low molecular weight immunoglobulins. *Developmental and Comparative Immunology* 7:721-724.
Anderson, D.P., van Muiswinkel, W.B. and Roberson, B.S. (1984) Effects of chemically induced immune modulation on infectious diseases of fish. ***In***: *Chemical Regulation of Immunity in Veterinary Medicine* pp. 187-211, Alan Liss Inc., New York, N.Y.
Avtalion, R.R. (1981) Environmental control of the immune response in fish. ***In***: *Critical Reviews in Environmental Control*, pp. 163-188 Volume 11, CRC Press, Boca Raton.
Badet, M.T., Chateaureynaud, P. and Mayer, G. (1983) Immunitary relations between mother and embryo during gestation. A comparative study in lower and higher vertebrates. *Developmental and Comparative Immunology* 7:731-734.
Baldo, B.A. and Fletcher, T.C. (1973) C-reactive protein-like precipitins in plaice. *Nature* 246:145-146.
Bayne, C. J. and Gerwick, L. (2001) The acute phase response and innate immunity of Fish. *Developmental and Comparative Immunology* 25:725-743.
Blazer, V.S. and Wolke, R.E. (1984) The effects of α-tocopherol on the immune response and non-specific resistance factors of rainbow trout (*Salmo gairdneri* Richardson). *Aquaculture* 37:1-9.
Braun-Nesje, R., Kaplan, G. and Seljelid, R. (1982) Rainbow trout macrophages *in vitro*: Morphology an phagocytic activity. *Developmental and Comparative Immunology* 6:281-291.
Brown, C.L. and George, C .J. (1985) Age-dependent accumulation of macrophage aggregates in the yellow perch, *Perca flavescens* (Mitchill). *Journal of Fish Diseases* 8:135-138.
Cannon, M.S., Mollenhauer, H.H., Cannon, A.M., Eurell, T.E. and Lewis, D.H. (1980) Ultrastructural localization of peroxidase activity in neutrophil leukocytes of *Ictalurus punctatus*. *Canadian Journal of Zoology* 58:1139-1143.
Clawson, C.C., Finstad, J. and Good, R.A. (1966) Evolution of the immune response. V. Electron microscopy of plasma cells and lymphoid tissue of the paddlefish. *Laboratory Investigation* 15:1830-1847.
Clerx, J.P.M., Castel, A., Bol, J.F. and Gerwig, G.J. (1980) Isolation and characterisation of the immunoglobin of pike (*Esox lucius* L.). *Veterinary Immunology and Immunopathology* 1:125-144.
Corbel, M.J. (1975) The immune response in fish: a review. *Journal of Fish Biology* 7:539-563.
Dixon, B. and Stet, R.J.M. (2000) The relationship between major histocompatibility receptors and innate immunity in teleost fish. *Developmental and Comparative Immunology* 25:683-699
Ellis, A.E. (1980) Antigen-trapping in the spleen and kidney of the plaice *Pleuronectes platessa* L. *Journal of Fish Diseases* 3:413-426.
Ellis, A.E. (1982) Difference between the immune mechanisms of fish and higher vertebrates. pp. 1-30. ***In***: *Microbial Diseases of Fish. **ed.*** Roberts, R.J. Society for General Microbiology, Academic Press.
Ellis, A.E. (1986) The function of teleost fish lymphocytes in relation to inflammation. *International Journal of Tissue Reactions* 8:263-270.
Ellis, A.E. (2001) Innate host defense mechanisms of fish against viruses and bacteria. *Developmental and Comparative Immunology* 25:827-839.
Evans, D.L., Carlson, R.L., Graves, S.S. and Hogan, K.T. (1984) Nonspecific cytotoxic cells in fish (*Ictalurus punctatus*). IV. Target cell binding and recycling capacity. *Developmental and Comparative Immunology* 8:823-833.
Ferguson, H.W. (1984) Renal portal phagocytosis of bacteria in rainbow trout (*Salmo gairdneri* Richardson): ultrastructural observations. *Canadian Journal of Zoology* 62:2505-2511.
Ferguson, H.W., Claxton, M.J. and Lesperance, J. (1984) The effect of temperature and starvation on the clearance of bacteria from the bloodstream of rainbow trout (*Salmo gairdneri* Richardson). *Journal of Leukocyte Biology* 35:209-216.
Ferguson, H.W., Claxton, M.J., Moccia, R.D. and Wilkie, E.J. (1982) The quantitative clearance of bacteria from the bloodstream of rainbow trout (*Salmo gairdneri*). *Veterinary Pathology* 19:687-699.
Finn, J.P. and Nielsen, N.O. (1971) The effect of temperature variation on the inflammatory response of rainbow trout. *Journal of Pathology* 105:257-268.
Fishman, J.A., Daniele, R.P. and Pietra, G.G. (1979) Lung defenses in the African lungfish (*Protopterus*): Cellular responses to irritant stimuli. *Journal of the Reticuloendothelial Society* 25:179-195.
Fletcher, T.C. (1986) Modulation of nonspecific host defenses in fish. *Veterinary Immunology and Immunopathology* 12:59-67.
Goetz, F.W, Planas, J.V. and MacKenzie, S. (2003) Tumor necrosis factors. *Developmental and Comparative Immunology* 28:487-497.
Hazel, J.R. (1984) Effects of temperature on the structure and metabolism of cell membranes in fish. *American Journal of Physiology* 246:R460-R470.
Horne, M.T., Tatner, M., McDerment, S., Agius, C. and Ward, P. (1982) Vaccination of rainbow trout, *Salmo gairdneri* Richardson, at low temperatures and the long-term persistence of protection. *Journal of Fish Diseases* 5:343-345.
Hunt, T.C. and Rowley, A.F. (1986) Leukotriene B4 induces enhanced migration of fish leucocytes *in vitro*. *Immunology* 59:563-568.
Ingram, G.A. (1980) Substances involved in the natural resistance of fish to infection - a review. *Journal of Fish Biology* 16:23-60.
Kindle, K.R. and Whitmore, D.H. (1986) Biochemical indicators of thermal stress in *Tilapia aurea* (Steindachner). *Journal of Fish Biology* 29:243-255.

Kollner, B., Fischer, U., Rombout, J.H.W.M., Taverne-Thiele, J.J. and Hansen, J.D. (2004) Potential involvement of rainbow trout thrombocytes in immune functions: a study using a panel of monoclonal antibodies and RT-PCR. *Developmental and Comparative Immunology* 28:1049-1062.
Koppenheffer, T.L. (1987) Serum complement systems of ectothermic vertebrates. *Developmental and Comparative Immunology* 11:279-286.
Lamers, C.H.J. (1986) Histophysiology of a primary immune response against *Aeromonas hydrophila* in carp.
Lamers, C.H.J. and De Haas, M.J.H. (1985) Antigen localization in the lymphoid organs of carp *(Cyprinus carpio)*. *Cell and Tissue Research* 242:491-498.
Lamers, C.H.J. and Parmentier, H.K. (1985) The fate of intraperitoneally injected carbon particles in cyprinid fish. *Cell and Tissue Research* 242:499-503.
MacArthur, J.I., Fletcher, T.C. and Thomson, A.W. (1983) Distribution of radiolabeled erythrocytes and the effect of temperature on clearance in the plaice *(Pleuronectes platessa* L.*)*. *Journal of the Reticuloendothelial Society* 34:13-21.
MacArthur, J.I., Thomson, A.W. and Fletcher, T.C. (1985) Aspects of leucocyte migration in the plaice, *Pleuronectes platessa* L. *Journal of Fish Biology* 27:667-676.
MacArthur, J.I., Fletcher, T.C., Pirie, B.J.S., Davidson, R.J.L. and Thomson, A.W. (1984) Peritoneal inflammatory cells in plaice, *Pleuronectes platessa* L.: effects of stress and endotoxin. *Journal of Fish Biology* 25:69-81.
Marx, J., Hilbig, R. and Rahmann, H. (1984) Endotoxin and prostaglandin E1 fail to induce fever in a teleost fish. *Comparative Biochemistry and Physiology* 77:483-487.
McCumber, L.J., Sigel, M.M., Trauger, R.J. and Cuchens, M.A. (1983) RES structure and function of the fishes. pp. 393-422. *In*: *The Reticuloendothelial System*. Vol. 3 *Phylogeny and Ontogeny*. ***eds***. Cohen and Sigel, Plenum Publ. Corp.
Miller, N.W. and Tripp, M.R. (1982) An immunoinhibitory substance in the serum of laboratory held killifish, *Fundulus heteroclitus* L. *Journal of Fish Biology* 20:309-316.
Moody, C.E., Serreze, D.V. and Reno, P.W. (1985) Non-specific cytotoxic activity of teleost leukocytes. *Developmental and Comparative Immunology* 9:51-64.
Nakanishi, T., Fischer, U., Dijkstra, J.M., Hasegawa, S., Somamoto, T., Okamoto, N. and Ototake, M. (2002) Cytotoxic T cell function in fish. *Developmental and Comparative Immunology* 26:131-139.
Nash, K.A., Fletcher, T.C. and Thomson, A.W. (1986) Migration of fish leucocytes *in vitro*: the effect of factors which may be involved in mediating inflammation. *Veterinary Immunology and Immunopathology* 12:83-92.
Nash, K.A., Fletcher, T.C. and Thomson, A.W. (1987) Effect of opsonization on oxidative metabolism of plaice (*Pleuronectes platessa* L.) neutrophils. *Comparative Biochemistry and Physiology* 86(B):31-36.
Neumann, N., Stafffor, J. L., Barreda, D., Ainsworth, A. J. and Belosevic, M. (2000) Antimicrobial mechanisms of fish phagocytes and their role in host defense. *Developmental and Comparative Immunology* 25:807-825.
Nikoskelainen, S., Bylund, G. and Lilius, E.M. (2003) Effect of environmental temperature of rainbow trout (*Oncorhynchus mykiss*). *Developmental and Comparative Immunology* 28:581-592.
O'Neill, J.G. (1980) Temperature and the primary and secondary immune responses of three teleosts, *Salmo trutta, Cyrpinus carpio* and *Notothenia rossii*, to MS2 bacteriophage. pp. 123-130
In: *Phylogeny of Immunological Memory*. ***ed***. Manning, M.J., Elsevier/North Holland Biomedical Press.
O'Neill, J.G. (1981) The humoral immune response of *Salmo trutta* L. and *Cyprinus carpio* L. exposed to heavy metals. *Journal of Fish Biology* 19:297-306.
Ourth,D.O. and Bachinski, L.M. (1987) Bacterial sialic acid modulates activation of the alternative complement pathway of channel catfish (*Ictalurus punctatus*). *Developmental and Comparative Immunology* 11:551-564.
Peters, G. and Schwarzer, R. (1985) Changes in hemopoietic tissue of rainbow trout under influence of stress. *Diseases of Aquatic Organisms* 1:1-10.
Peters, J.L., Lapatra, S., Vazzana, M. and Sunyer, J.O. (2004) Anaphylatoxin-like molecules generated during complement activation induce a dramatic enhancement of particle uptake in rainbow trout phagocytes. *Developmental and Compartative Immunology* 28:1005-1021.
Pickering, A.D. (1984) Cortisol-induced lymphocytopenia in brown trout, *Salmo trutta* L. *General and Comparative Endocrinology* 53:252-259.
Prendergast, R.A., Lutty, G.A. and Scott, A.L. (1983) Directed inflammation: the phylogeny of lymphokines. *Developmental and Comparative Immunology* 7:629-632.
Reite, O.B. (1998) Mast cells/eosinophilic granule cells of teleostean fish: a review focusing on staining properties and functional responses. *Fish and Shellfish Immunology* 8, 489-513.
Reynolds, W.W., Covert, J.B. and Casterlin, M.E. (1978) Febrile responses of goldfish *Carassius auratus* (L.) to *Aeromonas hydrophila* and to *Escherichia coli* endotoxin. *Journal of Fish Diseases* 1:271-273.
Ruben, L.N. (1984) Some aspects of the phylogeny of macrophage-lymphocyte immune regulation. *Developmental and Comparative Immunology* 8:247-256.
Saeji, J.P.J. (2002) Different capacities of carp leukocytes to encounter nitric oxide-mediated stress: a role for the intracellular reduced gluthathione pool. *Developmental and Comparative Immunology* 27:555-568.
Secombes, C.J. (1985) The *in vitro* formation of teleost multinucleate giant cells. *Journal of Fish Diseases* 8:461-464.
Secombes, C. J., Want, T., Hong, S., Peddie, S., Crampe, M., Laing, K. J., Cunningham, C. and Zou, J. (2001) Cytokines and innate immunity of fish. *Developmental and Comparative Immunology* 25:713-723.
Sohnle, P.G. and Chusid, M.J. (1983) The effect of temperature on the chemiluminescence response of neutrophils from rainbow trout and man. *Journal of Comparative Pathology* 93:493-497.
Stafford, J.L. and Belosevic, M. (2002) Transferrin and the innate immune response of fish: Identification of a novel mechanism of macrophage activation. *Developmental and Comparative Immunology* 27:539-554

Stave, J.W., Roberson, B.S. and Hetrick, F.M. (1983) Chemiluminescence of phagocytic cells isolated from the pronephros of striped bass. *Developmental and Comparative Immunology* 7:269-276.
Stolen, J.S., Gahn, T., Kasper, V. and Nagle, J.J. (1984) The effect of environmental temperature on the immune response of a marine teleost (*Paralichthys dentatus*). *Developmental and Comparative Immunology* 8: 89-98.
Tatner, M.F. (1986) The ontogeny of humoral immunity in rainbow trout, *Salmo gairdneri*. *Veterinary Immunology and Immunopathology* 12:93-105.
Tatner, M.F. and Manning, M.J. (1983) Growth of the lymphoid organs in rainbow trout, *Salmo gairdneri* from one to fifteen months of age. *Journal of the Zoological Society of London* 199:503-520.
Tatner, M.F. and Manning, M.J. (1985) The ontogenetic development of the reticulo-endothelial system in the rainbow trout, *Salmo gairdneri* Richardson. *Journal of Fish Diseases* 8:189-195.
Warr, G.W. and Simon, R.C. (1983) The mitogen response potential of lymphocytes from the rainbow trout (*Salmo gairdneri*) re-examined. *Developmental and Comparative Immunology* 7:379-384.
Yasuda, T., Endo, M., Sakai, T. and Kimura, M. (1984) Histochemical study on the granulocytes in the inflammation of carp. *Bulletin of the Japanese Society of Scientific Fisheries* 50:1375-1380.
Zeeman, M. (1986) Modulation of the immune response in fish. *Veterinary Immunology and Immunopathology* 12:235-241.

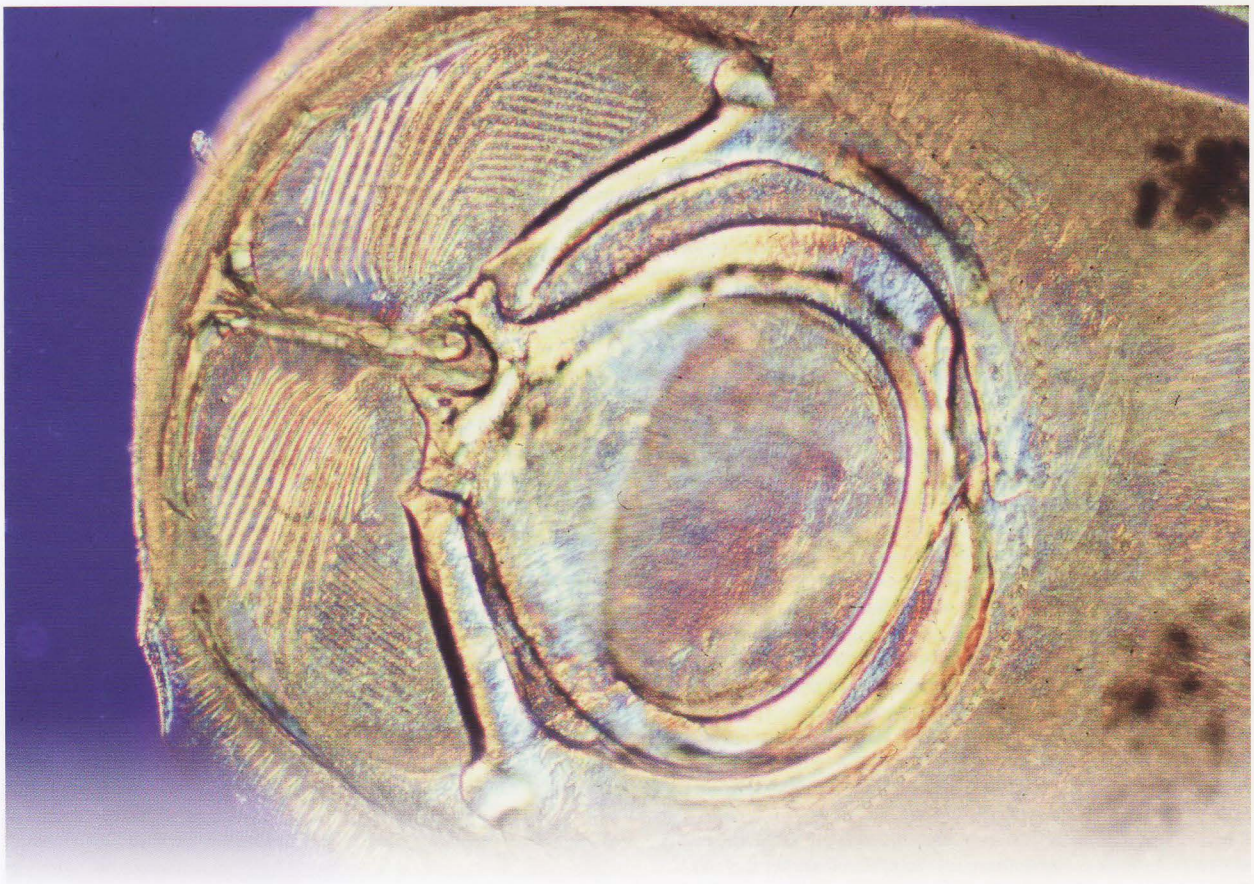





Gills and Pseudobranchs

CHAPTER 2

by David J. Speare and Hugh W. Ferguson

Succinctly stated by Olson (2002): ***"The fish gill is the most physiologically diversified vertebrate organ, and its vasculature the most intricate."*** With this key statement in mind, studying diseases of the fish gill is both compelling and complex. Gill tissues are frequently targeted by infectious and non-infectious processes, and are commonly examined during diagnostic, research, and forensic investigations. In line with the range of physiological functions carried out by the gill, the organ is structurally complex and composed of a variable mosaic of inducible cell types. The epithelial layer, in particular, is remarkably metaplastic in response to environmental and physiological triggers (for example cortisol) as well as during disease. Despite this, our understanding of the fundamental triggers for the cellular plasticity is only in its infancy and morphometric indices to allow adequate quantification of cellular responses to environmental change or disease are only now being defined.

The principal components of the gill are a connective tissue scaffold framing a vascular network providing blood flow primarily used for gas and ion exchange, and to a lesser extent for nutritive functions of the gill itself. For exchange purposes with the external environment, blood remains in arteries and arterioles, both before and after exchange (the arterioarterial or "respiratory" route). By contrast, nutritive blood flow leaves the gill via venous drainage (the arteriovenous route), part of which is sinusoidal (central venous sinusoid) within the network found within the core of each gill filament. The latter system is also referred to as the interlamellar system and it has functional, if not anatomical similarities to mammalian lymphatics.

At the tissue-water interface, the gill is covered by an epithelial layer that supports an extracellular biofilm, sometimes referred to as the "unstirred layer", with contributions from the host (cellular gycocalyx and secreted mucins) and the environment (bacteria and entrapped organic and inorganic debris). Gills have a necessarily intimate interface with their environment, providing for gaseous exchange as well as acid-base balance, osmoregulation and the excretion of nitrogenous waste products; in teleosts this is largely in the form of ammonia. These functions are accomplished by means of $Na^+/NH4^+$, Na^+/H^+ and $CL^-/HCO3_3^-$ coupled exchange mechanisms.

A common approach is to compare reactions of the gill with those in the mammalian lung. Despite the obvious differences, such as lack of an organized bronchial network, or a similar progressively subdivided tubular water delivery system to the gills, a benefit of this approach is an enhanced understanding, whether for diagnostic or research investigative purposes, of the connections between lesions and pathophysiological effects. Whereas our understanding of the pathobiology of pneumonic processes of mammalian and avian species has been the subject of intense study leading to biotechnological and molecular biological advances geared towards disease control, gill diseases of teleosts, although very common, remain poorly understood. Gill disease treatments are archaic, and are for the most part primarily aimed at pathogen control rather than host support.

Three alternative mechanistic routes describe the initial interaction of the gill to a disease-causing agent. These include colonization of the epicellular biofilm as exemplified by bacterial gill disease (BGD), the pathogenesis of which is similar to biofilm-mediated bronchopneumonias of mammals. A second route involves trapping of systemically distributed pathogens within the gill's phagocytic and endocytotically active cells; again comparatively this is similar to pulmonary intravascular macrophage-mediated interstitial (and embolic) pneumonia of mammals. A third common route of gill damage stems from the interactions of water-borne toxins with the lamellar epithelium, and comparatively this is similar to mammalian models of toxin-induced alveolitis, particularly when the underlying role of lipoxygenase-produced hydroperoxides is considered.

Despite differences in gill disease initiation, there is a tendency towards relative stereotypia in terms of second-



Fig 2.1A. Normal trout with operculum reflected to show gill arches beneath.



Fig 2.1B. Biopsy of gill from rainbow trout showing blood-filled central venous sinus.

ary tissue responses of the gill to disease and injury. A knowledge gap exists in terms of elucidating mechanisms responsible for the interrelationship of these lesions, and the effect that environmental variables have on the kinetics of lesion development and reversal. Stereotypia may imply that several of the gill responses, although potentially leading to pathophysiological sequelae, are nonetheless important defensive functions aimed at enhancing survival of fish that are challenged by disease. For example, lamellar fusion, perhaps the most common response of the gill and certainly one that reduces surface area for respiration, may benefit fish by reducing the numbers of receptor sites available to biofilm pathogens or toxins. Subsequent to damage, the gill will undergo repair, often quickly, and yet the cellular events of healing have only seldomly been studied. One striking difference compared to the mammalian lung is the remarkable absence of connective tissue that develops during the healing process.

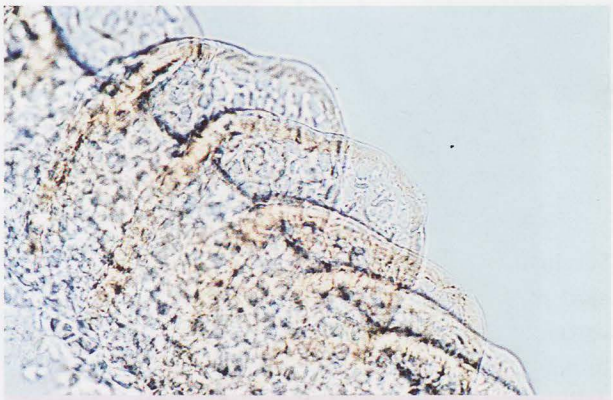

Fig 2.1C. Biopsy whole-mount showing blood-filled marginal channels along rims of lamellae.

Normal structure and function

Each of the four pairs of gill arches found in most teleosts is supported by a bony skeleton (cartilaginous in young fish). From the arch, diverging rows of filaments are given off, and on both sides of each filament are located the plate-like lamellae where gaseous exchange occurs (*Fig 2.1*). The efficiency of exchange, which in the case of oxygen is roughly 50-80%, is largely a function of the counter-current exchange between blood and water *i.e.* the blood flows in a direction opposite to that of the water. Efficiency of counter-current systems relies on a balance between ventilation and perfusion, and so-called "ventilation-perfusion mismatches" are possible in situations where blood flow remains high, but the rate of water flow over the gills is diminished. The converse is also possible, but less likely. Additionally, exchange efficiency is affected by the distance between the lamellar interface, and the blood flowing within pillar channels. This "diffusion-distance" is critically important because in many cases, gas exchange efficiency is limited by diffusion and many different types of gill disease can increase the lamellar thickness either by expanding the intercellular spaces with fluid, by inducing cellular hypertrophy, or by inducing the lamellar epithelium to build up into multiple layers (hyperplasia). In comparison to the diffusion distance across the alveolar septae of lungs, that of the lamellae is up to 10 fold greater. This is a remarkable difference, especially considering the relatively low concentration of oxygen in water, as compared to air. Bioquantification of the effective diffusion distance (from the outer edge of lamellar epithelium to the middle of the pillar channel (alternatively, 50% of the total lamellar thickness) can be performed on routine six micron histological sections,

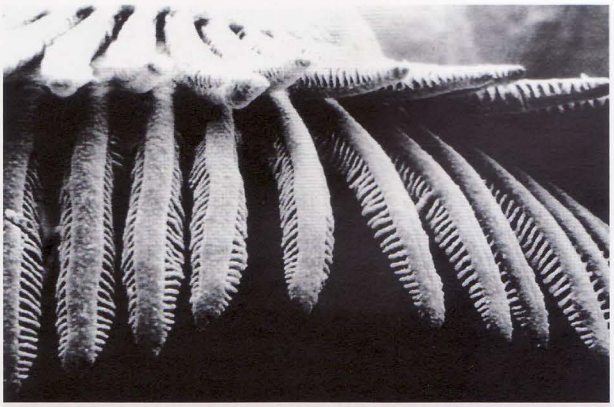

Fig 2.2A. SEM of entire holobranch from rainbow trout.

but is likely to be more accurate when using high resolution light microscropy and 1 micron sections of gills embedded in plastic for electron microscopy. Selection of only well-oriented lamellae is critical, as oblique sectioning can lead to distorted measurements.

Once blood leaves the lamellae it enters the efferent filamental arteriole which runs down the outer aspect of the filament to the arch, and then to the efferent branchial artery. Thus the major portion of the blood flow to the gill remains within arteries, and does not enter the venous system. In contrast, within the filament is the central venous sinusoid (CVS) a low-pressure, low-flow system that returns the smaller amount of "nutritive" blood back to the venous side of the circulation.

Water flow over the lamellae is continuous and uni-directional; this is achieved by means of alternating the buccal pump pushing water to the gills, and the opercular pump that maintains a negative pressure behind the gills when the mouth is opened during phase one of ventilation. Some species dispense with one or both of these mechanisms, relying instead on forward movement when swimming, to pass water over the gills simply by keeping the mouth open (ram ventilation). Other species have modifications to organs such as the gastrointestinal tract, skin or the swimbladder, to facilitate gaseous exchange (accessory breathing apparati); survival in poorly oxygenated waters is thereby enhanced.

Each lamella is best regarded as a thin envelope of cells, the two surfaces of which are supported (or more likely, held together) by pillar cells (*Figs 2.2 & 2.3*). Each respiratory surface comprises a double layer of epithelial cells joined at their margins by extensive interdigitations, and by desmosomes and tight junctions. Between these two layers is an interstitial space in which migrating inflammatory cells are often found, as well as possibly a resident population of macrophages (*Fig 2.3*). The inner layer of epithelial cells sits on a basement membrane that traverses the apposing inner faces of the lamella in grooves located within the pillar cells, thereby providing additional tensile support for the actomyosin fibrils found within the cytoplasm of the pillar cells. Where the ends of each pillar cell touch the basement membrane, they spread laterally to form wide flanges: thus each pillar cell is shaped like a spool. Where the flanges touch those from adjacent pillar

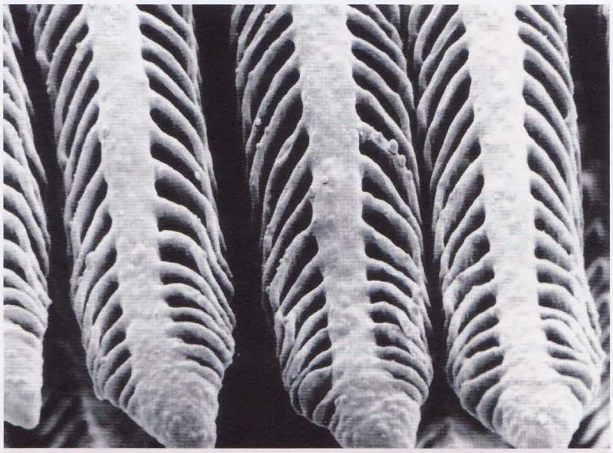

Fig 2.2B. SEM of portion of rainbow trout hemibranch showing several filaments, and lamellae on both sides. A degree of lamellar interdigitation is required for direct water flow between lamellae.



Fig 2.2C. High power SEM to show the roughened microridged surface of lamellar epithelial cells.



Fig 2.2D. High power SEM to show distribution of mucous cell orifices emerging randomly along the length of the filament.

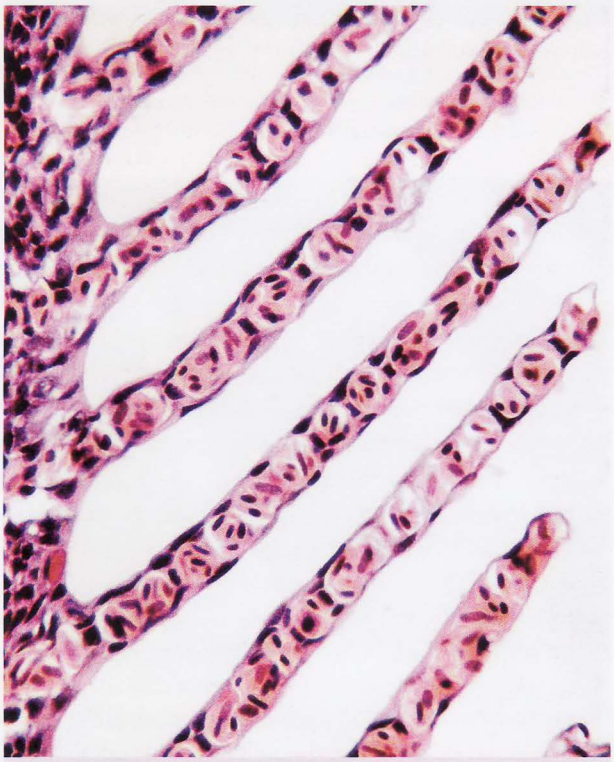

Fig 2.3A. Histological section of gill showing typical appearance of normal lamellae arising from a single filament.

cells, they are joined by desmosomes and tight junctions. Erythrocytes therefore percolate through the spaces created by this arrangement except at the outer margin of the lamella *(the marginal channel - see Fig 2.1C)* which has an endothelial lining and may be the preferred channel for blood flow. Membrane flexibility of erythrocytes is critical to allow them to move easily through the pillar channels.

Pillar cells have been examined with respect to their ability to regulate blood flow through pillar channels, but in addition to this role there is a growing body of evidence suggesting that pillar cells also constitute part of the reticuloendothelial (RE) system, and thus may be analogous in some respects to the intravascular pulmonary macrophage of the mammalian lung. Not only do they have the capacity to take up carbon particles, but they also frequently become colonized by intracellular pathogens. The literature has foreshadowed discovery of a gill RE system. Teleosts possess a poorly developed hepatic RE system; they do not possess Kupffer cells although this is also the case for some mammalian species. When this occurs in mammals, it is somewhat compensated by means of a robust pulmonary RE system. Unlike typical endothelial cells, pillar cells take up foreign matter, they share an antigenic profile with leukocytes, and they contain high levels of lysozyme. Furthermore, they are anatomically associated with fibrillar structures (pillars) that are similar to fibrillar components that support splenic reticulocytes. The rainbow trout gill has been shown to have cyclooxygenase-2 dependant eicosanoid-generating capabilities leading to the release of thromboxane B2 and lipoxins, but the cell types acting as the source of these inflammatory mediators have yet to be elucidated. Pillar cells may have a gatekeeping reticulocyte-like function; the critical first step in antigen uptake may occur within pillar cells and subsequently antigen may be transferred to other resident macrophages deeper within the branchial tissues.

Lamellar epithelium is thin, often attenuated, and contains small numbers of mitochondria. The outer layer of lamellar epithelium differs from the inner layer by having its outermost surface composed of convoluted finger-print-like microridges *(Fig 2.2C)*. Microridge tips are particularly rich in glycocalyx. It is suggested that in addition to greatly increasing the respiratory surface area, the ridges and their glycocalyx coating may aid in the interaction of secreted mucus with host cell surface. It is noteworthy that



Fig 2.3B. Cryoprocessed (liquid propane) TEM section of rainbow trout gill to show the pillar cells, pillar channels, and red blood cells within channels. Note also the presence of neutrophils (arrows) within the intercellular spaces separating the inner from the outer layer of lamellar epithelium.

a general characteristic of epithelial cells, in fish and in other animals, especially at environmental interfaces, is the presence of microridging. Generally speaking, microridge morphology, and the extent of the glycocalyx layer, are extremely sensitive to stress, the degree of cellular maturity, and perhaps directly, to environmental change, and this may affect the ability of secreted mucus to protect epithelial cells from infectious agents. Although theoretical, this may provide a morphological basis for the manner in which stress can lead to increases in gill disease frequency. Goblet cells *(Fig 2.4)* eosinophilic osmo-regulatory chloride cells and their associated "accessory" cells are also present in the lamellar epithelium, particularly at the base of the lamellae, and are more numerous in marine than in freshwater species. Under pathological conditions these cells are often found in increasing numbers along the length of lamellae. These cells are amenable to quantification, being easily identified without the use of special stains, thus yielding a morphometric index based on numbers of cells per lamella as a means of comparison between groups of fish.

Mucous cells are a prominent feature of the gill epithelium *(Fig 2.4)* and are generally similar anatomically to goblet cells described elsewhere. The biological importance of the mucus-rich interface between fish and their aqueous environment spans functions as diverse as ionoregulation, and mechanical and immunological protection. Mucus granules are packaged within the cytoplasm *(Fig 2.4B)* and within the same cell some of these packages can be electron-dense or relatively lucent. It is not yet known, however, whether this reflects the potential biochemical signature of granule contents such as the relative amounts of sulphated mucins as compared to sialic acid. Mucus granules (mucosomes) accumulate at one pole of the cells and the nucleus becomes progressively flattened as production proceeds. Mucous cells discharge their contents through apertures that communicate within the outer gill surface, often at the junction of three or more epithelial cells *(Figs 2.2D & 2.4A)*. Discharged mucosomes break down to release their contents (mucus) which associate with the glycocalyx and microridges of nearby epithelial cells *(Fig 2.4C)*. It is often chal-



Fig 2.3C. Outer margin of lamella from a normal trout showing the bilayer of epithelial cells, chloride cell (X), and pillar cell (arrow). *Courtesy of Dr. P-Y. Daoust.*

lenging to appreciate the extent of the mucous coat of the gill because most methods of fixation remove it. Only recently, with the use of techniques such as low temperature scanning electron microscopy, freeze substitution, or pre-fixation of the mucous coat with either osmium vapour or alcian blue, has the full extent of the mucous coat, and indeed the full extent of the cellular glycocalyx been visualized. Using these approaches, the glycocalyx appears to emerge perpendicularly from cellular microridging; above this is a narrow 0.1-0.5 micron electron-lucent zone, and a thicker (0.8 -1.3 micron) second layer of fibrillar electron-dense material that comprises the mucous-coat proper. A thin electron-dense lens forms the boundary layer or outermost edge of the mucous-coat. Although there is no evidence of an authochthonous bacterial flora in the mucous-coat, small amounts of cellular debris are normally found within it *(Fig 2.4C)*.

The granular eosinophilia of chloride cells is due to the presence of tubular mitochondria *(Fig 2.5B)* needed for their energetically expensive activities of osmoregulation: in seawater they are responsible for the net secretion of sodium chloride. Chloride cells have unique paracellular associations with neighbouring epithelial cells including tight junctional complexes. Chloride cells are also covered by microridges and a glycocalyx layer, although both are demonstrably different from those that cover epithelial cells. The apical plasmalemma of these cells, which is normally slightly concave and therefore slightly below the surface of neighbouring epithelial cells, can become

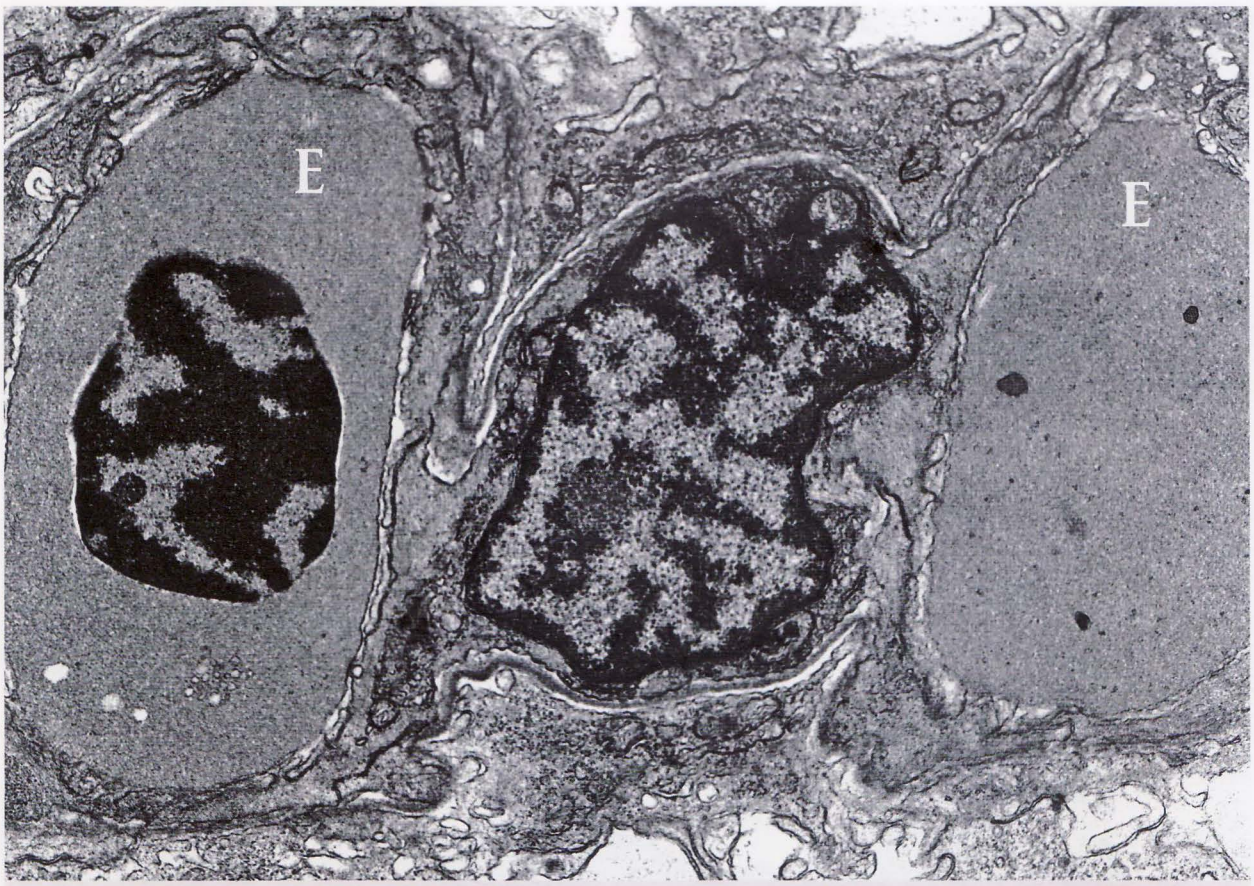

Fig 2.3D. Details of the pillar cell (nucleus in middle) and cytoplasmic flanges that form the pillar channels (flanking). E = erythrocyte.

prominently convex (thereby increasing the apical surface area exposed to the environment) when fish are confronted with osmoregulatory challenges resulting either from environmental change or disease. The degree of microridging of chloride cells appears variable, even in normal healthy fish, and has given rise to the terms alpha and beta chloride cells to denote those with minimal or elaborate glycocalyces, respectively. In some fish species, the alpha cells have much more Na^+, K^+ -ATPase immunoreactivity than do beta cells, and upon transfer of euryhaline freshwater fish to seawater, the beta cells undergo apoptosis, whereas the alpha cells undergo hypertrophy through an increase in the numbers of mitochondria.

Cells with histological similarities to mucous cells, eosinophilic sacciform cells, are found in some species, and even within the salmonid family their presence is variable. Frequently confused with intracellular parasites or other inclusions, sacciform cells have a distinctive ultrastructural appearance due to the presence of a large single droplet of eosinophilic material that may be similar to cholesterol (*Fig 2.5E*). Although their exact function is far from clear, sacciform cells have been noted to increase during some diseases, as has been reported for arctic char, but not rainbow trout, suffering from nodular gill disease (due to the amoeba *Cochliopodium*). Whether this metaplasia is purposeful, or merely a non-specific increase of a cell type responding to mitogens, is as yet undetermined.

At the base of the lamellae beneath the epithelium may be found small clumps of progenitor cells giving rise to the epithelial cells that subsequently travel up the lamellae (*Fig 2.5A*). By contrast, pillar cells replicate *in situ*. Transit time of epithelium from base to tip of lamella in young trout at 12°C is approximately 7-8 days, and while there are few studies that examine length of time needed for repair, expectations must be based on these sorts of figures. In addition to the progenitor zone, the two layers of epithelial cells along each edge of the lamellae also show differences that may reflect maturity. Whereas the outer layer has well-developed microridges, the inner



Fig 2.4A. SEM of mucous cell pores, and emerging membrane-bound mucigen granules, rainbow trout.

layer is less differentiated, and it is proposed that the inner layer migrates into the outer layer as the cells mature; linked to this would be the ability to dissolve and reform junctional complexes with neighbouring cells as needed. It is unknown whether lamellar epithelial cells are simply shed as they reach the lamellar tips, or instead are recycled through apoptosis. Apoptotic lamellar epithelial cells can be found, but not in great numbers and not preferentially towards the lamellar tips. Cell shedding would have the advantage of creating an ongoing rate of biofilm renewal, thus allowing the gill to shed surface-associated pathogens.

In the filament may be found the supporting cartilage, afferent and efferent filamental arterioles and other anastomosing vessels comprising the central venous sinus. Filamental epithelium contains large numbers of goblet cells, especially on the leading and trailing edges and at the base of the lamellae. Production of mucus increases when the gills are irritated by pollutants or parasites; similarly, quantitative and qualitative variations occur with other changes in water quality such as ammonia and calcium content. The negative charges of the mucus sialic acid groups effectively bind diffusible cations such as those of mercury, zinc, and copper. Thus the selective accumulation (from water) of heavy metals by the gills, reaching levels greatly exceeding those seen in other tissues, is explained by analysis which shows that

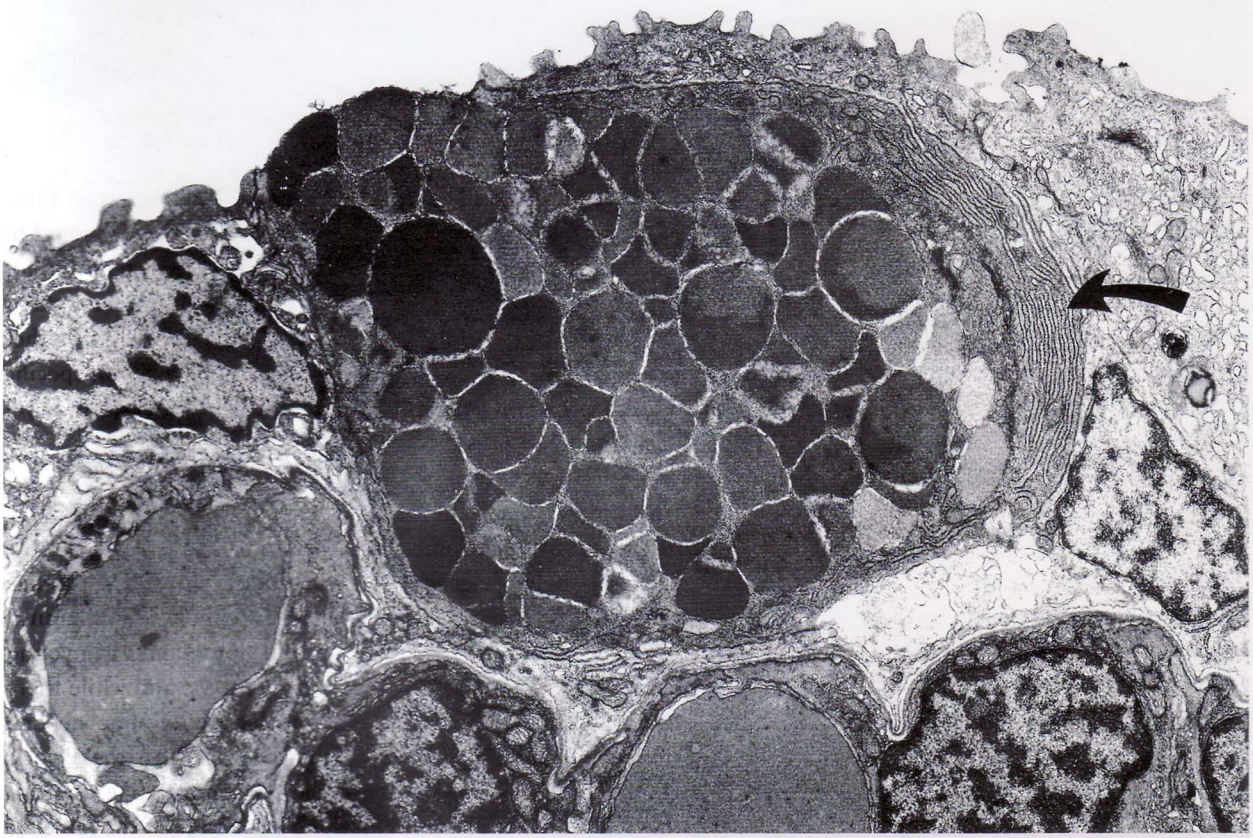

Fig 2.4B. TEM of mucous cell. Note the membrane-bound granules of variable electron density emerging from the apex of the cell. Arrow shows compressed stacks of Golgi and endoplasmic reticulum.

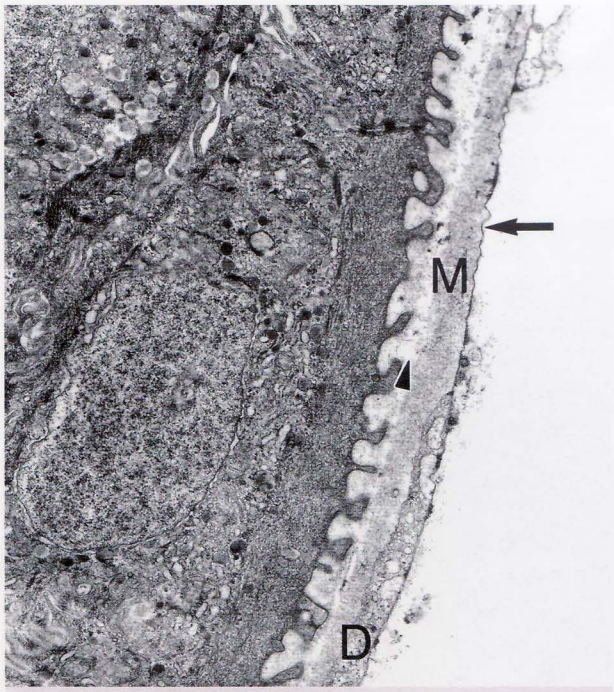

Fig 2.4C. TEM of fluorocarbon-fixed trout tissue. Note the extensive mucous layer (M), bounded by an electron-dense line (arrow). The secreted mucus lies over the top of the glycocalyx and the two layers are separated by a lucent zone (arrowhead). Some cellular debris (D) is contained within the mucus.

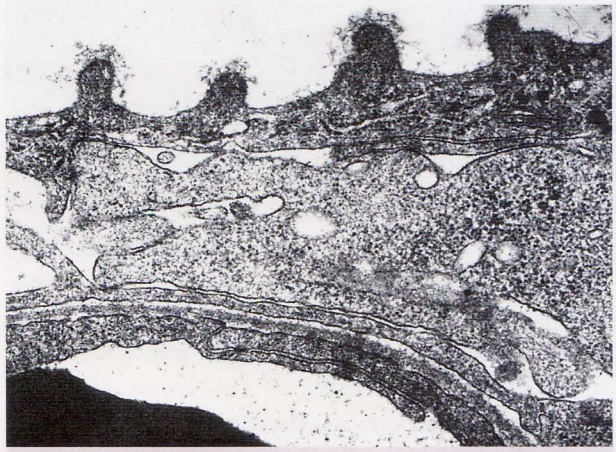

Fig 2.4D. TEM of microridges on the surface of normal lamellar epithelium. Note the corona of glycocalyx emerging from the microridge tips.

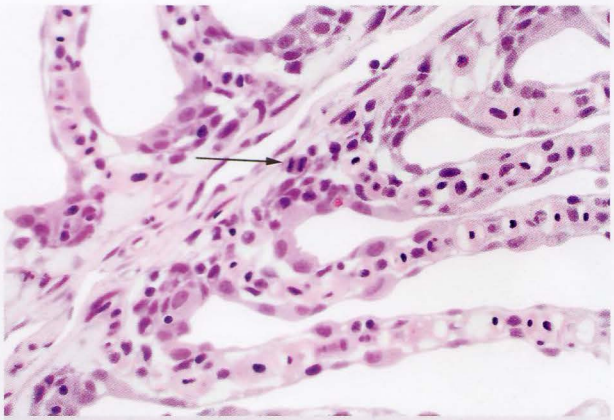

Fig 2.5A. Undifferentiated cell population deep within the lamellar base in this rainbow trout gill. One is in mitosis (arrow); it is as yet unknown whether the different types of epithelial cells covering the gill originate from a shared stem cell origin.

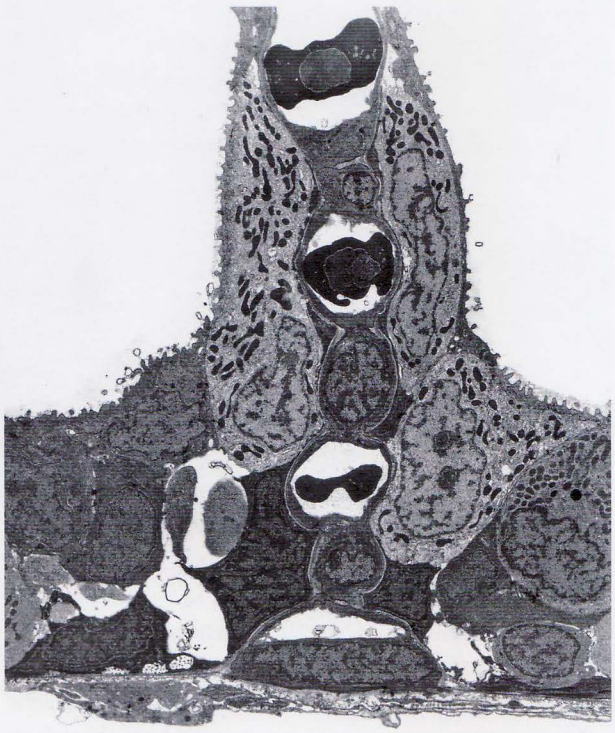

Fig 2.5B. TEM of lamellar base of rainbow trout showing several mitochondria-rich chloride cells.

approximately 80% of this resides initially within the mucus (see review by Satchell, 1984). Increases in the numbers, distribution, size, and histochemical staining characterstics of goblet cells are commonly reported during many types of gill disease and this is best viewed as a stereotypical response, much as it is in airway diseases of mammals. Although presumably a protective response, perhaps limiting the ability of pathogens to attach to underlying epithelium, or enhancing the rate of clearance of foreign particles, it can also be a double-edged sword. Enhanced mucus secretion can increase the dimension of the unstirred layer at the gill-water interface and presumably affect the characteristics of water flow between lamellae, and the rate of gas and ionic diffusion across the gill. Movement of the mucus blanket is

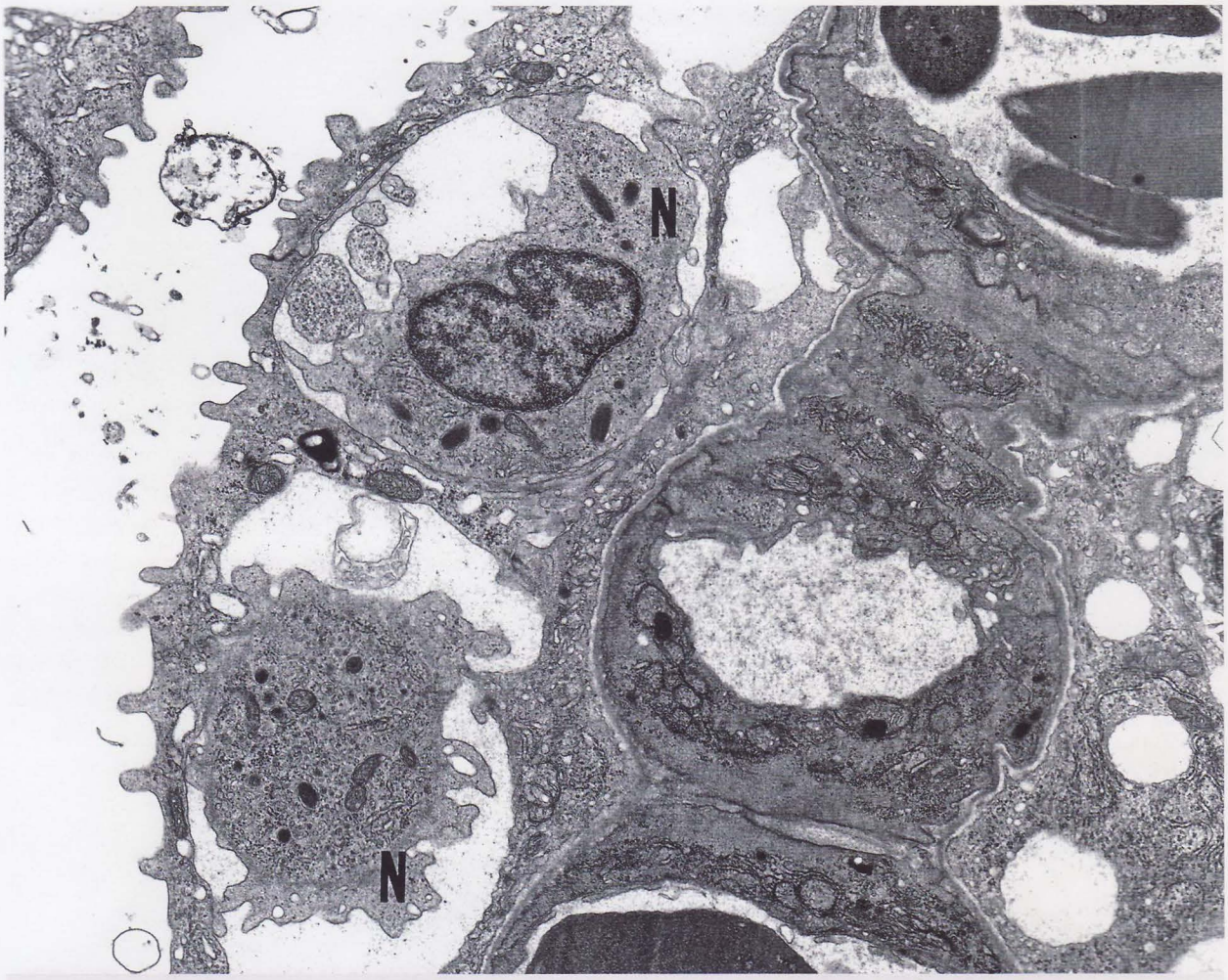

Fig 2.5C. TEM showing neutrophils (N) arrayed within the intercellular space of the lamellar epithelium.

facilitated by the massaging action of the water. Theoretically, water with high oxygen levels should lead to slower mucus flow, as less water needs to be pumped over the gills, and this has indeed been shown to be the case. Conversely, water with low oxygen levels would be expected to lead to higher mucus flow. Paradoxically this may not necessarily be true, as it has been shown that clearance is greatly reduced, possibly due to turbulence at the lamellar surface, the result of large increases in water flow. The practical implications for this include fish at low oxygen levels having an increased exposure to pathogens, or indeed to bath-administered vaccine.

Other cells found within the filamental interstitium include variable numbers of lymphocytes, macrophages, eosinophilic granular cells, neuroepithelial cells (containing 5-hydroxytryptamine) and rodlet cells. Recently, cells resembling dendritic cells (antigen presenting cells), replete with cytoplasmic Birbeck granules, have been discovered within the filament tissue and these findings support the hypothesis that the gill has a significant role in immune surveillance through antigen recognition, uptake and subsequent processing.

Rodlet cells are an enigma. They are found in very many species of teleost and within many tissues, although they are most commonly encountered within the gills, intestine, bile ducts, renal tubules *(see Figs 1.1B, 4.26E, & 8.21B)* and bulbus arteriosus. They are viewed by some as parasites, but their distribution in such a variety of species and tissues, their presence in larval fish and their failure to elicit any inflammatory response, prompt most histologists to view them as normal cells. They have a very characteristic flask-shaped appearance with often refractile eosinophilic "rods" in their cytoplasm.

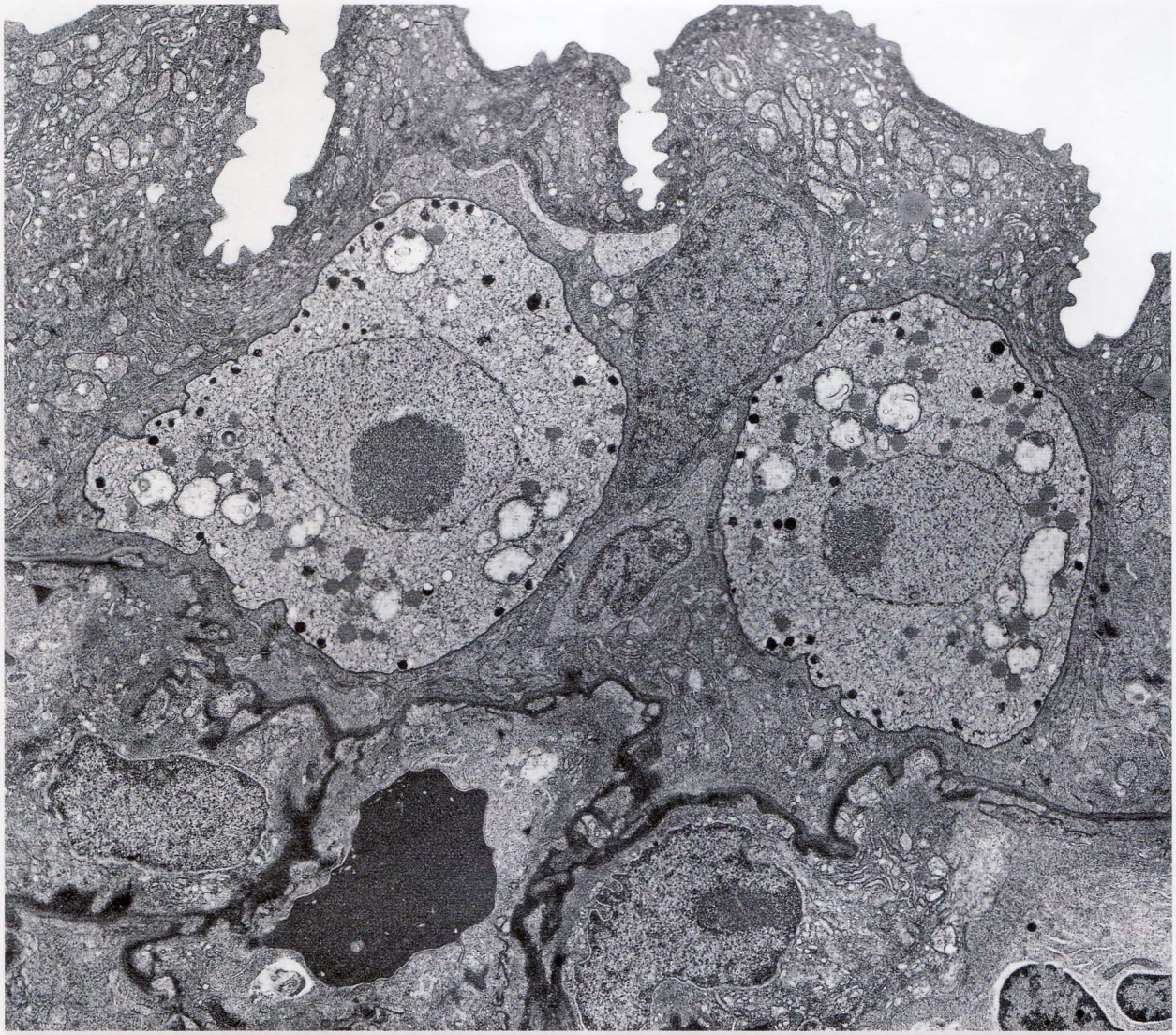

Fig 2.5D. Unidentified, but very characteristic, "X-cells" beneath lamellar epithelium of eelpout. *Courtesy of Dr. S. Desser.*

While on the subject of mystery cells, it is probably worth mentioning the large ovoid pale-staining "**X-cells**" (*Fig 2.5D*) which have been described from gills, from pseudobranchs, and from the skin. They are sometimes found in numbers large enough to suggest neoplasia (see also Chapter 13) although once again, whether the cells are of host origin or not is unknown. In the gills, they are found at the base and along the length of the lamellae, situated between the epithelial and pillar cells.

Movements of branchial arches, by means of the arch muscles, alter water flow, and under situations of increased demand, thereby recruit a higher proportion of filaments, probably the more dorsal ones. Possible consequences of this differential branchial irrigation, which under conditions of low demand, creates low flow "backwater" locations, include impaired removal of bacteria and other parasites. This idea is certainly borne out under practical diagnostic conditions when recovery of bacteria from dorsal locations on the arches is frequently more successful than from ventral ones.

In addition to differential irrigation, the lamellae may be differentially perfused with blood. Thus under resting conditions, only the proximal portions of the filaments may be utilized, and the ventral ones in favour of the dorsal. Such a regulatory ability is critical for the efficiency of respiration in order to avoid ventilation-perfusion mismatches. With respect to disease, the consequences of this type of regulation for the distribution of pathogens with differing oxy-



Fig 2.5E. TEM showing the large unbound cytoplasmic droplet characteristic of the eosinophilic sacciform cell. Material is secreted to the gill surface through an apical pore.

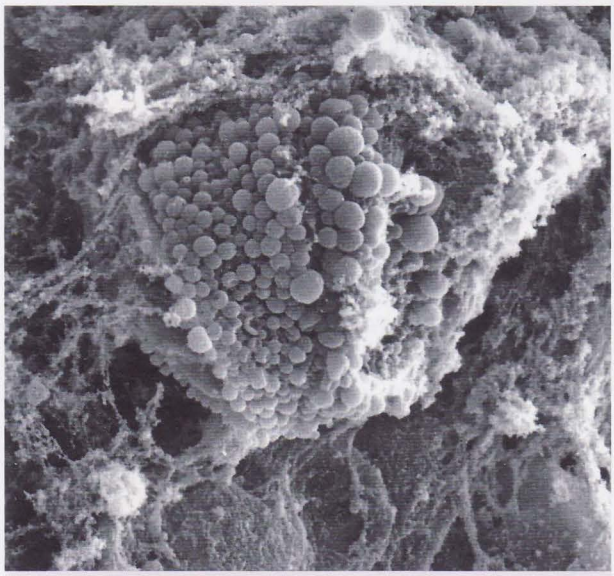

Fig 2.5F. Freeze fracture SEM showing the packed granules of an eosinophilic granular cell commonly found around the central venous sinus of the filament.

gen requirements are poorly understood but are possibly important. Certainly under conditions of high demand, with optimal irrigation of the respiratory surfaces plus maximum recruitment and utilization of lamellae, there will be increased opportunity for exposure to toxicants and other pathogens. This is backed up by experiments in rainbow trout in which uptake of methyl-mercury from the water correlates positively with oxygen consumption. Compared to mammals therefore, those very features that facilitate efficient uptake of oxygen from a medium that contains relatively little, mean that toxicants also have direct and immediate access to the respiratory surfaces. (In mammals of course, alveolar and bronchiolar air provide for a modicum of buffering capacity).

Response to injury

Clinical evidence of gill disease is manifested in a variety of ways, including increased rate of opercular movement, flaring of opercula (most easily seen from above the fish), and increased production of mucus, which can sometimes be seen streaming from the opercula, or creating foam on top of the water. Affected fish often darken, and they may gasp at the water surface; exposure to air probably causes collapse of the lamellae in some species, and a counter-productive reduction in effective surface area as a consequence. Affected fish may gather at the sides of tanks, or at the water inflow, where oxygen levels can be higher. Sometimes oxygen levels are in fact *lower* at the inflow than in the rest of the tank (seen with wellwater supplies) but the fish nevertheless still gather there, suggesting possibly a perceived need for flowing water rather than for oxygen *per se*. Alternatively, fish may congregate at the outflow, especially in cases of toxic insult (an attempt by the fish to escape). With time, there is erosion of the trailing edges of the opercula, and although the consequences of this lesion for overall efficiency of respiration are probably quite severe, neither the pathogenesis of the lesion nor the timing of its development is properly understood *(see Fig 14.2)*. Opercular erosion during the sequential development of BGD has been studied, and appears to reflect the consequence of bacterial adhesion to the inner thin wall of the trailing edge of the operculum; erosion of the opercular epithelial layer follows and the truncated trailing edge undergoes fibroplasia thus precluding normal regrowth. We can speculate that opercular erosion will affect the ability of the opercular cavity to seal itself during phase 1 of respiration when the buccal pump is drawing water in from the mouth.

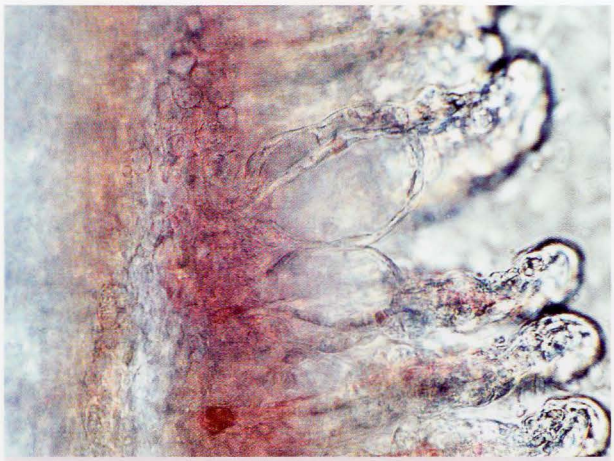

Fig 2.6A. Biopsy of trout gill showing perimortem artifactual development of "epithelial capillary separation" (ECS) which develops rapidly.

This would lead to a degree of water flow backwards from the opercular chamber crossing over the gills in a retrograde fashion, thus creating a situation similar to the less efficient tidal respiratory pattern of the mammalian lung. Considering the relative weight of water, and the high metabolic costs in fish associated with respiratory activity itself, such an inefficiency could lessen the ability of fish to survive in water of marginal oxygen tension and/or reduce the efficiency of feed conversion. Fish with eroded opercula are often noted to underperform their tank mates with respect to specific growth rates.

Correlation of clinical disease with obvious pathological change or the presence of pathogens is also poorly understood, as are the systemic consequences of gill disease. Considering the large surface area involved, the potential is great for rapid and clinically significant ionic and protein change following acute diffuse damage, and as with so much else in pathology, morphological change probably lags far behind functional impairment. Even at the later stage when there may be morphological correlates, interpretation of events is severely hampered by the flushing action of the water that effectively and immediately removes some of the evidence in the form of cellular and other inflammatory exudates. One study that did attempt to examine the clinical results of toxic gill damage demonstrated amongst other parameters, low plasma sodium, bicarbonate and chloride as well as low pO_2 and high pCO_2; haematocrit, blood glucose and total protein were also increased. These changes suggested osmoregulatory and acid-base imbalances as well as impaired gas exchange, and were considered the direct consequences of damage to lamellar epithelium and possibly chloride cells in particular. Recent work on amoebic gill disease (AGD) has sought to understand the associated gill pathology and systemic consequences with an eye towards developing disease-specific treatment modalities aimed at metabolic support of infected fish. Lamellar damage from treatment chemicals such as therapeutic levels of formalin, chloramine-T, hydrogen peroxide, and quaternary ammonia compounds has been intensively studied in juvenile salmonids relative to the temporally connected effects on growth and production performance through impacts on appetite, feed conversion indices, and seawater tolerance (in juvenile Atlantic salmon). Growth rates of salmonids infected with the microsporidian *Loma salmonae* show a dramatic decline. These are caused by reduced feed conversion efficiency, temporally linked to the onset of host inflammatory changes brought about by release of spores into gill tissue. Following the resolution of infections, compensatory growth, brought about by markedly increased voluntary feed intake, allows these fish to catch up to uninfected control cohorts, although feed conversion efficiency lags for several weeks as the gill undergoes remodelling.



Fig 2.6B. Histology of trout gill showing artifactual ECS with intercellular separation extending into the filament.

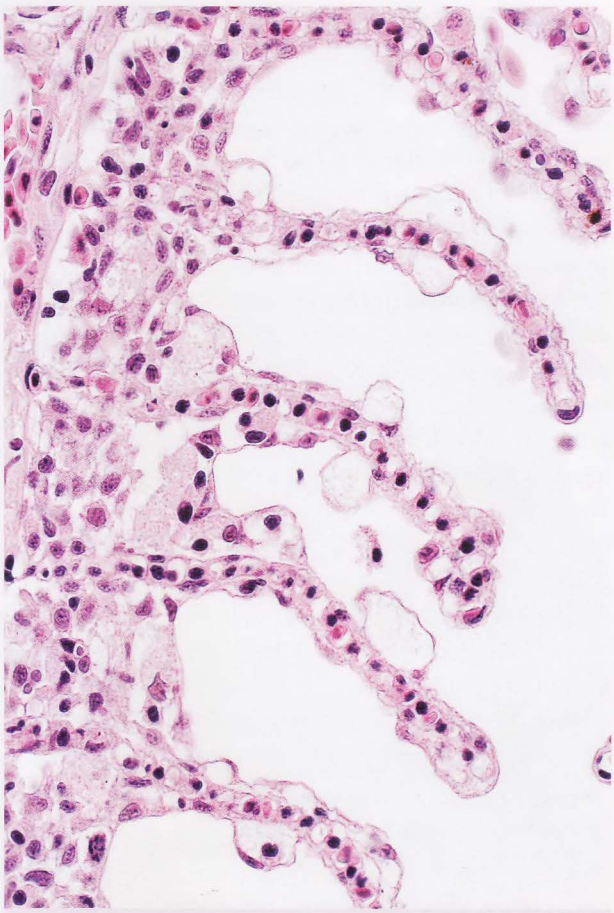

Fig 2.6C. Histology of Atlantic salmon gill showing pathological multifocal lamellar oedema.



Fig 2.7. Impression smear from a gill showing abundant mucus with entrapped debris as an example of an acute response to disease.



Fig 2.8A. SEM of trout gill showing rounded enlarged cells (hydropic degeneration) due to membrane damage from "therapeutic" levels of a quaternary ammonia compound.

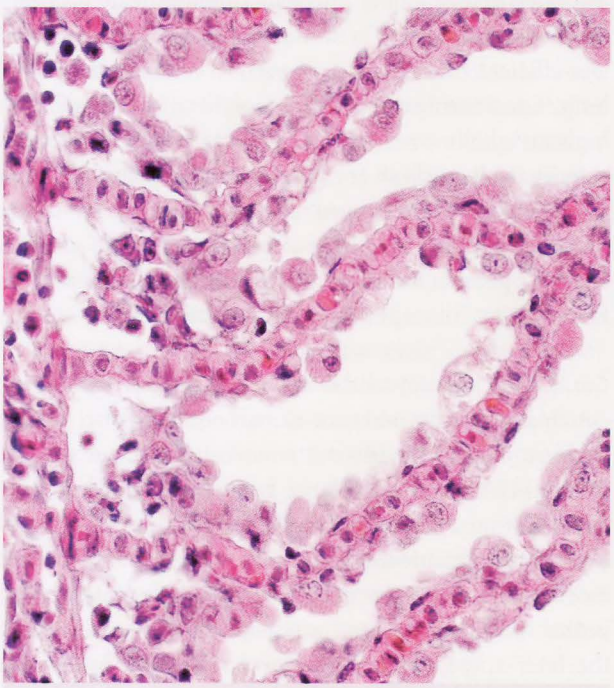

Fig 2.8B. Histology of trout gill showing diffuse hydropic degeneration of lamellar epithelial cells.

The development of a suite of quantifiable morphometric indicators of gill damage is a step that must be taken before research can reliably link gill lesions to clinical or systemic consequences of gill disease. Methods to compare surface area, diffusion distance, dimensions of the unstirred supralamellar layer of mucus, and indices of healing/regeneration in control and diseased fish give an estimate of the degree of architectural change and thus a means to compare between studies. For example, the

"lamellar fusion index", which determines the proportion of fused lamellae compared to normal, is a robust and relatively simple method with which to address relative functional surface area. A review of proportional morphometric approaches to document common gill lesions is provided in Sanchez *et al.*, 1997.

Distribution of lesions

The delicate structure of the gills responds to injury in a variety of ways depending on the type and severity of causative agent and the length of exposure. In most cases, lesions are diffuse among arches, although specific agents will target particular cells. For example, chloride cell degeneration and necrosis are seen in nitrite and cadmium toxicity whereas pillar cells are targeted by the microsporidian *Loma salmonae*. Alternatively, specific zones of the gill may be targeted, as seen in the massive epithelial hyperplasia and lamellar fusion affecting the distal third of the filaments in pantothenic acid deficiency, the classical "nutritional gill disease", and in nodular gill disease (NGD) due to amoebic colonization of gills of salmonids in freshwater. Rarely, a disease process restricts itself to one arch, while adjacent arches remain totally normal. In such cases, it is much easier for the fish to compensate for the loss of respiratory surface by increased perfusion or recruitment of lamellae and increased branchial irrigation. This may be so successful that the fish does not appear to be clinically sick. In pantothenic acid deficiency for example, there may be little need for compensation, as trout under resting conditions would not normally utilize the respiratory capacity of the distal filaments - that very area obliterated by the tissue response seen in this disease. Respiratory embarrassment only supervenes, therefore, if the lesions spread to involve more of the gill, when the respiratory reserve becomes exhausted and decompensation occurs. NGD is often clinically occult until trout are exposed to a treatment chemical, at which times even low doses of normally well-tolerated chemicals can cause massive mortality in fish whose gills have lost much of their respiratory reserve. Of course, before this happens, any fish so affected will be less able to cope with additional demands for oxygen required for swimming or metabolizing food. Deaths following a period of heavy feeding may be a clinical observation in such cases. Overgrowth and increased numbers of lamellae at tips of filaments are long-term compensatory mechanisms noted in rainbow trout and are probably also present in other species.



Necrosis. *Fig 2.9*A&B. Histology showing the progression from hydropic degeneration to cellular necrosis of lamellar epithelial cells in response to a suspected algal toxin. Note the pallor of degenerating cells and characteristic nuclear fragmentation as dying cells shed from the lamellae.

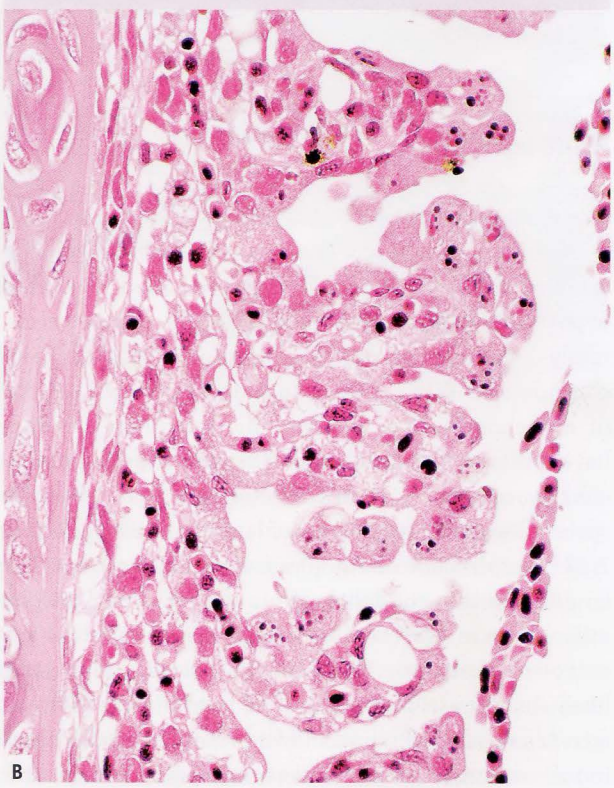

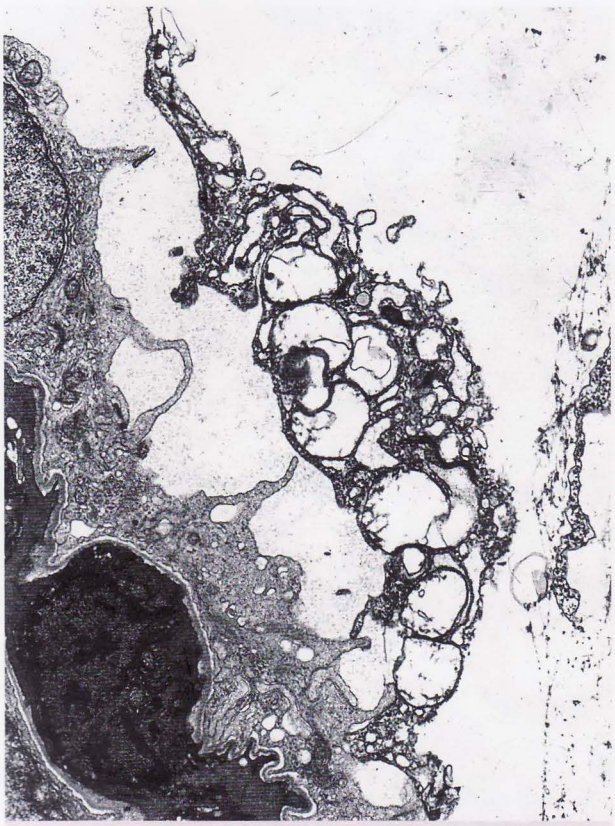

Fig 2.9C. Necrosis of lamellar epithelial necrosis showing high amplitude swelling of mitochondria, increased electron density of the cytoplasm, disintegration of the cell wall, and loss of attachment to subjacent cells. On histology, such a cell would appear enlarged and pale (as in **A&B**) due to intracellular oedema.



Fig 2.9D. SEM showing early repair after lamellar epithelial necrosis from chemical treatment. Note the new cells with reduced numbers of microridges.

Acute lesions

There is a constellation of gill lesions that are commonly described, but poorly understood, in studies on the acute effects of chemical pollutants. So-called "epithelial hypertrophy" of lamellar epithelial cells is more accurately defined as hydropic degeneration of epithelial and chloride cells **(*Fig 2.8*)** due to high-amplitude swelling of mitochondria and endoplasmic reticulum. "Epithelial capillary separation" or 'ECS', upon assessment with electron microscopy, is in fact interstitial oedema of the space between the two layers of lamellar epithelium **(*Fig 2.6*)**. The presence of autophagosomes and other cellular debris within epithelial cells is often mistaken at light microscopy as evidence of necrosis **(*Fig 2.9*)**; although necrotic cells can be found on the lamellae, it is more likely that they will simply be shed from the lamellar surface. Microridge blebbing and/or loss of discernible ridging are common acute reactions, as is pillar channel and sinusoidal congestion. Increased mucus secretion (often manifested in intensive culture as foaming of the water), is not always appreciable in histological sections because mucus is removed with fixatives; whole-mounts are often diagnostic of this response **(*Fig 2.7*)**.

It is *absolutely crucial* to appreciate, however, that virtually all of these lesions can be easily reproduced as artifacts due to poor fixation and/or the method of euthanasia. In our laboratories we find that anaesthesia followed by immediate fixation in Bouin's (no longer than 1-2 minutes before fixing) reduces artifact to a minimum. Lamellar oedema develops rapidly as a serious perimortem artifact. Blebbing of microridges can be induced by the use of fixatives with improper buffering and osmolality, or by increasing the duration of time from fixation to post-fixation procedures.

A more reliable (less prone to artifact) and obvious lesion may be distortion of lamellae with protrusion of cytoplasmic processes from epithelial cells to touch adjacent

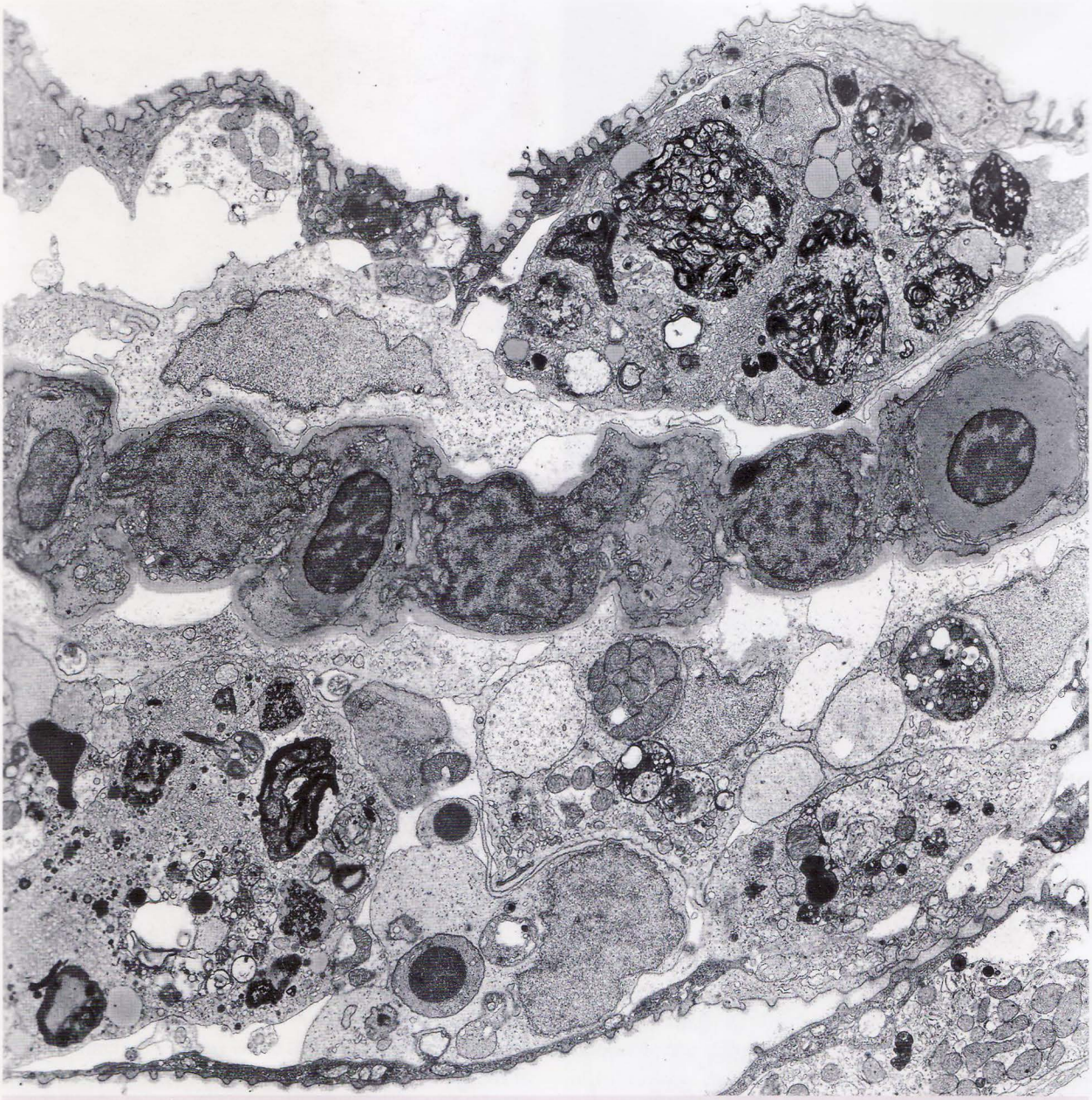

Fig 2.9E. TEM of lamella of trout exposed to mercury 24 hours previously, showing two large debris-containing cells (macrophages) just beneath the outer epithelial layer. *Courtesy of Dr. P-Y. Daoust.*

lamellae (lamellar synechiae) with subsequent lamellar fusion ***(Fig 2.10)*** by means of tight junctions.These responses, which can occur within 48 hours, are common in toxicity with heavy metals such as cadmium, mercury or copper. The mechanism(s) underlying such a response is unknown, although it is proposed that the toxicant alters the glycoprotein in the mucus covering of the cell, thereby affecting the negative charge of the epithelium and favouring adhesion to adjacent lamellae as a direct result. Alternatively, the mechanism may involve multiple steps, beginning with loss of the outer mature layer of lamellar epithelium, followed by recruitment of less mature epithelial cells that are forming and re-forming junctional complexes as they migrate outwards to replace the lost layer. Closely approximated lamellae may therefore become fused as epithelial cells from one fuse with those of the adjacent one. Under hypoxic situations, the act of "gasping" at the water surface, causing exposure of the lamellae to the air and hence collapse, may be a mechanism promoting fusion by bringing lamellae into closer



Fig 2.9F. Chloride cell degeneration and necrosis. Separation of the mitochondrial cristae due to organelle swelling is a characteristic feature of damage in these mitochondria-rich cells.

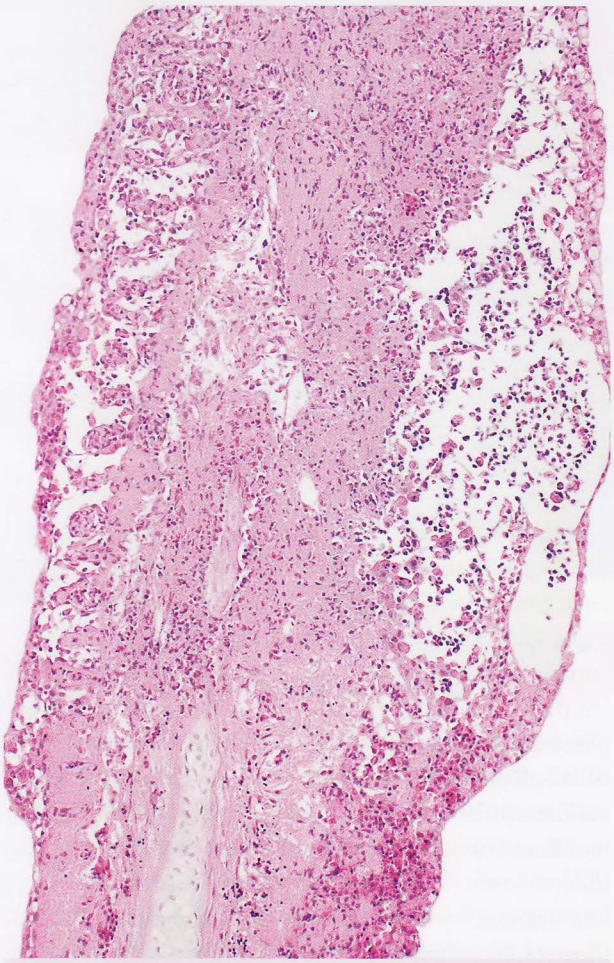

Fig 2.9G. Histology of trout with rainbow trout fry syndrome (RTFS) in which the pathogen is damaging filamental cartilage with consequential inflammation.

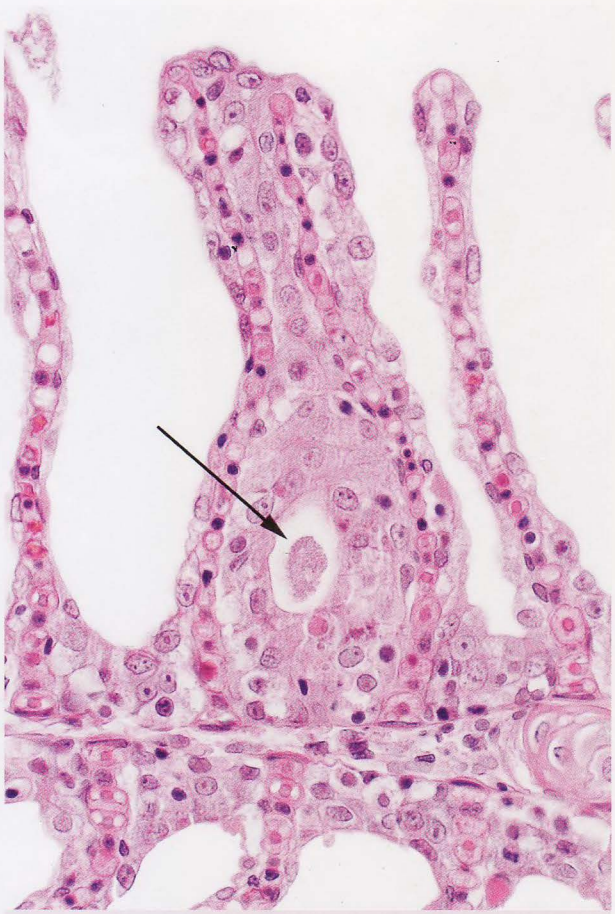

Fusion. *Fig 2.10A.* Lamellar fusion in this trout with BGD. A small pocket of bacteria can be seen between lamellae (arrow).

apposition. Whatever the reason, consequences of such a response include interference with the flow of water over the affected lamellar surface combined with an overall reduction in surface area. In addition, however, the normal route for exfoliation of epithelial cells is probably also disturbed: the piling up of these cells on the inner aspect of the "arch" created by the lamellar synechia may soon obliterate the inter-lamellar space, thereby compounding the gas-exchange situation even more. Alternatively, the cells may indeed slough, but be trapped by the walls of the "arch" - such aggregates appear as necrotic debris in the inter-lamellar space ***(Fig 2.10B)***. Thus the hypercellularity, so often described in association with gill disease may, at least in part, be the result of a failure of normal exfoliation, and although an increase in the rate of cell division (hyperplasia) is probably the dominant event seen under most of these circumstances, the distinction between the two processes is nevertheless a useful one to make. Hyperplasia of the progenitor zone is seen, but in addition, mitotic activity may be also encountered in

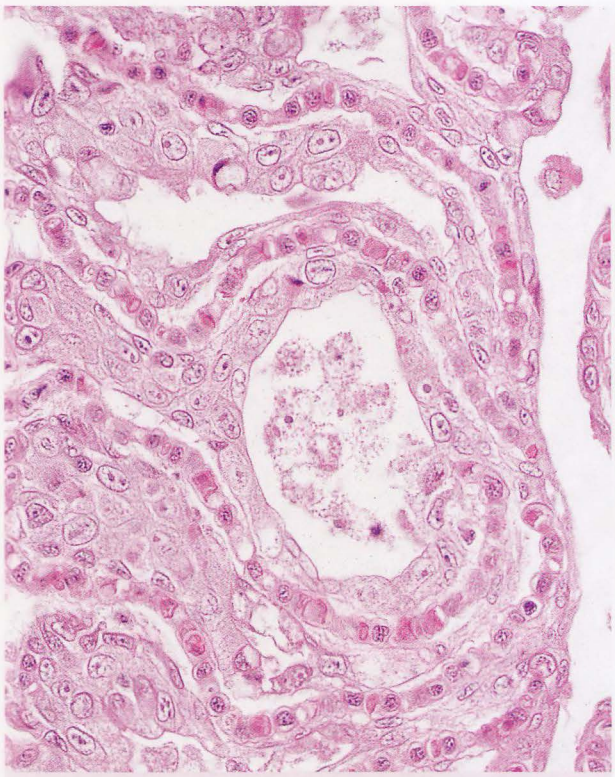

Fig 2.10B. Salmon showing exfoliated cells trapped by apposition of adjacent lamellae.

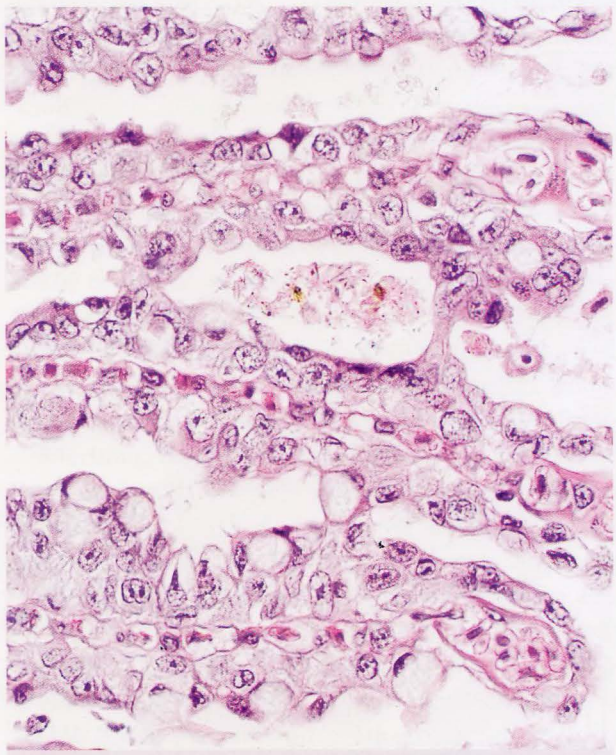

Fig 2.10C. Fusion of lamellae from adjacent filaments.



Fig 2.10D. SEM of lamellar fusion showing the migration of epithelial cells to stabilize a focal synechia.

epithelial cells far removed from the base of the lamellae, suggesting that they have retained their capacity for division.

Another acute response to branchial injury, associated with chemical or physical trauma (including rough handling at euthanasia), is aneurysm of lamellae (telangiectasia) in which there is breakdown of vascular integrity due to rupture of the pillar cells and a pooling of blood. Such lesions, which are easily recognized grossly as punctate red spots **(*Fig 2.12*)**, often thrombose, followed by resorption.

Haemorrhage is a feature of gill disease associated with blooms of the setae-bearing diatoms such as *Chaetoceros* and *Corethron* spp., possibly the result of physical damage caused by their shard-like silicate projections (setae). Other responses seen in this condition include a pronounced and dominating neutrophilic infiltration along with foreign-body type reactions surrounding the organisms which have become engulfed by the hyperplastic lamellar epithelium. Giant cells may occasionally also be seen attempting to invest the silica shells or spines **(*Fig 2.13D*)**. Haemorrhage also arises subsequent to the exposure of gills to oxidizing chemicals and agents that solubilize cell membranes. In either case, along with marked epithelial necrosis, pillar cell necrosis can occur and the consequent damage to pillar channel integrity allows pooling and extravasation of red blood cells.

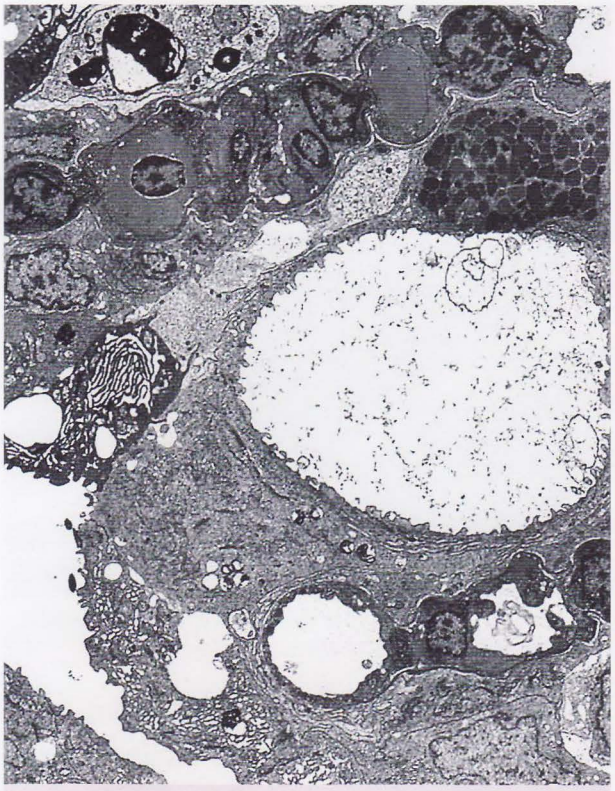

Fig 2.10E. TEM corresponding to changes shown in D showing the tight junctions that have formed between epithelial cells of adjacent lamellae.

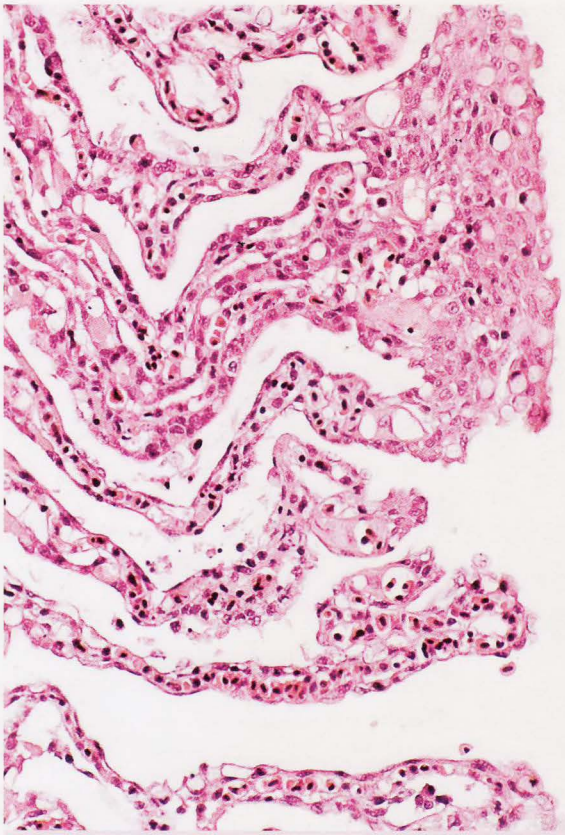

Hyperplasia. *Fig 2.11A.* Focal lamellar hyperplasia (trout).

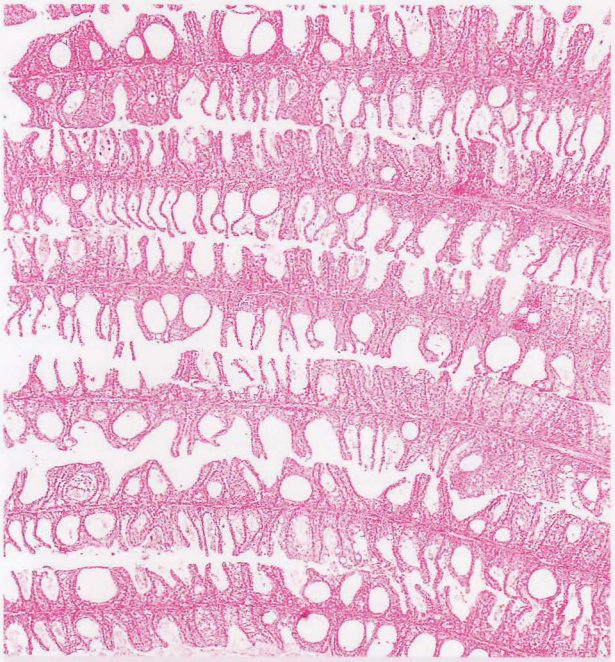

Fig 2.10F. Distinct "diagnostic" patterns of lamellar fusion sometimes exist, as seen here with "costiasis" creating a diffuse pattern in which synechiae are most common at lamellar tips.



Fig 2.11B. Hyperplasia causing grossly visible "clubbing" of filaments in salmon.



Fig 2.11C. Whole-arch hyperplasia, which can develop in some chronic parasitic diseases, may be multifocal (although regionally severe) rather than diffuse, and surprisingly - despite the apparent severity - fish with such lesions may not demonstrate clinical signs of respiratory disease.



Fig 2.11D. Experimental pantothenic acid deficiency ("nutritional gill disease") producing the characteristic clubbing of the distal third of filaments.

Chronic responses

Relatively mild responses include goblet and chloride cell hyperplasia, often extending out onto the lamellae in large numbers. Goblet cells may also show a significant shift from neutral mucin to acid mucin. More severe changes include marked epithelial hyperplasia usually with fusion of adjacent lamellae and obliteration of the interlamellar space (*Fig 2.11*). Sometimes adjacent filaments fuse, and rarely this may be so severe as to involve virtually the whole arch (*Fig 2.11C*). By contrast with this "proliferative gill disease", the term usually employed to denote these non-specific changes, experimentally induced chronic vitamin A toxicity causes hypoplasia and breakdown of epithelial integrity with lamellar distortion as a result. An influx of inflammatory cells (**branchitis**) is seen in most of the situations described above (*Fig 2.13*) although this may be difficult to appreciate, especially in the lamellae, where they are encountered in the subepithelial non-tissue spaces (possibly lymph spaces between the two epithelial cell layers). In chronic infections, especially parasitic disease, there may be large numbers of inflammatory cells along the filaments, including neutrophils, thrombocytes, lymphocytes and macrophages; they are most commonly found between epithelial cells, particularly when the epithelium has undergone spongiosis. Less commonly, inflammatory cells are found within the core of the filament itself, particularly in the area of the central venous sinusoid (*Fig 2.13A*). It is as yet unknown whether inflammatory cells reach lamellar interstitial tissue by migrating from pillar channels, or instead migrate from blood vessels within the filament. Additionally, it is likely that there is a population of inflammatory cells, most likely macrophages, resident within lamellar interstitial spaces and functioning in a surveillance capacity.

A cell type commonly encountered in many species, including salmonids, is an eosinophilic prominently granular cell similar histologically to the cell found in the submucosa of the intestinal tract and around the CNS. Its identity and complete range of functions are unknown, although it has many similarities to mammalian mast cells (see Reite, 1997) and certainly, their numbers increase in chronic disease, especially along the filaments.

Although intended as a protective response, any increase in thickness of the respiratory surface, due to increased quantities of mucus, or due to oedema, or hyperplasia of the epithelium, results in a greater distance for exchange of gases and metabolites with the water. Respiratory, osmoregulatory and excretory impairment are all possible consequences, particularly if the reaction is diffuse



Vascular damage. *Fig 2.12A.* Severe congestion of filament arteries and punctate areas of haemorrhage particularly towards the filament tips.

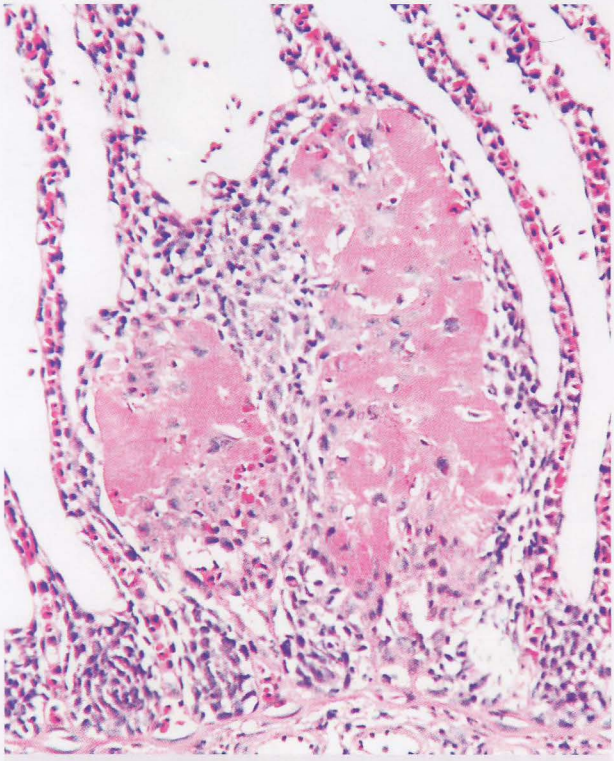

Fig 2.12B. Lamellar thrombosis in a trout.

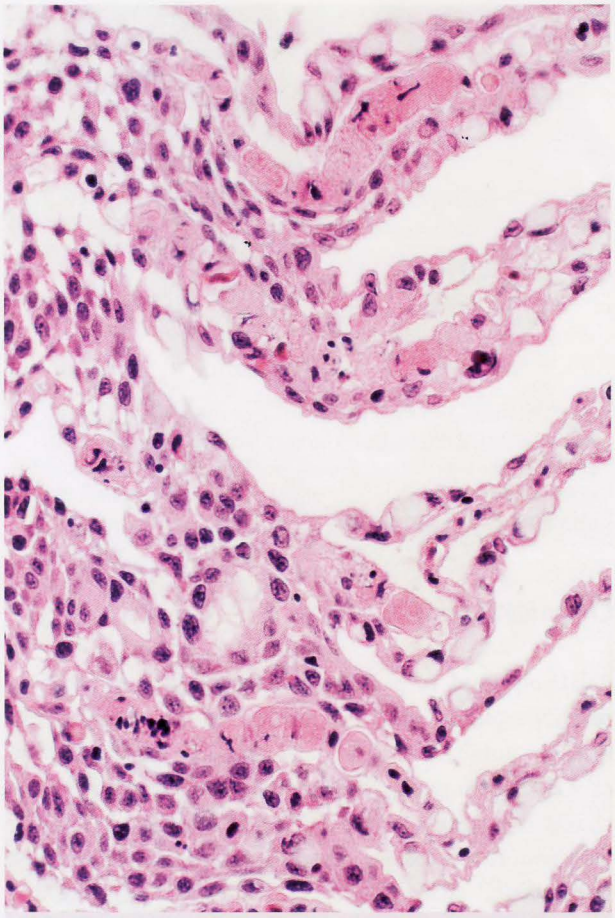

Fig 2.12C. Atlantic salmon with crustacean-induced lamellar thrombosis.

and affecting much of the gill. (It should be noted that the thickness of the gill membranes varies from species to species under normal conditions, in part due to differences in the thickness of the epithelial basement membrane. Thus sluggish fish tend to have thicker membranes than active ones).

Mechanisms of *repair* are poorly studied although it is well known from clinical observations that even severely damaged gills can make a relatively rapid and often amazingly complete recovery (*Fig 2.9D*). Acute responses such as lamellar oedema may recover within days. More chronic changes may take several weeks to repair. Recent studies, using hydrogen peroxide as an agent of cellular oxidant damage, have shown that in situations where lamellae are completely destroyed, lamellar repair begins within several weeks and is characterized by the production of vascular buds followed by formation of a pillar cell scaffold over which epithelium subsequently migrates. Overall, the process is very similar to the pattern of normal lamellar production that occurs at the tips of filaments. When lamellae are not completely destroyed, epithelial proliferation can proceed normally from the progenitor compartment at the base of the lamellae, while damaged pillar cells probably repair by *in situ* division of adjacent viable cells. Fibrosis is a remarkably rare event. Neovascularization within the filament, originating from the central venous sinusoid, has recently been demonstrated as a sequel to chronic deep branchitis in

salmon affected with *Loma salmonae*, perhaps in response to vascular damage caused by rupture of xenomas.

Specific conditions

Even though the gills excrete ammonia, it has long been considered that exposure to high levels of this and other metabolic waste products, as well as a variety of other non-specific agents, may irritate the lamellae which then respond in such a way as to create a favourable environment for subsequent colonization by more specific pathogens like bacteria or protozoa. The significance of unionized ammonia as a branchial irritant *per se* is now in question although there is no doubt that in high enough concentrations it can induce coma, probably by interfering with neurotransmitters in the brain. Similarly, high levels (approximately 6000 ppm) of the inert suspended solid kaolin fail to produce markedly significant change in young rainbow trout gills, although the branchial epithelium does phagocytose some of the particulate. So, high levels of suspended solids do not inevitably lead to gill damage. (The uptake of soluble and particulate antigen across the gill surface is important with respect to vaccines, possibly stimulating locally enhanced as well as general immunity). Waters high in iron, particularly after the water is oxygenated, are frequently cited as a cause of sudden severe gill disease in which lamellar fusion is a dominant lesion. Staining tissues with Perl's iron stain readily demonstrates a fine layer of iron precipitate within the mucous coat of the gill.

Bacterial gill disease (BGD) occurs in several species (probably most, given the correct conditions) but it is a particularly serious problem of intensive salmonid cul-



Fig 2.12D. Hybrid striped bass with *Streptococcus*-induced infarction.

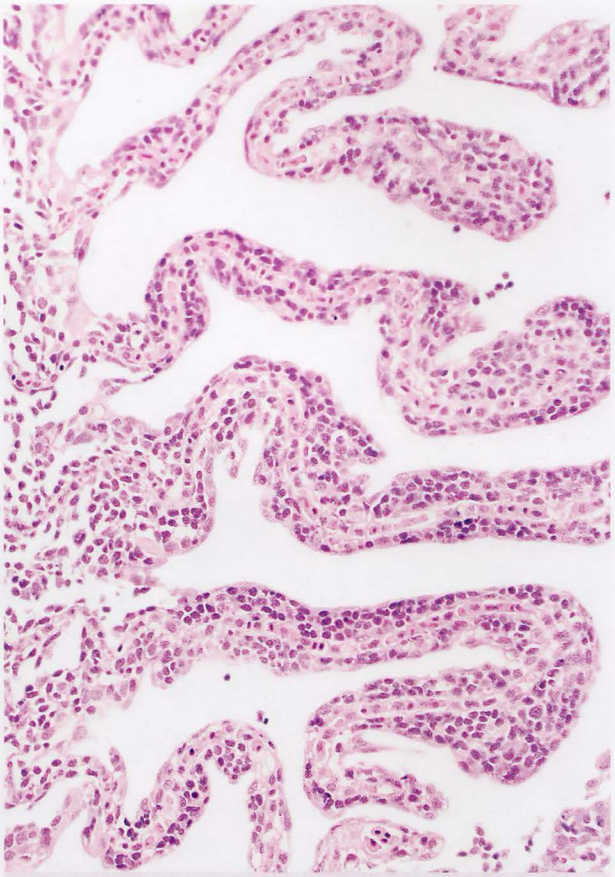

Fig 2.13B. Example of chronic branchitis showing influx of mononuclear cells which are most likely lymphocytes.

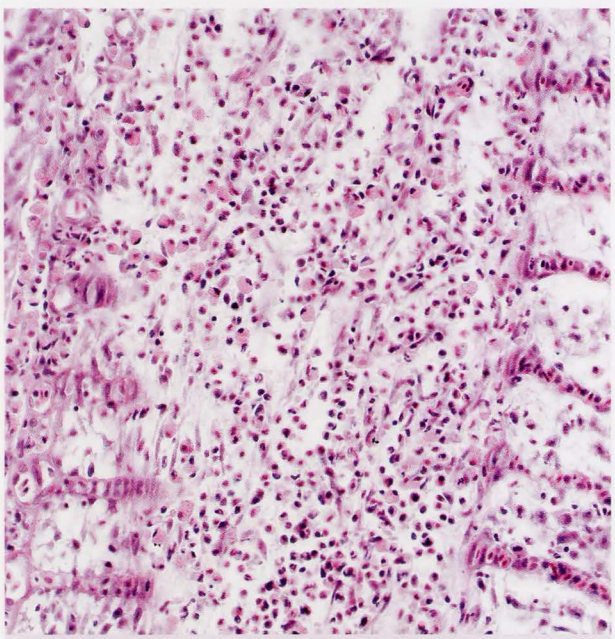

Inflammation. *Fig 2.13A.* Histology of trout gills showing a marked influx of neutrophils.

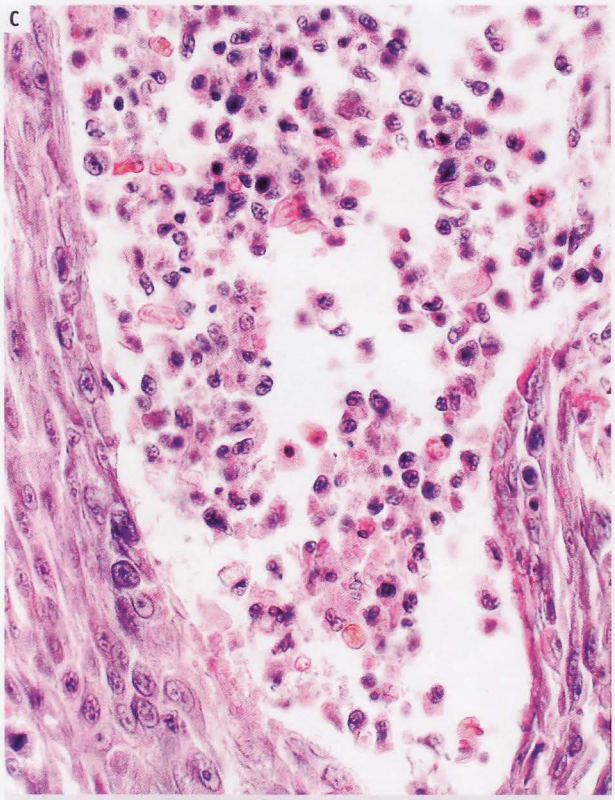

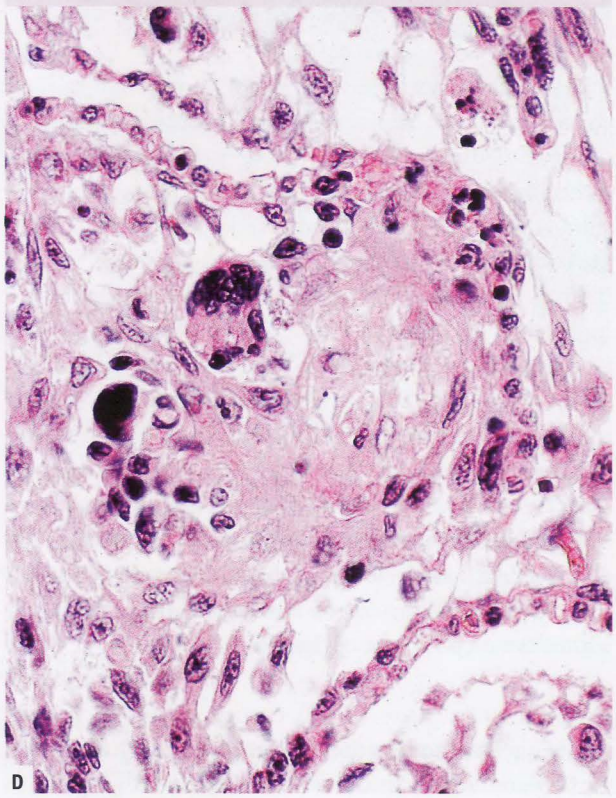

Fig 2.13C&D. Both acute and chronic responses in salmon to entrapped silica from diatom setae. A giant cell is shown in **D**, and refractile silica can be found within affected gills for months following a bloom.

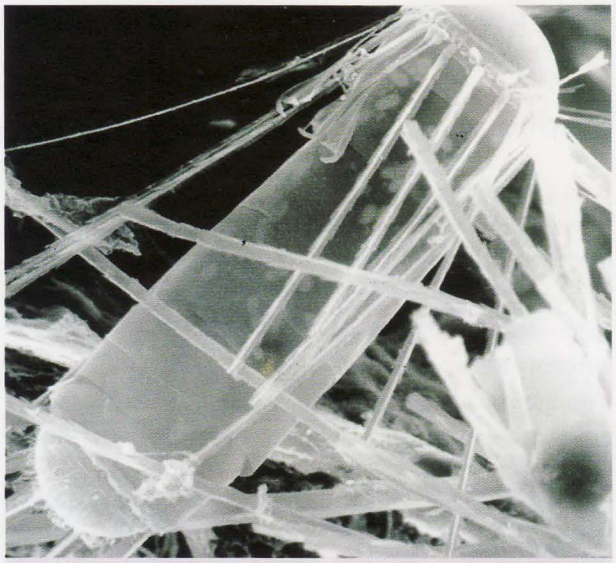

Fig 2.13E. SEM of diatom showing typical appearance. Note the backward-pointing setae, that act like a grass awn and impede easy dislodgement from between lamellae.



Fig 2.13F. Granulomatous and haemorrhagic filamental branchitis in a trout with BKD.

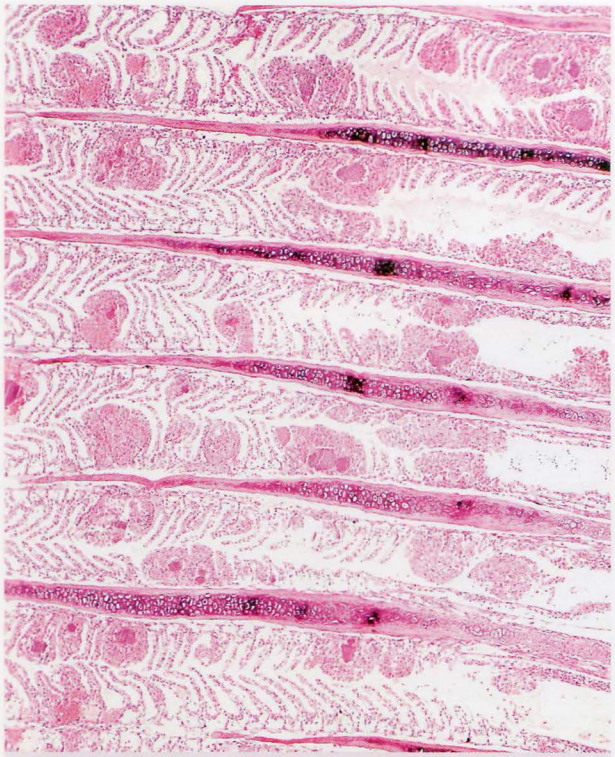

Fig 2.14 Embolic bacterial branchitis. Note the epithelial hyperplasia around each of the bacterial colonies."



Bacterial gill disease (BGD). *Fig 2.15A.* Marked opercular flaring in this trout that died from BGD. This may relate to lactic acid accumulation, and a degree of tetany, in the abductor muscles of the operculum and cliethrum.

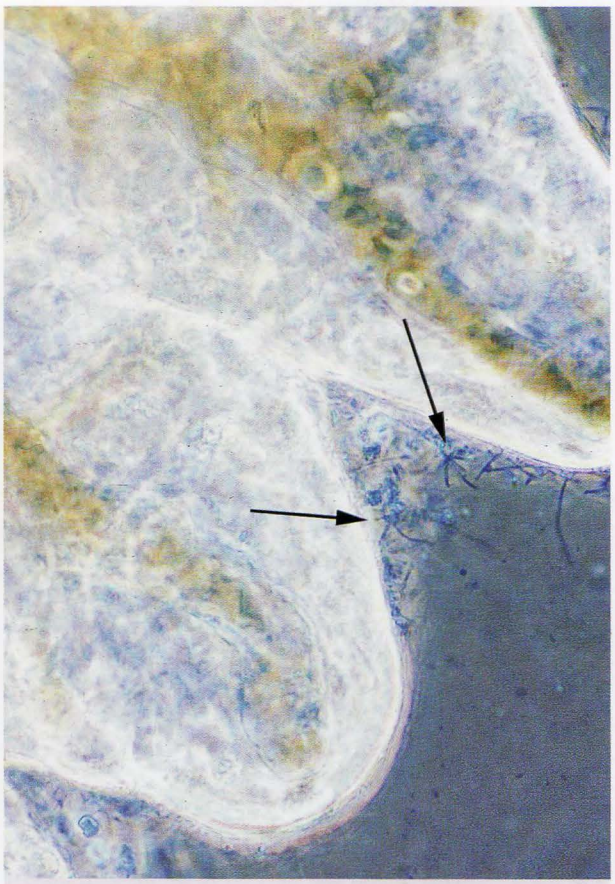

Fig 2.15B. Biopsy of fish with BGD. Arrows demonstrate the filamentous bacteria which, despite their length, can sometimes be hard to see especially when they lie flat on the gill epithelium.

ture, and in some parts of the world represents the most common diagnosis. The precise conditions predisposing to the disease are not yet known, although overcrowding appears to be a pre-eminent factor. It is characterized by the presence of filamentous bacteria on the gill surface of fish suffering clinically from respiratory distress (*Fig 2.15*). A mixed population of bacteria (biofilm) is usually isolated, although the condition is experimentally reproduced with *Flavobacterium branchiophilum*. The disease is most commonly seen in fry and fingerlings, but outbreaks do occasionally occur in populations of older fish with frequently serious results. Clinically, the fish have flared opercula (*Fig 2.15A*) often with erosion of the trailing edges, and the gills have clubbed filaments covered in excess mucus. In acute cases, the gills may be hyperaemic, whereas in the chronic response, when hyperplasia and mucus production are pronounced, they are usually pale. Histologically, microcolonies of fine thread-like bacteria can be seen attached to the lamellar epithelium (*Fig 2.15B&C*), often accompanied by debris trapped by the mucus. Ultrastructural examination reveals a close interdigitation of bacterial and host epithelial glycocalyces (*Fig 2.15D-F*). With time, there is lamellar fusion with entrapment of debris, obliteration of inter-lamellar spaces, and frequently mucous metaplasia. Although widespread degeneration of lamellar epithelial cells is a key feature of the disease, this is not readily detected at the light microscopic level; affected cells undergo blebbing of plasmalemma, and high amplitude swelling of mitochondria is an early sign of degeneration suggesting that the bacteria

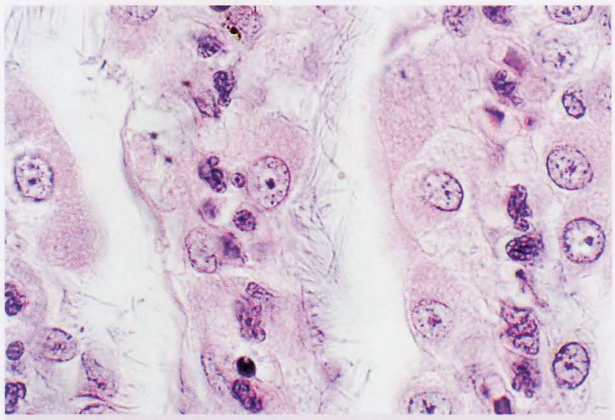

Fig 2.15C. Acute BGD in a wild-caught coho salmon from Lake Michigan. Epithelial cells subjacent to the bacteria have undergone marked hydropic change.

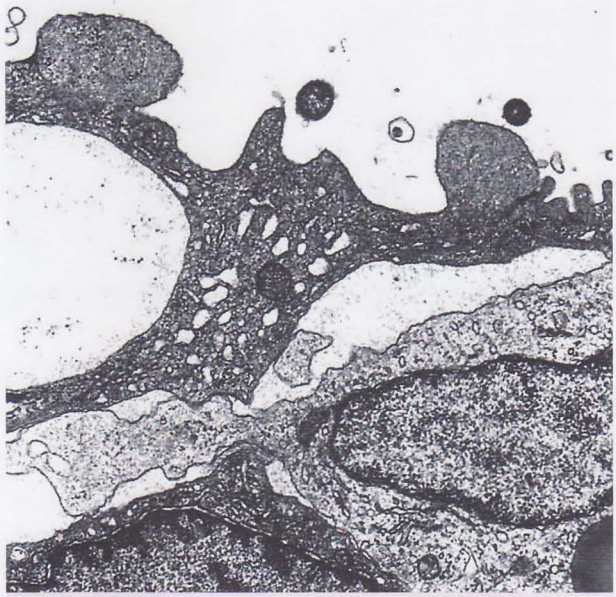

Fig 2.15D. TEM showing early lesions during the pathogenesis of BGD including blebbing of the epicellular microridges. Bacteria attach to the glycocalyx.

exert an influence on the apical surface membrane of colonized cells, thereby allowing an influx of water. In some cases, chloride cells may be targeted. Experimentally it has been shown that attachment of the bacteria to the gill surface results in a dramatic hypoxaemia, down to 30% of normal levels within 30 minutes, presumably due to marked vasoconstriction in the gills. This hypoxaemia can be counteracted using drugs such as indomethacin, suggesting that the pathogenesis of acute BGD resides in a prostanoid-dependent reduction in branchial blood flow. This probably explains why acutely affected fish can show such a remarkably rapid recovery after treatment.

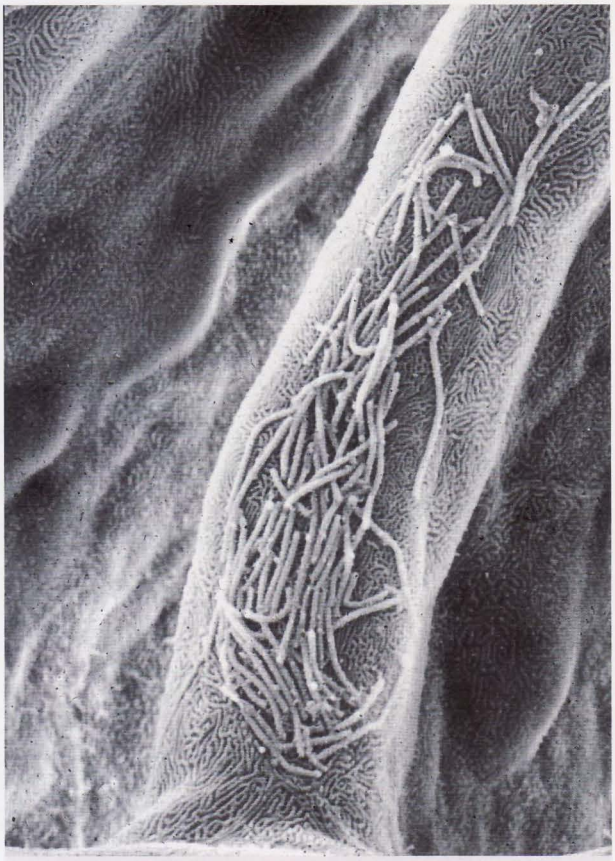

Fig 2.15E. SEM of trout gills 30 minutes after experimental challenge.



Fig 2.15F. SEM of naturally-occurring BGD in trout. Note similarity to *2.15E.*

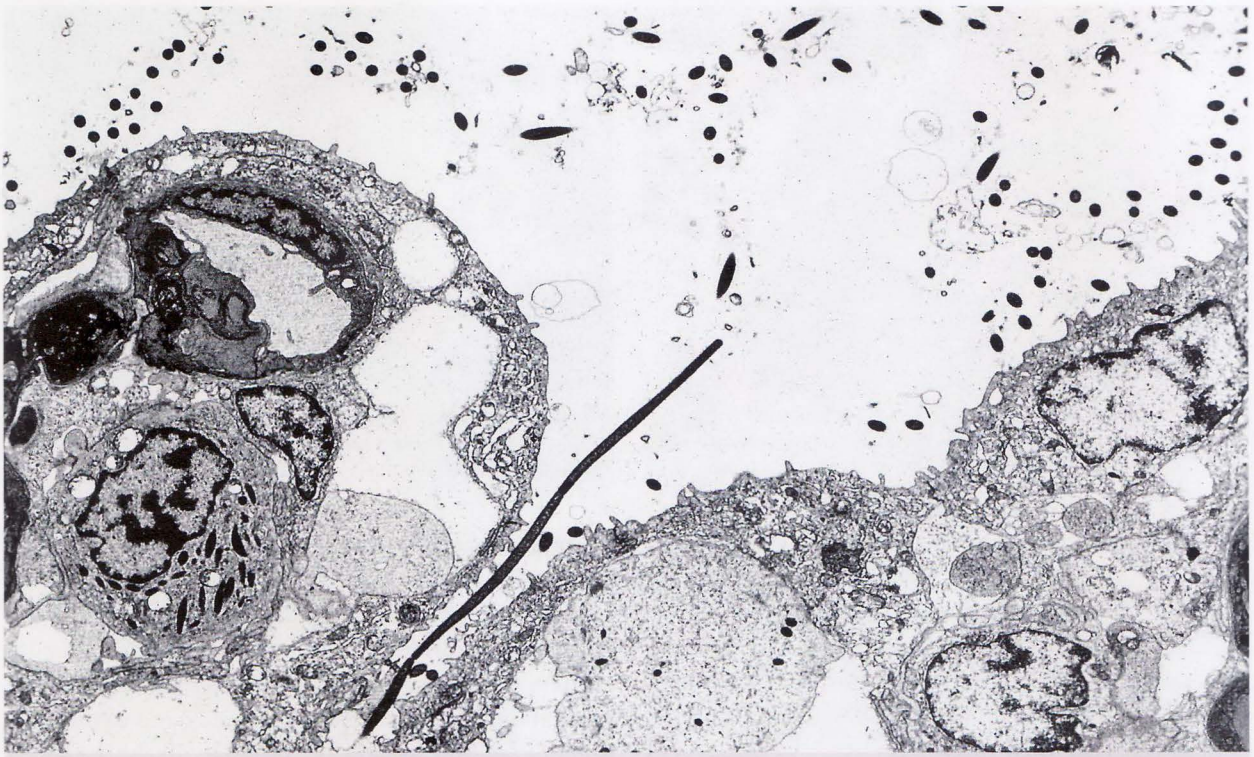

Fig 2.15G. TEM of naturally-occurring BGD in trout.



Fig 2.15H. Histology of chronic BGD in a trout showing the almost complete obliteration of normal filament architecture.

By contrast, atypical BGD, and columnaris disease caused by *Flavobacterium columnare* (formerly *Flexibacter columnaris*) along with mycoses, can also attack the gills **(Fig 2.16A-C)**, causing either lamellar shortening, or severe widespread necrosis of superficial and deep elements, respectively.

Nodular gill disease (NGD) is the name given to a disease condition of salmonids and non-salmonids, now reported from several parts of the world, in which there is massive epithelial proliferation leading often to almost total obliteration of an affected arch **(Fig 2.17)** and sometimes adhesion of the arch to the operculum. The grossly-visible pearly white nodular proliferations **(Fig 2.17A)** are associated with the presence of distinctive vacuolated densely-staining *Cochliopodium* amoebae arrayed in sheets over the surface of affected tissue **(Fig 2.17B-E)**. They are frequently associated with and often contain filamentous bacteria and are also found elsewhere in the branchial cavity, within the nares, and even on top of the head. The precise relationship between this condition and bacterial gill disease remains to be elucidated, but based on clinical surveys of the two conditions, it is common for poorly managed relapsing cases of BGD to precede NGD, thus suggesting that the amoebae are attracted to the bacteria-rich surface of the gills.

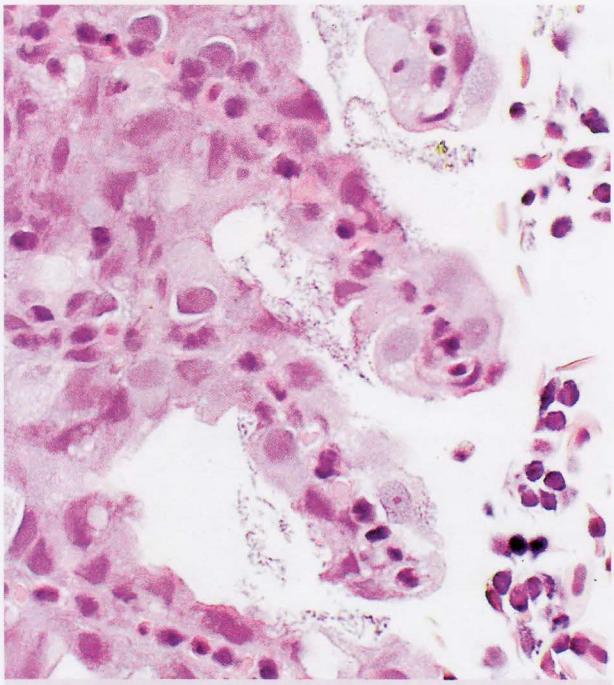

Fig 2.16A. Histology from "atypical" BGD in brown trout associated with a biofilm of nonfilamentous bacteria in close apposition to lamellar epithelium. Lamellae of affected fish are shortened.



Fig 2.16B. Acute gill necrosis in a koi carp with columnaris disease. The brown patches represent necrotic tissue.

Considering the extensive vascular network of the gills, it is hardly surprising to find their involvement in gas embolism associated with supersaturated water, and in bacteraemias *(Fig 2.14)* and viraemias. During gas bubble disease (GBD) for example, the presence of large gas bullae within the larger afferent vessels of the filament can cause endothelial erosion, exposure of subendothelial connective tissue and thereby, local activation of the clotting cascade leading to thrombus formation. In furunculosis for example, colonies of bacteria are frequently encountered within lamellae and filaments, sometimes



Fig 2.16C. Gill necrosis (mycotic branchitis) in a rainbow trout. Infarcted regions appear brown; discolouration can also arise from the entrapment of water-borne debris by the mat of hyphae.

causing ischaemic lesions. In bacterial kidney disease (BKD), the gills may contain large numbers of bacteria within pillar cells, macrophages, or epithelial cells; the latter may be often seen exfoliating from the lamellar surface. Alternatively, during severe cases of BKD in visceral organs, pillar channels develop an intense eosinophilia and "wire-loop" appearance, likely the result of deposition of antigen-antibody complexes. In viral haemorrhagic septicaemia (VHS), the pillar cells have been shown to actively phagocytose the rhabdoviruses, and during ISA, branchial endothelial damage is widespread, leading to severe congestion and haemorrhage, particularly within the filament. Lymphocystis virus may also localize in the gill, especially in pleuronectids, the resulting lesion being indistinguishable from its more common skin counterpart *(see Fig 3.30)*. Cytomegaly is seen in the lamellar epithelium in herpesvirus infection of marine flatfish, in the emerging herpesvirus of koi carp (see later), and in a proliferative branchitis that is seen in eels associated with an IPN-like virus (other lesions in this latter disease include a proliferative glomerulonephritis). The vascular network, and in particular the pillar cell system, is targeted during microsporidian gill disease of salmon (MGDS) caused by *Loma salmonae* *(Fig 2.18D&E)*. A complex host-pathogen interaction culminates in parasite-laden macrophages fusing with, and entering into the cytoplasm of pillar cells where final parasite maturation takes place, and during which the pillar cells undergo massive hypertrophy. Xenoma rupture permits the direct release of spores out through the affected lamellae and into the environment where they are available to infect other fish. In those situations where xenomas form within the endothelium of the filament arteries, xenoma rupture leads to an intense leu-



Nodular Gill Disease (NGD). *Fig 2.17A.* NGD in a speckled trout showing multi-focal areas of filament hyperplasia.



Fig 2.17B. Histology of NGD showing severe filament epithelial hyperplasia.

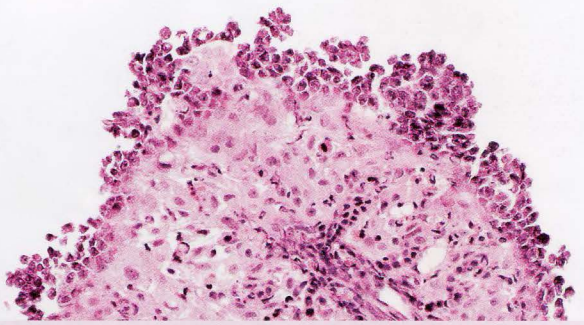

Fig 2.17C. Large numbers of densely staining and vacuolated amoebae (*Cochliopodium* sp.) sit on the surface of the hyperplastic epithelium, and can easily be mistaken for exfoliated epithelial cells.

kocytoclastic vasculitis, thrombogenesis, neovascularization, and a persistent inflammatory response.

Secondary fungal invasion with *Saprolegnia parasitica (diclina)* can be superimposed on any primary gill disease, sometimes with severe consequences due to infarction **(Fig 2.16C)**. If the branchial cavity is extensively affected, the thymus lying at the dorsal commissure may also become involved, with possible serious immunological consequences. This is relatively common in young fish under intensive culture conditions, when feeding practices are poor such that excess feed is available for fungal colonization. Fungal-laden mats of debris transfer the infection to the gill. A specific mycotic syndrome of the gills, "branchiomycosis" or "gill rot", was first described in 1912 by the German veterinarian Marianne Plehn (as were so many other fish diseases). It is particularly significant as a disease of young cultured carp in which gill lesions start as red haemorrhagic swellings, progressing to white then brown necrotic areas due to infarction from colonization of branchial vessels by the oxygen-seeking non-septate fungus.

Epitheliocystis is a chlamydia or rickettsia-like organism infecting the gills and skin of a variety of species in both fresh and saltwater **(Fig 2.19)**. Although infections are usually benign and regarded as incidental, acute diffuse lamellar necrosis is seen in Atlantic salmon, and proliferative gill lesions associated with mass mortality have been reported in carp fry. All major types of surface epithelial cells are infected including chloride and goblet cells which become hypertrophic. Mucophilosis is a condition again first described in carp by Marianne Plehn and although once considered to be due to an alga or fungus (*Mucophilus cyprini*), it is now considered to be probably identical to epitheliocystis. The recently emerged koi (carp) herpesvirus is an example of an intracellular pathogen of gill epithelial cells that appears to create a favourable environment for co-infection with a bacterial pathogen (columnaris disease) thus mimicking the common scenario in other production animals (cattle, sheep, swine) in which bacterial bronchopneumonias frequently have a viral interstitial pneumonic trigger.

A variety of protozoa are encountered in and on the gills including amoebae **(Fig 2.18)**, coccidia, microsporidia and myxozoa. Most myxozoa seem to evoke little response



Fig 2.17D. TEM of NGD showing several amoebae overlying and interdigitating with an epithelial cell (E). Note crescent-shaped nuclear chromatin, lipid droplets (L), vacuoles (V), and filamentous coat (FC) on the outer surface.

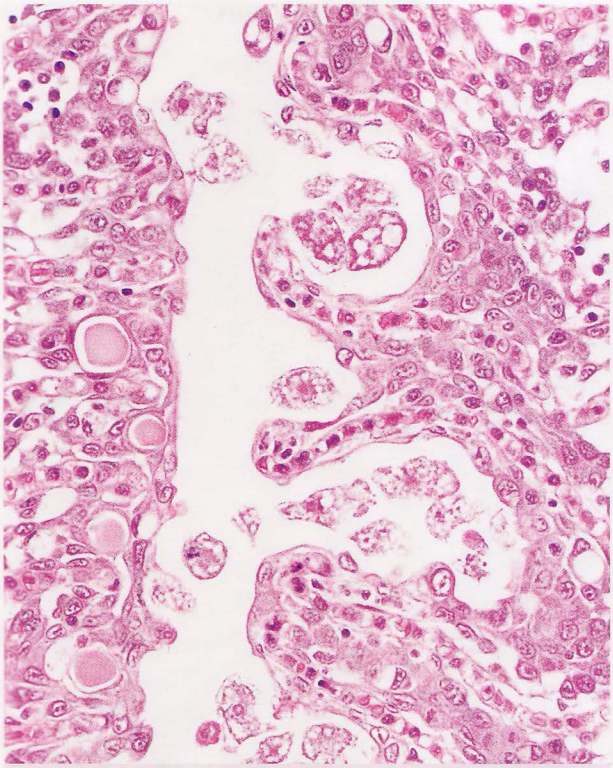

Fig 2.17E. Amoebic Gill Disease in coho salmon in saltwater.

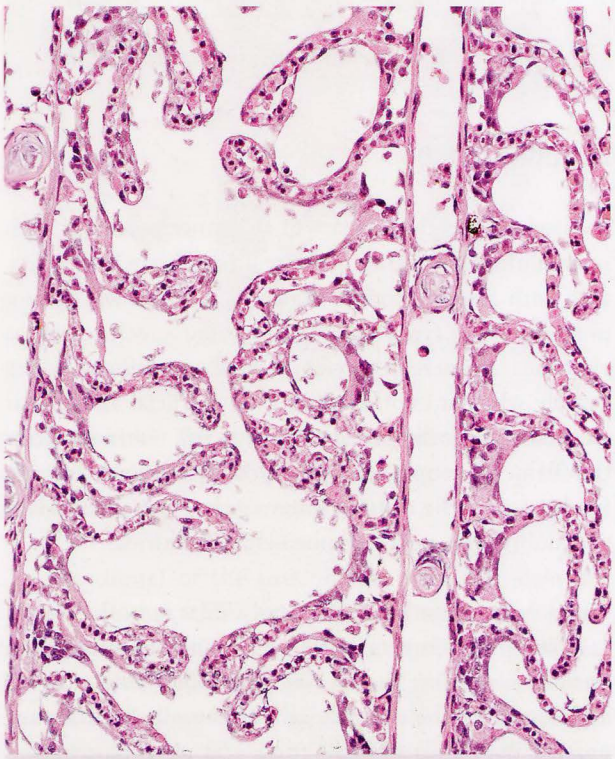

Fig 2.18A. Histology of costiasis in trout. These parasites can produce a characteristic reaction in gills.



Fig 2.18B. Histology of costiasis in a koi carp.

and are often encountered as incidental findings in routine diagnostic work. A few, such as *Myxobolus exiguus* however, are reported to cause serious lesions of gills and epidermis in fish of the genus *Mugil* on the Atlantic, Mediterranean and Black Sea coasts. Proliferative gill disease (PGD) of catfish is particularly damaging, and the marked inflammatory response within the central venous sinusoid, and hyperplasia of filament epithelium have led to the descriptive colloquial term "hamburger gill disease". Filaments from affected fish may be virtually obliterated by the large number of cysts present. Ciliates such as *Ichthyophthirius multifiliis* **(Fig 2.18C)**, trichodinids and *Chilodonella* spp. are also seen, as are the dinoflagellates and flagellates such as *Ichthyobodo* (*Costia*) *necator* **(Fig 2.18A&B)**. If extensive, many of these infections result in diffuse hyperplasia and inflammation that can often be severe enough to cause clinical disease. Within the gill parenchyma may be found metacercariae of digeneans, glochidia of molluscs or the eggs of sanguinicolids.



Fig 2.18C. Histology of *Ichthyophthirius* parasite in a trout. Although appearing to be superficial, the parasite is actually sitting on the basement membrane. Hence treatments can be difficult. Note the characteristic macronucleus.

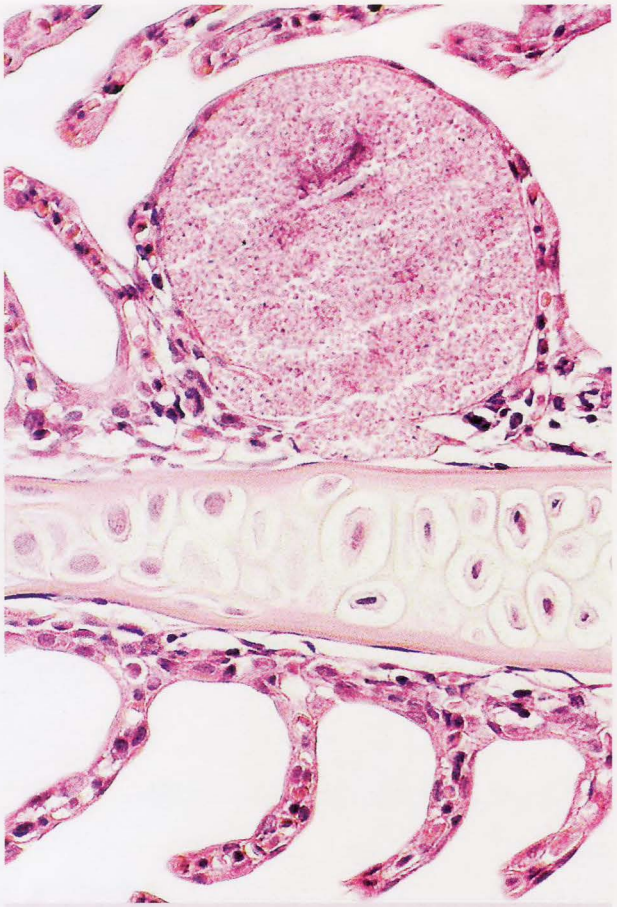

Fig 2.18D. Histology of the microsporidian *Loma salmonae* in trout.

Ectoparasitic metazoa are also frequently encountered, especially monogeneans. Many of these may cause few detectable effects on the host except for local damage imposed by the opisthaptor (hold-fast) ***(Fig 2.20B)***. Large numbers however, can cause emaciation and anaemia. *Gyrodactylus* is reported to have a synergistic action with the ciliate *Trichodina*, so that together, they cause significant damage.

Ergasilid copepods have extra-buccal digestion which leads to lysis of tissue and hyperplasia at the point of attachment ***(Fig 2.20C)***. *Lernaeocera branchialis* initially grasps the filament causing blanching and eventual infarction. In addition to eliciting a host inflammatory response comprising lymphocytes, granulocytes and macrophages, the sheer physical presence of these and other crustacean parasites may interfere with efficient irrigation of the gills, or cause pressure atrophy (so-called "crypting").

Pseudobranchs

Located on the dorsal part of the inner aspect of each operculum, these structures are a hemibranch *i.e.* a gill arch with a single row of filaments, each of which supports lamellae ***(see Fig 5.9A)***. In some species such as cyprinids, they are deeply embedded and difficult to see grossly, whereas in others they are superficial and appear as small red fleshy elevations. In many marine species the filaments erupt through the overlying epithelium to freely contact the outside water. Only a few species lack pseudobranchs, notably some eels and silurids.

Pseudobranch epithelial cells are similar in both covered and free arrangements, however, and in both marine and freshwater species. The specific pseudobranchial cells are also similar to the chloride cells of the gills in that they possess numerous mitochondria and an extensive network of cytoplasmic tubules. It should be noted that both chloride and pseudobranch cells may be found on free

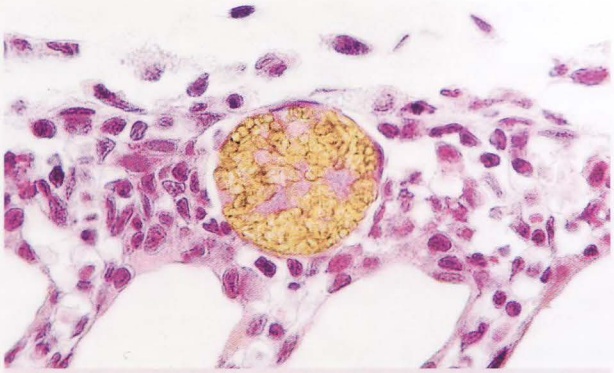

Fig 2.18E. Histology of the microsporidian *Loma salmonae* in trout.



Epitheliocystis. *Fig 2.19A.* Histology from a case in which epitheliocystis appears almost to obliterate the filament.

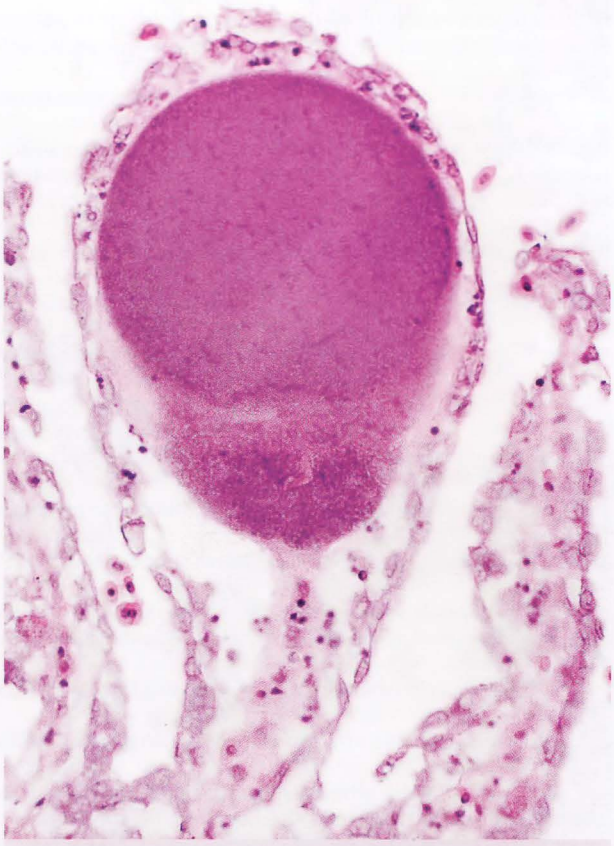

Fig 2.19B. Epitheliocystis from a goldfish.

pseudobranchs. The cells are located on a basal lamina with close proximity to the extensive network of blood vessels that supplies the organs.

The function(s) of the pseudobranchs is unknown although they are unlikely to have any respiratory value as they are already supplied by saturated arterial blood. They do have high carbonic anhydrase levels however, and it is believed that they are linked to the ocular choroid rete (choroid gland) for the purpose of supplying a well-oxygenated blood supply to the retina, possibly by "pre-conditioning" the blood to a point just above onset of the Root effect, prior to entering the choroid rete. Here, very little additional acidification would be required to liberate oxygen by the Root effect, and hence retinal acidification would be avoided. Other suggested roles include some involvement in osmoregulation and that of a sensory role. This is suggested by the presence of a large afferent innervation reaching the brain via the glossopharyngeal nerve, which does respond to pressure changes in the opercular chamber.

The pseudobranchs are frequently involved in bacteraemias and there can be extensive mineralization and destruction of the organs in intensively reared salmonids, often, but not invariably, associated with nephrocalcinosis *(see Fig 4.17)*. Necrosis is also seen in lipoid liver disease, although the pathogenesis of this lesion is unknown. Degeneration and necrosis of the epithelium is seen in columnaris disease and following exposure to a variety of toxicants especially herbicides, heavy metals and pesticides. Gas bubbles are also frequently seen in the pseudobranch in conditions of supersaturation.

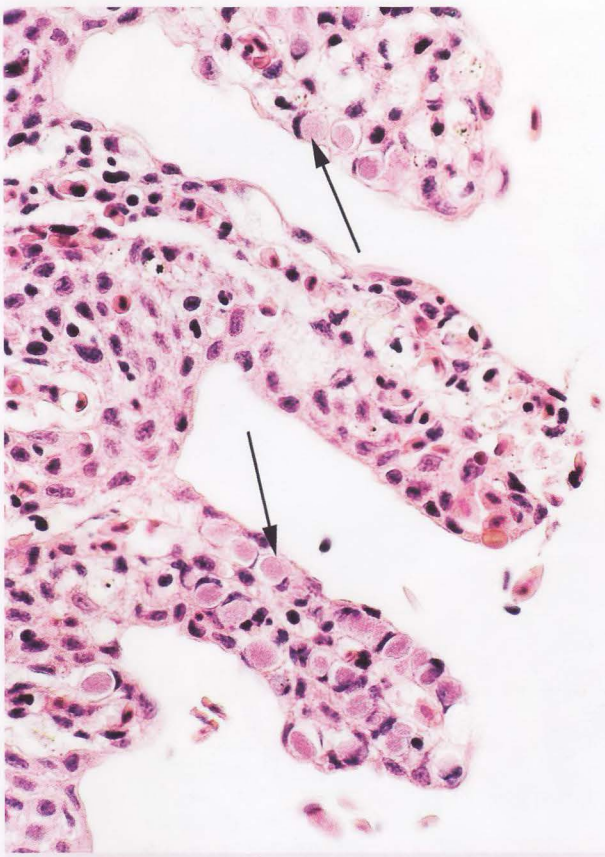

Fig 2.19C. Acute epitheliocystis in Atlantic salmon. In such cases there is associated necrosis and inflammation, and it is hard to view the organisms as merely incidental, although whether there are predisposing causes is unclear.



Fig 2.20B. Monogenean (*Diplectanum* sp.) in gill of Mediterranean seabass. Note the inflammatory response in the filament, including eosinophilic granular cells, which are common in such parasitic infections. *Parasite identification courtesy Dr. A. Shinn.*

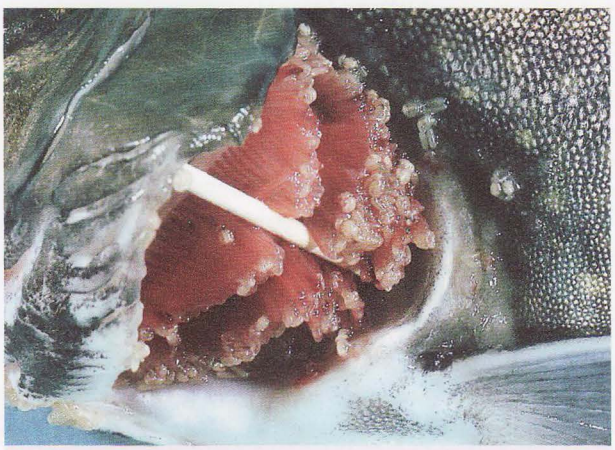

Fig 2.20A. Rainbow trout gill with *Salmincola* copepods. Such parasitism is often of concern to anglers catching affected fish.

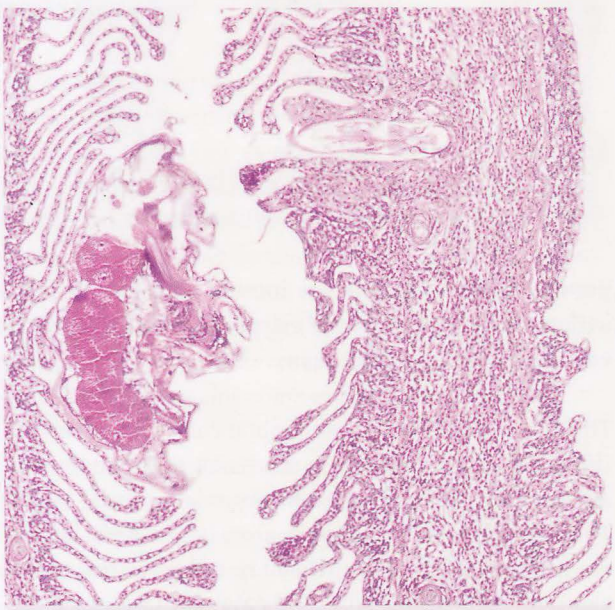

Fig 2.20C. Ergasilus sieboldi attached to the gill of rainbow trout. *Courtesy of Dr. C. Williams.*

References

Al-Kadhomiy, N.K. (1984) Vascular pathways in the gill filaments of the flounder, *Platichthys flesus* L. *Journal of Fish Biology* 24:105-114.

Albassam, M., Moore, J. and Sharma, A. (1987) Ultrastructural and clinicopathological studies on the toxicity of cationic acrylamide-based flocculant to rainbow trout. *Veterinary Pathology* 24:34-43

Arillo, A., Margiocco, C. and Melodia, F. (1979) The gill sialic acid content as an index of environmental stress in rainbow trout, *Salmo gairdneri*, Richardson. *Journal of Fish Biology* 15:405-410.

Barker, D.L. and Mills Westermann, J.E. (1986) Rodlet cells in teleost fish: some aspects of ecology and histochemistry. ***In** Pathology in Marine Aquaculture **eds**.* Vivares, C.P., Bonami, J-R. and Jaspers, E. pp. 247-258, European Aquaculture Society, Special Publ. No. 9.

Blazer, V.S. and Gratzek, J.B. (1985) Cartilage proliferation in response to metacercarial infections of fish gills. *Journal of Comparative Pathology* 95:273-280.

Bowers, A. and Alexander, J.B. (1981) Hyperosmotic infiltration: immunological demonstration of infiltrating bacteria in brown trout, *Salmo trutta* L. *Journal of Fish Biology* 18:9-13.

Brown, P. (1992) Gill chloride cell surface-area is greater in freshwater-adapted adult sea trout (*Salmo trutta*, L.) than those adapted to sea water. *Journal of Fish Biology* 40:481-484.

Burreson, E.M. and Sypek, J.P. (1981) *Cryptobia* sp. (Mastigophora: Kinetoplastida) from the gills of marine fishes in the Chesapeake Bay. *Journal of Fish Diseases* 4: 519-522.

Byrne, P.J. Ostland, V.E., Lumsden, J.S., MacPhee, D.D and Ferguson, H.W. (1995) Blood chemistry and acid-base balance in rainbow trout *Onchorynchus mykiss* with experimentally-induced acute bacterial gill disease. *Fish Physiology and Biochemistry* 14:509-518.

Chilmonczyk, S. and Monge, D. (1980) Rainbow trout gill pillar cells: Demonstration of inert particle phagocytosis and involvement in viral infection. *Journal of the Reticuloendothelial Society* 28:327-332.

Coughlan, D.J. and Gloss, S.P. (1984) Early morphological development of gills in smallmouth bass (*Micropterus dolomieui*). *Canadian Journal of Zoology* 62:951-958.

Crespo, S., Padros, F., Sala, R. and Marlasca, M.J. (1988) Gill structure of cultured *Salmo trutta fario* related to sampling techniques. *Diseases of Aquatic Organisms* 4:219-221.

Daoust, P.-Y. and Ferguson, H.W. (1983) Gill diseases of cultured salmonids in Ontario. *Canadian Journal of Comparative Medicine* 47:358-362.

Daoust, P.-Y. and Ferguson, H.W. (1985) Nodular gill disease: a unique form of proliferative gill disease in rainbow trout, *Salmo gairdneri* Richardson. *Journal of Fish Diseases* 8:511-522.

Daoust, P.-Y., and Ferguson. H.W. (1986) Potential for recovery in nodular gill disease of rainbow trout, *Salmo gairdneri* Richardson. *Journal of Fish Diseases* 9:313-318.

Daoust, P.-Y., Wobeser, G. and Newstead, J.D. (1984) Acute pathological effects of inorganic mercury and copper in gills of rainbow trout. *Veterinary Pathology* 21:93-101.

Davis, H.S., Hoffman, G.L. and Surber, E.W. (1961) Notes on *Sanguinicola davisi* (Trematoda: Sanguinicolidae) in the gills of trout. *Journal of Parasitology* 47:512-514.

Derksen, J.A., Ostland, V.E. and Ferguson, H.W. (1998) Particle clearance from the gills of rainbow trout *Oncorhynchus mykiss*. *Journal of Comparative Pathology* 118:245-256.

Desser, S.S. and Khan, R.A. (1982) Light and electron microscope observations on pathological changes in the gills of the marine fish *Lycodes lavalaei* Vladykov and Tremblay associated with the proliferation of an unidentified cell. *Journal of Fish Diseases* 5:351-364.

Duhamel, G.E., Kent, M.L., Dybdal, N.O. and Hedrick, R.P. (1986) *Henneguya exilis* Kudo associated with granulomatous branchitis of channel catfish *Ictalurus punctatus* (Rafinesque). *Veterinary Pathology* 23:354-361.

Dykova, I. and Lom, J. (1978) Histopathological changes in fish gills infected with myxosporidian parasites of the genus *Henneguya*. *Journal of Fish Biology* 12:197-202.

Dyková, I., Figueras, A., Novoa, B. and Casal, J.F. (1998) *Paramoeba* sp., an agent of amoebic gill disease of turbot *Scophthalmus maximus*. *Diseases of Aquatic Organisms* 33:137-141.

Farkas, J. (1985) Filamentous *Flavobacterium* sp. isolated from fish with gill diseases in cold water. *Aquaculture* 44:1-10.

Ferguson, H.W., Morrison, D., Ostland, V.E., Lumsden, J., and Byrne, P. (1992) Responses of mucus-producing cells in gill disease of rainbow trout (*Oncorhynchus mykiss*). *Journal of Comparative Pathology* 106:255-265.

Fischer-Scherl, T. and Hoffmann, R. (1986) Light- and electron-microscope studies on the pseudobranch of the golden orfe, *Leuciscus idus* L. *Journal of Fish Biology* 29:699-709.

Foskett, J.K., Bern, H.A., Machen, T.E. and Conner, M. (1983) Chloride cells and the hormonal control of teleost fish osmoregulation. *Journal of Experimental Biology* 106:255-281.

Gaino, E., Arillo, A. and Mensi, P. (1984) Involvement of the gill chloride cells of trout under acute nitrite intoxication. *Comparative Biochemistry and Physiology* 77:611-617.

Goldes, S.A., Ferguson, H.W., Daoust, P-Y. and Moccia, R.D. (1986) Phagocytosis of the inert suspended clay kaolin by the gills of rainbow trout, *Salmo gairdneri* Richardson. *Journal of Fish Diseases* 9:147-151.

Hughes, G.M. and Weibel, E.R. (1972) Similarity of supporting tissue in fish gills and the mammalian reticuloendothelium. *Journal of Ultrastructural Research* 39:106-114.

Hughes, G.M. and Perry, S.F. (1976) Morphometric study of trout gills: A light-microscopic method suitable for the evaluation of pollutant action. *Journal of Experimental Biology* 64:447-460.

Hughes, G.M. and Nyholm, K. (1979) Ventilation in rainbow trout (*Salmo gairdneri*, Richardson) with damaged gills. *Journal of Fish Biology* 14:285-288.

Karges, R.G. and Woodward, B. (1984) Development of lamellar epithelial hyperplasia in gills of pantothenic acid-deficient rainbow trout, *Salmo gairdneri* Richardson. *Journal of Fish Biology* 25:57-62.

Karlsson, L. (1983) Gill morphology in the zebrafish, *Brachydanio rerio* (Hamilton-Buchanan). *Journal of Fish Biology* 23:511-524.

Karlsson-Norrgren, L., Runn, P., Haux, C. and Forlin, L. (1985) Cadmium-induced changes in gill morphology of zebrafish, *Brachydanio rerio* (Hamilton-Buchanan), and rainbow trout, *Salmo gairdneri* Richardson. *Journal of Fish Biology* 27:81-95.

Karlsson-Norrgren, L., Bjorklund, I., Ljungberg, O. and Runn, P. (1986) Acid water and aluminium exposure: experimentally induced gill lesions in brown trout, *Salmo trutta* L. *Journal of Fish Diseases* 9:11-25.
Kern, G., Bosch, S.T., Unterhuber, E. and Pelster, B. (2002) Mechanisms of acid secretion in pseudobranch cells of rainbow trout (*Oncorhynchus mykiss*). *The Journal of Experimental Biology* 205:2943-2954.
Knight, J., Holland, J.W., Bowden, L.A., Halliday, K. and Rowley, A.F. (1995) Eicosanoid generating capacities of different tissues from the rainbow trout, *Oncorhynchus mykiss*. *Lipids* 30:451-458.
Köllner, B., Mundt, E. and Fischer, U. (1998) A monoclonal antibody recognizing a complex tubular structure in rainbow trout pillar cells. *Journal of Fish Biology* 53:853-865.
Kudo, S. and Kimura, N. (1983) Transmission electron microscopic studies on bacterial gill disease in rainbow trout fingerlings. *Japanese Journal of Ichthyology* 30:247-260.
Kumaraguru, A.K., Beamish, F.W.H. and Ferguson, H.W. (1982) Direct and circulatory paths of Permethrin (NRDC-143) causing histopathological changes in the gills of rainbow trout, *Salmo gairdneri* Richardson. *Journal of Fish Biology* 20:87-91.
Langdon, J.S., Thorpe, J.E. and Roberts, R.J. (1984) Effects of cortisol and ACTH on gill Na^+/K^+-ATPase, SDH and chloride cells in juvenile Atlantic salmon *Salmo salar* L. *Comparative Biochemistry and Physiology* 77:9-12.
Langdon, J.S., Gudkovs, N., Humphrey, J.D. and Saxon, E.C. (1985) Deaths in Australian freshwater fishes associated with *Chilodonella hexasticha* infection. *Australian Veterinary Journal* 62:409-413.
Laurent, P. and Dunel-Erb, S. (1984) The pseudobranch: morphology and function. ***In*** *Fish Physiology*, Vol. XB. pp. 285-323. ***eds***. Hoar, W.S. and Randall, D.J., Academic Press.
Laurent, P. and Perry, S.F. (1991) Environmental effects of fish gill morphology. *Physiological Zoology* 64:4-25.
Laurent, P., Dunel-Erb, S., Chevalier, C. and Lignon, J. (1994) Gill epithelial cells kinetics in a freshwater teleost, *Oncorhynchus mykiss* during adaptation to ion-poor water and hormonal treatments. *Fish Physiology and Biochemistry* 13:353-370.
Lumsden, J.S., Ferguson, H.W., Ostland, V.E. and Byrne, P.J. (1994) Detection of a layer of mucus covering lamellae of unstressed rainbow trout. *Cell and Tissue Research* 275:187-193.
Lumsden, J.S. and Ferguson, H.W. (1994) Isolation and partial characterization of rainbow trout (*Oncorhynchus mykiss*) gill mucin. *Fish Physiology and Biochemistry* 12:387-398.
Mallatt, J. (1985) Fish gill structural changes induced by toxicants and other irritants: A statistical review. *Canadian Journal of Fisheries and Aquatic Sciences* 42:630-648.
Malte, H. (1992) Effect of pulsatile flow on gas exchange in the fish gill: theory and experimental data. *Respiration Physiology* 88:51-62.
Mathias, J.A. and Barica, J. (1985) Gas supersaturation as a cause of early spring mortality of stocked trout. *Canadian Journal of Fisheries and Aquatic Sciences* 42:268-279.
Mattey, D.L., Morgan, M. and Wright, D.E. (1980) A scanning electron microscope study of the pseudobranchs of two marine teleosts. *Journal of Fish Biology* 16:331-343.
Meakins, R.H. and Kawooya, J. (1973) The effects and distribution of metacercaria on the gills of the fish *Tilapia zilli* (Gervais) 1848. *Zeitschrift Fur Parasitenkunde* 43:25-31.
Molnar, K. and Boros, G. (1981) A light and electron microscopic study of the agent of carp mucophilosis. *Journal of Fish Diseases* 4:325-334.
Morgan, M. (1974) Development of secondary lamellae of the gills of the trout, *Salmo gairdneri* (Richardson). *Cell and Tissue Research* 151:509-523.
Morrison, C.M. and Sprague, V. (1981) Electron microscopical study of a new genus and new species of microsporida in the gills of Atlantic cod *Gadus morhua* L. *Journal of Fish Diseases* 4:15-32.
Morrison, C.M. and Marryatt, V. (1986) Further observations on *Loma morhua* Morrison and Sprague, 1981. *Journal of Fish Diseases* 9:63-67.
Munshi, J.S.D. and Hughes, G.M. (1981) Gross and fine structure of the pseudobranch of the climbing perch, *Anabas testudineus* (Bloch). *Journal of Fish Biology* 19:427-438.
Naito, N. and Ishikawa, H. (1980) Reconstruction of the gill from single-cell suspensions of the eel, *Anguilla japonica*. *American Journal of Physiology* 238:R165-R170.
Neukirch, M. (1984) An experimental study of the entry and multiplication of viral haemorrhagic septicaemia virus in rainbow trout, *Salmo gairdneri* Richardson, after water-borne infection. *Journal of Fish Diseases* 7:231-234.
Nilsson, G. (1995) Extensive erythrocyte deformation in fish gills observed by in vivo microscopy: apparent adaptations for enhancing oxygen uptake. *Journal of Experimental Biology* 198:1151-1156.
Nilsson, S. and Sundin, L. (1998) Gill blood flow control. *Comparative Biochemistry and Physiology* 119A:137-147.
Niimi, A.J. and Morgan, S.L. (1980) Morphometric examination of the gills of walleye, *Stizostedion vitreum vitreum* (Mitchill) and rainbow trout, *Salmo gairdneri* Richardson. *Journal of Fish Biology* 16:685-692.
Nylund, A. and Kvenseth, A.M. (1998) A morphological study of the epitheliocystis agent in farmed Atlantic salmon. *Journal of Aquatic Animal Health* 10:43-55.
Olson, K.R. (2002) Gill circulation: regulation of perfusion distribution and metabolism of regulatory molecules. *Journal of Experimental Zoology* 293:320-335.
Olson, K.R. (2002) Vascular anatomy of the fish gill. *Journal of Experimental Zoology* 293:214-231.
Oronsaye, J.A.O. and Brafield, A.E. (1984) The effect of dissolved cadmium on the chloride cells of the gills of the stickleback, *Gasterosteus aculeatus* L. *Journal of Fish Biology* 25:253-258.
Ostland, V.E., Byrne, P.J., Lumsden, J.S., MacPhee, D.D., Derksen, J.A., Haulena, M., Skar, K., Mhyr, E., and Ferguson, H.W. (1999) Atypical bacterial gill disease: a new form of bacterial gill disease affecting intensively reared salmonids. *Journal of Fish Diseases* 22:351-358
Ototake, M. and Wakabayashi, H. (1985) Characteristics of extracellular products of *Flavobacterium* sp., a pathogen of bacterial gill disease. *Fish Pathology* 20:167-171.
Paperna, I. and Van As, J.G. (1983) The pathology of *Chilodonella hexasticha* (Kiernik) Infections in cichlid fishes. *Journal of Fish Biology* 23:441-450.
Paperna, I. and Alves De Matos, A.P. (1984) The developmental cycle of epitheliocystis in carp, *Cyprinus carpio* L. *Journal of Fish Diseases* 7:137-147.

Part, P., Svanberg, O. and Bergstrom, E. (1985) The influence of surfactants on gill physiology and cadmium uptake in perfused rainbow trout gills. *Ecotoxicology and Environmental Safety* 9:134-144.
Peters, G., Hoffmann, R. and Klinger, H. (1984) Environment-induced gill disease of cultured rainbow trout (*Salmo gairdneri*). *Aquaculture* 38:105-126.
Peters, G. and Hong, L.Q. (1985) Gill structure and blood electrolyte levels of European eels under stress. ***In***: Fish *and Shellfish Pathology. **ed.*** Ellis, A.E. Academic Press, London.
Philpott, C.W. (1980) Tubular system membranes of teleost chloride cells: osmotic response and transport sites. *American Journal of Physiology* 238:R171-R184.
Pic, P. and Lahitette, P. (1981) Effects of cytochalasin B on water, Na^+ and Cl^- exchanges in the gill of seawater adapted mullet *Mugil capito*. *Journal of Comparative Physiology* 141:523-529.
Poston, H.A. and Page, J.W. (1982) Gross and histological signs of dietary deficiencies of biotin and pantothenic acid in Lake trout, *Salvelinus namaycush*. *Cornell Veterinarian* 72:242-261.
Powell, M.D., Wright, G.M. and Speare, D.J. (1995) Morphological changes in rainbow trout (*Oncorhynchus mykiss*) gill epithelia following repeated intermittent exposure to chloramine-T. *Canadian Journal of Zoology* 73:154-165.
Powell, M.D., Speare, D.J. and Burka, J.F. (1992) Fixation of mucus on rainbow trout (*Oncorhynchus mykiss* Walbaum) gills for light and electron microscopy. *Journal of Fish Biology* 41:813-824.
Powell, M.D., Speare, D.J. and Wright, G.M. (1994) Comparative ultrastructural morphology of lamellar epithelial, chloride and mucous cell glycocalyx of the rainbow trout (*Oncorhynchus mykiss*) gill. *Journal of Fish Biology* 44:725-730.
Randall, D.J., Perry, S.F. and Heming, T.A. (1982) Gas transfer and acid/base regulation in salmonids. *Comparative Biochemistry and Physiology* 73B:93-103.
Robertson, J.C. and Hazel, J.R. (1998) Elevated 5'-nucleotidase and alkaline phosphodiesterase activities in trout gill localize to endothelial (pillar) cells. *Journal of Experimental Biology* 201:2011-9.
Rodgers, L.J. and Burke, J.B. (1981) Seasonal variation in the prevalence of 'red spot' disease in estuarine fish with particular reference to the sea mullet, *Mugil cephalus* L. *Journal of Fish Diseases* 4:297-307.
Rodriguez-Tovar, L.E., Wright, G.M., Wadowska, D.W., Speare, D.J. and Markham, R.J. (2002) Ultrastructural study of the early development and localization of *Loma salmonae* in the gills of experimentally infected rainbow trout. *Journal of Parasitology* 88:244-253.
Roubal, F.R. (1987) Gill surface area and its components in the yellowfin bream, *Acanthopagrus australis* (Gunther)(Pisces:Sparidae). *Australian Journal of Zoology* 35:25-34.
Roubal, F.R. (1987) Comparison of ectoparasite pathology on gills of yellowfin bream, *Acanthopagrus australis* (Günther) (Pisces: Sparidae): a surface area approach. *Australian Journal of Zoology* 35:93-100.
Rourke, A.W., Davis, R.W. and T.M. Bradley. (1984) A light and electron microscope study of epitheliocystis in juvenile steelhead trout, *Salmo gairdneri* Richardson. *Journal of Fish Diseases* 7:301-309.
Sanchez, J.G., Speare, D.J., Markham, R.J.F., Wright, G.M. and Kibenge, F.S.B. (2001) Localization of the initial development stages of *Loma salmonae* in rainbow trout (*Oncorhynchus mykiss*). *Veterinary Pathology* 38:540-546.
Sanchez, J.G., Speare, D.J. and Johnson, G.J. (1997) Morphometric and histochemical assessment of the branchial tissue response of rainbow trout, *Oncorhynchus mykiss* (Walbaum), associated with chloramine-T treatment. *Journal of Fish Diseases* 20:375-381.
Sanchez, J.G., Speare, D.J., Sims, D.E. and Johnson, G.J. (1998) Morphometric assessment of epidermal and mucous-biofilm changes caused by exposure of trout to chloramine-T or formalin treatment. *Journal of Comparative Pathology* 118:81-87.
Sanchez, J.G., Speare, D.J., Sims, D.E. and Johnson, G.J. (1997) Adaptation of a fluorocarbon-based non-aqueous fixation regime for the ultrastructural study of the teleost epithelial mucous coat. *Journal of Comparative Pathology* 117:165-170.
Sano, T., Okamoto, N. and Nishimura, T. (1981) A new viral epizootic of *Anguilla japonica* Temminck and Schlegel. *Journal of Fish Diseases* 4:127-139.
Satchell, G.H. (1984) Respiratory toxicology of fishes. pp. 1-50 ***In*** *Aquatic Toxicology*, Vol. 2, ***ed.*** Weber, L.J., Raven Press, New York.
Shariff, M. (1982) *Henenguya shaharini* sp.nov. (Protozoa: Myxozoa), a parasite of marble goby, *Oxyeleotris marmoratus* (Bleeker). *Journal of Fish Diseases* 5:37-45.
Smith, D.G. and Chamley-Campbell, J. (1981) Localization of smooth-muscle myosin in branchial pillar cells of snapper (*Chrysophys auratus*) by immunofluorescence histochemistry. *Journal of Experimental Zoology* 215:121-124.
Soderberg, R.W. (1985) Histopathology of rainbow trout, *Salmo gairdneri* Richardson, exposed to diurnally fluctuating un-ionized ammonia levels in static-water ponds. *Journal of Fish Diseases* 8:57-64.
Solangi, M.A. and Overstreet, R.M. (1982) Histopathological changes in two estuarine fishes, *Menidia beryllina* (Cope) and *Trinectes maculatus* (Bloch and Schneider), exposed to crude oil and its water-soluble fractions. *Journal of Fish Diseases* 5:13-35.
Speare, D.J. (1999) Nodular gill disease (Amoebic gill infestation) in arctic char, *Salvelinus alpinus*. *Journal of Comparative Pathology* 121:277-282.
Speare, D.J., Ferguson, H.W., Beamish, W.M., Yager, J.A. and Yamashiro, S. (1991) Pathology of bacterial gill disease: ultrastructure of branchial lesions. *Journal of Fish Diseases* 14:1-20.
Speare, D.J. and Ferguson, H.W. (1989) Fixation artifacts in rainbow trout (*Salmo gairdneri*) gills: a morphometric evaluation. *Canadian Journal of Fisheries and Aquatic Sciences* 46:780-785.
Speare, D.J., Carvajal, V. and Horney, B.S. (1999) Growth suppression and branchitis in trout exposed to hydrogen peroxide. *Journal of Comparative Pathology* 120:391-402.
Speare, D.J., Brackett, J. and Ferguson, H.W. (1989) Sequential pathology of the gills of Coho salmon with a combined diatom and microsporidian gill infection. *Canadian Veterinary Journal* 30:571-575.
Svendsen, Y.S., Dalmo, R.A. and Bøgwald, J. (1999) Tissue localization of *Aeromonas salmonicida* in Atlantic salmon, *Salmo salar* L., following experimental challenge. *Journal of Fish Diseases* 22:125-131.
Thune, R.L. and Rogers, W.A. (1981) Gill lesions in bluegill, *Lepomis macrochirus* Rafinesque, infested with *Cleidodiscus robustus* Mueller, 1934 (Monogenea: Dactylogyridae). *Journal of Fish Diseases* 4:277-280.

Torroba, M., Anderson, D.P., Dixon, O.W., Casares, F., Varas, A. and Alonso, L. (1993) In vitro antigen trapping by gill cells of the rainbow trout: an immunohistochemical study. *Histology and Histopathology* 8:363-367.
Wakabayashi, H. (1980) Bacterial gill disease of salmonid fish. *Fish Pathology* 14:185-189.
Wakabayashi, H., Egusa, S. and Fryer, J.L. (1980) Characteristics of filamentous bacteria isolated from a gill disease of salmonids. *Canadian Journal of Fisheries and Aquatic Science* 37:1499-1504.
Wakabayashi, H. and Iwado, T. (1985) Effects of a bacterial gill disease on the respiratory functions of juvenile rainbow trout. ***In***: *Fish and Shellfish Pathology.* ***ed.*** Ellis, A.E., Academic Press, London.
Wilkie, M.P. (1997) Mechanisms of ammonia excretion across fish gills. *Comparative Biochemistry and Physiology* 118A:39-50.
Wilson, J.M. and Laurent, P. (2002) Fish gill morphology: inside out. *Journal of Experimental Zoology* 293:-192-213.
Woodward, B. (1984) Symptoms of severe riboflavin deficiency without ocular opacity in rainbow trout (*Salmo gairdneri*). *Aquaculture* 37:275-281.
Wootten, R. and McVicar, A.H. (1982) *Dermocystidium* from cultured eels, *Anguilla anguilla* L., in Scotland. *Journal of Fish Diseases* 5:215-222.
Zapata, A.G., Torroba, M., Alvarez, F., Anderson, D.P., Dixon, O.W. and Wisniewski, M. (1987) Electron microscopic examination of antigen uptake by salmonid gill cells after bath immunization with a bacterin. *Journal of Fish Biology* 31:209-217.
Zenker, W.G.E., Ferguson, H.W., Barker, I.K. and Woodward, W. (1987) Epithelial and pillar cell replacement in gills of juvenile trout *Salmo gairdneri* Richardson. *Comparative Biochemistry and Physiology* 86A:423-428.



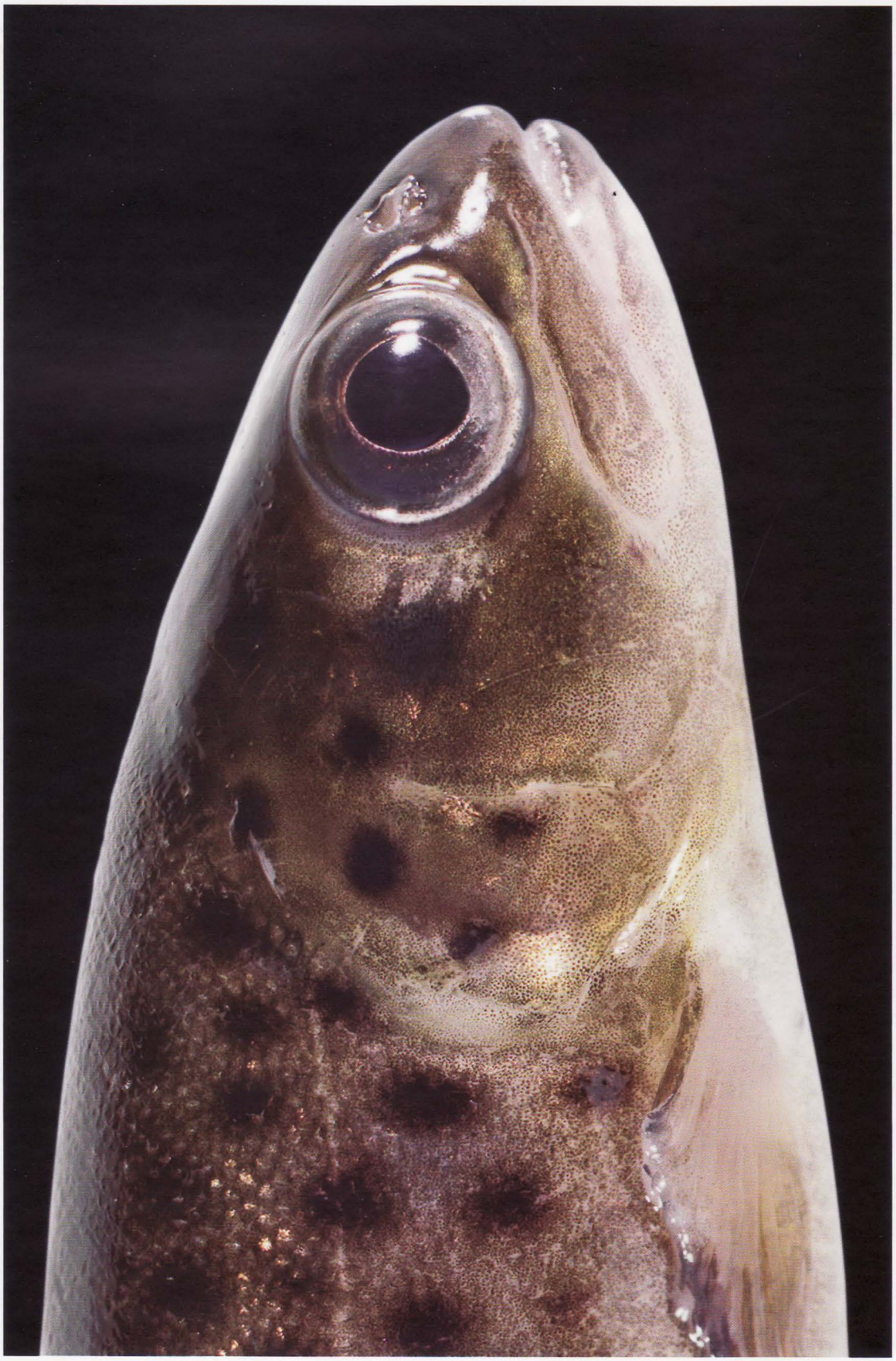



Skin

CHAPTER 3

Hugh W. Ferguson

Skin lesions in fish are common. This is a reflection firstly of the organ's relative delicacy, compared to that of mammals. Secondly, it functions as an osmotic barrier, and hence minor lesions may rapidly progress to major ones, particularly in freshwater. Thirdly, skin lesions are easily seen, especially so when many of them cause pronounced colour change. Examination of wet-mounted skin scrapings for the presence of parasites or bacteria, is almost essential to a diagnosis, as many of the protozoa in particular, are much more easily seen this way than in paraffin sections. On another practical note, Bouin's fixation can be a great help because of its demineralizing properties, thereby making sectioning easier in scaled species, especially in small but adult specimens; hence artifact is greatly reduced.

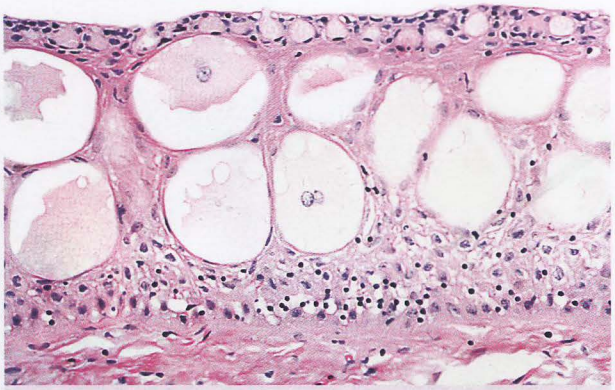

Fig 3.1. Normal skin from brown bullhead (catfish) which has no scales, but a relatively thick epidermis containing large pale club cells and smaller goblet cells above them.

Normal

There are great inter-species differences in teleost skin; some species have no scales while others have numerous large eosinophilic club cells (fright-substance cells or Shreckstoffzellen) within the epidermis ***(Fig 3.1)***. There are also however, large variations within a species and even with different locations on the same fish. For example, epidermal thickness in salmonids is greatest on top of the head and over the fins where no scales are found. In addition, age, sex and time of year all exert pronounced influences on the appearance and relative proportions of the different components of the skin. For these reasons, it is important to exercise care when examining pathological changes in this organ, and paired samples taken from the same location on the body of an apparently unaffected fish of the same age, sex and species, are recommended as an aid to correct interpretation. In addition, sampling lesions and adjacent apparently normal areas can be a major help when trying to decide on the significance of morphological changes and the presence of antigens; this approach of course applies to all organs, but seems especially important in skin.

The ***epidermis*** is a non-keratinizing (in most species) stratified squamous epithelium that varies in thickness from 3 or 4 cells up to approximately 20. A major difference from mammals is that in those teleosts that have no keratinized cells, the outermost epidermal cells are viable, and retain the capacity to divide; this has obvious implications for healing. In scanning electron microscopy these outer cells can be seen to have a fingerprint-like microridge pattern ***(Fig 3.2)***. In addition to the filament-containing or malpighian cells that comprise the majority component, other epidermal cell types include mucous or goblet cells that are largely responsible for secreting the cuticle (inapparent in routine H&E sections), large eosinophilic club cells (only some species), eosinophilic granule cells (unknown function), wandering leukocytes, and macrophages, which may contain melanin. There are variable numbers of lymphocytes in normal teleost epidermis, and these can greatly increase in number under some disease conditions; they can become especially abundant just above the basal layer. Although these are involved in local immune responses (so that for example cutaneous mucus antibody levels can rise independent of systemic humoral responses), the full significance of their participation has yet to be established. Some species like mudskippers (*Periophthalmus modestus*) have capillaries near the superficial layers, and lymphatics near the stratum germanitivum, both adaptations for air-breathing. Specialised structures within the epidermis include taste buds and neuromasts.

The ***dermis*** of scaled skin comprises an upper stratum spongiosum and a deep stratum compactum. In unscaled regions, stratum compactum is reduced. Large numbers

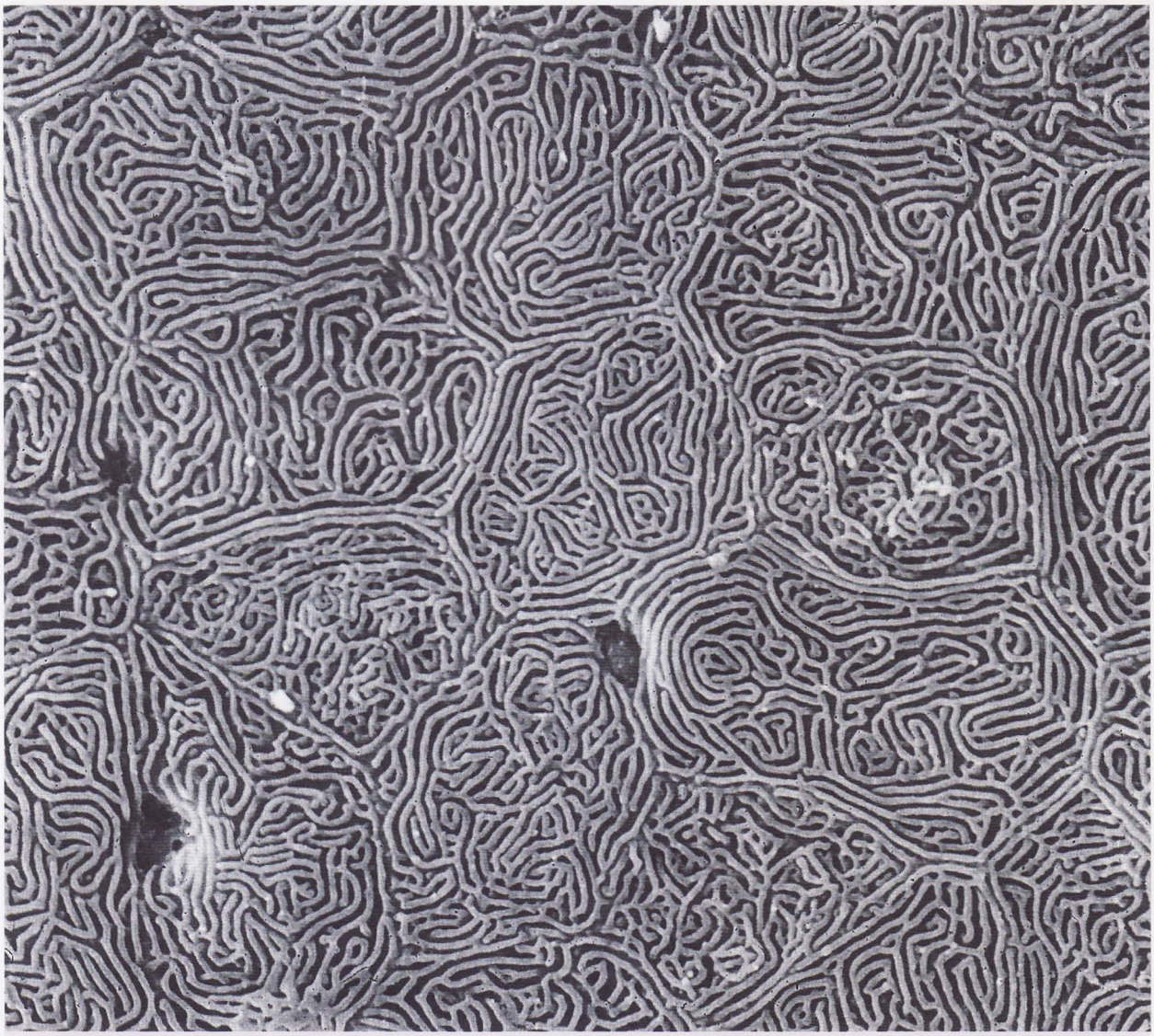

Fig 3.2. SEM of normal rainbow trout skin showing fingerprint-like microridged pattern of the outer epidermal cells and 3 mucus cell pores. The outline of individual cells can be seen. This material was fixed in aldehydes which rapidly remove the mucus covering normally present.

of a variety of pigment-cell types are present at different levels within the dermis: these include melanophores, xanthophores and iridophores. These latter contain reflective plates of guanine which thereby render a silvery appearance to the skin when orientated at 90° to the oncoming light. In transparent fish (like glass catfish) the arrangement of dermal collagen fibres resembles that seen in the cornea. ***Scales*** are a major feature of most species of teleosts **(*Fig 3.3*)**, and it is important to appreciate that, where present, they originate in scale-pockets in the *dermis* and become covered by a layer of epidermis as they emerge, often to overlap one another, thereby providing significant structural support and physical protection. Thus, scale-loss represents a very significant breach in the osmotic and/or physical defences of the fish. Scales comprise an outer reticulated osseous part with saw-tooth-like ridges, and an inner fibrillar layer that is uncalcified in some species and partially calcified in others. This latter consists of parallel collagen fibres embedded in an organic matrix. Scale modifications provide protection for the lateral line. This canal runs along both sides of the fish and joins up with a series of sensory canals on the head, including the infra- and supraoptic canals. They contain neuromasts, and connect to the outside water through pores in the scales. They can be a common site for lesions including improper closure, ulceration and even parasites **(*Fig 3.4*)**. A dermal component of the skeleton, scales represent a ready source of calcium, and



Fig 3.3. Normal trout skin showing overlapping distribution of scales: note the ridges on their outer surface. The epidermis (E) contains goblet cells but no club cells in this species.

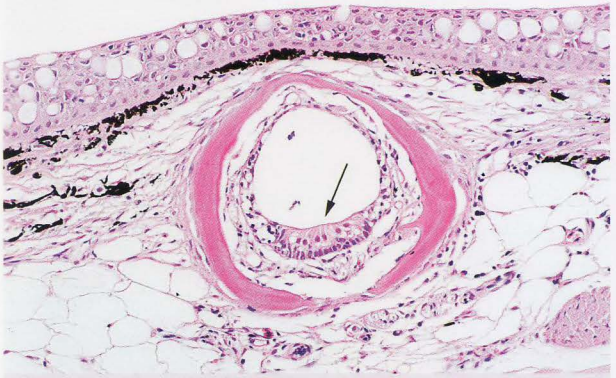

Fig 3.4A. Sensory canal from salmonid within encasing bone. Neuromasts can also be seen (arrow).

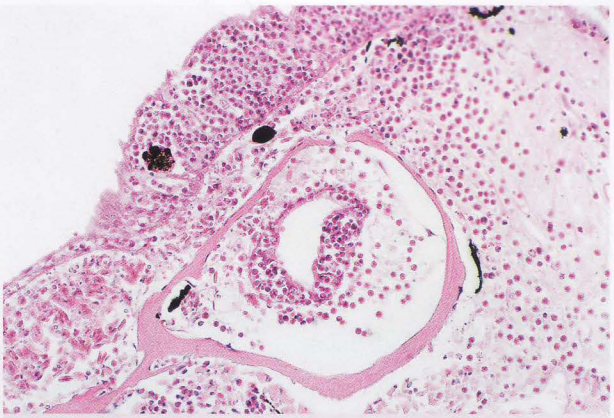

Fig 3.4B. Acute inflammation within and surrounding supra-optic canal.

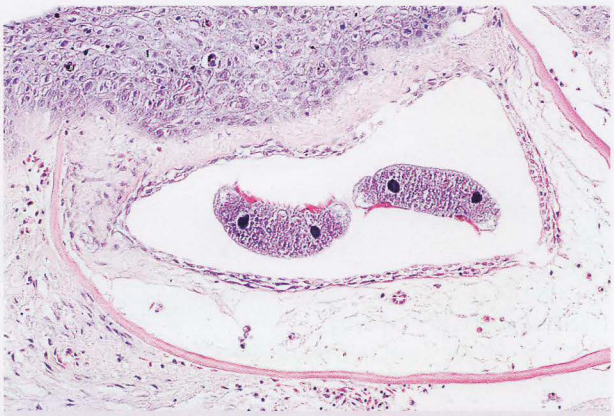

Fig 3.4C. Trichodinids within sensory canal, apparently having little effect.

during periods of starvation or pre-spawning, they may be resorbed in preference to the skeletal reserves.

Beneath the deep compact dermal layer, the loose relatively well-vascularized ***hypodermis*** provides a frequent avenue for lateral movement of pathogens and inflammatory processes.

Disease

Clinical signs of skin disease include hyperactivity, and obvious evidence of irritation such as rubbing against the sides or bottom of tanks or ponds; in so doing, the sides of the fish become visible from above and the behaviour is known as "flashing". In some cases the fish may even jump out of the water. As with gill disease, there is usually excess mucus production and this can result in foam accumulating on top of the water. Severe epidermal hyperplasia may produce a grossly visible white



Fig 3.5A&B. Skin lesions are common in intensively-reared fish. **A** shows post-spawned brown trout with dermatitis and dermal oedema, the latter a consequence of hypoproteinaemia brought on by over-vigorous stripping of unripe fish and resulting haemorrhage. **B** shows a rainbow trout with severe dermal erosion and ulceration of the tail. Dorsal fin is another common location. These types of lesions can often become secondarily infected.



film, although a necrotizing lesion that destroys epidermis as well as the underlying pigment cell layer (as with columnaris disease) can superficially resemble this. Some farmers will sometimes use disinfectant strong enough to cause "coagulation of mucus" – but this is almost certainly acute coagulative necrosis of epidermis! Necrosis of the dorsal fin is common in cultured rainbow trout especially in situations where the fish are overstocked (*Fig 3.5*). Similar lesions are seen in salmon under the same conditions although in these fish the tail is a more frequent target. "Yellow-pigmented bacteria" or "myxobacteria" (as these used to be called) are often associated with both of these conditions, and although the reason for the different predilection sites is unknown, merely reducing the stocking density can often effect a cure. Fish with severe skin disease may become lethargic and inappetant, although systemic involvement through loss of osmoregulatory control (see below) or septicaemia from secondary bacterial or fungal infections inevitably complicates the picture.

Although skin lesions are common, the variety of pathological changes tends to be more limited than in mammals. This may be partly explained by the absence of adnexal structures, and partly by the extreme and probably dominating osmotic forces that are very rapidly brought to bear once the initial "waterproof" barrier is breached. If or when this occurs, influx of the surrounding water may, in addition, dilute or flush away any antigens present, thereby reducing the need for inflammation. It is of interest to note that in salmonids, the neural lymph duct is blocked and the main lymphatic return to the heart must therefore be via the cutaneous vessels. (Recent detailed anatomical studies suggest that fish may not have true lymphatic vessels, but for the purpose of this discussion, the traditional view will be adhered to). In plaice (*Pleuronectes platessa*) and presumably most other teleosts, the total lymph volume of the muscle and skin is more than 4 times that of the circulating blood volume; and more than 80% of that lymph is dermal. The inference is that skin disease, or anything else that alters lymph volume, can profoundly alter the circulating blood picture both in terms of protein and electrolyte content, as well as relative haematocrit.

Epidermal cells are the main cells involved in ***wound closure***, and therefore in creating an environment suitable for scale regeneration. Restoration of epidermal integrity can happen within hours of ulceration, although

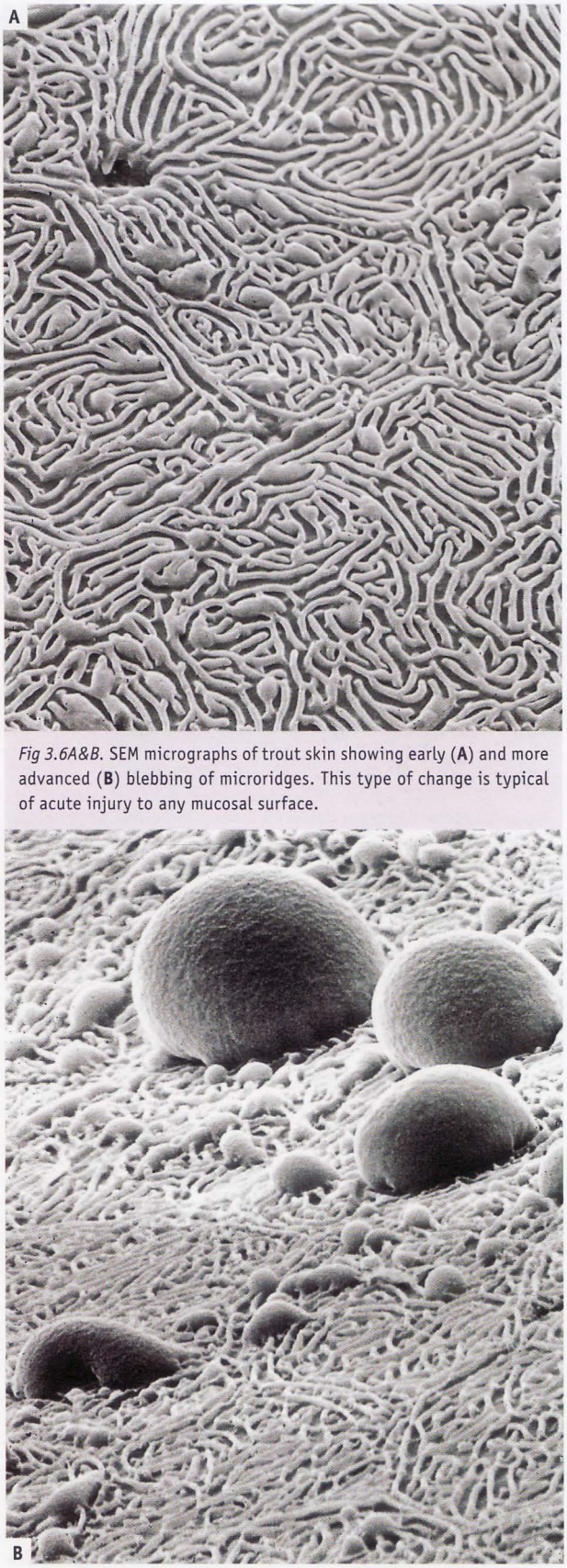

Fig 3.6A&B. SEM micrographs of trout skin showing early (**A**) and more advanced (**B**) blebbing of microridges. This type of change is typical of acute injury to any mucosal surface.



Fig 3.7A. Acute epidermal damage showing spongiosis and partial lifting from the underlying thickened basement membrane, although the layer of basal cells remains intact. Clumping of melanin granules in the underlying dermal melanocytes can also be seen, as can a few inflammatory cells.

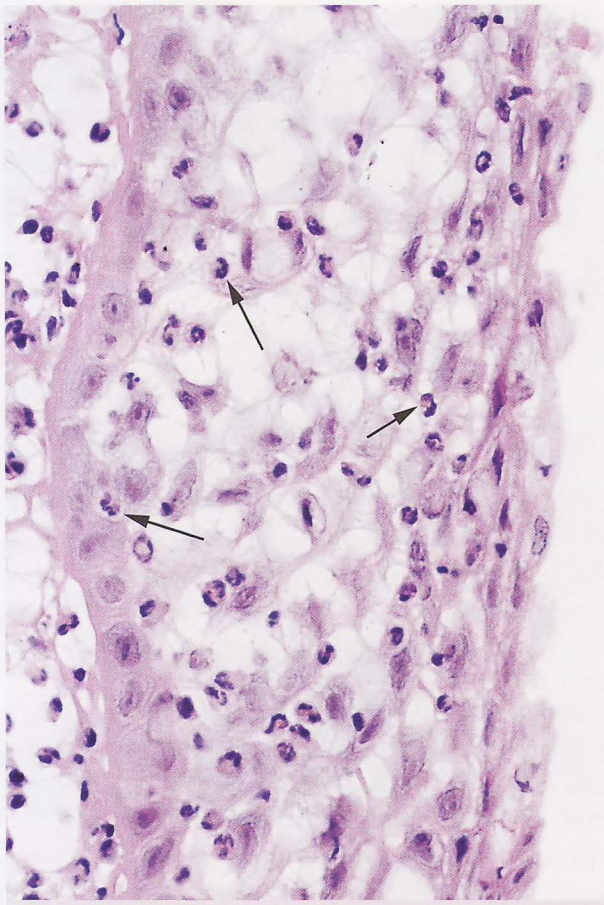

Fig 3.7B. Acute dermatitis showing spongiosis and moderate numbers of neutrophils (arrows) within epidermis and migrating up from dermis beneath. Once again, the basal progenitor cells remain sitting on basement membrane.

obviously it will be temperature dependant. As beautifully described by Sire, Boulekbache and Joly (1990) in otherwise normal fish, cells move over a basement membrane separated from the stratum compactum; as in mammals, fibronectin is crucial to this whole process, as are the cells lining the scale pocket. The processes involved when the skin is infected are possibly quite different.

With our present state of knowledge, classifying dermal disease in fish is probably best accomplished according to histological location:

Superficial disease

In almost all species the epidermis is avascular, and this fact imposes its own restrictions on the variety of potential responses to injury. Acute responses to insult include blebbing of epidermal microridges *(Fig 3.6)*, and discharge of goblet and club cells, although this may be difficult to appreciate histologically. Inter-cellular oedema (spongiosis) and intra-cellular oedema (hydropic degeneration) are more easily seen, and accompany the early stages of many parasitic and bacterial diseases *(Fig 3.7)*. If spongiosis is severe, cell-to-cell contact may totally break down with the consequent formation of vesicles or bullae. These tend to be more common just at or above the basal layer. They may become confluent with lifting and loss of epidermis *(Fig 3.8)*, leaving at most only a single row of cells resting on the basement membrane. Such a dermo-epidermal separation must be carefully differentiated from processing artifact, especially in scaled species. In mammals, ***pemphigus*** is a group of auto-immune skin diseases characterized by the formation of vesicles, bullae, erosions, acantholysis, and the production of antibodies directed against epithelial cells. Auto-immune skin diseases have not been described in fish, although the analogy has been drawn between pemphigus and the histological changes seen in the specific entity ulcera-

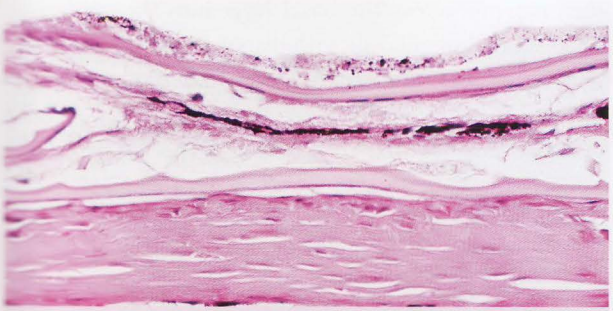

Fig 3.8A. Acute necrosis of epidermis which is no longer present.

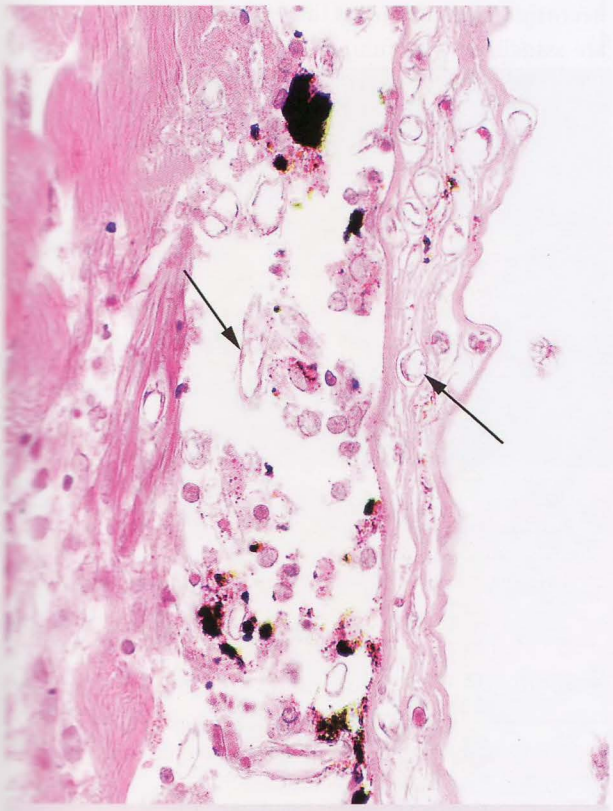

Fig 3.8B. Acute necrosis of epidermis with fungal hyphae in epidermis and invading down into dermis (arrows).

tive dermal necrosis (UDN) or Irish salmon disease of salmonids (Roberts & Bullock,1976). The condition is seen when Atlantic salmon (other salmonids are also susceptible) enter freshwater on their return migration prior to spawning **(*Fig 3.9*)**. Early lesions include breakdown in intercellular junctions, although the skin rapidly becomes secondarily infected, particularly with *Saprolegnia* sp. of fungi. Despite exhaustive research, with different hypotheses being favoured from time to time, the cause and pathogenesis of this historically important disease remain an almost complete mystery.



Fig 3.9. Ulcerative dermal necrosis (UDN) of sea-run brown trout. The lesions in this historically important disease are mainly epidermal. *Courtesy of Dr.T.T. Poppe.*

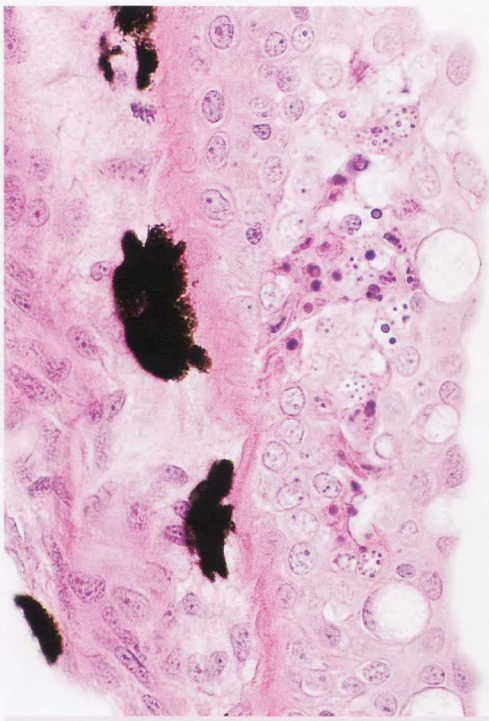

Fig 3.10A. Acute intra-epidermal necrosis in salmon fry, the result of toxin injection by nematocyst from *Hydra*.
Material courtesy of N. Shalit.

Damage to epidermis **(*Fig 3.10*)** leads to release of cytokines such as interleukin-1 that probably control release of mucus and club cell secretions, while leukotrienes are involved in modulating inflammation. Neutrophil infiltration into epidermis is a frequent accompaniment to early damage, and infiltration of vesicles by inflammatory cells to form "pustules" is also common, especially in the early stages of superficial bacterial or fungal diseases **(*Fig 3.11*)**. Individual malpighian cells may die with pyknosis



Fig 3.10B. White sucker showing several foci of dermal oedema and hyperaemia, with elevation of scales. These lesions were produced experimentally by injecting chemicals. *Courtesy of Dr. I. Smith.*

seen moving across the basal layer into the epidermis. Rupture of pigment cells with dispersion of granules may also be seen. If the osmotic barrier is broken, dermal oedema may be pronounced: such a process has been termed "waterlogging" in freshwater species, where the osmotic gradient tends to force water into the tissues. Under these circumstances dermal lymphatics become greatly dilated, and the whole dermis may be massively thickened. Diffuse dermal oedema may also accompany hypoproteinemia **(*Fig 3.13*)**.

If present, these changes may rapidly proceed to severe necrosis and sloughing of the epidermis. Examples of this are associated with fungal infection by *Saprolegnia diclina* **(*Fig 3.14*)**, and the bacterial conditions peduncle disease (*Flavobacterium psychrophilum* - **Fig 3.15**) columnaris dis-

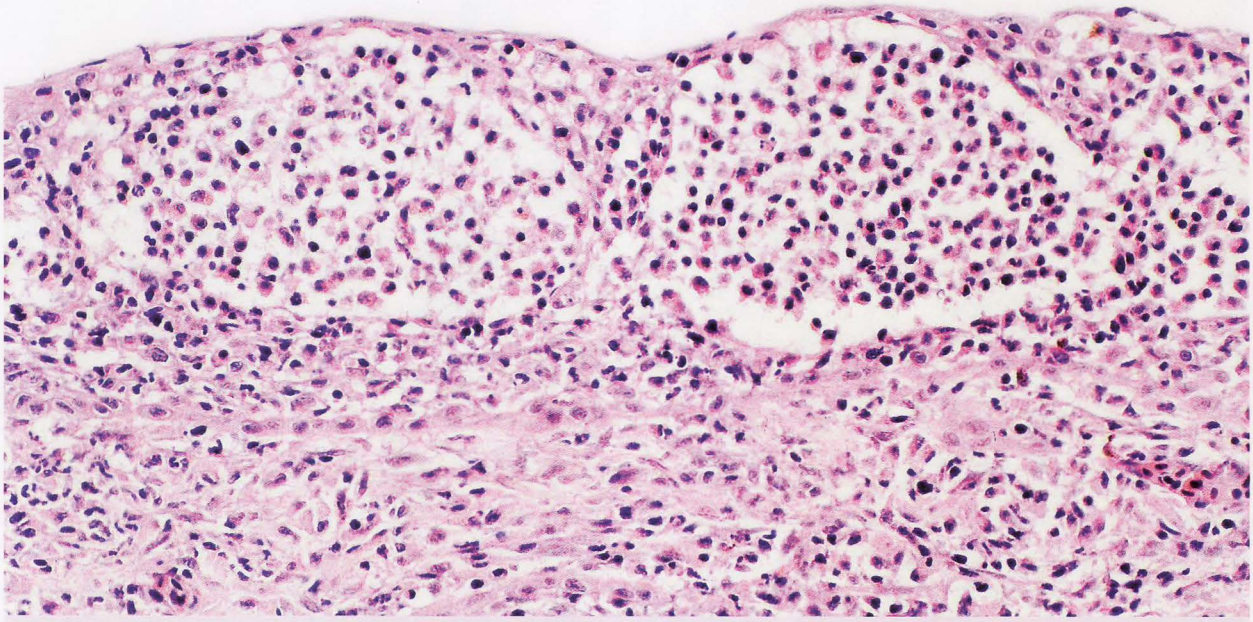

Fig 3.11. Acute dermatitis in salmon showing large influx of neutrophils into both dermis and epidermis, and the formation of "pustule"-like lesions.

and karyorrhexis or even apoptosis (phagocytosis by adjacent viable cells). A distinctive pattern of such changes is seen in sunburn **(*Fig 3.12*)**, when fish in very clear water are subjected to high levels of ultraviolet radiation: dermo-epidermal separation is also seen. Niacin in particular is important in protecting the skin of rainbow trout against the effects of ultraviolet-B irradiation.

Changes in the ***dermis*** that may accompany acute epidermal lesions include superficial dermal oedema and vascular dilation (occasionally haemorrhage) with pavementing and emigration of leukocytes. These may be

ease (*Flavobacterium columnare* - **Fig 3.16**) and carp erythrodermatitis (*Aeromonas salmonicida*). Waterlogging can be severe in these acute ulcerative dermatitides, extending usually deep into the hypodermis and even muscle, tracking down the fascial planes. Secondary invaders frequently obscure the primary insult and pathological response. "No mucus skin disease" is a popular name given to an acute superficial but ulcerative skin disease of trout **(*Fig 3.17*)**. Gently running a finger down the side of an affected fish certainly reveals a rough surface, but SEM shows that this is due largely to the tips of scales poking through. The cause of the disease is unknown although



Fig 3.12. Sunburn-induced acute epidermal necrosis in lake trout.



Fig 3.13A. Platy with marked dermal oedema as evidenced by elevation of scales. This fish was unable to maintain its osmotic balance due to renal compromise, the result of severe granulomatous inflammation due to mycobacteriosis. Oedema like this can also be seen due to hypoproteinaemia in freshwater fish, as well as dermal disease. *Courtesy Dr. S. Backman.*

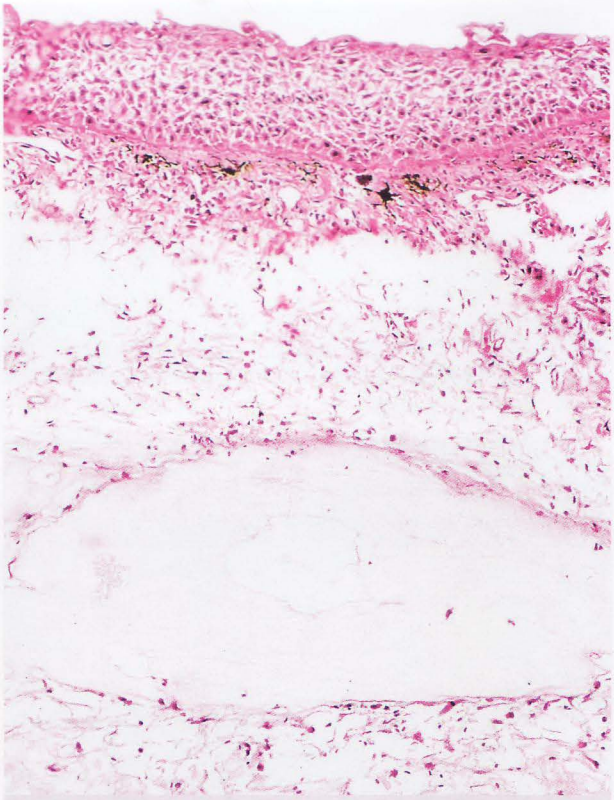

Fig 3.13B. Marked dermal oedema in a trout showing dilation of lymphatics. The lesions were the result of extensive monogenean infection.



Fig 3.14. Mycotic dermatitis in trout. The line of demarcation between viable and pale necrotic tissue is easily seen.

bacteria are associated. Ulcerative dermatitis is also seen in the marine environment associated with bacteria such as *Flexibacter* (now *Tenacibaculum*) *maritimus*, although of course the osmotic forces that accompany such lesions are reversed **(*Fig 3.18*)**.

Erosion and hypoplasia of epidermis are seen in vitamin A deficiency as well as vitamin A toxicity, but a much more common chronic response to a large variety of insults is hyperplasia, sometimes with the formation of pronounced dermal papillae and hyperpigmentation. It must be remembered that teleost epidermis is capable of division at all levels, and not just in the *stratum spinosum* as is usually the case in mammals. Epidermal hyperplasia accompanies chronic irritation by protozoan and metazoan parasites, toxins such as those injected by nematocysts **(*Fig 3.19*)**, bacteria (especially the "myxobacteria") and chemical or physical agents such as suspended solids, particularly it would seem, at low water temperatures. The protozoan parasite *Ichthyobodo necator* (*Costia*) induces hyperplasia of the outermost malphigian cells rather than those of the suprabasal layer. The resulting hyperplastic plaque, which is recognized grossly as a blue translucent sheen, may then slough off, leaving only a single layer of cells attached to the basal layer.

Ichthyophthirius multifiliis is one of the commonest protozoan infections of freshwater fish in the wild or culture

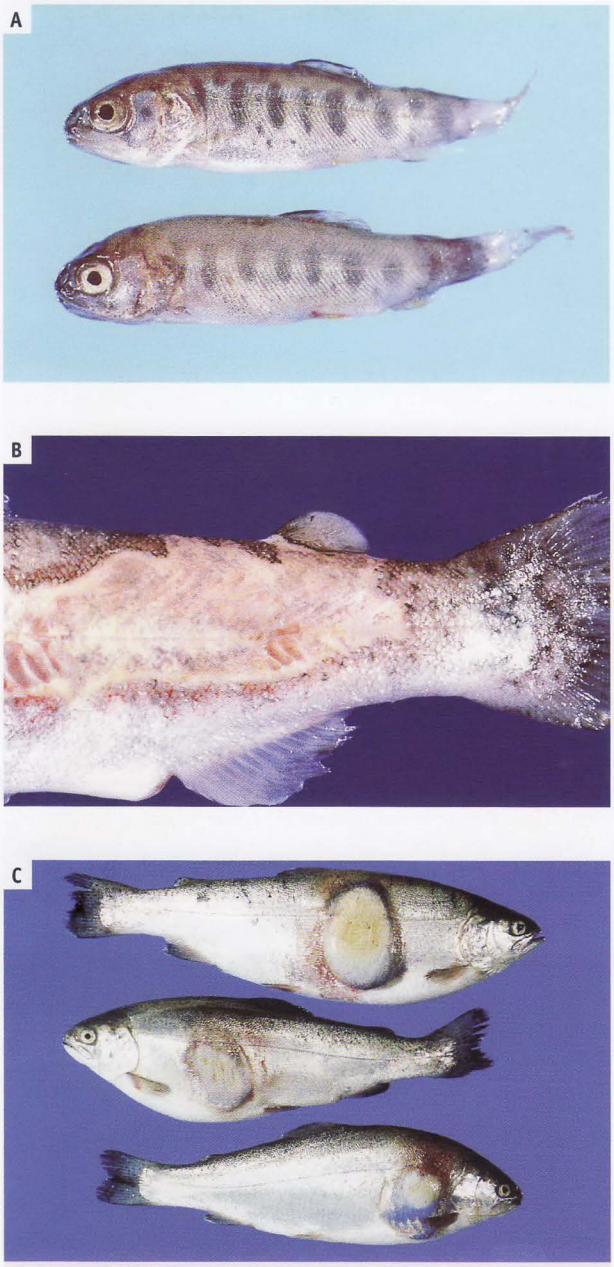

Fig 3.15A-C. Flavobacterium psychrophilum infection in trout showing three different dermal presentations. **A** shows the classical peduncle disease with necrosis of tissues distal to anal fin; **B** shows severe and extensive dermal necrosis, while **C** shows dermal necrosis with muscle necrosis, resulting in marked swelling. The superficial yellow colour in **B** & **C** is due to the bacteria themselves.

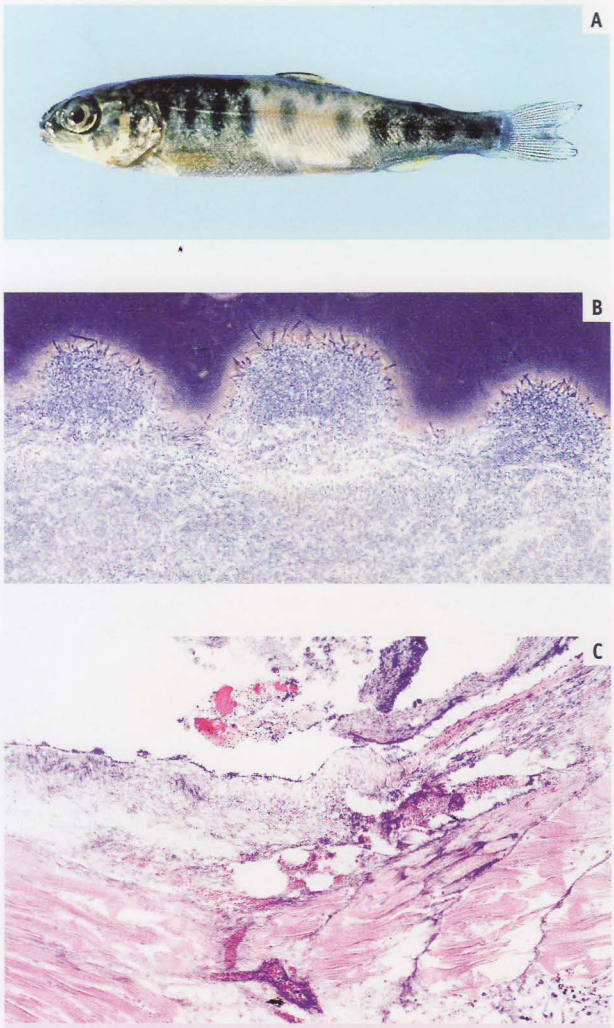

Fig 3.16A-C. Columnaris disease showing the classical saddlepatch lesion **(A)** the result of necrosis and sloughing, losing melanocytes in the process. The name derives from the columns or haystack-like aggregates of bacteria – in this case **(B)** seen on a fresh biopsy from a guppy. These filamentous bacteria can be hard to see in routine H&E sections, as they insinuate themselves between dermal collagen fibres, but they are often easily seen in a Giemsa-stained section **(C)** where they appear blue.

situation, as well as in the display aquarium. The ciliates are large enough to be grossly visible, and their multifocal distribution has earned them the popular name of "white spot" ***(Fig 3.20; see also Fig 2.18C)***. It has been shown experimentally that invasion of the epidermis (gills are also affected) by moderate numbers of the infective stage (trophont) causes little damage, and that by 40 hours (at 17°C) most of the parasites are situated on the basal lamina. Heavy infection, however, results in spongiosis and erosion, plus infiltration by neutrophils, and lymphocytes; hyperplasia is seen only following subsequent infections. If the hyperplastic tissue is itself parasitized, the trophont may fail to reach the basal lamina, with severe lysis of epidermis, and possibly dermo-epidermal separation, as the consequence. Maturation of the parasite following growth within the epidermis, sees its emergence into the surrounding water. If large numbers mature at the same time, the consequent damage to the skin may impose a substantial osmotic stress on the

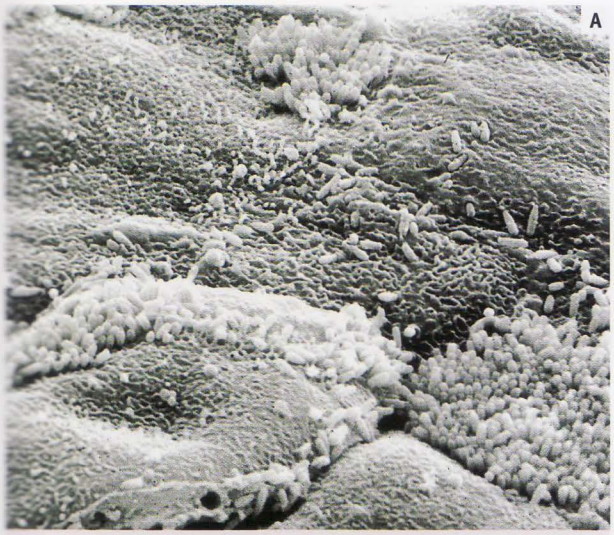

Fig 3.17A&B. "No mucus skin disease" of rainbow trout showing SEM of bacteria targeting mucus cell pores (**A**), and then using these "beach-heads" to under-run adjacent vaible cells. **B** shows a low-power SEM of fish with the tips of scales protruding through ulcerated skin.



fish. In some species, hyperplasia is also seen as one of the skin changes accompanying sexual maturation, and it can be experimentally reproduced with cortisol injections. Such fish are prone to develop secondary bacterial or fungal skin disease but the underlying pathogenesis of the lesions must be understood for a correct interpretation. Much less is known about other endocrine dermatoses but they are probably more important than is presently appreciated.



Fig 3.18A&B. Severe ulcerative dermatitis in halibut (**A**) and seabass (**B**), both associated with filamentous bacteria, likely *Tenacibaculum maritimus*.

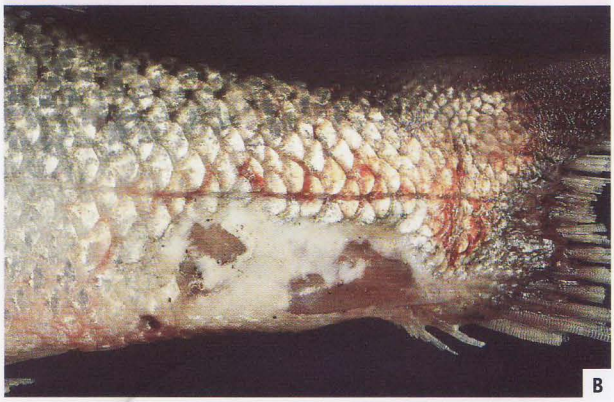

Pronounced epidermal hyperplasia must of course be differentiated from the diffuse neoplastic proliferations seen in a variety of species. Many of these reactions, termed "papillomatosis" and "pox" *(Fig 3.21)* are associated with virus or virus-like particles seen ultrastructurally: there is usually little dermal involvement, and this may help with interpretation, although it must be appreciated that chronic insult may predispose to neoplastic transformation, in which case the two types of response can merge together. Hyperplastic responses must also be differentiated from secondary sex characteristics typical of a range of species; examples include breeding tubercles in chubb *(Fig 3.22)*.

Deep disease

Severe dermal or subdermal lesions may involve the epidermis by extension, or cause pressure atrophy of dermis and epidermis by virtue of their space-occupying nature *(Fig 3.23)*. There may be loss of the normal complement of mucous and club cells, thinning of the epidermis, and even ulceration. These deep-seated lesions are quite common, and are found in diseases such as furunculosis (*Aeromonas salmonicida* - *Fig 3.24*)

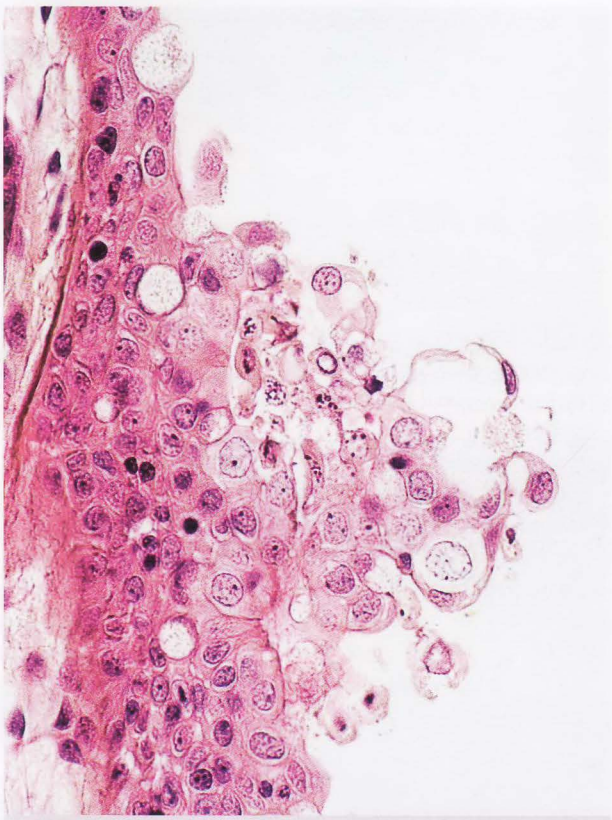

Fig 3.19. Salmon yolk-sac fry showing marked focal hyperplasia of epidermis due to nematocyst damage from hydra.
Material courtesy of N. Shalit.



Fig 3.21. "Carp pox", showing multiple foci of epidermal hyperplasia. These hyperplastic lesions are caused by *Herpesvirus cyprini*, and intra-nuclear inclusons can be seen in sections.
Courtesy of Dr. H. Schmidt.

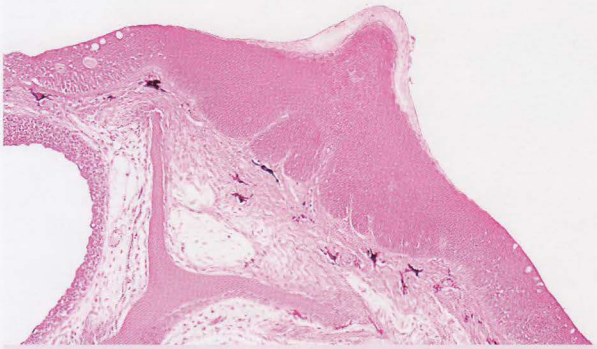

Fig 3.22. Breeding tubercle from a chub. These sorts of secondary sex characteristics should not be mistaken for lesions!



Fig 3.20. Ichthyophthirius multifiliis (white spot or "ich") in rainbow trout (**A**). Each spot represents a single parasite, and although appearing superficial, they are resting on the epidermal basement membrane. Infective stages, tomites, may often be seen within epidermis (arrow, **B**).

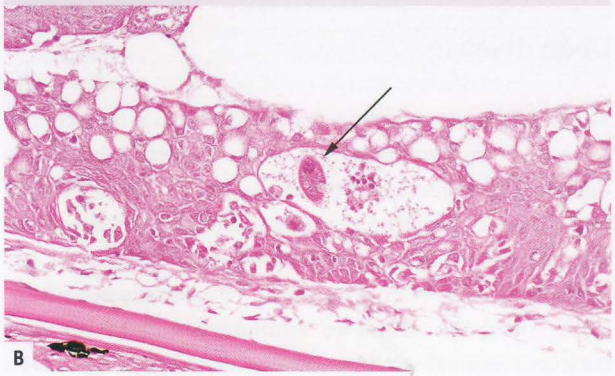

vibriosis (*Fig 3.25*), mycobacteriosis, and "enteric septicemia of catfish" (*Edwardsiella ictaluri*). The lesion in this latter disease may be deep enough to involve the cranial bones and cartilage, producing the so-called "hole-in-the-head" lesion - this should not be confused with another disease of the same name encountered in oscars and related species in which the grossly similar lesions are probably associated with bacterial infection of the sensory canal system, rather than the protozoa often mentioned. *Lactobacillus* (now *Carnobacterium*) *piscicola* can also cause sub-dermal blisters in salmonids, often as a post-spawning event. Another cause of deep ulcerative dermatitis and myositis is the condition "epizootic ulcerative syndrome" (EUS), caused by *Aphanomyces invadens*. This disease, which affects a range of different warmwater species, especially in S.E Asia but also North America, affects both farmed and wild fish and is more



Fig 3.23A. Rivulus marmoratus with large mycobacterial granuloma distending the peritoneal cavity.



Fig 3.23B&C. Cichlid with severe multifocal dermal ulceration over the head, the result of mycobacteriosis. The tuft of secondary fungal infection (**B**) marks the spot where the histology section was taken, shown in **C**. Photographing the fish underwater like this allows the fungi to be seen.

prevalent in cooler conditions (*Fig 3.23D and also Fig 12.19*). Mortality is variable but can be severe. Similar ulcerative lesions have been associated with the dinoflagellate *Pfiesteria piscicida* in estuarine wild fish populations in North America.

Dermal thrombosis is not infrequently seen in severe skin disease, and in bacteraemias, these may be septic; infarction is a possible consequence. Dermal haemorrhage, oedema, and fibrin exudation are also common accompaniments, and if long-standing, there may be dermal fibroplasia leading to fibrosis, usually of the stratum spongiosum (*Fig 3.26*). Scale resorption with osteoclasis is often encountered in these situations, but the significance or pathogenesis of the response is largely unknown. Possibly there is interference with the vascular supply to the scale pocket. Scales will readily regenerate however, and rows of osteocytes within dermis are easily recognized (*Fig 3.27*).

A good example of a chronic-active dermal or subdermal lesion is that associated with *Renibacterium salmoninarum*. The response, mainly in the muscle, may be so severe as to dissect the whole dermis away from the subcutis to produce large cavitations or blisters. Alternatively, the lesion may be a largely dermal one, sometimes centering

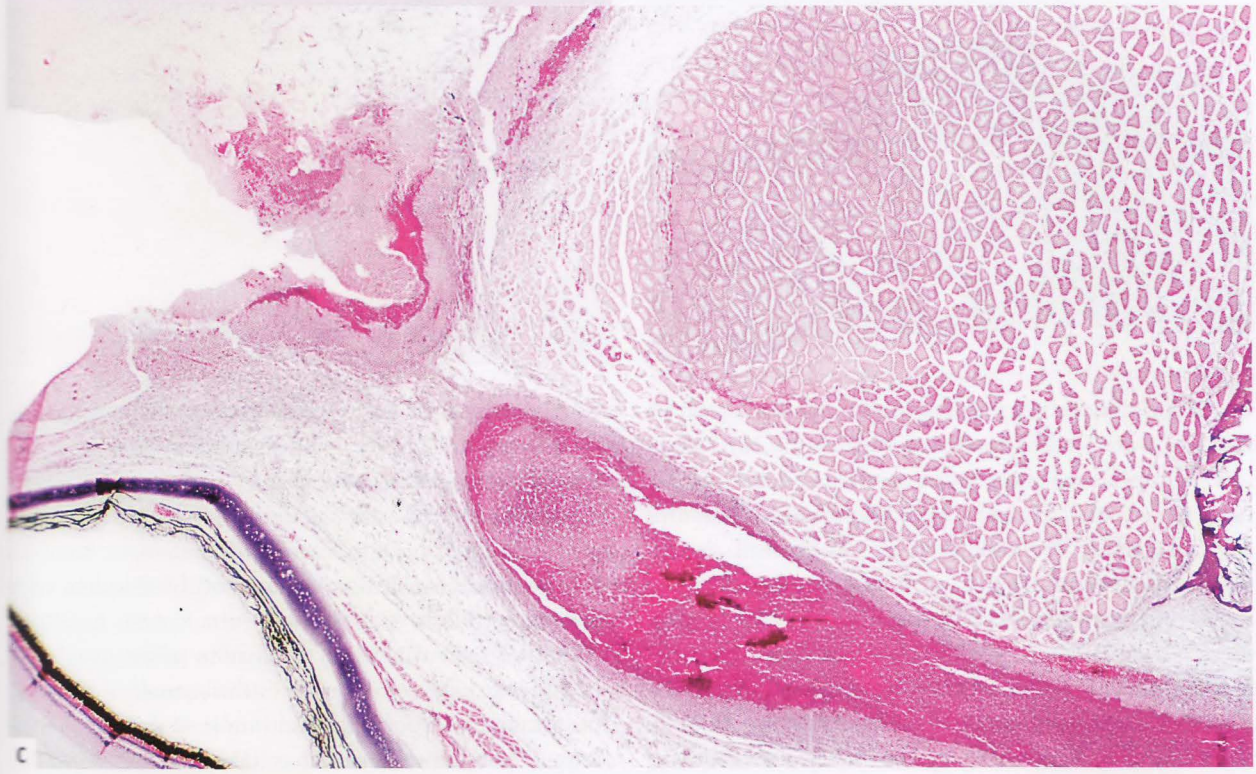



Fig 3.23D Atlantic menhaden with deep ulcerative dermatitis and myositis. This is a case of EUS (epizootic ulcerative syndrome) caused by *Aphanomyces invadens*. *Picture courtesy of Dr. W. Vogelbein.*

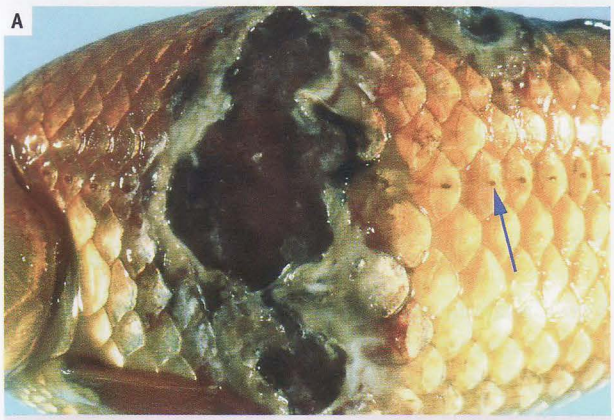

Fig 3.24A&B. Furunculosis in goldfish (**A**) and rainbow trout (**B**). Despite the name, these lesions tend to be seen only in the more resistant species, and even then, inconstantly. The arrow in **A** shows one of the pores along the lateral line.





Fig 3.25A&B. Vibriosis in farmed cod showing the deep-seated lesion round the dorsal fin (**A**). The dermal reaction is one of acute inflammation with haemorrhage (**B**).

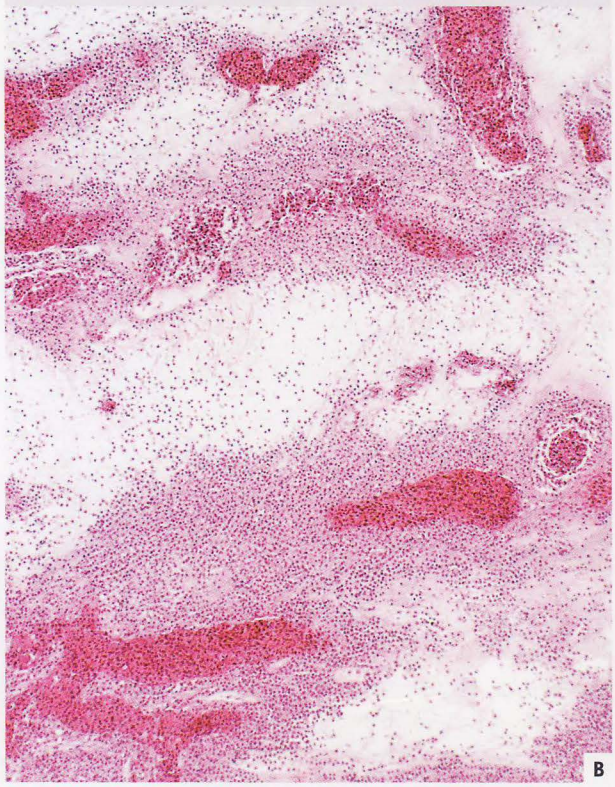

round scale-pockets to produce multifocal chronic-active dermatitis or so-called "spawning rash" (*Fig 3.28*). These lesions, which may occur in the absence of detectable lesions elsewhere in the body, including the kidney, resolve after spawning. The cellular response involves mainly neutrophils and macrophages; as seen in special stains, the latter are stuffed with bacteria.

A severe chronic lichenoid-type dermatitis is seen in the so-called "strawberry disease" (SD) of rainbow trout in freshwater (*Fig 3.29*). Although mortality is usually low, this condition may lead to 35% morbidity and rejection at processing plants. Macrophages and lymphocytes thicken the dermis and extend out into epidermis and down into underlying subcutis and even muscle. Scales are resorbed, leaving pockets of acute inflammation. The loss of this physical protection means that the skin becomes very susceptible to trauma, and even normal handling procedures such as grading can lead to pronounced dermal haemorrhage – hence the "strawberry-like" lesions. This antibiotic-responsive condition is of unknown aetiology, although recent work has linked the lesions to the



Fig 3.25C. Vibriosis in seacaged rainbow trout. The white rim surrounding the ulcer represents necrosis and swelling of dermal connective tissue. *Picture courtesy of J. Carmichael.*

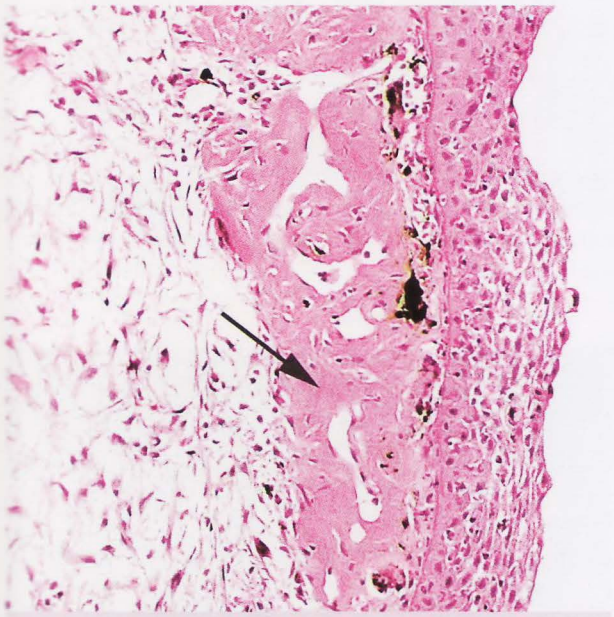

Fig 3.26. Dermal oedema associated with superficial fibrosis (arrow).

presence of *Flavobacterium psychrophilum* antigens. These antigens were not present in apparently normal skin from fish in affected cages, nor in apparently normal skin from fish with lesions. This relatively coldwater disease (lesions tend to disappear spontaneously above approximately 16°C) must be differentiated from another warmer water condition also of rainbow trout in freshwater (sometimes confusingly also referred to as SD). This latter condition is much more superficial, affecting epidermis mainly, and although inflammation is similarly chronic, it responds well to increased levels of dietary vitamin C.

Cytomegaly of dermal fibroblasts is encountered in the iridovirus disease lymphocystis. This is seen in many species, but especially in higher teleosts: clusters of individual cells enlarge greatly to produce grossly visible nodular aggregates **(Fig 3.30)**. Infected cells have a distinctive thick hyaline "capsule" to give them in section the appearance of eggs. Viral inclusion material within the cytoplasm may be lacy ("plaice-type") or large and cord-like with blebs ("flounder-type"). Healing is associated with the influx of mainly lymphoid cells: mortality is low in this disease, although fish may become reinfected. Cytomegaly of epidermal malpighian cells (gill epithelium also) with mild accompanying inflammation is also seen in herpesvirus infections of cod, turbot (*Scophthalmus maximus*), and probably other species including koi carp. Similar changes accompany iridoviral infection in sturgeon.

Myxozoans and microsporidians frequently have cysts in a dermal or subdermal location **(Fig 3.31)** and these may subsequently rupture to the outside liberating spores; they are however easily recognised and usually present no diagnostic problem. By contrast, pre-spore myxozoans which may be found in the same location, are much more difficult to diagnose. Although dermis is an unusual location for the lesions (kidney and spleen are the main targets) an example of this is found in proliferative kidney disease; the characteristic granulomatous response surrounding the "mother and daughter" stages of the parasites, creates a space-occupying lesion that may eventually ulcerate.

Metacercariae of digeneans are frequently found in the skin, often just beneath the epidermis. Whether or not the host mounts a significant response probably depends on the presence or absence of a parasitic capsule: its presence tends to correlate with little response. Several species however, do stimulate melanocytes; their investment of the parasite is grossly visible and gives rise to the popular name of "black spot disease" **(Fig 3.32)**. *Cryptocotyle lingua* is a digenetic metacercarial infection of marine fish with zoonotic potential; parasitic numbers may occasionally be high enough to produce a diffuse and generalised melanosis of the dermis, so that large areas of skin or indeed sometimes the entire fish appears black. Such changes need to be differentiated from the inherited *pigmentary anomalies* that form the basis for selective breeding programmes in aquarium species. Albinism is well documented in marine flatfish culture and this can



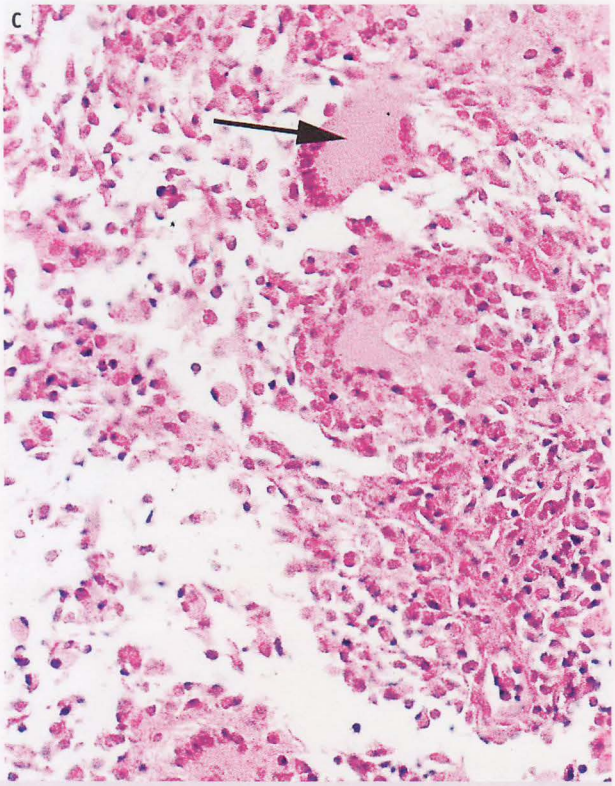

Fig 3.27A-C. Multinucleated osteoclasts can be seen piling up along this scale (**A**), in the process of resorption, while in **B** new scale growth is evidenced by the presence of this row of osteocytes (arrow). Multinucleated osteoclasts (they can also be uninucleate) must be differentiated from macrophage-derived giant cells (**C** arrow), which can be found in skin in response to a range of inciting agents, but especially chitin from metazoan parasites.

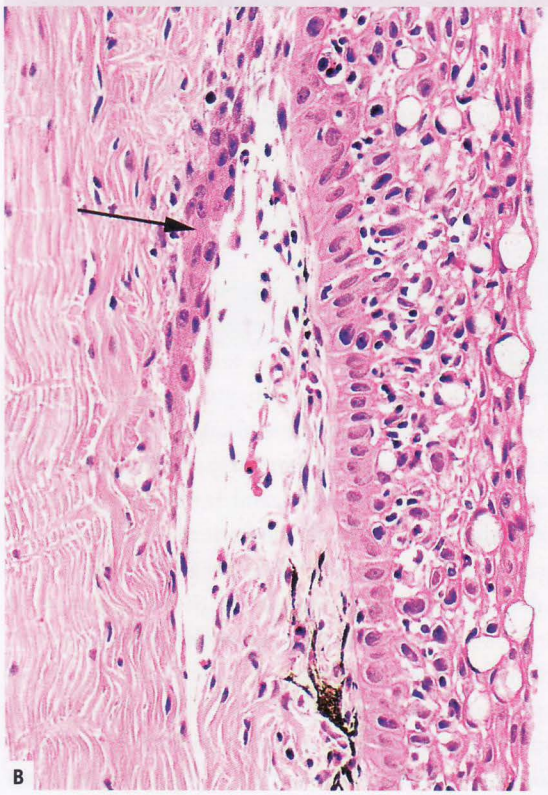

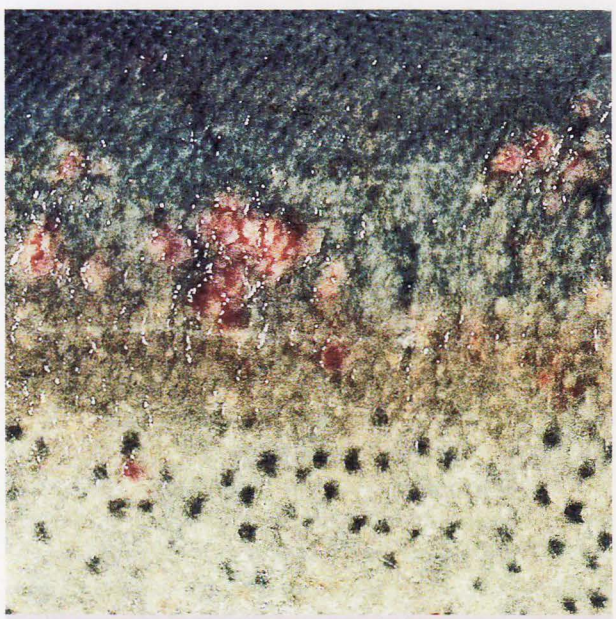

Fig 3.28. Close-up view of skin of broodstock rainbow trout with "spawning rash", a dermal variant of bacterial kidney disease. The multifocal granulomas centre on scale pockets, and may be present in the absence of lesions in other organs, even the kidney.



Fig 3.29. Strawberry disease of trout. The marked hyperaemia (**A**) is partly the result of scale resorption thereby reducing structural integrity; spaces where scales used to be located are shown in **B** (arrows). The dermis is greatly thickened due to a lymphoplasmacytic influx.

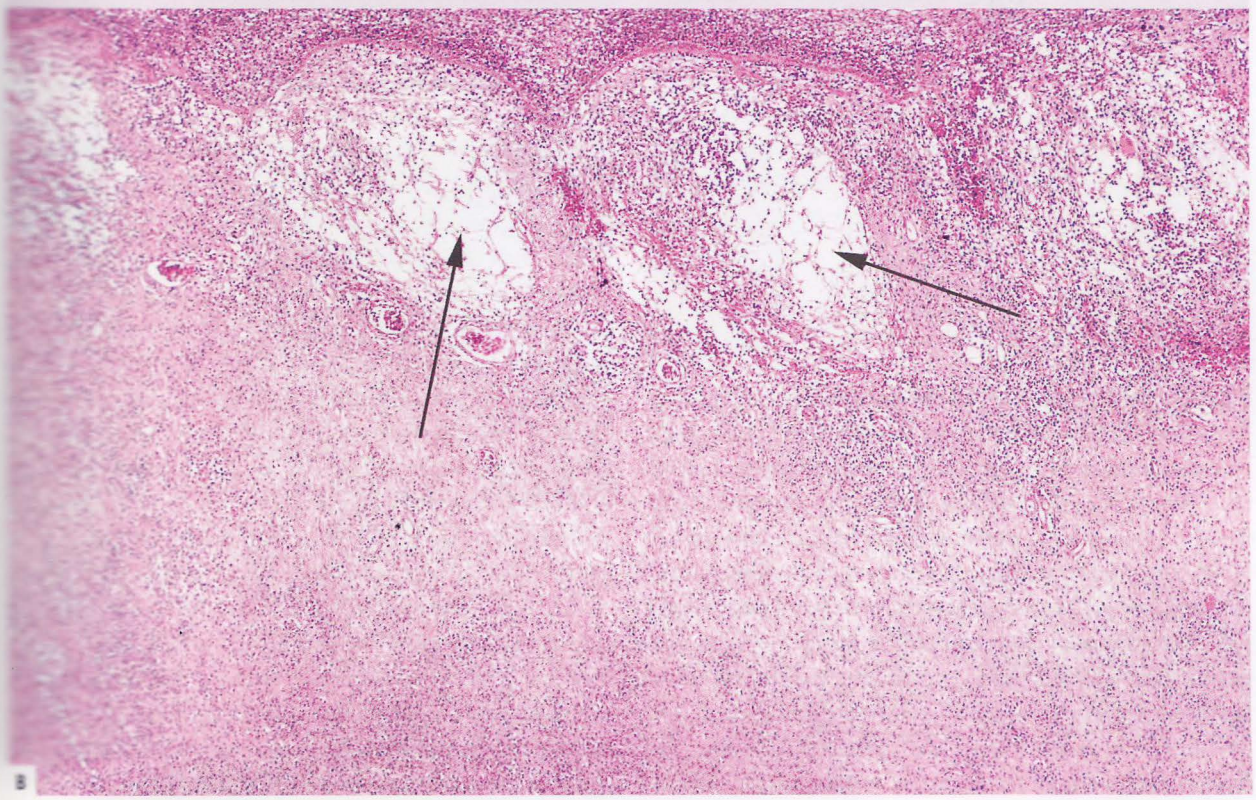



Fig 3.30A&B. Lymphocystis disease in seabass. The clusters of small "cysts" (arrow **A**) represent cytomegaly of dermal fibroblasts, all components of which are massively hypertrophic, including plasmalemma (**B**). The basophilic intra-cytoplasmic meshwork (arrow) represents iridoviral inclusion material.

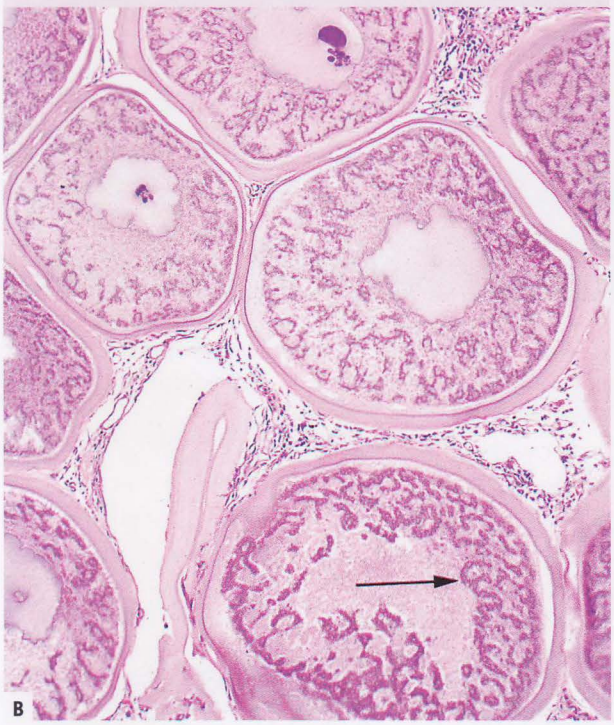



Fig 3.31. Small cyprinid with multiple subdermal myxozoan cysts. A needle aspirate and Giemsa-stained smear make for an easy diagnosis.



Fig 3.32. Black-spot disease in roach due to melanin accumulation around encysted digenetic metacercariae.

be either partial, giving a piebald appearance to the fish, or complete. It is suspected that higher than normal light levels may in part be responsible for the sometimes 50% incidence, although nutritional factors probably also play a major role. Halibut with low levels of pigmentation are more susceptible to fat necrosis in the subdermis. Generalized systemic infections often result in darkening of fish, due to a relaxation of nervous control over melanophores, as well as endocrine effects. Locally severe or space-occupying lesions may lead to regionalized colour changes due to compression of peripheral nerves. Eye disease such as cataract normally results in dark fish although the converse also occurs. Pigmentary lesions such as these are uncommon in wild fish, presumably at least in part because they fall easy victims to predators.

Dermal granulomas are quite common, and may be found with or without the presence of epithelioid cells and multi-nucleated giant-cells (*see Fig 3.27C*); these latter are usually foreign-body type, and although fish are capable of forming the classical Langhans-type, they have usually been seen only in experimental situations. It is important to differentiate multinucleated osteoclasts (uninucleate osteoclsts are also found) from foreign-body type giant cells, although of course the two may be found in the same lesion. Splendore-Hoeppli reactions (club colonies) as seen in botryomycosis in mammals, are rare in fish skin, although they are described in the spleen of salmon with *Pasteurella skyensis* infection.

Metazoan parasites are frequently incriminated in dermal disease, an example being various species of the copepod *Lepeophtheirus*. *L. salmonis* does not invariably cause pro-

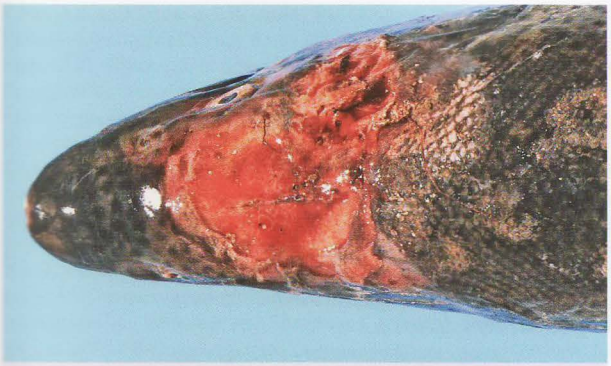

Fig 3.33. Severe dermal ulceration on the head of this Atlantic salmon has led to exposure of muscle and cranium; this is a consequence of "sealice" infection due to the copepod *Lepeophtheirus salmonis*.

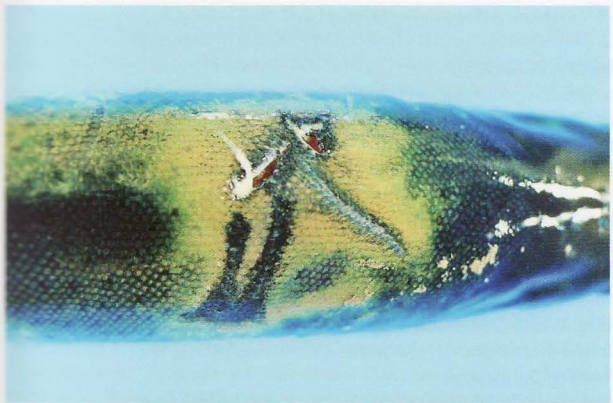

Fig 3.34. Trout showing typical stab wounds and raking marks by bird's beak.

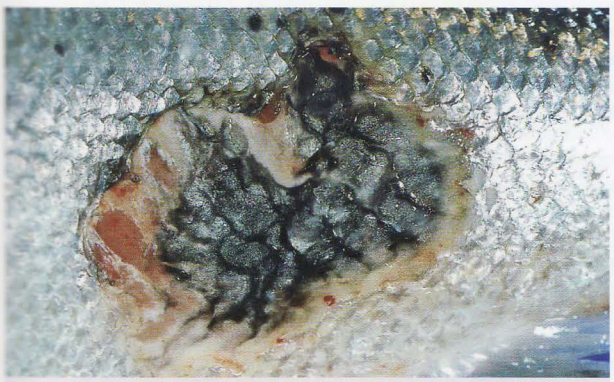

Fig 3.35. Atlantic salmon showing hypermelanisation in this abnormally healing ulcer, probably a consequence of low water temperatures. *Courtesy of Dr.T.T. Poppe.*

nounced damage as it browses over the skin, but under intensive farming conditions of Atlantic salmon, the parasites become concentrated, and severe ulcerative dermatitis may result, with loss of substantial areas of skin. On top of the head, the ulceration may be deep enough to involve the cranium **(*Fig 3.33*)**. Such situations are a cause for real concern, and raise welfare issues. Some copepods may be deeply embedded within the skin and yet elicit surprisingly little host response, mainly localized mild dermal fibrosis and epidermal hyperplasia. By contrast, others such as *Lepeophtheirus pectoralis*, which are only superficially attached to the skin and effect slight penetration, elicit massive dermal fibroplasia with haemorrhage in severe cases, and a chronic inflammatory infiltrate.

Some crustacea may elicit a host response which proliferates to such an extent that the point of attachment of the parasite becomes encased. The externally visible masses of tumour-like fibrous tissue may contain large numbers of melanocytes so as to appear grossly black. Some isopod crustacea in the family Cymothoidae form pouches (a zoocaecidium) in the flank of the host, with marked thinning of the overlying epidermis. The well-vascularized wall of the pouch acts as a food source.

By contrast with these space-occupying and local inflammatory responses, the branchiuran *Argulus* has a pre-oral stylet that not only causes local mechanical injury, but also releases digestive enzymes, giving rise to systemic as well as local effects. These then are just a few of the reactions caused by such parasites, which are not only seriously damaging *per se*, but in addition, pave the way for secondary attack by microorganisms.

Trauma from nets or rough handling, self-inflicted injury due to dermal irritation, or deep puncture type wounds from birds' beaks, may all cause severe erosion or dermal ulceration **(*Fig 3.34*)**.

As said already, wound healing is a temperature dependent process, but it appears that the epidermis is less susceptible to its influence than the dermis, the repair of which is greatly slowed by low water temperatures, and in some cases repair can be defective **(*Fig 3.35*)**. Nevertheless, fish skin shows a remarkable capacity for repair, as do so many other tissues, and despite sometimes enormous lesions, grossly visible scars are not an inevitable consequence. As in mammals, vitamin C deficiency impairs collagen formation and hence wound healing.

References

Agrawal, N. and Mittal, A.K. (1991) Epithelium of Lips and Associated Structures of the Indian Major Carp, *Catla-Catla*. *Japanese Journal of Ichthyology* 37(4):363-73.

Agrawal, N, and Mittal, A.K. (1992) Structure and Histochemistry of the Epithelia of Lips and Associated Structures of a Catfish *Rita rita*. *Japanese Journal of Ichthyology* 39(1):93-102.

Ahmed, A.T.A. and Egusa, S. (1980) Dermal fibrosarcoma in goldfish *Carassius auratus* (L.). *Journal of Fish Diseases* 3: 249-254.

Ajmal, M. and Hobbs, B.C. (1967) Causes and effects of Columnaris-type diseases in fish. *Nature* 215:141-142.

Amin, O.M. (1979) Lymphocystis disease in Wisconsin fishes. *Journal of Fish Diseases* 2:207-217.

Anders, K. and Möller, H. (1985) Spawning papillomatosis of smelt, *Osmerus eperlanus* L., from the Elbe estuary. *Journal of Fish Diseases* 8:233-235.

Appy, R.G. and Cone, D.K. (1982) Attachment of *Myzobdella lugubris* (Hirudinea: Piscicolidae) to logperch, *Percina caprodes*, and brown bullhead, *Ictalurus nebulosus*. *Transactions of American Microscopical Society* 101:135-141.

Aranishi, F. and Nakane, M. (1997) Epidermal proteases of the Japanese eel. *Fish Physiology and Biochemistry* 16(6):471-8.

Arillo, A. and Melodia, F. (1990) Protective Effect of Fish Mucus Against CR(VI) Pollution. *Chemosphere 20*(3-4):397-402.

Arthur, J.R. and Margolis, L. (1984) *Trichodina truttae* Mueller, 1937 (Ciliophora: Peritrichida), a common pathogenic ectoparasite of cultured juvenile salmonid fishes in British Columbia: redescription and examination by scanning electron microscopy. *Canadian Journal of Zoology* 62:1842-1848.

Bailey. S.W. (1937) An experimental study of the origins of lateral line structures in embryonic and adult teleosts. *Journal of Experimental Zoology* 76:187-233.

Bailey, J., Turnbull, J. and Ferguson, H.W. (2005) The Pathology of chronic erosive dermatopathy in Murray cod (*Maccullochella peelii peelii*). *Journal of Fish Diseases* 28:3-12.

Balebona, M.C., Morinigo, M.A., Faris, A,, Krovacek, K., Mansson, I. and Bordas, M.A. (1995) Influence of salinity and pH on the adhesion of pathogenic *Vibrio* strains to *Sparus aurata* skin mucus. *Aquaculture* 132(1-2):113-20.

Barnett, R.R., Akindele, T., Orte, C. and Shephard, K.L. (1996) Eosinophilic granulocytes in the epidermis of *Oreochromis mossambicus* gill filaments studied in situ. *Journal of Fish Biology 49*(1):148-56.

Barrow, G.I. and Hewitt, M. (1971) Skin infection with *Mycobacterium marinum* from a tropical fish tank. *British Medical Journal* 2:505-506.

Becker, C.D. and Fujihara, M.P. (1978) The bacterial pathogen *Flexibacter columnaris* and its epizootiology among Columbia River fish. A review and synthesis pp. 1-92. ***In*** American Fisheries Society, Monograph Number Two, Washington, D.C..

Blackstock, N. and Pickering, A.D. (1980) Acidophilic granular cells in the epidermis of the brown trout, *Salmo trutta* L. *Cell and Tissue Research* 210:359-369.

Blaxter, J.H.S. (1987) Structure and development of the lateral line. *Biological Reviews* 62:471-514.

Blazer, V. S., Lilley, J.H., Schill, W.B., Kiryu, Y., Densmore, C.L., Panyawachira, V. and Chinabaut, S. (2002) *Aphanomyces invadans* in Atlantic menhaden along the east coast of the United States. *Journal of Aquatic Animal Health* 14:1-10.

Blazer, V. S., Vogelbein, W.K., Densmore, C.L., May, E.B., Lilley, J.H. and Zwerner, D.E. (1999) *Aphanomyces* as a cause of ulcerative skin lesions of menhaden from Chesapeake Bay tributaries. *Journal of Aquatic Animal Health* 11:340-349.

Bordas, M.A., Balebona, M.C., Zorrilla, I., Borrego, J.J. and Morinigo, M.A. (1996) Kinetics of adhesion of selected fish-pathogenic *Vibrio* strains to skin mucus of gilt-head sea bream (*Sparus aurata* L). *Applied and Environmental Microbiology* 62(10):3650-4.

Brokken, L.J.S., Verbost, P.M., Atsma, W. and Bonga, S.E.W. (1998) Isolation, partial characterization and localization of integumental peroxidase, a stress-related enzyme in the skin of a teleostean fish (*Cyprinus carpio* L.). *Fish Physiology and Biochemistry* 18(4):331-342.

Buchmann, K. (1999) Immune mechanisms in fish skin against monogeneans – a model. *Folia Parasitologica* 46:1-9.

Bullock, A.M. and Roberts, R.J. (1980) Inhibition of epidermal migration in the skin of rainbow trout *Salmo gairdneri* Richardson in the presence of achromogenic *Aeromonas salmonicida*. *Journal of Fish Diseases* 3:517-524.

Bullock, A.M. and Roberts, R.J. (1981) Sunburn lesions in salmonid fry: a clinical and histological report. *Journal of Fish Diseases* 4:271-275.

Bullock, A.M. and Robertson, D.A. (1982) A note on the occurrence of *Ichtyobodo necator* (Henneguy, 1883) in a wild population of juvenile plaice, *Pleuronectes platessa* L. *Journal of Fish Diseases* 5:531-533.

Bullock, A.M., Roberts, R.J., Waddington, P. and Bookless, W.D.A. (1983) Sunburn lesions in koi carp. *Veterinary Record* 112:551.

Burkhardtholm, P., Escher, M. and Meier, W. (1997) Waste-water management plant effluents cause cellular alterations in the skin of brown trout. *Journal of Fish Biology* 50(4):744-58.

Burkhardtholm, P., Schmidt, H. and Meier, W. (1998) Heat shock protein (hsp70) in brown trout epidermis after sudden temperature rise. *Comparative Biochemistry and Physiology A - Molecular and Integrative Physiology* 120(1):35-41.

Burton, D. (1979) Differential chromatic activity of melanophores in integumentary patterns of winter flounder (*Pseudopleuronectes americanus* Walbaum). *Canadian Journal of Zoology* 57:650-657.

Burton, D. and Everard, B.A. (1991) The Effect of Androgen Treatment on the Epidermis of Post-Spawned Winter Flounder, *Pseudopleuronectes-Americanus* (Walbaum). *Journal of Fish Biology* 38(1):73-80.

Bylund, G., Valtonen, E.T. and Niemela, E. (1980) Observations on epidermal papillomata in wild and cultured Atlantic salmon *Salmo salar* L. in Finland. *Journal of Fish Diseases* 3:525-528.

Campbell, A.C. and Buswell, J.A. (1982) An investigation into the bacterial aetiology of 'black patch necrosis' in Dover sole, *Solea solea* L. *Journal of Fish Diseases* 5:495-508.

Carlisle, J.C. and Roberts, R.J. (1977) An epidermal papilloma of the Atlantic salmon I. Epizootiology, pathology and immunology. *Journal of Wildlife Diseases* 13:230-234.

Christiansen, J.S., Jobling, M., Amin, A.B. and Ribe, H. (1991) Histomorphological Changes in Epidermal Structure of Juvenile Arctic Charr (*Salvelinus-Alpinus* L) Subjected to Sustained Exercise. *Canadian Journal of Zoology* 69(9):2450-5.

Cipriano, R.C. and Heartwell, C.M. III. (1986) Susceptibility of salmonids to furunculosis: Differences between serum and mucus responses against *Aeromonas salmonicida*. *Transactions of American Fisheries Society* 115:83-88.

Cone, D.K. and Odense, P.H. (1984) Pathology of five species of *Gyrodactylus* Nordmann, 1832 (Monogenea). *Canadian Journal of Zoology* 62:1084-1088.
Cone, D.K., Miller, J.D. and Austin, W.K. (1980) The pathology of "saddle-back" disease of underyearling Atlantic salmon (*Salmo salar*). *Canadian Journal of Zoology* 58:1283-1287.
Coombs, S., Janssen, J., and Webb, J.F. (1987) Diversity of lateral line systems: Evolutionary and functional considerations. pp. 553-593 *In Sensory Biology of Aquatic Animals. Eds.* Atema, J., Fay, R.R., Popper, A.N. and Tavolga, W.N. Springer-Verlag, New York.
Copland, J.W. and Willoughby, L.G. (1982) The pathology of Saprolegnia infections of *Anguilla anguilla* L. elvers. *Journal of Fish Diseases* 5:421-428.
Cross, M.L, and Matthews, R.A. (1991) Identification of a New Granulocyte Type in the Skin of Carp *Cyprinus-Carpio* (L). *Journal of Fish Biology* 39(2):279-83.
Daniels, S.B., Herman, R.L. and Burke, C.N. (1976) Fine structure of an unidentified protozoon in the epithelium of rainbow trout exposed to water with *Myxosoma cerebralis*. *Journal of Protozoology* 23:402-410.
Davidson, G.A., Ellis, A.E. and Secombe, C.J. (1993) Novel cell types isolated from the skin of rainbow trout, *Oncorhynchus mykiss*. *Journal of Fish Biology* 42:301-6.
Delves-Broughton, J., Fawell, J.K. and Woods, D. (1980) The first occurrence of 'cauliflower disease' of eels *Anguilla anguilla* L. in the British Isles. *Journal of Fish Diseases* 3:255-256.
Desser, S.S., Molnar, K. and Weller, I. (1983) Ultrastructure of sporogenesis of *Thelohanellus nikolskii* Akhmerov, 1955 (Myxozoa: Myxosporea) from the common carp, *Cyprinus carpio*. *Journal of Parasitology* 69:504-518.
Dykstra, M.J and Kane, A.S. (2000) *Pfiesteria piscicida* and ulcerative mycosis of Atlantic menhaden – current status of understanding. *Journal of Aquatic Animal Health* 12:18-25.
Edwards, C.J. (1978) Algal infections of fish tissue: a recent record and review. *Journal of Fish Diseases* 1:175-179.
Ellis, A.E. and Wootten, R. (1978) Costiasis of Atlantic salmon, *Salmo salar* L. smolts in seawater. *Journal of Fish Diseases* 1:389-393.
Ellis, A.E., Dear, G. and Stewart, D.J. (1983) Histopathology of 'Sekiten-byo' caused by *Pseudomonas anguilliseptica* in the European eel, *Anguilla anguilla* L., in Scotland. *Journal of Fish Diseases* 6:77-79.
Emerson, C.J., Payne, J.F. and Bal, A.K. (1985) Evidence for the presence of a viral non-lymphocystis type disease in winter flounder, *Pseudopleuronectes americanus* (Walbaum), from the north-west Atlantic. *Journal of Fish Diseases* 8:91-10.
Fabacher, D.L. and Little, E.E. (1995) Skin component may protect fishes from ultraviolet-B radiation. *Environmental Science and Pollution Research* 2(1):30-2.
Fabacher, D.L. and Little, E.E. (1998) Photoprotective substance occurs primarily in outer layers of fish skin. *Environmental Science and Pollution Research* 5(1):4-6.
Fasulo, S., Mauceri, A., Tagliafierro, G., Ricca, M.B., Locascio, P. and Ainis, L. (1998) Immunoreactivity to calcium-binding proteins (CaBPs) in the epithelia of skin and gill of the catfish, *Heteropneustes fossilis*. *Italian Journal of Zoology* 65(2):149-153.
Ferguson, H.W., Hicks, B.D., Lynn, D.H., Ostland, V.E. and Bailey, J. (1987) Cranial ulceration in Atlantic salmon (*Salmo salar* L.) associated with *Tetrahymena* sp. *Diseases of Aquatic Organisms* 2:191-195.
Ferguson, H.W., Ostland, V.E., MacPhee, D.D., Lumsden, J.S., Byrne, P.J. and Speare, D.J. (1995) "No mucus skin disease" of rainbow trout (*Oncorhynchus mykiss*): a case report. *Journal of Fish Diseases* 18:49-57.
Ferguson, H.W. and McCarthy, D.H. (1978) Histopathology of furunculosis in brown trout *Salmo trutta* L. *Journal of Fish Diseases* 1:165-174.
Finn, J.P. and Nielson, N.O. (1971) The inflammatory response of rainbow trout. *Journal of Fish Biology* 3:463-478.
Fleury, H. J. A., Vuillaume, A. and Sochon, E. (1985) Isolation of an adeno-like virus from two cases of strawberry disease in rainbow trout. *Annales de l'Institut Pasteur Virologie*136E:223-228.
Foissner, W., Hoffman, G.L. and Mitchell, A.J. (1985) *Heteropolaria colisarum* Foissner & Schubert, 1977 (Protozoa: Epistylididae) of North American freshwater fishes. *Journal of Fish Diseases* 8:145-160.
Francis-Floyd, R., Roth, L., Ardelt, T.C., Andrew, M.A., Reed, P. and Rose, E. (1992) Contact dermatitis in green Moray eels (*Gymnothorax funebris*) exposed to fiberglass. *Journal of Zoo and Wildlife Medicine* 23:328-35.
Francis-Floyd, R. and Noga, E.J. (1994) Medical Management of Channel Catfish .1. Types of Skin and Gill Pathogens. *Compendium on Continuing Education for the Practicing Veterinarian* 16(6):808-14.
Francis-Floyd, R. and Noga, E.J. (1994) Medical Management of Channel Catfish. 2. Clinical Management of Skin and Gill Pathogens. *Compendium on Continuing Education for the Practicing Veterinarian* 16(11):1513-8.
Fraser, G. C., Callinan, R.B. and Calder, L.M. (1992) *Aphanomyces* species associated with red spot disease: an ulcerative disease of estuarine fish from eastern Australia. *Journal of Fish Diseases* 15:173-181.
Frerichs, G.N., Millar, S.D. and Roberts, R.J. (1986) Ulcerative rhabdovirus in fish in South-East Asia. *Nature* 322:216.
Garg, T.K., Deepa, V. and Mittal, A.K. (1995) Surface architecture of the opercular epidermis and epithelium lining the inner surface of the operculum of a walking catfish, *Clarias batrachus*. *Japanese Journal of Ichthyology* 42(2):181-5.
Genten, F. and Danguy, A. (1990) A Comparative Histochemical Analysis of Glycoconjugates in Secretory Cells of Fish Epidermis by Use of Biotinylated Lectins. *Zeitschrift Fur Mikroskopisch-Anatomische Forschung* 104(6):835-55.
Ghioni, C., Tocher, D.R. and Sargent, J.R. (1997) The effect of culture on morphology, lipid and fatty acid composition, and polyunsaturated fatty acid metabolism of rainbow trout (*Oncorhynchus mykiss*) skin cells. *Fish Physiology and Biochemistry* 16(6):499-513.
Gotonance, R., Watanabe, Y., Kamiya, H. and Ida, H. (1995) Characterization of Lectins from the Skin Mucus of the Loach *Misgurnus Anguillicaudatus*. *Fisheries Science* 61(1):137-40.
Grizzle, J.M., Schwedler, T.E. and Scott, A.L. (1981) Papillomas of black bullheads, *Ictalurus melas* (Rafinesque), living in a chlorinated sewage pond. *Journal of Fish Diseases* 4:345-351.
Grizzle, J.M., Chen, J.E., Williams, J.C. and Spano, J.S. (1992) Skin Injuries and Serum Enzyme Activities of Channel Catfish (*Ictalurus punctatus*) Harvested by Fish Pumps. *Aquaculture* 107(4):333-46.
Hackett, J.L., Lynch, W.H., Paterson, W.D. and Coombs, D.H. (1984) Extra-cellular protease, extracellular haemolysin, and virulence in *Aeromonas salmonicida*. *Canadian Journal of Fisheries and Aquatic Science* 41:1354-1360.

Håstein, T., Saltveit, J.S. and Roberts, R.J. (1978) Mass mortality among minnows *Phoxinus phoxinus* (L.) in Lake Tveitevatn, Norway, due to an aberrant strain of *Aeromonas salmonicida*. *Journal of Fish Diseases* 1:241-249.
Hawke, J. P., Grooters, A.M. and Camus, A.C. (2003) Ulcerative mycosis caused by *Aphanomyces invadans* in channel catfish, black bullhead, and bluegill from southeastern Louisiana. *Journal of Aquatic Animal Health* 15:120-127.
Hazen, T.C., Raker, M.L., Esch, G.W. and Fliermans, C.B. (1978) Ultrastructure of red-sore lesions on largemouth bass (*Micropterus salmoides*): Association of the ciliate *Epistylis* sp. and the bacterium *Aeromonas hydrophila*. *Journal of Protozoology* 25:351-355.
Hazen, T.C., Esch, G.W., Dimock Jr, R.V. and Mansfield, A. (1982) Chemotaxis of *Aeromonas hydrophila* to the surface mucus of fish. *Current Microbiology* 7:371-375.
Hedrick, R.P., Groff, J.M., Okihiro, M.S. and Mcdowell, T.S. (1990) Herpesviruses Detected in Papillomatous Skin Growths of Koi Carp (*Cyprinus-Carpio*). *Journal of Wildlife Diseases* 26(4):578-81.
Hertwig, I., Eichelberg, H. and Hentschel, J. (1992) Light and Electron Microscopic Studies of the Skin of the Palembang Puffer, *Tetraodon steindachneri* (Teleostei, Tetraodontidae). *Zoomorphology* 111(4):193-205.
Holt, R.A., Rehovec, J.S. and Fryer, J.L. (1993) Bacterial cold-water disease. pp.3-22 ***In***: *Bacterial Diseases of Fish* ***eds***. Inglis, V., Roberts, R.J. and Bromage, N.R. Blackwell Scientific, Oxford.
Huizinga, H.W., Esch, G.W. and Hazen, T.C. (1979) Histopathology of red-sore disease (*Aeromonas hydrophila*) in naturally and experimentally infected largemouth bass *Micropterus salmoides* (Lacepede). *Journal of Fish Diseases* 2:263-277.
Hussein, S.A. and Mills, D.H. (1982) The prevalence of 'cauliflower disease' of the eel, *Anguilla anguilla* L., in tributaries of the River Tweed, Scotland. *Journal of Fish Diseases* 5:161-165.
Hwang, P.P., Tsai, Y.N. and Tung, Y.C. (1994) Calcium balance in embryos and larvae of the freshwater-adapted teleost, *Oreochromis mossambicus*. *Fish Physiology and Biochemistry* 13(4):325-33.
Iger, Y. and Abraham, M. (1990) The Process of Skin Healing in Experimentally Wounded Carp. *Journal of Fish Biology* 36(3):421-37.
Iger, Y., Jenner, H.A. and Bonga, S.E.W. (1994) Cellular responses in the skin of rainbow trout (*Oncorhynchus mykiss*) exposed to Rhine water. *Journal of Fish Biology* 45(6):1119-32.
Iger, Y., Jenner, H.A. and Bonga, S.E.W. (1994) Cellular responses in the skin of the trout (*Oncorhynchus mykiss*) exposed to temperature elevation. *Journal of Fish Biology* 44(6):921-35.
Ingersoll, C.G., Sanchez, D.A., Meyer, J.S., Gulley, D.D. and Tietge, J.E. (1990) Epidermal Response to pH, Aluminum, and Calcium Exposure in Brook Trout (*Salvelinus-Fontinalis*) Fry. *Canadian Journal of Fisheries and Aquatic Sciences* 47(8):1616-22.
Ishimatsu, A., Iwama, G.K., Bentley, T.B. and Heisler. N. (1992) Contribution of the Secondary Circulatory System to Acid Base Regulation During Hypercapnia in Rainbow Trout (*Oncorhynchus mykiss*). *Journal of Experimental Biology* 170:43-56.
Jensen, N.J. and Larsen, J.L. (1979) The ulcus-syndrome in cod (*Gadus morhua*). I. A pathological and histopathological study. *Nordisk Veterinaer Medicin* 31:222-228.
Jensen, N.J., Bloch, B. and Larsen, J.L. (1979) The ulcus-syndrome in cod (*Gadus morhua*). III. A preliminary virological report. *Nordisk Veterinaer Medicin* 31:436-442.
Johansson, N., Svensson, K.M. and Fridberg, G. (1982) Studies on the pathology of ulcerative dermal necrosis (UDN) in Swedish salmon, *Salmo salar* L., and sea trout, *Salmo trutta* L., populations. *Journal of Fish Diseases* 5:293-308.
Johnson, R.A., Zabrecky, J., Kiryu, Y. and Shields, J.D. (2004) Infection experiments with *Aphanomyces invadans* in four estuarine fish species. *Journal of Fish Diseases* 27:1-9.
Jung, A., Johnson, P., Eastman, J.T. and Devries, A.L. (1995) Protein content and freezing avoidance properties of the subdermal extracellular matrix and serum of the Antarctic snailfish, *Paraliparis devriesi*. *Fish Physiology and Biochemistry* 14(1):71-80.
Kabata, Z. (1985) Diseases caused by metazoans: Crustaceans. ***In*** Diseases of marine animals Vol IV, Part 1. ***ed***. Kinne,O. pp321-397. Biologische Anstalt Helgoland, Hamburg, F.R.G.
Kanno, T., Nakai, T. and Muroga, K. (1990) Scanning Electron Microscopy on the Skin Surface of *Ayu Plecoglossus-Altivelis* Infected with *Vibrio-Anguillarum*. *Diseases of Aquatic Organisms* 8(1):73-5.
Kelly, R.K., Nielsen, O., Mitchell, S.C. and Yamamoto, T. (1983) Characterization of *Herpesvirus vitreum* isolated from hyperplastic epidermal tissue of walleye, *Stizostedion vitreum vitreum* (Mitchill). *Journal of Fish Diseases* 6:249-260.
Kfoury, J.R. Jr., Okamoto, N., Tanaka, M., Yoshimizu, M., LaPatra, S.E. and Maita, M. (1996) "Rash" Skin Disease of Rainbow Trout. *Fish Pathology*. 31:197-201.
Khangarot, B.S. and Tripathi, D.M. (1991) Changes in Humoral and Cell-Mediated Immune Responses and in Skin and Respiratory Surfaces of Catfish, *Saccobranchus-Fossilis*, Following Copper Exposure. *Ecotoxicology and Environmental Safety* 22(3):291-308.
Kiryu, Y., Shields, J.D., Vogelbein, W.K., Kator, H. and Blazer, V.S. (2005) Factors influencing the sporulation and cyst formation of *Aphanomyces invadans*, etiological agent of ulcerative mycosis in Atlantic menhaden, *Brevoortia tyrannus*. *Mycologia* 97:569-575.
Kishida, M. and Specker, J.L. (1994) Vitellogenin in the Surface Mucus of Tilapia (*Oreochromis Mossambicus*) - Possibility for Uptake by the Free-Swimming Embryos. *Journal of Experimental Zoology* 268(4):259-68.
Kotrschal, K. (1995) Ecomorphology of solitary chemosensory cell systems in fish: A review. *Environmental Biology of Fishes* 44(1-3):143-55.
Kranz, H., Peters, N., Bresching, G. and Stich, H.F. (1980) On cell kinetics in skin tumours of the Pacific English sole *Parophrys vetulus* Girard. *Journal of Fish Diseases* 3:125-132.
Lamas, J., Novoa, B. and Figueras, A. (1996) Orange nodules in the skin of cultured turbot *Scophthalmus maximus* containing lipofuscin-like pigments. *Diseases of Aquatic Organisms* 24(1):17-23.
Larsen, J.L. and Jensen, N.J. (1979) The ulcus-syndrome in cod (*Gadus morhua*). II. A bacteriological investigation. *Nordisk Veterinaer Medicin* 31:289-296.
Lindesjoo, E. (1994) Temporal Variation and Sexual Dimorphism of the Skin of Perch Perca *Fluviatilis* L: A Morphological Study. *Zeitschrift Fur Angewandte Ichthyologie* 10(2-3):154-66.
Lindesjoo, E. and Thulin, J. (1994) Histopathology of Skin and Gills of Fish in Pulp Mill Effluents. *Diseases of Aquatic Organisms* 18(2):81-93.
Lippitsch, E. (1990) Scale morphology and squamation patterns in cichlids (Teleostei, Perciformes): a comparative study. *Journal of Fish Biology* 37:265-291.

Lobb, C.J. (1987) Secretory immunity induced in catfish, *Ictalurus punctatus* following bath immunization. *Developmental and Comparative Immunology* 11:727-738.
Lock, R.A.C. and van Overbeeke, A.P. (1981) Effects of mercuric chloride and methylmercuric chloride on mucus secretion in rainbow trout, *Salmo gairdneri* Richardson. *Comparative Biochemistry and Physiology* 69:67-73.
Lom, J. (1981) Fish invading dinoflagellates: A synopsis of existing and newly proposed genera. *Folia Parasitologia* (PRAHA) 28:3-11.
Lopez-Vidriero, M.T., Jones, R., Reid, L. and Fletcher, T.C. (1980) Analysis of skin mucus of plaice *Pleuronectes platessa* L. *Journal of Comparative Pathology* 90:415-420.
Lopezdoriga, M.V. and Martinez, J.L. (1993) Fine Structure of Sacciform Cells in the Epidermis of the Brown Trout, *Salmo trutta*. *Journal of Zoology* 230(Part 3):425-32.
Lounatmaa, K. and Janatuinen, J. (1978) Electron microscopy of an ulcerative dermal necrosis (UDN)-like salmon disease in Finland. *Journal of Fish Diseases* 1:369-375.
Lowartz, S.M., Holmberg, D.L., Ferguson, H.W. and Beamish, F.W.H. (1999) Healing of abdominal incisions in sea lamprey larvae: a comparison of three wound closure techniques. *Journal of Fish Biology* 54:616-626.
Marshall, W.S., Bryson, S.E. and Wood, C.M. (1992) Calcium Transport by Isolated Skin of Rainbow Trout. *Journal of Experimental Biology* 166:297-316.
Martineau, D., Bowser, P.R., Wooster, G. and Forney, J.L. (1990) Histologic and ultrastructural studies of dermal sarcoma of walleye (Pisces: *Stizostedion vitreum*). *Veterinary Pathology* 27:340-6
Martineau, D., Bowser, P.R., Wooster, G.A. and Armstrong, L.D. (1990) Experimental transmission of a dermal sarcoma in fingerling walleyes (*Stizostedion vitreum vitreum*). *Veterinary Pathology* 27:230-4.
Martínez, J.L., Casado, A.and Enríquez, R. (2004) Experimental infection of *Flavobacterium psychrophilum* in fins of Atlantic salmon *Salmo salar* revealed by scanning elctron microscopy. *Diseases of Aquatic Organisms* 59:79-84.
McCarthy, D.H. and Roberts, R.J. (1980) Furunculosis of fish - the present state of our knowledge. *Advances in Aquatic Microbiology* 2:293-341.
McCarthy, D.H., Amend, D.F., Johnson, K.A. and Bloom, J.V. (1983) *Aeromonas salmonicida*: determination of an antigen associated with protective immunity and evaluation of an experimental bacterin. *Journal of Fish Diseases* 6:155-174.
McCraw, B.M. (1952) *Furunculosis of fish*. pp.1-87 *In*: Special Scientific Report: Fisheries No. 84, United States Department of the Interior, Fish and Wildlife Service.
McKenzie, R.A. and Hall, W.T.K. (1976) Dermal ulceration of mullet (*Mugil cephalus*). *Australian Veterinary Journal* 52:230-231.
McVicar, A.H. and White, P.G. (1979) Fin and skin necrosis of cultivated Dover sole *Solea solea* (L.). *Journal of Fish Diseases* 2:557-562.
Mellergaard, S. and Nielsen, E. (1995) Impact of oxygen deficiency on the disease status of common dab *Limanda limanda*. *Diseases of Aquatic Organisms* 22(2):101-14.
Mellergaard, S. and Nielsen, E. (1997) Epidemiology of lymphocystis, epidermal papilloma and skin ulcers in common dab *Limanda limanda* along the west coast of Denmark. *Diseases of Aquatic Organisms* 30(2):151-63.
Merrilees, M.J. (1975) Tissue interaction: Morphogenesis of the lateral-line system and labyrinth of vertebrates. *Journal of Experimental Zoology* 192:113-118.
Meyers, T.R., Short, S., Lipson, K., Batts, W.N., Winton, J.R. and Wilcock, J. (1994) Association of Viral Hemorrhagic Septicemia Virus with Epizootic Hemorrhages of the Skin in Pacific Herring *Clupea harengus pallasi* from Prince William Sound and Kodiak Island, Alaska, USA. *Diseases of Aquatic Organisms* 19(1):27-37.
Mittal, A.K. and Whitear, M. (1979) Keratinization of Fish Skin with Special Reference to the Catfish *Bagarius bagarius*. *Cell and Tissue Research* 202:213-30.
Mittal, A.K. and Garg, T.K. (1994) Effect of an Anionic Detergent - Sodium Dodecyl Sulphate Exposure on Club Cells in the Epidermis of *Clarias batrachus*. *Journal of Fish Biology* 44(5):857-75.
Miyazaki, T. and Plumb, J.A. (1985) Histopathology of *Edwardsiella ictaluri* in channel catfish, *Ictalurus punctatus* (Rafinesque). *Journal of Fish Diseases* 8:389-392.
Mohri, S., Cho, S.Y., Endo, Y. and Fujimoto, K. (1990) Lipoxygenase Activity in Sardine Skin. *Agricultural and Biological Chemistry* 54(7):1889-91.
Molnar, K. (1980) Cutaneous sphaerosporosis of the common carp fry. *Acta Veterinaria Academiae Scientiarum Hungaricae* 28:371-374.
Moore, J.D., Ototake, M. and Nakanishi, T. (1998) Particulate antigen uptake during immersion immunisation of fish: The effectiveness of prolonged exposure and the roles of skin and gill. *Fish & Shellfish Immunology* 8(6):393-407.
Morrison, C., Cornick, J., Shum, G. and Zwicker, B. (1981) Microbiology and histopathology of 'saddleback' disease of underyearling Atlantic salmon, *Salmo salar* L. *Journal of Fish Diseases* 4:243-258.
Mugiya, Y. and Watabe, N. (1977) Studies on fish scale formation and resorption - II. Effect of estradiol on calcium homeostasis and skeletal tissue resorption in the goldfish, *Carassius auratus*, and the killifish, *Fundulus heteroclitus*. *Comparative Biochemistry and Physiology* 57A:197-202.
Noceda, C., Sierra, S.G. and Martinez, J.L. (1997) Histopathology of UV-B irradiated brown trout *Salmo trutta* skin. *Diseases of Aquatic Organisms* 31(2):103-8.
Noga, E.J and Udomkusonsri, P. (2002) Fluorescein: a rapid, sensitive, nonlethal method for detecting skin ulceration in fish. *Veterinary Pathology* 39:726-731.
Noga, E.J., Botts, S., Yang, M.S. and Avtalion, R. (1998) Acute stress causes skin ulceration in striped bass and hybrid bass (*Morone*). *Veterinary Pathology* 35(2):102-107.
Noga, E.J. and Dykstra, M.J. (1986) Oomycete fungi associated with ulcera-tive mycosis in menhaden, *Brevoortia tyrannus* (Latrobe). *Journal of Fish Diseases* 9:47-53.
Northcott, S.J. and James, M.A. (1996) Ultrastructure of the glandular epidermis on the fins of male estuarine triplefins *Forsterygion nigripenne*. *Journal of Fish Biology* 49(1):95-107.
Obradovic, J., Maran, B. and Sabocanec, R. (1983) Papillomatosis in the sheat-fish, *Silurus glanis* L. *Journal of Fish Diseases* 6:83-84.
Olson, O.P. and Watabe, N. (1980) Studies on formation and resorption of fish scales. IV. Ultrastructure of developing scales in newly hatched fry of the sheepshead minnow, *Cyprinodon variegatus* (Atheriniformes: Cyprino-dontidae). *Cell and Tissue Research* 211:303-316.

Olson, D.P., Beleau, M.H., Busch, R.A., Roberts, S. and Krieger, R.I. (1985) Strawberry disease in rainbow trout, *Salmo gairdneri* Richardson. *Journal of Fish Diseases* 8:103-111.
Oris, J.T. and Giesy Jr., J.P. (1985) The photoenhanced toxicity of anthracene to juvenile sunfish (*Lepomis* spp.). *Aquatic Toxicology* 6:133-146.
Ostland, V.E., LaTrace, C., Morrison, D. and Ferguson, H.W. (1999) *Flexibacter maritimus* associated with a filamentous bacterial stomatitis in netpen-reared Atlantic salmon smolts in British Columbia. *Journal of Aquatic Animal Health* 11:35-44.
Ostland, V.E., Byrne, P.J., Hoover, G. and Ferguson, H.W. (2000) Necrotic myositis of rainbow trout: proteolytic characteristics of a crude extracellular preparation from *Flavobacterium psychrophilum*. *Journal of Fish Diseases* 23:329-336
Ototake, M., Iwama, G.K. and Nakanishi, T. (1996) The uptake of bovine serum albumin by the skin of bath-immunised rainbow trout *Oncorhynchus mykiss*. *Fish & Shellfish Immunology* 6(5):321-33.
Paperna, I., Sabnai, I. and Colorni, A. (1982) An outbreak of lymphocystis in *Sparus aurata* L. in the Gulf of Aquaba, Red Sea. *Journal of Fish Diseases* 5:433-437.
Park, J-Y., Kim, I-S., Lee, Y-J. and Kim, S-Y. (2004) Histology and morphometrics of the epidermis of the fins and sucking disc of the mudskipper, *Periophthalmus modestus* (Pisces, Gobiidae). *Korean Journal of Biological Science* 8:111-115.
Parisot, T.J. (1958) Tuberculosis of fish. *Bacteriological Reviews* 22:240-245.
Paterson, W.D., Douey, D. and Desautels, D. (1980) Isolation and identification of an atypical *Aeromonas salmonicida* strain causing epizootic losses among Atlantic salmon (*Salmo salar*) reared in a Nova Scotian hatchery. *Canadian Journal of Fisheries and Aquatic Science* 37:2236-2241.
Paull, G.C. and Matthews, R.A. (2001) *Spironucleus vortens*, a possible cause of hole-in-the-head disease in cichlids. *Diseases of Aquatic Organisms* 45:197-202.
Peleteiro, M.C. and Richards, R.H. (1985) Identification of lymphocytes in the epidermis of the rainbow trout, *Salmo gairdneri* Richardson. *Journal of Fish Diseases* 8:161-172.
Peters, N., Schmidt, W., Kranz, H. and Stich, H.F. (1983) Nuclear inclusions in the X-cells of skin papillomas of Pacific flatfish. *Journal of Fish Diseases* 6:533-536.
Pickering, A.D. and Richards, R.H. (1980) Factors influencing the structure, function and biota of the salmonid epidermis. *Proceedings Royal Society Edinburgh* 79:93-104.
Phromsuthirak, P. (1977) Electron microscopy of wound healing in the skin of *Gasterosteus aculeatus*. *Journal of Fish Biology* 11:193-206.
Poston, H.A. and Wolfe, M.J. (1985) Niacin requirement for optimum growth, feed conversion and protection of rainbow trout, *Salmo gairdneri* Richardson, from ultraviolet-B irradiation. *Journal of Fish Diseases* 8:451-460.
Pottinger, T.G., Pickering, A.D. and Blackstock, N. (1984) Ectoparasite induced changes in epidermal mucification of the brown trout, *Salmo trutta* L. *Journal of Fish Biology* 25:123-128.
Pulsford, A. and Matthews, R.A. (1982) An ultrastructural study of *Myxobolus exiguus* Thelohan, 1895 (Myxosporea) from grey mullet, *Crenimugil labrosus* (Risso). *Journal of Fish Diseases* 5:509-526.
Quilhac, A. and Sire, J.Y. (1998) Restoration of the subepidermal tissues and scale regeneration after wounding a cichlid fish, *Hemicromis bimaculatus*. *Journal of Experimental Zoology* 281(4):305-327.
Quiniou, S.M.A., Bigler, S., Clem, L.W. and Bly, J.E. (1998) Effects of water temperature on mucous cell distribution in channel catfish epidermis: a factor in winter saprolegniasis. *Fish & Shellfish Immunology* 8(1):1-11.
Ream, R.A., Theriot, J.A. and Somero, G.N. (2003) Influences of thermal acclimation and acute temperature change on the motility of epithelial wound-healing cells (keratocytes) of tropical, temperate and Antarctic fish. *Journal of Experimental Biology* 206:4539-4551.
Roberts, R.J. (1972) Ulcerative dermal necrosis (UDN) of salmon (*Salmo salar* L.). *Symposium of the Zoological Society of London* 30:53-81.
Roberts, R.J. (1975) The effect of temperature on diseases and their histo-pathological manifestations in fish. ***In*** The Pathology of Fishes, ***eds***. Ribelin, W.E. and Migaki, G. pp.399-428. University of Wisconsin Press, Madison, Wisconsin.
Roberts, R.J. and Bullock, A.M. (1976) The dermatology of marine teleost fish. II. Dermatopathology of the integument. *Oceanography and Marine Biology Annual Reviews* 14:227-246.
Roberts, R.J., Young, H. and Milne, J.A. (1971) Studies on the skin of plaice (*Pleuronectes platessa* L.) 1. The structure and ultrastructure of normal plaice skin. *Journal of Fish Biology* 4:87-98.
Roberts, R.J. and Hill, B.J. (1976) Studies on ulcerative dermal necrosis of salmonids. V. The histopathology of the condition in brown trout (*Salmo trutta* L.). *Journal of Fish Biology* 8:89-92.
Robertson, D.A. (1985) A review of *Ichthyobodo necator* (Henneguy,1883) an important and damaging fish parasite. ***In*** *Recent Advances in Aquaculture* Vol 2. ***eds***. Muir, J.F. and Roberts, R.J. Croom Helm, London & Sydney.
Robertson, D.A., Roberts, R.J. and Bullock, A.M. (1981) Pathogenesis and autoradiographic studies of the epidermis of salmonids infested with *Ichtyobodo necator* (Henneguy, 1883). *Journal of Fish Diseases* 4:113-125.
Rombough, P. J. (1998) Partitioning of oxygen uptake between the gills and skin in fish larvae: A novel method for estimating cutaneous oxygen uptake. *Journal of Experimental Biology* 201(11):1763-1769.
Rombout, J.H.W.M., Taverne, N., Vandekamp, M. and Tavernethiele, A.J. (1993)
Differences in Mucus and Serum Immunoglobulin of Carp (*Cyprinus carpio* L). *Developmental and Comparative Immunology* 17(4):309-17.
Russell, P.H. (1974) Lymphocystis in wild plaice *Pleuronectes platessa* (L.), and flounder, *Platichthys flesus* (L.), in British coastal waters: A histopathological and serological study. *Journal of Fish Biology* 6:771-778.
Saglio, P. and Fauconneau, B. (1985) Free amino acid content in the skin mucus of goldfish, *Carassius auratus* L.: influence of feeding. *Comparative Biochemistry and Physiology* 82A:67-70.
St. Louis-Cormier, E.A., Osterland, C.K. and Anderson, P.D. (1984) Evidence for a cutaneous secretory immune system in rainbow trout (*Salmo gairdneri*). *Developmental and Comparative Immunology* 8:71-80.
Sano, T., Fukuda, H., Furukawa, M., Hosoya, H. and Moriya, Y. (1985) A herpesvirus isolated from carp papilloma in Japan. pp. 307-311 ***In***: Fish and Shellfish Pathology. ***ed***. Ellis, A.E., Academic Press, London.
Sato, N., Yamane, N. and Kawamura, T. (1982) Systemic *Citrobacter freundii* infection among sunfish *Mola mola* in Matsushima Aquarium. *Bulletin of the Japanese Society of Scientific Fisheries* 48:1551-1557.

Sharples, A.D., Campin, D.N. and Evans, C.W. (1994) Fin erosion in a feral population of goldfish, *Carassius auratus* (L), exposed to bleached kraft mill effluent. *Journal of Fish Diseases* 17(5):483-93.
Sharples, A.D. and Evans, C.W. (1996) Pathology of fin erosion in goldfish *Carassius auratus*. *Diseases of Aquatic Organisms* 24(2):81-91.
Shephard, K.L. (1994) Functions for fish mucus. *Reviews in Fish Biology and Fisheries* 4(4):401-29.
Shiomi, K., Tsuchiya, S., Shimakura, K. and Kikuchi, T. (1992) Purification and Properties of a Proteinaceous Toxin in the Skin Mucus of the Japanese Eel. *Bulletin of the Japanese Society of Scientific Fisheries* 58(4):781-6.
Shotts, E.B. Jr., Talkington, F.D, Elliott, D.G, and McCarthy, D.H. (1980) Aetiology of an ulcerative disease in goldfish, *Carassius auratus* (L.): characterization of the causative agent. *Journal of Fish Diseases* 3:181-186.
Singh, S.K. and Mittal, A.K. (1990) A Comparative Study of the Epidermis of the Common Carp and the 3 Indian Major Carp. *Journal of Fish Biology* 36(1):9-19.
Sire, J-Y., Bouleekbache, H. and Joly, C. (1990) Epidermal-dermal and fibronectin cell-interactions during fish scale regeneration: immuno-fluorescence and TEM studies. *Biology of the Cell* 68:147-158.
Sohnle, P.G. and Chusid, M.J. (1983) Defense against infection with filamentous fungi in rainbow trout. *Comparative Biochemistry and Physiology* 74:71-76.
Smith, I.R., Baker, K.W., Hayes, M.A. and Ferguson, H.W. (1989) Ultrastructure of malpighian and inflammatory cells in epidermal papillomas of white suckers (*Catostomus commersoni*). *Diseases of Aquatic Organisms* 6:17-26.
Speare, D.J. and Mirsalimi, S.M. (1992) Pathology of the Mucous Coat of Trout Skin During an Erosive Bacterial Dermatitis - A Technical Advance in Mucous Coat Stabilization for Ultrastructural Examination. *Journal of Comparative Pathology* 106(3):201-11.
Strussmann, C.A., Nin, F. and Takashima, F. (1994) Microscale variation in epidermal thickness, distribution, and size of mucus and alarm substance cells in the skin of juvenile fancy carp (*Cyprinus carpio*). *Copeia* (4):956-61.
Svendsen, Y.S. and Bogwald, J. (1997) Influence of artificial wound and non-intact mucus layer on mortality of Atlantic salmon (*Salmo salar* L) following a bath challenge with *Vibrio anguillarum* and *Aeromonas salmonicida*. *Fish & Shellfish Immunology* 7(5):317-25.
Takagi, Y., Hirano, T. and Yamada, J. (1989) Scale regeneration of tilapia (*Oreochromis niloticus*) under various ambient and dietary calcium concentrations. *Comparative Biochemistry and Physiology* 92A:605-8.
Takemura, A. (1994) Vitellogenin-Like Substance in the Skin Mucus of Tilapia *Oreochromis-Mossambicus*. *Fisheries Science* 60(6):789-90.
Tatner, M.F., Johnson, C.M. and Horne, M.T. (1984) The tissue localization of *Aeromonas salmonicida* in rainbow trout, *Salmo gairdneri* Richardson, following three methods of administration. *Journal of Fish Biology* 25:95-108.
Trust, T.J., Ishiguro, E.E. and Atkinson, H.M. (1980) Relationship between *Haemophilus piscium* and *Aeromonas salmonicida* revealed by *Aeromonas hydrophila* bacteriophage. *FEMS Microbiology Letters* 9:199-201.
Uhazy, L.S. (1978) Lesions associated with *Philometroides huronensis* (Nematoda: Philometridae) in the white sucker (*Catostomus commersoni*). *Journal of Wildlife Diseases* 14:401-408.
Vagsholm, I. and Djupvik, H.O. (1998) Risk factors for skin lesions in Atlantic salmon, *Salmo salar* L. *Journal of Fish Diseases* 21(6):449-453.
Valtonen, T.E. and Keranen, A.L. (1981) Ichthyophthiriasis of Atlantic salmon, *Salmo salar* L., at the Montta hatchery in northern Finland in 1978-1979. *Journal of Fish Diseases* 4:405-411.
Ventura, M.T. and Paperna, I. (1985) Histopathology of *Ichthyophthirius multifiliis* infections in fishes. *Journal of Fish Biology* 27:185-203.
Watermann, B. (1982) An unidentified cell type associated with an inflammatory condition of the subcutaneous connective tissue in dab, *Limanda limanda* L. *Journal of Fish Diseases* 5:257-261.
Webb, J.F. (1980) Neuromast Morphology and Lateral Line Trunk Canal Ontogeny in Two Species of Cichlids: An SEM Study. *Journal of Morphology* 202:53-68.
Whitear, M., Mittal, A.K. and Lane, E.B. (1980) Endothelial layers in fish skin. *Journal of Fish Biology* 17:43-65.
Wiklund, T. and Bylund, G. (1993) Skin Ulcer Disease of Flounder *Platichthys flesus* in the Northern Baltic Sea. *Diseases of Aquatic Organisms* 17(3):165-74.
Willoughby, L.G. (1978) Saprolegnias of salmonid fish in Windermere: a critical analysis. *Journal of Fish Diseases* 1:51-67.
Wold, J.K. and Selset, R. (1977) Glycoproteins in the skin mucus of the char (*Salmo alpinus* L.). *Comparative Biochemistry and Physiology* 56B:215-8.
Woodhead, A.D. (1982) Skin lesions in the tail of the spiny dogfish, *Squalus acanthias* L. *Journal of Fish Diseases* 5:71-74.
Yamada, J. and Watabe, N. (1979) Studies on fish scale formation and resorption. I. Fine structure and calcification of the scales in *Fundulus heteroclitus* (Atheriniformes: Cyprinodontidae). *Journal of Morphology* 159:49-65.
Yamamoto, T., Kelly, R.K. and Nielsen, O. (1983) Epidermal hyperplasias of Northern Pike (*Esox lucius*) associated with herpesvirus and C-type particles. *Archives of Virology* 79:255-272.
Zuchelkowski, E.M., Pinkstaff, C.A. and Hinton, D.E. (1985) Mucosubstance histochemistry in control and acid-stressed epidermis of brown bullhead catfish, *Ictalurus nebulosus* (LeSueur). *The Anatomical Record* 212:327-35.





Kidney

CHAPTER 4

Renate Reimschuessel and Hugh W. Ferguson

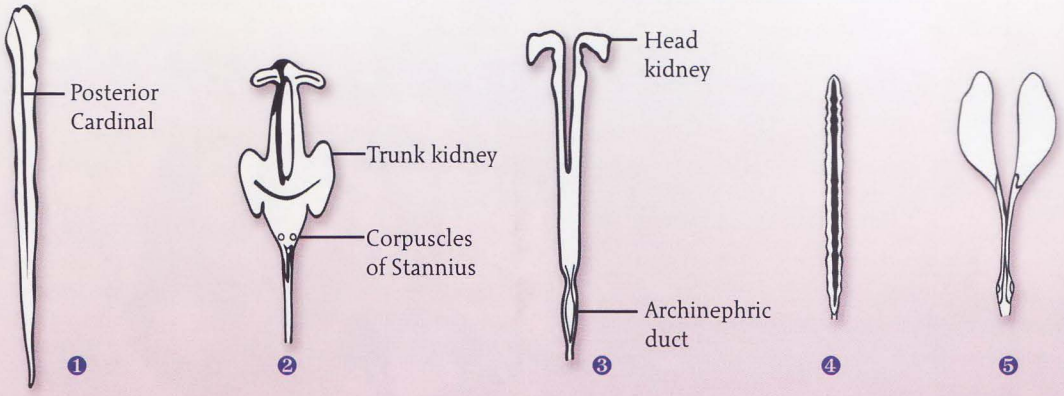

Fig 4.1. Gross morphology of the teleost kidney (*after Ogawa, in Hickman and Trump*). Most freshwater fish kidneys are in groups 1-3, while marine species also include groups 4 & 5 *(with permission)*.

General anatomy

This varies greatly between different species of fish, both grossly and histologically. Grossly, five main shapes are described (*Fig 4.1*). Often fused, it lies in a retroperitoneal location just ventral to the vertebral column, and can extend from the head region to the posterior abdomen as one organ, or it can have distinct head and trunk regions (*Fig 4.2A*). In general, the kidney in the cranial region (also called anterior or head kidney) contains primarily haematopoietic and lymphoid tissue with few if any renal tubules, while the kidney located along the trunk (also called posterior kidney) contains more renal tubules with a lesser amount of interstitial haematopoietic and lymphoid tissue. Renal arteries supply blood to the glomeruli via arterioles. The efferent arterioles then contribute blood to the peritubular capillaries. In many species, the other major source of blood to these capillaries is the renal portal system, which receives blood and lymph draining from the tail region of the fish. Thus both anterior and posterior regions of the kidney possess a sinusoidal system of blood vessels that are lined by highly phagocytic cells (*Fig 4.2B*). This dual blood supply imbues the kidney with a certain degree of resistance to the consequences of anoxic insults that target one particular supply. But the high trapping abilities also ensure that microbiological diseases target the organ.

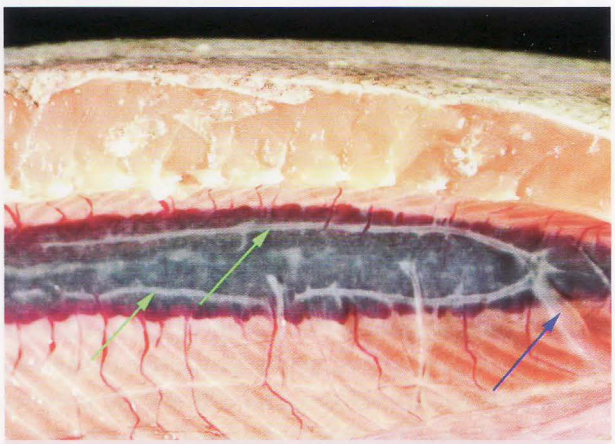

Fig 4.2A. Gross appearance of normal kidney in a brook trout. Ureters (green arrows) and urinary bladder (blue arrow) are easily seen.

Fish kidney also contains endocrine elements including thyroid follicles, corpuscles of Stannius, chromaffin cells and inter-renal tissue, the latter being located around major blood vessels, and which represent the equivalent of the mammalian adrenal medulla and cortex respectively. In elasmobranchs these can be visible with the unaided eye, while in most fish these tissues are microscopic. Corpuscles of Stannius may be seen as small white nodules located in the posterior kidney or at the junction of the anterior and posterior kidney. They should not be mistaken for parasites or granulomas! The grossly visible ureters fuse and may form a urinary bladder prior to ducting urine to the outside, posterior to the anus (*Fig 4.2A*).



Fig 4.2B. Renal portal system in rainbow trout showing macrophage resting on endothelium. Note the extensive pinocytotic activity within cytoplasm of endothelium, similar in some respects to the appearance of bone marrow endothelium in mammals.

The histological anatomy of the fish kidney is a wonderful example of how structure is driven by functional needs. Much of the excretory function of the mammalian kidney is fulfilled in fish by the gills; the function of fish nephrons is mainly osmoregulation. The primary task of a freshwater fish kidney is to produce copious dilute urine to counteract the passive influx of water across the gills. By contrast, saltwater fish need to conserve fluid, and this is achieved through alterations in the anatomy of nephrons.

A typical freshwater ***nephron*** consists of a glomerulus, neck segment, proximal tubules (which vary in the number of different segments), intermediate tubules and distal tubules **(*Fig* 4.2C)**. These connect to small collecting tubules which join larger collecting ducts that empty into the ureters. Fluid loss is limited in saltwater fish by reducing the size and number of glomeruli, and in some species (such as toadfish, goosefish and sygnathids) eliminating glomeruli altogether. Most nephrons in saltwater fish lack distal tubules, which in freshwater fish are responsible for diluting the glomerular filtrate. Teleosts have no cortical:medullary organization, although elasmobranchs do have a complex countercurrent system. These kidneys contain a tubular bundle with nephron segments arranged in parallel loops, surrounded by anastomosing capillaries enclosed by a peritubular sheath. They conserve urea to maintain the shark's extremely high blood osmolarity.

The ***glomeruli*** of different species of teleost vary greatly in number, size of the capillary tuft and in the thickness of the mesangium. In general the parietal epithelium is flattened and Bowman's space is rather small in sections of kidney preserved by immersion in fixative (as opposed to perfusion fixation, which can be achieved quite easily by catheterizing caudal vein and/or renal artery). Afferent and efferent glomerular arterioles are similar to those of mammals. In some species (*e.g.* the elasmobranch *Squalus acanthias*, the spiny dogfish) a juxtaglomerular apparatus is present with cells containing PAS positive granules similar to renin granules of mammals located in the smooth muscle cells surrounding the afferent arteriole. Recently, renin genes have been characterized from zebrafish and pufferfish, and their expression located near the developing nephrons of larval fish. Although there appears to be a renin-angiotensin system in teleost fish (not cyclostomes

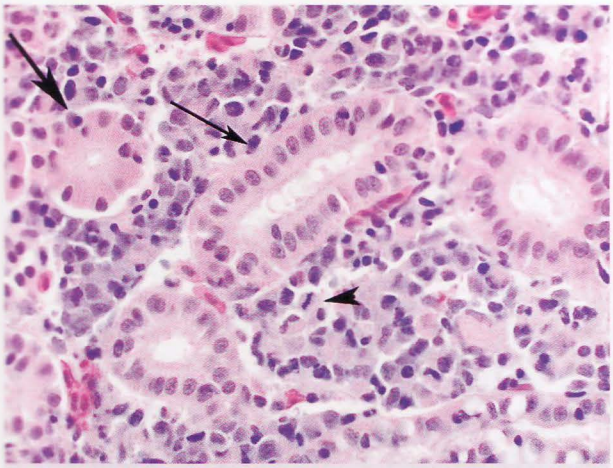

Fig 4.2C. Normal tubules in a posterior kidney of freshwater fish (goldfish). Proximal tubules with a wider lumen (thin arrow), distal tubule (thicker arrow) all surrounded by active haematopoietic tissue which contains a cell with a mitotic spindle (arrow head).

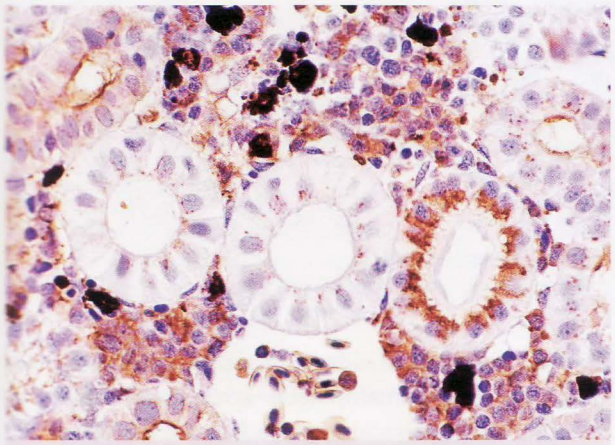

Fig 4.2D. Kidney from rainbow trout stained with tomato lectin to show differences between proximal (contains the brown stain in the apical epithelium) and distal segments of the nephron. *Material courtesy of Dr. D. Morris.*

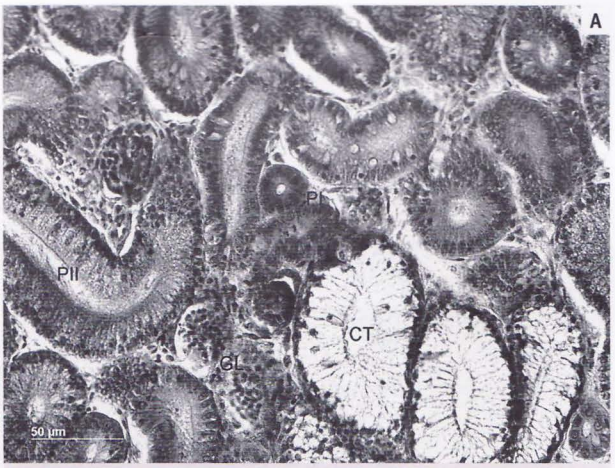

Fig 4.3. Normal stickleback collecting ducts (CT). **A** = male. The epithelial cells contain so much lipid they appear clear. Compare with **B** = female. *Figures courtesy of Dr. H. Hentschel.*



or elasmobranchs – see Chapter 11), the cells expressing the renin genes are not regularly identified in most fish kidney sections using routine staining procedures.

As with the glomerulus, the morphology of the individual nephron segments varies greatly from one species to the next. The neck segments generally are narrow and contain moderately basophilic cuboidal-to-columnar ciliated epithelial cells. These segments are usually short, and open into a wider proximal tubule. Proximal tubular epithelial cells are columnar with a prominent brush border, abundant apical vacuoles, mitochondria and a basilar nucleus. In some fish the first segment of the proximal tubule stains palely eosinophilic compared to the more intensely eosinophilic second segment, but this varies with species. The first proximal segment also tends to be the most active in uptake of substances from the tubular lumen and it therefore contains apical pinocytotic vacuoles. Intermediate tubules (some of which have brush border enzymes similar to those of proximal tubules) may have cilia, which help move the filtrate along the nephrons. Distal tubules may be somewhat difficult to differentiate from the proximal tubules when using routine H&E staining. They usually lack the prominent brush border seen in proximal tubules but again, species variations must be accounted for. Enzyme histochemistry can help distinguish distal tubules from proximal tubules, with proximal tubules positive for alkaline phosphatase and gamma glutamyltranspeptidase, while distal tubules are positive for ATPase. Lectin binding can also help differentiate proximal tubules from distal tubules (*Fig 4.2D*). Collecting tubules and ducts are located throughout the kidney. They have no brush border and the tubules are

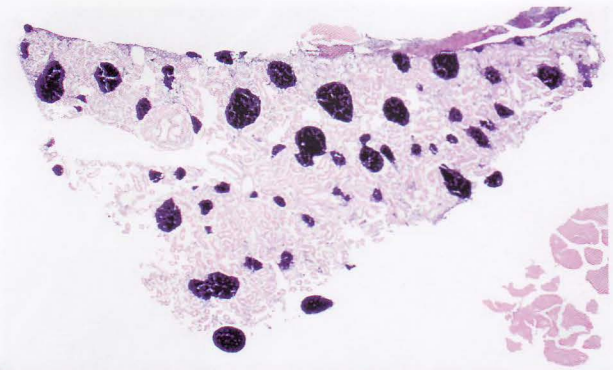

Fig 4.4. Melanomacrophage centres (MMC) can be quite prominent in normal kidneys, here seen in a French grunt. The amount of pigment within the centres also varies; they can appear pink, golden, brown or totally black.

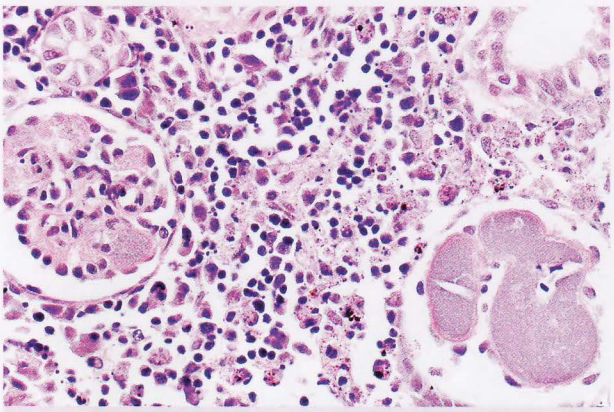

Fig 4.5. Glomeruli with a large number of bacteria within the vasculature. This is a case of acute BKD in a rainbow trout. Unusually for this disease, the bacteria are visible in this H&E.

surrounded by smooth muscle of varying thickness, with the largest ducts usually surrounded by a rather extensive muscular and connective tissue band. The epithelium is usually tall columnar shape and can have small lymphocyte-like cells intercalated between the epithelial cells. In some species rodlet cells can also be found in both tubules and collecting duct epithelium *(see Fig 4.26E)*. There can be marked variations in the appearance of the collecting duct epithelium as can be seen in the kidney of the stickleback (*Gasterosteus aculeatus*). Collecting ducts of the male stickleback may contain large quantities of acidic mucus at certain times of year, making the epithelium look clear in H&E staining *(Fig 4.3)*. These changes are linked to seasonal endogenous hormonal change. Stickleback kidney is used as an indicator for the presence of environmental oestrogens and androgens due to accumulations of a hyaline (and PAS positive) protein, *spiggin*, in their proximal tubules following exposure.

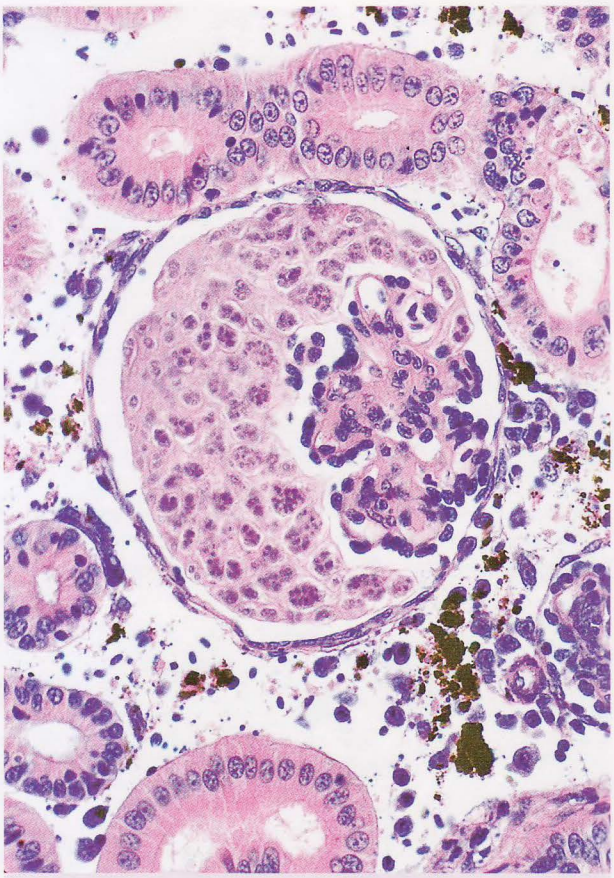

Fig 4.6A. Myxozoan extrasporogonic parasites filling most of Bowman's space in this rainbow trout.

The renal ***interstitium*** of both the anterior and posterior kidney contains haematopoietic and endocrine cells. Frequently, macrophage aggregates are also located in the interstitium; these are often called melanomacrophage centres. They can be diffusely located throughout the kidney, as in salmonids, or discrete membrane-limited centres, with differing pigments making them appear pale pink or golden. In some species they are black due to melanin *(Fig 4.4)*. The number and size of these centres, as well as their staining characteristics, can all vary with age and sex of the animal, as well as with infections and other general health stressors. In general, they increase in size and become darker and more numerous with age and/or disease.

Response of nephron to disease

Glomerular lesions are not uncommon but they are not seen as frequently as in higher vertebrates. Once again, interpretation is complicated by the morphological differences between species living in a variety of environ-

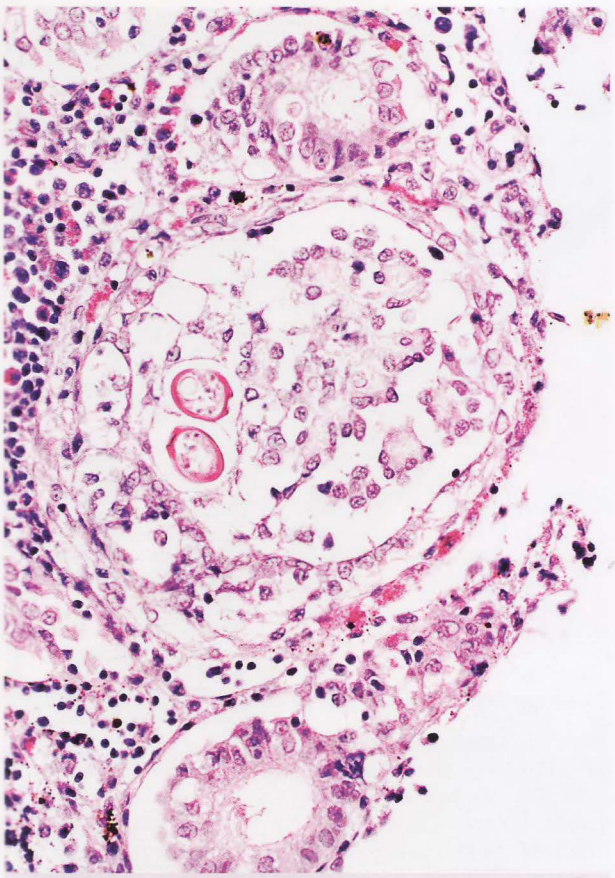

Fig 4.6B. Metazoan parasitic eggs have become lodged in this glomerulus.

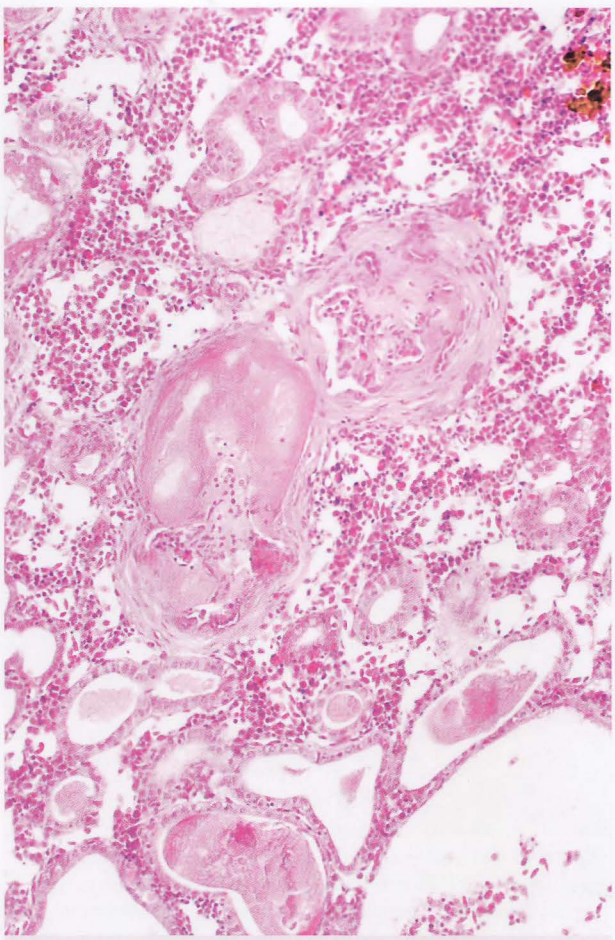

Fig 4.7. Chronic glomerulonephritis. Tubules surrounding the sclerotic glomeruli contain bright pink proteinaceous material, termed "casts" due to their appearance when viewing urine sediments by microscopy - they form "casts" of the tubules.

ments, and by the alterations that can occur when some species adapt to water of a different salinity, no doubt partly a reflection of the large physiological adaptations required. Glomerular involvement is seen in viraemias, bacteraemias (*Fig 4.5*), and parasitaemias (*Fig 4.6*), but acute glomerulonephritis is relatively uncommon compared to interstitial disease. In general, a full spectrum of pathological changes is seen, with synechial attachment of visceral to parietal epithelium, followed by proliferation of epithelial and mesangial components, and eventually sclerosis in chronic disease (*Fig 4.7*) which usually also involves Bowman's capsule. Proliferative glomerulonephritis is seen in eels associated with an IPN-like virus.

Diffuse or segmental thickening of the glomerular basement membranes is not uncommon in a variety of infectious and non-infectious conditions, including chronic viral haemorrhagic septicaemia (VHS) and bacterial kidney disease (*Fig 4.8*). Electron microscopy has shown that the thickening can be due to subendothelial electron dense deposits (*Fig 4.9*). Similar glomerular changes have been reported with diets deficient in essential fatty acids. Immune-complex mediated glomerulonephritis follows *Renibacterium salmoninarum* infection (bacterial kidney disease) in rainbow trout. Cystic glomeruli have been reported, but their aetiology remains uncertain.

Glomerular injury that may be invisible in wax sections may be inferred by observing consequential alterations in the proximal tubule. These will take up proteinaceous material that leaks through injured glomeruli, resulting in accumulation of homogeneous eosinophilic deposits (also described as "hyaline droplets") within the proximal tubular epithelium. It is important to note, however, that apparently normal fish will often have brightly eosinophilic droplets within the cytoplasm of proximal tubular epithelial cells (*Fig 4.10*). These may be fine and numerous, or large and few in number. Great care must therefore be exercised when interpreting the significance

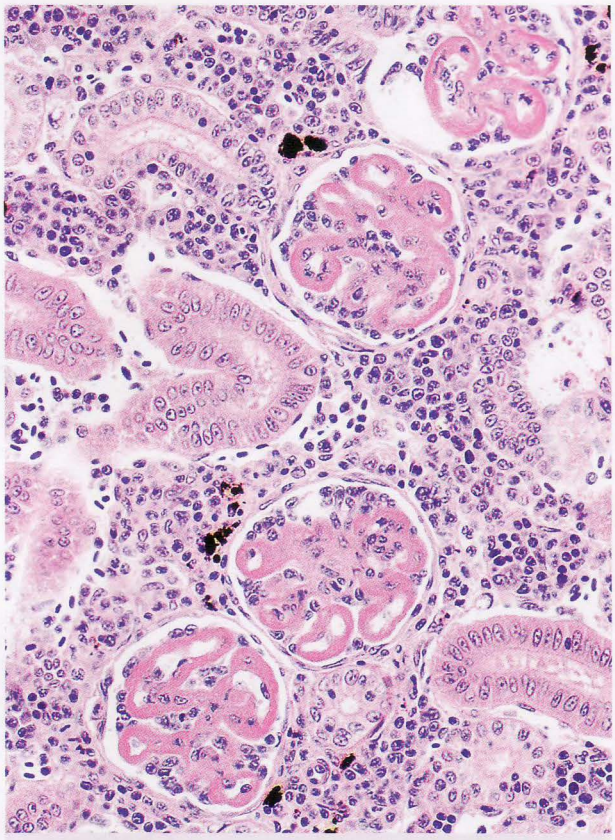

Fig 4.8. Marked thickening of the glomerular basement membranes in this Pacific salmon with chronic bacterial kidney disease to give the classical wire-loop appearance. The basement membranes in Pacific salmon tend normally to be prominent; another example of a species-specific variation.



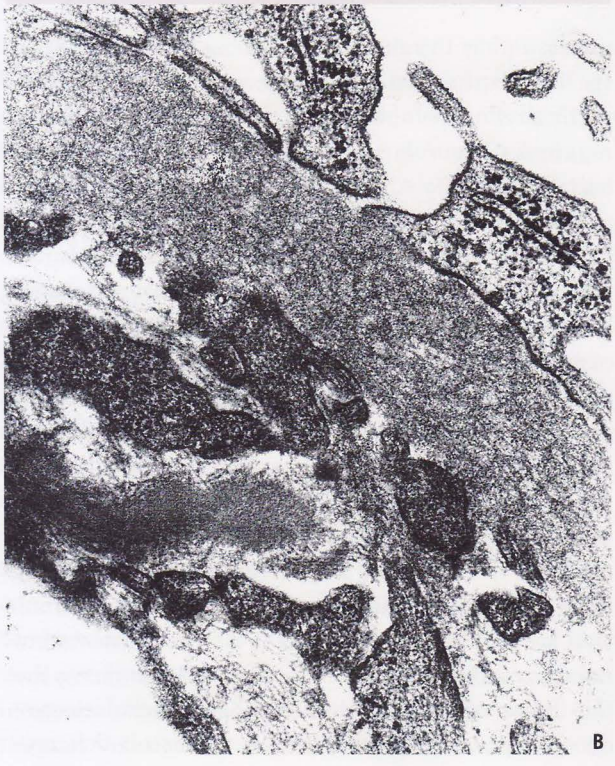

Fig 4.9 A&B. Glomerulonephritis in white perch showing in **A**, a normal capillary endothelium (fenestrated-arrow) with podocytes sitting outside. Compare with **B** where the basement membrane is thicker, and there are dense deposits beneath the endothelium. The podocyte processes do not seem thicker than normal, nor are they fused. These fish also had marked fibrinoid necrosis of afferent and efferent glomerular arterioles as well as some splenic vessels, suggesting a possible Shwartzman-like reaction (*see Fig 6.23*).

of tubular eosinophilic droplets since artifact and normal inter- and intra-species variations are all common. Such droplets have been identified following copper exposure in bullhead catfish and have been presumed by some authors to contain copper. This is not the case, however, as thin sections of the droplets examined by electron microscopy with energy dispersive x-ray analysis do not contain copper (or any other metal). Thus they appear to be proteinaceous material without copper accumulation. Eosinophilic droplets have also been noted in salmonids by some authors in association with toxicants and high ammonia levels (high levels of ammonia will increase the permeability of basement membranes). Glomerular vascular changes that may be accompanied by hyaline droplets in the tubules have recently been described in fish kidney for compounds such as trifluralin (a herbicide), Fumonisin B (a mycotoxin), 17B-oestradiol, the anti-inflammatory drug diclofenac and polyaromatic hydrocarbons. It is suggested that these changes are due to injury of the glomerular vasculature by these compounds.

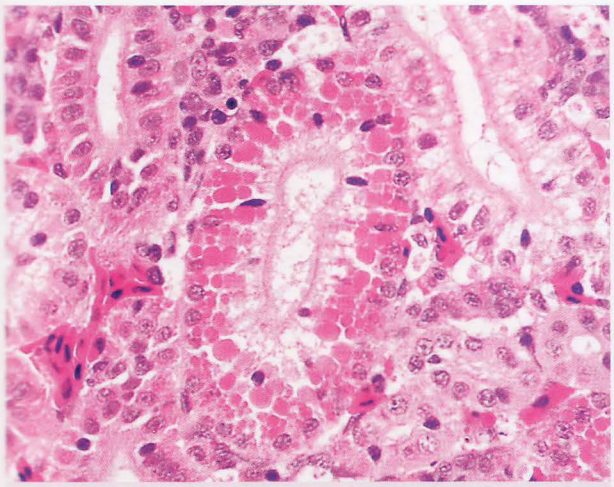

Fig 4.10A. Eosinophilic droplets within renal tubules can be found in apparently normal fish, here shown in a goldfish, as well as the result of renal injury. It is essential to be familiar with the normal histology of the tubules in different species of fish, under varying husbandry regimes.

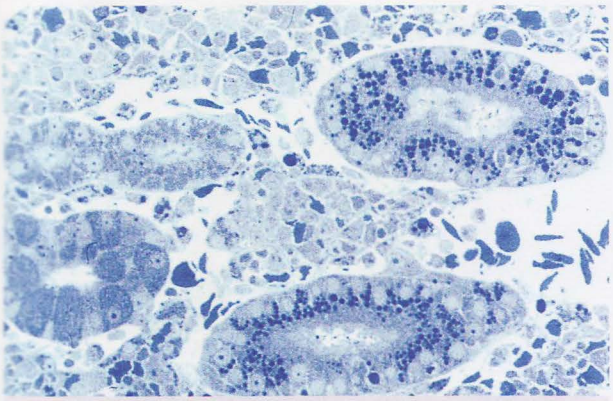

Fig 4.10B. Intracytoplasmic droplets (that were eosinophilic on H&E) in the kidney of a brown bullhead catfish exposed to copper sulphate. The droplets are primarily located in the apical portion of the cells, but some extend to the basal region by the nucleus. *Toluidine blue-stained Epon section.*

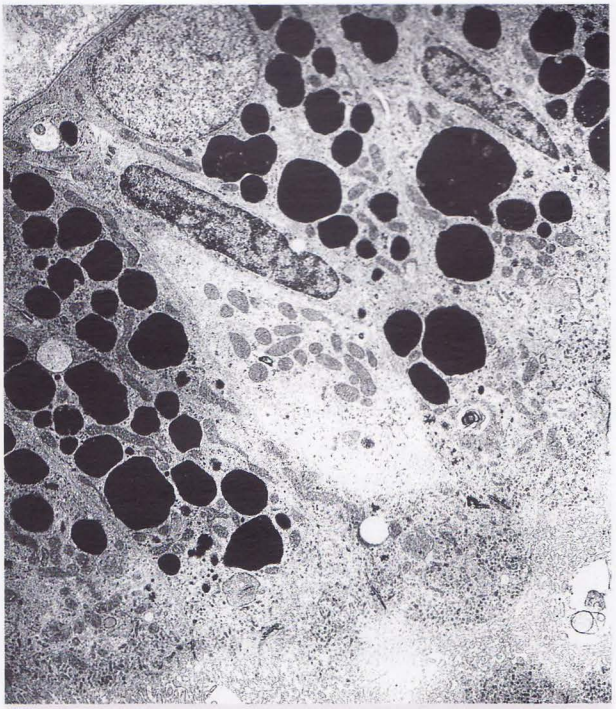

Fig 4.10C. Electron micrograph of intracytoplasmic droplets. Elemental analysis demonstrated that the droplets in this fish do not contain copper.

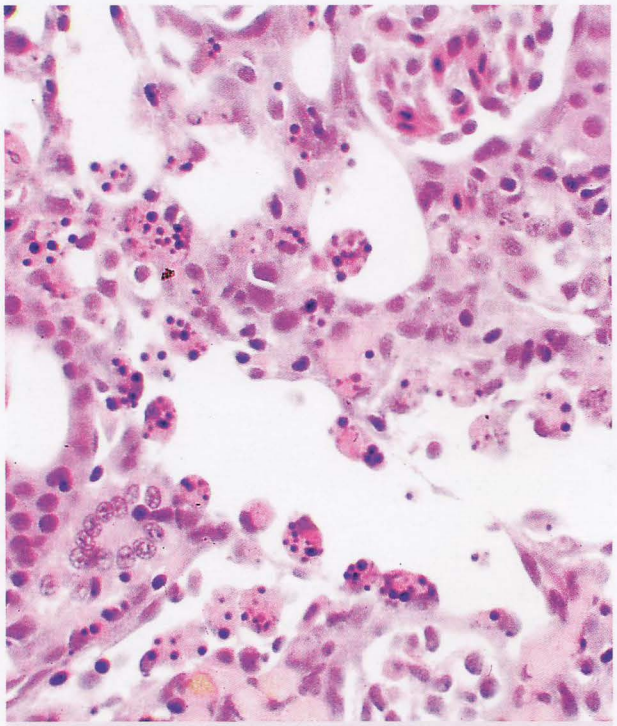

Fig 4.11. Tubular epithelial cell necrosis in a goldfish induced by gentamicin (50 mg/kg). Cells have very eosinophilic cytoplasm and fragmented nuclei. The cells are rounded but still remain adhered to the basement membrane.

Tubular lesions (nephrosis) in fish are similar to those seen in mammals. The kidney is a target organ for many metals and organic xenobiotic pollutants, and just as in mammals, certain segments of the tubule may be more susceptible to toxicity. For example, the proximal tubule is selectively injured by a number of metals including mercury, uranium, arsenic, nickel and cadmium. The heavy metals bind sulfhydryl groups on the cell membrane and induce changes that lead to cell death. Tubular cell death (necrosis or apoptosis) can also occur following ingestion of algal microcystin toxins, several antibiotics (gentamicin, erythromycin, sulphamerazine) or hydrocarbons such as hexachlorobutadiene (HCBD).

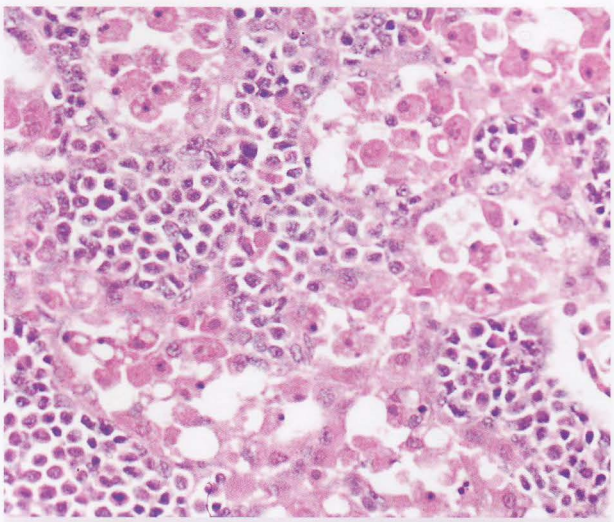

Fig 4.12A. Acute nephrosis of proximal tubular epithelium in a toadfish following a low dose of gentamicin (3 mg/kg). Necrotic cells have sloughed from the basement membrane. Toadfish have no glomeruli, so the only pathway for gentamicin excretion is through the tubular epithelium, resulting in massive cellular destruction.

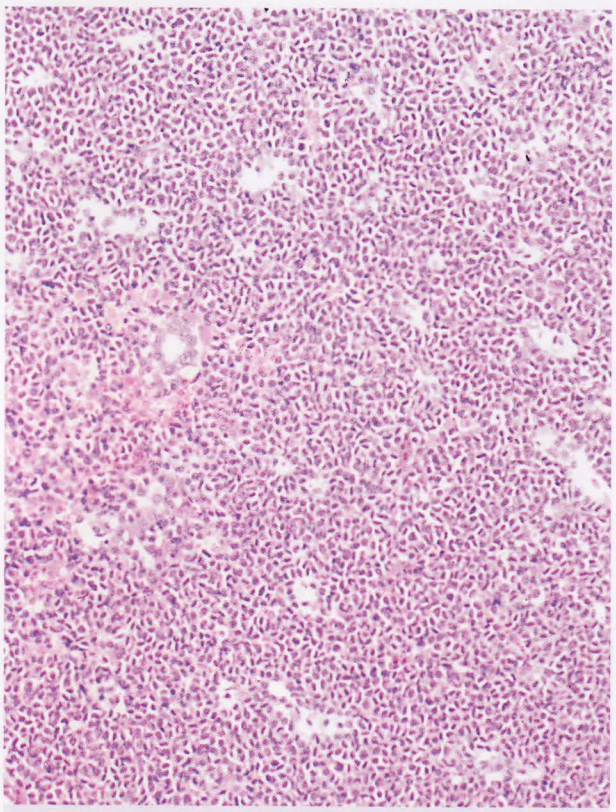

Fig 4.12B. Posterior kidney from a toadfish several weeks after treatment with gentamicin. All the proximal tubules are collapsed and the tubular epithelium is missing. Only a few small collecting tubules can be seen in the remaining haematopoietic tissue of the kidney. This sensitivity to gentamicin is due to the lack of glomeruli through which gentamicin is usually excreted.

In the case of gentamicin, proximal tubule cells undergo apoptosis, with nuclear fragmentation and condensation of the cytoplasm, making the cell hypereosinophilic (*Figs 4.11 & 4.12*). In the toadfish (which has only proximal tubules) this results in a posterior kidney containing a few collecting ducts in a sea of haematopoietic tissue. By contrast, necrosis induced by HCBD in goldfish causes extensive cell swelling (primarily in proximal segments 2 and 3) making the cells look clear in H&E sections (*Fig 4.13*). The segmental specificity can be seen at the junction between proximal segment 3 and the distal tubule, with the distal tubule cells normal in appearance adjacent to the injured cells of segment 3. Since the morphology of the injured tubule segments changes drastically, it is difficult using only H&E staining to identify which segment is injured. Enzyme histochemical stains such as

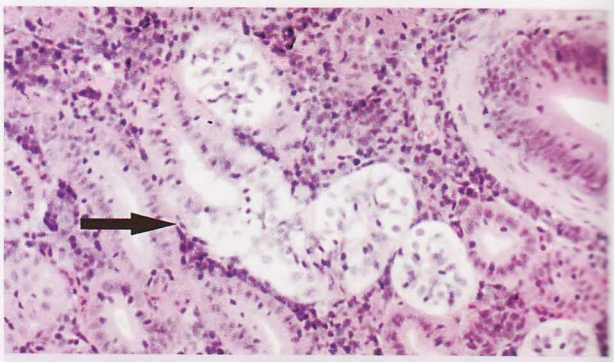

Fig 4.13A. Extensive vacuolar degeneration of proximal tubules in goldfish following hexachlorobutadiene (HCBD) exposure. Note the junction of the proximal tubule segment P3 and the distal tubule, where the epithelium is not vacuolated (arrow).

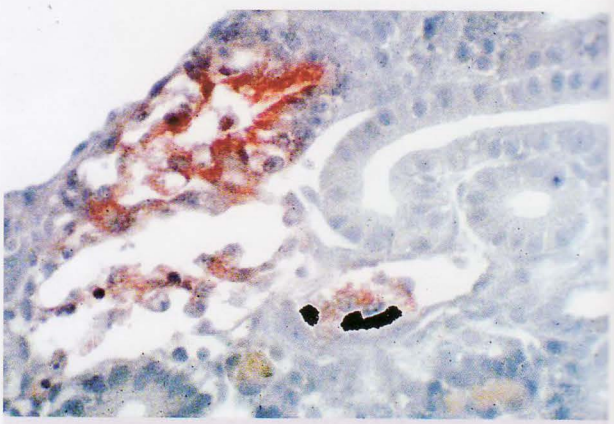

Fig 4.13B. Identification of the necrotic proximal tubule segments using enzyme histochemistry in HCBD exposed fish. Gamma glutamyltranspeptidase staining is evident in the remnants of injured tubules. Since injury often changes the morphology of the tubules, it can be necessary to use alternative techniques to identify which segments (P2 & P3) are affected by a toxicant.

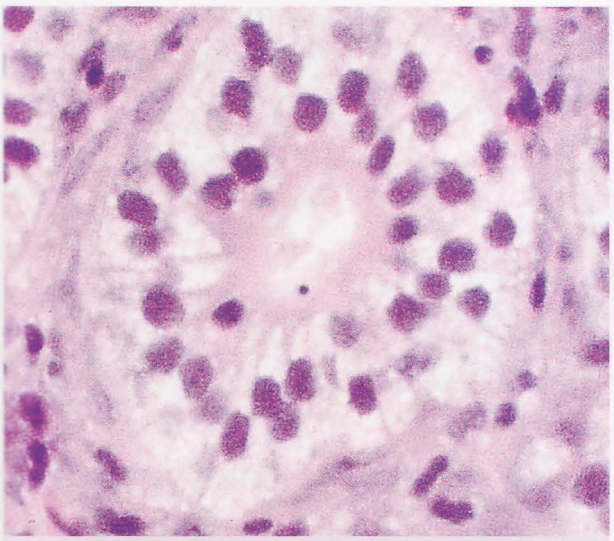

Fig 4.13C. Vacuolar degeneration in segment P1 of a goldfish following HCBD exposure. The vacuoles in this case are much smaller, which may be due to the lack of enzymes that metabolize HCBD in this segment.



Fig 4.13E. Electron micrograph of goldfish kidney after HCBD exposure shows that the vacuoles are greatly distended mitochondria.

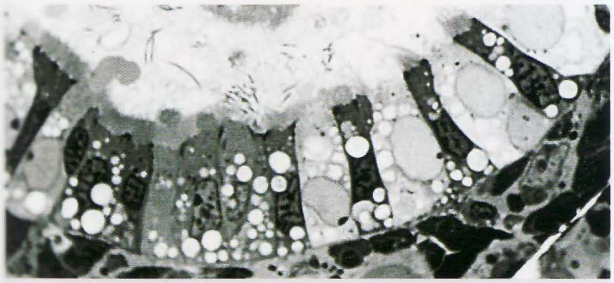

Fig 4.13D. High resolution section of Epon embedded tubule from a fish exposed to HCBD. The vacuoles are located throughout the entire cytoplasm, basal and apical regions.

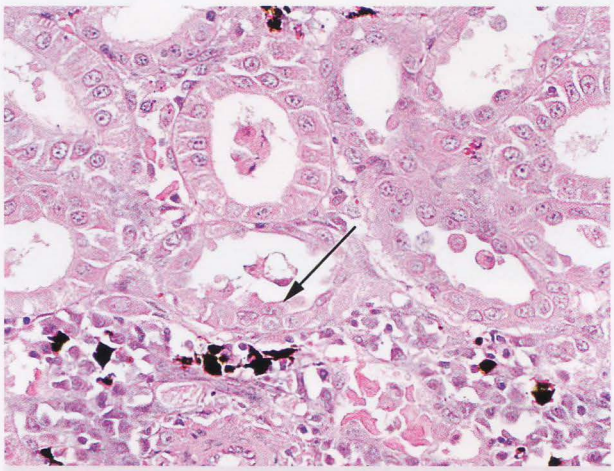

Fig 4.14A. Nephrosis in Atlantic salmon showing sloughed cells within tubular lumena, and early attempts at epithelial reduplication or regeneration (arrow).

gamma glutamyltranspeptidase can help identify which part of the nephrons is involved. Over time, HCBD induces cell injury in proximal segment 1 but to a lesser extent. The vacuoles are the result of mitochondrial swelling, and as mitochondrial function fails, the cell loses its ability to osmoregulate and it swells.

Necrotic tubular epithelial cells often slough into the lumen; even severe tubular injury however, can be repaired by regeneration. As in mammals, if the basement membrane is intact, epithelial cells divide and migrate along the membrane to repopulate the nephrons. In goldfish held at 22°C this process occurs approximately one week after inducing the injury. Unlike mammals, however, fish kidney can also produce nephrons *de novo* **(*Fig 4.14*)**. These arise from basophilic cell clusters in the interstitium, often near a collecting duct, and progress through the normal stages of nephron differentiation as seen in larval fish. As these small, basophilic nephrons develop, they penetrate an existing collecting duct, eventually becoming mature, functional nephrons. In goldfish, this process occurs about 2-4 weeks following the injury. Developing nephrons can also be found in normal fish kidneys, especially if the animal is growing. However, finding them in large numbers in adult fish can indicate a previous episode of renal tubular injury. The time course of renal injury, repair and nephron neogenesis is temperature-dependant. In zebrafish kept at 30°C and given a toxic dose of gentamicin, the injury phase lasts 1-2 days after

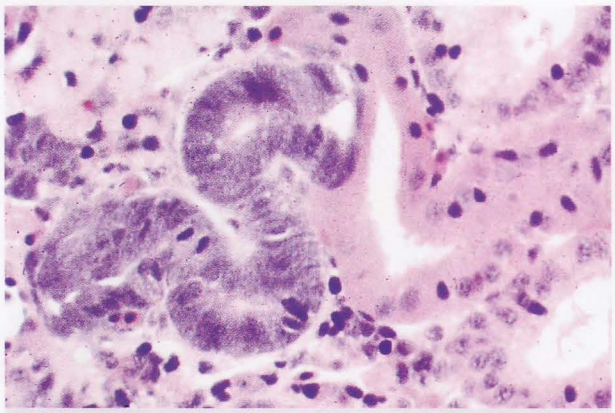

Fig 4.14B. Newly developing, intensely basophilic, nephrons can be found normally in young fish. Nephron neogenesis also occurs following tubular injury (induced by toxicants or infectious agents). Finding many such nephrons in the kidneys of adult fish can indicate previous renal damage.

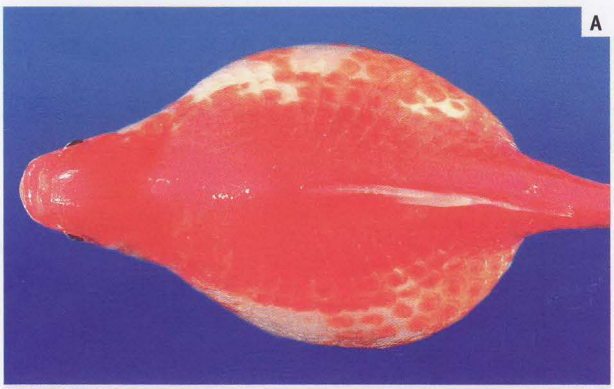

Fig 4.15A-C. Goldfish with polycystic renal disease.

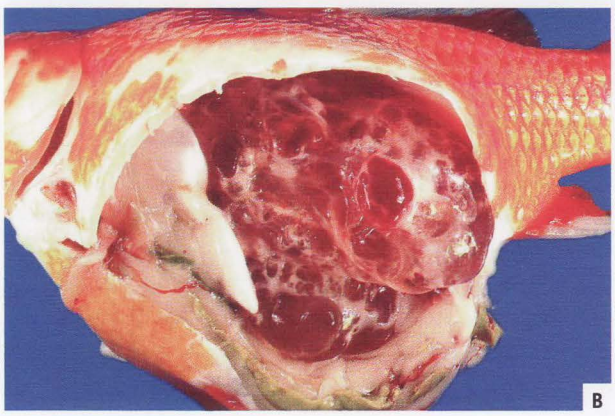

the dosing, the repair phase is 3-4 days and the neogenic phase begins around day 7 post-dosing. In zebrafish kept at 20-22°C, the time course of injury, repair and neogenesis is similar to that of goldfish maintained at the same temperature.

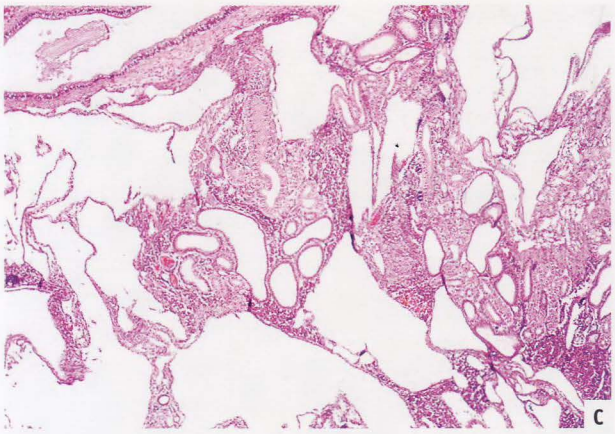

In cases where tubular injury is sustained, the nephrons may become cystic. This can occur with chronic chemical injury, resulting in kidneys with grossly visible cysts throughout the parenchyma. Polycystic kidneys can also occur as a developmental anomaly or as a result of obstructed flow. They are common in goldfish ***(Fig 4.15)***, and although some have associated them with pollutants, they seem able to occur in apparently normal water. Cystic ureters or neoplasms (nephroblastomas and renal adenocarcinoms) can also result in grossly observable abdominal distension and general tubular dilation ***(Fig 4.16)***.

Renal tubules may contain material in their lumen. This is frequently seen following tubular necrosis. Distal tubules and collecting ducts contain cell debris and eosinophilic proteinaceous material in their lumen forming "casts" which are sometimes excreted in the urine as cylindrical masses ***(see Fig 4.7)***. Mineral deposits are also frequently encountered within tubules, collecting ducts, and ureters of both farmed and wild fish. Calcium deposits appear as dense granular material staining a deep purple with H&E within the lumen or along the lumenal edge of the epithelial cells. Special stains such as Von Kossa's can help identify the material as a calcium phosphate deposit.

Where there is extensive mineralization in the kidney the condition is known as nephrocalcinosis. It is especially common in intensively reared rainbow trout and brook trout in which the grossly visible chalky-white caseous material can distort the normal appearance of the kidney ***(Fig 4.17)***. Mortality is usually low and although food conversion efficiency is probably impaired, the major concern about the condition centres round a reduction in carcase quality at slaughter. In severe cases, the muscle dorsal to the kidney may also be affected. Histologically, mineral deposits within the parenchyma elicit a pronounced



Fig 4.16A&B. Trout with blocked ureter. This is usually a "one-of" type of lesion.

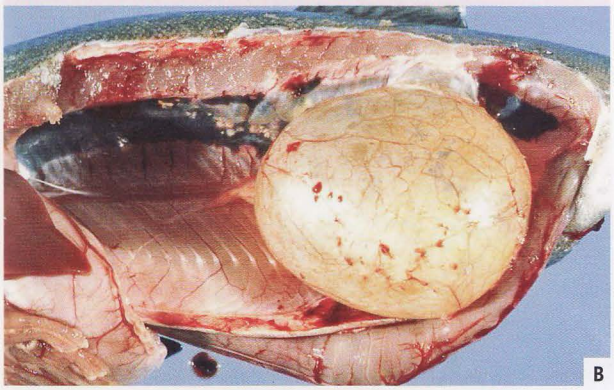

granulomatous response involving both tubules and interstitium, and resulting in fibrosis with ballooning of tubules and collecting ducts. Associated lesions include gastric submucosal granulomas. The cause (or causes) of the condition are often unknown in individual cases, although high CO^2 levels are implicated and have experimentally reproduced the lesions, as indeed have magnesium deficiency, selenium toxicity ***(Fig 4.18)*** and a diet low in minerals. The disease frequently appears in an advanced or essentially "end-stage" form, and it is likely that several very different aetiologies could end up producing similar lesions. Concurrent disease such as BKD can sometimes complicate the diagnosis.

Similar chronic renal changes are seen in "visceral granuloma", a condition of trout reported in North America and in gilthead bream (*Sparus aurata*) in Israel and differentiated from nephrocalcinosis by widespread involvement of other visceral organs and mesentery. The cause is unknown, but thought to have a dietary association; in the gilthead bream, the renal tubules are packed with tyrosine crystals, which, however, disappear as the condition advances, suggesting they may not be the primary problem.



Fig 4.17A&B. Intensively cultured rainbow trout with nephrocalcinosis. The grey masses are gritty when sectioned and can be cavitated.

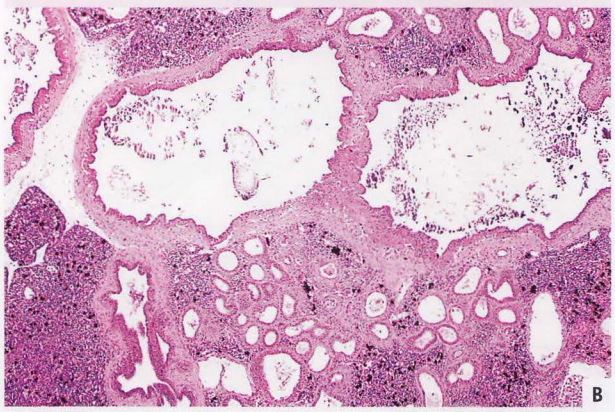



Fig 4.17C. Calcified material within the lumen of tubules. The basophilic amorphous material appears black when stained with Von Kossa.

Heavy metals or feed binders have been considered the cause of comparable granulomatous conditions in farmed turbot (*Scophthalmus maximus*). Oxalate and other crystals are also occasionally seen within the tubules (and renal but not splenic macrophage centres) of a variety of species, particularly wild and aquarium fish; their significance is usually unknown, although they have been linked with pyridoxine deficiency in trout and vitamin A deficiency in clown fish ***(Fig 4.19)***.



Fig 4.18. Experimentally produced selenium toxicity causing nephrocalcinosis: collecting ducts and ureters are filled with mineral.

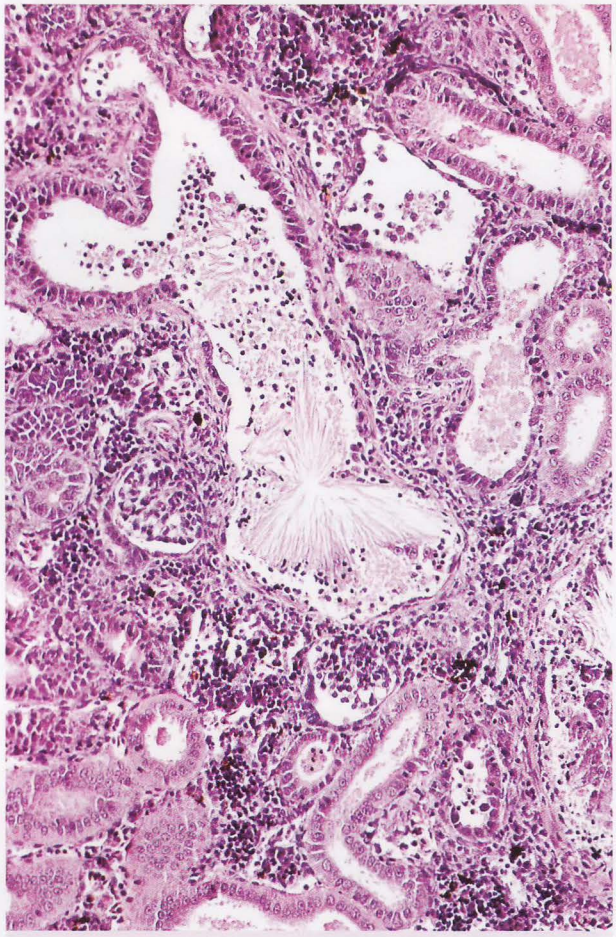

Fig 4.19. Rainbow trout with acute degeneration and necrosis of tubular epithelium. Large numbers of sloughed and dead epithelial cells are present in the lumen, together with inflammatory cells, mainly neutrophils, that are also present in large numbers in the interstitium. One tubule contains prominent crystalline deposits: whether these are the cause or the result of the tubulonephritis is unknown. Fish with lesions like these, however, often have large numbers of Gram-negative bacilli in their kidneys; these are encountered on impression smears only, and their significance is unknown.

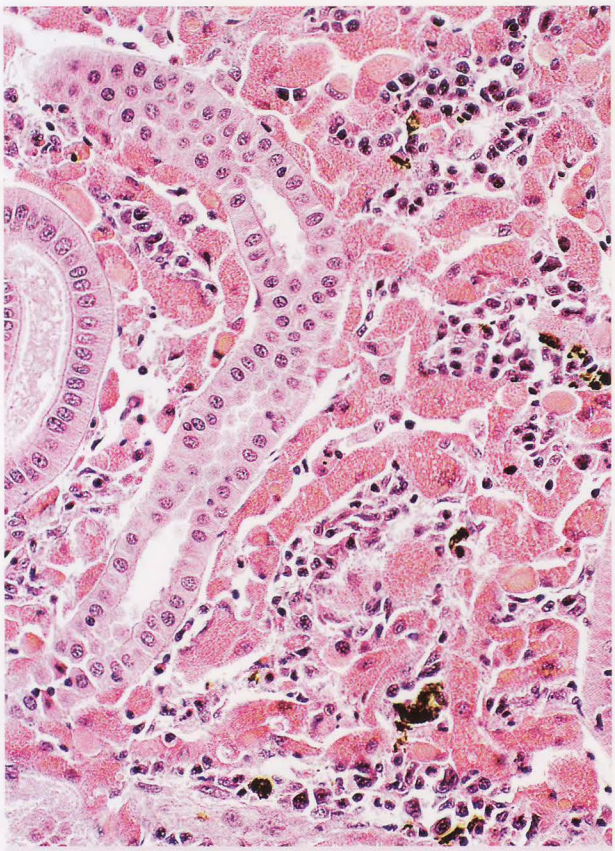

Fig 4.20. Female broodstock rainbow trout after spawning. This fish had to resorb many eggs, and the resulting bright eosinophilic lipoprotein droplets can be seen within the interstitium.

Response of interstitium to disease

Renal interstitial injury can be difficult to interpret due to the variations in normal anatomy of different fish species, as well as the additional tissues found within fish renal parenchyma. For example, the quantity of haematopoietic tissue present varies among fish species, making it difficult to assess cell proliferation or cell loss unless one is familiar with a given species. As already said, the dual blood supply, both a renal portal and arterial system, may increase the opportunity for concurrent disease and affect assessment, *e.g.* congestion can look like haemorrhage, requiring close examination of the vessel boundaries for interpretation. On the other hand the dual supply tends to mitigate or obviate infarction or hypoxaemic damage except when large areas of proliferation or degeneration are present.

Evaluation of renal interstitial pathology often requires an understanding of the pathogen as well as the cellular

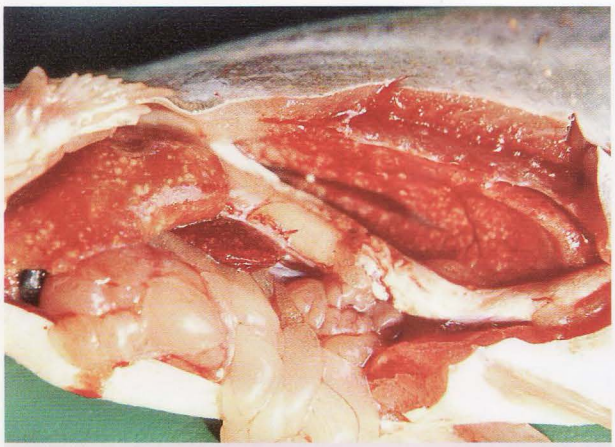

Fig 4.21A. Edwardsiella ictaluri infection in *Pangasius* showing multifocal granulomas in many organs. Gross lesions gave this disease in Vietnam the name "white spot disease".

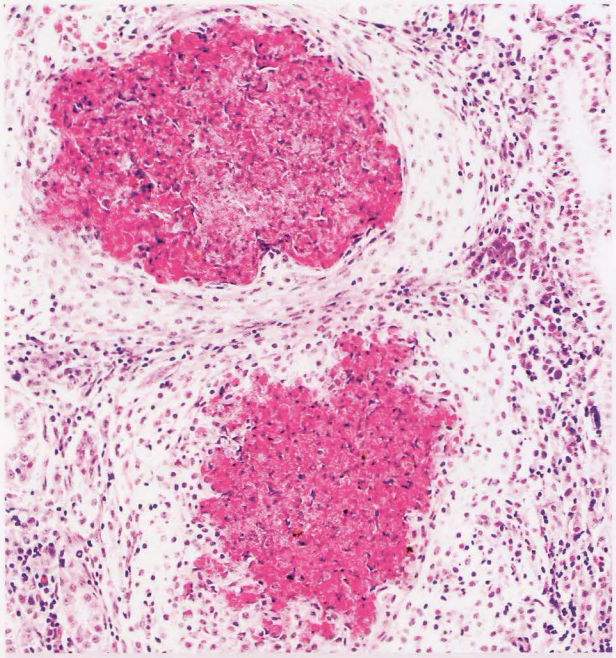

Fig 4.21B. Hybrid striped bass showing multifocal areas of interstitial necrosis with pre-caseous cores. The rickettsia-like bacteria associated with these lesions have similarities to *Francisella. Material courtesy Dr. V. Ostland.*

response. Fortunately, the cellular reactions in the kidney are similar to those in other organs, although some features should be borne in mind. For example, cellular hypertrophy is more difficult to assess since cells comprising haematopoietic tissue are normally diverse, and resident or migrating inflammatory cells occur in small numbers in healthy tissue. A left shift can sometimes be encountered in situations of high demand for neutrophils, and lipoprotein-laden macrophages can fill the

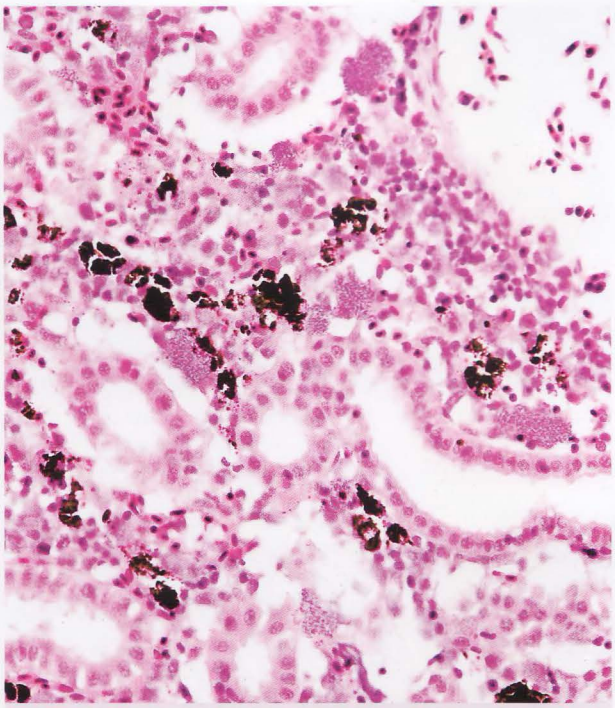

Fig 4.22A. Furunculosis (*Aeromonas salmonicida*) in brown trout. Colonies of organisms are associated with the endothelial lining of the peritubular capillaries, part of the renal portal system. There is very little associated necrosis or inflammatory response.

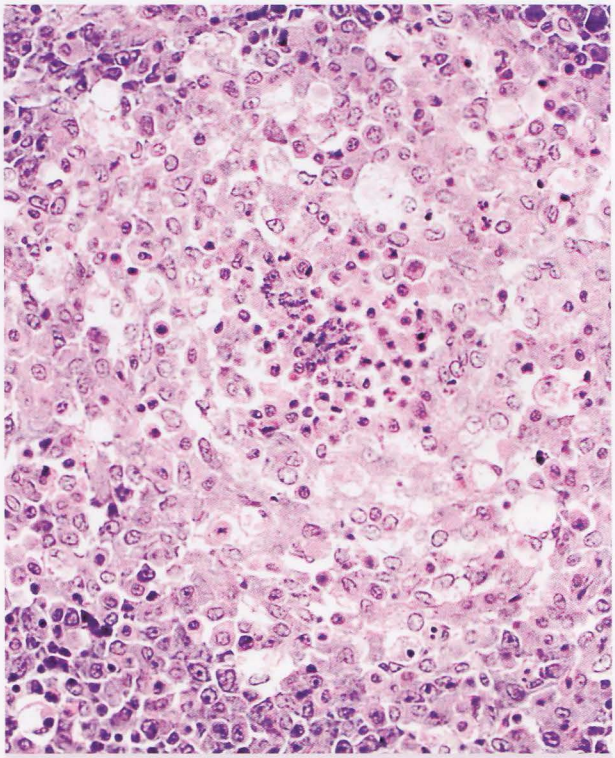

Fig 4.22B. Furunculosis in farmed cod, in which necrosis is more obvious.

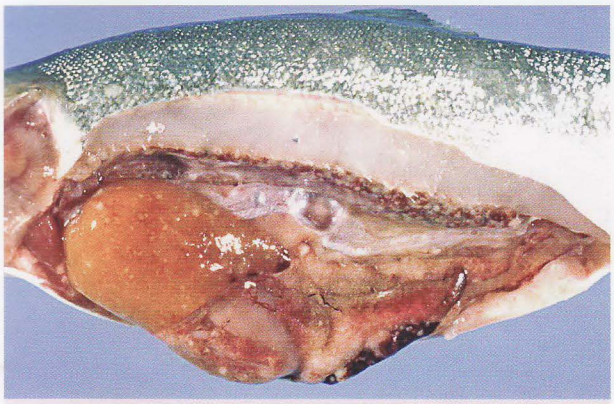

Fig 4.23A. Atlantic salmon with bacterial kidney disease (BKD) due to *Renibacterium salmoninarum* showing multifocal granulomas throughout many organs.

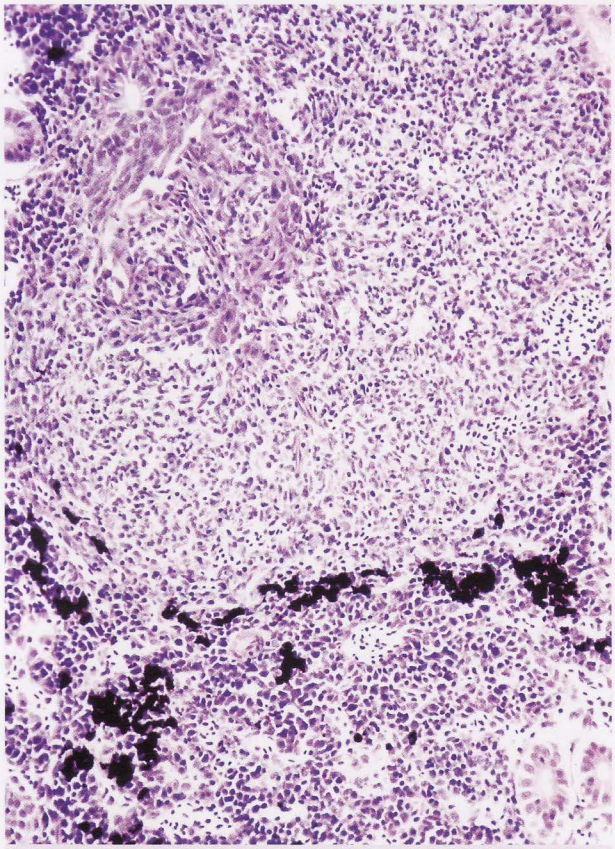

Fig 4.23B. BKD in trout showing typical interstitial granulomatous response and loss of tubules within the reaction. Note the line of melanomacrophages delineating the edge of the lesion.

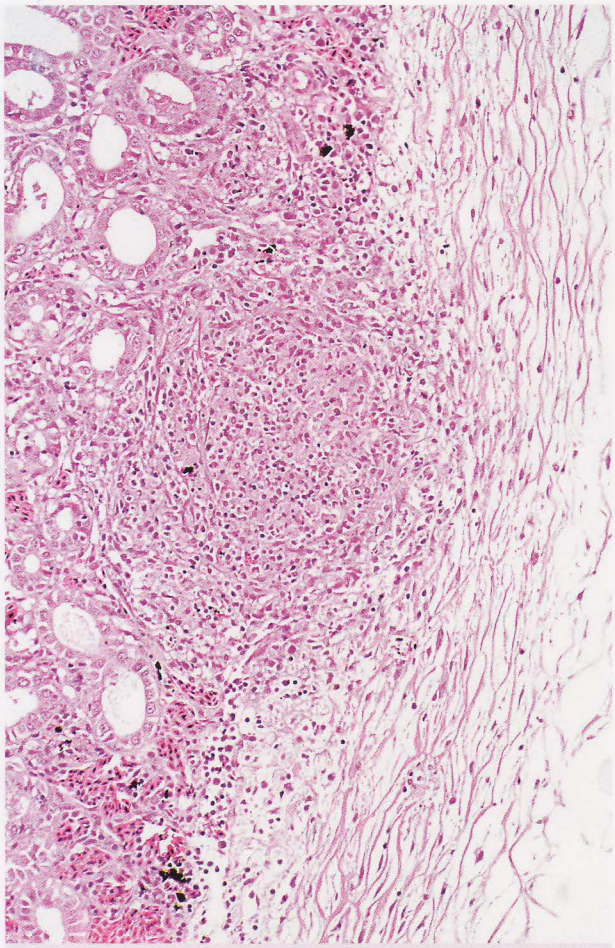

Fig 4.23C. BKD lesion erupting through the capsule. Such lesions lead to peritonitis.

interstitium in post-spawning egg-resorbing broodstock (*Fig 4.20*) but familiarity with the species is crucial for any confidence in this interpretation. Compared to those tissues with more uniform morphology, necrotic and apoptotic change in the interstitium may need to be severe in order to be apparent. Migratory invasive cells such as neutrophils and macrophages collect *en masse* in the interstitium in response to acute inflammatory stimuli but the more common inflammatory response involves chronic walling-off or segregation of offending agents forming well-defined granulomata. These reactions may also distort normal tubular architecture and other structures in the kidney, and if extensive, affect their function. Lesions in the interstitium due to bacteria, viruses and fungi can also affect nephrons directly, but often their effects are indirect due to extension of the lesion through the interstitium. Collateral damage to tubules or glomeruli, corpuscles of Stannius, interrenal and chromaffin cells may have a more profound effect on mortality and morbidity than the primary injury.

Systemic infectious diseases (bacteria, viruses and fungi), will frequently cause inflammatory responses in the renal interstitium. Acute inflammatory responses include oedema, necrosis, and cellular swelling, especially if combined

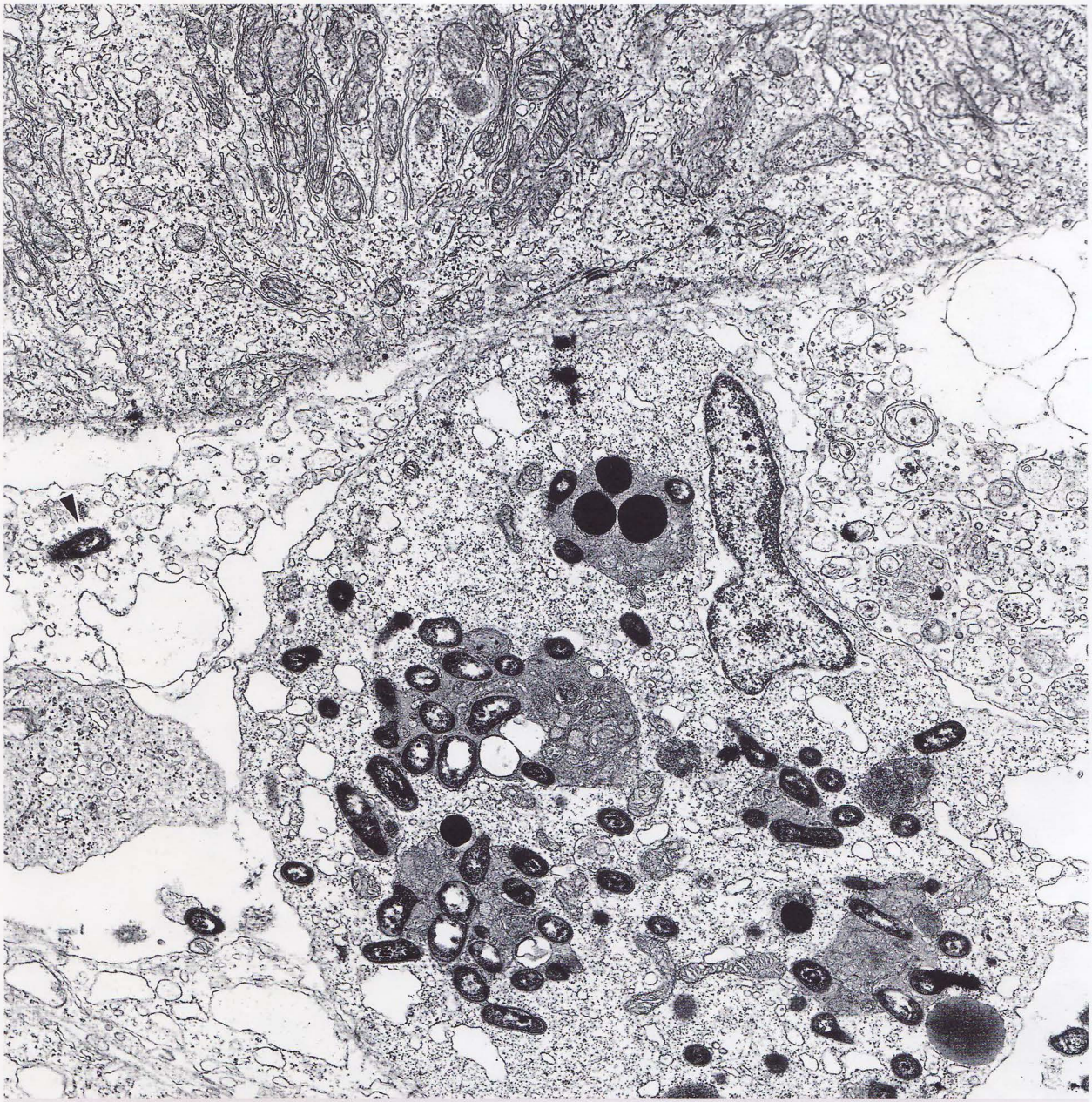

Fig 4.23D&E. TEM of coho salmon with BKD showing large number of bacteria within a renal portal macrophage, often within phagolysosomes. Compare with **E** overleaf which shows in the same fish a single neutrophil sitting in a sea of bacteria, and yet containing a single bacterium. These pictures illustrate the different roles played by these 2 cells.

with invasion of neutrophils, although in many species these are hard to identify. Chronic interstitial disease is characterized by inflammatory infiltrates of macrophages and lymphocytes. Granulomatous or fibrous responses occur with certain pathogens.

Bacterial pathogens frequently localize in the interstitium probably partly due to the extensive blood supply and trapping abilities of the organ, and in acute bacteraemias such as those associated with acute *Aeromonas, Pseudomonas, Vibrio* or *Enterobacteriaceae* infection, the organisms are frequently associated with the portal vasculature. Some of them can cause extensive liquefactive necrosis of interstitial and tubular components. For example, *Edwardsiella ictaluri* in catfish results in necrotic foci in multiple organs, including the renal interstitium **(*Fig 4.21*)**. This organism also produces haemolysins that cause widespread haemorrhage. *Edwardsiella tarda* infec-



tions also cause acute foci of necrosis, but as the lesions progress they develop a much more pyogranulomatous reaction. *Aeromonas salmonicida*, the cause of furunculosis, arrives rapidly via the haematogenous route and multiplies quickly in the renal interstitium, but by contrast there is in some species (*e.g.* salmonids) an almost complete lack of obvious lesions or cellular response **(*Fig* 4.22)**. *Lactobacillus* infections tend to occur after stressful situations like spawning or poor water quality conditions. An example of a less infective and adaptive pathogen, *L. piscicola* is often found in fish without disease; it invades opportunistically and with less aggressive infectivity, allowing the fish inflammatory system to respond over time. Although *Lactobacillus* characterizes an acute infection, the decreased pathogenicity allows much more cellular response with invading neutrophils and macrophages and exudation of large amounts of fibrin in attempts to control the bacteria. Accordingly, interpretation of the lesions requires the integration of bacterial characteristics, ambient temperature and tissue responses.

Bacterial kidney disease (BKD) of salmonids is a classic study in the effects of chronic inflammatory response **(*Fig* 4.23)**. Caused by *Renibacterium salmoninarum*, a small

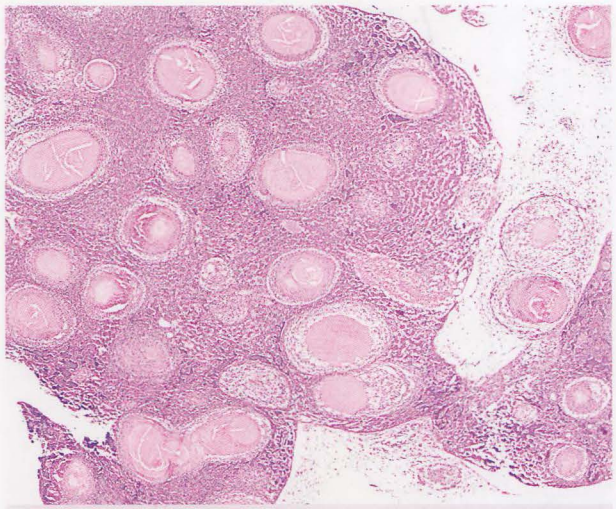

Fig 4.24. Extensive multifocal granulomatous nephritis in this goldfish, due to a chronic *Mycobacterium marinum* infection.

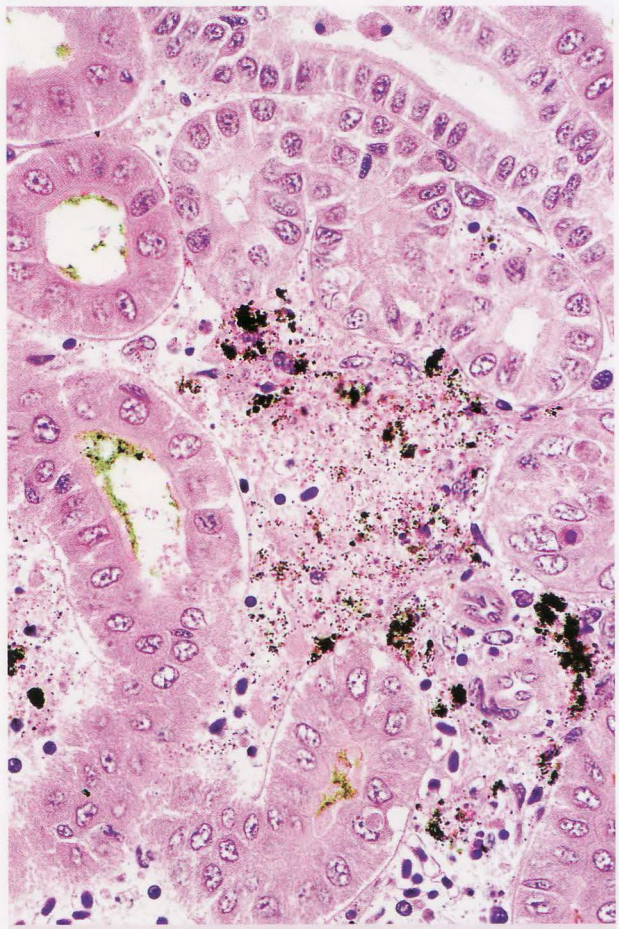

Fig 4.25A. Experimentally produced IHN in rainbow trout. There is marked necrosis of all interstitial elements, including melanomacrophages; pyknotic debris and melanin granules are scattered throughout. The adjacent tubule is mainly normal. *Material courtesy Dr. C. Smith.*

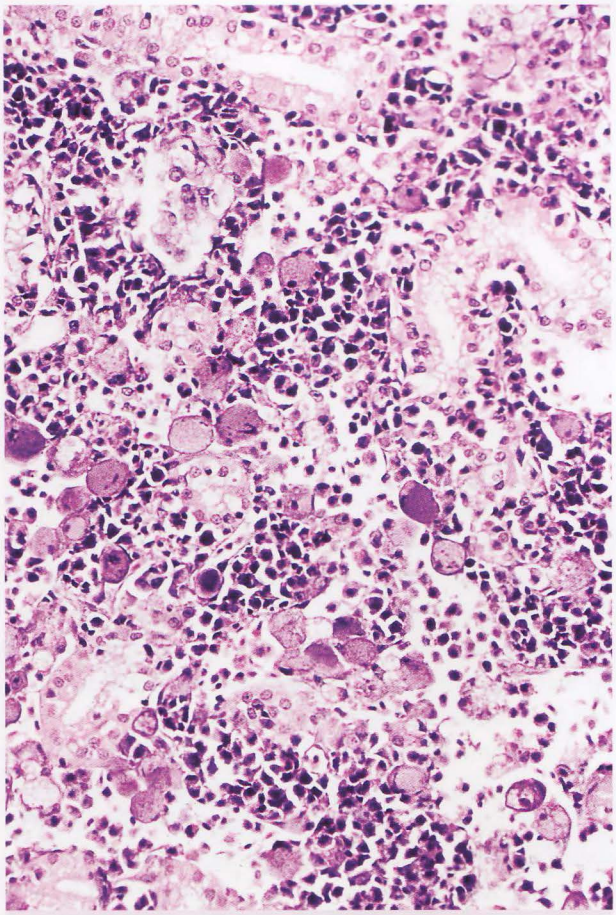

Fig 4.25B. Naturally-occurring iridovirus infection of kidney in farmed grouper. The purple-staining enlarged cells are mesothelial cells full of virions. *Material courtesy Dr. S. Kueh.*

Gram positive diplobacillus, the organism can reside in almost any organ of fish but occurs commonly in the kidney probably due to its profound vascularity and filtering abilities. *R. salmoninarum* will proliferate within macrophages after uptake, building infective doses while protected from immune responses. The organism favours an intracellular location, and the host response is pyogranulomatous, progressing to granulomatous. Normally there is ample time to respond, as the organism is not especially invasive, so large discrete granulomata form; these are seen grossly as white lesions. In addition to anterior and posterior kidney which may be massively enlarged, granulomas may be present in spleen, liver and elsewhere in the viscera. Rupture through renal capsule results in peritonitis. Occasionally infection at lower temperatures is accompanied by perinephritis, perisplenitis, perihepatitis and pericarditis. The ovary and developing eggs may also be affected, allowing for vertical transmission of the disease.

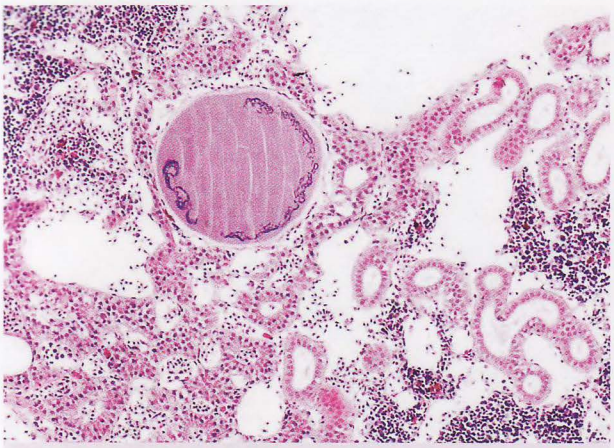

Fig 4.25C. Although lymphocystis disease almost always targets dermal fibroblasts, occasionally it will become systemic, as seen in this seabass.

BKD lesions are characterised microscopically by fibrous encapsulation by epithelioid cells and mixed inflammatory response with central necrosis. The response is dominated by macrophages, which are often stuffed full of bacteria, and by neutrophils that occasionally contain one or two, thereby emphasizing the sometimes very different roles these cells play in teleosts by comparison with mammals. Of interest, the bacteria are often virtually impossible to see in a routine H&E stained section, despite almost obliterating cells by sheer numbers; a Gram- or PAS-stained section or an impression smear reveals the extent of tissue involvement. Fibrin exudation is seen in some locations, especially when there are vascular lesions, which are quite common. These can take the form of necrosis of the media or endothelium, and in severe cases limited haemorrhage or thrombosis may also be evident. Glomerular vascular lesions can be pronounced ***(see Fig 4.8)***.

Young and Chapman (1978) provide an excellent ultrastructural description of the developing lesions in the nephrons of experimentally and naturally-infected brook trout. In the glomerulus they showed subendothelial electron-dense deposits as the earliest change; with time, deposits were also noted in the mesangium which proliferated. Fusion of foot processes, thickening of basement membrane and blebbing of endothelial cells were noted later. Tubular damage was also seen; changes observed included swollen endoplasmic reticulum and mitochondria, and eventually evidence of irreversible damage such as ruptured mitochondria. Infiltration by neutrophils and macrophages was seen, with some fibrosis at a later stage. BKD is largely an interstitial reaction with secondary involvement of the nephron, probably due to interference

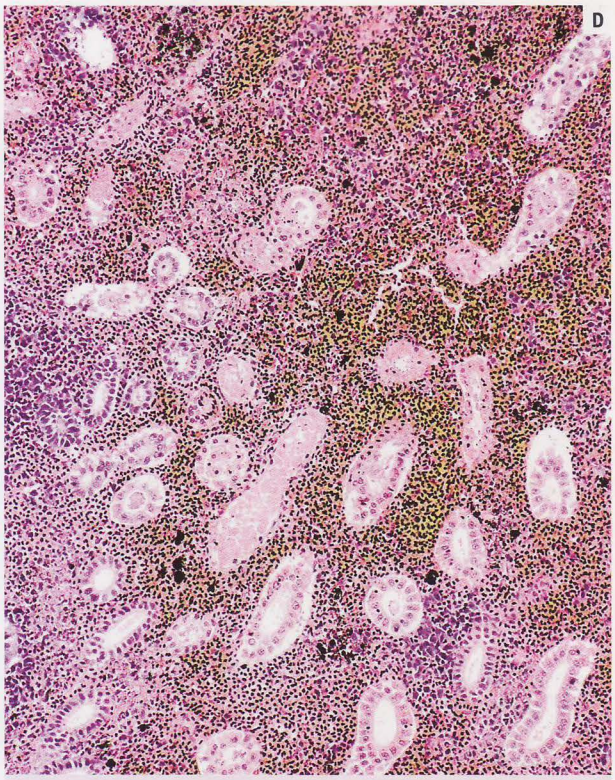

Fig 4.25D&E. Haemorrhagic kidney syndrome of Atlantic salmon showing marked renal interstitial haemorrhage and acute tubular necrosis with eosinophilic casts. This orthomyxoviral disease is the North American version of infectious salmon anaemia in Europe where hepatic necrosis is the common lesion.

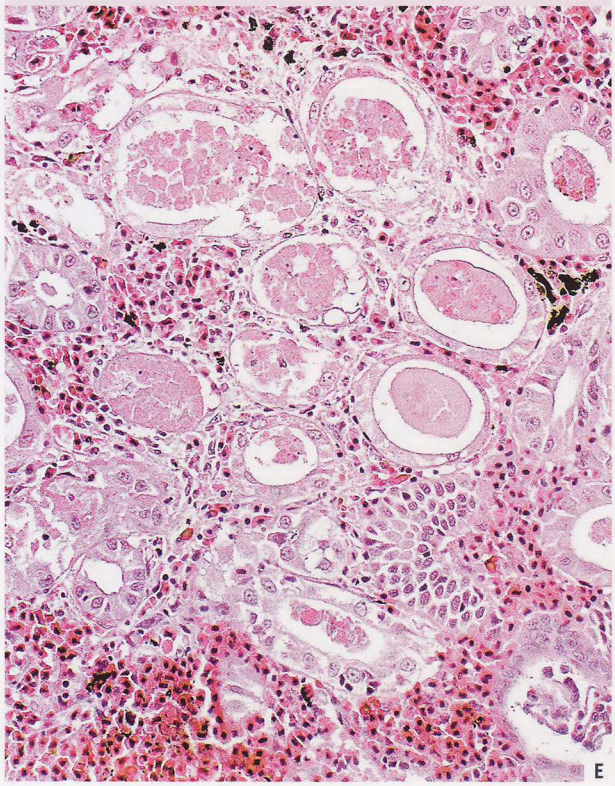

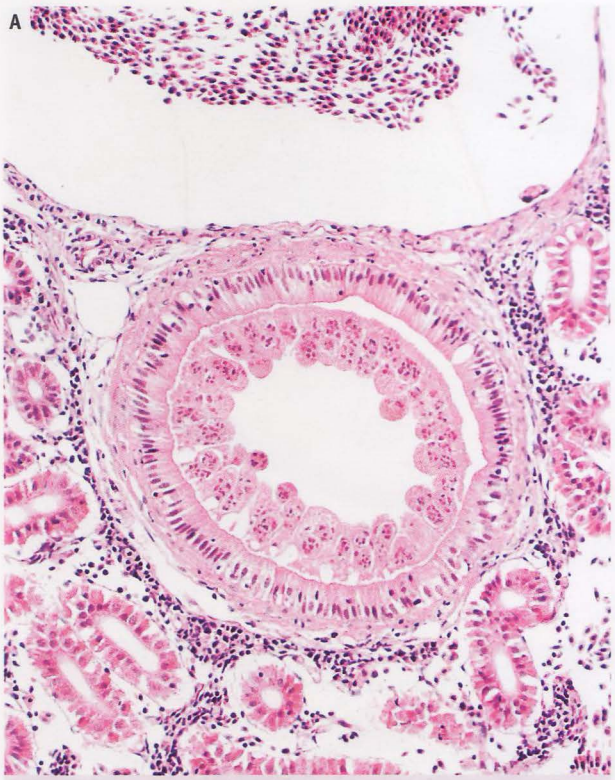

Fig 4.26A&B. Extrasporogonic myxozoans within renal tubules of cod and mummichog respectively. Such coelozoic species often cause relatively little damage, compared to their histozoic counterparts.

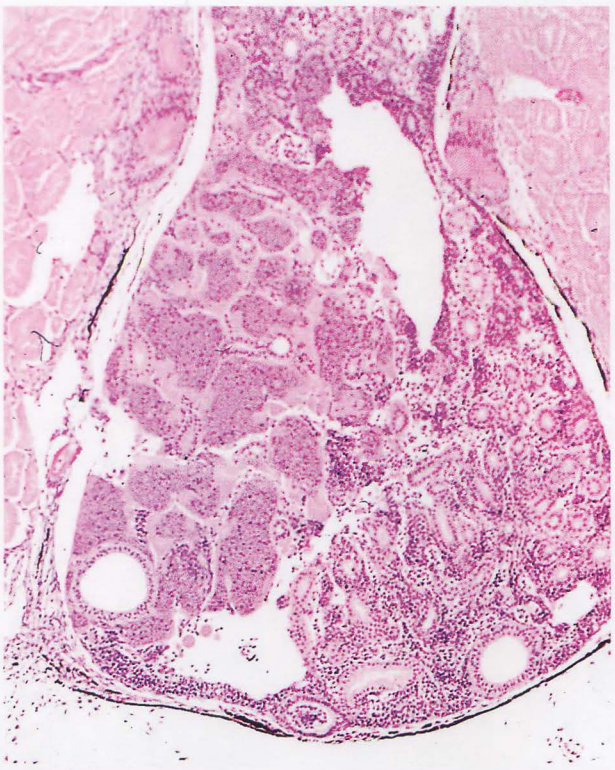

Fig 4.26C. Extrasporogonic myxozoan stages of *Kudoa* sp. extending throughout the kidney of Atlantic medhaden. These stages were also present in other organs including liver and muscle.



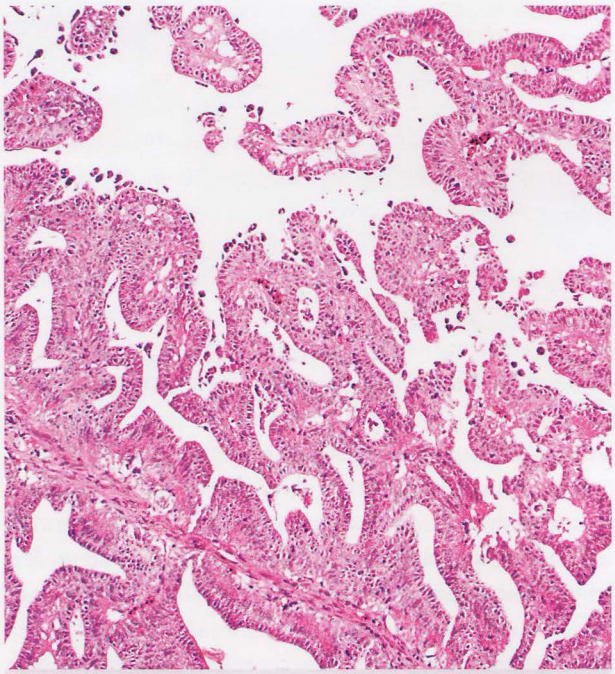

Fig 4.26D. Hoferellus carassii can induce an almost neoplastic-like hyperplasia of renal tubular epithelium. This serious disease can cause up to 20% mortality.



Fig 4.26E. Common shiner with several *Trichodina* present as an incidental finding within urethral lumen. Numerous rodlet cells (arrow) may also be seen.



Fig 4.27A. Kidney of large mouth bass infected with *Acolpenteron ureteroecetes*. The small golden brown focus is a large cluster of eggs.

with blood supply by compression of expanding granulomata. This however, is probably determined by route of infection, the renal portal macrophages acting as an early nidus, with later spread to endothelium and underlying haematopoietic elements.

Macrophages spreading bacteria is also seen with mycobacterial infections. These organisms survive in the cytoplasm and incite a granulomatous response, in some cases so severe that over half of the kidney parenchyma

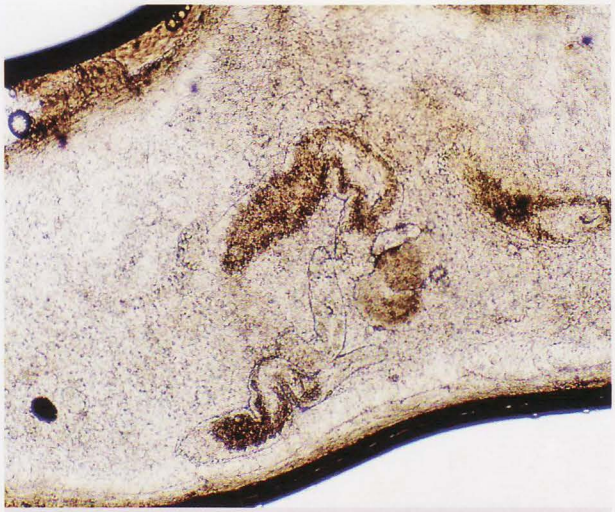

Fig 4.27B. Acolpenteron ureteroecetes parasites in a wet mount ureter preparation from an infected large mouth bass.

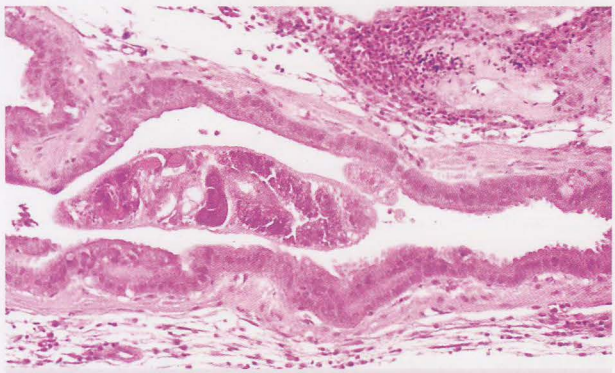

Fig 4.27C. Acolpenteron ureteroecetes parasites in the ureter. The haptor holds onto the epithelium, sometimes causing ulcerations or hyperplastic responses.

can be replaced by granulomata (*Fig 4.24*). If severe, osmotic balance can be destroyed and the fish presents with dermal oedema (*see Fig 3.13A*). *Nocardia* spp. can also cause granulomatous lesions, and also stain acid fast with Ziehl-Nielsen stain.

Viral disease can also produce lesions in the renal haematopoietic tissue (*Fig 4.25*). Infectious haematopoietic necrosis and viral haemorrhagic septicaemia (VHS) of salmonids, or hirame rhabdovirus (HIRRV) all lead to acute interstitial damage. There is marked necrosis of all elements including haematopoietic tissue, vascular endothelium of the renal portal system and in later stages, tubules too. Spring viraemia of carp (SVC) is another rhabdovirus that causes destruction of renal tissue. Lesions are most prominent in the haematopoietic tissue, but destruction of tubules occurs in severe cases.



Proliferative kidney disease (PKD) in rainbow trout. *Fig 4.28A.* There is marked hyperplasia of interstitium with the kidney thrown into bulbous ridges. The reddening is the result of secondary *Yersinia* infection.

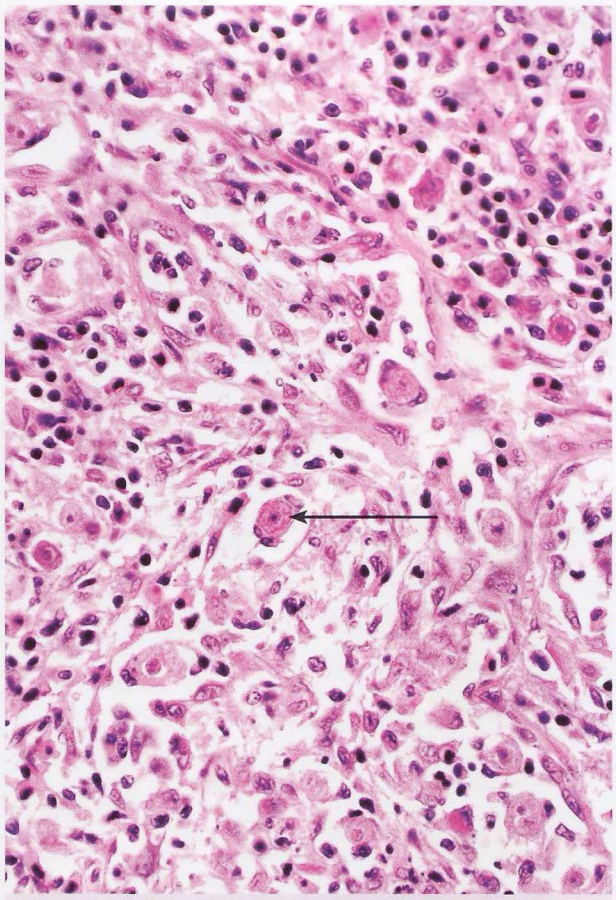

Fig 4.28B. PKD in Arctic char showing typical appearance of interstitium. Large numbers of extrasporogonic stages of the parasite can be seen (arrow). Note the lack of melanomacrophages.

The herpes viruses affecting salmonids, channel catfish and carp also produce haematopoietic and tubular necrosis, one of many examples of infective agents spanning the total range of tissues in the fish kidney. A viral disease of koi carp similar to, but distinct from koi herpesvirus (KHV), carp interstitial nephritis and gill necrosis virus, (CNGV) also causes interstitial nephritis. Oedema and haemorrhage may accompany any virus disease that affects vascular endothelium. In some cases, cells underlying the epithelium are greatly hypertrophied due to large numbers of virions in the infected cells, such as seen with iridoviral diseases. These include grouper iridovirus in Taiwan (TGIV), infectious spleen and kidney necrosis virus (ISKNV), Red Sea bream iridovirus (RSIV), sea bass iridovirus (SBIV), and African lamprey iridovirus (ALIV). These iridoviral diseases induce interstitial necrosis as well as proliferation of enlarged cells which may be present within anterior and posterior kidney. Cells infected with lymphocystis virus are also occasionally found in renal interstitium.

Infectious salmon anaemia virus (ISAV) in Atlantic salmon and rainbow trout leads to a slowly progressive disease with low mortality but a mix of acute and chronic lesions depending on progression. Acute pathological changes include interstitial haemorrhage, tubular necrosis and oedema. The more chronic presentation leads to ascites, anaemia and linear hepatic necrosis. Severe renal disease is the typical presentation of Atlantic salmon in N. America ("hemorrhagic kidney syndrome"), while hepatic lesions are more typically European. ISAV infection affects both anterior and posterior kidney as well as other tissues, including liver and heart. The lesions are vascular in origin, with virions being localized in endocardial cells, as well as in the renal haematopoietic tissue. Renal haemorrhage is most likely due to the endothelial damage promoted by the virus, with tubular injury being caused by secondary ischaemic necrosis. In surviving fish, there appears to be less effect on vessels and more on anterior kidney and more severe anaemia. Lesions in anterior kidney may be the result of a direct effect on haematopoietic cells by apoptosis or necrosis or both. Both lesions would contribute to the anaemia.

Renal interstitium is targeted by many other factors that affect the haematopoietic tissues. In addition to tubular injury, metals such as zinc can reduce the amount of peritubular lymphoid tissue. Lead and tin also affect haematopoiesis, with yellow brown pigments such as haemosiderin and lipofuscin accumulating in the anterior and posterior kidney due to lysis of fragile erythrocytes. Heart failure may produce a similar lesion, with

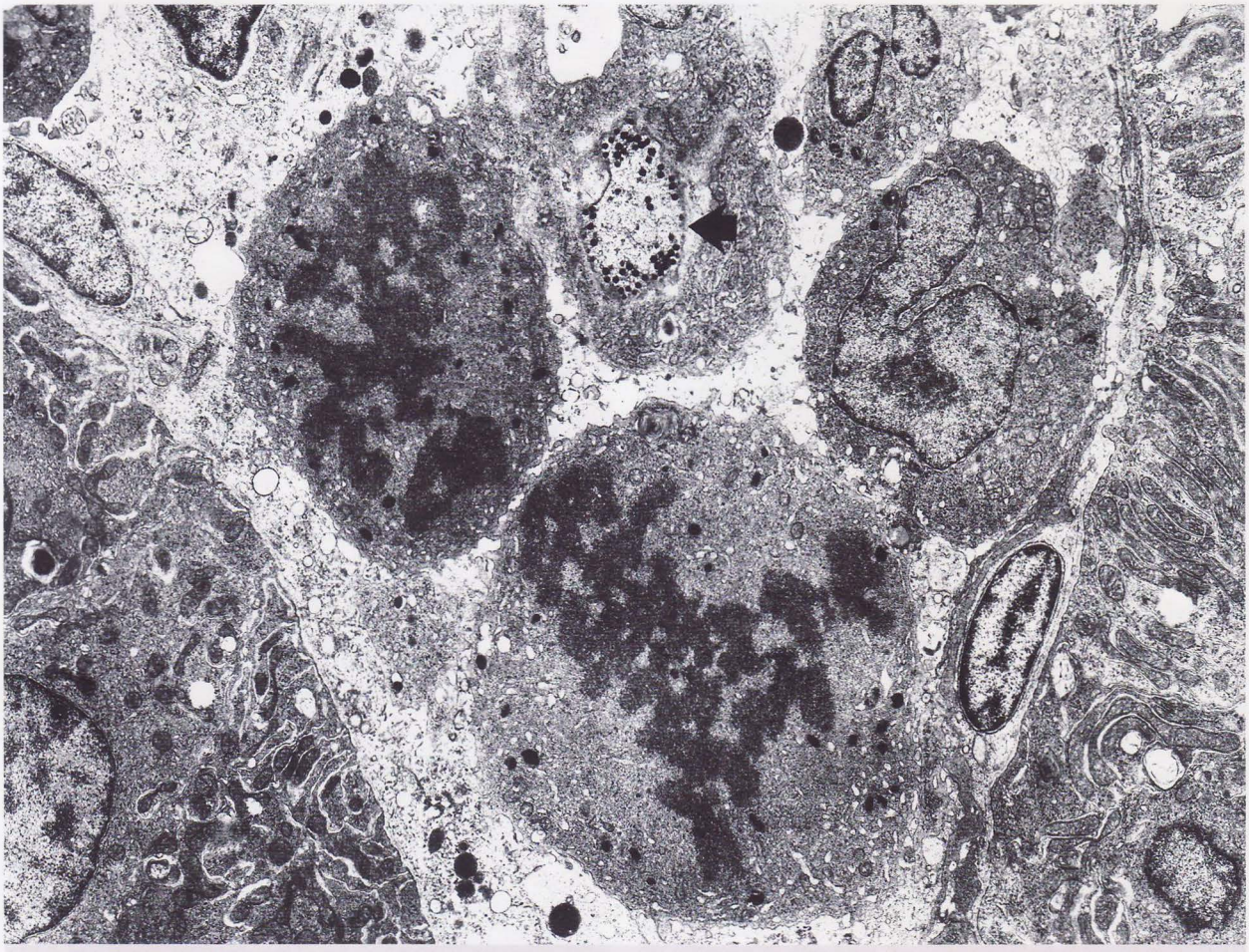

Fig 4.28C. TEM of kidney from trout with PKD showing 2 neutrophils in mitosis, an indication of the level of mitotic activity taking place. Parasite is shown (arrow).

iron positive material located in the macrophage aggregates (melanomacrophage centres or MMC) in the renal interstitium. Renal MMC may also reflect changes due to cachexia, anorexia, poor nutrition or chronic inflammation in other parts of the body, with pigmentation increasing dramatically in catabolic events. Renal interstitial MMC can also accumulate exogenous materials such as ferritin or carbon particles administered experimentally, although these may subsequently redistribute to the splenic MMC.

Fungal diseases that cause pathological change in the kidney tend to be systemic fungal infections that have spread following invasion through a skin lesion. Species reported in the kidney include *Fusarium, Exophiala, Ochroconis, Paecilomyces, Ichthyophonus, Aphanomyces* and *Saprolegnia* spp. In relatively mild cases there are areas of focal necrosis with chronic inflammation and granulomata formation. In severe cases there is extensive liquefactive necrosis adjacent to chronically inflamed infected tissues. Agents such as *Exophiala* and *Ichthyophonus* are easily detected on H&E staining due to their pigmentation and thick capsule respectively. Others may be more difficult and require special stains (Giemsa or silver based stains) to be adequately diagnosed. Fungal diseases can cause severe mortality but their effect on kidney is not often the direct cause of death.

Parasites

Parasites, especially protozoa are frequently encountered in sections of kidney, sometimes with little associated inflammatory response **(*Fig 4.26*)**. Parasites such as the myxozoa can reside in the glomerular vasculature (*Polysporoplasma sparis*) or as has been seen with *Chloromyxum* spp., they can fill Bowman's space **(*see Fig 4.6A*)**. Some protozoa locate within the renal tubules, for example coccidia and myxozoa. *Sphaerospora* spp. myxozoa

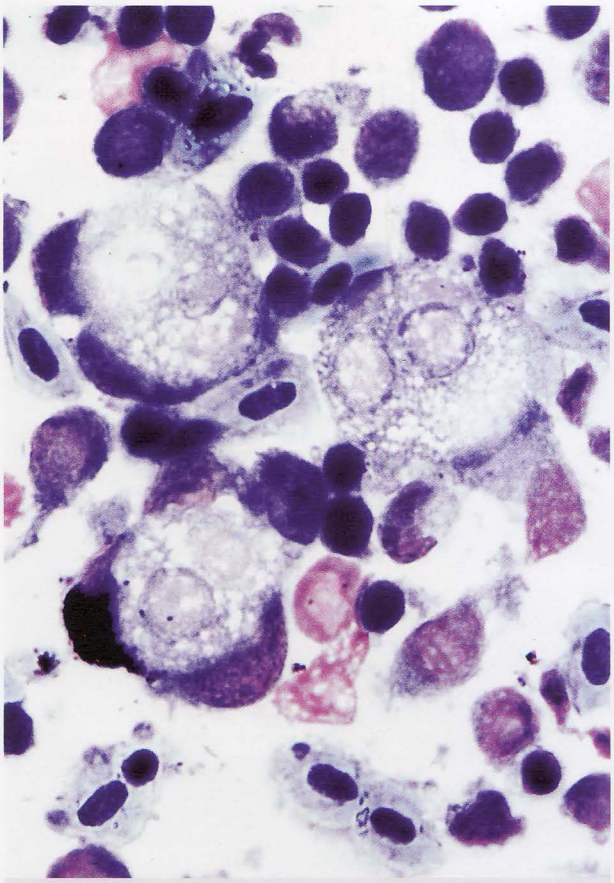

Fig 4.28D. Giemsa-stained impression smear from kidney of trout with PKD, showing 3 parasites containing "daughter cells" surrounded by macrophages, one of them a melanomacrophage.

are frequently seen. Protozoa targeting the renal interstitium include primarily myxozoa, microsporidians (*Nucleospora, Glugea*), and occasionally flagellates such as *Spironucleus* spp. The economically important salmonid pathogen causing proliferative kidney diseases (PKD) has extrasporogonic stages that extend throughout the interstitium. An extrasporogonic stage of *Kudoa* spp. has also been noted in visceral organs, including the kidney. Invasive protozoa such as the ciliate *Uronema* or amoebae can also be located throughout the kidney parenchyma. Protozoa can also be located in the collecting ducts, ureters and bladder. Occasionally parasites, their eggs or spores can be found in fish urine.

Metazoan parasites include cestodes (*e.g. Diphyllobothrium* spp.), digenetic trematodes (*e.g. Phyllodistomum, Centrocestus, Clonorchis* spp.) and monogenetic trematodes (*e.g. Acolpenteron, Kritskyia, Philureter, Urogyrus* spp.). In the case of the digenetic trematodes, the parasites do not specifically target the kidney and are often primarily located in muscle tissue. The monogenetic trematodes, for example *Acolpenteron ureteroecetes*, however, are true renal pathogens of bass **(Fig 4.27)**. The eggs of this parasite can migrate into the smaller collecting ducts and are sometimes located in granulomata within the renal interstitium. The adult parasites live in the collecting ducts and ureters causing some damage to the epithelium. In heavy infections there is chronic interstitial nephritis, and glomerular fibrosis with extensive fibrosis and inflammation surrounding the collecting ducts. Eosinophilic granule cell (EGC) infiltrates may be associated with parasitic infections. Metazoan parasites can also be located in the glomerulus.

PKD, one of the most serious diseases of farmed salmonids, is caused by *Tetracapsuloides bryosalmonae*, a myxozoan parasite. This chronic interstitial disease, caused by an extrasporogonic stage of the parasite, is affected in severity by ambient temperature producing different lesions and different responses at different temperatures. As the primary target organ, the kidney may become so massively enlarged as to be visible externally along the lateral line **(Fig 4.28)**. Exophthalmia, ascites and anaemia are other gross features, probably the result of the disease on vascular integrity, leading to haemorrhage, and reduction of haematopoietic capability due to the proliferative lesions. Both anterior and posterior portions of the kidney may be thrown into grey bulbous ridges or discrete nodules, depending on the severity of involvement. Splenomegaly is usually present and indeed may be one of the earliest indications of infection. Histopathology reveals multifocal granulomatous inflammation, widely disseminated in many organs in severely affected fish but invariably present in kidney and possibly spleen, even in mild infections. Early lesions centre on the interstitium, and as a feature accompanying this and many other granulomatous renal lesions, there is an apparent reduction in melanin; the reason for this is unknown although it may be related to macrophage activation. The response in all organs comprises mainly macrophages and lymphocytes, although in the kidney there is also hyperplasia of the neutrophil series. The reactions centre round the characteristic large eosinophilic primary (mother) and secondary (daughter) cells. The endothelium of the portal vessels is a frequent location for the parasites due to phagocytosis by the resident phagocytes and often large aggregates of cells may be seen virtually obliterating the lumen of the vessel **(see Fig 6.25A)**. These vascular lesions can be seen in many other organs.

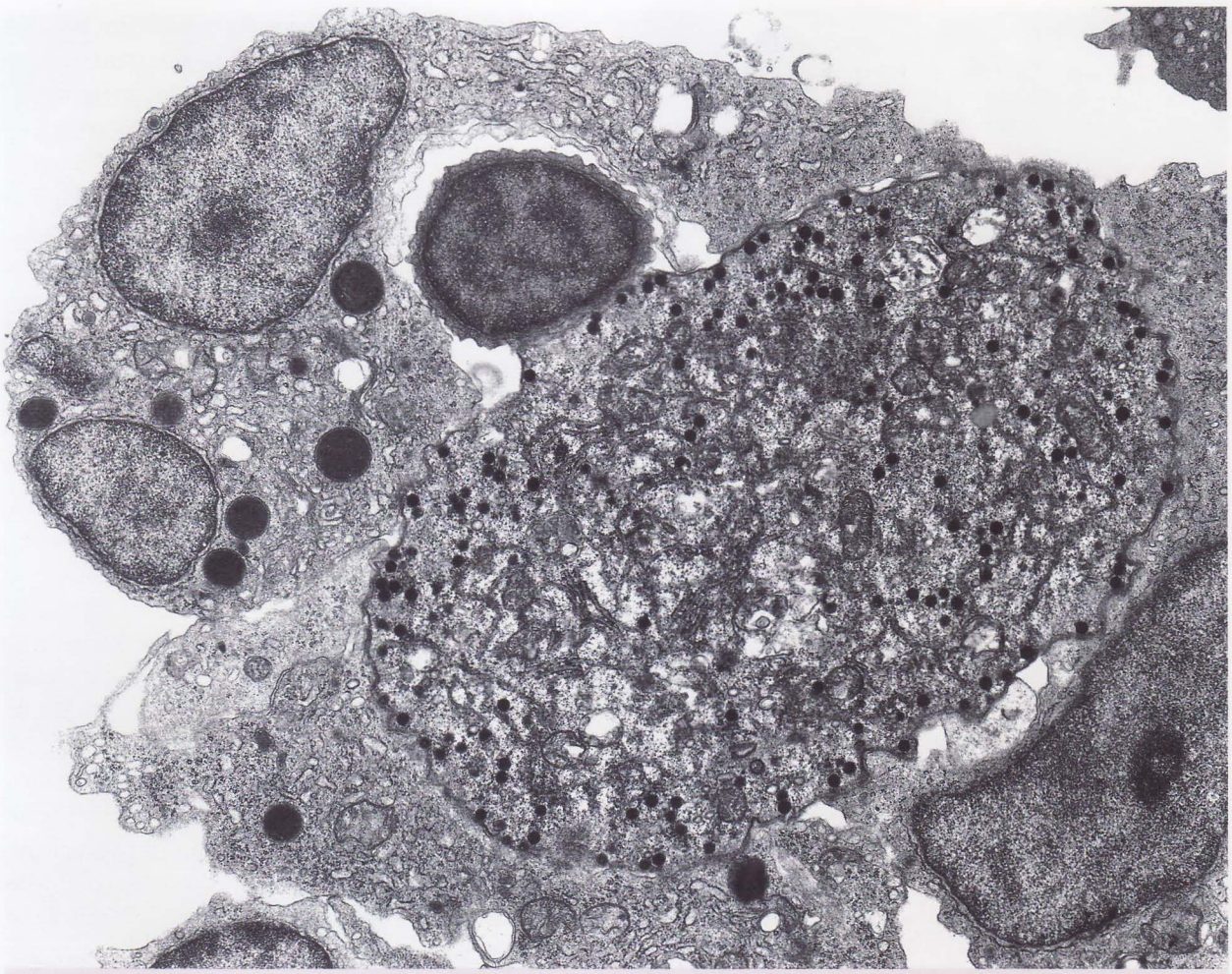

Fig 4.28E. TEM of buffy coat preparation showing a similar picture to *4.28D*. A lone parasite is surrounded by macrophages, and a single lymphocyte.

The ultrastructural appearance of the parasites is very characteristic, largely due to the presence within the primary cells alone, of small spherical electron-dense bodies that are closely associated with the plasmalemma and may be Golgi derived. As the disease progresses, there may be destruction of nephrons, possibly by compression, although it is probably the concurrent anaemia that accounts for the often heavy mortality, rather than renal failure. Recovered fish may have mild fibrosis, but in most cases it is very difficult to see any evidence of previous damage, illustrating yet again the great recuperative powers of teleost kidney.

References

Ahne, W., Bjorklund, H.V., Essbauer, S., Fijan, N., Kurath, G. and Winton, J. R. (2002) Spring viremia of carp (SVC). *Diseases of Aquatic Organisms* 52:261-272.

Arkush, K.D., Mendoza, L., Adkison, M.A. and Hedrick, R.P. (2003) Observations on the life stages of *Sphaerothecum destruens* n.g., n.sp., a mesomycetozoean fish pathogen formerly referred to as the rosette agent. *Journal of Eukaryotic Microbiology* 50:430-8. *Erratum in: Journal of Eukaryotic Microbiology* (2004) 51:259.

Athanassopoulou, F., Karagouni, E, Dotsika, E., Ragias V., Tavla, J., Christofilloyanis, P. and Vatsos, I. (2004) Efficacy and toxicity of orally administrated anti-coccidial drugs for innovative treatments of *Myxobolus* sp. infection in *Puntazzo puntazzo*. *Diseases of Aquatic Organisms* 62:217-226.

Bonga, S. E. (1973) Morphometrical analysis with the light and electron microscope of the kidney of the anadromous three-spined stickleback *Gasterosteus aculeatus*, form trachurus, from fresh water and from sea water. *Zeitschrift fur Zellforschung und Mikroskopische Anatomie* 137:563-588.

Bruno, D.W. (1986) Histopathology of bacterial kidney disease in laboratory infected rainbow trout, *Salmo gairdneri* Richardson, and Atlantic salmon, *Salmo salar* L, with reference to naturally infected fish. *Journal of Fish Diseases* 9:523-537.

Chao, C.B., Chen, C.Y., Lai, Y.Y., Lin, C.S. and Huang, H.T. (2004) Histological, ultrastructural, and in situ hybridization study on enlarged cells in grouper *Epinephelus* hybrids infected by grouper iridovirus in Taiwan(TGIV). *Diseases of Aquatic Organisms* 58:127-142.

Chen, H.H., Brittelli, M.R. and Muska, C.F. (1985) Two cases of lymphosarcoma in channel catfish exposed to N-methyl-N'-nitro-N-nitrosoguanidine. *Journal of the National Cancer Institute* 74:933-939.

Cheung, P.J., Nigrelli, R.F. and Ruggieri, G.D. (1980) Studies on the morphology of *Uronema marinum* Dujardin (Ciliatea: Uronematidae) with a description of the histopathology of the infection in marine fishes. *Journal of Fish Diseases* 3:295-303.

Clifton-Hadley, R.S., Bucke D. and Richards R.H. (1984) Proliferative kidney disease of salmonid fish: a review. *Journal of Fish Diseases* 7:363-377.

Clifton-Hadley, R.S., Bucke, D. and Richards, R.H. (1987) A study of the sequential clinical and pathological changes during proliferative kidney disease in rainbow trout *Salmo gairdneri* Richardson. *Journal of Fish Diseases* 335-352.

Cooley, H.M., Evans, R.E. and Klaverkamp, J.F. (2000) Toxicology of dietary uranium in lake whitefish (*Coregonus clupeaformis*). *Aquatic Toxicology* 48:495-515.

Cowey, C.B., Knox, D., Adron, J.W., George, S. and Pirie, B. (1977) The production of renal calcinosis by magnesium deficiency in rainbow trout (*Salmo gairdneri*). *British Journal of Nutrition* 38:127-135.

Cribb, T.H., Chisholm, L.A. and Bray, R.A. (2002) Diversity in the Monogenea and Digenea: does lifestyle matter? *International Journal for Parasitology* 32:321-328.

de Ruiter, A. J. (1981) Testosterone-dependent changes in vivo and in vitro in the structure of the renal glomeruli of the teleost *Gasterosteus aculeatus* L. *Cell and Tissue Research* 219:253-266.

de Ruiter, A. J. and Mein, C.G. (1982) Testosterone-dependent transformation of nephronic tubule cells into serous and mucous gland cells in stickleback kidneys in vivo and in vitro. *General and Comparative Endocrinology* 47:70-83.

Desser, S.S., Molnar, K. and Horvath, I. (1983) An ultrastructural study of the myxosporeans, *Sphaerospora angulata* and *Sphaerospora carassii*, in the common carp, *Cyprinus carpio* L. *Journal of Protozoology* 30:415-422.

Du Plessis, S. S. (1948) A gyrodactyloid parasite from the ureters of largemouth bass at the Jonkershoek Inland Fish Hatchery, South Africa. *Transactions of the American Fisheries Society* 75:105-109.

Dykova, I., Lom, J. and Korting, W. (1990) Light and electron microscopic observations on the swimbladder stages of *Sphaerospora renicola*, a parasite of carp (*Cyprinus carpio*). *Parasitology Research* 76:228-237.

Dykova, I., Lom, J. and Machackova, B. (1998) *Cochliopodium minus*, a scale-bearing amoeba isolated from organs of perch *Perca fluviatilis*. *Diseases of Aquatic Organisms* 34:205-210.

Earnest-Koons, K.A., Schachte, J.H. Jr. and Bowser, P.R. (1997) Lymphosarcoma in a brook trout. *Journal of Wildlife Diseases* 33:666-669.

Elger, M., and Hentschel, H. (1983) Glomerular disease in cultured rainbow trout, *Salmo gairdneri* Richardson, suffering from presumptive chronic viral haemorrhagic septicaemia. *Journal of Fish Diseases* 6:211-229.

Eszterbauer, E. and Szekely, C. (2004) Molecular phylogeny of the kidney-parasitic *Sphaerospora renicola* from common carp (*Cyprinus carpio*) and *Sphaerospora* sp. from goldfish (*Carassius auratus auratus*). *Acta Veterinaria Hungarica* 52:469-478.

Evenden, A.J., Grayson, T.H., Gilpin, M.L. and Munn, C.B. (1993) *Renibacterium salmoninarum* and bacterial kidney disease -- the unfinished jigsaw. *Annual Review of Fish Diseases* 3:87-104.

Ferguson, H.W. (1984) Renal portal phagocytosis of bacteria in rainbow trout (*Salmo gairdneri* Richardson): ultrastructural observations. *Canadian Journal of Zoology* 62:2505-2511.

Ferguson, H.W. and Adair, B.M. (1977) Protozoa associated with proliferative kidney disease in rainbow trout (*Salmo gairdneri*). *Veterinary Record* 100:158-159.

Ferguson, H.W. and Needham, E.A. (1978) Proliferative kidney disease in rainbow trout *Salmo gairdneri* Richardson. *Journal of Fish Diseases* 1:91-108.

Ferguson, H.W., Moccia, R.D. and Down, N.E. (1982) An epizootic of diffuse glomerulonephritis in white perch (*Roccus americanus*) from a heavily polluted industrial basin in Lake Ontario. *Veterinary Pathology* 19:638-645.

Fijan, N. (1999) Spring viremia of carp and other diseases and agents of warm-water fish. ***In*** *Fish diseases and disorders, Volume* 3: *Viral, bacterial and fungal infections.* (***eds***. Woo, P.T.K. and Bruno, D.W.) pp.177-244. CAB International Oxon, New York.

Fischer, W.J. and Dietrich, D.R. (2000) Pathological and biochemical characterization of microcystin-induced hepatopancreas and kidney damage in carp (*Cyprinus carpio*). *Toxicology and Applied Pharmacology* 164:73-81.

Fischthal, J.H. and Allison, L.N. (1941) *Acolpenteron ureteroecetes* Fischthal and Allison, 1940, a monogenetic trematode from the ureters of the black basses, with a revision of the family Calceostomatidae (Gyrodactyloidea). *Journal of Parasitology* 27:517-524.

Folmar, L.C., Gardner, G.R., Schreibman, M.P., Magliulo-Cepriano, L., Mills, L.J., Zaroogian, G., Gutjahr-Gobell, R., Haebler, R., Horowitz, D.B. and Denslow, N.D. (2001) Vitellogenin-induced pathology in male summer flounder (*Paralichthys dentatus*). *Aquatic Toxicology* 51:431-441.

Gardner, G.R., Yevich, P.P., Harshbarger, J.C. and Malcolm, A.R. (1991) Carcinogenicity of Black Rock Harbor sediment to the eastern oyster and trophic transfer of Black Rock Harbor carcinogens from the blue mussel to the winter flounder. *Environmental Health Perspectives* 90:53-66.
Gibson-Kueh, S., Netto, P., Ngoh-Lim, G.H., Chang, S.F., Ho, L.L., Qin, Q.W., Chua, F.H., Ng, M.L. and Ferguson, H.W. (2003) The pathology of systemic iridoviral disease in fish. *Journal of Comparative Pathology* 129:111-119.
Gilad, O., Yun, S, Zagmutt-Vergara, F.J., Leutenegger, C.M., Bercovier, H. and Hedrick, R.P. (2004) Concentrations of a Koi herpesvirus (KHV) in tissues of experimentally infected *Cyprinus carpio* koi as assessed by real-time TaqMan PCR. *Diseases of Aquatic Organisms* 60:179-187.
Gumpenberger, M., Hochwartner, O. and Loupal, G. (2004) Diagnostic imaging of a renal adenoma in a Red Oscar (*Astronotus ocellatus* Cuvier, 1829). *Veterinary Radiology and Ultrasound* 45:139-142.
Guo, F.C. and Woo, P.T. (2004) Experimental infections of Atlantic salmon *Salmo salar* with *Spironucleus barkhanus*. *Diseases of Aquatic Organisms* 61:59-66.
Hahlbeck, E., Katsiadaki, I., Mayer, I., Adolfsson-Erici, M., James, J. and Bengtsson, B. (2004) The juvenile three-spined stickleback (*Gasterosteus aculeatus* L.) as a model organism for endocrine disruption. II. Kidney hypertrophy, vitellogenin and spiggin induction. *Aquatic Toxicology* 70:311-326.
Harrison, J.G. and Richards, R.H. (1979) The pathology and histopathology of nephrocalcinosis in rainbow trout *Salmo gairdneri* Richardson in fresh water. *Journal of Fish Diseases* 2:1-12.
Hawkins, W.E., Tate, L.G. and Sarphie, T.G. (1980) Acute effects of cadmium on the spot *Leiostomus xanthurus* (Teleostei): tissue distribution and renal ultrastructure. *Journal of Toxicology and Environmental Health* 6:283-295.
He, J.G., Deng, M., Weng, S.P., Li, Z., Zhou, S.Y., Long, Q.X., Wang, Q.Z. and Chan, S.M. (2001) Complete genome analysis of the mandarin fish infectious spleen and kidney necrosis iridovirus. *Virology* 291:126-139.
Hedrick, R.P., Baxa, D.V., De Kinkelin, P., and Okamura, B. (2003) Malacosporean-like spores in urine of rainbow trout react with antibody and DNA probes to *Tetracapsuloides bryosalmonae*. *Parasitology Research* 92: http://parasitology.informatik.uni-wuerzburg.de/login/n/h/j_003-0986-3.html.html Accessed 4/18/05.
Helmboldt, C.F. and Wyand, D.S. (1971) Nephroblastoma in a striped bass. *Journal of Wildlife Diseases* 7:162-165.
Hentschel, H. (1979) The kidney of a teleost, *Spinachia spinachia*. II. Histochemical identification of sialic acid-containing glycoprotein and fine structure of mucus secreting cells. *Tissue and Cell* 111:517-531.
Hentschel, H. and Elger, M. (1988) The distal nephron in the kidney of fishes. *Advances in Anatomy, Embryology, and Cell Biology* 108:1-151.
Hickman, C.P., Jr. and Trump, B.F. (1969) The kidney. ***In*** Fish Physiology, vol 1, (***eds***. Hoar, W.S. and Randall, D.J.) pp 91-239. Academic Press, New York.
Hicks, B.D. and Geraci, J.R. (1984) A Histological assessment of damage in rainbow trout, *Salmo gairdneri* Richardson fed rations containing erythromycin. *Journal of Fish Diseases* 7:457-466.
Hicks, B.D., Hilton, J.W. and Ferguson, H.W. (1984) Influence of dietary selenium on the occurrence of nephrocalcinosis in the rainbow trout, *Salmo gairdneri* Richardson. *Journal of Fish Diseases* 7:379-389.
Higgins, M.J., Kent, M.L., Moran, J.D., Weiss, L.M. and Dawe, S.C. (1998) Efficacy of the fumagillin analog TNP-470 for *Nucleospora salmonis* and *Loma salmonae* infections in chinook salmon *Oncorhynchus tshawytscha*. *Diseases of Aquatic Organisms* 34:45-49.
Hoffmann, R. and Lommel, R. (1984) Haematological studies in proliferative kidney disease of rainbow trout, *Salmo gairdneri* Richardson. *Journal of Fish Diseases* 7:323-326.
Holzer, A.S., Sommerville, C. and R. Wootten, R. (2004) Molecular relationships and phylogeny in a community of myxosporeans and actinosporeans based on their 18S rDNA sequences. *International Journal of Parasitology* 34:1099-1111.
Huang, C., Zhang, X, Gin, K.Y. and Qin, Q.W. (2004) In situ hybridization of a marine fish virus, Singapore grouper iridovirus with a nucleic acid probe of major capsid protein. *Journal of Virological Methods* 117:123-128.
Jones, S., Prosperi-Porta, G., Dawe, S., Blackbourn, J., Taylor, K., Lowe, G. and Osborn, A. (2004) Proliferative renal myxosporidiosis in spawning coho salmon (*Oncorhynchus kisutch*) in British Columbia and Washington. *Folia Parasitologica. (Praha)* 51:221-227.
Katsiadaki, I., Scott, A.P. and Mayer, I. (2002) The potential of the three-spined stickleback (*Gasterosteus aculeatus* L.) as a combined biomarker for oestrogens and androgens in European waters. *Marine Environmental Research* 54:725-728.
Kent, M. L. and Bishop-Stewart, J.K. (2003) Transmission and tissue distribution of *Pseudoloma neurophilia* (Microsporidia) of zebrafish, *Danio rerio* (Hamilton). *Journal of Fish Diseases* 26:423-426.
Kent, M.L., Eaton, W.D. and Casey, J.W. (1997) Plasmacytoid leukemia of chinook salmon. *Leukemia* 11:Suppl 3:170-171.
Kent, M.L., Khattra, J., Hedrick, R.P. and Devlin, R.H. (2000) *Tetracapsula renicola* n. sp. (Myxozoa : Saccosporidae); the PKX myxozoan--the cause of proliferative kidney disease of salmonid fishes. *Journal of Parasitology* 86:103-111.
Kent, M.L., Powell, M.D., Kieser, D., Hoskins, G.E, Speare, D.J., Burka, J.F., Bagshaw, J., and Fournie, J.W. (1993) Unusual eosinophilic granule cell proliferation in coho salmon (*Oncorhynchus kisutch*). *Journal of Comparative Pathology* 109:129-140.
Kim, J. H., Ogawa, K. and Wakabayashi, H. (1999) Lectin-reactive components of the microsporidian *Glugea plecoglossi* and their relation to spore phagocytosis by head kidney. *Diseases of Aquatic Organisms* 39:59-63.
Kotak, B.G., Semalulu, S., Fritz, D.L., Prepas, E.E., Hrudey S.E. and Coppock, R.W. (1996) Hepatic and renal pathology of intraperitoneally administered microcystin-LR in rainbow trout (*Oncorhynchus mykiss*). *Toxicon* 34:517-525.
Lacy, E.R. and Reale, E. (1985a) The elasmobranch kidney I. Gross anatomy and general distribution of the nephrons. *Anatomy and Embryology* (Berl).173:23-34.
Lacy, E.R. and Reale, E. (1985b) The elasmobranch kidney. II. Sequence and structure of the nephrons. *Anatomy and Embryology* (Berl).173:163-186.
Lacy, E.R. and Reale, E. (1986) The elasmobranch kidney. III. Fine structure of the peritubular sheath. *Anatomy and Embryology* (Berl).173:299-305.
Lacy, E.R. and Reale, E. (1990) The presence of a juxtaglomerular apparatus in elasmobranch fish. *Anatomy and Embryology* (Berl).182:249-262.
Langvad, F., Pedersen, O. and Engjom, K. (1985) A fungal disease caused by *Exophiala* sp. nova in farmed Atlantic salmon in western Norway. ***In***: *Fish and Shellfish Pathology.* (***ed***. Ellis, A.E.) pp 323-328 Academic Press, Orlando.
Leknes, I.L. (2002) Uptake of foreign ferritin in platy *Xiphophorus maculatus* (Poeciliidae: Teleostei). *Diseases of Aquatic Organisms* 51:233-237.

Liang, P., Jones, C.A., Bisgrove, B.W., Song, L., Glenn, S.T., Yost, H.J. and Gross, K.W. (2004) Genomic characterization and expression analysis of the first nonmammalian renin genes from zebrafish and pufferfish. *Physiological Genomics* 16:314-322.
Lom, J. and Dykova, I. (1999) Myxosporea (Phylum Myxozoa). ***In*** *Fish diseases and disorders, Volume 1: protozoan and metazoan infections* (***ed***. Woo, P.T.K.) pp. 27-96. CAB International Oxon, New York.
Lom, J. and Nilsen, F. (2003) Fish microsporidia: fine structural diversity and phylogeny. *International Journal for Parasitology* 33:107-127.
Lukes, J. (1993) A coccidian (Apicomplexa: Eimeriidae) with extracytoplasmally located stages in the kidney tubules of golden carp (*Carassius auratus gibelio* L.) (Cyprinidae). *Folia Parasitologica (Praha)* 40:1-7.
Marselas, G.A., Stoskopf, M.K., Brown, M.J. and Reimschuessel, R. (1998) Abdominal ascites in electric eels (*Electrophorus electricus*) associated with hepatic hemochromatosis and elevated water pH. *Journal of Zoo and Wildlife Medicine* 29:413-418.
Masahito, P., Ishikawa, T., Okamoto, N. and Sugano, H. (1992) Nephroblastomas in the Japanese eel, *Anguilla japonica* Temminck and Schlegel. *Cancer Research* 52:2575-2579.
McDowell, A.G., Kane, A.S. and Reimschuessel, R. (1999) Chronic renal damage in largemouth bass, *Micropterus salmoides*, due to a monogenetic trematode infection. *Proceedings of the International Association for Aquatic Animal Medicine* 30:25-27.
Mendonca, H.L. and Arkush, K.D. (2004) Development of PCR-based methods for detection of *Sphaerothecum destruens* in fish tissues. *Diseases of Aquatic Organisms* 61:187-197.
Meyers, T.R. and Hendricks, J.D. (1985) Histopathology. ***In*** *Fundamentals of aquatic toxicology*, (***eds***. Rand, G.M. and Petrocelli, S.R.) pp 283-331. Hemisphere Publishing Co., New York.
Mladineo, I. (2003) Myxosporidean infections in Adriatic cage-reared fish. *Bulletin European Association of Fish Pathologists* 23:113-122.
Molnar, K. (1980) Renal sphaerosporosis in the common carp *Cyprinus carpio* L. *Journal of Fish Diseases* 3:11-19.
Molnar, K. (1993) The occurrence of *Sphaerospora renicola* K-stages in the choroidal rete mirabile of the common carp. *Folia Parasitologica (Praha)* 40:175-180.
Montero, D., Blazer, V.S, Socorro, J., Izquierdo, M.S. and Tort, L. (1999) Dietary and culture influences on macrophage aggregate parameters in gilthead seabream (*Sparus aurata*) juveniles. *Aquaculture* 179:523-534.
Montero, D., Socorro, J., Tort, L., Caballero, M.J., Robaina, L.E., Vergara, J. M. and Izquierdo, M.S. (2004) Glomerulonephritis and immunosuppression associated with dietary essential fatty acid deficiency in gilthead sea bream, *Sparus aurata* L., juveniles. *Journal of Fish Diseases* 27:297-306.
Mourier, J.P. (1976) Effects of an antiandrogen, cyproterone acetate, on the kidney of the three-spined stickleback (*Gasterosteus aculeatus* L.). *Cell and Tissue Research* 173:357-366.
Muhvich, A.G., Reimschuessel, R., Lipsky, M.M. and Bennett, R.O. (1988) *Fusarium solani* isolated from newborn bonnethead sharks, *Sphyrna tiburo* (L.). *Journal of Fish Diseases* 12:57-62.
Munkittrick, K.R., Moccia, R.D. and Leatherland, J.F. (1985) Polycystic kidney disease in goldfish (*Carassius auratus*) from Hamilton Harbour, Lake Ontario, Canada. *Veterinary Pathology* 22:232-237.
Nakatsuru, Y., Minami K., Yoshikawa, A, Zhu, J., Oda, H., Masahito, P., Okamoto, N., Nakamura, Y. and Ishikawa, T. (2000) Eel WT1 sequence and expression in spontaneous nephroblastomas in Japanese eel. *Gene* 245:245-251.
Nelson, K., Jones, J., Jacobson, S. and Reimschuessel, R. (1999) Elevated BUN levels in goldfish as an indicator of gill dysfunction. *Journal of Aquatic Animal Health* 11:52-60.
Nylund, A., Karlsbakk, E., Saether, P.A., Koren, C., Larsen, T., Nielsen, B.D., Broderud, A.E., Hostlund, C., Fjellsoy, K.R., Lervik, K. and Rosnes, L. (2005) *Parvicapsula pseudobranchicola* (Myxosporea) in farmed Atlantic salmon *Salmo salar*. Tissue distribution, diagnosis and phylogeny. *Diseases of Aquatic Organisms* 63:197-204.
Nylund, A., Plarre, H., Hodneland, K., Devold, M., Aspehaug, V., Aarseth, M., Koren, C. and Watanabe, K. (2003) Haemorrhagic smolt syndrome (HSS) in Norway: pathology and associated virus-like particles. *Diseases of Aquatic Organisms* 54:15-27.
Ogoshi, M., Inoue, K. and Takei, Y. (2003) Identification of a novel adrenomedullin gene family in teleost fish. *Biochemical and Biophysical Research Communications* 311:1072-1077.
Otis, E.J., Wolke, R.E. and Blazer, V.S. (1985) Infection of *Exophiala salmonis* in Atlantic salmon (*Salmo salar*). *Journal of Wildlife Diseases* 21:61-64.
Palenzuela, O., Alvarez-Pellitero, P. and Sitja-Bobadilla, A. (1999) Glomerular disease associated with *Polysporoplasma sparis* (Myxozoa) infections in cultured gilthead sea bream, *Sparus aurata* L. (Pisces: Teleostei). *Parasitology* 118:245-256.
Pane, E.F., Bucking, B., Patel, M. and Wood, C.M. (2005) Renal function in the freshwater rainbow trout (*Oncorhynchus mykiss*) following acute and prolonged exposure to waterborne nickel. *Aquatic Toxicology* 72:119-133.
Paperna, I. and DiCave, D. (2001) Kidney sphaerosporosis with extrasporogonic stages in the blood in *Baryancistrus* sp. (Loricaridae) from Amazonian Brazil. *Parasite.* 8:71-74.
Paperna, I.H. (1982) Kudoa infection in the glomeruli, mesentery and peritoneum of cultured *Sparus aurata* L. *Journal of Fish Diseases* 5:539-543.
Paperna, I.H., Harrison, J.G. and Kissil, G.W. (1980) Pathology and histopathology of a systemic granuloma in *Sparus aurata* (L.) cultured in the Gulf of Aqaba. *Journal of Fish Diseases* 3:213-221.
Petrinec, Z., Pepeljnjak, S., Kovacic, S. and Krznaric, A. (2004) Fumonisin B1 causes multiple lesions in common carp (*Cyprinus carpio*). *Deutsche Tierarztliche Wochenschrift* 111:358-363.
Pikarsky, E., Ronen, A., Abramowitz, J., Levavi-Sivan, B., Hutoran, M., Shapira, Y., Steinitz, M., Perelberg, A., Soffer, D. and Kotler, M. (2004) Pathogenesis of acute viral disease induced in fish by carp interstitial nephritis and gill necrosis virus. *Journal of Virology* 78:9544-9551.
Plumb, J.A. (1999) Edwardsiella Septicaemias. ***In*** *Fish diseases and disorders, Volume 3: Viral, bacterial and fungal infections.* (***eds***. Woo, P.T.K. and Bruno, D.W.) pp. 479-521. CAB International Oxon, New York.
Poleksic, V. and Karan, V. (1999) Effects of trifluralin on carp: Biochemical and histological evaluation, *Ecotoxicology and Environmental Safety* 43:213-221.
Poynton, S.L., Fraser, W., Francis-Floyd, R., Rutledge, P., Reed, P.and Nerad, T. (1995) *Spironucleus vortens* from freshwater angelfish *Pterophyllum scalare*: morphology and culture. *Journal of Eukaryotic Microbiology* 42:731-742.
Prophet, E. B., Mills, B., Arrington, J.B. and Sobin, L.H. (1992) *Laboratory Methods in Histotechnology.* Armed Forces Institute of Pathology, American Registry of Pathology, Washington, DC.

Qureshi, T.A. and Sultan, R. (1976) Thyroid follicles in the head-kidney of teleosts. *Anatomischer Anzeiger* 139:332-336.
Reimschuessel, R., Bennett, R.O, May, E.B. and Lipsky, M.M. (1990a) Renal tubular cell regeneration, cell proliferation and chronic nephrotoxicity in the goldfish (*Carassius auratus*) following exposure to a single sublethal dose of hexachlorobutadiene. *Diseases of Aquatic Organisms* 8:211-224.
Reimschuessel, R., Bennett, R.O, May, E.B. and Lipsky, M.M. (1990b) Development of newly formed nephrons in the goldfish kidney following hexachlorobutadiene-induced nephrotoxicity. *Toxicological Pathology* 18, 32-38.
Reimschuessel, R., Chamie, S.J. and Kinnel, M. (1996) Evaluation of gentamicin-induced nephrotoxiciosis in the toadfish, *Opsanus tau*. *Journal of the American Veterinary Association* 209:137-139.
Reimschuessel, R., Gieseker, C.M., Driscoll, C., Baya, A., Kane, A.S., Blazer, V.S., Evans, J.J., Kent, M.L., Moran, J.D. and Poynton, S.L. (2003) *Kudoa clupeidae* spores and myxosporean plasmodial infection, associated with ulcerative lesions in young Atlantic menhaden *Brevoortia tyrannus*, (Latrobe) (Clupeidae) in a tributary of the Chesapeake Bay. *Diseases of Aquatic Organisms* 53:143-166.
Reite, O.B. (2005) The rodlet cells of teleostean fish: their potential role in host defense in relation to the role of mast cells/eosinophilic granule cells. *Fish and Shellfish Immunology* 19:253-267.
Rim, H.J., Kim, K.H., Joo, K.H., Kim, J.S., Eom, K.S. and Chung, M.S. (1996) The infestation states and changing patterns of human infecting metacercariae in freshwater fish in Kyongsang-do and Kyonggi-do, Korea. *Korean Journal of Parasitology* 34:95-105.
Roberts, R.J. and Rodger, H.D. (2001) The pathophysiology and systematic pathology of teleosts. ***In*** *Fish Pathology* (***ed***. Roberts, R.J.) pp 55-132. Saunders Press, London.
Rudat, S., Steinhagen, D., Hetzel, U., Drommer, W. and Korting, W. (2000) Cytopathological observations on renal tubule epithelium cells in common carp *Cyprinus carpio* under *Trypanoplasma borreli* (Protozoa: Kinetoplastida) infection. *Diseases of Aquatic Organisms* 40:203-209.
Rutenburg, A.M., Kim, H., Fischbein, J.W., Hanker, J.S., Wasserkrug, H.L. and. Seligman, A.M. (1969) Histochemical and ultrastructural demonstration of G-glutamyl transpeptidase activity. *Journal of Histochemistry and Cytochemistry* 17:517-526.
Sami, S., Fischer-Scherl, T., Hoffmann, R.W. and Pfeil-Putzien, C. (1992) Immune complex-mediated glomerulonephritis associated with bacterial kidney disease in the rainbow trout (*Oncorhynchus mykiss*). *Veterinary Pathology* 29:169-174.
Sathyanesan, A.G. (1966) The structure of the glomerular cystic tumor present in the topical freshwater catfish, *Mystus vittatus* (Bloch). *Transactions of the American Microscopical Society* 85:53-57.
Schwaiger, J., Ferling, H., Mallow, U., Wintermayr, H. and Negele, R.D. (2004) Toxic effects of the non-steroidal anti-inflammatory drug diclofenac. Part I: histopathological alterations and bioaccumulation in rainbow trout. *Aquatic Toxicology* 68:141-150.
Seagrave, C.P., Bucke, D. and Alderman, D.J. (1980) Ultrastructure of a haplosporean-like organism: the possible causative agent of proliferative kidney disease in rainbow trout. *Journal of Fish Biology* 16:453-459.
Sedlaczek, J. (1991) *Chloromyxum* sp. (Myxosporidia) in der Niere von Salmo *trutta f. fario* (Osteichthyes). *Angewandte Parasitologie* 32:137–142.
Smart, G.R., Knox, D., Harrison, J.G., Ralph, J.A., Richards, R.H. and Cowey, C.B. (1979) Nephrocalcinosis in rainbow trout *Salmo gairdneri* Richardson; the effect of exposure to elevated CO2 concentrations. *Journal of Fish Diseases* 2:279-289.
Smith, C.E., Holway, J.E. and Hammer, G.L. (1973) Sulphamerazine toxicity in cutthroat trout brood fish (*Salmo clarki*). *Journal of Fish Biology* 5:97-101.
Sorenson, E.M. (1991) *Metal poisoning in fish*. CRC Press, Boston, MA.
Stentiford G.D., Longshaw, M., Lyons, B.P, Jones, G., Green, M. and Feist, S.W. (2003) Histopathological biomarkers in estuarine fish species for the assessment of biological effects of contaminants, *Marine Environmental Research* 55:137-159.
Stephens, F.J., Raidal, S.R. and Jones, B. (2004) Haematopoietic necrosis in a goldfish (*Carassius auratus*) associated with an agent morphologically similar to herpesvirus. *Australian Veterinary Journal* 82:167-169.
Thophon, S., Pokethitiyook, P., Chalermwat, K., Upatham, E.S. and Sahaphong, S. (2004) Ultrastructural alterations in the liver and kidney of white sea bass, *Lates calcarifer*, in acute and subchronic cadmium exposure. *Environmental Toxicology* 19:11-19.
Viozzi, G.P. and Brugni, N.L. (2003) *Acolpenteron australe* sp.n. (Dactylogyridae: Dactylogyrinae), a new species from the ureters of *Percichthys trucha* (Perciformes:Percichthyidae) in Patagonia (Argentina). *Folia Parasitologica (Praha)* 50:105-108.
Way, K., Bark, S.J., Longshaw, C.B., Denham, K.L., Dixon, P.F., Feist, S.W., Gardiner, R., Gubbins, M.J., Le Deuff, R.M., Martin, P.D., Stone, D.M. and Taylor, G.R. (2003) Isolation of a rhabdovirus during outbreaks of disease in cyprinid fish species at fishery sites in England. *Diseases of Aquatic Organisms* 57:43-50.
Weber, L. P., Hill Jr., R.L. and Janz, D.M. (2003) Developmental estrogenic exposure in zebrafish (*Danio rerio*): II. Histological evaluation of gametogenesis and organ toxicity. *Aquatic Toxicology* 63:431-446.
Weber, L.P., Balch, G.C., Metcalfe, C.D. and Janz, D.M. (2004) Increased kidney, liver, and testicular cell death after chronic exposure to 17alpha-ethinylestradiol in medaka (*Oryzias latipes*). *Environmental Toxicology and Chemistry* 23:792-797.
Woo, P.T.K. and Poynton, S. (1995) Diplomonadida, Kinetoplastida and Amoebida. ***In*** *Fish diseases and disorders, Volume 1: Protozoan and metazoan infections* (***ed***. Woo, P.T.K.) pp. 27-96. CAB International Oxon, New York.
Wood, E.M. and Yasutake, W.T. (1956) Histopathology of kidney disease in fish. *American Journal of Pathology* 32:845-857.
Woodhead, A.D. (1979) Thyroid tumours in the senile guppy, *Lebistes reticulatus* (peters). *Experimental Gerontology* 14:211-215.
Yasutake, W.T. (1978) Histopathology of yearling sockeye salmon (*Oncorhynchus nerka*) infected with infectious hematopoietic necrosis (IHN). *Fish Pathology* 14:59-64.
Young, C.L. and Chapman, B. (1978) Ultrastructural aspects of the causative agent and renal histopathology of bacterial kidney disease in brook trout (*Salvelinus fontinalis*). *Journal of the Fisheries Research Board of Canada* 35:1234-1248.
Zapata, A. (1979) Ultrastructural study of the teleost fish kidney. *Developmental and Comparative Immunology* 3:55-65.
Zaroogian, G., Gardner, G., Horowitz, D.B., Gutjahr-Gobell, R., Haebler, R. and Mills, L. (2001) Effect of 17beta-estradiol, o,p'-DDT, octylphenol and p,p'-DDE on gonadal development and liver and kidney pathology in juvenile male summer flounder (*Paralichthys dentatus*). *Aquatic Toxicology* 54:101-112.





Spleen, Thymus, Reticulo-Endothelial System, Blood CHAPTER 5

by Edward J. Noga

This chapter will cover most of the major lymphoid organs in fish, but lymphoid tissues elsewhere (*e.g.* kidney) are covered in their respective chapters. The solid lymphoid tissues are composed of a reticular cell framework supporting both migratory and resident cell populations. In elasmobranchs, solid lymphoid tissue can be fairly well-demarcated (*e.g.* GALT-like foci in gut), but in teleosts it is always less defined than in mammals, forming loose aggregations that somewhat resemble their mammalian counterparts.

Spleen

Teleosts lack lymph nodes and the spleen is one of the two major filtering organs in the vascular system (the other being the kidney), removing foreign agents and effete blood cells. In many species, the spleen is also the major site of erythropoiesis. It may also function in antibody production, although the kidney is the major site for B-cell proliferation and antibody secretion. The importance of the spleen in these different functions varies greatly among species and is somewhat reflected in the relative amounts of red and white pulp in the parenchyma.

The spleen is usually a solitary, dark red organ in the peritoneal cavity adjacent to the gut wall, although in some elasmobranchs and teleosts, smaller accessory spleens may also be present, and this can even vary with the individual **(*Fig 5.1*)**. The same basic elements are typically present as in higher vertebrates: blood vessels, red pulp, white pulp and ellipsoids. The spleen is covered by a thin, fibrous capsule with little evidence of contractile ability. In a few teleosts, pancreatic tissue is present in the subcapsular region. Fine trabeculae extend into the parenchyma and separate red pulp from white pulp. Red pulp is an extensive, interconnecting system of splenic cords and sinusoids, consisting mainly of erythroid cells and thrombocytes, and usually comprises the majority of the splenic parenchyma. Splenic cords are a mesh of reticular cells with foci of various blood cells. White pulp, consisting mainly of lymphoid cells, typically surrounds arterial vessels, melanomacrophage centres and ellipsoids (see below), or forms small clusters in the parenchyma.



Splenic architecture. *Fig 5.1A.* Normal gross appearance of spleen in rainbow trout. Note the smaller accessory spleen.

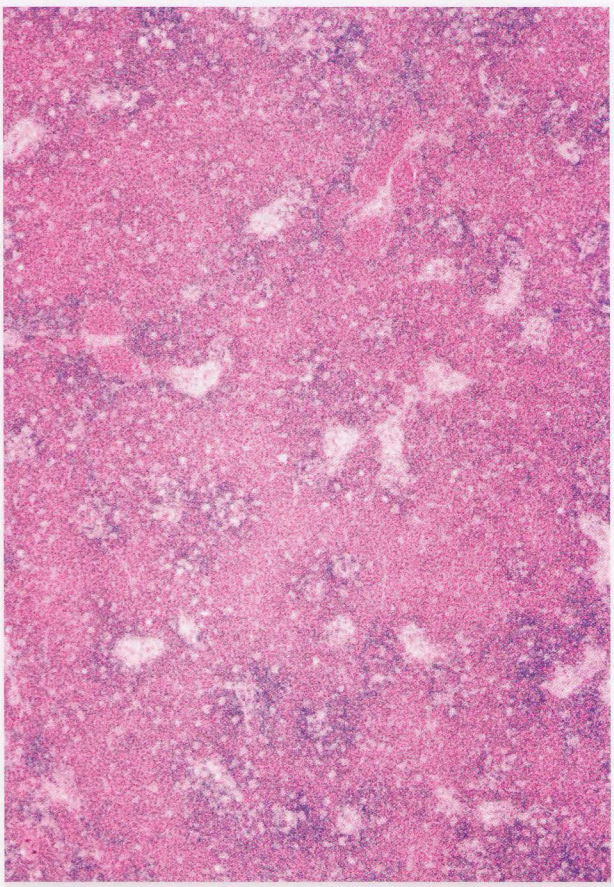

Fig 5.1B. Normal spleen microanatomy in a yellow perch. The parenchyma is mostly red pulp, with areas of white pulp prominent around ellipsoids.

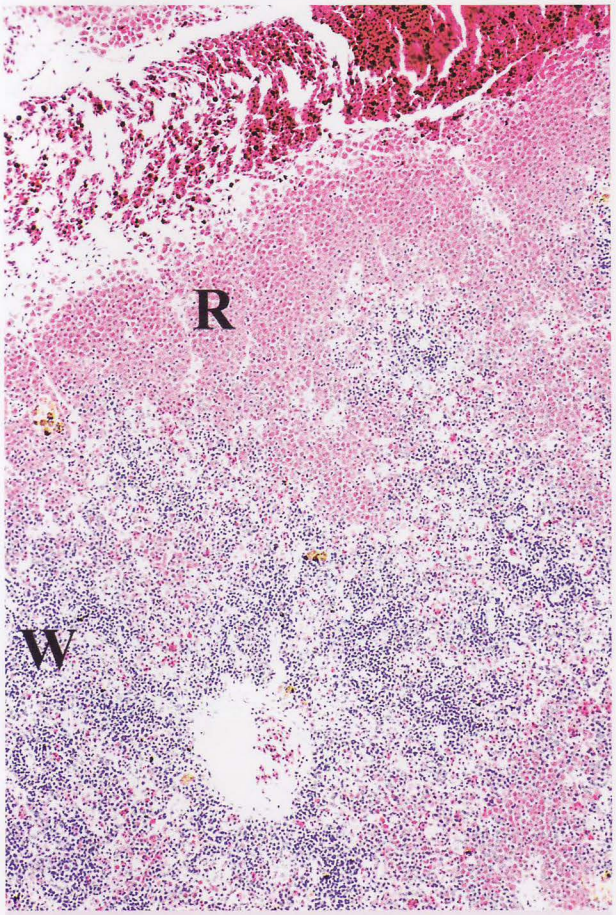

Fig 5.1C. Normal spleen microanatomy in *Pangasius* catfish to show the well demarcated areas of red (R) and white (W) pulp.

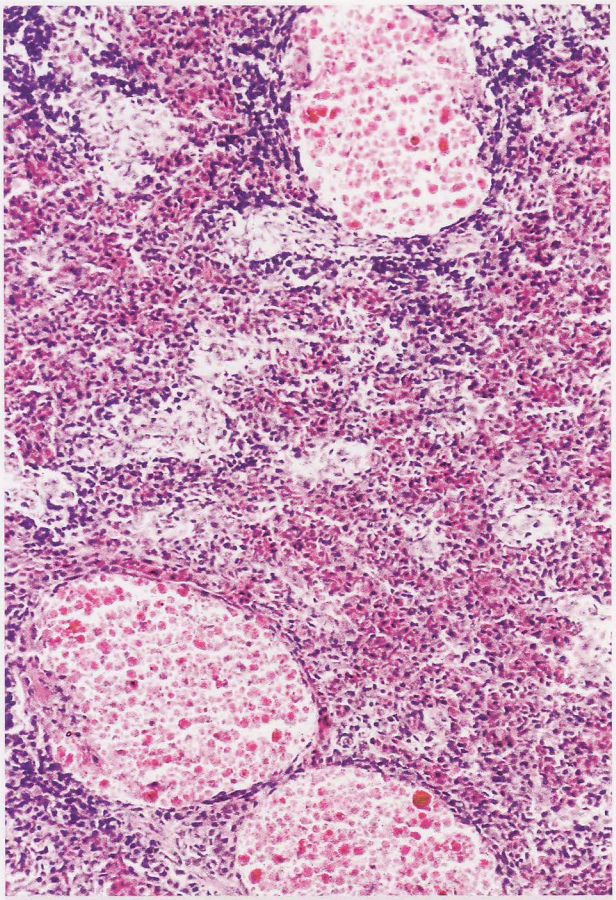

Fig 5.2A. Normal spleen of turbot. Note the circumscribed appearance of the melanomacrophage centres (MMC) containing golden pigment.

The melanomacrophage (MM) is a characteristic immune cell type of teleosts, and is prevalent in spleen. The MM is a phagocyte containing varying amounts of pigment, including melanin (black), haemosiderin, ceroid, or lipofuscin (yellow-pink to golden brown) localized in vacuoles. In salmonids, these cells are typically solitary or form loose aggregates, but in other teleosts they form discrete, encapsulated foci known as melanomacrophage centres (MMC), that are often found near blood vessels **(*Fig 5.2*)**. MM and MMC are also found in kidney, liver and many other sites, including gonad, thyroid and even thymus. MMC serve as repositories for end-products of cell breakdown, such as phospholipids. Chronically stressed fish, including those that are unhealthy, live in polluted environments, or are in a catabolic state (*e.g.* starvation) tend to have more and larger MMC. The size and number of MMC also increase as fish age, and MMC pigment tends to be darker (melanin) in aged or unhealthy fish. Thus, age-matched fish of the same species must be compared for valid evaluation of MMC pathology. It is worth noting that not all studies have been able to show a relationship between MMC and pollution.

Ellipsoids are periarterial sheaths of macrophages and reticular cells, supported by reticulin fibers, that are formed at the termination of splenic arterioles **(*Fig 5.3*)**. The ellipsoid lumen is lined by a specialized myoendothelium and its outer wall is surrounded by endothelium-lined, blood-filled spaces. A few species, such as dace, do not have ellipsoids. Foreign bodies, such as bacterial cells, are trapped by the ellipsoids and may be seen within the fine reticular meshwork or intracellularly within the phagocytic cells of the sheaths.

In the ellipsoids, foreign bodies and metabolic by-products (*e.g.* iron-containing pigments from phagocytosed erythrocytes) are transferred to the MMC within macrophages. Soluble antigen is also trapped in the ellipsoids as an immune complex with IgM and complement factor 3 (C3); it has been suggested that this antigen is

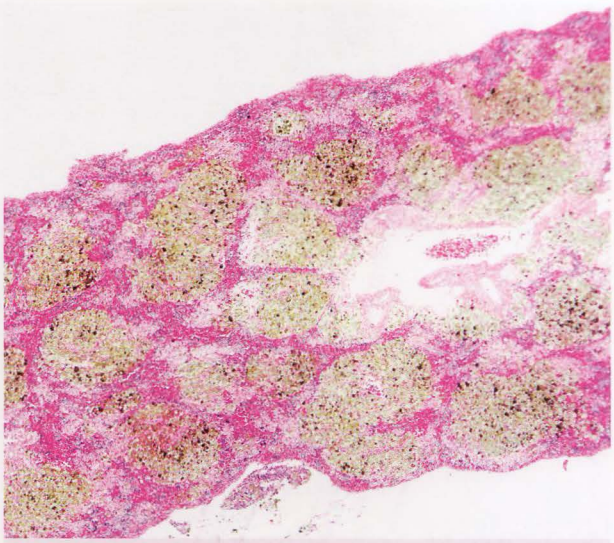

Fig 5.2B. Hypertrophy and hyperplasia of MMC in a *Tilapia aurea*. MMC have replaced most of the splenic parenchyma.

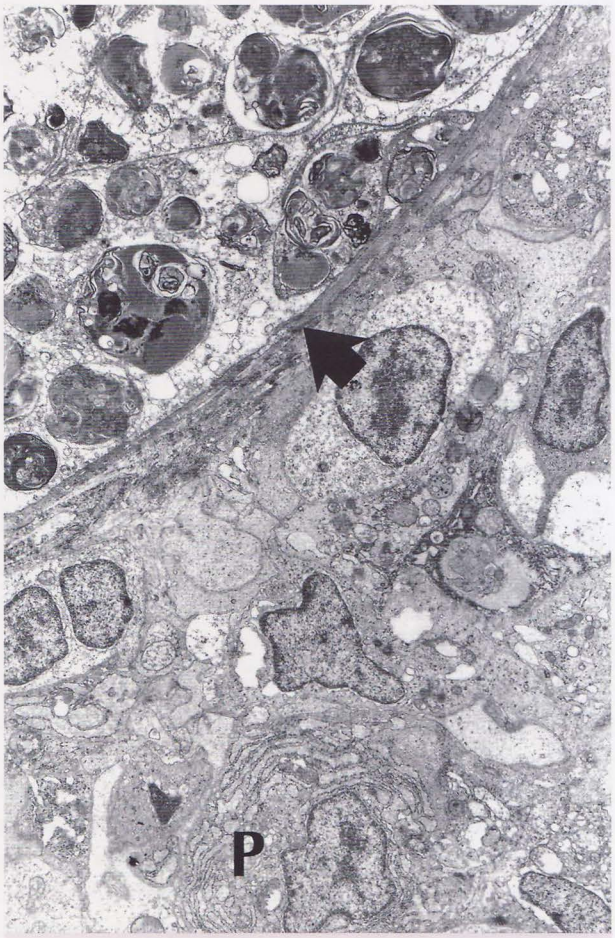

Fig 5.2C. TEM of MMC in turbot to show the capsule (arrow) containing debris-filled cells and immunocompetent cells around, including a plasma cell (P).

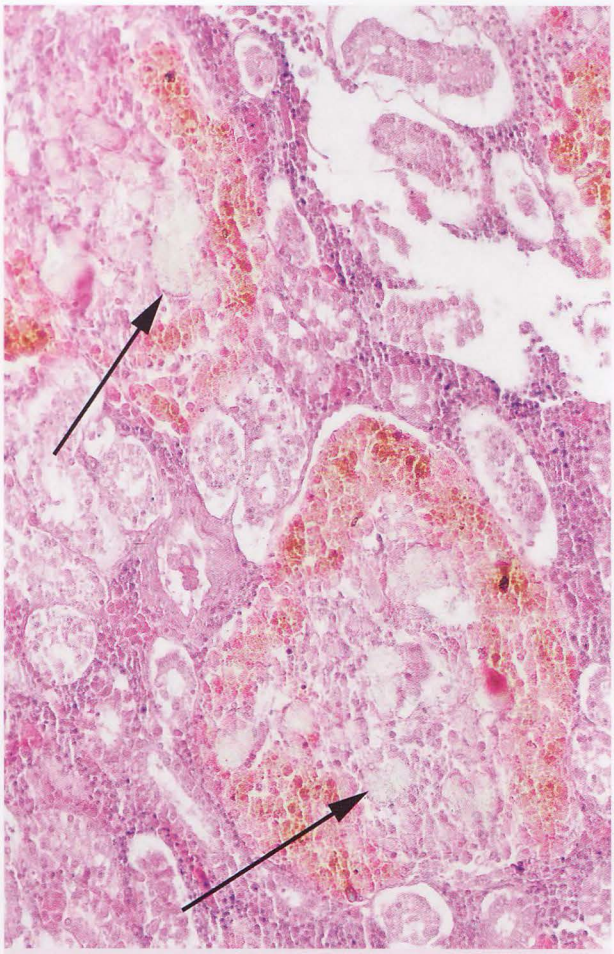

Fig 5.2D. MMC in kidney of aquarium fish containing oxalate crystals (arrows). Any kind of hard-to-digest material will be taken here, whether antigenic or not.

also transported from ellipsoids to melanomacrophage centres. The appearance of antigen at MMC coincides with an increase in antibody expression at these structures, prompting speculation that the ellipsoid-MMC complex might be the primitive analogue of the germinal centre, but this is yet to be substantiated and some feel that MMC are only repositories for scavenged material and simply represent a metabolic dump. In chronic diseases, there may be an increase in white pulp, especially around the ellipsoids and MMC, and in some cases, large numbers of plasma cells may be present. Pathogens trapped at other sites, such as the extensive macrophage network in the renal portal system, may also localize to the spleen, probably carried there within macrophages. One hour after injection of rainbow trout with killed bacteria, the spleen contains only 1.5% of the inoculum, but by 18 hours, it contains 30% of all bacteria in the body.

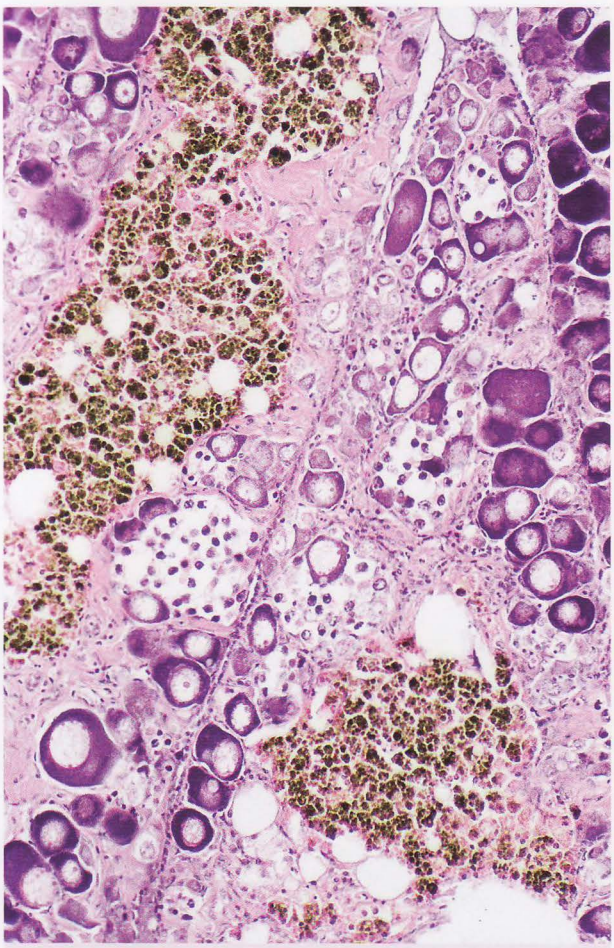

Fig 5.2E. Large MMC's in ovary. High cell turnover results in large quantities of phospholipids; these too are placed in MMC.

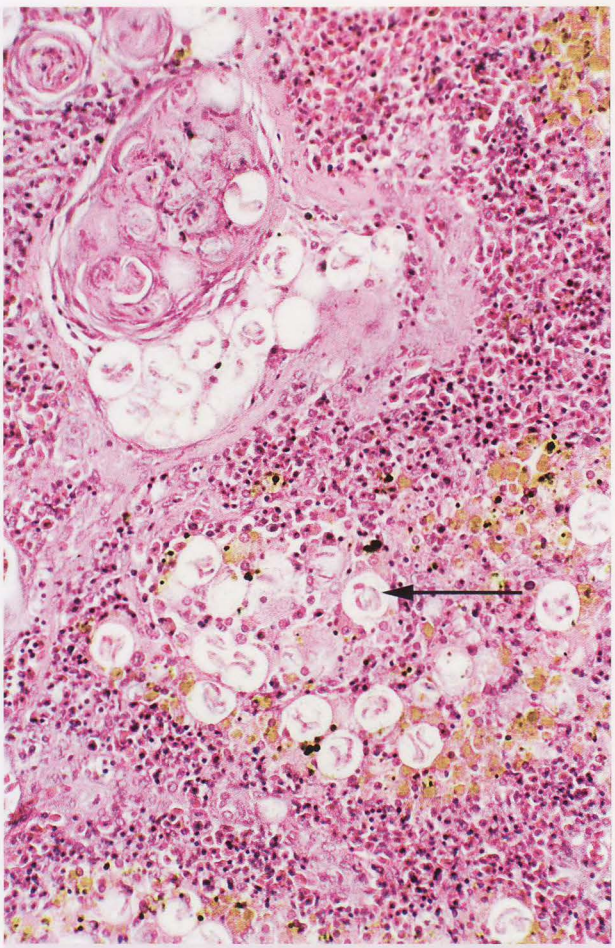

Fig 5.2F. Cyprinid spleen showing numerous coccidia within MMC's (arrow).

Pathogens trapped in the splenic parenchyma may cause necrosis **(Figs 5.4 – 5.6)**, a characteristic of certain viral infections such as the iridovirus responsible for epizootic haematopoetic necrosis virus (EHNV). A hallmark of many systemic iridovirus infections in fish is the presence of significantly hypertrophied, basophilic, virus-infected cells whose tissue distribution suggests that the virus is mesotheliotropic. In the spleen and other organs, these hypertrophied cells are suspected of causing damage due to infarction from occlusion of blood vessels.

If loss of vascular integrity is extensive, it may also cause marked enlargement of the spleen, as seen in the orthomyxoviral infectious salmon anaemia (ISA). Bacterial pathogens are frequently trapped, and these may release toxin, causing necrosis and splenomegaly (*e.g. Aeromonas* spp.) and toxin production is probably responsible for the splenomegaly observed in rainbow trout fry syndrome (RTFS) caused by *Flavobacterium psychrophilum*. *Piscirickettsia* infects splenic macrophages, causing necrosis and splenomegaly **(Fig 5.7)**. Splenomegaly is also seen in some haemoparasite infections, notably *Trypanoplasma salmositica* and *Haemogregarina sachai*. It may also occur in healthy salmonids during spawning, where it is thought to be due to splenic blood storage. Conversely, asphyxia, severe exercise, or certain drugs may cause release of erythrocytes stored in the spleen, with a consequent rise in haematocrit. In acute haemolytic crises as seen for example in acute erythrocyte inclusion body syndrome (EIBS), most of the blood pigments accumulate in the spleen rather than the kidney, and the ellipsoidal sheaths can be replete with haemosiderin (breakdown product of haemoglobin), appearing dark brown (this must be differentiated from haematin, resulting from the use of unbuffered formalin). Chronic erythrocyte lysis, such as due to Vitamin E deficiency, also causes splenomegaly and prominent haemosiderosis that is present as a fine stippling in Perl's Prussian blue-stained sections. Lipoid liver

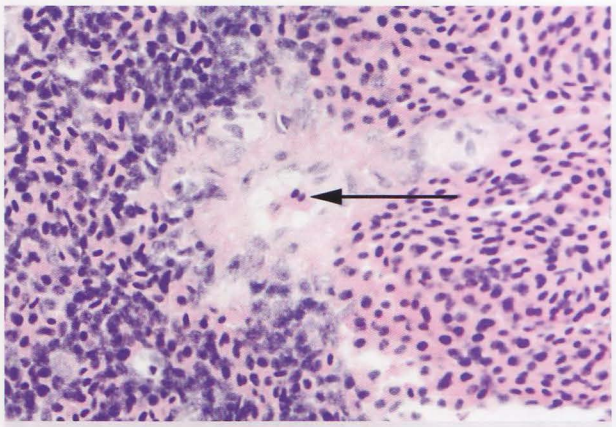

Fig 5.3A. An ellipsoid in yellow perch spleen. Note the red blood cells (arrow) in the lumen of the vessel.

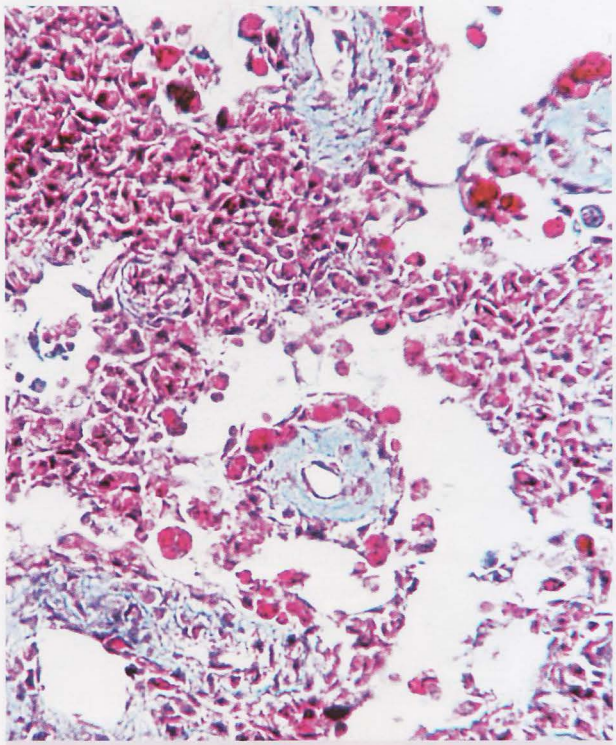

Fig 5.3B. Ellipsoids are often hard to see in routine H&E sections. The reticulin is well shown in this MSB-stained section from a turbot. The red-stained cells round the periphery are macrophages containing *Haemogregarina* protozoa.

disease also causes haemosiderosis in spleen and ceroid accumulation in macrophages.

In view of its filtering function, it is not surprising that a myriad of systemic infections involve the spleen to some degree. Thus, the spleen is commonly involved in chronic granulomatous bacterial and parasitic diseases. Severe lesions can greatly distort its gross appearance, forming

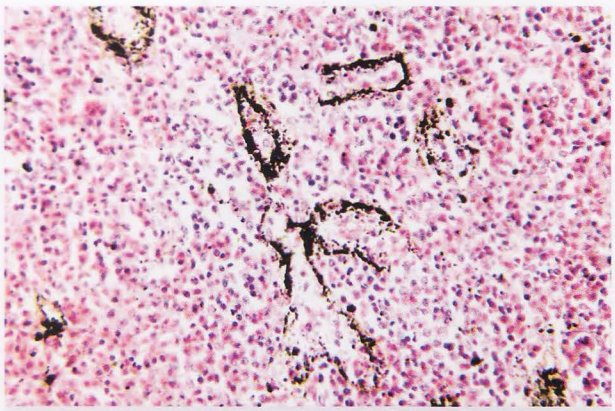

Fig 5.3C. Another way of seeing ellipsoids is to inject material such as Indian ink into the bloodstream. It gets trapped in the ellipsoids, here seen in a bullhead catfish.

white focal nodules on or within the parenchyma. Some of the best examples include mycobacteriosis, bacterial kidney disease, pasteurellosis, proliferative kidney disease, blood fluke (*Sanguinicola inermis*) infection and piscirickettsiosis **(*Fig 5.7B*)**.

The phagocytes involved in piscine granulomatous disease often have features that are very different from those in mammals. The epithelioid macrophages, in addition to having phagolysosomes and other typical features, can also display cytological characteristics of true epithelial cells, including desmosomes and tonofilaments, as well as being cytokeratin-positive **(*Fig 5.8*)**. Resident macrophages in the liver of several catfish species also form desmosome-like connections to endothelial cells. However, not all piscine epithelioid cells and macrophages have these features. Interestingly, a diversity of normal fish tissues that are not considered true epithelia (*e.g.* fibroblasts) also express cytokeratins, suggesting that the tissue-expression pattern of certain cytokeratins was only restricted later in evolution.

Thymus

This paired lymphoid organ is on the dorsomedial aspect of the branchial cavity **(*Fig 5.9*)**. It is usually covered by a thin layer of epithelium. The epithelium extends trabeculae into the thymic parenchyma, forming a three-dimensional lattice that supports the thymocytes, the predominant cell type and other immune cells, mainly macrophages. In some species, a cortex, with more thymocytes, and a medulla, with more epithelial cells, can be distinguished. Epithelial cysts similar to mammalian Hassall's corpuscles are present in some fish. The thymus can be detected in

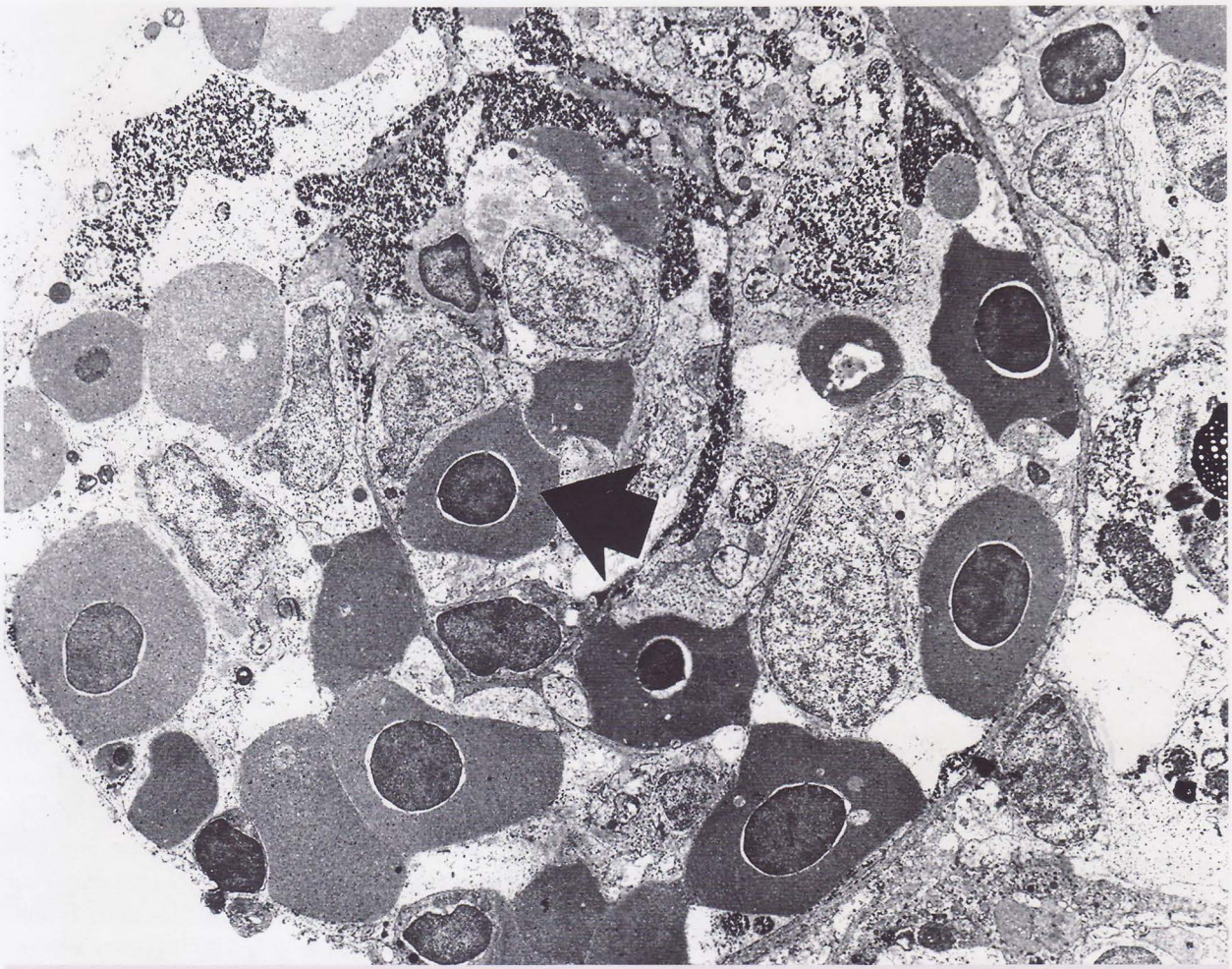

Fig 5.3D. TEM of ellipsoid in plaice injected with Indian ink, seen within reticular cells in the wall of the ellipsoid. The arrow shows an erythrocyte within the lumen of the axial vessel.

some species a few days before hatching, whereas in others like plaice, it is seen only after metamorphosis of the larvae. Thymic involution with maturity, as occurs in mammals, does not occur in all fish species. Apoptotic thymocytes can be common, depending upon life stage. The thymus may also vary in size and histological appearance with seasonal or hormonal cycles. The thymus appears to function, as it does in mammals, as a site of differentiation of lymphocytes involved in cell-mediated immunity, prior to their migration to peripheral lymphoid organs.

The relatively superficial location of the thymus would seem to make it quite vulnerable, but in addition, a unique feature of teleost thymus is the presence of pores on the thymic surface, suggesting that the thymus might be even more readily exposed to antigen. In young fish with severe bacterial or water mould infections of the branchial cavity, necrosis of the epithelium overlying the thymus is common, with subsequent invasion and destruction of thymic parenchyma. Thymic architecture can be severely disrupted even when the water mould infection does not directly involve the thymus. The significance of these observations and the implications for the possible induction of immune tolerance or suppression has not been assessed. Change in gross appearance of the thymus, specifically thymic haemorrhage, has been associated with stress in some fish. Thymomas are not uncommon *(see Fig 13.10A)* and if nothing else, their location alone makes a diagnosis on gross appearance relatively easy!

Reticulo-endothelial system (RES)

The RES comprises a network of highly phagocytic cells that line small blood vessels. Their precise location has been dealt with under the appropriate organ systems, but to summarize, they are found in the splenic ellipsoids, in the

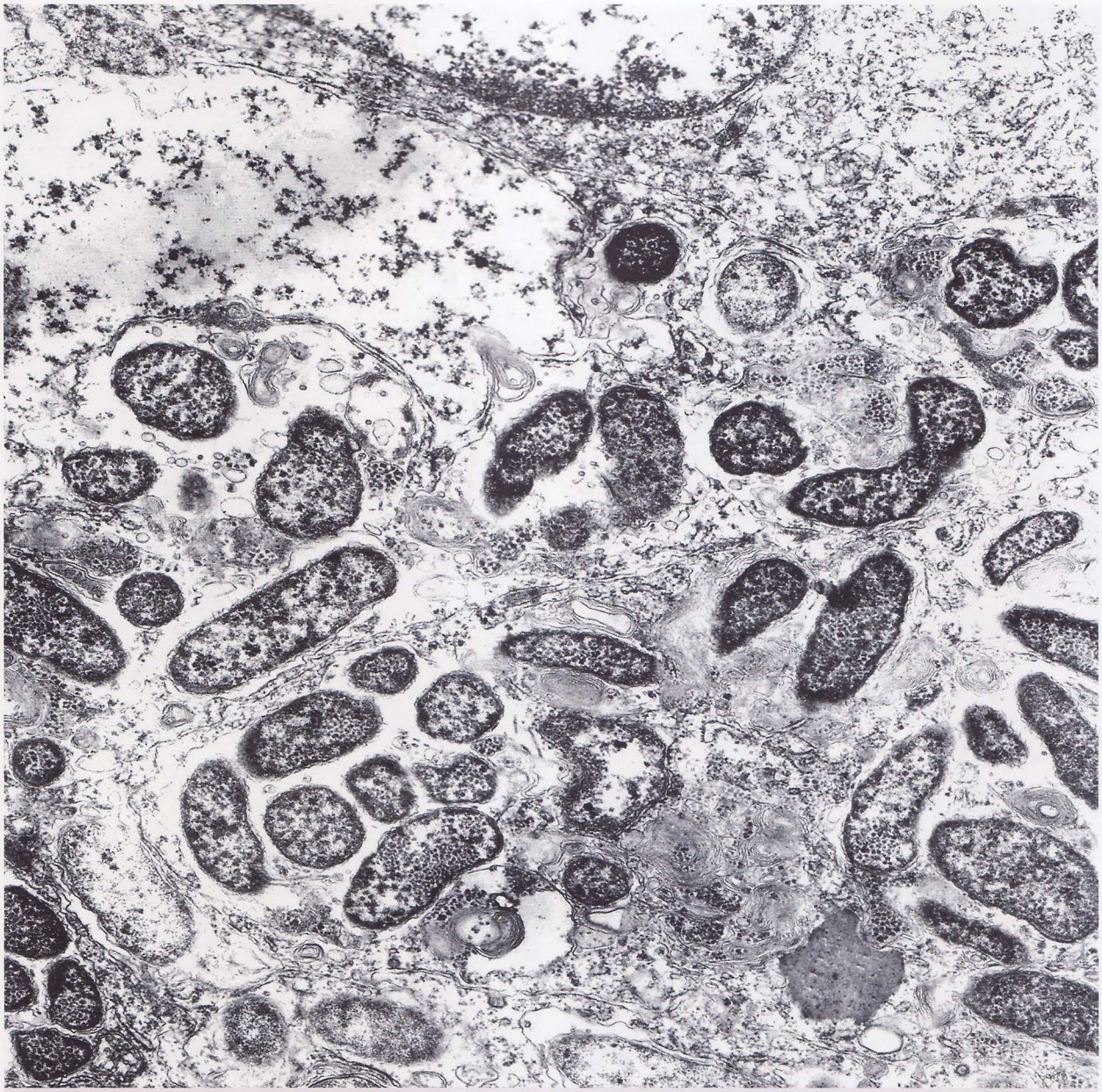

Fig 5.3E. Bacteria are also trapped by ellipsoids. Here we see a TEM of *Vibrio salmonicida*; note the lack of necrosis. *Material courtesy Dr. T. Håstein.*

sinusoids and peritubular capillaries of the kidney (renal portal system), in the peritoneal cavity as free cells, and as the cells forming the endothelial lining (endocardium) for the myocardial trabeculae in the atrium and to a lesser extent the ventricle. Resident phagocytic cells with some morphological and cytochemical similarities to mammalian Kupffer cells have been reported (possibly wrongly) in the liver of some fish such as brown bullhead (*Ictalurus melas*), rainbow trout and channel catfish, but most agree that they are absent in the great majority of teleosts examined so far.

It is likely that circulating monocytes are the main source for histiocytes, as well as for macrophages in inflammatory lesions. Whether monocytes are the source of histiocytes in larval tissues such as kidney, and whether these cells become self-sustaining by *in situ* replication, or still require replacement by circulating cells, are unknown. Other cells with limited phagocytic abilities include pillar and lamellar epithelial cells in the gills, fat-storing cells (cells of Ito) in the liver, thrombocytes, the retinal pigmented epithelium (RPE) of the eye, and possibly the ependymal lining of the ventricles in the brain and the epidermal epithelial cells.

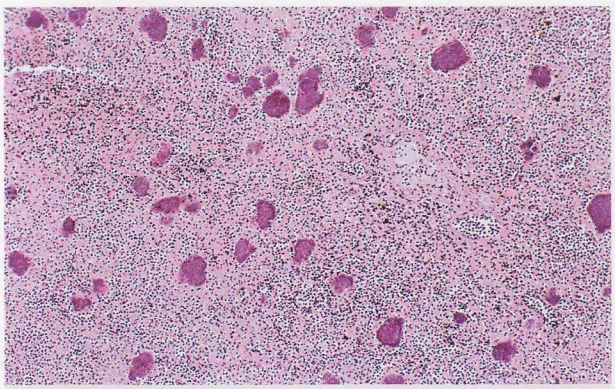

Splenic pathology: acute lesions. *Fig 5.4A.* Spleen of a brown trout with furunculosis (*Aeromonas salmonicida* infection). The bacteria have been trapped by the ellipsoids and have formed numerous intensely basophilic microcolonies.

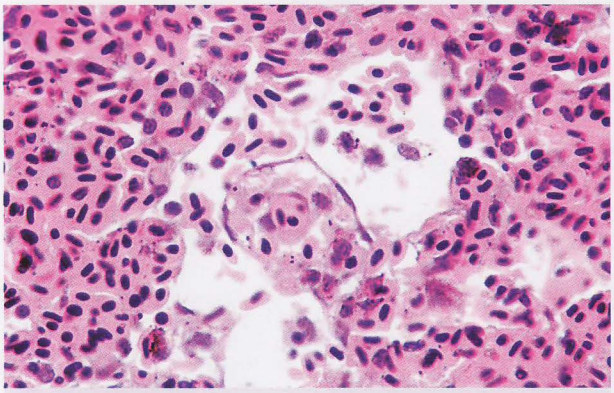

Fig 5.4B. Bacteria trapped by ellipsoids can lead to lysis, destruction of vascular integrity, and splenomegaly due to haemorrhage. Interpreting such changes can be difficult. Here we can just make out an ellipsoid in acute furunculosis in brown trout, but the reticular cells are necrotic.

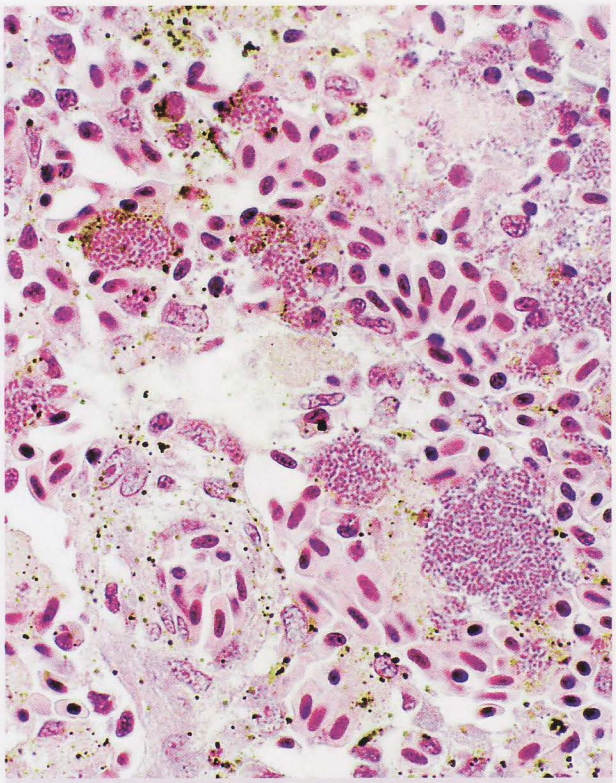

Fig 5.4C. Higher power view of *Fig 5.4A* showing bacteria trapped in ellipsoids. Some of the brown pigment derives from lysed melanomacrophages.

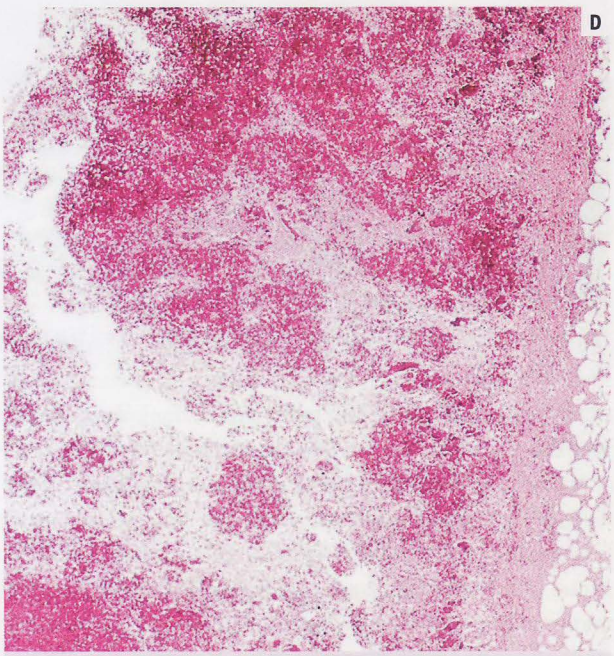

Fig 5.4D-F. Rainbow trout fry syndrome (*Flavobacterium psychrophilum*) can target the spleen. Here we see acute haemorrhagic and necrotic splenitis (**D**) involving the capsule (**E**). Sometimes bacteria can be seen on the capsular surface (**F**).

Blood

Teleost blood volume is typically about 3-4% of body weight, compared to about 5-8% for elasmobranchs and other vertebrates. It is generally recognized that fish do not have a true lymphatic system as defined using mammalian criteria, but there certainly exists a substantial secondary vascular network ("secondary circulation") in a number of organs. Secondary circulation probably occurs in the gill of all teleosts but in some species is also present in skin, peritoneal lining, oral mucosa and/or dorsal segmental vessels. The secondary circulation runs in parallel with the primary blood circulation and is distinguished from the latter by its origin. It arises from the walls of certain primary arteries as many (often hundreds) short, arteriole-sized vessels that then re-anastomose to form a secondary

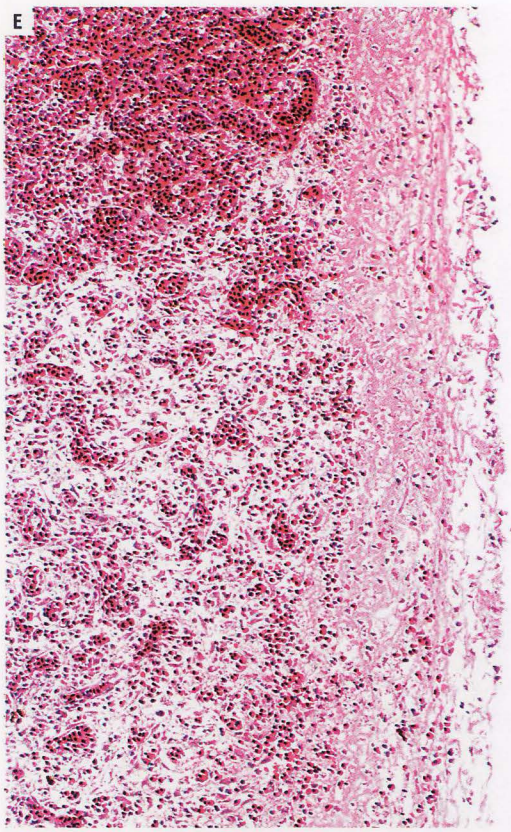

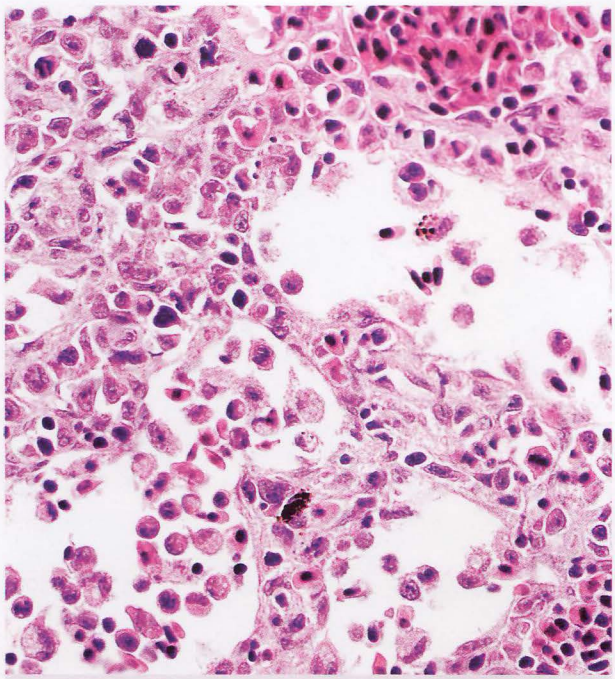

Fig 5.4G. In acute bacteraemias and viraemias we can often see activation and mobilization of inflammatory cells, best observed within tissues like spleen and renal interstitium. Here large numbers of neutrophils and a few melanomacrophages can be seen within the lumen of these splenic vessels.

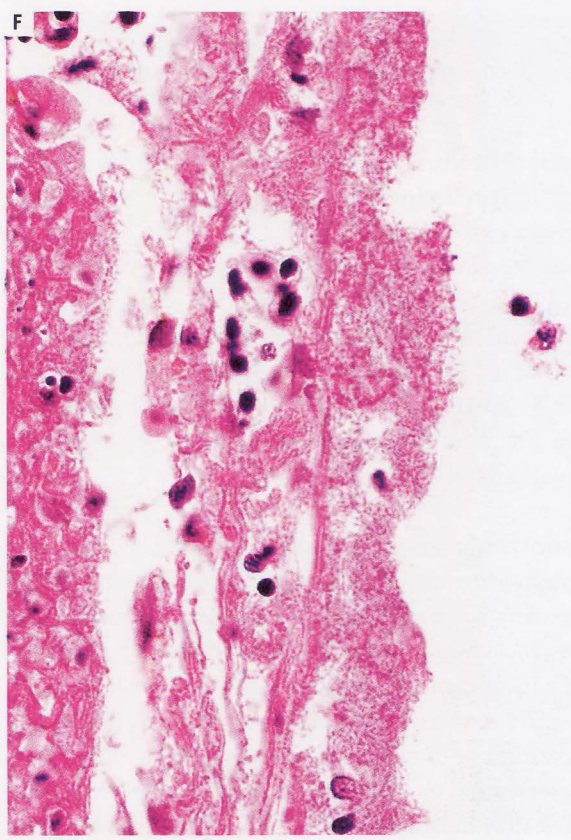

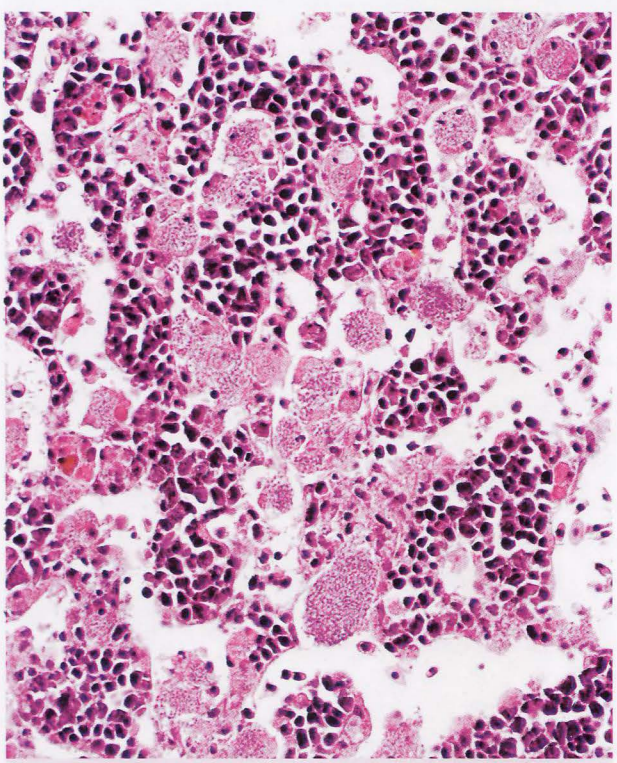

Fig 5.5A. Photobacterium trapped in large numbers within the spleen of this sole.

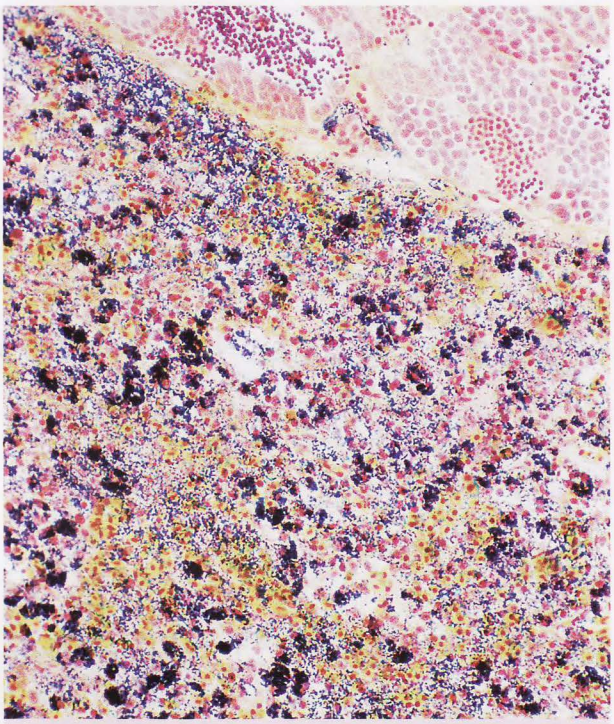

Fig 5.5B. Streptococci almost obliterate by sheer numbers the architecture of the spleen in this danio. *Gram stain.*

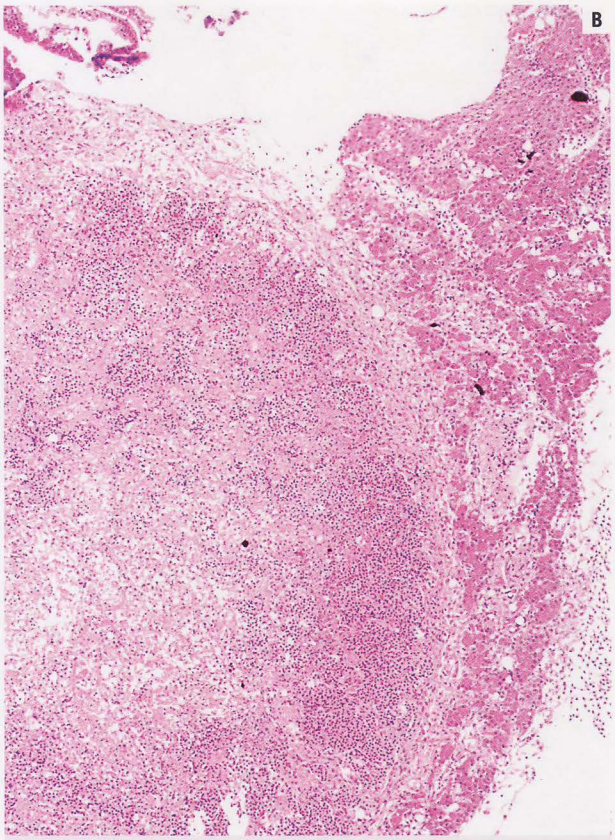

Fig 5.6B-D. Acute mycotic splenitis in seabass. There is pronounced destruction of splenic architecture (**B**) and although the brown-coloured fungal hyphae are well demonstrated in H&E, here seen moving out through the capsule into the surrounding pancreas (**C** – arrow), they are more easily seen in PAS-stain (**D**).

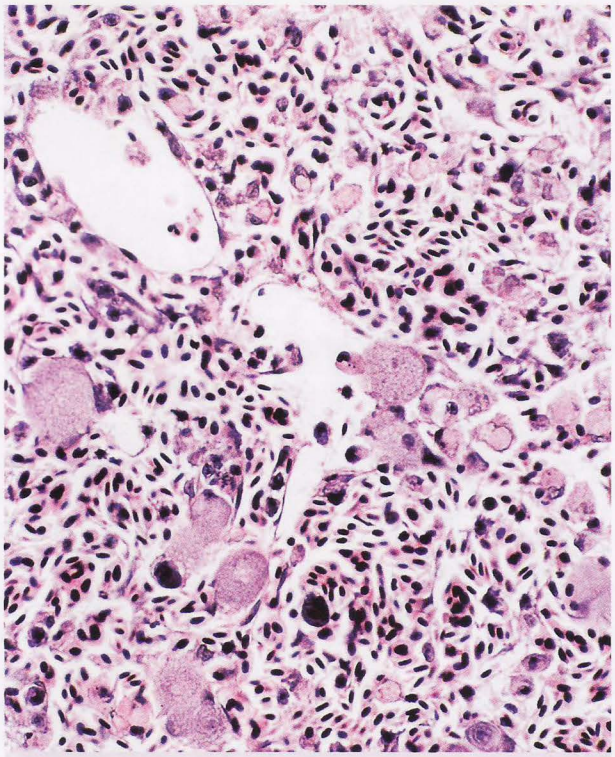

Fig 5.6A. Iridovirus infection in the splenic vascular tissue of a grouper. Note the subendothelial location of the hypertrophied, basophilic, virus-infected cells. *Courtesy Dr. S. Gibson-Kueh.*

arterial network. It is believed that this secondary blood supply usually drains back into the primary systemic veins. Its venous effluent typically has a very low haematocrit because erythrocytes are mainly excluded by microvillous guard cells. The physiological function of the secondary circulation is unknown, although supplying nutrients and osmoregulation have been suggested. The volume of the secondary circulation is about 5% of body weight, making it about 1.5 times larger than that of the primary circulation.

Leukocyte responses. A substantial effort has been made in trying to identify useful haematological indicators of disease in fish, but many factors can confound haematological values, including age, sex, diet, species (and strain), time of year, environment (*e.g.* temperature), and sampling methods such as type and duration of anaesthetic and sampling site (cardiac or caudal vein). When collecting blood from diseased fish, it is crucial to also take samples from clinically healthy individuals of the same age, under the same

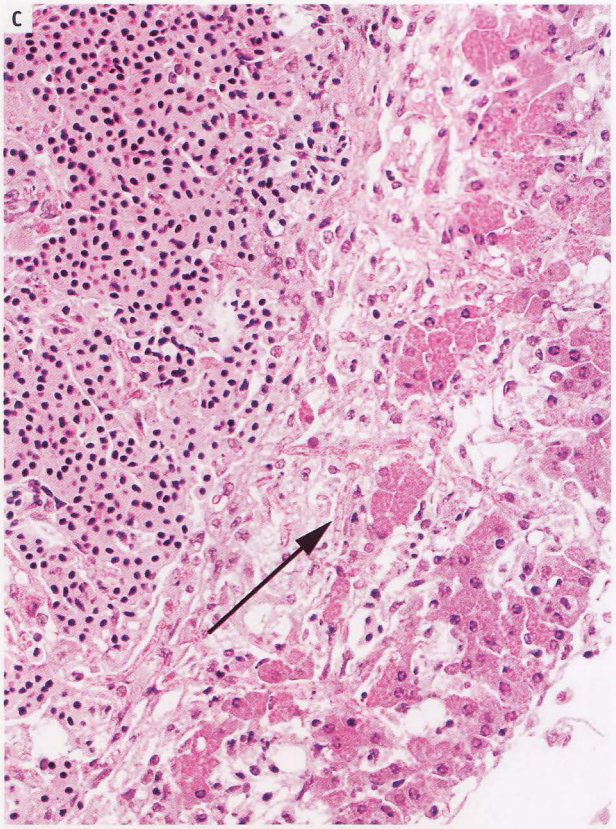

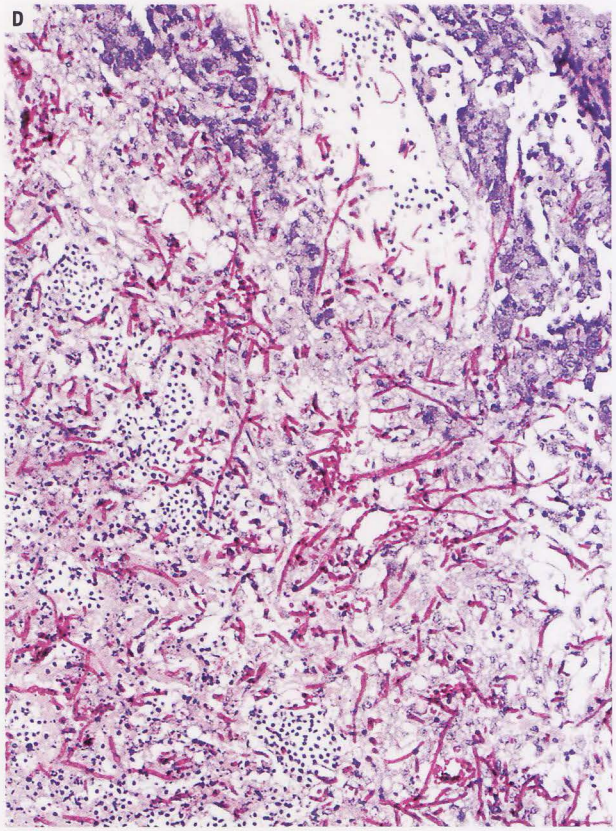



Splenic pathology: chronic lesions. *Fig 5.7A.* Splenomegaly in this rainbow trout with proliferative kidney disease. Although the capsular surface is still quite shiny (indicating a lack of fibrin) it has a slightly pebbled look due to the chronic inflammation within.

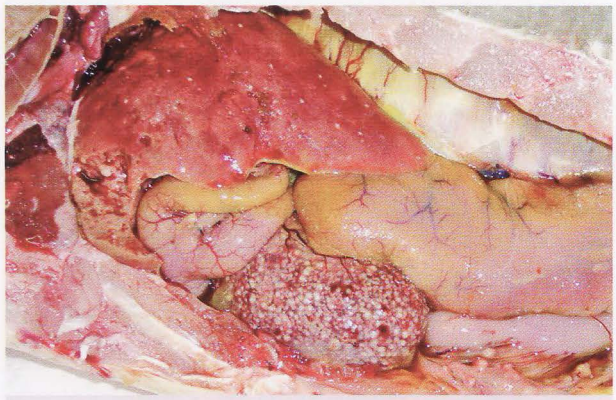

Fig 5.7B. Seabass with multifocal granulomatous splenitis due to rickettsia. *Picture courtesy Dr. P. Kantham.*

conditions, and using the same methods. Also, osmotic effects can easily dominate and obscure real changes, unless these are taken into account. One must be cautious in making broad generalizations about leukocyte responses to various infectious diseases of fish because studies have been sporadic and in some cases contradictory. However, a fairly consistent leukocyte response is seen in certain rhabdoviral infections, such as infectious haematopoetic necrosis, spring viraemia of carp and viral haemorrhagic septicaemia, which cause severe leukopaenia due to damage to the haematopoetic organs. Leukopaenia has also been associated with a number of Gram-negative septicaemias, including *Aeromonas, Yersinia* and *Edwardsiella*. Lymphopaenia and neutrophilia have also been reported in some of these infections. Leukocytic responses to parasites are variable. Eosinophilia has not been reported as a feature of parasitosis, although mast cells are often seen in inflammatory responses to metazoan parasites.

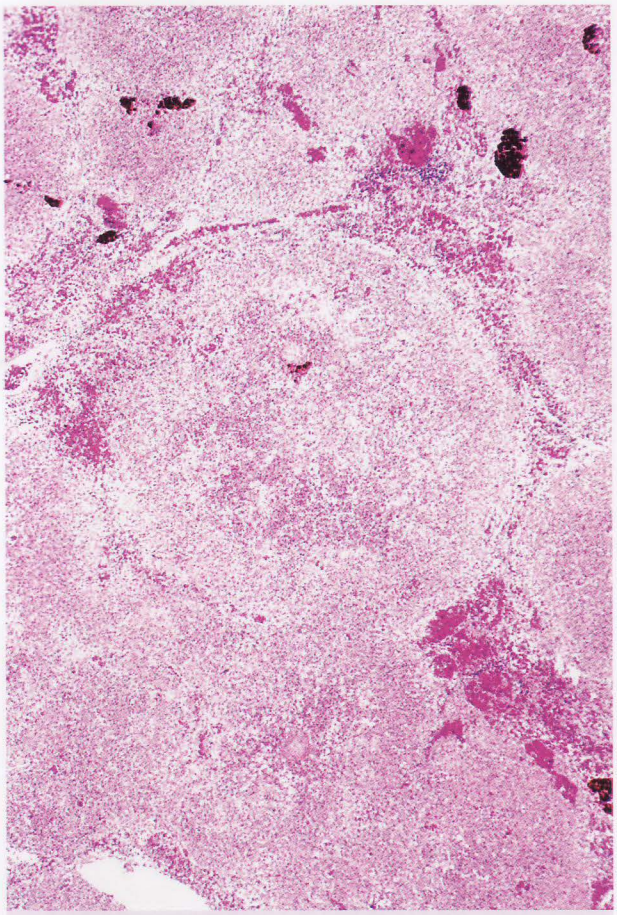

Fig 5.7C. Histopathology from **B.** The granulomatous lesions centre on the ellipsoids where the pathogens were originally trapped.

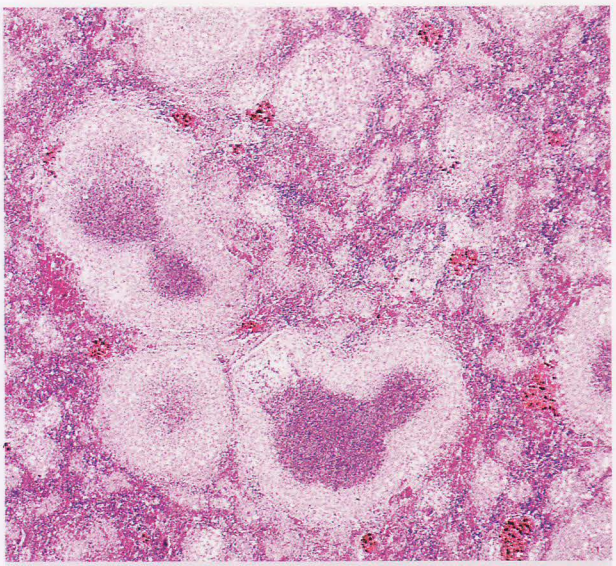

Fig 5.7D. Multifocal granulomatous splenitis in cod due to *Loma*-like microsporidia. Note the pre-caseous cores to some of the lesions.

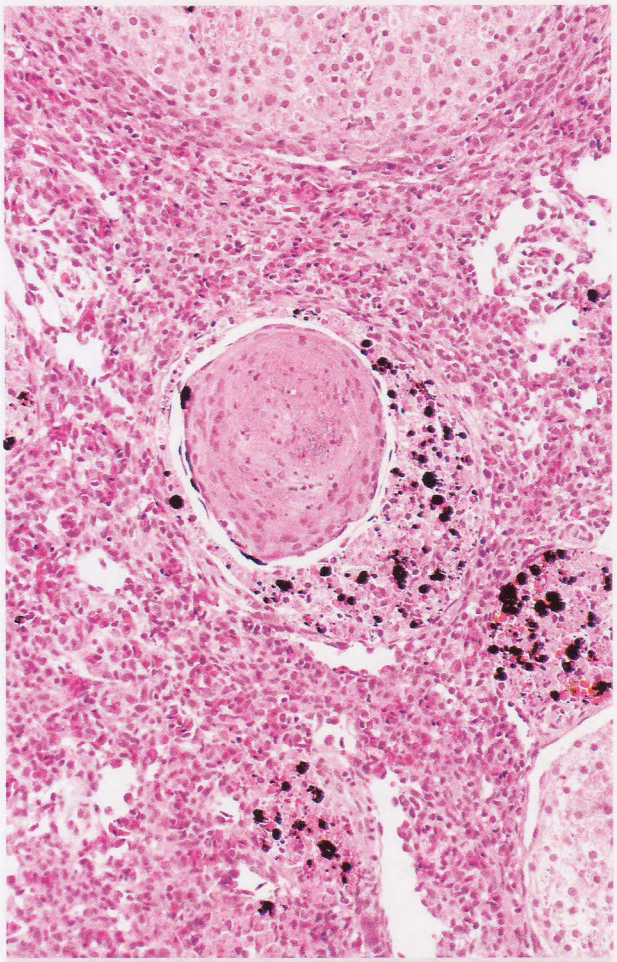

Fig 5.7E. Mycobacterial granulomatous splenitis. Note the granuloma *within* the MMC.

Change in leukocyte numbers is a very sensitive indicator of stress in fish. While the response to environmental insults varies with the type and severity of the stress, it often leads to a leukopaenia associated with lymphopaenia and sometimes neutrophilia, which is very similar to the classic leukocytic response to stress in mammals. Leukopaenia has been associated with stress imposed by a number of factors, including high temperature, temperature shock, crowding, transport, confinement and some toxins. Even brief stresses (less than one minute of handling) may cause a transient lymphopaenia. Leukocytosis can sometimes be inferred from histological sections; large numbers of white cells can sometimes be seen pouring into sinusoids in tissues like spleen and kidney *(Fig 5.4G)*.

Anaemias. Piscine erythrocytes are flattened elliptical cells. As in all other vertebrates except mammals, they are nucleated, although anucleate erythrocytes are seen in a very few species. Fish erythrocytes increase in size as they mature and a relatively high proportion of immature

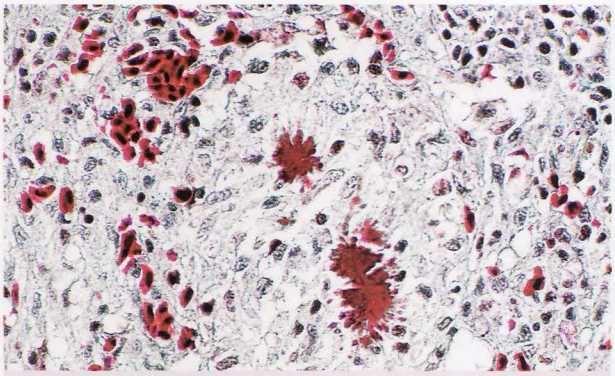

Fig 5.7F. Splendore-Hoeppli reaction within the spleen of this Atlantic salmon. Such lesions are not uncommon in *Pasteurella skyensis* infections, and may indicate immune hypersensitivity. *Martius scarlet-blue.*

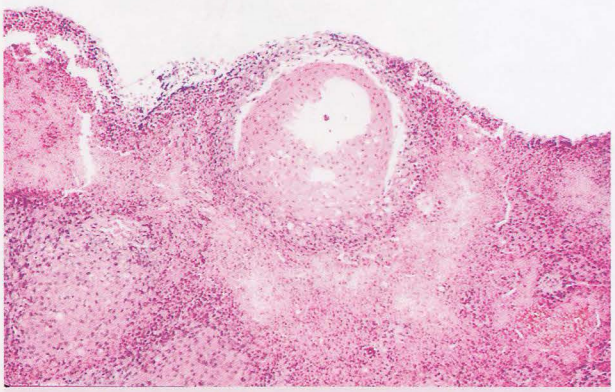

Microarchitecture of piscine granulomas. *Fig 5.8A.* Splenic granuloma due to acid-fast bacterial infection in Atlantic menhaden. Note the epithelium-like appearance of the granuloma.

cells (polychromatocytes) are normally present in the circulation. Nuclear chromatin of erythrocytes is typically clumped, and vestiges of endoplasmic reticulum and Golgi may be seen.

The ability of many teleosts to survive in a relative or functional absence of haemoglobin is well established. A few species, like the Antarctic icefish (*Chaenocephalus aceratus*) have no erythrocytes, relying entirely on plasma for gaseous transport. Compensatory mechanisms during even severe acute, blood loss (*e.g.* 70% reduction of haematocrit in rainbow trout) enable resting levels of oxygen uptake to be maintained. A very important mechanism is increased cardiac output, which is achieved almost entirely by increasing stroke volume rather than heart rate, thereby pumping greater volumes of blood through the gills (facilitated by decreasing peripheral vascular resistance). Thus, even very low haematocrit might cause few clinical signs. In addition, because fluid appears to move readily across many tissues, a volume of interstitial fluid equivalent to the entire blood volume can be mobilized during haemorrhagic hypotension. The usual gross manifestation of anaemia in the gills is branchial pallor, but this must not be confused with excess mucus, epithelial cell hyperplasia, or even post-mortem drainage of blood from the gills. Anaemia may also cause visceral pallor.

Anaemias may be classified according to number, size and haemoglobin concentration of the erythrocytes. Or they may be classified as responsive (regenerative) or non-responsive. Alternatively, they may be classified according to the pathophysiological mechanism, as due to blood-loss (haemorrhage), increased rate of breakdown (haemolytic) or reduced rate of production (hypoplastic). The latter classification is the most useful from a diagnostic standpoint.

Haemorrhagic anaemias are occasionally seen following trauma, especially to the gills, or following minor medical procedures, especially cardiac puncture for blood sampling. In species with a compact outer layer to the myocardium, and hence coronary vessels, an inappropriately placed hypodermic needle may cause acute pericardial haemorrhage, and sometimes cardiac tamponade. An alternative sequel is haemoperitoneum, especially if there have been multiple attempts at sampling. Abdominal (intraperitoneal) haemorrhage is also encountered after stripping eggs during artificial spawning, especially if the handlers are inexperienced or the fish are not ripe. Water temperature may dictate the severity of the consequences (high temperature necessitates high oxygen requirement and hence increased dependence on haemoglobin) and the speed of recovery.

Acute haemorrhage of the gills accompanies the mass exodus of *Sanguinicola klamathensis* miracidia. Under these situations, there will be increased numbers of circulating polychromatocytes (regenerative anaemia). Piscine polychromatocytes are smaller than mature erythrocytes, and as already said, they increase in size as they age (the converse of the mammalian situation), which is important to bear in mind if trying to classify a piscine anaemia as "microcytic".

External parasites such as leeches or fish lice (*Argulus*) can also cause blood loss anaemia, as can some bacterial or viral diseases where vascular endothelium is destroyed. Examples of the latter include viral haemorrhagic septicaemia of

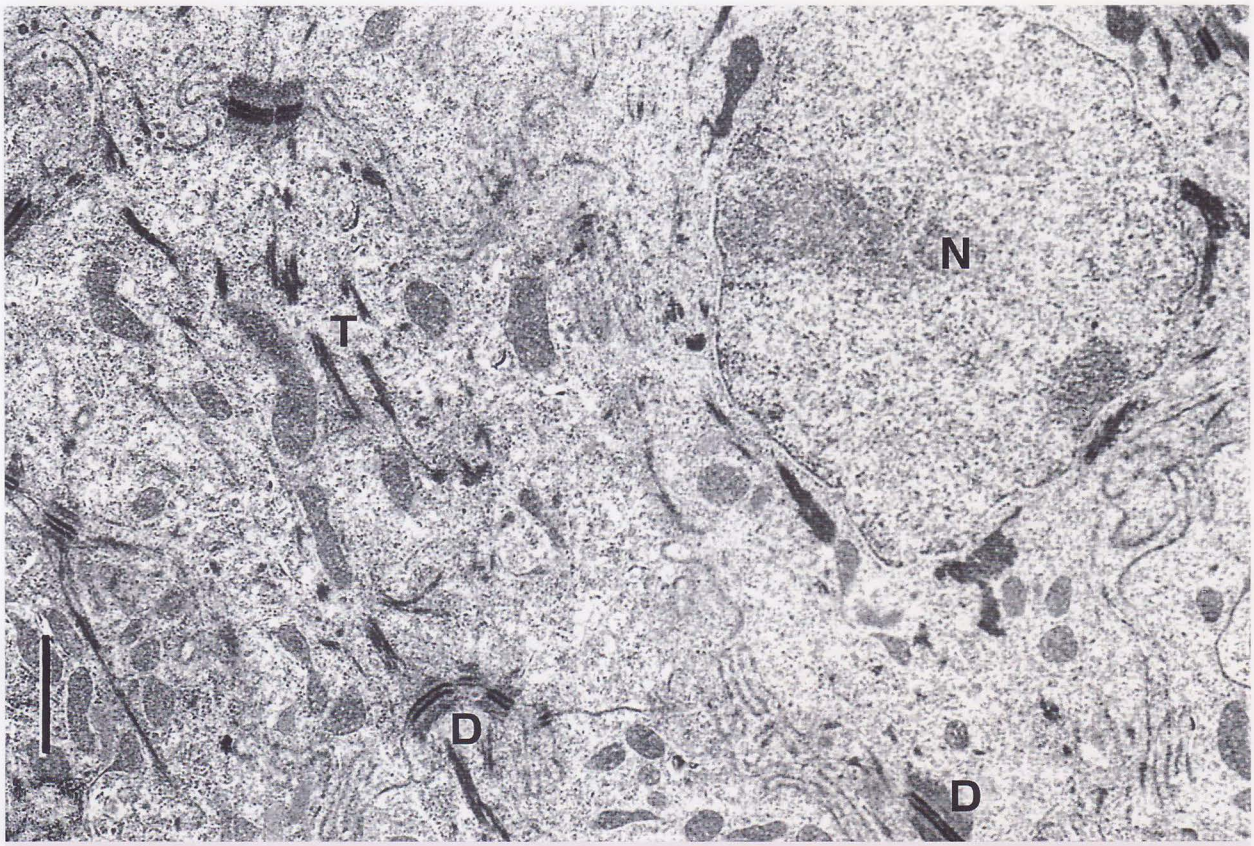

Fig 5.8B. Transmission electron micrograph of lesions in Fig *5.8A* showing epithelioid cells with numerous desmosomes (D) and tonofilaments (T). Note cytoplasmic interdigitations. Bar = 1 µm.

salmonids and channel catfish virus disease. Rainbow trout fry syndrome due to infection by *Flavobacterium psychrophilum* can cause severe anaemia, presumably due to haemorrhagic necrosis in the spleen. Dermal ulcers, such as those associated with *Aeromonas salmonicida* or epizootic ulcerative syndrome (*Aphanomyces invadans* infection), may also cause anaemia from haemorrhage. Vitamin K deficiency in trout leads to visceral haemorrhage because it is required for prothrombin and thromboplastin synthesis; hence coagulation is impaired. Acute abdominal haemorrhage is sometimes seen in fish with excessively fatty livers. While it is likely that this is often traumatic in origin due to extreme friability of the organ, the possibility of impaired production of clotting factors is also possible. Haemolytic anaemias are characterized by haemosiderin accumulation in the spleen: if pronounced, the ellipsoidal sheaths become clearly demarcated with pigment, followed by heavy pigment accumulation within the MMC. Pigment may also be seen in renal tubular epithelium although there is usually little indication for nephrosis, as might be expected, assuming that haemoglobin is nephrotoxic, as it is in mammals. Unless there is concurrent destruction or suppression of haematopoietic tissue, the anaemia will be regenerative, and the number of polychromatocytes will increase.



Fig 5.8C. Diffuse granulomas in the spleen of a tilapia due to mycobacteriosis. Note the onion-skin-like appearance to the lesions.

Common infectious causes of haemolytic anaemia include infection with erythrocytic necrosis viruses (ENV), iridoviruses that produce intracytoplasmic viral inclusions in erythrocytes of salmonids, cod (*Gadus morhua*),



Fig 5.9A. **Thymus.** Normal thymus shown within the branchial cavity of this young rainbow trout. Cortex and medulla are easily seen. Note the pseudobranch (P) just ventral to the thymus.

and Atlantic herring (*Clupea harengus*), among others. Erythrocytic inclusion body syndrome (EIBS), caused by a togavirus, can also produce severe anaemia in salmonids. Other causes include bacterial haemolysins, notably from *Vibrio* spp., and from haematozoa such as *Trypanoplasma, Trypanosoma* and *Haemogregarina* spp. *(see Figs 1.2A&B)*.

Toxic causes of haemolytic anaemia include exposure to either chlorine or chloramines that are used as disinfectants in municipal water supplies. Chloramine can also cause methaemoglobin formation by oxidizing oxyhaemoglobin to methaemoglobin. By far the most common cause of methaemoglobinemia in fish is nitrite, the product of ammonia detoxification in all aquatic ecosystems. In severe cases, it can impart a tan colour to the gills and a brown colour to the blood ("brown blood disease"). In some fish there is a reduction in total haemoglobin concentration, suggesting increased removal of erythrocytes from the circulation.

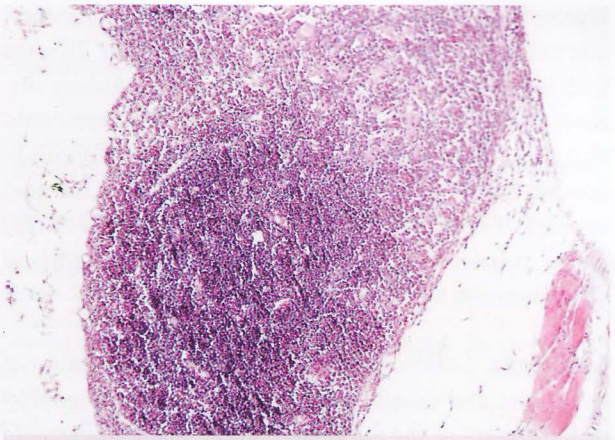

Fig 5.9B. Microscopic appearance of normal thymus.

Anaemia is a feature of lipoid liver disease in salmonids, and probably other species being fed diets containing highly oxidized oils or in which there is a vitamin E deficiency. There is increased erythrocyte turnover due to increased fragility, and incomplete maturation of polychromatocytes, consistent with vitamin E being needed for cell membrane integrity *(see Fig 1.2D)*.

Hypoplastic anaemias can be due to either deficient haemoglobin synthesis or deficient erythrocyte production. Folic acid and vitamin B12 have complementary roles and a deficiency of either will cause anaemia: salmon and trout with inadequate B12 develop a hypochromic anaemia whereas with folic acid, erythrocytes are normochromic but macrocytic. Other nutrient deficiencies leading to anaemia include niacin, pyridoxine, inositol, riboflavin and vitamin C. Iron deficiency anaemia of fish is probably only seen experimentally and even then, only when the water is very low in minerals, as adequate levels will otherwise be absorbed, probably mainly via the gills. All nutrient-associated anaemias are rare with use of fresh, commercially prepared feeds.

Viral infections that target haematopoetic tissue can cause severe anaemias. ISA primarily infects haematopoetic tissue and endothelial cells lining the liver and heart, leading to severe anaemia, as well as vascular damage/leakage, notably in the kidney in North America, leading to the very different presentation of "haemorrhagic kidney syndrome" *(see Fig 4.25)*. ISA can kill cells via either apoptosis or necrosis. Other viruses targeting the haematopoetic tissue and causing anaemia include infectious haematopoietic necrosis virus *(see Fig 4.25)* and hirame rhabdovirus (HRV).

Myelophthisic anaemia due to fibrosis of haematopoietic tissue may occur in chronic granulomatous diseases such as PKD, mycobacteriosis, or bacterial kidney disease. Tumours involving haematopoietic tissue could also cause myelophthisic anaemia. There are several idiopathic anaemias in fish, including "no blood disease" in channel catfish that causes severe anaemia (Hct < 10) and is suspected of being caused by either nutritional deficiency or a toxin.

Leukaemia. Leukaemia is the neoplastic proliferation of leukocytes and usually leads to the presence of neoplastic leukocytes in the peripheral blood. The best example of this myeloproliferative disease in fish is the retrovirus-associated lymphosarcoma of northern pike in which the creamy white nodules in a variety of tissues ***(see Fig 13.9)*** reflect a leukaemic increase in circulating lymphocytes. The pathogenesis of the anaemia that accompanies this disease is uncertain.

It is important to distinguish uncontrolled cell proliferation (neoplasia) from normal proliferative responses to various insults (leukocytosis). Differentiating these two responses is not always easy, especially if a cause is not readily apparent. The haemoprotozoan *Haemogregarina sachai* causes leukocyte proliferation, resulting in nodules of lymphoreticular tissue throughout the body, as well as anaemia, monocytosis and neutrophilia. It is differentiated from lymphosarcoma by the observation of the apicomplexan protozoan within parasitized leukocytes ***(see Fig 1.2B&C)***. "Plasmacytoid leukaemia" primarily affects Chinook salmon and is most likely caused by infection with a microsporidian, *Enterocytozoon salmonis*, although a retrovirus has also been detected in affected leukocytes. It is characterized by proliferation and infiltration of immature plasma cells (plasmablasts) into the viscera and ocular tissue and sometimes severe anaemia (Hct of 2).

Acknowledgement:
Hugh Ferguson supplied most of the images.

References

Abelli, L., Baldassini, M.R., Meschini, R. and Mastrolia, L. (1998) Apoptosis of thymocytes in developing sea bass *Dicentrarchus labrax* (L.). *Fish and Shellfish Immunology* 8:13-24.

Ahne. W., Bremont, M., Hedrick, R.P., Hyatt, A.D. and Whittington, R.J. (1997) Special topic review: Iridoviruses associated with epizootic haematopoietic necrosis (EHN) in aquaculture. *World Journal of Microbiology & Biotechnology* 13:367-373.

Alexander, N., Laurs, R.M., McIntosh, A. and Russell, S.W. (1980) Haematological characteristics of albacore, *Thunnus alalunga* (Bonnaterre), and skipjack, *Katsuwonus pelamis* (Linnaeus). *Journal of Fish Biology* 16:383-395.

Åsbakk, K. and Dalmo, R.A. (1998) Atlantic salmon (*Salmo salar* L.) epidermal Malphigian cells – motile cells clearing away latex beads in vitro. *Journal of Marine Biotechnology* 6:30-34.

Bamford, O.S. (1974) Oxygen reception in the rainbow trout (*Salmo gairdneri*). *Comparative Biochemical Physiology* 48:9-76.

Barber, D.L. and Westermann, J.E. (1975) Morphological and histochemical studies on a PAS-positive granular leukocyte in blood and connective tissues of *Catostomus commersoni Lacepede* (Teleostei: Pisces). *American Journal of Anatomy* 142:205-220.

Barton, B.A., Morgan, J.D. and Vijayan, M.M. (2002) Physiological and condition-related indicators of environmental stress in fish. pp. 111-148 ***In***: *Biological Indicators of Aquatic Ecosystem Stress* (***ed.*** Adams, S.M.), American Fisheries Society, Bethesda, MD.

Bernstein, R.M., Schluter, S.F. and Marchalonis, J.J. (1997) Immunity. pp. 217-242.
In: *The Physiology of Fishes*, 2nd Ed. (***ed***. Evans, D.H.), CRC Press, Boca Raton, FL.

Blaxhall, P.C. (1972) The haematological assessment of the health of freshwater fish. A review of selected literature. *Journal of Fish Biology* 4:593-604.

Blaxhall, P.C. (1983) Electron microscope studies of fish lymphocytes and thrombocytes. *Journal of Fish Biology* 22:223-229.

Bower, S.M. and Margolis, L. (1985) Effects of temperature and salinity on the course of infection with the haemoflagellate *Cryptobia salmositica* in juvenile Pacific salmon, *Oncorhynchus* spp. *Journal of Fish Diseases* 8:25-33.

Bruno, D.W. (1986) Changes in serum parameters of rainbow trout, *Salmo gairdneri* Richardson and Atlantic salmon, *Salmo salar* L., infected with *Renibacterium salmoninarum*. *Journal of Fish Diseases* 9:205-212.

Bruno, D.W. and Munro, A.L.S. (1986) Haematological assessment of rainbow trout, *Salmo gairdneri* Richardson and Atlantic salmon, *Salmo salar* L., infected with *Renibacterium salmoninarum*. *Journal of Fish Diseases* 9:195-204.

Buckley, J.A. (1976) Heinz body hemolytic anemia in coho salmon (*Oncorhynchus kisutch*) exposed to chlorinated wastewater. *Journal of the Fisheries Research Board of Canada* 34:215-224.

Burggren, W.W. and Cameron, J.N. (1980) Anaerobic metabolism, gas exchange, and acid-base balance during hypoxic exposure in the channel catfish, *Ictalurus punctatus*. *Journal of Experimental Zoology* 213:405-416.

Cameron, J.N. (1984) Acid-base status of fish at different temperatures. *American Journal of Physiology* 246:R452-R459.

Cannon, M.S., Mollenhauer, H.H., Eurell, T.E., Lewis, D.H., Cannon, A.M. and Tompkins, C. (1980) An ultrastructural study of the leukocytes of the channel catfish, *Ictalurus punctatus*. *Journal of Morphology* 164:1-23.

Casillas, E., Myers, M.S., Rhodes, L.D. and McCain, B.B. (1985) Serum chemistry of diseased English sole, *Parophrys vetulus* Girard, from polluted areas of Puget Sound, Washington. *Journal of Fish Diseases* 8:437-449.

Cipriano, R.C. and Holt, R.A. (2005) *Flavobacterium psychrophilum*, cause of bacterial cold-water disease and Rainbow Trout Fry Syndrome. Fish Disease Leaflet No. 86. United States Dept. of the Interior. U.S. Geological Service, National Fish Health Research Laboratory, Kearneysville, WV.

Conroy, D.A. (1972) Studies on the haematology of the Atlantic salmon (*Salmo salar* L.). *Symposium of the Zoological Society of London* 30:101-127.

Dalmo, R.A., Ingebrigtsen, K. and Bogwald, J. (1997) Non-specific defence mechanisms in fish, with particular reference to the reticuloendothelial system (RES). *Journal of Fish Diseases* 20:241-273.

Dalwani, R., Dave, J.M. and Datta, K. (1985) Alterations in hepatic heme metabolism in fish exposed to sublethal cadmium levels. *Biochemistry International* 10:33-42.

Doolittle, R.F. and Surgenor, D.M. (1962) Blood coagulation in fish. *American Journal of Physiology* 203:964-970.

Dykova, I. and Lom, J. (1979) Histopathological changes in *Trypanosoma danilewskyi* Laveran & Mesnil, 1904 and *Trypanoplasma borelli* Laveran & Mesnil, 1902 infections of goldfish, *Carassius auratus* (L.). *Journal of Fish Diseases* 2:381-390.

Eddy, F.B. (1982) Osmotic and ionic regulation in captive fish with particular reference in salmonids. *Comparative Biochemistry and Physiology* 73:125-141.

Eddy, F.B., Lomholt, J.P., Weber, R.E. and Johansen, K. (1977) Blood respiratory properties of rainbow trout (*Salmo gairdneri*) kept in water of high CO^2 tension. *Journal of Experimental Biology* 67:37-47.

Evans, W.A. (1974) Growth, mortality, and hematology of cutthroat trout experimentally infected with the blood fluke *Sanguinicola klamathensis*. *Journal of Wildlife Diseases* 10:341-346.

Evelyn, T.P.T., Kent, M.L. and Poppe, T.T. (1998) Bacterial diseases. pp. 17-35 ***In***: *Diseases of Seawater Netpen-Reared Salmonid Fishes* (***eds.*** Kent, M.L. and Poppe, T.T.) Pacific Biological Station, Nanaimo, British Columbia.

Facey, D.E., Blazer, V.S., Gasper, M.M. and Turcotte, C.L. (2005) Using fish biomarkers to monitor improvements in environmental quality. *Journal of Aquatic Animal Health* 17:263-266.

Fang, L-S. (1987) Study on the heme catabolism of fish. *Comparative Biochemistry and Physiology* 88B:667-673.

Fange, R. and Nilsson, S. (1985) The fish spleen: structure and function. *Experientia* 41:152-158.

Ferguson, H.W. (1976) The ultrastructure of plaice (*Pleuronectes platessa*) leucocytes. *Journal of Fish Biology* 8:139-142.

Ferguson, H.W. (1976) The relationship between ellipsoids and melano-macrophage centres in the spleen of turbot (*Scophthalmus maximus*). *Journal of Comparative Pathology* 86:377-380.

Ferguson, H.W. and Roberts, R.J. (1975) Myeloid leucosis associated with sporozoan infection in cultured turbot (*Scophthalmus maximus* L.). *Journal of Comparative Pathology* 85:317-323.

Fletcher, P.E. and Fletcher, G.L. (1980) Zinc- and copper-binding proteins in the plasma of winter flounder (*Pseudopleuronectes americanus*). *Canadian Journal of Zoology* 58:609-613.

Fletcher, G.L. and Smith, J.C. (1980) Evidence for permanent population differences in the annual cycle of plasma "antifreeze" levels of winter flounder. *Canadian Journal of Zoology* 58:507-512.

Foda, A. (1973) Changes in hematocrit and hemoglobin in Atlantic salmon (*Salmo salar*) as a result of furunculosis disease. *Journal of the Fisheries Research Board of Canada*. 30:467-468.

Froehly, M.F. and Deschaux, P.A. (1986) Presence of tonofilaments and thymic serum factor (FTS) in thymic epithelial cells of a freshwater fish (Carp:*Cyprinus carpio*) and a seawater fish (Bass:*Dicentrarchus labrax*). *Thymus* 8:235-244.
Gibson-Kueh, S., Netto, P., Ngoh-Lim, G.H., Chang, S.F., Ho, L.L., Qin, Q.W., Chua, F.H.C., Ng, M.L. and Ferguson, H.W. (2003) The pathology of systemic iridoviral disease in fish. *Journal of Comparative Pathology* 129:111-119.
Gingerich, W.H., Pityer, R.A. and Rach, J.J. (1987) Estimates of plasma, packed cell and total blood volume in tissues of the rainbow trout (*Salmo gairdneri*). *Comparative Biochemistry and Physiology* 87A:251-256.
Graham, M.S., Haedrich, R.L. and Fletcher, G.L. (1985) Hematology of three deep-sea fishes: A reflection of low metabolic rates. *Comparative Biochemistry and Physiology* 80:79-84.
Grammeltvedt, A.F. (1974) A method of obtaining chromosome preparations from rainbow trout (*Salmo gairdneri*) by leucocyte culture. *Norwegian Journal of Zoology* 22:129-134.
Haaparanta, A., Valtonen, E.T., Hoffmann, R. and Holmes, J. (1996) Do macrophage centres in freshwater fishes reflect the differences in water quality? *Aquatic Toxicology* 34:253-272.
Hampton, J.A., Klaunig, J.E. and Goldblatt, P.J. (1987) Resident sinusoidal macrophages in the liver of the brown bullhead (*Ictalurus nebulosus*): an ultrastructural, functional and cytochemical study. *Anatomical Record* 219:338-346.
Harder, W. (1975) *Anatomy of Fishes*. Part I. Text. E Schweitzerbart'sche Verlagsbuchhandlung (Nägele u. Obermiller), Stuttgart.
Hawke, J.P. and Khoo, L.H. (2004) Infectious diseases. pp. 387-443 ***In***: Tucker C.S. and Hargreaves, E.J. (***eds.***). *Biology and Culture of Channel Catfish*. Elsevier, Amsterdam.
Heckman, J.R., Allendorf, F.W. and Wright, J.E. (1971) Trout leukocytes: Growth in oxygenated cultures. *Science* 173:246-247.
Herraez, M.P. and Zapata, A.G. (1986) Structure and function of the melano-macrophage centres of the goldfish *Carassius auratus*. *Veterinary Immunology and Immunopathology* 12:117-126.
Hew, C.L., Slaughter, D., Fletcher, G.L. and Joshi, S.B. (1981) Antifreeze glycoproteins in the plasma of Newfoundland Atlantic cod (*Gadus morhua*). *Canadian Journal of Zoology* 59:2186-2192.
Hille, S. (1982) A literature review of the blood chemistry of rainbow trout, *Salmo gairdneri* Richardson. *Journal of Fish Biology* 20:535-569.
Honma, Y. and Tamura, E. (1984) Histological changes in the lymphoid system of fish with respect to age, seasonal and endocrine changes. *Developmental and Comparative Immunology* Suppl 3:239-244.
Houston, A.H., Mearow, K.M. and Smeda, J.S. (1976) Further observations upon the hemoglobin systems of thermally-acclimated freshwater teleosts: pumpkinseed (*Lepomis gibbosus*), white sucker (*Catostomus commersoni*), carp (*Cyprinus carpio*), goldfish (*Carassius auratus*) and carp-goldfish hybrids. *Comparative Biochemistry and Physiology* 54:267-223.
Hrubec, T.C. and Smith, S.A. (2000) Chapter 174. Hematology of fish. pp. 1120-1125 ***In***: Feldman, B.F., Zinkl, J.G. and Jain, N.C. (***eds.***), *Schalm's Veterinary Hematology*, 5th Edition, Williams and Wilkins, New York.
Jensen, F.B. (2003) Nitrite disrupts multiple physiological functions in aquatic animals. *Comparative Biochemistry and Physiology* 135A:9-24.
Joseph, T, Cepica, A., Brown, L., Ikede, B.O. and Kibenge, F.S.B. (2004) Mechanism of cell death during infectious salmon anemia virus infection is cell type-specific. *Journal of General Virology* 85:3027-3036.
Kawatsu, H. (1966) Studies on the anemia of fish. 1. Anemia of rainbow trout caused by starvation. *Bulletin of the Freshwater Fisheries Research Laboratory* 15:167-173.
Kawatsu, H. (1976) Studies on the anemia of fish. VII. Folic acid anemia in brook trout. *Bulletin of the Freshwater Fisheries Research Laboratory* 25:21-28.
Kelenyi, G. (1972) Phylogenesis of the azurophil leucocyte granules in vertebrates. *Sep. Exp.* 28:1094-1096.
Kiceniuk, J.W. and Jones, D.R. (1977) The oxygen transport system in trout (*Salmo gairdneri*) during sustained exercise. *Journal of Experimental Biology* 69:247-260.
Klontz, G.W. (1972) Haematological techniques and the immune response in rainbow trout. *Symposium of the Zoological Society of London* 30:89-99.
Kobayashi, K.A. and Wood, C.M. (1980) The response of the kidney of the freshwater rainbow trout to true metabolic acidosis. *Journal of Experimental Biology* 84:227-244.
Lane, H.C. (1980) The response of the haemoglobin system of fed and starved rainbow trout, *Salmo gairdneri* Richardson, to bleeding. *Journal of Fish Biology* 16:405-411.
Lester, R.J.G. and Budd, J. (1979) Some changes in the blood cells of diseased coho salmon. *Canadian Journal of Zoology* 57:1458-1464.
Lester, R.J.G. and Desser, S.S. (1975) Ultrastructural observations on the granulocytic leucocytes of the teleost *Catostomus commersoni*. *Canadian Journal of Zoology* 53:1648-1657.
Lin, H.T., Lin, H.Y. and Yang, H.L. (2005) Histology and histochemical enzyme-staining patterns of major immune organs in *Epinephelus malabarius*. *Journal of Fish Biology* 66:729-740.
Lom, J., Dykova, I. and Pavlaskova, M. (1983) "Unidentified" mobile protozoans from the blood of carp and some unsolved problems of myxosporean life cycles. *Journal of Protozoology* 30:497-508.
Mackie, I.M. and Wardle, C.S. (1971) Electrophoretic identification of lymph from muscle tissue of plaice (*Pleuronectes platessa* L.). *International Journal of Biochemistry* 2:409-413.
Margiocco, C., Arillo, A., Mensi, P. and Schenone, G. (1983) Nitrite bioaccumulation in *Salmo gairdneri* Richardson, and hematological consequences. *Aquatic Toxicology* 3:261-270.
Mattisson, A.G.M. and Fange, R. (1977) Light- and electronmicroscopic observations on the blood cells of the Atlantic hagfish, *Myxine glutinosa* (L.). *Acta Zool. (Stockholm)* 58:205-221.
McCarthy, D.H., Stevenson, J.P. and Roberts, M.S. (1973) Some blood parameters of the rainbow trout (*Salmo gairdneri* Richardson). *Journal of Fish Biology* 5:1-8.
McDonald, D.G., Hobe, H. and Wood, C.M. (1980) The influence of calcium on the physiological responses of the rainbow trout, *Salmo gairdneri*, to low environmental pH. *Journal of Experimental Biology* 88:109-131.
Miller, W.R. III, Hendricks, A.C. and Cairns, J. Jr. (1983) Normal ranges for diagnostically important hematological and blood chemistry characteristics of rainbow trout (*Salmo gairdneri*). *Canadian Journal of Fisheries and Aquatic Sciences* 40:420-425.
Mulcahy, M.F. (1967) Serum protein changes in diseased Atlantic salmon. *Nature* 215:143-144.
Munkittrick, K.R. and Leatherland, J.F. (1983) Haematocrit values in feral goldfish, *Carassius auratus* L., as indicators of the health of the population. *Journal of Fish Biology* 23:153-161.

Nichols, D.J. (1987) Fluid volumes in rainbow trout, *Salmo gairdneri*: application of compartmental analysis. *Comparative Biochemstry and Physiology* 87A:703-709.
Nikinmaa, M. and Soivio, A. (1979) Oxygen dissociation curves and oxygen capacities of blood of a freshwater fish, *Salmo gairdneri*. *Annals Zool. Fennici* 16:217-221.
Nikinmaa, M. and Soivio, A. (1980) The oxygen-binding properties of erythrocyte suspensions of *Salmo gairdneri* and of haemolysates in various buffers in the physiological pH range. *Annals Zool. Fennici* 17:43-46.
Noga, E.J. (2000) Chapter 61. Fish leukocyte responses. pp. 433-439 ***In:*** Feldman, B.F., Zinkl, J.G. and Jain, N.C. (***eds.***), *Schalm's Veterinary Hematology*, 5th Edition, Williams and Wilkins, New York.
Noga, E.J., Dykstra, M.J. and Wright, J.F. (1989) Chronic inflammatory cells with epithelial cell characteristics in teleost fishes. *Veterinary Pathology* 26:429-437.
Olson, K.R. (1997) The Cardiovascular System. pp. 129-154 ***In:*** *The Physiology of Fishes*, 2nd Ed. (***ed***. Evans, D.H.), CRC Press, Boca Raton, FL.
Page, M. and Rowley, A.F. (1983) A cytochemical, light and electron microscopical study of the leucocytes of the adult river lamprey, *Lampetra fluviatilis* (L. Gray). *Journal of Fish Biology* 22:503-517.
Palachek, R.M. and Tomasso, J.R. (1984) Toxicity of nitrite to channel catfish (*Ictalurus punctatus*), tilapia (*Tilapia aurea*), and largemouth bass (*Micropterus salmoides*): Evidence for a nitrite exclusion mechanism. *Canadian Journal of Fisheries and Aquatic Sciences* 41:1739-1744.
Perry, S.F. and Vermette, M.G. (1987) The effects of prolonged epinephrine infusion on the physiology of the rainbow trout, *Salmo gairdneri*. I. Blood respiratory, acid-base and ionic states. *Journal of Experimental Biology* 128:235-253.
Poston, H.A., Combs, G.F. Jr. and Leibovitz, L. (1976) Vitamin E and selenium interrelations in the diet of Atlantic salmon (*Salmo salar*): Gross, histological and biochemical deficiency signs. *Journal of Nutrition* 106:892-904.
Pottinger, T.G. and Pickering, A.D. (1987) Androgen levels and erythrocytosis in maturing brown trout, *Salmo trutta* L. *Fish Physiology and Biochemistry* 3:121-126.
Press, C.M. and Evensen, Ø. (1999) The morphology of the immune system in teleost fishes. *Fish & Shellfish Immunology* 9:309-318.
Quentel, C. and Aldrin, J.F. (1986) Blood changes in catheterized rainbow trout (*Salmo gairdneri*) intraperitoneally inoculated with *Yersinia ruckeri*. *Aquaculture* 53:169-186.
Quesada, J., Villena, M.I. and Agulleiro, B. (1990) Structure of the spleen of the sea bass (*Dicentrarchus labrax*): a light and electron microscopic study. *Journal of Morphology* 206:273-281.
Railo, E., Nikinmaa, M. and Soivio, A. (1985) Effects of sampling on blood parameters in the rainbow trout, *Salmo gairdneri* Richardson. *Journal of Fish Biology* 26:725-732.
Reite, O.B., and Evensen, Ø. (2006) Inflammatory cells of teleostean fish: A review focusing on mast cells/eosinophilic granule cells and rodlet cells. *Fish & Shellfish Immunology* 20:192-208
Reno, P.W., Kleftis, K., Sherburne, S.W. and Nicholson, B.L. (1986) Experimental infection and pathogenesis of viral erythrocytic necrosis (VEN) in Atlantic cod, *Gadus morhua*. *Canadian Journal of Fisheries and Aquatic Sciences* 43:945-951.
Reshetnikov, Y.S. (1976) The application of biochemical indices in the investigation of Salmonidae. *Ichthyologia* 8:91-99.
Richards, R.H. and Pickering, A.D. (1979) Changes in serum parameters of *Saprolegnia*-infected brown trout, *Salmo trutta* L. *Journal of Fish Diseases* 2:107-206.
Roch, M. and Maly, E.J. (1979) Relationship of cadmium-induced hypocalcemia with mortality in rainbow trout (*Salmo gairdneri*) and the influence of temperature on toxicity. *Journal of the Fisheries Research Board of Canada* 36:1297-1303.
Romano, LA and Marozzi, V.A. (2004) Epithelio-reticular cell thymoma in carp, *Cyprinus carpio* L.: an ultrastructural study. *Journal of Fish Diseases* 27:369-373.
Sekhon, S.S. and Beams, H.W. (1969) Fine structure of the developing trout erythrocytes and thrombocytes with special reference to the marginal band and the cytoplasmic organelles. *American Journal of Anatomy* 125:353-374.
Shieh, H.S. (1978) Changes of blood enzymes in brook trout induced by infection with *Aeromonas salmonicida*. *Journal of Fish Biology* 12:13-18.
Smail, D.A. and Egglestone, S.I. (1980) Virus infections of marine fish erythrocytes: prevalence of piscine erythrocytic necrosis in cod *Gadus morhua* L. and blenny *Blennius pholis* L. in coastal and offshore waters of the United Kingdom. *Journal of Fish Diseases* 3:41-46.
Smith, C.E. (1968) Hematological changes in coho salmon fed a folic acid deficient diet. *Journal of the Fisheries Research Board of Canada* 25:151-156.
Smith, C.E. and Halver, J.E. (1969) Folic acid anemia in coho salmon. *Journal of the Fisheries Research Board of Canada* 26:111-114.
Soivio, A. and Oikari, A. (1976) Haematological effects of stress on a teleost, *Esox lucius* L. *Journal of Fish Biology* 8:397-411.
Soivio, A., Mikinmaa, M. and Westman, K. (1980) The blood oxygen binding properties of hypoxic *Salmo gairdneri*. *Journal of Comparative Physiology* 136:83-87.
Steffensen, J.F. and Lomholt, J.P. (1992) The secondary vascular system. pp. 185-217 ***In:*** *The Cardiovascular System* (***eds***. Hoar, W.S., Randall, D.J. and Farrell, A.P.) Academic Press, London.
Takashima, F. and Hibiya, T. (1995) *An atlas of fish histology: normal and pathological features*. Kodansha Ltd., Tokyo.
Van Muiswinkel, W.B., Lamers, C.H. and Rombout, J.H. (1991) Structural and functional aspects of the spleen in bony fish. *Research in Immunology* 142:362-6.
Wardle, C.S. (1971) New observations on the lymph system of the plaice *Pleuronectes platessa* and other teleosts. *Journal of the Marine Biology Association of the U.K.* 51:977-990.
Woodward, J.J., Casillas, E., Smith, L.S. and D'Aoust, B.G. (1979) Rapid decompression stress accelerates fibrinolysis in fingerling salmon. *Journal of the Fisheries Research Board of Canada* 36: 592-594.
Yamamoto, K., Itazawa, Y. and Kobayashi, H. (1985) Direct observation of fish spleen by an abdominal window method and its application to exercised and hypoxic yellowtail. *Japanese Journal of Ichthyology* 31:427-433.
Yoffey, J.M. (1928) A contribution to the study of the comparative histology and physiology of the spleen, with reference chiefly to its cellular constituents. *Journal of Anatomy* 63:314-344.
Zapata, A, Chiba, A. and Varas, A. (1996) Cells and tissues of the immune system of fish. pp. 1-62 ***In:*** *The Fish Immune System* ***eds.*** Iwama G. and Nakanishi, T., Academic Press, New York.





Cardiovascular System

CHAPTER 6

by Trygve T. Poppe and Hugh W Ferguson

La coeur a ses raisons que la raison ne connaît point!
Blaise Pascal 1623-1662.

At a time when people in western societies are being encouraged to consume more fish in order to prevent cardiovascular diseases, it is indeed ironic that fish themselves suffer from numerous cardiac diseases.

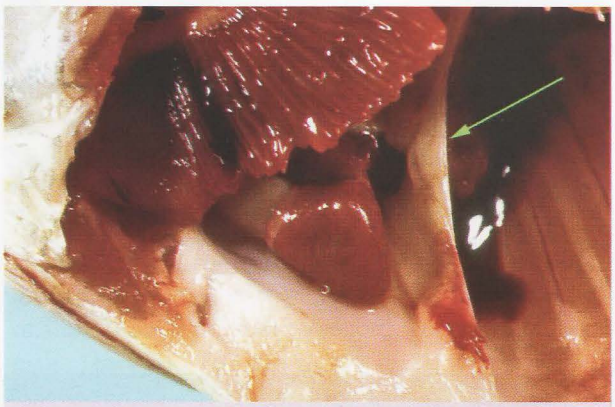

Fig 6.1. The location of the heart within the pericardial cavity of an Atlantic salmon (ventricle in systole). The conspicuous septum transversum (arrow) forms the caudal constraint of the pericardial cavity.

The teleost heart is a four-chambered low-pressure pump located caudo-ventrally to the gill cavity in an almost inelastic pericardial sac, and separated from the abdominal cavity by the fibrous septum transversum ***(Fig 6.1)***. The four chambers are (in sequence): the sinus venosus, the atrium, the ventricle and the highly elastic bulbus arteriosus (contractile conus arteriosus in elasmobranchs) that ensures a continuous blood flow and an even pressure to the gills ***(Fig 6.2)***. The shape of the heart, and particularly the ventricle, is highly variable and reflects the functional needs of that particular species. A "typical" ventricle is therefore hard to describe. In general, active, fast-swimming fish (*e.g.* salmonids, scombrids, clupeids) have a muscular pyramidal ventricle with a marked apex pointing caudoventrally. Pyramidal ventricles are always associated with a distinct outer compact myocardium supplied with oxygenated blood via the coronary artery branching off from the hypobranchial artery. There is a strong correlation between shape and function in these hearts and the pyramidal shape may provide some mechanical advantage for developing higher blood pressure. Elongate fish such as the eel usually have tubular ventricles, while a sac-like or rounded ventricle with an indistinct apex is common in a wide range of other species, including elasmobranchs. No outer compact muscular layer is present in the latter two types.

In sequence, venous blood enters the sinus venosus from the paired and U-shaped *vv. cardinalis communis* (ducts of Cuvier) embedded in the septum transversum and *vv. hepaticae*. The sinus venosus is a thin-walled sac and constitutes an integral part of the septum transversum. In salmonids, the wall is mostly connective tissue, while in other species, myocardial cells or even smooth muscle cells (*e.g.* cyprinids) may constitute a considerable part of the wall. In many fish, specialised sinoatrial pacemaker tissue modulating the heart rate is present near the sino-atrial orifice; this is sometimes seen by chance in histological section. Heart rate is mainly influenced by vagal inhibition and temperature. The volume of the sinus venosus is equivalent to the atrium, which is the next chamber.

The thin-walled atrium is irregularly shaped, like a sac with auricles. Its volume is equivalent to that of the ventricle, or slightly larger. Most of its lumen is filled by a loose, spongy myocardium. Blood is drawn from the atrium via the atrioventricular valves into the ventricle as it is dilated. The shape and organization of this chamber reflect the physiological needs of the species. It is able to deliver small amounts of blood at a relatively high pressure in, for example, salmonids, or larger amounts of blood at low pressure in sedentary fish. Morphological and physiological differences exist between the outer compact and the inner spongy myocardium in fish with pyramidal ventricles. The inner myocardium is a spongy interlacing meshwork of trabeculae that essentially fills the functional lumen of the ventricle. Spongy myocardium derives its oxygen directly from the venous blood being pumped, but high levels of myocardial myoglobin in the spongy portion provide protection against anoxic damage during episodes of low oxygen tension and during high activity. Metabolism in spongy myocardium is mainly glycolytic, while that in



Fig 6.2A. Heart from a wild, normal Atlantic salmon showing sizes and relationships of the different components. The sac-like atrium sits dorsocranially to the pyramidal ventricle. The entrance to the atrium is via the sinus venosus (arrow) which is an integrated part of the septum transversum. The white, pear-shaped bulbus arteriosus projects cranially to the left.

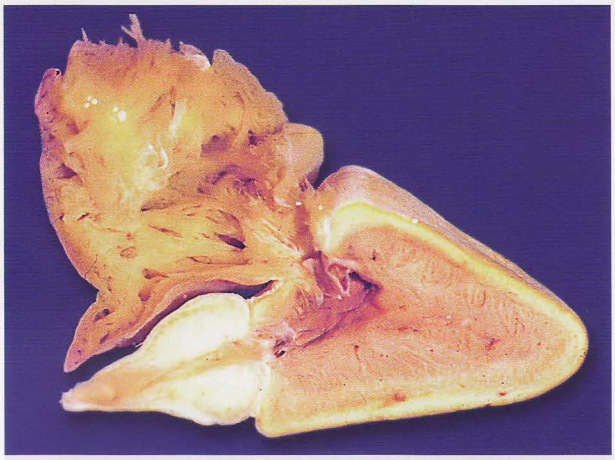

Fig 6.2B. Formalin-fixed heart from a wild, normal Atlantic salmon cut in the midsagittal axis revealing the loose, spongy atrial myocardium, the outer compact ventricular myocardium, the inner, spongy layer and the thick, elastic wall of the bulbus arteriosus.

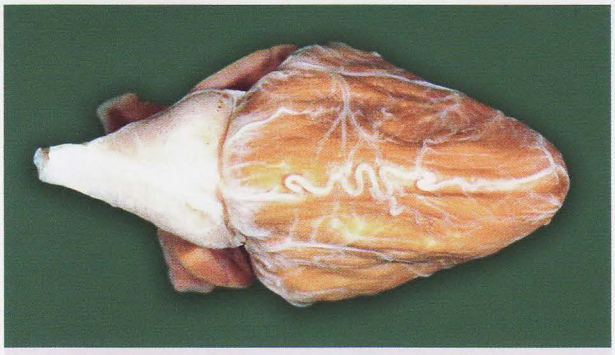

Fig 6.2C. Ventral view of a salmon ventricle showing the coronary artery and its branches.



Fig 6.2D. Heart from Atlantic salmon. The wall of the atrium is thin and almost translucent compared to the massive wall of the muscular ventricle. *Photographed under water.*

compact myocardium is mainly oxidative. The two layers are usually separated by a thin layer of connective tissue. The thickness of the outer compact layer usually increases with age, but may show considerable variation depending on life stage, sex, and physiological demands. The relative thickness of the outer compact layer is greater in male than in female fish, and is thicker in anadromous than in resident fish. It may consist of up to three layers of muscular bundles, often arranged in sworls or loops **(*Fig 6.3*)**.

The ventricle generates a relatively high pressure and pumps the blood into the pear- or onion-shaped bulbus arteriosus which is highly elastic and up to 30 times more distensible than the human aorta; it can store from 25 to 100% of the stroke volume, thereby dampening the ventricular pulse pressure. Retrograde flow of blood is prevented by a set of semilunar valves. The dilated bulbus will gradually contract, creating an even pressure and blood flow to the ventral aorta (depulsator). Both ventricular orifices (atrioventricular and ventriculobulbar) are aligned along the mid-sagittal plane.

The wall of the bulbus consists of fibroelastic tissue and some smooth muscle; in elasmobranchs it is also contractile and is termed the conus arteriosus. In a very few species, islets of hyaline cartilage surrounded by a collagenous capsule may be found in the wall of the bulbus. The lateral attachments of the valve leaflets are inserted into this capsule. The significance is unknown, but it has been suggested that mechanical stimulation may initiate cartilaginous growth and that these foci may play a role in the function of the bulbo-ventricular valves. The finding of such foci in fish with no known normal occurrence of cartilaginous elements is difficult to explain, but may be the result of cardiac overload.

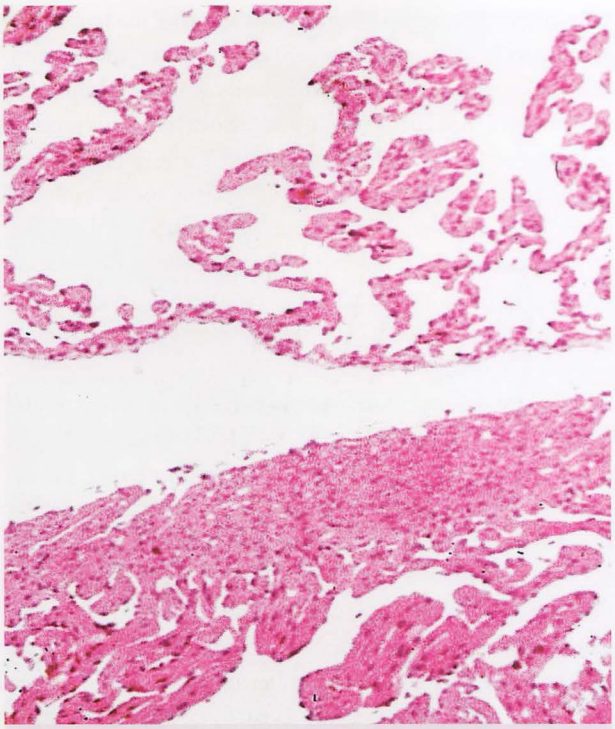

Fig 6.3A. Histology of the heart from Fig 6.2D revealing the thin and fragile atrial wall on top and the ventricle with a thick outer and a spongy inner myocardium.

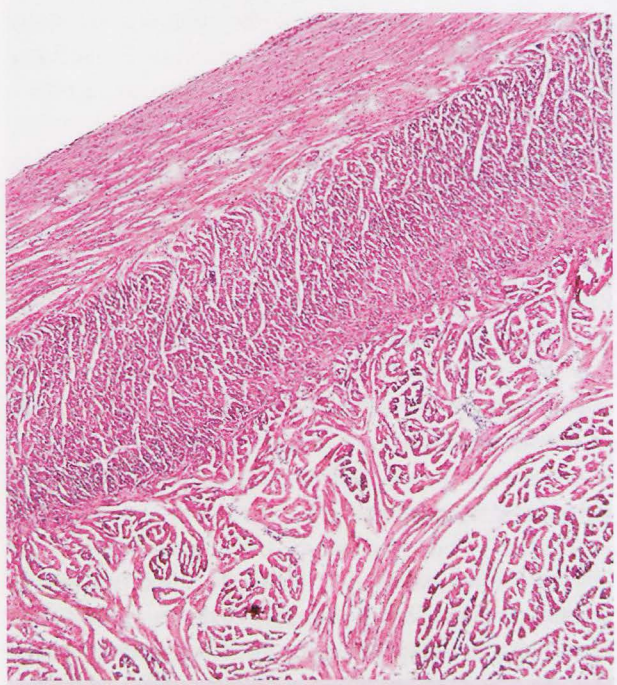

Fig 6.3B. Ventricle of an adult rainbow trout with a well-developed outer compact myocardium. The thickness of this layer increases with age, and is thicker in males and in anadromous fish. Note the two layers of the outer compact myocardium, and the inner, spongy myocardium.

The walls of the heart consist of three layers:

- The epicardium covering the entire surface of all chambers usually consists of a thin squamous epithelium over a thin layer of connective tissue. Some haematopoietic tissue may be normally present in the epicardium and should not be misinterpreted as an inflammatory response. In some species, thyroid follicles may also be found here; these should not be taken as evidence of neoplastic spread of this tissue that in teleosts is normally diffuse!
- The myocardium. Cardiac myocytes have a centrally located nucleus, a diameter of 1-12.5 µm (mammals:10-25 µm), contain numerous mitochondria and variable amounts of myoglobin. Myocytes in the outer compact layer have a larger diameter than those in the inner spongy layer, giving the latter a shorter diffusion distance from the outside to the centre of the cell and a higher ratio of sarcolemmal area to intracellular volume. Possibly because of this, T-tubules are also reduced, compared to mammals. There is a thin connective tissue layer separating the spongy and compact layers, thereby excluding blood from the ventricular lumen. Cardiac myocytes are capable of regeneration, even in older individuals. They have both hyperplastic and hypertrophic growth in contrast to post-embryonic mammals where the growth is hypertrophic only. It is likely that the high degree of intraspecific cardiac plasticity seen for example in salmonids, is related to the fact that hypertrophic and hyperplastic growth are retained throughout life. Fish inhabiting environments with fluctuating temperatures have an amazing cardiac plasticity and capacity to maintain maximum cardiac output (and maximum power output) across a broad temperature range in environments with fluctuating temperatures. Myocardial cells are organized in a syncytium with specialized intercalated discs towards neighbouring cells **(*Fig 6.3E*)**. The trabeculae are somewhat thicker in the spongy ventricular myocardium than in the atrium and constitute the majority of the ventricular mass in most species. Demands on the heart increase with sexual maturation and spawning, particularly in males. Elevated levels of androgens will stimulate cardiac growth and increase the proportion of compact myocardium. Teleost muscle cells are able to utilize both fatty acids and carbohydrates for fuel, while elasmobranchs only utilize carbohydrates.
- The endocardium covers all internal surfaces and is in direct contact with the blood **(*Fig 6.4*)**. This one-cell-thick layer may be highly phagocytic in some species (*e.g.* Atlantic cod, plaice), particularly in the atrium, and the specialized endocardial cells here are capable of removing all major categories of biological macromolecules and waste prod-

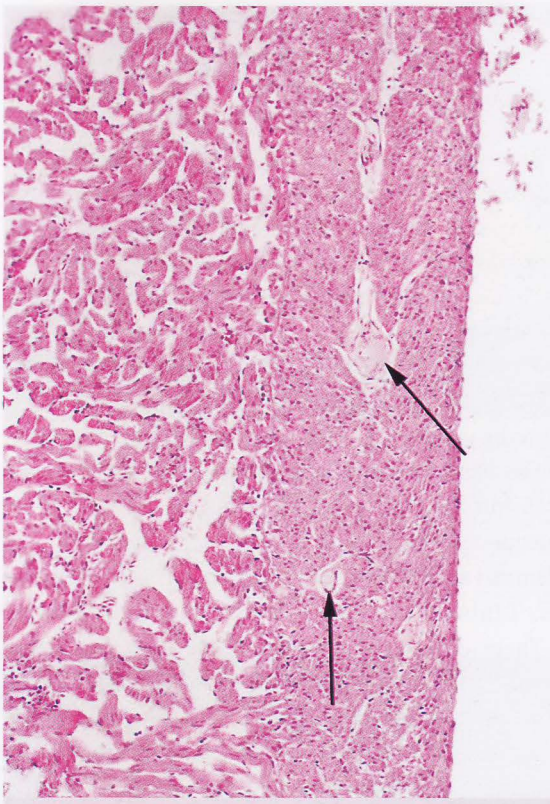

Fig 6.3C. Ventricle from rainbow trout to show coronary vessels (arrows) within the compact outer layer.



Fig 6.3D. SEM of salmon atrium showing the meshwork of muscle fibres, each lined by endocardium.

ucts (proteins, polysaccharides, lipids and nucleic acids) by means of endocytotic receptors. In other species (*e.g.* salmonids and cyprinids) similar cells are found lining the sinusoids of the renal portal system. Both locations provide a large contact area between blood-borne antigens and phagocytic cells, but pathological lesions in the endocardium may severely affect the normal function of the heart. In addition to avid endocytotic properties, endocardium also has profound detoxification capabilities, supplied as it is with cytochrome p450, the levels of which are second only to hepatocytes. These properties no doubt conspire to render the endocardium superbly placed to monitor and possibly even, to some extent, regulate infectious disease processes that have a major systemic component. At the same time, however, this places the heart at serious risk should it encounter something more than mildly pathogenic. Unlike the mammalian heart, teleost myocardium is capable of regeneration, so the long-term consequences of myocardial damage may not be as profound as they are in mammals, should the animal survive.

In contrast to mammals, the pericardial sac is quite rigid and as the ventricle contracts, a subambient pressure is created, making the atrium expand and fill with blood from the sinus venosus. Stroke volume and heart rate determine the cardiac output. In contrast to mammals, fish increase cardiac output mainly through increases in stroke volume rather than heart rate, and atrial contraction is the primary determinant of ventricular filling. The filling of the atrium is achieved through *vis-a-fronte* (forces from in front, "aspirating effect") and *vis-a-tergo* (forces from behind, "pressure") mechanisms. The *vis-a-fronte* force is the result of ventricular contraction energy that distends the soft atrium as a result of sub-ambient intrapericardial pressure generated by ventricular contraction within the rigid pericardial cavity. The *vis-a-tergo* forces are the result of kinetic energy and potential in venous circulation and/or sinus contraction.

Cardiac anomalies

Farmed fish are usually less active than their wild counterparts. An abundant food supply is always available and the functional demands on the heart may vary considerably. Several cardiac abnormalities have been identified in farmed salmonids in recent years (***Fig 6.5***). Although the aetiology (ies) remains obscure, most of them appear to be associated with intensive breeding and feeding and as such are considered as production diseases. Typically,

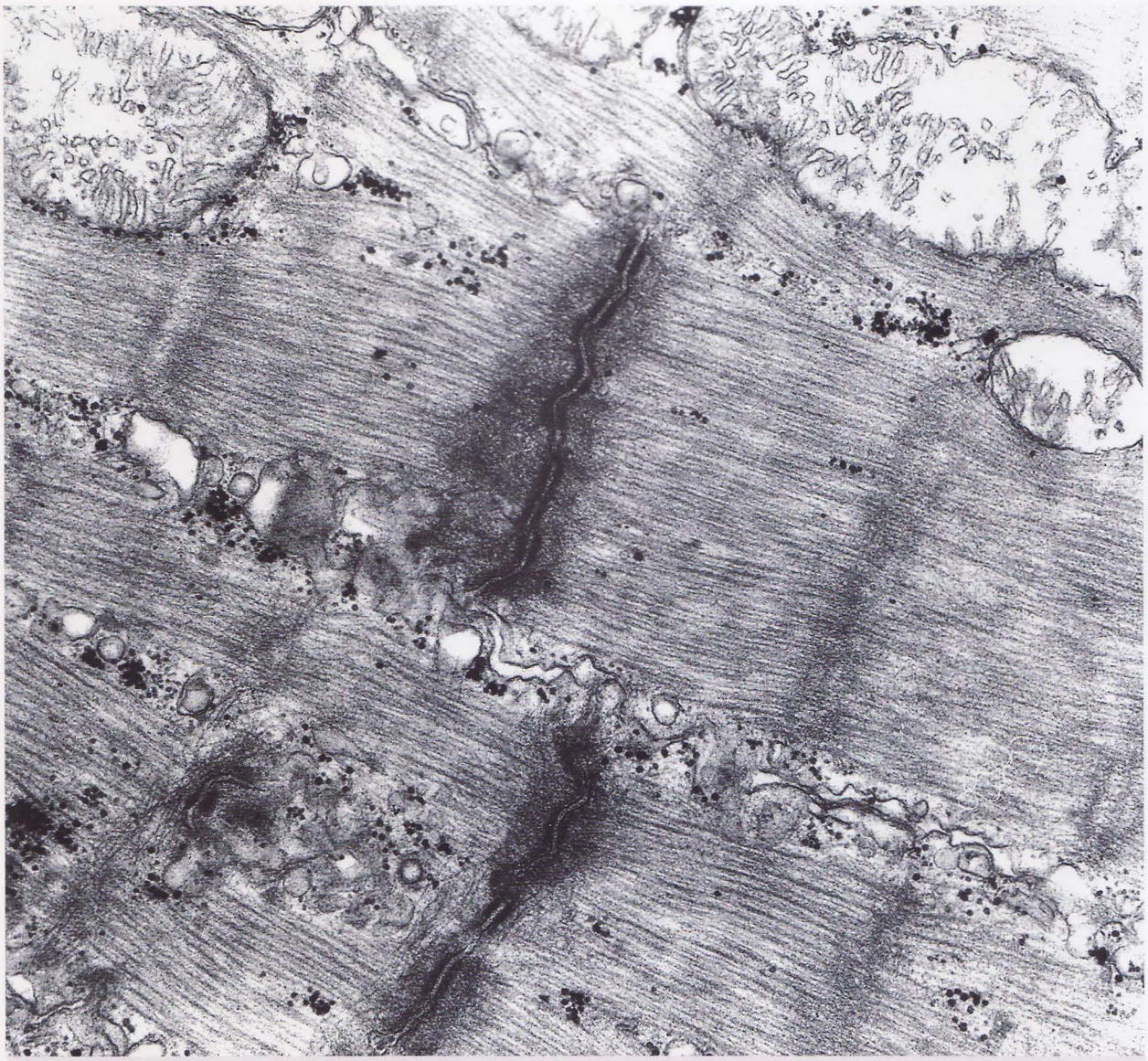

Fig 6.3E. TEM of plaice ventricle showing intercalated discs. Z bands and a faint M band are also visible, but no T-tubule system is obvious, and sarcoplasmic reticulum is greatly reduced compared to mammals.

fish with such disorders are vulnerable to stress and low oxygen levels during crowding, treatment, transportation and handling, and succumb first. One of the best-known of these abnormalities is aplasia or hypoplasia of the septum transversum whereby the caudal constraint of the pericardial cavity disappears and the heart becomes embedded in a depression under or in front of the liver **(*Fig 6.6*)**. There is good evidence that this condition is the result of high temperature (≥9°C) during incubation of the eggs and the yolk-sac stage. Abnormal location of the heart (*situs inversus*) within the normal cardiac cavity occurs fairly commonly in farmed Atlantic salmon. In this condition, the heart is located more or less upside-down with the apex pointing dorsally leading to an abnormal shape of the ventricle. Both conditions result in abnormal (and ineffective) shape of the ventricle and wrong alignment of the bulbar/ventricular longitudinal axis with resulting impairment of cardiac function.

Although the fish heart is known to be highly plastic and easily adapts to new physical and physiological demands, there appears to be little doubt that severe and life-threatening abnormalities occur more commonly in intensively reared fish. Such lesser known abnormalities include hypoplasia of the outer compact layer of the ventricular myocardium **(*Fig 6.7*)**, sometimes with herniation of the

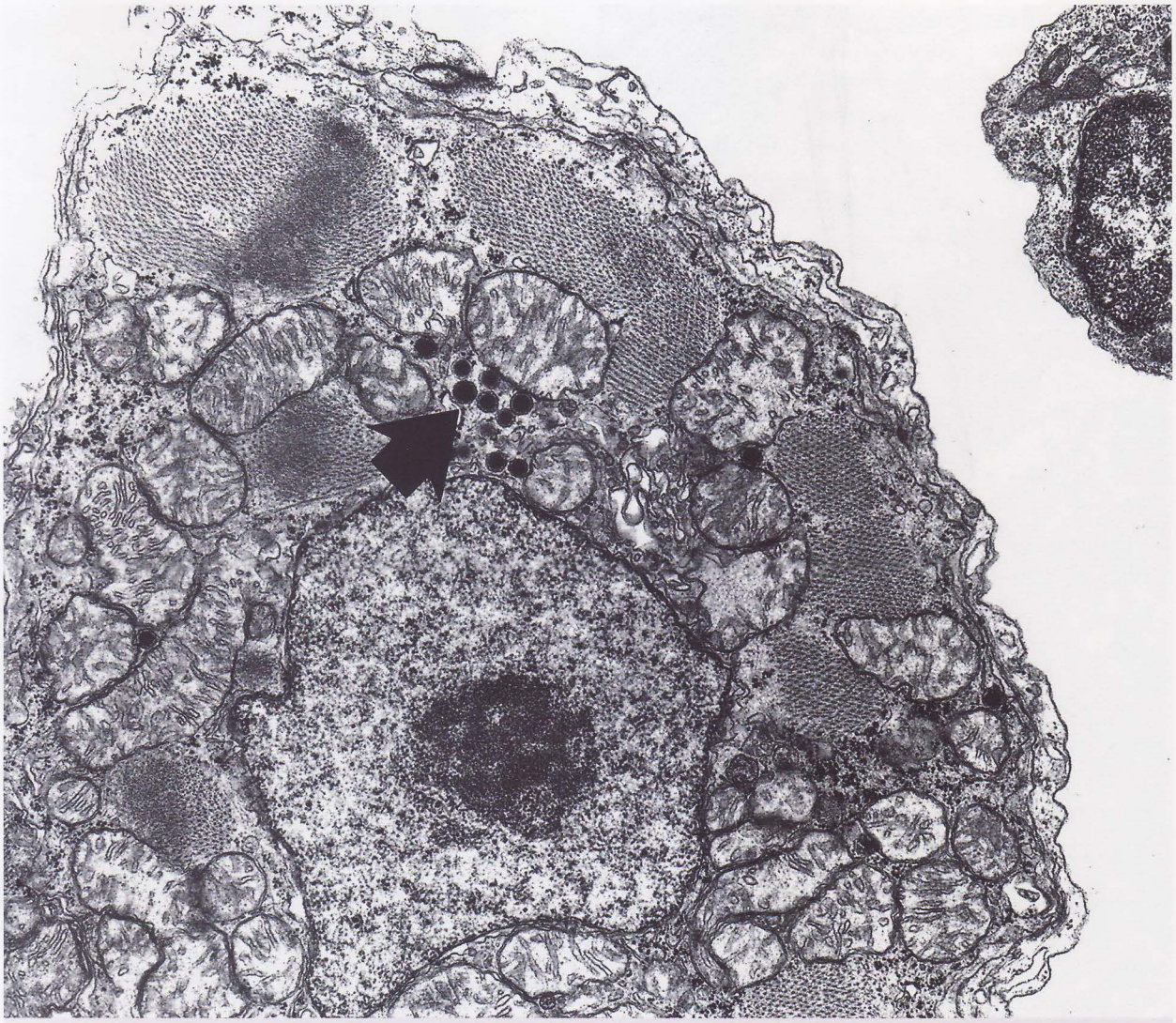

Fig 6.3F. A single myocardial cell from a plaice is shown here in transverse section showing prominent nucleus and nucleolus. A cluster of dense-cored vesicles is shown (arrow). The cell is lined by a thin but distinct endocardial cell.

distended atrium through the ventral body wall, aberrant shape of the ventricle (generally rounder or "flatter" than the normal pyramidal shape), and ventricular aneurisms (*Fig 6.8*). In many of these conditions, accompanying pathological changes typically include epicardial fat deposits, epicarditis and general congestion.

Response of myocardium to injury

Amongst other reasons, the endocytotic and detoxification powers of the endocardium ensure that the heart is frequently involved in a wide range of different diseases, and its examination should never be overlooked. Deciding whether lesions are centred mainly on endocardium, with secondary myocardial and epicardial involvement, or whether the disease is mainly myocardial, is not always easy. Inflammatory and repair mechanisms are well illustrated in the specific disease examples that follow, but once again it must be appreciated that cardiac myocytes are capable of regeneration, although the precise mechanisms that underpin this ability have still to be determined.

Pericarditis. Bacterial colonization, probably resulting from lymph drainage into the pericardial sac, occurs commonly in bacterial septicaemias. Impressive confluent bacterial colonization of the sub-epicardial space may be seen in infection with both typical and atypical *Aeromonas salmonicida*, resulting in severe and conspicuous thickening. Pericarditis is common in *Renibacterium salmoninarum* infections and here too the epicardial layers may grow to

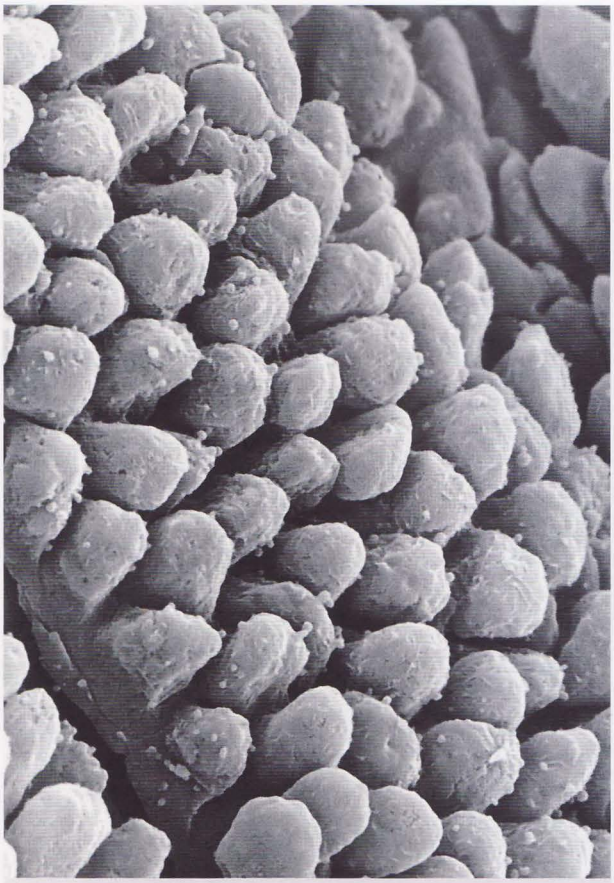

Fig 6.4A. SEM showing characteristic scavenger endothelial cells covering the muscular trabeculae of the atrium of an Atlantic cod (*Gadus morhua*). *Picture courtesy of Dr. T. Seternes.*

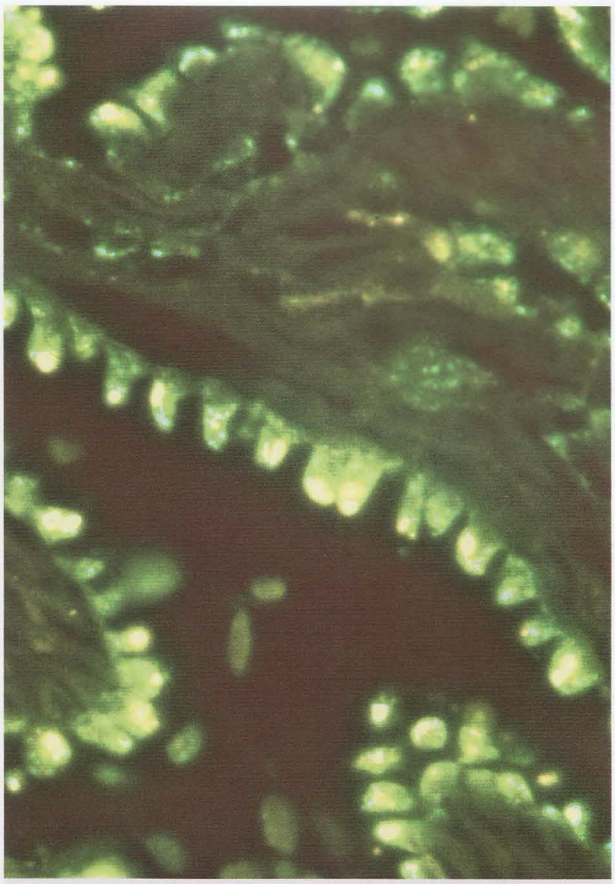

Fig 6.4B. Fluorescence micrograph of Atlantic cod atrium 2 days after intravenous injection of FITC-labelled LPS. Note the strong fluorescence in endocardial cells. *Picture courtesy of Dr. T. Seternes.*

a formidable thickness in chronic cases. Such severe pericarditis usually has restrictive consequences, and compromise of the cardiovascular system is common. Similar pericardial changes are seen in mycobacteriosis. *Pasteurella skyensis* in Atlantic salmon causes a more acute fibrinous lesion ***(Fig 6.9)***.

Parasitic invasion by digeneans and cestodes may be accompanied by severe and highly cellular fibro-granulomatous epicarditis, sometimes to the point of constriction, and with synechiae to the pericardial wall. Adhesions (synechiae) between the epicardium and the pericardial wall have also been described as an idiopathic condition in farmed halibut. Moderate to severe epicarditis is frequently associated with severe cardiac diseases such as cardiomyopathy syndrome (CMS) and heart and skeletal muscle inflammation (HSMI), but mild changes can occur as a more-or-less normal finding, or "background noise" in farmed Atlantic salmon in seawater. Fluid in the pericardial cavity will reduce the *vis-a-fronte* effect, and synechiae will reduce the free motility of the ventricle, both contributing to reduced cardiac output.

Lesions in valves. Compared to mammals these are not very common, although examples of septic valvular endocarditis are sometimes seen ***(Fig 6.10)***. Severe functional failure with reflux has been shown in farmed rainbow trout and Atlantic salmon using colour-flow Doppler.

Bacterial septicaemias. With its central location, endocytotic abilities and exposure to the circulating blood, the heart is a key organ in several bacterial and viral diseases. The interface between compact and spongy myocardium appears to be a predilection site for many pathogens, and is therefore a good starting point when looking for lesions. In bacteraemias, either bacterial colonies (as in furunculosis caused by *Aeromonas salmonicida* subsp. *salmonicida*) or scattered individual bacterial cells (as in vibriosis and yersiniosis) are frequently found here. The pathophysiological explanation for this particular location is not known, but

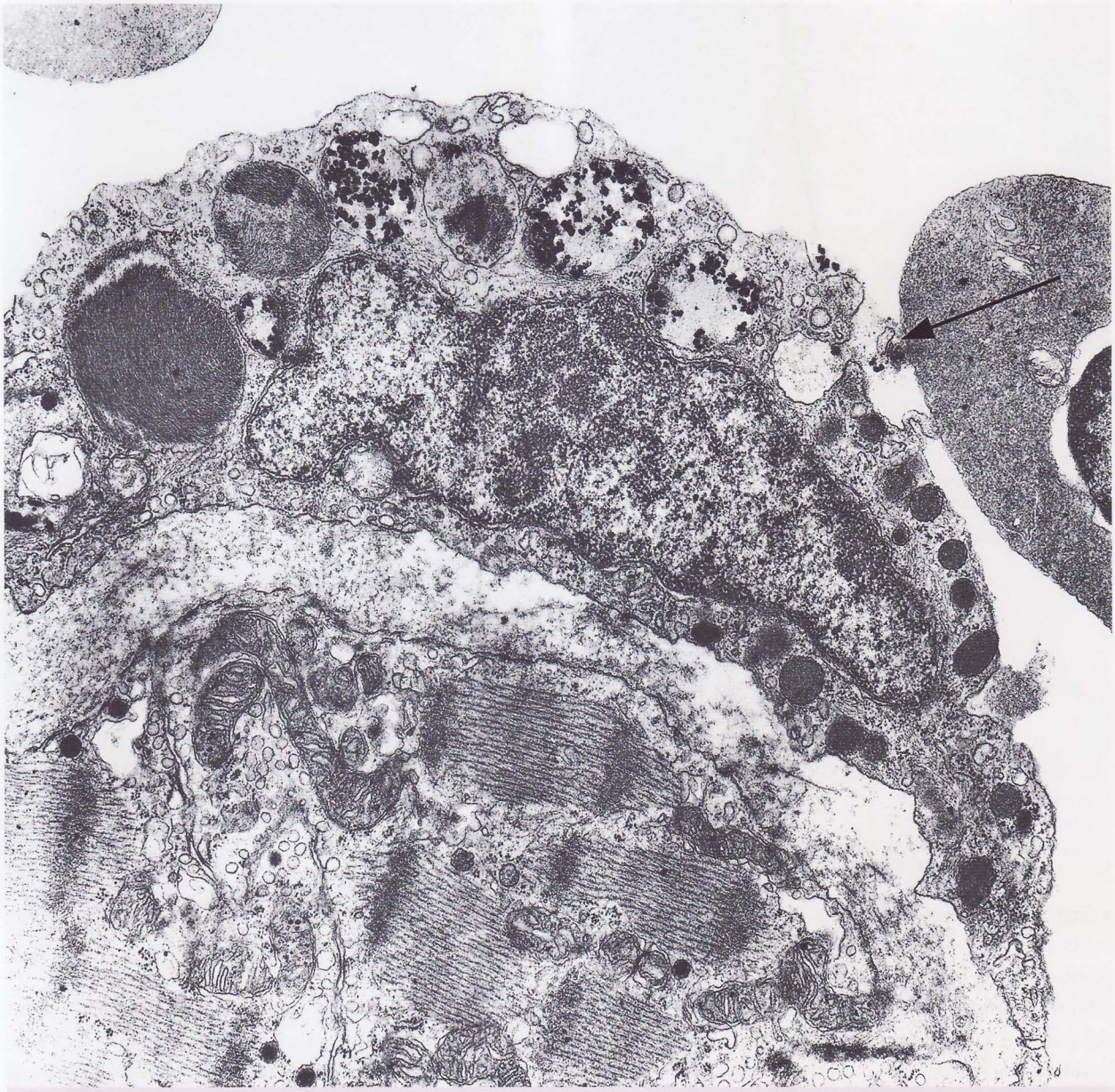

Fig 6.4C. TEM of plaice atrium injected intravenously with carbon particles. These have been phagocytosed by the endocardium, and are sitting within phagolysosomes within the cytoplasm. The arrow shows a macropinocytotic vesicle caught in the act of endocytosing more carbon.

may be as simple as the fact that organisms are attracted to interfaces or are lodged in the presumably low-flow periphery of the ventricular lumen. The two muscular layers also represent different metabolic and functional compartments. Presence of pathogens may or may not be accompanied by degenerative or reactive changes, depending on agent and time post-infection. In acute septicaemias, fibrinoid necrosis is common, while *Renibacterium salmoninarum* for example will cause a classical pyogranulomatous myocarditis. Similarly, *Flavobacterium psychrophilum* can cause a severe acute necrotizing myocarditis in young salmonids, along with the more usual splenic lesions of rainbow trout fry syndrome (RTFS). In older fish, however, the lesions can be much more chronic and hypercellular, and resemble in some respects those seen in cardiomyopathy syndrome of salmon (CMS); bacteria in these lesions are hard to see, and more sophisticated molecular techniques may be required to establish the presence of the antigen. Nevertheless cardiac functioning can be severely impaired. Other pathogens commonly found in the heart include *Lactococcus* spp., *Pseudomonas* spp., *Vibrio* spp., and *Mycobacterium* spp. Nocardiosis is also sometimes seen.



Fig 6.5. Ventricular shape is highly plastic, especially in species with a pyramidal ventricle. The pointed, pyramidal shape of wild Atlantic salmon (right) is considered the most effective. Farmed salmon (left) often have smaller rounded ventricles that are less effective pumps. Note conspicuous coronary vessels and fat deposits in the farmed fish.

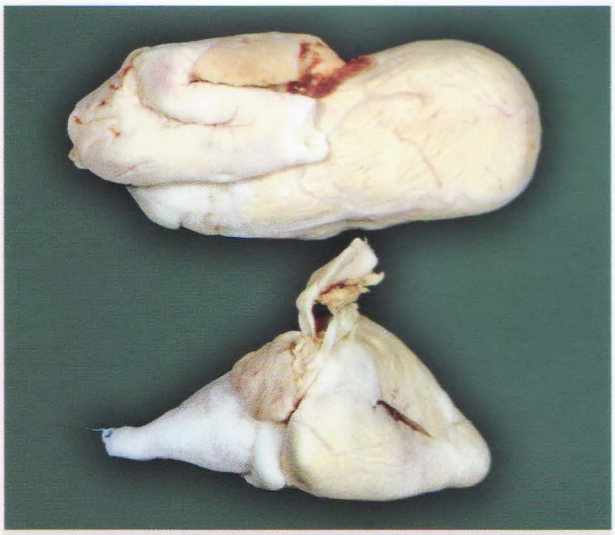

Fig 6.6B. Heart from salmon with absent septum transversum (top) and a normal salmon of equivalent size (bottom).

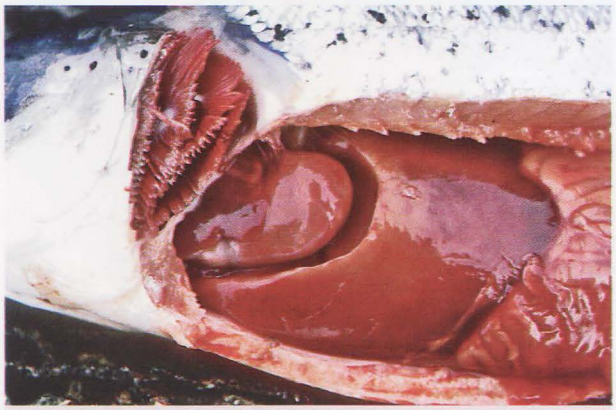

Fig 6.6A. Hypoplasia or aplasia of septum transversum removes the caudal constraint of the pericardial cavity. The heart is therefore pushed into the abdominal cavity cranially or ventrally to the liver, often leaving an impression in the hepatic parenchyma. This abnormal location leads to aberrant shape and compromised cardiac function. The condition may be caused by high temperatures during egg incubation and early life stages, or prenatal stress.

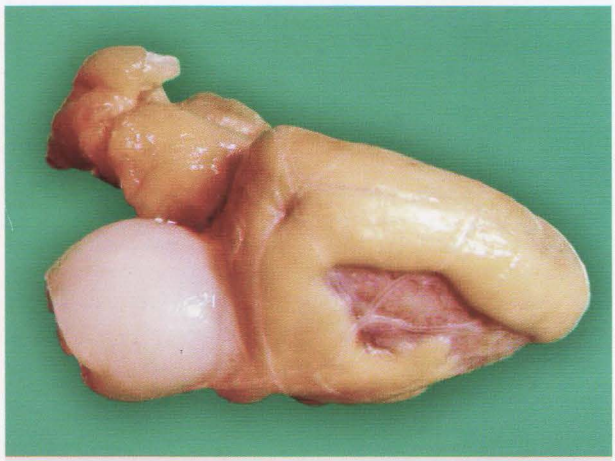

Fig 6.7A. Rainbow trout with ventricular defect due to partial absence of compact myocardium. Whether this is the result of aplasia/hypoplasia or atrophy is unknown.

Viral septicaemias. Almost any viraemia can lead to multifocal lesions in myocardium. Generalized viral diseases such as viral haemorrhagic septicaemia (VHS) and infectious haematopoietic necrosis (IHN), both caused by rhabdoviruses, cause severe vessel damage and multifocal myocarditis. Herpesviral infection of rainbow trout can cause severe sub-acute necrotizing myocarditis, although liver lesions with hepatocellular syncitial formation are possibly the more obvious lesion in this disease.

Fungal infections. Systemic fungal infections include those caused by *Exophiala* spp., *Phoma* spp. and *Ichthyophonus hoferi* (recently reclassified, and not a true fungus). The latter has a particular affinity for active muscle like myocardium **(Fig 6.13)**, but all may manifest themselves in the heart. Lesions vary from granulomatous myocarditis and epicarditis in the case of *Ichthyophonus*, to diffuse mycelium infiltration with accompanying necrosis of the myocardium, in the case of *Exophiala* and *Phoma*.

Parasites. Numerous parasites may be found in different compartments of the heart with metacercariae of digeneans probably being the most common **(Fig 6.14)**. Encapsulated larvae of the cestodes *Diphyllobothrium dendriticum* and *D. ditremum* are typically found among visceral organs

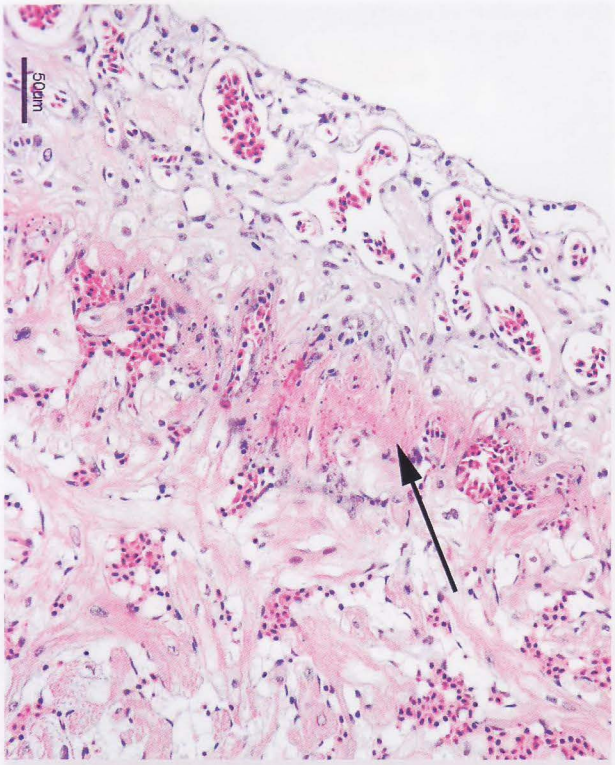

Fig 6.7B. Hypoplasia of outer, compact myocardium. Note conspicuous marginal vascularization, fibrinoid necrosis (arrow) and vacuolation of myocytes in spongy myocardium. This condition appears to have many similarities to Pompe's disease in humans.



Fig 6.8. Formalin-fixed heart from farmed Atlantic salmon broodfish with ventricular aneurisms. The endocardium is protruding through slits in the myocardial wall creating cauliflower-like protrusions.

in many wild salmonids, but may also be found in the heart. Serious cardiac disease with rupture of the atrial wall following blockage of the atrioventricular orifice by metacercariae of *Diphyllobothrium dendriticum* has been reported in brown trout in Finland. (Increased activity of the parasite at temperatures above 12°C coincides with increased cardiac activity). Accompanying lesions included massive chronic myocarditis around the larvae in the atrial wall. Encapsulated metacercariae of the marine digenean *Cryptocotyle lingua* in the skin and gills of marine fish typically evoke a strong melanomacrophage response causing "black spot disease". In small fish, cercariae may penetrate into the heart where the metacercariae become surrounded by a focal myocarditis. Other digeneans frequently encountered include *Ichthyocotylurus* and *Stephanostomum* spp. These are typically found in the epicardium and are usually accompanied by a mild to severe epicarditis. Sanguinicolids are sometimes encountered as incidental observations. The microsporidian *Loma* is commonly encountered in myocardium, although its significance is hard to assess.

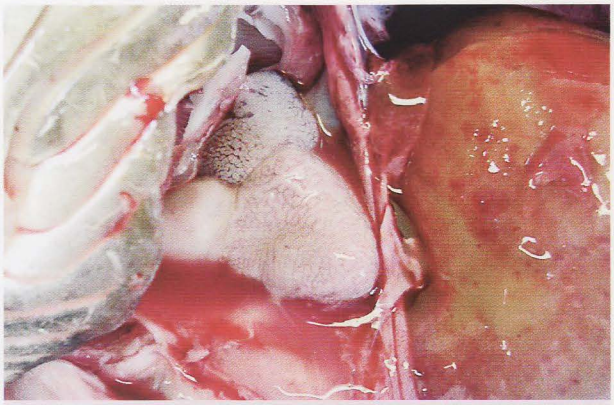

Fig 6.9A. Bacterial pericarditis (*Lactobacillus*) in Atlantic salmon broodfish. Bacteria cover virtually the entire heart. *Picture courtesy of Dr. B. Tørud.*

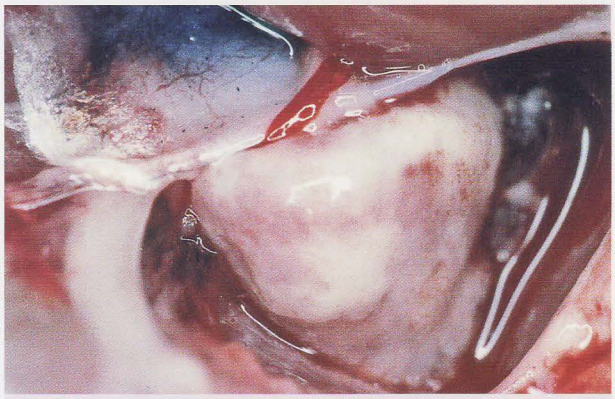

Fig 6.9B. Fibrinous pericarditis in Pacific salmon due to bacterial kidney disease. Such severe lesions lead to impaired cardiac performance.

The haematophagous crustacean parasite *Lernaeocera branchialis* of certain gadoids inserts a chitinous cephalic anchor ("antler") directly into the ventral aorta and bul-

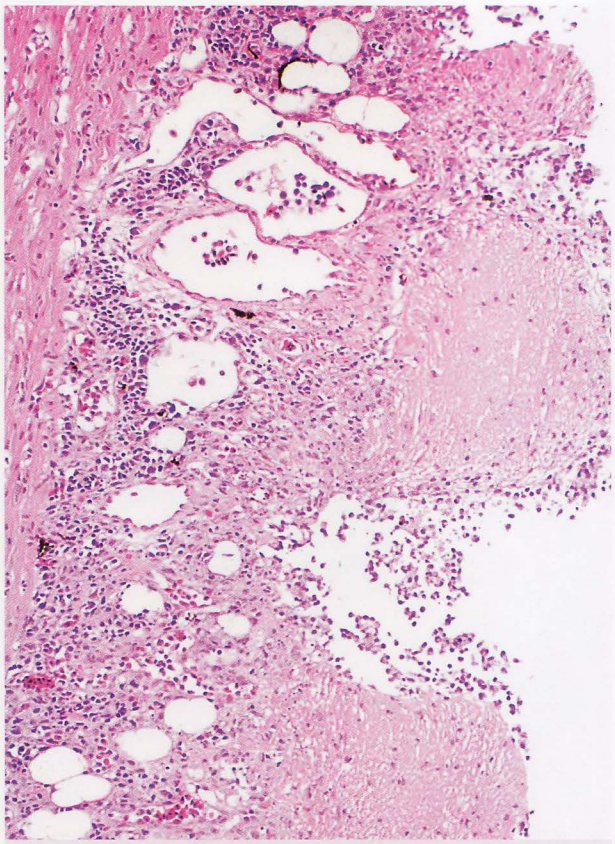

Fig 6.9C. Fibrinous pericarditis in Atlantic salmon due to *Pasteurella skyensis*.

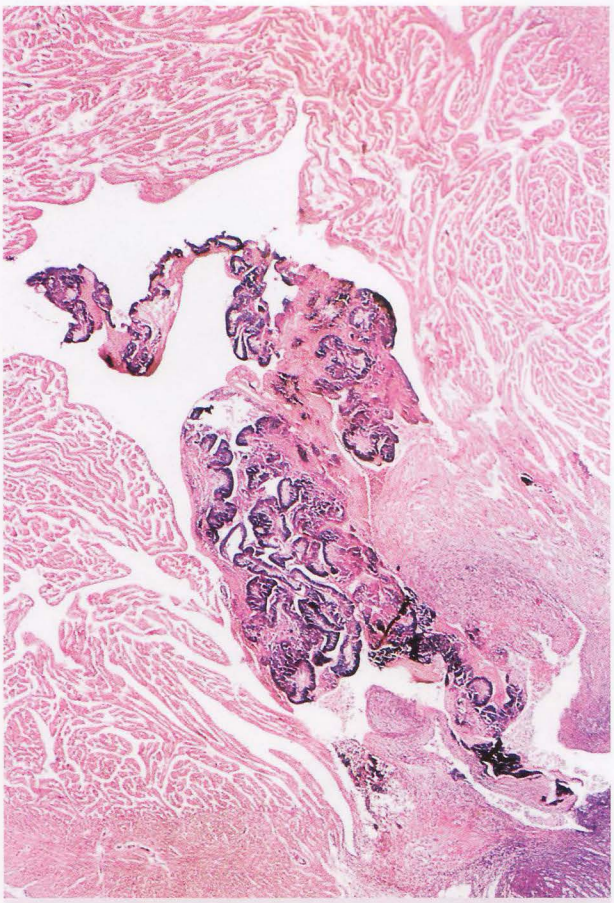

Valvular lesions in salmonids. *Fig 6.10A.* Septic vegetative valvular endocarditis of semilunar valves in rainbow trout. *Yersinia ruckeri* was isolated from this fish, although this would be an unusual finding in ERM, despite the vascular damage this organism causes.

bus arteriosus and may cause physical obstruction with resultant reduction of cardiac output. The fish responds to the damage with granulation tissue, but is able to remodel these structures to an amazing extent to allow for the maintenance of cardiac output.

Nutritional cardiomyopathy. Coldwater teleosts such as salmonids tend to have higher levels of polyunsaturated fatty acids (PUFA) than do their warmwater counterparts. These are required in order to maintain membrane fluidity at low water temperatures. Heart muscle is one of the tissues that is especially high in phospholipids, even compared to white fibre skeletal muscle. The phospholipid-rich cardiac membranes also have iron-containing proteins that can initiate and augment oxidative chain reactions. Classical cardiomyopathy caused by inadequate levels of vitamin E and/or selenium, appears to occur less commonly now than a few years ago, probably as a result of increased knowledge about the nutritional needs of intensively farmed fish. Lesions include increased eosinophilia and loss of striation followed by fragmentation of myocytes. Massive necrosis with calcification of the outer compact myocardium has occasionally been observed in Atlantic salmon broodstock possibly as a result of total obliteration of the coronary vessel, although whether this lesion can be directly attributed to nutrition is debatable.

Specific diseases

Pancreas disease (PD). Seen in farmed Atlantic salmon, characteristic lesions in this alphaviral disease include acute peroxidative-type necrosis of cardiac myocytes in the atrium and in both compact and spongy layers of the ventricle. Hyaline degeneration with marked eosinophilia and shrunken nuclei occur together with pancreatic necrosis. Inflammation is usually only mild to moderate, although mural (endocardial) thrombosis is sometimes encountered. In recovering survivors, myocardial hypercellularity with regeneration of cardiac myocytes may be observed, accompanied by mitotic figures, particularly in the compact/spongy interface of the ventricular myocar-

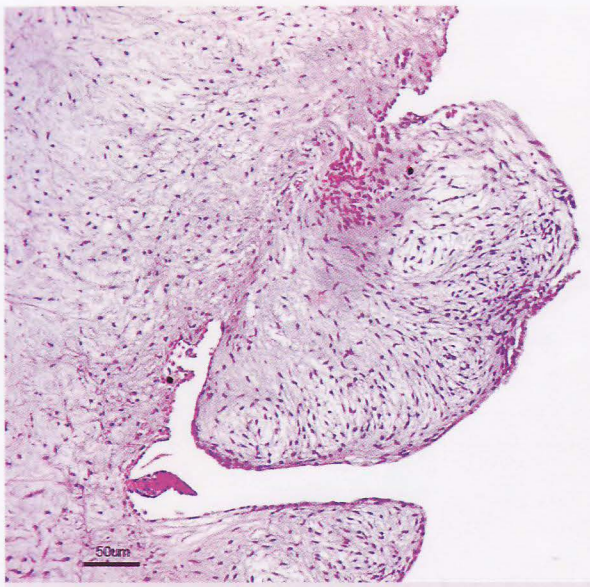

Fig 6.10B. Proliferative, nodular processes on semilunar valves of farmed Atlantic salmon. The aetiology is unknown, but there can be little doubt that such protuberances impair the function of the valves.

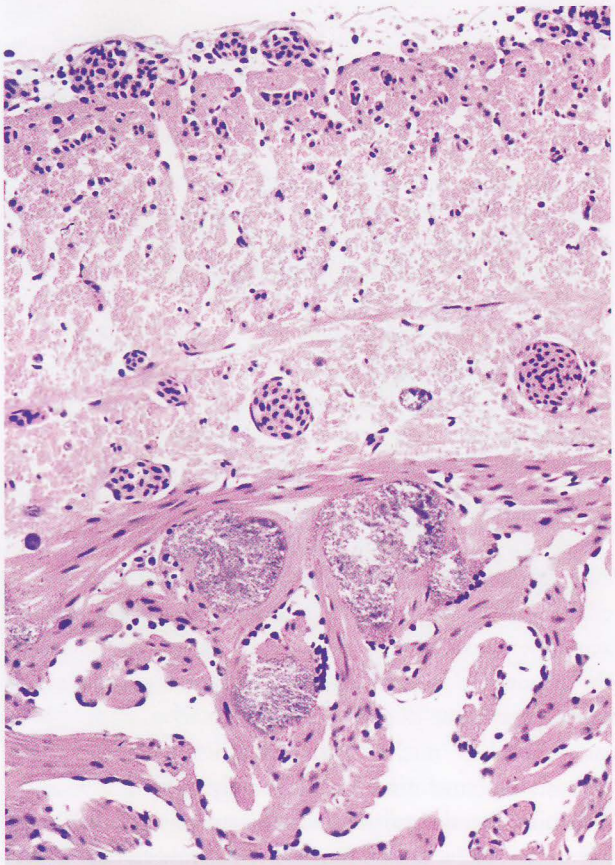

Fig 6.11A. Bacterial colonies in the compact/spongy interface of a sea-caged Arctic char (*Salvelinus alpinus*). This interface is a predilection site for lesions in many diseases, both infectious and non-infectious.

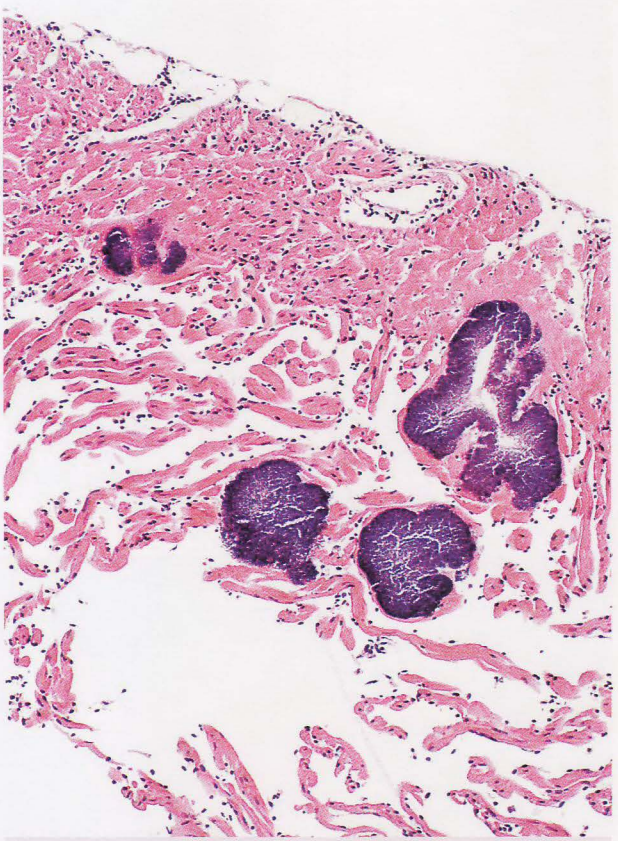

Fig 6.11B. Bacterial myocarditis caused by *Aeromonas salmonicida* in rainbow trout. Such large colonies, with very little surrounding necrosis, are almost pathognomonic for furunculosis in several species.

dium. Large, active-looking nuclei will be observed and there may be proliferation of endocardial cells and mild epicarditis. A similar alphaviral disease of rainbow trout, sleeping disease (SD), may cause comparable lesions in the heart, but these are not as pronounced as those seen in PD; the main lesions in SD are to be found in axial muscle, especially red fibres.

Of interest was an early paper on the clinical chemistry of PD that showed a marked decline in antioxidant status of affected fish including blood and hepatic vitamin E levels, down to 7% of normal. The full significance of these observations was unknown at the time, although it was suggested that they were probably the *result* of the disease, rather than the *cause* of it. Crucially, there were no precedents in the literature at that time correlating shifts in antioxidant status ("oxidative stress") with infectious disease, except *in vitro*. It was 6 years later before this process was demonstrated *in vivo* for an influenza A viral infection in mice. Now, of course, this is a well-recognized phenomenon in a range of diseases affecting man, including HIV and chronic

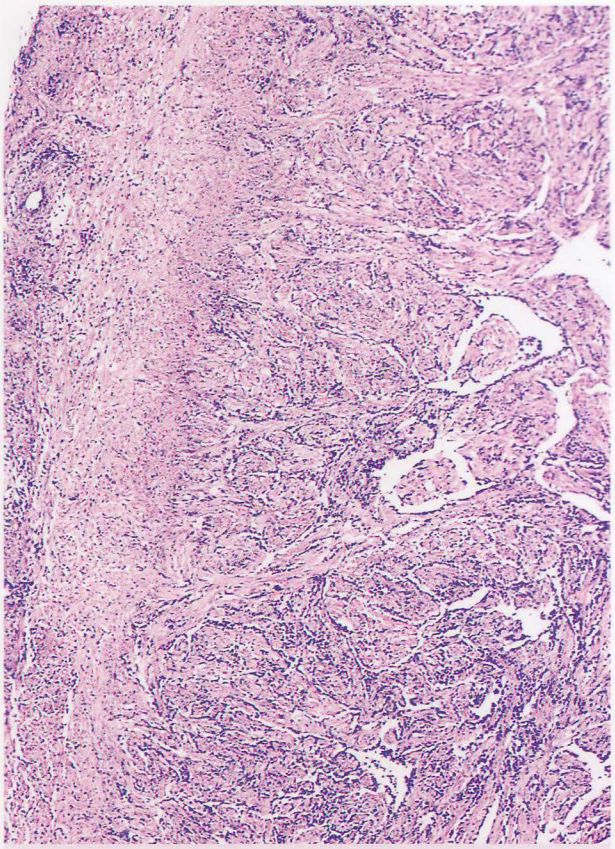

Fig 6.11C. Severe myocarditis in rainbow trout. Such hearts contain antigens to *Flavobacterium psychrophilum*, but whether these are causal is unknown.

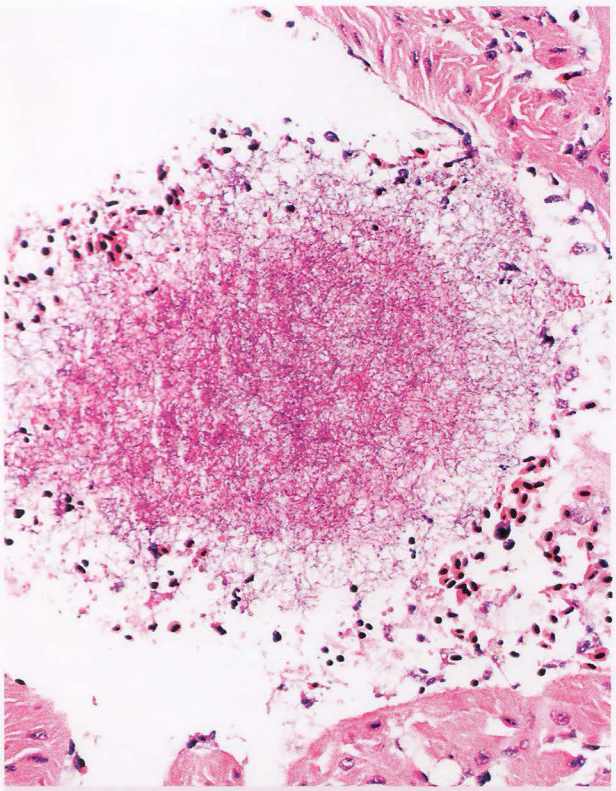

Fig 6.11D. Early nocardiosis in Atlantic salmon showing the filamentous bacterial colony attached to endocardium. *Courtesy Dr. D.D MacPhee.*

fatigue syndrome. The possibility exists, therefore, that some of the types of recently encountered heart disease in salmonid fish are a reflection more of oxidative stress and lipid peroxidation, rather than the direct action of virus on myocardium. Events in this particularly susceptible tissue are possibly being driven by systemic viral infections that have cardiac disease as one of their clinical and pathological manifestations without necessarily localizing there, at least as regards myocardium. The combination of high phagocytic and detoxification capabilities of a high surface area endocardium that is in intimate contact with a tissue (myocardium) containing especially high levels of phospholipids, renders an oxidative stress type of pathogenesis a possible or even a likely scenario for some types of viral (and possibly even bacterial) infections.

Heart and skeletal muscle inflammation (HSMI). This is best characterized as a myocarditis, with marked infiltration by a mixed cell population including neutrophils and macrophages. Typical lesions in this presumed viral disease (so far diagnosed only in Norway and Scotland) of farmed

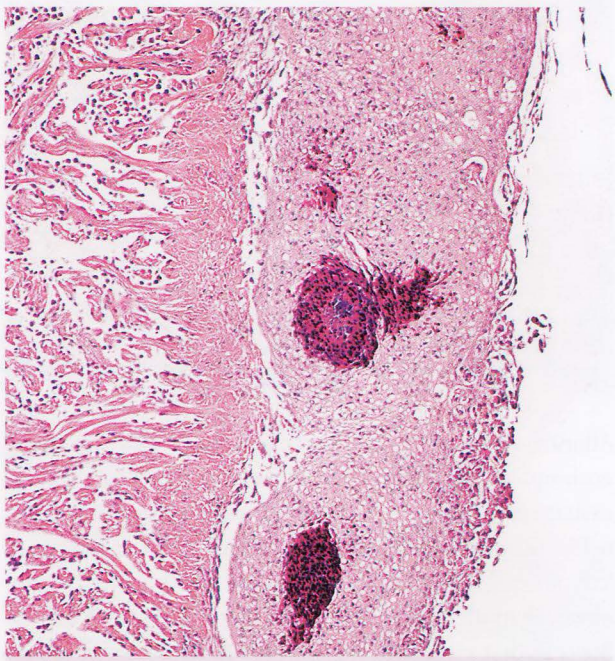

Fig 6.12. Granulomatous pericarditis in farmed cod due to *Vibrio*. The inflammatory response in this host is quite different to that seen in vibriosis in salmonids.

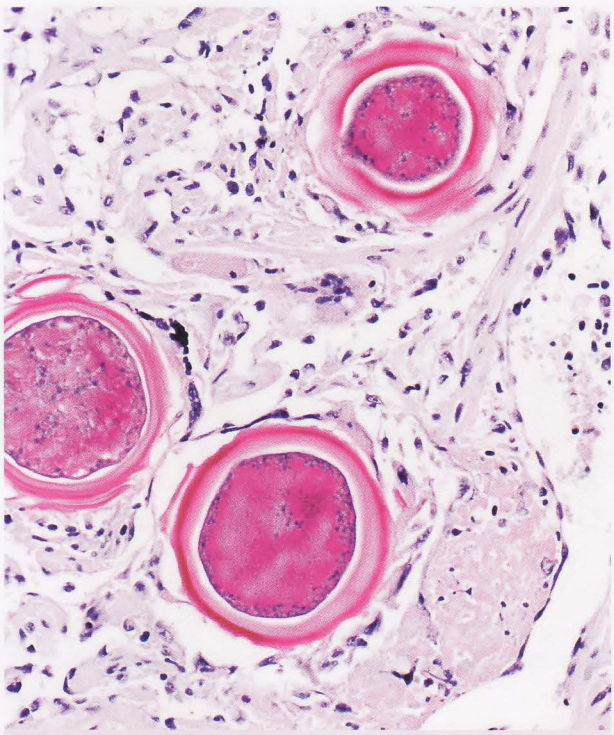

Fig 6.13A. Ichthyophonus hoferi in the ventricle of rainbow trout. Double-walled, PAS-positive spores are characteristic. There is limited inflammatory response around the spores. Active muscle, like the myocardium, is targeted by this pathogen.

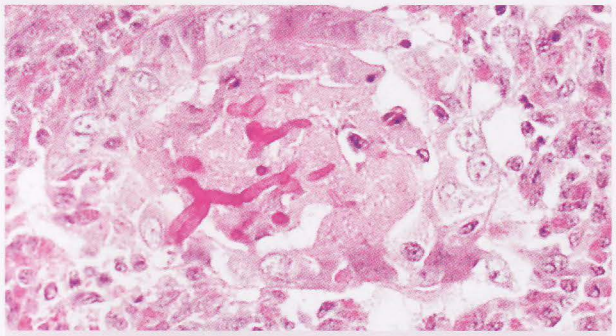

Fig 6.13B. PAS-positive septate and branched hyphae are of *Phoma herbarum* in the myocardium of Atlantic salmon smolt. There is extensive tissue necrosis around the pathogen. *Periodic acid-Schiff.*

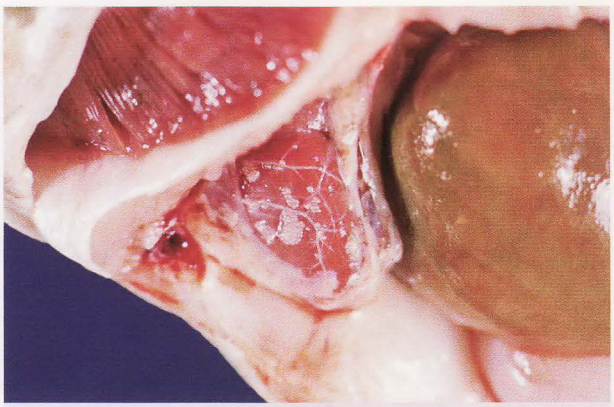

Fig 6.14A. Brown trout with numerous metacercariae of the digenetic trematode *Ichthyocotylurus* sp. on the epicardial surface. There is minimal inflammatory response and the epicardial surface is still shiny.

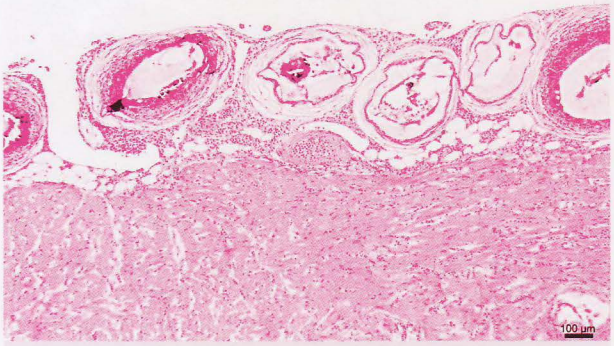

Fig 6.14B. Metacercariae of the digenetic trematode *Ichthyocotylurus* sp. in the epicardium of whitefish (*Coregonus lavaretus*).

Atlantic salmon include loss of striation and increased eosinophilia, degeneration, vacuolation and subsequent cavitation of myocytes of the ventricular spongy layer **(*Fig 6.15*)**. Lesions also include karyorhexis, and compensatory karyomegaly of myocytes. "Nests" of small nuclei may be observed in affected myocytes and are possibly reserve satellite cells that are mobilized from the subendocardial space. The suggestion is that these represent a stage in myocardial regeneration. They are also seen in cardiomyopathy syndrome (CMS). In the compact layer, which is usually less severely affected, lesions are sometimes accompanied by elongated nuclei of the Anitschkow-type with a marked, wavy chromatin pattern. Atrial lesions are similar to those seen in spongy ventricular myocardium, but again are usually milder, and in some cases may be inapparent. CMS and PD are obvious differential diagnoses but HSMI can be differentiated pathologically from these by the absence of pancreatic lesions typical for PD and the fact that, while CMS lesions may be very similar to those of HSMI, the former tend to be restricted to the spongy myocardium, although ventricle and atrium are both affected. In addition, and as the name suggests, skeletal muscle is very severely affected in HSMI. The more generalized rhabdomyopathy of PD, which can affect oesophagus too, produces lesions in which inflammation is much less severe. Another, but less obvious differential are the lesions that accompany chronic *Flavobacterium psychrophilum* infection, although of course these are found in rainbow trout **(*see Fig 6.11C*)**.

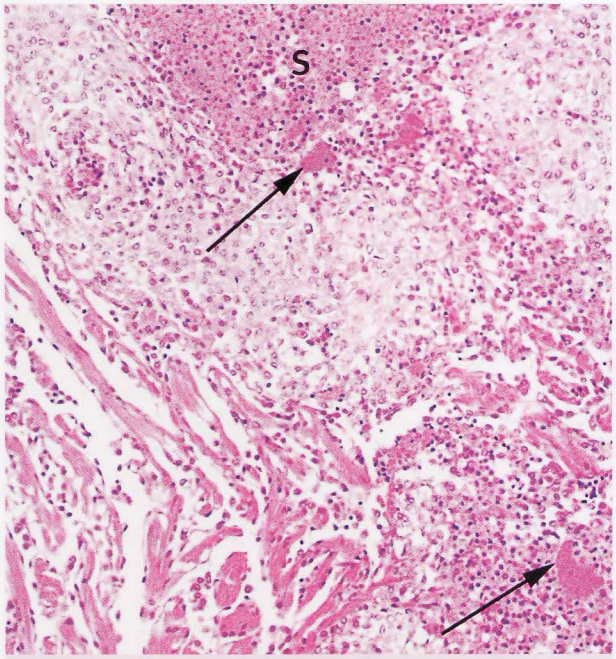

Fig 6.14C. Cod with chronic granulomatous myocarditis due to *Loma*-like microsporidian infection. The large mass of spores (**S**) is surrounded by a dense cellular wall. The success of this response has been compromised by secondary bacterial infection with *Aeromonas salmonicida* (arrows).

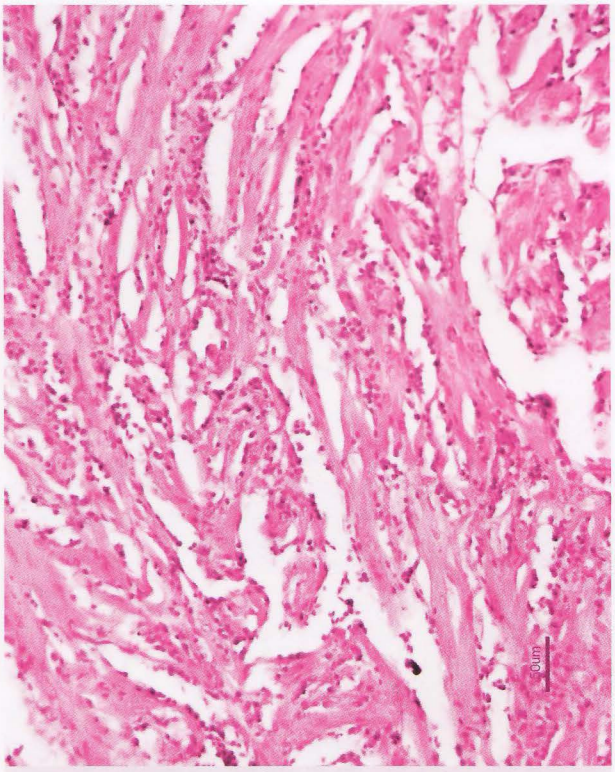

Fig 6.15B. HSMI showing myocarditis with infiltration by neutrophils and macrophages, loss of striation and increased eosinophilia.

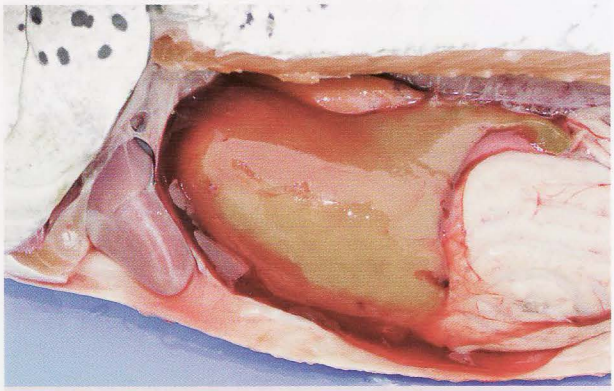

Heart and skeletal muscle inflammation (HSMI) in Atlantic salmon. *Fig 6.15A.* Atlantic salmon showing increased peritoneal fluid and a fibrin coating over the liver. *Picture courtesy of Dr. T. Turnbull.*

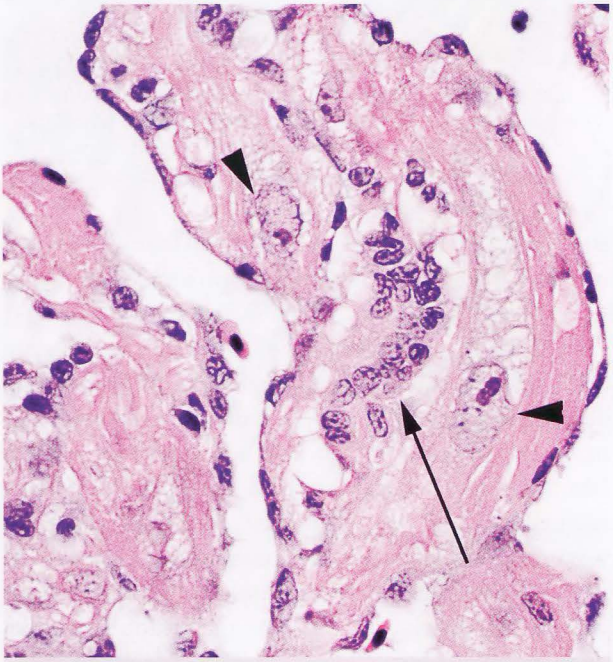

Fig 6.15C. These multinucleate nests in myocardium (arrow) can be seen in some hearts in cases of HSMI, and CMS; some nuclei can be arranged in rows. Together, they suggest regeneration of cardiac myocytes. In this case the nest of nuclei has a hypertrophic myocyte nucleus on both sides (arrowheads).

Cardiomyopathy syndrome (CMS) of Atlantic salmon targets the atrium and the spongy myocardium of the ventricle, and like HSMI, is mainly a myocarditis. This severe disease of unknown aetiology develops slowly and typically causes mortality in large fish just prior to slaughter. Early lesions include subendocardial infiltration by mononuclear leukocytes, myocyte degeneration and necrosis, macrophage invasion and mural thrombosis (*Fig 6.16*). Eventually the majority of the spongy myocardium is affected, particularly the atrium in terminal stages. Active, hyper-

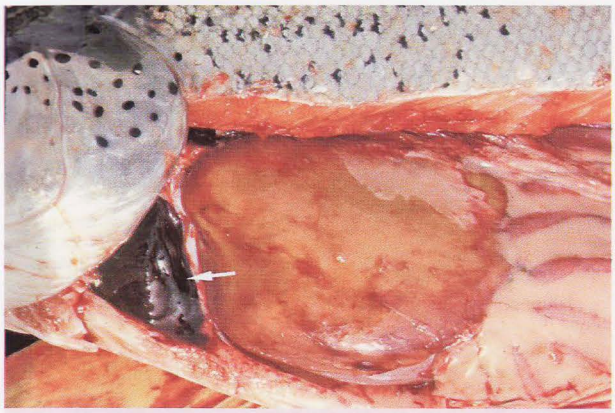

Cardiomyopathy syndrome (CMS) in Atlantic salmon. *Fig 6.16A.* Haemopericardium following terminal rupture of the atrium or sinus venosus. The entire pericardial cavity is filled by blood or blood clots leading to compression of the ventricle and impaired output (cardiac tamponade). Note the fibrin on the capsular surface of the liver.

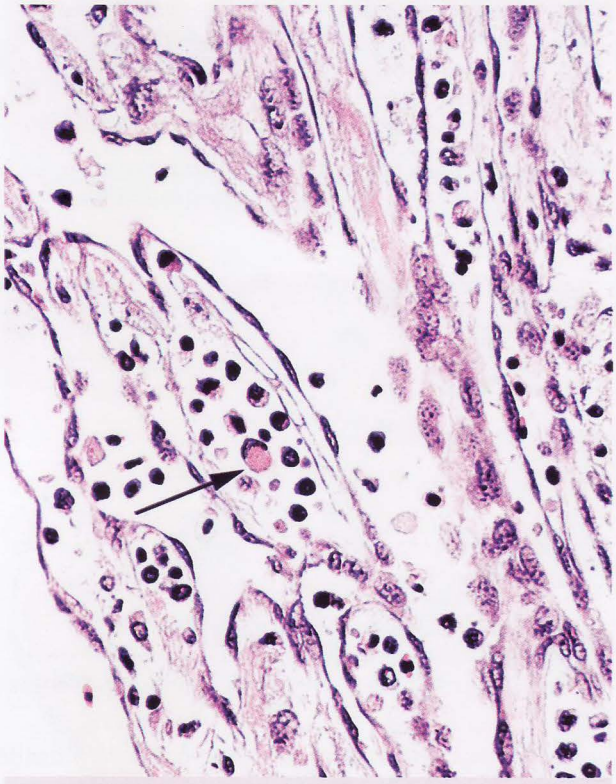

Fig 6.16B. Severe necrosis of myocardium sees influx of mononuclear cells and macrophages, some of which can be seen here full of brown-staining debris (arrow).

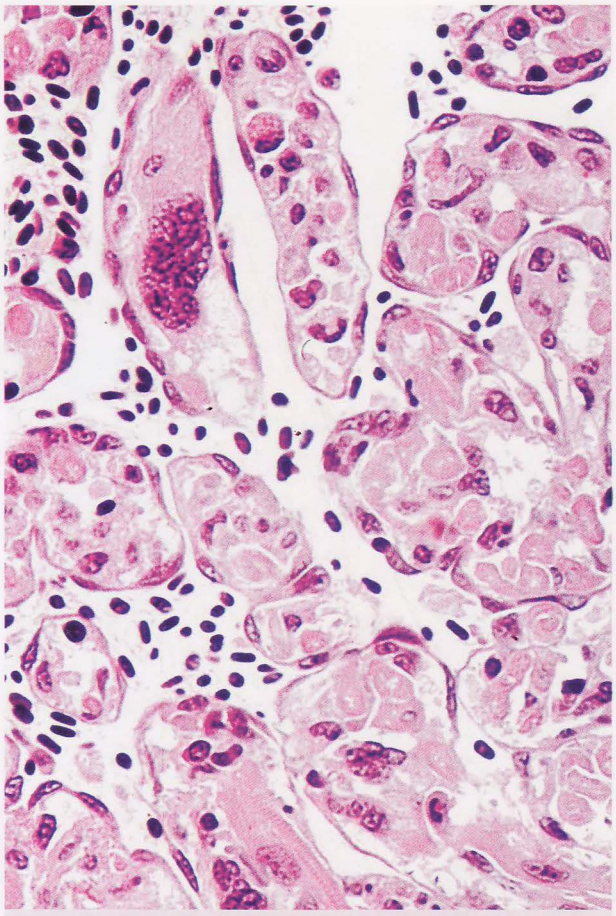

Fig 6.16C. Some cells show marked nuclear hypertrophy; is this compensatory hypertrophy?

trophic endocardial cells encase little more than tubes empty of any muscle fibres, but often filled with small mononuclear lymphocyte-like cells and macrophages replete with debris. Accompanying lesions include scattered mural thrombi in the ventricle, large thrombi in the atrium, myocyte karyomegaly (compensatory hypertrophy?), aggregates of multinucleated giant cells and epicarditis. Terminal rupture of the sinus venosus or atrium with resultant haemopericardium typically occurs as large thrombi lodge in the atrial trabeculae and obstruct the passage to the ventricle. By means of diagnostic ultrasound, intravitally formed thrombi are easily seen displacing prograde and retrograde during each cardiac cycle in the Ducts of Cuvier in terminal stages of the disease. Dead and moribund fish show signs of severe congestive heart failure with markedly distended pericardial cavity (cardiac tamponade), venous congestion, ascites, fibrinous perihepatitis and severe abdominal haemorrhage. CMS causes heavy losses of large, valuable fish in Norwegian salmon farms and has also been diagnosed in Scotland and the Faeroe Islands. Wild fish with CMS-like lesions have been found in a couple of Norwegian rivers. The aetiology of this disease is not known and although viral particles (nodavirus-like) have been demonstrated, the findings are not consistent.



Fig 6.16D. SEM of ventricular myocardium from fish with CMS showing pits in the plasmalemma.

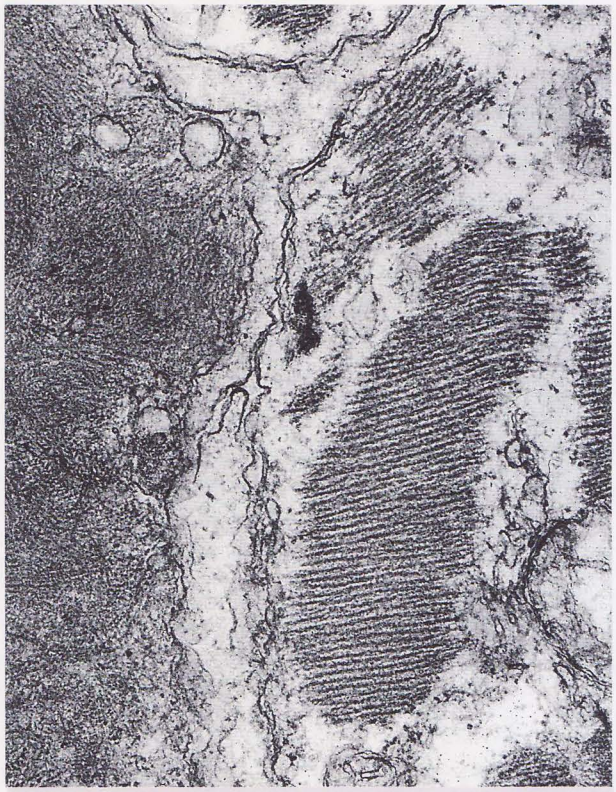

Fig 6.16E. TEM of CMS ventricle showing adjacent cells; the one on the left shows lysis of myofibrils, while that on the right is relatively normal.

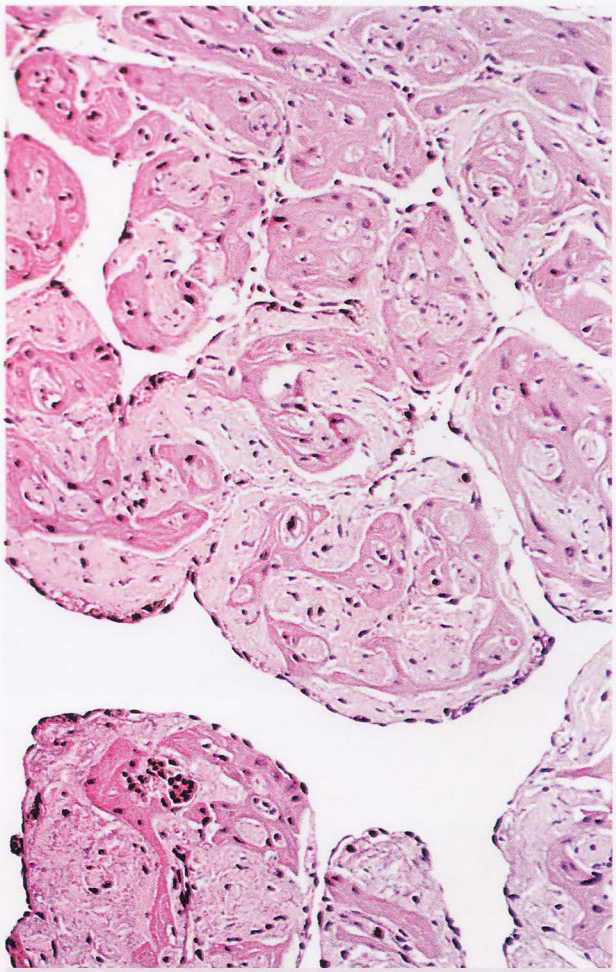

Fig 6.17. Sub-endocardial fibrosis in farmed Atlantic salmon. In this condition of unknown aetiology, there is substantial fibrosis between the myocardial cells and the endocardium. This may occur as an idiopathic condition or be associated with other cardiac diseases.

Sub-endocardial fibrosis. The aetiology and pathogenesis of this rare disease in farmed Atlantic salmon are unknown (*Fig 6.17*). A similar condition has been described in humans and cats where several theories on aetiology have been launched. These include post-viral endomyocarditis, hypoxia, haemodynamic overload and autoimmune disease. In salmon the abnormality has occurred as an idiopathic condition, or in connection with CMS and cardiac abnormalities. Microscopic lesions include a thick layer of blue-grey fibres of collagen and elastic fibres running parallel to the surface and clearly demarcated from the underlying myocardium giving the spongy myocardium a characteristic barred appearance. Although the aetiology is unknown, it is tempting to compare it with the condition in turkeys suffering from ventricular hypertrophy and dilatation due to pressure overload and resulting in "round heart disease".

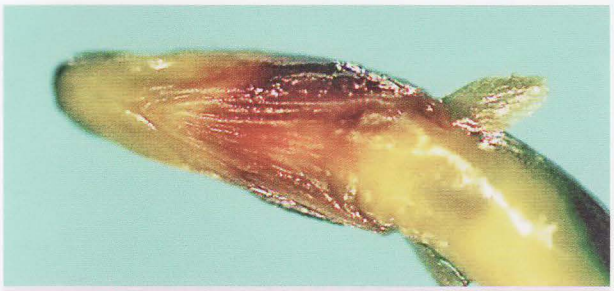

Fig 6.18A. Eel with *Aeromonas* infection showing marked peripheral hyperaemia round the head. *Picture courtesy of Dr. S. Backman.*

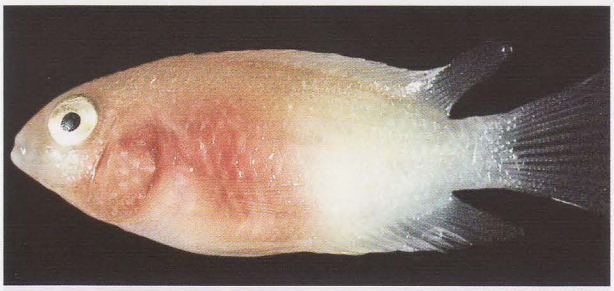

Fig 6.18B. Cichlid with peritonitis due to "cichlid bloat" showing marked peripheral hyperaemia.

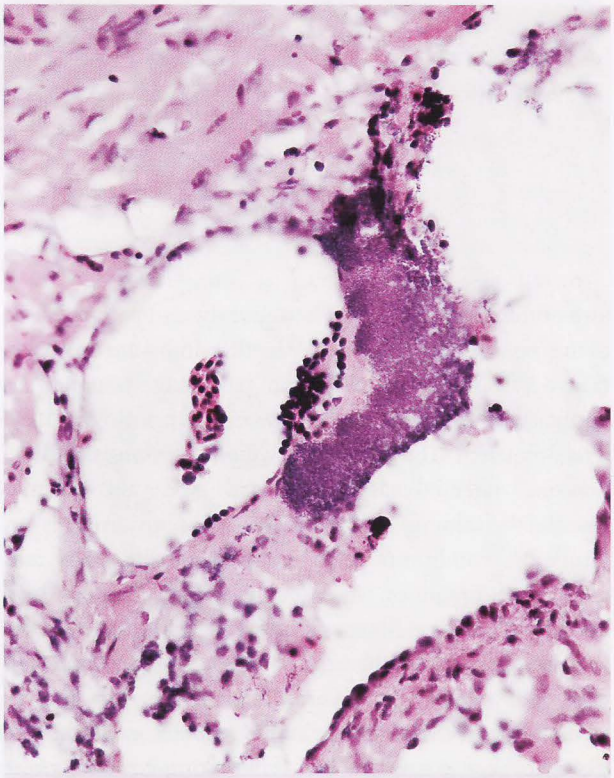

Fig 6.19A. Necrosis of coronary vessel in brown trout with furunculosis. Note the early mural thrombus on the intimal aspect of the vessel.

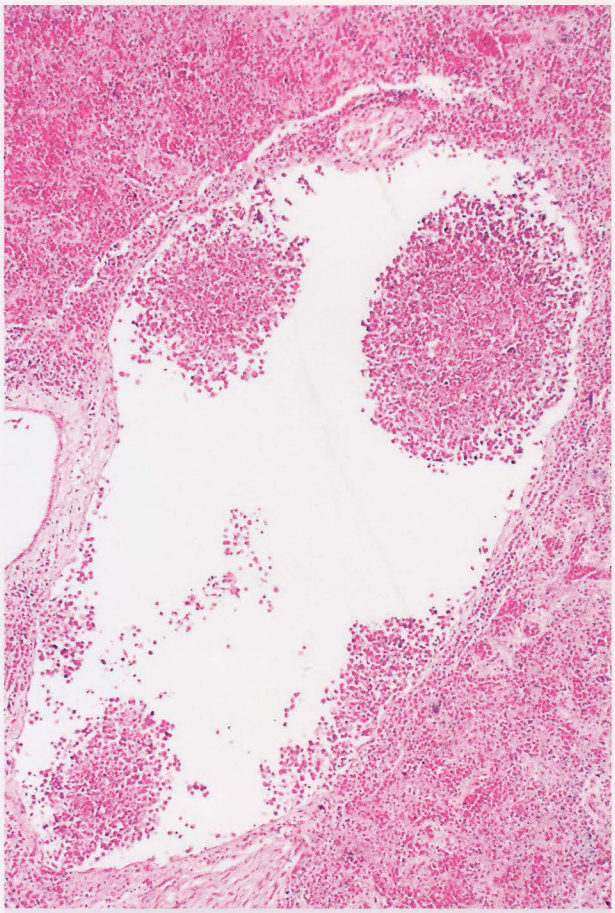

Fig 6.19B. Multiple septic thrombi in vessel of cod with vibriosis.

Vessels

In general, the smooth muscle in fish arterioles has less fibrillar material than in their mammalian counterparts, probably a reflection of the lower blood-pressure found in fish. Capillaries are anatomically similar to those found in mammals, but they are much more permeable. They consist of a single layer of squamous endothelial cells surrounded by a basement membrane. Ostial valves are present where tributary veins open into longitudinal veins and prevent retrograde flow during skeletal muscle contraction thereby assisting venous return. Venules are structurally similar to those in mammals, but have thinner walls and less smooth muscle.

Secondary circulation

Fish have a second vascular system ("the secondary circulation") that is believed to be the progenitor of a real lymphatic system as found in higher vertebrates. This system is directly connected to the primary circulation and has

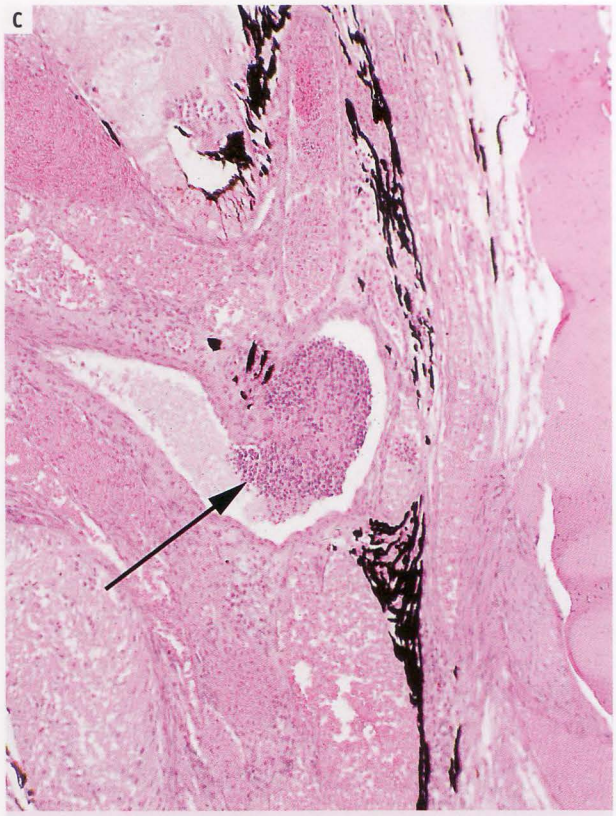

Fig 6.19C&D. Vibriosis in Atlantic salmon showing thrombus (arrow) in main vessel supplying retina, which is consequently infarcted (**D**).

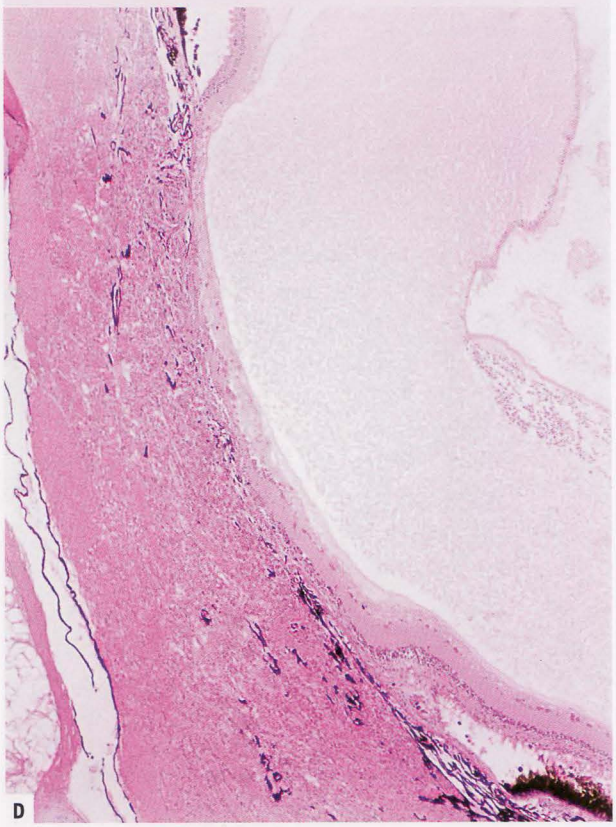

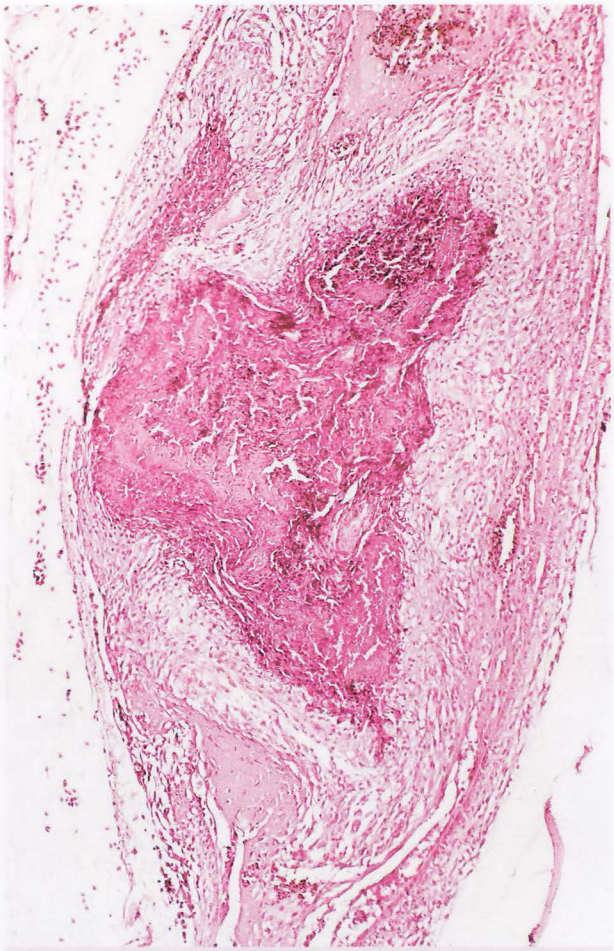

Fig 6.19E. Streptococcus iniae infection in reef fish from Barbados, showing vasculitis and virtual obliteration of branchial vessel. Clinically this would lead to hypoxaemia and respiratory distress.

been observed in gills, fins, skin, oral mucosa and near the peritoneal lining. This system forms a second artery-capillary-vein circuit in parallel with the primary system and is presumed to drain into the cutaneous veins, the caudal vein and the branchial veins of the gill. Erythrocytes are restricted from this circulation due to the narrow diameter of the vessels, indicating that respiration is not a major factor.

Vascular lesions

Compared to mammals, teleost capillaries are highly permeable. The reason for this is unknown although the relatively low blood pressures found in fish would not seem to demand tight intercellular junctions in order to prevent leakage, as are required in mammals. Whatever the reason, one of the consequences is that blood proteins, including the large IgM-type molecules, which by and large

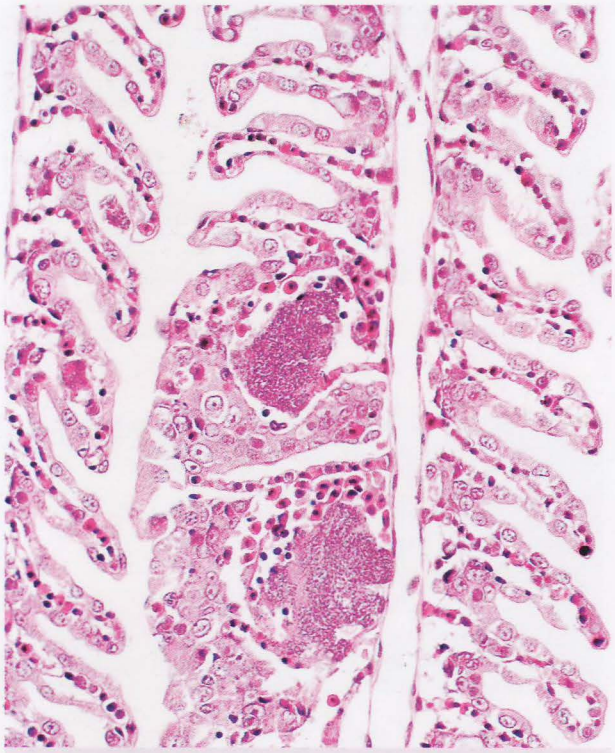

Fig 6.19F. Furunculosis in rainbow trout showing embolic spread to gills. The proliferative response of the lamellar epithelium is typical in this disease.

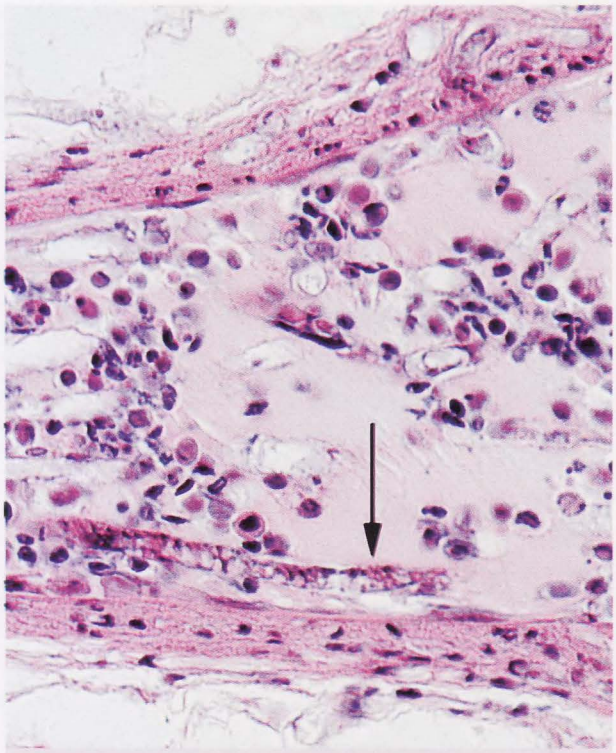

Fig 6.20. Saprolegnia infection in young salmonids can spread through major vessels, as can be seen in the lumen of this aorta (arrow).

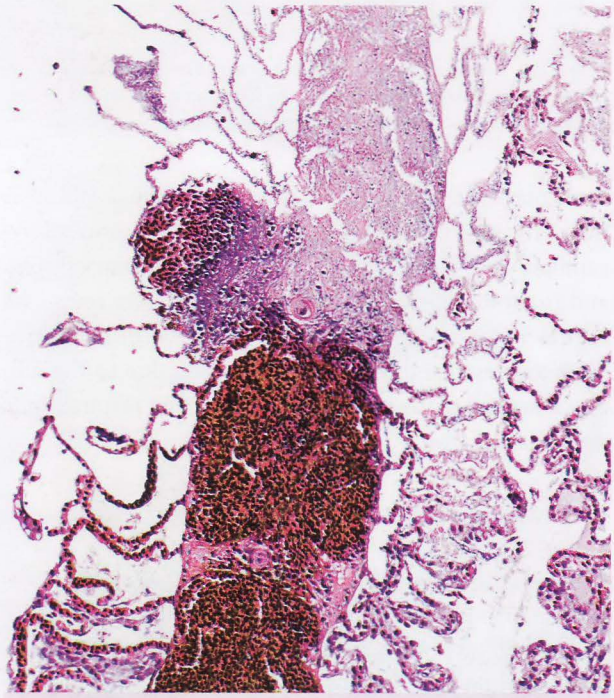

Fig 6.19G. Flexibacter (Tenacibaculum) maritimus infection in Atlantic salmon causing pronounced necrosis of branchial filamental vessel and subsequent infarction. Infarcted tissue is seen at the top.

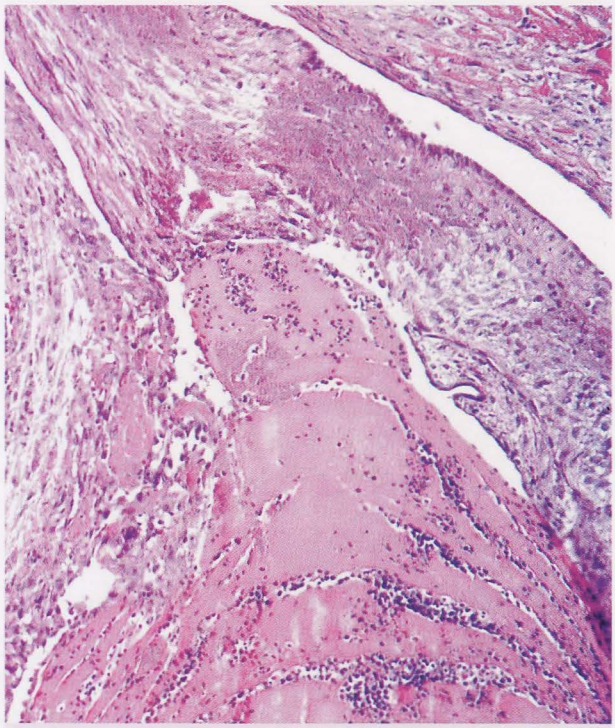

Fig 6.21. Dissecting aneurysm in bulbus of coho salmon caused by bacterial kidney disease.

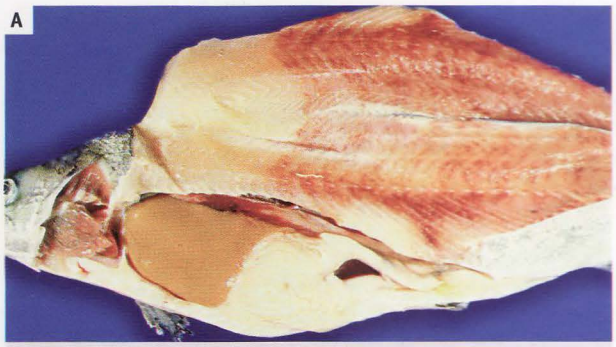

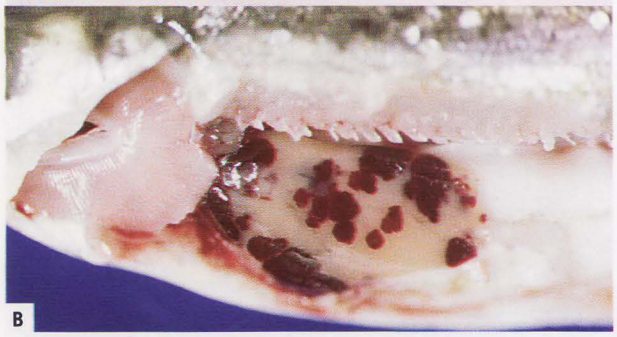

Haemorrhagic smolt syndrome (HSS) in Atlantic salmon.
Fig 6.22A&B. Gross lesions showing extensive haemorrhage in muscle and liver parenchyma. This rather alarming necropsy finding needs to be differentiated from septicaemic disease. Note the pale gills (**B**).

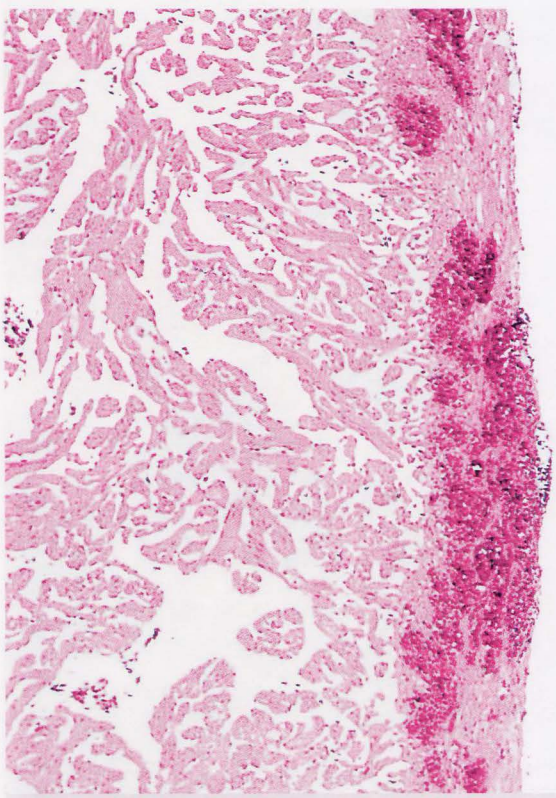

Fig 6.22C. Haemorrhage in the outer compact myocardium of the ventricle of this fish with HSS.

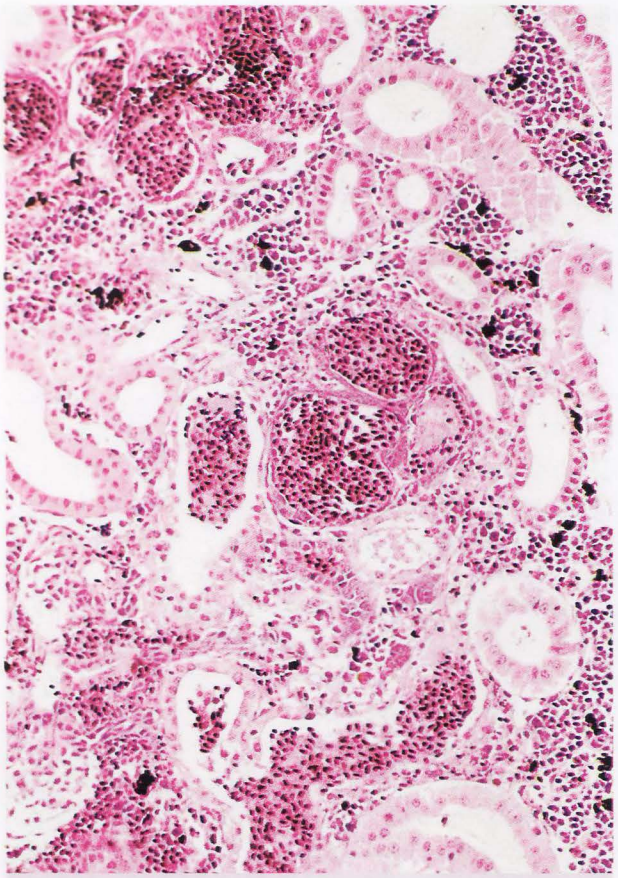

Fig 6.22D. Although not widely recognized, some of the major lesions in HSS are renal. Here are seen nephrosis, and haemoglobinuria.

are the major ones found in teleosts, have relatively little difficulty in leaving the circulation. Thus when skin damage is extensive, from trauma or severe parasitism, even if there is little actual haemorrhage, haemodilution or haemoconcentration are distinct possibilities, depending on whether the fish is in fresh or salt water. Certainly it has been shown in the later stages of the specific entity "ulcerative dermal necrosis" (UDN) in Atlantic salmon (the fish are in freshwater when this disease develops), that as the animal becomes progressively overhydrated, serum protein levels can fall by 60%. In freshwater, the dermal lymphatics would speed such a response, rapidly removing the inflowing water. Similar changes have also been observed in brown trout suffering from extensive saprolegniasis.

Vascular lesions are quite common in fish. One of the most frequently observed is peripheral hyperaemia and haemorrhage encountered in toxaemias and bacteraemias; this is most easily seen at the base of the fins, round the eyes and occasionally (classically, but infrequently, in enteric

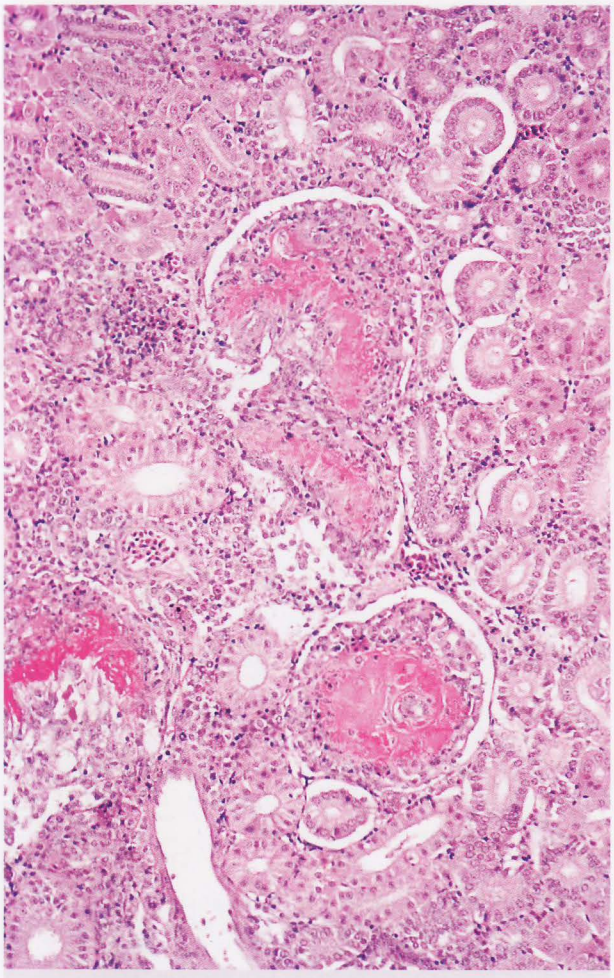

Fig 6.23. Severe acute necrotizing glomerulonephritis in wild white perch. There is marked fibrinoid necrosis of both afferent and efferent glomerular arterioles, and aneurysm of some tuft capillaries, with haemorrhage as a consequence. The pathogenesis of the lesion is unknown, but large numbers of fish may be affected. The lesions have some similarities to the Shwartzman reaction seen in mammals.

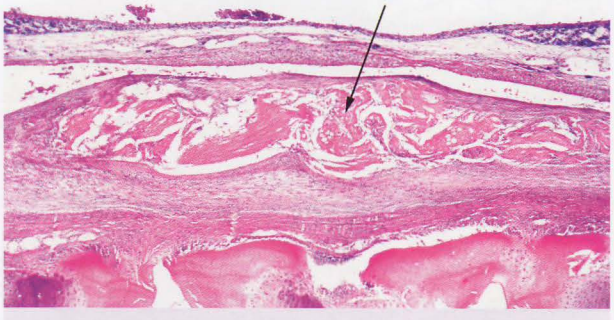

Fig 6.24. Aortic stenosis in rainbow trout. The greatly thickened wall of the aorta almost obliterates the lumen. The cause of the stenosis, prolapsed intervertebral disc material, is shown (arrow).

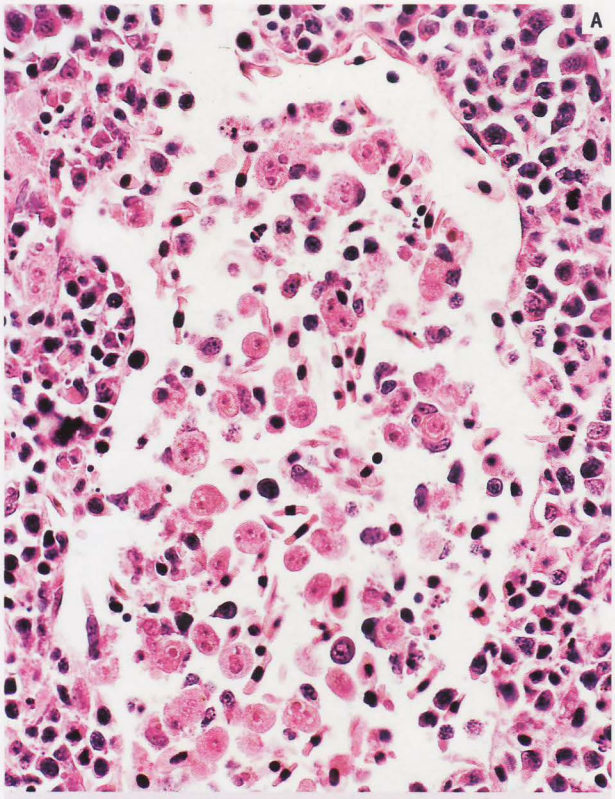

Fig 6.25. Proliferative kidney disease in Arctic char showing early thrombus formation in renal vessels (**A**) and choroid rete of eye (**B**). Parasites are shown (arrows).

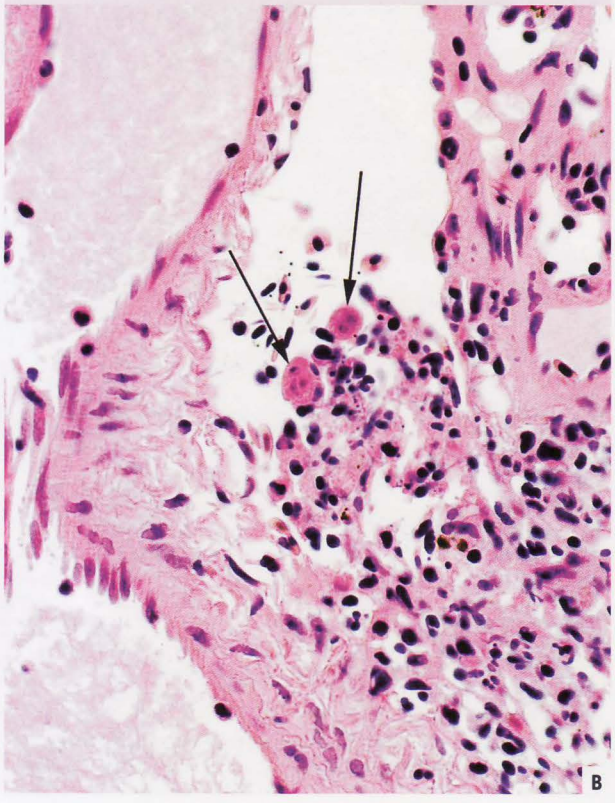

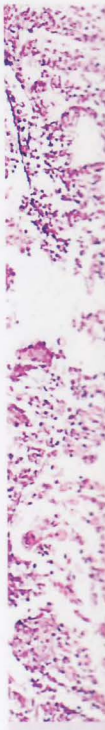

Fig 6.26. L
of parasit
also dama



Fig 6.27.
associate



Fig 6.26. Loma vasculitis in Atlantic salmon showing accumulations of parasites within the lumen of this branchial vessel (arrows) but also damage and thrombosis to the bottom of the image.

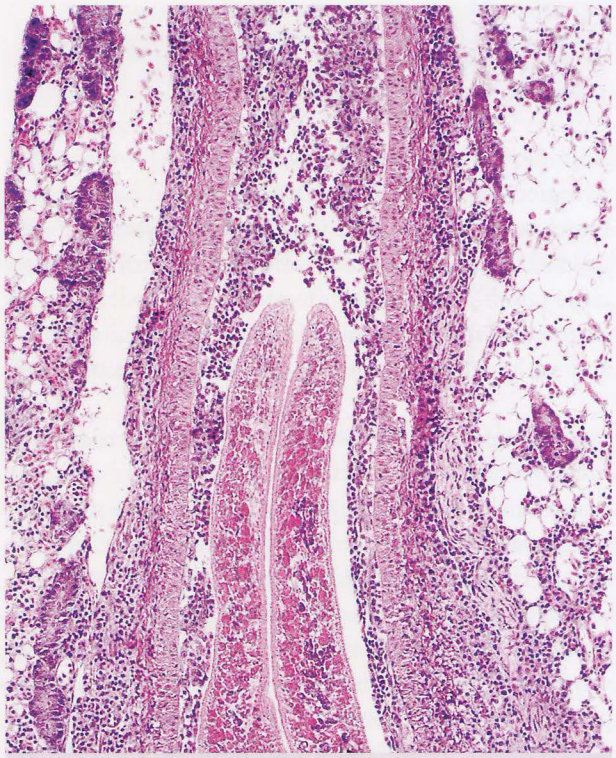

Fig 6.27. Sanguinicola fluke within mesenteric vessel of white sucker, associated with moderate inflammation of surrounding mesenteric fat.

redmouth disease) round the mouth **(Fig 6.18)**. In many bacteraemias, especially those associated with *Aeromonas salmonicida*, *Vibrio* spp., *Streptococcus* spp., yellow-pigmented bacteria (such as *Flexibacter* or *Tenacibaculum*) and *Renibacterium salmoninarum*, careful examination will frequently reveal septic thrombosis and occasional infarcts in a variety of tissues **(Fig 6.19)**. Some fish with *Renibacterium* infection may have extensive vascular involvement, lesions comprising necrosis of media and endothelium, with fibrin exudation or thrombosis as a consequence.

Most of the rhabdoviruses of fish also have an affinity for vascular endothelium, and consequently, the clinicopathological picture in such diseases is dominated, especially in the early stages, by punctate haemorrhaging and/or vasculitis. Vasculitis was seen in the recent outbreak of VHS in drum in Ontario. The orthomyxo-like virus of infectious salmon anaemia in Norway and Scotland typically produces pronounced haemorrhagic lesions in the liver. By contrast, the lesions in Canada are almost exclusively renal interstitial haemorrhage **(see Fig 4.25)**. Mycotic invasion of vessels is reported in branchiomycosis of cyprinids in which the fungus *Branchiomyces sanguinis* grows into the lumen of the branchial vessels. Other fungi, including *Saprolegnia* are occasionally seen in, or closely associated with blood vessels; this is notable in the gastrointestinal tract of small fish, but any vessel may be involved including the aorta **(Fig 6.20)**.

Aneurysms of branchial vessels (sometimes referred to as telangiectasis) are a common finding in a variety of circumstances, especially acute toxic exposure **(see Fig 2.12)**, but they are also easily produced by rough handling and euthanasia procedures (such as spinal severance). The aneurysms thrombose, fibrose and are eventually repaired. Dissecting aneurysms are occasionally encountered, especially in the bulbus arteriosus, possibly as a consequence of the marked stress and strain normally imposed on this highly distensible structure. Causes, or at least associated organisms, include bacteria **(Fig 6.21)** and digenetic metacercariae such as *Ascocotyle tenuicollis*, as reported in the mosquito fish (*Gambusia affinis*).

Punctate haemorrhage in most organs, including muscle, is also a feature of "haemorrhagic smolt syndrome" **(Fig 6.22)**. The aetiology of this sometimes alarming-looking condition, which occurs during smoltification in farmed Atlantic salmon, is not settled, although it has been linked to the presence of several viruses. Although poorly re-



Fig 6.28. Ova (arrow) within lumen of bulbus arteriosus. How they get here is unknown, but they are occasionally associated with limited vascular response, as seen here in this mummichog.

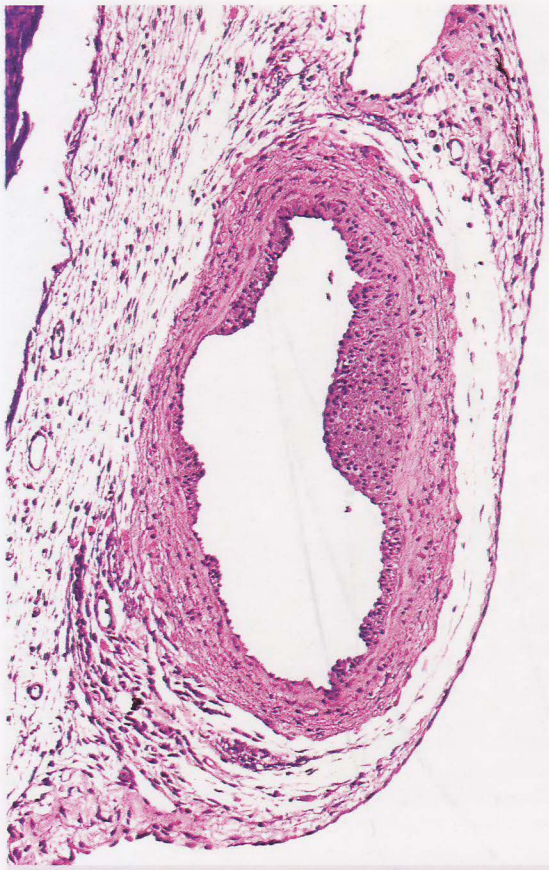

Myointimal hyperplasia ("arteriosclerosis") in salmonids. *Fig 6.29A.* Atlantic salmon broodfish with characteristic myointimal proliferation that bulges into the vascular lumen
Picture courtesy of Dr. S.L. Seierstad.

ported, associated lesions include often severe nephrosis and renal interstitial fibrosis. It is not known whether these are the direct result of oxidative damage from the associated haemoglobinuria and tubular haemorrhage. Fibrinoid necrosis of the afferent and efferent glomerular arterioles, similar in some respects to the Shwartzman reaction in mammals, is reported in white perch (*Morone americane*) ***(Fig 6.23)***. Although associated with subendothelial electron-dense deposits ***(see Fig 4.9)*** suggesting the possibility of an immune-complex mediated lesion, the cause and pathogenesis of the condition remain unknown.

Aortic thrombosis and stenosis are seen in salmonids, often associated with extrusion of disc material presumably via the vertebral arteries. The resulting paralysis due to spinal cord injury is compounded by hypoxia due to interference with aortic flow. Lesions are commonest at the main flexure point, just below the dorsal fin ***(Fig 6.24)***. As expected, posterior incoordination and paralysis are the clinical presentation, together with erosion of skin and tail fins. The cause of the condition, which may affect large numbers of fish, is often undetermined, although electrical discharge from lightning strike or that associated with faulty equipment should always be considered.

In proliferative kidney disease (PKD) of salmonids, macro-phages and lymphocytes cluster round the prespore myxozoan parasites; this response can occur within vessels, especially in the kidney but also elsewhere, and the cellular aggregates, closely apposed to or possibly coming through the endothelium, can be so extensive as to suggest obliteration of the lumen ***(Fig 6.25)***. The microsporidian *Loma* has caused endarteritis of epizootic proportions in juvenile chinook salmon. Pathological changes include acute inflammation, necrosis and eventual obliteration of the vessel lumen leading to infarction of tail muscles. Gill vessels may also be affected ***(Fig 6.26)***.



Fig 6.29B. SEM of 2 myointimal nodules. Note minimal disruption of the vessel. *Picture courtesy of Dr. E.O. Koppang.*

Adult sanguinicolid flukes, for example *Sanguinicola inermis* residing in the branchial and other vessels **(*Fig 6.27*)**, release eggs that hatch in the gill capillaries. These then migrate out of the vessels causing haemorrhage and possibly death; low water temperatures are reported to slow hatching with endothelial proliferation and encapsulation a possible consequence. Eggs may also be found in the kidney where they may cause renal dysfunction. Host ova are sometimes found in vessels, as an incidental observation **(*Fig 6.28*)**.

The "sand-grain grub" is the metacercaria of the heterophyid trematode *Apophallus brevis*. It is found in yellow perch, causing bony cysts within the lumen of the peripheral vasculature, especially of the axial musculature, but also of the extrinsic muscles of the eye. Of interest are the concentric rings within the bone suggesting annual growth increments as seen in scales and other bony structures in fish.

Arteriosclerosis. This condition has evoked considerable interest, not least because of the obvious parallels to the disease with the same name in human medicine. Characteristic lesions are described from the coronary artery of several salmonid species where the lesions typically occur near the bifurcation of the vessel ventrally on the bulbus arteriosus. This lesion occurs so commonly that it can be questioned whether it is a true pathological condition and it is tempting to call it "a normal abnormality" or a "fact of life" that appears to be equally common in farmed and wild fish. Lesions are characterized by proliferation of smooth muscle cells (myointimal hyperplasia) with disruption of the elastic lamina **(*Fig 6.29*)**. They protrude into the vascular lumen and may occlude as much as 50% of the vessel lumen. The lesions may resemble early mammalian arteriosclerosis, but calcium and lipid inclusions are not found in such lesions in fish. Numerous researchers have looked into the aetiology of this condition. Present consensus appears to be that there is a link to fast growth resulting in stress on the bulbus arteriosus and thereby stretching (overstretching?) of the coronary artery with subsequent vascular injury. Enhanced growth rate therefore appears to increase the rate of development of these lesions. Sexual maturation apparently plays a secondary role as injection of sex hormones may increase the number and severity of lesions. Lesion severity and prevalence appear to accumulate as the fish get older and mature sexually. The physiological significance of the lesions are unclear, but it is well known that intact coronary circulation is important for the maximum performance of *in vitro* perfused hearts. This circulation is therefore particularly important when the heart is working hard and under hypoxic conditions. In rare cases, the coronary artery may become totally blocked with resultant necrosis and dystrophic calcification of the outer compact myocardium. It has been experimentally shown in rainbow trout that new vessel growth can re-establish coronary blood flow following ablation of the coronary artery. Spontaneous intimal proliferations are also described in pike.

REFERENCES

Amin, A.B. and Poppe, T.T. (1989) Subendocardial fibroelastosis in Atlantic salmon: A case report. *Bulletin of the European Association of Fish Pathologists* 9:86-87.

Agnisola, C. and Tota, B. (1994) Structure and function of the fish cardiac ventricle: Flexibility and limitations. *Cardioscience* 5:145-153.

Bell, J.G., Dick, J.R., Sargent, J.R. and McVicar, A.H. (1992) Dietary linoleic acid affects phospholipids fatty acid composition in heart and eicosanoid production by cardiomyocytes from Atlantic salmon (*Salmo salar*). *Comparative Biochemistry & Physiology A* 103:337-342.

Blanco, C., Lopez, D., de Andres, A.V., Schib, J.L., Gallego, A., Duran, A.C. and Sans-Coma, V (2001) Cartilage in the bulbus arteriosus of teleostean fishes. *Netherlands Journal of Zoology* 51:361-370.

Boucher, P. and Baudin Laurencin, F. (1996) Sleeping disease and pancreas disease: comparative histopathology and acquired cross-protection. *Journal of Fish Diseases* 19:303-310.

Brocklebank, J. and Raverty, S. (2002) Sudden mortality caused by cardiac deformities following seining of preharvest farmed Atlantic salmon (*Salmo salar*) and by cardiomyopathy of postintraperitoneally vaccinated Atlantic salmon parr in British Columbia. *Canadian Veterinary Journal* 43:129-130

Brodeur, J.C., Ytrestøyl, T., Finstad, B. and Scott McKinley, R. (1999) Increase of heart rate without elevation of cardiac output in adult Atlantic salmon (*Salmo salar*) exposed to acidic water and aluminium. *Canadian Journal of Fisheries and Aquatic Sciences* 56:184-190

Claireaux, G., McKenzie, D., Gaylene Genge, A., Chatelier, A., Aubin, J. and Farrell, A.P. (2005) Linking swimming performance, cardiac pumping ability and cardiac anatomy in rainbow trout. *The Journal of Experimental Biology* 208:1775-1784

Coucelo, J., Coucelo, J. and Azevedo, J. (1996) Ultrasonography characterization of heart morphology and blood flow of lower vertebrates. *The Journal of Experimental Zoology* 275:73-82

Farrell, A.P. (2002) Coronary arteriosclerosis in salmon: growing old or growing fast? *Comparative Biochemistry and Physiology Part A* 132:723-735.

Farrell, A.P. (1990) From hagfish to tuna: a perspective on cardiac function in fish. *Physiological zoology* 64:1137-1164

Farrell, A.P. and Jones, D.R. (1992) The Heart. ***in*** *Fish Physiology*, Vol. XIIA. (***eds.*** Hoar, W.S., Randall, D.J. and Farrell, A.P.) pp 1-88. Academic Press, San Diego.

Ferguson, H.W. (1975) Phagocytosis by the endocardial lining cells of the atrium of plaice (*Pleuronectes platessa*). *Journal of Comparative Pathology* 85:561-569.

Ferguson, H.W., Kongtorp R.T., Taksdal, T., Graham, D. and Falk, K. (2005) An outbreak of disease resembling heart and skeletal muscle inflammation in Scottish farmed salmon, *Salmo salar* L., with observations on myocardial regeneration. *Journal of Fish Diseases* 28: 119-123.

Ferguson, H.W., Rice, D.A. and Lynas, J.K. (1986) Clinical pathology of myodegeneration ("pancreas disease") in Atlantic salmon (*Salmo salar*). *Veterinary Record* 119:297-299.

Ferguson, H.W., Poppe, T.T. and Speare, D.J. (1990) Cardiomyopathy syndrome in farmed Norwegian salmon *Salmo salar.* *Diseases of Aquatic Organisms* 8:225-231.

Ferguson, H.W., Roberts, R.J., Richards, R.H., Collins, R.O. and Rice, D.A. (1986) Severe degenerative cardiomyopathy associated with pancreas disease in Atlantic salmon, *Salmo salar* L. *Journal of Fish Diseases* 9:95-98.

Franklin, C.E. and Axelsson, M. (1994) Coronary hemodynamics in elasmobranchs and teleosts. *Cardioscience* 5:155-161.

Gamperl, A.K. and Farrell, A.P. (2004) Cardiac plasticity in fishes: environmental influences and intraspecific differences. *The Journal of Experimental Biology* 207:2539-2550.

Gattuso, A., Mazza, R., Imbrogno, S., Sverdrup, A., Tota, B. and Nylund, A. (2002) Cardiac performance in *Salmo salar* with infectious salmon anaemia (ISA): putative role of nitric oxide. *Diseases of Aquatic Organisms* 52:11-20.

Graham, M.S. and Farrell, A.P. (1992) Environmental influences on cardiovascular variables in rainbow trout, *Oncorhynchus mykiss* (Walbaum). *Journal of Fish Biology* 41:851-858.

Grotmol, S., Totland, G.K. and Kryvi, H. (1997) Detection of a nodavirus-like agent in heart tissue from reared Atlantic salmon *Salmo salar* suffering from cardiac myopathy syndrome (CMS). *Journal of Fish Diseases* 29:79-84.

Hennet, T., Peterhans, E., and Stocker, R. (1992) Alterations in antioxidant defences in lung and liver of mice infected with influenza A virus. *Journal of General Virology* 73:39-46.

Kongtorp, R.T., Kjerstad, A., Taksdal, T., Guttvik, A. and Falk, K. (2004) Heart and skeletal muscle inflammation in Atlantic salmon, *Salmo salar* L.: a new infectious disease. *Journal of Fish Diseases* 27:61-63.

Kongtorp, R.T., Taksdal, T. and Lyngøy, A. (2004) Pathology of heart and skeletal muscle inflammation (HSMI) in farmed Atlantic salmon *Salmo salar*. *Diseases of Aquatic Organisms* 59:217-224.

Kaada, I. and Hopp, P. (1995) Laks med deformerte hjerter og midannede hjertesekker (Salmon with heart deformities and abnormal pericardial sacs). *Bulletin of the Norwegian Veterinary Association* 107:773-776.

Maisch, B., Risti, A.D., Hufnagel, G. and Pankuweit, S. (2002) Pathophysiology of viral myocarditis. The role of humoral immune responses. *Cardiovascular pathology* 11:112-122.

McLoughlin, M., Nelson, R.N., Rowley, H.M., Cox, D.I. and Grant, A.N. (1996) Experimental pancreas disease in Atlantic salmon *Salmo salar* post-smolts induced by salmon pancreas disease virus (SPDV). *Diseases of Aquatic Organisms* 26:117-224.

Mercier, C., Aubin, J., Lefrancois, C. and Claireaux, G. (2000) Cardiac disorders in farmed adult brown trout, *Salmo trutta* L. *Journal of Fish Diseases* 23:243-249.

Muller, F. (1992) Reactive oxygen intermediates and human immunodeficiency virus (HIV) infection. *Free Radical Biological Medicine* 13: 651-657.

Munro, A.L.S., Ellis, A.E., McVicar, A.H., McLay, H.A. and Needham, E.A. (1984) An exocrine pancreas disease of farmed Atlantic salmon in Scotland. *Helgolander Meeresuntersungen* 37: 571-586.

Nelson, R.T., McLoughlin, M.F., Rowley, H.M., Platten, M.A. and McCormick, J.I. (1995) Isolation of a toga-like virus from farmed Atlantic salmon *Salmo salar* with pancreas disease. *Diseases of Aquatic Organisms* 22:25-32.

Olson, K.R.(2000) Circulatory system. ***In:*** *The Laboratory Fish* ***ed.*** Ostrander pp 161-171 and 369-378. Academic Press, San Diego.

Peterhans, E. (1979) Sendai virus stimulates chemiluminescence in mouse spleen cells. *Biochemistry and Biophysiology Research Communications* 91:383-392.

Peterhans, E., Grob, M., Burge, T. and Zanoni, R. (1987) Virus-induced formation of reactive oxygen intermediates in phagocytic cells. *Free Radicle Research Communications* 3:39-46.
Poppe, T.T., Johansen, R. and Tørud, B. (2002) Cardiac abnormality with associated hernia in farmed rainbow trout *Oncorhynchus mykiss*. *Diseases of Aquatic Organisms* 50:153-155.
Poppe, T.T., Midtlyng, P. and Sande, R.D. (1998) Examination of abdominal organs and diagnosis of deficient septum transversum in Atlantic salmon, *Salmo salar* L., using diagnostic ultrasound imaging. *Journal of Fish Diseases* 21:67-72.
Poppe, T.T. and Seierstad S.L. (2003) First description of cardiomyopathy syndrome (CMS)-related lesions in wild Atlantic salmon *Salmo salar* in Norway. *Diseases of Aquatic Organisms* 56:87-88.
Poppe, T.T. and Taksdal, T. (2000) Ventricular hypoplasia in farmed Atlantic salmon *Salmo salar*. *Diseases of Aquatic Organisms* 42:35-40.
Poss, K., Wilson, L. and Keating, M. (2002) Heart regeneration in zebra fish. *Science* 298:2188.
Powell, M.D., Nowak, B.F. and Adams, M.B. (2002) Cardiac morphology in relation to amoebic gill disease history in Atlantic salmon *Salmo salar* L. *Journal of Fish Diseases* 25:209-215
Rahkonen, R., Aalto, J., Koski, P., Särkkä, J. and Juntunen, K. (1996) Cestode larvae *Diphyllobothrium dendriticum* as a cause of heart disease leading to mortality in hatchery-reared sea trout and brown trout. *Diseases of Aquatic Organisms* 25:15-22.
Richards, R.S., Roberts, T.K., McGregor, N.R., Dunstain, R.H. and Butt, H.L. (2000) Blood parameters indicative of oxidative stress are associated with symptom expression in chronic fatigue syndrome. *Redox Report* 5:35-41.
Sanchez-Quintana, D., Garcia-Martinez, V., Climent, V. and Hurle, J.M. (1995) Morphological analysis of the fish heart ventricle: Myocardial and connective tissue architecture in teleost species. *Annals of Anatomy* 177:267-274.
Sande, R.D. and Poppe, T.T. (1995) Diagnostic ultrasound examination and echocardiography in Atlantic salmon (*Salmo salar*). *Veterinary Radiology and Ultrasound* 36:551-558.
Shima, T. and Namba, K. (1996) Roles of the pectoral musculoskeletal framework and the pericardium in cardiac function in carp. *Fisheries Science* 62:715-718.
Sorensen, K.K., Melkko, J. and Smedsrod, B. (1998) Scavenger-receptor-mediated endocytosis in endocardial cells of Atlantic cod *Gadus morhua*. *Journal of Experimental Biology* 201:1707-1718.
Stegeman, J.J., Miller, M.R. and Hinton, D.E. (1989) Cytochrome p450IA1 induction and localization in endothelium of vertebrate (teleosts) heart. *Molecular Pharmacology* 36:723-729.
Tota, B. and Gattuso, A. (1996) Heart ventricle pumps in teleosts and elasmobranchs: A morphodynamic approach. *The Journal of Experimental Zoology* 275:162-171.

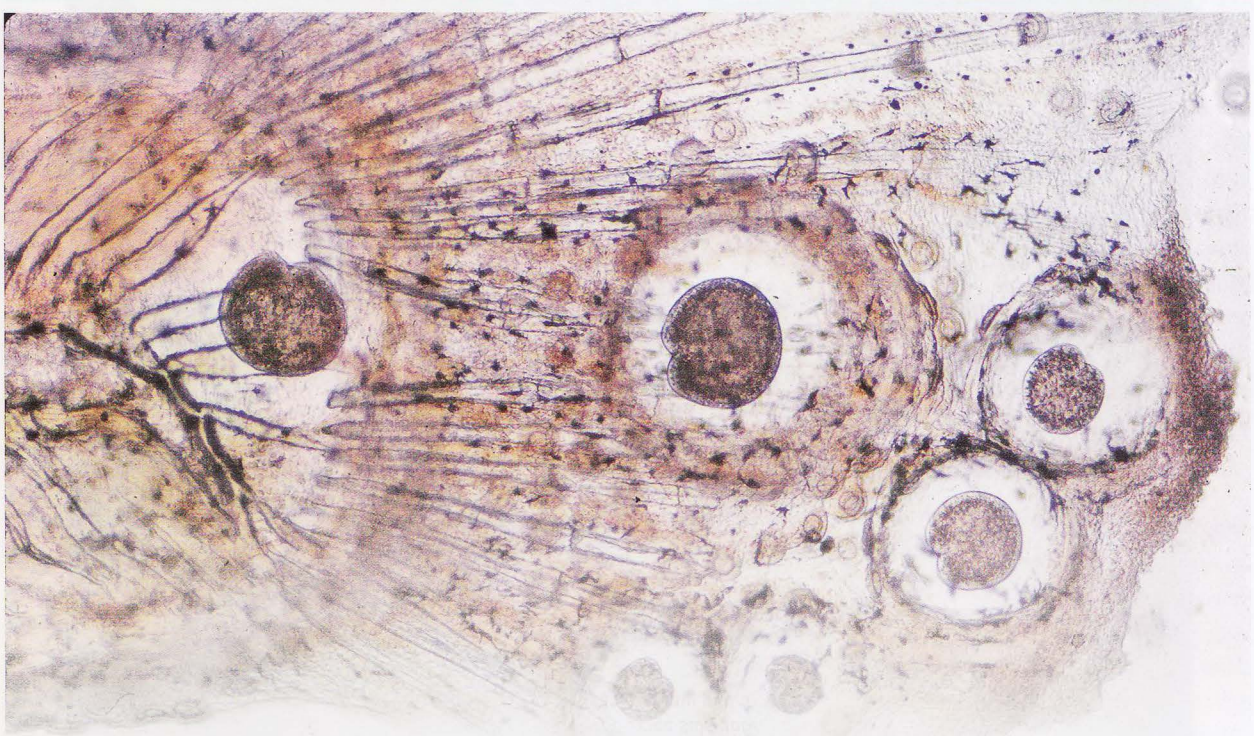





Gastrointestinal Tract, Swimbladder, Pancreas and Peritoneum

CHAPTER 7

by John S. Lumsden

Gastrointestinal tract

The great variety of ecological niches occupied by teleosts is reflected in the diversity of patterns of organization of their gastrointestinal (GI) tract. Compared to mammals, the teleost GI tract is histologically simple, probably because it is so easy to provide an aqueous vehicle for the digestive products and also because in some species at least, the rate of digestion can be slow; hence less complex digestive glands and a less well-developed muscular apparatus are needed.

The oral cavity and pharynx are lined by a thin stratified squamous epithelium containing abundant mucus-secreting cells. Fungiform and filiform papillae may be found, and most species have teeth that vary greatly in shape; some species have isodont dentition (all teeth alike in shape) while others are heterodonts. The tooth consists of an enamel coating, a dentine layer and a pulp core. Pharyngeal teeth are common in herbivores or molluscivores and this area may appear segmentally enlarged on gross examination but this is normal.

The oesophagus is short and thick-walled, the muscularis comprising interweaving striated muscle fibres that may extend as far as the stomach. The stratified cuboidal or columnar epithelium may be ciliated, and it contains numerous goblet cells and occasionally taste buds. In addition, multi-cellular serous or cardiac glands may be found posteriorly. The mucosa is thrown into longitudinal folds that end at the stomach, giving way to rugae. The serosa contains prominent nerve fibres of the vagus.

The stomach itself is highly variable and indeed is absent entirely in most larvae and about 15% of all adult species (a good example of this is the cyprinids). Where present, the gastric mucosa typically contains both fundic and pyloric glands. The submucosa of some species contains large numbers of coarse eosinophilic granular cells, in addition to lymphatics, blood vessels and nerve fibres. The stomach and the remainder of the intestinal tract have circular and longitudinal folds of smooth muscle. The stomach is highly distensible, particularly in fish that consume few but large meals such as the deepwater predator *Chiasmodon niger* (black swallower), and the size of the stomach within individuals of the same species can vary with the type of commercial diet that is fed. Gastrointestinal physiology is largely comparable between fish and mammals. Control of motility is complex and similar to mammals as it is influenced by the presence of food, by numerous hormones and by autonomic nervous control. One major difference is that the stomach of some fish (salmonids for example), secrete acid predominantly in response to a stimulus (ingesta). This may be one reason why there are few or no lesions associated with gastric hyperacidity apart from those questionable publications correlating gastric erosion with consumption of biogenic amines.



Fig 7.1A. Necrotic stomatitis in a shiner caused by *Flavobacterium columnare*. Similar lesions are common in aquarium species, the bacteria often growing to produce a grossly visible matt, the so-called "cotton-wool mouth".

As in mammals, carnivores tend to have a shorter intestine than herbivores and in these latter species there is extensive coiling, and possibly large caecal pouches designed for fermentative microbial digestion. Many species have pyloric caeca, blind-ending diverticula with multi-folded intestinal-type epithelium, located at the anterior end of the intestine. Some species have longitudinal folding of the mucosa, but only a few have anything resembling the intestinal villi of mammals. Additional-

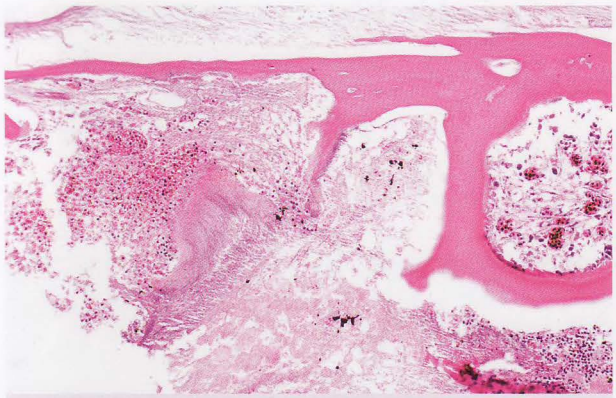

Fig 7.1B. Ulceration of the oral epithelium with filamentous bacterial invasion of periodontal and periosteal connective tissue and necrosis of bone.



Fig 7.2A. Atlantic salmon with focal necrotizing stomatitis (dermatitis and cellulitis) caused by *Tenacibaculum maritimum*. Note the distinctive plaques of yellow pigmentation often present on the edges of these lesions. A similar pigmentation is often seen associated with lesions of coldwater disease caused by *Flavobacterium psychrophilum*.

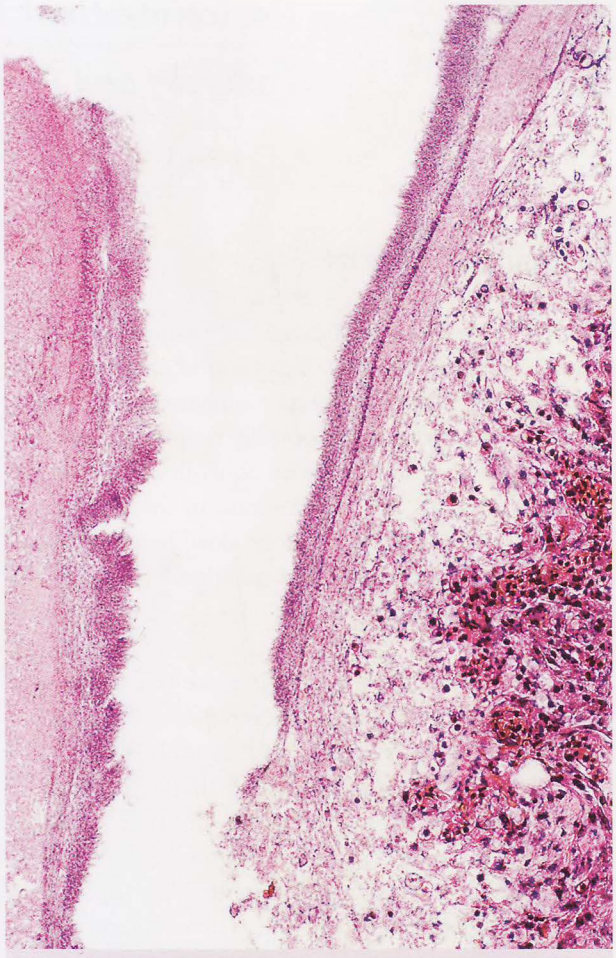

Fig 7.2B. Seabass with ulceration of oral epithelium and infiltration of subepithelial collagen by filamentous bacteria (again probably *Tenacibaculum* spp.) with prominent dermal oedema and haemorrhage.

ly, there are no distinct crypt compartments in fish and hence alteration of the villous/crypt ratio, a very common hallmark of diarrhoeic disease of mammals, cannot occur in most fish. Alterations in intestinal epithelial differentiation (altered epithelial generation and/or loss from fold tips) do occur in fish but investigation of this phenomenon requires techniques such as morphometrics. The variability in intestinal fold height (complex *vs.* simple folds) also adds to the challenge.

The mucosa is not divisible into regions on the basis of histology *i.e.* the small and large intestine of mammals is not present, although a rectum is present and in some species this is separated by a connective tissue annulus ("intestinal valve"). There may, however, be some functional differentiation, with the proximal, middle and distal segments specializing in lipid, protein and ionic regulation respectively. The mucosal lining is of simple columnar type, the cells possessing microvilli (forming the brush border) and in some species, occasional cilia. Lymphocytes and rodlet cells are not uncommon in the mucosa and nor are apoptotic cells. These latter represent effete cells phagocytosed by adjacent viable ones, the remnants appearing as brightly eosinophilic spherical inclusions; they are especially prominent during periods of starvation. Such physiologically "normal" opposites of mitosis should not be mistaken for parasites nor for viral inclusions. The lamina propria and submucosa of several species contain large numbers of eosinophilic granular cells and variable quantities of lymphoid tissue. The role of eosinophilic granular cells, which in some respects are analogous to mucosal mast cells and stain similarly, is becoming clearer. They contain antimicrobial peptides and degranulation can increase vascular permeability and

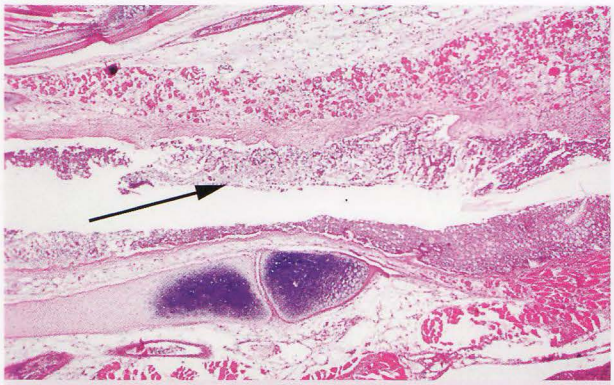

Fig 7.3. Mycotic oesophagitis in Atlantic salmon fry. The mucosa is virtually replaced by fungal hyphae (arrow).

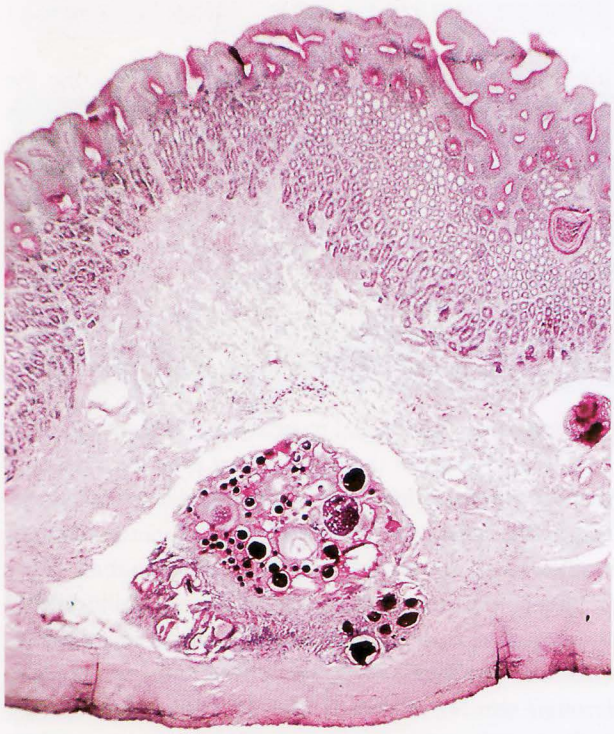

Fig 7.4. Stomach wall from a flounder with systemic "mycosis". Note the variably-sized PAS-positive *Ichthyophonus*-type spores within distended submucosal vessels with resultant oedema/thrombosis.

promote neutrophil adhesion, suggesting that they are intimately involved in innate immunity and inflammation. Their role in altering gastrointestinal motility and intestinal permeability requires further study including their involvement in mucosal hypersensitivity responses, which are also poorly understood. In general, many of those species without a stomach tend to have greater quantities of lymphoid tissue than those that have one (an attempted compensation for increased antigenic exposure?). A random sampling of clinically healthy cyprinids for example, may reveal a marked variability in the cellular population of the lamina propria and submucosa. The cells are usually lymphocytes with fewer macrophages and variable numbers of eosinophilic granular cells and care should be exercised regarding the over-interpretation of the significance of this cellular population in the construction of a diagnosis of enteritis.

Disease

Oral cavity. Lesions of the mouth, jaw and rostrum, even those primarily affecting the external epithelium and dermis are often dealt with under the oral cavity. A classic example is enteric redmouth caused by *Yersinia ruckeri*, in which there is often marked reddening, caused by petechial haemorrhage and hyperaemia of the jaw. The disease is primarily a bacterial septicaemia with faecal shedding from subclinical carriers posing a significant risk for transmission of the organism. While enteric redmouth is the best-known example, similar lesions of the jaw caused by bacterial septicaemias are not uncommon, for instance with *Vibrio splendidus* infection in farmed turbot. Metacercariae of *Bucephalus polymorphus* can induce inflammation in the subcutis of the oral cavity, but a more impressive lesion is that caused by the isopod crustacean *Cymothoa exigua*, which attaches to, feeds from, and eventually replaces the tongue of its host.

The oral cavity is a relatively common location for growth of *Flavobacterium columnare*. This condition is known as "cotton-wool mouth" in the aquarium hobby and appears as the name suggests. Walleye raised in Ontario undergo a massive die-off shortly after starting on commercial crumble feeds at an approximate weight of 0.5g. Mortality can approach 40% and the fish have marked ulceration of the oral mucosa. The histopathology is similar to that described for the skin except that relatively small lesions are fatal, in part due to inability of the fish to eat and subsequent rapid starvation. The paucity of underlying tissue means that the lesion progresses to the mandible and maxillae quickly, with marked water-logging of the remaining tissue. Similar lesions have been described in salmonids (*Fig 7.1*). Abrasion of the oral mucosa by feed is possibly the predisposing incident and the lesions can progress as far as the oesophagus. Fungi can produce a similar reaction and occasionally hyphae may also be seen intermingled with the filamentous bacteria.

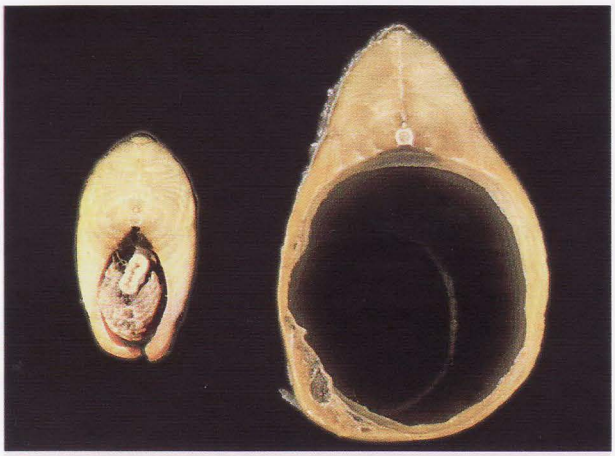

Fig 7.5. Dramatic gastric dilation in a Chinook salmon smolt with GDAS and a normal age and sized-matched fish. Both of these fish had been in seawater for three weeks. Note the compression of the peritoneal organs.

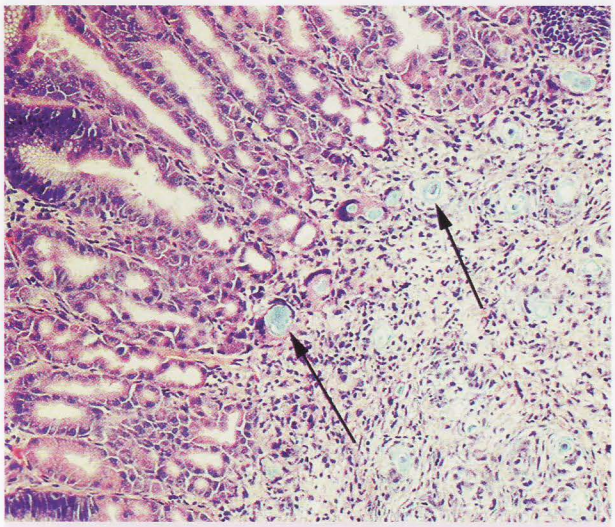

Fig 7.6. Stomach wall from a cage-reared rainbow trout with numerous foci of mineral in the lamina propria (arrows). These deposits are associated with a granulomatous response, that includes giant cells.

Necrotizing stomatitis is a significant disease of Atlantic salmon in seawater that is caused by *Tenacibaculum maritimum* (formerly *Flexibacter maritimus*). There is necrotizing glossitis and stomatitis that can progress to a necrotizing cellulitis with osteitis/chondritis and may be severe enough to perforate the ventral jaw. The lesion seems to start adjacent to teeth **(*Fig 7.2*)**. Histologically, the lesions and the morphology of the organism are generally similar to those of columnaris disease, and can be just as hard to see in H&E sections, particularly when low numbers are present. Gram stains, or modified Gram stains are also not often very revealing with Giemsa typically the most useful.

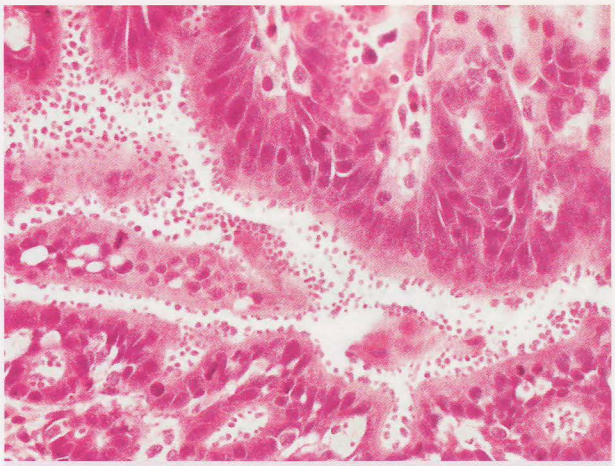

Fig 7.7A. Very numerous epicellular 5-10µm organisms in the stomach of a pot-belly seahorse. The epithelium is minimally hyperplastic. *Courtesy of Dr. S. Russell.*

Idiopathic "jaw ulcers" have been described affecting the maxilla of wild Atlantic tomcod and also the mandible of wild smelt. The lesions in the tomcod are typically a focal necrotizing dermatitis with extensive granulomatous subepidermal inflammation that often extends into the maxilla producing a granulomatous osteitis that deforms the upper jaw. The cause of these lesions is not determined but the prevalence in wild fish is relatively high (in one study, 3.8% of 1674 fish).

Oesophagus. The skeletal muscle of the oesophagus may be affected by any of the diseases that produce a generalized myopathy. An example is pancreas disease of salmon where impairment of function (leading to an inability to swallow) may or may not occur depending on the severity of the lesion, but would potentially create difficulty in movement of food to the stomach and perhaps interference with pneumatic duct function. Mycotic oesophagitis is often seen in salmonids and other fry. Although the pathogenesis is unknown, it may relate to impaction of the oesophagus by an incorrect food particle size with secondary fungal involvement **(*Fig 7.3*)**.

Stomach. The stomach and intestine are well vascularized and possess extensive secondary vascular channels that drain the mucosa. These vessels are relatively indistinct in normal tissues but can become prominent in bacteraemia/viraemias. They will be dilated and congested/hyperaemic or may contain thrombi. The submucosal blood vessels are a particularly common location for vascular alterations associated with septicaemias. Viruses that target the endothelium, such as the rhabdoviruses that cause viral

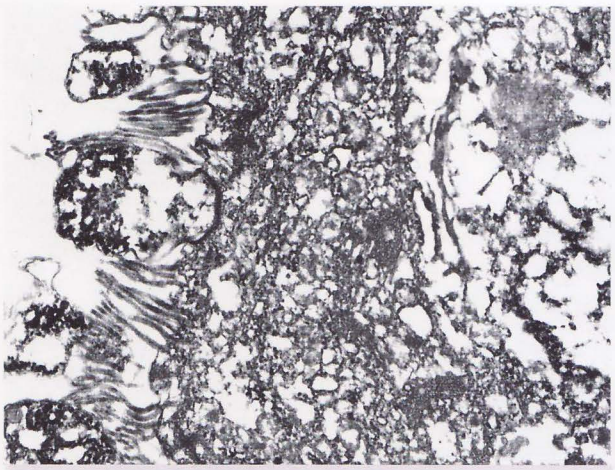

Fig 7.7B. A *Cryptosporidium*-like organism from the stomach of another seahorse that is displacing the microvilli.
Courtesy of Dr. S. Frasca.



"Cichlid bloat" (CB) in African cichlids.
Fig 7.8A. Cichlid showing marked abdominal distension.



Fig 7.8B. Stomach from fish with CB showing multifocal granulomas distending the lamina propria.

haemorrhagic septicaemia (VHS) and infectious haematopoietic necrosis (IHN), can cause extensive vascular damage and thrombosis, but the transmural gastric infarctions associated with disseminated intravascular coagulation (DIC) commonly seen in mammals, do not seem to occur in fish. An example of a systemic disease that affects the gastric submucosa is to be seen with the North American isolates of VHSv, which also cause hepatocellular necrosis and meningoencephalitis in wild Pacific herring. Freshwater drum in Lake Ontario recently experienced a major die-off associated with a North American strain of VHSv. Affected fish typically had an extensive multi-systemic fibrinoid vasculitis with thrombosis, a feature typical of this virus group's endotheliotropic nature. While the heart and brain were the major targets, the GI vessels of the lamina propria and submucosa were also affected.

Granulomas caused by piscine mycobacteriosis are commonly found in the stomach and elsewhere in the intestine but are often incidental findings. These GI granulomas are rarely adjacent to the mucosa so the policy of screening faeces for acid-fast organisms to eliminate carriers is probably not useful, although it has been proposed in hobby circles and on the internet.

Mycotic gastritis is relatively common in a wide range of species and particularly affects larval fish. *Saprolegnia*, *Phoma*, the yeast *Candida*, and a range of other groups, have been reported to produce a necrotizing gastritis, and (pseudo)hyphae are visible in the mucosal remnants with invasion into deeper tissues and systemically. These are distinct from the systemic diseases that localize in the submucosal vessels **(*Fig 7.4*)** and elsewhere such as *Exophiala salmonis*. In those cases where invasion is via the gastric lumen with primary mucosal necrosis, likely associations, particularly in larval fish, would be dietary alterations and/or heavy environmental contamination.

Gastric dilation and air sacculitis (GDAS) has been described under a variety of names, but most commonly, the

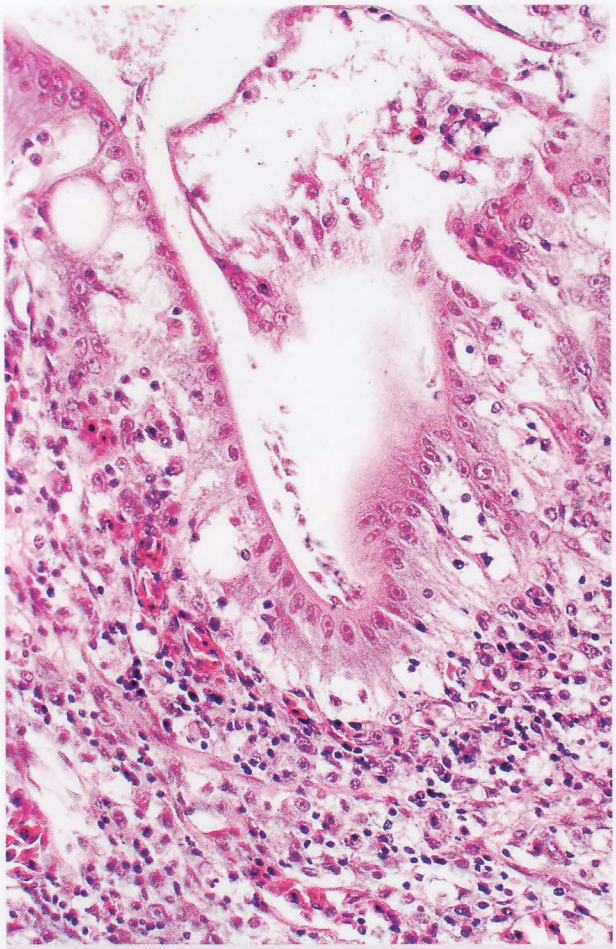

Fig 7.8C. Flagellated protozoa typical of *Cryptobia* in lumen of stomach from fish with CB.

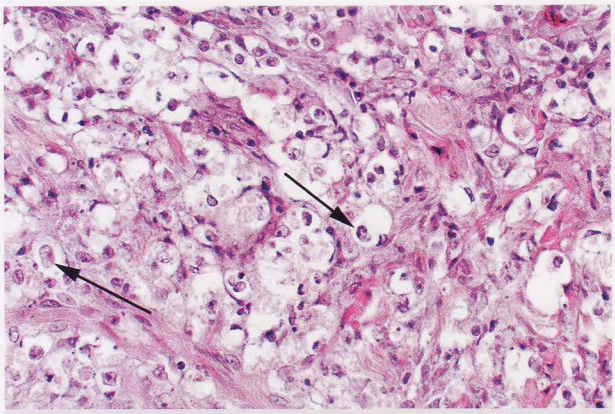

Fig 7.8D. Some CB gastric granulomas are associated with flagellated protozoa (possibly *Cryptobia*) - arrows.



Fig 7.8E. TEM of formalin-fixed tissue from **D** showing protozoa with flagellum typical for *Cryptobia*.

colloquial term "bloat" is used. Affected fish have a flaccid, dilated, thinned and enlarged stomach or a fluid-filled enlarged swimbladder, or most commonly, both abnormalities. Very poor production performance occurs in affected Chinook salmon in New Zealand. Spectacularly affected fish (*Fig 7.5*) can be veritable dirigibles, and when netted, the body wall ruptures. The stomach typically contains large amounts of oil that is regurgitated onto the water surface, usually the first symptom of the condition. By contrast, histological lesions are not so dramatic and are limited to dilation of the lumen, diminished or absent rugal folds, and thinning of the muscularis. Epithelial erosion or ulceration is consistently absent and no nerve lesions are noted. The proximal intestine is occasionally dilated as well. The pathophysiology of GDAS is not completely clear. The condition has been related to diet and those diets that activate the "ileal brake" delay gastric emptying and promote GDAS. Gastric motility *per se* is relatively normal even in fish that are moderately to severely affected.

There appear to be at least four different "bloat" pre-sentations in farmed salmonids. GDAS can be separated from the remaining presentations by the consistent involvement of the swimbladder in affected populations. There is a form of bloat that is basically pica, occurring relatively commonly on the West coast of Canada, and probably any other area where logging or similar practices occurs. Affected fish often have wood chips lodged at the pylorus. Inflammation due to intraperitoneal vaccination (see later)

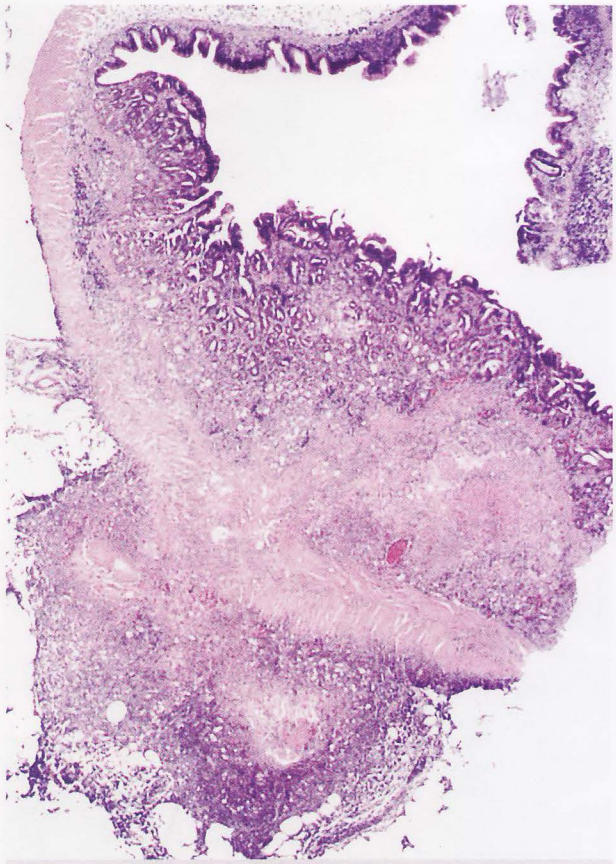

Spironucleosis in Siamese fighting fish (A,B) and angelfish (C). *Fig 7.9A.* Stomach showing severe full-thickness gastritis and perforation with large granuloma on serosal surface.

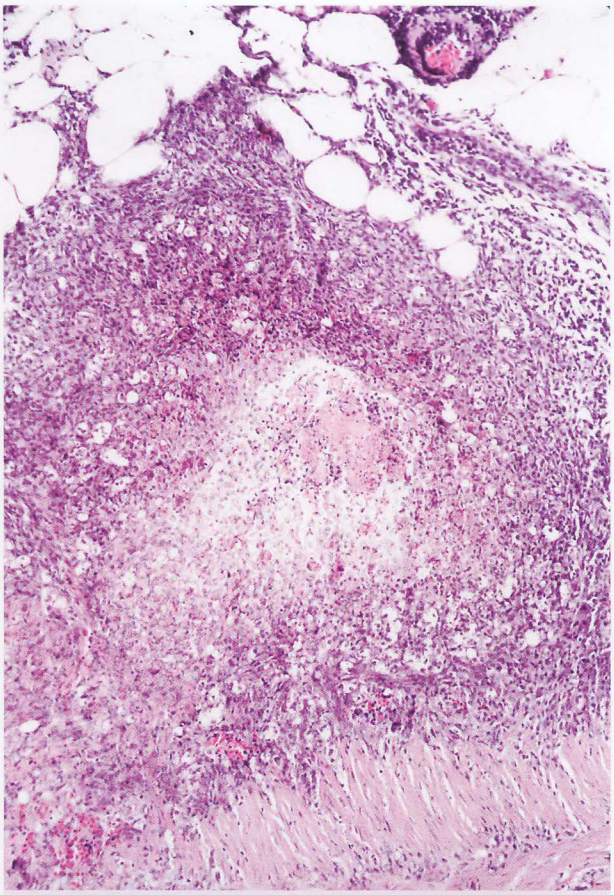

Fig 7.9B. High power view of serosal response showing necrotic core.

can be so extensive as to cause constrictive fibrosis that impinges on the pylorus leading to a similar presentation with or without pica. A third syndrome ("water belly") is described in Atlantic salmon that appears to be closely related to osmotic stress and can be exacerbated by cold temperatures. This form is not thought to be related to diet and can apparently resolve in some instances. The last syndrome is not well described but seems to occur sporadically in more than one cultured salmonid species in seawater. This condition presumably involves gastric dilation and is said to resolve with short-term starvation. A detailed pathological description of these latter forms is required. The original study linking gastric dilation with diets containing excessive biogenic amines has not been repeated.

Salmonids in seawater can have deposition of mineral (amorphous to granular basophilic material) in the submucosa of the stomach (*Fig 7.6*). If there are only small amounts, it may be difficult to detect with little or no associated inflammation. Such fish often have nephrocalcinosis, although very extensive mineralization with granulomatous inflammation, effacement of the lamina propria, and in extreme cases ulceration of the mucosa, can occur in fish without any evidence of renal tubular mineralization.

Parasites are relatively commonly found in the stomach. These may be apparently incidental such as the epicellular and mucosal piscicryptosporidia (*Fig 7.7*) of cichlids and other fish, and numerous microsporidians and myxozoans. These latter are mostly well-adapted to their hosts and usually cause only a space-occupying effect with the formation of cysts, xenomas or sporophorocysts in the cells of the muscular layers. Examples include *Glugea* and *Myxobolus*. Submucosal granulomatous gastritis is also seen in *Haemogregarina sachai* infections of turbot and *Anisakis simplex* infections in cod. If the lesions induced are particularly expansive they may produce atrophy of the gastric glands. Some can produce significant clinical disease.

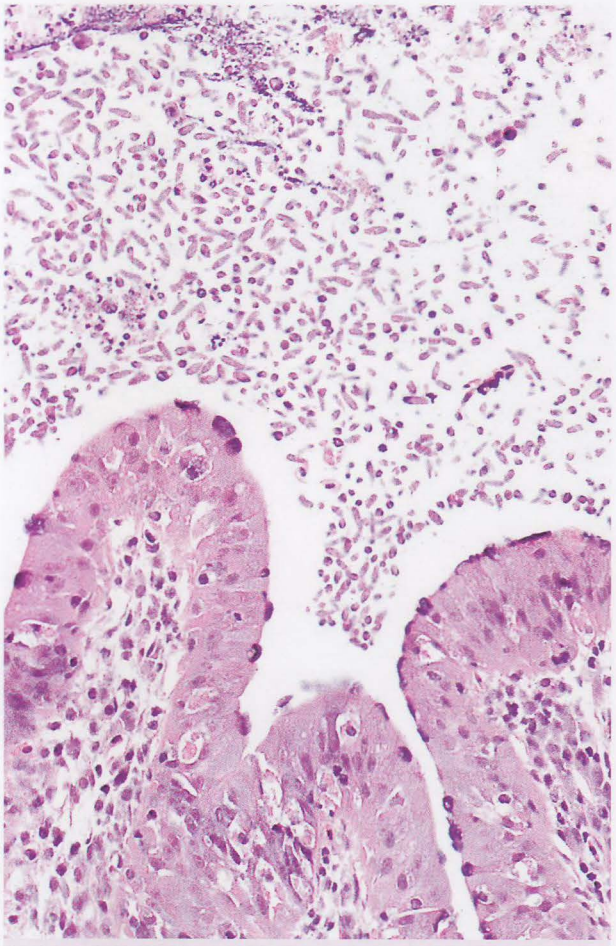

Fig 7.9C. Angelfish showing typical appearance of *Spironucleus* in GI lumen.

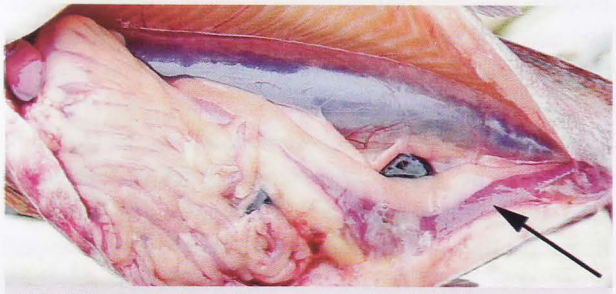

Fig 7.10A. Catarrhal enteritis in a rainbow trout with "summer enteritis" showing congestion of distal intestine (arrow). *Picture courtesy Dr. J. Turnbull.*

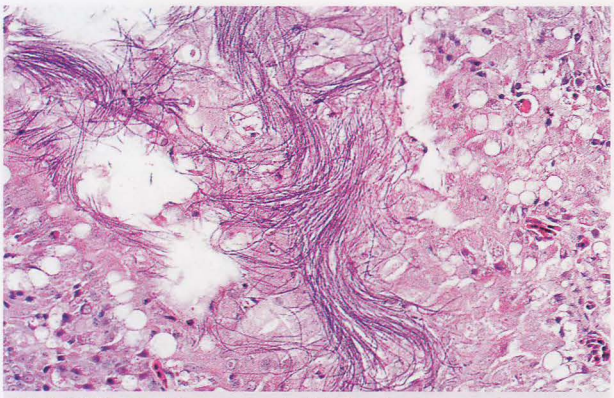

Fig 7.10B. Trout with summer enteritis showing large numbers of filamentous bacteria, plus intestinal epithelial degeneration and sloughing.

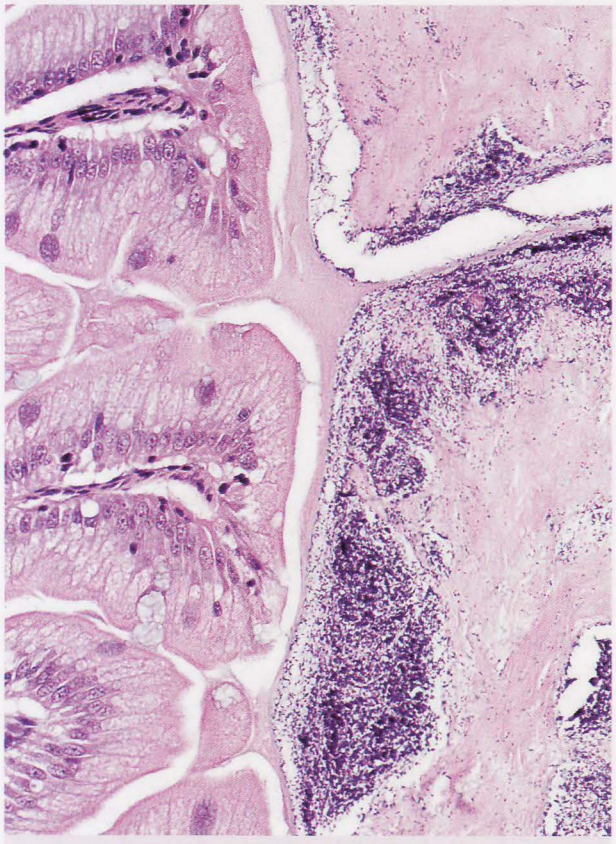

Fig 7.11. Intestinal bacterial overgrowth. This is seen most commonly in captive fish, with spoiled food the first suspicion.

Another condition that has been termed "bloat" by hobbyists occurs particularly commonly in African cichlids and is a significant problem for specialists who maintain *Tropheus* spp. and "mbuna" from Tanganyika and Malawi, respectively. These fish are vegetarians and in the wild primarily scrape algae and epiphytes. Fish present very characteristically, with a two to three day history of lethargy, separation from the group, anorexia, and toward the end of the course, an enlarged abdomen. Fish typically have ascites and grossly and histopathologically the outlines of the stomach are obscured by copious granulomatous inflammation (***Fig 7.8***). The stomach wall is markedly thickened predominantly by macrophages, the mucosa is effaced, and if the correct section is examined, the stom-



Fig 7.12A-C. Segmental necrohaemorrhagic enteritis of cod. The intestinal wall is devitalized with fibrin on the serosal surface. This view could be mistaken for intestinal torsion with ischaemic necrosis. *Courtesy Dr. D. Sutherland.*



Fig 7.12B. The entire intestinal wall is necrotic. The epithelium has sloughed and there is marked transmural oedema and intense haemorrhage.

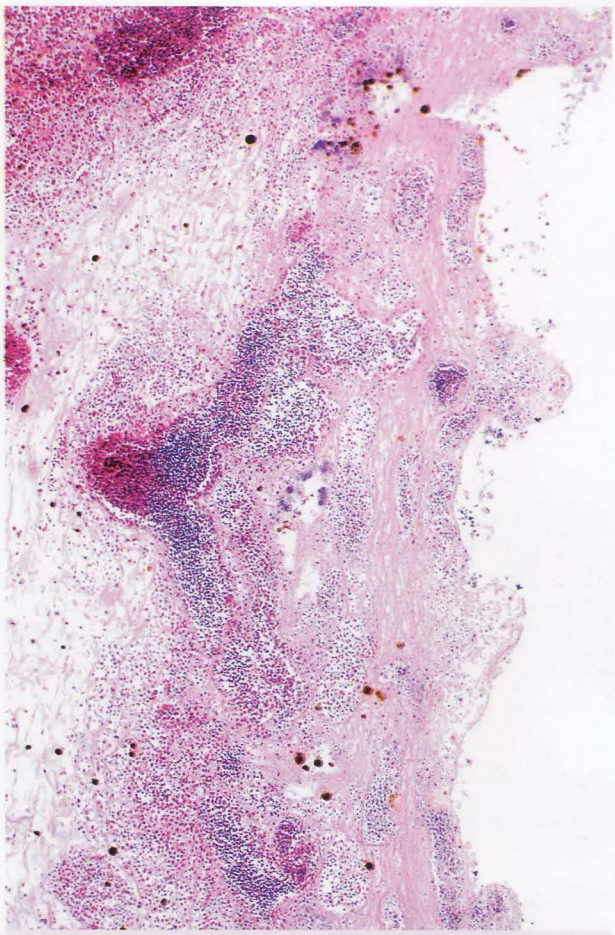

Fig 7.12C. There are multifocal bacterial microcolonies within expanded secondary vascular spaces. Most of the red cells have lysed leaving nuclear ghosts.

ach wall may be perforated. Within the cytoplasm of macrophages in the remnants of the stomach wall, can be found large numbers of small ~10µm comma-shaped protozoa resembling *Cryptobia*. A species of *Clostridium* has also been implicated in the pathogenesis, but this was probably merely exploiting the pre-existing granulomatous gastritis. The extensive granulomatous peritoneal inflammation is the source of ascites and can be the cause of death, whether or not there is secondary infection. This condition has been associated with high protein diets although groups of fish fed brine shrimp alone can live happily throughout their life. The condition can be induced simply by a change in feed or by feeding a plant diet that is too rich. The protozoa are presumably always present and it is an imbalance in gastric flora (such as proliferation of *Clostridium* spp.) that facilitates proliferation and/or penetration. Mucosal and submucosal granulomatous gastritis has also been described for *Cryptobia* spp. in cyprinids and for *Hexamita* (probably *Spironucleus*) in Siamese fighting fish. The latter also commonly produce a transmural gastritis and peritonitis with dissemination ***(Fig 7.9)***.

Intestine. Pathological examination of the intestinal tract of fish is problematic since artifacts due to autolysis occur quickly. Even in large fish for which dissection is possible,

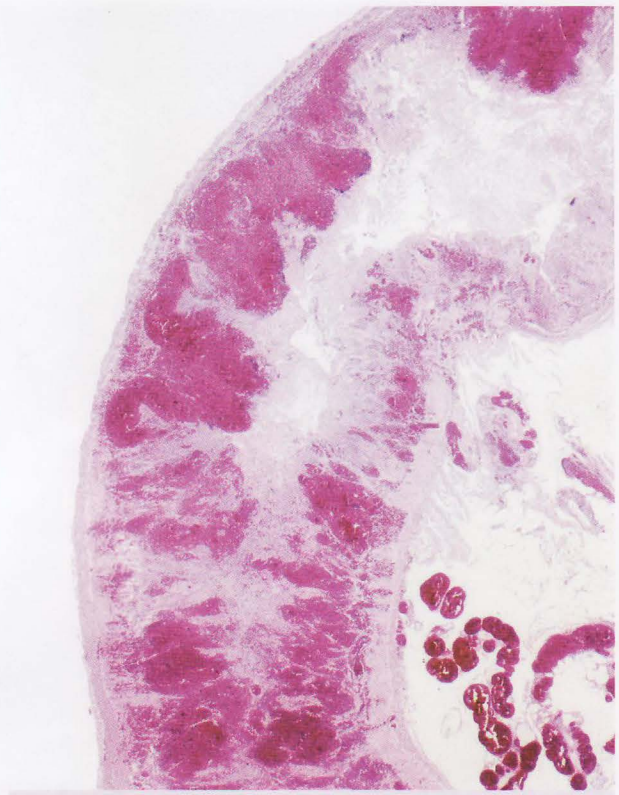

Fig 7.12D. Haemorrhagic enteritis of seabass.

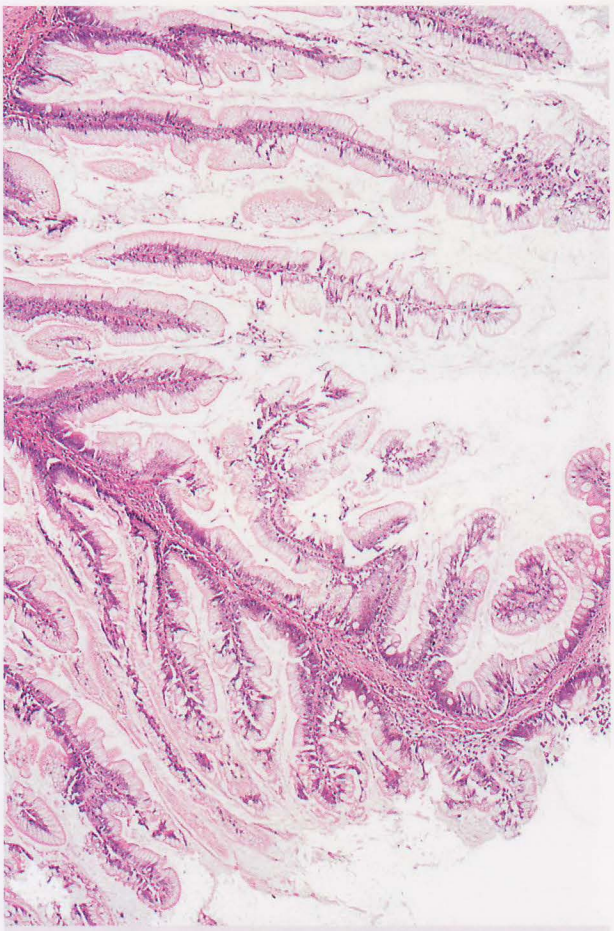

Fig 7.13B. Shows the hindgut of a fish fed the control diet.

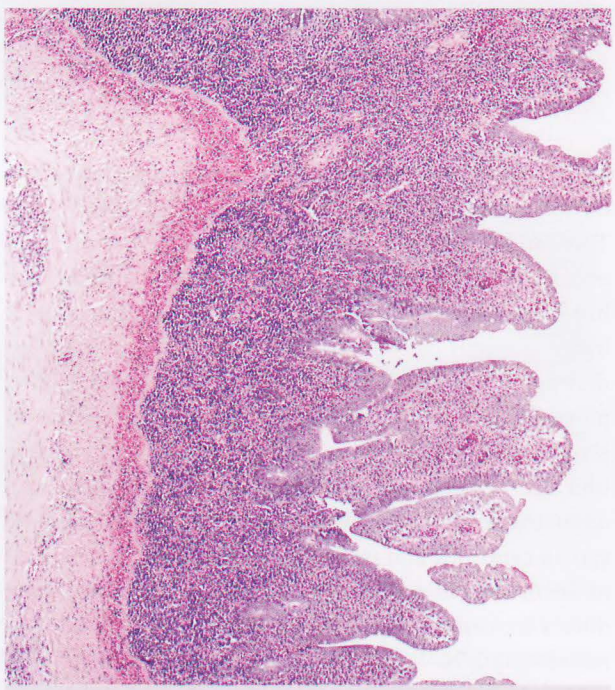

Fig 7.13A. Soya-induced enteritis in the hindgut of an Atlantic salmon. The intestinal folds are widened and reduced in height and the lamina propria is expanded by a morphologically mixed population of inflammatory cells. Compare with the control in **B**.

the intestinal tract is rarely incised to allow fixative to enter the lumen. The majority of smaller fish routinely have a body wall removed but are then usually fixed otherwise intact. It is very common on a histological slide to see one intestinal segment that is completely autolysed adjacent to one that is relatively well-preserved. The intestine is often affected in any disease with a systemic component, as mentioned previously for the stomach. The sites targeted are the lamina propria and the submucosa, with the epithelium directly affected only in severe involvement. A relevant example is enteric septicaemia of catfish caused by *Edwardsiella ictaluri*. Infected fish can have extensive infiltrates of neutrophils, macrophages and lymphocytes into the lamina propria and submucosa and these cells will spill over into the epithelium in small numbers. Another excellent example of this pattern of infection occurs with *Piscirickettsia salmonis* in salmon and trout. Piscirickettsiosis is a systemic disease that affects most organs including the liver, spleen and kidney but also severely affects the subepithelial intestine. Large numbers of macrophages

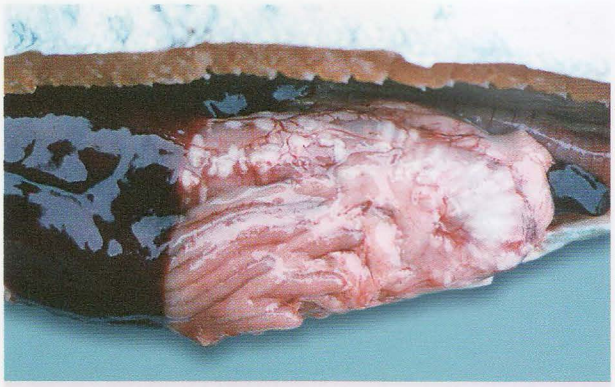

Fig 7.14. Brown trout with multifocal granulomatous enteritis due to larval *Diphyllobothrium dentriticum*.



Fig 7.15A. Tench showing extensive granulomatous inflammation with granulation tissue that focally expands the intestinal well and surrounds the scoleces of *Monobothrium. Courtesy Dr. C. Williams.*

containing numerous intracellular organisms expand the lamina propria and submucosa. As for many rickettsial diseases the vasculature is targeted with vasculitis/vascular thrombosis and the intestinal epithelial necrosis described may be partly ischaemic. Inflammation in these locations,

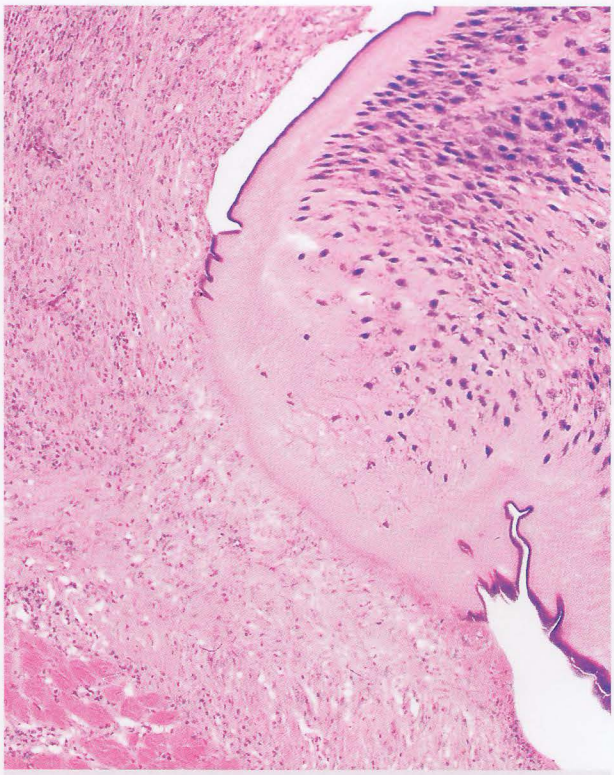

Fig 7.15B. Attachment site of *Monobothrium* with focal effacement of epithelium. *Courtesy Dr. C. Williams.*

particularly in the lamina propria, can influence epithelial maturation causing apparent epithelial hyperplasia as occurs in the gills. Extensive inflammatory infiltrates can also interfere with intestinal absorption, promote electrolyte loss and contribute to poor growth. Hyperaemia, congestion and haemorrhage can all cause reddening of the rectum/anus and this is one of the stereotypical lesions in septicaemic fish. Rectal prolapse can occur but it is more commonly seen with space occupying lesions of the posterior abdomen.

The intestine is however, the primary target of relatively few infectious agents, save for parasites. The diffuse necrotizing enteritides commonly seen in mammals (parvovirus, *Clostridium*, etc.) are rarely reported in fish, although they are becoming more common. That is not to say that the gastrointestinal tract is not intimately involved in the pathogenesis of the majority of infectious diseases of fish. Along with the gills it is the most important route for entry of infectious agents and is the most significant route for shedding and consequently transmission of disease. Examples of bacterial or viral agents that target the epithelium include IPNv, IHNv, CCDv, and various *Vibrio* spp.



Fig 7.16. Carp showing marked thinning and expansion of the intestinal lumen occupied by large numbers of *Bothriocephalus*. *Courtesy Dr. C. Williams.*

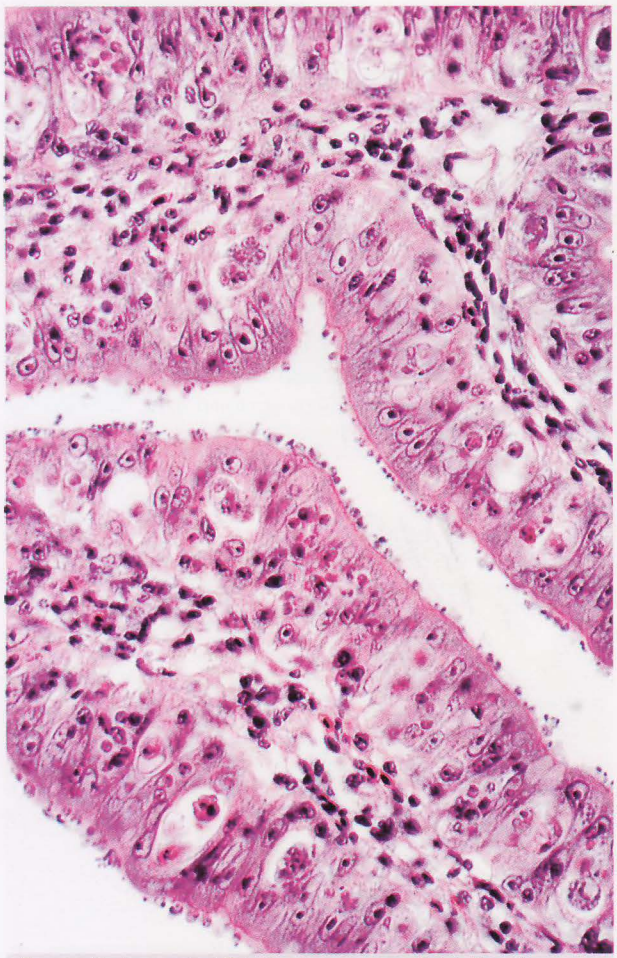

Fig 7.17. Marine tropical fish showing numerous "blebs" on the brush border of the intestine as well as coccidia within the epithelium. Such parasites may be *Cryptosporidium* but these must be differentiated from other coccidia such as *Epieimeria* or some myxozoa that also have developmental stages within the brush border.

IPNv can cause a necrotizing pancreatitis (see later) but also causes catarrhal enteritis with numerous apoptotic enterocytes in pyloric caeca and the proximal intestine. Similar to salmonid fry infected with IHNv, there may be abdominal enlargement, exophthalmia and faecal casts. IHNv can cause intestinal epithelial necrosis/apoptosis, an infiltration of a mixed population of inflammatory cells in the lamina propria and occasionally degranulation and necrosis of the eosinophilic granular layer. Although the latter has been purported to be pathognomonic for IHNv, it is not always present in either natural or experimental disease. In a recent outbreak of widespread mortality affecting multiple species of fish including freshwater drum (see above) and goby, the latter were noted to have severe, diffuse necrotizing enteritis. Grossly, the intestine was translucent, markedly dilated and fluid-filled with numerous serosal petechial haemorrhages. Histopathologically the intestine was the most severely affected organ although foci of necrosis were noted in the spleen, kidney and elsewhere.



Fig 7.18A. Spironucleosis in rainbow trout fry showing exophthalmia and abdominal distension.



Fig 7.18B. Long trailing faecal cast typical of spironucleosis can also be seen with viral infections such as IHNv and IPNv.

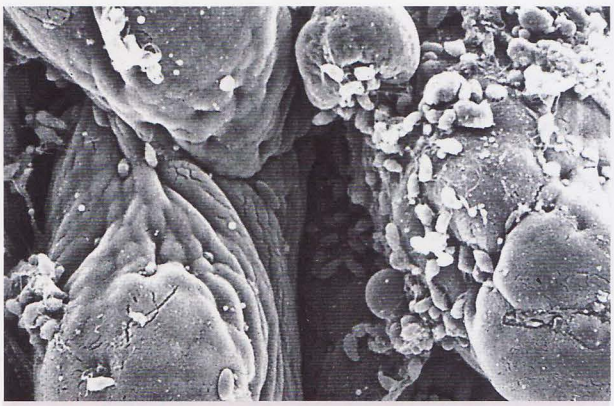

Fig 7.19A. Pyloric caeca from fish in *7.18* showing large numbers of flagellates on mucosal surface.

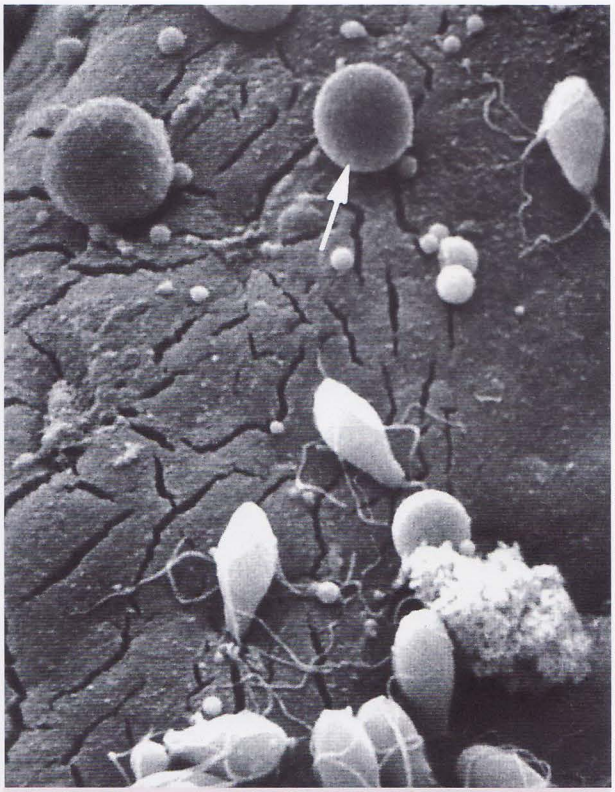

Fig 7.19B. High power view of mucosal surface showing several pear-shaped flagellates and several large "blebs" (arrow). The cracking of the brush-border is artifact.

Vibrio species are inhabitants of the intestine and several can cause necrotizing enteritis with younger fish most commonly affected. The disease "intestinal necrosis" (Chokan-hakudaku-sho) is caused by *Vibrio ichthyoenteri* and affects cultured flounder larvae. Diseased fish characteristically have opaque intestines, and in experimental infections develop focal epithelial degeneration and necrosis that progress to a marked diffuse necrotizing enteritis. Development of a mature acid-producing stomach in larval fish is correlated with reduced susceptibility to disease. A disease called "summer enteric syndrome" in rainbow trout associated with characteristic large filamentous intestinal bacteria has recently been described. The organism is a sporulating segmented filamentous bacterium (SFB) called *Candidatus Arthromitus* that is present in typical cases but cannot be grown on media *in vitro*. A consistent clinical sign is the presence of copious yellow mucoid faeces with gross lesions including a reddened intestine containing mucoid contents that fill the lumen. The mucosa is diffusely haemorrhagic and the wall thickened by oedema. The histological lesions are most severe in the pyloric stomach and caeca and consist of diffuse epithelial necrosis and the presence of large numbers of spore-filled filamentous bacteria **(*Fig 7.10*)**.

Teleost intestinal lumena normally contain relatively few bacteria in comparison to mammals, at least when examined by light microscopy. The presence in sections of visible numbers of bacteria is interpreted as abnormal and may indicate a dietary problem, but enterotoxaemia should also be considered **(*Fig 7.11*)**. Cases of moribund fish with obvious bacterial overgrowth have involved the feeding of spoiled food. There are several examples of recently emerging enteritides in fish that deserve mention. "Bacterial enteritis syndrome of juvenile cod" is a recently identified condition characterized by a severe diffuse necrotizing transmural enterits **(*Fig 7.12*)**. Numerous bacterial microcolonies are present within the devitalized tissue, which has an appearance similar to that of necrohaemorrhagic enteritis in juvenile mammals caused by *Clostridum perfringens*. The severity and nature of the lesions suggest that potent exotoxins are produced by the responsible organism. An entity known as "skinny

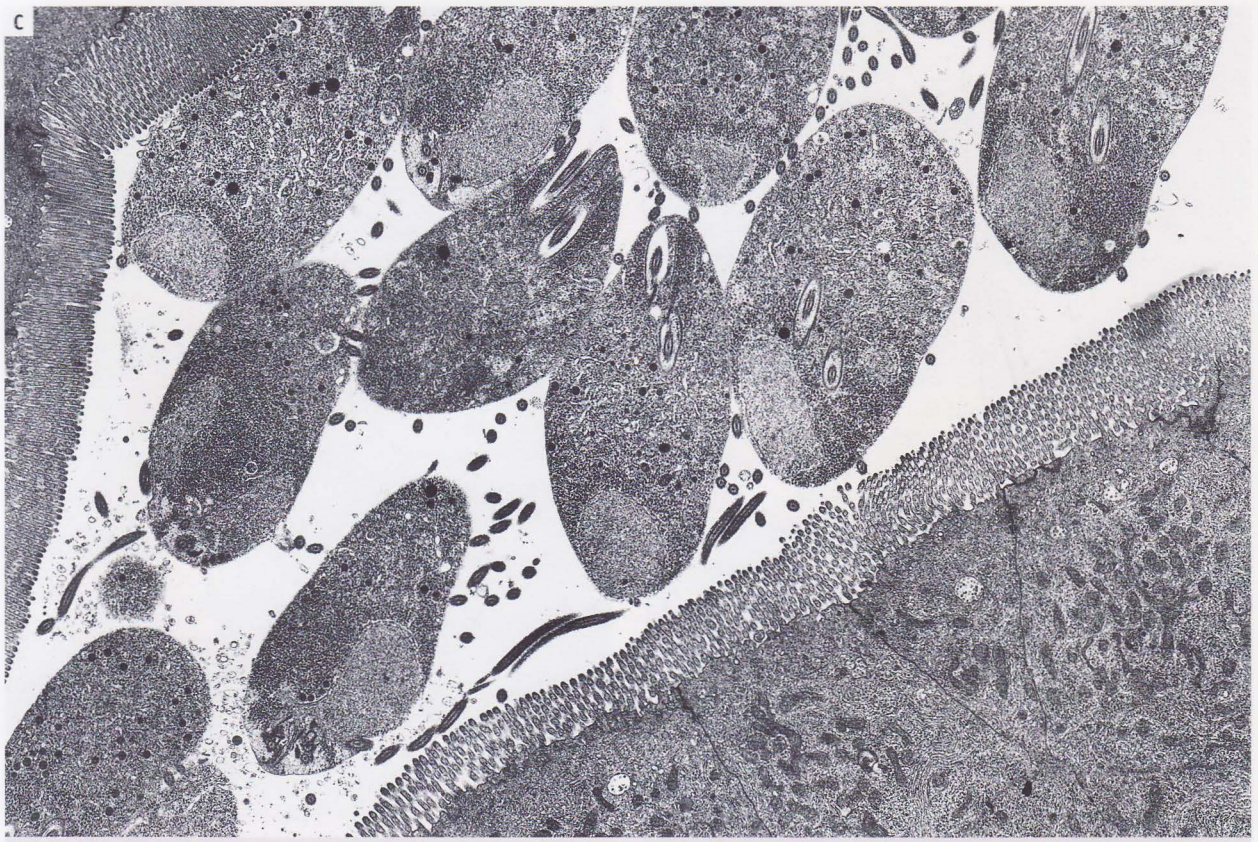

Fig 7.19C&D. Low and high power of *Spironucleus* within lumen of pyloric caeca. Note that despite their close apposition to the mucosal surface the brush border appears absolutely normal, as do the terminal web, mitochondria, and other details of the enterocytes.

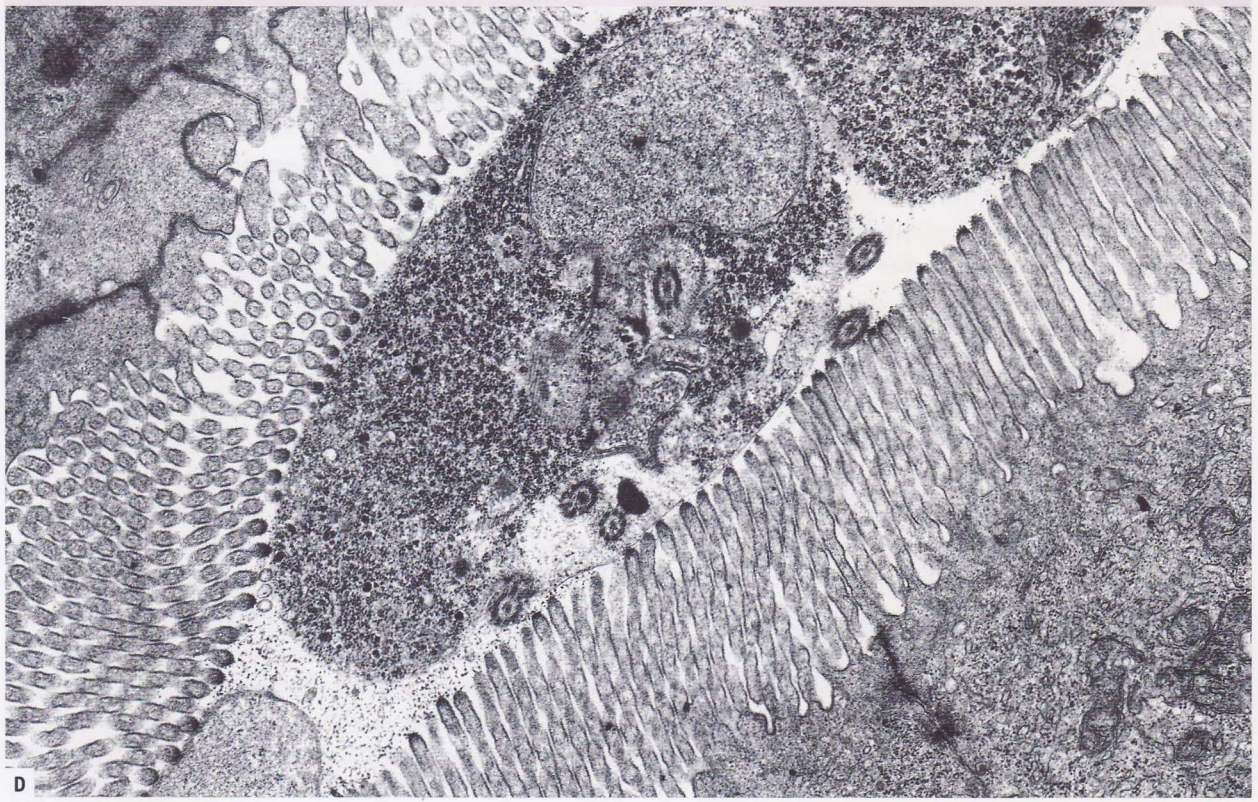

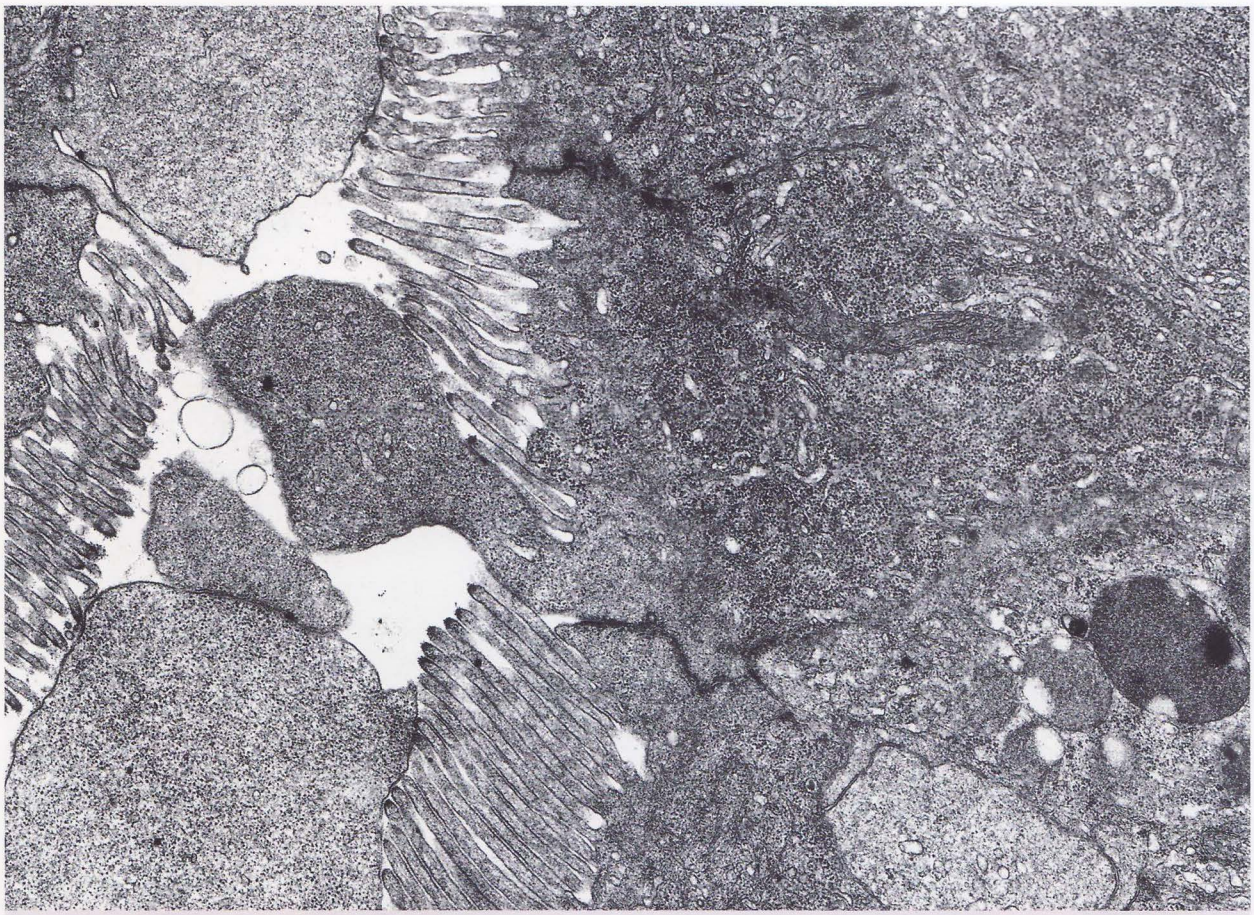

Fig 7.19E. Virtually the only pathological change accompanying spironucleosis is blebbing of the enterocytes into the lumen, representing ballooning dilatation of one or several microvilli. See SEM of blebbing in **B**.

pot-belly" disease is associated with Asian seabass that are emaciated and have enlarged abdomens with a reddened anal region and faecal casts. Early lesions are limited to a mononuclear-rich infiltrate in the lamina propria with numerous epithelial bacterial microcolonies. These lesions progressed to full thickness necrotizing and granulomatous enteritis with numerous caseonecrotic cores, perforation of the intestine, peritonitis and bacteraemia. In one outbreak *Edwardsiella ictaluri* was identified by immunhistochemistry to be associated with the lesions, but whether the same applies to all outbreaks remains to be determined.

An interesting cause of enteritis in salmonids, studied particularly in Atlantic salmon, is that induced by feeding excessive dietary protein derived from soybeans. This is one of the few examples of enteritis in fish that has been confirmed to be associated with altered intestinal epithelial differentiation. Lesions in the distal intestine include shortened and widened folds (reminiscent of villous atrophy in mammals), a lamina propria expanded by large numbers of macrophages and neutrophils with increased numbers of eosinophilic granular cells and loss of apical epithelial vacuolization *(Fig 7.13)*. The components of soybean meal responsible for the enteritis have yet to be precisely determined but the full range of lesions is present within seven days and resolves completely within three weeks after removal of soybean meal from the diet. It has been shown that feeding soybean meal is associated with an increased proliferation of distal intestinal epithelial cells, loss of apical epithelial vacuoles (no absorption) but increased goblet cell numbers in starved fish, increased number of goblet cells and the appearance of epithelial "indentations" in intestinal folds. These latter probably reflect an accumulation of epithelial cells on the fold and could be due to reduced loss of epithelial cells with "piling up" and crowding.

Toxic enteropathies in fish are rarely described and several of those that are reported require additional studies for

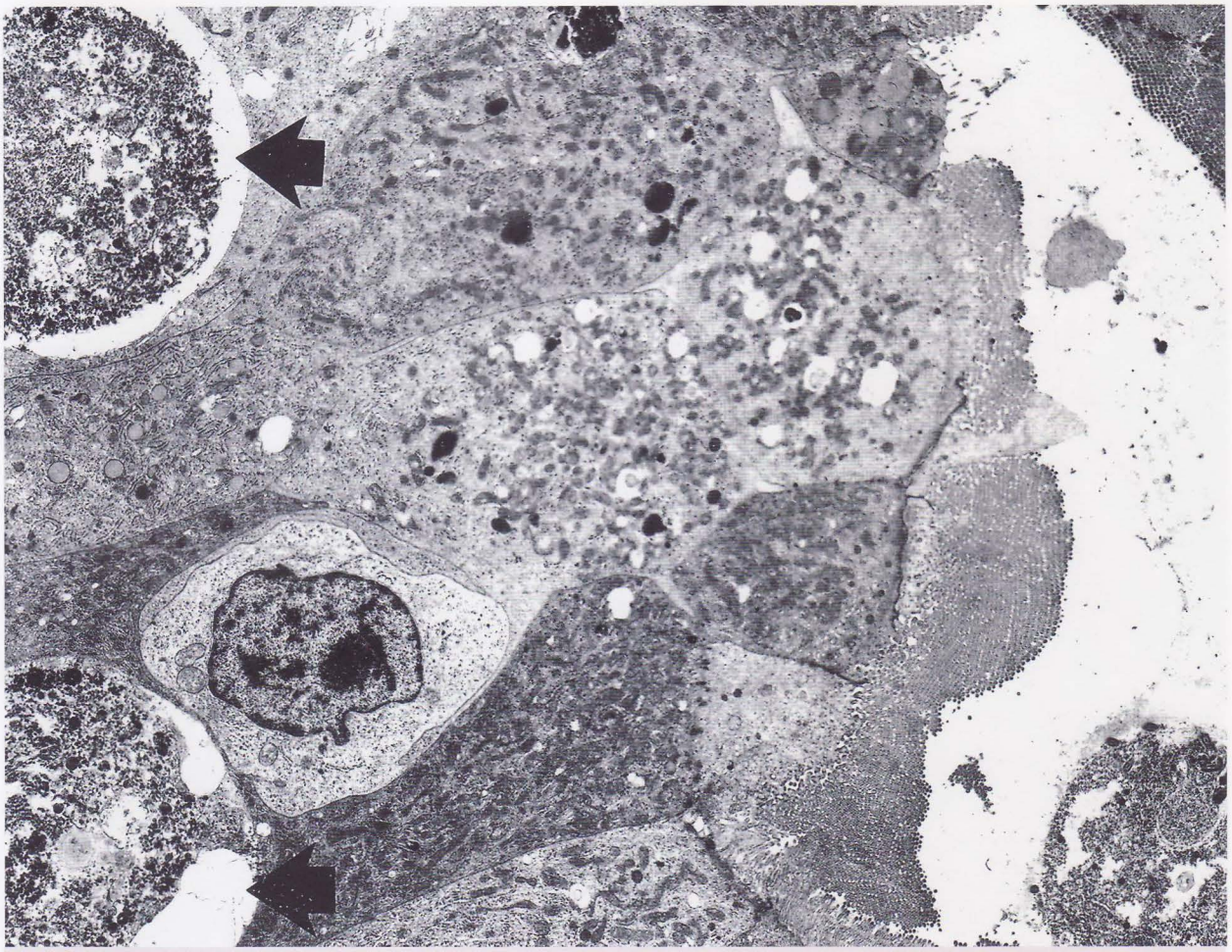

Fig 7.19F. Section of pyloric caeca from fish with spironucleosis showing the remnants of 2 necrotic cells (arrows) that have been phagocytosed by adjacent viable enterocytes. Between them can be seen a theliolymphocyte.

confirmation. Interestingly, intestinal epithelial necrosis has been reported in seabass in which *Photobacterium damsela* subsp. *piscicida* was grown within peritoneally-implanted dialysis sacs (Poulos *et al.* 2004). *Vibrio carchariae* has also been shown to produce an extracellular toxin that produces intestinal epithelial necrosis in a variety of marine fish. Ultrastructural alterations of the brush border and marked distention of intercellular spaces have been reported in cadmium, lead and endosulfan toxicity in fish.

Gastrointestinal parasites, particularly cestodes, nematodes and acanthocephalans are very commonly seen in fish but it is the exception where clinical disease is apparent. They may, however, be significant in terms of their effects on population health and productivity. Acanthocephalans, *Pomphorynchus* spp. for example, can be present in very large numbers, and cause substantial focal necrotizing and granulomatous lesions in the intestinal wall. A fibrous capsule with macrophages and eosinophilic granular cells is present and this reaction may extend to the serosal surface causing a localized peritonitis if penetration of the intestinal wall occurs. The pathogenicity of an acanthocephalan infection is the result of a combination of the worm burden plus the depth of penetration. Lightly to moderately parasitized fish can be clinically normal. The granulomatous reaction to pleurocercoids of *Diphyllobothrium* spp. may be seen grossly as nodular white foci on the serosal surface of the intestine **(*Fig 7.14*)**, but these lesions are not diagnostic as a variety of species of worms cause similar reactions in a range of fish **(*Fig 7.15*)**. Lesions may also be found in the stomach wall, visceral organs and the abdominal cavity in mesenteries. Peritonitis producing visceral adhesions is common in these infections. *Bothriocephalus acheilognathi* is a pseudophyllidean tapeworm found in the intestine of carp and related species. Heavily parasitized fish will become progressively emaciated and develop enlarged abdomens.



Fig 7.20. Multifocal intestinal microsporidian cysts that may be classfied as xenomas or sporophorocysts depending on the (intra)cellular location.

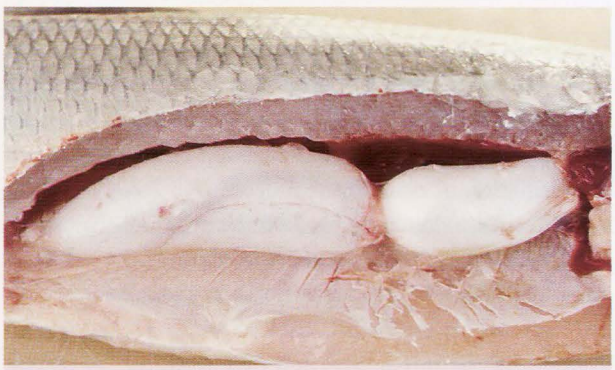

Fig 7.21. Swimbladder morphology typical of cyprinids with a central waist and without a pneumatic duct (physoclist). *Courtesy Dr. T.T. Poppe.*

Gross pathological lesions include dilated, thin-walled and transparent intestinal segments and a catarrhal to mildly haemorrhagic enteritis **(*Fig 7.16*)**. The tapeworms may be so numerous as to cause intestinal blockage. The bothria engulf intestinal folds and produce epithelial erosion and ulceration with infiltration of macrophages, lymphocytes and eosinophilic granular cells.

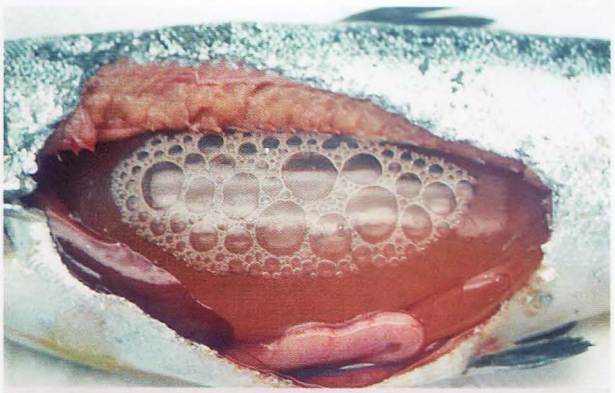

Fig 7.22. Large amounts of fluid in the swimbladder, with or without foreign bodies, is abnormal. *Courtesy Dr. T.T. Poppe.*

As with metazoa, apicomplexan protozoa **(*Fig 7.17*)** can be found in the intestine, intestinal serosa and peritoneal cavity and are particularly common in wild fish although cultured fish can also be affected. *Tilapia nilotica* maintained in a closed colony that had been directly imported from Egypt had large numbers of *Cryptosporidium* located at the edge of the apical intestinal epithelium (epicellular). Seahorse fry raised in aquaria were parasitized by a similar organism **(*see Fig 7.7*)**, although their clinical significance is not as clear. The largest number of organisms was typically present in the gastric epithelium. In these cases, there are very small (~5µm) apical epicellular forms in the proximal epithelium.

Coccidia may cause diffuse or nodular infestations in fish, with the former more likely to produce clinical disease. Nodular lesions are caused by focal proliferation of the organism with concomitant epithelial hyperplasia. *Goussia* is one of the best-described genera and while intestinal infections are most common, swimbladder (and other) infestations can also occur **(*see Fig 7.28*)**. *Goussia carpelli* causes mild to moderate disease in carp. Experimental infection with *G. carpelli* was associated with increased epithelial proliferation at the base of affected intestinal folds initially, followed by necrosis of epithelial cells during merogamy and gametogamy. Rapid replication of immature epithelium occurred to regenerate epithelial integrity within a few days.

Hexamita salmonis (now *Spironucleus salmonis*) can be associated with poor growth, morbidity and mortality in salmonids. Many fish health workers consider it non-pathogenic when it remains in the intestinal tract. Clinical disease due to intestinal infection does occur however, and rainbow trout fry may have exophthalmia, a distended fluid-filled





Fig 7.23. Two examples of pathogens producing lesions with a distinct vascular orientation, leading to thickening of the swimbladder submucosa and wall. **A** is a systemic microsporidian infection, possibly *Loma* spp., producing a vasculitis affecting blood vessels of the adventitia, while **B** represents a systemic *Lactococcus garviae* experimental infection in rainbow trout. *Material from **B** courtesy Dr. J. Del Pozo.*



Fig 7.24. The grossly over-inflated swimbladder in this rainbow trout has become ventrally displaced at its caudal end. Such a lesion must be differentiated from cystic dilatation of a ureter due to hypoplasia or acquired blockage: this is rare in our experience however.

abdomen and faecal casts **(*Fig 7.18*)**.Wet mounts of faeces reveal myriad flagellated protozoa that can be hard to see in histological sections even after perfusion of the intestine with agarose before fixation or ligation of the intestine. Histological lesions are limited to excessive vacuolation and apoptosis of the intestinal epithelium, and ultrastructurally as mucosal blebbing **(*Fig 7.19*)**. Experimental treatment with metronidazole resolves clinical signs, supporting a role for the organism in clinical disease. *Spironucleus* spp. may also cause sporadic systemic disease in salmonids, notably Arctic char and Atlantic salmon.

Myxozoan and microsporidian infections of the GI tract are common and most species that localize in other tissues penetrate the GI epithelium. The local effect of the majority is inconsequential and lesions may be limited to the formation of cysts in the mucosa **(*Fig 7.20*)** or in the muscularis and serosa. This latter is common in microsporidia such as *Pleistophora*. Those that produce diffuse intestinal infections are more important as a cause of clinical disease. An example is the diffuse, necrotizing and granulomatous transmural enteritis produced by *Ceratomyxa shasta* in rainbow trout and other salmonids. Experimental infections in susceptible strains of trout initially stimulate focal lymphocytic lamina proprial infiltrates in response to small numbers of trophozoites. Proliferation of trophozoites corresponds to an influx of large numbers of macrophages and lymphocytes with necrosis of the epithelium, loss of mucosal folds and penetration by the trophozoites into the submucosa and muscularis. The intestine is devitalized in severe infections and trophozoites are found systemically and in the serosanguinous

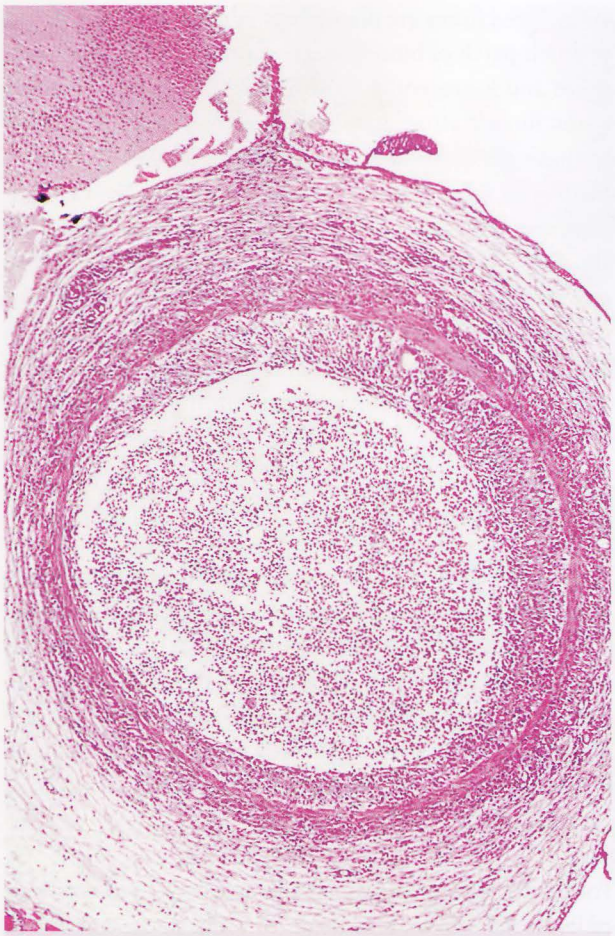

Fig 7.25. Splake with chronic severe swimbladder inflammation showing erosion and ulceration of the epithelium and filling of the lumen with debris and inflammatory cells.



Fig 7.26A. Chinook salmon with marked abdominal enlargement.

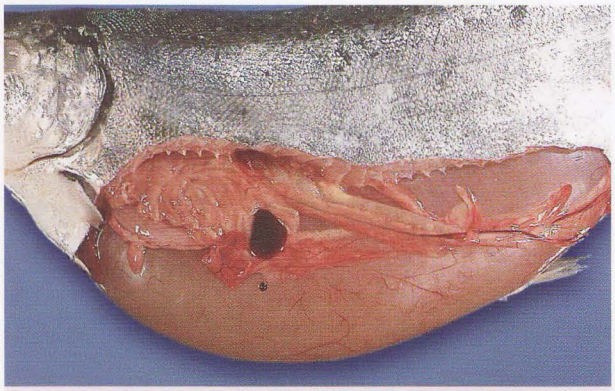

Fig 7.26B. The same fish as **A**, with massive expansion of the swimbladder and marked atrophy of remaining abdominal organs. This swimbladder contained approximately 2L of thick, cloudy and foul-smelling fluid.

ascitic fluid. Similar inflammatory responses of variable severity have been described for *Myxidium leei* or similar *Myxidium* spp. in seabream, drum and turbot.

Gastrointestinal "accidents", torsions, volvulus and intussusceptions, that are so common in domestic animals, particularly large animals, probably occur more commonly than are currently recognized in fish but they are rarely reported. One of the few examples includes an intestinal torsion resulting in ischaemic necrosis in a channel catfish. The fish also had a hypoplastic swimbladder and the additional "space" in the peritoneum was thought to be the predisposing cause. Factors that are probably responsible for the rarity of these occurrences include the short length of the GI tract in many species, the relative lack of weight of material in the intestine, which is not necessarily suspended by taut mesenteries, and in species with longer intestinal tracts, the extensive intervening tissues such as liver.

Swimbladder

The swimbladder is the most important buoyancy organ in teleosts and the vast majority of species have one. In some species it may also have respiratory capabilities. Alternative names include the gas- or air-bladder. It can comprise a single chamber as in salmonids or have several chambers as in cyprinids (*Fig 7.21*). It is composed of a thin layer of cuboidal, surfactant-producing epithelium that overlies a thin adventitia, a variably thick muscular layer that may be composed of smooth and/or skeletal muscle, and finally a submucosal layer where most blood vessels are found. Many fish have low numbers of cells resembling lymphocytes within the epithelium. Fish are either physostomes (with a patent duct once fully formed) or physoclists (duct not patent) and many physoclists are temporarily physostomatous (euphysoclists) with a short interval where the swimbladder and oesophagus are connected. The majority of soft-rayed fishes are physostomes while

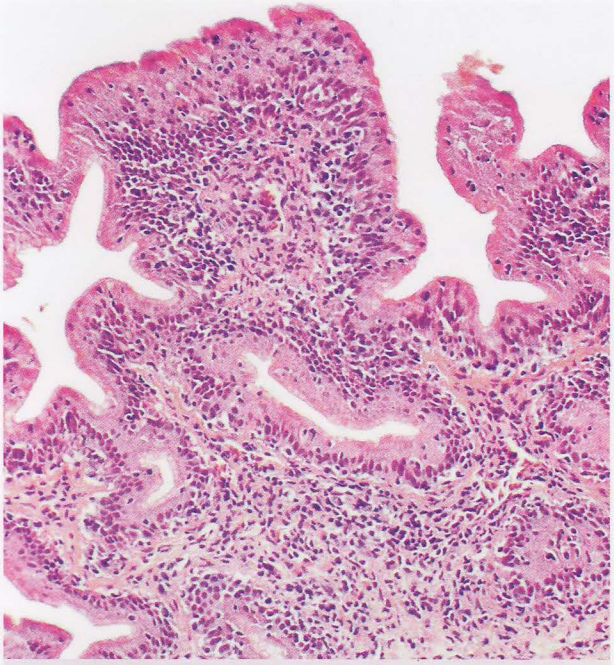

Fig 7.27. Swimbladder from Chinook salmon with GDAS showing marked epithelial hyperplasia and inflammation of swimbladder near pneumatic duct.

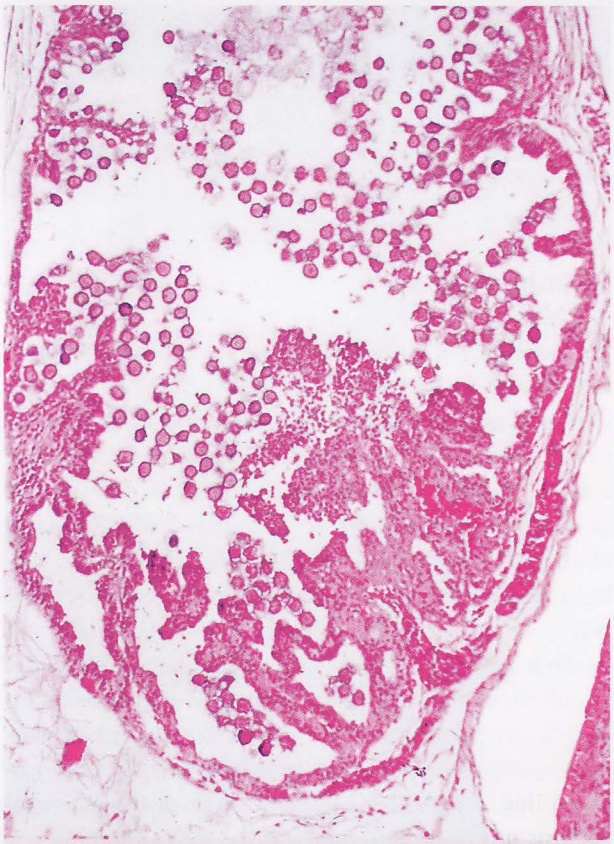

Fig 7.28. Lumen of a cichlid swimbladder containing numerous *Goussia*-type coccidia. Note the hyperplasia of the epithelial lining.

spiny-rayed fishes are physoclists. A *rete mirable* composed of a rich patch of blood vessels supplies the bladder with gases and is present in most fish, while the oval removes gases for deflation and is present in physoclists. Both of these are focal areas rich in blood vessels. The swimbladder in most fish is filled with gases (O_2, N_2, CO_2) except very deep-dwelling fish, whose lumen is filled with short-chain fatty acids that have relative buoyancy. Excessive fluid, particularly cloudy fluid, in the swimbladder should be considered abnormal, as should foreign bodies **(*Fig 7.22*)**. Post-mortem examination of the swimbladder may reveal small amounts of water in the bladder due to relaxation of the pneumatic duct.

Disease

Lesions in the swimbladder are not commonly reported, possibly because it is not routinely examined, and is usually only included by chance in sagittal or transverse whole body sectioning of smaller fish. This is also because it collapses on sectioning and is difficult to arrange properly in the cassette. But it is commonly involved in systemic disease, and lesions can frequently be found if sought **(*Fig 7.23*)**.

Poor development or lack of inflation of the swimbladder of larval fish can lead to death or reduced growth and is associated with skeletal and muscular malformations. This is one of the major events in larval culture that contributes to the poor survival and performance of newly cultured species. Larval fish that are unable to rise to the surface will not be able to inflate the bladder with air. Water with excessive surface oil will impair their ability to fill the bladder with subsequent reduction in productivity.

Variation in the size and shape of the swimbladder is not uncommon, particularly in intensively raised fish. One study in Atlantic salmon noted the presence of abnormally shaped swimbladders with a pneumatic duct that exited the oesophagus at the normal location but that joined the swimbladder ventrally at the caudal pole. Affected fish had abnormal swimming behavior and were colloquially termed "side-swimmers". Swimbladder over-inflation can occur for a number of reasons including inflammation, blockage of pneumatic duct, and rapid reduction in baric pressure. Fish that are caught at depth (as little as 10-20 feet sometimes) can have marked abdominal enlargement and may also have exophthalmia when they are brought to the surface. The swimbladder may be covered with ex-

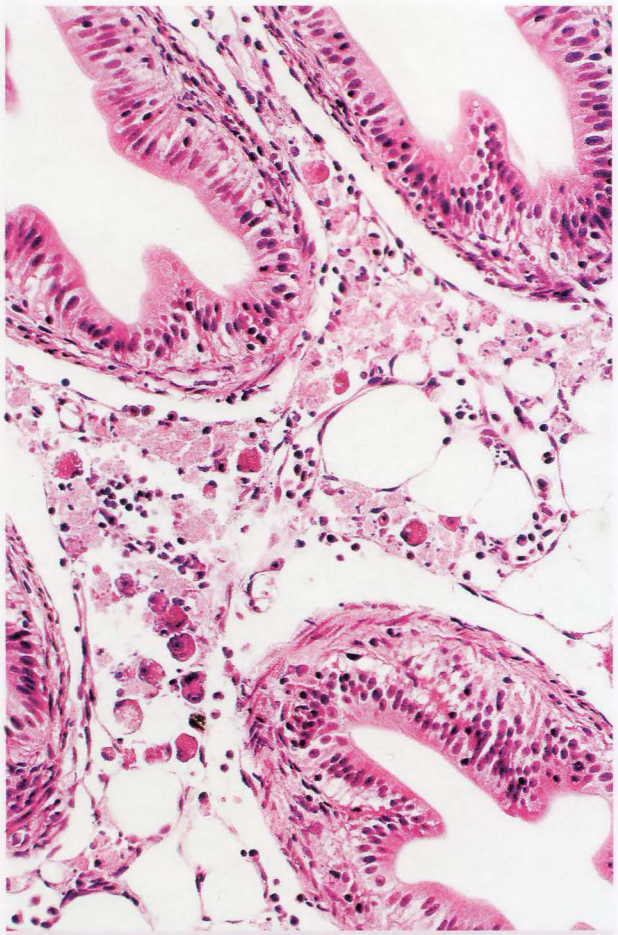

Infectious pancreatic necrosis. *Fig 7.29A.* Acute IPN in Atlantic salmon showing rounding up and necrosis of acinar cells. Pyloric caecal epithelium looks mostly normal.

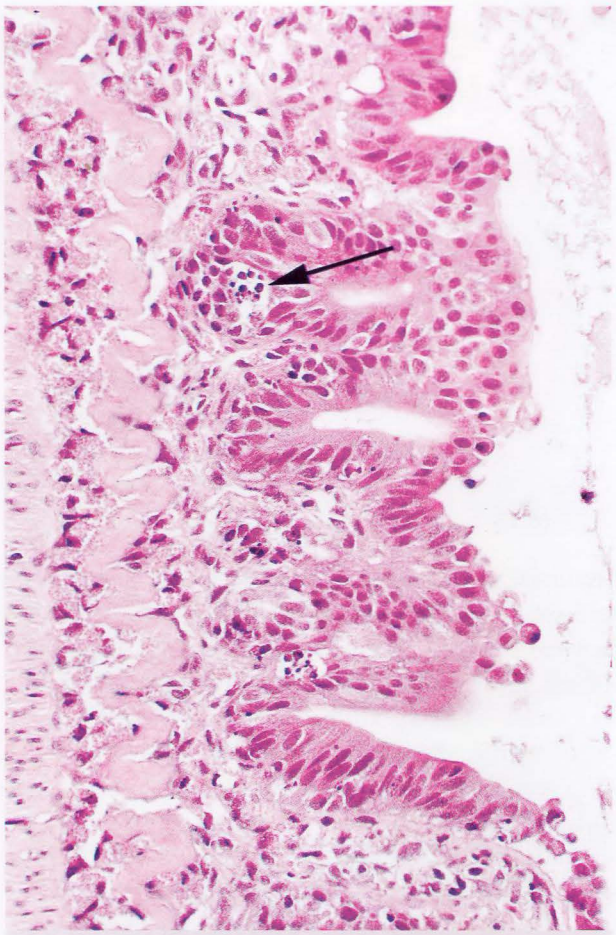

Fig 7.29B. Acute IPN in Atlantic salmon showing nests of necrotic cells within mucosa (arrow) and exfoliating epithelial cells.

tensive haemorrhages and may even rupture. Puncture of the swimbladder with a needle or other instrument can remedy the immediate over-inflation but may lead to contamination and inflammation.

Most commonly, swimbladder over-distension is due to physiological perturbations of acid/base balance. Hobby fish that receive greater individual attention are noted relatively frequently to have buoyancy problems and a swimbladder abnormality is one of the most likely causes. More dramatic procedures such as pneumocystoplasty are occasionally performed to relieve chronic over-inflation. Benthic African cichlids (*Frontosa* spp.) caught at a depth of 30-40 metres may have the over-inflated swimbladder punctured at the surface. It is not coincidental that it is these fish that are most likely to have subsequent buoyancy problems when later housed in aquaria! Pathological changes are minimal and the abnormality is most likely biochemical. Conditions characterized by an occult over-inflation of the swimbladder are known by a number of names including "swimbladder stress or distress syndrome". All syndromes are notable for a lack of histopathological lesions, difficulty in maintenance in the water column and varying degrees of abdominal enlargement (*Fig 7.24*). The pathogenesis of the lesion is thought to be an imbalance of gas production (or removal presumably). Oxygen is released from erythrocytes due to the "Root effect", which is relative acidosis of erythrocytes partly due to uptake of CO_2 from the action of carbonic anhydrase. Oxygen diffuses from the *rete mirable* into the swimbladder due to a gradient between venous and arterial blood vessels created by the countercurrent blood flow of the *rete mirable* and the relative acidosis (production of lactic acid) and hyperosmolarity in arterial blood. Nitrogen and CO_2 also diffuse along this gradient. Any condition that leads to systemic acidosis or increased CO_2 in the blood might exacerbate oxygen release or heighten the blood-swimbladder gas gradient. Carbonic anhydrase inhibitors (acetazolamide)



Fig 7.29C&D. Atlantic salmon with IPN showing typical eosinophilic casts within lumen of pyloric caeca.

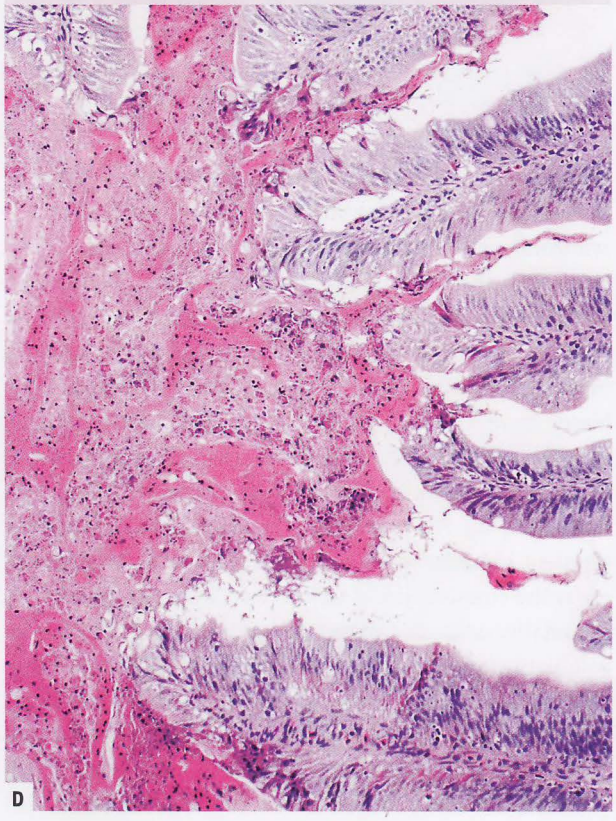

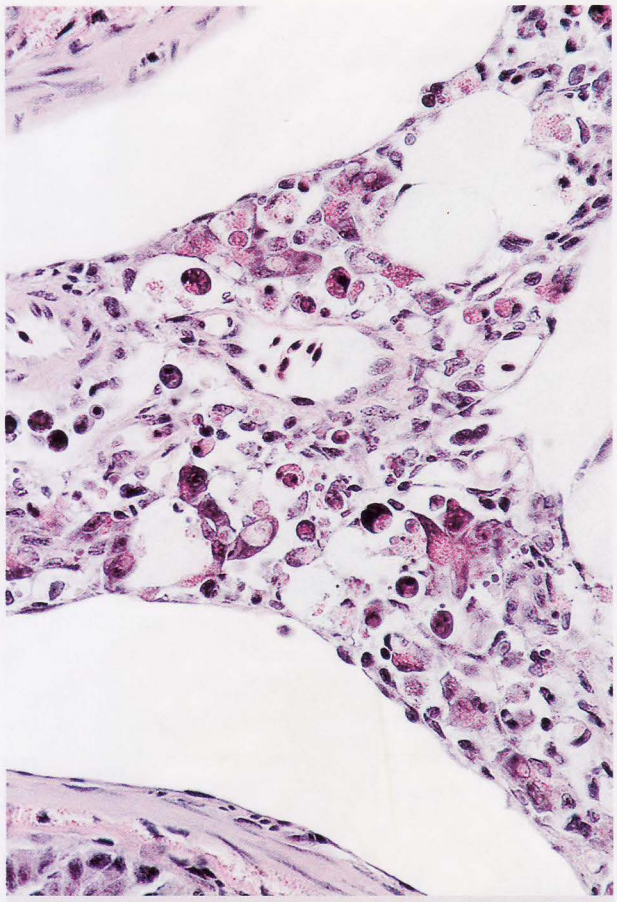

Fig 7.30A. Acute experimentally-produced pancreas disease (PD) in Atlantic salmon showing rounding up and necrosis of acinar cells. *Material courtesy of Dr. M. McLoughlin.*

have been used in sygnathids in aquaria to treat over-inflated swimbladders. This treatment is also used for gas bubble disease due to supersaturation, which naturally affects the swimbladder as well, but also for brood pouch emphysema. Most instances of swimbladder distress are not specifically associated with a single causal event. In some species, there is an association with high stocking density and high environmental CO_2. Typically most farmers will measure oxygen levels, but not CO_2 as this is more complicated, and in apparently good quality water with adequate oxygen, they will feed heavily, with swimbladder problems the result. If performed quickly (typically within 48 hours) reducing stocking density can lead to recovery. Seabass (*Dicentrarchus labrax*) infected with viral encephalopathy and retinopathy virus (nodavirus) can have swimbladder hyperinflation and clinical signs of altered buoyancy. The pathophysiology of this lesion has not been described but could be due to the tropism of the virus for the CNS and nerves.

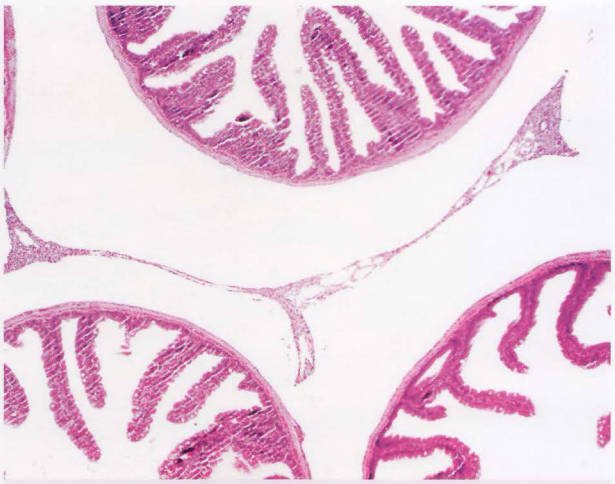

Fig 7.30B. Atlantic salmon with chronic PD showing virtually complete loss of pancreas as well as supporting fat.

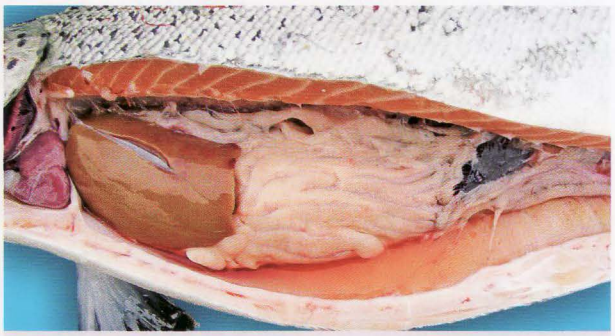

Fig 7.31. Serosanguinous fluid in the peritoneal cavity can be a common lesion associated with many infectious diseases, that may or may not target blood vessels. Here is an example of HSMI in Atlantic salmon. *Courtesy of Dr. T. Turnbull.*

The gross pathology of aerocystitis is relatively stereotypical. Systemic bacteraemias and viraemias may produce petechial haemorrhages (as for any organ) even though the number of blood vessels in the swimbladder wall is relatively low (and therefore diffusional loss of gases is minimized). Haemorrhage can be marked when the swimbladder is a target organ as in largemouth bass virus. Largemouth bass virus is an iridovirus that produces no to variable mortality with characteristic marked reddening of the swimbladder wall. A detailed histopathological description of this infection in natural outbreaks appears to be lacking in the literature. Chronic aerocystitis produces progressive thickening and opacity of the swim bladder wall due to epithelial hyperplasia (see below) and inflammation with oedema of all layers (*Fig 7.25*). Increased vascularity due to hyperaemia/congestion of pre-existing vessels and angiogenesis to support ongoing inflammation is typical.

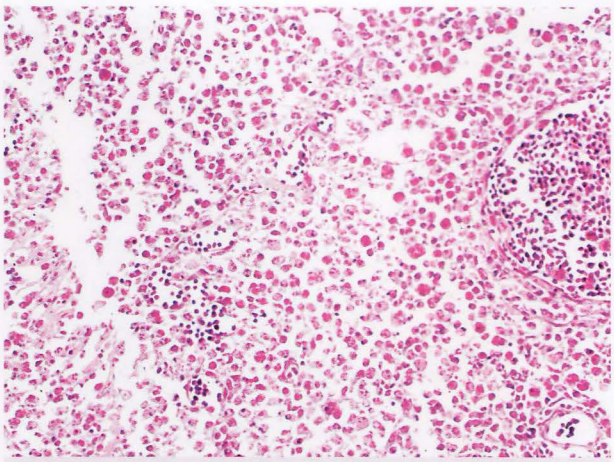

Fig 7.32A. Large numbers of trophozoites of *Ceratomyxa shasta* within the peritoneal cavity mixed with macrophages and neutrophils.

Chinook salmon with "gastric dilation and air sacculitis" (GDAS) had all of the above gross lesions (*Fig 7.26*). The lumen was filled with viscous septic exudates but had only mild to moderate inflammatory foci in the lamina propria, muscularis and adventitia and these were focal, not diffuse. In any diagnostic case for which histopathological samples alone are examined, the presence of a few small inflammatory foci in a swimbladder, particularly if accompanied by oedema of the adventitia and submucosa, should be an indication that a more severe air sacculitis is present. The lumenal contents of the swimbladder (similar to that of the intestine) are not well maintained through fixation, embedding and sectioning. Smears of exudates taken from fish with GDAS have numbers of morphologically-mixed bacteria with fewer fungi and algae, along with viable and necrotic neutrophils. The foci within the swimbladder wall however, are composed of lymphocytes and macrophages predominantly (not unlike the situation with chronic arthritides in mammals). These foci increase in intensity towards the pneumatic duct (hinting at route of exposure) and often extend into the oesophagus. Epithelial hyperplasia, with marked occasionally papillary folding is often present, but even when the lumen is completely filled with a septic exudate, epithelial erosion is minimal (*Fig 7.27*). Given the toxic soup of mediators and proteases within the lumen, this is somewhat surprising. The degree of inflammation varies, probably with the numbers and types of organisms present. Perhaps not surprisingly, the proliferation of organisms, and the severity of aerocystitis are worst in summer. Groups of fish removed from the GDAS-associated feed have a marked reduction in severity of the inflammation within weeks.

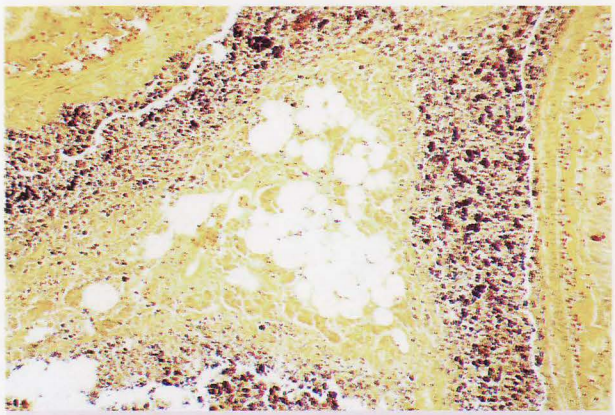

Fig 7.32B. Granulomatous peritonitis with pancreatic effacement due to extension of *Renibacterium salmoninarum* into the peritoneal cavity. Note the extremely large numbers of Gram-positive organisms. *Brown and Brenn stain.*



Fig 7.33A. Severe diffuse granulomatous peritonitis; an adverse reaction to intraperitoneal vaccination. The viscera are all firmly adhesed.

There are a few aetiologies deserving specific mention as agents of an aerocystitis. Mycotic infections of the swimbladder are relatively common and can often result from direct invasion via the pneumatic duct. Management strategies that aggressively move the fish to a progressively larger pellet size can result in the smaller fish having pellets lodged in the oesophagus at the duct diverticulum with resultant contamination. A wide range of fungal types, including *Phoma* and *Saprolegnia* have been noted in affected swimbladders and fish may be affected systemically. The swimbladder of Atlantic salmon parr may also be the target of *Phialophora* spp., which cause a haemorrhagic and necrotizing aerocystitis with minimal stimulation of inflammatory cells. In contrast, many fungi stimulate a granulomatous reaction, particularly as hyphae invade through the submucosa and muscular wall and affect blood vessels.

Protozoan and metazoan parasites affect the swimbladder to a lesser extent than the intestine, but several are notable for their effects **(*Fig 7.28*)**. The aetiology of swimbladder inflammation of carp (SBI) was historically controversial partly because SBI occurred commonly with clinical cases of rhabdoviral spring viremia of carp, but also due to the fact that it is difficult to identify different developmental stages of myxozoans by morphology alone. The gross lesions of SBI are similar to those already described in air sacculitis, except for the marked patches of haemorrhage and layers of fibrin on the outer surface of the swimbladder in severe cases. In cases without subsequent bacterial involvement, the lumen is not affected. The adventitia and submucosa are the most typical locations of the 17-30 µm multicellular stages of *Sphaerospora renicola* and the lesions are haemorrhagic with macrophages and other leukocytes, often necrotic and with fibrin exudation from vessels. Pansporoblasts and spores are found in the renal tubules.

Infections of the swimbladder of European eels with *Anguillicola crassus* are considered to have emerged approximately 20 years ago following introduction of the Japanese eel to Europe. Larvae, in paratenic or intermediate hosts, are ingested and then migrate to the swimbladder. The lumen may contain up to 100+ live and dead adults. The histopathology is characterized by the marked hyperplasia of the epithelium, marked vascularization of the tunica propria, dilation and congestion of the blood vessels of the *rete* and the presence of live and dead worms, eggs and larvae in the lumen of the swimbladder. Live and dead larvae are also present in the submucosa and externa and are surrounded by oedema, granulomatous inflammation and fibrosis. L_3 do not stimulate an inflammatory response but the reaction to L_4 stages is marked. Similar granulomatous foci may be found in the muscularis and serosa of the intestine. Another nematode affecting the swimbladder of salmonids is *Cystidicola* spp., and extreme burdens may occur. The pathogenicity of these worms appears to be low, although *Cystidicola farionis* in Arctic charr are thought to be a cause of increased long-term mortality.

Toxic effects on the formation or function of the swimbladder are rarely reported. A study of the effects of exposure of sticklebacks and medaka to increasing concentrations of fabric softener (ditallow dimethyl ammonium chloride) produced a swimbladder without a normal lumen, malformation or persistence of a pneumatic duct and dysplasia

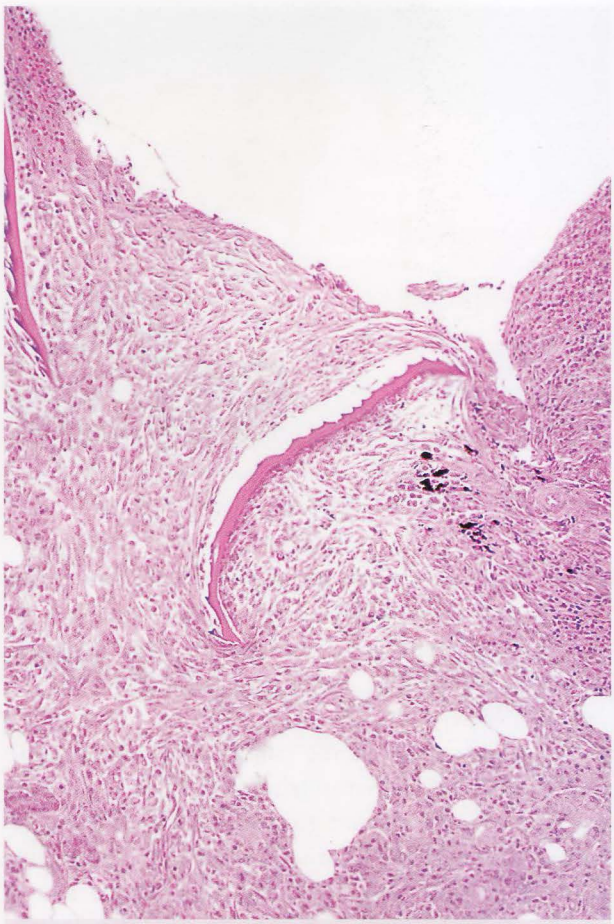

Fig 7.33B. Foreign bodies (dermal scales) introduced into the peritoneum via injection (blunt hypodermic needle?) that are encased in a sheet of macrophages.

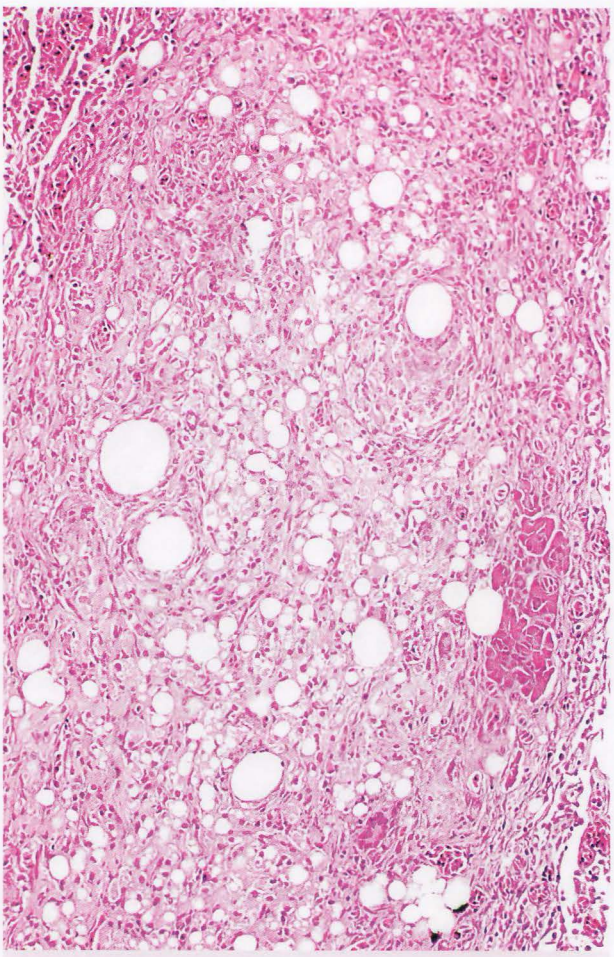

Fig 7.33C. Marked granulomatous response to peritoneal vaccination. Remnants of vaccine can still be seen as clear vacuoles.

of the bladder epithelium in both species. This was interpreted to be a teratogenic effect although it would be interesting to understand the effect of exposure to other surfactants since normal mammalian pulmonary function requires adequate and timely surfactant production. Exposure of seabream to TCDD (a dioxin) produced an increase in numbers of larvae with uninflated swimbladders.

Pancreas

Most fish do not have a discrete pancreas. Rather the groups of exocrine acini are found within the abdominal fat, for example between the pyloric caeca of salmonids, or around the biliary ducts in the liver (hepatopancreas) and less commonly in other locations such as in the spleen. Ectopic groups of pancreatic acini can sometimes be encountered in locations as unusual as the notch between the bulbus and ventricle of the heart. The pancreas can therefore rival the thyroid for variation in anatomic locations, which of course should not be misinterpreted as metastasis. Interlobular ductules merge to form the pancreatic duct that runs with the bile duct to the intestine. The location of the acini within hepatopancreas predisposes small to moderate portions to damage by extension from biliary parasites. These might also interfere with duct patency but the proportion affected relative to total pancreatic mass would likely be small. Brown bullheads sampled for hepatic neoplasia surveys commonly have numerous nematodes in bile ducts causing extensive granulomatous and necrotizing cholangiohepatitis that can extend to affect pancreatic acini. Atrophy of the exocrine pancreas can also occur in fish that are starved. There is loss in number and size of cytoplasmic zymogen granules with reduction in tissue mass.

The exocrine pancreas is a specific target for many infectious diseases (see below) but because of its location and close association with blood vessels, it is involved by ex-

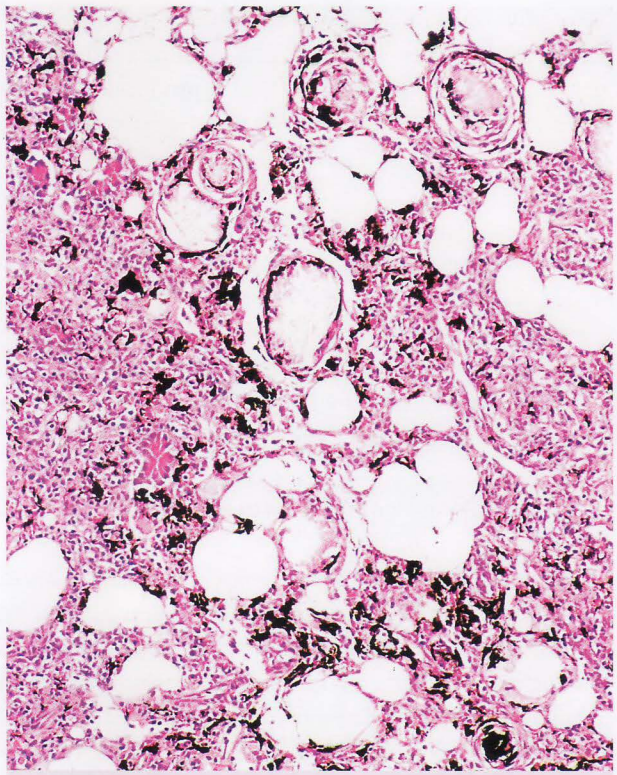

Fig 7.33D. Numerous melanomacrophages can be present within adverse reactions and the peritoneum can be grossly black.

tension in many systemic diseases, including bacteraemias and viraemias. IPNv is the best known example of an agent with a tropism for the pancreas, but IHNv, pancreas disease virus, sleeping disease virus and *Herpesvirus salmonis* also target this organ. For all of these, the initial lesion is multifocal-to-coalescing areas of necrosis with pathognomonic syncytia produced in infections with the latter. The lesion can vary in severity depending on the host species and strain but also depending on viral strain. This is best characterized for IPNv infection **(Fig 7.29)**. In general, infection is common but disease less so; the most important economic impact is undoubtedly reduced growth performance. Recent evidence has shown that some strains are capable of causing severe mortality in fry with marked necrosis lesions in the liver as well as pancreas. IPNv can also cause focal necrosis in the renal interstitium and hyaline degeneration of skeletal muscle and there is some evidence that the former lesion is more common than pancreatic lesions. Fish that survive IPNv infection can shed virus from the intestine and other mucosae and can become occult carriers that recrudesce with stress; a likely explanation for the disease in Norway primarily affecting post-smolts after transfer to sea cages.



Fig 7.34. Sucker with pleurocercoids of *Ligula intestinalis* producing a considerable space-occupying effect. *Courtesy Dr. G. Wobeser.*

IHNv also causes pancreatic necrosis, but other tissues are affected more severely with necrosis in the liver, spleen, renal interstitium, and intestine, as well as other organs.

Pancreas disease of Atlantic salmon is caused by an alpha-virus similar to that isolated from cases of sleeping disease of rainbow trout. Pancreas disease virus characteristically targets the exocrine pancreas but also the myocardium and skeletal muscle. Peroxidative loss of exocrine tissues is accompanied by limited inflammation and eventually by thin strands of pancreatic residuum between pyloric caeca **(Fig 7.30)**. The range of lesions in rainbow trout with sleeping disease is similar to that of pancreas disease in Atlantic salmon except that the skeletal lesions in SD are especially severe, while pancreatic involvement is minimal. Regeneration of exocrine acini does occur in PD and recovery can be relatively complete with a few residual mononuclear cells remaining as evidence of previous infection. Fish recovered from PD often have small groups of acini surrounding pancreatic ducts with very little inflammation. Resultant exocrine pancreatic insufficiency is likely the cause of impaired growth and increased incidence of runting (pinheads or slinks).

The extensive granulomatous inflammatory response induced by intraperitoneal vaccination, most likely has a marked impact on the exocrine pancreas and subsequent production of digestive enzymes. A potential reason for the marked variability seen with negative vaccination reactions may be the degree of impact on the pancreas. The ultimate impact of these lesions here and elsewhere is a substantial decrease in growth performance most impor-

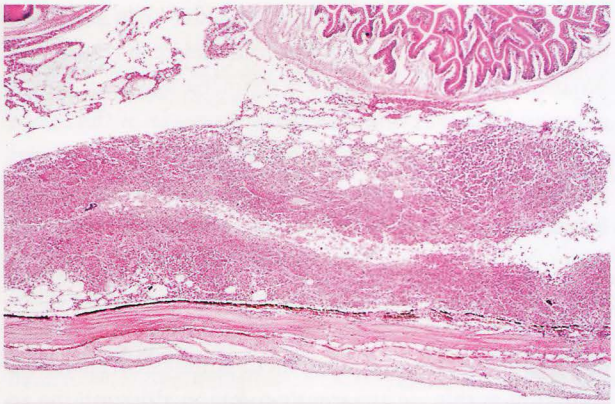

Mycotic peritonitis. *Fig 7.35A. Fusarium solani* peritonitis in desert pupfish.

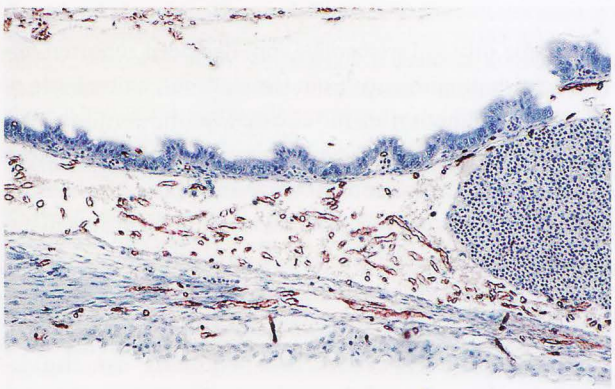

Fig 7.35B. Immunohistochemical staining of this *Saprolegnia* infection in rainbow trout shows the numerous hyphae. *Courtesy Dr. V. Ostland.*

tantly due to chronic pancreatic enzymatic insufficiency. The extensive granulomatous inflammation and often fibrosis in response to deposited vaccine adjuvant likely precludes sufficient pancreatic regeneration that may more likely occur following the acute necrotizing pancreatitis caused by viral agents. Reduced growth and necrosis and apoptosis have been reported to occur in the pancreas and numerous other tissues of carp in response to exposure to fumonisin B1. The effect of *Fusarium*-derived fumonisins in mammals is relatively well understood, but the implications for herbivorous species of fish could be significant and confirmation of these lesions is required.

Any inflammatory process that occurs in the abdominal pancreas or peritoneum may also extend to involve the copious adipose tissue. Pansteatis or "yellow fat disease" in contrast, is an example of a disease that specifically targets adipocytes. Consumption of a diet predominantly composed of unsaturated fatty acids (fish or fish oils) that is usually deficient in vitamin E are common associations in affected carnivorous mammals. Primary steatitis or pansteatitis does occur in fish and is proposed to be associated with vitamin E deficiency. In rainbow trout and striped jack, a generalized myopathy was also present and dysfunction of the pneumatic duct was the likely cause of the air sacculitis described in rainbow trout. Fat necrosis (saponification of fat with mineralization) characterized by lacy bluish mineral filling adipocyte cytoplasm is not very prominent compared with mammals, but the presence of extensive histiocytic and lymphocytic inflammation with giant cells is consistent, and these were present in affected Sunapee trout and striped jack.

Any parasite found within the peritoneal cavity may affect the integrity or function of the pancreas either indirectly through a space-occupying effect or by inadvertent migration and/or inflammation so produced. Typically the impact on the function of such a diffuse organ would be limited and clinical effects negligible. Occasionally however the pancreas itself may be a target, or a significant portion of the tissue may be affected indirectly. Examples include *Calyptospora funduli* in killifish in which the exocrine pancreas is largely replaced with only remnants of atrophic acini and ducts peripheral to developing stages of the organism; *Myxobolus osborni* in pumpkinseeds; *Glugea anomala* in sticklebacks; granulomatous pancreatitis in response to digenetic metacercariae; or extensive infestations of one of several of the parasites described below affecting the peritoneal cavity.

Peritoneum

The peritoneal cavity is often involved in any disease process that extends from a major parenchymal organ. Bacteraemias and viraemias very commonly produce foci of necrosis or may target blood vessels, resulting in serosanguinous ascitic fluid that may be copious enough to enlarge the abdomen *(Fig 7.31)*. Petechial and ecchymotic haemorrhages are very often present on the serosa of the intestine and other organs. Excessive granulomatous inflammation will often "spill over" into the abdominal cavity. Notable examples include BKD, PKD, ceratomyxosis, piscine mycobacteriosis and diphyllobothriosis *(Fig 7.32)*. The peritoneal cavity normally has a substantial resident population of macrophages that react quickly to irritants. The peritoneal cavity of some fish is normally heavily melanized and this must be differentiated from the focal melanization that can surround encysted meta-

cercariae of digeneans. A more extensive melanization due to infiltration of melanomacrophages can occur in severe inflammatory reactions, such as due to intraperitoneal vaccination, and these can sometimes track into skeletal muscle.

Extensive granulomatous inflammation that can efface the peritoneal cavity with resultant compromise of function and motility via space-occupying lesions and adhesions are well documented in farmed salmonids in which a commercial intraperitoneal vaccine has been administered ***(Fig 7.33)***. At a minimum, mild to moderate lesions are now expected in all vaccinated fish. Severe lesions can produce extensive adhesions and markedly reduce growth performance. The variably extensive sheets of macrophages enmeshed in swaths of proliferating fibroblasts, is characteristic. Moderate numbers of lymphocytes and eosinophilic granular cells can also be present, as can foreign body type giant cells ***(see also Figs 1.6C & 1.7)***. A notable characteristic of such inflammatory infiltrates, are the clear, circular-shaped empty spaces where oil adjuvant has been deposited, surrounded by a dense wall of macrophages. The use of oil-adjuvanted vaccines is widespread as they do provide protection from several bacterial diseases. Administration, however, can result in decreased growth, at least in Atlantic salmon, and the subsequent lesions, which can be severe, would not be tolerated in other species. A cost-benefit analysis of their use should be performed, but the variables that influence excessive inflammation and therefore decreased performance, are not yet understood. Testing alternative adjuvants that cause less inflammation and still provide adequate immunostimulation continues.

The peritoneal cavity is a convenient location for deposition of more than vaccines. Injection of "pit" tags or of telemetry devices for identification of fish or monitoring movement, respectively, is common. These ideally stimulate a minimal localized inflammatory reaction that immobilizes the object, although occasionally they may be "extruded" from the peritoneum by excessive inflammation that breaches the dermis and epidermis, typically, but not always, through the original route of injection.

The peritoneal cavity is also a common site for metazoan coelozoic parasites ***(Fig 7.34)***. Well-known examples of larval cestodes include *Ligula intestinalis* and *Protocephalus ambloplitis*, while an example of a nematode is *Philonema agubernaculum*. These may stimulate minimal inflammation or may irritate peritoneal macrophages, stimulate migration of neutrophils and eosinophilic granular cells and eventually produce extensive adhesions between abdominal organs. They may also have a dramatic space-occupying effect and *Ligula* is a most striking example of this. Compression and atrophy of abdominal organs can occur with marked abdominal enlargement. Larval nematodes in the swimbladder and cestodes similar to *Ligula* in the peritoneum were noted in whitefish from Lake Huron caught in commercial nets. The whitefish were extremely emaciated, the abdomen and swimbladder were filled with larvae and the internal organs were atrophied. Whitefish in such poor condition as this are apparently common although the severity of the parasitic burden is likely a reflection of the ongoing collapse of the foodchain rather than the pathogenicity of the parasites *per se*.

Peritonitis due to *Lactobacillus* spp. has been reported following stripping of eggs from female trout, an example of direct contamination via the cloaca. Mycotic peritonitis occurs commonly in sac fry, typically by direct extension from a contaminated environment via the yolk sac. Hyphae can be extremely numerous and there is often little inflammation, possibly reflecting the speed with which infected fish die ***(Fig 7.35)***. Mycotic peritonitis in older fish often stimulates a dramatic granulomatous response that may efface the peritoneal cavity. "Yolk peritonitis" can also occur with yolk protein globules free in the peritoneal cavity surrounded by a histiocytic response.

Acknowledgement:
Unless otherwise stated,
Hugh Ferguson supplied almost all of the figures.

References

Anders, K. and Yoshimizu, M. (1994) Role of viruses in the induction of skin tumours and tumour-like proliferations of fish. *Diseases of Aquatic Organisms* 19:215-232.

Afonso, A., Lousada, S., Silva, J., Ellis, A.E. and Silva, M.T. (1998) Neutrophil and macrophage responses to inflammation in the peritoneal cavity of rainbow trout *Onchorhynchus mykiss*. A light and electron microscopic cytochemical study. *Diseases of Aquatic Organisms* 34:27-37.

Angulo, L., Lopez, J.E., Vicente, J.A. and Saborido, A.M. (1994) Haemorrhagic areas in the mouth of farmed turbot, *Scophthalmus maximus* (L.). *Journal of Fish Diseases* 17:163-169.

Baevorford, G. and Krogdahl, A. (1996) Development and regression of soybean meal induced enteritis in Atlantic salmon, *Salmo salar* L., distal intestine: a comparison with the intestines of fasted fish. *Journal of Fish Diseases* 19:375-387.

Bartholomew, J.L., Smith, C.E., Rohovec, J.S. and Fryer, J.L. (1989) Characterization of the host response to the myxosporean parasite, *Ceratomyxa shasta* (Noble), by histology, scanning electron microscopy and immunological techniques. *Journal of Fish Diseases* 12:509-522.

Boucher, P. and Laurencin, F.B. (1996) Sleeping disease and pancreas disease: comparative histopathology and acquired cross-protection. *Journal of Fish Diseases* 19:303-310.

Bovo, G., Nishizawa, K., Maltese, C., Borghesan, F., Mutinelli, F., Montesi, F. and de Mas, S. (1999) Viral encephalopathy and retinopathy of farmed marine fish species in Italy. *Virus Research* 63:143-146.

Bowater, R.O., Thomas, A., Shivas, R.G. and Humphrey, J.D. (2003) Deuteromycotic fungi infecting barramundi cod, *Cromileptes altivelis* (Valenciennes), from Australia. *Journal of Fish Diseases* 26:681-686.

Branson, E., Riaza, A. and Alvarez-Pellitero, P. (1999) Myxosporean infection causing intestinal disease in farmed turbot, *Scophthalmus maximus* (L.) (Teleostei: Scophthalmidae). *Journal of Fish Diseases* 22:395-399.

Braunbreck, T. and Appelbaum, S. (1999) Ultrastructural alterations in the liver and intestine of carp *Cyprinus carpio* induced orally by ultra-low doses of endosulfan. *Diseases of Aquatic Organisms* 36:183-200.

Britt, T., Weisse, C. Weber, S.E., Matzkin, Z. and Klide, A. (2002) Use of pneumocystoplasty for overinflation of the swim bladder in a goldfish. *Journal of the American Veterinary Medical Association* 221:690-693.

Cone, D.K. (1983) A *Lactobacillus* sp. from diseased female rainbow trout, *Salmo gairdneri* Richardson in Newfoundland, Canada. *Journal of Fish Diseases* 5:479-485.

Crespo, S., Nonnotte, G., Colin, D.A., Leray, C., Nonnette, L. and Aubree, A. (1986) Morphological alterations induced in trout intestine by dietary cadmium and lead. *Journal of Fish Biology* 28:69-80.

Csaba, G., Kovacs-Gayer, E., Bekesi, L., Bucsek, J., Szakolczai, K. and Molnar, K. (1984) Studies into the possible protozoan aetiology of swimbladder inflammation in carp fry. *Journal of Fish Diseases* 7:39-56.

Dezfuli, B.S., Giari, L., Simoni, E., Bosi, G. and Manera, M. (2002) Histopathology, immunohistochemistry and ultrastructure of the intestine of *Leuciscus cephalus* (L.) naturally infected with *Pomphorhynchus laevis* (Acanthocephala). *Journal of Fish Diseases* 25:7-14.

Duncan, I.B. (1978) Evidence for an oncovirus in swim bladder fibrosarcoma of Atlantic salmon *Salmo salar* L. *Journal of Fish Diseases* 1:127-131.

Dykova, I. and Lom, J. (1978) Tissue reaction of the three-spined stickleback *Gasterosteus aculeatus* L. to infection with *Glugea anomala* (Moniez, 1887). *Journal of Fish Diseases* 1:83-90.

Fairgrieve, W.T., Meyers, M.S., Hardy, R.W. and Dong, F.M. (1994) Gastric abnormalities in rainbow trout (*Oncorhynchus mykiss*) fed amine-supplemented diets or gizzard-erosion-positive fish meal. *Aquaculture* 127:219-232.

Ferguson, H.W. (1979) Scanning and transmission electron microscopical observations on *Hexamita salmonis* (Moore, 1922) related to mortalities in rainbow trout fry *Salmo gairdneri* Richardson. *Journal of Fish Diseases* 2:57-67.

Ferguson, H.W. and Moccia, R.D. (1980) Disseminated hexamitiasis in Siamese fighting fish. *Journal of the American Veterinary Medical Association* 177:854-857.

Ferguson, H.W., Rosendahl, S. and Groom, S. (1985) Gastritis in Lake Tanganyika cichlids (*Tropheus duboisii*). *Veterinary Record* 116:687-689.

Ferguson, H.W., Roberts, R.J., Richards, R.H., Collins, R.O. and Rice, D.A. (1986) Severe degenerative cardiomyopathy associated with pancreas disease in Atlantic salmon, *Salmo salar* L. *Journal of Fish Diseases* 9:95-98.

Gibson-Kueh, S., Crumlish, M. and Ferguson, H.W. (2004) A novel 'skinny pot-belly' disease in Asian seabass fry, *Lates calcarifer* (Bloch). *Journal of Fish Diseases* 27:731-735.

Frelier, P.F., Elston, R.A., Loy, J.K. and Mincher, C. (1994) Macroscopic and microscopic features of ulcerative stomatitis in farmed Atlantic salmon *Salmo salar*. *Diseases of Aquatic Organisms* 18:227-231.

Friedmann, B.R. and Shutty, K.M. (1999) Effect of timing of oil film removal and first feeding on swim bladder inflation success among intensively cultured striped bass larvae. *North American Journal of Aquaculture* 61:43-46.

Greenwell, M.G. (2002) Sygnathid health management. ***In*** *Seahorse husbandry in public aquaria*, (***eds***. Bull, C.D. and Mitchell, J.S.) pp 15-23. John D. Shedd Aquarium, Chicago, Illinois.

Grizzle, J.M., Putnam, M.R., Fournie, J.W. and Couch, J.A. (1988) Microinjection of chemical carcinogens into small fish embryos: exocrine pancreatic neoplasm in *Fundulus grandis* exposed to N-methy-N-nitro-N-nitroso-guanidine. *Diseases of Aquatic Organisms* 5:101-105.

Heidel, J.R., Rockey, D.D. and Duimstra, J.R. (1992) Acinar cell carcinoma of the pancreas in coho salmon *Oncorhynchus kisutch*. *Diseases of Aquatic Organisms* 13:151-154.

Hemmer, N., Steinhagen, D., Drommer, W. and Korting, W. (1998) Changes of intestinal epithelial structure and cell turnover in carp *Cyprinus carpio* infected with *Goussia carpelli* (Protozoa: Apicomplexa). *Diseases of Aquatic Organisms* 34:39-44.

Herman, R.L. and Kircheis, F.W. (1985) Steatitis in Sunapee trout, *Salvelinus alpinus oquassa* Girard. *Journal of Fish Diseases* 8:237-239.

Hoole, D. and Nisan, H. (1994) Ultrastructural studies on intestinal response of carp, *Cyprinus carpio* L., to the pseudophyllidean tapeworm, *Bothriocephalus acheilognathi* Yamaguti, 1934. *Journal of Fish Diseases* 17:623-629.

Jaquemond, F. (2004) Separated breeding of perch fingerlings (*Perca fluviatilis*) with and without initial inflated swim bladder: comparison of swim bladder development, skeletal confirmation and growth performances. *Aquaculture* 239:261-273.

Kennedy, C.R. and Fitch, D.J. (1990) Colonization, larval survival and epidemiology of the nematode *Anguillicola crassus*, parasitic in the eel, *Anguilla anguilla*, in Britain. *Journal of Fish Biology* 36:117-131.

Kent, M.L., Ellis, J., Fournie, J.W., Dawe, S.C., Bagshaw, J.W. and Whitaker, D.J. (1992) Systematic hexamitid (Protozoa: Diplomonadida) infection in seawater pen-reared chinook salmon *Oncorhynchus tshawytsha*. *Diseases of Aquatic Organisms* 14:81-89.
Kim, D.H., Han, H.J., Kim, S.M., Lee, D.C. and Park, S.I. (2004) Bacterial enteritis and the development of the larval digestive tract in the olive flounder *Paralichthys olivaceus* (Temminck and Schlegel). *Journal of Fish Diseases* 27:497-505.
Kovacic, S., Petrinec, Z., Pepeljnjak, S. and Segvic-Klaric, M. (2004) Toxic effects of fumonisin B_1 in the carp (*Cyprinus carpio* L.). *Praxis Veterinaria*. 52:183-192.
Knudsen, R., Amundsen, P. A. and Klemetsen, A. (2002) Parasite-induced host mortality: indirect evidence from a long-term study. *Environmental Biology of Fishes* 64:257-265.
Lair, S., Mailhot, Y., Higgins, R., Belanger, D., Berthiaume, L., de Lafontaine, Y. and Martineau, D. (1997) Jaw ulcers in Atlantic tomcod, *Microgadus tomcod* (Walbaum), from the St. Lawrence River. *Journal of Fish Diseases* 20:11-17.
Lee, K.K., Liu, P.C. and Chuang, W.H. (2002) Pathogenesis of gastroenteritis caused by *Vibrio carchariae* in cultured marine fish. *Marine Biotechnology* 4:267-277.
Lumsden, J.S., Clark, P., Hawthorn, S., Minamikawa, M., Fenwick, S.G., Haycock, M. and Wybourne, B. (2002) Gastric dilation and air sacculitis in farmed chinook salmon *Onchorhynchus tshawytsha* (Walbaum). *Journal of Fish Diseases* 25:155-163.
Lumsden, J.S., Wybourne, B., Hawthorn, S., and Minamikawa, M. (2004) Gastric dilation and air sacculitis in Chinook salmon *Oncorhynchus tshawytscha* (Walbaum) and its relationship to commercial diet, a glomerulonephritis and to serum biochemistry. *Journal of Fish Diseases* 25:155-163.
Marty, G.D., Freiberg, E.F., Meyers, T.R., Wilcock, J., Farver, T.B. and Hinton, D.E. (1998) Viral hemorrhagic septicemia virus, *Ichthyophonus hoferi*, and other causes of morbidity in Pacific herring *Clupea pallasi* spawning in Prince William Sound, Alaska, USA. *Diseases of Aquatic Organisms* 32:15-40.
Matsuyama, T. and Iida, T. (2002) Tilapia mast cell lysates enhance neutrophil adhesion to cultured vascular endothelial cells. *Fish and Shellfish Immunology* 13:243-250.
McAllister, P.E. and Owens, W.J. (1995) Assessment of the virulence of fish and molluscan isolates of infectious pancreatic necrosis virus for salmonid fish by challenge of brook trout, *Salvelinus fontinalis* (Mitchell). *Journal of Fish Diseases* 18:97-103.
McKnight, I.J. and Roberts, R.J. (1976) The pathology in infectious pancreatic necrosis. I. The sequential histopathology of the naturally occurring condition. *British Veterinary Journal* 132:76-85.
McKnight, I.J. (1978) Sarcoma of the swim bladder of Atlantic salmon (*Salmo salar*). *Aquaculture* 13:55-60.
McLoughlin, M.F., Nelson, R.N., McCormick, J.I. Rowley, H.M. and Bryson, D.B. (2002) Clinical and histopathological features of naturally occurring pancreas disease in farmed Atlantic salmon, *Salmo salar* L. *Journal of Fish Diseases* 25:33-43.
Michel, C., Bernardet, J.F., Daniel, P., Chilmonczyk, S., Urdaci, M. and de Kinkelin, P. (2002) Clinical and aetiological aspects of a summer enteritic syndrome associated with the sporulating segmented filamentous bacterium '*Candidatus Arthromitus*' in farmed rainbow trout, *Oncorhynchus mykiss* (Walbaum). *Journal of Fish Diseases* 25:533-543.
Midtlyng, P.J. and Lillihaug, A. (1998) Growth of Atlantic salmon *Salmo salar* after intraperitoneal administration of vaccines containing adjuvants. *Diseases of Aquatic Organisms* 32:91-97.
Midtlyng, P.J. (1997) Vaccinated fish welfare: protection versus side-effects. ***In*** *Fish Vaccinology* (***eds.*** Gudding, R., Lillehaug, A., Midtlyng, P.J. and Brown, F.) *Development of Biological Standards* 90:371-379.
Mitchell, L.G., Ginal, J. and Bailey, W.C. (1983) Melanotic visceral fibrosis associated with larval infections of *Posthodiplostomum minimum* and *Proteocephalus* sp. in bluegill, *Lepomis macrochirus* Rafinesque, in central Iowa, USA. *Journal of Fish Diseases* 6:135-144.
Molnar, K., Baska, F., Csaba, G., Glavatis, R. and Szekely, S. (1993) Pathological and histopathological studies of the swimbladder of eels *Anguilla anguilla* infected by *Anguillicola crassus* (Nematoda: Dracunculoides). *Diseases of Aquatic Organisms* 15:41-50.
Molnar, K. (1996) Nodular cocccidiosis of the pikeperch *Stizostedion lucioperca* and Volga perch *Stizostedion volgensis*. *Diseases of Aquatic Organisms* 27:35-41.
Moyle, P.B. and Cech, J.J. (2000) Bouyancy and thermal regulation. ***In*** *Fishes: An introduction to ichthyology* (***eds.*** Moyle, P.B. and Cech, J.J.) pp 77-82. Prentice Hall, New Jersey.
Muroga, K., Yasunobu, H., Okada, N. and Masumura, K. (1990) Bacterial enteritis of cultured flounder *Paralichthys olivaceus* larvae. *Diseases of Aquatic Organisms* 9:121-125.
Murphy, T.M., Rodger, H.D., Drinan, E.M., Gannon, F., Kruse, P. and Korting, W. (1992) The sequential pathology of pancreas disease in Atlantic salmon farms in Ireland. *Journal of Fish Diseases* 15:401-408.
Newton, J.C., Wolfe, L.G., Grizzle, J.M. and Plumb, J.A. (1989) Pathology of experimental enteric septicemia of channel catfish, *Ictalurus punctatus* (Rafinesque), following immersion-exposure to *Edwardsiella ictaluri*. *Journal of Fish Diseases* 12:335-347.
Olsson, C. and Holmgren, S. (2001) The control of gut motility. *Comparative Biochemistry and Physiology* A 128:481-503.
Ortiz-Delgado, J.B. and Sarasquete, C. (2004) Toxicity, histopathological alterations and immunohistochemical CYP1A induction in the early life stages of the seabream, *Sparus aurata*, following waterborne exposure to B(a)P and TCDD. *Journal of Molecular Histology* 35:29-45.
Paperna, I. and Vilenkin, M. (1996) Cryptosporidiosis in the gourami *Trichogaster leeri*: description of a new species and a proposal for a new genus, *Piscicryptosporidium*, for species infecting fish. *Diseases of Aquatic Organisms* 27:95-101.
Pasnik, D.J., Khoo, L. and Gaunt, P.S. (2003) Gastrointestinal torsion in a channel catfish (*Ictalurus punctatus*). *Journal of Wildlife Disease* 39:238-240.
Plumb, J.A., Grizzle, J.M., Young, H.E., Noyes, A.D. and Lamprecht, S. (1996) An iridovirus isolated from wild largemouth bass. *Journal of Aquatic Animal Health* 8:265-270.
Poppe, T.T., Hellberg H., Griffiths D. and Meldal, H. (1997) Swimbladder abnormality in farmed Atlantic salmon *Salmo salar*. *Diseases of Aquatic Organisms* 30:73-76.
Poppe, T.T. and Breck, O. (1997) Pathology of Atlantic salmon *Salmo salar* intraperitoneally immunized with oil-adjuvanted vaccine. *Diseases of Aquatic Organisms* 29:219-226.
Poulos, C., Bakopoulos, V., Zolota, V. and Dimitriadis, G.J. (2004) Histopathological findings after sea bass (*Dicentrarchus labrax* L.) exposure to extracellular products of *Photobacterium damsela* subsp. *piscicida* produced *in vivo*. *Aquaculture Research* 35:931-936.
Poynton, S.L., Fard, M. R. S., Jenkins, J. and Ferguson, H.W. (2004) Ultrastructure of pathogenic diplomonad flagellates from fish: characterization of *Spironucleus salmonis* n. comb. from Northern Irish rainbow trout *Oncorhynchus mykiss*, and a diagnostic guide for recognition of species. *Diseases of Aquatic Organisms* 60:49-64.

Randall, D., Burggren, W. and French, K. (2002) Gas exchange and acid-base balance. *In Animal Physiology* (***eds***. Randall, D., Burggren, W. and French, K.) pp 525-578. W.H. Freeman, New York.
Rimmer, D.W. and Wiebe, W.J. (1987) Fermentative microbial digestion in herbivorous fishes. *Journal of Fish Biology* 31:229-36.
Roberts, R.J., Richards, R.H. and Bullock, A.M. (1979) Pansteatitis in rainbow trout *Salmo gairdneri* Richardson: a clinical and histopathological study. *Journal of Fish Diseases* 2:85-92.
Roberts, R.J. (2001) The pathophysiology and systemic pathology of teleosts. ***In*** *Fish Pathology* 3rd edn. (***ed***. Roberts, R.J.) Bailliere Tindall, London.
Rorvik, K-A., Skjervold, P.O., Fjaera, S.O. and Stein, S.H. (2000) Distended, water-filled stomach in seawater farmed rainbow trout, *Oncorhynchus mykiss* (Walbaum), provoked experimentally by osmoregulatory stress. *Journal of Fish Diseases* 23:15-18.
Sanden, M., Berntssen, M.H.G., Krogdahl, A., Hemre, G.I. and Bakke-McKellep, A.M. (2005) An examination of the intestinal tract of Atlantic salmon, *Salmo salar* L., parr fed different varieties of soy and maize. *Journal of Fish Diseases* 28:317-330.
Smith, I.R., Ferguson, H.W. and Hayes, M.A. (1989) Histopathology and prevalence of epidermal papillomas epidemic in brown bullhead, *Ictalurus nebulosus* (Lesueur), and white sucker, *Catostomus commersoni* (Lacepede), populations from Ontario, Canada. *Journal of Fish Diseases* 12:373-388.
Speare, D. (1998) Non-infectious disorders associated with intensive aquaculture husbandry. ***In*** *Fish Diseases and Disorders* (***eds.*** Leatherland, J.F. and Woo, P.T.K.) pp 303-333. CABI publishing, New York.
Staurnes M., Andorsdottir G. and Sundby, A. (1990) Distended, water-filled stomach in sea-farmed rainbow trout. *Aquaculture* 90:333-343.
Taraschewski, H. (2000) Host-parasite interactions in acanthocephala: a morphological approach. *Advances in Parasitology* 46:1-179.
Taksdal, T., Stangeland, K. and Dannevig, B.H. (1997) Induction of infectious pancreatic necrosis (IPN) in Atlantic salmon *Salmo salar* and brook trout *Salvelinus fontinalis* by bath challenge of fry with infectious pancreatic necrosis virus (IPNV) serotype Sp. *Diseases of Aquatic Organisms* 28:39-44.
Taksdal, T., Ramstad, A., Strangeland, K. and Dannevig, B.H. (1998) Induction of infectious pancreatic necrosis (IPN) in covertly infected Atlantic salmon, *Salmo salar* L., post-smolts by stress exposure, by injection of IPN virus (IPNV) and by cohabitation. *Journal of Fish Diseases* 21:193-204.
Trotter, A.J., Pankhurst, P.M. and Hart, P.R. (2001) Swimbladder malformation in hatchery-reared striped trumpeter *Latris lineata* (Latridae). *Aquaculture* 198:41-54.
Trotter, A.J. Pankhurst, P.M. and Battaglene, S.C. (2004) Morphological development of the swim bladder in hatchery-reared striped trumpeter *Latris lineata*. *Journal of Applied Ichthyology* 20:394-401.
Uldal, A. and Buchmann, K. (1996) Parasite host relations: *Hexamita salmonis* in rainbow trout *Oncorhynchus mykiss*. *Diseases of Aquatic Organisms* 25:229-231.
Umaporn, S. and Noga, E.J. (2001) Peptide antibiotics in mast cells of fish. *Nature* 414:268-269.
Wada, S., Hatai, K. and Kubuta, S.S. (1991) Histopathological study of cultured striped jack with yellow fat disease. *Fish Pathology* 26:61-67.
Wester, P.W. and Roghair, C.J. (1992) Teratogenic effect in the gas gland of fish induced by the fabric softener ditallow dimethyl ammonium chloride. *Diseases of Aquatic Organisms* 12:207-213.
Weston, J., Villoing, S., Bremont, M., Castric, J., Pfeffer, M., Jewhurst, V., McLoughlin, M., Rodseth, O., Christie, K.E., Koumans, J. and Todd, D. (2002) Comparison of two alphaviruses, salmon pancreas disease virus and sleeping disease virus, by using genome sequence analysis, monoclonal reactivity, and cross-infection. *Journal of Virology* 76:6155-6163.
Willens, S., Dunn, J.L. and Frasca, Jr., S. (2004) Fibrosarcoma of the brood pouch in an aquarium-reared lined seahorse (*Hippocampus erectus*). *Journal of Zoo and Wildlife Medicine* 35:107-109.

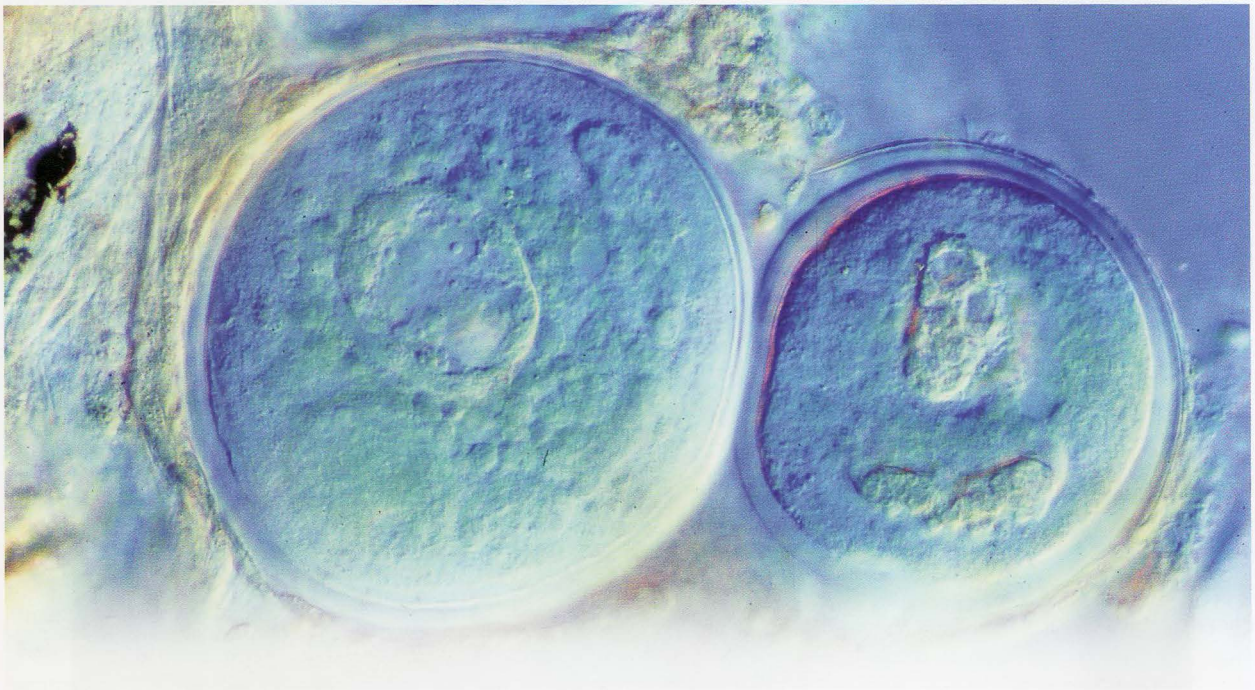





Liver

CHAPTER 8

by Øystein Evensen

Normal structure and function

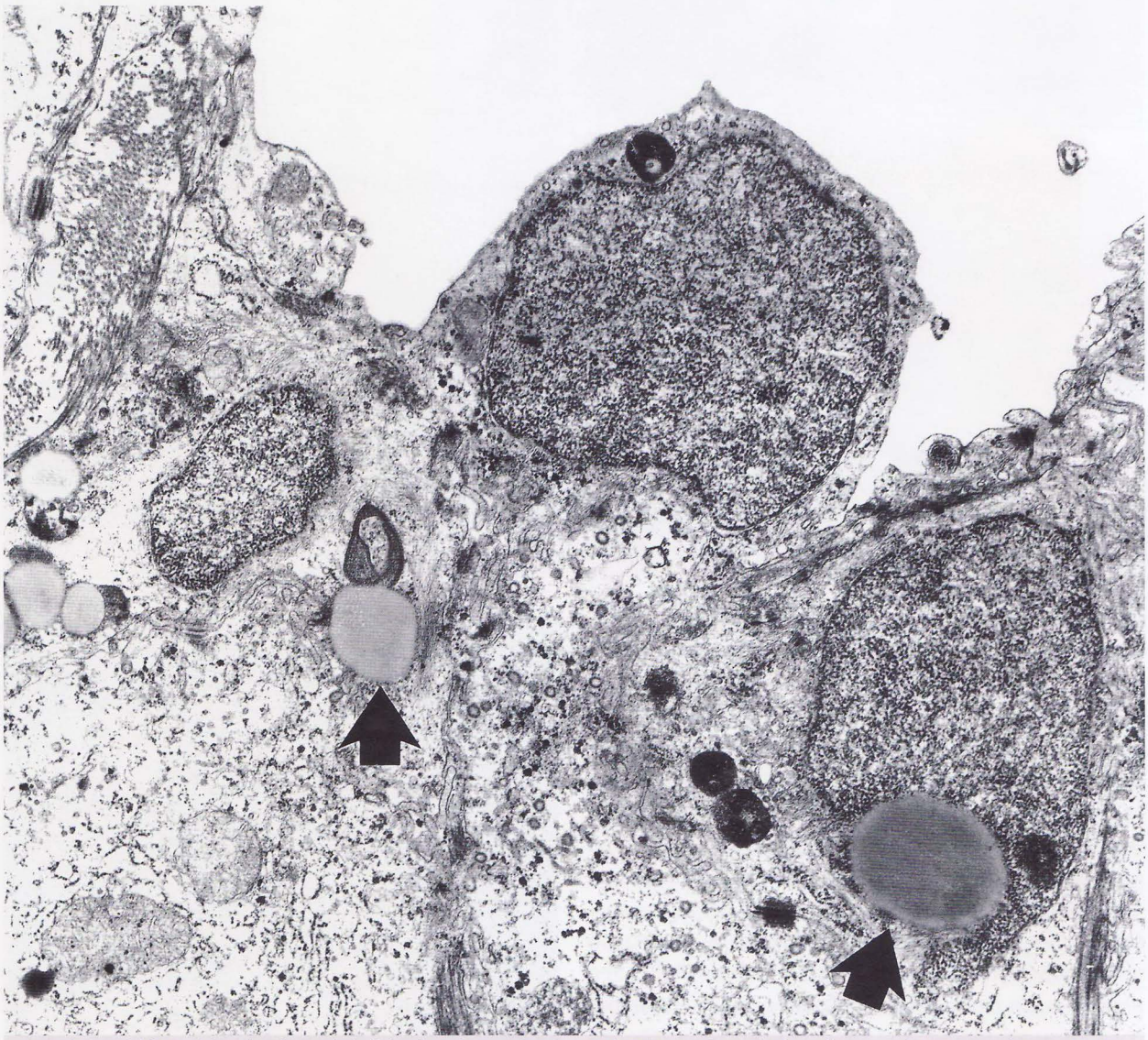

Fig 8.1. Sinusoid from plaice showing endothelial cell nucleus projecting out into lumen. Beneath this cell are two fat-storing cells showing fat globules in their cytoplasm (arrows). No Kupffer cells are present.

Gross anatomy. In many fish species the liver is a discrete organ in the anterior portion of the abdominal cavity. In others it is split into lobes that interdigitate with the intestine and may run the length of the abdominal cavity. Fish liver serves similar metabolic functions to those in mammals and the liver has an important role in maintaining the body's metabolic homeostasis that includes processing of carbohydrates, proteins, lipids, and vitamins. The liver also plays a key role in detoxification and in the synthesis of serum proteins, like albumin, fibrinogen, complement factors and acute phase proteins.

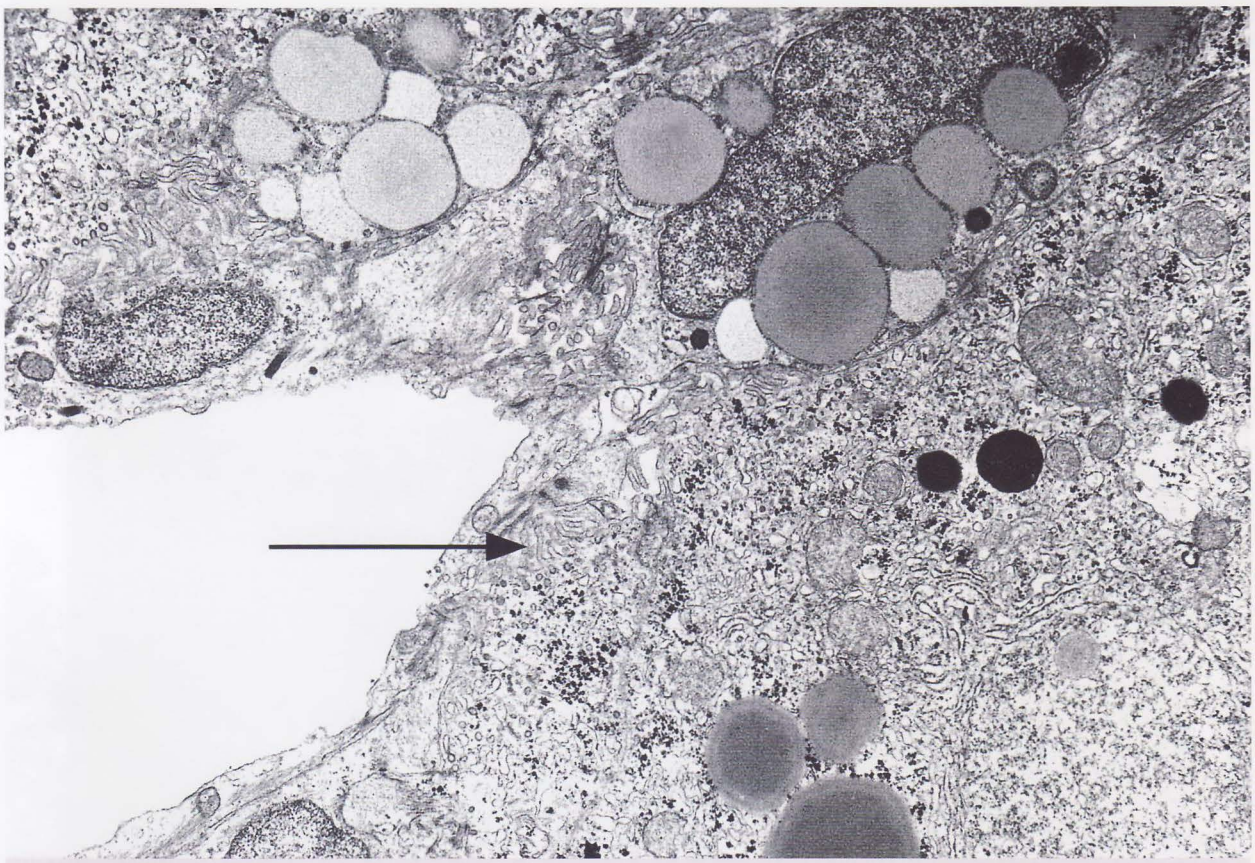

Fig 8.2. Sinusoid from plaice showing fat-storing cells. Note the finger-like projections within the space of Disse (arrow).

Histology. The microarchitecture of the liver varies among species, but there are some general traits that are found in the majority of species examined. The sinusoidal endothelial cells form a cytoplasmic sheet about 70 - 100 nm in average thickness. Neighbouring endothelial cells can overlap and interdigitate. The nuclei of the endothelial cells are usually elongated and protrude into the sinusoidal lumen ***(Fig 8.1)***. These should not be mistaken for Kupffer cells, which are not found in teleosts. Cytoplasmic organelles are generally sparse in endothelial cells and for the most part located near the nucleus. Small mitochondria, rough endoplasmic reticulum (RER), free ribosomes, and occasionally a Golgi complex are found. Numerous pinocytotic and/or micropinocytotic vesicles are present along the sinusoidal surface or subendothelially, indicating high endocytotic and/or exocytotic activity. Microtubules are frequently found, especially in the most attenuated regions of the cells. The endothelium is fenestrated by small, intracellular pores, typically 80-120 nm in diameter and, unlike mammals, the fenestrae lack a diaphragm.

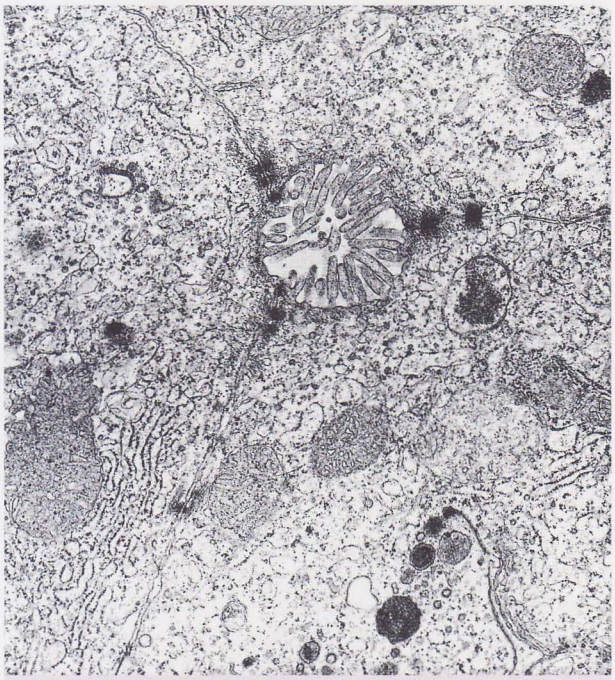

Fig 8.3. Three hepatocytes contribute to the intercellular bile canaliculus. Note the tight junctions and microvilli.

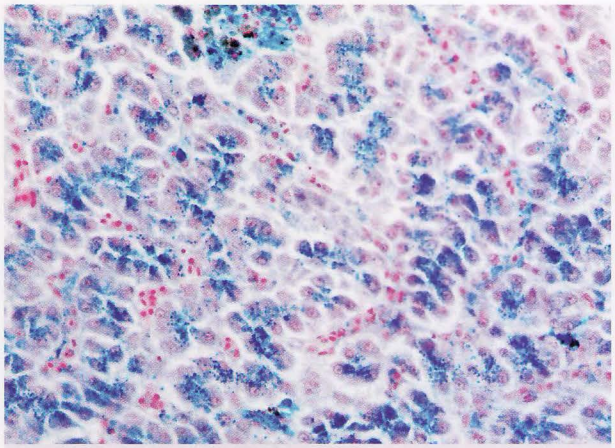

Fig 8.4. Butterfly fish with hepatic siderosis. *Prussian blue stain.*

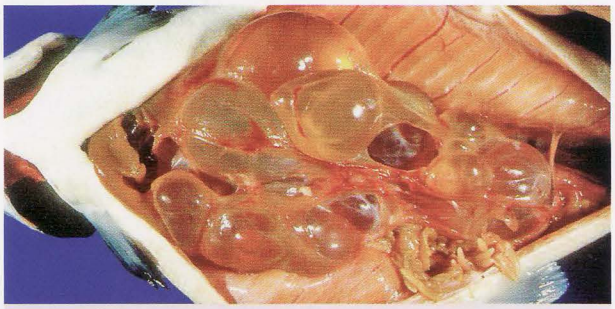

Hepatic cysts. *Fig 8.5A.* This Atlantic salmon had a massively distended abdominal cavity! *Picture courtesy Dr. T.T. Poppe.*

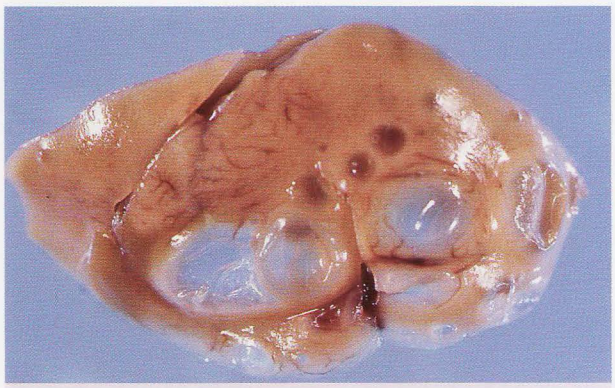

Fig 8.5B. Similar, although less spectacular lesion in this rainbow trout.

The endothelium rests on fibrillar strands forming basement membrane-resembling material, but no distinct membrane is found. The fenestrae provide an open communication between the sinusoidal lumen and the space of Disse that measures 1.5-2.5 µm in width and contains thin microvilli that project from the underlying parenchymal cells. Cross-striated collagen fibrils

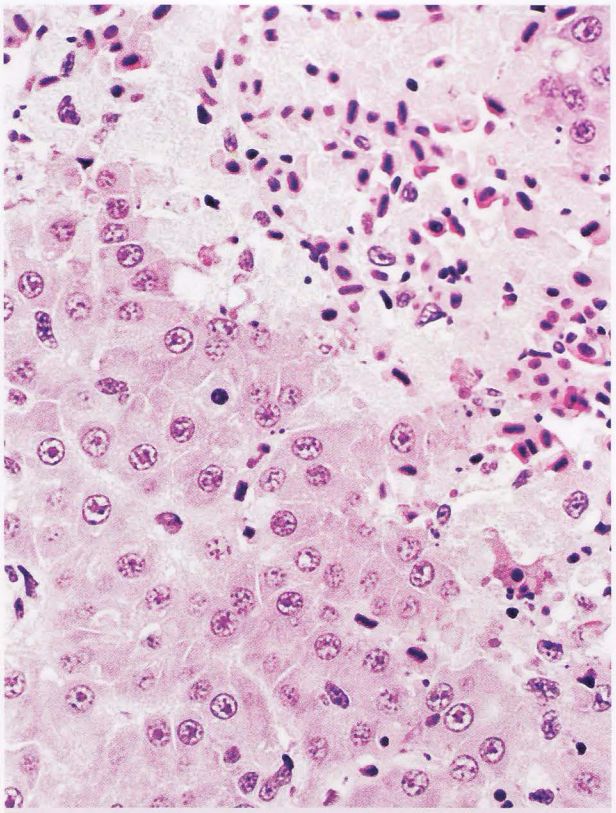

Fig 8.6. Lytic necrosis in this liver is seen in most of the hepatocytes in the top right of the picture. The normal architecture here has been lost.

representing reticular fibres traverse the space in which are also found perisinusoidal stellate cells **(*Fig 8.2*)**, often referred to as cells of Ito or fat-storing cells in higher vertebrates. They are located immediately underneath the endothelial lining, and in salmonids have elongated nuclei plus one or several cytoplasmic, non-membrane bound paranuclear lipid droplets. Typical findings also include a well-developed Golgi apparatus and abundant RER but poorly developed smooth endoplasmic reticulum (SER) and little cytoplasmic glycogen. Mitochondria are usually few and small.

In salmonids a non-classified, non-parenchymal cell type has also been found wedged in between hepatocytes, termed interhepatocytic cell (IHC). The shape is irregular and elongated with cytoplasmic processes extending towards centrotubular bile canaliculi, and with a minor part of their surface exposed to the space of Disse. A constant finding in IHC's is the presence of electron-dense, membrane-bounded organelles (0.2-0.5 µm in diameter), ultrastructurally resembling microbodies. IHC's can on occasions have features typical of activated macrophages.

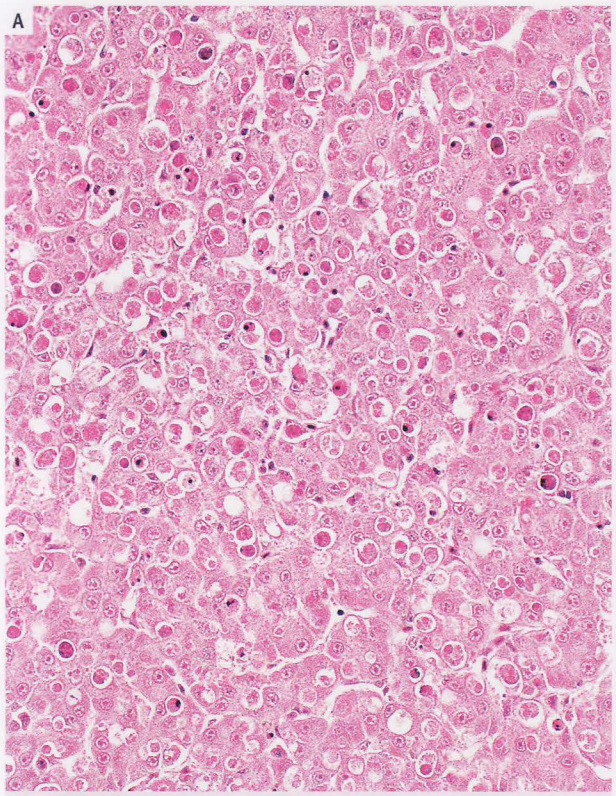

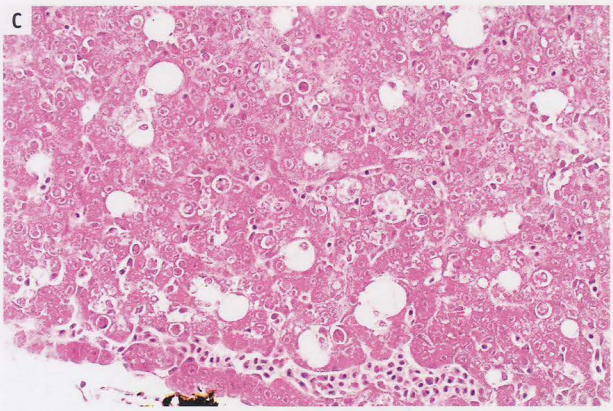

Fig 8.7A-C. All show low and high power views of single cell necrosis with "individualization" of hepatocytes. Such changes are commonly seen in early stages of viral disease. **A**&**B** are Atlantic salmon with IPN, while **C** is a grouper with nodaviral infection.

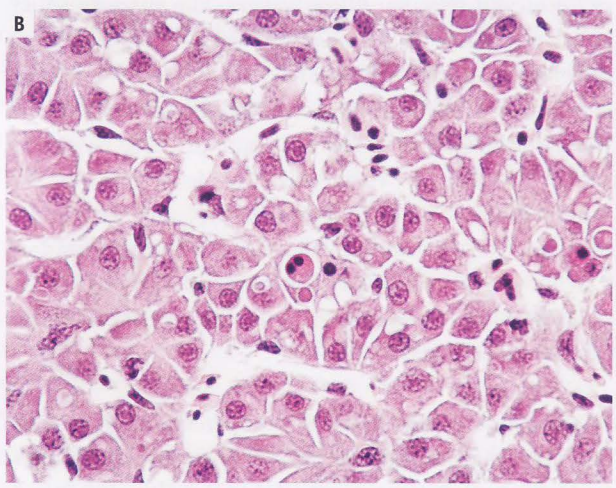

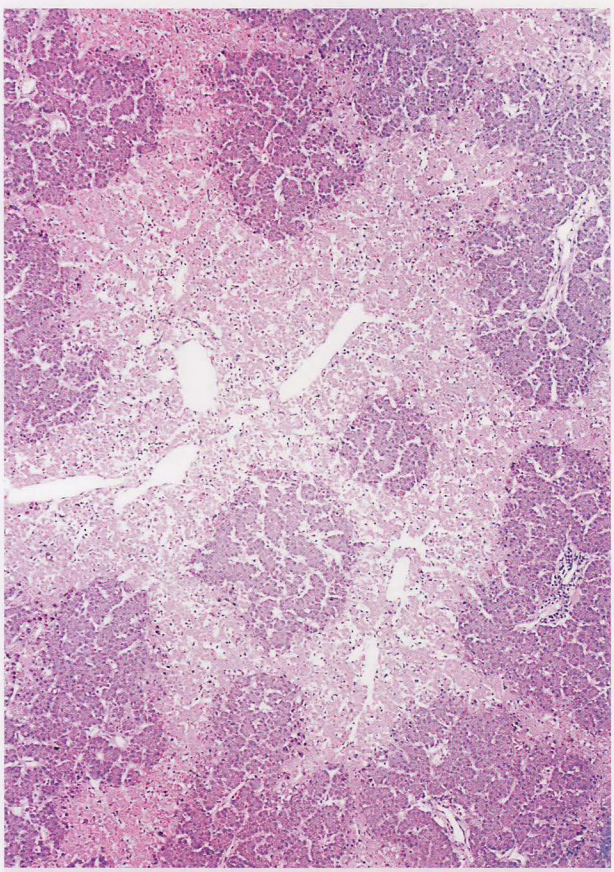

Fig 8.8. Cardiac failure in this rainbow trout with RTFS-induced myocarditis has led to a liver showing extensive anoxic necrosis, but still retains its architecture. The more basophilic areas are still-viable hepatocytes.

Hepatocytes possess microvilli that increase the cell surface area facing the subendothelial space of Disse ***(Fig 8.2)***. Glycogen deposits can frequently be found and can occupy up to half of the cytoplasmic area. RER is typically arranged in concentric layers around the nucleus, and mitochondria are often elongated. Golgi complexes are frequently found at the biliary pole along with sparse amounts of SER. The bile canaliculi are contributed to by up to 4 to 8 hepatocytes, adjoined by tight junctions and desmosomes at the apices ***(Fig 8.3)***. Microvilli project from hepatocytes and fill up the canalicular lumen. Hepatocyte appearance varies greatly between species and also with season, nutritional status, age, sex and pollutant exposure, especially with regard to fat and endo-

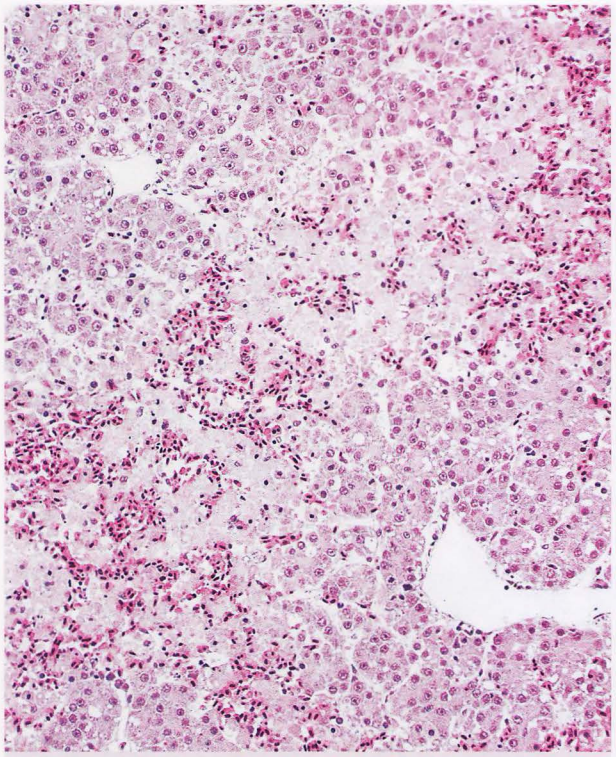

Fig 8.9. Necrosis of liver from Atlantic salmon with ISA. Associated haemorrhage into the necrotic areas is typical.

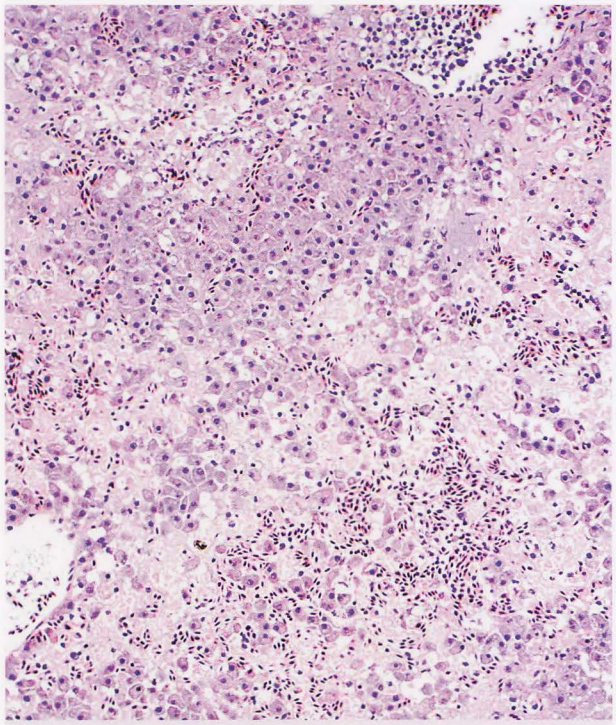

Hepatitis. *Fig 8.10A.* Atlantic salmon parr with IPN showing severe acute haemorrhagic hepatitis. Such fish may show little in the way of pancreatic lesions although these may occur later.

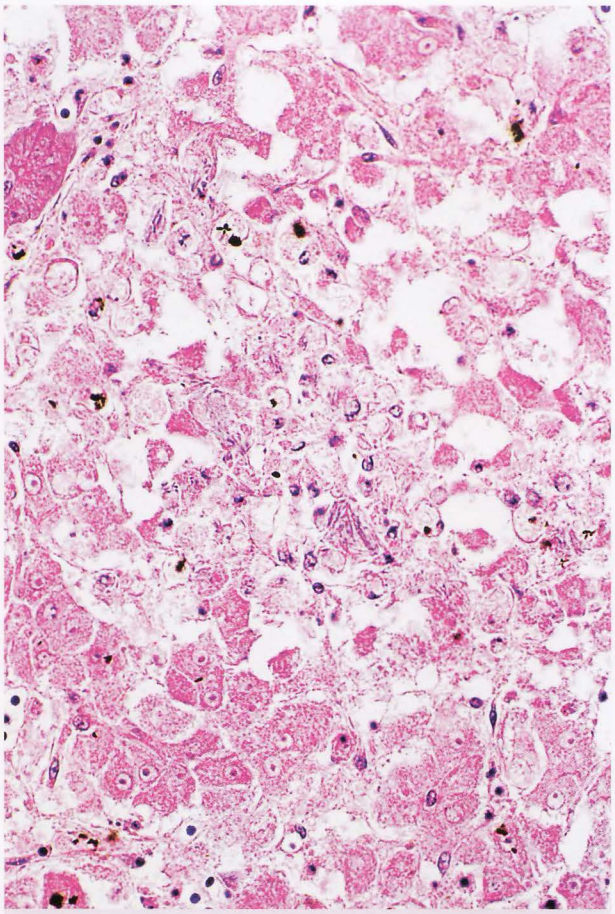

Fig 8.10B. Acute multifocal necrosis in this *Pangasius* catfish with *Edwardsiella ictaluri* infection.

plasmic reticulum content. For example, hepatocytes from starved milkfish are smaller than normal and they have smaller nuclei with condensed chromatin; there is loss of stored glycogen but an increase in mitochondrial size and iron-containing dense bodies.

The hepatocytes of the piscine liver are arranged as a *muralium duplex*, also referred to as a dual-plated muralium. Liver lobuli, as found in mammals with the classical hexagonal pattern around a central vein (terminal hepatic venule), are not found in fish (see below). The early investigators of the 19th century studying piscine liver anatomy considered it a net-like, tubular gland. In later studies this view was opposed and a laminar model was proposed, later supported by several studies. Despite this, the tubular concept has stood its ground and a majority of more recent studies favour this theory. The discrepancy in the literature reflects not only real interspecies variation, but also differences in interpretation by the observers. In rainbow trout both models have been proposed in two separate studies.



Fig 8.10C. Multifocal granulomatous hepatitis in this rainbow trout with *Ichthyophonus* infection. Note the fibroplastic walling-off response round the spores. *PAS stain.*

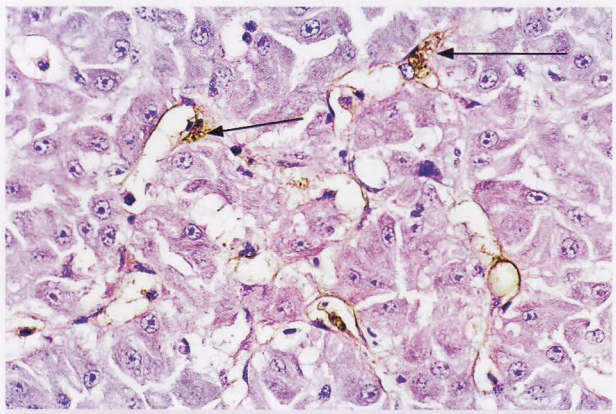

Fig 8.11. Atlantic salmon with *Pasteurella skyensis* infection showing bacterial antigen within the fat-storing cells (arrows). *Immunohistochemistry picture courtesy Dr. L. Foyle.*



Lipoid liver disease in rainbow trout. *Fig 8.12A.* Both these fish show patchy pallor to their liver. The bottom fish also has splenomegaly.

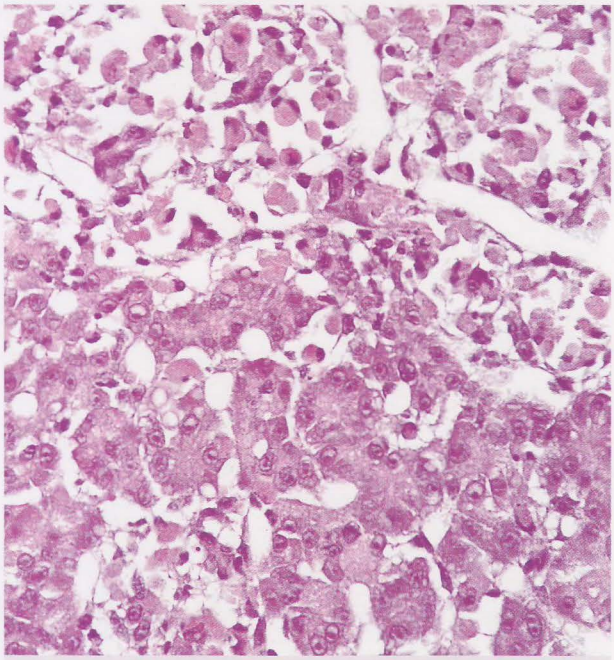

Fig 8.12B. Ceroid accumulation within hepatocytes of trout with LLD. Those at the top are severely affected.

There is still the possibility of a remodelling of the organ with age from a primitive tubular gland towards the more sophisticated dual-plated muralium. Age of the fish can thus be a source of variation. In humans the ultimate *muralium simplex* is not reached until an age of about 5 years. Melanomacrophage centres (MMC) are found in the liver of many teleosts and they are believed to represent the equivalent of germinal centres of birds and mammals. They consist of aggregates of macrophages containing various pigments such as haemosiderin, lipofuscin, and melanin.

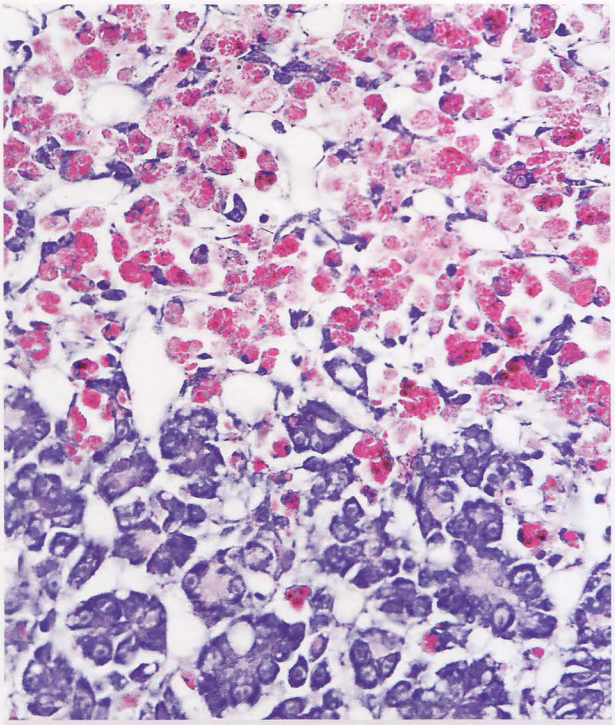

Fig 8.12C. Same section as **B**. Ceroid is acid fast. *Ziehl-Nielsen stain.*

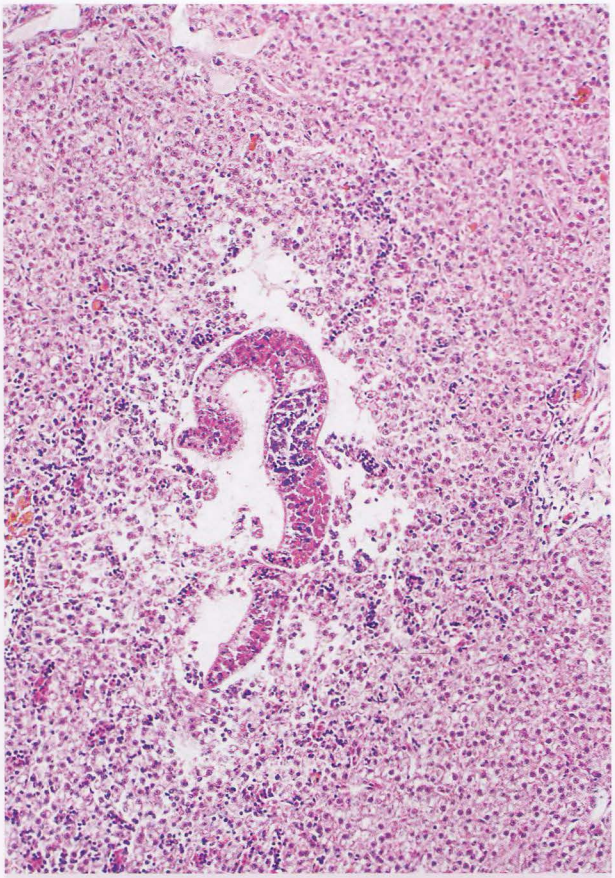

Fig 8.13B. Acute necrosis in this white sucker liver due to the migrating activities of the parasite.

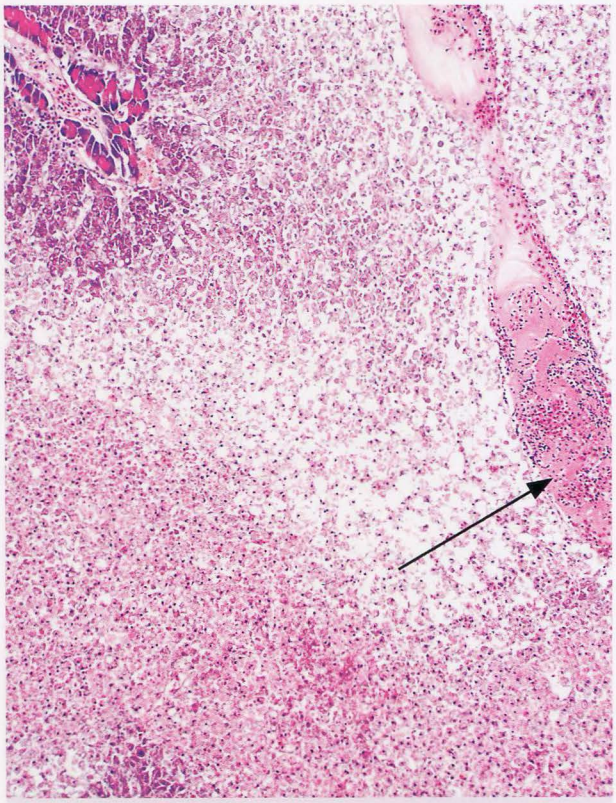

Fig 8.13A. Hepatic infarction in this seabass, the result of a large thrombus (arrow).

Comparative anatomy. The terminology used to describe hepatic injury in higher vertebrates is based on the classical lobular pattern where a hexagonal lobule is centered around a central vein. The portal tracts with the bile ducts, the hepatic artery and the portal vein branches (triads), are found at three of the apices. Typical triads are not regularly found in fish, but "diads" can be more regularly seen, composed of a biliary tract and a vein or an arteriole.

The acinus is the functional unit of the mammalian liver that has been divided into three zones representing metabolic regions, increasingly distant from the arterial blood supply. The central vein is located the farthest away from the oxygenated blood. The lobular structure and the portal tracts are not found in the fish liver and as a consequence, the acinus cannot be defined and therefore no classical zonal pattern is discernible. This means that the terminology used in higher vertebrates that is based on the referred anatomical entities cannot be applied to classify or describe pathological changes of the liver of fish. This will be further discussed in the ensuing paragraphs.

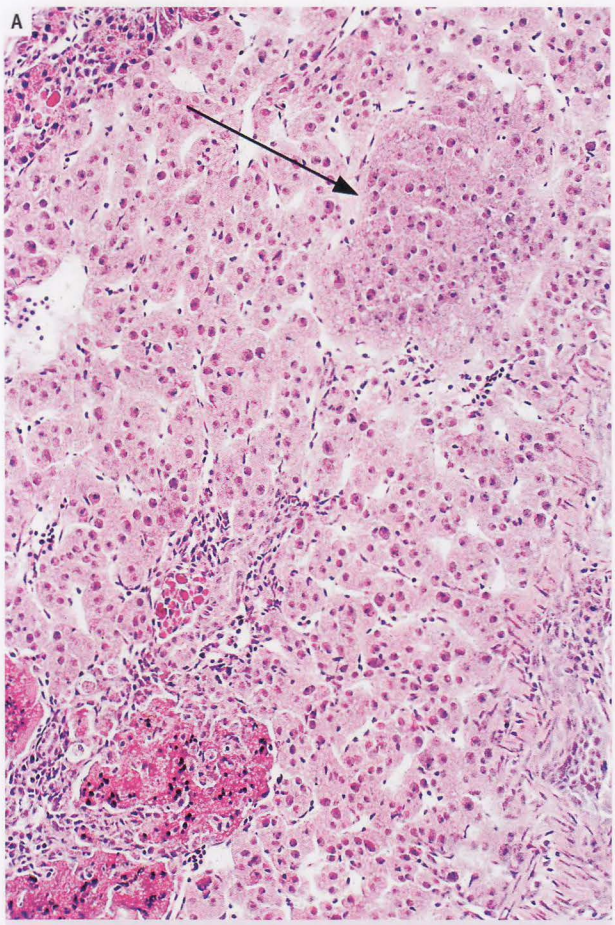

Viral hepatitis. *Fig 8.14A&B.* Reovirus-like hepatitis in young halibut. Note the caseonecrotic lesions an the bottom left of the picture and the syncitium at the top (arrow). The TEM shows large number of virus particles within hepatocytes.

General responses to injury

As in mammals, the liver of fish is vulnerable to a variety of circulatory, microbial, toxic, metabolic and neoplastic injuries. The lesions can be primary with direct damage to the liver (hepatitis for example) or be a secondary event resulting from generalised disease. The repertoire of responses to injury is limited and there are in principle 5 different categories of responses:

Degeneration and intracellular accumulations. The hepatocyte appearance varies, as mentioned earlier, and there is need to exercise great care whenever interpreting intracellular accumulations in fish liver. This is especially true for fatty change, as the liver in several species normally stores large quantities of lipid *e.g.* Atlantic cod (*Gadus morhua*) during spawning periods. Despite all these considerations, hepatic steatosis or fatty degeneration is occasionally encountered and may be either diffuse or patchy, and in the form of large or small cytoplasmic vacuoles in hepatocytes. Fish such as trout utilize dietary carbohydrates poorly, and an excess can accumulate in hepatocytes as glycogen. As well as leading to hepatomegaly, this also results in impaired liver function as demonstrated by reduced clearance of sulphobromophthalein (BSP) from the plasma.

Hepatic siderosis is sometimes seen in aquarium fish and may be associated with syncytial cell formation of hepatocytes (*Fig 8.4*). Whether this condition represents an iron storage problem or a metabolic defect is unknown. Progressive accumulation of copper within hepatocytes is described in a variety of vertebrates including dogs (Bedlington and West Highland White terriers) and man (Wilson's disease). High hepatic copper levels have been reported in feral white perch from the Chesapeake Bay area, the accumulations being associated with fibrosis around biliary tracts, inflammation, and enlarged melano-macrophage centres and disruption of architecture in older fish. Whether the copper was responsible for the cholangiohepatitis or whether high levels (often greater than 1,000 µg/g wet weight) are normal in this species, remains to be determined. Certainly other species occupying the same body of water had much lower levels, similar to those encountered in fish in the Great Lakes (often of the order of 2.0-10.0 µg/g wet weight).

Hepatic cysts are quite frequently encountered, often at slaughter (*Fig 8.5*). Only if they are massive do they usually cause much of a problem, and are regarded as incidental. Their pathogenesis is unknown.

Necrosis and apoptosis. Any significant damage to the liver may result in necrosis of hepatocytes. Hepatocytes are typically found to be swollen, a consequence of disrupted osmoregulation. When these changes ultimately lead to rupture, they are recognised histopathologically as lytic necrosis (*Fig 8.6*). Early evidence of the change is heralded by rapid condensation of nuclear chromatin, followed by increased eosinophilia of the cytoplasm and shrinkage ("individualization") from adjacent viable hepatocytes. Cell death by apoptosis is typically found in immunologically or toxin-mediated disease or in virus infections (*Fig 8.7*). The changes appear as single cell involvement, morphologically recognised as cells that round up to form shrunken or pyknotic cells with fragmented nuclei. Remnants of the cell may be phago-

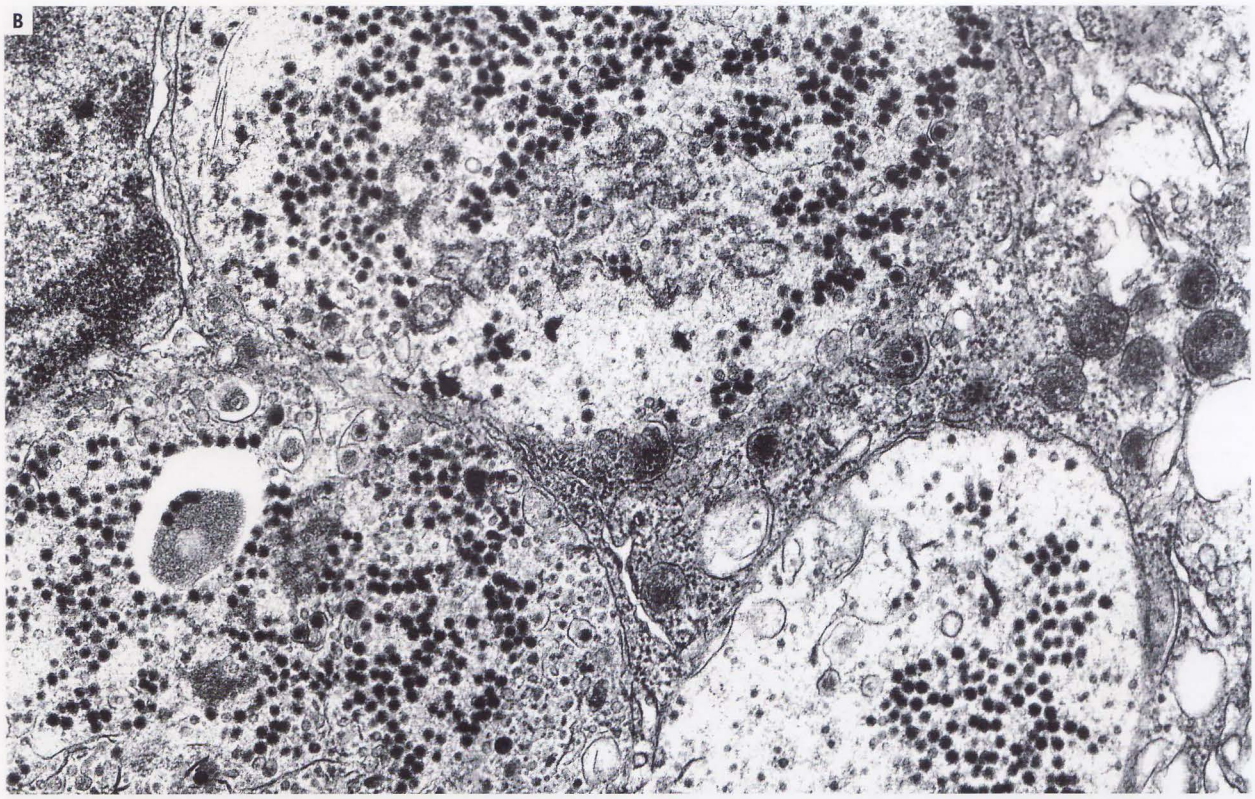

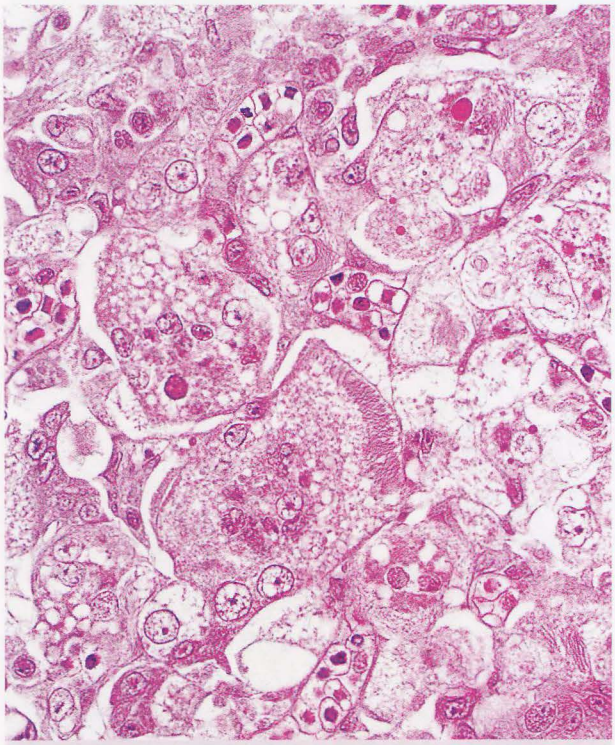

Fig 8.14C. Herpesvirus-like hepatitis in rainbow trout can produce these bizarre-looking hepatocytes; such changes can be difficult to differentiate from toxin-induced lesions (see Fig 8.20). Myocardium is also affected in this disease.

cytosed by surrounding cells. Necrosis of single hepatocytes is encountered quite frequently in septicaemic (bacterial) and toxic disease while apoptosis of hepatocytes is seen in virus infections such as infectious pancreatic necrosis virus. Necrotic changes are typically accompanied by an inflammatory cell infiltrate in contrast to apoptosis that will not result in generation of pro-inflammatory signals following uptake in scavenger phagocytes. Anti-inflammatory cytokines such as transforming growth factor ß (TGF-ß) will dominate and down-regulate the inflammatory responses.

Liver necrosis of higher vertebrates typically exhibits a zonal distribution, referred to as centrilobular necrosis, midzonal or periportal. Liver necrosis with a distribution pattern similar to zonal necrosis can also be seen around veins in the liver parenchyma. They are seen in toxic exposure and in anoxia associated with cardiovascular failure (*e.g.* cardiomyopathy syndrome of Atlantic salmon – ***see Fig 6.16***), severe gill disease, or with gill netting, when the opercula become progressively clamped shut, thereby preventing irrigation ***(Fig 8.8)***. Passive venous congestion is encountered in severe cardiac disease such as that seen in some cases of bacterial kidney disease where there is a restrictive pericarditis and cardiac tamponade ***(see Fig 6.9B)***.

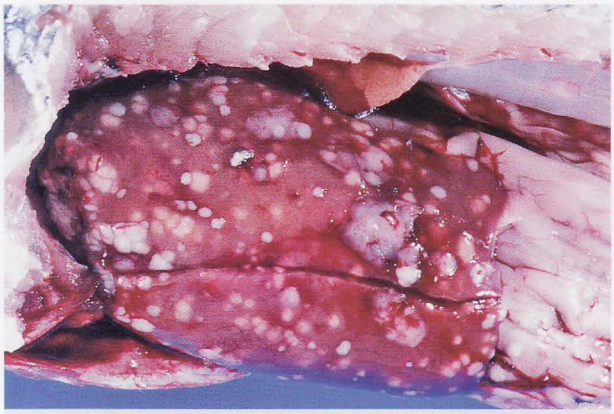

Fig 8.15A. Multifocal granulomatous hepatitis due to bacterial kidney disease in this rainbow trout. Lesions are present on and just beneath the capsular surface, as well as throughout the parenchyma. Such lesions may show slight adhesion to the body wall.

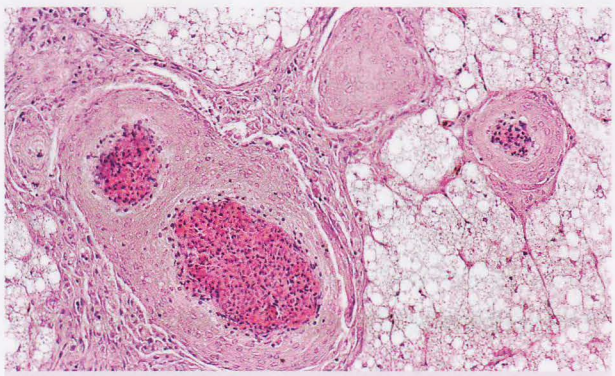

Fig 8.15B. Multifocal granulomatous bacterial hepatitis in cod. Note how well circumscribed are the lesions. Note too the quantity of lipid within surrounding hepatocytes, normal for this species.

As mentioned earlier, care must be exercised in the use of terminology describing liver changes in fish because of the different microanatomy. Advanced liver necrosis in infectious salmon anaemia infections has been described as bridging necrosis ***(Fig 8.9)*** but proper use of the term "bridging" is probably conditional on the presence of a well-defined lobular structure. So, unless it can be shown that the changes span adjacent lobules in a central to central, portal to portal or portal to central fashion, this term should probably not be used. We are therefore left with few adequate terms that can be used to describe liver changes in fish. The changes seen in this disease should thus be referred to as zonal with similarities of a bridging pattern. Focal liver necrosis can typically be found in association with small foci of bacteria, like *Moritella viscosa* infections in Atlantic salmon, particularly at early stages of infection. Sub-massive necrosis is seen in acute infectious pancreatic necrosis (IPN) infections of salmonid fry ***(Fig 8.10)***.

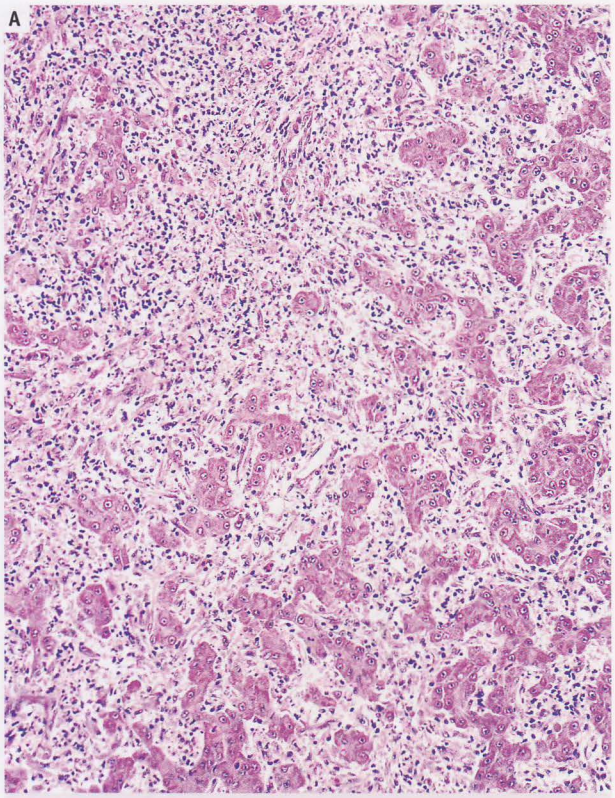

Fig 8.16A&B. Advancing face of inflammatory reaction in this salmon with piscirickettsial hepatitis. The influx of macrophages and neutrophils (mostly the former in this picture) has dissected apart the hepatocytes into islands. Some hepatocytes contain rickettsia.

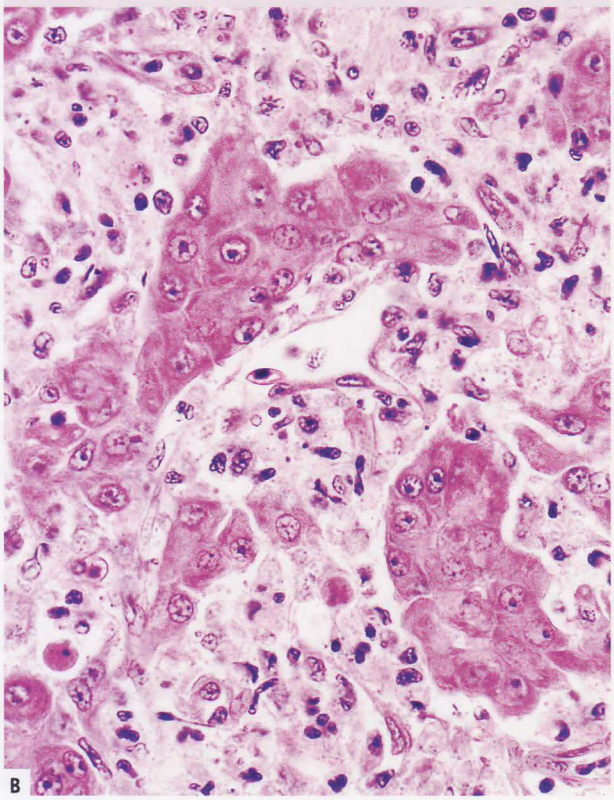

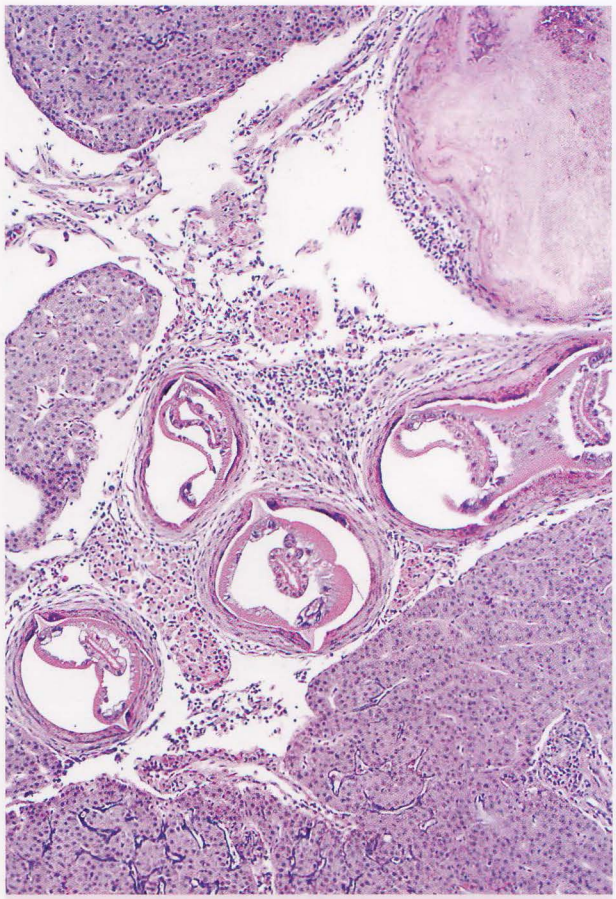

Fig 8.17. Walleye liver showing large numbers of ascarid-like nematodes cut in cross section. Note the lateral alae on the parasites, and the associated inflammation.



Fig 8.18. Vaccine-induced capsular hepatitis in this Atlantic salmon.



Fig 8.19. Aquarium cichlid with hepatic pallor and fragility due to lipidosis. There is haemorrhage within the parenchyma and also on the dermis of the fish. Interference with the normal production of clotting factors is a distinct possibility.

Melanomacrophage centres can be found scattered throughout the parenchyma in some fish species. It is worth mentioning again that the liver of fish lacks the Kupffer cell system lining the sinusoids of higher vertebrates and hence there is a limited capacity to trap circulat-ing anti-gens in fish liver; most of the responsibility for this activity falls to the macrophages in kidney and spleen. Similar to mammals however, fish hepatocytes have high detoxification capabilities, with cytochrome p450's playing a major role. Endocardium in fish also plays a major role in this process, however, with cytochrome p450 levels second only to hepatocytes.

Inflammation. Infiltration of acute or chronic inflammatory cells is referred to as *hepatitis*. Frequently, hepatocellular necrosis precedes the infiltration of inflammatory cells, but the converse can also happen. The inflammation can be focal or diffuse, depending on the primary cause. Acute lesions are seen in a range of diseases, such as IPN virus infections in post smolts and the changes can have a multifocal distribution. Infiltration of inflammatory cells is at best moderate and is a mixed response including lymphocytes and neutrophilic cells. Chronic hepatitis is often of the granulomatous type (see below) and the nature of the changes is reliant on the aetiology. More details are given under *Specific diseases*.

Regeneration. As in mammals, the liver has a high regenerative capability. Following necrosis, as long as the connective tissue framework is left intact, complete regeneration can occur. During periods of regeneration, thickened strands of hepatocytes can be seen, sometimes with disorganisation of the parenchymal structure, but typically with formation of small nodules of hepatocytes. Mitotic figures, binucleate cells and cytomegaly are all relatively common observations in hepatocytes during regeneration.

Fibrosis. Fibrous tissue forms in response to inflammation or as a result of a toxic insult to the liver. In mam-



Toxic hepatopathy is on the increase, possibly linked to algal blooms. *Fig 8.20A-C.* Rainbow trout grossly showing injection of vasculature, but giving no real clue to the bizarre appearance of the hepatocytes (B&C) that show changes including necrosis, cytomegaly, and nuclear enlargement.

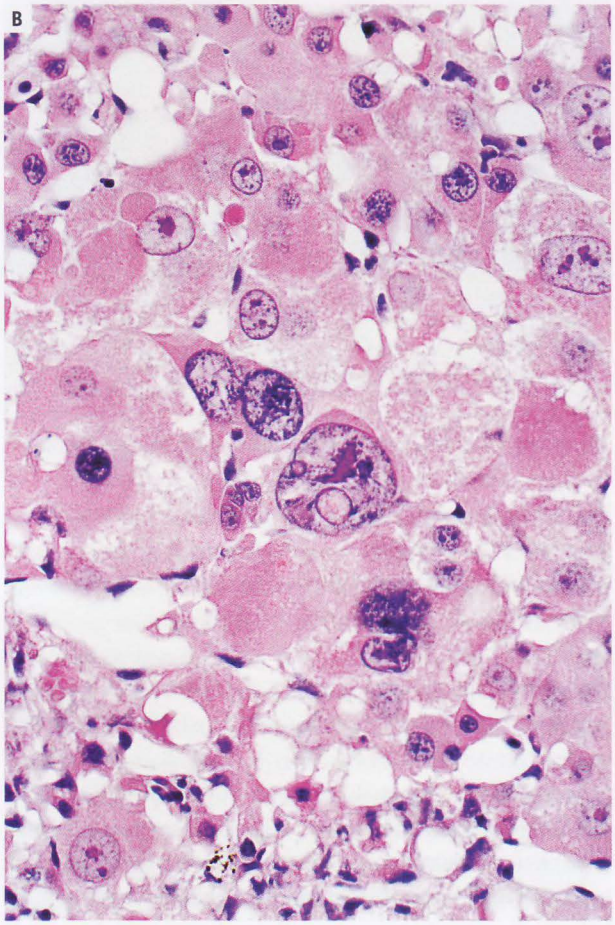

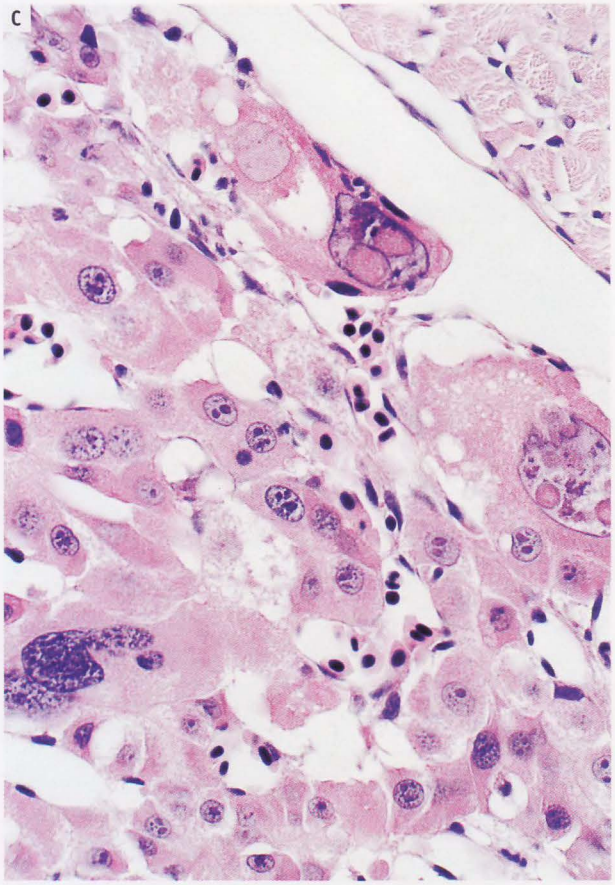

mals fibrosis is generally an irreversible response to hepatic damage but it is a rare sequel in fish. Fibrosis around portal tracts, as seen in mammals, is uncommon in fish, and when seen, is usually associated with granulomatous inflammatory changes in the liver parenchyma. Cirrhosis, which in mammals is recognised as a continuing process of fibrosis and an end-point stage of liver disease, is not commonly seen in fish. This is despite teleosts having large numbers of fat storing cells in the space of Disse between the sinusoid endothelium and hepatocytes *(Fig 8.2)*. In mammals these cells are responsible for collagen production in cirrhosis. Their involvement in granulomatous hepatitis is reported in fish, and they are especially prominent in lipoid liver disease (see later), often bulging into the sinusoid. They also have limited powers of antigen trapping, the likely caveat being that this must first traverse the fenestrated endothelium *(Fig 8.11)*.

Clinical consequences of liver disease

Unlike mammals, jaundice is not a commonly observed clinical feature in fish, although in toxic liver failure and in haemolytic diseases, an increase in bile pigments in the serum is measured. In addition, there is a strange condition of Northern pike recorded from both Sweden and Canada, in which there is a buccal or generalized green discolouration of the tissues. The significance or cause of this "green pike syndrome" is unknown.

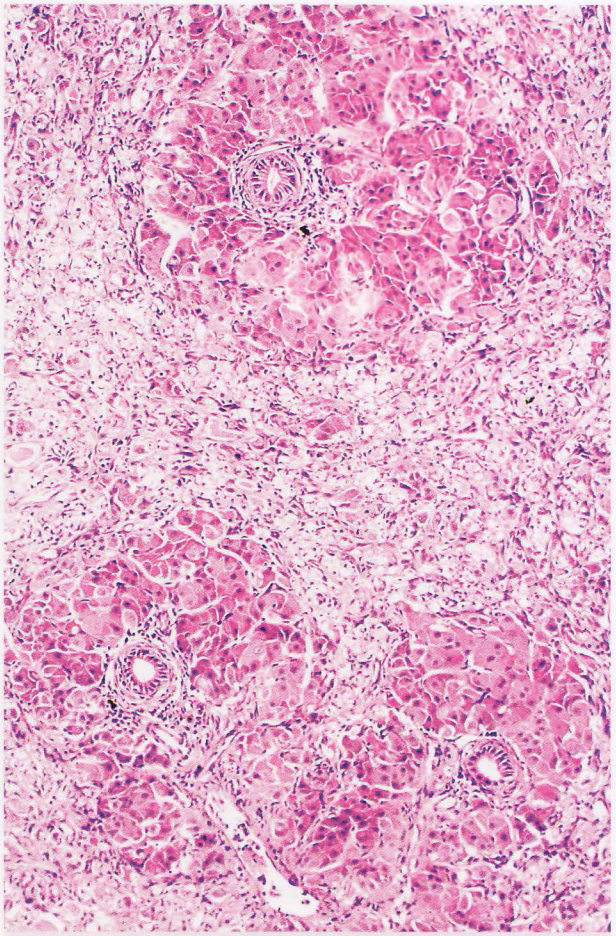

Fig 8.20D. Salmon with net-pen liver syndrome, another example of a disease linked to algal toxins. Again there is necrosis and concurrent reaction in hepatocytes.

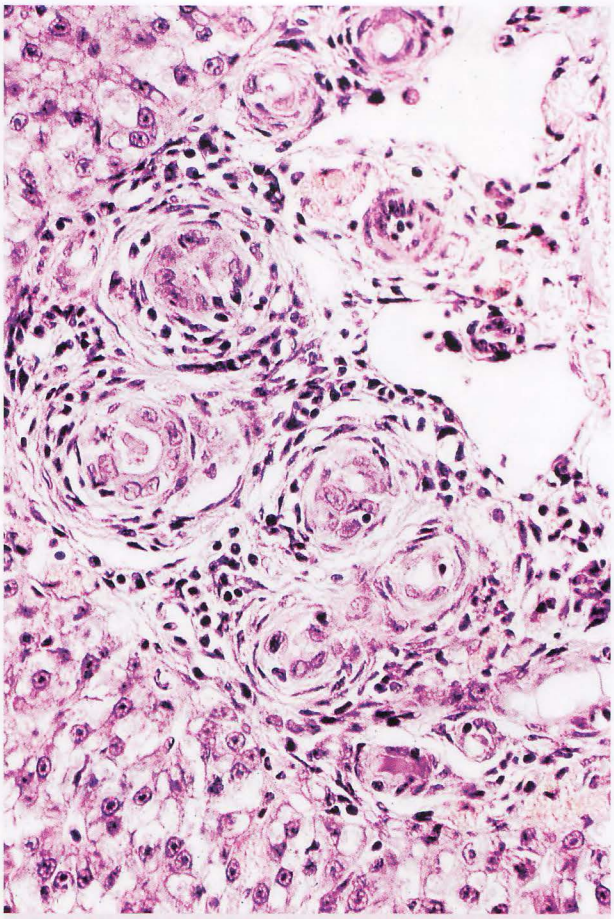

Fig 8.21A. Bile duct hyperplasia in this white sucker, with associated influx of inflammatory cells. Such changes are common in polluted sites.

Specific diseases

Nutritional aetiologies. A condition seen in salmonids which renders the liver pale due to anaemia as well as from the large patchy deposits of lipid metabolites, is "lipoid liver disease" ***(Fig 8.12)***. This condition is no longer common but was seen in Atlantic salmon and rainbow trout (other species such as brown trout seem less susceptible) and is associated with feeding rancid fats. The high levels of polyunsaturated fats needed in fish diets render them prone to oxidative change, especially if they are stored in moist and warm conditions. Antioxidants are usually added, but under severe conditions even their protection may be overcome. Lipid products, mainly ceroid, accumulate within hepatocytes, fat-storing cells, and macrophages, which may aggregate round the biliary tracts. The pigment shows auto-fluorescence under ultraviolet light, and has ultrastructurally typical membranous whorls. Anoxic change due to the often severe anaemia and the toxic action of the rancid fats themselves can complicate the histopathological interpretation. The anaemia is a result of increased red cell fragility and therefore faster breakdown, plus a failure of maturation of immature erythrocytes, probably a consequence of the vitamin E deficiency induced by the rancid fats. Haemosiderin from the erythrocytes is deposited in large quantities in the spleen. Consumption of available endogenous antioxidants such as glutathione and vitamin E/selenium may predispose the hepatocytes to lipid peroxidation from other normally innocuous sources, thereby complicating the pathogenesis even more. In severe cases, necrosis of striated muscles can also be seen, such as those associated with opercular movement. The ensuing impairment of gill irrigation no doubt contributes to the clinical consequences of the anaemia. Mineralization of pseudobranch can also be seen, although the pathogenesis or consequence of this lesion is unknown.

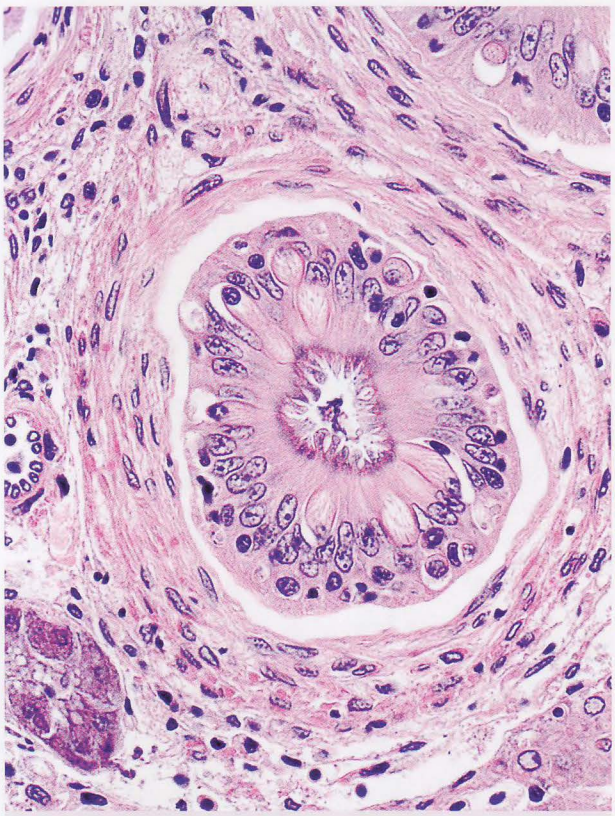

*Fig 8.21*B. Bile duct showing mild increase in surrounding connective tissue, and moderate influx of inflammatory cells. Note the rodlet cells (normal) within the duct epithelium.

Hepatitis. Multifocal hepatitis is seen in bacteraemias, but not as frequently or as severely as in mammals. Septic thrombi within sinusoids and veins (possible central veins), are also seen **(*Fig 8.13*)** and these may cause ischaemic lesions. Infarction as a result of such lesions or necrotic tracts due to parasitic migration is also sometimes encountered. These foci of necrotic cells can create a microenvironment suitable for the growth of anaerobes, and large bacilli can therefore occasionally be encountered within these lesions. Multifocal hepatic necrosis is also seen in many viral diseases such as infectious haematopoietic necrosis (IHN) of salmonids, viral haemorrhagic septicaemia infection of rainbow trout and channel catfish virus disease as well as in the adeno-virus-like disease of cultured sturgeon. Severe acute necrosis is seen in IPN in salmonids, cardiohepatic syndrome in salmonids (possibly herpesvirus) plus reoviral hepatitis in halibut; in the latter case, lesions include syncytial hepatocyte formation **(*Fig 8.14*)**.

Granulomatous hepatitis. Infection with *Renibacterium salmoninarum* causing bacterial kidney disease **(*Fig 8.15*)**, *Tetracapsuloides bryosalmonae* causing proliferative kidney disease (PKD), and *Piscirickettsia salmonis* causing salmon rickettsial syndrome (SRS) all result in granulomatous hepatitis. The histopathological changes will vary with disease resistance in the host and the virulence of the infectious agent. In BKD, the liver changes can be observed to be well-circumscribed granulomas with peripheral fibroplasia, a rim of monocytes/macrophages and epithelioid cells, admixed with a few lymphocytes and with an inner sector dominated by lymphocytes. The central core of the granulomas may or may not show degeneration and necrosis. The number of neutrophils in the granulomas will vary, from a few to a significant number. For the latter, the changes will be referred to as pyogranulomatous hepatitis. *P. salmonis* infection typically show less well organised granulomatous inflammation **(*Fig 8.16*)**, particularly at early stage of infection in which may be seen an advancing wall of fibroplasia and a higher degree of central necrosis. The number of neutrophils within the granulomas will usually be high, typical of a pyogranulomatous hepatitis.

Granulomatous hepatitis is also associated with various protozoan and metazoan parasites **(*Fig 8.17*)**. An example is hepatic coccidiosis of wild and cultured cyprinids and other species and experimental infections of Atlantic sal-mon with *Spironucleus barkhanus*. Although the parasites often evoke a mild to moderate multifocal granulomatous response, in the killifish *Fundulus grandis*, *Calyptospora funduli* (an eimerian) can be present in numbers large enough to replace 85% of the liver and pancreas. A commercially important coccidian hepatitis is also reported in blue whiting. Larval nematodes of the genus *Anisakis* can be present in numbers large enough to represent a space-occupying threat to normal functioning. Similarly, *Capillaria* spp. may cause hepatic destruction if the infection is massive, either by virtue of the parasites themselves or their eggs. The disseminated granulomatous infections so common in aquarium fish, such as those caused by *Mycobacterium*, often involve the liver, although usually to a much lesser degree than kidney or spleen. Severe hepatic necrosis accompanies acute *Aspergillus* spp. infection in cultured tilapia and multi-focal hepatitis is also seen in Atlantic salmon associated with the fungus *Exophiala*. Peritonitis associated with intraperitoneal vaccination with oil-adjuvanted vaccines, will often involve the hepatic capsule, and the inflammatory response may be seen to extend some way into the underlying parenchyma **(*Fig 8.18*)**.

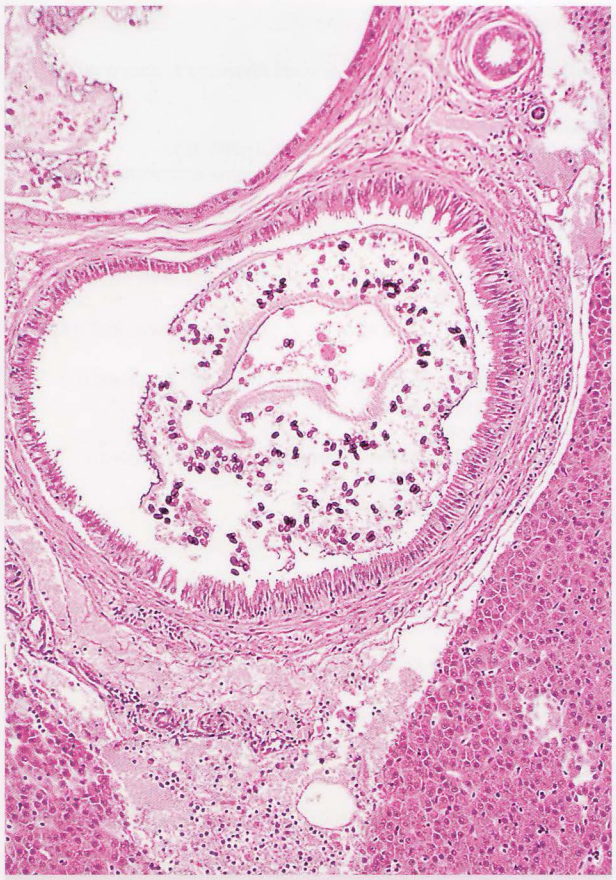

Fig 8.22. Myxozoan *Zschokkella* sp. within lumen of the bile duct. A cursory glance may suggest debris rather than parasite.

Vascular responses. Petechial or ecchymotic haemorrhages are often seen in bacteraemias and viraemias. Acute exposure to toxins, such as aflatoxin derived from the fungus *Aspergillus flavus* which grows on oil seeds can give similar changes. Hepatic pallor is seen in anaemia and fat storage which in extreme cases may also render the liver soft and friable leading to haemorrhage of a spontaneous nature (a consequence of impaired production of clotting factors?), or as a result of trauma ***(Fig 8.19)***.

Hepatotoxins. In winter flounder (*Pseudopleuronectes americanus*) a condition of exposure to hepatotoxins has been observed where the hepatocytes appear either electron-lucent with histological features of necrosis, or electron-dense with a shrunken and irregular shape and a highly condensed cytoplasm, resembling apoptosis, or with vacuolated hepatocytes showing signs of chronic cell injury with numerous autophagic vacuoles. Another hepatotoxic disease due to an algal toxin, known as "netpen syndrome", is seen in British Columbia ***(Fig 8.20)***. Affected salmon in cages have little chance to escape from algal blooms.

Biliary tract

Cholangitis and cholangiohepatitis are both encountered, the associated inflammatory response being primarily lymphoid with some peribiliary fibrosis in the more advanced or chronic cases ***(Fig 8.21)***. It is important to differentiate such an infiltrate from haematopoiesis which is sometimes seen in this ancillary location in times of high demand or as a normal event in very young fish. Protozoa or metazoa are sometimes seen within bile ducts and gall bladder ***(Fig 8.22)*** and although they may provide a ready explanation for any associated inflammation, in many cases the cause of the response is unknown. Fish in heavily polluted areas may have prominent cholangitis with increased numbers of ducts as well as metaplastic changes in the duct epithelium or even frank necrosis, and it has been suggested that the often high incidence of associated bile duct and hepatocyte carcinomas in these fish is not merely coincidence, but a direct result of such pollution. A dramatic example of peribiliary fibrosis in farmed fish is seen in "hepato-renal syndrome" of marine flatfish.

Lesions in the gallbladder often parallel those found in the bile ducts, but the organ should not be overlooked, especially on gross examination, as it can give an indication of how the fish was feeding. For example, the gallbladder in starved Atlantic salmon increases to 20% of liver weight by 36 hours, and the bile changes from straw-coloured to green to blue after 1, 4 and 6 days respectively. Enlargement of the gallbladder and thickening of its wall is seen in various myxozoan infections that may also involve bile ducts and sometimes extend out into the hepatic parenchyma. For example, *Myxidium oviformis* in Atlantic salmon causes severe cholangiohepatitis and inflammation of the gallbladder with emaciation of the host. The myxozoan *Ceratomyxa* may cause damage severe enough to result in total loss of the gallbladder. Virtually the only gross lesion seen with experimental arsenic toxicity in rainbow trout is fibrosis of the gallbladder wall. In green sunfish, there is an increased number of electron-dense bodies within both nucleus and cytoplasm. Gallstones are occasionally encountered in a variety of species: one report describes them in tilapia (*O. mossambicus*) subjected to adverse environmental conditions. The significance or precise aetiology of the condition is rarely determined.

Acknowledgement:
Hugh Ferguson supplied virtually all the images for this chapter.

References

Biagianti-Risbourg, S. (1991) Fine structure of hepatocytes in juvenile grey mullets: *Liza saliens Risso, L. ramada Risso and L. aurata Risso (Teleostei, Mugilidae). Journal of Fish Diseases* 39:687-703.
Braunbeck, T., Gorgas, K., Storch, V. and Volkl, A. (1987) Ultrastructure of hepatocytes in golden ide (*Leuciscus idus melanotus* L.; *Cyprinidae*: *Teleostei*) during thermal adaptation. *Anatomical Embryology* (Berl)175(3):303-313.
Bunton, T.E., Baksi, S,M., George, S.G. and Frazier, J.M. (1987) Abnormal hepatic copper storage in a teleost fish (*Morone americana*). *Veterinary Pathology 24*(6):515-524.
Evensen, Ø., Thorud, K.E. and Olsen, Y.A. (1991) A morphological study of the gross and light microscopic lesions of infectious anaemia in Atlantic salmon (*Salmo salar*). *Research in Veterinary Science* 51(2):215-222.
Hampton, J.A., McCuskey, P.A., McCuskey, R.S. and Hinton, D.E. (1985) Functional units in rainbow trout (*Salmo gairdneri*) liver: I. Arrangement and histochemical properties of hepatocytes. *Anatomical Record* 213(2):166-175.
Hampton, J.A., Lantz, R.C., Goldblatt, P.J., Lauren, D.J. and Hinton, D.E. (1988) Functional units in rainbow trout (*Salmo gairdneri*, Richardson) liver: II. The biliary system. *Anatomical Record* 221(2):619-634.
Hampton, J.A., Lantz, R.C. and Hinton, D.E. (1989) Functional units in rainbow trout (*Salmo gairdneri*, Richardson) liver: III. Morphometric analysis of parenchyma, stroma, and component cell types. *American Journal of Anatomy* 185(1):58-73.
Hering, E. (1867) Über den Bau der Wirbeltierleber. *Archive für Mikroskopische Anatomie* 3:88-114.
Hinton, D.E., R.L. Snipes, and Kendall, M.W. (1972) Morphology and enzyme histochemistry in the liver of largemouth bass (*Micropterus salmoides*). *Journal of the Fisheries Research Board of Canada* 29:531-534.
Hinton, D.E. and Pool, C.R. (1976) Ultrastructure of the liver in channel catfish *Ictalurus punctatus* (Rafinesque). *Journal of Fish Biology*, 8:209-219.
Langer, M. (1979) Histologische Untersuchungen an der Teleosteerleber. I. Der Aufbau der Leberparenchyms. *Zeitschrift für Mikroskopische Anatomische Forschung* 93:829-848.
Leatherland, J.F. and Sonstegard, R.A. (1988) Ultrastructure of the liver of Lake Erie Coho salmon from post-hatching until spawning. *Cytobios* 54:195-208.
MacSween, R.N.M. and Scothorne, R.J. (1987) Developmental anatomy and normal structure. ***In*** *Pathology of the liver* 2nd edition (***eds***. MacSween, R.N.M., Anthony, P.P and Scheuer, P.J.) pp1-45. Churchill Livingstone, Edinburgh.
McCuskey, P.A., McCuskey, R.S. and Hinton, D.E. (1986) Electron microscopy of cells of the hepatic sinusoids in rainbow trout (*Salmo gairdneri*). ***In*** *Cells of the hepatic sinusoids* Vol 1 (***eds***. Kirn, A., Knook, D.L. and Wisse, E.) pp489-494. Kupffer Cell Foundation, Rijswijk, The Netherlands.
Santi, N., Vakharia, V.N. and Evensen, Ø. (2004) Identification of putative motifs involved in the virulence of infectious pancreatic necrosis virus. *Virology* 322(1):31-40.
Santi, N., Sandtrø, A., Sindre, H., Song, H., Hong, J.R., Thu, B., Wu, J.L., Vakharia, V.N. and Evensen, Ø. (2005) Infectious pancreatic necrosis virus induces apoptosis in vitro and in vivo independent of VP5 expression. *Virology* [Epub ahead of print]
Scarpelli, D.G., Greider, M.H. and Frajola, W.J. (1963) Observations on hepatic cell hyperplasia, adenoma, and hepatoma of rainbow trout (*Salmo gairdneri*). *Cancer research* 23:848-857.
Simon, R.C., Dollar, A.M. and Smuckler, E.A. (1967) Descriptive classification of normal and altered histology of trout livers. ***In*** *Trout hepatoma research conference papers* (***eds.*** Halver, J.E. and Mitchell, I.A.) pp18-28. Bureau of Sport Fisheries and Wildlife, Washington, Research report 70.
Speilberg, L., Evensen, Ø. and Nafstad, P. (1994) Liver of juvenile Atlantic salmon, *Salmo salar* L.: a light, transmission, and scanning electron microscopic study, with special reference to the sinusoid. *Anatomical Record* 240(3):291-307.
Speilberg, L., Evensen, Ø. and Dannevig, B.H. (1995) A sequential study of the light and electron microscopic liver lesions of infectious anemia in Atlantic salmon (*Salmo salar* L.). *Veterinary Pathology* 32(5):466-78.







Nervous System

CHAPTER 9

by David Speare and Salvatore Frasca Jr.

Brain

The teleost brain, which on average accounts for about 0.3% of the body weight, can be divided into the same basic regions as other vertebrate brains; however, differences exist in the proportions of these different regions both in comparison to mammals and also even between different teleost species. Telencephalon, diencephalon, mesencephalon, metencephalon and myelencephalon are identifiable in the teleost brain, but may vary in relative size and shape depending on the species. Structural variations in brain of teleosts have been described and related to factors such as body length and shape, *e.g.* fish with stout bodies, such as *Rita rita*, have been described as having a brain that is short and thick in contrast to those with eel-like body forms, such as *Macrognathus aculeatus*, which have a relatively thin and elongate brain, while the brain of *Heteropneustes fossilis* is dorsally compressed when compared to others. In addition, comparative functional and neuroanatomical investigations have identified, at least in the two most intensely studied species, the zebrafish (*Danio rerio*) and goldfish (*Carassius auratus*), gross morphological and histological differences in the brain of at least two sensory systems, *e.g.* the visual and gustatory systems. It is therefore imperative that the comparative pathologist be familiar with both the gross and histologic features of normal teleost brain(s) in order to make accurate decisions regarding non-lesions versus lesions, as well as deciphering the anatomic location and distribution of lesions, which may be noteworthy to comparative neuropathological investigations and may impact correlative assessments of toxicological effect, tropism of infectious agents and clinical signs.

Structures referable to each of the five regions are identifiable grossly and allow the teleost brain to be divided into a forebrain, midbrain and hindbrain for comparative purposes. The forebrain is composed of the telencephalon, located anteriorly and represented by the olfactory lobes and the cerebrum, and the diencephalon, forming a narrow swath between the cerebrum and the structures of the midbrain. Olfactory lobes are located at the anteriormost aspect of the cerebrum and are attached to olfactory bulbs by the olfactory tracts, which can vary considerably in length depending on the species. Extending beneath the midbrain and visible grossly along the ventral surface, the diencephalon is expanded to form the large median infundibulum and the inferior (hypothalamic) lobes, which lie lateral to the infundibulum. The midbrain has as its most prominent and distinctive feature the paired, rounded, smooth and protuberant optic lobes, which lie dorsal to the other mesencephalic structures beneath it. The optic chiasm is identifiable on the ventral surface anterior to the infundibulum and tracts of each optic nerve can be seen to blend into the base of each optic lobe. The hindbrain is comprised of the cerebellum, located posterior to the optic lobes along mid-line and dorsal to the second structural component of the hindbrain, the medulla oblongata, which extends posteriorly to become the spinal cord **(*Fig 9.1*)**.

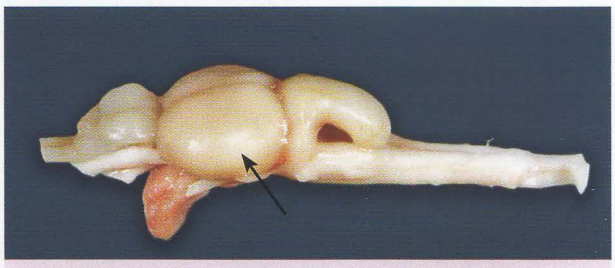

Fig 9.1. Brain of an Atlantic salmon smolt demonstrating the anatomical relationships of structures that comprise the five major regions of the brain. Arrow shows optic lobes. *Courtesy of Dr. T.T. Poppe.*

The telencephalon is much reduced by comparison with mammals and is comprised mainly of the olfactory lobes and cerebrum. Lateral ventricles are not obvious. The cerebrum of teleosts is markedly different in histologic appearance from that of mammals in that it lacks a neocortex, the distinctive six-layered structure with which mammalian pathologists are so familiar, but which is a type of cortex present only in mammals. The cerebrum of teleosts lacks any appreciable layered arrangement but consists instead of fields of neurons interconnected and supported by an extensive neuropil.



Fig 9.2A. Anatomic locations of the pituitary gland and saccus vasculosus along the ventral mid-line of the brain beginning at the level of the diencephalon.

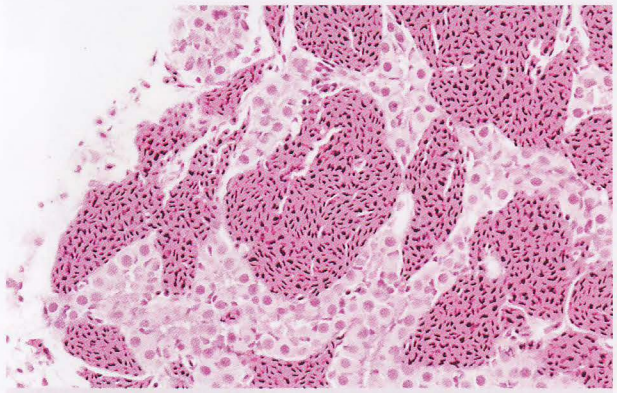

Fig 9.2B. Histologic structure of the saccus vasculosus, which is composed of ribbons of cuboidal epithelium supported by a fibrovascular stroma with prominent sinusoids.



Fig 9.3A. Transverse section of brain at level of mesencephalon indicating relative anatomical locations of optic tectum and tegmentum to third ventricle. Also identifiable are the inferior lobes of the hypothalamus (diencephalon).

The diencephalon, also known as the thalamencephalon or the "between brain" for its anatomic location and function of relaying information between the cerebrum and the rest of the brain, is the site of the pineal body, located dorsally in the epithalamus. The pineal organ, whose neuroepithelial wall is surrounded by a dense plexus of highly-fenestrated blood vessels is a non-image-forming photodetector connected to the brain via the pineal stalk and it is situated beneath a relatively depigmented "pineal window"; the organ, by virtue of photopigments, is designed to detect slowly changing ambient light levels for photic control of seasonal physiology. The pituitary gland is located ventrally in the midline recess of the infundibulum between the inferior lobes. The hypothalamus, consisting of the infundibulum and the two inferior lobes, is the major anatomic structure of the diencephalon and functions to regulate the pituitary gland. Behind the infundibulum of the pituitary lies the saccus vasculosus, a highly vascularized tissue resembling the choroid plexus of mammals; the saccus vasculosus produces cerebrospinal fluid for the third ventricle with which its lumen is continuous **(*Fig 9.2*)**. The saccus dorsalis, located on the roof of the epithalamus and continuous with the pineal gland, is also a fluid-secreting plexus similar to the *tela choroidea* posterior which overlies the roof of the 4th ventricle; at this location the roof is particularly thin (*velum posticum*). The aforementioned circumventricular organs (CVO) which are phylogenetically conserved, are unique by virtue of their cellular contacts with two fluid phases – blood and cerebrospinal fluid. Within the CVOs the blood-brain barrier (BBB) is deficient; tight junctions between endothelial cells are lacking and the glial cells that typically girdle brain capillaries are more loosely apposed, thereby creating relatively large perivascular spaces. These features are favourable for fluid-brain exchange, making the CVOs functional as "gates" through the BBB. Additionally the reduced meninges around CVOs (*meninx primitiva*) are often rich in macrophages, and in older fish these can be laden with lipofuscins and other products of cellular breakdown.

The mesencephalon is typically the largest and most obvious region when the cranium is removed. It is divided into the optic tectum and tegmentum, which form the roof and floor of the third ventricle, respectively. The optic tectum of teleosts is the anatomical termination of the retinal ganglion cell axons, and its size relative to the other regions of the brain has been postulated to reflect the degree of dominance of the visual sense in different species *i.e.* fish are said to have an "optic brain". The optic tectum is divided grossly into two optic lobes **(*see Fig 9.1*)** and across a wide variety of teleosts it has a characteristic laminar histological architecture that consists of five

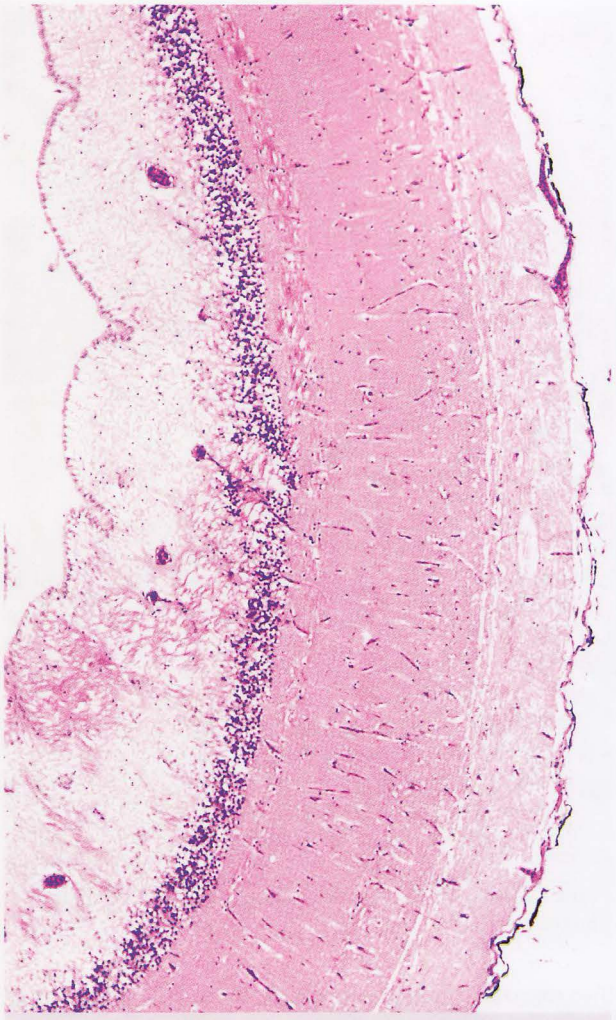

Fig 9.3B. Histologic structure of optic tectum, arranged in layers distinguishable by relative content of axons and neurons.

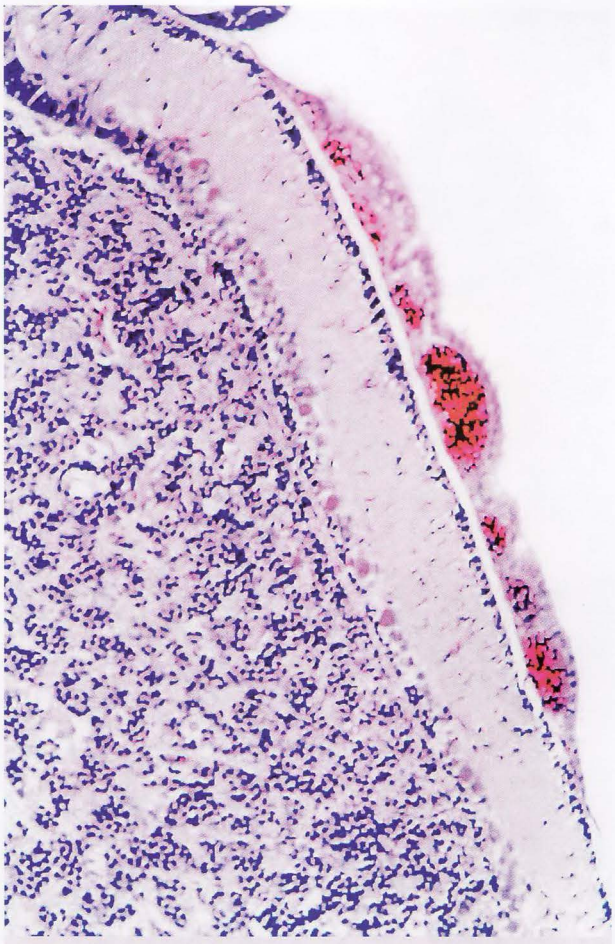

Fig 9.4. Histologic architecture of the cerebellum of teleosts is akin to that of mammals, with recognizable molecular, Purkinje cell and inner granule cell layers. Note that the normal polarity and layering of Purkinje neurons is not as distinctive as in mammals.

principal layers, some of which can be further subdivided depending on the degree of differentiation exhibited by different species. Beginning with the innermost layer of small cells lining the third ventricle and ending with the outermost layer subjacent to the pial surface, the arrangement of layers is as follows: *stratum griseum periventriculare, stratum fibrosum profundum, stratum griseum centrale, stratum plexiforme et fibrosum externum* and *stratum fibrosum marginale.* Layers of the optic tectum are distinguished by their relative content of nonmyelinated versus myelinated axons and presence or absence of neurons ***(Fig 9.3)***. Considering the prominent gross appearance of the optic lobes and their multi-layered histological arrangement, it is critical in comparative analyses that the pathologist raised classically on mammalian tissues not confuse the optic tectum with the neocortex of mammals. It may seem absurd, but stranger things have happened!

The cerebellum is the major component of the metencephalon. The body of the cerebellum lies along the midline, dorsal to the medulla oblongata, and extends posteriorly to varying lengths depending on the species. In salmonids, the cerebellum forms an anterior conical extension that lies beneath the optic tectum and is referred to as the cerebellar valvula. The cerebellum performs the same function of sensorimotor coordination in teleosts as it does in other vertebrates. Although it lacks the multiple folia of its more complex mammalian counterpart, it shares the same histological structure, consisting of an outer molecular, central Purkinje cell and inner granule cell layer that overlie centrally located white matter ***(Fig 9.4)***.

The medulla oblongata is responsible for the majority of the hindbrain and is continuous caudally with the spinal cord. It includes origins of cranial nerves VII (facial), VIII (vestibuloacoustic), IX (glossopharyngeal) and X (vagus),

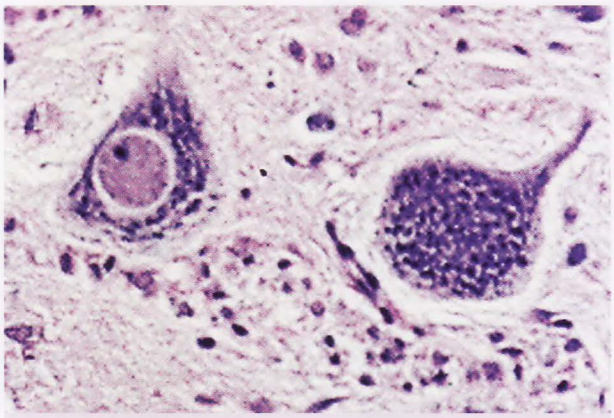

Fig 9.5. Neurons of the teleost brain are similar to those of mammals and contain abundant Nissl substance, *i.e.* rough endoplasmic reticulum, in their cytoplasm, as in this example. *Nissl Stain.*

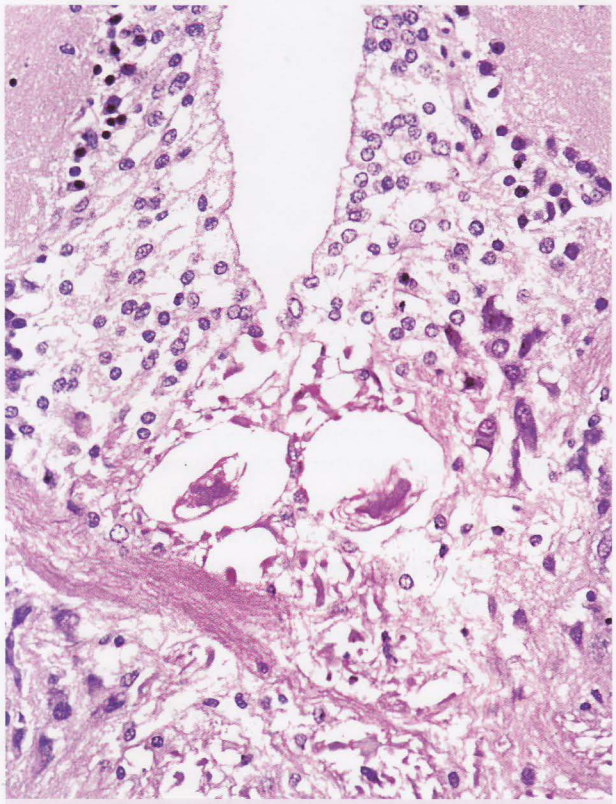

Fig 9.6. Paired, myelinated, large diameter Mauthner axons in subependymal medullary neuropil arise from large neurons (not shown) that have their origin in the medulla oblongata.

and it is the site of origin of the Mauthnerian system, a neuromuscular specialization that is particularly well developed in teleosts, although absent in sharks and rays. It comprises a pair of very large neurons located centrally in the medulla that mediate the startle response typical of many fish.

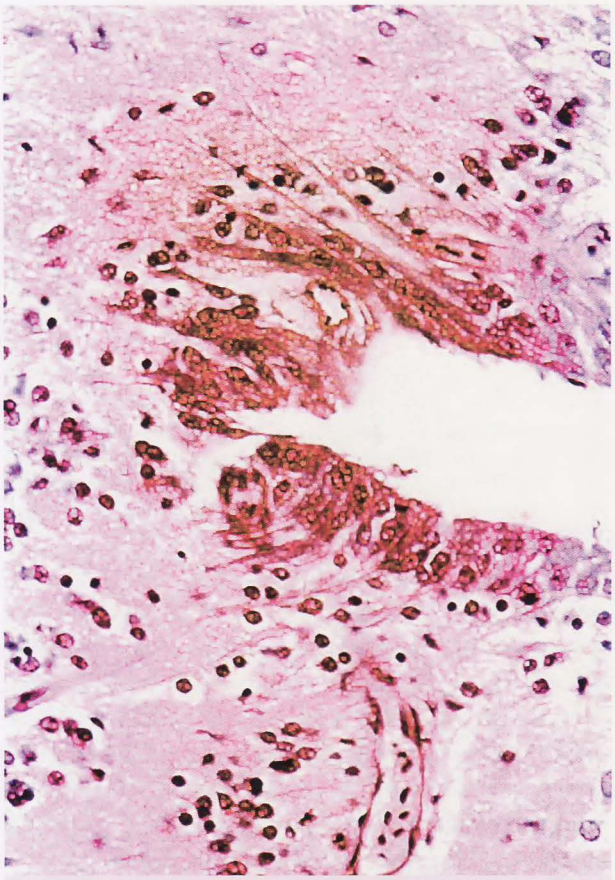

Fig 9.7. Ependymal cells have elongate, tanycyte-type, cytoplasmic processes.

Two principal cell types constitute the cellular elements of the brain, and the spinal cord too; these are the neurons and neuroglia. Neurons of fish have the same structural features as those of other vertebrates, *e.g.* dendrites, soma and axon, can possess nonmyelinated or myelinated axons, and have been demonstrated to have extensive rough endoplasmic reticulum, free ribosomes and Golgi apparatus characteristic of vertebrate neurons **(*Fig 9.5*)**. Teleosts have two conspicuous populations of large and specialized neurons. The first are the Purkinje neurons of the cerebellum, which are arranged somewhat similar to those in mammals, *i.e.* with dendrites extending into the overlying molecular layer and axons extending through the inner granule cell layer and into the underlying white matter. It is noteworthy, however, that their normal polarity and the layering are not as distinctive as in mammals **(*see Fig 9.4*)**. The second are the Mauthner cells, the integral components of the Mauthnerian system (referred to in the description of the medulla oblongata). The Mauthner cells, *i.e.* two neurons in total, lie on either side of midline in the medulla oblongata; each possesses enlarged dendrites



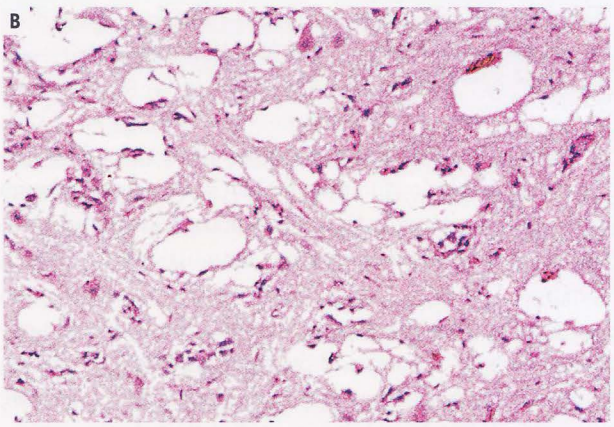

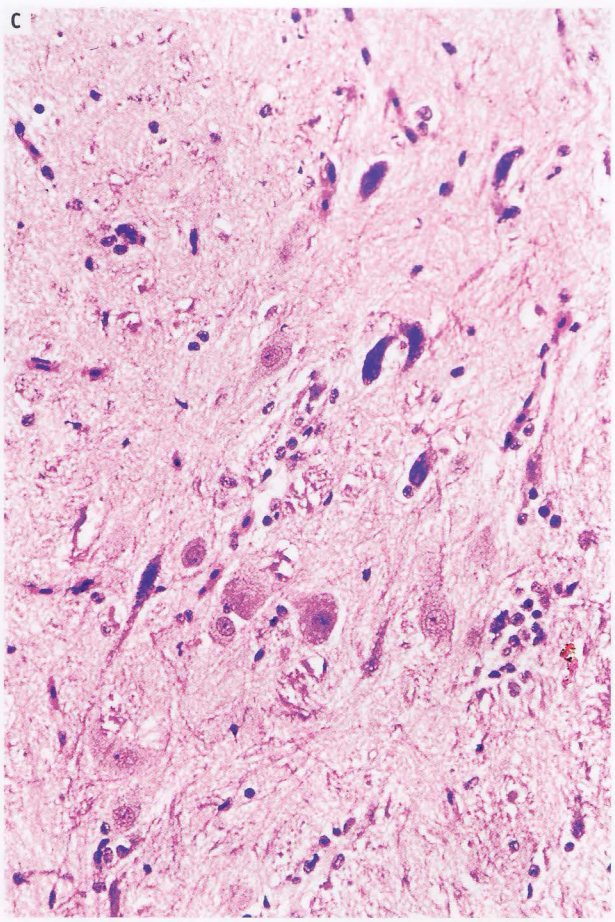

Fig 9.8A-C. Histological sections of brains can be prepared with the organ *in situ* in the case of smaller specimens (**A**), which facilitates examination of circumventricular organs and meninges, determination of lesion distribution, and inclusion of anatomically and functionally related structures, *e.g.* cranial nerve ganglia and semicircular canals. *Artifacts* of histologic processing and handling are also encountered in histologic preparations of teleost brain including vacuolation of neuropil (**B**) and dark neurons (**C**).

that synapse with cranial nerve VIII and a single, heavily myelinated, giant axon that crosses to the opposite side of the medulla and descends the length of the spinal cord, synapsing with motor neurons that innervate muscle fibers in each body segment of the trunk and tail *(Fig 9.6)*. Firing of the Mauthner cells causes a rapid, unilateral, and powerful tail flip, the so-called Mauthner-initiated startle response that teleosts exhibit when frightened.

The central macroglial cells identified in teleosts include astrocytes, oligodendroglia, and ependyma, which are distinguishable in routine tissue sections by their nuclear morphology and histologic context. Astrocytes of several teleosts are immunoreactive for glial fibrillary acidic protein and vimentin in separate immunohistochemical studies. Although earlier works omitted discussion on whether the fish brain contains microglia, this important defense cell, a key feature of many pathological alterations, has now been positively identified in several teleosts and has been isolated in cell culture from goldfish. In the spinal cord, it is estimated that fish have tenfold more microglia than mammals. *In vitro*-isolated microglia from goldfish are phagocytic, and are spatially and temporally associated with neuronal regeneration in experimentally induced brain lesions. Additionally they comprise the principal cellular response during Wallerian degeneration following axonal disruption. Tomato lectin histochemistry has been used to identify microglia in teleosts, as it has in mammals, taking advantage of its high affinity for the poly-N-acetyl lactosamine residues that are specifically associated with microglia. Two forms

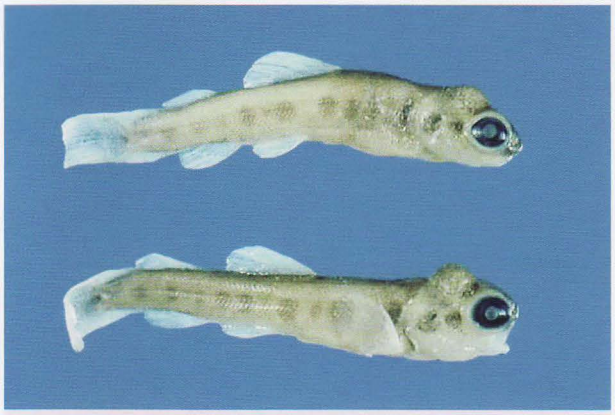

Fig 9.9A. Acquired external hydrocephalus in salmon fry may be associated with oedema of the middle layer of the endomeninx, resulting in outpouching of the cranial vault and a focal swelling on the top of the head.

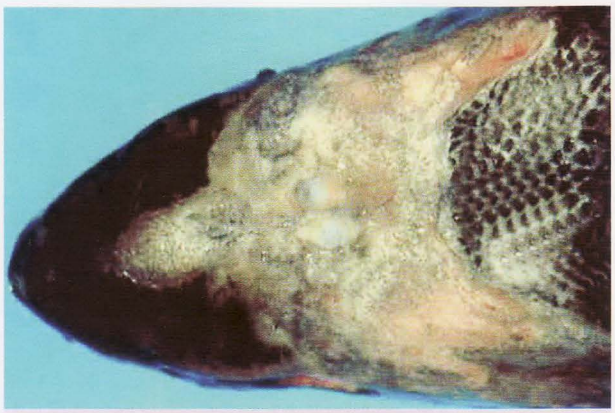

Fig 9.10. Severe, locally extensive, cranial ulceration from sea lice infestation can result in exposure of the cranial vault and dorsal regions of the brain but should not be misinterpreted as exencephaly.

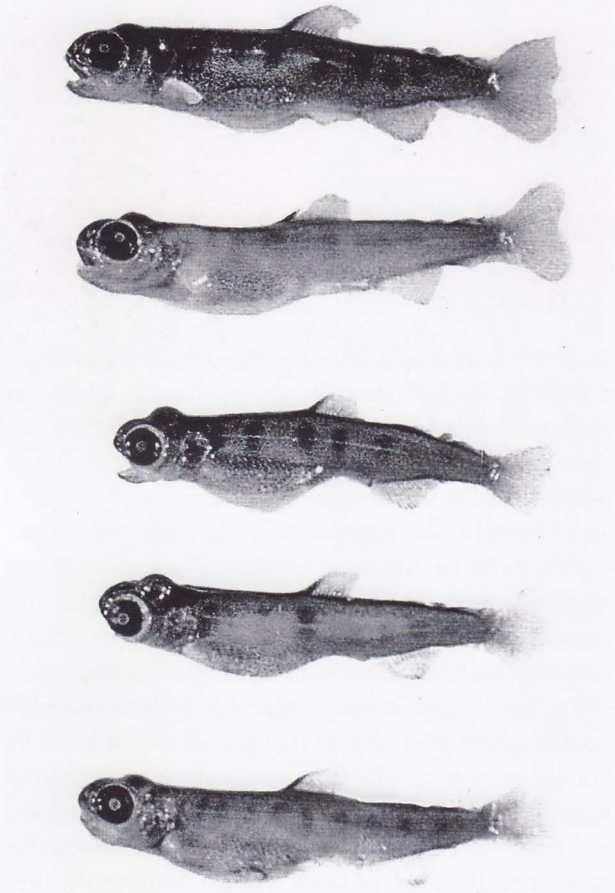

Fig 9.9B. Coho salmon fry each exhibiting a pronounced focal swelling on top of the head due to a cranial defect. The cause of this condition is unknown, although suspected to be associated with exposure to teratogenic agents, such as malachite green, which has been shown to specifically target cranial tissues and has been used in hatcheries to control fungal growth on incubating eggs.

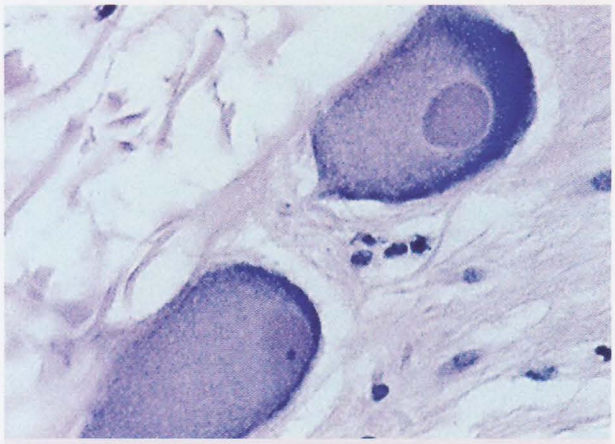

Fig 9.11. Central chromatolysis in a teleost brain. Note the central dissolution and peripheral margination of Nissl substance in the cytoplasm of these neurons.

of microglia are predominant in fish, one resembles the ramified morphology in mammalian counterparts whereas the other, present in the ependymal region of the optic tectum, is a smaller rounded cell with little cytoplasm.

In mammals, the immature ependyma, derived from neuroectoderm, is the origin of the macroglial cells, *i.e.* astrocytes, oligodendrocytes and mature ependyma, as well as neurons. In teleosts, it is reported that the immature ependyma is similarly pluripotent, but also that mature ependymal cells have retained the embryonic capacity for differentiation. The inference of course, and one that rocks the firmly established belief in the neurosciences that adult vertebrates must make do with a fixed number of neurons, is that damaged brain tissue can be *regenerated* and indeed this has been experimentally shown to be the case, although there are species differences. Evidence

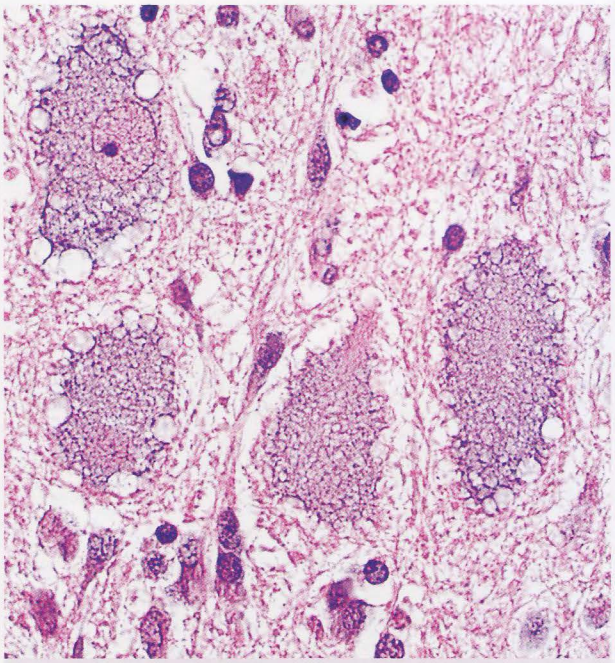

Fig 9.12. Peripheral cytoplasmic vacuolation of neurons can be a *bona fide* cellular lesion resulting from such subcellular alterations as mitochondrial and vacuolar swelling; however, care must be taken to distinguish such changes from artifactitious vacuolation of cells and neuropil.

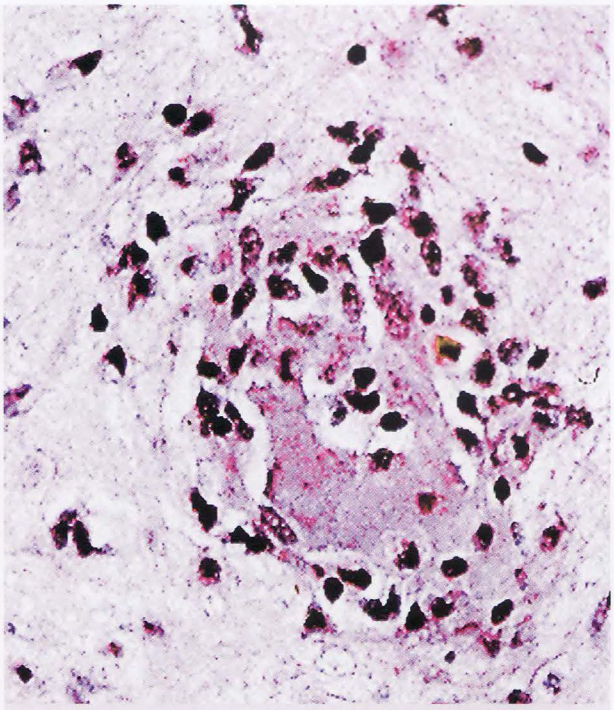

Fig 9.13. Neuronophagia. Glial cells have surrounded a neuron and infiltrated its cytoplasm as part of the process of division and phagocytosis of the soma.

for ependymal reactivity can be sometimes encountered in routine diagnostic material where the cells may be seen streaming into the ventricular lumen in cases of severe encephalitis. During regeneration, zones of high proliferative activity are located near the ventricular surfaces, particularly the wall of the third ventricle and from here neurons migrate into the parenchyma. Proliferating cells from specific ventricular and paraventricular zones during instances of neurogenesis and regeneration in adult teleosts have been shown to lie in close apposition to GFAP-positive processes, suggesting that radial glial fibers support the migration of newly proliferated brain cells to target loci. Somatostatin, which is up-regulated in radial glia and several other cell types in association with proliferation and migration of new cells, has been postulated to be a regulatory factor in neuronal regeneration. Teleost ependymal cells possess large quantities of glycogen and numerous large mitochondria suggesting specialized metabolic activity. A specialized subpopulation of elongated ependymal cells, tanycytes, contact the surface of ventricles with apical processes, and extend radially out to the pial surface via basal processes through which they are capable of transporting markers and possibly also pathogens from the pia to the ventricles and *vice versa* **(Fig 9.7)**.

Energy metabolism of the fish brain has recently been reviewed (Soengas and Aldegunde, 2002). As with other vertebrates, metabolite transport into fish brains from the systemic circulation, including the transport of glucose, is limited by existence of a blood-brain barrier (BBB); the BBB by virtue of tight endothelial junctions, prominent basement membrane, and perivascular astrocytic processes is also important in limiting the ingress of pathogens from the circulation into the parenchyma.

The CNS is surrounded by layers of cells that collectively constitute the meninges; an important defense function is to maintain the outer blood-cerebrospinal fluid barrier, and this, in mammals, is controlled by leptomeningial cells of the arachnoidea. The structural organization of the meninges of lower vertebrates differs considerably from the meninges of mammals, and assigning homologous terminology is therefore difficult. The endomeninx and the actomeninx are separated by intermeningeal adipose tissue. The endomeninx has two layers, separated by an intermediate barrier. The outer layer is composed of 3-7 layers of densely packed fusiform cells connected by gap junctions; the intermediate layer, formed by a single layer of flattened cells with well developed tight junctions, acts as a barrier for intercellular movement of material

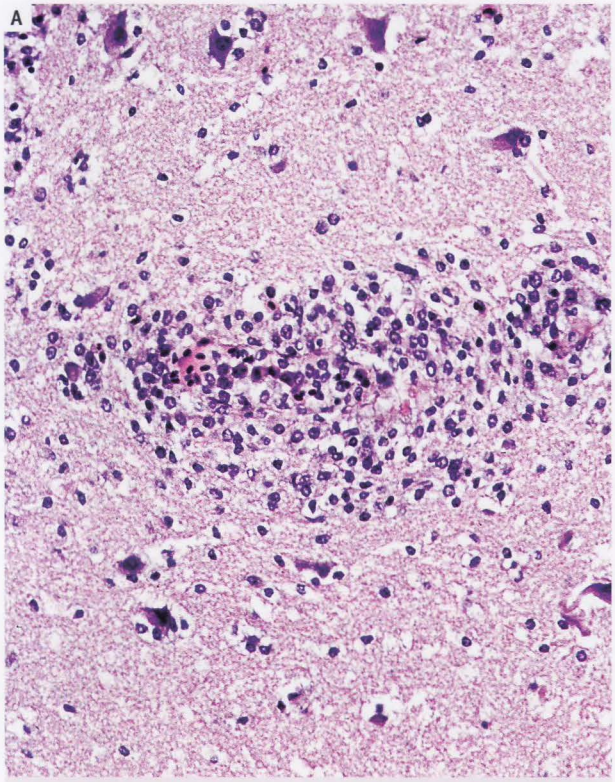

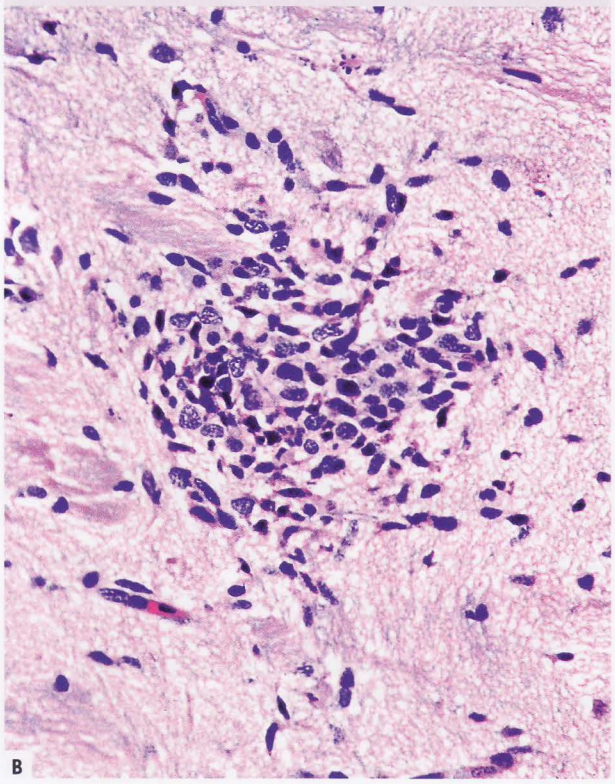

Foci of gliosis. *Fig 9.14A&B.* In this focus of perivascular gliosis, a small diameter blood vessel, is located at the centre of an aggregate of glial cells *e.g.* astrocytes and microglia. More chronic, or advanced, foci of gliosis can be difficult to interpret when remnants of diseased neurons or blood vessels are absent (**B**).



Fig 9.15A. Granulomatous ventriculitis and ependymitis characterized by infiltrates of macrophages located in the lumen of the ventricle and within the ependymal layer, with proliferation of ependymal cells.

between the layers of the endomeninx. The inner layer has large intercellular spaces filled with granular matrix and collagen fibres and reticular cells that are connected by only a few desmosomes. Immediately below the inner layer of the endomeninx is the glia limitans of the brain parenchyma. The glia consists of a basement membrane, astrocytic processes, and terminal projections of tanycytes (thereby connecting the glia to the ventricles). Caruncho *et al.* (1993) concluded that the three layers of the endomeninx, together, represent an equivalent to the leptomeninx. An equivalent to the epidural space of mammals is represented in fish by the wide extrameningeal space between the outer layer of the endomeninx and the cranial bone. In addition to the connective cells that form the majority of this meningeal architecture, low to high numbers of inflammatory cells are also present. Sturgeons have abundant meningeal myeloid tissue in the form of a saddle-shaped lymphomyeloid organ near the perivagal region that can be mistaken for a granulomatous reaction. The meninges of teleosts produce unique secretory proteins (ependymins) that are the predominant protein

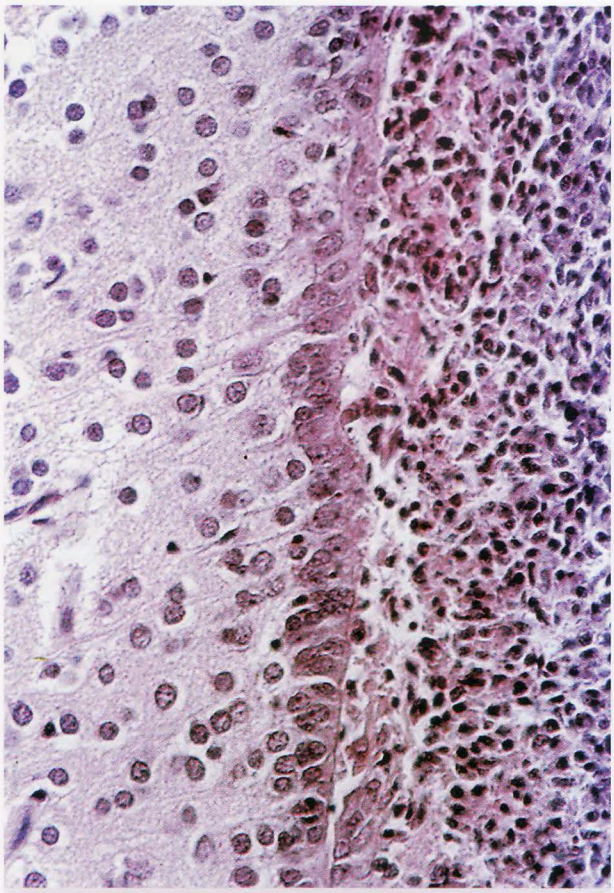

Fig 9.15B. Granulomatous ventriculitis characterized by infiltrates of macrophages limited to the ventricular lumen with intact ependyma.

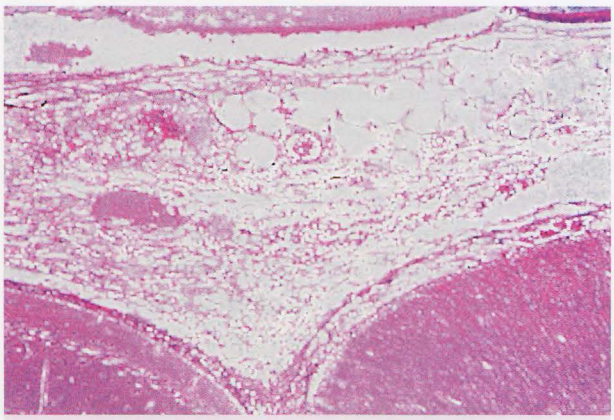

Fig 9.16. Endomeningitis and pachymeningitis in a teleost. Inflammatory infiltrates expand the layers closest to the surface of the brain, *i.e.* the endomeninx, and occupy the space separating the meninges from the calvaria.

constituents of the cerebrospinal fluid (CSF). Ependymins are not found in mammals and are thought to represent a new class of extracellular matrix proteins that play a role in neuronal regeneration.

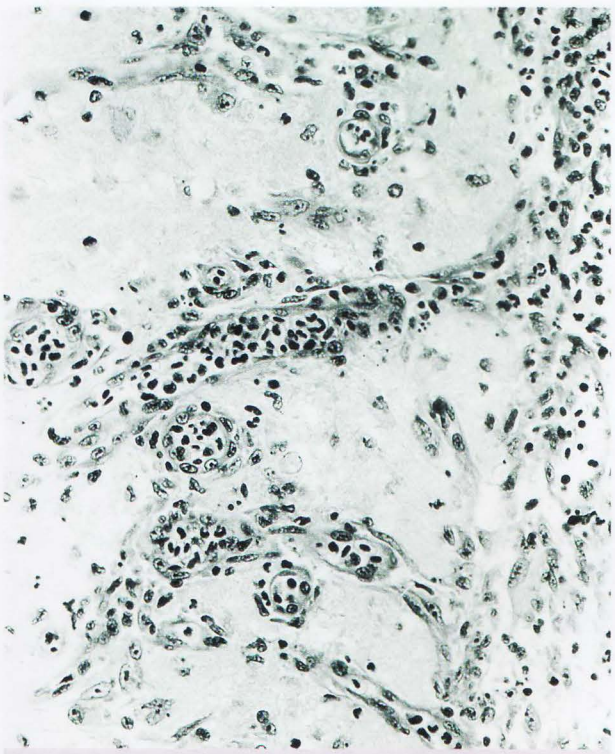

Extension of inflammation from meninges to brain. *Fig 9.17A.* Inflammatory infiltrates originating from the endomeninx advance into the brain along pial reflections that accompany blood vessels, as the latter penetrate the parenchyma. Note that there is hypertrophy of endothelium lining affected blood vessels.

General responses of the brain to disease

There is still relatively little information on the general pathology of fish nervous tissue, and although basic responses are probably the same as in other vertebrates, a detailed study is nevertheless necessary. A particularly unique area that must be explored, with respect to diagnostic histopathology through pattern-analysis recognition, is the role of CNS repair in the brain of fish. Lesions that are persistent markers of brain damage in mammals are likely to regress in fish as regeneration proceeds.

CNS tissues are often overlooked in routine diagnostic histopathology, in part because the brain can be challenging and time-consuming to harvest and, moreover, because upon harvest it often collapses and is difficult to orient for further sectioning. Nevertheless the CNS can be a vital source of information not only for detecting diseases specific to the CNS, but also to detect pathogens that may have found a niche where they are protected from antimicrobial agents that have otherwise made their detection occult in other organs. In smaller fish, those weighing less

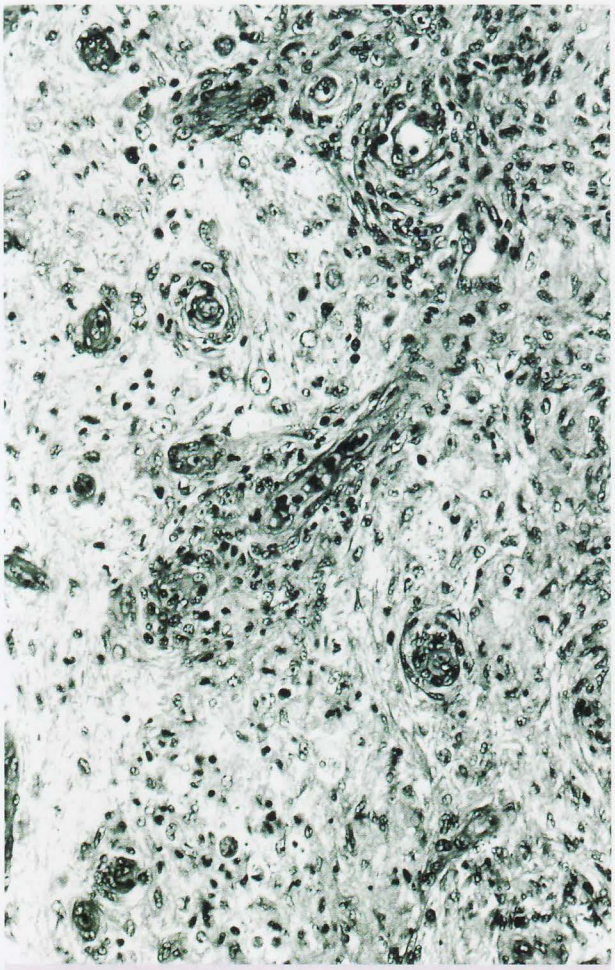

Fig 9.17B. Perivascular spaces (spaces of Virchow-Robin) are expanded by infiltrates of mononuclear cells, accompanied by perivascular gliosis as extension progresses to become chronic.



Fig 9.18A. Granulomatous meningoencephalitis of bacterial kidney disease (BKD) demonstrating optic nerve as a possible route of *Renibacterium salmoninarum* infection.

than 6 grams, the brain can easily be included in histology cassettes simply by preparing sagittal, transverse, or longitudinal sections through the cranium depending on whether the pathologist wishes to examine circumventricular organs and meninges, or to determine whether lesions are unilateral or bilateral as may be the case for the optic tectum. Examination of the brain, within its normal surrounds of meninges and cranial nerves provides an enhanced opportunity to detect and understand lesions affecting the CNS; sectioning is aided by immersion for 24h in a decalcifying solution, although this can lead to artifactual perineuronal and perivascular vacuolation that can be mistaken for spongiosus or oedema respectively. As in mammals, excessive and immediate handling can induce dark neurons in histologic sections of the teleost brain as well, and this should be recognized as a nonlesion *(Fig 9.8)*.

Developmental malformations of the brain, stemming from infectious and toxic agents as well as genetic factors, are common in domestic animals because of the high degree of differentiation of the CNS; nevertheless, comparable lesions are rarely described in fish. Some treatment chemicals used in hatcheries are associated with oedema of the middle layer of the endomeninx, ultimately resulting in an outpouching of the cranial vault, particularly over the pineal gland where the vault is relatively thin. The term meningocoele is not necessarily appropriate because there is no evidence that the outpouching depends on a primary defect of neural tube closure; acquired external hydrocephalus may be a better term *(Fig 9.9)*. Similarly, exposure of the brain to the environment secondary to the effects of severe "sea-lice" infestations in salmon, or cannibalism in eels, is not a true example of exencephaly because it is not linked to a primary neural tube defect *(Fig 9.10)*.



Fig 9.18B. Renibacterium salmoninarum can be demonstrated in cytoplasm of ependymal cells using immunoflourescent antibody testing in cases of BKD.

Cytopathology of the nervous system is challenging, and to quote Jubb and Huxtable (1993) *"Nervous tissue is highly specialized and structurally complex, and neuropathology has always tended to be set apart as an arcane specialist area, to be entered by only a select few"*. Fish nervous tissue presents the same difficulties, and is further compounded by the frequency of tissue artifacts stemming from collection methods, rapid autolysis, choice of fixative solutions, and potential species differences; this combination frequently leads to overinterpretation of diagnostic materials.

Initial signs of neuronal degeneration include nuclear margination and dispersal of Nissl graules *i.e.* rough endoplasmic reticulum, a process known as chromatolyis that is seen in teleost brain, as in mammals **(*Fig 9.11*)**. The detection of vacuoles, especially peripherally within neurons, typically denotes mitochondrial swelling and cellular degeneration, but this is also a very common artifact, which in fish and mammals is frequently seen in the cerebellar Purkinje cells and larger motor neurons **(*Fig 9.12*)**.

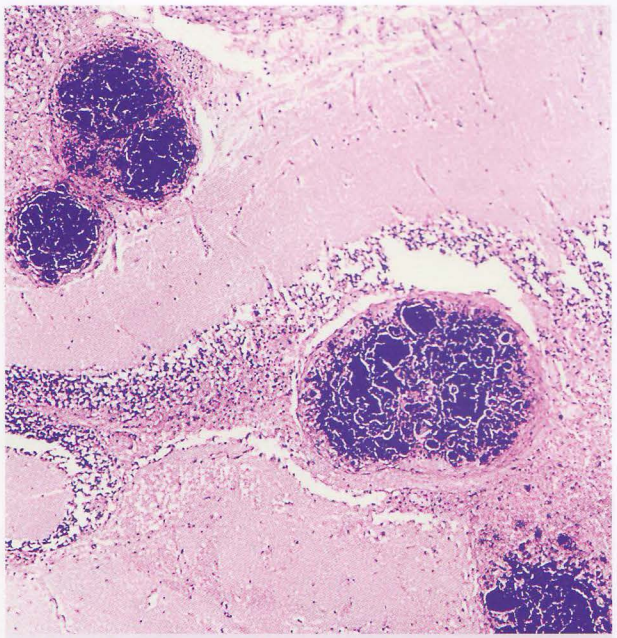

Fig 9.19A. Granulomatous endomeningitis and ventriculitis in a lined seahorse. Multifocal granulomatous infiltrates expand the endomeninx and occupy the optic ventricle.



Fig 9.19B. Severe granulomatous ventriculitis in farmed cod, the result of *Vibrio* infection. The pyogranulomatous response has created an almost diphtheritic membrane lining the ventricle.

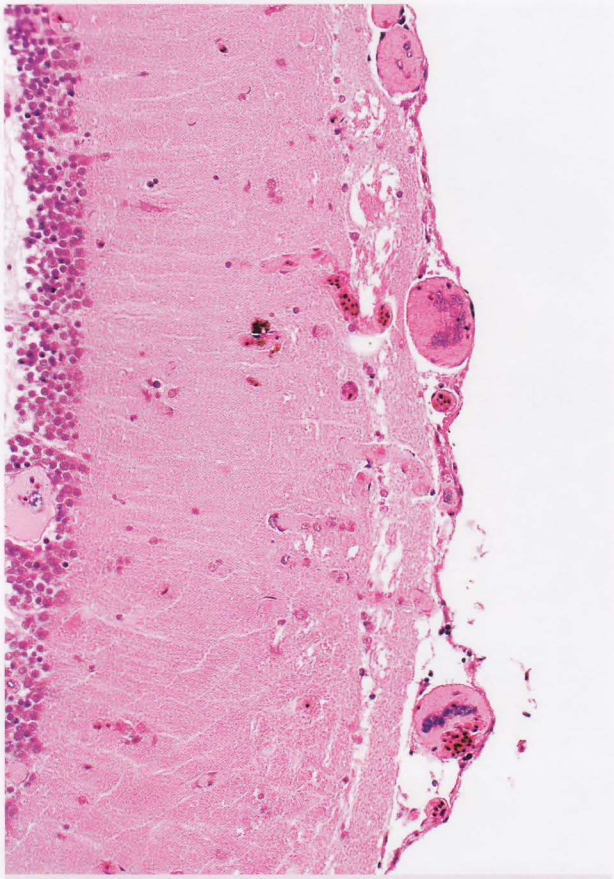

Fig 9.20. Septicaemic pasteurellosis in a Mediterranean sole. Bacteria are located in lumena of meningeal blood vessels.

Cell swelling and cytoplasmic vacuolation can be prominent features of lysosomal storage diseases of mammals, but similar conditions have not yet been reported in fish. Similarly, viral inclusion bodies are not readily detected by routine histopathology in fish brain. In most animals, during senescence there is a gradual accumulation of ceroid pigments within neurons and a gradual continual loss of neurons, but neither of these events has been documented in the brain of fish.

Neuronal death typically leads to satellitosis (accumulation of glial cells around the neuron), followed by neuronophagia (digestion of neuron by glial cells) ***(Fig 9.13)***. In mammals, neuronophagia is the sequel to neuronal death and typically is seen with viruses or toxins that directly, or indirectly, affect neurons. In teleosts, however, it is sometimes difficult to differentiate perineuronal gliosis from glial accumulations around smaller blood vessels (perivascular gliosis or "cuffing") ***(Fig 9.14)*** the latter suggestive of reactions to a blood-borne pathogen, not necessarily neurotropic, crossing the blood brain barrier.

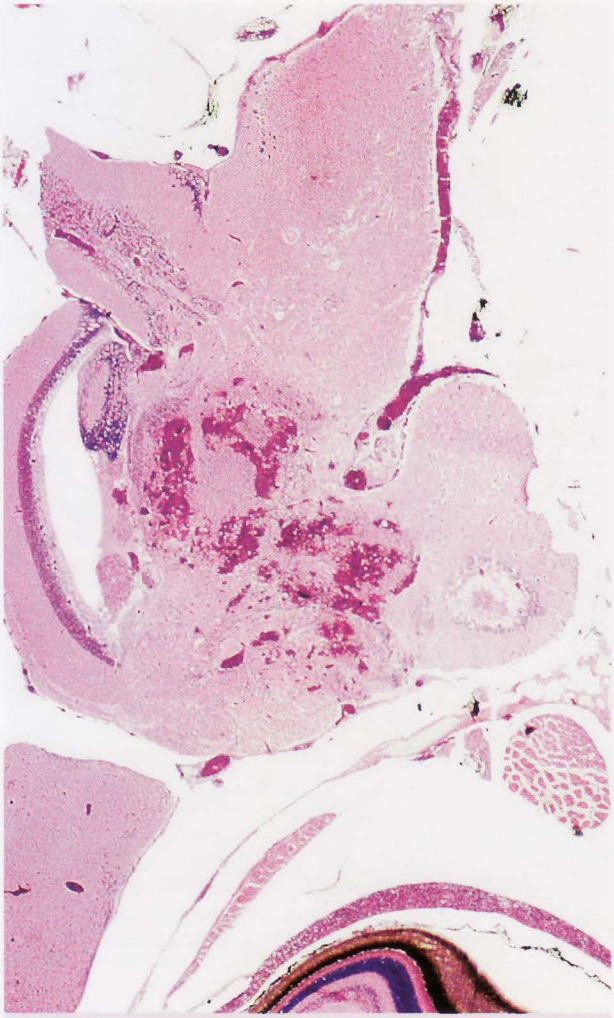

Rickettsiosis in seabass. *Fig 9.21A.* Rickettsial infection in seabass is associated with haemorrhagic encephalitis.

Astrocytes are an abundant interstitial cell in the CNS particularly in the perivascular and glial zones where they create a dense network of end feet thus creating the BBB and contributing to the glia limitans. Astrogliosis, the proliferation and swelling of cells and their processes, occurs around areas of brain injury and may remain as a persistent marker of damage; reactive astrocytes that acquire abundant eosinophilic cytoplasm, an eccentric nucleus and prominent processes are termed "gemistocytes". Microglial cells, a cell type derived from blood monocytes and whose role in the fish brain is only now being uncovered, are difficult to distinguish from astrocytes in routinely stained histological preparations, particularly when microglia undergo responsive hypertrophy and transform into rounded cells ***(see Fig 9.14)***. Focal proliferation is termed "microgliosis" and when these cells become full of ingested CNS debris they become

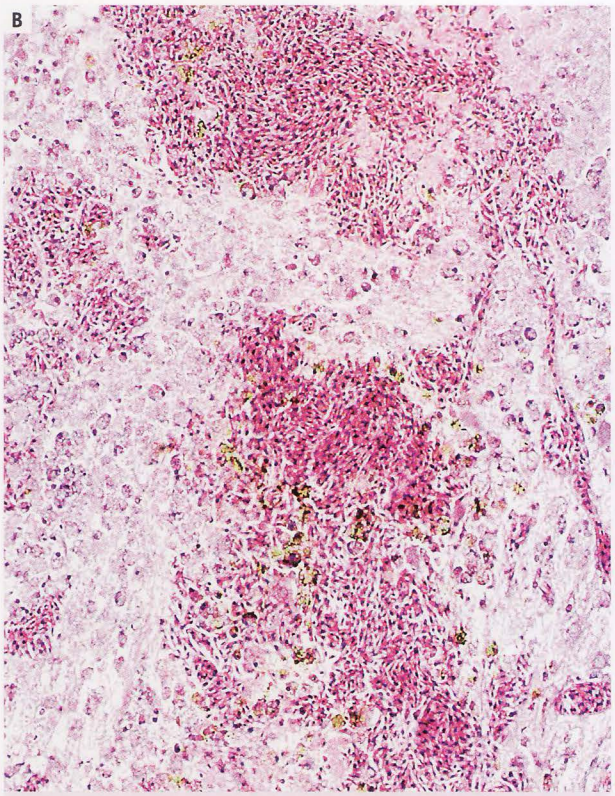

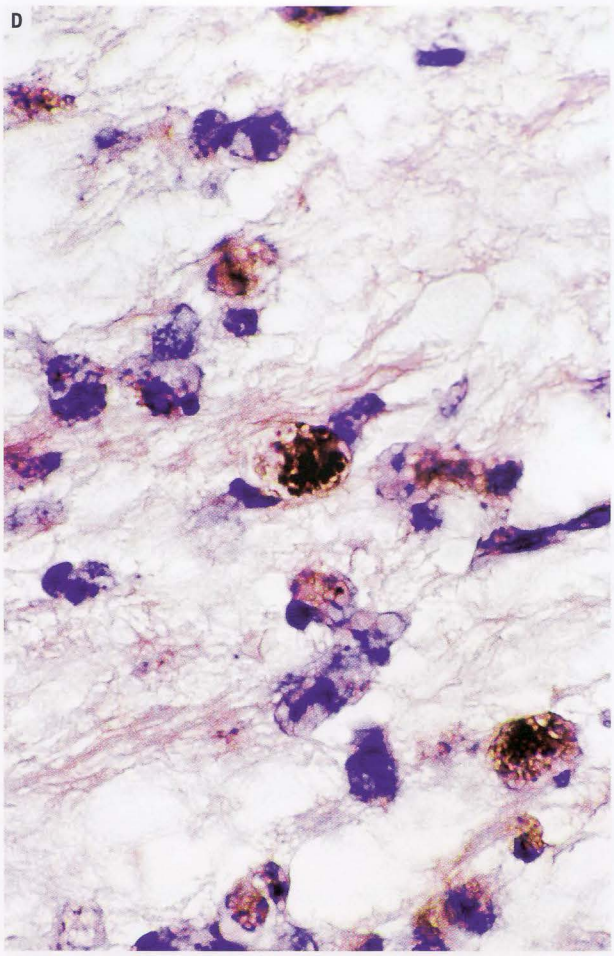

Fig 9.21B. Microglia and macrophages with basophilic stippling of cytoplasm infiltrate foci of haemorrhage. Rickettsia are demonstrable by immunohistochemical staining (**C**) and are present in distended cytoplasm of mononuclear phagocytes (**D**).

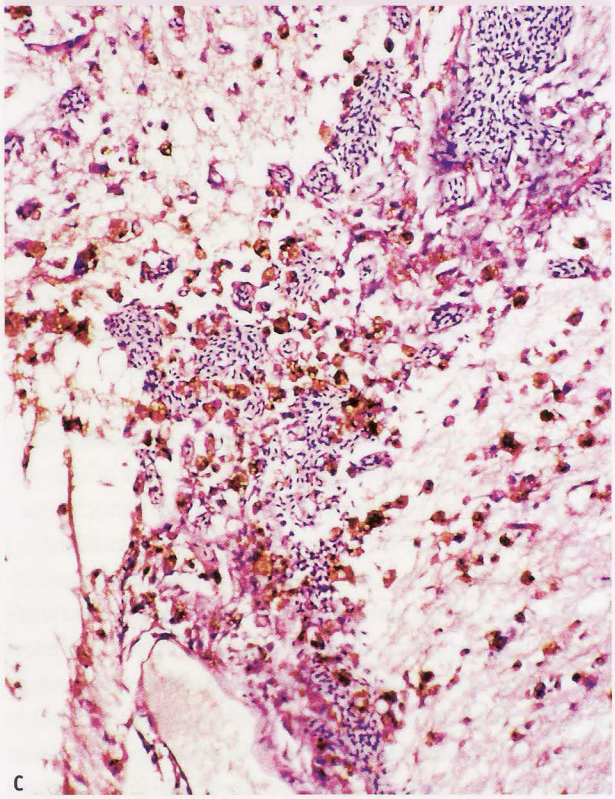

foamy and are termed "gitter cells". Microglia can also contribute to perivascular cuffs (external to the space of Virchow-Robin) that develop around the brain's microcirculation during systemic infectious diseases.

Inflammation in the CNS and routes of pathogen invasion. A consideration of the routes by which infective organisms reach the CNS, and the relevant terminology of host response to infection, is of considerable importance because of its significance to captive fish populations, in particular, regarding systemically distributed pathogens. Inflammation within the brain is termed encephalitis; within the spinal cord, myelitis; of the CVO organs, choroiditis when the choroid plexi are affected; ventriculitis specifically describes inflammation contained within the lumen of a ventricle, and ependymitis when the ependymal region is involved *(Fig 9.15)*. Specific spatial terminology for meningeal inflammation (meningitis) is less straightforward, but the similarity of the fish endomeninx to the leptomeninges of mammals suggests that the mammalian term leptomeningitis



Fig 9.22. Focal protuberant swellings on the top of heads, as in this case of encephalocoele, are seen in congenital and acquired cranial malformations.

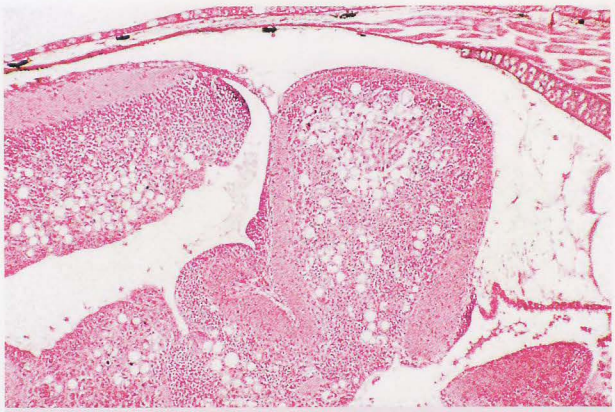

Fig 9.23B. Vacuolation of Purkinje cell and inner granule cell layers of the cerebellum.



Nodaviral encephalitis in barramundi and Mediterranean seabass.
Fig 9.23A. Vacuolation typical of nodaviral encephalitis can involve multiple regions of the brain but often targets the cerebellum, as in this example.

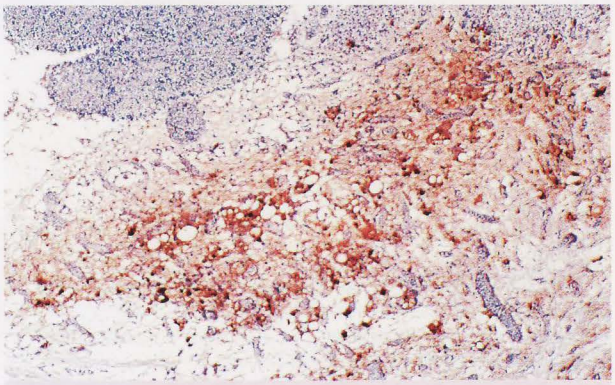

Fig 9.23C. Nodavirus antigen is demonstrable in foci of vacuolation and microgliosis by immunohistochemical staining; seabass.

should be replaced with endomeningitis, when inflammation is located in the space separating the meninges from the cranial vault. The term pachymeningitis, used in mammals to denote inflammation of the dura mater, is arguably the best term *(Fig 9.16)*. Combining the terms is typical: encephalomyelitis refers to inflammation of the brain and spinal cord; meningoencephaltis (mammalian term) refers to inflammation involving the meninges and the brain, and in fish this could be replaced with the term endomeningoencephalitis. The addition of modifying adjectives, denoting severity and dominant type of cellular infiltration, completes the morphological diagnosis and these criteria are of considerable importance in deciding on the class of infecting agent and accurately communicating results between pathologists.

Although less frequently examined than other organs, there is a growing body of literature suggesting that the fish CNS is as frequently involved in systemic infections as the mammalian CNS. Despite the significance of the resulting inflammation in the brain, research into factors influencing the localization of pathogens in the CNS and the course of infection within the compartments of the CNS has lagged, even for conditions affecting humans.

In mammals and in fish, infectious agents may take several similar routes to reach the CNS. Transmission of bacteria along nerve routes including the 1st and 2nd cranial nerves has been demonstrated for bacterial pathogens of fish and likely represents non-directed and non-neurotropic movements along tissue spaces facilitated by the close anatomical relationship between the meninges and the formation of the perineurium at the site where spinal nerves emerge from the meninges. Haematogenous distribution is probably the most common route, and it is not surprising that this targets the macrophage-rich circumventricular organs

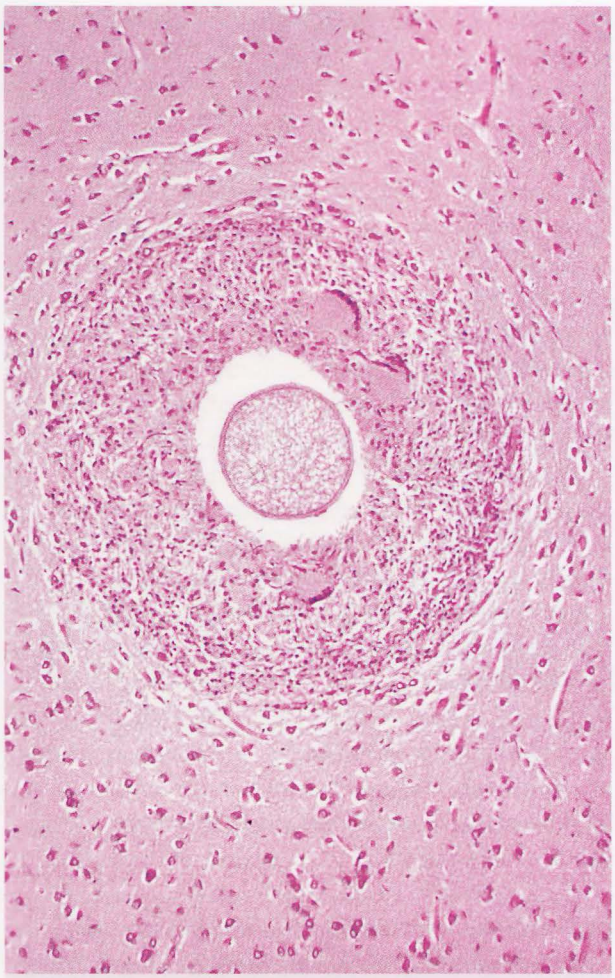

Fig 9.24. Granuloma formation in the brain of a pike with *Ichthyophonus*. Note the multinucleate giant cells and inner collar of epithelioid macrophages that comprise the wall of the granuloma, which surrounds a spherical *Ichthyophonus* spore with a smooth, double-contoured wall.

with their extensive vascularization and fenestrated endothelium. Also, the relatively rich normal population of mononuclear cells at these sites (as opposed to the resident non-recruited populations of microglia within the brain parenchyma itself) predisposes the CVO sites to infection with systemically distributed intracellular pathogens due to recruitment of blood monocytes. Extension can then occur from the CVO sites either laterally into the adjacent endomeninx or more deeply into the ventricles as part of the movement of cerebrospinal fluid. In addition to the metaplastic abilities of teleost ependymal cells, they are also capable of endocytosis of pathogens and through their elongated basal processes can serve to translocate pathogens from the ventricle into the brain parenchyma, thus completing the CVO-ventricular-ependymal route of pathogen access into the brain parenchyma.



Fig 9.25. Common shiner with cranium removed to reveal slight bubbling appearance to meninges. This is due to massive numbers of metacercariae replacing large portions of the brain.

Extension of infection from the meninges into the brain parenchyma can also occur via direct extension through the glia-limitans. The degree of resistance afforded by the glia-limitans has been shown to be species dependant. An alternative route is afforded by the pial reflections that accompany blood vessels as they enter the brain parenchyma from the meninges; the resulting perivascular spaces (space of Virchow-Robin) that surround parenchymal microvasculature effectively communicate between the parenchyma and meninges **(*Fig 9.17*)**.

Although viewed as the most common general mechanism by which pathogens relevant to human medicine can enter the brain, one of the least understood issues in the pathogenenesis and pathophysiology of microbial infections of the CNS is how microbes within blood circulation directly invade capillaries within the cerebral parenchyma. In most clinical scenarios, invasion of the nervous system occurs in the context of systemic disease and follows bacterial dissemination via the bloodstream. For extracellular pathogens, direct binding of bacteria to brain endothelial cells is followed by invasion/translocation through the BBB facilitated by actin-mediated cytoskeletal changes to endothelium; a high degree of bacteraemia facilitates successful crossing. An alternative general view is that the primary mechanism involves increased permeability of the BBB, and this may be secondary to inflammation of the meninges and release of cytokines such as tumour necrosis factor alpha or bacterial cell wall lipopolysaccharides. In contrast, intracellular bacteria such as *Streptococcus iniae*, employ different strategies including the use of mononuclear phagocytes as vectors (*Trojan-horse* mechanism) allowing passage across the BBB, and relevant fish models are now being developed to study this further.

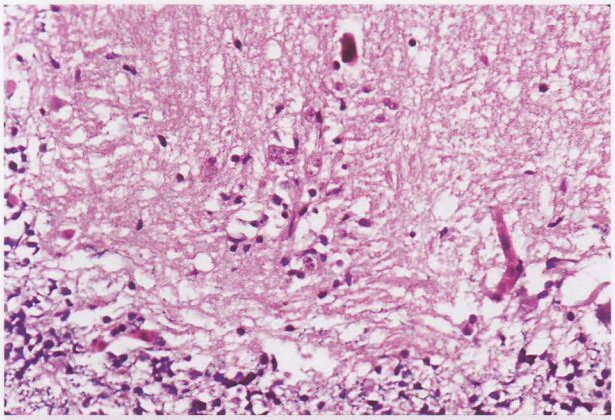

Myxozoan encephalitis of Atlantic salmon smolts. *Fig 9.26A.* A loose aggregate of glial cells accompanies a myxozoan developmental stage in the molecular layer of the cerebellum. *Haematoxylin, eosin and luxol fast blue stain.*

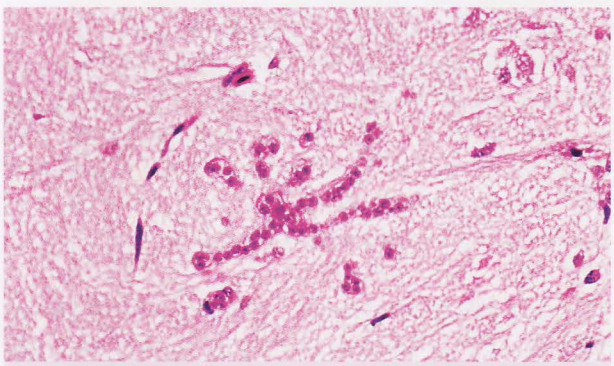

Fig 9.26B. Membrane-bound tubular structures containing multiple cells characterize the myxozoan stage in the neuropil.

Specific examples of diseases affecting the brain

A number of bacterial diseases can affect neural tissues, usually as part of systemic or regional infections. Meningitis and encephalitis are reported in *Edwardsiella ictaluri* infection of channel catfish; it is suggested that the pathogen may utilize a retrograde route along olfactory nerves to reach the telencephalon. Encephalitic lesions are also seen in *Streptococcus iniae* infection in cultured yellowtails; granulomatous lesions extend from the meninges into the ventricle and granule cell layer of the cerebellum. Streptococcal meningitis and meningoencephalitis are conditions that have received considerable attention, leading to refinement of experimental models in a variety of fish species. Granulomatous meningoencephalitis is often seen in diagnostic submissions of salmonids with severe bacterial kidney disease and frequently in Atlantic salmon that have been treated for BKD; the incidence of severe persistent neural lesions in the relative absence of systemic lesions suggests that the brain should always be examined **(*Fig 9.18*)**. Epizootics of meningitis in several species of estuarine fish in the Gulf of Mexico and Florida were associated with Gram-positive filamentous anaerobes identified as *Eubacterium tarantellus*. Granulomatous meningoencephalitis consisting of focal infiltrates of macrophages or granulomas or both can be seen in cases of disseminated mycobacteriosis, which is a frequently diagnosed condition in seahorses and seadragons **(*Fig 9.19*)**. Discrete granulomas, caused by various *Mycobacterium* spp., are often noted in submissions of ornamental fish from hobbyists; the meninges, and in particular the CVO sites, are the most common locations to find these. Examples of subacute suppurative meningitis are occasionally encountered in routine diagnostic work, although the precise cause is seldom established. Septicaemic pasteurellosis, caused by *Photobacterium* spp. (formerly *Pasteurella*) can present with septic thrombi or bacterial emboli in blood vessels of the meninges and brain **(*Fig 9.20*)**. Rickettsiae, obligate intracellular bacteria, have been identified as the cause of haemorrhagic encephalitis in seabass, wherein microglia and macrophages can be shown to harbour the bacteria in their cytoplasm **(*Fig 9.21*)**.

Until recently, viral encephalitides of fish were rarely reported. Herpesvirus of channel catfish can cause neuronal vacuolation and oedema of both brain and spinal cord. Similarly, pike fry rhabdovirus is said to cause hydrocephalus in young fish with massive fluid accumulation in the third ventricle, plus haemorrhage and congestion of the cranial vessels; the lesion manifests itself as a distinct "blip" on the head **(*Fig 9.22*)**. During experimental epizootic haematopoietic necrosis, Atlantic salmon develop vacuolar degeneration of the optic lobe, optic nerve and cerebellum. The lesions correlate well with clinical observations of blindness and depression. Similar lesions (vacuolating encephalopathy plus haematopoietic necrosis) have recently been reported from naturally-occurring outbreaks of disease in trout, and from which a morphologically similar iridovirus has also been recovered. The rapid emergence of viral nervous necrosis (VNN) or "fish encephalitis" caused by the piscine nodavirus (Betanodaviridae) in many parts of the world and in many species of intensively cultured marine fish provides a new and important example of a pathogen with relative neurotropism and a host-pathogen interaction leading to neuronal death and consequent spongiosis. Pernasal infection as a

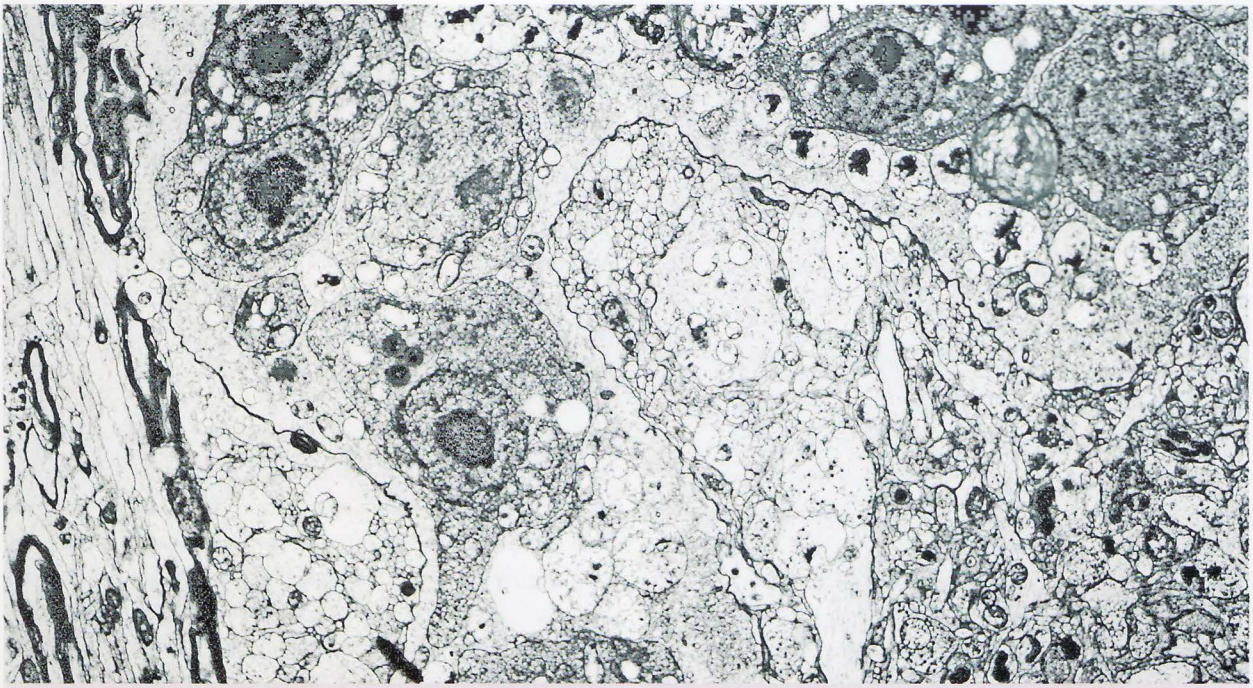

Fig 9.26C. Ultrastructure of these structures reveals that they are insinuated between nerve fibers and have a plasmodium-like architecture with cell-in-cell arrangements characteristic of myxozoa. Note the myelinated nerve fibers along the margin of the plasmodium and the absence of spores or sporogeny.

putative invasion route of the virus was experimentally demonstrated by Tanaka *et al.* (2004); the most severe neuropathology was demonstrated in the olfactory lobe with vacuolation, microgliosis, and perivasculitis. The cerebellum was also targeted, as evidenced by damage to Purkinje cells, and lesions were also noted in the medulla oblongata beside the *fasciculus longitudinalis medialis* **(Fig 9.23)**. Macrophage-like cells (possibly microglia) have been shown to be a site of viral persistence in subclinically affected fish (Johansen *et al.* 2002) and these authors note the possibility that other anatomical lesions may regress due to neuronal regeneration.

Exophiala salmonis has been associated with epizootic outbreaks of disease in farmed cut-throat trout. The brain was the primary focus for the fungus, with later involvement of the eye and other tissues. In contrast, Langdon and McDonald (1987) describe the sequential invasion of *Exophiala pisciphila* into the CNS of Atlantic salmon and noted that the fungus invaded through cranial structures of the lateral line system, subsequently creating fistulae through cranial cartilage and ultimately invading the brain. Invasion of the semicircular canals was believed to account for the "whirling" behaviour. As might be expected, in both case descriptions, the host response was necrotizing and granulomatous and comprised of macrophages, giant cells and lymphocytes. Similarly, *E. jeanselmi* has been noted to invade the cranial vault of flatfish. *Saprolegnia* has similar potential. A domed swelling over the optic tectum in Atlantic salmon fry was determined to represent severe acquired hydrocephalus due to extension into the pituitary and adjacent ventral brain from a fulminating necrotizing stomatitis and branchitis due to this water mould. In addition, brain, meninges, and spinal cord may be infected along with coelomic viscera by spores of *Ichthyophonus hoferi* in cases of systemic ichthyophoniasis. Spores of *Ichthyophonus* typically elicit granuloma formation, often including multinucleate giant cells **(Fig 9.24)**.

There are numerous reports documenting invasion of the nervous system by parasites. Hoffman and Hoyme (1958) described the neuropathology of experimental infection of the stickleback by cercariae of the trematode *Diplostomum baeri eucaliae*. Following skin penetration, the parasites migrated to the brain, localizing particularly in the choroid plexi which became hyperplastic. The associated granulomatous response was not reported to affect nervous function although occasionally hemorrhage did cause death. By contrast, metacercariae of another fluke *Ornithodiplostomum ptychocheilus* encysted within the brain of minnows have been shown to alter the behaviour

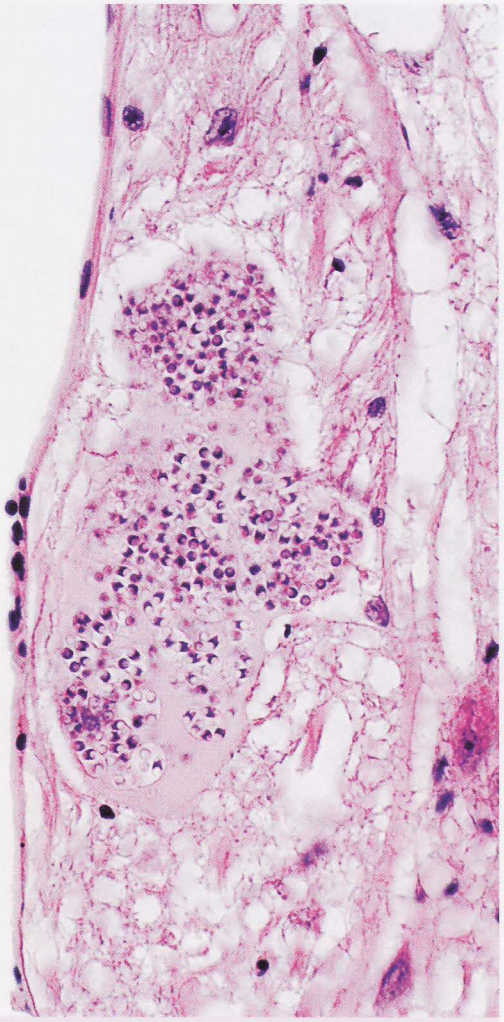

Fig 9.27. Microsporidian cysts within spinal cord. These small 1-2 micron sized spores clearly show the central band that represents the coiled polar filament.

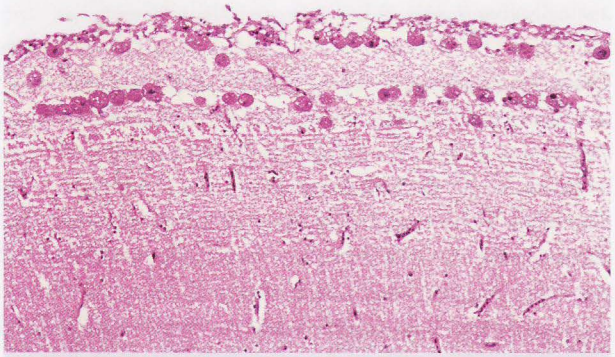

Fig 9.28. Ciliates of *Uronema* sp. invade the meninges and neuropil of the optic tectum. Note the absence of inflammatory infiltrates in the neuropil, although a minimal histiocytic infiltrate of the overlying endomeninx is present in this example.

of the fish so that their schools were less compact, divided more frequently and occupied positions closer to the water surface than control schools; optomotor responses, innate behaviours that link visual stimuli with motor performance, were reduced. Such an effect would probably favour predation by the parasite's final host **(*Fig 9.25*)**. Similarly, paralysis has been reported to be the result of severe cranial diplostomiasis in the Argentine fish (*Basilichthys microlepidotus*). Adult sanguinicolid flukes are also occasionally encountered in the meninges: an example is *Sanguinicola idahoensis* in rainbow trout.

Other parasites found in the brain include myxozoans and microsporidians. *Myxobolus hendricksoni* is found in the optic lobes and cerebellum as well as ventricles and meninges of the fathead minnow; host response is minimal even though large areas of the brain may be replaced by the parasites. Spinal curvature may be a consequence of some myxozoan infections *e.g. Myxobolus cerebralis* (see later under Spinal Cord); such is the case with the encephalotropic species *Myxobolus buri* of yellowtail and probably also *Triangula percae* in redfin perch. Emaciation and uncoordinated darting, along with rolling and pitching are symptoms described in the tricolour sharkminnow (*Balantiocheilos melanopterus*) due to compression, rather than inflammation, of brain parenchyma in the medulla oblongata and mesencephalon resulting from cysts of the neurotropic *Myxobolus balantiocheili*. Encephalitis and mass mortality of netpen-reared Atlantic salmon was associated with histopathologic evidence of a myxozoan developmental stage in the brains of affected smolts. During epizootics of parasitic encephalitis, affected smolts displayed circling or gyrating swimming patterns, inappropriate postures in the water column and apparent unconsciousness, and the presentation of neurological signs and mass mortality was coined "nervous mortality syndrome". Later investigations revealed that smolts reared at sites of previous episodes of neurologic disease developed parasitic encephalitis characterized by focal aggregates of macrophages and glial cells and that the ultrastructure of the parasite was consistent with an intercellular presporogonic multicellular developmental stage of a histozoic myxozoan **(*Fig 9.26*)**. Molecular characterization of this myxozoan by small subunit RNA gene sequence analysis revealed that it had greatest nucleotide identity with neurotropic species of the genus *Myxobolus*. In contrast to many other examples of myxozoan encephalitis, nervous mortality syndrome represents a unique presentation of epizootic neurologic disease associated

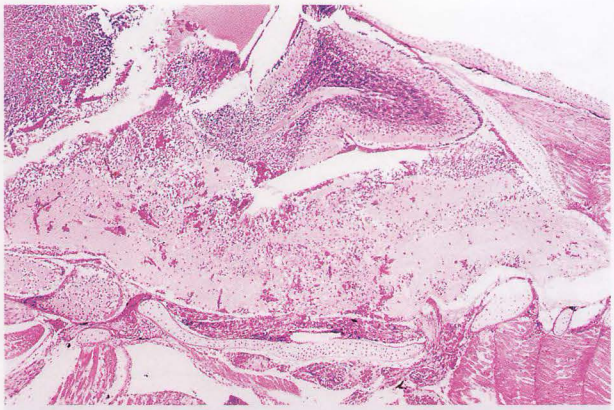

Fig 9.29. Encephalomalacia accompanied by congestion and haemorrhage extends to include mesencephalic structures, base of the cerebellum and anterior medulla.



Fig 9.30. Histologic architecture of the spinal cord of a rainbow trout fry. The grey matter takes the shape of an inverted Y, with two laterally projecting ventral horns populated with neurons and an ependyma-lined central canal. *Haematoxylin, eosin and luxol fast blue stain.*

with the vegetative stages of a myxozoan parasite in the absence of detectable sporogeny.

The microsporidian *Spraguea* (*Nosema*) *lophii* is found in the cerebrospinal ganglia of angler fish (*Lophius* sp.) where it evokes grossly visible xenoma formation; clinical disease is not reported however. By contrast, *Pseudoloma neurophilia*, a CNS-trophic xenoma-forming microsporidian infecting the hind brain, spinal cord and nerve roots of zebrafish causes fish to become emaciated, scoliotic, and lethargic. The ability of this parasite to spread extensively within facilities that provide zebrafish for laboratory and biomedical research has significant implications warranting further study on whether occult infections may impart artifactual research results, particularly to behavioural studies. A commercially significant example within the salmon farming industry is represented by *Microsporidium cerebralis*, the cause of "spinner disease" in Atlantic salmon, in which the parasite infects and destroys neurons within the myelencephalon particularly caudally in the medulla oblongata, in some instances including the Mauthner cells. In this example, degenerate neurons contain spores, and, as is noted for other vertebrates, early in their degeneration they develop a ground-glass appearance accompanied by satellitosis. Cell swelling is followed by karyolysis, neuronophagia, and glial cell accumulation; the final result is spongiosis of the neuropil. Degeneration of motor neurons and inflammation in the region of the *fasciculus longitudinalis lateralis* (motor tract) and nerve root of the vestibular acoustic nerve located just lateral to the Mauthner cells is the likely explanation for the altered, and characteristic, spinning behaviour of infected fish **(*Fig 9.27*)**.

The ciliates *Ichthyophthirius multifiliis* and *Tetrahymena corlissi*, and their marine counterparts *Cryptocaryon irritans* and *Uronema marinum*, respectively, may occasionally be found within meninges and brain when infections are heavy, and especially when the epithelium of the nares or orbit is parasitized. An unusual feature of some heavy infections by *Tetrahymena* sp. and *Uronema* sp. is the lack of host response despite, in some cases, a remarkable degree of neuropil invasion **(*Fig 9.28*)**. In contrast, during scuticociliatosis in farmed turbot caused by *Philasterides dicentrarchi*, severe encephalitis and meningitis are described. *Spironucleus barkhanus* can sometimes be found in extremely large numbers within the meninges of salmonids with systemic spironucleosis; once again, associated inflammation is limited.

The impact of toxicants on brain energy metabolism of fish has largely focused on the effects of organic pesticides and heavy metals. The pesticide carbaryl causes characteristic vacuolation of the optic tectum in salmonids. The insecticide endosulfan causes oedema, meningitis and encephalitis in tilapia. The response is characterized by an influx of eosinophilic granular cells and small foci of glial scarring in the long term. In general, pesticide exposure leads to a reduction in brain glycogen which may be related to increased energetic demands to cope with the toxic effects, or more directly because the normal flux of glucose across the BBB is impaired. Aflatoxin has been shown to cause cerebral oedema and meningitis following experimental administration in rohu. Experimental brevetoxin (red tide toxin) exposure of embryonic medaka resulted in cranial defects and meningocoeles.



Fig 9.31. Intervertebral disc luxation in a rainbow trout. In this transverse section of the spine, there is compression of the ventral spinal cord by a dorsal extrusion of disc material.

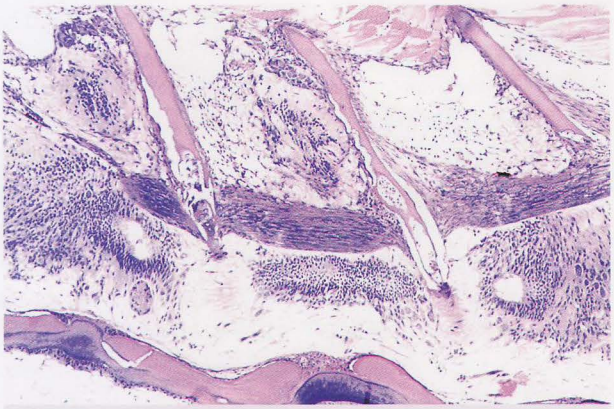

Fig 9.32. Compression of the spinal cord at the site of vertebral curvature in a rainbow trout fry infected with *Myxobolus cerebralis*. There is vacuolation and rarefaction of white matter at the site of compression (interpreted as myelomalacia), as well as foci of chondritis with intralesional myxozoan spores in the cartilaginous cores of dorsal spinal processes.
This material kindly provided by Dr. R. P. Hedrick.

High ammonia levels induce convulsions or coma, probably due to interference with neurotransmitters, but there are no reported lesions similar to those seen in mammals *i.e.* intramyelinic oedema causing spongy change to white matter. Instead, a marked proliferation of the meninges, sufficiently severe to displace the eye and create an acquired meningocoele has been observed in fathead minnows, although this lesion is not seen in salmonids. The lesion, which regressed when fish were moved to freshwater, was limited to the meninges of the brain and did not extend to the spinal cord, and the proliferative mass, although presumed to be endomeninx also contained rodlet cells, adipocytes, macrophages, and perivascular deposits of melanin.

Thiamine deficiency has been reported to be the cause of polioencephalomalacic lesions in clinically affected herring with spongy degeneration of the periventricular ependyma, focal thalamic neuronal necrosis and meningeal and ventricular haemorrhage. Despite similar clinical disease in rainbow trout, investigators have failed to confirm these findings in experimentally produced deficiency. Clinical evidence of severe nervous dysfunction in young cultured splake (lake trout x brook trout hybrid) was associated with marked hemorrhagic encephalomalacia (*Fig 9.29*). Although of unknown cause, the lesions tended to have a laminar distribution at the white/grey matter interface in several parts of the brain. In mammals, possible causes would include thiamine "deficiency", lead poisoning and "salt poisoning," whereas in poultry, vitamin E deficiency would be a possibility.

Because of its high energy requirements, the brain is a common target organ during hypoxia, and is protected in some species such as catfish but not salmonids, by high resting levels of ATP or alternatively, as demonstrated in the "anoxic resistant" bullhead catfish, by glycogen stores that permit effective anaerobic glycolysis. Strategies in other resistant species include increased use of alternative glycolytic end products such as ethanol. In contrast, the "anoxic sensitive" brain typical of many teleosts is unable to produce ATP using anaerobic pathways at rates high enough to meet ATP requirements. Reduced ATP levels cause neurons to become progressively depolarized, while the extracellular compartment becomes flooded with excitatory neurotransmitters that lead to neuronal death. During hypoxia, fish increase the rate of delivery of glucose to the brain by increasing blood glucose levels or by increasing cerebral blood flow, and a reduction in brain energy demand has been observed in anoxia-tolerant teleosts such as goldfish. In mammals, anoxia preferentially targets neurons as opposed to glial cells, and Purkinje cells and neurons deep within the cer-



Fig 9.33. Blacktail, or posterior regional melanosis, secondary to infection by *Myxobolus cerebralis*, resulting from collapse of vertebral foramina and compression of spinal nerves. *This image kindly provided by Dr. S. L. Poynton.*

ebrum are selectively the most vulnerable. To date, the differential vulnerability of fish neurons to anoxia has not been reported.

Age-related degenerative changes are rarely described for fish brain. At the time of writing, there are no published data relating to the occurrence of transmissible spongiform encephalopathies in fish. Although *corpora arenacea*, deposits of calcium and magnesium salts, are common in the mammalian pineal gland, these have not been reported in fish even though the fish pineal gland has a high calcium content. Multilamellar bodies have been noted by Wang *et al.* (1995) to develop within the endomeninx and may represent accumulations of proteins secreted by inner layer cells.

Spinal cord

Originating through the foramen magnum, the spinal cord extends the length of the vertebral column and terminates in a neurosecretory endocrine structure, the urophysis. On transverse section, the cord is divided into grey and white matter such that the grey matter forms an inverted Y comprised of a single dorsal horn and two ventral ones, which is in contrast to the typical H-shaped arrangement of grey matter in the spinal cords of mammals. A central canal lined by ependyma runs the length of the cord **(*Fig 9.30*)**. Located in the white matter beneath the central canal and between the ventral horns, lie the large myelinated axons of the Mauthner neurons located in the medulla. A growth-related increase in the numbers of neurons is reported in several species, including salmonids, and appears to correlate with the increase in numbers of red and white muscle fibres. Astrocytes, which are critical in neurogenesis and gliogenesis, have been shown to be unevenly distributed in the spinal cord of zebrafish, located mostly in the grey matter and arranged in tandem longitudinal arrays with projections that connect to nearby blood vessels, neurons and also to the surface of the spinal cord, hypothesized as forming a metabolic network for the spinal cord.

Disease

Changes may be associated with space-occupying lesions, such as tumours, or with traumatic damage to the vertebral column as seen in lightning strike. Compression of the spinal cord can result from intervertebral disc luxation **(*Fig 9.31*)** or from lateral, dorsal or ventral curvatures of the vertebral column, which can be seen in whirling disease, caused by the myxozoan parasite *Myxobolus cerebralis* **(*Fig 9.32*)**. In addition to the compressive effects on the spinal cord and neurosensory apparatus of the semicircular canals seen in whirling disease as a consequence of vertebral and cranial deformations, respectively, collapse of vertebral foramina and compression of the spinal nerves that innervate chromatophore units of the dermis result in a regional melanosis of the peduncle and tail, such that the posterior part of the fish turns dark, called by some "blacktail" **(*Fig 9.33*)**. A posterior paralysis has been described in sea-bream associated with *Aeromonas hydrophila* infection that tracked along inter-myotomal fascia to the spinal cord. Traumatic cord damage is also seen in young rainbow trout as a result of material from intervertebral discs ventrally extruded at the point of maximum flexure, beneath the dorsal fin. The resulting posterior paralysis may be compounded by ischaemic damage due to concomitant aortic thrombosis **(*see Fig 6.24*)**. Cord lesions include haemorrhage and malacia, with swollen eosinophilic axons, and with time, mild perivascular migration of leukocytes and gemistocytic (reactive) astrocytosis.

Myxozoans have been described within the axons of minnows and lungfish, and are also seen in goldfish. In minnows, pre-spore stages were present within brainstem, dorsal roots and even sinoatrial pacemaker, while spores identified as *Myxobolus* were found in the dorsal root ganglia and spinal canal. These locations strongly suggest that the parasites migrated down the axons and out along the dorsal roots into the ganglia where they matured into spores. Despite occupying many axons which had greatly increased in diameter and had attenuated myelin

sheaths, obvious clinical disease in the fish was lacking, possibly because a thin peripheral rim of axoplasm still remained, even in heavily parasitized axons. A glial response in minnows was present only in brainstem, along with perivascular cuffing. A response was seen, however, in the cord of the lungfish, possibly because the parasites in this latter species did not restrict themselves to the axons. It should surely come as little surprise to those with any experience of this amazing group of parasites, to find that it is the myxozoa that have been capable of exploiting this highly unusual but very well protected niche within the fish. In the case of *M. cerebralis*, the causative agent of whirling disease, for example, El-Matbouli *et al.* (1995) demonstrated that developmental stages migrate from epidermis to the target site of sporogony, the cranial and vertebral cartilages, via peripheral nerves, spinal cord and brain.

Acknowledgement:
Hugh Ferguson supplied many of the images for this chapter.



References

Alfei, L. and Sesti, G. (1984) Neuronal increase in the trout (*Salmo trutta fario*) spinal cord during development. *Cellular and Molecular Biology* 30:471-478.

Ali, N.M. (1984) Mast cells enter a teleost's brain by Xth cranial nerve in response to *Diplostomum phoxini* (Trematoda). *Experientia* 40:197-198.

Barker, D.E., MacKinnon, A.M., Boston, L., Burt, M.D.B, Cone, D.K., Speare, D.J., Griffiths, S., Cook, M., Ritchie, R. and Olivier, G. (2002) First report of piscine nodavirus infecting wild winter flounder *Pleuronectes americanus* in Passamaquoddy Bay, New Brunswick, Canada. *Diseases of Aquatic Organisms* 49:99-105.

Bernstein, J.J. (1970) 1. Anatomy and physiology of the central nervous system. ***In** Fish Physiology, **eds.*** Hoar, W.S. and Randall, D.J. Volume IV *The Nervous System, Circulation, and Respiration.* Academic Press, New York.

Bowmaker, J.K. and Wagner, H-J. (2004) Pineal organs of deep-sea fish: photopigments and structure. *Journal of Experimental Biology* 207: 2379-2387.

Brocklebank, J.R., Speare, D.J. and Kent, M.L. (1995) Microsporidian encephalitis of farmed Atlantic salmon (*Salmo salar*) in British Columbia. *Canadian Veterinary Journal* 36:631-633.

Bundgaard, M. and Cserr, H.F. (1991) Barrier membranes at the outer surface of the brain of an elasmobranch, *Raja erinacea*. *Cell and Tissue Research* 265:113-120.

Cardone B. and Roots, B.J. (1990) Comparative immunohistochemical study of glial filament proteins (glial fibrillary acidic protein and vimentin) in goldfish, octopus and snail. *Glia* 3:180–192.

Carmichael, J.W. (1966) Cerebral mycetoma of trout due to a *Phialophora*-like fungus. *Sabouraudia* 6:120-123.

Caruncho, H.J., Pinto da Silva, P. and Anadon, R. (1993) *Journal of Submicroscopical and Cytological Pathology* 25:397-406.

Castejon, O.J. (1983) Light, scanning and transmission electron microscopy study of fish cerebellar capillaries. *Scanning Electron Microscopy* 1:153-160.

Castejon, O.J. and Caraballo, A.J. (1980) Light and scanning electron microscopic study of cerebellar cortex of teleost fishes. *Cell and Tissue Research* 207:211-226.

Chaudhuri, J.D. (2000) Blood brain barrier and infection. *Medical Science Monitor* 6:1213-1222.

Cserr, H.F. and Bundgaard, M. (1984) Blood-brain interfaces in vertebrates: a comparative approach. *American Journal of Physiology* 246:277-288.

Dahl, D.C., Crosby, J., Sethi, J.S. and Bignami, A. (1985) Glial fibrillary acidic (GFA) protein in vertebrates: immunofluorescence and immunoblotting study with monoclonal and polyclonal antibodies. *Journal of Comparative Neurology* 239:75–88.

De Kinkelin, P. (1980) Occurrence of a microsporidian infection in zebra danio *Brachydanio rerio* (Hamilton-Buchanan). *Journal of Fish Diseases* 3:71-73.

DiAngelo, C.R. and Heath, A.G. (1987) Comparison of *in vivo* energy metabolism in the brain of rainbow trout, *Salmo gairdneri* and bullhead catfish, *Ictalurus nebulosus* during anoxia. *Comparative Biochemistry and Physiology* B. 88:297-303.

Dowding, A.J., Maggs, A. and J. Scholes, J. (1991) Diversity amongst the microglia in growing and regenerating fish CNS: immunohistochemical characterization using FL.1 antimacrophage monoclonal antibody. *Glia* 4:345-364.

Drevets, D.A., Sawyer, R.T., Potter, T.A. and Campbell, P.A. (1995) *Listeria monocytogenes* infects human endothelial cells by two distinct mechanisms. *Infection and Immunity* 63:4268-4276.

Drevets D.A., Leenen, P.J.M. and Greenfield, R.A. (2004) Invasion of the central nervous system by intracellular bacteria. *Clinical and Microbiological Reviews* 17:323-347.

Egusa, S. (1985) *Myxobolus buri* sp.n. (Myxosporea: Bivalvulida) parasitic in the brain of *Seriola quinqueradiata* Temminck et Schlegel. *Fish Pathology* 19:239-244.

Eldar, A., Bejerano, Y., Livoff, A.,Horovitcz, A. and Bercovier, H. (1995) Experimental streptococcal meningo-encephalitis in cultured fish. *Veterinary Microbiology* 43:33-40.

El-Matbouli M., Hoffman, R.W. and Mandok, C. (1995) Light and electron microscopic observations on the route of the triactinomyxon-sporoplasm of *Myxobolus cerebralis* from epidermis into rainbow trout cartilage. *Journal of Fish Biology* 46:919-935.

Fange, R. (1986) Lymphoid organs in sturgeons (acipenseridae). *Veterinary Immunology and Immunopathology* 12:153-161.

Ferguson, H.W., Lom, J. and Smith, I. (1985) Intra-axonal parasites in the fish *Notropis cornutus* (Mitchill). *Veterinary Pathology* 22:194-196.

Fleury, J., Gherardi, R. and Poireir. (1984) Pathology of perivascular spaces in the central nervous system. *Annals of Pathology* 4:249-257.

Frasca Jr., S., Poynton, S.L., West, A.B. and Van Kruiningen, H.J. (1998) Epizootiology, pathology, and ultrastructure of the myxosporean associated with parasitic encephalitis of farmed Atlantic salmon (*Salmo salar*) in Ireland. *Diseases of Aquatic Organisms* 32:211-225.

Frasca Jr., S., Linfert, D.R., Tsongalis, G.J., Gorton, T.S., Garmendia, A., Hedrick, R.P., West, A.B. and Van Kruiningen, H.J. (1999) Molecular characterization of the myxosporean associated with parasitic encephalitis of farmed Atlantic salmon (*Salmo salar*) in Ireland. *Diseases of Aquatic Organisms* 33:221-233.

Furukawa, E. and Omura, Y. (1997) Scanning and transmission electron microscopic study on a multilayered basement membrane in the pineal organ of the ayu *Plecoglossus altivelis*. *Archives of Histology and Cytology* 60:511-517.

Ghali, R.P., Herx, L.M., Maa, A. and Levine, R.L. (2000) Mononuclear cell proliferation and hyperplasia during Wallerian degeneration in the visual systems of the goldfish in the presence and absence of regenerating optic axons. *Brain Research* 854:178-188.

Halliday, M.M. (1974) Studies on *Myxosoma cerebralis*, a parasite of salmonids. III. Some studies on the epidemiology of *Myxosoma cerebralis* in Denmark, Scotland and Ireland. *Nordisk Veterinaer Medicin* 26:165-172.

Halliday, M.M. (1974) Studies on *Myxosoma cerebralis*, a parasite of salmonids. IV. A preliminary immunofluorescent investigation of the spores of *Myxosoma cerebralis*. *Nordisk Veterinaer Medicin* 26:173-179.

Hanke, A.R., Backman, S., Speare, D.J. and Friars, G.W. (1991) An uncommon presentation of fungal infection in Atlantic salmon fry. *Journal of Aquatic Animal Health* 3:192-197.

Huang, S.H. and Jong, A.Y. (2001) Cellular mechanisms of microbial proteins contributing to invasion of the blood-brain barrier. *Cellular Microbiology* 3:277-287.
Hauwel, M., Furon, E., Canova, C., Griffiths, M., Neal, J. and Gasque, P. (2005) Innate (inherent) control of brain infection, brain inflammation and brain repair: the role of microglia, astrocytes, "protective" glial cells and stroma ependymal cells. *Brain Research Reviews* 48:220-233.
Hoffman, G.L. and Hoyme, J.B. (1958) The experimental histopathology of the "tumor" on the brain of the stickleback caused by *Diplostomum baeri eucaliae* Hoffman and Hundley, 1957 (Trematoda: Strigeoidea). *Journal of Parasitology* 44:374-378.
Hoffmann, W. (1992) Goldfish ependymins: cerebrospinal fluid proteins of meningeal origin. *Progressive Brain Research* 91:13-17.
Hoffman, W. and Schwarz, H. (1996) Ependymins: meningeal-derived extracellular matrix proteins at the blood-brain barrier. *International Review of Cytology* 165:121-158.
Houalla, T. and Levine, R.L. (2003) The isolation and culture of microglia-like cells from the goldfish brain. *Journal of Neuroscience Methods* 131:121-131.
Hylland, P. and Nilsson, G.E. (1999) Extracellular levels of amino acid neurotransmitters during anoxia and forced energy defiency in crucian carp brain. *Brain Research* 823:49-58.
Iglesias, R., Parama, A., Alvarez, M.F., Leiro, J., Fernandez, J. and Sanmartin, M.L. (2001) *Philasterides dicentrarchi* (Ciliophora, Scuticociliatida) as the causative agent of scuticociliatosis in farmed turbot *Scophthalmus maximus* in Galicia (NW Spain). *Diseases of Aquatic Organisms* 46:47-55.
Johansen, R., Ranheim, T., Hansen, M.K., Taksdal, T. and Totland, G.K. (2002) Pathological changes in juvenile Atlantic halibut *Hippoglossus hippoglossus* persistently infected with nodavirus. *Diseases of Aquatic Organisms* 50:161-169.
Johnson, A.K. and Gross, P.M. (1993) Sensory circumventricular organs and brain homeostatic pathways. *FASEB* 7:678-686.
Jubb, K.V.F., C.R. Huxtable (1993) The Nervous System. ***In***: *Pathology of Domestic Animals* 4th Edition, ***eds***. Jubb, K.V.F., Kennedy, P.C. and Palmer, N. Volume 1. Academic Press, New York.
Kawai H., Arata, N. and Nakayasu, H. (2001) Three-dimensional distribution of astrocytes in zebrafish spinal cord. *Glia* 36:406-413.
Kent, M.L. and Hoffman, G.L. (1984) Two new species of Myxozoa, *Myxobolus inaeguus* sp. n. and *Henneguya theca* sp. n. from the brain of a South American knife fish, *Eigemannia virescens* (V). *Journal of Protozoology* 3:91-94.
Kent, M.L. and Bishop-Stewart, J.K. (2003) Transmission and tissue distribution of *Pseudoloma neurophila* (Microsporidia) of zebrafish, *Danio rerio* (Hamilton). *Journal of Fish Diseases* 26:423-426.
Kimm-Brinson, K.L. and Ramsdell, J.S. (2002) The red tide, brevetoxin, induces embryonic toxicity and developmental abnormalities. *Environmental Health Perspectives* 109:377-381.
Krahn, V. (1982) The pia mater at the site of entry of blood vessels into the central nervous system. *Anatomical Embryology* 164:257-263.
Kruger, L. and Maxwell, D.S. (1967) Comparative fine structure of vertebrate neuroglia: teleosts and reptiles. *Journal of Comparative Neurology* 129:115-142.
Langdon, J.S. and McDonald, W.L. (1987) Cranial *Exophiala pisciphila* infection in *Salmo salar* in Australia. *Bulletin of European Association of Fish Pathologists* 35:117-119.
Langdon, J.S., Humphrey, J.D., Williams, L.M., Hyatt, A.D. and Westbury, H.A. (1986) First virus isolation from Australian fish: an iridovirus-like pathogen from redfin perch, *Perca fluviatilis* L. *Journal of Fish Diseases* 9:263-268.
Levsen, A., Alvik, T. and Grotmol, S. (2004) Neurological symptoms in tricolour sharkminnow *Balantiocheilos melanopterus* associated with *Myxobolus balantiocheili* n. sp. infecting the central nervous system. *Diseases of Aquatic Organisms* 59:135-140.
Lewis, D.H. and Udey, L.R. (1978) Meningitis in fish caused by an asporogenous anaerobic bacterium. Fish Disease Leaflet 56, United States Department of the Interior, Washington.
Lutz, P.L. and Nilsson, G.L. (1997) Contrasting strategies for anoxia brain survival – glycolysis up or down. *Journal of Experimental Biology* 200:411-419.
Ma, P.M. (1993) Tanycytes in the sunfish brain: NADPH-diaphorase histochemistry and regional distribution. *Journal of Comparative Neurology* 336:77-95.
Major, R.D., McCraren, J.P. and Smith, C.E. (1975) Histopathological changes in channel catfish (*Ictalurus punctatus*) experimentally and naturally infected with channel catfish virus disease. *Journal of the Fisheries Research Board Canada* 32:563-567.
Markiw, M.E. and Wolf, K. (1974) *Myxosoma cerebralis*: Isolation and concentration from fish skeletal elements - sequential enzymatic digestions and purification by differential centrifugation. *Journal of the Fisheries Research Board Canada* 31:15-20.
Marquet, E. and Sobel, H. (1970) A protozoon in the central nervous system of the lungfish *Polypterus enlicheri*. *Journal of Protozoology* 17:71-76.
Matthews, D. and Cooke, B.C. (2003) The potential for transmissible spongiform encephalopathies in non-ruminant livestock and fish. *Reviews of Science Technology* OIE 22:283-296.
Matthews, J.L., Brown, A.M., Larison, K., Bishop-Stewart, J.K., Rogers, P. and M.L. Kent. (2001) *Pseudoloma neurophilia* n.g., n.sp., a new microsporidium from the central nervous system of the zebrafish (*Danio rerio*). *Journal of Eurkaryotic Microbiology* 48:227-233.
McFarland, W. N., Pough, F.H., Cade, T.J. and Heiser, J.B. (1979) The bony fishes-osteichthyes. pp 177-220. ***In***: *Vertebrate Life*. Macmillan Publishing Co., Inc. New York.
Meyer, F.P. and Jorgenson, T.A. (1983) Teratological and other effects of malachite green on development of rainbow trout and rabbits. *Transactions of the American Fisheries Society* 112:818-824.
Mitchell, L.G., Seymour, C.L, and Gamble, J.M. (1985) Light and electron microscopy of *Myxobolus hendricksoni* sp. nov. (Myxozoa: Myxobolidae) infecting the brain of the fathead minnow, *Pimephales promelas Rafinesque*. *Journal of Fish Diseases* 8:75-89.
Miyazaki, T. and Plumb, J.A. (1985) Histopathology of *Edwardsiella ictaluri* in channel catfish, *Ictalurus punctatus* (Rafinesque). *Journal of Fish Diseases* 8:389-392.
Momose, Y., Kohno, K. and Ito, R. (1988) Ultrastructural study of the meninx of the goldfish brain. *Journal of Comparative Neurology* 270:327-336.
Neely, M.N., Pfeifer, J.D. and Caparon, M. (2002) Streptococcus-zebrafish model of bacterial pathogenesis. *Infection and Immunology* 70:3904-3914.

Omura, Y., Ueno, S. and Ueck, M. (1986) Cytochemical demonstration of acid phosphatase activity in the pineal organ of the rainbow trout, *Salmo gairdneri*. *Cell and Tissue Research* 245:171-176.
Rao, P.D.P. (1967) Studies on the structural variations in the brain of teleosts and their significance. *Acta Anatomica* 68:379-399.
Roberts, R.J. (1978) The pathophysiology and systemic pathology of teleosts. ***In Fish Pathology, ed.*** Roberts, R.J., Bailliere Tindall, London.
Rodger H. D., Turnbull, T., Scullion, F.T.D., Sparrow, D. and Richards, R.H. (1995) Nervous mortality syndrome in farmed Atlantic salmon. *Veterinary Record* 137:616-617.
Rupp B., Wulliman, M.F. and Reichert, H. (1996) The zebrafish brain: a neuroanatomical comparison with the goldfish. *Anatomical Embryology* 194:187-203.
Sahoo, P.K., Mukherjee, S.C., Nayak, S.K. and Dey, S. (2001) Acute and subchronic toxicity of aflatoxin B1 to rohu, *Labeo rohita* (Hamilton). *Indian Journal of Experimental Biology* 39:453-458.
Schwassman, H. O. and Kruger, L. (1968) Anatomy of visual centers in teleosts. pp 1-16 ***In***: *The Central Nervous System and Fish Behavior, **ed.*** Ingle, D. University of Chicago Press, Chicago.
Scullion F.T., Scullion, M.G., Sparrow, D., Rodger, H.D. and Sheahan, B.J. (1996) Encephalitis and mass mortality of farmed salmon smolts in an isolated sea bay in Ireland. *Veterinary Record* 138:161-162.
Shepherd G. M. (1983) A comparative overview of the vertebrates. pp. 29-45 ***In***: *Neurobiology.* Oxford University Press, Oxford.
Shirikashi, S. and Goater, C.P. (2005) Chronology of parasite-induced alteration of fish behaviour: effects of parasite maturation and host experience. *Parasitology* 130:177-183.
Smith, C.E. (1984) Hyperplastic lesions of the primitive meninx of fathead minnows, *Pimephales promelas*, induced by ammonia: species potential for carcinogen testing. *National Cancer Institute Monograph* 65:119-125.
Smith, J.R. (1984) Fish neurotoxicology. ***In*** *Aquatic Toxicology,* Volume 2. ***ed.*** Weber, L.J., Raven Press, New York.
Speare , D.J., Ostland, V.E. and Ferguson, H.W. (1993) Pathology associated with meningoencephalitis during bacterial kidney disease of salmonids. *Research in Veterinary Science* 54:25-31.
Speare, D.J. (1995) Differences in patterns of meningoencephalitis due to bacterial kidney disease in farmed Atlantic and chinook salmon. *Research in Veterinary Science* 62:79-80.
Stephens, E.B., Newman, M.W., Zachary, A.L. and Hetrick, F.M. (1980) A viral aetiology for the annual spring epizootics of Atlantic menhaden *Brevoortia tyrannus* (Latrobe) in Chesapeake Bay. *Journal of Fish Diseases* 3:387-398.
Soengas, J.L. and Aldegunde, M. (2002) Energy metabolism of the fish brain. *Comparative Biochemistry and Physiology* B 131:271-296.
Summers B.A., Cummings, J.F. and de Lahunta, A. (1995) Principles of neuropathology, pp.1-67 ***In***: *Veterinary Neuropathology.* Mosby-Year Book, Inc., St. Louis, Missouri.
Tanaka S., Takagi, M. and Miyazaki, T. (2004) Histopathological studies on viral nervous necrosis of sevenband grouper, *Epinephelus septemfasciatus* Thunberg, at the grow-out stage. *Journal of Fish Diseases* 27:385-399.
Tsuneki, K. (1986) A survey of about seventeen circumventricular organs in brains of various vertebrates with special reference to lower groups. *Journal fur Hirnforschung* 27:441-470.
Torikata, C., Mukai, M. and Kageyama, K. (1989) Spontaneous olfactory neuroepithelioma in a domestic medaka (*Oryzias latipes*). *Cancer Research* 49: 2994-2998.
Van Ginneken V., Nieveen, R., Van Eersel, M.R., Van den Thillart, G. and Addink, A. (1996) Neurotransmitter levels and energy status in brain of fish species with and without the survival strategy of metabolic depression. *Comparative Biochemistry and Physiology* B 114:189-196.
Velasco A., Caminos, E., Vecino, E., Lara, J.M. and Aijón, J. (1995) Microglia in normal and regenerating visual pathways of the tench (*Tinca tinca* L., 1758; Teleost): A study with tomato lectin. *Brain Research* 705:315–324.
Ventura, M.T. and Paperna, I. (1985) Histopathology of *Ichthyophthirius multifiliis* infections in fishes. *Journal of Fish Biology* 27:185-203.
Xie, Y., Kim, K.J and Kim, K.S. (2004) Current concepts on *Escherichia coli* K1 translocation of the blood-brain barrier. *FEMS Immunology and Medical Microbiology* 42:272-279.
Vigh, B., Szel, A., Debreceni, K., Fejer, Z., Manzano e Silva, M.J. and Teichmann, I. (1998) Comparative histology of pineal calcification. *Histology and Histopathology* 13:851-870.
Voogd, J., Nieuwenhuys, R., van Dongen, R. and ten Donkelaar, H. J. (1998) Mammals. pp 1637-2097 ***In***: *The Central Nervous System of Vertebrates, **eds.*** Neiuwenhuys, R., ten Donkelaar, H.J. and Nicholson, C. Springer, Berlin.
Wang, J., Murray, M. and Grafstein., B. (1995) Cranial meninges of goldfish: age-related changes in morphology of meningeal cells and accumulation of surfactant-like multilamellar bodies. *Cell and Tissue Research* 281:349-358.
Yasutake, W.T. and Wales, J.H. (1983) Nervous system. pp.104-117 ***In***: *Microscopic anatomy of salmonids: an atlas.* United States Department of the Interior Fish and Wildlife Service Resource Publication 150, Washington, D.C.
Zlotkin, A., Chilmonczyk, S., Eyngor, M., Hurvitz, A., Ghittina, C. and Eldar, A. (2003) Trojan horse effect: phagocyte-mediated *Streptococcus iniae* infection of fish. *Infection and Immunity* 71:2318-2325.
Zupanc, G.K.H. (1999) Neurogenesis, cell death and regeneration in the adult gymnotiform brain. *Journal of Experimental Biology* 202:1435-1436.
Zupanc G.K.H. (2001) Adult neurogenesis and neuronal regeneration in the central nervous system of teleost fish. *Brain Behavior and Evolution* 58:250-275.
Zupanc, G.K.H. and Clint, S.C. (2001) Radial glia-mediated up-regulation of somatostatin in the regenerating adult fish brain. *Neuroscience Letters* 309:149-152.
Zupanc G. K. H., Clint, S.C., Takimoto, N., Hughes, A.T.L., Wellbrock, U.M. and Meissner, D. (2003) Spatio-temporal distribution of microglia/macrophages during regeneration in the cerebellum of adult teleost fish, *Apteronotus leptorhynchus*: a quantitative analysis. *Brain Behavior and Evolution* 62:31-42.





The Eye

CHAPTER 10

by Erling Olaf Koppang and Ellen Bjerkås

Normal structure and function

The purpose of the eye (*bulbus oculi*) is to project optical images of the surroundings onto the retina where they are recorded and transmitted to the brain for recognition and interpretation. To fulfil this aim, the construction of the eye must establish an optical axis, which is composed of the cornea, anterior chamber, lens, and vitreous body (*Fig 10.1*). The axis must be transparent and it must remain so, as any reduction will impair its function. Minor distortions of the optical axis cause major disruption of the projected optical image. To an animal, this may be life-threatening, and nature has invested heavily in constructing the eye in a manner that maintains and secures its precise function. Further, the optical axis must be able to regulate the light scattering, or focus the light that is projected onto the retina. Some deep-water species possess asymmetric, tubular eyes, while others possess no eyes at all, but these are the exceptions. In general, the globular construction of the eye, as found in most fish species, is ideally suited to minimising changes in shape due to alterations in water pressure. The construction and function of the organ are aimed solely at one single task: to maintain a functional optical axis, and this must be achieved despite the demands of life in an aqueous environment under sometimes extreme conditions. While these conditions are not experienced by mammals, the camera-type architecture of the eye in the two groups is remarkably similar, making it one of the most sophisticated and specialized organs throughout the animal kingdom.

The globe of fish is attached to the orbit by three pairs of striated muscles. These are the dorsal, lateral, ventral and medial rectus muscles and the dorsal and ventral oblique muscles. These muscles allow the eye to be turned in any direction. The ability for voluntary eye movement varies between species, and therefore some species track objects mainly by changing their body position. Three major arteries enter the eye. These are the ophthalmic artery (*arteria ophthalmica*), which receives its blood from

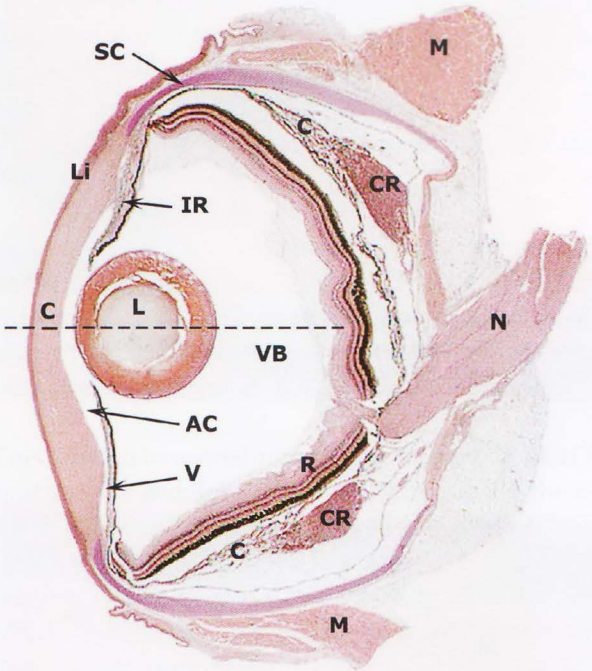

Fig 10.1. **Internal structures of the Atlantic salmon eye, lateral view.** A dotted line indicates the optical axis. Following structures are indicated by letters: **SC**: scleral cartilage. **Li**: limbus. **C**: cornea. **CR**: choroid rete. **C**: choroid. **IR**: iris. **R**: retina. **L**: lens. **AC**: anterior chamber. **V**: ventral ciliary cleft. **M**: external muscles. **N**: optic nerve. **VB**: vitreous body.

the pseudobranch and enters the eye caudodorsally to the optic nerve (*nervus opticus*) (*Fig 10.2*). It branches out in the capillaries of the choroid rete (see under the uveal tract). The second vessel is the retinal artery (*a. retinalis*) which is a branch of the internal carotid artery (*a. carotis interna*). The retinal artery enters the eye ventral to the optic nerve, but it also branches out to supply this nerve, the eye muscles and the periocular tissues. After entering the eye, this artery, like the ophthalmic artery, forms a structure similar to the choroid rete, but much smaller. A branch enters the falciform process (*processus falciforme*) and nourishes the retractor lentis muscle. Blood from both of the above mentioned arteries feeds the choroid. Finally, the iris is supplied by the iris artery which derives from the external carotid artery (*a. carotis externa*).

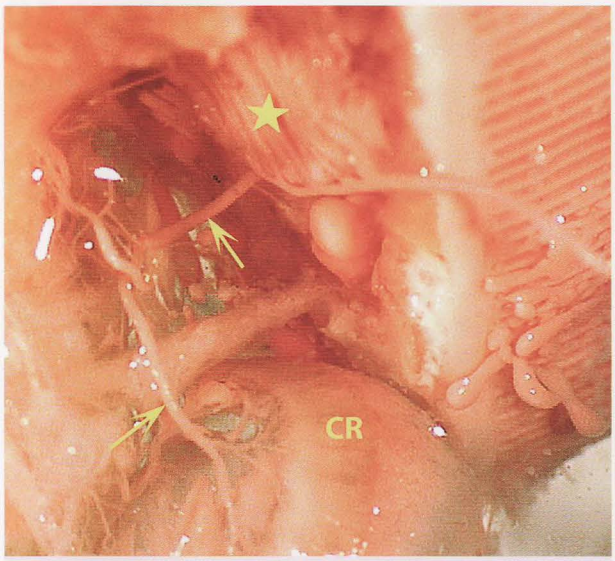

Fig 10.2. Arteria ophthalmica. Corrosion casting. The vessel (arrows) originates from the pseudobranch (asterisk) and terminates in branches forming the choroid rete (**CR**).

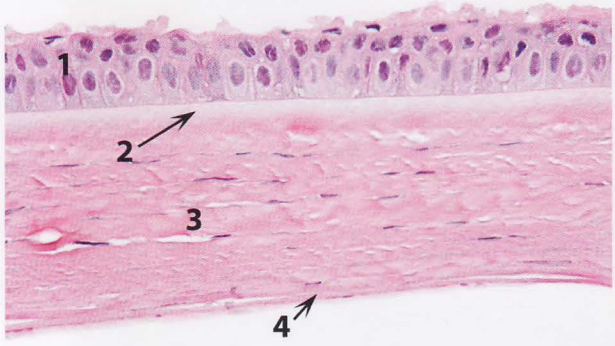

Fig 10.3. Cornea of Atlantic salmon. The epithelium is of the multi-layered squamous, non-keratinised type (**1**) resting on the Bowman's membrane (**2**). The stroma (**3**) is the main layer of the cornea and consists of tightly bound collagen fibres (corneal lamellae) embedded in an extracellular matrix, and finally, the Descement's membrane and the corneal endothelial cells (**4**) form the inner surface of the cornea.

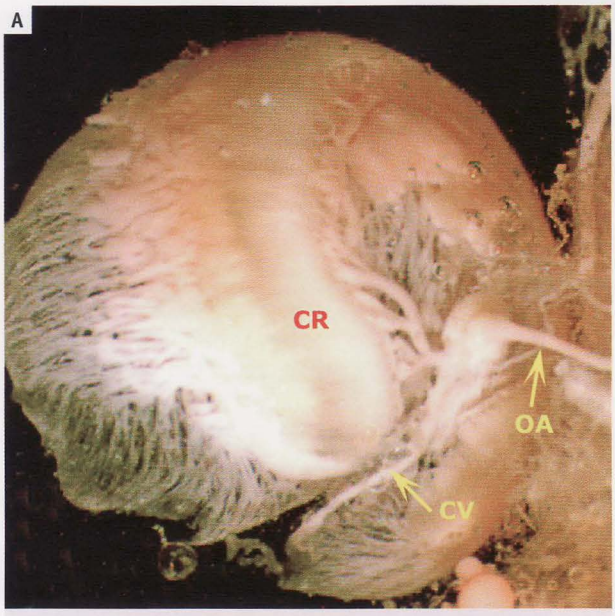

Fig 10.4A&B. Corrosion casting of blood vessels of the eye of an Atlantic salmon. The body of the choroid rete (**CR**) forms a broad incomplete ring that is open at the choroid fissure, and numerous small choroid vessels are branching off. The ventral choroid vein (**CV**) runs along the choroid fissure. The ophthalmic artery (**OA**) is supplying the choroid rete, shown in **B**, along with retina to the right.

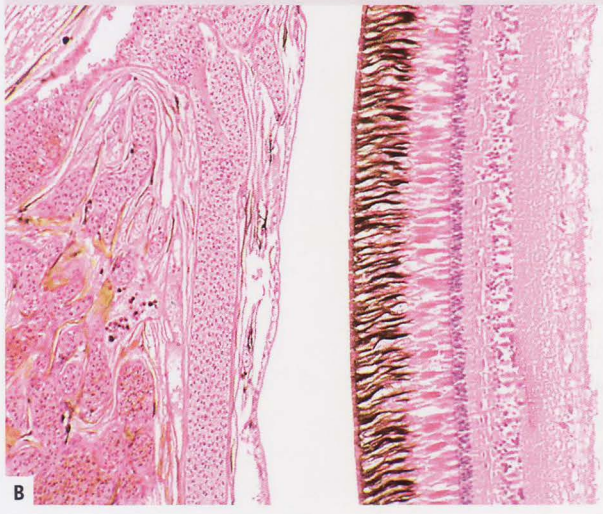

Generally, the camera-type eye of vertebrates is composed of three distinct concentric tissue layers surrounding the core elements of the internal structures of the optical axis, *viz.* the anterior chamber, the lens and the vitreous body. It should be noted that the eyes of different fish species vary considerably in size related to the body mass. Some deep-water species have disproportionately large eyes to optimise the limited light available, while in others, like cave fish, development of the optic primordia is arrested and subsequently degenerates.

The outer structures of the eye

Layer 1: *The external layer or fibrous tunic* (Tunica fibrosa). The globe is surrounded by a tough and fibre-rich layer termed the sclera (*Fig 10.1*). The sclera continues into the limbus region, that surrounds the cornea. Together, these three structures form Layer 1 or the outermost layer of the eyeball, the *tunica fibrosa*. Even though they are continuously arranged, the sclera, limbal region and cornea must be regarded separately, as their anatomy and functions are highly diverse.

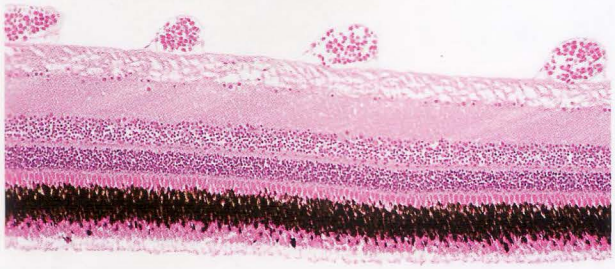

Fig 10.5. While the retina of most species of teleosts is avascular, some do have pre-retinal vessels, as shown here.

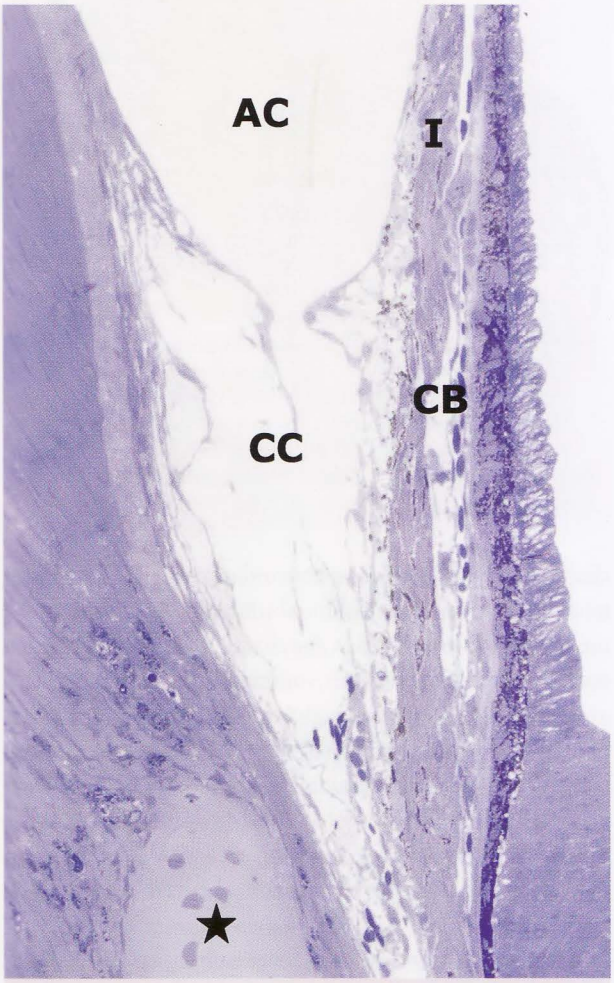

Fig 10.6. The ventral iridocorneal angle or ciliary cleft forms the filtration slit. The lumen of the anterior chamber (AC) continues into the ciliary cleft (CC) through valve-like structures. Note how the ciliary cleft terminates ventrally adjacent to small blood vessels in which the erythrocytes appear as dense-blue cells. The scleral cartilage is marked (asterisk), and the iris (I) and ciliary body (CB) are indicated. *Semithin section stained with toluidine blue.*

The sclera contains collagen bundles and scattered fibroblasts. It is divided into three layers, the outermost being the episclera that surrounds the sclera and finally the *lamina fusca*. In fish, the sclera contains a cartilaginous structure, the scleral cartilage, that is embedded in the sclera caudal to the limbus ***(Fig 10.1)***. Some species, like the tetras, the tuna and the sturgeon, harbour plates of bone within or outside the sclera, which is a phenomenon also observed in many birds. The purposes of these structures are probably to secure the shape of the eye in different situations in the face of a relatively low intraocular pressure.

The limbus comprises the junction between the sclera and the cornea. In addition to being well vascularised, the whitish-appearing collagen fibres of the sclera are replaced by fibres that have a different structural organization, and which continue into the transparent cornea.

Compared to terrestrial animals, the cornea ***(Fig 10.3)*** is relatively flat and does not serve any function in the refraction of light. In mammals, it consists of five distinct layers, while in fish the layers are not as well defined. The anatomy is complicated by the seemingly missing eyelids of fish. Nevertheless, the outer dermal structures of the skin do cover the eye. In some species, like the cod, this transparent dermal cover is not attached to the underlying cornea, and a precorneal slit is formed. In other species like salmonids, the epithelium of the cornea is fused with its dermal cover, making the structures both macro- and microscopically inseparable. The cornea consists of non-pigmented, stratified squamous non-keratinizing epithelial cells attached to a thick basement membrane. The subepithelial stroma is considered to be analogous to Bowman's membrane in mammals, forming the surface of the corneal stroma. The stroma rests on a distinct Descemet's membrane. The innermost layer of the cornea is the endothelium, which serves to maintain corneal transparency through its dehydrating pump function. Leukocyte numbers in the cornea are limited, and immunohistochemistry has revealed that such cells disappear towards the centre of the structure. There are no blood vessels in the cornea, but in mammals, it is innervated by abundant nerves, and this is probably also true for fish.

Layer 2: *The uveal tract or the vascular layer.* The uveal tract forms the main layer for blood supply and immune reactions in the eye. It can be divided into 3 parts: choroid,



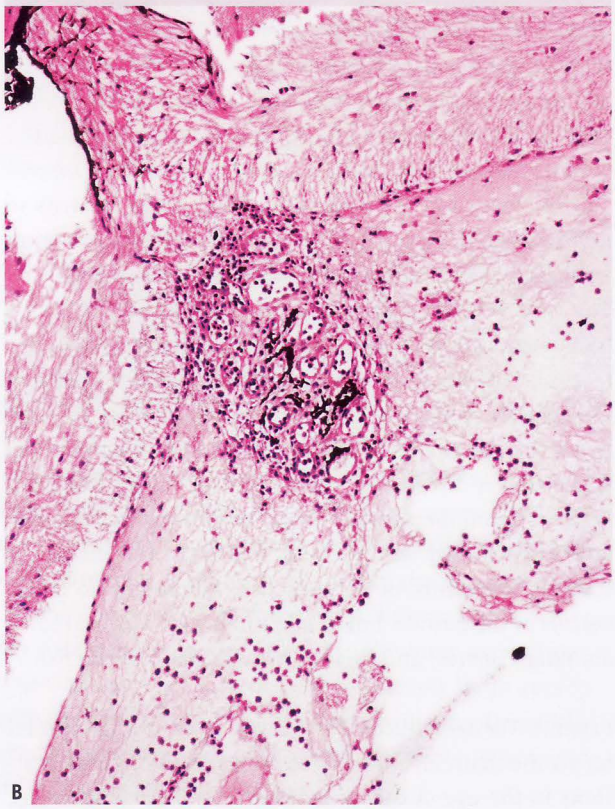

Fig 10.7A&B. The falciform process (**A**) is thought to aid in oxygenation of the retina. It can also be a source of inflammatory cells as shown in **B**.

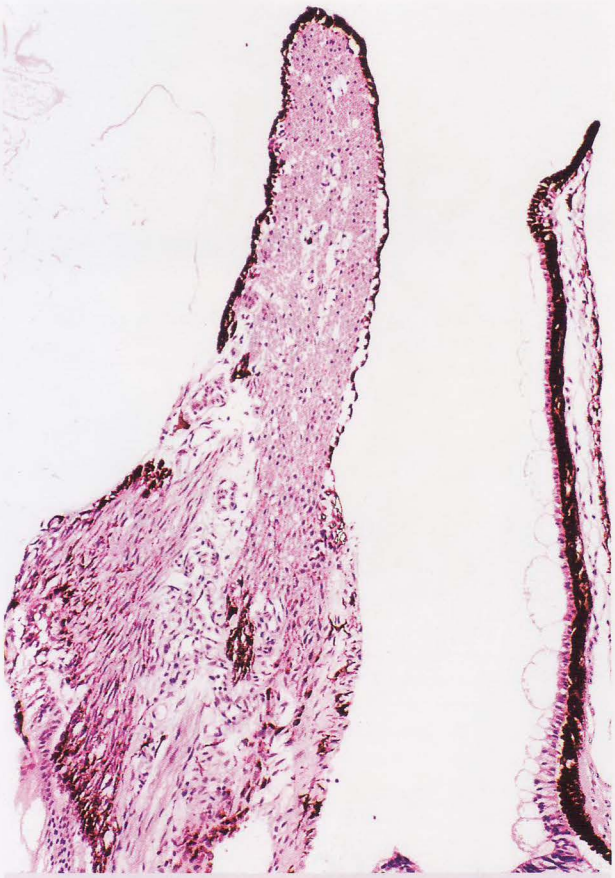

Fig 10.8. Retractor lentis muscle in Atlantic salmon with iris to the right.

choroid rete and iris. The choroid consists of loose connective tissue containing abundant leukocytes and melanocytes. In many fish species the outer choroid also contains guanine crystals, making it silvery (*argentea*) and when this continues onto the anterior iris stroma, it contributes to the "eyeshine" seen in many species, especially those (such as *Scorpanidae, Clinidae* and *Batrachoidea*) in which there is no tapetum and little choroidal melanin. The argentea may serve some camouflage function by distracting predators away from the dark pupil.

The choroid is divided into three sub-layers. The *suprachoroidea* is attached to the sclera and contains melanocytes. Beneath is found the *lamina vasculosa* with larger vessels, while in intimate contact with the retina is the lamina *choriocapillaris* containing multiple small vessels. In fish, a special vascular structure is located within the choroid. This structure is termed the choroid rete, choroid body or choroid gland (*corpus choroidalis*) **(*Figs 10.1 & 10.4*)** and is shaped like a horse-shoe, with the curved part dorsally and the open part ventrally. It consists of a



Fig 10.9A. Normal retina from Atlantic salmon. The various layers are indicated with numbers starting with the (**1**) pigment epithelium, (**2**) the rods and cones, (**3**) the outer nuclear layer consisting of the nuclei of the cells of the rods and cones, (**4**) the outer plexiform layer, (**5**) the inner nuclear layer, (**6**) the inner plexiform layer, (**7**) the ganglion cell layer and finally (**8**) the layer of ganglion cell axons. The vitreous body (**9**) is located adjacent to the retina.

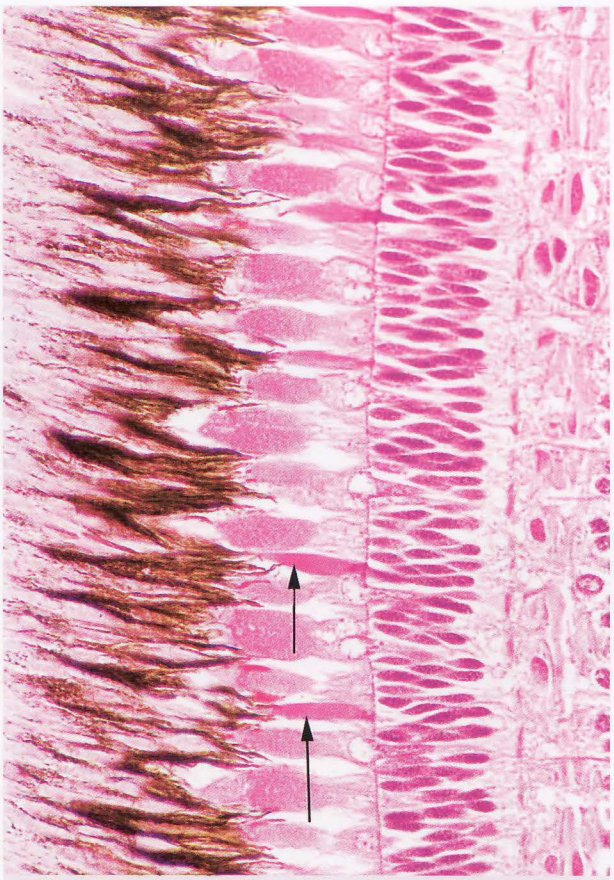

Fig 10.9B. High power view of normal trout retina to show rods (arrows) and several binucleate cones.

capillary counter-current system formed by the ophthalmic artery and vein. The ophthalmic artery receives its blood from the pseudobranch, which is developed from the first of the five gill arches. The functions of the pseudobranch and the choroid rete appear to be intimately linked to enzymatically acidifying the arterial blood, via the action of carbonic anhydrase, thereby elevating the arterial oxygen pressure. Even though the choroid rete is sometimes referred to as the choroid gland, it probably has no gland function. It has also been suggested that it possesses immune capabilities, as it filters both afferent and efferent blood and contains cells that seem to be involved in antigen trapping. From the choroid rete, the arterial blood enters arterial vessels branching throughout the choroid. Further, small branches enter the innermost layer of the choroid, the *lamina choriocapillaris* where the blood comes into intimate contact with the retina. In contrast to mammals, the retina of most fish is avascular, and the elevated oxygen pressure of arterial blood in the *lamina choriocapillaris* is needed in order to obtain functional oxygen concentrations in the retina. In species where the retina is vascularised ***(Fig 10.5)***, including the catfish and the eel, both the pseudobranch and the choroid rete are missing.

Compared to mammals, the ciliary body (*corpus ciliare*) of fish is rudimentary, but the limited structure still seems to serve a function by producing aqueous humour. The production of aqueous humour is located to the epithelium of the rudimentary ciliary body and basal part of the iris, which utilises a bicarbonate pump mechanism. This double-cell layer originates from the formation of the retina in embryogenesis. The inner layer, adjacent to the posterior chamber, consists of large cells with morphological features typical for cells involved in secretion. The produced aqueous humour flows through the pupil, fills the anterior chamber and is collected in the ventral iridocorneal angle (see description of the anterior chamber) ***(Figs 10.1 & 10.6)***.

The iris surrounds the pupil and the rostral part of the lens. It is nourished by a branch of the external carotid ar-



Fig 10.10. Anterior synechia, namely attachment of the iris to the lens capsule. If extensive, there can be interuption to fluid drainage, possible outward bowing of iris ("iris bombé"), and increased intra ocular pressure.

tery. In mammals, the iris comprises dilator and sphincter muscles to regulate the size of the pupil, and thus the light exposure of the retina is controlled. An analogous, but rudimentary system exists in fish, although to a degree in accordance with their habitat: for instance, it is not developed in deep-water fish where light levels are very low.

The uvea of teleosts contains an additional structure that is missing in higher vertebrates and termed the falciform process (*processus falciforme*) **(*Fig 10.7*)**. This structure is formed like a ridge protruding through the retina at the choroid fissure and is embedded in the vitreous body. It is located ventrally in the eye and stretches from the anterior termination of the choroid rete to the back of the lens. The falciform process is highly vascularised and most probably serves to nourish the retina and the vitreous body. The *retractor lentis* muscle **(*Fig 10.8*)**, receives its blood from a branch of the retinal artery. A vein and a motor nerve to the muscle pass through the falciform process. The vein terminates in several small branches ventral to the iridocorneal angle and is probably involved in drainage of the aqueous humour from the anterior chamber.

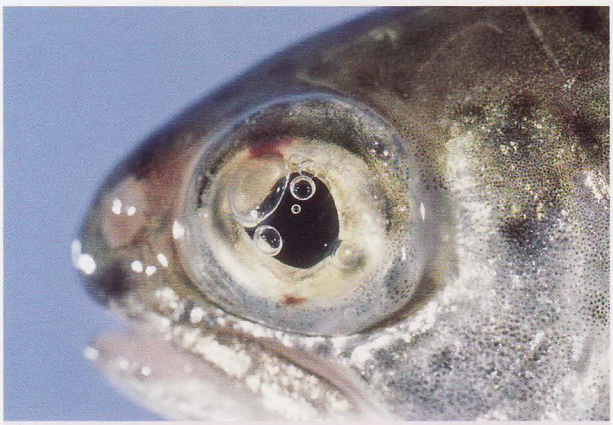

Gas bubble disease. *Fig 10.11A.* Small gas bubbles in the anterior chamber of rainbow trout.

In mammals, populations of macrophages, professional antigen-presenting cells (dendritic cells) and lymphocytes have been described within the uveal tract. In fish the studies are scarce, but immunoreactivity against a MHC class II marker suggests that the immunogenic properties of the Atlantic salmon uveal tract are similar to its mammalian counterpart.

Layer 3. *The retina.* The innermost and optically functional layer of the eye consists of the retina **(*Figs 10.5 & 10.9*)** the purpose of which is to record images that are projected through the optical axis. Here, the images are transcribed into nerve signals that are passed through the optic nerve to the brain to be recognised and interpreted. The outermost layer, which is in intimate contact with the *lamina choriocapillaris* of the choroid, consists of the retinal pigment epithelium (RPE) in which the photoreceptors, the rods and cones, embed their outer segments. Rods are most sensitive to light. Different populations of cones on the other hand are sensitive to the red, green or blue region of the visible spectrum. The retina of salmonids also possesses specialised cones that are maximally sensitive to ultraviolet light, and this may also be true for other species. Some species have binucleate or even trinucleate cones, features unique to teleosts. The ratio of these photo-receptive cells varies considerably between fish species, mainly in accordance with their habitat. For instance, most deep-sea fishes have pure-rod retinae, and there are examples of multilayered arrangements of these cells. The next layer of the retina is the external nuclear layer which contains the nuclei of the rods and cones. Then follows the outer plexiform layer containing synapses between the photoreceptor cells and the bipolar neurons of the inner nuclear layer, con-



Fig 10.11B&C. Massive retro-retinal gas bubbles result in unilateral loss of vision in this aquarium species, largely due to distortion of retina, as shown in **C**.

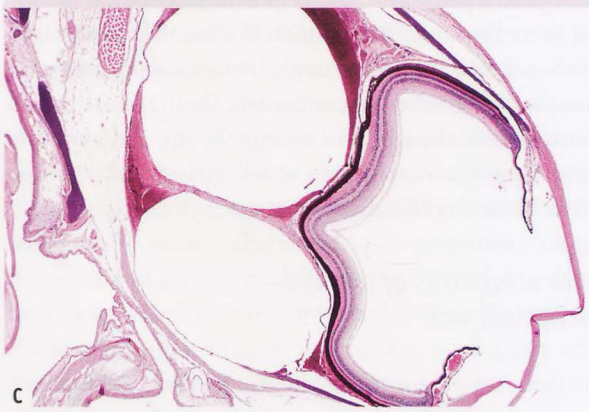

necting them to the ganglion cells in synapses found in the inner plexiform layer. The nuclei of the ganglions are located in the ganglion cell layer, which send their axons through optic nerve fibres that fuse in the optic nerve and leave the eye.



Fig 10.11D. Retrobulbar gas has pushed the eye forwards and out of the orbit, resulting in exophthalmia in this cod.

A special structure, the *tapetum lucidum*, is located beneath the photoreceptors. It reflects light, thus making "eyeshine" in fish a common phenomenon. It has been speculated that its purpose is to enhance the light sensititvity of the eye. The position and the quality of the *tapetum lucidum* vary considerably between different fish species. Some species harbour a tapetum in the choroid, whereas in others, it is associated with the retinal pigment epithelium, and in teleosts, the latter location is the more common. The *tapetum lucidum* may reflect light over a broad spectrum depending on varying pigmentation and physical composition, usually adapted to the habitat of a given species. For instance, a guanine-type tapetum is encountered in many species. Violet, green, yellow/brown, orange or red eye reflection may thus be seen dependant on tapetum location and composition.

Species that inhabit waters with high light levels, but require to see also in dim light, have developed mechanisms to protect the photoreceptors; *occlusible tapeta*, and photoreceptor motility. In the former of these mechansisms, melanin granules are mixed with the reflecting granules within the cytoplasm of the retinal pigmented epithelium (RPE), and can mask or unmask them, depending on light levels. In the second mechanism, photoreceptors (usually rods, but cones too) slide into deep recesses within the RPE, thereby shielding themselves in bright light. Unlike the rapid mammalian response of iris contraction, these responses in fish take quite some time, probably a reflection of normal dawn-dusk timescales.

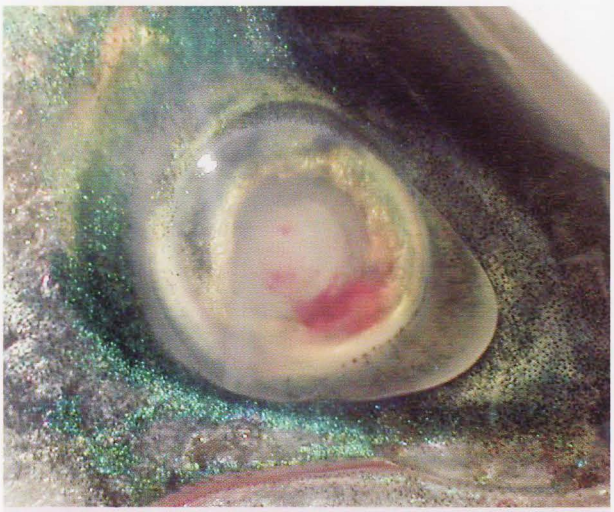

Fig 10.12A. Handling injury in salmon. Rough handling may cause intraocular haemorrhage. In addition, the lens is cataractous.



Fig 10.12B. Pacific salmon with severe sub-acute bacterial panophthalmitis showing haemorrhage into the anterior chamber (hyphaema), and keratitis with perforation (*picture courtesy of Dr. S. Backman*).

Depending on species there may be significant differences in the distribution of photoreceptors in the retina. The *fovea* represents an area with a high concentration of photoreceptors, most often cones, but some deep-sea species may also have pure rod-foveas. The *fovea* may be seen as a pronounced pit-shaped depression in the retina, most often in the temporal part. In addition, other areas of high photoreceptor density (multiple fovea) may be found in different areas within the retina. In some species, including salmon and trout parr, the fovea is located in the ventro-temporal region, allowing high visual acuity when approaching a prey from below.

Highly specialised predator fish such as swordfishes, tunas and sharks have a special vascular arrangement to heat the eyes. In swordfish, this arrangement is located in an extraocular muscle, and heated blood warms the retina so that temporal resolution is improved.



Keratitis. *Fig 10.13A.* Keratitis in Arctic charr. Note the loss of tissue in the middle and the corneal oedema. Such lesions often progress to corneal perforation and collapse of the eye.

In embryogenesis, the retina is developed from the brain, and these structures share several features. Like the brain, the retina is an immune privileged structure. Immune reactions and especially inflammatory changes within the retina could lead to irreversible damage, although fish possess a unique ability to regenerate damaged nervous tissue, including the retina. Despite its immune privileged status, the retina of the Atlantic salmon has been shown to harbour MHC class II positive cells which indicate the ability to present exogenous antigen. Care should be taken to extrapolate these results to other fish species, however. In mammals, the abundance of leukocyte populations in the retina varies to a surprising extent between different species.

Inner structures of the eye – the optical axis

The three layers described above, the sclera/limbus/cornea, uvea and retina, establish the limits of the globe. To address the functional anatomy of the eye, we will now follow the light pathway as it passes the various structures that form the optical axis ***(Fig 10.1)***. It is vitally important that this axis remains transparent. Thus, it is devoid of blood vessels and immune-related cells.



Fig 10.13B. Keratitis in farmed cod due to *Pseudomonas anguilliseptica*, showing normal (top) and affected.

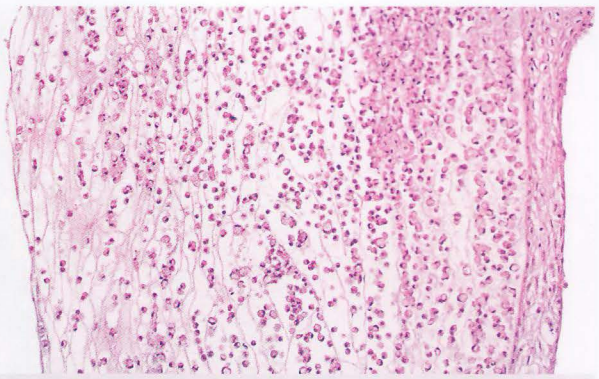

Fig 10.13C. Section of cornea from **B**, showing within the cornea, oedema and large numbers of inflammatory cells, leading to fibre separation and opacity.

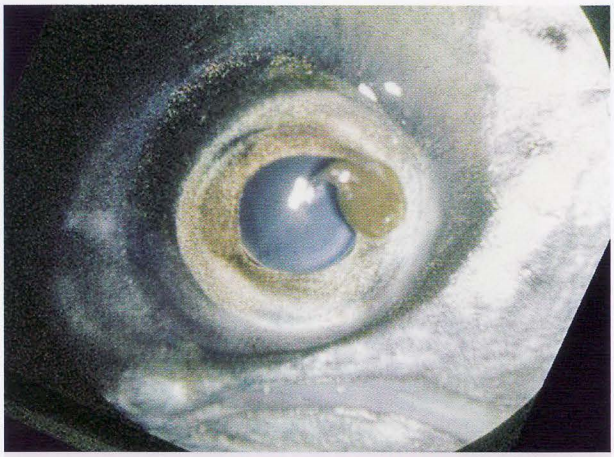

Fig 10.14. Sea lice (*Lepeophtheirus salmonis*) may occasionally attach to the cornea causing epithelial damage.

Light enters the eye through the cornea, the external layer of the eye, and passes through the anterior chamber. This chamber is limited anteriorly by the corneal endothelium, posteriorly by the iris and the lens protruding through the pupil and peripherally by the iridocorneal angle. The chamber is filled with the aqueous humour, which is produced by specialised cells located on the posterior surface of the iris and the rudimentary ciliary body in the posterior chamber. The fluid flows from the posterior chamber through the pupil and into the anterior chamber. In the Atlantic salmon and brown trout, the dorsal and lateral aspects of the anterior chamber have a continuous annular ligament and no ciliary cleft, whereas this cleft is found only in a limited area of the ventral region. The aqueous humour is further drained into aqueous-collecting veins, which fuse to form the ventral choroid vein.

As in mammals, a limited number of leukocytes, presumably macrophages, patrol the anterior chamber. They are probably released through the aqueous producing endothelial cells and follow the fluid to the filtration angle from where they depart into the circulatory system.

The pupil is formed by the edges of the iris and it functions to regulate the quantity of light gaining access to the photoreceptors, although this capability is minimal in most species. The light then passes on through the posterior chamber which in reality is a very limited space anterior to, and at the equatorial area of the lens (limited by the iris, ciliary body, the lens and the vitreous body). The teleost lens is spherical and protrudes through the pupil opening, the anterior part of the lens almost touching the back of the cornea. In this way the lens creates a wide-angle vision field. The spherical shape compensates for the almost complete lack of light refraction by the cornea due to the water environment. Dorsally the lens is attached to the rudimentary ciliary body through the strong suspensory ligament. Unlike the mammalian lens, the piscine lens is minimally elastic, and because of its rigidity, accommodation cannot occur by change in lens shape. The position of the lens is adjusted by the



Fig 10.15A&B. The choroid is a frequent site for embolic trapping of pathogens. **A** shows *Ichthyophonus*, and **B**, mycobacterial granulomas (arrow).

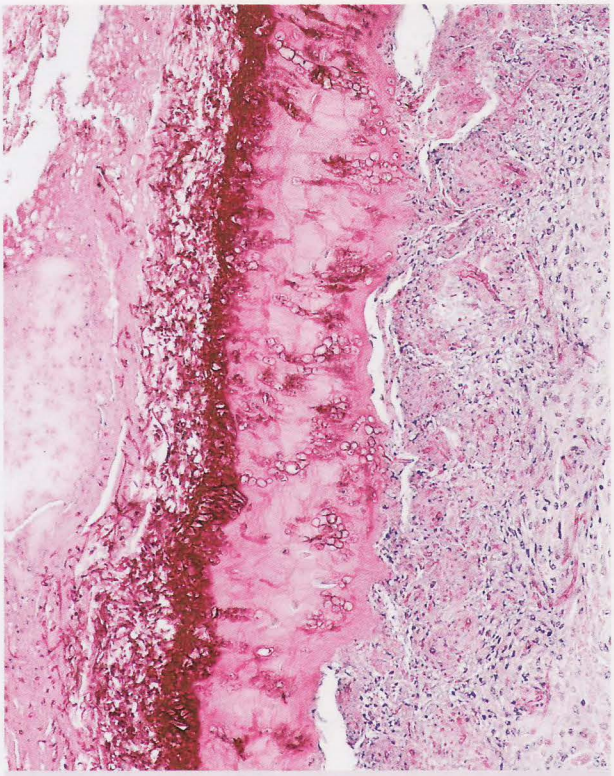

Fig 10.16. Mycotic panophthalmitis in cod, showing large numbers of hyphae moving through scleral cartilage. *Periodic acid-Schiff stain.*

retractor lentis muscle extending from the ventral floor of the globe to the ventral part of the lens. Thus, accommodation occurs by the lens being moved posteriorly or anteriorly through contraction or relaxation of this muscle respectively. The central part of the lens, the nucleus, is surrounded by the lens cortex. The deep cortex is termed the perinucleus and can usually be easily distinguished in salmon. The lens epithelium consists of a single layer of cells and extends over the whole of the lens, apart from a small area at the posterior pole. The whole lens is surrounded by the epithelium basement membrane, which forms the lens capsule. The capsule is thinnest at the posterior pole. Salmonids have a vertical suture line at the anterior pole and a horizontal line at the posterior pole. As in other species, the lens is nourished by the aqueous humour. For the lens to maintain its regular protein structure, it is dependent on sufficient supply of certain amino acids. The presence of the amino acids methionine and cysteine is especially important to avoid deficiency-caused aggregation of lens proteins and scattering of light (cataract). The metabolic activity in the piscine lens is considered to be high. This may also render it susceptible to metabolic change caused either by malnutrition or by a deficiency in absorption of essential nutrients.

From the lens, the light passes through the vitreous body (*corpus vitreum*) before it reaches the retina. By volume, the vitreous body is the dominating structure of the eye. It consists of a transparent gel containing about 99% water plus a few cells that synthesize negligible amounts of collagen and hyaluronic acid molecules. The structure is static and it functions to maintain the structure of the eye



Cataract. *Fig 10.17A.* This experimentally-produced classical zinc deficiency cataract is rarely seen these days, but other nutritionally-induced lesions are.

and to pass light from the lens to the retina. Leukocyte populations do not occur in the normal vitreous body.

Response of eyes to injury

Due to the eye's vital importance combined with its delicate and highly sophisticated and specialized structure and function, the animal invests great efforts in maintaining a functional eye, and this is reflected in its response to injury. The eye is an immune privileged organ. Specifically, the cornea, anterior chamber, lens, vitreous body and retina are immune privileged tissues and sites, which in reality embrace the structures of the optical axis. The mechanisms of immune privilege have in particular been addressed in the cornea and anterior chamber of mammals. These studies have identified powerful local immune suppressive mechanisms. The aqueous humour of the anterior chamber contains a number of inflammatory down-regulating factors, including transforming growth factor-β, α-melanocyte-stimulating hormone, vasoactive intestinal peptide and calcitonin gene-related peptide. These products are constitutively produced by the cells of the ocular microenvironment. Interestingly, as their names suggest, several of these factors were primarily identified as having quite other functions at other sites in the organism. Immune privilege may be defined as the prolonged, often indefinite survival of tissue grafts at special sites in the body. The reason for the immune privileged status within the optical axis is naturally to avoid disturbances caused by inflammatory reactions that could impair vision. However, this does not imply a total suppression of all aspects of immune responsiveness to ocular antigens. The aim is to modulate the immune reactions so that protection is present, but with



Fig 10.17B. Epithelial proliferation, is a frequent finding in cataract in fish.

a minimum of undesirable repercussions for the optical axis. In mammals, there are also physical barriers that protect the most delicate structures of the eye, being the blood-retinal and blood-aqueous barriers. These barriers have not been described in fish, but similar constructions probably exist.

The uveal tract contains abundant immune-related cells and may be regarded as the lymphovascular organ of the eye. As a rule it is involved in any form of inflammation within the eye. In mammals, it is common to differentiate between inflammatory reactions in the posterior, anterior and entire uveal tract, but so far, such studies have not been conducted in fish. Inflammatory reactions of the

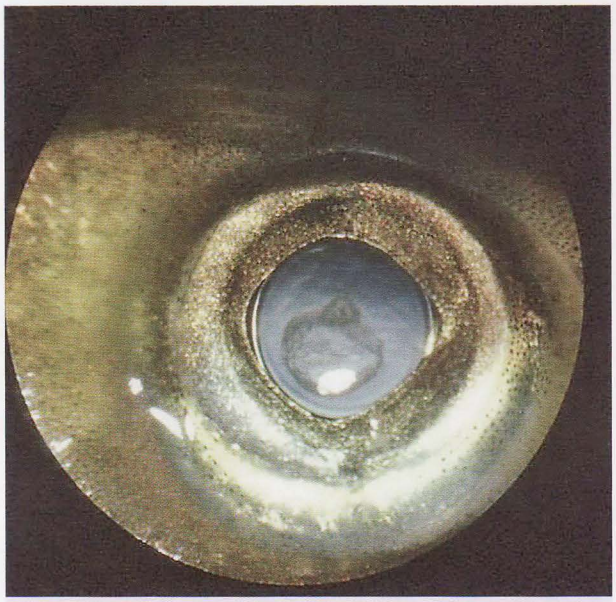

Fig 10.17C. Anterior epithelial proliferation and posterior cortical cataract in Atlantic salmon.

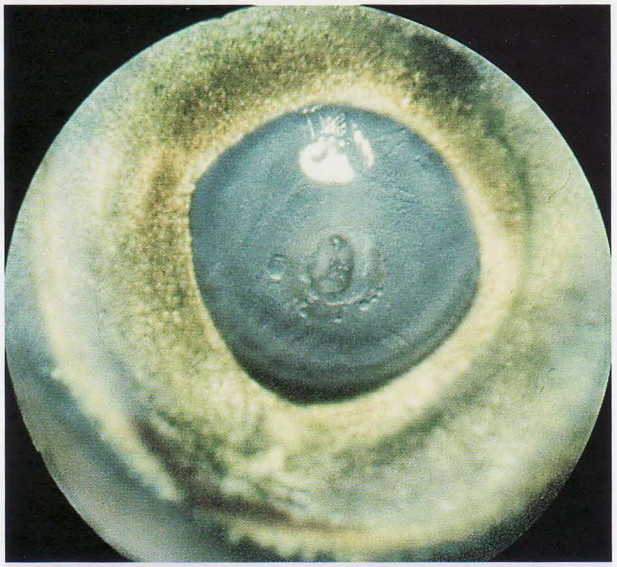

Fig 10.18. Rapidly progressing cataract in Atlantic salmon. The lens is swollen, filling the whole pupil opening, and there are visible vacuoles, representing accumulation of fluid. Such lenses are prone to rupture.

uveal tract are commonly termed "uveitis", *intraocular inflammation* or IOI. When the anterior segment, the iris is involved, this condition may be associated with an increased release of macrophages into the aqueous. Next, this may lead to occlusion of the filtration angle in the anterior chamber. An occlusion will necessarily imply increased intraocular pressure (IOP), the outcome being a condition termed glaucoma. Glaucoma is a generic term used to describe diseases in which the IOP is increased to a level high enough to induce damage to tissues within the eye. In mammals, glaucoma is clinically diagnosed by measuring the intraocular pressure, and multiple disorders may lead to the condition. If the occlusion persists, the blood supply to the eye is impaired. Both as a consequence of abnormal IOP and ischaemia due to impaired microcirculation, the eye structures, primarily the optic nerve head and the retina, may undergo irreversible damage. Glaucoma has been described as an experimental model in zebra fish, but there are no published reports of this condition in other fish species with confirmed elevated intraocular pressure *(Fig 10.10)*.



Lens rupture is not an infrequent finding in rapidly-progressing cataract. *Fig 10.19A.* Partial cataract and iris atrophy due to low-grade lens-induced uveitis in a wolffish. The lens ruptured the previous year with extrusion of the nucleus into the vitreous. This has left a small opacity, while the remaining lens is transparent.

Injury may arise either as a consequence of trauma, infection or tumour development. As in other organs, the eye reacts with inflammation, although the response is greatly modulated by its immune privileged status. If inflammation is confined to the internal tissues of the globe limited by the sclera, it is termed *endophthalmitis*, while if episcleral tissues are also involved, the condition is referred to as *panophthalmitis*.

Injuries caused by trauma. Compared to most mammals, the fish eye is much more exposed to its environment. It lacks the protection of eyelids in terms of the

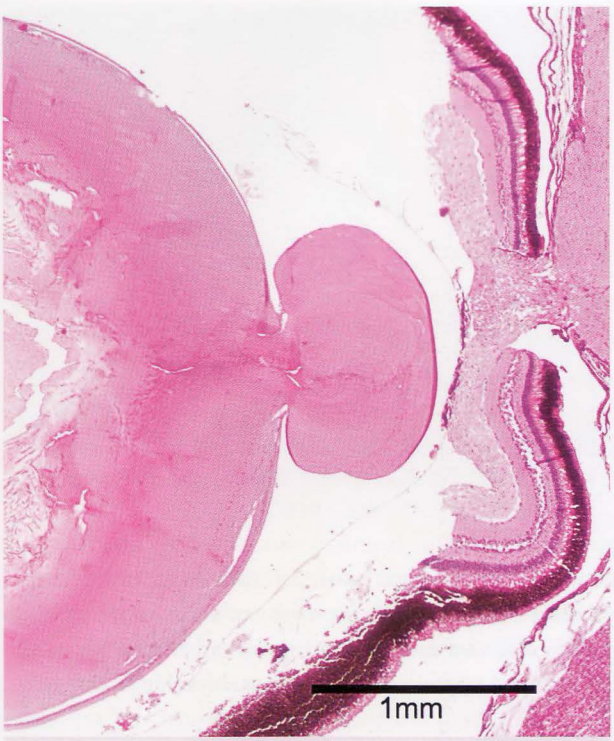

Fig 10.19B. Partial rupture at the posterior pole with extrusion of lens material in a cod with cataract.



Fig 10.20. Gilquinia larval cestode in eye of farmed salmon, located between retina and lens. They wrap themselves around the back of the lens, and although lesions are limited, fish seem remarkably upset!

normal construction of these structures, as well as the tear film, which is highly antimicrobial in mammals. Trauma may arise as a result of all forms of insult, *i.e.* chemical, thermal, toxic or actinic, but most frequently from mechanical injuries. Depending on the character and localization of the trauma, the inflammatory and repair processes will take different pathways. As a general rule, macrophages gather in the traumatized tissue, the clean-up process is initiated, and where original tissue cannot be replaced, it is substituted with fibrous tissue and scarring, consequently leading to loss of function. However, fish have remarkable powers of regeneration, and unlike mammals, these include the ability for retinal regeneration, a process that has attracted much attention in neuroscience research.

Here we will particularly mention two kinds of trauma that may be more frequently observed by fish practitioners. Blunt pressure or blows to the eye frequently induce *intraocular haemorrhage*. Such haemorrhage normally arises from the uvea, and if originating from the iris, blood may be observed in the anterior chamber (known as hyphaema – ***Fig 10.12***). Histological examination may reveal fluid accumulation in all parts of the eye including the retina. Detachment of the retina is a possible consequence. The other condition frequently encountered is *traumatised cornea*. Depending on the nature of the lesion, corneal ulcers are divided into epithelial, stromal, deep stromal and finally perforating ulcers. The two former may heal without the involvement of blood vessels, whereas the deeper type heals by growth of blood vessels branching from the limbus and the formation of granulation tissue. To evaluate the nature of the ulcer, fluorescein-Na may be used for staining of the cornea. As in mammals, superficial corneal ulcers heal by increased mitotic activity and migration of epithelial cells. Stromal ulcers and chronic ulcers heal by blood vessel ingrowth and secondary pigmentation, while infiltration of inflammatory cells and granulation tissue formation are moderate in fish.

Injuries caused by infection. Infectious agents may enter the eye from the environment and are then termed *exogenous* infections. If the infective agent reaches the eye via the blood, the infection is *endogenous*. In fish that are prone to bacteraemia and viraemia, most ocular infections are of endogenous character. The choroid rete, which filters both afferent and efferent blood, is frequently seen to contain colonies of bacteria in infected fish, and severe granulomatous changes have been described in fish with generalised inflammation. Aside from the highly vascularised uveal tract, the avascular tissues of the optical axis form an ideal environment for infectious agents. In mammals, infections at these sites are difficult to treat due to the inaccessibility of drugs. The reluctant inflammatory response of the ocular tissues in the optical axis also facilitates establishment of infectious agents. For



Eyeflukes. *Fig 10.21A. Diplostomum* flukes can be seen in the cortical layer where there is a concurrent cataract development.



Fig 10.21B. Large numbers of flukes were also present in this lens, but there is more pronounced cataract.

instance, in the cornea, traumatic ulcers are frequently followed by infections with various bacteria or fungi. In contrast to melanocytes in the skin, such cells in the uvea do not normally secrete melanosomes. Nevertheless, these organelles may be released due to degeneration and rupture of cells and subsequently be engulfed by macrophages. Here, they may be easily mistaken for bacteria. Therefore, special staining procedures for bacteria and melanin may be used to make a differentiation.

Specific ocular disease

Congenital disease. There is considerable species variation in the ocular structures in fish, and knowledge of the normal anatomy of the species in question is essential to prevent misdiagnosis. Some malformations even exist as a species-related and genetically selected trait, as for example exophthalmia in certain ornamental fish. The most common congenital diseases include cyclopia and microphthalmia / anophthalmia. Cyclopia occurs occasionally in all fish species, but has primarily been described in Atlantic salmon. Difference in the speed of development between the structures of the forebrain and nasal organ compared to the rest of the head causes the malformation, which may occur concurrent with maldevelopment of the jaws and fins. Involvement of teratogenic factors caused by environmental pollution has been suspected in some cases. Microphthalmia has been diagnosed in strains of farmed Atlantic salmon as a potential hereditary problem, but may be seen in all fish species as an incidental finding. Anophthalmia (no eye) can occur spontaneously in any fish and must be distinguished from a phthisical (shrunken) eye following injury or infection.

Exophthalmia and buphthalmia. These two acquired conditions may be difficult to distinguish clinically, as the presence of protruding eyes is a feature in both. Exophthalmia implies a protruding normal-sized eye, while in buphthalmia the globe itself is enlarged. Exophthalmia may be caused by space-occupying retrobulbar lesions or swelling. The condition is also a common sign of generalized illness in fish, and can be seen both in connection with infectious diseases as well as cardiac disease. Buphthalmia is most commonly caused by intraocular gas accumulation, but may also develop secondary to intraocular infection. Buphthalmia has also been suggested as a secondary result of generalized ocular disease related to subzero water temperatures in the Atlantic salmon.

Gas accumulation (gas bubble disease – "pop eye"). Gas bubbles can form within the eye or in the periocular region. Intraocular gas accumulation causes secondary buphthalmia or the eyes may become exophthalmic due to retrobulbar gas accumulation ***(Fig 10.11)***. In both cases, the eyes are more exposed to secondary trauma, and in addition, intraocular gas accumulation may cause irreversible changes in the choroid, retina and the optic nerve head. The gas bubbles are caused by an increase in the dissolved gas pressure above ambient air pressure (supersaturation) with either nitrogen or oxygen. Gas supersaturation may occur naturally and under aquarium and farming conditions, as an acute or a chronic condi-

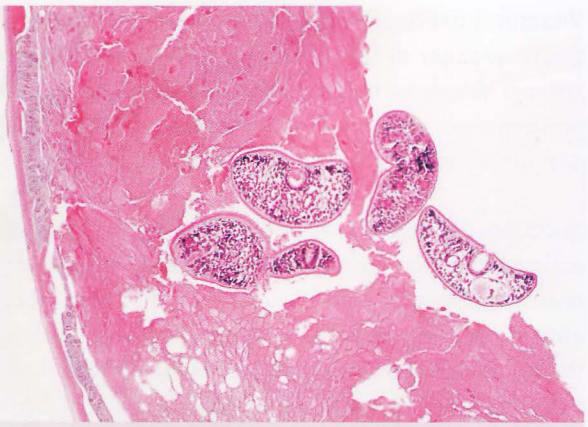

Fig 10.21C. *Diplostomum*-induced cataract. The flukes are surrounded by abnormal cortical lens fibres and proliferation of lens epithelium.

tion. The acute form causes clinical signs similar to the decompression disease seen in human divers, while in the subacute and chronic forms, the fish may slowly deteriorate due to secondary disease. This may also include non-specific secondary ocular signs such as cataract and suppurative panuveitis and panophthalmitis. The panophthalmitis may be caused by either corneal injury of an exposed eye, or may develop as a result of injury to intraocular structures.

In the Atlantic halibut, gas bubble formation may be caused by increased levels of carbon dioxide without necessarily a preceding gas supersaturation. It is suspected that the condition is the result of acidaemia augmented by high feeding rates, and thereby changes in the carbonic anhydrase-mediated control of gas secretion in the choroidal gland, and that this production is in part also influenced by hydrostatic pressure. The same condition is thought to be also present in farmed cod raised in shallow waters. In an old study on cod with similar signs, intraperitoneal injection of carbonic anhydrase inhibitors was shown to have a preventive effect. Gas bubble accumulation in the eyes is not uncommonly diagnosed in modern cod farms. Observations by the farmers indicate that gas bubble formation both in farmed cod and halibut occur in periods with changing water temperatures and in periods with stress.

Intraocular infection. As with exophthalmia, intraocular infection is usually encountered as part of a systemic disease picture, but this is not always so, and some agents preferentially locate to the eye. Several infectious agents have been isolated from fish with panophthalmitis, including *Vibrio* spp. in Atlantic salmon and cod, *Renibacterium salmoniarum* in rainbow trout, brown trout and coho salmon, *Streptococcus* spp. in rainbow trout, as well as *Staphylococcus aureus* in silver carp. Progressive panophthalmitis was described in chinook salmon, associated with two different Gram-positive bacteria; *Mycobacterium neoaurum* and an unidentified *Rhodococcus* sp. A Gram-negative rod has been isolated from Atlantic salmon with the disease *Varracalbmi* ("bloody eye"). Clinical signs in infectious ocular disease may vary. In the most severe cases, the infection may rapidly spread to affect the whole eye, causing rupture of the globe and complete destruction of ocular structures. Opacification of the cornea (keratitis) is frequently seen in less severe cases. In chronic, mild infection the cornea may appear clear, facilitating examination of deeper structures of the eye. Uveal reactions are usually mild in fish, but cataract due to change in the composition of the aqueous humour may be a finding in low-grade chronic infection.



Fig 10.22A. Early rickettsial infection in retina of seabream.

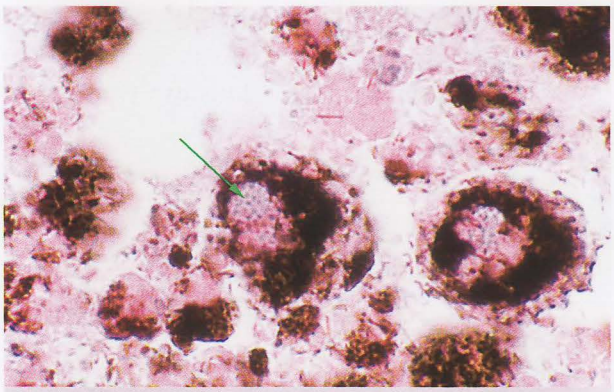

Fig 10.22B. RPE can become phagocytic. Here can be seen rickettsia (arrow) within the RPE in this seabass.

Scleritis. Scleritis may be associated with generalized panophthalmic disease. Several species of myxozoans may also be encountered within the scleral cartilage, often as an incidental finding. However, a specific form of necrotic scleritis associated with *Flavobacterium psychrophilum* has been described in rainbow trout and Atlantic salmon. Ophthalmic signs vary in severity from exophthalmia, through corneal erosions, intraocular haemorrhage and eventually end-stage phthisis of the eye. A typical finding is pyogranulomatous inflammation and necrosis of developing bone and cartilage of the head region in growing fish, including the scleral cartilage (colourfully known as "dissolving head disease").

Corneal ulcers. Corneal ulcers may develop because of mechanical damage or as part of generalized infection. Rough netting or handling of the fish may cause small injuries, which may heal rapidly under optimal conditions. Under poor environmental conditions, however, the ulcer may become secondarily infected with opportunistic bacteria or fungi (in particular *Saprolegnia* spp.) and may progress to corneal rupture and panophthalmitis ***(Fig 10.12)***. A condition claimed to cause destruction of eye especially in farmed Atlantic halibut, is the so-called "eye-snapping". Modern farming conditions may facilitate aggression and biting between fish, and the eyes have been considered to be especially exposed and therefore vulnerable. It is not clear, however, whether the fish show increased interest in an already diseased eye (for example due to gas bubble disease), or if it is a result of attacks on normal eyes. The former explanation may be the case in a number of the phthisical eyes seen in this species.

Keratitis. Nutritional causes of keratitis include deficiency of riboflavin and thiamine, and also of vitamin A. Vitamin A deficiency has been reported to cause hyperplastic changes in the corneal epithelium and increased stromal thickness in hatchery trout. Similar conditions are frequently seen in captive reptiles, where there is a concurrent conjunctival and orbital gland swelling.

Infectious keratitis ***(Fig 10.13)*** is most often a sign of generalised infection and may be caused by bacteria (*Aeromonas, Staphylococcus* spp. *Pseudomonas* spp. and others), viruses (*Lymphocystis*) and parasitic protozoa (*Ichthyophthirius*). *Lymphocystis* infection causes mainly skin disease in a wide range of teleosts, but an ocular form of the disease has been described in which the choroid, iris and optic nerve are infected. *Ichthyophthirius* causes a disease commonly referred to as "white spot," affecting the skin, gills, and cornea; in the latter location it is found on the basement membrane.

Although mostly affecting other parts of the body, monogenetic trematodes (class *Monogenea*, for example *Gyrodactylus* spp.) and crustaceans (class *Crustacea*) may also cause injury through piercing and penetration into the cornea ***(Fig 10.14)***. At the penetration sites, bullae develop, and these are associated with corneal opacity. Concurrently there may be oedema and erosion of the bulbar conjunctiva, as well as uveitis. Copepods especially attacking the eyes have been described in the Pacific sleeper sharks, causing corneal ulceration, heterophilic keratitis, ulcerative conjunctivitis accompanied by epithelial hyperplasia and anterior segment changes. Similar lesions have been described in the Pacific arrowtooth flounder, and it is most likely that infestation with copepods with an ocular preference may occur in other species as well.

Uveitis. (inflammation of iris, ciliary body and choroid). Many diseases of the eye as well as systemic diseases can cause inflammation of the uvea. Diseases affecting the choroid include gas bubble disease, septicaemia, and specific infections for example *Flexibacter, Pseudomonas, Mycobacterium* ***(Figs 10.15 & 10.16)***. Water-borne toxins may also be a cause of inflammation. Lens-induced uveitis is frequently diagnosed in connection with rapidly developing cataracts in fish, and as in mammals, the uveitis is caused by leakage of (altered) lens protein through the lens capsule. The uveitis affects parts of, or the whole uvea, and the falciform process may also be involved ***(see Fig 10.7B)***. The miosis seen in mammals with acute uveitis is far less pronounced in teleosts due

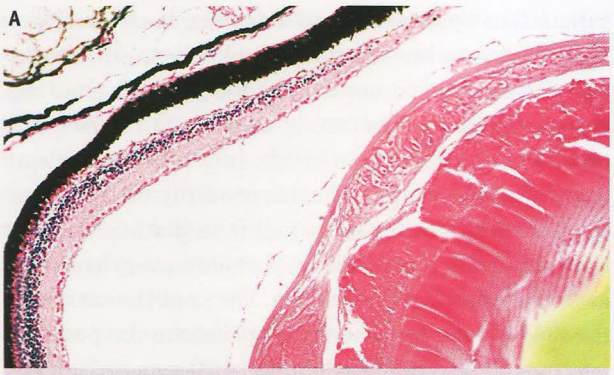

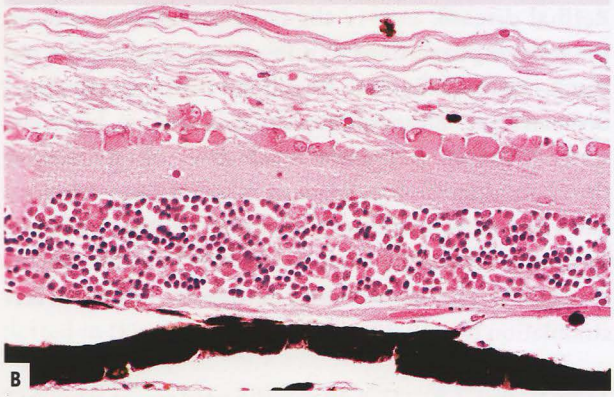

Fig 10.23A&B. Light-induced retinal atrophy in fish is common, especially in aquarium species that are forced to reside in brighly lit displays. Central retinal atrophy is the most common presentation, with loss of all layers, sometimes together with cataract, both of which are seen in **A**. High power of discus retina in **B** shows complete loss of photoreceptors, while other layers are relatively normal. Fortunately the teleost retina can regrow.

to the rudimentary iris muscles, although it is present to a mild degree in the acute stage.

Cataract. Cataracts may be divided into *primary* or *secondary* disease. In primary cataract, opacity of the lens is the only sign of disease in the eye, while in secondary cataract the lens changes occur as a consequence of other intraocular disease. This may be either infection, as described earlier, or the composition of the aqueous humour may be altered because of degenerative processes in the eye. Primary cataract is a common cause of reduced vision or blindness in farm-raised fish, and the disease has been extensively studied in Atlantic salmon. Compared to other species that primarily utilize olfaction, salmon are dependent on vision for normal food consumption, and the presence of cataract affects growth rate. In addition to the economic impact of reduced growth, the problem also raises welfare issues. The cataractogenic factor(s) may be present permanently or for only a period of time. If the causal agent is removed or disappears spontaneously, new cortical fibres growing in the periphery of the lens may develop normally. Gradually, a peripheral ring of normal lens tissue is formed around the cataractous changes, which are compressed towards the middle of the lens.

A wide variety of risk factors for primary cataracts have been described in farmed fish. These include nutritional imbalances, rapid growth, variation in water temperature, exposure to ultraviolet light, gas supersaturation, change in water salinity, genetic susceptibility, environmental toxins, toxic side effects of drug treatment, and parasitic infestation (*e.g.* flukes). Regardless of the initial cause, however, the lens shows mainly the same cataractous changes ***(Figs 10.17 & 10.18)***. The anterior cortical changes are often associated with concurrent proliferation of the lens epithelium, although there can occasionally be a loss. The proliferation can be seen with a slit-lamp biomicroscope as a well-defined subcapsular opacity at the anterior lens pole, which lies just behind the cornea. During rapidly developing cataract the lens imbibes water resulting in cortical morgagnial degeneration to form "Morgagnian globules". This leads to subsequent swelling of tissue within the capsular bag, which may rupture in the posterior region with extrusion of the lens nucleus into the posterior part of the eye ***(Fig 10.19B)***. Lens-induced uveitis occurs concurrently, but is less severe than in mammals. Signs of uveitis may be seen in fish with rapidly developing cataracts, with iris neovascularisation, rupture of vessels on the iris surface, hyphaema, darkening of the iris and mild miosis. More slowly developing cataract frequently occurs, with less dramatic changes, but these may also lead to complete opacity of the lens. Most cataracts are bilateral, although initial changes may be seen in only one eye.

Transient cataract related to osmotic imbalance may be seen, especially in anadromous fish, and is not uncommon shortly after transfer from freshwater to seawater. Exposing parr before smoltification to saltwater leads to osmotic cataract, presenting as swelling of lens fibres around the anterior lens pole. The osmotic effect on the lens may be reversible, but serious or repeated osmotic stress will lead to permanent damage. Osmotic cataracts have also been described in wild migrating postsmolts from Northern Europe. The cause of this remains unresolved but reduced vision may represent a contributing cause of the non-return of wild salmon to the rivers, as visually impaired fish may be an easy target for predators in the sea.

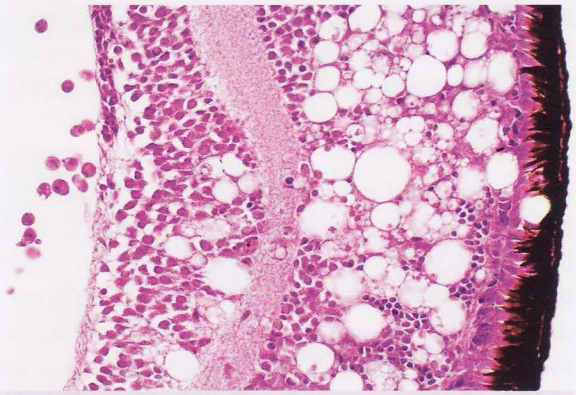

Fig 10.24. Retinitis caused by nodavirus in grouper. Uveitis and vacuoles are the typical findings which are seen in all layers of the retina in this case.

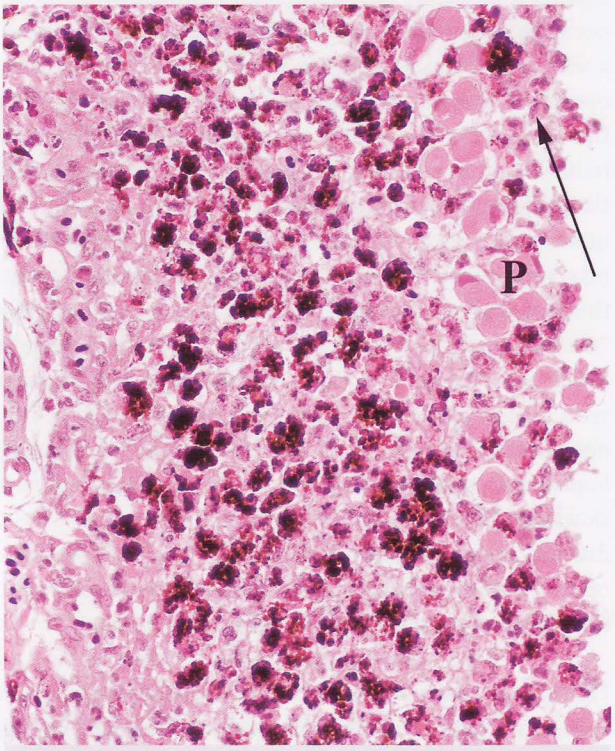

Fig 10.25. Severe sub-acute uveitis in trout, showing destruction of normal cellular organization. The brightly eosinophilic photoreceptors (**P**) are rounded up and are in the process of being phagocytosed by transforming RPE. Moderate numbers of neutrophils can be seen throughout (arrow). It is not known if such a retina can regenerate.

The eye is a target for a whole range of parasites ***(Fig 10.20)***. One of the most common however, is invasion by digenetic trematodes (eye flukes, subclass Digenea) (primarily *Diplostomum* spp.). These cause cataract in wild-caught as well as in farmed fish and represent a problem in many fisheries ***(Fig 10.21)***. A few flukes will not cause serious lens opacity. In massive attacks, however, trematodes can cause lens luxation, as well as lens capsule rupture and subsequent uveitis, which may also include secondary retinal detachment, in addition to cataract. The metacercariae develop in snails and, following release from the snail, penetrate the skin of nearby fish. After penetration, the immature flukes rapidly migrate throughout the body and, if the number of parasites is very high, may even cause death of the host fish. The predilection site for the flukes is the eye where they penetrate the posterior lens capsule and migrate into the cortex where they can easily be clinically observed in live fish. Occasional flukes are also found in the vitreous. Ingestion of infected fish by birds (the eye is a common target) completes the life cycle of the flukes.

Retinal disease. Due to the large species' variation in the relative proportions of different cells within the retina, it may be difficult to establish a diagnosis of retinal degeneration, although several causes have been described. The most common is infection, often affecting the choroid and retina concurrently, but toxic reactions and excess light may also cause retinal injury. As in mammals, the retinal pigmented epithelium can undergo hyperplasia and even become phagocytic given correct stimulation ***(Fig 10.22 and 10.25)***.

A case of possible hereditary retinal degeneration has been described in Atlantic salmon. Nutritional imbalance may also result in retinal degeneration, and both vitamin A and C deficiencies have been reported. Many fish species lack the ability to synthesize vitamin C and depend on a supply through feed. Vitamin C deficiency primarily causes changes in bones and skin. In addition however, retinal changes are also seen, presenting initially as central retinal degeneration, later progressing to affect the whole retina. Additional signs may be intraocular haemorrhage and secondary cataract development. Spontaneously-occurring retinal degenerations are known to occur in fish, including goldfish (*Carassius auratus*) where the retina undergoes degeneration concurrent with protrusion and enlargement of the globe. The zebrafish has been extensively used in research as a model for retinal degeneration caused by different factors. There is reason to believe that spontaneous retinal degeneration occurs also in other fish species, either because of hereditary or environmental factors, including poor water quality. Slowly progressive light-induced retinal degeneration has been described in the goldfish and

in captive Atlantic menhaden (*Brevoortia tyrannus*) after exposure to continuous light or fluorescent lighting, respectively **(*Fig 10.23*)**. Spontaneous diabetic retinopathy occurs in carp (*Cyprinus carpio*) with the vessels becoming tortuous and dilated before finally rupturing. Light induced retinopathy is commonly seen in species that normally inhabit waters with low light intensity, but which are suddenly exposed to high light levels in an aquarium situation so that people can see them! Similar changes are also encountered in farming conditions, and the recent enthusiasm for continuous light regimes must be viewed with a degree of caution.

Piscine nodaviruses are the causative agents of the disease viral encephalopathy and retinopathy (VER). Clinical signs of acute VER include anorexia, changes in skin pigmentation and neurological signs. There is a high mortality rate, up to 100%. VER has been reported from many marine fish species in all parts of the world except Africa. In Northern Europe nodavirus infections were first described in turbot and later in the Atlantic halibut, and sole. VER outbreaks in cod have been reported both from Scotland and Canada. Experimental studies have also shown spotted wolfish to be susceptible to nodavirus, but so far no natural VER outbreaks have been reported in this species.

The main target organ for nodavirus is the central nervous system, including the brain, spinal cord and retina, although sometimes the retina shows the most convincing histopathological changes. Characteristic lesions of VER include necrosis and lipid vacuolation in the brain and all layers of the retina **(*Fig 10.24*)**. The degenerative changes may be accompanied by inflammation. Fish that survive acute outbreaks of VER might show no CNS changes after some time. This might be due to the fact that teleosts have the ability to produce new neurons and regenerate retinal tissue even as adults, which leads to continuous regeneration and growth of CNS throughout their life. It is possible that the nodavirus infection persists as long as the fish lives. Ocular disease, even with permanent blindness, is common in the broodstock of Atlantic halibut. In addition to chronic gas bubble disease, long-standing subclinical nodaviral infection should probably also be considered.

Acknowledgement:

Professor Inge Bjerkås and Dr. David Griffiths, Norwegian School of Veterinary Science, Oslo, and Dr. Christoph Mülling, Freie Universität Berlin are thanked for providing images. Professor Inge Bjerkås is thanked for critical reading of the manuscript. Hugh Ferguson supplied many of the images.

References

Ali, M.A. (ed.) (1974) *Vision in Fishes*. New Approaches in Research. Plenum Press, New York.
Ali, M.A. and Anctil, M. (1976) *Retinas of Fishes*. An Atlas. Springer-Verlag, New York.
Arnott, H.J., Maciolek, N.J. and Nicol, J.A.C. (1970) Retinal tapetum lucidum:a novel reflecting system in the eye of teleosts. *Science* 169:478-480.
Backman, S., Ferguson, H.W., Prescott, J.F. and Wilcock, B.P. (1990) Progressive panophthalmitis in Chinook salmon, *Oncorhynchus tshawytscha* (Walbaum): a case report. *Journal of Fish Diseases* 13:354-353.
Barnett, C.H. (1951) The structure and function of the chorodial gland of teleostean fish. *Journal of Anatomy* 85:113-119.
Benz, G.W., Borucinska, J.D., Lowry, L.F. and Whiteley, H.E. (2002) Ocular lesions associated with attachment of the copepod *Ommatokoita elongata* (Lernaeopodidae: Siphonostomatoida) to corneas of Pacific sleeper sharks *Somniosus pacificus* captured off Alaska in Prince William Sound. *Journal of Parasitology* 88:474-481.
Block, B.A. (1986) Structure of the brain and eye heater tissue in marlins, sailfish, and spearfishes. *Journal of Morphology* 190:169-189.
Bjerkås, E. (1998) Oftalmologi hos oppdrettsfisk. ***In*** *Veterinær oftalmologi* (***ed***. Bjerkås, E.) pp149-161. Tell Forlag, Vollen i Asker, Norway.
Bjerkås, E., Holst, J.C. and Bjerkås, I. (2003) Osmotic cataract causes reduced vision in wild Atlantic salmon postsmolts. *Diseases of Aquatic Organisms* 55:151-159.
Bjerkås, E. and Sveier, H. (2004) The influence of environmental and nutritional factors on osmoregulation and cataract in Atlantic salmon (*Salmo salar* L). *Aquaculture* 235:101-122.
Bjerkås, I. and Griffiths, D.J. (2002) Drainage of aqueous humor in salmonid fish. ***In*** *Proceedings of the XXIVth Congress of the European Association of Veterinary Anatomists* (***ed***. Misek I.) pp45. Brno, Czech Republic.
Blaylock, R.B., Overstreet, R.M. and Morton, A. (2005) The pathogenic copepod *Phrixocephalus cincinnatus* (Copepoda: Pennellidae) in the eye of arrowtooth flounder, *Atherestes stomias*, and rex sole, *Glyptocephalus zachirus*, from British Columbia. *Bulletin of the European Association of Fish Pathologists* 25:116-123.
Bohl, M. (1997) Gas bubble disease of fish (in German) *Tierarztliche Praxis* 25:284-288.
Bolker, J.A. and Thomson, K.S. (1992) Abnormal craniofacial development in cyclopic salmonid fishes. *Journal of Morphology* 211:23-29.
Bridges, C.D.B. and Delisle, C.E. (1974) Evolution of visual pigments. *Experimental Eye Research* 18:323-332.
Bridges, C.R., Berenbrink, M., Müller, R. and Waser, W. (1998) Physiology and biochemistry of the pseudobranch: an unanswered question? *Comparative Biochemistry and Physiology* 119A:67-77.
Burnside, B. and Ackland, N. (1984) Effects of circadian rhythm and cAMP on retinomotor movements in the green sunfish, *Lepomis cyanellus*. *Investigative Opthalmological Visual Science* 25:539-545.
Collins, B.K., Collier, L.L. and Collins, J.S. (1993) Retina and lenticular lesions in vitamin-C-deficient juvenile red drum, *Sciaenops-Ocellatus* (L). *Journal of Fish Diseases* 16:229-237.
Copeland, D.E. (1974) The anatomy and fine structure of the eye of teleost. I. The choroid body in *Fundulus grandis*. *Experimental Eye Research* 18:547-561.
Copeland, D.E. (1976) The anatomy and fine structure of the eye in teleost. IV. The choriocapillaris and the dual vascularization of the area centralis in *Fundulus grandis*. *Experimental Eye Research* 22:169-179.
Copeland, D.E. and Brown, D.S. (1976) The anatomy and fine structure of the eye in teleosts. V. Vascular relations of choriocapillaris, lentiform body and falciform process in rainbow trout (*Salmo gairdneri*). *Experimental Eye Research* 23:15-27.
Crescitelli, F., McFall-Ngai, M. and Horwitz, J. (1985) The visual pigment sensitivity hypothesis: further evidence from fishes of varying habitats. *Journal of Comparative Physiology* 157:323-333.
Dukes, T.W. and Lawler, A.R. (1975) The ocular lesions of naturally occurring lymphocystis in fish. *Canadian Journal of Comparative Medicine* 39:406-410.
Dehadrai, P.V. (1966) Mechanism of gaseous exophthalmia in the Atlantic cod, *Gadus morhua* L. *Journal of the Fisheries Research Board of Canada* 23:909-914.
Douglas, R.H., Partridge J, C. and Marshall, N.J. (1998) The eyes of deep-sea fish I: lens pigmentation, tapeta and visual pigments. *Progress in Retinal and Eye Research* 17:597-636.
Easter, S.S. Jr. (1971) Spontaneous eye movements in restrained goldfish. *Vision Research* 11:333-342.
Eckelbarger, K.J., Scalan, R. and Nicol, J.A.C. (1980) The outer retina and tapetum lucidum of the snook *Centropomus undecimalis* (Teleostei). *Canadian Journal of Zoology* 58:1042-1051.
Edelhauser, H.F., Van Horn, D.L. and Schultz, R.O. (1969) Corneal opacity associated with eye disease in hatchery-reared lake trout. *Proceedings of the Society for Experimental Biology and Medicine* 130: 835-838.
Ferguson, H.W., Hawkins, L., MacPhee, D.D. and Bouchard, D. (2004) Choroiditis and cataracts in Atlantic salmon (*Salmo salar* L) recovering from subzero water temperatures. *Veterinary Record* 155:333-334.
Fernald, R.D. (2000) Evolution of eyes. *Current Opinion in Neurobiology* 10:444-450.
Flamarique, I.N. (2002) Partial re-incorporation of corner cones in the retina of the Atlantic salmon (*Salmo salar*). *Vision Research* 42:2737-2745.
Fritsches, K.A., Brill, R.W. and Warrant, E.J. (2005) Warm eyes provide superior vision in swordfishes. *Current Biology* 15:55-58.
Grahn, B,H,, Wilcock, B.P., Ferguson, H.W. and Sheppard, M. (1993) Retinal degeneration in chinook salmon (*Oncorhynchus tshawytscha*). *Proceedings of the American College of Veterinary Ophthalmologists* pp 41-42.
Grotmol, S., Totland, G.K., Thorud, K. and Hjeltnes, B.K. (1997) Vacuolating encephalopathy and retinopathy associated with a nodavirus-like agent: A probable cause of mass mortality of cultured larval and juvenile Atlantic halibut *Hippoglossus hippoglossus*. *Diseases of Aquatic Organisms* 29:85-97.
Grotmol, S., Bergh, O. and Totland, G.K. (1999) Transmission of viral encephalopathy and retinopathy (VER) to yolk-sac larvae of the Atlantic halibut *Hippoglossus hippoglossus*: occurrence of nodavirus in various organs and possible route of infection. *Diseases of Aquatic Organisms* 36:95-106.
Harder, W. (1964) Anatomie der Fische. Das Auge. ***In*** *Handbuch der Binnenfischerei Mitteleuropas*, (***eds***. Demoll, R., Maier, H.N. and Wundsch, H.H.) pp195-206. E. Schweizerbart´sche Verlagsbuchhandlung, Stuttgart, Germany.
Herrick, C.J. (1941) The eyes and optic paths of the catfish, *Ameiurus*. *Journal of Comparative Neurology* 75:255-286.
Hitchcock, P.F. and Raymond, P.A. (1992) Retinal regeneration. *Trends in Neuroscience* 15:103–108.

Hughes, S.G., Riis, R.C., Nickum, J.G. and Rumsey, G.L. (1981) Biomicroscopic and histologic pathology of the eye in riboflavin deficient rainbow trout (*Salmo gairdneri*). *Cornell Veterinarian* 71:269-279.
Johansen, R., Ranheim, T., Hansen, M.K., Taksdal, T. and Totland, G.K. (2002) Pathological changes in juvenile Atlantic halibut *Hippoglossus hippoglossus* persistently infected with nodavirus. *Diseases of Aquatic Organisms* 50:161-169.
Ketola, H.G. (1979) Influence of dietary zinc on cataracts in rainbow trout (*Salmo gairdneri*). *Journal of Nutrition* 109:965-969.
Koppang, E.O., Bjerkås, E., Bjerkås, I., Sveier, H. and Hordvik, I. (2003) Vaccination induces major histocompatibility complex class II expression in the Atlantic salmon eye. *Scandinavian Journal of Immunology* 58:9-14.
Koppang, E.O., Haugarvoll, E., Hordvik, I., Poppe, T.T. and Bjerkås, I. (2004) Granulomatous uveitis associated with vaccination in the Atlantic salmon. *Veterinary Pathology* 41:122-130.
Kreuzer, R.O. and Sivak, J.G. (1984) Spherical aberration of the fish lens: interspecies variation and age. *Journal of Comparative Physiology* 154:415-422.
Lee, W.R. (2002) *Ophthalmic Histopathology (2nd edition)*. Springer-Verlag, London, U.K.
Link, B.A., Gray, M.P, Smith, R.J. and John, S.W. (2004) Intraocular pressure in zebrafish: comparison of inbred strains and identification of a reduced melanin mutant with raised IOP. *Investigative Ophthalmology and Visual Science* 45:4415-4422.
Loewenstein, M.A. and Bettelheim, F.A. (1979) Cold cataract formation in fish lenses. *Experimental Eye Research* 28:651-663.
Lönnström, L., Wiklund, T. and Bylund, G. (1994) *Pseudomonas anguilliseptica* isolated from Baltic herring *Clupea harengus membras* with eye lesions. *Diseases of Aquatic Organisms* 18:143-147.
Matty, A.J., Menzel, D. and Bardach, J.E. (1958) The production of exophthalmos by androgens in two species of teleost fish. *Journal of Endocrinology* 17:314-318.
Munday, B.L., Kwang, J. and Moody, N. (2002) Betanodavirus infections of teleost fish: a review. *Journal of Fish Diseases* 25:127-142.
Nicol, J.A.C. (1980) Studies on the eyes of toadfishes *Opsanus*. Structure and reflectivity of the stratum argenteum. *Canadian Journal of Zoology* 58:114-121.
Nicol, J.A.C. and Arnott, H.J. (1973) Studies on the eyes of gars (*Lepiso steidae*) with special reference to the tapetum lucidum. *Canadian Journal of Zoology* 51:501-508.
Nicol, J.A.C. and Zyznar, E.S. (1973) The tapetum lucidum in the eye of the big-eye *Priacanthus arenatus Cuvier*. *Journal of Fish Biology* 5:519-522.
Ostland, V.E., McGrogan, D.G. and Ferguson, H.W. (1997) Cephalic osteochondritis and necrotic scleritis in intensively reared salmonids associated with *Flexibacter psychrophilus*. *Journal of Fish Diseases* 20:443-451.
Partridge, B.L. and Pitcher, T.J. (1980) The sensory basis of fish schools: Relative roles of lateral line and vision. *Journal of Comparative Physiology* 135:315-325.
Richardson, N.L., Higgs, D.A. and Beames, R.M. (1986) The susceptibility of juvenile chinook salmon (*Oncorhynchus tshawytscha*) to cataract formation in relation to dietary changes in early life. *Aquaculture* 52:237-243.
Rusoff, A.C. and Easter Jr., S.S. (1980) Order in the optic nerve of goldfish. *Science* 208:311-312.
Schwanzara, S.A. (1967) The visual pigments of freshwater fishes. *Vision Research* 7:121-148.
Shariff, M., Richards, R.H. and Sommerville, C. (1980) The histopathology of acute and chronic infections of rainbow trout *Salmo gairdneri* Richardson with eye flukes, *Diplostomum* spp. *Journal of Fish Diseases* 3:455-465.
Sommer, A.I., Amundsen, M., Rasmussen E. and Mennen, S. (2004) Susceptibility of spotted wolffish *Anarhichas minor* to experimental infection with nodavirus and infectious pancreatic necrosis virus. *Diseases of Aquatic Organisms* 59:101-108.
Speare, D.J. (1990) Histopathology and ultrastructure of ocular lesions associated with gas bubble disease in salmonids. *Journal of Comparative Pathology* 103:421-432.
Starkey, W.G., Ireland, J.H., Muir, K.F., Jenkins, M.E., Roy, W.J., Richards, R. and Ferguson, H.W. (2001) Nodavirus infection in Atlantic cod and Doversole in the UK. *Veterinary Record* 149:179-181.
Streilein, J.W. (1999) *Immune Response and the Eye*. Karger, Basel, Switzerland.
Streilein, J.W. (2003) Ocular immune privilege: the eye takes a dim but practical view of immunity and inflammation. *Journal of Leukocyte Biology* 74:179-185.
Tian, N.M. and Price, D.J. (2005) Why cavefish are blind. *Bioessays* 27:235-238.
Ubels, J.L. and Edelhauser, H.F. (1982/83) Healing of corneal epithelial wounds in marine and freshwater fish. pp. 613-619 ***In***: Current Eye Research, Vol. 2, IRL Press Ltd., Oxford.
Ubels, J.L. and Edelhauser, H.F. (1987) Effects of corneal epithelial abrasion on corneal transparency, aqueous humor composition, and lens of fish. *Progressive Fish Culturist* 49:219-224.
Valheim, M., Hoyel, S., Hastein, T., Myhr, E., Speilberg, L. and Ferguson, H.W. (2000) Varracalbmi: a new bacterial panophthalmitis in farmed Atlantic salmon, *Salmo salar* L. *Journal of Fish Diseases* 23:61-70.
Von Sallmann, L., Halver, J.E., Collins, E. and Grimes, P. (1966) Thioacetamide-induced cataract with invasive proliferation of the lens epithelium in rainbow trout. *Cancer Research* 26:1819-1825.
Wagner, H.-J., Fröhlich, E., Negishi, K. and Collin, S. P. (1998) The eyes of deep-sea fish II: functional morphology of the retina. *Progress in Retinal and Eye Research* 17:637-685.
Walls, G.L. (1967) The Vertebrate Eye and its Adaptive Radiation. Hafner Publishing Co., New York.
Williams, D.L. and Brancker, W.M. (2004) Intraocular oxygen tension in normal and diseased eyes of farmed halibut. *Veterinary Journal* 167:81-86.
Wittenberg, J.B. and Wittenberg, B.A. (1974) The choroid rete mirabile of the fish eye. I. Oxygen secretion and structure comparison with the swimbladder rete mirabile. *The Biological Bulletin* 146:116-136.
Zadunaisky, J.A. (1972) The electrolyte content, osmolarity and site of secretion of the aqueous humor in two teleost fishes (*Carassius auratus* and *Diplodus sargus*). *Experimental Eye Research* 14:99-110.
Zadunaisky, J.A. (1973) The hypotonic aqueous humor of teleost fishes. *Experimental Eye Research* 16:397-401.





Endocrine and Reproductive Systems

CHAPTER 11

by John F. Leatherland and Hugh W. Ferguson

In this chapter we examine the reproductive system and endocrine system of fish, with respect to reported pathological conditions. Whilst the concept of a reproductive "system" may be valid, the paradigm of an endocrine system as such is no-longer accepted as a functional reality. The concept of an endocrine "system", *per se* has largely been replaced by the recognition of widespread intercellular chemical signalling pathways that are linked to complex intracellular signalling pathways. These intercellular signalling chemicals may be produced and be active locally in an autocrine or paracrine manner, or they may be produced by cells of the nervous system, the "classical" endocrine glands or by cells of the immune system. Many of the hormones that are known to be synthesized by and released from cells of the "classical" endocrine glands of teleost fish are now also known to be expressed in multiple peripheral non-endocrine sites. In addition, many of these peripheral sites play a significant role in the biotransformation of signalling chemicals, including the traditional hormones. In some instances these locally produced regulatory chemicals exert their effect at the site of production, but in other cases the peripheral tissues may contribute to a common serum hormone pool. The dispersed nature of the endocrine "system" makes it impossible to catalogue fully pathological conditions that are endocrine related. Many of the diseases that affect other body systems may well have an endocrine component to their aetiology. For the purpose of this survey, the focus will be placed on those glandular structures that are known to synthesize and secrete signalling chemicals, and are generally recognised as the "classical" endocrine glands. These comprise the "glands" of the central nervous system (hypothalamus, posterior pituitary gland, pineal, and urophysis), the anterior pituitary gland, the ultimobranchial gland, the thyroid tissue, the interrenal tissue, the steroid secreting cells of the gonads, and the gastrointestinal hormones (including the pancreatic hormones). Other factors that are more widely synthesized, such as the natriuretic peptides, insulin-like growth factor (IGF), somatostatin (SRIF) and the peripherally-synthesized factors that are homologous to the hypothalamic hormones, will be mentioned for the sake of completeness. Similarly, a brief description of the normal is given here, even when no specific lesions are mentioned.

Pathological changes, even for the "classical" endocrine glands or tissues, are rarely reported and in routine examinations the tissues are often given only a cursory inspection. As a consequence, examples of specific lesions are limited. The dispersed nature of some of the endocrine tissues in teleosts further exacerbates the problem of identifying endocrine lesions. For example, the hypothalamic hormones are produced by cells that are located in several regions of the hypothalamus, the thyroid and interrenal tissue is not usually present as discrete glands, and the endocrine elements of the gastrointestinal tract are dispersed among the mucosal and submucosal elements of much of that organ system. Thus, many cases of endocrine pathology may fail to be recognized.

Neuroendocrine tissues

Pineal gland. This light sensitive neuroendocrine structure projects from the roof of the diencephalon. It lies between the eyes, just beneath a midline thinning of the cranial cartilage in bony fishes, and is covered by a well-vascularized capsule and meninges. As in mammals, the pineal gland in fish is known to secrete the indole amine, melatonin, as well as some neurotransmitter substances. Elevated plasma melatonin levels have been recorded during the night in several teleostean species, and many tissues contain melatonin receptors suggesting a widespread influence of the hormone on many cellular functions. The pineal appears to play the role of mediator between photoperiod and the control of daily and seasonal rhythms, such as the regulation of reproductive cycles, growth and seasonal migrations. Its importance in continuous light regimes in aquaculture is presently a focus of research.

Hypothalamus. Groups of neurones in the hypothalamus of teleosts synthesize amine or peptide hypophyseal hor-mones that are transported via the axons of these

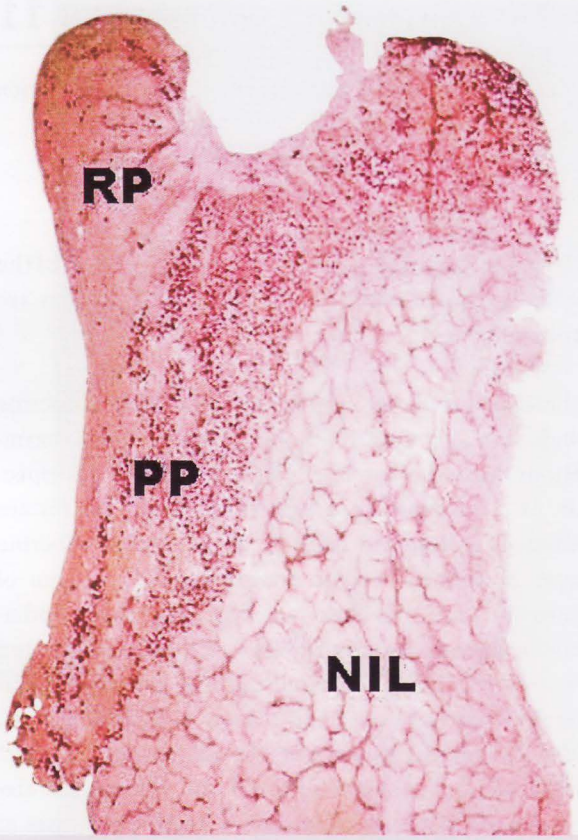

Fig 11.1A. Sagittal section through the pituitary gland of a sexually mature coho salmon. The pars distalis comprises the rostral (RP) and proximal (PP) components, and the pars intermedia and pars nervosa are interdigitated to make up the neurointermediate lobe (NIL). *Alcian blue-periodic acid Schiff-orange G.*

cells and released at synaptic terminals in the pituitary gland. Some of these, the neurohypophyseal hormones such as arginine vasotocin and isotonin, are released from the posterior regions of the pars nervosa (see under Pituitary gland, below), where they enter the general circulation. Other hypophyseal hormones are released in the anterior regions of the pars nervosa that are interdigitated with the anterior pituitary gland, or pars distalis. Many of these factors are thought to be involved directly or indirectly in the regulation of the activity of the pars distalis and pars intermedia cells. Novel hypophyseal factors are being discovered annually, and there is a long list of known factors that have been identified by immunohistochemistry, or on the basis of gene expression using RT-PCR technology. Among the better known are the peptides that are involved in the regulation of the synthesis and release of the hormones of the pars distalis: growth hormone releasing hormone (GHRH), corticotropin releasing hormone (CRH), thyrotropin releasing hormone (TRH), gonadotropin releasing hormone (GnRH), and somatostatin (SRIF), particularly SRIF-14, but also other isoforms of SRIF in some species. It should be emphasized that these factors are named after the roles that they play in the hypothalamic regulation of pituitary gland activity in mammals, and their name may not accurately reflect their roles in teleosts. For example, in several species, GnRH, and not GHRH is the major factor in the regulation of growth hormone synthesis and release. In addition to the factors involved in regulating pars distalis activity, two peptides are known to affect the synthesis and release of melanotropin (melanophore stimulating hormone [MSH]) from the melanotropic cells of the pars intermedia, namely melanotropin releasing factor (MRF) and melanotropin inhibiting factor (MIF).

In addition to the above, several other factors have been identified that appear to play various roles in regulating pars distalis function either directly or indirectly by modulating the secretion of hypophyseal hormones, including dopamine, bombesin, enkephalin, FMRFamide-related peptides, galanin, gastrin-like peptides, ghrelin, norepinephrin, neuropeptide-Y, serotonin, teneurin C-terminus associated peptide, vasointestinal peptide, and neuroexcitatory amino acids, such as glutamatic acid and γ-amino butyric acid (GABA), among others. Also, there is considerable evidence to suggest that the neurophysial hormones may also play a role in regulating the secretion of some pars distalis function.

Urophysis. This is a neuroendocrine or neuro-haemal complex, the so-called caudal neurosecretory system, that is located on the ventral aspect of the distal end of the spinal cord in teleosts. In most species the urophysis is evident grossly as a distinct swelling, and comprises the terminal regions of axons that originate in the Dahlgren cells that are resident in the spinal cord. The unmyelinated axons terminate on capillary walls in the neuro-haemal complex. Two major products have been identified, urotensin I and II, that are structurally similar to CRH, and SRIF, respectively. These factors have been linked to various vasoactive responses in fish, notably causing an increase in blood pressure, and vasoconstriction in urinary bladder, intestinal tract, and reproductive tract. Other effects have also been reported, including a lipogenic action, and ionoregulatory responses, some of which may well be caused by their effect on short-circuit currents across epithelial cells, and a consequent control over salt and water movement across epithelia such as the urinary bladder found in some species.

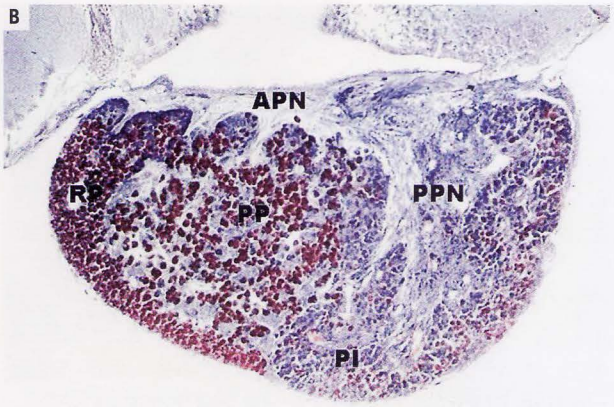

Fig 11.1B&C. Sagittal sections through the pituitary glands of adult anadromous threespine sticklebacks at two stages of migration; (**B**) was taken from a fish adapted to sea water, and (**C**) from a post-spawned fish in fresh water. The pars distalis is comprised of the rostral (RP) and proximal (PP) components, but the interdigitation of the anterior component of the pars nervosa (APN) is more evident than in the salmon. Also, the interdigitation of the pars intermedia (PI) and the posterior component of the pars nervosa (PPN) forming the neurointermediate lobe is less intricate. Note the increase in the number and size of prolactin cells in the RP of the freshwater-adapted fish (**C**), and the vascularization of the PPN. *Cleveland-Wolfe trichrome.*

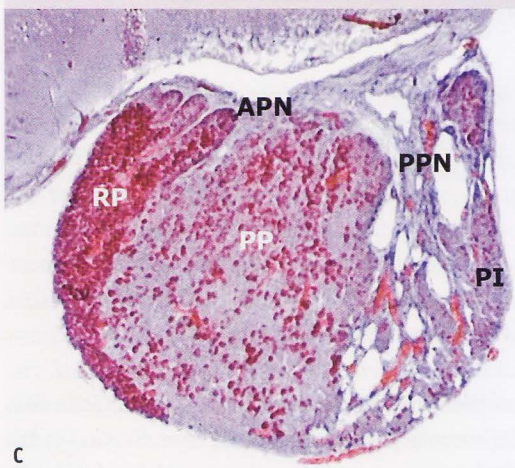

Pituitary gland. The pituitary gland in fish is a complex neuro-epithelial structure, which, although somewhat variable in structure between species, is remarkably similar within the major classes. As in other vertebrates, it is derived embryologically from a down pushing of the infundibulum of the brain (forming the pars nervosa) and an upgrowth of the roof of the mouth which gives rise to the partes distalis and intermedia of the adult ***(Fig 11.1)***. In birds and mammals this upgrowth, termed Rathke's pouch, is a hollow ball of cells, but in the few species of teleosts that have been studied to date, the upgrowth comprises a solid mass of cells.

The pars nervosa (neurohypophysis) ***(Fig 11.1B)*** comprises glial cells, termed pituicytes, together with neurosecretory axons originating in neurones lying in the hypothalamus; collectively, the group of hypothalamic neurones giving rise to the axons of the pars nervosa is called the pre-optic nucleus. The role(s) of the pituicytes is currently unknown, but they appear to be phagocytic in the normal pars nervosa. Two pars nervosa hormones are known in teleosts, isotocin (4-serine, 8-isoleucine oxytocin) and arginine vasotocin. Unfortunately, despite considerable ongoing interest in the pharmacology and physiology of the neurohypophyseal octapeptides in fish, relatively little is known about their role. Pressor effects have been reported in a few species after arginine vasotocin treatment, and spawning behaviour has been induced in killifishes by intracranial administration of arginine vasotocin, but antidiuretic actions, similar to those well-established in mammals, are not properly substantiated.

The anterior pituitary or adenohypophysis in teleosts comprises the rostral and proximal pars distalis and the pars intermedia ***(Fig 11.1)***. In most species the rostral pars distalis comprises corticotropic cells, which form a layer of cells in the dorsal region of the rostral pars distalis adjacent to the anterior part of the pars nervosa ***(Fig 11.2A)***, and prolactin (PRL) secreting cells. For salmonid and anguillid species, the region of the rostral pars distalis that contains the PRL secreting cells, comprises follicles, each follicle having a small lumen ***(Fig 11.2B)***. The epithelium of the follicle contains both PRL secreting cells and non-granulated cells (see below), both of which are in contact with the lumen and the basal membrane of the follicle. The functional significance of the follicular morphology is not known. It was originally viewed as the remains of the embryonic Rathke's pouch, but embryologically these follicles developed as schizocoeles, from the solid anterior pituitary anlage. In other species, such as the gasterostids and cichlids, only the non-granulated cells are in contact with the lumen. The PRL secreting cells are in close contact with the basal region of the non-granulated cells.

In some species thyrotropic hormone (TSH) secreting cells may also be present in the rostral pars distalis. The proximal pars distalis contains acidophilic somatotropic (growth hormone [GH]-secreting) cells, which tend to be ventrally located, and basophilic gonadotropic and thyrotropic cells that tend to associate with the pars nervosa in the dorsal region of the proximal pars distalis ***(Figs 11.2C)***.

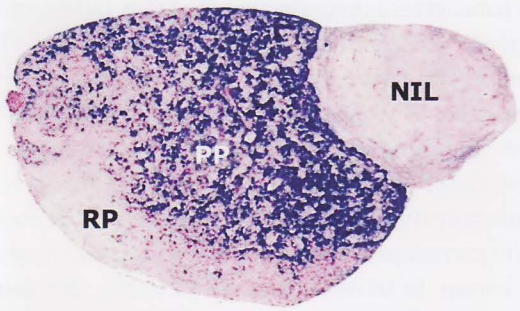

Fig 11.1D. Parasagittal section through the pituitary gland of an adult carp showing similar zonation of the gland into rostral (RP) and proximal pars distalis (PD) and neurointermediate lobe (NIL).

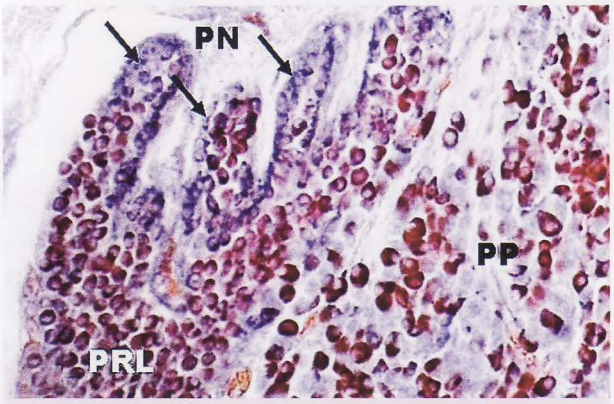

Fig 11.2A. Stickleback pituitary gland showing the separation of the rostral pars distalis into dorsal ACTH cells (arrows) lying in contact with the anterior pars nervosa (PN), and the more ventral prolactin (PRL) cells. The proximal pars distalis (PD) comprises acidophilic growth hormone cells (red) and basophilic cells (blue) that comprise thyrotrophs or gonadotrophs. *Cleveland Wolfe trichrome.*

In addition to the hormone producing cells of the pars distalis and pars intermedia, non-granulated cells, the so-called "stellate" cells, are found throughout these two regions. They may form follicles as described above for the rostral pars distalis in salmonid species, or clusters, which do not appear to have a lumen. They are thought to play a phagocytic role, and may facilitate the transport of secreted hormone from the basilar laminae towards the vascular complex in the pituitary, or maintain the basilar laminae.

The majority of the pars intermedia cells are melanotropic cells that synthesize the pro-hormone proopiomelanocortin (POMC) peptide, which is converted intracellularly by peptidases into several smaller peptides. Depending on the nature of the peptidases, the final products of biotransformation of POMC may yield a range of peptides. One of these, α-MSH is one of the products of the melanotropic cells, but β-endorphin and β-lipotropic hormone

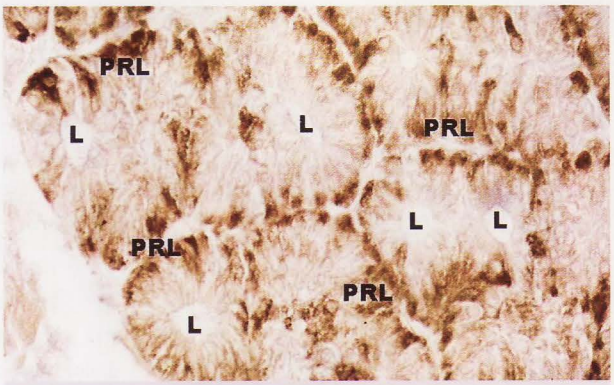

Fig 11.2B. Rostral pars distalis of a juvenile trout showing the follicular arrangement of the prolactin (PRL) cells surrounding a lumen (L). The epithelium of the follicle comprises both PRL cells and non granulated cells. Section immunostained with anti-salmon PRL antibody; sites of PRL appear as a brown stain.

(β-LPH) may also be released. Despite its name, α-MSH does not appear to influence melanophore pigment cells of the skin, as it does in some amphibia. The roles of the melanotropic cell POMC derivatives in teleosts remain unknown, although there is some evidence to suggest a role for α-MSH in the stress-response of some species, possibly enhancing cortisol secretion.

A second pars intermedia cell type is present is some teleosts. These cells synthesize and secrete the hormone somatolactin (SL), a protein hormone that belongs to the prolactin/growth hormone family. The roles of the hormone are still unclear, but the cells appear to respond cytologically when fish are subjected to altered reduced calcium levels and changes in background colour, and SL may enhance gonadal steroidogenesis.

In terms of the function of pars distalis hormones in fish, only a brief summary will be provided here. Several of the pars distalis hormones are themselves regulators of the activities of other endocrine glands or tissues. TSH and the two forms of gonadotropins that have analogy to the luteinizing hormone (LH) and follicle stimulating hor-mone (FSH) of higher vertebrates, regulate many aspects of the synthesis and secretion of thyroid hormones and gonadal steroids, respectively. The corticotropic cells, along with the melanotropic cells and many other tissues, synthesize the pro-hormone POMC, which is converted intracellularly by peptidases into adrenocorticotropic hormone (ACTH) and β-lipotropic hormone (β-LPH). ACTH is a major factor in the regulation of steroidogenesis by the cells of the interrenal gland, but it is not known whether β-LPH plays a physiological role in fish.

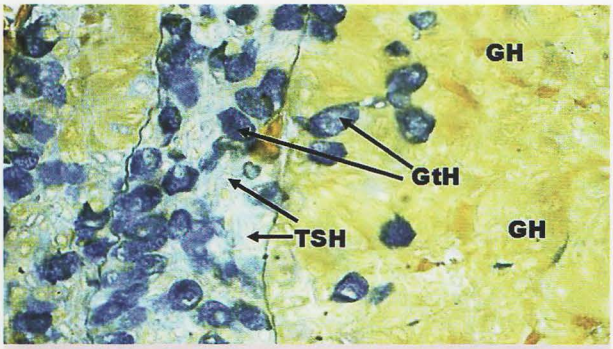

Fig 11.2C. Proximal pars distalis of a juvenile trout showing the orange-stained acidophilic growth hormone (GH) cells and the basophilic gonadotrophs (GtH) and thyrotrophs (TSH). *Alcian blue-periodic acid Schiff-orange G.*

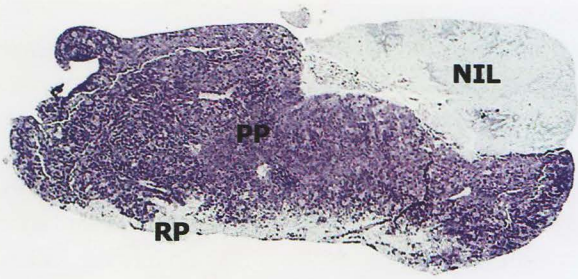

Fig 11.3. Parasagittal section through the pituitary gland of a sterile adult carp x goldfish hybrid showing adenomatous basophil cells associated with the proximal pars distalis (PD). The rostral (RP) and neurointermediate lobe (NIL) are still present. This fish was of similar size and age to the one from which the pituitary gland shown in *Fig 11.1D* was taken.

Other pars distalis hormones, such as PRL and GH, which together with SL make up a family of hormones, are known to have diverse action in many tissues in fish. The categories into which the numerous known PRL effects are gathered include water and electrolyte balance, growth and development, metabolism, reproduction, brain function and behaviour, and the regulation of immune responses. The role of PRL in freshwater osmotic and ionic regulation by euryhaline teleosts is one of the best-studied aspects of the hormone's many roles. PRL possibly acts by enhancing ion uptake from the ambient environment and lowering the permeability of the gill epithelium to water, but its enhancement of mucus secretion by gills, and its effects on the binding of calcium to the gill membranes, which indirectly changes the permeability of the gill epithelium to water and possibly also to sodium, potassium and hydrogen ions, may contribute to its overall action.

GH has a well-established growth-enhancing effect in teleosts, as shown by increased growth rates in fish administered GH and in transgenic fish that are over-expressing the GH gene. As for PRL, however, GH also appears to have numerous other effects in aspects of metabolic regulation, iono- and osmoregulation, be-haviour and early embryo development. GH stimulates the production of insulin-like growth factor 1 (IGF-1) by the liver, and some of the responses attributed to GH might be IGF-1 regulated events. Also, as for several other pituitary hormones, GH gene expression has been found in several extra-pituitary tissues of teleost fish, including the gonad.

There are no existing reports of pathological conditions of the pineal or hypothalamus of teleosts. Pituitary cysts are common in sticklebacks, and although their significance or pathogenesis is unknown, their prevalence does increase with capture and handling. They have also been reported in salmonids, cyprinids and in minnows exposed to the herbicide trifluralin. In addition, basophilic adenomas have been reported in guppy, molly, an Indian catfish and in carp x goldfish hybrids ***(Fig 11.3)***. These adenomas are commonly associated with sterility and tumourous gonadal lesions. The adenomatous pituitary may represent compensatory hyperplasia and hypertrophy induced by low gonadal steroid hormone levels that initiate chronic stimulation of the gonadotrophs by stimulating hypothalamic factors such as GnRH.

Thyroid tissue

In adult bony fishes the thyroid gland is usually described as being diffuse, with follicles concentrated around the ventral aorta ***(Fig 11.4A)***. However, recent work in trout suggests that the thyroid comprises a series of interconnected tubular elements, rather than follicles, at least until the late juvenile stage. This might explain some of the earlier, and widely reported "irregularly shaped" thyroid follicles in several teleosts. It might also explain the trabeculate nature of some thyroid neoplasms (see below).

In species such as pink salmon, the thyroid tissue is not dispersed through the pharyngeal region and has the appearance of a consolidated saddle-shaped gland ***(Fig 11.4B)***, although it is not encapsulated. In some other species, such as the swordfish (*Xiphias gladius*) and the various species of coral reef parrot fishes, the thyroid gland is encapsulated and somewhat resembles the glandular

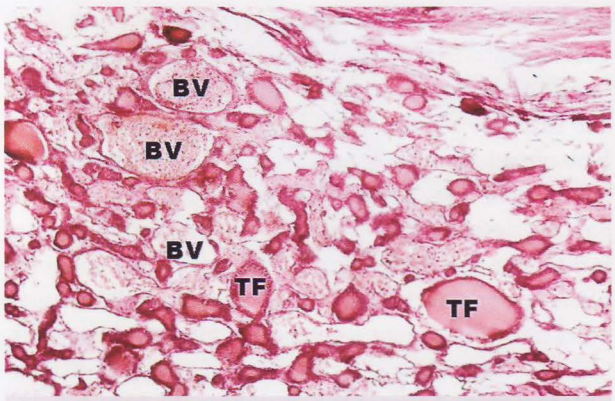

Fig 11.4A. Thyroid follicles (TF) in the lower jaw of an adult rainbow trout. The follicles are located in the areolar connective tissue surrounding the ventral aorta, and in close contact with a complex of blood vessels (BV).

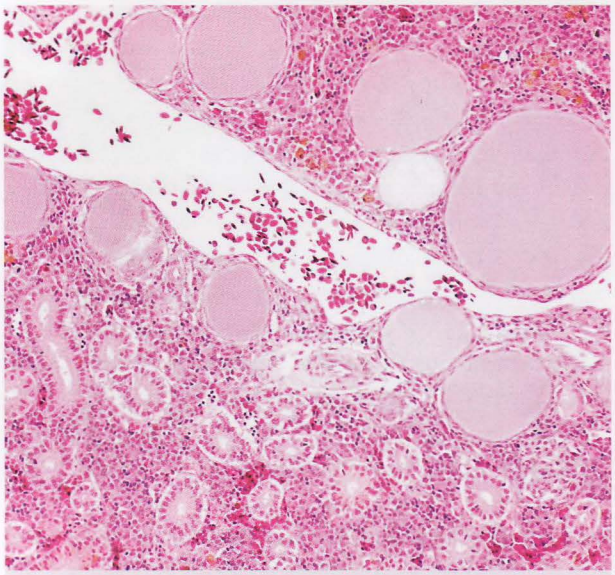

Fig 11.4B. Thyroid follicles in kidney of normal cyprinid.

tissue of tetrapod vertebrates. However, the very thin connective tissue capsule may not play the role that it does in tetrapods. In fact, the tissue may be held together more by the close association of follicles than by the capsule, *per se*, with the boundaries of the gland being defined by adjacent structures rather than by encapsulation. The encapsulation may be more coincidental than functional.

Ectopic thyroid foci are commonly found in some species; these may be present in the eye, kidney, spleen, heart and other tissues. In carp and goldfish, thyroid tissue is consistently present in both the pharyngeal region and the anterior (head) kidney. Moreover, there is evidence that this morphological separation might have physiological



Fig 11.5. Rainbow trout showing distortion of the skull and opercular bones; this was experimentally produced by feeding thyroid hormones (T3).

relevance since it appears that the thyroid tissue of the head kidney is more responsive to TSH stimulation than the pharyngeal thyroid.

The microstructure of the thyroid gland in teleosts is essentially similar to that of tetrapods; the thyroid tissue comprises epithelial cells, that vary in size depending on the degree of TSH stimulation. The cells form a tight epithelium surrounding a colloid-filled lumen, and have microvilli and occasional cilia projecting into the follicular lumen.

Thyroxine (T_4) is the major product released from the thyroid gland; peripheral monodeiodination of T_4 to produce triiodothyronine (T_3) takes place in the liver, kidney and other tissues. The actions of the thyroid hormones at the cellular level in fish are not as well understood as they are in mammals, but the expression of genes encoding for the two known isoforms (α and β) of T_3 receptors (TR) have been found in several tissues of several species of bony fishes. Although some membrane-related responses to T_3 have been reported, mostly in mammals, the best known mode of action of TRs is as a ligand activated transcription factor that binds to the thyroid response element (TRE) of T_3-responsive genes. TR forms heterodimers the retinal X receptor (RXR); binding of T_3 to TR and RXR allows the heterodimer to attach to the TRE, and this is one factor in the initiation of the expression of a particular gene. Homodimers can also exert a similar response. The presence of the TRE nucleotide sequence in a gene is indicative of a role for T_3 in the activation of that gene. Many expressible genes have been shown to contain the TRE palindromic sequence, suggesting that T_3 plays many roles at a cellular regulatory level. This may explain why, as with the glucocorticoids, it has been difficult to specifically describe the functions of the hormone.

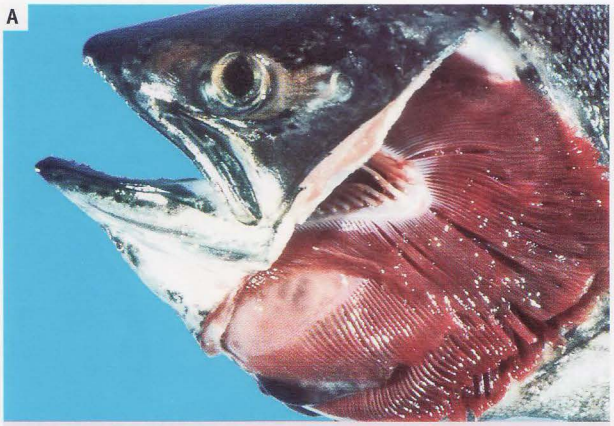

Fig 11.6A&B. Great Lakes coho salmon showing the multi-nodular enlargement of the thyroid in this case of goitre. (**B**) shows view from inside the mouth.

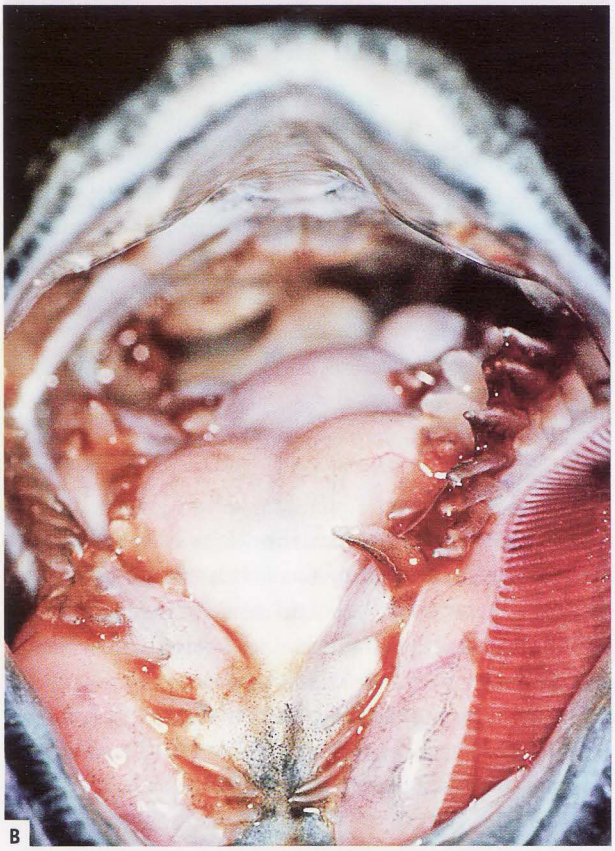

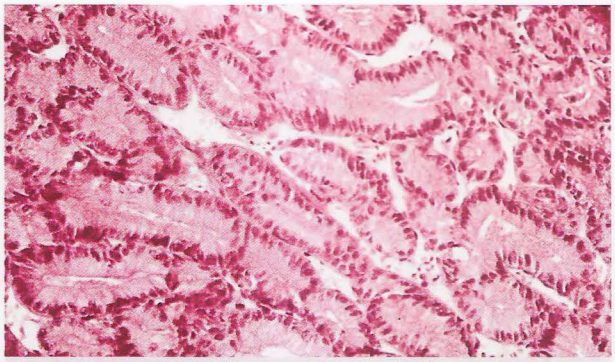

Fig 11.7A. Thyroid tissue from a nodule of Great Lakes coho salmon showing one form of the lesion. The tissue has the appearance of tubules, the thyrocytes are greatly enlarged compared with the normal condition, and the colloid is virtually absent from the lumen of most follicles.

In very general terms, T_3 may play a role in growth regula-tion in bony fish (most probably acting as a permissive hormone for the action of GH); it may act specifically on the growth of muscle, bone and cartilage, as evidenced by retardation of the growth of these tissues in radiothyroidectomized fish. Addition of thyroid hormones to the diet increases skull bone growth and causes hyperplasia of connective tissue in the inter-orbital area **(*Fig 11.5*)**. The thyroid hormones also play a part in pigment and guanine deposition, particularly during the smoltification process of salmon, and T_3 synergizes with gonadotropins in the stimulation of estradiol secretion by the ovarian follicles. Osmoregulatory functions have also been proposed, possibly indicating a protective role for the thyroid hormones during seawater adaptation.

Peak thyroid hormone secretion in teleosts is most commonly associated with major metabolic events in the life cycle of the fish, such as the phase of rapid growth, gonadal growth, or developmental changes associated with the parr-smolt transformation in salmon, suggesting that the hormones are important regulators of energy partitioning events in teleost fish. This concept is supported by observations of altered thyroid hormone economy in fasted fish and those subjected to dietary manipulation, particularly of dietary lipid content. Interestingly, plasma T_3 levels fall markedly in salmon as they undergo their reproductive migration. This has been interpreted as a mechanism that allows the mobilization of energy reserves, thus facilitating the migratory process.

Although low dietary iodide has been shown to produce thyroid hyperplasia in mammals and birds, it is remarkably difficult to induce such iodide-deficiency hyperplasia in fishes because the major source of iodide is obtained from the ambient water across the gill epithelium. Nevertheless, thyroid hyperplasia is not uncommon in wild fish and captive stock, even when the captive stock is maintained in seawater that is rich in iodide. Epizootics of thyroid hyperplasia are found in Great Lakes coho, chinook and pink salmon, and it has also been reported in *Salmo* and *Salvelinus* species from the same regions **(*Figs 11.6 & 11.7A-C*)**. Although originally considered to have

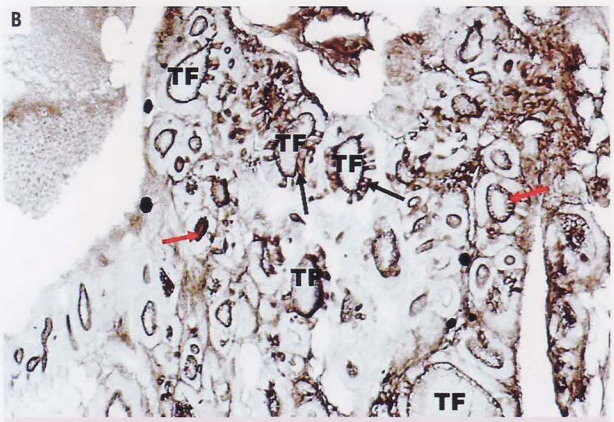

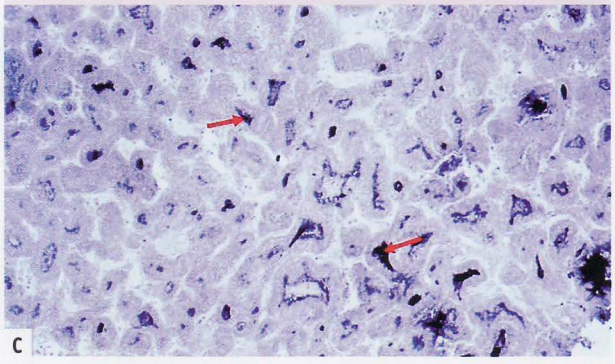

Fig 11.7B&C. Thyroid tissue from a nodule of Great Lakes coho salmon, immunostained with anti-thyroxine (T_4) antibody to show the distribution of T_4 in the tissue. The sites of T_4 presence show as brown. In (**B**), there is immunostaining in some thyrocytes as well as in the periphery of the colloid in the follicle lumena; in (**C**), which depicts a microfollicular lesion, there is virtual absence of T_4 immunostaining.

a dietary iodide-deficient aetiology, most evidence to date suggests that it is brought about by the presence of goitrogens (pollutants?) in the lake systems; a similar aetiology has been proposed to explain the presence of thyroid lesions in both bony and cartilaginous fish held in aquaria in many parts of the world (*Fig 11.7E*). Thyroid hypertrophy and hyperplasia, resembling the lesions found in oncorhynchids from the Great Lakes, is also found in trout fed diets that contain canola meal (*Fig 11.7D*). Canola meal, which contains the goitrogen glucosintolate, can be converted by tissues to form perchlorates that inhibit iodide incorporation into the thyroid tissue. Epizootics are sometimes seen also in farmed seabass; the history of these episodes often suggests a dietary cause, although this is rarely proved.

Fish with grossly visible lesions have a mass of reddish tissue extending around the ventral aorta, often forming a compact mass in the ventral and lateral pharyngeal areas. In severe cases the lesion invades bone, cartilage, muscles and blood vessels. This apparently aggressive behaviour

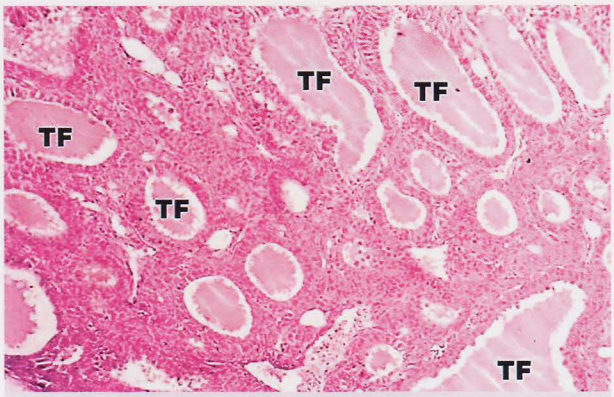

Fig 11.7D. Thyroid tissue from a rainbow trout fed a canola meal-based diet. Compare the appearance of the tissue with that shown in *Fig 11.4A*.

has led some workers to report the lesions as adenocarcinomas, but the invasive nature of the thyroid tissue is most likely a reflection of the unencapsulated nature of the gland in bony fish (*Fig 11.7F*). Histologically, the epithelial cells are generally large, and the colloid is either absent or greatly reduced (*Figs 7A-C*). Some researchers report that the lesions are alleviated by iodide prophylaxis, but that has not been found to be successful in all instances. The goitre in some species may be accompanied by increased numbers of melanomacrophage centres, which are occasionally encountered within the parenchyma of the thyroid in normal fish. Ulcerations and necrotic cysts, filled with blood-stained fluid, may also be present.

The thyroid is not infrequently involved in systemic diseases such as mycobacteriosis in which granulomas may cause compression atrophy or necrosis of follicles. Migrating parasites, such as digenetic metacercariae, may result in local inflammation of the thyroid, but the significance of this and other similar lesions is hard to ascertain, and the observations are usually regarded as incidental; certainly, an associated hypothyroidism is not reported, and nor are lymphocytic or autoimmune thyroiditis.

Interrenal tissue

Interrenal cells. The interrenal cells of teleosts lie along the major blood vessels (posterior cardinal veins) of the anterior (head) kidney and represent the equivalent of the mammalian adrenal cortex (*Fig 11.8A*). They have a pale eosinophilic granular cytoplasm with a prominent nucleolus in a rounded nucleus, although their histological appearance varies greatly in response to stress, drugs, salinity changes and reproduction.

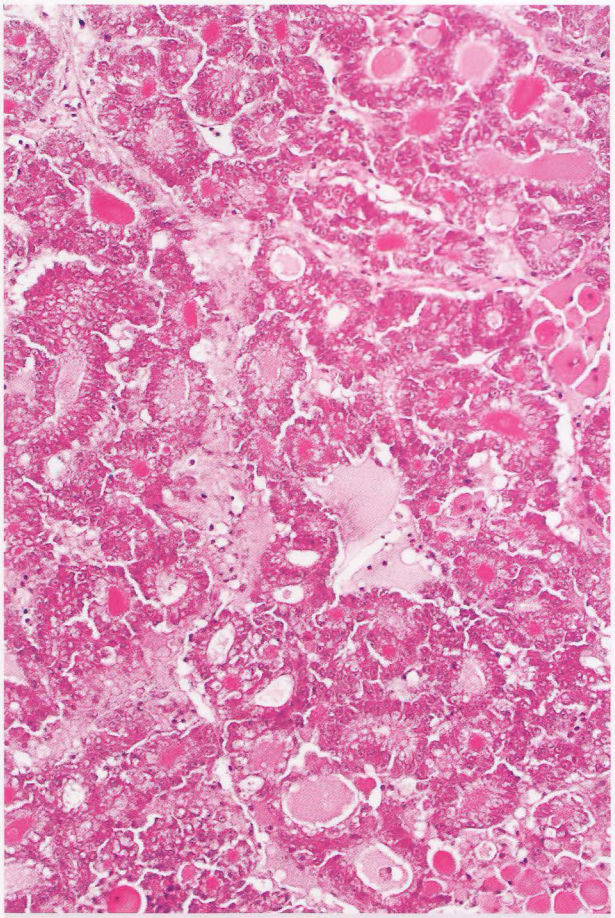

Fig 11.7E. Hypertrophied and hyperplastic thyroid tissue in this colloid goitre from a grunt held in a recirculating water facility. This same animal had invasion of thyroid tissue into each eye.

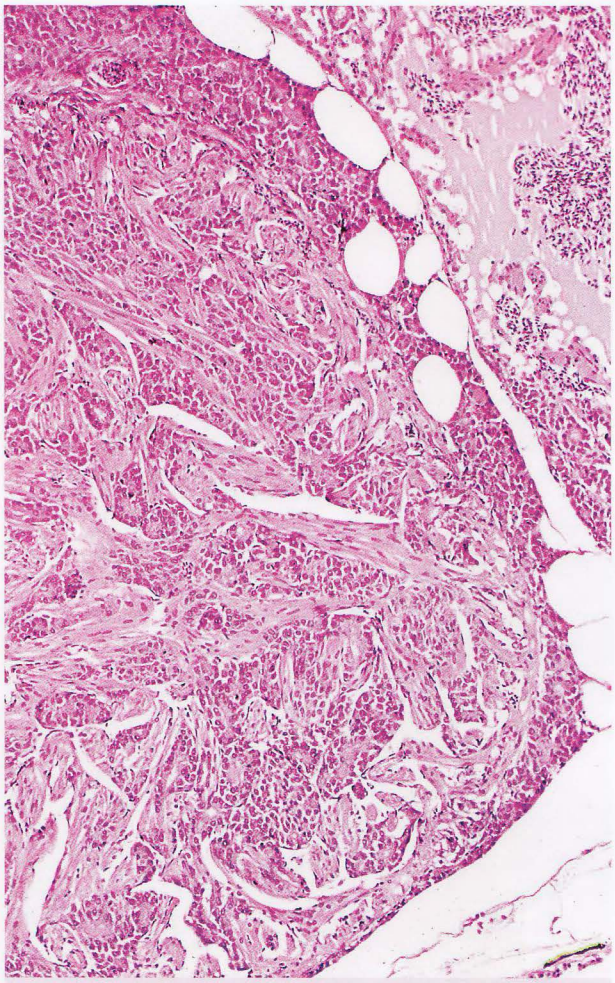

Fig 11.7F. Heart from diamond killifish with massively hyperplastic thyroid, showing infiltration of the atrial and ventricular myocardium by thyroid cells. Although probably not neoplastic, it is hard to imagine that the invading cells are not in some way compromising cardiac function, and that they are therefore behaving as a malignancy. Can we term this "malignant hyperplasia"?!

The interrenal cells produce corticosteroids, the most quantitatively important of which in teleosts is cortisol, although cortisone and 11-deoxycortisol have also been found. The corticosteroids exert their effect on target tissues by binding to receptors that are in the same family as the TR. The glucorticoid receptor (GR) is associated with a glucocorticoid response element (GRE), a palindromic sequence of nucleotide bases that lie up-stream of the genes that are under transcription control by these steroids. The presence of the GRE in the transcription region of genes is an indication of the need for glucocorticoid for the expression of that gene. As genomic sequencing becomes more prevalent, it is becoming apparent that glucocorticoids are required as a receptor ligand for the transcription of an estimated 20% of all genes that are normally expressed in the genome. Because of this multiple and complex action of these steroids, it is perhaps not surprising that their specific role in normal physiological processes is poorly understood in fish. Cortisol has potent effects on intermediary metabolism, and there is some evidence to suggest that cortisol is important for seawater adaptation in euryhaline species. In addition, cortisol levels are elevated after exposure of teleosts to some (but not all) stressors, suggesting that cortisol is a major factor in the stress response. Several stressors have been shown to increase the susceptibility of teleosts to disease, and treatment with cortisol appears to lower their resistance to fungal, bacterial and trypanosome infection and disease. It is therefore possible that there is a final common pathway mediated via cortisol that causes depopulation of lymphoid tissues with a concomitant lymphocytopoenia and possibly also a neutrophilia. It is also possible that the lymphocyte subpopulations show differential sensitivities, just as in mammals where T and

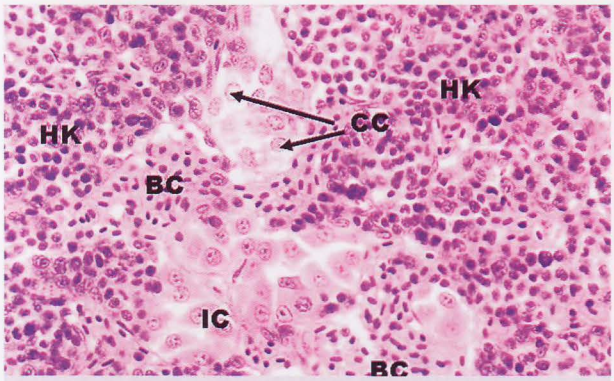

Fig 11.8A. Section through anterior (head) kidney of a juvenile rainbow trout showing clusters of steroid-secreting interrenal cells (IC) and chromaffin cells (CC) among the haematopoietic tissue of the kidney; BC = blood cells.

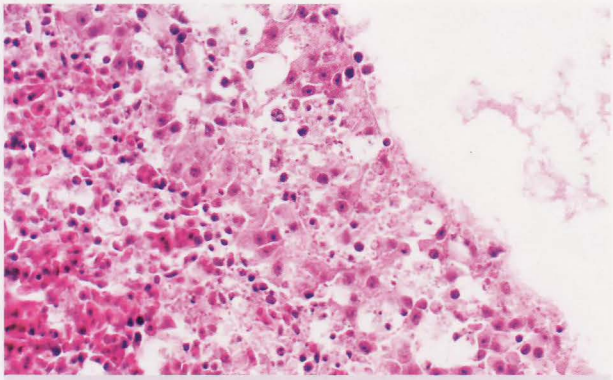

Fig 11.9. High power micrograph of anterior kidney from a goldfish with a severe and widely disseminated bacterial disease. There is marked necrosis of interrenal tissue and haemorrhage into the surrounding haematopoietic tissue.

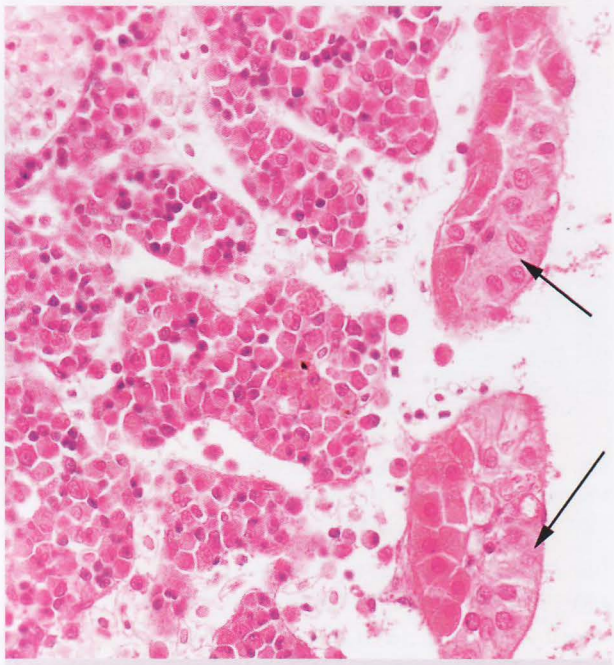

Fig 11.8B. Section through anterior kidney of fathead minnow to show interrenal cells lining vein. Pale staining chromaffin cells are also present (arrows).

B lymphocytes react differently to catecholamines. However, there are several well-established "distressful" situations (such as during extreme debilitating parasitaemia) when plasma cortisol levels are not elevated.

Corticosteroid synthesis and release are under the control of pituitary ACTH, and thus hypophysectomy leads to atrophy of the interrenal cells (as does any disease process that involves the pituitary gland). The cells become smaller with a smaller nucleus, an indistinguishable nucleolus, and they have less active mitochondria and Golgi. By contrast, cold, excess handling, bacterial endotoxins, anaesthesia, heavy metals, detergents, and the stress of spawning are just a few situations under which the interrenal cells become hypertrophic and may start to radiate in large numbers into the parenchyma of the kidney **(*Fig 11.8B*)**. At least some of these cellular responses appear to be due to the activation of the aryl hydrocarbon receptor (AhR) in the interrenal cells; there is evidence to show that the AhR is involved in the expression of the gene encoding for steroid acute regulatory (StAR) protein, which facilitates the transfer of cholesterol into the mitochondria of steroidogenic cells. The delivery of cholesterol into the inner compartment of the mitochondria, where it is converted to pregnenolone, is the rate-limiting step in interrenal (and gonadal) steroidogenesis.

As discussed above α-MSH also probably has corticotropic activity in many fish. α-MSH-regulated production of cortisol is not limited by the negative feedback control that regulates the ACTH-interrenal relationship. Thus, this peptide may permit the release of extremely large amounts of cortisol from the interrenal cells at certain stages of the life cycle (*e.g.* during the late stages of reproduction and migration in salmonids). A relationship between cortisol secretion and hormones other than ACTH and α-MSH has been suggested. These include GH, T_3, arginine vasotocin, catecholamines, angiotensin II, and several chemokines.

Interrenal cells are occasionally involved in acute bacteraemias and viraemias **(*Fig 11.9*)** and compression atrophy may also be found in the severe granulomatous nephritides. Whether these observations see a systemic reflection is unknown.

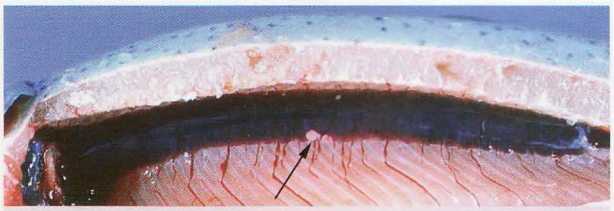

Fig 11.10. Gross view of kidney from brook trout showing corpuscles of Stannius located along the margin (arrow).

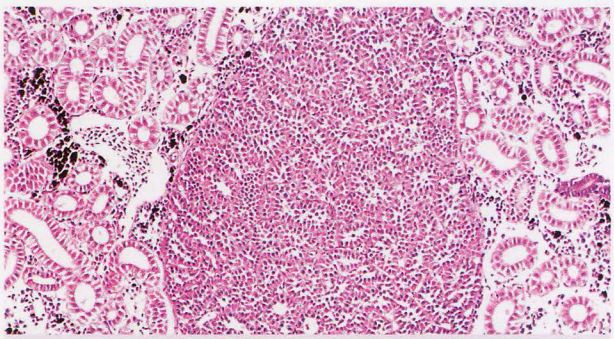

Fig 11.11. Histology of normal corpuscle of Stannius in Atlantic salmon.

Chromaffin cells. These cells are homologous to the adrenal medulla of mammals. They are mixed amongst the interrenal cells adjacent to the posterior cardinal veins of the head kidney in teleost fish ***(Figs 11.8A&B)***. They tend to be paler than the interrenal cells, and their nucleus is larger and more pleomorphic. However, as with the interrenal cells, their appearance varies considerab-ly in response to physiological, pharmacological and pathological situations. They synthesize and secrete epinephrine and norepinephrin, and dopamine and enkephalin have also been found to be present in some species. A common function in fish appears to be the regulation of heart rate and force of cardiac contraction. In addition, catecholamines have been shown to bring about systemic vasoconstriction and a branchial lamellar vasodilation in teleosts. Catecholamines have also been shown to alter respiratory functions of blood, and to modify the activity of the chloride cells in the gills.

The catecholamines are released into the blood following stressful situations; such release usually precedes the release of cortisol, and is generally considered to represent the so-called "primary stress response". Almost any unusual disturbance of the fish such as the sampling method itself, will elicit a release into the blood of the catecholamines; thus details of the roles of the hormones in normal physiology are difficult to establish.

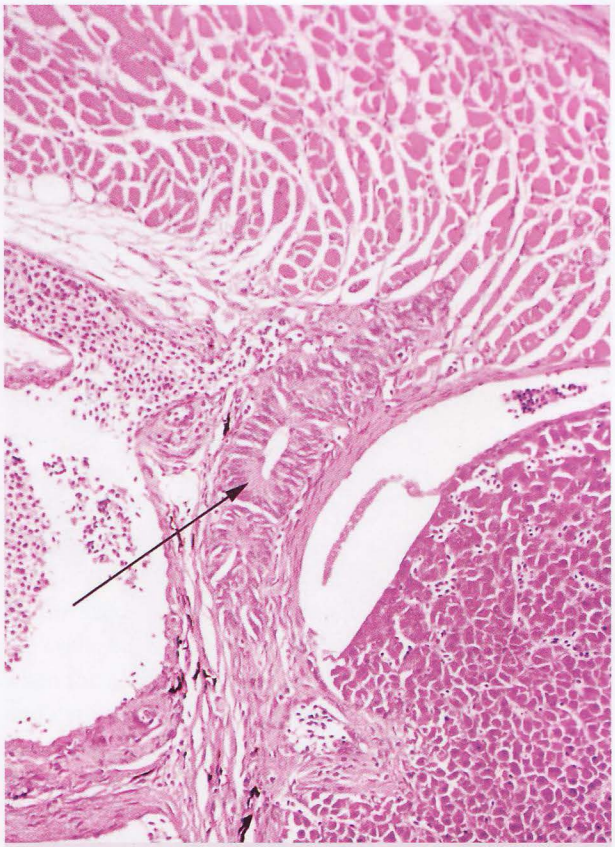

Fig 11.12. Ultimobranchial gland in young rainbow trout (arrow) situated beneath the oesophagus in the septum separating the heart from the abdominal cavity.

Renin-angiotensin system. The renin-angiotensin system is found throughout vertebrates except in cyclostomes and elasmobranchs. The enzyme renin is produced by the juxtaglomerular cells, modified smooth muscle cells of the afferent glomerular arterioles. The enzyme appears as cytoplasmic granules in the cells, and is released into the blood where it catalyses the conversion of angiotensinogen to form angiotensin I, which in turn is cleaved to form angiotensin II.

It is likely that angiotensin II acts in fish in a manner similar to mammals, in which there is an increase in blood pressure by smooth muscle contraction, and sodium retention by the kidney. However, the sodium-retention effect, which in mammals is regulated by aldosterone secreted from the adrenal cortex, is probably regulated by a different mechanism in fish. Moreover, because blood pressure is much lower in fish than in mammals, there may not be a role for angiotensinogen II in the local regulation of blood pressure in the microcirculation of tissues, as there is in mammals.

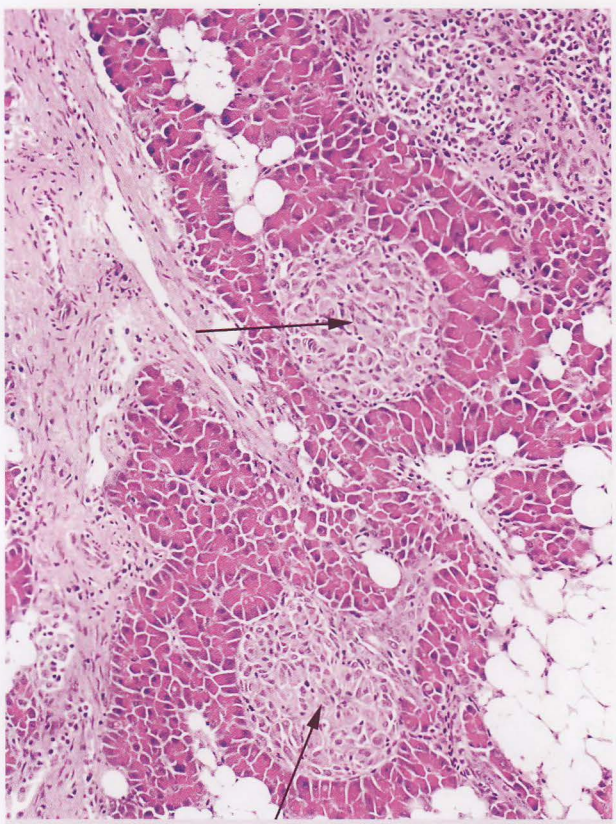

Fig 11.13A. Islets of Langerhans in salmon (arrows). The vaccine-related granulomatous peritonitis (top right) is starting to encroach on pancreas.

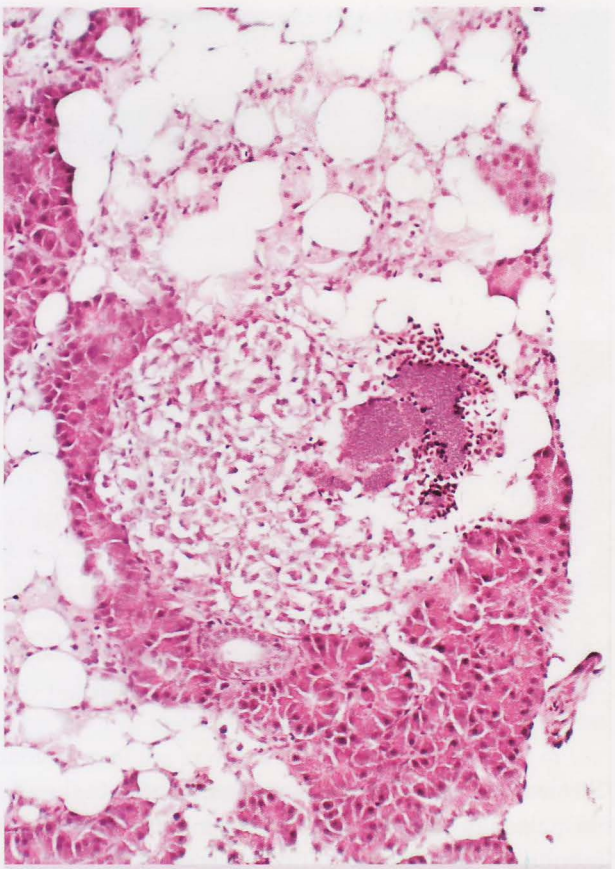

Fig 11.13B. Islet involvement in furunculosis in salmonid.

In eels, plasma renin levels increase when the fish are transferred from fresh water to seawater, and they decrease in eels transferred from seawater to fresh water, providing some evidence of an osmoregulatory role for the renin-angiotensin system. One possible mode of action of angiotensin II is to initiate drinking of seawater, one of the adaptations of marine fishes, and reduce glomerular filtration rates. In trout, haemorrhage severe enough to cause a reduction in renal perfusion pressure will activate a baroreceptor response and renin release. Of interest, renin levels in trout also increase with increasing levels of environmental non-ionized ammonia, thereby causing a rise in aortic pressure, and possibly an associated rise in glomerular filtration rate. Could this help explain the eosinophilic droplets seen in increasing numbers in the cytoplasm of renal tubular epithelial cells of fish exposed to high levels of ammonia? ***(see Fig 4.10).***

No specific pathological changes of the juxtaglomerular cells have been described, but the involvement of the kidney in so many acute and chronic inflammatory diseases suggests that it is a distinct possibility. In particular, one wonders if the oedema sometimes associated with the severe granulomatous nephritides such as bacterial kidney disease may in part be the result of reduced renin release due to compression atrophy of juxtaglomerular cells.

Corpuscles of Stannius. These discrete encapsulated structures are probably unique to holostean and teleostean fish. They are situated in the renal parenchyma, usually at the lateral borders and approximately mid-way along the length ***(Fig 11.10)***. In some species, such as salmonids, they lie just beneath the capsule and appear as pale white nodules. In other species they lie deeply embedded within the parenchyma and are not visible except on cut surfaces. They should not be mistaken for granulomas, although they often are!

The glands are divided into cords or lobules by connective tissue septae, that are well-supplied with blood vessels and nerves; they have a portal system with blood derived from the caudal vein that then drains back into the renal parenchyma. In some species the lobules are composed of two cell types, granular (type I) and non-granu-

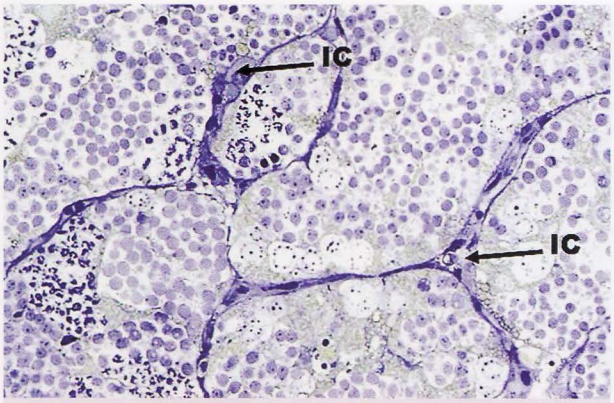

Fig 11.14A. Testicular tissue of a sexually immature goldfish showing the lobular nature of the seminiferous tubules. Lipid-rich Sertoli cells can be identified by the brown stain, which represents osmium-stained lipid droplets in the Sertoli cell cytoplasm. Only small numbers of interstitial cells (IC) are present. Much of the gonad comprises early stages of germ cells, but no spermatids are present. *Epon-embedded tissue, Azure II.*

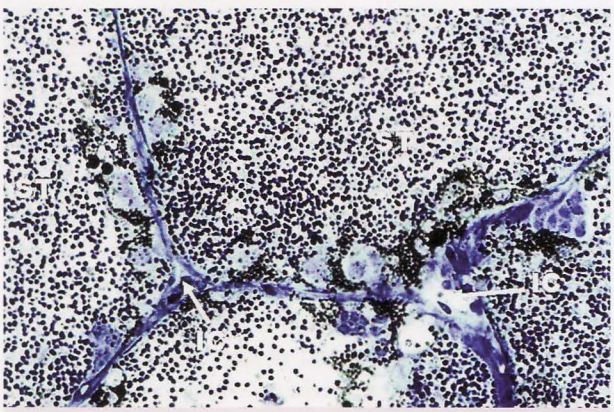

Fig 11.14B. A later stage of maturation than *Fig 11.4A* showing spermatids in lumen of lobules. *Epon-embedded tissue, Azure II.*

lar (type II). Although the functions of the corpuscles of Stannius are incompletely understood, they are known to synthesize a protein or glycoprotein hormone called stanniocalcin, which is involved in calcium homeostasis. The hormone blocks branchial uptake of calcium, possibly by blocking the passive entry of calcium via calcium ion channels. Removal of the gland from teleosts (termed either Stanniectomy or Stanniosomatiectomy) causes hypercalcaemia, suggesting that it is a potent hypocalcaemic agent.

As with the other renal endocrine elements, the corpuscles of Stannius are occasionally seen to be involved in acute viraemias and bacteraemias, and may be compressed in the severe granulomatous diseases. They are also occasionally involved in nephrocalcinosis.

Ultimobranchial gland

The gland is derived from the last branchial pouch in embryonic fish, and in the adult lies just ventral to the oesophagus in the transverse septum separating the heart from the abdominal cavity **(*Fig 11.12*)**. In some species it is a single organ whereas in most others, including salmonids, it is paired. It comprises small follicles of columnar cells supplied by a capillary network that drains directly into the sinus venosus. The cells produce calcitonin, a protein hormone that decreases plasma calcium levels in mammals. In fact, salmon calcitonin has a greater biological potency in mammals than any of the known mammalian calcitonins because of its longer half-life in the circulation. However, to date, there has been little conclusive evidence of a direct involvement of calcitonin in calcium homeostasis in fish. Calcitonin may be involved in calcium regulation at specific parts of a life cycle, such as during egg production and ovulation, when the ultimobranchial epithelium decreases in height and cytoplasmic granularity, and when calcitonin levels in females are higher than in males. Specific roles for the hormone have yet to identified.

Pancreatic and gastrointestinal hormones

The endocrine portion of the pancreas is represented by the islets of Langerhans, which in most teleosts, as they are in mammals, are scattered throughout the exocrine pancreas **(*Fig 11.13*)**. In some species the islets are very large, often visible grossly, and form "Brockman bodies" or "principal islets". The fine capsule that encompasses the islets encloses several cell types including alpha cells (glucagon-like peptide), beta cells (insulin) and delta cells (SRIF). The hormone, pancreastatin, which has been shown to inhibit the release of insulin in response to glucose in mammals, has also been found in the islets of trout.

Alterations in blood insulin levels in teleosts appear to be much more closely related to changes in amino acid metabolism, and there is some debate as to whether insulin is involved to any significant degree in carbohydrate metabolism of carnivorous fish which usually have a relatively low dietary intake of carbohydrates. Carnivorous fish, including the salmonids, are generally considered to be essentially diabetic as regards their ability to cope with dietary glucose. However, insulin levels are markedly elevated in trout shortly after feeding experimental

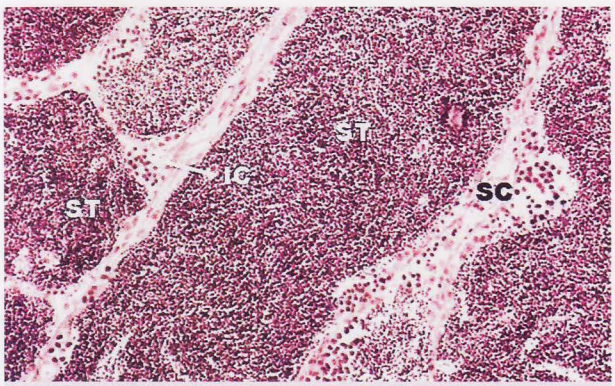

Fig 11.14C. Testis of a sexually mature carp. This tissue was fixed in Bouin's fluid and embedded in paraffin wax and lacks the detail of Figs *11.14 A&B*, but it shows the Sertoli cells (SC) and interstitial cells (IC) quite well; note the abundance of spermatids (ST) in the lumen of the testicular lobules.

diets containing high carbohydrate levels, suggesting a possible connection of insulin to the regulation of carbohydrate metabolism.

The role of glucagon in fish is poorly understood. Indeed, fish glucagon has yet to be isolated and chemically characterized, and much of the information available regarding the effect of glucagon on fishes has been obtained using mammalian glucagon preparations. Mammalian glucagon generally elicits hyperglycaemia and results in metabolic changes in the liver that are indicative of a role in gluconeogenesis.

As with glucagon, the role(s) of islet SRIF in fishes is poorly understood. SRIF-14 is secreted from the hypothalamus in most vertebrates, where it plays a regulatory role by inhibiting the secretion of GH from the pars distalis. The SRIF secreted in the islets of Langerhans is a larger peptide; SRIF-22 and SRIF-24 have been found in catfish and salmonids, respectively. In mammals, SRIF appears to act at the level of the islet cells by inhibiting the release of both insulin and glucagon from the alpha and beta islet cells. In this manner SRIF has a modifying effect on the glucagon and insulin response to changes in blood metabolites. SRIF-inhibition of insulin secretion has been found in teleosts. In addition, SRIF levels in the major blood vessels around the gastrointestinal tract alter depending on the type of food being digested within the gut, suggesting that SRIF may also play an endocrine role at sites other than those of the islets themselves. It is unknown whether similar interactions occur in fishes, although the morphological similarities between fish and tetrapods might indicate a similar relationship be-

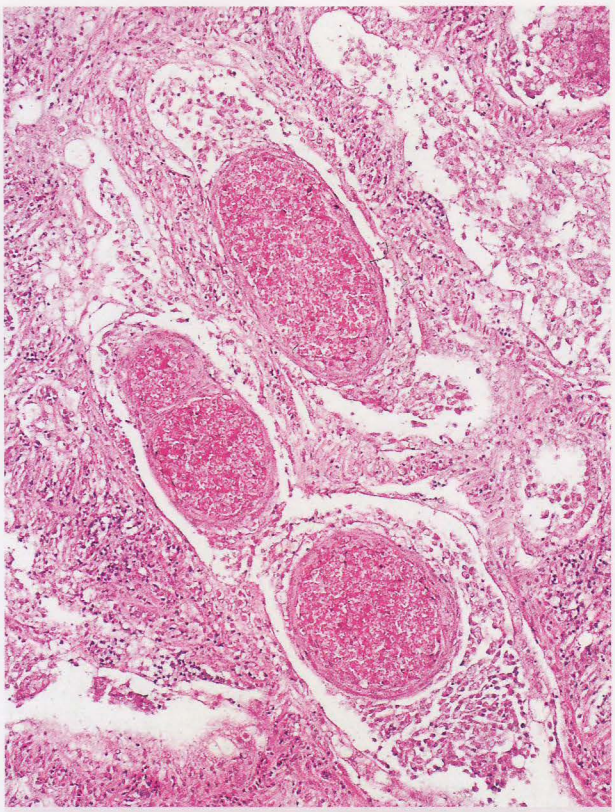

Fig 11.15. Testis of seabass almost obliterated by *Sphaerospora* myxozoan infection.

tween the islet cells in the two groups. SRIF does appear to have actions at non-pituitary and non-islet sites in fishes. It affects the binding of GH to hepatocytes and thus inhibits the expression of mRNA encoding for IGF-1, which together with its insulin-suppressive actions might be one factor regulating growth and energy partitioning events.

The endocrine pancreas is frequently involved in conditions that affect the exocrine portion, including bacteraemias and viraemias **(see Fig 7.29)**, parasitic diseases such as coccidiosis that may almost totally obliterate the entire organ, and "pancreas disease", an alphaviral disease of farmed Atlantic salmon in which rhabdomyopathy is a major lesion, and which is associated with consumption of antioxidants **(see Fig 7.30)**. Rancid silkworm pupae were incriminated as the cause of "Sekoke disease" of farmed carp, a condition reported to result in a diabetes-like syndrome with degranulation of islet beta cells, and degeneration of capillaries in retina and glomerulus as just some of the lesions. A severe degenerative myopathy of skeletal muscle was also described in this disease and may in fact be the most significant lesion.

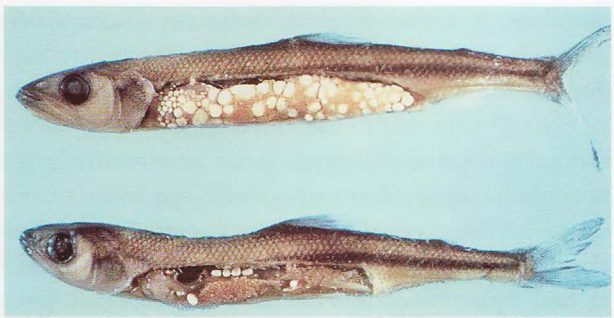

Fig 11.16. Smelt with microsporidian *Glugea* infection of the ovary. Infected cells are creamy and markedly hypertrophic.

The roles of the gastro-intestinal hormones in fish are not well understood. Gastrin is produced by the stomach wall (in those species that have one) and leads to acid production by the mucosa. It also stimulates the growth of gastric and intestinal mucosa, and as in other vertebrates, histamine leads to a dose-dependent release of acid. Immunoreactive secretin, which in mammals leads to pancreatic secretion, has been shown by immunohistochemistry to be present in teleosts. Similarly, many mammalian or mammalian-like gastrointestinal neuropeptides have been documented as being present in the intestinal tract of fish, including bombesin, cholecystokinin, enkephalin, gastric inhibitory peptide, ghrelin, neuropeptide-Y, neurotensin, serotonin, tachykinins, and vasoactive peptide, but their various functions remain to be determined.

Reproductive system

Teleost fish exhibit tremendous variety in breeding patterns and although the presence of both males and females is the commonest pattern, self-fertilizing hermaphroditism, parthenogenesis (development from an unfertilized egg) and gynogenesis (spermatozoa stimulates egg to develop but does not contribute genetic material) are all found. Moreover, sex reversal in adults is very common in coral-reef fish. The number of eggs produced by a particular species has a rough parallel with the amount of care accorded them: thus a pelagic species such as the cod that broadcasts the eggs in open water, may produce many millions per season, whereas sticklebacks that build complex nests and protect the developing eggs, may produce only 30-100. Compare too with fish such as the guppy that incubates the eggs internally and bears live young.

Testes. These are either lateral paired organs, or a single fused medial organ situated in the dorsal abdomen



Fig 11.17. Microsporidian-induced xenomas within ovary of this zebra danio.

below the swimbladder. They may vary greatly in size depending on the age of the fish and the season. Mature spermatozoa are conducted to the genital orifice by two *ducti deferens* that merge caudally. The testis itself lies within a thin *tunica albuginea* and comprises tubules or lobules that contain spermatogonia either along their entire length (salmonids and cyprinids amongst others) or at their distal end (antheriniforms). The caudal portion of the testis in some species such as ictalurids and some cyprinids is comprised of non-germinal secretory epithelial cells that may be involved in sperm storage or supplying nutrients to the sperm, or in contributing to the fluid component of the ejaculate.

The tubules or lobules of the spermatogenic component of the testis **(*Figs* 11.14A-C)** comprise Sertoli cells that, as in mammals, form an uninterupted epithelial barrier between the lumen and the extracellular compartment (the blood-testis barrier). In the interstitium are found incomplete layers of boundary cells around each tubule or lobule, and small numbers of Leydig cells; a lymphatic system akin to that seen in mammals is not present.



Fig 11.18. Ovarian cyst taken from a sexually mature Arctic charr. *Courtesy of M.N. Khan.*

Progesterone, 17α-hydroxyprogesterone, 17, 20β-dihydroxy-4-pregnen-3-one, androstenedione, 11β-hydroxyandrostenedione, testosterone, 11β-hydroxytestosterone, 11-ketotestosterone and 17β-estradiol have been isolated from the testes of several teleosts. The details of the interactions between the Sertoli and Leydig cells in the steroidogenic pathways in fishes are not well understood.

Inflammatory changes including haemorrhage may accompany bacteraemias and viraemias, or trauma from migrating parasites such as the nematode *Philometra* that may encyst within the testes, or in the case of the New Zealand snapper, cause total atrophy. Granulomas are also encountered in diseases such as bacterial kidney disease and mycobacteriosis. As in mammals, release of tubular antigens results in an autoimmune response and orchitis, and this has formed the basis for an immunization process aimed at sterilizing intensively cultured fish. Nevertheless, even in widely disseminated bacterial infections, the testes often remain remarkable oases of histological relative normality, a feature of probably no small comfort to the fish! A few protozoa are found in the testes **(*Fig 11.15*)**, examples being the myxozoans *Agarella gracilia* Kudo in the S. American lungfish *Lepidosiren paradoxa*, *Sphaerospora testicularis* in seabass, the microsporidian *Pleistophora longifilis* Schuberg which is recorded from the testis of *Barbus flaviatilis* in Germany, and the coccidian *Eimeria brevoortiana*, sporocysts of which are present in the testis of menhaden and are shed with the milt. Parasitic castration is occasionally seen due to the space-occupying effects of parasites such as the larval tapeworm *Ligula* present within the peritoneal cavity **(*see Fig 7.34*)**, although indirect effects of a heavy ectoparasitic load may also cause failure of proper maturation of gonads.

Ovary. Ovarian organization varies greatly in teleosts as might be expected in a group with egg layers as well as live-bearers. Typically, ovaries are paired or bilobed elongated structures suspended from the dorsal abdominal wall by mesovaria and enclosed by a *tunica albuginea* containing fibrous tissue and smooth muscle. A short oviduct conducts eggs to the outside via an exit between the anus and urinary pore. Salmonids do not have a complete oviduct and eggs are released dorsally to empty into the peritoneal cavity, gaining access to the outside via a pore behind the anus. The parenchyma of the ovary comprises lamellae containing germinal and follicular epithelium in a well-vascularized connective tissue stroma. Development of eggs from oogonia starts within the lamellae but they are shed into the ovarian lumen with an investment of thecal cells: thus a follicle comprises oocyte, a hyaline zona radiata (*zona pellucida* in some texts), columnar follicular cells (*zona granulosa*), and theca on the outside. The thecal and granulosal cells comprise the steroidogenic tissue of the ovary. The thecal cells, under the primary influence of gonadotropins, synthesize androgens, such as androstene dione and testosterone as their primary end product steroids. Some of these pass into the blood system, and some pass into the granulosa cells where they are converted, by P450 aromatase activity into oestrogens. The primary oestrogen in teleost fishes is 17β-estradiol, but smaller amount of estriol are also produced. Prior to ovulation, the expression of enzymes that promote the production of androgens is reduced and steroidogenic enzymes are expressed that convert pregnenolone into progestogens that promote the final stages of oocyte maturation and probably also the ovulation process. These so-called maturation inducing steroids (MIS), in addition to their role at the gonad level, are also conjugated by the liver to produce soluble forms of steroids that are released and act as pheromones in the coordination of spawning.

The primary ovarian oestrogen, 17β-estradiol is one of the primary factors involved in the stimulation of synthesis of vitellogenin, the phospholipoprotein that is a main constituent of the yolk of the oocytes. 17β-estradiol also promotes the mobilization of lipid reserves thus enhancing serum triglycerides levels. The incorporation of vitellogenin and triglycerides into the oocytes accounts

for the increased size of these cells during gonadal maturation. 17β-estradiol also stimulates hepatic synthesis of proteins that form the chorion of the oocyte. These cellular responses to 17β-estradiol were once thought to act solely via oestrogen receptors (ERs) that acted as ligand-activated transcription factors, thus regulating gene expression. However, evidence has accrued that shows oestrogen interactions with plasma membrane associated ERs, and possibly also with orphan receptors, such as ER-related receptor alpha. In addition to the membrane associated ERs, the MIS progestogens in fish are also thought to promote ovulation by liganding with membrane associated progestogens receptors (PRs) on the oocytes. Thus the steroids exert both local and peripheral effects. Some steroids (as well as thyroid and other hormones) are present in the oocyte. These may play a role in early development of embryos, although evidence to date shows that the embryo can biotransform biologically-active steroids to produce molecules that do not have a marked affinity for steroid receptors.

Histological examination of ovarian tissue commonly reveals eggs at all stages of development and degeneration and atresia. For some species, such as cyprinids, this is due to the fact that selected groups of oocytes undergo maturation, with spawning activity through a reproductive period being rhythmic. For salmonid species that have synchronized spawning of all of the viable oocytes at a single time, the appearance of the oocytes may be more uniform, but even here there will be variation due to the degeneration of some oocytes before ovulation. In these cases, granulosa cells invade prior to macrophage invasion.

Failure of ovulation leads to atresia and sometimes extensive fibrosis and adhesions to the peritoneal cavity or viscera. Large numbers of melanomacrophages within the stroma are a frequent accompaniment to these changes. Excessively rough handling at manual stripping can cause similar lesions. Post-spawning peritonitis due to enteric and other bacteria is another possible consequence of such procedures.

Bacterial infections of the ovary include *Renibacterium salmoninarum*, the organism being present within the eggs at ovulation. Colonies of bacteria are seen within the parenchyma in diseases such as furunculosis and vibriosis and may lead to heavily infected spawning fluids. Protozoan infections include the myxozoan *Wardia ovinocua* Kudo in *Lepomis humilis* and the microsporidians *Glugea* **(Figs 11.16&17)** and *Pleistophora ovariae*, a specific infection of the golden shiner *Notemigonus crysoleucas* in which the ovaries are the prime target. The large cysts are considered to reduce fecundity, cause pressure atrophy of adjacent uninfected ova and parenchyma, and lead to sterility.

Philometra is found in the ovaries as well as testes and although there may be little effect on egg production, in some cases there is haemorrhage, fibrosis, and an increased number of melanomacrophages. Visceral parasites such as the larval cestode *Ligula* will cause pressure atrophy of ovaries, and a heavy ectoparasitic load may inhibit proper maturation of eggs probably due to competition for nutrients: malnutrition can of course have a similar effect. Ovarian abnormalities, including gonadal cysts **(Fig 11.18)** that are not related to infectious disease, and numbers of atretic follicles are higher in fish from heavily polluted sites and there may be impaired egg production. The appearance of intersex fish, displaying either testicular-like tissue in the ovary, or ovarian follicles in the testis, has also been reported in fish taken from contaminated sites. Moreover, the phenotypic females of hybrid forms may display testicular-associated tumours such as seminomas, dysgerminomas, teratomas, and Sertoli cell tumours.

References

Aluru, N., Renaud, R., Leatherland, J.F. and Vijayan, M.M. (2005) Ah receptor-mediated impairment of interrenal steroidogenesis involves StAR protein and P450scc gene attenuation in rainbow trout. *Toxicology Science* 84:260-269.

Arillo, A., Uva, B. and Vallarino, M. (1981) Renin activity in rainbow trout (*Salmo gairdneri* Rich.) and effects of environmental ammonia. *Comparative Biochemistry and Physiology* 68:307-311.

Arnold-Reed, D.E. and Balment, R.J. (1989) Steroidogenic role of the caudal neurosecretory system in the flounder, *Platichthys flesus*. *General and Comparative Endocrinology* 76:267-273.

Bailey, J.R. and Randall, D.J. (1981) Renal perfusion pressure and renin secretion in the rainbow trout, *Salmo gairdneri*. *Canadian Journal of Zoology* 59:1220-1226.

Ball, J.N. and Baker, B.I. (1969) The pituitary gland: anatomy and histophysiology. ***In Fish Physiology, eds.*** Hoar, W.S. and Randall, D.J. Vol. 2: 1-110. New York: Academic Press.

Balment, R.J., Warne, J.M., Tierney, M. and Hazon, N. (1993) Arginine vasotocin and fish osmoregulation. *Fish Physiology and Biochemistry* 11:189-194.

Barrington, E.J.W. and Dockray, G.J. (1972) Cholecystokinin-pancreozymin-like activity in the eel, (*Anguilla anguilla*). *General and Comparative Endocrinology* 19:80-87.

Batten, T.F.C., Cambre, M.L., Moons, L. and Vandesande, F. (1990) Comparative distribution of neuropeptide-immunoreactive systems in the brain of the green molly, *Poecilia latipinna*. *Journal of Comparative Neurology* 302:893-899.

Benjamin, M. (1985) Experimental studies on cysts in the prolactin zone of the pituitary in the nine-spined stickleback, *Pungitius pungitius* L. *Journal of Comparative Pathology* 95:57-64.

Bjenning, C. and Holmgren, S. (1988) Neuropeptides in the fish gut. An immunohistochemical study of evolutionary patterns. *Histochemistry* 88:155-163.

Björnsson, B.T., Haux, C., Bern, H.A. and Deftos, L.J. (1989) 17β-Estradiol increases plasma calcitonin levels in salmonid fish. *Endocrinology* 125:1754-1760.

Björnsson, B.T., Johansson, V., Benedet, S., Einarsdottir, I.E., Hildahl, J., Agustsson, T. and Jönsson, E. (2002) Growth hormone endocrinology of salmonids: Regulatory mechanisms and mode of action. *Fish Physiology and Biochemistry* 27:227-242.

Bonnelye, E., Kung, V., Laplace, C., Galson, D.L. and Aubin, J.E. (2002) Estrogen receptor-related receptor alpha impinges on the estrogen axis in bone: potential function in osteoporosis. *Endocrinology* 143:3658-3670.

Brinn, J.E. (1973) The pancreatic islets of bony fishes. *American Zoologist* 13:653-665.

Burckhardt-Holm, P. and Holmgren, S. (1989) A comparative study of neuropeptides in the intestine of two stomachless teleosts (*Poecilia reticulata, Leucisces idus melanotus*) under conditions of feeding and starvation. *Cell and Tissue Research* 225:245-252.

Burke, M.G. and Leatherland, J.F. (1984) Seasonal changes in testicular histology of brown bullheads, *Ictalurus nebulosus Lesueur*. *Canadian Journal of Zoology* 62:1185-1194.

Cameron, C., Moccia, R.D. and Leatherland, J.F. (2005) Growth hormone secretion from arctic charr (*Salvelinus alpinus*) pituitary gland *in vitro*: Effects of somatostatin-14, insulin-like growth factor-I, and nutritional status. *General and Comparative Endocrinology* 141:93-100.

Chakraborti, P.K., Weisbart, M. and Chakraborti, A. (1987) The presence of corticosteroid receptor activity in the gills of the brook trout, *Salvelinus fontinalis*. *General and Comparative Endocrinology* 66:323-332.

Chan, D.K.O. (1975) Cardiovascular and renal effects of urotensins I and II in the eel, *Anguilla rostrata*. *General and Comparative Endocrinology* 27:52-61.

Chan, D.K.O. (1977) Comparative physiology of the vasomotor effects of neurohypophysial peptides in the vertebrates. *American Zoologist* 17:751-761.

Chan, D.K.O. and Woo, N.Y.S. (1977) Effect of glucagon on the metabolism of the eel, *Anguilla japonica*. *General and Comparative Endocrinology* 35:216-225.

Chan, D.K.O. and Bern, H.A. (1976) The caudal neurosecretory system: A critical evaluation of the two hormone hypothesis. *Cell and Tissue Research* 174:339-354.

Conlon, J.M., Deacon, C.F., Hazon, N., Henderson, I.W. and Thim, L. (1988) Somatostatin-related and glucagons-related peptides with unusual structural features from the European eel (*Anguilla anguilla*). *General and Comparative Endocrinology* 72:181-189.

Coupland, R.E. (1979) Catecholamines. pp. 309-340 ***In Hormones and Evolution, ed.*** Barrington, E.J.W. Vol. 1, Academic Press, London.

Cristy, M. (1974) Effects of prolactin and thyroxine on the visual pigments of trout, *Salmo gairdneri*. *General and Comparative Endocrinology* 23:58-62.

Danulat, E. and Mommsen, T.P. (1990) Norepinephrine: a potent activator of glycogenolysis and gluconeogenesis in rockfish hepatocytes. *General and Comparative Endocrinology* 78:12-22.

Daughady, W.H., Kapadia, M., Yanow, C.E., Fabrick, K. and Mariz, I.K. (1985) Insulin-like growth factor I and II of non-mammalian sera. *General and Comparative Endocrinology* 59:316-325.

Davis, M.S. and Shuttleworth, T.J. (1985) Pancreatic peptides regulate Cl- secretion in the marine teleost gill. *Peptides* 6:379-382.

Dawauchi, H. (1988) The melanotropic peptides: structure and chemistry. ***In The Melanotropic Peptides***, Vol. I, ***ed.*** Hadley, M.E., CRC Press, Boca Raton.

Dockray, G.J. (1978) Comparative biochemistry and physiology of gut hormones. *Annual Reviews of Physiology* 41:83-96.

Duston, J. and Bromage, N. (1986) Photoperiodic mechanisms and rhythms of reproduction in the female rainbow trout. *Fish Physiology and Biochemistry* 2:35-51.

Ehrman, M.M., Melroe, G.T., Moore, C.A., Kittilson, J.D. and M.A. Sheridan. (2002) Nutritional regulation of somatostatin expression in rainbow trout, *Oncorhynchus mykiss*. *Fish Physiology and Biochemistry* 26:309-314.

Eilertson, C.D., O'Connor, P.K., and Sheridan, M.A. (1991) Somatostatin-14 and somatostatin-25 stimulate glycogenolysis in rainbow trout, *Oncorhynchus mykiss*, liver incubated *in vitro*: a systemic role for somatostatins. *General and Comparative Endocrinology* 82:192-196.

Epple, A., Hathaway, C. B. and Nibbio, B. (1989) Circulatory catecholamines in the eel: origins and functions. *Fish Physiology and Biochemistry* 7:273-278.

Epple, A. and Lewis, T.L. (1973) Comparative histophysiology of the pancreatic islets. *American Zoologist* 13:567-590.
Falcón, J. and Collin, J.-P. (1991) Pineal-retinal relationships: rhythmic biosynthesis and immunocytochemical localization of melatonin in the retina of the pike (*Esox lucius*). *Cell and Tissue Research* 265:601-611.
Falcón, J., Thibault, C., Begay, V., Zachmann, A. and J.-P. Collin, J-P. (1992) Regulation of the rhythmic melatonin secretion by fish pineal photoreceptor cells. pp. 167-198 ***In*** *Rhythms in Fishes,* ***ed***. Ali, M.A. Plenum Press, New York.
Farbridge, K.J. and Leatherland, J.F. (1986) A comparative immunohistochemical study of the pars distalis in six species of teleost fishes. *Fish Physiology and Biochemistry* 1:63-74.
Flik, G. (1990) Hypocalcin physiology. ***In*** *Progress in Comparative Endocrinology,* ***eds***. Epple, A., Scanes, C.G. and Stetson, M.H. Wiley-Liss, New York.
Foster, G.D. and Moon, T.W. (1987) Metabolism in sea raven (*Hemitripterus americanus*) hepatocytes: The effects of insulin and glucagon. *General and Comparative Endocrinology* 66:102-115.
Foster, G.D. and Moon, T.W. (1986) Cortisol and liver metabolism of immature American eels, *Anguilla rostrata* (LeSeur). *Fish Physiology and Biochemistry* 1:113-124.
Fryer, J.N. (1989) Neuropeptides regulating the activity of goldfish corticotropes and melanotropes. *Fish Physiology and Biochemistry* 7:21-27.
Grier, H.J., Linton, J.R., Leatherland, J.F. and De Vlaming, V.I. (1980) Structural evidence for two different testicular types in teleost fishes. *American Journal of Anatomy* 159:331-345.
Haruta, K., Yamashita, T. and Kawashima, S. (1991) Changes in arginine vasotocin content in the pituitary of the medaka (*Oryzias latipes*) during osmotic stress. *General and Comparative Endocrinology* 83:327-336.
Holloway, A.C. and Leatherland, J.F. (1998) Neuroendocrine regulation of growth hormone secretion in teleost fishes with emphasis on the involvement of gonadal sex steroids. *Reviews Fish Biology* 8:1-21.
Holloway, A.C., Lin, L. and Leatherland, J.F. (1999) Localization of the N-methyl-D-aspartate R1 receptor in the pituitary gland of immature rainbow trout (*Oncorhynchus mykiss*). *Anatomical and Histological Embryology* 28:199-203.
Holloway, A.C., Sheridan, M.A. and Leatherland, J.F. (1997) Estradiol inhibits plasma somatostatin 14 (SRIF-14) levels and inhibits the response of somatotrophic cells to SRIF-14 challenge in vitro in rainbow trout, *Oncorhynchus mykiss. General and Comparative Endocrinology* 106:407-414.
Holloway, A.C., Sheridan, M.A., Van Der Kraak, G. and Leatherland, J.F. (1999) Correlations of plasma growth hormone with somatostatin, gonadal steroid hormones and thyroid hormones in rainbow trout during sexual recrudescence. *Comparative Biochemistry and Physiology* 123B:251-260.
Holmgren, S., Vaillant, C. and Dimaline, R. (1982) VIP-, substance P-, gastrin/CCK-, bombesin-, somatostatin- and glucagon-like immuno-reactivities in the gut of the rainbow trout, *Salmo gairdneri. Cell and Tissue Research* 223:141-150.
Iigo, M., Kesuka, H., Aida, K. and Hanyu, L. (1991) Circadian rhythms of melatonin secretion from superfused goldfish (*Carassius auratus*) pineal glands *in vitro*. *General and Comparative Endocrinology* 83:152-158.
Kaiya, H., Kojima, M., Hosoda, H., Riley, L.G., Hirano, T., Grau, E.G. and Kangawa, K. (2003) Amidated fish ghrelin: Purification, cDNA cloning in Japanese eel and its biological activity. *Journal of Endocrinology* 176:415-423.
Karsi, A., Waldbieser, F.C., Small, B.C., Liu, Z. and Wolters, W.R. (2004) Molecular cloning of proopiomelanocortin cDNA and multi-tissue mRNA expression in channel catfish. *General and Comparative Endocrinology* 137:312-321.
Kenyon, C.J., Chester Jones, I. and Dixon, R.N.B. (1980) Acute responses of the freshwater eel (*Anguilla anguilla*) to extracts of the corpuscles of Stannius opposing the effects of stanniosomatiectomy. *General and Comparative Endocrinology* 41:531-538.
Khan, M.N., Renaud, R.L. and Leatherland, J.F. (1996) Plasma steroid hormone provile in an anovulatory Arctic charr, *Salvelinus alpinus* (L.), exhibiting ovarian cysts. *Journal of Fish Diseases* 19:389-394.
Khan, M.N., Renaud, R.L. and Leatherland, J.F. (1997) Steroid metabolism by embryonic tissues of Arctic charr, *Salvelinus alpinus*. *General and Comparative Endocrinology* 105:344-357.
Lamers, A.E., Flik, G., Atsma, W. and Wendelaar Bonga, S.E. (1992) The role of di-acetyl ∝-melanocyte-stimulating hormone in the control of cortisol release in the teleost *Oreochromis mossambicus. Journal of Endocrinology* 135:285-292.
Larson, B.A. and Madani, Z. (1991) Increased urotensin I and II immunoreactivity in the urophysis of *Gillichthys mirabilis* transferred to low salinity water. *General and Comparative Endocrinology* 83:379-387.
Leatherland, J.F. (1994) Reflections on the thyroidology of fishes: from molecules to humankind. *Guelph Ichthyology Reviews* 2:2-67.
Leatherland, J.F., Lin, L. and Renaud, R. (2005) Effect of glutamate and somatostatin-14 on basal and cAMP-stimulated steroidogenesis by rainbow trout (*Oncorhynchus mykiss*) ovarian follicles, *in vitro*. *Comparative Biochemistry and Physiology* 140B:647-656.
Leatherland, J.F. and Sonstegard, R.A. (1980) Seasonal changes in thyroid hyperplasia, serum thyroid hormone and lipid concentrations, and pituitary gland structure in Lake Ontario coho salmon, *Oncorhynchus kisutch* Walbaum and a comparison with coho salmon from Lakes Michigan and Erie. *Journal of Fish Biology* 16:539-562.
Leatherland, J.F., Moccia, R.D. and Sonstegard, R.A. (1978) Ultrastructure of the thyroid gland in goitered coho salmon (*Oncorhynchus kisutch*). *Cancer Research* 38:149-158.
Lederis, K. (1977) Chemical properties and the pharmacological actions of urophysial peptides. *American Zoologist* 17:823-832.
Lovejoy, D.A. and Balment, R.J. (1999) Evolution and physiology of the corticotropin-releasing factor (CRF) family of neuropeptides in vertebrates: a review. *General and Comparative Endocrinology* 115:1-22.
Madsen, S.S. (1990) The role of cortisol and growth hormone in seawater adaptation and development of hypoosmoregulatory mechanisms in sea trout parr (*Salmo trutta trutta*). *General and Comparative Endocrinology* 79:1-11.
Manzon, L.A. (2002) The role of prolactin in fish osmoregulation: A review. *General and Comparative Endocrinology* 125:291-310.
Marshall, W.S. and Bern, H.A. (1981) Active chloride transport by the skin of a marine teleost is stimulated by urotensin I and inhibited by urotensin II. *General and Comparative Endocrinology* 43:484-491.
Matty, A.J. (1986) Nutrition, hormones and growth. *Fish Physiology and Biochemistry* 2:141-150.
Matty, A.J. (1985) *Fish Endocrinology*. Timber Press, Portland.
Melroe, G.T., Ehrman, M.M., Kittilson, J.D. and Sheridan, M.A. (2004) Growth hormone and insulin-like growth factor-1 differentially stimulate the expression of preprosomatostatin mRNAs in the Brockman bodies of rainbow trout, *Oncorhynchus mykiss*. *General and Comparative Endocrinology* 136:353-359.
Mercure, F., Holloway, A.C., Tocher, D., Sheridan, M.A., Van Der Kraak, G. and Leatherland, J.F. (2001) Influence of plasma lipid changes in response to 17β-estradiol stimulation on plasma growth hormone, somatostatin, and thyroid hormone levels in immature rainbow trout. *Journal of Fish Biology* 59:605-615.

McBride, J.R. and van Overbeeke, A.P. (1969) Hypertrophy of the interrenal tissue in sexually maturing sockeye salmon (*Oncorhynchus nerka*) and the effect of gonadectomy. *Journal of the Fisheries Research Board of Canada* 26:2975-2985.
Moccia, R.D., Leatherland, J.F. and R.A. Sonstegard, R.A. (1981) Quantitative interlake comparison of thyroid pathology in Great Lakes coho (*Oncorhynchus kisutch*) and chinook (*Oncorhynchus tschawytscha*) salmon. *Cancer Research* 41:2200-2210.
Mommsen, T.P. and Moon, T. (1989) Metabolic actions of glucagons-family hormones in liver. *Fish Physiology and Biochemistry* 7:279-288.
Murat, J.C., Plisetskaya, E.M. and Woo, N.Y.S. (1981) Review. Endocrine control of nutrition in cyclostomes and fish. *Comparative Biochemistry and Physiology* 68A:149-158.
Navarro, I., Rojas, P., Capilla, E., Albalat, A., Castillo, J., Monstserrat, N., Codina, M. and Gutiérrez, J. (2002) Insights into insulin and glucagon responses in fish. *Fish Physiology and Biochemistry* 27:205-216.
Nishimura, H. (1985) Evolution of the renin-angiotensin system and its role in control of cardiovascular function in fishes. ***In**: Evolutionary Biology of Primitive Fishes, **eds.*** Foreman, R.E., Gorbman, A., Dodd, J.M. and Olsson, R. Plenum Press, New York.
Nozaki, M. (1985) Tissue distribution of hormonal peptides in primitive fishes. ***In**: Evolutionary Biology of Primitive Fishes, **eds**.* Foreman, R.E., Gorbman, A., Dodd, J.M. and Olsson, R. Plenum Press, New York.
Nozaki, M., Miyata, K., Oota, Y., Gorbman, A., and Plisetskaya, E.M. (1988) Co-localization of glucagons-like peptide and glucagons immunoreactivities in pancreatic islets and intestine of salmonids. *Cell and Tissue Research* 252:371-378.
O'Grady, S.M., Field, N., Nash, N.T. and Rao, M.C. (1985) Atrial natriuretic factor inhibits Na-K-C1 cotransport in teleost intestine. *American Journal of Physiology* 249:C531-C534.
Ono, M., Takayama, Y., Rand-Weaver, M., Sakata, S., Yasunaga, T., Noso, T. and Kawauchi, H. (1990) CDNA cloning of somatolactin, a new pituitary protein related to growth hormone and prolactin. *Proceedings National Academy Science* U.S.A. 87:4330-4335.
Pang, P.K. (1973) Endocrine control of calcium metabolism in teleosts. *American Zoologist* 13:775-792.
Perrott, M.N. and Balment, R.J. (1990) The renin-angiotensin system and the regulation of plasma cortisol in the flounder, *Platichthys flesus*. *General and Comparative Endocrinology* 78:414-420.
Perry, V. and Funkenstein, B. (1999) Cellular distribution of insulin-like growth factor II (IGF-II) mRNA and hormonal regulation of IGF-I and IGF-II mRNA expression in rainbow trout testis (*Oncorhynchus mykiss*). *Fish Physiology and Biochemistry* 20:219-229.
Petkam, R., Renaud, R.L., Freitas, A.M.M.S., Canario, A.V.M. and Leatherland, J.F. (2004) *In vitro* metabolism of progesterone, androgens and estrogens by rainbow trout embryos. *Fish Physiology and Biochemistry* 27:117-128.
Pierson, P.M., Lamers, A., Flik, G. and Mayer-Gostan, N. (2004) The stress axis, stanniocalcin, and ion balance in rainbow trout. *General and Comparative Endocrinology* 137:263-271.
Planas, J.V., Swanson, P., Rand-Weaver, M. and Dickhoff, W.W. (1992) Somatolactin stimulates in vitro gonadal steroidogenesis in coho salmon, *Onchorhynchus kisutch*. *General and Comparative Endocrinology* 87: 1-5.
Plisetskaya, E.M., Ottolenghi, C., Sheridan, M.A., Mommsen, T.P. and Gorbman, A. (1989) Metabolic effects of salmon glucagons and glucagon-like peptide in coho and chinook salmon. *General and Comparative Endocrinology* 73:205-216.
Plisetskaya, E.M., Leibush, B.N. and Bondareva, V.M. (1976) The secretion of insulin and its role in cyclostomes and fishes. ***In** The Evolution of Pancreatic Islets, **eds**.* Grillo, T.A.I., Leibson, L.G. and Epple, A. Permagon Press, London.
Qian, X., D., Barsyte-Lovejoy, L., Wang, B., Chewpoy, N., Gautam, A.A., Chawaf, and Lovejoy, D.A. (2004) Cloning and characterization of teneurin C-terminus associated peptide (TCAP)-3 from the hypothalamus of an adult rainbow trout (*Oncorhynchus mykiss*). *General and Comparative Endocrinology* 137:205-216.
Raine, J.C., Cameron, C., Vijayan, M.M., LaMarre, J. and Leatherland, J.F. (2005) The effect of elevated oocyte triiodothyronine content on development of rainbow trout embryos and expression of mRNA encoding for thyroid hormone receptor. *Journal of Fish Biology* 65:206-226.
Redding, J.M. and Patiño, R. (1993) Reproductive physiology. ***In**:* The *Physiology of Fishes, **ed**.* Evans, D.H. CRC Press, Boca Raton.
Rodriguez, M. and Specker, J.L. (1991) In vitro effects of arginine vasotocin on testosterone production by testes of rainbow trout (*Onchorhynchus mykiss*). *General and Comparative Endocrinology* 83:249-257.
Sakamoto, T., McCormick, S.D., and Hirano, T. (1993) Osmoregulatory actions of growth hormone and its mode of action in salmonids: a review. *Fish Physiology and Biochemistry* 11:155-164.
Saito, D., Shi, Q., Ando, H. and Urano, A. (2004) Attenuation of diurnal rhythms in plasma levels of melatonin and cortisol, and hypothalamic contents of vasotocin and isotocin mRNAs in pre-spawning chum salmon. *General and Comparative Endocrinology* 137:62-68.
Sangiao-Alvarellos, S., Míguez, J.M. and Soengas, J.L. (2005) Actions of growth hormone on carbohydrate metabolism and osmoregulation of rainbow trout (*Oncorhynchus mykiss*). *General and Comparative Endocrinology* 141:214-225.
Schreck, C.B., Bradford, C., Fitzpatrick, M.S. and Patino, R. (1989) Regulation of the interrenal of fishes: Non-classical control mechanisms. *Fish Physiology and Biochemistry* 7:259-265.
Schreibman, M.P., Leatherland, J.F. and McKeown, B.A. (1973) Functional morphology of the teleost pituitary gland. *American Zoologist* 13:719-742.
Sheridan, M.A., Plisetskaya, E.M., Bern, H.A. and Gorbman, A. (1987) Effects of somatostatin-25 and urotensin II on lipid and carbohydrate metabolism of coho salmon, *Oncorhynchus kisutch*. *General and Comparative Endocrinology* 66:405-414.
Sherwood, N.M. and Parker, D.B. (1990) Neuropeptide families: An evolutionary perspective. *Journal of Experimental Zoology Suppl.* 4:63-74.
Slooff, W. and Klootwijk-Van Dijk, E. (1982) Hermaphroditism in the bream, *Abramis brama* (L.). *Journal of Fish Diseases* 5:79-81.
Stefan, Y. and Falkmer, S. (1980) Identification of four endocrine cell types in the pancreas of *Cottus scorpius* (Teleostei) by immunofluorescence and electron microscopy. *General and Comparative Endocrinology* 42:171-178.
Summerfelt, R.C. (1964) A new microsporidian parasite from the golden shiner, *Notemigonus crysoleucas*. *Transactions of the American Fisheries Society* 93:6-10.
Suzuki, N., Yamamoto, K., Sasayama, Y., Suzuki, T., Kurokawa, T., Kambegawa, A., Srivastav, A.K., Hayashi, S. and S. Kikuyama, S. (2004) Possible direct induction by estrogen of calcitonin secretion from ultimobranchial cells in the goldfish. *General and Comparative Endocrinology* 138:121-127.
Takei, Y. and Balment, R.J. (1993) Biochemistry and physiology of a family of eel natriuretic peptides. *Fish Physiology and Biochemistry* 11:183-188.
Takei, Y., Joss, J.M.P., Kloas, W. and Rankin, J.C. (2004) Identification of angiotensin I in several vertebrate species: Its structural and functional evolution. *General and Comparative Endocrinology* 135:286-292.

Thorndyke, M.C. and S. Falkmer, S. (1985) Evolution of gastro-entero-pancreatic endocrine systems in lower vertebrates. *In*: *Evolutionary Biology of Primitive Fishes*, ***eds***. Foreman, R.E., Gorbman, A., Dodd, J.M. and Olsson, R. Plenum Press, New York.
Very, N.M. and Sheridan, M.A. (2002) The role of somatostatins in the regulation of growth in fish. *Fish Physiology and Biochemistry* 27:217-226.
Vigna, S.R. (1985) Functional evolution of gastrointestinal hormones. ***In***: *Evolutionary Biology of Primitive Fishes*, ***eds***. Foreman, R.E., Gorbman, A., Dodd, J.M. and R. Olsson. Plenum Press, New York.
Wagner, G.F. and Friesen, H.G. (1989) Studies on the structure and physiology of salmon teleocalcin. *Fish Physiology and Biochemistry* 7:367-374.
Wagner, G.F., Hampong, M., Park, C.M. and Copp, D.H. (1986) Purification, characterization, and bioassay of teleocalcin, a glycoprotein from salmon. *General and Comparative Endocrinology* 63:481-491.
Yokote, M. (1970) Sekoke disease, spontaneous diabetes in carp, *Cyprinus carpio*, found in fish farms. I. Pathological study. *Bulletin Freshwater Fisheries Research Laboratory* 20:39-72.
Yokote, M. (1970) Sekoke disease, spontaneous diabetes in carp, *Cyprinus carpio*, found in fish farms. V. Hydrocortisone diabetes in carp. *Bulletin Freshwater Fisheries Research Laboratory* 20:161-174.
Zaccone, G., Lauwerijns, J.M., Fasulo, S., Tagliafierro, G., Ainis, L. and Licata, A. (1992) Immunocytochemical localization of serotonin and neuropeptides in the neuroepithelial endocrine cells of teleost and lungfish gills. *Acta Zoology* 73:177-183.
Zachmann, A., Ali, M.A. and Falcón, J. (1992) Melatonin and its effects in fishes: An Overview. ***In*** *Rhythms in Fishes*, ***ed***. Ali, M.A. Plenum Press, New York..
Zucker, A. and Nishimura, H. (1981) Renal responses to vasoactive hormones in the aglomerular toadfish, *Opsanus tau*. *General and Comparative Endocrinology* 43:1-9.





Musculoskeletal System

CHAPTER 12

by Jimmy Turnbull

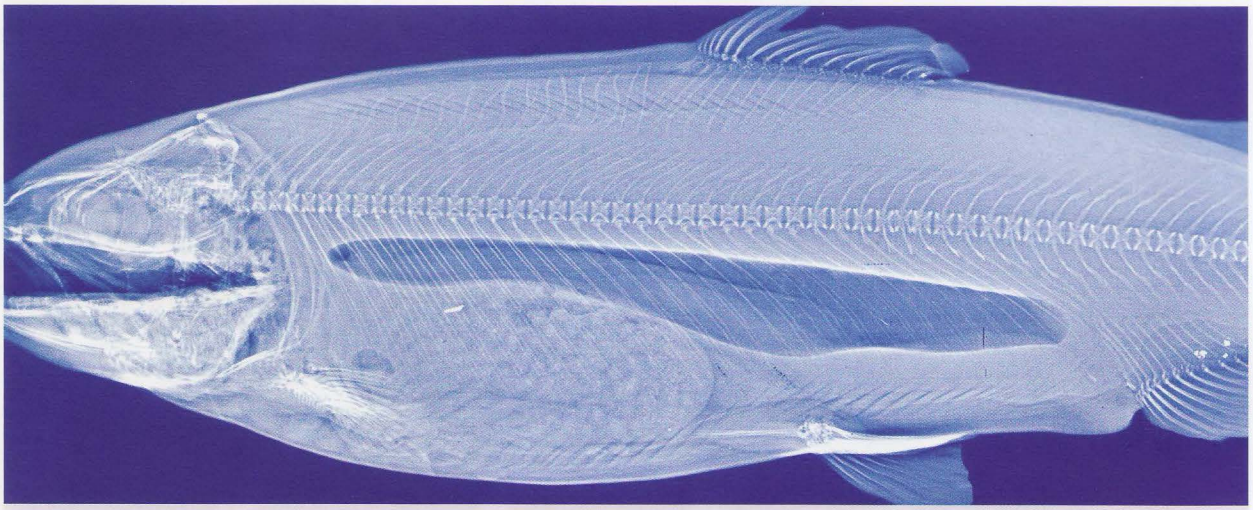

Fig 12.1A. Radiograph of normal rainbow trout to show skeleton. Other organs such as swimbladder and pyloric caeca are also well illustrated. Fish lend themselves nicely to examination of skeletal lesions by radiography.

It is because of the musculoskeletal system that most of us are interested in fish; it makes them good to eat or fun to catch. Yet despite its importance and the wide range of pathological entities affecting it, this system often receives scant attention during routine diagnosis. There is extraordinary variation in the appearance of fish from the ideal streamlined fusiform shape like tuna with the widest cross-section 36% along its length to animals like seadragons that can be hard even to recognize as fish. Despite this diversity of forms the basic musculoskeletal system remains remarkably consistent.

Skeleton

This includes many components such as scales, teeth, connective tissue, fin rays, tendons, ligaments, and all of the associated supporting cells. Here we will concentrate on the more obvious elements, bone and cartilage. The main vertebral column develops from the notochord, an elongated rod of tissue in the larval fish, into a series of connected vertebrae. The notochord common to all embryonic chordates persists into the adult stages of fish either as a rod-like structure in lungfish, as a very substantial structure in fish such as the sturgeon, or as a series of small beads of tissue between adjacent vertebrae.

The bone of some advanced teleost fishes is said to lack osteocytes or to be acellular due to the apparent lack of osteocyte lacunae. However, in a study on members of the family Sparidae the authors concluded that absence of visible or conventional osteocyte lacunae did not mean that the cells themselves were absent. Two types of bone were described in the mandibles; both were types of cellular bone that differed from each other and from conventional (mammalian) cellular bone. The types were tubular (or previously "acellular") and collagen or Sharpey fibre bone.

Osteogenesis is similar in other respects to mammals with endochondral and intramembranous (dermal) ossification. Both of these processes contribute to the formation of the cranium (of fish and mammals). In long bones growth must occur both at the end of the shaft and over the surface of the joint. Fish accomplish this by ending the bone with a simple plug of cartilage. This system is effective until the bone has to bear weight, when cartilage is found to be too flexible, and hence the necessity for growth plates in terrestrial animals. Some of the bones of the cranium and gill arches contain spongy bone but, unlike mammals, this is not a site of haematopoiesis.

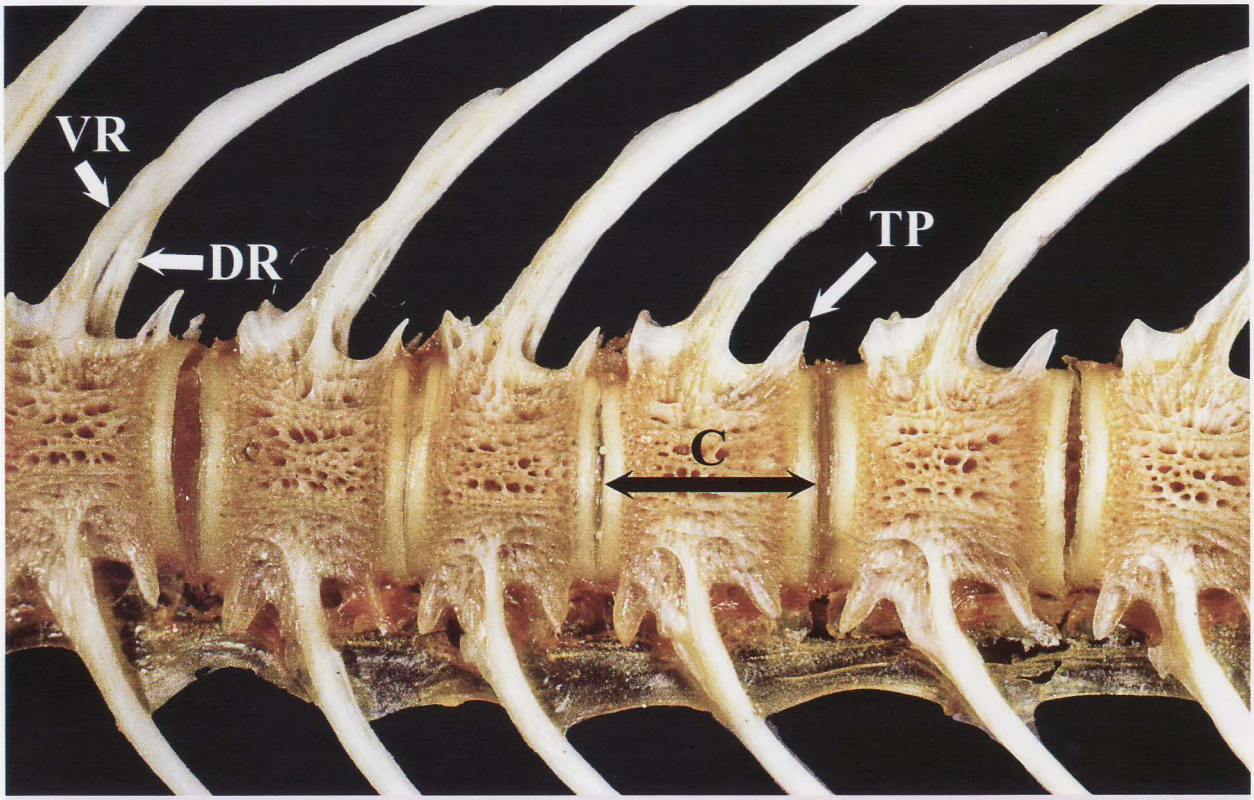

Fig 12.1B. This image is of the ventral aspect of the spinal column in the abdominal region. The spongy bone of the centra **(C)** is clearly visible as are the intravertebral spaces between the centra and the transverse processes **(TR)**. The ventral **(VR)** and dorsal ribs **(DR)** are visible only in some areas. Behind the abdominal cavity the ventral ribs fuse to form the haemal arch. The dorsal ribs are those typically found in tetrapods. *Picture courtesy of Dr. T.T. Poppe.*

The vertebrae are modified according to the region of the body, with the first two (atlas and axis) adapted to attach the cranium, and those in the main body of the fish bearing ribs on the transverse processes **(Fig 12.1)**. Throughout the spine, arches above the main vertebral bodies accommodate the spinal cord. The articulation of fish vertebrae is less complex than that of terrestrial vertebrates, as they lack interdigitating processes and articulate by simple apposition.

The intervertebral discs or joints of the perch (*Perca flavescens*) have been studied in some detail. The joint is formed by external ligaments (or chorda sheath) connecting the rims of adjacent centra. The tissue, located within the ligaments, is derived from the notochord and consists of the elastic externa, the fibrous sheath, and the notochordal cells that have at least three morphologically distinct regions. First, a peripheral single layer of columnar to squamous cells sits on a basement membrane immediately under the fibrous sheath. Second come several layers of cells, each containing a large central vacuole. Third, in the deepest part of the joint, several layers of attenuated cells surround intracentral fluid-filled lacunae, that form a transverse septum across the joint. The fluid-filled intra- and inter-cellular vacuoles probably function to resist the compressive and tensile stresses in the joint.

Much to the annoyance of many humans when faced with the prospect of eating a fish, bony fish have a complex arrangement of ventral ribs and dorsal ribs or intramuscular bones. In salmonids the dorsal ribs or "pin bones" are straight and relatively easy to remove, but in some fish they are very numerous and remain behind in even the most carefully prepared fillet!

Repair and remodelling of bone in teleosts involves osteocytes and osteoclasts **(Fig 12.2)**. Bone reabsorption through the action of mono-nucleated and multi-nucleated osteoclasts plays an important role in skeletal development, in disease and healing in advanced bony fish with cellular and acellular bone. There is also evidence for osteocytic osteolysis in teleosts as part of mineral homeostasis. Both mono and multi-nucleated osteoclasts are seen in the zebra danio (*Danio rerio*). The mono-nucleat-

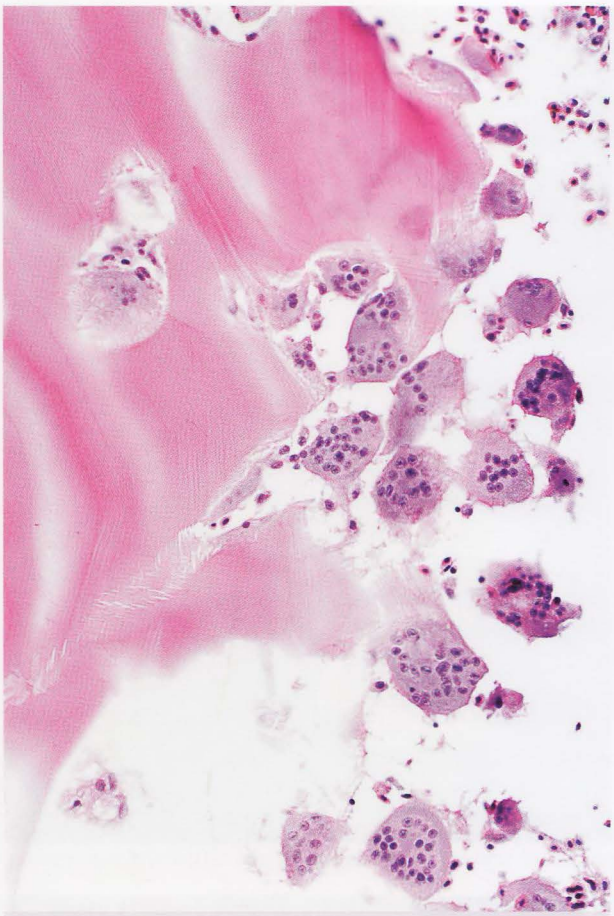

Fig 12.2. Goldfish bone showing multinucleated osteoclastic remodelling.

ed cells predominate in juveniles, while multi-nucleated cells become more prevalent in adults, although in neural arches and nasal bone the mono-nucleated cells remain the predominant type of osteoclast even in the adult. Osteoclasts can sometimes be difficult to detect in routine sections but may be visualised through the use of specific tartrate-resistant-acid-phosphotase (TRAP) stains. A study in tilapia (*Oreochromis niloticus*) demonstrated that starvation lead to a decreased turnover rate in acellular bone. Turnover was increased when food became available again and there was a brief period of increased or compensatory bone growth.

Scales are composed of collagen fibres, a matrix of albuminoid material and a mixture of calcium phosphate and carbonate ***(Fig 12.3)***. They act as a major mineral reserve and are preferentially demineralised to maintain mineral homeostasis during spawning migration in salmonids and in other circumstances such as cadmium toxicity. They may also be reabsorbed as a result of dermal inflammation ***(see "strawberry disease" Fig 3.29)***. Scales can be replaced if lost, and in some cases, damage to the skin can also lead to the development of scales where they were not previously present, as seen for example following damage to the skin of normally scaleless leather carp, a strain of the common carp (*Cyprinus carpio*). In some aberrant individuals the normal arrangement of the scales may be reversed with the free edge pointing forward.

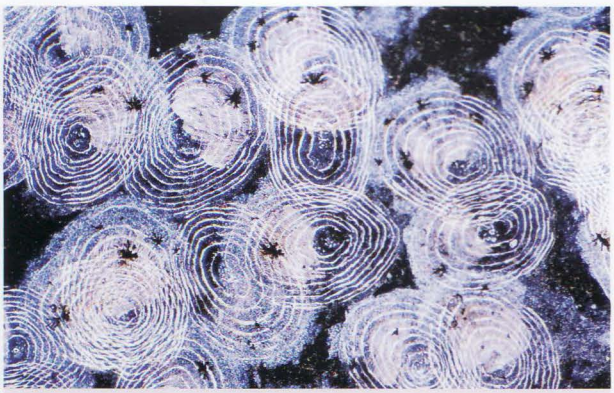

Fig 12.3. Scales from rainbow trout. This was the view after an over-enthusiastic skin scrape!

Many claims are made for the role of scales, from the reasonable, for example mechanical protection, to the more absurd such as protection from the cold. Scales do provide a hard layer under the relatively delicate epithelium, and while they may protect deeper tissues, this should increase susceptibility to epidermal injury. They may also provide protection from penetrating wounds, directed from the front of the fish and spread the energy of blunt trauma, thereby reducing localised damage and limiting the depth to which abrasive wounds penetrate.

Skeletal pathology

The development of a normal musculoskeletal system requires the combination of synchronised development of the various components and appropriate mechanical forces. Any condition or agent affecting these basic requirements will result in abnormalities. It is also possible for factors to act synergistically to increase the severity of deformities, for example vitamin C deficiency and an unsuitable egg or embryo incubation temperature.

The pathogenesis of damage during embryonic development can be complex. For example, a suite of abnormalities is observed in association with exposure to specific polycyclic aromatic hydrocarbons. These soft tissue and

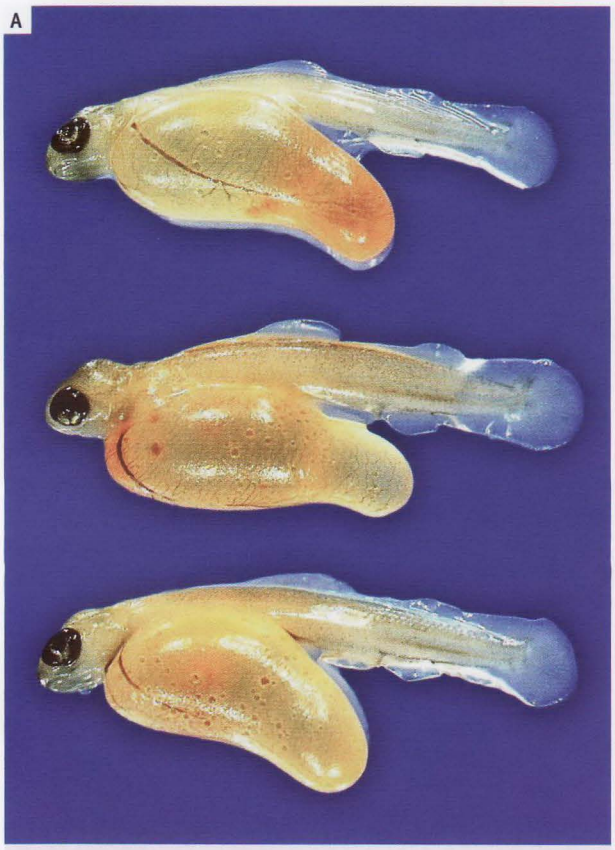



Fig 12.4A-D. **A-C** show yolk-sac trout larvae. Those in **A** are normal, while **B** & **C** show a range of abnormalities. Those in **C** were fixed in formalin first and they are green because they had been treated with malachite green. Those in **D** show Siamese twinning. Many of these abnormalities are seen in low numbers in many batches of fry; they are more prevalent when broodstock are too old, however, and they are also seen following exposure to a range of toxicants.







Fig 12.5. Adult Arctic charr showing marked spinal deformity, the result of higher-than-optimal incubation temperatures. This lesion is not always seen in young fish, but becomes more obvious later in life, probably reflecting some progressive developmental imbalance.

skeletal abnormalities appear to result from a primary effect on cardiac conduction leading to developmental abnormalities in the neural tube and craniofacial skeleton (*Fig 12.4*). Damage to the embryo can result from exposure of the broodstock or gametes to pollutants; for example, the offspring of female trout exposed to high concentrations of selenium are affected through deposition of selenium in the eggs. There are many descriptions of exposure to potential causes and the associated clinical signs; in some cases identification of such associations has led to successful prevention of the problem. However, there are relatively few examples where the detailed pathogenesis of the condition has been properly investigated. Examples of proposed causes include abiotic factors such as low dissolved oxygen in the early post-fertilisation period, leading to defects in the centrum, and temperature effects in several species (*Fig 12.5*), low pH and salinity and other harsh incubation conditions. There are genetic causes of spinal deformities and many studies have identified increased prevalence of deformities associated with triploidy. Dietary effects on skeletal development have been recently reviewed (see Cahu *et al.* 2003).

Developmental abnormalities have also been associated with many pollutants including heavy metals, especially cadmium and lead (causes neuronal degeneration), zinc, and others such as endocrine disrupting substances. In larval *Clarias gariepinus* deformities of the notochord were observed due to excessive muscular contraction through acytylcholinesterase inhibition after exposure to malathione. This raises questions regarding the interpretation of the impact of toxicants. Simple LD_n figures do not provide information on sub-lethal effects such as musculoskeletal defects. Neither can these be accurately estimated from data on natural populations, due to the lack of control over exposure. In addition, any fish suffering from developmental abnormalities in wild populations may not survive to participate in the sampling exercise.

In later life the range of aetiologies resulting in skeletal lesions is greater due to the larger impact of biotic agents. Again, while there are numerous reports of association between potential causes and resulting clinical or histopathological lesions, the pathogenesis has rarely been fully described.



Fig 12.6A&B. An example **(A)** of abnormal "short tail" in Atlantic salmon (above) compared to a more normal although very thin penmate (below). **B** shows fused vertebrae in this spinal column. *Both pictures courtesy of Dr. T.T. Poppe.*

and might be used in mate selection as an indication of fitness. This relationship, however, would appear to be far from simple in fish models.

A commonly reported abnormality is vertebral compression (also referred to as platyspondyly or short tails). In one study the length of the vertebrae was found on X-ray to be reduced, and associated with a change to the normal "X" pattern of vertebral centra. Affected centra had inward bending of the vertebral edges (Witten *et al.* 2005). This was associated with metaplasia of the notochord tissue into cartilage. It is possible that either the bone or the notochord changes are the primary lesion, although it seems more likely that changes in the notochord preceded those in the bone. Notochord cells can initiate the conversion of the notochord into cartilage as a reaction to mechanical force, but a certain amount of mechanical load is required to maintain the integrity of the intervertebral disc. Under normal circumstances transformation of notochord tissue is restricted to older fish.



Initially bone may fail to grow, or grow abnormally (dysplasia) and throughout life normal bone is continually undergoing reabsorption and remodelling, through the actions of osteoclasts and osteocytes. These processes may lead to loss of bone (osteoporosis or loss of mineral) or the formation of excess bone or abnormal tissue (for example ankylosing spondylitis, fusion of elements of the spine). Disease affecting the spine may appear grossly as deviation from the normal curvature, compression or shortening of some regions (*Fig 12.6*). Deviations of the spine are classified according to the direction of the abnormal curve, that is lordosis (ventral), kyphosis (dorsal) or scoliosis (lateral). Certainly skeletal abnormalities in fish are not a recent phenomenon since they have been detected in the Miocene fossil record. It has been suggested that deviations from normal bilateral symmetry may be an indication of environmental or genetic stress,

The remnants of the notochord are also subject to infectious disease. The plasmodia of *Myxobolus buckei* develop within intervertebral joints of juvenile cyprinids. The host inflammatory response involves proliferating fibroblasts and osteogenic cells. The parasite causes a radial expansion of the centra and extensive dorsal and ventral outgrowths of the vertebrae leading to compression of the spinal cord and blood vessels running through the neural and haemal spines.

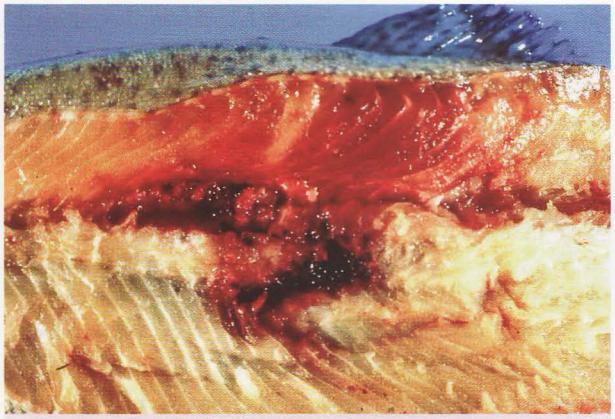

Fig 12.7. Rainbow trout showing fractured spinal column, the result of electrocution due to lightning strike. This would have caused marked contraction of muscles; fracture just below the dorsal fin is the commonest location for such lesions, presumably because this is the fulcrum for contraction. *Figure courtesy of R.D. Moccia.*

Any disease that causes severe damage to muscle will eventually distort the skeleton. Therefore whenever malformations are encountered, it is important to appreciate that the underlying lesion may lie in muscle, its innervation, or in the skeleton. Anaesthetics may aid in differentiating between muscular or neural lesions and those of the skeleton; if the skeletal abnormality disappears or greatly lessens during anaesthesia, it is more likely that the lesion is muscular. A dramatic example of the interrelationships between these components is found in lightning strike; severe contraction of the body muscle may break the spinal column at the flexure point **(*Fig* 12.7)**.

Since many causes of musculoskeletal deformation result in similar clinical appearance, a very wide range of genetic, physical, chemical and infectious factors have been associated with a relatively limited number of pathological entities. For this reason investigation of aetiology cannot rely on simple association, but requires the demonstration of cause and effect. For example, exposure to environmental pollution has been proposed as the cause of abnormalities in some cases where more detailed studies have identified other causes such as parasitic infections. In other cases there is strong circumstantial evidence that pollution was the cause, since removal of the source of pollution led to a marked reduction in the prevalence of abnormalities. What is frequently lacking in many such cases are the baseline data that predate the pollution event. One of the few examples of studies providing comprehensive baseline information examined extensive archived materials compiled by James J. Johnstone (1870-1932) (Heron *et al.* 1988).

There is, nevertheless, strong evidence for a toxic aetiology for many skeletal abnormalities. As already mentioned, exposure to cadmium can result in demineralisation and osteoporosis, and the effects of exposure to trifluralin have been well documented. The observed dysplasia consists of semi-symmetical hypertrophy of vertebrae, up to 20 times the normal size. Foci of osteoblasts and fibroblasts are observed actively laying down bone and bone precursors. The processes result in dorsal vertebral growth into the neural canal, ventral compression of renal ducts, and longitudinal fusion of vertebrae.

There are many reports of nutritional diseases, notably vitamin C deficiency, leading to "broken back syndrome" due to osteoporosis and dysplasia related to the formation of under-hydroxylated collagen and to the delayed calcification of the bone **(*Fig* 12.8)**. Many other nutrients are required to maintain a normal skeleton, including phosphorus and calcium in appropriate balance and riboflavin. "Screamer disease" reported in Chilean Atlantic salmon (*Salmo salar*) was characterised by ankylosis of the mandibular articulation, spinal foreshortening, fracture of vertebrae and rarefaction of osseous and cartilaginous tissues including the operculum. This was associated with a combination of vitamin C and phosphorus deficient diets and high temperatures at seawater transfer **(*Fig* 12.9)**.

As well as diet, husbandry conditions can influence the growth of a normal skeleton. As the Mediterranean seabass and seabream (*Dicentrarchus labrax* and *Sparus aurata*) industries have developed, there has been a continuing problem with spinal abnormalities. Blame was initially placed on failure of swimbladder inflation due to oil on the water surface. While keeping the water surface clean is important, not all deformities were due to swimbladder problems, and in some case failure to inflate the swimbladder resulted from earlier damage to the notochord. Spinal deformities are also seen in fry with normal swimbladder development that are required to undertake abnormal or excessive exercise.

Bacterial diseases that target the skeleton include the yellow-pigmented bacteria such as *Flavobacterium psychrophilum* **(*Fig* 12.10)**. In addition to lysis of cranial cartilage in young fish (given the colourful name of dissolving head disease) scleral cartilage is also affected, leading to exophthalmia, and indeed this may be one of the earliest signs that a population is infected. Spinal column is also involved, and in particular the intervertebral discs,



Fig 12.8A-C. **A** & **B** show vitamin A toxicity in rainbow trout, with marked spinal deformity. It is interesting that the toxicity lesions closely mimic the deficiency ones; this may reflect the limited number of mechanisms associated with spinal deformities leading to a convergence of clinical signs over a wide range of aetiologies. **C** shows vitamin C deficiency in catfish, the so-called "broken back syndrome".



leading to deformity in surviving fish. Mycotic infections are also sometimes encountered, but usually following dermal ulceration.

Numerous parasites affect the spine including *Myxobolus buri*, a well-documented myxozoan parasite that causes scoliosis of cultured yellowtail *Seriola quinqueradiata*. Others include bony dysplasia and proliferation observed in cyprinids associated with digenetic metacercariae (Heterophyidae). One of the best known parasitic diseases affecting the skeleton is "whirling disease" caused by *Myxobolus (Myxosoma) cerebralis*, although several other species of myxozoan parasites develop within cartilage, causing lysis, and may lead to skeletal abnormalities ***(Fig 12.11)***. While "whirling disease" is becoming a bigger problem in wild populations it has also been misdiagnosed in some cases and may not be a major problem as previously suggested, especially in South America. Once they are within the fish, the myxozoans develop and form spores in the cartilage of the head and vertebrae of young fish, causing lysis and subsequent deformation; involvement of the labyrinth may also be seen, doubtless contributing to the whirling behaviour from which the disease derives its name. Other parasites with an affinity for cranial skeletal tissues include diplomonad flagellates, the presumptive cause of "hole in the head disease" of oscars (*Astronotus ocellatus*), discus (*Symphysodon discus*) and other aquarium cichlids ***(Fig 12.12)***. However, the pathogenisis of this disease is far from clear and the condition may begin with a bacterial infection in the lateral line complex. Erosion of the cranium has also been associated with *Tetrahymena* sp. in young Atlantic salmon ***(Fig 12.13)***.

Proliferation of branchial cartilage can occur in response to encysted digenetic metacercariae. Again the pathogenesis of this lesion is unclear although it is possibly related to altered oxygen tensions affecting the more usual fibroplastic response.

Muscle

The connective tissue that connects the skin and appendages to the underlying skeleton and musculature is referred to as the membranous skeleton. This is most obviously seen in the division of the muscle into four quadrants. These separating septa combine with the ribs and the skin to direct the energy of muscular contraction into propulsive force. Sharks rely on skin for this function to a greater extent than teleosts due to their lack of a bony skeleton. The muscle blocks or myomeres are further separated and connected by the myosepta. The myomeres can be seen on the side of a skinned fish or as the flakes of flesh in a cooked fish. The arrangement of these muscles is complex, with overlapping and interdigitating myomeres. Muscles that control the other median and paired fins can also play an important locomotive role in some species.

There are two main types of muscle fibres and several minor types. Red "slow" fibres are well vascularised and contain numerous mitochondria; these are often as numerous as in mammalian myocardium. In many species, red muscle is located as a wedge along the lateral line ***(Fig 12.14)*** or may be associated with opercula or with other fins where they are used predominantly for locomotion. Graham and Dickson (2004) reviewed the astonishing adaptation of tunas to high performance swimming and endothermy, including a more central and extensive distribution of red muscle.

c



Separating the red from the white "fast" fibres are the intermediate or "pink" fibres. In some species, like salmonids, these fast aerobic fibres comprise a thin scattering situated between the red and white muscle, whereas in others such as carp they are much more extensive. White fibres are the only ones seen in larval fish; in growing fish they can have a wide range of diameters, becoming more uniform in adults. They are not as well vascularised as red fibres and have a lower number of mitochondria with less well-developed cristae (internal membranous divisions), although these features may be affected by nutritional and toxic factors. Whereas red fibres have multiple terminal innervation, white fibres have in addition, polyneuronal innervation, another feature unique to higher teleosts. It might be assumed that this arrangement reduces the likelihood of denervation atrophy as seen in mammals.

Whereas the number of muscle fibres is fixed around the time of birth in mammals, in many species of fish, muscle fibre numbers increase throughout a large part of their life. This increase, which originates from myosatellite cells, must have a significant influence on the reparative potential of fish muscle following even severe disease.

Inflammatory, degenerative and reparative responses in fish muscle are similar to those of mammals, with myophagia, regeneration, and fibrosis all occurring, but at rates proportional to the temperature. Repair involves multiplication of sarcolemmal nuclei, myophagia and myosatellite cell proliferation producing central rowing of nuclei (*Fig 12.15*).

Muscle pathology

Degeneration of muscle has been experimentally produced in salmonids fed a vitamin E and selenium deficient diet, particularly at low water temperatures where requirements would appear to be higher. This "nutritional muscular dystrophy" (NMD) appears to be entirely analogous to similar syndromes seen in other intensively reared animals, especially pigs, cattle and poultry. Lesions include hyaline and granular degeneration of fibres with loss of striation. Repair follows the typical pattern, and mineralisation and inflammation are usually minimal. There are many reports of NMD in intensively cultured fish occurring in channel catfish (*Ictalurus punctatus*), ayu (*Plecoglossus altivellis*), as well as in "Sekoke disease" of common carp and others.





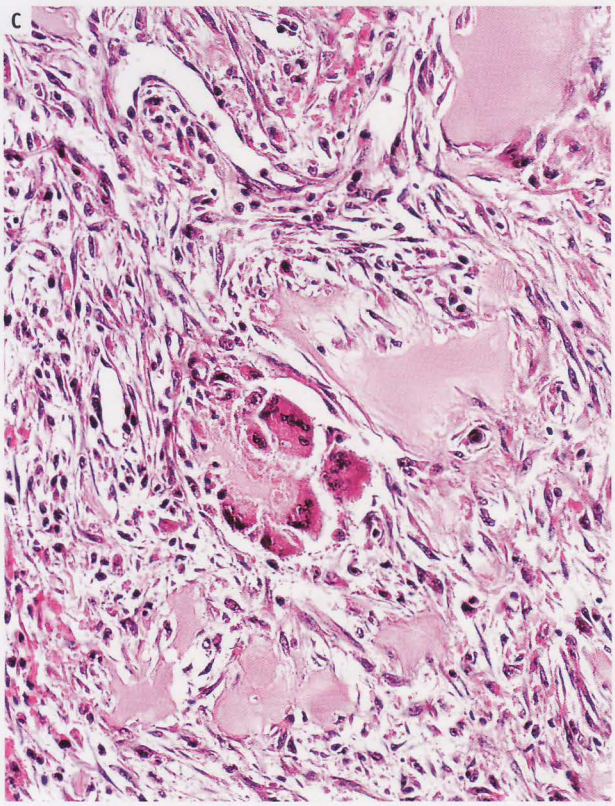

Fig 12.9A-C. **A** shows "Screamer disease" in farmed Atlantic salmon. The opercula are fixed open due to ankylosis of the mandibular articulation, the end result of phosphorus imbalance. The fish irrigate their gills by ram ventilation. **B** & **C** show the gross and histopathology of another somewhat similar condition in Atlantic salmon, in which poor dietary manipulations resulted in profound reabsorption of bone especially in the head region, with collapse and downward displacement of the intermandibular tissue and replacement of mandibular bone by fibrous tissue; or "fibrous osteodystrophy". *Figure A courtesy of Dr. T.T. Poppe.*

"Sekoke disease" is associated with rancid oil in the silkworm pupae that were incorporated into the carp diet. One of the best recognized entities is "lipoid liver disease" in salmonids. In addition to the accumulation of abnormal lipid products within the liver, the fish are anaemic, and they also have often marked degeneration and necrosis of muscles, notably those used in respiration. Nutritional pathology can also be compounded by starvation; if the striated oesophageal muscles are affected to any extent, the fish may be unable to swallow any food it does manage to reach. In addition, severely affected fish may be unable to maintain their position in the water column and, in systems with high water flow, suffer damage due to contact with the net or tank sides. This in turn can lead to secondary fungal and bacterial infections, further complicating the clinical picture.

In addition to the large range of infectious conditions affecting skeletal muscle, this tissue is often the site of haemorrhage due to vascular fragility associated with systemic infections. Some bacterial diseases, such as furunculosis (*Aeromonas salmonicida*) vibriosis, and *Flavobacterium psychrophilum*, result in multifocal liquefactive necrosis of muscle, especially in the subacute or chronic



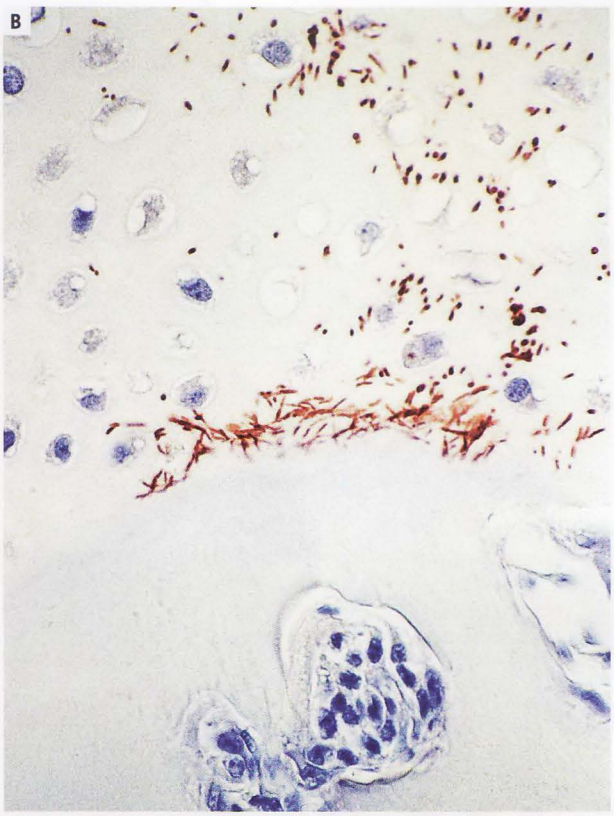

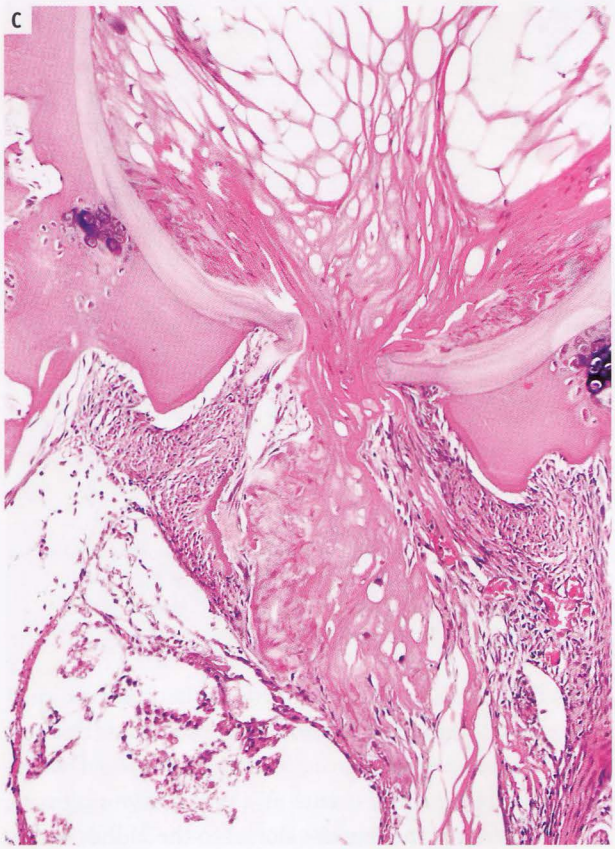

Disc disease. *Fig 12.10A-C.* **A** & **B** show *Flavobacterium psychrophilum* infection of the intervertebral disc (**A**) and cranial cartilage (**B**) in this juvenile rainbow trout. Note how the bacteria favour the cartilage rather than the bone. **C** shows disc luxation, with extruded material leaking out through the capsule. This material may cause pressure necrosis of spinal cord and/or lead to stenosis and thrombosis of aorta. *Figure B courtesy of Dr. V.E. Ostland.*

stages of these diseases (*Fig 12.16*). The affinity of such organisms for vascular endothelium and connective tissue respectively suggests that at least some of these lesions may be infarcts. Certainly the lesions are usually haemorrhagic and pulpy and often rupture through the overlying skin. Cavitation of muscle is seen in bacterial kidney disease (*Renibacterium salmoninarum*), and if the lesions are present in the subcutis, the usually straw-coloured flocculent contents create large blisters visible on gross external examination. Alternatively, the lesions may be so large as to grossly distort the whole fish (*Fig 12.17*). The chronic myositis that accompanies these lesions is usually very pronounced, the cellular infiltrate comprising neutrophils and macrophages; many of the latter are full



Fig 12.11A. Shiner with myxozoan infection of spinal column (arrow). Many myxozoa show an affinity for cartilage; once this ossifies as the fish matures, it is no longer susceptible.

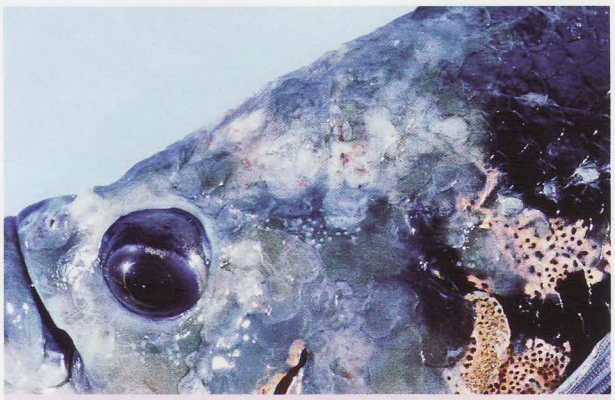

Fig 12.12. "Hole in the head disease" in this oscar. Despite historical associations with flagellates such as *Spironucleus*, bacterial infections of the lateral line system seem more common.

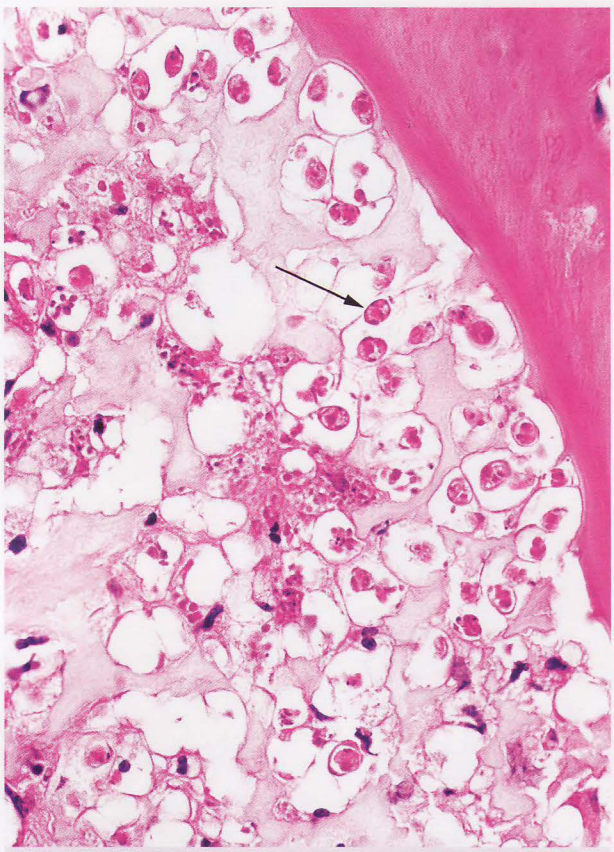

Fig 12.11B. Rainbow trout with "whirling disease" showing cranial bone-cartilage interface. Note foci of chondrolysis that contain various stages of developing myxozoa. A maturing spore is shown (arrow). The bone is relatively normal.

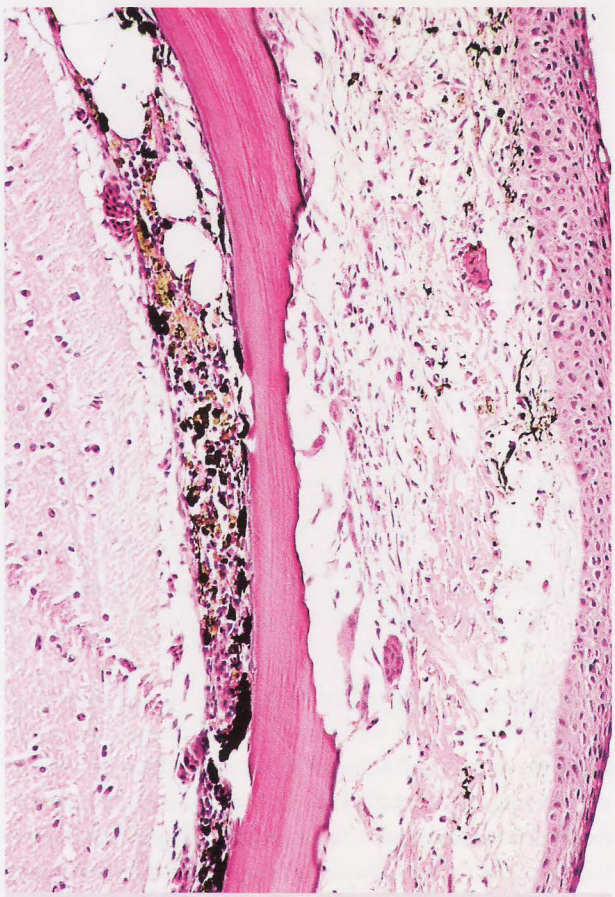

Fig 12.13. Lysis and osteoclasis of cranium in this young Atlantic salmon. The lesions were associated with *Tetrahymena* infection.

of bacteria although they can usually be observed only with special stains. Similar lesions are seen in salmonids with *Carnobacterium piscicola* (formerly *Lactobacillus*) infection, which frequently occurs as a post-spawning event, and cavitation of the muscles dorsal to the kidney is also seen in unusually severe cases of nephrocalcinosis with downgrading of the carcase as a consequence. Other systemic bacterial infections can affect the muscle such as mycobacteriosis, resulting in multifocal chronic cellular inflammatory foci.

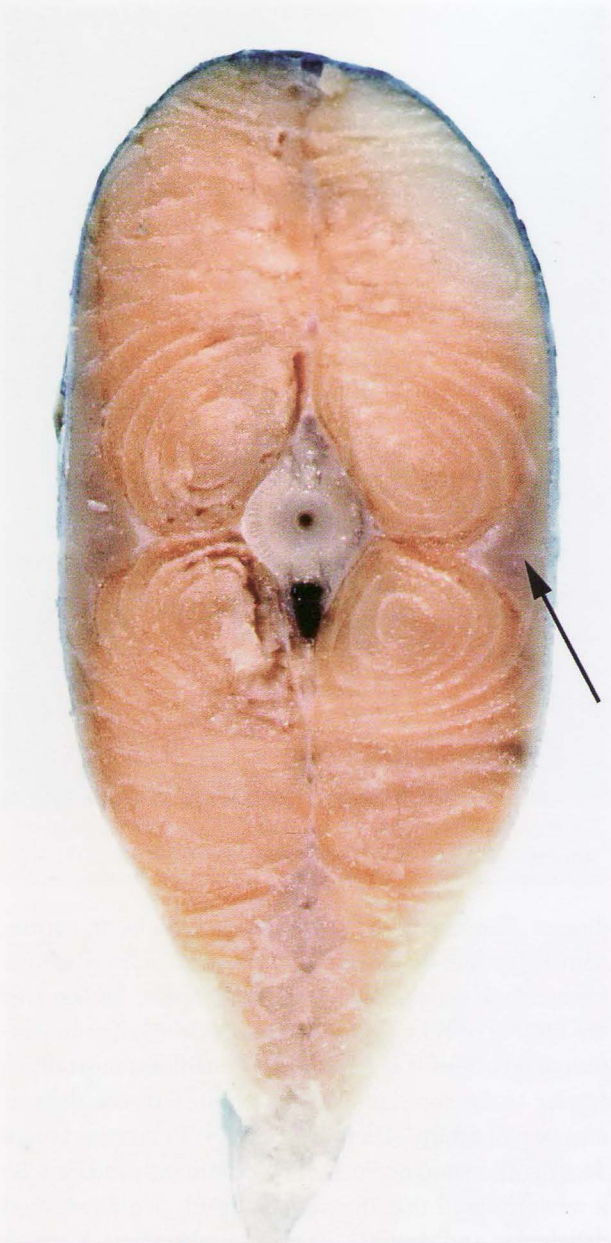

Fig 12.14. Transverse section through the tail of a salmonid showing the wedge-shaped strip of "red" muscle fibres (arrow) running bilaterally just below the lateral line.

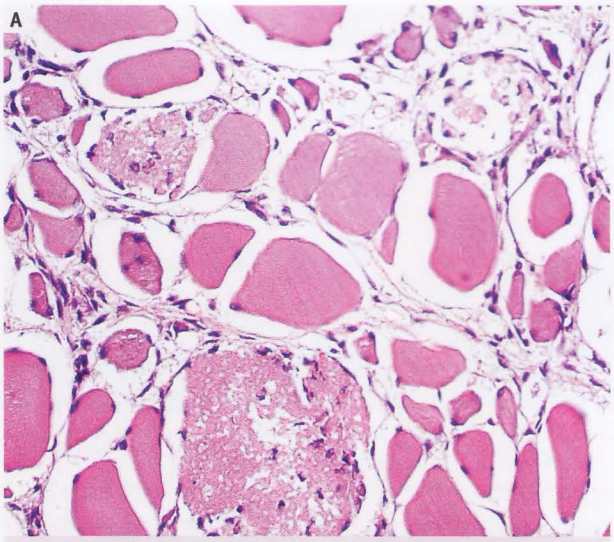

Fig 12.15A&B. Necrosis (**A**) and regeneration (**B**) of skeletal muscle of Atlantic salmon with pancreas disease. The cells present within the necrotic fibres in **A** are macrophages removing debris. The regenerating fibres in **B** are the basophilic ones (arrow) that show central rowing of nuclei.



There are a group of related conditions with overlapping lesions including skeletal muscle pathology. These are "pancreas disease" (PD) an alphavirus infection of Atlantic salmon in the sea and a possibly associated condition "sudden death syndrome" (SDS). A closely related virus is responsible for "sleeping disease" (SD) of farmed rainbow trout and possibly also a condition of seawater-reared trout known as "summer pathology". "Heart and skeletal muscle inflammation" (HSMI) is another presumed viral condition of intensively reared Atlantic



Fig 12.16A&B. Severe haemorrhagic myositis with lysis of muscle in rainbow trout. Both are bacterial diseases, with **A** due to *Flavobacterium psychrophilum* and **B** due to *Aeromonas salmonicida*.

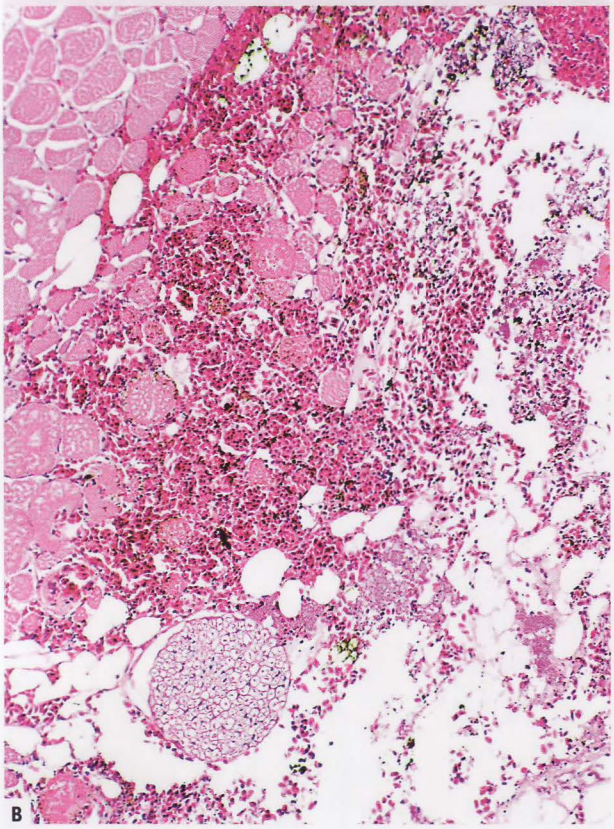

salmon. The precise relationships between these conditions is still unclear since some of the aetiologies have not yet been resolved.

In a sequential pathology study, PD skeletal muscle lesions developed at the same time as the pancreatic and cardiac changes become apparent. Other workers suggested that white muscle necrosis is seen in acutely affected fish and that red muscle lesions are mainly observed in those fish in the chronic or recovery phases of the



Fig 12.17. Large cavitating abscess in wild-caught speckled trout. Although BKD was suspected, no bacteria were found.

disease. The lesions are typically peroxidative in nature, namely hyaline degeneration with swollen eosinophilic fragmented sarcoplasm, with subsequent invasion of the muscle cells by macrophages. Evidence of regeneration of myocytes is seen (*Fig 12.15*). Highest mortalities appear to be correlated with the most severe skeletal muscle pathology. SDS is associated with massive severe degeneration and necrosis of predominantly red muscle; it was proposed that this was the result of a nutritional deficiency, and exercise stress brought about through an outbreak of PD. SD is a condition of rainbow trout associated with a virus related to the PD alphavirus; the skeletal muscle pathology is similar in character to PD but in most cases it is much more severe and in addition, there is often involvement of a few inflammatory cells, probably a reflection of the severity of the lesions. HSMI affects Atlantic salmon following transfer to the sea and is initially observed as anorexia and abnormal swimming. Although it has been demonstrated that HSMI is transmissible by means of ultrafiltrates (and is presumed therefore to be viral), the aetiology is still unclear. While morbidity can be high, mortality does not usually exceed 20%. Most affected fish have lesions in the heart and

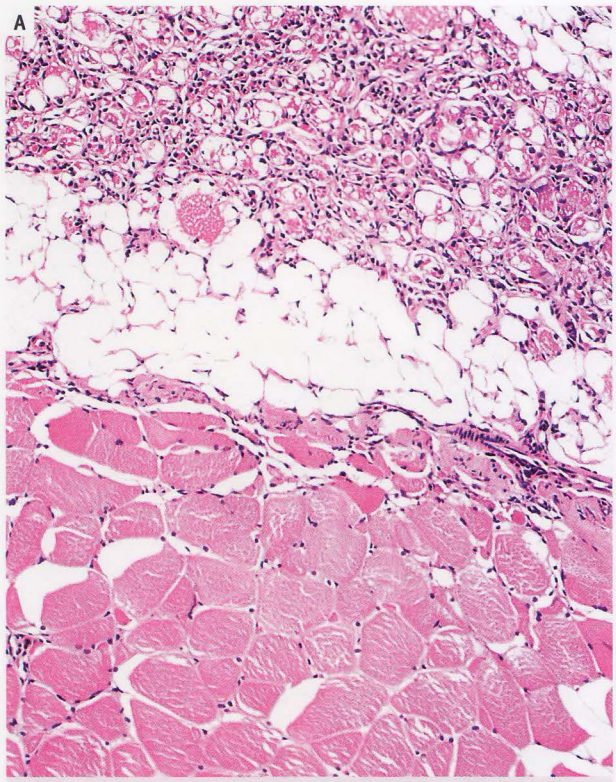

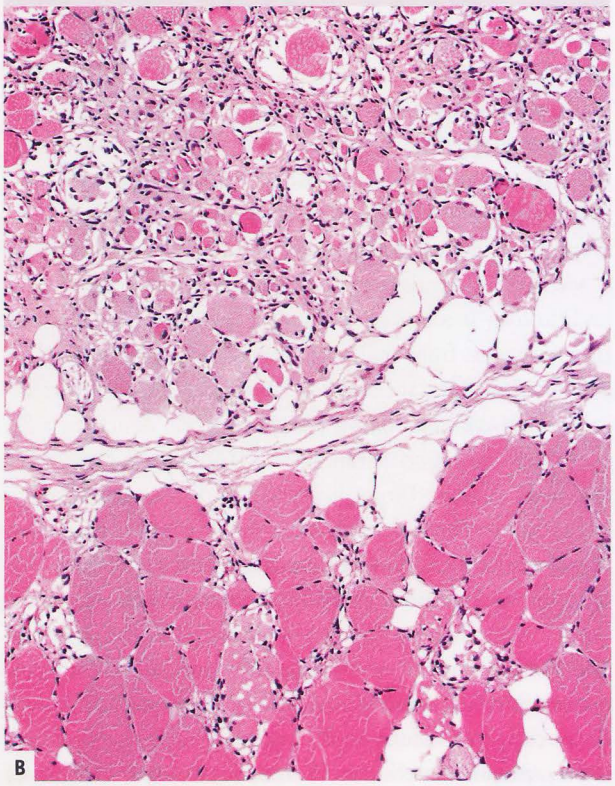

Fig 12.18A&B. Sub-acute necrotic myositis in salmonids, targeting mainly red muscle (to the top in both). In **A** the lesions were seen in the alphaviral "sleeping disease" in rainbow trout, while **B** is from a case of the presumed viral disease "heart and skeletal muscle inflammation" in Atlantic salmon.

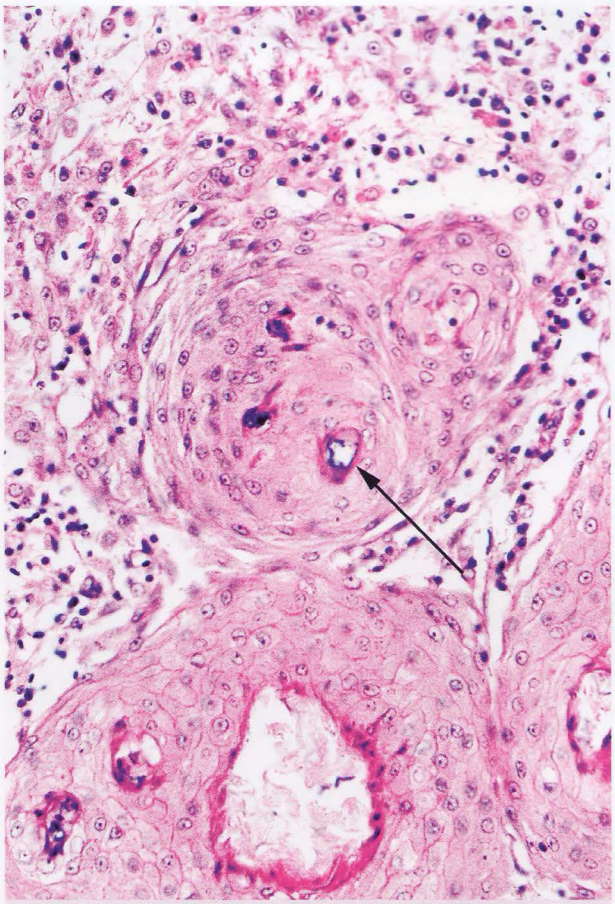

Fig 12.19. Granulomatous dermatitis and myositis in Atlantic menhaden surrounding fungal hyphae (arrow). This is a case of epizootic ulcerative syndrome (EUS) caused by *Aphanomyces invadens*. *Picture courtesy of Dr. W. Vogelbein.*

skeletal muscle but some individuals will have lesions in only one of these tissues. Lesions are more common and severe in the red muscle but may be seen in white muscle as well (*Fig 12.18*). Lesions may also be prevalent among asymptomatic fish within the population. The relative lack of pancreatic lesions helps to differentiate HSMI from PD.

Any disease with dermal lesions interfering with osmotic integrity in freshwater, such as ulceration, will result in water-logging of the underlying muscle; inflammation under these circumstances is usually minimal. This is particularly obvious where *Saprolegnia* spp. are involved. By contrast the disseminated fungal diseases cause a granulomatous myositis; one example is *Ichthyophonus hoferi* (no longer considered to be a fungus but thought to belong to a clade at the early divergence of fungi and animals). However, the most significant disseminated fungal infection is "Epizootic Ulcerative Syndrome" (EUS) now the

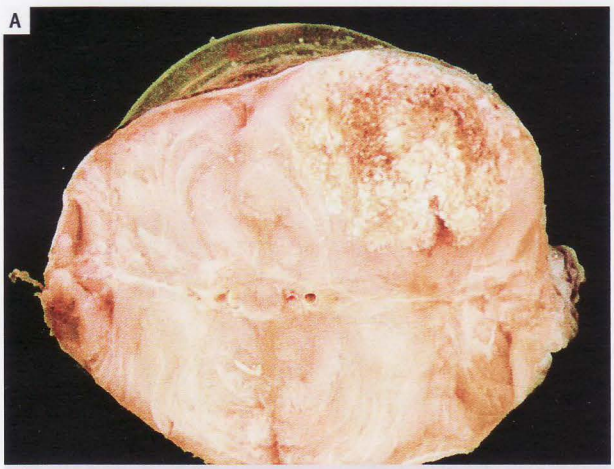

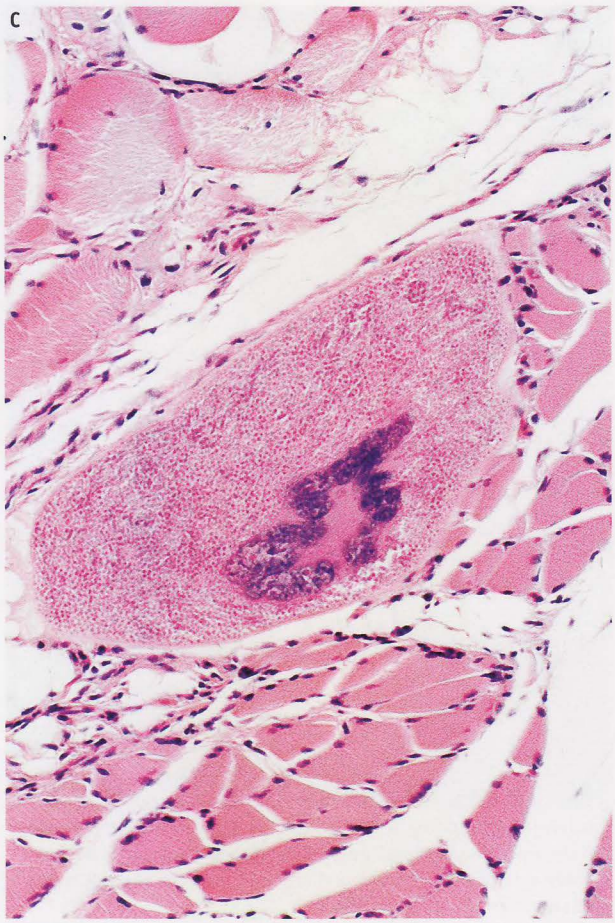

Parasitic myositis. *Fig 12.20A-E.* Creamy tumour-like lesions that are typical of some myxozoan species are shown in **A**, while **B** shows *Kudoa* infection of muscle in Atlantic salmon. The fibre at the bottom contains developing spores, while at the top is a pronounced inflammatory response that follows release. **C** shows cytomegaly of myocyte due to intracellular microsporidian infection; note the lack of any inflammatory response, and the massively enlarged nucleus. **D** shows another microsporidian infection with no host response, at this stage, *Pleistophora hyphessobryconis*, the cause of "neon tetra disease". **E** shows *Tetrahymena corlissi* infection of a guppy; the massive number of ciliates overwhelms the host.

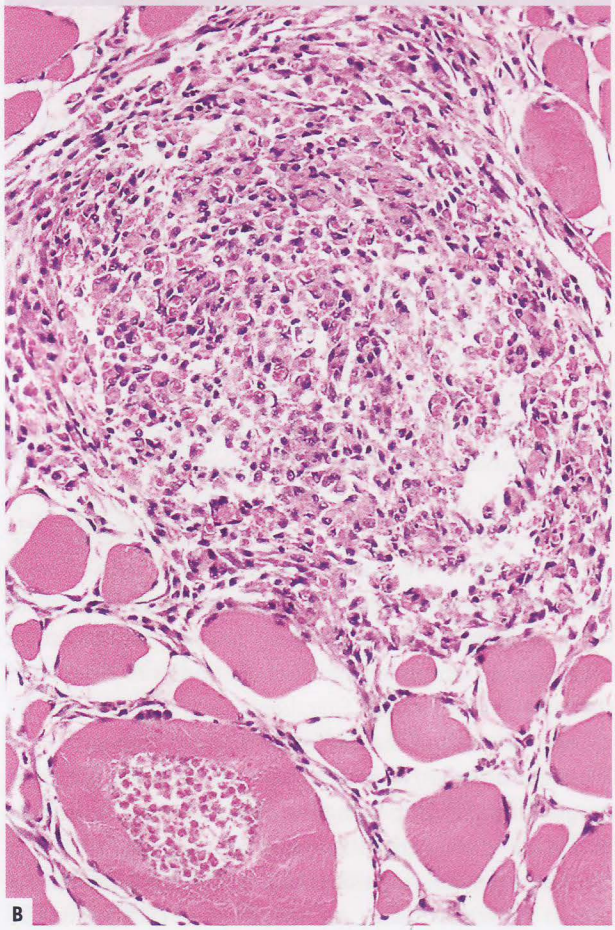

agreed name for a very extensive and serious condition affecting a wide range of wild and farmed fish species. It was first reported in Japan and Australia and has now spread across Asia; outbreaks are also reported in the USA. The disease is also known as "red spot disease", and more accurately as "mycotic granulomatosis". The fungus involved in EUS is *Aphanomyces invadens*, (also known as *A. piscicida*, *A. invaderis* and EUS-related *Aphanomyces*). Histopathology is required to confirm the diagnosis. Early lesions progress from shallow haemorrhagic dermatitis with little obvious fungal involvement **(*Fig 12.19*)** to severe locally extensive necrotizing granulomatous dematitis with severe degeneration of the muscle. The fungus penetrates the body passing through muscle and connective tissue eliciting a strong inflammatory response and granulomas are formed around the penetrating hyphae, which can be seen on H&E sections or with special fungal stains.

Microsporidian and myxozoan infections of muscle are responsible for many economically significant diseases. These can be so extensive as to cause grossly visible milky-white opaque blotches or streaks, reducing the value of



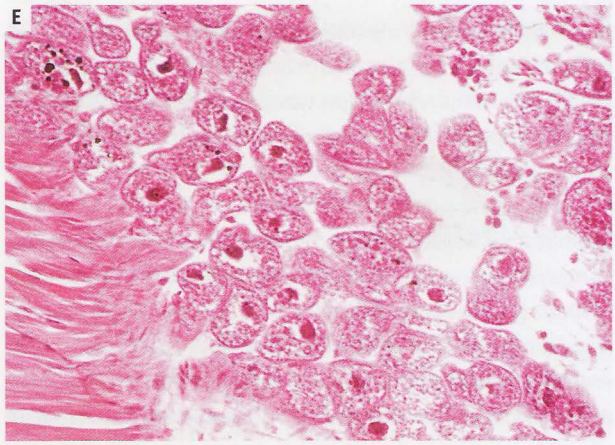

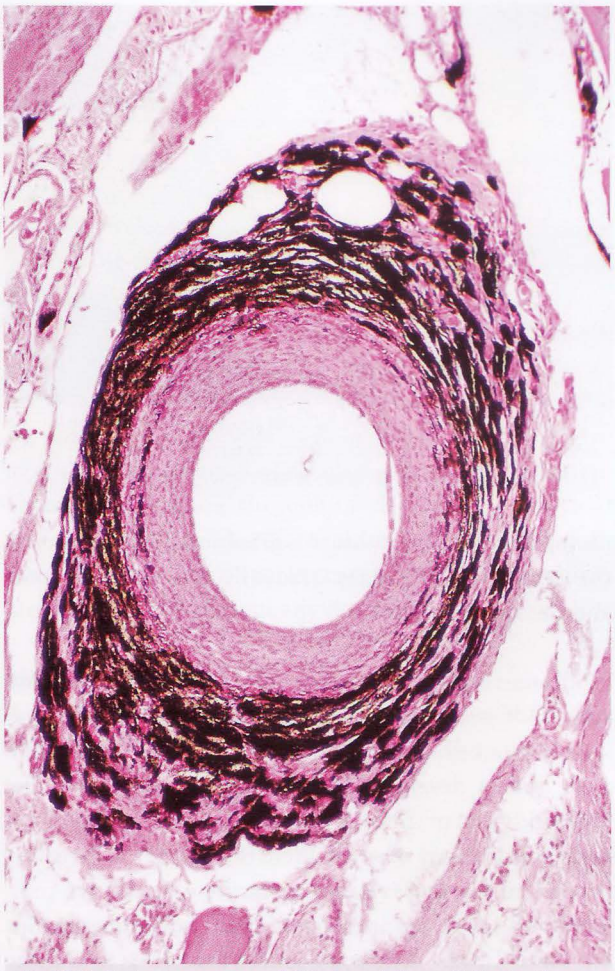

Fig 12.21. Typical appearance of "black-spot disease", the host's melanin-rich encapsulation of some species of digenetic trematode metacercariae.

the fish (*Fig 12.20*). Examples include the myxozoan *Henneguya salminicola* affecting Pacific salmon, and the microsporidian *Pleistophora macrozorcidis* affecting ocean pouts (*Macrozoarces americanus*). Individual or multiple "cysts" or xe-nomas within the muscle have the gross appearance of neoplasms. "Neon tetra disease" is an example of a microsporidian (*Pleistophora hyphessobryconis*) muscle infection of an aquarium species (*Paracheirodon innesi*). The tissue responses to microsporidian infections are described by Dykova and Lom (1980) and these vary with the species of parasite involved. With *Pleistophora* spp. infections, the parasite does not induce hypertrophy of the myocyte but rather replicates within the sarcoplasm, eventually occupying and destroying it. A significant inflammatory response develops only when the cell ruptures and comprises an infiltrate of macrophages, which phagocytose the released spores. By contrast, in genera such as *Glugea*, *Spraguea* (=*Nosema*) and *Ichthyosporidium*, the intracellular parasites replicate and cause cytomegaly, which in turn leads to pressure atrophy and encapsulating fibroplasia. A large xenoma with a refractile wall and filled with refractile spores may elicit the formation of granulation tissue. This often signals the start of degenerative changes in the xenoma wall, its invasion by the surrounding fibroblasts, and eventual



Fig 12.22A&B. "Walleye myopathy". The cause of this condition is unknown, but the histopathological response of ongoing caseonecrotic and granulomatous inflammation is quite distinctive.

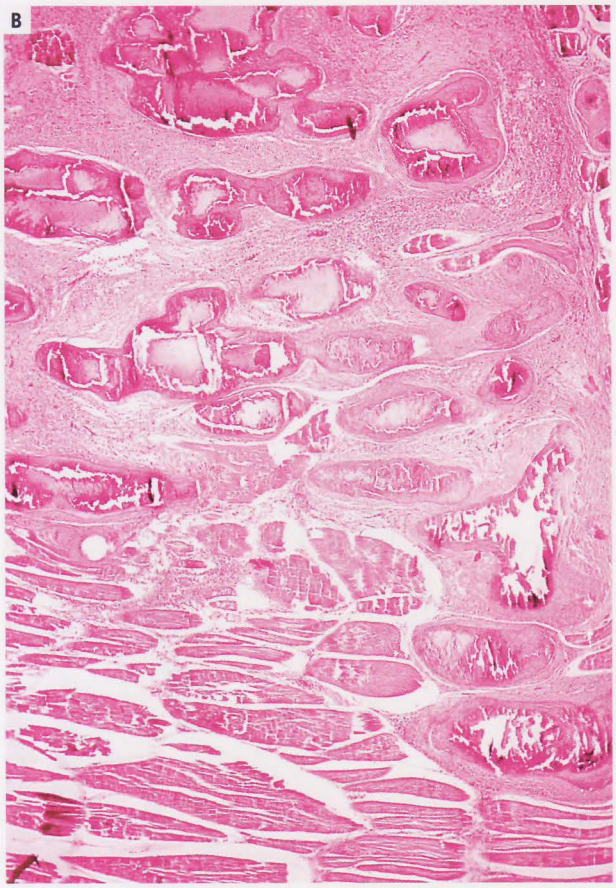

disappearance. The result is a granuloma with spores at the centre; macrophages gradually remove the spores and the lesion resolves.

While microsporidia are intracellular and affect a wide variety of vertebrates and invertebrates, myxozoa are largely intercellular, and infect mainly fish. A few myxozoan genera develop intra-cellularly in skeletal muscle, for at least part of their life cycle. Classification is based on spore morphology of which there is a wonderful diversity. In section, the spores have a refractile wall and are commonly 10 to 12 µm in diameter although some species are much larger. Myxozoan spores contain 1 to 6 polar capsules that stain intensely with toluidine or methylene blue. Microsporidian spores also have a refractile wall but are only 1 to 2 µm in diameter (and of interest are both Gram and Ziehl-Nielsen positive, which can sometimes help to identify them in section). Many myxozoan species inhabit organ cavities (coelozoic) but in general, the serious pathogens are those that develop within tissues (histozoic), of which skeletal muscle is a prime target. The initial host inflammatory response to the developing stages is usually minimal and any appreciable reaction develops only later. In some species the skin overlying the "cysts" ulcerates with the consequent release of spores, while in others the host response completely eliminates the parasites. Various species of the genus *Kudoa* are notable for their economic impact through post-mortem damage to muscle **(*Fig 12.20*)**. Some authors suggest that the parasites release myolytic enzymes after the death of the fish, resulting in rapid liquefaction but there is also a report of pre-mortem muscle degeneration. The presence of heavy infections of at least some species can be detected by wet mount examination of the opercular muscles.

Granulomatous myositis is also seen in severe cases of "proliferative kidney disease" or PKD (*Tetracapsuloides bryosalmonae*), where the parasite is so widely disseminated as to involve muscle. Acute myodegeneration and inflammation are also associated with the opportunist ciliates *Tetrahymena* spp. and scuticociliates *Uronema* spp., in guppies (*Poecilia reticulate*), salmonids and marine aquarium fish.

Metazoan diseases of muscle include encysted metacercariae of digeneans, that may or may not evoke a melanin response; if they do, the parasites become a grossly visible "black spot" **(*Fig 12.21*)**. The host response is otherwise usually minimal, with mild fibrosis, although in unusual cases parasites may be present in numbers large enough to cause ulceration of the body wall. A much more dramatic response is mounted against *Lernea* spp. which inserts part of its crustacean body into the muscle and evokes severe acute inflammation. Larval nematodes such as the anisakids *Phocanema* spp. and *Contracaecum* spp. are found within the muscle. Although the effect on the fish is usually minimal, some of these parasites are zoonotic. Their prevalence in the muscle can be reduced

by immediate gutting, since they migrate from the peritoneal cavity after death of the fish.

There are also a number of well-known myopathies of unknown aetiology. For example, myopathies are seen in wild walleye and in the Siamese fighting fish (*Betta splendens*) under aquarium conditions. Both of these conditions present as a severe necrotizing and granulomatous myositis, the degenerating muscle undergoing caseonecrotic change and becoming the focus for a pronounced inflammatory response (**Fig 12.22**). The reason for this very different response (compared with NMD) is unknown, but it suggests much more severe and ongoing damage with loss of myosatellite cells as well as myocytes, thereby inhibiting regeneration. Mineralisation and melanisation of muscle can be seen in salmonids as a response to depots of vaccine, and although the pathogenesis of these responses is unclear, the economic consequences due to rejection in the processing plant are not to be underestimated.

Finally, consideration must be given to the possibility that unusual muscle lesions may be the result of trauma from the activities of two or four-legged predators, particularly deep puncture wounds from beaks or gaffs.

Fins

Most fish have paired (pectoral, pelvic) and median fins (dorsal, caudal or tail and adipose). While these fins are all present in the classic form in some fish, for example salmonids, all may be absent or modified in other fishes. The position of the fins can vary, with the pelvic fins migrating forward in higher bony fishes to lie close to the pectoral fins. The fins have undergone a wide range of adaptation for reproduction, defence and locomotion. Fins of bony fish may contain hard unsegmented rays or spines, or soft segmented rays. The soft segmented fin rays (lepidotricha) consist of two hemitricha, thick acellular collagenous semi-circles or reniforms in cross section. These create a central space in the lepidotricha, which contains neural and vascular elements. Distally the lepidotricha terminate in a number of stiff spicules (actinotricha) that support the edge of the fin. The hemitricha are controlled by the pteryiophoral muscles which not only allow erection and retraction of the fins but also lateral bending, providing a complex range of propulsion and hydrodynamic control.

Much has been written of so-called "fin rot". This is a term loosely used to describe any erosion or inflammation of the fins and is usually but not exclusively a condition of farmed fish. While there are undoubtedly some specific infectious conditions affecting the fins, including parasites, fungi, bacteria and viruses, much of the fin damage observed results initially from physical injury. This can be through intentional aggressive attacks by tank-mates, accidental damage during feeding and other activities, or contact with tank or nets. It would, however, be a misleading oversimplification to ignore the complex interactions and confounding relationships in the aetiology of fin damage. For example while increasing stocking density is frequently cited as a cause of fin damage, this association is mediated through species, social interactions and water quality. Therefore under some circumstances even susceptible fish species can be reared at very high stocking density without any sign of fin damage.

Acknowledgement:

A big thanks to Hugh Ferguson for supplying almost all of the images.

References

Andrades, J.A., Becerra, J. and Fernandez-Llebrez, P. (1996) Skeletal deformities in larval, juvenile and adult stages of cultured gilthead sea bream (*Sparus aurata* L.). *Aquaculture* 141:1-11.

Backiel, T., Kokurewicz, B. and Ogorzalek, A. (1984) High incidence of skeletal anomalies in carp, *Cyprinus carpio*, reared in cages in flowing water. *Aquaculture* 43:369-380.

Bahgat, F.J., King, P.E. and Shackley, S.E. (1989) Ultrastructural changes in the muscle tissue of *Clupea harengus* L. larvae induced by acid pH. *Journal of Fish Biology* 34:25-30.

Bandyopadhyay, M.P., Aditya, A.K. and Mitra, S. (1998) Impact of chronic exposure of cadmium chloride on skeletal structures and mineral content in *Anabas testudineus* (Bloch). *Journal of Ecotoxicology and Environmental Monitoring* 8:269-274.

Banu, A.N.H., Islam, M.A., Chowdhury, M.B.R. and Chandra, K.J. (1999) Pathogenicity of *Aeromonas hydrophila* artificially infected to Indian major carp (*Cirrhinus mrigala* Ham.). *Bangladesh Journal of Fisheries Research* 3:187-192.

Barahona-Fernandes, M.H. (1982) Body deformation in hatchery reared European sea bass *Dicentrarchus labrax* (L). Types, prevalence and effect on fish survival. *Journal of Fish Biology* 21:239-249.

Beccera, J., Montes, G.S., Bexiga, S.R.R. and Junqueira, L.C.U. (1983) Structure of the tail of teleosts. *Cell and Tissue Research* 230:127-137.

Bernal, D., Dickson, K. A., Shadwick, R. E. and Graham, J. B. (2001) Analysis of the evolutionary convergence for high performance swimming in lamnid sharks and tunas. *Comparative Biochemistry And Physiology - Part A: Molecular & Integrative Physiology* 129:695-726.

Berntssen, M., Waagbo, R., Toften, H. and Lundebye, A. (2003) Effects of dietary cadmium on calcium homeostasis, Ca mobilization and bone deformities in Atlantic salmon (*Salmo salar* L.) parr. *Aquaculture Nutrition* 9:175-183.

Boucher, P. and Laurencin, F.B. (1996) Sleeping disease and pancreas disease: Comparative histopathology and acquired cross-protection. *Journal of Fish Diseases* 19:303-310.

Boudreau, M., Courtenay, S.C., Maclatchy, D.L., Berube, C.H. and Parrott, J.L. (2004) Utility of morphological abnormalities during early-life development of the estuarine mummichog, *Fundulus heteroclitus*, as an indicator of estrogenic and antiestrogenic endocrine disruption. *Environmental Toxicology and Chemistry* 23:415-425.

Cahu, C., Zambonino-Infante, J. and Takeuchi, T. (2003) Nutritional components affecting skeletal development in fish larvae. *Aquaculture* 227:245-258.

Callinan, R.B., Paclibare, J.O., Reantaso, M.K.B., Lumanlan-Mayo, S.C., Fraser,G.C. and Gogolewsky, R.P. (1995) *Aphanomyces* species associated with epizootic ulcerative syndrome (EUS) in the Philippines and red spot disease (RSD) in Australia: preliminary comparative studies. *Diseases of Aquatic Organisms* 21:233-238.

Canning, E.U. (1977) Microsporidia. ***In*** *Parasitic Protozoa. Babesia, Theileria, Myxosporida, Microsporidia, Bartonellaceae, Anaplas mataceae, Ehrlichia, and Pneumocystis.* (***ed.*** Kreier, J.P.) Volume IV, pp. 155-196. Academic Press, New York.

Canning, E.U., Hazard, E.I. and Nicholas, J.P. (1979) Light and electron-microscopy of *Pleistophora* sp. from skeletal muscle of *Blennius pholis*. *Protistologica* 25:317-332.

Chatain, B. (1994) Abnormal swimbladder development and lordosis in sea bass (*Dicentrarchus labrax*) and sea bream (*Sparus auratus*). *Aquaculture* 119:371-379.

Ching, H.L. (1984) Comparative resistance of Oregon (Big Creek) and British Columbia (Capilano) juvenile chinook salmon to the myxozoan pathogen, *Ceratomyxa shasta*, after laboratory exposure to Fraser River water. *Canadian Journal of Zoology* 62:1423-1424.

Cone, D.K. and Anderson, R.C. (1977) Myxosporidan parasites of pumpkinseed (*Lepomis gibbosus* L.) from Ontario. *Journal of Parasitology* 63:657-666.

Couch, J.A., Winstead, J.T., Hansen, D.J. and Goodman, L.R. (1979) Vertebral dysplasia in young fish exposed to the herbicide trifluralin. *Journal of Fish Diseases* 2:35-42.

Cowey, C.B., Degener, E., Tacon, A.G.J., Youngson, A. and Bell, J.G. (1984) The effect of vitamin E and oxidized fish oil on the nutrition of rainbow trout (*Salmo gairdneri*) grown at natural, varying water temperatures. *British Journal of Nutrition* 51:443-451.

Dabrowski, K., El-Fiky, N., Koeck, G., Frigg, M. and Wieser, W. (1990) Requirement and utilization of ascorbic acid and ascorbic sulfate in juvenile rainbow trout. *Aquaculture* 9:17-337.

Daisei, A., Masamichi, N. and Yoshihisa, F. (1995) Strain difference of vertebral abnormality in the guppy *Poecilia reticulate*. *Tohoku Journal of Agricultural Research* 46:29-34.

Davies, A.J., Andrews, T., Upton, N.P.D. and Matthews, R.A. (1998) Kudoa as a contributary cause of muscle necrosis in gobies. *Bulletin of the European Association of Fish Pathologists* 18:62-66.

Davison, W. and Goldspink, G. (1977) The effect of prolonged exercise on the lateral musculature of the brown trout (*Salmo trutta*). *Journal of Experimental Biology* 70:1-12.

Dykova, I. and Lom, J. (1980) Tissue reactions to microsporidian infections in fish. *Journal of Fish Diseases* 3:265-283.

Ferguson, H.W., Poppe, T. and Speare, D.J. (1990) Cardiomyopathy in farmed Norwegian salmon. *Diseases of Aquatic Organisms* 8:225-231.

Ferguson, H.W., Rice, D.A. and Lynas. J.K. (1986) Clinical pathology of myodegeneration (pancreas disease) in Atlantic salmon (*Salmo salar*). *Veterinary Record* 119:297-299.

Ferguson, H.W., Roberts, R.J., Richards, R.H., Collins, R.O. and Rice, D.A. (1986) Severe degenerative cardiomyopathy associated with pancreas disease in Atlantic salmon, *Salmo salar* L. *Journal of Fish Diseases* 20:95-98.

Fjolstad, M. and Heyeraas, A.L. (1985) Muscular and myocardial degeneration in cultured Atlantic salmon, *Salmo salar* L., suffering from 'Hitra disease'. *Journal of Fish Diseases* 8:367-372.

Geerlink, P.J. and Vidler, J.J. (1987). The relationship between structure and bending properties of teleost fin rays. *Netherlands Journal of Zoology* 37:59-80.

Graham, J.B. and Dickson, K.A. (2004) Tuna comparative physiology. *The Journal of experimental biology* 207:4015-4024.

Hamilton, A.J. and Canning, E.U. (1987) Studies on the proposed role of *Tubifex tubifex* (Muller) as an intermediate host in the lifecycle of *Myxosoma cerebralis* (Hofer, 1903). *Journal of Fish Diseases* 10:145-151.

Hatai, K., Egusa, S., Takahashi, S. and Ooe, K. (1977) Study on the pathogenic fungus of mycotic granulomatosis-I. Isolation and pathogenicity of the fungus from cultured ayu infected with the disease. *Fish Pathology* 11:129-133.

Hattori, M., Sawada, Y., Kurata, M., Yamamoto, S., Kato, K. and Kumai, H. (2004) Oxygen deficiency during somitogenesis causes centrum defects in red sea bream, *Pagrus major* (Temminck et Schlegel). *Aquaculture Research* 35:850-858.
Hawke, J.P., Grooters, A.M. and Camus, A.C. (2003) Ulcerative mycosis caused by *Aphanomyces invadans* in channel catfish, black bullhead, and bluegill from southeastern Louisiana. *Journal of Aquatic Animal Health* 15:120-127.
Herman, R.L. and Kircheis, F.W. (1985) Steatitis in Sunapee trout, *Salvelinus alpinus oquassa* Girard. *Journal of Fish Diseases* 8:237-239.
Heron, F., Bucke, D., Chubb, J,C. and Wallace, I.D. (1988) Re-appraisal of the James Johnstone collection of examples of diseased fish materials. ICES, Copenhagen (Denmark), Bergen, Norway October 1988.
Hine, P.M. (1980) A review of some species of *Myxidium Butschli*, 1882 (Myxozosporea) from eels (*Anguilla* spp.). *Journal of Protozoology* 27:260-267.
Hoffman, G.L. and Hutcheson, J.A. (1970) Unusual pathogenicity of a common metacercaria of fish. *Journal of Wildlife Diseases* 6:109-114.
Holloway, H.L. Jr. and Smith, C.E. (1982) A myopathy in North Dakota walleye, *Stizostedion vitreum* (Mitchill). *Journal of Fish Diseases* 5:527-530.
Holm, J., Palace, V.P., Wautier, K., Evans, R.E., Baron, C.L., Podemski, C., Siwik, P. and Sterling, G. (2003) An assessment of the development and survival of wild rainbow trout (*Oncorhynchus mykiss*) and brook trout (*Salvelinus fontinalis*) exposed to elevated selenium in an area of active coal mining. pp. 257-273 ***in*** *The Big Fish Bang. Proceedings of the 26th Annual Larval Fish Conference* (***eds***. Browman, H.I. and Skiftesvik, A.B.). 22-26 July 2002, Norwegian Institute of Marine Research and the University of Bergen. Norway,.
Hughes, D.R., Bassett, J.R. and Moffat, L.A. (1994) Histological identification of osteocytes in the allegedly acellular bone of the sea breams *Acanthopagrus-Australis, Pagrus Auratus* and *Rhabdosargus Sarba* (Sparidae, Perciformes, Teleostei). *Anatomy and Embryology* 190:163-179.
Incardona, J.P., Collier, T.K. and Scholz, N.L. (2004) Defects in cardiac function precede morphological abnormalities in fish embryos exposed to polycyclic aromatic hydrocarbons. *Toxicology and Applied Pharmacology* 196:191-205.
Izyumov, Y.G., Kas'yanov, A.N., Talikina, M.G., Papchenkova, G.A. and Kas'yanova, N.V. (2002) Variability of Vertebra Number and Anomalies of Axial Skeleton in Experimental Fingerlings of Roach *Rutilus rutilus* after Exposure Parent Spermii to Toxicants. *Journal of Ichthyology* 42:104-108.
Johnson, D.W. and Katavic, I. (1984) Mortality, growth and swim bladder stress syndrome of sea bass (*Dicentrarchus Labrax*) larvae under varied environmental conditions. *Aquaculture* 38:67-78.
Johnston, I.A. (1982) Physiology of muscle in hatchery raised fish. *Comparative Biochemistry and Physiology* 73:105-124.
Kacem, A., Meunier, F.J., Aubin, J. and Haffray, P.A. (2004) Histo-morphological characterization of malformations in the vertebral skeleton of rainbow trout (*Oncorhynchus mykiss*) after various triploidization treatments. *Cybium* 28:15-23.
Kas'yanov, A.N., Izyumov, Yu.G., Kas'yanova, N.V. and Papchenkova, G.A. (2002) Variability of Vertebral Number and Abnormalities of Axial Skeleton in the Roach *Rutilus rutilus* Yearlings After the Influence of Extreme Temperatures and Low pH on Early Embryos. *Journal of Ichthyology* 42:622-626.
Kent, M.L., Watral, V.G., Whipps, C.M., Cunningham, M.E., Criscione, C.D., Heidel, J.R., Curtis, L.R., Spitsbergen, J. and Markle, D.F. (2004) A Digenean Metacercaria (*Apophallus* sp.) and a Myxozoan (*Myxobolus* sp.) associated with Vertebral Deformities in Cyprinid Fishes from the Willamette River, Oregon. *Journal of Aquatic Animal Health* 16:116-129.
Khan, M.H., Marshall, L., Thompson, K.D. and Lilley, J.H. (1998) Susceptibility of five fish species (Nile tilapia, rosy barb, rainbow trout, stickleback and roach) to intramuscular injection with the oomycete fish pathogen, *Aphanomyces invadans*. *Bulletin of the European Association of Fish Pathologists* 18:192-197.
Kihara, M., Ogata, S., Kawano, N., Kubota, I. and Yamaguchi, R. (2002) Lordosis induction in juvenile red sea bream, *Pagrus major*, by high swimming activity. *Aquaculture* 212:149-158.
Kilarski, W. and Kozlowska, M. (1985) Histochemical and electronmicroscopical analysis of muscle fiber in myotomes of teleost fish (*Noemacheilus barbatulus* L.). *Gegenbaurs Morphol Jahrb* 131:55-72.
Kongtorp, R.T., Kjerstad, A., Taksdal, T., Guttvik, A. and Falk, K. (2004) Heart and skeletal muscle inflammation in Atlantic salmon, *Salmo salar* L.: a new infectious disease. *Journal of Fish Diseases* 27:351-358.
Kongtorp, R.T., Taksdal, T. and Lyngoey, A. (2004) Pathology of heart and skeletal muscle inflammation (HSMI) in farmed Atlantic salmon *Salmo salar. Diseases of Aquatic Organisms* 59:217-224.
Lagler, K.E., Bardach, J.E., Miller, R.R. and May Passino, D.R. (1977) *Ichthyology 2nd Ed.* John Wiley & Sons, New York.
Lester, R.J.G. and Kelly, W.R. (1984) Ankylosing spondylosis in the giant perch, *Lates calcarifer* (Bloch). *Journal of Fish Diseases* 7:193-197.
Lien, N., Hong, T. Adriaens, D. and Janssen, C.R. (1997) Morphological abnormalities in African catfish (*Clarias gariepinus*) larvae exposed to malathion. *Chemosphere* 35:1475-1486.
Lim, C. and Lovell, R.T. (1978) Pathology of the Vitamin C deficiency syndrome in Channel catfish (*Ictalurus punctatus*). *Journal of Nutrition* 108:1137-1146.
Lindesjoo, E. and Thulin, J.A. (1992) Skeletal deformity of northern pike (*Esox lucius*) related to pulp mill effluents. *Canadian Journal of Fisheries and Aquatic Sciences* 49:166-172.
Lom, J. and Noble, E.R. (1984) Revised classification on the class *Myxosporea Butschli*, 1881. *Folia Parasitologica* 31:193-205.
Longshaw, M., Frear, P. and Feist, S.W. (2003) *Myxobolus buckei* sp n. (Myxozoa), a new pathogenic parasite from the spinal column of three cyprinid fishes from the United Kingdom. *Folia Parasitologica* 50:251-262.
Longshaw, M., Frear, P.A. and Feist, S.W. (2005) Descriptions, development and pathogenicity of myxozoan (Myxozoa: Myxosporea) parasites of juvenile cyprinids (Pisces: Cyprinidae). *Journal of Fish Diseases* 28:489-508.
Lotz, J.C., Hsieh, A.H., Walsh, A.L., Palmer, E.I. and Chin, J.R. (2002) Mechanobiology of the intervertebral disc. *Biochemical Society Transactions* 30:853-858.
Madsen, L., Arnberg, J. and Dalsgaard, I. (2000) Spinal deformities in triploid all-female rainbow trout (*Oncorhynchus mykiss*). *Bulletin of the European Association of Fish Pathologists* 20:206-208.
Margolis, M.L., Kent, M.L. and Bustos, P. (1996) Diseases of salmonids resembling myxosporean whirling disease, and the absence of *Myxosoma cerebralis*, in South America. *Diseases of Aquatic Organisms* 25:33-37.
Markiw, M.E. and Wolf, K. (1978) *Myxosoma cerebralis*: Fluorescent antibody techniques for antigen recognition. *Journal of the Fisheries Research Board of Canada* 35:828-832.

Markiw, M.E. and Wolf, K. (1983) *Myxosoma cerebralis* (Myxozoa: Myxosporea) etiologic agent of salmonid whirling disease requires tubificid worm (Annelida: Oligochaeta) in its life cycle. *Journal of Protozoology* 30:561-564.
Matthews, R.A. and Matthews, B.F. (1980) Cell and tissue reactions of turbot *Scophthalmus maximus* (L.) to *Tetramicra brevifilum* gen. n., sp. n. (Microspora). *Journal of Fish Diseases* 3:495-515.
McLoughlin, M.F., Nelson, R.N., McCormick, J.I., Rowley, H.M. and Bryson, D.B. (2002) Clinical and histopathological features of naturally occurring pancrease disease in farmed Atlantic salmon, *Salmo salar* L. *Journal of fish Diseases* 25:33-43.
Mitchell, L.G. (1977) Myxosporida. ***In*** *Parasitic Protozoa.* (***ed.*** Kreier, J.P.) Volume IV, pp. 115-154. Academic Press, New York.
Miyazaki, T. (1986) A histopathological study on the carp fed tocopherol deficient diets including oxidized methyl linolate. *Fish Pathology* 21:73-79.
Miyazaki, T. and Plumb, J.A. (1986) A histopathological study on a natural case of broken-back syndrome of the channel catfish. *Bulletin of the Faculty of Fisheries Miyazaki University* 13:11-16.
Moss, M.L. (1965) Studies on the acellular bone of teleost fish. V. Histology and mineral homeostasis of freshwater species. *Acta Anatomica* 60:262-276.
Munro, A.L.S., Ellis, A.E., McVicar, A.H., McLay, H.A. and Needham, E.A. (1984) An exocrine pancreas disease of farmed Atlantic salmon in Scotland. *Helgolander Meeresunters* 37:571-586.
Murai, T. and Andrews, J.W. (1978) Riboflavin requirement of channel catfish fingerlings. *Journal of Nutrition* 108:1512-1517.
Murphy, T.M., Rodger, H.D., Drinan, E.M., Gannon, F., Kruse, P. and Korting, W. (1992) The sequential pathology of pancreas disease in Atlantic salmon farms in Ireland. *Journal of Fish Diseases* 15:401-408.
Murthy, V.K., Reddanna, P., Bhaskar, M. and Govindappa, S. (1981) Muscle metabolism of freshwater fish, *Tilapia mossambica* (Peters), during acute exposure and acclimation to sublethal acidic water. *Canadian Journal of Zoology* 59:1909-1915.
Newsome, C.S. and Piron, R.D. (1982) Aetiology of skeletal deformities in the Zebra Danio fish (*Brachydanio rerio*, Hamilton-Buchanan). *Journal of Fish Biology* 21:231-237.
Olsen, A.B., Melby, H.P., Speilberg, L., Evensen, Ø. and Håstein, T. (1997) *Piscirickettsia salmonis* infection in Atlantic salmon *Salmo salar* in Norway - epidemiological, pathological and microbiological findings. *Diseases of Aquatic Organisms* 31:35-48.
Pavlov, D.A. and Moksness, E. (1997) Development of the axial skeleton in wolffish, *Anarhichas lupus* (Pisces, Anarhichadidae), at different temperatures. *Environmental Biology of Fishes* 49:401-416.
Poppe, T.T., Hastein, T., Froslie, A., Koppang, N. and Norheim, G. (1986) Nutritional aspects of haemorrhagic syndrome ('Hitra Disease') in farmed Atlantic salmon *Salmo salar. Diseases of Aquatic Organisms* 1:155-162.
Reimchen, T.E. (1997) Parasitism of asymmetrical pelvic phenotypes in stickleback. *Canadian Journal of Zoology* 75:2084-2094.
Roberts, R. J. and Bullock, A. M. (1976) The dermatology of marine teleost fish. II. Dermatopathology of the integument. *Oceanography and Marine Biology Annual Reviews* 14:227-246.
Roberts, R.J., Hardy, R.W. and Sugiura, S.H. (2001) Screamer disease in Atlantic salmon, *Salmo salar* L., in Chile. *Journal of Fish Diseases* 24:543-549.
Rodger, H.D., Murphy, T.M., Drinan, E.M. and Rice, D.A. (1991) Acute skeletal myopathy in farmed Atlantic salmon *Salmo salar.* *Diseases of Aquatic Organisms* 12:17-23.
Rodger, H.D., Turnbull, T. and Richards, R.H. (1994) Myopathy and pancreas disease in salmon: a retrospective study in Scotland. *Veterinary Record* 135:234-235.
Roubal, F. R. and Bullock, A. M. (1988) The mechanism of wound repair in the skin of juvenile Atlantic salmon, *Salmo salar* L., following hydrocortisone implantation. *Journal of Fish Biology* 32:545-555.
Sadler, J., Pankhurst, P.M. and King, H.R. (2001) High prevalence of skeletal deformity and reduced gill surface area in triploid Atlantic salmon (*Salmo salar* L.). *Aquaculture* 198: 369-386.
Sato, M., Kondo, T., Yoshinaka, R. and Ikeda, S. (1983) Effect of water temperature on the skeletal deformity in ascorbic acid-deficient rainbow trout. *Nippon Suisan Gakkaishi* 49:443-446.
Schmitz, R.J. (1995) Ultrastructure and function of cellular-components of the intercentral joint in the percoid vertebral column. *Journal of Morphology* 226:1-24.
Sfakianakis, D.G., Koumoundouros, G., Divanach, P. and Kentouri, M. (2004) Osteological development of the vertebral column and of the fins in *Pagellus erythrinus* (L. 1758). Temperature effect on the developmental plasticity and morpho-anatomical abnormalities. *Aquaculture* 232:407-424.
Siau, Y. (1980) Observation immunologique sur des poissons du genre *Mugil* parasites par la Myxosporidie *Myxobolus exiguus* Thelohan, 1895. *Zeitschrift Fur Parasitenkunde* 62:1-6.
Sinclair, N.R. (1972) Studies on the heterophyid trematode *Apophallus brevis*, the "sand-grain grub" of yellow perch (*Perca flavescens*). II. The metacercaria: position, structure, and composition of the cyst; hosts; geographical distribution and variation. *Canadian Journal of Zoology* 50:577-584.
Sprague, V. and Hussey, K.L. (1980) Observations on *Ichthyosporidium giganteum* (Microsporida) with particular reference to the host-parasite relations during merogony. *Journal of Protozoology* 27:169-175.
Srivastava, A.K. and Srivastava, A.K. (1990) Skeletal anomalies in Indian catfish (*Heteropneustes fossilis*) exposed to malathion. *Journal of Environmental Biology* 11:45-49.
St-Hilaire, S., Ribble, C., Whitaker, D.J. and Kent, M.L. (1997) Evaluation of a nondestructive diagnostic test for *Kudoa thyrsites* in farmed Atlantic salmon (*Salmo salar*). *Aquaculture* 156:139-144.
Sugiura, S.H., Hardy, R.W. and Roberts, R.J. (2004) The pathology of phosphorus deficiency in fish - a review. *Journal of Fish Diseases* 27:255-265.
Takagi, Y. (2001) Effects of starvation and subsequent refeeding on formation and resorption of acellular bone in tilapia, *Oreochromis niloticus*. *Zoological Science* 18:623-629.
Tave, D., Bartels, J.E. and Smitherman, R.O. (1983) Saddleback: a dominant, lethal gene in *Sarotherodon aureus* (Steindachner) (*Tilapia aurea*). *Journal of Fish Diseases* 6:59-73.
Tiwary, B.K. and Ray, A.K. (2004) Alterations in air-sac and skeleton of triploid *Heteropneustes fossilis. Journal of Fish Biology* 64:268-272.

Tucker, B.W. and Halver, J.E. (1984) Ascorbate-2-sulfate metabolism in fish. *Nutrition Reviews* 42:173-179.
Turnbull, J.F., Richards, R.H. and Robertson, D.A. (1996) Gross, histological and scanning electron microscopic appearance of dorsal fin rot in farmed Atlantic salmon (*Salmo salar* L.) parr. *Journal of Fish Diseases* 19:415-427.
Van Leeuwen, J.L. (1999) A mechanical analysis of myomere shape in fish. *Journal of Experimental Biology* 202: 3405-3414.
Wang, D., Ueng, J.P. and Huang, B.Q. (2004) Structural Changes in the Muscular Tissue of Thornfish (*Terapon jarbua*, Forsskal) under TBT (tributyltin) Exposure. *Journal of the Fisheries Society of Taiwan* 31:225-234.
Weatherley, A.H., Gill, H.S. and Rogers, S.C. (1980) Growth dynamics of mosaic muscle fibres in fingerling rainbow trout (*Salmo gairdneri*) in relation to somatic growth rate. *Canadian Journal of Zoology* 58:1535-1541.
Wieser, W., Lackner, R., Hinterleitner, S. and Platzer, U. (1987) Distribution and properties of lactate dehydrogenase isoenzymes in red and white muscle of freshwater fish. *Fish Physiology and Biochemistry* 3:151-162.
Witten, P.E., Gil-Martens, L., Hall, B.K., Huysseune, A. and Obach, A. (2005) Compressed vertebrae in Atlantic salmon *Salmo salar*: evidence for metaplastic chondrogenesis as a skeletogenic response late in ontogeny. *Diseases of Aquatic Organisms* 64:237-246.
Witten, P.E., Hansen, A. and Hall, B.K. (2001) Features of mono- and multinucleated bone resorbing cells of the zebrafish *Danio rerio* and their contribution to skeletal development, remodeling, and growth. *Journal of Morphology* 250:197-207.
Witten, P.E., Villwock, W. and Watermann, B. (1999) About the use of radiological, histological, and enzyme histochemical procedures to visualise bone resorption at developing and at pathological altered skeletons of advanced teleosts. ***In*** *Diseases of aquatic organisms/Krankheiten der aquatischen Organismen* (***ed.*** Wedekind, H.) pp188-200. Institut fuer Binnenfischerei, Gross Glienicke, Germany.
Witten, P.E., Villwock, W., Peters, N. and Hall, B.K. (2000) Bone resorption and bone remodelling in juvenile carp, *Cyprinus carpio* L. *Journal of Applied Ichthyology* 16:254-261.
Wobeser, G. and Smith, N.W. (1975) Proliferative bone lesions in Lake White fish (*Coregonus clupeaformis*). *Journal of the Fisheries Research Board of Canada* 32:2065-2068.
Wolf, K., Markiw, M.E., Cruz, J.M., Galhano, M.H., Eiras, J. and Herman, R.L. (1981) Non-Myxosporidan Blacktail of Salmonids. *Journal of Fish Diseases* 4:355-357.
Yokoyama, H., Freeman, M.A., Yoshinaga, T. and Ogawa, K. (2004) *Myxobolus buri*, the myxosporean parasite causing scoliosis of yellowtail, is synonymous with *Myxobolus acanthogobii* infecting the brain of the yellowfin goby. *Fisheries Science* 70:1036-1042.
Zimmer, M.A. (1984) Idiopathic skeletal muscle necrosis in bluegills. *Journal of the American Veterinary Medical Association* 185:1371-1373.
Zinn, J.L., Johnson, K.A., Sanders, J.E. and Fryer, J.L. (1977) Susceptibility of salmonid species and hatchery strains of chinook salmon (*Oncorhynchus tshawytscha*) to infections by *Ceratomyxa shasta*. *Journal of the Fisheries Research Board of Canada* 34:933-936.





Neoplasia

CHAPTER 13

by Daniel Martineau and Hugh W. Ferguson

Cancer, the uncontrolled proliferation and dispersal of autologous cells throughout their host, affects all forms of pluricellular life on earth from plankton to elephants. This disease is probably inherent to such life forms because it is the ultimate, although relatively rare, consequence of accumulated mutations in DNA and all modern forms of multicellular life are based on DNA. The inherent biological limitations in the fidelity of DNA replication make the occurrence of mutations inevitable as the numbers of cell divisions increase. This explains why even in the absence of major mutagens such as chemicals, viruses and radiation, there would still be a baseline number of cancers due to chance alone, and that given long enough, any multicellular organism would end up developing cancer.

These considerations imply that the incidence of cancer increases in old age, and also helps to explain why it is higher in inhabitants of developed countries and in their companion animals, because better hygiene, higher living standards, better medical and veterinary care have all extended lifespan. Conversely, cancer is not as frequent in inhabitants of developing countries and in farmed animals because of their generally shorter life. Similarly, cancer is relatively rare in wildlife because harsh environmental conditions and predation reduce their lifespan. It is thus surprising that some populations of wild fish have the highest cancer rates among vertebrates. This has led to the hypothesis that chemical pollution might be the causal agent.

It is commonly thought that retroviruses, most importantly the Rous sarcoma virus of the chicken, provided the basic concepts for modern understanding of the molecular pathogenesis of cancer by bringing into light the role of oncogenes. It is less well known that at about at the same time as Dr. Peyton Rous was carrying out seminal experiments into acellular transmission of tumours in chickens, the concept of oncogenes was formulated in 1928 from crossing different species of small ornamental Mexican fish belonging to the genus *Xiphophorus*. More recently it was shown that hepatocellular carcinoma in trout was caused by a natural toxin, aflatoxin, thereby contributing again to establishing a major modern paradigm and becoming one of the first animal models of cancer. Fish pathogens have also contributed to completing the picture on retroviruses. Walleye dermal sarcoma (WDS) is a common skin tumour of walleye (*Stizostedion vitreum vitreum*) caused by a retrovirus (WDSV) for which a new retroviral genus, the epsilonretroviruses, has been created. With the exception of rare multicentric fibrosarcomas of young cats due to the feline sarcoma virus, WDS is the only sarcoma caused by a type C oncovirus (*e.g.* the alpha- and deltaretroviruses) that occurs in nature with a significant prevalence.

The nature of cancer in fish

As the most ancient vertebrates, fish have been affected by cancer for longer than any vertebrate. It seems reasonable to assume, therefore, that fish may have evolved more strategies to survive cancer than more "complex" and recent vertebrates. Conversely, cancer cells may have better adapted to the diverse ecological niches of their host. Fish tumours show intermediate forms between malignancy and normalcy. For instance, walleye dermal sarcoma (WDS) has earned its designation based on the anaplastic appearance of tumour cells, a feature usually associated with malignancy in mammals. Yet the biological behaviour of that tumour is clearly benign. In nature, although tumours are multicentric, they are generally restricted to the dermis; they originate from the flattened single cellular lining of scales within the dermis. WDS develops in the fall, and regresses in the spring on all affected fish. Yet, despite this benign behaviour, walleye fingerlings inoculated with tumour cells rapidly develop tumours that invade the adjacent tissue and kill the host. Moreover, the rapidity with which the tumour grows and invades walleye fingerlings depends on water temperature.

Viruses

Effect of human activity on viral transmission

To avoid the transmission of infectious agents, modern production of food animals necessitates the segregation of animals by age groups. In addition, buildings and equipment are also disinfected after animals are sent for slaughter. This is the so-called "all in all out" system. In general,

	VIRUS	HUMAN and NON-HUMAN PRIMATES	MAMMALS other than PRIMATES	BIRDS	FISH	LETHAL
DNA viruses	Papillomavirus	Epithelial, frequent	Epithelial, rare[1]			
	Herpesvirus	Epithelial, frequent Haematopoietic, frequent Mesenchymal, rare		Haematopoietic, frequent		
	Leporipox		Mesenchymal, rare		(-)	+
	Hepadnavirus	Epithelial, frequent[2]	Epithelial, frequent[3]	Epithelial, rare[4]		
RNA viruses	Flaviviridae[5]	Epithelial, frequent				
	Retrovirus		Epithelial, rare			
		Haematopoietic, rare	Haematopoietic, frequent	Haematopoietic, frequent	Haematopoietic, frequent[6]	
			Mesenchymal, rare	Mesenchymal, rare	Mesenchymal, frequent[7]	+ and (-)

Empty boxes = No cancer reported

1 Cancer common only in cattle in Kenya and Scotland; requires co-carcinogen
2 Human Hepadnavirus HBV causes chronic hepatitis followed by hepatocellular carcinoma
3 Cancer common only in woodchucks
4 Duck hepatitis virus
5 Hepatitis C virus causes chronic hepatitis followed by hepatocellular carcinoma
6 Lymphosarcoma is common in pike and muskellunge. A retrovirus has been isolated from plasmacytoid leukaemia in salmon but tumour cells are also infected by a microsporidian parasite, which obscures the aetiological role of the retrovirus in tumour development.
7 Frequent in walleye, hooknose and Atlantic salmon

Table 13.1. Virally-induced cancers (malignant tumours) in humans and free-ranging and domestic animals, excluding laboratory rodents.

fish farmers apply these same principles: fish of the same age are kept apart from other age groups, and individual ponds are cleaned and disinfected as thoroughly as possible after fish are netted out. Obviously lakes and rivers cannot be sanitized this way. Yet extensive sport fishing coupled with restocking of fish as practised in numerous lakes, can favour the transmission of infectious agents, in the same way that extensive rearing of animals practised without an "all in all out" system or age group segregation can favour disease transmission. The end result is the same, namely an increase in the prevalence of infectious disease, including virally-transmitted cancers.

Despite an idyllic appearance, Oneida Lake, New York state, is nevertheless a semi-industrial walleye farm. In Canadian provinces, where lakes are relatively unaltered, the prevalence of WDS is between 1 and 7.3 %. By contrast, in Oneida Lake, one of the most extensively exploited lakes in North America, WDS affects up to one in four adult walleye fish. Several factors favour viral transmission leading to a high prevalence of tumours. The walleye population of that lake has been maintained at a high density by extensive restocking since the beginning of the 20th century. Concurrently, predators of walleye including pike that spawn in seasonally flooded wetland, have been eliminated indirectly through destruction of their spawning grounds for residential or agricultural development and by regulation of the lake water level. Other native species such as salmon and eels had long disappeared because of locks, dams and extensive commercial exploitation.

The elimination of walleye predators and competitors has resulted in the survival of adult walleye even when they bear multiple tumours, when they would be eliminated in other lakes with richer biodiversity by interspecies competition or predation. During spawning, older tumour-bearing walleyes rub against young walleyes, inoculating them with virions. In addition, extensively managed spawning involves annual crowding and handling of roughly 15 % of the total walleye population, which again favour the transmission of viruses between fish.

WDS thus provides an example where loss of biodiversity favours the higher prevalence of a tumour, and these considerations may be extended to other populations of wild fish affected by high tumour prevalence. Tumour prevalence in fish has been used as an indicator of industrial pollution; strong positive correlations have been demonstrated between epidermal and hepatic tumours of wild fish and industrial contamination of water and sediments. Heavy pollution also reduces biodiversity by favouring fish species with low oxygen requirements. This has to be borne in mind when dealing with high tumour prevalence in a fish species whose competitors and predators have been eliminated from a given body of water, because the transmission rates of oncogenic viruses such as retroviruses, papillomaviruses or hepadnaviruses might be facilitated, mimicking chemical carcinogenesis by increasing prevalence of sarcoma, leukaemia, papilloma and hepatocellular carcinoma. Pollutants found in the liver and other tissues of these fish might act "merely" as promoters while the virus would be the real initiator.

The same consideration can of course be applied to tumour epizootics occurring in commercial marine farms. For instance, in 1976, in Scotland, an outbreak of an aggressive mesenchymal tumour was reported in pen-reared Atlantic salmon. This neoplasm, a swimbladder fibrosarcoma, affected 4.6 % of the fish. Numerous "type C" viral particles were observed by TEM in tumours.

Oncogenic viruses

Like any living organism, the evolutionary success of a virus is measured by the number of its descendants. This is why a virus that induces cancer is a failed virus (evolutionarily) because plainly, cancer kills its host, and a dead host cannot transmit viruses, at least actively. There are exceptions: for instance, a virus that triggers high viraemia followed by the release of numerous viable virions into the host's environment before the host dies can make an evolutionary champion of a lethal virus, but again, this is the exception.

DNA viruses

The ubiquity of papillomavirus and papillomata in the skin of mammals and birds is strikingly replaced in fish by the frequent association of herpesviruses with papillomas. Indeed, the only evidence linking papillomavirus to fish papillomata are a few reports of TEM observations of papillomavirus-like particles in papillomata whereas in contrast, this evidence is clearly documented for herpesviruses. However, the few fish herpesviruses that have been sequenced bear little sequence homology with other herpesviruses of mammals and birds and consequently little can be said about the mechanisms leading to the development of fish papillomas induced by herpesviruses.

The epithelial cells of fish, including hepatocytes, seem resistant to viral transformation ***(Table 1)***. The absence of conspicuous carcinomas induced by fish viruses could be due to several reasons such as the relative simplicity of fish epidermis compared to that of mammals. In contrast to the stratified squamous epithelium of mammals, superficial cells in fish epidermis are still viable and poorly keratinized. Thus differentiation is less complex and takes place through fewer steps and presumably through fewer cell divisions. Simply put, there are fewer opportunities in fish for the cell differentiation and DNA replication machineries to make mistakes.

The mechanisms leading to cell transformation by the major oncogenic DNA viruses are starting to be well understood. In short, tumour-inducing DNA viruses normally use the cell cycle machinery to their advantage. In a grossly simplified metaphor, the cell cycle can be compared to a "merry-go-round" with an operator whose function is to stop the machine in case of accidents (and so kids do not become sick!). At the cellular level his/her role is played by tumour suppressor genes, such as p53 and Rb, cellular proteins that act as brakes and safeguards to keep the cell cycle from spinning uncontrollably. To reactivate the DNA machinery of their host, small DNA tumour viruses throw a wrench at the operator, the result being that the ride will not stop even if an accident happens !

In the normal cell, tumour suppressor genes prevent uncontrolled proliferation by triggering an arrest of the cell

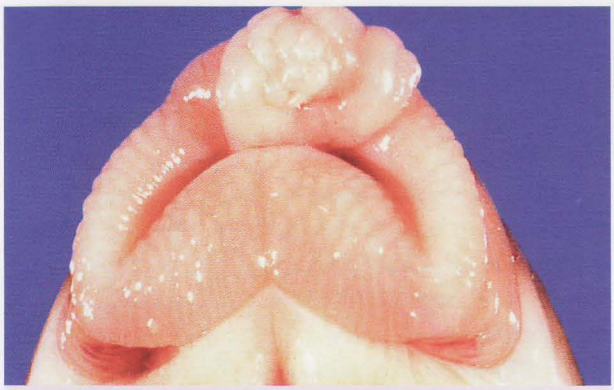

Papillomas. *Fig 13.1A.* White sucker with lip papilloma. *Courtesy Dr. G. Kirby.*

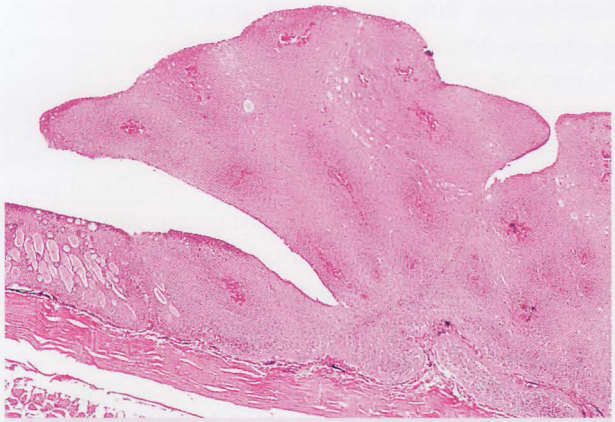

Fig 13.1B. Histopathology of typical brown bullhead papilloma, showing transition from normally populated epidermis to monomorphic and hyperplastic.

cycle or by causing cell death. These genes are recessive, meaning that all copies have to be non-functional in order for the cancer phenotype to appear. In humans the loss of function of tumour suppressor genes - such as Rb and p53 - is extremely common, and is probably a precondition for allowing cancer cells to escape autoprogrammed death (apoptosis). Several tumour suppressor genes have been characterized in fish. Many fish families such as cyprinids (carps), catostomids (suckers), cyprinodontiforms (*Xiphophorus*) and salmonids are chromosomally hyperploid. This feature may protect them against cancer since their genome is expected to contain more copies of tumour suppressor genes such as Rb or WT-1 which are less likely to be inactivated coincidentally together than they would in a diploid genome. This hypothesis would exclude p53, however, since the active form of p53 is a tetramer that can be inactivated by the presence of a single mutated copy of the protein.



Fig 13.1C. Some papillomas can appear plaque-like rather than typically wart-like.

Because of hyperploidy, the tumour suppressor system of fish may be somewhat redundant in protecting fish from tumour development due to viruses (and chemical carcinogenesis). Although interference with tumour suppressor genes is not a feature of oncogenic mammalian and avian herpesviruses, the situation could be different in fish. Finally, in terrestrial animals and in humans, ultraviolet light contributes to skin cancers, and it has been hypothesized that skin infection with papillomavirus contributes also by inhibiting apoptosis. Because water partially blocks ultraviolet light, fish could be spared this collaboration between radiation and viruses (and/or chemicals).

RNA viruses

In humans, DNA viruses are the major viruses responsible for causing cancer while only two RNA viruses are presently known to be involved. The flavivirus causing hepatitis C leads to liver cancer indirectly, by causing chronic hepatitis and regeneration. A single RNA virus, a retrovirus, human T-cell leukaemia virus type I, is *directly* related to cancer in humans ***(Table 1)***. In contrast there are probably more than thirteen retroviruses causing neoplasms in fish. This number, comparable to that of other animal retroviruses that cause tumours, is most likely a gross underestimate because, amongst the 20,000 known fish species, the diseases of only a relatively few commercially important species have been studied in some detail. It would seem there is a gradient where retroviruses become a more frequent cause of cancer in vertebrates with increasingly older ancestry. They end up being the only cancer-inducing viruses in fish. This might be a reflection of the fact that fish and retroviruses have evolved together for longer than have other animals with other tumour viruses. It could also be because RNA is the first form of life and fish are the first



Fig 13.1D&E. "Papillomatosis" of salmon. These lesions tend to regress with declining water temperatures. *D courtesy Dr. R. Collins.*

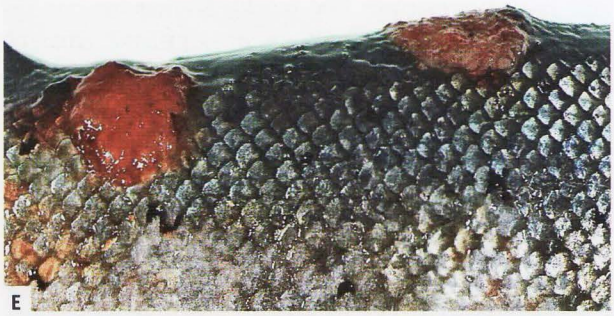

vertebrates to have appeared on earth. Note also that the epithelium of "older" vertebrates seems more *resistant* to viral transformation.

Retroviruses cause epizootic cancer in fish, including walleye dermal sarcoma, northern pike lymphosarcoma and Atlantic salmon swimbladder fibrosarcoma. These viruses are highly adapted to the specialized ecological niche of their host. Reverse transcriptase (RT) is an enzyme central to the replication of retroviruses. RT activity of both walleye dermal sarcoma virus (WDSV) and of the pike lymphosarcoma retrovirus, is sensitive to temperature. In addition it has been shown that the control unit of WDSV, the long terminal repeat (LTR), is also temperature responsive. No doubt these adaptations reflect the ectothermy (poikilothermy) of their hosts, and their purpose is probably to maximize viral production by tumour cells in the spring when water temperature is near its yearly low. This peak in viral production also coincides with spawning, when fish rub against each other, causing skin abrasion and viral inoculation.

In contrast to both DNA and RNA tumour viruses, WDSV infectious particles are not retained in tumours. Production and release of virions into the environment by tumour



Squamous cell carcinoma. *Fig 13.2A.* SCC in cichlid. Such lesions must be carefully distinguished from the secondary sex characteristics that can affect such species.

cells are part of the natural cycle of WDSV. The current working model is that the virus slowly triggers the proliferation of infected cells from fall to spring. In spring, when the tumour-bearing fish congregate for spawning, virion production starts *en masse* and almost simultaneously a viral protein and/or the host immune system trigger lysis of tumour cells, thereby releasing large numbers of virions into the environment. Most likely, other retroviruses also take advantage of the life cycle of their piscine hosts. For instance, northern pike lymphosarcoma also seasonally regresses, like WDS.

Oncogenes and tumour suppressor genes

Gene mutations contribute to cancer in two ways: they can inappropriately activate a gene involved in the regulation of normal cell division or differentiation. Such genes are called "proto-oncogenes" when they are intact, and are termed "oncogenes" when they are affected by an activating mutation. Oncogenes may increase the speed of the "merry-go-round", increasing the rate of cell division. Gene mutations may also interfere with genes that normally control cell growth (such as the tumour suppressor gene p53), thereby taking the brakes off the merry-go-round.

It is little known that the concept of an oncogene was voiced as early as 1928 following observations on a small ornamental Mexican fish, *Xiphophorus*, when it was found that hybrids between spotted platyfish (*Xiphophorus maculatus*) and non-spotted swordtails (*Xiphophorus helleri*), two members of the *Xiphophorus* genus, often developed malignant melanoma. It was found much later that the *Tu* gene, suitably named *Tu* from "tumour gene", was the oncogene responsible for this melanoma, and that it was a tyrosine

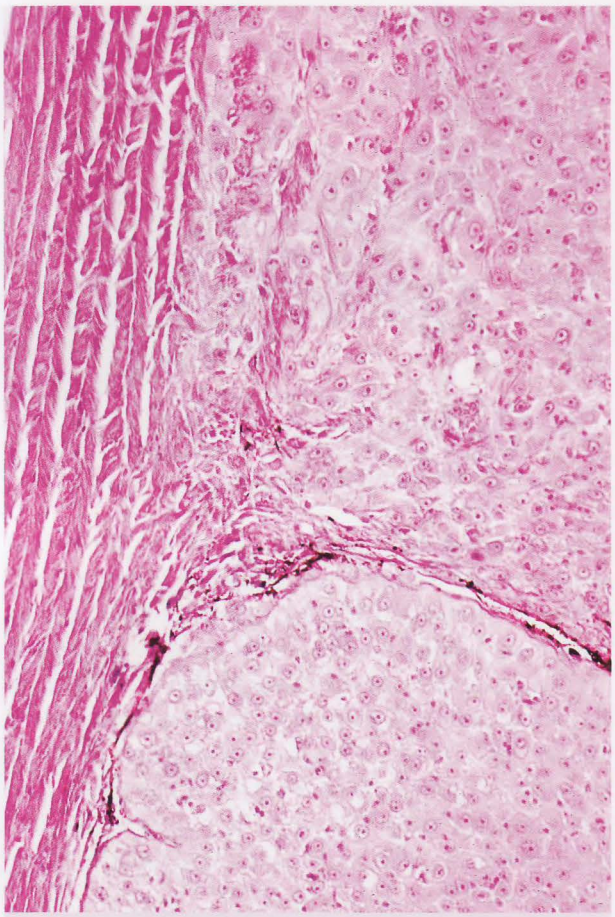

Fig 13.2B. Histopathology of SCC showing the migration of malignant epidermal cells down through the limiting basement membrane.



Fig 13.3. Fibroma in rod-caught salmon. The angler's sole interest revolved around whether he could eat the fish or not!

kinase receptor whose sequence is very similar to the human epidermal growth (EGF) receptor. Accordingly its name was changed to *Xmrk* for ***X****iphophorus* **m**elanoma **r**eceptor **k**inase.

Mutations can activate proto-oncogenes by at least three mechanisms: they can occur at very specific sites in the coding region of proto-oncogenes, resulting in a hyperactive protein product. They can also occur in the control region of the gene, causing an overproduction of an otherwise normal protein. Thirdly, the proto-oncogene can be reproduced to multiple copies during DNA replication, a process appropriately named gene amplification, which leads to overproduction of the protein product. To trigger a tumour, or an uncontrolled spin of the merry-go-round even in the face of an accident, many conditions must be met. A single mutation is simply not enough. Oncogenic retroviruses have been traditionally classified into two groups depending on the rapidity with which they cause a tumour when inoculated into a suitable host. Retroviruses that quickly trigger tumour development in a high percentage of inoculated animals, a few days or weeks after inoculation, have been termed "acutely transforming". These viruses carry an oncogene that they have "stolen" from the host cell. Soon after integration into its host genome, the foreign oncogene triggers uncontrolled cell proliferation. All viruses carrying an oncogene, except the Rous sarcoma virus, are "replication defective" that is they cannot replicate without the help of a complete virus (and termed for these reasons "helper, replication competent virus") because the oncogene has replaced viral genes that are necessary for replication. This incapacity to replicate on their own explains why retroviruses carrying oncogenes – and tumours caused by them - rarely occur in nature. Proto-oncogenes can also become oncogenes in a non-infected normal cell if they undergo a mutation due to a spontaneous DNA mutation in the face of radiation, other mutagens, or due to the inherent chemical instability of DNA.

The second group of transforming retroviruses leads to tumour development within weeks or months after inoculation. These viruses, the "slowly transforming" oncoviruses, do not carry an oncogene; rather they transform the infected cell by inserting their genetic material near a proto-oncogene thereby deregulating their expression, an event suitably termed "insertional mutagenesis". The preference of retroviruses for integration sites is very general - they tend to integrate into active regions of the genome. It is the extent of the viraemia, and thus the number of cells infected by the virus and the number of infections per cell that determine whether integration will occur or not - by mere chance – near a proto-oncogene and whether regulation of that gene will be overtaken by the inserted retrovirus.





Fig 13.4A-C. **Dermal sarcoma of walleye**, all showing various presentations from a single hard nodule, to a disfiguring lesion on the head, to a large ulcerated lesion on the flank. Such lesions are usually hard and bony. *Figure C courtesy Dr. G. Wobeser.*



The speed with which walleye dermal sarcoma virus causes tumours when experimentally inoculated suggests that it carries an oncogene(s). The high number of virions produced by tumour cells in the spring also suggests that WDSV is replication competent, in contrast to all other acutely transforming retroviruses, except the archetypical Rous sarcoma virus. Characterization of the complete WDSV genome has confirmed that WDSV carries an oncogene, a cyclin-like gene. Cyclins are a family of genes whose members are key regulators of the cell cycle. The cyclin-like gene found in WDSV may have been "stolen" in the distant past from its host or even from a different animal, maybe even an ectoparasite of the walleye host. It might just as likely be an entirely viral creature (a "viral" oncogene) that has evolved wholly from a viral gene. Regardless, WDSV is the first retrovirus found to carry an oncogene directly involved in the cell cycle, resembling in this very important aspect the above described DNA tumour viruses, those that throw wrenches at the merry-go-round operator! Intriguingly, human herpesvirus 8, the virus that causes all forms of Kaposi's sarcomas in human, also carries a cyclin-like gene (remember that oncogenic DNA viruses, in contrast with oncogenic RNA viruses, like to interfere with the cell cycle). In addition, the biological behaviour and many morphological features of the classic form of Kaposi's sarcoma match many gross and histopathological features of WDS. Like WDS, classic Kaposi's sarcoma is a mesenchymal, nodular, multicentric tumour composed of sheets of fibroblastic cells growing in and restricted to the dermis. Thus it is reasonable to think that the recent characterization of the WDSV cyclin-like gene might help explain the mechanisms of viral tumourigenesis in Kaposi's sarcoma. For instance, human skin is much colder than the body core temperature. Temperature might play a role in regulating the expression of human herpesvirus 8, just as it plays a role in the regulation of WDSV.

Just as crippling the "operator" of the merry-go-round is by itself not enough to cause the ride to start spinning out of control, factors other than the cyclin-like gene (integration near an oncogene or into a tumour suppressor gene) will be found to explain the development of WDS, either in its benign or malignant form.

Chemical carcinogens

Because of the relative rarity of cancer in mammals and the long time that usually separates exposure to a carcinogen and cancer development, it is difficult to establish an epidemiological relationship between cancer and a chemical carcinogen. Yet in 1775, London surgeon Percival Pott used the diversity of human livelihoods to identify an environmental carcinogen. He remarked that the City's chimney sweepers had a high prevalence of scrotal cancer and rightly deduced that the soot lodged in their groin was the probable cause. This was one of the first demonstrations of chemical carcinogenicity. Similarly, modern researchers have used the diverse ecological niches of fish to identify environmental carcinogens.



Fig 13.5A. Lipoma in a brown bullhead.



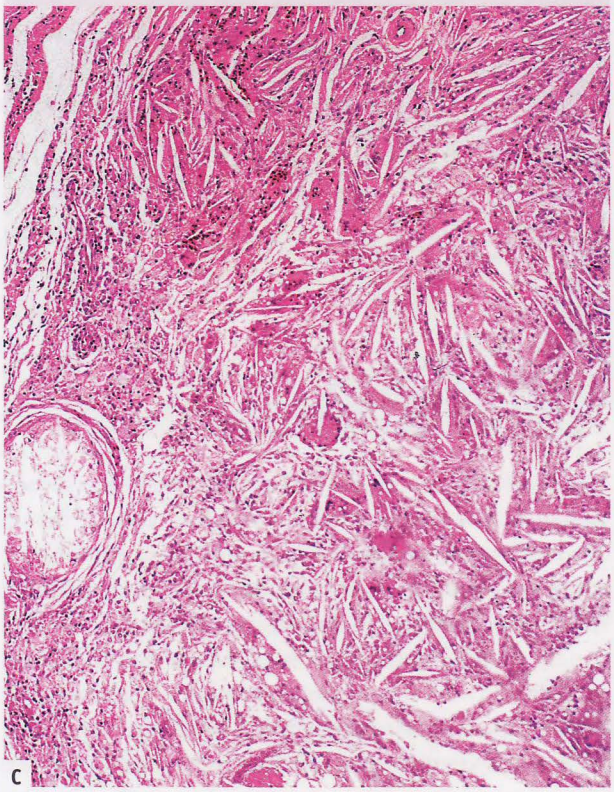

Fig 13.5B&C. Cholesteatoma in a mullet. Note the cholesterol-like crystals.

There are more species of fish than birds and mammals combined. As the most numerous and the most diverse group of vertebrates, fish occupy all depth and temperature layers of the world's oceans, lakes and rivers. Among those ecological niches, bottom dwelling fish, the "chimney sweepers" of the water column, occupy the niche most impacted by chronic pollution because many major man-made carcinogens such as polycyclic hydrocarbons (PAH's) are hydrophobic. Because of this property, once in water, they quickly adsorb to any nearby solid particle in suspension, and accompany the particle in their fall down into the sediments. Bottom-dwelling fish have been found with high prevalence of labial papillomas and hepatic tumours. The presence of PAH's in sediments was subsequently associated epidemiologically and experimentally to the development of these tumours.

PAH's have long been known both as tumour "initiators" and "promoters". Initiators are compounds that induce a mutation whose effects remain latent until the mutated cell is treated with a promoter, a general term used to designate any factor (generally a chemical, but also trauma) that stimulates cell division. The occupational hazards – and trauma - associated with scrounging through sediment with one's lips probably act as promoters in the development of papillomata in bottom feeders.

During a survey of fish inhabiting a polluted segment of the St Lawrence Estuary in Quebec, we found that lake whitefish (which are salmonids) were the only species to have a high prevalence of liver tumours. Known bottom-dwelling fish such as bullhead and suckers captured in the same habitat were not affected. Interestingly the concentrations of heavy metals and organochlorinated compounds were much more elevated in the tissues of the lake whitefish than in those of bullhead and suckers. But we then discovered that among salmonids, lake whitefish are very unusual because they are bottom-dwellers. In parallel, beluga whales are members of a rarefied club of tooth whales that feed on bottom invertebrates. Beluga whales living in the St Lawrence Estuary are also affected by cancer and this is probably because they feed on bottom invertebrates contaminated with PAH's that have been released in huge amounts by local aluminum smelters. Thus, both beluga and lake whitefish are probably affected by cancer because they share peculiar feeding habits that distinguish them from other members of the distant taxonomic group to which they belong.

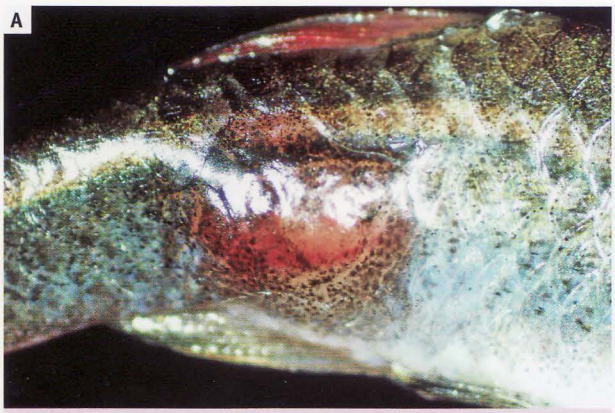

Fig 13.6A&B. Tetra with haemangioma. Note the proliferation of small blood vessels.

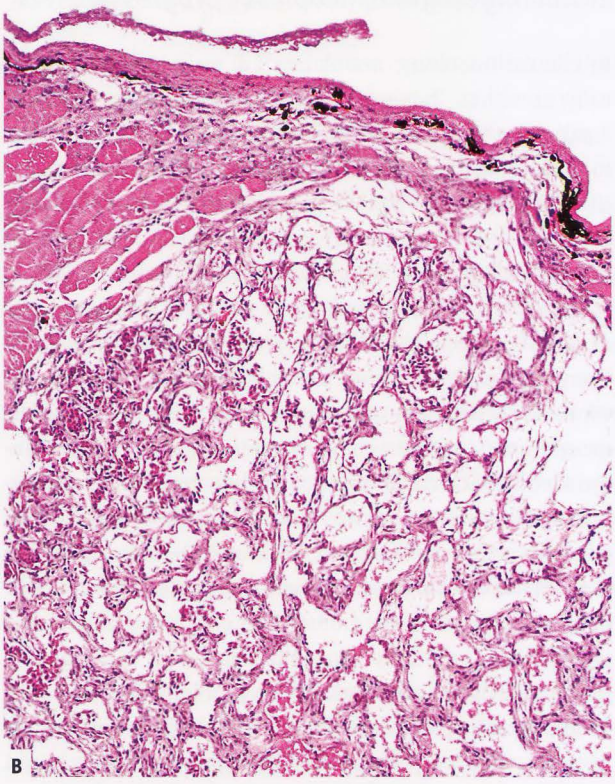

Oncogenes and chemical carcinogenesis

Chemical carcinogens induce tumours through mutations in DNA. Oncogenes and tumour suppressor genes are the target of mutations by chemical carcinogens. To activate an innocent proto-oncogene into an oncogene, there exist only a very limited number of sites within the gene and a very narrow range of mutations possible. Inactivation of the proto-oncogene is much more likely to happen if mutations occur elsewhere. This results in the same mutation being found in many cancers regardless of the causal mutagen. For instance, *ras* is mutated in up to 1 of 4 human cancers, and always in the 12th, 13th, or 61st codon. It is also at these exact sites that mutations occur in a number of experimental and spontaneous tumours in both laboratory and domestic animals. This lack of specificity disappointed early molecular epidemiologists who were looking for a signature mutation that would betray a specific chemical carcinogen. Aflatoxin is one of the most powerful known carcinogens as measured *in vitro*, and it is a major cause of human cancer in Africa and Asia. It is produced by a fungus *Aspergillus flavus* that frequently contaminates corn, rice and peanuts stored in humid conditions on these tropical continents. Very low concentrations of aflatoxin are sufficient to cause hepatocellular carcinoma in trout. The toxin reliably causes mutations in trout *ras* on codon 12; this is the same codon that is mutated in rodents treated experimentally with many different carcinogens.

More success was met with tumour suppressor genes because they are much more "permissive". Inactivating mutations can occur almost anywhere along the gene because loss of function of *any* protein is much more likely to happen than a gain of function when a mutation is introduced at random within the gene coding for that protein. Over the last few decades, this fundamental difference has allowed us to determine that several chemical carcinogens leave a characteristic signature *e.g.* a specific mutation at a specific site on tumour suppressor genes such as p53 and Rb. This molecular epidemiological approach has been applied in flounder. For instance, exposing flounders to benzo[a]pyrene has caused specific mutations in the p53 gene.

Classification of neoplasms

Most systems of classification and interpretation of neoplasms have been developed from clinical oncology in human medicine. These systems have been developed over many years to deal with neoplastic lesions that present clinical health problems in human patients. They are based on recognizable phenomena that characterize the identity and behaviour of neoplasms, and attempt to orient clinical management practices in directions indicated by the important salient features of the neoplasm presented. The general objective of pathological examination of neoplasms of human patients is to enable clinical oncologists to select an appropriate therapeutic protocol from those demonstrated to be the most beneficial for various established categories of neoplasms. Because many advanced

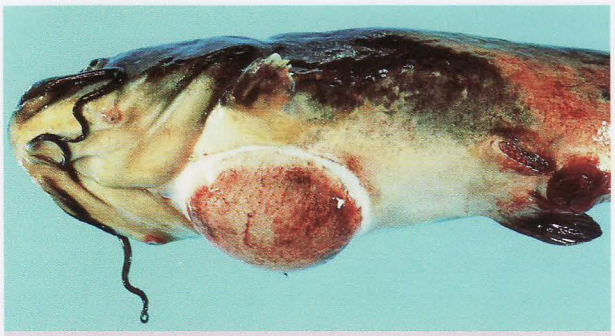

Fig 13.6C. A catfish that had become trapped on an outflow pipe, and almost eviscerated with the suction. Note the tumour-like lesion - can we call this a "dermal suckoma"?!



Fig 13.7. Gill neoplasms are rare. Here is a chondroma of the arch.

neoplasms have few adequately successful established therapeutic protocols, the classification systems are in a state of constant flux, with an ever increasing number of phenomena (morphological, immunological, biochemical, *etc.*) being identified. The resulting catalogues of types and subtypes of human neoplasms are large, with confusing nomenclature systems that are probably too complex for systematic classification of fish neoplasms.

Accordingly, complex classification systems that attempt to accommodate the full breadth of phenotypic diversity in neoplasms of many species of fish could complicate rather than clarify the higher priority efforts to characterize and prevent the major disease processes leading to important neoplasms in fish.

The combined influences of *selection*, *diversification* and *growth* explain the biology of neoplastic disease. The majority of "early" atypical lesions are reversible or non-progressive (*i.e.* "benign") but have changes that predispose them to subsequent changes, some of which lead to harmful ("malignant") growth behaviour. Progression through the various stages depends on the *intensity of selection* and the *rate of diversification*, each of which is influenced in different ways by the intensity of oncogenic insults on the target tissue. The biology of a particular neoplasm depends on its phenotypic changes, its native behavioural growth patterns and its acquired novel characteristics that are the result of diversification and heterogeneity. Some neoplasms such as those of haematopoietic tissue may be malignant early in the sequence because the cells are normally able to spread to other tissues. Others may not even be noticed during the early stages and are recognized as harmful neoplasms only when they are very advanced, for example neoplasms of parenchymal or structural tissues.

Evaluating stages of neoplastic progression

In clinical oncology, neoplasms are evaluated prognostically as either "benign" (non aggressive, innocuous) or "malignant" (aggressive, harmful). While this is very useful when making decisions for surgical or chemotherapeutic management of tumours in individual patients, such a division is not always easily achieved by histopathological assessment, or even understood in molecular biological terms. Moreover, in experimental or population oncology of fish where individual therapy is not performed, the terms "benign" and "malignant" are possibly even inappropriate especially when it is appreciated that, with relatively few exceptions (lymphosarcoma of northern pike or aflatoxin-induced hepatic carcinomas of rainbow trout which metastasize) fish tumours do not often appear to behave in a particularly aggressive manner. Prognostication (*i.e.* deciding a neoplasm is malignant because eventually it would have become harmful if the animal had continued to survive) is imprecise, especially when the criteria for making such judgements are not reported. The problems that can arise from imprecise prognostic assessment of fish neoplasms are obvious when we consider how regulatory agencies might deal with "malignant" rather than "benign" neoplasms in fish in polluted environments or in chemical carcinogenicity assays.

Since the stage of tumour progression is an important measure of the cumulative effects of carcinogenic insults over time, it is especially important for pathologists evaluating animals in carcinogenicity assays to precisely assess the stage of a neoplasm. This should be based on factors such as growth rate, invasiveness, heterogeneity, location and metastatic behaviour. By so doing, the present biological behaviour (*i.e.* stage) of a particular tumour is implied.

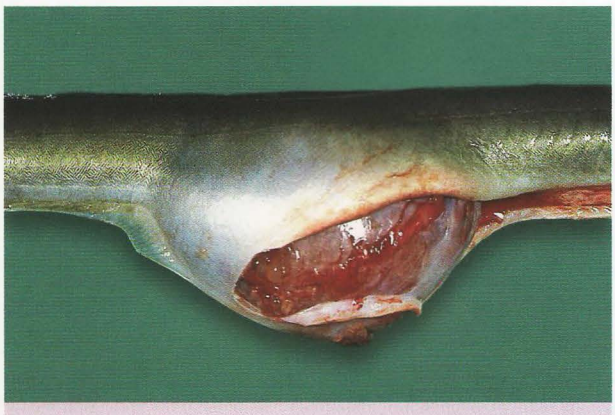

Fig 13.8A. Nephroblastoma in eel.

Assessment of neoplasms in fish populations

From the foregoing it should have become obvious that the objectives for pathologists required to identify and interpret neoplasms in fish are not all the same. For example, neoplasms that occur frequently in wild fish need to be considered with either an epidemiological perspective towards possible causes and prevention of the disease, or with a public health perspective towards reducing potential risk for anyone eating the fish or for the co-inhabitants of their extended natural environment. By comparison, pathologists evaluating experimentally-produced neoplasms in fish need a perspective towards the causes and pathogenetic mechanisms of carcinogenesis. From a broader comparative perspective of the differences in behaviour of neoplasms in all species, pathologists can characterize unusual aspects of fish neoplasms that might eventually lead to new preventive and therapeutic strategies applicable to human neoplasms.

From the basis of known mechanisms of carcinogenesis, initial evaluation of populations of fish with neoplasms needs to have the following in mind:

1. **Target Organ** (topographical occurrence). This aids in attempts to identify classes of carcinogenic influences with known capacity to induce neoplasms in this tissue, and directs further attention to the pathological processes that might be present in the surrounding non-neoplastic tissue.

2. **Stage of neoplastic progression.** This enables an assessment of the duration and intensity of carcinogenic influences in relation to age, bearing in mind the age-related mechanisms of proliferation required for initiation and promotion. The major stages are altered focal (preneoplastic) proliferations, and established neoplasms with expansive, diversified, invasive and metastatic behaviour. Despite possessing histological criteria for malignancy, fish tumours metastasize much less commonly than their mammalian equivalents, although the reasons for this are unknown. Fish cells may lack the ability to express secretory proteases or membrane glycoproteins required for successful metastatic spread. Alternatively, the hypothesis that immune surveillance is involved in defence against some neoplasms needs to be assessed in the light of differences between fish and mammalian immune systems.

3. **Epidemiology.** Sporadic tumours in old or otherwise normal populations of fish are put aside as rare accidents due to cumulative molecular events in a single population of cells. Clustered tumours, on the other hand, draw attention to the likelihood that one or more distinct categories of tissue insults has given rise to the increased incidence. For example, the increased occurrence of liver tumours in rainbow trout originally lead to the identification of aflatoxin as a food-borne liver carcinogen. Also, the frequent occurrence of skin and liver tumours in fish in polluted rivers or marine environments has stimulated intensive efforts to identify and eliminate carcinogens in industrial effluents.

4. **Host aspects.** The age at which neoplasms develop, particularly in younger fish, is an important lead to the further identification of possible pathogenetic and aetiological influences. Neoplasms in young fish usually reflect exposure to potent viral or chemical carcinogens during developmental growth, whereas tumours in very old fish usually reflect a weaker and possibly multifactorial chronic carcinogenic insult. Comparing bottom dwelling species (such as brown bullheads or white suckers) with free-swimming ones (such as salmonids or carp) may help identify effects due to habitat or to species differences in, for example, levels of detoxifying enzyme systems. Similarly, different strains of fish may have differing sensitivities to carcinogens, so that tumour incidence in one location is higher than in another. Hybridization may also enhance susceptibility: this is seen in the carp/goldfish hybrids which develop gonadal tumours, or in the swordtail/platy hybrids which develop melanomas.

5. **Pathogenetic mechanisms.** The non-neoplastic tissues are examined carefully for evidence of processes

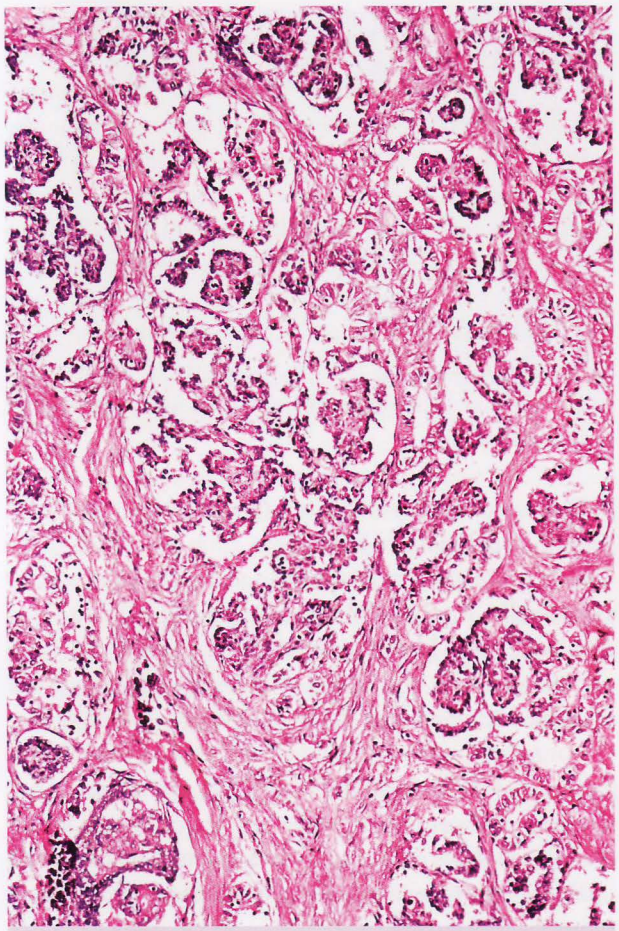

Fig 13.8B. Histopathology of nephroblastoma in a trout.

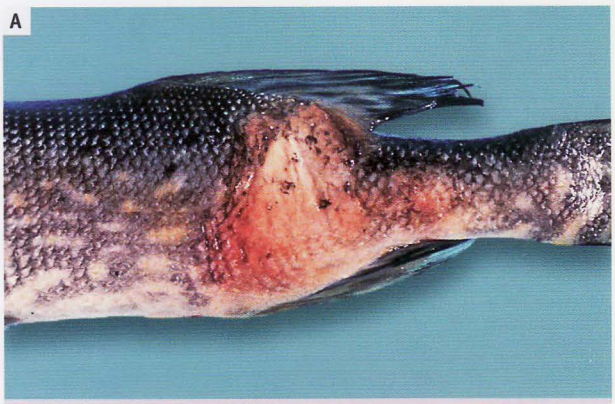

Fig 13.9A&B. Lymphosarcoma is relatively common in pike and muskellunge. The lesion in **B** shows severe ulceration.

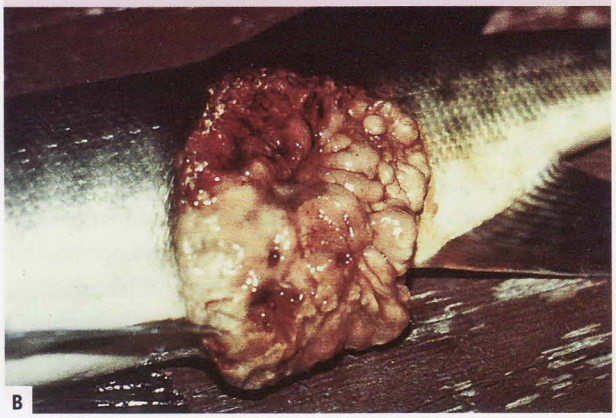

that may have contributed to the pathogenesis of the neoplasm observed. For example, if there are many other small pre-neoplastic lesions in neighbouring tissue, there is a strong possibility that the animal has been exposed to a major genotoxic insult. Also the size of these other preneoplastic lesions and the degree of normal cell proliferation may indicate the intensity of a mitogenic promotional influence. Most importantly, the tissue is examined for evidence of ongoing necrosis or atrophy, each of which can contribute to a reciprocal promotional effect on preneoplastic lesions. In this case, the effects on the surrounding tissue may then indicate the nature of the major carcinogenic insult. Similarly, chronic regenerative proliferation, fibroblastic or angiogenic repair, or lympho-proliferative inflammatory reactions may be relevant in explaining the pathogenesis of neoplasms of fibroblasts, endothelial cells or haematopoietic cells. Some chemically-induced neoplasms have an altered biochemical phenotype such as elevations in various glutathione-dependent or other detoxification enzyme systems. This phenotype can be detected by appropriate immuno- or enzyme-histochemical methods and its presence may suggest that the tumour has arisen because it is resistant to a toxic insult. Obviously, such interpretations give some lead towards defining aetiological agents (viruses, parasites, chemicals, *etc.*) and more importantly, the mechanisms by which they contribute to the process as a whole.

6. **Aetiological mechanisms.** The previous assessments can, as explained, provide an idea of what might be involved in causing the tumours. This needs to be confirmed by a process of identifying, if possible, the nature of the major aetiological agents involved, in conjunction with the previously established pathogenetic mechanisms they elicit. It is important to remember that the multiple stages may be influenced by separate aetiological influences, such that many cancers have a multifactorial aetiology. While this complicates the search for aetiological agents, it is a reality that should not be overlooked by searching for a single agent that explains everything in the tissue. A further complication is that the agent may not be present in the tissues, especially in the neoplasms,

by virtue of the fact that many neoplasms arise as populations *resistant* to the agent. Accordingly, the search for the agent should focus on the environment, or on the pathologically altered surrounding tissue. For example, it is possible to detect DNA adducts in target tissues of fish exposed to some carcinogens in polluted environments.

7. **Molecular mechanisms.** As already explained in the first section of this chapter, some chemical and viral carcinogens generate characteristic alterations in genes for growth regulation and characterization of the genetic alteration in a group of tumours may sometimes help to explain the type of virus or chemical involved in their generation. For example, the point mutations in the *ras* oncogene in liver and skin neoplasms of mammals differ for different classes of genotoxic carcinogens. Also, for most viruses, it is relatively easy to identify evidence of persistent viral infection, either by immunological or nucleic acid hybridization techniques, if the appropriate probes are available. This strategy is presently unsuited to studies of a single neoplasm; rather it should be reserved for detailed evaluation of idiopathic tumours that occur with unusually high frequencies.

8. **Histogenetic and phenotypic characterization.** These studies, which use microscopic features and probes for specific differentiated functions of histological cell types, help to identify the cell of origin in the target organ. However, this approach is prone to error when used on advanced neoplasms because during phenotypic diversification they may have lost certain markers, or they may newly express proteins that are not characteristically expressed in the parent cell type. For example, some advanced hepatic neoplasms have differentiated features of hepatocytes and also of bile ducts, making it impossible to determine if such a tumour is of hepatocytic or bile epithelial origin. However, if this approach is reserved for groups of neoplasms, as explained in item 7 above, and interpreted in conjunction with recognition of early preneoplastic lesions that have not changed substantially from the parent cell type, the major target cell types can be identified more reliably.

Common neoplasms in fish

As already stated, classification of fish neoplasms is largely based on mammalian criteria, and there seems little point therefore in merely reiterating these with detailed histological descriptions. Accordingly the reader is referred to the standard texts such as Moulton, 1990. A brief overview of some of the more common neoplasms found in fish is nevertheless considered worthwhile, if for no other reason than to underline the fact that they are morphologically similar to their counterparts in other vertebrates. Differences can arise, however, because of cells or tissue organizations unique to teleosts. In keeping with the rest of the book, a systemic approach has been adopted. For reviews on fish tumours, see Lucke & Schlumberger, 1949; Mawdesley-Thomas, 1971; Budd and Roberts, 1978; and Peters, 1984.



Fig 13.10A. Thymoma in speckled trout.

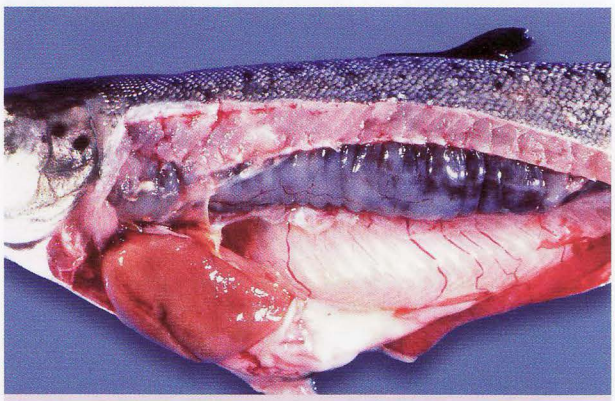

Fig 13.10B. Lymphosarcoma in Atlantic salmon commonly affects renal tissue.

Skin. In general, skin tumours are quite commonly encountered and diagnosed, partly of course because they are easily seen! The most common skin tumours are generally termed *papillomas*, although their morphology is not always papillary (wart-like) with supporting ingrowing fingers of dermal fibrous tissue typical of classical papillomas of mammals (***Fig 13.1***). Many are flatter and sometimes called "hyperplastic plaques". These lesions are discrete

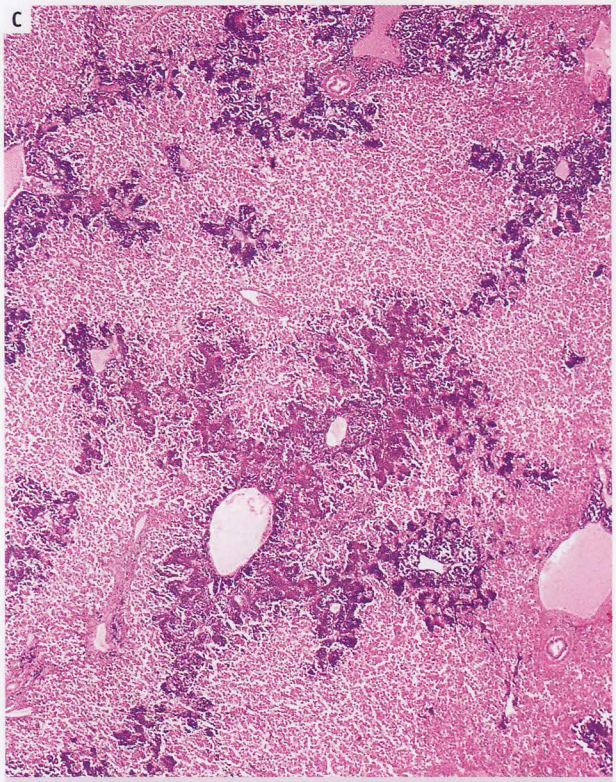

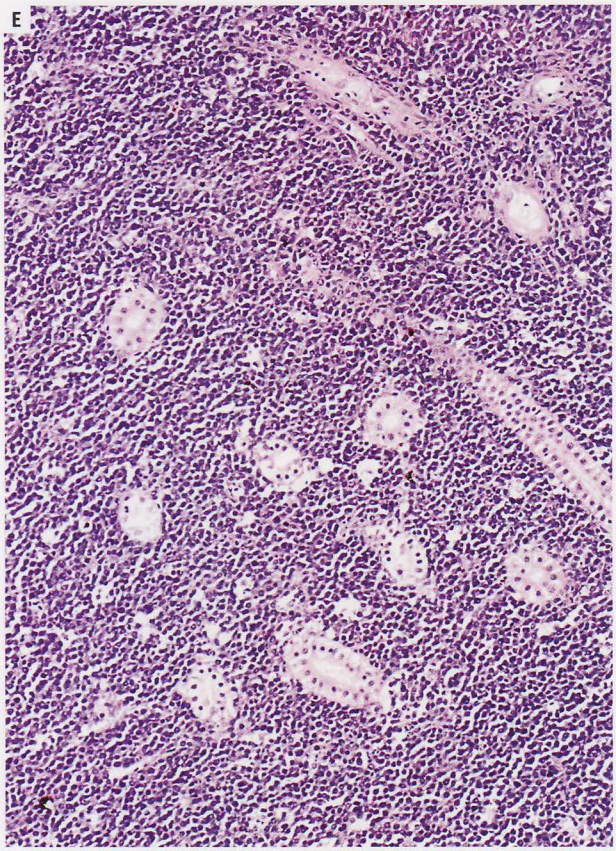

Fig 13.10C-E. Histopathology of **B** showing lymphomatous invasion of liver (**C**), lamina propria of intestine (**D**) and kidney (**E**). Such a monomorphic population of neoplastic cells is usually easily distinguished from reactive populations seen in the renal interstitium in situations of increased demand for inflammatory cells.

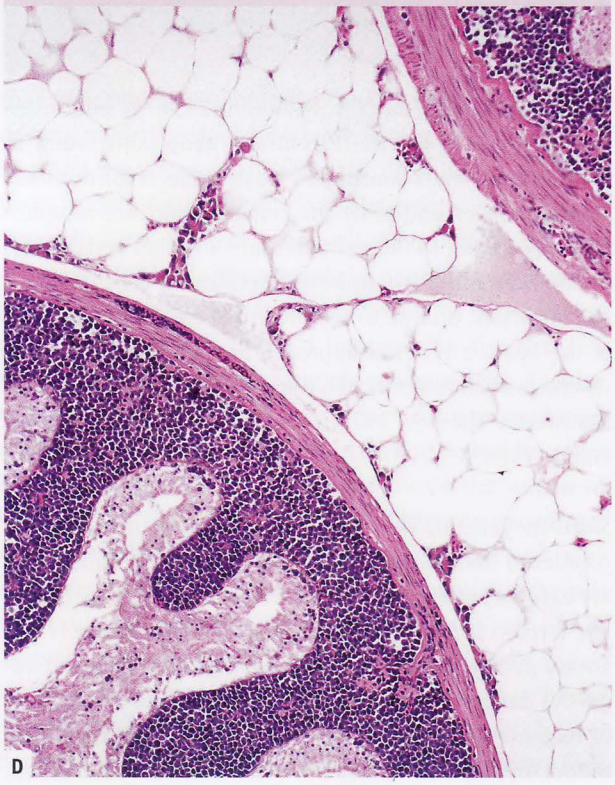

expansive growths of altered epidermis (malpighian cells) that tend to obliterate the other goblet cells and club cells by displacement or necrosis. The proliferative epithelium is often spongiotic with focally intense lymphoid cell infiltrates. Papillomas, especially those on the lips, frequently ulcerate due to constant abrasion, supporting the view that physical injury may have a role in promoting their growth. Papillomas are common on Great Lakes fish, especially on the lips of brown bullheads and virtually anywhere on the body surface of white suckers. Virus-like particles have been seen ultrastructurally in papillomas from both of these species of fish, but no viral agent has been firmly implicated or identified. The frequent occurrence of these lesions on fish in industrially polluted locations has lead to suspicions that chemicals may have a role in initiating or promoting these lesions, in conjunction with a viral agent. Some papillomas in bullheads may progress towards locally invasive lesions, more appropriately termed squamous cell carcinomas (see later).

Papillomatosis of the European eel ("cauliflower disease") is a condition producing particularly florid lesions, most commonly round the mouth, and these may be large

A

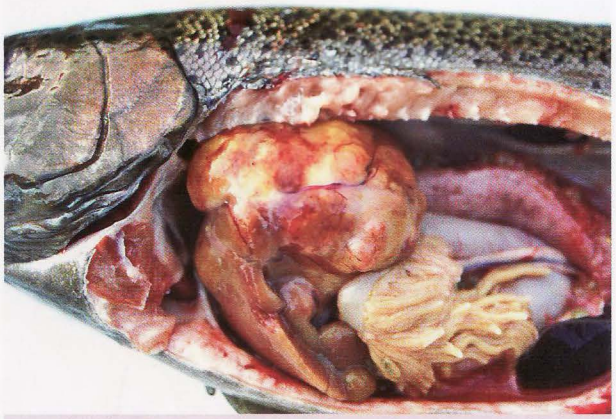

Fig 13.11A&B. Aflatoxin-induced hepatic carcinoma in broodstock rainbow trout. Despite the small remnant of normal liver, this fish seemed to be in good body condition, except for the liver mass which distorted the abdominal wall.

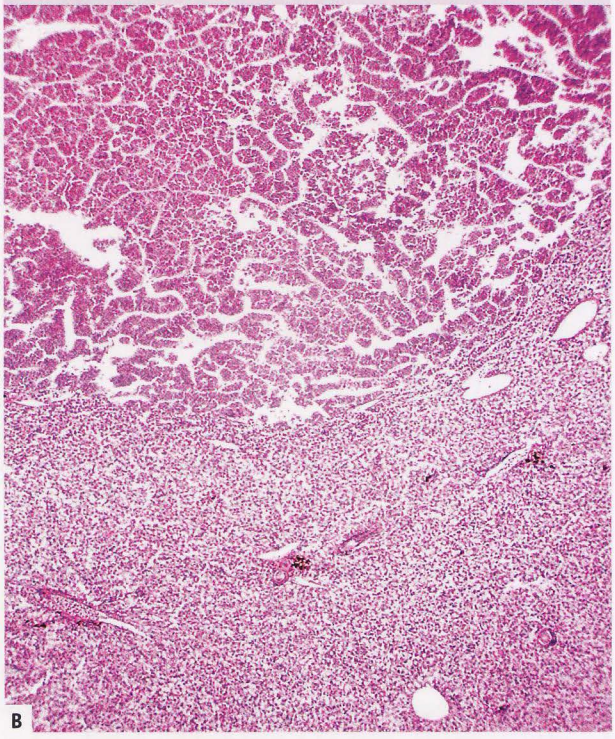

B

enough to interfere with feeding and respiration. They are most frequently seen (up to 30% of the population) in young fish in the summer in brackish water, and it is interesting that the lesions regress with lower water temperatures or higher salinities. Once again, a viral aetiology is suspected but not confirmed. Hyperplastic epidermal plaques are seen in "papillomatosis" of Atlantic salmon. These lesions are most common in young fish in freshwater in August or September, and although they usually spontaneously regress with no apparent damage, some may become secondarily infected.

Oncorhynchus masou virus ("yamame tumour virus") is a herpesvirus that naturally causes disease in young masu salmon ("yamame") populations in Japan. Survivors show a remarkably high incidence (60%) of skin tumours including papillomas and basal cell tumours that are most commonly located round the mouth, then the caudal fin, operculum and eye. In the Pacific flatfish papillomas, there is a proliferation of malpighian cells which often become replaced by large, clear, rounded cells, "x-cells", which lack the epidermal features of desmosomes and tonofilaments and which have the ultrastructural hallmarks of degeneration *e.g.* swollen mitochondria. The identity of these "x-cells" is unknown **(*see Fig 2.5D*)** and a debate centres even on whether they are host cells or not (protozoa?), similar to the perplexing identity of "rodlet cells" **(*see Figs 1.1B & 4.26E*)**. In some areas the incidence of these papillomas correlates with heavy pollution, while in others (Queen Charlotte Islands in British Columbia) sand sole may have infection levels of 30% despite inhabiting apparently pollutant-free water. Nevertheless, there has to date been no successful transmission of the disease.

Squamous cell carcinomas are less common **(*Fig 13.2*)**, but in one survey of fish from Hamilton Harbour, Lake Ontario, out of 25 brown bullheads necropsied because of grossly visible skin lesions, 10 were subsequently diagnosed as having early squamous cell carcinomas. The relevant criteria were an unusually proliferative basal epithelium with loss of basal lamina, and invasion of basal cells down into the underlying dermis and muscle and up into the overlying epidermis. In most cases, these arose from co-existing papillomas: in only one animal did the carcinoma appear to arise from a moderately hyperplastic rather than papillomatous area of epidermis. Tumours with criteria typical of SCC have recently been transmitted to rudd.

Pigment cell tumours include melanomas, erythrophoromas, xanthophoromas and guanophoromas. Of these, melanomas are by far the commonest, and may show a greatly increased incidence in hybrids (as do other tumours) such as the swordtail/platy hybrid, in which there appears to be repression of the gene controlling melanophore production. As in mammals, some of the melanomas in fish may be amelanotic and there may be considerable variation in cellular morphology from round to fusiform or spindle-shaped with a distinct "neural" appearance. Erythrophoromas are also composed of spindle-shaped cells and often are multi-nucleate with a fine granular cytoplasm.

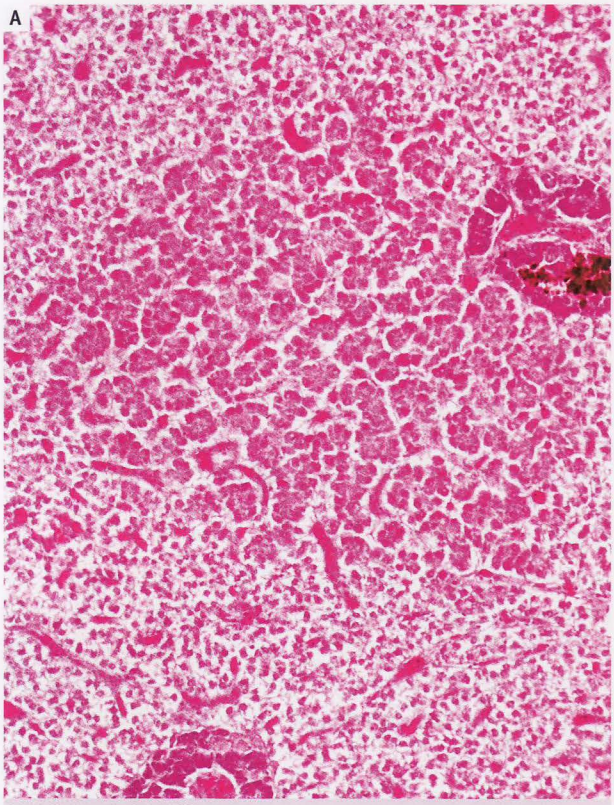

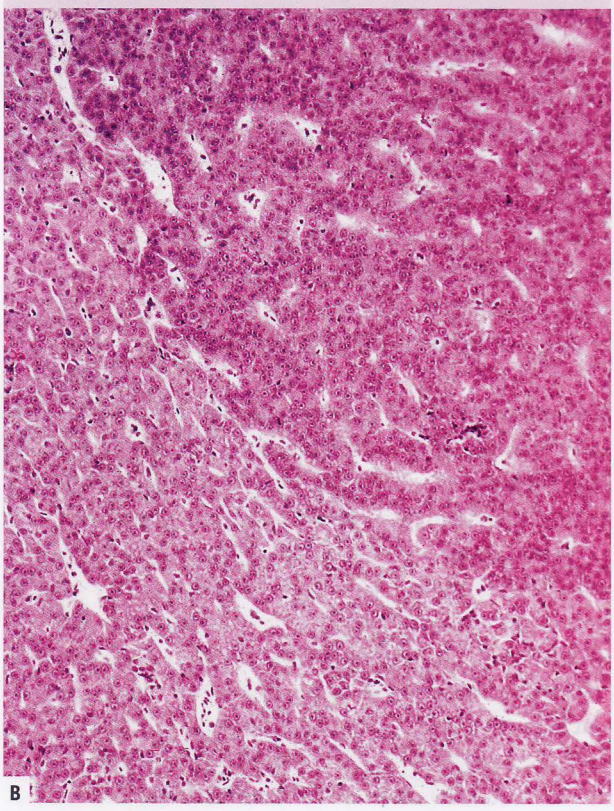

Fig 13.12A-C. These show progression of liver tumours in white suckers from an altered focus of hepatocytes (**A**) through to hepatoma (**B**) and on to hepatocellular carcinoma (**C**).

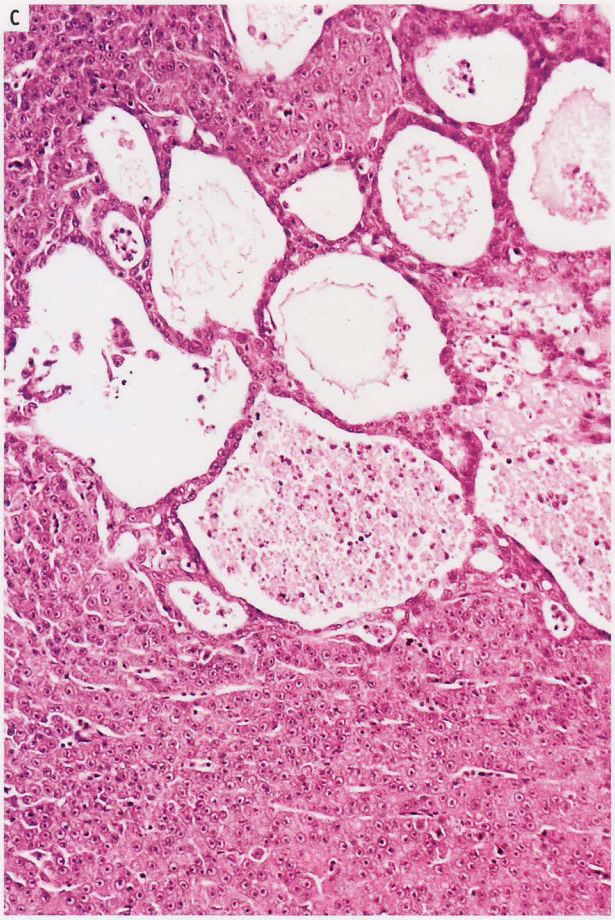

Fibromas and *fibrosarcomas* are relatively common spindle cell tumours affecting a wide variety of different species ***(Fig 13.3)***. They are often loosely organized (and some of these may be termed myxomas) but occasionally may be hard, or extremely hard, as is the case with the specific entity "dermal sarcoma of walleye" caused by a retrovirus ***(Fig 13.4)***. These latter tumours arise from dermal elements and cause multifocal hard nodular lesions on the body surface: they may be extremely disfiguring, locally invasive, and may ulcerate. They are not infrequently found in association with a herpes-virally induced epidermal hyperplasia and/or lymphocystis disease. Neurofibroma-like tumours are sometimes seen, and are well recognised in damselfish, where they have been compared to neurofibromatosis of man, although in damselfish they can be transmitted horizontally.

Lipomas are occasionally encountered ***(Fig 13.5)*** but they are much less common than fibromas: they too may cause dermal ulceration. Subdermal lesions with lipid or cholesterol-like crystals are rarely seen; they have been called *cholesteatomas*. *Haemangiomas* comprised of benign

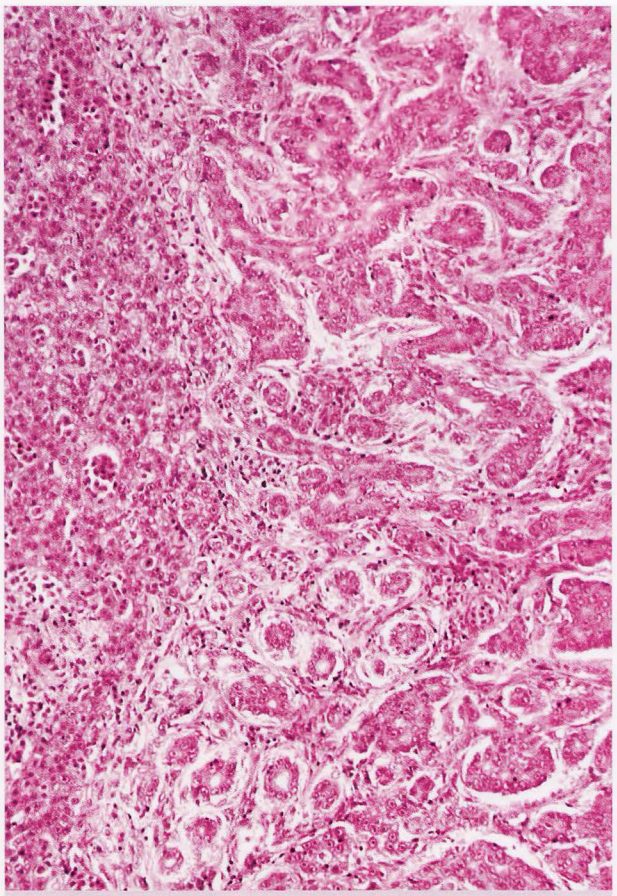

Fig 13.12D. Bile duct carcinoma in white sucker.

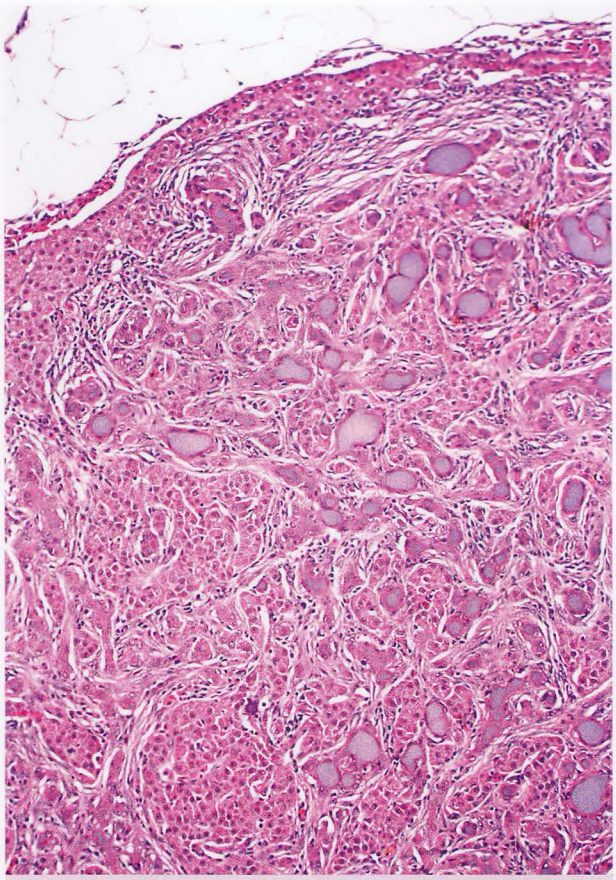

Fig 13.12E. Bile retention in liver tumour of white sucker. The bile stains as slate-blue in this slide.

proliferations of small blood vessels, are sometimes encountered in the dermis, although occasionally also in the trunk musculature ***(Fig 13.6)***.

Gills and pseudobranchs. Gill tumours are rare, which is interesting, considering their often much greater surface area (and hence greater exposure to carcinogens) than the skin, in which tumours are so common. A chondroma arising from filamental or arch cartilage ***(Fig 13.7)*** a fibroma of the arch, and one possible adenoma, represent some of the mere handful of spontaneous neoplasms diagnosed in our laboratories. Branchial lamellar papillomas have been experimentally produced in medaka using N-methyl-N^1-nitro-N-nitrosoguanidine. Pseudobranchial "tumours" are not uncommon, especially in Atlantic and Pacific cod and other gadoids. Histologically they are comprised of large pale cells which appear virtually identical to the "X-cells" seen in the Pacific flatfish "papillomas". Inevitably the question arises once again as to whether these cells are of host or parasitic origin (indeed a proliferation of similar cells is reported in the *gills* of some marine fish, just to confound the situation!). The incidence rate in Atlantic cod may be 2% round Nova Scotia and confined mainly to 1, 2 or 3 year old fish. Incidence in Pacific fish tends to be higher.

Kidney. In general, renal neoplasia in fish is relatively uncommon although nephroblastomas and adenocarcinomas are both reported. In the former, there is proliferation of pluripotential "blast" type embryonic cells to form most of the cellular elements normally encountered in the posterior excretory portion ***(Fig 13.8)***. Thus there is usually a proliferation of epithelial cells that in places try to form tubules or glomeruli. Connective tissue is present in variable amounts, and either fibrous tissue or cartilage may dominate from one location to the next. We have seen nephroblastomas both in wild fish (smelt, eel) and in farmed rainbow trout. The renal adenocarcinomas we have encountered have had a papillary appearance.

Haematopoietic tissues. Lymphosarcoma is well described from northern pike in Scandinavia, Ireland and



Fig 13.12F. Carcinoma in liver of mature Atlantic salmon. *Picture courtesy Drs. B. Tørud & O.B. Dale.*



Fig 13.13A&B. Angel fish with tumour of tooth germ. Such large masses usually lead to problems due to inability to feed.

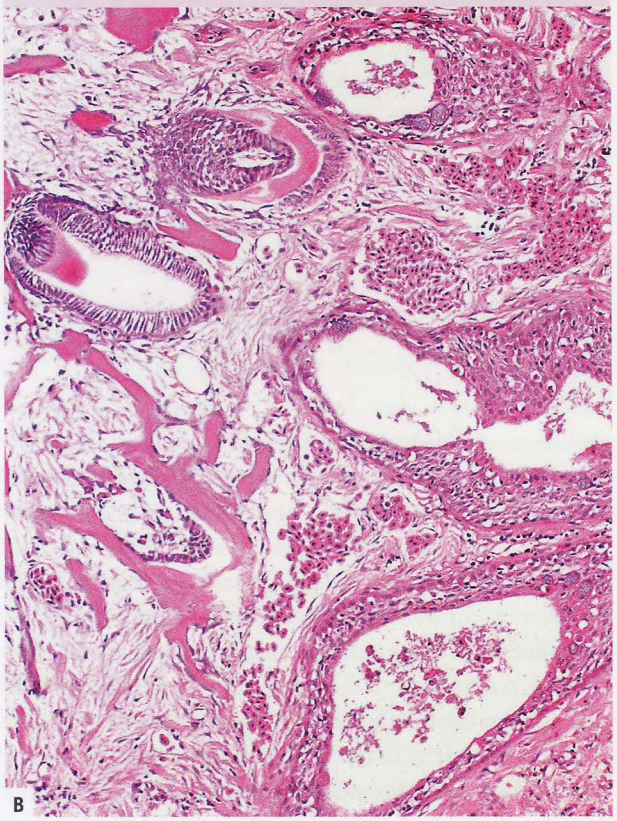

North America, and in the latter location, muskellunge are also affected **(*Fig 13.9*)**. As with similar disease in mammals, a retrovirus is associated, and there has been successful experimental transmission using cell-free extracts. Many fish with lymphosarcoma have hyperplastic epidermal plaques in which it is relatively easy to see C-type particles. The lesions are widely disseminated and may be leukaemic. They start often as small nodules in the skin which may ulcerate, and then they invade the underlying muscle. In late stages, spleen, liver and kidney are affected. The disease is approximately 99% fatal to muskellunge, but less so with pike, and in this species, recovery may even be the norm. Disease incidence in muskellunge is highest in the spring, and by summer, many fish have died. In the Baltic, the disease was not recorded until the 1950's and there is a suggestion that the incidence has increased in line with pollution, especially with chlorinated hydrocarbons.

Lymphosarcoma of thymic origin (*thymoma*) is also found, and has been reported several times from salmonids **(*Fig 13.10*)**. In most instances, the tumour is leukaemic. Occasionally there is diffuse involvement of the kidney; such lesions must be carefully differentiated from the granulomatous nephritides, so common in salmonids and other species. Some protozoan-induced granulomas comprised of a largely monomorphic cell population have sometimes been mistakenly identified as lymphoma (*e.g. Haemogregarina* infection). Another example of such confusion is seen in "marine anaemia" or "plasmacytoid leukaemia" of chinook salmon; although retrovirus is associated, so too are microsporidia, and the relative importance of either is unclear. Certainly it has been shown experimentally that the condition can be transmitted using cell-free extracts.

Liver. Hepatomas and hepatic carcinomas are quite common tumours in fish. Rainbow trout, like ducks and turkeys, are exquisitely sensitive to aflatoxin, a product of the mould *Aspergillus flavus* that grows on peanuts and other oil seeds under warm humid conditions **(*Fig 13.11*)**. In the 1960's, aflatoxin caused large numbers of farmed rainbow trout to develop both hepatocellular and bile duct carcinomas. This is one of the relatively few examples of a fish tumour that has been shown regularly to

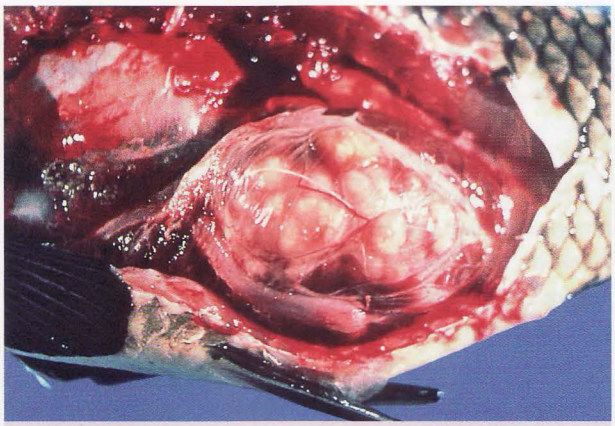

Fig 13.14. Carp x goldfish hybrid with gonadal tumour. Large proportions of a population can be affected in this way.

metastasize - often to the kidney in this particular case. Because of the susceptibility of the liver of various small fish (*e.g.* medaka) to chemical carcinogens, this organ is a major focus in short-term bioassays for carcinogens. These fish resemble mammals in their susceptibility to hepatocarcinogenic nitrosamines.

A variety of hepatic tumours is seen in wild populations of fish, often in areas of high industrial pollution (see for example the lake whitefish example earlier in the chapter). Examination of a population of white suckers on a spawning run up Oakville Creek in Lake Ontario showed roughly 17% to have advanced hepatic tumours of both hepato-cellular and bile duct types **(*Fig 13.12*)**. In some cases, as might be expected, both were found together in the same liver. Early changes were often represented by small nodules of morphologically altered cells - an increase in nuclear/cytoplasmic ratio or staining intensity, were common changes. More advanced lesions were discrete nodules or multiloculated hepatocellular carcinomas, some of which were extensively invasive within the liver. The bile duct epithelium frequently showed inflammatory, degenerative and metaplastic change before presumably progressing to discrete cholangiomas or invasive carcinomas. In general, the hepatocellular carcinomas were very cystic and haemorrhagic while the bile duct carcinomas were solid and often contained retained bile, giving them a grossly distinct colour. Despite locally aggressive behaviour and cytological pleomorphism and heterogeneity, only one of these liver tumours was seen to metastasize, in this case to the heart.

Another component of the liver in some species is the melanomacrophage centre, and we have once seen a



Fig 13.15A&B. Spindle-cell tumour in goldfish. The pallisading of the spindle-shaped cells suggests the possibility of a neurofibroma (Schwannoma).



melano-histiocytoma, characterized by large aggregations of the cells tending to obliterate normal parenchyma, and by the presence of multinucleated syncitial giant cells.

Gastrointestinal tract and swimbladder. Teeth tumours include ameloblastomas, invasive tumours of the odontogenic epithelium (*syn.* adamantinoma and enameloblastoma). Odontomas are considered to be malformations. Ameloblastomas are not uncommon, especially in salmonids, and are also reported in the Atlantic cunner (*Tautogolabrus adspersus*), a fish that grazes barnacles and

clams and that may therefore suffer mechanical damage. An interesting tumour is found around the mouth of angelfish; lesions involve the lips usually of females, and contain abortive attempts at tooth formation suggesting that they are of tooth origin ***(Fig 13.13)***. They are often large enough to interfere with feeding. A high percentage of fish in a tank can be similarly affected, suggesting the possibility of an infectious aetiology, and indeed retroviruses have been seen ultrastructurally. Other than the retrovirus-associated fibrosarcoma of Atlantic salmon that occurred in Scotland in caged fish in epizootic proportion, there are only a few reports of swimbladder tumours in other species, notably cod. Tumours in the stomach and intestine are uncommon although a tumour of the cod stomach was one of the first recorded (mid 18th century). So-called adenomatous polyps are recognized in cultured yellowtails, sea bream and eels in Japan although the significance of these pinhead-sized proliferations is unknown. A few peritoneal mesotheliomas are also reported.

Endocrine and reproductive system.

Thyroid. Differentiating physiological hyperplasia ***(goitre - see Fig 11.7)*** from neoplasia becomes very difficult in the thyroid, especially so when it is appreciated that in most teleost species the thyroid is a diffuse organ, with follicles normally scattered in often remote sites such as kidney, splenic capsule, or epicardial surface. Thus the assumption of metastasis is usually mistaken, and reports of thyroid "carcinoma" should be viewed in this light. Nevertheless, the extremely aggressive and invasive behaviour that some of these goitres demonstrate, infiltrating muscle, bone, and even myocardium ***(see Fig 11.7F)***, means that in a biological sense they are indeed acting as malignancies.

Gonads. Leiomyomas and fibroleiomyomas are quite common tumours of the testis of the yellow perch in the Great Lakes and indeed one study showed 8% of susceptible fish to be affected. A lesser number of ovaries have similar tumours. Carp/goldfish hybrids in the Great Lakes and elsewhere also have a very high incidence of gonadal tumours ***(Fig 13.14)***. As with the tumours in yellow perch, these may grow to a large size, causing space-occupying problems. Sertoli cell tumours, interstitial cell tumours and seminomas are also reported as individual cases, again often in hybrids; so too are ovarian papillary adenocarcinomas.

Musculoskeletal. Rhabdomyomas are usually reported as individual cases although an epizootic has been described in cultured ayu in Japan. The tumours were seen in approximately 1% of fish, affecting mainly the trunk and tail muscles and grossly distorting the fish. In the absence of obvious virus involvement, chemotherapeutics were suspected as the cause. Other than hyperostoses (reactive bone), which are not infrequently found, an example being in the mandible of pike in the Great Lakes, bone tumours are not common. They are sometimes encountered, however, in salmonid vertebrae, usually at the fulcrum of flexure beneath the dorsal fin, and a traumatic aetiology should probably be suspected. Other individually reported cases occur in a variety of other species, and indeed represent some of the earliest recorded tumours.

Nervous tissue. There are a few reports of central nervous system tumours (ependymomas) although by contrast, peripheral nerve tumours are quite common, especially those associated with the skin. Neurofibromas (formed from endo- and epineurial connective tissue) and neurilemmomas (derived from Schwann cells) are the two commonly reported, although they are difficult to differentiate from fibromas or sometimes melanomas, especially the amelanotic-melanomas ***(Fig 13.15)***. While usually seen as isolated cases, they may occur in high frequency in some populations: such is the case reported for several *Lutianus* spp. (snappers) along the Florida coast, affecting the nerve branches of roughly 1% of the population. The possibility of granulomata should always be borne in mind however. Ganglioneuromas are rarely reported. Spontaneous olfactory neuroepitheliomas are occasionally reported and are typically large, disfiguring and histologically composed of undifferentiated neuroblasts with a tendency to form rosettes; in some instances these tumours can display a high degree of differentiation as noted by the presence of an organoid appearance and ciliated olfactory sensory cells.

An epizootic (12 of 100,000) of neuroblastomas was reported in coho salmon raised in chlorinated-dechlorinated water; they were located in the skeletal muscle adjacent to the dorsal fin. The suggestion is that the halogenation of the water may have produced carcinogens.

Eye. A variety of tumours involving the eye have been reported: they include ocular fibromas, neurofibromas of the limbus, lymphosarcoma and retinoblastoma. The best known ocular tumour, however, is the melanoma of the swordtail/platy hybrids. Neoplastic cells may be seen extending from the choroid through the sclera to form usually densely-pigmented retrobulbar masses.

References

Ahne, W., Anders, M., Halder, M. and Yoshimizu, M. (1990) Isolation of picornavirus-like particles from the European smelt, *Osmerus eperlanus* (L.). *Journal of Fish Diseases* 13:167–168

Bernstein, J.W. (1984) Leukaemic lymphosarcoma in a hatchery-reared rainbow trout, *Salmo gairdneri* Richardson. *Journal of Fish Diseases* 7:83-86.

Black, J.J. (1983) Field and laboratory studies of environmental carcinogenesis in Niagara River fish. *Journal of Great Lakes Research* 9:326-334.

Brittelli, M.R., Chen, H.H.C. and Muska, C.F. (1985) Induction of branchial (gill) neoplasms in the Medaka fish (*Oryzias latipes*) by N-methyl-N'-nitro-N-nitrosoguanidine. *Cancer Research* 45:3209-3214.

Budd, J., Schroder, J.D. and Davey-Dukes, K. (1975) Tumors of the yellow perch. ***In:*** *The Pathology of Fishes.* ***eds.*** Ribelin, W.E. and Migaki, G. The University of Wisconsin Press, Madison.

Budd, J. and Roberts, R.J. (1978) Neoplasia of teleosts. ***In*** *Fish Pathology,* ***ed.*** Roberts, R.J. Bailliere Tindall, London.

Bylund, G., Valtonen, E.T. and Niemela, E. (1980) Observations on epidermal papillomata in wild and cultured Atlantic salmon *Salmo salar* L. in Finland. *Journal of Fish Diseases* 3:525-528.

Coulombe, R.A. Jr., Bailey, G.S. and Nixon, J.E. (1984) Comparative activation of aflatoxin B1 to mutagens by isolated hepatocytes from rainbow trout (*Salmo gairdneri*) and coho salmon (*Oncorhynchus kisutch*). *Carcinogenesis* 5:29-33.

Duncan, I.B. (1978) Evidence for an oncovirus in swimbladder fibrosarcoma of Atlantic salmon *Salmo salar* L. *Journal of Fish Diseases* 1:127-131.

Eaton, W.E. and Kent, M.L. (1992) A retrovirus in chinook salmon (*Oncorhynchus tshawytscha*) with plasmacytoid leukemia and evidence for the etiology of the disease. *Cancer Research* 52:6496-6500.

Egidius, E.C., Johannessen, J.V. and Lange, E. (1981) Pseudobranchial tumours in Atlantic cod, *Gadus morhua* L., from the Barents Sea. *Journal of Fish Diseases* 4:527-532.

Fujimoto, Y., Madarame, H., Yoshida, H., Moriguchi, R., Kodama, K. and Iizawa, H. (1986) Pathomorphological observations on epidermal papilloma of flatfish (*Liopsetta obscura*). *Japanese Journal of Veterinary Research* 34:81-103.

Getchell, R.G., Casey, J.W. and Bowser, P.R. (1998) Seasonal occurrence of virally induced skin tumors in wild fish. *Journal of Aquatic Animal Health* 10:191-201.

Gorlin, R.J. (1972) Odontogenic tumors in mammals and fish. *Oral Surgery Oral Medicine and Oral Pathology* 33:86-90.

Grizzle, J.M. and Williams Jr., E.H. (1983) Dermal fibroma in a redband parrotfish, *Sparisoma aurofrenatum* (Valenciennes). *Journal of Fish Diseases* 6:205-209.

Grizzle, J.M., Schwedler, T.E. and Scott, A.L. (1981) Papillomas of black bullheads, *Ictalurus melas* (Rafinesque), living in a chlorinated sewage pond. *Journal of Fish Diseases* 4:345-351.

Grizzle, J.M. and Goodwin, A.E. (1998) Neoplasms and related lesions. ***In*** *Fish Diseases and Disorders, Non-infectious Disorders,* Volume 2, ***eds.*** Leatherland, J.F. and Woo, P.T.K. CABI Publishing, New York.

Hanjavanit, C. and Mulcahy, M.F. (2004) Squamous cell carcinoma in rudd *Scardinius erythrophthalmus*: histopathology, ultrastructure, and transmission. *Diseases of Aquatic Organisms* 61:215-226.

Harshbarger, J.C., Spero, P.M. and Wolcott, N.M. (1993) Neoplasms in wild fish from the marine ecosystem emphasizing environmental interaction. ***In***: Couch, J.A. and Fournie, J.W. (***eds***) *Pathobiology of marine and estuarine organisms.* CRC Press, Boca Raton, USA.

Harshbarger, J.C., Shumway, S.E and Bane, G.W. (1976) Variably differentiating oral neoplasms, ranging from epidermal papilloma to odontogenic amelo-blastoma, in cunners [(*Tautogolabrus adspersus*) Osteichthyes; Perciformes: Labridae]. *Progress in experimental Tumor Research* 20:113-128.

Huizinga, H.W. and Budd, J. (1983) Nephroblastoma in the smelt, *Osmerus mordax* (Mitchill). *Journal of Fish Diseases* 6:389-391.

Hussein, S.A. and Mills, D.H. (1982) The prevalence of 'cauliflower disease' of the eel, *Anguilla anguilla* L., in tributaries of the River Tweed, Scotland. *Journal of Fish Diseases* 5:161-165.

Ishikawa, T., Masahito, P. and Takayama, S. (1978) Olfactory neuroepithelioma in a domestic carp (*Cyprinus carpio*). *Cancer Research* 38:3954-3959.

Ishikawa, T. and Takayama, S. (1979) Importance of hepatic neoplasms in lower vertebrate animals as a tool in cancer research. *Journal Toxicolology and Environmental Health* 5:537-550.

Kent, M.L. and Dawe, S.C. (1990) Experimental transmission of a plasmcytoid leukemia of chinook salmon *Oncorhynchus tshawytscha.* *Cancer Research* 50(17):5679S-5681S.

Kimura, I., Morikawa, S., Kiriyama, T. and Kitaori, H. (1983) An epizootic occurrence of rhabdomyoma and a case of ganglioneuroma in hatchery-reared ayu, *Plecoglossus altivelis* Temminck & Schlegel. *Journal of Fish Diseases* 6:195-200.

Kranz, H., Peters, N., Bresching, G. and Stich, H.F. (1980) On cell kinetics in skin tumours of the Pacific English sole *Parophrys vetulus* Girard. *Journal of Fish Diseases* 3:125-132.

Landolt, M.L. and Kocan, R.M. (1984) Lethal and sublethal effects of marine sediment extracts on fish cells and chromosomes. *Helgolander Meeresunters* 37:479-491.

Leatherland, J.F. and Down, N.E. (2001) Tumours and related lesions of the endocrine system of bony and cartilaginous fishes. *Fish and Fisheries* 2:59-77.

Lucke, B. and Schlumberger, H.G. (1949) Neoplasia in cold-blooded vertebrates. *American Physiological Society* 29:91-126.

Lumsden, J.S. and Marshall, S. (2003) Sporadic neoplasms of farmed chinook salmon, *Oncorhynchus tshawytscha* (Walbaum), from New Zealand. *Journal of Fish Diseases* 26:393.

Majeed, S.K. Jolly, D.W. and Gopinath, C. (1984) An outbreak of liver cell carcinoma in rainbow trout, *Salmo gairdneri* Richardson, in the U.K. *Journal of Fish Diseases* 7:165-168.

Manera, M. and Biavati, S. (1994) An immunohistochemical technique used to demonstrate the transition form of a squamous cell carcinoma in a mirror carp, *Cyprinus carpio* L. *Journal of Fish Diseases* 17:93–96.

Manier, J.F., Raibaut, A., Lopez, A. and Rioux, J-A. (1984) A calcified fibroma in the common carp, *Cyrpinus carpio* L. *Journal of Fish Diseases* 7:283-292.

Martineau, D., Bowser, P.R., Renshaw, R.R. and Casey, J.W. (1992) Molecular characterization of a unique retrovirus associated with a fish tumor. *Journal of Virology* 66:596-599.
Martineau, D., Bowser, P.R., Wooster, G.A. and Armstrong, L.D. (1990) Experimental transmission of a dermal sarcoma in fingerling walleyes (*Stizostedion vitreum vitreum*). *Veterinary Pathology* 27:230-234.
Masahito, P., Ishikawa, T. and Takayama, S. (1984) Spontaneous spermatocytic seminoma in African lungfish, *Protopterus aethiopicus* Heckel. *Journal of Fish Diseases* 7:169-172.
Mawdesley-Thomas, L.E. (1971) Neoplasia in Fish: A Review. *Current Topics in Comparative Pathobiology* 1:87-170.
McCain, B.B., Gronlund, W.D., Myers, M.S. and Wellings, S.R. (1979) Tumours and microbial diseases of marine fishes in Alaskan waters. *Journal of Fish Diseases* 2:111-130.
Metcalfe, C.D. and Sonstegard, R.A. (1984) Microinjection of carcinogens into rainbow trout embryos: An *in vivo* carcinogenesis assay. *Journal of the National Cancer Institute* 73:1125-1132.
Moulton, R.E. (1990) Tumors in Domestic Animals. Third Edition, University of California Press, Los Angeles.
Morrison, C.M. and MacDonald, O.A. (1995) Epidermal tumors on rainbow smelt and Atlantic salmon from Nova Scotia. *Journal of Aquatic Animal Health* 7:241–250.
Murchelano, R.A. and Edwards, R.L. (1981) An erythrophoroma in ornamental carp, *Cyprinus carpio* L. *Journal of Fish Diseases* 4:265-268.
Nishimoto, M. and Varanasi, U. (1985) Benzo[a]pyrene metabolism and DNA adduct formation mediated by English sole liver enzymes. *Biochemical Pharmacology* 34:263-268.
Park, E-H. and Kim, D.S. (1984) Hepatocarcinogenicity of diethylnitrosamine to the self-fertilizing hermaphroditic fish *Rivulus marmoratus* (Teleostomi: Cyprinodontidae). *Journal of the National Cancer Institute* 73:871-876.
Peters, G. (1976) The papillomatosis of the European eel (*Anguilla anguilla* L.): Analysis of seasonal fluctuations in the tumor incidence. *Archiv fuer Fischereiwissenschaft* 27:251-263.
Peters, G. and Peters, N. (1979) The influence of salinity on growth and structure of epidermal papillomas of the European eel *Anguilla anguilla* L. *Journal of Fish Diseases* 2:13-26.
Peters, N. (1984) Diseases caused by neoplasia. ***In*** *Diseases of Marine Animals*. Vol. IV, Part 1. ***ed***. Kinne, O. Biologische Anstalt Helgoland, Hamburg.
Peters, N., Peters, G., Stich, H.F., Acton, A.B and Bresching, G. (1978) On differences in skin tumours of Pacific and Atlantic flatfish. *Journal of Fish Diseases* 1:3-25.
Roberts, R.J. (2001) Neoplasia of teleosts. pp. 151–168, ***in*** *Fish pathology*. ***ed***. Roberts, R.J., Saunders, London.
Sano, T., Fukuda, H., Okamoto, N. and Kaneko, F. (1983) Yamame tumor virus: Lethality and oncogenicity. *Bulletin Japanese Society Scientific Fisheries* 49:1159-1163.
Sano, T., Fukuda, H. and Furukawa, M. (1985) *Herpesvirus cyprini*: biologic and oncogenic properties. *Fish Pathology* 20 381–388.
Scarpelli, D.G. (1976) Neoplasia in poikilotherms. ***In*** *Cancer: A Comprehensive Treatise*. ***Ed***. Becker, F.F. Vol. 4, Plenum Press.
Schmale, M.C., Hensley, G. and Udey, L.R. (1983) Multiple schwannomas in the bicolor damselfish, *Pomacentrus partitus* (Pisces, Pomacentridae). *American Journal of Pathology* 112:238–241.
Schmale, M.C., Hensley, G.T. and Udey, L.R. (1986) Neurofibromatosis in the bicolor damselfish (*Pomacentrus partitus*) as a model of von Recklinghausen neurofibromatosis. *Annals New York Academy of Science* 486:386–402.
Schultz, M.E. and Schultz, R.J. (1982) Diethylnitrosamine-induced hepatic tumors in wild *vs.* inbred strains of a viviparous fish. *Journal of Heredity* 73:43-48.
Smith, C.E., Peck, T.H., Klauda, R.J and McLaren, J.B. (1979) Hepatomas in Atlantic tomcod *Microgadus tomcod* (Walbaum) collected in the Hudson River estuary in New York. *Journal of Fish Diseases* 2:313-319.
Smolowitz, R., Hanley, J. and Richmond, H. (2002) A three-year retrospective study of abdominal tumors in zebrafish maintained in an aquatic laboratory animal facility. *Biological Bulletin* 203:265–266.
Spitsbergen, J.M., Tsai, H.W., Reddy, A., Miller, T. and Arbogast, D. (2000) Neoplasia in zebrafish (*Danio rerio*) treated with 7,12-dimethylbenz[a]anthracene by two exposure routes at different developmental stages. *Toxicological Pathololgy* 28:705–715.
Swain, L. and Melius, P. (1984) Characterization of benzo[a]pyrene metabolites formed by 3-methylcholanthrene-induced goldfish, black bullhead and brown bullhead. *Comparative Biochemistry and Physiology* 79:151-158.
Thornton, S.C., Diamond, L. and Baird, W.M. (1982) Metabolism of benzo[a]pyrene by fish cells in culture. *Journal Toxicology Environmental Health* 10:157-167.
Walker, R. (1969) Virus associated with epidermal hyperplasia in fish. *National Cancer Institute Monograph* 31:195-207.
Warr, G.W., Griffin, B.R., Anderson, D.P., McAllister, P.E., Lidgerding, B. and Smith, C.E. (1984) A lymphosarcoma of thymic origin in the rainbow trout, *Salmo gairdneri* Richardson. *Journal of Fish Diseases* 7:73-82.
Williams, D.E. and Buhler, D.R. (1983) Purified form of cytochrome P-450 from rainbow trout with high activity toward conversion of aflatoxin B1 to aflatoxin B1-2,3-epoxide. *Cancer Research* 43:4752-4756.
Winqvist, G., Ljungberg, O. and Hellstroem, B. (1968) Skin tumours of Northern Pike (*Esox lucius* L.). II. Viral particles in epidermal proliferations. *Bulletin Office international d'Epizootics* 69:1023-1031.
Yamamoto, T., MacDonald, R.D., Gillespie, D.C. and Kelly, R.K. (1976) Viruses associated with lymphocystis disease and dermal sarcoma of walleye (*Stizostedion vitreum vitreum*). *Journal of the Fisheries Research Board of Canada* 33:2408-2419.





Physiological and Clinical Pathology

CHAPTER 14

by Mark D.Powell

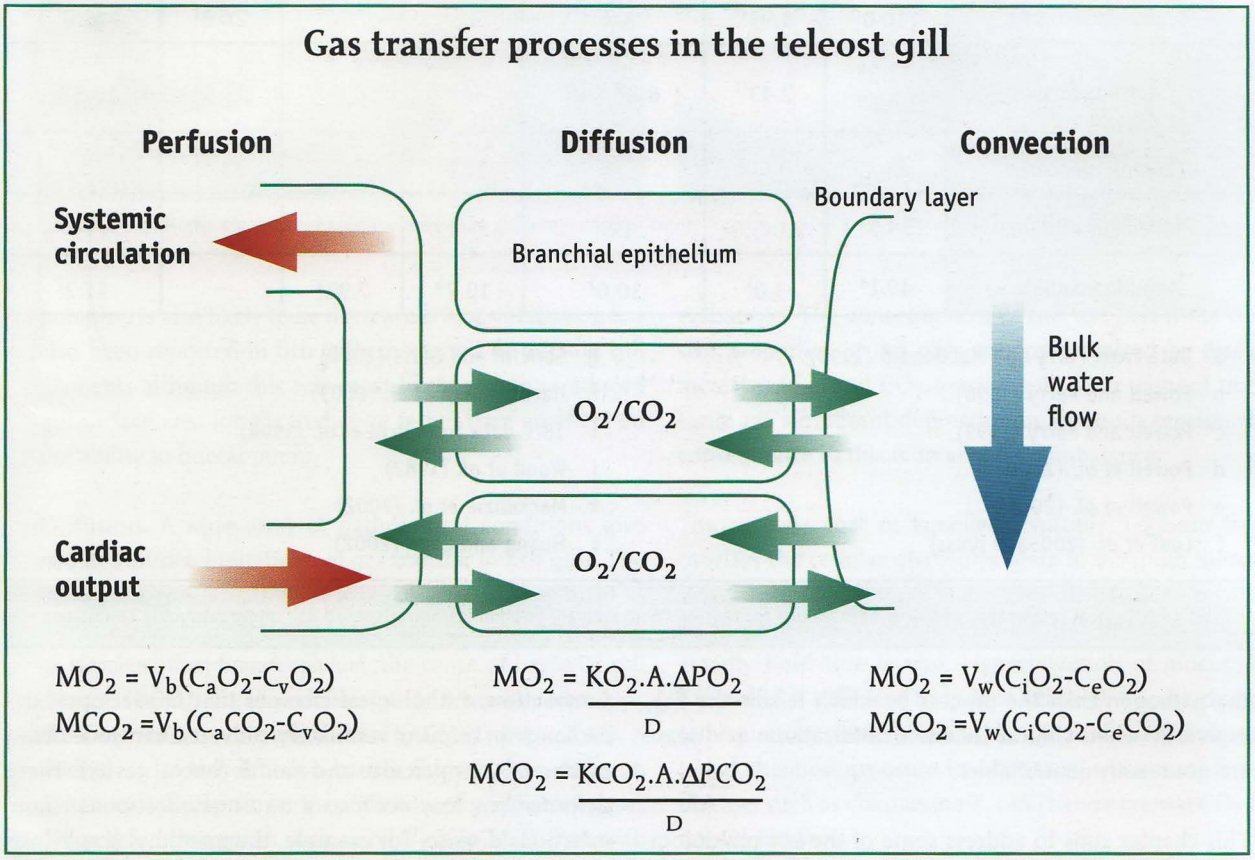

Fig 14.1. Schematic of respiratory gas (O_2 and CO_2) transfer processes in the fish gill. Mgas is the rate of exchange of each gas, $C_a$gas and $C_v$gas are the arterial (oxygenated) and venous (deoxygenated) gas concentrations of the blood respectively, $C_i$gas and $C_e$gas are the inspired and expired gas concentrations of the water respectively, Kgas is the gas specific diffusion constant, A is the surface area over which diffusion occurs, D is the thickness of the diffusion barrier (blood-water diffusion distance), ΔPgas is the partial pressure diffusion gradient for each gas, V_b is the cardiac output and V_w is the ventilatory water flow rate.

"Physiologists do everything twenty four hours too early; pathologists do everything twenty four hours too late"

There appears to be a clear, if unintentional, division between fish physiologists and pathologists. The physiologist is primarily concerned with understanding the mechanisms and integration of processes in healthy animals. The pathologist on the other hand, tends to focus on the abnormal (usually a tissue response) and most frequently the cause of that abnormality. Integrating the two approaches, ***pathophysiology***, is fundamentally important to understanding the short and long-term consequences for the animal, and therefore what sorts of treatment or control responses are most appropriate. Unfortunately, disease (be it infectious or otherwise) is rarely restricted to a single physiological system and physiological systems rarely operate independently, rather integratively. The consequence of this integration is that mortality often occurs earlier in a diseased fish than would be expected physiologically in a healthy animal.

One reason for the paucity of pathophysiological information is the fact that diseased fish struggle to survive the rigours of experimental procedures including canulation and instrumentation. It is also easier to identify

Species	P_aO_2 (mmHg)	P_aCO_2 (mmHg)	C_aO_2 (mL 100 mL^{-1})	C_aCO_2 (mM)	pH	Hct (%)	Hb (g 100mL^{-1})
Oncorhynchus mykiss (FW)	133.2[a]	~2.0[b]	8.2[a]	8.2[b]	7.85	22.5[c]	6.74[c]
Salmo salar (SW)	110.0[d]	1.95[d]	8.2[e]	5.5[f]	7.90[e]	26.0[f]	10.0[f]
Cyprinus carpio	23.2[a] 38.0[g]	2.43[g]	6.8[g]-7.4[a]	--	7.92[g]	33.6[h]	10.37[h]
Thunnus albacares[i]	79.2[i]	3.90[i]	--	13.5[i]	7.85[i]	33.4[i]	--
Platichthys stellatus	34.9[a]	2.0-3.0[j]	4.6[a]	6.0-8.0[j]	7.95[j]	22.5[j]	--
Anguilla anguilla	49.1[a]	3.0[k]	10.0[k]	10.7[k]	7.92[k]	--	17.2[l]

a Data from Perry and MacDonald (1993)
b Powell and Perry (1996)
c Powell and Perry (1999)
d Powell *et al.* (2000)
e Powell *et al.* (2005)
f Leef *et al.* (2005a *in press*)
g Soncini and Glass (2000)
h Harikrishnan *et al.* (2003)
i 18°C data from Brill *et al.* (1992)
j Wood *et al.* (1982)
k Mackenzie *et al.* (2002)
l Huang and Chen (2002)

Table 14.1. Typical respiratory and acid-base values for resting (non-actively swimming) non-diseased fish under normoxic conditions

the pathogen than the process by which it kills the fish, especially when clinical lesions or indications of disease are not readily quantifiable.

This chapter aims to address some of the key physiological systems in which research has started to elucidate the pathophysiology of disease in fish. Where possible, normal ranges are shown, along with examples of intensively studied disease models, chosen not because of the aetiological agent, but because of their physiological implications.

Respiration

Respiratory and acid base values for fish blood can vary considerably between species, with primary distinctions between active fish such as salmonids and more sedentary species such as flatfish ***(Table 14.1)***. The physiological processes of respiration in fish can be divided essentially into three main compartments, namely convection, diffusion and perfusion, with the rate of exchange of respiratory gases being modeled mathematically ***(Fig 14.1)***. Based upon this model, pathological factors that affect any aspect of these systems will have an impact on the rate of respiratory gas transfer.

Convection. Pathological changes that impact upon gas exchange in terms of ventilatory convection include deformation of the operculae and mouth (buccal cavity). These deformations may occur as a result of infectious or non-infectious disease. For example, the mandibular ankylosis of "screamer disease" reported in Chilean Atlantic salmon, and the equivalent "drop jaw" deformities often seen in cultured salmonids and pleuronectids ***(see Fig 12.9)*** mean that adduction of the lower jaw cannot occur. As a consequence, the fish must rely upon ram-ventilation by constant swimming in order to irrigate the gills. However, the overall impact of this type of deformity is probably low since the cost of breathing remains constant and independent of the exercise level of the fish. Oxygen uptake itself (MO_2) does not appear to be directly limited by ventilation, as this can increase 10-15 times, whereas MO_2 can usually increase only approximately 5 times. Other factors including gill perfusion and diffusion characteristics of the gill also impact on MO_2 ***(Fig 14.1)***. The overall metabolic cost of this deformity is therefore likely to be low although this has never been specifically measured. Similarly, if operculae are eroded or shortened and fail to seal at their trailing edge, a condition commonly seen in intensively-reared fish ***(Fig 14.2)*** then the efficiency of buccal and opercular

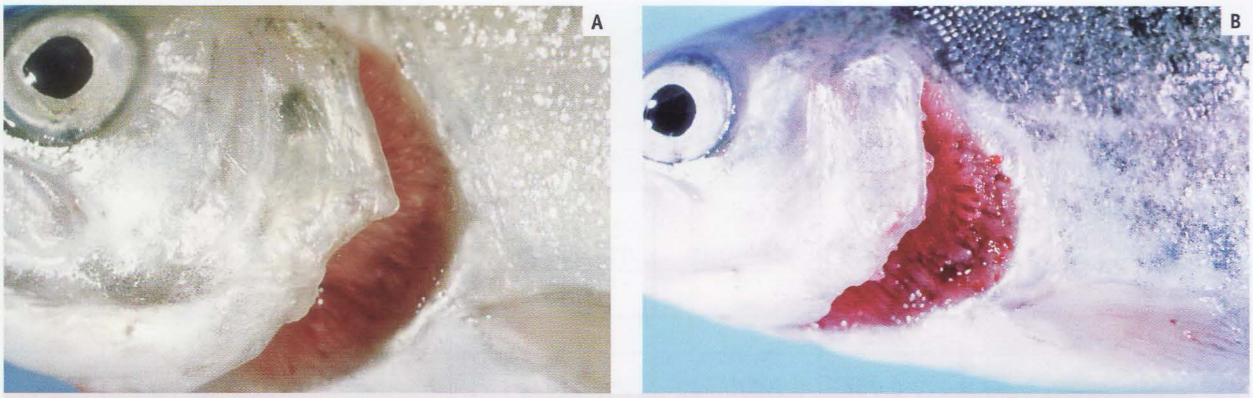

Fig 14.2A&B. Moderate and severe opercular erosion in farmed rainbow trout. The impact that such lesions have on the ability of the fish to pump water is poorly understood.

pumping is also likely to be decreased. Ram ventilation has also been reported in fish with shortened or missing gill filaments although this was most likely due to a reduced gill surface area for gas exchange rather than an effect on the ability to buccal pump.

Diffusion. A wide array of pathological conditions give rise to diffusive limitations of gas transfer in fish gills. The most common is epithelial hyperplasia that may arise as a consequence of branchial irritation by pathogens such as *Flavobacterium branchiophilum*, the cause of bacterial gill disease (BGD), *Cochliopodium* spp. or *Neoparamoeba* spp., the cause of amoebic gill disease (AGD) ***(see Fig 2.17)***. A thickening of the diffusion barrier (blood-water diffusion distance) will impact on the diffusion of respiratory gases (as well as other gases such as NH^3) ***(Fig 14.1)***. Fish with AGD have lower arterial oxygen tension and elevated arterial CO_2 tension compared to unaffected fish. Similarly, chloride cell hyperplasia caused either hormonally or after acclimation to low calcium water also results in elevated arterial CO_2 tension and marginal reduction in arterial O_2 tension. In these cases, increased diffusion barrier thickness has a clear impact upon respiratory gas transfer. However, when affected fish are challenged with hypoxia, arterial O_2 tensions decline at a lower rate than non-diseased fish, suggesting that O_2 tension is being defended. By contrast, arterial CO_2 tension does not decline at the same rate. This suggests that the transfer of O_2 and CO_2 is limited by different processes in fish gills, and in trout, CO_2 excretion has indeed been shown to be limited more by diffusion than is oxygen uptake which has been shown to be primarily perfusion limited. The main reason for this difference is that CO_2 excretion is limited by the slowest step in CO_2 excretion, namely the diffusion of HCO_3^- from plasma into the red blood cell across the Cl^-/HCO_3^- anion exchanger. The consequences of this are that if the diffusive properties of the gills are compromised by disease, increases in blood CO_2 tension will occur without necessarily any significant depression in blood O_2 tension. The consequence of this is an acid-base imbalance.

The mucous coat of lamellae (typically 1-3 μmm thick) overlays the cellular glycocalyx of up to 0.9 μmm thick depending upon cell type. *In vitro*, mucus has been reported as an impediment to O_2 diffusion but this may not necessarily hold true *in vivo*. Hypersecretion of mucus can, however, be sufficient to induce subtle but acute changes to respiratory gas tensions in the blood. For example, sublethal chemical exposure to often-used treatments for gill disease, such as chloramine-T, can change arterial CO_2 but not O_2 tensions.

Perfusion. The perfusion of the gill is primarily governed by cardiac output, ventral aortic blood pressure and subsequently branchial vascular resistance. Measurements of gill perfusion are rare in disease studies and to date no studies have investigated the effects of disease of gill blood flow distribution. However, perfusion and distribution of blood through the teleost gill are under the control of adrenergic, cholinergic, serotoninergic, peptidergic and potentially nitrergic control (see review by Donald 1998). Whether any changes in gill blood flow distribution occur directly as a result of disease or else as a consequence of inflammation or a stressor associated with disease remains to be investigated.

Cardiovascular system

The cardiovascular system of fishes is intimately linked with the respiratory system and cardiovascular parameters

Species	Na^+ mM	K^+ mM	Ca^{++} mM	Cl^- mM	Glucose mg/dL	Lactate mg/dL (mM)	Osmolality mmol/kg
Oncorhynchus mykiss (FW)[b]	123-164	3.3-3.5	5.5-6.4	120-147	63-144	4-17	296-340
Salmo salar (SW)[b]	140-165	-	3.5-12.5	-	-	(2[g]-4[h])	-
Salmo trutta (FW)	-	-	-	109[e]	52[e]	-	-
Salvelinus fontinalis (FW)[k]	157	2.5	3.0	127	-	(3.1)	321
Salvelinus namaycush (FW)[i]	157-174	1.0-6.1	2.7-3.5[i]	-	76-100[i]	-	-
Anguilla anguilla (FW)[b]	143-150	1.8-2.3	2.3	88	-	-	-
Anguilla anguilla (SW)[b]	164-183	3.2-3.4	2.4-5.5	140	-	-	-
Anguilla rostrata (FW)[b]	138-151	2.8	3.2-3.3	70-111	-	-	252-308
Esox lucius (FW)[b]	122-128	2.0-2.2	5.0-5.6	105[e]	25-71[b]	-	274[b]
Ictalurus punctatus (FW)[b]	139	3.6	3.4	114[e]-131[b]	29.1[e]-64.5[b]	-	-
Cyprinus carpio (FW)[a]	142	2.0	6.0	107	111[b]	-	293
Paralichthys spp. (SW)[a]	180	4.0	3	160	-	-	337
Micropterus dolomieu (FW)[b]	128-140	8-10	5-7	111-128	35-95[f]	11.2-98[f]	-
Lampetra fluviatilis (FW)[c]	120	3.9	2.5	104	-	-	270[d]
Petromyzon marinus (SW)[c]	156	32	3.5	159	-	-	333

a Randall *et al.* (1997)
b Stoskopf (1993)
c Karnaky (1998)
d Moyle and Cech (2000)
e Wedemeyer *et al.* (1991)
f Largemouth bass
g Powell and Nowak (2003)
h Harris *et al.* (2004)
i Edsall and Swink (2001)
j Edsall (1999)
k Byrne *et al.* (1991)

Table 14.3. Typical plasma electrolyte, glucose, lactate and osmolality values for freshwater (FW) and saltwater (SW) fish.

Species	Relative Atrial Mass[a] %	Relative Ventricular Mass[a] %	$\dot{Q}$[1] (mL min^{-1} kg^{-1})	f_H[k] (beat min^{-1})	SV[l] (mL kg^{-1})	VAP[m] (mmHg)	DAP[n] (mmHg)	Vascular Resistance (mmHg mL^{-1} min^{-1} kg^{-1})	
								R_{gill}	R_{sys}
Oncorhynchus mykiss[b]	0.007-0.013	0.03-0.10	17.6	38	0.46	39.0	31.0	0.46	1.76
Salmo salar	0.010-0.058[c]	0.108-0.520[c]	19.0[d]	-	-	58.0[e]	31.0[d]	-	1.86[d]
Salmo trutta	-	-	22.0[d]	-	-	-	41.7[d]	-	2.26[d]
Katsuwonus pelamis[b,f]	0.061	0.38	132.0	126	1.08	87.3	40.2	0.36	0.30
Thunnus albacares[b,f]	0.056	0.29	115.0	97	1.30	89.7	32.6	0.49	0.28
Anguilla spp.[b]	0.007-0.013	0.10-0.03[g]	10.0-11.5	30-54	0.21-0.3	28.4-38.6	18.9-23.5	0.96-1.34	1.89-2.08
Gadus morhua[b]	-	-	17.3-19.2	41-43	0.39-0.51	36.8	23.3-24.0	0.70-0.74	1.21-1.39
Pagothenia borchgrevinki[b]	0.040	0.16	29.6	11.3	2.16	28	-	0.95[h]	
Cyprinus carpio[i]	-	-	15.3	16.7	0.77	-	-	-	-

a relative to total body mass
b data from Farrell (1993)
c data from Powell *et al.* (2002)
d 6h post-surgical measurements Leef *et al.* (2005) *in press*
e Powell *et al.* (2002)
f spinalized
g *Anguilla dieffenbachia*
h total peripheral resistance
i 15°C data from Steyk and Farrell (2002)
j cardiac output
k cardiac frequency
l cardiac stroke volume
m ventral aortic pressure
n dorsal aortic pressure

Table 14.2. Typical cardiovascular data of resting (non-actively swimming) non-diseased fish.

Habitat type	Fish species	Acidosis	Alkalosis
Freshwater	*Oncorhynchus mykiss*[a,b,c,d]	↑H^+ ATPase on pavement cell apical membrane	↑Cl^-/HCO_3^- exchangers on chloride cell apical membrane
	Ictalurus nebulosus[d,e]	↓Chloride cell fractional surface area ↑Na^+ influx, no effect on Cl^- influx	↑Chloride cell fractional surface area no effect on Na^+ influx, ↑Cl^- influx
Marine	*Myoxocephalus octodecimspinous*[f]	↑Na^+/H^+ exchanger on chloride cell apical membrane ↑Na^+ influx	

a Goss and Wood (1991)
b Goss *et al.* (1994)
c Goss *et al.* (1993)
d Goss *et al.* (1992b)
e Goss *et al.* (1992a)
f Claibourne (1998)

Table 14.4. Summary of molecular, biochemical, ionic and morphological gill responses to acid-base disturbances.

can vary considerably between species depending upon lifestyle of the species concerned ***(Table 14.2)***. Non-infectious cardiovascular diseases in fish have been well documented, including arteriosclerosis ***(see Chapter 6)***.

Dietary polyunstaturated fatty acids (PUFA) and in particular eicosapentanoic acid (EPA), arachadonic acid (AA) and eicosatetranoic acid (ETA), have mitogenic activities in fish cardiac tissue. Although not fully understood, nutritional deficiencies in omega-3 PUFA reduce heart size with a depletion of both compact and spongy layers, resulting in a very thin ventricular wall. Reduced cardiac muscle mass would lead to high stroke volume but depleted force of blood ejection, resulting in reduced cardiac output and ventral aortic pressure.

Changes in cardiac shape and a variety of cardiomyopathies are becoming a significant problem in cultured fish especially salmonids ***(see also Chapter 6)*** although the consequences of such disease on cardiovascular performance are rarely assessed. A reduction of the cardiac trabeculae (myopathy) may lead to increased volume within the heart although the force of contraction could be compromised. Ventricular hypoplasia is often associated with rounding of the ventricle from its normal pyramidal shape that in turn would lead to a reduction in the contractile efficiency. Increase in the afterload on the heart (ventral aortic pressure) has been proposed as an explanation for the change in ventricular shape (ventricular elongation and myopathy of the spongy layer) of Atlantic salmon with amoebic gill disease, where hypertension has been described as a key feature of this disease. A similar hypertension has also been described in the Antarctic fish *Pagothenia borchgrevinki* with branchial X-cell disease. The identity of the X-cells is speculative ***(see Fig 2.5D)*** although most recently a microsporidian infection has been attributed to the X-cell pseudotumours seen in flatfishes. The hypertension associated with X-cell disease may occur through partial occlusion of the gill lamellar vasculature resulting in an increase in branchial vascular resistance and hence increased peripheral vascular resistance.

Cardiovascular failure in fish does not equate directly with that in mammals. Because of the ability of cardiac muscle to metabolise lactate, local ischaemic lesions are not common. As a consequence there has been little investigation of the enzymes associated with cardiovascular disorders and disease.

Cytokine	Species	Reference
TNFα	*Oncorhynchus mykiss*	Laing *et al.* (2001)
TGFβ	*Oncorhynchus mykiss*	Secombes *et al.* (1998)
IL-1β	*Oncorhynchus mykiss*	Secombes *et al.* (1998) Pleguezuelos *et al.* (2000)
	Salmo salar	Zou *et al.* (2000)
	Dicentrarchus labrax	Scapigliati *et al.* (2001)
	Pleuronectes platessa	Zou *et al.* (2000)
	Cyprinus carpio	Zou *et al.* (2000)
	Scyliorhinus canicula	Bird *et al.* (2002)
IL-2	*Ctenopharyngodon idellus*	Guo (2001)
	Oncorhynchus mykiss	Blohm *et al.* (2003)
IL-6 and related subfamily	*Cyprinus carpio*	Fujiki *et al.* (2003)
IL-8	*Oncorhynchus mykiss*	Zhang et al. (2002) Laing et al. (2002)
	Paralichthys olivaceus	Lee *et al.* (2001)
	Triakis scyllia	Inoue *et al.* (2003)
	Chimera phantasma	Inoue *et al.* (2002)
IL-10	*Fugu rubripes*	Zou *et al.* (2003)
IL-12	*Fugu rubripes*	Yoshiura *et al.* (2003)
IL-13	*Oncorhynchus mykiss*	Lockyer *et al.* (2001)
Cytokine receptors		
IL-1	*Oncorhynchus mykiss*	Sangrador-Vegas *et al.* (2000)
	Salmo salar	Subramanian *et al.* (2002)
IL-13	*Oncorhynchus mykiss*	Lockyer *et al.* (2001)

Table 14.5. Examples of cytokines and receptors identified to date in various fish species

Ionregulation

The process of ionregulation in fishes is complex and multifactorial and has been reviewed extensively (see review by Karnaky 1998). In terms of pathophysiology, plasma electrolytes are often measured without necessarily giving clear guidance to what these changes mean. In reality, a fish will defend and closely regulate its ionic content, the main differences between species being mostly attributable to the environment *e.g.* salinity (***Table 14.3***). Sustained changes in blood electrolytes, therefore, tend to represent the ante-mortem state of the animal, often once the animal has reached a "point of no return". Short-term changes in electrolytes are useful measures of acclimation and adaptation to environmental stress, but they may not necessarily reflect a pathological state. For example, the transfer of euryhaline fish from freshwater to seawater will induce acute ionic disturbances that are usually corrected within

Species	ALT[1] (μ/L)	AST[2] (μ/L)	AlkPhos[3] (m/L)	LDH[4] (μ/L)	Creatinine (mg/dL)	T. Bili[5] (mg/dL)	T.Protein[6] (g/dL)
Oncorhynchus mykiss	7-12	158-368	50-200	250-1000	0.2-0.5	0-2	-
Carassius auratus	106	900	-	-	-	-	3.4
Cyprinus carpio	-	-	-	-	0.56	-	4.2
Ictalurus punctatus	17.5	95	20	172	-	0.4	2.2-4.0
French grunt	2.5	30	-	-	0.2	0	3.2
Blue tang	5.5	19.2	-	-	1.9	0.08	2.9
Solea solea	<29	<89	-	-	-	0-0.14	5.7-6.2
Nurse shark	4.4	18.5	-	74	0.4	-	2.6-3.5

1 Alanine aminotransferase
2 Aspartate aminotrasferase
3 Alkaline phosphatase
4 Lactate dehydrogenase
5 Total bilirubin
6 Total protein

Table 14.6. Examples of liver function serum chemistry for a range of fish species (modified from Stoskopf 1993)

2-7 days depending upon the physiological capacity of the fish. Failure to acclimate will result in a persistent osmoregulatory compromise that will result either in poor growth or else death.

Ionoregulatory dysfunction will have different consequences for freshwater and saltwater fish, whereas euryhaline fish may show plasticity in their response. In freshwater fish the uptake of electrolytes from the water is a continuous and energetically expensive battle against passive diffusion and osmotic movements of water. Disruption of the ion uptake processes either by direct action upon the transporters involved, or by breach of the integument, will therefore lead to an enhanced efflux of electrolytes and an osmotic influx of water. Saltwater fish, on the other hand, face a net gain of electrolytes and branchial processes facilitate excretion of excess ions, with a net efflux of water.

Integumental damage. Physical trauma and pathogen-related damage to the integument are the main causes of ionic disturbance in fish. Scale loss through rough handling, or fin biting due to social hierarchy and aggression both have the potential to lead to osmo/ionoregulatory failure. For example, lamprey attacks breaching the integument of the fish reduce plasma electrolyte concentrations. The entry and exit of parasites in the integument (or gills) are another common cause of ionoregulatory dysfunction but they appear to occur episodically. For example, infestation with *Ichthyophthirius multifiliis* ("ich") results in acute changes in plasma electrolytes as well as changes in whole body ionic permeability. These episodic changes in electrolyte levels and ionic physiology coincide with the entry of theronts and the exit of the mature trophozoites and tomonts from under the branchial and cutaneous epithelium and can be sensitively detected by measurement of the net whole body ion flux.

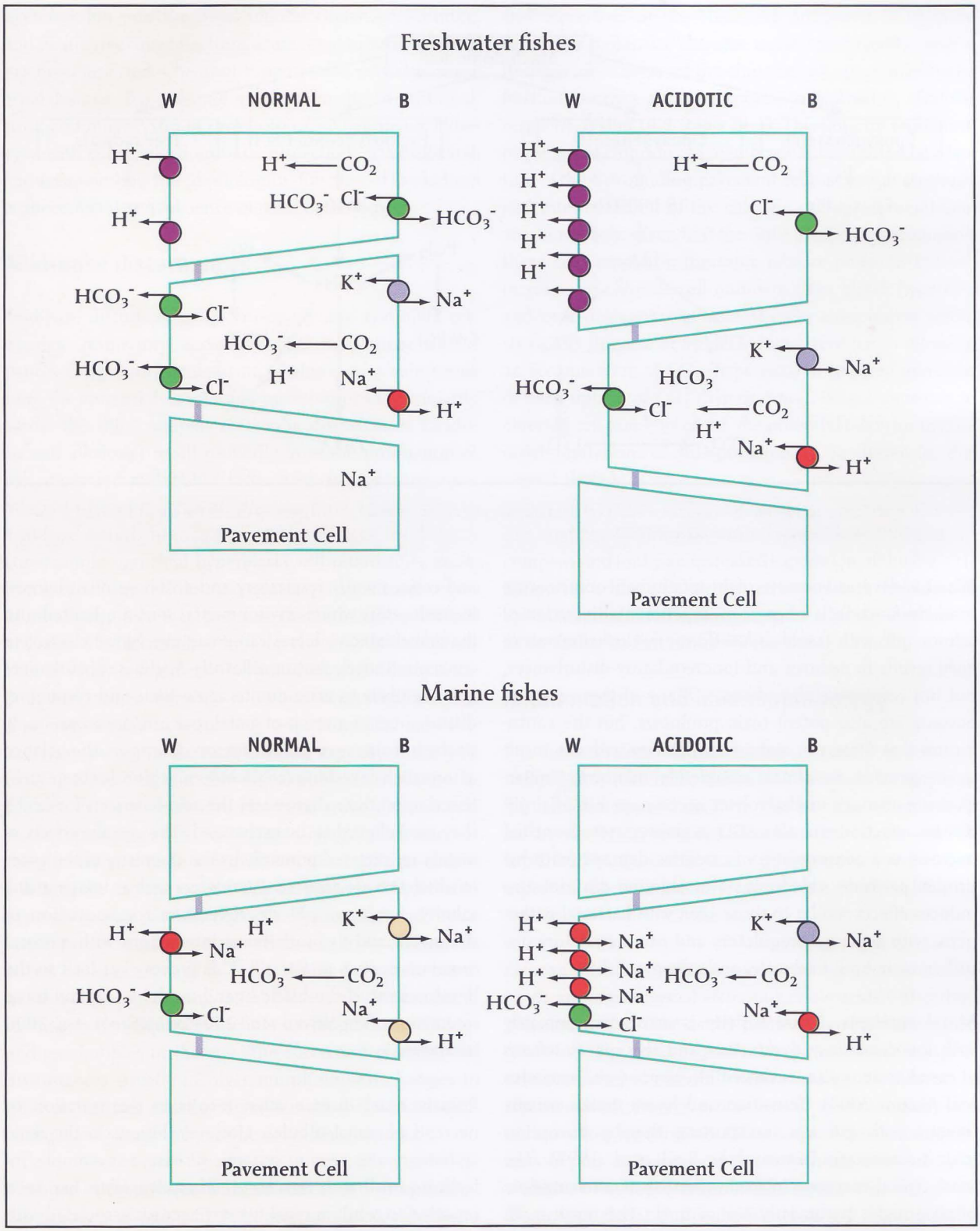

Fig 14.3. Model for the mechanism of acid-base exchanges in the gills of freshwater and marine fish following acidosis. In freshwater fish proton excretion is enhanced by the insertion of H^+ ATPase pumps into the apical membrane of pavement cells and HCO_3^- excretion is down-regulated by the reduction of chloride cell apical HCO_3^-/Cl^- transporters. In marine fish, proton excretion is facilitated by H^+/Na^+ antiporters (NHE) in the chloride cell apical membrane (*simplified from Claibourne 1998*).

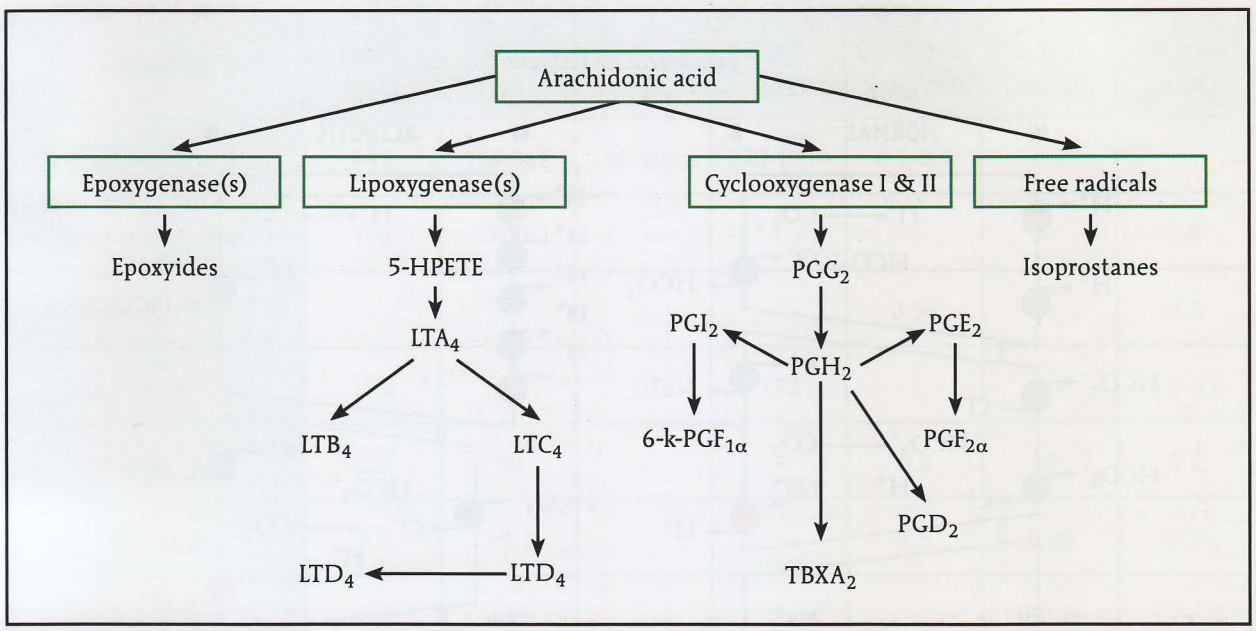

Fig 14.4. Arachidonic acid metabolism and the products of lipoxygenase and cyclooxygenase activity giving rise to the leukotriene and prostaglandin cascades (*modified from Katzung 2001*).

Where widespread necrosis of the integument occurs, acute ionic dysfunction is often seen. Experimental infection of salmon gills with *Tenacibaculum* (formerly *Flexibacter*) *maritimum* results in necrosis and ionoregulatory disturbances, but not respiratory disturbances. Many of these sorts of bacteria are also potent toxin producers, but the contribution that these can make, in synchrony with the insult to integument, are almost completely unknown. Similarly, acute changes in electrolytes accompany bacterial gill disease infection and also AGD in severe cases. Branchial necrosis as a consequence of oxidative damage (with hydrogen peroxide, chloramine-T or chlorine dioxide) also induces effects similar to those seen with bacterial pathogens, with acute ionoregulatory and osmoregulatory disturbances in both freshwater and saltwater fish.

Metal toxicosis. Metal toxicity is associated primarily with ionoregulatory dysfunction and the specific effects of metal toxicosis are reviewed elsewhere (see Fernandes and Mazon 2003). Transition and heavy metals usually interact with gill ion transporters, thereby disrupting ionic homeostasis (reviewed by Reid *et al.* 1997). The most typical response in freshwater fish is an acute loss of electrolytes particularly Na^+ and Cl^-. The result is an attempt to increase the number of transport sites through the ion-transporting chloride cells which may become hypertrophic and/or hyperplastic. This in turn is likely to cause an increase in the diffusion thickness of the gill, and consequently respiratory and acid-base disturbances. In freshwaters where environmental ions are limited and the branchial ionic losses exceed uptake, blood electrolyte concentrations decline significantly. Acid-base disturbances also are likely to arise due to acute ionic and respiratory disturbances as a result of metal toxicosis driven primarily by the imbalance of the strong ion difference, the balance of ions such as sodium (acid ions) and chloride (basic ions) based upon their charge and the acid-base ions for which they are believed to be exchanged. The specific effects of metals are dictated primarily by the chemistry of the water in which fish are exposed. Parameters such as temperature, salinity, hardness, pH *etc.* determine the speciation of the metal, and its biochemical interactions with mucosal membranes such as the gill. This process has lead to the development of the biotic ligand model to explain these interactions (see Niyogi *et al.* 2004 or McGreer *et al.* 2000 for reviews).

Primary renal disease often results in degeneration or necrosis of renal tubules. However, lesions in the renal system are also seen in systemic disease. For example, infection of fish with *Flavobacterium psychrophilum* has been reported to result in renal tubular necrosis associated with eosinophilic droplets in the renal tubular epithelium, a change seen in many bacterial and protozoal infections including bacterial kidney disease. In haemorrhagic smolt syndrome, necrosis of the glomeruli results in the loss of

haemoglobin into the renal tubules (haemoglobinuria), and in aquareovirus infections acute renal tubular necrosis has been reported. Chemical toxicosis also may also cause renal lesions. For example sulphamerazine in cutthroat trout and microcystin in carp both cause nephrosis. However, with either infectious or non-infectious agents little is known about how the physiological function of the kidney is affected as a consequence of renal pathology.

Acid-base disturbances

Acid-base disturbances fall principally into two main categories; respiratory and metabolic. Respiratory disturbances (respiratory acidosis or alkalosis) as a rule result from the enhanced or retarded excretion of CO_2 primarily across the gills, whereas metabolic disturbances (acidosis and alkalosis) result primarily from the production of the anaerobic metabolite lactic acid and/or compensation with bicarbonate. Fish diseases tend to give rise to acid-base disturbances as a secondary effect of the disease. For example branchial hyperplasia will retard CO_2 excretion (see above) and thus a respiratory acidosis will occur. Alternatively, fish that become stressed during disease episodes may accumulate high levels of lactate or be unable to repay a significant oxygen debt particularly if the branchial oxygen diffusion is limited. Hyperventilation is a primary means of regulating respiratory acid-base disturbances owing to the high diffusive capacity of the gills to CO_2. Since CO_2 is highly diffusive, hyperventilation facilitates its rapid excretion. However, some pathological states compromise this. For example, chemical irritation of the gill may lead to an accumulation of mucus that in turn will limit the excretion of CO_2, or the presence of epithelial hyperplasia may partially restrict CO_2 excretion and thus a respiratory acidosis develops which can have deleterious effects on systems such as the carbonic anhydrase-based gas secretion processes in swimbladder and choroid gland of the eye. Consequences include swelling of swimbladder and gas bubbles in the eye. The correction of metabolic disturbances usually involves morphological changes in gill structure and possibly kidney function; if marked, such changes may mask the presence of other diseases.

Changes in the molecular, biochemical and morphological structure of gills will differ with regard to whether a fish is freshwater, marine or euryhaline (for review see Claibourne 1998; *Table* 14.4). A freshwater fish will correct acid-base disturbances by changing the expression of an H^+-ATPase transporter on the pavement cells of the gills and expression of the HCO_3^-/Cl^- antiporter in chloride cells. The molecular changes occur concurrently, with a decrease or increase of the chloride cell apical membrane fractional surface area in response to acidosis or alkalosis respectively (***Fig 14.3, Table 14.4***). This physical regulation of the apical chloride cell membrane is thought to be a feature of the surrounding pavement cells although synthesis and internalization of the chloride cell apical membrane are more likely, given that the tight junctions surrounding these cells remain in the same relative position. Indeed, increases in chloride cell numbers often match hyperoxic and/or hypercapnic exposure whereby a respiratory acidosis occurs because of either reduced ventilation allowing an accumulation of CO_2 (hyperoxia) or reduced excretion or even uptake of CO_2 (hypercapnia). Where increases in chloride cell numbers occur, the potential exists for the diffusive limitations of gill epithelium to be altered (as discussed above).

The model in marine fish is somewhat different. Acidosis is compensated for by an increased expression of the Na^+/H^+ antiporter in the gills on the pavement and chloride cell apical membranes. The correction of alkalosis is believed to be similar to that for freshwater fish.

Inflammation and immunopathology

The inflammatory cascade in fish is poorly understood compared to mammals, although indications to date suggest a high degree of similarly. The immune system of fish has been recently reviewed elsewhere (see Iwama and Nakanishi 1996, Bernstein *et al.* 1998) but the non-humoral aspect of the inflammatory cascade has received little attention.

Eicosanoids. In mammals and lower vertebrates, eicosanoids are derivatives of eicosapolyenoic acids (20 carbon polyunsaturated fatty acids) particularly arachidonic acid (***Fig 14.4***). The physiological roles of eicosanoids in higher vertebrates have been well characterized as modulators of reproductive hormonal processes and vaso-regulatory and inflammatory functions. In fish, however, the vasoactive effects of prostaglandins are not well characterized despite evidence of their presence. In eel (*Anguilla anguilla*), plaice (*Platichthys flesus*) and rainbow trout, gill homogenates and filaments synthesise prostaglandin $F_{2\alpha}$ ($PGF_{2\alpha}$) and E_2 (PGE_2) from an arachidonic acid precursor. Few studies have examined the effects of prostaglandins in the vasculature of fishes. $PGF_{2\alpha}$ constricts the coronary artery of

rainbow trout, skate (*Raja nasuta*) and mako shark (*Isurus oxyrichus*). In the eel PGE_2 causes a bradycardia, biphasic changes in ventral aortic blood pressure from hypo- to hypertension, but only hypotension in the dorsal aorta. Importantly this leads to an increase in gill resistance, but a decrease in systemic vascular resistance. In rainbow trout, PGE_2 causes a similar decrease in dorsal aortic pressure but in contrast to the eel, an increase in heart rate. In the Atlantic cod (*Gadus morhua*), PGE_2 reduces dorsal aortic pressure and heart rate, but shows biphasic effects on stroke volume of the heart. However, $PGF_{2\alpha}$ causes an increase in ventral aortic pressure and reduction in cardiac output leading to an increase in gill vascular resistance. The consequences of these effects are poorly understood in fish.

It is likely that most cells can be induced to produce prostaglandins synthesised by a cyclooxygenase (COX 1 and 2) mediated pathway and using aracidonic acid as the precursor. The function of these eicosanoids in fish appears, on the whole, to be comparable to that in mammals albeit from limited research with only a few species (Zou *et al.* 1999). As in mammals they appear to be significant in mediating inflammatory processes as part of the immune response with all of the eicosanoid compounds (prostaglandins, leukotrienes, thromboxanes and lipoxins ***(Fig 14.4)*** known to be released from fish leucocytes. Although in mammals prostaglandins (particularly PGE_1) may act as pyrogens inducing fever, such a phenomenon appears to be absent in ectothermic fish, although they may show behavioural "fever" by selecting water of a higher temperature.

The use of anti-inflammatory drugs including indomethacin to block prostaglandin synthesis has been shown to be effective at reducing branchial inflammation in catfish infected with the myxozoan *Aurantiactinomyxon* sp. Similarly, the hypoxaemia due to vasoconstriction that accompanies bacterial gill disease can be blocked by the use of indomethacin. By contrast, attempts to reduce the branchial inflammatory response seen in other proliferative diseases such as amoebic gill disease (caused by *Neoparamoeba* sp.) in Atlantic salmon and *Loma salmonae* xenomas in rainbow trout using oral indomethacin have proved unsuccessful.

To date, much of the work on inflammatory physiology of eicosanoids in fish has concentrated on the leukotrienes, in particular LTB_4 ***(Fig 14.4)*** due to their direct involvement with inflammatory processes and interactions with pro-inflammatory cells and their ability to augment phagocytosis and act as chemo-attractants for neutrophils. LTC_4, D_4 and E_4 all appear to be critically important components of "slow reacting substance of anaphylaxis" (SRS-A).

Vasoactive amines, acute phase proteins and cytokines. Vasoactive amines including serotonin, bradykinins and tachykinins are all released as inflammatory compounds and exert a range of vasoactive effects on fish blood vessels. In addition other molecules equivalent to C3 and C5, which are metabolized to C3a and C5a respectively, have pro-inflammatory effects on mast cells and basophils.

C-reactive protein has been identified in fish, and has been reported to increase in acute inflammation. Indeed serum amyloid A transcription has been reported to be enhanced in hepatocytes following stimulation by macrophage-related cytokines. Recent attention has focused on cytokines, including tumour necrosis factor alpha (TNFα), TGFβ and interleukins (IL) which have been reported in several fish species ***(Table 14.5)***. These aspects of the non-specific immune system act as leukocytic attractants, they activate macrophages, and they appear to be up-regulated in inflammation processes and in response to agents such as peptidoglycan or LPS. They are also inducible with immunostimulants such as CpGs, nucleotide supplements and Ergosan.

Musculoskeletal system

Changes in muscle enzymes are less commonly seen in diseases in which the lesions are multi-focal, even when these are severe. By contrast, early reports on field outbreaks of the alphaviral-caused pancreas disease of Atlantic salmon, in which myopathy is generalized, showed marked elevations in creatine kinase levels, and pronounced declines in plasma and hepatic levels of vitamin E, down to 7% of normal. More recent work failed to confirm these findings, and myopathy occurred independent of blood or muscle vitamin E concentrations. The consequence of red muscle necrosis is likely to depend upon the gait and performance strategy of each species of fish (relative different amounts of red and white muscle). Fish with an active swimming lifestyle such as thunniform fishes or salmonids will have a high proportion 50-60% of white (anaerobic, glycolytic) muscle fibres relying upon red muscle fibres (0.5-30% of myotomal mass) for motor control and slow sustained swimming. Depending upon the type of muscle undergoing myopathy, the clinical effects will differ. Myopathy of either red or white muscle may lead to increases in circulating ATP, glycogen and creatine kinase. The latter is re-

portedly associated with red muscle myopathy. Given the relatively high concentrations of K^+ in muscle cells, generalized skeletal myopathy would be expected to result in the release of K^+ into the blood stream. A generalized myopathy can be seen in some diseases such as lipoid liver disease, but often the red fibres working the opercula can be specifically targeted; the consequences of this lesion on the ability of the fish to irrigate its gills are unknown.

Liver enzymes

Changes in liver enzyme concentrations ***(Table 14.6)*** usually reflect a metabolic disruption due to a toxicological insult, but responses can be very species-specific and can vary greatly from one environment to the next. For example, while even frequent exposure to formalin in many species results in few detectable changes, in others such as the olive flounder, it can result in a cytopoenia manifested by increased haemoglobin concentrations and the presence of many immature erythrocytes accompanying increases in alkaline phosphatase (AlkPhos), aspartate aminotransferase (AST) and lactate dehydrogenase (LDH). Potassium permanganate toxicity has also been reported to increase alanine aminotransferase (ALT) but not LDH in channel catfish. In contrast, intraperitoneal exposure of silver carp (*Hypophthalmichtys molitrix*) to pure microcystin resulted in increases in ALT, AST and LDH with a concomitant reduction in total plasma protein. Similarly, some viral conditions have been reported to cause an increase in ALT, AST and LDH in rainbow trout. Despite the reporting of changes in liver-associated enzyme activity, the mechanisms by which many of these changes occur remain obscure, although it seems likely that they will parallel those seen in mammals.

Conclusions and future directions

Although there is an increasing understanding of how diseases work in fish, many useful comparisons are greatly hampered by lack of a database. Until this is compiled, bearing in mind the variations seen with age, plane of nutrition, time of year, sex, and water chemistry, how can we possibly know what is abnormal in terms of physiological and clinical measurements for fish? While our understanding of a few species like salmonids is quite extensive, we know very little about a fraction of the 25,000 or more extant species of fish. This relative ignorance is becoming increasingly critical as new species are being investigated for commercial culture or for ornamental purposes, and is especially so when in some situations fish are regarded as useful indicators over environmental wellbeing.

Acknowledgements:
Thanks go to G. Partridge, W. Davison, and M. Taylor for their help.

References

Adams, M.B. and Nowak, B.F. (2001) Distribution and structure of lesions in the gills of Atlantic salmon, *Salmo salar* L., affected with amoebic gill disease. *Journal of Fish Diseases* 24:535-542.

Afonso, J.M., Montero, D., Robiana, L., Astorga, N., Izquierdo, M.S. and Gines, R. (2000) Association of lordosis-scoliosis-kyphosis deformity in gilthead seabream (*Sparus aurata*) with family structure. *Fish Physiology and Biochemistry* 22:159-163.

Agnisola, C. and Tota, B. (1994) Structure and function of the fish cardiac ventricle-flexibility and limitation. *Cardioscience* 5:145-153.

Aguire, P. and Gatlin, D.M. (1999) Dietary vitamin C requirement for red drum *Sciaenops ocellatus*. *Aquaculture Nutrition* 5:247-249.

Akiyama, T., Kabuto, H., Hiramatsu, M., Murai, T. and Mori, K. (1989) Effects of dietary 5-hydroxy-L-tryptophan for prevention of scoliosis in tryptophan-deficient chum salmon fry. *Nippon Suisan Gakkaish* 55:99-104.

Akiyama, T., Murai, T. and Nose, T. (1986) Oral administration of serotonin against spinal deformity of chum salmon fry induced by tryptophan deficiency. *Nippon Suisan Gakkaish* 52:1249-1254.

Arkush, K.D., Frasca, S. and Hedrick, R.P. (1998) Pathology associated with the rosette agent, a systemic protist infecting salmonid fishes. *Journal of Aquatic Animal Health* 10:1-11.

Bayne, C.J. and Gerwick, L. (2001) The acute phase response and innate immunity of fish. *Developmental and Comparative Immunology* 25:725-43.

Beckman, B. and Mustafa, T. (1992) Arachidonic acid metabolism in gill homogenate and isolated gill cells from rainbow trout, *Oncorhynchus mykiss*. The effects of osmolality, electrolytes and prolactin. *Fish Physiology and Biochemistry* 10:213-222.

Bell, J.G., McVicar, A.H., Park, M.T. and Sargent, J.R. (1991) High dietary linoleic acid affects the fatty acid compositions of individual phospholipids from tissues of Atlantic salmon (*Salmo salar*): association with stress susceptibility and cardiac lesion. *Journal of Nutrition* 121:1163-1172.

Bernstein, R.M., Schluter, S.F. and Marchalonis, J.J. (1998) Immunity. ***In*** *The physiology of fishes 2nd edition* (***ed.*** Evans, D.H.) pp215-242. CRC press Inc., Boca Raton.

Bindon, S.D., Gilmour, K.M., Fenwick, J.C. and Perry, S.F. (1994a) The effects of branchial chloride cell proliferation on respiratory function in the rainbow trout *Oncorhynchus mykiss*. *Journal of Experimental Biology* 197:47-63.

Bindon, S.D., Fenwick, J.C. and Perry, S.F. (1994b) Branchial chloride cell proliferation in the rainbow trout, *Oncorhynchus mykiss*: implications for gas transfer. *Canadian Journal of Zoology* 72:1395-1402.

Bird, S., Wang, T., Zou, J., Cunningham, C. and Secombes, C.J. (2002) The first cytokine sequence within cartilaginous fish: IL-1β in the small spotted catshark (*Scyliorhinus canicula*). *Journal of Immunology* 168:3329-3340.

Blohm, U., Siegl, E. and Kollner, B. (2003) Rainbow trout (*Oncorhynchus mykiss*) sIgM leucocytes secrete and interleukin-2 like growth factor after mitogenic stimulation *in vitro*. *Fish and Shellfish Immunology* 14:449-465.

Bowden, L.A, Fiore, S, Restall, C.J, Serhan, C.N, Rowley, A.F. (1997) Characterization of the binding of leukotriene B_4 to macrophages of the rainbow trout *Oncorhynchus mykiss*. *Journal of Experimental Biology* 200:155-160.

Brill, R.W., Bushnell, P.G., Jones, D.R. and Shimizu, M. (1992) Effects of acute temperature change, *in vivo* and *in vitro*, on the acid-base status of blood from yellowfin tuna (*Thunnus albacares*). *Canadian Journal of Zoology* 70:654-662.

Brown, J.A. and Bucknall, R.M. (1985) Antidiuretic and cardiovascular sactions of prostaglandin E_2 in the rainbow trout *Salmo gairdneri*. *General and Comparative Endocrinology* 61:330-337.

Brown. J.A., Gray, C.J., Hattersley, G. and Robinson, J. (1991) Prostaglandins in the kidney, urinary bladder and gills of the rainbow trout and European eel adapted to freshwater and seawater. *General and Comparative Endocrinology* 84:328-335.

Brown, L.L. and Bruno, D.W. (2002) Infectious diseases of coldwater fish in freshwater. ***In***: *Diseases and Disorders of finfish in cage culture* (***eds***. Woo, P.T.K., Bruno, D.W. and Lin, L.H.S.). CABI publishing, New York.

Brubacher, J.L., Secombes, C.J., Zou, J. and Bols, N.C. (2000) Constitutive and LPS-induced gene expression in a macrophage-like cell line from the rainbow trout (*Oncorhynchus mykiss*). *Developmental and Comparative Immunology* 24:565-574.

Brun, E., Poppe, T.T., Skrudland, A. and Jarp, J. (2003) Cardiomyopathy syndrome in farmed Atlantic salmon *Salmo salar*: occurrence and direct financial losses for Norwegian aquaculture. *Diseases of Aquatic Organisms* 56:241-247.

Bruno, D.W. (1990) Jaw deformity associated with farmed Atlantic salmon (*Salmo salar*). *Veterinary Record* 126:402-403.

Bruno, D.W. and Poppe, T.T. (1996) *A colour atlas of salmonid diseases*. Academic Press, London.

Byrne, P.J., Ostland, V.E., Lumsden, J.S., MacPhee, D.D. and Ferguson, H.W. (1995) Blood chemistry and acid-base balance in rainbow trout *Oncorhynchus mykiss* with experimentally-induced acute bacterial gill disease. *Fish Physiology and Biochemistry* 14:509-518.

Byrne, P.J., Ferguson, H.W., Lumsden, J.S. and Ostland, V.E. (1991) Blood chemistry of bacterial gill disease in brook trout *Salvelinus fontinalis*. *Diseases of Aquatic Organisms* 10:1-6.

Cahu, C., Zambonio Infante and Takeuchi, T. (2003) Nutritional components affecting skeletal developments in fish larvae. *Aquaculture* 227:245-258.

Cameron, J.N. and Polhemus, J.A. (1974) Theory of CO_2 exchange in trout gills. *Journal of Experimental Biology* 60:183-194.

Claibourne, J.B. (1998) Acid-base regulation. ***In***: *The physiology of fishes 2nd edition* (***ed.*** Evans, D.H.) pp177-198. CRC press Inc Boca Raton.

Cusack, R.R., Groman, D.B., MacKinnon, A.M., Kibenge, F.S.B., Wadowska, D. and Brown, N. (2001). Pathology associated with an aquareovirus in captive juvenile Atlantic halibut *Hippoglossus hippoglossus* and an experimental treatment strategy for a concurrent bacterial infection. *Diseases of Aquatic Organisms* 44:7-16.

Dabrowski, K., Moreau, R. and El-Saidy, D. (1996) Ontogenic sensitivity of channel catfish to ascorbic acid deficiency. *Journal of Aquatic Animal Health* 8:22-27.

Darwish, A.M., Griffin, B.R., Straus and Mitchell, A.J. (2002) Histological and hematological evaluation of potassium permanganate exposure in channel catfish. *Journal of Aquatic Animal Health* 14:134-144.

Davis, S.W. (1994) Effect of indomethacin on the development of proliferative gill disease. *Journal of Aquatic Animal Health* 6:122-125.

Davison, W. and Franklin, C.E. (2003) Hypertension in *Pagothenia borchgrevinki* caused by X-cell disease. *Journal of Fish Biology* 63:129-136.

Daxboeck, C., Davie, P.S., Perry, S.F. and Randall, D.J. (1982) Oxygen uptake in a spontaneously ventilating blood-perfused trout preparation. *Journal of Experimental Biology* 101:35-45.

Donald, J.A. (1998) Autonomic nervous system. ***In***: *The physiology of fishes 2nd edition* (***ed***. Evans, D.H.) pp407-439. CRC press Inc. Boca Raton.
Dougall, D.S., Woods, L.C., Douglass, L.W. and Soares, J.H. (1996) Dietary phosphorus requirement of juvenile striped bass *Morone saxitillis*. *Journal of the World Aquaculture Society* 27:82-91.
Edsall, C.C. and Swink, W.D. (2001) Effects of nonlethal sea lamprey attack on blood chemistry of lake trout. *Journal of Aquatic Animal Health* 13:51-55.
Egusa, S. (1985) *Myxobolus buri* sp.n. (Myxosporea: Bivalulida) parasitic in the brain of *Seriola quiqueradiata* Temmick et Schlegel. *Fish Pathology* 19:239-244.
Ecknam, E. and Norrgren L. (2003) Pathology and immunohistochemstry in three species of salmonids after experimental infection with *Flavobacterium psychrophilum*. *Journal of Fish Diseases* 26:529-538.
Ellis, A.E. (2001) Innate host defense mechanisms of fish against viruses and bacteria. *Developmental and Comparative Immunology* 25:827-839.
Ewing, M.S., Black, M.C., Blazer, V.S. and Kocan, K.M. (1994) Plasma chloride and gill epithelial response of channel catfish to infection with *Ichthyophthirius multifiliis*. *Journal of Aquatic Animal Health* 6:187-196
Farrell, A.P. (1993) Cardiovascular system. ***In***: *The physiology of fishes* (***ed***. Evans, D.H.) pp219-250. CRC press Inc. Boca Raton.
Farrell, A.P. and Davie, P.S. (1991a) Coronary vascular activity in the skate, *Raja nasuta*. *Comparative Biochemistry and Physiology* C 99: 555-560.
Farrell, A.P. and Davie, P.S. (1991b) Coronary artery reactivity in the mako shark (*Isurus oxyrinchus*). *Canadian Journal of Zoology* 69:375-379.
Farrell, A.P., Johansen, J.A., Moyes, C.D., Steffensen, J.F., West, T.G. and Saurez, R.K. (1990) Effects of exercise training and coronary ablation on swimming performance, heart size and cardiac enzymes in rainbow trout, *Oncorhynchus mykiss*. *Canadian Journal of Zoology* 68:1174-1179.
Farrell, A.P. and Johansen, J.A. (1995) Vasoactivity of the coronary artery of rainbow trout, steelhead trout and dogfish: lack of support for non-prostanoid endothelium derived relaxation factors. *Canadian Journal of Zoology* 73:1899-1911.
Farrell, A.P. and Steffensen, J.F. (1987) Coronary ligation reduced the maximal sustained swimming speed in chinook salmon, *Oncorhynchus tschwaytscha*. *Comparative Biochemistry and Physiology* 87A:35-37.
Ferguson, H.W., Poppe, T.T. and Speare, D.J. (1990) Cardiomyopathy in farmed Norwegian salmon. *Diseases of Aquatic Organisms* 8:225-231.
Fernandes, M.N. and Mazon, A. (2003) Environmental pollution and fish gill morphology. ***In***: *Fish Adaptations* (***eds***. Val, A.L. and Kapoor, B.G) pp 203-225 Science Publishers Inc, Enfield, NH.
Fischer, W.J. and Dietrich, D.R. (2000) Pathological and biochemical characterization of microcystin-induced hepatopancreas and kidney damage in carp (*Cyprinus carpio*). *Toxicology and Applied Pharmacology* 164:73-81.
Franklin, C.E., McKenzie, J.C., Davison, W. and Carey P.W. (1993) X-cell gill disease obliterates the lamellar blood supply in the Antarctic teleost, *Pagothenia borchgrevinki* (Boulenger 1902) *Journal of Fish Diseases* 16:249-254.
Fujiki, K., Nakao, M. and Dixon, B. (2003) Molecular cloning and characterization of a carp (*Cyprinus carpio*) cytokine-like cDNA that shares sequence similarity with IL-6 subfamilliy cytokines CNTF, OSM and LIF. *Developmental and Comparative Immunology* 27:127-136.
Goss, G.G., Wood, C.M., Laurent, P. and Perry, S.F. (1994) Morphological responses of the rainbow trout (*Oncorhynchus mykiss*) gill to hyperoxia, base ($NaHCO_3$) and acid (HCl) infusions. *Fish Physiology and Biochemistry* 12:465-477.
Goss, G.G. and Perry, S.F. (1993) Physiological and morphological regulation of acid-base status during hypercapnia in rainbow trout (*Oncorhynchus mykiss*). *Canadian Journal of Zoology* 71:1673-1680.
Goss, G.G., Laurent, P. and Perry, S.F. (1992) Evidence for a morphological component in acid-base regulation during environmental hypercapnia in brown bullhead (*Ictalurus nebulosus*). *Cell and Tissue Research* 268:539-552.
Goss, G.G., Perry, S.F., Wood, C.M. and Laurent, P. (1992) Mechanisms of ion and acid-base regulation at the gills of freshwater fish. *Journal of Experimental Zoology* 263:143-159.
Greco, A.M., Fenwick, J.C. and Perry, S.F. (1996) The effects of softwater acclimation on gill structure in the rainbow trout *Oncorhynchus mykiss*. *Cell and Tissue Research* 285:75-82.
Greco, A.M., Gilmour, K.M., Fenwick, J.C. and Perry, S.F. (1995) The effects of softwater acclimation on respiratory gas transfer in the rainbow trout *Oncorhynchus mykiss*. *Journal of Experimental Biology* 198:2557-2567.
Guo, Q. (2001) Identification of an interleukin-2 substance in splenocyte culture supernatant of grass carp *Ctenopharyngodon idellus* and Chinese soft-shelled turtle *Trionyx siensis*. *ACTA Hydrobiologica Sinica* 25:21-27.
Haga, Y., Suzuki, T., Kagechika, H. and Takeuchi, T. (2003) A retinoic acid recepetor-selective agonist causes jaw deformity in Japanese flounder, *Paralichtys olivaceus*. *Aquaculture* 221:381-392.
Halver, J.E. and Hardy, R.W. (1994) L-ascorbyl-2-sulfate alleviates Atlantic salmon scurvy (43781). *Proceedings of the Society for Experimental Biology and Medicine* 206:421-424.
Harikrishnan, R., Nisha Rani, M. and Balasundaram, C. (2003) Hematological and biochemical parameters in common carp, *Cyprinus carpio*, following herbal treatment for *Aeromonas hydrophila* infection. *Aquaculture* 221:41-50.
Harris, J.O., Powell, M.D., Attard, M.G. and Green, T. (2004) Efficacy of chloramine-T as a treatment for amoebic gill disease (AGD) in marine Atlantic salmon (*Salmo salar* L.). *Aquaculture Research* 35:1448-1456.
Hilton, J.W., Cho, C.Y. and Slinger, S.J. (1978) Effect of hypervitaminosis A on the development of ascorbic acid deficiency in underyearling rainbow trout (*Salmo gairdneri* R.). *Aquaculture* 13:325-330.
Hong, S., Zou, J., Crampe, M., Peddie, S., Scapigliati, Bols, N., Cunningham, C. and Secombes, C.J. (2001) The production and bioactivity of rainbow trout (*Oncorhynchus mykiss*) recombinant IL-1β. *Veterinary Immunology and Immunopathology* 81:1-14.
Hong, S., Peddie, S., Campos-Perez, J.J., Zou, J. and Secombes, C.J. (2003) The effect of intraperiotneally administered recombinant IL-1β on immune parameters and resistance to *Aeromonas salmonicida* in the rainbow trout (*Oncorhynchus mykiss*). *Developmental and Comparative Immunology* 27:801-812.
Huang, C.-Y. and Che, J.-C. (2002) Effects on acid-base balance, methaemoglobinemia and nitrogen excretion of European eel after exposure to elevated ambient nitrite. *Journal of Fish Biology* 61:712-725.
Hughes, D. (1992) Lower jaw deformity in farmed Tasmanian Atlantic salmon *Salmo salar* (Salmoniformes, teleostei). Final report. ***In***: *Barriers and Breakthroughs Saltas research and development review* pp 17-64, Saltas, Hobart.
Hughes, G.M. and Nyholm, K. (1979) Ventilation in rainbow trout (*Salmo gairdneri*, Richardson) with damaged gill. *Journal of Fish Biology* 14: 285-288.

Inoue, Y., Endo, M., Haruta, C., Taniuchi, T., Morito, T. and Nakanishi, T. (2003) Molecular cloning and sequencing of the silver chimera (*Chimaera phantasma*) interleukin-8 cDNA. *Fish and Shellfish Immunology* 15:269-274.
Inoue, Y., Haruta, C., Usui, K., Moritomo, T. and Nakanishi, T. (2003) Molecular cloning and sequencing of the banded dogfish (*Triakis scyllia*) interleukin-8 cDNA. *Fish and Shellfish Immunology* 14:275-281.
Iwama, G.K. and Farrell, A.P. (1998) Disorders of the cardiovascular and respiratory systems. ***In***: *Fish diseases and disorders Vol 2*. Non infectious disorders (***eds***. Leatherland, J.F. and Woo, P.T.K.) pp245-278. CAB International, New York.
Iwama, G.K., Boutilier, R.G., Heming, T.A., Randall, D.J. and Mazeaud, M. (1987) The effects of altering gill water flow on gas transfer in rainbow trout. *Canadian Journal of Zoology* 65:2466-2470.
Iwama, G. and Nakanishi, T. (1996) The fish immune system. *Fish Physiology vol 15* (***eds***. Hoar, W.S., Randall, D.J. and Farrell, A.P.). Academic press Ltd., London.
Janvier, J.J. (1997) Cardiovascular and ventilatory effects of prostaglandin E_2 in the European eel *Anguilla anguilla*. *Journal of Comparative Physiology B* 167:517-526.
Joergensen, J.B., Lunde, H., Jensen, L., Whitehead, A.S. and Robertson, B. (2000) Serum amyloid A transcription in Atlantic salmon (*Salmo salar* L.) hepatocytes is enhanced by stimulation with macrophage factors, recombinant human IL-1β, IL-6 and TNFα or bacterial lipopolysaccharide. *Developmental and Comparative Immunology* 24:553-563.
John, T.M., George, J.C., Hilton, J.W. and Slinger, S.J. (1979) Influence of dietary ascorbic acid on plasma lipid levels in the rainbow trout. *International Journal of Vitamin and Nutritional Research* 49:400-405.
Jones, D.R. and Randall, D.J. (1978) The respiratory and circulatory systems during exercise in fish. ***In***: *Fish Physiology Volume 7* (***eds***. Hoar, W.S. and Randall, D.J.) pp 425-450. Academic Press, New York.
Jorgensen, J.B., Zou, J., Johansen, A. and Secombes, C.J. (2001) Immunostimulatory CpG oligodeoxynucleotides stimulate expression of IL-1β and interferon-like cytokines in rainbow trout macrophages via a chloroquine-sensitive mechanism. *Fish and Shellfish Immunology* 11:673-682.
Jung, S.H., Sim, D.S., Park, M., Jo, Q. and Kim, Y. (2003) Effects of formalin on haematological and blood chemistry in olive flounder, *Paralichtys olivaceus* (Temmick et Schegel). *Aquaculture Research* 34:1269-1275.
Kanazawa, A., Teshima, S-I., Koshio, S., Higashi, M. and Itoh, S. (1992) Effect of L-ascorbyl-2-phosphate-Mg on the yellowtail *Seriola quinqueradiata* as a vitamin C source. *Nippon Suisan Gakkaish* 58:337-341.
Karnaky, K.J. (1998) Osmotic and ionic regulation.
In: *The physiology of Fishes* (2nd edition) (***ed***. Evans, D.H.). pp157-167. CRC Press Inc., Boca Raton.
Katzung, B.G. (2001) *Basic and Clinical Pharmacology* (8th edition) McGraw Hill Sydney.
Khattra, J.S., Gresoviac, S.J., Kent, M.L., Myers, M.S., Hedrick, R.P. and Devlin, R.H. (2000) Molecular detection and phylogenetic placement of a microsporidian from English sole (*Pleuronectes vetulus*) affected by X-cell psuedotumours. *The Journal of Parasitology* 86:867-871.
Knight, J., Holland, J.W, Bowden, L.A., Halliday, K. and Rowley, A.F. (1995) Eicosanoid generating capacities of different tissues from rainbow trout, *Oncorhynchus mykisss*. *Lipids* 30:451-458.
Koenig, J. (1979) Vitamins, macro and micro-mineral trace-elements in fish nutrition. *Oceanis* 5:131-144.
Kono, T., Watanuki, H. and Sakai, M. (2002) The activation of interleukin-1b in serum of carp, *Cyprinus carpio*, injected with peptidoglycan. *Aquaculture* 212:1-10.
Laing, K.J., Wang, T., Zou, J., Holland, J., Hong, S., Bols, N., Hirono, I., Aoki, T. and Secombes C.J. (2001) Cloning and expression analysis of rainbow trout *Oncorhynchus mykiss* tumour necrosis factor-α. *European Journal of Biochemistry* 268:1325-1322.
Laing, K.J., Zou, J.J., Wang, T., Bols, N., Hirono, I., Aoki, T. and Secombes, C.J. (2002) Identification and analaysis of an interleukin 8-like molecule in rainbow trout *Oncorhynchus mykiss*. *Developmental and Comparative Immunology* 26:433-444.
Lee, E.Y., Park, H.H., Kim, Y.T., Chung, J.K. and Choi, T.J. (2001) Cloning and sequence analysis of the interleukin-8 gene from flounder (*Paralichthys olivaceus*). *Gene* 274:237-243.
Lee, K-J., Kim, K-W. and Bai, S.C. (1998) Effects of different dietary levels of L-ascorbic acid on growth and tissue vitamin C concentration in juvenile Korean rockfish, *Sebastes schegeli* (Hilgendorf). *Aquaculture Research* 29:237-244.
Leef, M.J., Harris, J.O. and Powell, M.D. (2005) Respiratory pathogenesis of amoebic gill disease (AGD) in experimentally infected Atlantic salmon (*Salmo salar*). *Diseases of Aquatic Organisms* (in press).
Lin, H. and Randall, D.J. (1991) Evidence for the presence of an electrogenic proton pump on the trout gill epithelium. *Journal of Experimental Biology* 161:119-134.
Lin, H., Pfeiffer, D.C., Vogl, A.W., Pan, J. and Randall, D.J. (1994) Immunolocalization of proton-ATPase in the gill epithelia of rainbow trout. *Journal of Experimental Biology* 195:169-183.
Lindenstrom, T., Buchmann, K. and Secombes, C.J. (2003) *Gyrodactylus derjavini* infection elictits IL-1β expression in rainbow trout skin. *Fish and Shellfish Immunology* 15:107-115.
Lockyer, A.E., Jones, C.S., Noble, L.R., Verspoor, E., Holland, J. and Secombes, C.J. (2001) Isolation and characterisation of a putative interleukin 13 receptor α2 sequence from rainbow trout (*Oncorhynchus mykiss*). *Fish and Shellfish Immunology* 11:541-546.
Lopez-Albors, O., Gil, F., Ramirez-Zarzoasa, G., Latorre, R., Garcia-Alcazar, A., Abellan, E., Lanco, A., Vazquez, J.M. and Moreno, F. (1995) Early muscle injuries in a standard reared stock of sea bass *Dicentrachus labrax* (L.). *Aquaculture* 138:69-76.
Low, C., Wadsworth, S., Burrells, C. and Secombes, C.J. (2003) Expression of immune genes in turbot (*Scophthalmus maximus*) fed a nucleotide supplemented diet. *Aquaculture* 221:23-40.
Mackenzie, D.J., Taylor, E.W., Dalla Valle, A.Z. and Steffensen, J.F. (2002) Tolerance of acute hypercapnic acidosis by the European eel (*Anguilla anguilla*). *Journal of Comparative Physiology B* 172:339-346.
Maeno, Y., Sorimachi, M., Ogawa, K. and Egusa, S. (1990) *Myxobolus spinacurvatura* sp. n. (Myxosporea: Bilvalulida) parasitic in deformed mullet, *Mugil cephalus*. *Fish Pathology* 25:37-41.
Malte, H. and Weber, R.E. (1985) A mathematical model for gas exchange in the fish gill based on non-linear blood gas equilibrium curves. *Respiration Physiology* 62:359-374.
Marx, J., Hilbig, R. and Rahmann, H. (1984) Endotoxin and prostaglandin E1 fail to induce fever in teleost fish. *Comparative Biochemistry and Physiology A* 77A:483-487.

McCoy, M.A., McLoughlin, M.F., Rice, D.A. and Kennedy, D.G. (1994) Pancreas disease in Atlantic salmon (*Salmo salar*) and vitamin E supplementation. *Comparative Biochemistry and Physiology A* 109A:905-912.
McGeer, L.C., Playle, R.C., Wood, C.M. and Calvez, F. (2000) A physiologically based biotic ligand model for predicting the acute toxicity of waterborne silver to rainbow trout in freshwaters. *Environmental Science and technology* 34:4199-4207.
Miyazaki, T. and Plumb, J.A. (1986) A histopathological study of a natural case of broken-back syndrome of channel catfish. *Bulletin of the Faculty of Fisheries Mie University* 13:11-16.
Moyle, P.B. and Cech, J.J. (2000) *Fishes: an introduction to ichthyology (4th edition)*. Prentice Hall, Upper Saddle River, NJ.
Munday, B.L., Zilberg, D. and Findlay, V. (2001) Gill disease of marine fishes caused by infection with *Neoparamoeba pemaquidensis*. *Journal of Fish Diseases* 24:497-507.
Murphy, T.M., Rodger, H.D., Drinan, E.M., Gannon, F., Kruse, P. and Korting, W. (1992) The sequential pathology of pancreas disease in Atlantic salmon farms in Ireland. *Journal of Fish Diseases* 15:401-408.
Niyogi, S., Couture, P., Pyle, G., McDonald, D.G. and Wood, C.M. (2004) Acute cadmium biotic ligand model characteristics of laboratory-reared and wild yellow perch (*Perca flavescens*) relative to rainbow trout (*Oncorhynchus mykiss*). *Canadian Journal of Fisheries and Aquatic Sciences* 61:942-953.
Nylund, A., Plarre, H., Hodneland, K., Devold, M., Aspenhaug, V., Aarseth, M., Koren, C. and Watanabe, K. (2003). Haemorrhagic smolt syndrome (HSS) in Norway: pathology and associated virus-like particles. *Diseases of Aquatic Organisms* 54: 15-27.
Olsen, K.R. (1998) The cardiovascular system. ***In*** *The physiology of fishes 2nd edition* (***ed***. Evans, D.H.) pp129-154. CRC press Inc., Boca Raton.
Partridge,G.J. and Creeper, J. (2004) Skeletal myopathy in juvenile barramundi, *Lates calcarifer* (Bloch), cultured in potassium-defficicent saline groundwater. *Journal of Fish Diseases* 27:523-530,
Peddie, S., Zou, J., Cunningham, C. and Secombes, C.J. (2001) Rainbow trout (*Oncohynchus mykiss*) recombinant IL-1β and derived peptides induce migration of head-kidney leucocytes *in vitro*. *Fish and Shellfish Immunology* 11:697-709.
Peddie, S., Zou, J. and Secombes, C.J. (2002a) A biologically active IL-1β derived peptide stimulates phagocytosis and bactericidal activity in rainbow trout, *Oncorhynchus mykiss* (Walbaum) head kidney leucocytes *in vitro*. *Journal of Fish Diseases* 25:351-360.
Peddie, S., Zou, J. and Secombes, C.J. (2002b) Immunostimulation in the rainbow trout (*Oncorchynchus mykiss*) following intraperitoneal administration of Ergosan. *Veterinary Immunology and Immunopathology* 86:101-113.
Peddie, S., McLauchlan, P.E., Ellis, A.E. and Secombes, C.J. (2003) Effects of intraperiotneally administered IL-1β-derived peptides on resistance to viral haemorrhagic septicaemia in rainbow trout *Oncorhynchus mykiss*. *Diseases of Aquatic Organisms* 56:195-200.
Perry, S.F. and Gilmour, K.M. (1996) An evaluation of factors limiting carbon dioxide excretion by trout red blood cells *in vitro*. *Journal of Experimental Biology* 180:39-54.
Perry, S.F. and McDonald, D.G. (1993) Gas exchange. ***In***: *The physiology of fishes* (***ed***. Evans, D.H.) pp251-278. CRC press Inc., Boca Raton.
Perry, S.F. (1986) Carbon dioxide excretion in fishes. *Canadian Journal of Zoology* 64:565-572.
Piiper, J. (1989) Factors affecting gas transfer in respiratory organs of vertebrates. *Canadian Journal of Zoology* 67:2956-2960.
Pleguezuelos, O., Zou, J., Cunningham, C. and Secombes, C.J. (2000) Cloning, sequencing and analysis of expression of a second IL-1β gene in rainbow trout (*Oncorhynchus mykiss*). *Immunogenetics* 51:1002-1011.
Poppe, T.T. and Seirstad, S.L. (2003) First description of cardiomyopathy syndrome (CMS)-related lesions in wild Atlantic salmon *Salmo salar* in Norway. *Diseases of Aquatic Organisms* 56:87-88.
Poppe, T.T. and Taksdal, T. (2000) Ventricular hypoplasia in farmed Atlantic salmon *Salmo salar*. *Diseases of Aquatic Organisms* 42:35-40.
Powell, M.D., Harris, J.O., Carson, J. and Hill, J.V. (2005a) Effects of gill abrasion and experimental infection with *Tenacibaculum maritimum* on the respiratory physiology of Atlantic salmon *Salmo salar* affected by amoebic gill disease. *Diseases of Aquatic Organisms* 63:169-174.
Powell, M.D., Carson, J. and van Gelderen, R. (2004) Experimental induction of gill disease in Atlatnic salmon *Salmo salar* smolts with *Tenacibaculum maritimum*. *Diseases of Aquatic Organisms* 61:179-185.
Powell, M.D. and Nowak, B.F. (2003) Acid-base and respiratory effects of net confinement in amoebic gill disease affected Atlantic salmon (*Salmo salar*). *Journal of Fish Biology* 62:51-63.
Powell, M.D., Nowak, B.F. and Adams, M.B. (2002a) Cardiac morphology in relation to amoebic gill disease history in Atlantic salmon, *Salmo salar* L. *Journal of Fish Diseases* 25:209-215.
Powell, M.D., Forster, M.E. and Nowak, B.F. (2002b) Apparent vascular hypertension associated with amoebic gill disease affected Atlantic salmon (*Salmo salar*) in Tasmania. *Bulletin of the European Association of Fish Pathologists* 22:328-333.
Powell, M.D., Fisk, D. and Nowak, B.F. (2000) Effects of graded hypoxia on Atlantic salmon infected with amoebic gill disease. *Journal of Fish Biology* 57:1047-1057.
Powell, M.D. and Perry, S.F. (1999) Cardio-respiratory effects of chloramine-T exposure in rainbow trout. *Experimental Biology Online* 4:5.
Powell, M.D., Haman, F., Wright, G.M. and Perry, S.F. (1998) Respiratory responses to graded hypoxia of rainbow trout (*Oncorhynchus mykiss*) following repeated intermittent exposure to chloramine-T. *Aquaculture* 165:27-39.
Powell, M.D. and Perry, S.F. (1997) Respiratory and acid-base disturbances in rainbow trout blood during exposure to chloramine-T under hypoxia and hyperoxia. *Journal of Fish Biology* 50:418-428.
Powell, M.D. and Perry, S.F. (1996) *Respiratory and acid-base disturbances in rainbow trout (Oncorhynchus mykiss) blood during exposure to* chloramine-T, paratoluenesulphonamide and hypochlorite. *Canadian Journal of Fisheries and Aquatic Sciences* 53:701-708.
Powell, M.D., Wright, G.M. and Speare, D.J. (1995) Morphological changes in rainbow trout (*Oncorhynchus mykiss*) gill epithelia following repeated intermittent exposure to chloramine-T. *Canadian Journal of Zoology* 73:154-165.
Powell, M.D., Speare, D.J. and Wright, G.M. (1994) Comparative ultrastructural morphology of lamellar epithelial, chloride and mucous cell glycocalyx of the rainbow trout (*Oncorhynchus mykiss*) gill. *Journal of Fish Biology* 44:725-730.
Randall, D.J., Burggren, W. and French, K. (1997) *Eckert Animal Physiology mechanisms and adaptations (4th edition)*. W.H. Freeman, New York
Randall, D.J., Lin, H. and Wright, P.A. (1991) Gill water flow and chemistry of the boundary layer. *Physiological Zoology* 64:26-38.
Randall, D.J. and Daxboeck, C. (1984) Oxygen and carbon dioxide transfer across fish gills.
In: *Fish Physiology* (***eds***. Hoar, W.S. and Randall, D.J.) pp 263-314. Academic Press, New York.
Rehulka, J. (2003) Haematological analysis in rainbow trout *Oncorhynchus mykiss* affected by viral haemorrhagic scepticemia (VHS). *Diseases of Aquatic Organisms* 56:185-193.

Reid, S.D., McDonald, D.G. and Wood, C.M. (1997) Interactive effects of temperature and pollutant stress. ***In***: *Global Warming: implications for freshwater and marine fish.* (***eds.*** Wood, C.M. and McDonald, D.G.) pp325-349 Cambridge University Press, Cambridge.
Robertson, O.H., Wexler, B.C. and Miller, B.F. (1961) Degenerative changes in the cardiovascular system of the spawning Pacific salmon (*Oncorhynchus tshwaytscha*). *Circulation Research* 9:826-834.
Roberts, R.J., Hardy, R.W. and Sugira, S.H. (2001) Screamer disease in Atlantic salmon, *Salmo salar* L., in Chile. *Journal of Fish Diseases* 24:543-549.
Rodger, H.D., Murphy, T.D., Drinan, E.M. and Rice, D.A. (1991) Acute skeletal myopathy in farmed Atlantic salmon *Salmo salar.* *Diseases of Aquatic Organisms* 12:17-23.
Sadler, J., Pankhurst, P.M. and King, H.R. (2001) High prevalence of skeletal deformity and reduced gill surface area in triploid Atlantic salmon (*Salmo salar* L.). *Aquaculture* 198:369-386.
Sakaguchi, S., Hara, T., Matsusato, T., Shibahara, T., Yamagata, Y., Kawai, H and Maeno, Y. (1987) Scolisosis of cultured yellowtail caused by parasitic *Myxobolus buri. Bulletin of the National research Institute for Aquaculture (Japan)* 12:79-86.
Sangrador-Vegas, A., Martin, S.A.M., O'Dea, P.G. and Smith, T.J. (2000) Cloning and characterization of the rainbow trout (*Oncorhynchus mykiss*) type II interleukin-1 receptor cDNA. *European Journal of Biochemistry* 267:7031-7037.
Scapigliati, G., Buonocore, F, Bird, S., Zou, J., Pelegrin, P., Falasca, C., Prugnoli, D. and Secombes, C.J. (2001) Phylogeny of cytokines: molecular cloning and expression analysis of sea bass *Dicentrarchus labrax* interleukin-1β. *Fish and Shellfish Immunology* 11:711-726.
Secombes, C.J. (1996) The nonspecific immune system: cellular defenses. ***In***: *The fish Immune System.* ***eds.*** Iwama, G. and Nakanishi, T. pp63-103 Academic Press Ltd, London.
Secombes, C., Zou, J., Daniels, G., Cunningham, C., Koussounadis, A. and Kemp, G. (1998) Rainbow trout cytokine and cytokine receptor genes. *Immunological reviews* 166:333-340.
Secombes, C.J., Wang, T., Hong, S., Peddie, S., Crampe, M., Laing, K.J., Cunningham, C. and Zou, J. (2001) Cytokines and innate immunity in fish. *Developmental and Comparative Immunology* 25:713-723.
Singh, N.N., Das, V.K. and Srivastava, A.K. (1997) Formothion and propoxur induced ionic imbalance and skeletal deformity in a catfish, *Heteropneustes fossilis. Journal of Environmental Biology* 18:357-363.
Smith, C.E., Holway, J.E. and Hammer, G.L. (1973) Sulphamerazine toxicity in cut throat trout broodfish, *Salmo clarkii* (Richardson). *Journal of Fish Biology* 5:97-101.
Soncini, R. and Glass, M.L. (2000) Oxygen and acid-base status related drives to gill ventilation in carp. *Journal of Fish biology* 56:528-541.
Speare, D.J, Ferguson, H.W., Beamish, F.W.M.,Yager, J.A. and Yamashiro, S. (1991) Pathology of bacterial gill disease: sequential development of lesions during natural outbreaks of disease. *Journal of Fish Diseases* 14:21-32.
Srivastava, K.C. and Mustafa, T. (1984) Arachidonic acid metabolism and prostaglandins in lower animals. *Molecular Physiology* 5:53-60.
Stecyk, J.A. and Farrell, A.P. (2002) Cardiorespiratory responses of common carp (*Cyprinus carpio*) to severe hypoxia at three acclimation temperatures. *Journal of Experimental Biology* 205:759-76.
Stenslokken, K-O., Sundin, L. and Nilsson, G.E. (2002) Cardiovascular effects of prostaglandin $F_{2\alpha}$ and prostaglanding E_2 in Atlantic cod (*Gadus morhua*). *Journal of Comparative Physiology B* 172:363-369.
Stoskopf, M.K. (1993) *Fish medicine.* W.B. Saunders Co., Philapdelphia.
Subramanian, S., Stasberg, C., Olsen, L., Zou, J., Secombes, C.J. and Cunningham, C. (2002) Cloning of a *Salmo salar* interleukin-1 receptor-like cDNA. *Developmental and Comparative Immunology* 26:415-431.
Sullivan G.V., Fryer, J.N. and Perry, S.F. (1995) Immunolocalisation of proton pumps (H^+-ATPase) in pavement cells of rainbow trout gill. *Journal of Experimental Biology* 198:2619-2629.
Sullivan, G.V., Fryer, J.N. and Perry, S.F. (1996) Localization of mRNA for the proton pump (H^+-ATPase) and Cl^-/HCO_3^- exchanger in the rainbow trout gill. *Canadian Journal of Zoology* 74:2095-2103.
Tassakka, A. and Sakai, M. (2004) Expression of immune-releated genes in the common carp (*Cyprinus carpio* L.) after stimulation by CpG oligodeoxynucleotides. *Aquaculture* 242:1-12.
Tucker, B.W. and Halver, J.E. (1984) Acorbate-2-sulfate metabolism in fish. *Nutrition Reviews* 42:173-179.
Tumbol, R.A., Powell, M.D. and Nowak, B.F. (2001) Ionic effects of *Ichthyophthirius multifiliis* infection in goldfish *Carassius auratus.* *Journal of Aquatic Animal Health* 13:20-26.
Ultsch, G.R. and Gros, G. (1979) Effects of branchial mucus on diffusion of O_2 in carp *Cyprinius carpio.* *Comparative biochemistry and Physiology* 62A:685-689.
Vajcova, V., Navratil, S. and Palikova, M. (1998) The effect of intraperitoneally applied pure mycroystin LR on haematological and morphological indices of silver carp (*Hypophthalmichthys molitrix* Val.). *Acta Veterinaria* 67:281-287.
Vines, C.A., Robbins, T., Griffin, F.J. and Cherr, G.N. (2000) The effects of diffusible creosote-derived compounds on development in pacific herring (*Clupea pallasi*). *Aquatic Toxicology* 51: 225-239.
Webb, P.W. (1993) Swimming. ***In***: *The physiology of fishes* (***ed.*** Evans, D.H.) pp47-73. CRC press Inc., Boca Raton.
Wedemeyer, G.A., Barton, B.A. and McLeay, D.J. (1991) Stress and acclimation. ***In***: *Methods for fish biology* (***eds.*** Moyle, P.B and Schreck, C.B.) pp451-489. American Fisheries Society, Bethesda.
White, A., MacArthur, J.I. and Fletcher, T.C. (1984) Distribution of endotoxin and its effects on concentrations of C-reactive protein and cortisol in the plaice (*Pleuronectes platessa* L.). *Comparative Biochemistry and Physiology C* 79C:97-101.
Wood, C.M., McDonald, D.G. and McMahon, B.R. (1982) The influence of experimental anaemia on blood acid-base regulation *in vivo* and *in vitro* in the starry flounder (*Platichthys stellatus*) and the rainbow trout (*Salmo gairnderi*). *Journal of Experimental Biology* 96:221-237.
Wood, C.M. (1991) Branchial ion and acid-base transfer in freshwater teleost fish: environmental hyperoxia as a probe. *Physiological Zoology* 64:68-102.
Yohsiura, Y., Kiryu, I., Fujiwara, A., Suetake, H., Nakanishi, T. and Ototake, M. (2003) Identification and characterization of *Fugu* orthologues of mammalian interleukin-12 sub units. *Immunogenetics* 55:296-306.
Zhang, H., Thorgaard, G.H. and Ristow, S.S. (2002) Molecular cloning and genomic structure of an interleukin-8 receptor-like gene from homozygous clones of rainbow trout (*Oncorhynchus mykiss*). *Fish and Shellfish Immunology* 13:251-258.

Zou, J, Neumann N.F, Holland, J.W., Belosevic, M. Cunningham, C., Secombes, C.J. and Rowley, A.F. (1999) Fish macrophages express a cyclo-oxygenase-2-homologue after activation. *Biochemistry Journal* 340:153-159.

Zou, J., Wang, T., Hong, S., Cunningham, C. and Secombes, C.J. (2000) Role of interleukin-1β in immune response of rainbow trout. *Fish and Shellfish Immunology 10*:289-298.

Zou, J., Clark, M.S. and Secombes, C.J. (2003) Characterisation, expression and promoter analysis of an interleukin 10 homologue in the puffer fish, *Fugu rubripes*. *Immunogenetics* 55:325-335.





Page numbers in ***italics*** indicate figures

Acanthocephalans 184
Accessory breathing apparati 27
Accessory cells - see under Lamellae
Acid-base values ***338***
  disturbances 347
  gill responses to distrurbances ***342, 345***
Acolpenteron ***110***
Acute phase responses, proteins 348
Adjuvants 17
Aerocystitis 191-193
Aeromonas hydrophila 239
Aeromonas salmonicida - see under Furunculosis
Aflatoxin 215, 321, ***327***, 330
Albinism 79
Algal blooms 43, ***212,*** 215
Ammonia 47, 237
Amoeba 51, ***55***
  amoebic gill disease 339
Anaemias 132-136
  in lipoid liver disease 213
  in PKD 136
Aneurysm, dissecting ***160***
Angiotensin 277
Anguillicola 192
Anisakids 306
Antigen uptake across gills 47
Aortic stenosis ***162***
Aphanomyces invadens 76, ***303***
Apoptosis 316
Arachidonic acid, metabolism ***346***
Argulus 83
Arteriosclerosis ***165***
Artifacts, in brain ***223***
Ascarids 211
Aspergillus 214-215, 321
Astrocytes 230
Atypical bacterial gill disease 51, ***52***

Babesioma mariae ***13***
Bacterial enteritis syndrome 181
Bacterial gill disease (BGD) ***49-51***
  atypical BGD ***52***
Bacterial kidney disease (BKD) 17, ***94, 96, 104-106***
  in brain ***228-229***
  in eye 259
  in gills ***48***, 52
  in heart ***150***
  in liver ***210,*** 214
  in muscle 299, ***302***
  in ovary 283
  in peritoneum ***192***
  in skin - see under Spawning rash
  in spleen 125
  in testes 282
  in vessels ***160***
Bile ducts ***202, 213***
  carcinoma ***329***
Bile retention, in neoplasia ***329***
Biogenic amines 169
Black spot disease 18, ***82,*** 150, ***305***
Blacktail ***239***
Bladder, urinary ***91***
  gas - see under Swimbladder
Bloat 173
Blood 128-135
  secondary circulation 128
Blood-brain barrier 225
Blood gases, values ***338***
Blood sampling methods 12
Blood vessels 158-165
Bone 289
  remodelling 290
Bouin's fixative 11, 65
Bothriocephalus ***180,*** 184
Brain 219-239
  cytopathology 228
  developmental malformations 228
  regeneration 224
  routes of infection 231
Branchitis 15
Branchiomycosis ***52***, 53, ***163***
Breeding tubercle, in skin ***76***
Brockman bodies 279
Broken back syndrome 295, ***297***

Brown blood disease 135
Bucephalus polymorphus 171

Calcitonin 279
Calcium regulation 279
Calyptospora (Eimeria) 195, 214
Candida 173
Candidatus Arthromitus 181
Canola meal, as goitrogen 274
Capillaria 214
Capillary permeability 161
Carbonic anhydrase 259, 347
Carcinogenesis 321
Carcinogens 319
Cardiac tamponade ***156***
Cardiohepatic syndrome 214
Cardiomyopathies 342
Cardiomyopathy syndrome ***156***
Cardiovascular system, clinical chemistry ***340***
Carnobacterium 299
Carp erythrodermatitis 72
Carp pox ***75***
Castration, parasitic 196
Cataract ***255-259,*** 261
Catecholamines 277
Cauliflower disease 326
Ceratomyxa shasta 186, ***191,*** 215
Cerebellum ***221***
Cerebrum 219
Ceroid ***206-207***
Chaetoceros 43, ***48***
Channel catfish virus disease 234
Chilodonella 55
Chitin 17, 80
Chlamydia - see under Epitheliocystis
Chloride cells – see under Gills
Cholesteatoma ***320***
Chondroma ***322***
Choroid gland, choroid rete – see under Eye
  association with pseudobranch 57
Chromaffin cells 91, ***276***
Chromatolysis ***224,*** 229
Cichlid bloat ***158, 173-174***
Circumventricular organs 220
Clinical pathology 337-355
  chemistry data ***341***
Clostridia 177, 181
Club cells ***65***
Club colonies - see under Splendore-Hoeppli reactions

Coccidia
  in gills 53
  in intestine 185
  in liver 214
  in pancreas 195, 280
  in spleen ***124***
  in swimbladder 185, ***188***
Cochliopodium – see under Nodular gill disease
Columnaris disease
  in gills 51, ***52***
  in mouth ***169,*** 171
  in skin ***74***
Coma, in ammonia toxicity 47
Complement 15
Contracaecum 306
Copepods
  in eye 260
  in gills 56, ***58***
  in heart 151
  in skin ***83***
Corethron 43
Corpuscles of Stannius 91, ***277***
Corticosteroids 275
Cortisol 19, 275
Costiasis ***44, 55,*** 73
Cotton-wool mouth - see under Columnaris disease
Cotylurus ***154***
Cryptobia ***12, 174***
Cryptocaryon 237
Cryptocotyle lingua 79, 150
Cryptosporidium ***172, 180***
Cuticle 65
Cyclins 319
Cystidicola 192
Cytochrome *p450* 144
Cytokeratin 125
Cytokines and receptors ***343***

Deficiency
  magnesium 101
  pantothenic acid ***39***
  pyridoxine 102
  riboflavin 260
  selenium 297
  thiamine 238, 260
  vitamin A 102, 260
  vitamin C 262, 291, ***297***
  vitamin E 297
  zinc ***255***

Denervation atrophy 297
Dermal sarcoma, of walleye ***319***
Dermatitis ***70***
Dermis 65
Diabetes 280
Diatoms 15, ***48***
Diphyllobothrium ***179,*** 184
Diplostomum 235
Disseminated intravascular coagulation (DIC) 19
Dissolving head disease 260, 295
DNA viruses 315

Edwardsiella 17, 76, ***103,*** 106, 178, 183, ***205,*** 234
Eicosanoids, production in gill 28
Eimeria – see Coccidia
Ellipsoids ***125-128***
Embolism, to gills ***49***
Encephalocoele ***232***
Endocrine system 267-281
Endotoxin 15
Enteric redmouth disease (ERM) 171
Enteric septicaemia of catfish 76, 178
Enteritis 177-187
  catarrhal 180
  haemorrhagic ***178***
  necrotic ***177***
  soya-induced ***178***
Enterocytozoon salmonis 136
Enteropathies, toxic 183
Eosinophilic granular cell
  in CNS ***16***
  in gills ***36***, 45
  in gut 170
  necrosis of, in IHN 180
Ependyma 127, ***222***
Ependymins 226
Epidermis 65, ***66, 69***
Epinephrine, norepinephrin 277
Epitheliocystis 53, ***57-58***
Epithelioid cells ***134***
Epizootic haematopoietic necrosis (EHN) 124, 234
Epizootic ulcerative syndrome (EUS) 76, ***78, 303***
Ergasilids ***58***
Erythrocyte inclusion body syndrome (EIBS) 124
Erythropoiesis 121
Eubacterium 234
Euthanasia 13
Exophiala 112, 214, 235
Exophthalmia 258

Eye 245-265
  accommodation 254
  aqueous production 249
  argentea 248
  bladder cells in cataract ***261***
  blood supply 245, ***246***
  cataract - see under Cataract
  choroid gland (*rete*) ***246,*** 248-249, ***254***
  ciliary body 249
  ciliary cleft ***247***
  cornea ***246***
  eyefluke ***258-259***
  eye heater 252
  eyelids, lack thereof 247
  eyeshine 248, 251
  falciform process ***248,*** 250
  filtration angle ***247***
  fovea 253
  glaucoma 256
  hyphaema ***252,*** 257
  immune privilege 255
  iris ***247-248***
    iris bombé 250
  keratitis ***252-253,*** 260
  lens 254
    epithelial proliferation ***255-256***
    rupture ***256-257***
  limbus 247
  retina ***247, 249,*** 250
    retinal pigmented epthelium 250, ***260***
  retinopathy ***261,*** 262
  retractor lentis muscle ***248***
  sclera 246-247
  synechia ***250***
  tapetum lucidum 251
  uveal tract 247
  uveitis 256, 261

Fat necrosis 195
Fat-storing cells ***201-202***
Fever 15
Fibroma ***318***
Fibronectin 70
Filament - see under Gill
Fins 307
Fixatives, fixation 11, 30, 40, 65, ***66***
Flavobacterium branchiophilum ***49,*** 339
Flavobacterium columnare (formerly *Flexibacter columnaris*) - see under Columnaris disease

Flavobacterium psychrophilum ***74,*** 78, ***128-129,*** 148, ***153,*** 260, ***299, 302***
Flexibacter (Tenacibaculum) maritimus ***75, 160***
Folic acid 135
Foreign body reactions 15
in gills 43, ***48***
in peritoneal cavity ***193***
Formalin 11
Francisella ***103***
Fright substance cells - see under Club cells
Fungus
in eye ***254***
in gill disease ***52***, 53
in heart 149
in kidney 112
in muscle ***303***
in oesophagus ***171***
in peritoneum ***195***
in skin disease ***71, 73***
in spleen ***130-131***
in stomach 173
in swimbladder 192
in vessels ***160***
Furunculosis
in gills ***49***, 52, ***160***
in heart ***152, 155***
in kidney ***103***
in muscle ***302***
in ovary 283
in skin 72, ***78***
in spleen ***128***
in vessels ***158***
Fusarium solani 112, ***195***

Gallbladder 215
Gallstones 215
Gas embolism, gas bubble disease
in eye ***250-251***
in gills 52
in pseudobranch 57
Gas transfer processes, in gills ***337***
Gastric dilation and air sacculitis (GDAS) ***172***
Gastritis 172-177
Gastro-intestinal tract 169-187
hormones 281
Gemistocytes 230
General pathology 14
Germinal centres 123
Giant cells ***17***
in brain ***233***
in gills 43, ***48***
in skin ***80***
Gills - 25-62
artifacts 40
branchiomycosis 53
branchitis 45, ***47-48***
chronic responses to injury 45
chloride cells 29, 31
degeneration ***42***
hyperplasia 339
normal ***30, 33***
clubbing ***44***
distribution of lesions 39
epithelial capillary separation ***37***
eosinophilic granular cells (EGC's) 36, 45
filaments, cells within interstitium 32, 34
fusion 45
inflammation 45, ***48***
glycocalyx 30, ***33***
haemorrhage 43
infarction of ***47***
lamellae 26-30
accessory cells 29
aneurysm 43, ***46***
central venous sinusoid ***26***, 27, 32
cytomegaly 52
degeneration and necrosis ***39-43***
epithelial cells 28
fusion of ***42-44***
hyperplasia 43, ***44***
hypoplasia 45
macrophages, resident 45
marginal channel ***26***, 28, *30*
microridges 28, ***33***, 40
oedema ***38***, 40
pillar cells 26, 28, ***29-31***, 52
progenitor cells, zone 31, ***33***, 43, 46
sacciform cells 31, ***36***
synechia 41, ***43***
telangiectasis, see aneurysm
thrombosis ***46***
toxic damage 37, ***38, 41***
mucous cell and mucus ***28***, 29, ***32, 38,*** 40, 45
movement of mucus 34
normal structure and function 26-36
pillar cells - see under Lamellae
progenitor cells - see under Lamellae
repair 46

response to injury 25, 36-47
"rot" 53
Gilquinia ***257***
Gitter cells 230
Glial cells 223
Gliosis ***226***
Glochidia 55
Glossopharyngeal nerve 57
Glucagon 279
Glugea 175, 195, ***281,*** 305
Goblet cells - see under Mucus
Goitre ***273***
Goitrogens 273
Gonadal tumours ***331***
Goussia 185, ***188***
Green pike syndrome 212
Growth hormone (GH) ***271***
Guanine 66
Gyrodactylus 56, 260

Haemogregarina sachai ***12***
Hamburger gill disease 55
Hassall's corpuscles 125
Haemangioma ***321***
Haemogregarina ***12, 125,*** 136, 175
Haemorrhagic kidney syndrome (HKS) ***108***
Haemorrhagic syndrome ***127***
Haemorrhagic smolt syndrome (HSS) ***161,*** 346
Heart 141-167
anomalies 144
consequences of disease 146
coronary vessels ***144***
endocardium 143, ***147-148***
epicardium 143
myocardial degeneration - see under Cardiomyopathy
normal 141
regeneration ***155***
valve lesions 147, ***151-152***
Heart and skeletal muscle inflammation (HSMI) ***155, 191,*** 301, ***303***
Henneguya 304
Hepatic carcinoma ***328, 330***
aflatoxin-induced ***327***
Hepatic cysts ***203,*** 208
Hepatopathy, toxic ***212***
Hepatorenal syndrome 215
Herpesvirus
association with papillomas 315
in brain 234
in gills 52
in heart 149
in liver ***209,*** 214
in pancreas 194
in skin ***76,*** 79
Hirame rhabdovirus 110, 135
Histiocytes 125
Hitra disease ***127***
Hoferellus ***109***
Hole-in-the-head disease 76, 296, ***300***
Hybridization, in relation to neoplasms 323
Hydra, acute dermal necrosis caused by ***71, 76***
Hydrocephalus ***224***
Hypodermis 67
Hypothalamus ***220,*** 267
Hypoxaemia, due to BGD 50
Hypoxia 238

Ichthyobodo necator – see under Costiasis
Ichthyocotylurus ***154***
Ichthyophthirius multifiliis 55, ***56,*** 73, ***76,*** 237, 260
Ichthyophonus ***17, 154, 171, 206, 233***
Indomethacin 50, 348
Infarction ***159-160, 207***
Infectious haematopoietic necrosis (IHN) ***107,*** 135, 149, 173, 180, 214
Infectious pancreatic necrosis (IPN) 180, ***189-190, 205,*** 214
Infectious salmon anaemia (ISA) 52, 111, 124, 135, ***205***
Inflammation 14, 17, 347
mediators 49, ***346***
Inositol 135
Insulin 279
Intercalated discs, in heart ***145***
Interhepatocytic cell (IHC) 203
Interrenal cells 91, 274, ***276***
Intervertebral disc 290
disease ***299***
luxation ***238***
Intraocular pressure 247
Ionoregulation, clinical chemistry 343
Iridophores 66
Iridovirus ***107***
Irish salmon disease - see under Ulcerative dermal necrosis
Islets of Langerhans ***278***
Isopod crustacea 83, 171

Jaundice 212
Juxtaglomerular cells 92, 278

Kaposi sarcoma 319
Keratitis – see under Eye
Kidney 91-119
  damage to endocrine elements 104
  glomerulonephritis **95-96**
  interstitium 94, 102
  nephron 92, 94
  normal anatomy 91
  tubular disease **97-102**
  polycystic **100**
  repair **99-100**
Kudoa **109, 304**
Kupffer cells, absence in fish, 127, 202

Lactic acid **49**
Lactobacillus (Carnobacterium) piscicola 76, 106, **150,** 196
Lactococcus **186**
Largemouth bass virus 191
Larval deformity **292**
Lateral line 66
Lepeophtheirus salmonis **83**
Lernea 306
Lernaeocera branchialis 56, 151
Leukaemia 136
Leukocytes **14-18**
  responses 130
Leydig cells 282
Lichenoid-type dermatitis 78
Lightning strike 239, **295**
Ligula **194,** 283
Lipid peroxidation, in heart 153
Lipoid liver disease **12**, 57, 124, **206,** 213, 297
Lipoma **320**
Liver 201-217
  bile duct disease 215
  chemistry values **344,** 349
  hepatitis 211
  necrosis **204**
  zonal necrosis **204**
Loma 37, 38, 46, 52, **56-57, 132, 155, 163, 186**
Lymphatics 159
  in gills 25
  in skin 69
Lymphocystis disease
  in eye 260
  in gills 52
  in kidney **108**
  in skin 79, **82**
Lymphocyte **13, 14**
  in skin 65
Lymphosarcoma **324-326**

Malignant hyperplasia, of thyroid **275**
Malignant melanoma 317
Malpighian cells 65
Marine anaemia 330
Mast cells 17
Mauthner axons **222**
Medulla oblongata 221
Melanomas and other pigment cell tumours 327
Melanomacrophages **17-18**
Melanomacrophage centres (MMC) **94, 122-124,** 206
Melanophores 66
Melatonin 267
Melanotropin 268
Meninges 225
Meningitis **227**-228
Mesencephalon 220
Metacercariae of digeneans
  in brain **233**
  in heart **154**
  in mouth 171
  in muscle **305**
  in skin **82**
Metal toxicity, impact on ionoregulation 346
Methaemoglobin 135
Microsporidia, tissue responses to 304
  in CNS **236**
  in gills 37, 53
  in intestine **186**
  in kidney 113
  in muscle **304**
  in ovary **280**
  in skin 79
  in spleen **132**
  in swimbladder **186**
  in vessels – see under *Loma*
Monobothrium **179**
Monocytes 127
Monogeneans
  in gills **58**
  in skin **73**

Morgagnian globules, in lens 261
Morphometry 38
Mucophilosis - see under Epitheliocystis
Mucus
  cells
    in gills 29, ***32***
    in skin ***65-67***
  excess production of 33, 67
  hyperplasia 45
  impact on gas exchange 339
  metaplasia 49
  "no mucus skin disease" 72, ***75***
Muscle 296-307
  dystrophy 297
  regeneration ***301***
Musculoskeletal enzymes 348
Mycobacteriosis 17
  in brain ***229***
  in eye ***254***
  in heart 149
  in kidney ***107***
  in liver 214
  in skin ***77***
  in spleen ***132-134***
  in stomach 173
  in testes 282
  in thyroid 274
Mycotic - see under Fungus
Myelophthisic anaemia 136
Myocarditis ***152-154***
Myopathy (see also under Nutritional muscular dystrophy) ***306***
Myxobacteria 69
Myxidium leei 187
Myxobolus 55, 175, 195, 236
  M. cerebralis ***238-239***
Myxozoa
  in axons 239
  in brain ***234-235***
  in cartilage ***300***
  in gills 55
  in kidney ***94, 109***
  in liver ***215***
  in muscle ***304***
  in skin 79, ***82***
  in stomach 175
  in swimbladder 192

Natural killer cells 19
Necropsy procedure 13
Nematocyst, damage to skin ***71, 76***
Nematodes
  in liver ***211***
  in muscle 306
  in swimbladder 192
Neon tetra disease ***305***
Neoplasia, neoplasms 313-334
Nephroblastomas ***323-324***
Nephrocalcinosis ***101,*** 299
Nephrosis 97
Nervous mortality syndrome 236
Net-pen liver syndrome ***213,*** 215
Neurofibromas ***331***
  in damselfish 328
Neuroglia 222
Neuro-haemal complex 268
Neuromasts 66
Neuronophagia ***225***
Neurons ***222***
Neurosecretory system 268
Neurotransmitters, in ammonia toxicity 237
Neutrophils ***13, 15, 16, 29, 34, 47***
Niacin 72, 135
No blood disease 136
Nocardia ***153***
Nodavirus 190, ***232, 262,*** 263
Nodular gill disease (NGD) 31, 39, 51, ***53-54,*** 339
Notochord 289
Nutritional gill disease 39
Nutritional muscular dystrophy (NMD) 297
Nutritional cardiomyopathy 151

Ochroconis 112
Oesophagus 169
Oestrogen 282
Oncorhynchus masou virus (Yamame tumour virus) 327
Oncogenes 317
Oncogenic viruses 315
Opercula, erosion and flaring 36, ***49, 339***
Optic brain 220
Optic lobes ***219, 221***
Ornithodiplostomum 235
Osteoclasts ***80, 291***
Osteodystrophy, fibrous ***298***
Osteogenesis 289
Ova, within heart ***164***
Ovary 282
  atresia 283

cyst **282**
Oxalate crystals **123**
Oxygen 293

P53 315
Pacemaker, cardiac 141
Pancreas 193-195
hormones 279
Pancreas disease 152, **190-191,** 194, 280, **301**
Pansteatitis 195
Pantothenic acid deficiency 39, **45**
Papillomatosis **76, 317**
Pasteurella **17, 151, 206, 230**
Peduncle disease 72, **74**
Pemphigus 70
Pericarditis 147, **150-151**
Peritoneum 195-196
Peritonitis, vaccine-induced **192-194**
Peritubular capillaries, in kidney 91
Pfiesteria 77
Phagocytosis 15
Philometra 282, 283
Philonema 196
Phoma herbarum **154,** 173
Photobacterium **129,** 184
Pigment cells - in skin 66
Pillar cells – see under Gills
Pike fry rhabdovirus 234
Pineal gland 220, 267
Piscirickettsia 124, 178
Pituitary **220,** 269, **268-271**
cysts 271
Plasmacytoid leukaemia 136, 330
Pleistophora 304
Polycyclic hydrocarbons 320
Polycystic kidney disease, in goldfish **100**
Polyunsaturated fatty acids, impact on heart 342
Pompe's disease 150
Pre-optic nucleus 269
Prolactin **270**
Proliferative gill disease 45, 55
Proliferative kidney disease (PKD) **111-114**
in liver 214
in muscle 306
in peritoneum 195
in spleen **131**
in vessels **162**
Prostaglandins 347
Prostanoids 15, 50
Proteinuria 95
Proteocephalus 196
Prothrombin 134
Pseudobranchs 56
mineralization of, in association with nephrocalcinosis 57
Pseudomonas **253**
Purkinje cells **221**
Puss 17
Pyridoxine 135

Radiography 289
Rainbow trout fry syndrome (RTFS) **42,** 124, **128-129**
Renal portal system 91, **92**
Renibacterium salmoninarum - see under Bacterial kidney disease
Renal disease, clinical chemistry 346
Renin-angiotensin system 92, 277
Reoviral hepatitis **208-209,** 214, 347
Reproductive system 281-283
Respiration, clinical chemistry 338
Reticuloendothelial system 28, 126
Retina – see under Eye
Retinal pigmented epithelium (RPE) 127
Retroviruses 316
Riboflavin 135
Rickettsia **131, 210,** 214, **230-231, 259-260**
Rodlet cells **12,** 34, **110,** 170, **214**
Root effect 57
RNA viruses 316

Saddlepatch disease - see under Columnaris disease
Saccus vasculosus **220**
Salmincola **58**
Sandgrain grub 165
Sanguinicolids 55, 151, **163,** 236
Saprolegnia diclina (parasitica)
in eye 260
in gills 53
in peritoneum **195**
in skin **71, 73**
in stomach 173
in vessels **160**
Scales 66, **291**
scale regeneration 69, 77
scale resorption **80**
Scoliosis 294
Screamer disease **298,** 338
Sealice **83, 224, 253**

Secondary cirulation 159
Sekoke disease 280, 297
Septum transversum, aplasia ***149***
Sertoli cells 282
Shreckstoffzellen - see under Club cells
Shwartzman reaction ***162***
Siamese twinning ***292***
Siderosis, hepatic ***203***
Skeleton 289-296
Skin 65-89
Skinny pot-belly disease 181
Sleeping disease 152, 194, 300, ***303***
Soya-induced, enteritis ***178,*** 183
Spawning rash 78, ***80***
Sphaerospora 112, 192, ***280***
Spiggin 94
Spinal column 290
  deformity ***293-297***
Spinal cord 239-240
Spironucleus ***175-176, 180-184,*** 214, 237
Spleen 121-134
Splendore-Hoeppli reaction 17, ***18,*** 82
Splenomegaly 124
Spondylitis ***294***
Spring viraemia of carp (SVC) 110
Squamous cell carcinoma ***317-318***
Staphylococcus 259
Stomach 169
Stomatitis ***169-170***
Strawberry disease 78, ***81***
Streptococcus ***129,*** 233, 259
Stress, related to corticosteroids 275
Subendocardial fibrosis ***157***
Sudden death syndrome 300
Summer enteritis ***176***
Summer pathology 301
Sunburn 72, ***73***
Supersaturation of water 261
Supraoptic canals 66, ***67***
Swimbladder ***185***, 187-193, 295
  inflammation 189, 192
  swimbladder distress syndrome ***186,*** 189

Tail rot ***68, 74***
Tanycytes 225
Teeth 169
Temperature, effects on immune system 19
Tenacibaculum (Flexibacter) maritimum ***170***
Testes ***279-280,*** 281
Tetracapsuloides 113
Tetrahymena 237, ***300***
Thiamine 238
Thrombocyte ***13, 15***
Thrombosis, septic ***158-159***
Thymoma 126, ***325***
Thymus 125-126
  involvement in gill disease 53
Thyroid 271, ***272***
  follicles, in kidney 91, ***272***
  hyperplasia ***273-274***
  tumours in, 332
Thyrotropic hormone (TSH) 269
Thyroxine (T4) 272
Tongue louse 171
Toxicity
  aflatoxin 237
  algae ***39***
  ammonia 237
  arsenic 97
  benzo[a]pyrene 321
  brevetoxin 237
  cadmium 41, 97, 293
  carbaryl 237
  chloramines 135
  chloramine-T 37, 339
  chlorine 135
  copper 41, 96
  diclofenac 96
  dioxin 193
  endosulfan 237
  fabric softener 192
  fumonisin 96
  gentamicin ***97***
  heavy metals 293
  herbicides 295
  hexachlorobutadiene (HCBD) ***98-99***
  hydrogen peroxide 46
  iron 47
  lead 111, 293
  malachite green ***224, 292***
  malathione 293
  mercury 36, ***41,*** 97
  microcystin 347
  nickel 97
  oxidising agents 43
  oxalates 101
  polyaromatic hydrocarbons 96, 291, 320
  quaternary ammonia compounds 37

selenium **102,** 293
sulphamerazine 347
suspended solids 47
tin 111
trifluralin 96, 295
uranium 97
vitamin A 45, 73, **296**
zinc 111, 293
Tyrosine crystals 101
Trichodina 56, **67, 110**
Triiodothyronine (T3) 272
Triploidy 293
Trypanoplasma 124
Tumours - see under Neoplasia
tumour suppressor genes 315, 317
Tyrosine kinase receptor 317

Ulcerative dermal necrosis (UDN) **71**
Ultimobranchial gland 279
Ultraviolet radiation 72, 261
Ultrastructural fixatives 11
Ureters **91, 101**
Urinary bladder **91**
Uronema **236**
Urophysis 268
Urotensin 268

Vaccine-induced lesions **192-194, 211,** 307
Vagus 169
Valvular endocarditis 147
Vasoactive amines 348
Ventriculitis 231
Vertebrae 290
Vessels 158
vasculit is 163
Vibrio salmonicida **127**
Varracalbmi 260
Vibriosis
in brain **229**
in eye 259
in GI tract 181
in muscle 298
in skin **78-79**
in heart **153, 158**
Viral haemorrhagic septicaemia (VHS)
in brain 173
in gills 52
in heart 149, 173
in gastro-intestinal tract 173
in kidney 110
in vasculitis **163**
Viral nervous necrosis 234
Visceral granuloma 101
Vitamin deficiency, toxicity, treatment
A 45
C 79, 83, 135
E **12,** 124, 151
K 134
Vitellogenin 283

Walleye dermal sarcoma 313, **319**
Walleye myopathy **306**
Waterbelly 175
Waterlogging of skin 69
Whirling disease 296, **300**
White spot disease – see under
Ichthyophthirius multifiliis
Wound healing in skin 69, 83

X-cells **35**
Xmrk 318
Xanthophores 66
Xenoma 52

Yersinia ruckeri 16, 171
Yellow-pigmented bacteria 69
Yolk peritonitis 196

Zschokkella **215**

