

Avian

A Practitioner's Guide to

Necropsy

By: Robert E. Schmidt & Drury R. Reavill
Zoological Education Network ©2003

Click to
begin

FOREWORD

The inspiration for this CD came from over 30 years of doing avian necropsies, obtaining lesion photographs and giving talks on avian systemic pathology. We felt that a guide with abundant lesion photographs and associated cytology, when indicated, would be of value for avian clinicians faced with the necessity of a necropsy examination.

With the advent of CD technology, such a project, using all color photographs, became feasible. We hope that this necropsy guide will be of value to avian practitioners as an accessible and practical reference that can be used in the clinical setting.

Robert E. Schmidt
DVM, PhD, Dipl ACVP

Drury R. Reavill
DVM, Dipl ABVP-Avian, Dipl ACVP

[to contents page](#)



CONTENTS

Chapter 1 Setting up for the Necropsy

Chapter 2 External Examination, Initial Incision, Skin and Subcutis

Chapter 3 Peritoneum, Mesentery and Serous Membranes

Chapter 4 Cardiovascular System

Chapter 5 Liver

Chapter 6 Lymphatic and Hematopoietic (Immune) System

Chapter 7 Gastrointestinal System and Pancreas

Chapter 8 Respiratory System

Chapter 9 Endocrine Glands

Chapter 10 Reproductive System

Chapter 11 Urinary System

Chapter 12 Nervous System

Chapter 13 Special Sense Organs

Chapter 14 Musculoskeletal System

Authors

Search

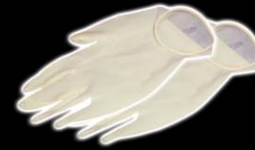Credits

To page 1

Back

CHAPTER 1

Getting Started



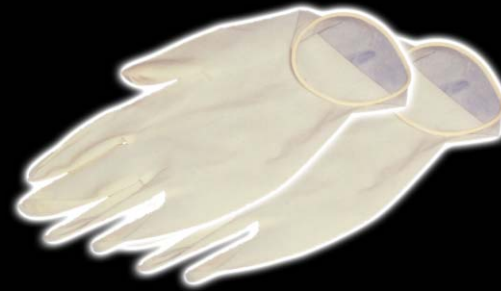Diagnostic pathology is an important area of avian practice. Surgical biopsy and necropsy are valuable tools, not only to achieve a diagnosis but also to support the practitioner in evaluating future cases. Although it would be ideal to submit whole animals to a qualified pathologist for necropsy, time and money constraints dictate that the practitioner must perform most of them in-house. This guide is designed to offer direction in performing a necropsy of birds and recognizing gross lesions and cytology (if applicable) of common disease processes.

GENERAL CONSIDERATIONS

In many cases, only histologic specimens will be submitted to the pathologist; therefore, a complete (but concise) history and summary of physical findings must accompany the submission. Age, sex and bird species are important guides to the types of diseases to be considered.

Although economic factors usually limit the number of tissues sent to the pathologist, a complete set should be saved in case additional material is needed based on the histologic findings or the potential for legal action. Ten percent neutral buffered formalin is the best all-around fixative to have available. When tissue selection is limited, those organs with obvious gross lesions and those from systems affected by clinical signs have priority. If there are no obvious clinical indicators or gross lesions, other criteria are necessary. In cases of true sudden death, organs such as the heart, brain, lung and some endocrine glands should be submitted. In chronic disease, the gastrointestinal tract and liver may contain important changes. In all animals under one year of age, the immune system should be examined.

At the time of necropsy, necessary samples for microbiology, toxicology or any other special procedure should be properly obtained, identified and saved properly (Fig 1.1, Fig 1.2, Fig 1.3, Fig 1.4).



CHAPTER 1

Getting Started

To perform a necropsy of most birds, a large scalpel, scissors, forceps and a pair of large poultry shears are sufficient instruments, although a Stryker saw may be useful, particularly with large birds (Fig 1.5).

Minimal requirements for appropriate protective equipment include coats or aprons and gloves (Fig 1.6). Masks and other safety equipment may be indicated in specific cases, depending on the size of the animal and possible zoonotic concerns.

INTERPRETING THE APPEARANCE OF LESIONS

Although specific lesions will be described in individual chapters, some general observations apply to all tissues/organs:

- The relative lack or excess of blood contributes to the size, color and consistency of an organ.
- Color changes may be antemortem or postmortem. As more necropsies are performed and the changes noted are

correlated with histologic results, the differences will become more obvious.

- The postmortem condition as well as antemortem changes, such as cellular infiltration and connective tissue proliferation, can affect changes in consistency.
- Tissue loss may result in symmetrical or asymmetrical changes in organ size and weight and can be indicative of generalized disease or localized problems with blood supply.
- Abnormal excess of tissue may indicate hypertrophy, hyperplasia or neoplasia.

At the conclusion of the necropsy, the results should be written for the record and for future laboratory submission. The lesions are best documented by a full description (rather than a diagnosis). For example, “the lung was reddened” is preferable to “the lung was hemorrhagic.” Parameters such as size, shape, color, consistency and smell should be noted and quantitated when possible.



CHAPTER 2

External Examination, Initial Incision, Skin and Subcutis

The necropsy begins with an examination of the skin and feathers (Fig 2.1). Skin and feather disorders are common in pet avian species and can indicate a primary or secondary problem. Because the skin has a limited range of response to insults, a variety of causes will lead to similar clinical signs and, in many cases, similar lesions.

The skin may vary from grossly normal to severely inflamed and possibly necrotic. In assessing the gross morphologic changes, the effect of self-trauma must be considered. Examination includes the distribution of lesions, relative conditions of the skin and feathers, and presence of plaques, ulcers and exudates.

Several diagnostic procedures are available in order to gain information about skin lesions:

- History (diet, husbandry, exposure to toxins)
- Physical examination (distribution of lesions, relative condition of the skin and feathers, presence of plaques, ulcers and exudates)
- Scraping (may or may not reveal the presence of mites)

- Impression smear (inflammation vs. neoplasia)
- Feather pulp smear (may reveal inflammatory processes within the pulp)
- Culture (if done correctly)
- Aspiration of follicle by sterile needle/syringe (if folliculitis is suspected)
- Laboratory tests or radiographic examination (if thorough examination rules out primary disease)

After the skin has been incised, the subcutis can be examined for lesions (Fig 2.2, Fig 2.3).

CONGENITAL AND ACQUIRED MALFORMATIONS

True genetic disorders are poorly documented in pet birds. Feather cysts are occasionally seen in all species; however, in certain species of canaries that have soft feathering (e.g., Norwich or Gloucester strains), there is an apparent inherited disposition. Yellow-white material (keratin) accumulates, resulting in an oval or



CHAPTER 2

External Examination, Initial Incision, Skin and Subcutis

elongated swelling of the feather follicle (Fig 2.4). The gross lesion must be differentiated from a follicular abscess or neoplasia.

Abnormalities of the beak or claws can result from a variety of disorders that interfere with growth of the germinal epithelium of the beak or claw keratin.

Constricted toe syndrome is seen in young birds and involves the entire toe, beginning with a swelling of the toes and eventual necrosis distal to the area of constriction.

INFECTIOUS DISEASE

Parasitic

Several different types of mites are found affecting both feathered and unfeathered skin. The cere and legs are commonly affected (Fig 2.5). Severe hyperkeratosis and acanthosis leads to variable gross thickening, irregularity and flaking. Malformations can result in chronic cases. Mites are either superficial or deep and, with magnifica-

tion, may be seen moving in open spaces that occur in some extensive lesions.

Lice are uncommon in well cared for pet birds and, unless the infestation is severe, no gross lesion is seen.

Mycotic

Folliculitis due to dermatophytes may result in gross swelling of follicles with variable hyperkeratosis and crust formation (Fig 2.6). In some unusual cases of fungal infection, necrotizing lesions not associated with feather follicles are seen. These may appear as nodules with caseous centers. In cases of superficial infection by small yeasts (*Malassezia* sp.), there may be no gross change. In some small passerines, the skin is mildly thickened and crusty.

Bacterial

Bacterial skin disease in pet birds may take two forms: 1) folliculitis often associated with *Staphylococcus* sp., where there is swelling of the perifollicular skin with a variable amount of reddening; and 2) generalized bacter-



CHAPTER 2

External Examination, Initial Incision, Skin and Subcutis

ial dermatitis (pyoderma), which may be pruritic, leading to self-trauma that results in a more severe lesion. Reddening, induration and crust formation are associated with necrosis ([Fig 2.7](#)).

Severe bacterial pododermatitis (bumblefoot) is usually secondary to trauma with subsequent dermatitis and cellulitis leading to swelling and abscessation of the foot/toes ([Fig 2.8](#)) A mixed inflammatory infiltrate is noted on smears of the lesion ([Fig 2.9](#)).

Mycobacterial infection of the skin may occur as a part of systemic mycobacterial disease or as a local problem. Grossly it can resemble an abscess due to other bacteria or fungi or present as an area of localized thickening and induration.

Viral

Papillomavirus can cause multiple proliferative skin lesions that may superficially resemble mite infestation. The condition has been identified in African grey parrots, some finches and canaries. Similar lesions are seen in

cockatiels but have not been proved to be due to the virus.

Polyomavirus was originally reported as a disease of budgerigars with feather abnormalities as primary lesions. Remaining feathers may have had a variety of abnormalities, including dystrophy of the primaries and a lack of down feathers ([Fig 2.10](#)).

Feather changes are usually not as prominent in larger psittacine birds, which may show hemorrhagic feathers and variable subcutaneous hemorrhage ([Fig 2.11](#)). Non-psittacine birds with polyomavirus infection usually have no gross feather changes.

Poxvirus is seen in over 60 avian species. Canaries, blue-fronted Amazon parrots, lovebirds and Pionus parrots are the most common pet birds affected. In the cutaneous form, lesions are common on the head, face and feet, but can also be present in feather tracts in severe infections.

The lesions are proliferative and present as papules, pustules and nodules, with a possible crust. The lesions



CHAPTER 2

External Examination, Initial Incision, Skin and Subcutis

can have a rough or smooth surface, depending on chronicity, self-trauma and degree of secondary bacterial infection ([Fig 2.12](#), [Fig 2.13](#), [Fig 2.14](#)). Impression smears of the lesion may contain cytoplasmic inclusion bodies as well as inflammatory cells ([Fig 2.15](#)).

Herpesvirus (Pacheco's disease) typically causes systemic infection that can include occasional involvement of the epidermis of the skin or feathers, leading to necrosis and inclusion body formation. Because the generalized disease is usually catastrophic, little attention is paid to what may be grossly minimal skin lesions.

In some psittacine birds, particularly macaws and cockatoos, proliferative lesions of the lower legs and feet have been considered to be due to a cytomegalic herpesvirus. In cockatoos, there are solitary or multiple proliferative nodules, while macaws typically have roughened skin and/or plaque formation, often with depigmentation ([Fig 2.16](#)).

Circovirus is a systemic disease leading to a variety of clinical signs in numerous psittacine and nonpsittacine birds. In psittacine birds, skin lesions may develop acutely or chronically. Nestlings usually exhibit acute infections, which are expressed as feather necrosis and pulp hemorrhage. There may be severe shedding of affected feathers ([Fig 2.17](#)). Chronic disease is generally seen in older birds, with dystrophic feathers replacing normal ones at molting. Powder down may be the first feathers affected in cockatoos.

Grossly, affected feathers are stunted and may have thickened sheaths, pulp hemorrhage, annular constrictions of the calamus, and curling or stress lines on the vanes. Discoloration of feathers may be the initial sign in some birds ([Fig 2.18](#)). Beak lesions are less common than feather changes. Variable necrosis and loss of keratin be seen. Occasionally, lesions are limited to specific sites, such as periocular skin ([Fig 2.19](#)).

External gross lesions are not often seen in nonpsittacine birds. Feather dystrophy similar to that



CHAPTER 2

External Examination, Initial Incision, Skin and Subcutis

seen in psittacines has been reported in pigeons, doves and finches. In some psittacine birds mixed infections with polyomavirus and circovirus are found, with a variety of feather and skin changes.

NON-INFECTIOUS DISEASE

Nutritional/Metabolic

Specific and non-specific nutritional problems can result in poor feather and skin disease. These include vitamin, mineral and amino acid deficiencies as well as generalized malnutrition. Depigmentation, altered pigmentation, improper molting and poor quality feathers can be seen. Gross changes are rarely specific.

Vitamin A deficiency may lead to scaly skin, poor feather quality and focal hyperkeratosis, particularly of the feet. The uropygial gland may become enlarged with yellow caseous-appearing material present instead of the typical secretion product (Fig 2.20).

Lack of carotenoids in the diet can lead to dilution of skin and feather color, because carotene is a component

of yellow, orange, red and green feather color. Tyrosine deficiency can lead to poor melanin production and color changes. Any deficiency (such as amino acids) that results in protein deficiency and alterations in feather structure can lead to color changes due to changes in light scattering (Fig 2.21).

Physical/Environmental Agents

Trauma, burns, excessive cold and other physical factors often cause skin lesions. Loss of feathers, varying degrees of hemorrhage, necrosis and superficial crust formation are seen. Severe necrosis and sloughing of the epidermis (and possibly portions of the dermis) can be seen in injuries due to both heat and cold. Discoloration of the lesions is variable. Subcutaneous edema, hemorrhage and hematoma formation are possible (Fig 2.22, Fig 2.23, Fig 2.24). Severe frostbite may lead to complete loss of digits.

Self-trauma is secondary to pruritis or behavioral problems. Shredded and hemorrhagic feathers may be present. In some birds the trauma can be severe with



CHAPTER 2

External Examination, Initial Incision, Skin and Subcutis

large areas of ulceration and hemorrhage resulting (Fig 2.25).

Endocrinopathy

Endocrine disorders can lead to generalized feather loss and abnormal feathering, usually with no observable skin lesion. Hypothyroidism is the most commonly encountered disorder in pet birds, but there is no specific pattern or feature that grossly indicates an endocrine disorder (Fig 2.26, Fig 2.27).

Hypersensitivity

Allergic skin disease in birds is occasionally reported but is not well documented, and confirmation can be difficult. Gross changes include feather loss, reddening and occasionally surface exudates. Some of the gross lesions may be secondary to self-trauma.

A condition known as “Amazon foot necrosis” is seen in Amazon parrots. Although its exact pathogenesis has not been determined, there is speculation that it represents a

delayed hypersensitivity reaction following staphylococcal dermatitis.

Gross lesions are seen in unfeathered skin of the leg and foot and begin as erythematous areas, often followed by severe self-trauma leading to ulceration. In some cases, staphylococci are found in the lesion.

Chronic Internal Disease

In many cases of chronic internal disease, including infectious, degenerative and neoplastic conditions, there is poor feather quality and loss of feathers (Fig 2.28). These changes are not grossly specific, although in some cases of chronic renal disease, the lesion in the skin and subcutis is suggestive of the underlying problem (Fig 2.29).

MISCELLANEOUS CONDITIONS

A number of noninfectious skin problems are sporadically seen in the skin, although the cause is usually not known.



CHAPTER 2

External Examination, Initial Incision, Skin and Subcutis

Calcosis circumscripta is an unusual condition in birds that presents as nodular lesions with a white, chalky appearance.

Follicular malformations and dystrophy are occasionally seen. The most recognized has been called “polyfolliculitis,” which is a misnomer because in many cases there is no inflammation. The condition, which is seen in budgerigars, cockatiels and lovebirds, presents as multiple feather shafts growing from a single follicle. Feathers are thick and short and may have retained sheaths. They may present as fluctuant subcutaneous swellings that contain slightly viscid fluid.

NEOPLASIA

Epithelial tumors: The uncommon papillomas of the skin usually present as papillary growths on the face; they may be viral-induced in African grey parrots.

Squamous cell carcinomas are often ulcerated and hemorrhagic as well as infiltrative. They tend to grow slowly and can become large if not treated (Fig 2.30, Fig 2.31).

They can occur anywhere in the skin and also within the uropygial gland where they must be differentiated from primary tumors of the gland. Impression smears may be helpful in classifying the lesion as a neoplasm (Fig 2.32).

Basal cell tumors can present as solitary nodules and may also originate in feather cysts. Uropygial gland tumors can be either adenomas or carcinomas, and gross differentiation is difficult of the enlarging mass in the region of the uropygial gland. In some cases, the mass is ulcerated.

Mesenchymal tumors include myxomas and those of a fibrous and adipose connective tissue or vascular origin. In addition, lymphosarcoma and mast cell tumors may be found. Gross differentiation can be difficult with malignant tumors.

Lipomas are common and have the gross appearance of a mass of normal fat (Fig 2.33).

Liposarcomas are less common than lipomas and are usually fatty appearing, poorly demarcated masses. Hemangiomas and hemangiosarcomas occur in the skin



CHAPTER 2

External Examination, Initial Incision, Skin and Subcutis

and subcutis with about the same frequency in pet birds ([Fig 2.34](#)).

Fibrosarcoma is common in pet birds but fibromas are infrequently diagnosed. These tumors present as firm nodules or masses. Benign tumors are encapsulated, but sarcomas may have indistinct margins ([Fig 2.35](#), [Fig 2.36](#)).

Some connective tissue tumors contain large amounts of extracellular mucin and morphologically are called myxofibromas or myxomas, depending on the cell-to-ground substance ratio.

Dermal lymphosarcoma can present as solitary or multiple masses or diffuse thickening of the skin with loss of feathers ([Fig 2.37](#)). Mast cell tumors have been reported only in chickens and owls.

Melanocytic tumors: Melanoma has been diagnosed in several psittacine birds, but the tumor is not common and is usually malignant. These tumors are brown-black raised masses with poorly defined margins; they often occur on the face and may involve the beak ([Fig 2.38](#)).

Granular cell tumors, which are small smooth nodules, are found infrequently in birds (seen primarily in psittacine birds, particularly Amazon parrots).

Hemangiomas and hemangiosarcomas are tumors developing from vascular endothelium. They appear as circumscribed, soft, red-to-black swellings in the skin and subcutis. Hemangiosarcomas can be locally invasive and multicentric. They appear to metastasize late in the tumor development.

NON-NEOPLASTIC PROLIFERATIVE LESIONS

Xanthomatosis is a condition of uncertain etiology. Xanthomas are seen most commonly in cockatiels and budgerigars and usually present as a variable-sized, yellow mass on the wing ([Fig 2.39](#)).



CHAPTER 2

External Examination, Initial Incision, Skin and Subcutis

FURTHER READING

Andre JP, Delverdier M, Cabanie D, Bartel G: Malignant melanoma in an African grey parrot. *J Assoc Avian Vet* 7:83-85, 1993.

Brush AH: The origin of feathers: A novel approach. In Farner DS, et al (eds): *Avian Biology Vol IX*. New York, Academic Press, 1993, pp 121-162.

Ferrer L, Ramis A, Fernandex J, Majo N: Granulomatous dermatitis caused by a *Mycobacterium* *gavense* in 2 psittacine birds. *Vet Derm* 8:213-219, 1997.

Garcia A, Latimer KS, Niagro FD, et al: Avian

polyomavirus infection in three black-bellied seed crackers (*Pyrenestes ostrinus*). *J Assoc Avian Vet* 7:79-82, 1993.

Graham DL: The avian integument. *Proc Assoc Avian Vet*, 1985, pp 33-52.

Hadley NF: Integumental lipids of plants and animals: Comparative function and biochemistry. *Advances Lipid Res* 24:303-320, 1991.

Jacobson ER, Mladinich CR, Clubb S, et al: A papilloma-like virus infection in an African grey parrot. *J Am Vet Med Assoc* 183:1307-1308, 1983.

Latimer KS: Oncology. In Ritchie BW, Harrison GJ, Harrison LR (eds): *Avian Medicine: Principles and Application*. Lake Worth, Wingers Publishing, 1994, pp 640-672.

Latimer KS, Niagro FD, Rakich PM, et al: Comparison of DNA dot-blot hybridization immunoperoxidase staining and routine histopathology in the diagnosis of psittacine beak and feather disease in paraffin-embedded cutaneous tissues. *J Assoc Avian Vet* 6:165-168, 1992.

McDonald SE, Lowenstine LJ, Ardans AA: Avian pox in blue-fronted Amazon

parrots. *J Am Vet Med Assoc* 179:1218-1222, 1981.

Pass DA: Pathology of the avian integument: A review. *Avian Pathol* 18:1-72, 1989.

Patnaik AK: Histologic and immunohistochemical studies of granular cell tumors in 7 dogs, 3 cats, one horse and one bird. *Vet Pathol* 30:176-185, 1993.

Pizarro M, Villegas P, Rodriques A, et al: *Filaris* is (*Pelecitus* sp.) in the cervical subcutaneous tissue of a pigeon with trichomoniasis. *Avian Dis* 38:385-389, 1994.



CHAPTER 2

External Examination, Initial Incision, Skin and Subcutis

FURTHER READING

(CONTINUED)

- Pye GW, Carpenter JW, Goggin JM, et al: Metastatic squamous cell carcinoma in a salmon-crested cockatoo (*Cacatua moluccensis*). *J Avian Med Surg* 13:192-200, 1999.
- Quist CF, Latimer KS, Goldade SL, et al: Granular cell tumor in an endangered Puerto Rican Amazon parrot (*Amazona vittata*). *Avian Pathol* 28:345-348, 1999.
- Raidal SR: Viral skin diseases of birds. *Sem Avian Exot Pet Med* 4:77-82, 1995.
- Raidal SR, Riddoch PA: A feather disease in Senegal doves (*Streptopelia senegalensis*) morphologically similar to psittacine beak and feather disease. *Avian Pathol* 6:829-836, 1997.
- Ramis A, Latimer KS, Niagro FD, et al: Diagnosis of psittacine beak and feather disease (PBFD) viral infection, avian polyomavirus infection, adenovirus infection and herpesvirus infection in psittacine tissues using DNA in-situ hybridization. *Avian Pathol* 23:643-657, 1994.
- Ramis A, Latimer KS, Gilbert X, et al: A concurrent outbreak of psittacine beak and feather disease virus and avian polyomavirus infection in budgerigars (*Melopsittacus undulatus*). *Avian Pathol* 27:43-50, 1998.
- Rece RL: Observations on naturally occurring neoplasms in birds in the state of Victoria, Australia. *Avian Pathol* 21:3-32, 1992.
- Ritchie BW, Niagro FD, Lukert PD, et al: A review of psittacine beak and feather disease. *J Assoc Avian Vet* 3:143-150, 1989.
- Schmidt RE: Pathologic aspects of the skin and feathers. In Roskopf WJ Jr, Woerpel RW (eds): *Diseases of Cage and Aviary Birds* 3rd ed. Baltimore, Williams & Wilkins, 1996, pp 387-396.
- Schmidt RE: Morphologic diagnosis of avian neoplasms. *Sem Avian Exot Pet Med* 1:73-79, 1992.
- Spearman RFC, Hardy J: Integument. In King AS, McLelland J (eds): *Form and Function in Birds* Vol 3. New York, Academic Press, 1989, pp 1-52.
- Tell LA, Woods LW, Mathews KG: Basal-cell carcinoma in a blue-fronted Amazon parrot (*Amazona aestiva*). *Avian Dis* 41:755-759, 1997.
- Trinkaus K, Wenisch S, Leiser R, et al: Psittacine beak and feather disease



CHAPTER 2

External Examination, Initial Incision, Skin and Subcutis

FURTHER READING

(CONTINUED)

infected cells show a pattern of apoptosis in psittacine skin. Avian Pathol 27:551-561, 1998.

Tsai SS, Chang SF, Chi YC, et al: Unusual lesions associated with avian poxvirus infection in rosy-faced lovebirds (*Agapornis roseicollis*). Avian Pathol 26:75-82, 1997.

Wheeldon DB, Culbertson MR Jr: Feather folliculoma in the canary (*Serinus canarius*). Vet Pathol 19:204-206, 1982.

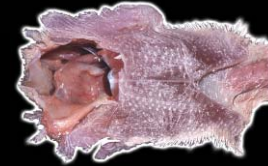Woods LW, Latimer KS: Circovirus infection of

nonpsittacine birds. J Avian Med Surg 14:154-163, 2000.



CHAPTER 3

Peritoneum, Mesentery, and Serous Membranes



After examining the skin and subcutis, the peritoneal cavity should be carefully opened (Fig 3.1). Before extending the incision, the amount and characteristics of fluid, if any, should be noted. The incision is extended through the rib cage and cranially to the angle of the jaw to open the entire peritoneal cavity, deep tissues of the neck, and oral cavity (Fig 3.2).

The rib cage is then removed and the mandible cut to expose the oral cavity (Fig 3.3). At this time all serous membranes, the mesenteries and peritoneal surfaces can be examined and the position and size of organs noted.

In addition, the thyroid glands, which are present above the thoracic inlet, should be located and saved for histologic examination at this time in order to prevent their being overlooked. Examination of the endocrine system will be discussed in Chapter 9.

INFLAMMATORY DISEASE

Inflammation of serous membranes can be infectious or noninfectious and localized or generalized. Infectious peritonitis can be the result of septicemia, extension from air sacs, perforation of the gastrointestinal tract, or penetrating wounds. Specific infections include viral, bacterial, mycotic and parasitic.

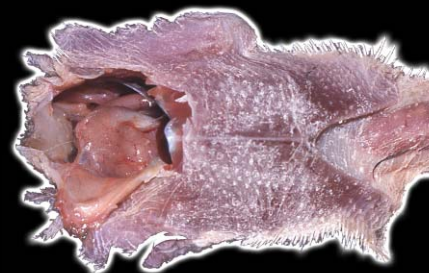Avian viral serositis is an uncommon viral infection of neonatal and juvenile psittacines in which the causative agent is Eastern equine encephalomyelitis (EEE) virus. Gross lesions include abdominal distension due to slightly viscous, yellow fluid that may contain fibrin particles. Birds usually have an enlarged liver (Fig 3.4).

Herpesvirus infection may lead to petechiation of the peritoneum and mesenteries (Fig 3.5).

Peritonitis is caused by a variety of bacterial organisms. In severe cases peritoneal surfaces and mesenteries are reddened, and mucopurulent yellow-white exudate, fibrin and hemorrhage may be present (Fig 3.6). There is a

CHAPTER 3

Peritoneum, Mesentery, and Serous Membranes



variable amount of cloudy fluid present and in some cases, only small yellow foci are seen (Fig 3.7). Cytologic examination of the fluid will show variable numbers of heterophils and macrophages (Fig 3.8). The latter may contain bacteria in their cytoplasm. In acute cases free bacteria may also be found.

Mycotic infections usually originate in lungs and air sacs and extend to peritoneal surfaces. The gross appearance of acute fungal infections can be similar to bacterial infections, but chronic cases may have yellow-white granulomatous masses on serous membranes (Fig 3.9).

Filarial nematodes can be present in the peritoneum but are usually very difficult to find at necropsy. Protozoal infections of parenchymal organs can lead to peritoneal hemorrhage (see below).

Noninfectious peritonitis is commonly seen secondary to urate deposition or egg yolk contamination. In cases of severe visceral gout, grey-white material may be present on all serous surfaces (Fig 3.10). Cytologic examination of the serous surface indicates a primarily mononuclear

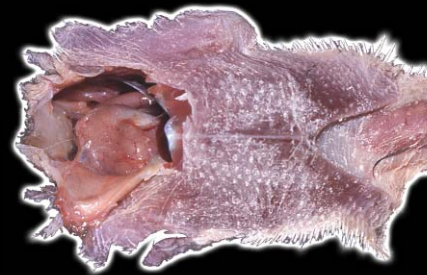inflammatory response and numerous fragmented urate crystals (Fig 3.11).

In cases of yolk peritonitis, a variable amount of viscous, yellow-grey fluid is found (Fig 3.12). Cytologic examination of fluid from a case of yolk peritonitis will show numerous large macrophages with foamy cytoplasm (Fig 3.13), and amorphous dark blue-purple globules.

NONINFLAMMATORY LESIONS

A variety of problems can lead to fluid accumulation in the peritoneal cavity. These include cardiovascular disease, liver disease, renal disease, nutritional/metabolic disorders and trauma. Evaluation of the fluid may be of benefit in determining the underlying problem.

Traumatic hemorrhage in the peritoneal cavity can result from external penetrating wounds or rupture of internal organs following blunt peritoneal trauma (Fig 3.14). Infection/necrosis of large parenchymal



CHAPTER 3

Peritoneum, Mesentery, and Serous Membranes

organs and severe hepatic lipidosis can also cause parenchymal rupture. Protozoal infections of parenchymal organs can lead to peritoneal hemorrhage.

Transudates may result from any of the conditions mentioned. Transudates are usually of low protein content, not viscid, and are usually clear to yellow or red-yellow if there is some associated hemorrhage (Fig 3.15).

Transudates are variably cellular, but the cell population is usually mononuclear, consisting of lymphocytes, histiocytes and sloughed mesothelial cells. In cases of metabolic liver disease there may be numerous lipid-containing macrophages (Fig 3.16).

NEOPLASTIC DISEASE

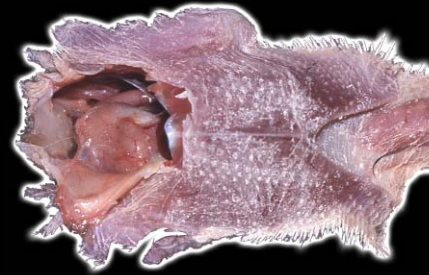Primary tumors of the serous membranes are infrequently seen. Mesothelioma has been rarely, if ever, reported in birds. As part of a multicentric process, lymphosarcoma may involve the serous membranes, leading to thickening and opacity of the serosa (Fig 3.17). Numer-

ous immature lymphoid cells are seen cytologically in peritoneal fluid from a bird with lymphosarcoma involving serous membranes and/or abdominal organs (Fig 3.18).

Carcinomas of the ovary and oviduct may implant on serosal surfaces, appearing as numerous nodules. Clumps of neoplastic cells may be found in smears of peritoneal fluid (Fig 3.19).

CHAPTER 3

Peritoneum, Mesentery, and Serous Membranes



FURTHER READING

Gaskin JM, Homer BL, Eskelund KF: Preliminary findings in avian viral serositis: A newly recognized syndrome of psittacine birds. *J Assoc Avian Vet* 5:27-34, 1991.

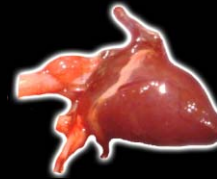Gregory CR, Latimer KS, Niagro FD, Roberts AW, et al; Investigations of Eastern equine encephalomyelitis virus as the causative agent of psittacine proventricular dilatation syndrome. *J Avian Med Surg.* 1997; 11; 3; 187-193

Harcourt-Brown NH, Gough RE, Drury SE, et al: Serositis in two black-capped

conures (*Pyrrhura rupicola*): A possible viral cause. *J Avian Med Surg* 11 (3): 187-193, 1997.

CHAPTER 4

Cardiovascular System



After examining organs *in situ*, the cardiovascular system can be evaluated. The pericardium, pericardial sac, heart and major vessels are observed, and the heart and attached arteries and veins are removed.

There are a few differences between the avian and mammalian cardiovascular system. Birds have a larger heart compared to their body mass. Their left AV valve is a true bicuspid valve with cusps and chordae tendineae, but the right AV valve is only a muscular flap. The aorta arises from the right rather than the left aortic arch and curves to the right in birds. Birds also have a renal portal system (see Chapter 11).

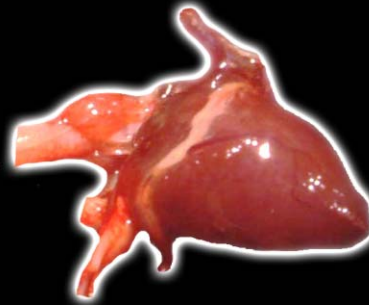NORMAL ORGANS

The pericardial sac should be translucent and contain minimal clear, slightly amber fluid. The shape of the heart is roughly conical (Fig 4.0). Thickening or flaccidity of the heart wall is considered abnormal. The heart is brick red, and fat is normally found within the coronary grooves and portions of the epicardium. Color changes,

particularly to green or black, may be indicative of antemortem or postmortem autolysis. Major blood vessels should be flexible and smooth to the touch on both the intimal and adventitial surfaces. The heart is opened in the path of the blood flow if possible; however, complete hemisection may be done in small birds. In cases of sudden death or if there is any suspicion of clinical heart disease, multiple sections from different areas of the heart are needed for optimal histologic examination.

CONGENITAL ANOMALIES

Ventricular septal defects are uncommon and may appear as a circular opening between the ventricles. Epicardial keratinaceous cysts present as yellow nodules containing keratin and may be mistaken for abscesses. Various aortic anomalies and malpositions have been reported. The only gross change noted externally may be cardiomegaly and flaccidity leading to an irregular shape (Fig 4.1).



CHAPTER 4

Cardiovascular System

PERICARDIAL DISEASE

Pericardial lesions can be infectious, noninfectious or neoplastic. In cases of infection, the pericardium is variably thickened and gray to yellow-white, with red foci seen occasionally. The lesions may be multifocal, or the pericardium may have a “shaggy” appearance. In less severe cases, a few plaques are seen. There may be adhesions to the epicardium (Fig 4.2). Pericardial fluid may be increased, gray-yellow and cloudy in appearance, and may have flocculent material present.

In chronic disease, there can be abscess formation and localization. Mycobacterial infections usually present grossly as large irregular masses that can mimic neoplasia. They are relatively firm and gray-white and occur most often near the heart base. Visceral urate deposition (gout) may have a gross appearance similar to an infectious pericarditis (Fig 4.3, Fig 4.4, Fig 4.5), although the tissue is often more shiny and smooth than the

exudate seen in infectious conditions. The urate deposition can be multifocal or diffuse.

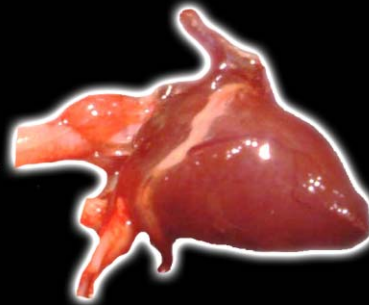Primary pericardial tumors are not documented in pet birds. Effusion may accompany primary heart and pericardial diseases and may be a part of systemic problems, including right-sided heart failure and hypoproteinemia. The gross appearance of an effusion will depend on whether it is a transudate, modified transudate or exudate. After some time, effusions will often present as gel-like material in the pericardial sac (Fig 4.6).

HEART DISEASE

Diseases of the heart can be divided into inflammatory, noninflammatory and neoplastic.

Inflammatory Disease

Several viruses cause myocardial lesions in pet birds. Polyomavirus is seen in psittacine birds and can also cause heart disease in finches. In budgerigars, gross lesions include hydropericardium, cardiomegaly and



CHAPTER 4

Cardiovascular System

hemorrhage. The myocardium may have patchy, pale areas. In non-budgerigar psittacines and finches, gross lesions are similar to those of budgerigars (Fig 4.7, Fig 4.8).

Proventricular dilatation disease affects psittacine and non-psittacine birds. Many birds have heart lesions regardless of the clinical course of the disease. Grossly there may be slight dilatation of the ventricles and occasional pale foci and streaks (Fig 4.9).

Togavirus has been considered the cause of avian viral serositis. Heart lesions in this disease may include a fibrous epicarditis with a gray-yellow exudate and excessive, cloudy pericardial fluid (Fig 4.10).

Bacterial infection of the heart may lead to endocarditis, myocarditis, epicarditis or a combination of these. Gross changes in myocarditis are multifocal to confluent yellow-white foci (Fig 4.11, Fig 4.12, Fig 4.13) that extend into the myocardium. In advanced cases, the large yellow nodules must be differentiated from other types of infection and neoplasia. Endocarditis may involve the wall or

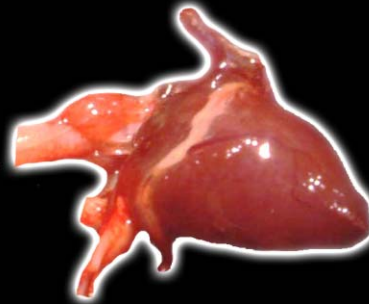valves. Lesions are usually friable and vary from red-gray to yellow. Lesions may be seen on the chordae tendinae.

Mycobacterial infections are usually secondary to hematogenous dissemination or extension from cervical or thoracic air sacs and usually involve the aorta or pericardium at the base of the heart.

Mycotic infections of the heart are infrequent. When present, they may be the result of extension from air sacs and usually involve the epicardium and superficial myocardium. Chronic gross lesions are nodular or diffuse, gray-white and friable, and are usually found at the heart base (Fig 4.14). With obvious extension from air sacs, they may have the typical green coloration that can be seen when the organisms are exposed to air. In immunocompromised individuals, *Aspergillus* sp., *Candida* sp. and other fungi and can become septicemic and cause myocarditis with lesions grossly similar to bacterial infections.

CHAPTER 4

Cardiovascular System



Protozoal myocarditis is seen in some cases of systemic infection by *Sarcocystis* sp. In some New World psittacine birds (macaws and conures) the disease is usually subclinical without gross lesions. Amazon parrots and Old World psittacine birds usually have an acute disease with pneumonia and septicemia, which can result in small white foci and streaks in the myocardium.

Parasitic disease of the cardiovascular system is due primarily to filarioid nematodes of the genus *Chandlerella*. In pet birds the condition seems to be most prominent in cockatoos. Nematodes, which are approximately 1.5 cm white filarial worms, may be found in the right heart. In addition, focal endocardial hypertrophy and intimal hypertrophy of intramural vessels are noted.

Inflammation can also be a part of noninfectious disease conditions. Deposition of urate crystals in the epicardium or occasionally myocardium results in white-gray foci or streaks similar to those described for the pericardium. Similar crystalline material may be seen cytologically in the pericardial fluid (Fig 4.15).

Non-septic valvular endocarditis, with formation of nodules and accumulation of inflammatory cells and fibrin, has been seen as a secondary condition in cases of severe frostbite.

Noninflammatory Disease

In cachectic birds, fat in the coronary grooves and epicardium may appear clear and watery (serous atrophy) as well as being reduced in quantity.

Deposition of mineral may occur for several reasons, including nutritional and metabolic disorders, toxicity and areas of inflammation. Gray-white streaks and patches appear in the pericardium, epicardium and/or myocardium. Gross differentiation from urates may not be possible, and both lesions may be present in some cases (Fig 4.16).

Epicardial fat with some infiltration can be seen in birds, but excessive fat is usually associated with a bird that is obese. The fat appears normal but can infiltrate the myocardium.

CHAPTER 4

Cardiovascular System



Lipofuscin may accumulate in cells, including cardiac myocytes, secondary to a variety of disease processes. It usually indicates emaciation or chronic disease. It is usually considered an incidental necropsy finding and, if severe, the myocardium may have a brown discoloration. The pigment can also occur in vitamin E deficiency.

Hypertrophic cardiomyopathy is characterized by ventricular thickening leading to a loss of ventricular volume. Dilated cardiomyopathy presents as a left-sided problem, with the left ventricle becoming thin and flabby.

Myocardial degeneration may be the result of vascular problems, vitamin E/selenium deficiency or some toxins. The gross appearance of an affected heart varies from white streaks and patches to large pale areas, some of which may appear as depressed areas. If there has been mineralization, affected areas are gritty when cut. Hydropericardium may be present (Fig 4.17).

Noninflammatory swelling of true heart valves (endocardiosis) occurs occasionally. The cause is usually

not determined. Affected valves are grossly swollen and usually smooth and firm (Fig 4.18).

Myocardial Toxicity

Although various drugs and chemicals are potentially cardiotoxic in birds, there are very few documented cases. Natural and experimental poisoning by avocados has been seen in ostriches, canaries and budgerigars. Gross lesions include subcutaneous edema and hydropericardium, and there may be small gray-white foci or streaks in the myocardium.

Proliferative Disease of the Myocardium

Hypertrophic cardiomyopathy has been discussed. Sporadic cases of myofiber hypertrophy or hyperplasia are seen secondarily as compensatory responses to conditions that lead to increased cardiac workload. These changes include pulmonary disease, vascular disease, congenital anomalies and possibly chronic renal disease.

CHAPTER 4

Cardiovascular System



Grossly the affected portion of myocardium is thickened, and the lumen of the affected ventricle(s) is reduced.

Several types of tumors are seen in the heart of birds. Rhabdomyoma or myosarcoma is usually pale and firm and may be multiple. Hemangiomas and hemangiosarcomas are found in the myocardium as red-black masses that may be friable and bleed easily. We have seen primary fibrosarcomas of the myocardium. These tumors present as firm gray-white masses.

Lymphosarcoma may involve the myocardium alone or as part of generalized disease in birds. The tumor is yellow-white or gray and may be diffuse, or found in multiple masses. Malignant melanoma is brown-black and may be multiple.

BLOOD VESSEL LESIONS

After removing the heart, the attached arteries should be examined. Remaining large vessels should be

grossly examined, particularly for color and thickness. In some cases, palpation of the arteries will impart more information about thickening or wall irregularity than will visual inspection.

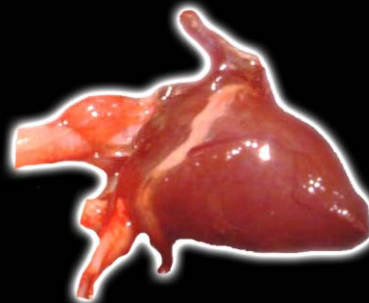Arteritis, phlebitis and lymphangitis are infrequently encountered in pet birds. Bacterial infections can result in associated vasculitis in any organ. Mycobacterial arteritis is seen associated with lesions involving the pericardium and base of the heart and is similar to what has previously been described (Fig 4.19).

Several types of fungi, both ascomycetes and zygomycetes, will cause vasculitis associated with primary disease of any organ. The only gross lesion in many of these diseases may be hemorrhage, although obvious necrosis or proliferative changes may also be present.

Although not common in pet birds, paramyxovirus-1 (PMV-1), and togavirus (Western encephalomyelitis) can cause vasculitis. Grossly in both infections there will be

CHAPTER 4

Cardiovascular System



hemorrhages, particularly in the serosa of the gastrointestinal tract.

Aneurysmal dilatation of blood vessels is not common in pet birds. Occasional uncomplicated aneurysms are noted as variably-sized dilatations in arteries. Dissecting aneurysm is found in many avian species. These lesions are usually considered to be associated with a copper deficiency. Grossly there is dilatation and on section, the dissecting band of hemorrhage is noticeable (Fig 4.20). Affected arteries may rupture (Fig 4.21), with hemorrhage and clots noted in adjacent tissue/spaces. Thrombosis may also be present.

Atherosclerosis is seen most often in Amazon parrots, African grey parrots and macaws, although it occurs sporadically in a variety of species. Obesity, fatty liver and other evidence of a nutritional/metabolic problem may also be present. A diet that contains a large percentage of high fat seeds is a common cause.

The gross lesions are usually seen in the aorta and brachiocephalic arteries but can be found throughout the

vascular system. The arterial wall is variably thickened and yellow (Fig 4.22, Fig 4.23), and contains roughened yellow intimal plaques. Associated aneurysmal dilatation and/or increased arterial resistance with resultant left- and right-sided heart failure may lead to hypertrophy of ventricular walls and possible ventricular dilatation.

Mineralization of blood vessels with no other morphologic change is seen in cases of severe renal failure, chronic dietary imbalance of calcium and phosphorus, and vitamin D₃ toxicity. The change is typically in arteries or arterioles and can be found in any organ or tissue. The only gross indication may be a gritty feel to the tissue if the lesion is widespread or associated with other soft tissue mineralization. In larger arteries, raised, firm, irregular plaques may be seen. These are usually gray-white and may have a shiny appearance.

Among pet birds, amyloidosis is more common in small passerines. The amyloid is usually considered to be secondary to chronic disease processes or stress. Amyloid may be deposited in the walls of blood vessels but is usu-

CHAPTER 4

Cardiovascular System



ally not detected grossly. If other soft tissue is involved, soft, pale areas may be seen.

Septic and nonseptic thrombi may be found in any tissue, depending on the cause. In a large vessel, they will usually be obvious but may be overlooked on gross examination if found only in small arteries ([Fig 4.24](#)).

Lymphangiectasia is an unusual lesion that may present as numerous dilated, fluid-filled spaces in any organ ([Fig 4.25](#)). Proliferative lesions include hemangioma and hemangiosarcoma and can occur in any organ, but are most common in the skin and subcutis. They have been described in [Chapter 2](#).



CHAPTER 4

Cardiovascular System

FURTHER READING

Bachmaier K, Neu N, de la Maza LM, et al: Chlamydia infections and heart disease linked through antigenic mimicry. *Science* 283:1335-1339, 1999.

Baptiste KE, Pyle RL, Robertson JL, et al: Dissecting aortic aneurysm associated with a right ventricular arteriovenous shunt in a mature ostrich (*Struthio camelus*). *J Avian Med Surg* 11:194-200, 1997.

Beehler BA, Montali RJ, Bush M: Mitral valve insufficiency with congestive heart failure in a pukeko. *J Am Vet Med Assoc* 177:934-937, 1980.

Freeman KP, Hahn KA, Adams WH, et al: Radiation therapy for hemangiosarcoma in a budgerigar. *J Avian Med Surg* 13:40-44, 1999.

Gaskin JM, Homer BL, Eskelund DK: Preliminary findings in avian viral serositis: A newly recognized syndrome of psittacine birds. *J Assoc Avian Vet* 5:27-34, 1991.

Greenacre CB, Mann KA, Latimer KS, et al: Adult filarioid nematodes (*Chandlerella* sp.) from the right atrium and major veins of a ducorp's cockatoo (*Cacatua ducorpsii*). *J Assoc Avian Vet* 7:135-137, 1993.

Harari J, Miller D: Ventricular septal defect and bacterial endocarditis in a whistling swan. *J Am Vet Med Assoc* 183:1296-1297, 1983.

Hargis AM, Stauber E, Casteel S, et al: Avocado (*Persea americana*) intoxication in caged birds. *J Am Vet Med Assoc* 194:64-66, 1989.

Helfer DH, Schmitz JA, Grumbein SL, et al: Myocarditis-encephalopathy in canaries. *Proc West Poult Dis Conf*, 1982, p 92.

Isaza R, Buergelt C, Kollias GV: Bacteremia and vegetative endocarditis associated with a heart

murmur in a blue-and-gold macaw. *Avian Dis* 36:1112-1116, 1992.

Johnson JH, Phalen DN, Graham DL, et al: Atherosclerosis in parrots. *Proc Assoc Avian Vet*, 1992, pp 87-93.

Oglesbee BL, Oglesbee MJ: Results of postmortem examination of psittacine birds with cardiac disease: 26 cases (1991-1995). *J Am Vet Med Assoc* 212: 1737-1742, 1998.

Page CD, Schmidt RE, English JH, et al: Antemortem diagnosis and treatment of sarcocystosis in two species of psittacines.



CHAPTER 4

Cardiovascular System

FURTHER READING

(CONTINUED)

J Zoo Wildl Med 23:77-85, 1992.

Phalen DN, Hays HB, Filippich LJ, et al: Heart failure in a macaw with atherosclerosis of the aorta and brachiocephalic arteries. J Am Vet Med Assoc 209:1435-1440, 1996.

Pipo R, Broadstone RV, Murphy CJ: Lethal oculocardiac reflex in a cockatiel. Vet Comp Ophthalmol 6:2729, 1996.

Puette M, Latimer KS, Norton TM: Epicardial keratinaceous cyst in a tawny frog-mouth (*Podargus*

strigoides plumiferus). Avian Dis 39:201-203, 1995.

Randolph JF, Moise NS, Graham DL, et al: Bacterial endocarditis and thromboembolism of a pelvic limb in an emu. J Am Vet Med Assoc 185:1409-1410, 1994.

Speer B: Selected avian pediatric viral diseases. Sem Avian Exotic Pet Med 2(3):125-135, 1993.

Vanhooser SL, Stair E, Edwards MR, et al: Aortic rupture in ostrich associated with copper deficiency. Vet Human Toxicol 36:226-227, 1994.

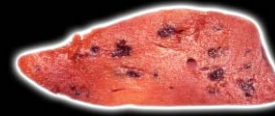Vice CAC: Myocarditis as a component of psittacine proventricular dilatation syndrome in a patagonian conure. Avian Dis 36:1117-1119, 1992.

Vink-Nooteboom M, Schoemaker NJ, Kik MJL, et al: Clinical diagnosis of aneurysm of the right coronary artery in a white cockatoo (*Cacatua alba*). J Small Anim Pract 39:533-537, 1998.

Wack RF, Kramer LW, Anderson NL: Cardiomegaly and endocardial fibrosis in a secretary bird (*Sagittarius serpentarius*). J Assoc Avian Vet 8:76-80, 1994.

CHAPTER 5

Liver



The cranial aspect of both liver lobes surrounds the ventral surface of the heart apex. After removal of the heart, the liver should be examined.

NORMAL LIVER

The avian liver is comprised of right and left lobes that fuse on the midline in the dorsal mid to cranial third (Fig 5.0). Cranially and caudally, the lobes are completely separated. Additional subdivision into dorsal and ventral sections may occur in the right or left lobe. The right lobe is usually larger than the left lobe; however, lobes can be of equal size, but rarely is the left lobe of the liver larger than the right. The ventral surface of the liver is in direct contact with the sternum and, in the majority of birds, the normal liver does not extend beyond the caudal edge of the sternum. Extension beyond this point usually indicates hepatomegaly. The gall bladder, when present, is located on the visceral surface of the right lobe. It may be pear-shaped or long and cylindrical and may extend cau-

dally to the level of the cloaca in some species. The proventriculus, ventriculus and spleen are in contact with, and leave impressions on, the visceral surface of the liver. The right and left hepatic peritoneal cavities are completely enclosed by the posthepatic septum, parietal peritoneum, dorsal and ventral mesenteries, and left hepatic ligaments. Fluid leaking from the liver capsule is trapped within the hepatic peritoneal spaces and does not enter the intestinal peritoneal space.

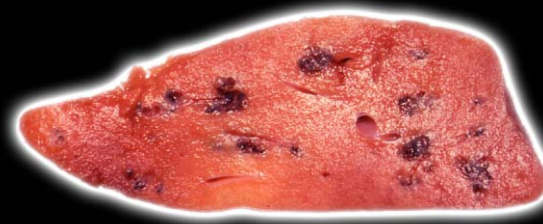The liver should be examined in situ, and any perihepatic fluid or exudate present should be noted and saved for cytology and possible chemical analysis.

CONGENITAL ANOMALIES

In young birds, congenital lesions such as biliary cysts are occasionally seen (Fig 5.1), but other anomalous lesions have not been reported. These cysts vary in size and contain clear yellow-green fluid. If the cyst wall is thin, the cyst may appear yellow, while in other areas it

CHAPTER 5

Liver



has a red-purple appearance due to the overlying hepatic parenchyma.

INFECTIOUS DISEASES

Viruses

A number of viral diseases cause hepatic lesions in various species. Psittacine herpesviruses are a heterogeneous group of avian herpesviruses with three to five serotypes recognized. One serotype is most commonly associated with acute fatal disease (Pacheco's disease) seen in many species of parrots. An identical disease caused by a herpesvirus (probably a PsHV) is reported to have occurred in toucans.

Grossly, birds that die from Pacheco's disease are typically well muscled and have adequate body fat. Occasionally there will be some degree of atrophy of the pectoral muscle mass. The liver may be enlarged and friable, but the disease can progress so quickly that the liver seems normal grossly. In these cases, there may be focal areas of discoloration that represent foci of necrosis.

Whether the liver is enlarged or not, it often has a variable yellow-gray mottling with or without hemorrhage (Fig 5.2, Fig 5.3). Diffuse color changes in the liver may be mistaken for hepatic lipidosis. Occasionally intranuclear inclusion bodies can be seen in impression smears (Fig 5.4).

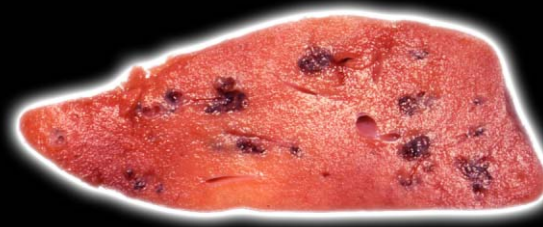Herpesvirus infections also occur in a number of other species of birds that are kept in captivity. These infections include duck virus enteritis, crane herpesvirus and pigeon/falcon herpesvirus. Hepatic necrosis and inclusion bodies are common findings in birds with these infections.

Cytomegalic herpesvirus has been a cause of systemic disease in finches. The primary clinical signs and lesions are seen in the respiratory tract (see Chapter 8), but the liver also may be affected. Gross changes include yellow-white foci typical of necrosis.

Avian polyomavirus (APV) occurs predominately in psittacine birds. However, a disease with similar histologic features has also been reported in a green

CHAPTER 5

Liver



aracaris (probably a psittacine virus based on genetic analysis) and in passerine species. The virus or viruses causing disease in passerines remain to be genetically characterized. Although the histologic lesions vary between budgerigars and nonbudgerigar parrots, the virus that causes disease in these birds is the same.

Infected birds shed virus in droppings, oral secretions and feather and skin dander with inhalation the most likely route of infection. It has been speculated that vertical transmission occurs in budgerigars.

The vast majority of APV infections are asymptomatic. Disease and death are usually seen in nestling parrots less than 14 weeks old. Macaws, conures, caiques, Eclectus and ring-necked parrots are most likely to die. Small outbreaks of APV disease in adult birds have been reported, but are rare.

Gross lesions vary with the species affected. Affected budgerigars are typically 10 to 20 days old, stunted and have abnormal or delayed feather development, skin discoloration, abdominal distension, perihepatic effusion

and ascites, hydropericardium, hepatomegaly with focal areas of necrosis, and widely scattered petechial hemorrhages. Budgerigars that survive the acute infection will often fail to develop their primary wing and tail feathers, or these feathers will be dystrophic.

Non-budgerigar parrots with APV disease are typically well grown, well muscled and have substantial body fat. Gross lesions are striking, including a generalized pallor of all tissues with subcutaneous and subserosal hemorrhages. The liver is typically enlarged and friable and may have varying degrees of mottling ([Fig 5.5](#), [Fig 5.6](#), [Fig 5.7](#)). Less commonly, ascites and pericardial effusion are present. Similar lesions are also seen in adult birds with APV disease. Disease in nestling cockatoos, Amazon parrots and African grey parrots is relatively uncommon, and liver lesions in these birds are less prominent or absent. In finches, the liver may be enlarged, with mottling and hemorrhage seen in some cases ([Fig 5.8](#)).

CHAPTER 5

Liver



Adenovirus infections are most commonly recognized as incidental lesions in parrots that died of other causes. This is particularly true in lovebirds, cockatiels and budgerigars, where characteristic inclusion bodies are sporadically found in renal tubular cells and there is no specific gross change. Acute necrotizing pancreatitis, a multisystemic disease, and hepatic necrosis all are attributed to adenovirus infections in lovebirds.

A fatal adenovirus infection causing hepatitis is seen in the nestlings of Senegal parrots and related genera. The disease occurs sporadically within aviaries. Affected parrots typically present acutely ill or are found dead. The liver is discolored red-black, and scattered yellow-gray areas may be present (Fig 5.9).

Circovirus (psittacine beak and feather disease virus) infections can involve the liver, but it is not a common extracutaneous site. Liver lesions are usually present only in young birds with systemic disease but can be seen in some older birds that die with severe feather damage. Often the liver appears normal, but there may

be enlargement and scattered discolored foci, particularly in immunosuppressed birds that have secondary bacterial infections (Fig 5.10). The liver lesion may be the most striking lesion seen at necropsy. If the possibility of circovirus infection is not considered and the bursa of Fabricius not examined histologically, the primary problem may be overlooked.

Paramyxovirus, reovirus, hepadnavirus, togavirus, rotavirus, parvovirus, orbivirus and coronavirus can occasionally cause hepatic lesions in birds. In cases of hepatic disease that have lesions consistent with a viral infection but no change specific to one of the common causes of pet bird hepatitis and necrosis, these viruses can be considered as differential etiologic possibilities.

Paramyxovirus 3 is most common in pet species. The liver is usually a secondarily affected organ, with primary infections seen in the respiratory or gastrointestinal tracts. Grossly, the liver may be enlarged.

Most reovirus disease cases in parrots are reported in birds that had been in quarantine or recently released

CHAPTER 5

Liver



from quarantine. Gross lesions are not specific. Hepatomegaly with focal depressed discolored areas of the hepatic capsular and cut surfaces are the most common lesions described.

Hepadnavirus (duck hepatitis B) is one of several viral agents causing hepatitis in ducks. The disease is often subclinical, but there can be persistent infections and vertical transmission. The virus causes hepatic enlargement and necrosis grossly.

None of the above viruses causes specific gross changes; therefore, electron microscopy, viral isolation or DNA probes are necessary for an etiologic diagnosis.

Bacteria

The liver is commonly targeted by systemic bacterial infections in birds. Both gram-positive and gram-negative bacteria cause hepatitis. *Staphylococcus* and *Streptococcus* spp. are the most common gram-positive organisms isolated from the liver. They generally disseminate through the blood from chronic necrotizing skin lesions or may reach the liver by extension from adjacent

air sacs. *Clostridia* spp. are gram-positive rods of intestinal origin that cause hepatitis.

Gram-negative bacteria cause most systemic bacterial infections of psittacine birds. Members of the Enterobacteriaceae, including *E. coli*, *Klebsiella* sp., *Proteus* sp., *Enterobacter* sp., *Salmonella* sp., *Pseudomonas* sp. and *Yersinia pseudotuberculosis*, are common isolates. Systemic infections with these organisms usually result from invasion from the gut and, less frequently, by extension up the biliary tree.

Gross lesions caused by *Staphylococcus* and *Streptococcus* include variable hepatic swelling and multifocal to confluent yellow-white foci within the parenchyma (Fig 5.11). There may be abscess formation in chronic cases. Varying degrees of hemorrhage may be present in cases of clostridial hepatitis.

Hepatitis caused by gram-negative bacteria results in a grossly swollen and congested liver (Fig 5.12). The liver may be markedly enlarged and meaty in subacute to chronic infections. Gray-white-yellow foci can be seen

CHAPTER 5

Liver



throughout the parenchyma in variable size and numbers.

Mycobacterium avium (MA), serotypes 1, 2, 3 and 8, and *Mycobacterium genavense* (MGE) are the most common mycobacteria that infect birds. Probably all species of birds are susceptible to mycobacterial infection. When outbreaks do occur, they are most frequent in collections of captive waterfowl, zoo birds, grey-cheeked parakeets (*Brotogeris pyrrhopterus*), canary-winged parakeets (*B. versicolorus*), certain species of tropical doves and Australian finches.

Mycobacteriosis is a chronic disease, and birds that die with this disease are typically thin or emaciated. Mycobacterial disease can be localized or diffuse. Following ingestion, the mycobacteria first colonize cells in the intestines, and from there spread widely. Any organ system can be affected, but the liver, spleen, lung, air sac, skin and bone marrow are most commonly involved.

Affected livers may contain yellow to gray-tan, soft nodules or be diffusely enlarged (Fig 5.13, Fig 5.14,

Fig 5.15). In early cases there may be minimal gross hepatic change. In waterfowl, larger granulomatous lesions tend to develop (Fig 5.16).

Two genera of obligate intracellular bacteria cause avian hepatitis. Psittacosis or ornithosis is a disease caused by *Chlamydophila psittaci* (formerly *Chlamydia psittaci*). Within this species are 8 serovars: serovar A and E are found in pet birds; serovar B is enzootic in pigeons. All avian serovars are potentially zoonotic, and psittacosis is a reportable disease. The disease in psittacine birds has variable manifestations. Subclinical infections are common, especially in cockatiels. New World parrots are often affected with a severe multisystemic disease.

Hepatic enlargement is a common finding in birds with psittacosis. Affected livers may have minimal gross changes, but most are enlarged. Occasionally there is capsular thickening and exudation (Fig 5.17). The liver can become severely enlarged and diffusely discolored (Fig 5.18) or may contain gray-yellow foci of necrosis (Fig 5.19). Impression smears stained by the Gimenez

CHAPTER 5

Liver



method may contain intracytoplasmic organisms (Fig 5.20).

The second obligate intracellular bacterium is *Bacillus piliformis*, a rod-shaped, gram-positive organism that cannot be grown in cell-free media. It affects a wide variety of mammals and has been reported in a cockatiel. Grossly the liver is enlarged, pale and mottled, and contains numerous foci of necrosis.

Fungi

The liver is usually involved in mycotic infections as a result of extension from the lung or air sacs or as a result of hematologic spread. Several species of *Aspergillus* are the most common organisms affecting the liver, but other fungi are occasionally identified. Systemic *Candida* infections, particularly in immunosuppressed birds, may result in liver invasion.

Gross lesions are similar to those caused by bacteria and viruses. Affected livers are enlarged and contain multifocal gray-white areas of necrosis.

Protozoan Parasites

Both protozoan and metazoan parasites cause avian liver disease. Protozoal pathogens come from several taxonomic groups. Within the phylum Apicomplexa, *Toxoplasma gondii*, *Sarcocystis* sp. and *Atoxoplasma* can all cause significant liver disease. Affected livers are typically enlarged, have rounded edges and are diffusely mottled. In some cases there may be green discoloration (Fig 5.21). A soft friable liver is found in acute infections, while in chronic infections, the liver may be firm. Lesions caused by the three organisms are similar. Grossly the changes can also be confused with cases of chlamydophilosis and bacterial infections.

Birds affected by hepatic cryptosporidiosis often have no gross hepatic lesions.

Hemoprotozoa, including organisms from the genera *Plasmodium*, *Leucocytozoon*, and *Hemoproteus*, are capable of inducing hepatic disease. Hepatic lesions caused by infection with *Plasmodium* sp. include liver enlargement

CHAPTER 5

Liver



and, particularly in falcons, a diffuse gray-black discoloration (Fig 5.22).

Leukocytozoon schizogony occurs in macrophages and hepatocytes. Grossly affected livers are variably enlarged and pale and contain numerous dark, red-black, raised foci. These foci bleed when incised (Fig 5.23).

Hemoproteus is usually considered nonpathogenic. Gross lesions are not seen, but histologically schizonts can be found in endothelial cells of the liver vasculature.

Trichomonas gallinae can cause disease in a variety of birds. Trichomoniasis is generally confined to the oral cavity and esophagus. However, in squabs, trichomoniasis can become generalized, and the liver is commonly involved. Affected livers are enlarged with focal to coalescing areas of caseous necrosis. Fibrinous casts of the liver (and, less commonly, ascites) are seen in more severe cases.

Histomoniasis is predominately a disease of turkeys, but also causes significant problems in quail, ruffed grouse and chickens. It is transmitted within the eggs of

Heterakis gallinarum that are ingested by the earthworm. Infection occurs when free-ranging birds eat infected earthworms. The disease is characterized by a typhlitis (see Chapter 7) and hepatitis. Grossly, the liver is enlarged and contains multiple, round, yellow-green, raised or depressed foci (Fig 5.24).

The phylum Microspora contains over 1000 species that infect a huge range of vertebrate and invertebrate hosts. Only a single species, *Encephalitozoon hellem*, is documented to infect birds. Disease appears to be most likely to occur in birds that are immunosuppressed. Concurrent infections with circovirus are common and may predispose to disease.

Target organs for *Enc. hellem* are the liver, kidney, spleen, intestine and, less commonly, the eye (see appropriate chapters). Disease, when it occurs, has predominated in flocks of budgerigars and flocks of lovebirds. Gross necropsy findings include pasted vents, pale voluminous feces, watery intestinal contents, and undigested seeds in the feces. Liver and spleen

CHAPTER 5

Liver



enlargement are variable findings, as is liver mottling. Histologic examination is necessary to differentiate the condition from other causes of hepatomegaly.

Metazoan Parasites

Trematodes have a complicated life cycle that involves one or more intermediate hosts. As a result, infections with these parasites are confined almost exclusively to free-ranging or wild-caught cage birds. Flukes, such as *Fasciola hepatica*, damage the liver by migrating through it to its predilection site, the bile ducts. Cockatoos and emus are reported to be parasitized by flukes that have a predilection site for the bile ducts. Once in the bile ducts, trematodes may cause little disease or gross thickening of the bile ducts. There may be gray-black pigmentation associated with the lesions (Fig 5.25). The flukes can be difficult to see without carefully examining individual lesions.

NONINFECTIOUS DISEASES

Hepatic lipidosis is a problem in a wide variety of birds, but the exact pathogenesis of hepatic lipidosis in pet species is often not determined. Excessive calorie intake, inadequate utilization of fat, hepatic enzyme defects, deficiency of dietary lipotrophs, or toxic damage are all possible causes. Hepatic lipidosis in pet birds seems to be most common in Amazon parrots, cockatiels, budgerigars, macaws, rose-breasted cockatoos, and young of other cockatoo species.

Grossly affected livers are enlarged, pale and/or yellow and friable (Fig 5.26). In severe cases, the liver is waxy and very friable. Mild degrees of lipidosis are commonly seen in birds that have been in a negative calorie balance prior to death.

Visceral urate deposition (gout) can be seen in the liver capsule and parenchyma. The exact pathogenesis may not always be obvious, but the condition is often secondary to renal disease or inadequate water intake. Grossly

CHAPTER 5

Liver



the hepatic capsule contains gray-white plaques or streaks, and the urate deposits may completely obscure the underlying liver ([Fig 5.27](#)). Parenchymal lesions consist of multifocal areas that grossly cannot be distinguished from necrosis due to other causes.

Amyloidosis is the general term applied to several diseases characterized by the deposition of one of several forms of amyloid. Only amyloidosis caused by the deposition of AA amyloid has been described in birds. Amyloidosis is a common lesion in waterfowl and is more common in small passerines than in parrots. The distribution of organ involvement varies from bird to bird.

Grossly infiltrated organs may be pale, firm, and waxy or friable. Affected organs are enlarged, sometimes massively ([Fig 5.28](#)). On cut section, they stain with iodine. Amyloidosis grossly may resemble hepatic lipidosis.

Pigmentary hepatopathies are seen sporadically in a variety of birds. Iron pigment in the liver is a common

histologic finding in a number of disease conditions, but is usually not appreciated grossly.

Iron accumulation in hepatocytes (iron storage disease or ISD) is an entirely different entity from hemosiderosis. ISD is predominately a disease of captive mynahs, birds of paradise, quetzals, several species of toucans and fairy bluebirds. Infrequently it is seen in other species of birds including parrots.

Birds with ISD may die suddenly and be in good body condition or have chronic muscle wasting. Ascites is a common gross finding. The ascites may be secondary to liver disease or heart failure. The liver in birds with ISD is enlarged and gold-brown. Small, scattered dark foci may be seen ([Fig 5.29](#)).

Other conditions that can occasionally lead to gross hepatic pigmentation included bile pigment accumulation in the liver of birds with hepatic diseases that result in bile stasis, and lipofuscin pigment that accumulates in hepatocytes secondary to a variety of diseases.

CHAPTER 5

Liver



Chronic Active Hepatitis

Chronic active hepatitis, or cirrhosis, is relatively common in psittacine birds, particularly in Amazon parrots, cockatiels, macaws and budgerigars. Because of the chronicity of the lesion, the cause of the hepatitis can rarely be determined. Mycotoxin exposure and chronic infectious diseases, particularly chlamydophilosis are possible causes.

Grossly affected livers are variably shrunken, pale and fibrotic (Fig 5.30). The capsule is often thickened and the edges of the liver are rounded. In extreme cases, only small firm nodules replace the normal liver tissue. Perihepatic effusion is common. Vacuolation of hepatocytes can be noted cytologically in some cases (Fig 5.31).

Toxins

Liver lesions from toxins are not specific in most cases, and an etiologic diagnosis usually cannot be made on the basis of morphologic changes. In lead toxicosis, there may be some hepatic enlargement.

Proliferative Disease

Acquired biliary cysts are occasionally seen. They can be solitary or multiple and may appear yellow if thin walled (Fig 5.32). Nodular hyperplasia occurs as a part of chronic-active hepatitis (and sporadically for no observable reason). Affected livers are variably enlarged, and the lesion must be differentiated from neoplasia (Fig 5.33).

Primary epithelial tumors of the liver may be of hepatocellular or bile duct origin. Bile duct tumors are more common. Bile duct proliferation, and possibly tumor formation, is reported in association with internal papillomatosis. Affected birds are predominately macaws, Amazon parrots, and less frequently conures. Gross lesions consist of variably sized masses that vary in consistency from friable to firm and from gray to yellow-white to red-brown (Fig 5.34). They may be present in one or more lobes of the liver. They are typically multifocal and grow by expansion, crowding out the normal liver.

CHAPTER 5

Liver



Hepatocellular carcinomas tend to be red-brown and friable. Masses may be solitary or multiple.

Primary mesenchymal tumors of the liver include fibrosarcoma, lymphosarcoma, leiomyosarcoma, hemangioma and hemangiosarcoma, and myelolipoma. There are no specific gross features for these tumors. They present as solitary or multiple nodules or masses and are usually firm. The exception is hemangioma/hemangiosarcomas that may be friable and hemorrhagic ([Fig 5.35](#)).

Lymphosarcoma grossly may present with multiple gray-yellow foci that mimic some severe infectious diseases ([Fig 5.36](#)); however, in severe cases, entire the entire lobe may be replaced by the tumor.

The liver may be the primary site of malignant melanoma. Grossly, multiple, gray-black nodules are seen. Potentially any carcinoma, sarcoma, or melanoma can metastasize to the liver; however, metastatic liver disease is uncommon.

CHAPTER 5

Liver



FURTHER READING

Barton JT, Bickford AA, Cooper GL, et al: Avian paramyxovirus type 1 infections in racing pigeons in California: I. Clinical signs, pathology, and serology. *Avian Dis* 36:463-468, 1992.

Battison AL, Machin KL, Archer FJ: Ascites and hepatic cirrhosis in a cockatiel (*Nymphicus hollandicus*). *J Am Anim Hosp Assoc* 32:237-242, 1996.

Bauck L: Nutritional problems in pet birds. *Sem Avian Exotic Pet Med* 4:3-8, 1995.

Bernier G, Morin M, Marsois G: A generalized

inclusion body disease in the budgerigar (*Melopsittacus undulatus*) caused by a papovavirus-like agent. *Avian Dis* 25:1083-1092, 1981.

Clipsham R: Avian pathogenic flagellated enteric protozoa. *Sem Avian Exotic Pet Med* 4:112-12, 1995.

Clyde VL, Orosz SE, Munson L: Severe hepatic fibrosis and bile duct hyperplasia in four Amazon parrots. *J Avian Med Surg* 10:252-257, 1996.

Coleman CW: Bile duct carcinoma and cloacal prolapse in an orange-winged Amazon parrot (*Amazona amazonica*)

amazonica) *J Assoc Avian Vet* 5:87-89, 1991.

Degernes LA, Trasti S, Healy LN, et al: Multicystic biliary adenocarcinoma in a blue and gold macaw (*Ara ararauna*). *J Avian Med Surg* 12:100-107, 1998.

Eskens U, Kaleta EF, Unger G: An enzootic disease caused by a herpesvirus-Pacheco-parrot-disease in a stock of psittacine birds. *Tierarztl praxis* 22:542-553, 1994.

Flammer D, Butterworth H, Whitt DA: Atoxoplasmosis in canaries. *J Am Fed Avic* 15:24-26, 1989.

Garcia A, Latimer KS, Niagro FD, et al: Avian

polyomavirus infection in three black-bellied seed crackers (*Pyrenestes ostrinus*). *J Assoc Avian Vet* 7:79-82, 1993.

Garcia A, Latimer KS, Niagro FD, et al: Diagnosis of polyomavirus-induced hepatic necrosis in psittacine birds using DNA probes. *J Vet Diag Invest* 6:308-314, 1994.

Gaskin JM: Avian reoviruses: Are they for real? *J Am Fed Avic* 16:24-26, 1988.

Graham DL: Characterization of a reo-like virus and its isolation from and pathogenicity for parrots. *Avian Dis* 31:411-419, 1987.

CHAPTER 5

Liver



FURTHER READING

(CONTINUED)

Griener LA, Sheridan BW: Malaria (*Plasmodium relic-tum*) in penguins at the San Diego Zoo. *Am J Vet Clin Path* 1:7-17, 1967.

Hillyer EV, Moroff S, Hoefer H: Bile duct carcinoma in two out of ten Amazon parrots with cloacal papil-lomas. *J Assoc Avian Vet* 5:91-95, 1991.

Jackson MK, Phillips SN: Necrotizing hepatitis in pet birds associated with *Pseudomonas fluorescens*. *Avian Dis* 40:473-476, 1996.

King AS, McLelland J: *Birds, Their Structure and*

Function. London, BalliereTindall, 1984, pp 106-107.

LaBonde J: Toxicity in pet avian patients. *Sem Avian Exotic Pet Med* 4:23-31, 1995.

Lafferty SL, Fudge AM, Schmidt RE, et al: Avian polyomavirus infection and disease in a green aracarís (*Pteroglossus viridis*). *Avian Dis* 43: 577-585, 1999.

Latimer KS, Rakich PM, Nia gro FD, et al: An updated review of psittacine beak and feather disease. *J Assoc Avian Vet* 5:211-220, 1991.

Lee KP, Henry NW, Rosen-berger JK: *Comparative*

pathogenicity of six avian adenovirus isolates in the liver. *Avian Dis* 22:610-619, 1978.

Leeson S, Diaz G, Summers JD: Aflatoxins. In *Poultry Metabolic Disorders and Mycotoxins*. Guelph, Uni-versity Books, 1995, pp 249-280.

Lenhoff RJ, Luscombe CA, Summers J: Acute liver injury following infection with a cytopathic strain of duck hepatitis B virus. *Hepatology* 29:563-571, 1999.

McLelland J: *A Color Atlas of Avian Anatomy*. Philadel-phia, WB Saunders Co, 1991.

McFerran JB, Adair B, McC: Avian adenoviruses: A review. *Avian Pathol* 6:189-217, 1977.

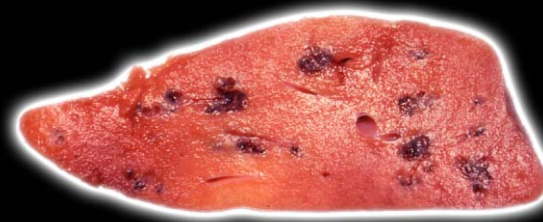Oros J, Rodriguez JL, Fernandez A, et al: Simul-taneous occurrence of *Salmonella arizonae* in a sulfur-crested cockatoo (*Cacatua galerita galerita*) and iguanas. *Avian Dis* 42:813-823, 1998.

Page CD, Greiner EC, Schmidt RE: Leucocyto-zoonosis in crested oropendolas (*Psaracoli-us decumanus*). *AAV Today* 1:155-157, 1987.

Page CD, Haddad K: Cocci dal infections in birds. *Sem Avian Exotic Pet Med* 4:138-144, 1995.

CHAPTER 5

Liver



FURTHER READING

(CONTINUED)

Phalen DN, Wilson VG, Graham DL: Epidemiology and diagnosis of avian polyomavirus infection. *Proc Assoc Avian Vet*, 1991, pp 27-31.

Phalen DN, Wilson VG, Graham DL: A practitioner's, guide to avian polyomavirus testing and disease. *Proc Assoc Avian Vet*, 1994, pp 251-257.

Poonacha DB, Williams PD, Stamper RD: Encephalitozoonosis in a parrot. *J Am Vet Med Assoc* 186:700-702, 1985.

Rae M: Hemoprotozoa of caged and aviary birds.

Sem Avian Exotic Pet Med 4:131-137, 1995.

Randall CJ, Lees S, Higgins RJ, et al: Microsporidian infection in lovebirds (*Agapornis* spp). *Avian Pathol* 15:223-231, 1986.

Reavill DR: Fungal diseases. In Roskopf W, Woerpel R (eds): *Diseases of Cage and Aviary Birds*. Baltimore, Williams and Wilkins, 1996, pp 586-595.

Ritchie BW: *Avian Viruses: Function and Control*. Lake Worth, Wingers Publishing, 1995.

Rossi G: A poorly differentiated hepatic hemangiosarcoma in an Amazona

farinosa parrot. *Avian Pathol* 27:427-430, 1998.

Saunders GK, Sponenberg DP, Marx KL: Tyzzer's disease in a neonatal cockatiel. *Avian Dis* 37:891-894, 1993.

Schmidt RE: Morphologic diagnosis of avian neoplasms. *Sem Avian Exotic Pet Med* 1:73-79, 1992.

Schmidt RE, Hubbard GB: Liver gall bladder and pancreas. In *Atlas of Zoo Animal Pathology Vol II*. Boca Raton, CRC Press, 1987, pp 61-82.

Shane SM, Camus A, Strain MG, et al: Avian tuberculosis. *Avian Dis* 37:1172-1176, 1993.

Stephens CP, On SLW, Gibson JA: An outbreak of infectious hepatitis in commercially reared ostriches associated with *Campylobacter coli* and *Campylobacter jejuni*. *Vet Microbiol* 61:183-190, 1998.

Vanrompay D, Ducatelle R, Haesebrouck F: Chlamydia psittaci infections: A review with emphasis on avian chlamydiosis. *Vet Microbiol* 45:93-119, 1995.

Vaughan JL, Charles JA, Boray JC: Fasciola hepatica infection in farmed emus (*Dromaius novaehollandiae*). *Aust Vet J* 75:811-813, 1997.

CHAPTER 5

Liver



FURTHER READING

(CONTINUED)

Wadsworth PF, Majeed SK, Brancker WM, et al: Some hepatic neoplasms in non-domesticated birds. *Avian Pathol* 7:551-555, 1978.

Wilson RB, Holscher M, Hodges JR, et al: Necrotizing hepatitis associated with a reo-like virus infection in a parrot. *Avian Dis* 29:568-571, 1985.

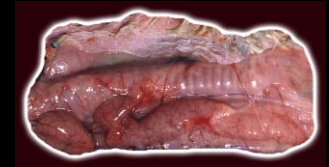Woods LW, Plumlee KH: Avian toxicoses: Veterinary diagnostic laboratory perspective. *Sem Avian Exotic Pet Med* 8:32-35, 1999.

Young P: Selected herpesviral diseases of birds. *Sem Avian Exotic Pet Med* 4:62-71, 1997.

Zinke A, Kahnt K, Kaup FJ, et al: Chronic-active hepatitis in a blue-fronted Amazon (*Amazona aestiva aestiva*): Clinical, laboratory and morphological findings. *Kleintierpraxis* 44:447, 1999.

CHAPTER 6

Lymphatic and Hematopoietic (Immune) System



The immune system of birds includes a wide variety of tissues. During the necropsy, these tissues should be examined after the liver and before the gastrointestinal tract in order to preserve the architecture and the relationship to other organs of the two major components, the spleen and bursa of Fabricius.

NORMAL ORGANS

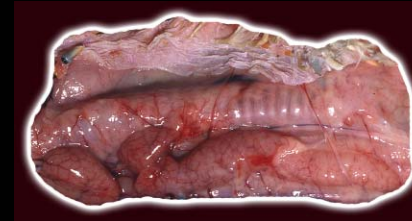
The innate immune system of birds includes the epidermis; secretions into the gastrointestinal, urogenital and respiratory tracts; inflammation; and cell phagocytosis. Further, the immune system is composed of two types of lymphoid tissue, primary and secondary. The thymus and the bursa of Fabricius are primary lymphoid tissues. The thymus is comprised of 3-8 pale pink, flattened, irregularly shaped masses, which extend along the length of both sides of the neck close to the jugular vein (Fig 6.1). The thymus of the pet bird involutes at approximately the same time that the bird is weaned.

In most birds, the bursa of Fabricius is a dorsal median diverticulum of the proctodeum that contains the bursal lymphoid follicles. It appears grossly as a light cream-colored saccular organ with inner folds. If congested it may be pale red (Fig 6.2, Fig 6.3). Ratites are unusual in that the bursa of Fabricius is diffuse, has a reversed cortex and medulla, and is contained submucosally in the dorsal wall of the cloaca. The bursa of Fabricius reaches its maximum size before the bird is sexually mature and then undergoes involution (Fig 6.4).

The secondary lymphoid tissues include the spleen, Harderian gland, pineal gland, bone marrow, and a diffuse system of perivascular lymphoid aggregates. Solitary and aggregated lymphoid nodules are more numerous in the digestive tract with scattered nodules in the oropharynx around the choanal opening and the pharyngeal opening of the auditory tubes. These nodules are unencapsulated aggregates of lymphocytes and small numbers of plasma cells and macrophages.

CHAPTER 6

Lymphatic and Hematopoietic (Immune) System



The spleen is located at the right side of the junction of the proventriculus and ventriculus. It is round to oval in most psittacines, elongated with a slight curve in passerines, triangular in ducks and geese, and spherical in many poultry species (Fig 6.5).

The Harderian gland is located ventral and posteromedial to the globe of the eye.

The bone marrow is the main source of granulocyte production in late embryonic life and after hatching. It is not a primary immune organ as in mammals. Grossly the normal marrow is red (Fig 6.6).

DISEASES OF THE BURSA OF FABRICIUS

Atrophy

The bursa of Fabricius normally involutes as the bird matures leaving only a small number of follicular remnants. Nonspecific stresses, such as malnutrition, poor management or infection, can result in premature atrophy of the bursa and potential immunosuppression.

Grossly the organ may not be visible when the cloaca is opened (Fig 6.7).

Viral Disease

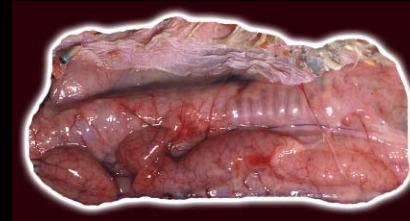
Psittacine Circovirus

The virus responsible for psittacine beak and feather disease is a 14-16 nm nonenveloped virion belonging to the family Circoviridae. All psittacine species are considered susceptible to infection by this virus; however, disease is predominately confined to parrots of African and Australasian distribution and is most common in birds less than three years of age. Unique circoviruses infect doves, racing pigeons, canaries, finches, geese and the Southern black-backed gull.

Primary circovirus replication occurs at the portals of entry in the bursa of Fabricius and/or gastrointestinal tract lymphoid tissue. Secondary virus replication occurs in the liver and thymus and probably other tissues. Atrophy of the primary lymphoid organs is the typical finding on gross examination.

CHAPTER 6

Lymphatic and Hematopoietic (Immune) System



Young African grey parrots have a specific presentation of peracute PBFV viral infection, characterized by the absence of feather and beak abnormalities. Splenomegaly is a common gross finding. The bursa of Fabricius and thymus are usually small (Fig 6.8).

Avian Polyomavirus (APV)

Nestlings dying with APV disease will have swelling and often hemorrhage and edema within or adjacent to the bursa of Fabricius (Fig 6.9, Fig 6.10). This disease is acute rather than chronic like circovirus, and the gross bursal changes reflect acute disease.

Other Viruses

Many of the common pet bird viral infections will result in damage to the lymphoid follicles of the bursa of Fabricius. These include Pacheco's disease, parvovirus of ducks and geese, avian influenza, and adenovirus in poultry and psittacines birds. Affected bursas are small and may be difficult to find grossly.

Bacteria

Bacterial infections of the bursa of Fabricius are uncommon. They may represent localization of a systemic disease or an extension from a cloacal infection, in which case the bursa of Fabricius may be enlarged, irregular and have caseous foci.

Yeast

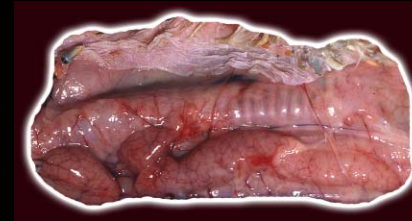
Yeast infections of the bursa of Fabricius are very uncommon. They are most likely a localization of a systemic disease and are more commonly recognized in young cockatiels. The bursa of Fabricius may be difficult to identify grossly.

Toxins

There are a number of toxins that have resulted in severe lymphocytic depletion and lymphocytolysis of the bursa of Fabricius in free-ranging birds and poultry. These have included crude oil, excessive vitamin D, selenium, mycotoxins, and organotin compounds used as

CHAPTER 6

Lymphatic and Hematopoietic (Immune) System



pesticides, stabilizers, disinfectants, molluscicides, anthelmintics, and antitumor agents.

Malnutrition

Calorie-deficient diets and hypovitaminosis A will result in atrophy of the bursa of Fabricius in young birds.

Neoplasia

Tumors of the bursa of Fabricius are rare in psittacine birds. There is a single report of a spindle cell sarcoma arising within the bursa of a budgerigar. Lymphosarcoma is the classic poultry tumor of the bursa of Fabricius, which is induced by a chicken retrovirus. Affected bursas are enlarged and cream-white.

DISEASES OF THE THYMUS

Cysts

Rarely, thymic cysts are found as incidental lesions in birds. The etiology of the cystic development in birds is unknown; however, they may be dilations of persistent

thymopharyngeal ducts. They may be visible grossly as thin-walled areas, some of which contain clear fluid.

Atrophy

Premature thymic atrophy leads to a gross reduction in size (Fig 6.11). Viral diseases in birds commonly associated with the atrophy include circoviruses, Pacheco's disease virus, avian influenza, Marek's disease virus, and some strains of infectious bursal disease. Nutritional stress and exposure to corticosterone hormone can also induce thymic atrophy.

Hyperplasia

Enlarged, hyperplastic thymuses are occasionally seen in older birds (Fig 6.12). These may be preneoplastic lesions, but the exact cause is usually not determined.

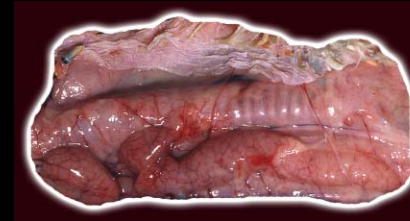
Neoplasia

Thymoma/Lymphosarcoma

Neoplasms of the thymus may arise from the epithelial cells or lymphocytes. The epithelial tumors are classified as thymomas, and the lymphoid tumors are thymic lym-

CHAPTER 6

Lymphatic and Hematopoietic (Immune) System



phosarcomas. The tumor masses may form anywhere in the subcutis of the neck, from the mandible to the thoracic inlet. These masses may be cystic and hemorrhagic (Fig 6.13).

DISEASES OF THE SPLEEN

Viral Disease

Avian Polyomavirus

Birds with avian polyomavirus disease typically have an enlarged and often hemorrhagic spleen. There may be yellow-white mottling that represents foci of necrosis (Fig 6.14). If there are numerous inclusion bodies, they may be seen cytologically (Fig 6.15).

Herpesvirus (Pacheco's disease)

The Pacheco's herpesvirus disease viruses commonly cause lesions of the spleen. Often there is splenomegaly, although this may be absent in birds with peracute disease. Affected spleens may have multiple white foci. The gross appearance is similar to that of polyomavirus and may not be distinguishable grossly.

Avipoxvirus

Avipoxvirus infection can result in a systemic disease as well as the classic cutaneous infection. The systemic disease is more common in house sparrows, canaries and other finches. Splenomegaly is seen, particularly in small passerine birds. This is due to marked splenic lymphoid proliferation in systemic canary pox infections (Fig 6.16).

Bacterial Disease

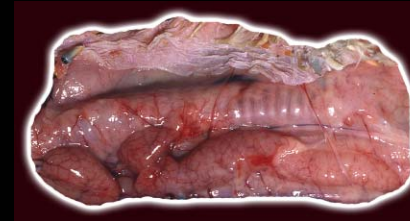
Salmonella

Salmonella is considered a primary pathogen, with some serotypes able to penetrate the mucosal barrier. Domestic poultry are the single, largest reservoir for Salmonella. Salmonella typhimurium is the most common psittacine and free-living avian isolate.

The disease progression in birds depends on the number of organisms present, the serotype, and the age, species and condition of the host. It ranges from peracute, to acute, to chronic, to a subclinical infection. The classic lesions include a nonspecific splenomegaly.

CHAPTER 6

Lymphatic and Hematopoietic (Immune) System



Mottling and gray-white necrotic foci may be seen (Fig 6.17).

Yersinia

Yersinia pseudotuberculosis is a gram-negative, non-spore forming rod bacterium with a zoonotic potential. Free-ranging birds and rodents that have access to aviaries are considered to be significant reservoirs of *Yersinia pseudotuberculosis*. Toucans are reported to be very susceptible to it. It has been incriminated in major epornitics of disease in canaries, lorikeets and mynahs. Gross lesions in the spleen include swelling and necrosis. In severe cases, caseous swellings and nodules resembling avian tuberculosis may be seen.

Other Bacterial Splenitis

Both systemic and localized bacterial disease may affect the spleen. With bacteremias, the spleen will enlarge and appear deep red with vascular congestion. Large gray-white foci representing lymphoid proliferation and/or areas of necrosis can often be seen (Fig 6.18).

Mycobacteria

Mycobacteria are acid fast and weakly gram-positive rods. The typical gross lesions are organ enlargement, including the spleen. Multiple focal to large coalescing firm, white masses may develop throughout the splenic parenchyma (Fig 6.19). In pet birds, the nodular masses (tubercles) do not calcify.

Chlamydophila psittaci

C. psittaci infections in birds commonly cause splenomegaly. The spleen color may range from dark red to purple, changes characteristic of a congested spleen. Alternately, the spleen may be pale as the result of increased numbers of histiocytes and plasma cells (Fig 6.20).

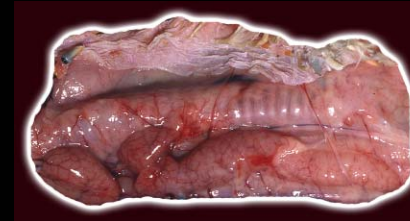
Protozoal Disease

Atoxoplasmosis

Atoxoplasma is an apicomplexa coccidian with a prolonged life cycle involving the reticuloendothelial system and intestinal epithelium. It is more commonly

CHAPTER 6

Lymphatic and Hematopoietic (Immune) System



recognized as a pathogen of passerines. The primary gross lesion is the great enlargement of the spleen and occasionally the liver.

Malaria (Plasmodium)

Plasmodium is one of three avian blood parasites that have life cycles with a schizogenous tissue phase and gametogenous sexual phase in host erythrocytes.

Although there are 25 plasmodium species found in birds, these rarely cause disease in psittacines. Some plasmodium can be associated with significant disease in gyrfalcons, peregrines, penguins and canaries. The spleen can be enlarged and black in some infected birds, particularly raptors (Fig 6.21).

Sarcocystis

Sarcocystosis is predominately a disease involving the skeletal muscle and lung. Birds surviving the acute phase will develop splenic enlargement that is grossly similar to that seen in bacterial and *Chlamydophila* infections (Fig 6.22).

Degenerative Disease

Amyloid

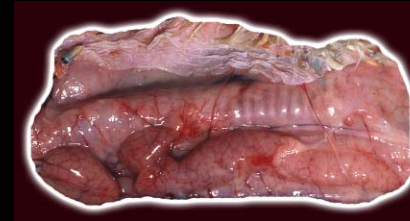
Amyloid is an insoluble pathologic proteinaceous substance deposited between cells in various tissues and organs of the body. In birds the amyloid is usually considered to be secondary. Systemic amyloidosis has been reported in finches, captive domestic and wild Anseriformes, especially of the Anatidae family (swans, geese and ducks), and in gallinaceous birds (domestic fowl and turkeys). Amyloidosis is less common in psittacine birds but when it does occur, it generally involves both the spleen and kidney. In finches, amyloid deposition is more common in the liver and spleen. Grossly the spleen will appear pale and will be firm when sectioned.

Hemosiderin

The accumulation of this iron-containing pigment is typically due to previous hemorrhage (including hemolytic anemia) or severe tissue congestion, resulting in breakdown and phagocytosis of the red blood cell

CHAPTER 6

Lymphatic and Hematopoietic (Immune) System



debris. Impaired use of iron, such as from systemic bacterial infections or from anemia of chronic disease, also leads to the increased presence of hemosiderin. This is a common mechanism in pet birds. In the spleen, large amounts of hemosiderin may lead to brown-black discoloration, but usually it is not grossly detected.

Histiocytic Lipid Accumulation

Birds with lipid metabolism problems, such as a severe fatty liver, may accumulate lipid in histiocytes in the spleen. Grossly these spleens may be small to slightly enlarged and are pale yellow ([Fig 6.23](#)).

Neoplasia

Lymphosarcoma

Multicentric lymphosarcoma is the most common lymphoid neoplasia in psittacine and passerine birds. Diffuse or nodular involvement is characteristic of pet bird lymphosarcoma. After the liver, the spleen is most commonly involved. Affected spleens are generally markedly enlarged and pale and may have hemorrhagic foci ([Fig 6.24](#)).

Myeloproliferative Disease

Myeloproliferative disorders are neoplastic proliferation of nonlymphoid hematopoietic cells. These neoplastic cells generally infiltrate the spleen, liver and bone marrow. The infiltration can result in massive enlargement of both the liver and spleen. Grossly, the tumor cannot be differentiated from lymphosarcoma.

Hemangioma and Hemangiosarcoma

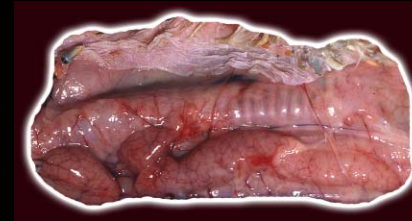
Hemangiomas are benign tumors of vascular endothelium. The malignant version is hemangiosarcoma, also known as malignant hemangioendothelioma or angiosarcoma. Hemangiomas are more commonly reported in budgerigars (*Melopsittacus undulatus*) than in other birds and usually occur in the skin or spleen. They are uncommonly described in larger psittacines.

Myelolipoma

Myelolipoma is an uncommon tumor that has been reported in the subcutis, spleen and multifocally in the liver. Myelolipomas behave like lipomas, with slow pro-

CHAPTER 6

Lymphatic and Hematopoietic (Immune) System



gressive growth. They are considered choristomatous (histologically normal tissue in an abnormal location) hematopoietic stem cell elements. Grossly they appear as masses of fat with hemorrhage and can resemble lipomas, xanthomas and fibrosarcomas. They may contain focal areas of mineralization or bone formation.

Fibrosarcoma

Fibrosarcomas are tumors that originate from fibrous connective tissue and are common neoplasms in birds. Based on literature reports, fibrosarcomas (malignant) appear to be more common than fibromas (benign). Fibrosarcomas and other soft tissue sarcomas are white-to-gray, raised or rounded, firm masses that have indistinct borders within the spleen.

Metastatic Carcinomas

Metastatic carcinomas to the spleen are rare with only metastatic gastric carcinoma reported. There is no specific gross appearance, but multiple small gray-white or yellow nodules may be seen.

LESIONS OF THE BONE MARROW

Lesions of the bone marrow are either hypo- or hypercellularity. Interpretation of erythrocytic vs granulocytic responses typically requires comparison with the peripheral blood counts and cytological examination of the bone marrow cells.

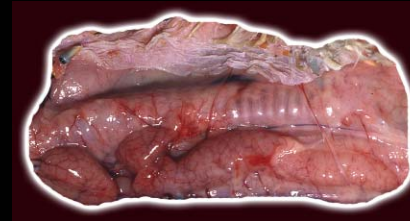
Infectious Disease

Inflammatory diseases caused by bacterial, chlamydia and fungi can result in granulocytic hyperplasia. Anemia induced by many disease processes will be associated with a similar gross appearance due to erythroid hypoplasia. The marrow will have a diffuse yellow appearance (Fig 6.25). Bone marrow hypoplasia is described with several viral infections. Severe leukopenia and anemia from bone marrow hypoplasia is common in young African grey parrots and pigeons infected with circovirus.

Mycobacterial infections can result in severe myeloid hyperplasia and bone marrow infiltrations of

CHAPTER 6

Lymphatic and Hematopoietic (Immune) System



macrophages. Granulomas similar to those seen in other organs may also be found in the bone marrow and will appear grossly as irregular nodular foci that have a different color and consistency than normal marrow.

Toxins

A number of toxins can result in bone marrow hypocellularity.

Lead poisoning interferes with several stages of heme synthesis. The bone marrow will be hypocellular and appear similar to that described above.

Proliferative Disease

Xanthoma

Xanthomas are not neoplasms, but are locally invasive and appear as masses commonly in the skin. They rarely occur in internal organs and even more rarely have been identified within the bone marrow. Xanthomas have been reported most frequently in psittacine and gallinaceous birds. They are considered common in cockatiels and

female budgerigars and grossly cannot be differentiated from granulomas.

Neoplastic Disease

Myeloproliferative Disorder

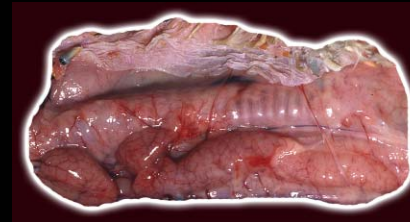
Myeloproliferative disorders are neoplastic proliferation of nonlymphoid hematopoietic cells that originate in the bone marrow. In poultry, this neoplasm is associated with retrovirus infections, although a viral etiology has not been proven in psittacine or other pet birds.

Hemangiosarcoma

Hemangiosarcoma, also known as malignant hemangioendothelioma or angiosarcoma, is a malignant tumor of vascular endothelium. In birds they are locally invasive, metastatic, and multicentric. In the diaphysis of long bones, they have an aggressive osteolytic radiographic appearance. Grossly, there will be associated bone production and the tumor will be friable and hemorrhagic.

CHAPTER 6

Lymphatic and Hematopoietic (Immune) System



FURTHER READING

Atoji Y, Yamamoto Y, Suzuki Y: Thymic epithelial cysts in the pigeon. *Anat Anz* 181:365-70, 1999.

Coleman CW, Oliver R: Lymphosarcoma in a juvenile blue and gold macaw (*Ara araruna*) and a mature canary (*Serinus canarius*). *J Assoc Avian Vet* 8:64-68, 1994.

Coleman CW: Lymphoid neoplasia in pet birds: A review. *J Avian Med Surg* 9:3-7, 1995.

Fox JH, Greiner EC, Bain P, et al: Malaria in a captive emu (*Dromaius novaehollandiae*) from Florida.

Avian Dis 40:477-479, 1996.

García A, Latimer KS, Steffens WL, et al: Granulocytic sarcoma in a budgerigar (*Melopsittacus undulatus*). *Intl Virtual Conf Vet Med (IVCVM)*, University of Georgia College of Veterinary Medicine, 1998.

Goodwin MA: Cryptosporidiosis in birds: A review. *Avian Pathol* 18:365-384, 1989.

Graham DL: Special presentation: A color atlas of avian chlamydiosis. *Sem Avian Exotic Pet Med* 2:184-189, 1993.

Hacking MA, Sileo L: *Yersinia enterocolitica* and

Yersinia pseudotuberculosis from wildlife in Ontario. *J Wildl Dis* 10:452-457, 1974.

Harrington R, Blackburn BO, Cassidy D: Salmonellosis in canaries. *Avian Dis* 19:827-829, 1975.

Johnson-Delaney CA: The avian immune system and role in disease. *Proc Assoc Avian Vet*, 1989, pp 20-28.

Jones MP: Avian immunology: A review. *Proc Assoc Avian Vet*. 1994, pp 333-336.

Latimer KS: Oncology. In Ritchie BW, Harrison GJ, Harrison LR (eds): *Avian Medicine: Principles and Application*. Lake Worth,

FL, Wingers Publishing, 1994, pp 667-669.

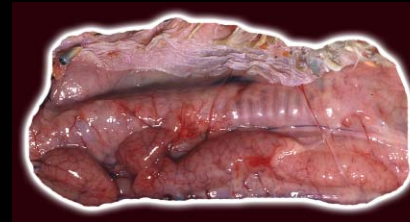
Latimer KS, Ritchie BW, Campagnoli RP, et al: Cutaneous T-cell-rich B-cell lymphoma and leukemic blood profile in an umbrella cockatoo (*Cacatua alba*). *Intl Virtual Conf Vet Med (IVCVM)*, University of Georgia College of Veterinary Medicine, 2000.

Leach MW: A survey of neoplasia in pet birds. *Sem Avian Exotic Pet Med* 1:52-64, 1992.

Maeda H, Ozaki K, Fukui S, et al: Thymoma in a java sparrow (*Padda oryzivora*). *Avian Pathol* 23:353-357, 1994.

CHAPTER 6

Lymphatic and Hematopoietic (Immune) System



FURTHER READING

(CONTINUED)

Moore FM, Petrak ML:

Chlamydia immunoreactivity in birds with psittacosis: Localization of chlamydiae by the peroxidase-antiperoxidase method. *Avian Dis* 29:1036-1042, 1985.

Nakamura K, Ogiso M,

Tsukamoto K, et al: Lesions of bone and bone marrow in myeloid leukemia occurring naturally in adult broiler breeders. *Avian Dis* 44:215-221, 2000.

O'Toole D, Haven T, Driscoll M, et al: An outbreak of Pacheco's disease in an

aviary of psittacines. *J Vet Diagn Invest* 4:203-205, 1992.

Page CD, Schmidt RE, English JH, et al: Antemortem diagnosis and treatment of sarcocystosis in two species of psittacines. *J Zoo Wildlife Med* 23:77-85, 1992.

Panigrahy B, Grimes JE, Rideout MJ, et al: Zoonotic diseases in psittacine birds: Apparent increased occurrence of chlamydia. *J Am Vet Med Assoc* 175:359-361, 1979.

Rae MA, Shafer D: Thymoma in caged birds. *Proc Assoc Avian Vet*, 1996, pp 101-108.

Ramos-Vara JA, Smith EJ, Watson GL: Lymphosarcoma with plasmacytoid differentiation in a scarlet macaw (*Ara macao*). *Avian Dis* 41:499-504, 1997.

Redig PT: Avian malaria. *Proc Assoc Avian Vet*, 1993, pp 173-181.

Schmidt RE: Neoplastic diseases. In Altman RB, Clubb SL, Dorrestein GM, Quesenberry K (eds): *Avian Medicine and Surgery*. Philadelphia, WB Saunders Co, 1997, pp 590-600.

Schmidt RE: Immune system. In Altman RB, Clubb SL, Dorrestein GM, Quesenberry K (eds): *Avian Medi-*

cine and Surgery. Philadelphia, WB Saunders Co, 1997, pp 645-652.

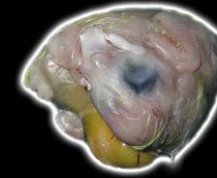Schoemaker NJ, Dorrestein GM, Latimer KS, et al: Severe leukopenia and liver necrosis in young African grey parrots (*Psittacus erithacus erithacus*) infected with psittacine circovirus. *Avian Dis* 44:470-478, 2000.

Sharma JM: Overview of the avian immune system. *Vet Imm & Immunopathol* 30:13-17, 1991.

Wade LL, Polack EW, O'Connell PH, et al: Multicentric lymphoma in a European starling (*Sturnus vulgaris*). *J Avian Med Surg* 13:108-115, 1999.

CHAPTER 7

Gastrointestinal System and Pancreas



The gastrointestinal tract can be easily examined after the heart and liver are removed. The oral cavity, cervical esophagus and crop are readily examined with an incision extending from the commissure of the beak to the thoracic inlet.

LESIONS OF THE BEAK

Normal Structure

The beak has maxillary and mandibular components that are covered by horny sheaths (rhamphotheca). This horny sheath is a layer of extremely thickened stratum corneum comprised largely of hard keratin with an underlying dermis that becomes continuous with the periosteum. The hardness varies with species; the beak is exceptionally hard in psittacine birds and is relatively soft in many waterfowl. The rhinotheca is the maxillary rhamphotheca and the gnathotheca is the mandibular rhamphotheca. A normal structure at hatching is the egg tooth. This enlargement at the dorsal aspect of the end of the beak is lost in the first few days after hatching (Fig 7.1).

Noninfectious Diseases

Deformities of the beak, such as variations in curvature and size, can be congenital or acquired. Genetically induced congenital deformities have been reported in budgerigars. are seen. Congenital deformities of uncertain cause are also described.

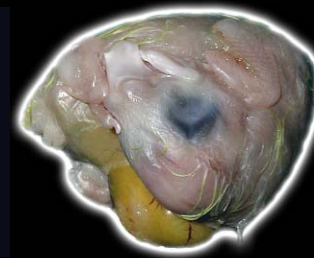A lateral deviation of the maxilla is a relatively common lesion in hand-fed nestling macaws as are beak deformities of hand-fed nestling cockatoos (Fig 7.2). In these birds, the curvature of the maxilla is increased, causing the tip of the maxilla to rest on the oral surface of the mandible. Some of these birds appear to have an overly long mandible or possibly a foreshortened maxilla.

Beak trauma is common and is most often the result of a bite wound from another bird. Male cockatoos are aggressive during the breeding season, and mate aggression is a common cause of crushed beaks and even more extensive injury to the face and head.

Malnutrition may cause softening and flaking of the beak. A report of the complete absence of vitamin A in

CHAPTER 7

Gastrointestinal System and Pancreas



the diet of nestling African grey parrots described transverse ridges in the rhinotheca of these birds. The beak grew out normally when a diet with adequate vitamin A was fed.

Clinical observations suggest that one cause of overgrowth of the beak of parrots is liver disease. These birds may have evidence of hemorrhage beneath the rhinotheca (Fig 7.3).

Infectious Diseases

The beak is a common target for a number of infectious disease processes.

Circovirus (psittacine beak and feather disease virus) commonly causes beak lesions in sulphur-crested cockatoos, Moluccan cockatoos, galahs and little corellas. Gross lesions include hyperkeratosis, elongation, ulceration, necrosis and fracturing of the keratin (see Chapter 2). Separation of the palatine mucosa from the rhinotheca may occur; eventually the distal beak may fracture, exposing the underlying bone.

Poxviruses can also affect the beak with lesions most common in non-psittacine birds. Classically, poxvirus infection causes raised proliferative lesions that may or may not be necrotic and secondarily infected. These lesions are seen on the surface of the beak or at the beak/skin margin (see Chapter 2).

Primary bacterial and fungal infections of the beak may be associated with trauma. These lesions present as variable areas of necrosis, inflammation and hemorrhage. The beak will often soften and become discolored. There may be hyperkeratosis and accumulation of necrotic debris (Fig 7.4).

Mites, such as *Knemidokoptes* sp., can cause inflammation and proliferation of the beak. The base of the affected beak is typically soft, and the surface has a fine honey-comb texture.

Neoplasms

Several types of neoplasia have been reported to metastasize to the beak, but squamous cell carcinomas and malignant melanomas are the most common.

CHAPTER 7

Gastrointestinal System and Pancreas



Fibrosarcoma is considered the most common primary beak tumor and is common in budgerigars and cockatiels. The beak area may also be a primary site of malignant melanoma. Grossly, all tumors are proliferative masses that distort the beak and surrounding soft tissue. There may be bone lysis.

LESIONS OF THE ORAL CAVITY

Normal Structure

Birds do not have a soft palate. The hard palate is divided caudally by the longitudinal V-shaped choanal fissure, which connects the oral and nasal cavities. Small, caudally projecting papillae line the oral margins of the choanal fissure. Caudal to the choana on the roof of the oral cavity is the infundibular fissure, which connects the oral cavity with the middle ear.

The shape of the tongue varies extensively according to the feeding habits of the bird. The tongue of finches, canaries and other captive passerine birds is long, slender, flat and cornified. Psittacine birds have a thick,

round and muscular tongue that is used for manipulating food. The tongue of lorries and lorikeets is densely covered with fimbria that evert when the tongue is protruded. These fimbria are used to gather pollen and nectar. At the base of the tongue are the laryngeal mound and the glottis. Birds do not have an epiglottis.

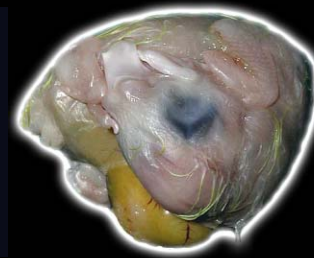Noninfectious Diseases

Noninfectious oral lesions include various types of trauma, which acutely may present as lacerations or abrasions with variable hemorrhage. Chronicity may include the formation of irregular thickenings in the affected area. Foreign bodies may penetrate the mucosa of the oral cavity and tongue and serve as a nidus for severe chronic inflammation and granuloma formation. These lesions must be differentiated from neoplasia.

Vitamin A is essential for the integrity of mucous membranes and the epithelium. Vitamin A deficiency is a common disease in cage birds. The absence of vitamin A results in squamous metaplasia of mucous glands and the epithelium in several organ systems. The small

CHAPTER 7

Gastrointestinal System and Pancreas



mucous glands in the oral cavity fill with keratin and expand to form submucosal nodules containing yellow-white and friable material (Fig 7.5). These lesions can be severe, resulting in obstruction of the choanal slit. Blunting of the choanal papillae is a subtler lesion that is seen in birds with early stages of vitamin A deficiency.

Infectious Diseases

Infectious agents causing oral disease in psittacine birds include viruses, bacteria, fungi, flagellates and nematodes.

Poxvirus infection results in mucosal proliferation and the formation of masses that may be partially necrotic. Grossly the oral mucosa is usually ulcerated and covered with caseous debris (Fig 7.6). Scattered yellow nodules may be seen (Fig 7.7). Differential diagnoses for this lesion include vitamin A deficiency, bacterial infection (particularly with *Pseudomonas* sp.), candidiasis and trichomoniasis. Amazon parrots (particularly blue-fronted Amazon parrots) have historically had a high

incidence of poxvirus infection, but this has significantly decreased with the closing of importation.

Herpesvirus and polyomavirus infections can cause acute necrosis, ulceration and hemorrhage of the oral mucosa (Fig 7.8). The gross change is not specific, and the diagnosis is made histologically. These lesions are often overlooked at necropsy due to the severity of the generalized disease process.

Bacterial infections, which may be secondary to vitamin A deficiency, cause necrosis of the oral mucosa and glands and must be differentiated from poxvirus lesions. Acute infections may cause hyperemia and focal necrosis (Fig 7.9), but chronic infections with gram-negative bacteria or mycobacteria will lead to granuloma formation.

The primary mycotic infection of the oral cavity is *Candida albicans*. Primary infections can occur, but the disease is usually secondary and a complete necropsy is usually necessary to determine the underlying cause. Grossly the mucosa is thickened and there may be gray-white plaques.

CHAPTER 7

Gastrointestinal System and Pancreas



Trichomoniasis is most common in pigeons and free-ranging birds. The oral form of the disease is rare in captive-raised psittacines and passerines species. Grossly, yellow-white nodules and plaques characterize oral trichomoniasis (Fig 7.10). The gross lesions may be similar to those seen with vitamin A deficiency, poxvirus infections, candidiasis and bacterial infections.

Capillaria sp. may cause variable inflammation with some hemorrhage. In some cases, gross changes are minimal or absent and the nematodes are an incidental finding at necropsy.

Neoplasms

Tumors of the oral cavity can be either of epithelial or mesenchymal origin. The most common neoplasm of the oral cavity is oral papillomatosis (Fig 7.11). This disease is most common in New World psittacines: macaws, conures, Amazon parrots and hawk-headed parrots. Oral lesions are particularly common in the larger macaws and are relatively rare in Amazon parrots. Papillomas are most commonly located along the margins of the choanal

fissure, at the base of the tongue, and on the glottis. The papillomatous lesions are white to pink, raised, and focal to locally extensive. Most have the typical cauliflower-like appearance. However, these lesions wax and wane, and smaller, slightly raised, discolored lesions that also represent this disease may be overlooked. Thickening of the choanal margin, discoloration of the choanal mucosa and blunting of the choanal mucosa are also subtle changes that may be associated with papillomatosis.

Squamous cell carcinomas and salivary gland carcinomas will present as yellow-white masses of the oral mucosa or tongue. In some cases, necrosis and hemorrhage are seen. When severe, there can be extensive destruction of oral structures (Fig 7.12).

Sarcomas reported in the oral cavity include fibrosarcoma and lymphosarcoma. Gross differentiation of these lesions from each other or from granulomas is difficult. Oral malignant melanoma is unusual unless associated with melanoma of the beak. It is similar grossly and histologically to the tumors of the beak.

CHAPTER 7

Gastrointestinal System and Pancreas



LESIONS OF THE ESOPHAGUS AND CROP

Normal Structure

The esophagus can be divided into the cervical esophagus, ingluvies (crop) and thoracic esophagus. The cervical esophagus is on the right side of the neck. Although not all birds have a crop, if present, it dilates to become a sac-like, highly distensible structure. When fully distended, the crop is nearly transparent. The crop varies in size and shape according to the species of bird. The crop of the parrot first bulges to the right and then to the left across the midline and fills most of the space between the bones of the clavicle. The crop of nestling parrots is proportionately larger than that of the adult bird.

Noninfectious Diseases

Primary noninfectious lesions of the crop include burns, foreign body penetration and vitamin A deficiency. Burns are secondary to hand feeding of overheated food and are usually found in the cranial-ventral portion of the

crop. Grossly, there may be reddening and edema. Blistering or necrosis occurs in severe cases (Fig 7.13).

Foreign bodies may penetrate the wall of the crop, leading to loss of food that migrates in the subcutis of the neck, resulting in wide spread inflammation and necrosis. Crop perforation is most common in birds that are being tube fed as nestlings or as part of therapy.

Vitamin A deficiency results in squamous metaplasia of esophageal glands and proliferation of crop mucosa. Secondary infections are common.

An ingluvolith that was primarily uric acid rather than calcium or struvite has been reported in a single budgerigar. Crop impaction can follow the ingestion of a number of foreign objects (Fig 7.14).

Lymphangiectasis, leading to grossly noted fluid-filled spaces in the submucosa, is occasionally seen. The cause is usually not determined (Fig 7.15).

Infectious Diseases

Poxvirus infection can lead to proliferative and necrotic lesions in the crop that are similar to those described in

CHAPTER 7

Gastrointestinal System and Pancreas



the oral cavity (Fig 7.16). Herpesvirus infection results in mucosal necrosis and hemorrhage.

Crop dilation and impaction with food can be seen in cases of proventricular dilatation disease (PDD)(Fig 7.17). Biopsy of the crop is a commonly used antemortem morphologic diagnostic tool for PDD because of the ease of access to the crop. Histologic lesions, however, are not as consistently found in the crop as they are in the proventriculus and ventriculus. Therefore, the absence of lesions in the myenteric ganglia of the crop does not rule out PDD.

Bacterial infections of the crop and esophagus can be primary or secondary. In severe infections of the crop, yellow-white nodules and plaques, hemorrhage, necrosis and a variable fibrinopurulent exudate affect the mucosal surface (Fig 7.18).

Yeast infection of the crop is usually a secondary infection but can also be a primary problem, particularly in cockatiels, lovebirds and finches. Gross changes are similar to those seen in the oral cavity, with necrosis and a

grey to yellow-white exudate on the mucosal surface (Fig 7.19). Often the crop wall appears as significantly thickened broad folds.

Trichomoniasis causes lesions of the crop in the budgerigar and thoracic esophagus in the cockatiels. The disease primarily affects adult birds and causes a proliferative lesion that can be caseous. Differential gross diagnoses include poxvirus and bacterial infections as well as vitamin A deficiency.

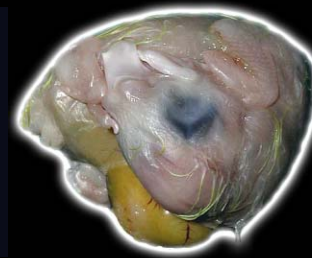Neoplasms

Neoplasms of the esophagus and crop include papillomas and carcinomas. Papillomas are proliferative masses that project into the lumen of the esophagus or crop. Mucosal papillomas of the crop and esophagus are most common in birds that also have oral and cloacal lesions.

Squamous cell carcinomas are found in the esophagus and crop. Carcinomas are both proliferative and invasive. Secondary infections of the diseased tissue are common. They present as variably sized, yellow-white masses that may contain areas of necrosis and hemorrhage (Fig 7.20).

CHAPTER 7

Gastrointestinal System and Pancreas



Carcinomas of the submucosal glands occur. These lesions are often large and involve much of the wall of the esophagus/crop with extension into surrounding tissue. They can be necrotic and hemorrhagic.

Tumors of smooth muscle origin (leiomyomas and leiomyosarcomas) result in large space-occupying masses that may become necrotic and hemorrhagic, although they can be asymptomatic when small.

LESIONS OF THE PROVENTRICULUS

Normal Structure

In most psittacine birds and common captive passerines, the proventriculus is a thick spindle-shaped organ. The wall is composed predominately of compound tubular glands.

The isthmus is a very short junction that serves as a transition between the proventricular and ventricular glands. Koilin production is not present in the orad portion of this junction. Caudally, a thin layer of koilin-like secretions is present at the transition to the ventriculus.

Noninfectious Diseases

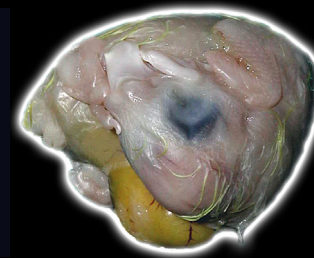Several noninfectious disease conditions are seen in the proventriculus. Gastric impactions that sometimes result in perforation are most common in young psittacines that ingest foreign material. Impacted birds have proventricular dilatation and the wall is flaccid (Fig 7.21). Perforation or rupture is characterized by hemorrhage and accumulation of ingesta in and around the affected area (Fig 7.22). In larger birds that are ground feeders, severe impaction can be associated with ingestion of rocks or other foreign material (Fig 7.23).

Birds with severe vitamin A deficiency may have metaplasia of proventricular glands, leading to gross thickening and accumulation of excessive keratin. This must be differentiated from caseous material due to inflammation/infection.

Severe mineralization of the proventricular mucosa is believed to be secondary to excessive dietary calcium and may possibly occur in birds ingesting excessive vitamin D₃. This lesion seems to be more common in

CHAPTER 7

Gastrointestinal System and Pancreas



macaws, particularly the blue and gold macaw, and cockatiels. Grossly the proventriculus may feel gritty.

Proventricular hemorrhage can be the result of various diseases or toxins as well as vascular disturbances (Fig 7.24).

Infectious Diseases

Infectious diseases affecting the proventriculus include viral, bacterial, mycobacterial, fungal and parasitic.

Viral Diseases

Proventricular dilatation disease (PDD) is a disease of the central and peripheral nervous systems, suspected to be of viral origin. One of the most common lesions associated with this disease occurs in the proventriculus. It is reported in many species of psittacine birds and may also occur in other species ranging from red-tailed hawks to Canada geese. Macaws, African grey parrots, cockatoos, and conures are the most commonly affected psittacine species.

The primary gross lesions seen in PDD include a thin body with loss of fat and muscle mass and flaccidity and dilatation of any portion of the gastrointestinal tract (with the proventriculus, ventriculus and crop being most commonly affected.) The dilated proventriculus may fill much of the left side of the coelomic cavity and displace the ventriculus to the right and cranially (Fig. 7.25). If the bird has been fed a seed diet, the proventriculus and ventriculus will be packed with seeds. Multifocal ulceration of the proventricular mucosa also occurs. Some birds will present for necropsy with minimal gross change in the digestive system.

Proventricular hemorrhage may result from Newcastle's disease, but the lesion is not pathognomonic.

Proventricular dilation is not pathognomonic for PDD. Any disease that causes partial or complete obstruction of the intestines will result in proventricular dilation.

Bacterial Diseases

Bacterial infections of the proventriculus can be primary or secondary. Gram-negative bacterial infections will

CHAPTER 7

Gastrointestinal System and Pancreas



present grossly as focal to diffuse hyperemia with variable necrosis and hemorrhage of the mucosa. Fibrin may be present. Yellow-white nodular areas may be seen on the serosal surface (Fig 7.26). In severe cases, the proventriculus may be perforated (Fig 7.27).

Mycobacteriosis has been reported in the proventriculus of passerine birds and is also seen in psittacine birds. Mycobacterial disease of the small intestine is far more common.

Fungal Diseases

An organism previously referred to as “megabacteria” is actually a novel anamorphic ascomycetous yeast, newly named *Macrorhabdus ornithogaster*. It is commonly found on the mucosal surface of the isthmus of budgerigars, canaries, finches, parrotlets, ostriches, and less frequently poultry. The organisms are relatively large (2 x 20-40 µm) and may be seen cytologically with smears of the proventriculus (Fig 7.28). The primary gross lesion associated with this infection is excessive mucus produc-

tion within the proventriculus. Chronically ill birds will present with severe weight loss.

Zygomycete fungi are a cause of proventriculitis in several avian species. Gross lesions are similar to bacterial infections, and erosions or ulcers are common.

Cryptosporidiosis of the proventriculus is seen in a variety of psittacine and small passerine birds. Often no gross lesion is reported, but there may be excessive mucus production and variable mucosal hypertrophy.

Parasitic Diseases

Ascarids and spiruroids, including *Spiroptera* sp. and *Dyspharynx* sp., can colonize the proventriculus. They require an intermediate arthropod host and thus are primarily seen in birds housed outdoors. In severe chronic infections, the wall of the proventriculus, particularly the mucosa, will be thickened, and the proventriculus may be distended. Hemorrhage is seen in severe cases, and nematodes may be found in the lumen (Fig 7.29). Perforation of the proventriculus may occur, but it is uncommon. Doves and pigeons are commonly infected

CHAPTER 7

Gastrointestinal System and Pancreas



with *Tetrameres* sp. These large roundworms cause the wall of the proventriculus to have a red beaded appearance (Fig 7.30).

Neoplasms

Neoplasms of the proventriculus include papillomas morphologically similar to those previously described. They are uncommon lesions and are most likely to occur in macaws, particularly the green-wing macaw. These birds generally have lesions of the esophagus and crop and often are chronically debilitated. Proventricular carcinomas are reported in several species of birds, but in companion birds they are most common in budgerigars, grey-cheeked parakeets and Amazon parrots. Proventricular carcinomas are often found at the proventricular-ventricular junction and are generally flat rather than nodular. If they extend to the serosal surface, there may be peritonitis, fibrin deposition and adhesion to the liver or other organs (Fig 7.31). Nodular proliferation is noted in the lumen (Fig 7.32).

Smooth muscle tumors are rare. Grossly and histologically, they are similar to those previously described.

LESIONS OF THE VENTRICULUS

Normal Structure

The ventriculus has a thick external muscularis that is necessary for grinding ingested feed. It is widest in vertical cross section and thinner in horizontal cross section. The ventricular glands secrete a carbohydrate/protein complex called the koilin. Secreted koilin produces a dense, thick, serrated layer that completely lines the ventriculus.

The need for a grinding stomach diminishes in species that feed predominately on liquid or easily digested food and in birds that eat whole prey. As a result, the ventriculus will either be thin-walled, relatively small or both in birds such as lorries and lorikeets, hummingbirds, some insectivorous birds and raptors. The size of the ventriculus not only varies with species but also can be altered in

CHAPTER 7

Gastrointestinal System and Pancreas



any bird by increasing the content of non-digestible fiber in the diet, with increasing amounts leading to a larger organ (Fig 7.33). This must be considered when determining the significance of ventricular size at necropsy.

Noninfectious Diseases

Noninfectious disease of the ventriculus includes trauma to the ventricular koilin and mucosa secondary to ingested foreign bodies. Depending on the species and thickness of the ventricular wall, there may be associated perforation. Grossly erosions, ulcers and hemorrhage are noted, and foreign material may be identifiable in the lesion.

Xanthomatosis is rare finding in the ventricular musculature. If the lesion is large enough, there is a nodular irregularity to the ventricular wall.

Vitamin E deficiency can lead to degeneration of the ventricular musculature. White foci and streaks may be seen (Fig 7.34).

Discoloration of the ventricular koilin and mucosa can follow the ingestion of some types of fruit (Fig 7.35). This must be distinguished from hemorrhage or other pathologic processes.

Infectious Diseases

Infectious diseases include PDD with the ventriculus becoming dilated and thin walled.

Adenovirus infections are typically multi-systemic, but in some birds, ventricular lesions are the only lesions noted. Grossly, small areas of necrosis and ulceration of the koilin and mucosa are noted.

Bacterial infections may be primary or secondary and result in necrosis, loss of koilin, ulceration of the underlying mucosa and hemorrhage (Fig 7.36). A fibrinous exudate may cover an underlying ulcer.

Ventricular mycosis is seen in a variety of pet birds and is especially common in finches. Fungal organisms (usually *Candida* sp.) are found in the koilin layer and occasionally in the mucosa. Gross changes are rarely seen.

CHAPTER 7

Gastrointestinal System and Pancreas



Metazoan infections of the ventriculus can lead to necrosis and hemorrhage of the mucosa and koilin (Fig 7.37), or be essentially incidental with little or no gross change, and small nematodes may not be seen at necropsy.

Papillomas and carcinomas of the ventriculus are reported and are morphologically similar to those of the proventriculus. Carcinomas are usually at the proventricular/ventricular junction; the exact site of origin may be difficult to determine in extensive tumors. These neoplasms may infiltrate into the ventricular muscle and extend laterally some distance from the primary site.

LESIONS OF THE SMALL AND LARGE INTESTINE

Normal Structure

The intestines of passerine and psittacine birds are relatively simple. The intestines of the budgerigar contain five loops before turning into the colon, which itself is relatively short. The first loop of the intestine is the duo-

denal loop (Fig 7.37a). Two shorter loops follow. In the middle of the second, the remnant of the yolk sac (the vitelline diverticulum) is found. This is considered the junction between the jejunum and ileum, although this is of little physiologic significance. The ileum is then comprised of two loops of similar length. Psittacine birds do not have ceca, and the cecum is poorly developed in common captive passerine birds. They are, however, important sites of disease in other species of birds.

Noninfectious Diseases

Noninfectious diseases of the intestinal tract of pet birds include trauma secondary to foreign bodies, ingested toxins and infrequent torsion or intussusception. Trauma and torsion are usually obvious at necropsy, but histologic examination of affected tissue may be necessary to rule out underlying disease. Torsion leads to distension of a portion of the intestine, and edema fluid may be present in the lumen. The intestinal wall is edematous and congested. Edema can also be seen in cases of severe malnutrition (Fig 7.38). Torsion

CHAPTER 7

Gastrointestinal System and Pancreas



can also lead to severe hemorrhage and red-black discoloration of the intestinal wall (Fig 7.39). True intussusception must be differentiated from agonal telescoping of a portion of the intestine. In true intussusception, there is edema and congestion with subsequent inflammation, fibrin deposition and adhesion formation.

Impaction of the intestines is usually the result of improper diet, ingestion of foreign material, and, in some cases, dehydration. The impacted section is dilated and firm, and foreign material and ingesta are present in the lumen (Fig 7.40).

Infectious Diseases

Numerous infectious agents affect the large and small intestines. Enteritis occurs to some degree in approximately 30% of birds with disease caused by psittacine herpesvirus (Pacheco's disease virus). The lesions are generally mild, but severe enteric necrosis and hemorrhage that is seen grossly on the mucosal and serosal surfaces may occur (Fig 7.41).

Occasionally polyomavirus infection leads to necrosis and hemorrhage of the intestinal tract (Fig 7.42).

Paramyxovirus-1 (exotic Newcastle's disease) can potentially infect many species of pet birds. Lesions are variable, but gross hemorrhage and necrosis are present in the intestines of some birds.

Adenovirus also causes hemorrhagic enteritis in pet birds. Gross necrosis and hemorrhage are noted.

Reovirus, coronavirus and rotavirus have been implicated as causes of avian viral enteritis, but their occurrence in pet birds is poorly documented. Gross lesions are nonspecific with edema and possible mucosal necrosis seen.

A variety of bacteria cause enteritis in psittacine birds. Gram-negative pathogens can be primary or secondary invaders. Most pathogenic enteric bacteria generally are invasive, resulting in significant lesions outside of the intestinal tract.

The gross lesions of a bacterial enteritis include redness, exudation, and in some cases ulceration of the mucosa

CHAPTER 7

Gastrointestinal System and Pancreas



(Fig 7.43, Fig 7.44). Diphtheritic membranes can be seen in severe cases (Fig 7.45). Gas or fluid may distend the intestine. Generally there is fecal soiling of the feathers of the vent, a lesion consistent with diarrhea.

Gram-positive bacteria also cause enteric disease. Enteritis and septicemia due to *Enterococcus hirae* is reported in ten psittacine species. This organism, however, is found in the feces of normal birds and may be a part of the normal flora.

Clostridial overgrowth of the intestines may result in fatal enteritis. Lesions are most severe in the small intestine and vary from focal to diffuse hemorrhage, necrosis and fibrin deposition. Although severe hemorrhage may be present, no other changes are noted in some cases (Fig 7.46). Ulcerative enteritis of quail is due to *Clostridium colinum* (Fig 7.47).

Mycobacterial infections occur sporadically in many species and they are especially common in grey-cheeked parakeets and red siskins. The primary site of infection for the *M. avium/intracellulare* complex and *M. genavense*,

the two most common causes of mycobacteriosis in birds, is the intestinal tract. Gross lesions include diffuse and/or nodular thickening and opacification of the intestinal wall (Fig 7.48, Fig 7.49).

Primary mycotic infections of the intestines are rarely reported. Secondary infections, particularly by *Candida* sp. or zygomycete fungi are occasionally seen, and the lesions are similar to those described in the upper gastrointestinal tract.

Giardia and *Hexamita* spp. are two flagellates that are considered to cause intestinal disease. These organisms may cause minimal gross change. Excessive fluid, excessive mucus and mucosal hyperemia are seen in some birds. Wet mounts of intestinal (particularly duodenal) scrapings from a bird that has just died are the most sensitive means of finding these organisms.

Two species of *Eimeria* (*E. dunsingi* and *E. haematodi*) and one species of *Isospora* (*I. psittaculæ*) are described in psittacine birds. The coccidium of canaries is *I. canaria*. These four organisms complete their life cycle in the

CHAPTER 7

Gastrointestinal System and Pancreas



intestine. Coccidia also infect many other species of birds including cranes, waterfowl and poultry.

Coccidial infections may be inapparent or result in disease. When disease occurs gross lesions vary from excessive fluid in the intestinal lumen to dilation and reddening of the intestine with grey-yellow foci visible on the serosal surface (Fig 7.50). A fibrino-necrotic enteritis occurs in severe cases. Different species of coccidia have different trophisms for specific portions of the intestinal tracts.

Cryptosporidiosis is reported in a wide range of birds, including ducks, chickens, psittacine birds and ostriches. Infection is not always associated with disease. Cryptosporidiosis is characterized grossly by mucosal thickening and excessive mucus production.

Although toxoplasmosis is uncommon in pet birds, it causes a systemic disease, and intestinal lesions may or may not occur. The intestines may be dilated and there may be pasting of the vent, suggesting diarrhea.

Although not seen in common pet species, *Histomonas* is a cause of typhlitis, particularly in Galliformes. Gross lesions are similar to those of turkeys, with enlargement of the ceca, mottling of the cecal wall and a caseous exudate in the lumen (Fig 7.51).

Metazoan parasites are infrequent causes of clinical disease in companion birds or those housed in well-managed aviaries. Cestodes are occasionally diagnosed at necropsy. There is usually no associated gross or histologic lesion. Cestodes are particularly common in Australian finches and wild-caught African grey parrots and cockatoos. These parasites will survive in their hosts for many years and have the potential for causing intestinal obstruction in rare cases.

Numerous nematode parasites may be found in the intestinal lumen in severe cases, and blockage of the intestines may occur (Fig 7.52, Fig 7.53). Of particular concern are roundworms, which are particularly common in Australian grass parakeets (*Neophema* sp.)

CHAPTER 7

Gastrointestinal System and Pancreas



and cockatiels that are raised in cages that reach the ground.

Acanthocephalids are rarely found in birds. As in mammals, they penetrate into the intestinal wall, and gross nodules are seen on the serosal surface.

Neoplasms

Primary neoplasms of the intestine include carcinoma and several types of sarcoma. Carcinomas are infrequent and present as variably sized masses that may be ulcerated on the mucosal surface. Sarcomas present as masses within the intestinal wall that vary from firm and red-brown to gray-white or yellow. Myxosarcoma will have a shiny myxoid appearance (Fig 7.54).

Lymphosarcoma and histiocytic sarcoma of the intestinal tract usually present as a diffuse or nodular thickening that must be differentiated from conditions such as mycobacteriosis.

LESIONS OF THE CLOACA

Normal Structure

The cloaca is the combined outflow tract of the digestive, urinary and reproductive tracts (Fig 7.54a). The colorectum enters into the coprodeum, the ventral aspect of the cloaca. Dorsally and separated by a horizontal fold from coprodeum is the urodeum into which the ureters empty. The oviduct in the female enters the urodeum from the left lateral wall. The deferent ducts enter the urodeum in the male. The urodeum and coprodeum open into the common chamber of the proctodeum.

Noninfectious Diseases

Impaction of the cloaca can result from a variety of causes including failure to pass an egg, intrinsic disease of the cloacal wall and loss of muscle tone due to viral-induced ganglioneuritis (PDD). Grossly there is dilatation of the cloacal wall and it may be irregularly thickened (Fig 7.55). The lumen may contain an egg, impacted fecal material or products of inflammatory dis-

CHAPTER 7

Gastrointestinal System and Pancreas



ease (Fig 7.56, 7.57). Abscesses of the cloacal wall may partially obstruct the cloaca or rupture into the lumen of the cloaca.

There are a variety of causes of cloacal prolapse. The prolapsed mucosa will appear nodular or proliferative, and there may be areas of necrosis and hemorrhage (Fig 7.58). Cloacal prolapse is especially common in tame umbrella cockatoos.

The use of barium in radiologic diagnosis can lead to a slight discoloration of the cloacal wall grossly, as the barium will be taken up by the mucosa of the cloaca.

Infectious Diseases

Infections affecting the cloaca are the same as those seen in the upper intestinal tract, and the gross and histologic features are similar. There may be thickening and necrosis of the cloacal wall with multiple abscess formation (Fig 7.59).

Neoplasms

Papilloma is the most common cloacal neoplasm and appears more common in New World parrots, particularly Amazon parrots and macaws. Papillomas occur in the cloacal mucosa near the junction with the skin but may extend into the cloaca for some distance. Lesions may be focal or diffuse (Fig 7.60). When the papillomas are large, they prolapse and may ulcerate (Fig 7.61).

In some birds there is an apparent correlation between the occurrence of cloacal papillomas and proliferative biliary, pancreatic or upper intestinal lesions, and these changes should be ruled out in affected birds. Evidence of papillomaviruses in these lesions has not been found. However, a high percentage of these lesions contain psittacine herpesviruses identical or closely related to those that cause Pacheco's disease.

Cloacal carcinoma is an infiltrative tumor that leads to thickening of the cloacal wall. Carcinomas are usually firm and gray-white (Fig 7.62).

CHAPTER 7

Gastrointestinal System and Pancreas



Smooth muscle tumors are infrequently reported. They present as thickened lesions of the cloacal wall, or they may protrude from the vent.

LESIONS OF THE EXOCRINE PANCREAS

Normal Structure

The largest portion of the pancreas lies within the loop of the duodenum. This portion of the pancreas extends cranially and may come in contact with the spleen. In psittacine birds, a portion of the pancreas parallels the abaxial side of the right duodenal loop (see Fig 7.37a). The normal pancreas is yellow to yellowish pink with a finely lobulated surface.

Noninfectious Diseases

Diseases affecting the exocrine pancreas may also affect the Islets of Langerhans. Specific diseases of the endocrine pancreas are covered in Chapter 9.

The pancreas is the target organ in cases of zinc toxicity. Gross lesions may not be noticeable, but in some cases

there can be marked discoloration and mottling (Fig 7.63).

Acute pancreatic necrosis is seen in psittacine birds, particularly quaker parakeets. Many of these birds die suddenly. Gross lesions include a firm pale or mottled pancreas, variable hemorrhage and adjacent fat necrosis characterized by firm yellow-white foci (Fig 7.64).

Pancreatic fibrosis of undetermined cause is also seen infrequently. Grossly the pancreas is firm and irregular (Fig 7.65).

Infectious Diseases

Viral and bacterial agents reported to cause pancreatitis include herpesvirus, polyomavirus, adenovirus, paramyxovirus (PMV-3), poxvirus, a variety of gram-negative bacteria and chlamydia. Gross lesions vary from none to hemorrhage and necrosis, and there may be a purulent exudate in cases of bacterial pancreatitis.

Paramyxovirus can cause chronic pancreatitis, particularly in *Neophema* sp. and small passerine birds. The affected organs are firm and irregular.

CHAPTER 7

Gastrointestinal System and Pancreas



Herpesvirus, polyomavirus, poxvirus, adenovirus and bacteria usually induce pancreatic necrosis and hemorrhage ([Fig 7.66](#)).

Parasitic pancreatitis can follow the plugging of pancreatic ducts by nematodes or trematodes. Grossly pancreatic ducts are thickened and prominent. Trematodiasis may result in brown-black pigmentation ([Fig 7.67](#)). Pancreatic trematodiasis is seen almost exclusively in Amboina king parrots.

Neoplasms

Bile duct hyperplasia and papilloma formation is seen in some birds with internal papillomatosis. These low-grade papillary adenocarcinoma generally have no gross lesions.

Carcinomas are usually infiltrative with poorly defined borders. Grossly there may be obvious infiltration of the adjacent small intestine and in severe cases most of the normal pancreatic architecture is lost. There may be severe adhesion formation, binding the intestines and other organs into a solid mass ([Fig 7.68](#), [Fig 7.69](#)).

These tumors occur most commonly in cockatiels. Abdominal effusion is another common manifestation of this disease.

CHAPTER 7

Gastrointestinal System and Pancreas



FURTHER READING

Anderson NJ: Recurrent deep foreign body granuloma in the tongue of an African grey parrot (*Psittacus erithacus erithacus timneh*). *J Avian Med Surg* 11:105-109, 1997.

Antinoff N, Hoefer H, Rosenthal KL, et. al: Smooth muscle neoplasia of suspected oviductal origin in the cloaca of a blue-fronted Amazon parrot (*Amazona aestiva*). *J Avian Med Surg* 11:268-272, 1997.

Bauk L: A clinical approach to neoplasia in the pet bird. *Sem Avian Exotic Pet Med* 1:65-72, 1992.

Campbell TW: Neoplasia. In Harrison GJ, Harrison LR, (eds): *Clinical Avian Medicine and Surgery*. Philadelphia, WB Saunders Co, 1986, pp 500-508.

Cannon C: Proventricular and ventricular obstruction with bedding materials. *J Assoc Avian Vets* 6:40, 1992.

Cheesman MT, Riddel C: Esophagitis due to a herpesvirus associated with mortality in a psittacine aviary. *Avian Dis* 39:3, 1995.

Clark FD: Proventricular dilatation syndrome in large psittacine birds.

Avian Dis 28:813-815, 1984.

Cooper JE, Lawton MPC, Greenwood, AG: Papillomas in psittacine birds. *Vet Rec* 119:535, 1988.

Clipsham R: Noninfectious diseases of pediatric psittacines. *Sem Avian Exot Pet Med* 1:22-23, 1993.

Clipsham R: Avian pathogenic flagellated enteric protozoa. *Sem Avian Exotic Pet Med* 4:112-123, 1995.

Clyde VL, Patton S: Diagnosis, treatment and control of common parasites in companion and aviary birds. *Sem Avian Exot Pet Med* 5:75-84, 1996.

Deriese LA, Chiens K, Dehert P, et. al: *Enterococcus hirae* infections in psittacine birds: Epidemiologic, pathological and bacteriological observations. *Avian Pathol* 24:523-531, 1995.

Dhillon AS: An outbreak of enteritis in a psittacine flock. *Proc Assoc Avian Vet*, 1988, pp 185-188.

Gerlach H: Viruses. In Ritchie BW, Harrison GJ, Harrison LR (eds): *Avian Medicine: Principles and Application*. Lake Worth, FL, Wingers Publishing, 1994, pp 863-948.

Gerlach H: Bacteria. In Ritchie BW, Harrison GJ, Harrison LR (eds): *Avian*

CHAPTER 7

Gastrointestinal System and Pancreas



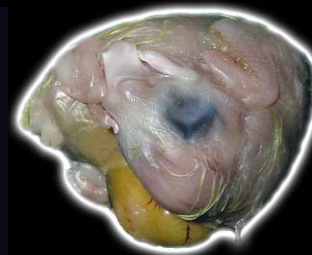FURTHER READING

(CONTINUED)

- Medicine: Principles and Application. Lake Worth, FL, Wingers Publishing, 1994, pp 949-989.
- Gomezvillamanlos JC, Delasmulas JMM, Hervas S, et al: Splenoenteritis caused by adenovirus in psittacine birds: A pathological study. *Avian Pathol* 24:553-563, 1995.
- Goodwin MA, Krabill VA: Cryptosporidiosis in birds: A review. *Avian Pathol* 18:365-384, 1989.
- Graham DL: Internal papillomatous disease. *Proc Assoc Avian Vet*, 1988, p 31.
- Graham DL: Acute pancreatic necrosis in Quaker parrots (*Myiopsitta monachus*). *Proc Assoc Avian Vet*, 1994, pp 87-88.
- Gregory CR, Ritchie BW, Latimer KS, et al: Proventricular dilatation disease: A viral epornitic. *Proc Assoc Avian Vet*, 1997, pp 43-52.
- Hess L, Bartick T, Hoefer H: *Clostridium tertium* infection in a Moluccan cockatoo (*Cacatua moluccensis*) with megacolon. *J Avian Med Surg* 12:30-35, 1998.
- Hillyer EV, Moroff S, Hoefer H, et al: Bile duct carcinoma in two out of ten Amazon parrots with cloacal papillomas. *J Assoc Avian Vets* 5:91-95, 1991.
- Hoefer HL: Diseases of the gastrointestinal tract. In Altman R, Clubb S, Dorrestein GM, Quesenberry K (eds): *Avian Medicine and Surgery*, Philadelphia, WB Saunders Co, 1997, p 421.
- Hubbard GB, Schmidt RE, Eisenbrandt DL: Fungal infections of ventriculi in captive birds. *J Wildl Dis* 21:25-28, 1985.
- Latimer KS, Rakich PM, Niagro FD, et al: An updated review of psittacine beak and feather disease. *J Assoc Avian Vet* 5:211-220, 1991.
- Latimer KS, Niagro FD, Rakich PM, et al: Investigation of parrot papilloma virus in cloacal and oral papillomas of psittacine birds. *Vet Clin Path* 26:158-163, 1997.
- Leach MW: A survey of neoplasia in pet birds. *Sem Avian Exotic Pet Med* 1:52-64, 1992.
- Ley DH: Avian cryptosporidiosis: An emerging disease. *Proc Intl Conf Zool Avian Med*, 1987, pp 299-303.
- Mannl A, Gerlach H, Leipold R: Neurotrophic gastric dilatation in Psittaciformes. *Avian Dis* 31:214-221, 1987.

CHAPTER 7

Gastrointestinal System and Pancreas



FURTHER READING

(CONTINUED)

McDonald S, Lowenstine L, Ardans A: Avian pox in blue-fronted Amazon parrots. *J Am Vet Med Assoc* 179:1218-1222, 1981.

Murphy J: Psittacine trichomoniasis. *Proc Assoc Avian Vet*, 1992, pp 21-24.

Murtaugh RJ, Ringler DS, Petrak ML: Squamous cell carcinoma of the esophagus in an Amazon parrot. *J Am Vet Med Assoc* 188:872-873, 1986.

Page CD, Haddad K: Coccidial infections in birds. *Sem Avian Exot Pet Med* 4:138-144, 1995.

Pass DA, Perry RA: The pathology of psittacine beak and feather disease. *Aust Vet J* 61:69-74, 1984.

Petrak ML, Gilmore CE: Neoplasms: *In* Petrak ML (ed): *Diseases of Cage and Aviary Birds* 2nd ed. Philadelphia, Lea and Febiger, 1982, pp 606-637.

Rae MA, Roskopf WJ: Mycobacteriosis in passerines. *Proc Assoc Avian Vet*, 1992, pp 234-242.

Ritchie BW, Niagro FD, Kyjert PD, et al: A review of psittacine beak and feather disease. *J Assoc Avian Vet* 3:143-150, 1985.

Roskopf W: Digestive system disorders. *In* Roskopf W, Woerpel R (eds): *Diseases of Cage and Aviary Birds* 3rd ed. Baltimore, Williams and Wilkins, 1996, pp 436-448.

Roudybush T: Growth, signs of deficiency and weaning in cockatiels fed deficient diets. *Proc Assoc Avian Vet*, 1986, pp 333-340.

Rupiper DJ: Hemorrhagic enteritis in a group of great-billed parrots (*Tanygnathus megalorynchos*). *J Assoc Avian Vets* 7:209-211, 1993.

Schmidt RE: Morphologic diagnosis of avian neoplasms. *Sem Avian Exotic Pet Med* 1:73-79, 1992.

Schmidt RE: Pathology of caged birds. *In* Roskopf W, Woerpel R (eds): *Diseases of Caged and Aviary Birds* 3rd ed. Baltimore, Williams and Wilkins, 1996, pp 857-879.

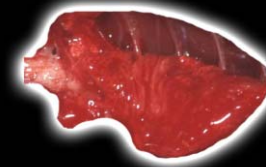
Speer BL: A clinical look at the avian pancreas in health and disease. *Proc Assoc Avian Vet*, 1998, pp 57-64.

Steinberg H: Leiomyosarcoma of the jejunum in a budgerigar. *Avian Dis* 32:166-168, 1988.

Sundberg JP, Junge RE, O'Banion MK, et al: Cloacal papillomas in psittacines. *Am J Vet Res* 47:928-932, 1988.

CHAPTER 8

Respiratory System



After removing the gastrointestinal tract, the respiratory system can be seen. The respiratory organs may be observed *in situ*, and the trachea, syrinx and lungs should be removed from the body. In some cases lung lesions may be present that only can be seen on the posterior aspect. At this time air sacs should be observed and if they seem abnormal, appropriate samples taken. In addition, the upper respiratory tract should be examined, and the nasal passages and sinuses opened.

NORMAL STRUCTURE

The cere is the thickened portion of integument that straddles the base of the nasal region. It may be feathered or bare, and it may or may not contain the nares (nostrils).

The external nares open into the nasal cavity, which is tubular in shape and separated into right and left chambers by the nasal septum. Along the lateral walls of the nasal cavity are scrolls of cartilaginous and bony nasal

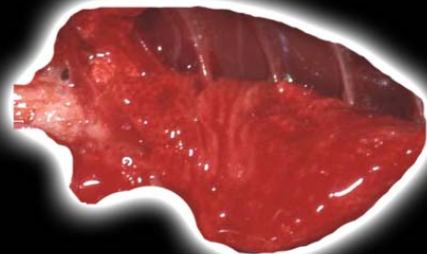
conchae. This caudal section connects dorsally with the infraorbital sinus, which is a large cavity under the skin primarily in the lateral region of the upper jaw. The right and left sinuses communicate in psittacines but not in passerines. Numerous diverticulae from the sinus extend around the eye and ear and into the maxillary and mandibular beak and pneumatized sections of skull. These diverticulae communicate with the cervicocephalic air sac at its caudal-most extent. Because of these interconnections, disease in one portion of the system has the potential to spread widely.

The nasal cavity opens into the oropharynx via the choana, a median slit-like structure in the palate. The rima glottis is the laryngeal opening into the trachea. The larynx is comprised of four laryngeal cartilages.

Closed cartilage rings (shaped like overlapping signet rings) form the avian trachea, with some species variations. Curassows and spoonbills have long tracheal coils between the skin and pectoral muscle. In penguins and toucans, the trachea is divided at the cranial end of

CHAPTER 8

Respiratory System



the neck into the left and right tubes by a medium cartilaginous septum. Emus and ruddy ducks have an inflatable sac-like diverticulum.

The syrinx is at the tracheal bifurcation within the thorax. Male ducks of the subfamily Anatinae have a syringeal bulla, which is an asymmetrical dilation on the left side of the syrinx.

The primary bronchi begin at the tracheal bifurcation and branch to form the secondary bronchi within the lung parenchyma.

Air sacs are thin-walled structures with limited vascularity. There are nine air sacs in companion birds: the unpaired clavicular, and the paired cervical, anterior thoracic, posterior thoracic and abdominal air sacs. The clavicular air sac extends into the humerus, coracoid, scapula and clavicle. The cervical air sacs are located between the lungs (Fig 8.0) dorsal to the esophagus, with extensions into the vertebrae. The abdominal air sacs penetrate into the intestinal peritoneal cavity. Except for the abdominal pair, each air sac is connected directly to a

secondary bronchus. The abdominal air sac connects to a primary bronchus. The cervicocephalic air sac is not part of the pulmonary air sac system and is not used in gas exchange.

DISEASES OF THE UPPER RESPIRATORY SYSTEM

Congenital Diseases

Choanal atresia is described in African grey parrots and an umbrella cockatoo (*Cacatua alba*). A persistent membrane or bony plate at the palate of the nasal cavity results in a closed choanal slit. Young birds will present with a chronic nasal or ocular discharge and, in some cases, the infraorbital sinuses will be distended with clear secretions.

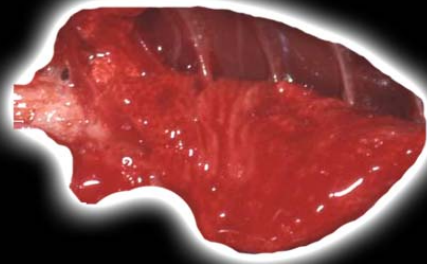Infectious Diseases

Bacterial

A number of gram-negative bacteria and occasionally gram-positive organisms can cause a bacterial sinusitis. Acute sinusitis is characterized by a serous discharge

CHAPTER 8

Respiratory System



with swelling and redness in the orbital area and nares (Fig 8.1).

Chronic infections are generally more common in cockatiels, Amazons, macaws and African greys. They are associated with a mucopurulent discharge and variable tissue distortion of the nares and beak or swelling of the periorbital sinuses and choanal slit region (Fig 8.2). There is loss or blunting of the palatine papilla and the formation of small pyogranulomas or granulomas in the mucosa. The sunken eye syndrome of macaws is associated with chronic bacterial sinusitis. The enophthalmia that occurs appears to be a sequela of an infection in the infraorbital sinus diverticulae around the eye.

Another specific syndrome attributed to a bacterial sinusitis is the lockjaw syndrome of cockatiels. A number of microorganisms have been isolated from the sinuses of affected birds including *Bordetella avium*, *Klebsiella* sp., *Aeromonas* sp., *Pseudomonas* sp., *Enterococcus* sp., *Staphylococcus* sp., *Streptococcus* sp., and *Bacillus* sp.

The disease generally affects young cockatiels three to ten weeks of age. Early lesions include a nasal and ocular discharge and swollen periorbital tissues. Nasal passages, sinuses and air spaces within cranial bones will contain mucopurulent inflammatory exudates. Osteomyelitis of the cranial bones and perineuritis are often present. The lesions in the sinuses and adjacent muscles of the temporomandibular joint are the most significant.

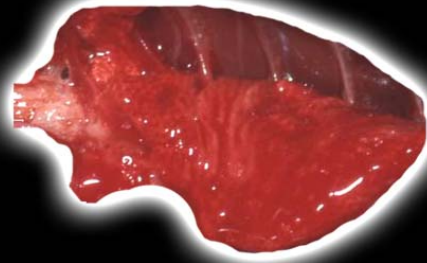
Mycotic

Members of the genus *Aspergillus* and the class Zygomycetes are capable of causing localized and/or disseminated disease. This group is characterized by the formation of hyphae in tissue.

Localized lesions have been described in the trachea, bronchi, sinus and nasal cavity. In nasal cavity infections, the respiratory region of the nose is more susceptible than the vestibular region. Most mycotic rhinitis infections in psittacines start unilaterally and have a mucopurulent discharge (Fig 8.3). The fungal organisms tend to invade into the sinuses, blood vessels, turbinate cartila-

CHAPTER 8

Respiratory System



ges and nasal bones. Demonstrating the organism cytologically, histologically or by culture is necessary to confirm the etiology.

Cryptococcus neoformans infrequently causes disease in birds but when it does, the respiratory tract appears to be the portal of entry. The lesions are of a myxomatous, gelatinous, tan to white material within the nasal and infraorbital sinuses, lungs, air sacs and brain. On exfoliative cytology, the organisms are narrow-based, budding, round yeast with a thick capsule. India ink stains demonstrate the large heteropolysaccharide capsule.

Noninfectious Diseases

Pet birds that are fed primarily a seed or cereal grain diet or have intestinal mucosal lesions that interfere with conversion of carotenoids to vitamin A may develop vitamin A deficiency. Vitamin A deficiency results in epithelial squamous metaplasia, which is manifested grossly as mucosal thickening of the oral cavity, conjunctiva, nasal lacrimal duct, upper alimentary tract and respiratory tract (Fig 8.4).

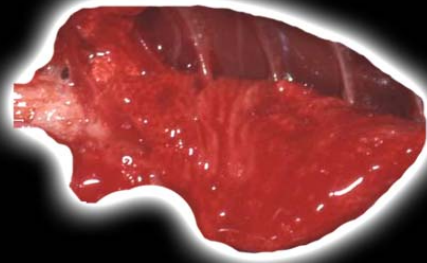
Keratinizing epithelium that blocks the ducts of submucosal mucus glands is the typical lesion. These glands enlarge and become secondarily infected, resulting in large keratin granulomas within the nasal or oral cavity. Some birds, especially African grey parrots, develop massive keratin rhinoliths that distort the nares and nasal sinus. Cytologic preparations will contain large metaplastic epithelial cells and, in cases of secondary infection, bacteria and inflammatory cells (Fig 8.5).

Neoplasia

Carcinoma and adenocarcinoma of the upper respiratory system may arise from the nasal or sinus mucosa or from glandular epithelium. These tumors can become quite large leading to distortion of the skull (Fig 8.6). They may impinge upon the brain in severe cases. Grossly the tumor is gray-white, firm and nodular.

CHAPTER 8

Respiratory System



Diseases of the Trachea

Viral Diseases

Herpesviruses are enveloped DNA virions that measure approximately 120 to 200 nm in diameter. Infectious laryngotracheitis of chickens, Amazon tracheitis virus, and parakeet herpesvirus are caused by alpha herpesviruses. Amazon tracheitis virus and parakeet herpesviruses have a tissue tropism for the respiratory tract. It is unusual for Pacheco's disease to affect the respiratory system.

The classic example of a herpesvirus outbreak that primarily targets the respiratory tract is infectious laryngotracheitis of chickens. This has also been recognized in Amazon parrots, brown-throated conures, Bourke's parakeets (*Neopsephotus bourkii*), whiskered lorikeets (*Oreopsittacus arfaki*), and rosellas (*Platycercus* sp.). Grossly the tracheal mucosa and lungs appear edematous, congested and hemorrhagic (Fig 8.7).

Finch cytomegalovirus is a host-specific beta herpesvirus. It appears to be a disease primarily of finches,

especially Gouldian finches, and is characterized by high mortality, conjunctivitis, tracheitis and bronchitis. Gross lesions include hyperemia and edema of the conjunctiva, air sac thickening and hyperplasia of the tracheal, syringeal and bronchial mucosa. The esophagus and nasal conchae may have focal diphtheritic lesions.

Bacterial Disease

With bacterial tracheitis, the mucosa is reddened and there can be multifocal necrosis and fibrin deposition (Fig 8.8). Cytologically, a pleocellular infiltrate and bacteria may be found (Fig 8.9).

Mycotic Disease

The fungal organisms associated with cases of mycotic tracheitis are the same as those producing mycotic sinusitis. Localized fungal lesions have been described in the trachea, bronchi, sinus, nasal cavity and body cavity. The lumen of the trachea, syrinx or bronchi will be partially to completely occluded with white to cream-colored fib-

CHAPTER 8

Respiratory System



rinocaseous material (Fig 8.10, Fig 8.11) The syrinx is a common site of primary infection.

Parasitic Disease

Trichomonads are flagellated protozoa that are primarily enteric pathogens. There are several closely related organisms that have been isolated from lesions in the upper respiratory tract of birds.

Trichomonas gallinae, normally a pathogen of the digestive tract of Columbiformes and raptors, is found within lesions of the respiratory sinuses and trachea of these species. Sinuses may be swollen (Fig 8.12), and the mucosa is covered with superficial dry caseous diphtheritic membranes. Caseous material fills the tracheal lumen. Another common location for these lesions is the pharynx, with possible obstruction of the choanal slit or the glottis.

These protozoa can be visualized on wet mount preparations. The exudates from infraorbital sinuses and intestinal contents will have many motile protozoa with an undulating membrane and flagella. They are pear-

shaped, 12-20 μm in length, 8-12 μm in width, and have a distinct nucleus.

Syngamus trachea, also commonly known as the "gapeworm," has been reported in psittacine birds only once. This nematode parasite inhabits the trachea, bronchi and bronchioles of waterfowl, Galliformes and occasionally kestrels and Columbiformes. The large, robust, bright red helminth appears Y-shaped because the male is attached to the female. *Cyathostoma* is a similar worm that can be found in ducks and geese.

Grossly the trachea may be hemorrhagic with many nematodes and eggs (Fig 8.13); however, in some cases there are nematodes with less evidence of hemorrhage (Fig 8.14).

Sternostoma tracheacolum, a parasitic rhinonyssid mite, is the tracheal mite of canaries and Gouldian finches (*Erythrura gouldiae*). Mites attach to the mucosa by embedding their legs into the connective tissue. Mucus from the host will coat the mites. They are recognized as small black masses within the lumen of the trachea.

CHAPTER 8

Respiratory System



Inhaled Toxins/Irritants

Exposure to gases produced by undiluted sodium hypochlorite (5% chlorine bleach) appears to induce tracheal lesions that can result in death. The initial lesion is tracheal hyperemia, followed by multifocal necrosis and diphtheritic membrane formation. Caseous material may cover the tracheal mucosa. These birds may also have yellowish, cloudy air sacs.

Inhaled ivermectin can result in respiratory distress and a necrotizing tracheitis. It is unknown if the inhaled ivermectin or the carrier is responsible.

Foreign bodies lodging in the trachea are not an uncommon problem. In cockatiels, millet seeds are the most common foreign bodies to become lodged at the tracheal bifurcation. Acutely the mucosa of the trachea becomes edematous and reddened, but if the lesion becomes chronic, exudate will develop.

Neoplastic Disease

Tumors of the trachea are rare in birds. Tracheal osteochondroma, which is the most common tracheal

tumor of dogs, was recognized in a psittacine bird. The tumor resulted in tracheal stenosis. The irregularly formed cartilage was ossified and protruded into the submucosal layer of the trachea.

DISEASES OF THE LOWER RESPIRATORY SYSTEM (LUNG)

Infectious Diseases

Viral Diseases

In the classic cases of avian polyomavirus, there is usually no gross lung lesion. Another form of avian polyomavirus is recognized in cockatoos. These birds have a chronic illness and are often emaciated. Grossly their lungs are moist and may have decreased buoyancy.

The Amazon tracheitis virus, parakeet herpesvirus and possibly other herpesviruses may cause pneumonia (see previous section on diseases of the trachea). The gross pulmonary lesions are edema and congestion. Upper respiratory tract disease (as described previously) and pneumonia can be caused by poxvirus infections. The

CHAPTER 8

Respiratory System



pneumonia is grossly nonspecific, with hyperemia, edema and possibly necrotic foci seen.

Bacterial Diseases

Bacterial pneumonia can occur from either inhalation of the bacteria or as part of a septicemic process. Grossly both processes will produce dark red lungs, occasionally with localized or multiple foci of abscessation ([Fig 8.15](#), [Fig 8.16](#), [Fig 8.17](#)). The lungs should be removed and examined on both sides, as occasionally lesions will not be seen on their anterior/ventral surface.

Nocardia is a gram-positive bacterium with branching filaments and an irregularly granular and beaded appearance. It is variably acid-fast. There are rare case reports of infections in birds. In most avian cases, the primary site of infection appears to be the respiratory tract with secondary involvement of other organs. The lung may have red to pink mottling and multiple grayish-white nodular lesions.

Mycobacteria are gram-positive, rod-shaped bacteria that stain with all acid-fast stains. In companion birds, *M.*

avium is the most common, although *M. genevense* is frequently recognized. The typical gross lesions are large, coalescing firm, white masses. In pet birds the nodular masses (tubercles) do not calcify. They are commonly found in the lung ([Fig 8.18](#)).

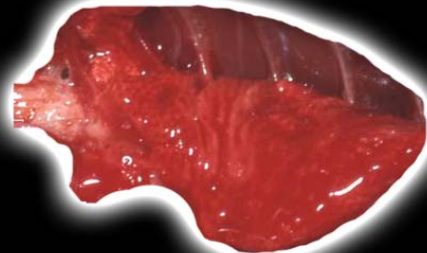
Mycotic Pneumonia

Aspergillus species are the most common fungi causing pneumonia in birds. Aspergillosis presents in several forms in pet birds. The type of gross lesion depends on the chronicity of the infection and the number of spores inhaled. Colonization may be limited to the site of primary infection.

The acute form results in solitary or multiple granulomas of the lungs ([Fig 8.19](#)) and is usually seen in young birds, raptors, waterfowl, poultry and recent imports. Penguins, pelagic waterfowl, gyrfalcons and birds (such as the ostrich) that originate from arid environments are extremely prone to aspergillosis if moved to a warm and humid environment.

CHAPTER 8

Respiratory System



The chronic pulmonary form is a slowly progressive disease. It is often the result of exposure to persistent low levels of spores in an immunocompromised bird. Grossly, the lesions include white to yellow plaques or nodules in the lung parenchyma with caseous, consolidated or necrotic centers and cavitation. Mycelial formation may lead to a greenish coloration of the lesions (Fig 8.20). In some cases the lungs may be almost completely effaced by a large mass lesion (Fig 8.21).

Other fungi that produce tissue hyphae are associated with pulmonary granulomas and pneumonia. These include *Penicillium* species and the class Zygomycetes, such as *Mucor*, *Rhizopus*, and *Absidia* species. The typical gross lesions consist of large granulomas in the lungs.

Pulmonary cryptococcosis (*Cryptococcus neoformans*) is generally an extension from the sinus infection (see previous description).

Protozoal Pneumonia

At least six species of sarcocystis infect birds. *Sarcocystis falcatula* appears to be the most significant in susceptible

pet birds that are inadvertent hosts. The North American opossum is the definitive host, and cowbirds and grackles are the intermediate hosts. Asexual reproduction of the protozoa occurs within the intermediate host's endothelium. This stage can result in serious or fatal disease in aberrant hosts.

The primary gross lesion in susceptible species is severe pulmonary congestion, edema or hemorrhage (Fig 8.22). Impression smears of lung tissue may contain organisms in some cases (Fig 8.23).

Toxoplasma

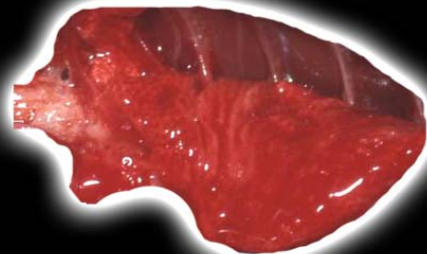
Toxoplasmosis is not common in birds in North America but is occasionally diagnosed. Grossly there is a nonspecific pneumonia with multiple hepatized foci (Fig 8.24).

Mites

Sternostoma tracheacolum is the tracheal mite of canaries and Gouldian finches (see previous discussion in the trachea section). Mites can be distributed throughout the

CHAPTER 8

Respiratory System



respiratory system, especially in juvenile birds. The mites, when present in the lungs, remain within the lumen of the primary, secondary, and rarely the tertiary bronchi and can be seen with careful observation.

Noninfectious Disease

Airborne Toxins

Documented reports of airborne pulmonary toxins are those caused by inhalation of pyrolysis products produced from overheated polytetrafluoroethylene-coated cooking pans, stove tops and coated heat lamps. The toxic products are made up of both gaseous and particulate materials.

The birds consistently have severely congested and hemorrhagic lungs (Fig 8.25). Watery red fluid may exude from the trachea and nares. Within the severely congested lungs, the lumen of the tertiary bronchi, atria and air capillaries are filled with abundant pale eosinophilic proteinaceous edema fluid.

Foreign Material Inhalation

The inhalation of foreign material occurs most commonly in hand-fed nestling psittacine birds and in sick birds that are being tube-fed. The presence of the material will elicit an inflammatory response with hemorrhage, congestion, fibrin accumulation and edema (Fig 8.26).

Hypersensitivity-associated Disease

Chronic obstructive pulmonary disease (macaw pulmonary hypersensitivity) with polycythemia appears most common in the blue and gold macaw. The lung lesions are generally advanced when polycythemia occurs. Grossly the lungs have a firm, rubbery texture and are moderately congested.

Vaccine-induced Reaction

A pulmonary lesion that has been associated with vaccine reactions in pet birds is suspected to be an anaphylactic reaction or type I hypersensitivity. Death occurs within minutes after the vaccination. The lungs

CHAPTER 8

Respiratory System



are congested, and there is loss of the air capillary lumen due to collapse.

Heart Failure Lung

Chronic pulmonary congestion results from heart failure. Grossly the lung is red and wet (Fig 8.27), and the lesion may be difficult to distinguish from other causes of severe edema and congestion.

Endogenous Lipid Pneumonia

Lipid pneumonia is an incidental and uncommon lesion of pet birds, for which the etiology is unknown. Many birds have concurrent atherosclerosis, liver disease or other lesions in the respiratory tract. The gross appearance is of white foci typically subtending the pleura of the lungs.

Embolic Pneumonia, Yolk and Bone Marrow

Egg yolk pneumonia is similar to foreign material inhalation pneumonia. The anatomy of the mesenteries provides access of the ovary and oviduct to the caudal abdominal air sacs. Any disease, trauma or neoplasm of

the reproductive tract during follicular development can result in rupture of the egg yolk material into the intestinal mesenteric space. Any disease of the caudal air sacs allows access of the yolk into the respiratory system and inhalation into the lung.

The lungs, especially in the caudal fields, will be severely hemorrhagic and coated with yolk material. The yolk will be associated with hemorrhage, fibrin deposition and edema.

Pneumoconiosis

Pneumoconiosis (anthrasilicosis) is the focal accumulation of dust-laden macrophages in the interatrial septa of the tertiary bronchi. These lesions generally suggest exposure to air-borne pollutants and appear incidental in sedentary pet birds. The lungs may have macroscopic miliary black foci, although usually the accumulations are not observed grossly.

CHAPTER 8

Respiratory System



Pulmonary Mineralization

Mineralization of the basement membranes of the pulmonary capillaries is seen sporadically in pet birds. Excess dietary calcium or severe renal disease may predispose to the development of this lesion. Excess dietary vitamin D3 has also been proposed to cause this lesion. Grossly, the foci in the lungs are generally at the periphery and are gray-white and gritty.

Neoplasia

Fibrosarcoma

Fibromas and fibrosarcomas are tumors that originate from fibrous connective tissue and are common neoplasms in pet birds. Fibrosarcomas are gray to white firm masses with irregular and indistinct borders. Fibrosarcomas are locally invasive although they rarely metastasize and have a moderate to high potential for recurrence, giving them a guarded prognosis.

Carcinoma

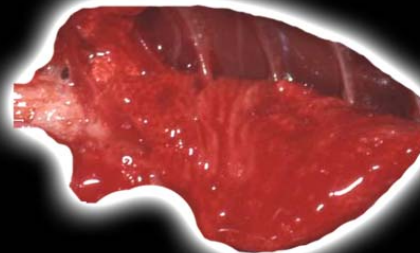
Primary pulmonary carcinomas are rare tumors of pet birds. The few cases reported may have arisen from the lung or the air sac. Grossly they may first present as superficial lesions after extending through the body wall ([Fig 8.28](#)). Multiple slightly firm gray-white foci may be identified in the lungs ([Fig 8.29](#)). In cases suspected as arising from either the lung or air sac, there has been extension of the lesion through the air sacs to bone, primarily of the right humerus.

Undifferentiated Pulmonary Tumors of Cockatiels

Massive discrete infiltrative pulmonary and air sac tumors have been recognized in cockatiels and occasionally in other birds. These tumors are large, firm, white to gray masses that replace areas of the lung ([Fig 8.30](#)). Often the bird dies when a tumor extends into the thoracic inlet, collapsing the interclavicular air sac and compressing the trachea. In some early cases, the tumor mass appears to arise from the mediastinal tissues. These tumors are so aggressive that they may invade vertebrae,

CHAPTER 8

Respiratory System



resulting in paralysis. These tumors may be associated with a polyomavirus.

Metastatic Tumors

Tumor metastases to the lungs of pet birds include adenocarcinoma and carcinoma from various primary sites, fibrosarcoma, hemangiosarcoma, liposarcoma, lymphosarcoma, melanoma, mesothelioma and osteosarcoma. Grossly, they all present as solitary or multiple masses (Fig 8.31). Identification of the primary site may be necessary for a definitive diagnosis in the case of poorly differentiated neoplasms.

LESIONS OF THE AIR SACS

Physical Agents/Trauma

Focal to diffuse subcutaneous pockets of air are most likely the result of a ruptured air sac. This condition has been described as secondary to trauma or from an underlying air sac infection. Air sac rupture is more commonly described in Amazons, macaws and cockatiels. The sites

are usually around the head, ear, dorsal cervical region and the flanks.

Infectious Disease

Bacterial Infection

The same bacterial organisms that cause pneumonia can cause air sacculitis. Grossly there may variable necrosis and yellow-white or gray exudate (Fig 8.32). With chronicity, large caseous masses may be found in the air sacs (Fig 8.33).

Mycobacterial Infection

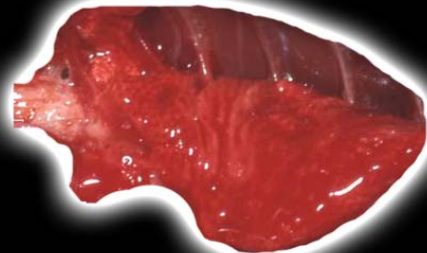
Air sacs can be involved in systemic mycobacteriosis. Air sac disease is characterized grossly by yellow-white nodules.

Chlamydophila Infection

The differential diagnosis for air sac lesions associated with chlamydophila can include chronic bacterial infections and mycotic air sacculitis. Grossly air sacs are thickened and opaque, and there may be some exudate.

CHAPTER 8

Respiratory System



Mycotic Air Sacculitis

The etiologic agents of mycotic air sacculitis are the same as those of mycotic sinusitis. *Aspergillus* species and Zygomycetes are the common organisms seen.

The inflammation and growth of the fungi generally efface the air sacs. In some cases, the exudate can be grossly similar to bacterial infection (Fig 8.34), while in others, there is green-black discoloration typical of mycotic infections with marked growth of organisms (Fig 8.35). This type of lesion contains potentially infective organisms, and appropriate necropsy safety precautions should be taken. In severe chronic cases there can be a dense off-white mass filling the air sac (Fig 8.36).

Parasitic Infection

Nematodes can occasionally be found on the air sacs of birds. *Serratospiculum auraculata* is the best described and is a primitive filarioid, common in falcons. The infections appear incidental. The adults and eggs of *Cyathostoma* species, nematodes of the family Syngamidae, are found

in air sacs, lungs, bronchi and trachea of raptors in the Falconiformes and Strigiformes families.

Trematodes are also occasionally found in the air sacs. They are usually considered to be an incidental finding (Fig 8.37). Affected air sacs may be slightly opaque, but usually no other lesion is seen.

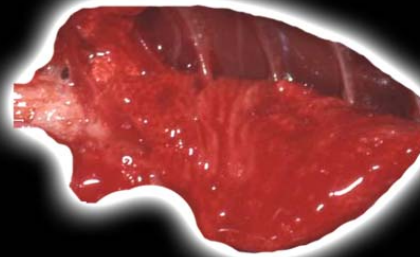
Neoplastic Disease

Air Sac Carcinomas

Air sac carcinomas are rare tumors that are difficult to definitively diagnose grossly as arising from the air sacs. The few cases described are in large mature psittacines. The initial presentation is of cystic masses or bony lesions primarily involving the right humerus. The cystic masses are fluid filled and have intraluminal large, friable, gray-brown, mottled polypoid masses (Fig 8.38). The tumors are poorly demarcated and unencapsulated. Finding areas where the tumor is continuous with the air sac reflection into the humerus and identifying it within the pulmonary parenchyma helps determine the origin.

CHAPTER 8

Respiratory System



FURTHER READING

Andre JP, Delverdier M, Cabanie P, et al: Malignant melanoma in an African grey parrot (*Psittacus erithacus erithacus*). J Assoc Avian Vet 7:83-85, 1993.

Andre J-P, Delverdier M: Primary bronchial carcinoma with osseous metastasis in an African grey parrot (*Psittacus erithacus*). J Avian Med Surg 13:180-186, 1999.

Bacciarini LN, Posthaus H, Pagan O, et al: *Nocardia nova* causing pulmonary nocardiosis of black cranes (*Limnocolax*

flavirostra). Vet Pathol 36:345-347, 1999.

Blandford TB, Seamon PJ, Hughes R, et al: A case of polytetrafluoroethylene poisoning in cockatiels accompanied by polymer fume fever in the owner. Vet Rec 96:175-178, 1975.

Brambilla C, Abraham J, Brambilla E, et al: Comparative pathology of silicate pneumoconiosis. Am J Pathol 96:149-170, 1979.

Brunner P, Meinel M: Fat-embolic vascular occlusions in avian lungs: Research of histologically determinable neutral fats in parrotlike birds (*Psittaciformes*). Vet Pathol 13:16-26, 1976.

Clipsham RC, Britt JO: Disseminated cryptococcosis in a macaw. J Am Vet Med Assoc 183:1303-1305, 1993.

Dennis PM, Heard DJ, Castleman WL: Respiratory distress associated with pulmonary fat emboli in an osprey (*Pandion haliaetus*). J Avian Med Surg 14:264-267, 2000.

Desmidt M, Ducatelle R, Uytendaele E, et al: Cytomegalovirus-like conjunctivitis in Australian finches. J Assoc Avian Vet 5:132-136, 1991.

Dorrestein GM, Buitelaar MN, van der Hage MH, et al: Evaluation of a bacteriological and mycological

examination of psittacine birds. Avian Dis 29:951-962, 1985.

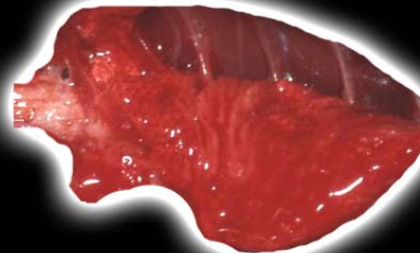
Dorrestein GM, van der Hage M, Kik M, et al: *Syngamus trachea*: An unusual infection in Vinaceous Amazons (*Amazona vinacea*). Proc Assoc Avian Vet, 2001, pp 59-65.

Fenwick B, Takeshita K, Wong A: A Moluccan cockatoo with disseminated cryptococcosis. J Am Vet Med Assoc 187:1218-1219, 1985.

Fitzgerald SD, Hanika C, Reed WM: Lockjaw syndrome in cockatiels associated with sinusitis. Avian Pathol 30:49-53, 2001.

CHAPTER 8

Respiratory System



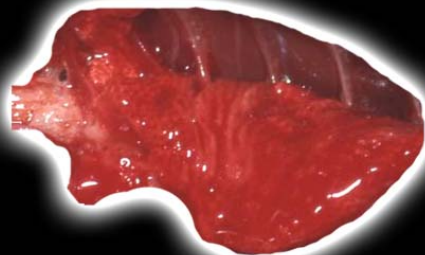
FURTHER READING

(CONTINUED)

- Hall RK, Bemis DA: A spiral bacterium found in psittacines. *Proc Assoc Avian Vet*, 1995, pp 345-347.
- Harcourt-Brown N: Comparative avian surgical anatomy. *Exotic DVM* 1(3):35-40, 1999.
- Harris D: Resolution of choanal atresia in African grey parrots. *Exotic DVM* 1(1):13-17, 1999.
- Hillyer EV, Orosz S, Dorrestein GM: Respiratory system. In Altman RB, Clubb SL, Dorrestein GM, Quesenberry K (eds): *Avian Medicine and Surgery*. Philadelphia, WB Saunders Co, 1997, pp 387-341.
- Jones MP, Orosz SE, Richman LK, et al: Pulmonary carcinoma with metastases in a Moluccan cockatoo (*Cacatua moluccensis*). *J Avian Med Surg* 15:107-113, 2001.
- Kennedy FA, Sattler-Augustine S, Mahler JR, et al: Oropharyngeal and cloacal papillomas in two macaws (*Ara spp.*) with neoplasia with hepatic metastasis. *J Avian Med Surg* 10:89-95, 1996.
- King AS, McLelland J: *Birds: Their Structure and Function*. London, Bailliere Tindall, 1984.
- Latimer KS, Niagro FD, Rakich PM, et al: Investigation of parrot papillomavirus in cloacal and oral papillomas of psittacine birds. *Vet Clin Pathol* 26:158-163, 1997.
- Lavoie M, Mikaelian I, Sterner M, et al: Respiratory nematodiasis in raptors in Quebec. *J Wild Dis* 35:375-380, 1999.
- McLelland JA: Respiratory system. In *A Color Atlas of Avian Anatomy*. Philadelphia, WB Saunders Co, 1991, pp 95-123.
- Okoye JOA, Gugnani HC, Okeke CN: Experimental infection of chickens with *Nocardia asteroides* and *Nocardia transvalensis*. *Avian Pathol* 20:17-24, 1991.
- Panigrahy B, Senne DA: Diseases of mynahs. *J Am Vet Med Assoc* 199:378-381, 1991.
- Parnell MJ, Hubbard GB, Fletcher KC, et al: *Nocardia asteroides* infection in a purple-throated sunbird (*Nectarinia sperapa*). *Vet Pathol* 20:497-500, 1983.
- Powers LV, Merrill CL, Degernes LA, et al: Axillary cystadenocarcinoma in a Moluccan cockatoo (*Cacatua moluccensis*). *Avian Dis* 42:408-412, 1998.
- Rombout PJ, Dormans JA, van Bree L, et al: Structural and biochemical

CHAPTER 8

Respiratory System



FURTHER READING

(CONTINUED)

effects in lungs of Japanese quail following a 1-week exposure to ozone. Environ Res 54:39-51, 1991.

Samour JH, Bailey TA, Cooper JE: Trichomoniasis in birds of prey (Order Falconiformes) in Bahrain. Vet Rec 136:358-362, 1995.

Sileo L, Sievert RR, Samuel MD: Causes of mortality of albatross chicks at Midway atoll. J Wildl Dis 26:329-338, 1990.

Smith BL, Poole WSH, Martinovich D: Pneumoconiosis in the captive New Zealand

and kiwi. Vet Pathol 10:94-101, 1973.

Stoltz JH, Galey F, Johnson B: Sudden death in ten psittacine birds associated with the operation of a self-cleaning oven. Vet Hum Toxicol 34:420-421, 1992.

Takeshita K, Fenwick B, Wong A: Cryptococcosis in captive cockatoos. Proc Assoc Avian Vet, 1986, pp 133-138.

Tidemann SC, McOrist S, Woinarski JC, et al: Parasitism of wild Gouldian finches (*Erythrura gouldiae*) by the air-sac mite *Sternostoma tracheacolum*. J Wildl Dis 28:80-84, 1992.

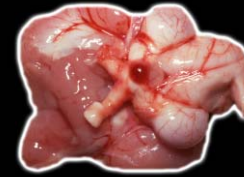Tsai SS, Chang TC, Kuo M, et al: Respiratory and intestinal

trichomoniasis in mule ducks. Avian Pathol 26:651-656, 1997.

Weissengruber G, Loupal G: Osteochondroma of the tracheal wall in a Fischer's lovebird (*Agapornis fischeri*, Reichenow 1887). Avian Dis 43:155-159, 1999.

CHAPTER 9

Endocrine Glands



As with the rest of the necropsy, the examination of the endocrine glands should be done each time at the same place in the procedure.

LESIONS OF THE PITUITARY GLAND

Removal and examination of the pituitary gland should be part of the examination of the brain (see Chapter 12). The pituitary gland is located in the sella turcica beneath the diencephalon and the optic chiasma. The pituitary is divided into the adenohypophysis and the neurohypophysis. In contrast to mammals, birds do not have a pars intermedia.

Inflammatory Disease

Infections of the oral cavity can become severe and extend to involve the pituitary. Grossly these lesions are yellow-white and often have the appearance of an abscess. There is necrosis of the pituitary gland and the surrounding bone. Bacteria, fungi and protozoa, such as

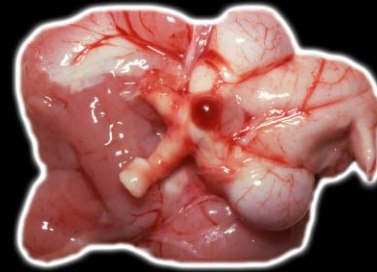Trichomonas sp., have been implicated and may be seen in the lesion.

The neurohypophysis may be affected by encephalitis involving the hypothalamus. Bacterial and viral infections are possible.

Severe trauma can lead to hemorrhage and secondary inflammation of the pituitary. The gross appearance may be dominated by the hemorrhage, with necrosis and inflammation being more prominent if the bird survives the traumatic incident.

Neoplasms

Adenomas and carcinomas have been reported, particularly in budgerigars. These tumors are usually red-brown and may extend outside of the sella turcica if large (Fig 9.1). They may compress the optic chiasma. There can be associated bone lysis. Adenomas grow by expansion, and there can be compression of adjacent brain. Adenomas are circumscribed, while the margins of carcinomas are less well differentiated.



CHAPTER 9

Endocrine Glands

LESIONS OF THE THYROID GLAND

The thyroid glands should be examined and removed after the initial incision and examination of the soft tissue of the neck (see Chapter 3).

The thyroid glands are paired and round to slightly oblong. They are found immediately lateral to the carotid arteries within the thoracic inlet. They are red-brown and similar to the syringeal muscle. The latter is sometimes confused with thyroid glands. Calcitonin-secreting cells are not present in avian thyroids except in doves and pigeons, where they are within the follicular epithelium. In other birds, they are in the ultimobranchial glands.

Congenital Lesions

Partial persistence of the caudal portion of the thyroglossal duct can lead to cyst formation within or adjacent to the thyroid gland.

Inflammatory Disease

Lymphocytic thyroiditis, which is similar to autoimmune disease of humans and dogs, has been seen in certain strains of chickens, and a morphologically similar lesion is seen sporadically in young African grey parrots. Affected glands are small and pale and may be slightly irregular.

Disseminated mycobacteriosis may involve the thyroid. Grossly the glands are enlarged, yellow-white and irregular.

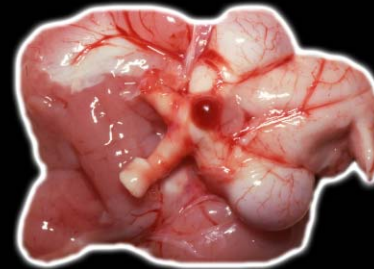
Inflammation of the soft tissue of the neck secondary to trauma or infection may involve the thyroid glands. The specific changes depend on the underlying cause.

Noninflammatory Disease

Apparent degenerative lesions are sporadically seen, particularly in budgerigars and cockatiels. Some older literature refers to the condition as dystrophy. Affected glands may be slightly enlarged, pale and irregular, becoming atrophied with chronicity (Fig 9.2). Foci of red-brown mottling may be seen.

CHAPTER 9

Endocrine Glands



Amyloid deposition is occasionally seen in the interstitium of the thyroid and is just one manifestation of generalized amyloidosis. Gross changes are usually not apparent, but the glands may be slightly enlarged, pale and friable.

Proliferative Disease

Thyroid hyperplasia (goiter) had been most commonly reported in budgerigars until recently when a high incidence in macaws, particularly blue and gold macaws, was described. The condition occurs sporadically in a wide variety of companion and other birds.

Thyroid hyperplasia is bilateral resulting in enlarged, red-brown or purple glands that apply pressure to the trachea, esophagus and other soft tissues of the neck and collapse the interclavicular air sac. Hyperplastic glands have a smooth surface (Fig 9.3).

Colloid goiter is considered the involutionary phase of thyroid hyperplasia. Colloid is produced, but endocytosis is decreased after T4 and T3 return to normal and TTH concentration is reduced. Affected glands are

enlarged and red-brown and have a translucent or glassy appearance on section. The condition usually cannot be differentiated from early hyperplasia grossly.

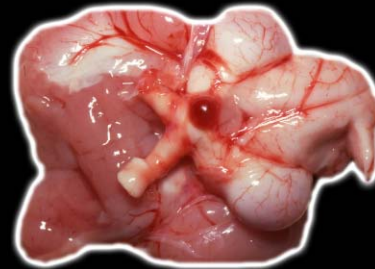Thyroid gland neoplasia presents as a unilateral swelling of the affected gland. The highest incidence of thyroid neoplasia occurs in budgerigars and cockatiels. Thyroid adenomas are most common. Thyroid adenomas are usually smooth and red-purple and may displace associated soft tissue (Fig 9.4).

PARATHYROID GLANDS

The parathyroid glands are examined at the same time as the thyroid gland. The avian parathyroid glands are paired structures that lie immediately caudal to the thyroid gland and immediately lateral to the carotid artery. They are ivory-colored, round and smooth. The parathyroids are often so small that they cannot be seen grossly if the bird is eating a diet with sufficient calcium.

CHAPTER 9

Endocrine Glands



The parathyroids of birds that are in a negative calcium diet may reach 2-3 mm in diameter.

Proliferative Disease

Hypertrophy and hyperplasia of the parathyroid may be obvious grossly but can be difficult to detect if minimal (Fig 9.5). The enlarged parathyroids are gray-white to yellow, and the condition is bilateral (Fig 9.6). Two or all four glands may be enlarged. Affected birds may also have grossly observable bone disorders (see Chapter 13).

Parathyroid adenomas can be unilateral or occasionally bilateral. In most birds they cannot be differentiated from severe hyperplasia (Fig 9.7).

ADRENAL GLANDS

After removal of the gastrointestinal organs, the adrenal gland can be easily visualized. The avian adrenal glands are paired in most species, but in a few

birds they may be fused. Jackdaws have several small accessory glands embedded in the epididymis.

Adrenal glands are pink-to-orange flattened tissues that lie at the medial and cranial aspect of the ventral surface of the cranial division of the each kidney (Fig 9.7a). Birds, unlike mammals, do not have a defined cortex and medulla to their adrenal glands, and gross differentiation of interrenal and chromaffin cell areas is difficult.

Noninflammatory and Inflammatory Diseases

Generalized disease processes may involve any portion of the gland. Scattered foci of mineralization, which are usually only seen histologically, are sometimes found in the adrenal. Amyloidosis occurs sporadically and, when severe, the affected gland may be enlarged and have a uniform pale appearance.

Generalized inflammatory disease is usually the result of hematogenous extensions of systemic bacterial infections or extension from bacterial or fungal peritoneal or air sac infections. The exact character of the lesion depends on the etiologic agent. Grossly, in bacter-

CHAPTER 9

Endocrine Glands



ial and fungal disease of the adrenal gland, there may be hemorrhage and mottling, with necrotic foci and exudate seen in severe cases.

Systemic mycobacteriosis may involve the adrenal glands. Grossly there is often no obvious change.

A few lesions specific to the interrenal cells can be seen. Vacuolation of interrenal cells (associated with no other lesion) is seen in birds that die suddenly, particularly African grey parrots. The cause of the condition is not known. This lesion can be severe and may indicate that the bird was in adrenal failure, but as of yet, antemortem tests that might confirm the possibility have not been developed. Grossly the gland may be yellow-brown and variably mottled (Fig 9.8).

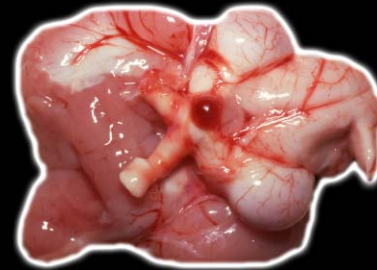Several viral diseases affect the chromaffin cells, including polyomavirus and paramyxovirus infections. Birds with proventricular dilatation disease may have adrenal gland involvement. Affected glands are slightly enlarged and pale and may have mild red-gray mottling (Fig 9.9).

Proliferative Diseases

Hyperplasia as seen in the cortex of mammalian adrenal glands is not documented in birds. Hypertrophy of interrenal cells associated with vacuolar changes consistent with degeneration does occur and may indicate chronic stress and eventual adrenal exhaustion. In a few severe cases necrosis of interrenal cells is seen. Usually there is no detectable gross change.

Adenomas and carcinomas of interrenal cell origin are reported sporadically. Some birds have abnormal feather growth (Fig 9.10), indicating that these tumors may be functional, but conclusive biochemical testing has not been performed. Grossly these tumors are lobulated and gray-yellow. Pheochromocytomas are not well documented.

A ganglioneuroma of the adrenal gland of birds is not distinctive grossly, presenting as a nonspecific enlargement adjacent to the gland or of the gland itself.



CHAPTER 9

Endocrine Glands

LESIONS OF THE PANCREATIC ISLETS

The pancreatic islets must be examined with the pancreas and appropriate tissue saved for histopathology.

Avian pancreatic islets are of three types: light, comprised of A and D cells; dark, comprised of B and D cells; and mixed, which contains A, B and D cells. A cells produce glucagon, B cells produce insulin, and D cells produce somatostatin.

Inflammatory Disease

Paramyxovirus infections can cause pancreatitis in several pet avian species. The inflammation can be severe enough to involve the pancreatic islets in some cases. There is usually no gross lesion.

Degenerative Disease

Degenerative changes in the pancreatic islets usually lead to diabetes mellitus. This condition is seen in a variety of pet species, supposedly being somewhat more

prevalent in toucans, although in our experience, most cases are in psittacine birds. No gross lesion is seen in these birds.

Proliferative Disease

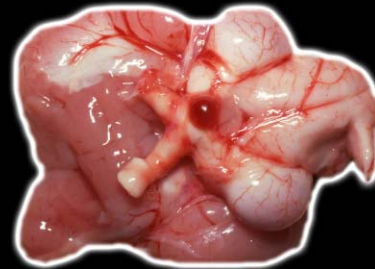
Islet cell hyperplasia and hypertrophy are occasionally seen, and are usually due to proliferation and enlargement of A cells associated with vague clinical signs and death. There is usually no grossly observable change, but small swellings in the body of the exocrine pancreas may be noted.

ULTIMOBANCHIAL BODY

The ultimobranchial bodies should be examined and removed with the thyroid and parathyroid glands. Avian ultimobranchial bodies are paired structures posterior to the parathyroid glands and immediately lateral to the carotid arteries. The ultimobranchial body in companion birds is typically 1.0-3.0 mm in diameter. It is difficult to locate in birds that have a moderate or exces-

CHAPTER 9

Endocrine Glands



sive amount of fat. The left body may attach to the parathyroid gland. The avian ultimobranchial body contains cords or islands of C cells, small vesicles and parathyroid nodules in a loose connective tissue stroma. The C cells produce calcitonin.

Lesions

Long-term hypercalcemia may result in be hypertrophy of the ultimobranchial bodies, which affects the size (>3.0 mm) and appearance (yellow-white nodules) (Fig 9.11).

CAROTID BODIES, PINEAL GLAND AND GASTROINTESTINAL ENDOCRINE SYSTEM

The carotid bodies are paired at each side of the thoracic inlet in contact with the medial surface of the parathyroid glands. In some birds, they may be embedded in the parathyroid gland. Accessory carotid bodies may occur in other sites including the adventitia of arteries. The cells of the carotid body are epithelioid

with a round nucleus and a finely granular cytoplasm. A thick capsule surrounds the carotid bodies.

The pineal gland is found between the cerebral hemispheres and the cerebellum. It is a dorsally divided projection of the diencephalon.

Cells of the gastrointestinal endocrine system are found in the mucosa of the GI tract with the greatest concentration in the proventriculus.

Lesions

A chemodectoma has been reported in a budgerigar, but no detailed description was given. Pinealomas, although rare, present as lobulated nodular growths of the gland. Lesions of the gastrointestinal endocrine system have not been reported.

CHAPTER 9

Endocrine Glands



FURTHER READING

Blackmore DK: The clinical approach to tumors in cage birds I: The pathology and incidence of neoplasia in cage birds. *J Small Anim Pract* 6:217-223, 1966.

Dillberger JE, Citino SB, Altman NH: Four cases of neoplasia in captive wild birds. *Avian Dis* 31:206-213, 1987.

Harms CA, Hoskinson JJ, Bruyette DS, et al: Development of an experimental model of hypothyroidism in cockatiels (*Nymphicus hollandicus*). *Am J Vet Res* 55:399-404, 1994.

King AS, McLelland J: Birds: Endocrine system. In King AS, McLelland J: Birds: Their Structure and Function. London, Bailliere Tindall, 1984, pp 200-213.

Lumeij JT: Endocrinology. In Ritchie BW, Harrison GJ, Harrison LR (eds): *Avian Medicine: Principles and Application*. Lake Worth, FL, Wingers Publishing, 1994, pp 582-606.

Oglesbee BL: Hypothyroidism in a scarlet macaw. *J Am Vet Med Assoc* 201:1599-1601, 1992.

Rae M: Endocrine disease in pet birds. *Sem Avian Exotic Pet Med* 4:32-38, 1995.

Randall CJ, Reece RL: Color Atlas of Avian Histopathology. London, Mosby-Wolfe, 1996, pp 223-228.

Reece RL: Observations on naturally occurring neoplasms in birds in the state of Victoria, Australia. *Avian Pathol* 21:3-32, 1992.

Sasipreeyajan J: Goiter in a cockatiel (*Nymphicus hollandicus*). *Avian Dis* 32:169-172, 1988.

Schmidt RE: Morphologic diagnosis of avian neoplasms. *Sem Avian Exotic Pet Med* 1:73-79, 1992.

Swaryo K, Tewari, Srivastav AK: Ultimobranchial body and parathyroid gland of the parrot *Psittacula psit-*

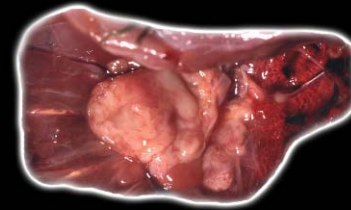
tacula in response to experimental hypercalcemia. *Arch Anat Microsc Morphol Exp* 75:271-277, 1986-87.

Treihou-Lahille F, Lasmoles F, Taboulet J, et al: Ultimobranchial gland of the domestic fowl: Two types of secretory cells involved in calcitonin metabolism. *Cell Tissue Res* 235:439-448, 1984.

Wadsworth PF, Jones DM: Some abnormalities of the thyroid gland in non-domesticated birds. *Avian Pathol* 8:279-284, 1979.

CHAPTER 10

Reproductive System



After removal of the gastrointestinal tract, the reproductive system can be visualized and examined.

MALE REPRODUCTIVE SYSTEM

The reproductive system of the male bird is composed of the testes, the efferent ducts, the seminal glomus in passerines, and a phallus in several unrelated birds. The paired testes are located on the cranio-ventral aspect of the cranial pole of each kidney just to the right and left of the midline.

Immature testes are somewhat flattened with a smooth surface and rounded cranial and caudal poles (Fig 10.0a). In immature birds, the left testicle is usually larger than the right (Fig 10.0b). The fully mature testes is yellow, rounded, but is longer than it is wide. When the bird is in breeding season, the enlarged testes will completely cover the ventral surface of the adrenal (Fig 10.0c). White cockatoos, the golden conure, blue and gold macaw,

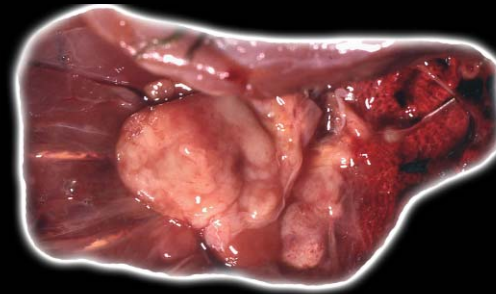
some species of passerine birds, and the keel-billed toucan have melanoblasts in the testicular interstitium, causing the testicles to appear black.

The efferent ducts include the rete teste, epididymis and the ductus deferens. The epididymis is under hormonal control and enlarges during the breeding season. Unlike mammals, it is not divided into a head, body and tail. The ductus deferens connects the epididymis to the urodeum and is located across the ventral surface of the kidney. In the nonbreeding season it is narrow and straight; however, it becomes torturous and distended with semen during the breeding season.

A copulating organ is seen only in waterfowl, screamers, cracids, ratites (including the kiwi), and tinamous. In the ostrich, kiwi and tinamous, there is no cavity. Dorsal sleeves are present in which the vas deferens ejects semen. A ventral elastic body with an inner layer of erectile tissue is seen. In the emu, cassowary, rhea and in Anseriformes, there is a cavity, which is a blind ending tube in Anseriformes.

CHAPTER 10

Reproductive System



Diseases of the Testicle

Congenital abnormalities of the testes are uncommon to rare, but may include abnormally shaped testicles, fusion of the cranial poles of the testes, hypoplasia and agenesis.

Non-inflammatory testicular lesions include degeneration and atrophy. Due to the seasonal variations, changes in the size of the testes or an absence of spermatogenesis must be carefully interpreted. Atrophy can be the end result of a degenerative process and has been associated with generalized malnutrition, including vitamin E deficiency.

Various toxins affect avian testicles. The changes are primarily degenerative without inflammation. In general, there will be reduced spermatogenesis regardless of the toxic agent. Cystic degeneration of seminiferous tubules has been reported with furazolidone toxicity. Copper fungicides can cause atrophy, and mercury has been reported to cause reproductive dysfunction.

Inflammatory disease of the testicle (orchitis) is not commonly reported but has been associated with a vari-

ety of causes. The characteristics of the lesion depend on the underlying cause. Bacterial and fungal infections may be due to extension from the peritoneal cavity or the air sacs, or these infections may be hematogenous. Mycobacterial and chlamydophila infections are also seen as a part of a more generalized problem. Grossly, the affected testicle is enlarged and reddened and may contain yellow-white foci.

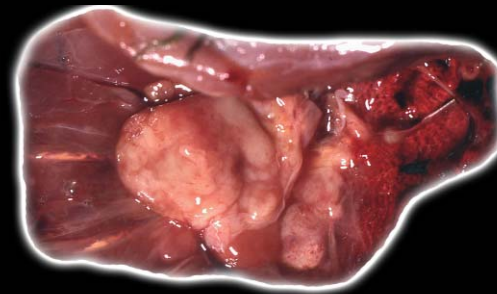
Tumors of the testicle cause obvious enlargement and frequent abdominal distension. Reported tumors include seminoma, sertoli cell tumor, interstitial cell tumor, lymphosarcoma, undifferentiated sarcoma and teratoma. In our experience, the highest incidence of testicular neoplasia occurs in the budgerigar.

Seminomas are tumors of immature germ cells. Grossly, they are cream to yellow-red and cause enlargement of the testis (Fig 10.1). On section, they are usually soft.

Sertoli cell tumors are generally firm, gray-white neoplasms that may appear nodular on section (Fig 10.2). Cystic spaces are sometimes present. Clinical signs of

CHAPTER 10

Reproductive System



feminization, including a change in cere color from blue to brown in budgerigars, is reported in birds with sertoli cell tumors.

Interstitial cell tumors may be cystic and are often orange-red due to steroid hormones and areas of hemorrhage.

Lymphosarcoma can involve the testicle; both grossly and histologically, these tumors may be confused with seminomas. However, testicular lymphosarcoma is usually just one manifestation of a multisystemic disease.

Teratomas do not have specific gross characteristics unless keratinaceous cysts or some other differentiated structure is seen.

Diseases of the Epididymis

Inflammation and neoplasia are reported in the epididymis. Inflammation is generally due to the same causes as in orchitis. Both carcinomas and sarcomas can arise in the epididymis, but are rare.

Diseases of the Phallus

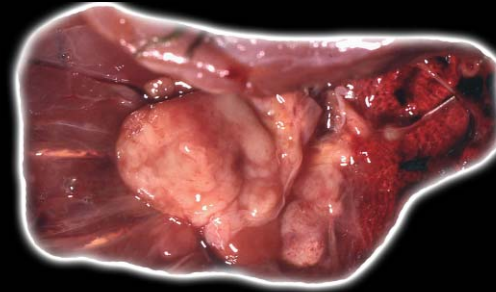
Prolapse of the phallus is frequently reported. It can either lead to, or be caused by, trauma, inflammatory disease or frostbite. It is usually diagnosed clinically (Fig 10.3).

FEMALE REPRODUCTIVE SYSTEM

The ovary is located on the ventral surface of the cranial ventral surface aspect of the cranial division of the left kidney. In juvenile birds, the ovary is yellow, flattened and somewhat triangular with its apex pointing cranially. In contrast to the juvenile testis, the juvenile ovary has a granular surface (Fig 10.3a). As the bird becomes sexually mature, secondary and tertiary follicles develop to form grape-like clusters prior to ovulation. The ovary is tightly adhered to the surface of the kidney, but becomes pendulous as the tertiary follicles fill with yolk. Only the left ovary is present in most species of birds. Exceptions include many birds of prey and the

CHAPTER 10

Reproductive System



brown kiwi. Pigmentation of the ovary also occurs in some species of birds, including white cockatoos and blue and gold macaws.

Following ovulation (Fig 10.3b), the follicle regresses and fills with granulosa cells that contain lipid. This is not a true corpus luteum as is seen in mammals, as there is no cellular multiplication. The thecal wall may rupture during this time, resulting in escape of yolk into the ovary or the peritoneal cavity.

Diseases of the Ovary

Congenital defects of the ovary are reported in birds. A retained right ovary is occasionally seen in birds that normally would have only a left ovary. Congenital ovarian cysts are most common in budgerigars and canaries. Grossly they are fluid-filled and thin-walled.

Hermaphroditism has been seen in some hybrid ducks, but is not commonly reported in pet birds.

Oophoritis can be secondary to infection of the peritoneal cavity or air sacs, or may be associated with hematogenous infection. Viruses, bacteria, fungi or

mycobacteria are possible causes. Grossly, the ovaries are enlarged, discolored and possibly hemorrhagic.

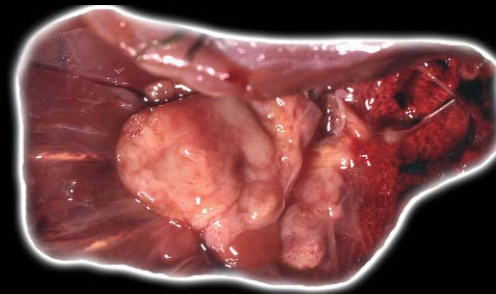
Noninfectious inflammation of the ovary is associated with rupture of follicles and extrusion of yolk material within the ovarian stroma. Grossly affected ovaries may be slightly enlarged and contain variably sized yellow foci. Secondary yolk-induced peritonitis is often present (Fig 10.4).

Several types of ovarian neoplasms are seen in birds. Granulosa cell tumors are reported to be the most common. Granulosa cell tumors are yellow, lobulated, irregular masses that are friable. They may become quite large and fill the abdominal cavity.

Ovarian carcinomas are variably sized, firm, gray-white and multilobular. They may also metastasize or implant on serosal surfaces of adjacent organs, the mesentery and the body wall (Fig 10.5). Tumor cells may be seen in smears of peritoneal fluid or impressions of neoplastic structures (Fig 10.6).

CHAPTER 10

Reproductive System



Dysgerminoma is the female analogue of the seminoma and is infrequently seen.

Arrhenoblastoma is histologically similar to the sertoli cell tumor. In mammals, these tumors are usually called ovarian stromal tumor, sertoli pattern. In chickens they are associated with masculinization, but masculinization is not seen in pet birds in our experience. The tumors are gray-white and lobulated.

Teratomas can become quite large, are usually irregular in appearance, and may incorporate bone or feathers in the mass (Fig 10.7).

Other tumors seen in the ovary include hemangiomas, lymphosarcoma, and those of adipose tissue, connective tissue and smooth muscle (Fig 10.8, Fig 10.9).

Oviduct

Normal Structure

After locating the oviduct it should be removed and opened. The oviduct is divided into five functional zones: the vagina, infundibulum, magnum, isthmus and

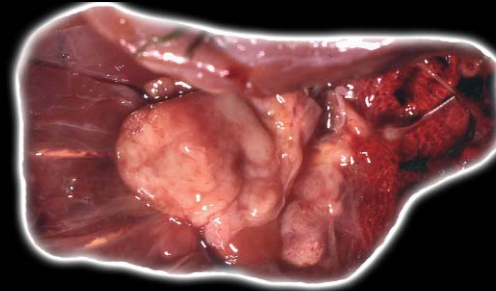
shell gland or uterus. The most cranial region adjacent to the ovary is the infundibulum.

The magnum is the longest and thickest portion of the oviduct. The wall is thickened due to numerous tubular glands that are lined by cuboidal columnar epithelium. The mucous region is found in the caudal few centimeters of the magnum. Most of the albumen and various minerals are deposited in the magnum. The isthmus is short and has thinner walls and less prominent folds than the magnum. The uterus or shell gland is a short region containing leaf-like lamellae. At the junction with the uterus is the vaginal sphincter. The vagina is S-shaped due to its smooth muscle and connective tissue wall. It is thicker than any other part of the oviduct.

The length and diameter of the oviduct vary dramatically between the breeding season and nonbreeding season. During the nonbreeding season, the oviduct is thin, slender, pink, linear, and of uniform diameter. The oviduct of juvenile birds is thin and nearly transparent, making it difficult to find at necropsy. The oviduct of

CHAPTER 10

Reproductive System



female birds that are in the process of laying will be greatly elongated, festooned, and will have a thickened wall and a greatly widened lumen. The oviduct may fill much of the left caudal celomic cavity displacing the intestines to the right (Fig 10.10).

Diseases of the Oviduct/Uterus

Congenital malformations of the oviduct include atresia, segmental aplasia and congenital cysts (Fig 10.11). These lesions may be associated with the developed left oviduct or a retained or incompletely regressed right oviduct. The cysts are usually fluid-filled.

Inflammation of the oviduct can be caused by either infectious or noninfectious etiologies. The oviduct is usually enlarged, reddened and friable, and a variable amount of exudate may be present. The appearance depends on the exact etiology and duration of the disease.

Noninfectious causes of inflammation may be mechanical secondary to improper egg maturation or formation. Peritonitis (see Chapter 3) can be a secondary

complication to either infectious or noninfectious salpingitis following penetration of the oviductal wall or rupture of the oviduct

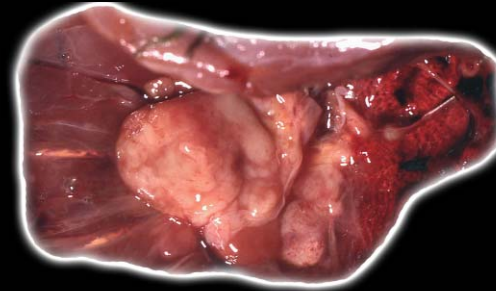
Oviductal torsion occasionally occurs and if not diagnosed leads to the death of the bird. There is often vascular compromise, and the oviduct will be edematous, red-black and friable.

Impaction of the oviduct is almost always a sequel to salpingitis or egg binding. Grossly a large area of oviductal swelling is seen (Fig 10.12). In addition to finding an abnormal impacted egg (Fig 10.13), there may be free yolk material, excess mucin and purulent material in the lumen. The impacted egg can lead to pressure necrosis of the oviductal wall. Large neoplasms may also be associated with impaction.

Proliferative and neoplastic changes of the oviduct include cystic hyperplasia and neoplasia. In hyperplasia, numerous cystic structures are seen grossly. These cysts may contain clear or cloudy fluid.

CHAPTER 10

Reproductive System



Primary neoplasms can be either adenomas or adenocarcinomas. These are firm, nodular, gray-white masses. In severe chronic cases, these tumors can also implant on peritoneal surfaces. Grossly, it may be difficult to differentiate tumors of oviduct origin from those of ovarian origin. Careful necropsy examination is necessary for differentiation in advanced cases.

Leiomyomas are a common tumor of the oviduct of chickens. Grossly these are red-brown. Lymphosarcoma may also cause gross thickening of the oviduct (Fig 10.14).

Diseases of the Cloaca

The cloaca is affected by a variety of inflammatory and neoplastic diseases that can lead to problems with fertility and/or egg laying. These disease processes may lead to fibrosis and stricture or blockage due to mass lesions (Fig 10.15) (see Chapter 7).

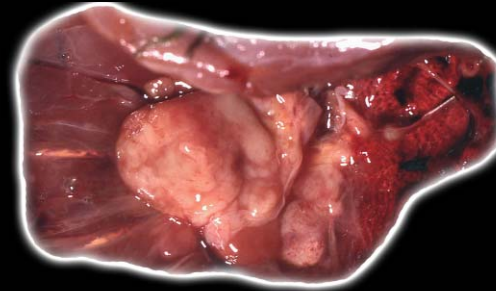
ABNORMAL EGGS

Soft-shelled eggs are sometimes a manifestation of vitamin A or D deficiency or calcium deficiency. Infections with the avian bronchitis virus or an adenovirus also cause soft or thin-shelled eggs in poultry. Rough shells are sometimes a manifestation of salpingitis (Fig 10.16). Organochlorine pesticides cause thin-shelled eggs. Other nutritional and toxic problems that can cause egg shell abnormalities including crude oil, nicotine and furazolidone toxicity. Eggs with abnormal shells can also be broken within the oviduct (Fig 10.17).

Ectopic eggs are sometimes an incidental necropsy finding but can be a cause of mortality, particularly if associated with peritonitis. Oviductal rupture or reverse oviductal peristalses are primary causes. At necropsy the ectopic egg may have a completely normal shell, particularly if there is a rupture of the caudal oviduct. If the rupture is more cranial or if there was reverse peristalsis, the egg may be soft shelled (Fig 10.18) or there may be only

CHAPTER 10

Reproductive System



yolk and albumen present in the peritoneal cavity. There is usually some degree of peritonitis.

Fetal Necropsy

Egg necropsies are often disappointing. Aviculturists will often leave the egg in the incubator for an extended period of time after the embryo died because they are not aware of its death. As a result, many embryos are severely autolytic by the time they reach the pathologist.

If there is failure to hatch, the first question to be answered is whether or not the egg is/was fertile. Fertilization of the ovum (yolk) initiates a series of cell divisions in the protoplasmic portion of the egg, which is seen grossly as a small white disc (blastodisc) present on the dorsal pole of the yolk. If there has been no fertilization, this small white area is all that is seen when the egg is examined.

A fertile egg will develop a blastoderm, which will appear as a small white area that enlarges and has a translucent center. Subsequently, there is embryo forma-

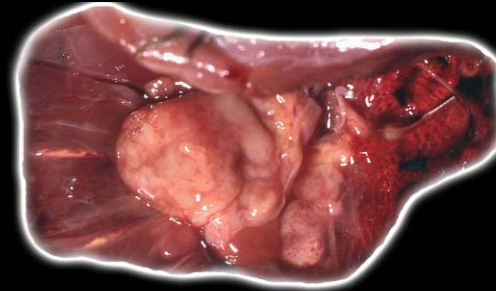
tion and by the end of the first third of incubation, organogenesis has usually taken place.

The first step of the egg necropsy is to evaluate the shell. If the shell is abnormal, then a problem with the hen should be suspected. The egg should be placed upright so that the widest end of the egg is up. The top of the egg should be cleaned and disinfected. A circular incision is made around the top of the egg with a sterile instrument, and the top of the egg is removed. This will expose the air cell. The underlying shell membrane can be cut with a sterile instrument and a culture taken through this opening. If bacteria are growing in the egg, the contents of the egg are typically fetid. If the infection occurred early in incubation, the contents may be curd-like and/or discolored.

Another 30% of fetal deaths occur within 1 or 2 days of hatching. If the incubator temperature is either too cold or too hot, weak and either dry or edematous chicks may be found. Weak chicks cannot penetrate the air cell with their beaks. Finally, airflow in the incubator is a critical

CHAPTER 10

Reproductive System



factor. Insufficient airflow impacts chick development and moisture loss from the egg.

If the egg is near hatching, the position of the embryo should be examined carefully before it is removed from the egg.

Techniques of fetal necropsy vary. Small embryos and fetuses (e.g., finches) can be grossly examined, fixed and processed as whole body sections. Larger chicks should be necropsied as any post-hatch bird. The yolk sac and other fetal and shell membranes should be submitted for histologic examination.

Gross lesions in chicks that are near hatching will be somewhat similar to those of post-hatch chicks. There are, however, some things that are unique to the developing chick. Excessive humidity in the incubator can lead to a severely edematous fetus ([Fig 10.19](#), [Fig 10.20](#)).

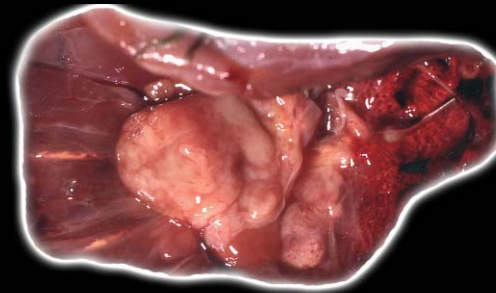
Inadequate humidity will have the opposite effect, and the fetus may be severely dehydrated. Cockatiel and macaw late-term fetuses have a higher incidence of soft tissue (particularly renal) mineralization.

The yolk sac and chorioallantois mediate mobilization and transepithelial transport of mineral deposits from the egg. Mineral transport involves plasma proteins that bind mineral and are initially synthesized by the yolk sac and later by the liver. This change can be seen in developing fetuses and may appear grossly as white gritty foci in the kidneys.

Because fetal death is often associated with stress, examination of the bursa of Fabricius is very important in the fetal necropsy. Although not an etiology-specific lesion, the finding of severe bursal lymphoid depletion/necrosis or hypoplasia is indicative of stress to the developing chick.

CHAPTER 10

Reproductive System



FURTHER READING

Anderson Brown AF, Robbins GES: The New Incubation Book. Great Britain, BPC Wheatons Ltd, 1994, pp 69-102.

Biswall G, Morrill CC: The pathology of the reproductive tract of laying pullets affected with Newcastle's disease. *Poult Sci* 33:880-897, 1953.

Beach JE: Diseases of budgerigars and other caged birds: A survey of post-mortem findings. *Vet Rec* 74:Part I:10-15, Part II:63-68, Part III:134-140, 1962.

Cooke AS: Shell thinning in avian eggs by environ-

mental pollutants. *Environ Pollut* 4:85-152, 1973.

Degernes LA: Abdominal mass due to chronic salpingitis in an African grey parrot (*Psittacus erithacus*). *Vet Radiol Ultrasound* 35:24-28, 1994.

Gorham SL, Ottinger MA: Sertoli cell tumors in Japanese quail. *Avian Dis* 30:337-339, 1986.

Gupta BN, Langham RF: Arrhenoblastoma in an Indian Desi hen. *Avian Dis* 12:441-444, 1968.

Hasholt J: Diseases of the female reproductive organs of pet birds. *J Small Anim Pract* 7:313-320, 1966.

Helmbolt CF, et al: Teratoma in a domestic fowl (*Gallus gallus*). *Avian Dis* 18:142-148, 1974.

King AS, McLelland J: Male reproductive system. In King AS, McLelland J: *Birds: Their Structure and Function* 2nd ed. London, Bailliere Tindall, 1984, pp 166-174.

King AS, McLelland J: Female reproductive system. In King AS, McLelland J: *Birds: Their Structure and Function* 2nd ed. London, Bailliere Tindall, 1984, pp 145-165.

Keymer IF: Disorders of the avian female reproductive system. *Avian Pathol* 9:405-419, 1980.

Leach MW: A survey of neoplasia in pet birds. *Sem Avian Exotic Pet Med* 1:52-64, 1992.

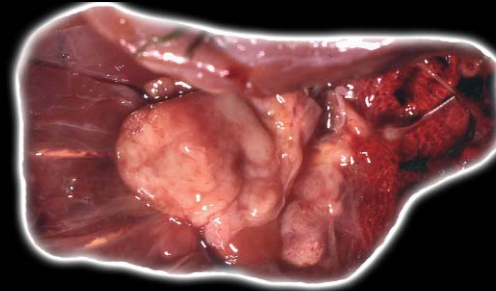
Lofts B, Murton RK: Reproduction in birds. In Farner DS, King JR (eds): *Avian Biology Vol III*. New York, Academic Press, 1973, pp 1-88.

Morton RR, Westwood NJ: Avian breeding cycles. In *Reproductive Apparatus of the Male*. Oxford, Clarendon Press, 1977, pp 47-76.

Reece RL: Reproductive diseases. In Burr E (ed): *Companion Bird Medicine*. Ames, Iowa State University Press, 1987, pp 89-100.

CHAPTER 10

Reproductive System



FURTHER READING

(CONTINUED)

Reece RL: Observations on naturally occurring neoplasms in birds in the state of Victoria, Australia. *Avian Pathol* 21:3-32, 1992.

Rigdon RH: Gonads in hermaphroditic ducks: A pathologic study. *Am J Vet Res* 28:1125-1131, 1967.

Schmidt RE: Morphologic diagnosis of avian neoplasms. *Sem Avian Exotic Pet Med* 1:73-79, 1992.

Shivanandappa T, Krishnakumarii MK, Majunder SK: Testicular atrophy in *Gallus domesticus* fed acute doses of copper

fungicides. *Poult Sci* 405-408, 1983.

Sitler WG: A sertoli cell tumor causing feminization in a brown leghorn capon. *J Endocrinol* 14:197-203, 1956.

Stoica G, Russo E, Hoffman JP: Abdominal tumor in a military macaw (Diagnosis: metastatic ovarian carcinoma). *Lab Anim* 18:17-20, 1989.

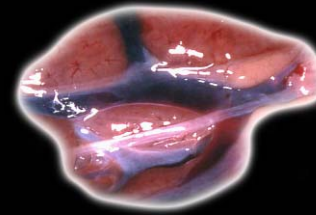
Thaxton JP, Parkhurst CR: Abnormal mating behavior and reproductive dysfunction caused by mercury in Japanese quail. *Proc Soc Exp Biol Med*, 1973, pp 144, 252-255.

Turk JP, Kim J, Gallera AM: Seminoma in a pigeon. *Avian Dis* 25:752-755, 1981.

Webb D, VanVleet JF: Cystic testicular degeneration in furazolidone toxicosis of sexually immature ducks. *Avian Dis* 39:693-700, 1990.

CHAPTER 11

Urinary System



After all the other viscera have been removed, the urinary organs can be seen. Avian kidneys are bilaterally symmetrical and lie within ventral depressions of the synsacrum known as the renal fossae (Fig 11.0). They are retroperitoneal and firmly fixed in place. Nerves from the lumbar and sacral plexi pass through the kidney, a feature that can lead to secondary neurologic problems with renal neoplasia or other renal lesions that impinge on these nerves. The kidneys are divided into the cranial, middle, and caudal divisions. The size and shape of these divisions is fairly consistent in psittacine birds but varies considerably in other species.

NORMAL ORGANS

There are 3 pairs of renal arteries: the cranial, middle and caudal. The caudal renal veins receive drainage from the intralobular veins. The most unique aspect of the avian kidney vasculature is the renal portal system. The joining of the paired external iliac veins and the caudal renal veins forms this vascular ring.

The ureter begins in the cranial division of the kidney and continues caudally in a groove on the ventral renal surface. It receives multiple primary branches, which in turn are made up of secondary branches, each of which drains the collecting ducts of the renal lobes. Each ureter terminates in the urodeum of the cloaca. Unless filled with urates or involved in some disease process, the ureters may be difficult to grossly visualize. After examining the kidneys in situ, they should be removed.

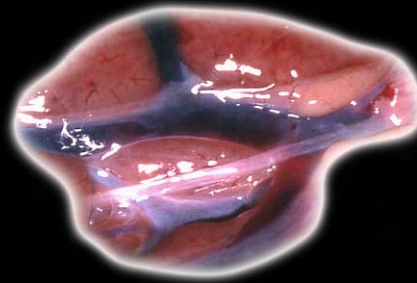
RENAL DISEASE

Congenital

Renal hypoplasia or aplasia occurs sporadically in birds. It may be unilateral with no clinical signs and is often diagnosed as an incidental necropsy finding. Divisional aplasia is common in some breeds of chickens. The cranial division is most likely to be absent. The middle and caudal divisions are less commonly affected. Compensatory hypertrophy of the opposite kidney is generally present.

CHAPTER 11

Urinary System



Renal cysts may be solitary or multiple. The condition usually results from failure of fusion of the cortical portions of the tubule with collecting tubules of ureteral origin. If the lesion is severe, the result will be renal failure. Cysts usually have smooth borders grossly (Fig 11.1).

Infectious Diseases

Viral

Viral diseases affecting the kidneys include adenoviruses and avian polyomavirus. Birds dying with a psittacine herpesvirus infection (Pacheco's disease) will uncommonly have inclusion bodies in the renal tubular epithelium, but no gross lesion is usually seen.

Adenovirus infection of the kidney is seen in a variety of psittacine birds. Grossly there may be some nonspecific renal enlargement. Polyomavirus infection may cause the kidneys to be slightly swollen, pale and wet (Fig 11.2).

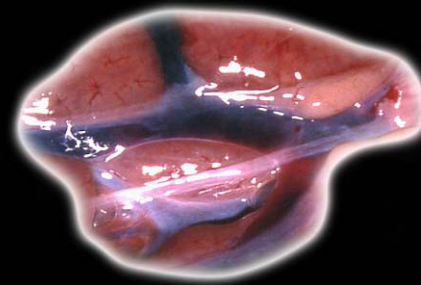
Ascites and anasarca are seen uncommonly in several species of nonbudgerigar parrots that are positive by PCR for avian polyomavirus infection. The anasarca and

ascites are attributed to a protein-losing nephropathy and/or decreased hepatic production of albumen following avian polyomavirus-induced hepatic necrosis.

Bacterial

Bacteria can enter the kidney either by ascending the ureters or by hematogenous spread. In either type of infection, the kidneys may be grossly enlarged and discolored (Fig 11.3) with varying degrees of necrosis. Necrotic areas appear grossly as variably sized, multifocal, white-yellow foci within the renal parenchyma (Fig 11.4, Fig 11.5, Fig 11.6).

A wide range of gram-positive and gram-negative bacteria is known to cause kidney disease either as an ascending infection or as part of a systemic disease. Mycobacterial and *Chlamydophila psittaci* infections are generally systemic infections. They can cause lesions in the kidney, but often do not. Mycobacterial lesions are similar to those found in other tissues. Necrosis and abscess formation is not always present, particularly



CHAPTER 11

Urinary System

early in the disease. Lesions caused by *C. psittaci* are grossly similar to those of bacteria.

Mycotic

Fungal infection of the kidney occurs as either an extension of a fungal infection of abdominal air sacs or as a component of systemic infection where a fungus has invaded a vessel resulting in fungal thrombosis of blood vessels.

Parasitic

Isospora and *Eimeria* spp. are found in the kidneys of nearly all species of wild ducks and geese. They are also commonly found in shore birds and less commonly seen in birds of prey. Lesions in adult birds are minimal with occasional obstruction and dilation of the tubules. Gross changes are often absent. Cryptosporidial infection of the kidney of birds is rare. Grossly kidneys may appear swollen and pale.

Encephalitozoon hellem is a potential cause of nephritis. Lesions are most commonly seen in lovebirds and

budgerigars. Gross changes may be absent, or small pale foci may be present in the renal parenchyma.

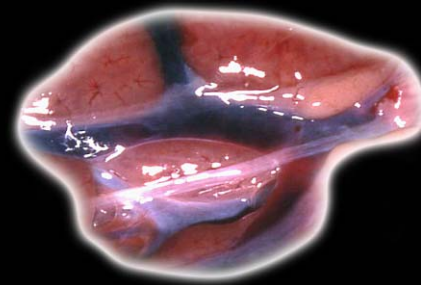
Systemic sarcosporidial infection can lead to interstitial nephritis, which may not be noted grossly.

Trematodes may be incidental findings or lead to clinical renal disease in some birds. These infections are most common in waterfowl. The flukes are found in collecting tubules in the medullary cone. Severe infections result in obstruction of the tubules and secondary dilation proximal to the block, but gross changes are usually difficult to see.

Schistosomiasis is common in waterfowl. These intravascular trematodes lay eggs that are trapped in small vessels creating a foreign body reaction and granuloma formation.

Inflammatory Disease of Undetermined Cause

Except as a sequela to polyomavirus infection (see previous), immune complex glomerulonephritis is not well documented in birds, and there are no specific gross changes.



CHAPTER 11

Urinary System

Non-infectious Disease

Dehydration

Dehydration results in reduced urine flow and sludging of the urate crystals within the tubules. If the dehydration is transient, this lesion is reversible. Persistent dehydration results in renal failure. Gross lesions are characterized by multifocal white to yellow-white foci or streaks that represent urate deposits (Fig 11.7). The gross appearance is similar to mineralization and severe nephritis; therefore, histology is necessary for differentiation.

Nutritional Disease

Metastatic mineralization of the kidney is a common lesion in nestling parrots and to a lesser extent in adult birds. It may vary from mild to severe, resulting in renal failure and systemic gout. This disease disproportionately affects nestling budgerigars, cockatiels and blue and gold macaws. A nutritional imbalance is suspected.

Mild cases of metastatic mineralization do not cause gross lesions. Advanced cases are grossly

indistinguishable from severe nephritis or nephrosis associated with dehydration (Fig 11.8).

Amyloidosis

Renal amyloidosis is most frequently observed in waterfowl and small passerine birds. Multiple organs in addition to the kidney are generally involved. Grossly there may be no discernible change, but in some birds the kidneys are pale and may contain multiple tan foci (Fig 11.9). The condition can resemble nephrosis.

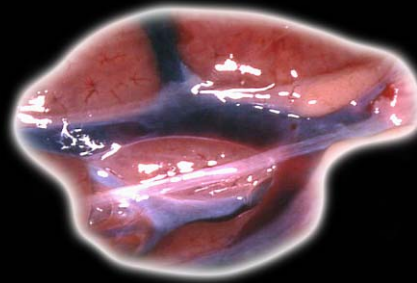
Vitamin A deficiency leads to squamous metaplasia of the epithelium of the ureters and collecting ducts, which in advanced cases, results in the ureteral epithelium being transformed to a keratinized epithelium. Partial or complete obstruction of the ureters follows (Fig 11.10).

Lipidosis

Renal lipidosis can be secondary to a high fat diet or chronic hepatic disease. The latter is relatively common in Amazon parrots and cockatiels that have a high

CHAPTER 11

Urinary System



incidence of chronic-active hepatitis. Grossly the kidneys are pale.

Iron storage disease primarily affects the liver, but iron pigment is also seen in renal tubular cells in many affected birds. Affected kidneys are deep red or red-brown (Fig 11.11).

Most renal toxins cause similar gross and histologic lesions and therefore a definitive etiologic diagnosis is often not possible based on histopathologic changes alone. Grossly kidneys may be swollen and pale. They contain fine white to pale yellow linear striations that represent tubules containing urates or mineralized foci. Numerous pinpoint, multifocal, white to pale-yellow foci will also be present on the serosal and cut surfaces of the kidney. Common causes of renal toxicity include vitamin D₃ and vitamin D₃ analogue-based rodenticides and the aminoglycosides, gentamicin and amikacin. Heavy metals, such as lead and zinc, can cause acute tubular necrosis. Gross changes vary from none to swollen pale yellow kidneys (Fig 11.12).

Mycotoxins

Several mycotoxins, including oosporein, citrinin and ochratoxin, have been shown to cause disease in poultry or domestic waterfowl. Gross lesions resemble those of other toxins, or there may be no gross lesion at all.

Salt

Excessive salt ingestion leads to renal problems that results in urate deposition and gross changes (as previously described).

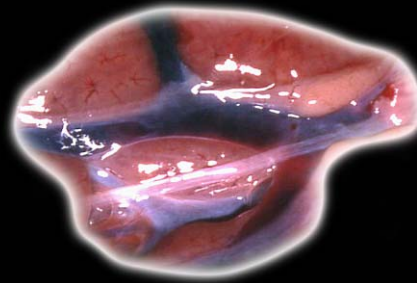
Physical or other nephropathies, such as acute hypoxia/ischemia, can lead to tubular necrosis, proteinuria and urate deposition. Lesions are similar to the various problems discussed under metabolic disorders, and differential diagnoses include many of these conditions.

Hemorrhage

Renal hemorrhage may be secondary to trauma, ischemia or a variety of primary disease conditions. The hemorrhage may be visible grossly and can affect both interstitium and tubules.

CHAPTER 11

Urinary System



The end result of many of the above conditions can be chronic renal disease (end-stage kidney) with severe fibrosis (Fig 11.13). Kidneys may be somewhat small, firm, nodular and pale.

Glomerulonephritis

The deposition of immune complexes in the mesangium or glomerular basement membranes is a common finding in humans and other mammals, but is very rare in birds outside of avian polyomavirus disease. In mammals, glomerulonephritis is usually secondary to neoplasia, immune-mediated disease, or an infectious disease. Characterization of the glomerular lesions often requires electron microscopy.

Neoplastic Disease

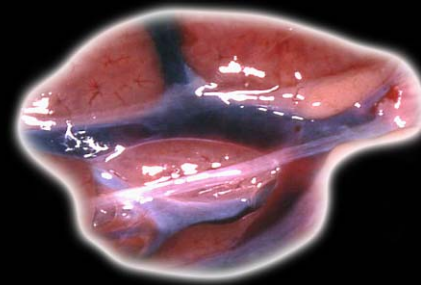
Renal tumors are reported in many species of birds, but are particularly common in the budgerigar. Renal carcinoma is the most common tumor of the kidney; however, adenoma, nephroblastoma, cystadenoma, fibrosarcoma

and lymphosarcoma are also reported to occur in the avian kidney.

Renal adenomas are usually localized nodular swellings, often in the cranial pole of the kidney. They are light tan to white and fluctuant (Fig 11.14). Renal carcinomas are large, somewhat friable, and vary from tan to red-brown (Fig 11.15). Large aberrant epithelial cells may be seen cytologically (Fig 11.16).

Embryonal nephromas (nephroblastomas) are most commonly reported in chickens but are also found in psittacines and small passerine birds. They are usually unilateral but may be bilateral and are grossly similar to carcinomas (Fig 11.17). Lymphosarcoma may be isolated to the kidney but usually is a part of generalized neoplastic disease. Grossly the kidneys are pale and may appear mottled. They are moderately firm. The cell infiltration is either nodular or diffuse.

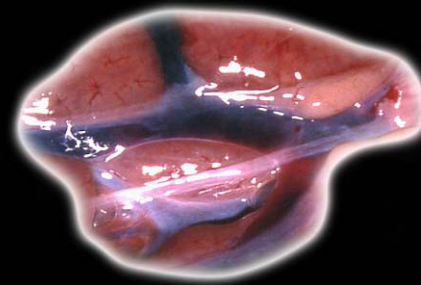
Other primary sarcomas are possible but are rarely reported, and metastatic tumors are infrequent.



CHAPTER 11

Urinary System

Metastatic tumors are not usually seen in the kidney with the exception of malignant melanoma. Grossly there may be brown-black foci and masses.



CHAPTER 11

Urinary System

FURTHER READING

Coleman CW, Oliver R: Lymphosarcoma in a juvenile blue and gold macaw (*Ara araruana*) and a mature canary (*Serinus canarius*). *J Assoc Avian Vet* 8:64-68, 1994.

Cross G: Paramyxovirus-1 infection (Newcastle disease) of pigeons. *Sem Avian Exotic Pet Med* 4:92-95, 1995.

Flammer K, Clark CH, Drewes LA, et al: Adverse effects of gentamycin in scarlet macaws and galahs. *Am J Vet Res* 51:404-407, 1990.

Gardiner CH, Imes GD: *Cryptosporidium* sp. in the kidneys of a black-throated finch. *J Am Vet Med Assoc* 185:1401-1402, 1984.

Glahn RP: Mycotoxins and the avian kidney: Assessment of physiological function. *Worlds Poultry Sci J* 49:242-250, 1993.

Graham DL: A color atlas of avian chlamydiosis. *Sem Avian Exotic Pet Med* 2:184-189, 1993.

Holz P, Phelan J, Slocombe R, et al: Zinc toxicosis as a cause of sudden death in orange-bellied parrots (*Neophema chrysogaster*). *J Avian Med Surg* 14:37-41, 2000.

Johnson OW: Urinary organs. *In* King AS, McLelland J (eds): *Form and Function in Birds Vol I*. New York, Academic Press, 1979, pp 183-235.

King AS, McLelland J: Urinary system. *In* King AS, McLelland J (eds): *Birds: Their Structure and Function*. London, Bailliere Tindall, 1984, pp 175-186.

LaBonde J: Toxicity in pet avian patients. *Sem Avian Exotic Pet Med* 4:23-31, 1995.

McLelland J: Urogenital system. *In* McLelland J (ed): *A Color Atlas of Avian Anatomy*. Philadelphia, WB Saunders Co, 1991, pp 66-84.

Mori F, Touchi A, Suwa T, et al: Inclusion bodies containing adenovirus-like particles in the kidneys of psittacine birds. *Avian Pathol* 18:197-202, 1989.

Page CD, Haddad K: Coccidial infections in birds. *Sem Avian Exotic Pet Med* 4:136-144, 1995.

Schmidt RE: Morphologic diagnosis of avian neoplasms. *Sem Avian Exotic Pet Med* 1:73-79, 1992.

Schmidt RE, Hubbard GB: *Atlas of Zoo Animal Pathology Vol II*. Boca Raton, CRC Press, 1987, pp 83-96.

Schoemaker NJ, Lumeij JT, Beyen AC: Polyuria and



CHAPTER 11

Urinary System

FURTHER READING

(CONTINUED)

polydipsia due to vitamin and mineral over-supplementation of the diet of a salmon-crested cockatoo (*Cacatua moluccensis*) and a blue and gold macaw (*Ara ararauna*). *Avian Pathol* 26:201-209, 1997.

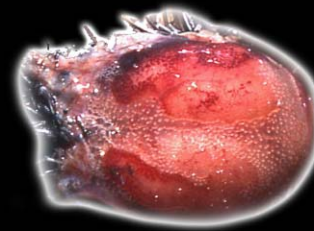
Sturkie PD: Kidneys: Extra renal salt excretion and urine. In Sturkie PD (ed): *Avian Physiology*. New York, Springer-Verlag, 1986, pp 359-382.

Zwart P, Vroeghe C, Boostsma R, et al: Glomerular hypervascularity: A congenital defect in a canary (*Serinus canarius*).

Avian Pathol 3:59-60, 1974.

CHAPTER 12

Nervous System



After removing all visceral organs, the nervous system can be examined. The skin should be removed from the head to expose the skull (Fig 12.1). There are several ways to remove the brain. For most small birds, careful cutting of the skull with poultry shears or rongeurs will expose the brain for examination. If there were no nervous system clinical signs and no indication of brain disease, the brain of most small birds can be examined by bisecting the entire head and brain with a sharp scalpel or knife prior to brain removal (Fig 12.2).

NORMAL ORGAN

The avian brain is covered by the semi-opaque and relatively tough meninges (Fig 12.2a). The cerebral hemispheres are lissencephalic (there are no sulci or gyri), tapered to a point rostrally and rounded caudally. There are paired optic lobes. These project laterally under the ventral surface of the cerebral hemispheres. The cerebellum is relatively large and has the characteristic folia

seen in other animals. However, it has only a middle lobe; the lateral lobes found in mammals are absent. Birds have four ventricles in the brain. The villous choroid plexus projects into the lateral ventricles along the walls and from the roof of the 3rd and 4th ventricles.

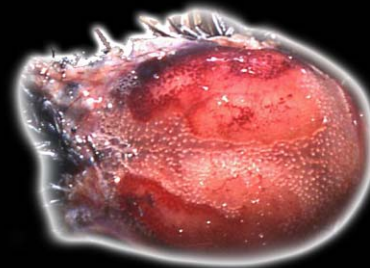
LESIONS OF THE CENTRAL NERVOUS SYSTEM (BRAIN)

Congenital Anomalies

A variety of sporadic defects have been reported in birds, particularly poultry. Documented anomalies in pet birds are less frequent and include a meningomyelocele in a scarlet macaw and hydrocephalus in a variety of psittacine birds. The latter seems to be more prevalent in older birds indicating a possible acquired rather than congenital lesion. It usually involves the lateral ventricles, which are grossly distended, and leads to compression of the overlying cortex (Fig 12.3). If ruptured, the cortical tissue collapses and becomes flaccid. Excessive fluid will drain from the area of

CHAPTER 12

Nervous System



rupture. Lafora body neuropathy and a genetic defect leading to lysosomal storage disease in emus are reported but no gross lesion is seen.

Inflammatory Disease

Inflammatory disease of the central nervous system can be noninfectious or infectious. Noninfectious diseases that can cause inflammatory lesions include some toxins, autoimmune disease and immune-mediated conditions, none of which have been well documented in pet birds. Viruses, bacteria, fungi, protozoa and metazoan parasites can cause inflammatory disease of the central nervous system.

Viral Disease

A variety of viruses cause nervous system disease. In many there is no gross lesion even though the bird may have had clinical nervous signs. Paramyxovirus (PMV) must be considered. A number of paramyxoviruses cause neurologic disease in birds, and PMV 1,2,3 and 5 have been documented in pet birds. PMV 1 is the cause of

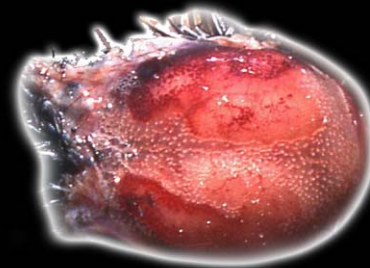
Newcastle disease in domestic poultry. PMV 3 is the most common cause of encephalitis in psittacine and small passerine birds.

Togaviruses, including eastern equine encephalitis (EEE) and western equine encephalitis (WEE), are seen in emus, and EEE is considered to be the cause of avian viral serositis in psittacine birds. Gross central nervous system lesions, other than possible hemorrhage, are not seen with EEE or WEE. Gross lesions of viral serositis are limited to parenchymal organs ([see Chapter 3](#)).

Proventricular dilatation disease (PDD) appears to be caused by a virus, not yet characterized, which affects both the autonomic nerves, particularly those of the digestive system ([see Chapter 7](#)), and the central nervous system. Central nervous system disease often accompanies disease of the nerves of the digestive tract, and microscopic central nervous system lesions may be the predominate feature of some infections. PDD does not cause gross lesions in the central nervous system.

CHAPTER 12

Nervous System



Influenza A virus has occasionally been isolated from psittacine birds, including African grey parrots, cockatoos, budgerigars and mynahs and other Passeriformes. There are occasional reports of influenza virus-induced neuronal disease, resulting in gross hemorrhage.

West Nile virus causes systemic disease as well as central nervous system lesions and has infected a variety of pet and wild birds. Grossly, meningeal and brain congestion and hemorrhage are found (Fig 12.4). There may also be calvarial hemorrhage, which must be differentiated from postmortem congestion (Fig 12.5).

Adenovirus: Neurologic signs associated with adenovirus infection are most common in cockatiels and budgerigars. No gross lesion is present.

Avian polyomavirus: In some outbreaks in budgerigars, significant microscopic (but not gross) cerebellar lesions may be seen.

Bacterial Infection

Numerous bacteria, including *Staphylococcus* sp., *Salmonella* sp., *E. coli*, *Pseudomonas* sp. and *Klebsiella* sp. are possible causes of meningitis, encephalitis and myelitis. Gross lesions are absent in many cases, but exudate can occasionally be seen in the meninges and, in chronic cases, abscesses can be found in the brain.

Chlamydophila psittaci will affect serous membranes throughout the body and can induce a non-suppurative meningitis, which is usually not appreciable grossly.

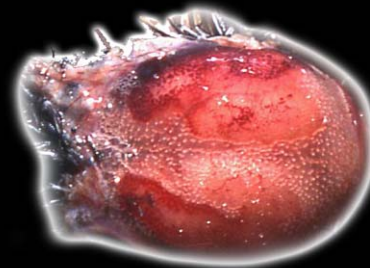
Mycobacterial infection of the central nervous system is usually part of a systemic process. Gross lesions are proliferative and grey-white or yellow.

Fungal Infection

As with bacterial disease, fungal infections can be blood-borne or may occur secondary to extension from the nasal cavity or sinuses. The brain, spinal cord and meninges all may be affected. Gross changes depend on the chronicity of the lesion and vary from none to the presence of granulomas.

CHAPTER 12

Nervous System



Parasitic Infection

Several protozoa, including *Sarcocystis falcatula*, *Toxoplasma gondii* and *Leukocytozoon* sp., may cause brain lesions. The most common in pet species is *S. falcatula*. Gross changes are usually not present in the brain.

Leukocytozoon infection may lead to the formation of megaloschizonts in the brain. On careful gross examination, these may present as small white foci but they are difficult to see.

Wandering nematode parasites can cause severe lesions in the avian brain. *Baylisascaris procyonis* is the most common and is usually the result of ingestion of food contaminated with raccoon feces. In severe cases there can be grossly noticeable malacia and hemorrhage. *Chandlerella quiscalis* is a filarid of grackles. The adult worm lives in the ventricles of the brain and microfilaria are readily demonstrated in the blood. Young emus, 2-6 months of age, can be devastated by this parasite. If severe, hemorrhage and malacia may be seen.

Microfilariasis, with plugging of the small vessels in the brain, ischemia and clinical disease, is a condition that is most prevalent in free-ranging or wild-caught cockatoos but could be found in any bird with subcutaneous or peritoneal cavity filariasis. There is usually no gross change.

Noninflammatory Disease

Infectious Disease

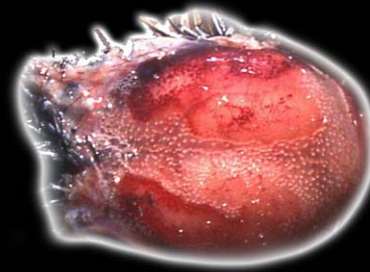
Spongiform encephalopathy results from an abnormal conformational change in brain glycoprotein that creates infectious proteins called prions. A condition resembling bovine spongiform encephalopathy is reported to occur in psittacine birds. Gross lesions are not seen.

Physical/Traumatic

One of the most common causes of traumatic brain damage is aggression from cage mates or attack by free-ranging predatory birds on unprotected captive birds. There is often, but not always, associated bruising and hemorrhage of the skin and subcutis over the skull, and

CHAPTER 12

Nervous System



in severe cases, there may be damage to the external portion of the skull.

When there has been trauma, the meninges and brain will be hemorrhagic (Fig 12.6), and the hemorrhage will extend into the brain parenchyma. It is usually better to fix the brain before gross coronal sectioning, but it can be done when the brain is fresh if there is a sharp blade available. Internal hemorrhage may be minimal or extensive (Fig 12.7, Fig 12.8, Fig 12.9). If there is only severe congestion, either antemortem or postmortem, no hemorrhage will be noted when the brain is incised.

Occasionally the brain may be edematous and swollen with no obvious hemorrhage (Fig 12.10).

Postmortem pooling of blood in venous sinuses of the calvarium (Fig 12.11) must be differentiated from traumatic head injuries (Fig 12.12). This postmortem artifact is very common and will not be associated with damage to the skin and/or brain or meningeal hemorrhage.

Cases of brain hemorrhage and malacia without any identifiable cause are sporadically seen. Hemorrhage into the brain and spinal cord may also occur in cases of "conure bleeding syndrome," a problem of conures of which the etiology and pathogenesis are not well understood (Fig 12.13). Morphologically, these lesions resemble the traumatic lesion described.

Thrombosis can lead to acute ischemia and hemorrhage. A common cause of thrombosis in female birds is yolk emboli.

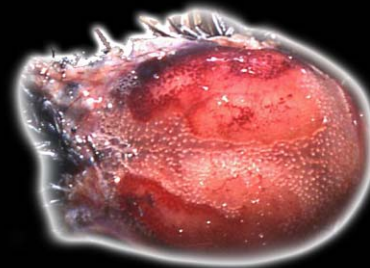
Toxic Neuropathy

Toxins known to cause problems in the avian brain include lead, zinc, sodium, poisonous plants, mycotoxins and insecticides. Gross changes are not usually seen.

Mycotoxins cause encephalomalacia, which may be grossly visible if severe. Organic phosphate and carbamate insecticides can lead to demyelination in the spinal cord and peripheral nerves. No gross lesion is seen.

CHAPTER 12

Nervous System



Nutritional Deficiencies

Vitamin E deficiency affects several organ systems including cardiac, ventricular, and skeletal muscle and skin. It may cause encephalomalacia in poultry and emus and occasionally in psittacine birds. Grossly there may be hemorrhage and edema of the brain (Fig 12.14), but often no lesion is seen. Brain lesions believed to be associated with vitamin E deficiency occur in great-billed parrots.

Proliferative Lesions

A variety of primary and metastatic tumors are reported in the avian brain and spinal cord. Although much of the literature concerns domestic poultry, most tumors are also found in pet birds.

Meningiomas are of variable shape. They are firm and gray-white to yellow. If there has been any hemorrhage, they may be slightly reddened.

Avian meningeal tumors not morphologically typical are also occasionally seen. There may also be minimal invasion of the brain.

Choroid plexus papilloma are present as well-defined papillary structures within ventricles. They are gray-white to red.

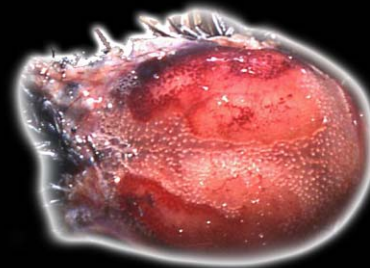
Primary tumors of glial cells, glioblastoma multiforme, astrocytoma and oligodendroglioma, are all seen in birds. Grossly these tumors may be difficult to detect, particularly in early stages. There may be some enlargement and distortion or dislocation of normal structures (Fig 12.15). Asymmetry can often be noted on coronal sections of brain. If there is necrosis or hemorrhage, the area of tumor may resemble an abscess or infarct.

Medulloblastoma and neuroblastoma are primary tumors of neuronal cells that have not been documented in companion bird species

Metastatic tumors of the brain, including metastatic carcinomas, various sarcomas (e.g., lymphosarcoma and hemangiosarcoma) and malignant melanoma have been seen in the avian brain.

CHAPTER 12

Nervous System



LESIONS OF THE SPINAL CORD

Unlike mammals, the spinal cord is the same length as the spinal canal and extends to the last caudal vertebra. Therefore, birds do not have a cauda equina, and spinal nerves pass laterally to the adjacent intervertebral foramina. There are cranial and caudal enlargements in the area of the brachial and lumbosacral plexi. In the dorsal midline of the lumbosacral enlargement is the rhomboidal sinus, which is unique to birds. The rhomboidal sinus separates the left and right dorsal columns leaving a cleft occupied by the gelatinous (or glycogen) body. The ventral part of the gelatinous body encloses the spinal canal. The function of the gelatinous body is unknown. The lesions seen in the spinal cord are similar to those seen in the brain. Gross changes are usually not seen, although hemorrhage and tumors may be noticeable (Fig 12.16).

LESIONS OF THE PERIPHERAL NERVOUS SYSTEM

The structure of the peripheral nervous system is similar to that of mammals. Peripheral nerves can be involved in a variety of infectious and noninfectious diseases. In many conditions there is no gross lesion.

Viral Disease

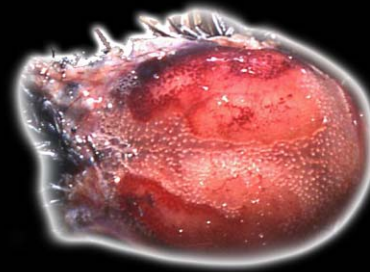
Proventricular dilatation disease affecting the peripheral nerves can lead to gross changes of the heart (see Chapter 4) or gastrointestinal tract (see Chapter 7). West Nile virus can also cause a peripheral neuritis that usually has no gross change.

Other Infections

Bacterial, mycobacterial and fungal infections can involve adjacent peripheral nerves with lesions typical of the primary problem.

CHAPTER 12

Nervous System



Noninflammatory Disease

Toxins

Arsenic toxicity can lead to a peripheral neuropathy. Gross lesions are not seen.

Trauma

Many cases of trauma lead to noninflammatory nerve degeneration associated with direct nerve involvement or secondary to compression. There is no gross change.

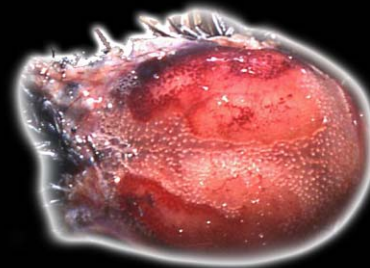
Nutritional Deficiencies

Riboflavin (Vitamin B₂) deficiency leads to classical “curled toe paralysis” in chickens and can cause polyneuritis and degeneration in a variety of birds. Grossly there may be slight swelling and discoloration of large nerves such as the sciatic.

Neoplastic Disease

Schwannomas are sporadically seen in pet birds. They can be single or multiple white, firm nodules.

Ganglioneuromas are also seen in pet birds, particularly involving the adrenal gland and associated ganglia. Grossly there may be enlargement and distortion of the adrenal gland.



CHAPTER 12

Nervous System

FURTHER READING

Aguilar RF, Shaw DP, Dubey JP, et al: Sarcocystis-associated encephalitis in an immature northern goshawk (*Accipiter gentilis atricapillus*). J Zoo Wildl Med 22:466-469, 1991.

Aye PP, Morishita TY, Grimes S, et al: Encephalomalacia associated with vitamin-E-deficiency in commercially raised emus: Case report. Avian Dis 42:600-605, 1998.

Bermudez AJ, Freischutz B, Yr RK, et al: Heritability and biochemistry of gangliosidosis in emus (*Dromaius novaehollandiae*). Avian Dis 41:838-849, 1997.

Bicknese EF: Review of sarcocystosis. Proc Assoc Avian Vet, 1993, pp 52-58.

Bossart GD: Neurofibromas in a macaw (*Ara chloroptera*): Morphologic and immunocytochemical diagnosis. Vet Pathol 20:773-776, 1983.

Chevillat NF, Stone H, Riley J, et al: Pathogenesis of virulent Newcastle disease in chickens. J Am Vet Med Assoc 161:169-179, 1972.

Gaskin JM, Homer BL, Eskelund KH: Preliminary findings in avian viral serositis: A newly recognized syndrome of psittacine birds. J Assoc Avian Vet 5:27-34, 1991.

Gregory CR, Latimer KS, Niagro FD, et al: A review of proventricular dilatation syndrome. J Assoc Avian Vet 8:69-75, 1994.

Henshel DS: Developmental neurotoxic effects of dioxin and dioxin-like compounds on domestic and wild avian species. Environ Toxicol Chem 88-98, 1998.

Jones MP, Orosz SE: Overview of avian neurology and neurological diseases. Sem Avian Exot Pet Med 5:150-164, 1996.

Garnham PCC, Duggan AJ, Sinden RE: A new species of *Sarcocystis* in the brain of two exotic birds. Ann

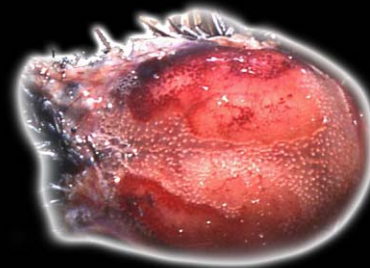
Parasit 54:393-400, 1979.

Kwiecien JM, Smith DA, Key DW, et al: Encephalitis attributed to larval migration of *Baylisascaris* species in emus. Can Vet J 34:176-178, 1993.

Latimer KS, Niagro FD, Stefens III WL, et al: J Vet Diagn Invest 8:291-295, 1996.

Leach MW, Higgins RJ, Lowenstine LJ, et al: Paramyxovirus infection in a Moluccan cockatoo (*Cacatua moluccensis*) with neurologic signs. AAV Today 2:87-90, 1988.

Quist CF, Ritchie BR, McClure H, et al: Spongiform



CHAPTER 12

Nervous System

FURTHER READING

(CONTINUED)

encephalopathy in three psittacine birds. *Proc Assoc Avian Vet*, 2000, pp 205-206.

Rae M: Hemoprotozoa of caged and aviary birds. *Sem Avian Exotic Pet Med* 4:131-137, 1995.

Reece RL, Butler R, Hooper PT: Cerebellar defects in parrots. *Aust Vet J* 63:197-198, 1986.

Schmidt RE, Goodman GJ, Higgins RJ, et al: Morphologic identification of papovavirus in a Moluccan cockatoo (*Cacatua moluccensis*) with neurologic

signs. *AAV Today* 1:107-108, 1987.

Smit TH, Rondhuis PR: 1976. Studies on a virus isolated from the brain of a parakeet (*Neophema* sp.). *Avian Pathol* 5:21-30, 1976.

Steele KE, Linn MJ, Schoep RJ, et al: Pathology of fatal West Nile virus infections in native and exotic birds during the 1999 outbreak in New York City, New York. *Vet Pathol* 37:208-224, 2000.

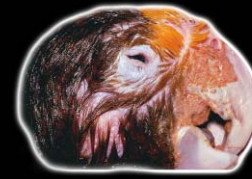Suedmeyer WK: Diagnosis and clinical progression of three cases of proventricular dilatation syndrome. *J Assoc Avian Vet* 6:159-163, 1992.

Teglas MB, Little SE, Latimer KS, et al: *Sarcocystis*-associated encephalitis and myocarditis in a wild turkey (*Meleagris gallopavo*). *J Parasit* 84:661-663, 1998.

Woods LW, Plumlee KH: Avian toxicooses: Veterinary diagnostic laboratory perspective. *Sem Avian Exotic Pet Med* 8:32-35, 1999.

CHAPTER 13

Special Sense Organs



EYE

Relative to most other animals, birds have large eyes. They are recessed and fill most of the space in the rostral skull. The shape of the eye varies significantly between species, but in most companion birds it is spherical with an anterior to posterior flattening. The eye is surrounded dorsally, rostrally, ventrally and medially to some extent by the infraorbital sinus.

Normal Structure

The cornea and sclera comprise the fibrous tunic of the eye. At the junction of the anterior and posterior chambers, the sclera is reinforced by a ring of overlapping bones called the scleral ossicles. The number varies from 10-18 depending on the species. The sclera surrounding the posterior chamber is thick and has two layers: a cartilage layer and a thick fibrous layer. In some species the scleral cartilage around the optic nerve is ossified.

The vascular tunic is comprised of the choroid, ciliary body and iris, and the avian lens is softer than the mammalian lens, having a fluid-filled lens vesicle between the annular pad and body of the lens.

The neural tunic (retina) is relatively thick and, unlike in mammals, does not contain blood vessels.

The pecten projects from the retina into the vitreous at the exit of the optic nerve. It is markedly vascular and may be active in nutrition of inner retinal layers. Its size and morphology vary by species. Conical pectens are seen only in the kiwi; vaned pectens in rheas, ostriches and tinamous; and pleated pecten in most other birds.

Removal of the eyes at necropsy is best done by using blunt curved scissors. Minimal traction is put on the bulbar conjunctiva, and the scissors are used to cut all muscular and other attachments. Careful dissection will result in an intact globe. All extraneous tissue should be trimmed before placing the eye in fixative.

CHAPTER 13

Special Sense Organs



Diseases of the Eye and Adnexa

Developmental anomalies include cryptophthalmos (continuous skin over the globe with no evidence of lid formation) and agenesis of eyelids, symblepharon, improperly draining nasolacrimal ducts, and corneal dermoids. Microphthalmia is probably the most commonly reported anomaly, with a small globe being obvious grossly ([Fig 13.1](#)).

There may be anomalies of all segments of the eye associated with disturbances of optic vesicle involution or embryonic fissure closure. Many of these may not be visible grossly and if suspected, the eyes should be fixed and examined histologically.

Ocular Adnexa

Blepharitis is often an extension of periocular dermatitis due to a variety of causes. Viruses that may affect the eyelids include poxvirus, circovirus (psittacine beak and feather disease virus, polyomavirus and papillomavirus. Acute changes in poxvirus infection include mild inflammation and edema with a serous ocular discharge. With

chronicity there is ulceration of the lids and a proliferative mass may form ([Fig 13.2](#)). The exudate may become purulent due to secondary bacterial infection.

Circovirus infection can lead to acute lesions in the peri-orbital skin that may be difficult to differentiate from poxvirus infection grossly. Polyomavirus can cause blepharitis as part of generalized infection in budgerigars. Papillomas, which are reported to be caused by a papillomavirus, are in rare instances found on the skin of the face and eyelids of African grey parrots ([see Chapter 2](#)).

Bacterial infection can be primary in the eyelid or secondary to dermatitis of the periorbital skin. Gross changes are variable, from reddening and swelling to ulceration ([Fig 13.3](#)).

Knemidokoptes sp. infections present as crusts and/or scales and commonly involve the periorbital skin. Fungi can cause nonspecific inflammation as in any other location.

CHAPTER 13

Special Sense Organs



Noninfectious Diseases

Vitamin A deficiency may cause periorbital epidermal hyperplasia and hyperkeratosis with secondary infections possible.

Neoplastic lesions of the eyelids potentially include all of the tumors reported in the skin of birds (see Chapter 2). Xanthomas are also seen in the eyelids, including the third eyelid.

Lacrimal glands may become infected with bacteria leading to swelling and abscessation. The swelling must be differentiated from possible gland or periorbital neoplasia. Grossly the lesion is fluctuant, and purulent material may be expressed.

Lacrimal gland neoplasia is infrequently seen in birds. Carcinoma appears to be most common, in our experience. The tumors present as firm gray-white masses.

Lesions of the Conjunctiva

Lesions of the conjunctiva may be primary or associated with diseases of the lids and periorbital skin. They can involve palpebral or bulbar conjunctive or the nictitating membrane. Secondary lesions are most commonly associated with sinusitis and therefore may be due to a variety of infectious agents including viruses, bacteria, chlamydophila and mycoplasma. In some cases conjunctival lesions may indicate a generalized infection or septicemia.

Primary disease may be infectious or noninfectious. Infectious disease may have similar gross signs including reddening and ocular discharge regardless of cause. Poxvirus infection causes lesions similar to those of the eyelids. A herpesvirus is the cause of conjunctivitis in Gouldian finches. Grossly the conjunctiva is swollen due to edema and congestion. There is a serous exudate in the conjunctival sac.

Adenovirus and paramyxovirus-2 can cause conjunctivitis as a part of generalized disease. Lesions are

CHAPTER 13

Special Sense Organs



nonspecific unless inclusion bodies are found histologically.

Bacterial conjunctivitis has been associated with a variety of organisms. In early cases, affected conjunctival sacs are minimally swollen and reddened (Fig 13.4). When more severe, there is greater swelling and reddening, and the third eyelid may protrude (Fig 13.5). In chronic cases, multifocal to confluent yellow-white foci are seen. Mycobacterial infection leads to proliferative lesions that have a similar gross appearance.

Conjunctivitis is a fairly common feature of *Chlamydophila psittaci* and *Mycoplasma* sp. infections in birds. *C. psittaci* causes conjunctival reddening with a serous or purulent exudate. Mycoplasmosis is seen occasionally in individual companion birds, and we have seen it in flocks of commercial budgerigars. It is also suspected to be one of the causes of the chronic conjunctivitis seen in cockatiels, but this remains to be proven. *Mycoplasma gallisepticum* is widespread in free-ranging house finches in North America. Several other species of

Native American birds are also reported to be susceptible to this organism. Affected birds have swollen conjunctival membranes and a serous to mucopurulent discharge.

Fungi causing conjunctivitis include *Aspergillus* sp., *Candida* sp. and *Cryptococcus neoformans*. Gross lesions are similar to those of chronic bacterial infections. Cryptosporidial conjunctivitis is occasionally seen. Gross changes are minimal and nonspecific. Nematodes that can cause conjunctivitis include *Oxyuris mansoni*, which irritates the conjunctiva and may enter the lacrimal ducts, and *Thelazia* sp., which can be found in the conjunctival sac of birds with mild inflammatory changes.

Philophthamus gralli is a trematode that is the cause of severe chronic conjunctivitis, primarily in waterfowl. Gross lesions include swelling and reddening of the conjunctiva. Generally multiple flukes are present and they are large enough to be seen with the unaided eye (Fig 13.6).

CHAPTER 13

Special Sense Organs



Noninfectious causes of conjunctivitis include foreign bodies that lead to generalized or focal swelling due to a granulomatous reaction (Fig 13.7). Physical irritants such as smoke aerosols or chemical fumes can cause nonspecific conjunctival inflammation. Vitamin A deficiency can result in metaplasia and hyperkeratosis of conjunctival epithelium with formation of large semicircular plaques of sloughed squamous cells in the ventral conjunctival recesses.

Proliferative lesions include conjunctival papillomas and tumors such as squamous cell carcinoma and melanoma. Histology is usually needed for a definitive diagnosis.

Lesions of the Cornea

Keratitis will present grossly as corneal opacity with possible reddening if there is vascularization. In severe cases there may be ulceration. It can be associated with a variety of causes.

Infectious keratitis can be due to any of the agents described as causes of conjunctivitis. In birds, bacterial

and mycotic infections are the most common. Gross changes are similar, with ulceration and proliferation of cream-yellow caseous-appearing material (Fig 13.8, Fig 13.9, Fig 13.10, Fig 13.11).

Microsporidial keratitis is occasionally seen in psittacine birds. Gross changes include conjunctival reddening and corneal opacity. Noninfectious keratitis is usually secondary to trauma; however, unless there is foreign material found in the lesion, the cause is usually inferred to be due to a lack of any infectious agent.

Noninflammatory corneal lesions are infrequently seen. Stromal degeneration secondary to previous inflammation is seen in a variety of pet species. Grossly there is corneal opacity.

Lesions of the Lens

Lens luxation may be secondary to trauma or inflammation leading to zonule lysis. Careful gross sectioning of the eye is necessary to be sure the lens was not displaced artifactually.

CHAPTER 13

Special Sense Organs



Cataracts may be congenital or acquired, and are hereditary in some canaries (Yorkshire and Norwich). The condition appears to be caused by an autosomal recessive gene. Acquired cataracts have been associated with nutritional deficiencies, trauma, toxins, aging, infection and inflammation of the eye. Cataracts present as lens opacities (Fig 13.12).

Lesions of the Uveal Tract (Iris, Ciliary Body and Choroid)

Uveitis may be anterior, posterior or diffuse, involving the entire uveal tract. Suppurative uveitis may be secondary to penetrating trauma, extension from the corneal or sclera, or the result of localization of systemic infections. Grossly there may be fibrin clots in the anterior chamber, hemorrhage, hypopyon and hyphema.

Synechia is adherence of the iris to either the cornea (anterior) or the lens (posterior). It is a sequella to an inflammatory lesion in the anterior chamber and may be grossly visible.

Lesions of the Retina

Retinitis may be caused by a variety of infectious agents, be secondary to trauma, or be associated with diseases of the central nervous system. Gross lesions are usually not seen unless severe.

Retinal degeneration is potentially due to a variety of causes, e.g., toxins, nutrition and hypoxia. No gross lesion is seen.

Retinal detachment can also be secondary to trauma or inflammation of the retina and/or choroid. The condition must be differentiated from postmortem or artifactual detachment, and this usually requires histologic examination.

Lesions of the Optic Nerve

Lesions of the optic nerve are similar to those seen in the brain and are due to the same causes. These lesions are usually not grossly visible.

CHAPTER 13

Special Sense Organs



Lesions of the Eye as a Whole

Panophthalmitis may result from trauma or a variety of infectious agents as listed for the various segments of the eye. A sequela of chronic panophthalmitis is phthisis bulbi. Affected eyes are shrunken and may be collapsed.

Glaucoma

Glaucoma is occasionally reported in birds. Grossly the affected eye is enlarged, and the lens may be luxated.

Ocular Neoplasia

Tumors of skin and subcutis affecting the eyelids have been previously mentioned. Squamous papilloma, squamous cell carcinoma, malignant melanoma and basal cell tumors are seen. Adnexal tumors include adenomas and adenocarcinomas of the lacrimal gland. Orbital neoplasia includes chondroma, infiltrative carcinoma, lymphosarcoma and teratoma. The gross appearance is of an orbital mass that displaces the eye. Intraocular malignant melanomas can arise in the uveal tract. These tumors

may or may not be grossly visible, but if so, are usually brown-black.

Primary intraocular tumors are rarely reported in birds. Medulloepithelioma, an embryonic tumor of the CNS and retina, is reported in cockatiels. This tumor usually presents as an undiagnosed red/gray and somewhat friable intraocular mass ([Fig 13.13](#)). The tumor may extend through the orbit and impinge on the brain. Intraocular Marek's disease is seen in chickens ([Fig 13.14](#)).

Orbital Disease

Inflammation or neoplasia in the orbit can impact the eye even if the fibrous tunic is not penetrated. Trauma and localization of systemic disease can lead to retrobulbar abscessation.

CHAPTER 13

Special Sense Organs



EAR

Normal Structure

The avian external ear has a short canal extending vertically and caudally from the external acoustic meatus to the tympanic membrane. The external meatus is small, usually circular and opens on the side of the head. In most birds, it is usually covered by specialized contour feathers called ear coverts. The middle and internal ears cannot be examined routinely by gross observation, and histology must be done if disease problems are suspected. Portions of the skull containing the ears should be removed after brain removal and examination of the nasal cavity and fixed prior to decalcification.

Diseases of the Ear

Otitis externa is uncommon in birds. Potential causes include bacteria, fungi and arthropod parasites. There may be problems associated with extension of skin disease. The gross appearance may be altered by self-trauma. Hemorrhage, necrosis and exudate are seen.

Carcinoma of the glands of the external ear canal is occasionally seen. It may present as a chronic condition with thickening of the ear canal as well as a localized mass lesion that can extend towards the angle of the jaw and the upper cervical region (Fig 13.15, Fig 13.16).

Middle ear: Otitis media is rarely reported. Various infections are possible, which may be secondary to oral/pharyngeal disease with extension via the pharyngotympanic tube.

Inner ear: Congenital lesions have been reported in Belgian Waterslager canaries. There are often multiple abnormalities associated with dysgenesis of the pars inferior of the otocyst. These are diagnosed only histologically.

Otitis interna can be due to paramyxovirus infection, particularly in Australian grass parakeets (*Neophyma* sp.). Lesions can lead to "twisted neck," "stargazing" and similar syndromes (Fig 13.17). Poxvirus can also affect the inner ear. The diagnosis is made histologically.

CHAPTER 13

Special Sense Organs



Ototoxicity and acoustic trauma can lead to transitory or permanent loss of sensory epithelium. No gross lesion is seen.

OLFACTORY/TASTE ORGANS

The avian olfactory organ arises as an area of thickened ectoderm on the ventrolateral surfaces of the head. Axons of the receptor cells form the olfactory nerve and cranial nerve 1 and terminate in the olfactory bulb. The olfactory receptors are in the nasal mucosa of the caudal nasal concha. Gross changes involving this tissue may arise from associated respiratory tract lesions. Taste receptors vary by species. No diseases of these receptors have been documented.

SOMATOSENSORY RECEPTORS

These organs give information about the physical condition of the internal and external environment. They respond to mechanical, thermal or chemical stimuli. They

occur in the integument, tendons, muscles and joint capsule. Any trauma, infectious disease or tumor that damages one of the above structures could be the cause of a decrement in function. Inflammation of dermal receptors could cause sensation and lead to feather picking or self-trauma. The gross appearance depends on the particular disease process involved.



CHAPTER 13

Special Sense Organs

FURTHER READING

Bang BG, Wenzel BM: Nasal cavity and olfactory system. In King AS, McLelland J (eds): Form and Function in Birds Vol 3. New York, Academic Press, 1985, pp 195-225.

Brooks DE, Greiner EC: Conjunctivitis caused by *Thelazia* sp. in a Senegal parrot. J Am Vet Med Assoc 183:1305-1306, 1983.

Brooks DE: Avian cataracts. Sem Avian Exotic Pet Med 6:131-137, 1997.

Busch TJ: Corneal dermoids in a goose. New Zeal Vet 33:189-190, 1985.

Buyukmihci N, Murphy CJ, Schulz T: Developmental ocular disease of raptors. J Wildl Dis 24:207-213, 1988.

Canny CJ, Ward DA, Patton S, et al: Microsporidian keratoconjunctivitis in a double yellow-headed Amazon parrot (*Amazona ochrocephala oratrix*). J Avian Med Surg 13:279-286, 1999.

Desmidt M, Ducatelle R, Uytendaele E, et al: Cytomegalovirus-like conjunctivitis in Australian finches. J Assoc Avian Vet 5:132-136, 1991.

Dukes TW, Fox GA: Blindness associated with retinal dysplasia in a prairie fal-

con. J Wildl Dis 19:66-69, 1983.

Gilger BC, McLaughlin SA, Smith P: Uveal malignant melanoma in a duck. J Am Vet Med Assoc 206:1580-1582, 1995.

Graham DL: Poxvirus infection in a spectacled Amazon parrot (*Amazona albitrons*). Avian Dis 22:340-343, 1978.

Hirose K, Westrum LE, Stone JS, et al: Dynamic studies of ototoxicity in mature avian auditory epithelium. Ann NY Acad Sci 884:389-409, 1999.

Kern TJ, Paul-Murphy J, Murphy CJ, et al: Disorders of the third eyelid in birds:

17 cases. J Avian Med Surg 10:12-18, 1996.

Keymer IF: Cataracts in birds. Avian Pathol 6:335-341, 1977.

King AS, McLelland J: Birds: Their Structure and Function 2nd ed. London, Bailliere Tindall, 1984, pp 284-314.

Kühne R, Lewis B: External and middle ears. In King AS, McLelland J (eds): Form and Function in Birds Vol 3. New York, Academic Press, 1985, pp 227-271.

Leach MA: Survey of neoplasia in pet birds. Sem Avian Exotic Pet Med 1:52-64, 1992.

CHAPTER 13

Special Sense Organs



FURTHER READING

(CONTINUED)

Luttrell MP, Stallknecht DE, Fischer JR, et al: Natural *Mycoplasma gallisepticum* infection in a captive flock of house finches. *J Wildl Dis* 34:289-296, 1998.

Pocknell AM, Miller BJ, Neufeld JL, et al: Conjunctival mycobacteriosis in 2 emus (*Dromaius novaehollandiae*). *Vet Pathol* 33:346-348, 1996.

Schmidt RE, Toft JD II: Ophthalmic lesions in animals from a zoologic collection. *J Wildl Dis* 17:267-275, 1981.

Schmidt RE, Hubbard GB: Special sense organs. In

Atlas of Zoo Animal Pathology Vol II. Boca Raton, CRC Press, 1987, pp 125-133.

Slatter DH: Hereditary cataracts in conures. *J Am Vet Med Assoc* 183:872-874, 1983.

Stillman AJ: Avian vision. In Farner OJ, King JR (eds): *Avian Biology III*. New York, Academic Press, 1973, pp 349-383.

Stanz KM, Miller PE, Cooley AJ, et al: Mycobacterial keratitis in a parrot. *J Am Vet Med Assoc* 206:1177-1180, 1995.

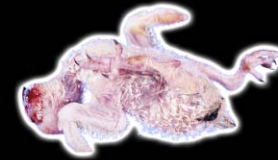Tudor DC, Yard C: Retinal atrophy in a parakeet. *Vet Med Sm Anim Clin* 73:1456, 1978.

Weisleder P, Lu Y, Park TJ: Anatomical basis of a congenital hearing impairment: Basilar papilla dysplasia in the Belgian waterslager canary. *J Comp Neurol* 369:292-301, 1996.

Willis AM, Wilkie DA: Avian ophthalmology. *J Avian Med Surg* 13:245-251, 1999.

CHAPTER 14

Musculoskeletal System



After all other organ systems have been examined, the skeletal muscle and bone can be observed for gross changes and appropriate samples taken for histology.

SKELETAL MUSCLE

Normal

Birds have both red and white muscle fibers in most muscles (Fig 14.0). Red and white fibers are differentiated by their myoglobin content. Two-joint muscles, which span articulations between their origin and insertion, comprise most of the important strong muscles of birds. When taking samples of skeletal muscle, enough should be included so the pathologist may prepare sections to be able to examine fibers by cross-section and longitudinally.

Diseases of Skeletal Muscle

Congenital muscular dystrophy is reported in chickens and turkeys but not in pet birds. The lesion is

characterized by irregular atrophy with myofibers lost and replaced by fat.

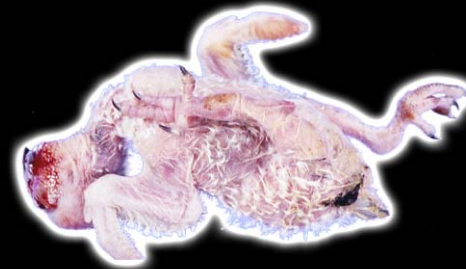Arthrogryposis is a term for congenital flexure or contracture of joints secondary to failure of proper skeletal muscle development (Fig 14.1). There is atrophy of muscles that is secondary to congenital neurologic problems. Affected myofibers are lost and replaced by fibrous tissue.

Noninflammatory diseases of skeletal muscle include atrophy as a common reaction to disuse, denervation, generalized chronic disease, nutritional deficiencies, local compression and aging. Grossly there is a diminution of muscle size (Fig 14.2, Fig 14.3). In birds, particularly budgerigars, disuse atrophy may occur secondary to nerve damage caused by renal tumors.

Pectoral muscle mass is an important indicator of how long the bird was in a catabolic state prior to death. Birds that die acutely will have robust pectoral muscle mass. Subacute disease with decreased food consumption results in muscle wasting. Birds with chronic disease

CHAPTER 14

Musculoskeletal System



often have severe loss of pectoral muscle mass. Smaller birds with higher metabolic rates lose fat and muscle mass faster than larger species.

Hypertrophy of skeletal muscle is usually a compensatory change that results in an enlarged muscle mass.

Steatosis is seen sporadically in obese birds, particularly obese Amazon parrots. An extensive increase in intramuscular fat with replacement of myofibers is noted. The cause is usually malnutrition; however, metabolic disorders should be considered.

Trauma results in hemorrhage, edema and gross disruption of muscles. The affected area may become yellow-brown with chronicity (Fig 14.4). The extent of muscle reaction will depend on whether the injured area develops a secondary infection. Intramuscular injections usually lead to some necrosis and hemorrhage. Massive muscle necrosis is associated with some forms of compounded long-acting doxycycline formulations.

Vitamin E or selenium deficiencies are implicated in muscle disease in picivorous birds fed a diet of

improperly frozen and thawed fish. Any diet containing rancid polyunsaturated fat may cause similar lesions. A similar disease is seen in other species of birds (including companion birds), although the exact cause is often not readily determined, even though a vitamin E/selenium deficiency is suspected. Great-billed parrots may be particularly at risk for reasons that are not apparent.

Gross lesions of vitamin E and selenium deficiency include white streaks and patches in striated muscle (Fig 14.5).

Riboflavin deficiency leads to degeneration of neuromuscular end plates and skeletal muscle resulting in “curled-toe paralysis” (Fig 14.6).

Exertional or capture myopathy results in muscle necrosis with yellow foci and hemorrhage in acute cases. With chronicity, firm white streaks are noted.

Hyperthyroidism and hyperadrenocorticism can lead to myofiber degeneration or atrophy.

Toxins, such as ionophores used as coccidiostats and growth promoters, gossypol and plants such as Cassia

CHAPTER 14

Musculoskeletal System



sp., have caused skeletal muscle lesions in ostriches, quail and other African free-ranging birds. Gross changes may not be noted.

Inflammatory Diseases

Although not common, a variety of infectious agents can cause myositis. The infections can be associated with trauma, extension from adjacent tissue or hematogenous spread of infection.

Viral myositis is uncommon. Polyomavirus infection in large psittacine birds may cause skeletal muscle lesions. Gross pallor and variable hemorrhage are seen (Fig 14.7, Fig 14.8).

Bacterial infections can be aerobic or anerobic. They rarely are limited to skeletal muscle but usually also involve subcutis, fascia or bone. Necrosis and accumulation of yellow caseous material is seen in severe lesions.

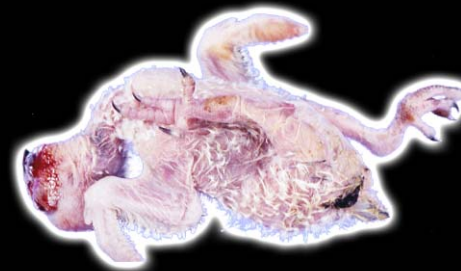Mycotic infections are often due to local extension from air sacs or systemic disease. Nonspecific areas of necrosis and, in some cases, abscess formation may be present.

Parasitic infections of skeletal muscle associated with visceral larva migrans (*Baylisascaris procyonis*) are possible as incidental findings. Mites (*Laminosioptes cysticola*) can invade skeletal muscle in some cases. Gross changes vary from small white foci that may be mineralized to abscess formation and tracts that may lead to the skin. Finding the parasite or fragments is necessary for a definitive diagnosis.

Sarcocystosis is a disease of many species of birds. Most *Sarcocystis* sp. are generally adapted to their host and cause little disease. Ducks are commonly affected with *S. riyeli*. Large protozoal cysts (rice grains) are found in the pectoral muscles of these birds (Fig 14.9). Sarcocytosis is generally an incidental finding in most species of New World parrots. Gross changes may not be seen, but if the infection is severe, small white foci or steaks may be present.

CHAPTER 14

Musculoskeletal System



Proliferative Disease

Primary neoplasms of striated muscle include rhabdomyoma and rhabdomyosarcoma, although they are infrequently reported in pet birds.

While benign tumors are tan-red and resemble normal skeletal muscle, rhabdomyosarcomas have irregular borders and may be tan to gray.

As in mammals, lymphosarcoma is one of the few tumors that will commonly invade skeletal muscle; it appears as a gray-white mass. Malignant melanoma can invade skeletal muscle, usually associated with skin and subcutaneous lesions. The tumor is usually pigmented, but amelanotic types are seen. Metastatic tumors are rare in skeletal muscle.

TENDONS AND LIGAMENTS

Specific conditions of either tendon or ligament are infrequently diagnosed. Possible problems include physical damage following trauma, inflammation of ten-

don sheaths and neoplasia. The ligament of the extensor propatagialis muscle is often injured when wings are immobilized as part of treatment for fracture of the bones of the wings. In systemic gout, urate tophi commonly form on the sheaths of the flexor tendons of the antebrachium and on the tendons of the feet (Fig 14.10).

Infectious agents affecting the tendons of poultry include *Mycoplasma synoviae*, other bacteria and a reovirus. These diseases first start as an arthritis and spread locally to involve the tendons.

Tendon sheath sarcomas are possible, but rarely seen.

BONE AND CARTILAGE

As well as examining bone visually, a long bone should be broken to be sure it is adequately mineralized (Fig 14.10a). If there is a problem with matrix formation of mineralization, the bone will bend rather than break. Digital compression of the skull will also give the prosector an idea of bone strength (Fig 14.10b).

CHAPTER 14

Musculoskeletal System



Normal Structures

Birds have only a single ear ossicle (columella/stapes). They have an additional bone in the shoulder, the coracoid, which is not present in other animals. Birds also have articulated ribs, and their ribs have prominent uncinate processes, a feature shared with reptiles. The bird's sternum is a broad bone that covers most of the ventrum of the celomic cavity. A prominent keel or carina projects from the sternum and acts as an attachment for the pectoral muscles. Thoracic vertebrae 1 through 6 are fused to form the notarium. Thoracic vertebrae 7 and 8 are fused together with the combined lumbar vertebrae, ilium, pubis and ischium to form the synsacrum.

The bird's wing also has a reduced number of bones. The 3 metacarpal bones are fused. A third short digit, the alula articulates with the leading edge of the fused metacarpal bones. There are only 2 carpal bones, the radial and ulnar.

The hind limb also has several fused bones. The tibia is fused with the proximal tarsal bones and is referred to as

the tibiotarsus. The distal tarsal bones fuse with a single tarsal bone to become the tarsometatarsus.

Air sacs extend into many bones, replacing the marrow. The degree of pneumatization is somewhat species specific.

Diseases/Lesions of Bone

Direct physical injury leads to osteoblastic proliferation (from the osteogenic layer of the periosteum) and new bone formation, which is grossly appreciated as irregular thickening. Bone necrosis is seen secondary to neoplasia, vascular lesions or osteomyelitis. Fracture repair is similar to mammals. Fractures can result in severe hemorrhage in the surrounding tissue ([Fig 14.11](#)). With healing, there is initial hematoma formation followed by mesenchymal cell proliferation, which matures into osteoblasts that form the woven bone of the callus. Eventually the woven bone is replaced by lamellar bone.

CHAPTER 14

Musculoskeletal System



Abnormalities of Development

Developmental anomalies can be genetic, adaptational or due to teratogens. Congenital long bone deformities are the most commonly recognized bone malformations. Other miscellaneous anomalies include brachygnatha, polydactylia, syndactyly, scoliosis and spina bifida (Fig 14.12, Fig 14.13, Fig 14.14, Fig 14.15). These conditions are primary structural defects associated with localized problems during embryogenesis.

Chondrodystrophies: Tibial dyschondroplasia is seen in turkeys, chickens and ducks but is not reported in pet birds. Grossly an unmineralized core of cartilage extends from the articular cartilage of the tibia distally into the diaphysis.

Nutritional/Metabolic Disease

Nutritional chondrodystrophy: Deficiencies of manganese, choline, biotin, nicotinic acid, zinc or pyridoxine cause a generalized disorder of growth of long bones in poultry, and similar lesions are seen in companion birds. Bones become short and joints enlarge.

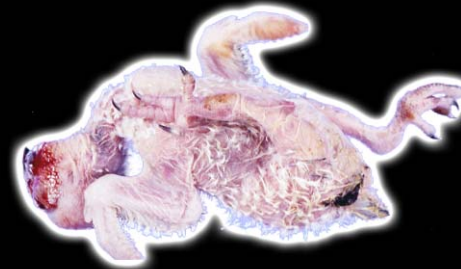Osteopenia is characterized by a reduction of bone mass with the remaining bone normally mineralized. Causes of osteopenia/osteoporosis include starvation, calcium, copper, phosphorous or vitamin D₃ deficiencies and reduced physical activity. Grossly the cortical bone has reduced thickness, increased porosity and may appear lacy (Fig 14.16). The bone is easily fractured and may bend when pressure is applied.

Rickets and osteomalacia: The name applied to this condition depends on the age of the bird. Rickets is seen in birds in which the skeleton is still growing. Osteomalacia occurs in birds that are fully grown. These problems are due to a failure of mineralization of the matrix leading to bone deformities and fractures.

Rickets is the result of the failure of mineralization of newly deposited osteoid. Grossly, the joints of birds with rickets are swollen (Fig 14.17). Bones are soft and the metaphyses are flared. Curving deformities of long bones and folding fractures are common. There may be marked

CHAPTER 14

Musculoskeletal System



swelling of the costochondral junctions of the ribs (Fig 14.18).

Osteodystrophy: Fibrosa is characterized by increased osteoclastic resorption of bone and replacement of the bone with fibrous tissue. It is the result of persistently elevated parathyroid hormone, which can be a physiologic response to persistently low blood calcium for any reason, or the result unregulated release of parathyroid hormone from a neoplasia of the parathyroid.

Birds with secondary hyperparathyroidism have soft bones that may bend, fracture or become deformed due to increased osteoclastic resorption of cancellous bone and fibroplasia.

Vitamin A deficiency: Vitamin A is needed for osteoclast function. With a deficiency there is failure of bone remodeling, causing bone thickening and irregularity with compression of adjacent soft tissue. The condition is infrequent but seems to involve the vertebrae rather than long bones.

Polyostotic hyperostosis: Polyostotic hyperostosis is the development of medullary bone in locations such as the femur, ulna and radius, bones of the pectoral girdle and vertebrae, which would normally not develop medullary bone. This condition is thought to be associated with reproductive disorders, such as ovarian tumors and ovarian cysts, that cause prolonged estrogen secretion. Affected bones are hard and difficult to break.

Degenerative Bone Disease/Trauma

Osteochondrosis is a focal area of disordered endochondral ossification in an area of growth that was previously normal. It can occur in the epiphysis (articular or nonarticular) and the growth plate. Nonarticular sites include areas of tendon and ligament attachment. Articular cartilage sites are associated with necrosis and cartilage dissection.

Ischemia necrosis of bone may be caused by neoplastic interruption of vascular supply, primary vascular disease, infection and trauma, with or without fracture.

CHAPTER 14

Musculoskeletal System



Bone that has undergone aseptic necrosis has a dry chalky appearance grossly.

Bone cysts apparently secondary to trauma have been seen in a cockatoo and cockatiels. Grossly the lesion contained hemorrhagic fluid covered by an osseous shell.

Inflammatory Bone Disease

Osteomyelitis is usually infectious and may be caused by a variety of aerobic and anaerobic bacteria, mycobacteria and fungi. The infection can be localized or part of a generalized disease. Grossly osteomyelitis is characterized as a swelling of soft tissue and irregularity of the affected bone. There may be an associated fracture that may be difficult to differentiate from a primary fracture. Caseous material is often present in the lesion.

Proliferative Bone Disease

Exostosis/enostosis/osteophytes are depositions of woven bone occurring on periosteal or medullary surfaces of cortical compacta as well as on the surfaces of

cancellous bone. These lesions are single or multiple hard masses that may affect any bone.

Osteopetrosis in chickens can be caused by retroviruses that lead to increased osteoblastic proliferation or decreased osteoclastic resorption. There is a marked diaphyseal thickening (Fig 14.19).

Primary neoplasia can arise from bone, cartilage or marrow. Metastatic tumors may also affect bone.

Osteomas are benign neoplasms of bone. They are seen sporadically in pet birds. They present as large hard swellings in any location but are most common in the skull or vertebrae (Fig 14.20).

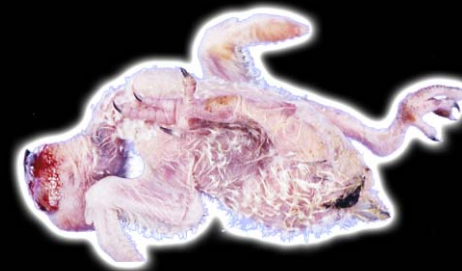Osteosarcomas are the most common primary tumor of bone and usually appear as a firm gray-white masses that replace normal bone (Fig 14.21).

Chondromas are firm masses comprised of well-differentiated cartilage. They are infrequently seen and have no particular site predilection.

Osteochondroma is infrequently reported in pet birds; however, in a cockatiel, we have seen one tumor that was

CHAPTER 14

Musculoskeletal System



comprised of bone trabeculae covered by a cartilage cap (Fig 14.9). It was a solitary nodule.

Fibrosarcoma can arise in the medullary space and may be difficult to differentiate from nonproductive osteosarcoma.

Hemangiosarcoma may also be seen in the medullary cavity. There may be associated fractures. The tumors are usually reddish brown and there may be excessive associated hemorrhage.

Metastases/secondary tumors: Air sac carcinomas may involve pneumatized bones by extension. Grossly they are firm masses often involving the shoulder or upper wing (Fig 14. 22). They are gray-white with hemorrhagic foci (Fig 14.23), and their exact site of origin is usually difficult to determine.

Other carcinomas may metastasize to bones. Grossly there is usually proliferative new bone formation and associated soft tissue swelling.

Diseases of the Joints

Congenital dysplasia, luxation or subluxation is seen in many avian species (Fig 14.24). The causes are often multifactorial, including genetics, nutrition and trauma.

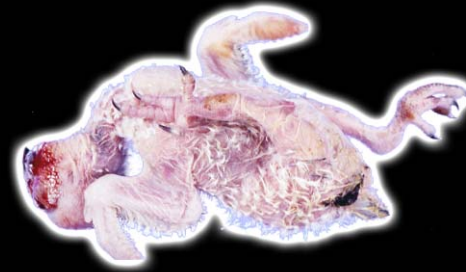Infectious arthritis in birds may be due to *Chlamydomydia psittaci*, *Mycoplasma* sp. or reovirus. Affected joints are swollen, and the overlying skin may be mottled (Fig 14.25). Grossly in acute cases, there is synovial swelling and redness (Fig 14.26).

Noninfectious arthritis is most often secondary to articular urate deposition (gout). Affected joints and adjacent tissue are swollen, and yellow-white foci may be seen (Fig 14.27). In some cases there can be inflammation and scaling of the skin (Fig 14.28); when incised, there is chalky or caseous appearing material within the joint and adjacent soft tissue (Fig 14.29).

Joint hemorrhage without any inflammatory component is usually from trauma; however, in conures, the possibility of "conure bleeding syndrome" is a differential diagnosis. Synovial sarcoma is occasionally report-

C H A P T E R 14

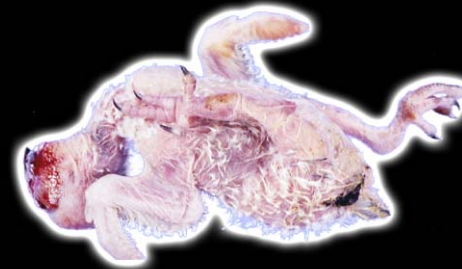Musculoskeletal System



ed in birds. The tumor is similar to that seen in mammals and is characterized by gross destruction of the joint and bone associated with a proliferative mass.

CHAPTER 14

Musculoskeletal System



FURTHER READING

Back WJ: The avian skeletal-muscular system. In Farner DS, King JR, Parkes KC (eds): Avian Biology IV. New York, Academic Press, 1974, pp 120-250.

Baumgartner R, Hatt J-M, Dobeli M, et al: Endocrinologic and pathologic findings in birds with polyostotic hyperostosis. J Avian Med Surg 9:251-254, 1995.

Brown R: Sinus, articular and subcutaneous *Mycobacterium tuberculosis* infection in a juvenile red-lored parrot. Proc Assoc Avian Vet, 1990, pp 305-308.

Droual R, Chin RP, Rezvani M: Synovitis, osteomyelitis and green liver in turkeys associated with *Escherichia coli*. Avian Dis 40:417-42, 1996.

George JC, Berger AS: Avian Myology. New York, Academic Press, 1966, pp 6-18.

Giddings RF, Richter AG: Multiple exostoses in a black-masked blue lovebird (*Agapornis personata*). J Avian Med Surg 14:59-58, 2000.

Grone A, Swayne DE, Nagode LA: Hypophosphatemic rickets in rheas (*Rhea americana*). Vet Pathol 32:324-327, 1995.

Tully T, Mitchell M, Heatley J, et al: Trauma-induced periosteal bone cysts in psittacine species. Proc Am Assoc Zoo Vet and IAAAM, 2000, p 311.

Hillyer EV, Anderson MP, Greiner E, et al: An outbreak of sarcocystis in a collection of psittacines. J Zoo Wildl Dis 22:434-445, 1991.

Kogekar N, Spurgeon TL, Simon MC, et al: Proliferative fibromatosis in avian skeletal muscle caused by cloned recombinant avian leukosis viruses. Cancer Res 47:2083-2091, 1987.

Labat ML: Retroviruses, immunosuppression and

osteopetrosis. Biomed Pharm 40:85-90, 1986.

Martin HD, Kabler R, Sealing L: The avian coxofemoral joint. J Assoc Avian Vet 23:22-30, 1989.

Newton CD, Berger AS: Avian fracture healing. J Am Vet Med Assoc 170:620-625, 1977.

Orth MW, Cook ME: Avian tibial dyschondroplasia: A morphological and biochemical review of the growth-plate lesion and its causes. Vet Pathol 31:403-414, 1994.

Powers LV, Merrill CL, Degernes LA, et al: Axillary cystadenocarcinoma in a Moluccan cockatoo (*Cacatua moluccensis*).

CHAPTER 14

Musculoskeletal System



FURTHER READING

(CONTINUED)

Avian Dis 42:408-412, 1998.

Schmidt RE: Morphologic diagnosis of avian neoplasms. Sem Avian Exotic Pet Med 1:73-79, 1992.

Smith JH, Neill PJ: Pathogenesis of *Sarcocystis falcatula* (Apicomplexa: Sarcocystidae) in the budgerigar (*Melopsittacus undulatus*). III. Pathologic and quantitative parasitologic analysis of extrapulmonary disease. J Parasitol 75:270-287, 1989.

Stone EG, Walser MM, Redig PT, et al: Synovial chondro-

matosis in raptors. J Wildl Dis 35:137-140, 1999.

Squire BT, More SJ: Factors on farms in eastern Australia associated with the development of tibiotarsal rotation in ostrich chicks. Aust Vet J 76:110-117, 1998.

Thorp BT: Skeletal disorders in the fowl: A review. Avian Pathol 23:203-236, 1994.

Tully TN, Pechman RD, Cornick J, et al: A subchondral cyst in the distal tibiotarsal bone of an ostrich (*Struthio camelus*). J Avian Med Surg 9:41-44, 1995.

Tully TN, Hodgkin C, Morris JM, et al: Exertional myopathy in an emu (*Dromaius*

noveahollandiae). J Avian Med Surg 10:96-100, 1996.

Van Den Horst H, Van Der Hage M, Wolvekamp P, et al: Synovial cell sarcoma in a sulphur-crested cockatoo (*Cacatua galerita*). Avian Pathol 25:179-186, 1996.

Weissengruber G, Loupal G: Osteochondroma of the tracheal wall in a Fischer's lovebird (*Agapornis fischeri*, Reichenow 1887). Avian Dis 43:155-159, 1999.

AUTHORS

ROBERT E. SCHMIDT

DVM, PhD, Dipl ACVP

Robert Schmidt received his DVM degree in 1962 from the University of California, Davis. During this time, he developed an interest in avian species. He joined the Air Force Veterinary Corps and performed necropsies at the National Zoo during his Air Force Institute of Pathology residency. He was board certified by the American College of Veterinary Pathologists in 1968. He then pursued a PhD degree at Oklahoma State University, which he received in 1973. Since that time, he has served as a veterinary pathologist with Zoo/Exotic Pathology Service, which has a special interest in birds, reptiles, amphibians, fish, lab mammals, small mammals and zoo animals.

DRURY R. REAVILL

DVM, Dipl ABVP - AVIAN,
Dipl ACVP

Dr. Reavill is a 1986 graduate of Colorado State University, School of Veterinary Medicine. She spent six years as an associate veterinarian and then worked as a clinical consultant interpreting avian and exotic animal laboratory values before achieving diplomate status in the American College of Veterinary Pathology. Dr. Reavill is the owner of Zoo/Exotic Pathology Service, which specializes in avian, reptiles, fish, amphibians, lab animals and other exotic species submitted from private practitioners and zoos throughout the United States, Europe and China. She is a published author and speaks at veterinary conferences and online courses.

CREDITS

[Back](#)

Selected images from Pathology of Pet and Aviary Birds by Robert E. Schmidt, Drury R. Reavill and David N. Phalen, ©2003 Iowa State Press, a Blackwell Publishing Company. Reprinted from Seminars in Avian and Exotic Pet Medicine, Vol 12, Schmidt RE: Practical gross pathology, pages 59-61. ©2003, with permission from Elsevier. For the use of selected additional photos, the authors acknowledge the following: Drs. Alan Fudge, Michael Garner, Douglas Mader, Brian Speer, WB Saunders Co, a Harcourt Health

Sciences Co, Michelle Curtis-Velasco, Tracy McNamara, and Scott Echols. Special thanks to Dr. David N. Phalen.



Zoological Education Network

Designed by: Patrick Kenny

Edited by: Linda Harrison

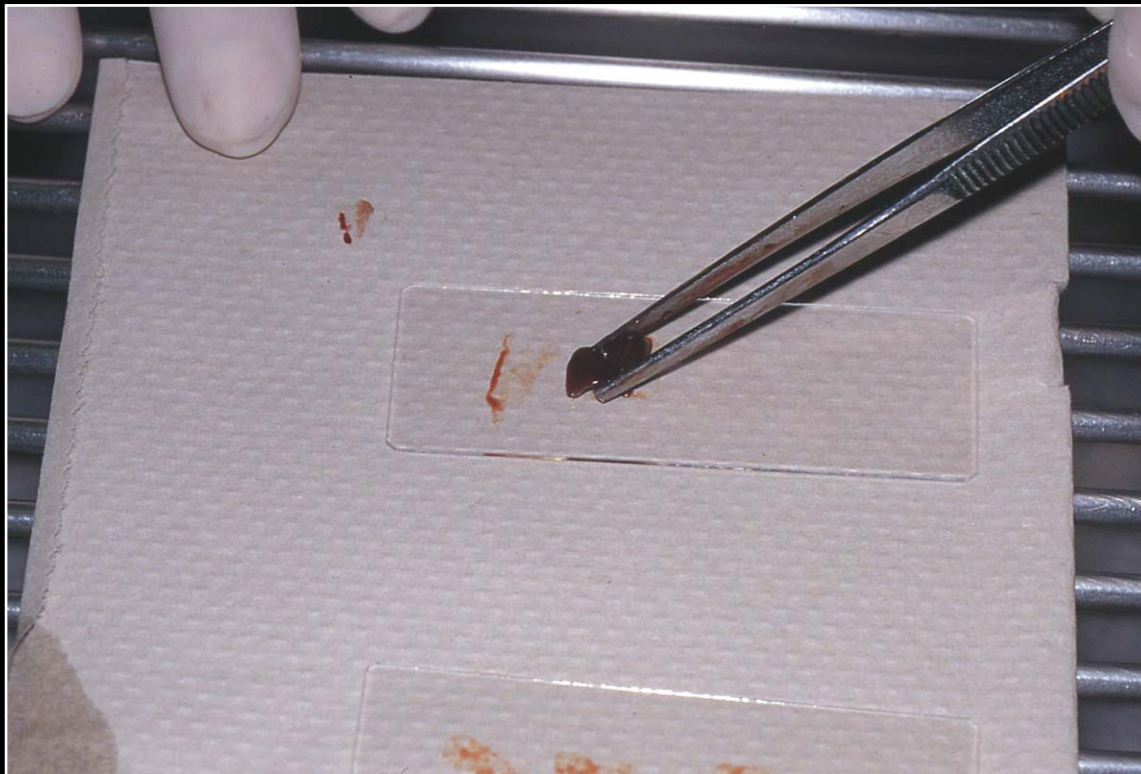Marketing Director: Dana O'Donoghue

www.exoticdvm.com ISBN: 0-9706395-0-3 Necropsy CD

C H A P T E R 1

Getting Started

Figure 1.1



Impression cytology of an organ. The tissue should be blotted on absorbent paper between each slide impression.

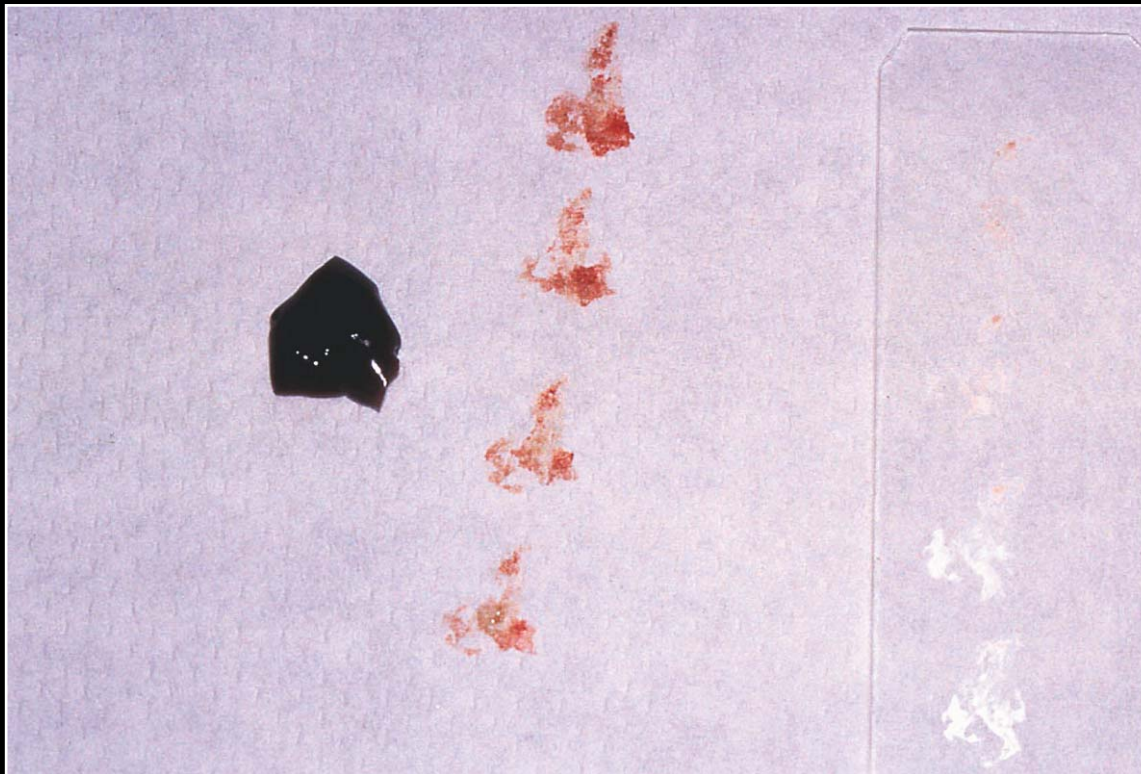
Next fig.

Back

C H A P T E R 1

Getting Started

Figure 1.2



Appearance of unstained impression smear and tissue.

Prev. fig. Next fig.


Back



CHAPTER 1

Getting Started

Figure 1.3



Syringe used to aspirate fluids during necropsy.

Prev. fig. Next fig.

Back



CHAPTER 1

Getting Started

Figure 1.4



Bacterial culture swabs and formalin jar for collecting samples.

Prev. fig. Next fig.

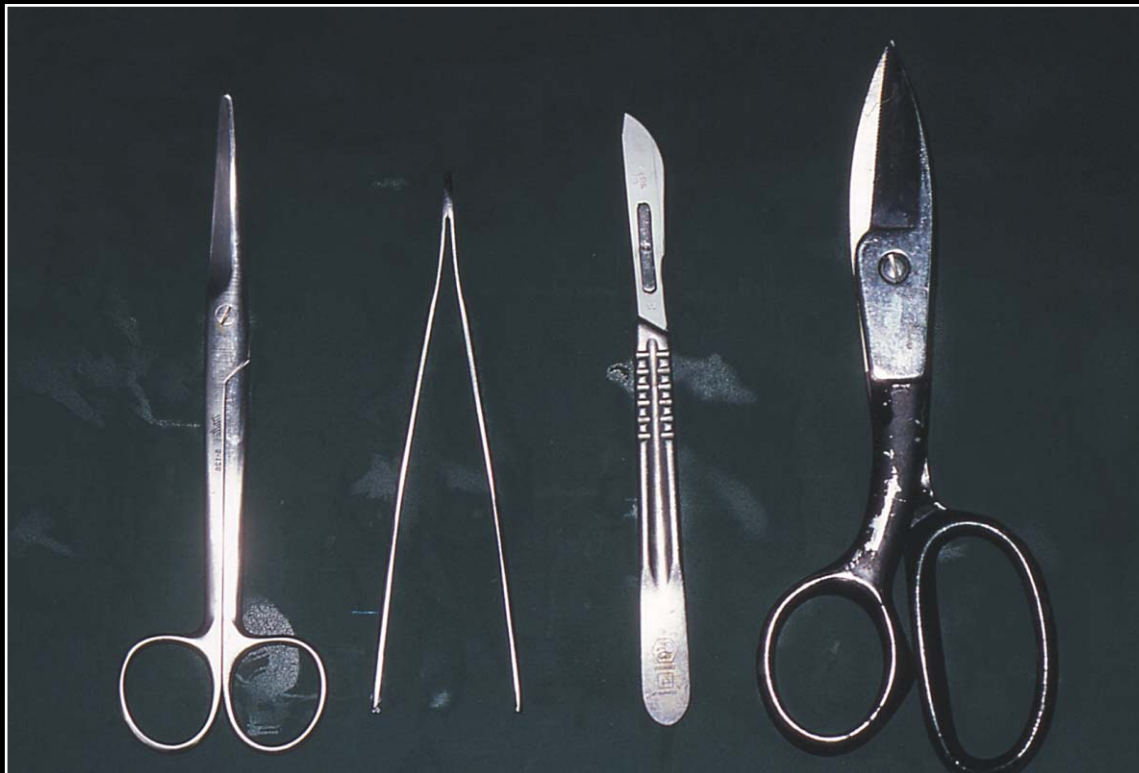Back



C H A P T E R 1

Getting Started

Figure 1.5



Minimal number of instruments for performing a necropsy.

Prev. fig. Next fig.

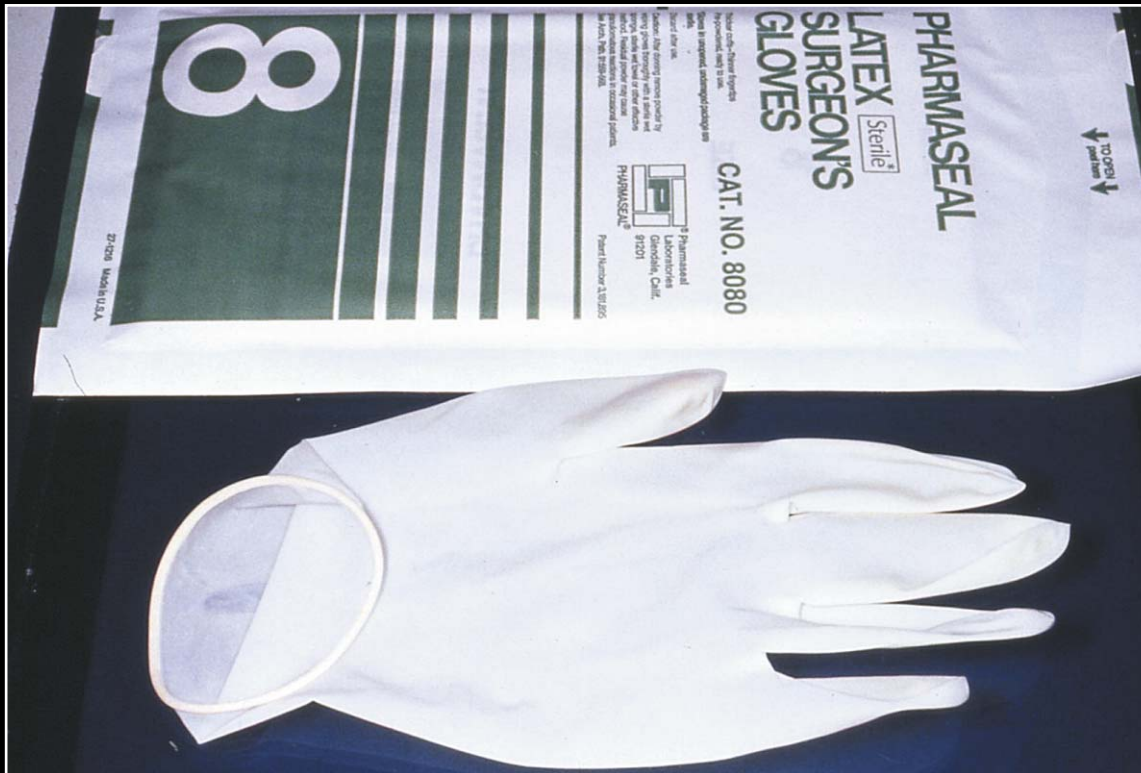Back



CHAPTER 1

Getting Started

Figure 1.6



Gloves should always be used during necropsy.

Prev. fig.

Back

C H A P T E R 2

External Examination, Initial Incision, Skin and Subcutis

Figure 2.1



Bird in position for necropsy.

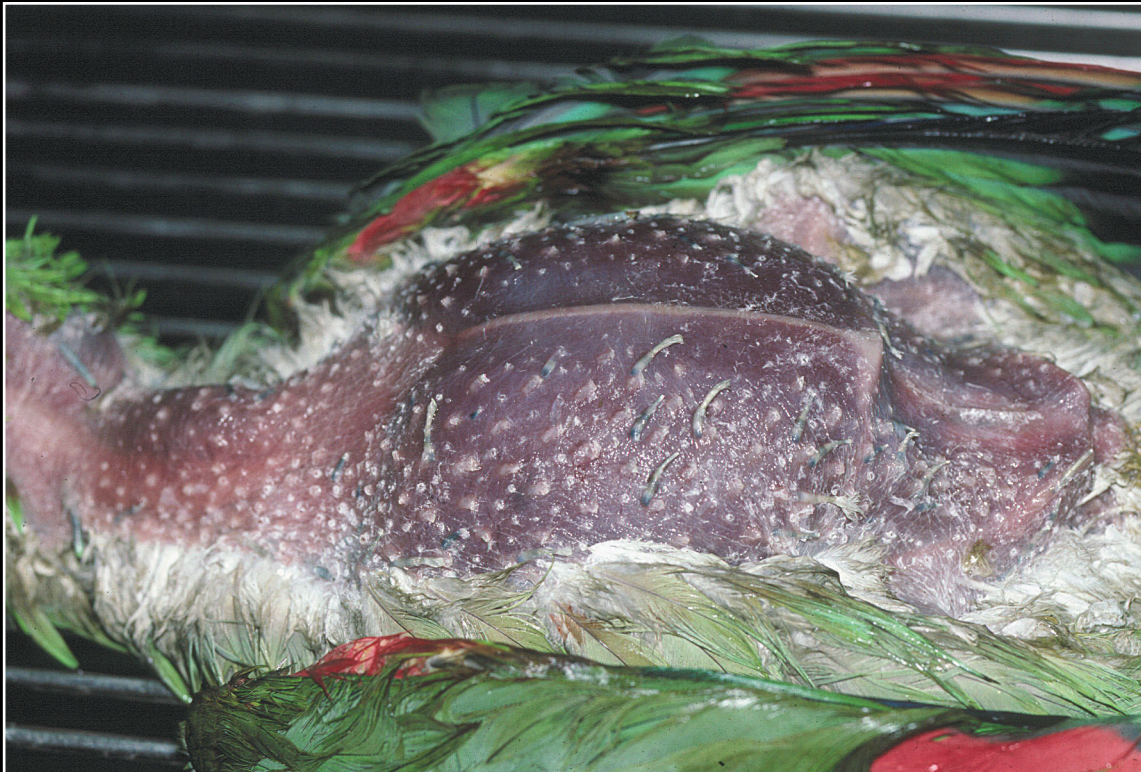Next fig.

Back

CHAPTER 2

External Examination, Initial Incision, Skin and Subcutis

Figure 2.2



Initial skin incision and exposure of subcutis and muscle.

Prev. fig. Next fig.

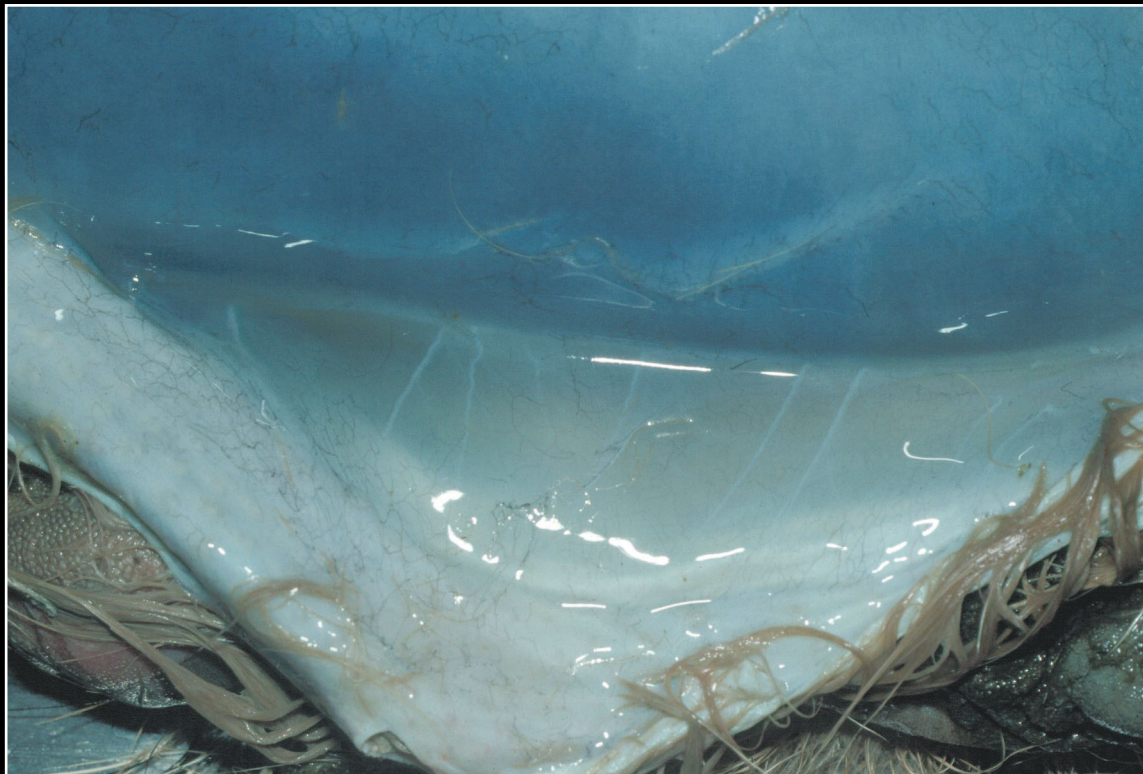
Back



CHAPTER 2

External Examination, Initial Incision, Skin and Subcutis

Figure 2.3



Marked subcutaneous edema associated with incubator temperature and humidity problems.

Prev. fig. Next fig.

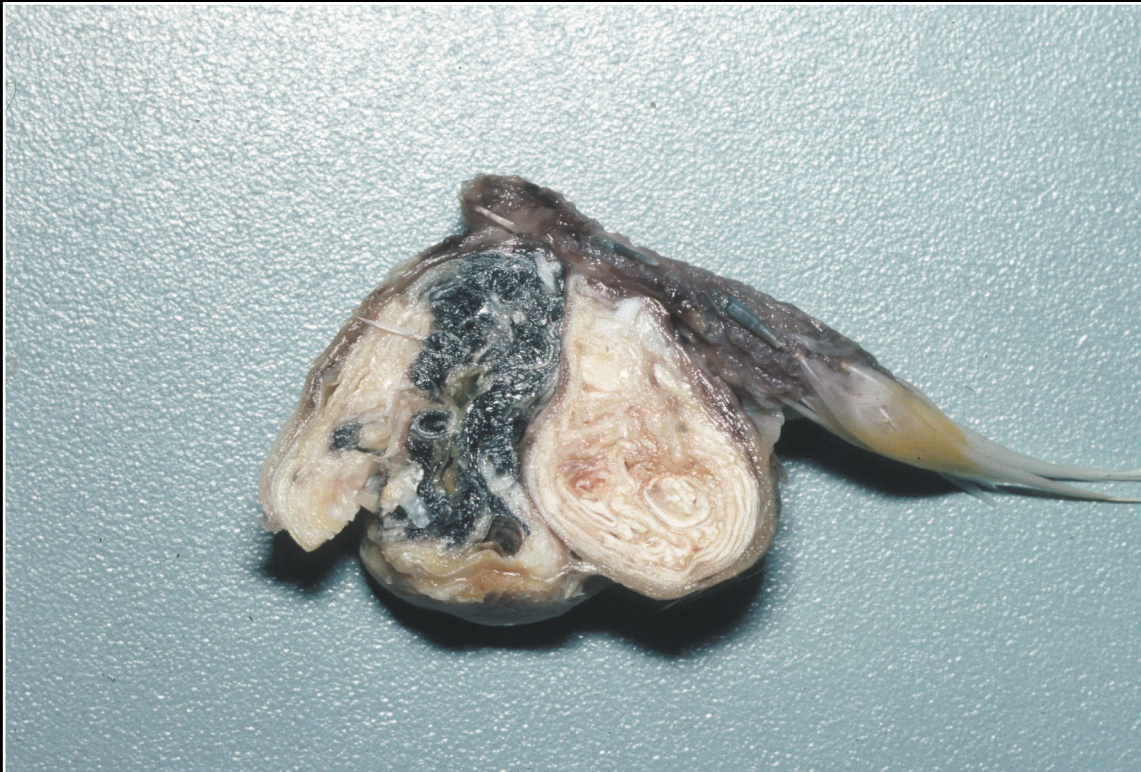Back



CHAPTER 2

External Examination, Initial Incision, Skin and Subcutis

Figure 2.4



Feather cyst. Note laminations of keratin. The lesion must be differentiated from an abscess or neoplasm.

Prev. fig. Next fig.

Back



CHAPTER 2

External Examination, Initial Incision, Skin and Subcutis

Figure 2.5



Typical appearance of dermatitis associated with mite infestation.

Prev. fig. Next fig.

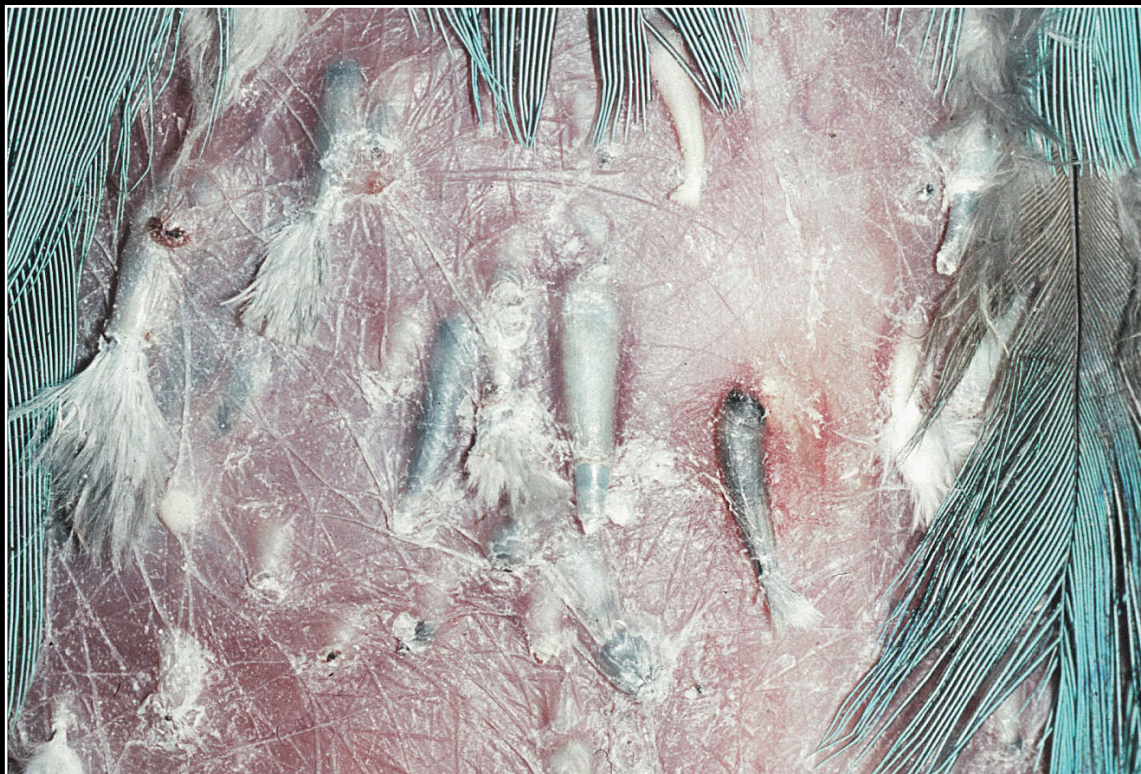Back



CHAPTER 2

External Examination, Initial Incision, Skin and Subcutis

Figure 2.6



Feather follicle enlargement and reddening of the skin due to mycotic infection.

Prev. fig. Next fig.

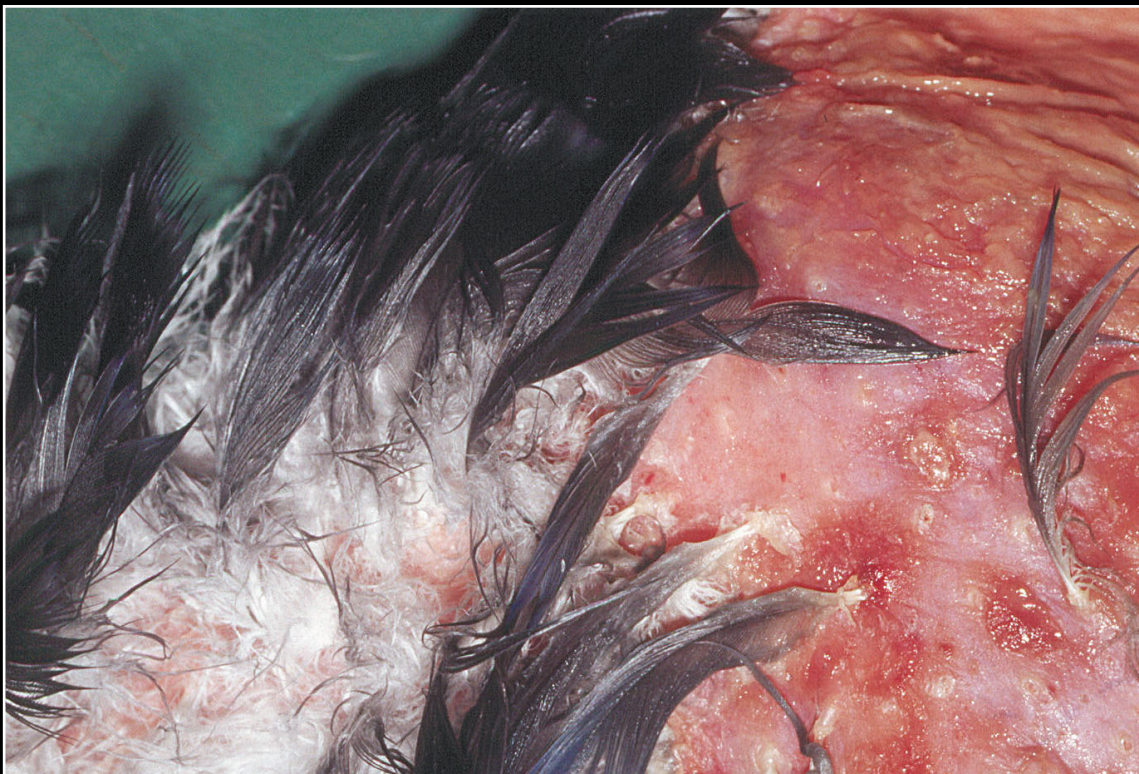Back



CHAPTER 2

External Examination, Initial Incision, Skin and Subcutis

Figure 2.7



Severe pyoderma with loss of feathers and erythema.

Prev. fig. Next fig.

Back



CHAPTER 2

External Examination, Initial Incision, Skin and Subcutis

Figure 2.8



Severe bacterial pododermatitis (bumblefoot).

Prev. fig. Next fig.

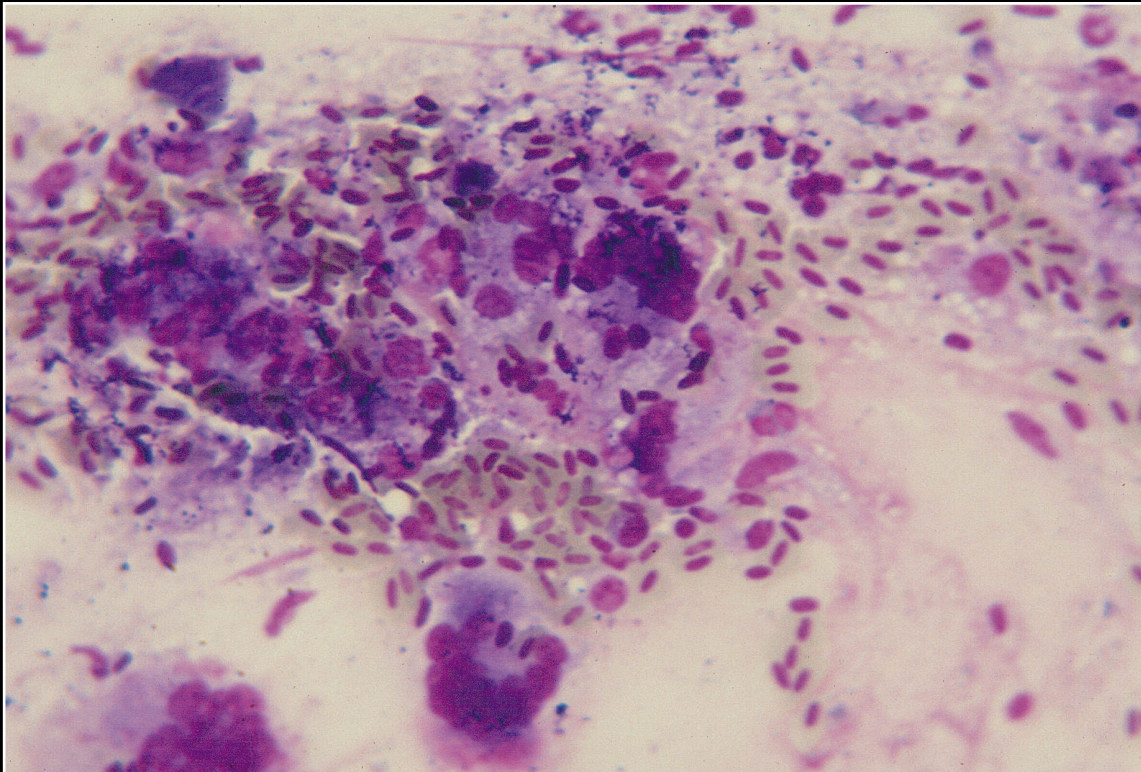
Back



CHAPTER 2

External Examination, Initial Incision, Skin and Subcutis

Figure 2.9



Smear of exudate from pododermatitis. Macrophages and heterophils predominate. As the lesion matures, more macrophages will be seen. Bacteria are not always noted.

Prev. fig. Next fig.

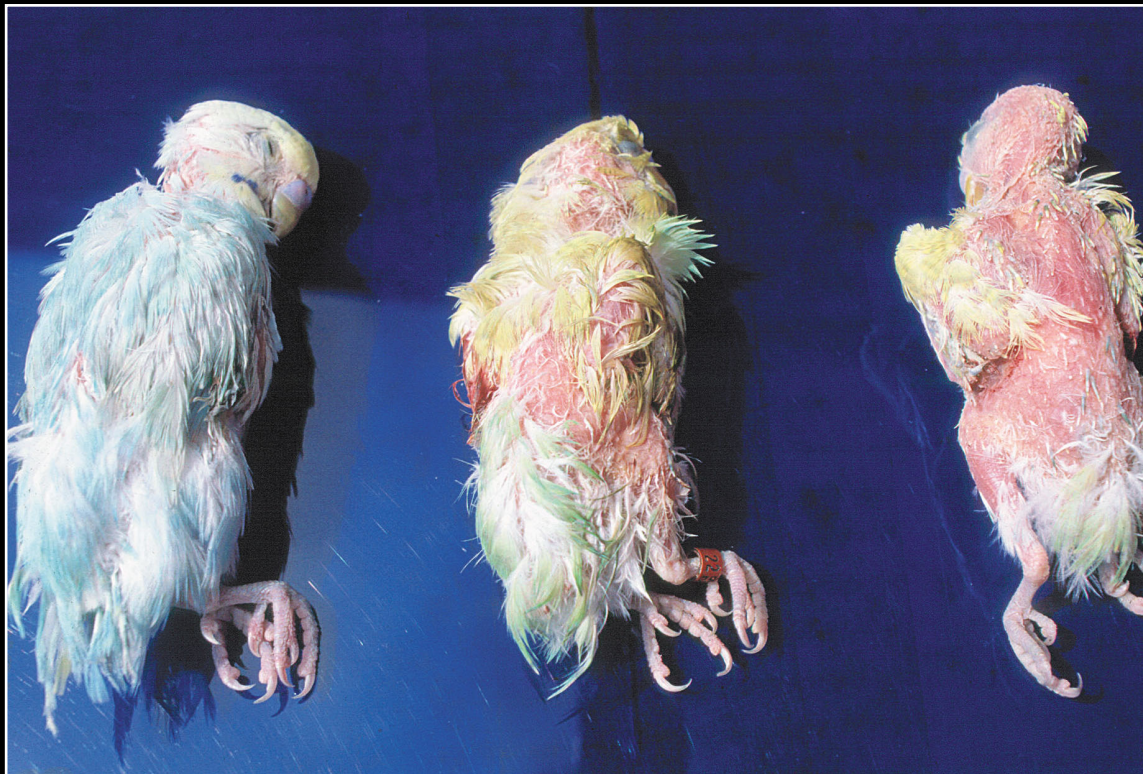Back



CHAPTER 2

External Examination, Initial Incision, Skin and Subcutis

Figure 2.10



Marked feather loss in budgerigars with polyomavirus infection.

Prev. fig. Next fig.

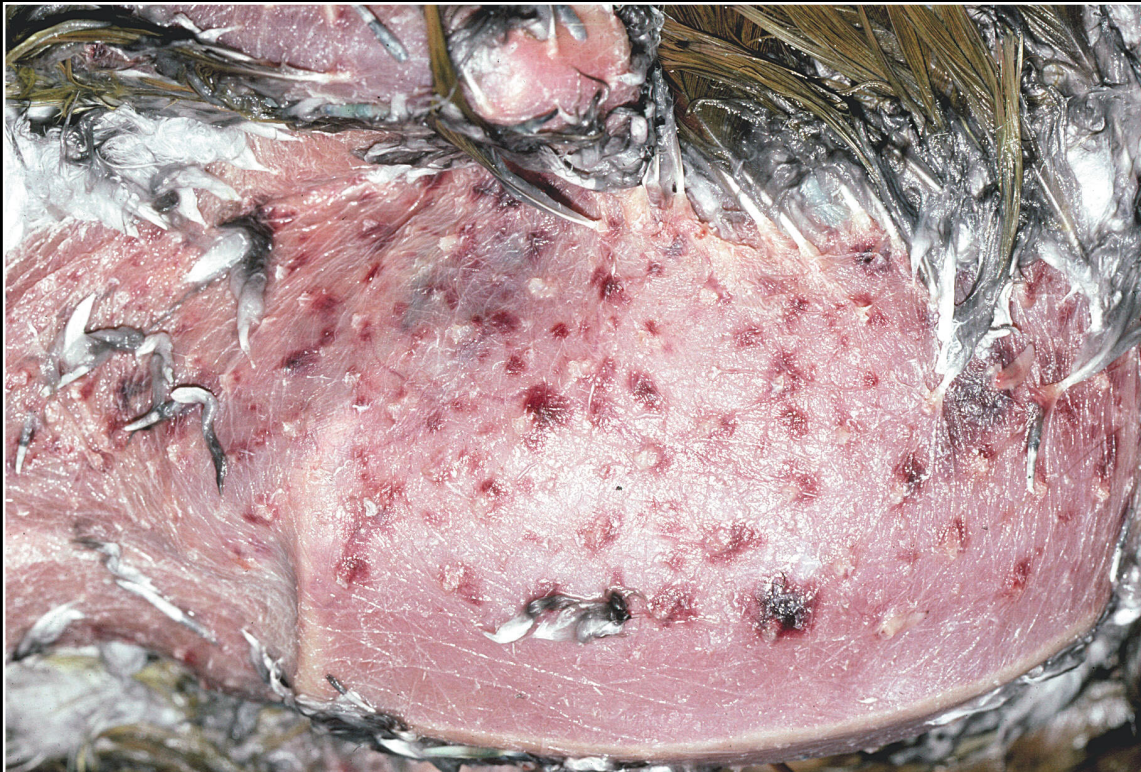Back



CHAPTER 2

External Examination, Initial Incision, Skin and Subcutis

Figure 2.11



Follicular and dermal hemorrhage seen in polyomavirus infection.

Prev. fig. Next fig.

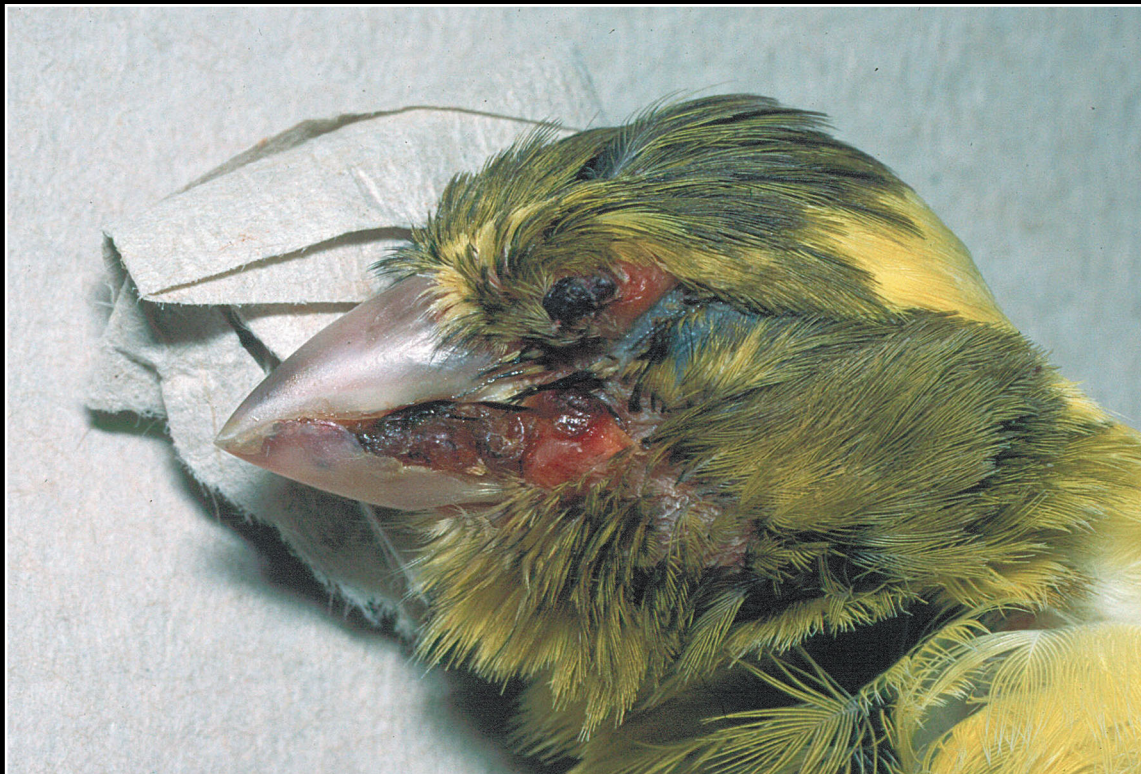Back



CHAPTER 2

External Examination, Initial Incision, Skin and Subcutis

Figure 2.12



Typical appearance of cutaneous pox in canaries.

Prev. fig. Next fig.

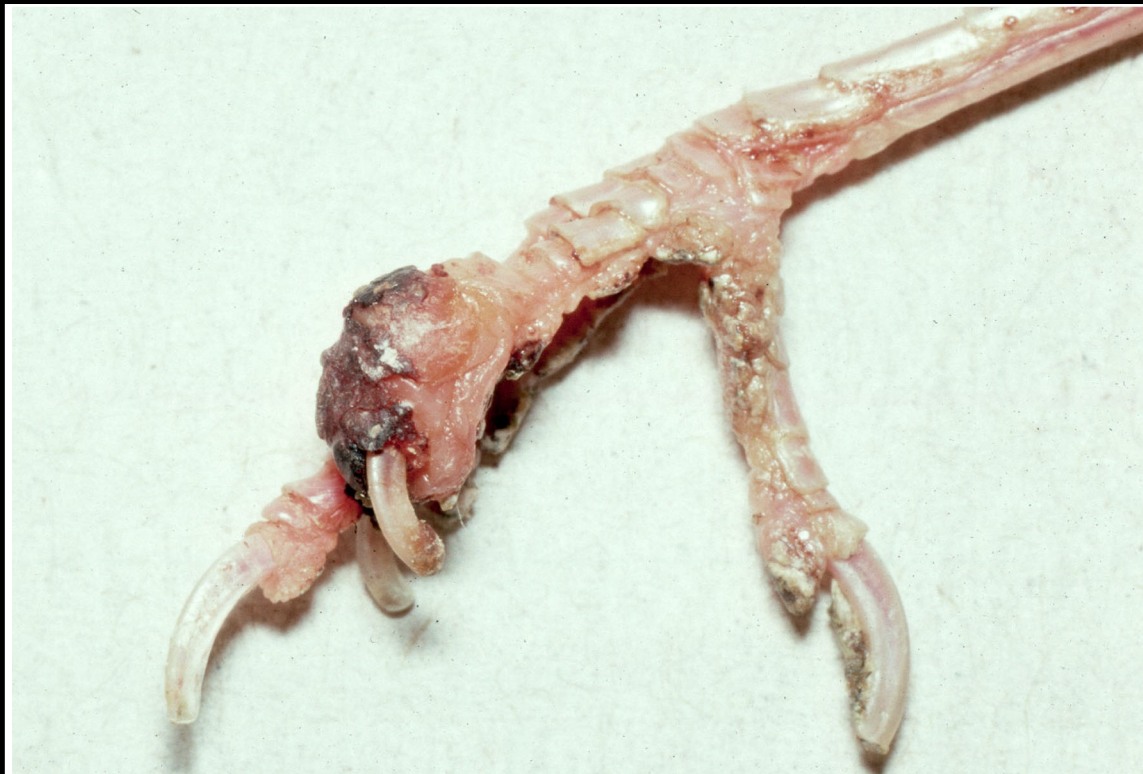Back



CHAPTER 2

External Examination, Initial Incision, Skin and Subcutis

Figure 2.13



Cutaneous pox in canaries also often involves the feet.

Prev. fig. Next fig.

Back



CHAPTER 2

External Examination, Initial Incision, Skin and Subcutis

Figure 2.14



Typical appearance of poxvirus infection in pigeons.

Prev. fig. Next fig.

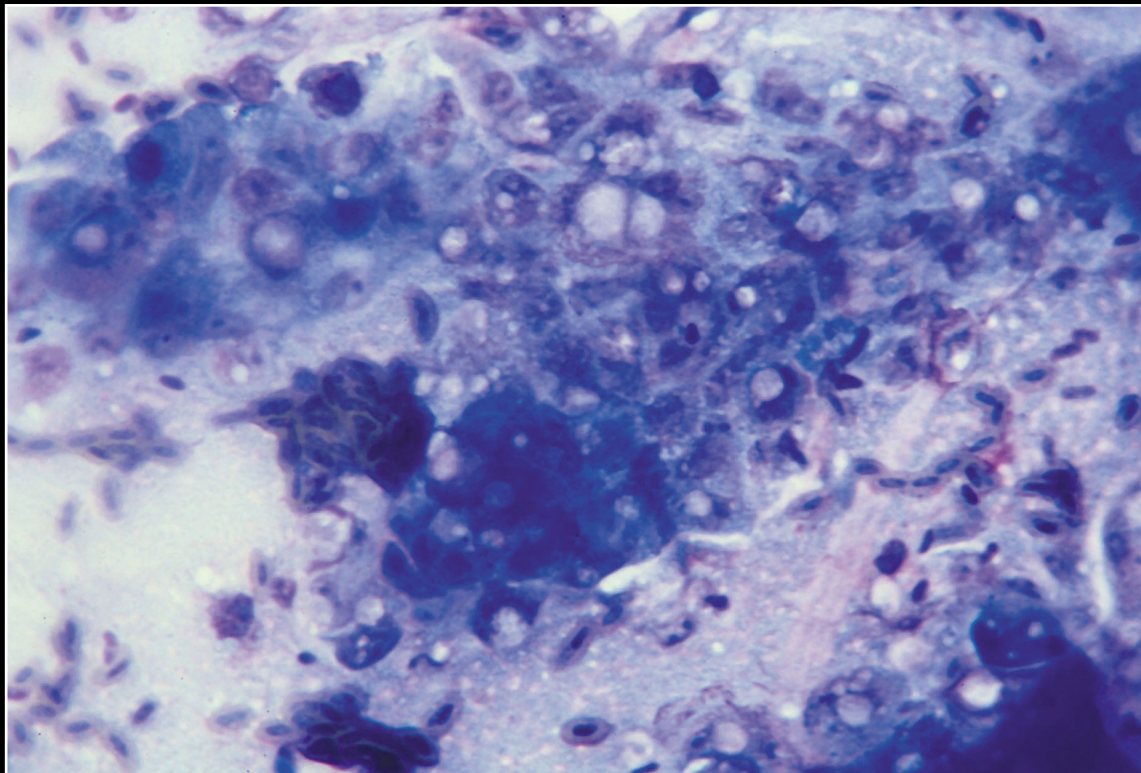
Back



CHAPTER 2

External Examination, Initial Incision, Skin and Subcutis

Figure 2.15



Smear of poxvirus lesion. Although not always visible, cytoplasmic inclusion bodies are seen along with inflammation consistent with a secondary bacterial infection.

Prev. fig. Next fig.

Back



CHAPTER 2

External Examination, Initial Incision, Skin and Subcutis

Figure 2.16



Cutaneous herpesvirus infection. Note thickening and discoloration of epidermis of the right foot.

Prev. fig. Next fig.

Back



CHAPTER 2

External Examination, Initial Incision, Skin and Subcutis

Figure 2.17



Typical appearance of circovirus infection in a cockatoo.

Prev. fig. Next fig.

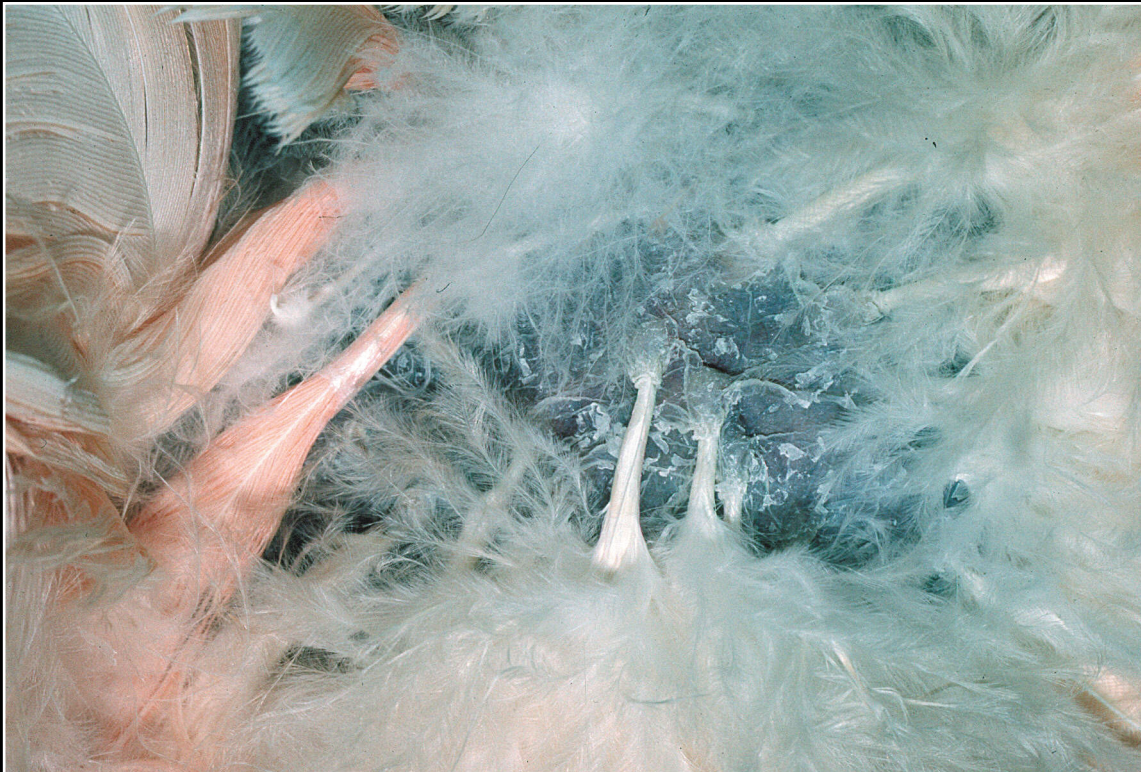Back



CHAPTER 2

External Examination, Initial Incision, Skin and Subcutis

Figure 2.18



Skin and feather changes in circovirus infection.

Prev. fig. Next fig.

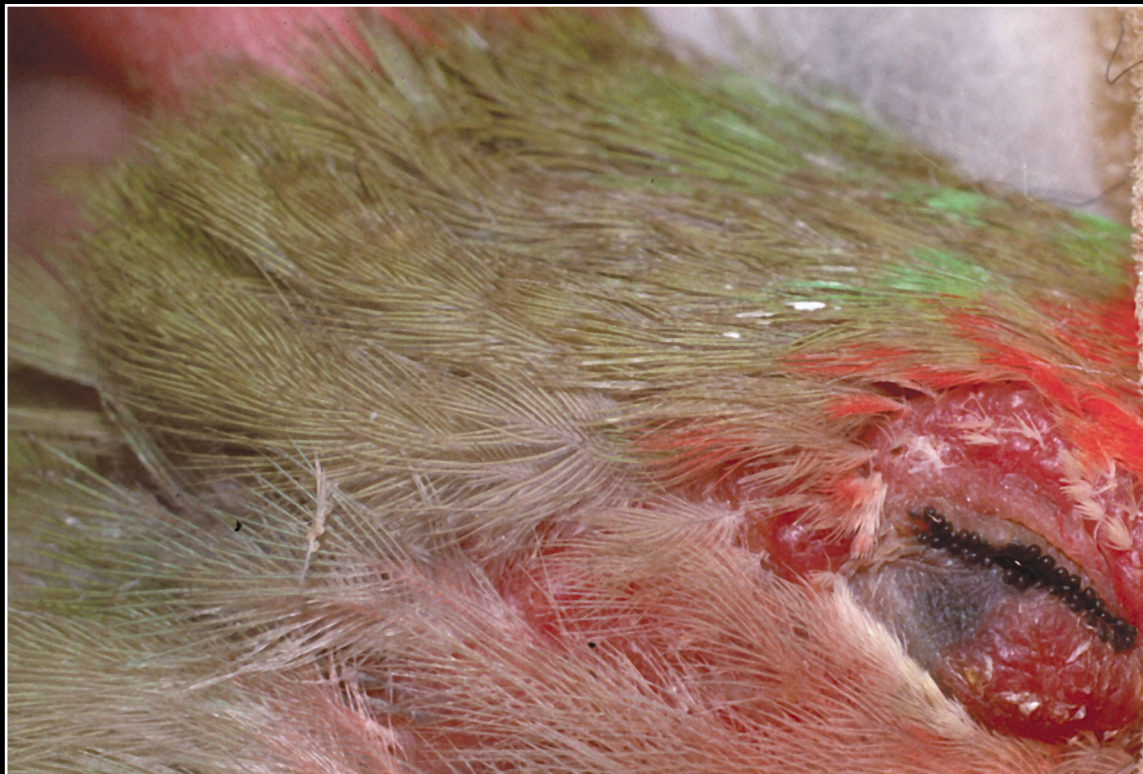Back



CHAPTER 2

External Examination, Initial Incision, Skin and Subcutis

Figure 2.19



Circovirus infection in a lovebird. Periocular lesions may be the only change seen.

Prev. fig. Next fig.

Back



CHAPTER 2

External Examination, Initial Incision, Skin and Subcutis

Figure 2.20



Vitamin A deficiency leading to squamous metaplasia, hyperkeratosis and uropygial gland enlargement. There can be secondary infection.

Prev. fig. Next fig.


Back



CHAPTER 2

External Examination, Initial Incision, Skin and Subcutis

Figure 2.21



Poor feather quality and color change that can result from nutritional disorders.

Prev. fig. Next fig.

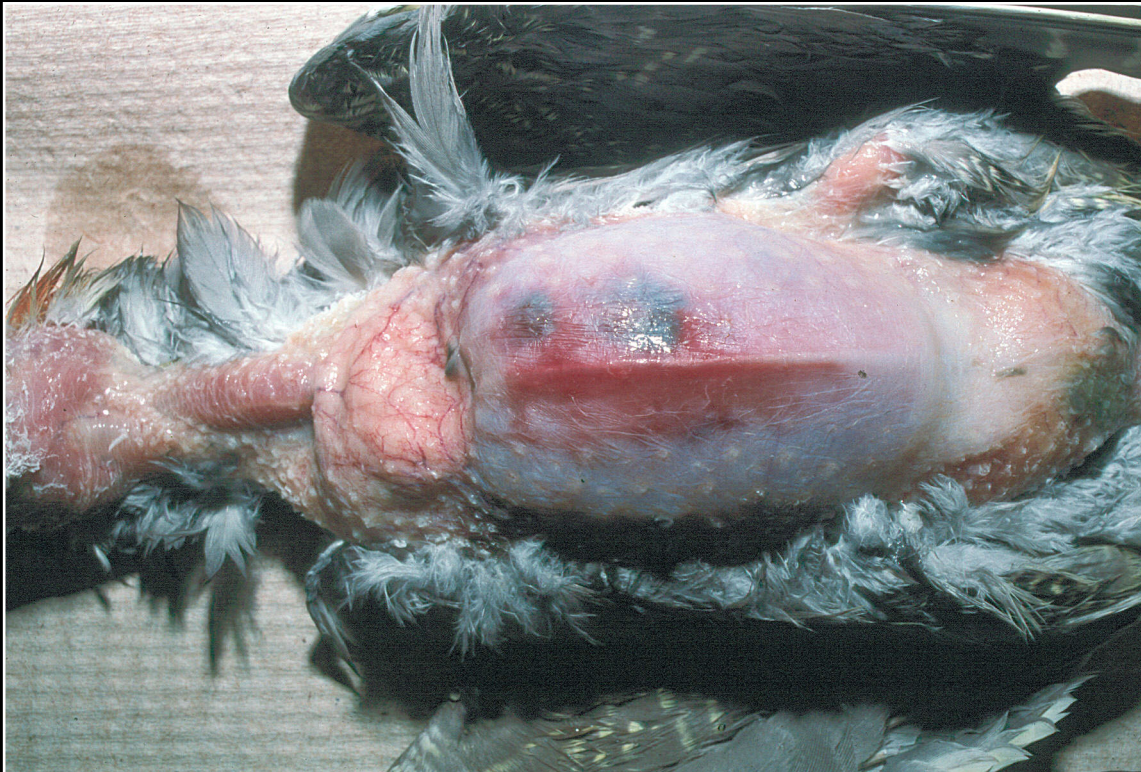Back



CHAPTER 2

External Examination, Initial Incision, Skin and Subcutis

Figure 2.22



Traumatic bruising and hemorrhage.

Prev. fig. Next fig.

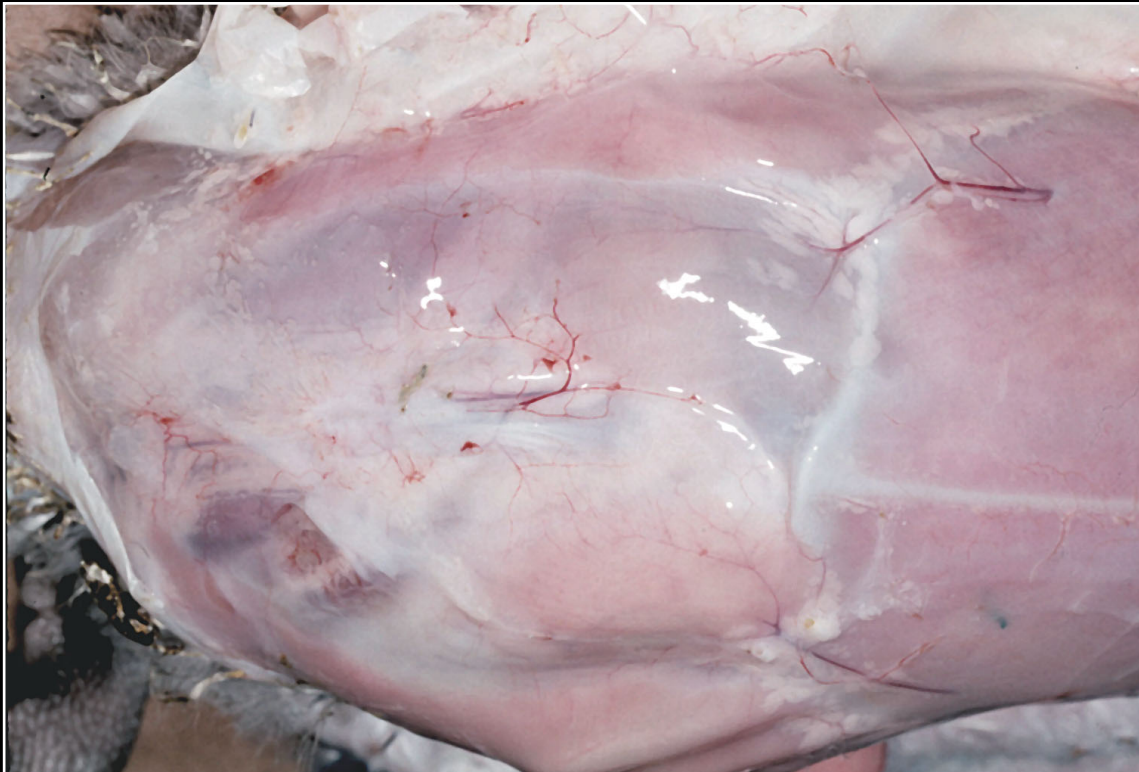Back



CHAPTER 2

External Examination, Initial Incision, Skin and Subcutis

Figure 2.23



Marked subcutaneous edema.

Prev. fig. Next fig.

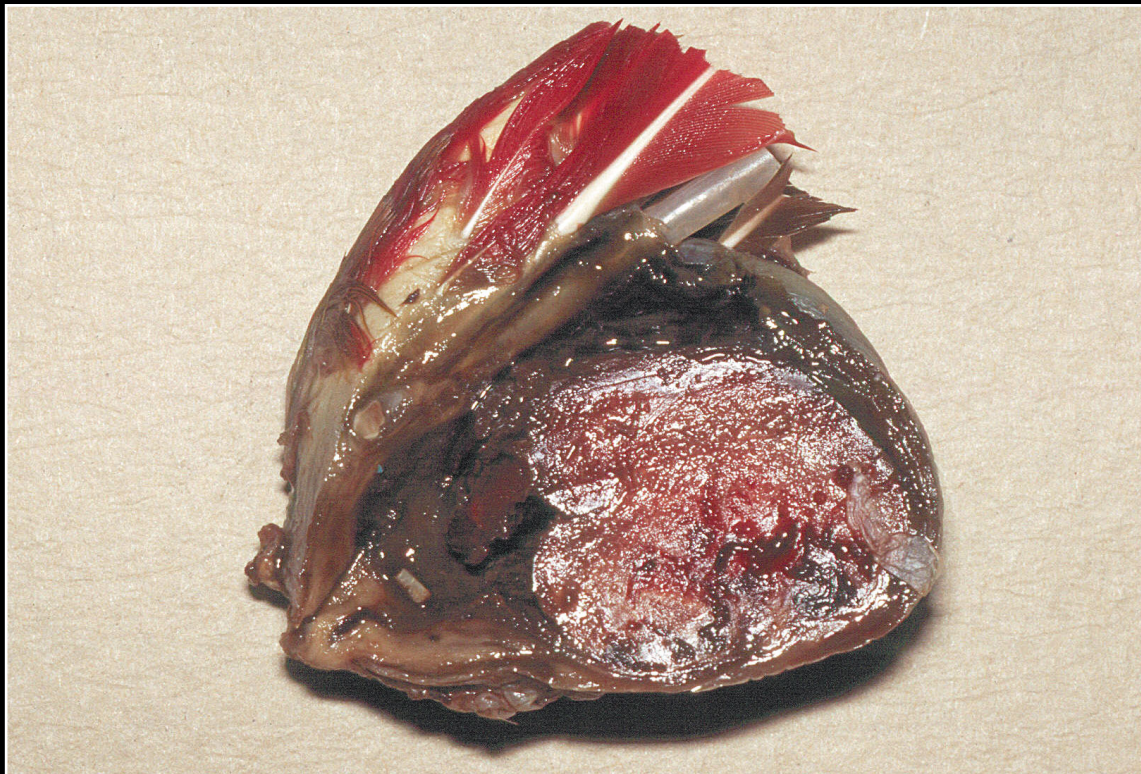Back



CHAPTER 2

External Examination, Initial Incision, Skin and Subcutis

Figure 2.24



Large hematoma on the wing. This lesion must be differentiated from neoplasia.

Prev. fig. Next fig.

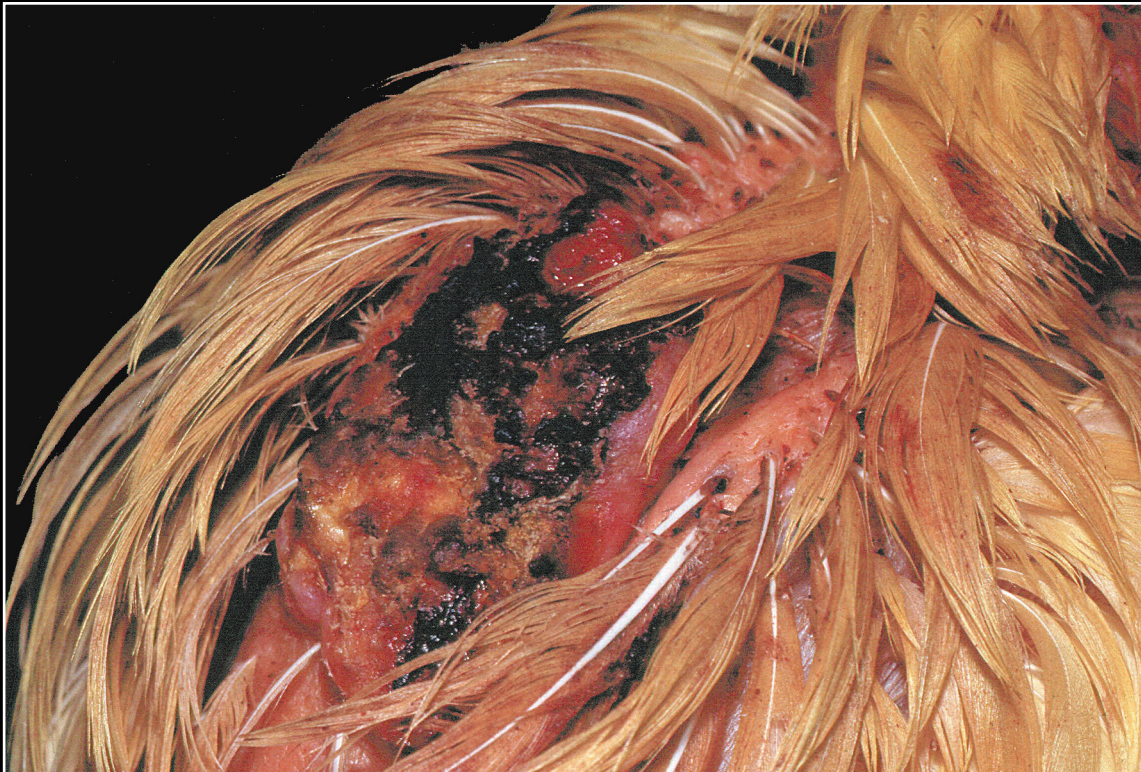Back



CHAPTER 2

External Examination, Initial Incision, Skin and Subcutis

Figure 2.25



Severe dermal injury due to self trauma.

Prev. fig. Next fig.

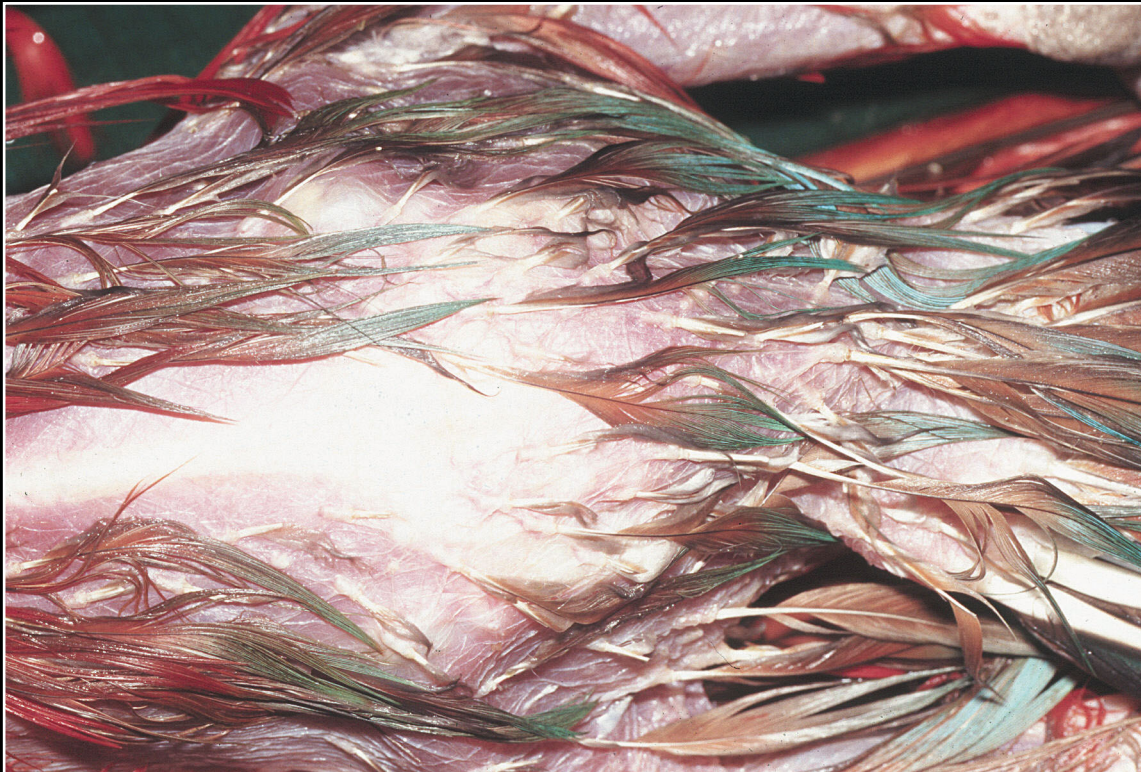
Back



CHAPTER 2

External Examination, Initial Incision, Skin and Subcutis

Figure 2.26



Poor feather quality and loss of feathers secondary to hypothyroidism.

Prev. fig. Next fig.

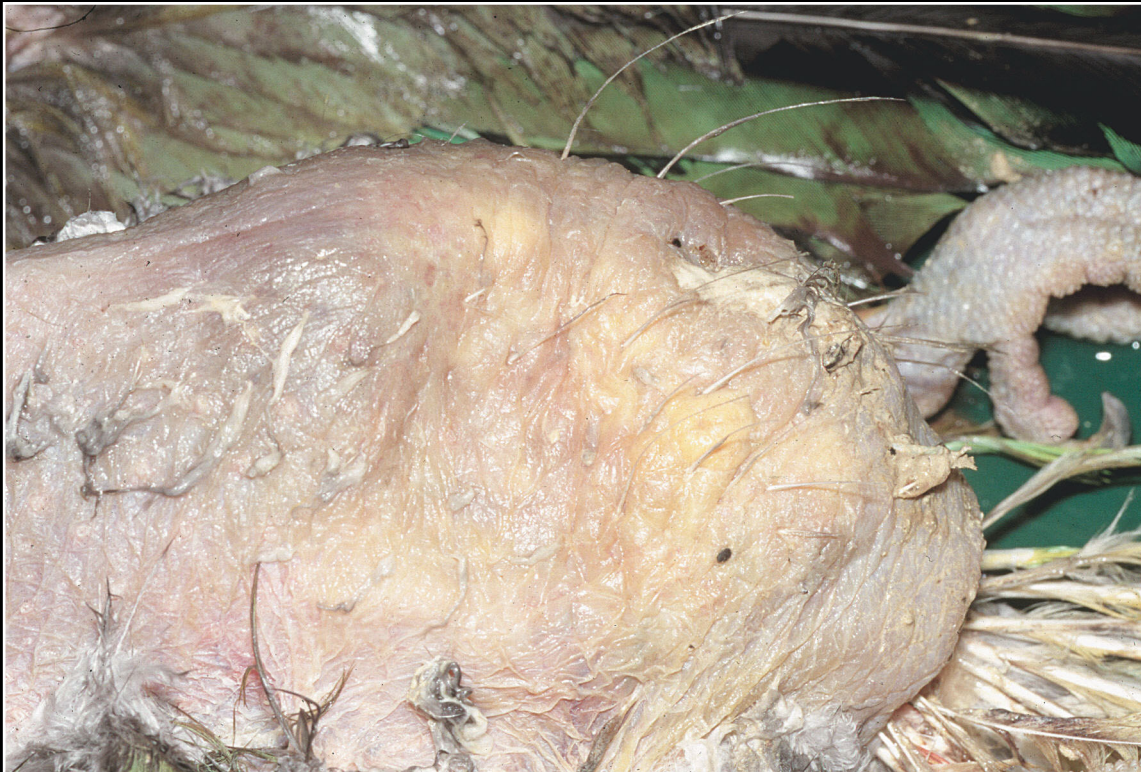Back



CHAPTER 2

External Examination, Initial Incision, Skin and Subcutis

Figure 2.27



Excessive fat deposits in the skin secondary to goiter and hypothyroidism.

Prev. fig. Next fig.


Back



CHAPTER 2

External Examination, Initial Incision, Skin and Subcutis

Figure 2.28



Feather stress bars — a nonspecific response to a variety of stresses during feather formation.

Prev. fig. Next fig.

Back



CHAPTER 2

External Examination, Initial Incision, Skin and Subcutis

Figure 2.29



Dermal and subcutaneous urate deposits. These are usually associated with renal disease or severe metabolic problems.

Prev. fig. Next fig.

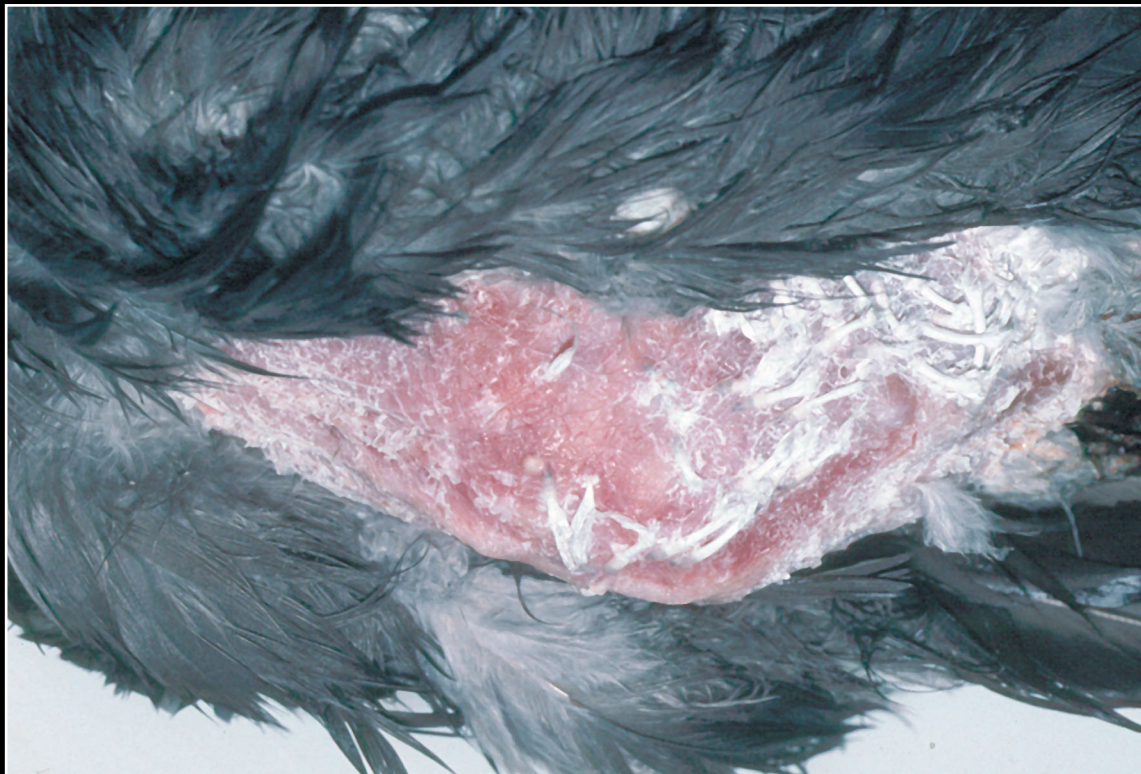
Back



CHAPTER 2

External Examination, Initial Incision, Skin and Subcutis

Figure 2.30



Squamous cell carcinoma. There is an irregular thickening of the skin without ulceration.

Prev. fig. Next fig.

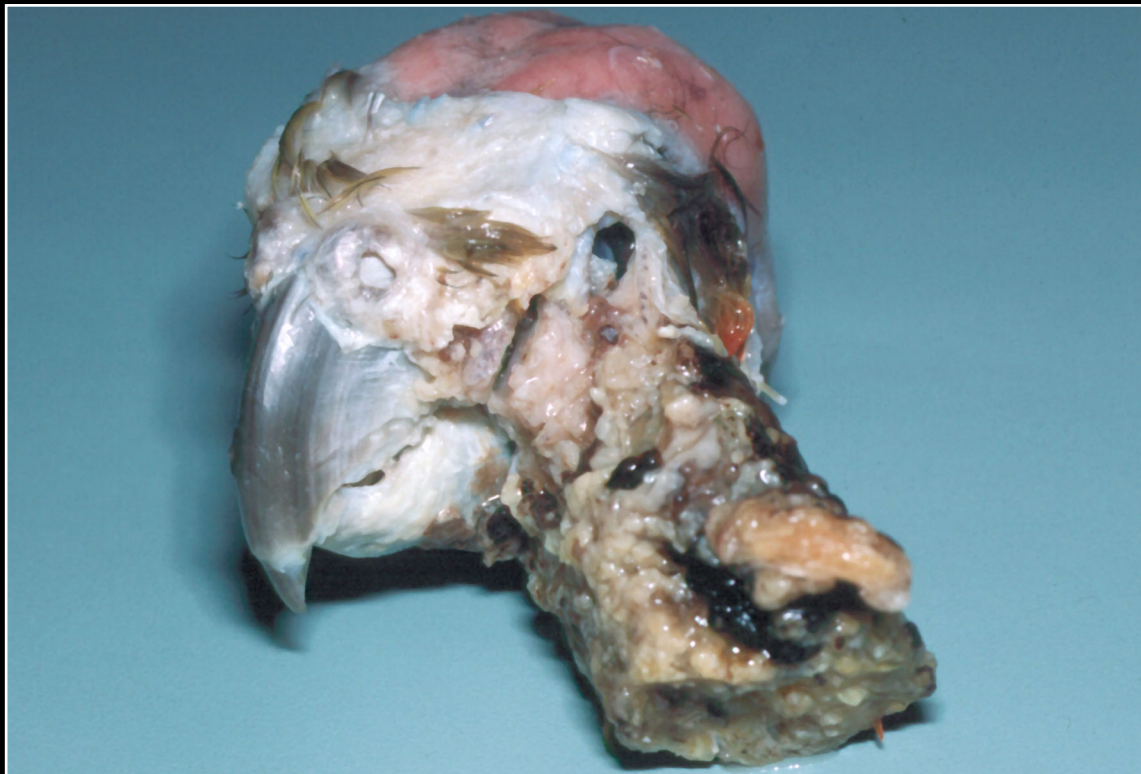
Back



CHAPTER 2

External Examination, Initial Incision, Skin and Subcutis

Figure 2.31



Squamous cell carcinoma. Note severe skin damage and extension of process involving the head and neck.

Prev. fig. Next fig.

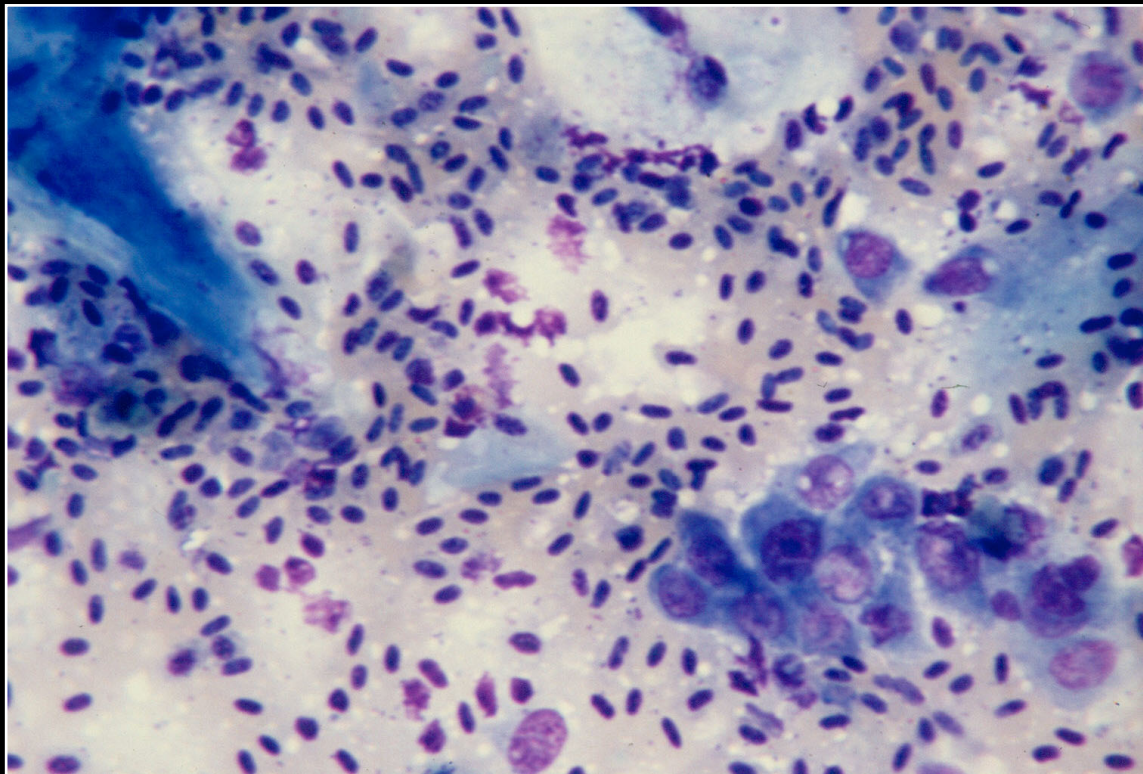
Back



CHAPTER 2

External Examination, Initial Incision, Skin and Subcutis

Figure 2.32



Smear of squamous cell carcinoma. Note clumps of neoplastic epithelial cells as well as erythrocytes and scattered inflammatory cells.

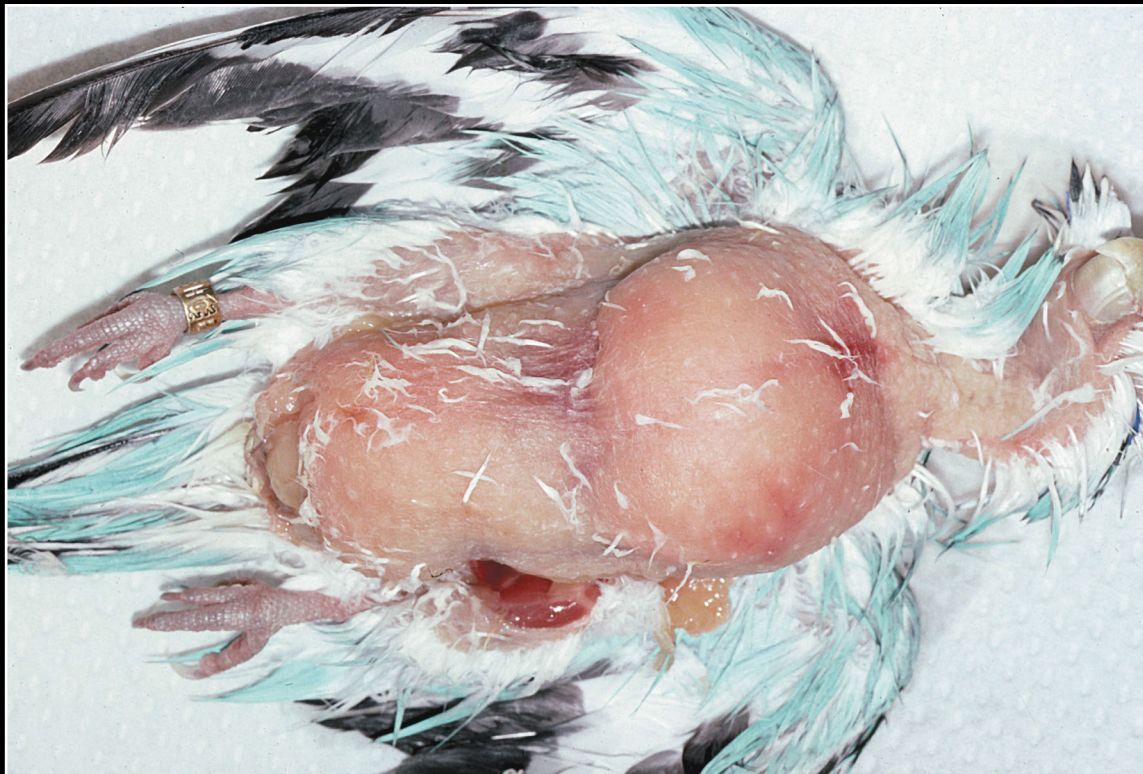
Prev. fig. Next fig.

Back

CHAPTER 2

External Examination, Initial Incision, Skin and Subcutis

Figure 2.33



Typical appearance of subcutaneous lipoma.

Prev. fig. Next fig.

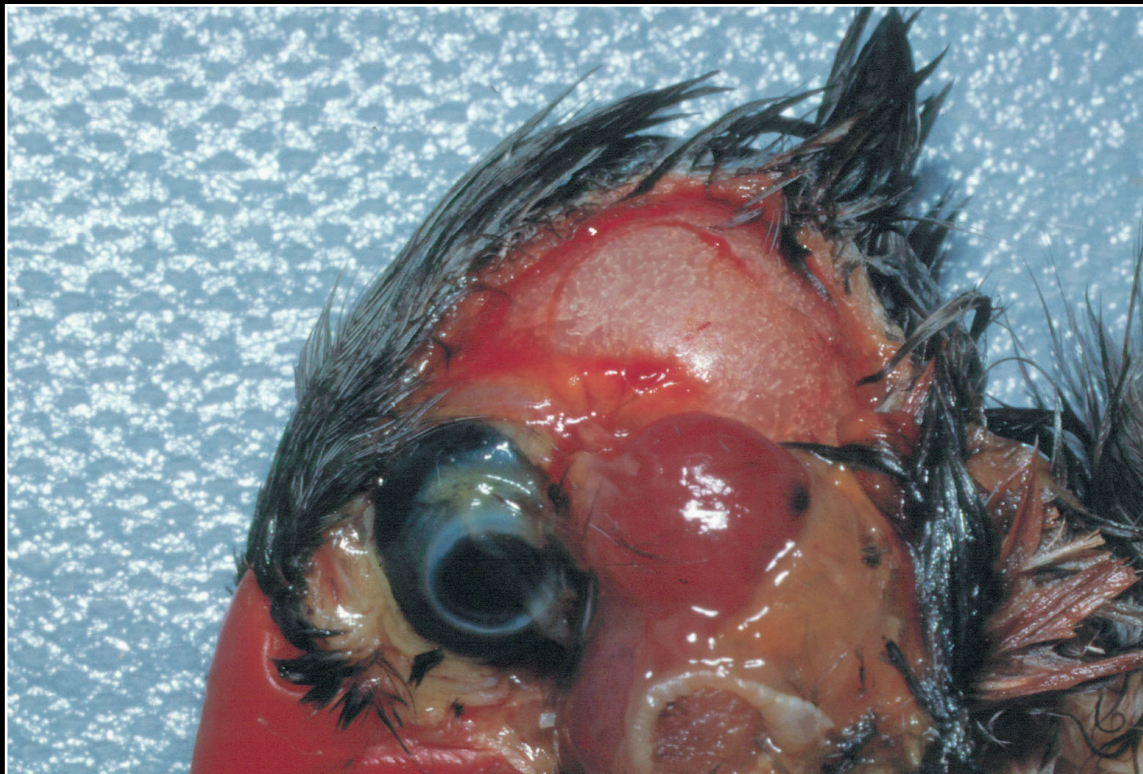
Back



CHAPTER 2

External Examination, Initial Incision, Skin and Subcutis

Figure 2.34



Circumscribed red mass typical of hemangioma.

Prev. fig. Next fig.

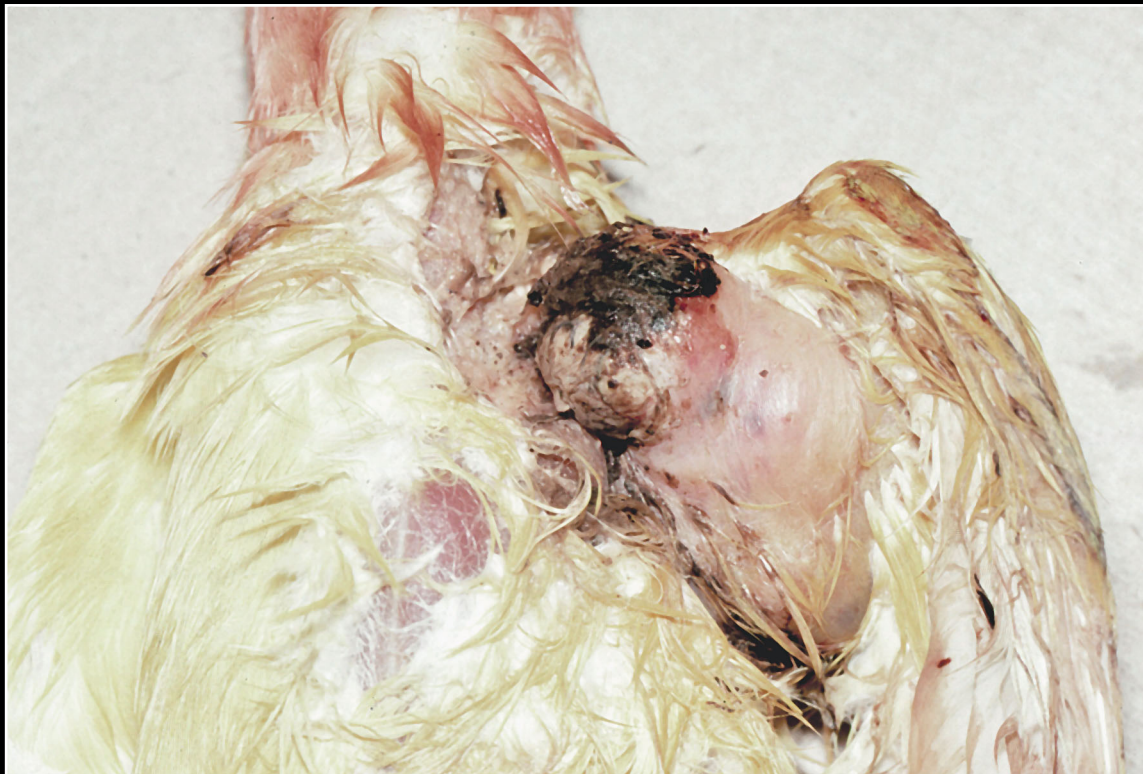
Back



CHAPTER 2

External Examination, Initial Incision, Skin and Subcutis

Figure 2.35



Ulcerated fibrosarcoma involving subcutis and skin. As these lesions enlarge, they can infiltrate bone.

Prev. fig. Next fig.

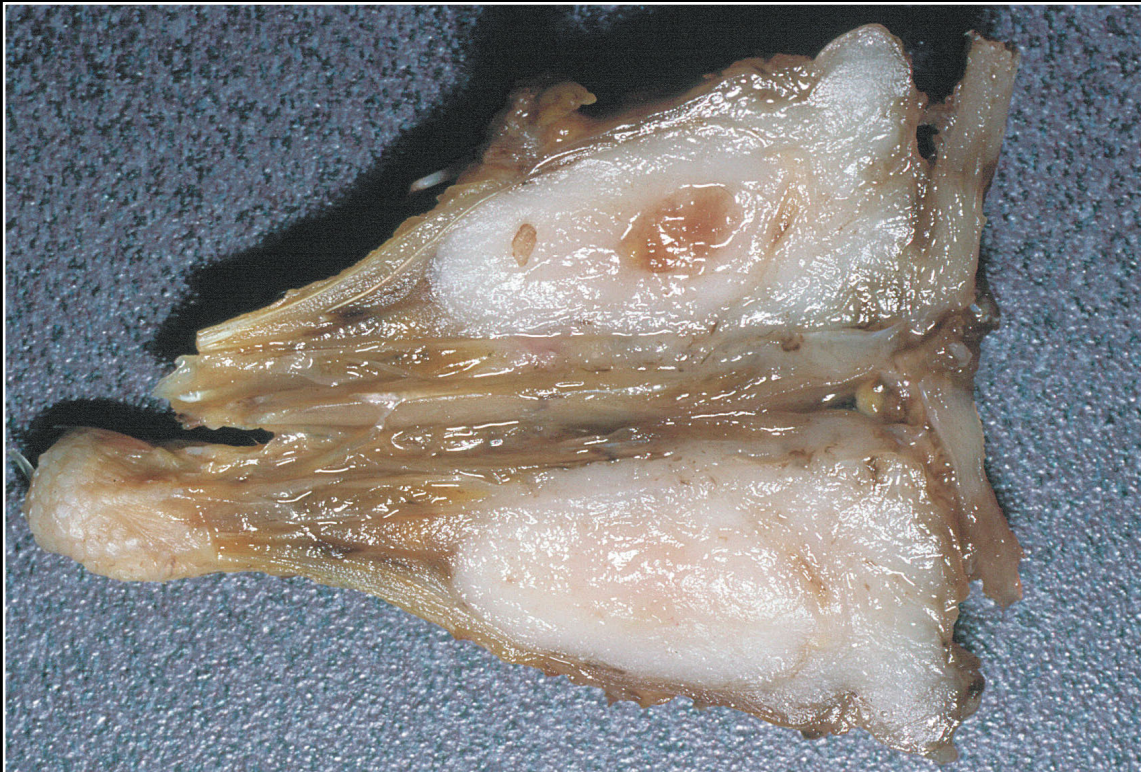Back



CHAPTER 2

External Examination, Initial Incision, Skin and Subcutis

Figure 2.36



Fibrosarcoma replacing bone. These tumors are typically firm and yellow-white, but a definitive diagnosis cannot be made grossly.

Prev. fig. Next fig.

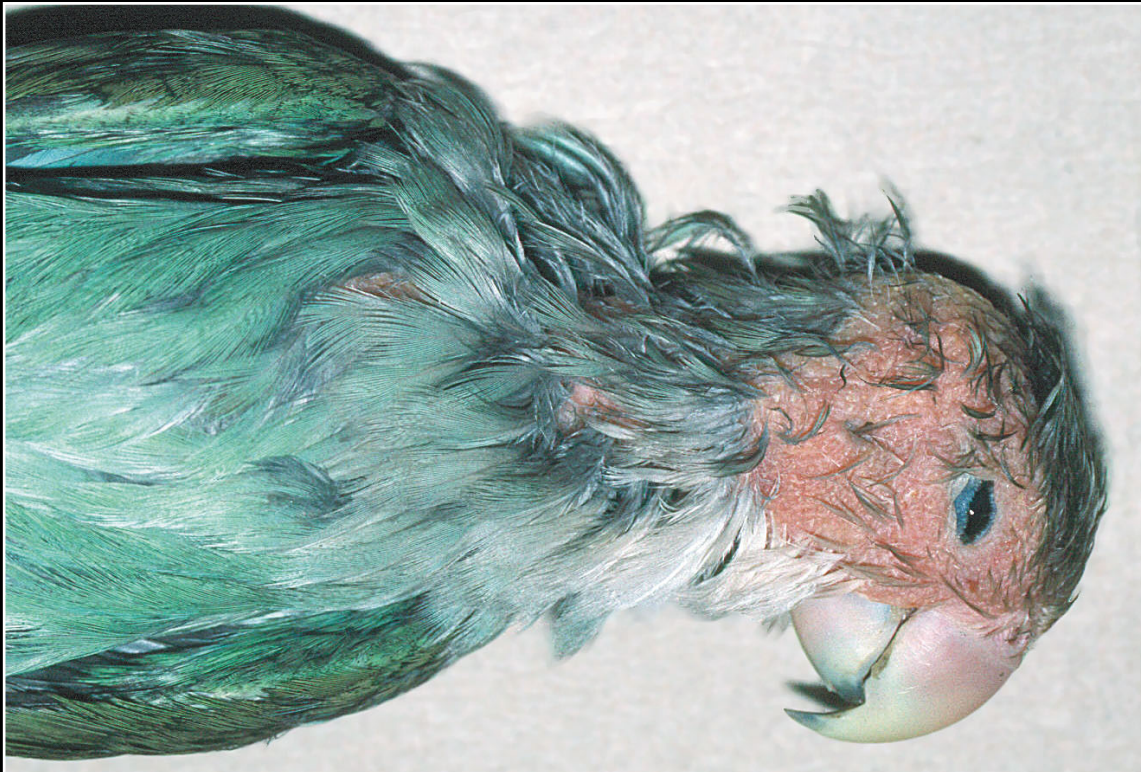Back



CHAPTER 2

External Examination, Initial Incision, Skin and Subcutis

Figure 2.37



Thickened, discolored skin due to infiltrate of neoplastic lymphoid cells. Cutaneous lymphosarcoma can present in several different ways.

Prev. fig. Next fig.

Back



CHAPTER 2

External Examination, Initial Incision, Skin and Subcutis

Figure 2.38



Malignant melanoma. These tumors often involve the face/head and usually are pigmented.

Prev. fig. Next fig.

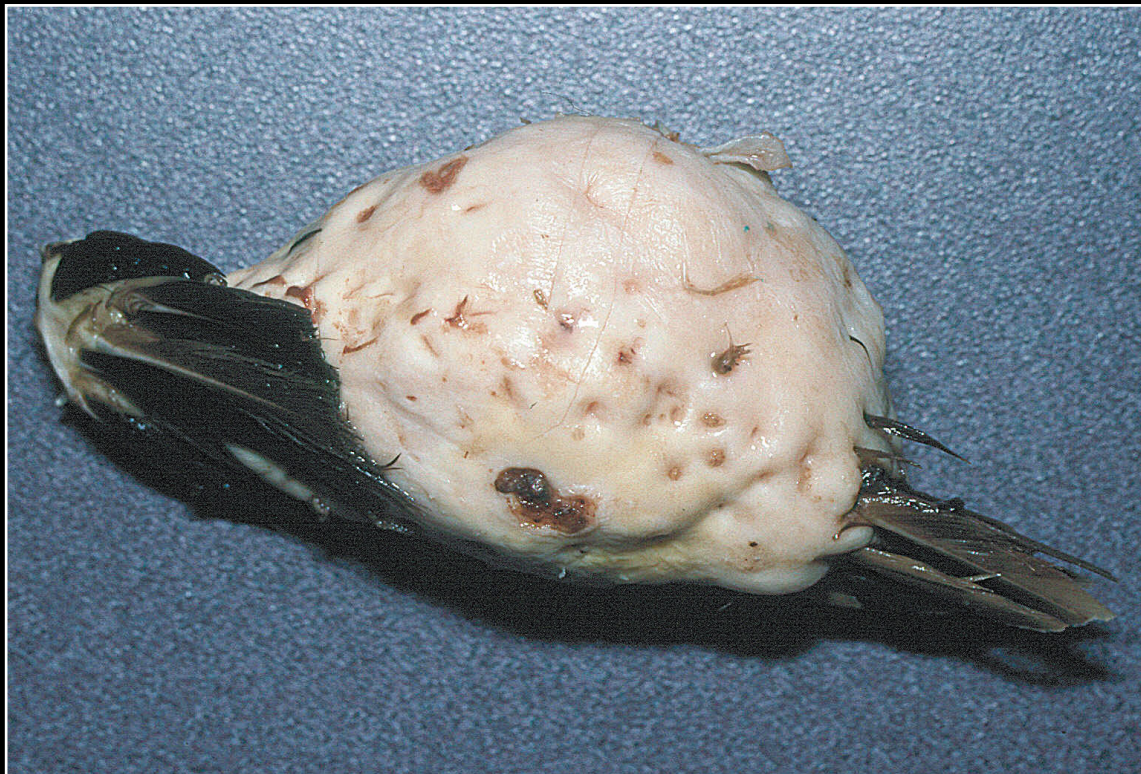Back



CHAPTER 2

External Examination, Initial Incision, Skin and Subcutis

Figure 2.39



Xanthoma on the wing. Although benign, they can become quite large and destroy normal tissues.

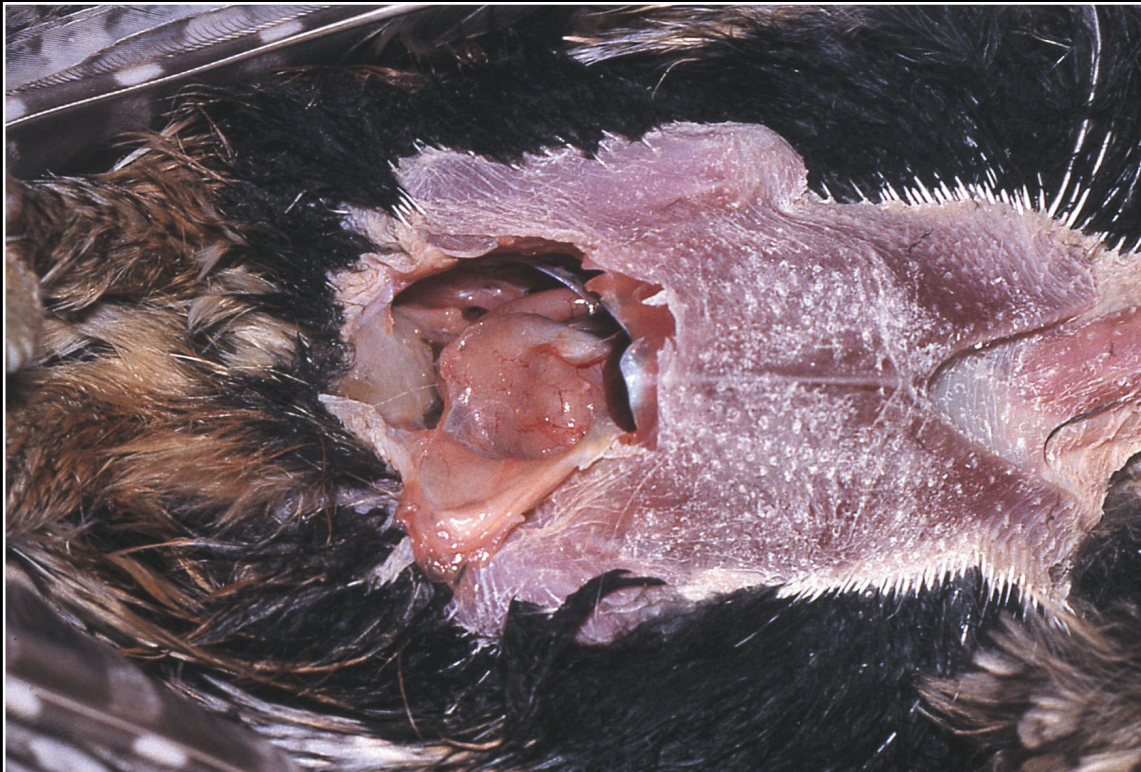Prev. fig.

Back

CHAPTER 3

Peritoneum, Mesentery, and Serous Membranes

Figure 3.1



Initial opening of the lower portion of the peritoneal cavity. Organ position and size and characteristics of any fluid or other material should be noted.

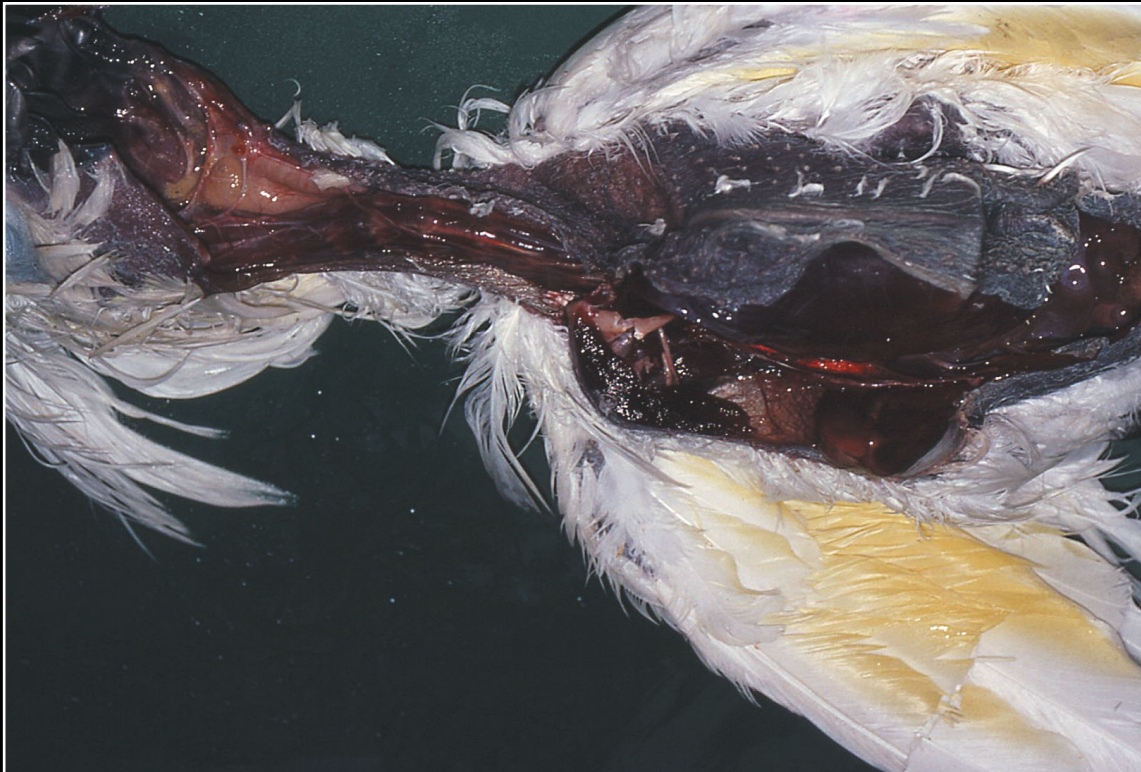Next fig.

Back

CHAPTER 3

Peritoneum, Mesentery, and Serous Membranes

Figure 3.2



Continuation of incision to open the entire peritoneal cavity, deep tissues of the neck, and oral cavity.

Prev. fig. Next fig.

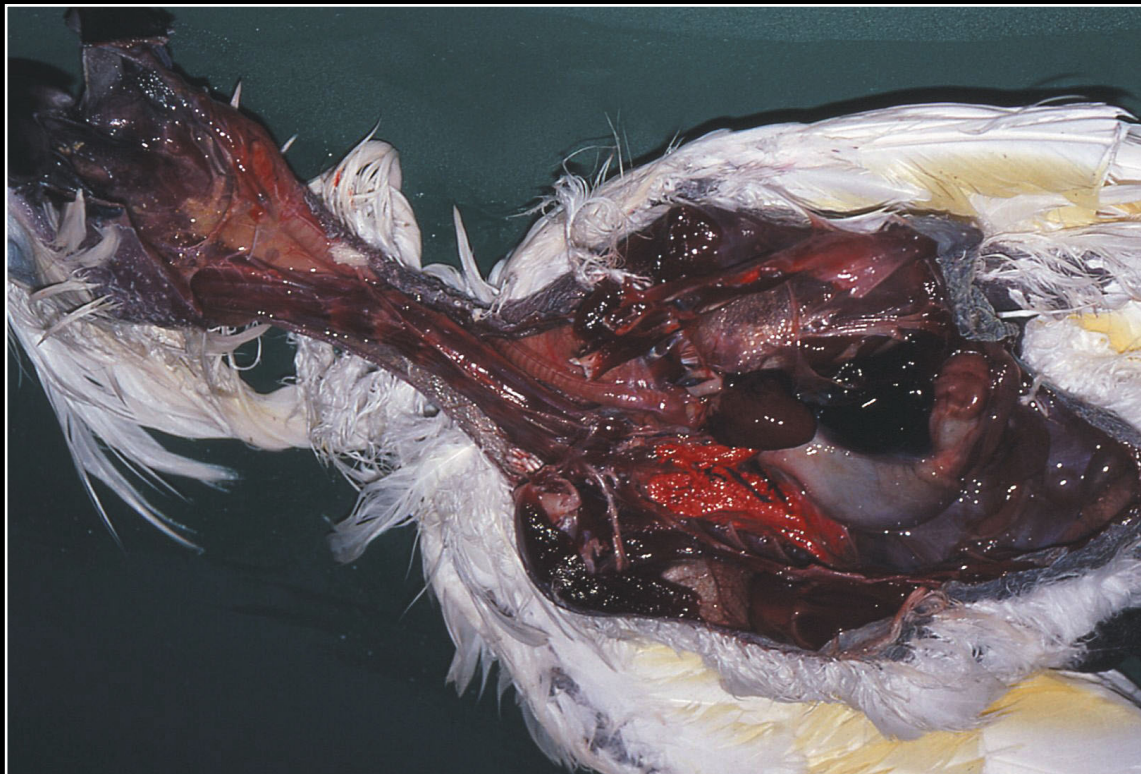
Back



CHAPTER 3

Peritoneum, Mesentery, and Serous Membranes

Figure 3.3



Organ exposure after initial deep incision.

Prev. fig. Next fig.

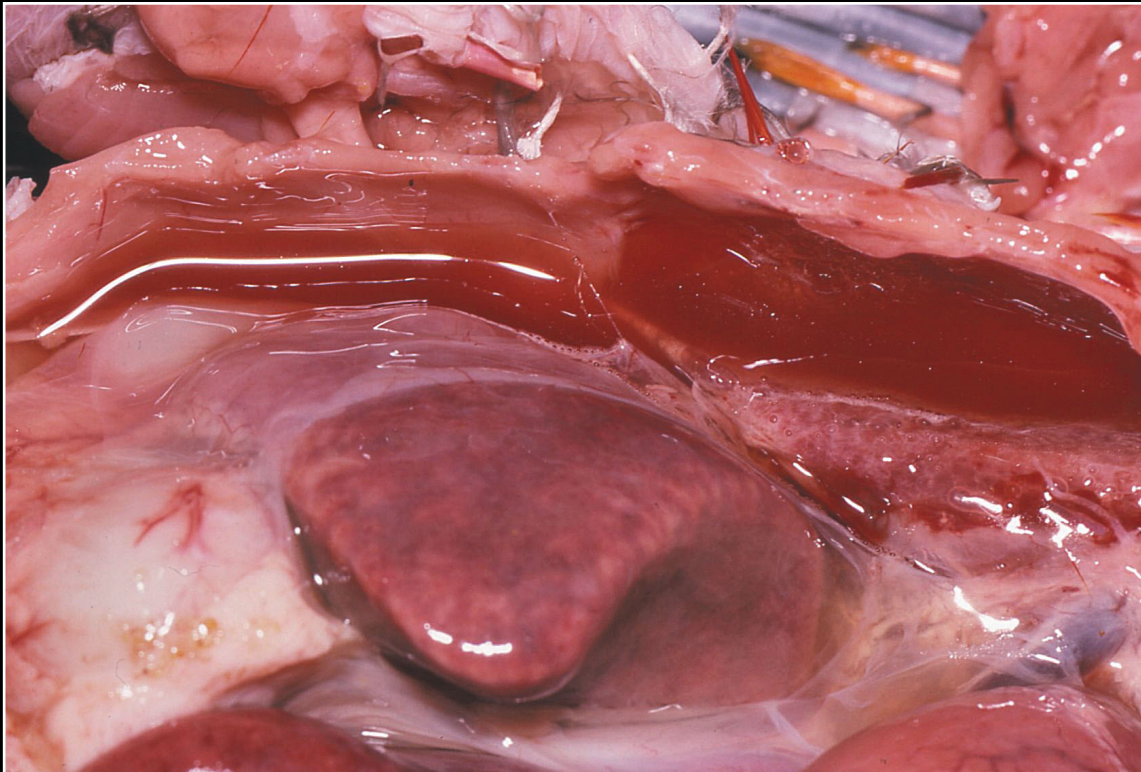Back



CHAPTER 3

Peritoneum, Mesentery, and Serous Membranes

Figure 3.4



Clear yellow fluid and hepatic enlargement in a bird with avian viral serositis.

Prev. fig. Next fig.

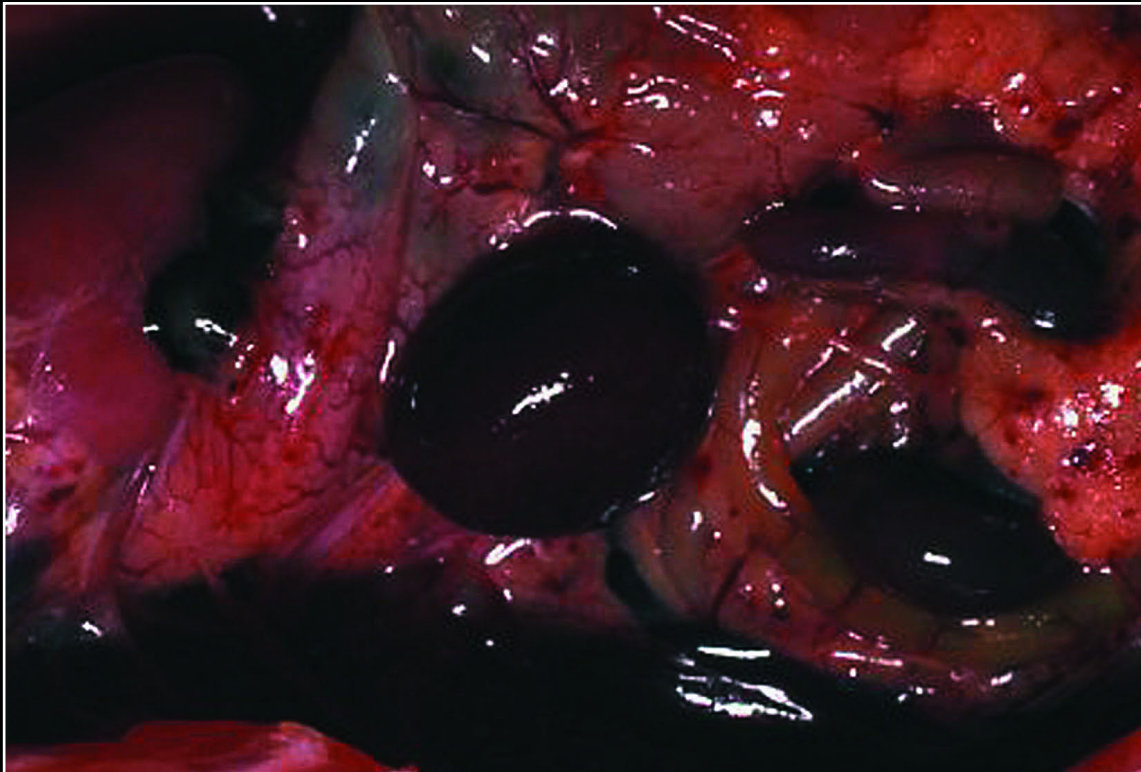
Back



CHAPTER 3

Peritoneum, Mesentery, and Serous Membranes

Figure 3.5



Serosal and mesenteric hemorrhage due to herpesvirus infection (Pacheco's disease).

Prev. fig. Next fig.

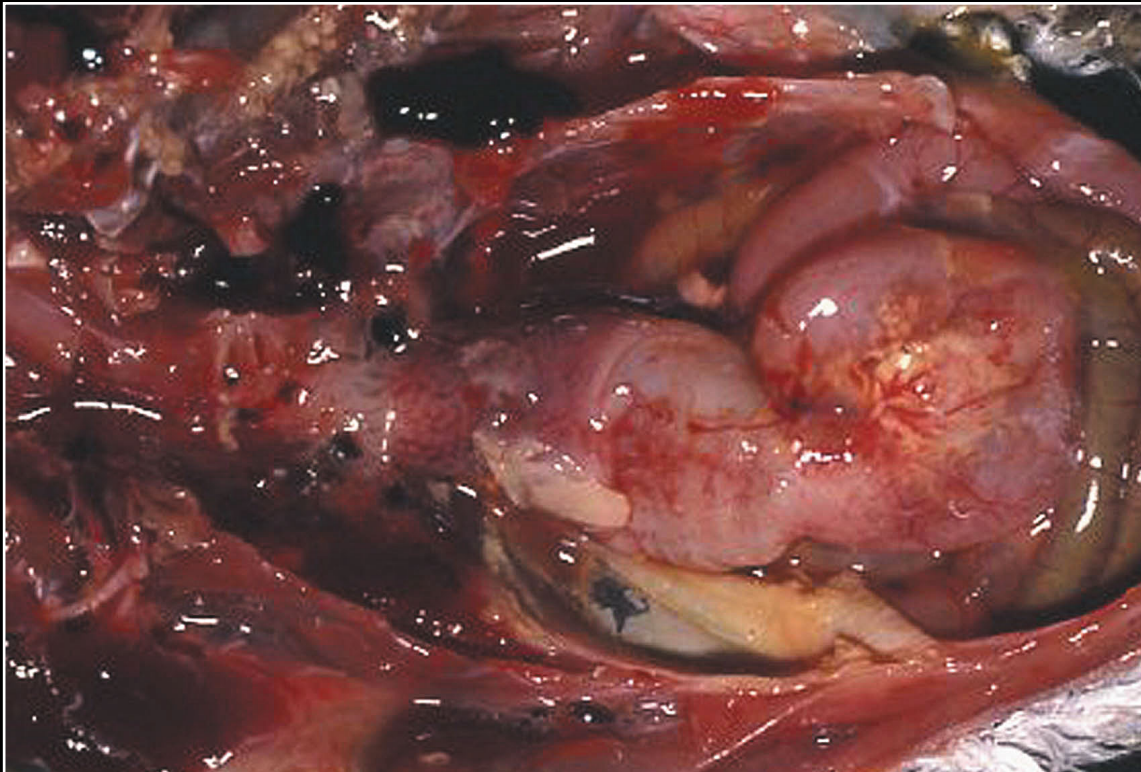
Back



CHAPTER 3

Peritoneum, Mesentery, and Serous Membranes

Figure 3.6



Mucopurulent exudate, fibrin and hemorrhage associated with bacterial peritonitis.

Prev. fig. Next fig.

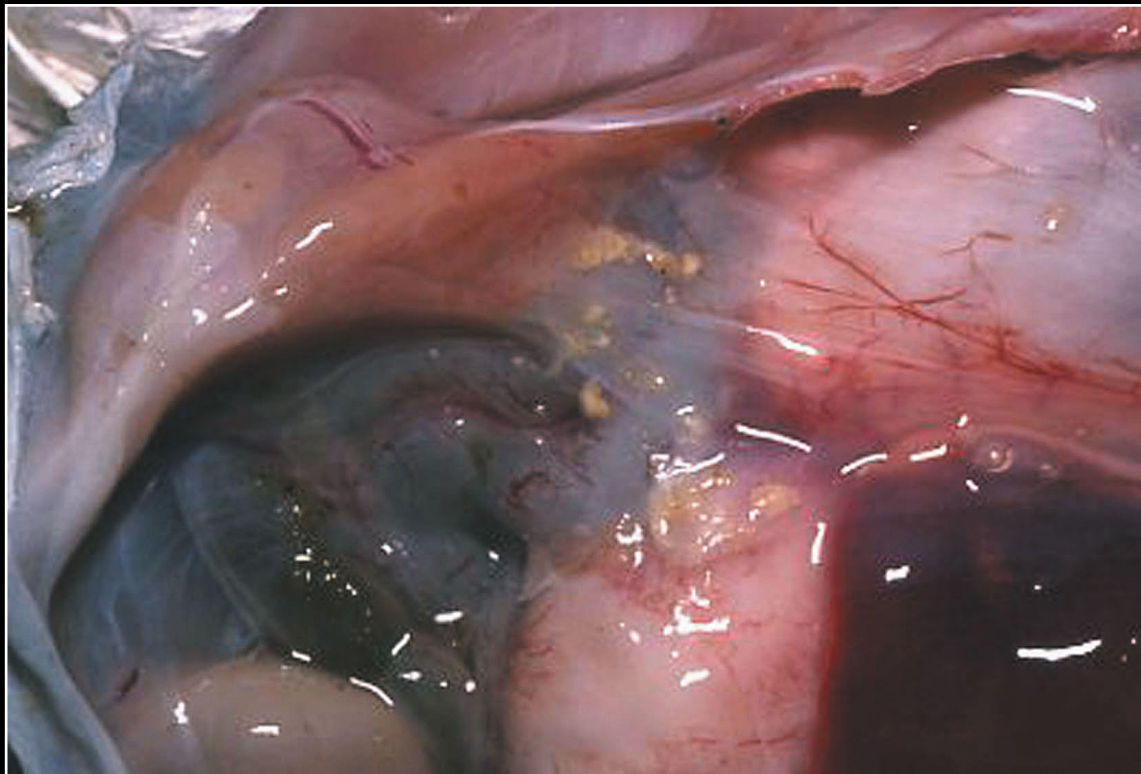
Back



CHAPTER 3

Peritoneum, Mesentery, and Serous Membranes

Figure 3.7



Multiple granulomas in chronic bacterial peritonitis.

Prev. fig. Next fig.

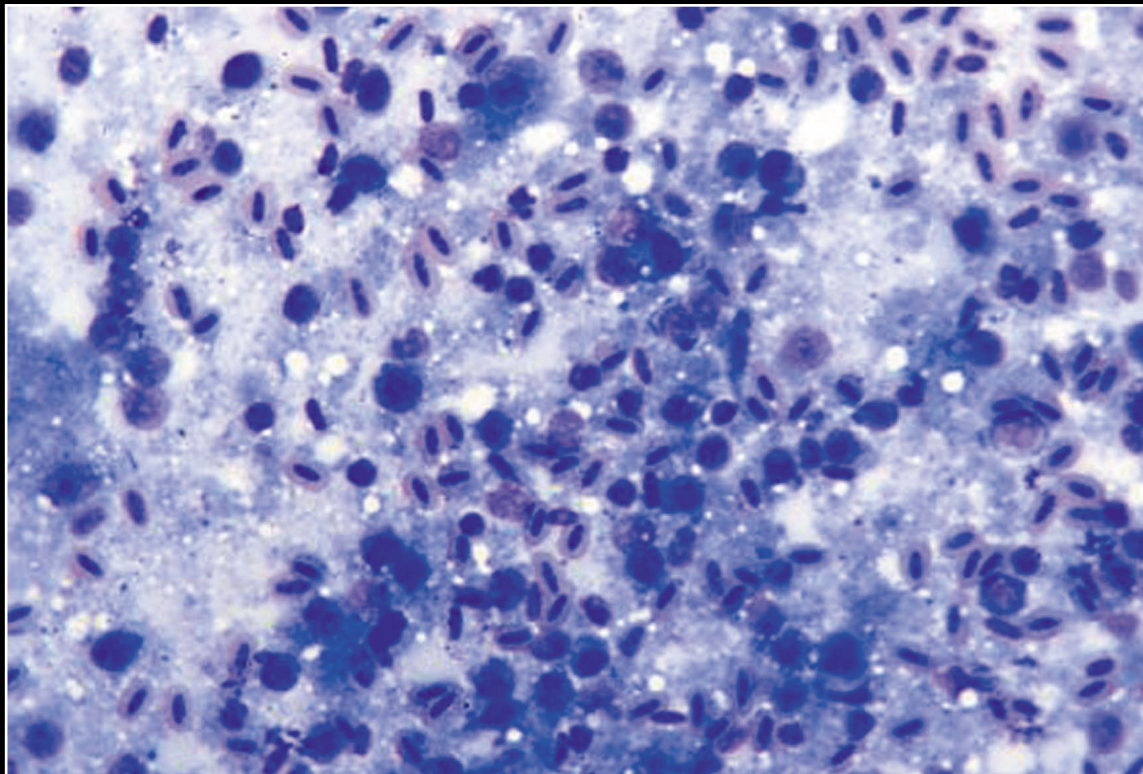
Back



CHAPTER 3

Peritoneum, Mesentery, and Serous Membranes

Figure 3.8



Pleocellular inflammation associated with septic peritonitis. Bacteria are difficult to see but are present free and in macrophages.

Prev. fig. Next fig.

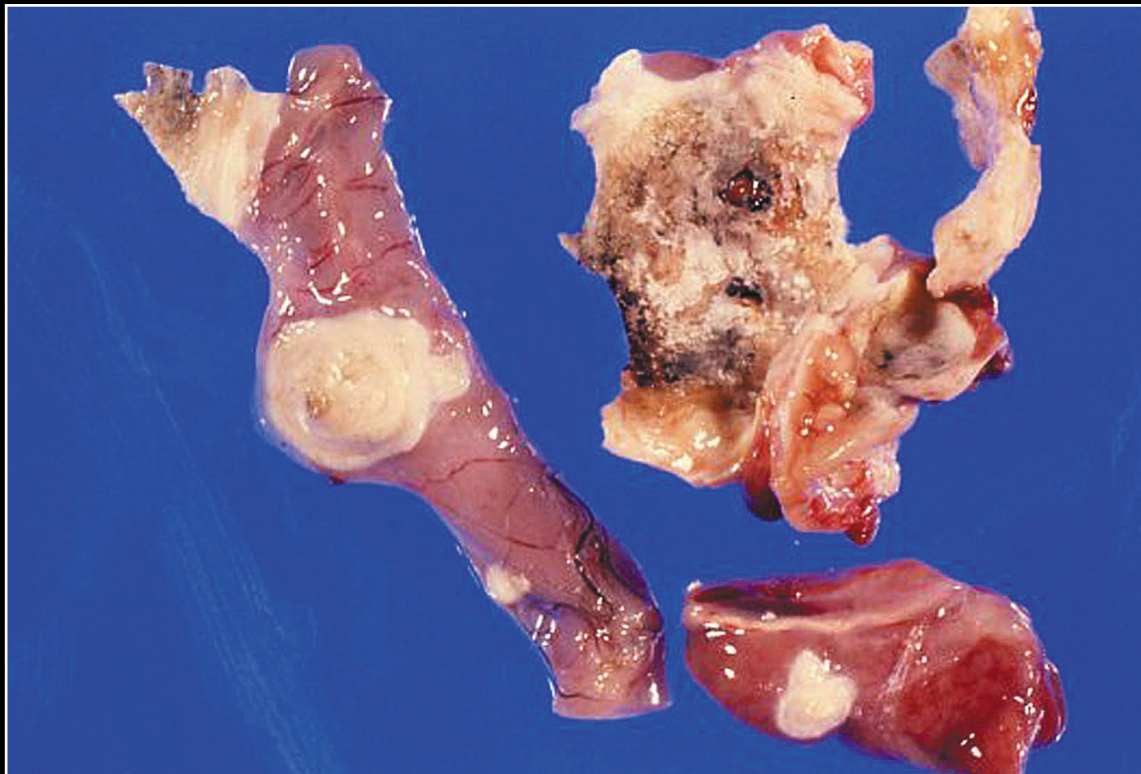
Back



CHAPTER 3

Peritoneum, Mesentery, and Serous Membranes

Figure 3.9



Large mycotic granulomas on serosal surfaces.

Prev. fig. Next fig.

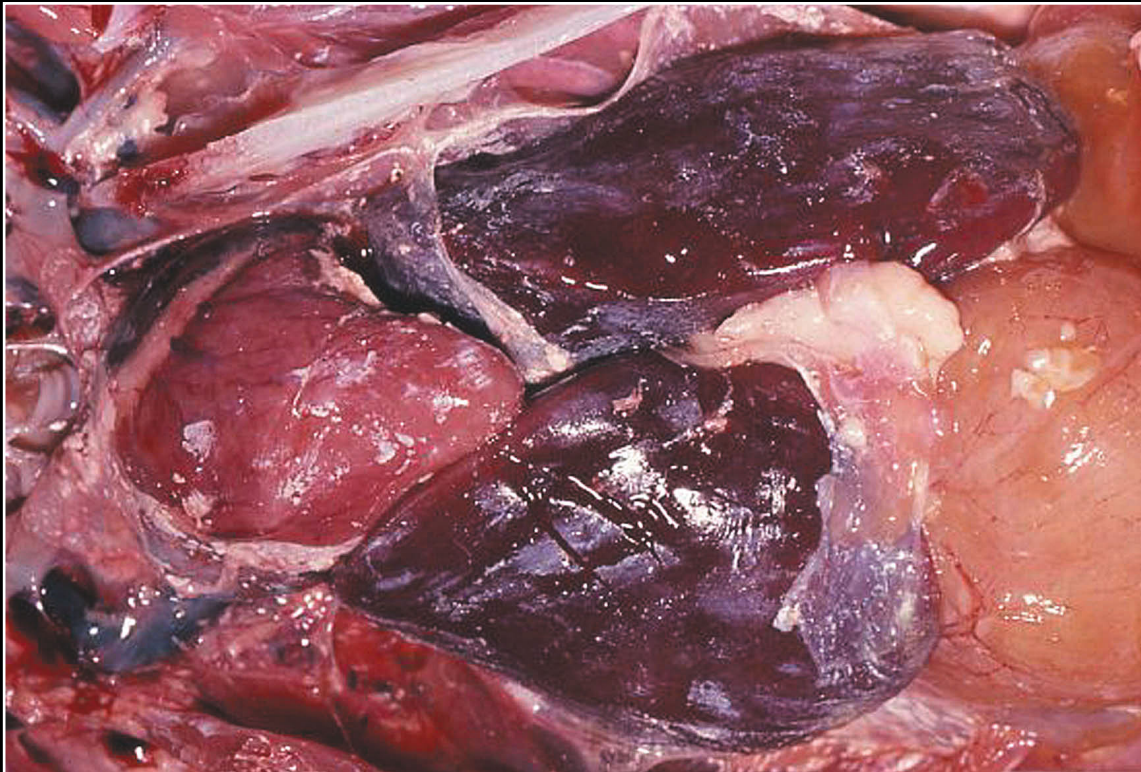
Back



CHAPTER 3

Peritoneum, Mesentery, and Serous Membranes

Figure 3.10



Disseminated urate deposition in mesenteries and on serosal surfaces.

Prev. fig. Next fig.

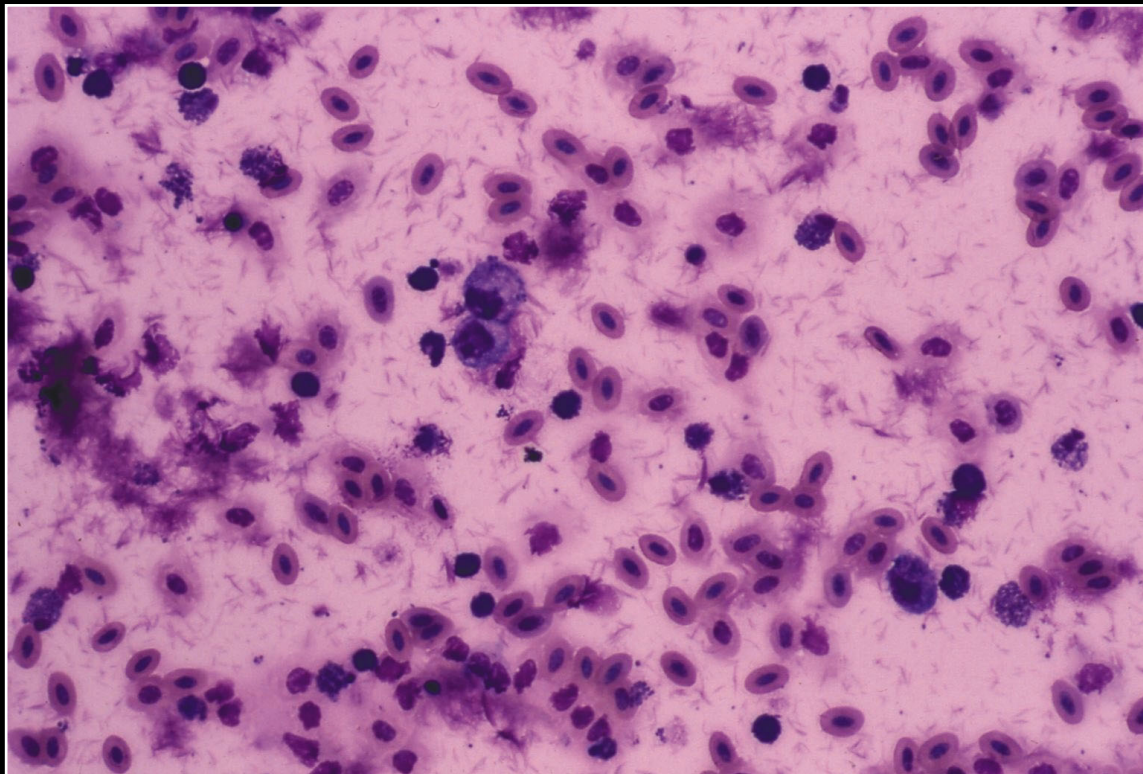
Back



CHAPTER 3

Peritoneum, Mesentery, and Serous Membranes

Figure 3.11



Fluid from peritoneal cavity with visceral urate deposition. There is a pleocellular inflammatory response and numerous fragments of urate crystals.

Prev. fig. Next fig.

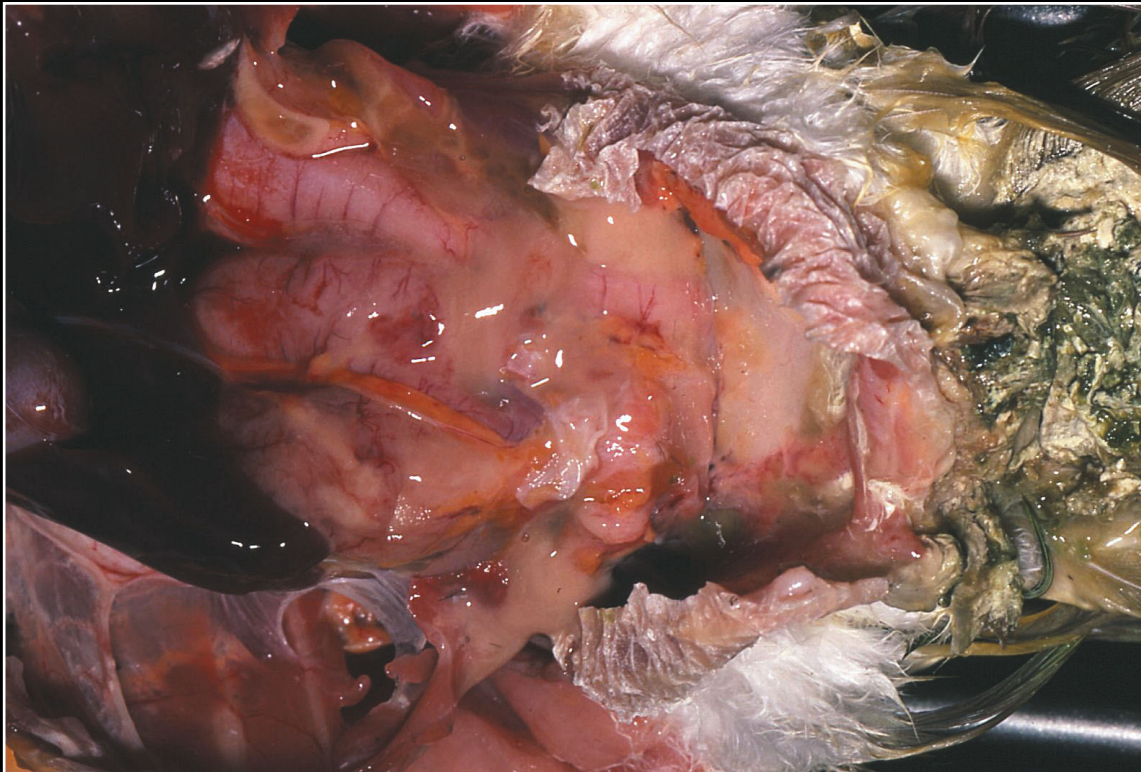
Back



CHAPTER 3

Peritoneum, Mesentery, and Serous Membranes

Figure 3.12



Yolk peritonitis resulting in large amounts of yellow-gray material in the peritoneal cavity.

Prev. fig. Next fig.

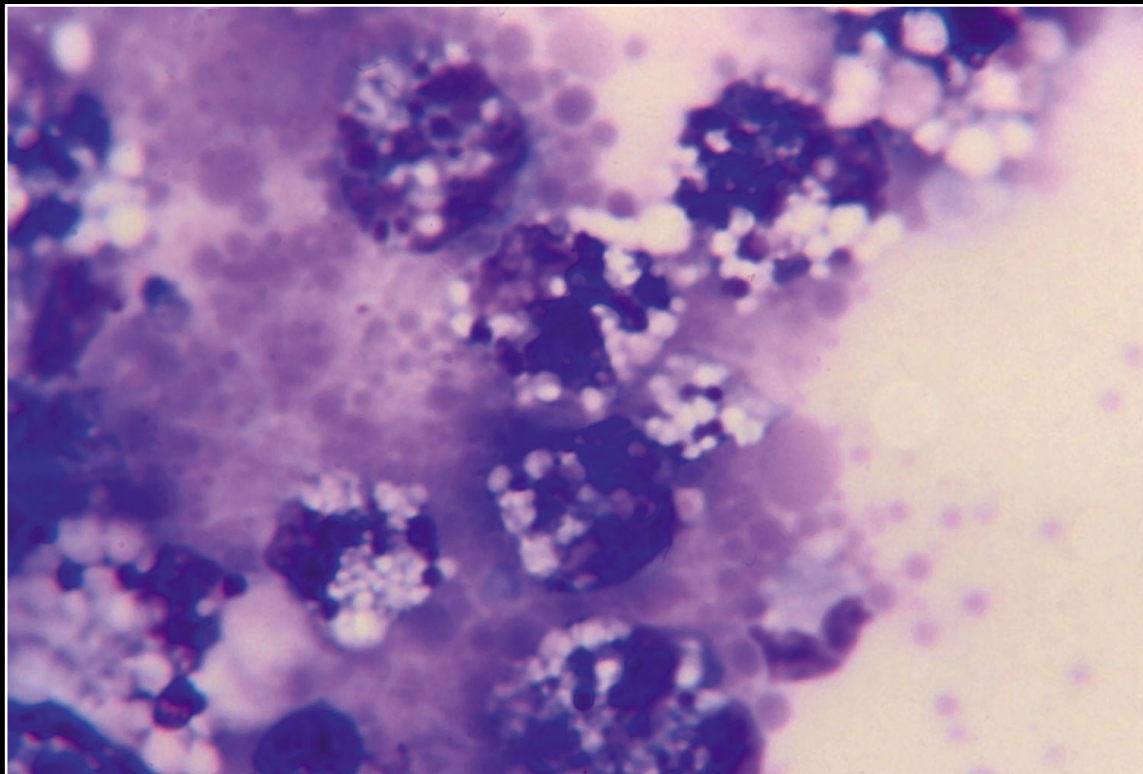
Back



CHAPTER 3

Peritoneum, Mesentery, and Serous Membranes

Figure 3.13



Large macrophages with foamy cytoplasm and globules of amorphous blue-purple material consistent with yolk protein.

Prev. fig. Next fig.

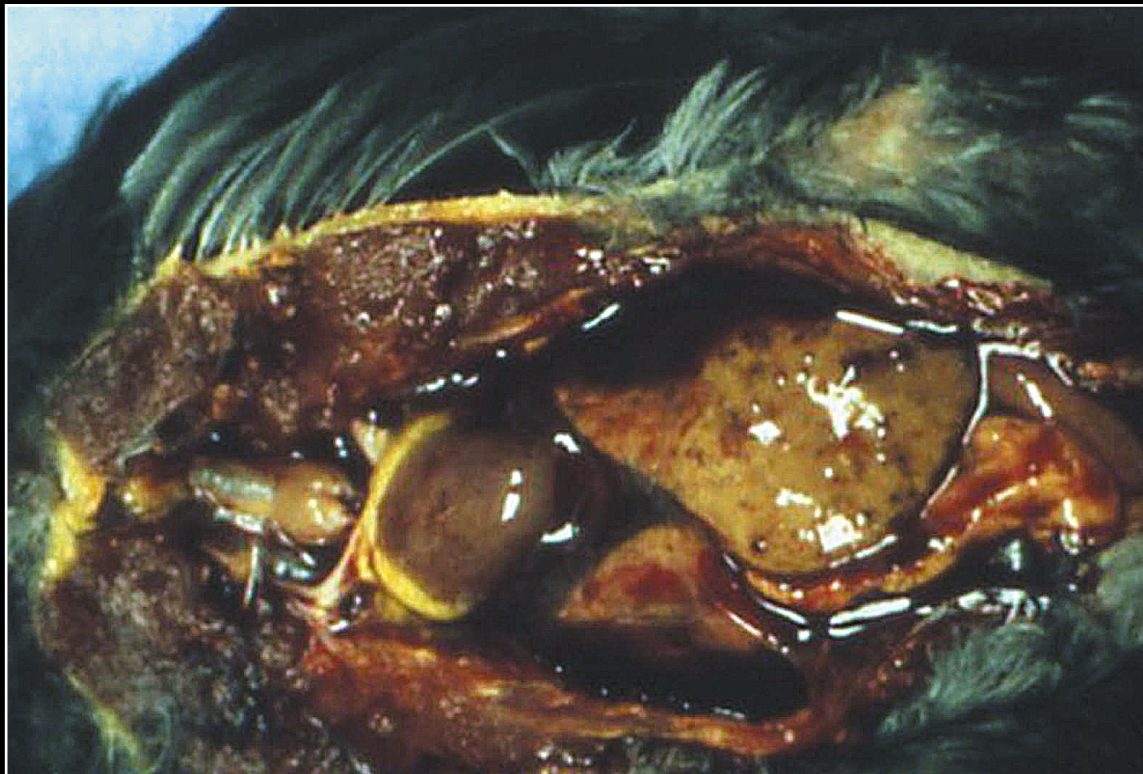Back



CHAPTER 3

Peritoneum, Mesentery, and Serous Membranes

Figure 3.14



Hemorrhage in the peritoneal cavity can be the result of trauma or severe infection/necrosis of large parenchymal organs such as the liver.

Prev. fig. Next fig.

Back



CHAPTER 3

Peritoneum, Mesentery, and Serous Membranes

Figure 3.15

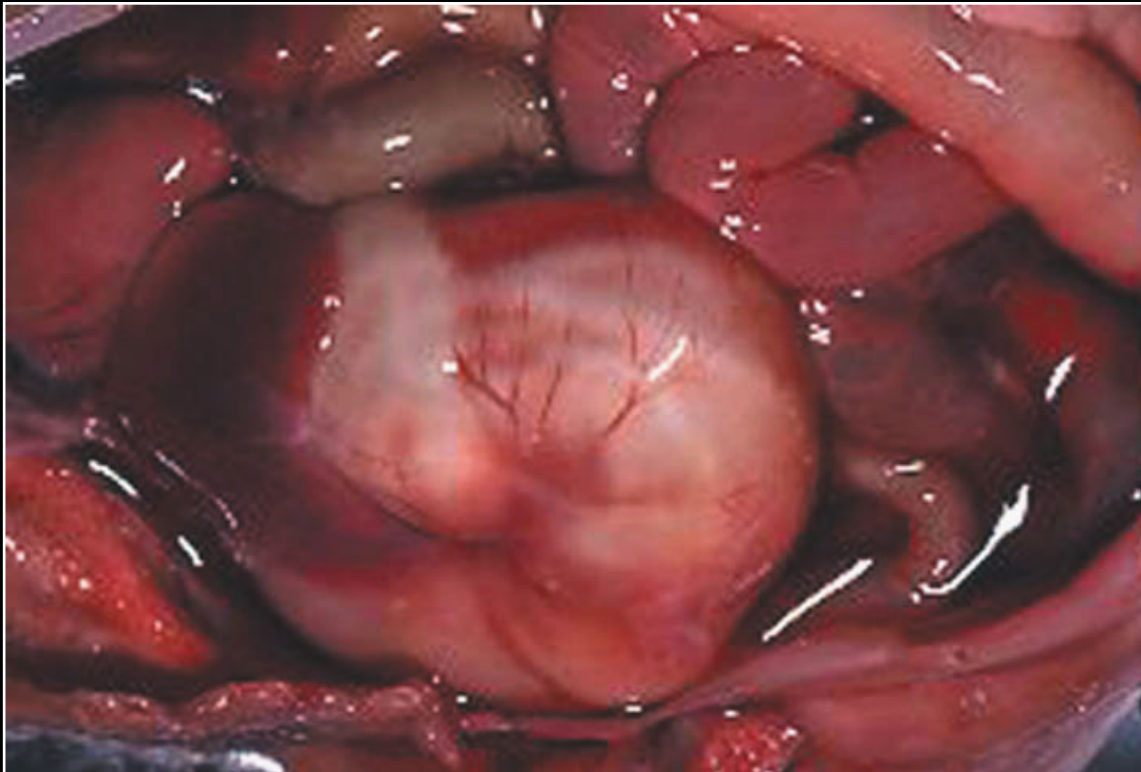

Fig 3.15 Transudates are usually clear to yellow or red-yellow if there is some associated hemorrhage.

Prev. fig. Next fig.

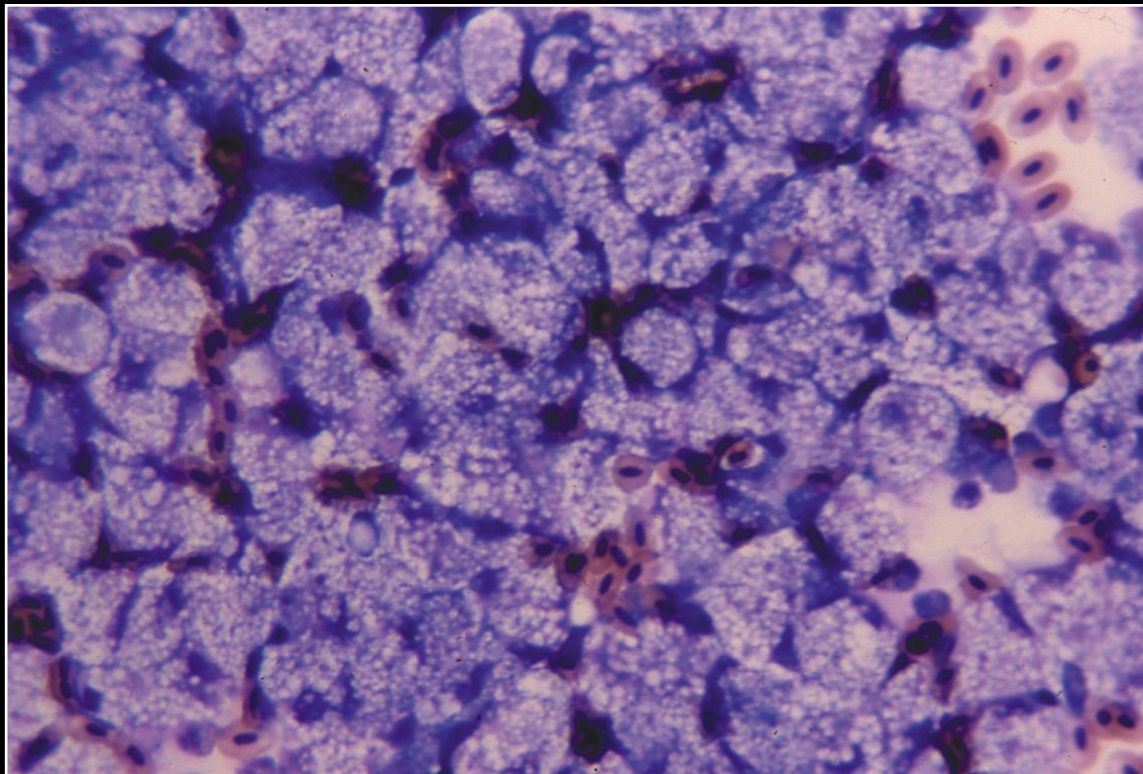
Back



CHAPTER 3

Peritoneum, Mesentery, and Serous Membranes

Figure 3.16



If there is significant hepatic disease, the transudate may contain large numbers of macrophages with abundant foamy cytoplasm.

Prev. fig. Next fig.

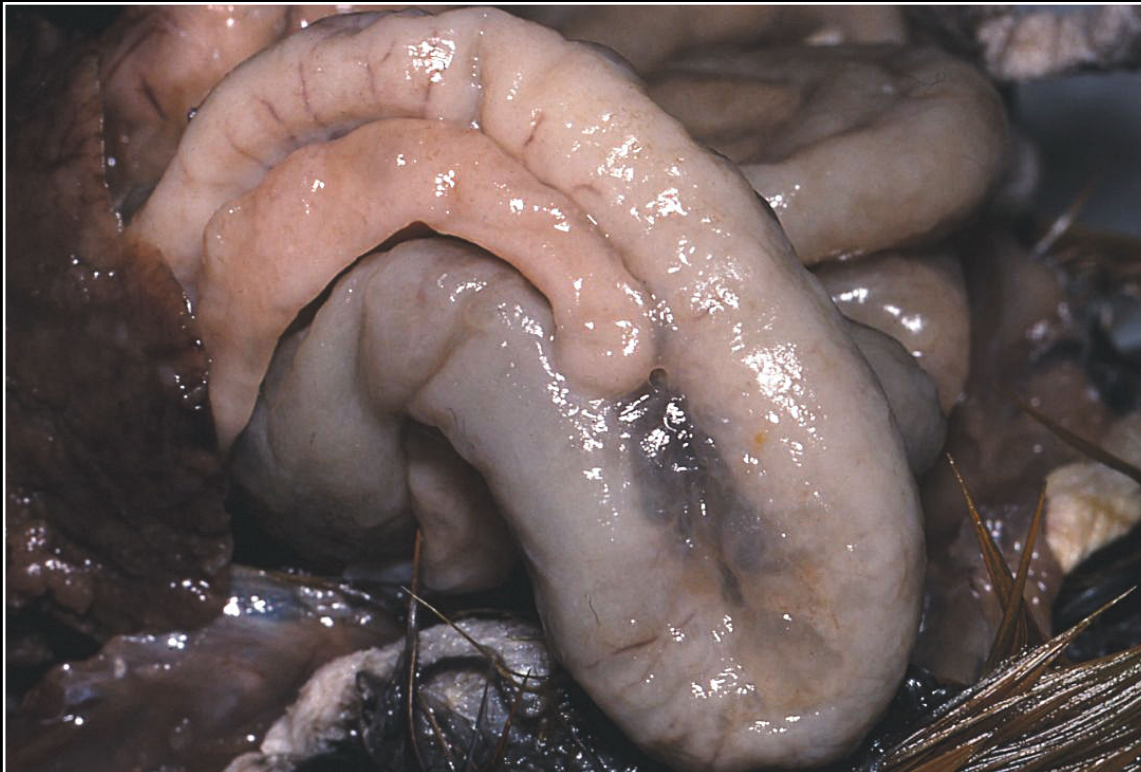Back



CHAPTER 3

Peritoneum, Mesentery, and Serous Membranes

Figure 3.17



Lymphosarcoma involving serous membranes. The intestinal serosa is thickened and opaque.

Prev. fig. Next fig.

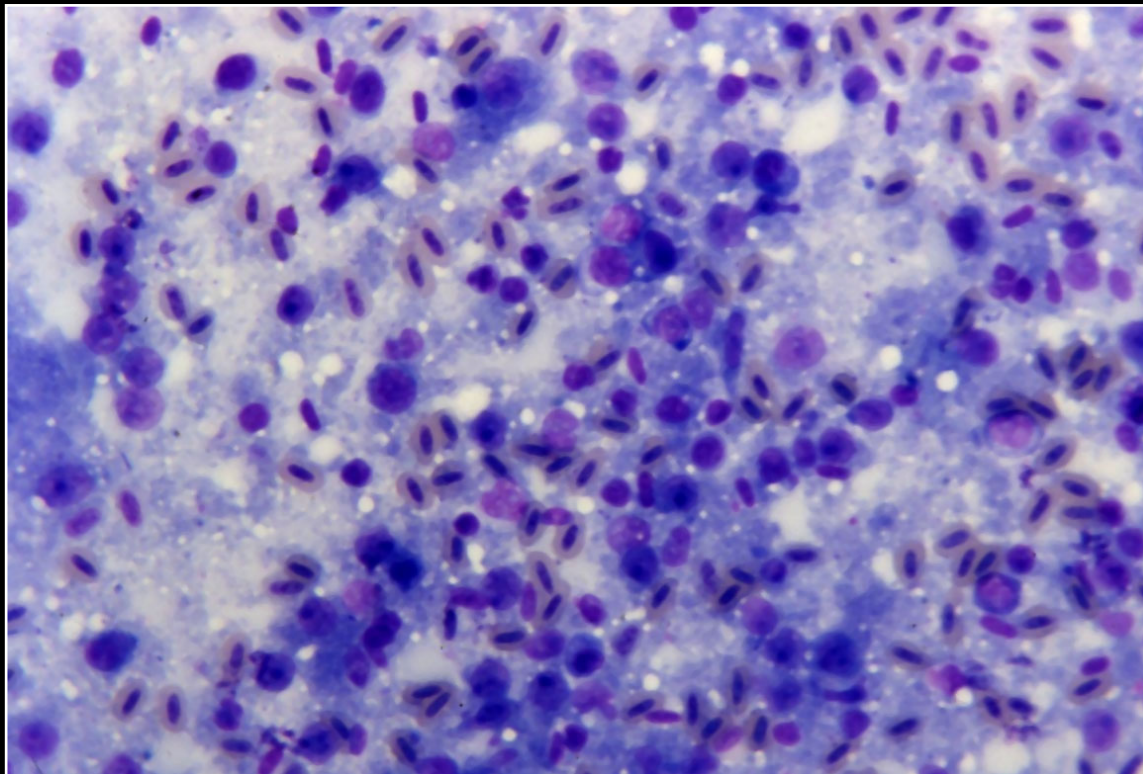
Back



CHAPTER 3

Peritoneum, Mesentery, and Serous Membranes

Figure 3.18



Numerous immature lymphoid cells are seen cytologically in peritoneal fluid from a bird with lymphosarcoma involving serous membranes and/or abdominal organs.

Prev. fig. Next fig.

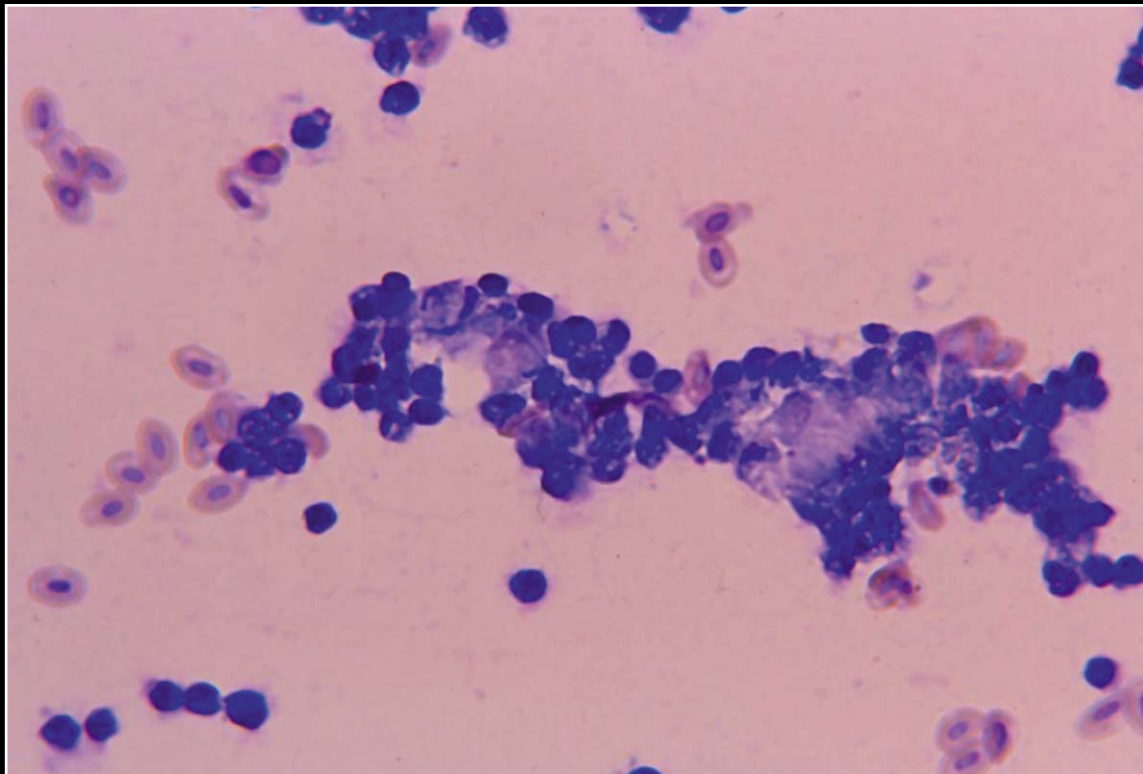
Back



CHAPTER 3

Peritoneum, Mesentery, and Serous Membranes

Figure 3.19



Clumps of neoplastic cells present in abdominal fluid of a bird with ovarian carcinoma. The cells are anaplastic with hyperchromatic nuclei and are forming clusters typical of carcinoma.

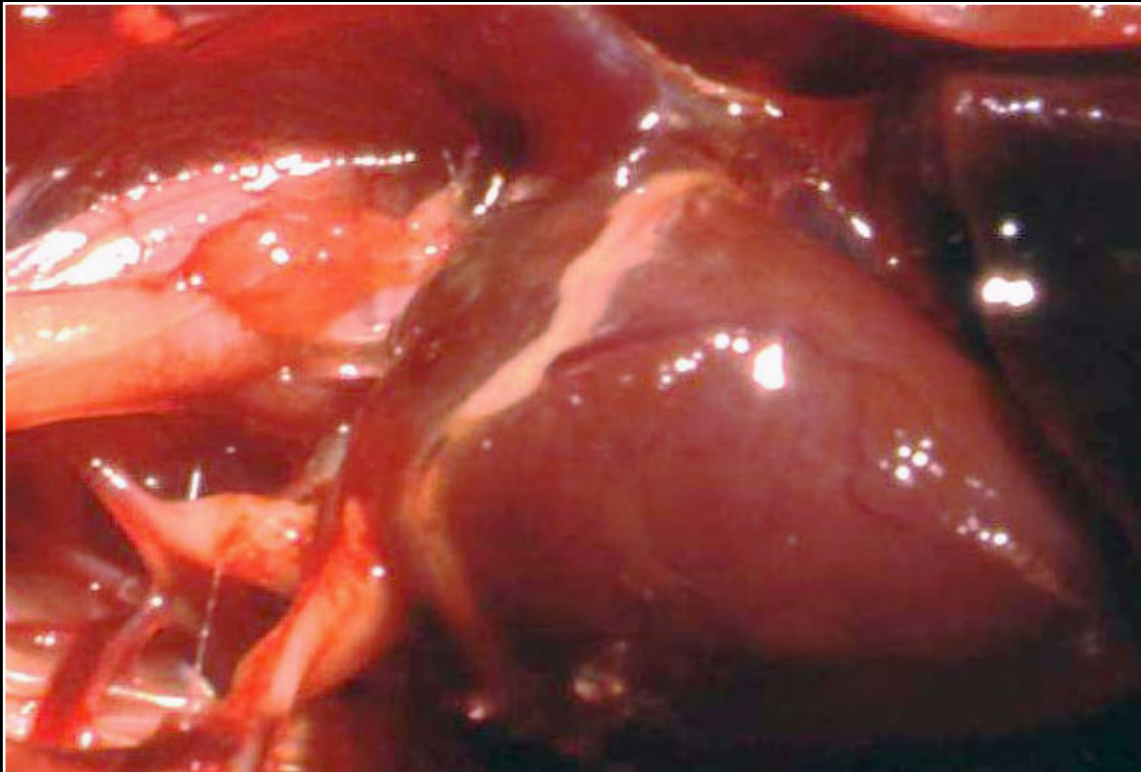
Prev. fig.

Back

C H A P T E R 4

Cardiovascular System

Figure 4.0



Normal heart.

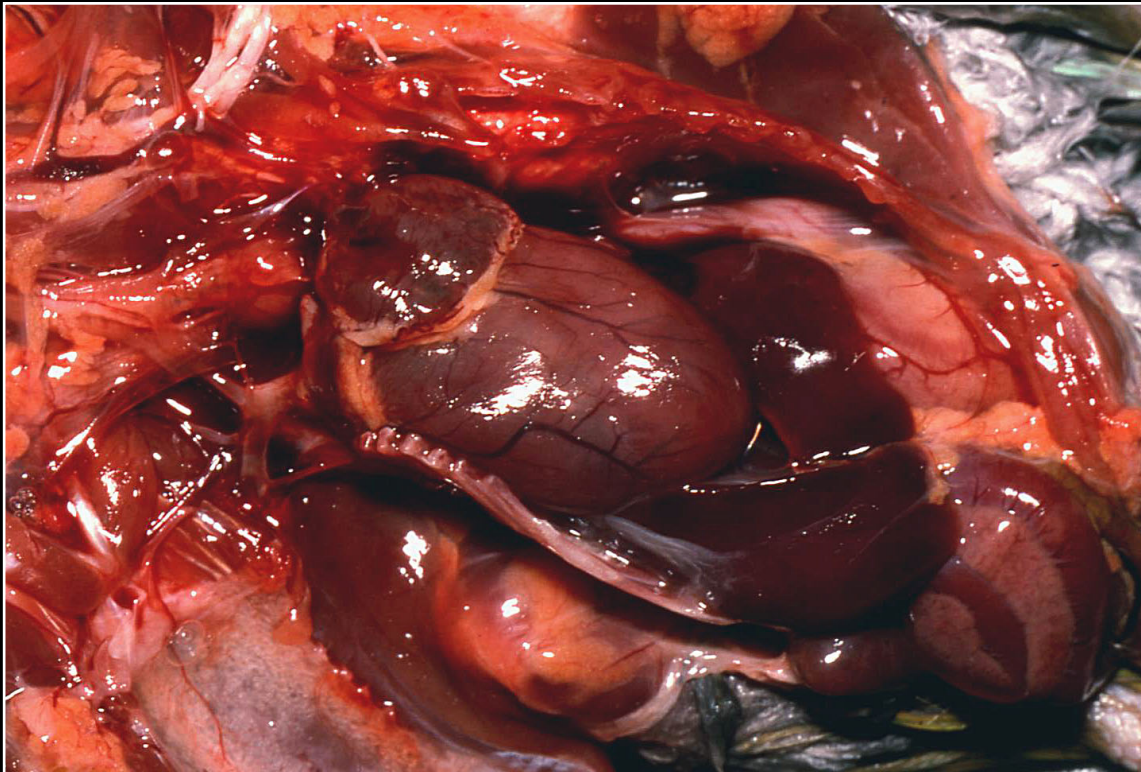
Next fig.

Back

C H A P T E R 4

Cardiovascular System

Figure 4.1



Flabby, dilated heart often seen in association with various congenital anomalies.

Prev. fig. Next fig.

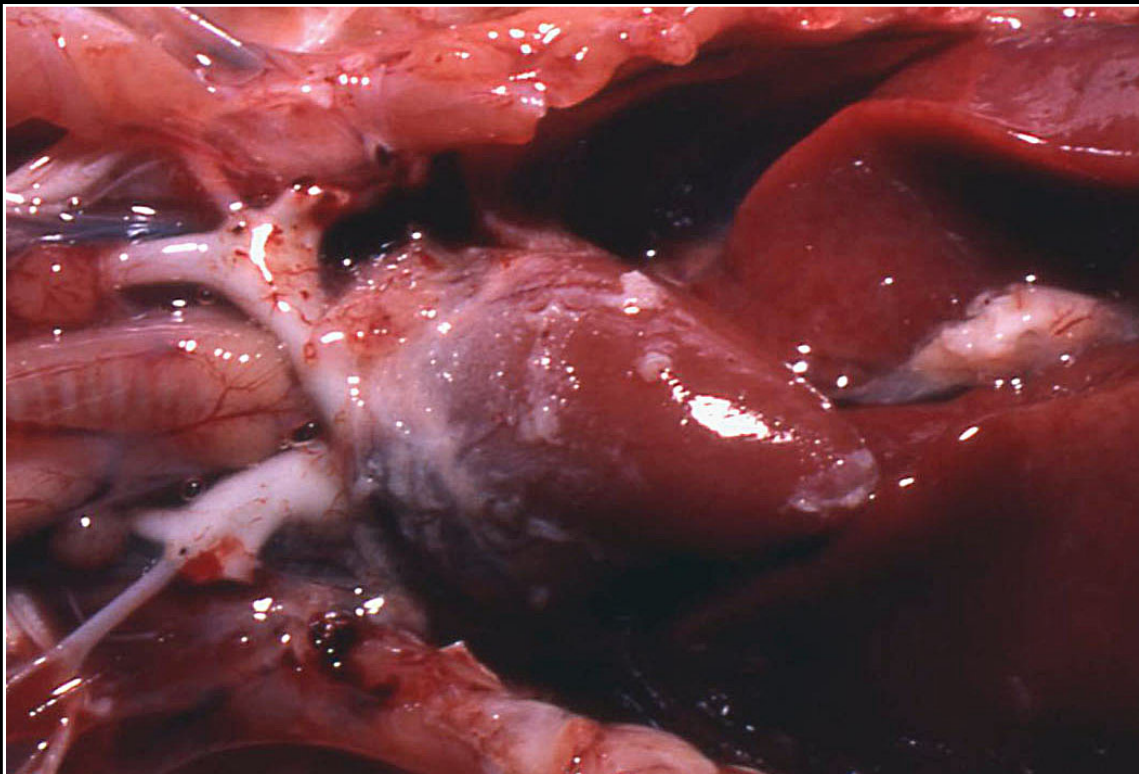
Back



C H A P T E R 4

Cardiovascular System

Figure 4.2



Multiple plaques seen in bacterial pericarditis.

Prev. fig. Next fig.

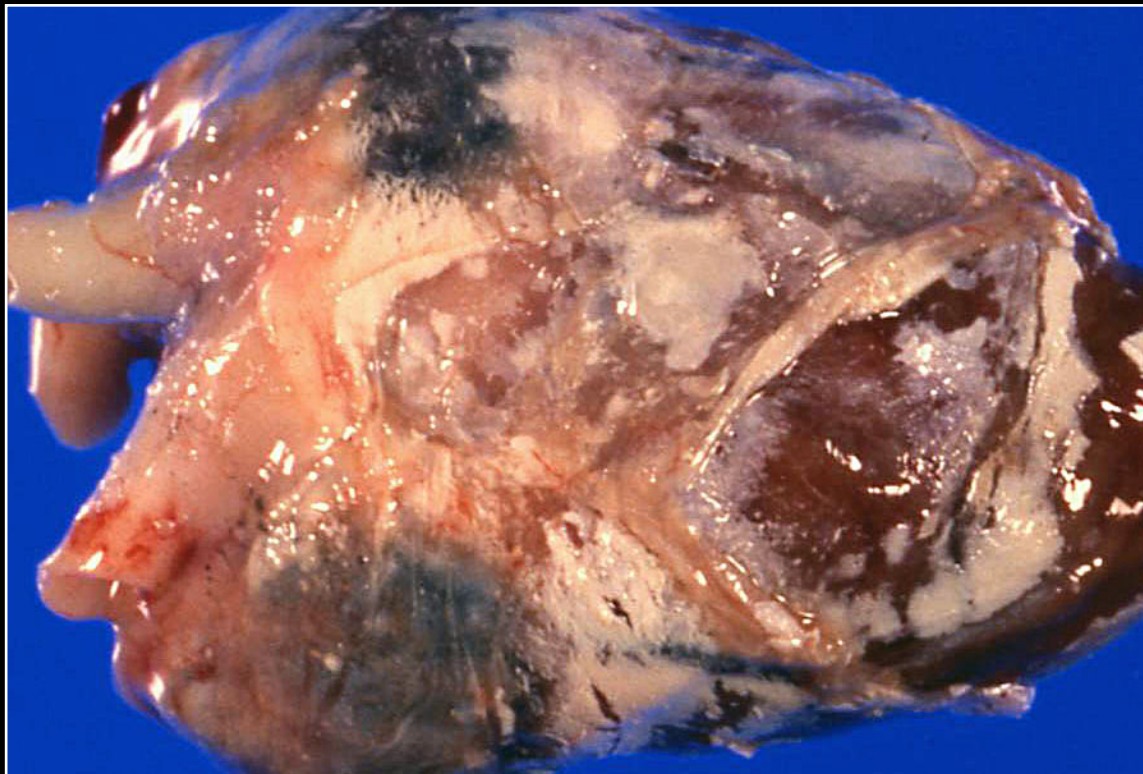
Back



C H A P T E R 4

Cardiovascular System

Figure 4.3



Gray-white pericardial urate deposition. Note the difference from the cream-white pericardial fat deposits.

Prev. fig. Next fig.

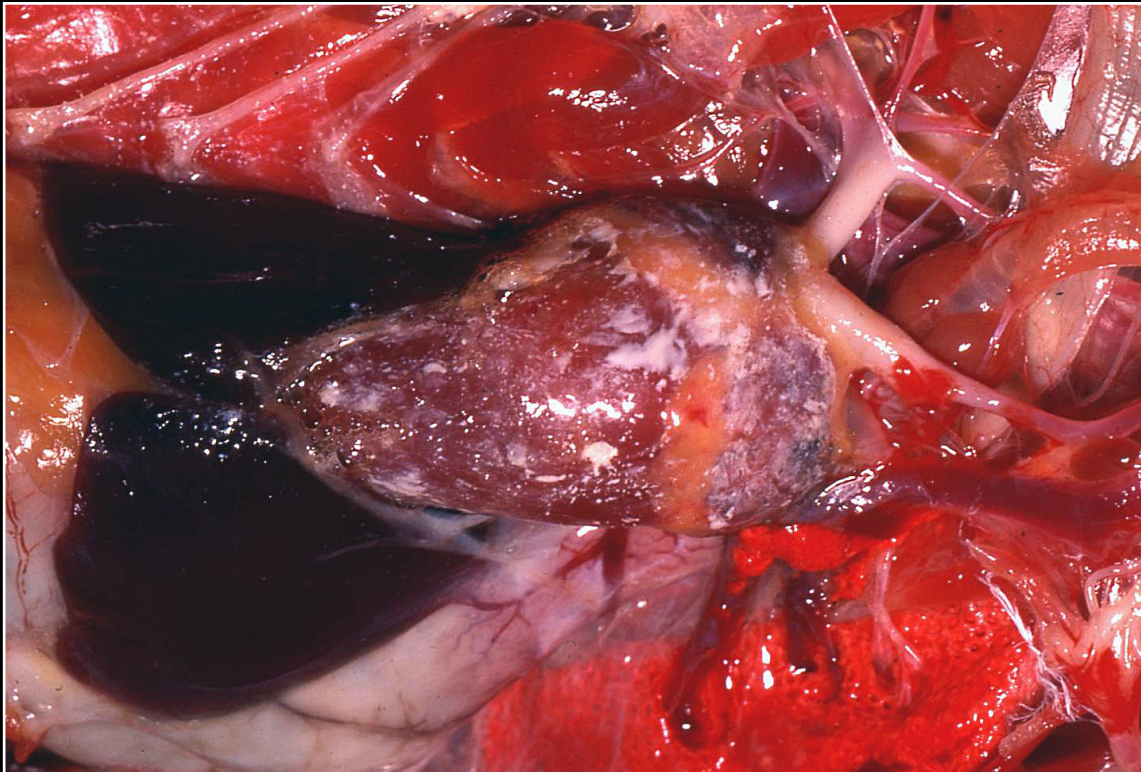
Back



C H A P T E R 4

Cardiovascular System

Figure 4.4



Multifocal to confluent urate deposits in the pericardium.

Prev. fig. Next fig.

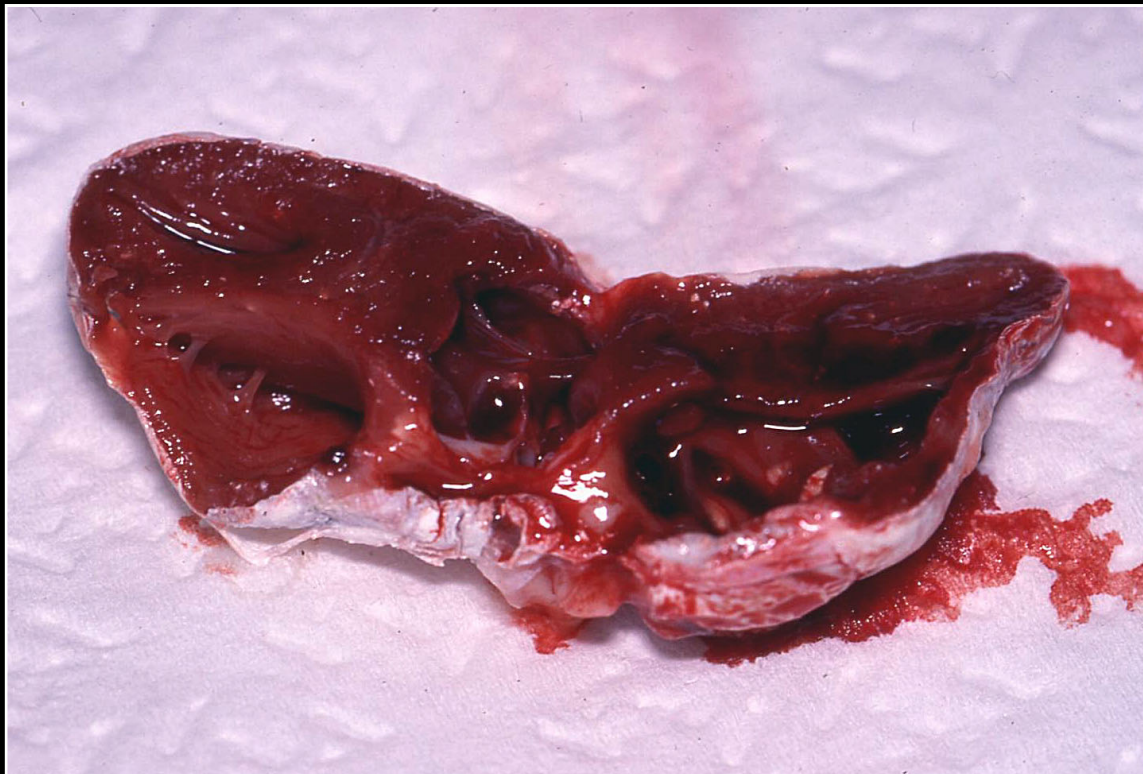
Back



C H A P T E R 4

Cardiovascular System

Figure 4.5



Severe diffuse pericardial thickening due to urate deposition.

Prev. fig. Next fig.

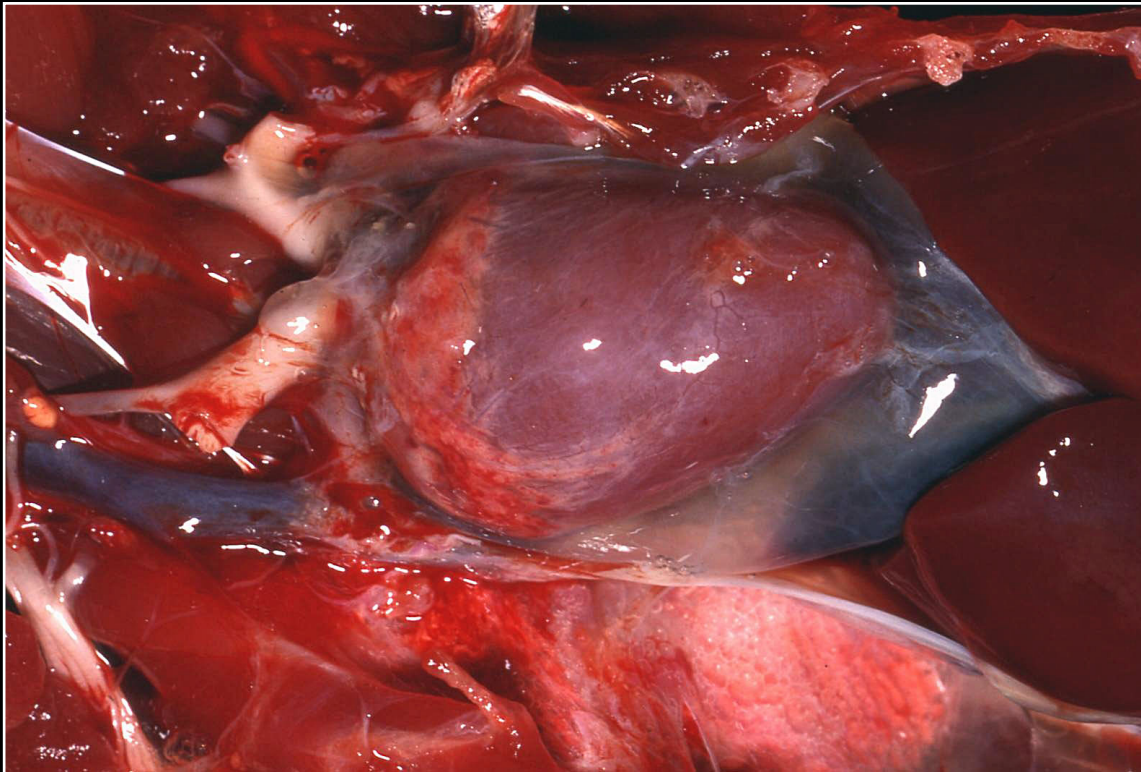
Back



C H A P T E R 4

Cardiovascular System

Figure 4.6



Effusion in the pericardial sac with formation of translucent gel-like material.

Prev. fig. Next fig.

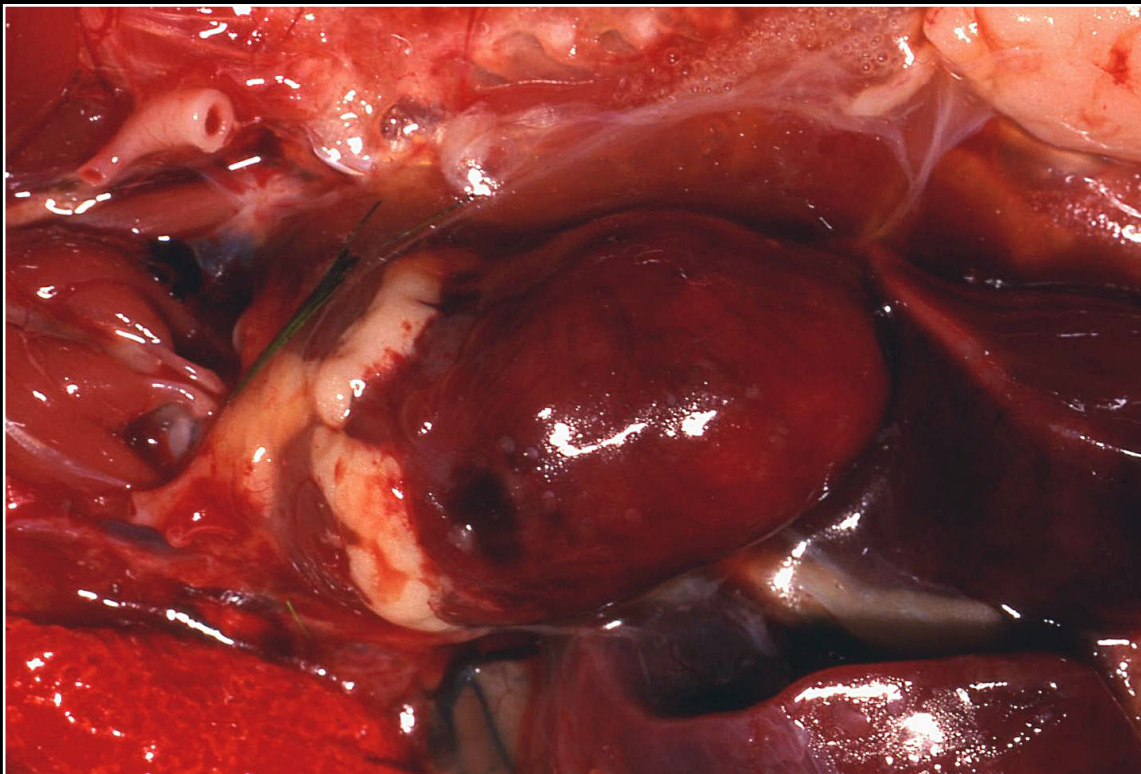
Back



C H A P T E R 4

Cardiovascular System

Figure 4.7



Myocardial hemorrhage and scattered pale foci due to polyomavirus infection.

Prev. fig. Next fig.

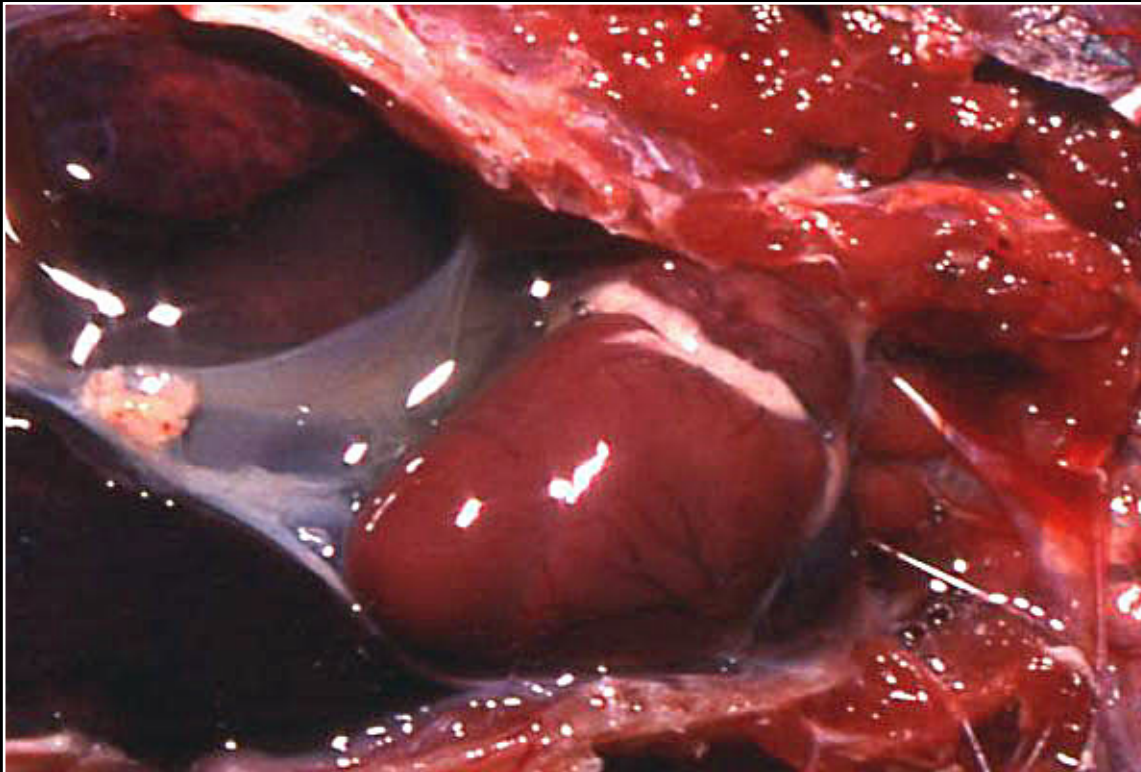
Back



C H A P T E R 4

Cardiovascular System

Figure 4.8



Hydropericardium secondary to polyomavirus infection.

Prev. fig. Next fig.

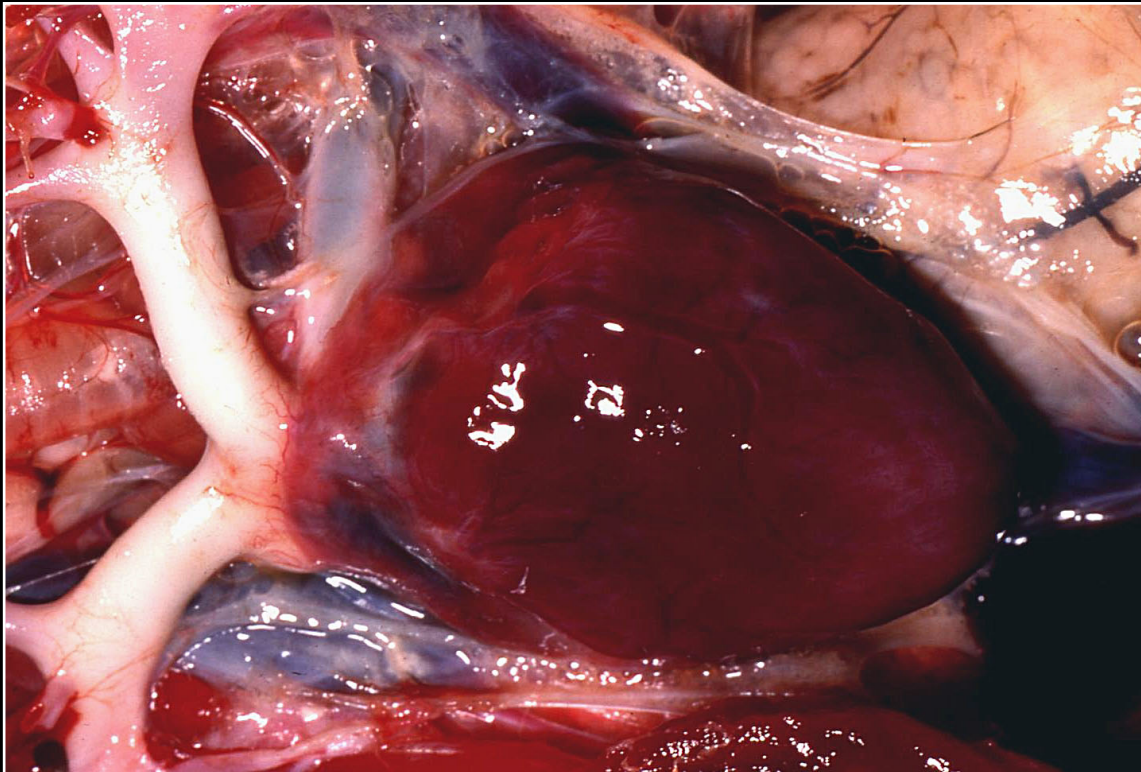
Back



C H A P T E R 4

Cardiovascular System

Figure 4.9



Scattered pale foci in the myocardium of a bird with proventricular dilatation disease.

Prev. fig. Next fig.

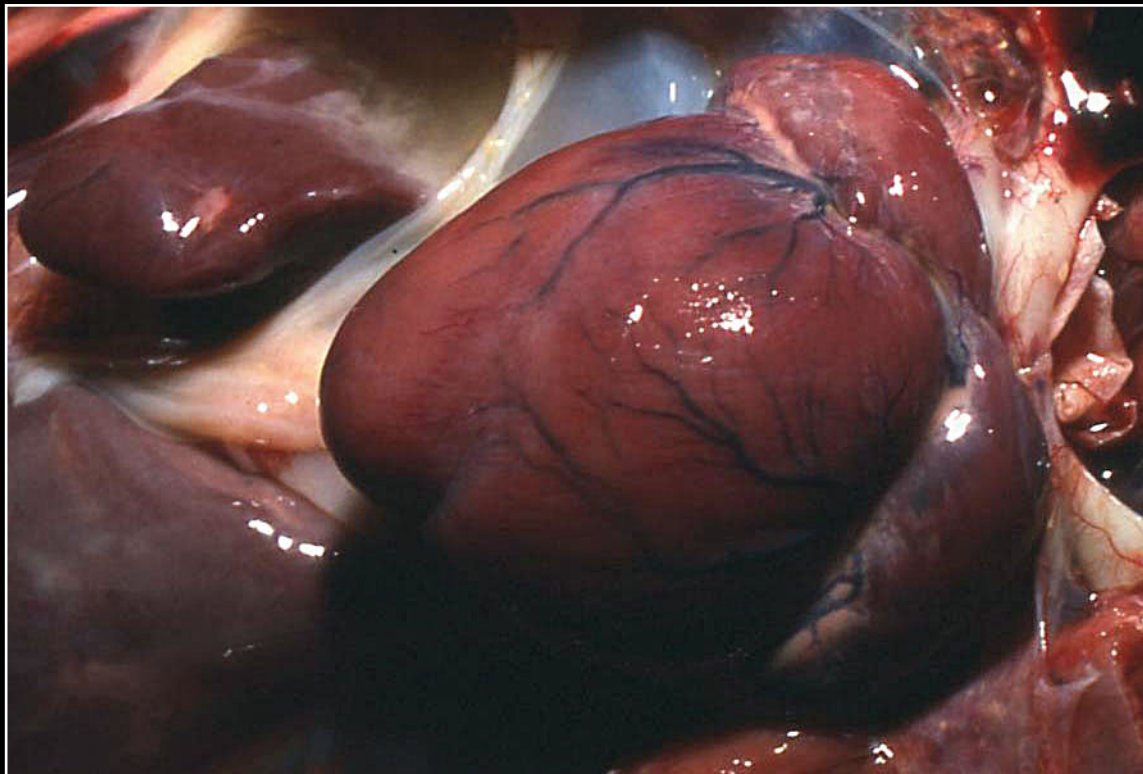
Back



CHAPTER 4

Cardiovascular System

Figure 4.10



White discoloration of some portions of the epicardium and excessive fluid in the adjacent portion of the celomic cavity in a bird with togavirus infection (avian viral serositis).

Prev. fig. Next fig.

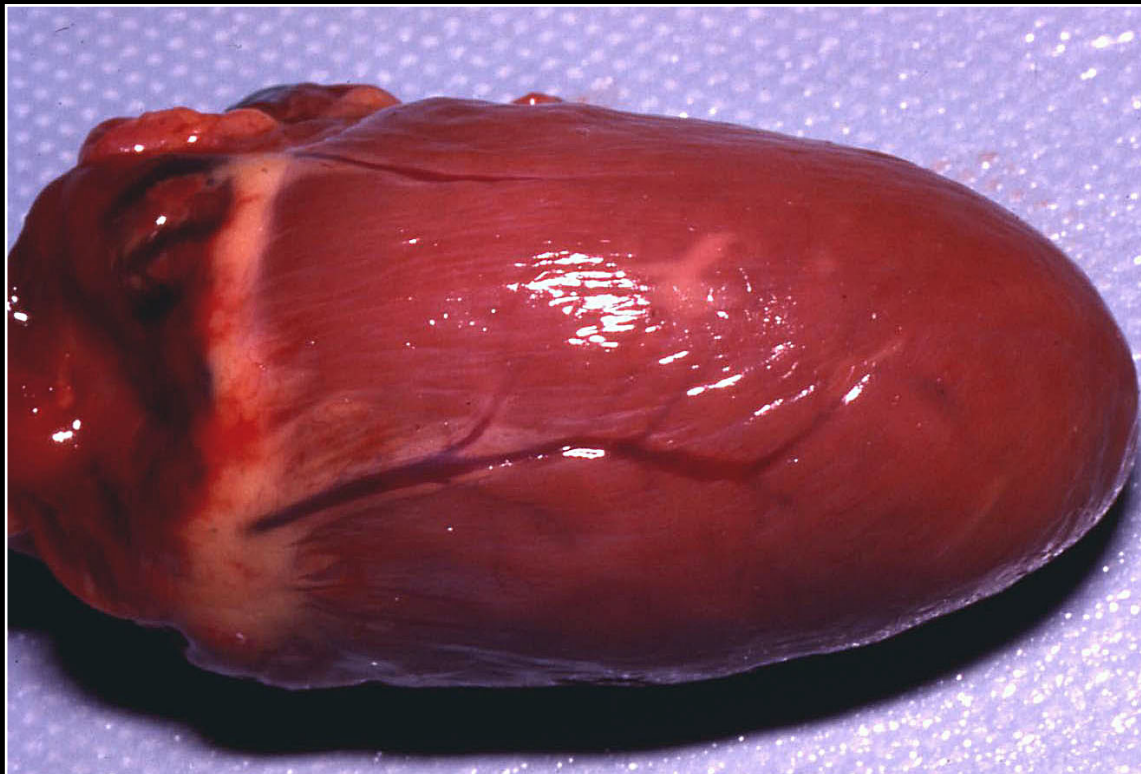
Back



C H A P T E R 4

Cardiovascular System

Figure 4.11



Multifocal pale areas in the epicardium and myocardium due to bacterial infection.

Prev. fig. Next fig.

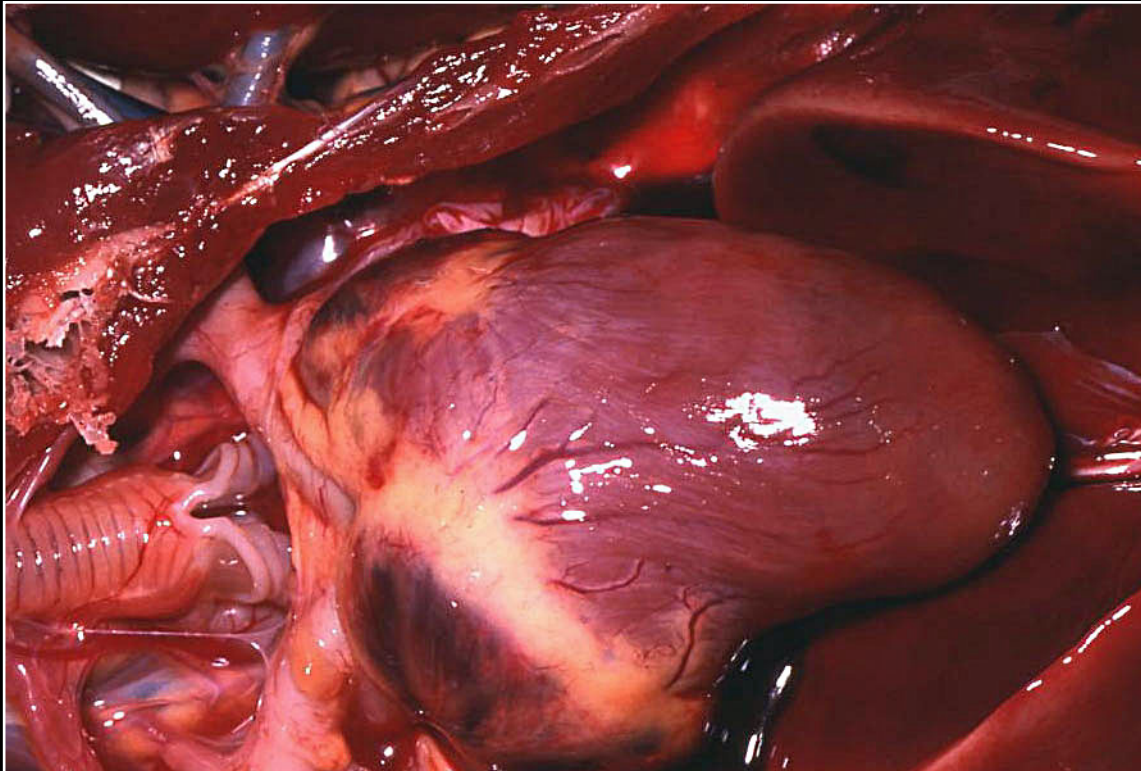
Back



C H A P T E R 4

Cardiovascular System

Figure 4.12



Extensive pale foci in the myocardium of a bird with bacterial myocarditis.

Prev. fig. Next fig.

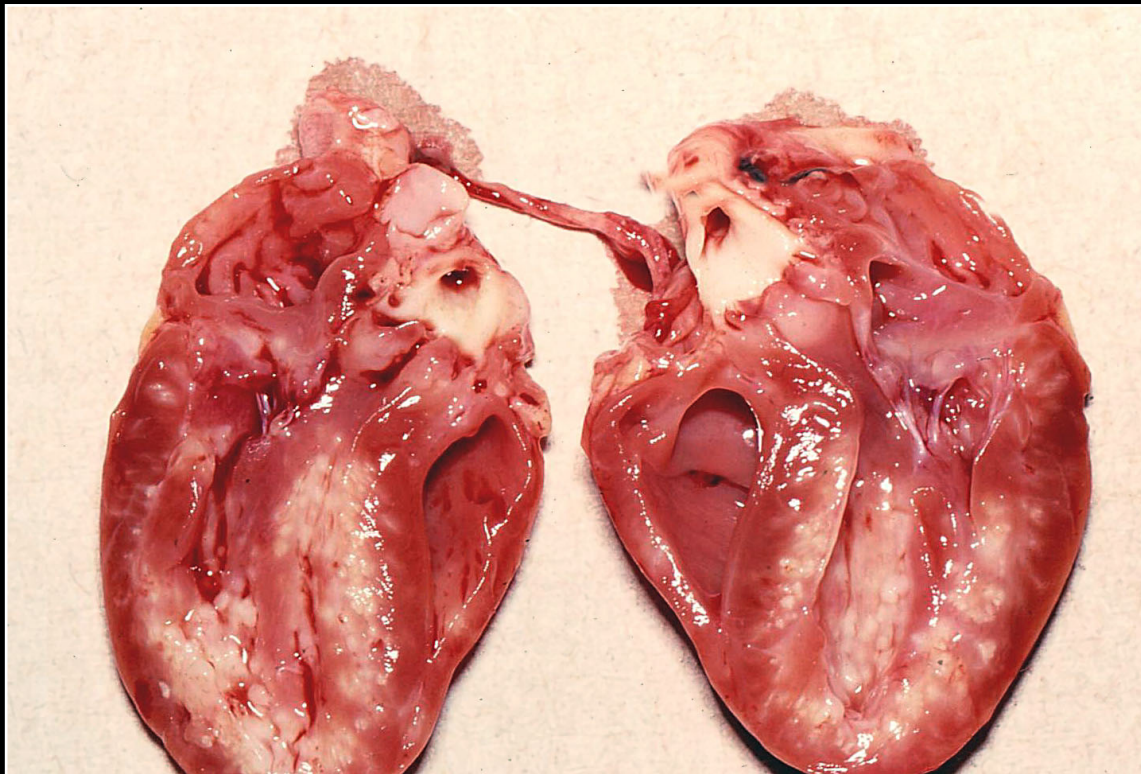
Back



C H A P T E R 4

Cardiovascular System

Figure 4.13



Extensive myocardial necrosis and inflammation in bacterial myocarditis, leading to marked paleness of the myocardium.

Prev. fig. Next fig.

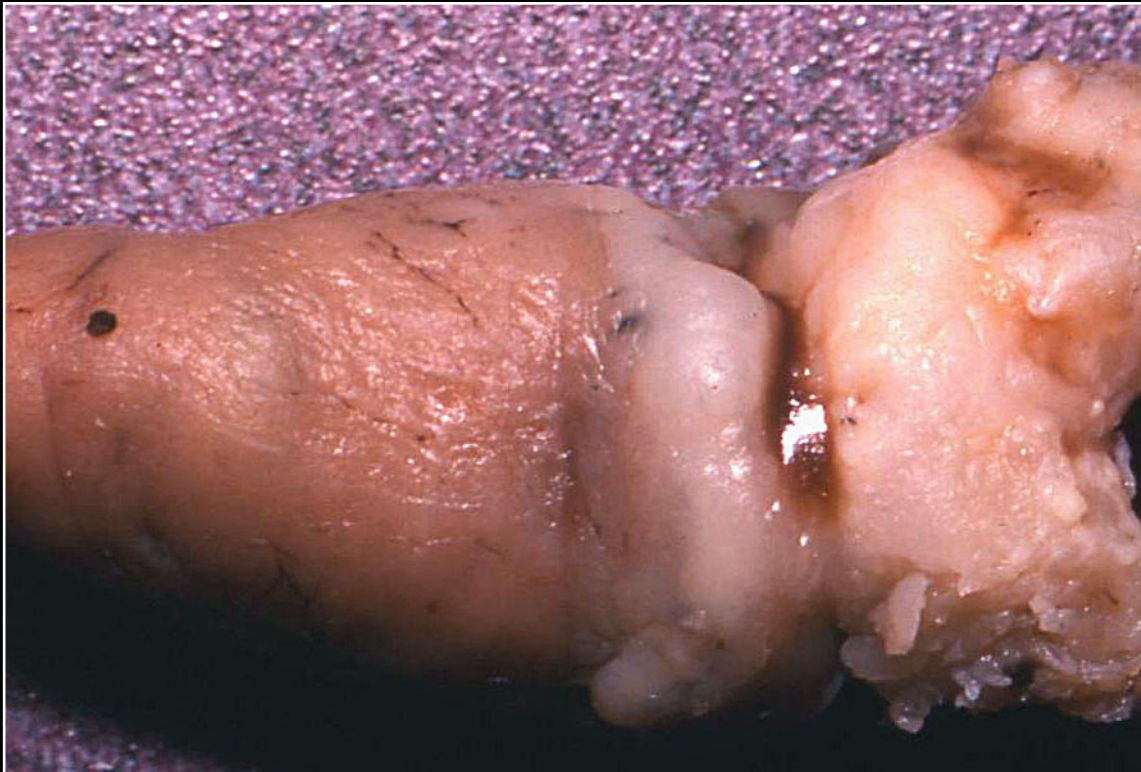
Back



C H A P T E R 4

Cardiovascular System

Figure 4.14



Large mass at the base of the heart due to mycotic infection (fixed specimen).

Prev. fig. Next fig.

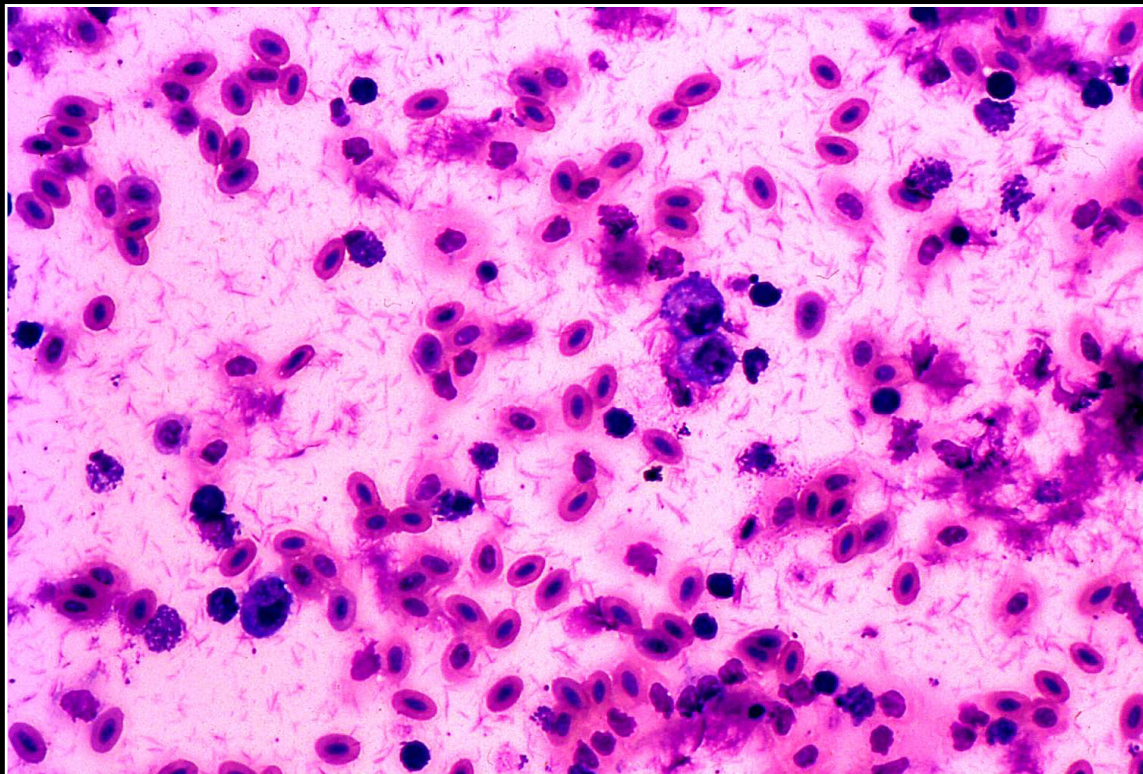
Back



CHAPTER 4

Cardiovascular System

Figure 4.15



Numerous urate crystals (and erythrocytes) in cytologic preparation of pericardial fluid in a bird with visceral urate deposition.

Prev. fig. Next fig.

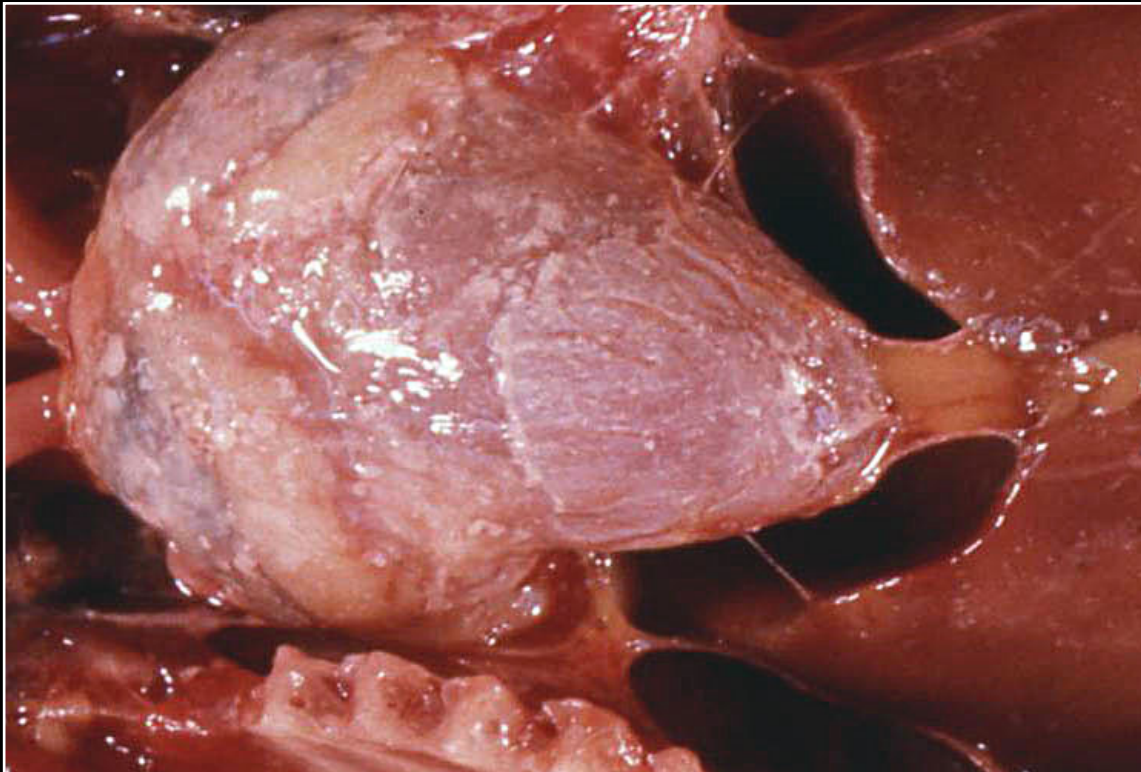
Back



C H A P T E R 4

Cardiovascular System

Figure 4.16



Marked epicardial and myocardial mineralization secondary to vitamin D toxicity.

Prev. fig. Next fig.

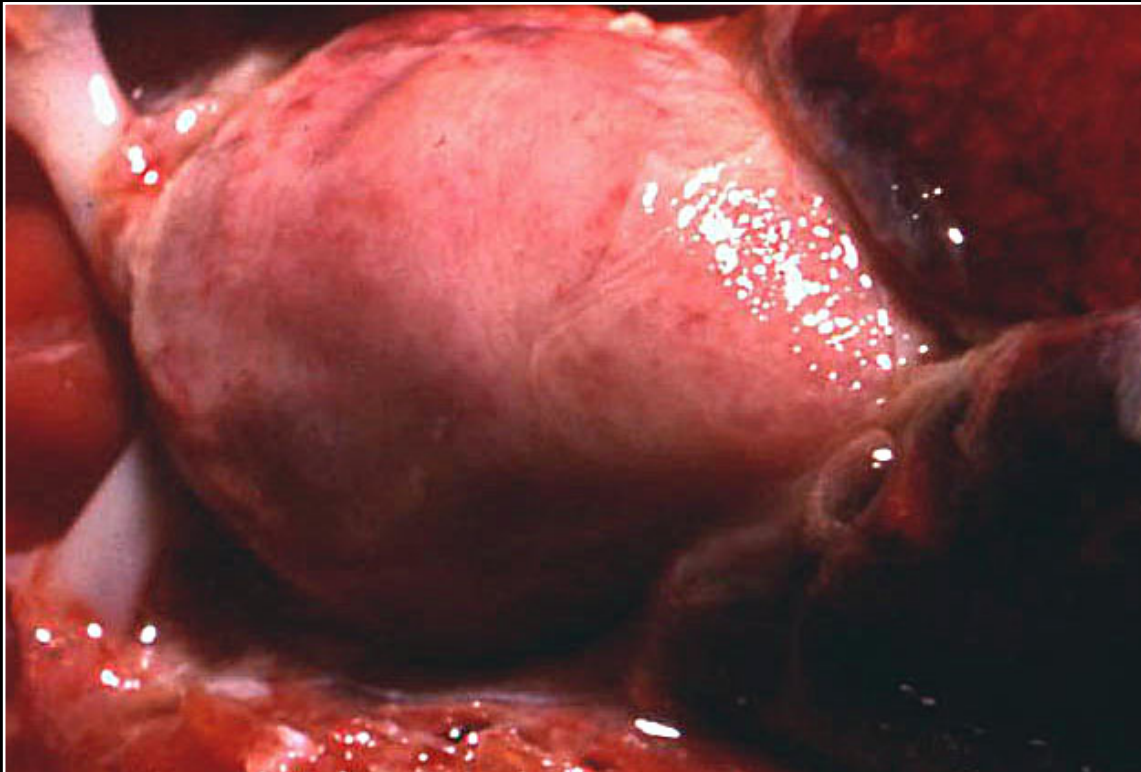
Back



C H A P T E R 4

Cardiovascular System

Figure 4.17



Pale irregular myocardium in a bird with severe nutritional myodegeneration.

Prev. fig. Next fig.

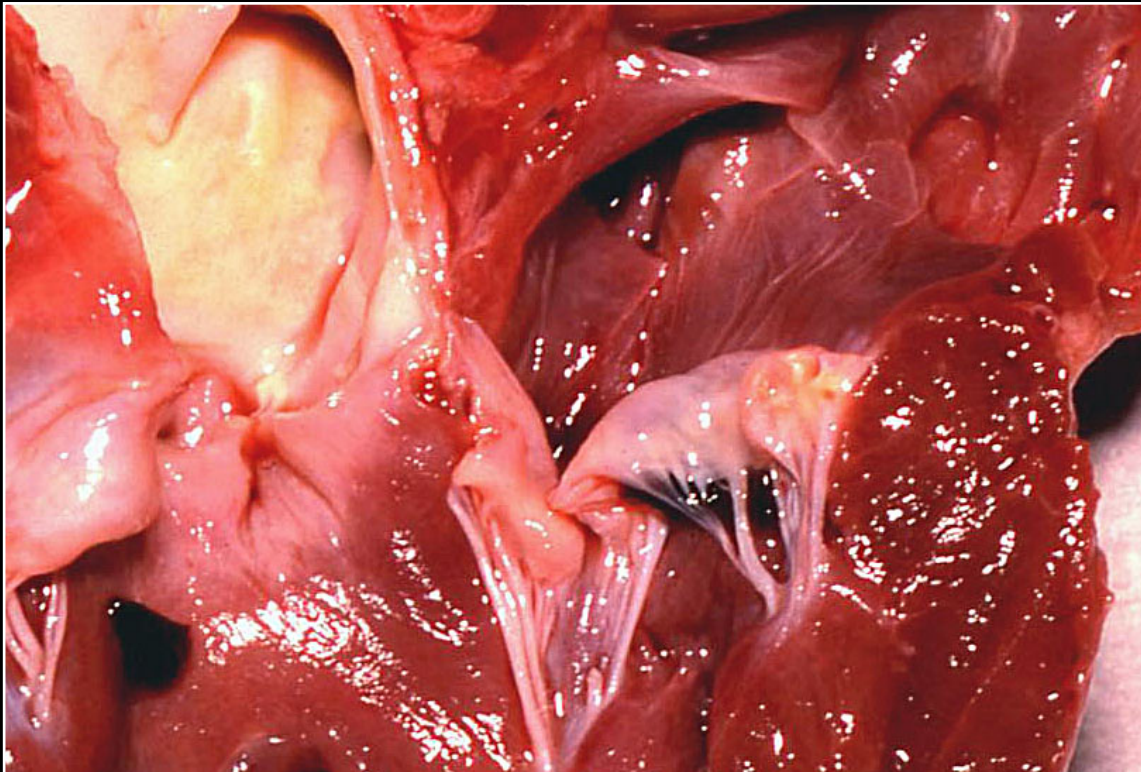
Back



C H A P T E R 4

Cardiovascular System

Figure 4.18



Endocardiosis with smooth swelling of heart valves and no indication of inflammation.

Prev. fig. Next fig.

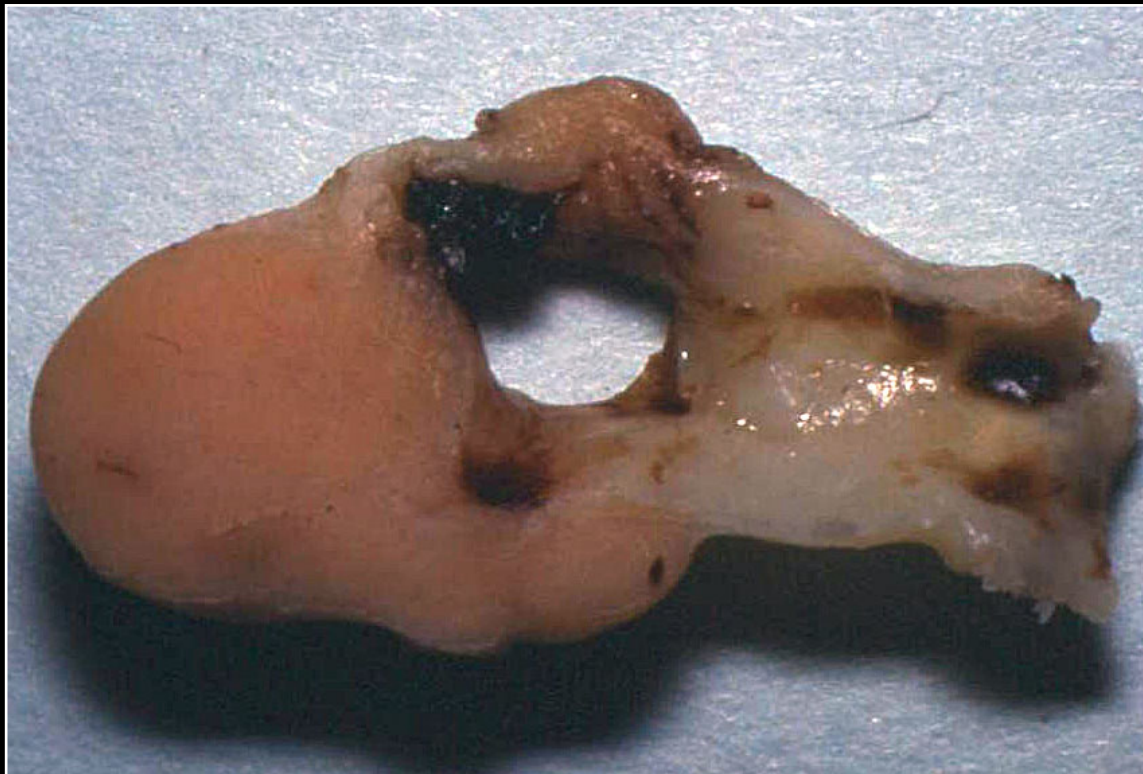
Back



C H A P T E R 4

Cardiovascular System

Figure 4.19



Severe thickening of the base of the heart and aorta due to mycobacteriosis.

Prev. fig. Next fig.

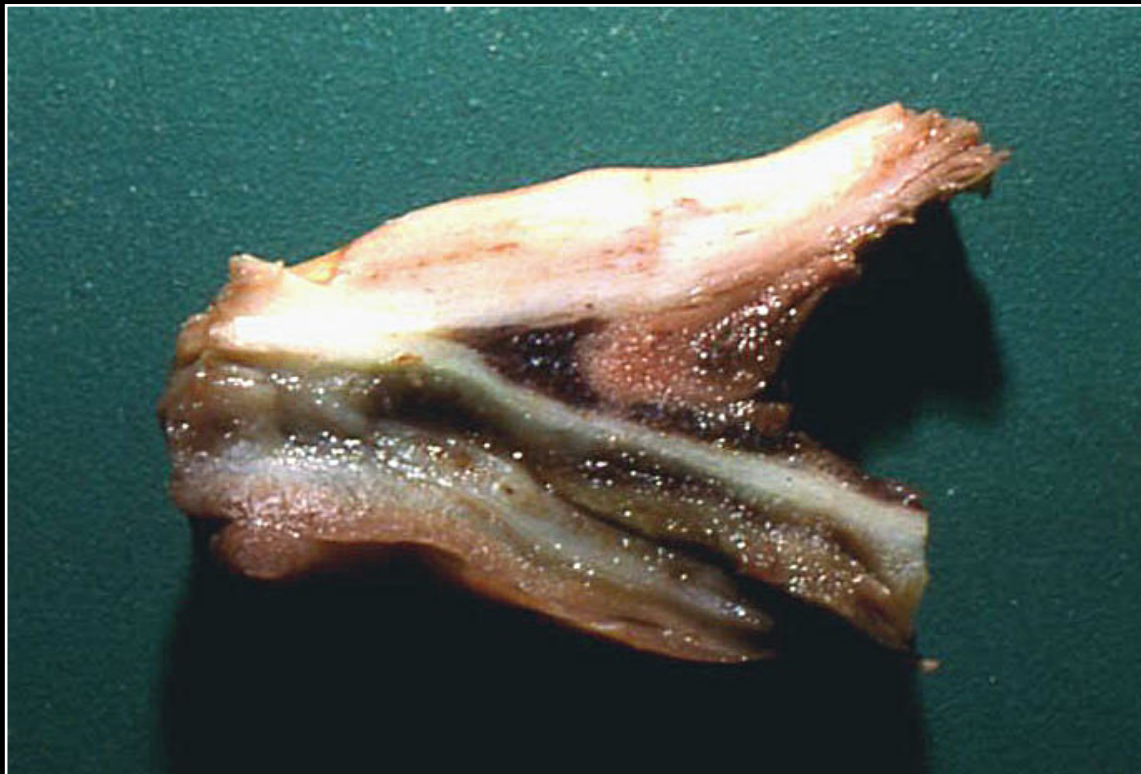Back



C H A P T E R 4

Cardiovascular System

Figure 4.20



Dissection and separation of aortic walls by hemorrhage associated with aneurysmal dilatation of the aorta.

Prev. fig. Next fig.

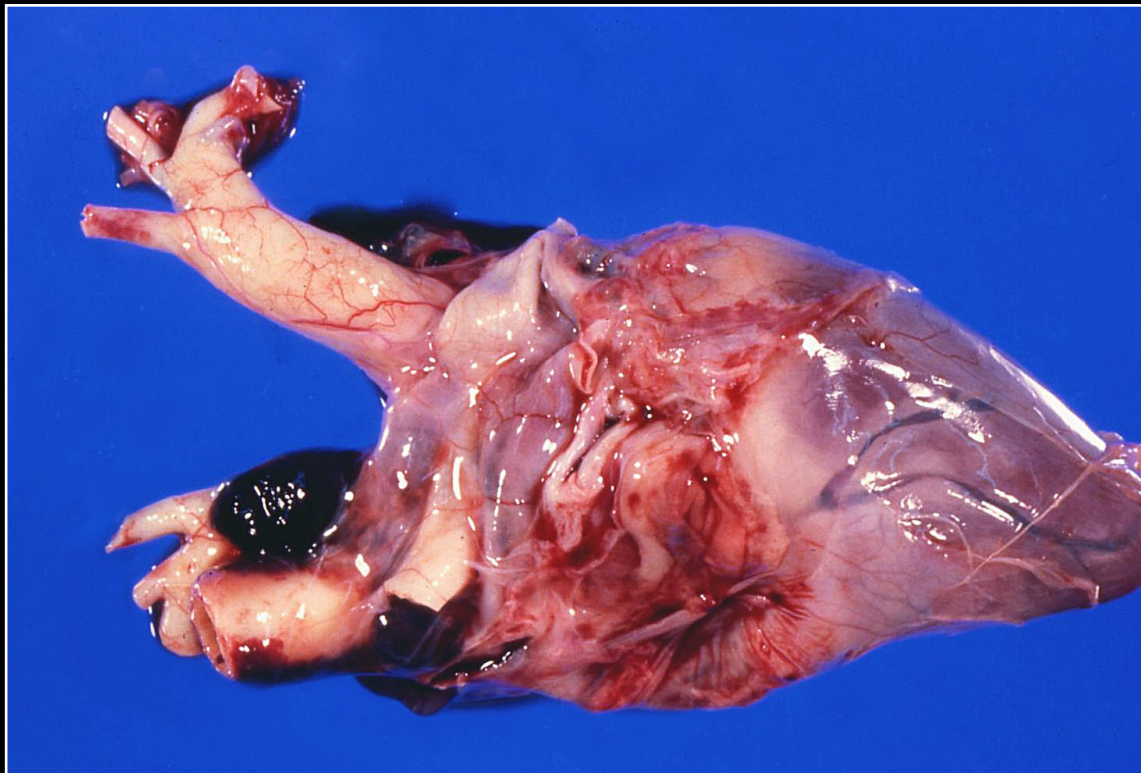
Back



C H A P T E R 4

Cardiovascular System

Figure 4.21



Dissecting aneurysm with associated hemorrhage.

Prev. fig. Next fig.

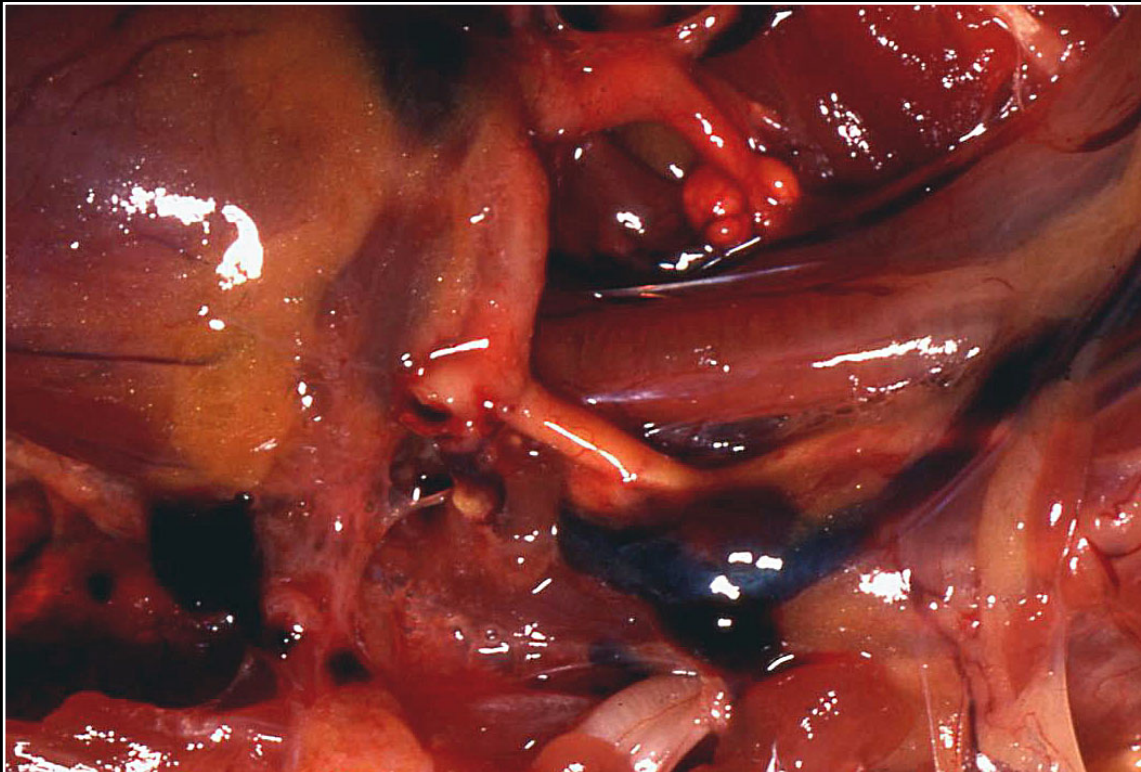
Back



C H A P T E R 4

Cardiovascular System

Figure 4.22



Markedly yellow, thickened arteries in a bird with atherosclerosis.

Prev. fig. Next fig.

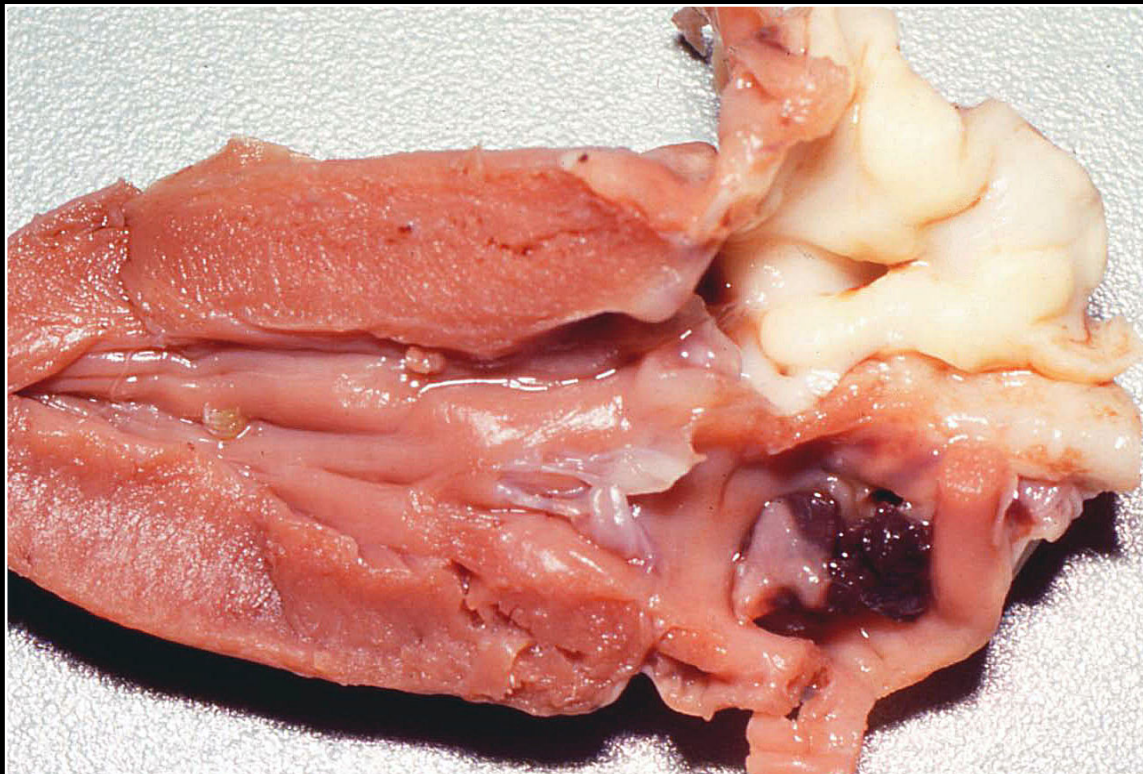
Back



C H A P T E R 4

Cardiovascular System

Figure 4.23



Severe aortic thickening due to atherosclerosis.

Prev. fig. Next fig.

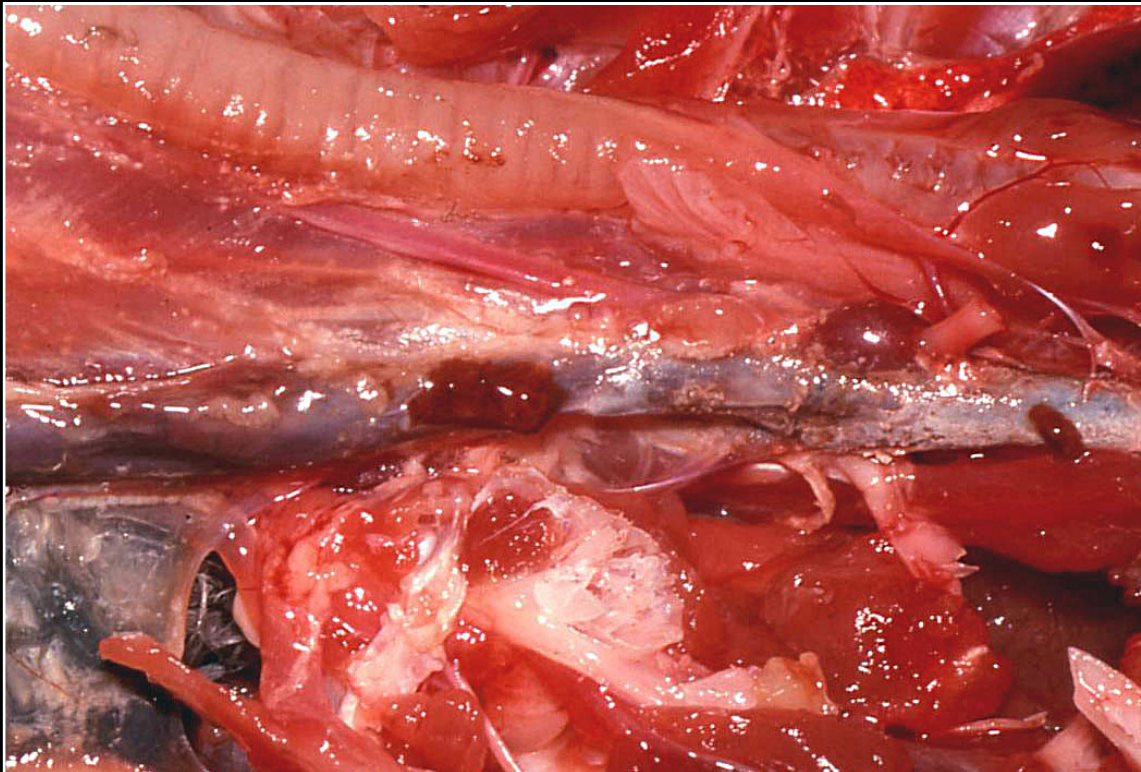Back



C H A P T E R 4

Cardiovascular System

Figure 4.24



Severe aortic thrombosis.

Prev. fig. Next fig.

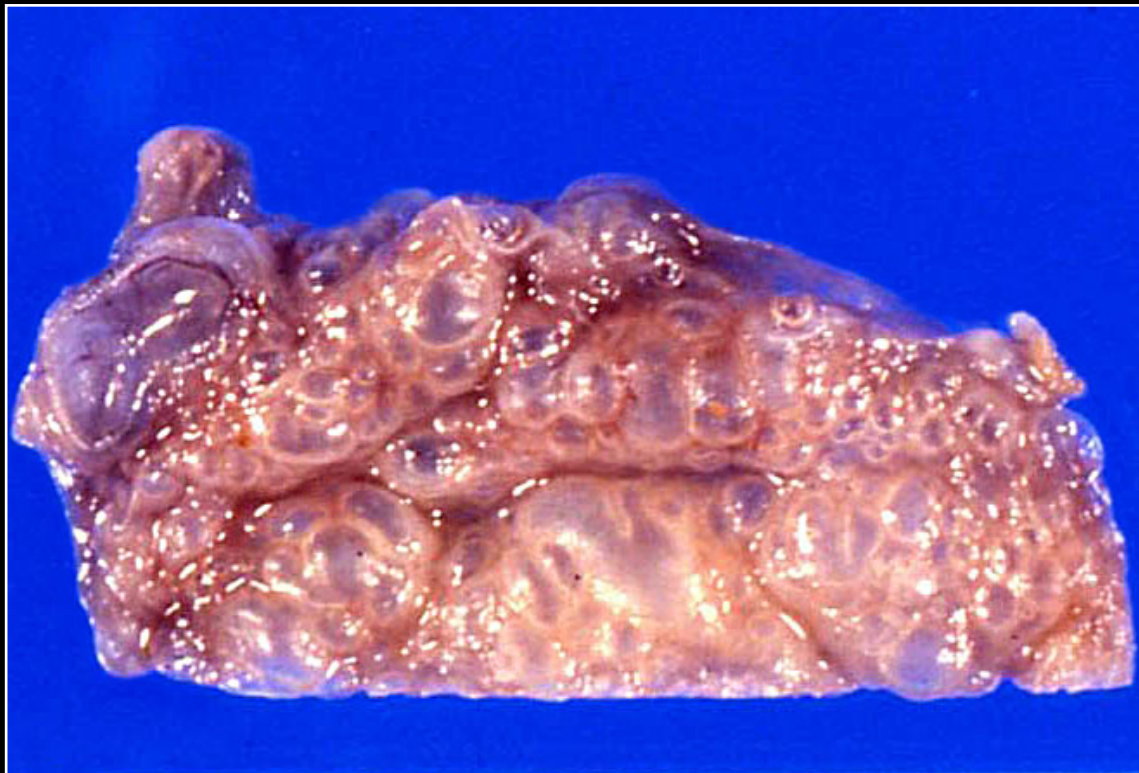Back



C H A P T E R 4

Cardiovascular System

Figure 4.25



Lymphangiectasia involving the crop. Note the numerous fluid-filled spaces.

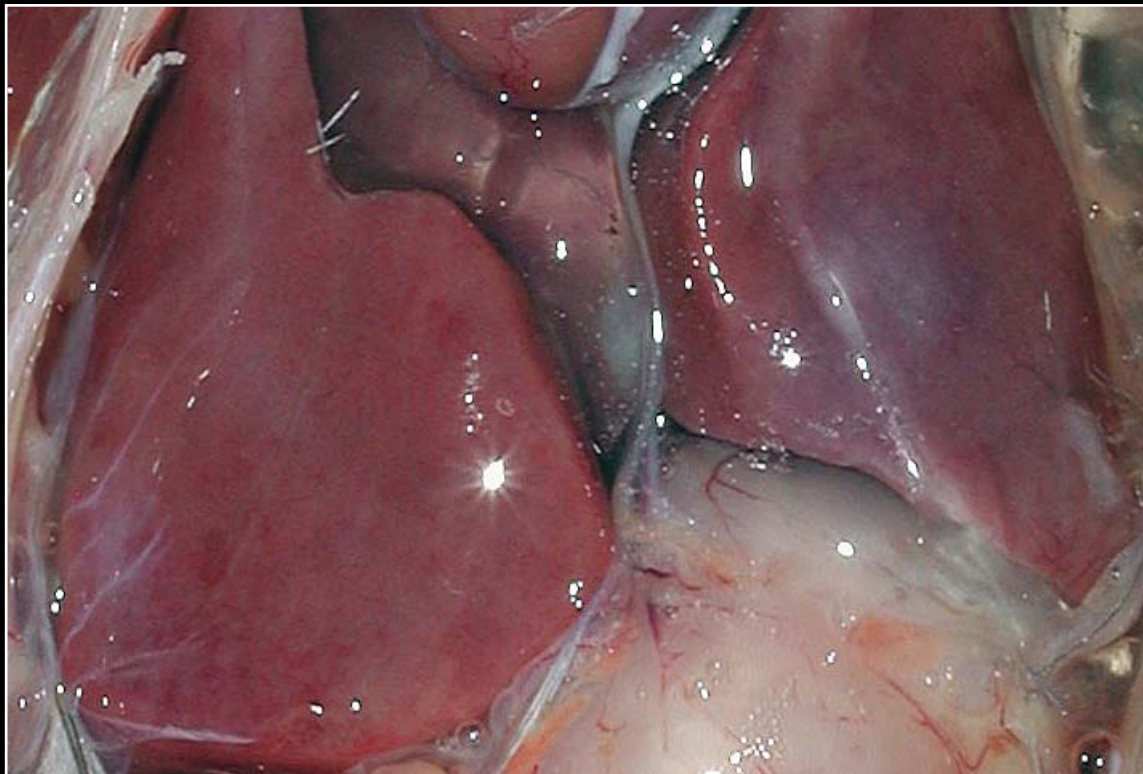
Prev. fig.

Back

CHAPTER 5

Liver

Figure 5.0



Normal liver.

Next fig.

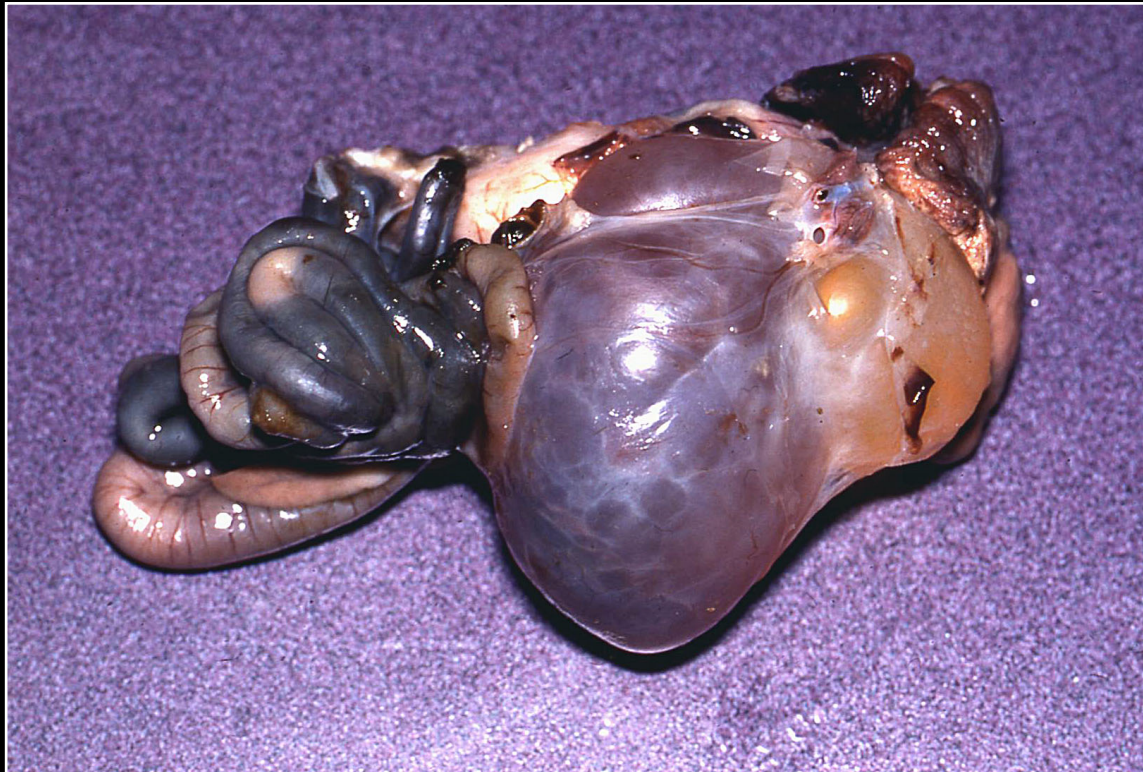
Back



C H A P T E R 5

Liver

Figure 5.1



Congenital biliary cyst in a Pionus parrot. Note the large irregular structure that appears yellow in some areas due to fluid.

Prev. fig. Next fig.

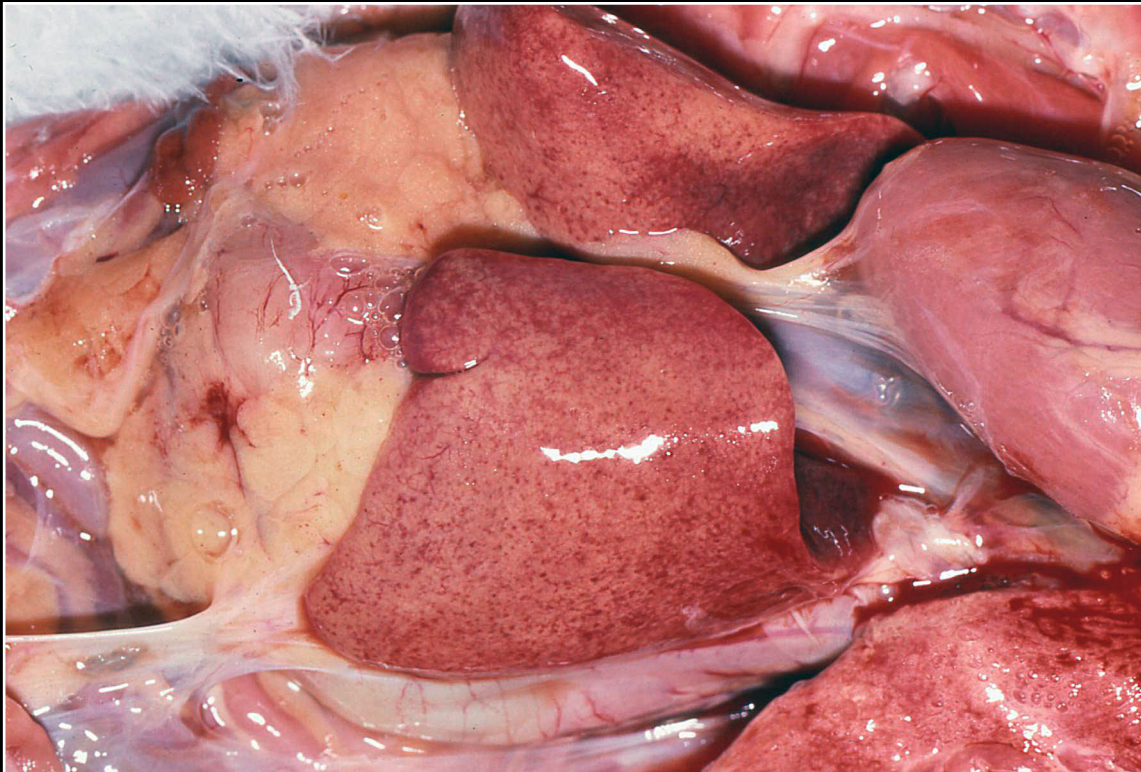
Back



C H A P T E R 5

Liver

Figure 5.2



Herpesvirus infection in an African grey parrot. Note mild swelling and paler resembling lipidosis.

Prev. fig. Next fig.

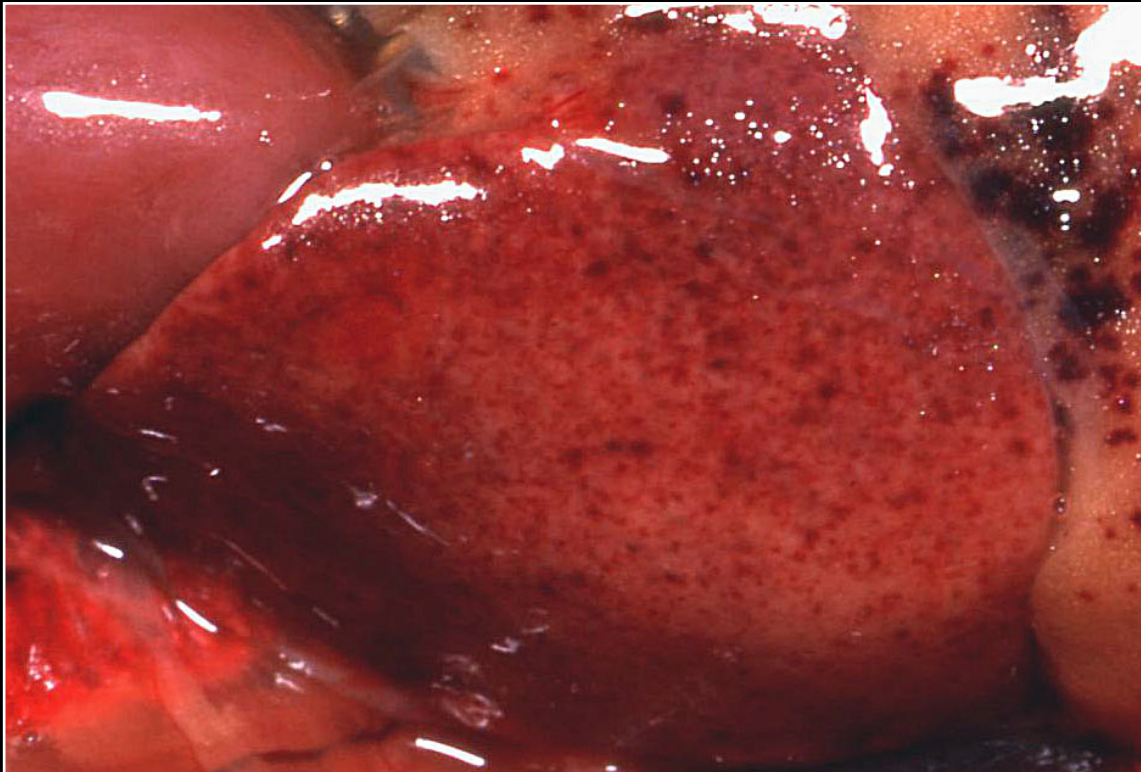
Back



C H A P T E R 5

Liver

Figure 5.3



Herpesvirus infection in a cockatiel. Extensive hepatic and extrahepatic hemorrhage is noted.

Prev. fig. Next fig.

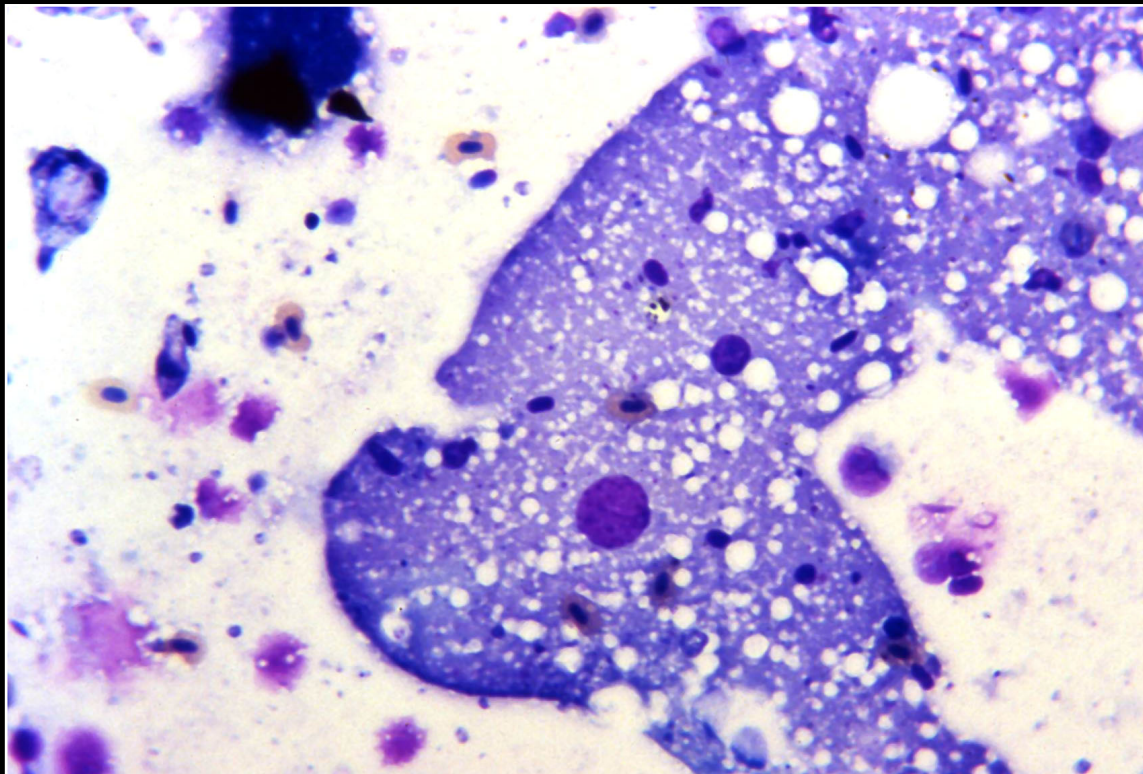
Back



CHAPTER 5

Liver

Figure 5.4



Cytology impression smear from the liver of a blue-fronted Amazon that died of herpesvirus infection. An intranuclear inclusion filling a nucleus is seen. These can be difficult to interpret cytologically.

Prev. fig. Next fig.

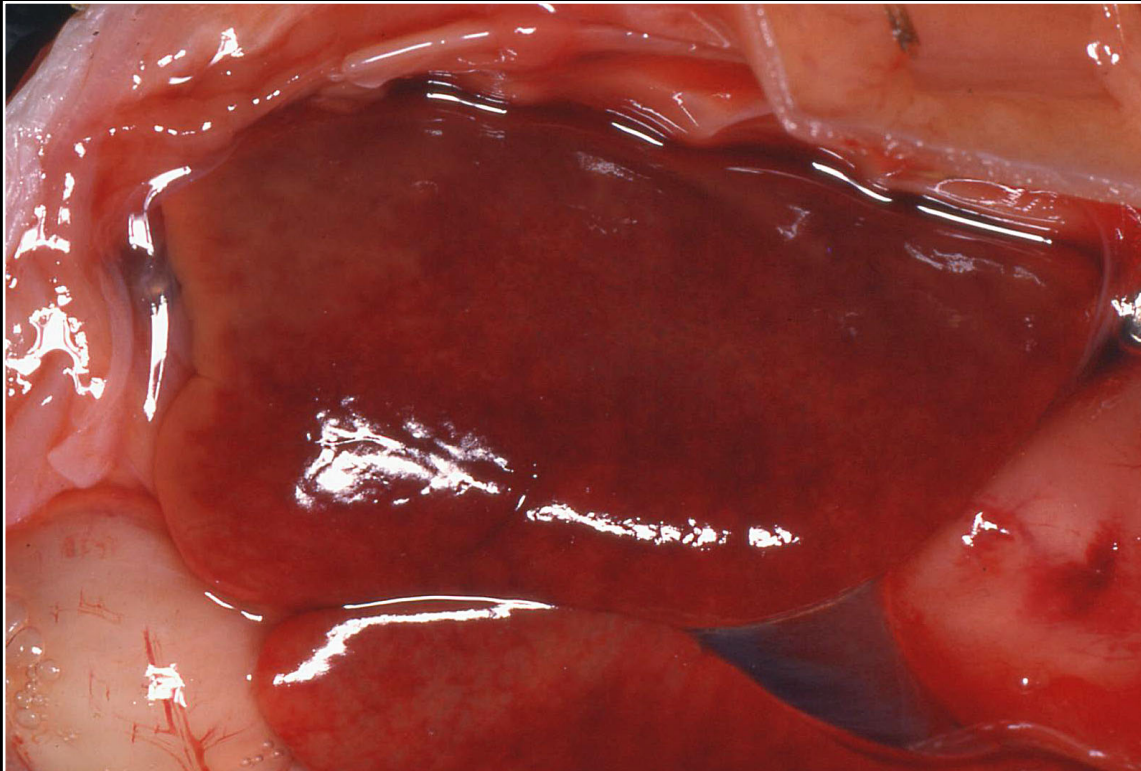
Back



CHAPTER 5

Liver

Figure 5.5



Mild swelling and mottling of the liver of a macaw with polyomavirus infection.

Prev. fig. Next fig.

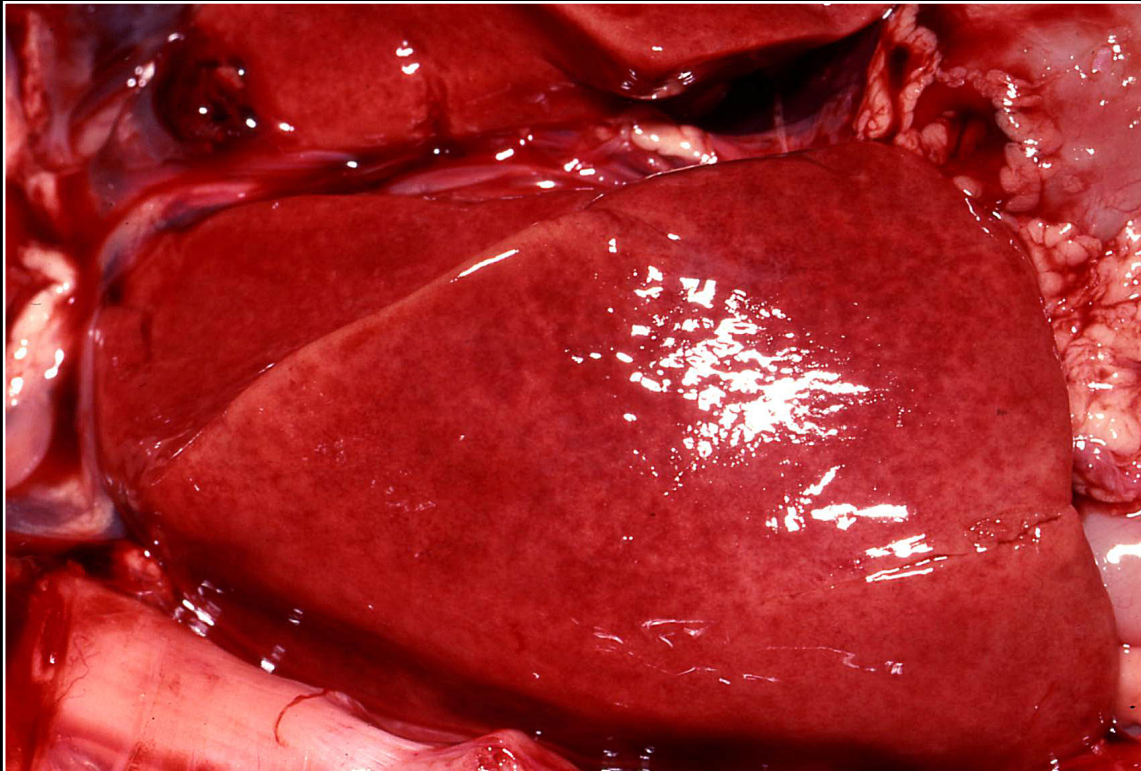
Back



C H A P T E R 5

Liver

Figure 5.6



Moderate discoloration of the liver in a macaw with polyomavirus infection.

Prev. fig. Next fig.

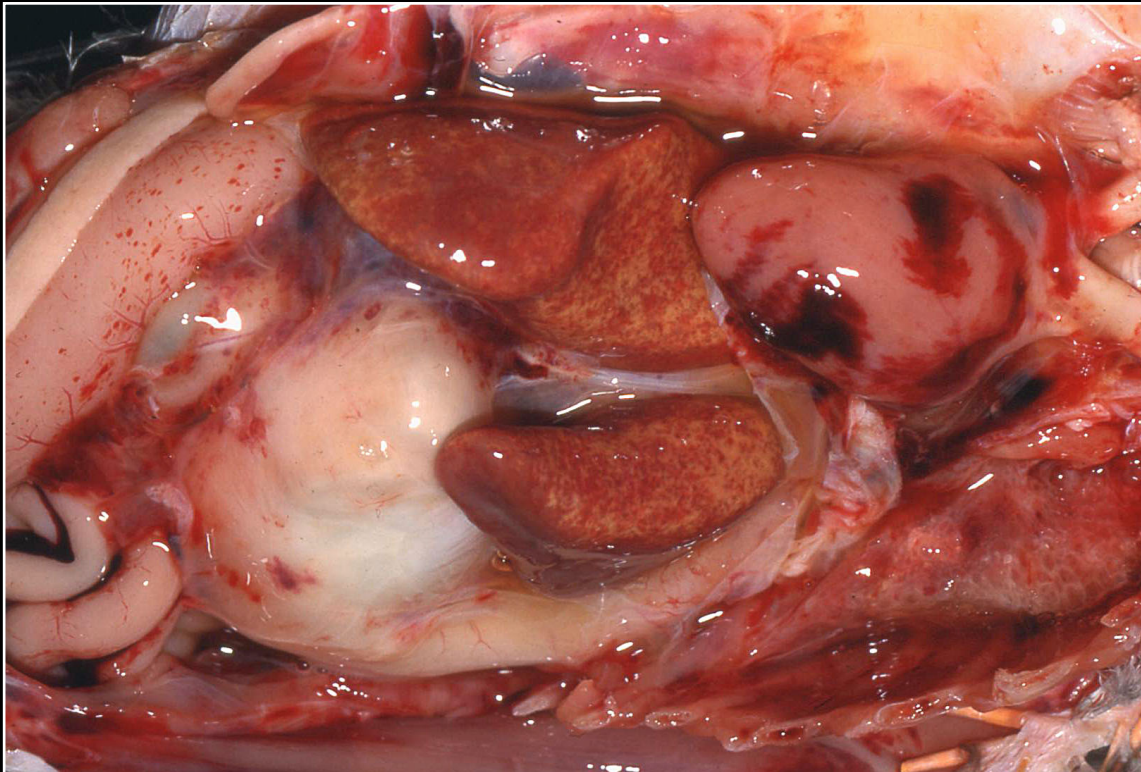
Back



C H A P T E R 5

Liver

Figure 5.7



Macaw liver with severe lesions due to polyomavirus infection.

Prev. fig. Next fig.

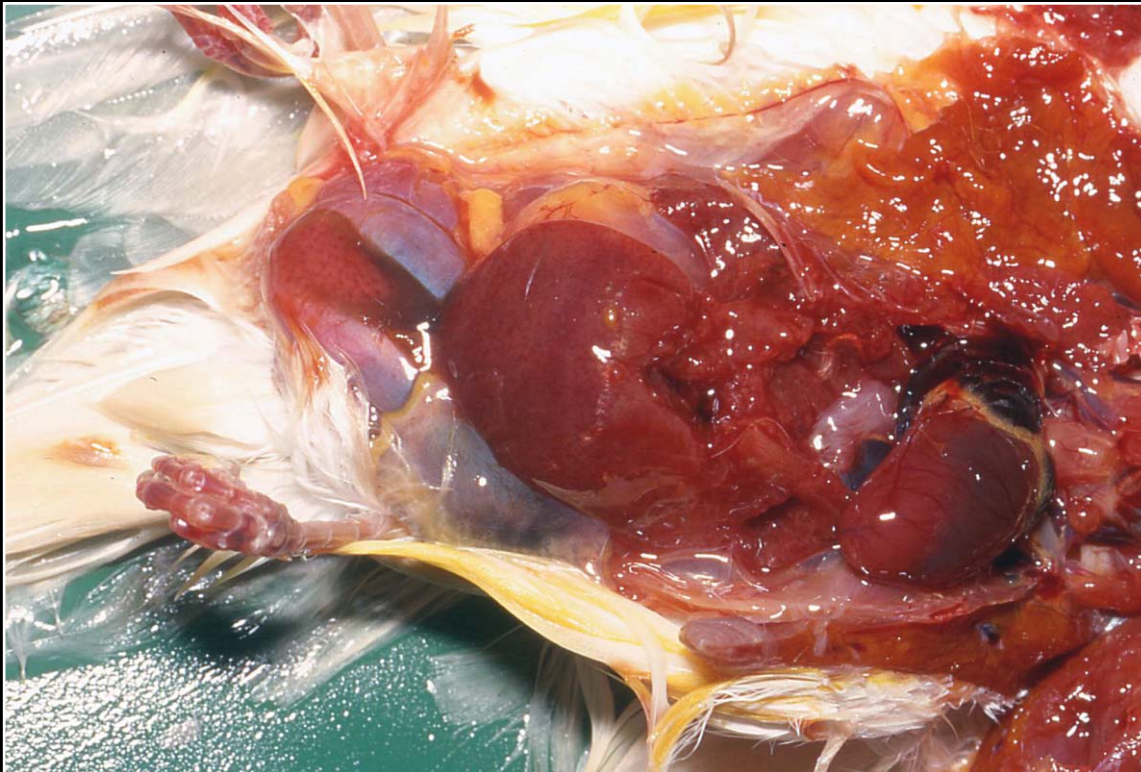
Back



C H A P T E R 5

Liver

Figure 5.8



Enlarged liver in a finch with polyomavirus infection.

Prev. fig. Next fig.

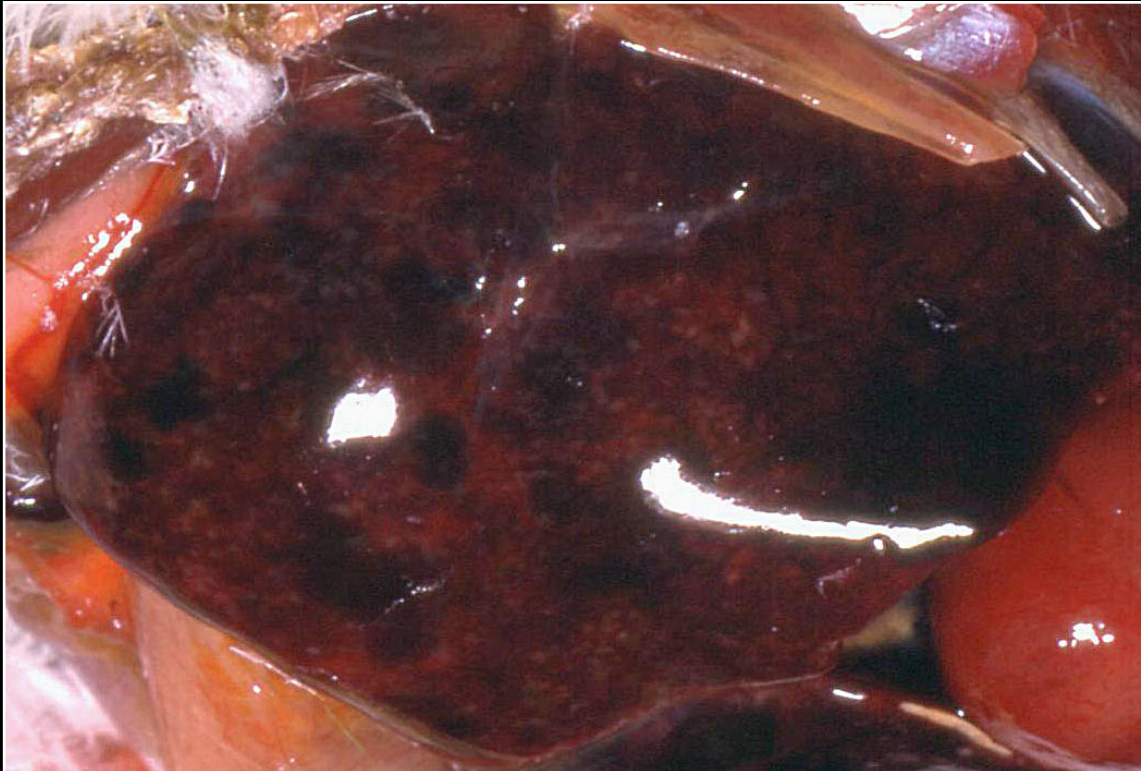Back



C H A P T E R 5

Liver

Figure 5.9



Large mottled liver with dark areas of necrosis and hemorrhage in a Senegal parrot with adenovirus infection.

Prev. fig. Next fig.

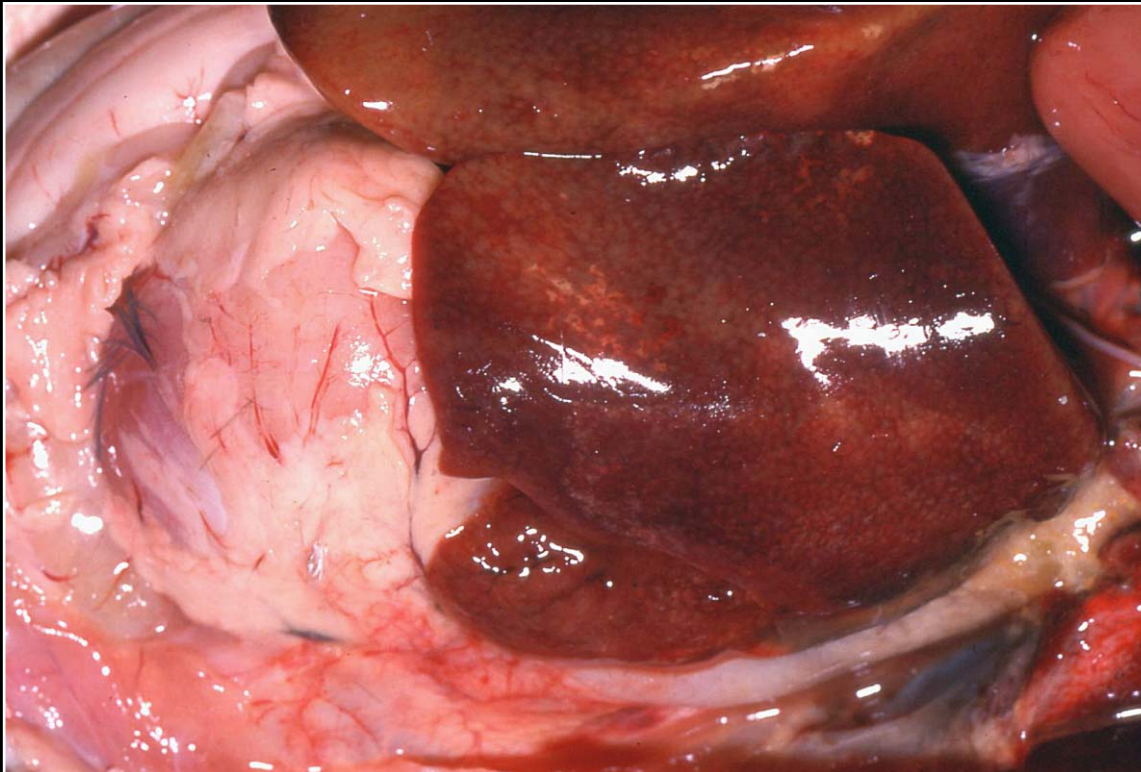
Back



C H A P T E R 5

Liver

Figure 5.10



Enlargement and foci of necrosis in a liver from an African grey parrot with systemic circovirus infection. The hepatic lesions are primarily due to a secondary bacterial infection.

Prev. fig. Next fig.

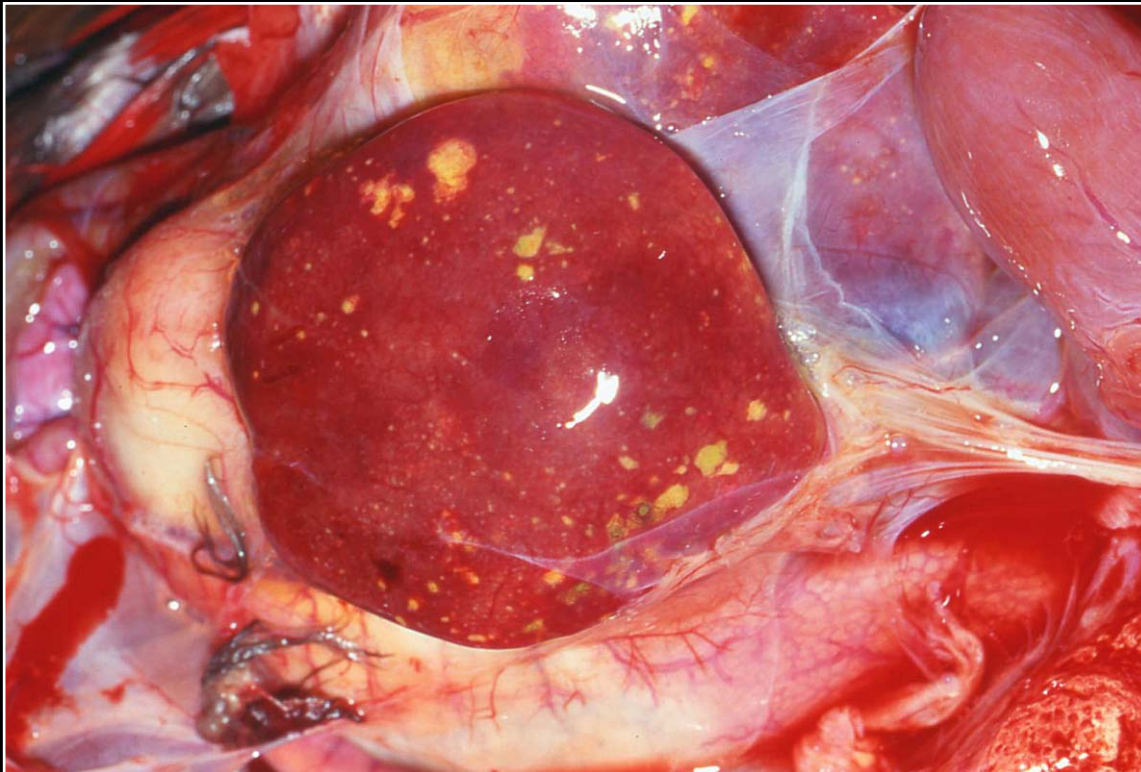
Back



C H A P T E R 5

Liver

Figure 5.11



Bacterial infection of the liver of a macaw. Variable-sized foci of necrosis and microabscessations are seen.

Prev. fig. Next fig.

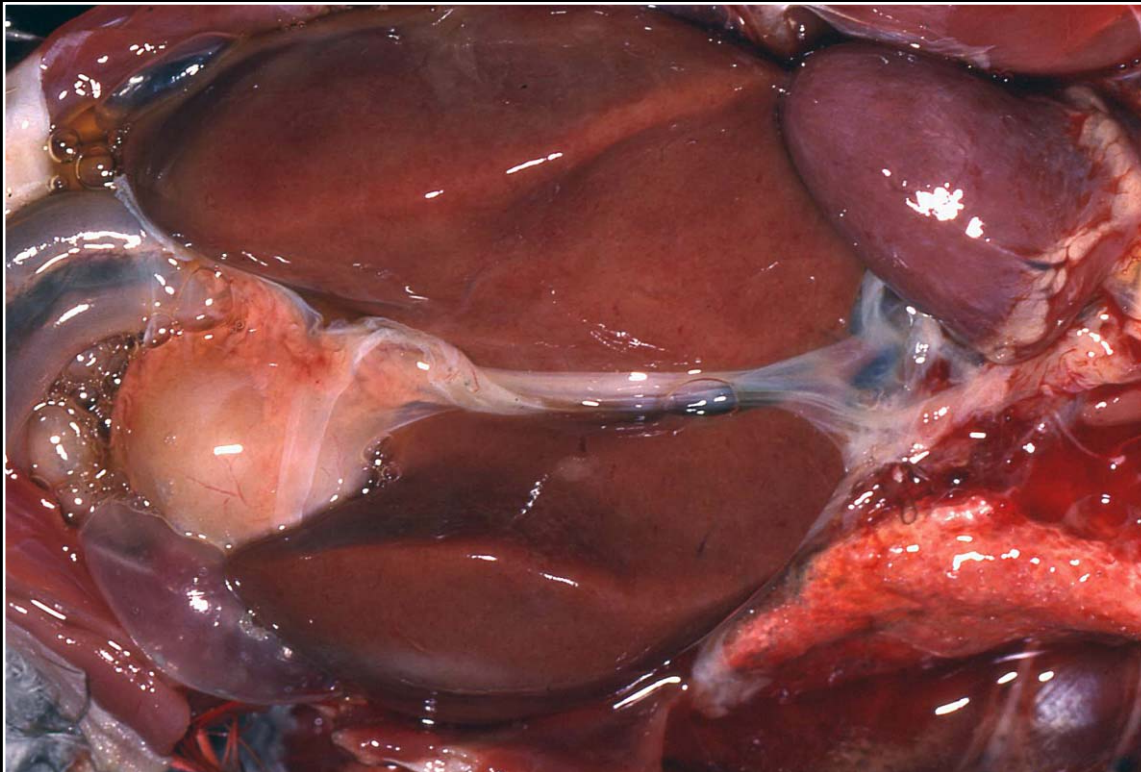
Back



C H A P T E R 5

Liver

Figure 5.12



Salmonella sp. infection in a macaw. The liver is swollen and finely mottled.

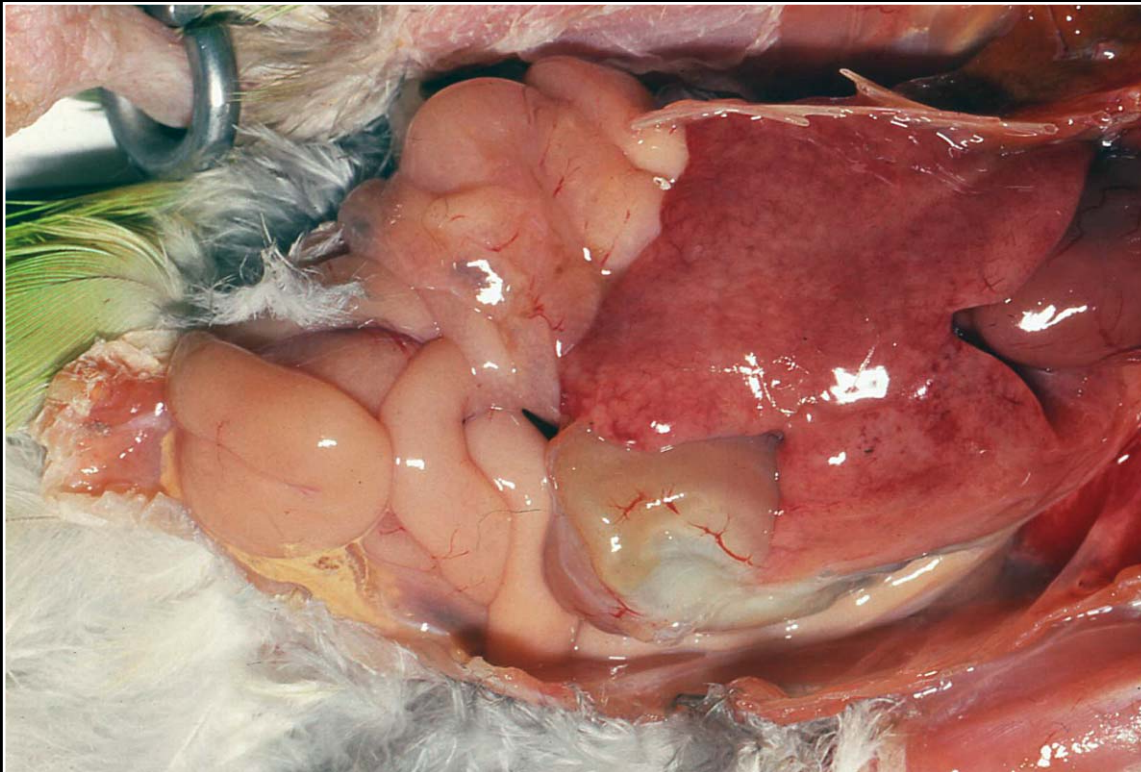
Prev. fig. Next fig.

Back

C H A P T E R 5

Liver

Figure 5.13



Early mycobacterial hepatitis in a grey-cheeked parakeet. The liver is swollen, and numerous small raised foci are seen.

Prev. fig. Next fig.

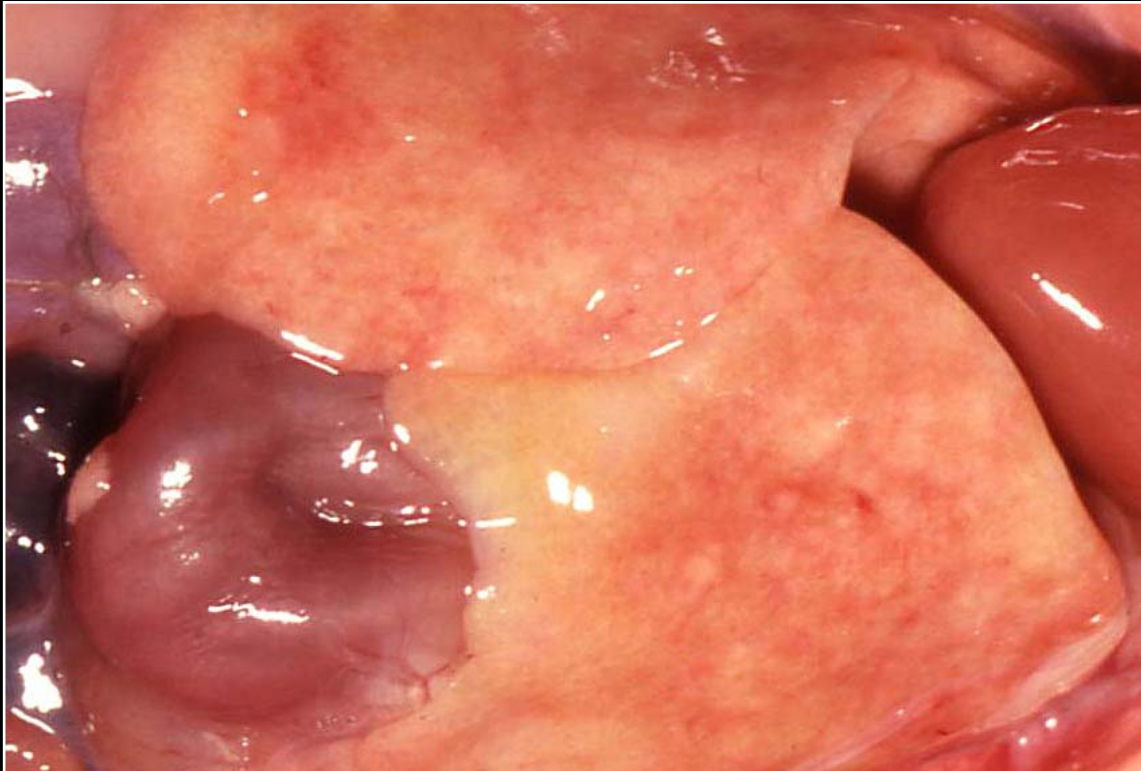Back



C H A P T E R 5

Liver

Figure 5.14



Chronic mycobacterial hepatitis with diffuse swelling and discoloration in a grey-cheeked parakeet.

Prev. fig. Next fig.

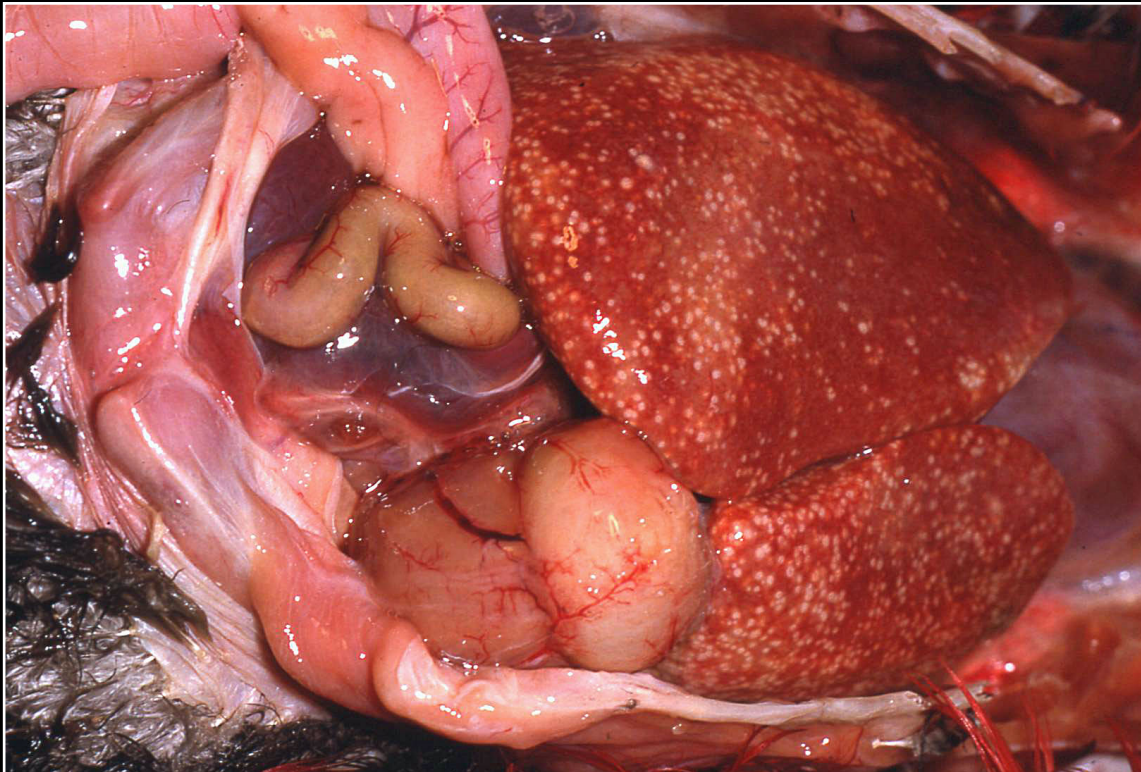
Back



C H A P T E R 5

Liver

Figure 5.15



Diffuse small microabscesses and early granulomas in mycobacterial hepatitis in a green-winged macaw.

Prev. fig. Next fig.

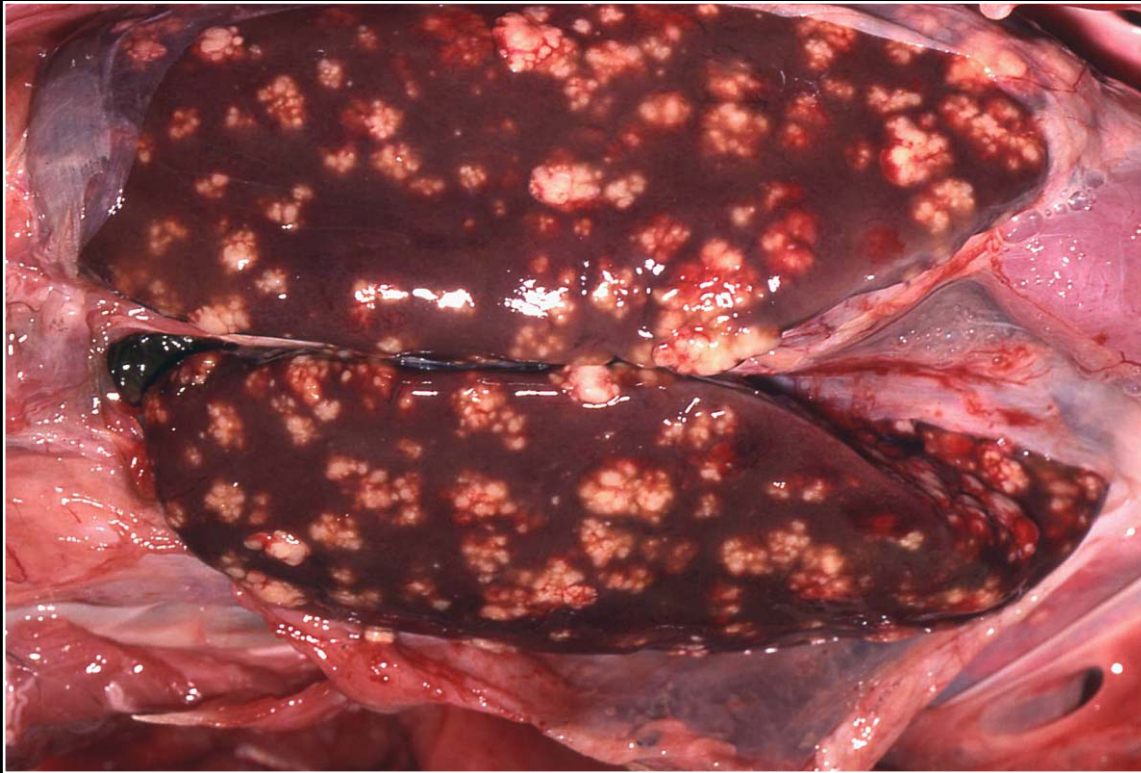
Back



CHAPTER 5

Liver

Figure 5.16



Large granulomas in the liver of a penguin with mycobacterial infection.

Prev. fig. Next fig.

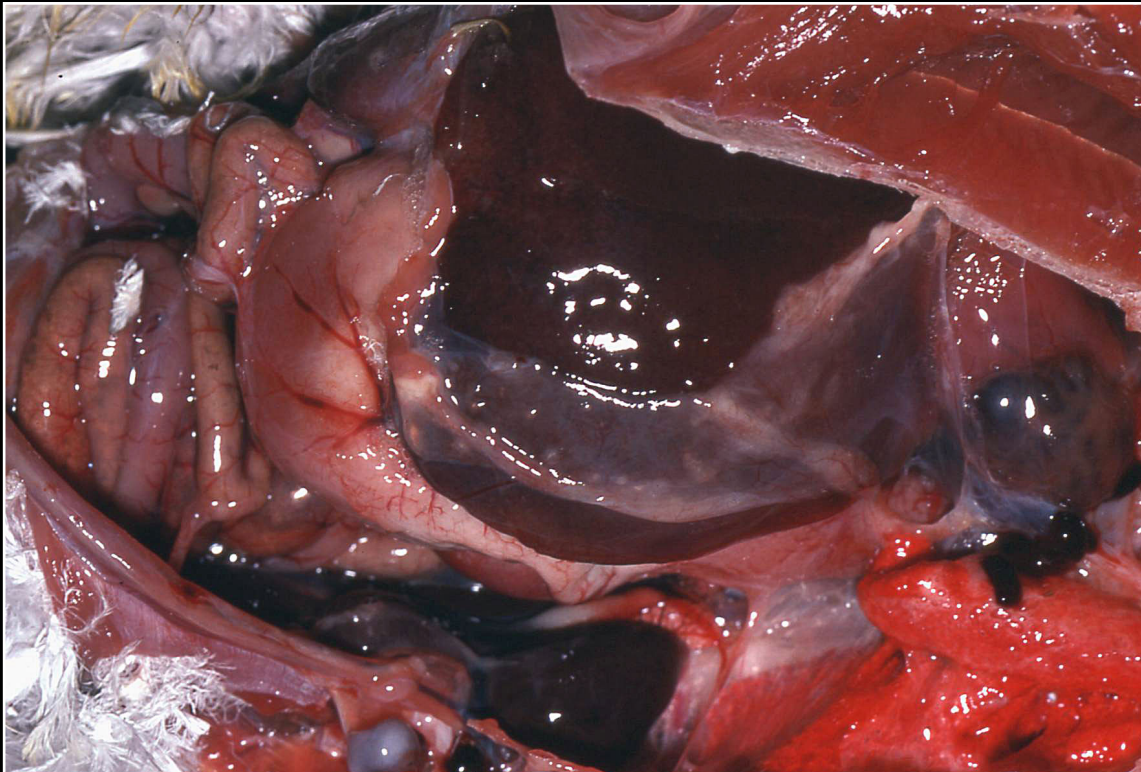
Back



C H A P T E R 5

Liver

Figure 5.17



Chlamydophilosis in an Amazon parrot with hepatic enlargement and cap-sular exudate formation.

Prev. fig. Next fig.

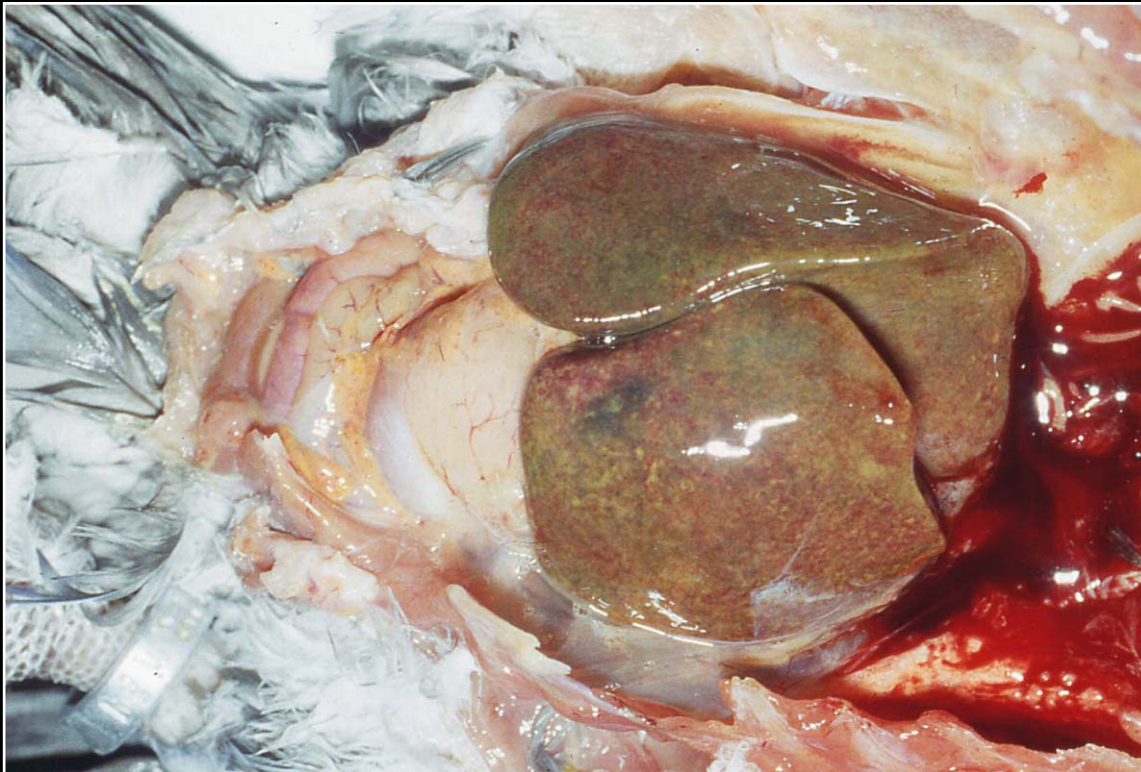
Back



C H A P T E R 5

Liver

Figure 5.18



Severe, diffuse necrosis and discoloration in a liver from an African grey parrot with chlamydophilosis.

Prev. fig. Next fig.

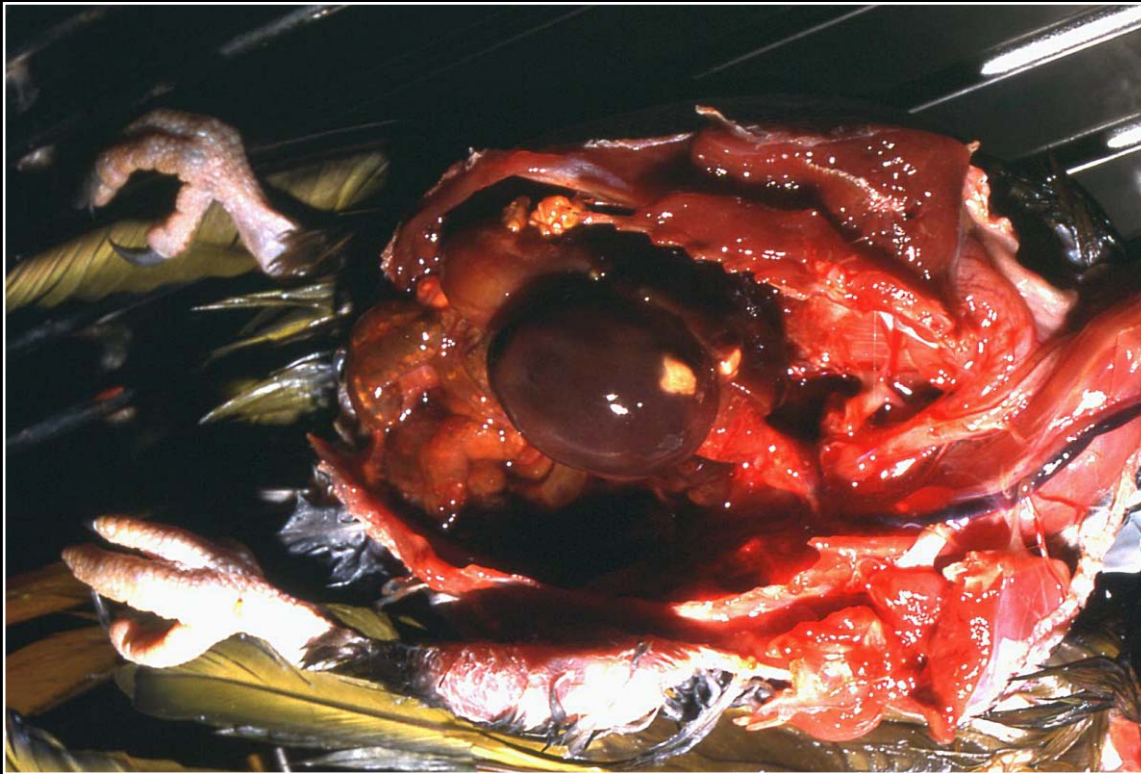
Back



C H A P T E R 5

Liver

Figure 5.19



Hepatic enlargement and abscess formation in the liver of a conure with chlamydophila infection.

Prev. fig. Next fig.

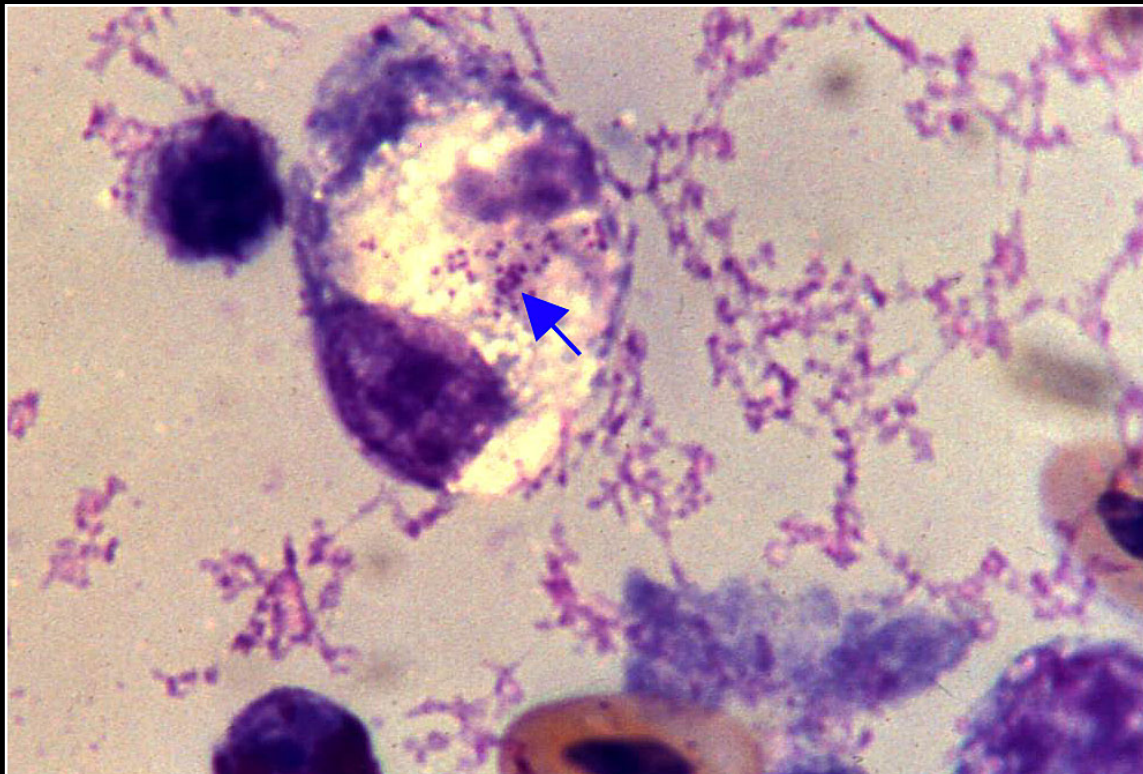
Back



C H A P T E R 5

Liver

Figure 5.20



Intracytoplasmic *Chlamydophila* organisms noted on Gimenez-stained liver impression smears (arrow).

Prev. fig. Next fig.

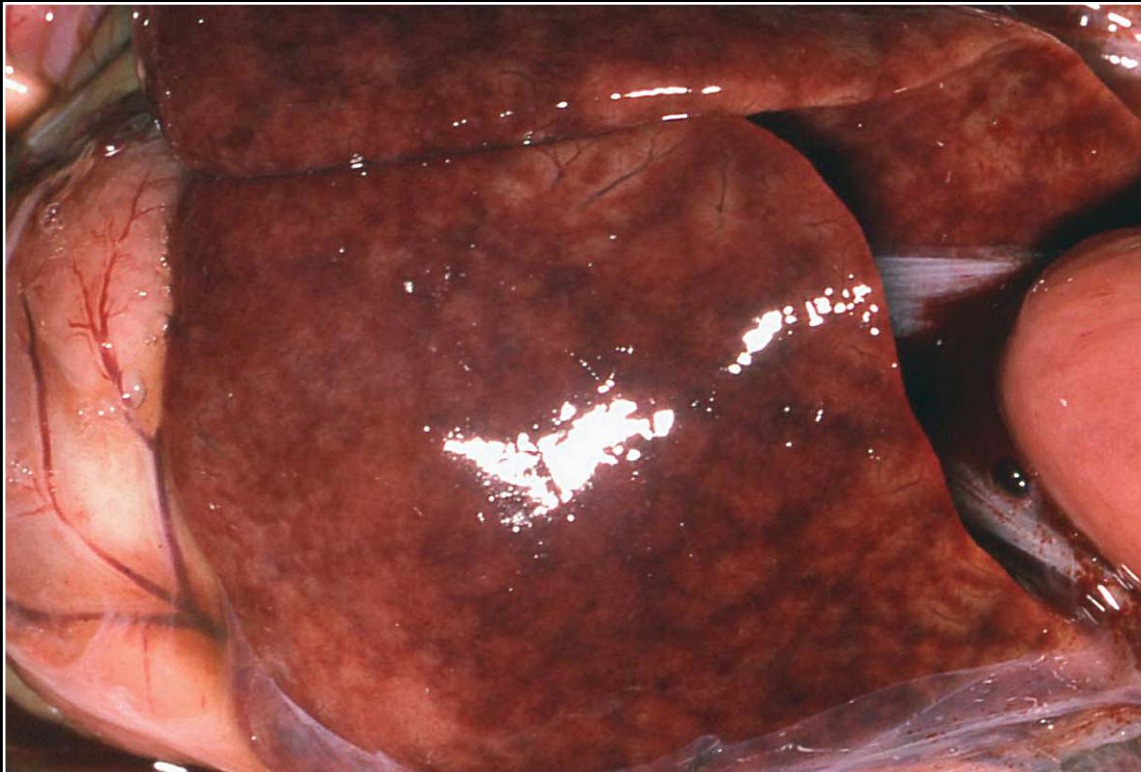
Back



C H A P T E R 5

Liver

Figure 5.21



Systemic sarcosporidiosis in an African grey parrot with marked swelling and mottling of the liver.

Prev. fig. Next fig.

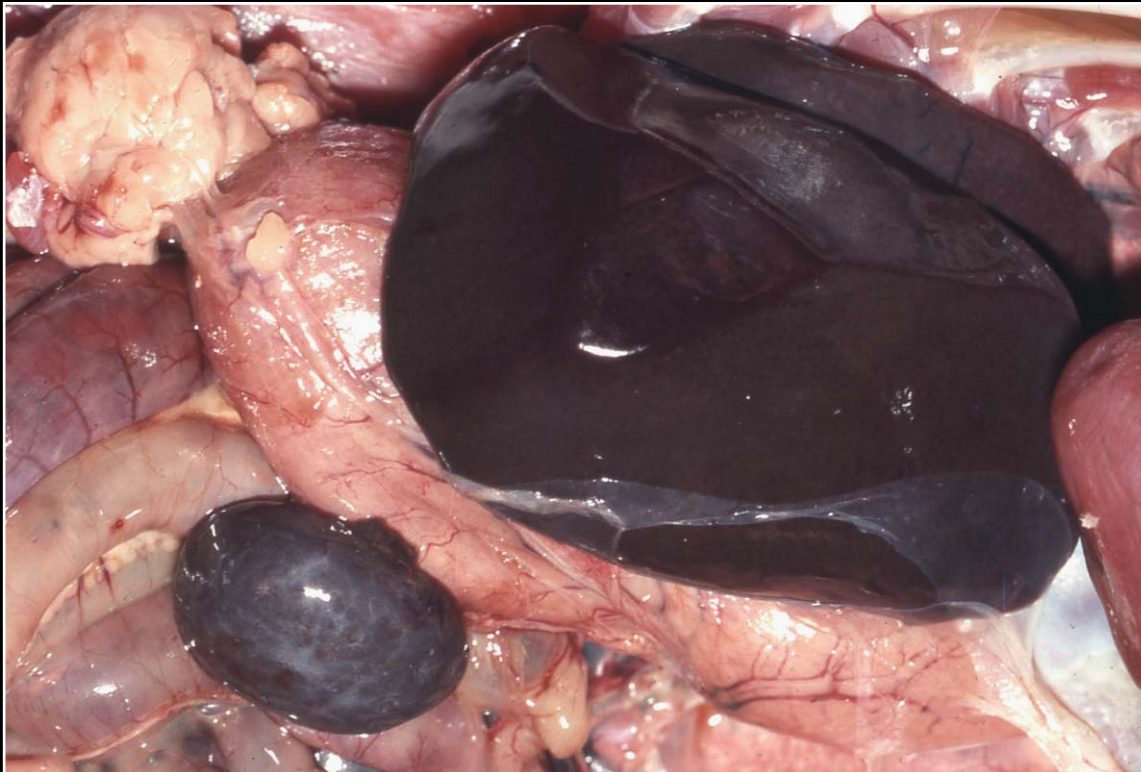
Back



C H A P T E R 5

Liver

Figure 5.22



Diffusely dark gray-black liver, which is common in falcons with *Plasmodium* sp. infection.

Prev. fig. Next fig.

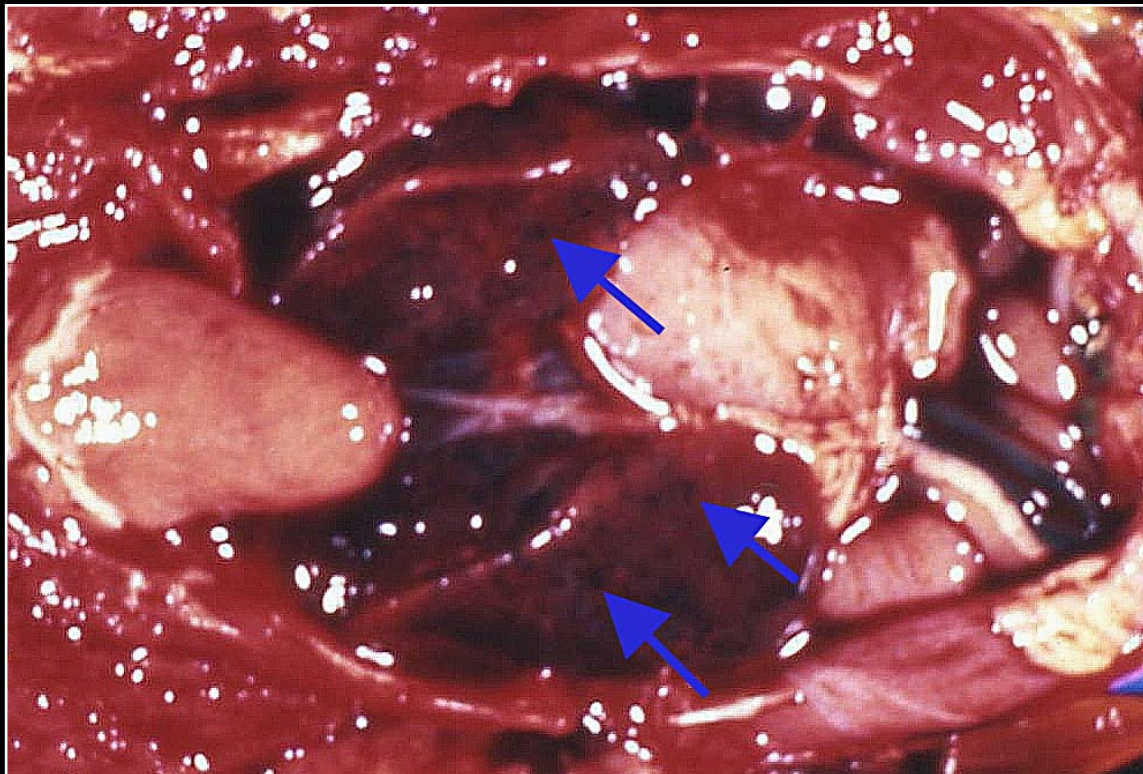
Back



C H A P T E R 5

Liver

Figure 5.23



A conure with *Leukocytozoon* sp. infection shows an enlarged liver with red-black mottling and some hemorrhage.

Prev. fig. Next fig.

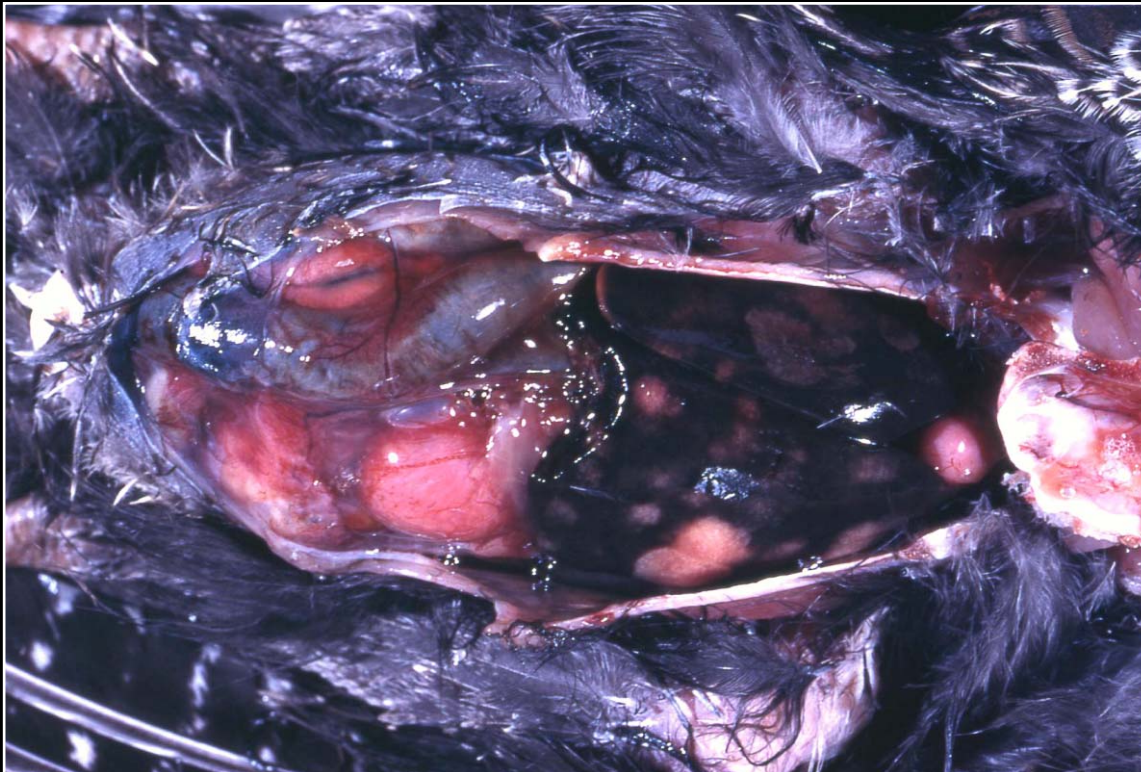
Back



C H A P T E R 5

Liver

Figure 5.24



Severe hepatic enlargement and abscess formation in a turkey with *Histomonas* infection.

Prev. fig. Next fig.

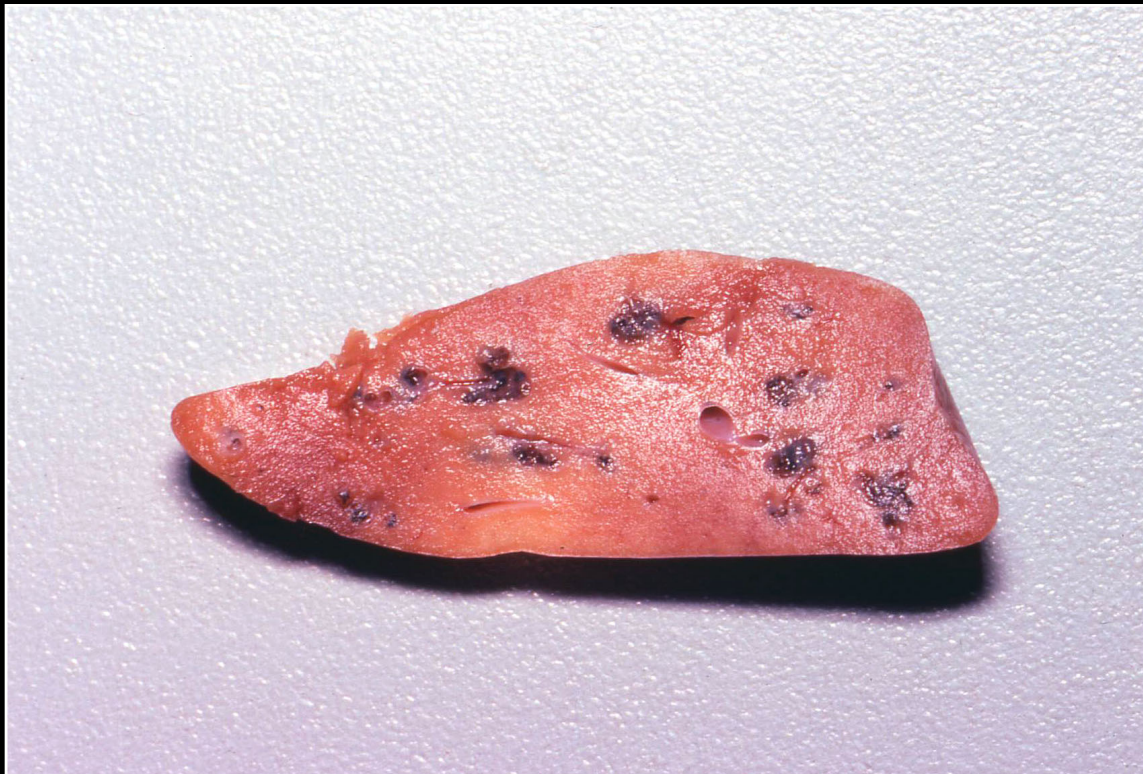Back



C H A P T E R 5

Liver

Figure 5.25



Liver fluke infection in a cockatoo. Note the black discoloration associated with dilated bile ducts. Flukes are present but difficult to see.

Prev. fig. . Next fig.

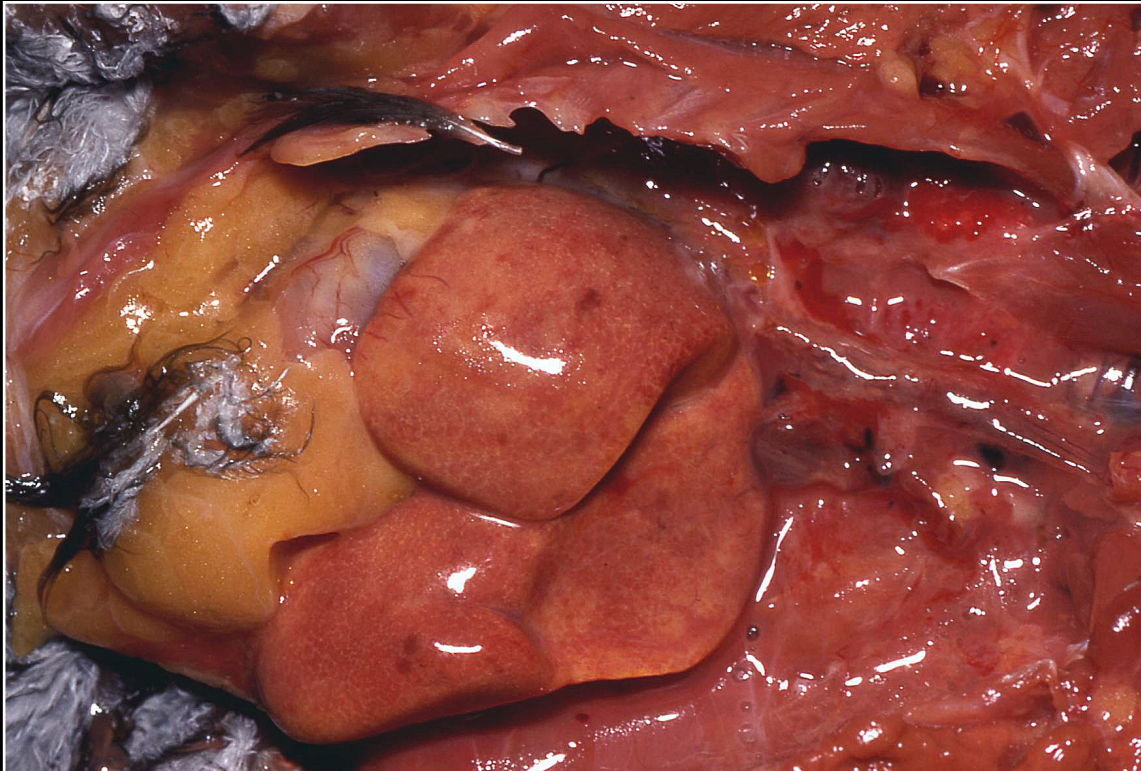
Back



CHAPTER 5

Liver

Figure 5.26



Fatty liver in a conure. Note enlargement and discoloration, with hepatic parenchyma having almost the same color as the abdominal fat.

Prev. fig. Next fig.

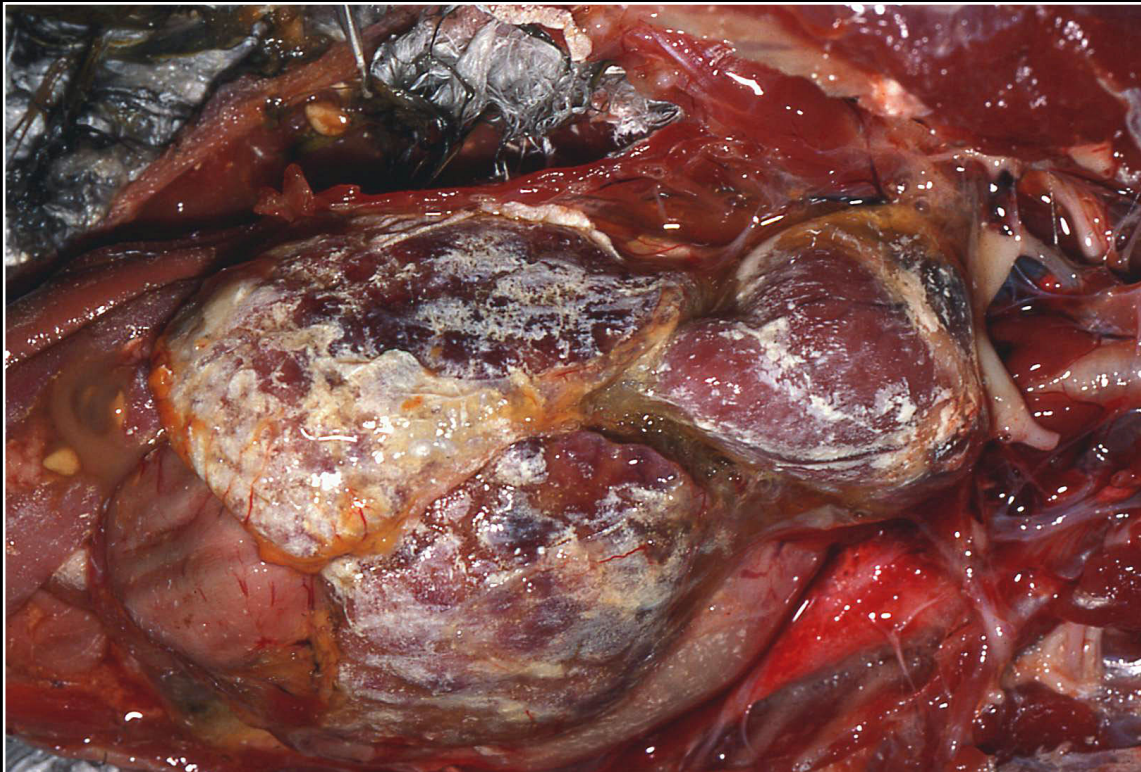
Back



CHAPTER 5

Liver

Figure 5.27



Severe hepatic urate deposition. The lesion must be differentiated from inflammation or infection of the hepatic capsule.

Prev. fig. Next fig.

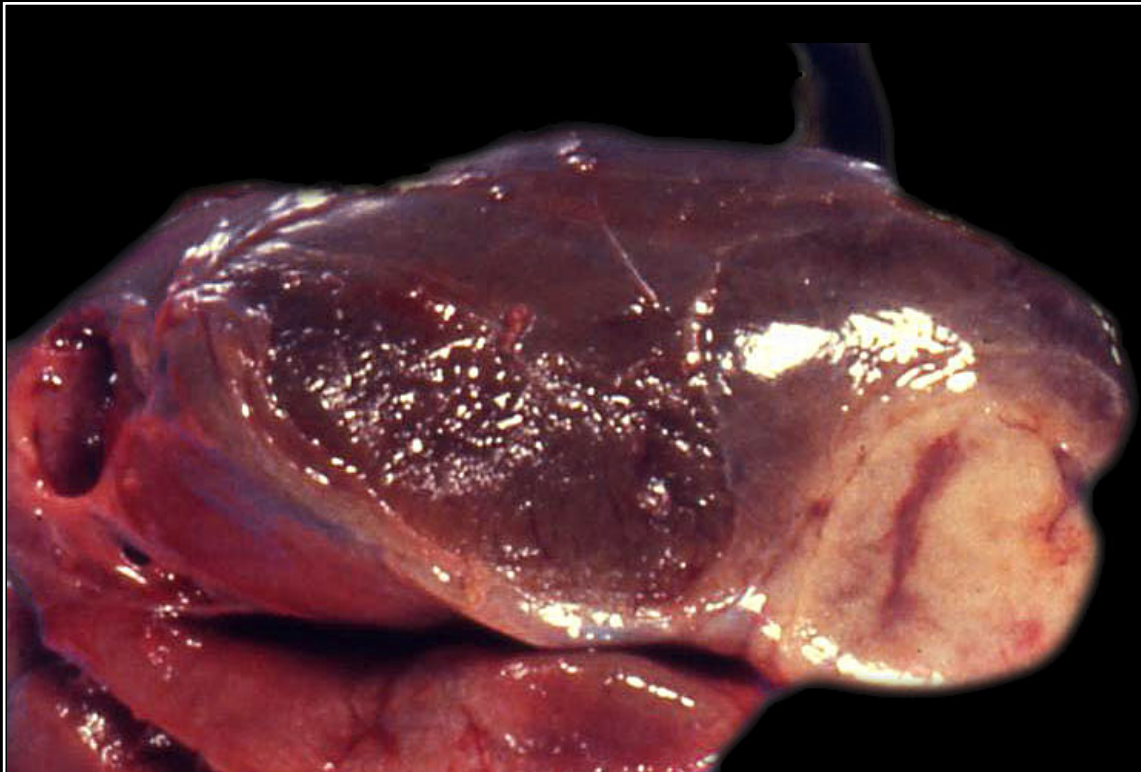
Back



C H A P T E R 5

Liver

Figure 5.28



Severe amyloidosis involving primarily one lobe of the liver from a pigeon. Although usually generalized, some areas may be more prominent grossly.

Prev. fig. Next fig.

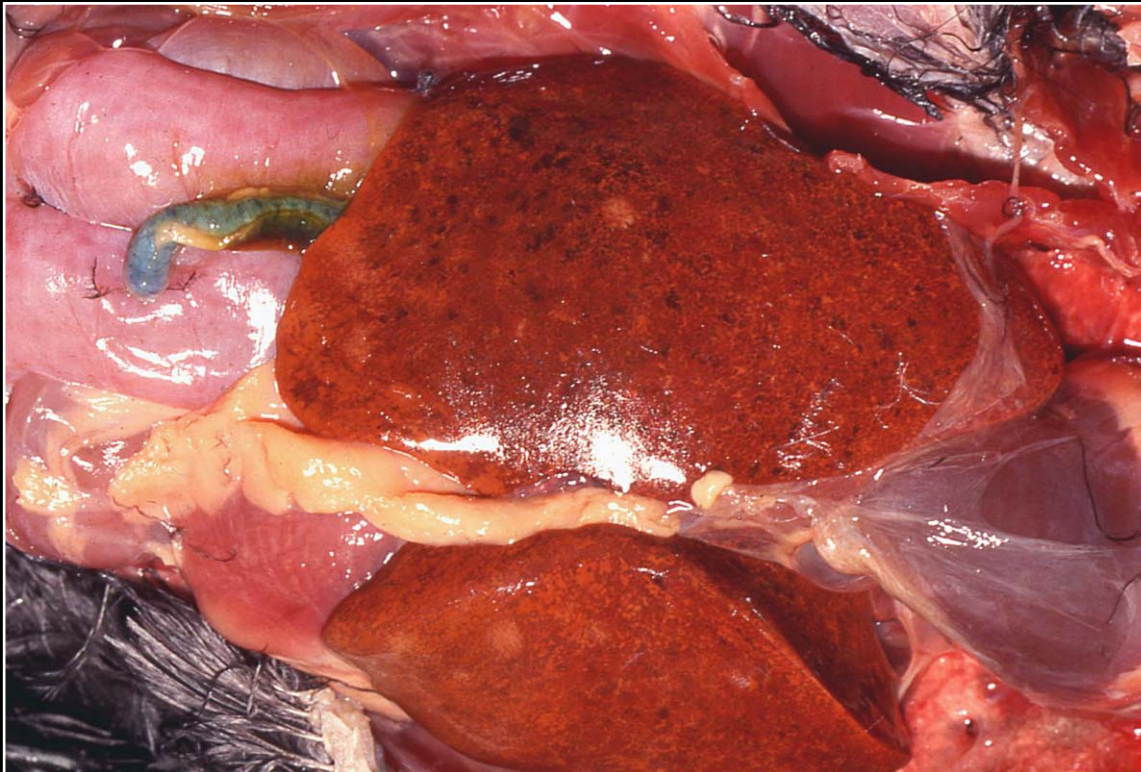
Back



CHAPTER 5

Liver

Figure 5.29



Iron storage disease in a hornbill. There is a diffuse gold-brown discoloration as well as multiple dark foci representing accumulations of iron pigment.

Prev. fig. Next fig.

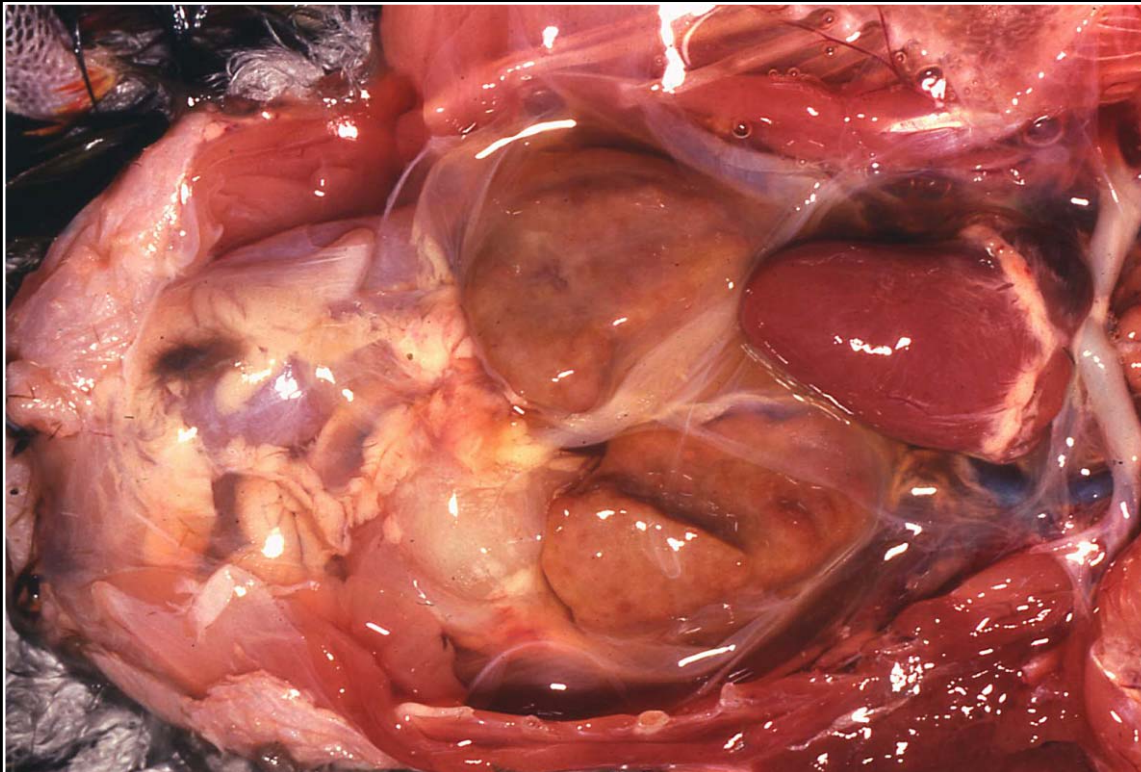
Back



C H A P T E R 5

Liver

Figure 5.30



Pale nodular liver typical of chronic-active hepatitis.

Prev. fig. Next fig.

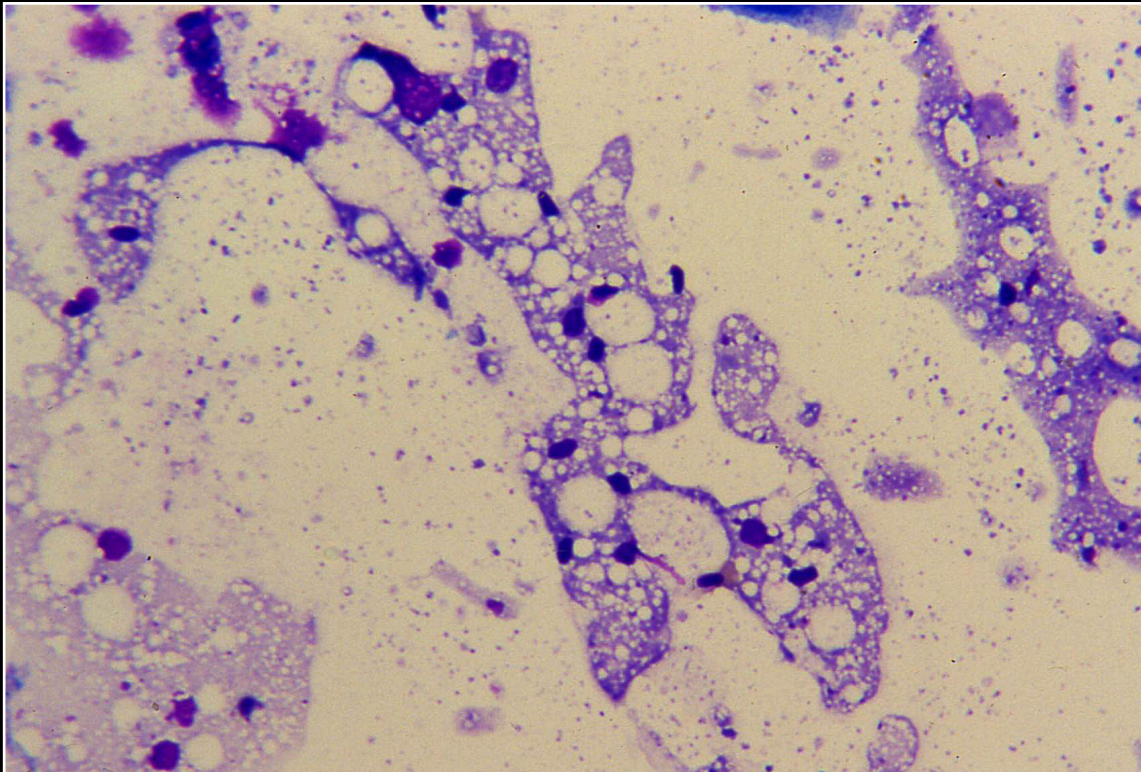
Back



CHAPTER 5

Liver

Figure 5.31



Cytologic appearance of vacuolated hepatocytes in a case of chronic-active hepatitis.

Prev. fig. Next fig.

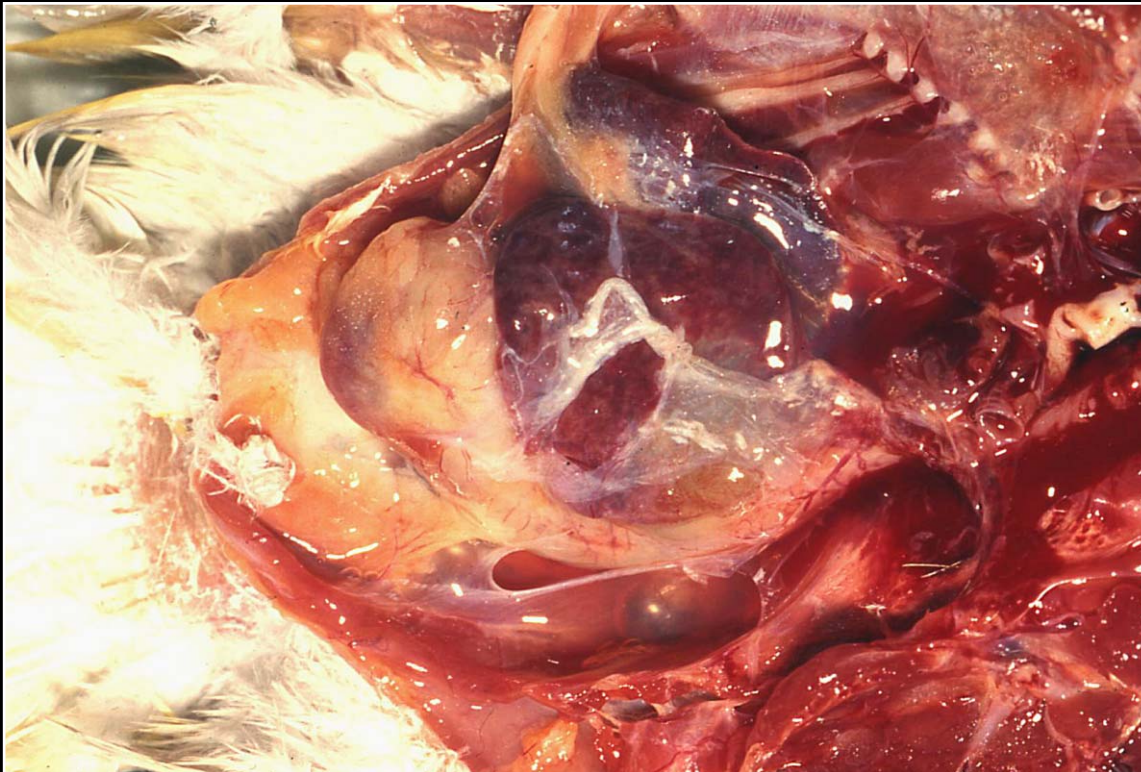
Back



C H A P T E R 5

Liver

Figure 5.32



Small biliary cysts are seen, and a large thin-walled cyst appears yellow.

Prev. fig. Next fig.

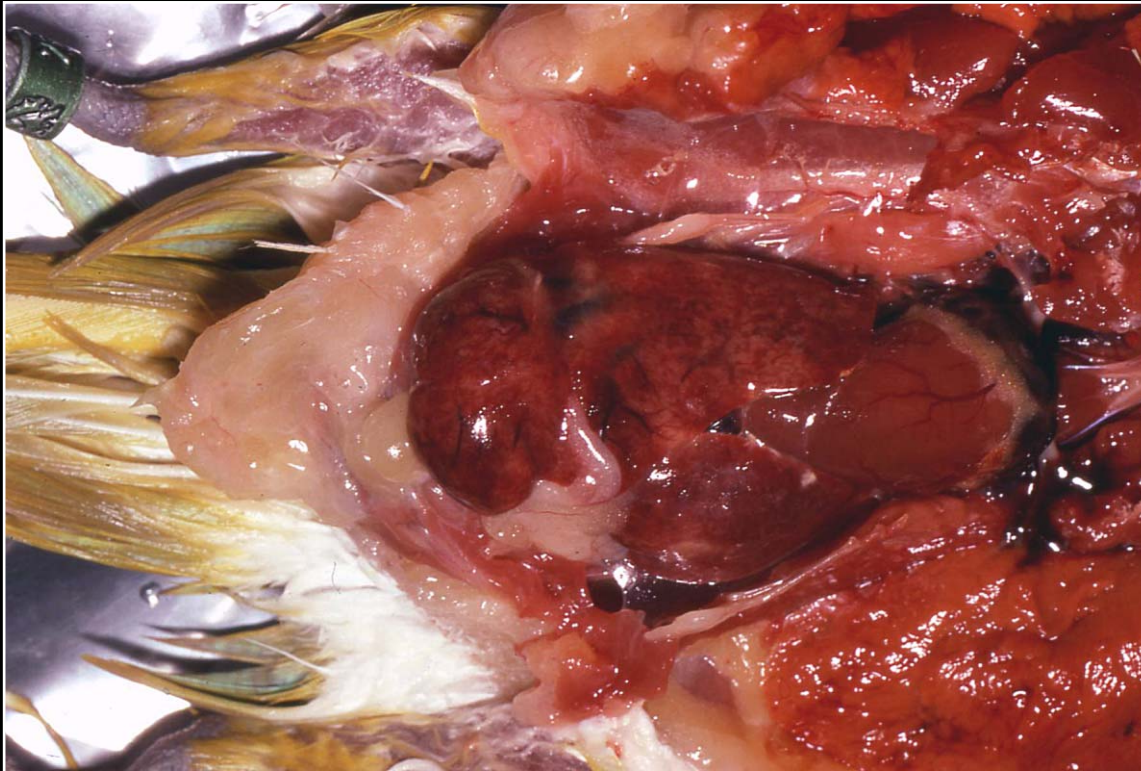
Back



C H A P T E R 5

Liver

Figure 5.33



Irregular enlargement seen in nodular hyperplasia.

Prev. fig. Next fig.

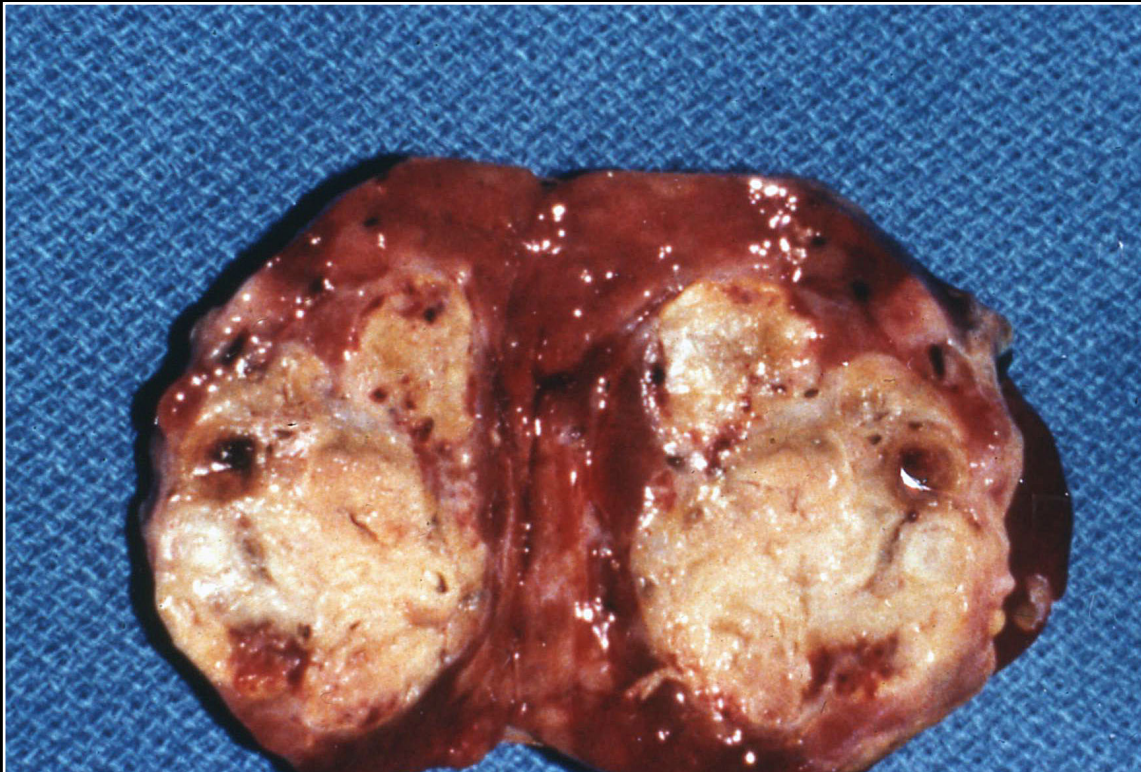Back



C H A P T E R 5

Liver

Figure 5.34



Typical appearance of bile duct carcinoma replacing hepatic parenchyma.

Prev. fig. Next fig.

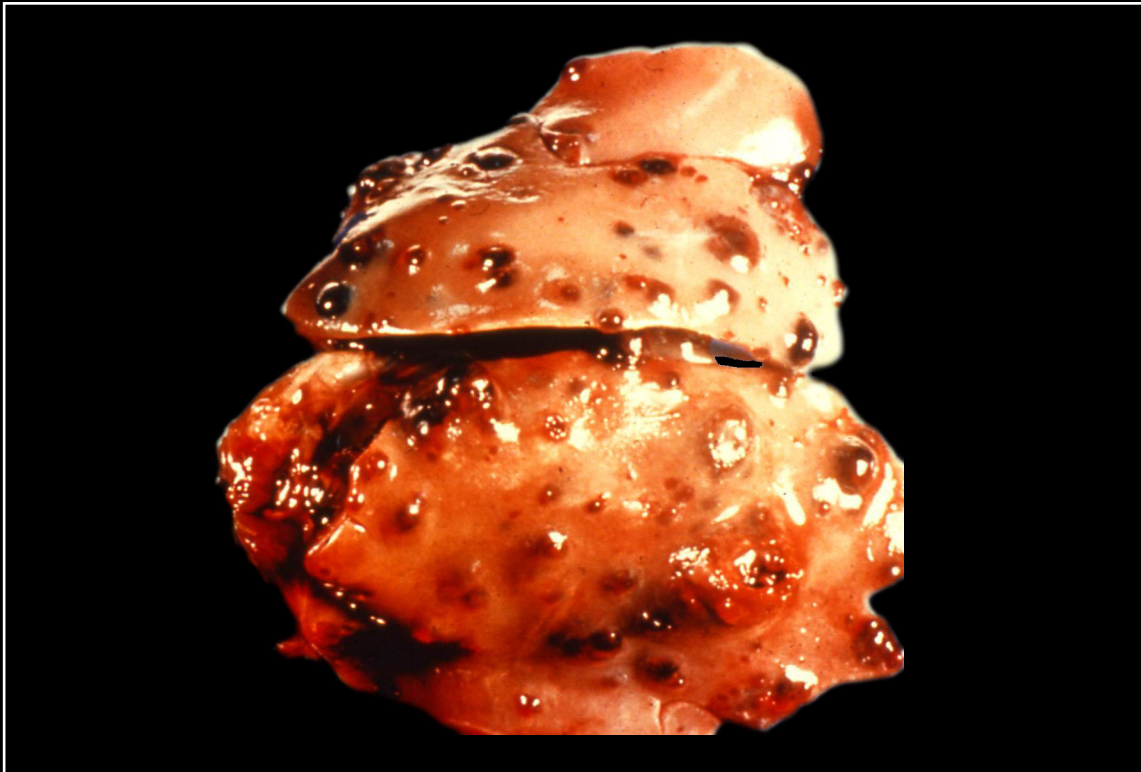Back



C H A P T E R 5

Liver

Figure 5.35



Multiple red nodules seen in hemangiosarcoma.

Prev. fig. Next fig.

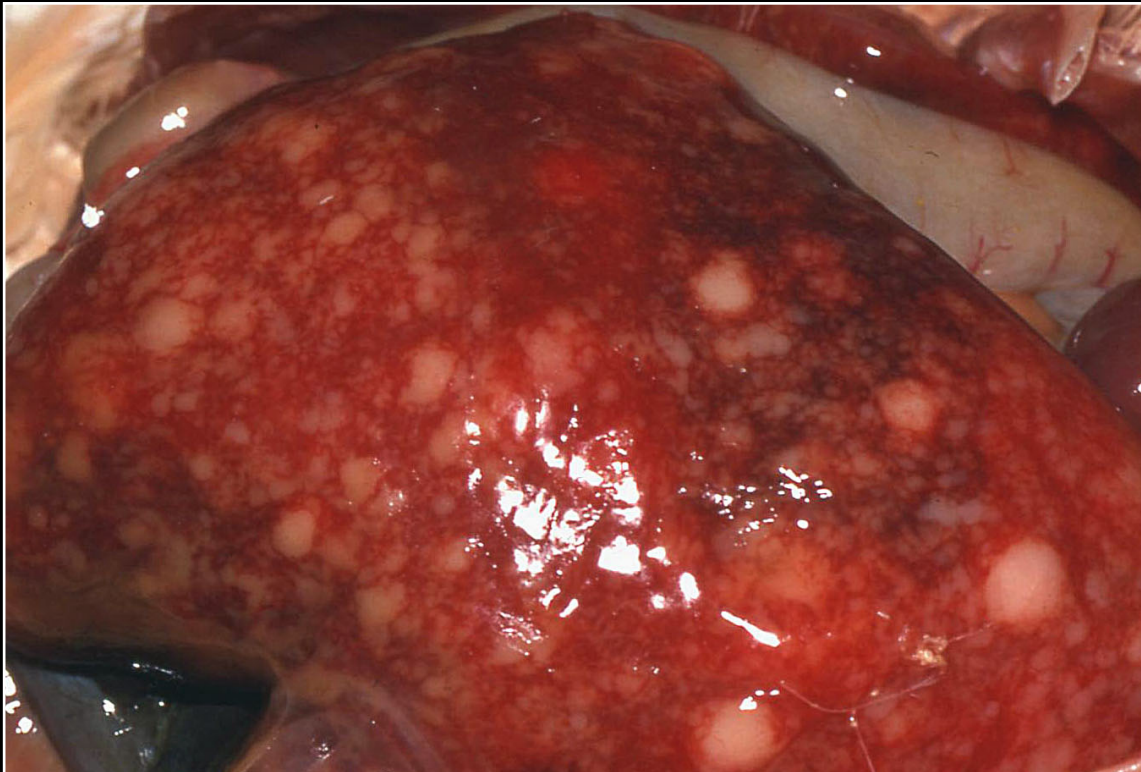
Back



C H A P T E R 5

Liver

Figure 5.36



Multifocal to confluent gray-white areas in a liver from a cockatoo with lymphosarcoma.

Prev. fig.

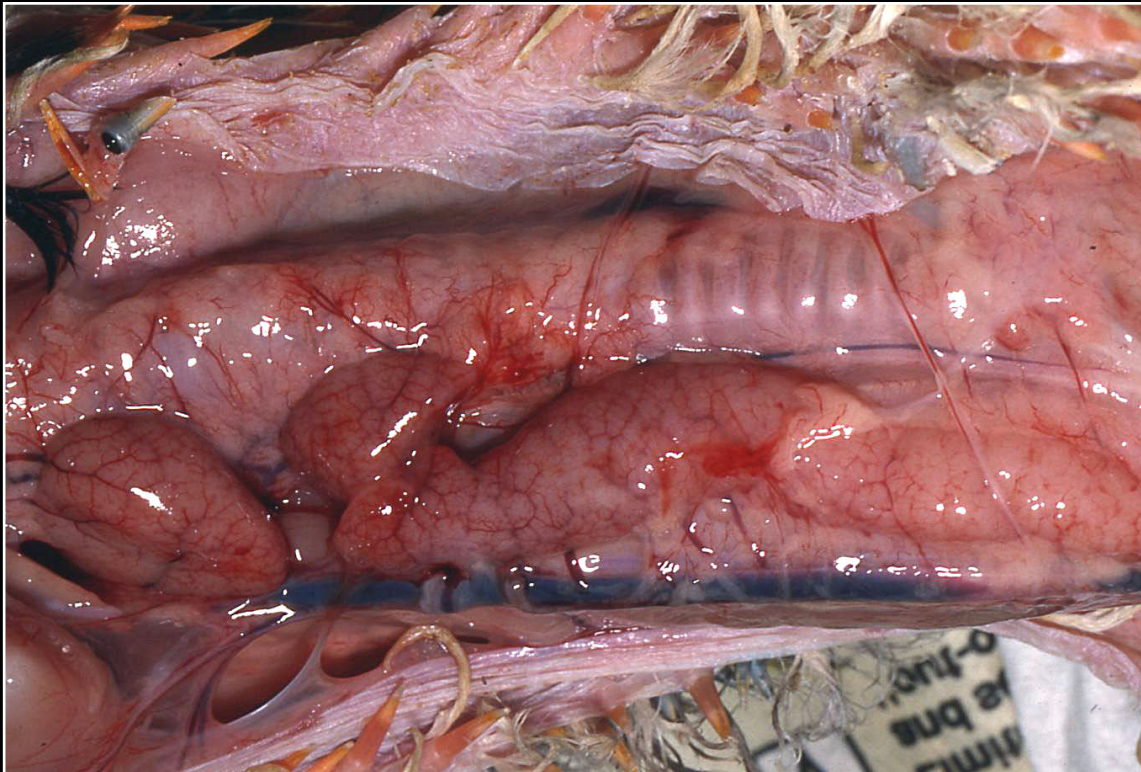
Back



CHAPTER 6

Lymphatic and Hematopoietic (Immune) System

Figure 6.1



Normal thymus in a young macaw. Tissue is present from the angle of the jaw almost to the thoracic inlet.

Next fig.

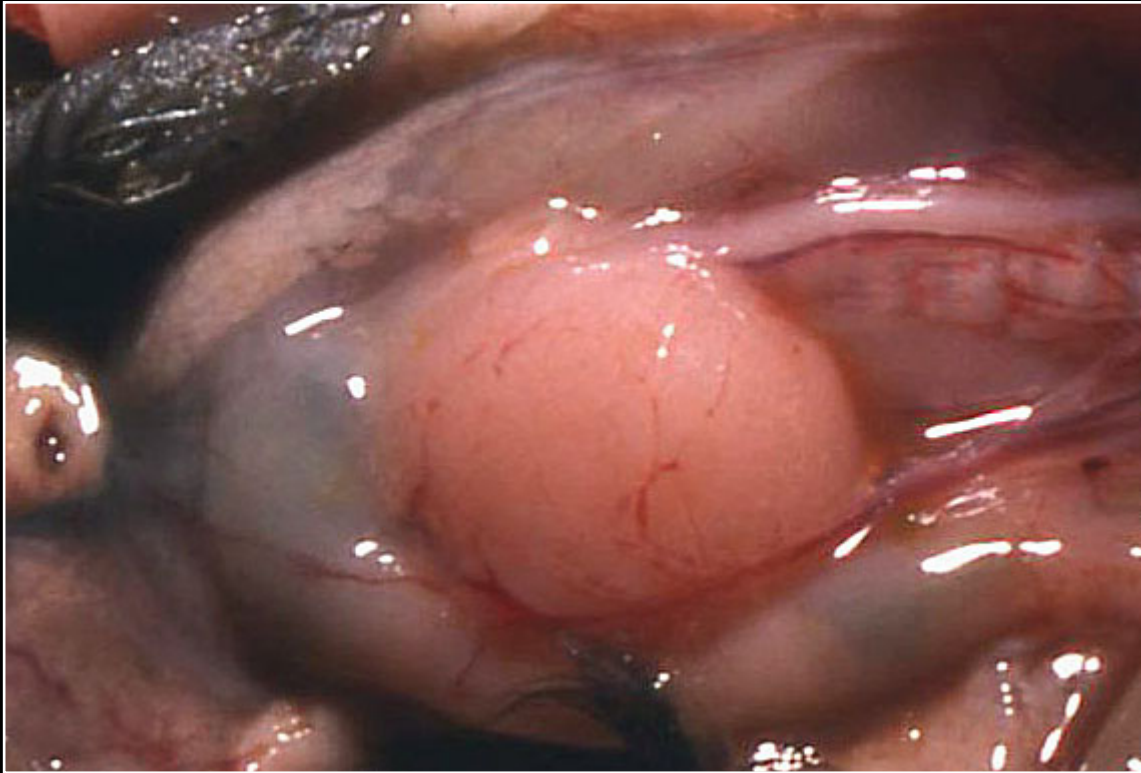
Back



CHAPTER 6

Lymphatic and Hematopoietic (Immune) System

Figure 6.2



Normal bursa of Fabricius in a rosella.

Prev. fig. Next fig.

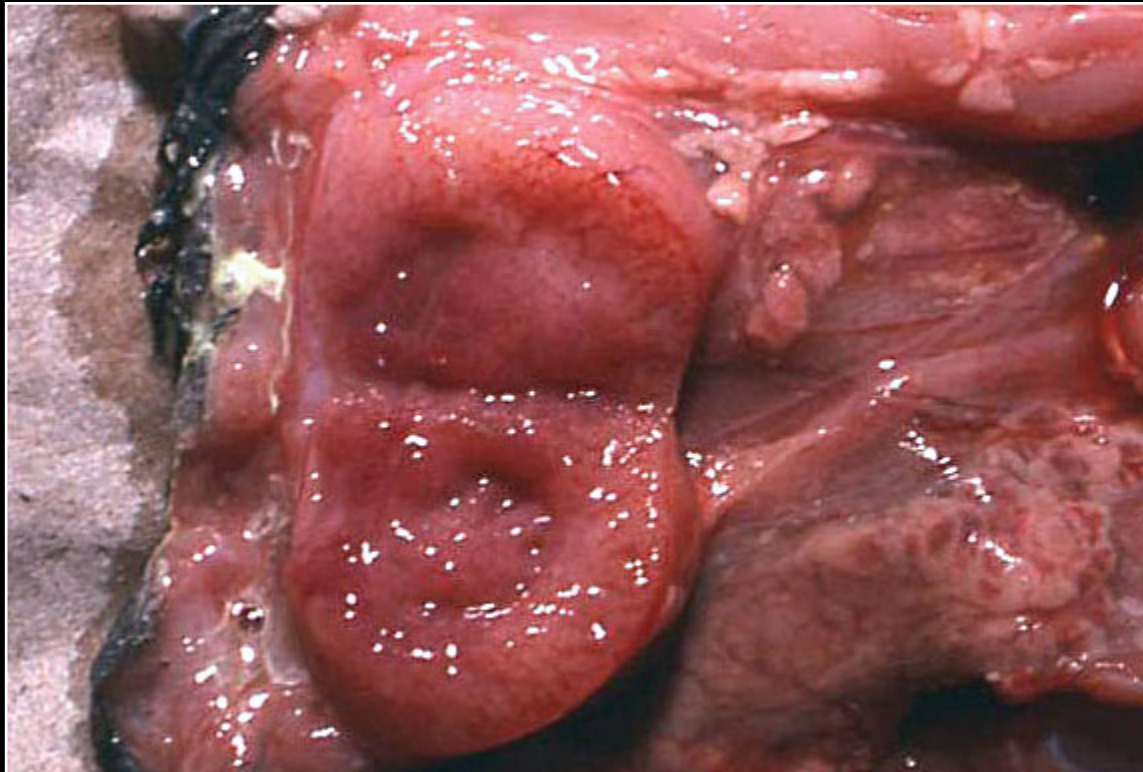
Back



CHAPTER 6

Lymphatic and Hematopoietic (Immune) System

Figure 6.3



Interior of normal bursa of Fabricius of a cockatiel. There is mild congestion.

Prev. fig. Next fig.

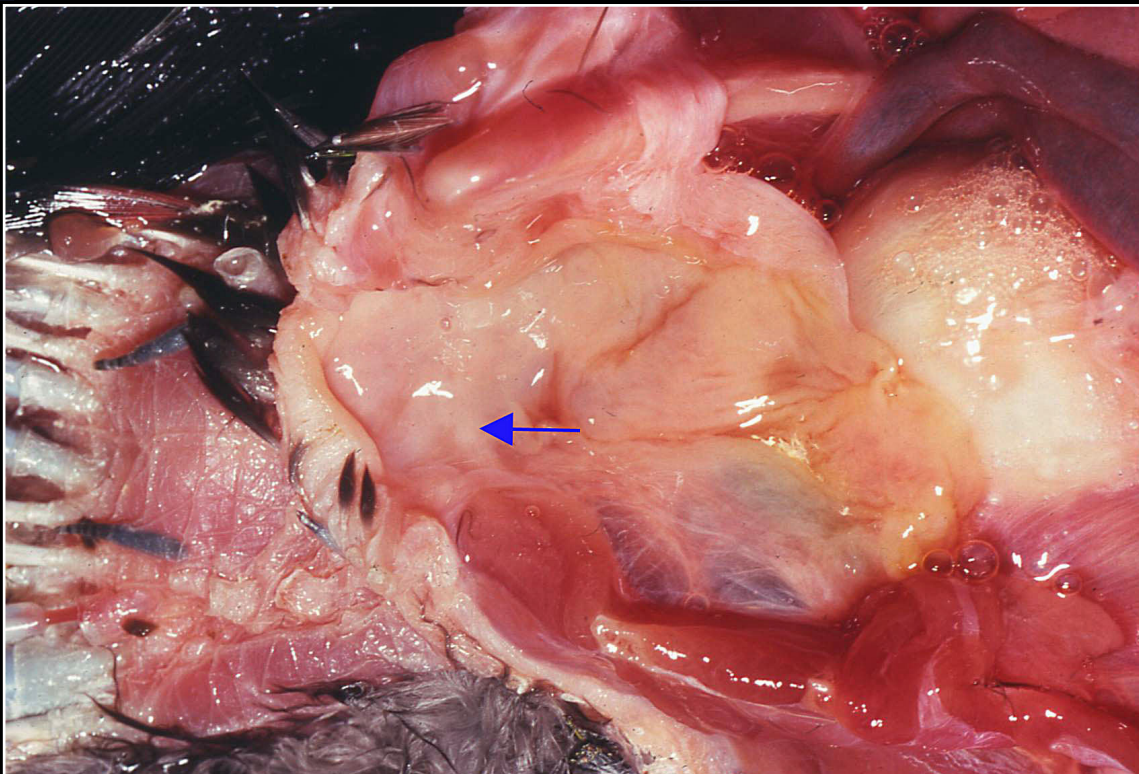
Back



CHAPTER 6

Lymphatic and Hematopoietic (Immune) System

Figure 6.4



Cloaca of a 10-year-old hawk-headed parrot. Note minimal gross enlargement in area of bursa of Fabricius (arrow).

Prev. fig. Next fig.

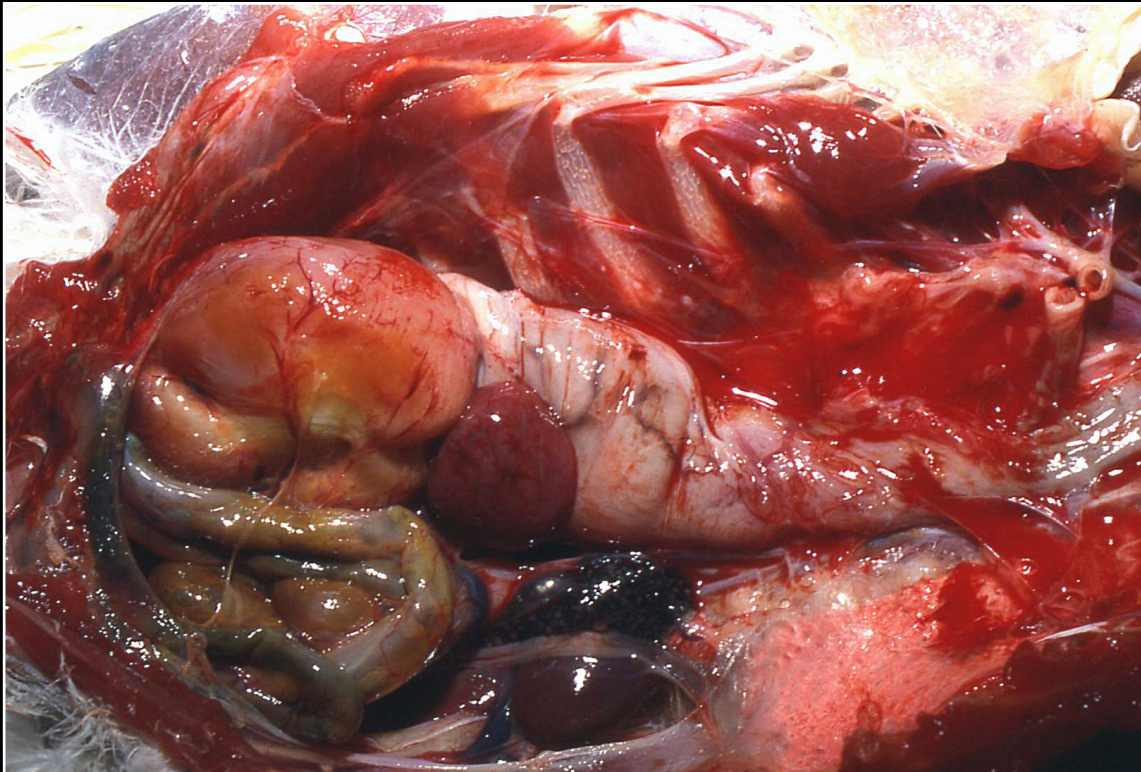
Back



CHAPTER 6

Lymphatic and Hematopoietic (Immune) System

Figure 6.5



Rotation of the proventriculus and ventriculus to illustrate the position of the spleen.

Prev. fig. Next fig.

Back



CHAPTER 6

Lymphatic and Hematopoietic (Immune) System

Figure 6.6



Normal red appearance of bone marrow.

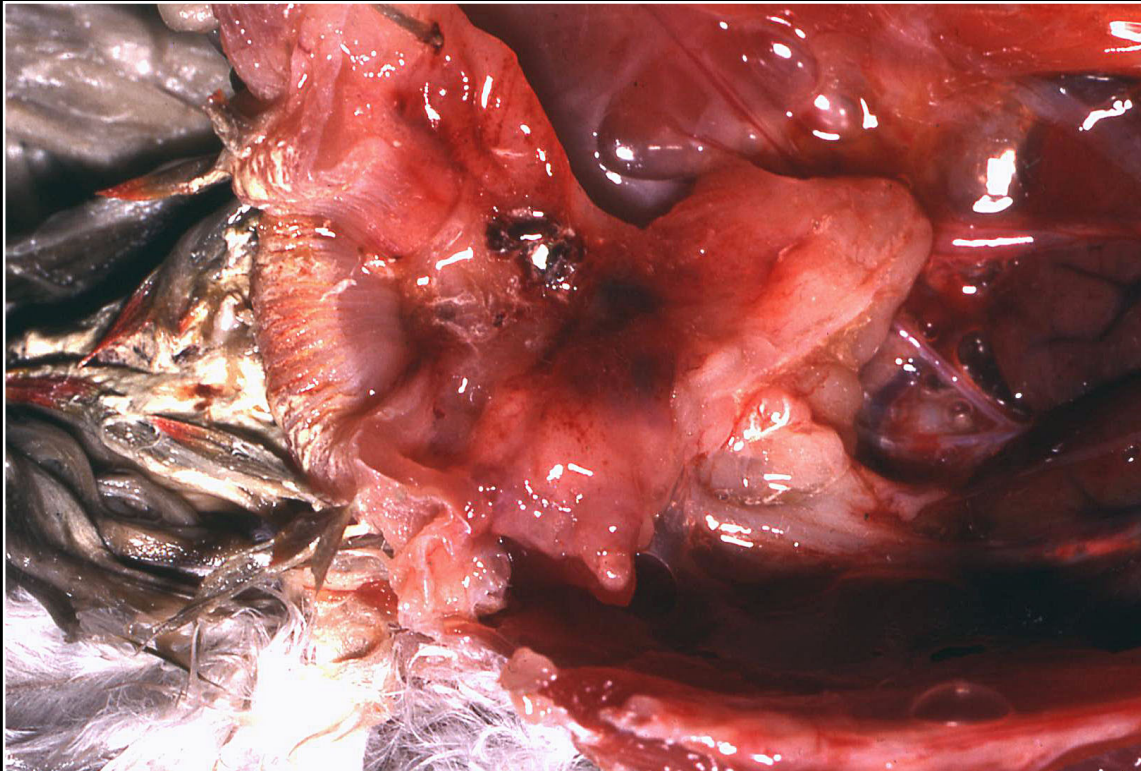
Prev. fig. Next fig.

Back

CHAPTER 6

Lymphatic and Hematopoietic (Immune) System

Figure 6.7



Cloacal region of a young thick-billed parrot. Severe bursal atrophy with the organ essentially not visible.

Prev. fig. Next fig.

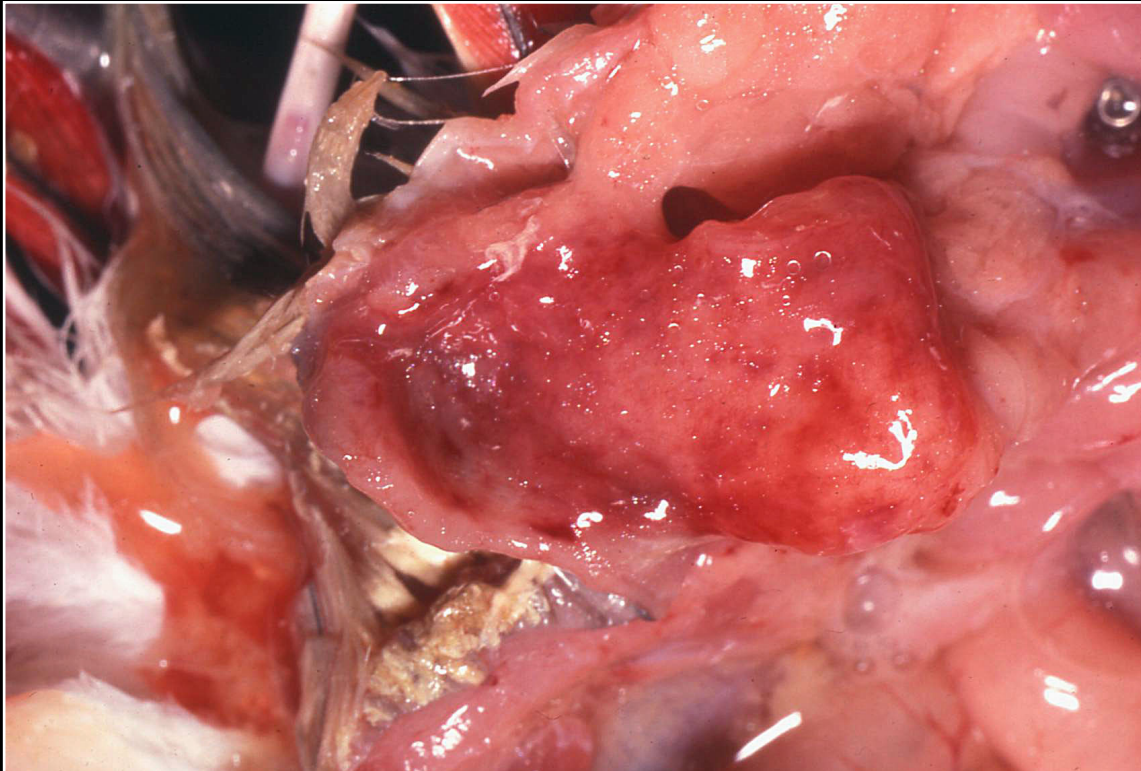
Back



CHAPTER 6

Lymphatic and Hematopoietic (Immune) System

Figure 6.8



Small bursa in a young African grey parrot with systemic circovirus infection.

Prev. fig. Next fig.

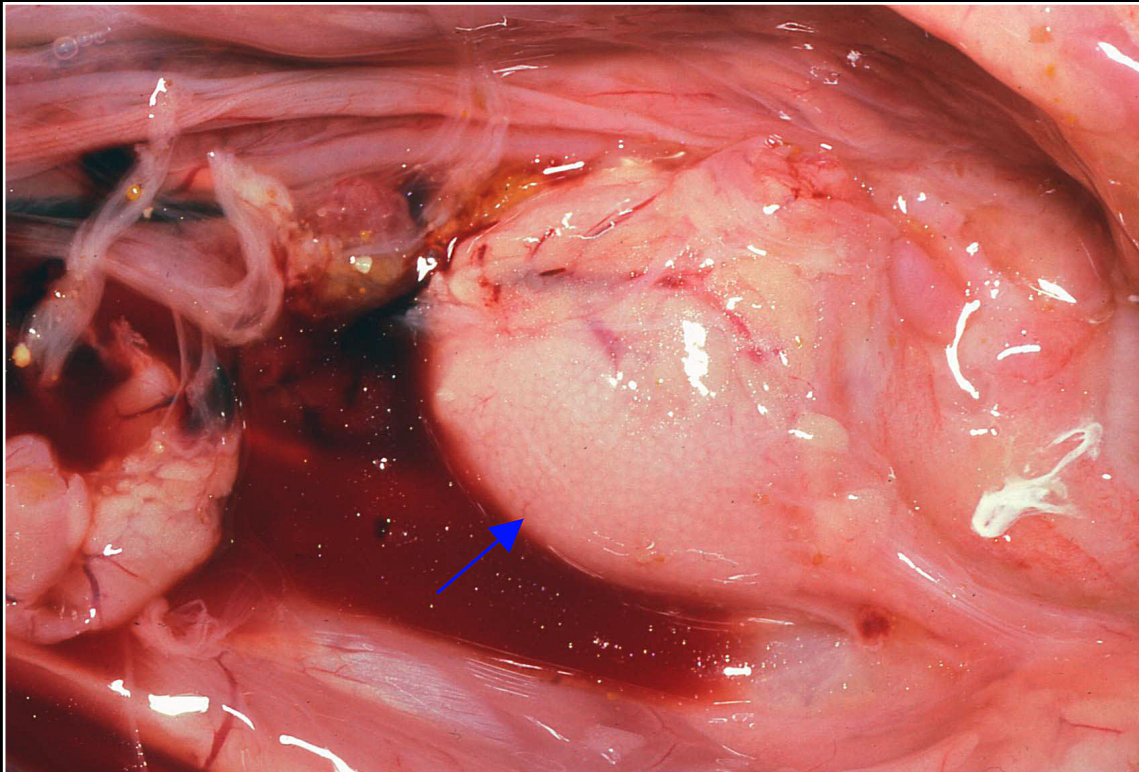
Back



CHAPTER 6

Lymphatic and Hematopoietic (Immune) System

Figure 6.9



Slightly edematous bursa of Fabricius (arrow) from a cockatoo with polyomavirus infection. Some adjacent hemorrhage is seen.

Prev. fig. Next fig.

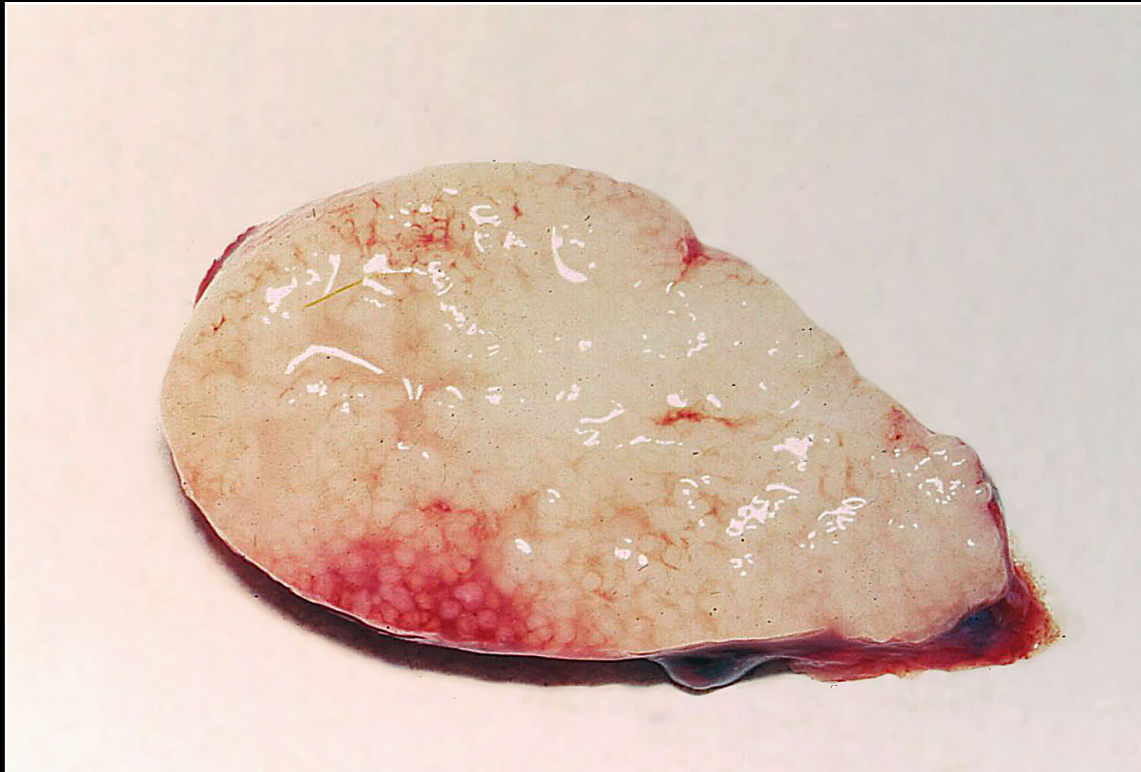Back



CHAPTER 6

Lymphatic and Hematopoietic (Immune) System

Figure 6.10



Hemorrhage and edema of the bursa of Fabricius from a blue and gold macaw with polyomavirus infection.

Prev. fig. Next fig.

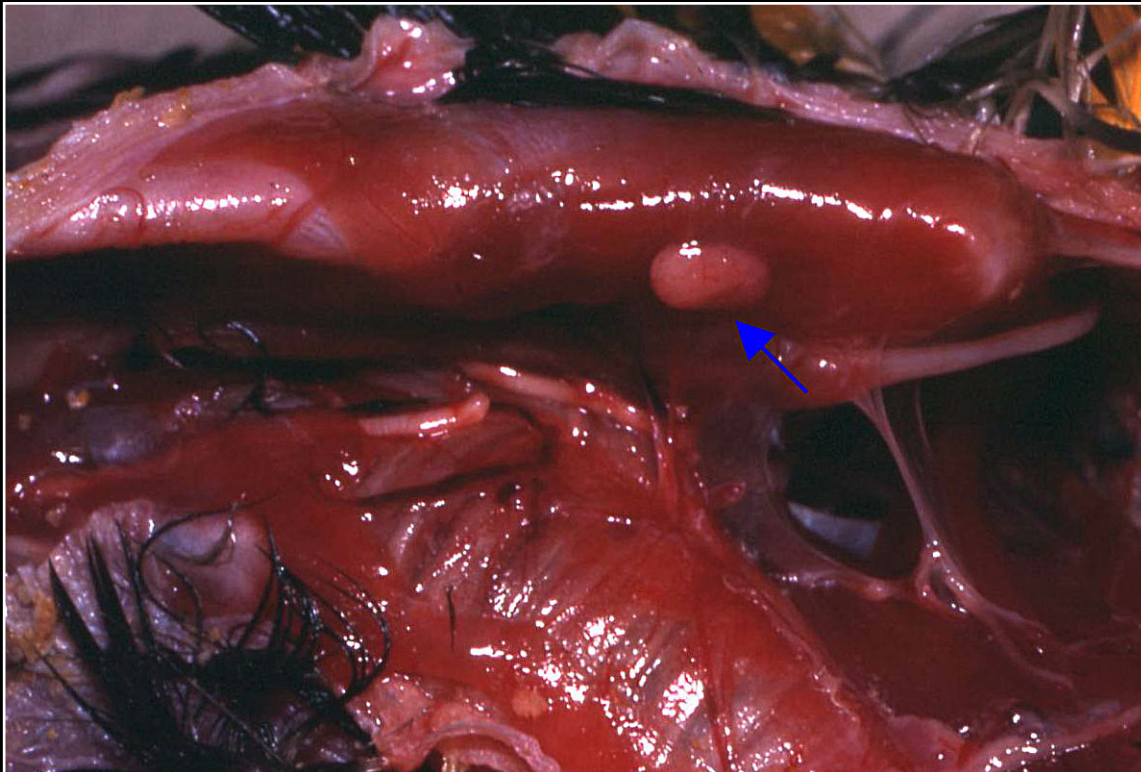
Back



CHAPTER 6

Lymphatic and Hematopoietic (Immune) System

Figure 6.11



Thymic remnant in a young African grey parrot with systemic circovirus infection.

Prev. fig. Next fig.

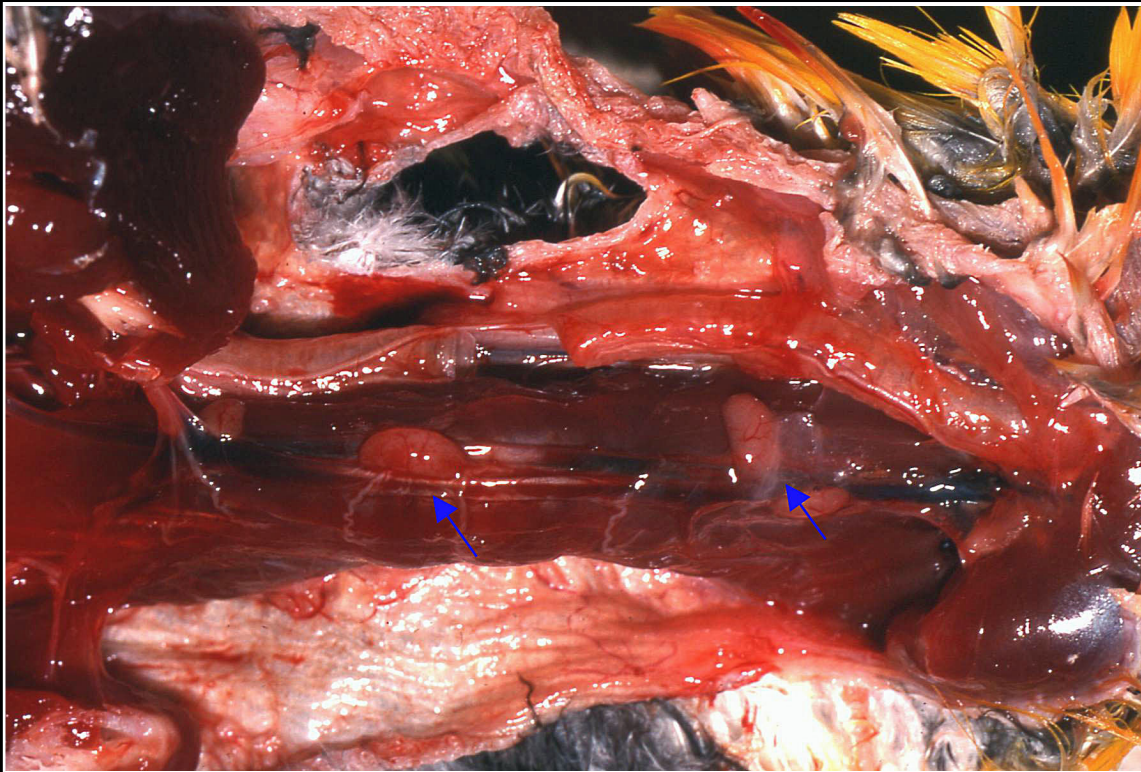
Back



CHAPTER 6

Lymphatic and Hematopoietic (Immune) System

Figure 6.12



Hyperplastic thymus in a mature caique. Two large lobules are seen (arrows).

Prev. fig. Next fig.

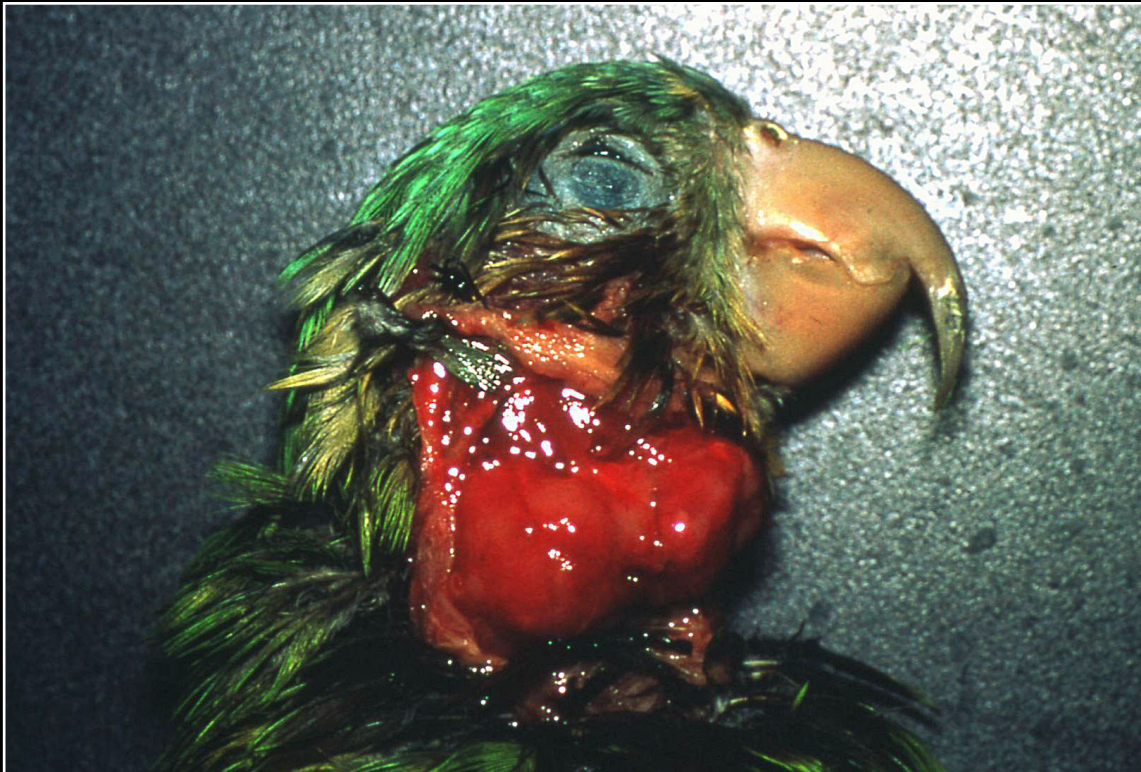
Back



CHAPTER 6

Lymphatic and Hematopoietic (Immune) System

Figure 6.13



Lymphosarcoma causing extreme enlargement of the thymus of a grey-cheeked parakeet.

Prev. fig. Next fig.

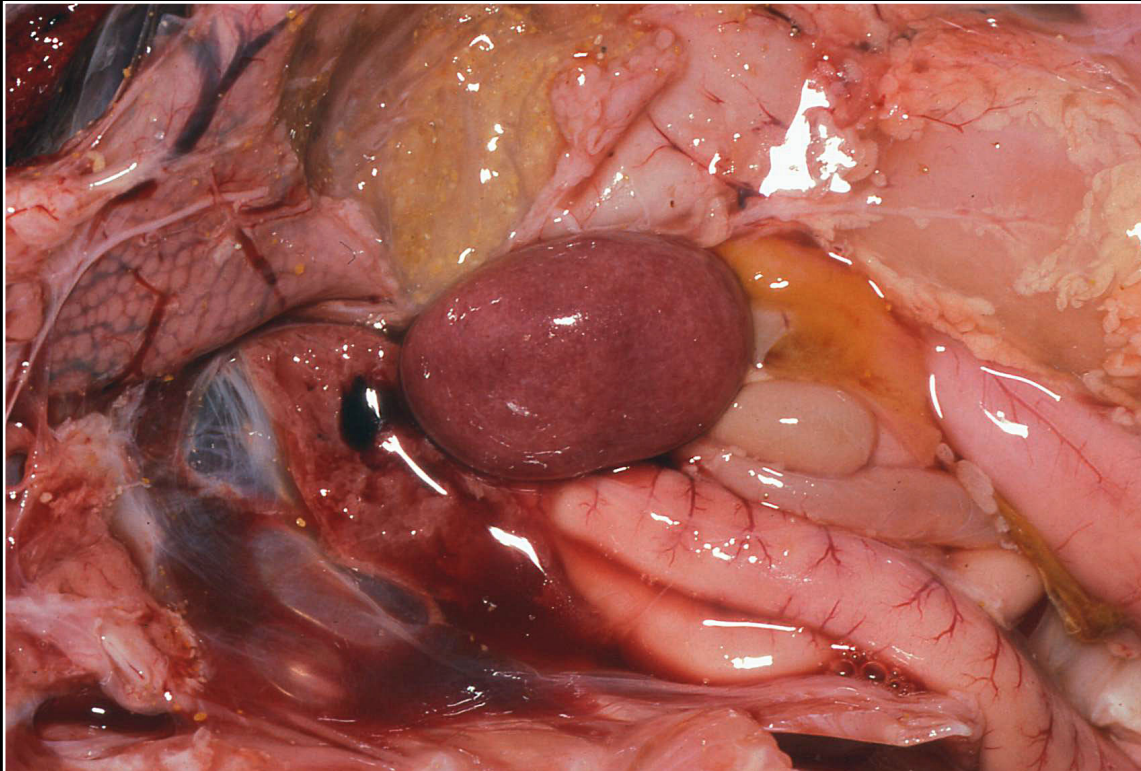
Back



CHAPTER 6

Lymphatic and Hematopoietic (Immune) System

Figure 6.14



Enlarged mottled spleen from a cockatoo with polyomavirus infection.

Prev. fig. Next fig.

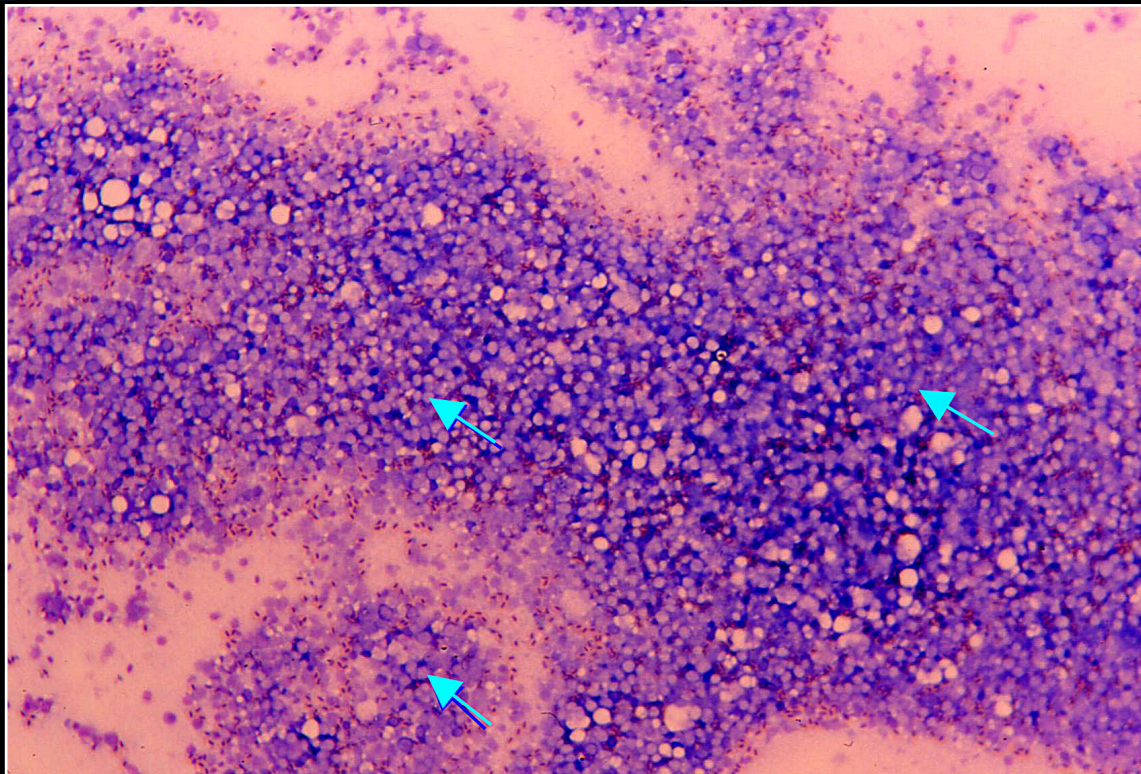
Back



CHAPTER 6

Lymphatic and Hematopoietic (Immune) System

Figure 6.15



Impression smear of the spleen from a bird with polyomavirus infection. Numerous inclusion bodies are seen within karyomegalic nuclei (arrows). These should not be confused with clear spaces seen in the smear.

Prev. fig. Next fig.

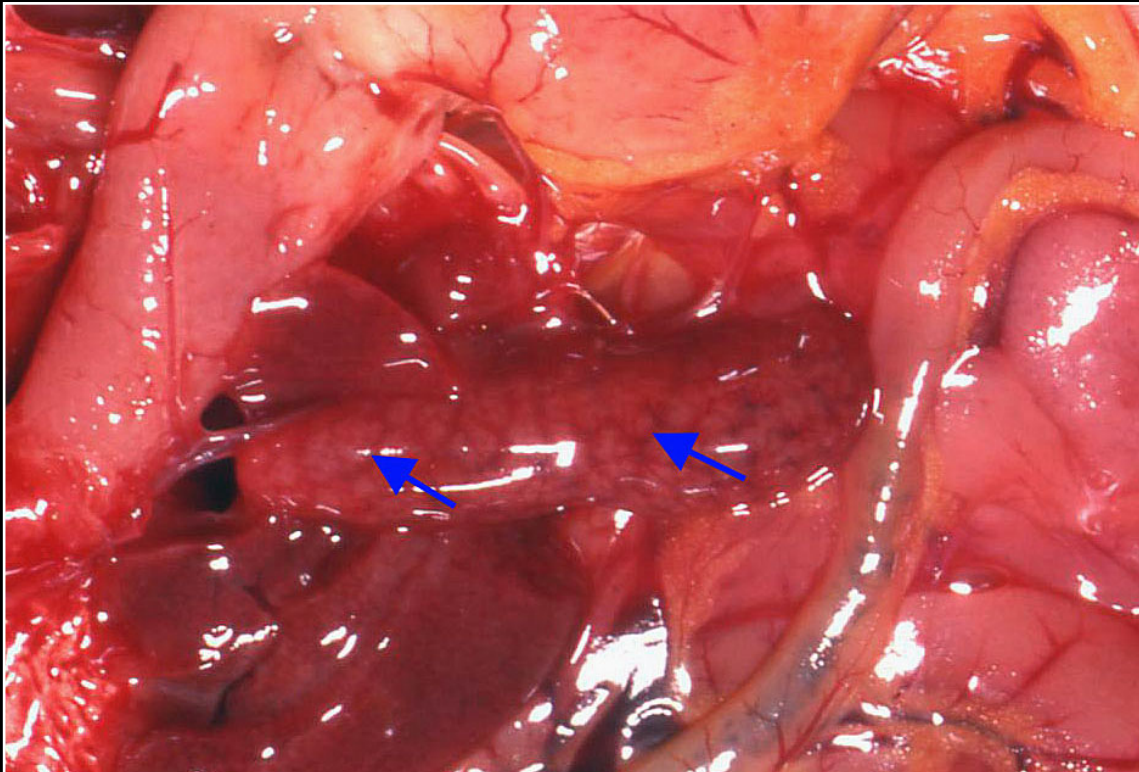
Back



CHAPTER 6

Lymphatic and Hematopoietic (Immune) System

Figure 6.16



Enlarged spleen from a canary with poxvirus infection. Arrows indicate pale lobular areas that represent foci of marked lymphoid hyperplasia.

Prev. fig. Next fig.

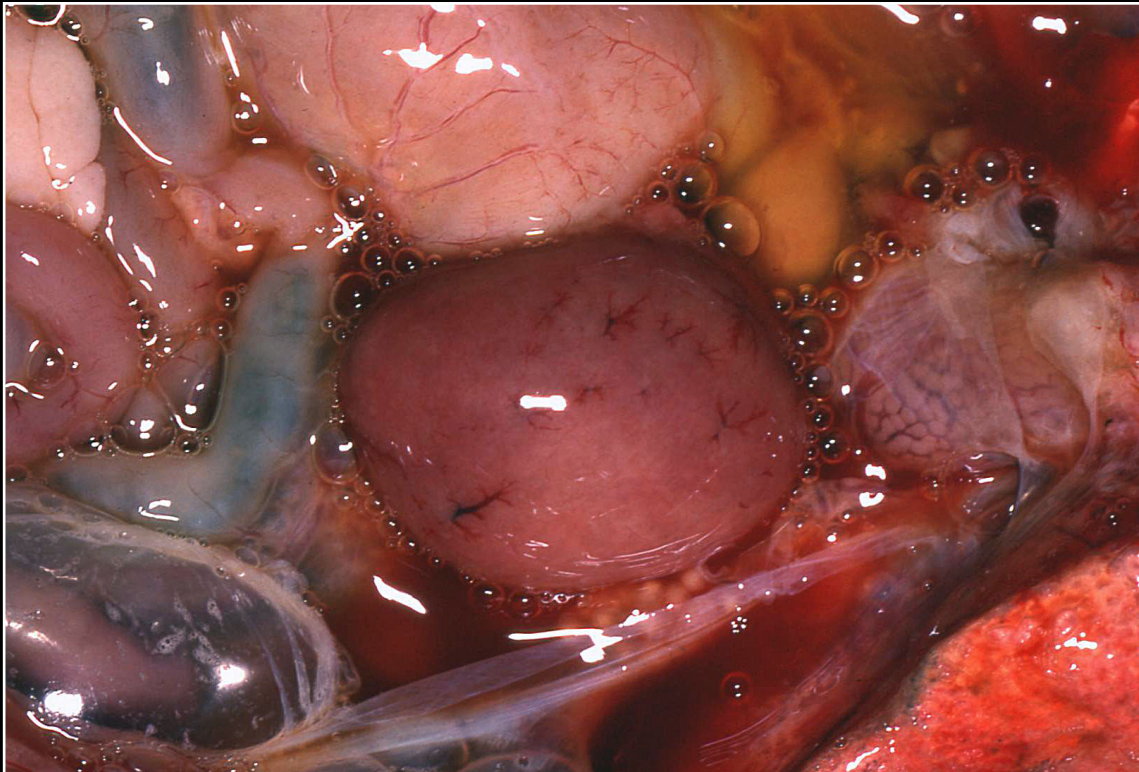
Back



CHAPTER 6

Lymphatic and Hematopoietic (Immune) System

Figure 6.17



Splenic enlargement in a macaw with salmonellosis. This is a nonspecific gross lesion.

Prev. fig. Next fig.

Back



CHAPTER 6

Lymphatic and Hematopoietic (Immune) System

Figure 6.18



Enlarged spleen with multiple gray-white foci typical of a variety of bacterial infections.

Prev. fig. Next fig.

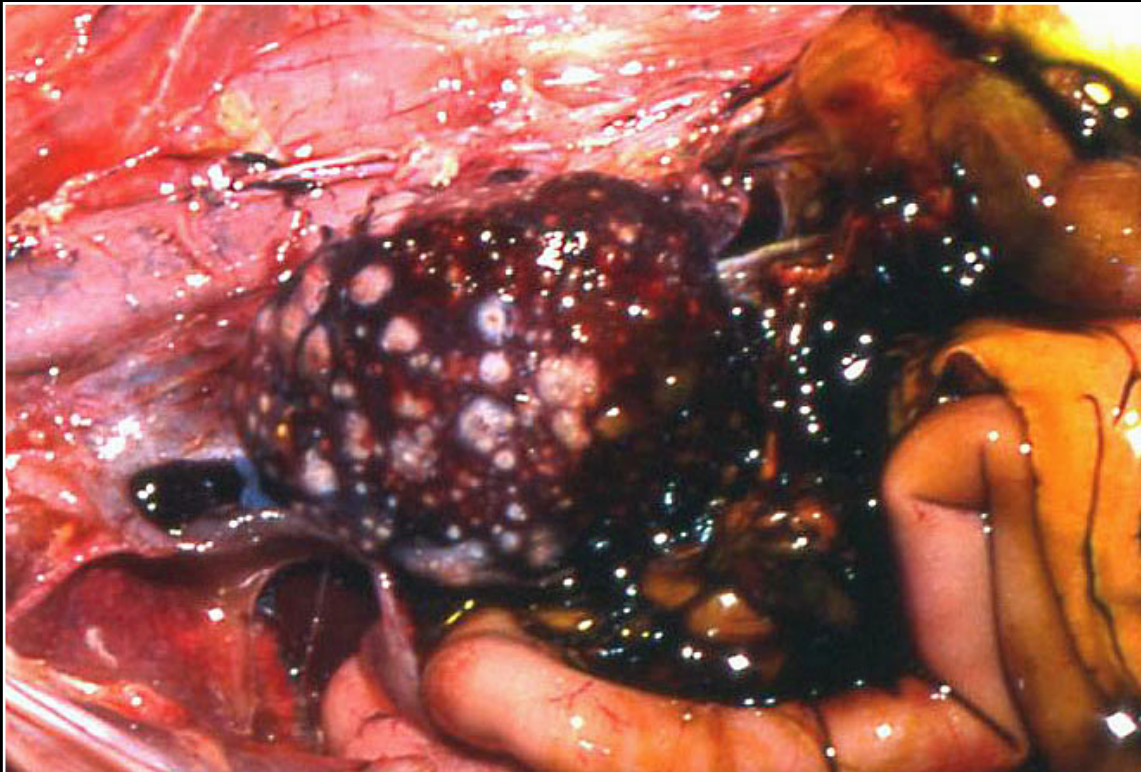
Back



CHAPTER 6

Lymphatic and Hematopoietic (Immune) System

Figure 6.19



Mycobacteriosis in a crane resulting in splenic enlargement and multiple large white foci.

Prev. fig. Next fig.

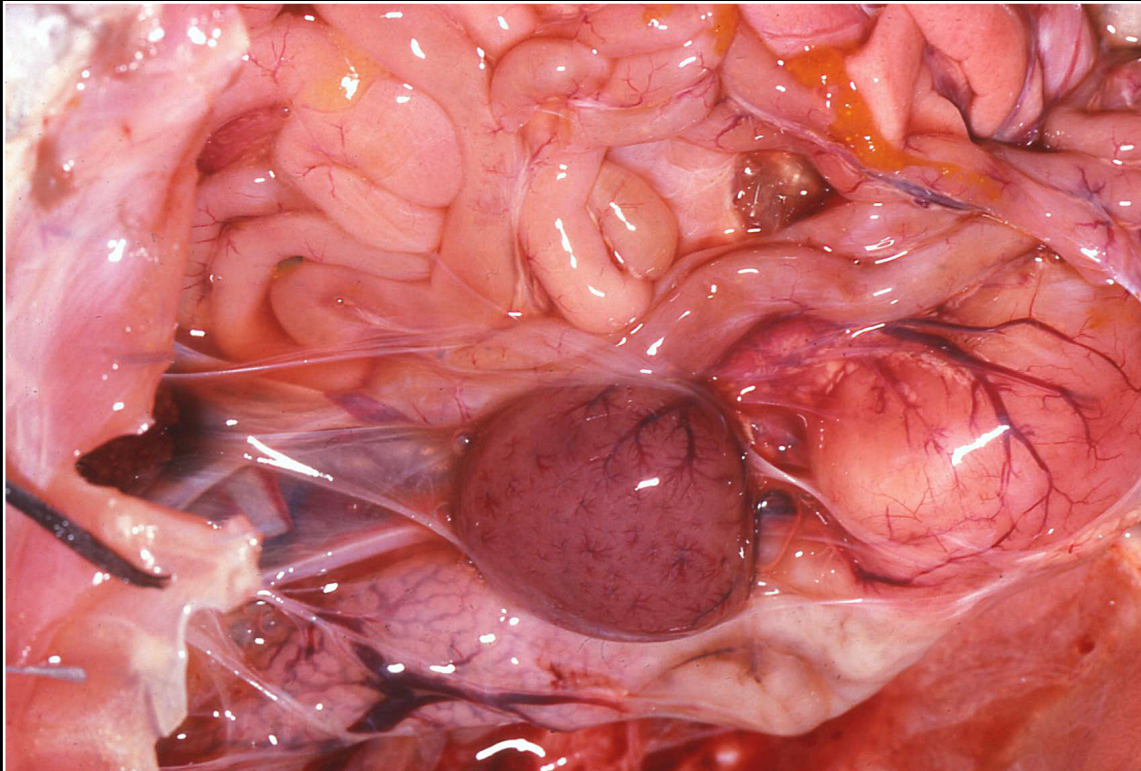
Back



CHAPTER 6

Lymphatic and Hematopoietic (Immune) System

Figure 6.20



Enlarged pale red-purple spleen in an African grey parrot with chlamydo-philosis.

Prev. fig. Next fig.

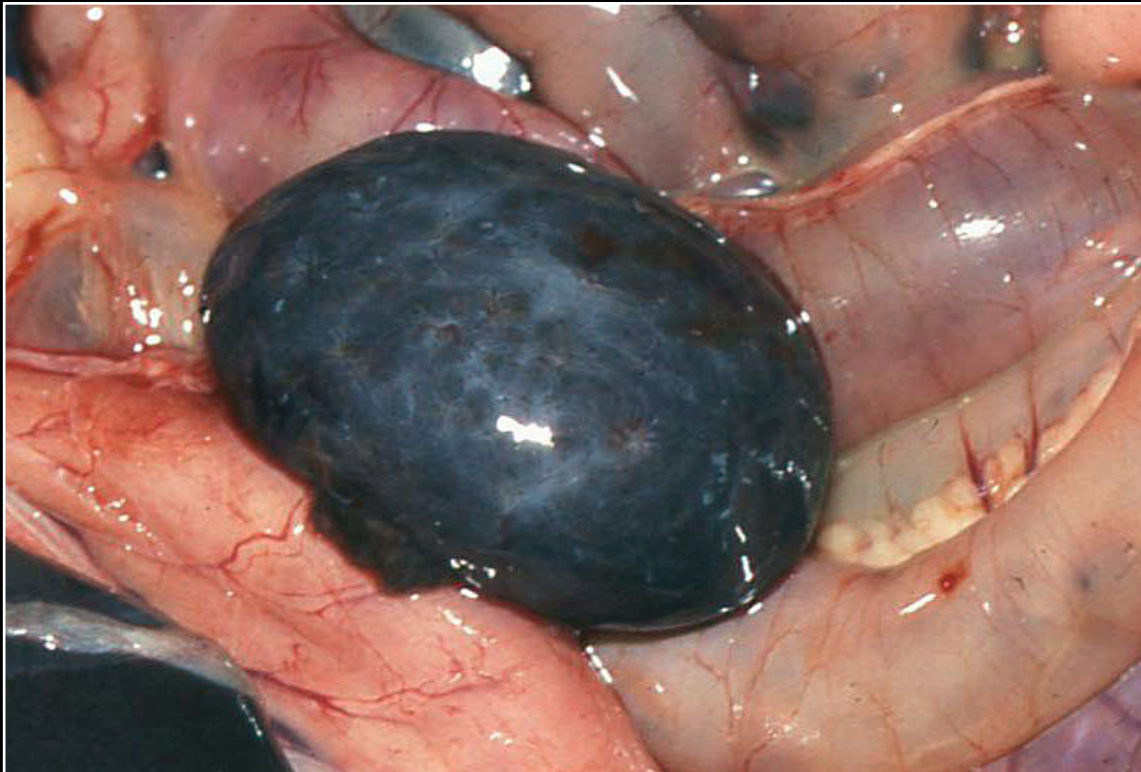Back



CHAPTER 6

Lymphatic and Hematopoietic (Immune) System

Figure 6.21



Markedly enlarged and almost black spleen in a falcon with plasmodium infection (malaria).

Prev. fig. Next fig.

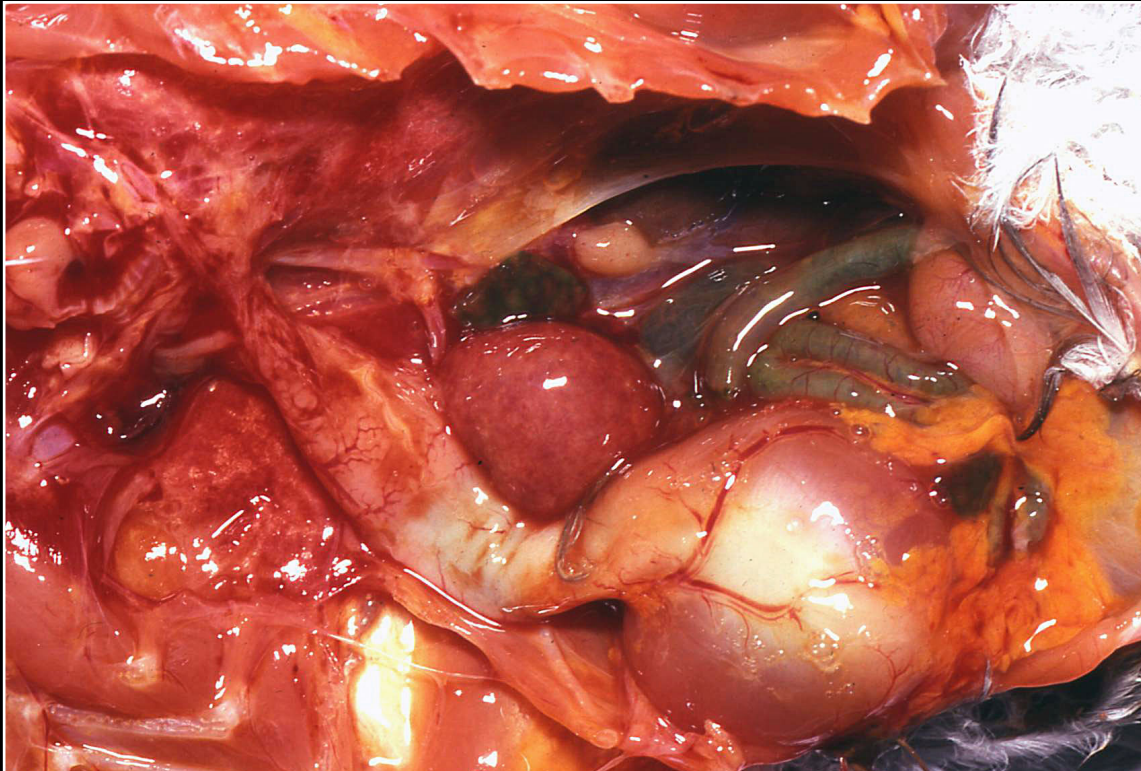
Back



CHAPTER 6

Lymphatic and Hematopoietic (Immune) System

Figure 6.22



Enlarged spleen in a cockatiel with sarcosporidiosis.

Prev. fig. Next fig.

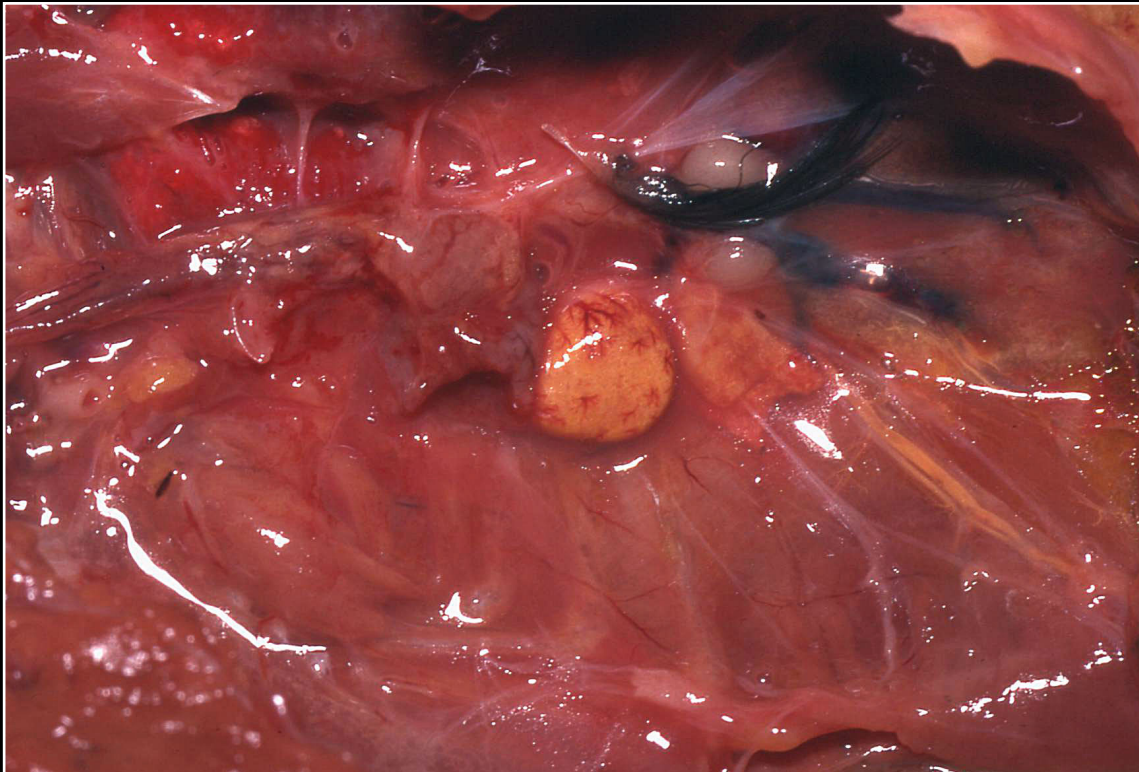
Back



CHAPTER 6

Lymphatic and Hematopoietic (Immune) System

Figure 6.23



Yellow spleen in a cockatiel with severe fatty liver and lipemia.

Prev. fig. Next fig.

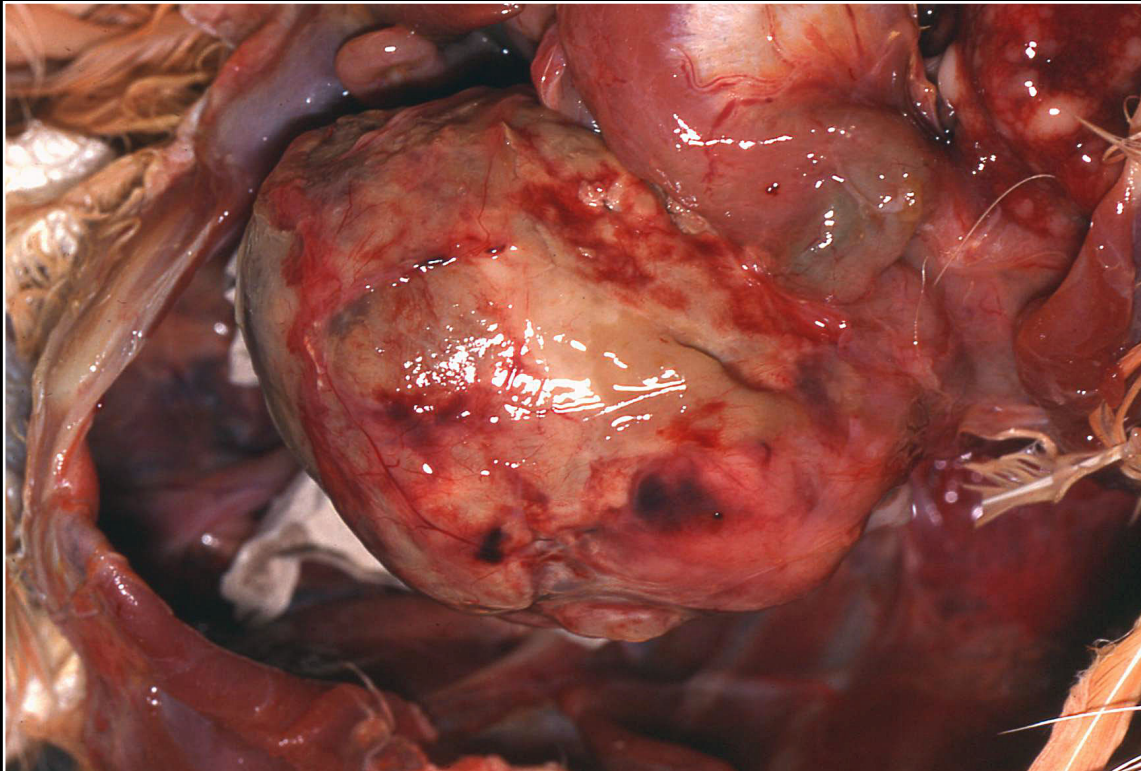
Back



CHAPTER 6

Lymphatic and Hematopoietic (Immune) System

Figure 6.24



Markedly enlarged spleen in a cockatoo with lymphosarcoma.

Prev. fig. Next fig.

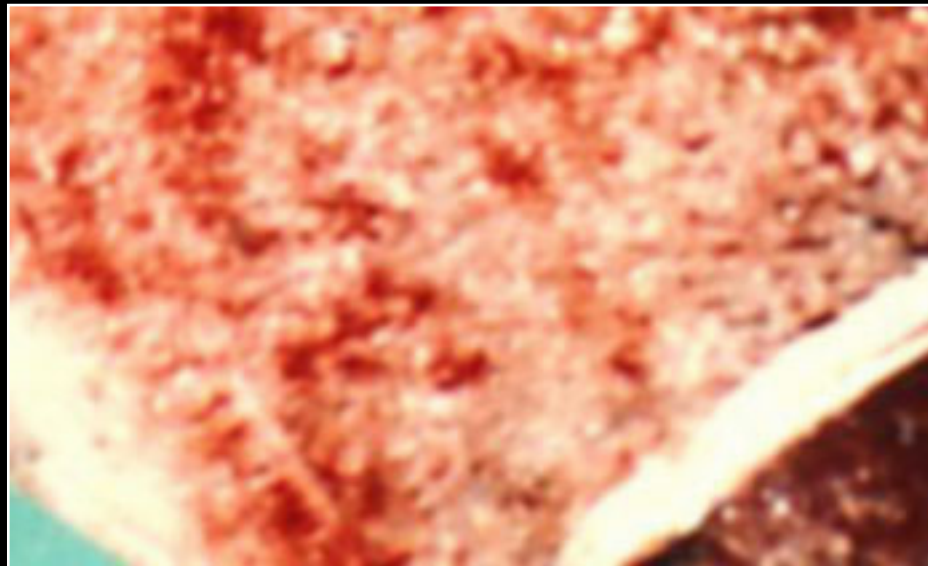Back



CHAPTER 6

Lymphatic and Hematopoietic (Immune) System

Figure 6.25



Diffuse yellow/fatty appearance of hypoplastic bone marrow.

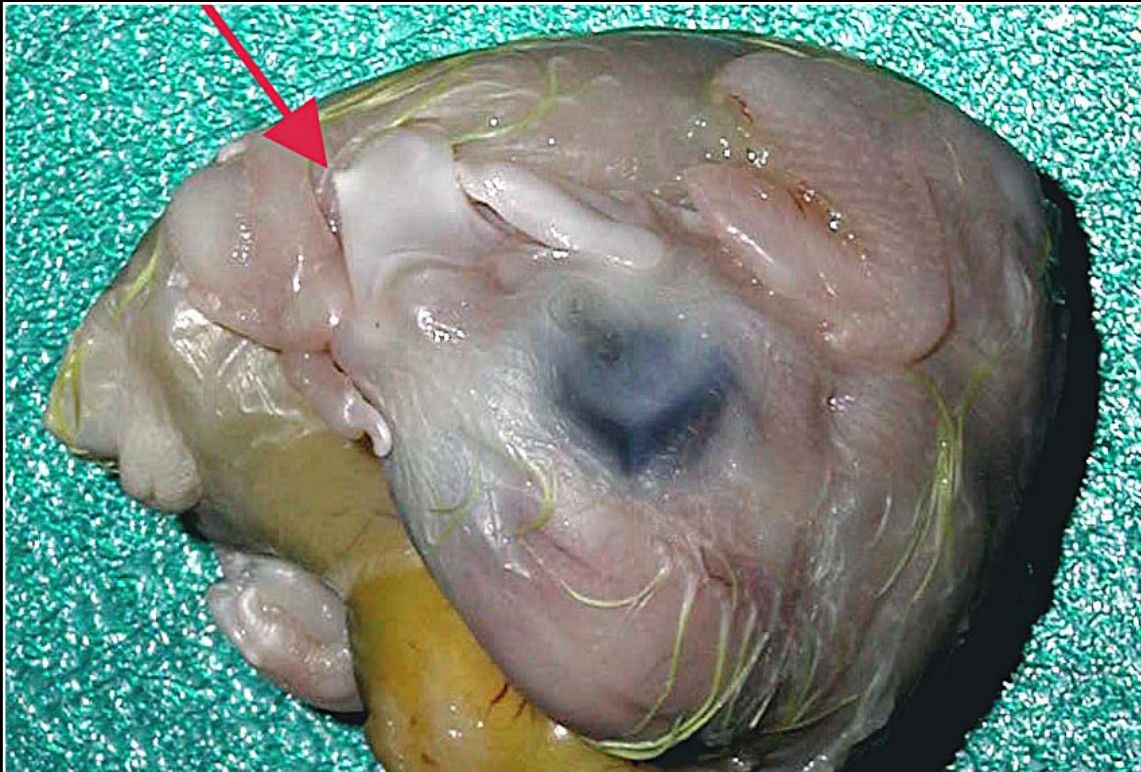
Prev. fig.

Back

CHAPTER 7

Gastrointestinal System and Pancreas

Figure 7.1



Normal egg tooth (arrow).

Next fig.

Back



C H A P T E R 7

Gastrointestinal System and Pancreas

Figure 7.2



Lateral beak deviation of undetermined cause.

Prev. fig. Next fig.

Back



C H A P T E R 7

Gastrointestinal System and Pancreas

Figure 7.3



Severe elongation of the beak in chronic liver disease.

Prev. fig. Next fig.

Back



C H A P T E R 7

Gastrointestinal System and Pancreas

Figure 7.4



Toucan with severe beak necrosis associated with a fungal infection.

Prev. fig. Next fig.

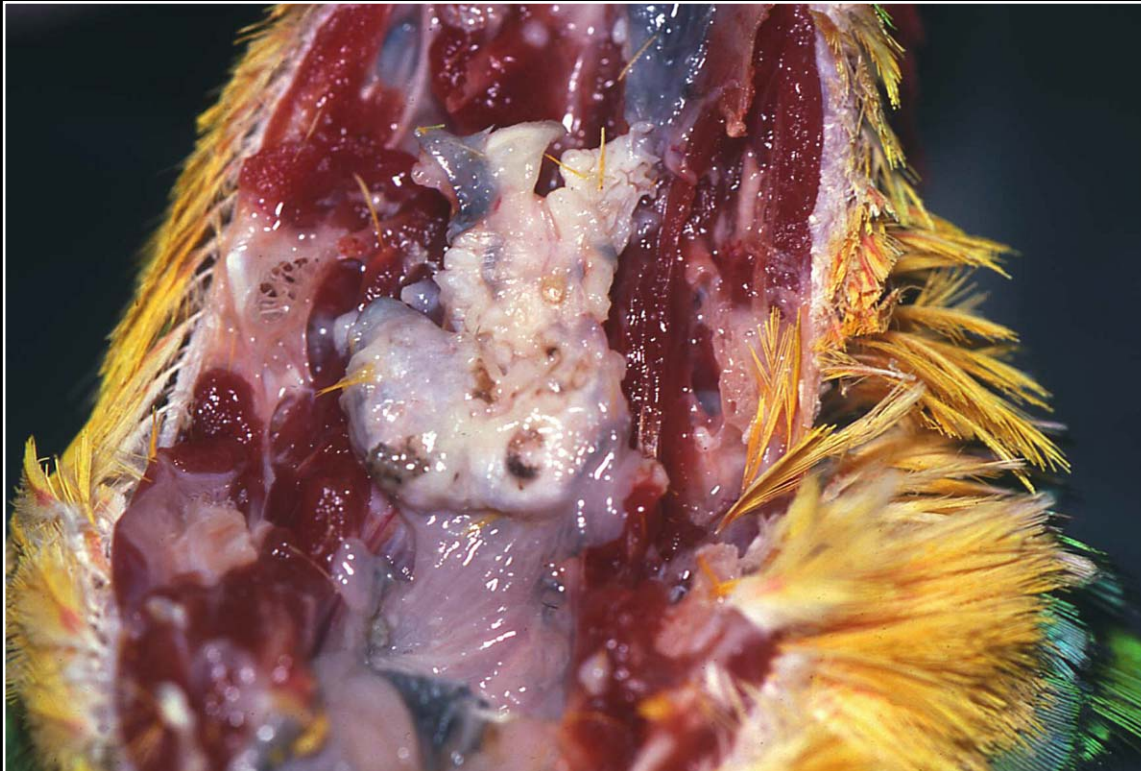
Back



C H A P T E R 7

Gastrointestinal System and Pancreas

Figure 7.5



Proliferative lesion in the oral cavity due to vitamin A deficiency with resultant squamous metaplasia of submucosal glands.

Prev. fig. Next fig.

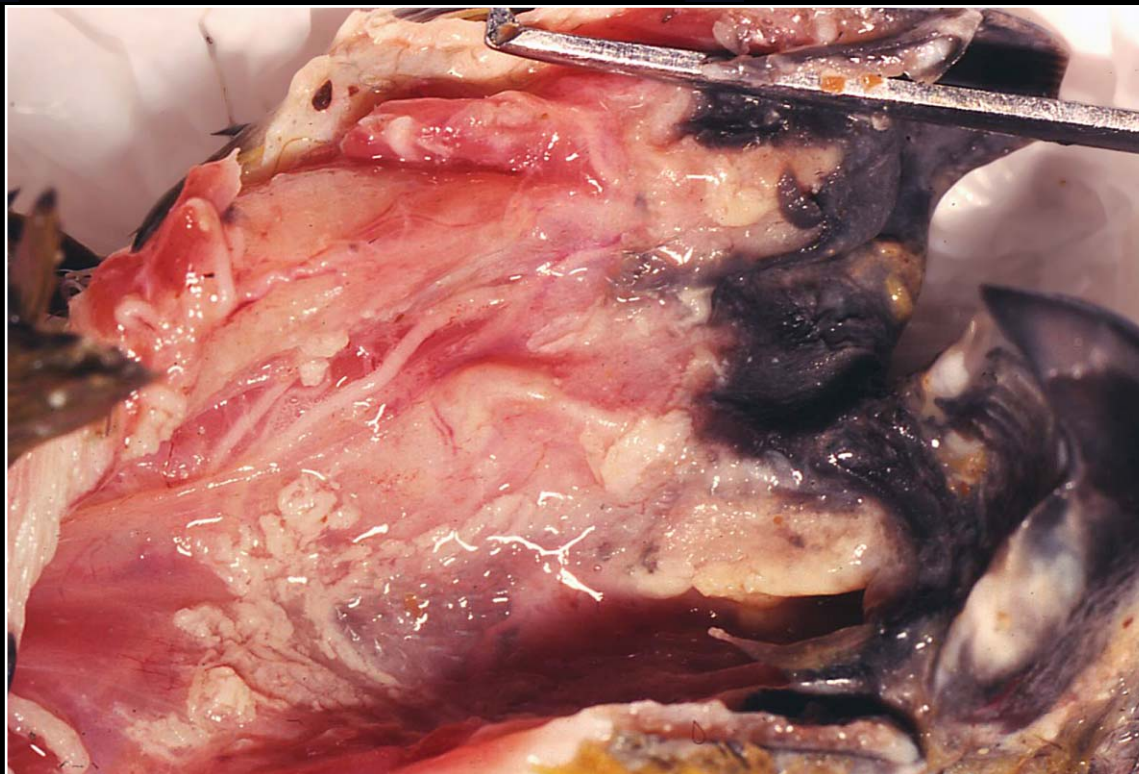
Back



CHAPTER 7

Gastrointestinal System and Pancreas

Figure 7.6



Oral mucosal hyperemia necrosis and accumulation of yellow-white, caseous-appearing material in poxvirus infection.

Prev. fig. Next fig.

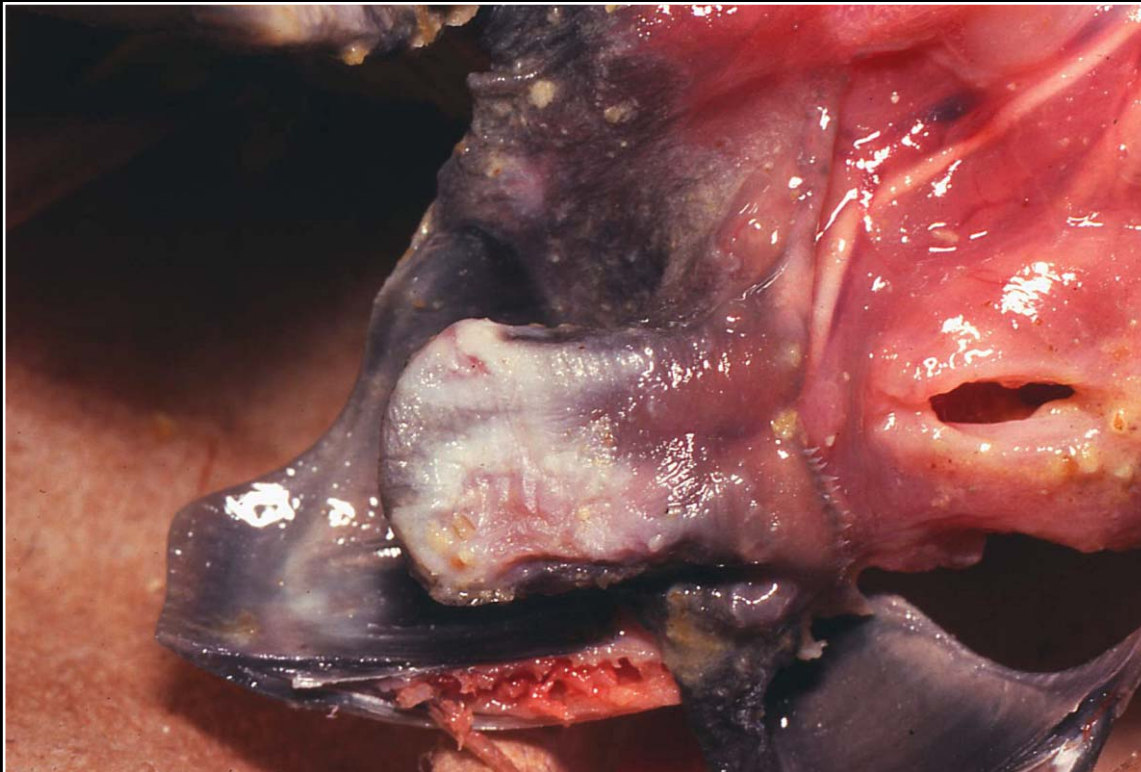
Back



CHAPTER 7

Gastrointestinal System and Pancreas

Figure 7.7



Scattered yellow nodules in poxvirus infection of the oral cavity.

Prev. fig. Next fig.

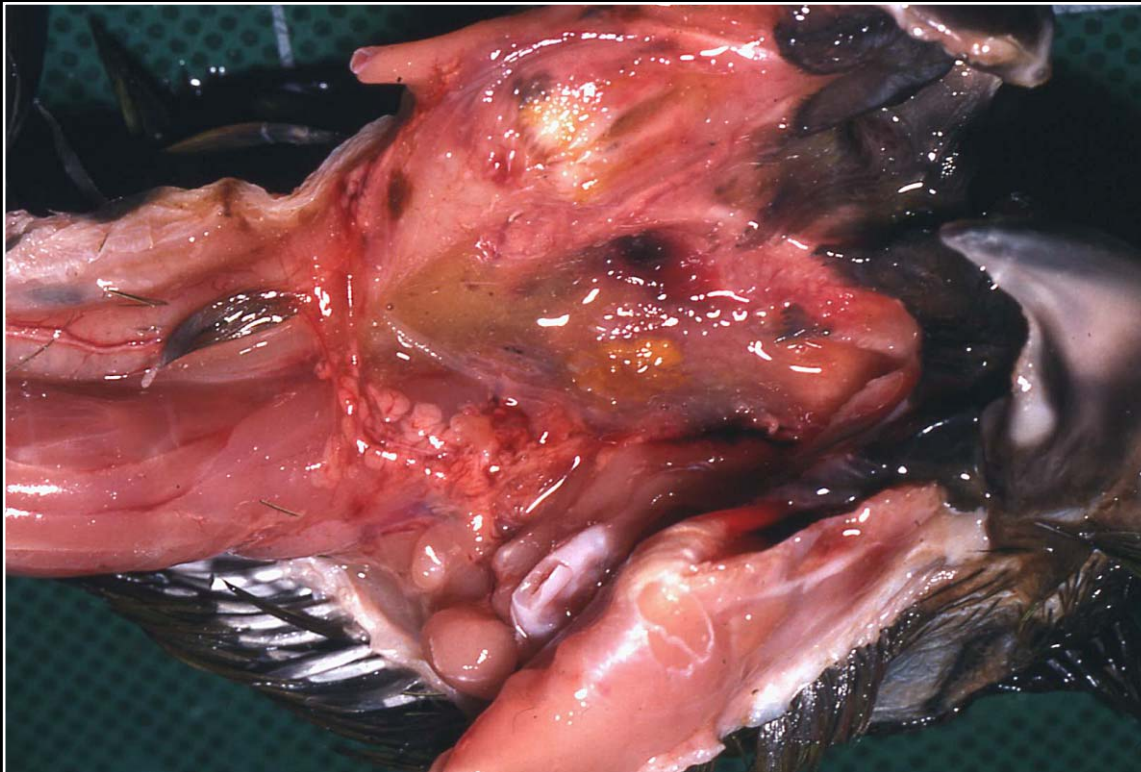
Back



C H A P T E R 7

Gastrointestinal System and Pancreas

Figure 7.8



Polyomavirus-induced hemorrhage and necrosis of the oral mucosa.

Prev. fig. Next fig.

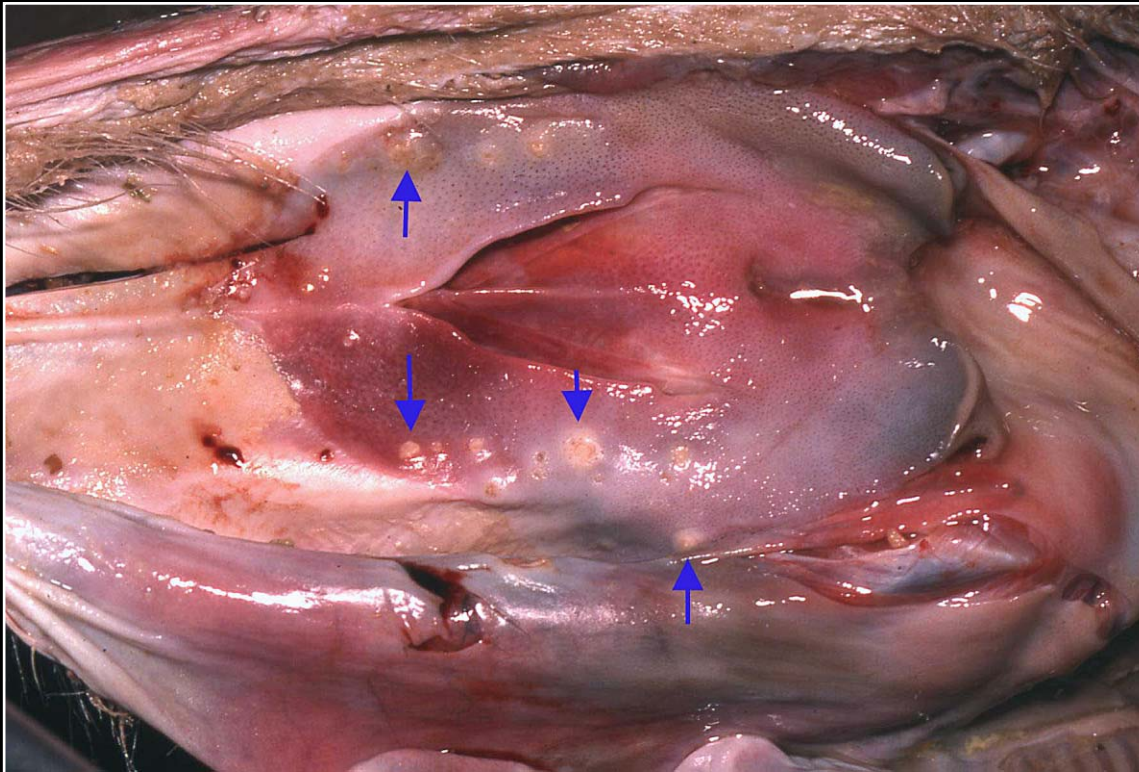
Back



CHAPTER 7

Gastrointestinal System and Pancreas

Figure 7.9



Generalized mucosal hyperemia and multifocal necrosis (arrows) in bacterial stomatitis.

Prev. fig. Next fig.

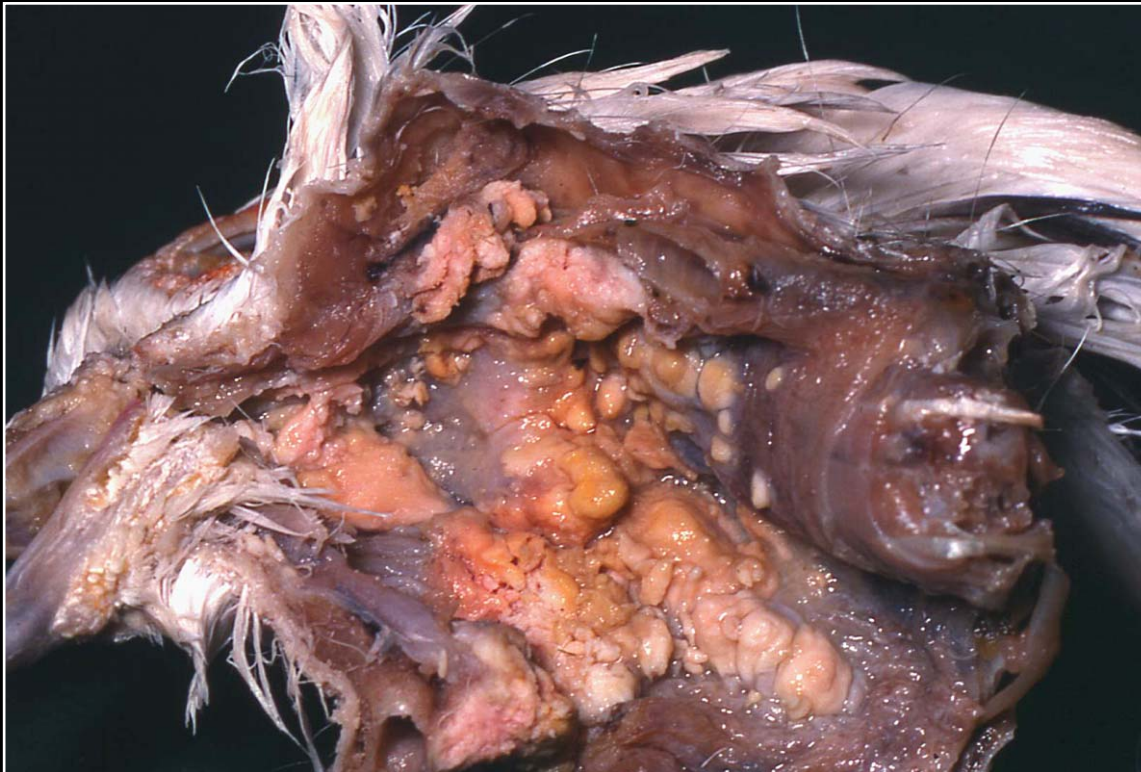Back



C H A P T E R 7

Gastrointestinal System and Pancreas

Figure 7.10



Severe oral trichomoniasis in a pigeon. Numerous plaques and nodules are seen.

Prev. fig. Next fig.

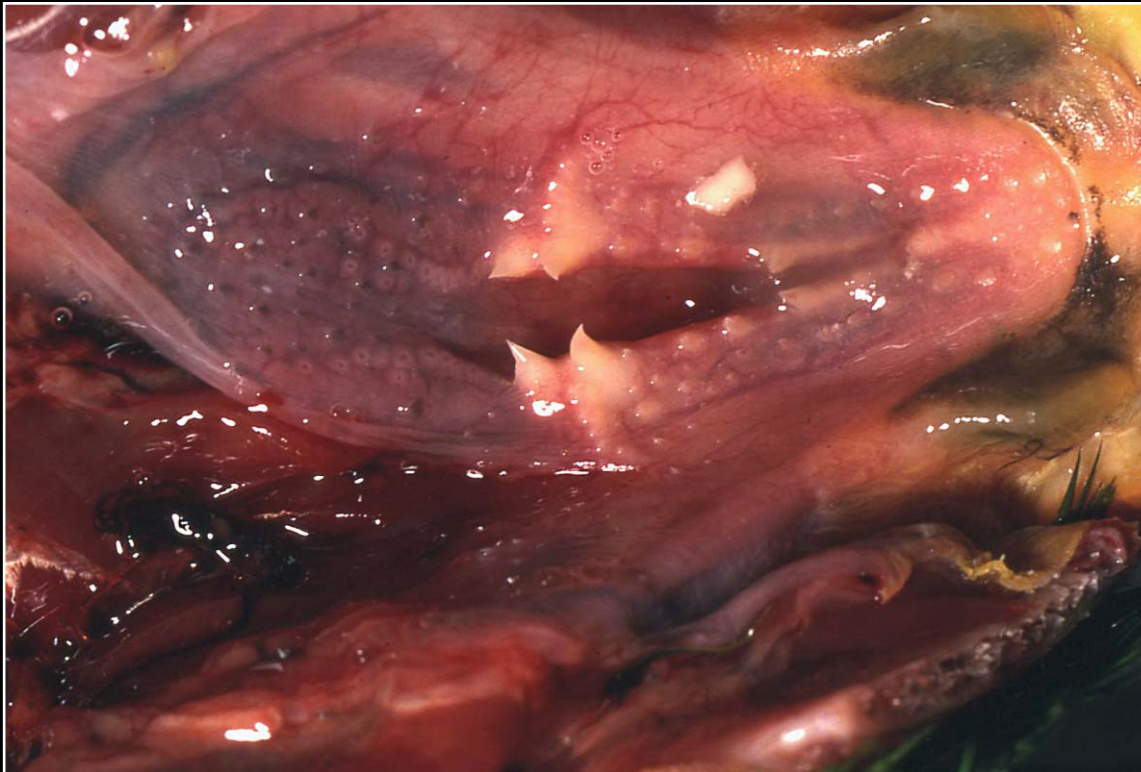
Back



CHAPTER 7

Gastrointestinal System and Pancreas

Figure 7.11



Scattered papillomas of varying sizes along the choanal slit.

Prev. fig. Next fig.

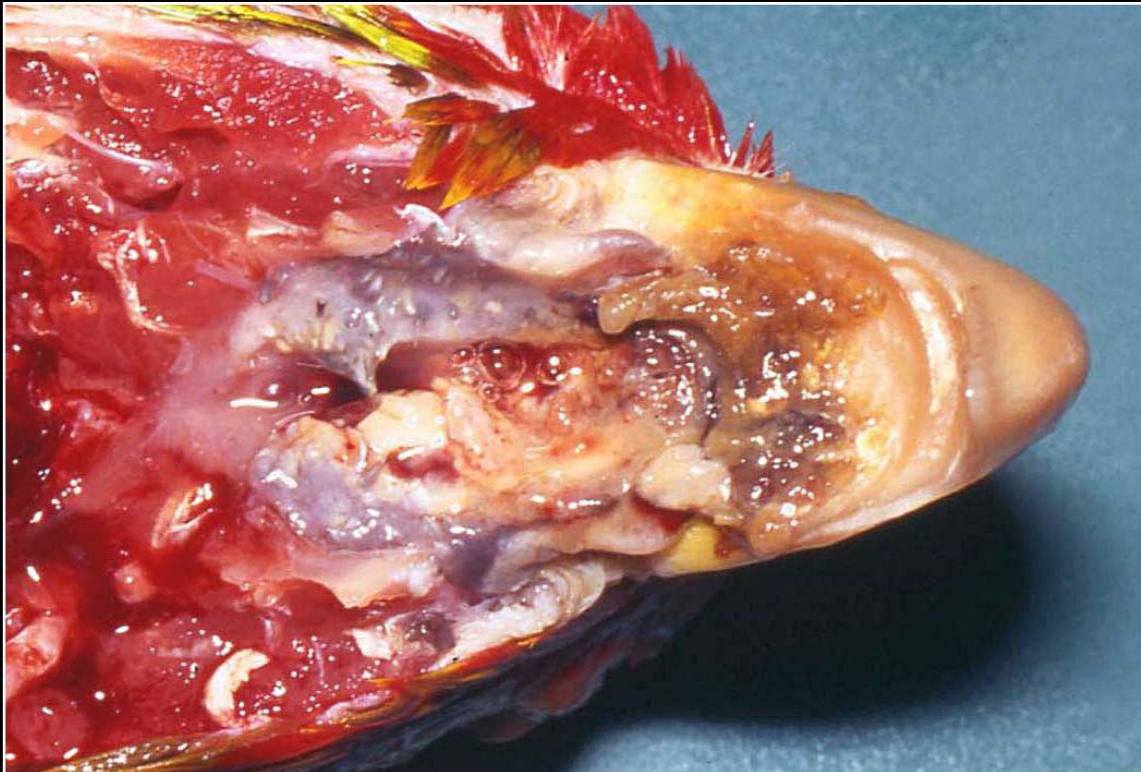
Back



C H A P T E R 7

Gastrointestinal System and Pancreas

Figure 7.12



Extensive damage to the oral cavity by large infiltrative squamous cell carcinoma.

Prev. fig. Next fig.

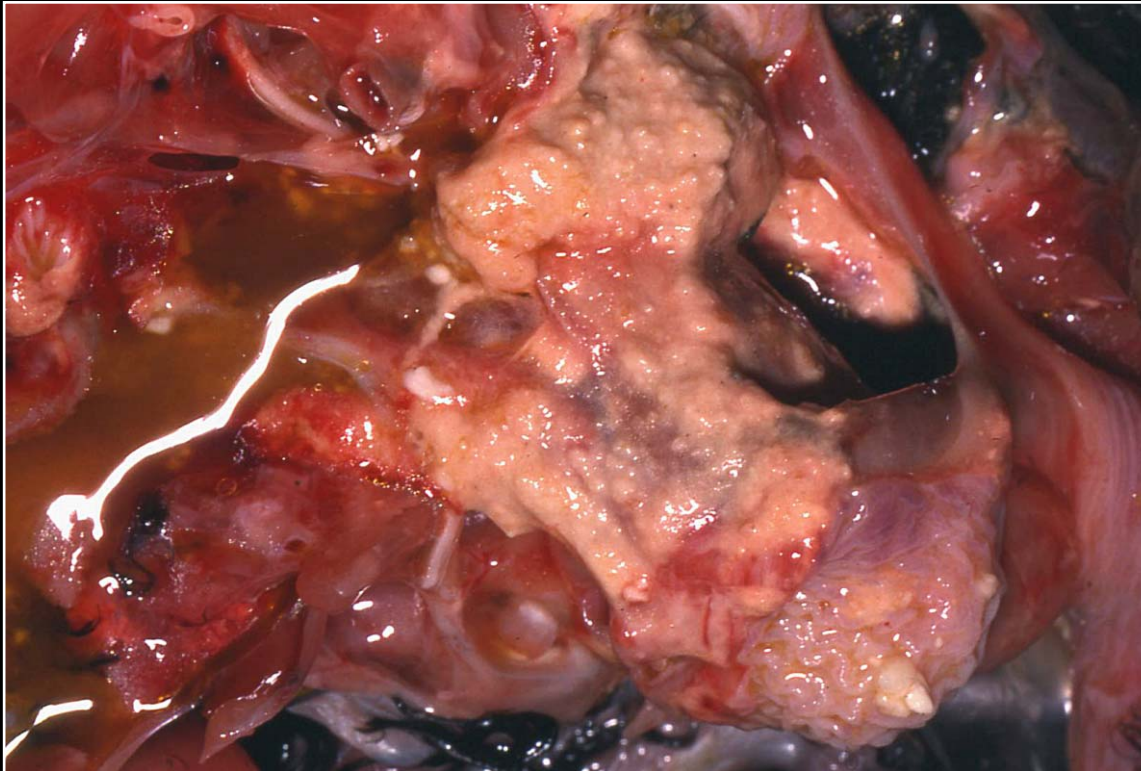
Back



C H A P T E R 7

Gastrointestinal System and Pancreas

Figure 7.13



Hyperemia, necrosis and accumulation of fluid in crop that was burned.

Prev. fig. Next fig.

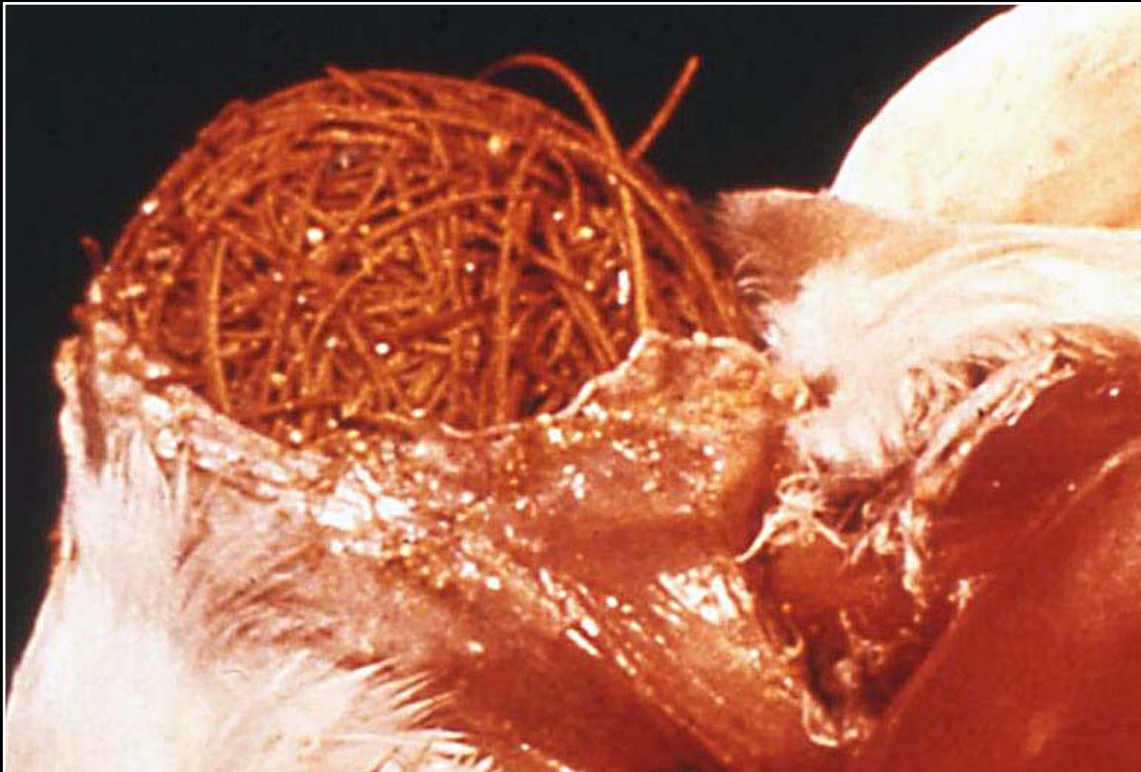Back



C H A P T E R 7

Gastrointestinal System and Pancreas

Figure 7.14



Impaction of the crop following foreign material ingestion.

Prev. fig. Next fig.

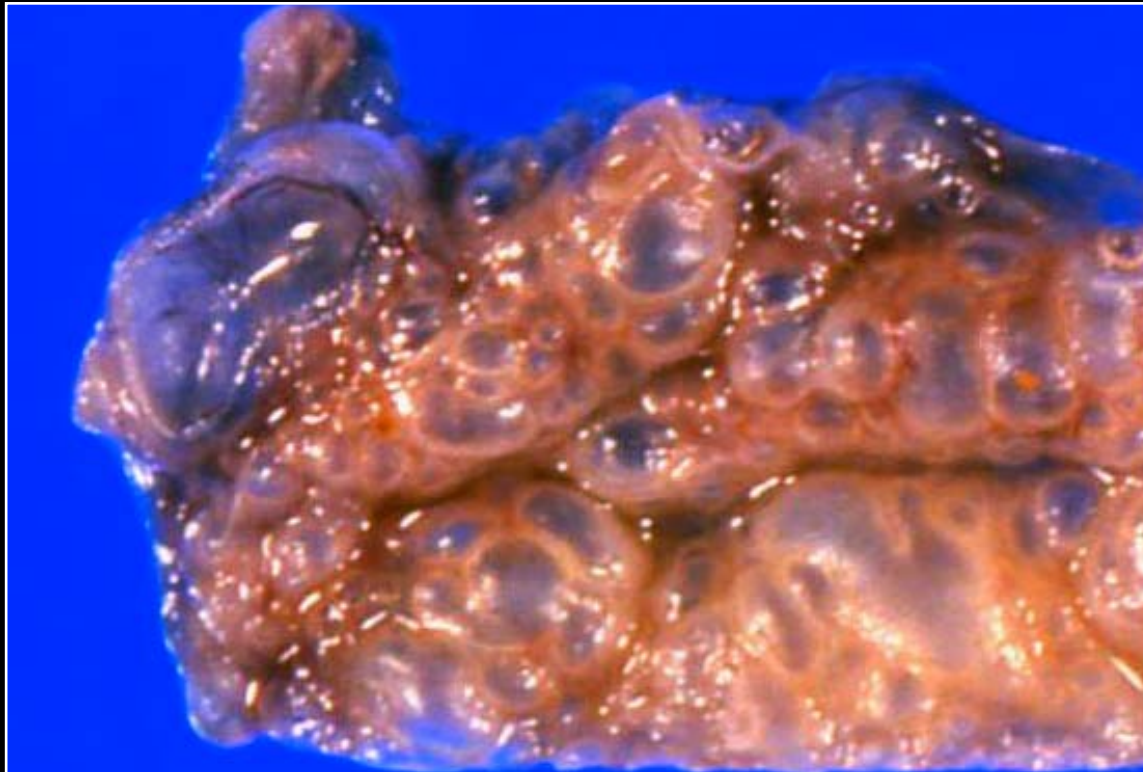
Back



C H A P T E R 7

Gastrointestinal System and Pancreas

Figure 7.15



Numerous dilated crop lymphatics. The cause of this unusual occurrence was not determined.

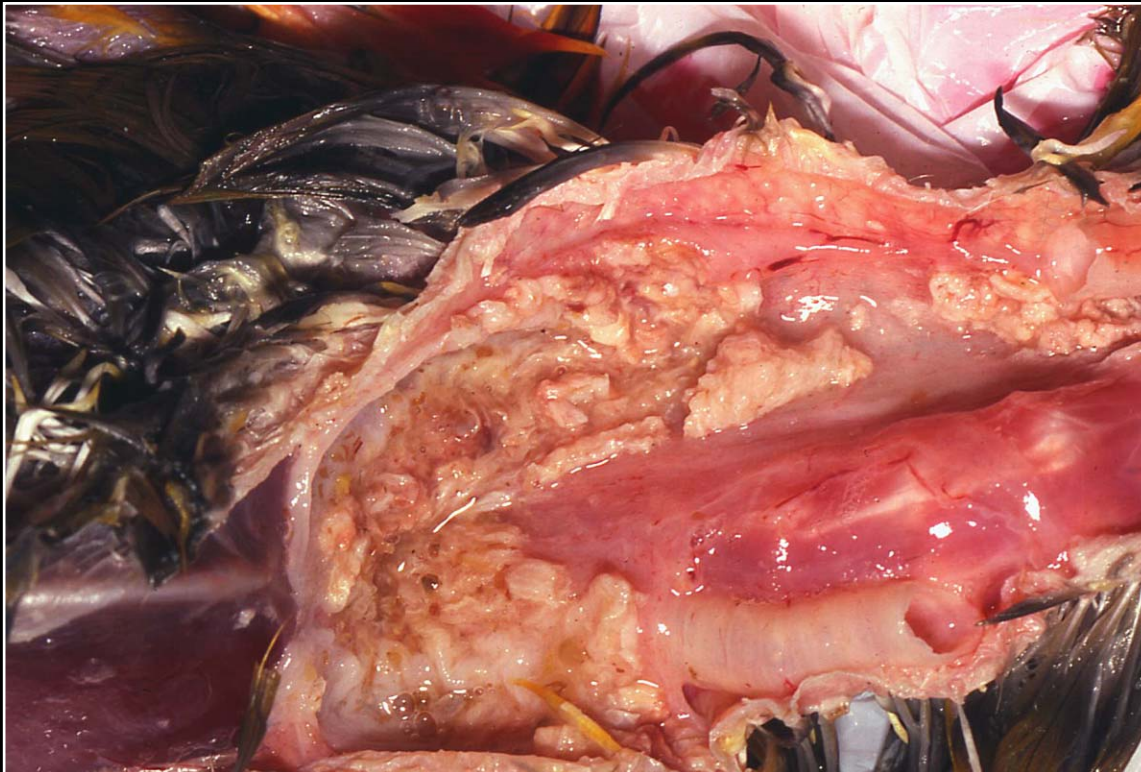
Prev. fig. Next fig.

Back

CHAPTER 7

Gastrointestinal System and Pancreas

Figure 7.16



Poxvirus ingluvitis with variable necrosis and accumulation of necrotic debris.

Prev. fig. Next fig.

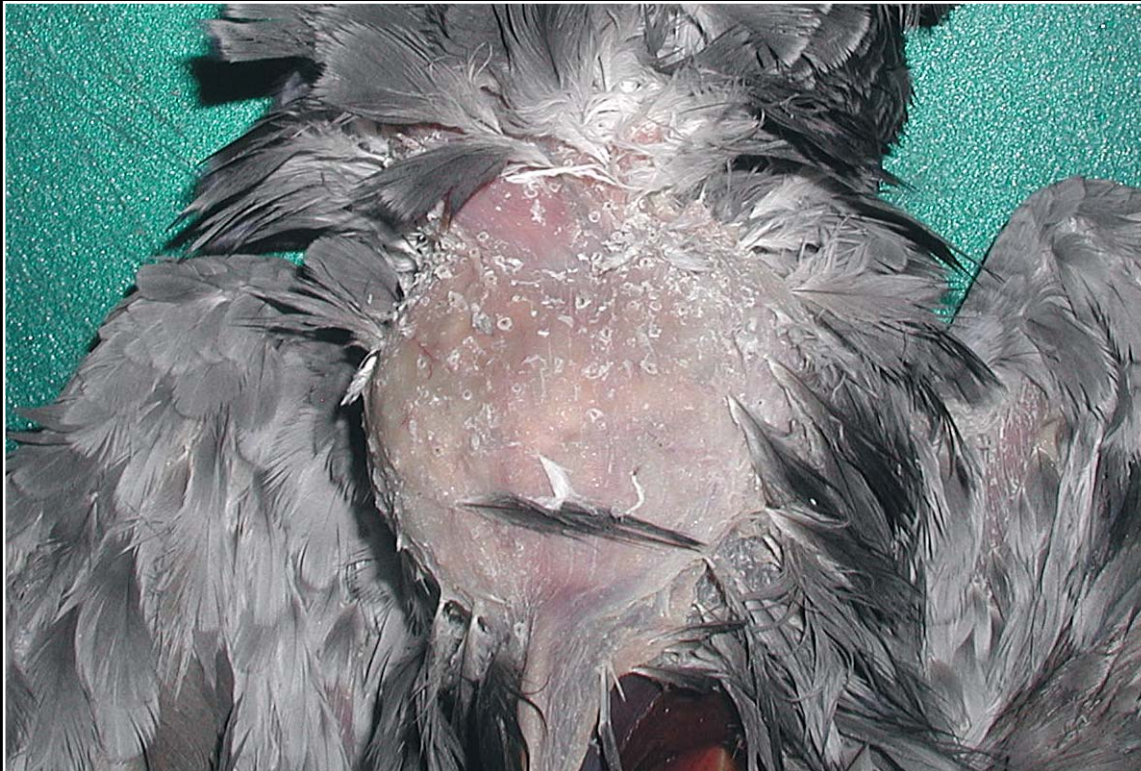Back



CHAPTER 7

Gastrointestinal System and Pancreas

Figure 7.17



Dilated, impacted crop in a bird with proventricular dilatation disease. The large swelling is visible on external examination.

Prev. fig. Next fig.

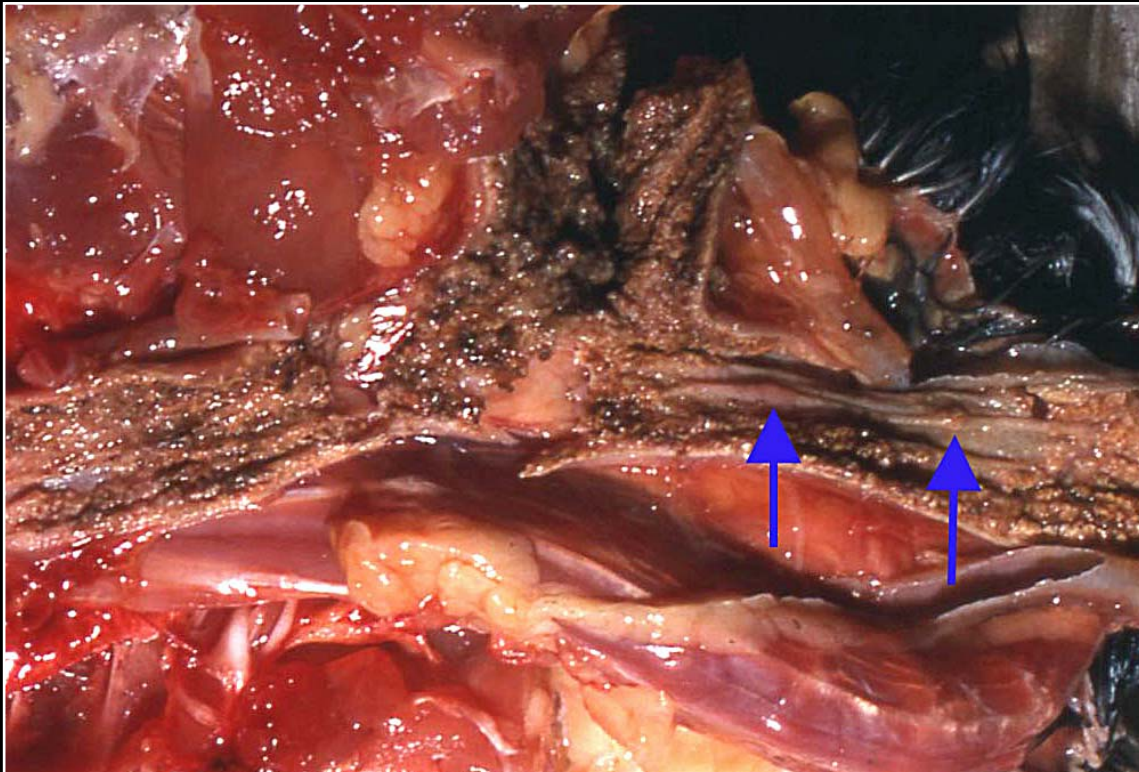
Back



CHAPTER 7

Gastrointestinal System and Pancreas

Figure 7.18



Bacterial infection of the esophagus and crop. Multiple foci of plaque formation and necrosis are present (arrows) and much of the brown material noted is exudate mixed with some food material.

Prev. fig. Next fig.

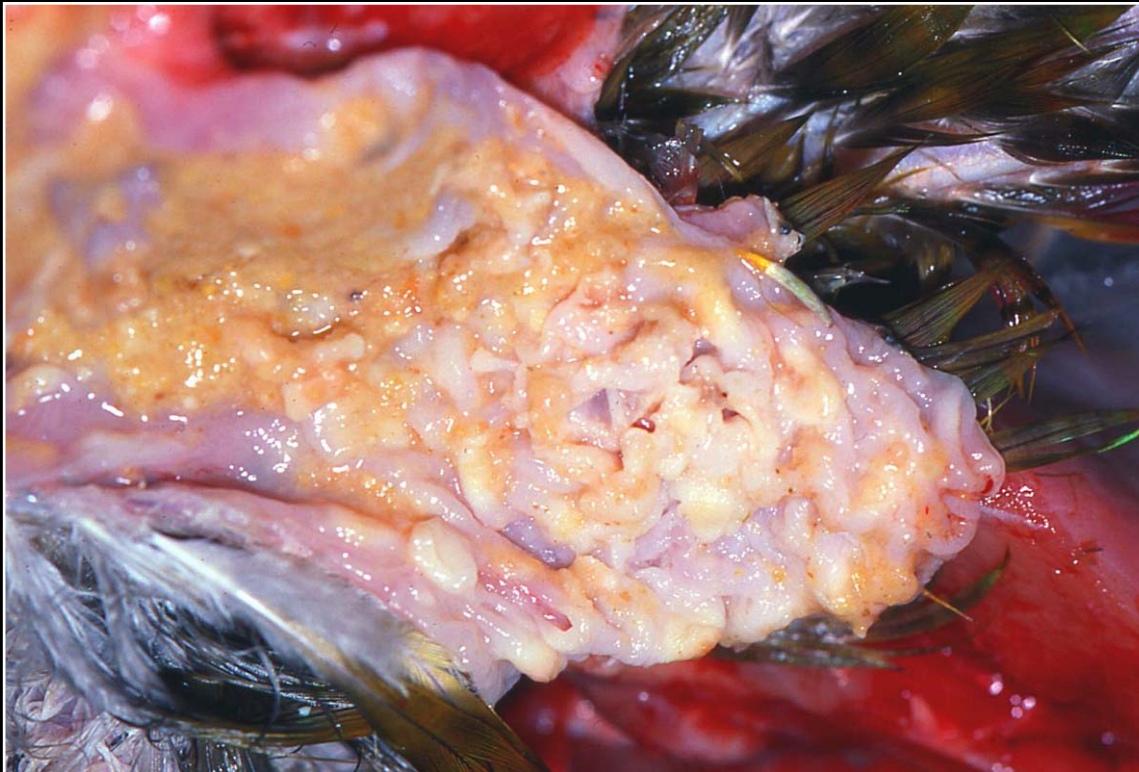Back



C H A P T E R 7

Gastrointestinal System and Pancreas

Figure 7.19



Thickened crop mucosa and yellow-white exudate in a bird with candidiasis.

Prev. fig. Next fig.

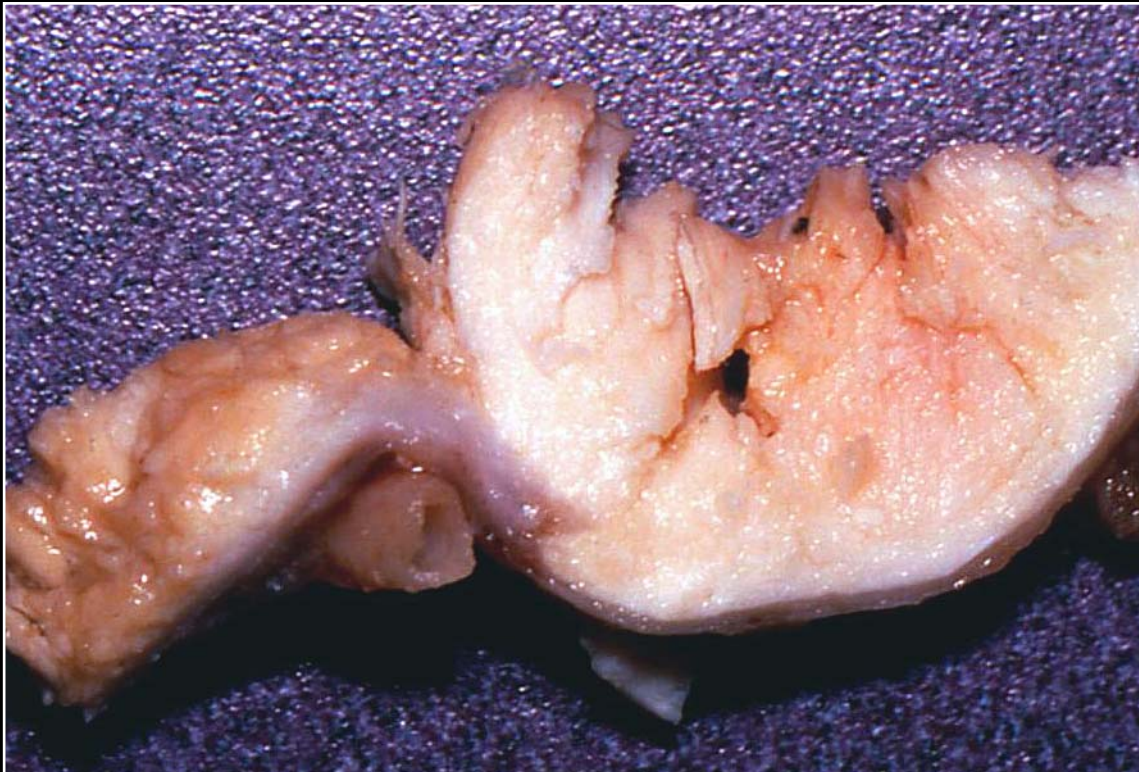Back



CHAPTER 7

Gastrointestinal System and Pancreas

Figure 7.20



Squamous cell carcinoma effacing the wall of the crop and filling the lumen. Grossly the tumor could not be differentiated from a carcinoma of the submucosal glands.

Prev. fig. Next fig.

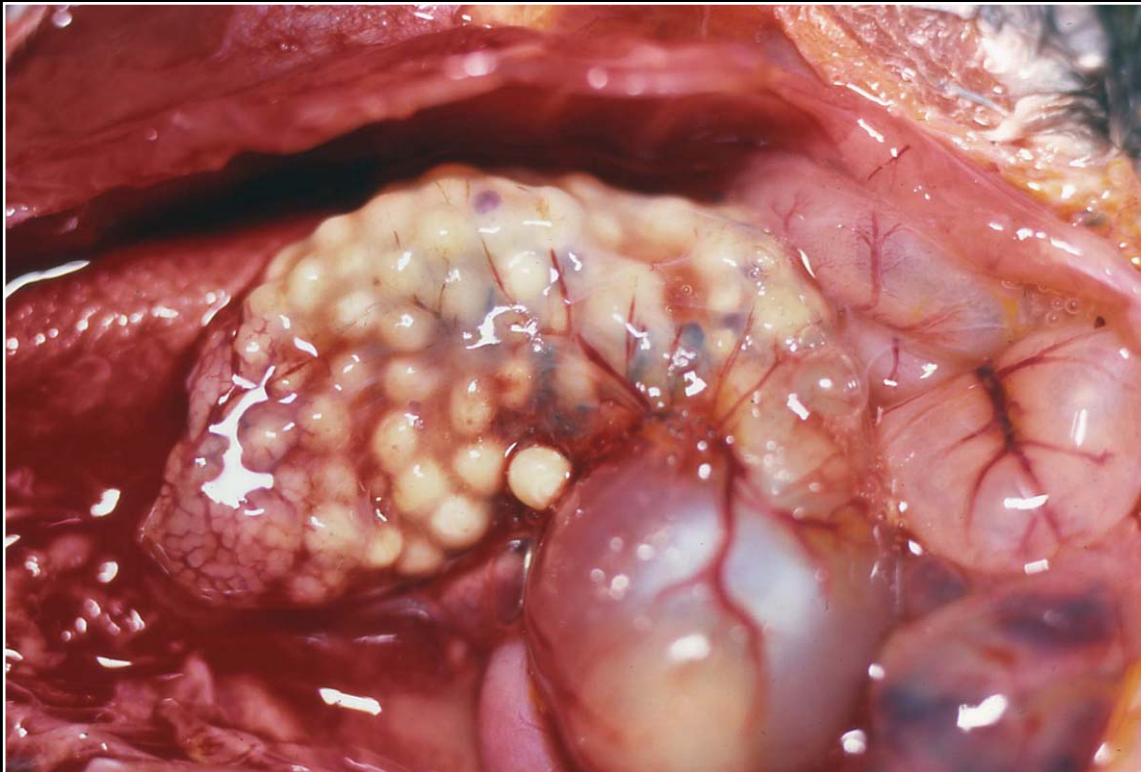
Back



CHAPTER 7

Gastrointestinal System and Pancreas

Figure 7.21



Dilated thin-walled proventriculus due to impaction. The ingesta can be clearly seen.

Prev. fig. Next fig.

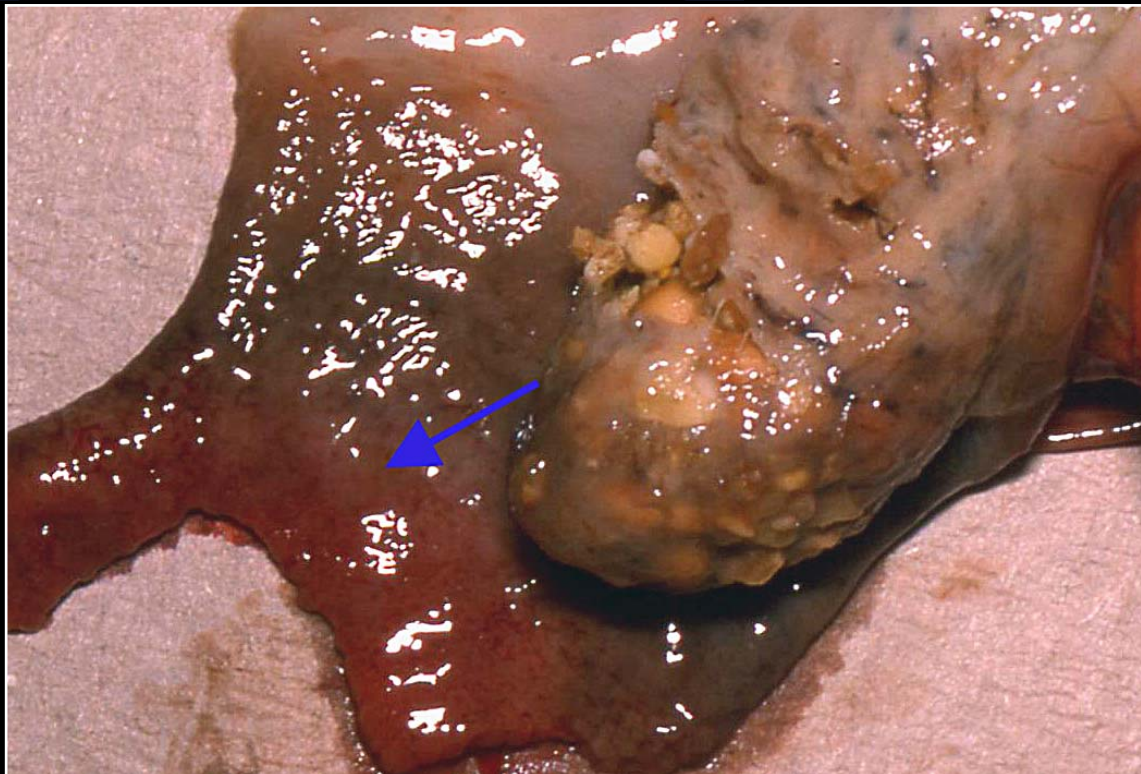
Back



C H A P T E R 7

Gastrointestinal System and Pancreas

Figure 7.22



Severe congestion and hemorrhage around an area of proventricular perforation (arrow).

Prev. fig. Next fig.

Back



C H A P T E R 7

Gastrointestinal System and Pancreas

Figure 7.23



Ingestion of rocks leading to proventricular impaction.

Prev. fig. Next fig.

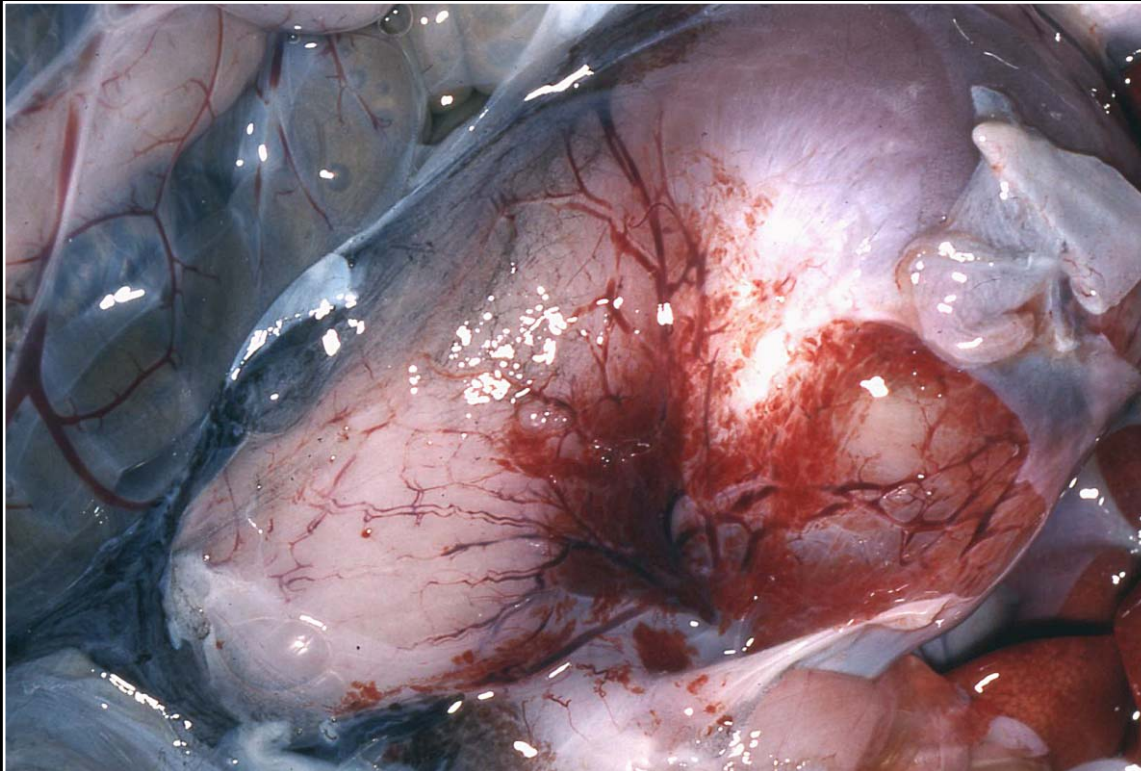
Back



C H A P T E R 7

Gastrointestinal System and Pancreas

Figure 7.24



Proventricular serosal hemorrhage. This can be an agonal/hypoxic change as well as an indicator of systemic disease.

Prev. fig. Next fig.

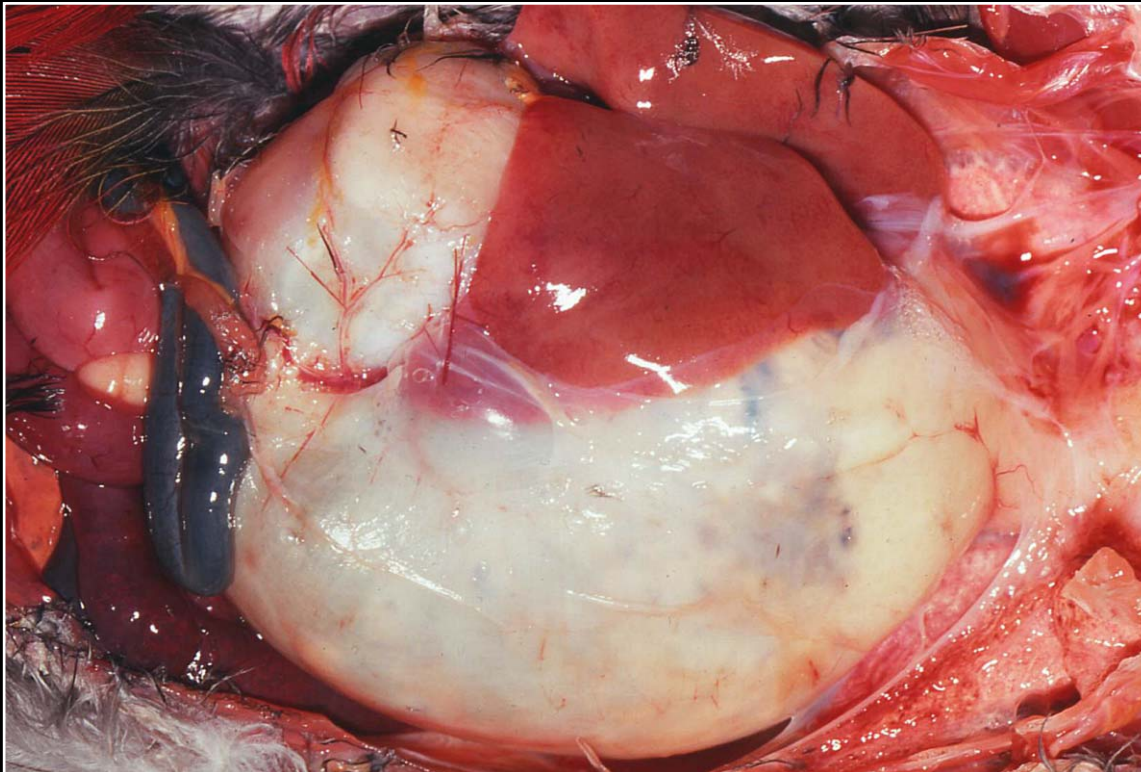
Back



C H A P T E R 7

Gastrointestinal System and Pancreas

Figure 7.25



Massive dilatation of the proventriculus in proventricular dilatation disease.

Prev. fig. Next fig.

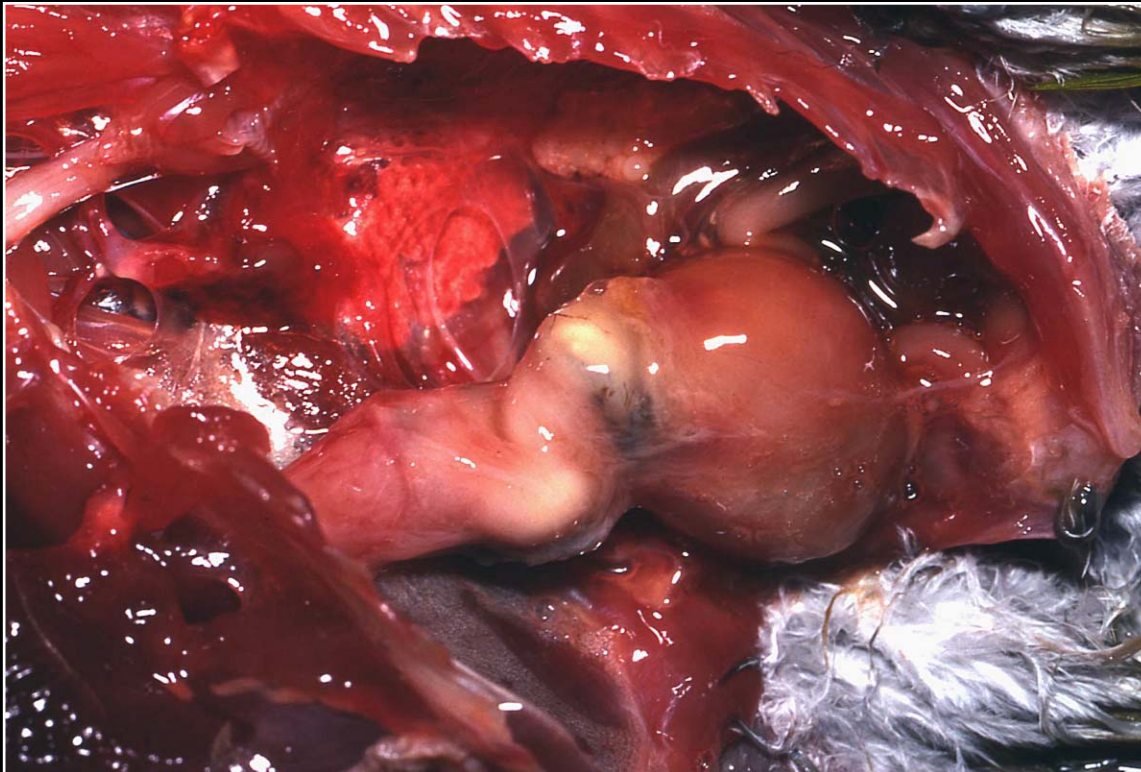
Back



C H A P T E R 7

Gastrointestinal System and Pancreas

Figure 7.26



Bacterial proventriculitis. Nodular areas of abscess formation are seen.

Prev. fig. Next fig.

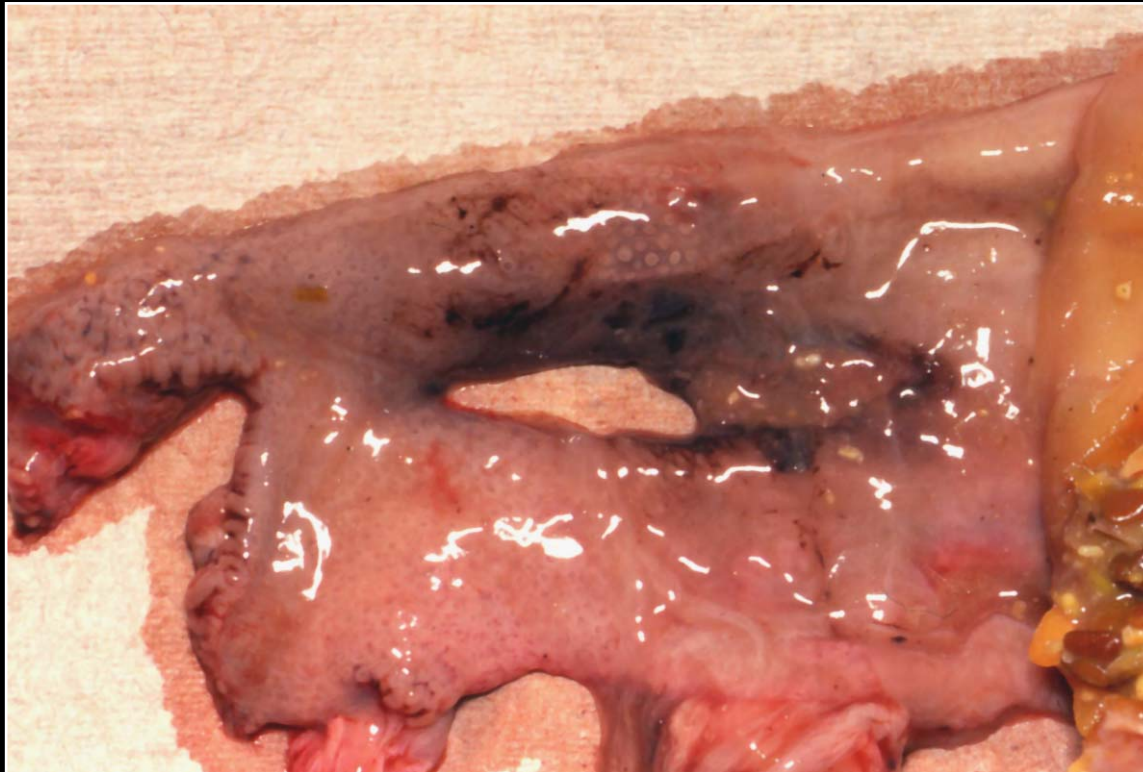
Back



C H A P T E R 7

Gastrointestinal System and Pancreas

Figure 7.27



Perforation of ventriculus in area of bacterial infection.

Prev. fig. Next fig.

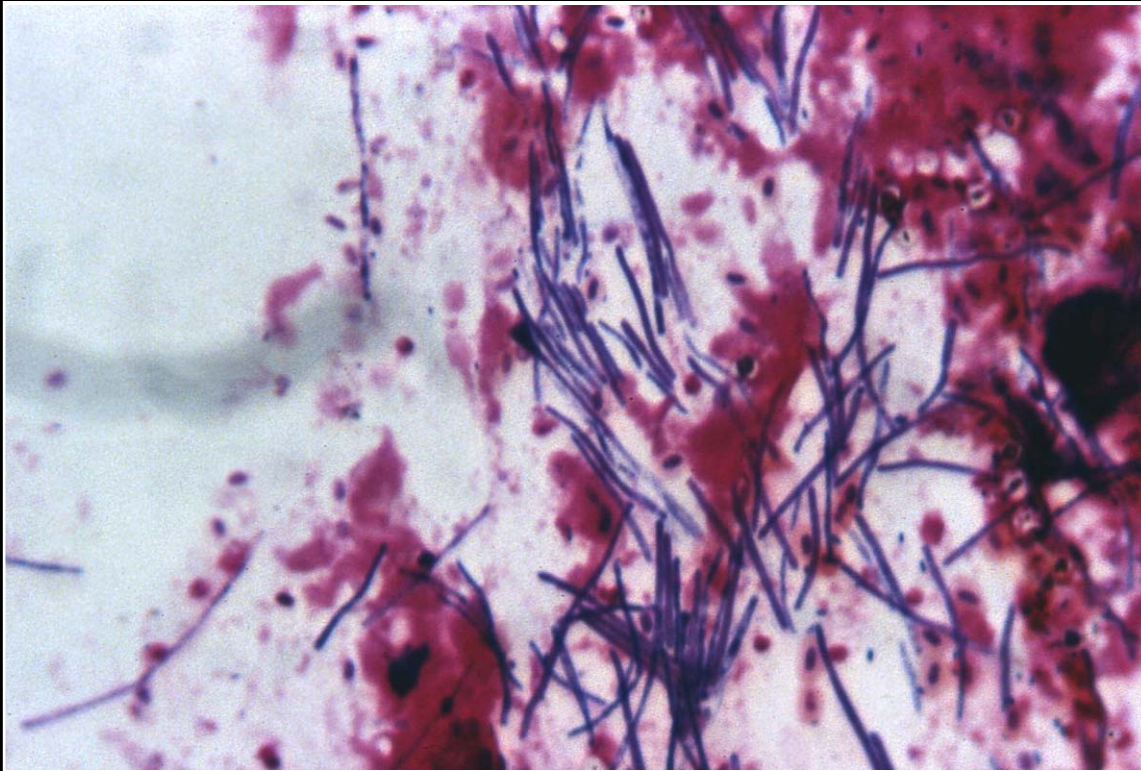
Back



CHAPTER 7

Gastrointestinal System and Pancreas

Figure 7.28



Numerous gastric yeast organisms ("megabacteria") as seen in smear of proventricular contents.

Prev. fig. Next fig.

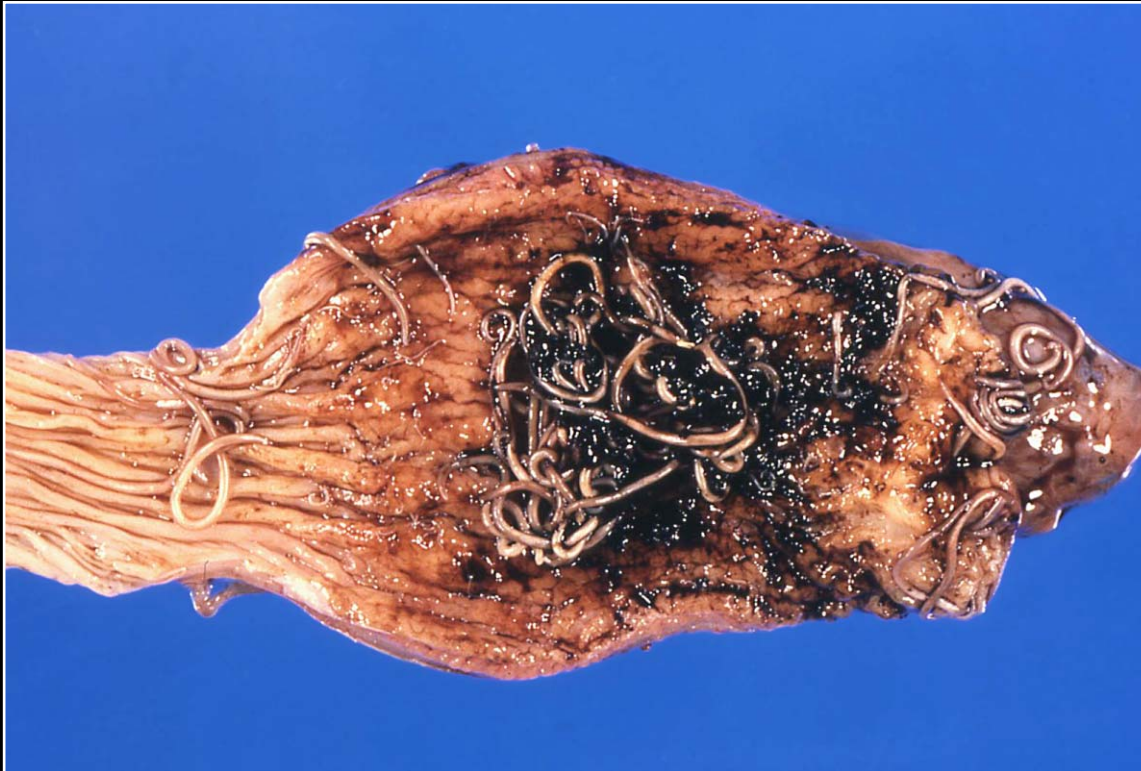Back



CHAPTER 7

Gastrointestinal System and Pancreas

Figure 7.29



Ascarid infection of the proventriculus. The proventricular mucosa is thickened and hemorrhagic.

Prev. fig. Next fig.

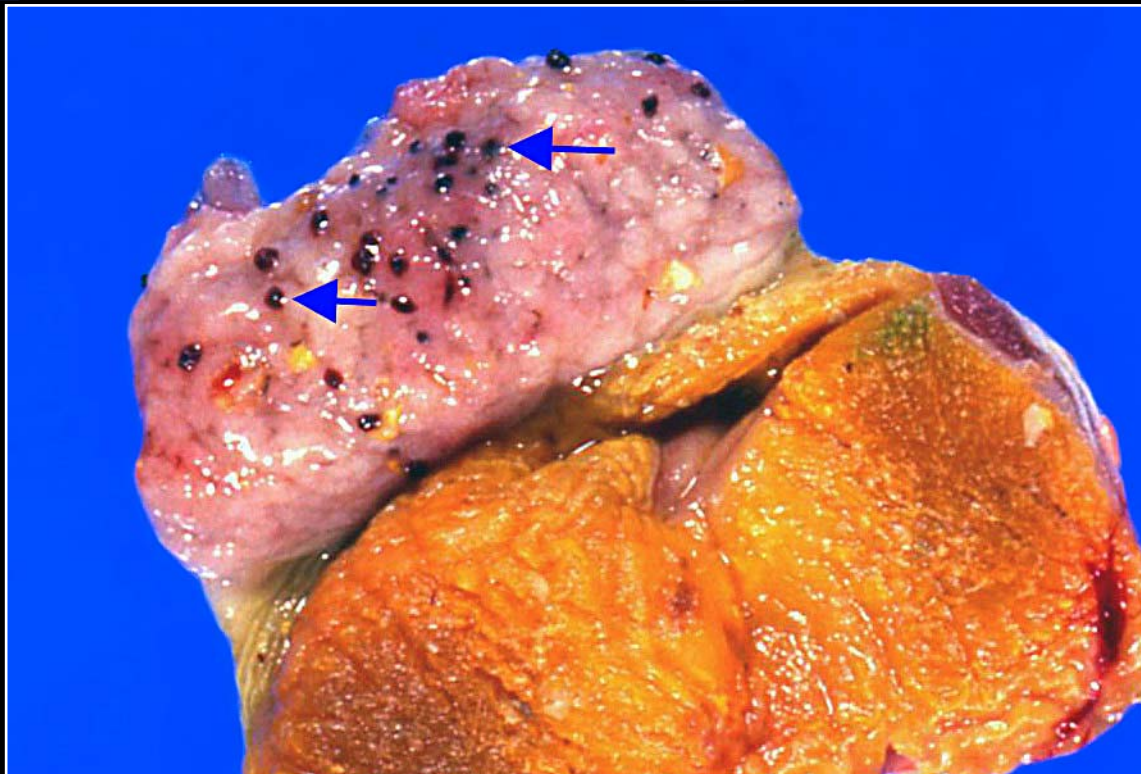
Back



C H A P T E R 7

Gastrointestinal System and Pancreas

Figure 7.30



Tetrameres infection of the proventriculus of a pigeon. Note numerous round, hemorrhagic foci (arrows)

Prev. fig. Next fig.

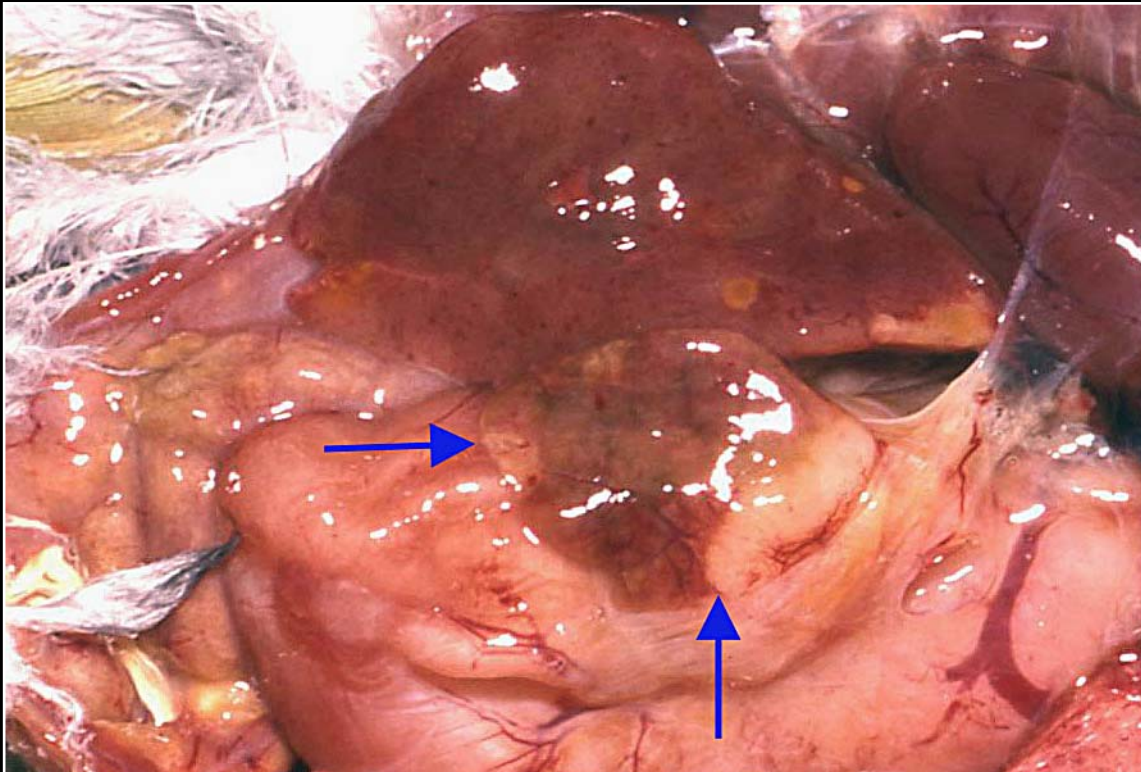
Back



C H A P T E R 7

Gastrointestinal System and Pancreas

Figure 7.31



Proventricular carcinoma with flat growth that is distorting the proventriculus and has led to adhesion of the liver to the infiltrating mass (arrows).

Prev. fig. Next fig.

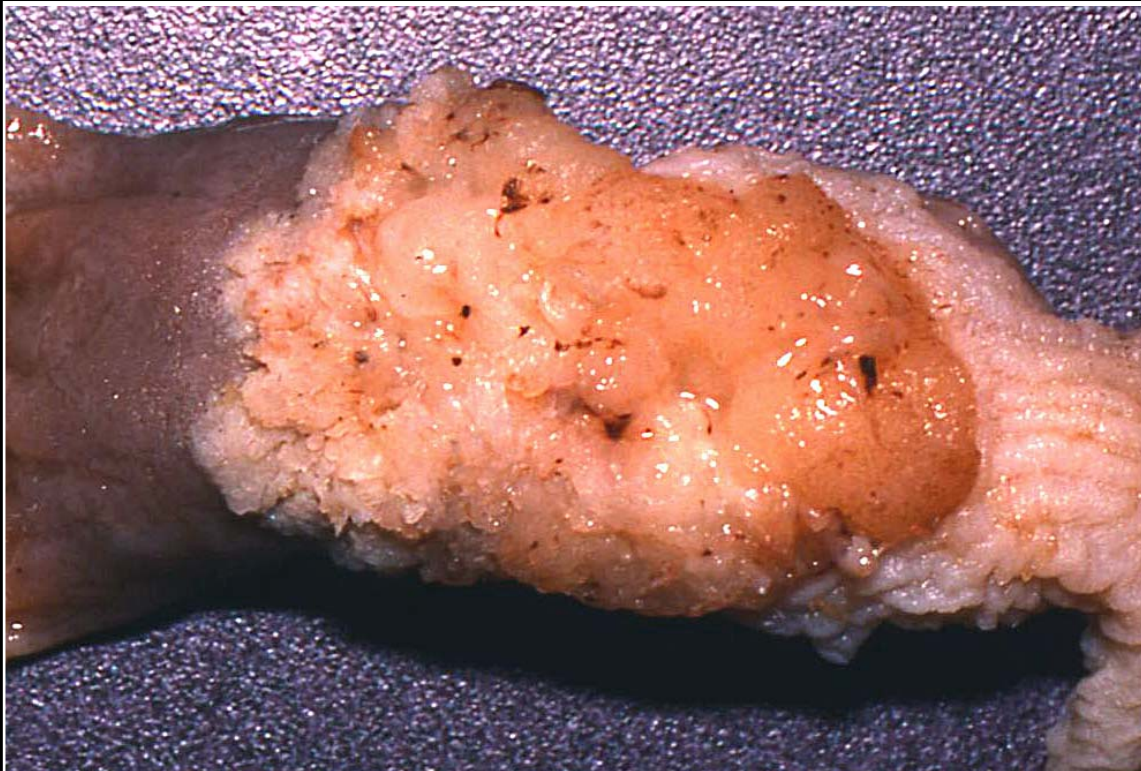Back



CHAPTER 7

Gastrointestinal System and Pancreas

Figure 7.32



Mucosal appearance of proliferative proventricular carcinoma.

Prev. fig. Next fig.

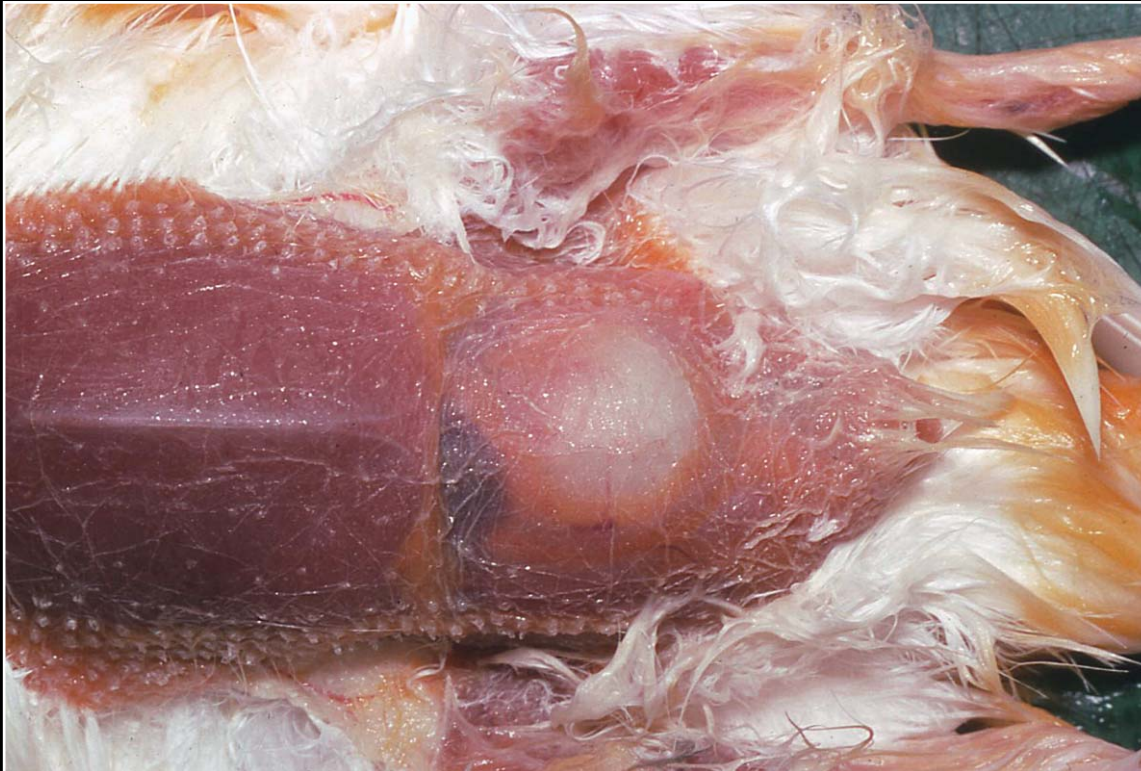Back



C H A P T E R 7

Gastrointestinal System and Pancreas

Figure 7.33



Ventricular hypertrophy possibly secondary to improper diet. The organ is enlarged and easily visible through the body wall.

Prev. fig. Next fig.

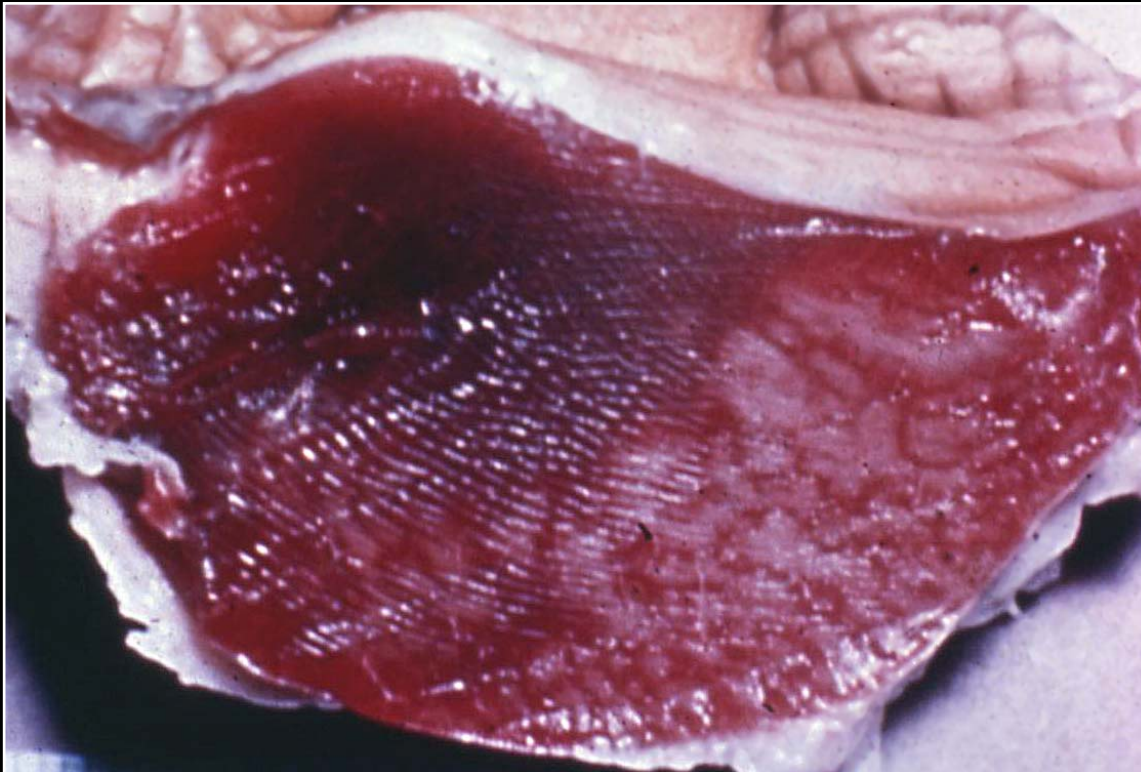
Back



C H A P T E R 7

Gastrointestinal System and Pancreas

Figure 7.34



Vitamin E deficiency leading to numerous white streaks in the ventricular musculature. These areas indicate myodegeneration.

Prev. fig. Next fig.

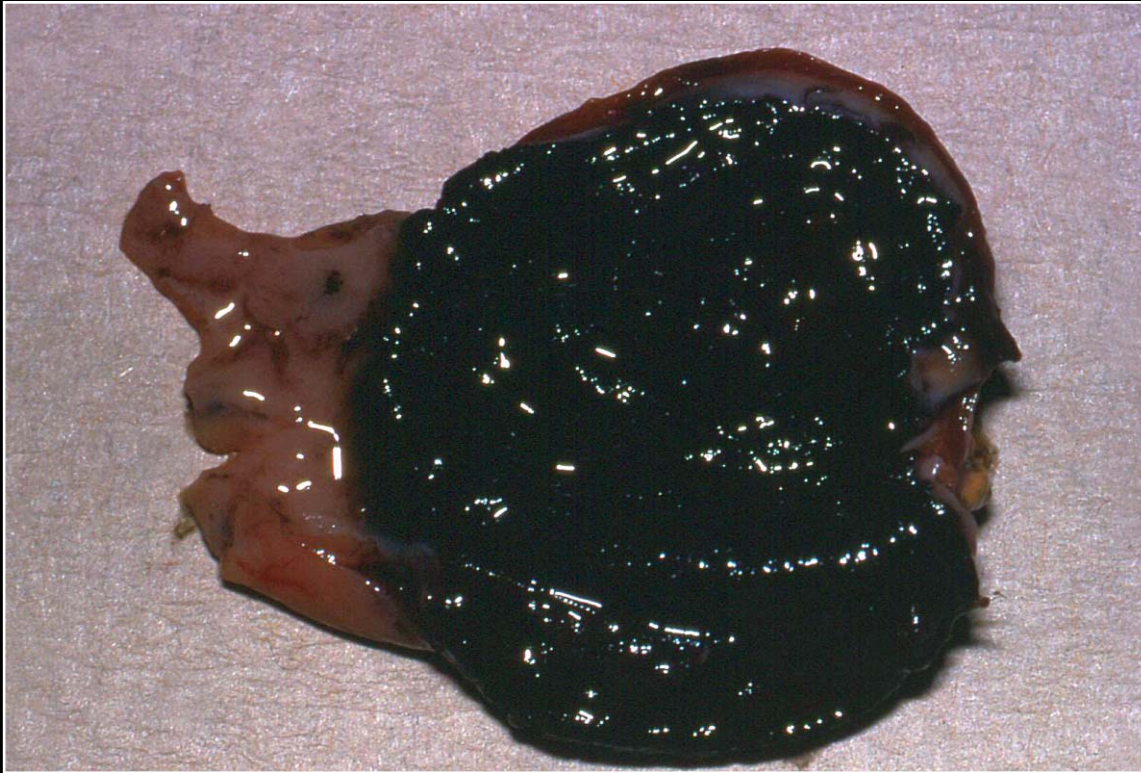
Back



C H A P T E R 7

Gastrointestinal System and Pancreas

Figure 7.35



Discoloration of the ventricular koilin and mucosa due to eating purple grapes.

Prev. fig. Next fig.

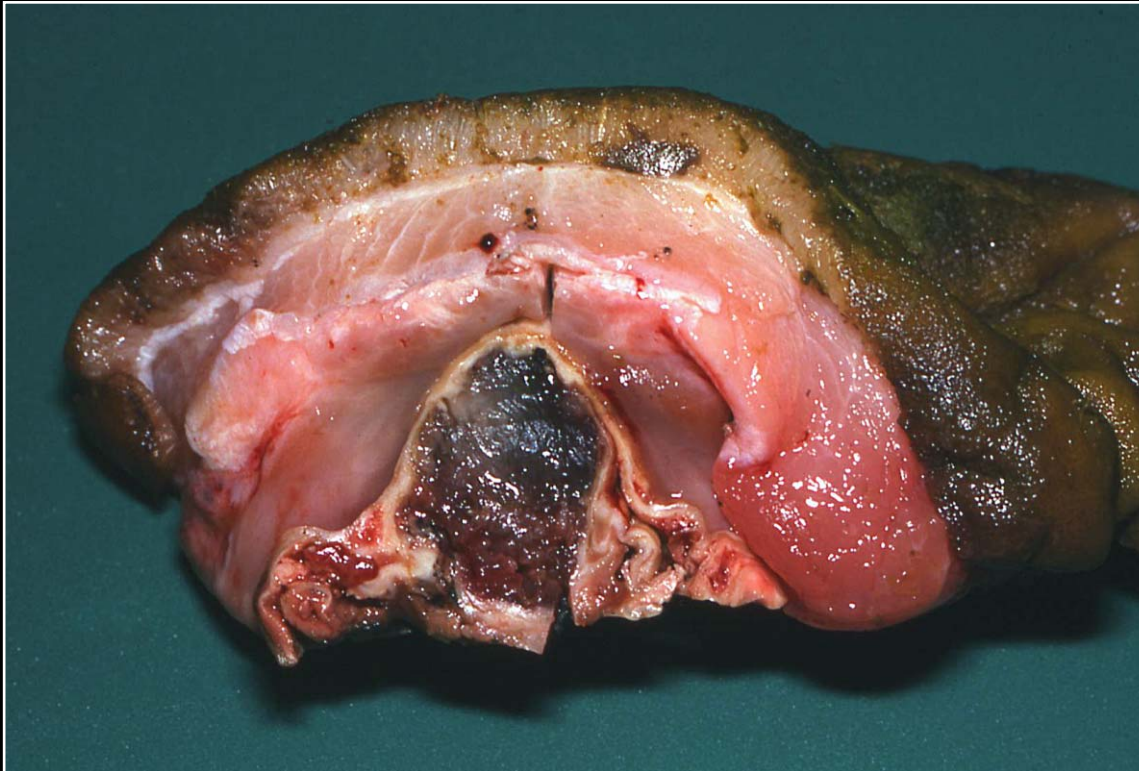
Back



C H A P T E R 7

Gastrointestinal System and Pancreas

Figure 7.36



Ventricular bacterial infection with severe necrosis and hemorrhage.

Prev. fig. Next fig.

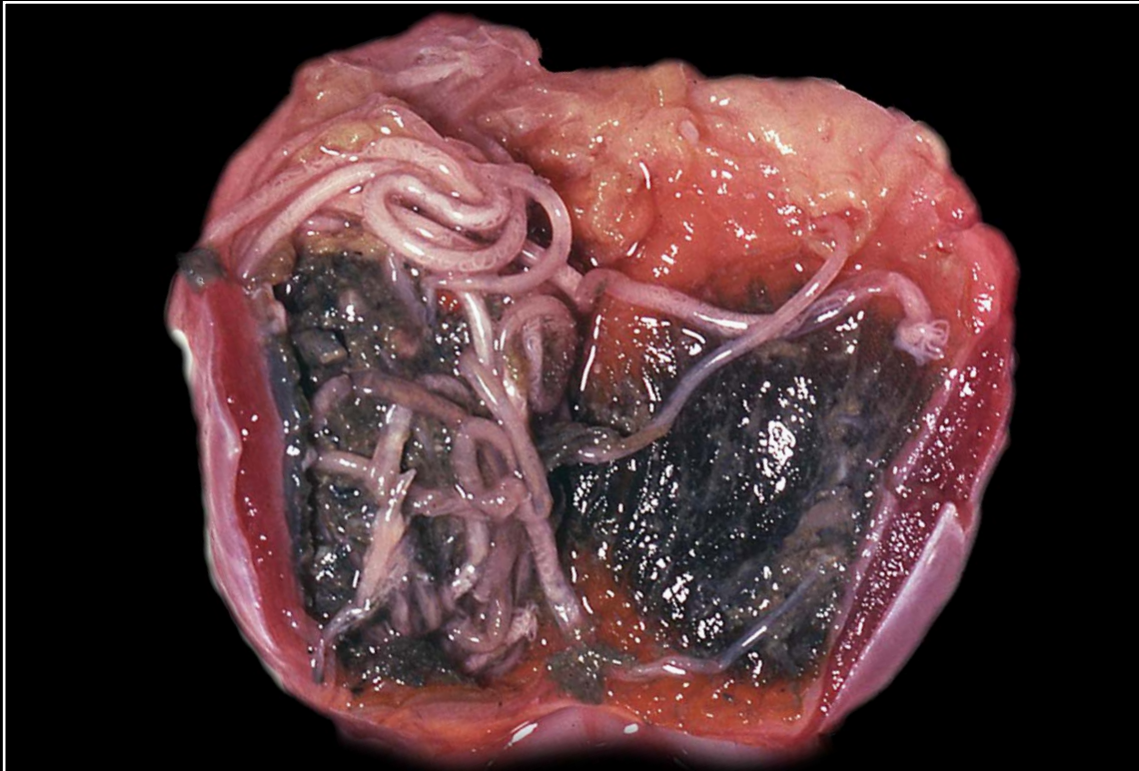
Back



C H A P T E R 7

Gastrointestinal System and Pancreas

Figure 7.37



Nematodiasis of the ventriculus with associated necrosis and hemorrhage.

Prev. fig. Next fig.

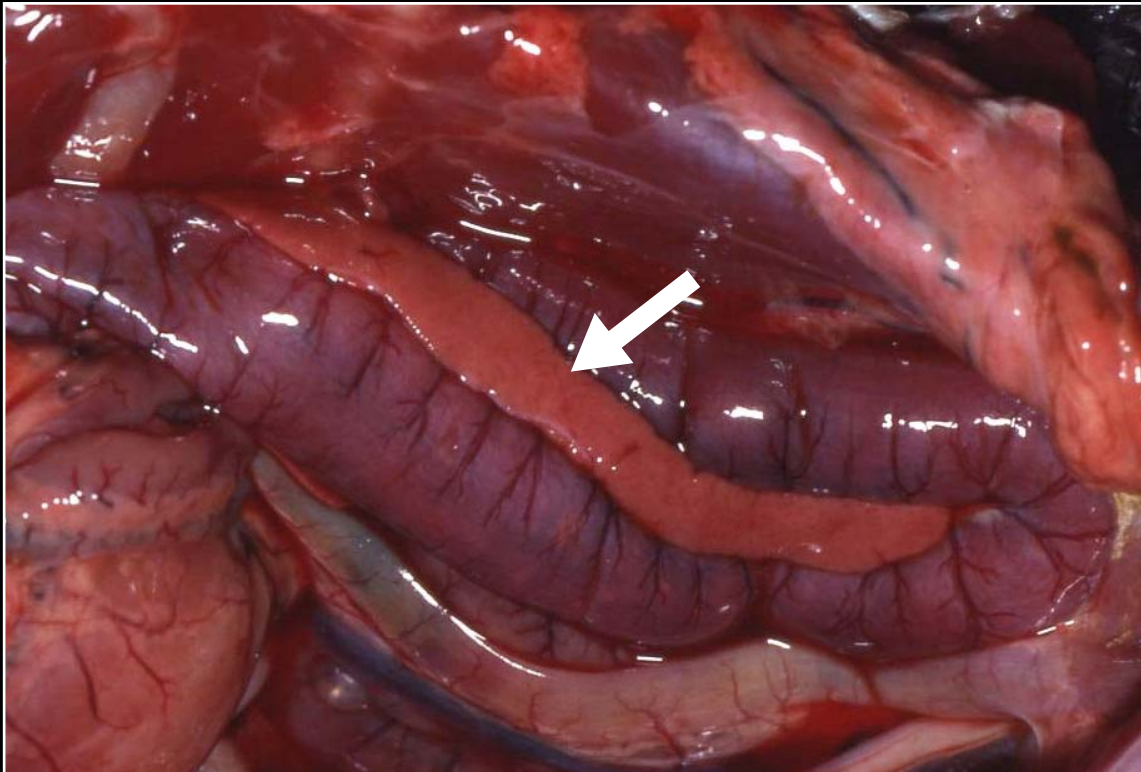
Back



C H A P T E R 7

Gastrointestinal System and Pancreas

Figure 7.37a



Normal duodenal loop of the intestines with a portion of the pancreas shown parallel to the abaxial side of the right loop.

Prev. fig. Next fig.

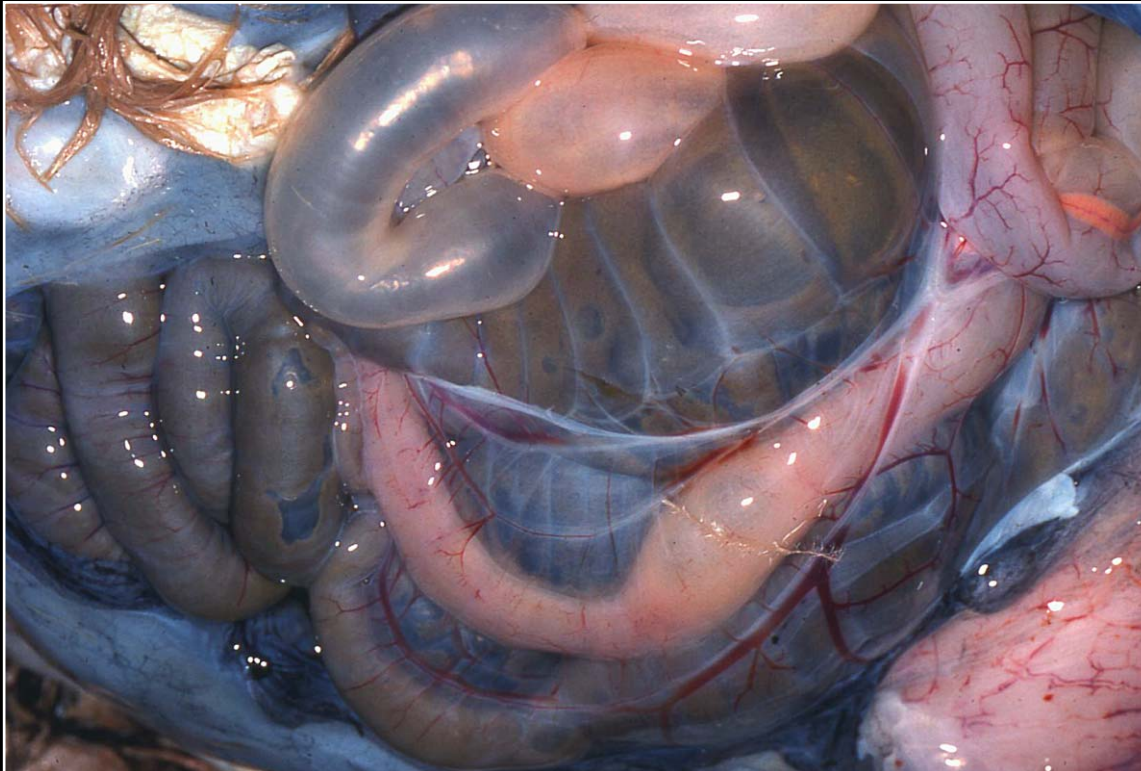
Back



C H A P T E R 7

Gastrointestinal System and Pancreas

Figure 7.38



Intestinal and peritoneal edema secondary to malnutrition and serous atrophy of fat.

Prev. fig. Next fig.

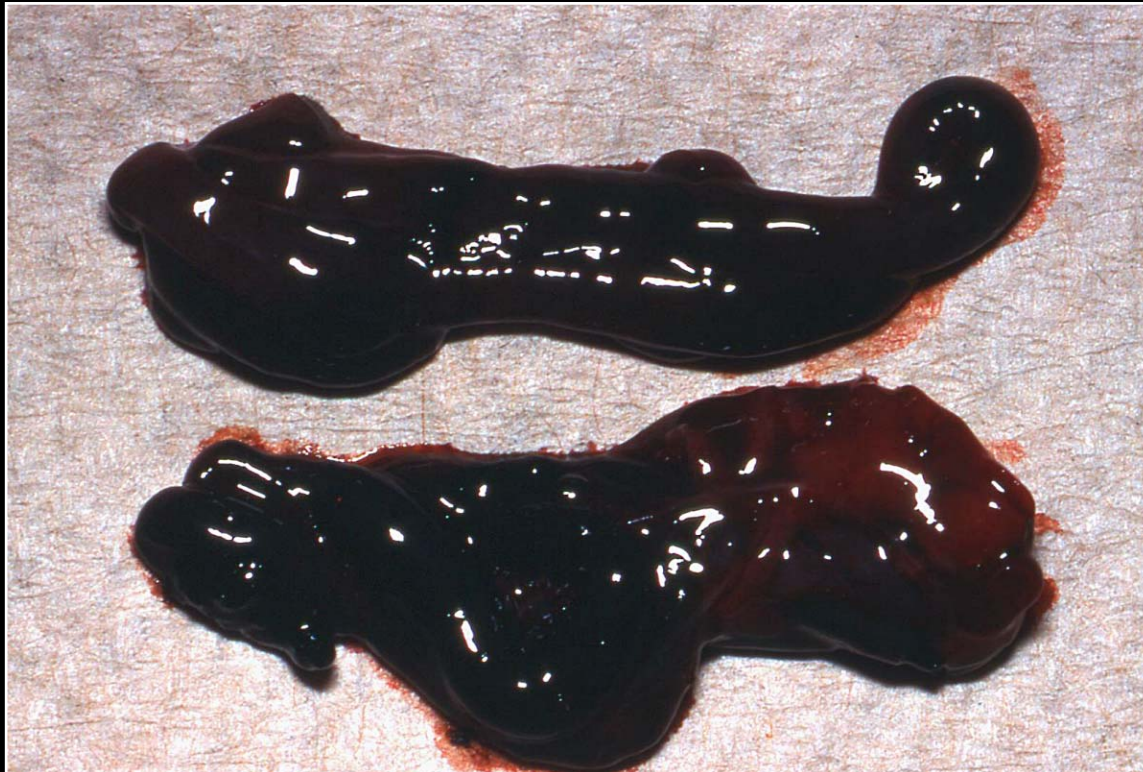Back



C H A P T E R 7

Gastrointestinal System and Pancreas

Figure 7.39



Red-black, hemorrhagic intestinal sections as the result of intestinal torsion.

Prev. fig. Next fig.

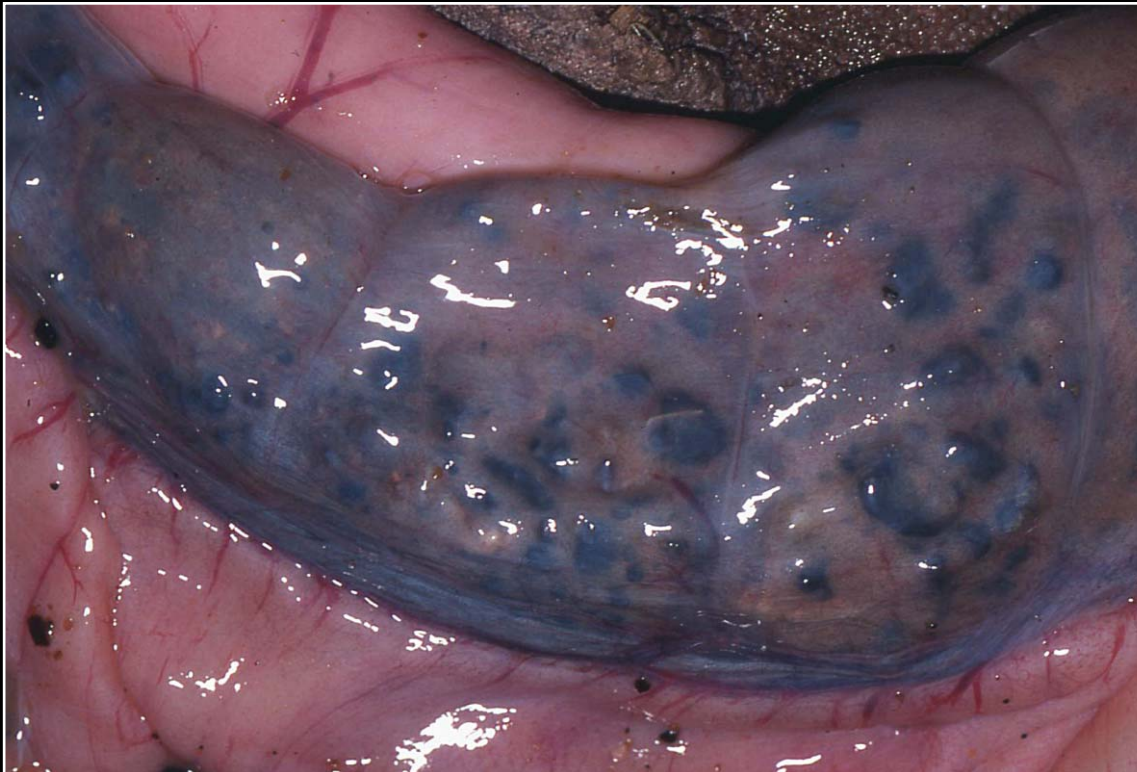
Back



CHAPTER 7

Gastrointestinal System and Pancreas

Figure 7.40



Intestinal dilatation and impaction due to ingestion of rocks. This can happen to ground-feeding birds that may not be discriminating feeders.

Prev. fig. Next fig.

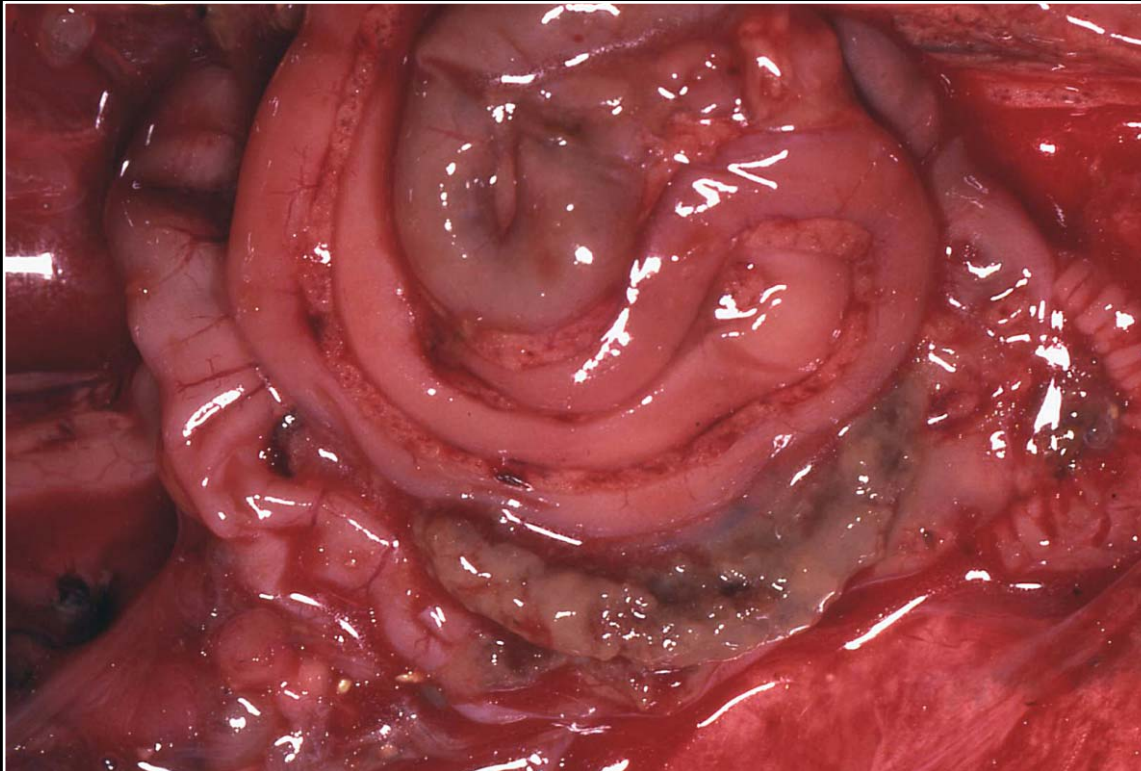
Back



CHAPTER 7

Gastrointestinal System and Pancreas

Figure 7.41



Intestinal serosal hyperemia and hemorrhage and hemorrhagic ascites in a bird with herpesvirus infection (Pacheco's disease).

Prev. fig. Next fig.

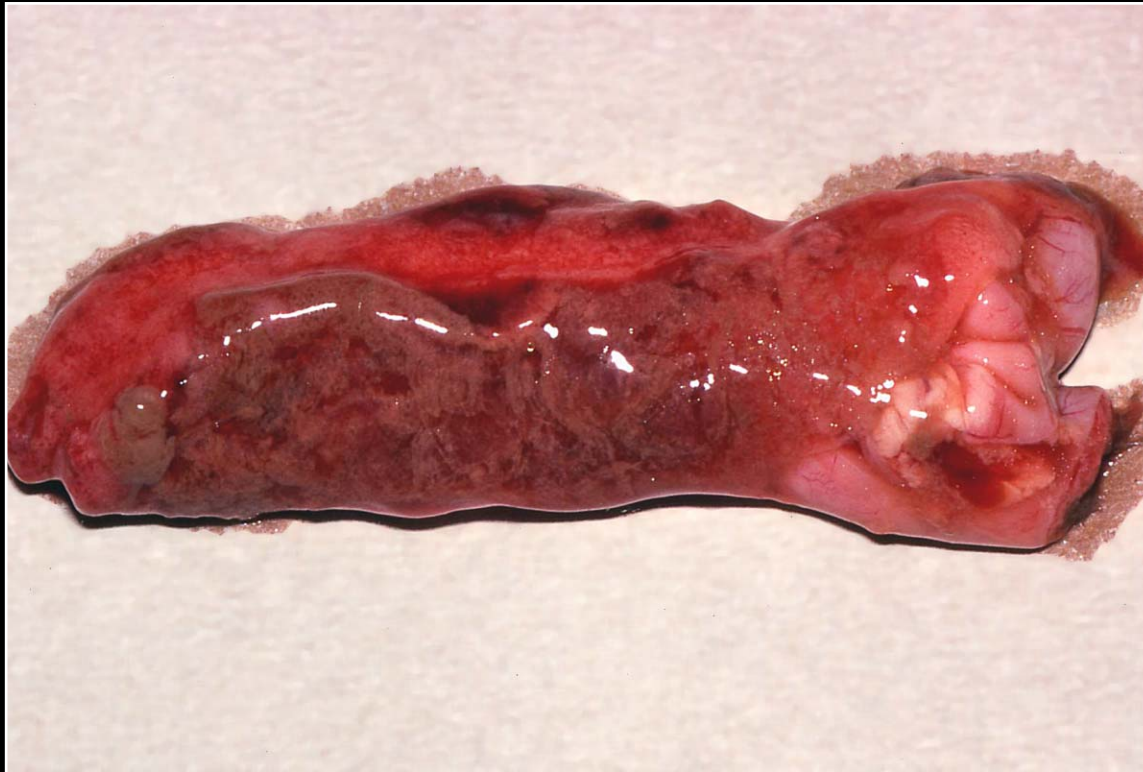Back



CHAPTER 7

Gastrointestinal System and Pancreas

Figure 7.42



Intestinal hemorrhage and necrosis associated with polyomavirus infection.

Prev. fig. Next fig.

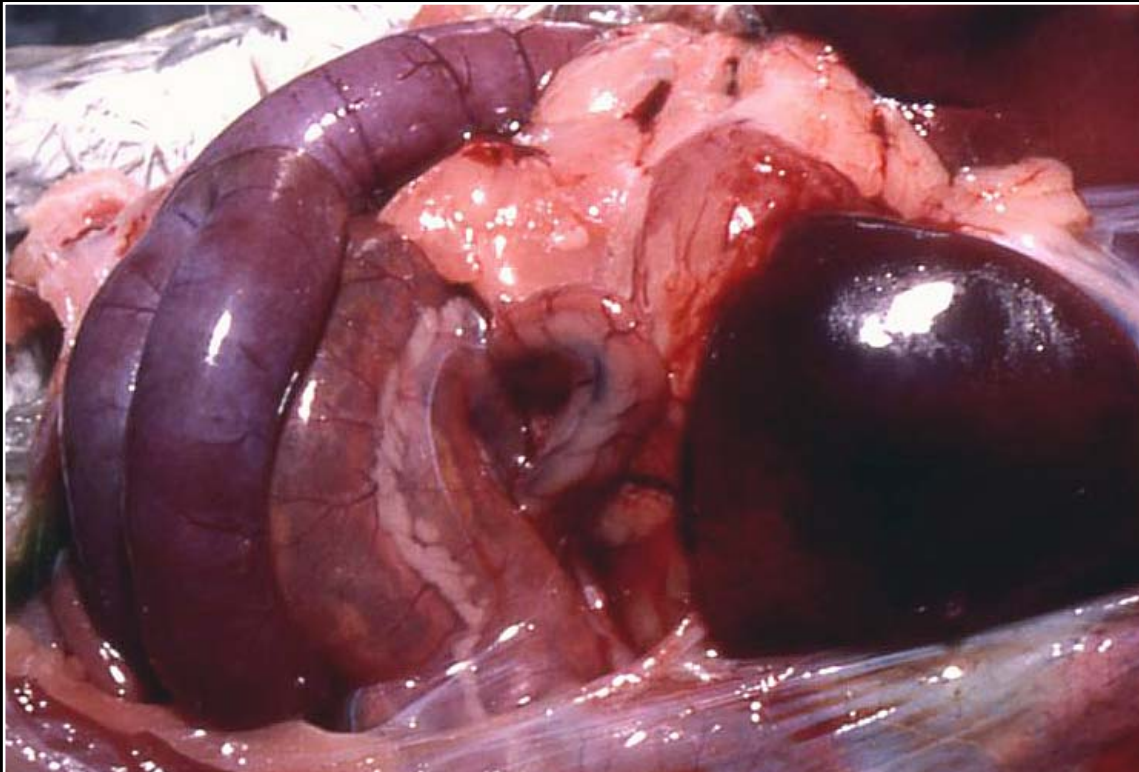
Back



CHAPTER 7

Gastrointestinal System and Pancreas

Figure 7.43



Gram-negative bacterial enteritis leading to severe reddening of the intestinal wall.

Prev. fig. Next fig.

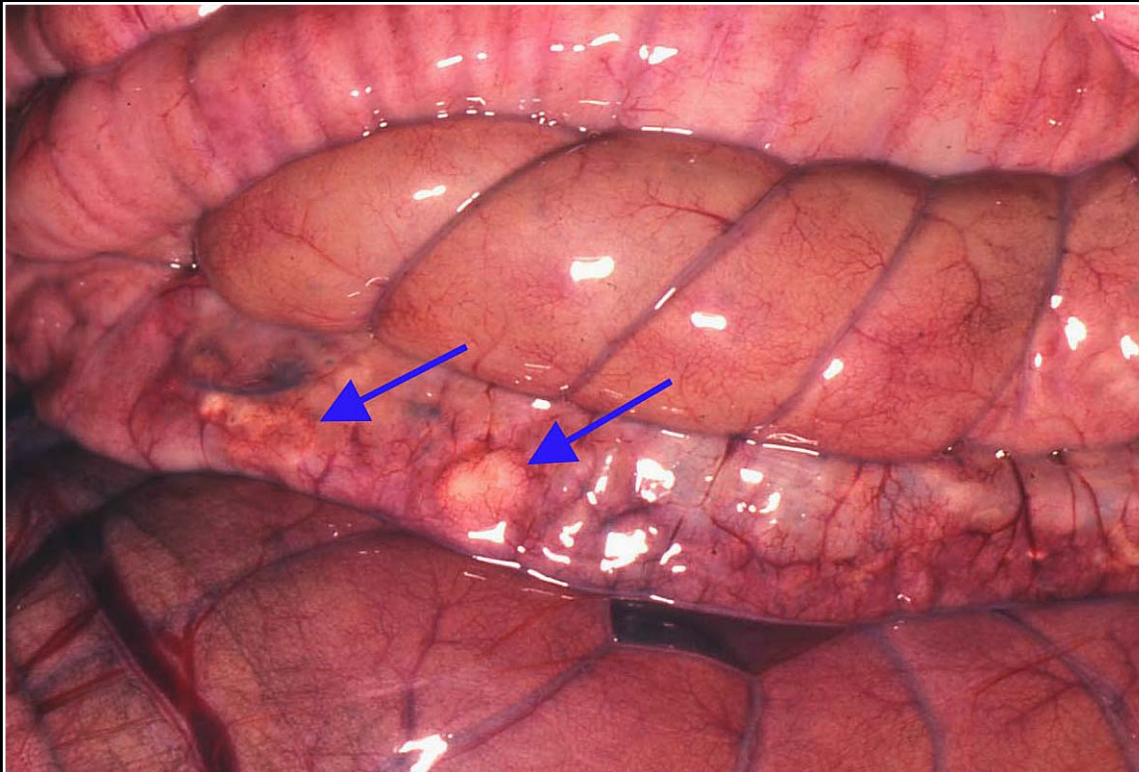
Back



CHAPTER 7

Gastrointestinal System and Pancreas

Figure 7.44



Bacterial enteritis leading to necrosis and abscessation of the intestinal wall (arrows).

Prev. fig. Next fig.

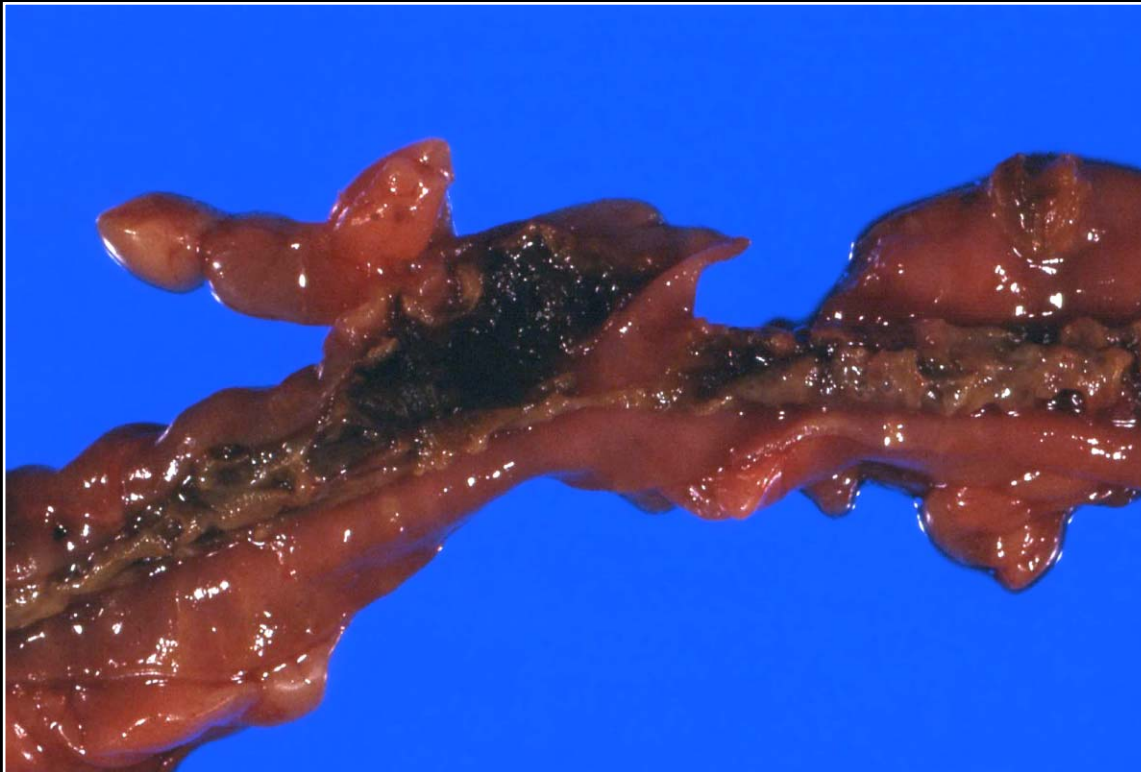
Back



C H A P T E R 7

Gastrointestinal System and Pancreas

Figure 7.45



Diphtheritic membrane formation in a severe case of bacterial enteritis.

Prev. fig. Next fig.

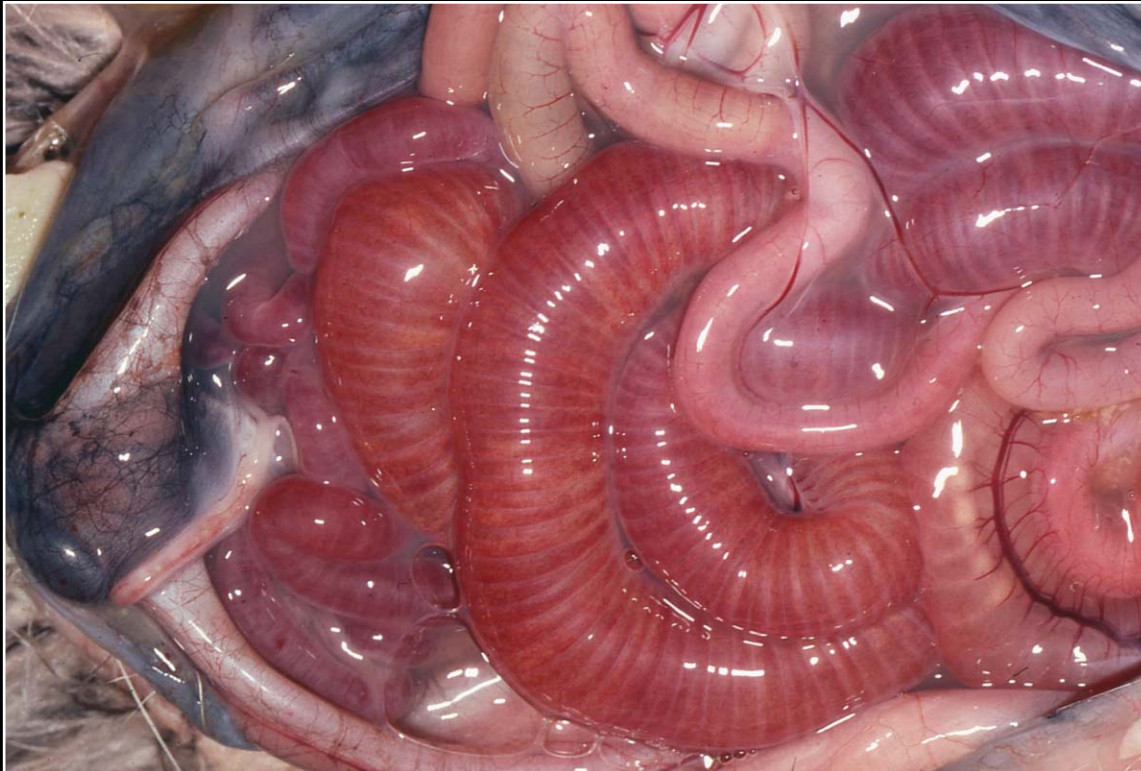Back



C H A P T E R 7

Gastrointestinal System and Pancreas

Figure 7.46



Severe intestinal hemorrhage due to *Clostridial* infection and enterotoxemia.

Prev. fig. Next fig.

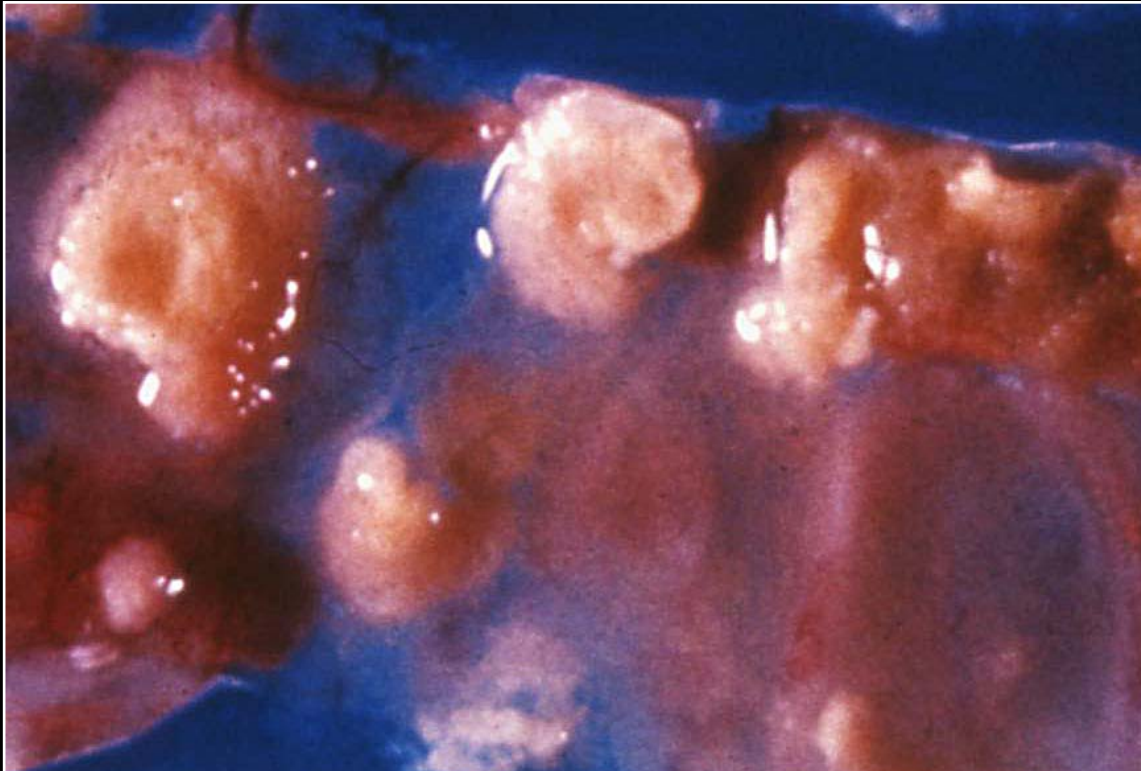
Back



C H A P T E R 7

Gastrointestinal System and Pancreas

Figure 7.47



Numerous intestinal ulcers in a quail with ulcerative enteritis caused by *Clostridium colinum*.

Prev. fig. Next fig.

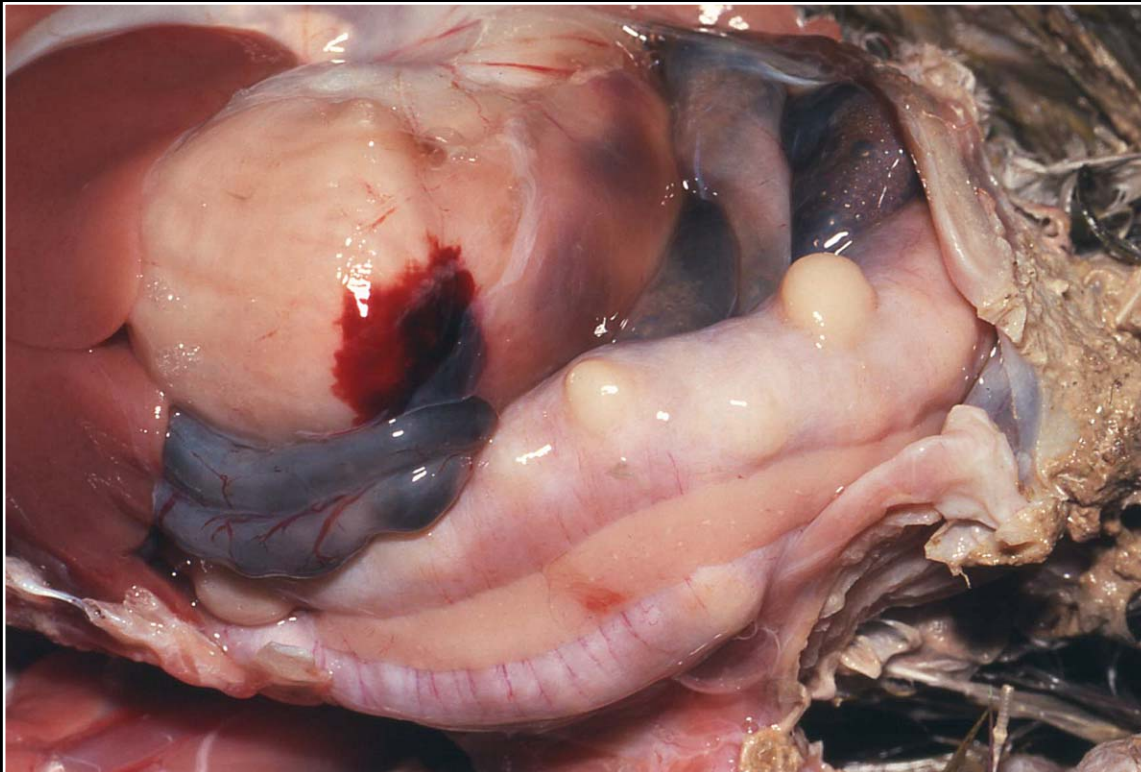
Back



CHAPTER 7

Gastrointestinal System and Pancreas

Figure 7.48



White nodular foci in the intestine of a bird with mycobacteriosis.

Prev. fig. Next fig.

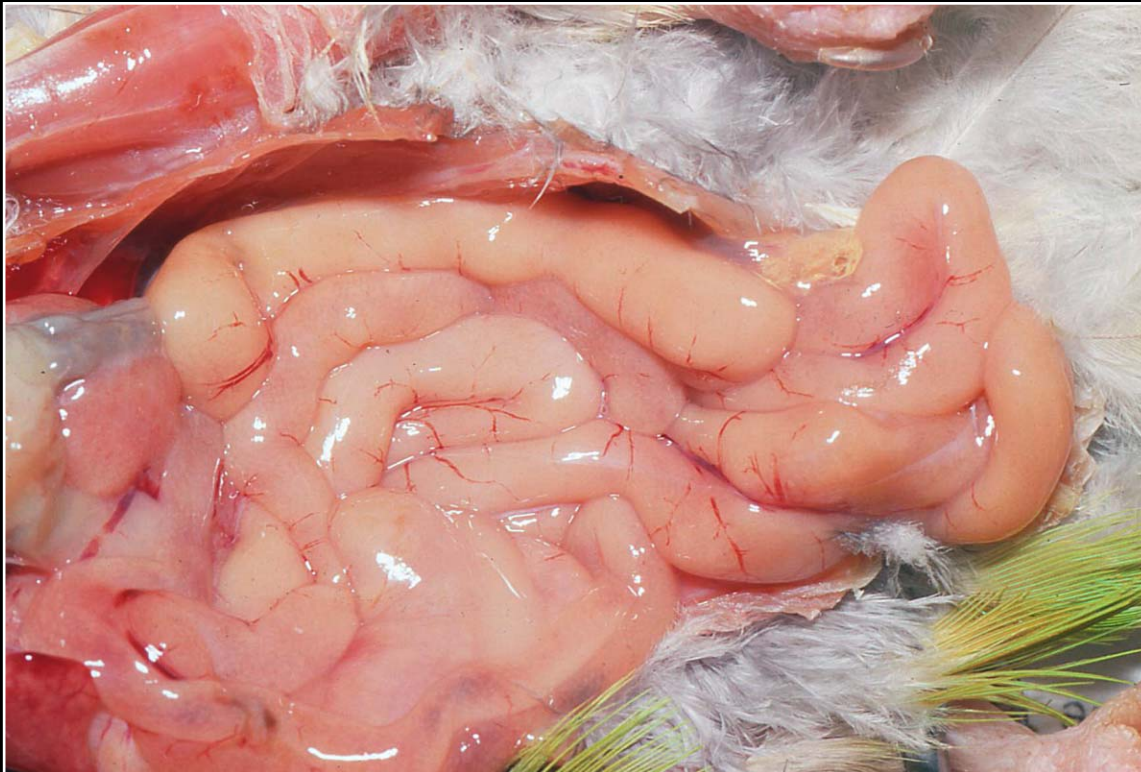
Back



CHAPTER 7

Gastrointestinal System and Pancreas

Figure 7.49



Diffuse white, opaque thickening of the small intestine in mycobacteriosis.

Prev. fig. Next fig.

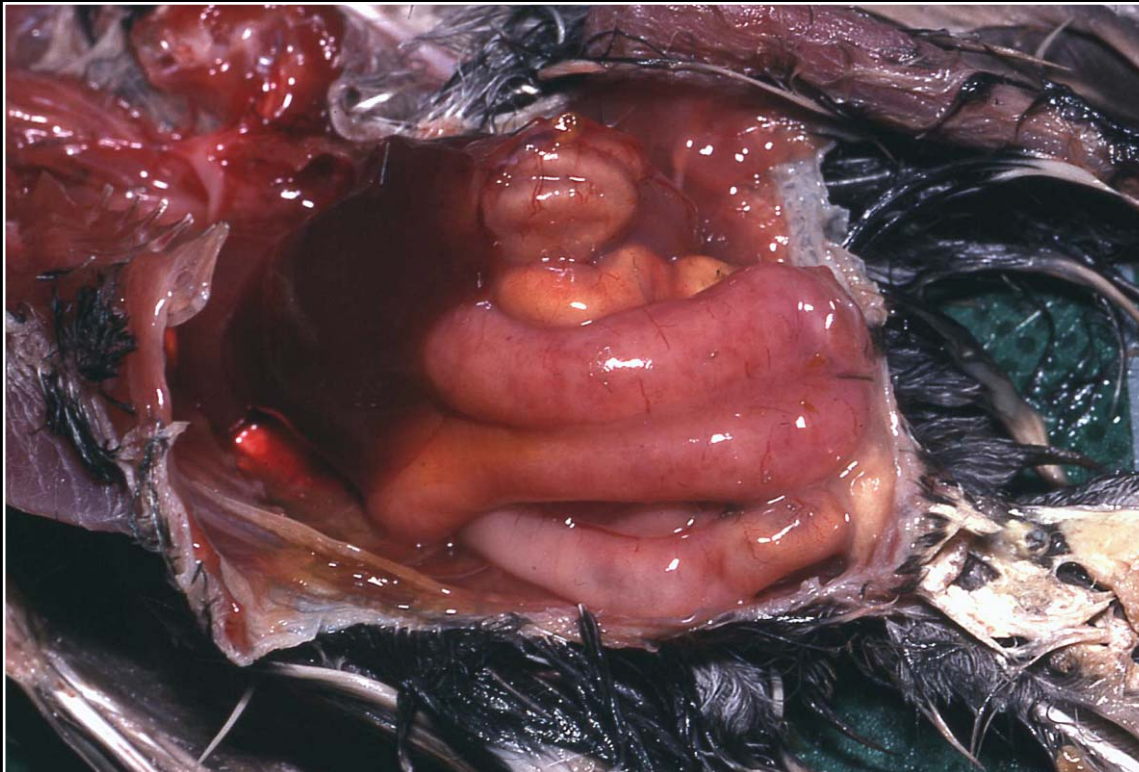
Back



CHAPTER 7

Gastrointestinal System and Pancreas

Figure 7.50



Dilated, reddened intestine with areas of necrosis due to severe coccidial infection.

Prev. fig. Next fig.

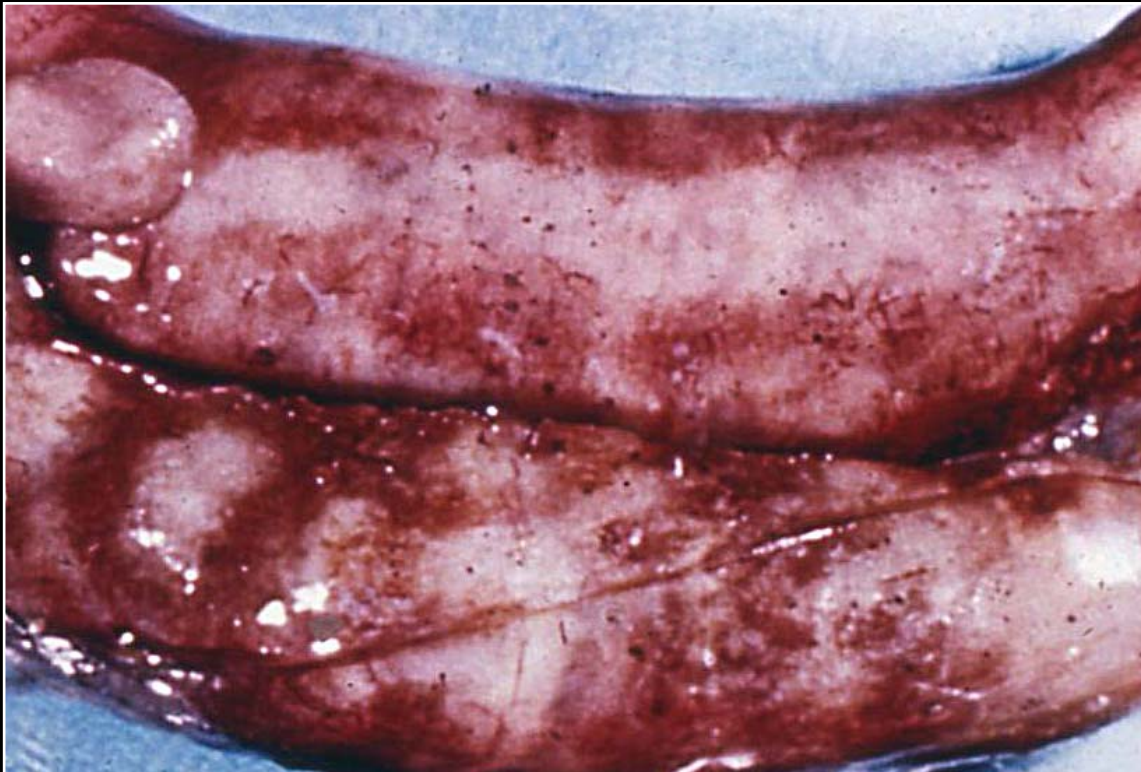Back



C H A P T E R 7

Gastrointestinal System and Pancreas

Figure 7.51



Histomoniasis with marked cecal enlargement and hemorrhage seen on the serosal surface.

Prev. fig. Next fig.

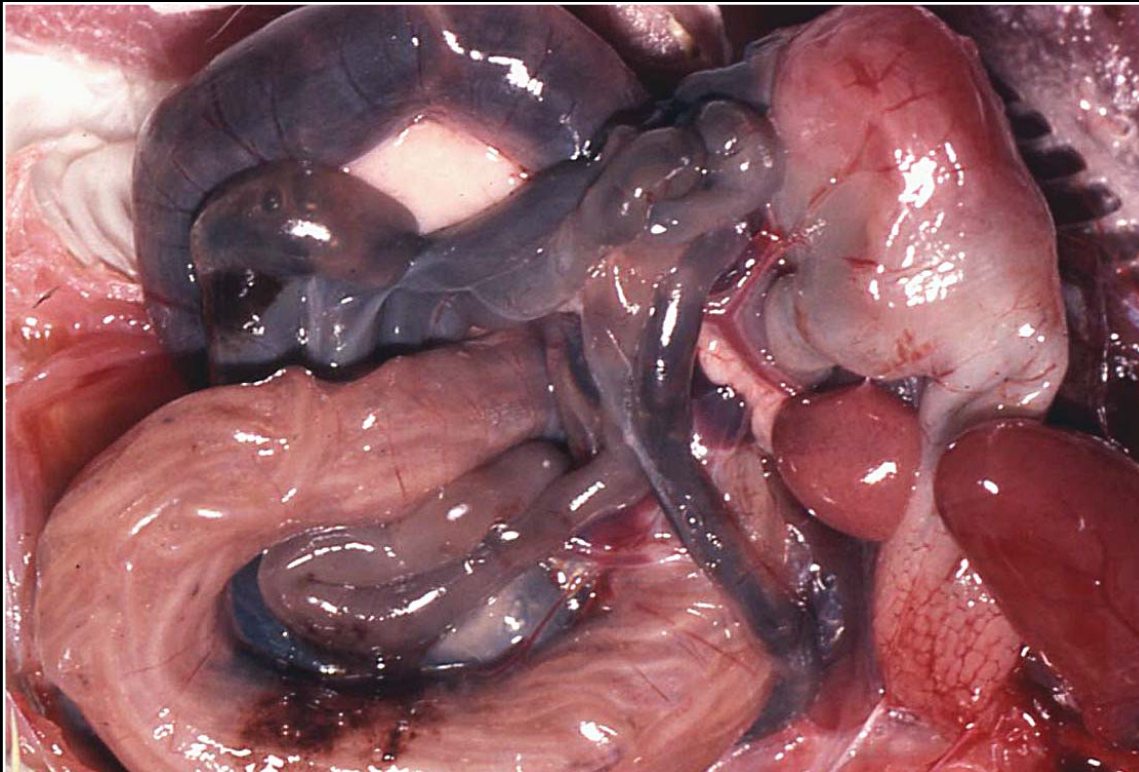
Back



CHAPTER 7

Gastrointestinal System and Pancreas

Figure 7.52



Severe nematodiasis of the intestine. There is dilatation and thinning of the wall and the nematodes can be seen in the lumen.

Prev. fig. Next fig.

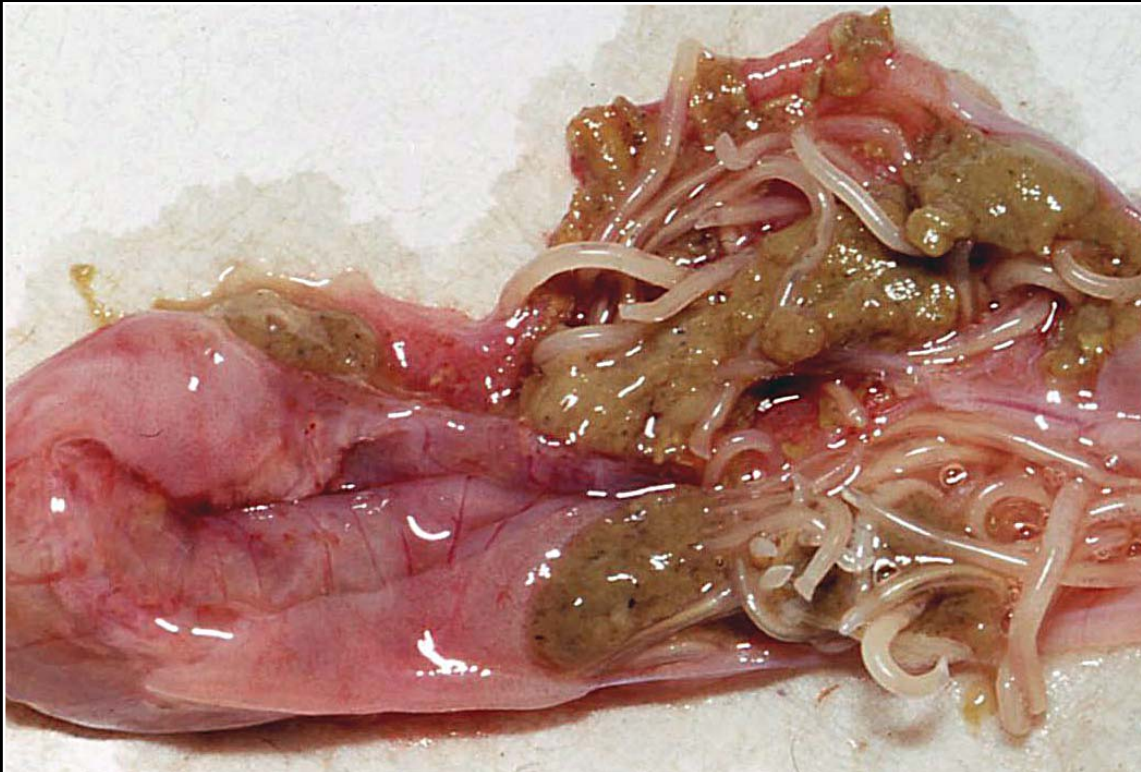Back



C H A P T E R 7

Gastrointestinal System and Pancreas

Figure 7.53



Numerous nematodes noted within the intestinal contents after opening the intestinal tract.

Prev. fig. Next fig.

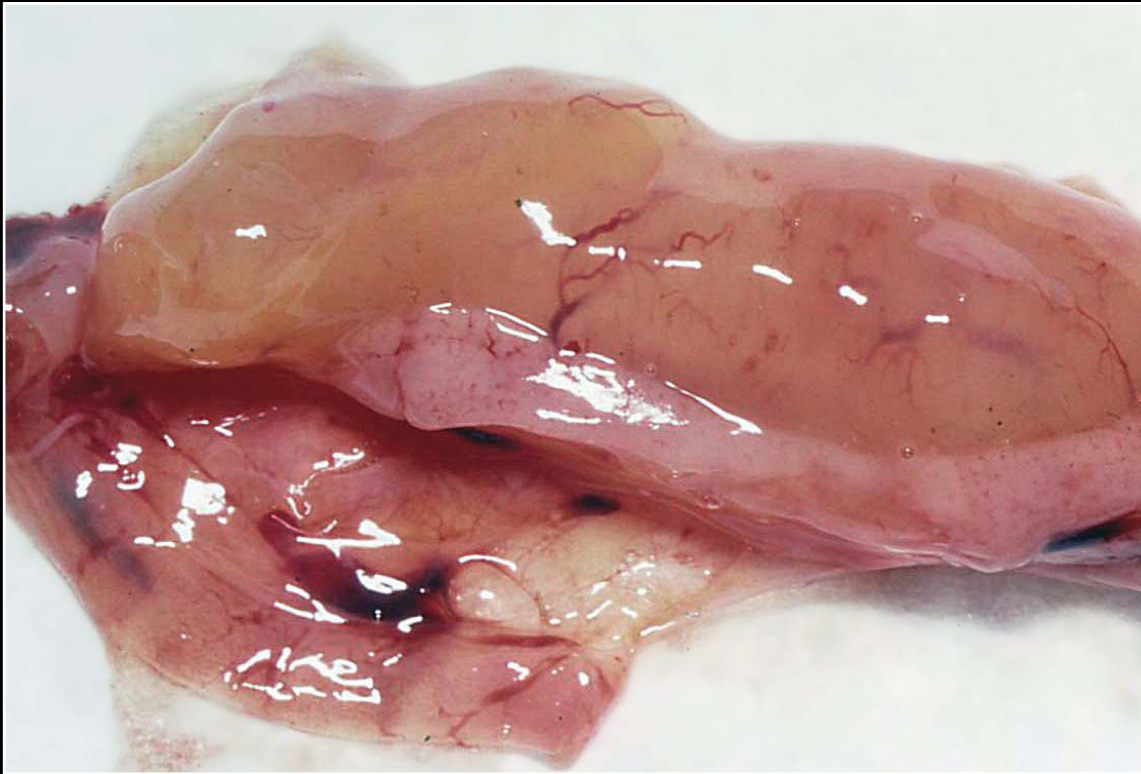
Back



C H A P T E R 7

Gastrointestinal System and Pancreas

Figure 7.54



Myxosarcoma of the intestine that is effacing and displacing the normal tubular architecture.

Prev. fig. Next fig.

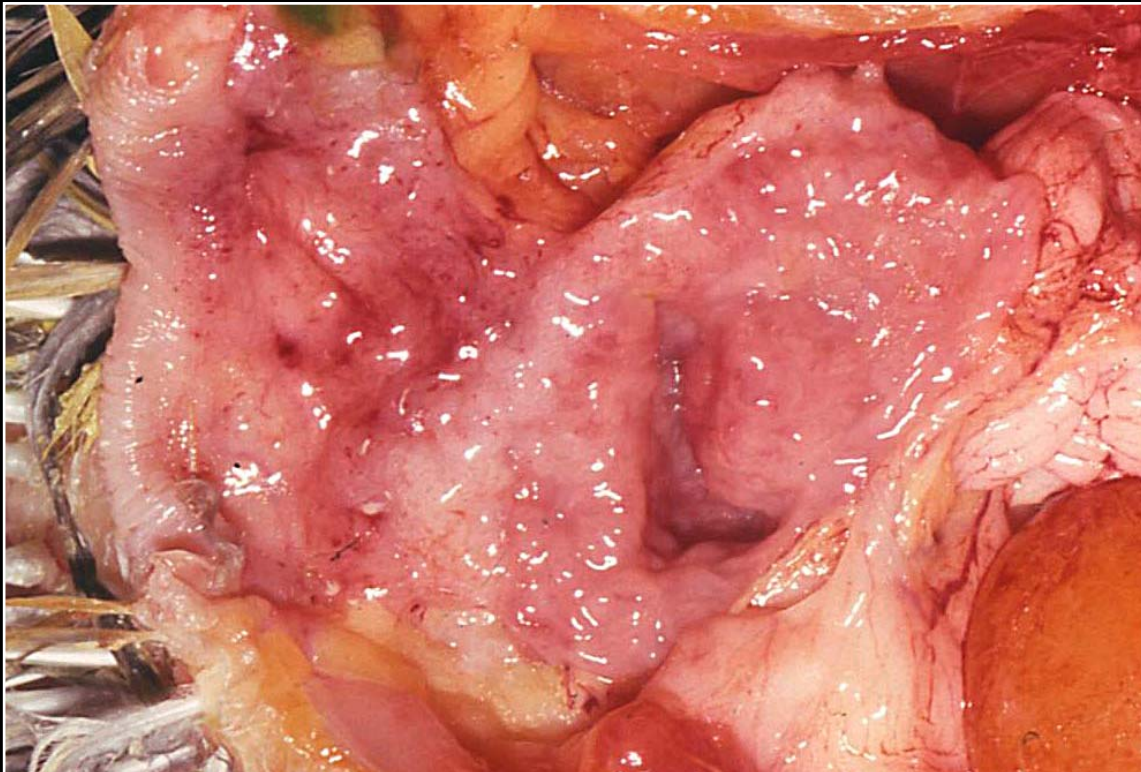
Back



C H A P T E R 7

Gastrointestinal System and Pancreas

Figure 7.54a



Normal cloaca.

Prev. fig. Next fig.

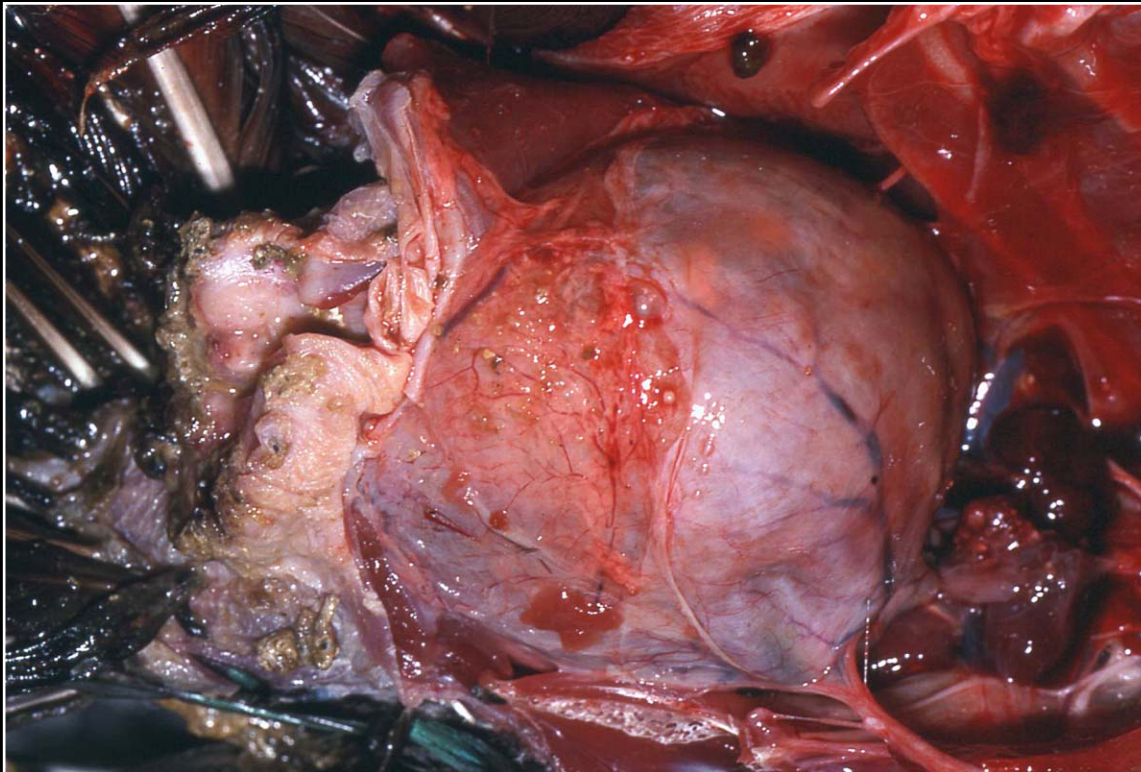
Back



C H A P T E R 7

Gastrointestinal System and Pancreas

Figure 7.55



Marked cloacal distention associated with PDD and impaction.

Prev. fig. Next fig.

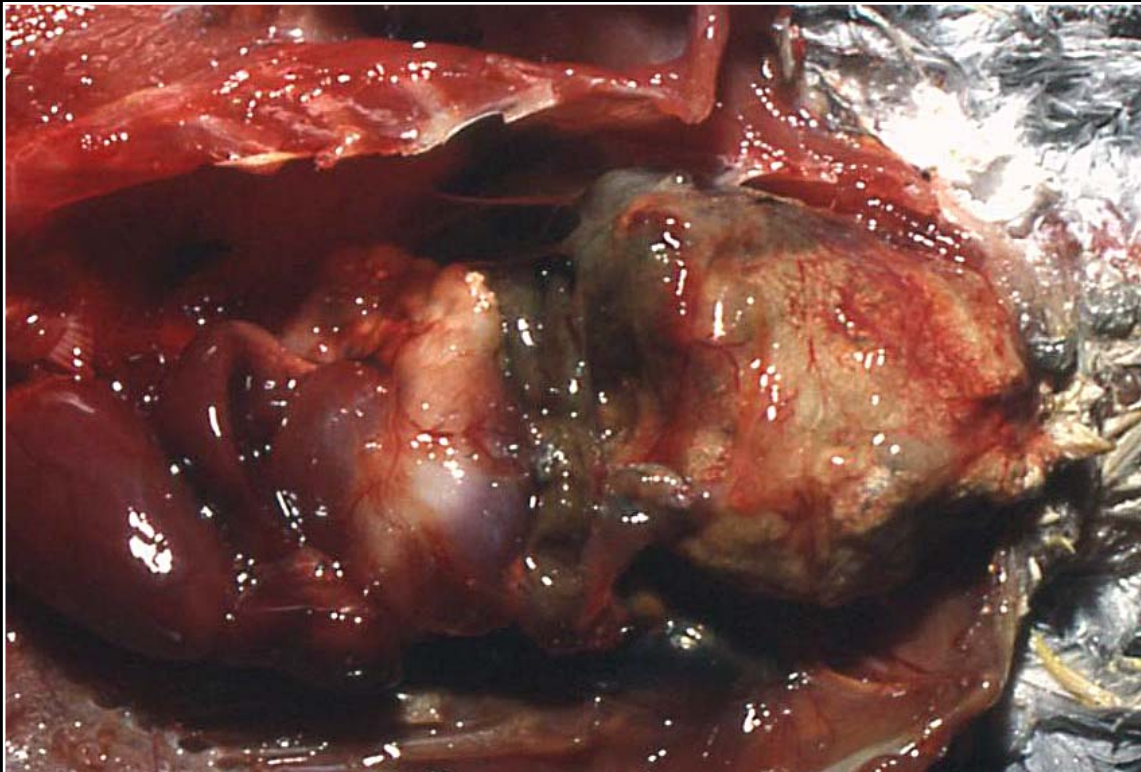
Back



C H A P T E R 7

Gastrointestinal System and Pancreas

Figure 7.56



Impacted mass within cloaca. This can be the result of a number of different pathologic conditions.

Prev. fig. Next fig.


Back



C H A P T E R 7

Gastrointestinal System and Pancreas

Figure 7.57



Cloacolith removed from impacted cloaca.

Prev. fig. Next fig.

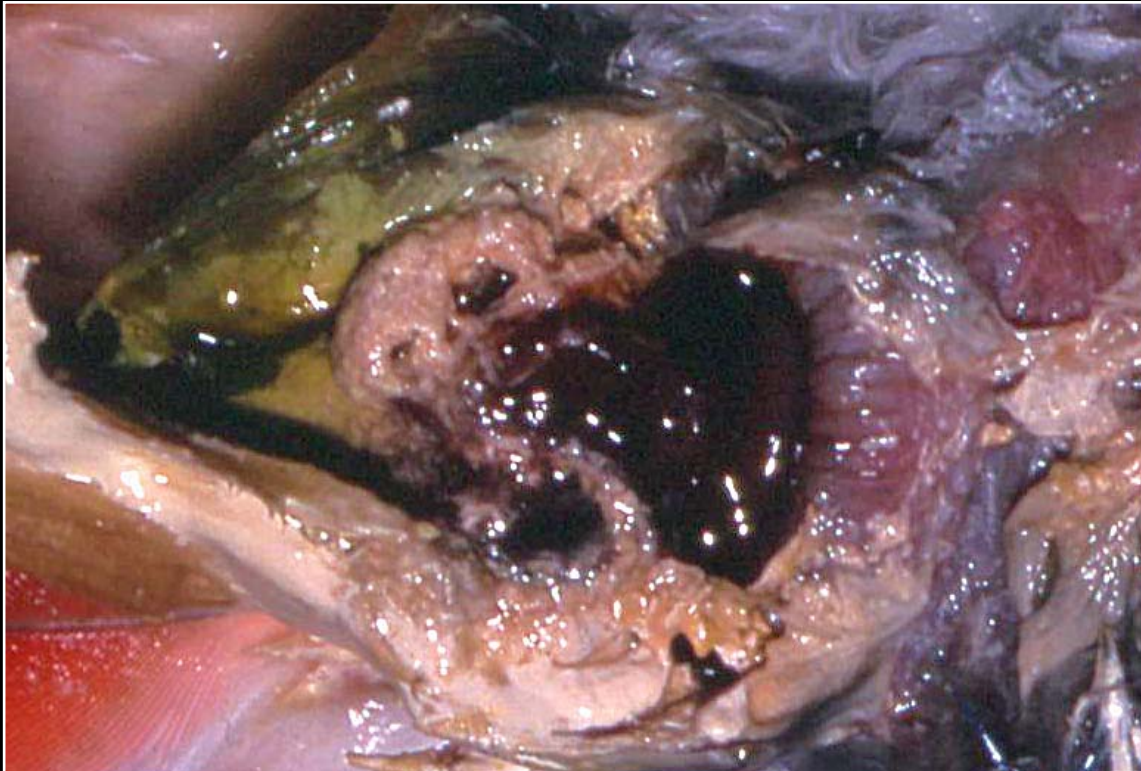
Back



C H A P T E R 7

Gastrointestinal System and Pancreas

Figure 7.58



Cloacal prolapse. The vent/cloaca has been opened and the hyperemic and edematous prolapsed mucosa can be seen.

Prev. fig. Next fig.

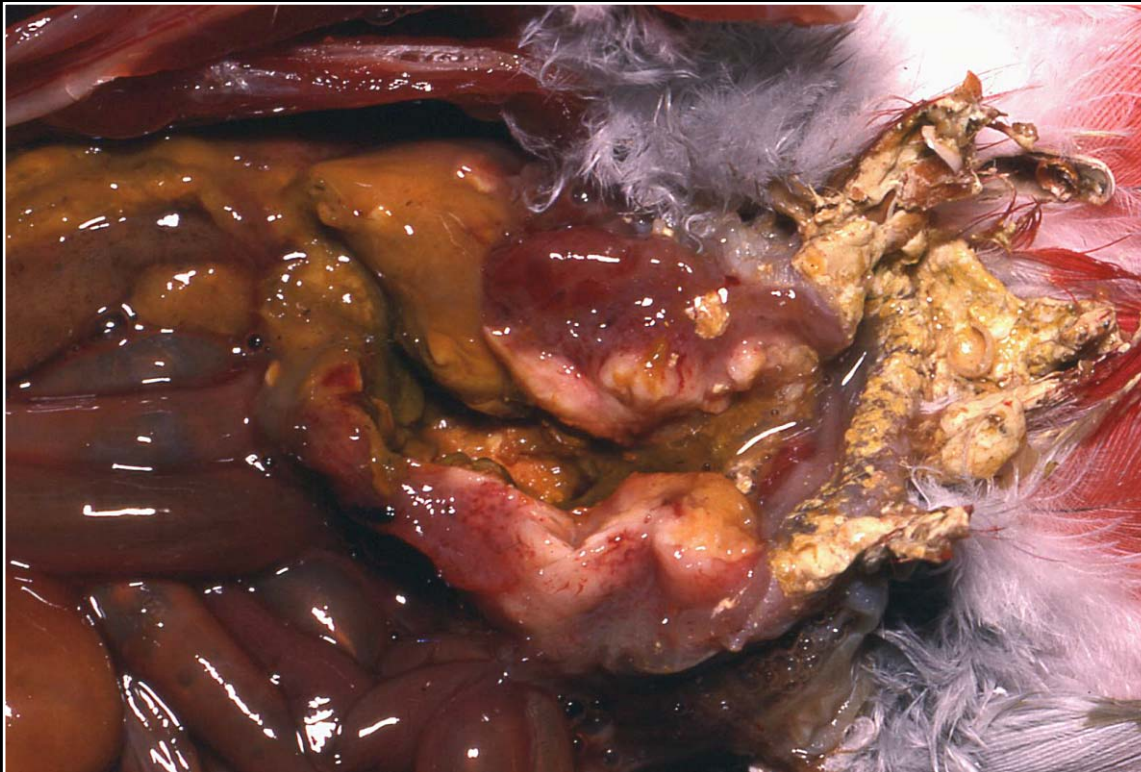Back



CHAPTER 7

Gastrointestinal System and Pancreas

Figure 7.59



Severe bacterial cloacitis with thickening of the wall and scattered abscess formation.

Prev. fig. Next fig.

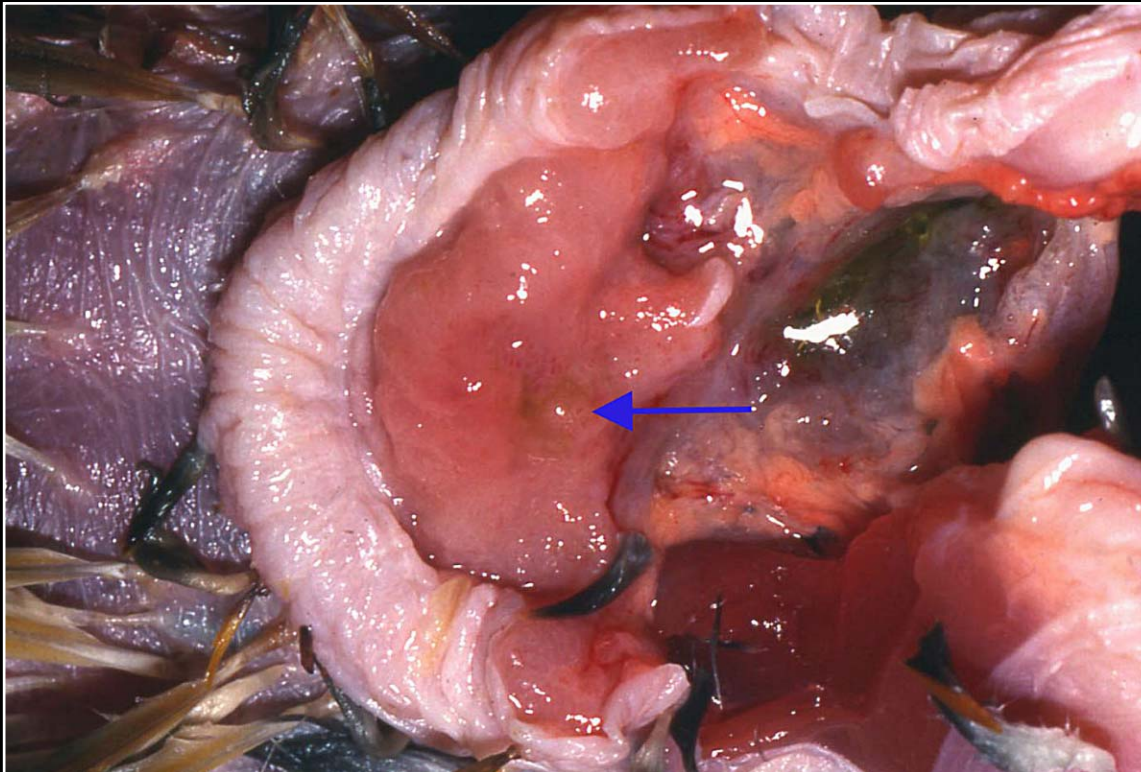
Back



C H A P T E R 7

Gastrointestinal System and Pancreas

Figure 7.60



Opened cloaca to illustrate papilloma formation (arrow).

Prev. fig. Next fig.

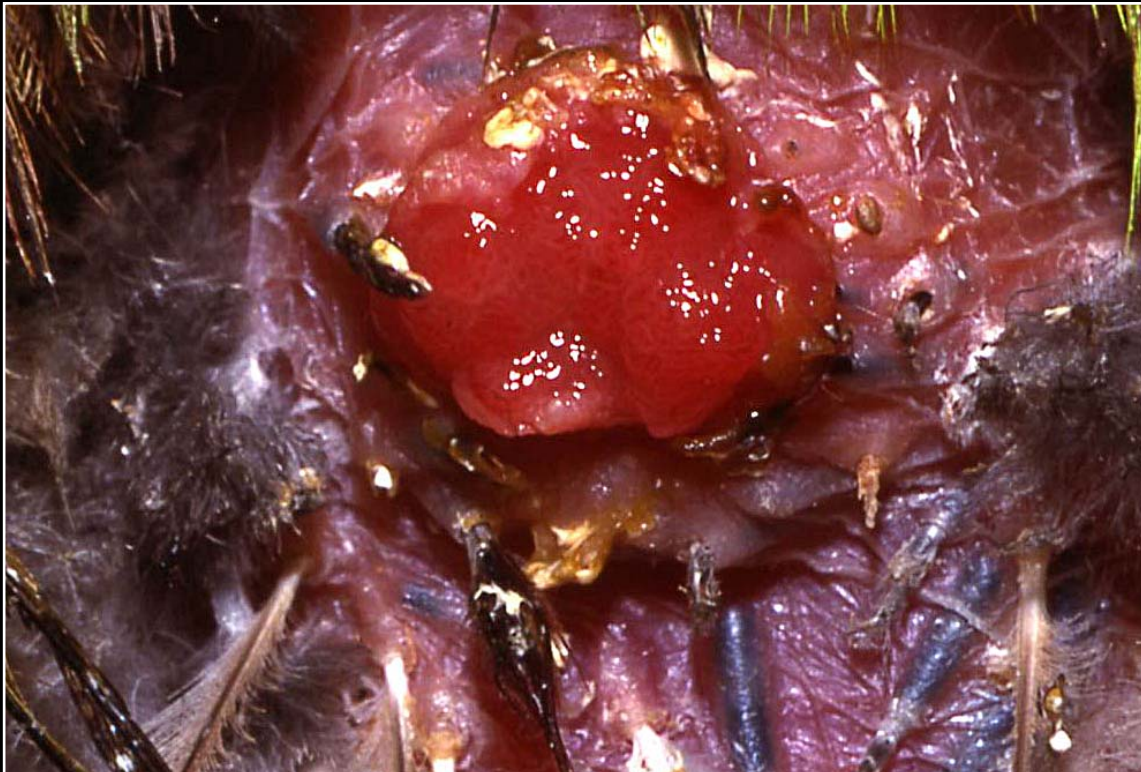
Back



CHAPTER 7

Gastrointestinal System and Pancreas

Figure 7.61



More severe cloacal papillomatosis with lesions visible externally. This must be differentiated from cloacal prolapse in some cases.

Prev. fig. Next fig.

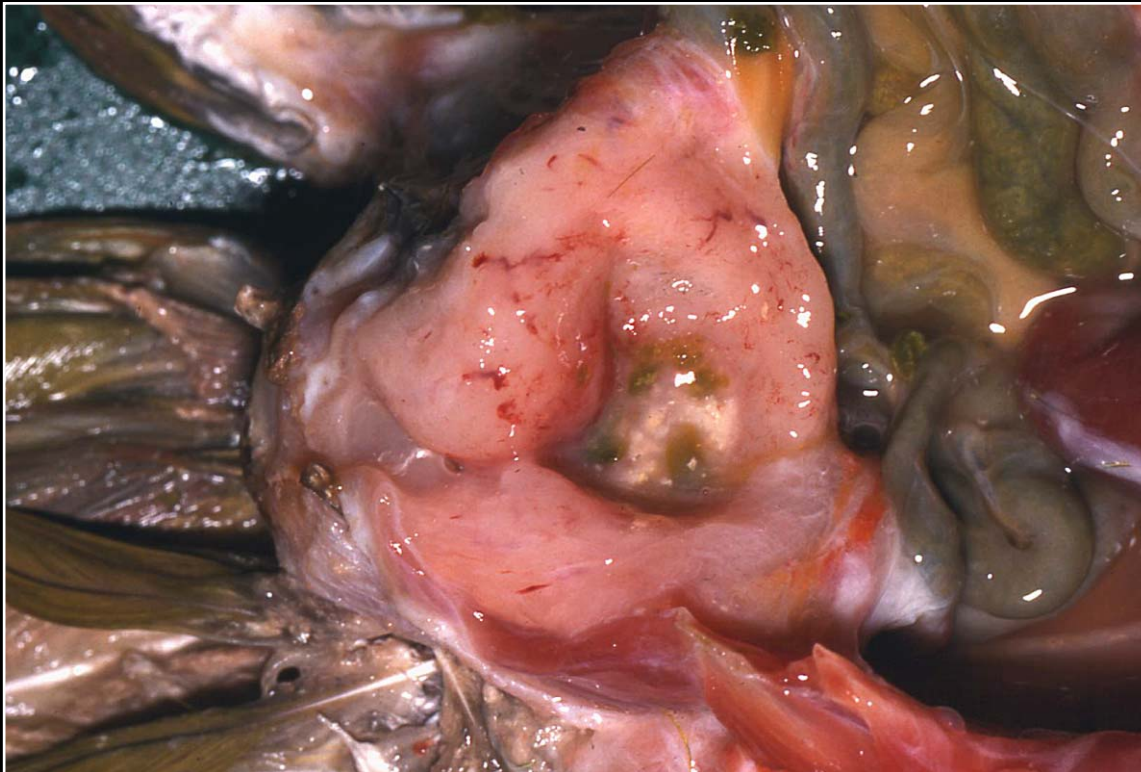
Back



CHAPTER 7

Gastrointestinal System and Pancreas

Figure 7.62



Massively thickened cloacal wall due to infiltrative carcinoma. The lesion is firm and diffuse.

Prev. fig. Next fig.

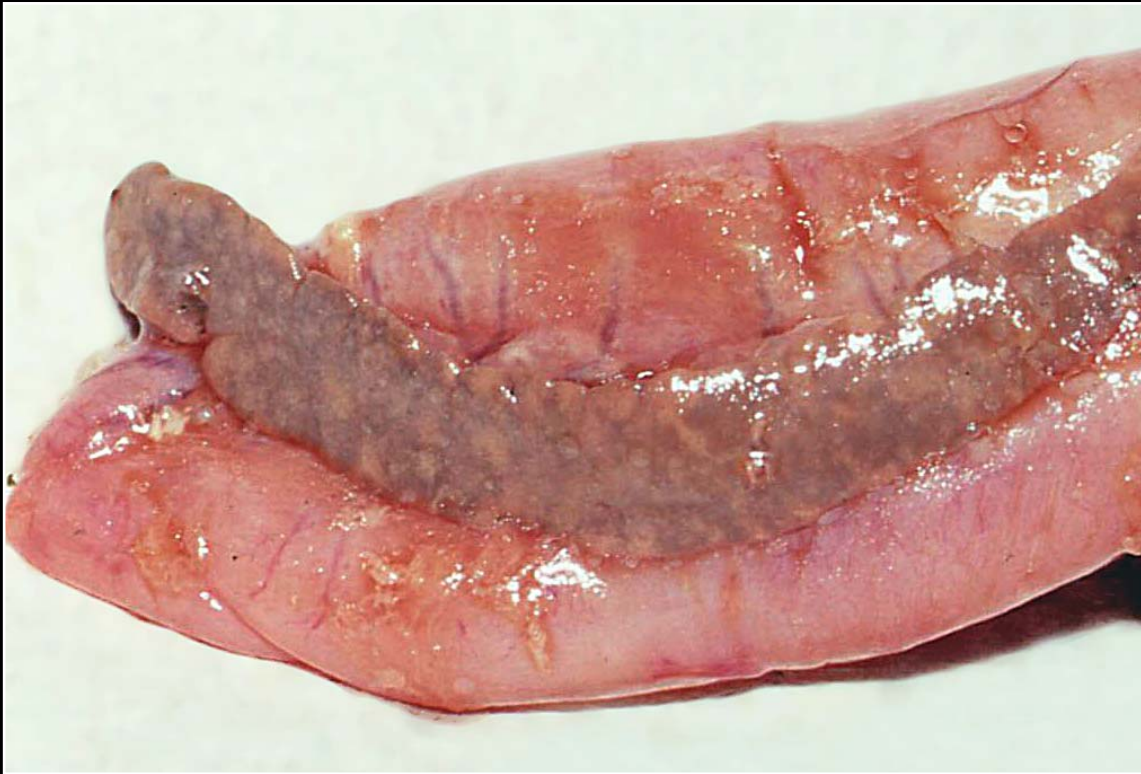Back



C H A P T E R 7

Gastrointestinal System and Pancreas

Figure 7.63



Severe pancreatic discoloration and mottling in a bird with zinc toxicity.

Prev. fig. Next fig.

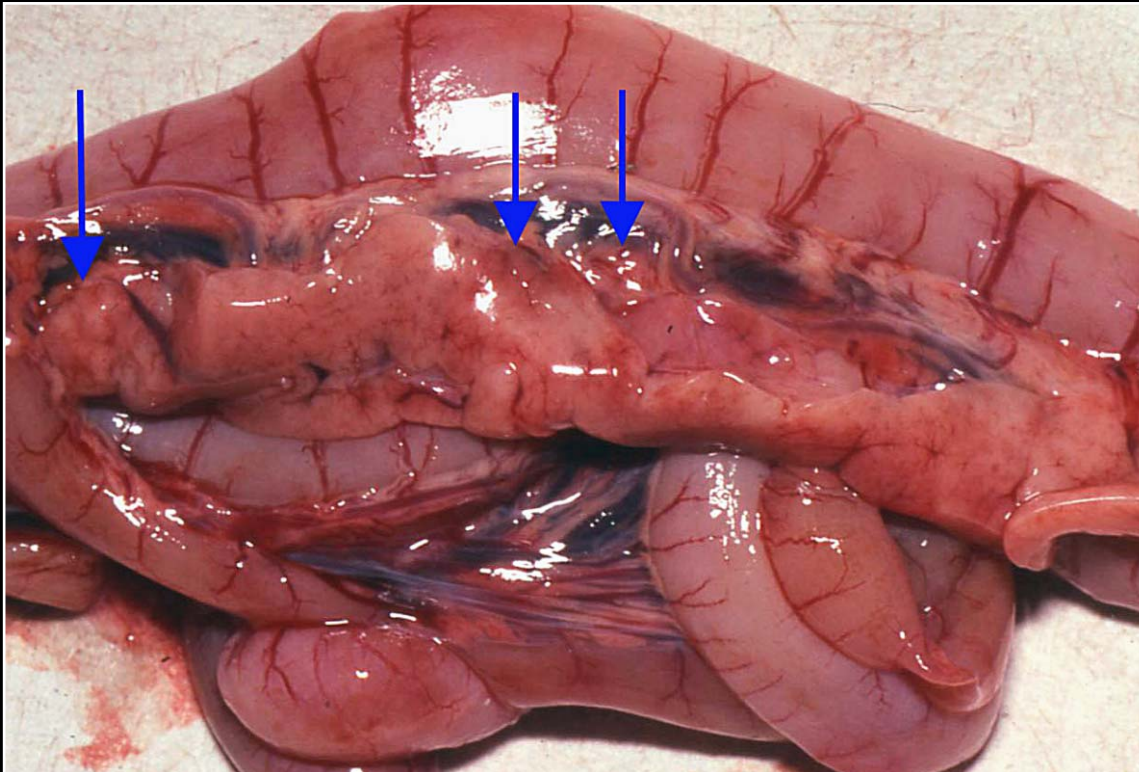
Back



CHAPTER 7

Gastrointestinal System and Pancreas

Figure 7.64



Acute pancreatic necrosis. The pancreas is mottled and congested and multiple nodular/hemorrhagic foci are seen (arrows). One of these involves the peripancreatic mesentery.

Prev. fig. Next fig.

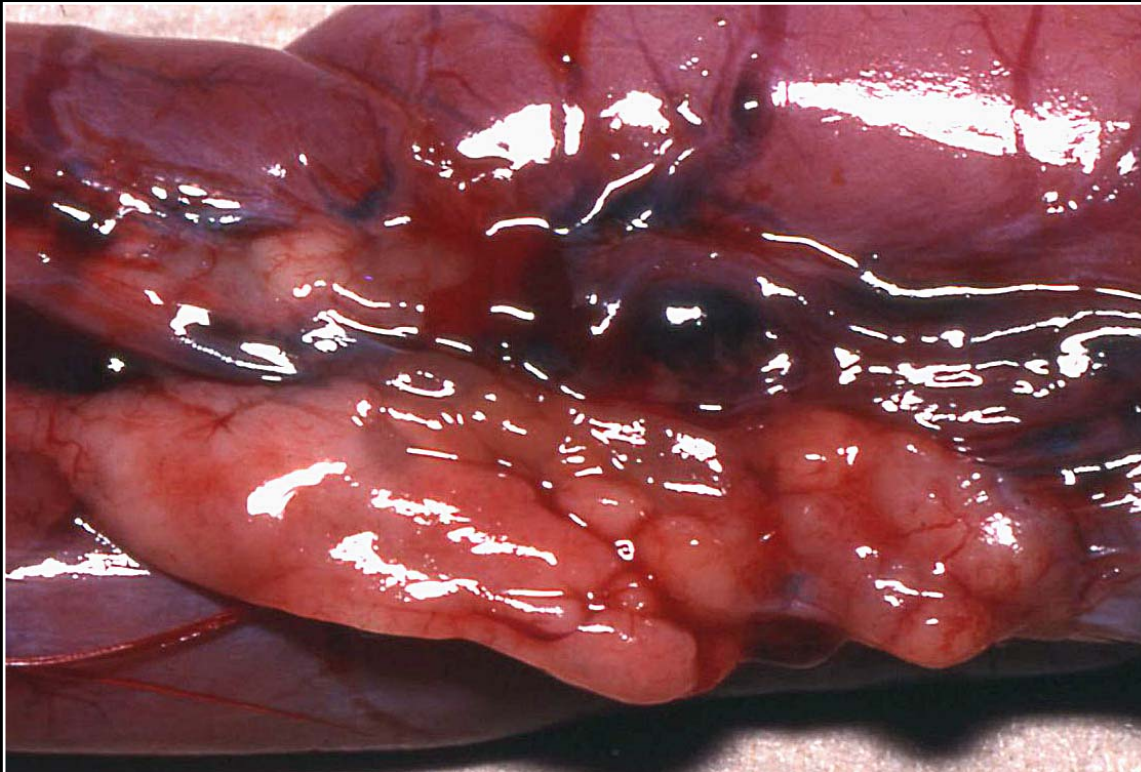
Back



C H A P T E R 7

Gastrointestinal System and Pancreas

Figure 7.65



Fibrosis of the pancreas with numerous pale firm nodular areas seen.

Prev. fig. Next fig.

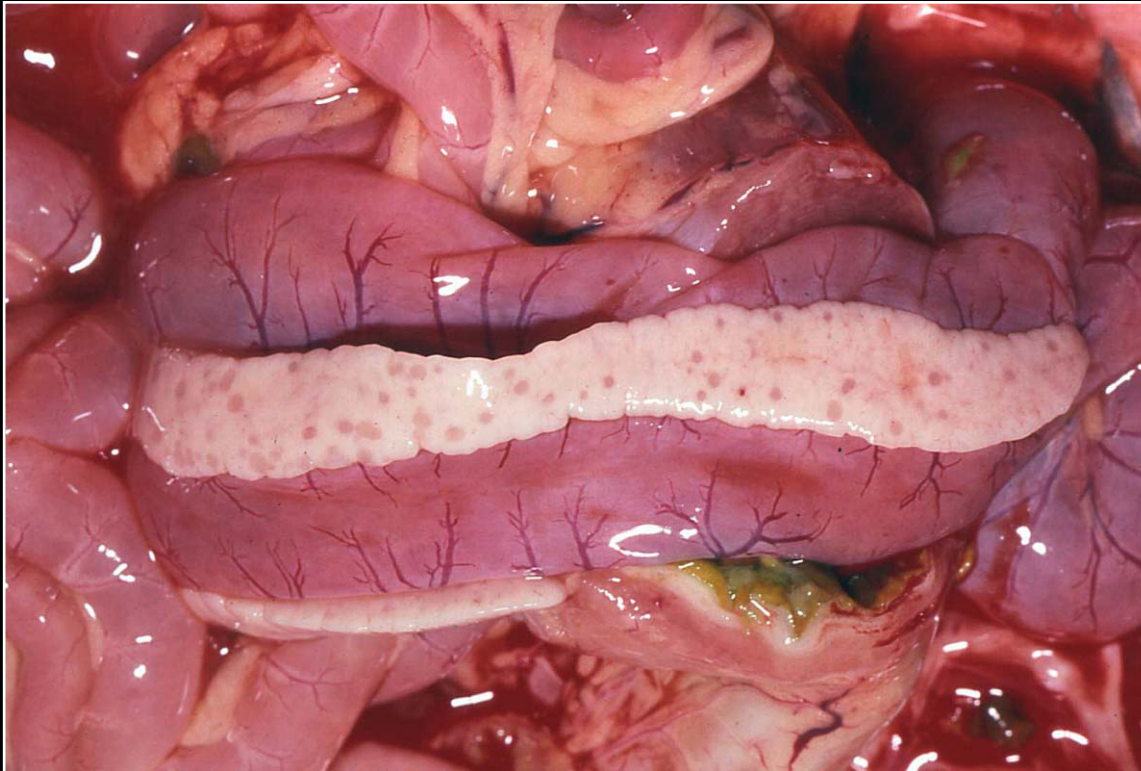
Back



C H A P T E R 7

Gastrointestinal System and Pancreas

Figure 7.66



Multiple small foci of necrosis and hemorrhage in the pancreas of a bird with Pacheco's disease.

Prev. fig. Next fig.

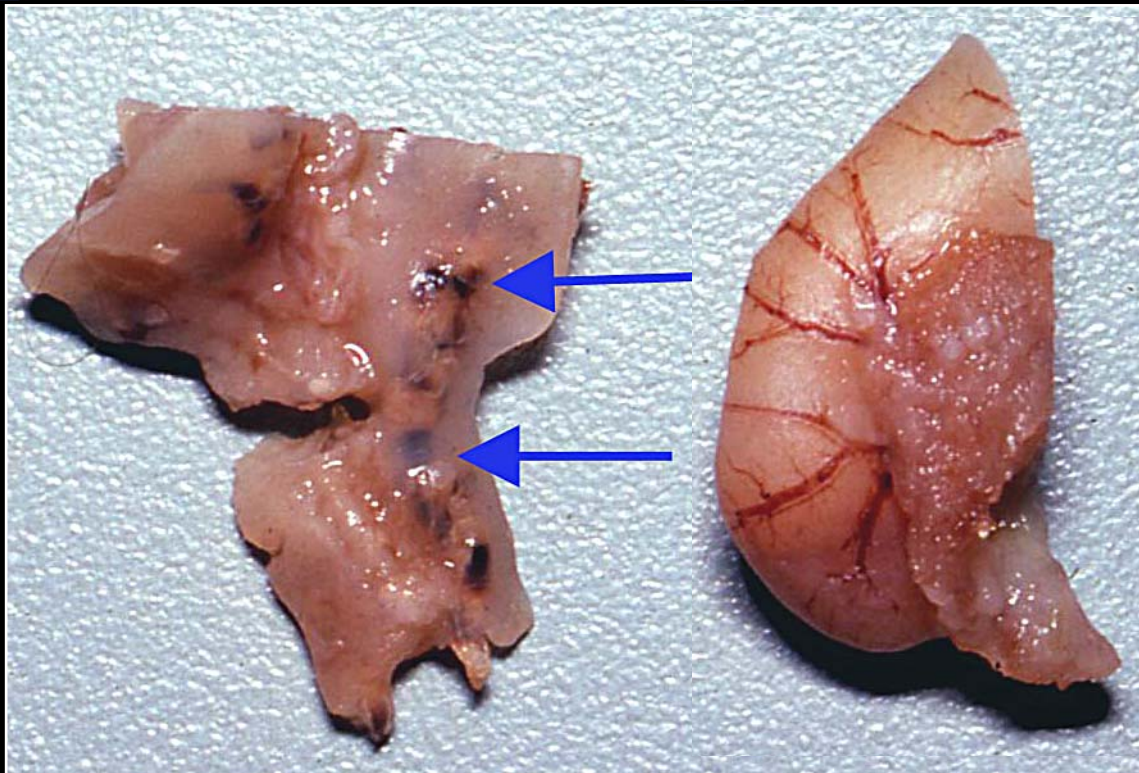
Back



C H A P T E R 7

Gastrointestinal System and Pancreas

Figure 7.67



Amboina king parrot with pancreatic trematodiasis. The pancreas is roughened and numerous brown-black foci are seen (arrows).

Prev. fig. Next fig.

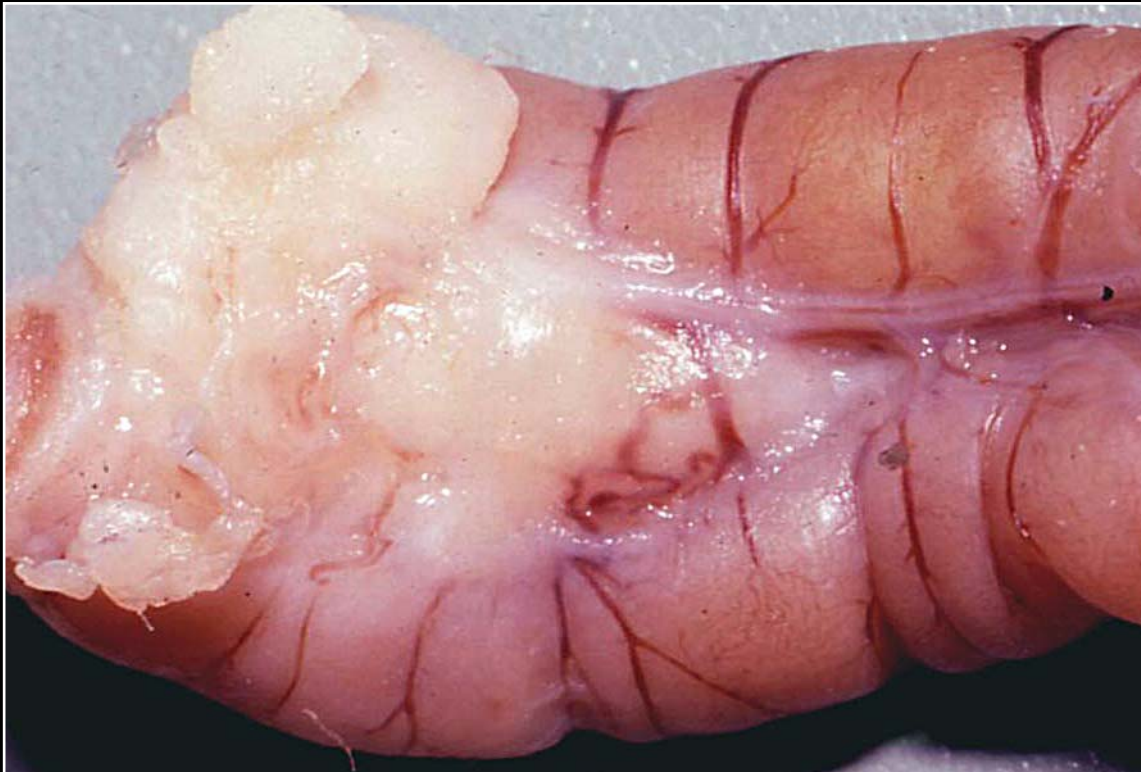Back



C H A P T E R 7

Gastrointestinal System and Pancreas

Figure 7.68



Pancreatic carcinoma effacing normal architecture and infiltrating into the intestinal wall.

Prev. fig. Next fig.

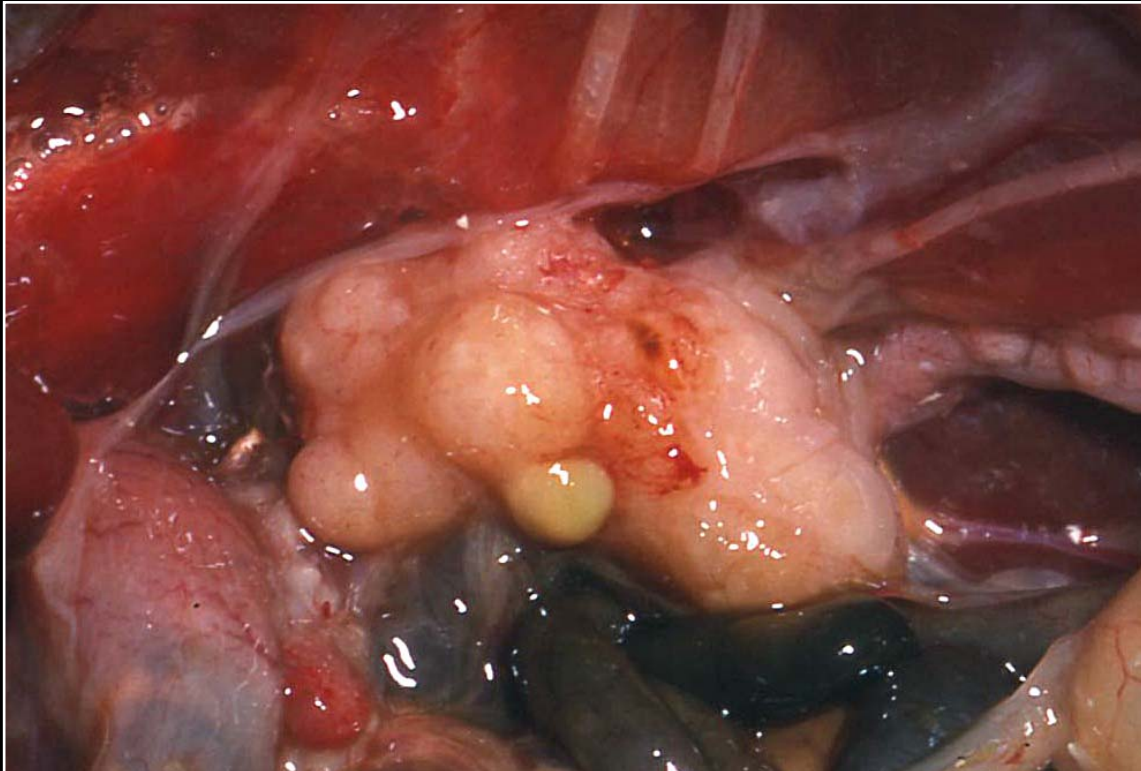
Back



C H A P T E R 7

Gastrointestinal System and Pancreas

Figure 7.69



Pancreatic carcinoma. Large irregular mass is seen displacing abdominal organs.

Prev. fig.

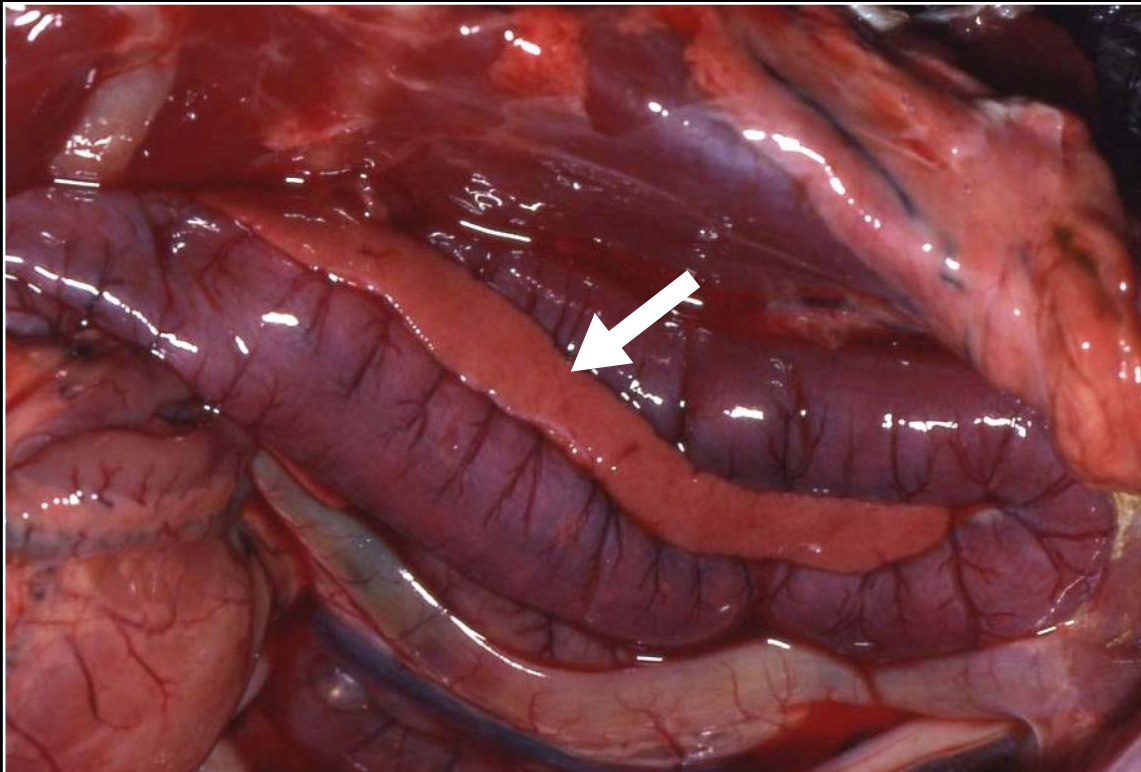
Back



C H A P T E R 7

Gastrointestinal System and Pancreas

Figure 7.37a



Normal duodenal loop of the intestines with a portion of the pancreas shown parallel to the abaxial side of the right loop.

Prev. fig. Next fig.

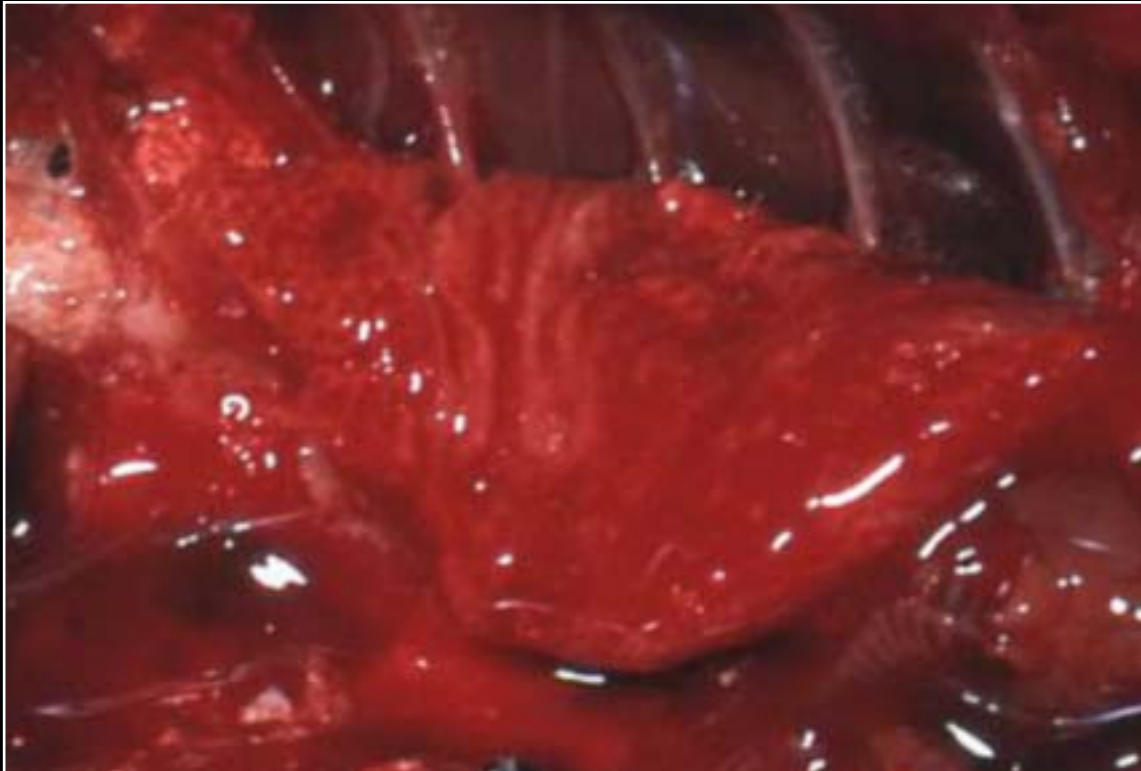
Back



C H A P T E R 8

Respiratory System

Figure 8.0



Normal lungs

Next fig.

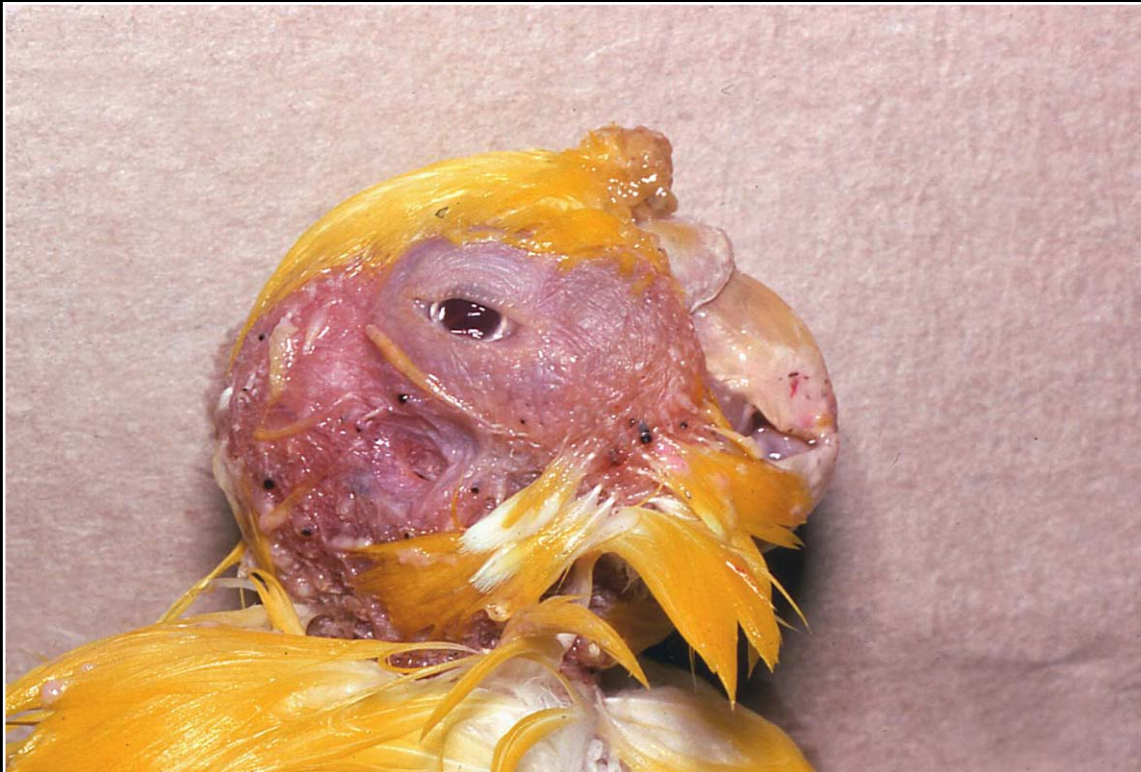Back



C H A P T E R 8

Respiratory System

Figure 8.1



Typical external gross appearance of sinusitis.

Prev. fig. Next fig.

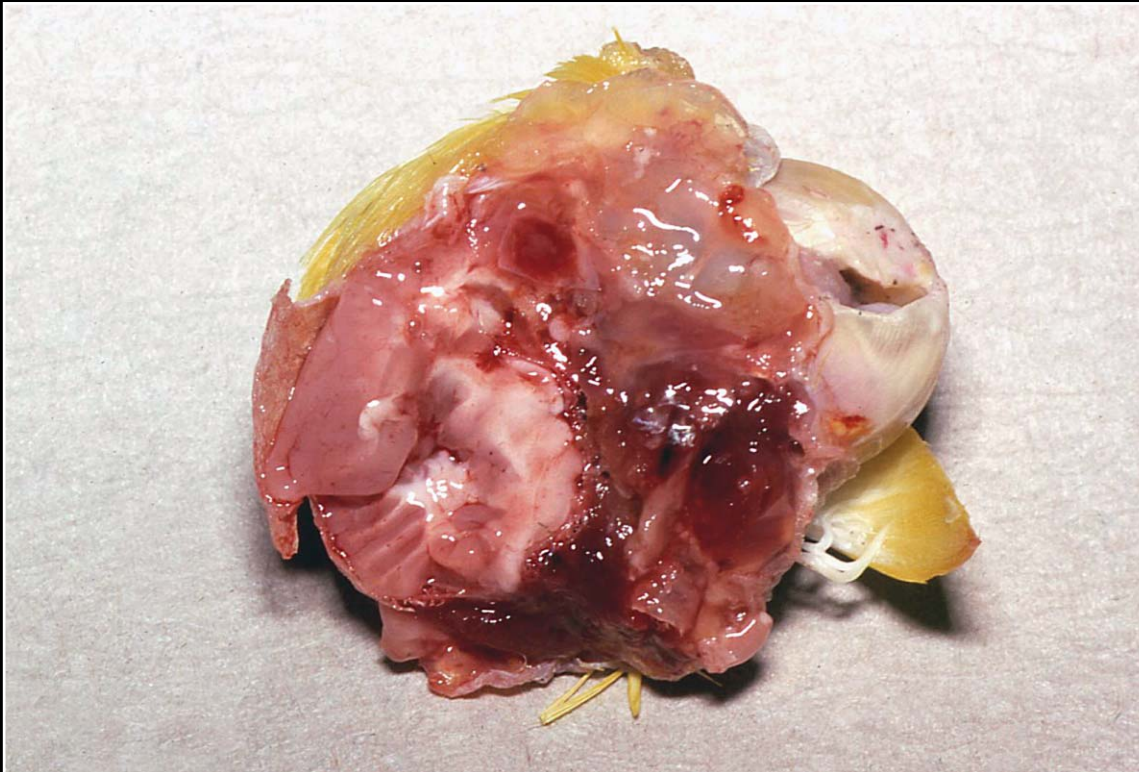
Back



C H A P T E R 8

Respiratory System

Figure 8.2



Distortion of tissue and mucopurulent discharge in bacterial sinusitis.

Prev. fig. Next fig.

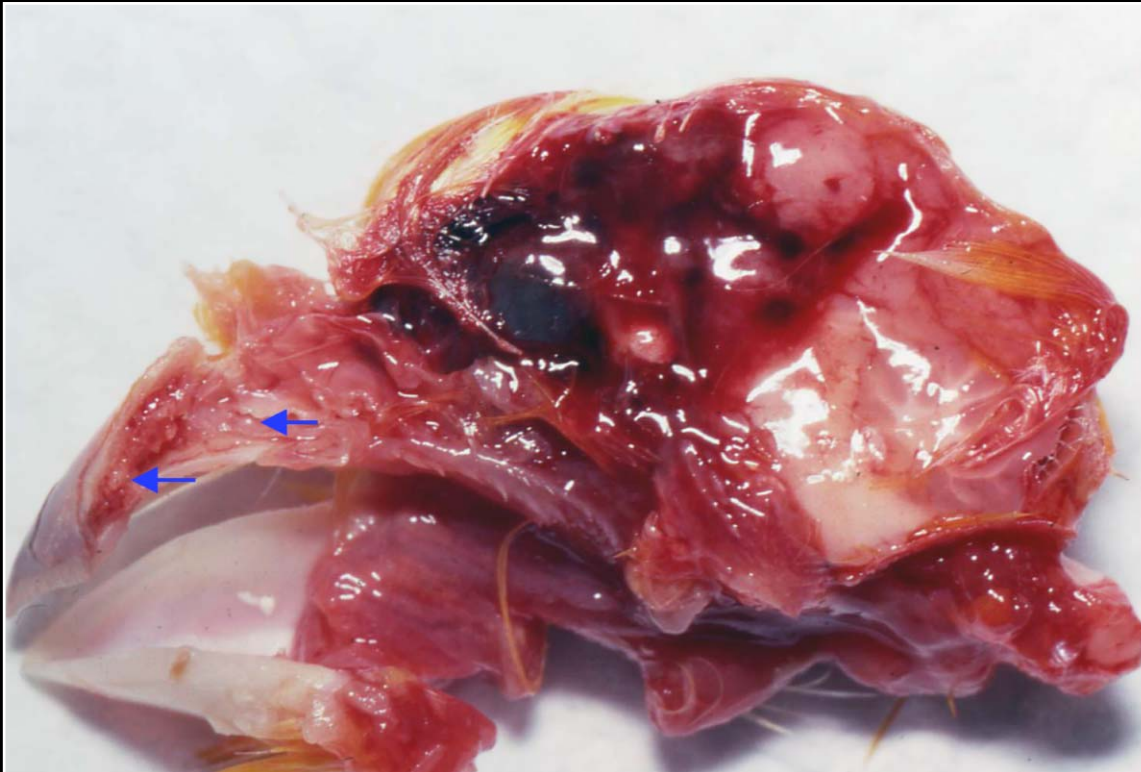Back



C H A P T E R 8

Respiratory System

Figure 8.3



Mycotic sinusitis in a canary. Note excess mucus and small gray-white foci (arrows) in mucosa. Grossly the lesion is similar to that of bacterial sinusitis.

Prev. fig. Next fig.

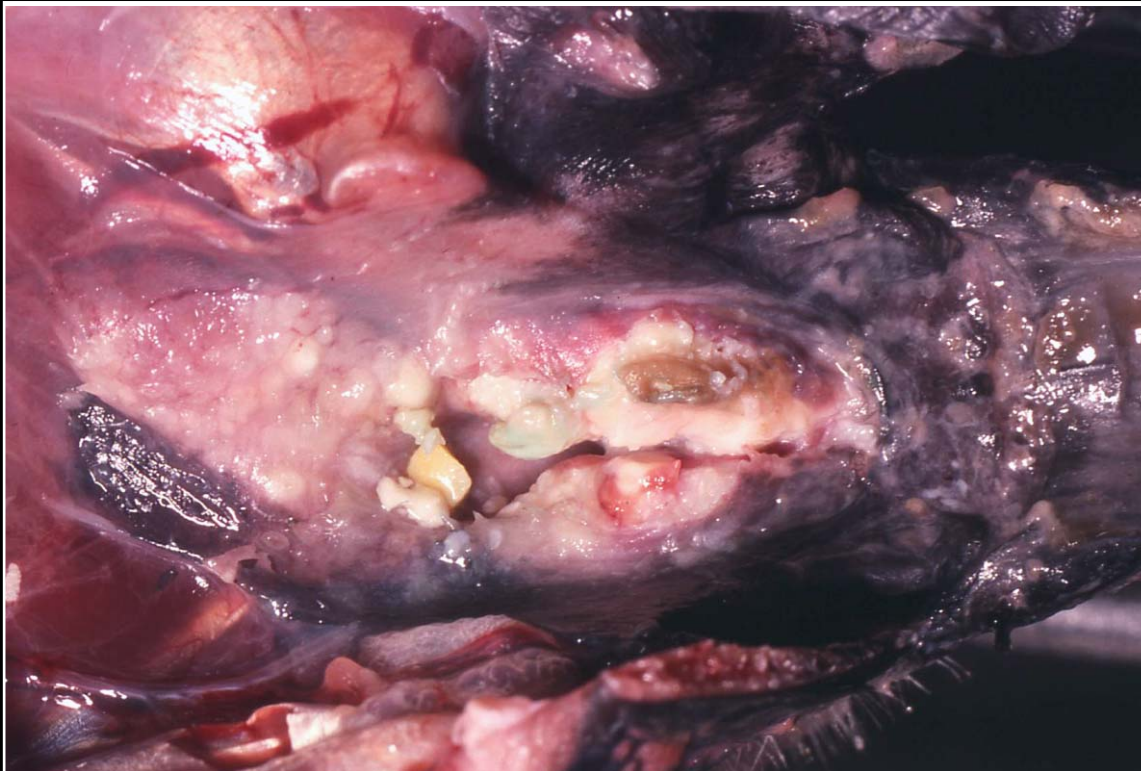Back



C H A P T E R 8

Respiratory System

Figure 8.4



Vitamin A deficiency leading to swelling and yellow-white exudate involving the choana and extending into the upper respiratory system in an African grey parrot.

Prev. fig. Next fig.

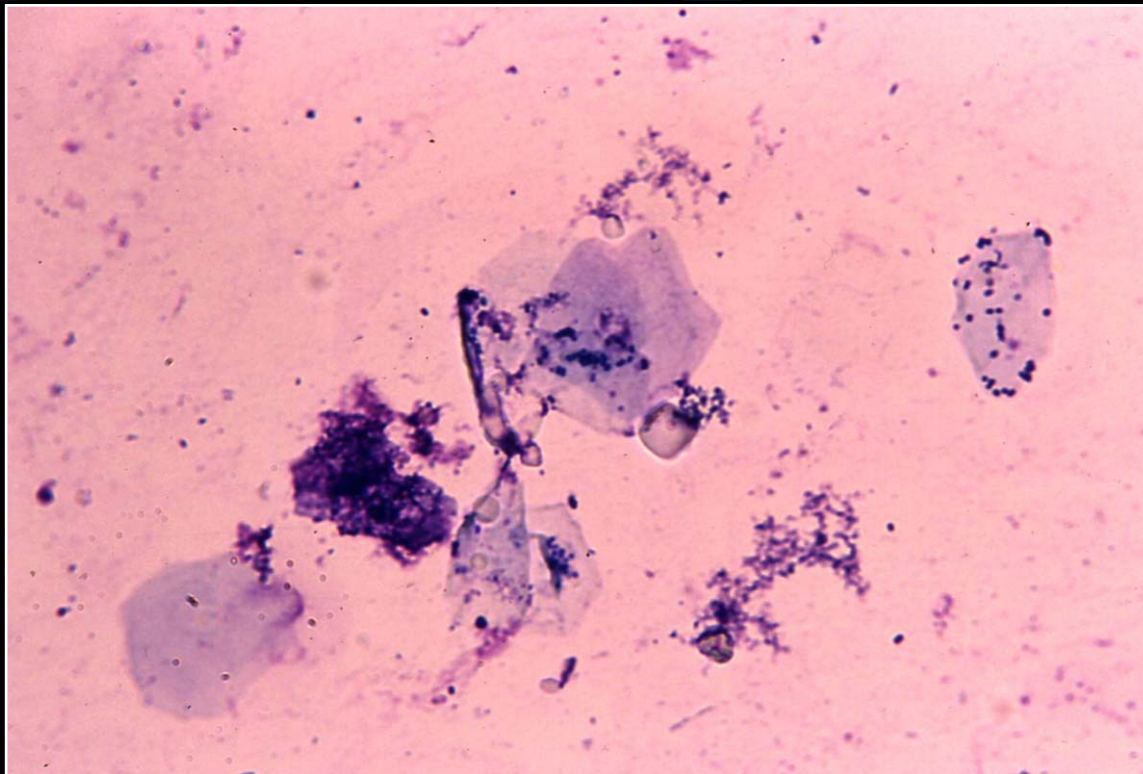
Back



CHAPTER 8

Respiratory System

Figure 8.5



Large metaplastic epithelial cells from the sinus of a bird with vitamin A deficiency. Some bacteria are also seen, indicating a possible secondary infection.

Prev. fig. Next fig.

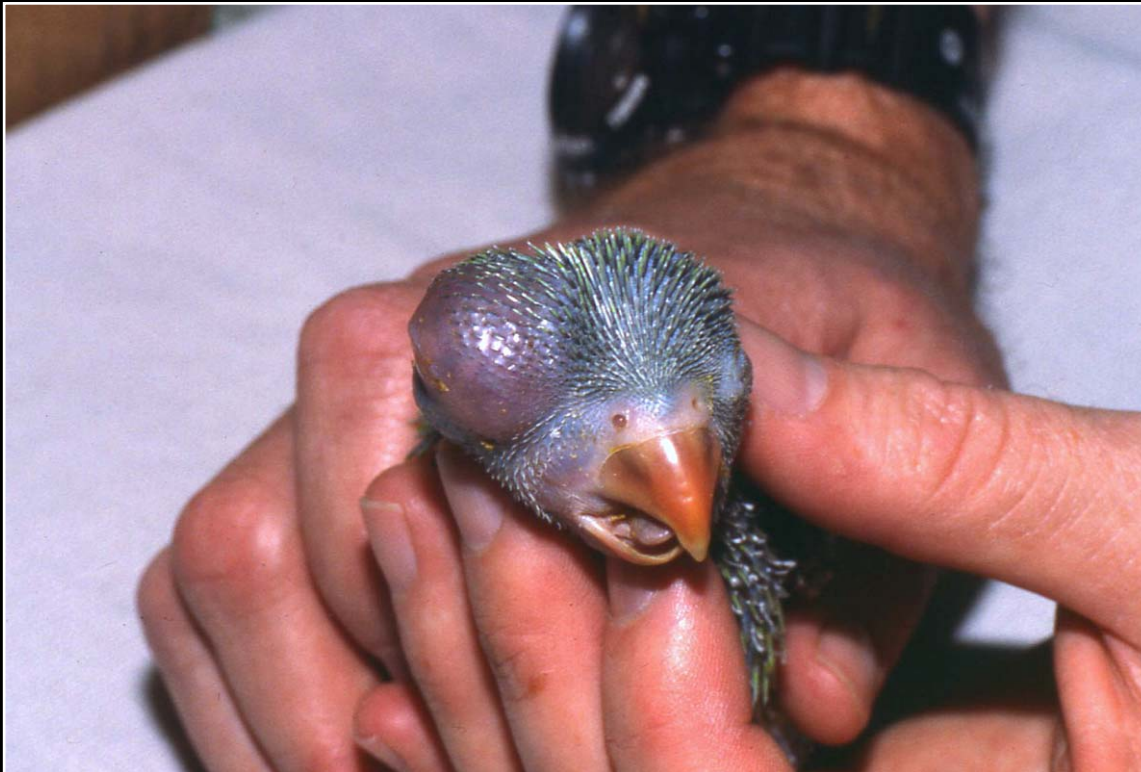Back



C H A P T E R 8

Respiratory System

Figure 8.6



Carcinoma of the infraorbital sinus distorting the architecture of the skull.

Prev. fig. Next fig.

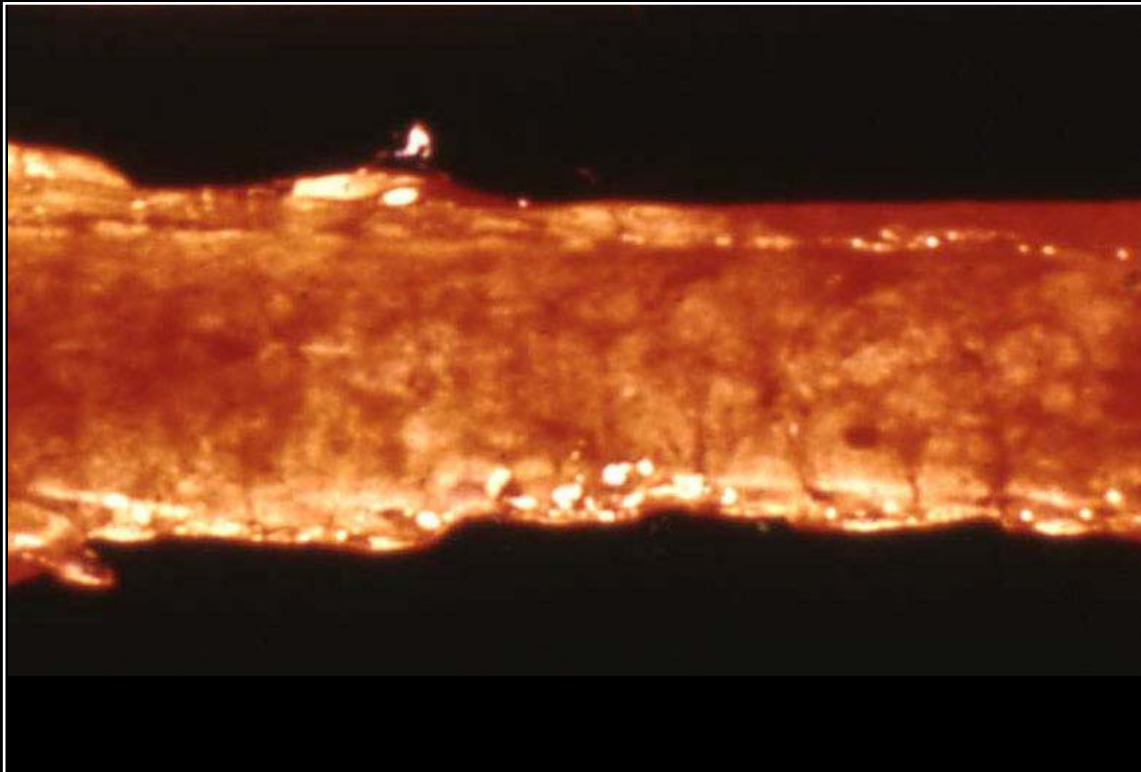
Back



C H A P T E R 8

Respiratory System

Figure 8.7



Severely reddened and necrotic trachea from a chicken with infectious laryngotracheitis.

Prev. fig. Next fig.

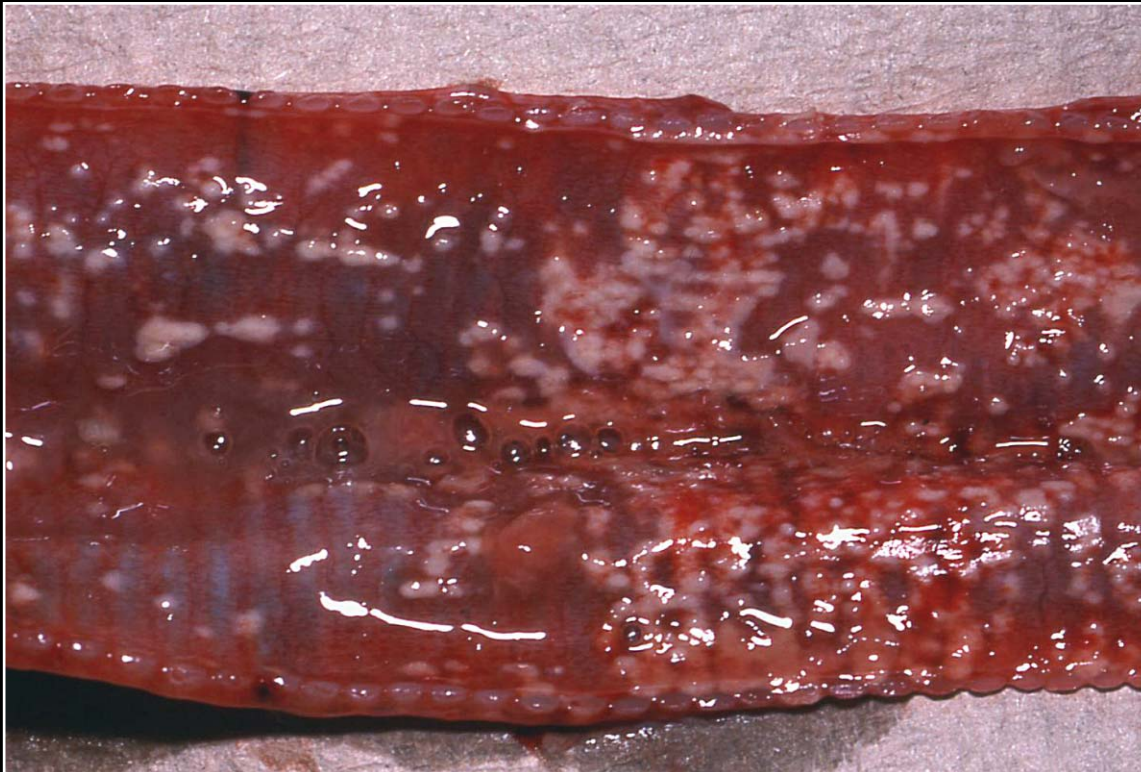
Back



C H A P T E R 8

Respiratory System

Figure 8.8



Bacterial tracheitis in an ostrich. Note severe mucosal hyperemia with necrosis and fibrin deposition.

Prev. fig. Next fig.

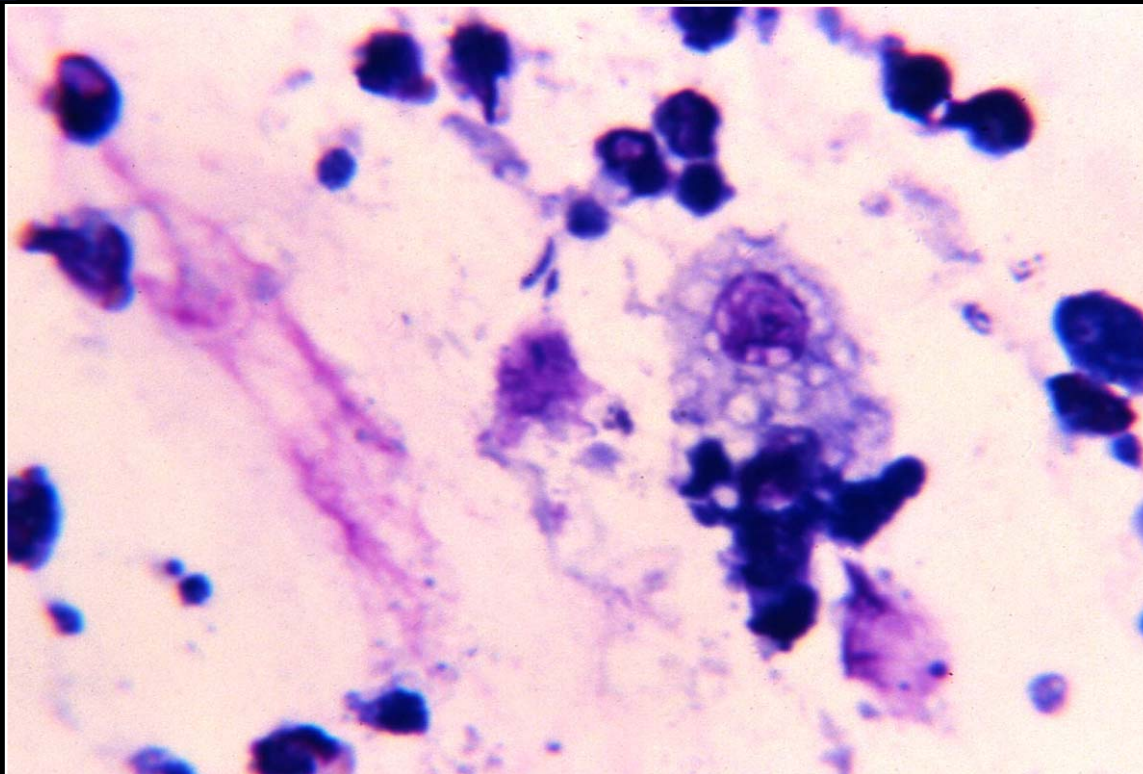
Back



C H A P T E R 8

Respiratory System

Figure 8.9



Cytologic preparation from a case of bacterial tracheitis. A mixed inflammatory infiltrate and some rod-shaped bacteria are seen.

Prev. fig. Next fig.

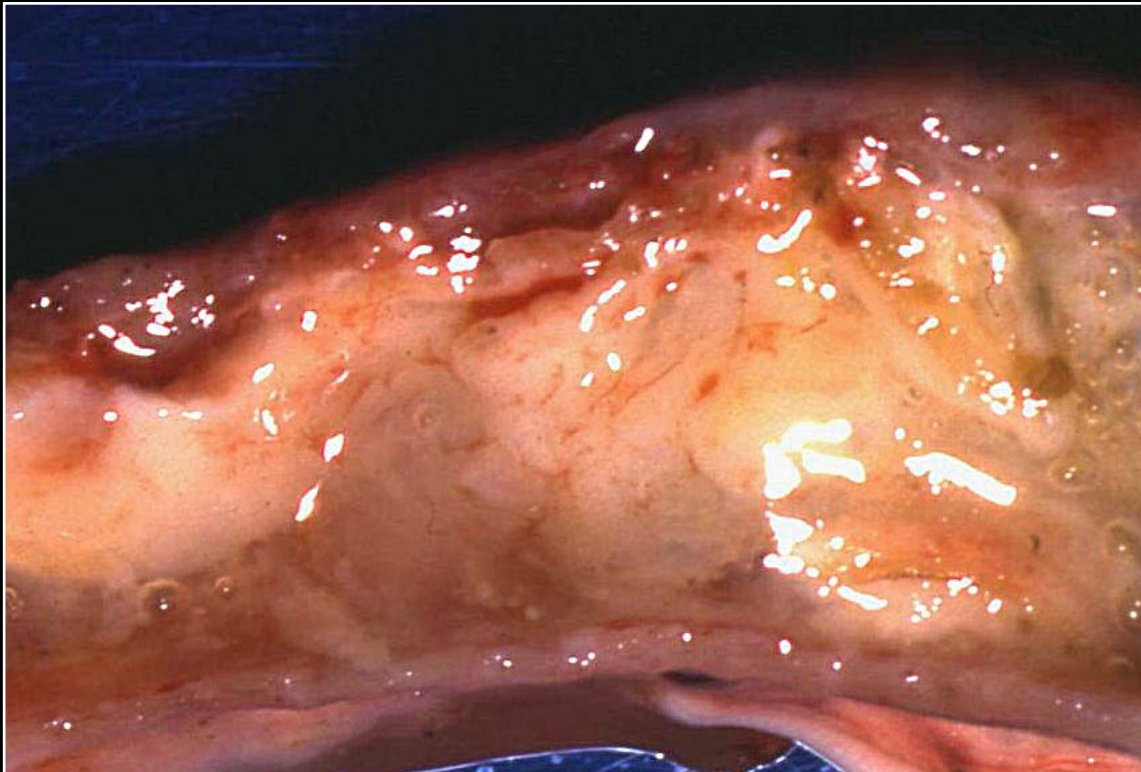
Back



C H A P T E R 8

Respiratory System

Figure 8.10



Mycotic tracheitis. The lumen is occluded by fibrinonecrotic material.

Prev. fig. Next fig.

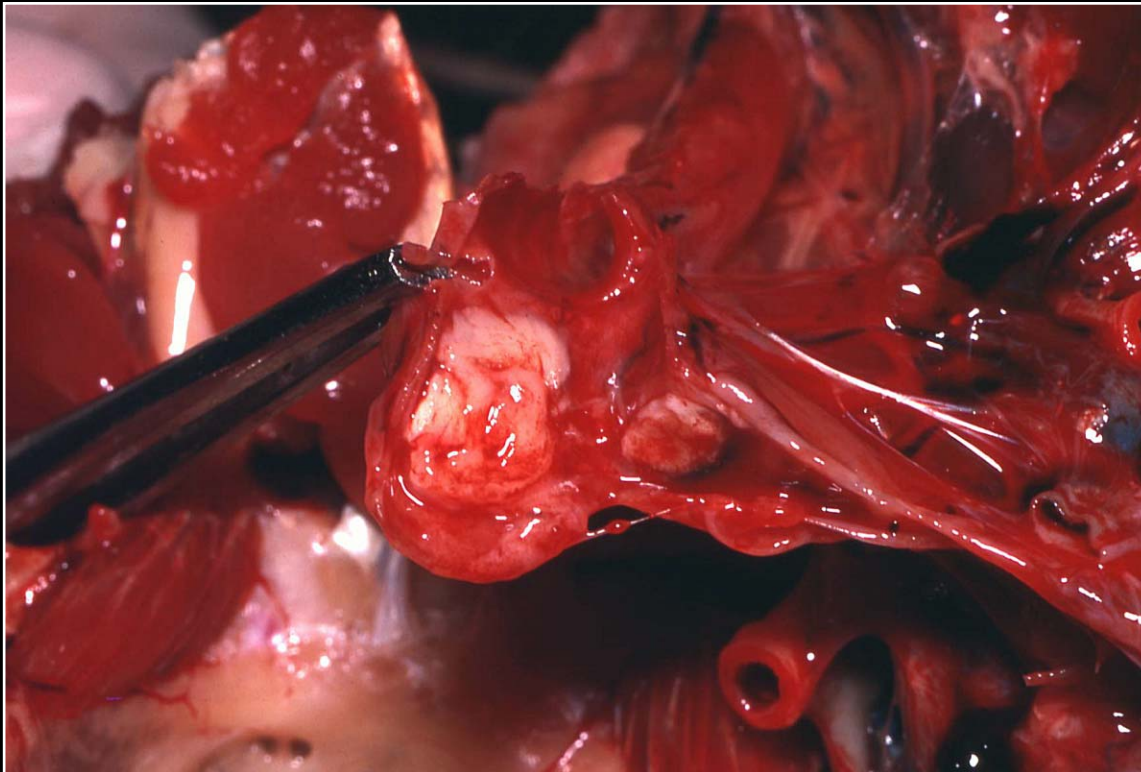
Back



C H A P T E R 8

Respiratory System

Figure 8.11



Exudate plugging of the syrx in a macaw with aspergillosis.

Prev. fig. Next fig.

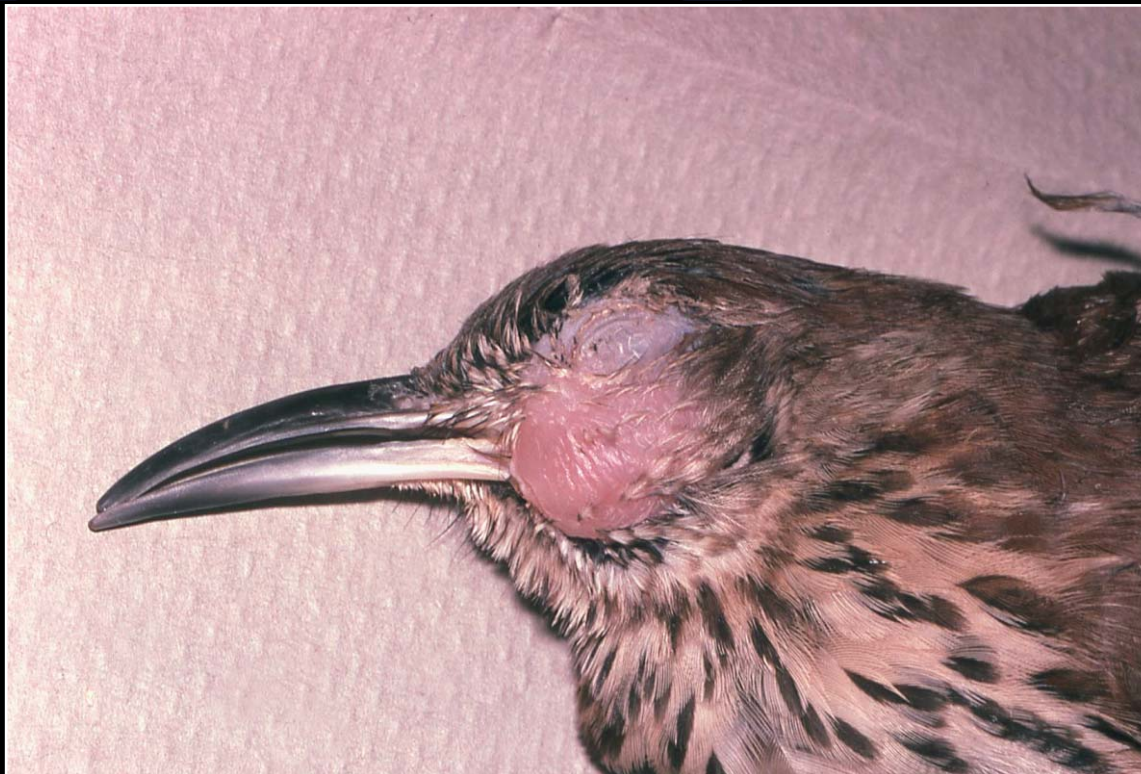Back



C H A P T E R 8

Respiratory System

Figure 8.12



Swollen sinus due to infection by *Trichomonas* sp.

Prev. fig. Next fig.

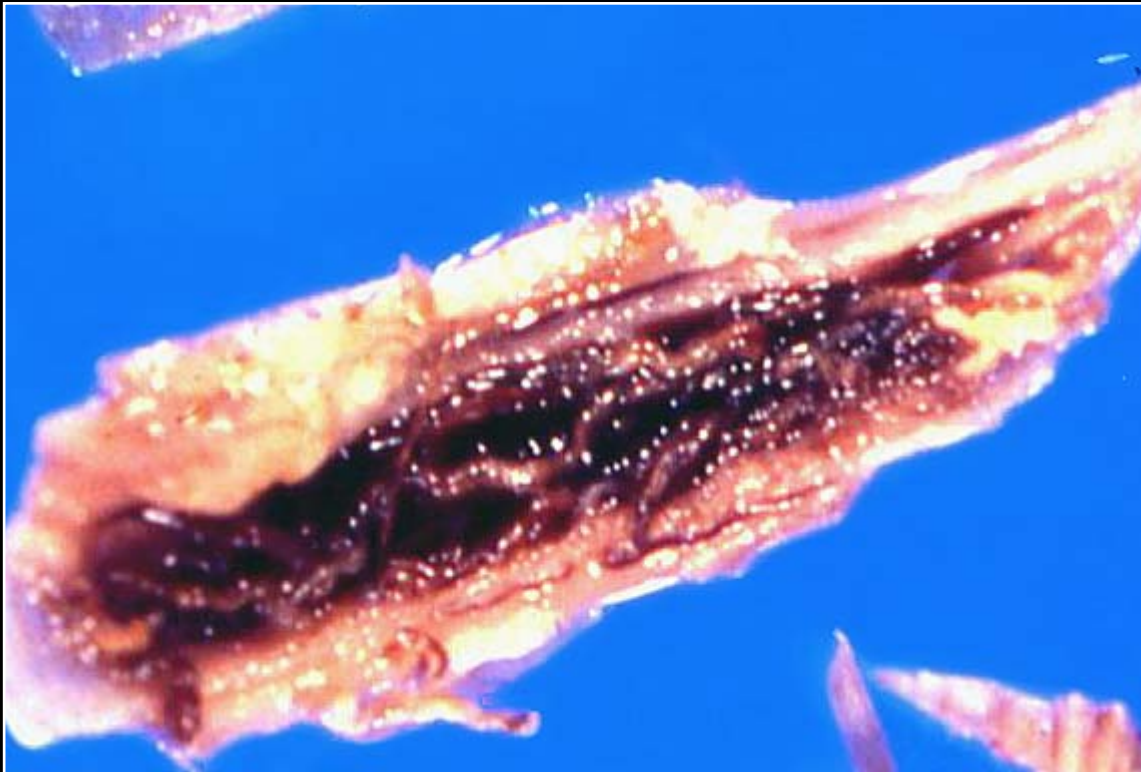
Back



C H A P T E R 8

Respiratory System

Figure 8.13



Severe tracheal hemorrhage due to *Cyathostoma* sp. in a duck.

Prev. fig. Next fig.

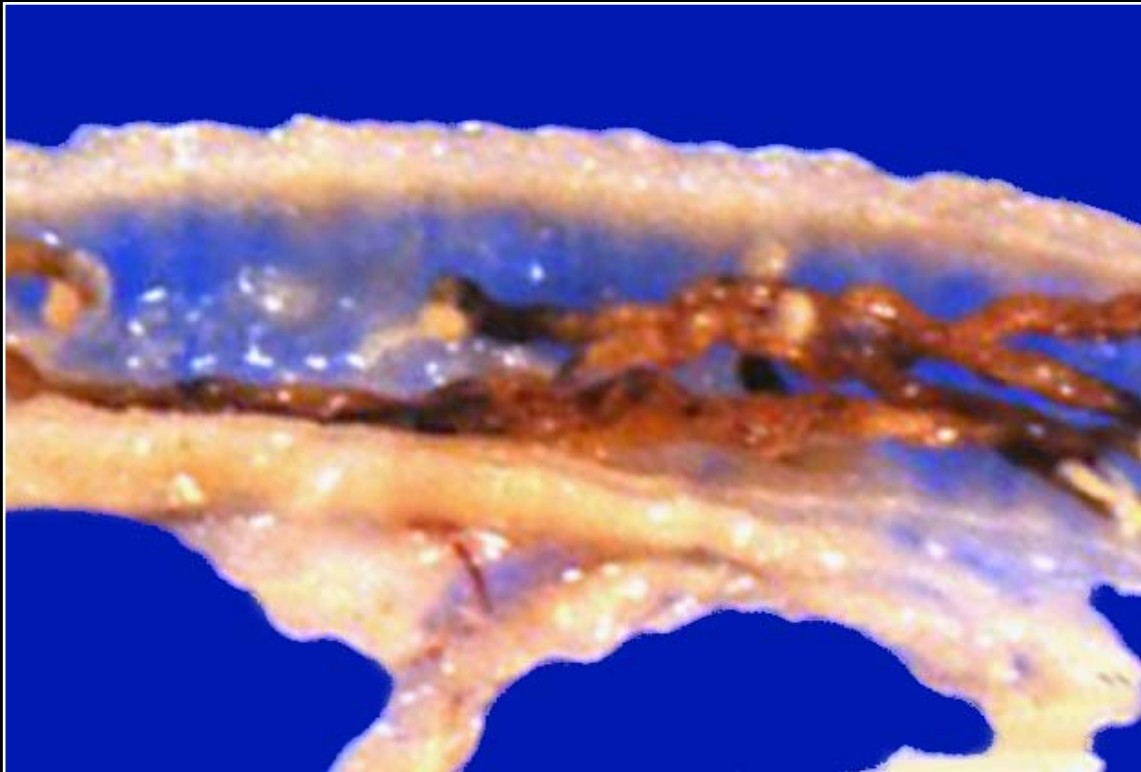
Back



C H A P T E R 8

Respiratory System

Figure 8.14



Syngamus in a trachea without the severe hemorrhagic reaction.

Prev. fig. Next fig.

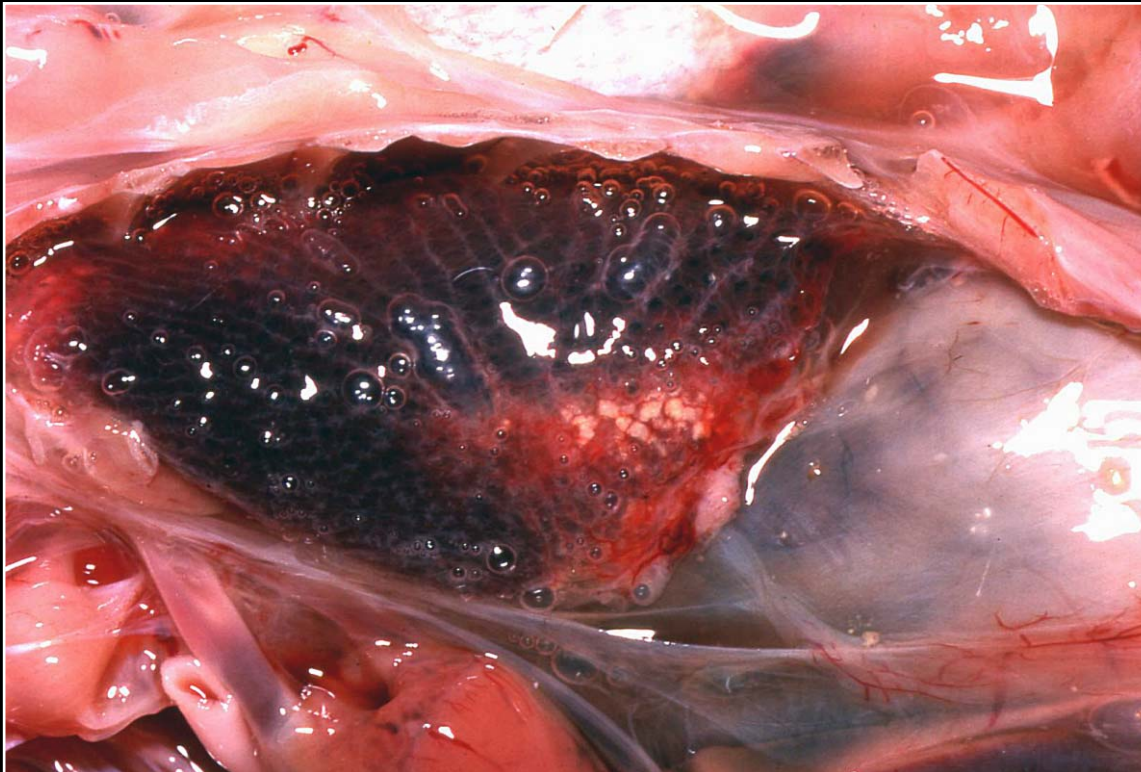
Back



C H A P T E R 8

Respiratory System

Figure 8.15



Dark red lung containing focal yellow areas of necrosis and exudation.

Prev. fig. Next fig.

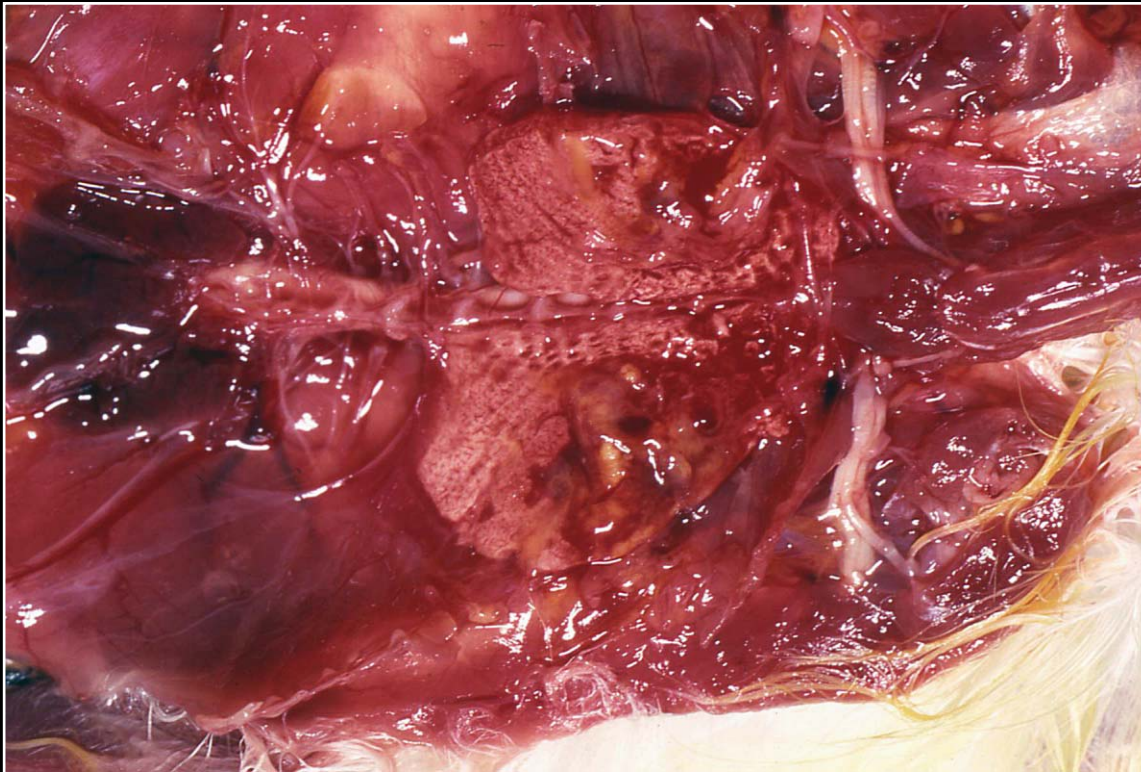
Back



C H A P T E R 8

Respiratory System

Figure 8.16



Foci of necrosis and abscessation in both lungs of a canary with bacterial pneumonia.

Prev. fig. Next fig.

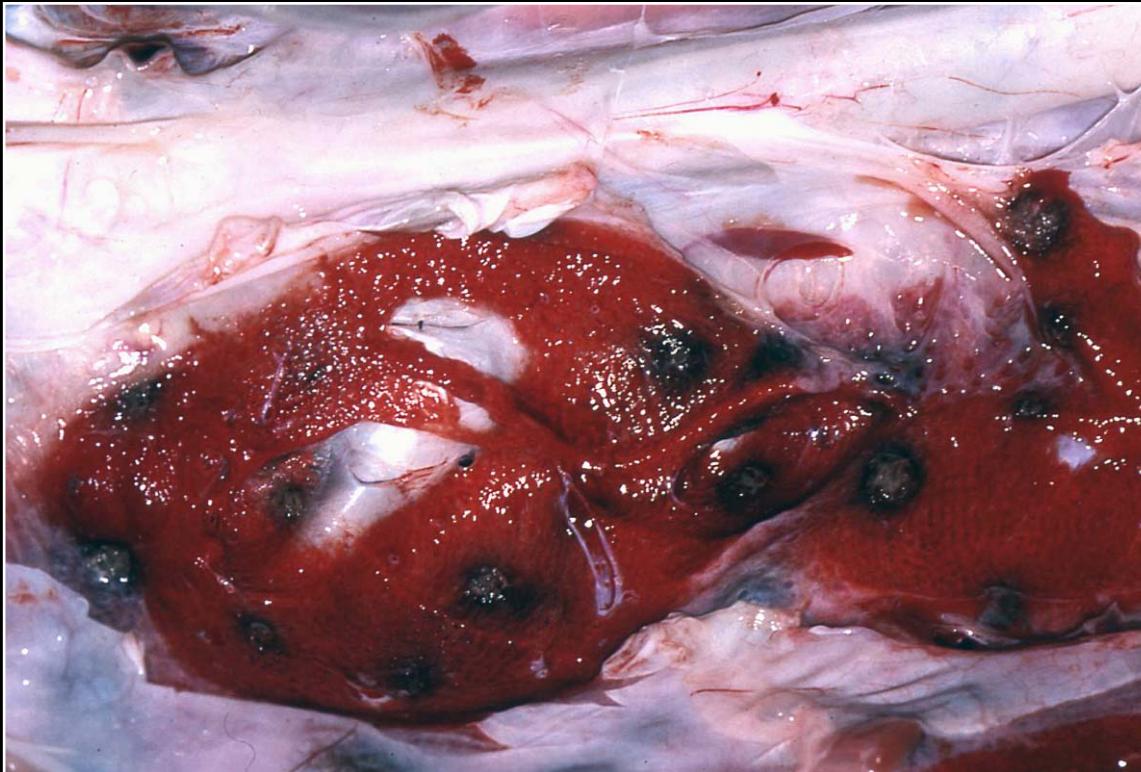
Back



C H A P T E R 8

Respiratory System

Figure 8.17



Multiple foci of necrosis due to bacterial infection in an ostrich lung.

Prev. fig. Next fig.

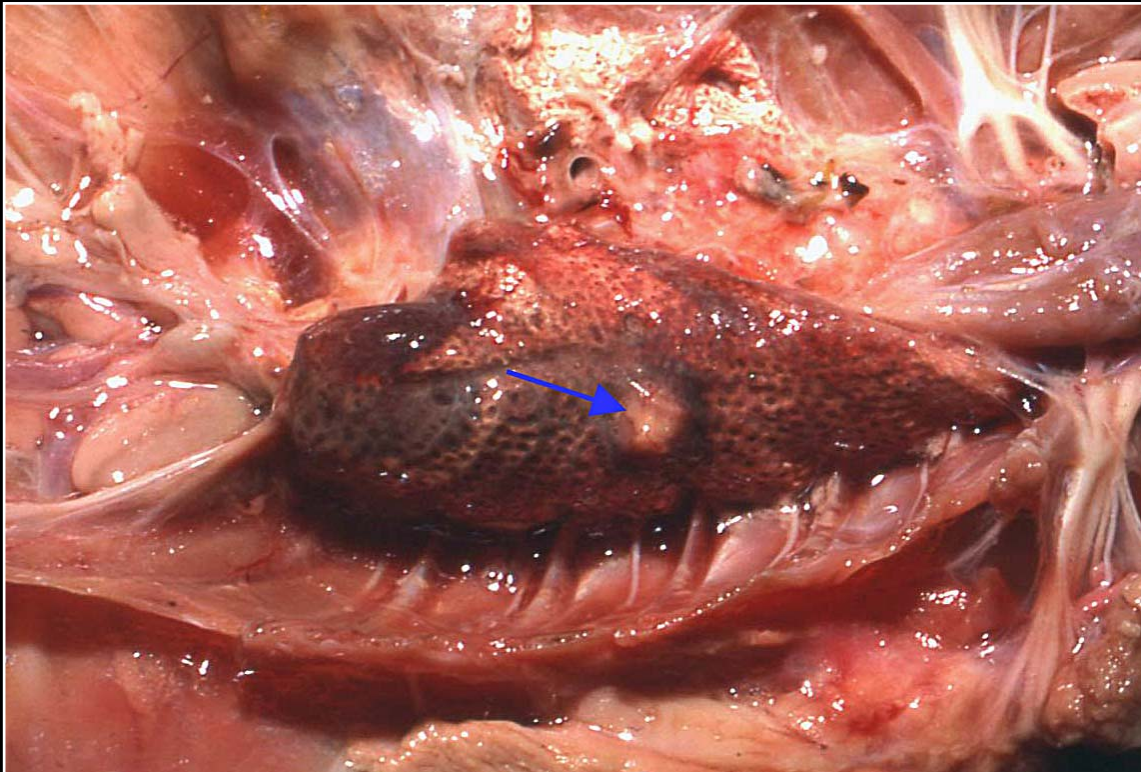
Back



C H A P T E R 8

Respiratory System

Figure 8.18



Granuloma formation in an African grey with systemic mycobacteriosis (arrow).

Prev. fig. Next fig.

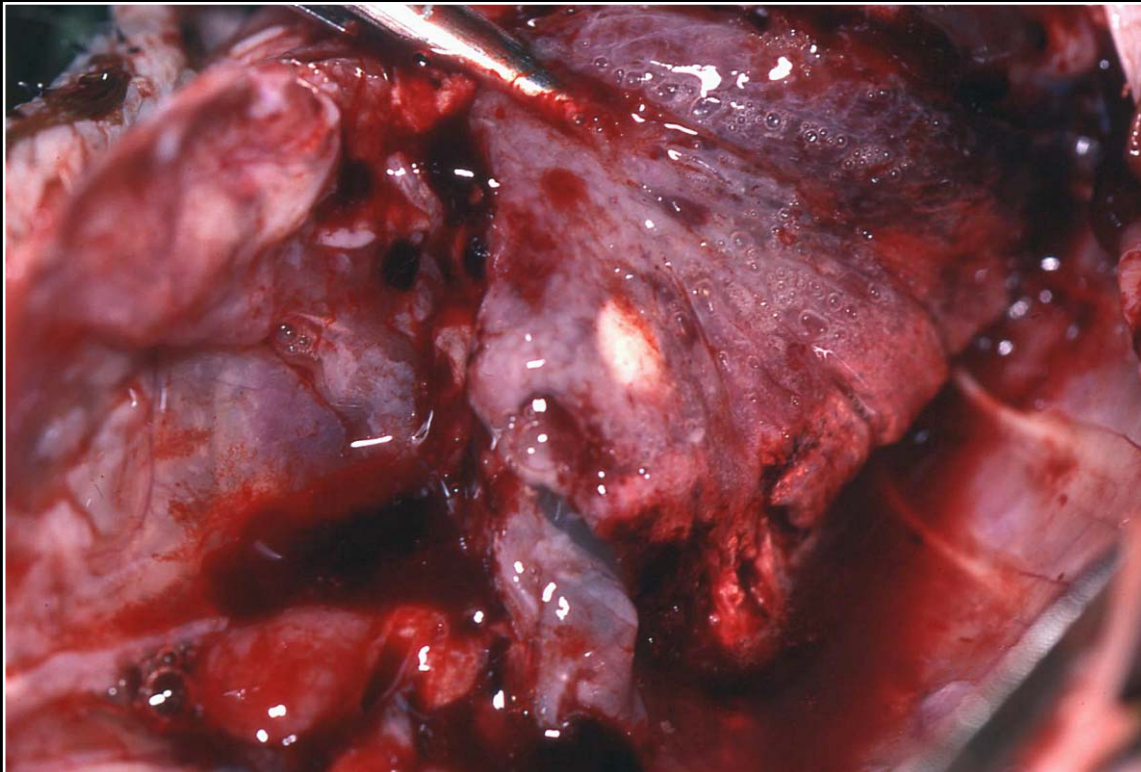
Back



C H A P T E R 8

Respiratory System

Figure 8.19



Small granuloma in the lung of an Amazon parrot with acute mycotic pneumonia.

Prev. fig. Next fig.

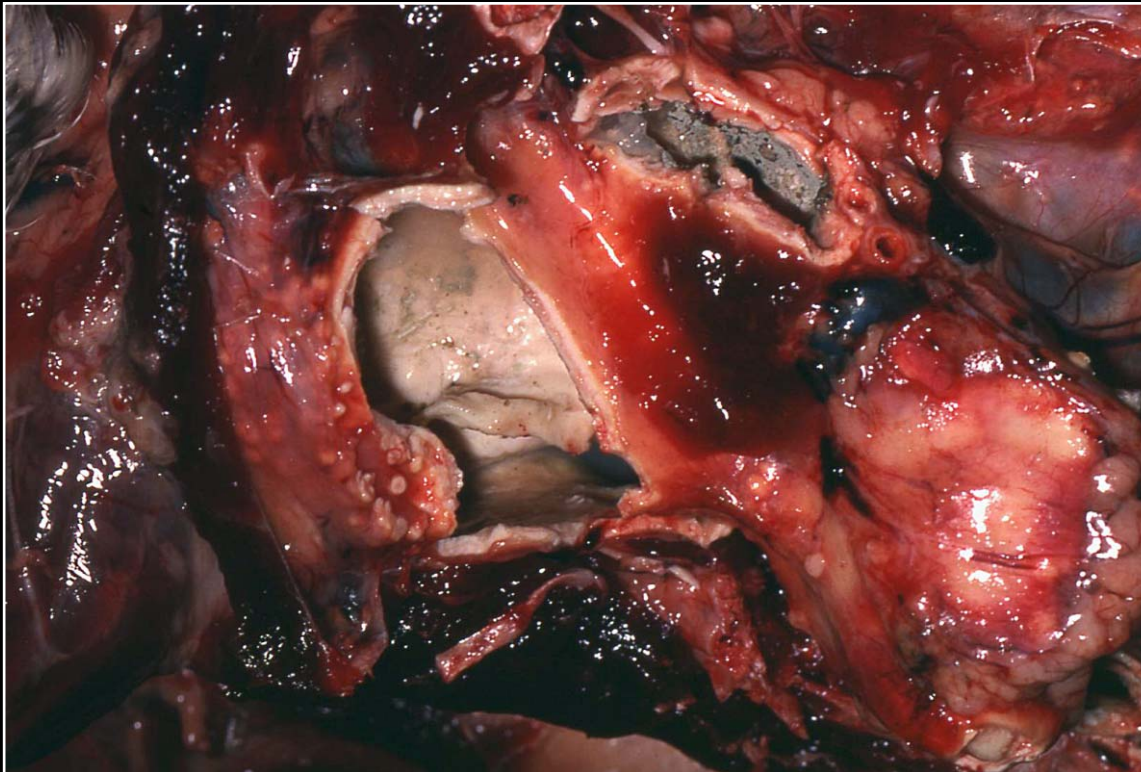
Back



C H A P T E R 8

Respiratory System

Figure 8.20



Severe chronic *Aspergillus* pneumonia with multiple lesions and cavitation. Note the greenish color associated with mycelial growth.

Prev. fig. Next fig.

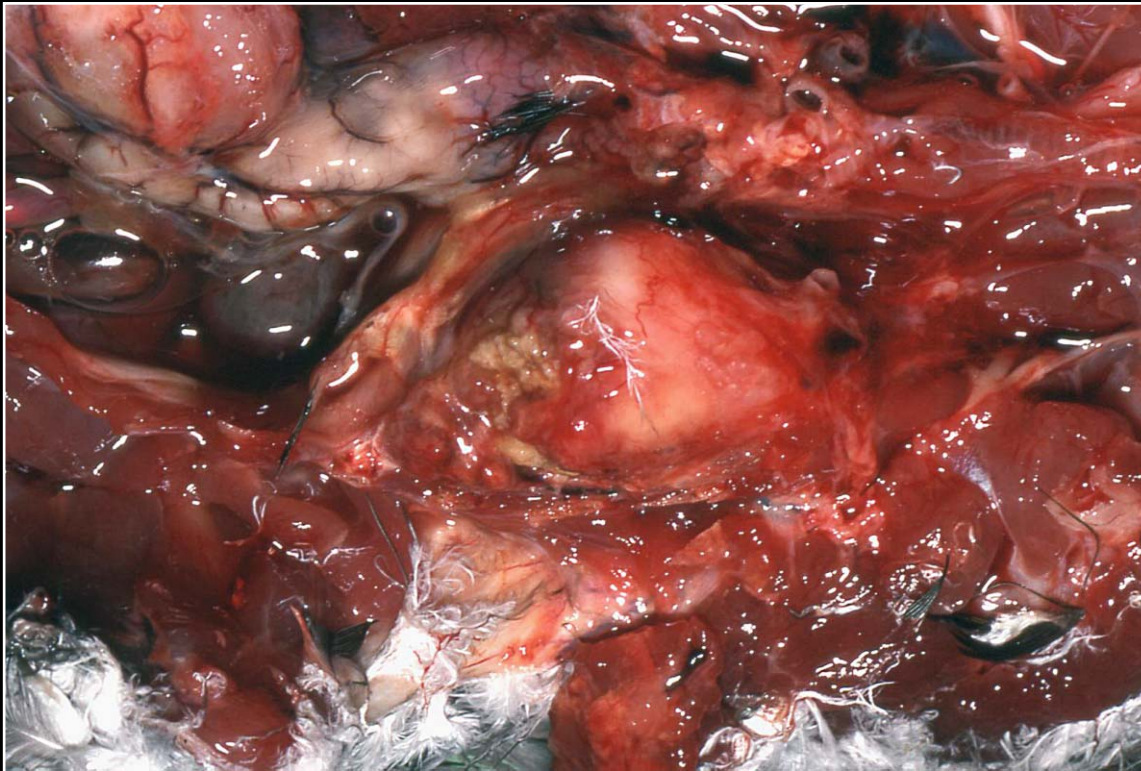
Back



C H A P T E R 8

Respiratory System

Figure 8.21



Severe chronic mycotic pneumonia with almost complete effacement of the lung and formation of a large mass lesion.

Prev. fig. Next fig.

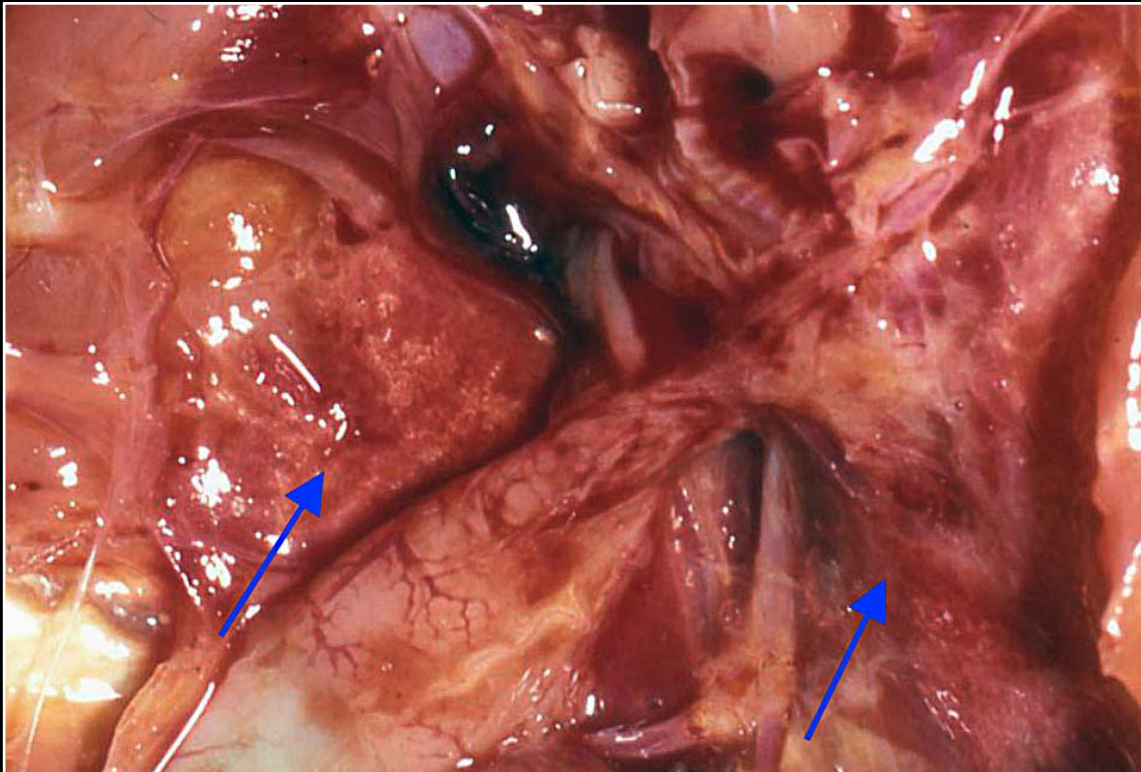
Back



C H A P T E R 8

Respiratory System

Figure 8.22



Collapsed, reddened areas in the lung of a cockatiel with sarcosporidiosis (arrows).

Prev. fig. Next fig.

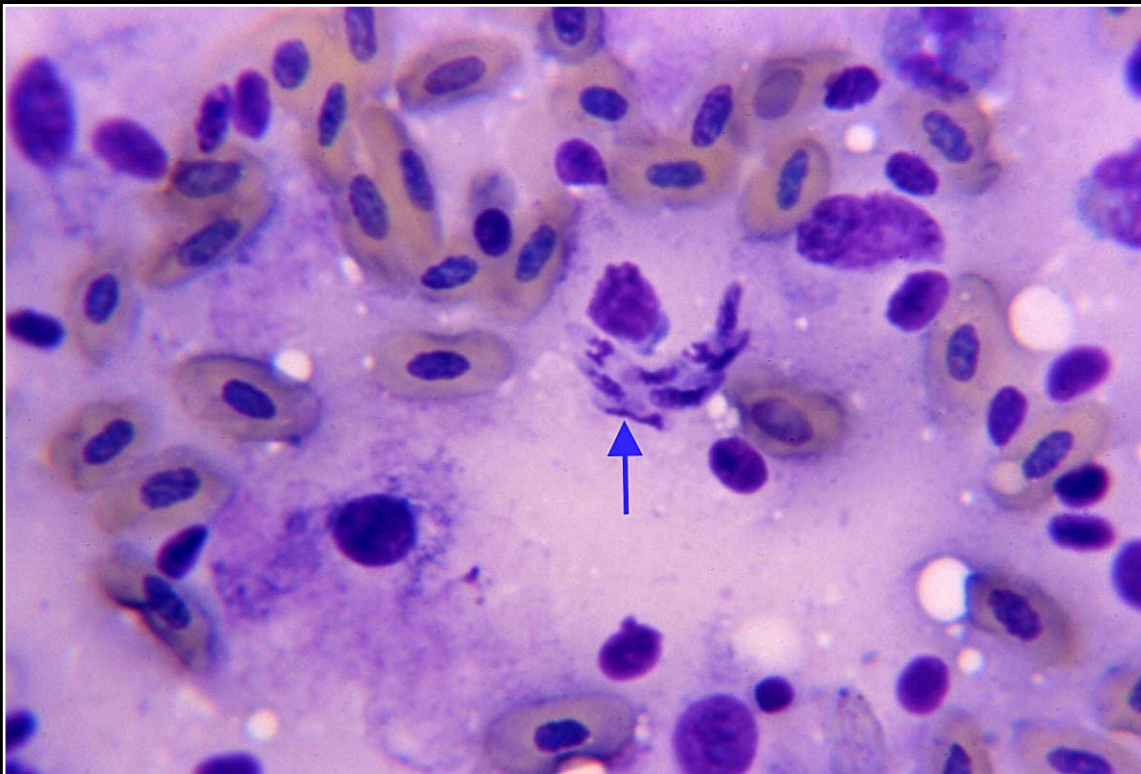
Back



C H A P T E R 8

Respiratory System

Figure 8.23



Impression smear of avian lung containing merozoites of *Sarcocystis* sp. (arrow).

Prev. fig. Next fig.

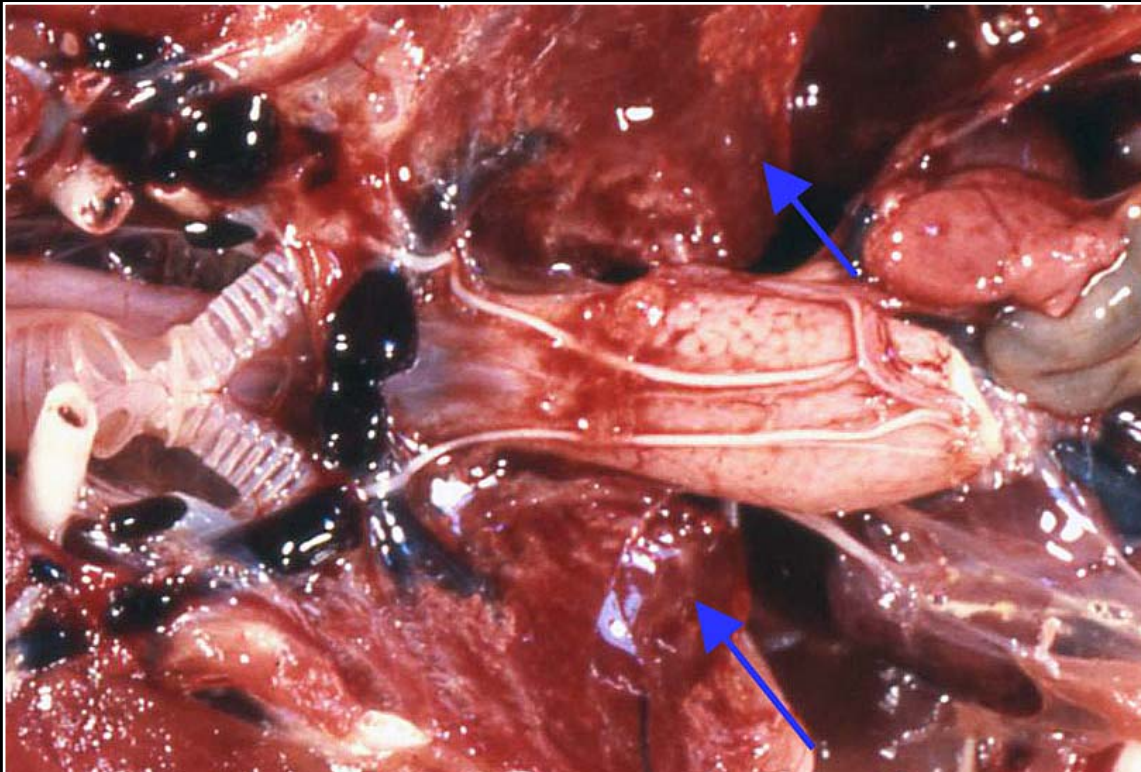
Back



C H A P T E R 8

Respiratory System

Figure 8.24



Foci of collapse and discoloration in the lung of a pigeon with toxoplasmosis (arrows).

Prev. fig. Next fig.

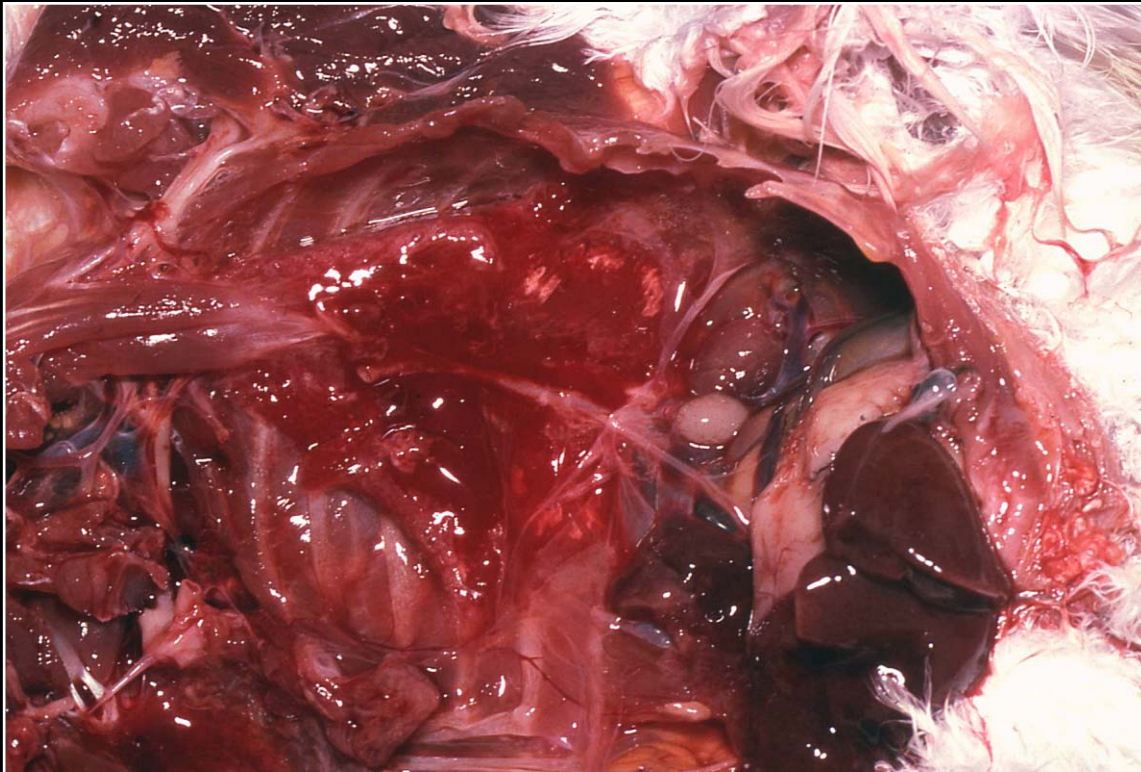
Back



C H A P T E R 8

Respiratory System

Figure 8.25



Wet reddened lungs typical of inhaled toxins such as Teflon® fumes.

Prev. fig. Next fig.

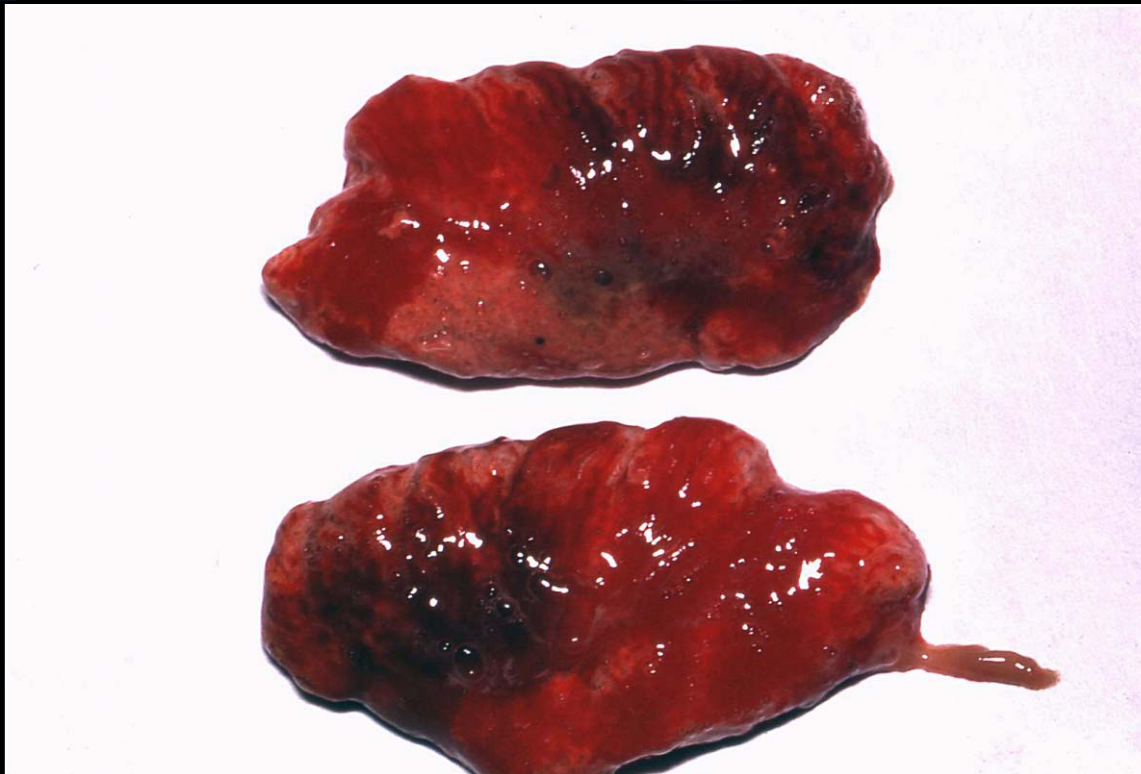Back



C H A P T E R 8

Respiratory System

Figure 8.26



Irregular distribution of congestion, hemorrhage and consolidation in the lungs of a macaw with inhalation pneumonia.

Prev. fig. Next fig.

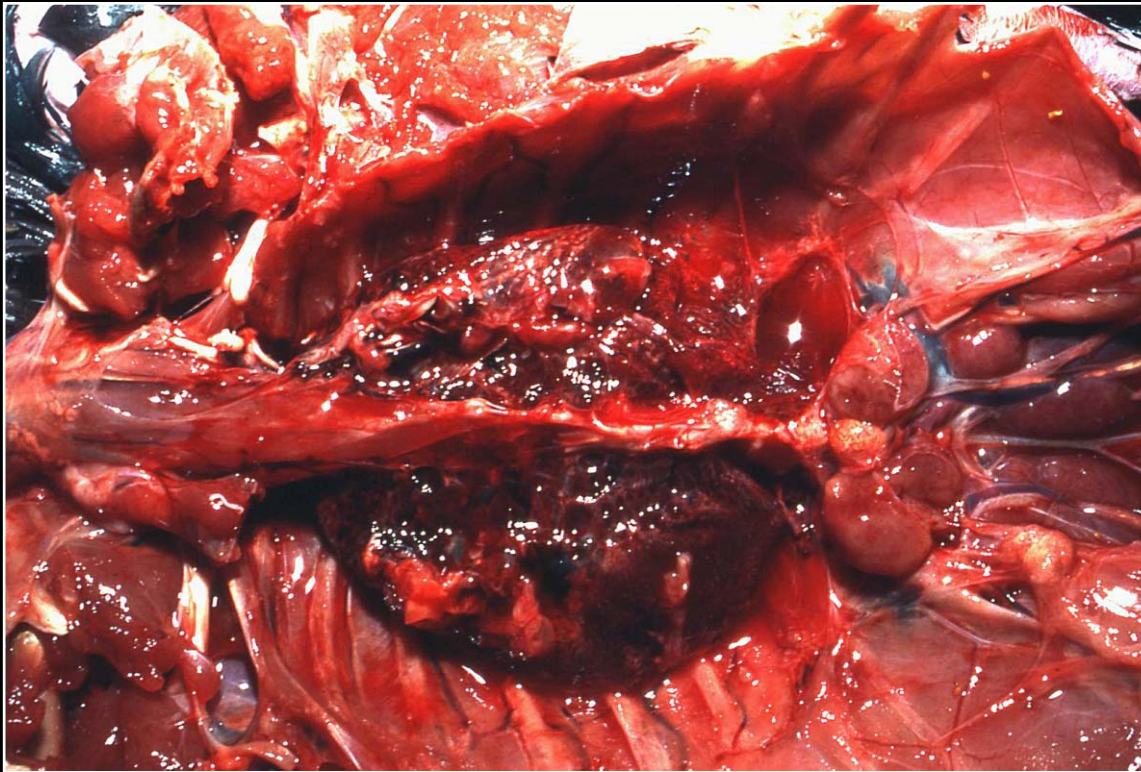
Back



C H A P T E R 8

Respiratory System

Figure 8.27



Severe pulmonary congestion and edema due to heart failure.

Prev. fig. Next fig.

Back



C H A P T E R 8

Respiratory System

Figure 8.28



Pulmonary carcinoma invasive through the body wall. The superficial mass lesion was the presenting problem.

Prev. fig. Next fig.

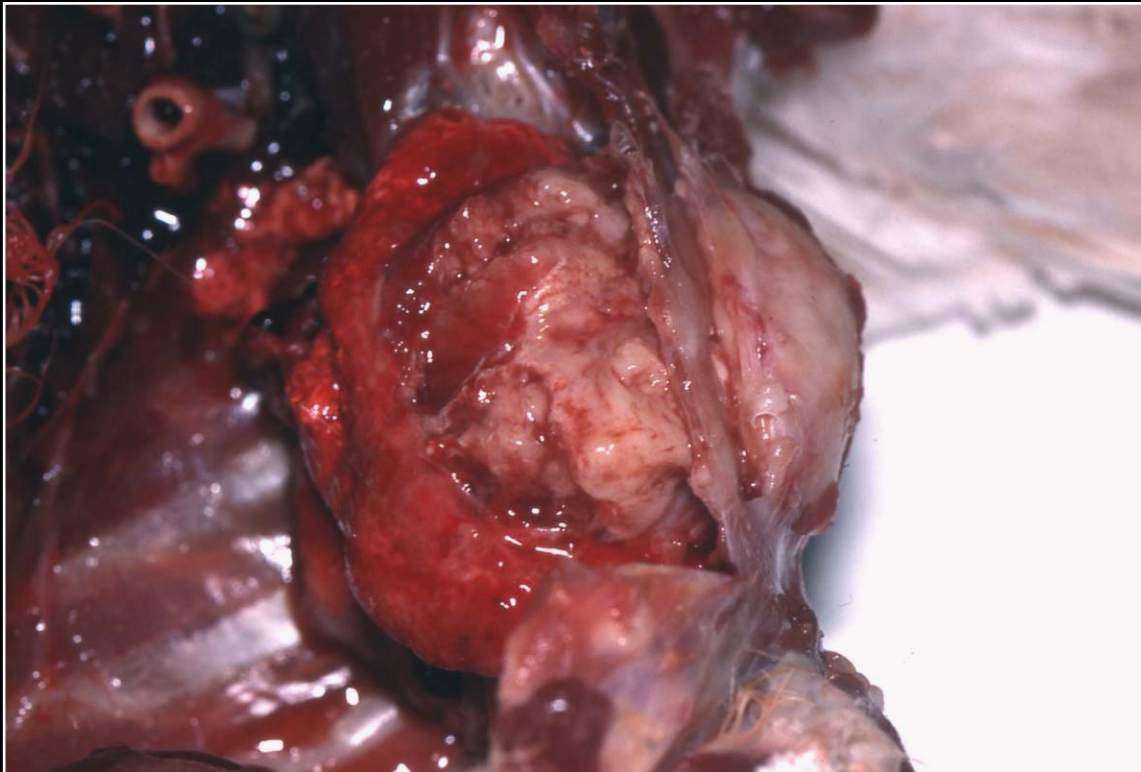
Back



C H A P T E R 8

Respiratory System

Figure 8.29



Multiple sites of pulmonary carcinoma effacing and replacing lung tissue.

Prev. fig. Next fig.

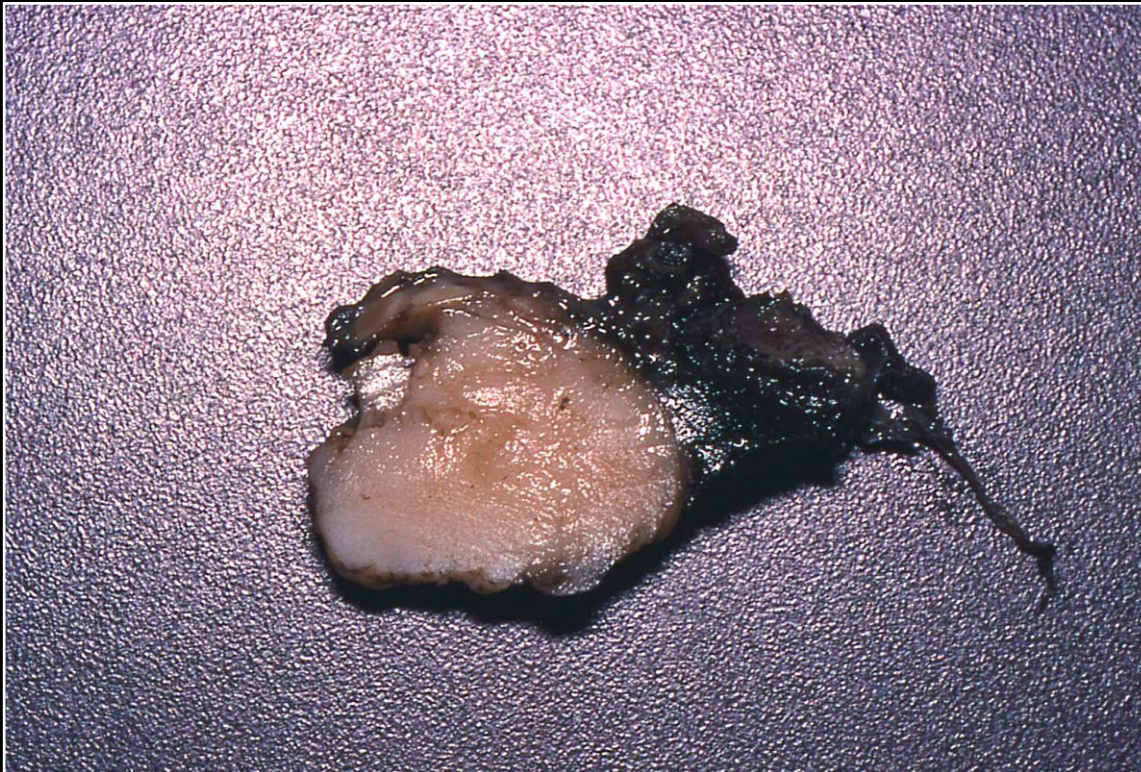Back



C H A P T E R 8

Respiratory System

Figure 8.30



Replacement of pulmonary parenchyma by tumor tissue in a cockatiel with an undifferentiated pulmonary neoplasm (fixed tissue).

Prev. fig. Next fig.

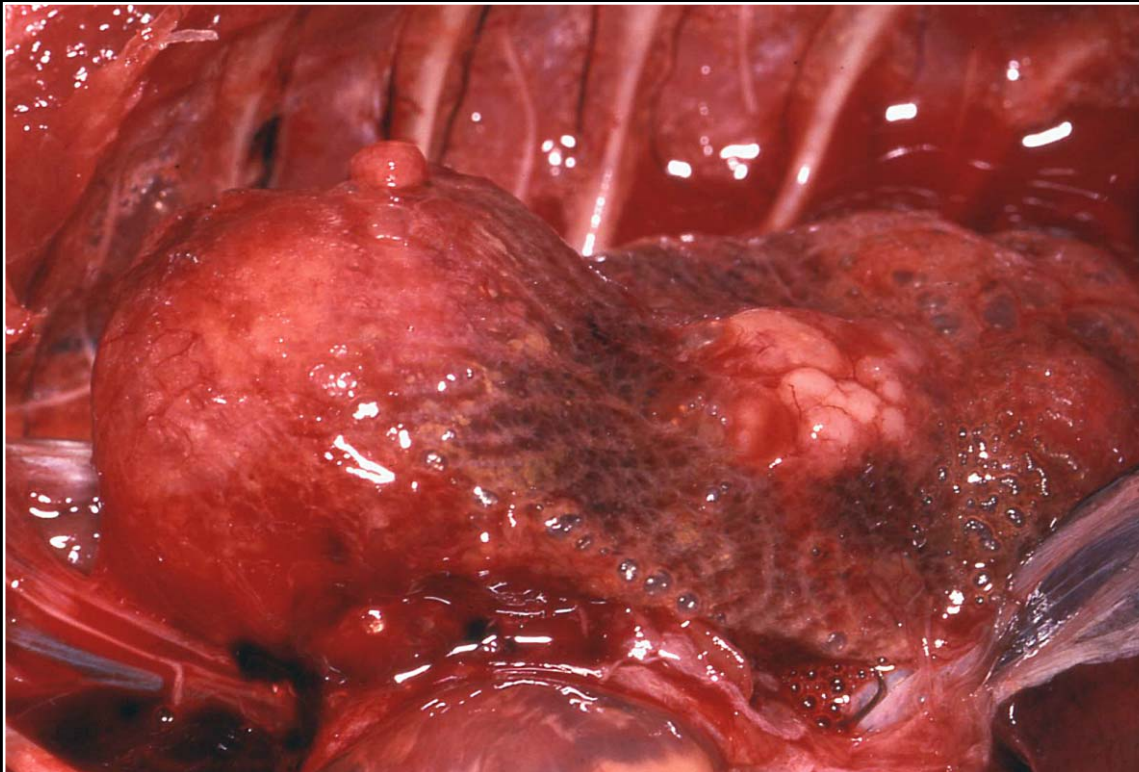
Back



C H A P T E R 8

Respiratory System

Figure 8.31



Multiple nodules of metastatic undifferentiated sarcoma of the wing located in the lung of a macaw.

Prev. fig. Next fig.

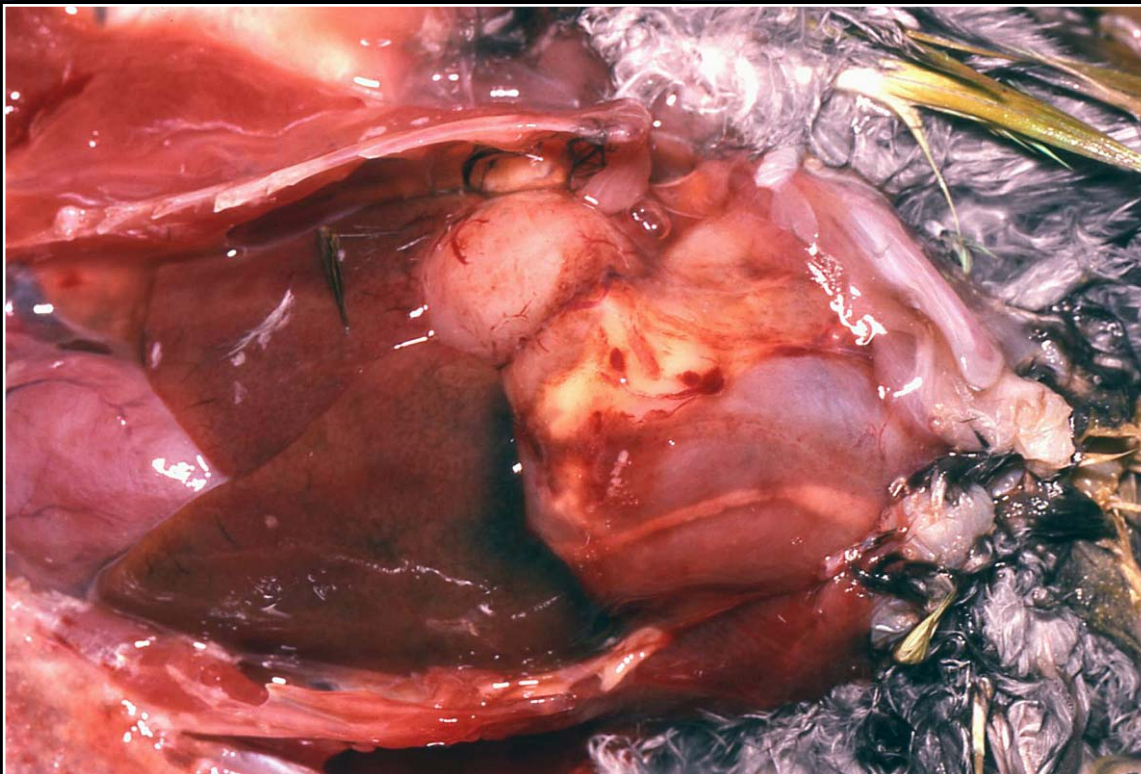
Back



C H A P T E R 8

Respiratory System

Figure 8.32



Bacterial air sacculitis in an Amazon parrot. There is early abscess formation and adhesion of air sacs to the pericardium.

Prev. fig. Next fig.

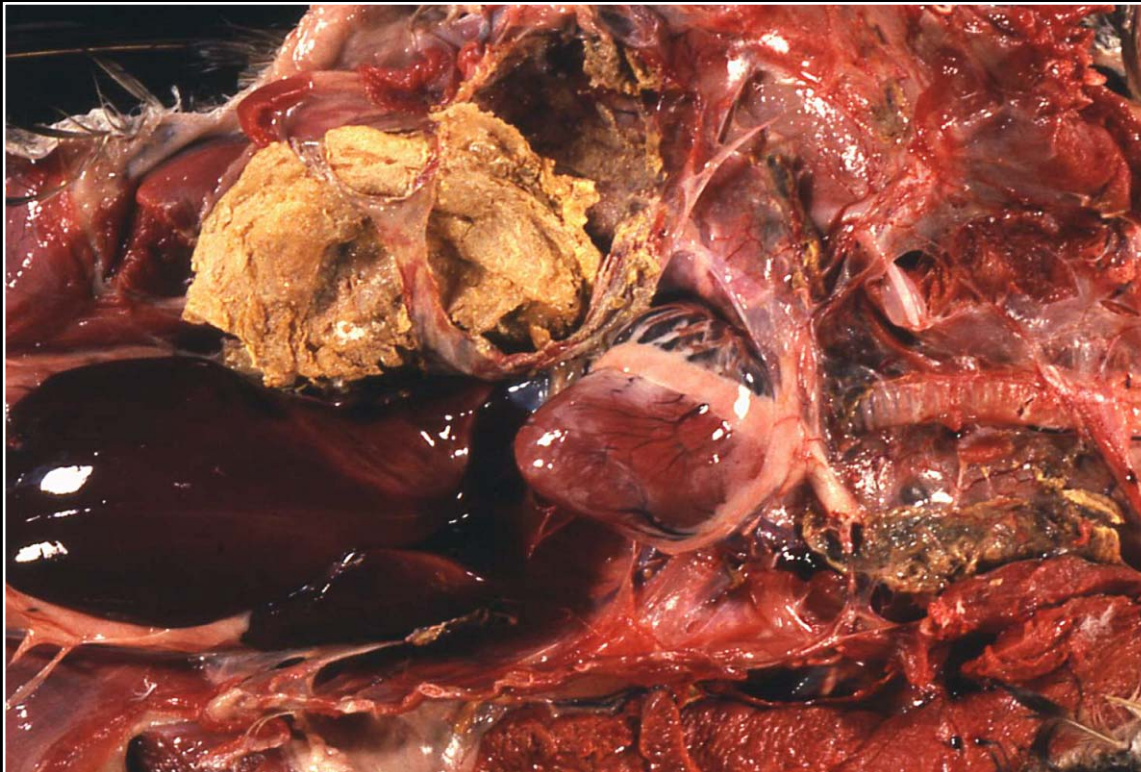
Back



C H A P T E R 8

Respiratory System

Figure 8.33



Severe chronic bacterial air sacculitis in a cormorant with the formation of abundant caseous exudate.

Prev. fig. Next fig.

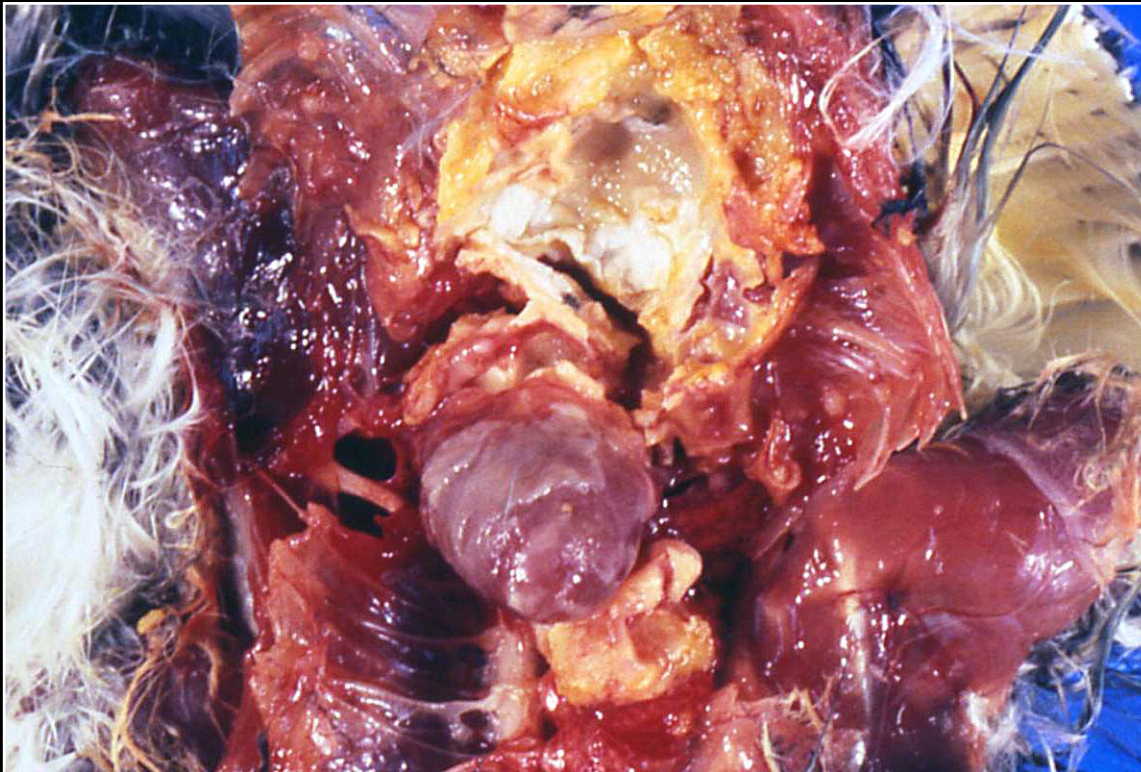
Back



CHAPTER 8

Respiratory System

Figure 8.34



Mycotic air sacculitis with caseous exudate similar to that seen in bacterial infections. Culture or histopathology is usually needed to identify organisms.

Prev. fig. Next fig.

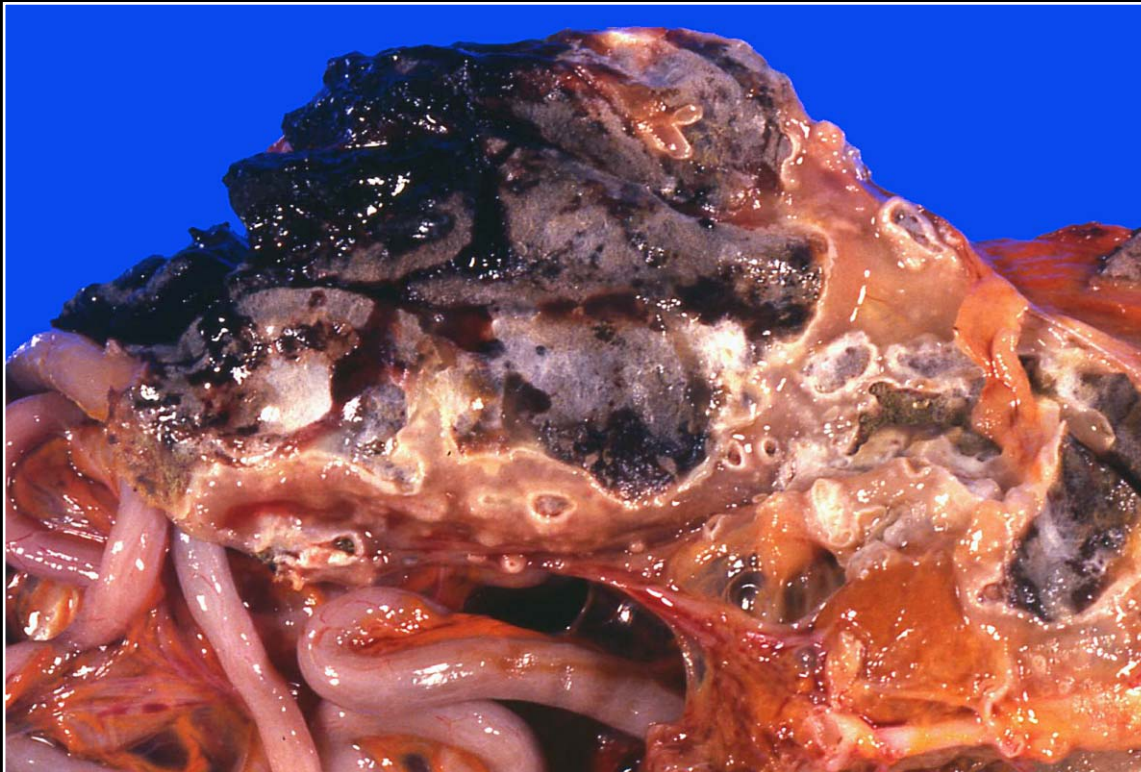Back



C H A P T E R 8

Respiratory System

Figure 8.35



Typical mycotic air sacculitis with marked growth of organisms and green-black discoloration.

Prev. fig. Next fig.

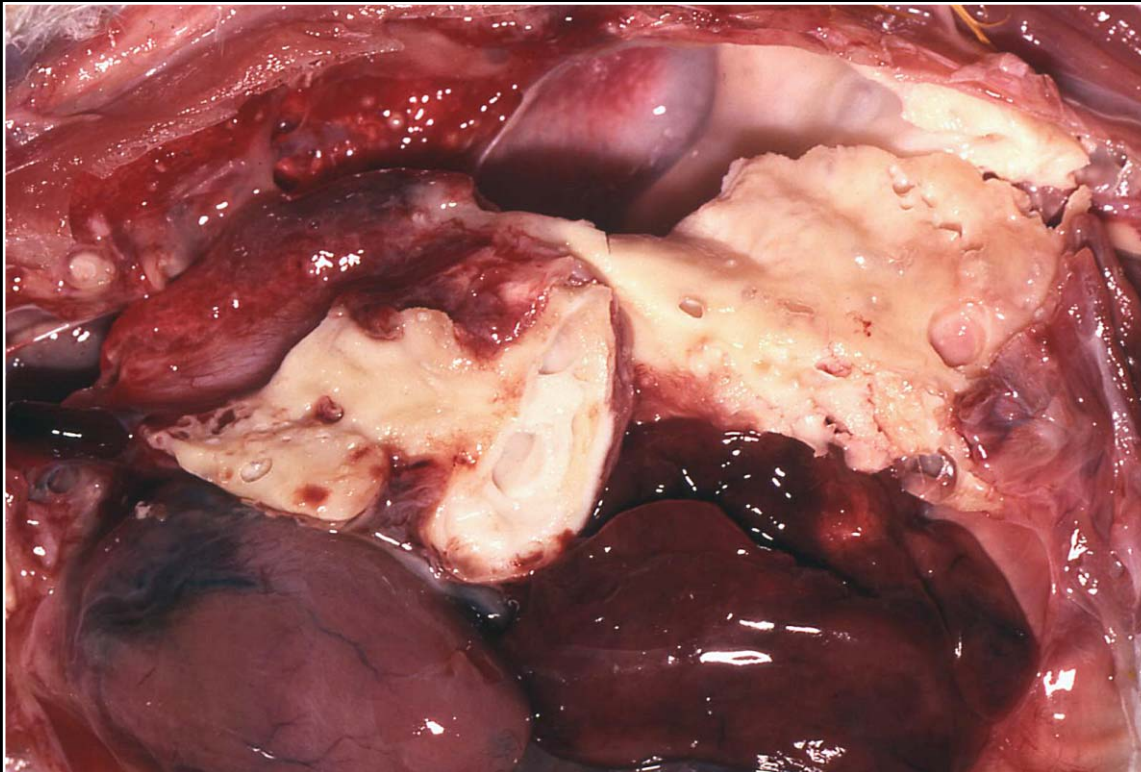
Back



C H A P T E R 8

Respiratory System

Figure 8.36



Severe chronic mycotic air sacculitis leading to a solid-appearing mass in the air sacs.

Prev. fig. Next fig.

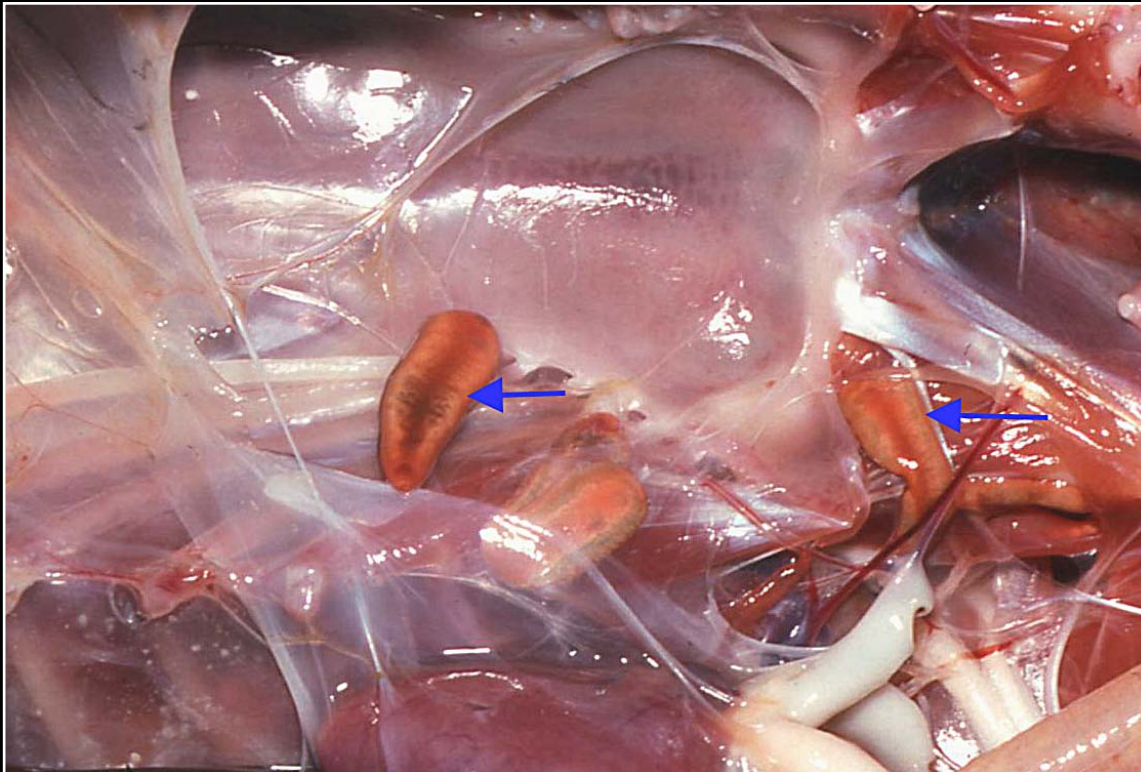
Back



C H A P T E R 8

Respiratory System

Figure 8.37



Trematodes present in slightly opaque air sacs (arrows).

Prev. fig. Next fig.

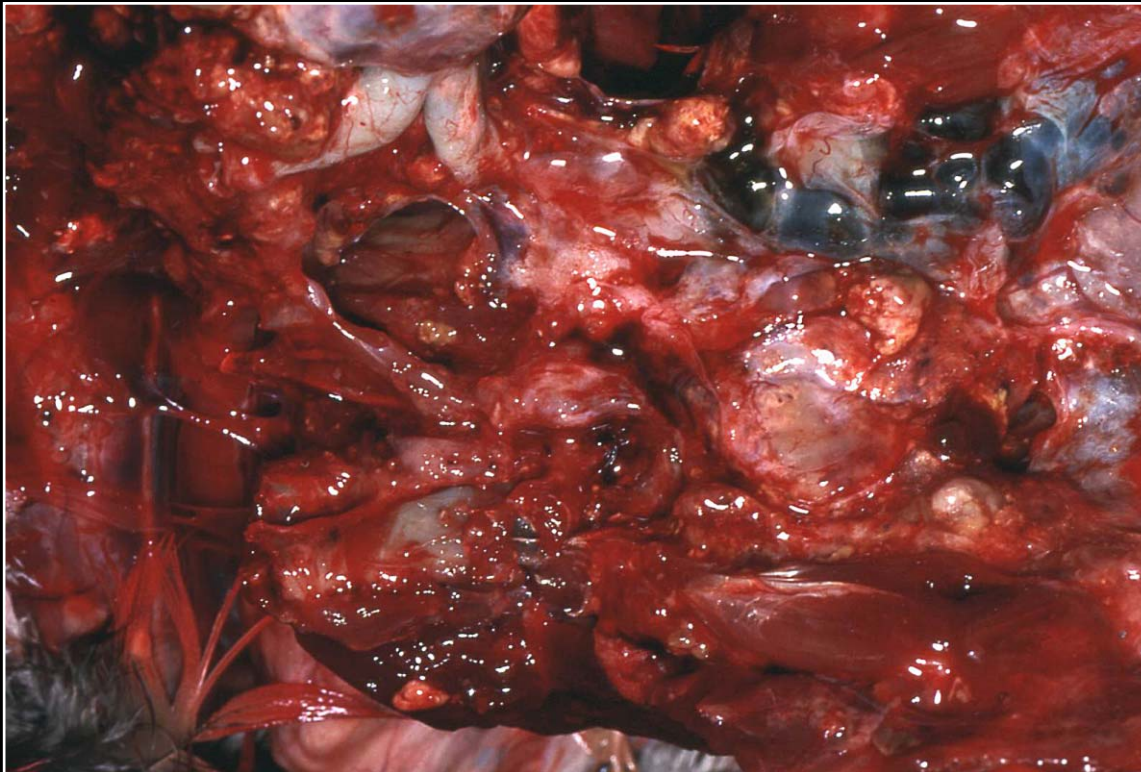
Back



C H A P T E R 8

Respiratory System

Figure 8.38



Multiple to confluent neoplastic masses in disseminated air sac carcinoma.

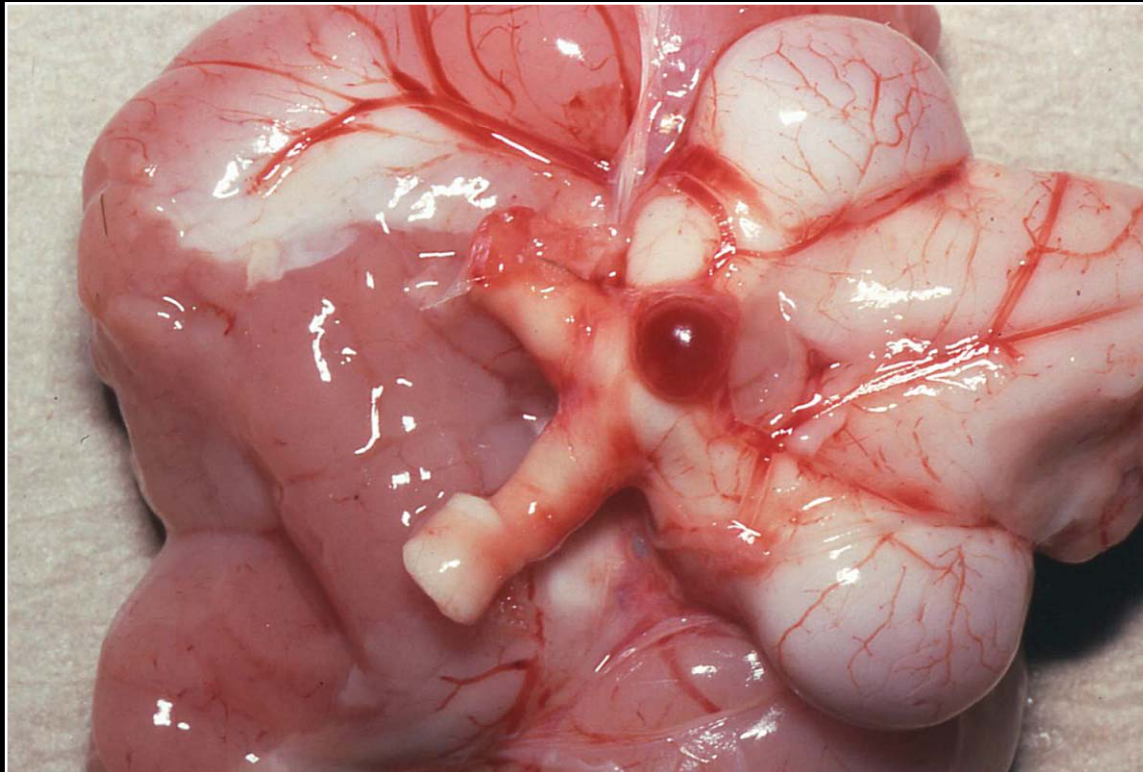
Prev. fig.

Back

C H A P T E R 9

Endocrine Glands

Figure 9.1



Pituitary adenoma. The tumor is dark red and has smooth margins. Note compression of the optic chiasm.

Next fig.

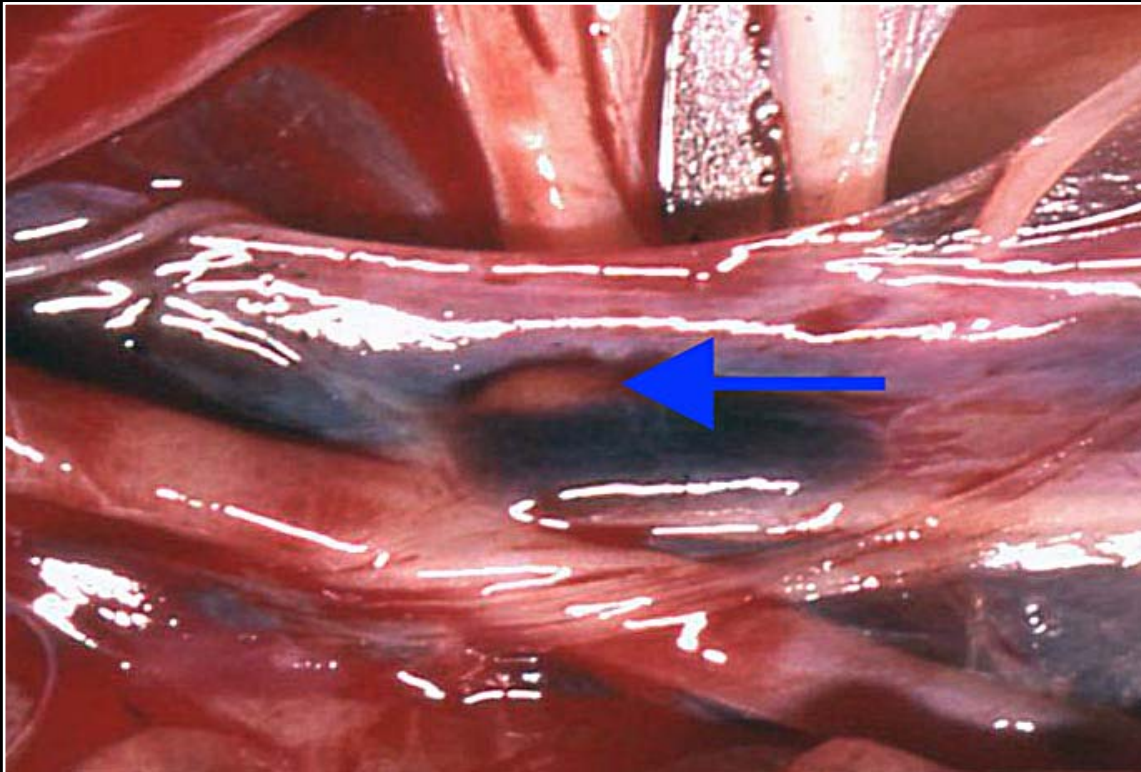
Back



C H A P T E R 9

Endocrine Glands

Figure 9.2



Small, thin thyroid gland that appears tan-brown. This is typical of chronic thyroid gland degeneration.

Prev. fig. Next fig.

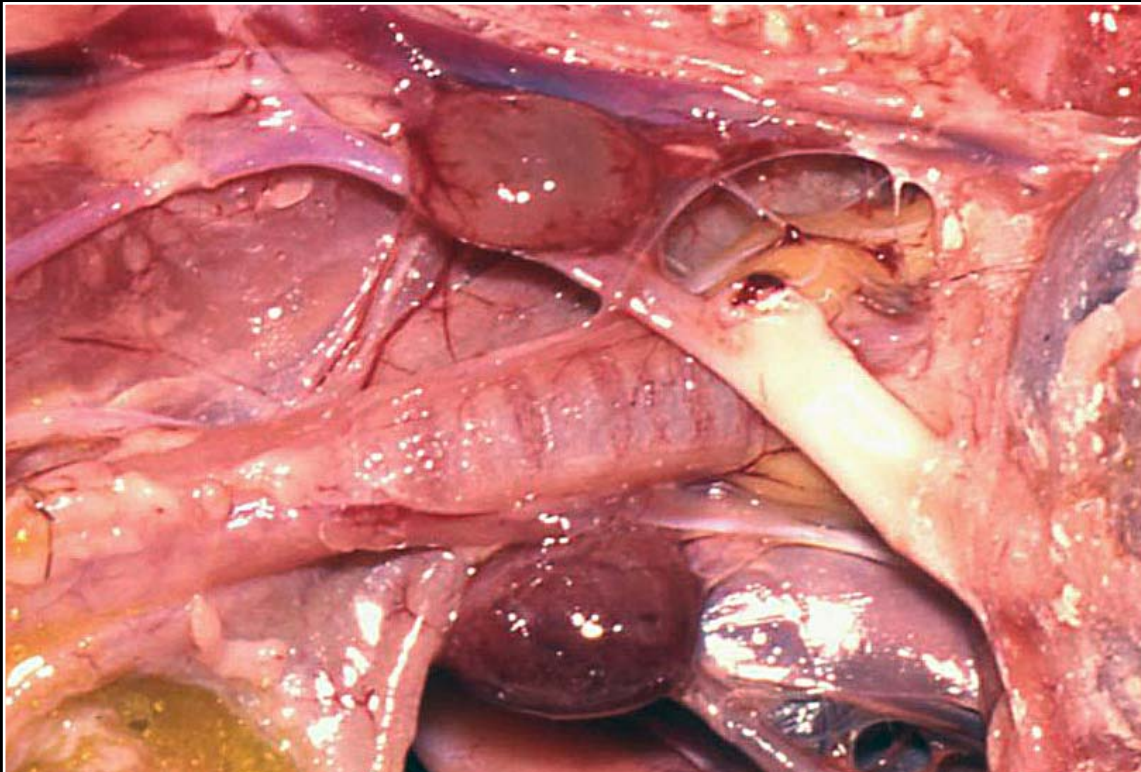
Back



C H A P T E R 9

Endocrine Glands

Figure 9.3



Thyroid hyperplasia in a blue and gold macaw. The glands are bilaterally enlarged, smooth and red-brown.

Prev. fig. Next fig.

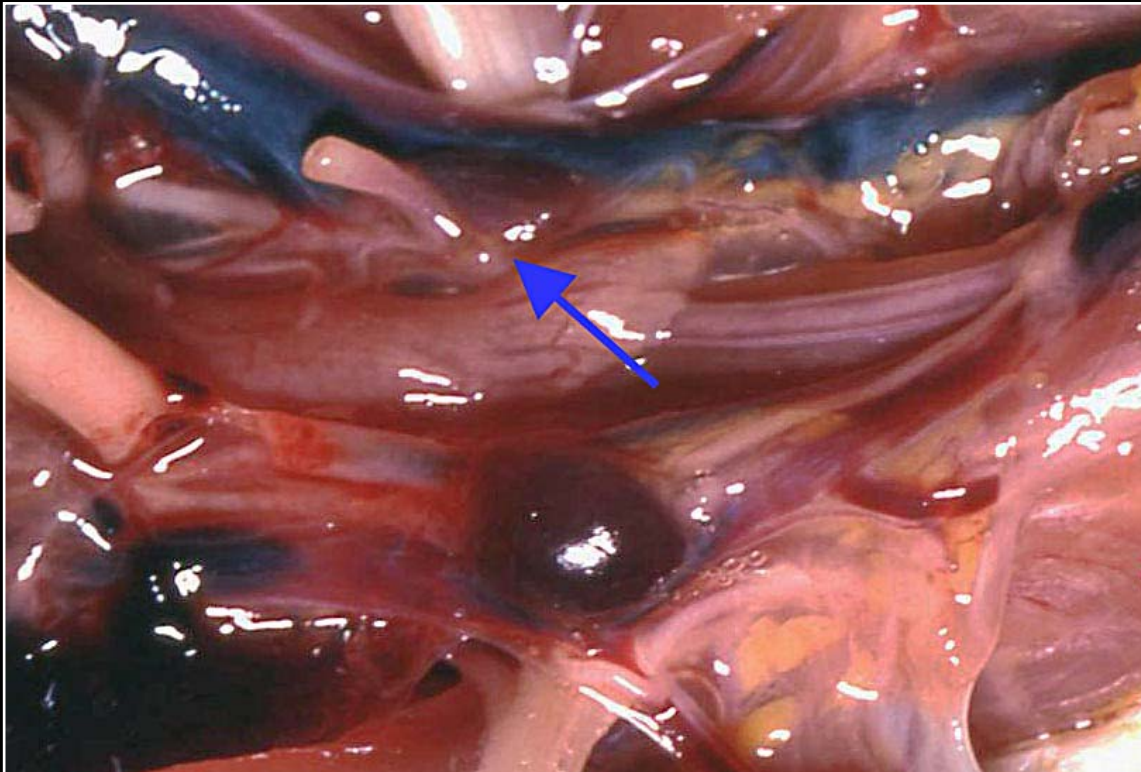
Back



C H A P T E R 9

Endocrine Glands

Figure 9.4



Thyroid adenoma in a cockatiel. The tumor is red-purple and smooth. Note normal contralateral thyroid (arrow).

Prev. fig. Next fig.

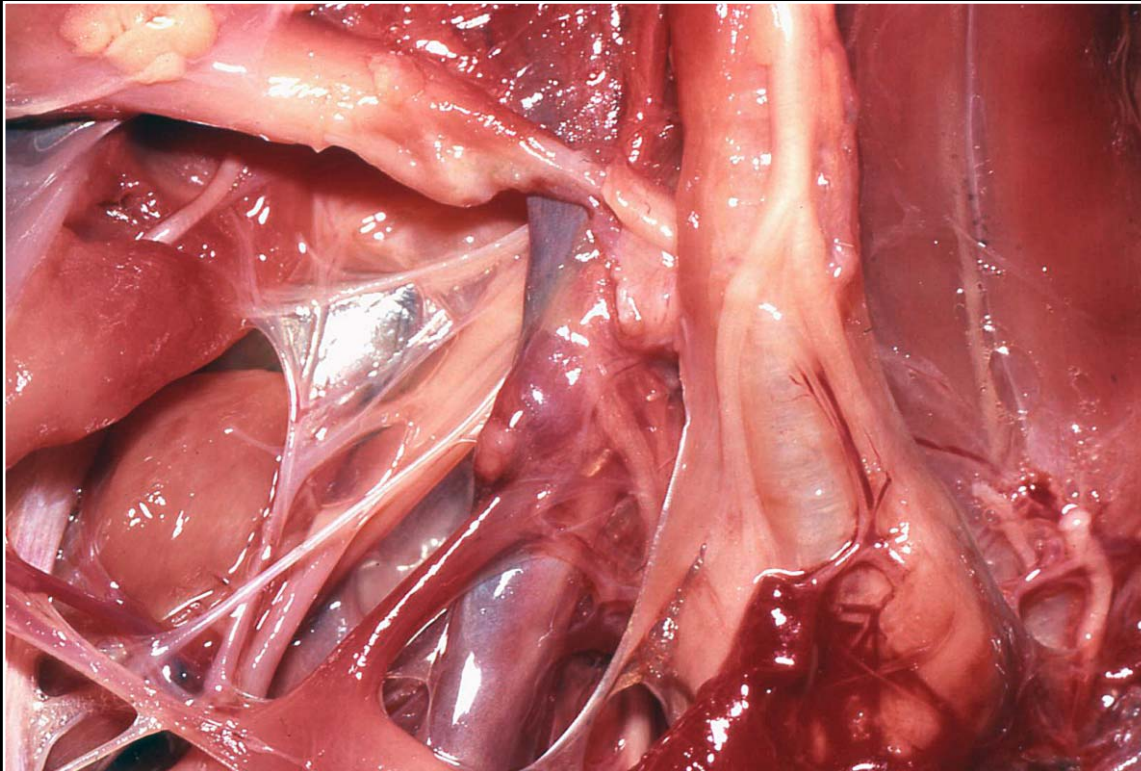
Back



C H A P T E R 9

Endocrine Glands

Figure 9.5



Mildly enlarged, hyperplastic parathyroid gland. There is a slight color differentiation and swelling.

Prev. fig. Next fig.

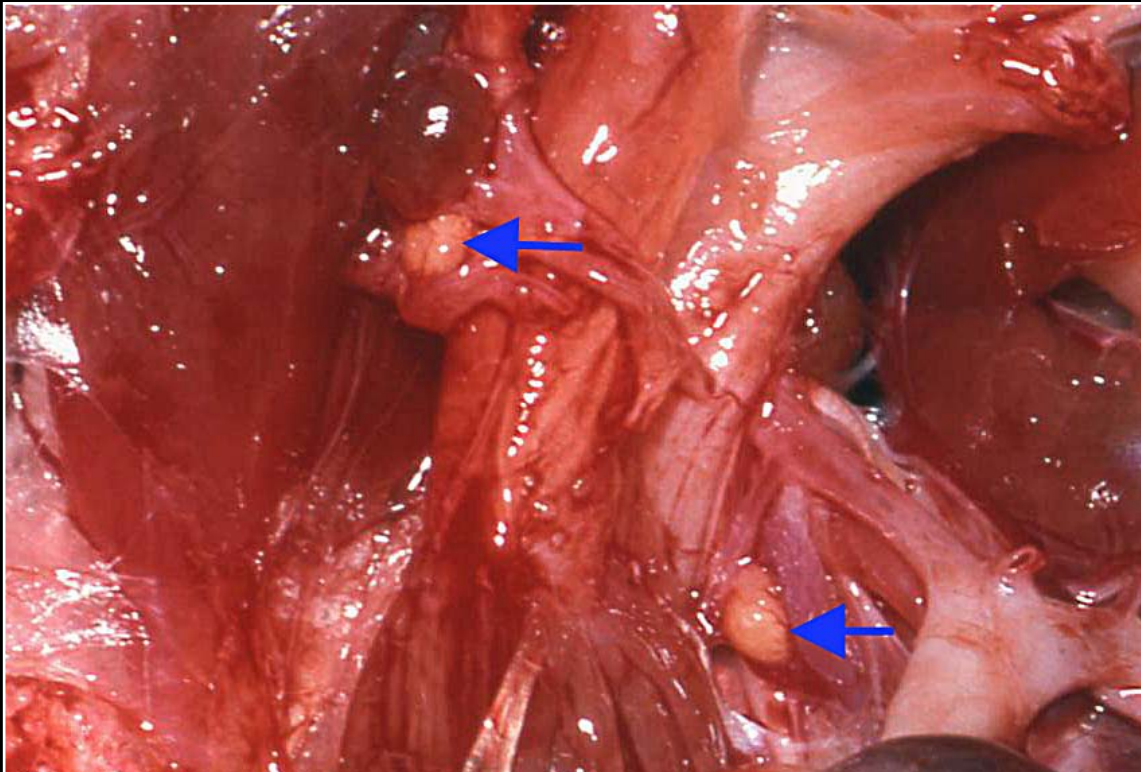
Back



CHAPTER 9

Endocrine Glands

Figure 9.6



As a result of hyperplasia, the parathyroid glands are bilaterally enlarged and yellow-white (arrows). Note that the parathyroids on the left are further caudal to the thyroid than those on the right.

Prev. fig. Next fig.

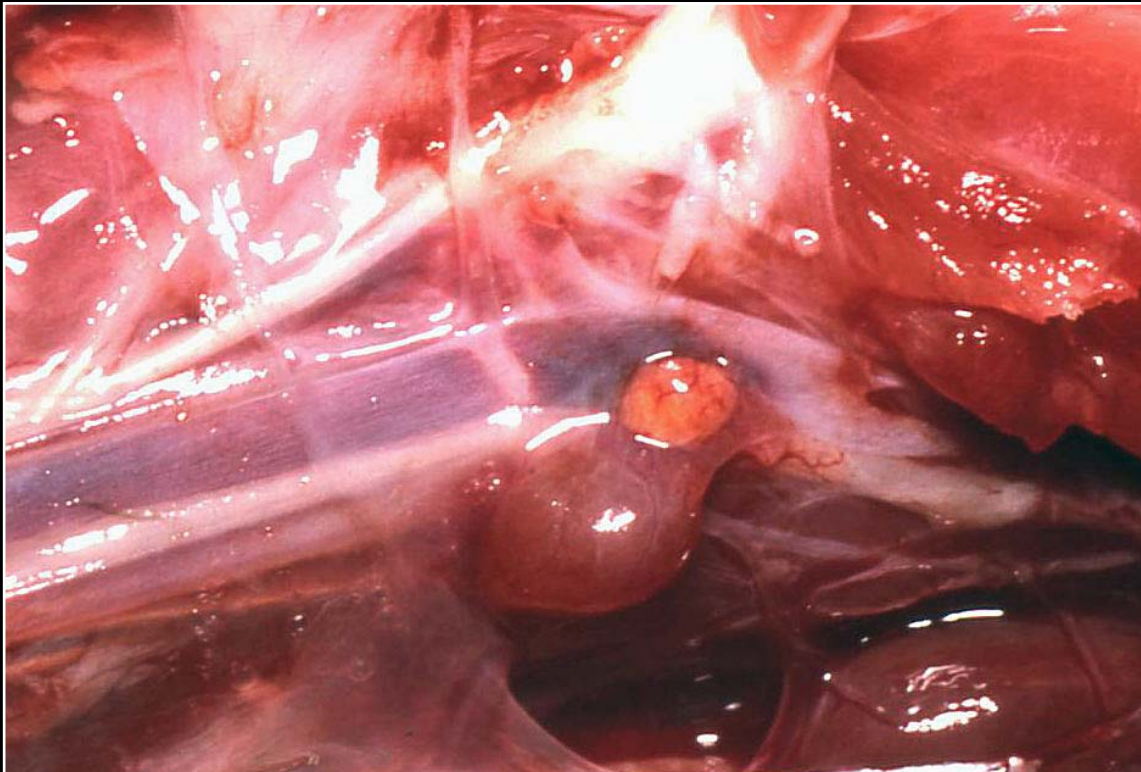
Back



C H A P T E R 9

Endocrine Glands

Figure 9.7



Unilaterally enlarged parathyroid gland consistent with adenoma. Note gross similarity to hyperplastic glands.

Prev. fig. Next fig.

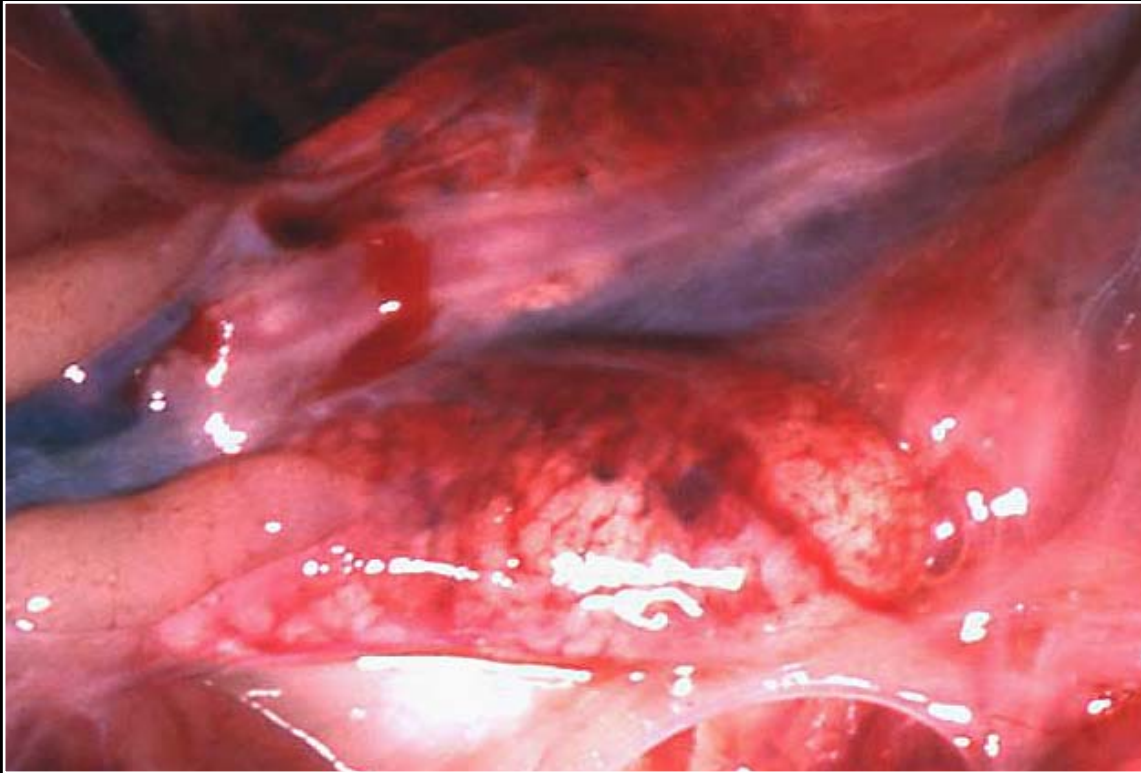Back



C H A P T E R 9

Endocrine Glands

Figure 9.7a



Normal adrenal glands.

Prev. fig. Next fig.

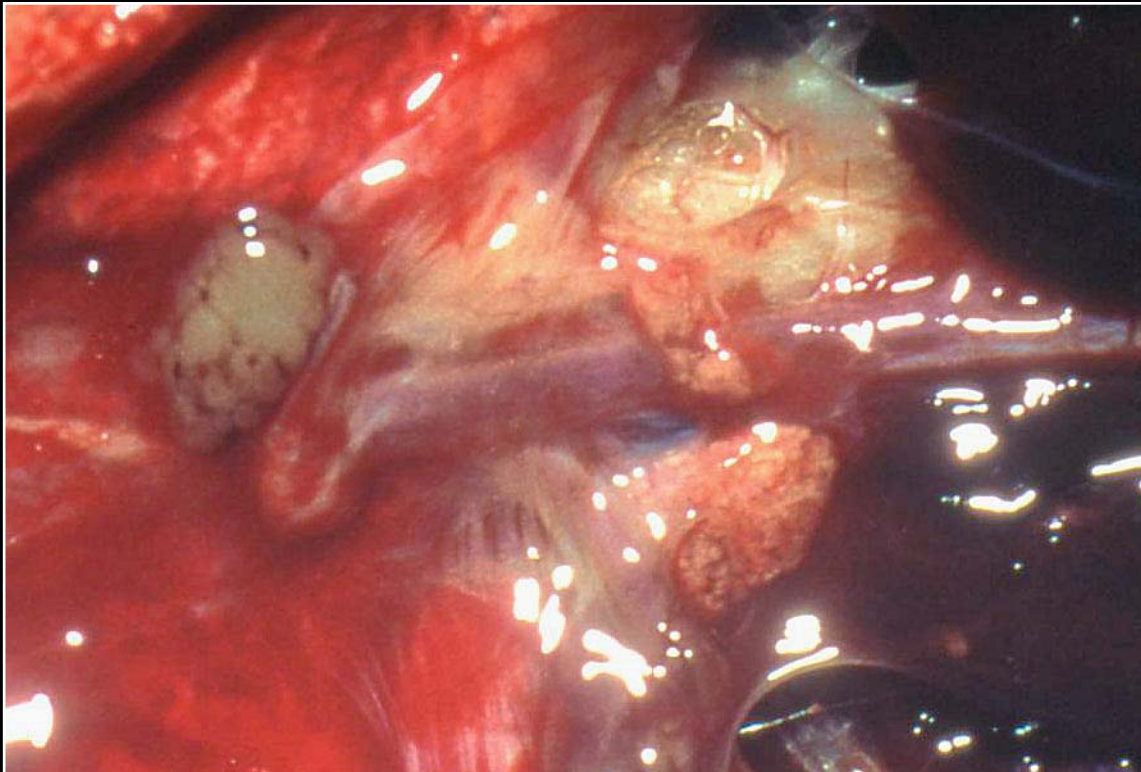
Back



C H A P T E R 9

Endocrine Glands

Figure 9.8



Mottled, yellow-brown adrenal glands representative of adrenal degeneration in an African grey parrot.

Prev. fig. Next fig.

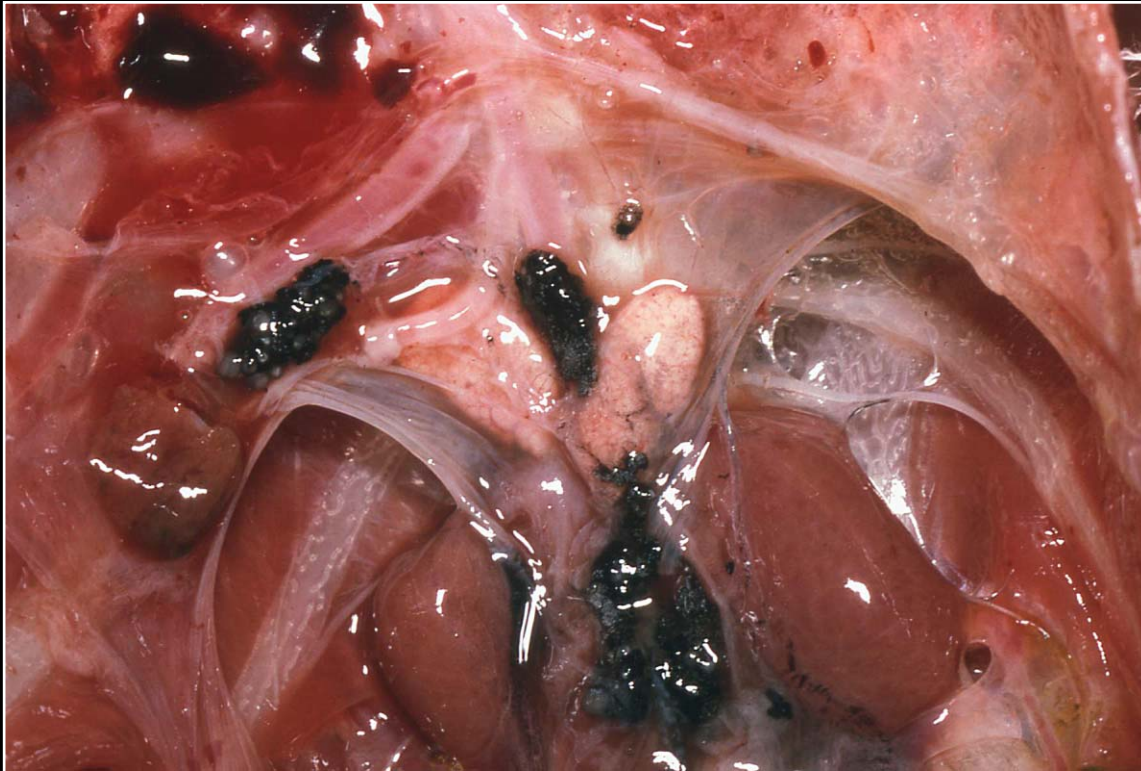
Back



C H A P T E R 9

Endocrine Glands

Figure 9.9



Pale, slightly mottled adrenal glands in a bird with proventricular dilatation disease.

Prev. fig. Next fig.

Back



C H A P T E R 9

Endocrine Glands

Figure 9.10



Poor feathering in a budgerigar with a possible functional adrenal (interrenal cell) tumor.

Prev. fig. Next fig.

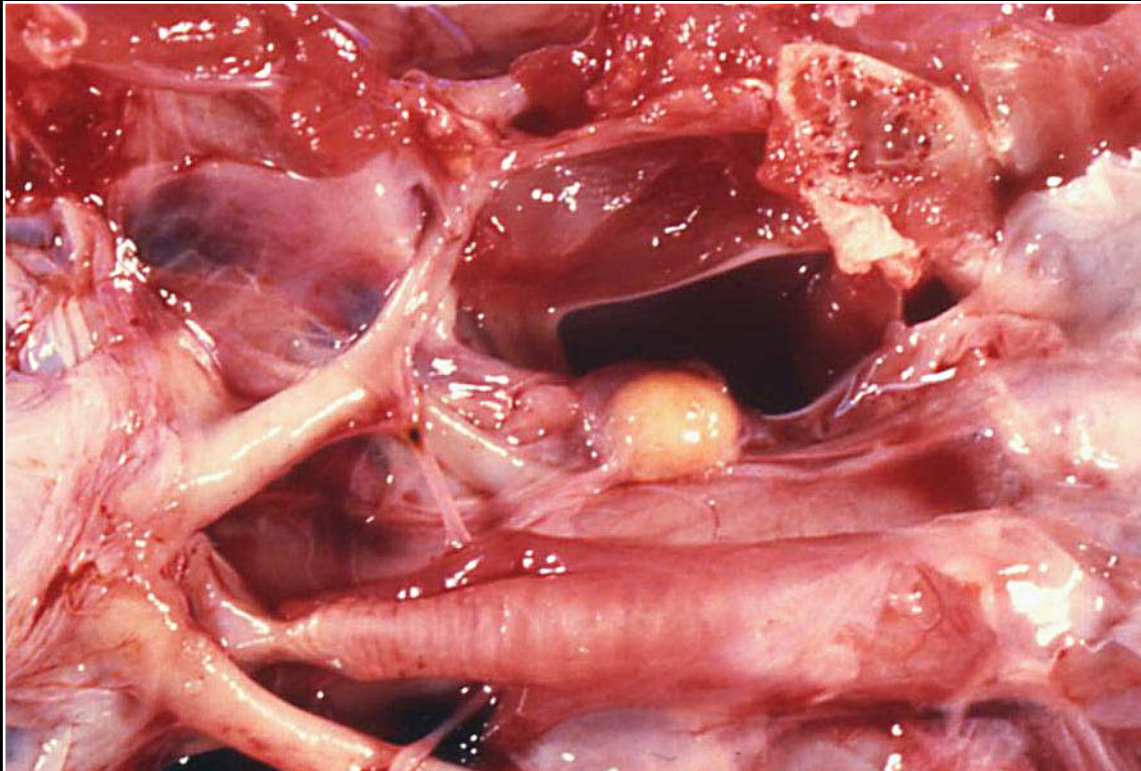
Back



C H A P T E R 9

Endocrine Glands

Figure 9.11



Enlarged ultimobranchial body that was hypertrophied and cystic on section.

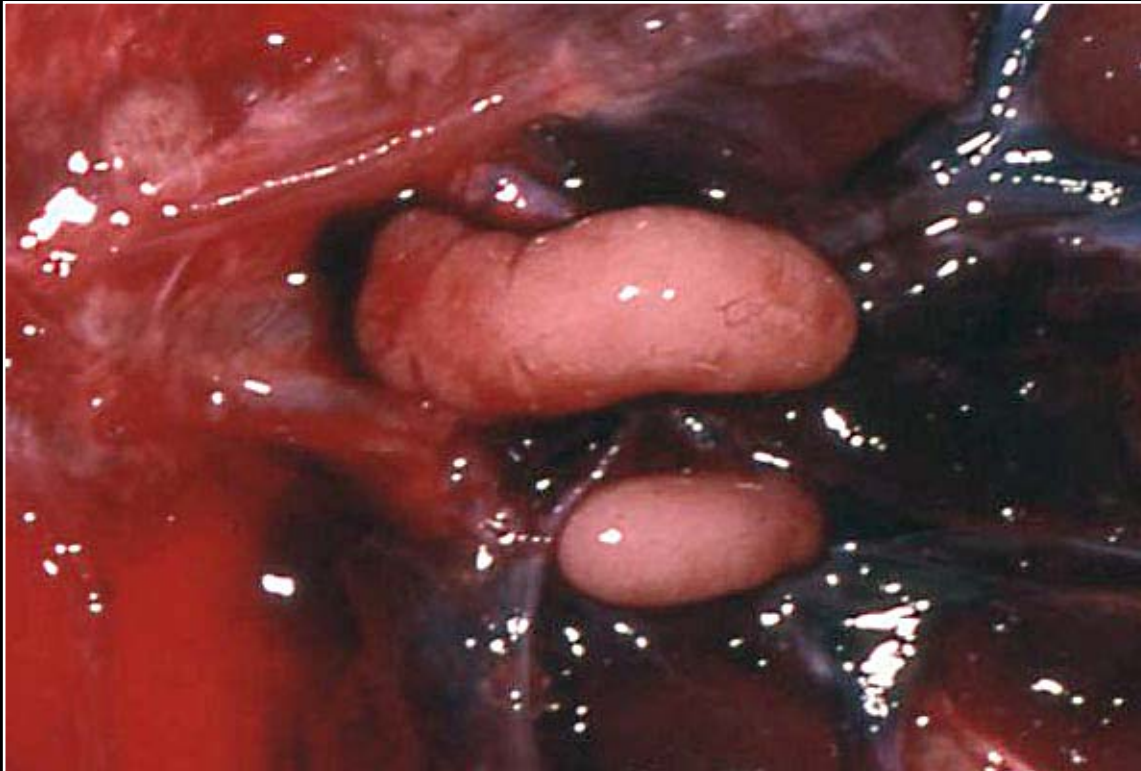
Prev. fig.

Back

C H A P T E R 10

Reproductive System

Figure 10.0a



Immature testes are smooth and somewhat flattened.

Next fig.

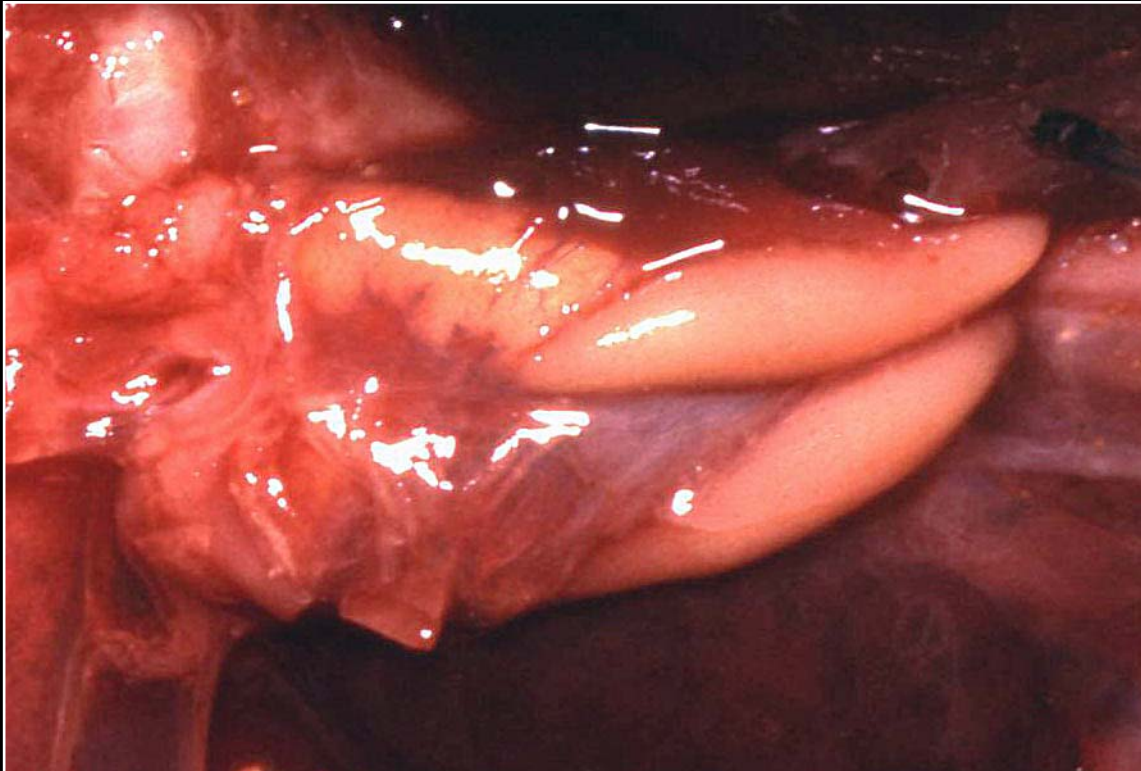
Back



C H A P T E R 10

Reproductive System

Figure 10.0b



The left testis is often larger than the right in immature birds.

Prev. fig. Next fig.

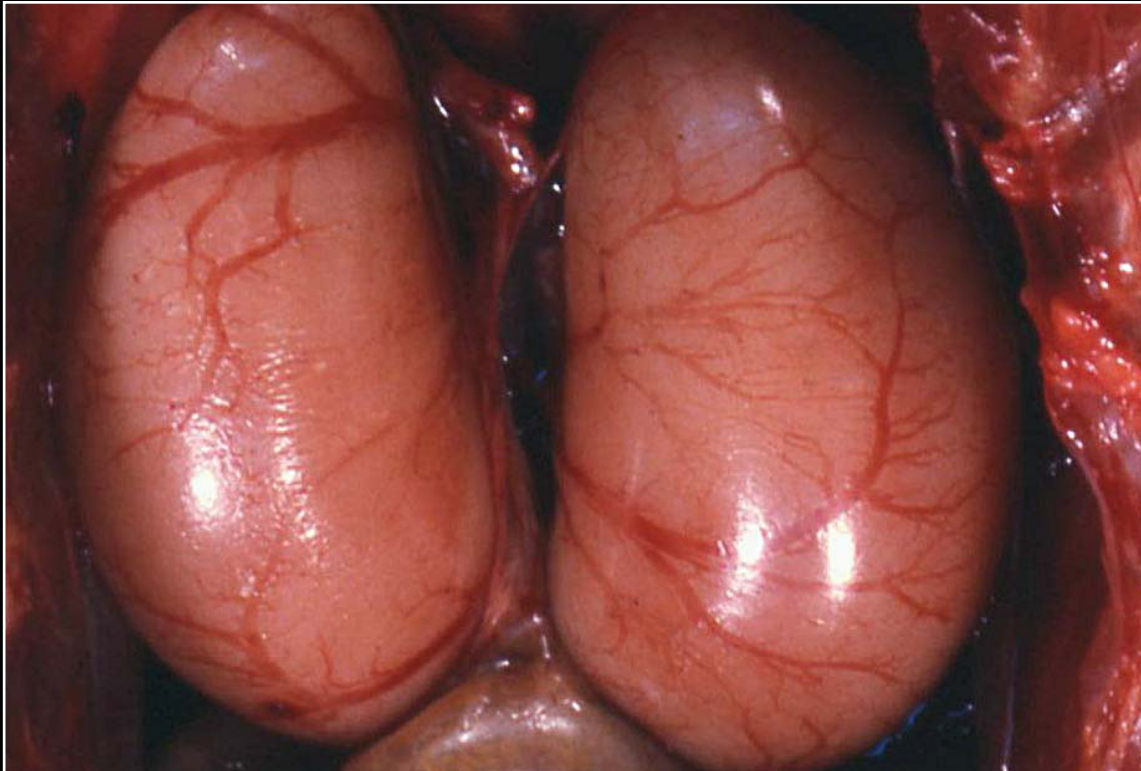
Back



C H A P T E R 10

Reproductive System

Figure 10.0c



The testes become very enlarged during breeding season.

Prev. fig. Next fig.

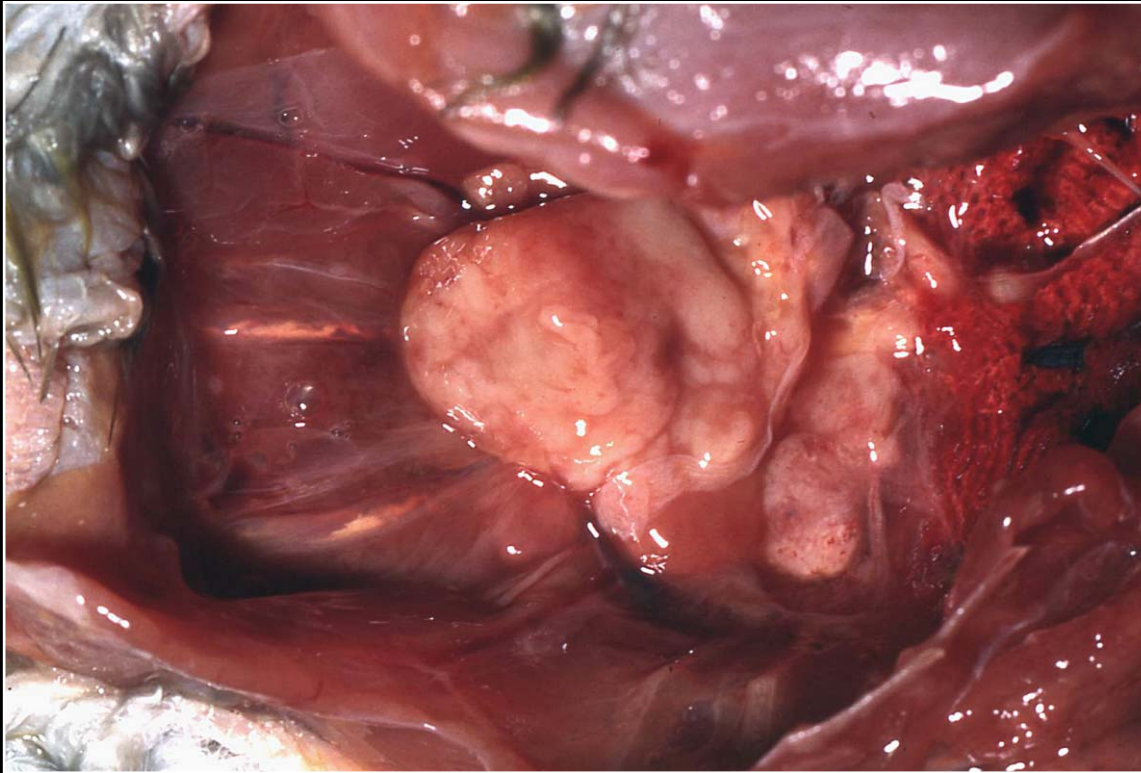
Back



C H A P T E R 10

Reproductive System

Figure 10.1



A seminoma tumor is typically cream to yellow.

Prev. fig. Next fig.

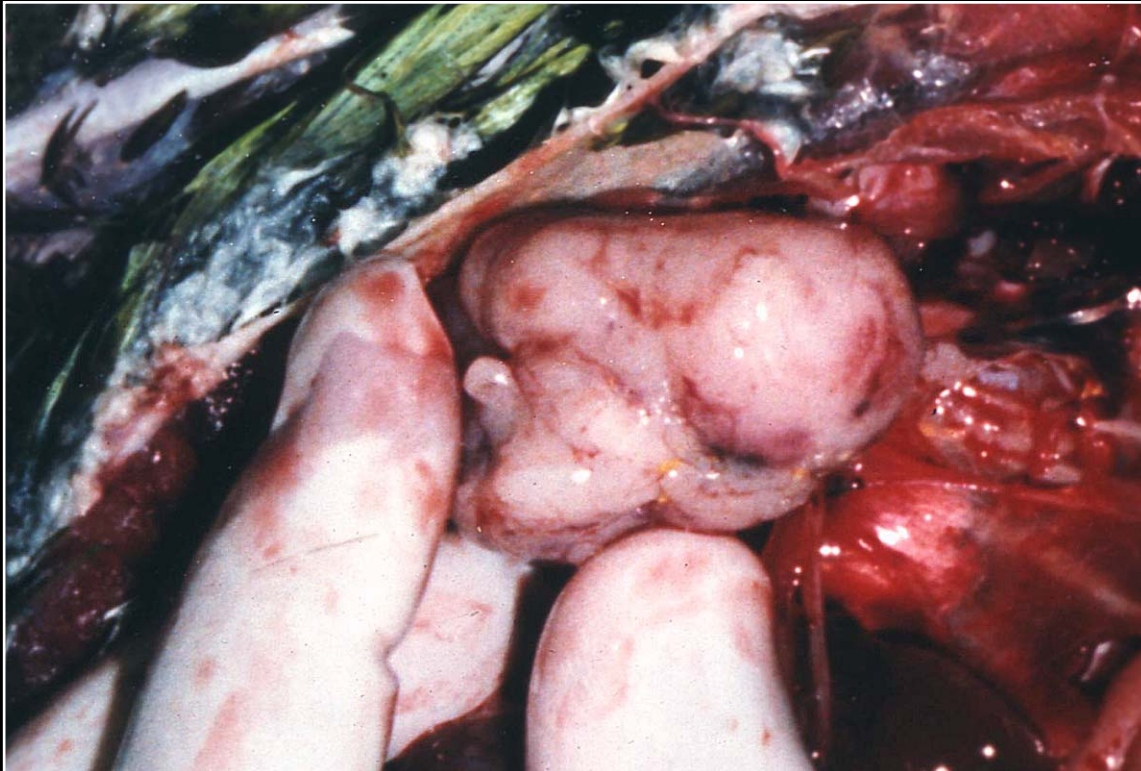
Back



C H A P T E R 10

Reproductive System

Figure 10.2



Sertoli's cell tumors are white and usually more nodular than seminomas.

Prev. fig. Next fig.

Back



C H A P T E R 10

Reproductive System

Figure 10.3



Prolapsed phallus of undetermined cause.

Prev. fig. Next fig.

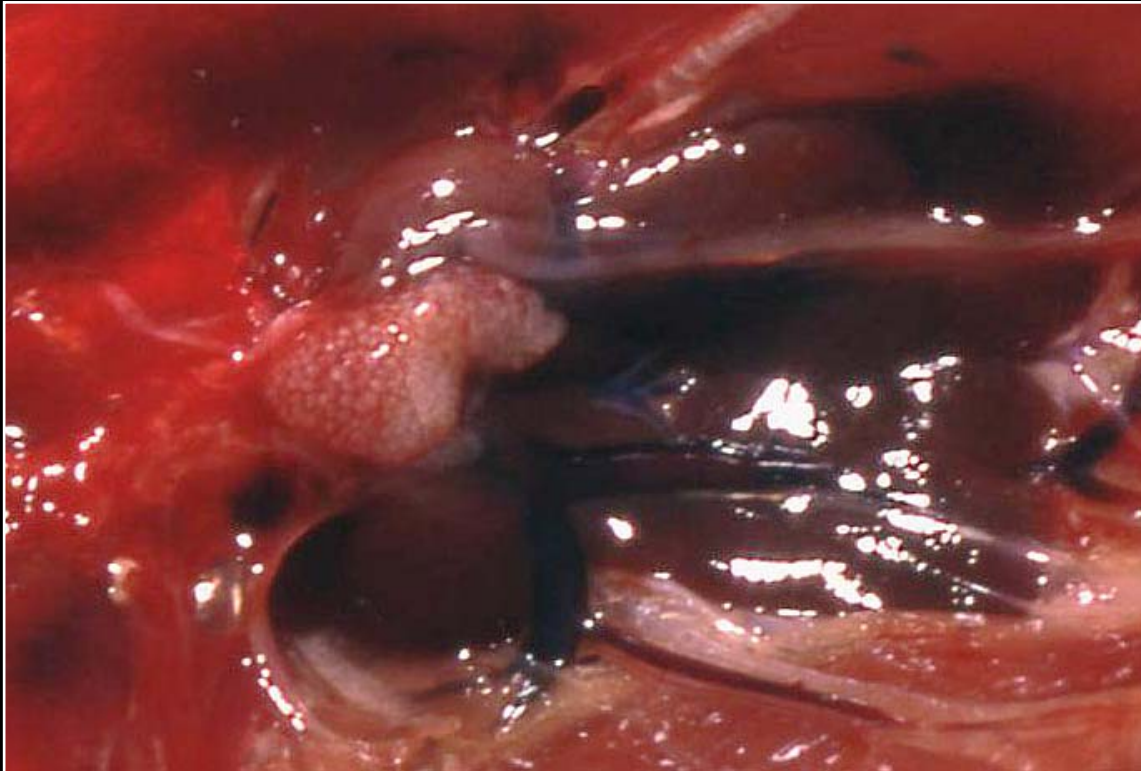
Back



C H A P T E R 10

Reproductive System

Figure 10.3a



Normal juvenile ovary.

Prev. fig. Next fig.

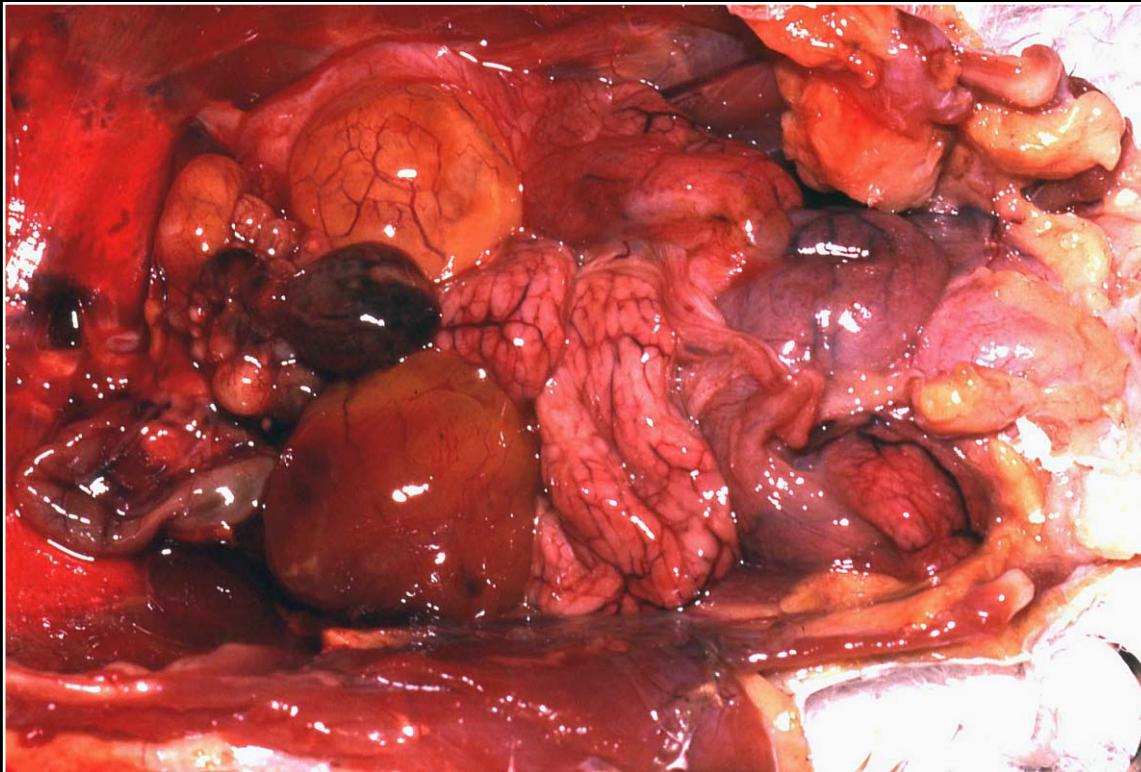Back



C H A P T E R 10

Reproductive System

Figure 10.3b



A normal post-laying ovary and oviduct/uterus in a mature bird.

Prev. fig. Next fig.

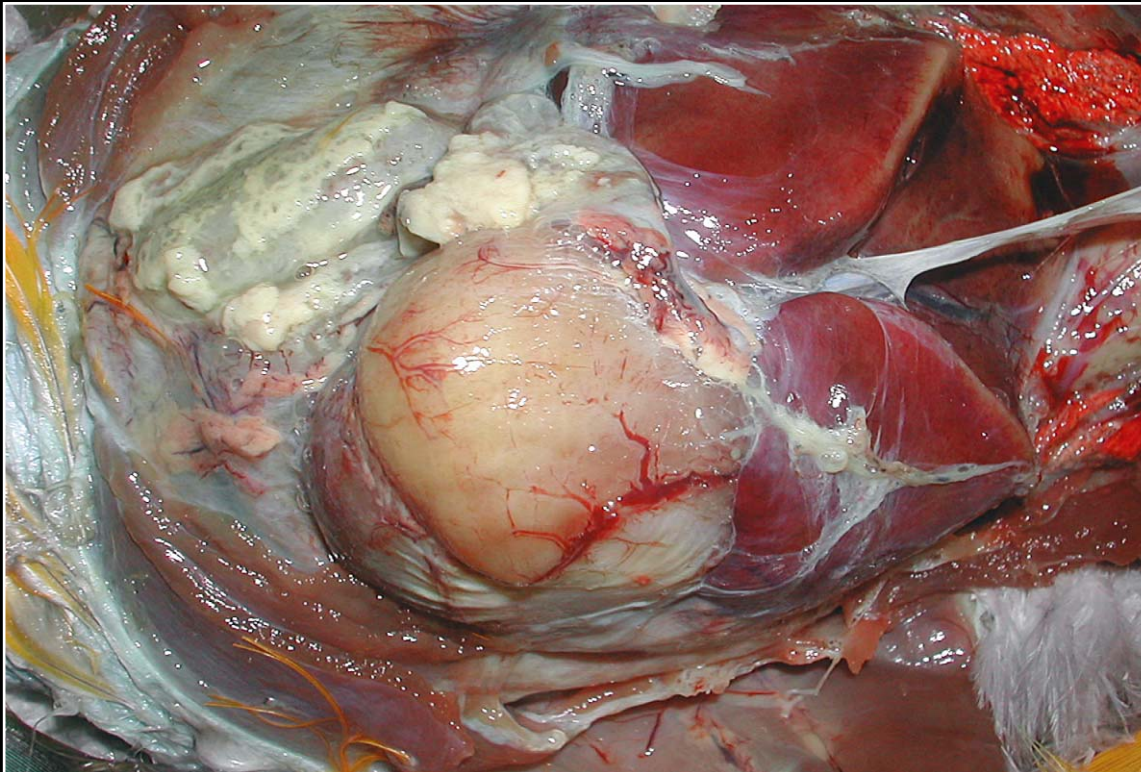
Back



C H A P T E R 10

Reproductive System

Figure 10.4



Massively enlarged ovarian follicle associated with oophoritis and evidence of yolk peritonitis.

Prev. fig. Next fig.

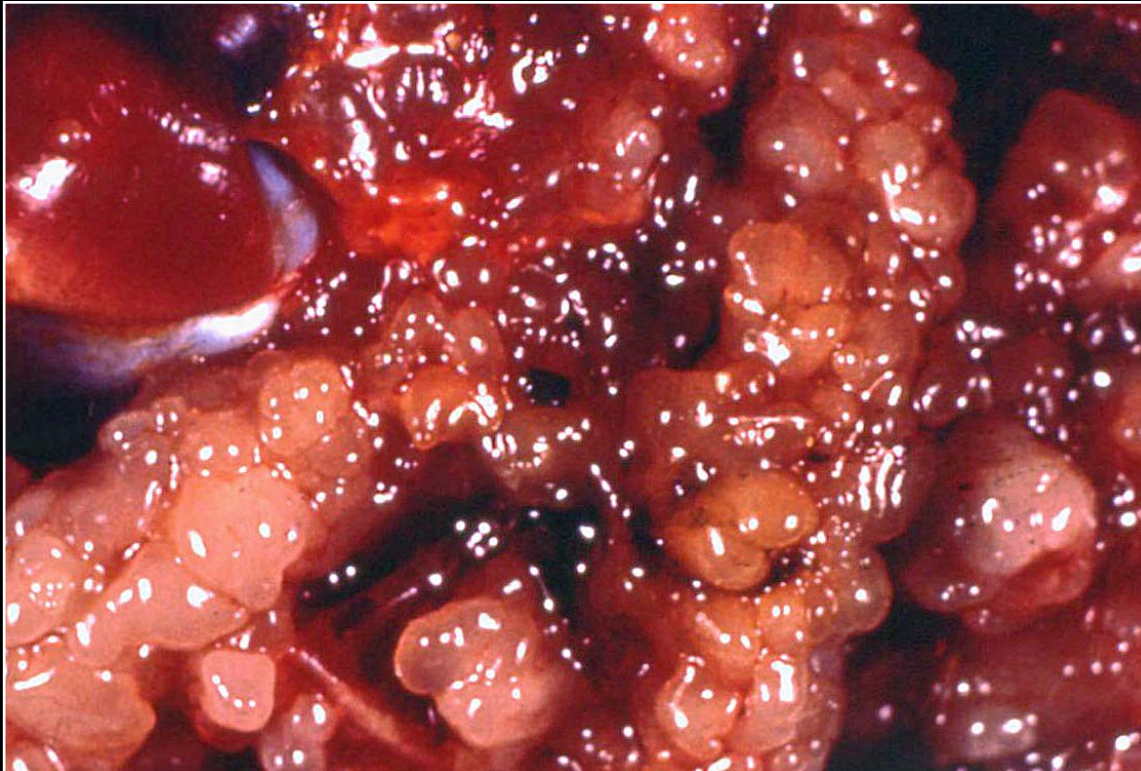
Back



C H A P T E R 10

Reproductive System

Figure 10.5



Ovarian carcinoma with numerous follicular structures replacing the normal ovary and implanting within the peritoneal cavity.

Prev. fig. Next fig.

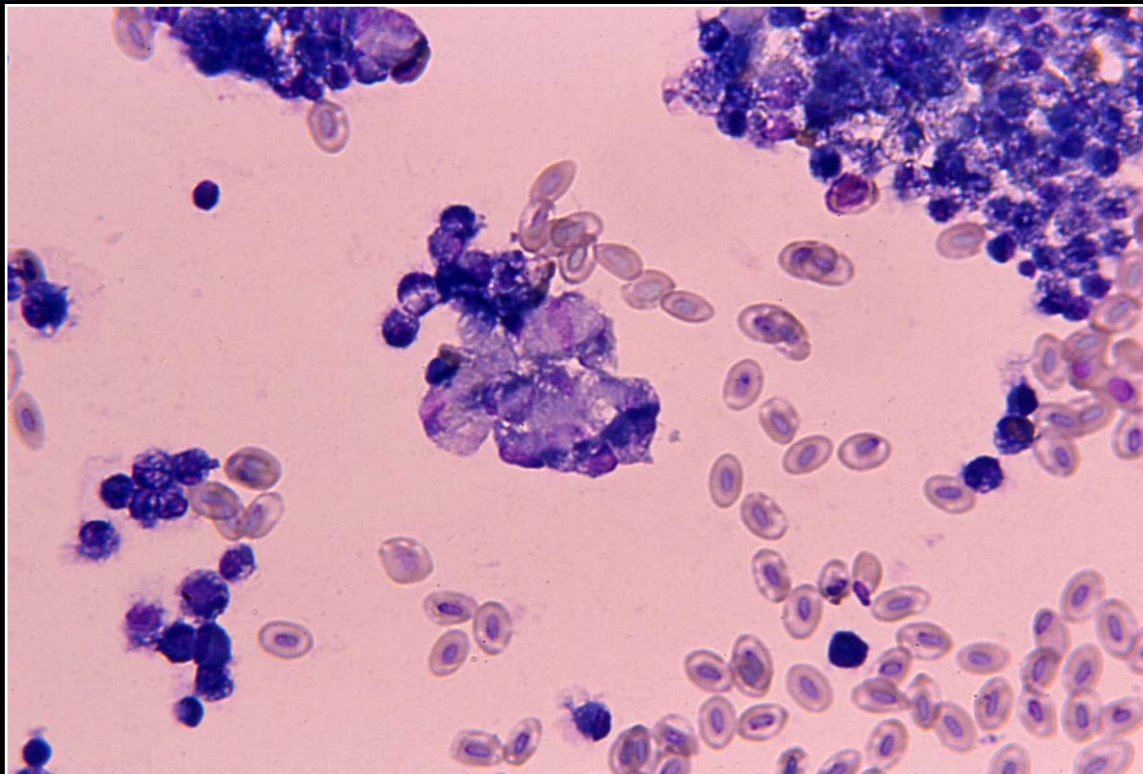
Back



C H A P T E R 10

Reproductive System

Figure 10.6



Sheets of neoplastic epithelial cells and abnormally dividing cells in ovarian carcinoma.

Prev. fig. Next fig.

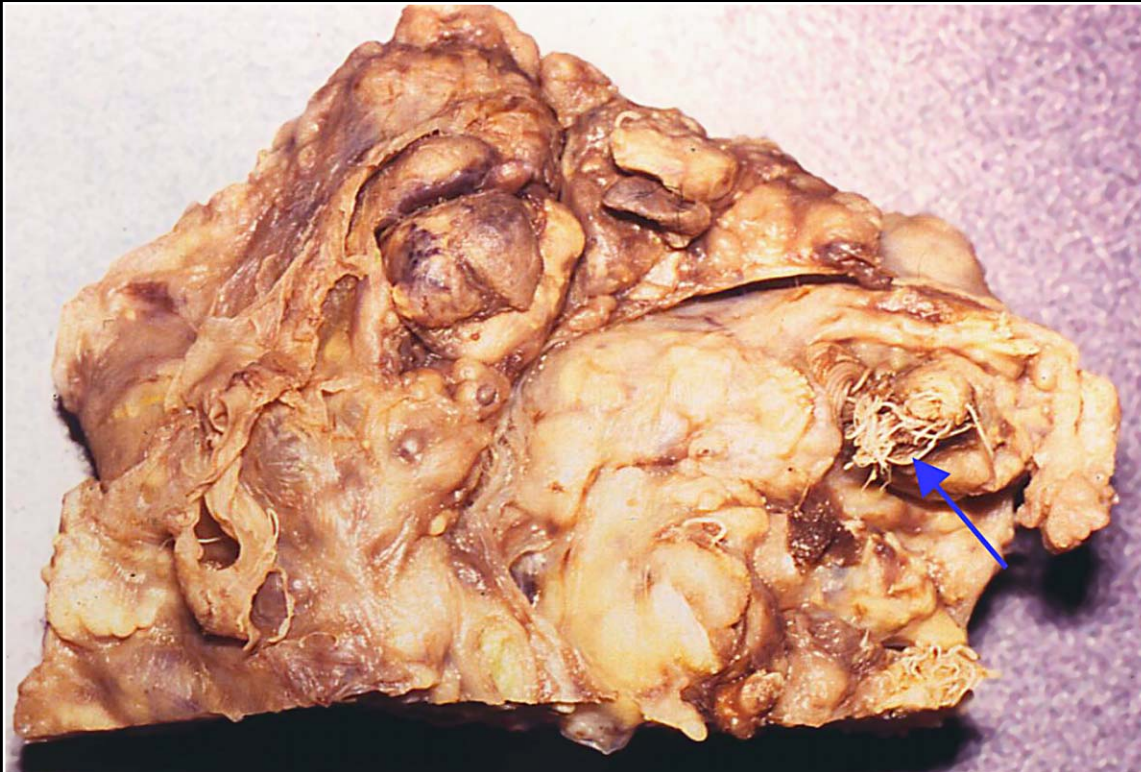
Back



C H A P T E R 10

Reproductive System

Figure 10.7



Ovarian teratoma in a duck. Structures resembling feathers are noted (arrow).

Prev. fig. Next fig.

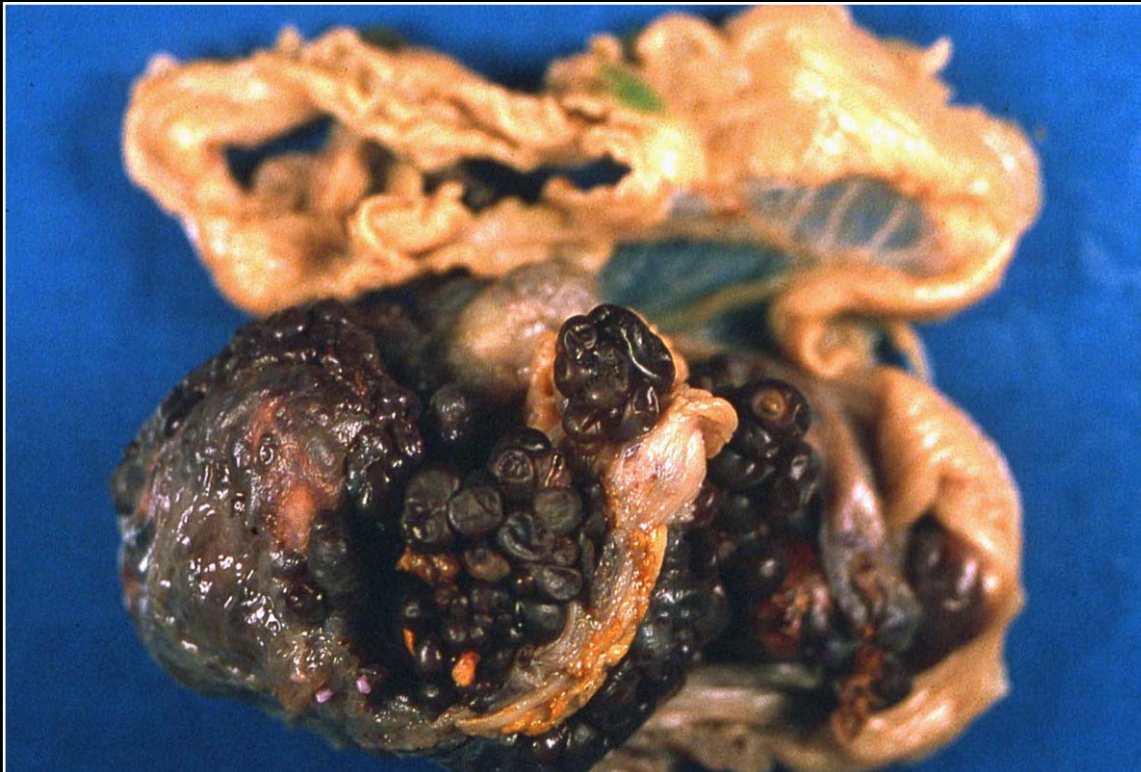Back



C H A P T E R 10

Reproductive System

Figure 10.8



Ovarian hemangiosarcoma. Note distortion of the ovary and red-black appearance of much of the tumor.

Prev. fig. Next fig.

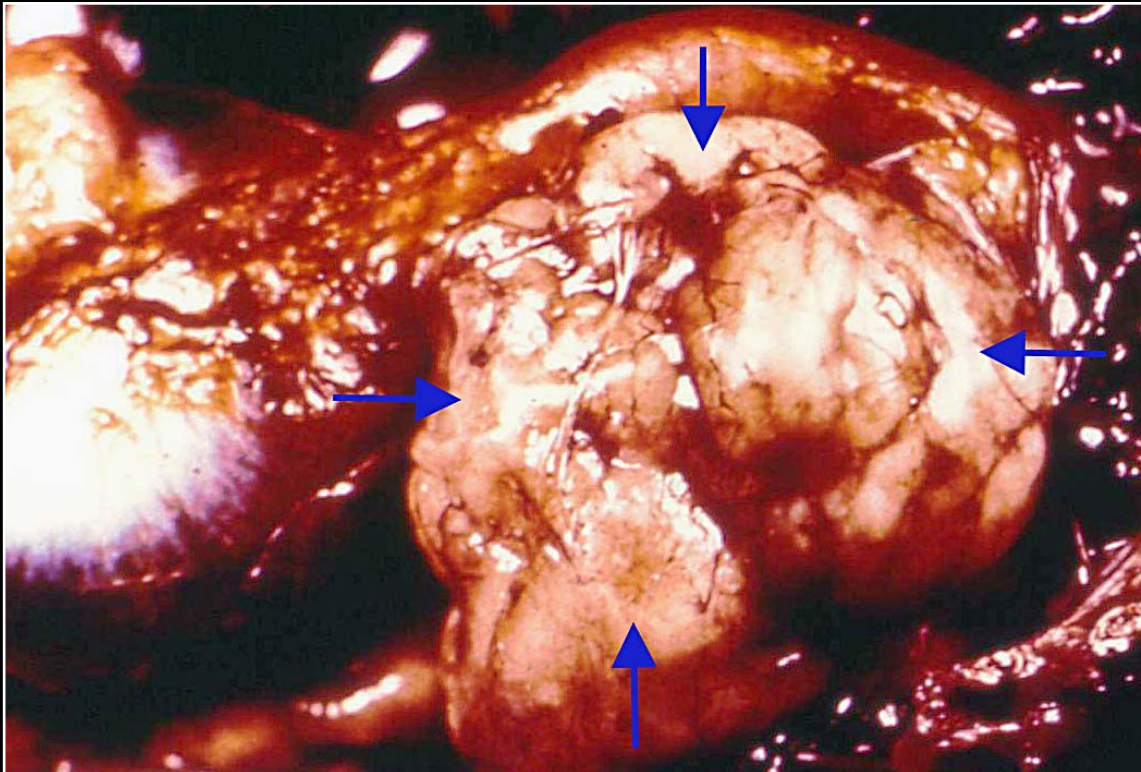
Back



C H A P T E R 10

Reproductive System

Figure 10.9



Large irregular cream-white ovary due to replacement of parenchyma by lymphosarcoma.

Prev. fig. Next fig.

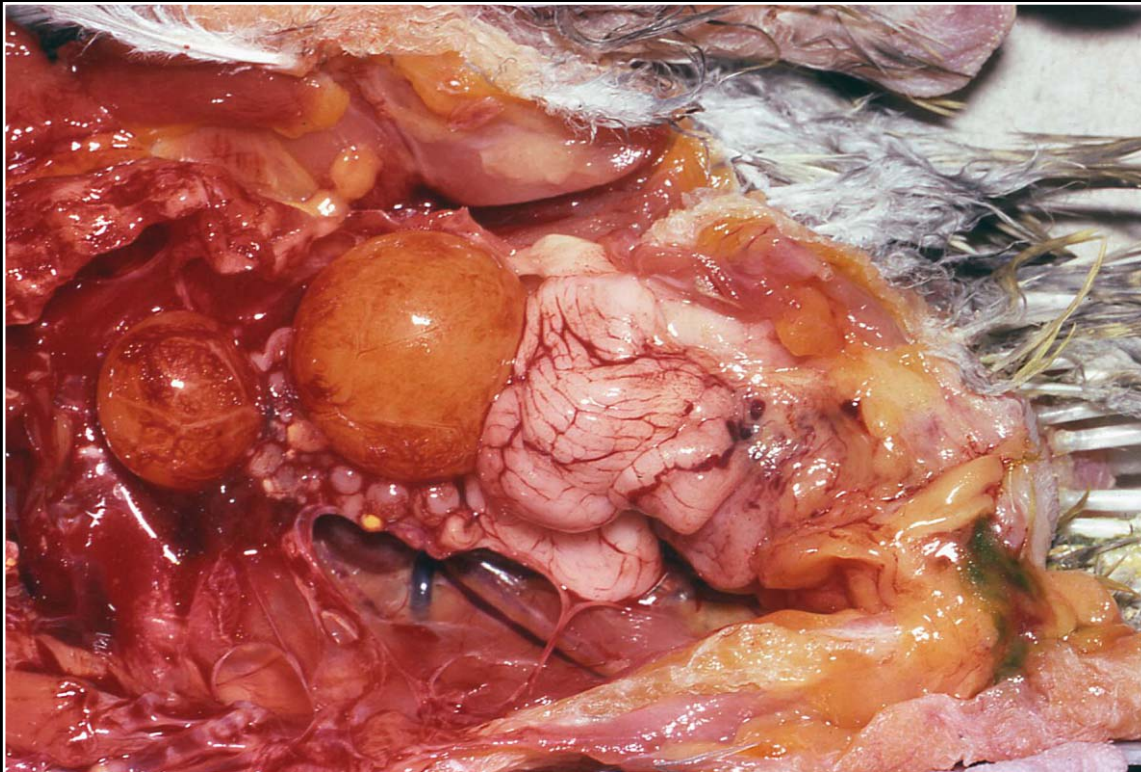
Back



C H A P T E R 10

Reproductive System

Figure 10.10



Normal post-laying ovary and oviduct/uterus.

Prev. fig. Next fig.

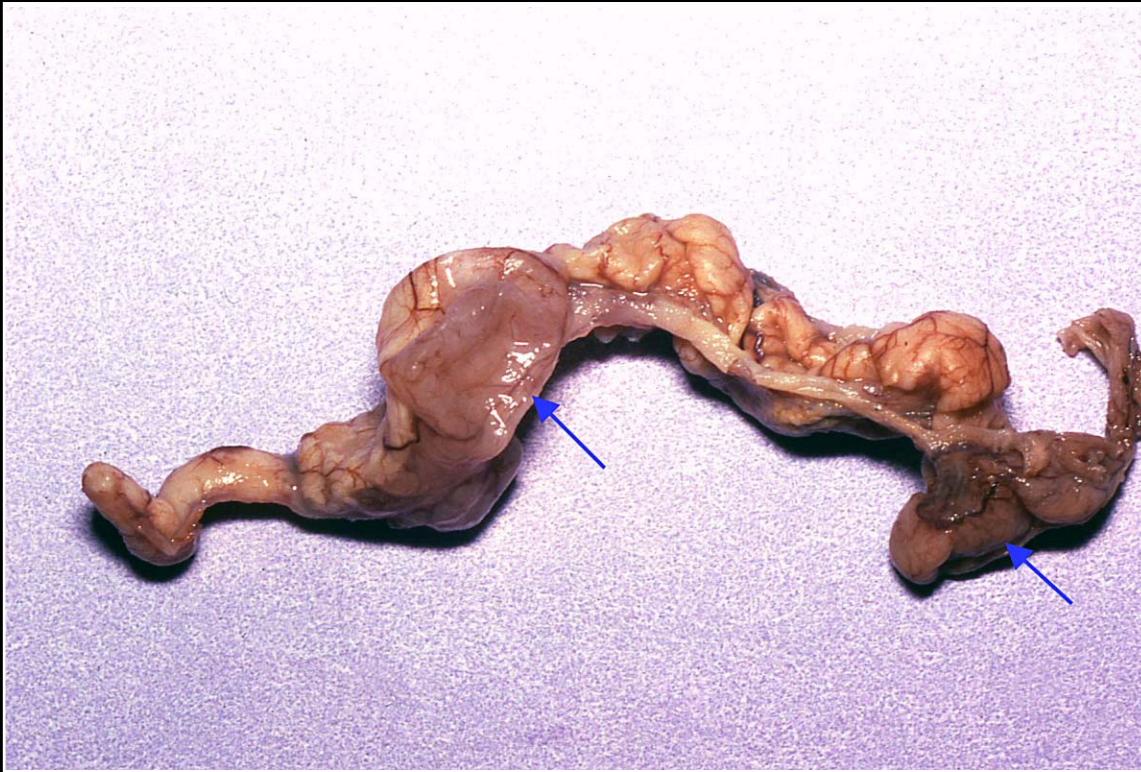Back



C H A P T E R 10

Reproductive System

Figure 10.11



Oviduct with multiple cystic foci (arrows) that have collapsed after losing their fluid.

Prev. fig. Next fig.

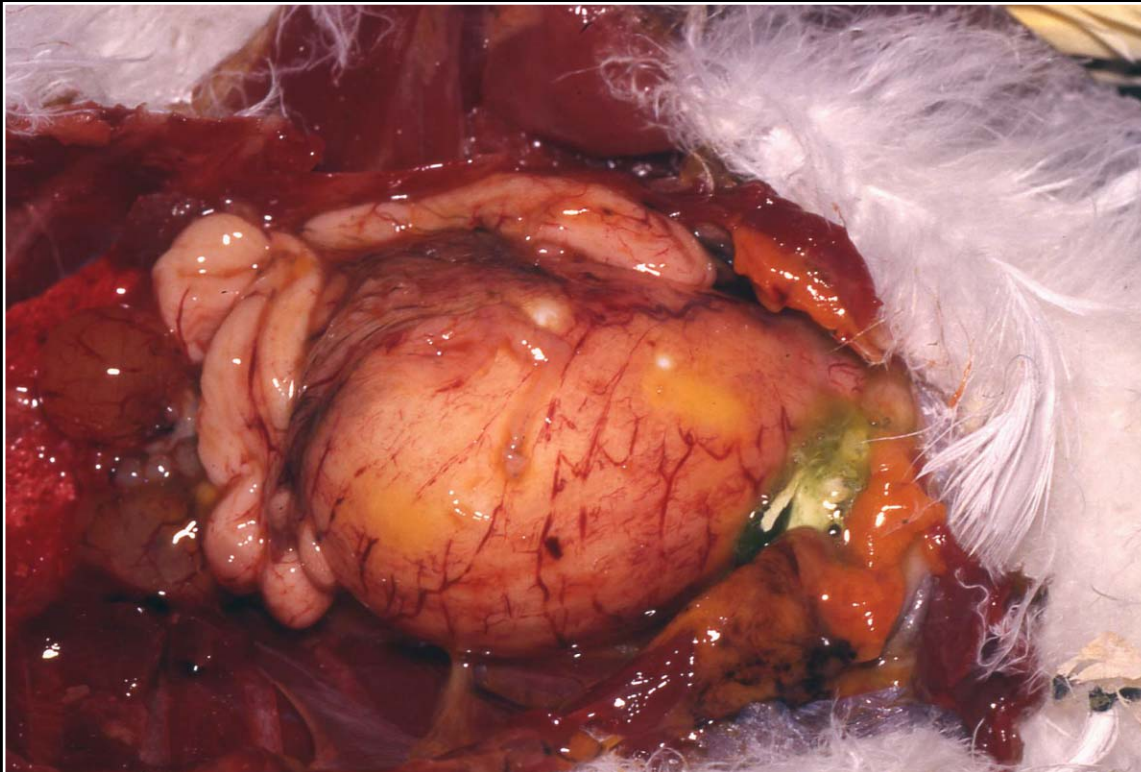
Back



C H A P T E R 10

Reproductive System

Figure 10.12



Large swelling in the oviduct of a cockatoo with a retained egg.

Prev. fig. Next fig.

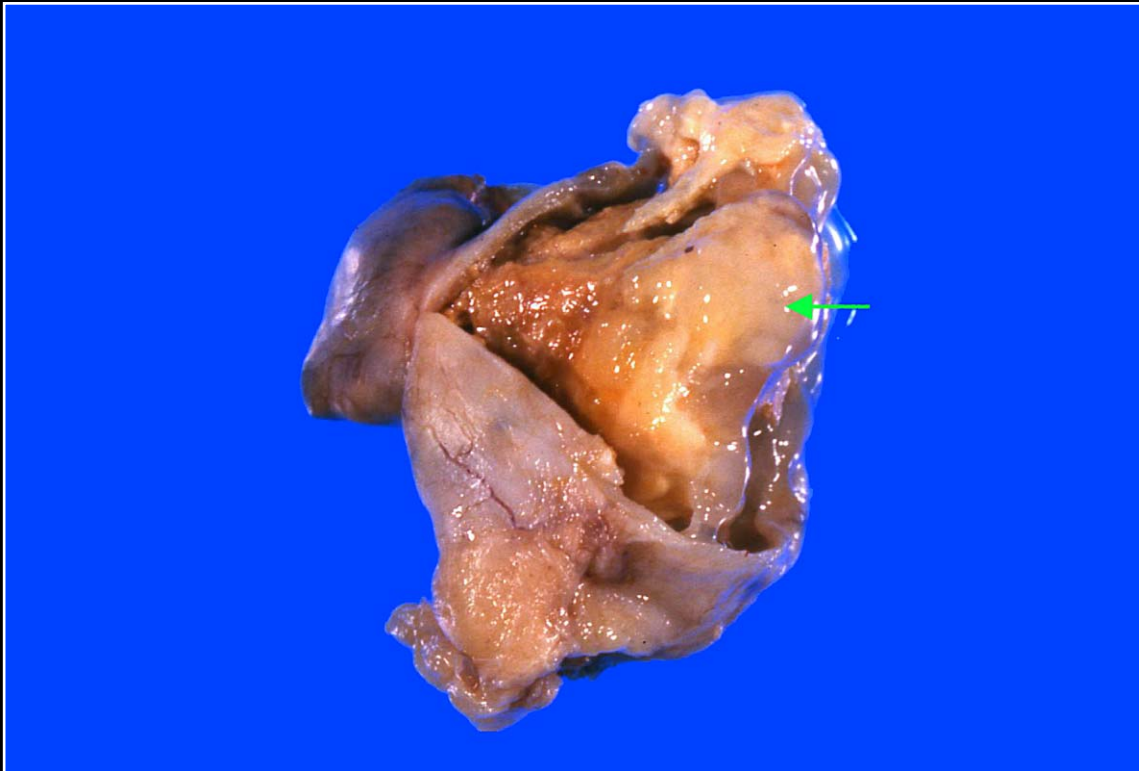
Back



C H A P T E R 10

Reproductive System

Figure 10.13



Abnormal egg noted on incising the abnormal oviduct.

Prev. fig. Next fig.

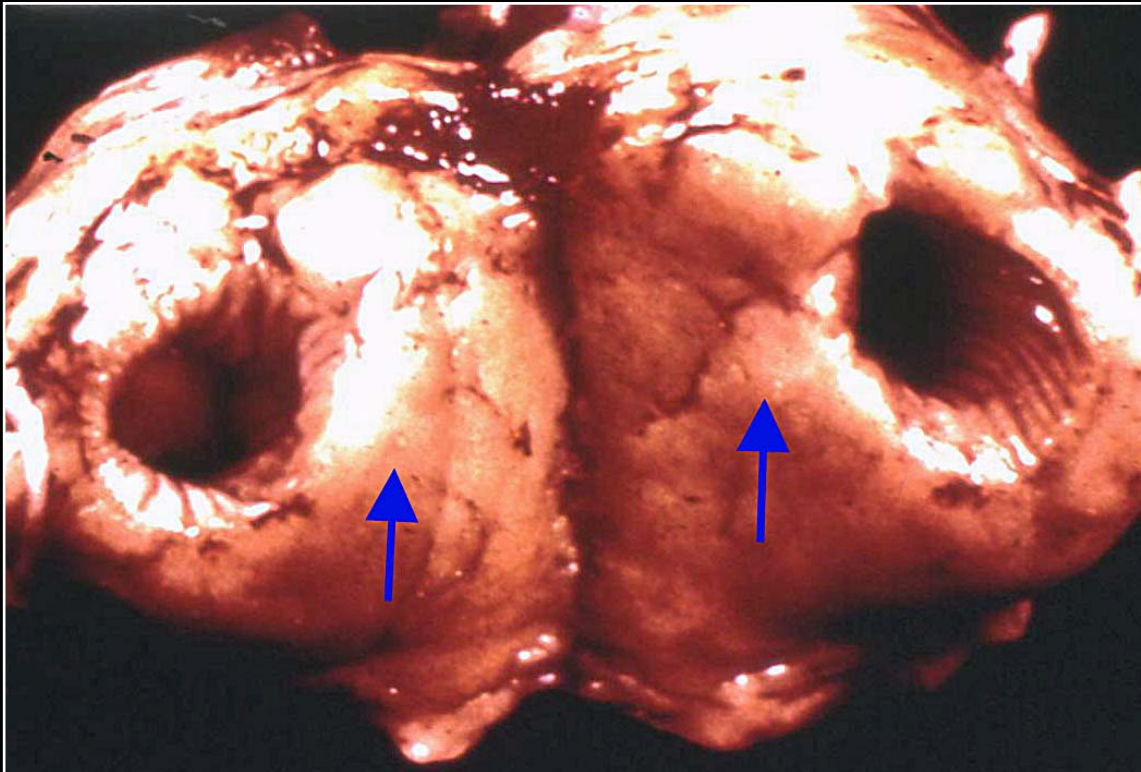
Back



C H A P T E R 10

Reproductive System

Figure 10.14



Thickening of the oviduct due to lymphosarcoma.

Prev. fig. Next fig.

Back



C H A P T E R 10

Reproductive System

Figure 10.15



Feather loss, debris accumulation and lower abdominal swelling due to blockage of cloaca by a retained egg.

Prev. fig. Next fig.

Back



C H A P T E R 10

Reproductive System

Figure 10.16



Roughened egg with ridges. Salpingitis can be one cause of this condition.

Prev. fig. Next fig.

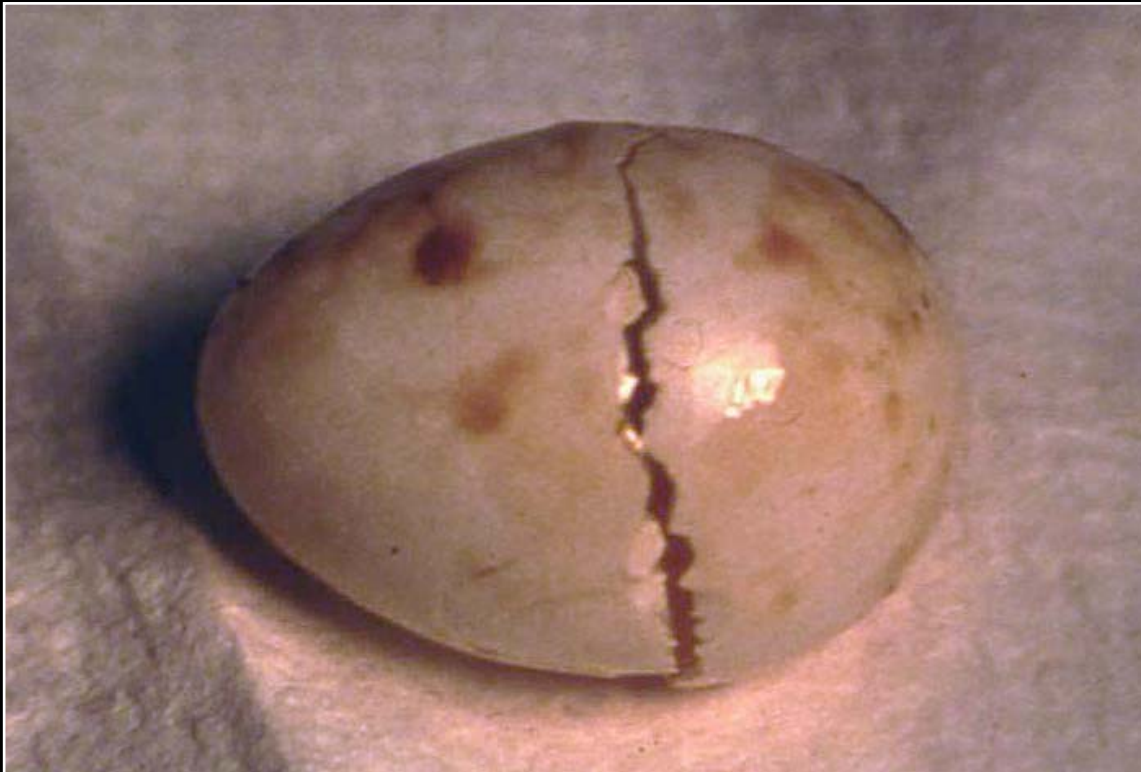Back



C H A P T E R 10

Reproductive System

Figure 10.17



Breakage of abnormal egg within the oviduct.

Prev. fig. Next fig.

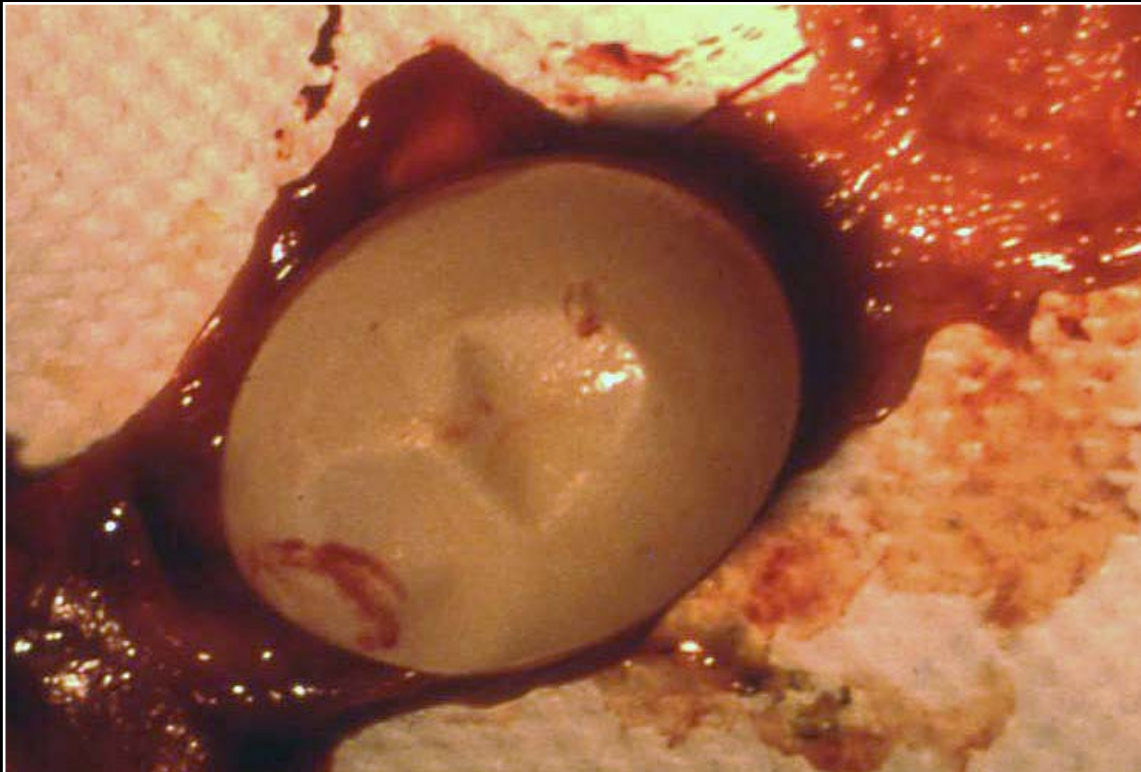
Back



C H A P T E R 10

Reproductive System

Figure 10.18



Soft-shelled egg due to insufficient available calcium.

Prev. fig. Next fig.

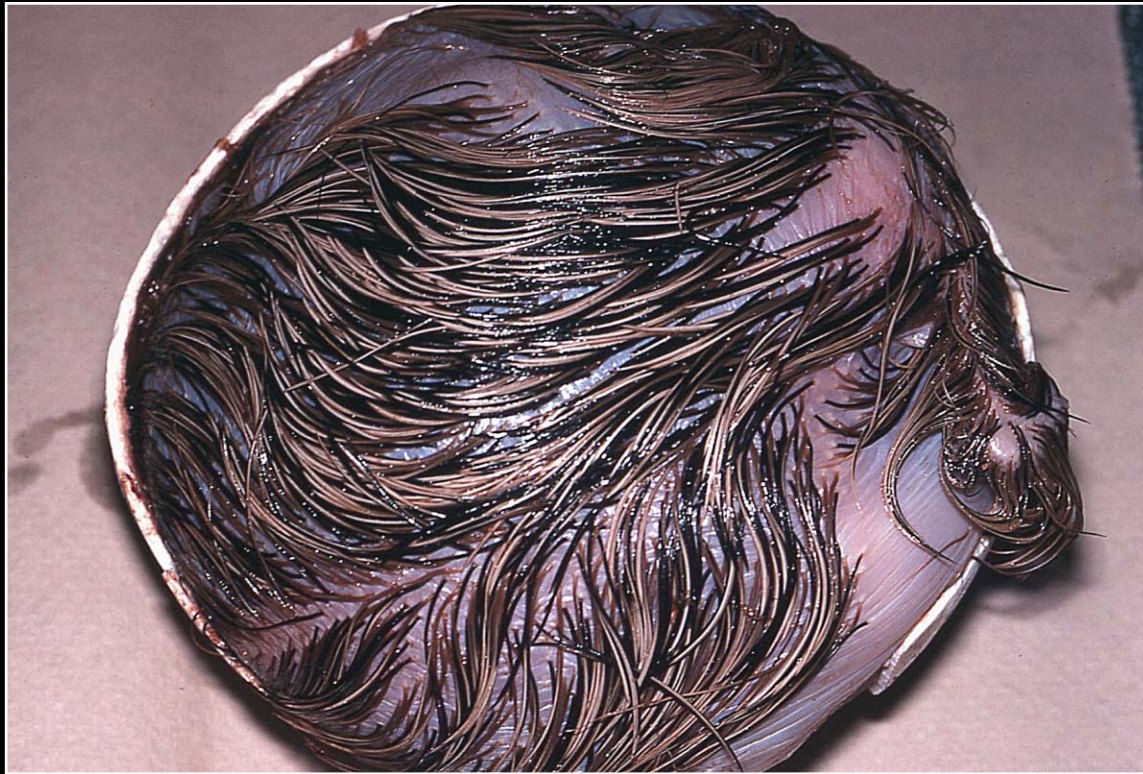Back



C H A P T E R 10

Reproductive System

Figure 10.19



Edematous chick due to excessive incubator humidity.

Prev. fig. Next fig.

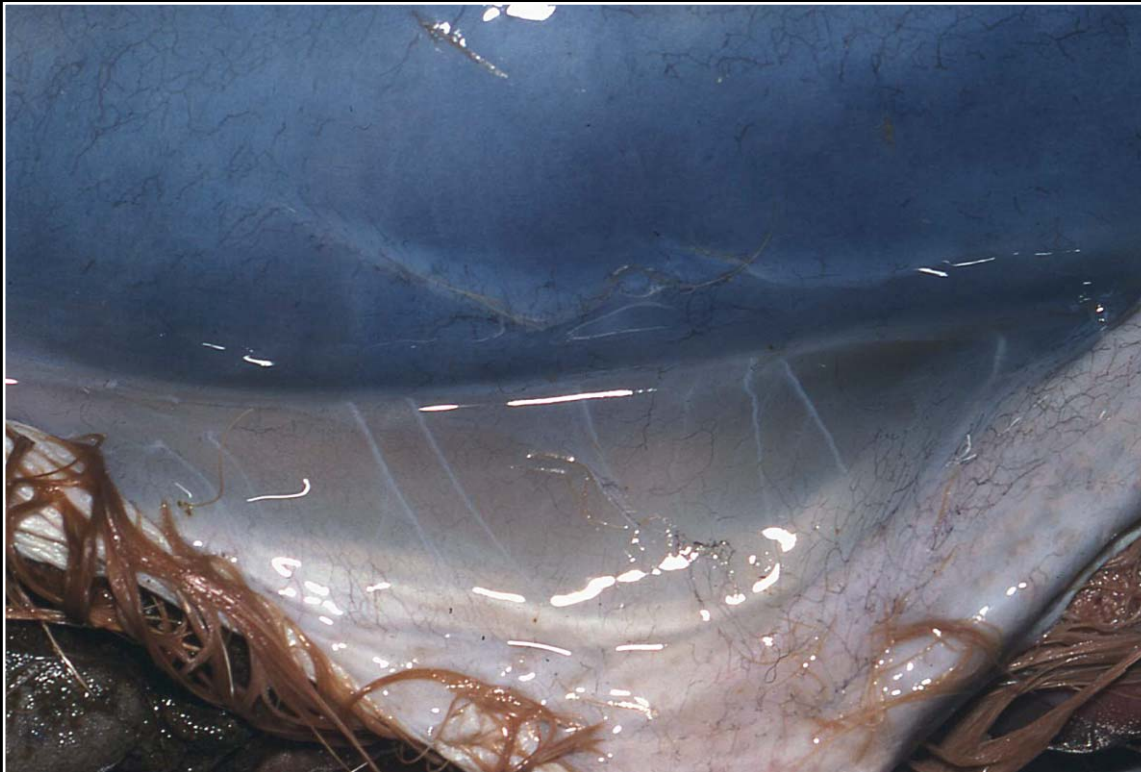Back



C H A P T E R 10

Reproductive System

Figure 10.20



Detail of edematous skin of chick shown in Fig 19.

Prev. fig.

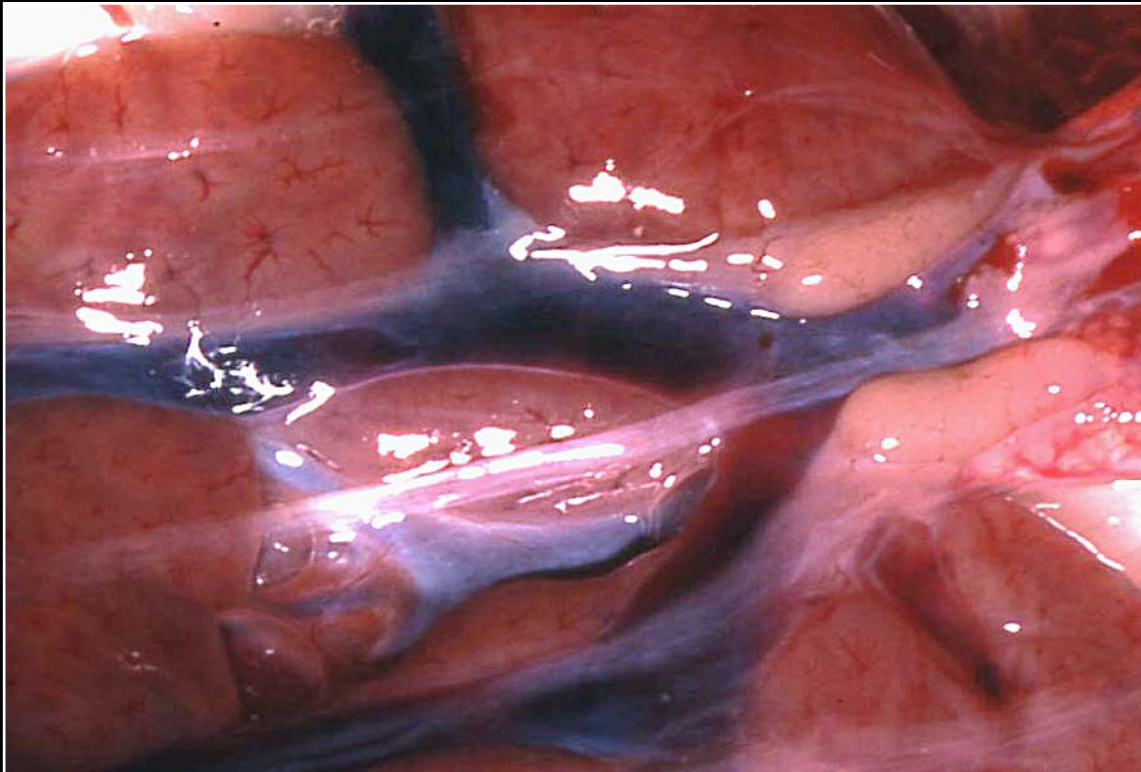
Back



C H A P T E R 11

Urinary System

Figure 11.0



Normal avian kidneys.

Next fig.

Back



C H A P T E R 11

Urinary System

Figure 11.1



Congenital polycystic kidney. Note multiple cystic areas (arrows).

Prev. fig. Next fig.

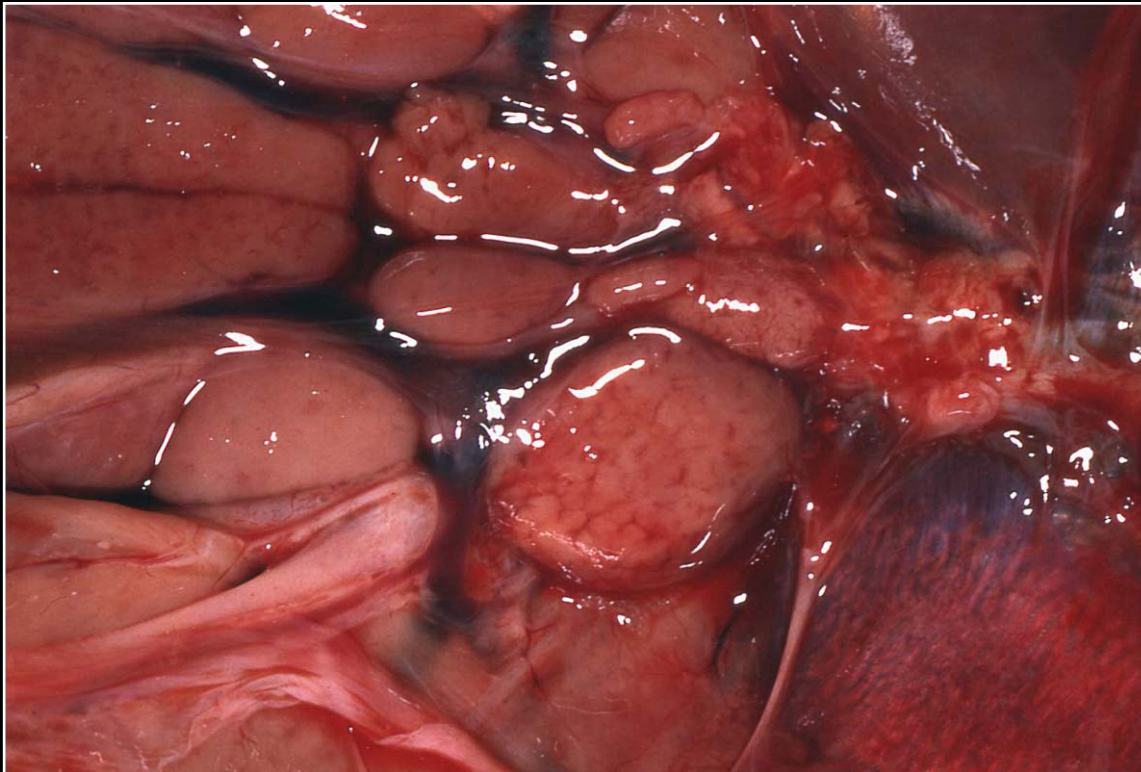
Back



C H A P T E R 11

Urinary System

Figure 11.2



Enlarged, pale, edematous-appearing kidney seen in polyomavirus infection. Also note ascitic fluid.

Prev. fig. Next fig.

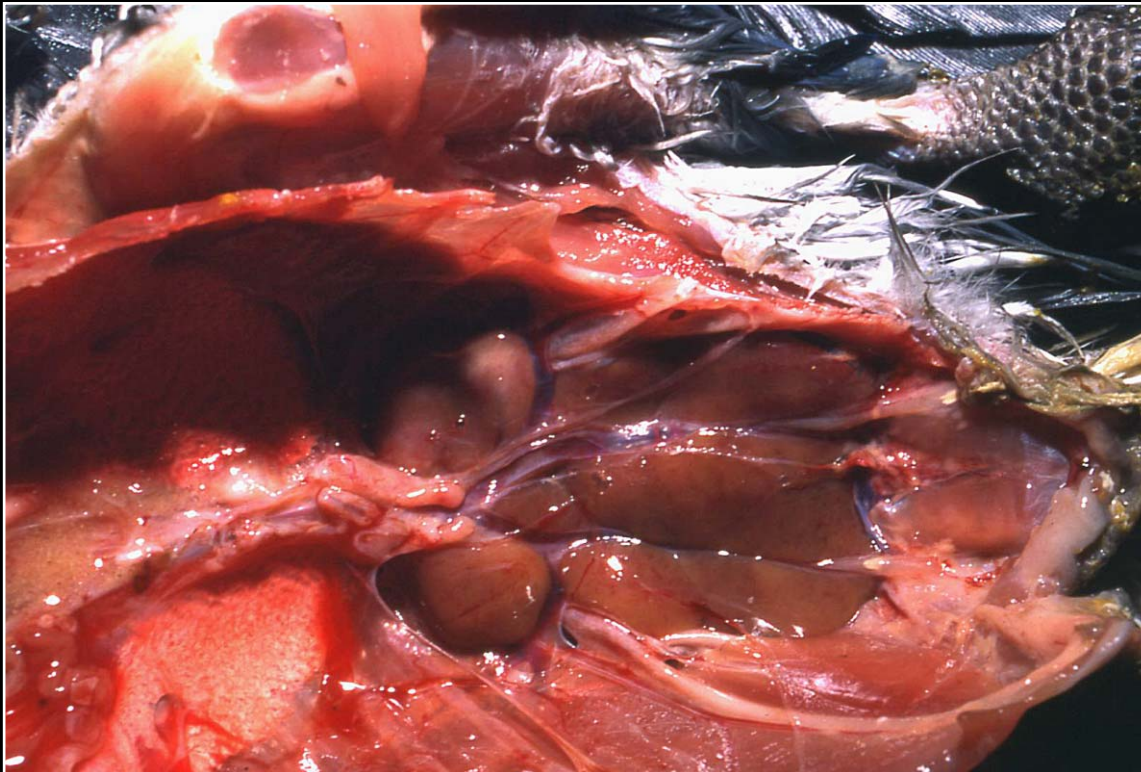
Back



C H A P T E R 11

Urinary System

Figure 11.3



Diffuse enlargement and discoloration of the kidney due to a bacterial infection.

Prev. fig. Next fig.

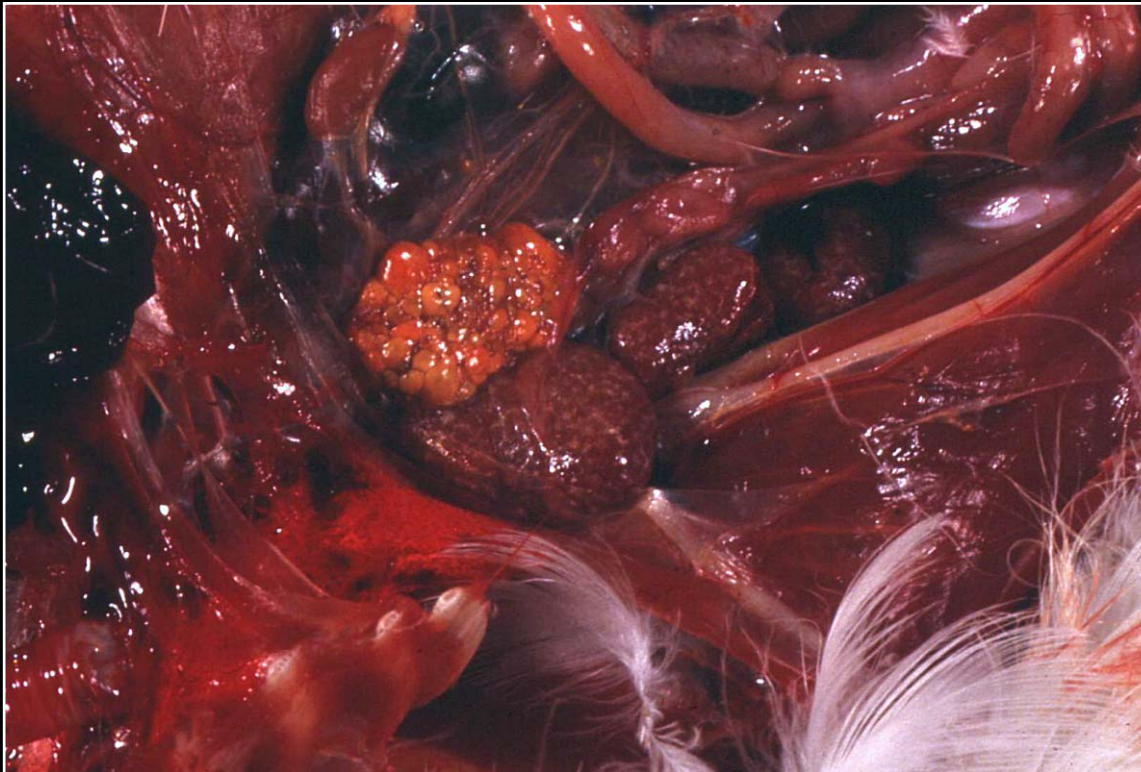
Back



C H A P T E R 11

Urinary System

Figure 11.4



Bacterial nephritis in a cockatoo with multifocal small areas of renal necrosis.

Prev. fig. Next fig.

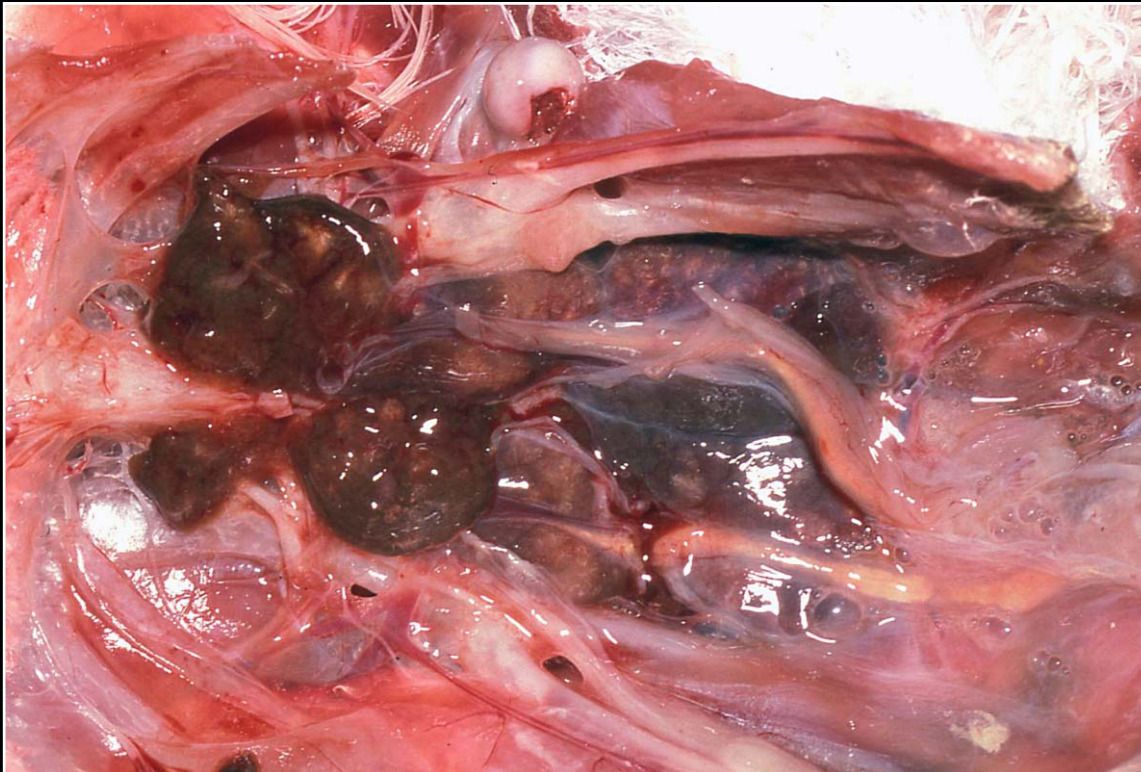
Back



C H A P T E R 11

Urinary System

Figure 11.5



Bacterial nephritis more advanced than in Fig 11.14 is shown here with larger yellow foci and nodule formation.

Prev. fig. Next fig.

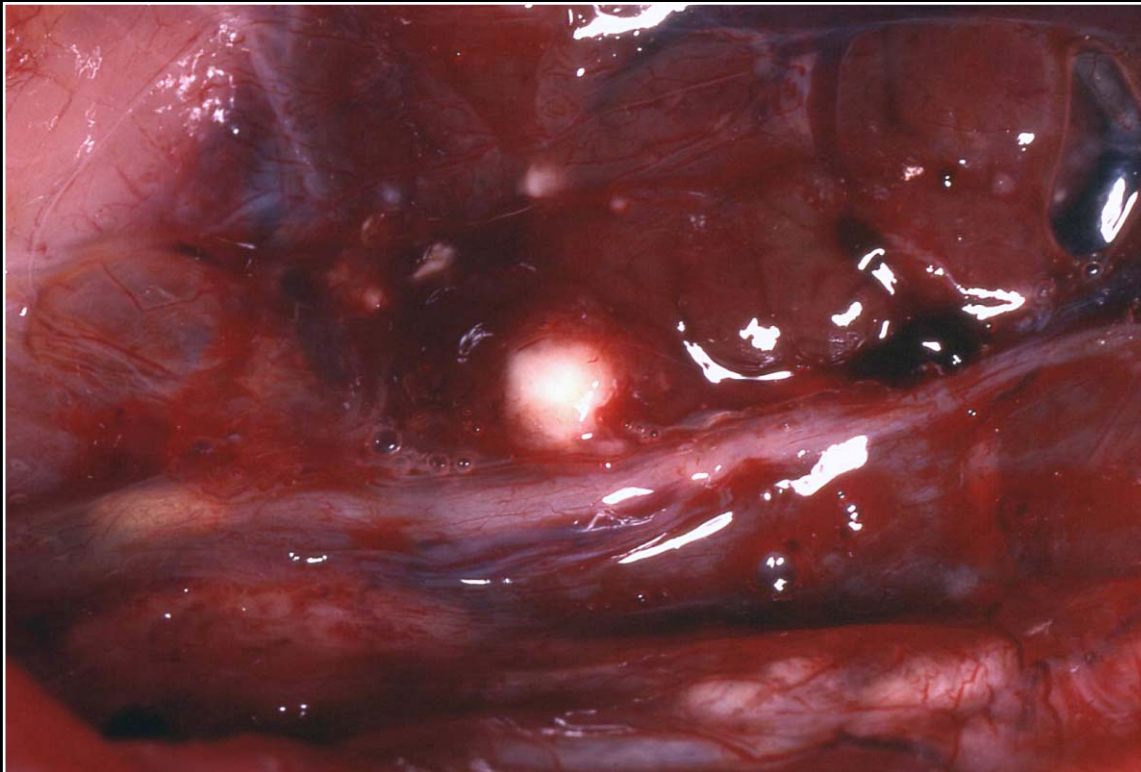Back



C H A P T E R 11

Urinary System

Figure 11.6



Formation of several large renal abscesses in a cockatoo with disseminated salmonellosis.

Prev. fig. Next fig.

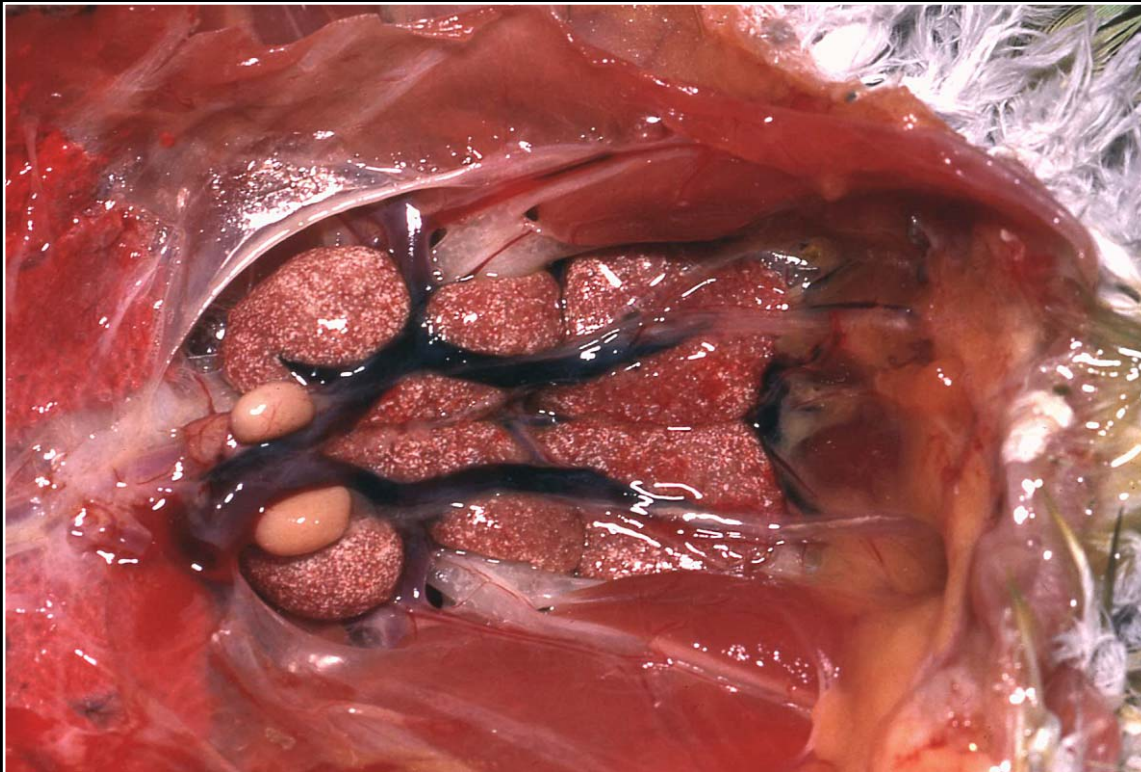
Back



C H A P T E R 11

Urinary System

Figure 11.7



Diffuse urate deposition following prolonged dehydration.

Prev. fig. Next fig.

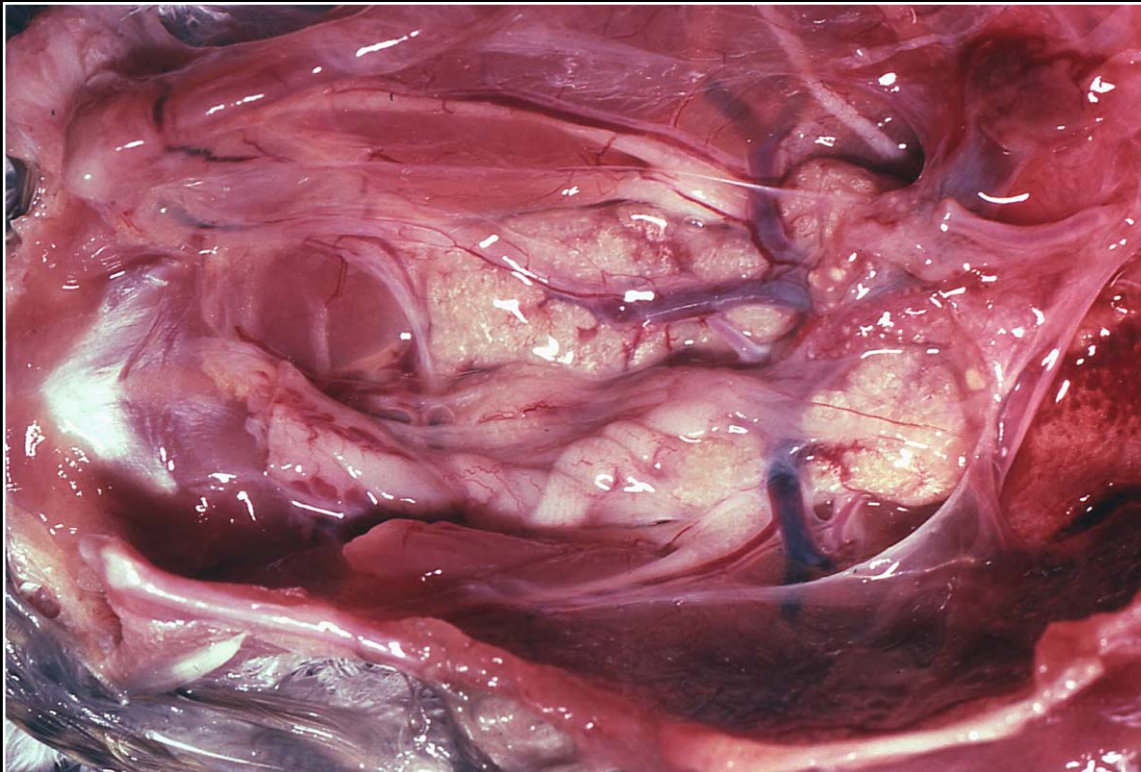
Back



C H A P T E R 11

Urinary System

Figure 11.8



Pale kidneys with multiple foci of mineralization.

Prev. fig. Next fig.

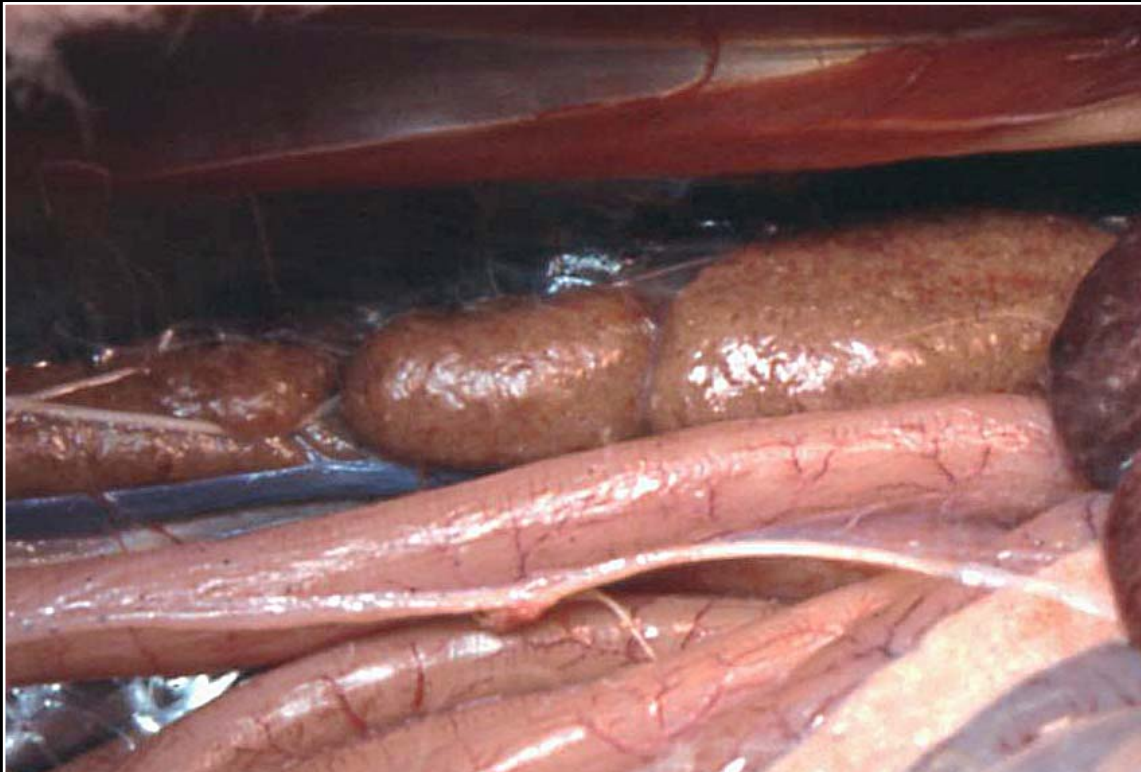Back



C H A P T E R 11

Urinary System

Figure 11.9



Renal amyloidosis. Note multiple tan foci.

Prev. fig. Next fig.

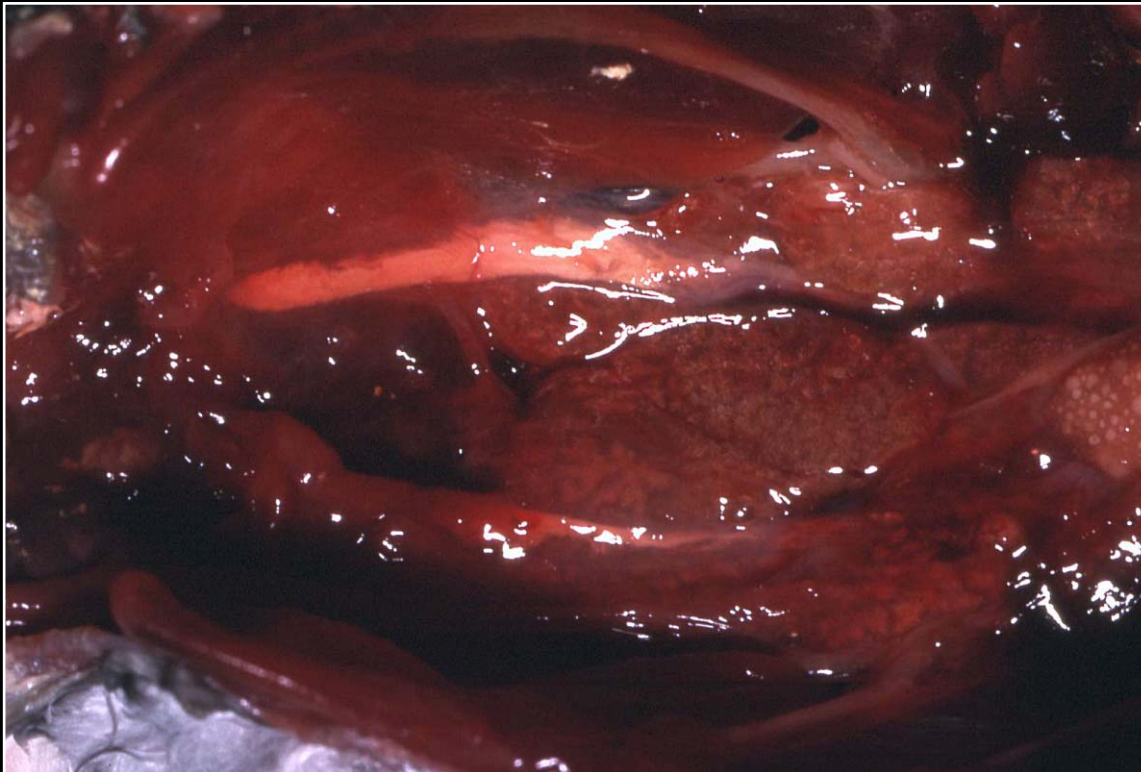Back



C H A P T E R 11

Urinary System

Figure 11.10



Obstructed ureter as can be seen in vitamin A deficiency and other urinary disease.

Prev. fig. Next fig.

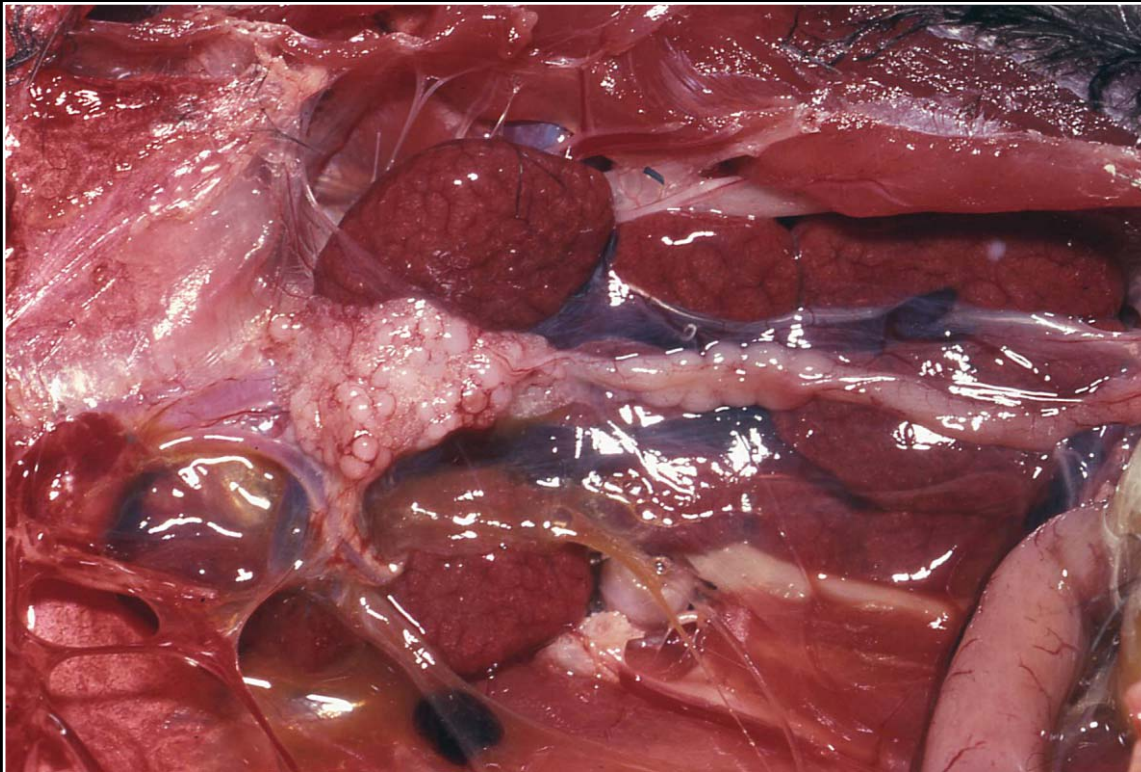
Back



C H A P T E R 11

Urinary System

Figure 11.11



Toucan with iron storage disease. Note deep red-brown kidneys.

Prev. fig. Next fig.

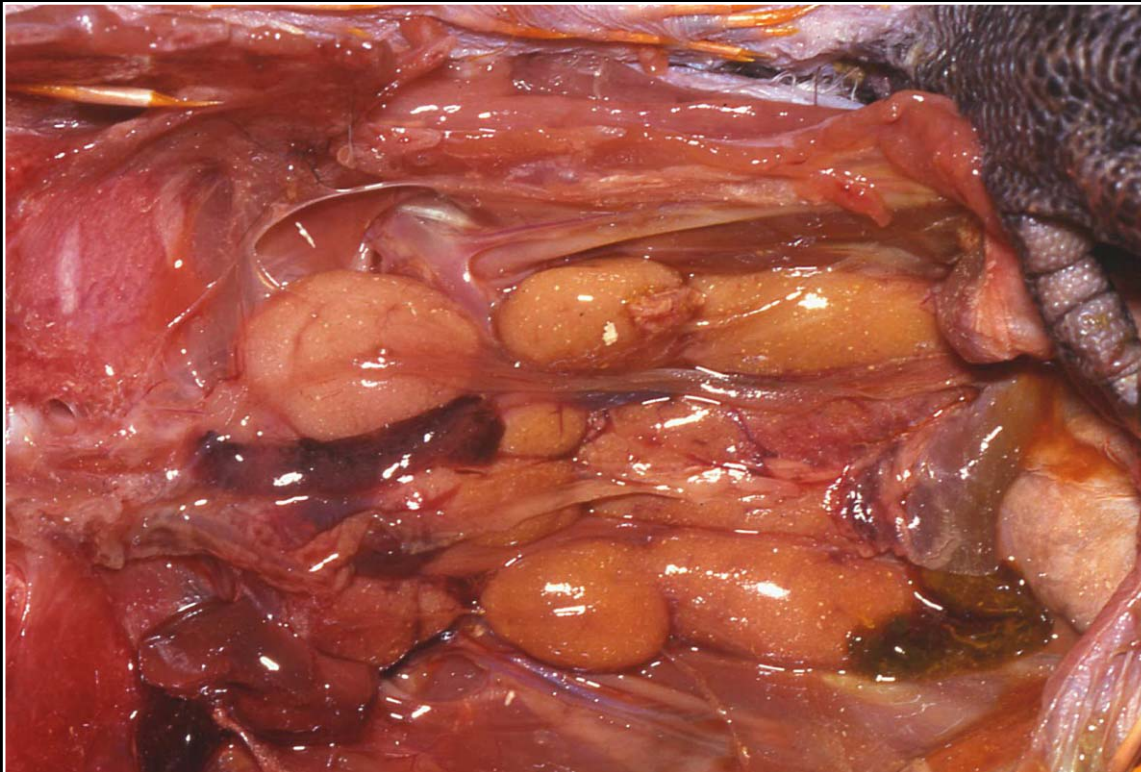
Back



C H A P T E R 11

Urinary System

Figure 11.12



Swollen, pale yellow kidneys in a macaw with vitamin D toxicity.

Prev. fig. Next fig.

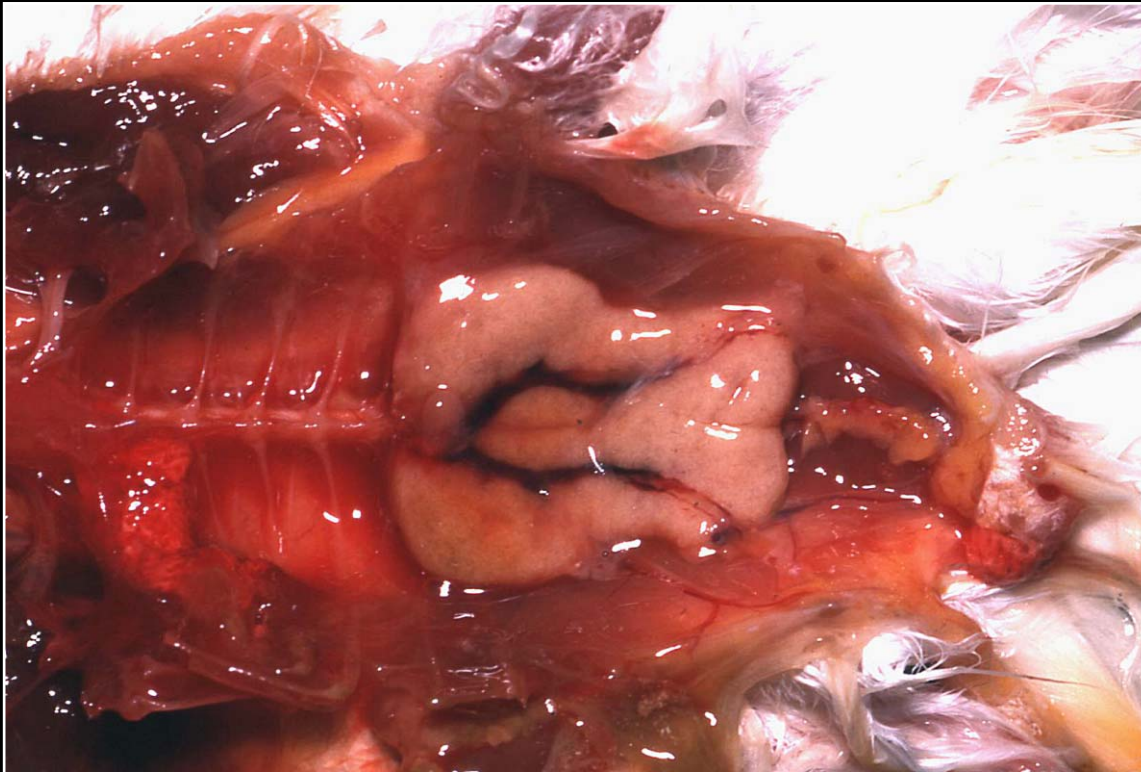Back



C H A P T E R 11

Urinary System

Figure 11.13



Chronic renal disease with fibrosis. The kidneys are somewhat small, pale, firm and nodular.

Prev. fig. Next fig.

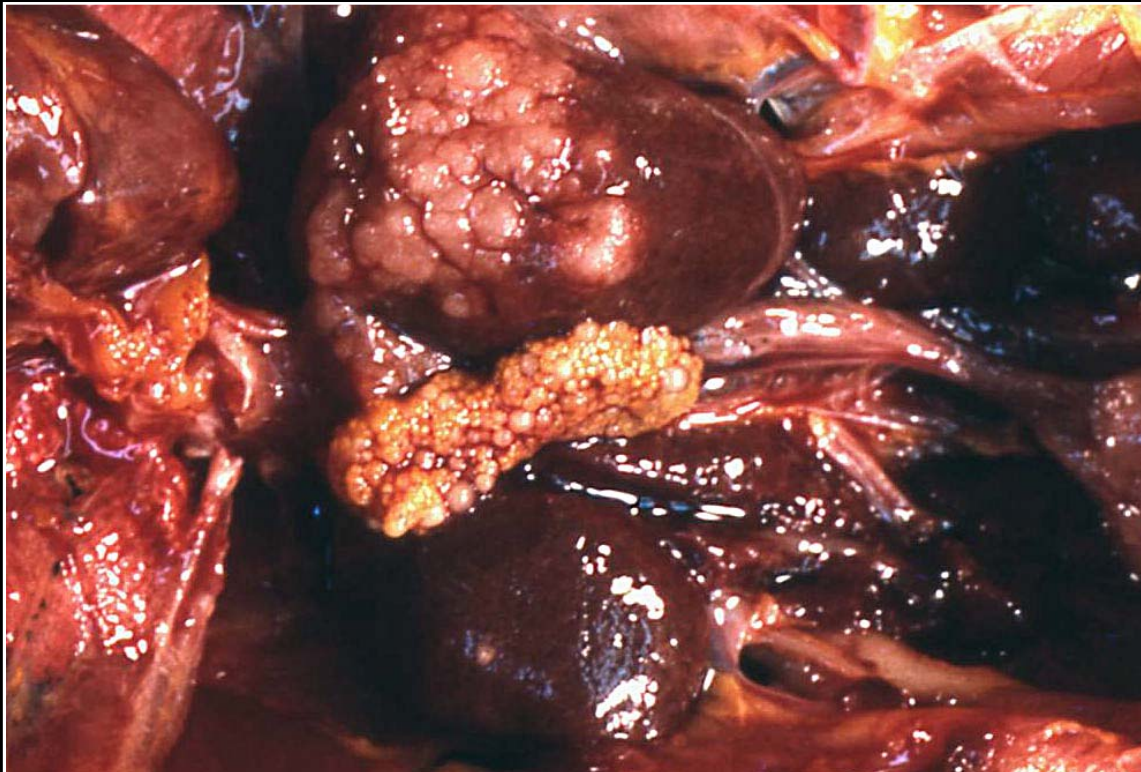
Back



C H A P T E R 11

Urinary System

Figure 11.14



Nodular swelling at the cranial pole of the kidney typical of renal tubular adenoma.

Prev. fig. Next fig.

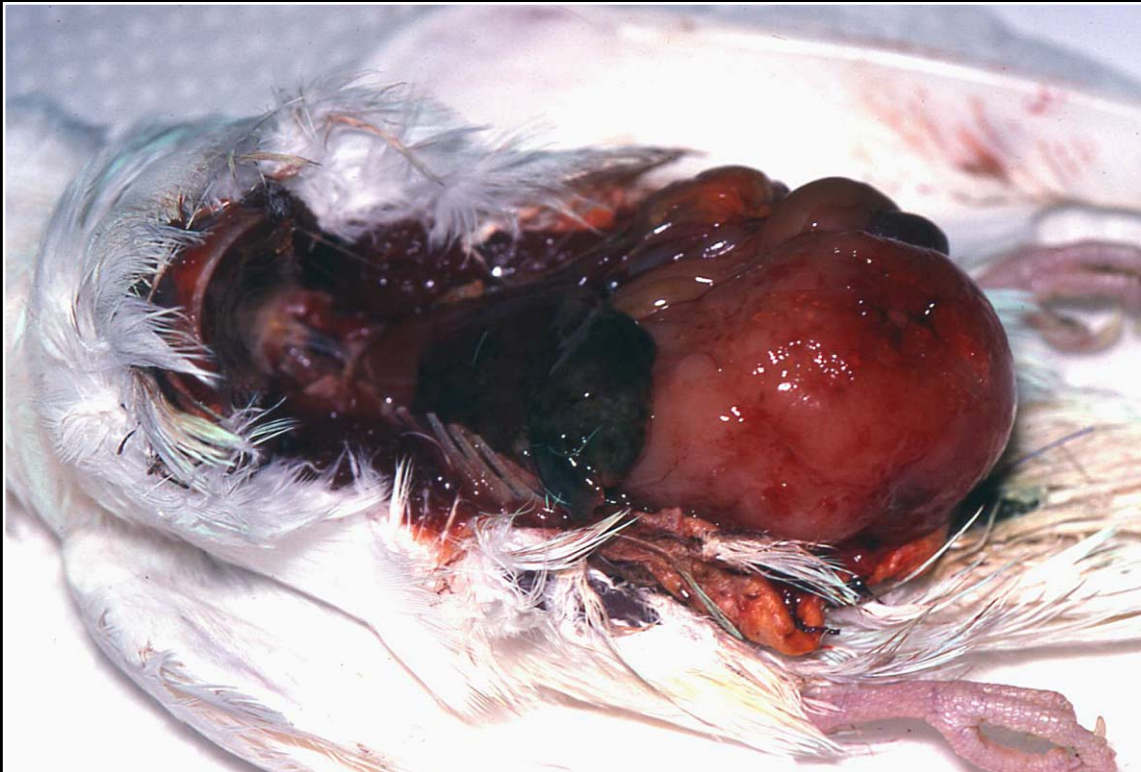Back



C H A P T E R 11

Urinary System

Figure 11.15



Extremely large renal carcinoma displacing other abdominal organs.

Prev. fig. Next fig.

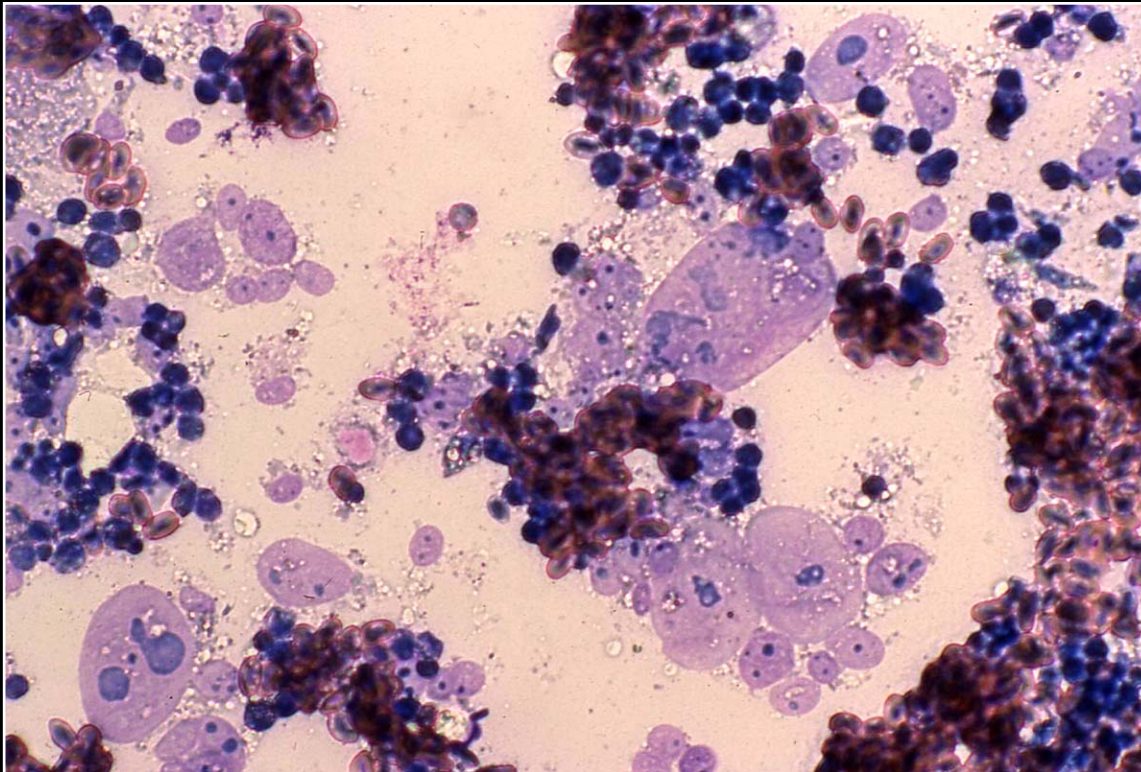
Back



C H A P T E R 11

Urinary System

Figure 11.16



Numerous anaplastic epithelial cells present in impression smear of renal carcinoma.

Prev. fig. Next fig.

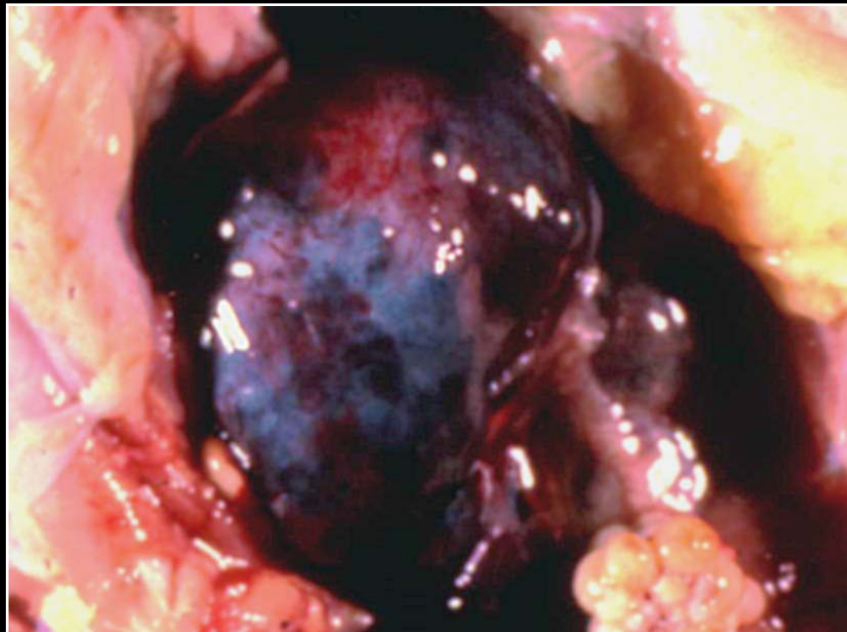
Back



C H A P T E R 11

Urinary System

Figure 11.17



Embryonal nephroma. The lobulated appearance is similar to the gross appearance of renal carcinoma.

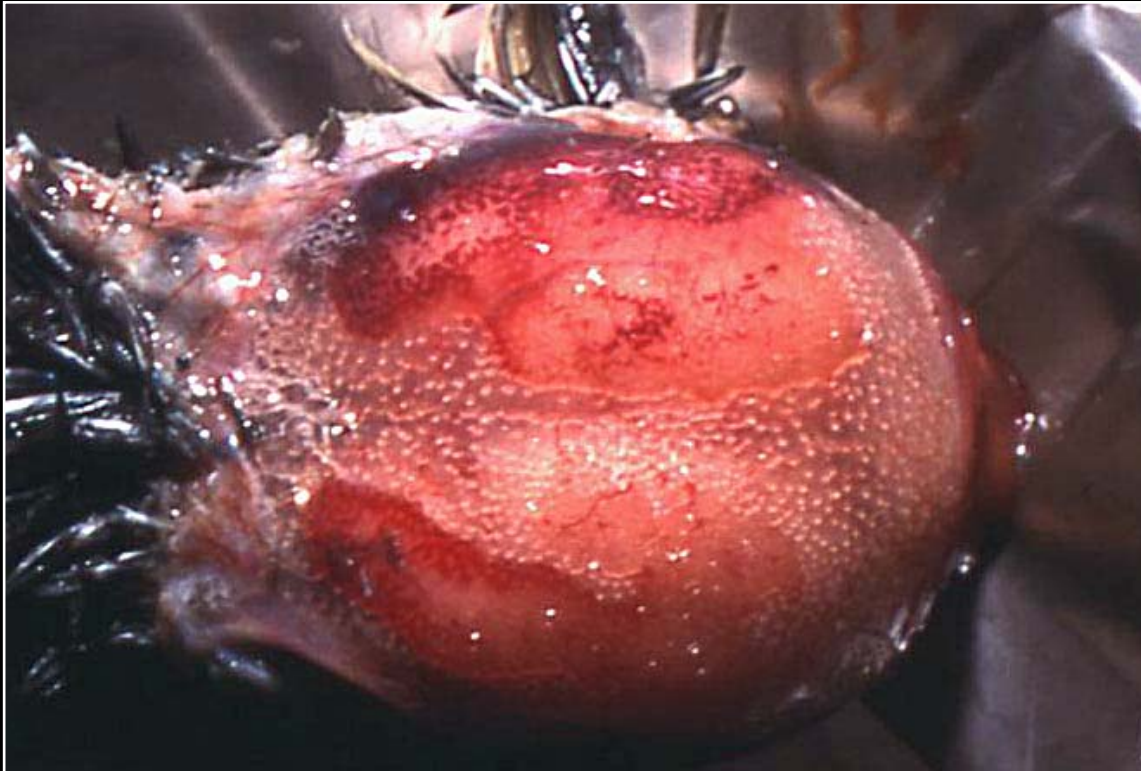
Prev. fig.

Back

C H A P T E R 12

Nervous System

Figure 12.1



Exposure of the skull prior to removal of bone to expose the brain.

Next fig.

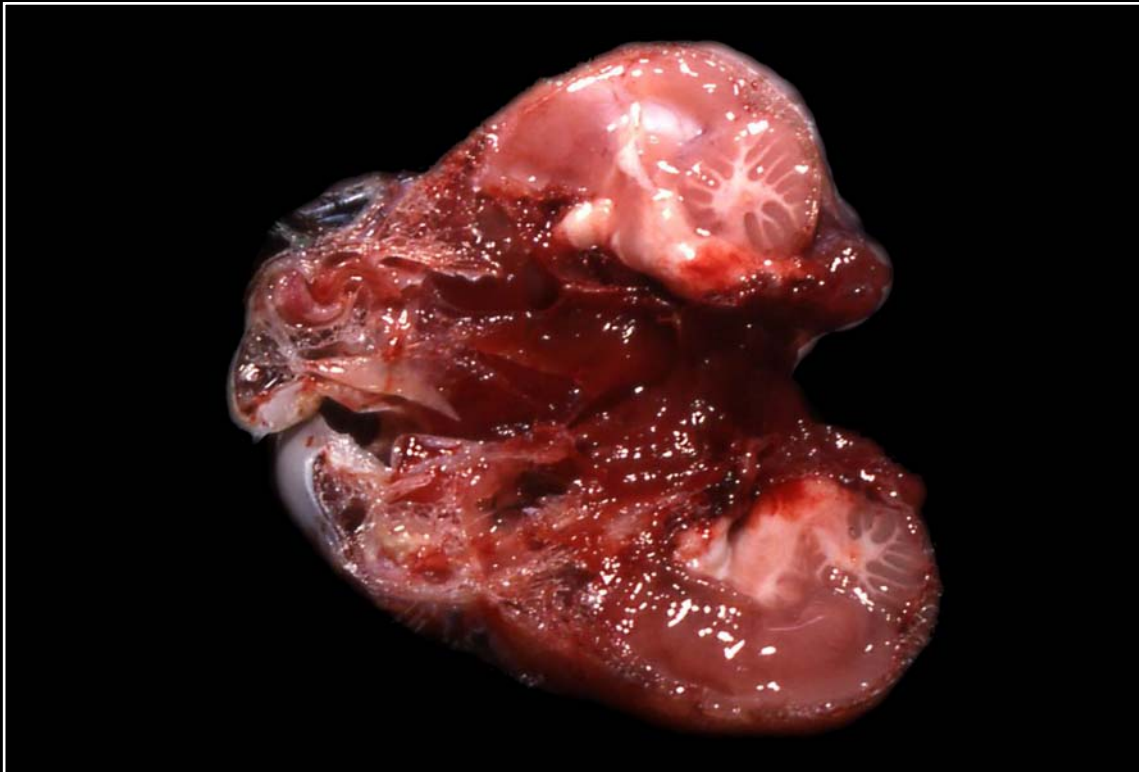
Back



C H A P T E R 12

Nervous System

Figure 12.2



Exposure of the brain by bisecting the entire head.

Prev. fig. Next fig.

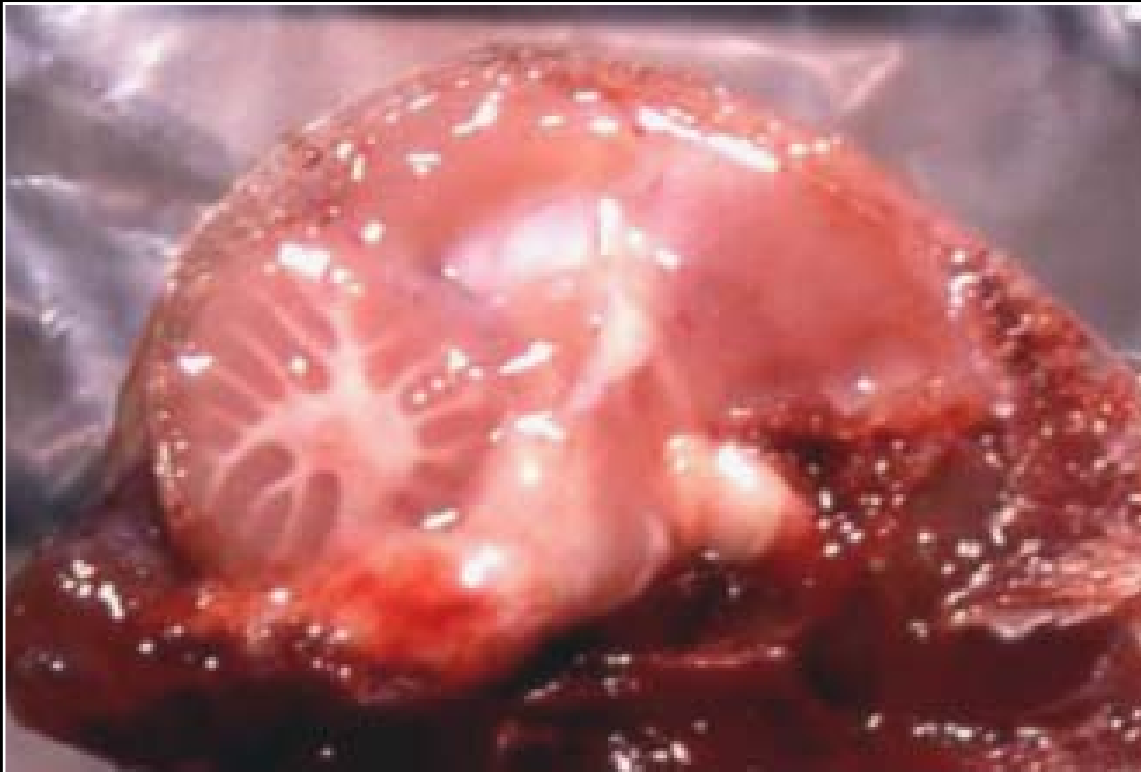Back



C H A P T E R 12

Nervous System

Figure 12.2a



Normal avian brain.

Prev. fig. Next fig.

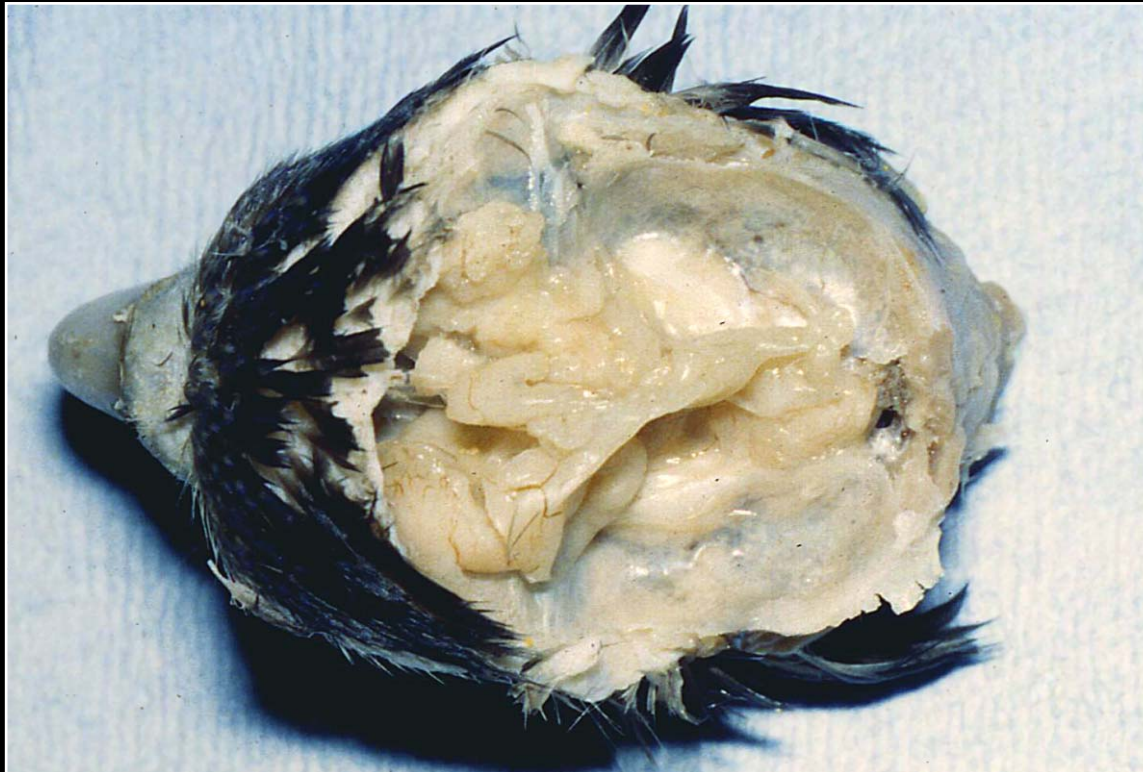Back



CHAPTER 12

Nervous System

Figure 12.3



Hydrocephalus in an African grey parrot. The extremely thin outer cortex has collapsed and ruptured, leaving large areas that contain fluid and some of the basilar brain structures.

Prev. fig. Next fig.

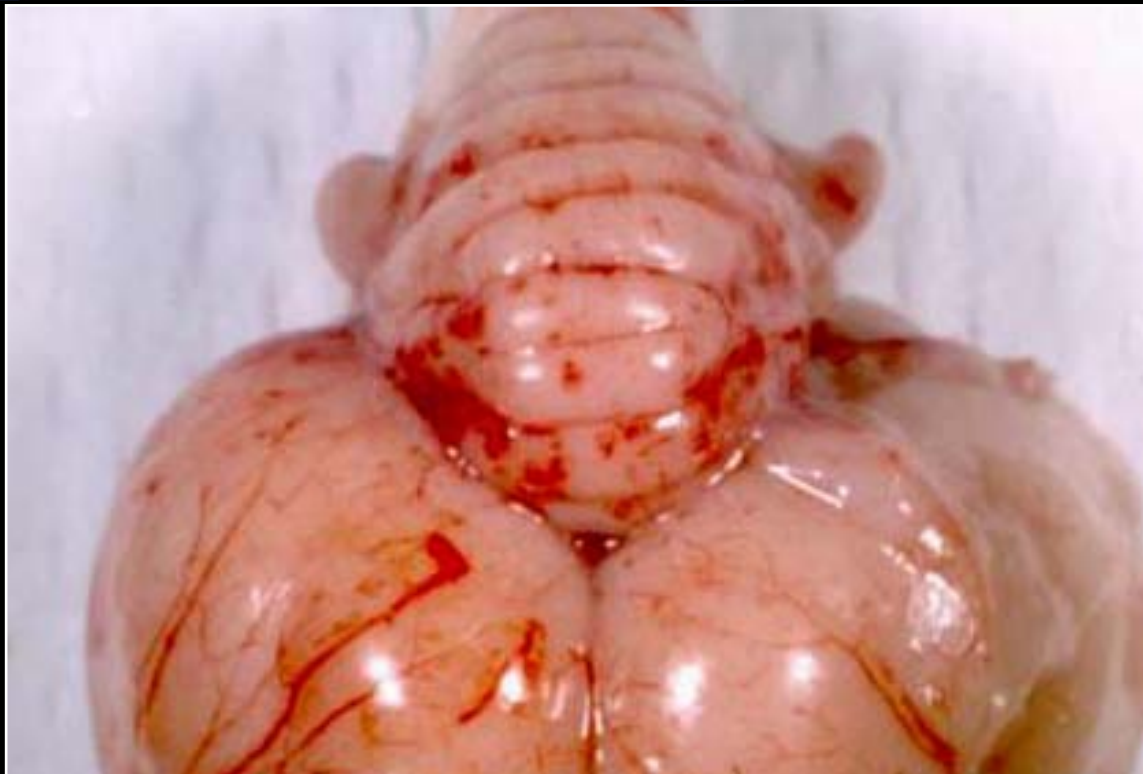
Back



C H A P T E R 12

Nervous System

Figure 12.4



Multifocal meningeal hemorrhage seen in West Nile virus infection.

Prev. fig. Next fig.

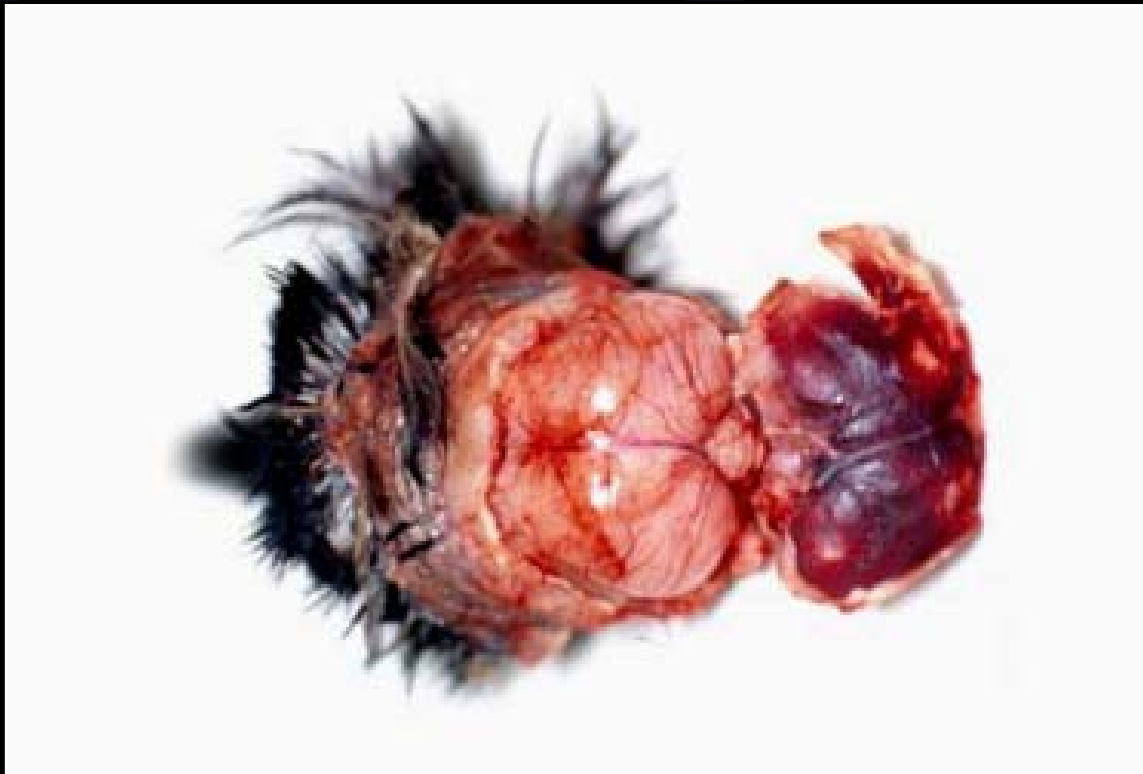Back



C H A P T E R 12

Nervous System

Figure 12.5



Diffuse calvarial hemorrhage in West Nile virus infection.

Prev. fig. Next fig.

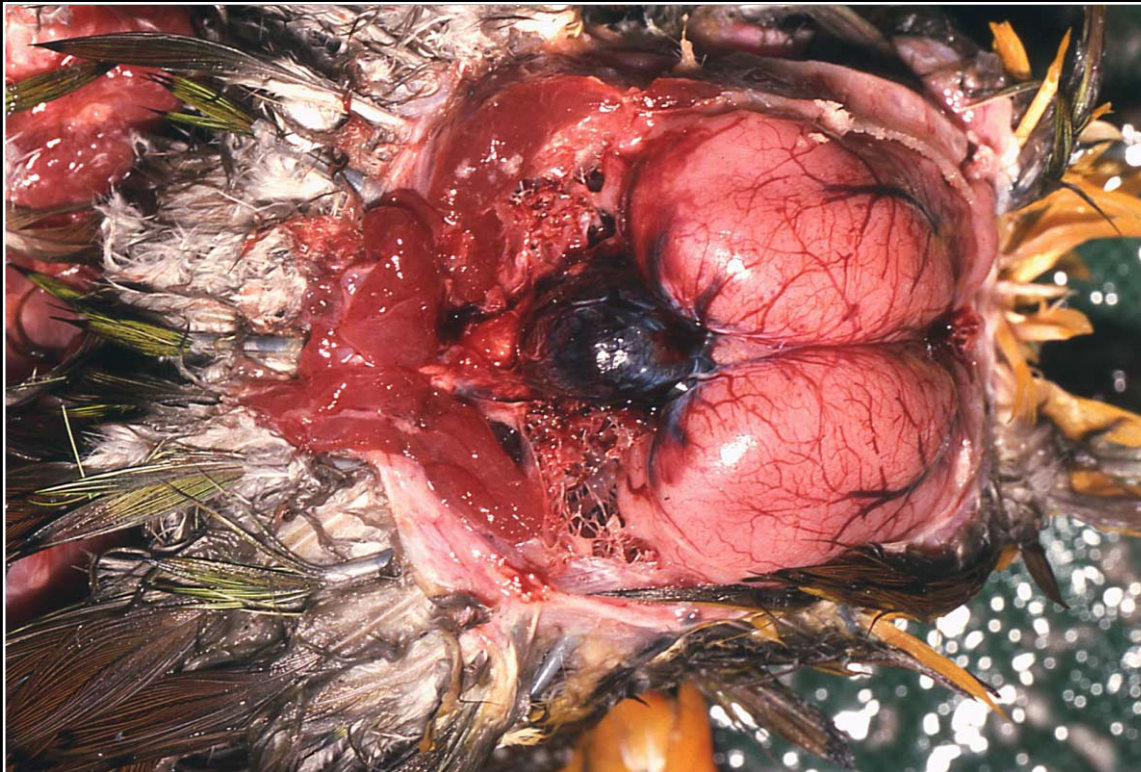
Back



C H A P T E R 12

Nervous System

Figure 12.6



Brain hemorrhage following trauma. Surface change such as this must be differentiated from severe postmortem congestion.

Prev. fig. Next fig.

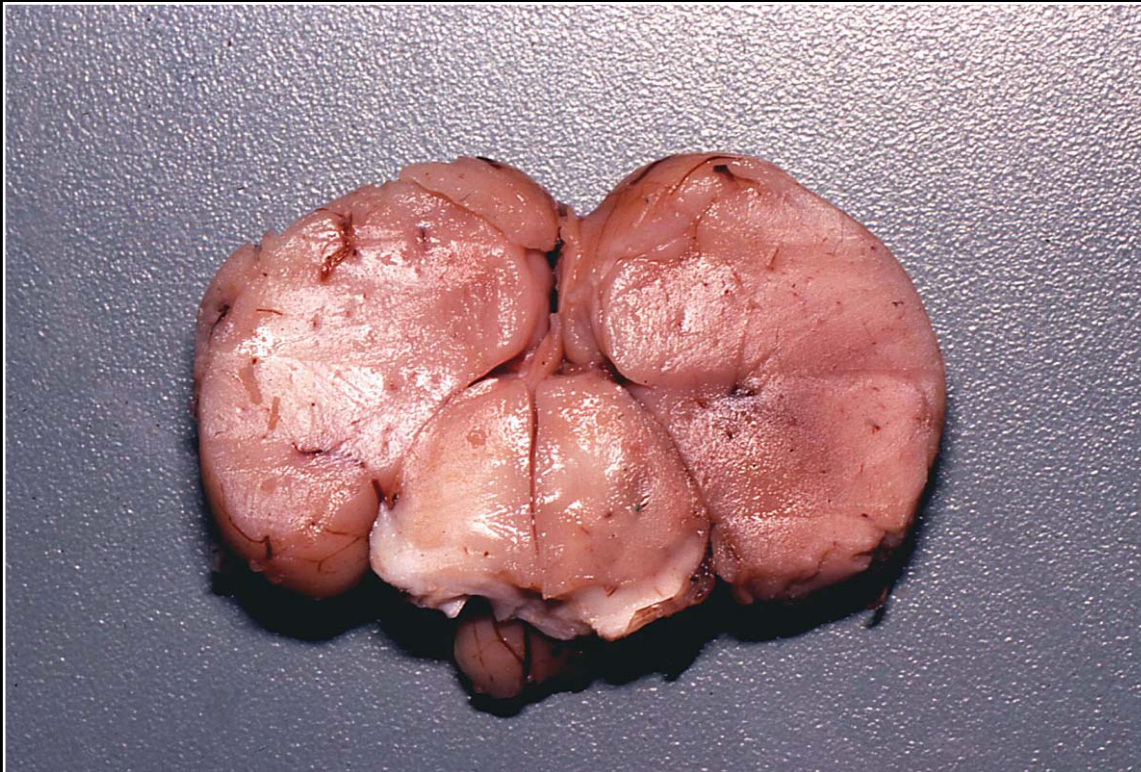
Back



C H A P T E R 12

Nervous System

Figure 12.7



Minimal brain hemorrhage (right side) associated with trauma.

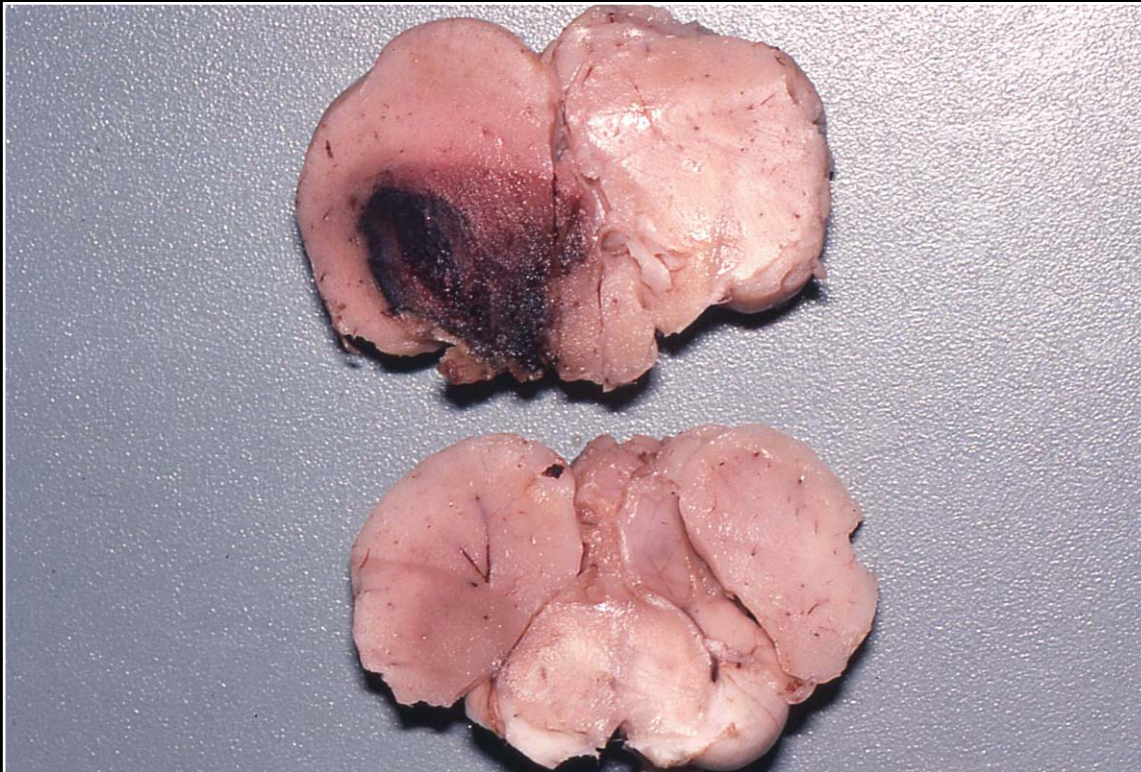
Prev. fig. Next fig.

Back

C H A P T E R 12

Nervous System

Figure 12.8



Moderately extensive post-traumatic brain hemorrhage.

Prev. fig. Next fig.

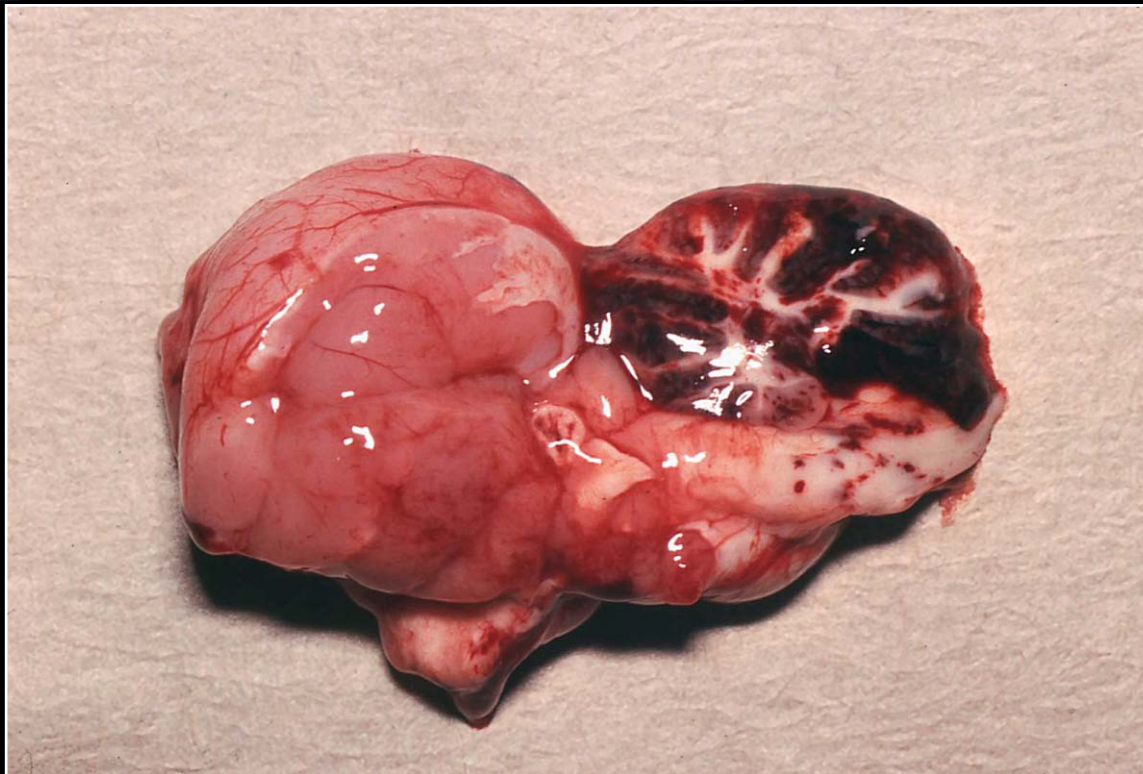
Back



C H A P T E R 12

Nervous System

Figure 12.9



Severe post-traumatic brain hemorrhage involving the entire cerebellum.

Prev. fig. Next fig.

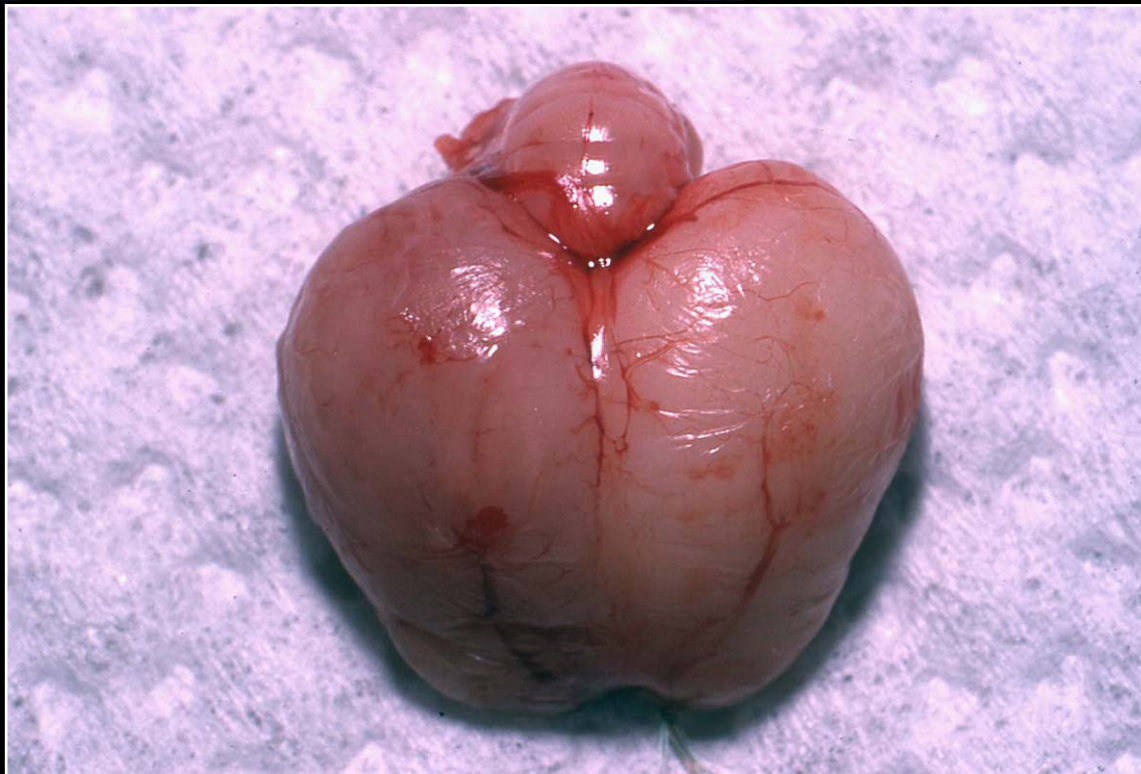
Back



C H A P T E R 12

Nervous System

Figure 12.10



Swollen, edematous brain following trauma. No obvious hemorrhage is seen.

Prev. fig. Next fig.

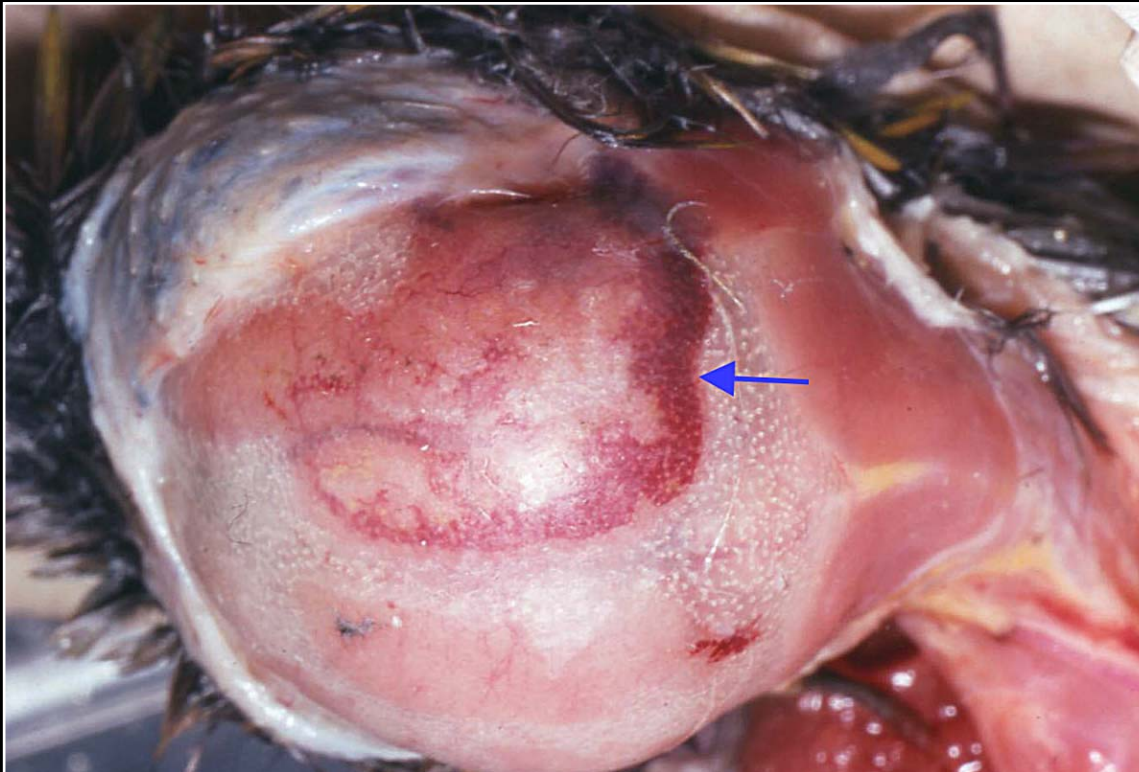
Back



C H A P T E R 12

Nervous System

Figure 12.11



Postmortem pooling of blood (arrow) in the calvarium. This must be differentiated from a post-traumatic lesion and from possible West Nile virus infection.

Prev. fig. Next fig.

Back



C H A P T E R 12

Nervous System

Figure 12.12



Blood in the calvarium due to a traumatic head injury in a young bird with a translucent skull.

Prev. fig. Next fig.

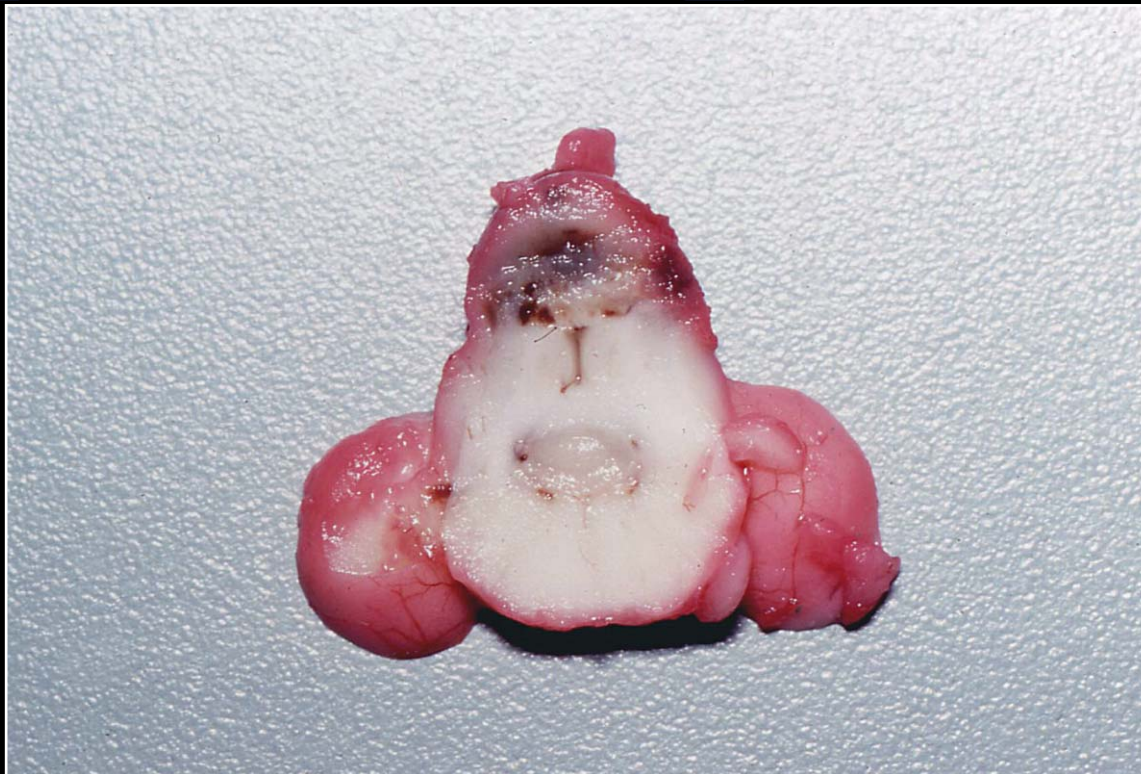
Back



C H A P T E R 12

Nervous System

Figure 12.13



Focal severe brain hemorrhage in a conure with "conure bleeding syndrome."

Prev. fig. Next fig.

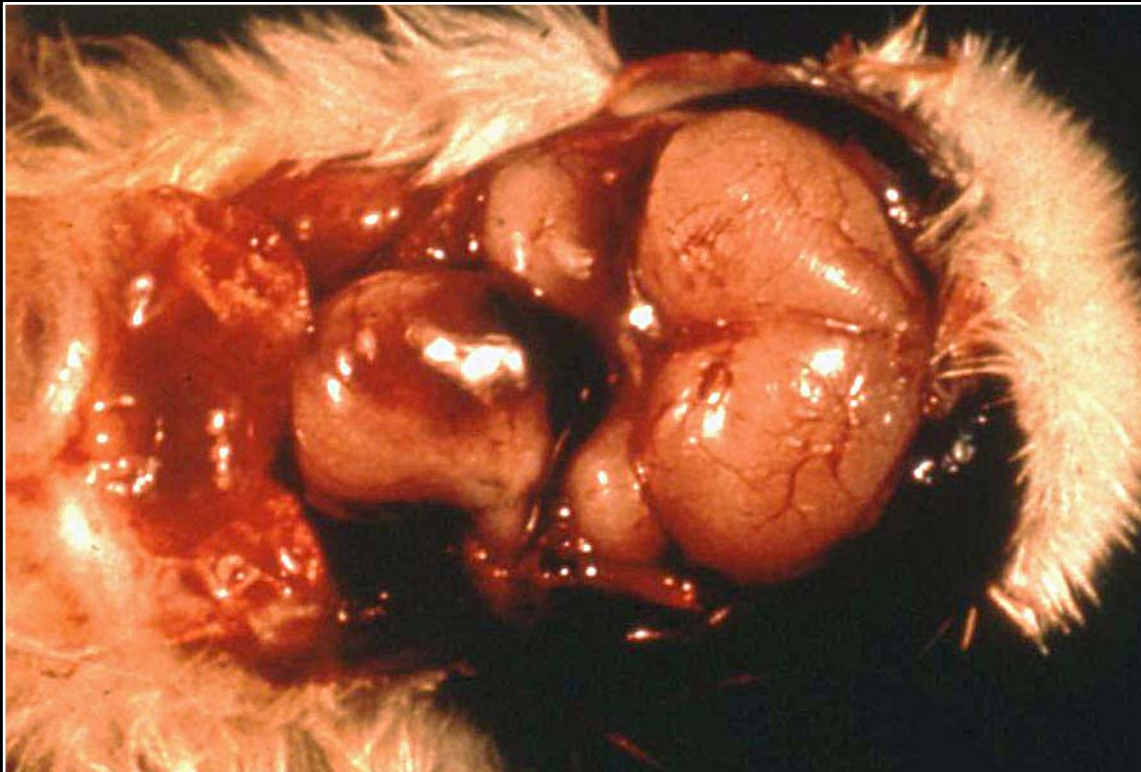Back



C H A P T E R 12

Nervous System

Figure 12.14



Chicken with vitamin E deficiency leading to brain hemorrhage.

Prev. fig. Next fig.

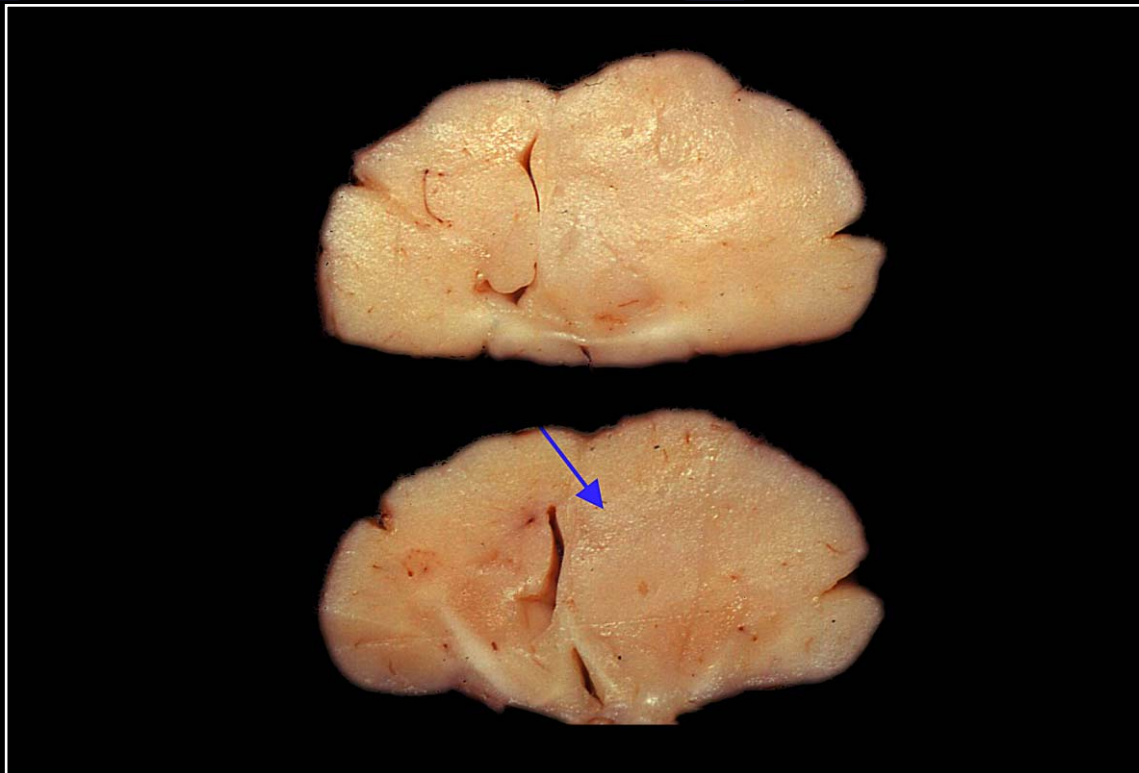
Back



C H A P T E R 12

Nervous System

Figure 12.15



Coronal sections of brain with a poorly defined neoplastic mass (arrow) that is distorting normal architecture and compressing the ventricle. The tumor was a glioma.

Prev. fig. Next fig.

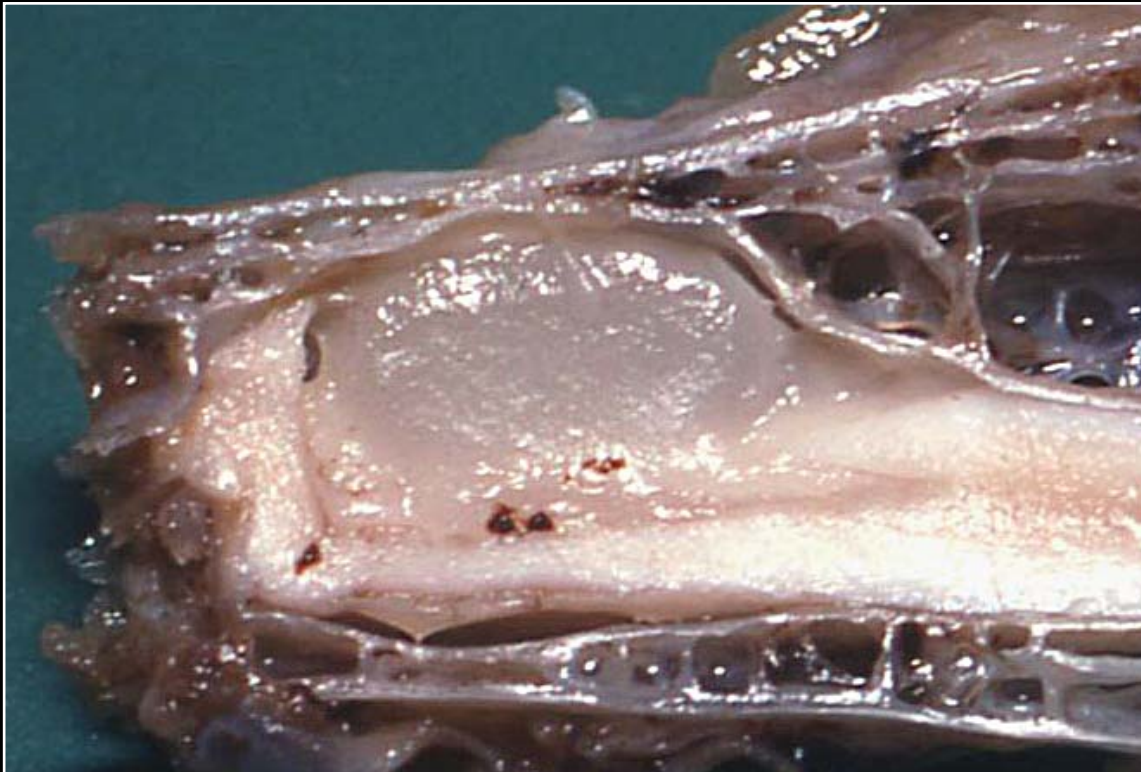
Back



C H A P T E R 12

Nervous System

Figure 12.16



Subdural lipoma compressing the spinal cord and causing an asymmetrical distortion of the bony spinal canal.

Prev. fig.

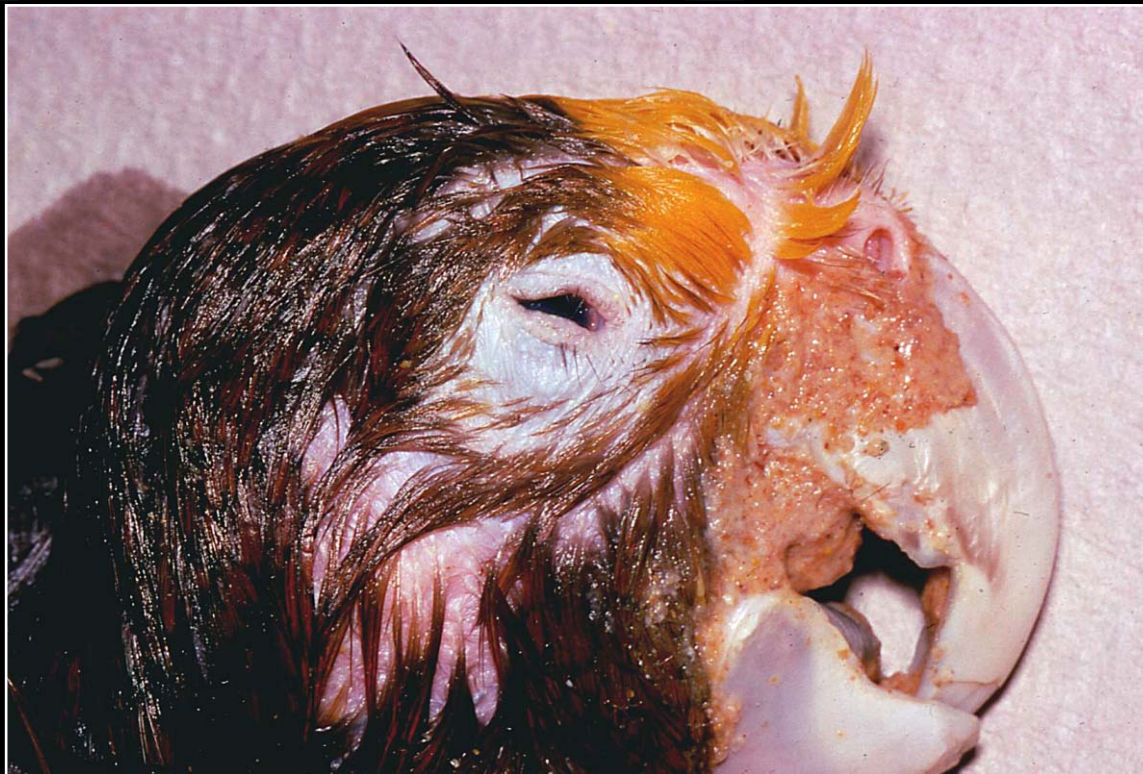
Back



C H A P T E R 13

Special Sense Organs

Figure 13.1



Amazon parrot with mild microphthalmia. Note slightly smaller lid opening.

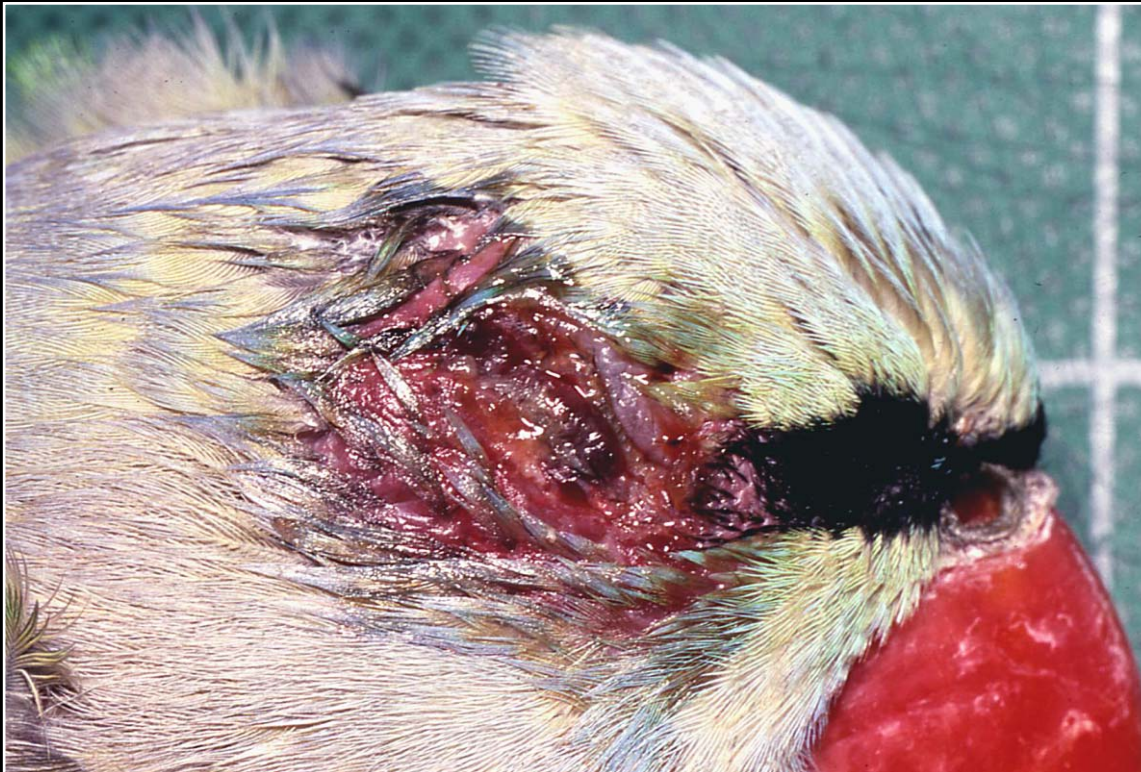Next fig.

Back

C H A P T E R 13

Special Sense Organs

Figure 13.2



Severe blepharitis due to poxvirus infection showing exudation, necrosis and early proliferative change.

Prev. fig. Next fig.

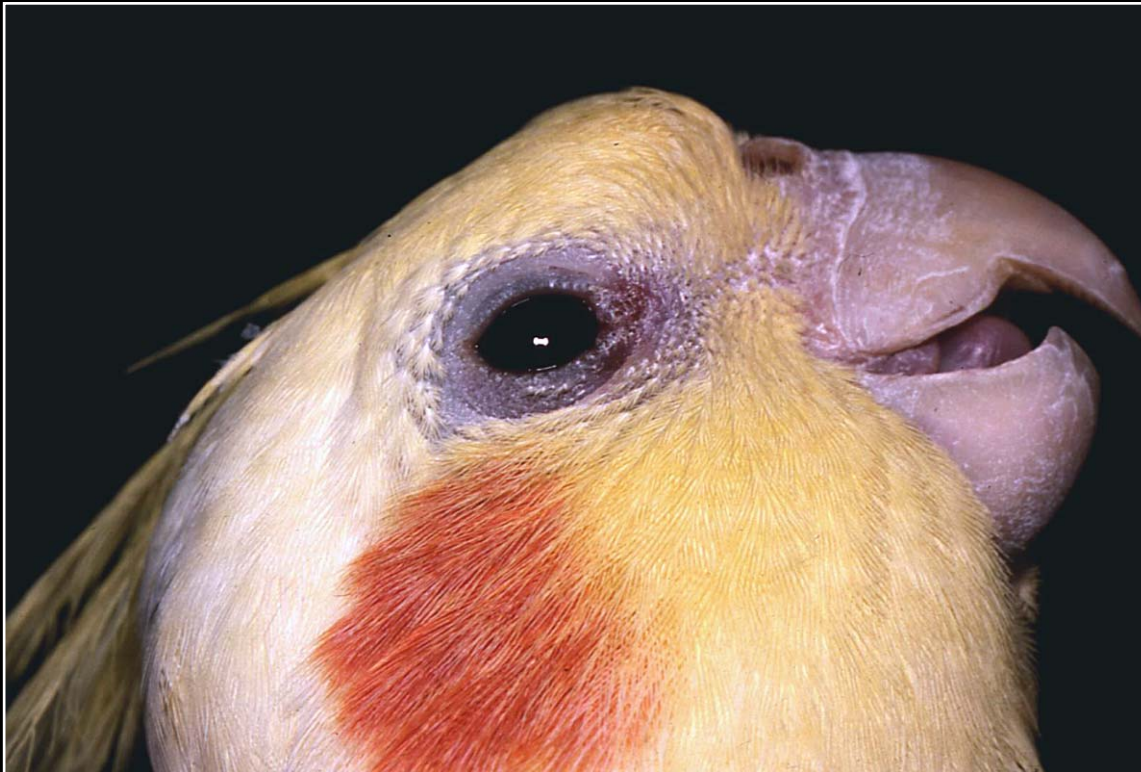Back



C H A P T E R 13

Special Sense Organs

Figure 13.3



Focal reddening and slight proliferation in bacterial-caused blepharitis.

Prev. fig. Next fig.

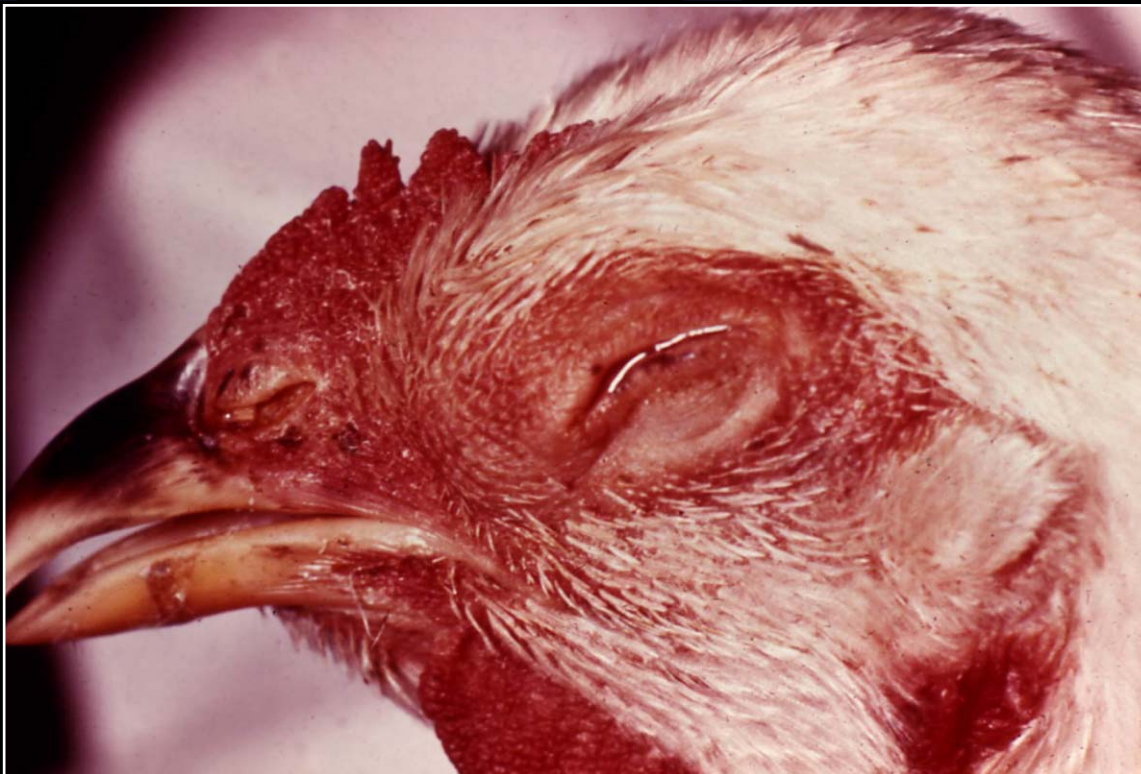Back



C H A P T E R 13

Special Sense Organs

Figure 13.4



Early conjunctivitis (coryza) caused by *Hemophilus* sp. in a chicken.

Prev. fig. Next fig.

Back



C H A P T E R 13

Special Sense Organs

Figure 13.5



Bacterial conjunctivitis with severe swelling and protrusion of the nictitating membrane.

Prev. fig. Next fig.

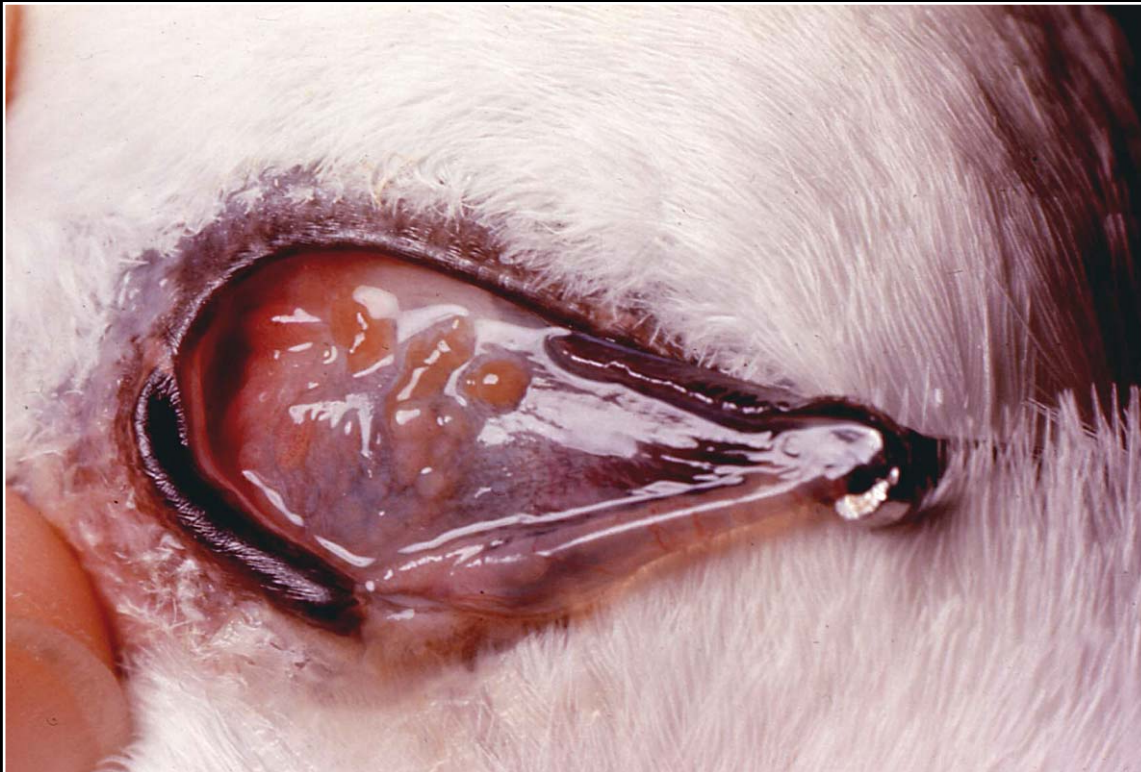
Back



C H A P T E R 13

Special Sense Organs

Figure 13.6



Philophthalmus gralli infection leading to conjunctival reddening and thickening. Numerous flukes are noted embedded in the conjunctiva.

Prev. fig. Next fig.

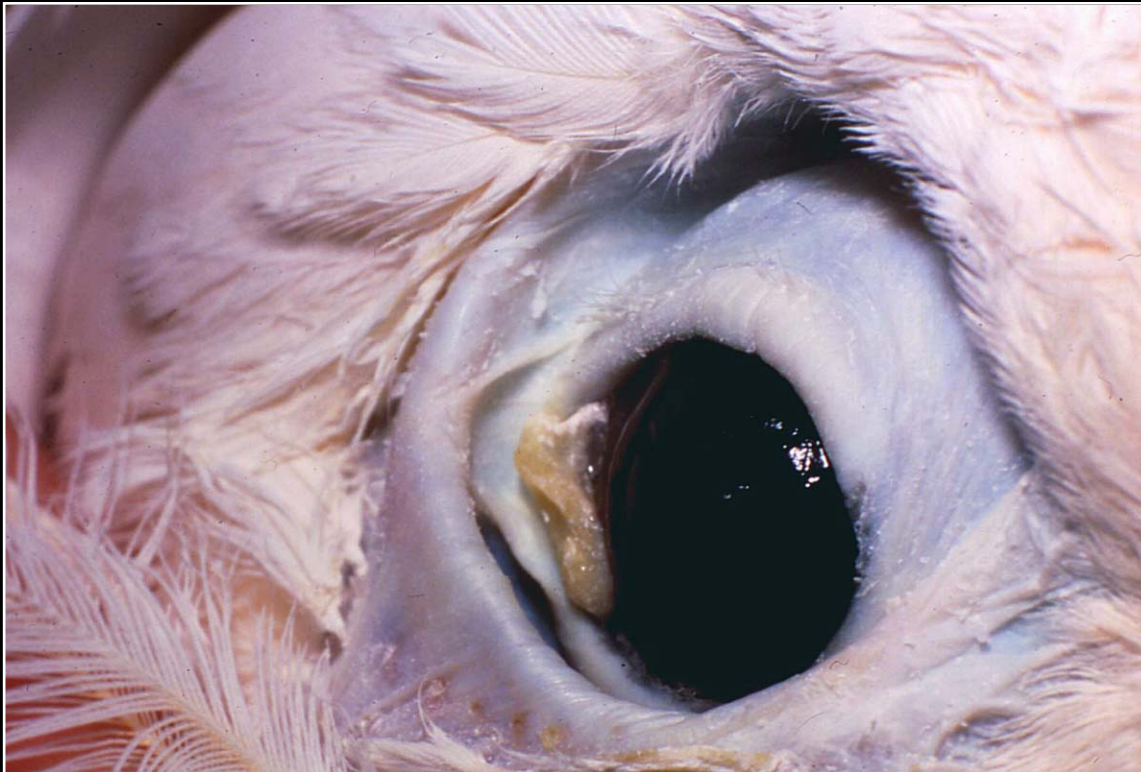
Back



C H A P T E R 13

Special Sense Organs

Figure 13.7



Granulomatous conjunctivitis due to a foreign body.

Prev. fig. Next fig.

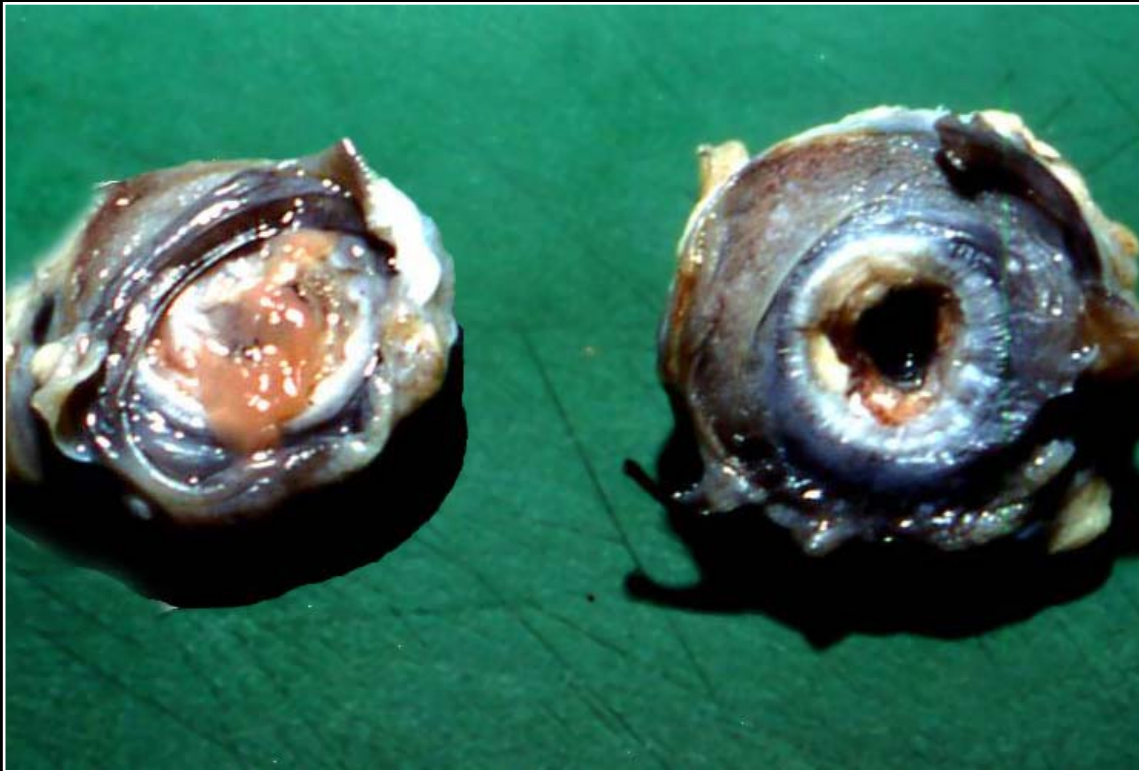Back



C H A P T E R 13

Special Sense Organs

Figure 13.8



Bacterial-induced bilateral keratitis with ulceration and variable accumulation of cream-yellow exudate.

Prev. fig. Next fig.

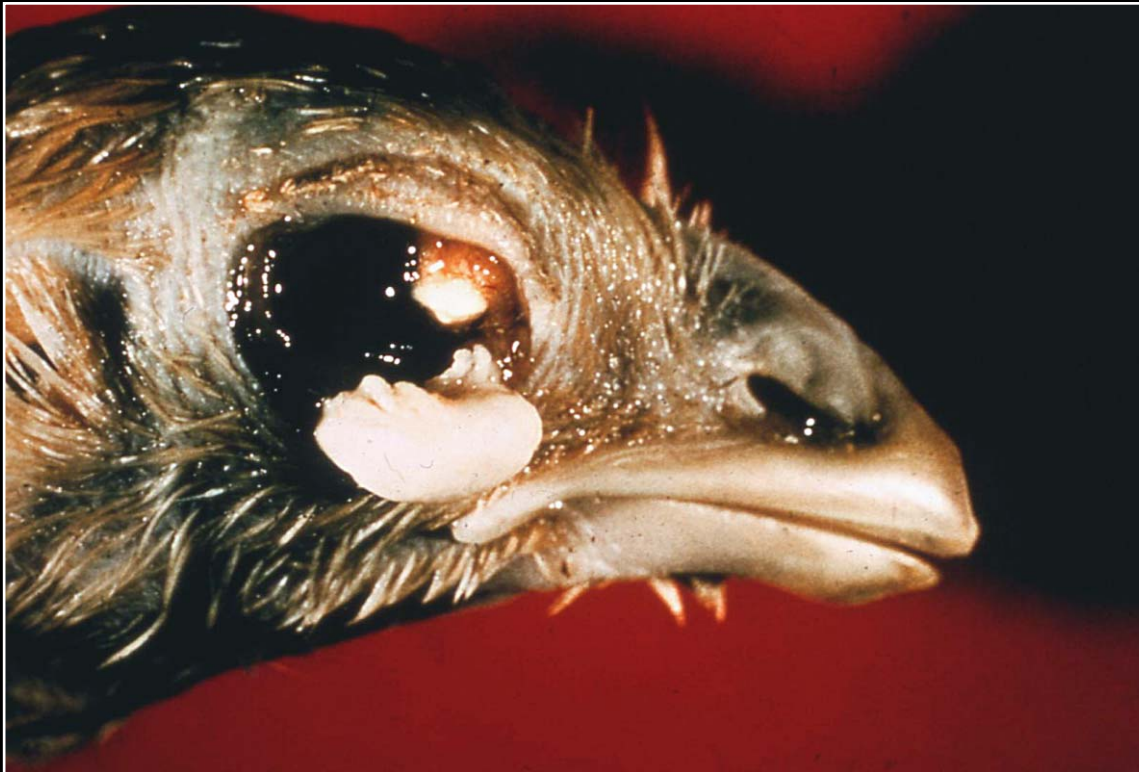Back



C H A P T E R 13

Special Sense Organs

Figure 13.9



Mycotic keratitis with multiple foci of exudate accumulation.

Prev. fig. Next fig.

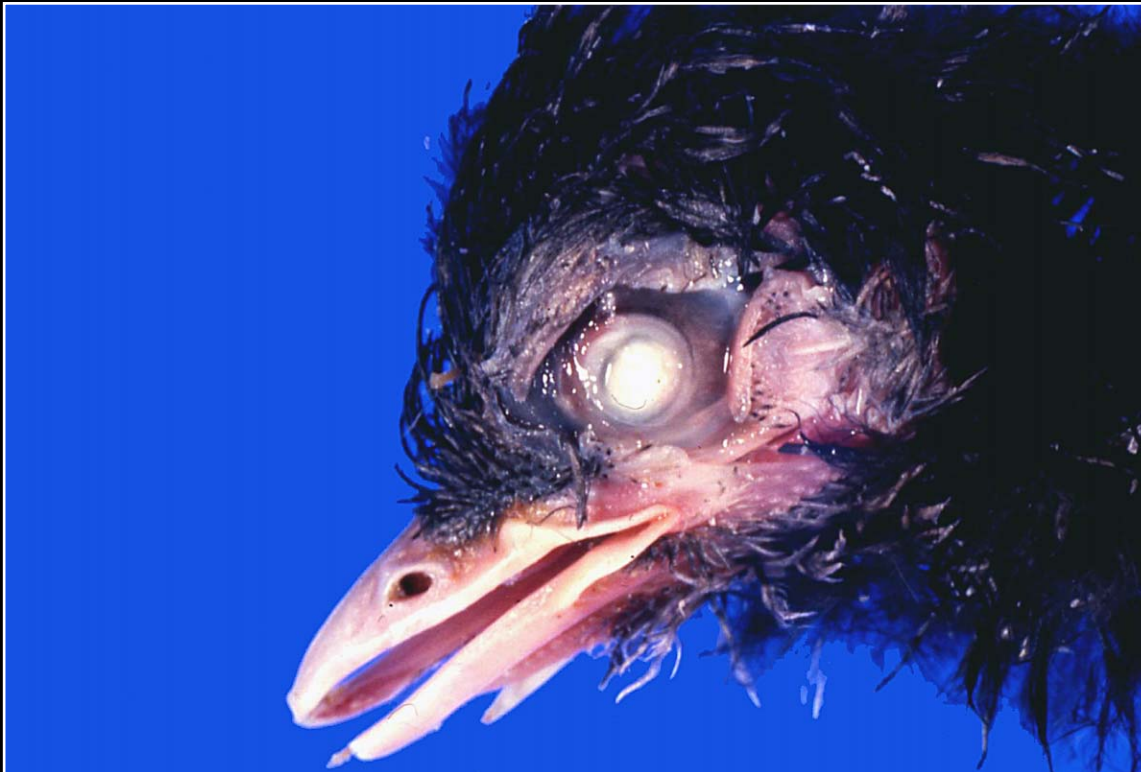
Back



C H A P T E R 13

Special Sense Organs

Figure 13.10



Severe mycotic keratitis with exudate covering the entire cornea.

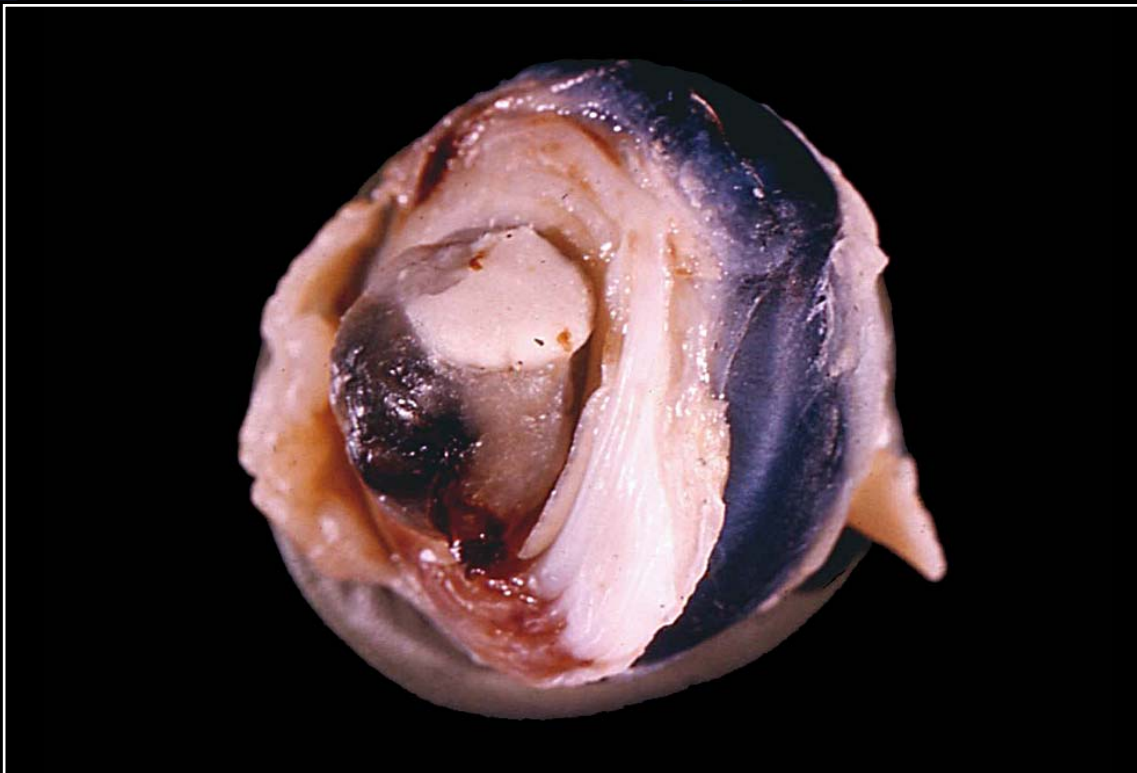
Prev. fig. Next fig.

Back

C H A P T E R 13

Special Sense Organs

Figure 13.11



Hemorrhage, necrosis and exudate accumulation in chronic mycotic keratitis.

Prev. fig. Next fig.

Back



C H A P T E R 13

Special Sense Organs

Figure 13.12



Cataractous lens with irregular opacity. The cause cannot be determined from the gross appearance.

Prev. fig. Next fig.

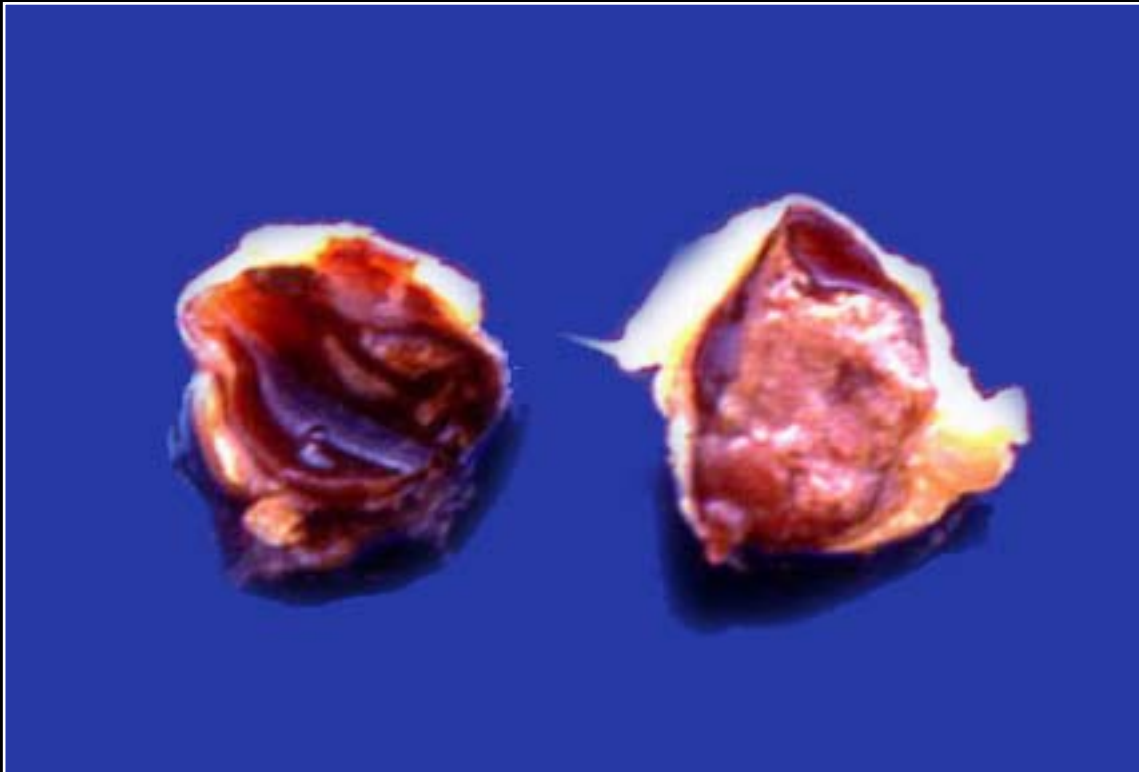
Back



C H A P T E R 13

Special Sense Organs

Figure 13.13



Intraocular medulloepithelioma. Grossly this cannot be differentiated from other neoplasms or possible granulomatous disease.

Prev. fig. Next fig.

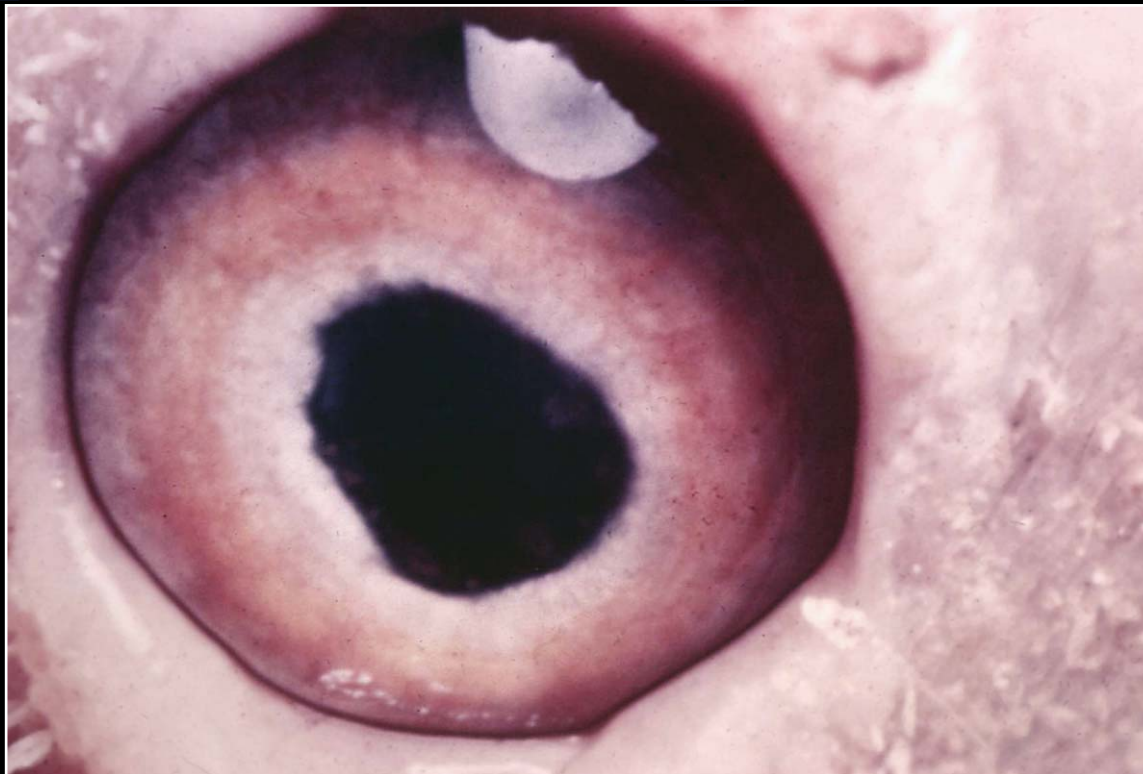Back



C H A P T E R 13

Special Sense Organs

Figure 13.14



Marek's disease with infiltration of the iris, which is thickened, white and has an irregular margin.

Prev. fig. Next fig.

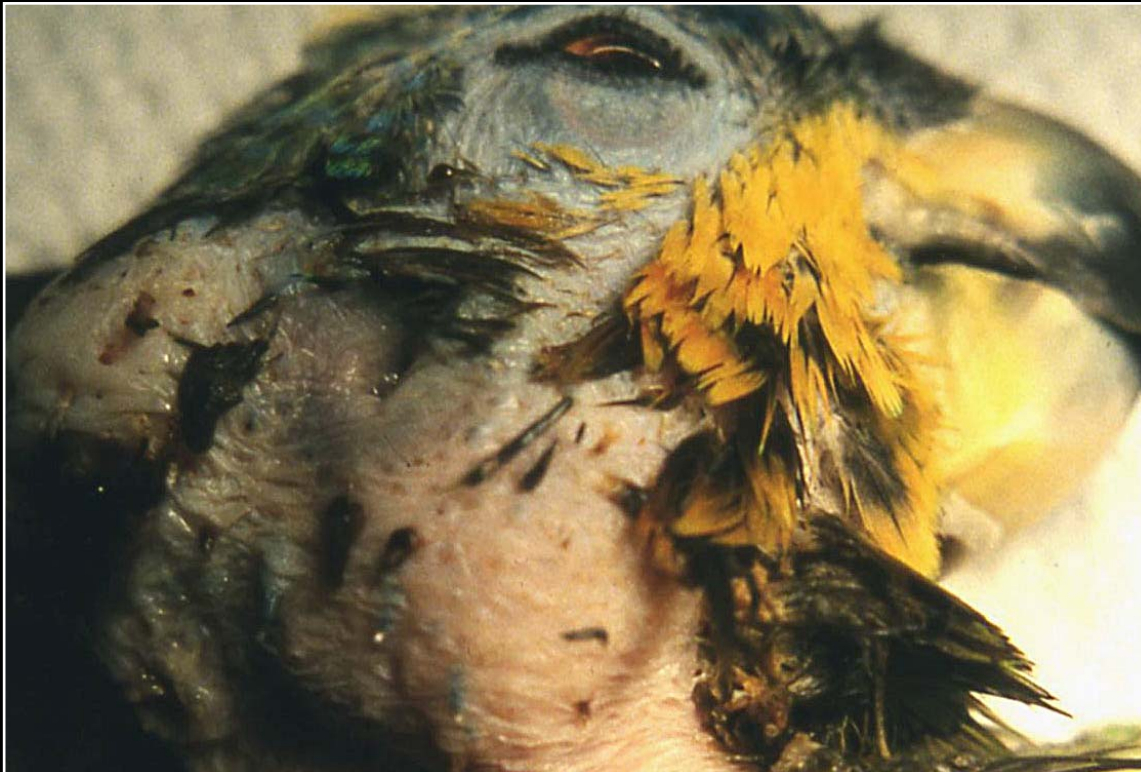Back



C H A P T E R 13

Special Sense Organs

Figure 13.15



Large swelling that proved to be an invasive carcinoma of the glands of the external ear canal.

Prev. fig. Next fig.

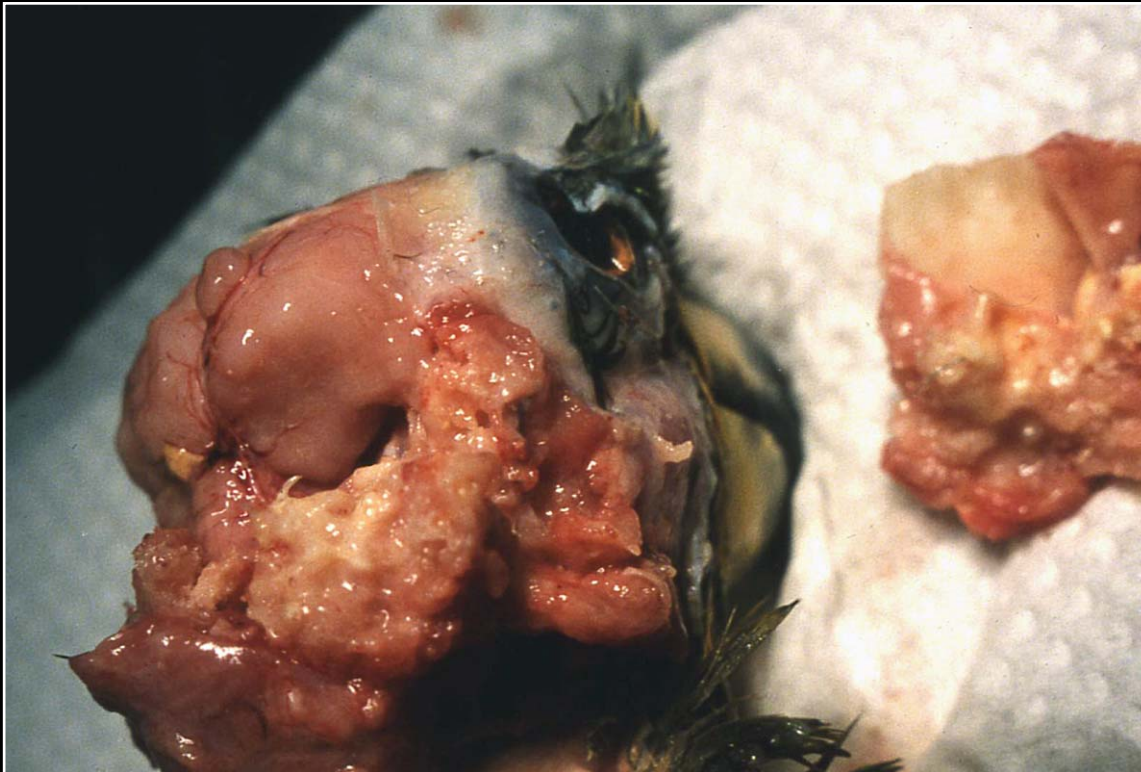Back



C H A P T E R 13

Special Sense Organs

Figure 13.16



Detail of lobulated external ear canal carcinoma.

Prev. fig. Next fig.


Back



C H A P T E R 13

Special Sense Organs

Figure 13.17



Severe tilting of head in a *Neophyma* sp. with otitis interna due to paramyxovirus infection.

Prev. fig.

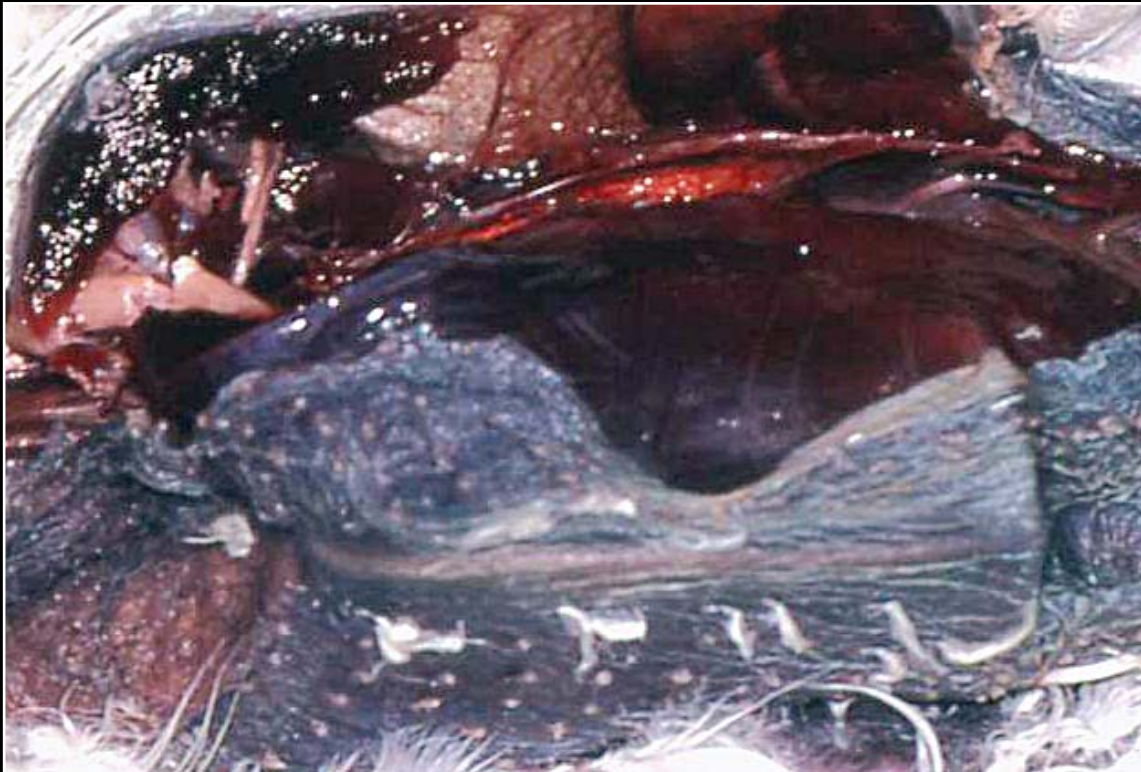Back



C H A P T E R 14

Musculoskeletal System

Figure 14.0



Normal skeletal muscle.

Next fig.


Back



C H A P T E R 14

Musculoskeletal System

Figure 14.1



Multiple joint contractures due to muscle atrophy. The condition is typical for arthrogryposis.

Prev. fig. Next fig.

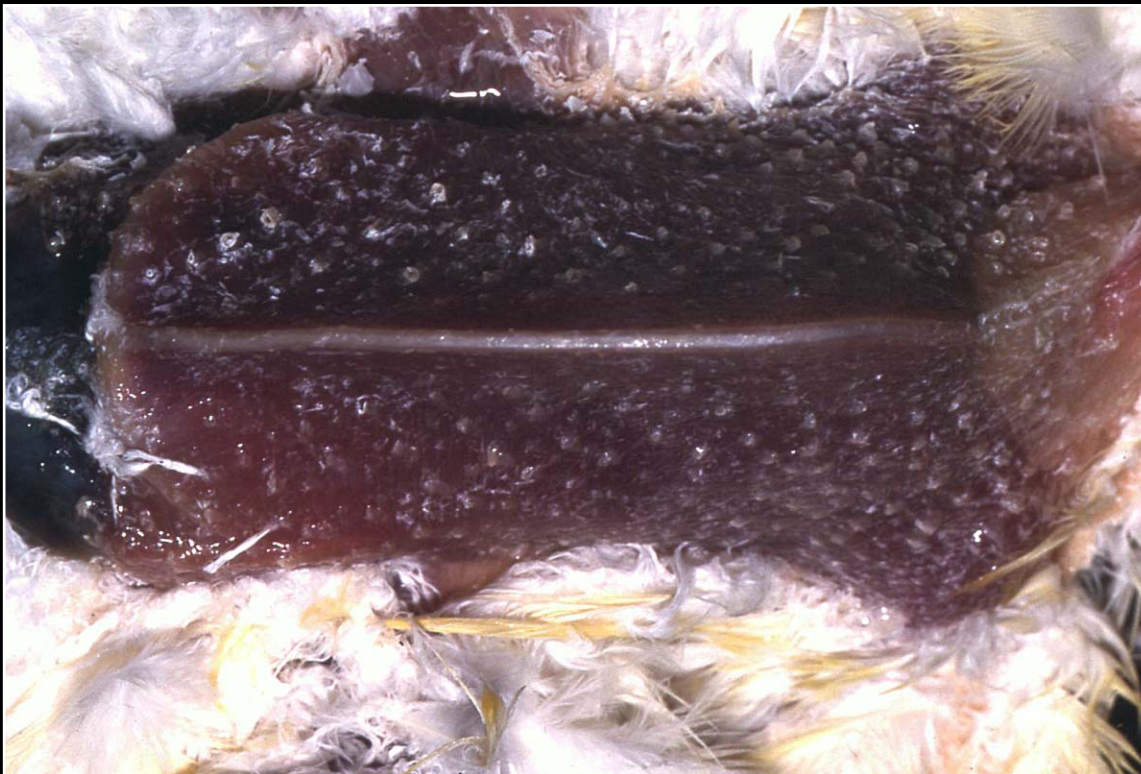Back



C H A P T E R 14

Musculoskeletal System

Figure 14.2



Moderate to severe muscle atrophy. The pectoral muscles are a good indicator of atrophy due to nutritional problems, chronic disease and disuse.

Prev. fig. Next fig.

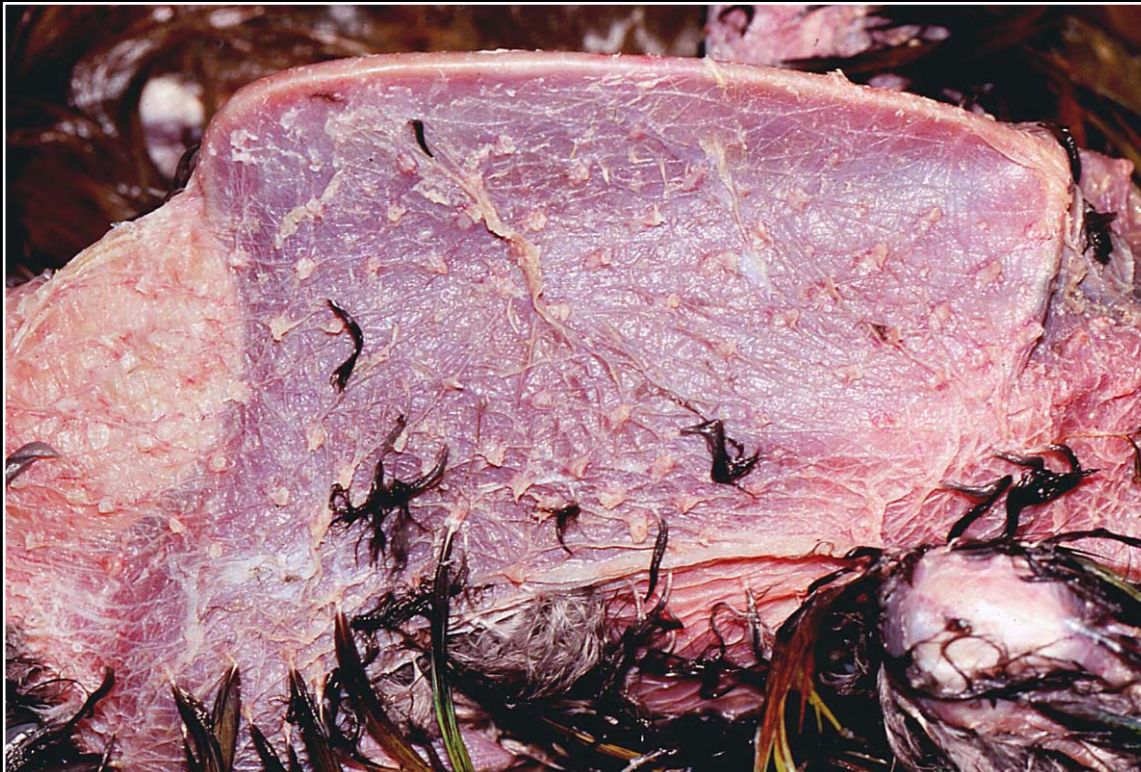Back



C H A P T E R 14

Musculoskeletal System

Figure 14.3



Severe pectoral muscle atrophy leading to a prominent keel.

Prev. fig. Next fig.

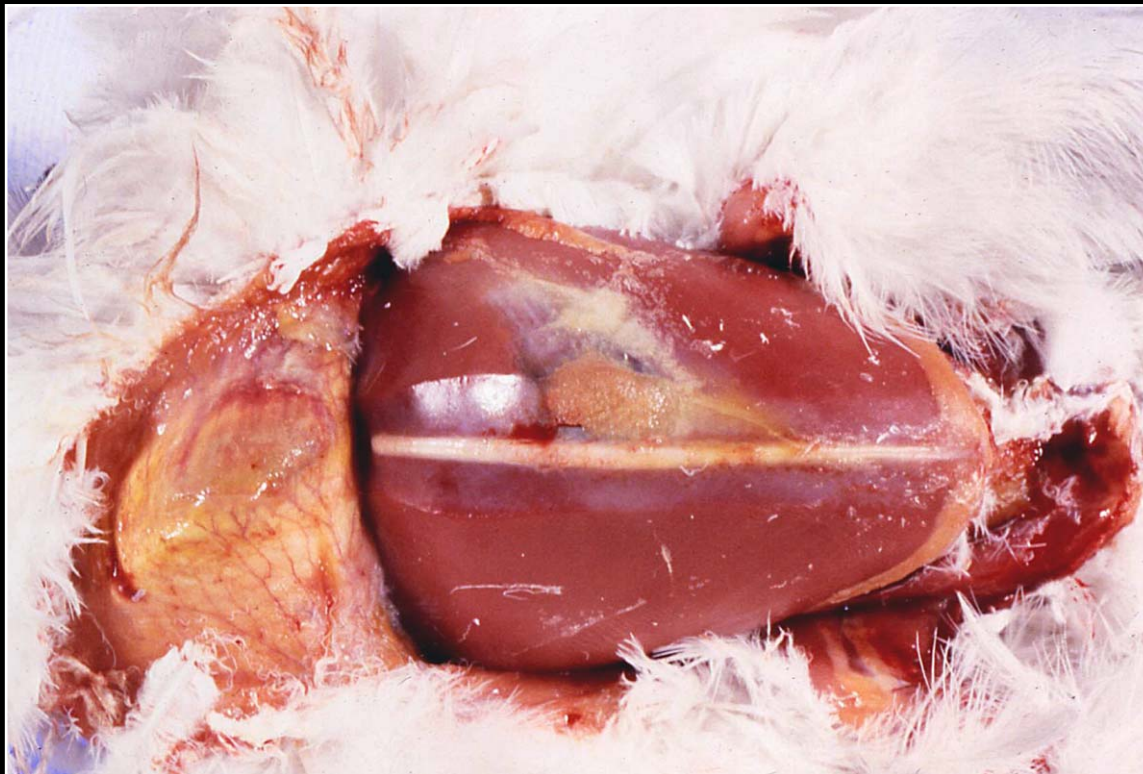Back



C H A P T E R 14

Musculoskeletal System

Figure 14.4



Chronic trauma-induced bruising and necrosis. The lesion becomes yellow-tan with age.

Prev. fig. Next fig.

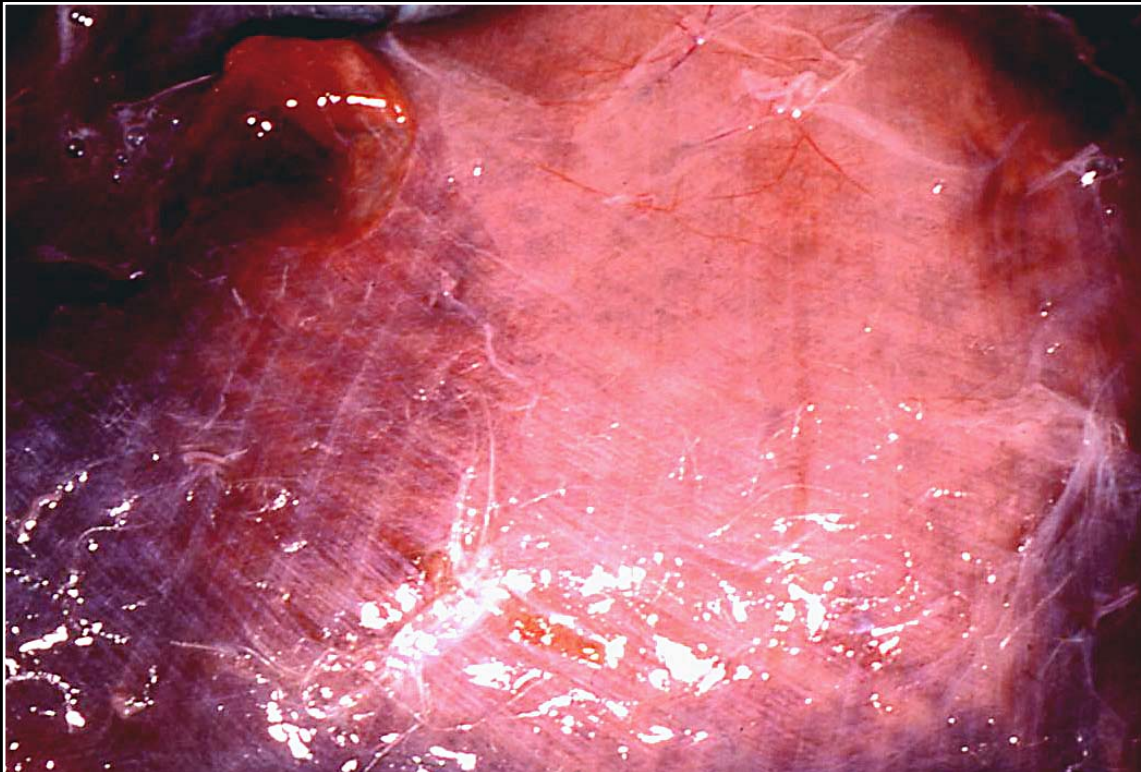
Back



C H A P T E R 14

Musculoskeletal System

Figure 14.5



Severe myodegeneration (pale tissue) secondary to vitamin E deficiency.

Prev. fig. Next fig.

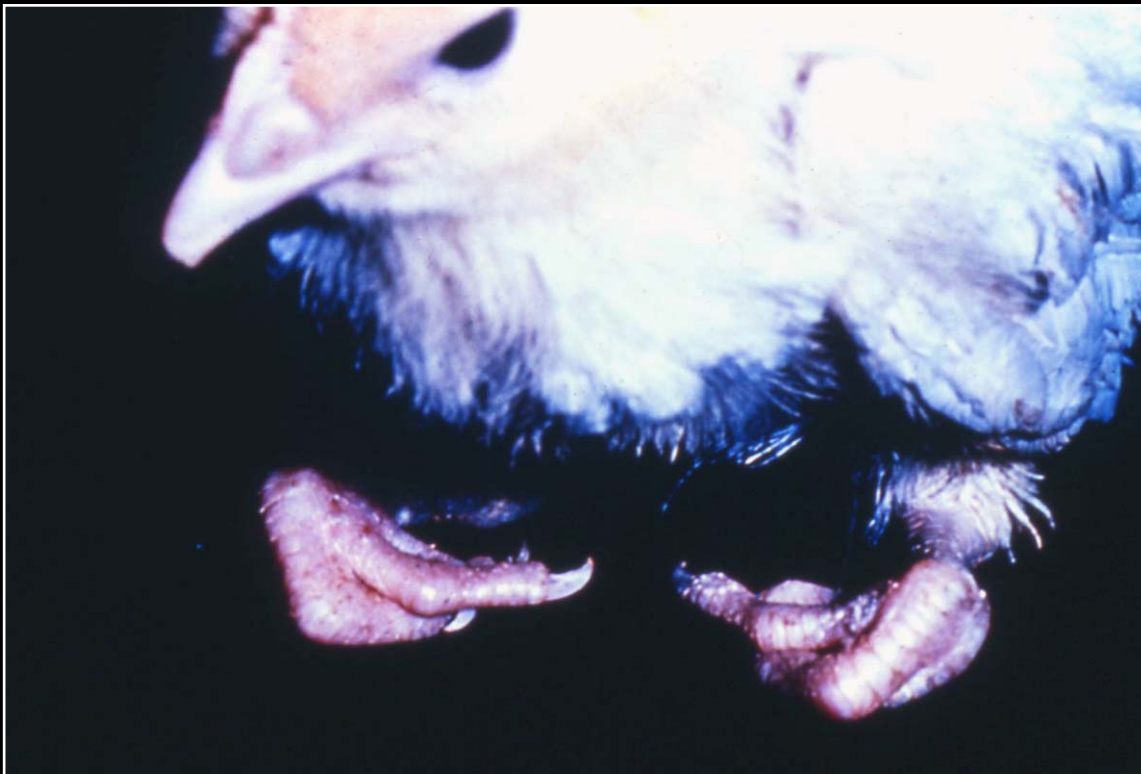Back



C H A P T E R 14

Musculoskeletal System

Figure 14.6



Curled-toe paralysis due to riboflavin deficiency.

Prev. fig. Next fig.

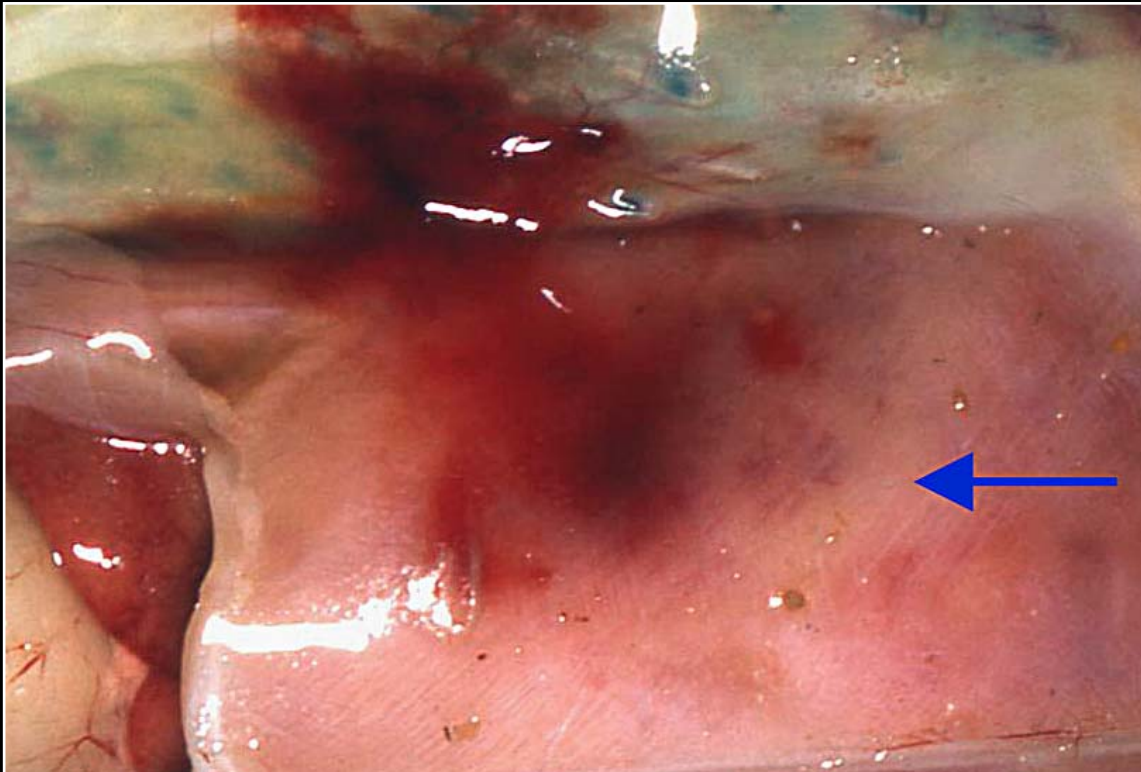
Back



C H A P T E R 14

Musculoskeletal System

Figure 14.7



Polyomavirus infection resulting in areas of pallor (arrow) and hemorrhage of the muscle and subcutis.

Prev. fig. Next fig.

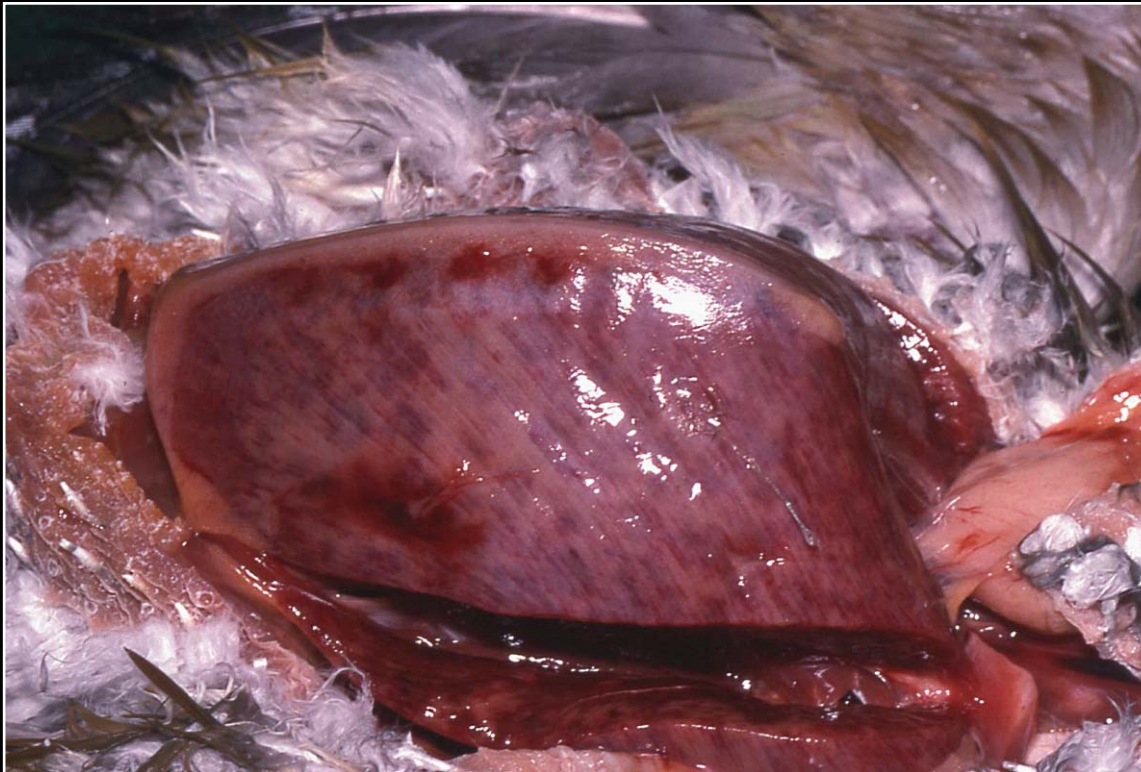
Back



C H A P T E R 14

Musculoskeletal System

Figure 14.8



Severe necrosis and hemorrhage of the pectoral muscles due to polyomavirus infection.

Prev. fig. Next fig.

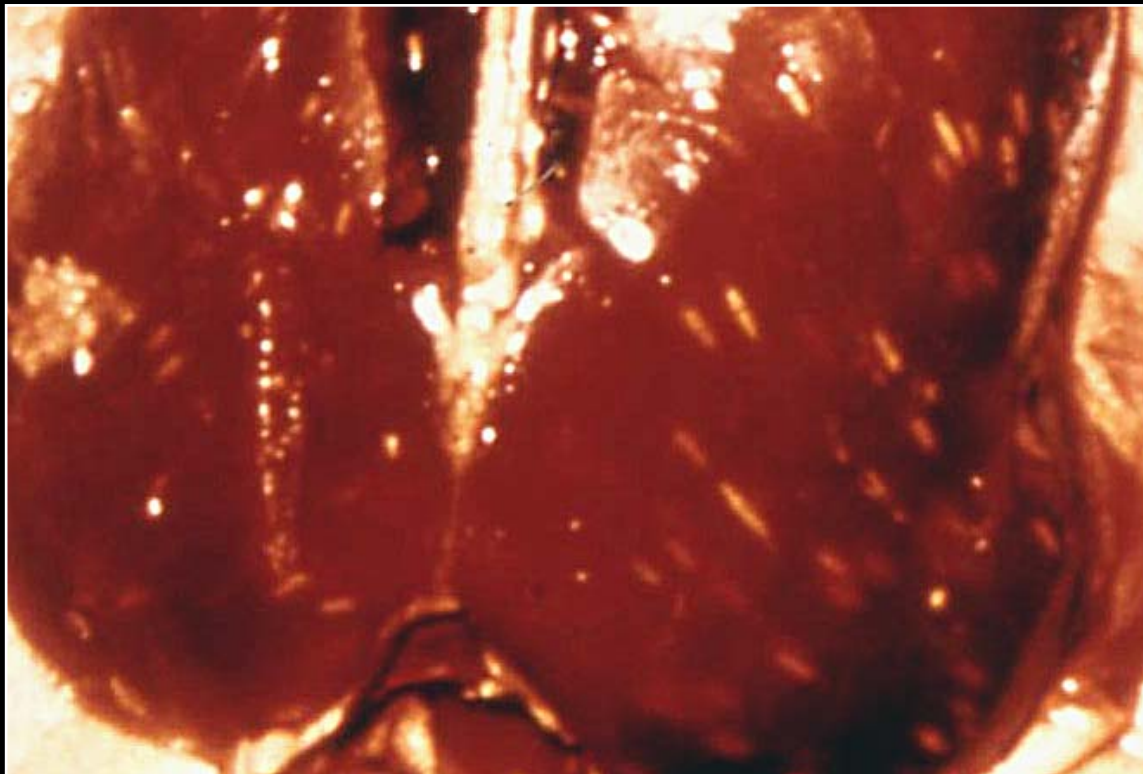
Back



C H A P T E R 14

Musculoskeletal System

Figure 14.9



Sarcocystis infection of the pectoral muscles of a duck. Note numerous round or elongated white foci in the muscle.

Prev. fig. Next fig.

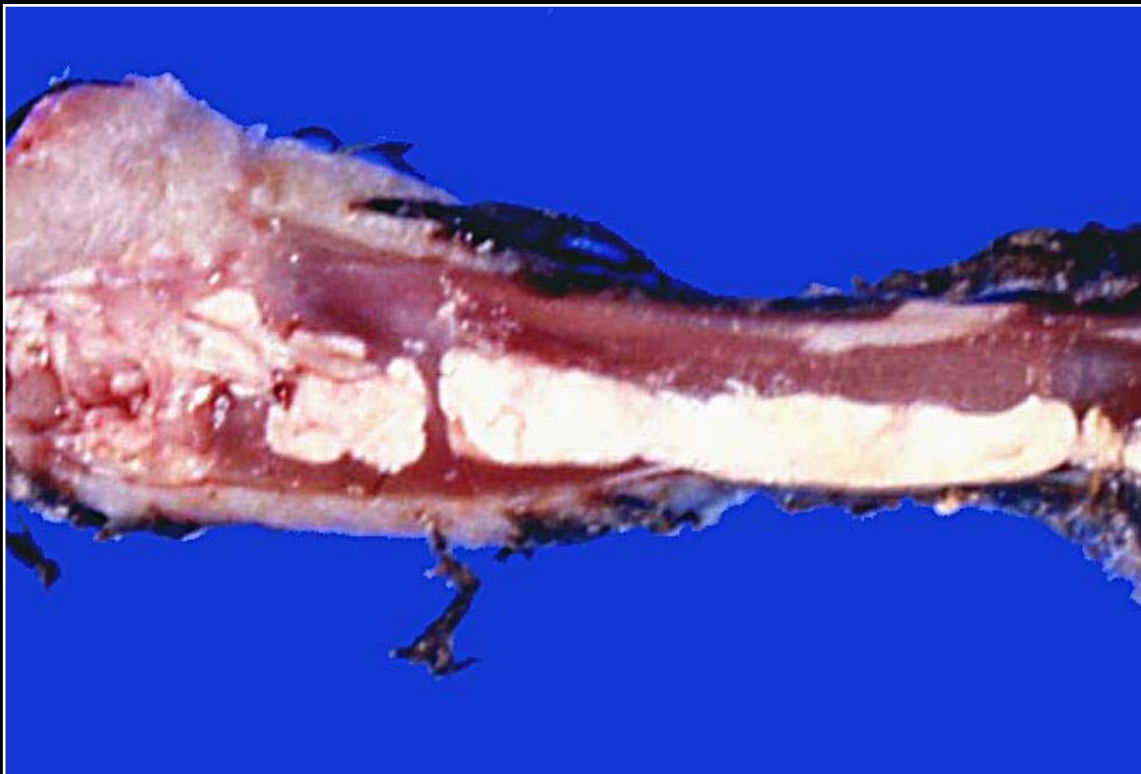Back



C H A P T E R 14

Musculoskeletal System

Figure 14.10



Severe urate deposition affecting flexor tendon sheaths.

Prev. fig. Next fig.

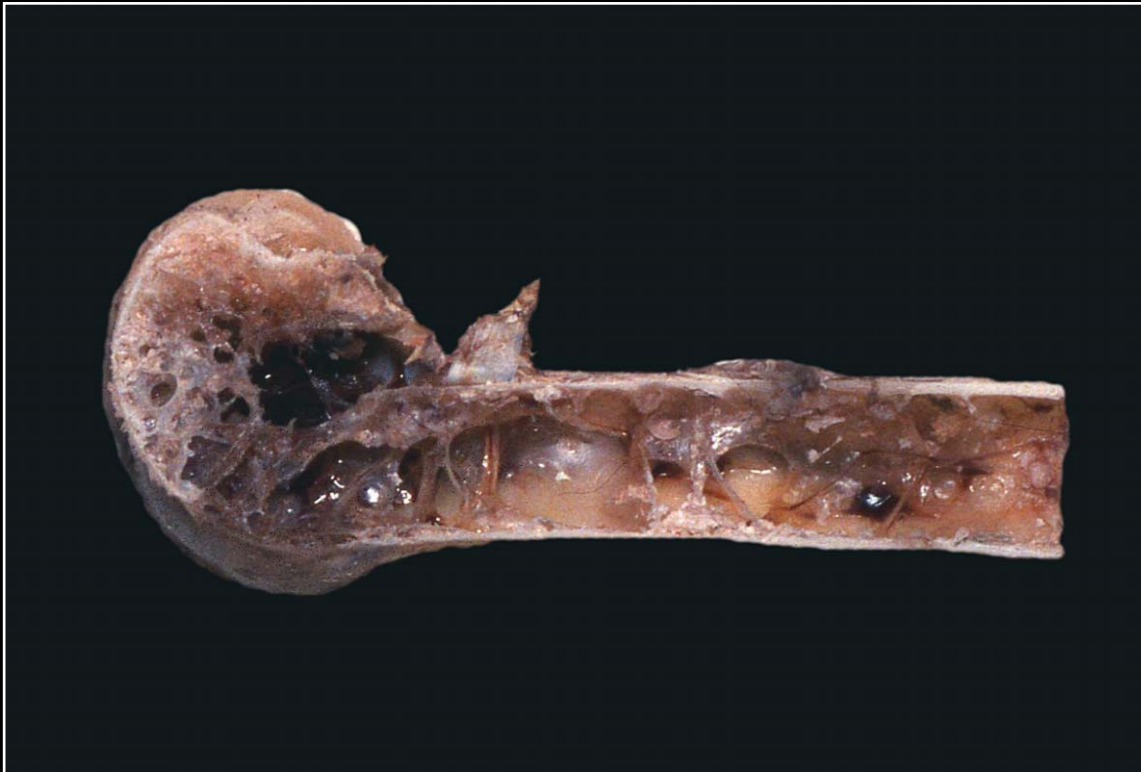Back



C H A P T E R 14

Musculoskeletal System

Figure 14.10a



Normal long bone.

Prev. fig. Next fig.

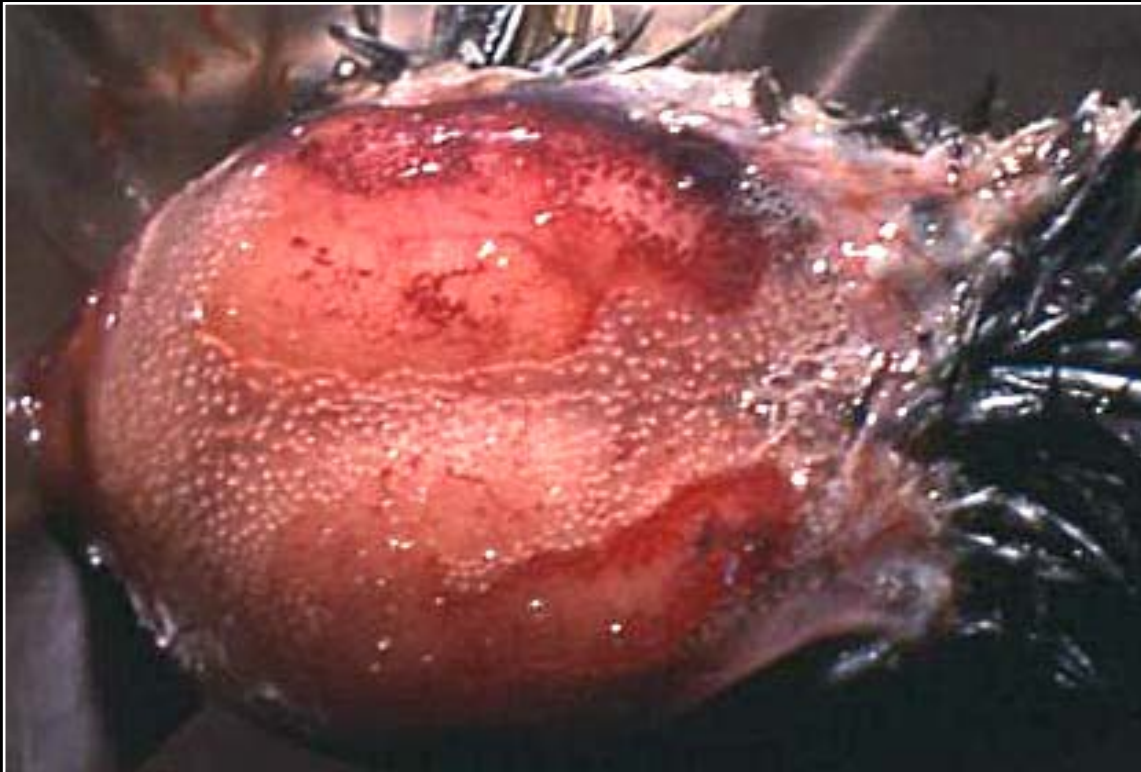
Back



C H A P T E R 14

Musculoskeletal System

Figure 14.10b



Normal skull.

Prev. fig. Next fig.

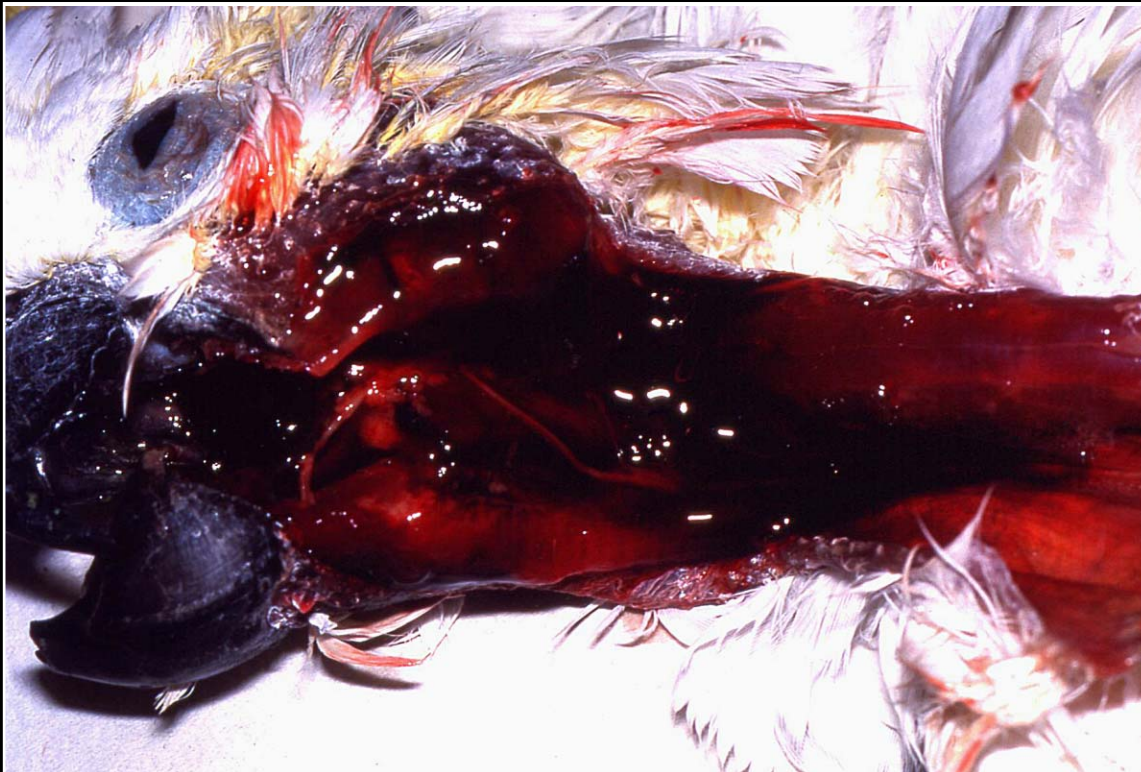Back



C H A P T E R 14

Musculoskeletal System

Figure 14.11



Traumatic fracture of the zygomatic bone with severe associated hemorrhage.

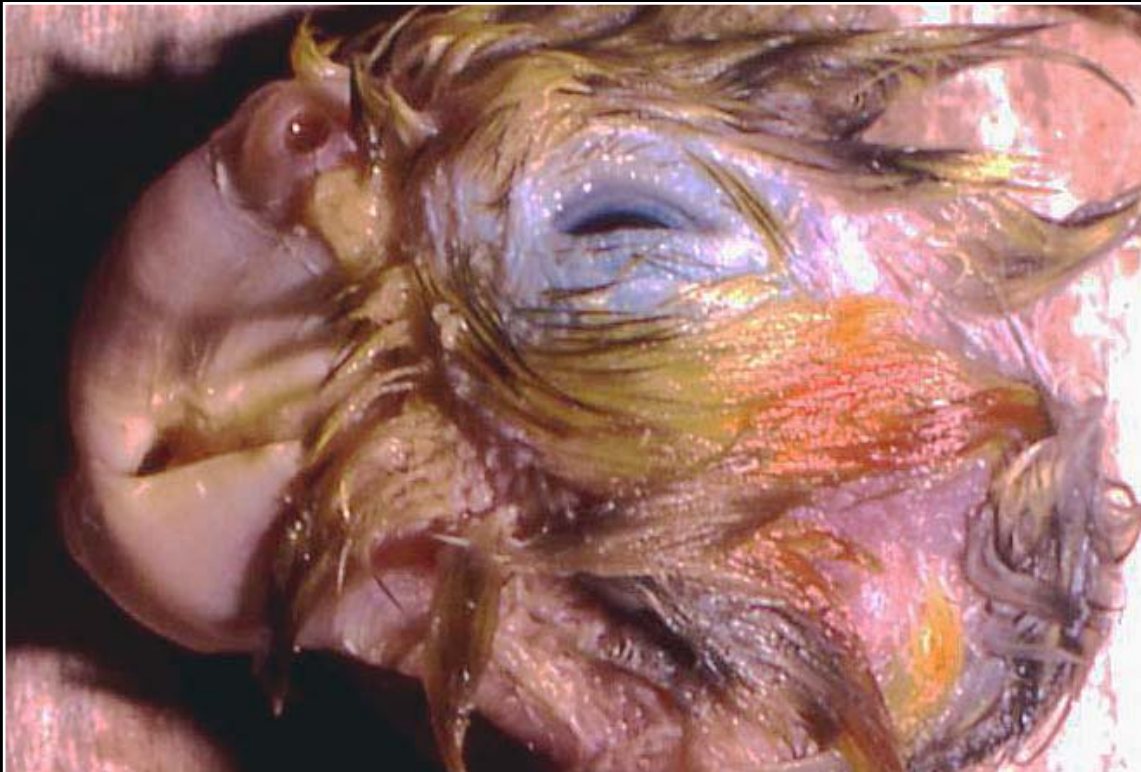Prev. fig. Next fig.

Back

C H A P T E R 14

Musculoskeletal System

Figure 14.12



Congenital brachygnathia of undetermined cause.

Prev. fig. Next fig.

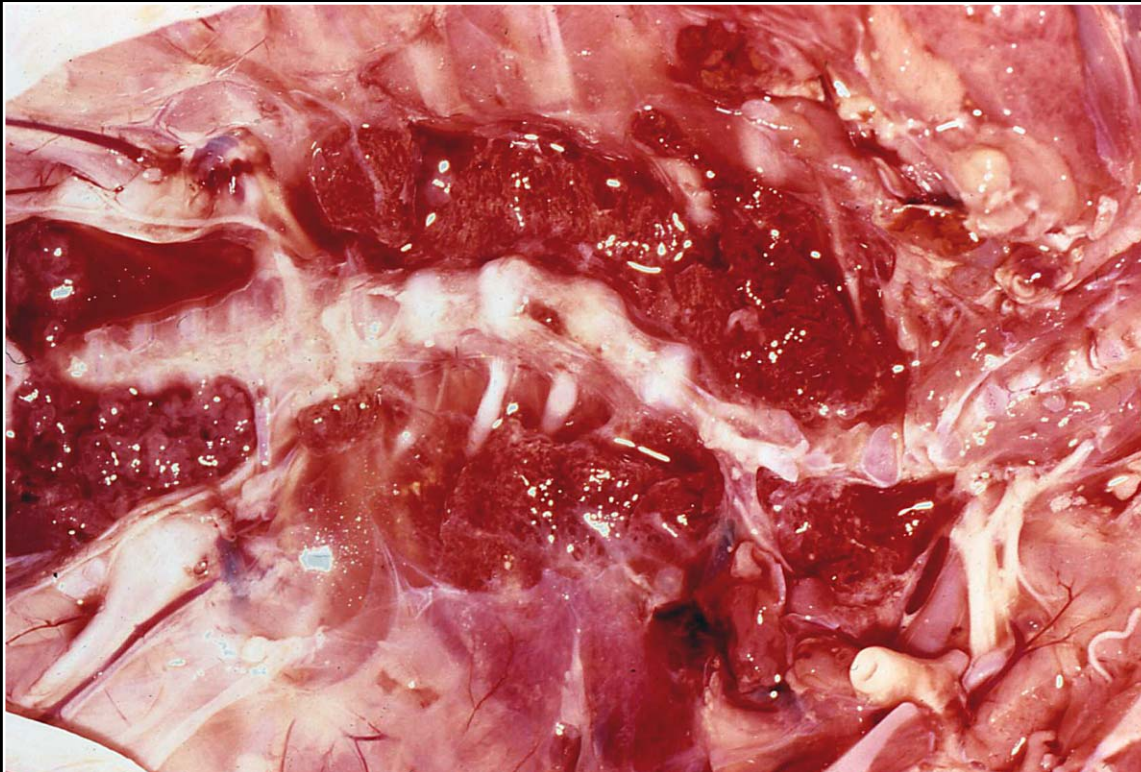Back



C H A P T E R 14

Musculoskeletal System

Figure 14.13



Severe scoliosis in a macaw.

Prev. fig. Next fig.

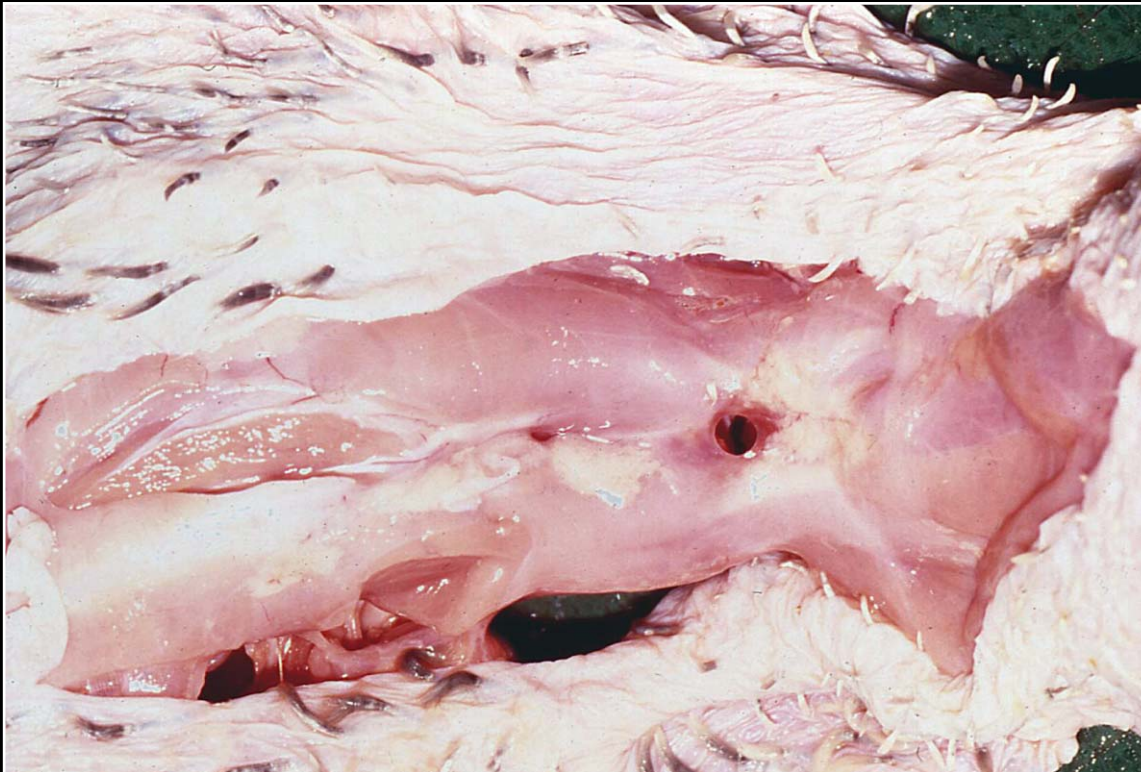
Back



C H A P T E R 14

Musculoskeletal System

Figure 14.14



Spina bifida presenting as an opening in the dorsal portion of the back.

Prev. fig. Next fig.

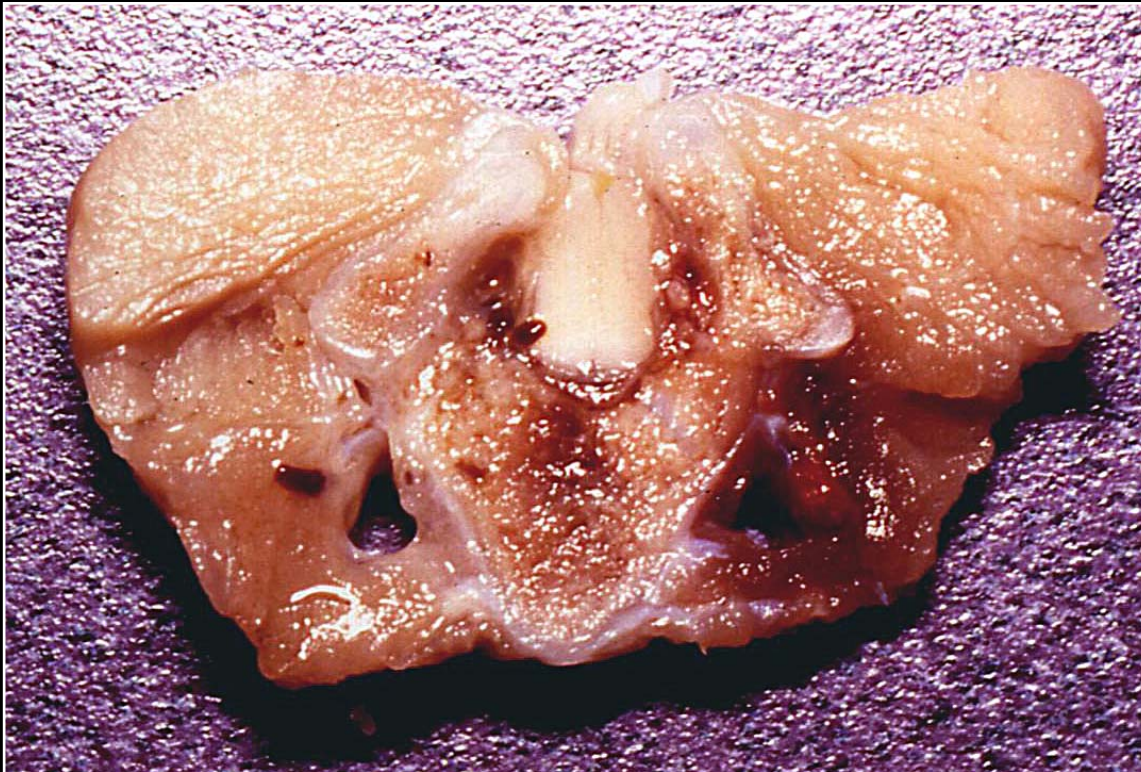Back



C H A P T E R 14

Musculoskeletal System

Figure 14.15



Spina bifida with herniation of the spinal cord. Note the incomplete dorsal vertebral spines.

Prev. fig. Next fig.

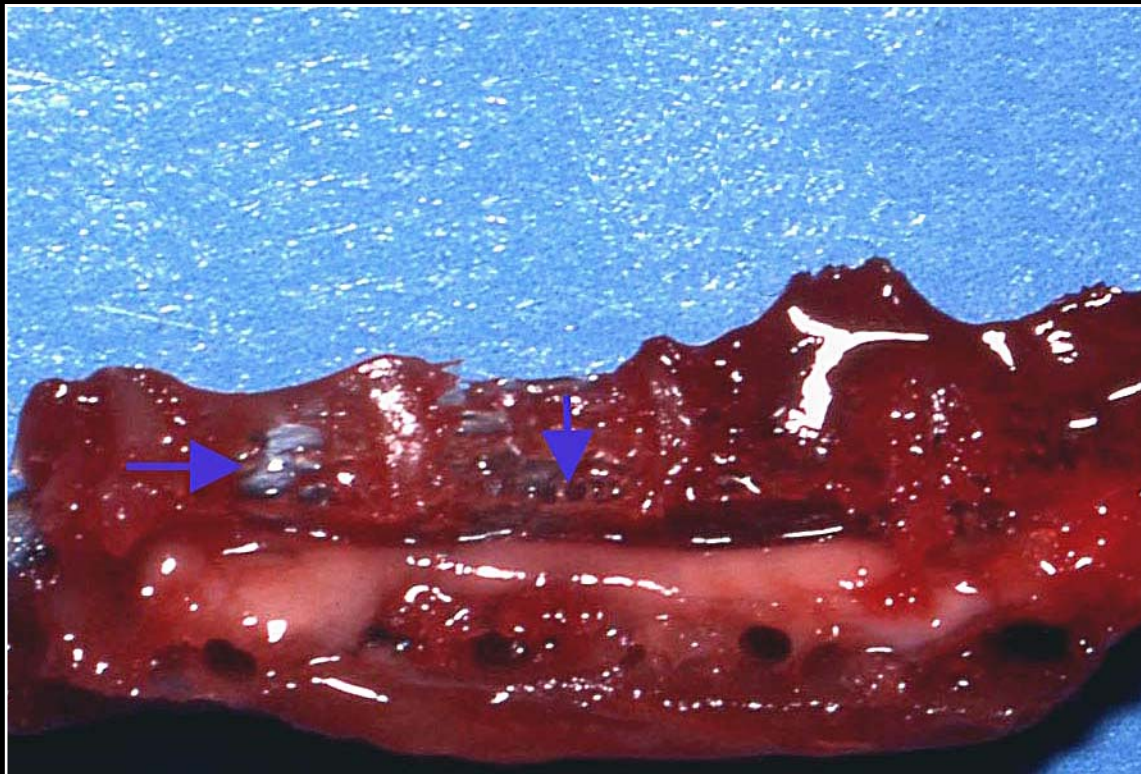
Back



C H A P T E R 14

Musculoskeletal System

Figure 14.16



Severe osteopenia secondary to chronic egg laying. Note the lacy appearance and holes (arrows) in the vertebral bodies. The oval mark indicates the spinal cord.

Prev. fig. Next fig.

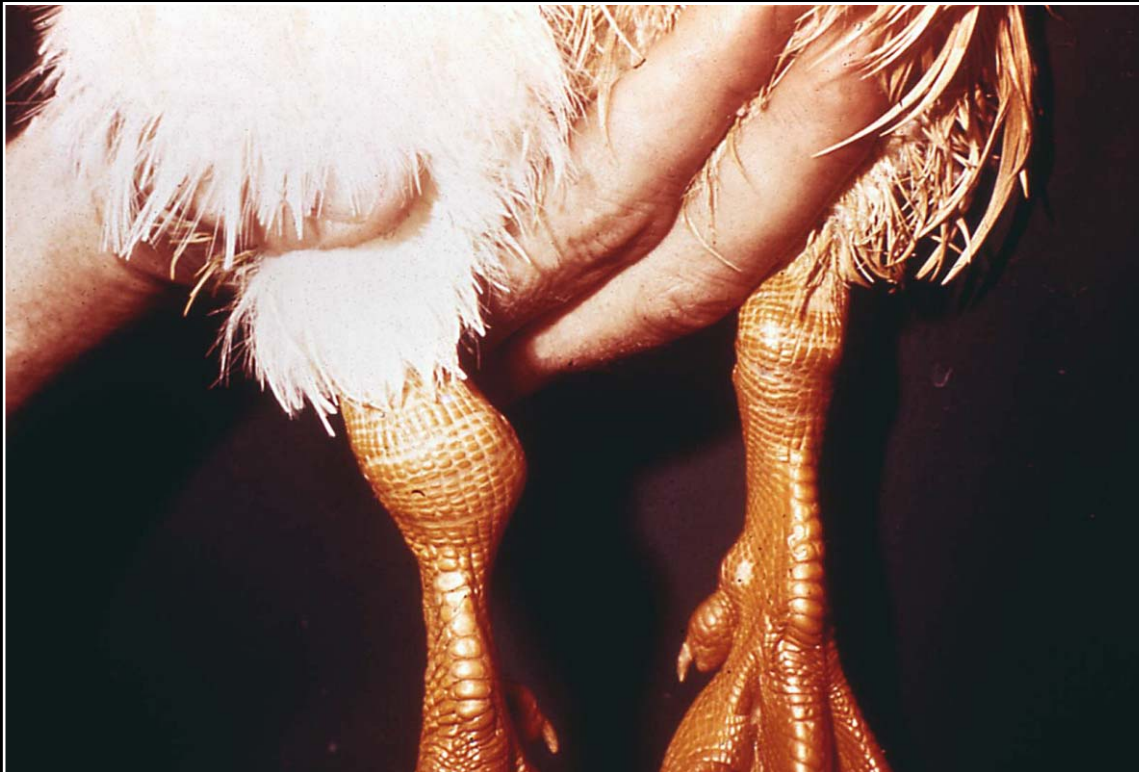Back



C H A P T E R 14

Musculoskeletal System

Figure 14.17



Severely swollen joints in a duck with rickets. The condition must be differentiated from arthritis and severe articular urate deposition.

Prev. fig. Next fig.

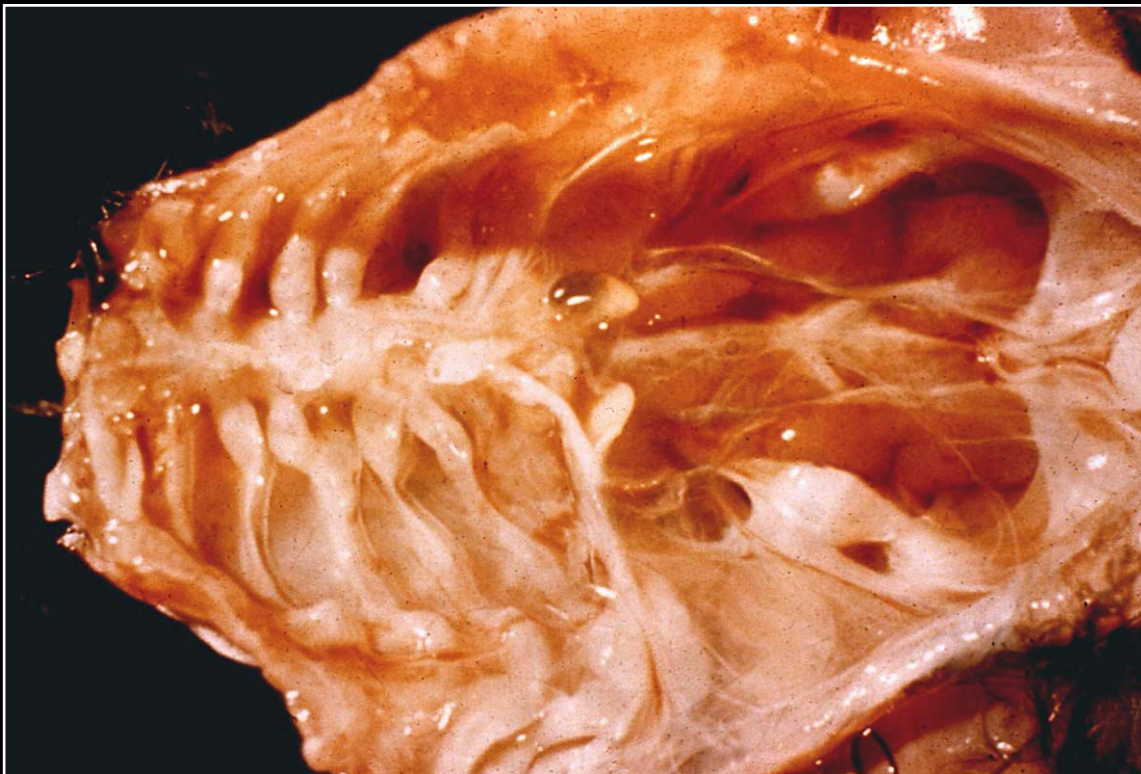
Back



C H A P T E R 14

Musculoskeletal System

Figure 14.18



Rickets leading to generalized costochondral swelling of the ribs.

Prev. fig. Next fig.

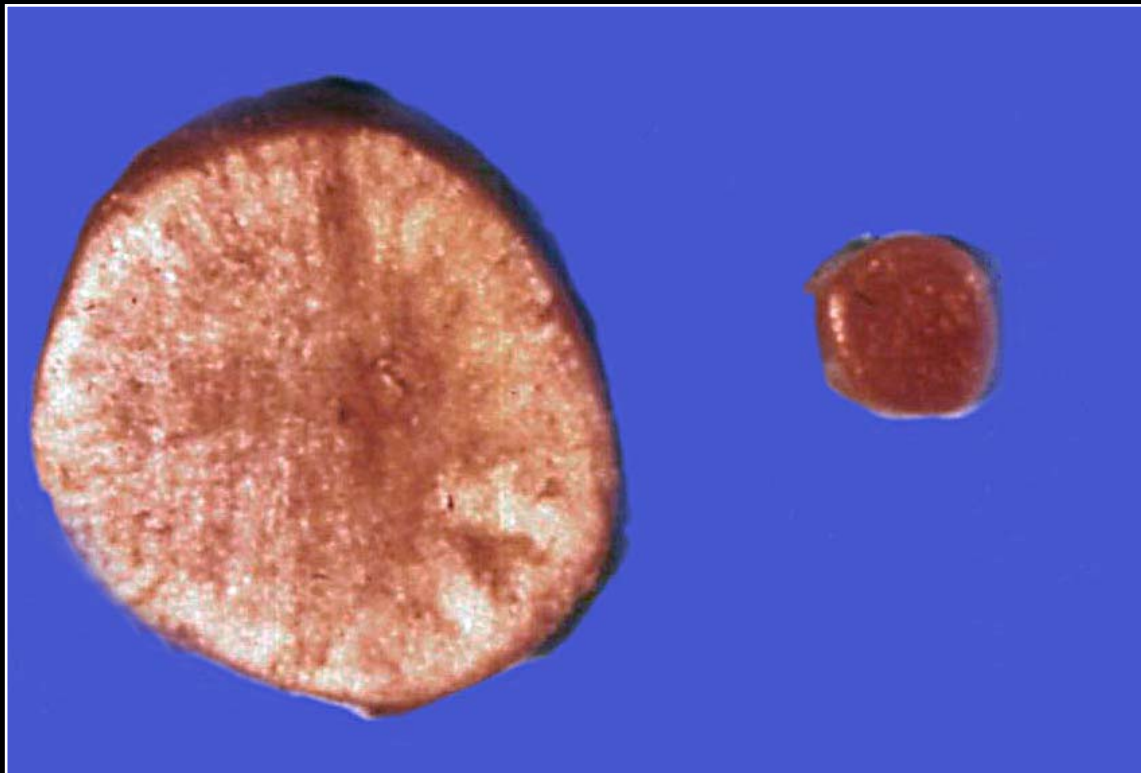
Back



C H A P T E R 14

Musculoskeletal System

Figure 14.19



Osteopetrosis affecting the long bone of a chicken. Compare the thickness with the normal bone.

Prev. fig. Next fig.

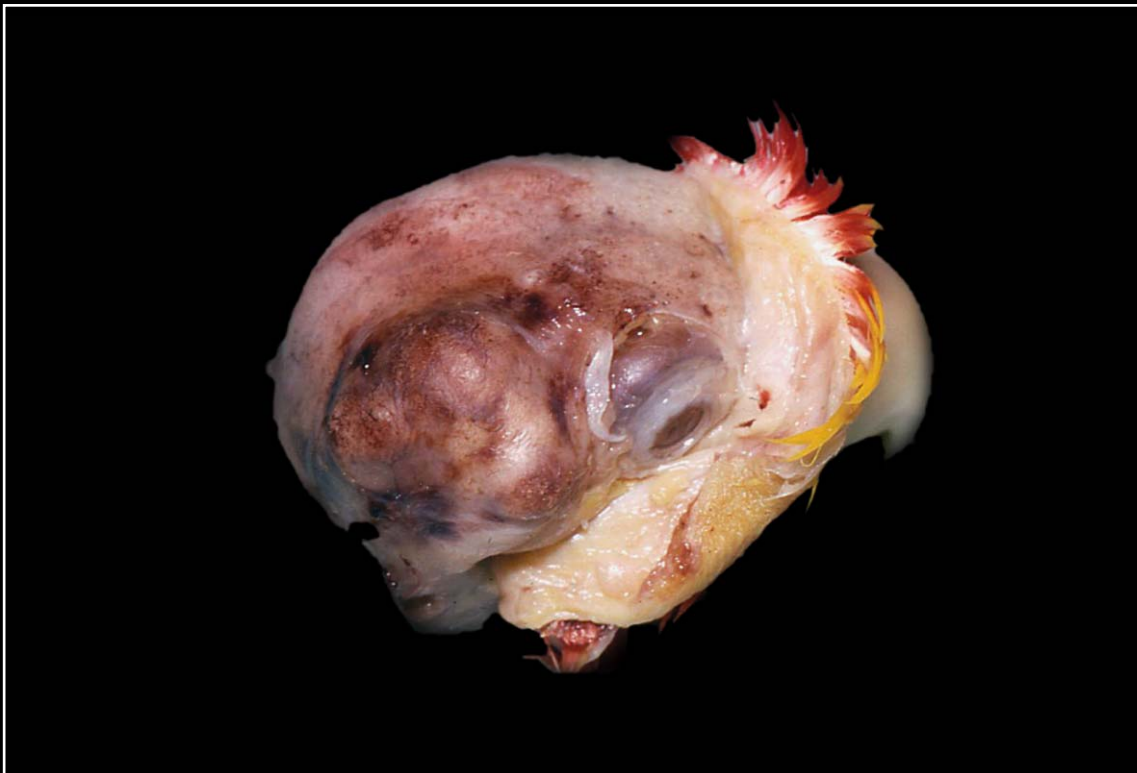Back



C H A P T E R 14

Musculoskeletal System

Figure 14.20



Osteoma of the skull resulting in large bony growth and pressure on the brain and other soft tissues.

Prev. fig. Next fig.

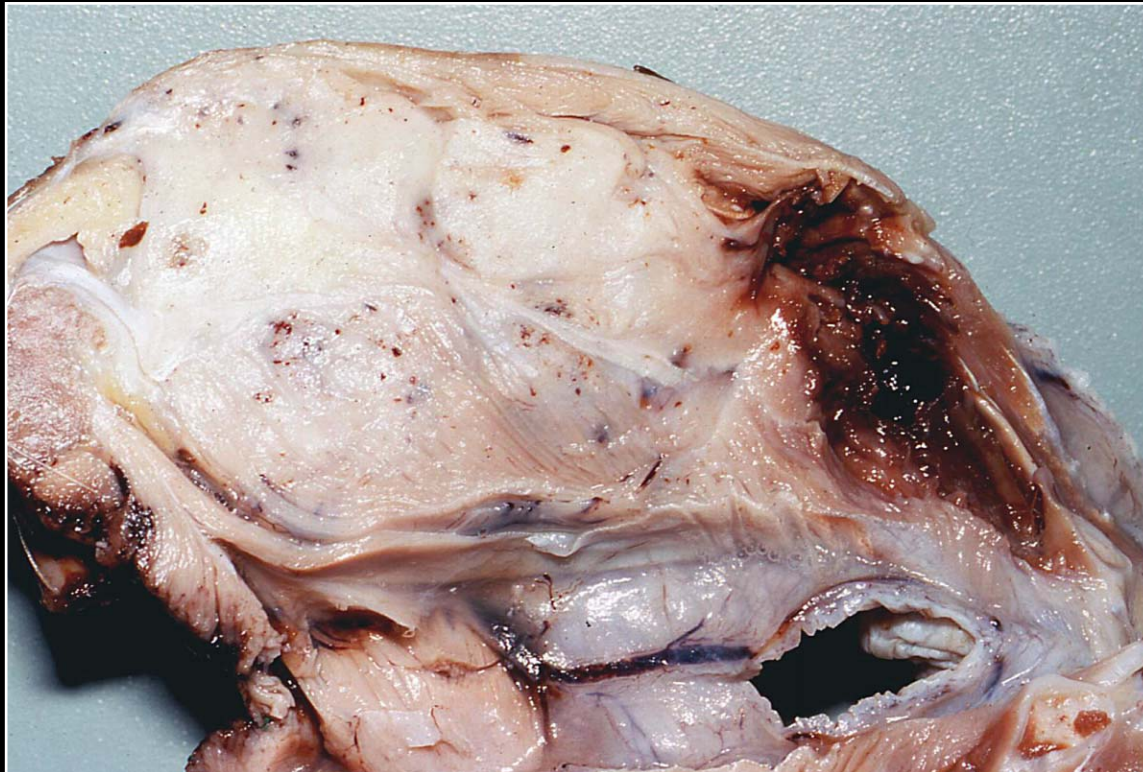
Back



C H A P T E R 14

Musculoskeletal System

Figure 14.21



Large osteosarcoma replacing normal bone. The mass is infiltrative and normal bone/soft tissue margins are difficult to determine grossly.

Prev. fig. Next fig.

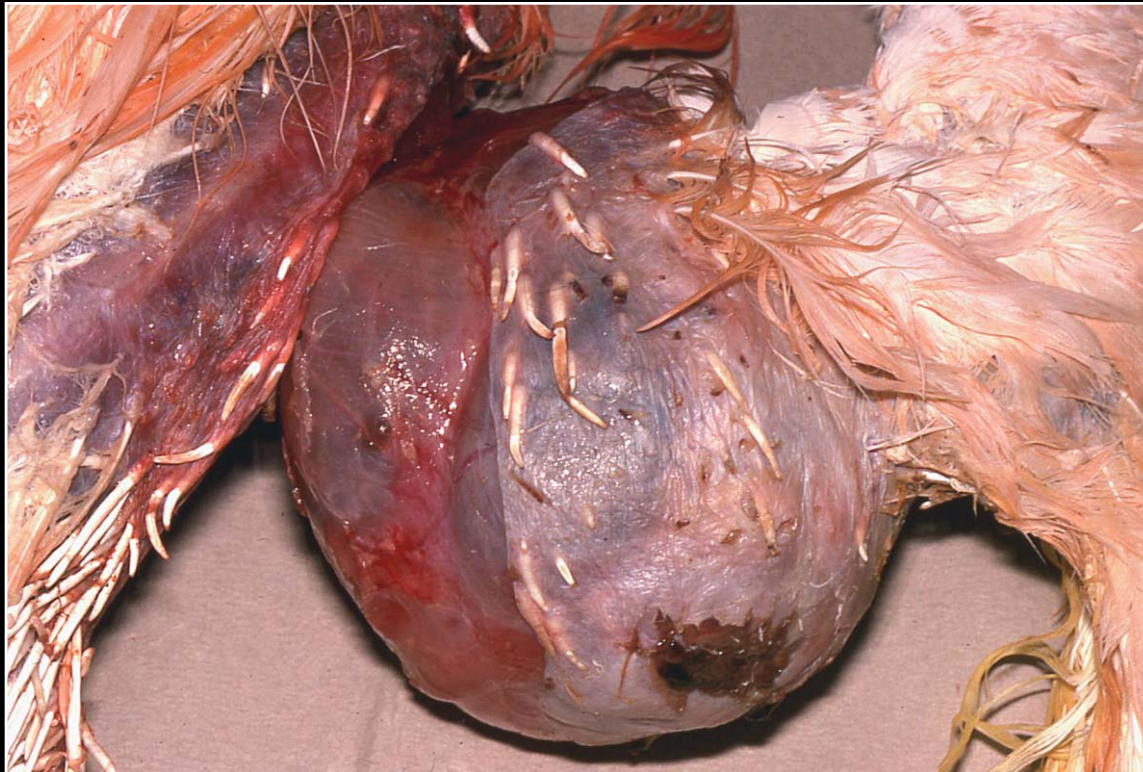
Back



C H A P T E R 14

Musculoskeletal System

Figure 14.22



Large mass involving the shoulder region. The tumor is an air sac carcinoma that has infiltrated into bone and surrounding soft tissue.

Prev. fig. . Next fig.

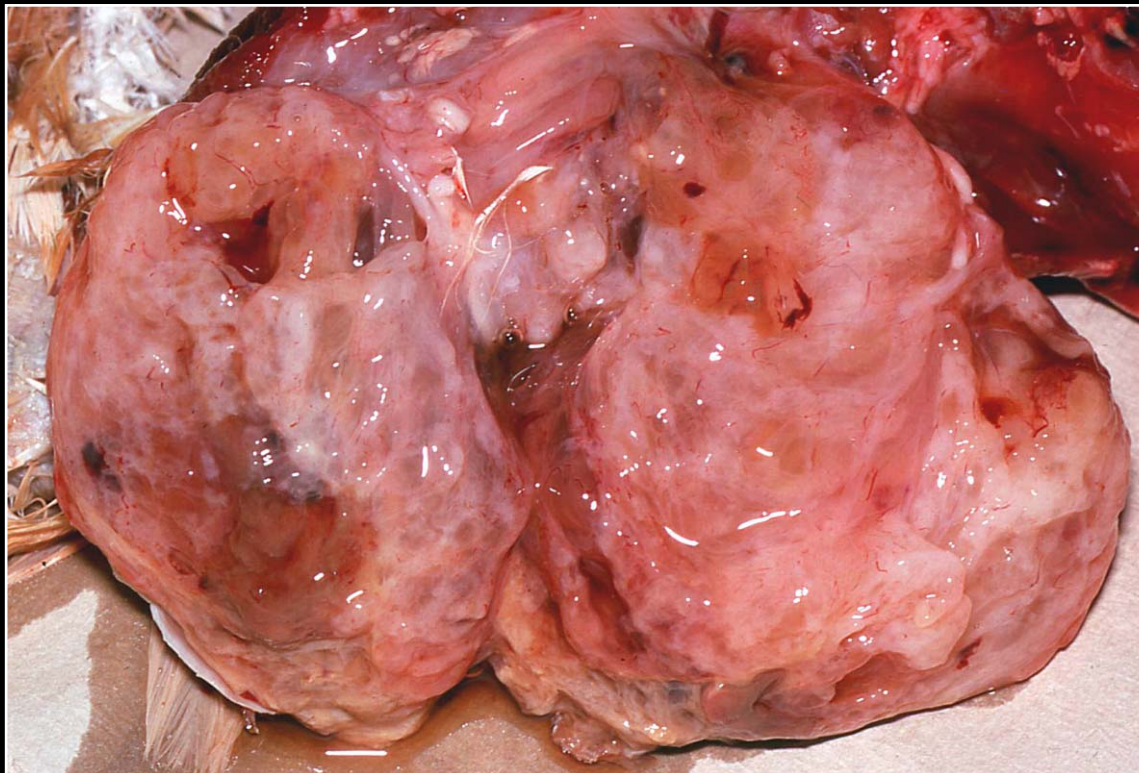
Back



C H A P T E R 14

Musculoskeletal System

Figure 14.23



Section through air sac carcinoma involving bone. The mass is comprised of proliferative and necrotic areas with some hemorrhage seen. The origin of the tumor cannot be determined with certainty by gross observation.

Prev. fig. Next fig.

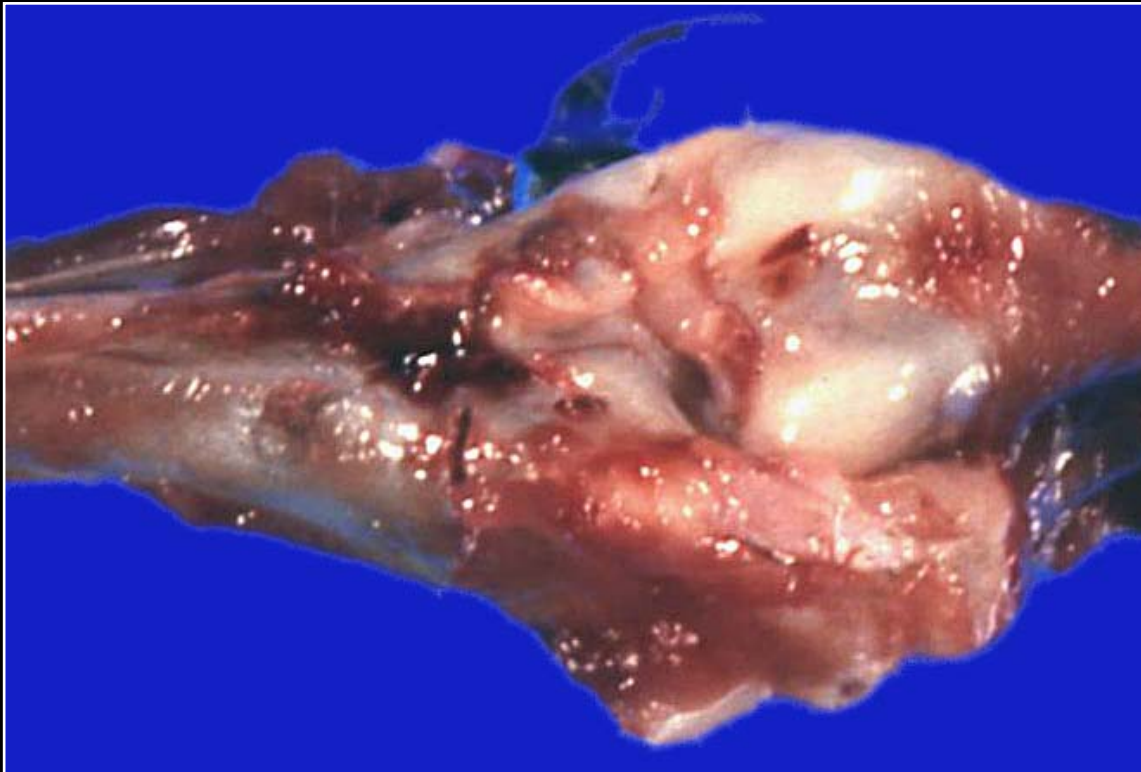
Back



C H A P T E R 14

Musculoskeletal System

Figure 14.24



Congenitally misaligned joint of undetermined cause.

Prev. fig. Next fig.

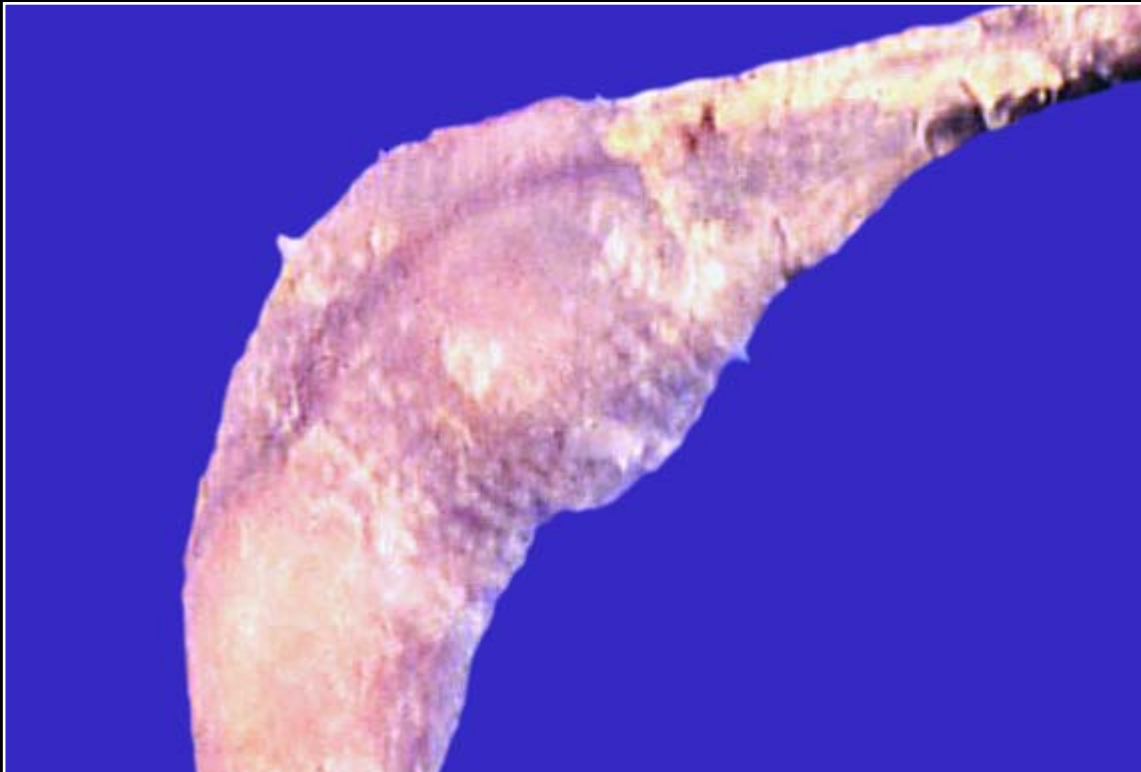Back



C H A P T E R 14

Musculoskeletal System

Figure 14.25



Enlarged joint with yellow mottling of the overlying skin in a case of bacterial arthritis.

Prev. fig. Next fig.

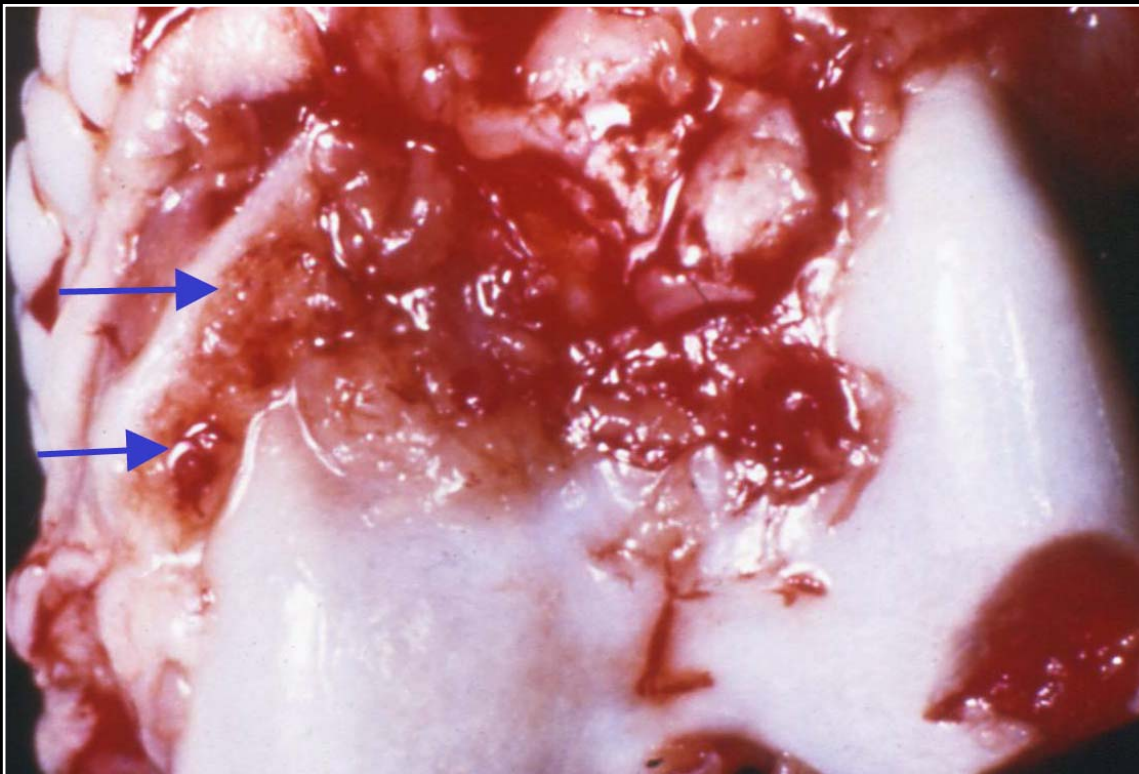
Back



C H A P T E R 14

Musculoskeletal System

Figure 14.26



Mycoplasma infection leading to synovial proliferation and reddening (arrows).

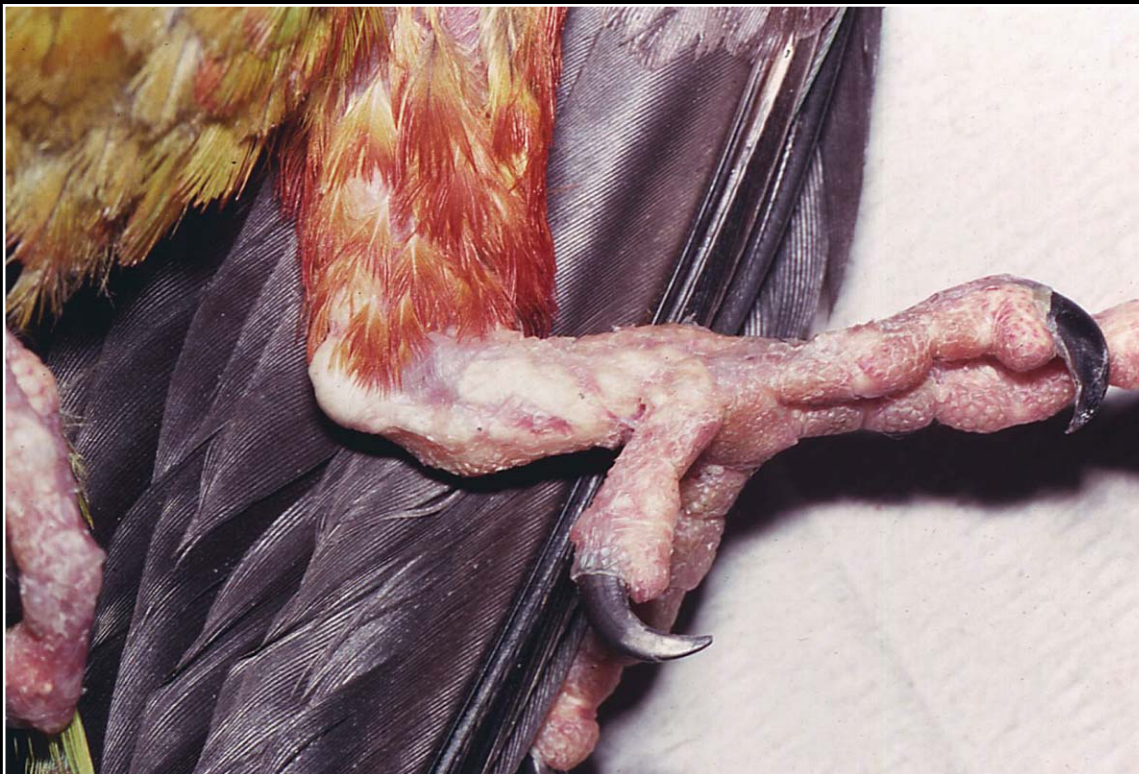
Prev. fig. Next fig.

Back

C H A P T E R 14

Musculoskeletal System

Figure 14.27



Articular and soft tissue urate deposition. Note the irregular swelling and yellow-white foci.

Prev. fig. Next fig.

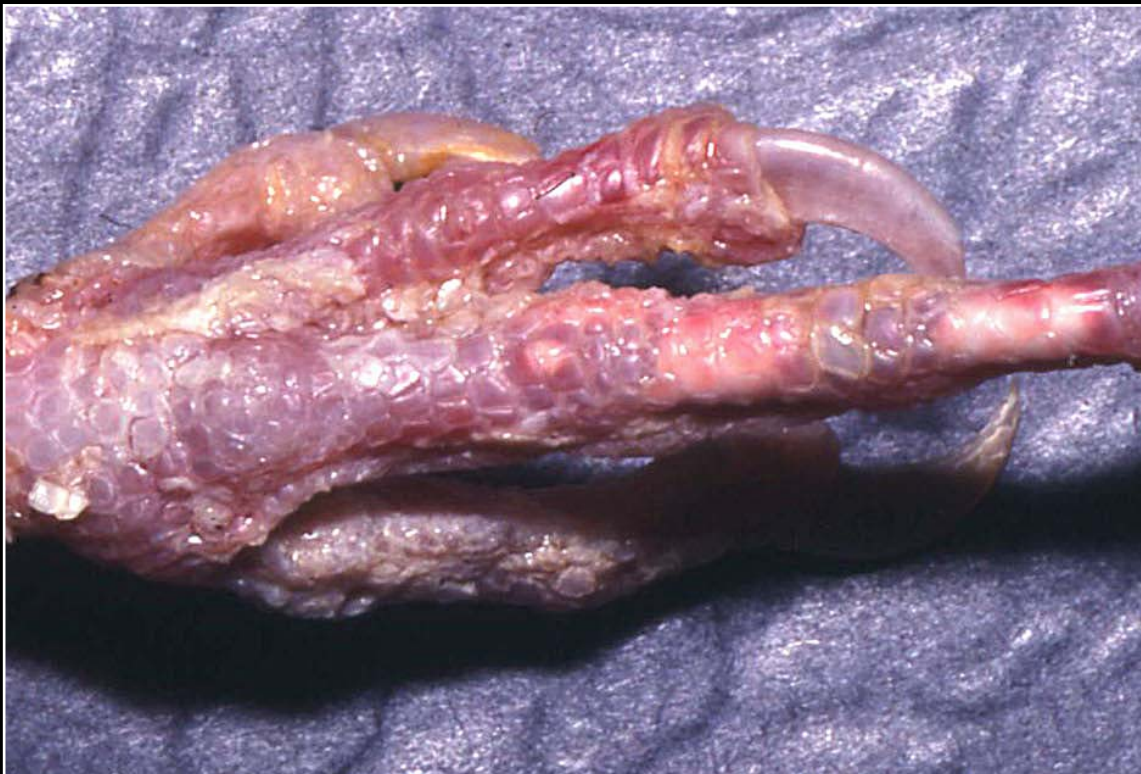Back



C H A P T E R 14

Musculoskeletal System

Figure 14.28



Articular and soft tissue urate deposition with severe reddening, scaling and tissue necrosis.

Prev. fig. Next fig.

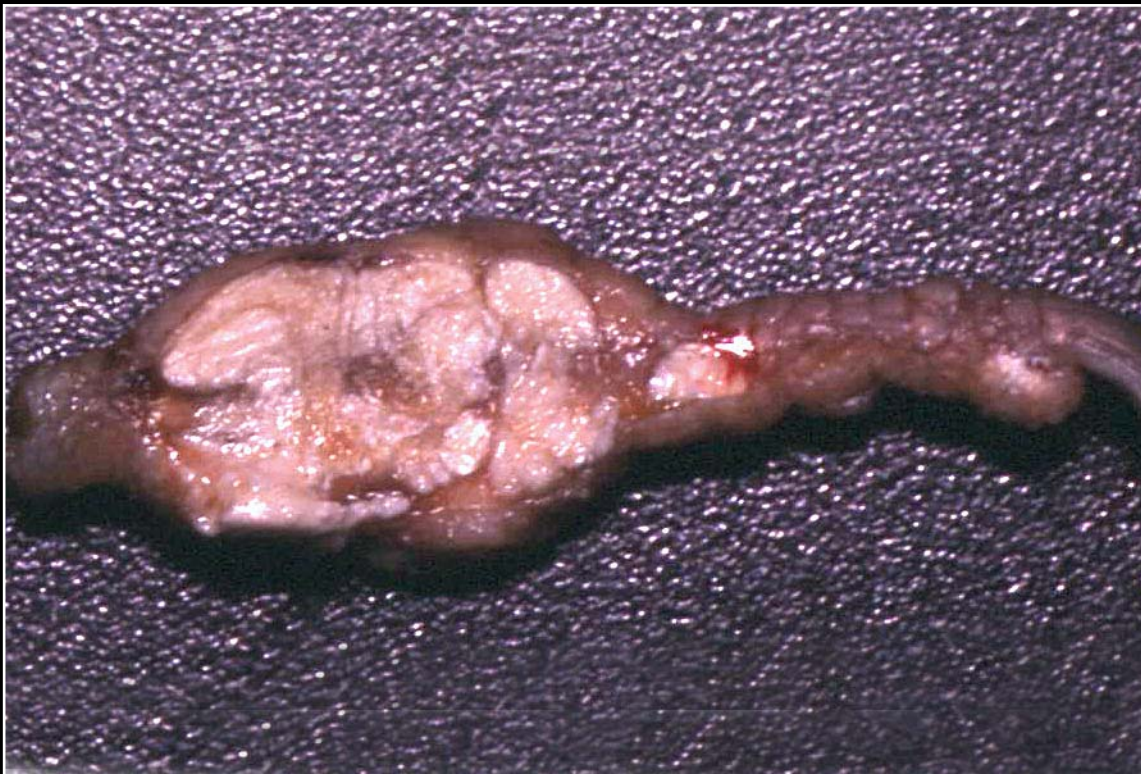Back



C H A P T E R 14

Musculoskeletal System

Figure 14.29



Section of affected joint and adjacent tissue with numerous chalky, white confluent foci of urate deposition.

Prev. fig.

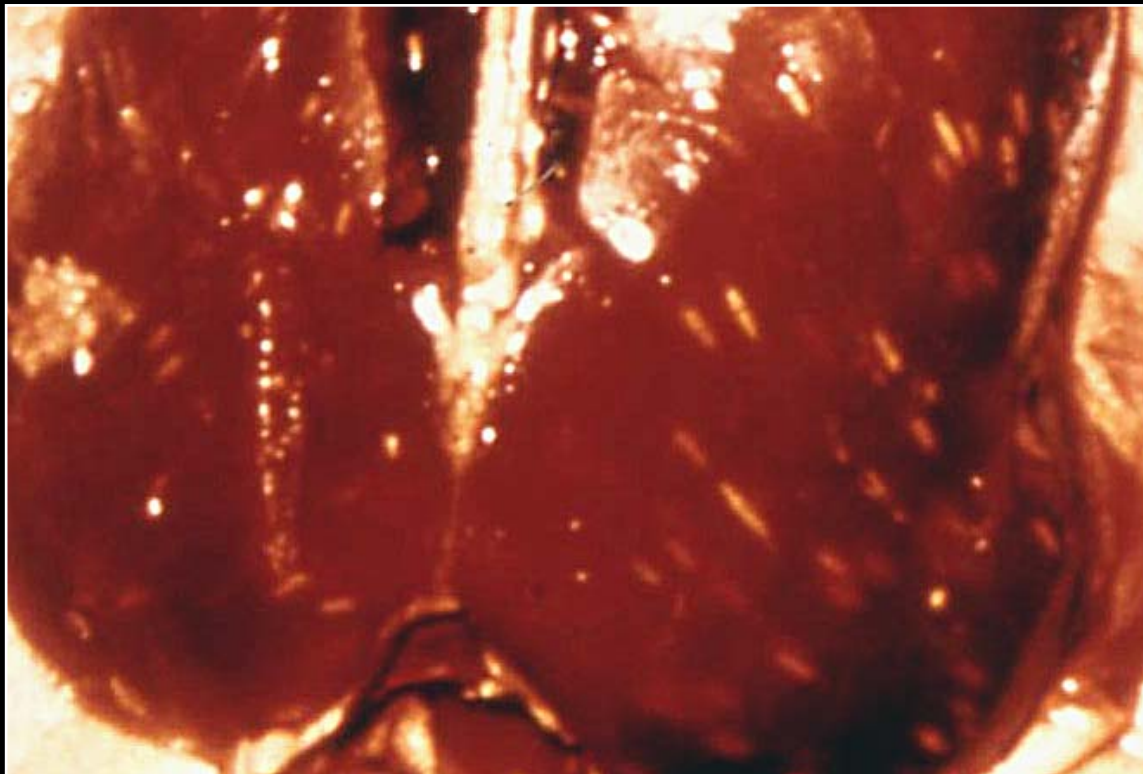
Back



C H A P T E R 14

Musculoskeletal System

Figure 14.9



Sarcocystis infection of the pectoral muscles of a duck. Note numerous round or elongated white foci in the muscle.

Prev. fig. Next fig.

Back

