

Fungal Biology

Arti Gupta
Nagendra Pratap Singh *Editors*

Fungal Diseases in Animals

From Infections to Prevention



Springer

Fungal Biology

Series Editors

Dr. Vijai Kumar Gupta

Biorefining and Advanced Materials Research Center

Scotland's Rural College (SRUC), SRUC Barony Campus, Parkgate

Dumfries, Scotland

United Kingdom

Maria G. Tuohy

School of Natural Sciences

National University of Ireland Galway

Galway, Ireland

Fungal biology has an integral role to play in the development of the biotechnology and biomedical sectors. It has become a subject of increasing importance as new fungi and their associated biomolecules are identified. The interaction between fungi and their environment is central to many natural processes that occur in the biosphere. The hosts and habitats of these eukaryotic microorganisms are very diverse; fungi are present in every ecosystem on Earth. The fungal kingdom is equally diverse, consisting of seven different known phyla. Yet detailed knowledge is limited to relatively few species. The relationship between fungi and humans has been characterized by the juxtaposed viewpoints of fungi as infectious agents of much dread and their exploitation as highly versatile systems for a range of economically important biotechnological applications. Understanding the biology of different fungi in diverse ecosystems as well as their interactions with living and non-living is essential to underpin effective and innovative technological developments. This series will provide a detailed compendium of methods and information used to investigate different aspects of mycology, including fungal biology and biochemistry, genetics, phylogenetics, genomics, proteomics, molecular enzymology, and biotechnological applications in a manner that reflects the many recent developments of relevance to researchers and scientists investigating the Kingdom Fungi. Rapid screening techniques based on screening specific regions in the DNA of fungi have been used in species comparison and identification, and are now being extended across fungal phyla. The majorities of fungi are multicellular eukaryotic systems and therefore may be excellent model systems by which to answer fundamental biological questions. A greater understanding of the cell biology of these versatile eukaryotes will underpin efforts to engineer certain fungal species to provide novel cell factories for production of proteins for pharmaceutical applications. Renewed interest in all aspects of the biology and biotechnology of fungi may also enable the development of “one pot” microbial cell factories to meet consumer energy needs in the 21st century. To realize this potential and to truly understand the diversity and biology of these eukaryotes, continued development of scientific tools and techniques is essential. As a professional reference, this series will be very helpful to all people who work with fungi and should be useful both to academic institutions and research teams, as well as to teachers, and graduate and postgraduate students with its information on the continuous developments in fungal biology with the publication of each volume.

More information about this series at <http://www.springer.com/series/11224>

Arti Gupta • Nagendra Pratap Singh
Editors

Fungal Diseases in Animals

From Infections to Prevention

 Springer

Editors

Arti Gupta
Department of Zoology
Dr. Ram Manohar Lohia Avadh University
Gonda, Faizabad, Uttar Pradesh, India

Nagendra Pratap Singh
Department of Zoology
K.S.Saket P.G.College
Ayonda, Uttar Pradesh, India

ISSN 2198-7777

ISSN 2198-7785 (electronic)

Fungal Biology

ISBN 978-3-030-69506-4

ISBN 978-3-030-69507-1 (eBook)

<https://doi.org/10.1007/978-3-030-69507-1>

© Springer Nature Switzerland AG 2021

This work is subject to copyright. All rights are reserved by the Publisher, whether the whole or part of the material is concerned, specifically the rights of translation, reprinting, reuse of illustrations, recitation, broadcasting, reproduction on microfilms or in any other physical way, and transmission or information storage and retrieval, electronic adaptation, computer software, or by similar or dissimilar methodology now known or hereafter developed.

The use of general descriptive names, registered names, trademarks, service marks, etc. in this publication does not imply, even in the absence of a specific statement, that such names are exempt from the relevant protective laws and regulations and therefore free for general use.

The publisher, the authors, and the editors are safe to assume that the advice and information in this book are believed to be true and accurate at the date of publication. Neither the publisher nor the authors or the editors give a warranty, expressed or implied, with respect to the material contained herein or for any errors or omissions that may have been made. The publisher remains neutral with regard to jurisdictional claims in published maps and institutional affiliations.

This Springer imprint is published by the registered company Springer Nature Switzerland AG
The registered company address is: Gewerbestrasse 11, 6330 Cham, Switzerland

Preface

Fungal growths affect human and animal well-being. Many of the natural pathogens of laboratory animals may alter host physiology, rendering the host unsuitable for many experimental uses. While the number and prevalence of few pathogens have declined considerably, many still turn up in laboratory animals and represent unwanted variables in research. Investigators using laboratory animals in biomedical experimentation should be aware of the profound effects that many of these agents can have on research. What does the future hold regarding the natural pathogens of laboratory animals? The choice of which animal model to use must carefully address issues of the type of human disease to mimic, the parameters to follow and collect the appropriate data to answer those questions being asked. Overall, animal models of fungal infection will continue to deepen our understanding of how these infections occur, progress and can ultimately be controlled and eliminated.

This book provides a valuable source of information to biological and biomedical scientists as well as clinical and doctoral, UG, and PG researchers working in the area of fungal infections and diseases of laboratory animal species including mice and rats. To overcome this problem, we offer recent research that introduce some antifungal medicines that work by either killing the fungal cells – for example, by affecting a substance in the cell walls, causing the contents of the fungal cells to leak out and the cells to die – or preventing the fungal cells from growing and reproducing. We incorporate what we consider the most vital infectious agents documented in lab animals. Also, efforts have been made to incorporate however much data as could reasonably be expected from natural outbreaks of disease. However, a lot of data will likewise be incorporated from experimental, lab-based in vitro study trials that maybe based on conditions like the course and dosage to those of natural infections.

Fungal Diseases in Animals: From Infections to Prevention Volume II covers fungal infection as a keystone reference, which reflects state-of-the-art research and current emerging issues in fungal biology and biotechnology in the animal system. The importance of fungal infections in both human and animals has increased over the past decades. This book represents an overview of the different categories of fungal infections that can be encountered in animals originating

from environmental sources with or without transmission to humans. In addition, the endemic infections with indirect transmission from the environment, the zoonophilic fungal pathogens with near-direct transmission, the zoonotic fungi that can be directly transmitted from animals to humans, mycotoxicoses and antifungal resistance in animals will also be discussed. Zoonotic agents are naturally transmitted from vertebrate animals to humans and vice versa. Fungi are relatively uncommon causes of disease in healthy and immunocompetent humans and nonhuman vertebrates, even though hosts are constantly exposed to infectious propagules. Mycotoxins are also a major concern for public health. The majority of antifungal agents including the polyenes, the azoles, and the echinocandins that are used in humans are also used in animals for the treatment of fungal infections. Similarly, many limitations also occur in some animal species, including variable pharmacokinetics, adverse effects, drug interactions, and antifungal resistance. The development of animal models for dermatophyte research is required to evaluate new treatments against dermatophytoses or to increase knowledge about fungal pathogenicity factors or host immune response mechanisms. Fish fauna is reeling under great pressure from myriad of factors like disease, pollution, stress, climate change, habitation destruction, and anthropogenic pressures. However, an atrocity of a disease is apprehended liable for the most substantial economic fatalities in fresh water fish, particularly disease by fungal infections. The appearance of ravaging emerging infectious diseases (EIDs), systemic mycosis, and epizootic ulcerative disease by fungal and fungal-like pathogens is presenting a global threat to food security. Microbial taxonomists and biologists relied on culture-dependent approach, morphology, and physiology to describe fungal communities associated with fish. The guinea pig has been the most frequently used animal model to evaluate efficacy of antifungal compounds against dermatophytes, while mouse models have been preferred to study the immune response generated during the disease. Nematophagous fungi are considered as a potential group of soil microorganism specialized in trapping and digesting the plant parasitic nematode, thus resulting in suppressing its population. It has been estimated that nematode causes serious economical losses, and there are more than 200 known species that possess varying degree of parasitic and saprophytic ability. To accomplish penetration and colonization of nematode cuticle, cysts and eggs, these fungi form various mycelial structures that include constricting ring, knobs, hyphal tip, or spores. These fungi have been broadly classified as endophytic trap forming or opportunistic fungi that are getting great attention as biological control agents against different nematodes. In this book, we have reviewed the current state of knowledge on the mechanism of fungal attraction, recognition, infection, extracellular hydrolytic enzymes, and pathogenesis of nematophagous fungi. Nematodes management strategies involved in infection against nematodes by various nematophagous fungi are also summarized for *Catenaria anguillulae*, *Beauveria bassiana*, *Metarhizium anisopliae*, *Paecilomyces lilacinus*, *Arthrobotrys oligospora*, and *Drechmeria coniospora* in view of exploration of these fungi as a biocontrol agent. Hence, the book provides current considerations and strategies to access the annoying fungal pathogen groups as well as metagenomic analyses of its

novelties at phylogenetics, genomics, secretomics, metabolomics, proteomics, and transcriptomics levels. In addition, pathogen description, understanding, distribution, and recent expansions are also discussed.

The book volume comprises ten chapters. In Chap. 1, emphasis is given by Fatima on the most important fungal diseases infecting bovines and their impacts on animal health, agriculture, and biodiversity, as well as methods of treatment and prevention. In Chap. 2, presented by Avnish et al., proper storage and maintenance of hygienic conditions for livestock is shown to be a better way to protect the animals from toxicity. The prevention of mycotoxins has been regulated by legal decisions and laws. Prevention is the only option at present due to a lack of appropriate detection methods and diagnostic tests for presence of mycotoxins in food and animals. In Chap. 3, Hilal and Wani suggest that a few (*geophilic*) species normally live in the environment, but occasionally act as parasites. The zoophilic and geophilic species are sometimes transmitted from animals to people. It is also possible for humans to transmit anthropophilic dermatophytes to animals, although this seems to be uncommon. Chapter 4 by Ravindra and Rajrani highlights the concept of the omics and image-based data of host-pathogen interactions into mathematical network models. This integrated modeling helps to elucidate the mechanism of the host-fungal interaction and to identify the biomarkers and the drug targets for novel therapeutic treatment strategies. In Chap. 5, Fatima describes fungal diseases of animals with symptoms and their cure by natural products, and environmental conditions play an important role in increasing the spread of disease, which is often found in humid and warm seasons compared to temperate zones and Saharian zones. In Chap. 6, Anamika et al. discuss types of fungal infections in different lab models and methods of fungal infections diagnosis and treatment. Chapter 7 by Shiv et al. deal with the fungi found in soil (*geophilic* organisms), animals (*zoophilic*), and humans (*anthropophilic*). Dermatophyte spores can survive more than a year under humid and mild temperature conditions. Animals may be infected by close contact with other infected animals or soil fungi during digging or rooting. Dermatophytes require keratin for growth, thus infect keratinized tissue only. Animal exposure to fungi does not always cause infection. In Chap. 8, Mustafa et al. review the most common fungal infections in dogs, including aspergillosis, dermatophytosis, blastomycosis, histoplasmosis, rhinosporidiosis, sporotrichosis, geotrichosis and phaeohyphomycosis, and antifungal agents currently available for therapy. In Chap. 9, Amara proposes to spread worldwide awareness about fungi, pathogenic fungi, previous methods of protection and treatment, as well as the advances that happened in fungal immunity science. Chap. 10, provides an overview of veterinarians and other animal health professionals who should take action to demand more resources for improving the monitoring of antifungal resistances in veterinary clinics and animal facilities worldwide by Sergio et al.

Gonda, UP, India
Ayonda, UP, India

Arti Gupta
Nagendra Pratap Singh

Acknowledgments

First and foremost, we would like to thank God for his never ending grace, mercy, and provision during what ended up being one of the toughest times of our lives.

We are indebted to the many people who helped bring this book to light. We wish to thank Mr. Eric Standard, Senior Editor, Botany, Springer; Dr. Jacco Flipsen; Ms. Susan Safren; Dr. Maria G. Tuohy, Series Editor, Fungal Biology, Springer; and Mr. Vignesh Viswanathan, Project Coordinator, Springer, for generous assistance and patience in publishing this volume.

Dr. Arti Gupta gives special thanks to her husband Mr. Saket Agrawal and her son Reyansh, who encouraged her to start the work and helped persevere through the process to finally to publish it.

Dr. Nagendra Singh gives his special regards to his family for their constant invaluable support and motivation in putting everything together. We both also give special thanks to all faculty colleagues and senior faculties of our teams.

Gonda, UP, India
Ayonda, UP, India

Arti Gupta
Nagendra Pratap Singh

Contents

1	Fungal Diseases of Bovines.	1
	Djadouni Fatima	
2	Mycotoxins and Their Consequences in Livestock	15
	Jacklin Mary Anthony, Monika Asthana, and Avnish Kumar	
3	Candidiasis and Dermatophytosis: Infections and Their Prevention	35
	Hilal Ahmad Ganaie and Manzoor Ahmad Wani	
4	Application of Systems Biology Approaches for Host-Fungal Interaction in Animals	49
	Ravindra Kumar and Rajrani Ruhel	
5	Ovine Fungal Diseases	63
	Djadouni Fatima	
6	Histopathologic Diagnosis of Fungal Infections of Lab Animals	73
	Abhilasha Shourie, Rajeev Singh, and Anamika Singh	
7	Current Perspective of Dermatophytosis in Animals.	93
	Shiv Shanker Gautam, Navneet, Neelesh Babu, and Sanjay Kumar	
8	Fungal Diseases and Therapy in Dogs.	105
	Hidayet Tutun, Ezgi Sababoglu, Adnan Ayan, and Mustafa Sevindik	
9	Improving Animal Immunity to Prevent Fungal Infections with Folk Remedies and Advanced Medicine.	127
	Amro Abd Al Fattah Amara	
10	Antifungal Resistance in Animal Medicine: Current State and Future Challenges.	163
	Sergio Álvarez-Pérez, Marta E. García, Blanca Anega, and José L. Blanco	
	Index.	181

Contributors

Sergio Álvarez-Pérez Department of Animal Health, Faculty of Veterinary Medicine, Universidad Complutense de Madrid, Madrid, Spain

Veterinary Clinical Hospital, Universidad Complutense de Madrid, Madrid, Spain

Amro Abd Al Fattah Amara Protein Research Department, Genetic Engineering, and Biotechnology Research Institute, City of Scientific Research and Technological Applications, Universities and Research Center District, New Borg El-Arab, Alexandria, Egypt

Blanca Anega Department of Animal Health, Faculty of Veterinary Medicine, Universidad Complutense de Madrid, Madrid, Spain

Jacklin Mary Anthony Escola Superior Agrária de Coimbra (ESAC), IPC, Coimbra, Portugal

Monika Asthana Department of Biotechnology, School of Life Sciences, Dr. Bhimrao Ambedkar University, Agra, UP, India

Adnan Ayan Faculty of Veterinary Medicine, Department of Genetics, Van Yuzuncu Yil University, Van, Turkey

Neelesh Babu Department of Botany and Microbiology, Gurukul Kangri University, Haridwar, Uttarakhand, India

José L. Blanco Department of Animal Health, Faculty of Veterinary Medicine, Universidad Complutense de Madrid, Madrid, Spain

Veterinary Clinical Hospital, Universidad Complutense de Madrid, Madrid, Spain

Djadouni Fatima Biology Department, Faculty of Natural Sciences and Life, Mascara University, Mascara, Algeria

Hilal Ahmad Ganaie Department of Zoology, Govt. Degree College (Boys), Pulwama, Jammu and Kashmir, India

Marta E. García Department of Animal Health, Faculty of Veterinary Medicine, Universidad Complutense de Madrid, Madrid, Spain

Veterinary Clinical Hospital, Universidad Complutense de Madrid, Madrid, Spain

Shiv Shanker Gautam Department of Microbiology, College of Basic Sciences and Humanities, G.B. Pant University of Agriculture and Technology, Pantnagar, Uttarakhand, India

Avnish Kumar Department of Biotechnology, School of Life Sciences, Dr. Bhimrao Ambedkar University, Agra, UP, India

Ravindra Kumar Biometric Research Program, Division of Cancer Treatment and Diagnosis, Medical Center Drive, National Cancer Institute, NIH, Rockville, MD, USA

Sanjay Kumar Department of Botany and Microbiology, Gurukul Kangri University, Haridwar, Uttarakhand, India

Navneet Department of Botany and Microbiology, Gurukul Kangri University, Haridwar, Uttarakhand, India

Rajrani Ruhel Department of Plant and Microbial Biology, North Carolina State University, Raleigh, NC, USA

Ezgi Sababoglu Faculty of Veterinary Medicine, Department of Microbiology, Burdur Mehmet Akif Ersoy University, Burdur, Turkey

Mustafa Sevindik Bahçe Vocational School, Department of Food Processing, Osmaniye Korkut Ata University, Osmaniye, Turkey

Abhilasha Shourie Department of Biotechnology, Faculty of Engineering and Technology, Manav Rachna International Institute of Research and Studies, Faridabad, HR, India

Anamika Singh Department of Botany, Maitreyi College, University of Delhi, New Delhi, India

Rajeev Singh Department of Environmental Studies, Satyawati College, University of Delhi, New Delhi, India

Hidayet Tutun Faculty of Veterinary Medicine, Department of Pharmacology and Toxicology, Burdur Mehmet Akif Ersoy University, Burdur, Turkey

Manzoor Ahmad Wani Department of Botany, Govt. Degree College (Boys), Pulwama, Jammu and Kashmir, India

About the Editors



Arti Gupta obtained her Ph.D. from Mahatma Jyotiba Phule Rohilkhand University, Bareilly, India, in 2010 in animal science. Dr. Gupta's current research interests are animal biotechnology, molecular plant biotechnology, molecular animal biotechnology, bioprocess technology, and microbiology. Since July 2014 to till date, Dr. Arti has been working at Sri Avadh Raj Singh Smarak Degree College and is engaged in some editorial work with Springer Nature. Dr. Gupta has 10 years of teaching and research experience in plant and animal biotechnology and microbial biotechnology.

Dr. Gupta has received University Topper Gold Medal in M.Sc. (biotech.) from Ch.C.S. University, Meerut; Young Scientist Award (gold medal) from the Zoological Society of India, Lucknow; Best Poster Presenter award from *Asian Journal of Experimental Science*, Jaipur; Best Poster Presenter award from the International Consortium of Contemporary Biologists (ICCB); Madhawai-Shyam Educational Trust, Ranchi, Fellowship Award from the International Consortium of Contemporary Biologist (FICCB) and Madhawai Shyam Educational Trust (FMSET); and Dr. V.P. Agarwal Gold Medal from D.A.V. (P.G.) College, Muzaffarnagar. In her honour one monograph, 07 Book Chapters, 32 National and International research papers, 7 edited books (02 in CRC press, Taylor & Francis and 05 in Springer Nature). Under the process of publication, she has issued 22 abstracts in National and International Symposia/ Seminars / Conferences / Workshops have been attended. Dr. Gupta has lifetime membership of the Indian Science

Congress Association, Biotech Research Society of India, Zoological Society of India, and International Consortium of Contemporary Biologist.



Nagendra Pratap Singh is a leading researcher and assistant professor in the Department of Zoology, K.S. Saket P.G. College (affiliated to Dr. Ram Manohar Lohia Avadh University), Uttar Pradesh, India. He has experience and expertise in the area of fish biology and fungal disease in fishes and other animals. He has received his Ph.D. degree in fish biology from Dr. Ram Manohar Lohia Avadh University, Faizabad. Dr. Singh's work is focused on "Studies on taxonomy, ecology and biological traits of fresh water catfish *Mystus vitattus* (Bloch.) in Ghaghra Belt of Eastern Uttar Pradesh, India." He is a postgraduate in zoology and graduated in botany and zoology in the years 2004 and 2002, respectively, from K.S. Saket P.G. College, Ayodhya, Faizabad. He has published a dozen research articles in national and international journals of repute. Dr. Singh is an active member of the Academy of Innovative Research, Purvanchal Academy of Science, Jaunpur, U.P., India. He is also a member of the advisory committee of the national conference on "Climate and Environmental Changes: Impact, Challenges and Solutions" sponsored by CST, U.P., India.

Chapter 1

Fungal Diseases of Bovines



Djadouni Fatima

1.1 Introduction

Yeasts are found ubiquitously in nature, in association with plants, mammals and insects. Accordingly, animals are continually exposed to multiple genera of yeasts via various routes. Depending on the interaction between host mucosal defence mechanisms and fungal virulence factors, yeast colonization may be transient or persistent, with either systemic or local disease.

Bovinae is a subfamily of ruminant mammals of the biological family Bovidae, which includes several important species of farm animals, particularly the species *Bos taurus* cow or zebu, gayal, buffalo and yak, knowing that the family of cattle includes other subfamilies and in particular that of goats with goats and sheep (Table 1.1). Generally there are ten genera in this family includes *Bison*, *Bos*, *Boselaphus*, *Bubalus*, *Pseudoryx*, *Syncerus*, *Taurotragus*, *Tetracerus*, *Tragelaphus* and *Pseudonovibos* (Wilson and Reeder 2005).

These animals have a great importance for the agricultural sector and economy and provide the mainly basic raw materials for industrial processing such as meat, milk, head, skin, gelatin, wool, cashmere and soil compost. But the latter may be exposed to a range of diseases usually caused by viruses, bacteria, fungi, prions and parasites which cause not only suffering and death but also severe economic implications (Aiello and Mays 2016).

1.2 Fungal Diseases Transmission

Fungi are a group of non-photosynthetic microorganisms which live as saprophytes in the soil and on dead organic matter or as parasites of plants and animals including man. Fungal diseases are often caused by fungi that are common in the environment

D. Fatima (✉)

Biology Department, Faculty of Natural Sciences and Life, Mascara University,
Mascara, Algeria

e-mail: djadouni.fatima@univ-mascara.dz

© Springer Nature Switzerland AG 2021

A. Gupta, N. Pratap Singh (eds.), *Fungal Diseases in Animals*, Fungal Biology,
https://doi.org/10.1007/978-3-030-69507-1_1

Table 1.1 Summary of the representative species and whether they were considered domesticated (MacEachern et al. 2009)

Subfamily Bovinae			
Tribe	Representative species	Domesticated	Note
Tragelaphini	<i>Taurotragus oryx</i> (eland)	No	Undomesticated
Bovini	<i>Syncerus caffer</i> (African buffalo)	No	Undomesticated
Bovini	<i>Bubalus bubalis</i> (water buffalo)	Yes	Domesticated in India and Asia
Bovini	<i>Bubalus carabensis</i> (swamp buffalo)	Yes	Domesticated in East Asia
Bovini	<i>Bison bison</i> (bison)	No	Undomesticated
Bovini	<i>Bos grunniens</i> (yak)	Yes/no	Domesticated in Asia and some wild species still exist
Bovini	<i>Bos taurus</i> (domestic cow)	Yes	Domesticated in Mideast
Bovini	<i>Bos javanicus</i> (Bali cattle)	Yes/no	Domesticated in Indonesia and some wild species still exist
Bovini	<i>Bos gaurus</i> (gaur)	No	Some history, but in general considered undomesticated
Bovini	<i>Bos frontalis</i> (mithun)	Yes	May be a domestic version of <i>B. gaurus</i>

and dominant in soil, water, plants, vertebrates and invertebrates (Cockcroft 2015). Various means of transmission of fungal diseases can be through direct or indirect contact including the following:

- Direct contact with other animals (e.g. livestock)
- Transfer infections by grooming, sexual activity and bites
- By vectors (e.g. biting flies, mosquitoes, ticks)
- Through the air and shared water and/or feed
- Waste products (e.g. urine, faeces)
- Watercourses, run-off and dung heaps
- Animal ecosystems
- Environment pollution related to waste water (e.g. crops and insect diseases)
- Environment changes (e.g. climate, heat stress, water availability)

1.3 Principal Bovine Fungal Diseases

1.3.1 Epizootic Lymphangitis

The most common form of this disease is an ulcerative, suppurative, spreading dermatitis and lymphangitis. However, other forms, including pneumonia or ulcerative conjunctivitis, also occur. It is clinically characterized by a spreading suppurative inflammation of cutaneous lymphatic vessels, lymph nodes and adjacent skin.

Epizootic lymphangitis spreads most readily where large numbers of animals are assembled and is a result from infection by a dimorphic fungus, *Histoplasma capsulatum* var. *farciminosum*. This fungus has also been known as *H. farciminosum*, *Cryptococcus farciminosus*, *Zymonema farciminosus* and *Saccharomyces farciminosus*. *H. capsulatum* var. *farciminosum* exists as yeast in animal tissues and a saprophytic mycelium in the environment (Spesivtseva and Noskov 1959; Radostits et al. 2007).

However, the disease is more common in tropical and subtropical regions than in temperate zones, and sporadic cases have been reported from other parts of the world. Currently, *H. capsulatum* var. *farciminosum* is endemic in some countries in the Mediterranean region and in parts of Africa and Asia including India, Pakistan and Japan. *H. capsulatum* var. *farciminosum* is a thermally dimorphic fungal soil saprophyte. The mycelial form is present in soil, while the yeast form is usually found in lesions. This fungus is highly resisted to the effects of physical and chemical agents. It may survive for up to 10 weeks in non-sterile water at 26 °C (Spesivtseva and Noskov 1959; Radostits et al. 2007).

The mode of disease transmission includes transmission by direct or indirect contact of fungi with traumatized skin, by biting flies, by ticks or by inhalation of fungi spores. Direct contact with infective materials through injured skin or through cutaneous abrasions is the most common mode of infection. Spread of infection can also occur by indirect contact through feeds and water (Abdisa 2017).

Surgical excision of lesions combined with antifungal drugs (amphotericin B) could be used. Intravenous dosing of iodide may be used, particularly in endemic areas. The intravenous injection of 100 ml of sodium iodide of a 10% solution, repeated weekly for 4 weeks is recommended (Gabal 1984; Rochette et al. 2003).

1.3.2 Ringworm (*Dermatomycosis*)

Bovine dermatophytosis caused by *Trichophyton verrucosum* is a disease that affects many species, livestock in tropical and subtropical areas such as African countries. This skin disease is present worldwide and is responsible for high economic losses in cattle farming. The disease is caused by a group of keratinophilic filamentous fungi called dermatophytes (club lamb fungus) in the genera *Trichophyton*, *Microsporum* and *Epidermophyton*. *T. verrucosum* and *T. mentagrophytes* var. *mentagrophytes* have been the major agents encountered (Table 1.2) (Papini et al. 2009; Nweze 2011).

Ringworm infections acquired from animals usually involve direct contact with infected dogs or cats or contact with contaminated material. The infected animals may not show obvious signs of infection. Close confinement, host factors (age, immunocompetence, the type of breed, host grooming behaviour), dietary factor deficiencies, condition of exposed skin in prolonged wetting are thought to be important predisposing factors. In addition, affected animals initially develop characteristically discrete, scaling patches of hair loss with grey-white crust that later become a thickly suppurated crust whose location is highly variable.

Table 1.2 Antifungal drugs in use^a in cattle with dermatomycosis (Rochette et al. 2003)

Antifungal (trade name)	Formulations	Indications	Treatment schedule
Enilconazole (Imaverol)	Emulsifiable solution	<i>Trichophyton</i> , <i>Microsporum</i>	Wash or spray with diluted emulsion (2000 p.p.m.) four times at 3–4-day intervals
Clinafarm	Antimycotic disinfectant	<i>Trichophyton</i>	For disinfecting of environment with spray or smoke generator
Griseofulvin (Fulcin, Grisovin)	7.5% powder feed additive	<i>Trichophyton</i> , <i>Microsporum</i>	10 mg/kg body weight for 7 days in mild infections; in severe cases 2–3 weeks
Natamycin (Mycophyt)	Suspension	<i>Trichophyton</i> , <i>Microsporum</i>	Spray suspension two times with interval of 4–5 days; retreat remaining lesions after 14 days
Thiadiazine (Defungit)	Powder for dilution	<i>Trichophyton</i> , <i>Microsporum</i>	0.5% dilution repeat two to three times with interval of 2–4 days; if no bensuldazin cure, repeat schedule after 14 days
Thiabendazole (in 90% DMSO)	4% solution, ointment	<i>Trichophyton</i> , <i>Microsporum</i>	Washing with solution

DMSO dimethyl sulphoxide

^aDrugs in bold are officially licensed as veterinary products for cattle in most of the EEC countries

Cattle ringworm is rapidly spreading in the herd via infected propagules (hyphae and specialized fungal spores named arthrospores). The disease is responsible for great economic losses due to skin injuries and many casualties in animal products (wool, meat, etc.) (Mignon and Monod 2011; Swai and Sanka 2012).

1.3.3 Aspergillosis

Aspergillus species are saprophytic filamentous fungi, class *Eurotiomycetes*, *Trichocomaceae* family; they are commonly found in soil, where they thrive as saprophytes, with an occasional potential to infect living hosts including plants, insects, birds and mammals. *Aspergillus fumigatus* is the main species responsible for aspergillosis, mycotic pneumonia, gastroenteritis, mastitis, placentitis and abortions in ruminants, domestic animals and especially cows worldwide with several economic losses, chiefly in areas of intensive rearing, whereas *A. flavus*, *A. nidulans* and *A. niger* are secondary. *A. fumigatus* is a ubiquitous saprophytic fungus and an opportunist pathogen and survives in a wide range of environmental conditions (Seyedmousavi et al. 2015).

Furthermore, aspergillosis fungal diseases affected bovines in all age groups and often occur in the last third of gestation. Mycotic placentitis is a major worldwide cause of abortion in cattle, generally occurring in the third trimester of pregnancy. Also, placentitis and abortion are common features associated with bovine

aspergillosis and can account for up to 20% of bovine abortions. *A. nidulans* and *A. fumigatus* have also been described as causal agents of bovine mastitis (Puntenney et al. 2003; Bakr et al. 2015).

However, the main portal entry of fungi is the respiratory and gastrointestinal tracts. In addition, *A. pneumonia* caused a fatal disease bronchopulmonary aspergillosis with a hard sign that includes pyrexia; rapid, shallow and stertorous respiration; nasal discharge; a moist cough and appearances of multiple discrete granulomas in the lungs, and the disease grossly resembles tuberculosis. Primary pulmonary infections are mainly established subsequent to exposure to heavy loads of spores from mouldy feed stuffs in damp buildings (closed farm) that have a mouldy smell or obvious mould growth. Also tuberculosis and aspergillosis have been reported in cattle with underlying mycotic lymphadenitis (Zmeili and Soubani 2007).

In cows, the gastrointestinal tract (omasum) is the primary site of mycotic lesions caused by *A. fumigatus* which produces mycotoxicosis such as gliotoxin and tremorgens that are toxic to cattle and cause deterioration, protein deficiency, malnutrition, diarrhoea, irritability, abnormal behaviour and occasionally death (Tresallet et al. 2010).

Moreover, a neurological syndrome in dairy cattle associated with consumption of contaminated foodstuffs by strains of *A. clavatus* has been described. *A. clavatus* is known to produce several tremorgenic metabolites such as patulin and clavatul that are selectively neurotoxic to animals. Enilconazole antifungal is recommended for use in animals against aspergillosis by wash lesions with 0.2% solution 4 times at 3 to 4 days intervals (Seyedmousavi et al. 2013; Finnie et al. 2011).

1.3.4 Mycotic Mastitis

Bovine mastitis is a disease caused by a wide variety of microorganisms such as *A. fumigatus*, *Candida albicans*, *C. kefyr*, *Cryptococcus neoformans*, *Trichosporon*, *Toluroopsis*, *Prototheca zopfii*, *Trichosporon mucoides* and *Saccharomyces* species, but mastitis due to filamentous fungi mostly *A. fumigatus* has been reported occurring as sporadic cases affecting a small percentage of cows or as outbreaks affecting the majority of animals. However, the disease causes large economical losses and damages to the dairy industry (Pachauri et al. 2013; Adebisi and Oluwayelu 2018).

Antibiotic therapy, micronutrient inadequacy especially vitamin A and zinc, contamination of teat dips, intramammary infusions, mouldy surroundings, feed and fodder algal contamination by *Prototheca zopfii*, pollution of drinking water and livestock grazing polluting regions with sludge are the most common factors of disease prevalence. In addition, *Candida* spp. were included in mycotic cases of bovine mastitis especially *C. glabrata* and *C. krusei* (Pachauri et al. 2013; Adebisi and Oluwayelu 2018).

On the other hand, samples from the subclinical mastitis group showed a diversity of *Candida* species, including *C. zeylanoides*, *C. norvegica*, *C. viswanathii*, *C. guilliermondii*, *C. crusei* and *C. tropicalis* (Elad et al. 1995; Malinowski et al. 2001; Dudko et al. 2010). Mastitis symptoms include abnormalities such as a watery appearance of milk, flakes, clots or pus in milk.

Also, the disease can be identified by external symptoms such as swelling, heat, redness, hardness or pain of the udder. Nystatin, sulfadiazine and prednisolone are the main antifungal drugs for mycotic mastitis; it is taken two times daily, for a single period of seven consecutive days. In addition, mastitis control and prevention requires an effort in improving the milking system, cattle feeding and hygiene, housing conditions and breeding policy (Geraldo et al. 2012; Kuria and Gathogo 2013).

1.3.5 Sporotrichosis

Sporotrichosis is a subacute or chronic infection caused by the saprophytic thermophilic fungus *Sporothrix schenckii* and *Sporothrix chilensis* that are found worldwide in high-humidity and high-temperature regions and river valleys. The disease is caused by members of the fungal genus *Sporothrix* of *Ophiostomataceae* family and order *Ophiostomatales*.

However, *S. schenckii* is now known to contain several individual species including *S. schenckii* sensu stricto, *S. brasiliensis*, *S. globosa*, *S. luriei*, *S. mexicana*, *S. pallida*, *S. albicans*, *S. nivea*, *S. stylites*, *S. humicola*, *S. chilensis*, *S. splendens*, *S. narcissi* and *S. inflata* complex (Aiello and Moses 2016; Rodrigues et al. 2016a).

These species were normally growing as saprophytes in the environment and may be present on vegetation and inorganic debris and soil. When fungal spores are accidentally inoculated into the skin (most often via sharp pieces of vegetation), some species of *Sporothrix* transform from filamentous moulds into yeasts and proliferate. In most cases, these organisms remain confined to the skin and lymphatic, causing relatively superficial lesions such as erythematous nodules, ulcers and plaques (Téllez et al. 2014; Rodrigues et al. 2016b).

Without treatment, these lesions may persist for months or years, or even indefinitely. Uncommonly, the organisms invade deeper tissues, including bone, joints and various internal organs, or disseminate widely in the skin. Disseminated infections, including rare instances of pulmonary sporotrichosis from inhaled organisms, can be life-threatening (Zhou et al. 2014; Zhang et al. 2015).

However, various antifungal drugs, such as itraconazole, ketoconazole, amphotericin B and fluconazole, have been used to treat sporotrichosis in animals at least one month. In addition, potassium or sodium iodide can also be employed in the cutaneous or lymphocutaneous forms. Other treatments that have been used in cutaneous sporotrichosis, either alone or in conjunction with antifungal drugs, include surgical removal, cryotherapy and thermotherapy (Rodrigues et al. 2014; Borba-Santos et al. 2015).

1.3.6 *Paracoccidioidomycosis*

Geographically, the disease occurs most commonly in Latin America, Brazil, Colombia, Venezuela and Argentina and around humid forests (subtropical or tropical). Among domestic animals, positivity rates have been reported to be higher in equines (64%) than sheep (41%) and cattle (40%) (Costa et al. 1995; Mendes et al. 2017a).

Paracoccidioidomycosis disease is an acute to chronic systemic infection caused by a thermally dimorphic fungus *Paracoccidioides brasiliensis* and *Blastomyces dermatitidis* (Elad et al. 1995). The natural habitat of *P. brasiliensis*, its environmental niche and life cycle in nature remain unknown, but it is presumed that the fungus is able to survive and proliferate in the soil, from where it has previously been isolated. However, many factors such as human migration, expansion of agricultural frontiers, climate and environmental changes as well as modifications in agricultural and social practices are beginning to influence the occurrence of infection and disease induced by *Paracoccidioides* spp. (Bagagli et al. 2006; Mendes et al. 2017b).

The disease has been shown to occur in several species of domestic and wild animals and is transmitted in an airborne manner, in animals, by inhalation of infective conidia present in the environment or through injuries of the skin and mucous membranes. This systemic granulomatous disease can affect any organ in the body, predominantly the lungs, organs rich in mononuclear phagocyte system cells, the mucous membrane of the upper aerodigestive tract and the skin and adrenal glands. Sulfonamides, ketoconazole, amphotericin B and itraconazole are the most common antifungal drugs indicated in the treatment of paracoccidioidomycosis (Travassos et al. 2008; Martinez 2015).

1.3.7 *Fungal Abortions*

The disease is a widespread disease in many regions of the world, causing significant economic losses. At that, mycotic abortion or mycotic placentitis is caused by many fungi and yeast and is a cosmopolitan, sporadic infection of the genital tract of animals, particularly the cows. Among the fungi, *Aspergillus fumigatus* and *Mortierella wolffii* are identified as the cause of bovine abortion in over 60% of the cases; they have a distinct seasonal pattern and occurring especially in the summer (Al Humam 2014; Pal 2015).

However, zygomycetes including *Absida*, *Mortierella*, *Rhizomucor* and *Rhizopus* accounted for about 20% of cases, and the remaining 20% were caused by a wide range of opportunistic filamentous fungi and yeasts, but the exact mode of transmission of infection is not known. The fungus can be isolated from foetal stomach contents and foetal internal organs on mycological media. *Mortierella* abortion is usually associated with feeding of silage with a higher than optimal pH and eating mouldy hay, grass, straw, etc. (Al Humam 2014; Pal 2015).

Table 1.3 Dual mycotic infections of bovine abortion causative fungi demonstrated in placental tissues (Pal 2015)

<i>Aspergillus flavus</i>	+ <i>Absidia corymbifera</i>
<i>Aspergillus fumigatus</i>	+ <i>Absidia corymbifera</i>
<i>Aspergillus fumigatus</i>	+ <i>Rhizomucor pusillus</i>
<i>Aspergillus fumigates</i>	+ <i>Rhizopus arrhizus</i>
<i>Candida albicans</i>	+ <i>Mucor</i>
<i>Emericella nidulan</i>	+ <i>Absidia corymbifera</i>

Aborting cattle may subsequently develop a fatal mycotic pneumonia after haematogenous spread from the placenta or uterus. In addition, the common environmental *Mucor/Absidia* fungi are sporadic cases of abortion, in cattle. Also, they are reported to be among the secondary invaders in cases of mycotic rumenitis and enteritis in cattle, though they are rarely cultured (Mangiaterra et al. 1999; Gaastra et al. 2010).

Despite the seriousness of the disease, no antifungal chemotherapeutic agent is recommended for the treatment of mycotic abortion in bovine. However, the treatment of hay with fungicides during haymaking is essential to prevent the growth of fungi, and the animals should be kept in clean, well-ventilated, hygienic and dry sheds/byres/pens as humidity favour the development of many fungal pathogens (Mangiaterra et al. 1999; Gaastra et al. 2010) (Table 1.3).

1.3.8 Cutaneous Pythiosis

The disease has been reported in several regions of tropical, subtropical and temperate climate, more particularly in swamps or flooded areas, and it has also been reported in Southern USA, Mexico, Venezuela, Brazil, Africa, Asia, Australia and New Zealand. This disease occurs in sporadic and epidemic form in several domestic animal species, such as canine, bovine, cats, sheep, dogs and tropical animals.

Pythiosis insidiosus is an emerging tropical disease silently killing, caused by the oomycete *Pythium insidiosum* which is a fungus-like organism that, in contrary to other species of *Pythium*, shows pathogenicity to several animal classes (Ono et al. 2001; Pal and Mahendra 2014). Infection source is exogenous through aquatic environments where the organisms live as a saprobe. Hence, pythiosis can be considered as a waterborne para-fungal disease. This disease is characterized by granulomatous ulcerative lesions, mainly in cutaneous and subcutaneous tissues, and it may be life-threatening in some cases (Pal and Mahendra 2014).

In animals such as cats, dogs, horses and cattle, pythiosis is an osseous, subcutaneous or pulmonary infection. Equine pythiosis is marked by chronic ulcerated lesions with numerous yellow coral-like bodies (“kunkers”) on the limbs, chest and abdomen. In addition, dogs and horses may also present with intestinal obstruction due to *Pythium granuloma* in the duodenum or jejunum.

Thus, the common sites of infection in animals are cutaneous/ subcutaneous tissues and the gastrointestinal tract. In addition, this filamentous organism initially affects the skin, and subcutaneous tissues, but can involve adjacent tissues like tendons, ligaments, and bone and invade the gastrointestinal tract or other tissues, and organs, resulting in multisystemic disease (Martins et al. 2012; Granta et al. 2016).

The incubation period of pythiosis is not clearly defined, but the disease is more likely to develop weeks to months after exposure with a contaminated environment. The conventional treatment of the cutaneous form is aggressive surgery and limb amputation, but it cannot be indicated to all anatomical sites, due to the requirement of a large margin resection. The difficulty in detecting the hyphae infection in the tissue results in high recurrence rates.

Antifungal drugs are ineffective for the treatment of pythiosis, because *Pythium* species may lack the drug-target ergosterol. Recently, a new group of antifungal drugs such as caspofungin, micafungin or anidulafungin is applied. The immunotherapeutic vaccine is another treatment option because the favourable outcomes were observed in some patients and animals. However, the vaccine efficacy is usually limited (Pires et al. 2014).

1.3.9 *Pithomycotoxicosis*

The disease has appeared in many parts of the world such as New Zealand, Australia, South Africa, France, Spain, Uruguay, Argentina and Brazil, especially in temperate zones. It is called facial eczema or facial dermatitis, caused by the ingestion of high quantity of *Pithomyces chartarum* spores during grazing, which contain a potent hepatotoxin named sporidesmin that was absorbed into the portal bloodstream and taken to the liver where it generates oxygen free radicals which damage cell membranes, causing inflammation and destruction of animal tissues (Di Menna et al. 2009).

Animal deaths, condemnations of jaundiced carcasses, loss of body weight and reduced fertility in sheep and lower milk yields in dairy cattle are the economic losses of this disease. The saprophytic fungus *P. chartarum* grows on dead vegetable matter at the base of the pasture and proliferate in warm, humid weather and light rain (in late summer and autumn), where hepatotoxin production causes pericholangitis and the occlusion of bile ducts, resulting in a reduction in the excretion of phylloerythrin, a photodynamic metabolite produced by the microbial degradation of chlorophyll in the rumen (Pinto et al. 2005; Di Menna et al. 2009).

Sporidesmin is released from ingested spores in the upper digestive tract, absorbed into the portal bloodstream and taken to the liver, where it generates oxygen free radicals which damage cell membranes. Thus, gastrointestinal disorders are the first signs of intoxication in affected animals, where the second sign is characterized by high plasma levels of phylloerythrin and the animal becomes sensitive to sunlight (photosensitization) especially on more exposed and non-pigmented areas of skin (Parkinson et al. 2010; Little et al. 2011).

In addition, cholangiohepatitis, ductal hyperplasia and fibrosis are also seen histologically. Control method of facial eczema was by avoiding toxic pasture, detected by *P. chartarum* spore counts on herbage; later by reducing fungus pasture populations by spray application of substituted thiabendazole fungicides and later still by protecting animals with oral doses of zinc at close to toxic levels. In addition, animals can be protected against ingested sporidesmin by zinc salts (zinc oxide or zinc sulphate) (Toth et al. 2007; Read et al. 2016).

1.3.10 Zygomycosis (*Mucormycosis*)

Zygomycosis is deep, progressive and rapidly invasive subcutaneous mycosis caused by fungi that belong to the class *Zygomycetes* (including *Entomophthorales* and *Mucorales*). Geographically, zygomycosis occurs mostly in tropical and subtropical areas (Americas, Australia, Asia and Africa) (Jensen et al. 1994; Richardson 2009).

The disease is caused by moulds belonging to the order *Mucorales*, *Mucoraceae* family, which subdivides into the genera *Lichtheimia*, *Absidia*, *Mucor*, *Rhizomucor* and *Rhizopus*. In addition, only a few cases of infection have been reported by the other groups of *Mucorales* such as *Cunninghamellaceae* (*Cunninghamella bertholletiae* spp.) and the *Saksenaceae* (*Saksenaea vasiformis*), *Mortierellaceae* (*Mortierella* spp.) and *Syncephalastraceae* (*Syncephalastrum racemosum*) (Jensen et al. 1994; Richardson 2009).

Mucorales are thermo-tolerant moulds that are ubiquitous in nature and are widely found on organic substrates, including bread, decaying fruits, vegetable matter and crop debris, normal soils between growing seasons, compost piles and animal excreta. However, zygomycosis is predominantly transmitted by inhalation, ingestion or traumatic inoculation of spores, whereas the highest levels of fungal spores were found in the autumn and summer, and the lowest in the winter and spring (Pal 2000, 2007).

Thereby, inhalation of spores into the nasal cavity from the dusty environment produces disease in the susceptible host. Infection occurs through contact of traumatized or abraded skin or wound with fungi that contaminated objects, and cutaneous zygomycosis results from inoculation of fungal spores into the dermis (Pal 2000, 2007; Katharine et al. 2016). In addition, mucormycosis or phycomyces manifestations include abortion, mastitis, gastrointestinal infections, pneumonia, cutaneous lesions and disseminated diseases. The treatment of this disease involves surgical debridement and elimination of infected and necrotic tissues and the use of liposomal amphotericin B and posaconazole antifungal drugs (Jensen et al. 1996; Greenberg et al. 2004; Pal 2015; Pal et al. 2015).

Acknowledgements I am very grateful to series editors Gupta, Vijai Kumar, Tuohy and Maria G for providing me the opportunity to participate in the preparation of this book.

References

- Abdisa T (2017) Review on equine epizootic lymphangitis and its impact in Ethiopia. *J Vet Med Res* 4(5):1087
- Adebiyi AI, Oluwayelu DO (2018) Zoonotic fungal diseases and animal ownership in Nigeria. *Alex J Med* 54(4):397–402. <https://doi.org/10.1016/j.ajme.2017.11.007>
- Aiello S E, Mays A (2016) The Merck veterinary manual, 11th edn. Published by Wiley, 3326 pages
- Aiello SE, Moses MA (2016) The Merck veterinary manual, 11th edn. Merck and Co, Kenilworth, NJ. Sporotrichosis, *Sporothrix schenckii*. p 644–5, 1863
- Al Humam NA (2014) An epidemic of abortion in a commercial dairy farm in the eastern region, Kingdom of Saudi Arabia. *Global J Dairy Farm Milk Prod* 2:74–80
- Bagagli E, Bosco SM, Theodoro RC, Franco M (2006) Phylogenetic and evolutionary aspects of *Paracoccidioides brasiliensis* reveal a long coexistence with animal hosts that explain several biological features of the pathogen. *Inf Gen Evol* 6(5):344–351. <https://doi.org/10.1016/j.meegid.2005.12.002>
- Bakr EM, Abd El-Tawab AM, Elshemey TM, Abd El- Rhman AH (2015) Diagnostic and therapeutic studies on mycotic mastitis in cattle. *Alex J Vet Sci* 46(1):138–145. <https://doi.org/10.5455/ajvs.189682>
- Borba-Santos LP, Rodrigues AM, Gagini TB, Fernandes GF, Castro R, de Camargo ZP, Nucci M, Lopes-Bezerra LM, Ishida K, Rozental S (2015) Susceptibility of *Sporothrix brasiliensis* isolates to amphotericin B, azoles, and terbinafine. *Med Mycol* 53(2):178–188. <https://doi.org/10.1093/mmy/myu056>
- Cockcroft P (2015) Bovine medicine, 3rd edn. Published by Wiley, 656 pages
- Costa EO, Diniz LS, Netto CF (1995) The prevalence of positive intradermal reactions to paracoccidioidin in domestic and wild animals in São Paulo, Brazil. *Vet Res Commun* 19(2):127–130. <https://doi.org/10.1007/bf01839278>
- Di Menna ME, Smith BL, Miles CO (2009) A history of facial eczema (pithomycotoxicosis) research. *N Z J Agr Res* 52:345–376. <https://doi.org/10.1080/00288230909510519>
- Dudko P, Kostro K, Kurpisz M (2010) Adaptation of Microstix®-*Candida* slide-test for diagnosis of bovine mastitis. *Acta Vet Brno* 79:113–120. <https://doi.org/10.2754/avb201079010113>
- Elad D, Shpigler NY, Winkler M, Klinger I, Fuchs V, Saran A, Faingold D (1995) Feed contamination with *Candida crusei* as probable source of mycotic mastitis in dairy cows. *J Am Vet Med Assoc* 207(5):620–622
- Finnie JW, Windsor PA, Kessell AE (2011) Neurological diseases of ruminant livestock in Australia. II: toxic disorders and nutritional deficiencies. *Aust Vet J* 89(7):247–253
- Gaastra W, Lipman LJA, Cock DE, Exel TK, Pegge RBG, Scheurwater J, Vilela R, Mendoza L (2010) *Pythium insidiosum*. *Vet Microbiol* 146(1–2):1–16. <https://doi.org/10.1016/j.vetmic.2010.07.019>
- Gabal MA (1984) The effect of amphotericin B, 5-fluorocytosine and nystatin on *Histoplasma farciminosum* in vitro. *Zentralbl Veterinarmed B* 31(1):46–50. <https://doi.org/10.1111/j.1439-0450.1984.tb01279.x>
- Geraldo MC, Ulisses de P, Aparecida GM, Nivaldo da S (2012) Yeast mastitis outbreak in a Brazilian dairy herd. *Braz J Vet Res Anim Sci*, São Paulo 49(3):239–243
- Granta D, Glassb R, Hansenc R, Vilelad R, Mendozae L (2016) Cutaneous pythiosis in a Red Brangus beef calf cured by immunotherapy. *Med Mycol Case Rep* 14:1–3. <https://doi.org/10.1016/j.mmcr.2016.11.005>
- Greenberg RN, Scott LJ, Vaughn HH (2004) Zygomycosis (mucormycosis): emerging clinical importance and new treatment. *Curr Opin Infect Dis* 17(6):517–525. <https://doi.org/10.1097/00001432-200412000-00003>
- Jensen HE, Olsen SN, Aalbaek B (1994) Gastrointestinal aspergillosis and zygomycosis of cattle. *Vet Pathol* 31(1):28–36. <https://doi.org/10.1177/030098589403100104>

- Jensen HE, Aalbek B, Lind P, Krogh V (1996) Immunohistochemical diagnosis of systemic bovine zygomycosis by murine monoclonal antibodies. *Vet Pathol* 33(2):176–183. <https://doi.org/10.1177/030098589603300207>
- Katharine R, Gyeong-Dong L, Ji-Hoon J, Kyung-Min S, Eun-Seob S, Ravi G, Chang-Yul K, Kyungsuk L, Seungwon S, Han-Sang Y, Yong H, Hyoung-Ah K (2016) Epizootiological characteristics of viable bacteria and fungi in indoor air from porcine, chicken, or bovine husbandry confinement buildings. *J Vet Sci* 17(4):531–538. <https://doi.org/10.4142/jvs.2016.17.4.531>
- Kuria JKN, Gathogo SM (2013) Concomitant fungal and *Mycobacterium bovis* infections in beef cattle in Kenya. *Onderstepoort J Vet Res* 80(1) Art. #585, 4 pages. <https://doi.org/10.4102/ojvr.v80i1.585>
- Little S, Malmo J, Debenham A, Cullen N, Mulvaney C, Sawyer I, Archibald H, Norwood P, Van Wees H (2011) A review of facial eczema (pithomycotoxicosis). Dairy Australia, Australia, 36 pages. ISSN: 978-0-646-91438-1
- MacEachern S, McEwan J, McCulloch A, Mather A, Savin K, Goddard M (2009) Molecular evolution of the Bovini tribe (Bovidae, Bovinae): is there evidence of rapid evolution or reduced selective constraint in domestic cattle? *BMC Genomics* 10:179. <https://doi.org/10.1186/1471-2164-10-179>
- Malinowski E, Kłosowska A, Lassa H (2001) Variability among etiological agents of mastitis in cows. *Pol J Vet Sci* 4:41–44
- Mangiaterra ML, Giusiano GE, Alonso JM, Gorodner JO (1999) *Paracoccidioides brasiliensis* infection in a subtropical region with important environmental changes. *Bull Soc Pathol Exot* 92(3):173–176
- Martinez R (2015) Epidemiology of paracoccidioidomycosis. *Rev Inst Med Trop Sao Paulo* 57(19):11–20. <https://doi.org/10.1590/S0036-46652015000700004>
- Martins TB, Kommers GD, Trost ME, Inkelmann MA, Figuera RA, Schild AL (2012) A comparative study of the histopathology and immunohistochemistry of pythiosis in horses, dogs and cattle. *J Comp Pathol* 146(2–3):122–131. <https://doi.org/10.1016/j.jcpa.2011.06.006>
- Mendes JF, Klafke GB, Albano AP, Cabana ÂL, Teles AJ, de Camargo ZP, Xavier MO, Meireles MCA (2017a) Paracoccidioidomycosis infection in domestic and wild mammals by *Paracoccidioides lutzii*. *Mycoses* 60(6):402–406. <https://doi.org/10.1111/myc.12608>
- Mendes RP, Cavalcante RS, Marques SA, Marques MEA, Venturini J, Sylvestre TF, Mi PAM, Pereira AC, da Silva JF, Fabro AT, Bosco SMG, Bagagli E, Hahn RC, Levorato AD (2017b) Paracoccidioidomycosis: current perspectives from Brazil. *Open Microbiol J* 11:224–282. <https://doi.org/10.2174/1874285801711010224>
- Mignon B, Monod M (2011) Zoonotic infections with dermatophyte fungi. In: Palmer L, Soulsby L, Torgerson P, David WGB (eds) *Textbook of Zoonoses: biology, clinical practice, and public health control*, 2nd edn. Oxford University Press, New York. <https://doi.org/10.1093/med/9780198570028.003.0077>
- Nweze EI (2011) Dermatophytoses in domesticated animals. *Rev Inst Med Trop Sao Paulo* 53(2):94–99. <https://doi.org/10.1590/s0036-46652011000200007>
- Ono MA, Bracarense APFRL, Morais HSA, Trapp SM, Belitardo DR, Camargo ZP (2001) Canine paracoccidioidomycosis: a seroepidemiologic study. *J Med Mycol* 39(3):277–282. <https://doi.org/10.1080/mmy.39.3.277.282>
- Pachauri S, Varshney P, Dash SK, Gupta MK (2013) Involvement of fungal species in bovine mastitis in and around Mathura India. *Vet World* 6(7):393–395. <https://doi.org/10.5455/vetworld.2013.393-395>
- Pal M (2000) Zygomycosis: Amycotic zoonosis. *Veterinarian* 24:14
- Pal M (2007) *Veterinary and medical mycology*, 1st edn. Indian Council of Agricultural Research Institute, New Delhi, 401 pages
- Pal M (2015) Growing role of fungi in mycotic abortion of domestic animal. *J Bacteriol Mycol* 2(1):1009
- Pal M, Mahendra R (2014) Pythiosis: an emerging oomycetic disease of humans and animals. *Int J Livestock Res* 4(6):1–9. <https://doi.org/10.5455/ijlr.20140929104047>

- Pal M, Parthiba D, Raj M, Samajpati N, Manna K (2015) Zygomycosis: an emerging and re-emerging life threatening mycosis of humans and animals. *J Botan Soc Bengal* 69(2):127–132
- Papini R, Nardoni S, Fanelli A, Mancianti F (2009) High infection rate of *Trichophyton verrucosum* in calves from Central Italy. *Zoon Pub Health* 56(2):59–64. <https://doi.org/10.1111/j.1863-2378.2008.01157.x>
- Parkinson TJ, Vermunt JJ, Malmo J (2010) Diseases of cattle in Australasia: a comprehensive textbook. New Zealand Veterinary Association Foundation for Continuing Education, Wellington, 849 pages
- Pinto C, Santos VM, Dinis J, Peleteiro MC, Fitzgerald JM, Hawkes AD, Smith BL (2005) Pithomycotoxicosis (facial eczema) in ruminants in the Azores, Portugal. *Vet Rec* 157(25):805–810. <https://doi.org/10.1136/vr.157.25.805>
- Pires L, Bosco Sd MG, Baptista MS, Kurachi C (2014) Photodynamic therapy in *Pythium insidiosum*: an *in vitro* study of the correlation of sensitizer localization and cell death. *PLoS One* 9(1):e85431. <https://doi.org/10.1371/journal.pone.0085431>
- Puntunney SB, Wang Y, Forsberg NE (2003) Mycotic infections in livestock: recent insights and studies on etiology, diagnostics and prevention of hemorrhagic bowel syndrome, In: Southwest Nutrition and Management Conference, Phoenix, University of Arizona, Department of Animal Science, Tucson, p. 4963
- Radostits O, Gay C, Hinchcliff KW, Constable PD (2007) Veterinary medicine. A textbook of the diseases of cattle, horses, sheep, pigs, and goats, 10th edn. Saunders Elsevier, Edinburgh, 2065 pages. ISBN 9780702039911
- Read E, Edwards J, Deseo M, Rawlin G, Rochfort S (2016) Current understanding of acute bovine liver disease in Australia. *Toxins (Basel)* 9(1):8. <https://doi.org/10.3390/toxins9010008>
- Richardson M (2009) The ecology of the Zygomycetes and its impact on environmental exposure. *Clin Microbiol Infect* 15(5):2–9. <https://doi.org/10.1111/j.1469-0691.2009.02972.x>
- Rochette F, Engelen M, Vanden Bossche H (2003) Antifungal agents of use in animal health: practical applications. *J Vet Pharmacol Ther* 26(1):31–53. <https://doi.org/10.1046/j.1365-2885.2003.00457.x>
- Rodrigues AM, de Hoog GS, de Cassia Pire D, Brihante RSN, da Costa Sidrim JJ, Gadelha MF et al (2014) Genetic diversity and antifungal susceptibility profiles in causative agents of sporotrichosis. *BMC Infect Dis* 14(1):219. <https://doi.org/10.1186/1471-2334-14-219>
- Rodrigues AM, de Hoog GS, de Camargo ZP (2016a) *Sporothrix* species causing outbreaks in animals and humans driven by animal–animal transmission. *PLoS Pathog* 12(7):e1005638. <https://doi.org/10.1371/journal.ppat.1005638>
- Rodrigues AM, Cruz Choappa R, Fernandes GF, De Hoog GS, Camargo ZP (2016b) *Sporothrix chilensis* sp. nov. (Ascomycota: Ophiostomatales), a soil-borne agent of human sporotrichosis with mild-pathogenic potential to mammals. *Fungal Biol* 120(2):246–264. <https://doi.org/10.1016/j.funbio.2015.05.006>
- Seyedmousavi S, Guillot J, de Hoog GS (2013) Phaeohyphomycoses, emerging opportunistic diseases in animals. *Clin Microbiol Rev* 26(1):19–35. <https://doi.org/10.1128/CMR.00065-12>
- Seyedmousavi S, Guillot J, Arne P, de Hoog GS, Mouton JW, Melchers WJG, Verweij PE (2015) *Aspergillus* and aspergilloses in wild and domestic animals: a global health concern with parallels to human disease. *Med Mycol* 53(8):765–797. <https://doi.org/10.1093/mmy/myv067>
- Spesivtseva NA, Noskov AI (1959) Epizootic lymphangitis in camels. *Trudy Vses Institute Vet Sanit Ectopar* 14:86
- Swai ES, Sanka PN (2012) Bovine dermatophytosis caused by *Trychophyton Verrucosum*: a case report. *Vet World* 5(5):297–300. <https://doi.org/10.5455/vetworld.2012.297-300>
- Téllez MD, Batista-Duharte A, Portuondo D, Quinello C, Bonne-Hernández R, Carlos IZ (2014) *Sporothrix schenckii* complex biology: environment and fungal pathogenicity. *Microbiol* 160(Pt11):2352–2365. <https://doi.org/10.1099/mic.0.081794-0>
- Toth B, Csosz M, Dijksterhuis J, Frisvad JC, Varga J (2007) *Pithomyces chartarum* as a pathogen of wheat. *J Plant Pathol* 89(3):405–408

- Travassos LR, Taborda CP, Colombo AL (2008) Treatment options for paracoccidioidomycosis and new strategies investigated. *Expert Rev Anti-Infect Ther* 6(2):251–262. <https://doi.org/10.1586/14787210.6.2.251>
- Tresallet C, Seman M, Hoang C et al (2010) Gastric perforation from potential primary digestive aspergillosis. *Surgery* 148(1):158–159
- Wilson DE, Reeder DM (2005) Mammal species of the world. A taxonomic and geographic reference, 3rd edn. Johns Hopkins University Press, Baltimore. 2142 pages. ISBN 0-8018-8221-4
- Zhang Y, Hagen F, Stielow B, Rodrigues AM, Samerpitak K, Zhou X, Feng P, Yang L, Chen M, Deng S, Li S, Liao W, Li R, Li F, Meis JF, Guarro J, Teixeira M, Al-Zahrani HS, Pires de Camargo Z, Zhang L, de Hoog GS (2015) Phylogeography and evolutionary patterns in *Sporothrix* spanning more than 14,000 human and animal case reports. *Persoonia* 35:1–20. <https://doi.org/10.3767/003158515X687416>
- Zhou X, Rodrigues AM, Feng P, Hoog GS (2014) Global ITS diversity in the *Sporothrix schenckii* complex. *Fungal Divers* 66(1):153–165. <https://doi.org/10.1007/s13225-013-0220-2>
- Zmeili OS, Soubani AO (2007) Pulmonary aspergillosis: a clinical update. *Q J Med* 100(6):317–334. <https://doi.org/10.1093/qjmed/hcm035>

Chapter 2

Mycotoxins and Their Consequences in Livestock



Jacklin Mary Anthony, Monika Asthana, and Avnish Kumar

2.1 Introduction

Mycotoxins are secondary metabolites of a fungus that produce toxic effects in another organism. These show high cytotoxic effect by disrupting cell structures such as membranes, and processes such as protein, DNA and RNA synthesis. They have low molecular weight (approximately 700 Da) but vary in structure and from species to species. These toxins could be present with destructive cytotoxicity in an organism even after removal of fungal pathogen. Thus, lack of visible appearance of fungus does not negate presence of mycotoxins. They are observed in cereal grains as well as nuts, coffee, cocoa, spices, oil seeds, dried peas, beans and fruit before, during and after harvest, in various environmental conditions (Abdel-Wahhab and Kholif 2008).

Mycotoxins are specific to temperate and tropical region based on the presence of fungi in the area. It has been estimated that about 25% of all crops worldwide are affected by moulds or fungi (Binder 2007) mainly during storage. The absence of mould or fungi is not a guarantee of mycotoxin-free crop as these can be present intact in a crop even after the producer fungi is dead. Mycotoxins may be heat stable and these cannot be destroyed by canning or other processes.

The term “mycotoxin” become highly important after death of thousands of turkeys in 1962 near London, England, due to the mysterious turkey X disease which was later linked to feeding of peanut (groundnut) contaminated with secondary metabolites of *Aspergillus flavus* (Pitt 2013). These mycotoxins called aflatoxins

J. M. Anthony

Escola Superior Agrária de Coimbra (ESAC), IPC, Coimbra, Portugal

M. Asthana · A. Kumar (✉)

Department of Biotechnology, School of Life Sciences, Dr. Bhimrao Ambedkar University, Agra, UP, India

© Springer Nature Switzerland AG 2021

A. Gupta, N. Pratap Singh (eds.), *Fungal Diseases in Animals*, Fungal Biology,
https://doi.org/10.1007/978-3-030-69507-1_2

(AF) from *A. flavus* were the first mycotoxins to be identified in 1965. The well-known antibiotic penicillin is also a mycotoxin (Speight 2012).

Mycotoxin-producing moulds belong to the genera *Aspergillus*, *Penicillium* and *Fusarium*. Till date, there are about 200 fungal species known to produce more than 400 mycotoxins (Liew and Mohd-Redzwan 2018). Some of the most agriculturally important mycotoxins, i.e. aflatoxins, fumonisins, trichothecenes, ochratoxins, sterigmatocystins (STCs) and zearalenones (ZEAs), are the only few mycotoxins being regulated or tested routinely (Streit et al. 2013; Wu et al. 2014; Urusov et al. 2015; Anfossi et al. 2016) despite the regular discovery of new ones. In addition, some mycotoxins (named as masked mycotoxins, e.g. zearalenone–glycoside) cannot be identified in these routine testing because of their modification after conjugation with plant metabolites (Anfossi et al. 2016). These masked or hidden mycotoxins get freed from conjugated molecules in human or animal alimentary canal and have shown their toxic effects (Liew and Mohd-Redzwan 2018). Children also have variation in immunological and physiological sensitivity to neurotoxins including endocrine susceptibility. It makes them more vulnerable to the toxicity of mycotoxins (Raiola et al. 2015). The exposure of mycotoxins and their economic impact on human and animal health are a global concern compounded by a range of regulatory challenges which often vary among countries. The effects of mycotoxins for a specific dose are more on children due to their lower body weight as compared to adults.

Secondary metabolite production in fungi may be by one of many metabolic pathways, for instance *Trichothecenes*, which are produced by the terpene pathway and rubratoxin by the tricarboxylic acid pathway. Some like aflatoxins may be produced by more than one route, e.g. the polyketide or amino acid pathway. Some are produced by a combination of routes as in the case of cyclopiazonic acid. In the host body mycotoxins may be removed by either bioactivation or detoxification. Detoxification occurs via enzyme-mediated biotransformation. These enzymes are induced endogenous enzymes including CYP450 isoforms and other enzymes of the host cells or digestive microbial flora. At lower concentration of toxins, these enzymes can alter the toxin to make its elimination through urine, faeces and milk feasible. At higher concentrations, toxins strongly inhibit this type of induction and may become fixed in animal or human tissues. Some of their metabolites like metabolite of AFB1, i.e. AFBO and FB1, lead to carcinogenesis by direct binding to or alteration of DNA. The accumulation of mycotoxins and their metabolites can elicit oxidative stress and alterations in the mitochondrial number and function that further impose adverse effects on cell metabolism by DNA damage and genome instability, cell cycle arrest, changes of cell organization and morphology, apoptosis and cell death (Wen et al. 2016).

Mycotoxin-contaminated forage highly affects the feed intake by animal and makes them weaker. Additionally, the remaining residues of mycotoxins in edible animal products, milk, meat and offal, could show detrimental effects on human health. Thus, various international agencies like WHO, European Food Safety Authority (EFSA), International Programme on Chemical Safety (IPCS), Food and Drug Administration (USA), etc. have set maximum tolerance limits for these in

feeds and milk. Experimental testing indicated refusal of toxic dose at 4–5 ppm deoxynivalenol (a trichothecene) in feed in dogs (Beagles and Brittany spaniels) and 7.5 ppm in cats. Vomiting in dogs and cats at 8–10 mg/kg concentration range has been observed. Anecdotal incidences of vomiting and feed refusal (breeds not specified) were also seen at approximately 1 to 4 ppm vomitoxin concentrations (Talcott 2013).

Mycotoxins rarely cause death in animals but manifest minor chronic troubles. There are several genetic, environmental and physiological factors which may interact in the pathogenesis shaping metabolism and toxicity which on exposure to a specific mycotoxin make diagnosis and confirmation of disease a challenge. After worldwide awareness about mycotoxin-caused illnesses, more than 100 countries have adopted regulations (van Egmond et al. 2007). Potential mycotoxicoses are better contained by rigorous testing of animal feed for fungal contamination apart from a strict control of how the feed is cultivated, harvested and stored. In most cases where the plant material is mild to moderately contaminated, mycotoxins can be diluted or even eliminated by suitable methods. Upon ingestion of contaminated feed by animals, efforts of reducing the bioavailability of mycotoxins in the GI tracts through adsorbents may be made.

2.2 Classification of Mycotoxins

Mycotoxins have been classified differently by researchers or groups according to their profession. Clinicians group mycotoxins based on affected organ as hepatotoxins, nephrotoxins, neurotoxins, immunotoxins and so forth. Cell biologists mention them as teratogens, mutagens, carcinogens and allergens. Organic chemists classify them by their chemical structures (e.g. lactones, coumarins). Biochemists give importance to biosynthetic origins and classify them as polyketides, amino acid derived, etc. Physicians name them by the illnesses they cause, e.g. St. Anthony's fire, stachybotryotoxicosis. Mycologists categorize them as per name of fungus producing them, e.g. *Aspergillus* toxins, *Penicillium* toxins, etc.

At present none of these classifications is entirely satisfactory. For example, aflatoxin is a hepatotoxic, mutagenic, carcinogenic, difuran-containing, polyketide-derived *Aspergillus* toxin. Zearalenone is a *Fusarium* metabolite with potent estrogenic activity. In this chapter let us focus on mycotoxins associated with food grains and ultimately mycotoxins which cause disease to human beings and livestock. The epidemic infections among livestock and humans are due to contaminated grain crop and their mycotoxins such as ergot alkaloids, aflatoxins and trichothecene. Several other mycotoxins together with ochratoxins, fumonisins, zearalenone and phomopsins causes infection mainly in livestock, but association with human diseases remains approved by scientific proof. Some of the major mycotoxins are classified below (Bennett and Klich 2003).

2.2.1 Aflatoxins

The first mycotoxin, aflatoxin, was recognized as a problem in Turkey's 'X' disease in UK poultry industry, and after killing more than 100,000 birds, it raised the research and economical importance of mycotoxins. Aflatoxins are potentially carcinogenic, mutagenic, immunosuppressive agents of fungi released by *Aspergillus flavus*, *A. parasiticus*, *A. fumigatus* and/or *Penicillium islandicum* in dried food and groundnut meal. They are identified as suspected causes of liver cancer in human beings. Other clinical symptoms due to aflatoxin poisoning are jaundice, portal hypertension, rapidly developing ascites, etc. Annually, aflatoxins can destroy an estimated 25% or more of the world's food crops; to minimize this economic loss, it is very important to determine even very low concentration in foods and feedstuff (https://www.who.int/foodsafety/FSDigest_Aflatoxins_EN.pdf visited on 28/12/2019). Many analytical techniques for aflatoxin detection as well as quantification have been described ranging from simpler thin-layer chromatography (TLC) to mass spectroscopy to the very sensitive high-performance liquid chromatography (HPLC). In the last few decades, enzyme-linked immunosorbent assay (ELISA) and electrochemical immunosensors have also been used for this purpose. About 18 variants of aflatoxins have been detected in food grains. The most abundant form is B₁ and other major forms are aflatoxin B₂, G₁ and G₂, while M₁ and M₂ are less significant (Wacoo et al. 2014).

2.2.2 Ochratoxins

Ochratoxins (OTAs) investigated initially in northern Europe and Africa in cereals are produced mainly by *Penicillium viridicatum* or *Aspergillus ochraceus* in maize, peanuts, beans, etc. OTAs are recognized as severely nephrotoxic which may become embryotoxic, teratogenic, and immunotoxic on further higher doses (Reddy and Bhoola 2010). OTAs are detected routinely by various methods adopted by individual laboratories. The detection methods are conventional chromatographic methods, high-performance liquid chromatography (HPLC), liquid chromatography tandem mass spectrometry (LC-MS/MS), affinity probe capillary electrophoresis (APCE) assay, fluorescein-tagged OTA aptamer (F-Apt-O)-based assays, immunoassays, enzyme-linked immunosorbent assays (ELISA), chemiluminescent ELISA and other OTA-specific DNA aptamer-related techniques. Aptamer-related techniques are comparatively newer detection methods with high sensitivity and accuracy (Ha 2015).

2.2.3 Zearalenone

Members of *Fusarium* such as *F. moniliforme* and *F. graminearum* produce zearalenone, a phenolic resorcylic acid lactone in maize and other cereals. Symptoms associated with zearalenone (ZEN) were first reported in the 1960s by two separate groups of investigators in livestock feed in swine in Minnesota, USA (Christensen et al. 1965). In 1963, herds of young swine in Minnesota had symptoms which included tumefaction of the vulva, prolapsed vagina and hypertrophy of the mammary glands. The feed was suspected for these symptoms and was given to guinea pigs and white rats which developed enlarged uteri, thus confirming the contamination in feed. The next year (1964), another group fed a swine herd with grain containing 30% mould-ridden corn and 70% sound corn and reported the development of similar symptoms. Mouldy corn contains two compounds which were initially coded as F1 and F2 (Christensen 1963). Of these, F1 tested as ergosterol (Christensen et al. 1965) and F2 as zearalenone (Urry 1966). Urry (1966) named F2 as zearalenone (ZEN) based on its structure and name of the producer fungus (*Fusarium graminearum*; teleomorph *Gibberella zeae*).

2.2.4 Trichothecenes

These are field toxins instead of storage toxins. Trichothecenes is a group of mycotoxins produced by members of genera *Fusarium*, *Myrothecium*, *Acremonium* (*Cephalosporium*), *Cylindrocarpon*, *Dendrodochium*, *Myrothecium*, *Trichoderma*, *Trichothecium* and *Stachybotrys* (Rai and Varma 2010; Bottalico and Perrone 2002). These mycotoxins can be identified in cereal crops such as wheat, barley, oats, rye, maize and rice (Yazar and Omurtag 2008) and other crops such as soybeans, potatoes, sunflower seeds, peanuts and bananas. These survive even processing of contaminated cereals for food preparation. Thus, it has been identified in bread, breakfast cereals, noodles and beer too (Bennett and Klich 2003). The mycotoxins are further classified into type A trichothecenes mainly including T-2, HT-2 and DAS and type B trichothecenes including DON, NIV, 3-acetyldeoxynivalenol and 15-acetyldeoxynivalenol (Ueno et al. 1975).

Trichothecenes have toxic effects on both humans and animals, manifested by subepidermal haemorrhage, several local irritations and cell or tissue necrosis. They are also responsible for anorexia, nausea, vomiting, gastroenteritis and haematological disorders (Pestka and Casale 1990). All trichothecenes attack the 60S ribosomal subunit, exhibiting toxicity through translational inhibition. They also inhibit synthesis of protein, RNA and DNA as well as mitochondrial and electron chain function. Inhibition of protein synthesis occurs through interference with peptidyl transferase activity. Trichothecenes can also stimulate lipid peroxidation, alter cell membrane function and neurotransmitter levels, induce

apoptosis and gene expression of numerous chemokines and cytokines, modulate immune responses as well as activate mitogen-activated protein kinases (MAPKs).

2.3 Factors Affecting the Growth of Mycotoxins

Based on growth conditions, there are three groups of factors – physical, chemical and biological – responsible for growth regulation of mycotoxins. These are discussed in some detail below.

2.3.1 Physical Factors

The locations of cereals or food are either field or storage house (cold stores, warehouse). The moisture and temperature as well as light intensity at these sites directly regulates the growth of fungi and ultimately mycotoxins.

2.3.1.1 Moisture

Moisture is involved in spore germination and growth of fungi. Saprophytic and decay fungi growing in the field require a higher moisture level in the substrate (22–25% wet weight) than those found in storage, if other factors are considered constant. Storage fungi can grow on substrates with 13–18% moisture level. Hesseltine (1976) experimentally suggested an optimal moisture level for aflatoxin formation in solid substrates. They were also germinated spores of rust fungi and *Helminthosporium* in distilled water.

2.3.1.2 Temperature

Sorenson et al. (1967) studied the effect of temperature on aflatoxin formation in rice and showed that it could be produced at about 11 °C to slightly above 36°C. Under these conditions aflatoxin G1 formation does not exactly parallel aflatoxin B formation. Although *Aspergillus* grows at temperatures ranging from 6–8 °C up to 44–45 °C; however at temperatures above 37 °C, no aflatoxin is formed.

2.3.2 Chemical Factors

2.3.2.1 CO₂

Sanders et al. (1968) studied the effect of CO₂ on peanuts sprayed with spores of a known aflatoxin-producing strain of *A. flavus* at varied relative humidity and CO₂ levels but constant temperature. The production of aflatoxin was greatly reduced at high CO₂ level and low relative humidity. At 60% CO₂, no visible growth or sporulation was observed at 86% relative humidity while fungal spore and hyphae were abundant in air at this humidity.

2.3.2.2 Oxygen

All mycotoxin-producing fungi can grow in an environment having 80% CO₂ and 20% O₂ (Taniwaki et al. 2010). A decrease in oxygen level affects growth and development of fungal hyphae and spore germination. However, the lack of O₂ does not mean that mycelia or spores are killed. A reduction of oxygen level while controlling other conditions like pH, temperature and moisture can degrade the aflatoxin. Thus, nuts can be preserved longer during storage by reducing O₂ level (Scussel et al. 2011).

2.3.2.3 Mineral Nutrition

Similar to other eukaryotic living beings, fungi need a number of trace elements such as iron and zinc in their nutrition. Therefore, it is considered that these and other trace elements are essentially needed by fungi for mycotoxin production. Steele et al. (1973) investigated the optimum presence of 0.055–2.2 mg/l zinc, 0.004–0.04 mg/l copper and 1.2–24 mg/l iron for the production of ochratoxin A by *Aspergillus ochraceus* NRRL 3174. Removing or reducing any of these elements resulted in poor growth and no ochratoxin formation.

2.3.3 Biological Factors

2.3.3.1 Plant Stress

Plant physiologist believes that plants under stress are highly vulnerable to fungal infection. APRES (1981) studied the plants grown under drought conditions for formation of aflatoxin in peanuts. Peanut plants were grown in two different cities and planted in adjacent plots, one irrigated and one non-irrigated. They were harvested at three different times. It was observed that level of aflatoxin and *A. flavus* was not proportionate to each other, but aflatoxin level was directly dependent on

the *A. flavus* activity, regulated by physical and chemical conditions. Overmature or damaged peanuts were prone to aflatoxin contamination.

2.3.3.2 Transmission of Mycotoxins

Mycotoxins can be transmitted from contaminated food (meat, eggs, milk, dairy products) and crops to animals or humans. Crops may be contaminated in the field or during storage, and if the same are utilized for cooking bread and other grain-based products, then these will also contain mycotoxins (Fig. 2.1).

Mycotoxin-producing fungi can grow on a wide range of crops/feed including cereal, grain, beans, peas, groundnuts and fruits. Fungal growth can also occur in the field or during transport and storage. Each mycotoxin-producing fungal species can produce various types of mycotoxins depending on climatic and environmental conditions. A number of mycotoxins can thus be present in a contaminated feed/crop. Individual mycotoxins rarely occur in isolation. This increases the toxicity.

Mycotoxins can invade seeds during storage or at the crop stage in the field. Sometime fungal growth can occur during storage and if they have already released mycotoxins, then one can observe a high load of mycotoxins before seeds are

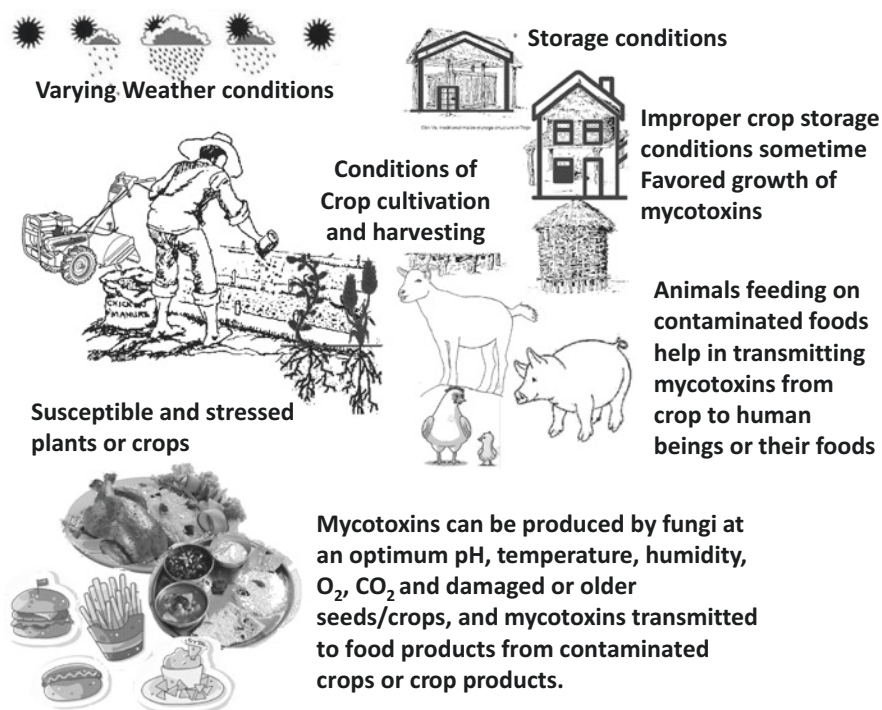


Fig. 2.1 Possible transmission route of mycotoxins from food chain to animals and human beings

received in feed mills or farms. Hence, preventing the occurrence of mycotoxins in feed ingredients can be a very difficult task. Non-homogeneous dispersion of mycotoxins in livestock feed makes it difficult to analyse. They may even go undetected in assays with perfect sampling procedures (Binder 2007).

2.3.3.3 Effect of Mycotoxins on Livestock

Many mycotoxins are potential carcinogens or threat to immune system as well as organ systems (kidney/liver). Mycotoxins survive during food and beer/spirits and wine preparation if grain or grapes are contaminated. Livestock health is at risk due to the level and the duration of exposure by mycotoxins. Mycotoxins could also interfere with bacterial cultures required for various food-processing activities, e.g. yoghurt and cheese making.

2.4 Mycotoxins in Pigs

Pigs are very sensitive to mycotoxins. The level and extent of exposure to mycotoxin(s) in feed and the age or immunity of the pig determine the degree to which animals are affected. In general, pigs that are young and of breeding age are more susceptible.

Mycotoxin contamination exposure can reduce the performance in growing and breeding pigs. It affects their immunity and health status and sometimes becomes fatal. A long and high-dose exposure may cause irreversible tissue damage that will compromise performance long after mycotoxins have been removed from the feed (Bennett and Klich 2003).

Pig feed has been reported to be contaminated with mainly AFB1, OTA (Ochratoxins), FB1 + FB2 (Fumonisin), T-2 + HT-2, DON (trichothecenes) and ZEA (zearalenones). DON mycotoxins can be responsible for digestive problems including feed refusal, vomiting and lesions of the gastrointestinal tract including weaker immune response (Smith et al. 2012). Fumonisin B1 consumption by gestating sows showed considerable damage to foetuses in utero thus resulting to economical losses in farm. Zearalenone is also a risk for reproduction in sows (Kanora and Maes 2009).

2.4.1 Factors That Causes Mycotoxins to Enter a Normal Pig

- (a) The growth of mycotoxin-producing fungi (*Aspergillus* spp., *Fusarium* spp., *Penicillium* spp. and *Claviceps* spp.) can occur at various stages during the production process of animals and plants. Mould can grow during feed processing, especially when the mixer increases temperature and humidity in

the feed. Mould growth and mycotoxin production can also occur in insufficiently cleaned silos, transport systems and feeders at farm level. The fungi can contaminate various feed components like maize, wheat, barley, millet, peanuts, peas and oily feedstuffs. The production of mycotoxins is enhanced by factors like the humidity of the substrate (10–20%), the relative humidity ($\geq 70\%$), the temperature (0–50 °C, depending on the fungal species) and the availability of oxygen (Kanora and Maes 2009).

- (b) Mycotoxins may directly transmit to normal healthy pig from infected pig during sexual intercourse.
- (c) The mycotoxin transmission is also associated with the health status of pig and other toxic entities.

2.4.2 Mycotoxin Effect on Pigs and Its Associated Signs and Symptoms

- (a) *Aflatoxins* have shown carcinogenic, immunosuppressive, hepatotoxic and nephrotoxic effects on pigs.
- (b) *Ochratoxin A* can cause decrease health performance (reduced weight gain), nephrotoxicity and gastrointestinal effects.
- (c) *Ergot alkaloids* are responsible for reproductive defects and pathological complications. These effects can be observed by shrunken udders, stillbirths, reduced pregnancy rate, vasoconstriction in ear and necrosis of tails and hooves.
- (d) *Zearalenone* also affects the reproductive system of male and female, manifested by disturbed cycle, conception nymphomania, feminization, impaired semen quality and testicular atrophy.
- (e) *Deoxynivalenol (DON)* is associated with vomiting in swine and therefore sometime also known as vomitoxin.

2.5 Mycotoxins in Poultry

Mycotoxin infection in poultry may show a significant loss of meat productivity (Filazi et al. 2017) and poses a serious risk to human health. Poultry birds may metabolize mycotoxins in their alimentary canal, liver or kidneys in accordance with their chemical nature. Their metabolized derivatives then transfer to human beings through meat and eggs which leads to undesirable health effects. Toxicity of the mycotoxins and their derivatives depends on the amount of absorption, number of the metabolites formed, exposure period and sensitivity. Major mycotoxins which affect poultry species are aflatoxins (AF), ochratoxin A (OTA), fumonisins (FUM), deoxynivalenol (DON) and T-2 toxin.

2.5.1 Factors That Cause Mycotoxins to Enter in Healthy Poultry

The factors affecting poultry are similar to those affecting pigs. Environmental and biological factors including the breed and the offspring of infected species are responsible for ill effects of mycotoxins. The transmission routes of mycotoxins are ingestion of fungal spores, which are readily carried in the air or feed. High grain humidity and damage due to insects as well as poor storage conditions are major predisposing causes. Once toxins have been formed, it is difficult to avoid their biological effects as fungal spores and formed toxins are generally highly resistant. They also increase susceptibility to bacterial diseases.

2.5.2 The Effect of Major Mycotoxins on Poultry

2.5.2.1 Aflatoxins

They are usually found in feed ingredients used for poultry animals. Most extensive forms of aflatoxins (AF) include B1, B2, G1 and G2 (termed as AFB1, AFB2, AFG1 and AFG2, respectively). Among these AFB1 is most widespread and biologically active mycotoxin which causes decreased weight gain; poor feed efficiency; reduced egg production and egg weight; liver cirrhosis; reduced serum protein level; carcass bruising; poor pigmentation; reduced enzyme level and metabolism of starch, protein, lipids, and nucleic acids; and suppressed immune system. Domestic turkeys have been observed to be significantly more susceptible to aflatoxin B1 compared to their wild counterparts. This has been linked to the loss of GST (glutathione S-transferases) alleles which afforded some resistance to the toxin through aflatoxin B1 protective glutathione S-transferases. This is just another instance of unintentional loss of helpful genes as a result of intensive breeding for traits useful for the poultry industry (Filazi et al. 2017). Murugesan et al. (2015) also reported a “remarkable loss” of rare alleles and single-nucleotide polymorphisms in commercial chicken breeds due to similar practices.

2.5.2.2 Ochratoxins

Among this group of mycotoxins, ochratoxin A (OTA) is the most prevalent in poultry animals. Toxicity symptoms include general weakness, anaemia and lower food consumption which translate into lower egg production and growth rates at lower dietary concentrations to excessive mortality at higher doses (Filazi et al. 2017). Pathophysiological studies showed a decrease in urine concentration and kidney performance, degeneration and ultrastructural alterations in integrity (Huff et al. 1975; Glahn et al. 1988, 1989). Murugesan et al. (2015) opined that there could be

an increase in relative weights of liver, spleen, pancreas, gizzard and testes if fed with OTA-contaminated foods.

2.5.2.3 Fumonisin

In comparison to horses and swine, two susceptible species, chicks and turkeys, are relatively resistant to the toxic effects of fumonisin (FB1). Mild to moderate toxicity was reported in chicks, ducks and turkeys. The primary effect of FB in chicks, ducks and turkeys is reduced rate of body weight gain and liver pathology. Chicks can show multifocal hepatic necrosis and biliary hyperplasia (Ledoux et al. 1992; Weibking et al. 1993), Hepatocellular hyperplasia and increased extramedullary hematopoiesis (Murugesan et al. 2015).

2.5.2.4 Trichothecenes

They show toxic effects as oral lesions, growth retardation, abnormal feathering, decreased egg production and egg shell quality, regression of the bursa of Fabricius, peroxidative changes in liver, abnormal blood coagulation, leucopenia and proteinemia and immunosuppression. Dietary concentrations of 3–4 mg/kg of T-2 toxin leads to affected broiler performance where a lower dietary concentration (0.4 mg/kg) can reduce the performance of ducks (Murugesan et al. 2015; Pettersson 2012). T-2 concentrations for oral lesions are lower (0.4 mg/kg) than concentrations for weak chick performance.

2.5.3 Diagnosis

Mycotoxin infection should be diagnosed in a farm having a history of sign and symptoms of intoxication. A confirmation of intoxication involves detection and quantification of specific mycotoxins. In poultry a non-homogeneous mycotoxin dispersion and high volume of feeds and ingredients make diagnosis difficult. However, a simultaneous feed analysis and necropsy with related diagnostic tests can increase the chances of diagnosis. Frequent and multiple sampling from different sites may also increase the confirmation of a mycotoxin formation zone (hot spot). Samples should be collected at sites of ingredient storage, feed manufacture and transport, feed bins and feeders.

Concurrent diseases can adversely affect production and should be considered. Sometimes, mycotoxicosis is suspected but not confirmed by feed analysis. In these situations, a complete laboratory evaluation can exclude other significant diseases. Mycotoxin formation can be localized in a batch of feed or grain. Fungal activity increases as feed is moved from the feed mill to the feeder pans. Samples should be collected and submitted in separate containers. It should be noted that airtight

plastic/glass containers are not suitable for long-term storage only as they cause rapid deterioration of feed and grain.

2.5.4 Treatment

Removal of the source and causes of toxins is most effective treatment. Prevention can be managed by adding antifungal in feed preservatives. Feed with increased protein levels may also be beneficial. A mycotoxin-detoxifying agent dose of soluble vitamin A, C and E and selenium (0.2 ppm) in finely divided 1% copper sulphate for 7-day feed has been suggested; it can be given for 7 days wherever approved (Dvorska et al. 2007; Galvano et al. 2001).

2.6 Mycotoxins in Cattle

Dairy products are an important part of human diet and may pose a serious concern for human health if cattle are contaminated with mycotoxins since some mycotoxin metabolites like aflatoxin M1 may be excreted in milk (Whitlow and Hagler Jr 2005). Mycotoxins such as aflatoxins, fumonisins and trichothecenes and the occurrence of toxigenic fungi in feed and silage for dairy cattle may cause general, unspecific problems for animal production, such as reduced feed intake or feed acceptability. Mycotoxicoses may be recognized by large number of abrasions in organs including liver, kidneys, epithelial and central nervous system and various tissues according to the nature of particular mycotoxins. Thus, mycotoxicoses can cause significant losses to the animal industry worldwide (Goncalves et al. 2015).

2.6.1 The Effect of Major Mycotoxins in Cattle

Extremes in weather conditions may promote mycotoxin contamination of crops in the field, during harvest, or stored grains/cereals, with obvious detrimental results for cattle. A loss in crop yield is also observed if the spores in soil and/or water infect plants growing in the field. Fungal growth and the production of mycotoxins are proportional to each other. Mycotoxins majorly linked with cattle health are aflatoxin by *Aspergillus*; deoxynivalenol, zearalenone, T-2 toxin and fumonisin by *Fusarium*; and ochratoxin and PR toxin by *Penicillium*, and ergot mycotoxins may be common in certain feedstuffs (Whitlow and Hagler Jr 2005).

2.6.2 Aflatoxins

These are highly toxic, mutagenic and carcinogenic molecules in nature. Aflatoxin B1 is a carcinogen and excreted in milk in the form of aflatoxin M1. Cows consuming diets containing 30 ppb aflatoxin can produce milk containing aflatoxin residues above the FDA action level of 0.5 ppb. Acute aflatoxicosis in mammals has symptoms of inappetence, lethargy, ataxia, rough hair coat and pale, enlarged fatty livers. Chronic aflatoxicosis results in lower milk production, jaundice, loss of appetite, more susceptibility to diseases and obstruction with vaccine induced immunity in livestock. It may infect cattle through contaminated cereals, peanuts and cottonseed grown in warm and humid climates (Whitlow and Hagler Jr 2005).

2.6.3 Deoxynivalenol

This is the most commonly detected mycotoxin by *Fusarium* in feed. The impacts of DON on cattle are not well recognized. However, some clinical reports showed a relationship between DON contamination of diets and poor performance of cattle. It is also observed that pure DON added to diets does not have toxicity similar to feeds contaminated naturally with DON (Foster et al. 1986). DON family can be interrelated to symptoms that are different or more severe than expected.

2.6.4 T-2 Toxin

This occurs in a low proportion of feed samples and is associated with reduced feed consumption, loss in yield, gastroenteritis, intestinal haemorrhage, reduced reproductive performance and death. T-2 toxin is associated with gastroenteritis and intestinal haemorrhages. Weaver et al. (1980) showed that T-2 was associated with feed refusal and gastrointestinal lesions in a cow, but did not show a haemorrhagic syndrome. Cows exposed to T-2 may suffer from bloody diarrhoea, low feed intake, minimized milk production and absence of oestrus cycles (Kegl and Vanyi 1991). Serum immunoglobulins and complement proteins were lowered in calves receiving T-2 toxin (Mann et al. 1983).

2.6.5 Fumonisin B1

It was first isolated in 1988 from *Fusarium verticillioides*. Identified as a causative agent of leucoencephalomalacia in horses, pulmonary oedema in swine and hepatotoxicity in rats, it is thought to be a carcinogen and considered as a promoter

of oesophageal cancer in humans (Marasas 1995). Fumonisin is structurally similar to sphingosine and at high concentrations is toxic to myelin sheath and other parts of nerve tissues. These can block sphingolipid biosynthesis and therefore results in deterioration of concerned tissues. Fumonisins have been reported as potent toxins to beef cattle, dairy cattle and other ruminants (Whitlow and Hagler Jr 2005).

2.6.6 Diagnosis and Treatment

Diagnosis of mycotoxin infection is possible only by a multifarious approach. The presence of mycotoxins is confirmed by detection in either feedstuffs or animal tissues with a combination of previous history of mycotoxicosis. Detection of more than one mycotoxin in feedstuffs may lead to different clinical signs as toxicological properties including lesions may differ from single mycotoxin in experimental animals. Concerted effects of mycotoxins on each other may enhance or minimize mutual effects. Immunosuppressive mycotoxins may cause secondary infection of viruses, bacteria, or other parasites which is more noticeable than the primary infection. Therefore immunosuppression by mycotoxin must be diagnosed carefully by thorough clinical examination, appropriate diagnostic testing and proper historical evaluation.

Feed grains should be tested at harvesting and storage facilities. Further, maintenance of clean and dry storage conditions including spray or mixing of acids (e.g. propionic acid) is suggested to control the growth of moulds, but this is effective only before formation of toxins. An already formed mycotoxin cannot be removed by adding acid additives. At present we still lack of any antidote for mycotoxins, though some mycotoxins like aflatoxin can be effectively removed from feedstuffs by absorption with the help of aluminosilicates. The traditional method of air exclusion in silage storage as reducing the time of storage of prepared feed is also an effective way of avoiding mycotoxin formation.

2.7 Prevention and Control

Instead of removing and treating a mycotoxin infection, it is suggested that preventive measure and avoiding or reducing the exposure time and dose is the better approach. Recognition of risk factors can be helpful in management of prevention. Mycotoxicoses cannot be completely treated with medical therapy after diagnosis, and mycotoxins may even survive after treatment.

Since mycotoxins can enter crops during harvesting, storage or preparation of food and may contaminate both animals and humans, the infection of fungus and their mycotoxins should be prevented at all the steps of crop cultivation, processing and animal rearing.

2.7.1 Primary Prevention

A disciplined plan of suitable preharvest, harvest and postharvest prevention of crop infection can minimize mycotoxin infection. Development of fungal-resistant plant varieties is as vital as preventing infection of crops in field. Additionally, a low humidity and moisture content of seeds after harvesting and during storage is a preventive method for mycotoxin infection. Cold storage should be used for commodities. Applying fungicides and preservatives against fungal growth as well as prevention of seed damage by insect infestation is also useful to control mycotoxins. Only approved insecticides in recommended dosage should be applied.

2.7.2 Secondary Prevention

This is inevitable if some fungi have entered the chain at early phase. The growth of existing fungi should be removed or stopped to prevent further damage and contamination. Suggested steps included re-drying the products to prevent growth of infested fungi, removal of damaged/contaminated seeds, inactivation or detoxification of mycotoxins and protection of stored products by reversing the conditions that favour fungal growth.

2.7.3 Tertiary Prevention

This level of prevention is implemented if the feed and crops are heavily infected by fungi. In such a situation, both of the above preventions are not effective since it is too late to completely stop toxic fungi and reduce their toxin formation. However, some measures should be taken to prevent the transfer of fungi and mycotoxins to other foods and environment. The general practice recommends a complete destruction of the contaminated products. After that a detoxification is recommended to minimize the level of contamination.

Ultimately if all the above steps have been missed or failed and the fungus enters the food chain, the only way to prevent further spread is isolating the infected animals from healthy ones. Mating between healthy and infected animals should also be prevented.

2.8 Legal Disposition

Food and Drug Administration (FDA) is a regulatory body for toxicity in food and food products. It has given directions to limit aflatoxin to 20 parts per billion (ppb) in all foods and feed. It is a must for all agencies and manufacturers to test the food products at multilevel checkpoints during production. Testing agencies such as Grain Inspection Packers and Stockyards Administration must report the toxic levels of mycotoxins to the FDA. ELISA (enzyme-linked immunosorbent assay) can be used in testing as it is a cheaper and faster technique. The mean permissible level of mycotoxins in cow feed (whole-plant corn silage) to the total diet allowed by US Food and Drug Administration (FDA) or European Union can be calculated as $[(\text{mean concentration of mycotoxin detected} \times \text{estimated daily silage intake}) / (\text{maximum permissible mycotoxin in diet allowed or stipulated by US FDA or European Union} \times \text{total diet DMI})] \times 100$. Here DMI stands for dry matter intake (Ogunade et al. 2018).

2.9 Conclusion

Mycotoxin-producing fungi cause illness in humans and their livestock either directly or indirectly. Mycotoxicoses are the most common known diseases of fungi, and secondary metabolite toxins from *Aspergillus*, *Fusarium*, *Penicillium*, etc., are an important health hazard. Mycotoxins refer to any pharmacologically active metabolite responsible for vertebrate toxicity and have been classified into several chemically and source wise unrelated classes. These are formed in a strain-specific way and produce intricate and overlying toxigenic effects in susceptible organisms. They may cause carcinogenicity, inhibition of protein synthesis, immunosuppression, dermal irritation and other metabolic perturbations. Route of mycotoxin entry is usually ingestion of contaminated foods from crops or animals. Sometimes, inhalation of spores and direct dermal contact can also be reason of infection.

It is difficult to differentiate between mycotoxin infection and mycotoxicosis. Many times, moulds may be present without producing any toxin, and most of the time mycotoxins may remain after processing of food preparation. Thus, the demonstration of mould contamination is not the same thing as the demonstration of mycotoxin contamination. Nevertheless, there is enough data from various researches to conclude that mycotoxins pose a hazard to human and animal health, but simple detection of mycotoxins is not enough to show that they are the aetiological agents in a given veterinary or human health problem. Mycotoxicoses may thus be far more common than we think. It is easy to feature the symptoms of acute mycotoxin poisoning to other causes; the opposite is true of aetiology. Proving cancer and other chronic conditions as a result of exposure to mycotoxins is obviously difficult. In summary, in the lack of suitable analytical criteria and

confirmatory laboratory tests, mycotoxicoses will remain diagnostically scary diseases.

Acknowledgement Authors are thankful to Dr. Rohan D'souza for due help in preparing this manuscript.

References

- Abdel-Wahhab MA, Kholif AM (2008) Mycotoxins in animal feeds and prevention strategies: a review. *Asian J Anim Sci* 2(1):7–25
- Anfossi L, Giovannoli C, Baggiani C (2016) Mycotoxin detection. *Curr Opin Biotech* 37:120–126
- APRES Meeting Report at Savannah, Georgia, from July 21–24 (1981) Proceedings American Peanut Research Education Society Inc 13(1):1–182
- Bennett JW, Klich M (2003) Mycotoxins. *Clin Microbiol Rev* 16(3):497–516
- Binder EM (2007) Managing the risk of mycotoxins in modern feed production. *Anim Feed Sci Tech* 133:149–166
- Bottalico A, Perrone G (2002) Toxigenic *Fusarium* species and mycotoxins associated with head blight in small-grain cereals in Europe. *Eur J Plant Pathol* 108:611–624
- Christensen JJ (1963) Corn smut induced by *Ustilago maydis*. *Amer Phytopathol Soc Monogr* 2: pp. 41 pp. ref. 367
- Christensen CM, Nelson GH, Mirocha CJ (1965) Effect on the white rat uterus of a toxic substance isolated from *Fusarium*. *Appl Microbiol* 13(5):653–659
- Dvorska JE, Pappas AC, Karadas F, Speake BK, Surai PF (2007) Protective effect of modified glucomannans and organic selenium against antioxidant depletion in the chicken liver due to T-2 toxin-contaminated feed consumption. *Comp Biochem Physiol C Toxicol Pharmacol* 145:582–587
- Filazi A, Yurdakok B, Yurdakok B, Kuzukiran Ö, Kuzukiran Ö, Tansel U, Ufuk Ş, Şireli T (2017) Mycotoxins in poultry. In: Manafi M (ed) Poultry science. InTech, Rijeka, Croatia, pp 73–92
- Foster BC, Trenholm HL, Friend DW, Thompson BK, Hartin KE (1986) Evaluation of different sources of deoxynivalenol (vomitoxin) fed to swine. *Can J Anim Sci* 66:1149–1154
- Galvano F, Piva A, Ritieni A, Galvano G (2001) Dietary strategies to counteract the effects of mycotoxins: a review. *J Food Prot* 64:120–131
- Glahn RP, Wideman RF, Evangelisti JW, Huff WE (1988) Effects of ochratoxin A in combination with citrinin on kidney function of Single Comb White Leghorn pullets. *Poult Sci* 67:1034–1042
- Glahn RP, Sharp RS, Vena VE, Wideman RF, Huff WE (1989) Effects of chronic ochratoxin A and citrinin toxicosis on kidney function of Single Comb White Leghorn pullets. *Poult Sci* 68:1205–1212
- Goncalves BL, Corassin CH, Oliveira CAF (2015) Mycotoxicoses in dairy cattle: a review. *Asian J Anim Vet Adv* 10:752–760
- Ha TH (2015) Recent advances for the detection of ochratoxin A. *Toxins (Basel)* 7(12):5276–5300
- Hesseltine CW (1976) Conditions leading to mycotoxin contamination of foods and feeds. In: Rodricks JV (ed) Mycotoxins and other fungal related food problems, Advances in chemistry series, vol 149. American Chemical Society, Washington, DC, pp 1–22
- Huff WE, Wyatt RD, Hamilton PB (1975) Nephrotoxicity of dietary ochratoxin A in broiler chickens. *Appl Environ Microbiol* 30:48–51
- Kanora A, Maes D (2009) The role of mycotoxins in pig reproduction: a review. *Vet Med-Czech* 54(12):565–576
- Kegl T, Vanyi A (1991) T-2 fusariotoxicosis in a cattle stock. *Mag Allatorvosok* 46:467–471
- Ledoux DR, Brown TP, Weibking TS, Rottinghaus GE (1992) Fumonisin toxicity in broiler chicks. *J Vet Diagn Investig* 4:330–333

- Liew W-P, Mohd-Redzwan S (2018) Mycotoxin: its impact on gut health and microbiota. *Front Cell Infect Microbiol* 8:Article60:1–17
- Mann DD, Buening GM, Hook B, Osweiler GD (1983) Effects of T-2 mycotoxin on bovine serum proteins. *Am J Vet Res* 44:1757–1759
- Marasas WF (1995) Fumonisin: their implications for human and animal health. *Nat Toxins* 3(4):193–221. <https://doi.org/10.1002/nt.2620030405>
- Murugesan GR, Ledoux DR, Naehrer K, Berthiller F, Applegate TJ, Grenier B, Phillips TD, Schatzmayr G (2015) Prevalence and effects of mycotoxins on poultry health and performance, and recent development in mycotoxin counteracting strategies. *Poult Sci* 94(6):1298–1315
- Ogunade IM, Martinez-Tupia C, Queiroz OCM, Jiang Y, Drouin P, Wu F, Vyas D, Adesogan AT (2018) Silage review: mycotoxins in silage: occurrence, effects, prevention, and mitigation. *J Dairy Sci* 101(5):4034–4059
- Pestka JJ, Casale WL (1990) Naturally occurring fungal toxins. In: Hriaga S (ed) *Food contamination from environmental sources*. Wiley, New York, pp 613–638
- Pettersson H (2012) Mycotoxin contamination of animal feed. In: *Animal feed contamination effects on livestock and food safety*, Woodhead publishing series in food science, technology and nutrition. Woodhead Publishing, Oxford, pp 233–285
- Pitt JI (2013) Mycotoxins. In: Morris JG Jr, Morris P IV (eds) *Foodborne infections and intoxications*. Academic Press, Elsevier, New York, pp. 568
- Rai M, Varma A (2010) *Mycotoxins in food, feed and bioweapons*. Springer-Verlag, Berlin Heidelberg, pp. 405
- Raiola A, Tenore GC, Manys L, Meca G, Ritieni A (2015) Risk analysis of main mycotoxins occurring in food for children: an overview. *Food Chem Toxicol* 84:169–180
- Reddy L, Bhoola K (2010) Ochratoxins-food contaminants: impact on human health. *Toxins* 10(2):771–779
- Sanders TH, Davis ND, Diener UL (1968) Effect of carbon dioxide, temperature, and relative humidity on production of aflatoxin in peanuts. *J Am Oil Chemists' Soc* 45(10):683–685
- Scussel VM, Giordano BN, Simao V, Manfio D, Galvao S, Rodrigues MNF (2011) Effect of oxygen-reducing atmospheres on the safety of packaged shelled Brazil nuts during storage. *Int J Anal Chem* 2011, Article ID 813591, 9 pages
- Smith LE, Stoltzfus RJ, Prendergast A (2012) Food chain mycotoxin exposure, gut health, and impaired growth: a conceptual framework. *Advances in nutrition* (Bethesda, Md.) 3(4):526–531
- Sorenson WG, Hesseltine CW, Shotwell OL (1967) Effect of temperature on production of aflatoxin on rice by *Aspergillus flavus*. *Mycopathol Mycol Appl* 33:49–55
- Speight N (2012) Mycotoxin-related illness. In: Kohlstadt I (ed) *Advancing medicine with food and nutrients*, 2nd edn. CRC Press; Taylor & Francis Group, Boca Raton, FL, pp 821–850
- Steele JA, Davis ND, Diener UL (1973) Effect of zinc, copper, and Iron on ochratoxin A production. *Appl Environ Microbiol* 25:847–849
- Streit E, Schwab C, Sulyok M, Naehrer K, Krska R, Schatzmayr G (2013) Multimycotoxin screening reveals the occurrence of 139 different secondary metabolites in feed and feed ingredients. *Toxins* (Basel) 5:504–523
- Talcott PA (2013) Mycotoxins. In: Peterson ME, Talcott PA (eds) *Small animal toxicology*, 3rd edn. Elsevier, St. Louis, pp 677–682
- Taniwaki MH, Hocking AD, Pitt JI, Fleet GH (2010) Growth and mycotoxin production by fungi in atmospheres containing 80% carbon dioxide and 20% oxygen. *Int J Food Microbiol* 143(3):218–225
- Ueno Y, Sawano M, Ishii K (1975) Production of trichothecene mycotoxins by *Fusarium species* in shake culture. *Appl Microbiol* 30:4–9
- Urry WH (1966) The structure of zearalenone. *Tetrahedron Lett* 7(27):3109–3114
- Urusov AE, Zherdev AV, Petrakova AV, Sadykhov EG, Koroleva OV, Dzantiev BB (2015) Rapid multiple immunoenzyme assay of mycotoxins. *Toxins* (Basel) 7:238–254
- van Egmond HP, Schothorst RC, Jonker MA (2007) Regulations relating to mycotoxins in food: perspectives in a global and European context. *Anal Bioanal Chem* 389(1):147–157

- Wacoo AP, Wendi D, Vuzi PC, Hawumba JF (2014) Methods for detection of aflatoxins in agricultural food crops. *J Appl Chem* 2014, Article ID 706291, 15 pages
- Weaver GA, Kurtz HJ, Mirocha CJ, Bates FY, Behrens JC, Robison TS, Swanson SP (1980) The failure of purified T-2 mycotoxin to produce hemorrhaging in dairy cattle. *Can Vet J* 21:210–213
- Weibking TS, Ledoux DR, Bermudez AJ, Rottinghaus GE (1993) Effects of fumonisin B1 present in *Fusarium moniliforme* culture material, in Turkey poults. *Poult Sci* 72(Suppl. 1):197–199
- Wen J, Mu P, Deng Y (2016) Mycotoxins: cytotoxicity and biotransformation in animal cells. *Toxicol Res (Camb)* 5:377–387
- Whitlow, LW, Hagler WM Jr (2005). Mycotoxins in dairy cattle: occurrence, toxicity, prevention and treatment. In: *Proceeding of Southwest Nutrition Conference*, pp 124–138
- Wu F, Groopman JD, Pestka JJ (2014) Public health impacts of foodborne mycotoxins. *Annu Rev Food Sci Technol* 5:351–372
- Yazar S, Omurtag GZ (2008) Fumonisin, trichothecenes and zearalenone in cereals. *Int J Mol Sci* 9:2062–2090

Web Link Reference

https://www.who.int/foodsafety/FSDigest_Aflatoxins_EN.pdf visited on 28/12/2019

Chapter 3

Candidiasis and Dermatophytosis: Infections and Their Prevention



Hilal Ahmad Ganaie and Manzoor Ahmad Wani

3.1 Candidiasis

3.1.1 Introduction

The *Candida* species are the most opportunistic infections of the yeast throughout the globe. The most common among being the species of the genus *Candida albicans*. Even though this species of yeast is responsible for about 50–90% of human candidiasis, *Candida albicans* is part of the commensal flora of more than half of the healthy population. The colony formation by this yeast provides benefit to the host organism also because this limits the growth of many other fungi, and it also promotes the functioning of the immune system (Vazquez-Gonzalez et al. 2013; Brunke and Hube 2013). In the last two decades, a considerable increase in the incidence of deep fungal infections has been observed, not only in immune compromised patients but also related to nosocomial infections, and even in healthy population (Eggimann et al. 2003; Raman et al. 2013; Li et al. 2006). Thus, with the increased incidence of deep fungal infections (chronic candidiasis), the primitive idea that they were related to a restrict number of pathogenic fungi and specific geographical area was completely changed. Furthermore, with the rapid increase in candidiasis incidence, other *Candida* species and microorganisms besides *C. albicans* have been involved in such infections (McCullough et al. 1999; Lott et al. 2005). The balance between *C. albicans* and non-*Candida albicans* *Candida* (NCAC) species determines the profiles associated with virulence. So, the most common species are *C. albicans*, *C. tropicalis*, *C. glabrata*, *C. dubliniensis*, *C. parapsilosis*, *C. orthopsilosis*, *C. metapsilosis*, *C. krusei*, *C. famata*, *C.*

H. A. Ganaie (✉)

Department of Zoology, Govt. Degree College (Boys), Pulwama, Jammu and Kashmir, India

M. A. Wani

Department of Botany, Govt. Degree College (Boys), Pulwama, Jammu and Kashmir, India

© Springer Nature Switzerland AG 2021

A. Gupta, N. Pratap Singh (eds.), *Fungal Diseases in Animals*, Fungal Biology,
https://doi.org/10.1007/978-3-030-69507-1_3

35

guilliermondii and *C. lusitaniae*. Another relevant fact associated with virulence is their capacity to form biofilms with other species, which together with the presence of teleomorph forms (sexual phase of fungi in which the same biologic entity could have two different scientific names), makes the treatment difficult and alters the susceptibility profiles to traditional antifungal agents (Kim and Sudbery 2011; Ferreira et al. 2013; Silva et al. 2010).

3.1.2 Types of Candidiasis

3.1.2.1 Genital Candidiasis

The most common infection to the genital system is the vulvo-vaginal candidiasis (VVC). It is estimated that about 75% of women experience, at least once in their lifetime, an episode of vulvo-vaginal candidiasis, 40–50% experience at least one additional episode of infection, 20–50% remain without any clinical manifestation, and, 5% experience recurrent VVC episodes (Sobel 2007; Mayer et al. 2013). Although not being a threat to life, it is unpleasant and problematic, causing a variable degree of itching and whitish discharge, abundant, and flocculent. This infection is very common in pregnant women, especially in the last trimester of pregnancy, when a variation in progesterone, estradiol, and glycogen, associated with an increase in vaginal pH, favors the emergence of these infections. In this case, special attention should be given due to the potential occurrence of contamination of the fetus in the uterus, or even the child during childbirth. On the other hand, it has been observed that, in individuals with diabetes, the incidence of vaginal candidiasis is higher. Similarly, patients submitted to broad spectrum of antibiotic therapy, used to treat bacterial infections, and even the use of oral contraceptives, are also important factors associated with higher rates of incidence of VVC (Tarry et al. 2005; Geiger et al. 1995; Ahmad and Khan 2009). In men, balanitis, which usually appear after sexual contact, is characterized by the appearance of a rash, more or less prickly, followed by small pustules on rocking groove-preputial discharge, more or less abundant. Although this kind of injury is well defined, in particular cases, it can extend to the groin and perianal region. The major factors associated with this type of infections are antibiotic therapies, diabetes, and vaginal secretions of the sexual partner (David et al. 1997).

3.1.2.2 Intrauterine Candidiasis

During pregnancy, the intrauterine infection of candidiasis is frequent. It is important to avoid the occurrence of this type of intense vaginitis in the last few weeks of pregnancy, because it can complicate and extend to the uterus, infecting the child before birth. At childbirth, or in the first hours of life, it can be observed a widespread rash, maculopapular or pustular–vesicular. During the following weeks after

birth, the clinical status may be complicated, extending to other body locations, which usually are treated with local antibiotics (Rad et al. 2011; Longe 2005).

3.1.2.3 Anal Candidiasis

Anal candidiasis is an infection characterized by strong itching/pruritus, accompanied by burning sensation and localized erythema around the anus. Skin may appear macerated with circumscribed lesions, which may eventually invade the intergluteal groove (McGirt and Martins 2004; de Wet et al. 1999). This type of infection is most common in children, despite the frequency in women due to the use of hormonal contraceptives, intimate hygiene products, clothing, and their practice of oral and anal intercourse, functioning as transient colonization of local organisms shed from the intestinal tract. As candidiasis can be sexually acquired, males can be affected, because they may acquire infection from the gastrointestinal tract of their partners. However, in some cases, the factors causing that condition are still unknown, but seems that the main problem of this pathogenesis are secondary infections caused by aerobic and facultative anaerobes microorganisms, such as *Staphylococcus* spp., *Streptococcus* spp., and *Escherichia coli* (David et al. 1997; Mardh et al. 2003).

3.1.2.4 Nail Candidiasis

Candida species are not considered normal yeasts on nail flora. Therefore, this type of infection is a sign of colonization (secondary growth) despite primary infections of nail fold and nail bed with *Candida* species may also occur, which are related to a disease of the nails. Onychodystrophy or periungual tissue is related to nail disease. This type of infection may appear, such as paronychia and onychia. The paronychia is characterized by an inflammation, more or less painful, in peripheral skin nail, which appears red and brilliant. The predisposing factors are essentially sex, different traumas (e.g., in manicure), professional activity, and hormonal variations. Although infrequent in males, this infection can appear in cooks, confectioners, and employees of canning factories (Vazquez-Gonzalez et al. 2013; Develoux and Bretagne 2005). Usually, the nail injury itself, or onyxia (ingrown nail), is secondary to paronychia. It is characterized by a progressive striation, dyschromias (discoloration) and opacity of the nail plate, which ultimately becomes crumbly. This infection appears abruptly and painfully, leading to detachment of the nail, and can spread to other nails. Still, it can be observed fungal colonization in interdigital areas, by *Candida* species, commonly known as digital intertriginous. Preferentially, it is located in the hands and between the ring and middle fingers, although it can also appear in the corners of the fingers. It is commonly associated with professions or occupations in which there is a frequent contact with water. The injury erythema – scaly, itchy, and exudative – generally is well delimited peripherally, and the epidermis appears detached. It is less frequent in feet, but can reach one or more commissures of fingers (Vazquez-Gonzalez et al. 2013; Develoux and Bretagne

2005; McGirt and Martins 2004). Intertriginous can still be located at the level of the submammary, mainly in obese women, suprapubic fold, groin and intergluteal cleft. It is characterized by the appearance of small vesicles and pustules, which, by breakage, give rise to exudative red spots [1].

3.1.2.5 Oral Candidiasis

Oral and perioral candidiasis is a more common type of acute mucocutaneous candidiasis. This infection is characterized by the presence of small spots or whitish papules on the tongue, inside the cheeks and in the palate, forming a creamy and very adherent layer mucosa. In some cases, it may extend up and cover the tongue, palate, and pharynx. It can also reach up to the corners of the mouth. When this happens, it is labeled as angular cheilitis, being evidently a mucosal thickening and cracking. This type of candidiasis particularly affects people with immune system disorders and people with dental prostheses. It can be also found in patients receiving chemotherapy for cancer treatment or taking immunosuppressive drugs to protect transplanted organs or in patients infected by HIV. In children and young people, it may be involved with oral (“thrush”) and lingual disease. In addition, and despite being very rare, esophageal candidiasis can occur in patients infected by HIV and cancer (Okada et al. 2013; Dronda et al. 1996; Jin et al. 2004).

3.1.3 Predisposing Factors

Although *Candida* species is commensal to human organism and virtually present in healthy people, in the past two decades, an abnormal overgrowth in the gastrointestinal (GI), urinary, and respiratory tracts has been observed [2, 3, 6, 10, 56]. During some days after childbirth, that species colonize the mucosa of GI tract (40–50%) and upper respiratory passages, as well as the mouth, pharynx, and larynx. Normally, *C. albicans* lives smoothly in the inner warm creases and crevices of the GI tract (and vaginal tract in women). During pregnancy, *Candida* species colonization increases 30–40%, depending upon altered immune response, bacterial flora, positive variations in glycogen, and pH levels; however, mostly during the normal life cycle, other factors can affect, such as hygiene and oral contraceptive use, which contributes to 5–30% of the infections. In men, up to 10% of these species are found on the genitalia, in the transitional zone, between the mucous membrane and the skin (Longe 2005; Asmundsdottir et al. 2009). The overgrowth of *C. albicans* is an important cause of a wide variety of symptoms that affect directly the well-being of individuals, and therefore, there is an urgent need to recognize candidiasis as a complex medical syndrome and evaluate the magnitude of the problem regarding prevention, which passes through the control of risk factors. There are several factors that contribute to yeast infection, which means that candidiasis, and more especially chronic candidiasis, is a good example of a multifactorial

syndrome. In the next steps, the major and most important factors are explained, namely, decreased digestive secretions, dietary factors, nutrients deficiency, impaired immune system and underlying disease states, impaired liver function, drugs and prolonged use of antibiotics, and altered bowel flora.

3.1.4 Diagnosis

The diagnosis of the different types of infection of candidiasis cannot be made because the signs and symptoms are different with respect to the age, gender, resistance of the host, and exposure to environmental factors. However, there are some tools that can be used in the diagnosis and screen the infections of the yeast, namely, comprehensive digestive stool analysis (CDSA), laboratorial techniques, and questionnaire.

3.1.5 Signals and Symptoms

Despite fungi and other microbials being widespread in the environment, the systemic infections thrive very slowly. Most of the times, the individual infected does not have symptoms or visible signals. According to some authors, oral candidiasis is classified considering the following aspects: duration (acute or chronic), clinical features, color (erythematous/atrophic), location (median rhomboid glossitis, denture stomatitis, multifocal candidiasis, and angular cheilitis), presence of skin lesions, as well as oral lesions (mucocutaneous) and association with an immune compromised host (HIV associated). Other clinical aspects included hyperplastic or hypertrophic appearance, characterized by papillary hyperplasia of the palate, candida leukoplakia, and hyperplastic median rhomboid glossitis (Balch and Stengler 2004; Balch 2006).

3.1.6 Prevention

Considering the facts described above, and being *C. albicans* a commensal microorganism and that is present in all people, it is important to control the number and magnitude of its population. As prevention is the most effective treatment, much more than the eradication of the yeast with antifungal agents – synthetic or natural – it is fundamental to address and amend the predisposing factors. Therefore, maintaining a good personal hygiene is essential. Moreover, being woman more prone to this kind of infection, a good vaginal and oral hygiene is essential, in order to reduce the probability of candidiasis occurrence (Balch and Stengler 2004; Balch 2006). Since deep infections have been increasing, mainly in hospitals, the

following aspects should be considered: probes and catheters should be regularly monitored and removed, as soon as possible, and the frequency, duration, and amplitude of the quantities of antibiotics should be kept to a minimum (Wroblewska et al. 2002; Tamura et al. 2007). Not less important is to avoid certain risk factors, such as diets rich in sugar and poor in vitamins and minerals, or the use of antibiotics.

3.1.6.1 Alternative Treatment

Candida albicans is an opportunistic yeast that cause infectious but, in some levels, lives and grows inside most human bodies. In normal situations, *Candida* is not harmful because our bodies are able to keep it under control, mainly by immune cells and probiotic bacteria. However, some factors previously discussed, such as allergies, high-sugar diets, medications/drugs, and other factors that directly affect the normal balance of intestinal environment, can kill the friendly bacteria and stimulate the overgrowth of pathogenic microorganisms (Rehaume et al. 2010; Garcia-elorriaga and Rey-pineda 2013; Isolauri et al. 2002). Therefore, the best complementary treatment is to reduce and control *Candida* levels. Several recommendations/interventions are necessary according to each person. In most of the cases, direct therapy for *Candida* species destruction is advantageous, because it assists the body on lowering *Candida* species to controllable levels (Balch and Stengler 2004; Balch 2006).

3.2 Dermatophytosis

Dermatophytes are generally referred to as the group of fungus that mostly causes skin disease in animals and humans. *Microsporum*, *Epidermophyton*, and *Trichophyton* are the three genera of this group. There are about 40 species in these three genera. Dermatophytes obtain nutrients from keratinized material. The organisms colonize the keratin tissues causing inflammation as the host responds to metabolic by-products. Colonies of dermatophytes are usually restricted to the nonliving cornified layer of the epidermis because of their inability to penetrate viable tissue of an immune competent host. Invasion does elicit a host response ranging from mild to severe. Acid proteinases, elastase, keratinases, and other proteinases reportedly act as virulence factors. The development of cell-mediated immunity correlated with delayed hypersensitivity and an inflammatory response is associated with clinical cure, whereas the lack of or a defective cell-mediated immunity predisposes the host to chronic or recurrent dermatophyte infection.

There are various types of dermatophyte infections including *Tinea pedis*, *Tinea cruris*, *Tinea corpora*, *Tinea faciei*, *Tinea capitis*, and *Tinea manuum*. *Tinea pedis* or athlete's foot affects not solely athletes. It affects men more than women; it can be seen initially affecting the webs between the toes, before spreading to the sole of the foot in a "moccasin" pattern. *Tinea cruris* or jock itch of the feet is also involved.

The truth is that the feet get infected first from contact with the ground. The fungus spores are carried to the groin from scratching, from putting on underclothing or pants and frequently extend from the groin to the perianal skin and gluteal cleft. Tinea corpora or ringworm of the body appears red, scaly patches with well-defined, raised edges, central clearing and itchy. *Tinea faciei* or facial ringworm can be misdiagnosed for other conditions such as psoriasis and discoid lupus. It is aggravated by treatment with topical steroid or immunosuppressive creams. *Tinea capitis* or black dot ringworm infects the hair shafts where they are broken off just at the base, leaving a black dot just under the surface of the skin. *Tinea capitis* cannot be treated topically and must be treated systemically with antifungals. *Tinea capitis* or scalp ringworm is the most common cause of *Trichophyton tonsurans* in children and is the main cause of endothrix (inside hair) infections. *Trichophyton rubrum* is also a very common cause of favus, a form of *Tinea capitis* in which crusts are seen on the scalp. *Tinea manuum* or ringworm of the hands is mostly the case of *Tinea manuum*; only one hand is involved. Subsequently both feet are involved concurrently, thus the saying “one hand, two feet.” The simultaneous presence of more than one type of dermatophyte infection is common (e.g., *Tinea pedis* and *Tinea cruris* or *Tinea pedis* and *Tinea unguium*). Performance of a full skin examination including the skin, hair, and nails aids in the detection of additional sites of infection. Occasionally, patients develop a dermatophytid reaction, a secondary dermatitic reaction at a distant site that may reflect an immunologic reaction to the infection.

3.2.1 Treatment

Topical or systemic antifungal drugs with anti-dermatophyte activity are effective therapies. Most superficial cutaneous dermatophyte infections can be managed with topical therapy with agents such as azoles, allylamines, butenafine, ciclopirox, and tolnaftate. Nystatin, an effective treatment for *Candida* infections, is not effective for dermatophytes. Oral treatment with agents such as terbinafine, itraconazole, fluconazole, and griseofulvin is used for extensive or refractory cutaneous infections and infections extending into follicles or the dermis (e.g., Majocchi’s granuloma) or involving nails. Patients should not be treated with oral ketoconazole because of risk for severe liver injury, adrenal insufficiency, and drug interactions.

Although they can be effective and may accelerate resolution of the clinical manifestations of superficial dermatophyte infections, use of combination of antifungal and corticosteroid products that include medium- or high-potency corticosteroids (e.g., clotrimazole 1% betamethasone dipropionate 0.05%) is discouraged because corticosteroid therapy is not necessary for achieving cure and use of a topical corticosteroid introduces risk for topical corticosteroid-induced skin atrophy. Treatment failures have also been reported. On the other hand, immunosuppression may increase risk for dermatophyte infection and may contribute to the development of extensive or persistent disease. The possibility of an underlying immune disorder

should be considered in patients with particularly severe or treatment refractory disease.

Treatment is recommended to alleviate symptoms (pruritus), reduce risk for secondary bacterial infection, and limit spread of the infection to other body sites or other individuals. Topical antifungal therapy is the treatment of choice for most patients. Systemic antifungal agents are primarily reserved for patients who fail topical therapy. Topical drugs effective for *Tinea pedis* include azoles, allylamines, butenafine, ciclopirox, tolnaftate, and amorolfine. Amorolfine is not available in the United States. A meta-analysis of randomized trials published prior to February 2005 supports efficacy of topical therapy, finding strong evidence of superiority of topical antifungal agents (azoles, allylamines, ciclopirox, tolnaftate, butenafine, and undecanoate) over placebo. Allylamines may be slightly more effective than azoles; a meta-analysis of data from 11 trials that compared topical allylamines to topical azoles found slightly higher cure rates with allylamines (risk ratio of treatment failure 0.63, 95% CI 0.42–0.94). Topical antifungal treatment is generally applied once or twice daily and continued for 4 weeks. Shorter treatment courses may be effective; high cure rates have been obtained with terbinafine 1% cream applied to interdigital *Tinea pedis* for 1 week.

Patients requiring oral antifungal therapy are usually treated with terbinafine, itraconazole, or fluconazole. Griseofulvin can also treat *Tinea pedis*, but may be less effective than other oral antifungals and requires a longer duration of therapy. In a systematic review, terbinafine was found more effective than griseofulvin, while the efficacy of terbinafine and itraconazole were similar. Typical adult doses for griseofulvin for *Tinea pedis* are 1000 mg per day of griseofulvin microsize for 4–8 weeks or 660 or 750 mg per day of griseofulvin ultramicrosize for 4–8 weeks. Dosing for children is weight based with durations of treatment similar to adults.

Patients with hyperkeratotic *Tinea pedis* can benefit from combining antifungal treatment with a topical keratolytic, such as salicylic acid. Burow's (1% aluminum acetate or 5% aluminum subacetate) wet dressings, applied for 20 minutes two to three times per day or placing gauze or cotton between toes may be helpful as an adjunctive measure for patients with vesiculation or maceration. Interventions that may help to reduce recurrences include use of desiccating foot powders, treatment of shoes with antifungal powder, and avoidance of occlusive footwear.

In some cases, systemic treatment is an alternative for patients with extensive skin involvement and patients who fail topical therapy. Terbinafine and itraconazole are common treatments. Griseofulvin and fluconazole can also be effective, but they may require longer courses of therapy. Randomized trials support the efficacy of systemic therapy.

Leaves of *Catharanthus roseus* showed antifungal activity against *Microsporum gypseum*, *Trichophyton simii*, and *Malbranchea gypsea* or *Chrysosporium tropicum* and *C. tropicum*. In vitro antifungal activity was investigated by using different organic solvent of lemon, nerium, olive oil, and basil against *Microsporum canis*, *Microsporum gypseum*, *Trichophyton mentagrophytes*, *T. verrucosum*, and *Epidermophyton floccosum*. Plants of *Allium sativum*, *Cymbopogon martinii*, and *Catharanthus roseus* were screened for their antimycotic activity by using disc

diffusion method. Water extract methanol, free flavonoids, and bound flavonoids of various plants were tested against *Trichophyton rubrum*, *T. mentagrophytes*, and *Microsporum gypseum*. Free flavonoid and bound flavonoid extracts showed maximum inhibitory effect against pathogenic fungal species.

Antifungal activity of *Ranunculus sceleratus* and *Pongamia pinnata* (*P. pinnata*) was tested for anti-ringworm activity of five strains *Trichophyton rubrum*, *T. mentagrophytes*, *T. tonsurans*, *Microsporum gypseum*, and *Microsporum fulvum*. Leaves of *Calotropis* spp. were evaluated against *Trichophyton rubrum*, *T. tonsurans*, *T. mentagrophytes*, *Epidermophyton floccosum*, and *Aspergillus flavus* which showed antimycosis activity. In vitro antifungal activity of *Azadirachta indica* L., *Cassia tora* L., and *Lawsonia inermis* L. against three human pathogenic fungi, *Trichophyton rubrum*, *Trichophyton mentagrophytes*, and *Epidermophyton floccosum*. In vitro antifungal activity of different synthetic, herbal shampoos and natural products were tested against clinical isolated species like *Malassezia*, *Trichophyton*, and *Aspergillus* spp. Synthetic shampoos showed excellent inhibitory activity against *Trichophyton*, *Malassezia* spp., *Aspergillus flavus*, and *Aspergillus niger*.

Leaves of *Eucalyptus rostrata* show antidermatophytic activity against four fungi *Trichophyton mentagrophytes*, *Epidermophyton floccosum*, *Microsporum gypseum*, and *M. canis*. Leaves of neem also showed the antidermatophytic activity against 88 clinical isolates of dermatophytes. Leaf extract of *Pistia scleratus* showed antidermatophytic activity against *Trichophyton rubrum*, *Trichophyton mentagrophytes*, *Microsporum gypseum*, *Microsporum nanum*, and *Epidermophyton floccosum*. Hydro-alcoholic extract of *Eucalyptus camaldulensis* was tested against dermatophytes by using in vitro dilution technique.

Drynaria quercifolia used by tribals in Maharashtra was tested for antidermatophytic activity against *Trichophyton mentagrophytes*, *Microsporum canis*, *M. gypseum*, *T. rubrum*, and *Epidermophyton floccosum* by using agar dilution and disc diffusion method. The ethanol extracts isolated by thin layer chromatography was found to possess antidermatophytic activity with clear zone due to presence of triterpenes and coumarins (antifungal compounds). Root extracts of *Solanum dulcamara* were found to possess anti-dermatophytic activity against *Trichophyton rubrum*, *T. mentagrophytes*, and *Microsporum gypseum*. The best activity of root extract was found against *Microsporum gypseum* with inhibition zone of *Trichophyton mentagrophytes* which was found to be larger than ketoconazole. *Curcuma* species were screened for antidermatophytic activity of *Trichophyton rubrum* and *Microsporum canis* by broth dilution method. *Mentha piperita* leaves were tested in vitro against two species of *Trichophyton* and *Microsporum canis*. Ethanolic extract of leaves of *Mentha piperita* exhibited the strongest activity against *Trichophyton rubrum* and *Microsporum canis*.

Calotropis procera leaf extracts were tested against three different genera of dermatophytes, namely, *Microsporum*, *Trichophyton*, and *Epidermophyton*, by dilution agar method. The ethanolic extract of *Calotropis procera* leaves was found to be inhibited in all the species of dermatophytes. Various extracts of neem (*Azadirachta indica*) leaves possess antidermatophytic activity against dermatophytes isolated

from patients with dermatophytosis. India is rich in medicinal plants with antidermatophytic activity.

3.2.2 Communicability

Dermatophytes acquired from animals can be transmitted between people, but this is uncommon and the number of transfers is limited. In contrast, anthropophilic dermatophytes are readily spread from person to person. Anthropophilic dermatophytes can be transmitted to animals, although this seems to be rare.

3.2.3 Diagnostic Tests

Diagnosis is based on the history, physical examination, and microscopic examination of scrapings and hairs from the lesions, sometimes in conjunction with fungal culture and other techniques such as Wood's lamp examination and histology of the tissues. Some dermatophytes fluoresce when they are stimulated by the wavelengths of ultraviolet (UV) light in a Wood's lamp. Organisms that exhibit fluorescence include some strains of the zoophilic dermatophytes *M. canis* and *T. quinckeanum*, as well as a few anthropophilic species, such as *M. audouinii*, *T. tonsurans*, and *T. violaceum*, which are the most common agents in some regions, are not revealed by this technique. Certain topical preparations may mask the fluorescence, and alcohol can either suppress it or cause nonspecific fluorescence. Dermatophytes can often be detected by microscopic examination of infected hairs and skin or nail scrapings. Hyphae rounding up into arthroconidia are diagnostic, but hyphae alone could be caused by other fungi, including contaminants. In hairs, arthroconidia may be found outside (ectothrix) or inside (endothrix) the hair shaft. Skin scrapings should be taken from the edge of the lesion, and hairs should be plucked (not cut) from this area. The best hairs to select are those that fluoresce under a Wood's lamp or are broken or scaly. Nail scrapings are generally taken from the nail bed or from deeper portions of the nail after removing the outer layers (except in cases where the infection is entirely superficial). Samples are usually cleared with potassium hydroxide (KOH) or other agents to help visualize the organism. Various stains such as chlorazol black E, Parker blue-black ink, Swartz-Lamkin stain, or Congo red stain may be added. Fluorescence microscopy, using calcofluor white or other stains, can also be used to visualize dermatophyte structures. Fungal cultures, which identify the species of dermatophyte, can be useful in understanding the source of the infection and targeting preventive measure appropriately. Culture may also be necessary if the diagnosis is uncertain, or the infection is resistant to standard treatment. However, recommendations vary in the literature, and uncomplicated cases are not always cultured in practice. Samples for culture include hair, skin, and nail samples, as for microscopic examination. In some situations (e.g., infections in

sensitive sites or the identification of asymptomatic carriers), other techniques such as brushing the hair, using adhesive tape to collect samples, or rubbing the area with a sterile toothbrush or moistened, sterile cotton swab may also be effective. Colonies appear in 5 days to 4 weeks, depending on the organism. Colony morphology can differ with the medium. Descriptions are usually based on Sabouraud agar, but dermatophyte medium or other fungal culture media can also be used for isolation. Dermatophyte species can be identified by the colony morphology; the appearance of microconidia, macroconidia, and other microscopic structures; biochemical characteristics such as urease production; and nutritional requirements. Specialized tests such as the ability to penetrate hairs in vitro or mating tests (which are usually available only at reference laboratories) may be used occasionally. Differential media (e.g., bromocresol purple-milk solids glucose) can be helpful during differentiation. Some fungal cultures from infected people are negative. Histology (biopsy) is occasionally helpful, especially in deep mycoses and some infections of the nails. The organisms are visualized best with periodic acid–Schiff (PAS) staining, although they may also be found in hematoxylin–eosin-stained preparations. PCR tests have been published for a number of organisms, and molecular methods of diagnosis might become more common in the future.

3.3 Prevention

Controlling dermatophytes in animals can prevent some cases of zoonotic dermatophytosis in humans. Infected animals should be treated, and the premises and fomites cleaned and disinfected as much as possible. (Some environments can be difficult to decontaminate.) Contact with infected animals should be limited, and gloves and protective clothing should be used if these animals are handled. Better surveillance, improved living conditions, and improved treatments can decrease the overall prevalence of anthropophilic dermatophytes, while hygiene and prevention of contact are helpful in individual cases. Measures such as moisture control (e.g., in *Tinea pedis*) are important in reducing susceptibility to some forms of *Tinea*.

3.4 Conclusion

All people are exposed to a variety of candidiasis predisposing factors, and some of them are impossible to avoid. *Candidiasis* can affect different parts of the body (nails, GI tract, and vagina, among others) being characterized by several symptoms, which is often difficult to diagnose; additionally, the individual characteristics alter the manifestation of signals and symptoms. As this infection is very uncomfortable and, in some cases, offers a considerable health risk, the major and most important aspect is prevention. Therefore, there are several aspects to consider and include in the daily routine, which at first might seem in significant, but that could

provide a strength protection. To combat the infection, different procedures are necessary according to the pathologic conditions of the patient; if all daily care is considered, the probability of the infection occurrence will be considerably reduced. However, in face of an infection, a rapid intervention is necessary, and for this, other alternatives to antifungals and antimicrobials are necessary.

References

- Ahmad A, Khan AU (2009) Prevalence of *Candida* species and potential risk factors for vulvovaginal candidiasis in Aligarh, India. *Eur J Obstet Gynecol Reprod Biol* 144:68–71
- Asmundsdottir LR, Erlendsdottir H, Agnarsson BA, Gottfredsson M (2009) The importance of strain variation in virulence of *Candida dubliniensis* and *Candida albicans*: results of a blinded histopathological study of invasive candidiasis. *Clin Microbiol Infect* 15:576–585
- Balch PA (2006) Prescription for nutritional healing, 4th edn. Avery, editor. Penguin Group, London, p 869
- Balch JF, Stengler M (2004) Prescription for natural cures. John Wiley & Sons. I, editor, New Jersey, p 724
- Brunke S, Hube B (2013) Two unlike cousins: *Candida albicans* and *C. glabrata* infection strategies. *Cell Microbiol* 15:701–708
- David LM, Walzman M, Rajamanoharan S (1997) Genital colonisation and infection with *Candida* in heterosexual and homosexual males. *Genitourin Med* 73:394–396
- de Wet PM, Rode H, Van Dyk A, Millar AJW (1999) Candidiasis perianal-estudio comparativo de mupirocina y nistatina. *Int J Dermatol* 38:618–622
- Develoux M, Bretagne S (2005) Candidoses et levures diverses. *EMC Mal Infect* 2:119–139
- Dronda F, Alonso-Sanz M, Laguna F, Chaves F, Martinez Suarez JV, Rodriguez-Tudela JL et al (1996) Mixed oropharyngeal candidiasis due to *Candida albicans* and nonalbicans *Candida* strains in HIV-infected patients. *Eur J Clin Microbiol Infect Dis* 15:446–452
- Eggimann P, Garbino J, Pittet D (2003) Epidemiology of *Candida* species infections in critically ill non-immuno suppressed patients. *Lancet Infect Dis* 3:685–702
- Ferreira AV, Prado CG, Carvalho RR, Dias KST, Dias ALT (2013) *Candida albicans* and non-*C. albicans* *Candida* species: comparison of biofilm production and metabolic activity in biofilms, and putative virulence properties of isolates from hospital environments and infections. *Mycopathologia* 175:265–272
- Garcia-elorriaga G, Rey-pineda G (2013) Nutrition and intestinal microflora. *J Nutr Ther* 2:112–121
- Geiger AM, Foxman B, Sobel JD (1995) Chronic vulvovaginal candidiasis: characteristics of women with *Candida albicans*, *C. glabrata* and no *Candida*. *Genitourin Med* 71:304–307
- Isolauri E, Kirjavainen PV, Salminen S (2002) Probiotics: a role in the treatment of intestinal infection and inflammation? *Gut* 50:54–59
- Jin Y, Samaranayake LP, Samaranayake Y, Yip HK (2004) Biofilm formation of *Candida albicans* is variably affected by saliva and dietary sugars. *Arch Oral Biol* 49:789–798
- Kim J, Sudbery P (2011) *Candida albicans*, a major human fungal pathogen. *J Microbiol* 49:171–177
- Li SY, Yang YL, Chen KW, Cheng HH, Chiou CS, Wang TH et al (2006) Molecular epidemiology of long-term colonization of *Candida albicans* strains from HIV-infected patients. *Epidemiol Infect* 134:265–269
- Longe JL (2005) Yeast infection. In: Blanchfield DS, Fundukian L, Watts E (eds) *The Gale encyclopedia of alternative medicine*, vol 4, 2nd edn. Thomson GALE, Farmington Hills
- Lott TJ, Fundyga RE, Kuykendall RJ, Arnold J (2005) The human commensal yeast, *Candida albicans*, has an ancient origin. *Fungal Genet Biol* 42:444–451

- Mardh P-A, Novikova N, Stukalova E (2003) Colonisation of extragenital sites by *Candida* in women with recurrent vulvovaginal candidosis. *BJOG* 110:934–937
- Mayer FL, Wilson D, Hube B (2013) *Candida albicans* pathogenicity mechanisms. *Virulence* 4:119–128
- McCullough MJ, Clemons KV, Stevens DA (1999) Molecular epidemiology of the global and temporal diversity of *Candida albicans*. *Clin Infect Dis* 29:1220–1225
- McGirt LY, Martins CR (2004) Dermatologic diagnoses in the perianal area. *Clin Colon Rectal Surg* 17:241–245
- Okada M, Hisajima T, Ishibashi H, Miyasaka T, Abe S, Satoh T (2013) Pathological analysis of the *Candida albicans* infected tongue tissues of a murine oral candidiasis model in the early infection stage. *Arch Oral Biol. Elsevier Ltd*; 58:444–450
- Rad MM, Zafarghandi S, Abbasabadi B, Tavallaee M (2011) The epidemiology of *Candida* species associated with vulvovaginal candidiasis in an Iranian patient population. *Eur J Obstet Gynecol Reprod Biol. Elsevier Ireland Ltd*; 155:199–203
- Raman SB, Nguyen MH, Cheng S, Badrane H, Iczkowski KA, Wegener M et al (2013) A competitive infection model of hematogenously disseminated candidiasis in mice redefines the role of *Candida albicans* IRS4 in pathogenesis. *Infect Immun* 81:1430–1438
- Rehaume LM, Jouault T, Chamaillard M (2010) Lessons from the inflammasome: a molecular sentry linking *Candida* and Crohn's disease. *Trends Immunol. Elsevier Ltd*; 31:171–175
- Silva S, Henriques M, Oliveira R, Williams D, Azeredo J (2010) In vitro biofilm activity of non-*Candida albicans* *Candida* species. *Curr Microbiol* 61:534–540
- Sobel JD (2007) Vulvovaginal candidosis. *Lancet* 369:1961–1971
- Tamura NK, Negri MFN, Bonassoli LA, Svidzinski TIE (2007) Virulence factors for *Candida* spp recovered from intravascular catheters and hospital workers' hands. *Rev Soc Bras Med Trop* 40:91–93
- Tarry W, Fisher M, Shen S, Mawhinney M (2005) *Candida albicans*: the estrogen target for vaginal colonization. *J Surg Res* 129:278–282
- Vazquez-Gonzalez D, Perusquia-Ortiz AM, Hundeiker M, Bonifaz A (2013) Opportunistic yeast infections: candidiasis, cryptococcosis, trichosporonosis and geotrichosis. *J Ger Soc Dermatol* 11:381–394
- Wroblewska MM, Swoboda-Kopec E, Rokosz A, Krawczyk E, Marchel H, Luczak M (2002) Epidemiology of clinical isolates of *Candida albicans* and their susceptibility to triazoles. *Int J Antimicrob Agents* 20:472–475

Chapter 4

Application of Systems Biology Approaches for Host-Fungal Interaction in Animals



Ravindra Kumar and Rajrani Ruhel

4.1 Introduction

Fungi are the major pathogens of plant, insects, and ectothermic vertebrates, but there are only a few of them that can cause diseases in mammals (Casadevall et al. 2019). Interaction between pathogens and their host can induce changes both in the host and in the pathogen, which might result in either the clearing of the pathogen from host or the establishing the pathogen within the host. These host-pathogen interactions can be analyzed with the help of systems biology approaches which generates novel hypothesis or decipher the effects of particular molecules or genes across the biological network (Peters et al. 2019).

Systems biology aims to understand the complex and dynamic biological information in the larger picture and requires the integration of different type of omics data such as proteomics, genomics, transcriptomics, and metabolomics (Pinu et al. 2019). This approach unravels the intricate network of interactions between host and fungal pathogen and helps to elucidate the complex pathogenesis processes of fungal interactions. Sayers et al. (2019) developed a web-based integrative resource for the analysis of virulence factor of different pathogens including fungus that causes infectious disease in human and animals. Virulence factors are small molecules that allow the microbial pathogens to survive and leads to diseased state in host.

To understand the infection mechanism, the whole host-fungal interaction system is more useful instead of investigating pathogen or host separately and is crucial to develop more effective solution. The combined investigation of host-fungal

R. Kumar (✉)

Biometric Research Program, Division of Cancer Treatment and Diagnosis, Medical Center Drive, National Cancer Institute, NIH, Rockville, USA

R. Ruhel

Department of Plant and Microbial Biology, North Carolina State University, Raleigh, NC, USA

© Springer Nature Switzerland AG 2021

A. Gupta, N. Pratap Singh (eds.), *Fungal Diseases in Animals*, Fungal Biology, https://doi.org/10.1007/978-3-030-69507-1_4

interaction might provide the understanding about the infectious disease in a way giving insight into the following questions.

1. How to identify direct interaction between fungus and host proteins during the infection and/or invasion process?
2. What signaling pathways and processes of the pathogen/host are implicated?
3. How to detect the crosstalk among the pathogen-host biochemical network?
4. What are the specific and unspecific responses of the host to pathogen invasion?
5. What specific protein or pathways could be targeted to control fungal infection and invasion in animals?

4.2 Systems Biology of Infection

Systems biology is an interdisciplinary research field which focuses on the study of nonlinear interactions among biological entities through combination of mathematical and computational approaches to study host-fungal interaction in biological system. This host-fungal interaction may be between proteins, nucleotides, metabolites, and small ligands. The traditional research typically focuses on single gene or fewer genes. The systems biology approach is insightful to understand physiology and infectious disease at cellular and molecular, network level. Systems biology approaches are categorized into bottom-up and top-down, where the bottom-up focus on network reconstruction through mathematical models while top-down approaches involves metabolic network reconstruction using “omics” data generated through high-throughput genomic techniques using appropriate statistical and bioinformatics methodologies (Shahzad and Loor [2012](#)).

4.3 Data in Systems Biology and Analysis

Understanding the complex host fungal interaction requires high-throughput data as well as the annotations information available from public repositories (Table [4.1](#)).

4.3.1 Omics-Based Data

Fungal omics such as genomics, transcriptomics, proteomics, and metabolomics help to understand basic fungal biology and its associated functional implications. Due to recent advancement in sequencing techniques as well as a small size of the fungal genome, the analysis of the fungal genome and proteome data becomes much easier. The information obtained from omics data analysis may enhance our

Table 4.1 Web-based bioinformatics resources for fungal systems biology

Resources	Description	Website
AsperCyc	<i>Aspergillus</i> metabolic pathways	www.aspercyc.org
Aspergillus genome DB (AspGD)	AspGD is an organized collection of genetic and molecular biological information about the filamentous fungi of the genus <i>Aspergillus</i>	www.aspgd.org
Comparative fungal genomics platform (CFGP)	CFGP was designed for comparative genomics projects with diverse fungal genomes	http://cfgp.riceblast.snu.ac.kr
Candida genome DB (CGD)	A resource for genomic sequence data and gene and protein information for <i>Candida albicans</i> and related species	www.candidagenome.org
Ensembl Fungi	It is browser for fungal genomes	http://fungi.ensembl.org
FindFungi	Sequence classification pipeline to identify fungal sequences in public metagenome datasets	http://bioinformatics.czc.hokudai.ac.jp/findfungi/
FunCatDB	Gene-annotations	
Fungal databases	U.S. National Fungus Collections, ARS, USDA	https://nt.ars-grin.gov/fungalatabases/
FungiDB	It is an integrated genomic and functional genomic database for the fungi	www.fungidb.org
FungiFun	FungiFun is a user-friendly web tool for functional enrichment analysis of fungal genes and proteins	https://sbi.hki-jena.de/fungifun/fungifun.php
Omnifung	Data warehouse for omics data	www.omnifung.hki-jena.de
PhiBase	Database of virulence genes	www.phibase.org
Proteopathogen	Protein database for studying <i>Candida albicans</i> -host interaction	http://proteopathogen.dacya.ucm.es
UNITE	Web-based database and sequence management environment for the molecular identification of fungi	https://unite.ut.ee/

understanding about pathophysiology of infectious process and their underlying mechanisms of complex fungal biological process such as host-fungal interactions.

The free open source software “Bioconductor (Version 3.11)” provides 1904 software package, 961 annotation, and 392 experimental datasets for bioinformatics analysis and comprehension of high-throughput genomic data.

4.3.1.1 Genomics

The new sequencing technology generates huge genomics datasets at a low cost and in a short time. This enables to explore more genomic information of fungal pathogen and would help to improve the diagnostic methods. SNP identification is one of the important methods for characterization of variants of different pathogens

as well as to study the susceptibility of humans for different infections or pathogens. *Saccharomyces cerevisiae* is the first fungus whose complete genome sequence was available in 1996 (Goffeau et al. 1996); since then a number of human pathogen fungal genome have been published. The genome of *C. albicans* was published in 2004 (Jones et al. 2004), and the genome of *C. neoformans* and *A. fumigatus* were published in 2005 (Loftus et al. 2005; Nierman et al. 2005). There are also many freely sources available for different pathogenic fungal species (Table 4.1) such as Aspergillus Genome Database (AspGD) (Cerqueira et al. 2014) and Central Aspergillus Data Repository (CADRE) (Mabey et al. 2004) for *Aspergillus* and Candida Genome Database (CGD) (Skrzypek et al. 2017) and CandidaDB (d'Enfert et al. 2005) for *Candida* species. This freely available information allows researchers to identify and to investigate more about the host fungal interactions.

4.3.1.2 Transcriptomics

Pathogenic fungus during the course of infection process needs to effectively adapt to the host environment. These adaptation mechanisms are controlled by various transcriptional changes and it provides critical information regarding fungal pathogenesis (Amorim-Vaz and Sanglard 2015). The comparative analysis of the host and the fungal pathogen might help to design new antifungal drugs and to explore the clustered genes involved in the process of pathogenicity (Meijueiro et al. 2014).

Microarray, RNA-Seq, and nanoString are powerful tools to study the interaction between fungal pathogen and their host during the infection. *Cryptococcus neoformans* and *Aspergillus fumigatus* are the two important fungal species that cause high mortality in immune-compromised patients (Brown et al. 2012), and their transcriptomics study has already been performed (Chen et al. 2014; McDonagh et al. 2008). Bruno et al. in 2010 (Bruno et al. 2010) used RNA sequencing to generate a high-resolution transcriptome map of human pathogen *Candida albicans* under different environmental conditions and identified 602 new transcriptionally active regions (TARs).

Deep sequencing also has been used to identify novel functional small RNAs, which has a great implication in the regulation of global gene expression in human pathogenic fungus (Nicolas and Ruiz-Vazquez 2013). Arthanari et al. (2014) used RNA sequencing data from ABI SOLiD platform to identify 939 novel long noncoding RNA (lncRNA) and 477 new natural antisense transcripts (NAT) from ascomycete fungus *Neurospora crassa* under different light and temperature conditions. Gene Expression Omnibus (GEO) (Barrett et al. 2013; Edgar et al. 2002) and ArrayExpress (Rustici et al. 2013) are the freely publicly available databases of fungal transcriptomics data.

Some reported virulence factors have been found to be related to transcriptional reprogramming associated with phase transition from avirulent mycelia to pathogenic yeast. For instance, in case of *Paracoccidioides* spp., which causes paracoccidioidomycosis, the transition between these forms has been an important

virulence factor (Tavares et al. 2015). *Candida albicans*, responsible for candidiasis, under comprised immunity and other opportunistic conditions results in superficial mucosal colonization and establishment of the systemic infection (Cheng et al. 2013; Wartenberg et al. 2014). According to RNA-seq studies in mice, during the vaginal infections caused by *C. albicans*, overexpression of aspartyl-proteinases 4, 5, and 6 (SAP4–6) has been reported which are hypha-associated secreted enzymes and function as inflammasome activators (Bruno et al. 2015). The virulence factor for *Cryptococcus* is a transcription factor Rim101 that is involved in the cell wall composition regulation (O’Meara et al. 2013). Cell wall forms a barrier at host-pathogen interface and is part of immune system. The structural integrity of the cell wall is maintained by the cell wall integrity signaling pathway that involves various crucial kinases. Dual RNA-seq is a high-throughput sequencing for simultaneous transcriptomic analysis of pathogen and host to explore the regulatory networks during the fungal infection (Das et al. 2015; Rienksma et al. 2015; Westermann et al. 2012).

4.3.1.3 Proteomics

Proteomics is another tool for the examination of expression patterns in the biological system. Proteins are the functional determinants and might have various roles such as to build the cellular structure; to mediate signal transduction, involved in the gene regulation; to influence different cellular processes; or to function as enzyme. Proteomic studies were initially performed using 2D-PAGE followed by mass spectrometry. Mass spectrometry is still the gold standard for proteomic analysis in the field of systems biology.

The release of the genome sequences of *Candida albicans* (Braun et al. 2005; Jones et al. 2004) and *Aspergillus fumigatus* (Nierman et al. 2005) has been of great benefit for a more detailed insight into the evolution and pathogenesis of these medically important fungus since for these pathogenic fungus, 2D gel proteome reference maps are available (Kniemeyer et al. 2011). Vodisch et al. (2009) identified 334 different mycelial proteins via 2D gel electrophoresis of *Aspergillus fumigatus*.

4.3.2 Image-Based Data

Image-based systems biology approaches are important tools for the investigation and elucidation of pathobiology of fungal infection. It can be divided into four basic steps: (i) extraction of image data through experimental techniques, (ii) preprocessing of the data, (iii) quantitative characterization of biological processes, and (iv) and image-based model development (Fig. 4.1).

Multiphoton microscopy (MPM) and fluorescence microscopy is one of the most valuable tools for live-cell imaging in infection research (Ettinger and Wittmann 2014; Sun et al. 2017). For the analysis of host-pathogen interaction, a large number

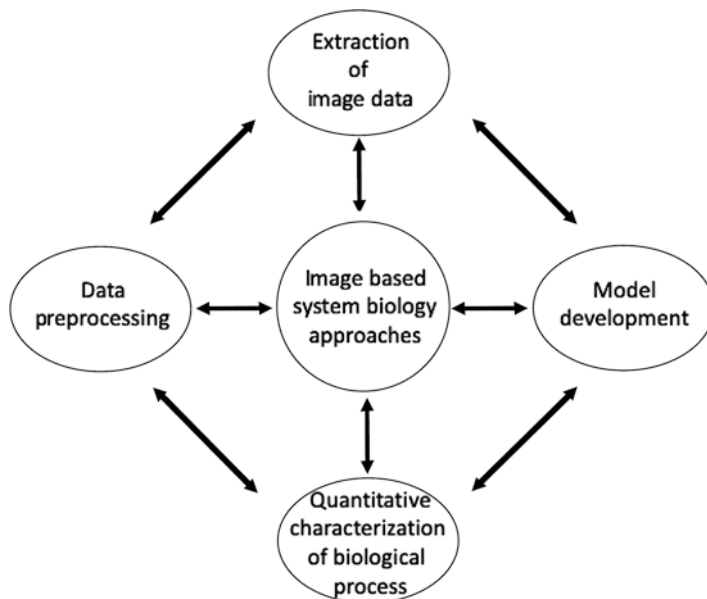


Fig. 4.1 Diagrammatic representation of image-based systems biology approaches

of images are required that can be obtained by different experimental approaches such as fluorescence microscopy and positron emission tomography-computed tomography (PET/CT). Ibrahim-Granet et al. (2003) described the detail analysis of interaction between *A. fumigatus* and phagocytes using fluorescence microscopy and manual image analysis.

Manual image data analysis with regard to host-pathogen interaction is time consuming, and also error-prone; on the other hand, an automated image data analysis can analyze a large amount of data in a shorter period of time and is not labor extensive. Mech et al. (2011) developed an automated image analysis for the host-pathogen interaction between *Aspergillus fumigatus* conidia with immune cells. They used confocal laser scanning microscopy images from macrophages with different *A. fumigatus* strains. In this study, phagocytosed cells were differentially stained with fluorescent dyes and visualized with confocal laser scanning microscope, leading to discrimination between macrophages, internalized conidia, and non-internalized conidia. Currently there are a number of image analysis tools available for fungal analysis (Brunk et al. 2018; Cairns et al. 2019; Mader et al. 2015; Wurster et al. 2019). All image analysis methods comprise mainly three main parts: (i) pre-processing, (ii) segmentation, and (iii) classification.

Image-based systems biology is a relatively new scientific approach that comprises imaging, quantitative characterization, and modeling. In host-fungal interactions, image-derived models have been used to investigate the phagocytosis of fungal spores and the growth of fungal hyphae (Mech et al. 2011). It enhances our understanding of many aspects of cell migration and interaction behavior of the

immune cells. Image-based systems biology focuses on the spatial factors and on cellular morphology (Horn et al. 2012).

4.4 Modeling

The computational modeling of networks of the genes, transcripts, proteins, and metabolites is of great importance in biomedical research to understand the molecular mechanism of the host-fungal interactions and helps to understand the complex regulatory mechanism. The aim of the modeling is to support the standardized design of experiments, to generate the hypothesis, and to validate the hypothesis. The modeling also allows the prediction of novel regulatory biological strategies (Horn et al. 2012). May and Anderson (1979) described the host-pathogen interaction through the evolutionary model. Due to the challenges of modeling of a complex system, only a few models of fungal-human interactome network have been studied (Horn et al. 2012). Rodrigues et al. (2018) developed transkingdom network (TransNet) analysis pipeline that allows to make biological inferences. They constructed a network using correlation between differentially expressed elements and integration of high-throughput data from different taxonomic kingdoms.

4.4.1 Network Modeling

Biological network modeling enables to study how the system can respond to the ever-changing external environment. Predictive power of such model enables the diagnosis by the prediction of biomarkers and drug targets. Cellular behavior of organism can be represented by gene regulatory network, protein-protein network, signaling network, and metabolic network. In the network modeling, the nodes represent molecular entities such as genes, proteins, and metabolites, and the edges represent the relationship between the nodes and can be modeled in different ways like directed or undirected edges (Horn et al. 2012). Aho et al. (2010) made an effort to reconstruct a model, which integrated the genomics, transcriptomics, proteomics, and metabolic data. Some of the biological networks of fungus that have been extensively studied in recent years have been discussed below.

4.4.1.1 Gene Regulatory Network

Gene regulatory network (GRN) is the network of genes that either interact physically or have genetic interaction to regulate a pathway or to carry out a specific role (Karlebach and Shamir 2008). Gene regulatory network helps to predict the gene that might function as central and key player in the network. It also describes the

relationship between the regulatory components and can help to predict their target gene (Guo et al. 2016). Among the fungal species, GRN studies has been extensively focused on *Saccharomyces cerevisiae* (Darabos et al. 2011; Guelzim et al. 2002; Hu et al. 2007; Kim et al. 2006; Lee et al. 2002; Pe'er et al. 2002; Segal et al. 2003), *Candida albicans* (Homann et al. 2009; Ramachandra et al. 2014), and *Fusarium graminearum* (Guo et al. 2016). Many computational methods such as Gaussian graphical model (Kishino and Waddell 2000; Schafer and Strimmer 2005), probabilistic Boolean network (Glass and Kauffman 1973; Kauffman 1969; Shmulevich et al. 2002), linear model, and regression and Bayesian network (Friedman et al. 2000; Pe'er et al. 2002; Segal et al. 2003) are available for GRN reconstruction. Pe'er et al. (2002) used Bayesian network to reconstruct yeast GRN. Tierney et al. (2012) generated the first interspecies computational model of host-pathogen interactions and used it to decipher the mechanism of microbial pathogenesis. They used RNA-Seq expression data from *Candida albicans* and bone marrow-derived dendritic cells from *M. musculus*.

4.4.1.2 Protein-Protein Interaction (PPI) Network

In the post-genomic era, genes and its corresponding proteins are very useful for the identification of intra- and interspecies protein interaction networks (Durmus et al. 2015). These protein-protein interaction (PPI) networks have been used to identify the host immune-associated genes and the pathogenic effector proteins associated with host infection. Wang et al. (2013) integrated multiple omics data and based on the inference of ortholog-based PPI and dynamic modeling of regulatory responses have constructed an interspecies PPI network for *Candida albicans* and zebrafish. Development of experimental techniques to produce large-scale molecular interaction data and further an increase in the amount of experimentally validated host-fungal PPI data provides opportunity to perform a number of computational studies to investigate infection mechanism for different pathogen types (Durmus et al. 2015).

4.4.1.3 Signaling Network

Signaling network is a cell-to-cell communication network that allows the cell to respond to external signals through the change in transcription. When the cell receives the external signal through its membrane, it activates the cascade of events and ultimately affects the transcriptional. These signals or stimulus can be of different type such as chemical, physical, radiation, pathogen, etc. An excellent example of a highly conserved signaling network within all eukaryotes is the Regulation of Ace2 and Morphogenesis (RAM) network (Kurischko et al. 2005; Nelson et al. 2003; Saputo et al. 2012). This network is most extensively studied in *Saccharomyces cerevisiae* and *Candida albicans* and is less characterized for pathogenic fungus.

4.4.1.4 Metabolic Network

During infection, the pathogen interacts with the host cell and it causes alterations in the level of metabolites by affecting the host metabolic pathways (Cakir et al. 2020). Metabolic network model describes the metabolic state of the cell, and it allows for an in-depth insight into the molecular mechanisms and systems level predictions of metabolism in a variety of organisms. Recently, Wang et al. (2018) used a systems biology approach to predict and characterize human gut microbial metabolite in colorectal cancer.

The first genome-scale metabolic model for *Saccharomyces cerevisiae* was presented in 2003 (Forster et al. 2003), and it was the first and the most studied genome-scale network reconstruction for the eukaryotic organism. Since eukaryotic organisms are very complex in nature, researchers are continuing applying their efforts to improve and upgrade information into the metabolic network. Till date a number of genome-scale reconstruction of metabolic networks have been released (Dobson et al. 2010; Duarte et al. 2004; Heavner et al. 2012; Herrgard et al. 2008; Mo et al. 2009; Nookaew et al. 2008; Osterlund et al. 2013; Zomorodi and Maranas 2010). *Saccharomyces cerevisiae* metabolic network has also been used as the basis for construction of metabolic models for other yeast, such as *Saccharomyces pombe* (Sohn et al. 2012), *Yarrowia lipolytica* (Loira et al. 2012), *Pichia pastoris*, and *Pichia stipites* (Caspeta et al. 2012). There are many researchers who are working on the tool development for reconstruction of genome-scale metabolic network (O'Brien et al. 2015; Pusa et al. 2020; Tefagh and Boyd 2020). Recently, Tefagh and Boyd in 2020 (Tefagh and Boyd 2020) proposed SWIFTCC and SWIFTCORE as effective methods for flux consistency checking and for the context specific reconstruction of genome-scale metabolic networks, while Pusa et al. (2020) developed a mathematical tool "MOOMIN" which uses genome-scale metabolic reconstruction to infer metabolic changes from differential expression data.

4.5 Conclusion and Future Implications

Unlike bacterial and viral infections, the fungal infections are uncommon and have been mainly associated with the immunocompromised patients due to conditions such as transplantation, tuberculosis, and HIV due to which they lead to a high mortality rate (Kumar and Ruhel 2019; Romani 2011). Understanding the intrinsic complexity of the invasive infection and exploring the transcriptional reprogramming in the host cells upon fungal infection might help to design more efficient and broad-range therapeutic strategies and drug targets. This would also expand the knowledge about the biomarkers for progression of the infection. Noncoding RNAs (ncRNAs) are emerging as important players in various stages of infection process such as colonization of cells and signaling and in other pathologically related functions. It would be interesting to explore the involvement of more players such as the noncoding RNAs along with the epigenetic factors during the host-fungal

interaction and its implications on the infection process. The study of ncRNAs by small RNA (sRNA) sequencing during the fungal infection in the host cells combined with transcriptomics data could be another approach.

The recent advanced high-throughput techniques such as RNA-seq, sRNA-seq, and dual-seq analysis have been of a great importance to understand the crosstalk between various pathways triggered by the fungus pathogen in the infected host cells. Expansion in the data repositories related to host-fungal interaction along with systems biology modeling could be helpful for personalized medicine which is an emerging research (Dix et al. 2016). Combining various approaches will be an important route for infection-related research over the next decade (Yeung et al. 2019). Integration of the experimental data, computational and mathematical model, and information from the database provide a better model (Fig. 4.2) which can be used to validate a working hypothesis as well as to test new computational models. In future, the modeling of host-fungal interaction networks will be important to

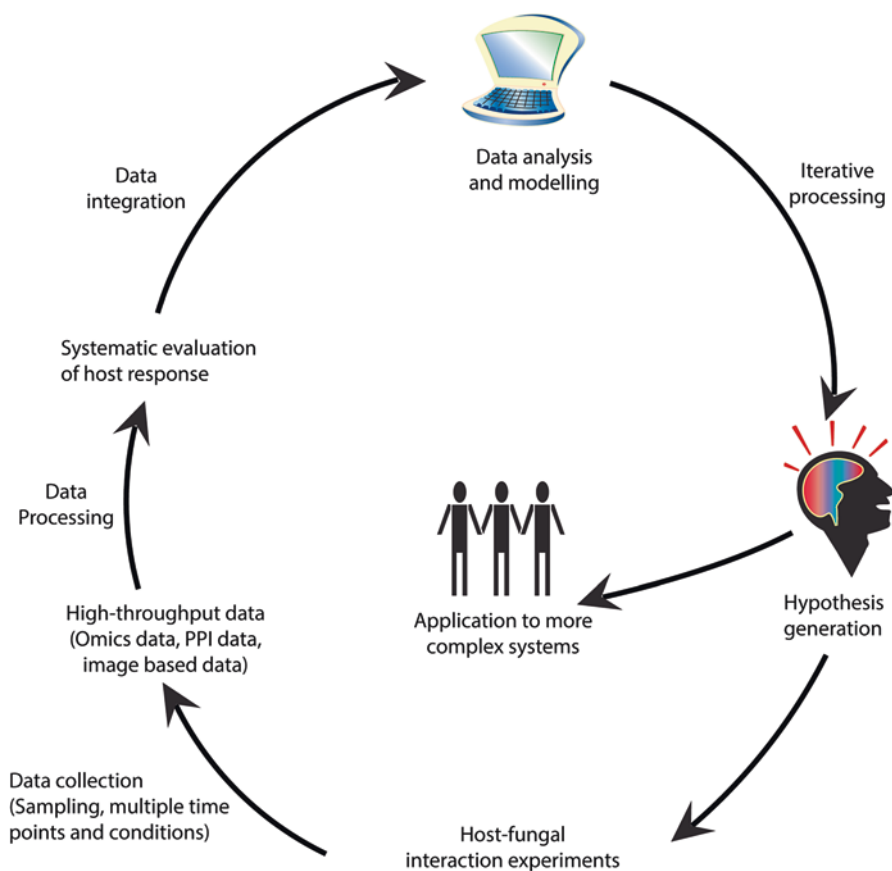


Fig. 4.2 An illustration of the various system approaches that can be applied to test the hypothesis to study host-fungal interactions

complement the experimental work to enhance the understanding of the system, to reduce animal experiments, and to generate and test hypothesis faster.

References

- Aho T et al (2010) Reconstruction and validation of RefRec: a global model for the yeast molecular interaction network. *PLoS One* 5(5):e10662
- Amorim-Vaz S, Sanglard D (2015) Novel approaches for fungal transcriptomics from host samples. *Front Microbiol* 6:1571
- Arthanari Y et al (2014) Natural antisense transcripts and long non-coding RNA in *Neurospora crassa*. *PLoS One* 9(3):e91353
- Barrett T et al (2013) NCBI GEO: archive for functional genomics data sets--update. *Nucleic Acids Res* 41(Database issue):D991–D995
- Braun BR et al (2005) A human-curated annotation of the *Candida albicans* genome. *PLoS Genet* 1(1):36–57
- Brown GD et al (2012) Hidden killers: human fungal infections. *Sci Transl Med* 4(165):165rv113
- Brunk M et al (2018) HyphaTracker: an ImageJ toolbox for time-resolved analysis of spore germination in filamentous fungi. *Sci Rep* 8(1):605
- Bruno VM et al (2010) Comprehensive annotation of the transcriptome of the human fungal pathogen *Candida albicans* using RNA-seq. *Genome Res* 20(10):1451–1458
- Bruno VM et al (2015) Transcriptomic analysis of vulvovaginal candidiasis identifies a role for the NLRP3 inflammasome. *MBio* 6(2):e00182–e00115
- Cairns TC et al (2019) A quantitative image analysis pipeline for the characterization of filamentous fungal morphologies as a tool to uncover targets for morphology engineering: a case study using apID in *Aspergillus niger*. *Biotechnol Biofuels* 12:149
- Cakir T et al (2020) Novel approaches for systems biology of metabolism-oriented pathogen-human interactions: a mini-review. *Front Cell Infect Microbiol* 10:52
- Casadevall A et al (2019) The ‘amoeboid predator-fungal animal virulence’ hypothesis. *J Fungi (Basel)* 5(1):10
- Caspeta L et al (2012) Genome-scale metabolic reconstructions of *Pichia stipitis* and *Pichia pastoris* and in silico evaluation of their potentials. *BMC Syst Biol* 6:24
- Cerqueira GC et al (2014) The *Aspergillus* genome database: multispecies curation and incorporation of RNA-Seq data to improve structural gene annotations. *Nucleic Acids Res* 42(Database issue):D705–D710
- Chen Y et al (2014) The *Cryptococcus neoformans* transcriptome at the site of human meningitis. *MBio* 5(1):e01087–e01013
- Cheng S et al (2013) Profiling of *Candida albicans* gene expression during intra-abdominal candidiasis identifies biologic processes involved in pathogenesis. *J Infect Dis* 208(9):1529–1537
- d’Enfert C et al (2005) CandidaDB: a genome database for *Candida albicans* pathogenomics. *Nucleic Acids Res* 33(Database issue):D353–D357
- Darabos C et al (2011) Additive functions in boolean models of gene regulatory network modules. *PLoS One* 6(11):e25110
- Das A et al (2015) Dual RNA sequencing reveals the expression of unique transcriptomic signatures in lipopolysaccharide-induced BV-2 microglial cells. *PLoS One* 10(3):e0121117
- Dix A et al (2016) Use of systems biology to decipher host-pathogen interaction networks and predict biomarkers. *Clin Microbiol Infect* 22(7):600–606
- Dobson PD et al (2010) Further developments towards a genome-scale metabolic model of yeast. *BMC Syst Biol* 4:145

- Duarte NC, Herrgard MJ, Palsson BO (2004) Reconstruction and validation of *Saccharomyces cerevisiae* iND750, a fully compartmentalized genome-scale metabolic model. *Genome Res* 14(7):1298–1309
- Durmus S et al (2015) A review on computational systems biology of pathogen-host interactions. *Front Microbiol* 6:235
- Edgar R, Domrachev M, Lash AE (2002) Gene expression omnibus: NCBI gene expression and hybridization array data repository. *Nucleic Acids Res* 30(1):207–210
- Ettinger A, Wittmann T (2014) Fluorescence live cell imaging. *Methods Cell Biol* 123:77–94
- Forster J et al (2003) Genome-scale reconstruction of the *Saccharomyces cerevisiae* metabolic network. *Genome Res* 13(2):244–253
- Friedman N et al (2000) Using Bayesian networks to analyze expression data. *J Comput Biol* 7(3–4):601–620
- Glass L, Kauffman SA (1973) The logical analysis of continuous, non-linear biochemical control networks. *J Theor Biol* 39(1):103–129
- Goffeau A et al (1996) Life with 6000 genes. *Science* 274(5287):546, 563–547
- Guelzim N et al (2002) Topological and causal structure of the yeast transcriptional regulatory network. *Nat Genet* 31(1):60–63
- Guo L et al (2016) Compartmentalized gene regulatory network of the pathogenic fungus *Fusarium graminearum*. *New Phytol* 211(2):527–541
- Heavner BD et al (2012) Yeast 5 – an expanded reconstruction of the *Saccharomyces cerevisiae* metabolic network. *BMC Syst Biol* 6:55
- Herrgard MJ et al (2008) A consensus yeast metabolic network reconstruction obtained from a community approach to systems biology. *Nat Biotechnol* 26(10):1155–1160
- Homann OR et al (2009) A phenotypic profile of the *Candida albicans* regulatory network. *PLoS Genet* 5(12):e1000783
- Horn F et al (2012) Systems biology of fungal infection. *Front Microbiol* 3:108
- Hu Z, Killion PJ, Iyer VR (2007) Genetic reconstruction of a functional transcriptional regulatory network. *Nat Genet* 39(5):683–687
- Ibrahim-Granet O et al (2003) Phagocytosis and intracellular fate of *Aspergillus fumigatus* conidia in alveolar macrophages. *Infect Immun* 71(2):891–903
- Jones T et al (2004) The diploid genome sequence of *Candida albicans*. *Proc Natl Acad Sci U S A* 101(19):7329–7334
- Karlebach G, Shamir R (2008) Modelling and analysis of gene regulatory networks. *Nat Rev Mol Cell Biol* 9(10):770–780
- Kauffman SA (1969) Metabolic stability and epigenesis in randomly constructed genetic nets. *J Theor Biol* 22(3):437–467
- Kim H, Hu W, Kluger Y (2006) Unraveling condition specific gene transcriptional regulatory networks in *Saccharomyces cerevisiae*. *BMC Bioinformatics* 7:165
- Kishino H, Waddell PJ (2000) Correspondence analysis of genes and tissue types and finding genetic links from microarray data. *Genome Inform Ser Workshop Genome Inform* 11:83–95
- Kniemeyer O et al (2011) Identification of virulence determinants of the human pathogenic fungi *Aspergillus fumigatus* and *Candida albicans* by proteomics. *Int J Med Microbiol* 301(5):368–377
- Kumar R, Ruhel R (2019) Emergence of invasive fungal infection: diagnosis and treatment in humans. In: Gupta A, Singh N (eds) Recent developments in fungal diseases of laboratory animals. *Fungal biology*. Springer, Cham, pp 131–148
- Kurischko C et al (2005) A role for the *Saccharomyces cerevisiae* regulation of Ace2 and polarized morphogenesis signaling network in cell integrity. *Genetics* 171(2):443–455
- Lee TI et al (2002) Transcriptional regulatory networks in *Saccharomyces cerevisiae*. *Science* 298(5594):799–804
- Loftus BJ et al (2005) The genome of the basidiomycetous yeast and human pathogen *Cryptococcus neoformans*. *Science* 307(5713):1321–1324

- Loira N et al (2012) A genome-scale metabolic model of the lipid-accumulating yeast *Yarrowia lipolytica*. *BMC Syst Biol* 6:35
- Mabey JE et al (2004) CADRE: the Central Aspergillus Data REpository. *Nucleic Acids Res* 32(Database issue):D401–D405
- Mader U et al (2015) Image-processing scheme to detect superficial fungal infections of the skin. *Comput Math Methods Med* 2015:851014
- May RM, Anderson RM (1979) Population biology of infectious diseases: part II. *Nature* 280(5722):455–461
- McDonagh A et al (2008) Sub-telomere directed gene expression during initiation of invasive aspergillosis. *PLoS Pathog* 4(9):e1000154
- Mech F et al (2011) Automated image analysis of the host-pathogen interaction between phagocytes and *Aspergillus fumigatus*. *PLoS One* 6(5):e19591
- Meijueiro ML et al (2014) Transcriptome characteristics of filamentous fungi deduced using high-throughput analytical technologies. *Brief Funct Genomics* 13(6):440–450
- Mo ML, Palsson BO, Herrgard MJ (2009) Connecting extracellular metabolomic measurements to intracellular flux states in yeast. *BMC Syst Biol* 3:37
- Nelson B et al (2003) RAM: a conserved signaling network that regulates Ace2p transcriptional activity and polarized morphogenesis. *Mol Biol Cell* 14(9):3782–3803
- Nicolas FE, Ruiz-Vazquez RM (2013) Functional diversity of RNAi-associated sRNAs in fungi. *Int J Mol Sci* 14(8):15348–15360
- Nierman WC et al (2005) Genomic sequence of the pathogenic and allergenic filamentous fungus *Aspergillus fumigatus*. *Nature* 438(7071):1151–1156
- Nookaew I et al (2008) The genome-scale metabolic model iN800 of *Saccharomyces cerevisiae* and its validation: a scaffold to query lipid metabolism. *BMC Syst Biol* 2:71
- O'Brien EJ, Monk JM, Palsson BO (2015) Using genome-scale models to predict biological capabilities. *Cell* 161(5):971–987
- O'Meara TR et al (2013) *Cryptococcus neoformans* Rim101 is associated with cell wall remodeling and evasion of the host immune responses. *MBio* 4(1):e00522–e00512
- Osterlund T et al (2013) Mapping condition-dependent regulation of metabolism in yeast through genome-scale modeling. *BMC Syst Biol* 7:36
- Pe'er D, Regev A, Tanay A (2002) Minreg: inferring an active regulator set. *Bioinformatics* 18(Suppl 1):S258–S267
- Peters JM, Solomon SL, Itoh CY, Bryson BD (2019) Uncovering complex molecular networks in host–pathogen interactions using systems biology. *Emerg Top Life Sci* 3(4):371–378
- Pinu FR et al (2019) Systems biology and multi-omics integration: viewpoints from the metabolomics research community. *Metabolites* 9(4):76
- Pusa T et al (2020) MOOMIN – Mathematical explORation of 'Omics data on a Metabolite Network. *Bioinformatics* 36(2):514–523
- Ramachandra S et al (2014) Regulatory networks controlling nitrogen sensing and uptake in *Candida albicans*. *PLoS One* 9(3):e92734
- Rienksma RA et al (2015) Comprehensive insights into transcriptional adaptation of intracellular mycobacteria by microbe-enriched dual RNA sequencing. *BMC Genomics* 16:34
- Rodrigues RR, Shulzhenko N, Morgun A (2018) Transkingdom networks: a systems biology approach to identify causal members of host-microbiota interactions. *Methods Mol Biol* 1849:227–242
- Romani L (2011) Immunity to fungal infections. *Nat Rev Immunol* 11(4):275–288
- Rustici G et al (2013) ArrayExpress update--trends in database growth and links to data analysis tools. *Nucleic Acids Res* 41(Database issue):D987–D990
- Saputo S et al (2012) The RAM network in pathogenic fungi. *Eukaryot Cell* 11(6):708–717
- Sayers S et al (2019) Victors: a web-based knowledge base of virulence factors in human and animal pathogens. *Nucleic Acids Res* 47(D1):D693–D700
- Schafer J, Strimmer K (2005) An empirical Bayes approach to inferring large-scale gene association networks. *Bioinformatics* 21(6):754–764

- Segal E et al (2003) Module networks: identifying regulatory modules and their condition-specific regulators from gene expression data. *Nat Genet* 34(2):166–176
- Shahzad K, Loor JJ (2012) Application of top-down and bottom-up systems approaches in ruminant physiology and metabolism. *Curr Genomics* 13(5):379–394
- Shmulevich I et al (2002) Probabilistic Boolean networks: a rule-based uncertainty model for gene regulatory networks. *Bioinformatics* 18(2):261–274
- Skrzypek MS et al (2017) The *Candida* genome database (CGD): incorporation of assembly 22, systematic identifiers and visualization of high throughput sequencing data. *Nucleic Acids Res* 45(D1):D592–D596
- Sohn SB et al (2012) Genome-scale metabolic model of the fission yeast *Schizosaccharomyces pombe* and the reconciliation of in silico/in vivo mutant growth. *BMC Syst Biol* 6:49
- Sun TY, Haberman AM, Greco V (2017) Preclinical advances with multiphoton microscopy in live imaging of skin cancers. *J Invest Dermatol* 137(2):282–287
- Tavares AH et al (2015) Transcriptomic reprogramming of genus *Paracoccidioides* in dimorphism and host niches. *Fungal Genet Biol* 81:98–109
- Tefagh M, Boyd SP (2020) SWIFTCORE: a tool for the context-specific reconstruction of genome-scale metabolic networks. *BMC Bioinformatics* 21(1):140
- Tierney L et al (2012) An interspecies regulatory network inferred from simultaneous RNA-seq of *Candida albicans* invading innate immune cells. *Front Microbiol* 3:85
- Vodisch M et al (2009) Two-dimensional proteome reference maps for the human pathogenic filamentous fungus *Aspergillus fumigatus*. *Proteomics* 9(5):1407–1415
- Wang YC et al (2013) Interspecies protein-protein interaction network construction for characterization of host-pathogen interactions: a *Candida albicans*-zebrafish interaction study. *BMC Syst Biol* 7:79
- Wang Q, Li L, Xu R (2018) A systems biology approach to predict and characterize human gut microbial metabolites in colorectal cancer. *Sci Rep* 8:6225
- Wartenberg A et al (2014) Microevolution of *Candida albicans* in macrophages restores filamentation in a nonfilamentous mutant. *PLoS Genet* 10(12):e1004824
- Westermann AJ, Gorski SA, Vogel J (2012) Dual RNA-seq of pathogen and host. *Nat Rev Microbiol* 10(9):618–630
- Wurster S et al (2019) Live monitoring and analysis of fungal growth, viability, and mycelial morphology using the IncuCyte NeuroTrack processing module. *MBio* 10(3):e00673–e00619
- Yeung A et al (2019) Using a systems biology approach to study host-pathogen interactions. *Microbiol Spectr* 7(2)
- Zomorodi AR, Maranas CD (2010) Improving the iMM904 *S. cerevisiae* metabolic model using essentiality and synthetic lethality data. *BMC Syst Biol* 4:178

Chapter 5

Ovine Fungal Diseases



Djadouni Fatima

5.1 Principal Ovine Fungal Diseases

Ovine and caprine animals (sheep and goats) are ruminant herbivores of a genus of mammals belonging to the large Bovidae family. These animals contribute significantly to the economy of farmers worldwide in Mediterranean as well as African, European, and Southeast Asian countries. These small ruminants are valuable assets because of their significant contribution to meat, milk, and wool production and potential to replicate and grow rapidly.

Several fungal diseases affecting sheep and goats may lead to mortality and morbidity losses and cause great economic losses. Pythiosis, aspergillosis, and ringworm are the common diseases that affect both bovine and ovine and have similar symptoms and are treated in the same ways as described in this section (Table 5.1).

5.1.1 *Phaeohyphomycosis*

Phaeohyphomycosis is caused by the black yeast *Cladosporium cladosporioides*, class *Dothideomycetes*, order *Capnodiales*, and *Davidiellaceae* family. These species are ubiquitous and isolated from almost any environmental source as soil, water, plant materials, and air where its spores are important in seasonal allergic disease. Infection occurs mainly through contact or skin puncture, especially through trauma involving wood. While these species are saprobic dematiaceous fungi, rarely they cause invasive disease in animals, only infrequently associated

D. Fatima (✉)

Biology Department, Faculty of Natural Sciences and Life, Mascara University,
Mascara, Algeria

e-mail: Djadouni.fatima@univ-mascara.dz

© Springer Nature Switzerland AG 2021

A. Gupta, N. Pratap Singh (eds.), *Fungal Diseases in Animals*, Fungal Biology,
https://doi.org/10.1007/978-3-030-69507-1_5

63

Table 5.1 Some infectious fungal diseases in sheep and goats

Disease	Causative organism	Transmission	Geographic distribution	Pathogenesis	Drug for treatment	References
Pneumocystosis	Opportunistic fungal pathogen <i>Pneumocystis carinii</i> Class Fungus (<i>Ascomycota</i>) Family <i>Pneumocystidaceae</i> Order <i>Pneumocystidales</i>	Direct contact Airborne routes (aerosol)	Worldwide	Fatal pneumonia in immunosuppressed hosts Abomasal and intestinal hemorrhage coupled with immune dysfunction	Pentamidine isethionate Trimethoprim sulfamethoxazole Atovaquone Trimetrexate	de Souza and Benchimol (2005) Sakakibara et al. (2013) Kondo et al. (2014)
Microsporidiosis	Emerging opportunistic fungal pathogens <i>Enterocytozoon bienersi</i> and <i>E. intestinalis</i> Class <i>Enterocytozoon</i> Family <i>Enterocytozoonidae</i> Order Chytridiopsida	Water sources	Worldwide	Infects the intestinal epithelial cells Lesions in kidneys Diarrhea	Fenbendazole	Wenker et al. (2002) Malčková et al. (2010) Zhao et al. (2015)
Scopulariopsis	Dematiaceous fungi <i>Scopulariopsis brevicaulis</i> and <i>S. brumptii</i> Class <i>Sordariomycetes</i> Family <i>Microasaceae</i> Order <i>Microascales</i>	Soil, air, in plant litter, paper, wood, dung, and animal remains	Worldwide	Hair loss and skin changes	Itraconazole D-biotin	Ozürk et al. (2009) Sallam and ALKolaibe (2010) Awad and Kraume (2011)

Disease	Causative organism	Transmission	Geographic distribution	Pathogenesis	Drug for treatment	References
Keratinophilic fungi	<i>Trichophyton mentagrophytes</i> , <i>T. verrucosum</i> , <i>Microsporum nanum</i> , <i>Arthroderma cuniculi</i> , <i>Ar. curyei</i> , <i>Acremonium kiliense</i> , <i>Alternaria alternata</i> , <i>Aspergillus flavus</i> , <i>A. versicolor</i> , <i>Cladosporium carrionii</i> , <i>Chrysosporium tropicum</i> , <i>Ch. anamorph</i> , <i>Acremonium kiliense</i> , <i>Aphanoascus fulvuscens</i> , <i>Paecilomyces lilacinus</i> , <i>Scopulariopsis brevicaulis</i> , and others	Hair, wool, cloven hooves, and horns of goats and sheep Contaminating working areas and dwelling places Wet and dirty surfaces	Worldwide	Infections of the skin like club fungus, athlete's foot, <i>Tinea</i> infection of some keratinized surfaces and ringworm of the hair and nails	Fluconazole, Ketoconazole Miconazole	El-Said et al. (2009) Eljack et al. (2011) Emenuga and Oyeke (2013) Kalaiselvi et al. (2014) Biswas et al. (2015)
Facial eczema (pithomycotoxicosis, photodermatitis)	<i>Pithomyces chartarum</i> Class <i>Dothideomycetes</i> Family <i>Pleosporaceae</i> Order <i>Pleosporales</i>	Presence of the mycotoxin sporidesmin in forage grasses	Subtropical countries and other localities with warmer climates such as New Zealand, United Kingdom, Europe, and Netherlands	Facial eczema Drooping ears and swollen eyes Skin lesions	Feeding cattle zinc or by using benzimidazole fungicides on pastures	Smith and Embling (1991) Ozmen et al. (2008) Di Menna et al. (2009) Refai et al. (2017a)

with human and animal opportunistic infections (Seyedmousavi et al. 2013; De Graham 2013).

C. cladosporioides causes pulmonary and cutaneous phaeohyphomycosis. In sheep, pulmonary infection is observed with respiratory distress signs, coughing, fever, anorexia, and death. At necropsy, abnormalities were confined to the lung, abomasums, lymph nodes, kidneys, liver, and heart. Severe hemorrhages were observed in the lungs, and vasculitis with thrombosis was apparent in various organs, which is suggestive of hematogenous dissemination (Haligur et al. 2010; Frank et al. 2011).

Moreover, subcutaneous phaeohyphomycosis is characterized by papulonodules; verrucous, hyperkeratotic, or ulcerated plaques; cysts; abscesses; pyogranuloma; or nonhealing ulcers or sinuses. However, phaeohyphomycosis is rarely seen in goats and is caused by free-living fungus *Peyronella glomerata*. The disease has been recorded in Central Asia but not in the United Kingdom. It forms papules and aural plaques on the ears. It appears to be self-limiting. The treatment of choice is aggressive surgical excision of local lesions, and antifungal treatment includes fluconazole, itraconazole, ketoconazole, posaconazole, terbinafine, and liposomal amphotericin B (Bensch et al. 2010; Sang et al. 2011, 2012).

5.1.2 Candidosis

Candidosis is a fungal disease affecting the mucous membranes and the skin and may cause infection of any organ or system or systemic infections. The disease is distributed worldwide in a variety of animals and is most commonly caused by yeast species of the genus *Candida* especially *Candida albicans* (Odds 1988; Refai et al. 2017a).

This yeast is a polymorphic fungus which grows in both yeast and filamentous forms and is the most commonly recorded species in sheep and goats besides other yeasts that are responsible for the mycotic mastitis and abortion diseases including *C. krusei*, *C. guilliermondii*, *C. tropicalis*, *C. lusitaniae*, *C. parapsilosis*, and *C. glabrata* (Khan et al. 2010; Hassan et al. 2012). Disease symptoms and treatment are described in “Fungal Bovine Diseases” (3.4 and 3.7) (Brilhante et al. 2015; Maneenil et al. 2015).

5.1.3 Cryptococcosis

Cryptococcosis is a systemic fungal disease that may affect the respiratory tract (especially the nasal cavity), eyes, nervous system (brain), and skin in different domestics. It occurs worldwide and affects immunocompromised animals, goats, and sheep causing pneumonia and mastitis but not of meningitis (Stilwell and Pissarra 2014; Refai et al. 2017b).

In addition, signs in animals may include sneezing, snorting, nasal discharge, eye problems, change in behavior, depression, disorientation, seizures, and difficulties with moving around. Moreover, the disease is caused by saprophytic and opportunistic fungal pathogens *Cryptococcus neoformans* or *C. gattii* through the inhalation of basidiospores from environment, ingestion of desiccated yeast cells, or more, rarely, direct cutaneous inoculation (Woldemeskel et al. 2002; Stilwell and Pissarra 2014; Refai et al. 2017b).

Cryptococcosis symptoms vary depending on the organ systems affected by the fungus. Often, symptoms are systemic and nonspecific, such as diminished appetite, weight loss, or lethargy. In sheep, and goats, the lesions are restricted to the respiratory system. Azole drugs including amphotericin B (with or without flucytosine), ketoconazole, fluconazole, itraconazole, and glucocorticoids are the most common antifungals used for treatment. In the case of subcutaneous or internal mass, surgery may be performed to remove it, followed by antifungal therapy (Woldemeskel et al. 2002; Lacasta et al. 2008; Chakraborty et al. 2014).

5.1.4 *Malasseziosis*

Malassezia dermatitis or otitis is a mycotic disease caused by some *Malassezia* species including *M. slooffiae*, *M. globosa*, *M. furfur*, *M. restricta*, and *M. sympodialis* and in particular *M. pachydermatis* that belong to the zoophilic yeast, division *Basidiomycota*. *Malassezia* spp. are lipophilic yeasts that belong to normal cutaneous or mucosal microbiota of many warm-blooded vertebrates; it is normally found in low numbers in the external ear canals, in perioral areas, in perianal regions, and in moist skin folds of some animals (Guillot and Bond 1999; Velegraki et al. 2015; Refai et al. 2017a).

Malassezia species are recognized as opportunistic pathogens that play a significant role in the development of different human and animal diseases such as otitis externa or seborrheic dermatitis. Malasseziosis occurs most commonly in animals with allergies, endocrinopathies (hypothyroidism, Cushing's disease), immunosuppressive diseases, and other skin diseases. Infection occurs either when hypersensitivity to the yeast develops or when there is overgrowth of the organism (Uzal et al. 2007; Gaitanis et al. 2012).

Malassezia dermatitis is uncommon in goats and sheep, where poor nutrition and debilitating underlying disease appear to be predisposing factors. Lesions are nonpruritic to mildly pruritic and nonpainful and are characterized by erythema, hyperpigmentation, scale, greasiness, yellow waxy crusts, lichenification, follicular orthokeratotic hyperkeratosis, and mild lymphocytic perivascular dermatitis. Lesions are multifocal, often over the back and trunk, and typically become generalized but tend to spare the head and legs (Bond 2010; Eguchi-Coe et al. 2011).

Malassezia otitis externa is common in cattle in South America. There is a ceruminous to suppurative otitis externa caused by predominantly thermotolerant *M. sympodialis* in the summer and a predominantly less thermotolerant species,

M. globosa in the winter (Duarte et al. 1999, 2003). The antifungals used to treat this disease are ketoconazole, itraconazole, fluconazole, and terbinafine (Bond et al. 2010; Cafarchia et al. 2012; Arendrup et al. 2014).

5.1.5 *Rhodotorulosis*

The disease results from infection with the genus *Rhodotorula*. Although the yeast is recovered worldwide from a variety of sources, infection is generally only seen in the immunocompromised host. The fungi from the genus *Rhodotorula* are imperfect basidiomycetous yeast belonging to the family *Cryptococcaceae* (Tuon and Costa 2008; Vazquez 2011).

Rhodotorula rubra (*R. mucilaginosa*) is the species most frequently associated with mammal infection. *Rhodotorula* species are commonly recovered from seawater, lakes, ocean water, plants, soil, air, and food and occasionally from humans. The genus *Rhodotorula* includes eight species, of which *R. mucilaginosa*, *R. glutinis*, and *R. minuta* were reported to cause mastitis in ruminants (Vazquez 2011; Wirth and Goldani 2012).

Among the few references about the pathogenicity of *Rhodotorula* spp. in animals, there are several reports of an outbreak of skin infections in chickens and a report of a lung infection in sheep, both caused by *R. mucilaginosa*. Amphotericin B, fluconazole, itraconazole, ketoconazole, posaconazole, voriconazole, and flucytosine are the main antifungal drugs for treatment animals (Wirth and Goldani 2012; Dhama et al. 2013).

5.1.6 *Conidiobolomycosis*

Conidiobolomycosis is a zygomycosis caused by fungi of the class *Zygomycetes*, order *Entomophthorales*, affecting humans and animals. The main *Conidiobolus* species involved are *C. coronatus*, *C. incongruus*, and *C. lamprauges*. *Conidiobolus* spp. are found mainly in soil, decaying vegetation, and insects of tropical and subtropical regions, in areas of high humidity, particularly in Central America, equatorial Africa, and India; however, cases have been reported worldwide including Brazil (Silva 2007; Aguiar et al. 2014; Weiblen et al. 2016).

In animals, conidiobolomycosis caused by *C. coronatus*, *C. lamprauges*, and *C. incongruus* are reported mainly as subcutaneous infections (granulomatous and necrotic) or rhinofacial, nasopharyngeal, or oral infections. These fungal infections are very important, since they compromise the health status of the sheep flock and cause serious economic losses to the sheep industry (Ubiali et al. 2013; El-Shabrawi et al. 2014). However, there was no effective treatment for the disease, but in 2013 a group of antifungal drugs was described from sheep including amphotericin B, azoles, echinocandins, and terbinafine, but only the terbinafine was active against

this fungus and the microorganism demonstrated resistance or reduced susceptibility to the other antifungal drugs evaluated (Tondolo et al. 2013; El-Shabrawi et al. 2014).

5.2 Conclusion

Biosecurity and hygiene; veterinary surveillance; health and welfare programs; buying, registering, and moving sheep and goats; appropriate grazing systems; and animal selection to improve resistance are the alternative management strategies to prevent and control disease in small ruminants.

References

- Aguiar GMN, Simões SVD, Santos SA, Marques ALA, da Silva TR, Dantas AFM, Correa FR (2014) Epidemiological aspects of conidiobolomycosis in sheep in the Northeastern Brazilian semiarid region. *Ciênc Rural* 44(12):2210–2216
- Arendrup MC, Boekhout T, Akova M, Meis JF, Cornely OA et al (2014) ESCMID/ECMM joint clinical guideline for the diagnosis and management of rare invasive yeast infections. *Clin Microbiol Infect* 20:76–98
- Awad MF, Kraume M (2011) Keratinophilic fungi in activated sludge of wastewater treatment plants with MBR in Berlin. *Mycol* 2(4):276–282
- Bensch K, Groenewald JZ, Dijksterhuis J, Starink-Willemse M, Andersen B, Summerell Crous PW (2010) Species and ecological diversity within the *Cladosporium cladosporioides* complex (*Davidiellaceae*, Capnodiales). *Stud Mycol* 67:1–94
- Biswas MK, Deb Nath C, Mitra T, Baidya S, Pradhan S (2015) Studies on dermatophytoses in sheep and goat in West Bengal, India. *Ind J Anim Health* 54(2):109–114
- Bond R (2010) Superficial veterinary mycoses. *Clin Dermatol* 28(2):226–236
- Bond R, Guillot J, Cabañes FJ (2010) *Malassezia* yeasts in animal disease. In: Boekhout T, Gueho E, Mayser P, Velegraki A (eds) *Malassezia* and the skin: science and clinical practice. Springer, Berlin, pp 271–299
- Brilhante RS, Silva ST, Castelo-Branco DS, Teixeira CE, Borges LC, Bittencourt PV, de Oliveira JS, Monteiro AJ, Bandeira TJ, Cordeiro RA, Moreira JL, Sidrim JJ, Rocha MF (2015) Emergence of azole-resistant *Candida albicans* in small ruminants. *Mycopathologia* 180(3–4):277–280
- Cafarchia C, Figueredo LA, Iatta R, Colao V, Montagna MT, Otranto D (2012) *In vitro* evaluation of *Malassezia pachydermatis* susceptibility to azole compounds using E-test and CLSI micro-dilution methods. *Med Mycol* 50:795–801
- Chakraborty S, Kumar A, Tiwari R, Rahal A, Malik Y, Dhama K, Pal A, Prasad M (2014) Advances in diagnosis of respiratory diseases of small ruminants: review article. *Vet Med Int*, Article ID 508304, 16 pages
- De Graham RD (2013) Farm animal medicine and surgery: for small animal veterinarians. CABI Amazon France, Chapter 5, 115 p
- de Souza W, Benchimol M (2005) Basic biology of *Pneumocystis carinii*. *Mem Inst Oswaldo Cruz Rio de Janeiro* 100:903–908
- Dhama K, Chakraborty S, Verma AK, Tiwari R, Barathidasan R, Kumar A, Singh SD (2013) Fungal/mycotic diseases of poultry-diagnosis, treatment and control: a review. *Pak J Biol Sci* 16:1626–1640

- Di Menna ME, Smith BL, Miles CO (2009) A history of facial eczema (pithomycotoxicosis) research. *N Z J Agri Res* 52:345–376
- Duarte EP, Melo MM, Hahn RC, Hamdan JS (1999) Prevalence of *Malassezia* spp. in the ears of asymptomatic cattle and cattle with otitis in Brazil. *Med Mycol* 37(3):159
- Duarte ER, Batista RD, Hahn RC, Hamdan JS (2003) Factors associated with the prevalence of *Malassezia* species in the external ears of cattle from the state of Minas Gerais, Brazil. *Med Mycol* 41:137–142
- Eguchi-Coe Y, Valentine BA, Gorman E, Villarreal A (2011) Putative *Malassezia* dermatitis in six goats. *Vet Dermatol* 22(6):497–501
- Eljack H, Abdo Elgabbar MA, Shuaib YA, Elham AS (2011) Case study *Trichophyton verrucosum* infection in a saanen goat (*Capra aegagrus hircus*). *U of K. J Vet Med Anim Prod* 2(2):131–141
- El-Said AHM, Sohair TH, El-Hadi AG (2009) Fungi associated with the hairs of goat and sheep in Libya. *Mycobiol* 37(2):82–88
- El-Shabrawi MHF, Arnaout H, Madkour L, Kamal MN (2014) Entomophthoromycosis: a challenging emerging disease. *Mycos* 57(3):132–137
- Emenuga VN, Oyeka CA (2013) Epidemiology, health effects and treatment of cutaneous mycoses of goat and sheep from some Eastern States of Nigeria. *Am J Inf Dis Microbiol* 1(6):106–110
- Frank C, Vemulapalli R, Lin T (2011) Cerebral phaeohyphomycosis due to *Cladophialophora bantiana* in a Huacaya alpaca (*Vicugna pacos*). *J Comp Pathol* 145:410–413
- Gaitanis G, Magiatis P, Hantschke M, Bassukas ID, Velegaki A (2012) The *Malassezia* genus in skin and systemic diseases. *Clin Microbiol Rev* 25:106–141
- Guillot J, Bond R (1999) *Malassezia pachydermatis*: a review. *Med Mycol* 37(5):295–306
- Haligur M, Ozmen O, Dorresteijn GM (2010) Fatal systemic cladosporiosis in a merino sheep flock. *Mycopathologia* 170:411–415
- Hassan AA, Manal AH, Sayed El Ahl RMH, Darwish AS (2012) Prevalence of yeast infections in small in ruminants with particular references to their treatment by some natural herbal extracts. *Bull Env Pharmacol Life Sci* 1(3):12–22
- Kalaiselvi G, Daniel NJC, Vidhya M (2014) Ringworm infection in a goat. A clinical case report. *Ind J Vet Anim Sci Res* 43(5):386–387
- Khan S, Raffid D, Mahammed J (2010) The effect of teat damage on the incidence of mastitis in sheep. *Vet Rec* 8(2):372–376
- Kondo H, Musoke G, Ssekiwunga H, Hatama S, Ishikawa Y, Kadota K (2014) Pneumocystis infection in goat kids in Uganda. *JARQ* 48(3):349–353
- Lacasta D, Ferrer LM, Ramos JJ, Gonz'alez JM, De las Heras M (2008) Influence of climatic factors on the development of pneumonia in lambs. *Small Rum Res* 80(1–3):28–32
- Malčeková B, Halánová M, Sulínová Z, Molnár L, Ravaszová P, Adam J, Halán M, Valocký I, Baranovič M (2010) Seroprevalence of antibodies to *Encephalitozoon cuniculi* and *Encephalitozoon intestinalis* in humans and animals. *Res Vet Sci* 89(3):358–361
- Maneenil G, Payne MS, Senthamarai Kannan P, Kallapur SG, Kramer BW, Newnham JP, Miura Y, Jobe AH, Kemp MW (2015) Fluconazole treatment of intrauterine *Candida albicans* infection in fetal sheep. *Pediatr Res* 77(6):740–748
- Odds FC (1988) *Candida* and Candidosis, 2nd edn. Baillere Tindall, London, 468 p
- Ozmen O, Sahinduran S, Haligur M, Albay MK (2008) Clinicopathological studies on facial eczema outbreak in sheep in Southwest Turkey. *Trop Anim Health Prod* 40(7):545–551
- Ozturk D, Adanir K, Turutoglu H (2009) Superficial skin infection with *Scopulariopsis brevicaulis* in two goats. A case report. *Bull Vet Inst Pulawy* 53:361–363
- Refai MK, El-Naggar AL, El-Mokhtar NM (2017a) Monograph on fungal diseases of sheep and goats: A guide for postgraduate students in developing countries. Cairo, Egypt, 174 p
- Refai MK, El-Hariri M, Alarousy R (2017b) Cryptococcosis in animals and birds: a review article. *Eur J Acad Ess* 4(8):202–223
- Sakakibara M, Shimizu C, Kadota K, Hatama S (2013) *Pneumocystis carinii* infection in a domestic goat (*Capra hircus domesticus*) with multibacillary paratuberculosis. *J Vet Med Sci* 75(5):671–674

- Sallam AMH, ALKolaibe AM (2010) Distribution pattern of dermatophytes and other keratinophilic fungi on goats hair and sheep wool, Taiz city, Yemen. *J Environ Sci* 39(3):345–356
- Sang H, Zheng XE, Kong QT, Zhou WQ, He W, Lv GX, Shen YN, Liu WD (2011) A rare complication of ear piercing: a case of subcutaneous phaeohyphomycosis caused by *Veronaea botryosa* in China. *Med Mycol* 49(3):296
- Sang H, Zheng XE, Zhou WQ, He W, Lv GX, Shen YN, Kong QT, Liu WD (2012) A case of subcutaneous phaeohyphomycosis caused by *Cladosporium cladosporioides* and its treatment. *Mycoses* 55:195–197
- Seyedmousavi S, Guillot J, de Hoogd GS (2013) Phaeohyphomycoses, emerging opportunistic diseases in animals. *Clin Microbiol Rev* 26:19–35
- Silva SMMS (2007) Epidemiology and symptoms of conidiobolomycosis in sheep in the State of Piauí, Brazil. *Pesq Vet Bras* 27(4):184–190
- Smith BL, Embling PP (1991) Facial eczema in goats: the toxicity of sporidesmin in goats and its pathology. *N Z Vet J* 39(1):18–22
- Stilwell G, Pissarra H (2014) Cryptococcal meningitis in a goat: a case report. *BMC Vet Res* 10:84
- Tondolo JS, Loreto ES, Dutra V, Nakazato L, Paula DAJ, Zanette RA, Alves SH, Santurio JM (2013) *In vitro* susceptibility of *Conidiobolus lamprauges* recovered from sheep to antifungal agents. *Vet Microbiol* 166(3–4):690–693
- Tuon FF, Costa SF (2008) *Rhodotorula* infection. A systematic review of 128 cases from literature. *Rev Iberoam Micol* 25:135–140
- Ubiali DG, Cruz RAS, De Paula DAJ, Silva MC, Mendonça FS, Dutra V, Nakazato L, Colodel EM, Pescador CA (2013) Pathology of nasal infection caused by *Conidiobolus lamprauges* and *Pythium insidiosum* in sheep. *J Comp Pathol* 149(2–3):137–145
- Uzal FA, Paulson D, Eigenheer AL, Walker RL (2007) *Malassezia slooffiae* associated dermatitis in a goat. *Vet Dermatol* 18(5):348–352
- Vazquez JA (2011) *Rhodotorula*, *Saccharomyces*, *Malassezia*, *Trichosporon*, *Blastoschizomyces* and *Sporobolomyces*. In: Kauffman CA, Pappas PG, Sobel JD, Dismukes WE (eds) *Essentials of clinical mycology*. Springer Link, New York, pp 227–239
- Veleglaki A, Cafarchia C, Gaitanis G, Iatta R, Boekhout T (2015) *Malassezia* infections in humans and animals: pathophysiology, detection, and treatment. *PLoS Pathog* 11(1):e1004523
- Weiblen C, Pereira DIB, Dutra V, Godoy I, Nakazato L, Sangioni LA, Santurio JM, Botton SA (2016) Epidemiological, clinical and diagnostic aspects of sheep conidiobolomycosis in Brazil. *Ciênc Rural Santa Maria* 46(5):839–846
- Wenker CJ, Hatt JM, Ziegler D, Mathis A, Tanner I, Deplazes P (2002) Microsporidiosis (*Encephalitozoon* spp.) of new world primates – an emerging disease? A seroepidemiological, pathological, and therapeutic survey in the Zurich Zoo. *Proc Eur Assoc Zoo Wildl Vets Sci Meet* 4:503–506
- Wirth F, Goldani ZL (2012) Epidemiology of *Rhodotorula*: an emerging pathogen: a review. *Interdiscip Perspect Infect Dis*, Article ID 465717, 7 pages
- Woldemeskel M, Tibbo M, Potgieter LND (2002) Ovine progressive pneumonia (Maedi-Visna): an emerging respiratory disease of sheep in Ethiopia. *Deutsche Tierärztliche Wochenschrift* 109(11):486–488
- Zhao W, Zhang W, Yang D, Zhang L, Wang R, Liu A (2015) Prevalence of *Enterocytozoon bieneusi* and genetic diversity of ITS genotypes in sheep and goats in China. *Infect Genet Evol* 32:265–270

Chapter 6

Histopathologic Diagnosis of Fungal Infections of Lab Animals



Abhilasha Shourie, Rajeev Singh, and Anamika Singh

6.1 Common Fungal Infections in Lab Animals

Fungal disease or mycosis can occur in laboratory animals due to several known or unknown reasons, such as exposure to fungal spores through contact, inhalation, or invasion through injury point. Lab animals which are experimentally stressed, diseased, or immunocompromised are at higher risk of gaining infections. Mycosis is caused in lab animals due to direct or indirect infections, which can originate from opportunistic and/or obligatory pathogenic fungi (Fisher et al. 2012). Opportunistic fungal pathogens mostly survive and replicate in the environment outside-host such as saprotrophs (Casadevall 2008) and invade normal hosts or immunosuppressed hosts on encountering them. Obligatory pathogens essentially need their hosts to complete their life cycle.

Fungal infections in lab animals can be categorized as superficial, subcutaneous, and systemic. Superficial fungal infections cause skin diseases and are called dermatophytosis. Common examples for fungal pathogens causing superficial infections are *Microsporum*, *Trichophyton*, or *Epidermophyton* (Connole et al. 2000). Subcutaneous or dermal mycoses infect the skin and extend into subcutaneous tissue and further to other tissues and organs. The infection occurs usually through a traumatic injury of the skin and direct inoculation of fungi into the subcutaneous tissue (Zijlstra et al. 2016); an example is candidiasis caused by *Candida* sp. which can be a superficial infection such as thrush; else it can be a disseminated infection

A. Shourie

Department of Biotechnology, Faculty of Engineering and Technology, Manav Rachna International Institute of Research and Studies, Faridabad, HR, India

R. Singh

Department of Environmental Studies, Satyawati College, University of Delhi, New Delhi, India

A. Singh (✉)

Department of Botany, Maitreyi College, University of Delhi, New Delhi, India

© Springer Nature Switzerland AG 2021

A. Gupta, N. Pratap Singh (eds.), *Fungal Diseases in Animals*, Fungal Biology, https://doi.org/10.1007/978-3-030-69507-1_6

73

affecting certain target organs, such as the eyes or kidneys. In systemic mycoses, the fungal pathogen infects the host at a single point of entry and spread to multiple organ systems. Opportunistic fungal pathogens which exist in the environment invade debilitated or immunosuppressed hosts causing opportunistic infections. The surrounding environment is the primary source of most infections, which can be acquired by inhalation, ingestion, or traumatic introduction of fungal elements. Types of systemic fungal infections that can be recognized in animals are intravenous; intraperitoneal; gastric; pulmonary such as intranasal, intratracheal, and inhalational; mucosal such as oropharyngeal and vaginal; and central nervous system mycoses such as intracranial, intracisternal, or intrathecal (Guarner and Brandt 2011). Primary systemic mycoses in lab animals are caused by fungal pathogens such as histoplasmosis, coccidioidomycosis, blastomycosis, and cryptococcosis. Lab animals under prolonged administration of antimicrobials or immunosuppressive agents are more likely to catch such infections by the opportunistic fungi that cause diseases such as aspergillosis and candidiasis, which may be focal or systemic (Dedeaux et al. 2018).

Many opportunistic fungi are able to inhabit a variety of substrates in the surroundings of lab animals, and some can be common contaminants of cultures (Dedeaux et al. 2018); therefore it is imperative to ascertain whether the fungus represents the true infection or comes from some contamination or colonization. Histopathology is regarded as one of the oldest, reliable, and cost-effective method of fungal diagnosis, which is largely based on the microscopic examination of the tissue, smears, lesions, and morphological features of the fungus. Sometimes, the morphological features of many fungi may be identical for histological and/or cytological features, and such overlapping features are likely to question the accuracy of histopathological identification (Schwarz 1982). In such cases, other diagnostic methods can be used which include serology, fungal culture, immunohistology, and molecular diagnosis such as in situ hybridization (Guarner and Brandt 2011).

6.2 Histopathology in Diagnosis of Fungal Diseases

In some fungal diseases such as cryptococcosis, blastomycosis, coccidioidomycosis, histoplasmosis, and rhinosporidiosis, this method is just adequate for diagnosis, and in certain diseases caused by *Pneumocystis jiroveci* (formerly *Pneumocystis carinii*), *Lacazia loboi*, (formerly *Loboa loboi*), and *Rhinosporidium seeberi*, histopathology is recognized as the most robust method of identification (Schwarz 1982). In a number of other diseases such as candidiasis, aspergillosis, zygomycosis, phaeohyphomycosis, hyalohyphomycosis, and oomycosis (pythiosis and lagenidiosis), histopathological method provides only presumptive diagnosis and their definitive diagnosis requires other methods to be employed such as culture or PCR-based techniques (Dedeaux et al. 2018).

Since histopathological diagnosis of fungi is largely based upon microscopic observation of fungal morphology and fungal infestation in various tissue sections, use of special/specific stains enhance the accuracy of diagnosis and eliminates the chances of misidentification (Surendran et al. 2014). Different types of fungi are differentiated on the basis of morphological features such as size and appearance (yeast form, hyphae, or dimorphic form), presence of capsule, thickness of the capsule, presence of septae, and budding pattern (Chandler and Watts 1995).

Among all other modern modes of diagnosis, histopathology still remains indispensable as a presumptive and/or definitive diagnostic tool for fungal disease diagnosis. It is largely based upon morphologic interpretation of histologic tissue sections, cytologic preparations, biopsy material, and culture morphologies. It takes advantage of distinctive morphology of different fungal strains and requires observer's capability for accurate identification and subsequent pathological correlation (Reller et al. 2001). It is particularly advantageous in the instances where the microorganism fails to grow in culture or it is fastidious (Watts and Chandler 1995).

6.2.1 Histopathologic Diagnosis of Dermatophytosis

Dermatophytosis is caused by dermatophytes which are responsible for most superficial fungal infections (Aly 1994) in lab animals generally known as "tinea." These fungal pathogens are recognized as keratinophilic fungi, i.e., they usually invade the keratinized tissues in animals such as the skin, hair, or nails (Dobrowolska et al. 2006). There are a number of animal species which are invaded by dermatophytes such as dogs, cats, cattle, sheep, goats, pigs, rodents, rabbits, and birds. These animals are likely to catch the infections through direct contact with the surroundings contaminated with the fungal spores.

Commonly found dermatophytic genera are *Trichophyton* and *Microsporum* of which zoophilic and zoonotic dermatophytic species are more pathogenic to laboratory animals than anthropophilic strains, for example, *Trichophyton verrucosum*, *T. mentagrophytes*, *Microsporum gypseum*, and *M. canis* (Fisher et al. 2012). Infection from these dermatophytes result into diseases such as tinea capitis, tinea pedis, and onychomycosis (Gupta et al. 2005). The fungi *Trichophyton* is geophilic, i.e., its natural habitat is soil; therefore the primary source of *Trichophyton* infection to animals is soil. The fungi *Microsporum* are naturally zoophilic, i.e., they are acquired from animals (Weitzman and Summerbell 1995). The dermatophytes infect both healthy and immunocompromised animals. These diseases are mostly contagious and are frequently transmitted from one animal to another, and if they are zoonotic, they can be transmitted from animals to humans (Bond 2010).

Accurate diagnosis of dermatophytosis in lab animals is necessary for prevention of its relapse or recurrence in animals and transmission of infection to humans. The symptoms of dermatophytic infections are superficial and therefore easy to diagnose

(Robert and Pihet 2008). These diseases in lab animals can be commonly and clearly manifested by gross lesions on skin, hair, and nails. However, to eliminate the possibilities of misidentifications owing to overlapping symptoms of few dermatological conditions, other diagnostic techniques such as antifungal susceptibility profiling or molecular diagnosis may be performed.

The conventional techniques for diagnosis of dermatophytosis include histopathology, trichography, and fungal culture (Moriello and De Boer 2014; Pollock 2003). The most convenient, simple, and rapid method of dermatophytosis identification is microscopic examination of the clinical specimen (Lousbergh et al. 1999). The lesions of alopecia, erythema, papules, scaling, or crusting at common locations such as head, ears, nails, and front limbs (Pollock 2003) are usually indicative of the dermatophytosis condition. The microscopic examination of hair or trichogram is carried out of diagnosis of fungal spores or hyphae. It usually involves a semi-invasive approach of plucking of hair and examining the hair tip, hair root, and shaft under the microscope (Bond 2010).

6.2.2 Histopathologic Diagnosis of Systemic Mycoses

Systemic mycotic diseases such as histoplasmosis, coccidioidomycosis, and cryptococcosis are regarded as primary systemic mycoses and occur usually in mammals such as ruminants and equines; birds such as poultry; fish; and crustaceans, but are rarely seen in reptiles (Jacobson et al. 2000). It is frequently observed in farmed fish (De Hoog et al. 2011).

The histopathological examination of biopsy material demonstrates the nature of invasive disease, and further culturing of microorganisms reveals the identity of the pathogen. Preliminary identification of microorganisms in tissue sections may allow for the culture of fastidious microorganisms that require special media or growth conditions. Rapid histologic assessment of tissues can be done using frozen sections, which do not involve the fixation and routine processing. Such analysis is done in the cases of rapidly progressive diseases that require emergent surgical debridement, such as rhinocerebral zygomycosis or necrotizing fasciitis (Frater et al. 2001).

Disease characterization also involves the analysis of host inflammatory response, which is helpful in differentiating among acute, chronic, and/or granulomatous inflammation. Granulomas with or without necrosis usually appear in many fungal infections, which are differentiated as pyogranulomatous inflammation, suppurative granulomas, and palisading granulomas. Necrotizing granulomas often occur in systemic fungal pathogens, such as *Histoplasma* sp. and *Coccidioides* sp. (Woods and Walker 1996). Certain fungi such as *Aspergillus* and members of *Zygomycetes* are angiotrophic, i.e., they have a predilection for vascular invasion; therefore they often cause tissue infarction (Frater et al. 2001).

6.2.3 *Role of Histochemical Stains in Fungal Diagnosis*

Histochemical stains play a very vital role in detecting a large number of pathogens; however, sensitivity and efficiency of the stains depend upon several factors such as number of microorganisms present in the sample and methods adopted for sample procurement and sample preparation (Woods and Walker 1996). The hematoxylin-eosin (HE) stain is the most widely used stain for histopathologic evaluation of tissue sections. A wide range of yeast cells and fungal hyphae can be stained and visualized simply using HE stain. However, some specific stains such as methenamine silver stain (GMS) or the periodic acid-Schiff (PAS) stain are more useful to visualize subtle details of fungal morphology (Chandler and Watts 1995; Woods and Walker 1996). Papanicolaou stain has been used to identify the fungal elements from organisms *Aspergillus* and *Candida* species (Greaves and Strigle 1985). Mayer’s mucicarmine and Alcian blue stain are specific mucin stains that stain the mucopolysaccharide capsule of *Cryptococcus neoformans* (Gazzoni et al. 2009) (Fig. 6.1).

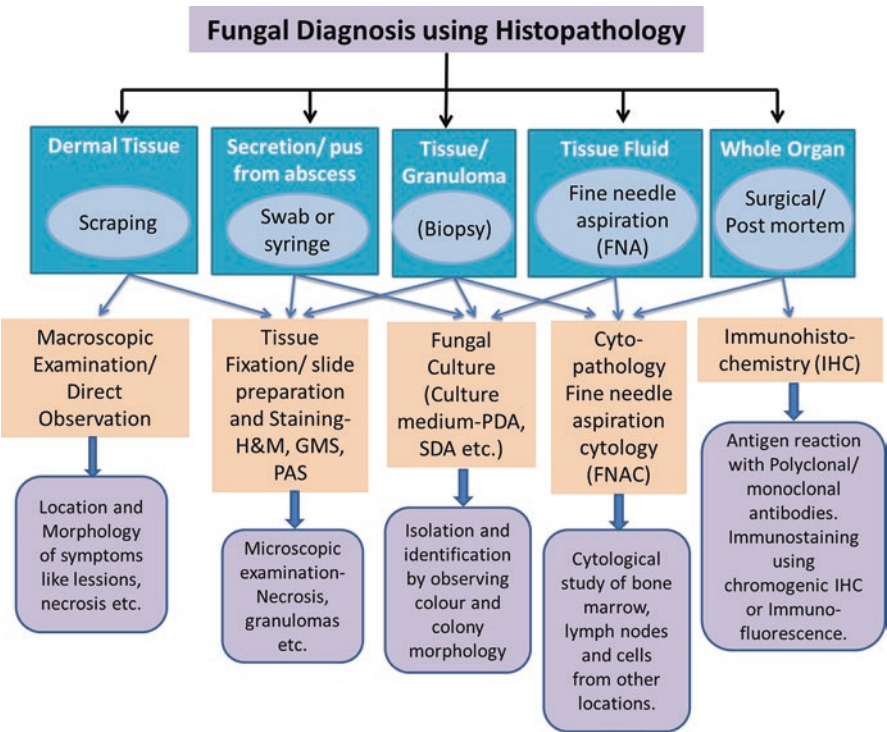


Fig. 6.1 Diagnosis of fungal infections using histopathological tools and techniques

6.3 Common Fungal Infections in Rats/Rabbits/Guinea Pigs and Their Diagnosis

Murine animals and rodents are the laboratory animals commonly used as/for experimental models. The accuracy and reliability of experimental results largely depend upon the animals' physical and physiological condition; thus any fungal infection can have profound impact on it. While they are treated as experimental subjects, they are often rendered compromised due to exposure to various experimental conditions and become more susceptible to fungal infections. The previously infected lab animals also become carriers of infection for healthy subjects. It is therefore imperative to correctly diagnose and treat the fungal infections in lab animals (Weitzman and Summerbell 1995).

Laboratory rats have been found to be infected with *T. mentagrophytes* that causes enzootic dermatophytosis manifested by alopecia, scaling, and erythema. The identification scheme involves observations of skin lesions and microscopic examination of colonies followed by molecular analysis for definitive diagnosis of specific strains (Baker 1998; Pollock 2003). Laboratory mice and rats have been diagnosed with indigenous yeast species *Candida pintolopesii* in their gastrointestinal tract as normal flora (Baker 1998).

Guinea pigs have been used as animal models for dermatophytoses as they demonstrate the clinical features comparable to the disease in humans. Etiologic agents *Trichophyton mentagrophytes* and *Microsporum canis* produce acute inflammatory infections in guinea pigs clinically identified by semiquantitative redness and lesion scores. Histopathological diagnosis of the dermatophytes involves microscopy and fungal culture, while molecular diagnosis through pan-dermatophyte PCR is reported to be more sensitive than microscopy (Saunte et al. 2008).

A rapid, accurate, and highly sensitive method of clinical diagnosis of rabbit-derived pathogenic dermatophytes is reported using microsatellite-primed polymerase chain reaction (PCR) in combination with a clustering method. The method is based upon detecting the DNA polymorphism fingerprints of amplified DNA fragments of *Trichophyton mentagrophytes*, *Microsporum gypseum*, and *Microsporum canis* using specific primer. The method could be highly useful in epidemic research of the dermatophytes (Miao et al. 2014).

6.4 Common Fungal Infections in Cattle and Their Diagnosis

Cattle serve as experimental models in biomedical research as their physiology and genome sequence are found closer to the humans as compared to rodents. Many livestock models are used to identify new cellular and molecular mechanisms regulating infertility and reproductive disorders such as polycystic ovarian syndrome (PCOS) in humans. There are many limitations to investigation and treatment of several prenatal and postnatal disorders in human fetuses, which have been overcome

by using pregnant sheep as model for in utero treatments for congenital birth defects (Hamernik 2019). Some fungal infections in cattle have been discussed further, which are of high relevance.

Bovine alimentary mycosis caused by *Mucor* and *Aspergillus* is termed as mucormycosis and aspergillosis, respectively, both of which are systemic mycosis and involve rumen, omasum, abomasum, reticulum, and intestine to a larger extent while omasoabomasal orifice and tongue to a lesser extent. Identification can be done through visualization of lesions and macroscopic focal hemorrhagic necrosis on various parts of alimentary canal. Histological diagnosis reveals thrombosis, coagulative necrosis, and typical fungal hyphae (Chihaya et al. 1992).

A common superficial mycosis occurring in cattle is dermatophytoses or ringworm, which affects the superficial keratin-rich body parts such as skin, hair, nails, and horns. Three main genera of dermatophytes are *Epidermophyton*, *Microsporum*, and *Trichophyton*, of which the most common pathogens causing disease in cattle are *Microsporum canis*, *M. gypseum*, *Trichophyton mentagrophytes*, and *T. verrucosum*. General manifestations of ringworm include circular white and itchy lesions, alopecia or hair loss, crusting of skin, inflammation, and erythema (Ahmad and Gholib 2016). Besides observation of clinical signs and symptoms, the diagnosis is based on microscopic examination of isolated pathogen hyphae and spores. *T. verrucosum* is cultured on Sabouraud dextrose agar medium containing chloramphenicol and actidion and examined for physical appearance of cultures such as color, texture, and shape and microscopic identification of septate hyphae and microconidia. Definitive diagnosis using PCR-based methods such as random amplified polymorphic DNA (RAPD), multiplex PCR, and specific nucleotide sequence are also suggested (Walid and Eman-abdeen 2018).

Mycotic mastitis in cows is caused mainly due to mold and yeast infection that occurs in mammary glands. The mold genera generally responsible for mycotic mastitis are *Aspergillus*, *Alternaria*, *Penicillium*, *Phoma*, and *Geotrichum*. The predominant yeast causing this disease is *Candida* sp.; other genera are *Trichosporon*, *Cryptococcus*, and *Saccharomyces*. The disease is characterized by sporadically occurring mammary gland inflammations, edematous fluid exudates, pain, redness, and decreased milk production. Subclinical mastitis is diagnosed through somatic cell count in milk followed by isolation and identification of fungi in mastitis milk after culture. Histopathological identification of fungal hyphae and spores is done in infected tissue after slaughter (Ahmad and Gholib 2016).

Mycotic mastitis is also reported in farm goats in their postpartum period, mainly characterized by purulent mammary secretion and progressive induration of the affected glands. Postmortem histological diagnosis revealed widespread acute and chronic mycotic lesions in the infected mammary glands consisting of fungal hyphae. Immunohistochemical diagnosis by indirect immunofluorescent labeling led to the identification of *Aspergillus fumigatus* as main pathogen, while zygomycotic hyphae could also be identified in a granulomatous lesion (Jensen et al. 1996).

A number of fungal infections have been associated with mycotic bovine abortions and stillbirths. Most frequent cause was reported to be the *Aspergillus*

fumigatus, while other causative organisms were *A. terreus*, *A. nidulans*, *A. flavus*, and *A. rugulosus*. Some genera of *Zygomycetes* such as *Rhizomucor* and *Rhizopus*, yeast *Candida*, and *Ascomycota* fungi *Pseudallescheria boydii* were also associated with mycotic abortions with varying frequency. Coexistence of several fungi was found to cause mixed infection. The histological diagnoses revealed the occurrence of mixed infection due to the presence of both septate and nonseptate hyphae in placental tissues (Knudtson and Kirkbride 1992).

6.5 Common Fungal Infections in Swine and Their Diagnosis

Swine have been used commonly in cardiovascular research due to many anatomic and physiological similarities, such as size of heart, coronary blood flow, myocardial contractility, patterns of atherosclerosis, and hemodynamics. Besides, they are also used largely as preclinical models involving surgical and interventional protocols for studying other organ systems including integumentary, digestive, and urological (Smith and Swindle 2006). The human genome sequence is similar to the genome sequences of pigs to a higher degree as compared with rodents; therefore, pigs are also considered as better models to study many human genetic diseases (Hamernik 2019).

Respiratory disease in pigs is associated with the fungal infection by an opportunistic fungi *Pneumocystis carinii* which inhabits the respiratory tract of pigs and occasionally cause interstitial pneumonia (Binanti et al. 2014). The immunohistochemical detection of *Pneumocystis* organisms was done using Grocott's staining of lung tissue obtained from slaughtered pigs. The *Pneumocystis* organisms could be observed in histologically normal lungs as well as in lungs with histological lesions. The histopathological diagnosis revealed the occurrence of bronchointerstitial pneumonia in infected pigs (Sanches et al. 2007).

Pneumocystis infection in pigs was also diagnosed through in situ hybridization (ISH) technique which enabled unambiguous detection of pneumocystis in paraffin wax-embedded lung tissues obtained from pigs with interstitial pneumonia postmortem. ISH involved designing of an oligonucleotide probe which could potentially hybridize with all representatives of the genus *Pneumocystis*, making it a robust and highly sensitive technique. It also proved to be superior to the traditional Grocott's methenamine-silver nitrate (GMS) staining method which failed to identify sections with only few *Pneumocystis* cells (Binanti et al. 2014).

6.6 Common Fungal Infections in Birds and Their Diagnosis

The laboratory birds are used as subjects in a variety of experimental setup pertaining to fundamental and applied research in medical sciences, veterinary sciences, pharmaceutical sciences, ecotoxicology, zoology, and many others. Mostly

domesticated birds are used in laboratory such as domestic fowl, domestic poultry, turkey, and quail. Wild birds and pigeons are less commonly used as laboratory birds. Fungal pathogens can cause diseases in all birds; however, immunocompromised subjects are more susceptible toward infections. The predisposing factors for causing fungal infections are exposure to fungal spores, overcrowding, poor sanitation, poor ventilation, warm environment, humidity, poor nutrition, and age and poor sanitation. The most common fungal pathogens in birds are *Aspergillus* spp. causing respiratory tract infections and *Candida* spp. causing gastrointestinal (GI) tract infections (Tell 2005). Some less common pathogens are *Macrorhabdus*, *Cryptococcus*, *Rhodotorula*, and *Mucor* (Imran and Ali 2014).

Aspergillosis is an opportunistic but non-transmittable infection, caused by many species of which *Aspergillus fumigatus* is the most common, others being *A. flavus*, *A. niger*, *A. glaucus*, and *A. nidulans*. (Perelman and Kuttin 1992). Acute aspergillosis occurs on inhalation of an overwhelming number of fungal spores over a short period of time, causing massive colonization of fungal mycelia in respiratory tract manifested as military granulomatous foci (McMillan and Petrak 1989). Chronic aspergillosis generally occurs in immunosuppressed or debilitating conditions. Diagnosis of aspergillosis is challenging due to nonspecific signs and involves reviewing history, physical examination, histopathology, biochemical tests, serology, hematology, radiography, endoscopy, and fungal culture. Mycotic keratitis, blepharitis, and dermatitis involving the eyelids and the head are observed. Histopathological diagnosis on the basis of lesions is not often definitive as the fungal filaments are quite similar and the manifestations of disease are not pathognomonic (Jones and Orosz 2000). Brain and heart along with organs of respiratory system such as larynx, trachea, and lungs are important for histopathological examination (McMillan and Petrak 1989).

Another fungal disease caused in birds is candidiasis, also known as thrush, which is common in domestic poultry and water fowls. The etiologic agent of this disease is the opportunistic yeast *C. albicans*, which is most abundant organism, while the less common pathogenic species are *C. tropicalis*, *C. glabrata*, *C. parapsilosis*, *C. krusei*, and *C. lusitaniae* (Tiwari et al. 2011). *C. albicans* is usually present in the gastrointestinal tract and causes endogenous infection due to yeast overgrowth. Clinical signs of the disease in birds include anorexia, crop stasis, white plaques in the oral cavity, regurgitation, and weight loss. Complete crop and GI stasis occurs in case of severe infections (Campbell 1986). Identification of disease is done by observing lesions which usually appear in the upper digestive tract. Histopathological diagnosis involves microscopic examination of cultured colonies of *Candida*, which can be isolated from feces, crops, gizzards, lungs, and livers. *Candida* spp. is identified on a gram stain, Romanowsky-type, or new methylene blue stain of the digested smear, feces, crop contents, or regurgitated material. Scrapings or impression smears from the crop or pharynx are also used for microscopic examination which shows budding yeast and hyphae (Tiwari et al. 2011).

6.7 Common Fungal Infections in Reptiles and Their Diagnosis

Fungal infections of primary and secondary nature may also occur in reptiles primarily due to their terrestrial habitat. Most common fungal mycoses in reptiles are hyalohyphomycoses in skin caused by the dermatophytes *Chrysosporium* (Johnson et al. 2011). Other fungal species found in skin lesions in reptiles include *Paecilomyces*, *Penicillium*, *Fusarium*, *Geotrichum*, *Mucor*, and *Aspergillus* (Jacobson et al. 2000). Severe ulcerative dermatitis on the ventral scales in a reticulated python (*Python reticulatus*) and in a boa constrictor (*Constrictor constrictor*) have been observed (Frank 1976).

Systemic mycoses are less common in reptiles, but have occasionally been observed in many cases. Histopathologic diagnosis has revealed muriform fungal elements in different internal organs of a snake (Jacobson et al. 2000). Phaeohyphomycosis in eyes and lungs of Galapagos tortoise (*Geochelone nigra*) (Manharth et al. 2005) and subcutaneous inflammation in an eastern box turtle (*Terrapene carolina*) (Joyner et al. 2006), caused by *Exophiala* species, is diagnosed by gross necropsy. Microscopic examination is done to characterize pigmented fungal hyphae and conidia present at necrotic sites.

Fungal disease in bones and carapace in an aldabra tortoise (*Geochelone gigantea*) is identified on histological examination involving biopsy of infected tissue. Phaeohyphomycosis in tortoise caused by *Exophiala oligosperma* mainly occurs in the superficial keratinized layers and further extend to deep bones (Stringer et al. 2009). Histological examination of biopsy specimen and stained tissue sections also diagnosed dematiaceous hyphae of fungi *Ochroconis humicola* causing foot lesions in the tortoise (*Terrapine carolina* var. *carolina*) (Weitzman et al. 1985).

Certain emerging obligate pathogenic fungi causing dermatomycoses and systemic mycoses in reptiles are reported which belong to families Onygenaceae and Clavicipitaceae. Members of family Onygenaceae of Ascomycota – *Nannizziopsis guarroi* and *Ophidiomyces ophidiicola* – cause deep fungal dermatitis in bearded dragons and free living snakes, respectively. Pathogenic fungi from family Clavicipitaceae are known to cause granulomatous glossitis, pharyngitis, dermatitis, and disseminated visceral mycosis in lizards, tortoises, turtles, and crocodiles. The pathogenicity of fungi is determined through histopathological evaluation involving the isolation and differentiation of fungal agents (Schmidt 2015).

Most common fungal infections in captive reptiles occur in integumentary system, respiratory system, and the gastrointestinal tract. Systemic mycoses are only diagnosed during postmortem investigations. Histopathological diagnosis involves microscopic identification and biopsies of infected tissues (Schumacher 2003).

6.8 Common Fungal Infections in Amphibians and Their Diagnosis

Amphibians catch fungal infections in a variety of ways such as directly from contaminated environment, traumatic injury, or transmission of pathogen from fish population. Some common fungal diseases identified in amphibians are chytridiomycosis, phaeohyphomycosis, zygomycoses, saprolegniasis, and ichthyophoniasis (Densmore and Green 2007). Chytridiomycosis is a fatal fungal disease of amphibians caused by a ubiquitous chytrid fungus *Batrachochytrium dendrobatidis* (Daszak et al. 1999). A number of amphibian species such as frogs, toads, and salamanders are susceptible to chytridiomycosis. It is keratinophilic or chitinophilic fungus, and histologically the infections of this fungus are limited mostly to keratinized epithelial cells of the skin and oral disc. The range of signs and symptoms of the disease include hyperkeratosis associated with dysecdysis, excessive skin shedding, erythema, and skin ulcerations, as seen in green tree frogs (*Litoria caerulea*) (Berger et al. 2005), while abduction of the hind legs and tail autotomy as observed in salamanders (Pasmans et al. 2004).

Many wild and captive frogs (*Hyla caerulea*, *Pternohylaf odiens*, *Phylllobates trinitatis*, *Rhacophorus* spp., and *Hyla septentrionalis*) are diagnosed with the disseminated systemic mycosis caused by fungi that belong to the genus *Phialophora*, *Fonsecaea*, and *Rhinocladiella*. The disease is manifested in form of granulomatous infection of internal organs in frogs. Histopathological diagnosis involves ulcers or nodules in the skin and lesions of internal organs such as spleen, liver, and kidney (Densmore and Green 2007). The lesions are observed to consist of granulomatous encephalomyelitis (Daszak et al. 1999).

Zygomycosis or mucormycosis is caused in many species of toads such as Wyoming toad (*Bufo baxteri*), giant toad (*Bufo marinus*), Colorado River toad (*Bufo alvarius*), and White's tree frog (*Philodryas caerulea*). The etiologic agents are *Mucor* spp. and *Rhizopus* spp. that belong to the fungal subclass *Zygomycetes*. External dermatitis involving multifocal hyperemic nodules with visible fungal growth in ventral integument are histologically identified. Systemic disease is manifested with nodules and granulomatous inflammation in internal organs (Densmore and Green 2007).

Saprolegnia or water mold causes saprolegniasis in freshwater salmonids. Usually it is a secondary pathogen but can infect the host directly on encounter. It is often called cotton mold due to its cottony appearance. The infection restricts to the epidermal layers causing necrosis on the skin, but may become fatal (Densmore and Green 2007).

6.9 Common Fungal Infections in Invertebrates and Their Diagnosis

Many invertebrates are used as subjects for laboratory experimentations such as annelids, arthropods, and molluscs. These are also susceptible to various fungi that are mostly acquired from their surroundings and can cause diseases. Crustaceans such as crabs and lobsters are infected by *Exophiala cancerae* (De Hoog et al. 2011) and *Fonsecaea brasiliensis* (Vicente et al. 2012) causing lethargy and loss of balance in animals (known as lethargic crab disease or LCD). Histopathological diagnosis is done on the basis of symptoms such as claw tetany, weak motor control of chelae and pereopods, necrosis, and tissue degeneration followed by the death in severe cases. Mollusks such as mussels are found to be infected with epizootic black yeast that belongs to the order *Chaetothyriales*. Most of these pathogens are detected in wild mussels while farmed mussels are mostly devoid of it.

Histological examination revealed occurrence of a variety of fungal spores between the digestive tubules of mussels. These spores belonged to *Psilocybe* sp., *Ulocladium* sp., and *Alternaria* sp., which were identified on the basis of their morphology (Kovacic et al. 2018). The histological identification is done by observing the features such as discoloration of mantle from creamy to brown or black. The brown/black coloration is due to accumulation of dense population of yeast cells which eventually infiltrate to the connective tissue and gonads.

Annelids such as earthworm can be infected by fungi *Exophiala jeanselmei*, identified as black spherical bodies in embryonic stages of *Octolasion tyrtaeum* and in cocoon albumen of *Eisenia foetida*. The black granules consist of fungal hyphae and cell aggregates. This fungus is saprotrophic and is commonly found in a variety of habitats such as soil, plants, water, and decaying wood. It has further adapted to become an opportunistic human pathogen causing phaeohyphomycosis, causing cutaneous and subcutaneous inflammation (Vakili 1993).

There is a large number of entomopathogenic fungal species which mostly belong to the phyla *Microsporidia*, *Chytridiomycota*, *Entomophthoromycota*, *Basidiomycota*, and *Ascomycota* (Vega et al. 2012). Certain fungal pathogens may cause fatal diseases in insects; these are *Beauveria* spp., *Cordyceps* spp., *Conidiobolus* spp., *Metarhizium* spp., and *Hirsutella* spp. Entomopathogenic fungi exhibit a wide range of mortality rates among infected populations of insects. The signs of mycoses in insects are identified on the basis of morphological and cultivation characteristics using taxonomic guidelines and characterization of fungal fruiting bodies. For example *Myriangium duriaei* causes mycoses on elongate hemlock scale (EHS), a small insect pest of order Hemiptera, which is characterized by the formation of black sclerotized masses on the scale surface. The early mycelial biomass on EHS typically shows white morphology and progressed to brown and finally black (Gouli et al. 2013).

Mycotoxins:

It is actually chemicals of fungal origin and toxin for animals; it is also known as mycotoxicoses. It is secondary metabolite produced by enzymatic action by metabolism of acetates, mevalonates, and malonite pathways. Mycotoxin is a big problem worldwide, as it leads to contamination of food. It is categorized by fungal species, structure, and mode of action. There are different mycotoxins such as aflatoxins, ochratoxins, trichothecenes, zearalenone, fumonisins, and tremorgenic toxins. These mycotoxins are agro-economically and public health-wise very important, causing severe diseases called acute or chronic mycotoxicoses. Mycotoxins produced by invading fungi can suppress immunity.

S. No	Fungal toxin (mycotoxin)	Toxicity
1.	Trichothecenes, verrucarins, sporidesmins	Dermatotoxic
2.	Aflatoxins, ochratoxin A, zearalenone, trichothecenes	Hematotoxic
3.	Trichothecenes, verrucarins, sporidesmins	Dermatotoxic
4.	Aflatoxins, ochratoxins, rubratoxins, sterigmatocystin	Hepatotoxic
5.	Zearalenone	Estrogenic
6.	Ochratoxin A	Nephrotoxic
7.	Trichothecenes	Gastrotoxic

Treatment of fungal diseases in animals: There are a number of methods for the treatment of fungal infection in lab which are known and are able to control it. In this section few important methods have been discussed in short. These are:

1. *Antifungal treatment:* A number of excellent therapies are used for the treatment of fungal infections in animals and in humans. Many pathogenic fungi are able to produce chemicals which can work against many human and animal diseases and are called as antifungal agents, such as bifonazole, clotrimazole, econazole, enilconazole (imazalil), ketoconazole, miconazole and parconazole, and triazole and fluconazole. Studies at the molecular level of fungal infection are very complex; fungal cell adopt specific mechanism in the presence of toxic drugs. Fungi generally mutate its drug target protein, and it causes reduction of drug target affinity, overexpression of target protein by mutating promoter region, degradation of drug, etc. These are few important resistance mechanisms of fungi. The similarities in biological aspects of fungi and animal host led to a drug development, which is based on features of fungal cells, for example, cell wall of fungi contains ergosterol, and it is a drug target because it is distinct from the cholesterol present in mammalian cells, azoles, echinocandins, and polyenes such as commercial antifungal drugs that successfully act on the cell wall.

There are specific mechanisms of resistance to antifungal drugs resistance, some of which are mentioned below:

1. Non-synonymous point mutation includes alteration of genes at genetic level, which changes the enzymes at amino acid sequence level and changes the function of enzymes (Lamb et al. 1997, Lamb et al. 2000, Katiyar and Edlind 2001, Sanglard et al. 1999, Miyazaki et al. 1998, Parkinson et al. 1995, Lopez-Ribot et al. 1999, Löffler et al. 1997, Vanden Bossche et al. 1990, White 1997, Franz et al. 1998).
2. The transcription level of genes encoding the enzymes gets increased which enhances the level of its expression (Marr et al. 1998).
3. The decreased concentrations of the drug molecules within fungal cells due to drug (Vermeulen et al. 2013; Seyedmousavi et al. 2014; Howard et al. 2009).

In recent years, researches identified and analyzed antifungal targets that improved due to improvements in genetic tool for the manipulation of fungal pathogens. This helps in the standardization of animal models for fungal infection.

Burch and Russell concept of three Rs

Reduction: Extensive literature search and based on experiment design; organizes a plot before large animal experimentation; collection of data for every animal and appropriate statistical test must apply for perfect analysis.

Refinement: Elimination of pain and search of perfect alternative animal, perfectly trained before execution of procedure, proper use of doses of anesthetics for painful procedure, uses of perfect thermoregulation system for experimentations.

Replacement: Analysis by using computers that is in silico method followed by in vitro such as cell culture and cell tissue culture methods.

There are different antifungal compounds that work against different fungal infections in different animals, and few of them are listed in Table 6.1.

4. Alteration of the biochemical and biosynthetic pathways results in lower level of target of antifungal drugs (Mellado et al. 2007)

There are many reports about different animal species such as yeast cells showing higher level of azole resistance. Azole and echinocandins are mainly used for treatment of animal fungal diseases. Along with this there are many limitations similarly, a lot of variation found in animal species too which have variable pharmacokinetics, drug interactions, and antifungal resistance.

2. *Drug combination:* Antifungal treatment has limitation, and based on this fact combination of drug is the new method for the treatment of fungal infections.

Table 6.1 List of antifungal agents and different disease controlled by them in different animals

S. No	Antifungal	Animal	Diseases
1.	Amphotericin B	Birds, dogs, cats, horses	Aspergillosis, candidiasis, histoplasmosis, coccidioidomycosis, sporotrichosis, mucormycosis, cryptococcosis, blastomycosis, histoplasmosis
2.	Thiabendazole	Birds, horses, rodents, rabbits, ruminants	Dermatophytosis
3.	Ketoconazole	Birds, dogs, cats	Aspergillosis, candidiasis, blastomycosis, histoplasmosis, cryptococcosis, coccidioidomycosis, malassezia dermatitis, and dermatophytosis
4.	Fluconazole	Birds, dogs, cats	Candidiasis, cryptococcosis, blastomycosis, aspergillosis, blastomycosis, coccidioidomycosis
5.	Itraconazole	Birds, dogs, cats, horses, rodents, rabbits, and fur animals	Aspergillosis, candidiasis, blastomycosis, histoplasmosis, cryptococcosis, sporotrichosis, coccidioidomycosis, dermatophytosis, malassezia dermatitis, mycotic keratitis
6.	Griseofulvin	Dogs, cats, horses, rodents, rabbits, and fur animals	Dermatophytosis, sporotrichosis, ruminants
7.	Clotrimazole	Birds (raptors), dogs, cats, rodents, rabbits, and fur animals	Aspergillosis, dermatophytosis, and malassezia dermatitis
8.	Enilconazole	Birds, dogs, cats, horses, ruminants, rodents, rabbits, and fur animals (dermatophytes and other pathogenic fungi)	Aspergillosis, dermatophytosis, dermatitis, malassezia
9.	Voriconazole	Birds, dogs, cats, horses	Aspergillosis, scedosporiasis, keratitis
10.	Flucytosine	Cats	Cryptococcosis
11.	Griseofulvin	Dogs, cats, horses, ruminants, rodents, rabbits, and fur animals	Dermatophytosis and sporotrichosis
12.	Posaconazole	Dogs, cats	Aspergillosis, mucormycosis

Combination of more than one drug is used for the treatment as it increases the efficacy and possibility of action on multiple targets at a time. The level of toxicity is reduced as less of drug is used (Chen et al. 2014). Combination of drug is used as it leads to improved activity, and using more than one drug can increase efficacy due to the possibility of action on more than one target; in addition, toxicity is reduced because less of the drug is used.

3. **Vaccines:** Vaccination is used against high-risk groups of fungal infections. Understanding the mechanism of fungal infection and pathogenic mechanism has supported the development of novel vaccines against fungal diseases.

Researchers have developed many vaccines which are durable, safe, and robust and able to control endemic infections (Shahid 2016).

4. *Alternative animal model for drug discovery*: This model was given by Burch and Russell in 1959, and it was described as “alternative animal model.” It has three action rules and is based on three Rs, refinement, reduction, and replacement.

In this, an alternative model or mini host is used for in vivo testing. Amoeba, nematodes, fish, insects, and chicken embryos are used for this, and the reasons behind its selection are that the neural system is poorly developed in these animals and almost they are painless, large number of animals can be used for experiments, the maintenance is cheaper as compared to traditional animals, and also there is a correlation between mammalian animals and alternative animals.

6.10 Conclusion

Fungal infections in laboratory animals may cause major loss of researches based on animal models. Fungal infections can be avoided in labs by taking some important precautions along with perfect experiment design. There are many more techniques which can help for the cure, and different fungal stains can be cured by using these methods. Uses of animal model is the base of high-level research for the welfare of human beings, and it is expensive in many ways, so proper care is necessary or successful results. Drug discovery research and validation of in silico experimental results need healthy animal model.

References

- Ahmad RZ, Gholib D (2016) Important mycotic diseases in animal livestock caused by some agriculture fungi in Indonesia. *Int J Trop Vet Biomed Res* 1(1):38–44
- Aly R (1994) Ecology and epidemiology of dermatophyte infections. *J Am Acad Dermatol* 31(3):S21–S25
- Baker DG (1998) Natural pathogens of laboratory mice, rats, and rabbits and their effects on research. *Clin Microbiol Rev* 11(2):231–266
- Berger L, Speare R, Skerratt LF (2005) Distribution of *Batrachochytrium dendrobatidis* and pathology in the skin of green tree frogs *Litoria caerulea* with severe chytridiomycosis. *Dis Aquat Org* 68(1):65–70
- Binanti D, Mostegl MM, Weissenbacher-Lang C, Nedorost N, Weissenböck H (2014) Detection of *Pneumocystis* infections by in situ hybridization in lung samples of Austrian pigs with interstitial pneumonia. *Med Mycol* 52(2):196–201
- Bond R (2010) Superficial veterinary mycoses. *Clin Dermatol* 28(2):226–236
- Campbell TW (1986) Mycotic diseases. In: Harrison GJ, Harrison LR (eds) *Clinical avian medicine and surgery: including aviculture*. W B Saunders Co., Philadelphia, p 466
- Casadevall A (2008) Evolution of intracellular pathogens. *Annu Rev Microbiol* 62:19–33
- Chandler FW, Watts JC (1995) Fungal diseases. *J Histotechnol* 18(3):247–252

- Chen X, Ren B, Chen M, Liu MX, Ren W, Wang QX et al (2014) ASDCD: antifungal synergistic drug combination database. PLoS One 9(1):e86499
- Chihaya Y, Matsukawa K, Ohshima K, Matsui Y, Ogasa K, Furusawa Y, Okada H (1992) A pathological study of bovine alimentary mycosis. J Comp Pathol 107(2):195–206
- Connole MD, Yamaguchi H, Elad D, Hasegawa A, Segal E, Torres-Rodriguez JM (2000) Natural pathogens of laboratory animals and their effects on research. Med Mycol 38(sup1):59–65
- Daszak P, Berger L, Cunningham AA, Hyatt AD, Green DE, Speare R (1999) Emerging infectious diseases and amphibian population declines. Emerg Infect Dis 5:735–748
- De Hoog GS, Vicente VA, Najafzadeh MJ, Harrak MJ, Badali H, Seyedmousavi S (2011) Waterborne *Exophiala* species causing disease in cold-blooded animals. Persoonia 27:46–72
- Dedeaux A, Grooters A, Wakamatsu-Utsuki N, Taboada J (2018) Opportunistic fungal infections in small animals. J Am Anim Hosp Assoc 54(6):327–337
- Densmore CL, Green DE (2007) Diseases of amphibians. Inst Lab Anim Res J 48(3):235–254
- Dobrowolska A, Stączek P, Kaszuba A, Kozłowska M (2006) PCR–RFLP analysis of the dermatophytes isolated from patients in Central Poland. J Dermatol Sci 42(1):71–74
- Fisher MC, Henk DA, Briggs CJ, Brownstein JS, Madoff LC, McCraw SL, Gurr SJ (2012) Emerging fungal threats to animal, plant and ecosystem health. Nature 484(7393):186–194
- Frank W (1976) Mycotic infections in amphibians and reptiles. In: Wildlife diseases. Springer, Boston, MA, pp 73–88
- Franz R, Kelly SL, Lamb DC et al (1998) Multiple molecular mechanisms contribute to a stepwise development of fluconazole resistance in clinical *Candida albicans* strains. Antimicrob Agents Chemother 42:3065–3072
- Frater JL, Hall GS, Procop GW (2001) Histologic features of zygomycosis: emphasis on perineural invasion and fungal morphology. Arch Pathol Lab Med 125(3):375–378
- Gazzoni AF, Severo CB, Salles EF, Severo LC (2009) Histopathology, serology and cultures in the diagnosis of *cryptococcosis*. Rev Inst Med Trop Sao Paulo 51(5):255–259
- Gouli V, Gouli S, Marcelino JA, Skinner M, Parker BL (2013) Entomopathogenic fungi associated with exotic invasive insect pests in Northeastern forests of the USA. Insects 4(4):631–645
- Greaves TS, Strigle SM (1985) The recognition of *Pneumocystis carinii* in routine Papanicolaou-stained smears. Acta Cytol 29(5):714–720
- Guarner J, Brandt ME (2011) Histopathologic diagnosis of fungal infections in the 21st century. Clin Microbiol Rev 24:247–280
- Gupta AK, Ryder JE, Chow M, Cooper EA (2005) Dermatophytosis: the management of fungal infections. Skinmed 4(5):305–310
- Hamernik DL (2019) Farm animals are important biomedical models. Anim Front 9(3):3–5
- Howard SJ, Cerar D, Anderson MJ et al (2009) Frequency and evolution of azole resistance in *Aspergillus fumigatus* associated with treatment failure. Emerg Infect Dis J 15:1068–1076
- Imran ZK, Ali RI (2014) The risk of several fungi associated with bird waste. Int J Med Sci Clin Invent 1:558–562
- Jacobson ER, Cheatwood JL, Maxwell LK (2000) Mycotic diseases of reptiles. Semin Avian Exotic Pet Med 9:94–101
- Jensen HE, De Los Monteros AE, Carrasco L (1996) *Caprine mastitis* due to aspergillosis and zygomycosis: a pathological and immunohistochemical study. J Comp Pathol 114(2):183–191
- Johnson RS, Sangster CR, Sigler L, Hambleton S, Pare JA (2011) Deep fungal dermatitis caused by the *Chrysosporium* anamorph of *Nannizziopsis vriesii* in captive coastal bearded dragons (*Pogona barbata*). Aust Vet J 89:515–519
- Jones MP, Orosz SE (2000) The diagnosis of aspergillosis in birds. Seminars Avian Exotic Pet Med 9:52–58
- Joyner PH, Shreve AA, Spahr J, Fountain AL, Sleeman JM (2006) Phaeohyphomycosis in a free-living eastern box turtle (*Terrapene Carolina carolina*). J Wildl Dis 42:883–888
- Katiyar SK, Edlind TD (2001) Identification and expression of multidrug resistance-related ABC transporter genes in *Candida krusei*. Med Mycol 39:109–116

- Knudtson WU, Kirkbride CA (1992) Fungi associated with bovine abortion in the northern plains states (USA). *J Vet Diagn Invest* 4(2):181–185
- Kovacic I, Pustijanac E, Ramšak A, Šebešćen D, Lipić S (2018) Variation of parasite and fungi infection between farmed and wild mussels (*Mytilus galloprovincialis* Lamarck, 1819) from the Adriatic Sea. *J Mar Biol Assoc U K* 98(8):1871–1879
- Lamb DC, Kelly DE, Schunck WH et al (1997) 2000. The mutation T315A in *Candida albicans* sterol 14 α -demethylase causes reduced enzyme activity and fluconazole resistance through reduced affinity. *J Biol Chem* 272:5682–5688
- Lamb DC, Kelly DE, White TC et al (2000) The R467K amino acid substitution in *Candida albicans* sterol 14 α -demethylase causes drug resistance through reduced affinity. *Antimicrob Agents Chemother* 44:63–67
- Löffler J, Kelly SL, Hebart H et al (1997) Molecular analysis of *cyp51* from fluconazole-resistant *Candida albicans* strains. *FEMS Microbiol Lett* 151:263–268
- Lopez-Ribot JL, Mc Atee RK, Perea S et al (1999) Multiple resistant phenotypes of *Candida albicans* coexist during episodes of oropharyngeal candidiasis in human immunodeficiency virus-infected patients. *Antimicrob Agents Chemother* 43:1621–1630
- Lousbergh D, Buntinx F, Piérard G (1999) Diagnosing dermatomycosis in general practice. *Fam Pract* 16(6):611–615
- Manharth A, Lemberger K, Mylniczenco N, Pinkerton M, Pessier AP, Kammeyer P, de Hoog S (2005) Disseminated phaeohyphomycosis due to an *Exophiala* species in a Galapagos tortoise, *Geochelone nigra*. *J Herpetolog Med Surg* 15(2):20–26
- Marr KA, Lyons CN, Rustad TR et al (1998) Rapid, transient fluconazole resistance in *Candida albicans* is associated with increased mRNA levels of CDR. *Antimicrob Agents Chemother* 42:2584–2589
- McMillan MC, Petrak ML (1989) Retrospective study of aspergillosis in pet birds. *J Assoc Avian Vet* 3:211–215
- Mellado E, Garcia-Effron G, Alcazar-Fuoli L et al (2007) A new *Aspergillus fumigatus* resistance mechanism conferring in vitro cross-resistance to azole antifungals involves a combination of *cyp51A* alterations. *Antimicrob Agents Chemother* 51:1897–1904
- Miao Z, Li S, Li D, Cai C, Cai Y (2014) Rapid detection for rabbit-derived dermatophytes using microsatellite-primed polymerase chain reaction. *J Mol Microbiol Biotechnol* 24(1):53–58
- Miyazaki H, Miyazaki Y, Geber A et al (1998) Fluconazole resistance associated with drug efflux and increased transcription of a drug transporter gene, *PDH1*, in *Candida glabrata*. *Antimicrob Agents Chemother* 42:1695–1701
- Moriello KA, De Boer DJ (2014) Treatment of dermatophytosis. In: Bonagura JD, Twedt DC (eds) *Kirk's current veterinary therapy XV*. Elsevier, St. Louis, MO, pp 449–451
- Parkinson T, Falconer DJ, Hitchcock CA (1995) Fluconazole resistance due to energy-dependent drug efflux in *Candida glabrata*. *Antimicrob Agents Chemother* 39:1696–1699
- Pasmans F, Zwart P, Hyatt AD (2004) Chytridiomycosis in the Central American bolitoglossine salamander (*Bolitoglossa doleini*). *Vet Rec* 154(5):153–153
- Perelman B, Kuttin ES (1992) Aspergillosis in ostriches. *Avian Pathol* 21:159–163
- Pollock C (2003) Fungal diseases of laboratory rodents. *Vet Clin North Am Exot Anim Pract* 6(2):401–413
- Reller LB, Weinstein MP, Procop GW, Wilson M (2001) Infectious disease pathology. *Clin Infect Dis* 32(11):1589–1601
- Robert R, Pihet M (2008) Conventional methods for the diagnosis of dermatophytosis. *Mycopathologia* 166(5–6):295–306
- Sanches EM, Pescador C, Rozza D et al (2007) Detection of *Pneumocystis* spp. in lung samples from pigs in Brazil. *Med Mycol* 45(5):395–399
- Sanglard D, Ischer F, Calabrese D et al (1999) The ATP binding cassette transporter gene *CgCDR1* from *Candida glabrata* is involved in the resistance of clinical isolates to azole antifungal agents. *Antimicrob Agents Chemother* 43:2753–2765
- Saunte DM, Hasselby JP, Brillowska-Dabrowska A, Frimodt-Møller N, Svejgaard EL, Linnemann D, Nielsen SS, Haedersdal M, Arendrup MC (2008) Experimental Guinea pig model of der-

- matophytosis: a simple and useful tool for the evaluation of new diagnostics and antifungals. *Med Mycol* 46(4):303–313
- Schmidt V (2015) Fungal infections in reptiles—an emerging problem. *J Exot Pet Med* 24(3):267–275
- Schumacher J (2003) Fungal diseases of reptiles. *Vet Clin North Am Exot Anim Pract* 6(2):327–335
- Schwarz J (1982) The diagnosis of deep mycoses by morphologic methods. *Hum Pathol* 13(6):519–533
- Seyedmousavi S, Mouton JW, Melchers WJ et al (2014) The role of azoles in the management of azole-resistant aspergillosis: from the bench to the bedside. *Drug Resist Updat* 17:37–50
- Shahid SK (2016) Newer patents in antimycotic therapy. *Pharm Pat Anal* 5:115–134
- Smith AC, Swindle MM (2006) Preparation of swine for the laboratory. *Inst Lab Anim Res* 47(4):358–363
- Stringer EM, Garner MM, Proudfoot JS, Ramer JC, Bowman MR, Heng HG, Bradway DS (2009) Phaeohyphomycosis of the carapace in an Aldabra tortoise (*Geochelone gigantea*). *J Zoo Wildl Med* 40:160–167
- Surendran KAK, Bhat RM, Bloor R, Nandakishore B, Sukumar D (2014) A clinical and mycological study of dermatophytic infections. *Indian J Dermatol* 59(3):262
- Tell LA (2005) Aspergillosis in mammals and birds: impact on veterinary medicine. *Med Mycol Suppl* 1:S7–S73
- Tiwari R, Wani MY, Dhama K (2011) Candidiasis (moniliasis, thrush or sour crop) in poultry: an overview. *Poult Technol* 6:110–111
- Vakili NG (1993) *Exophiala jeikei*, a pathogen of earthworm species. *J Med Vet Mycol* 31(4):343–346
- Vanden Bossche H, Marichal P, Gorrens J et al (1990) Mutation in cytochrome P-450-dependent 14 α -demethylase results in decreased affinity for azole antifungals. *Biochem Soc Trans* 18:56–59
- Vega FE, Meyling NV, Luangsa-ard JJ, Blackwell M (2012) Fungal entomopathogens. *Insect Pathol* 2:171–220
- Vermeulen E, Lagrou K, Verweij PE (2013) Azole resistance in *Aspergillus fumigatus*: a growing public health concern. *Curr Opin Infect Dis* 26:493–500
- Vicente VA, Orelis-Ribeiro R, Najafzadeh MJ, Sun J, Guerra RS, Miesch S, Ostrensky A, Meis JF, Klaassen CH, de Hoog GS, Boeger WA (2012) Black yeast-like fungi associated with Lethargic Crab Disease (LCD) in the mangrove-land crab, *Ucides cordatus* (Decapodidae). *Vet Microbiol* 158:109–122
- Walid SM, Eman-abdeen (2018) Overview on bovine dermatophytosis. *Int J Vet Sci Anim Husbandry* 3(2):16–19
- Watts JC, Chandler FW (1995) The surgical pathologist's role in the diagnosis of infectious diseases. *J Histotechnol* 18(3):191–193
- Weitzman I, Rosenthal SA, Shupack JL (1985) A comparison between *Dactylaria gallopava* and *Scolecobasidium humicola*: first report of an infection in a tortoise caused by *S. humicola*. *Sabouraudia J Med Vet Mycol* 23:287–293
- Weitzman I, Summerbell RC (1995) The dermatophytes. *Clin Microbiol Rev* 8(2):240–259
- White TC (1997) The presence of an R467K amino acid substitution and loss of allelic variation correlate with an azole-resistant lanosterol 14 α demethylase in *Candida albicans*. *Antimicrob Agents Chemother* 41:1488–1494
- Woods GL, Walker DH (1996) Detection of infection or infectious agents by use of cytologic and histologic stains. *Clin Microbiol Rev* 9(3):382–404
- Zijlstra EE, Van De Sande WW, Welsh O, Goodfellow M, Fahal AH (2016) Mycetoma: a unique neglected tropical disease. *Lancet Infect Dis* 16(1):100–112

Chapter 7

Current Perspective of Dermatophytosis in Animals



Shiv Shanker Gautam, Navneet, Neelesh Babu, and Sanjay Kumar

7.1 Introduction

Fungi are ubiquitous, free-living saprophytes and depend parasitically on its host. Animal fungal disease is based on host-pathogen interaction, immunocompetency of host, and constant exposure of fungal propagules. For disease establishment, fungi take advantages of host like nutritional requirement, niche establishment, reproduction, growth, and completion of life cycle (Seyedmousavi et al. 2018). Both adaptation and propagation mechanisms are equally responsible for fungal disease facilitation. Although the host defense system is sufficient at primary level as physical barrier, other than this fungal virulence mechanisms contribute to cause disease. The literature data estimated that fungi are the highest threat for animal-host and plant-host species and cause approximately 65% host loss (Fisher et al. 2012). In global scenario, the increased incidence of fungal disease may be worse due to climatic change (Garcia-Solache and Casadevall 2010) and antifungal resistance or tolerance (Kontoyiannis 2017).

Dermatophytosis is a superficial infection of keratinized epithelium and the most common fungal disease of broad range of domestic and wild animals and as well as in humans (Moretti et al. 2013). It belongs to three fungal genera including *Epidermophyton*, *Microsporum*, and *Trichophyton* together called as dermatophytes. Dermatophytes are similar to filamentous fungi and cause damage and utilization of the keratin of skin, hair, and nails (Shalaby et al. 2016). Nearly 40 species of dermatophytic fungal organisms have been identified (Weitzman and Summerbell 1995). The spread of disease happens through the soil (geophilic), humans to human

S. S. Gautam (✉)

Department of Microbiology, College of Basic Sciences and Humanities, G.B. Pant University of Agriculture and Technology, Pantnagar, Uttarakhand, India

Navneet · N. Babu · S. Kumar

Department of Botany and Microbiology, Gurukul Kangri University, Haridwar, Uttarakhand, India

© Springer Nature Switzerland AG 2021

A. Gupta, N. Pratap Singh (eds.), *Fungal Diseases in Animals*, Fungal Biology, https://doi.org/10.1007/978-3-030-69507-1_7

93

(anthropophilic), and animal to humans (zoophilic). The hot and humid climate favors the growth of dermatophytes. The animals generally show combination of symptoms like hair loss with patchy or circular, reddish or dark skin, itchiness, etc. Currently, topical azoles and allylamines are group of synthetic drugs that are used for treating this disease. Furthermore, nanoparticle-based remedies have been tested significantly and introduced in treatment of dermatophytosis. The metal oxide nanoparticles have substantial advantages because of their exclusive property of a large surface-to-volume ratio (Babu et al., 2019).

The synthetic drugs have high rates of clinical efficacy but the disease reoccurrence is another issue. The reoccurrence may be due to antifungal resistance or tolerance. The antifungal drug resistance consists of various mechanisms including nonsynonymous point mutations within the gene encoding the target enzyme leading to alterations in the amino acid sequence, high expression of the target enzyme through transcription of their respective genes, decreased concentrations of the drug due to drug efflux, changes in the biosynthetic pathway of the target of the antifungal drugs, etc. (Seyedmousavi et al. 2018). Therefore, using natural/plant-derived products based on antifungal drugs can be an alternative approach for such situation.

7.2 Etiological Agents and Taxonomy

The dermatophyte word is derived from Greek derma “skin” and phyton “plant.” The causal agents of dermatophytes are distributed into three asexual genera, namely, *Epidermophyton*, *Microsporum*, and *Trichophyton* belonging to the class *Deuteromycetes* (imperfect fungi) and order *Moniliales* (Maldonado 2011). The disease has been classified as geophilic (soil), anthropophilic (humans to human), and zoophilic (animal to humans) based on their habitat. In the above three, the zoophilic fungal organisms occur primarily in animals and cause infection to human via contact with infected animals. The *M. canis* affects to cat and dog, *M. equinum* to horse, *M. persicolor* to voles, *M. nanum* to pig, *T. verrucosum* to cattle, and species of *T. mentagrophytes* to rodents, rabbits, and hedgehogs (Moriello et al. 2017).

Dermatophytes have their own classification history suggested by many workers. Today, the five epidemiological importance dermatophytes including *M. audouinii*, *E. floccosum*, *T. schoenleinii*, *T. tonsurans*, and *T. mentagrophytes* had been described over the period of 1841–1875 (Seeliger 1985) on the basis of colony and microscopic morphology and nutritional and biochemical characteristics (Refai et al. 2013). Currently, the classification is based on genetics and molecular characteristics by targeting the ITS region of rDNA of three genera, i.e., *Trichophyton*, *Microsporum*, and *Epidermophyton* (Makimura et al. 1999; Kawasaki 2011). A recent multilocus phylogenetic study has restructured the taxonomy of dermatophytes into seven genera including *Trichophyton* (16 species), *Epidermophyton* (1 species), *Nannizzia* (9 species), *Microsporum* (3 species), *Lophophyton* (1 species), *Arthroderma* (21 species), and *Ctenomyces* (1 species), respectively (de Hoog et al. 2017).

7.2.1 Morphology

Dermatophytes produce colonies that differ in texture, color, and growth rate. There are three forms of colonies including membranous form, filamentous form, and granular-powdery form (Refai et al. 2013) as mentioned below:

7.2.1.1 Membranous Form

The colonies appeared as glabrous, waxy, humid, and faviform. It lacks the aerial mycelium, e.g., *M. ferrugineum*, *T. concentricum*, *T. violaceum*, and *T. verrucosum*.

7.2.1.2 Filamentous Form

The colonies look like cottony, fluffy, hairy, and velvety with aerial mycelium, e.g., *M. canis*, *M. nanum*, *T. rubrum*, and *E. floccosum*.

7.2.1.3 Granular-Powdery Form

This form shows excessive conidia and aerial mycelium absent, e.g., *M. equinum*, *T. mentagrophytes*, and *T. megnini*.

The microscopic structure of dermatophytes has the micro- and macroconidia, elongated and septate hyphae, undulant, and branching. Members of the genus *Epidermophyton* have macroconidia with broad clavate, thin or thick wall, and one to nine septa. In the genus *Microsporum*, macroconidia have rough wall and are spindle or fusiform and obovate. Microconidia are sessile or stalked with hyphae. In the genus *Trichophyton*, macroconidia have smooth, thin wall, with 1–12 septa, and are elongated, clavate, fusiform, or cylindrical. Microconidia may be globose, pyriform, clavate, sessile, or stalked (Fig. 7.1.).

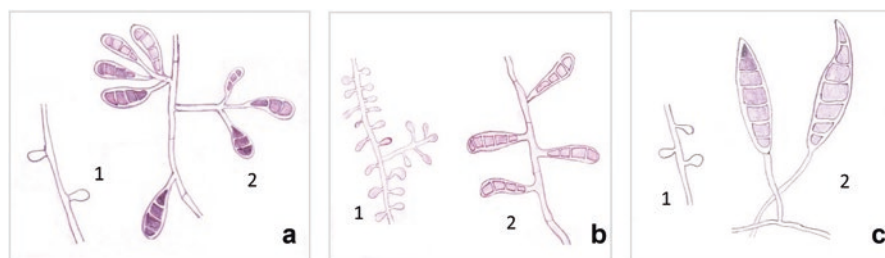


Fig. 7.1 Morphology of microconidia (1) and macroconidia (2) of dermatophytes genera (a) *Epidermophyton*, (b) *Trichophyton*, (c) *Microsporum*

7.3 Epidemiology

Dermatophytosis is significant in view of their global distribution, recurrence, individual to individual transmission, and morbidity (Kelly 2012). Even though dermatophytes are specific to its species, subsequently the clinical presentation may differ from region to region (Kelly 2012). For survival and growth, they infect only in keratinized epithelium not in mucosal membranes. In most of cases, anthropophilic organisms are responsible for the infection. The disease transmission could take place via exposure to desquamated cells and direct contact or inoculation of fungal propagules from infected animals. In aged or immune-compromised individuals, disease symptoms appear earlier on superficial layers of the skin (Hainer 2003). Dermatophytes are distributed globally but very frequent in tropical regions and may reach to outbreak proportions in other regions with higher humidity and overpopulation and with poor hygienic conditions. The major species with worldwide occurrence is *M. canis*, *T. verrucosum*, *A. benhamiae*, *T. equinum*, *M. equinum*, *T. gallinae*, *M. nanum*, *T. quinckeanum*, and *M. gypseum* (Moriello et al. 2017). In cattle dermatophytosis, the prevalence rate in Plateau State has been observed 11.0% of *T. verrucosum* (54.2%) and *T. mentagrophytes* (45.8%), respectively (Table 7.1). The animal age, breed, management practice, and season can be significantly associated with the occurrence of the disease ($p < 0.05$) (Dalis et al. 2019). Moreover, India has very hot and humid climate, and dermatophytosis is also prevalent in several states including Chennai, Madhya Pradesh, Andhra Pradesh, West Bengal, Gujarat, Chandigarh, and Karnataka (Bhatia and Sharma 2014).

7.4 Cultural Characteristics

For isolation and identification of dermatophytes, Sabouraud's dextrose agar (SDA) or potato dextrose agar (PDA) supplemented with antibiotics, i.e., chloramphenicol, gentamicin, or cycloheximide, are generally used. The fungi can be incubated at 20–25 °C for 4–6 weeks. For *T. verrucosum*, the temperature should higher at 30–32 °C. Similarly, Pal (2017) has been isolated *T. verrucosum* from the 4-year-old cow by culturing on SDA medium with chloramphenicol and actidione and small, compact, heap-shaped, white to gray color colonies observed after 14 days incubation at 37 °C. Some specific and enrichment media, i.e., Borelli lactritmel agar, brain heart infusion agar, Baxter's medium, Takasio medium, malt agar, bromocresol purple milk solid glucose agar, urea indole broth, Christensen's urea agar medium (for differentiation of *T. mentagrophytes* from *T. rubrum* and *T. soudanense*), etc., are used for the study of fungal morphology, conidiation, and pigments of dermatophytes (Rudramurthy and Shaw 2017).

Table 7.1 Distribution of major dermatophytes of animals and their reservoirs

Host animal	Dermatophytes	Geographic distribution	Mode of transmission	Symptoms	Ref.
Cat	<i>Microsporum canis</i> , <i>Arthroderma vanbreuseghemii</i>	Worldwide	Contact with sick cats or healthy carriers, soil, clothes, and fomites	Circular alopecia, desquamation, and occasionally erythematous margin with central healing	Frymus et al. (2013) and Moriello et al. (2017)
Dog	<i>Microsporum canis</i> , <i>Arthroderma vanbreuseghemii</i>	Worldwide	Direct contact and through fomites	Non-inflammatory scaly patches with alopecia	Moriello et al. (2017)
Cattle	<i>Trichophyton verrucosum</i> , <i>Trichophyton mentagrophytes</i>	Worldwide	Skin crust, direct contact	Skin with small, discrete, circumscribed, raised, grayish-white crusty, alopecic lesions	Moriello et al. (2017) and Dalis et al. (2019)
Guinea pigs	<i>Trichophyton mentagrophytes</i> , <i>Arthroderma benhamiae</i>	Worldwide	Direct contact, skin lesions, crusts, contaminated wooden boxes	Skin lesions with alopecia, hypotrichosis, erythema, and excoriations with or without pruritus	Kraemer et al. (2012) and Moriello et al. 2017
Hedgehogs	<i>Trichophyton erinacei</i> , <i>M. canis</i> , <i>M. gypseum</i> , <i>M. cookie</i>	Europe, East Asia, New Zealand	Skin lesions, direct contact	Earlier asymptomatic with <i>T. erinacei</i> , skin patches with alopecia	Abarca et al. (2017) and Moriello et al. (2017)
Rodent (mice, chinchillas)	<i>Arthroderma vanbreuseghemii</i>	Worldwide	Direct contact, skin lesions	Alopecia, hypotrichosis, erythema	Moriello et al. (2017)
Rabbit	<i>Arthroderma vanbreuseghemii</i> , <i>A. benhamiae</i>	Worldwide	Skin lesion, direct contact	Alopecia and crusts or no other clinical signs	Bartosch et al. (2019)
Horses	<i>Trichophyton bulbosum</i> , <i>T. equinum</i> , <i>Arthroderma vanbreuseghemii</i>	Worldwide	Fomites, skin, direct contact	Multifocal alopecic lesions with mild crusting	Moriello et al. (2017) and Chollet et al. (2015)
Monkey	<i>Trichophyton simii</i>	India	Skin direct contact	Skin abrasions, nail scraping	Beguina et al. (2013)

(continued)

Table 7.1 (continued)

Host animal	Dermatophytes	Geographic distribution	Mode of transmission	Symptoms	Ref.
Pig	<i>Microsporum nanum</i>	America, Europe, Asia, Australia	Through skin rashes, hogs, soil	Circinate lesions, erythematous patches with indurated periphery	Roller and Westblom (1986)
Voies	<i>Microsporum persicolor</i>	Europe, USA	Contaminated soil, skin contact	Localized erythematous and squamous or suppurative lesions (kerions) to extensive or generalized erythematous, alopecic, scaling, crusting, and eventually papular and pustular dermatoses	Carlotti (2002)

7.5 Transmission

Dermatophytosis is a superficial infection of keratinized epithelium including skin, hairs, and nails. It can be suspected in animals with lesions of erythema, papules, scaling, and crusting (Bond 2010; Pollock 2003). The disease transmits through the soil (geophilic), human to human (anthropophilic), and animal to human (zoo-philic). The geophilic species are found in the soil and associated with hair keratin, feathers, and horn. The animals and human can get infected after contact with contaminated soil (Moriello et al. 2017). *M. canis* is the most common infectious fungal agent in cat globally causing skin diseases. The fungal arthrospores can survive in environment for about a year. The dermatophytes can transmit through contact with sick cats or healthy carriers, soil, clothes, and other fomites (Frymus et al. 2013). Pal (2017) has been suggested to apply 2% solution of tincture iodine regularly for 2–3 weeks on lesions and removal of skin crusts with disposable spatula. The zoo-philic dermatophytes are adapted to animal hosts. Recent report also showed the transmission of dermatophytes by *Demodex* mites (*Demodex folliculorum*) a group of obligate parasites of the skin of mammals (Vanam et al. 2018).

7.6 Pathogenesis

The fungal arthrospores or hyphae give rise to threadlike hyphae and initiate the infection in the growing hair or in stratum corneum. The infection is followed by penetration in hair shaft and leads to inflammation and finally hair loss. At matured stage, clusters of arthrospores developed on the outer surface of hair shafts. The arthrospores are the chief source of reoccurrence of disease. The spores are highly resistant and can survive in a dry environment more than 12 months. In cat circular alopecia, desquamation and occasionally erythematous margin with central healing have appeared (Frymus et al. 2013). During host interaction, the dermatophytes also produce multiple enzymes with potential roles including polyketide synthases, non-ribosomal peptide synthetases, LysM, proteases, kinases, and pseudokinases. These enzymes enhance the interaction and pathogenicity of fungi with host (White et al. 2014). Other mechanisms may be described as changing in host immune response, adaptability to skin pH, fungal adhesion, sensation, and adaptation to host surface and tissues (Martinez-Rossi et al. 2016). The colonization of dermatophytes is limited to the dead keratinized tissues of stratum corneum and responsible for mild or intense inflammatory reaction. The dermatophytes produce keratinases which help skin invasion and cause delayed-type hypersensitivity responses after injecting into the skin of animals (Weitzman and Summerbell 1995).

7.7 Laboratory Diagnosis

Dermatophytosis is sometimes difficult to treat due to lack of proper diagnosis. Therefore, accurate diagnosis is essential step for management of this disease and prevention of relapse or recurrence (Rudramurthy and Shaw 2017). The isolation and identification of the dermatophytes and the antifungal susceptibility test can be helpful to initiate suitable therapy. For laboratory diagnosis, localization, and characterization of lesions, skin scrapings are collected and studied by direct microscopic examination, and furthermore, cultural characteristics can be done. The detailed methods are mentioned below.

7.7.1 Wood's Lamp

This method employs a handheld lamp having the source that emits ultraviolet radiations through the filters made up of nickel or cobalt glass. Florescence occurs due to the absorption of shorter wavelength light and the emission of longer wavelength light. This method is not very useful for the diagnosis in small animals as it is only a screening tool (Moriello et al. 2017).

7.7.2 Direct Visualization Under the Microscope

In order to visualize sample, various keratin digesting solutions are needed such as 10% or 20% potassium hydroxide (KOH) with or without dimethyl sulfoxide, 10% sodium hydroxide, Amann's chloral lactophenol, and detergents, i.e., sodium dodecyl sulfate (SDS). Several stains including cotton blue C4B or blue-black ink permanent or chlorazol black E stain which imparts deep blue or black color to fungal element are used. Additionally, several other stains such as periodic acid Schiff (PAS) are generally utilized to stain polysaccharide glycosaminoglycans and Congo red which stains β -D-glucans and fluorochromes (Rudramurthy and Shaw 2017).

7.7.3 Molecular Methods

The molecular approaches are highly specific and makes easier for dermatophytes detection in clinical samples. The multiplex RT-PCR (real-time PCR) was developed by Arabatzis et al. (2007) for the direct detection of the fungi in the clinical specimens. It limits the risk of contamination and helps in recognition of multiple species of dermatophytes using diverse species-specific probes. A real-time PCR can distinguish both dermatophytes and non-dermatophytes with a sensitivity of 97% when compared with culture (Sharma et al. 2006). Hayette and Sacheli (2015) identified several dermatophytes which were negative on microscopy. In 2008, PCR reverse line blot assay targeting ITS sequences has been utilized in order to identify the nine relevant dermatophytes of hair, nails and skin samples. Immobilized oligonucleotide probe that is present on the membrane was exposed to denatured PCR products followed by hybridization and washing and detected by using streptavidin peroxidase and chemiluminescence (Bergmans et al. 2008). PCR-ELISA-based method has been used for direct detection of clinical samples of dermatophytes including *T. rubrum*, *T. interdigitale*, *T. violaceum*, *M. canis*, and *E. floccosum* (Beifuss et al. 2011). PCR-RFLP has higher specificity for detection of dermatophytes by targeting the ITS region, 18S ribosomal DNA from nails, hairs, and skin (Elavarashi et al. 2013).

7.8 Treatment

Traditionally, topical therapy is recommended for the treatment of dermatophytosis. Azoles and allylamines has high efficacy. The azoles include econazole, ketoconazole, clotrimazole, miconazole, oxiconazole, sulconazole, and sertaconazole, respectively. The azoles interfere with cytochrome P450-dependent ergosterol synthesis and stop fungal cell proliferation (Refai et al. 2013). The systemic medication

included the itraconazole, fluconazole, griseofulvin, and terbinafine. Chiefly, itraconazole, fluconazole, terbinafine, ketoconazole, and griseofulvin have been effectively used in animals. Vaccination is also available for certain species, i.e., *T. verrucosum* and *T. mentagrophytes*, in livestock, farmed foxes, and rabbits, *T. equinum* in horses (Chollet et al. 2015), and *M. canis* in cats and dogs (Refai et al. 2013). But, in few years, these treatments have become ineffective which may be due to climate change, antifungal resistance, or tolerance. The hot and humid climate also supports the survival of dermatophytes on host body. The fungi easily travel from soil to animal/human or human to animal, and animal to human sequentially. The mechanisms behind drug resistance may be alteration of drug target sites, increased drug efflux, biofilm formation, etc. (Shivanna and Inamadar 2017). Finally, the synthetic drugs become ineffective after a while due to reoccurrence of disease.

Thus, natural/plant-derived products can be applied as an alternative approach to combat such situation. Ibrahim and El-Salam (2015) had reported 26 plant-derived essential oils against four dermatophytes, i.e., *M. canis*, *E. floccosum*, *T. rubrum*, and *T. mentagrophytes*. The oils of *Prunus armeniaca*, *P. dulcis* var. *amara*, *Olea europaea*, and *Mentha piperita* were found most effective. The Juniperus oil had antifungal activity against *M. canis*, *M. gypseum*, *T. rubrum*, *T. mentagrophytes*, and *E. floccosum* (Cavaleiro et al. 2006). Kakande et al. (2019) had reported the efficacy of *Tetradenia riparia* ethanol crude extract against three dermatophytes including *T. tonsurans*, *T. mentagrophyte*, and *M. audouinii*. A recent review paper by Sepahvand et al. (2018) has listed 24 medicinal plants against dermatophytes. These plants are *Azadirachta indica*, *Capparis spinosa*, *Anagallis arvensis*, *Juglans regia*, *Inula viscosa*, *Phagnalon rupestre*, *Plumbago europaea*, *Ruscus aculeatus*, *Ruta chalepensis*, *Salvia fruticosa*, *Artemisia judaica*, *Ballota undulate*, *Cleome amblyocarpa*, *Peganum harmala*, *Teucrium polium*, *Aegle marmelos*, *Artemisia sieberi*, *Cuminum cyminum*, *Foeniculum vulgare*, *Heracleum persicum*, *M. spicata*, *Nigella sativa*, and *Rosmarinus officinalis*, respectively. The antifungal properties of medicinal plants are due to presence of secondary active constituents, i.e., alkaloids, phenols, terpenes, flavonoids, phytosterols, anthocyanins, etc.

Furthermore, metal nanoparticles can enhance the currently available schemes to overcome dermatophytosis as they can deliver drug on the target site. These include the phospholipid vesicles, non-phospholipid vesicles, solid lipid nanoparticles, nanostructured lipid carriers, polymeric nanoparticles, polymeric micelles, nano-emulsions, and dendrimers. Among these lipid-based nanoparticles are considered as the most suitable carriers for the drugs (Bangia et al. 2019). Similarly, the antidermatophytic properties of silver nanoparticles has been reported against *T. rubrum* (Pereira et al. 2014), *Microsporum*, and *Trichophyton* (Ronavari et al. 2018) synthesized from fungal origin. Other therapies, i.e., photodynamic and adjuvant therapy, have their own importance against dermatophytosis. The photodynamic therapy involves the selective illumination of the target site with the light of a specific wavelength causing free radical generation, which causes the death of the cell. The aminolevulinic acid and methylene blue are well-known examples of photosensitizing agents and most frequently used (Sahni et al. 2018), while adjuvant therapy may

cause excessive proliferation of epidermal cells leading to thickening and scaling due to hyperkeratosis, which obstructs the absorption of the antifungal drug. Therefore, the adjuvant-based treatment is recommended where the moisturizing agent salicylic acid (3–6%) is used most of the time with the drug which helps to prevent transepidermal loss of water and helps the antifungal drug in absorption (Rajagopalan et al. 2018).

7.9 Conclusion and Future Prospects

Dermatophytosis is a contagious fungal disease of animals as well as in human. Currently, this disease has global impact especially in tropical and subtropical countries. The hot and humid conditions favor the transmission, growth, and survivability of dermatophytes. The fungi have well-adapted survival and growth mechanism in host. Proper sanitation and good hygienic condition may minimize the fungi. Animals should keep away from infected animals and humans and be checked routinely. Only successful treatment can control the disease. Synthetic drugs are prescribed for long duration use for complete removal of fungi inside animal body. The overuse may cause side effects and develop drug resistance in fungi. Resistance and tolerance are other survival routes for the dermatophytes. Therefore, naturopathy and plant-based products may be an effective alternative to overcome this problem.

References

- Abarca ML, Castella G, Martorell J, Cabanes FJ (2017) Trichophyton erinacei in pet hedgehogs in Spain: occurrence and revision of its taxonomic status. Med Mycol 55(2):164–172
- Arabatzis M, Bruijnesteijn van Coppenraet LE, Kuijper EJ, De Hoog GS, Lavrijsen AP, Templeton K, vander Raaij-Helmer EM, Velegraki A, Summerbell RC (2007) Diagnosis of common dermatophyte infections by a novel multiplex real-time polymerase chain reaction detection/identification scheme. Br J Dermatol 157(4):681–689
- Babu N, Pathak VM, Singh A, Navneet (2019) *Sonchus asper* leaves aqueous extract mediated synthesis of titanium dioxide nanoparticles. Pharma Innov 8(4):817–822
- Bangia R, Sharma G, Dogra S, Katare OP (2019) Nanotechnological interventions in dermatophytosis: from oral to topical, a fresh perspective. Expert Opin Drug Deliv 16(4):377–396
- Bartosch T, Frank A, Gunther C, Uhrla S, Heydel T, Nenoff P et al (2019) *Trichophyton benhamiae* and *T. mentagrophytes* target guinea pigs in a mixed small animal stock. Med Mycol Case Rep 23:37–42
- Beguín H, Goens K, Hendrickx M, Planard C, Stubbe D, Detandt M (2013) Is *Trichophyton simii* endemic to the Indian subcontinent? Med Mycol 51(4):444–448
- Beifuss B, Bezold G, Gottlober P, Borelli C, Wagener J, Schaller M, Korting HC (2011) Direct detection of five common dermatophyte species in clinical samples using a rapid and sensitive 24-h PCR–ELISA technique open to protocol transfer. Mycoses 54(2):137–145
- Bergmans AMC, Schouls LM, Van Der Ent M, Klaassen A, Böhm N, Wintermans RGF (2008) Validation of PCR–reverse line blot, a method for rapid detection and identification of nine dermatophyte species in nail, skin and hair samples. Clin Microbiol Infect 14(8):778–788

- Bhatia VK, Sharma PC (2014) Epidemiological studies on dermatophytosis in human patients in Himachal Pradesh, India. *Springerplus* 3(1):134–140
- Bond R (2010) Superficial veterinary mycoses. *Clin Dermatol* 28(2):226–236
- Carlotti B (2002) Dermatophytosis due to *Microsporium persicolor* (13 cases) or *Microsporium gypseum* (20 cases) in dogs. *Vet Dermatol*. <https://doi.org/10.1046/j.1365-3164.1999.00115.x>
- Cavaleiro C, Pinto E, Goncalves MJ, Salgueiro L (2006) Antifungal activity of *Juniperus* essential oils against dermatophyte, *Aspergillus* and *Candida* strains. *J Appl Microbiol* 100(6):1333–1338
- Chollet A, Wespi B, Roosje P, Unger L, Venner M, Goepfert C (2015) An outbreak of *Arthroderma vanbreuseghemii* dermatophytosis at a veterinary school associated with an infected horse. *Mycoses*. <https://doi.org/10.1111/myc.12301>
- Dalis JS, Kazeem HM, Kwaga JKP, Kwanashie CN (2019) Prevalence and distribution of dermatophytosis lesions on cattle in Plateau state, Nigeria. *Veterinary World* 12(9):1484–1490
- de Hoog GS, Dukik K, Monad M, Packeu A, Stubbe D, Hendrickx M et al (2017) Toward a novel multilocus phylogenetic taxonomy for the dermatophytes. *Mycopathologia* 182(1–2):5–31. <https://doi.org/10.1007/s11046-016-0073-9>
- Elavarashi E, Kindo AJ, Kalyani J (2013) Optimization of PCR-RFLP directly from the skin and nails in cases of dermatophytosis, targeting the ITS and the 18S ribosomal DNA regions. *J Clin Diagn Res* 7(4):646
- Fisher MC, Henk DA, Briggs CJ, Brownstein JS, Madoff LC, McCraw SL et al (2012) Emerging fungal threats to animal, plant and ecosystem health. *Nature* 484:186–194
- Frymus T, Gruffydd-Jones T, Pennisi MG, Addie D, Belak S, Boucraut-Baralon C et al (2013) Dermatophytosis in cats: ABCD guidelines on prevention and management. *J Feline Med Surg* 15(7):598–604. <https://doi.org/10.1177/1098612X13489222>
- Garcia-Solache MA, Casadevall A (2010) Global warming will bring new fungal diseases for mammals. *MBio* 1(1):e00061–e00010. <https://doi.org/10.1128/mBio.00061-10>
- Hainer BL (2003) Dermatophyte infections. *Am Fam Physician* 67(1):101–110
- Hayette MP, Sacheli R (2015) Dermatophytosis, trends in epidemiology and diagnostic approach. *Curr Fungal Infect Rep* 9(3):164–179
- Ibrahim SY, El-Salam MMA (2015) Anti-dermatophyte efficacy and environmental safety of some essential oils commercial and in vitro extracted pure and combined against four keratinophilic pathogenic fungi. *Environ Health Prev Med* 20(4):279–286
- Kakande T, Batunge Y, Eilu E, Shabohurira A, Abimana J, Akinola SA et al (2019) Prevalence of dermatophytosis and antifungal activity of ethanolic crude leaf extract of *Tetradenia riparia* against dermatophytes isolated from patients attending Kampala international university teaching hospital, Uganda. *Dermatol Res Pract*. <https://doi.org/10.1155/2019/9328621>
- Kawasaki M (2011) Verification of a taxonomy of dermatophytes based on mating results and phylogenetic analyses. *Med Mycol J* 52(4):219–295
- Kelly BP (2012) Superficial Fungal Infections. *Pediatr Rev* 33(4):22–37
- Kontoyiannis DP (2017) Antifungal resistance: An emerging reality and a global challenge. *J Infect Dis* 216(3):S431–S435. <https://doi.org/10.1093/infdis/jix179>
- Kraemer A, Mueller RS, Werckenthin C, Straubinger RK, Hein J (2012) Dermatophytes in pet Guinea pigs and rabbits. *Vet Microbiol* 157(1–2):208–213
- Makimura K, Tamura Y, Mochizuki T, Hasegawa A, Tajiri Y, Hanazawa R, Uchida K, Saito H, Yamaguchi H (1999) Phylogenetic classification and species identification of dermatophyte strains based on DNA sequences of nuclear ribosomal internal transcribed spacer 1 regions. *J Clin Microbiol* 37(4):920–924
- Maldonado YA (2011) Pneumocystis and other less common fungal infections. In: Infectious diseases of the fetus and newborn, 7th edn. <https://doi.org/10.1016/B978-1-4160-6400-8.00034-1>
- Martinez-Rossi NM, Peres NTA, Rossi A (2016) Pathogenesis of dermatophytosis: sensing the host tissue. *Mycopathologia* 182(1–2):215–227. <https://doi.org/10.1007/s11046-016-0057-9>
- Moretti A, Agnelli F, Mancianti F, Nardoni S, Righi C, Moretti I, Morganti G, Papini M (2013) Dermatophytosis in animals: epidemiological, clinical and zoonotic aspects. *G Ital Dermatol Venereol* 148:563–572

- Moriello KA, Coyner K, Paterson S, Mignon B (2017) Diagnosis and treatment of dermatophytosis in dogs and cats. *Vet Dermatol* 28:266–e68. <https://doi.org/10.1111/vde.12440>
- Pal M (2017) Dermatophytosis in an adult cattle due to *Trichophyton verrucosum*. *Anim Husb Dairy Vet Sci* 1. <https://doi.org/10.15761/AHDVS.1000106>
- Pereira L, Dias N, Carvalho J, Fernandes S, Santos C, Lima N (2014) Synthesis, characterization and antifungal activity of chemically and fungal-produced silver nanoparticles against *Trichophyton rubrum*. *J Appl Microbiol* 117(6):1601–1613
- Pollock C (2003) Fungal diseases of laboratory rodents. *Vet Clin North Am Exot Anim Pract* 6(2):401–413
- Rajagopalan M, Inamadar A, Mittal A, Miskeen AK, Srinivas CR, Sardana K et al (2018) Expert consensus on the management of dermatophytosis in India (ECTODERM India). *BMC Dermatol* 18(1):1–11
- Refai M, El-Yazid HA, El-Hariri M (2013) Monograph on dermatophytes – a guide for isolation and identification of dermatophytes, disease and treatment. <https://www.academia.edu>
- Roller JA, Westblom TU (1986) Microsporium nanum infection in hog farmers. *J Am Acad Dermatol* 15(5):935–939. [https://doi.org/10.1016/s0190-9622\(86\)70252-1](https://doi.org/10.1016/s0190-9622(86)70252-1)
- Ronavari A, Igaz N, Gopisetty MK, Szerencses B, Kovacs D, Papp C et al (2018) Biosynthesized silver and gold nanoparticles are potent antimycotics against opportunistic pathogenic yeasts and dermatophytes. *Int J Nanomedicine* 13:695–703
- Rudramurthy SM, Shaw D (2017) Overview and update on the laboratory diagnosis of dermatophytosis. *Clin Dermatol Rev* 1(3):3–11. https://doi.org/10.4103/CDR.CDR_35_17
- Sahni K, Singh S, Dogra S (2018) Newer topical treatments in skin and nail dermatophyte infections. *Indian Dermatol Online J* 9(3):149–164
- Seeliger HPR (1985) The discovery of *Achorion schoenleinii*. *Mykosen* 28:161–182
- Sepahvand A, Eliasy H, Mohammadi M, Safarzadeh A, Azarbaijani K, Shahsavari S, Alizadeh M, Beyranvand F (2018) A review of the most effective medicinal plants for dermatophytosis in traditional medicine. *Biomed Res Therapy* 5(6):2378–2388
- Seyedmousavi S, Bosco SMG, Hoog S, Ebel F, Elad D, Gomes RR et al (2018) Fungal infections in animals: a patchwork of different situations. *Med Mycol* 56(1):S165–S187. <https://doi.org/10.1093/mmy/myx104>
- Shalaby MFM, El-din AN, El-Hamd MA (2016) Isolation, identification, and in vitro antifungal susceptibility testing of dermatophytes from clinical samples at Sohag University hospital of Egypt. *Electron Physician* 8(6):2557–2567
- Sharma R, Rajak RC, Pandey AK, Graser Y (2006) Internal transcribed spacer (ITS) of rDNA of appendaged and non-appendaged strains of *Microsporum gypseum* reveals *Microsporum appendiculatum* as its synonym. *Antonie Van Leeuwenhoek* 89:197–202
- Shivanna R, Inamadar AC (2017) Clinical failure of antifungal therapy of dermatophytosis: Reoccurrence, resistance, and remedy. *Indian J Drugs Dermatol* 3(1):1–3
- Vanam HP, Mohanram K, Reddy KSR, Poojari SS, Anuradha PR, Kandi V (2018) First report of concomitant *Tinea faciei* and *Pityriasis folliculorum*: a dermatomicrobiological rarity. *Cureus* 10(7):e3017
- Weitzman I, Summerbell RC (1995) The dermatophytes. *Clin Microbiol Rev* 8:240–259
- White TC, Findley K, Dawson TL Jr, Scheynius A, Boekhout T, Cuomo CA, Xu J, Saunders CW (2014) Fungi on the skin: dermatophytes and Malassezia. *Cold Spring Harb Perspect Med* 4(8):a019802

Chapter 8

Fungal Diseases and Therapy in Dogs



Hidayet Tutun, Ezgi Sababoglu, Adnan Ayan, and Mustafa Sevindik

8.1 Aspergillosis

Aspergillosis is a fungal disease caused by *Aspergillus* species, usually settles in the respiratory tract, and sometimes causes systemic infections. Among the *Aspergillus* species, *A. fumigatus* is the leading species that causes disease in dogs (Connole 1990). However, there are different types of *Aspergillus* that cause disease in dogs such as *A. flavus*, *A. nidulans*, *A. terreus*, *A. niger*, and *A. deflexus* (Connole 1990).

Three main forms of aspergillosis in dogs are observed, namely, sinonasal aspergillosis (SNA), disseminated canine aspergillosis (DCA), and bronchopulmonary aspergillosis (Seyedmousavi et al. 2015). Cases of otitis have also been reported (Ghibaudo and Peano 2010; Goodale et al. 2016).

8.2 Canine Sinonasal Aspergillosis (SNA)

In veterinary medicine, infections of the upper respiratory tract with *Aspergillus* spp. are of great clinical importance in dogs (Day 2009). Sinonasal aspergillosis (SNA) is the most common form of aspergillosis seen in dogs (Connole 1990;

H. Tutun

Faculty of Veterinary Medicine, Department of Pharmacology and Toxicology,
Burdur Mehmet Akif Ersoy University, Burdur, Turkey

E. Sababoglu

Faculty of Veterinary Medicine, Department of Microbiology,
Burdur Mehmet Akif Ersoy University, Burdur, Turkey

A. Ayan

Faculty of Veterinary Medicine, Department of Genetics, Van Yuzuncu Yil University,
Van, Turkey

M. Sevindik (✉)

Bahçe Vocational School, Department of Food Processing, Osmaniye Korkut Ata University,
Osmaniye, Turkey

Seyedmousavi et al. 2015). Canine SNA is a common disease worldwide (Day 2009). SNA is predominantly caused by *A. fumigatus* (predominantly). However, various species such as *A. niger*, *A. nidulans*, and *A. flavus* have also been reported (Connole 1990; Sharman and Mansfield 2012).

Aspergillus species may cause SNA as an opportunistic primary pathogen or may participate secondary to the formation of infection in the presence of other predisposing factors (Benitah 2006). Localized tissue damage of the nasal mucosa is probably the most common predisposing factor for infection (Mortellaro et al. 1989). Factors that can predispose dogs to infection include injury to mucous membranes, catheter use, facial trauma, nasal foreign bodies, neoplasia, dental diseases, antibiotic use, and immunosuppressive drugs or other diseases (Benitah 2006; Day 2009; Sharman and Mansfield 2012; Seyedmousavi et al. 2015). Any breed of dog, especially medium to large size, with a dolichocephalic or mesaticephalic head is at risk (Peeters and Clercx 2007). It is very rare in brachycephalic dogs. German Shepherds and Rottweilers are commonly affected breeds (Seyedmousavi et al. 2015). Also, although most are young to middle-aged female animals, there is no specific age or gender predisposition (Börkür et al. 2003; Ferreira et al. 2011; Sharman and Mansfield 2012; Ballber et al. 2018).

Clinical signs are chronic seropurulent, mucopurulent, or sanguinopurulent nasal discharge (usually unilateral at the beginning, but becomes bilateral after destruction of the nasal septum), episodic epistaxis, regional nasal pain, sneezing, and nasal itching (Börkür et al. 2003; Benitah 2006; Day 2009; Abd Alfatah 2019). It can be stertor, stridor, or open mouth breathing (Schuller and Clercx 2007). Depigmentation, ulceration, or hyperkeratosis can be seen in the nasal planum. In advanced stages of the disease, facial deformity, ocular involvement, and epiphora may occur due to obstruction of the nasolacrimal ducts (Day 2009; Sharman and Mansfield 2012; Belda et al. 2018).

Clinical diagnosis of SNA in dogs is not simple, although clinical findings and course of the disease are suspicious for SNA. Methods such as radiology, computed tomography, or magnetic resonance imaging are used to evaluate the degree of tissue (bone) damage (Saunders et al. 2004; Day 2009; Valdes et al. 2018). In most cases, rhinoscopic examination is performed to identify a characteristic fungal plaque adhered to the mucosal surface and to determine the degree of local tissue damage (Saunders et al. 2004; Schuller and Clercx 2007; Day 2009; Valdes et al. 2018). Nasal cytology (lavage) can be used to identify fungal elements. Biopsies can also be collected for histopathological examination, and the fungal culture of such specimens should also be made (Schuller and Clercx 2007; Day 2009; Ballber et al. 2018; Valdes et al. 2018). Since a single diagnostic procedure does not have 100% sensitivity and specificity, it is recommended to use a combination of a number of procedures, including diagnostic imaging (computed tomography (CT) or radiography), rhinoscopy/sinuscopy, histopathology, cytology, fungal culture, serology, and molecular techniques (Benitah 2006; Day 2009; Sharman and Mansfield 2012; Seyedmousavi et al. 2015). Also, other common causes of chronic nasal disease should be considered and distinguished, including neoplasia, nasal foreign bodies, secondary rhinitis due to dental disease, and idiopathic lymphoplasmacytic rhinitis (Day 2009; Sharman and Mansfield 2012; Seyedmousavi et al. 2015).

8.3 Disseminated Canine Aspergillosis (DCA)

DCA is a relatively rare fatal disease in dogs. It is usually caused by *A. terreus* and *A. deflexus*. However, less frequently *A. fumigatus*, *A. flavus*, *A. niger*, *A. flavipes*, *A. versicolor*, *A. carneus*, *A. alabamensis*, and *A. deflexus* have also been reported (Robinson et al. 2000; Schultz et al. 2008; Burrough et al. 2012; Zhang et al. 2012; Seyedmousavi et al. 2015; Bennett et al. 2018). A case of disseminated aspergillosis caused by *A. caninus* in a 2-year-old Rottweiler dog was also reported recently (Yang et al. 2020). DCA is mainly seen in German Shepherd Dogs (Robinson et al. 2000; Taylor et al. 2015). Therefore, it has been suggested that genetic factors play an important role in susceptibility and pathogenesis, and IgA deficiency is a possible predisposing factor for disseminated aspergillosis (Berry and Leisewitz 1996; Bruchim et al. 2006). However, it has been reported that immunosuppression in any dog breed may pave the way for infection, and the use of corticosteroids may also be effective (Bruchim et al. 2006; Kalokhe et al. 2010). This disease has also been described in other breeds such as Dalmatian, English Setter, Pug, Rhodesian Ridgeback, Springer Spaniel, and Whippet (Kabay et al. 1985). Transuterine transmission by *A. terreus* has also been reported (Elad et al. 2008).

The clinical signs of DCA may come on suddenly or develop slowly within a few months. Its clinical manifestations are lethargy, discospondylitis, osteomyelitis, spinal column pain, spinal hyperpathia, vestibular abnormalities, ataxia, paraparesis, weight loss, anorexia, pyrexia, inflammatory ocular disease, uveitis, hematuria, urinary incontinence, lameness, renal failure, respiratory distress, generalized lymphadenopathy, and neurologic deficits (Robinson et al. 2000; Berry and Leisewitz 1996; Bruchim et al. 2006). Granulomatous inflammation is common in multiple organs, including bone, kidney, and spleen (Kabay et al. 1985; Berry and Leisewitz 1996; Bruchim et al. 2006).

Common abnormalities in complete blood count include normocytic normochromic anemia, leukocytosis, left shift, and neutrophil toxicity (Schultz et al. 2008). Hyperglobulinemia, azotemia, hypercalcemia, and/or hypoalbuminemia can be seen in the serum biochemical profile (Schultz et al. 2008; Bennett et al. 2018; Yang et al. 2020). Isosthenuria, hematuria, and pyuria are commonly found in urinalysis. Fungal hyphae can sometimes be seen in urinary sediment and aspirates from other affected areas such as lymph nodes, kidneys, pleural effusion, lung, bone, joint fluid, and transtracheal irrigation. Pyogranulomatous inflammation is frequently seen in cytological samples. CSF often shows neutrophilic pleocytosis in dogs with neurological findings (Schultz et al. 2008).

DCA in dogs can often be diagnosed with a combined approach using clinical signs, imaging techniques (radiography and computed tomography), and laboratory findings such as serology, cytology, mycology, and histopathology (Schultz et al. 2008). The diagnosis can be made by identifying fungal hyphae in tissue samples or urine or by detecting the fungal cell wall antigen galactomannan in blood or urine (Garcia et al. 2012). Since disseminated mycosis caused by other fungal species, including *Penicillium* spp., may mimic disseminated aspergillosis, fungal culture is required to confirm the clinical diagnosis and identify the specific pathogen (Schultz et al. 2008).

8.4 Bronchopulmonary Aspergillosis

Bronchopulmonary aspergillosis, like DCA, is also a rare disease in dogs and has been sporadically reported (Southard 1987; Kim et al. 2003; Adamama-Moraitou et al. 2011; Pavelski et al. 2018). Cases caused by *A. flavus*, *A. niger*, and *A. fumigatus* have been reported (Kim et al. 2003; Adamama-Moraitou et al. 2011). Nonspecific clinical signs such as depression, fever, and cough are observed (Adamama-Moraitou et al. 2011). Its diagnosis is similar to that of DCA (Seyedmousavi et al. 2015). Diffuse nodular lesions in the lung can be seen on chest radiographs, and differential diagnosis can be made with fungal culture of bronchoalveolar lavage samples (Kim et al. 2003; Seyedmousavi et al. 2015; Pavelski et al. 2018). Histopathology contributes to the diagnosis of mycotic bronchopneumonia, and the identification and confirmation of *Aspergillus* spp. can be done by PCR (Adamama-Moraitou et al. 2011).

Humoral mucosal immunity and cell-mediated immunity are of great importance in preventing *Aspergillus* infection. Also, cleaning maintenance equipment is essential to prevent fungal infection.

8.5 Dermatophytosis

Dermatophytosis (ringworm) mainly affects domestic animals. It is caused by zoophilic, geophilic, or anthropophilic fungal agents, especially *Microsporum canis*, *M. gypseum*, and *Trichophyton mentagrophytes*. It is a superficial fungal infection limited to keratinized epithelial tissue such as nail, paw, hair, and stratum corneum (Mattei et al. 2014; Moriello et al. 2017). It is an important skin disease that is contagious, infectious, and can be transmitted to humans (Moriello et al. 2017).

Immunosuppressive diseases are thought to make dogs predisposed to dermatophytosis (Mignon and Losson 1997). It has been described that Yorkshire Terrier dogs are predisposed to superficial dermatophytosis and subcutaneous dermatophytic infections, and the pathogenic agent is *M. canis* (Bergman et al. 2002; Brillhante et al. 2003; Cerundolo 2004; Cafarchia et al. 2004; Moriello et al. 2017). It has been reported that hunting and training dogs (German Shorthaired Pointers, Fox Terrier, Labrador Retriever, Belgian Shepherd, Beagle, Pointer, Jack Russell Terrier, German Shepherd, and Jagdterrier) are particularly susceptible to dermatophytosis caused by *M. persicolor* and *M. gypseum* (Carlotti and Bensignor 1999; Muller et al. 2011).

The hot and humid climate is the best condition for infection (Brilhante et al. 2003). Infection is transmitted through direct contact with infected animals or equipment contaminated with fungi such as grooming equipment (Chermette et al. 2008; Bagcigil et al. 2010). The incubation period of the infection is 1–3 weeks (Ganguly et al. 2017).

Although there are no clinical findings in many infected dogs, these dogs can be subclinically infected (Abd Alfatah 2019). When the infection progresses, hair loss, papules, scaling, crusting erythema, follicular obstruction, hyperpigmentation,

alopecia foci, changes in nail growth, and appearance can be seen. Lesions can be single or multiple and are localized anywhere in the dog, and multiple lesions may coalesce (Cerundolo 2004; Cafarchia et al. 2004; Chermette et al. 2008; Bagcigil et al. 2010; Abd Alfatah 2019). Pruritus is variable, generally minimal or absent. Dogs can develop nodular dermatophyte infections, mainly diagnosed by biopsy or cytological examination of aspirates (Moriello et al. 2017).

Infected hairs fluoresce bright green under lamp of Wood. With the exception of *Trichophyton schoenleinii*, fluorescence-producing dermatophytes are members of the *Microsporum* genus. The most important primary dermatophyte-producing fluorescence is *M. canis*. *M. gypseum*, one of the pathogenic agents causing dermatophytosis in dogs, has no fluorescence or is very light green in color. The characteristic green fluorescence observed in hair shafts infected with *M. canis* is caused by a water-soluble chemical metabolite (pteridine) found in the cortex or medulla of the hair (Moriello et al. 2017).

There is no gold-standard method for the diagnosis of dermatophytosis in dogs. Dermatophytosis infection is diagnosed using a range of complementary diagnostic tests, including Wood's lamp, direct microscopy, fungal culture, and biopsy. For examination with Wood's lamp, fluorescence is sought in hair shafts infected with *M. canis*, but false positive and negative results can be obtained. Therefore, failure to detect fluorescence does not mean that there is no infection (Moriello et al. 2017; Abd Alfatah 2019). The presence of fungal hyphae and/or ectothrix spores can be monitored by staining the fur and skin scrapings of infected dogs with dye (lactophenol cotton blue, India Ink) or by direct microscopic examination with unpainted potassium hydroxide. This examination is thought to be very important in the diagnosis of dermatophytosis (Mattei et al. 2014; Moriello et al. 2017; Abd Alfatah 2019). Definitive diagnosis of dermatophytosis is made by fungal culture. Skin scraping or biopsy specimens are inoculated into fungal culture medium such as Sabouraud's dextrose agar and dermatophyte test medium (Mattei et al. 2014; Abd Alfatah 2019). It may also be useful to detect dermatophyte DNA by polymerase chain reaction (PCR). However, a positive PCR test result does not necessarily indicate active infection. Because it has been reported that dead fungal organisms can also be detected by PCR in a successfully treated infection (Cafarchia et al. 2004; Mattei et al. 2014; Ganguly et al. 2017).

Hygienic measures should be implemented as well as good care should be taken of animals. The possibility of infection arises when it comes into contact with infected animals or contaminated environments. The best way to prevent infection is to avoid this contact.

8.6 Blastomycosis

Blastomycosis is a chronic, cutaneous, and systemic mycotic infection with purulent and granulomatous character caused by a dimorphic fungus *Blastomyces dermatitidis*. Blastomycosis is a systemic fungal infection that can be fatal if not diagnosed early (McMillan and Taylor 2008; Choptiany et al. 2009).

Blastomycosis is common in Canada, the south of the United States, and particularly in North America (Legendre et al. 1981; Choptiany et al. 2009; Benedict et al. 2012). Cases are most common in autumn, but can occur at any time of the year (Rudmann et al. 1992; Benedict et al. 2012). Blastomycosis occurs mainly in juveniles and large breed dogs (Selby et al. 1981; Rudmann et al. 1992; Arceneaux et al. 1998). It is most prevalent in Coonhounds, Pointers, and Weimaraner (Selby et al. 1981; Rudmann et al. 1992). In addition, Doberman Pinschers and Retrievers can be at risk for blastomycosis. It can occur to any breed of dog if they are exposed to microorganisms (Brömel and Sykes 2005). In some reports, the prevalence has been reported to be higher in males than in females (Legendre et al. 1981; Selby et al. 1981; Rudmann et al. 1992). In addition, while most cases are seen in stray dogs, they can also be found in pets (Brömel and Sykes 2005; Benedict et al. 2012). Dogs that live near waterways or hunt and excavate are more exposed to *B. dermatitidis* spores (Rudmann et al. 1992; Baumgardner et al. 1995; Arceneaux et al. 1998).

B. dermatitidis occurs in nature as saprophytic mycelial forms that form infective spores. Infected spores enter the body of susceptible hosts through respiration and turn into yeast form in tissues (Brömel and Sykes 2005). *B. dermatitidis* causes respiratory and/or disseminated infection. If the inhaled fungal spores are small and the animal is not immunocompromised, the infection may be confined to the respiratory tract and may have a few or no clinical signs. They form a primary infection in the lung and then spread to the body (lymph nodes, eyes, bones, central nervous system, kidneys, liver, spleen, skin, genitourinary system, heart, and adrenal glands) by hematogenous and lymphogenous ways. They cause granulomatous or pyogranulomatous inflammation in many organs (De Groote et al. 2000; Brömel and Sykes 2005; Yildiz et al. 2016). It has been reported that the most affected tissues are the respiratory system, lymphatic tissues, eyes, skin, and bones (Legendre et al. 1981; Bloom et al. 1996; Arceneaux et al. 1998). The most common clinical signs are nonspecific anorexia, weight loss, and fever (Legendre et al. 1981; Brömel and Sykes 2005). Respiratory abnormalities such as exercise intolerance, tachypnea, and cough are also common clinical findings (Legendre et al. 1981; Baumgardner et al. 1995; Brömel and Sykes 2005). Nodular or interstitial infiltrates, often referred to as “snowstorm pattern,” are seen on radiography (Schwartz 2017). Less commonly, thoracic radiographs show tracheal bronchial lymphadenopathy, masses, or cavitary lesions (Arceneaux et al. 1998). Draining skin tracts and lymphadenopathy are commonly found. Ulcerative and granulomatous type skin lesions are common (Legendre et al. 1981). Less commonly, bones, lymph nodes, central nervous system, genitourinary system, testis, and prostate may also be affected. Testicular enlargement and prostate enlargement are uncommon findings (Legendre et al. 1981; Totten et al. 2011). Cardiovascular blastomycosis has also been reported in dogs (Schmiedt et al. 2006).

In dogs with ocular lesions, findings such as endophthalmitis, uveitis, posterior segment disease and anterior segment disease, retinal detachment, panophthalmitis, glaucoma, photophobia, conjunctival hyperemia, miosis, blepharospasm, aqueous flare, and blindness have been reported (Legendre et al. 1981; Buyukmihci 1982; Bloom et al. 1996; Arceneaux et al. 1998). It has been reported that rupture of the

lens is a possible complication of the disease (Legendre et al. 1981; Hendrix et al. 2004; Brömel and Sykes 2005). Nonregenerative anemia, neutrophil leukocytosis (mostly left shift), monocytosis, lymphopenia, hyperglobulinemia, hypoalbuminemia, hypercalcemia, and hypoglycemia can be detected in blood parameters (Legendre et al. 1981).

Cytology and/or histopathology is accepted as the gold-standard method for the diagnosis of blastomycosis. Blastomycosis can be diagnosed by cytological examination of cerebrospinal fluid and samples taken from cutaneous lesions, peripheral lymph nodes, lungs, and bones by fine-needle aspiration biopsy and by histopathological examination of tissue and bone biopsy samples (Legendre et al. 1981; De Lorimier and Fan 2010). The diagnosis can also be made by culture method, but the diagnostic performance of both cytology and or histopathology methods is better than culture (Patel et al. 2010). In addition, the mycelium form of the fungus is not used because it increases the risk of infection of laboratory personnel (Denton et al. 1967). Surface antigens of *Blastomyces* can be detected by an enzyme immunoassay (EIA) from body fluids such as urine, serum, bronchoalveolar lavage fluid, and cerebrospinal fluid (Durkin et al. 2004; Spector et al. 2008). It is reported that EIA methods with antibody detection have higher sensitivity than antigen detection (Klein et al. 2006; Mourning et al. 2015). It has also been reported that the specificity of antibody EIA is high, but cross-reactions can be observed in dogs with histoplasmosis (Mourning et al. 2015). It has been reported that imaging techniques such as magnetic resonance imaging and tomography can be used in dogs with central nervous system blastomycosis (Legendre et al. 1981).

Since the clinical signs and symptoms of blastomycosis are similar to other respiratory tract infections, they are overlooked. A commercially available vaccine against blastomycosis is currently not available. A better understanding of the pathogenesis of blastomycosis and the host immune response against blastomycosis is required to facilitate early diagnosis and treatment of blastomycosis and to develop effective prevention and control strategies.

8.7 Histoplasmosis

Histoplasmosis is a noncommunicable systemic infection caused by a dimorphic, saprophytic soil fungus *Histoplasma capsulatum* (Mitchell and Stark 1980; Brömel and Sykes 2005; Sumithra et al. 2013). *H. capsulatum* has a worldwide distribution in temperate and subtropical climates. It is an endemic disease in the midwest and south of the United States (Colombo et al. 2011). In addition, it is the most frequently diagnosed systemic mycosis in dogs (Sumithra et al. 2013). It affects dogs of all age groups, but is especially seen in young person (Brömel and Sykes 2005). Several dog breeds, including Terriers, Pointers, Weimaraners, and Brittany Spaniels, have been reported to have an increased risk of histoplasmosis (Sumithra et al. 2013). Immunocompromised animals or dogs receiving immunosuppressive therapy are susceptible to histoplasmosis (Clinkenbeard et al. 1988; Mackie et al. 1997).

H. capsulatum easily grows on the surface of moist soils containing high nitrogen where the feces of poultry (avian) and bats are abundant, and the infection begins when the spores spilled into the environment are inhaled by sensitive living species (Lyon et al. 2004). Mycelial fragments transform into yeast form in host tissues, are phagocytosed by macrophages, and continue to multiply. The pathogenic agent spreads to other organs and tissues by hematogenous and lymphogenous ways (Sumithra et al. 2013).

Infection may be subclinical or cause clinical pulmonary granulomatous disease or disseminated infection (Tyre et al. 2007). Acute pulmonary histoplasmosis is rarely seen in dogs. In dogs, this form is characterized by dyspnea and cyanosis. Animals with chronic pulmonary histoplasmosis usually have mild symptoms of chronic cough, weight loss, and loss of appetite (Sumithra et al. 2013). Disseminated disease mainly affects the liver, spleen, lymph nodes, gastrointestinal tract, bone, bone marrow, and eyes (Tyre et al. 2007; Schumacher et al. 2013). In gastrointestinal infection, macrophages loaded with pathogens accumulate in the mucosa and submucosa, and edema and necrosis occur in the submucosa and associated lymph nodes. Ulcerative lesions can be seen. Granular to nodular appearance on the surface of the abdominal organs, granulomatous nodules, or pinpoint lesions within the viscera, focal, or diffuse granulomatous pneumonia, granulomatous dermatitis, mycotic osteomyelitis, and peritoneal effusion can be detected. It leads to hepatomegaly, splenomegaly, lymphadenopathy, and anemia (Sanford and Straube 1991; Schumacher et al. 2013). Endocarditis was reported in 41% of cases in which necropsies were performed in dogs (Mitchell and Stark 1980). Chronic diarrhea (usually with hematochezia or melena), weight loss, lethargy, malaise, pale mucous membranes, fever, anorexia, respiratory abnormalities, and lameness are common clinical signs. Ascites, optic neuritis, granulomatous chorioretinitis, oropharyngeal erosions, and central nervous system symptoms can also be seen (Reginato et al. 2014).

Histoplasmosis is suspected based on clinical and radiographic findings. The most common thoracic abnormalities in dogs with pulmonary histoplasmosis on radiographic examination are bronchointerstitial or interstitial lung pattern and hilar lymphadenopathy (Schulman et al. 1999; Sumithra et al. 2013). The terms “snow storm effect” and “cotton tuft” are used to describe pulmonary radiographic patterns. In dogs, tracheobronchial lymph nodes can rarely be found to be enlarged or mineralized (Sumithra et al. 2013).

Currently, the definitive diagnosis of *H. capsulatum* is made by identification with cytology or fungal culture. The scope of molecular diagnostic techniques and antigen detection tests in animals is being investigated (Wheat 2003). Although various techniques such as serum immunodiffusion tests and complement fixation tests are used to detect antibodies against *H. capsulatum*, more studies are needed (Cordeiro et al. 2011; Sumithra et al. 2013). Prevention of exposure to histoplasma-laden areas such as chicken coops, bird and bat roosts, and construction and excavation areas, and the prevention of bat manure or bird droppings' accumulation by keeping bats and birds away from buildings with chemical repellants are recommended protection methods (Sumithra et al. 2013). In addition, it has been declared that formalin solution (3–4%) is the most effective chemical (Bartlett et al. 1982).

8.8 Rhinosporidiosis

Rhinosporidiosis is a rare, noninfectious, and chronic granulomatous mycotic disease that is characterized by the polypoid growth of mucocutaneous tissues caused by *Rhinosporidium seeberi* (Hoff and Hall 1986; Caniatti et al. 1998). The disease is thought to be associated with contact with flowing and stagnant groundwater in both humans and animals (Arseculeratne 2002). In addition, local trauma in the nasal mucosa is a predisposing factor for rhinosporidiosis (Hoff and Hall 1986).

The infection is generally not fatal, and polypoid granulomatous masses in the nose are characteristic lesions of rhinosporidiosis (Rao and Jain 1971; Kennedy et al. 1995; Wallin et al. 2001). The disease in dogs is clinically characterized by wheezing, sneezing, unilateral seropurulent nasal exudate, and nosebleeds (Mosier and Creed 1984; Easley et al. 1986; Miller and Baylis 2009; Borteiro et al. 2018). Polyps can be seen in the nostrils and are pink and soft. They have a friable or fragile structure (Easley et al. 1986). It can also bleed easily and has small white spots (Caniatti et al. 1998).

Definitive diagnosis is made by histopathology. Endospores and sporangia are detected in native preparations (slides) made from nasal exudate and both in native preparations made from polyps and in stained sections (Sinha et al. 2012). It has also been reported that rhinosporidial disease can be confirmed from nasal swab samples with the specific polymerase chain reaction (PCR) test (Borteiro et al. 2018).

Its biology and risk factors have not been fully established. General hygienic conditions are recommended for protection.

8.9 Sporotrichosis

Sporotrichosis is a chronic, granulomatous, and often lymphocutaneous infection caused by the dimorphic fungus *Sporothrix schenckii* (Miranda et al. 2011). *S. schenckii* is commonly found in soil, water, and rotting plants. Sporotrichosis is common worldwide, especially in regions with high humidity and temperate climates (De Araujo et al. 2001; Ramírez-Soto et al. 2018). Although sporotrichosis is common in cats, it is rarely seen in dogs, and most of the cases published in the literature have been reported from the United States, France, Canada, Ontario, Italy, and especially Brazil (Koehne et al. 1971; Dion and Speckmann 1978; Moriello et al. 1988; Sykes et al. 2001; Schubach et al. 2006; Cafarchia et al. 2007; Whittemore and Webb 2007; Crothers et al. 2009; Rossi et al. 2013). It is more common in hunting dogs and dogs exposed to piercing objects in nature (Cafarchia et al. 2007). On the other hand, there are reported cases of dogs contacting cats (Viana et al. 2018).

The fungus is the main entry route to the body through traumatic wounds on the skin and often causes lymphangitis (Cafarchia et al. 2007). It has been explained that infection may occur with the sporadic inhalation of conidia (Schubach et al. 2006).

The most common clinical manifestation of sporotrichosis is chronic granulomatous lymphocutaneous infection (Cafarchia et al. 2007). Multiple, circular, alopetic lesions and ulcers in the extremities, brown-colored nodules, nonulcerative nodules on the auricle, and erosive lesions on the nose have been reported (Cafarchia et al. 2007; Mascarenhas et al. 2018; Viana et al. 2018). Respiratory symptoms such as sneezing, shortness of breath, and runny nose (Mascarenhas et al. 2018; Viana et al. 2018), and rarely osteoarticular and disseminated forms (Farias et al. 2015) have been reported.

The definitive diagnosis of infection is based on cytological examination of exudates, histological examination of the biopsy specimen, or isolation of *S. schenckii* with fungal culture (Miranda et al. 2011). It has been explained that serological methods (i.e., immunofluorescence test) can be used, but a positive result does not indicate an active infection, although it indicates exposure to the fungus (Cafarchia et al. 2007).

There are no known practical measures for preservation other than removing known contaminated materials. Infected animals, especially cats, should be detected and separated to prevent the spread of the microorganism. Skin wounds, which are the main entry route of the microorganism to the body, should be treated immediately, and animals should not be kept in areas where hard and sharp objects are in excess. In addition, general hygienic measures should be taken.

8.10 Geotrichosis

Geotrichosis is a fungal disease caused by *Geotrichum candidum* (Reppas and Snoeck 1999; Pal et al. 2002). *G. candidum* is found as a saprophyte or as a parasite in many natural sources, including soil, dairy, and plants (Lincoln and Adcock 1968). It has been described in animals that it is isolated either as part of the resident microflora or as a pathogen and is an opportunistic pathogen that can cause disease under appropriate conditions (Rhyan et al. 1990). *G. candidum* can cause disease in immunocompromised hosts (Reppas and Snoeck 1999; Pal et al. 2002). It has been rarely reported from dogs, and cases of pulmonary, cutaneous, oral, and disseminated geotrichosis have been reported (Rhyan et al. 1990; Pal 2005; Lee et al. 2010). The disease can progress rapidly and is fatal (Lincoln and Adcock 1968).

The symptoms of the infection vary according to the organ in which the disease occurs. Nodular erythematous skin lesions and signs of alopecia have been reported in cutaneous cases (Pal et al. 2002). Cough, fever, polydipsia, anorexia, difficulty in breathing, wheezing, vomiting, diarrhea, and icterus have been reported in pulmonary and disseminated cases (Lee et al. 2010). It has been reported that nodules in the lung and an increase in pleural fluid were detected on radiographic examination (Lincoln and Adcock 1968).

In pulmonary and disseminated cases, granulomas are detected in the organs (Lee et al. 2010). In addition, a significant increase in blood urea nitrogen and a high

icteric index have been reported hematologically. Clinical and histopathological findings are not sufficient to make a diagnosis (Lincoln and Adcock 1968). Fungus isolation and identification are essential for diagnosis (Lee et al. 2010). Characteristic rectangular arthrospores and septate hyphae are observed in direct microscopic examination of the stool (feces) with 15% KOH or in direct microscopic examination performed by staining with lactophenol cotton blue (Lee et al. 2010).

There is no known protection measure. As it is an opportunistic pathogen, animals should be kept away from stress and their immune system should be supported. In addition, general hygienic measures should be taken.

8.11 Phaeohyphomycosis

Phaeohyphomycosis is a mycotic infection caused by opportunistic, saprophytic, dematiaceous (pigmented) fungi (Dillehay et al. 1987). Several fungal species have been reported from canine infections such as *Ochroconis gallopavum* (Singh et al. 2006), *Bipolaris spicifera* (Waurzyniak et al. 1992; Giri et al. 2011; Rothenburg et al. 2017), *Phialemonium obovatum* (Lomax et al. 1986), *Alternaria infectoria* (Dedola et al. 2010), and *Cladosporium bantianum* (Schroeder et al. 1994; Lobetti 1996; Guillot et al. 2004). *C. bantianum* has been reported to be the most common fungus isolated among phaeohyphomycosis cases in dogs (Schroeder et al. 1994; Lobetti 1996; Guillot et al. 2004).

Predisposing factors for dogs have been reported to be immunosuppressive therapy or immunodeficient diseases. Cases of chronic skin, subcutaneous, mucosal, cerebral, or systemic infections, osteomyelitis, and nephritis in dogs have been reported (Dedola et al. 2010).

Clinical findings such as ulcerated cutaneous nodules, progressive weight loss, loss of appetite, polyuria, polydipsia, vomiting, hepatomegaly, nystagmus, loss of sensation in the right side of the face, seizure, neck stiffness, convulsions, circling, weakness of the extremities, postural deficits, falling to both sides, and altered mentation have been reported (Dedola et al. 2010).

Diagnosis can be made by direct microscopy, culture, histopathology, and molecular analysis (Ferrer et al. 2001). Numerous yellowish-green to black necrogranulomatous foci can be detected in the necropsy, liver parenchyma, spleen, renal cortex, and adrenal glands. Lesions in cerebral infections range from multifocal encapsulated abscesses to pyogranulomatous inflammation (Schroeder et al. 1994). Histopathological examination demonstrated pigmented fungal hyphae in the liver, spleen, kidneys, portal lymph node, and adrenals, as well as in the brain. Since Phaeohyphomycosis has various etiological agents and has similar morphology in tissue sections, specific identification can only be made by fungal culture method (Schroeder et al. 1994).

Stress conditions for prevention should be eliminated, and general hygienic measures should be taken.

8.12 Treatment Methods

8.12.1 *Aspergillosis*

Chemotherapy is generally used for the treatment of fungal diseases. The most widely used antifungal agents for treating canine SNA belong to the azole group comprising imidazoles (ketoconazole, clotrimazole, and enilconazole) and triazoles (fluconazole and itraconazole) (Sharman and Mansfield 2012). They all inhibit fungal wall synthesis by blocking 14 α -sterol demethylase which is a fungal cytochrome P450 enzyme (Maertens 2004). Also, topical azole drugs including clotrimazole and miconazole cause direct lytic effect on fungi (Mazu et al. 2016). Treatment of canine SNA is often challenging and consists of surgical debridement of involved tissues, administration of systemic antifungal, and application of topical antifungal agents. In cases where only the sinuses are involved, trephination is recommended to confirm the presence of the fungal infection and facilitate debridement and topical treatment (Day 2009). Topical antifungal treatment is regarded as the treatment of choice provided that the cribriform plate is intact. Topical antifungal solution is infused through a catheter. Topical application of enilconazole or clotrimazole is more effective than orally administered antifungal drugs for nasal aspergillosis in dogs (Mathews et al. 1998). A short, five-minute flushing of 1% topical clotrimazole solution followed by a 1% clotrimazole cream instilled as a depot agent after frontal sinus trephination has been used for SNA therapy (Sissener et al. 2006). The therapy compares favorably with topical clotrimazole (Mathews et al. 1998) and enilconazole (Sharp et al. 1993). Infusion of clotrimazole cream into the frontal sinus by trephination provides a fast and effective treatment technique for SNA.

Effective treatment of DCA in dogs has always been difficult due to low effectiveness of the available drugs such as Amphotericin B, itraconazole, high cost of drugs such as voriconazole, and the limited number of effective drugs against DCA (Kelly et al. 1995; Graybill et al. 2004; Corrigan et al. 2016). Recently, novel antifungal agents, including voriconazole, posaconazole, and echinocandin, have been used for treatment of DCA. These drugs are highly expensive for veterinary use and have to be used for dog's whole life. Posaconazole belonging to triazoles is most effective of the azoles on *Aspergillus* spp. Posaconazole administered at a dose of 5 mg/kg PO q12h seems to be safe and well tolerated for long-term DCA in dogs. Unfortunately, even if seemingly successful, relapses are quite common, and most of the dogs die. This drug should be considered as an option for treating DCA in dogs (Corrigan et al. 2016).

Similar to DCA, the treatment of bronchopulmonary aspergillosis with antifungal drugs is also difficult. The efficacy of itraconazole appears to be greater than that of fluconazole and ketoconazole for bronchopulmonary aspergillosis. Even if long-term antifungal medication relapses often occur following cessation of the antifungal therapy (Whitley et al. 2010).

8.12.2 *Dermatophytosis*

Dermatophytosis is treatable and curable disease. Treatment of dermatophytosis involves oral and/or topical formulations of azoles or allylamines (Gupta and Cooper 2008). As transmission of dermatophytosis happens through direct contact with an infected dog, topical therapy is critical to prevent or minimize the risk of spreading infection to humans and other animals (Moriello 2004). Topical antifungal agents used for treating generalized dermatophytosis in dog include lime sulfur, enilconazole, ketoconazole, terbinafine, or a miconazole/chlorhexidine shampoo. Although treatment with miconazole or chlorhexidine alone is poorly effective, their combination is more effective for topical therapy (Perrins et al. 2005). Oral treatment with antifungal agents is necessary for severe or disseminated cases. Oral medications used for dermatophytosis in dogs include griseofulvin, fluconazole, itraconazole, ketoconazole, and terbinafine. Among these drugs, itraconazole and terbinafine are the most effective and safe therapy. Ketoconazole and fluconazole are less effective compared to itraconazole and terbinafine. However, griseofulvin, ketoconazole, and fluconazole have more adverse effects (Legendre et al. 1996).

8.12.3 *Blastomycosis*

Animals with blastomycosis may be treated medically. Rarely, primary cutaneous or ocular blastomycosis may be treated by surgical excision (Bateman 2002). Treatment of choice for canine blastomycosis is limited to Amphotericin B, ketoconazole, terbinafine, and itraconazole. Amphotericin B and itraconazole continue to be the main medications used for treating dogs with blastomycosis. Itraconazole is the preferred agent due to its effectiveness similar to Amphotericin B, ease of use, low toxicity, and low cost (Needles 2017). Ketoconazole is rarely used due to its low effectiveness compared to itraconazole or Amphotericin B. The therapeutic potential of Amphotericin B is limited due to causing nephropathy in dogs (Rubin et al. 1989). Combination of Amphotericin B with an azole antifungal such as itraconazole, which allows for a decreased total dose of Amphotericin B to be administered, and the uses of liposomal or lipid-complexed form of Amphotericin B may lessen renal impairment in the dogs. Also, terbinafine has been used for treating blastomycosis in dogs occasionally in combination with azoles such as itraconazole (Wiebe and Karriker 2005; Sakai et al. 2011).

8.12.4 *Histoplasmosis*

Unfortunately, histoplasmosis is often fatal to dogs, and therefore, prolonged treatment (at least 6 months in most cases) with antifungal agents is required to successfully treat the disease. Newer azole antifungal agents including itraconazole and

fluconazole are used for treating canine histoplasmosis due to being less toxic and more effective than the old ones. Amphotericin B and ketoconazole cause more adverse effects in dogs, and relapse is common following withdrawal after therapy with these drugs. In dogs with severe disseminated histoplasmosis, combination therapy with Amphotericin B and itraconazole or Amphotericin B and ketoconazole may provide a more effective control of the infection (Lavelly and Lipsitz 2005). Corticosteroids can be used successfully in the treatment of dogs with airway obstruction secondary to hilar lymphadenopathy caused by chronic histoplasmosis (without dissemination) as well as an antifungal medication (Schulman et al. 1999).

8.12.5 *Rhinosporidiosis*

The single or multiple polyps with associated inflammation occur within the nasal cavity of dogs with rhinosporidiosis. Antifungal and antibacterial medications are not effective in the treatment of rhinosporidiosis in animals (Hill et al. 2010). Surgical excision, preferably with electrocautery, is the treatment of choice for this disease and may be curative when a single polyp is excised (Miller and Baylis 2009). However, relapse is most likely to occur after the surgery. Medical treatment can be performed if the lesion is inoperable or recurs in spite of repeated surgeries (Allison et al. 1986). Ketoconazole eliminated nasal discharge in a dog with rhinosporidiosis within 4 days, although the disease recurred 6 months later (Miller and Baylis 2009). Also, dapsone has been demonstrated to be useful in such patients (Vieson et al. 2012).

8.12.6 *Sporotrichosis*

Sporotrichosis in dogs is usually characterized by multiple cutaneous lesions, although osteoarticular and disseminated form may also develop (Sykes et al. 2001). Treatment of sporotrichosis in dogs has involved oral administration of itraconazole, terbinafine, ketoconazole, and potassium iodine. The iodine therapy causing severe adverse effects has been replaced by new drugs such as itraconazole for treating sporotrichosis in human and veterinary medicine. Although ketoconazole is effective in the treatment of canine sporotrichosis, relapses and drug toxicity may limit therapy (Goad and Goad 1986; Mayer et al. 2008). Itraconazole therapy (about 6 months) has been used successfully to treat canine sporotrichosis (Sykes et al. 2001; Whittemore and Webb 2007). Terbinafine can be also used as alternative to itraconazole in treatment of canine sporotrichosis since it is an effective and well-tolerated alternative to drug therapy of cutaneous sporotrichosis (Viana et al. 2018).

8.12.7 *Geotrichosis*

The cutaneous, oral, intestinal, pulmonary, and systemic geotrichosis have been reported in dogs (Rhyan et al. 1990; Sidhu et al. 1993; Pal 2005; Lee et al. 2010). Optimal therapeutic strategy for geotrichosis is unknown. In human, Amphotericin B, itraconazole, and voriconazole have been successfully used for treating geotrichosis (Sfakianakis et al. 2007; Durán Graeff et al. 2017). Information about antifungal agent used in geotrichosis treatment in dogs is limited. In a case report, ketoconazole (20 mg/kg) and metronidazole (25 mg/kg) were orally administered for a period of 3 weeks to a dog with intestinal geotrichosis. Also, oral prednisolone (2 mg/kg for the first 3 days and 1 mg/kg for the following 4 days) was tapered after 1 week of therapy. Canine intestinal geotrichosis got successfully cured using ketoconazole (Lee et al. 2010).

8.12.8 *Phaeohyphomycosis*

Phaeohyphomycosis is often poorly responsive to medical therapy. Systemic antifungal agents including Amphotericin B, lipophilic Amphotericin B, flucytosine, itraconazole, ketoconazole, voriconazole, posaconazole, and fluconazole are used for treating phaeohyphomycosis in small animals. Multiple drugs given in combination are more effective than a single-drug therapy (Rothenburg et al. 2017; Dedeaux et al. 2018). The most severe form of phaeohyphomycosis is disseminated disease, which commonly involves central nervous system (CNS) infection in dogs, and the disease in the patients has been mostly fatal (Anor et al. 2001). In a case of intracranial phaeohyphomycosis, after the granuloma was debulked, the dog was cured successfully by using fluconazole for 4 months, followed by voriconazole for further 10 months. Voriconazole belonging to triazole penetrates well into the CNS, making it the first choice for treatment of the infection in dogs (Bentley et al. 2011). A dog with disseminated cutaneous phaeohyphomycosis has been cured successfully by combination of systemic antifungals including Amphotericin B and itraconazole (Swift et al. 2006). In cases where lesions are suitable for focal or extensive surgical excision, a combined medical and surgical approach may be effective (Dedeaux et al. 2018).

8.13 Conclusion

Fungal infections of dogs are common all over the world. The infection may produce local infections involving the skin surface or systematic disease that can lead to fatal damage. As the symptoms of these infections can be similar to those of other

diseases that mimic a disseminated fungal infection, diagnosis and treatment are often delayed. The knowledge about clinical manifestations of each fungal infection and diagnostic methods, and early diagnosis of these infections are critical to effective treatment, prevention, and control. Diagnosis of these infections is difficult because of the lack of specific signs and symptoms, and rapid and accurate diagnostic tests. In addition, therapy for these infections, especially systemic diseases, is expensive due to drug costs, toxic due to high side effects of the drugs, and requires several weeks for treatment. Many fungal infections are zoonotic, and the infections can occur in both humans and animals and can be transmitted either by domestic pets or by wildlife animals. Among pet animals, dogs are responsible for transmission of these infections to owner and vice versa. The owners should be informed about the route of transmission to avoid these infections.

References

- Abd Alfatah ME (2019) A review on bacterial and fungal diseases in dogs. *JSM Vet Med Res* 2:1–7
- Adamama-Moraitou KK, Pardali D, Day MJ, Denning DW, Papazoglou L, Papastefanou A, Rallis TS (2011) *Aspergillus fumigatus* bronchopneumonia in a hellenic shepherd dog. *J Am Anim Hosp Assoc* 47(2):13–18
- Allison N, Willard MD, Bentinck-Smith J, Davis K (1986) Nasal rhinosporidiosis in two dogs. *J Am Anim Hosp Assoc* 188(8):869–871
- Anor S, Sturges BK, Lafranco L, Jang SS, Higgins RJ, Koblik PD, Lecouteur RA (2001) Systemic Phaeohyphomycosis (*Cladophialophora bantiana*) in a dog—clinical diagnosis with stereotactic computed tomographic-guided brain biopsy. *J Vet Intern Med* 15(3):257–261
- Arceneaux KA, Taboada J, Hosgood G (1998) Blastomycosis in dogs: 115 cases (1980–1995). *J Am Vet Med Assoc* 213(5):658–664
- Arseculeratne SN (2002) Recent advances in rhinosporidiosis and *Rhinosporidium seeberi*. *Indian J Med Microbiol* 20(3):119–131
- Bagcigil AF, Ikiz S, Ozgür NY, Ilgaz A (2010) Recovery of dermatophytes in pet grooming tools from veterinary clinics and pet grooming salons. *J Small Anim Pract* 51(1):39–42
- Ballber C, Hill TL, Bommer NX (2018) Minimally invasive treatment of sino-nasal aspergillosis in dogs. *J Vet Intern Med* 32(6):2069–2073
- Bartlett PC, Vonbehren LA, Tewari RP, Martin RJ, Eagleton L, Isaac MJ, Kulkarni PS (1982) Bats in the belfry: an outbreak of histoplasmosis. *Am J Public Health* 72:1369–1372
- Bateman BS (2002) Disseminated blastomycosis in a German shepherd dog. *Can Vet J* 43(7):550
- Baumgardner DJ, Paretsky DP, Yopp AC (1995) The epidemiology of blastomycosis in dogs: north central Wisconsin, USA. *J Med Vet Mycol* 33:171–176
- Belda B, Petrovitch N, Mathews KG (2018) Sinonasal aspergillosis: outcome after topical treatment in dogs with cribriform plate lysis. *J Vet Intern Med* 32(4):1353–1358
- Benedict K, Roy M, Chiller T, Davis JP (2012) Epidemiologic and ecologic features of blastomycosis: a review. *Curr Fungal Infect Rep* 6:327–335
- Benitah N (2006) Canine nasal aspergillosis. *Clin Tech Small Anim Pract* 21(2):82–88
- Bennett PF, Talbot JJ, Martin P, Kidd SE, Makara M, Barrs VR (2018) Long term survival of a dog with disseminated *Aspergillus deflexus* infection without definitive treatment. *Med Mycol Case Rep* 22:1–3
- Bentley RT, Faissler D, Sutherland-Smith J (2011) Successful management of an intracranial phaeohyphomycotic fungal granuloma in a dog. *J Am Vet Med Assoc* 239(4):480–485
- Bergman RL, Medleau L, Hnilica K, Howerth E (2002) Dermatophyte granulomas caused by *Trichophyton mentagrophytes* in a dog. *Vet Dermatol* 13(1):49–52

- Berry WL, Leisewitz AL (1996) Multifocal *Aspergillus terreus* discospondylitis in two German shepherd dogs. *J S Afr Vet Assoc* 67(4):222–228
- Bloom JD, Hamor RE, Gerding PA (1996) Ocular blastomycosis in dogs: 73 cases, 108 eyes (1985–1993). *J Am Vet Med Assoc* 209:1271–1274
- Börkür MK, Güzel M, Kocasarı Ş, Özkanlar Y (2003) Bir Köpekte Nazal Aspergillozis ve Sağaltımında Flukonazol Kullanımı. *YYÜ Vet Fak Derg* 14(2):91–93
- Borteiro C, Etcheverze J, de León N, Nieto C, Arleo M, Debat CM, Kolenc F, Ubilla M, Freire J, Dutra F (2018) Rhinosporidiosis in a dog from Uruguay and review of the literature. *Braz J Vet Pathol* 11(3):92–96
- Brilhante RS, Cavalcante CS, Soares-Junior FA, Cordeiro RA, Sidrim JJ, Rocha MF (2003) High rate of *Microsporum canis* feline and canine dermatophytoses in Northeast Brazil: epidemiological and diagnostic features. *Mycopathologia* 156(4):303–308
- Brömel C, Sykes JE (2005) Histoplasmosis in dogs and cats. *Clin Tech Small An P* 20:227–232
- Bruchim Y, Elad D, Klainbart S (2006) Disseminated aspergillosis in two dogs in Israel. *Mycoses* 49(2):130–133
- Burrough E, Deitz K, Kinyon J, Andreasen C, Frana T, Sutton D, Thompson E, Fu J, Wickes B, Hostetter J (2012) Disseminated aspergillosis in a dog due to *Aspergillus alabamensis*. *Med Mycol Case Rep* 1(1):1–4
- Buyukmihci N (1982) Ocular lesions of blastomycosis in the dog. *J Am Vet Med Assoc* 180(4):426–431
- Cafarchia C, Romito D, Sasanelli M, Lia R, Capelli G, Otranto D (2004) The epidemiology of canine and feline dermatophytoses in southern Italy. *Mycoses* 47(11–12):508–513
- Cafarchia C, Sasanelli M, Lia RP, de Caprariis D, Guillot J, Otranto D (2007) Lymphocutaneous and nasal sporotrichosis in a dog from southern Italy: case report. *Mycopathologia* 163(2):75–79
- Caniatti M, Roccabianca P, Scanziani E, Finazzi M, Mortellaro CM, Romussi S, Mandelli G (1998) Nasal rhinosporidiosis in dogs: four cases from Europe and a review of the literature. *Vet Rec* 142(13):334–338
- Carlotti DN, Bensignor E (1999) Dermatophytosis due to *Microsporum persicolor* (13 cases) or *Microsporum gypseum* (20 cases) in dogs. *Vet Dermatol* 10:17–27
- Cerundolo R (2004) Generalized *Microsporum canis* dermatophytosis in six Yorkshire terrier dogs. *Vet Dermatol* 15(3):181–187
- Chermette R, Ferreiro L, Guillot J (2008) Dermatophytoses in animals. *Mycopathologia* 166:385–405
- Choptiany M, Wiebe L, Limerick B, Sarsfield P, Cheang M, Light B, Hammond G, Macdonald K, Trepman E, Pappas P, Embil JM (2009) Risk factors for acquisition of endemic blastomycosis. *Can J Infect Dis Med Microbiol* 20(4):117–121
- Clinkenbeard KD, Cowell RL, Tyler RD (1988) Identification of Histoplasma organisms in circulating eosinophils of a dog. *J Am Vet Med Assoc* 192:217–218
- Colombo AL, Tobón A, Restrepo A, Queiroz-Telles F, Nucci M (2011) Epidemiology of endemic systemic fungal infections in Latin America. *Med Mycol* 49:785–798
- Connole MD (1990) Review of animal mycoses in Australia. *Mycopathologia* 111(3):133–164
- Cordeiro RA, Coelho CG, Brilhante RS, Sidrim JJ, Castelo-Branco DS, Moura FB et al (2011) Serological evidence of Histoplasma capsulatum infection among dogs with leishmaniasis in Brazil. *Acta Trop* 119:203–205
- Corrigan VK, Legendre AM, Wheat LJ, Mullis R, Johnson B, Bemis DA, Cepero L (2016) Treatment of disseminated aspergillosis with posaconazole in 10 dogs. *J Vet Intern Med* 30(1):167–173
- Crothers SL, White SD, Ihrke PJ, Affolter VK (2009) Sporotrichosis: a retrospective evaluation of 23 cases seen in northern California (1987–2007). *Vet Dermatol* 20(4):249–259
- Day MJ (2009) Canine sino-nasal aspergillosis: parallels with human disease. *Med Mycol* 47(Supplement_1):S315–S323
- De Araujo T, Marques AC, Kerdel F (2001) Sporotrichosis. *Int J Dermatol* 40(12):737–742
- De Groot MA, Bjerke R, Smith H, Rhodes IILV (2000) Expanding epidemiology of blastomycosis: clinical features and investigation of 2 cases in Colorado. *Clin Infect Dis* 30(3):582–584

- De Lorimier LP, Fan TM (2010) Delayed diagnosis of fungal osteomyelitis with early scintigraphic lesions in a dog. *Can Vet J* 51:1394–1396
- Dedeaux A, Grooters A, Wakamatsu-Utsuki N, Taboada J (2018) Opportunistic fungal infections in small animals. *J Am Anim Hosp Assoc* 54(6):327–337
- Dedola C, Stuart AP, Ridyard AE, Else RW, van den Broek AH, Choi JS, de Hoog GS, Thoday KL (2010) Cutaneous *Alternaria infectoria* infection in a dog in association with therapeutic immunosuppression for the management of immune-mediated haemolytic anaemia. *Vet Dermatol* 21:626–634
- Denton JF, Di Salvo AF, Hirsch ML (1967) Laboratory-acquired North American blastomycosis. *JAMA* 199(12):935–936
- Dillehay DL, Ribas JL, Newton JC Jr, Kwapien RP (1987) Cerebral phaeohyphomycosis in two dogs and a cat. *Vet Pathol* 24(2):192–194
- Dion WM, Speckmann G (1978) Canine otitis externa caused by the fungus *Sporothrix schenckii*. *Can Vet J* 19(2):44–45
- Durán Graeff L, Seidel D, Vehreschild MJ, Hamprecht A, Kindo A, Racil Z, Wisplinghoff H (2017) Invasive infections due to *Saprochaete* and *Geotrichum* species: report of 23 cases from the FungiScope Registry. *Mycoses* 60(4):273–279
- Durkin M, Witt J, Lemonte A, Wheat B, Connolly P (2004) Antigen assay with the potential to aid in diagnosis of blastomycosis. *J Clin Microbiol* 42(10):4873–4875
- Easley JR, Meuten DJ, Levy MG, Dykstra MJ, Breitschwerdt EB, Holzinger EA, Cattley RC (1986) Nasal rhinosporidiosis in the dog. *Vet Pathol* 23(1):50–56
- Elad D, Lahav D, Blum S (2008) Transuterine transmission of *Aspergillus terreus* in a case of disseminated canine aspergillosis. *Med Mycol* 46(2):175–178
- Farias MR, Assunção DL, Duarte G, Vandresen G, Werner J, Tarqeti U (2015) Canine bone sporotrichosis: a case report. *Sem Cienc Agrar* 36(3):1445–1450
- Ferreira RR, Ferreira L, Spanemberg A, Driemeier D, Machado ML, Bianchi SP, Schmidt D, Guillot J (2011) Canine sinonasal aspergillosis. *Acta Sci Vet* 39(4):1009
- Ferrer C, Colom F, Frases S, Mulet E, Abad JL, Alio JL (2001) Detection and identification of fungal pathogens by PCR and by ITS2 and 5.8S ribosomal DNA typing in ocular infections. *J Clin Microbiol* 39:2873–2879
- Ganguly S, Ahmad Para P, Showkat S (2017) Mycological investigation of dermatophytosis in dog: a case study. *J Entomol Zool Stud* 5(1):970–971
- Garcia RS, Wheat LJ, Cook AK, Kirsch EJ, Sykes JE (2012) Sensitivity and specificity of a blood and urine galactomannan antigen assay for diagnosis of systemic aspergillosis in dogs. *J Vet Intern Med* 26:911–919
- Ghibaud G, Peano A (2010) Chronic monolateral otomycosis in a dog caused by *Aspergillus ochraceus*. *Vet Dermatol* 21(5):522–526
- Giri DK, Sims WP, Sura R, Cooper JJ, Gavrilov BK, Mansell J (2011) Cerebral and renal phaeohyphomycosis in a dog infected with *Bipolaris* species. *Vet Pathol* 48(3):754–757
- Goad DL, Goad ME (1986) Osteoarticular sporotrichosis in a dog. *J Am Vet Med Assoc* 189(10):1326–1328
- Goodale EC, Outerbridge CA, White SD (2016) *Aspergillus* otitis in small animals--a retrospective study of 17 cases. *Vet Dermatol* 27(1):3–e2
- Graybill JR, Hernandez S, Bocanegra R, Najvar L (2004) Antifungal therapy of murine *Aspergillus terreus* infection. *Antimicrob Agents Chemother* 48:3715–3719
- Guillot J, Garcia-Hermoso D, Degorce F, Deville M, Calvie C, Dickele G, Delisle F, Chermette R (2004) Eumycetoma caused by *Cladophialophora bantiana* in a dog. *J Clin Microbiol* 42:4901–4903
- Gupta AK, Cooper EA (2008) Update in antifungal therapy of dermatophytosis. *Mycopathologia* 166(5–6):353–367
- Hendrix DV, Rohrbach BW, Bochsler PN, English RV (2004) Comparison of histologic lesions of endophthalmitis induced by *Blastomyces dermatitidis* in untreated and treated dogs: 36 cases (1986–2001). *J Am Vet Med Assoc* 224(8):1317–1322

- Hill SA, Sharkey LC, Hardy RM, Wilke VL, Smith MA, Anderson GM (2010) Nasal rhinosporidiosis in two dogs native to the upper Mississippi river valley region. *J Am Anim Hosp Assoc* 46(2):127–131
- Hoff B, Hall DA (1986) Rhinosporidiosis in a dog. *Can Vet J* 27(6):231–232
- Kabay MJ, Robinson WF, Huxtable CR, McAleer R (1985) The pathology of disseminated *Aspergillus terreus* infection in dogs. *Vet Pathol* 22(6):540–547
- Kalokhe AS, Roupael N, El Chami MF, Workowski KA, Ganesh G, Jacob JT (2010) *Aspergillus endocarditis*: a review of the literature. *Int J Infect Dis* 14(12):1040–1047
- Kelly SE, Shaw SE, Clark WT (1995) Long-term survival of four dogs with disseminated *Aspergillus terreus* infection treated with itraconazole. *Aust Vet J* 72:311–313
- Kennedy FA, Buggage RR, Ajello L (1995) Rhinosporidiosis: a description of an unprecedented outbreak in captive swans (*Cygnus* spp.) and a proposal for revision of the ontogenic nomenclature of *Rhinosporidium seeberi*. *J Med Vet Mycol* 33(3):157–165
- Kim SH, Yong HC, Yoon JH, Youn HY, Yoshioka N, Kano R, Hasegawa A (2003) *Aspergillus niger* pulmonary infection in a dog. *J Vet Med Sci* 65(10):1139–1140
- Klein BS, Squires RA, Lloyd JK, Ruge DR, Legendre AM (2006) Canine antibody response to *Blastomyces dermatitidis* WI-1 antigen. *Am J Vet Res* 61(5):554–558
- Koehne G, Powell HS, Hail RI (1971) Sporotrichosis in a dog. *J Am Vet Med Assoc* 159(7):892–894
- Lavelly J, Lipsitz D (2005) Fungal infections of the central nervous system in the dog and cat. *Clin Tech Small Anim Pract* 20(4):212–219
- Lee YJ, Hsu WL, Lin CF, Lee SW, Cheng FP (2010) Intestinal geotrichosis in a German shepherd. *Turk J Vet Anim Sci* 34(5):481–484
- Legendre AM, Walker M, Buyukmihci N, Stevens R (1981) Canine blastomycosis: a review of 47 clinical cases. *J Am Vet Med Assoc* 178(11):1163–1168
- Legendre AM, Rohrbach BW, Toal RL, Rinaldi MG, Grace LL, Jones JB (1996) Treatment of blastomycosis with itraconazole in 112 dogs. *J Vet Intern Med* 10(6):365–371
- Lincoln SD, Adcock JL (1968) Disseminated geotrichosis in a dog. *Pathol Vet* 5(3):282–289
- Lobetti RG (1996) Leukogram and serum globulin values in two dogs with systemic *Xylohypha bantiana* infection. *J S Afr Vet Assoc* 67(2):91–92
- Lomax LG, Cole JR, Padhye AA, Ajello L, Chandler FW, Smith BR (1986) Osteolytic phaeohyphomycosis in a German shepherd dog caused by *Phialemonium obovatum*. *J Clin Microbiol* 23(5):987–991
- Lyon GM, Bravo AV, Espino A, Lindsley MD, Gutierrez RE, Rodriguez I, Corella A, Carrillo F, Mcneil MM, Warnock DW, Hajjeh RA (2004) Histoplasmosis associated with exploring a bat-inhabited cave in Costa Rica, 1998–1999. *Am J Trop Med Hyg* 70:438–442
- Mackie JT, Kaufman L, Ellis D (1997) Confirmed histoplasmosis in an Australian dog. *Aust Vet J* 75:362–363
- Maertens JA (2004) History of the development of azole derivatives. *Clin Microbiol Infect* 10:1–10
- Mascarenhas MB, Lopes NL, Pinto TG, Costa TS, Peixoto AP, Ramadinha RR, Fernandes JI (2018) Canine sporotrichosis: report of 15 advanced cases. *Pesqui Vet Bras* 38(3):477–481
- Mathews KG, Davidson AP, Koblik PD, Richardson EF, Komtebedde J, Pappagianis D, Kass PH (1998) Comparison of topical administration of clotrimazole through surgically placed versus nonsurgically placed catheters for treatment of nasal aspergillosis in dogs: 60 cases (1990–1996). *J Am Vet Med Assoc* 213(4):501–506
- Mattei AS, Beber MA, Madrid IM (2014) Dermatophytosis in small animals. *SOJ Microbiol Infect Dis* 2(3):1–6
- Mayer UK, Glos K, Schmid M, Power HT, Bettenay SV, Mueller RS (2008) Adverse effects of ketoconazole in dogs—a retrospective study. *Vet Dermatol* 19(4):199–208
- Mazu TK, Bricker BA, Flores-Rozas H, Ablordepey SY (2016) The mechanistic targets of antifungal agents: an overview. *Mini Rev Med Chem* 16(7):555–578
- McMillan CJ, Taylor SM (2008) Transtracheal aspiration in the diagnosis of pulmonary blastomycosis (17 cases: 2000–2005). *Can Vet J* 49:53–55

- Mignon BR, Losson BJ (1997) Prevalence and characterization of *Microsporum canis* carriage in cats. *J Med Vet Mycol* 35(4):249–256
- Miller RI, Baylis R (2009) Rhinosporidiosis in a dog native to the UK. *Vet Rec* 164:210
- Miranda LH, Quintella LP, Menezes RC, dos Santos IB, Oliveira RV, Figueiredo FB, Lopes-Bezerra LM, Schubach TM (2011) Evaluation of immunohistochemistry for the diagnosis of sporotrichosis in dogs. *Vet J* 190(3):408–411
- Mitchell M, Stark DR (1980) Disseminated canine histoplasmosis: a clinical survey of 24 cases in Texas. *Can Vet J* 21:95–100
- Moriello KA (2004) Treatment of dermatophytosis in dogs and cats: review of published studies. *Vet Dermatol* 15(2):99–107
- Moriello KA, Franks P, Lewis DD, King R (1988) Cutaneouslymphatic and nasal sporotrichosis in a dog. *J Am Anim Hosp Assoc* 24:621–626
- Moriello KA, Coyner K, Paterson S, Mignon B (2017) Diagnosis and treatment of dermatophytosis in dogs and cats. Clinical consensus guidelines of the World Association for Vet Dermatol. *Vet Dermatol* 28(3):266–268
- Mortellaro CM, Franca PD, Caretta G (1989) *Aspergillus fumigatus*, the causative agent of infection of the frontal sinuses and nasal chambers of the dog. *Mycoses* 32(7):327–335
- Mosier DA, Creed JE (1984) Rhinosporidiosis in a dog. *J Am Vet Med Assoc* 185(9):1009–1010
- Mourning AC, Patterson EE, Kirsch EJ, Renschler JS, Wolf LA, Paris JK, Durkin MM, Wheat LJ (2015) Evaluation of an enzyme immunoassay for antibodies to a recombinant *Blastomyces adhesin-1* repeat antigen as an aid in the diagnosis of blastomycosis in dogs. *J Am Vet Med Assoc* 247(10):1133–1138
- Muller A, Guaguère E, Degorce-Rubiales F, Bourdoiseau G (2011) Dermatophytosis due to *Microsporum persicolor*: a retrospective study of 16 cases. *Can Vet J* 52(4):385–388
- Needles RK (2017) Successful treatment of blastomycosis in a 7-year-old, female golden retriever dog on Manitoulin Island, Ontario. *Can Vet J* 58(6):617
- Pal M (2005) Role of *Geotrichum candidum* in canine oral ulcers. *Rev Iberoam Micol* 22(3):183
- Pal M, Lee CW, Matsusaka N (2002) Occurrence of *Geotrichum candidum* in two cases of canine dermatitis. *J Vet Clin* 19:433–435
- Patel AJ, Gattuso P, Reddy VB (2010) Diagnosis of blastomycosis in surgical pathology and cytopathology: correlation with microbiologic culture. *Am J Surg Pathol* 34:256–261
- Pavelski M, Seixas SV, Warth JFG, Souza CD, Dittrich RL, Froes TR (2018) Fungal pneumonia in dogs and cats with pulmonary clinical signs in southern Brazil. *Pesqui Vet Bras* 38(4):696–702
- Peeters D, Clercx C (2007) Update on canine sinonasal aspergillosis. *Vet Clin North Am Small Anim Pract* 37(5):901
- Perrins N, Howell S, Moore M, Bond R (2005) Inhibition of the growth in vitro of *Trichophyton mentagrophytes*, *Trichophyton erinacei* and *Microsporum persicolor* by miconazole and chlorhexidine. *Vet Dermatol* 16:330–333
- Ramírez-Soto MC, Aguilar-Ancori EG, Tirado-Sánchez A, Bonifaz A (2018) Ecological determinants of sporotrichosis etiological agents. *J Fungi* 4(3):95
- Rao PVR, Jain SN (1971) Rhinosporidiosis in animals. *Ind J Otol* 23:106–109
- Reginato A, Giannuzzi P, Ricciardi M, De Simone A, Sanguinetti M, Porcellato I, Mandara MT (2014) Extradural spinal cord lesion in a dog: first case study of canine neurological histoplasmosis in Italy. *Vet Microbiol* 170:451–455
- Reppas GP, Snoeck TD (1999) Cutaneous geotrichosis in a dog. *Aust Vet J* 77(9):567–569
- Rhyan JC, Stackhouse LL, Davis EG (1990) Disseminated geotrichosis in two dogs. *J Am Vet Med Assoc* 197(3):358–360
- Robinson WF, Connole MD, King TJ, Pitt JI, Moss SM (2000) Systemic mycosis due to *Aspergillus deflectus* in a dog. *Aust Vet J* 78(9):600–602
- Rossi CN, Odaguiiri J, Larsson CE (2013) Retrospective assessment of the treatment of sporotrichosis in cats and dogs using itraconazole. *Acta Sci Vet* 41(1):1–5
- Rothenburg LS, Snider TA, Wilson A, Confer AW, Ramachandran A, Mani R, Rizzi T, Nafe L (2017) Disseminated phaeohyphomycosis in a dog. *Med Mycol Case Rep* 15:28–32

- Rubin SI, Krawiec DR, Gelberg H, Shanks RD (1989) Nephrotoxicity of amphotericin B in dogs: a comparison of two methods of administration. *Can J Vet Res* 53(1):23
- Rudmann DG, Coolman BR, Perez CM, Glickman LT (1992) Evaluation of risk factors for blastomycosis in dogs: 857 cases (1980–1990). *J Am Vet Med Assoc* 201(11):1754–1759
- Sakai MR, May ER, Imerman PM, Felz C, Day TA, Carlson SA, Noxon JO (2011) Terbinafine pharmacokinetics after single dose oral administration in the dog. *Vet Dermatol* 22(6):528–534
- Sanford SE, Straube U (1991) Disseminated histoplasmosis in a young dog. *Can Vet J* 32:692
- Saunders JH, Clercx C, Snaps FR, Sullivan M, Duchateau L, van Bree HJ, Dondelinger RE (2004) Radiographic, magnetic resonance imaging, computed tomographic, and rhinoscopic features of nasal aspergillosis in dogs. *J Am Vet Med Assoc* 225(11):1703–1712
- Schmiedt C, Kellum H, Legendre AM, Gompf RE, Bright JM, Houle CD, Schutten M, Stepien R (2006) Cardiovascular involvement in 8 dogs with blastomyces dermatitidis infection. *J Vet Intern Med* 20(6):1351–1354
- Schroeder H, Jardine JE, Davis V (1994) Systemic phaeohyphomycosis caused by *Xylohypha bantiana* in a dog. *J S Afr Vet Assoc* 65(4):175–178
- Schubach TM, Schubach A, Okamoto T, Barros MB, Figueiredo FB, Cuzzi T, Pereira SA, Dos Santos IB, Almeida Paes RD, Paes Leme LR, Wanke B (2006) *Canine sporotrichosis* in Rio de Janeiro, Brazil: clinical presentation, laboratory diagnosis and therapeutic response in 44 cases (1998–2003). *Med Mycol J* 44(1):87–92
- Schuller S, Clercx C (2007) Long-term outcomes in dogs with sinonasal aspergillosis treated with intranasal infusions of enilconazole. *J Am Anim Hosp Assoc* 43:33–38
- Schulman RL, McKiernan BC, Schaeffer DJ (1999) Use of corticosteroids for treating dogs with airway obstruction secondary to hilar lymphadenopathy caused by chronic histoplasmosis 16 cases (1979–1997). *J Am Vet Med Assoc* 214:1345–1348
- Schultz RM, Johnson EG, Wisner ER, Brown NA, Byrne BA, Sykes JE (2008) Clinicopathologic and diagnostic imaging characteristics of systemic aspergillosis in 30 dogs. *J Vet Intern Med* 22:851–859
- Schumacher LL, Love BC, Ferrell M, DeSilva U, Fernando R, Ritchey JW (2013) Canine intestinal histoplasmosis containing hyphal forms. *J Vet Diagnostic Investig* 25:304–307
- Schwartz IS (2017) Blastomycosis in mammals. In: *Emerging and epizootic fungal infections in animals, Medical microbiology*, pp 159–176
- Selby LA, Becker SV, Hayes HW (1981) Epidemiologic risk factors associated with canine systemic mycoses. *Am J Epidemiol* 113:133–139
- Seyedmousavi S, Guillot J, Arné P, de Hoog GS, Mouton JW, Melchers WJ, Verweij PE (2015) *Aspergillus* and aspergilloses in wild and domestic animals: a global health concern with parallels to human disease. *Med Mycol J* 53(8):765–797
- Sfakianakis A, Krasagakis K, Stefanidou M, Maraki S, Koutsopoulos A, Kofteridis D, Tosca A (2007) Invasive cutaneous infection with *Geotrichum candidum*—sequential treatment with amphotericin B and voriconazole. *Med Mycol J* 45(1):81–84
- Sharman MJ, Mansfield CS (2012) Sinonasal aspergillosis in dogs: a review. *J Small Anim Pract* 53(8):434–444
- Sharp NJH, Sullivan M, Harvey CE (1993) Treatment of canine nasal aspergillosis with enilconazole. *J Vet Intern Med* 7:40–43
- Sidhu RK, Singh KB, Jand SK, Joshi DV (1993) Cutaneous geotrichosis in a dog and its handler a case report. *Indian J Anim Res* 32(1):75
- Singh K, Flood J, Welsh RD, Wyckoff JH, Snider TA, Sutton DA (2006) Fatal systemic phaeohyphomycosis caused by *Ochroconis gallopavum* in a dog (*Canis familiaris*). *Vet Pathol* 43(6):988–992
- Sinha A, Phukan JP, Bandyopadhyay G, Sengupta S, Bose K, Mondal RK, Choudhuri MK (2012) Clinicopathological study of rhinosporidiosis with special reference to cytodagnosis. *J Cytol* 29(4):246–249
- Sissener TR, Bacon NJ, Friend E, Anderson DM, White RAS (2006) Combined clotrimazole irrigation and depot therapy for canine nasal aspergillosis. *J Small Anim Pract* 47(6):312–315

- Southard C (1987) Bronchopulmonary aspergillosis in a dog. *J Am Vet Med Assoc* 190:875–877
- Spector D, Legendre AM, Wheat J, Bemis D, Rohrbach B, Taboada J, Durkin M (2008) Antigen and antibody testing for the diagnosis of blastomycosis in dogs. *J Vet Intern Med* 22:839–843
- Sumithra TG, Chaturvedi VK, Rai AK, Sunita SC, Siju SJ, Remya V, Susan C (2013) A review and update on canine and feline histoplasmosis. *Asian J Anim Sci* 1:14–26
- Swift IM, Griffin A, Shipstone MA (2006) Successful treatment of disseminated cutaneous phaeo-hyphomycosis in a dog. *Aust Vet J* 84(12):431–435
- Sykes JE, Torres SM, Armstrong PJ, Lindeman CJ (2001) Itraconazole for treatment of sporotrichosis in a dog residing on a Christmas tree farm. *J Am Vet Med Assoc* 218(9):1440–1421
- Taylor AR, Young BD, Levine GJ, Eden K, Corapi W, Rossmeisl JH Jr, Levine JM (2015) Clinical features and magnetic resonance imaging findings in 7 dogs with central nervous system aspergillosis. *J Vet Intern Med* 29(6):1556–1563
- Totten AK, Ridgway MD, Sauberli DS (2011) *Blastomyces dermatitidis* prostatic and testicular infection in eight dogs (1992–2005). *J Am Anim Hosp Assoc* 47(6):413–418
- Tyre E, Eisenbart D, Foley P, Burton S (2007) Histoplasmosis in a dog from New Brunswick. *Can Vet J* 48:734–736
- Valdes ID, van den Berg J, Haagsman A, Escobar N, Meis JF, Hagen F, Haas PJ, Houbbraken J, Wösten H, de Cock H (2018) Comparative genotyping and phenotyping of *Aspergillus fumigatus* isolates from humans, dogs and the environment. *BMC Microbiol* 18(1):118
- Viana PG, Figueiredo A, Gremião I, de Miranda L, da Silva Antonio IM, Boechat JS, de Sá Machado AC, de Oliveira M, Pereira SA (2018) Successful treatment of canine sporotrichosis with terbinafine: case reports and literature review. *Mycopathologia* 183(2):471–478
- Vieson MD, Piñeyro P, LeRoith T (2012) A review of the pathology and treatment of canine respiratory infections. *Vet Med* 3:25–39
- Wallin LL, Coleman GD, Froeling J, Parker GA (2001) Rhinosporidiosis in a domestic cat. *Med Mycol J* 39(1):139–141
- Waurzyniak BJ, Hoover JP, Clinkenbeard KD, Welsh RD (1992) Dual systemic mycosis caused by *Bipolaris spicifera* and *Torulopsis glabrata* in a dog. *Vet Pathol* 29(6):566–569
- Wheat LJ (2003) Current diagnosis of histoplasmosis. *Trends Microbiol* 11:488–494
- Whitley NT, Cauvin A, Burton C, Bray J, Van Dongen P, Littlewood J (2010) Long term survival in two German shepherd dogs with *Aspergillus*-associated cavitary pulmonary lesions. *J Small Anim Pract* 51(10):561–561
- Whittemore JC, Webb CB (2007) Successful treatment of nasal sporotrichosis in a dog. *Can Vet J* 48(4):411–414
- Wiebe V, Karriker M (2005) Therapy of systemic fungal infections: a pharmacologic perspective. *Clin Tech Small Anim Pract* 20(4):250–257
- Yang W, Jones BR, Rossi G, Stephens N, Arthur I, Merritt A, Reese S, Langner K (2020) First case of a dog infected with *Aspergillus* (Phialosimplex) *caninus* in Australasia. *N Z Vet J* 68(4):231–237
- Yildiz K, Dokuzeylül B, Ulgen S, Or ME (2016) Blastomycosis: a systematical review. *Res Rev J Vet Sci* 2(1):84–88
- Zhang S, Corapi W, Quist E, Griffin S, Zhang M (2012) *Aspergillus versicolor*, a new causative agent of canine disseminated aspergillosis. *J Clin Microbiol* 50(1):187–191

Chapter 9

Improving Animal Immunity to Prevent Fungal Infections with Folk Remedies and Advanced Medicine



Amro Abd Al Fattah Amara

Abbreviations

ABPA	Allergic bronchopulmonary aspergillosis
ALS	Agglutinin-like sequence
CTL	Cytotoxic T lymphocytes
EC	Epithelial cells
IPA	invasive pulmonary aspergillosis
MHC	Major histocompatibility complex
NET	Neutrophil extracellular traps
NK	Natural killer
PAMP	Pathogen-associated molecular patterns
PBMC	Peripheral blood mononuclear cells
PRR	Pattern recognition receptors
TLR	Toll-like receptors

9.1 Introduction

Humans have historically taken great care of their animals, whether livestock or domestic—sometimes reaching a degree of sanctification. The pharaohs embalmed animals, believing they will accompany them in their next lifetime or return to life after death. Others believed animals to have the souls of their ancestors, who had returned to the worldly life as animals.

When animals reproduce, their offspring may have characteristics that are favored by humans and their local environment. Throughout history, human have

A. A. A. F. Amara (✉)

Protein Research Department, Genetic Engineering, and Biotechnology Research Institute,
City of Scientific Research and Technological Applications, Universities and Research Center
District, New Borg El-Arab, Alexandria, Egypt

© Springer Nature Switzerland AG 2021

A. Gupta, N. Pratap Singh (eds.), *Fungal Diseases in Animals*, Fungal Biology,
https://doi.org/10.1007/978-3-030-69507-1_9

127

chosen the most substantial and suitable animals for their environments. Calm-tempered animals were raised domestically, while aggressive ones were used for protection or in military actions. Humans have discovered that hereditary traits, and even sensory and moral qualities, are transmitted through heredity. An example of that is the Arabian horse, which is treated with great respect that has contributed to strains that are physically strong with the ability to withstand infections.

9.2 Nature Preserves Genes

When humans select animals based on their future characteristic, it is a simulation of what takes place naturally. Carnivores select old and weak animals to feed. Only strong males and females remain and reproduce. These natural or human-directed selections are one of many factors that help with resistance against pathogens and diseases, including fungal infections.

Fungal diseases were found to have three principal causes. The first reason is the exposure of a healthy animal to unfavorable conditions that lead to an infection. Such a case can be easily treated. Secondly, an animal's health may deteriorate to make them susceptible to a fungal infection. Health degeneration could be due to poor living conditions, bad food, genetic disease, or a particular infection. In this case, the treatment is complicated and the defect in the animal's body must be corrected, if possible; then, the fungal infection can be controlled. Third, conversely, healthy animal in a healthy environment may become susceptible to fungal infection, which indicates a hidden agent, such as a toxin in food. A fungal infection is an early warning sign for the presence of such toxins. The animal may have consumed food or crops containing materials that are harmful to the liver. After a time, this deteriorates the liver's function and leads to poor health of the animal, causing fungal infection.

By observing these fungal infections and searching for the real reason(s) for transforming the animal from resistant to suitable, many diseases (including fungal infections) can be controlled. Those who are not able to distinguish between the various causative agents of fungal infections may not be able to control them. Prolonged medical treatment also contributes to an animal's health deterioration. Fungal infections are based on both the animal's health and the environment where it resides. Most farmers can distinguish between the three general causes of fungal infections.

9.3 Why Fungi Are Different

Fungi include yeasts, rusts, smuts, mildews, molds, mushrooms, and toadstools. Fungi are eukaryotes that lack chlorophyll; they contain a nucleus, vacuoles, and mitochondria. They are approximately 80,000 recognized species in the kingdom.

Fungi are among the most widely distributed organisms on Earth and are of environmental and medical importance. Many fungi are free living in soil or water; others form parasitic or symbiotic relationships with plants or animals. The fungi can be distinguished from all other living organisms, including animals, by their principal modes of vegetative growth and nutrient uptake.

Fungi grow from the tips of filaments (hyphae) that make up the bodies of the organisms (mycelia). They digest organic matter externally before absorbing it into their mycelia. Fungi are everywhere in large numbers in the soil and the air; in lakes, rivers, and seas; on and in plants and animals; in food and clothing; and in the human body. With bacteria, fungi break down organic matter and release carbon, oxygen, nitrogen, and phosphorus into the soil and the atmosphere. Based on their structure and life cycle, they can be classified into five groups: Ascomycetes, Basidiomycetes, Zygomycetes, Oomycetes, and Deuteromycetes. The last group's hypha is septate, and thus there is no sexual spore (Hedayati et al. 2007). Fungal infections include ringworm, athlete's foot, and other dermatomycoses.

9.3.1 Fungal Cell Wall

The fungal cell wall generally consists mainly of chitin, which is a polysaccharide composed of long chains of N'-acetyl glucosamine (Duan et al. 2020; Huang and Huang 2019; Junior et al. 2019; Pathaw et al. 2020; Xie et al. 2012). The fungal cell wall contains other polysaccharides, the most significant of which is β -glucan; this is the site of action of the antifungal drug caspofungin (2001; Agarwal et al. 2006; Al-Baqsmi et al. 2020; Alam et al. 2012; Alonso et al. 2009; Bohme et al. 2009; Bortolus et al. 2019), a long polymer of D-glucose (not peptidoglycan as in bacteria) (Jawhara 2020). Fungi are insensitive to antibiotics, such as penicillin, which inhibit peptidoglycan synthesis. The fungal cell membrane contains ergosterol (Ahmad et al. 2018; Alcazar-Fuoli et al. 2006; Andrade-Pavon et al. 2019; Cai et al. 2016; Chaudhari et al. 2018; Datry et al. 2001; do Nascimento et al. 2018), in contrast to the human cell membrane, which contains transports cholesterol.

Each fungal species has unique glycan (Jawhara 2020), polymers, and proteins, interconnected to each other in the cell wall. Cell wall proteins are highly glycosylated and have negatively charged phosphate groups in their carbohydrate side chains, which impress the electrostatic charge. The selective action of amphotericin B (Abrahamsen et al. 1992; Adams et al. 2008; Albengres et al. 1998; Alcazar-Fuoli et al. 2006; Perumal et al. 2007; Sar et al. 2006) and azole drugs (Abraham and Vas 1990; Abrahamsen et al. 1992; Al-Marzouqi et al. 2009; Arthur et al. 2004), such as fluconazole (Al-Marzouqi et al. 2009; Alcazar-Fuoli et al. 2006) and ketoconazole (Korting and Schollmann 2009; Moran et al. 1997; Saini et al. 2005; Shindo 1990; von Paleske et al. 1987), on fungi is based on this difference in membrane sterols (Lemos et al. 2020; Shing et al. 2020; St Georgiev 2000).

9.3.2 Fungal Toxins and Allergic Responses

The best-known mycotoxicosis occurs after eating *Amanita* mushrooms. These fungi produce five toxins, two of which (amanitin and phalloidin) are among the most potent hepatotoxins. The toxicity of amanitin is based on its ability to inhibit cellular RNA polymerase, which prevents mRNA synthesis. Another mycotoxicosis, ergotism, is caused by the mold *Oaviceps purpurea*, which infects grains and produces alkaloids (e.g., ergotamine and lysergic acid diethylamide [LSD]) that cause pronounced vascular and neurologic effects. Other ingested toxins, aflatoxins, are coumarin derivatives. *A. flavus* is a common species of the Deuteromycetes group. *A. flavus* is also characterized by its ability to produce mycotoxins, a large and diverse group of fungal exotoxins. It commonly grows on improperly stored food, such as grain. The toxins produced by *A. flavus* are known as aflatoxins. Aflatoxins are highly toxic and induce tumors in some animals, especially in birds that feed on contaminated grain. They cause liver damage and tumors in animals and hepatic carcinoma in humans (Hedayati et al. 2007). Aflatoxins are ingested with spoiled grains and peanuts and are metabolized by the liver to the epoxide, a potent carcinogen. Aflatoxin B₁ induces a mutation in the *p*⁵³ tumor suppressor gene, leading to a loss of p⁵³ protein and a consequent loss of development control in the hepatocyte.

Hypersensitive responses to fungal spores, particularly those of *Aspergillus*, manifest mainly an asthmatic reaction (rapid bronchoconstriction mediated by immunoglobulin E), eosinophilia.

9.4 Fungal Therapy

The drugs used to treat bacterial diseases have no effect on fungal diseases. The most effective antifungal drugs, amphotericin B and the various azoles, exploit ergosterol in fungal cell membranes that is not found in bacterial or human cell membranes. Amphotericin B (Fungizone) disrupts fungal cell membranes at the site of ergosterol. The selective toxicity of amphotericin B and the azole group of drugs is in contrast to the cholesterol found in human cell membranes and the absence of sterols in bacterial cell membranes. Azole drugs, such as itraconazole, fluconazole, and ketoconazole, inhibit the synthesis of ergosterol. The selective toxicity of echinocandins, such as caspofungin, is based on a cell wall in fungi and inhibits the synthesis of β -glucan, which is found in fungal cell walls but not in bacterial cell walls. Human and animal cells do not possess a cell wall. Echinocandins inhibit the synthesis of D-glucan, which is a constituent of the fungal cell wall.

9.5 Fungal Entry to Host

Fungi have hydrophobic cell surfaces, which is important for adherence to biomaterials. Similarly, the development of the fungus into the host implies continuous biosynthesis and remodeling of their cell wall (Mora-Montes 2020). Pathogenic fungi are able to invade the host at different morphologies. Several medically important fungi are thermally dimorphic. They form unique structures at different temperatures. They exist as molds in the environment at ambient temperatures and as yeasts (or other structures) in human tissues at body temperature (Casaroto et al. 2019; Childers et al. 2019). Most fungi are obligate aerobes, few are facultative anaerobes, and none are obligate anaerobes. All fungi require an organic source of carbon, hence their frequent association with decaying matter.

9.5.1 Fungi Infiltration to the Epithelial Surfaces

Fungi have a flexible genetic element that helps them to adapt the different fluctuating parameters (Childers et al. 2020; Dominguez-Andres et al. 2019). The conversion from a saprophytic lifestyle to pathogens of humans or animals activate different genes and sensors. The various immune cells are the major antagonists to the survival of fungal pathogens. Ambient temperature is suddenly replaced with the restrictively high temperature of the human body. Ambient pH is replaced with acidic mucosal surfaces or neutral blood and tissues. Familiar sources of carbon and metal ions are missing in an environment where essential nutrients are sequestered from microbes to support host survival. Carbon dioxide and oxygen concentrations are reversed in host tissues, leaving fungi to cope with hypoxia and high levels of carbon dioxide (Tronchin et al. 2008).

In that respect, there are different rates of fungal entry into the bodies of animals and humans. Accidental skin infiltration (i.e., the host's passive barriers are breached traumatically) through clinically implanted medical devices, such as central venous catheters, offer an entry point for microbial seepage through a gap in the epithelial surface. Formation of an overlying biofilm may shield the embedded *Candida spp.* from therapeutic levels of antifungal medications (Nobile and Mitchell 2007). Epithelial cells have two general types, keratinized and nonkeratinized, and their vulnerability to fungal invasion differs. Only dermatophytes can break down the intact, dry, keratinized epidermis: other fungal pathogens rely on their content to penetrate epithelia that is rich in keratin, or that occlusion or maceration have weakened. For fungi that normally live in the gastrointestinal tract, the process of persorption may cause the gratuitous uptake of infective propagules into the bloodstream. *Aspergillus spp.*, *Cryptococcus neoformans*, Zygomycetes such as *Mucor* and *Rhizopus spp.*, and the dimorphic fungi *Blastomyces dermatitidis*, *Coccidioides immitis*, *Histoplasma capsulatum*, and *Paracoccidioides brasiliensis*

all normally gain access to the host through inhalation and all can potentially invade beyond the respiratory tract (Mendes-Giannini et al. 2000; Tronchin et al. 2008).

9.5.2 Fungal Attachment

A successful pathogen is one that can survive and evade detection by the host's innate immune defense (Kirkland and Fierer 2020). Fungal pathogens have adopted tactics that avoid host defense and later cause disease in at-risk patients. The anatomy and composition of the skin and mucous membranes provide a strong defense line to any microbial invasion. Fungal pathogens display a broad range of adhesions that are expressed at their surface. When introduced into the host, they can then adhere to a large variety of cell types and interact with many ligands present in various host sites, such as biological fluids, extracellular matrixes, or basement membranes. Attachment of conidia to the epithelial cells or to the underlying basement membrane was thought to play a crucial part in establishing the fungus and starting the disease in a receptive host. *Aspergillus fumigatus* has virulence factors, such as proteolytic enzymes, phospholipases, catalases, superoxide dismutases, and non-ribosomal peptide synthases involved in the synthesis of hydroxamate siderophores necessary for iron uptake. The interaction with plasma or extracellular matrix proteins was extensively investigated, but non-specific interactions also seem to contribute to adherence (Bouchara et al. 1999; Latge and Calderone 2002). *Candida spp.* expresses adhesions that are attachment factors, surface proteins. They are covalently linked to the β -glucan of the cell wall. Adhesions include the agglutinin-like sequence (ALS) protein and hyphal wall protein-1 (HWP1). They play a role in biofilm formation by helping cell-to-surface and cell-to-cell adherence (Nobile et al. 2006a; Nobile et al. 2006b).

9.6 The Efficacy of the Immune System

Traditional medicine does not directly discuss the immunity, but it describes an alternative term. Thus, there is an understanding of the differences between immunologically based good health and poor health. In Egypt, animal with health issues but without apparent symptoms of a known illness were called *ghasha*, which can be translated to “compromised.” The Egyptians correlated that to an issue with the animal's liver.

9.6.1 Folk Practices

9.6.1.1 Reactivating Animal Health

In Egypt, animals that showed the behavior of *ghasha* were treated by two particular methods: shocking the animal with a heated iron in a particular area or inserting cotton tissue under the animal's skin using a heated needle to burn pores into the skin, after which the skin is pulled and the tissue is passed from one pore to the other. Inserting this cotton tissue caused pus to be secreted in large amounts. After some weeks, the tissue was removed and usually there was positive progress in the animal's health. The process has been used by farmers in Egypt since ancient times (Fig. 9.1).



Fig. 9.1 Egyptian methods widely used by farmers to treat compromised animals and restart the immune system: (a) compromised buffalo, (b) fire ashes, (c) iron needle during its heating, (d) treating the animal with the heated iron needle, (e) two neighboring pores are formed to pass cotton tissue between, (f) another location prepared for the same process

9.6.2 Infection, Susceptibility, or Both

Microbes play key roles in the equilibrium of the land ecosystem. Many of them are hydrocarbon-degrading microbes. Hydrocarbons are the main origin of foods and energy. The microbes consider the body only as a movable mass of hydrocarbons, but these masses are protected physically and immunologically from a microbial attack. However, when there is a weakness in the immune system, microbes of different types start to attack humans and animals directly. They do their work spontaneously, only under the control of the surrounding biological, chemical, and physical factors. Opportunistic pathogens are nothing but microbes with extra degradation power—unable to harm when the body is healthy, but they can take advantage when the immune system is compromised (Du et al. 2020).

9.6.2.1 Turning the Opportunistic Pathogens into Lazy Microbes

Opportunistic infection is any infection caused by a microorganism that rarely causes disease in humans; it occurs in individuals with abnormally operating immune systems. Opportunistic pathogens may exist peacefully with us, but then suddenly attack us when the body has a weakness that invites them to perform.

9.6.2.2 Put Sugar Between Your Toes

Humans have long understood methods for keeping opportunistic pathogens calm. For example, in a simple Egyptian practice, individuals with bad foot odor were advised to put sugar between their toes just before sleep. *Candida albicans* and other pathogens prefer sugar to humans and would thus stop attacking human tissue. While they are happy with the sugar (and any useful natural beneficial microflora would be happy too), the tissue has time to rebuild itself and protect the body from the pathogens. Again, just water and our natural flora (i.e., normal hygiene practices) will be enough. This case is presented to highlight approaches aside from typical antimicrobial treatment that help in the recovery from fungal diseases. These simple treatments can be attempted before moving on to the more complicated ones.

9.6.2.3 The Fungal Smart Invasion

Opportunistic pathogens are early biological indicators that the immune system has a problem (Amara 2011). They should attract attention, including from scientists. Virulent fungal infections should be treated with a fast and serious response. However, slow infections should not be ignored. Ignored treatment due to unapparent illness might cause an acute infection. Any fungal infection should be considered as

a problematic disease because some infections grow by a rate compatible with the reduction in our immune capacity—a type of smart invasion. The quality of our immunity usually declines at a slow rate, normally due to certain health problem in our bodies. In contrast, a fungal infection for an immunocompetent individual shows a fast rate of symptoms but without real defense (Tronchin et al. 2008). Our understanding of the immune system/fungal relationship will help in the control, prevention, and treatment of fungal infections. Immune response at the mucosal sites is essential and preferred for the clearance of the infection and long-term protection.

9.6.3 Interactions Between Fungal Pathogens and the Immune System

1. All fungi and other microbes, even those who are friendly to us, are foreigners to our body. They could exist as microflora in superficial colonization forms. Even so, they will be attacked by the immune system if they are introduced to the body tissue or blood.
2. Fungi are exceptional microbes that could trick the immune system and invade our tissue. They are capable of slow, smart invasion and can trick both our observations and our immune system. Late treatment is usually difficult because fungi deeply invade the tissues (Tronchin et al. 2008).
3. Microflora can inhibit the development of pathogenic microbes, including fungi, by filling in any suitable place for settlement and by producing inhibitors for the pathogenic microbes. Continuous exposure to chemical factors such as detergent, alcohols, disinfectants, or perfumes can be a cause. Superficial exposure to antimicrobial agents is helpful for the pathogens. Particularly those microbes that remark such hydrocarbons antimicrobial agents as food, so they survive and become dominant while our microflora did not. Our microflora is a part of our body's defense (immune) mechanism. Thus, it is important to rebuild the microflora after losing it.
4. The body is a connected system. Deterioration (by physical, chemical, or biological factors) in any part of it will affect the other parts and make it susceptible to microbial infections.
5. Few fungal species are considered to be microflora, but the numbers are huge in the surrounding environment. They are ready to attack when they have a chance.
6. Creatures are created resistant to fungal infections. For some microbes, the various creatures are just a food either contain an antimicrobial agent or not.
7. Most fungi are hydrocarbon-degrading organisms, so most disinfectants are just food for them.
8. Opportunistic pathogens are mostly part of our microflora; however, if our immune system becomes weak (by whatever means), they attack us.

9. Pathogenic fungi are characterized by the number of virulence factors they experience.
10. Treatment of a fungus infection can be tricky. The treatment components might affect the body or cause more virulent mutants. Fungal treatment is immunologically based. The best antifungal agents either improve the immune system or maintain it as it is (Tronchin et al. 2008).
11. Microbes can weaken the immune system.
12. Microbes of different sizes cause different immune responses.
13. Dead fungi can activate the immune system and cause natural immunization upon their entry to our body. Some fungal infections/or dead fungi can protect against others, whereas weakened or attenuated fungi can facilitate the control of virulent ones. Scientists should use immunological tactics that have demonstrated success with bacteria and viruses because the immune system can be directed smartly or aggressively to offer full protection. Our understanding of case-by-case microbial and fungal treatments will aid in their control (Hussain and Amara 2006).
14. Some folk remedies and natural products have proven efficacy and should not be overlooked. Some cannot be explained scientifically right now, but future research should provide answers.

9.6.4 Infection or Susceptibility, which one is more climed?

Before the invention of the microscope, humans had some knowledge about these diseases. Ancient texts describe the transmission of diseases between animal/human, animal/animal, and human/human. Orders were issued for people to entirely avoid the movement of both animals and humans from an epidemic location to some other area. The word “infection” was identified clearly in old Arabic books written nearly 1400 years ago—and may have been used earlier in oral communication.

Indeed, the concept of infection was known, but what about susceptibility? How do microbes become suddenly active? In an open, clean area with low biodiversity, such as the desert, the emergence of an infection should raise questions. Research concerning *Pseudomonas aeruginosa*, the most famous opportunistic bacteria, has provided some answers (Amara 2011; Hussain and Amara 2006). However, even in highly sanitized area, fatal diseases can emerge when bodies either lack immunity or have not developed gradual resistance. In these cases, diseases may become more fatal and more aggressive. In other words, what causes an infection for some people will not affect others. Hence, there is a need to reevaluate our understanding of the contagion.

The immune memory should be built smartly, as it needed to be ready for defense against moderate versions of the contagion (which were created to build better defense against the strong ones). For example, contact with cows can lead to a cowpox infection, which protects against smallpox, a fatal disease. In another example, hens were subjected to continous lights and feed and isolated in a sanitized

condition, and protected with antibiotics, they build, approximately no resistance to infections. A farm containing 5000 hens could lose more than 70% of its number if a particular disease is transmitted (personal communication). In contrast the old farming process seldom faces such loss.

To simplify the contrast between infection and susceptibility, consider twins living in the same home: tooth plaque could occur in one but not the other. Twins who are genetically identical, live in the same home, and eat together should be identical in their susceptibility to diseases; however, only one may plaque because that twin did not brush his teeth after consuming sugary food (personal observation).

9.6.5 Immunity Building

The immune system possesses a memory for an infective disease. Thus, a pathogen may not seriously affect an animal who has a second infection from the same disease. Mammals have cross-protection between infections independently of T and B cells, and more recently memory properties of NK (natural killer) cells and macrophages, which are prototypical cells of innate immunity (Drummond et al. 2014; Netea et al. 2011). Monocytes stimulated in vitro with β -glucans, a component of fungal cell walls, were demonstrated to protect animals deficient in an adaptive immune system against lethal systemic candidiasis infections; this protection was attributed to epigenetic reprogramming (Netea 2013).

9.7 Folk Remedies for Animal Immunizations

9.7.1 Save the Young Turkeys

Egyptians have traditionally used a unique practice to raise turkeys. Young turkeys usually died in the Egyptian environment if not fed after their hatching with a mix of egg, cheese, and *Allium porrum*, a traditional folk mixture. The reason for the deaths of young turkeys is not known to farmers, and I do not know the source of this recipe, which was used in the village of my father. Recently, a more simple protein than the egg white lysozyme was used to investigate the power of cell wall degrading enzymes in bacterial ghost formation (Amara 2015a; Amara 2016b; Amara 2018; Amara et al. 2013a, b). The powerful force of the lysozyme on different microbes indicates that it is a universal cell wall degrading enzyme, explaining why egg was one component of this concoction. *Allium porrum* is rich in antimicrobial agents, which increases the chance of survival. Cheese is rich in probiotics, which aids in the immunity and in the digestion of the young turkeys. Thus, this could be one of the earliest primitive immunization tools.

9.7.2 *The immunized Hen*

Re-infection results in a memory of the previous infection, allowing antibodies to defend against them both. A third infection could have some antigens similar to the previous two. However, a third infection could be lethal for a hen that was not infected earlier, which could explain the response differences to epidemic diseases globally. Natural selection plays a big role in protection, protecting conservancy of the inherited components. Nevertheless, natural selection will remove any weak or sick animals.

9.8 Innate Immunity

The skin and mucosal surfaces act as physical barriers between the environment and deep tissues. Most cell types described previously are found in abundance in barrier tissues and are important in surveillance, maintaining commensal relationships, and providing protection from invasion (Drummond et al. 2014; Garcia-Carnero et al. 2020).

9.8.1 *A. Sites Contributing to the Innate Immune System*

9.8.1.1 Skin

Human skin is readily colonized by fungi, predominantly *Malassezia spp.* (Findley et al. 2013). Skin-resident dendritic cells (DCs) are easily positioned to encounter cutaneous pathogens and are needed for the installation of adaptive immune reactions. *Malassezia* is a pathogenic yeast that is associated with exacerbation of various skin diseases, including atopic eczema and atopic dermatitis (AD), in which barrier function and immune regulation are compromised (Saunders et al. 2012). *Malassezia*-derived products were proven to influence host responses, including generating cross-reactive T cells that exacerbated AD, down-regulation of human DC maturation, and proinflammatory cytokine production (Vlachos et al. 2012). *C. albicans* infections of the skin were recently shown to be controlled by different DC subsets resident in the skin, LC and Langerin⁺ dermal DCs, which were each responsible for driving Th17 and Th1 adaptive immunity, respectively (Drummond et al. 2014; Igyarto et al. 2011).

9.8.1.2 Respiratory Tract

Aspiration is a common route of exposure to fungal spores that could cause invasive pulmonary aspergillosis (IPA) and other disease, as well as sensitization and exacerbation of allergic reaction and asthma. Allergic bronchopulmonary aspergillosis (ABPA) is a hypersensitivity disorder to *A. fumigatus*, leading to serious asthma symptoms and affecting nearly 5 million people worldwide (Agarwal et al. 2013; Drummond et al. 2014).

9.8.1.3 Genital-Urinary Tract

The most common fungal pathogens colonizing the genital-urinary tract are *C. albicans* (Jaeger et al. 2013) and *Vulvovaginal candidiasis* (Jaeger et al. 2013). It is yet unclear why vaginal candidiasis occurs more frequently in some individuals. Animals deficient in IDO1, an enzyme promoting tolerant T-cell responses and producing tolerogenic kynurenines, were recorded to have increased susceptibility to *V. candidiasis*; treatment with kynurenines could ease disease (De Luca et al. 2013; Drummond et al. 2014).

9.8.2 Cell Barriers

9.8.2.1 Epithelial Cells

Epithelial cells (ECs) are the first point of contact with microbes. Although not characteristically considered immune cells, there are several examples of ECs contributing to the innate immune response, primarily through producing chemokines, such as interleukin (IL)-8. Corneal and bronchial ECs both produce inflammatory cytokines in response to *A. fumigatus* (Guo and Wu 2009). Mechanisms driving EC chemokine production were stimulated with antimicrobial peptides (Drummond et al. 2014; Wagener et al. 2013).

9.8.2.2 Immune Cells

Cells that are part of the innate immune system are characterized by inherited receptors with broad specificity and a rapid response time. Several cell populations contribute to antifungal responses. Predominant cell types used for antifungal defense include neutrophils, macrophages, DCs, NK cells, innate-like lymphocytes, and ECs.

9.8.2.3 Neutrophils

Neutrophils are highly phagocytic granulocytic polymorphonuclear cells. Neutrophils kill pathogens by producing reactive oxygen species, which kill phagocytosed microbes. Mice deficient in the neutrophil granule serine proteases elastase and/or cathepsin G are susceptible to fungal infections.

9.8.2.4 Monocytes/Macrophages

Monocytes and macrophages are Phagocytes family members. Phagocytes are large white cells that can swallow and digest microbes and other foreign particles. Monocytes are bloodborne cells circulating in the blood that differentiate into macrophages in tissues, which they infiltrate following an inflammatory signal. Monocytes produce chemical signals named monokines that are involved in the immune responses (Brummer et al. 1999; Dotis et al. 2008; Roilides et al. 1994, 1999; Wildfeuer et al. 1990, 1992). On their migration to the tissue, they become macrophages specialized in the tissue where they exist. Such tissues include lungs, kidneys, brain, and liver. Once in tissues, monocytes are differentiated to become macrophages, which further develop into a distinct functional phenotype, which is influenced by the cytokine milieu. Proinflammatory cytokines, particularly interferon γ (IFN- γ), drive a classically activated (M1) phenotype. The anti-inflammatory cytokines (such as TGF- β) drive otherwise activated (M2) macrophages. Different homeostatic activities include host defense, wound healing, and immune regulation (Mosser and Edwards 2008). The macrophage phenotype can have a profound effect on antifungal immunity. The immunity to pathogens requires pattern recognition receptors (PRRs) to trigger intracellular signaling cascades that start and direct innate and adaptive immune reactions (Drummond et al. 2014).

9.8.2.5 DCs

DCs are important innate cells involved in initiating immune responses and generating adaptive immunity via antigen presentation. DCs have attracted specific attention in their potential as effective targets for novel therapeutic and vaccine strategies. Plasmacytoid dendritic cells (pDCs), typically considered as antiviral cells, may be a protective part of pulmonary fungal pathogens. Animals resistant to *P. brasiliensis* infection were shown to get a mixed lung DC population, including pDCs, which susceptible mice lacked (Drummond et al. 2014; Pina et al. 2013).

9.8.2.6 NK Cells

NK cells are a type of white blood cells or lymphocytes. Like cytotoxic T lymphocytes (CTLs), NK cells have granules containing potent chemicals. NK cells are not able to recognize major histocompatibility complex (MHC) molecules or recognize cells having missing or low MHC class I molecules. They are able to attack different types of molecules (Camilli et al. 2018; Fernandez-Ruiz et al. 2015; Safdar 2010; Schmidt et al. 2013; Voigt et al. 2013; Zhang et al. 2018). NK cells in both mice and humans were described as having antifungal activity against a range of fungi such as *C. albicans*, *A. fumigatus* (Schmidt et al. 2013), *C. neoformans* (Islam et al. 2013), *Pneumocystis murina* (Kelly et al. 2013), and *P. brasiliensis* (Longhi et al. 2012). NK cells exert their effects through the direct killing of yeast using perforin, killing infected host cells, and secreting proinflammatory cytokines (Drummond et al. 2014; Schmidt et al. 2013).

9.9 Adaptive Immunity and Fungicidal Mechanisms of White Blood Cells

9.9.1 Sites Contributing to the Adaptive Immune System

9.9.1.1 Skin

The skin contains a network of DCs that can be divided into the epidermis-associated LCs and a collection of dermis-associated dermal DCs (Henri et al. 2010). On subcutaneous injection of *B. dermatitis* as a vaccine, DEC205⁺ skin-derived DCs migrated to the draining lymph nodes in a CCR7 dependent fashion, presented (or transferred) model antigen expressed by the yeast, and activated CD4⁺ T cells (Ersland et al. 2010). Dermal DCs were shown to specialize in antigen presentation and T-cell polarization functions in a cutaneous exposure model to *C. albicans* (Igyarto et al. 2011; Verma et al. 2014).

9.9.1.2 Lung

DCs in the lungs and airways are constantly exposed to inhaled spores and hyphal fragments. A network of DCs lines the airways, sampling inhaled antigens and shuttling into the mediastinal lymph nodes. CD103⁺ DCs can acquire soluble and apoptotic-cell-associated antigens from the respiratory tract and migrate to mediastinal lymph nodes under steady-state and inflammatory conditions. At the lymph node, CD103⁺ DCs cross-present antigens and activate CTLs (Desch et al. 2011). CD11b⁺ DCs differ from monocyte-derived DCs and specialize in cytokine and chemokine production (Beaty et al. 2007), also presenting antigens to CD4⁺ T cells in the mediastinal lymph node after migration (del Rio et al. 2007). On lung

exposure to *A. fumigatus* conidia, CD103+ DCs failed to take up and transport conidia to the mediastinal lymph node, whereas CD11b + DCs did transport conidia (Hohl et al. 2009). Lung CD11b + DCs were reduced in CCR2^{-/-} mice, relative to wild-type mice, following *A. fumigatus* exposure (Verma et al. 2014).

9.9.1.3 Intestine

DCs in the intestine are on the basolateral side of the epithelium, largely isolated from the gut microflora, and localized to the lamina propria (LP-DCs) and Peyer's patch (PP-DCs); both subsets in each region differentially regulate immune responses. *C. albicans*, a gut commensal, can cause systemic infection if the gut epithelial/DC barrier is breached or in the setting of broad-spectrum antibiotic use, leading to Candida overgrowth. Potent induction of Treg cells by LP-DCs in the mesenteric lymph node highlights the role of limiting inflammation in the gut to go up the epithelial barrier and prevent disseminated infection. Furthermore, heightened Th17 responses in the gut impair protective Th1 responses and worsen Candida infection (Bruno et al. 2020; Casaroto et al. 2019; Lang et al. 2019; Zelante et al. 2007). Although bone marrow-derived DCs produce IL-23 in response to Candida in vitro and IL-23, neutralization promoted fungal clearance in vivo (Verma et al. 2014).

9.9.2 Cell-Mediated Host Response to Fungal Aggression

After the success of the fungus in bypassing the first body barriers and the various innate immune structures, it suits the role of the adaptive immunity to fight this foreigner. During the action of the natural immune system, the adaptive immunity works intensively to bring out its elements. It coordinates both systems, the innate and the adaptive immune response, to eliminate the fungal infection and to produce a memory for it. Different reactions are due to different anatomical positioning of the infections, as well as different fungus and surface marker expression. Each of the helper, regulatory, and effector T- and B-cells are responding and integrated against the fungi (Verma et al. 2014).

9.9.2.1 Characterization and Function of DC and Monocyte Subsets

When DCs encounter antigens at the boundary of immunological defense sites, such as the skin, the airways of the lung, and ordaining nodes of the lymphatic system, DCs amplify the innate immune response by secreting cytokines that recruit and activate other white blood cells. After ingestion, processing, and presentation of antigens, DCs start and shape adaptive responses by promoting naïve T-cell differentiation into effector or regulatory T cells. Since the discovery of DCs, many

subsets were identified based on anatomical location, function, and surface marker expression (Steinman et al. 1975; Steinman and Cohn 1973, 1974; Verma et al. 2014).

9.9.2.2 Plasmacytoid DCs

pDCs are characterized by interferon (IFN)- α production in response to nucleic acids sensed by endosomal TLRs. They are characterized by surface expression of sialic acid binding immunoglobulin-like lectin H (Siglec H). pDCs recognize *A. fumigatus* DNA via TLR9 (Ramirez-Ortiz et al. 2008) and inhibit *Aspergillus* growth in vitro. pDCs accumulated in the lungs in a murine model of *Aspergillus pulmonary* infection (Ramirez-Ortiz et al. 2011). Their elimination enhances progression of infection. pDCs recognize and combat fungi in vivo (Li et al. 2011). This pDC subset fails to produce IFN- α after stimulation with TLR ligands. Nevertheless, they secrete elevated levels of IL-6 and IL-23 and prime antigen-specific Th17 cells in vivo (Verma et al. 2014).

9.9.2.3 Conventional DCs

Conventional DCs or resident DCs existing in the lymphoid tissue are comprised of two main subpopulations; CD8⁺ and CD4⁺CD8⁻ resident DCs. The spleen contains a third minor population of so-called double-negative DCs, which lack CD4 and CD8 expression and appear to be mostly similar in function to CD4⁺ CD8⁻ DCs (Luber et al. 2010). DCs acquire and cross-present *Histoplasma capsulatum* antigens to CTL by ingestion of live or killed yeasts or uptake of *Histoplasma*-containing apoptotic macrophages (Lin et al. 2005). Fungal antigens can be acquired and presented by resident DCs; the resident DC subpopulation(s) involved in vivo remain undefined. DC acquisition of antigen required ferrying of yeast from the skin to the lymph node by migratory and monocyte-derived DCs. Resident DCs in the skin-draining lymph nodes acquired and displayed antigen and primed antigen-specific CD4⁺ T cells (Ersland et al. 2010; Verma et al. 2014).

9.9.2.4 Migratory DCs

Migratory DCs (or tissue DCs) are immature DCs located mainly in peripheral tissues, such as the skin, lung, and gut. Migratory DCs line the surfaces of the body exposed to the surroundings and thus encounter fungi and other pathogens and antigens. The skin, lung, and intestine DCs share similarities, but each site has functional differences that are important in antifungal immunity (Verma et al. 2014).

9.9.2.5 Monocytes, Monocyte-Derived DCs, and Inflammatory DCs

Monocytes are derived from a macrophage-DC progenitor and, in the absence of inflammation, are found in the bone marrow and circulating at low levels in the blood and spleen. Monocyte-derived DCs have an outsized role in antifungal immunity through the induction of Th1 cells. CCR2^{-/-} mice show skewed Th2 responses and poorly controlled *H. capsulatum* infection compared to wild-type mice (Szymczak and Deepe Jr. 2009). Similar CCR2-dependent phenotypes are found in experimental infection with *A. fumigatus* or *C. neoformans*; that is, priming Th1 cells in response to fungi requires CCR2⁺ monocyte-derived inflammatory DCs (Ersland et al. 2010). The tissue environment has a striking role in inflammatory DC function, as the defect in CD4 + T-cell priming by these DCs during infection with *A. fumigatus* is restricted to the lung in CCR2^{-/-} mice and not to other lymphoid organs, such as the spleen (Hohl et al. 2009). Ly6C⁺ CCR2⁺ monocytes play a major role in delivering B. dermatitidis into skin-draining lymph nodes after subcutaneous vaccination; this shuttling function can be counterbalanced by other skin migratory DC subsets in CCR2^{-/-} mice (Ersland et al. 2010; Verma et al. 2014).

9.10 Recognition, Signaling, and Other Forms of Interactions

The innate immune system is the body's first line of defense against the foreign pathogens and performs indispensable work. The ability of the pathogen to invade the human host relies on its capability to evade and circumvent host defense mechanisms. Triggering of the host defense depends on proper detection of the invading pathogen. The mechanism responsible for the recognition is regulated by host PRRs that recognize conserved pathogen-associated molecular patterns (PAMPs) expressed by microbes, but not by the host (Richardson and Smith 1981). By PRRs recognizing microbial ligands, the innate defense system is triggered. A direct antifungal response results in either a phagocytic process or secreting microbicidal compounds. Cytokine and chemokine production take off. Antigen uptake and the triggering of the adaptive immune system is induced. The role of recognizing fungal pathogens was ascribed to a major class of PRRs, the TLRs. TLRs are expressed in various immune and nonimmune cell types. In the TLR family, TLR2 and levels of antifungal medications provide a secure harbor for genetic variance to arise (Netea et al. 2006; Tada et al. 2002; Tronchin et al. 2008).

9.10.1 PRRs

The three major PAMPs that are unique to fungi and set them apart from the mammalian host are chitin, α - and β -glucans, and mannans. The induction of an immune response begins with the innate recognition of the pathogen by PRRs, which drive early protective mechanisms that are necessary for host defense. Toll-like receptors (TLRs) and CLRs are the key families involved in antifungal immunity, and animals and humans lacking signaling adaptors shared by several PRRs stand to indicate more severe phenotypes than the single PRR deficiencies (Gross et al. 2006; O'Neill et al. 2013). TLRs initiate intracellular signaling pathways using myeloid differentiation primary response protein 88 (MyD88) or TRIF adaptor proteins, which finally activate transcription factors NF- κ B and the interferon regulatory factors (O'Neill et al. 2013). MyD88-deficient mice, which have defective TLR responses from multiple family members, have shown a role for TLRs in immunity to a range of pathogenic fungi, including *C. albicans* and *C. neoformans* (Biondo et al. 2005). TLR-dependent cellular responses that promote antifungal immunity include the production of type I interferons (IFNs) (Bourgeois et al. 2011). The innate recognition of these fungal PAMPs activates signaling cascades to induce the expression of MHC, costimulatory molecules, and cytokines by APC that influence the evolution of adaptive immunity, TLR and C-type lectins (CLR). TLR1–4, 6, 7, and 9 recognize a variety of fungal species through mostly undefined ligands (Bourgeois et al. 2011). TLRs involved in sensing fungal ligands are TLR2, TLR4, and TLR9 that recognize zymosan, phospholipomannan, O-linked mannans, glucuronoxylomannan, and fungal DNA. Mice lacking the signaling adaptor Myd88 are more susceptible to infection with *C. neoformans*, *C. albicans*, *A. fumigatus*, *B. dermatitidis*, and *Paracoccidioides brasiliensis* (Wuthrich et al. 2011), emphasizing important roles for TLR signaling in antifungal immunity, but also regarding the involvement of Myd88 in IL-1 signaling (Tronchin et al. 2008).

9.10.2 Regulatory T Cells

The appropriate regulation of responses generated against invading infectious agents is necessary to limit collateral damage to the host. In murine models of fungal infections, accelerated clearance of disease is achieved by altering the Treg cell activity. In candidiasis and paracoccidioidomycosis, signaling through the Toll-like receptor TLR2 and its downstream molecule MyD88 is necessary for prolonging survival of Treg cells (Loures et al. 2009). TLR2^{-/-} mice express fewer Treg cells under homeostasis and disease states (Tronchin et al. 2008).

9.10.3 *Dectin-1*

Dectin-1 is the archetypical and best studied non-TLR PRR (antifungal CLR) shown to link innate and adaptive immunity and instruct differentiation of Th1 and Th17 cells (Rivera et al. 2011). Dectin-1 is the best-described PRR that recognizes exposed β -glucans in the cell walls of many pathogenic fungi, including *C. albicans*, *A. fumigatus*, and *Pneumocystis carinii*. Dectin-1 is expressed primarily by myeloid cells and drives complex intracellular signaling pathways (Drummond and Brown 2011; Tronchin et al. 2008).

9.10.4 *Dectin-2*

The Dectin-2 family is comprised of Dectin-2, Mincle, MCL, DCIR, DCAR, and BDCA-2. Aside from DCIR, all of the other receptors have short cytoplasmic tails that lack signaling motifs and associate with the FcR- γ chain, an adaptor containing an ITAM motif (Graham and Brown 2009). Members of the Dectin-2 family have a single carbohydrate recognition domain and lack intracellular tails with signaling motifs, although there are some members that are exceptions (e.g., DCIR) (Kerscher et al. 2013). Dectin-2 binds high mannose-containing structures; accordingly, α -mannose and amannose-rich glycoprotein were recently identified as ligands (Kerscher et al. 2013). Dectin-2 associates with FcRg to drive intracellular signaling pathways, of which the best characterized is the Syk-CARD9 pathway, shared with Dectin-1 (Drummond et al. 2011; Tronchin et al. 2008).

9.10.5 *Mincle*

Mincle is another member of the Dectin-2 family that, like Dectin-2, associates with FcRg and signals through Syk-CARD9. Using deficient mouse models, Mincle was shown to play protective roles during infections with *C. albicans* (Wells et al. 2008). *Malassezia*-derived glyceroglycolipid and mannitol-linked fatty acids were recently described to activate Mincle-dependent cytokine production (Ishikawa et al. 2013). Cytokine production appears to be the main protective mechanism downstream from Mincle, as phagocytosis is unaffected in the absence of this PRR (Tronchin et al. 2008; Wells et al. 2008).

9.10.6 Mannose Receptor (CD206)

The MR has a short cytoplasmic tail that lacks classical signaling motifs. Its located downstream signaling pathway is unknown (Willment and Brown 2008). The mannose receptor (MR) recognizes a broad range of pathogenic microbes including bacteria, parasites, viruses, and fungi through terminally mannosylated molecules. Several antifungal activities downstream from the MR were shown, including producing IL-17 from human peripheral blood mononuclear cells (PBMCs) stimulated with *C. albicans* mannans (van de Veerdonk et al. 2009) and phagocytosis of *C. albicans* yeast in DCs. They are also hypothesized to be involved with sampling of phagosomes because of the late-stage recruitment pattern (Heinsbroek et al. 2005; Tronchin et al. 2008).

9.10.7 Complement Receptor 3

Complement receptor 3 (CR3) is an integrin made up of CD11b and CD18. It is part of the evolutionary ancient complement system that targets and attacks foreign microbes using functionally diverse complement proteins released by a proteolytic cascade. CR3 is involved with leukocyte adhesion, phagocytosis, and chemotaxis using mechanisms that can either be dependent or independent of other components of the complement system (Tronchin et al. 2008).

9.10.8 DC-SIGN

DC-SIGN is a human CLR expressed on myeloid cells that binds fucose/mannose-containing glycans. There are eight murine homologs (named SIGNR), which were used to study the probable antifungal activities of DC-SIGN. In vitro assays have shown SIGNR1 recognizing *C. albicans*, leading to cytokine production and activation of the respiratory burst. However, some of these functions seemed to depend on Dectin-1 signaling, suggesting a collaborative effort (Lanoue et al. 2004; Takahara et al. 2011; Tronchin et al. 2008).

9.10.9 IL-17 Defenses

IL-17 is classically associated with CD4⁺ Th17 cells. There was an increasing admiration of the importance of innate lymphoid sources of IL-17 (Cua and Tato 2010). These sources include NK T cells, $\gamma\delta$ T cells, CD4²CD8-TCRb⁺ cells, and “natural” Th17 cells, which do not need activation by a specific antigen and are therefore

considered innate. However, these innate “type 17” cells bear several similarities to conventional Th17 cells in that they express CCR6, IL-7R α , IL-23R, and the master transcription factor ROR- γ t (Tronchin et al. 2008).

9.10.10 *Th17 Immunity*

Th17 cells are a subset of CD4+ T cells that are developmentally distinct from Th1 and Th2 cells and are distinguished by the expression of cytokines IL-17A, IL-17F, and IL-22. The specialization of this T-cell lineage requires various cytokines and transcription factors. TGF- β and IL-6 prime the initial differentiation of naïve CD4+ T cells to Th17 cells, and IL-23 is necessary for maintenance and enlargement of these cells (Zuniga et al. 2013).

9.10.11 *Th1 Immunity*

The Th1 immune response is instrumental in host defense against most fungal pathogens. Following exposure, APCs produce IL-12, which is necessary for Th1 lineage commitment. Genetic variations in the IL-12 signaling pathway are related to a predisposition to a broad diversity of fungal diseases, such as cryptococcosis, candidiasis, paracoccidioido mycosis, and coccidioido mycosis (Jirapongsananuruk et al. 2012). Th1 cells orchestrate antifungal immune responses through the release of proinflammatory cytokines IFN- γ , TNF- α , and GM-CSF.

9.10.12 *Th2 Immunity*

Th2 immunity has a detrimental influence on the host. This genetic effect is hypothesized to predispose individuals to *C. albicans* by suppressing the fungicidal activity of macrophages encountering *C. albicans* yeasts (Cenci et al. 1993). The mechanisms by which Th2 cytokines dampen host immunity are multifactorial. Both IL-4 and IL-13 drive alternative activation of macrophages that is associated with uncontrolled fungal growth. These alternatively activated phagocytes display amplified levels of arginase-1, an enzyme that potentially diminishes the amount of nitric oxide required for fungicidal activity (Davis et al. 2006).

9.10.13 *Inflammasomes*

Inflammasomes are a recently identified family of proteins originally characterized for their important part in causing inflammation. They contain a carboxy-terminal leucine-rich repeat, a central nucleotide oligomerization domain, and an amino-terminal effector domain used to categorize inflammasomes into one of three classes: pyrin-containing NOD-like receptors (NLRPs), CARD-containing NOD-like receptors (NLRs), and a baculovirus inhibitor of apoptosis protein repeat (BIR) domain-containing class.

9.10.14 *T- and B-Cell Immunity*

It is acknowledged that activation of the adaptive arm of the immune system is necessary for resolution of a fungal infection in the host. The transition from innate to adaptive immunity is facilitated primarily by DCs, although macrophages contribute. These phagocytes process and present fungal antigens to naïve CD4+ T cells in class II MHC.

9.10.15 *CD8+ T Cells*

CD8 + T cells are vital for protection against viral pathogens and tumors; however, their relative contribution to host immunity against fungal infections is not as comprehensively understood as CD4+ T cells. In mice deficient in MHC Class II, CD8+ T cells suppress *H. capsulatum* infection by targeting macrophages laden with yeasts (Lin et al. 2005). The most likely mechanisms through which memory CD8+ T cells coordinate solution of pathogen in these models is by the release of IFN- γ and IL-17, and cytotoxic effects on infected cells. Thus, vaccines that elicit a robust CD8+ T-cell response can potentially be utilized as an alternative scheme to prevent fatal mycoses in immune-deficient patients.

9.10.16 *Humoral Immunity*

The impact of immunoglobulins and the B cells secreting them was well scrutinized in *C. neoformans* (Szymczak et al. 2013) and *C. albicans* (Saville et al. 2008). The clinical importance of immunoglobulins in mycoses is evident from reports that patients with B-cell defects, including X-linked hyper-IgM (de Gorgolas et al. 2005), hypogammaglobulinemia (Neto et al. 2000), and IgG2 deficiency (Marr et al. 2012), are susceptible to cryptococcosis. The mechanisms by which these

antibodies mediate protection in the host are broadly classified into direct and indirect mechanisms.

9.11 Fungal Ghosts

Evacuating microbes from their cytoplasmic content is a natural phenomenon. Pores could be introduced to the microbial cells as a result of different mechanisms (Amara 2016d; Dong et al. 2012; Laemmli 1970; Makino et al. 1999; Panthel et al. 2003), such as the evacuation of the gram-negative bacteria by the bacteriophage infections. The bacteriophage *E* lysis gene is used for evacuating the cells and turning them to ghosts by controlling its expression using a heat-sensitive promoter (Amara 2016d; Dong et al. 2012; Hensel et al. 2000; Panthel et al. 2003; Weibull 1956; Witte et al. 1992). Recently, the Sponge-Like protocol was introduced (Amara 2015b; Amara et al. 2013a, b, 2014b; Menisy et al. 2017a; Sheweita et al. 2019). Its main concept is using active chemical compounds that could introduce pores in the microbes and degrade the DNA at concentrations that did not change the surface antigens or the 3D structure (Amara et al. 2013a, b). This allows the evacuation of gram-negative and gram-positive bacteria, eukaryotes, and viruses (Amara 2015a, b, 2016a, c; Amara et al. 2013a, b, 2014a; El-Baky and Amara 2014; Hussain and Amra 2016; Menisy et al. 2017b; Park et al. 2016; Vinod et al. 2014, 2015; Wu et al. 2017). The Sponge-Like protocol was used to evacuate two types of fungi, *Aspergillus flavus* and *Aspergillus niger* (El-Baky et al., 2018a, b), and Oyster mushroom spores (Haddad et al. 2019).

These preliminary studies on fungal ghosts and their spores pave the way for many applications, including the immunological-related ones. A dead microbe with correct surface antigens can be used as a vaccine. In fact, I have spent a large part of my career researching DNA/plasmid isolations to provide a better understanding of microbial evacuations (Amara 2005, 2010, 2015c, 2016a, b, c, 2017a, b, c, 2018; El-Baky et al. 2018a, b).

9.12 Plants Involved in Folk Fungal Treatments

Traditional medicine has different usages for plants able to fight fungal infections. Plants that show antimicrobial activities for certain microbes have been used in treatment. Many attempts have been made to find new antifungal compounds from natural products from plants. Some plants used in traditional medicine show activities against some fungal infections, such as *Candida albicans*, *C. glabrata*, *C. tropicalis*, *C. krusei*, *C. guilliermondii*, *C. parapsilosis*, *C. pelliculosa*, *C. tropicalis*, *C. krusei*, *Microsporum gypseum*, *M. canis*, *Trichophyton mentagrophytes*, *T. violaceum*, *T. simii*, *T. rubrum*, *T. mentagrophytes*, *T. simii*, *Trichosporon asahii*, *T. rubrum*, *Epidermophyton floccosum*, *Magnaporthe grisea*, *Porphyromonas gingivalis*, *Aspergillus niger*, *Scopulariopsis brevicaulis*, *Cryptococcus spp.*, and *M. furfur*, as shown in Table 9.1.

Table 9.1 Examples of medicinal plants used to treat fungal infections in folk medicine

Plant name	Country/ Region	Fungal Infection	Reference
<i>Rhus tripartitum</i> (African sumac)	Tunisia	<i>Candida albicans</i>	(Abbassi and Hani 2011)
<i>Dracaena cinnabari</i> Balf. f. (Dracaenaceae) Dragon's blood (Dam Alakhwin)	Soqatra Island, Yemen	<i>Microsporium gypseum</i> and <i>Trichophyton mentagrophytes</i>	(Al-Fatimi 2018)
<i>Capparis spinosa</i> and <i>Juglans regia</i>	Palestine	<i>Microsporium canis</i> , <i>Trichophyton mentagrophytes</i> , and <i>Trichophyton violaceum</i>	(Ali-Shtayeh and Abu Ghdeib 1999)
<i>Ononis spinosa</i> L	Southeast Anatolia	<i>Candida albicans</i> standard strain (ATCC 95071), <i>Candida glabrata</i> , <i>Candida tropicalis</i> , <i>Candida krusei</i> , <i>Candida guilliermondii</i> , <i>Candida parapsilosis</i> , <i>Candida pelliculosa</i> , <i>Trichosporon asahii</i> , <i>Trichophyton rubrum</i>	(Altuner et al. 2010)
<i>Psidium guajava</i> L		<i>Candida albicans</i> , <i>Candida tropicalis</i> , and <i>Candida krusei</i>	(Bezerra et al. 2018)
<i>Astronium</i> sp	South America	<i>Candida albicans</i>	(Bonifacio et al. 2019)
<i>Larrea cuneifolia</i> and <i>L. divaricata</i> extracts	Argentina	<i>Candida albicans</i>	(Espino et al. 2019)
<i>Toddalia asiatica</i> (L.) Lam. (Rutaceae)	India	<i>Trichophyton rubrum</i> , <i>Trichophyton mentagrophytes</i> , <i>Trichophyton simii</i> , <i>Epidermophyton floccosum</i> , <i>Magnaporthe grisea</i> , and <i>Candida albicans</i> .	(Duraipandiyan and Ignacimuthu 2009)
<i>Pulsatilla patens</i>		<i>Candida glabrata</i>	(Laskai et al. 2018)
<i>Isodon flavidus</i>	Leigong Mountains Southwest of China	<i>Trichophyton rubrum</i> <i>Porphyromonas gingivalis</i> and <i>Candida albicans</i>	(Zhang et al. 2018)
<i>Acalypha indica</i> , <i>Cassia alata</i> , <i>Lawsonia inermis</i> , <i>Punica granatum</i> , <i>Thespesia populnea</i> and <i>Wrightia tinctoria</i>	Tamil Nadu, India	<i>Trichophyton rubrum</i> , <i>Epidermophyton floccosum</i> , <i>Aspergillus niger</i> , and <i>Scopulariopsis brevicaulis</i> . <i>Trichophyton mentagrophytes</i> and <i>Trichophyton simii</i> , <i>Aspergillus niger</i> , <i>Candida albicans</i> and <i>Cryptococcus</i> sp	(Ponnusamy et al. 2010)
<i>Ononis spinosa</i> L.		<i>Candida</i> strains	(Stojkovic et al. 2020)
<i>Alpinae officinarum</i>		Antifungal	(Zhou et al. 2007)

(continued)

Table 9.1 (continued)

Plant name	Country/ Region	Fungal Infection	Reference
<i>Eucommia ulmoides</i> Oliv. <i>Eucommiaceae</i> Engler		Antifungal.	(Huang et al. 2002)
<i>Mahonia fortunei</i> (Lindl.) Fedde <i>Berberidaceae</i>		Antifungal	(Li et al. 2007)
<i>Pseudostellaria heterophylla</i> (Miq.) Pax ex Pax et Hoffm. <i>Caryophyllaceae</i>		Antifungal	(Wang and Ng 2006)
<i>Melaleuca alternifolia</i> . <i>Melaleuca alternifolia</i>		<i>Malassezia furfur</i>	(Pooja et al. 2013)

9.13 Conclusion

The body has been created to resist any kind of infection. There are two main elements of the immune system: the innate and the adaptive. Other factors can strengthen or weaken the immune system. Humans have been able to distinguish diseases related to the immune system. Two general approaches have been used to regenerate it: heat shock and the insertion of foreign tissue (cotton) under an animal's skin. The immune system works collectively as one unit. Signals activate the effective agents that can control certain infections or illness. Despite the many natural and manmade tools for protection from infection, fungi still have the power to overcome most immune system tactics. Their power is associated with their size, nature of invasion (eukaryotic), mode of invasion, ability to trick the immune system, ability to differentiate, and capacity to colonize the tissues (Tronchin et al. [2008](#)).

Acknowledgement The author acknowledges the Microbial Ghost group in the City of Scientific Research and Technological Applications for their effort to convert the fungi to ghost cells.

Conflict of Interest The author declares that there are no conflicts concerning this study.

References

- Abbassi F, Hani K (2011) *In vitro* antibacterial and antifungal activities of *Rhus tripartitum* used as anti-diarrhoeal in Tunisian folk medicine. *Nat Prod Res* 26(23):2215–2218
- Abraham G, Vas SI (1990) Treatment of fungal peritonitis in patients undergoing continuous ambulatory peritoneal dialysis. *Am J Med* 88(6):699–700
- Abrahamsen TG, Gaustad P, Sund S, Hansen TW (1992) Disseminated fungal infections in neonates--risk factors, treatment and course. *Tidsskr Nor Lægeforen* 112(28):3548–3551
- Adams AI, Morimoto LN, Meneghini LZ, Bergold AM (2008) Treatment of invasive fungal infections: stability of voriconazole infusion solutions in PVC bags. *Braz J Infect Dis* 12(5):400–404
- Agarwal MB, Rath SA, Ratho N, Subramanian R (2006) Caspofungin: a major breakthrough in treatment of systemic fungal infections. *J Assoc Physicians India* 54:943–948
- Agarwal R, Chakrabarti A, Shah A, Gupta D, Meis JF, Guleria R, Moss R, Denning DW (2013) Allergic bronchopulmonary aspergillosis: review of literature and proposal of new diagnostic and classification criteria. *Clin Exp Allergy* 43(8):850–873
- Ahmad A, Wani MY, Patel M, Sobral A, Duse AG, Aqlan FM, Al-Bogami AS (2018) Synergistic antifungal effect of cyclized chalcone derivatives and fluconazole against *Candida albicans*. *Medchemcomm* 8(12):2195–2207
- Al-Baqsmi ZF, Ahmad S, Khan Z (2020) Antifungal drug susceptibility, molecular basis of resistance to echinocandins and molecular epidemiology of fluconazole resistance among clinical *Candida glabrata* isolates in Kuwait. *Sci Rep* 10(1):6238
- Al-Fatimi M (2018) Ethnobotanical survey of *Dracaena cinnabari* and investigation of the pharmacognostical properties, antifungal and antioxidant activity of its resin. *Plants (Basel)* 7(4)
- Al-Marzouqi AH, Elwy HM, Shehadi I, Adem A (2009) Physicochemical properties of antifungal drug-cyclodextrin complexes prepared by supercritical carbon dioxide and by conventional techniques. *J Pharm Biomed Anal* 49(2):227–233
- Alam MK, El-Ganiny AM, Afroz S, Sanders DA, Liu J, Kaminskyj SG (2012) *Aspergillus nidulans* galactofuranose biosynthesis affects antifungal drug sensitivity. *Fungal Genet Biol* 49(12):1033–1043
- Albengres E, Le Louet H, Tillement JP (1998) Systemic antifungal agents. Drug interactions of clinical significance. *Drug Saf* 18(2):83–97
- Alcazar-Fuoli L, Mellado E, Garcia-Effron G, Buitrago MJ, Lopez JF, Grimalt JO, Cuenca-Estrella JM, Rodriguez-Tudela JL (2006) *Aspergillus fumigatus* C-5 sterol desaturases Erg3A and Erg3B: role in sterol biosynthesis and antifungal drug susceptibility. *Antimicrob Agents Chemother* 50(2):453–460
- Ali-Shtayeh MS, Abu Ghdeib SI (1999) Antifungal activity of plant extracts against dermatophytes. *Mycoses* 42(11–12):665–672
- Alonso S, Arribi A, Vergas J, Martin MC, Arce B, Terleira A, Portoles A (2009) Pilot drug utilization study of systemic antifungal agents in the Hospital Clinico San Carlos. Proposal of a study method. *Rev Esp Quimioter* 22(3):127–134
- Altuner EM, Ceter T, Islek C (2010) Investigation of antifungal activity of *Ononis spinosa* L. ash used for the therapy of skin infections as folk remedies. *Mikrobiyol Bul* 44(4):633–639
- Amara AA (2005) Simple slot lysis and plasmid curing for determination the transfer of resistant factors within the pathogenic microbial strains. In: *Proceeding of Tagungsband zum 2. Gemeinsamen kongress der DGHM und VAAM Göttingen, Germany*. BioSpectrum, p 74
- Amara AA (2010) Introduction to the basic molecular microbiology protocols, 2nd edn. Schöling Verlage Germany
- Amara AA (2011) Opportunistic pathogens and their biofilm food for thought. Science against microbial pathogens: communicating current research and technology advances: edit by Mendez-Vilas. FORMATEX Microbiology Series No 3. 2:813–824
- Amara AA, Salem-Bekhit MM, Alanazi FK (2013a) Sponge-like: a new protocol for preparing bacterial ghosts. *Sci World J* 2013:7

- Amara AA, Salem-Bekhit MM, Alanazi FK (2013b) Plackett-Burman randomization method for bacterial ghosts preparation from *E. coli* JM109. *Saudi Pharm J* 22(3):273–279
- Amara AA, Neama AJ, Hussein A, Hashish EA, Sheweita SA (2014a) Evaluation the surface antigen of the *Salmonella typhimurium* ATCC 14028 ghosts prepared by "SLRP". *Sci World J* 2014:840863
- Amara AA, Neama AJ, Hussein A, Hashish EA, Sheweita SA (2014b, 2014) Evaluation the surface antigen of the *Salmonella typhimurium* ATCC 14028 ghosts prepared by "SLRP". *Sci World J*:840863
- Amara AA (2015a) Bacterial and yeast ghosts: *E. coli* and *Saccharomyces cerevisiae* preparation as drug delivery model ISIJ. *Biochemistry* 4(7):11–22
- Amara AA (2015b) Kostenlos viral ghosts, bacterial ghosts microbial ghosts and more. Schuling Verlag - Germany
- Amara AA (2015c) *Saccharomyces cerevisiae* ghosts using the sponge-like re-reduced protocol. *SOJ Biochem*:1–4
- Amara AA (2016a) The critical activity for the cell all degrading enzymes: could the use of the lysozyme for microbial ghosts preparation establish emergence oral vaccination protocol? *Int Sci Invest J* 5(2):351–369
- Amara AA (2016b) Lysozymes, proteinase K, bacteriophage *E* lysis proteins, and some chemical compounds for microbial ghosts preparation: a review and food for thought. *SOJ Biochem* 2(1):16
- Amara AA (2016c) Vaccine against pathogens: a review and food for thought. *SOJ Biochem* 2(2):1–20
- Amara AA (2017a) Cracking the microbial Cell Wall. *SOJ Vac Res* 6:363–369
- Amara AA (2017b) Smart green technology for microbial ghosts preparation. *IIOAB J* 8(5):53–54
- Amara AA (2017c) An invitation: case-by-case cell ghosts preparation. *Int Sci Invest J* 6(1):1–7
- Amara AA (2018) Fast plasmid slot lysis and gram-negative Bacteria ghost preparation protocol. *Austin J Proteom Bioinform Genom* 5(1):1025
- Andrade-Pavon D, Ortiz-Alvarez J, Sanchez-Sandoval E, Tamariz J, Hernandez-Rodriguez C, Ibarra JA, Villa-Tanaca L (2019) Inhibition of recombinant enzyme 3-hydroxy-3-methylglutaryl-CoA reductase from *Candida glabrata* by alpha-asarone-based synthetic compounds as antifungal agents. *J Biotechnol* 292:64–67
- Arthur RR, Drew RH, Perfect JR (2004) Novel modes of antifungal drug administration. *Expert Opin Investig Drugs* 13(8):903–932
- Beatty SR, Rose CE Jr, Sung SS (2007) Diverse and potent chemokine production by lung CD11b^{high} dendritic cells in homeostasis and in allergic lung inflammation. *J Immunol* 178(3):1882–1895
- Bezerra CF, Rocha JE, Nascimento Silva MKD, de Freitas TS, de Sousa AK, Dos Santos ATL, da Cruz RP, Ferreira MH, da Silva JCP, Machado AJT, Carneiro JNP, Sales DL, Coutinho HDM, Ribeiro PRV, de Brito ES, Morais-Braga MFB (2018) Analysis by UPLC-MS-QTOF and antifungal activity of guava (*Psidium guajava* L.). *Food Chem Toxicol* 119:122–132
- Biondo C, Midiri A, Messina L, Tomasello F, Garufi G, Catania MR, Bombaci M, Beninati C, Teti G, Mancuso G (2005) MyD88 and TLR2, but not TLR4, are required for host defense against *Cryptococcus neoformans*. *Eur J Immunol* 35(3):870–878
- Bohme A, Ruhnke M, Buchheidt D, Cornely OA, Einsele H, Enzensberger R, Hebart H, Heinz W, Junghans C, Karthaus M, Kruger W, Krug U, Kubin T, Penack O, Reichert D, Reuter S, Silling G, Sudhoff T, Ullmann AJ, Maschmeyer G (2009) Treatment of invasive fungal infections in cancer patients--recommendations of the infectious diseases working party (AGIHO) of the German Society of Hematology and Oncology (DGHO). *Ann Hematol* 88(2):97–110
- Bonifacio BV, Vila TVM, Masiero IF, da Silva PB, da Silva IC, de Oliveira Lopes E, Dos Santos Ramos MA, de Souza LP, Vilegas W, Pavan FR, Chorilli M, Lopez-Ribot JL, Bauab TM (2019) Antifungal activity of a hydroethanolic extract from *Astronium urundeuva* leaves against *Candida albicans* and *Candida glabrata*. *Front Microbiol* 10:2642

- Bortolus C, Billamboz M, Charlet R, Lecointe K, Sendid B, Ghinet A, Jawhara S (2019) A small aromatic compound has antifungal properties and potential anti-inflammatory effects against intestinal inflammation. *Int J Mol Sci* 20(2)
- Bouchara J-P, Sanchez M, Esnault K, Tronchin G (1999) Interactions between *Aspergillus fumigatus* and host matrix proteins. *Contrib Microbiol* 2:167–181
- Bourgeois C, Majer O, Frohner IE, Lesiak-Markowicz I, Hildering KS, Glaser W, Stockinger S, Decker T, Akira S, Muller M, Kuchler K (2011) Conventional dendritic cells mount a type I IFN response against *Candida* spp. requiring novel phagosomal TLR7-mediated IFN-beta signaling. *J Immunol* 186(5):3104–3112
- Brummer E, Chauhan SD, Stevens DA (1999) Collaboration of human phagocytes with LY 303366 for antifungal activity against *Aspergillus fumigatus*. *J Antimicrob Chemother* 43(4):491–496
- Bruno M, Kersten S, Bain JM, Jaeger M, Rosati D, Kruppa MD, Lowman DW, Rice PJ, Graves B, Ma Z, Jiao YN, Chowdhary A, Renieris G, van de Veerdonk FL, Kullberg BJ, Giamarellos-Bourboulis EJ, Hoischen A, Gow NAR, Brown AJP, Meis JF, Williams DL, Netea MG (2020) Transcriptional and functional insights into the host immune response against the emerging fungal pathogen *Candida auris*. *Nat Microbiol* 5:1516–1531
- Cai Z, Chai Y, Zhang C, Feng R, Sang H, Lu L (2016) Molecular characterization of Gbeta-like protein CpcB involved in antifungal drug susceptibility and virulence in *A. fumigatus*. *Front Microbiol* 7:106
- Camilli G, Tabouret G, Quintin J (2018) The complexity of fungal beta-glucan in health and disease: effects on the mononuclear phagocyte system. *Front Immunol* 9:673
- Casaroto AR, da Silva RA, Salmeron S, Rezende MLR, Dionisio TJ, Santos CFD, Pinke KH, Klingbeil MFG, Salomao PA, Lopes MMR, Lara VS (2019) *Candida albicans*-cell interactions activate innate immune defense in human palate epithelial primary cells via nitric oxide (NO) and beta-defensin 2 (hBD-2). *Cell* 8(7)
- Cenci E, Romani L, Mencacci A, Spaccapelo R, Schiaffella E, Puccetti P, Bistoni F (1993) Interleukin-4 and interleukin-10 inhibit nitric oxide-dependent macrophage killing of *Candida albicans*. *Eur J Immunol* 23(5):1034–1038
- Chaudhari AK, Singh VK, Dwivedy AK, Das S, Upadhyay N, Singh A, Dkhar MS, Kayang H, Prakash B, Dubey NK (2018) Chemically characterised *Pimenta dioica* (L.) Merr. essential oil as a novel plant based antimicrobial against fungal and aflatoxin B1 contamination of stored maize and its possible mode of action. *Nat Prod Res* 34(5):745–749
- Childers DS, Avelar GM, Bain JM, Larcombe DE, Pradhan A, Budge S, Heaney H, Brown AJP (2019) Impact of the environment upon the *Candida albicans* cell wall and resultant effects upon immune surveillance. *Curr Top Microbiol Immunol* 425:297–330
- Childers DS, Avelar GM, Bain JM, Pradhan A, Larcombe DE, Netea MG, Erwig LP, Gow NAR, Brown AJP (2020) Epitope shaving promotes fungal immune evasion. *MBio* 11(4)
- Cua DJ, Tato CM (2010) Innate IL-17-producing cells: the sentinels of the immune system. *Nat Rev Immunol* 10(7):479–489
- Datry A, Thellier M, Traore B, Alfa Cisse O, Danis M (2001) Antifungal drugs in the treatment of systemic candidiasis: susceptibility to antifungal drugs, drug resistance, pharmacological data. *Ann Fr Anesth Reanim* 20(4):389–393
- Davis K, Philpott S, Kumar D, Mendall M (2006) Randomised double-blind placebo-controlled trial of aloe vera for irritable bowel syndrome. *Int J Clin Pract* 60(9):1080–1086
- de Gorgolas M, Erice A, Gil A, Gutierrez J, Rivas P, Hernando C, Rodriguez MC (2005) Cryptococcal meningitis in a patient with X-linked hyper-IgM1 syndrome. *Scand J Infect Dis* 37(6–7):526–528
- De Luca A, Carvalho A, Cunha C, Iannitti RG, Pitzurra L, Giovannini G, Mencacci A, Bartolommei L, Moretti S, Massi-Benedetti C, Fuchs D, De Bernardis F, Puccetti P, Romani L (2013) IL-22 and IDO1 affect immunity and tolerance to murine and human vaginal candidiasis. *PLoS Pathog* 9(7):e1003486

- del Rio ML, Rodriguez-Barbosa JI, Kremmer E, Forster R (2007) CD103- and CD103+ bronchial lymph node dendritic cells are specialized in presenting and cross-presenting innocuous antigen to CD4+ and CD8+ T cells. *J Immunol* 178(11):6861–6866
- Desch AN, Randolph GJ, Murphy K, Gautier EL, Kedl RM, Lahoud MH, Caminschi I, Shortman K, Henson PM, Jakubick CV (2011) CD103+ pulmonary dendritic cells preferentially acquire and present apoptotic cell-associated antigen. *J Exp Med* 208(9):1789–1797
- do Nascimento JET, Rodrigues ALM, de Lisboa DS, Liberato HR, Falcão MJC, da Silva CR, Nobre Junior HV, Braz Filho R, de Paula Junior VF, Alves DR, de Moraes SM (2018) Chemical composition and antifungal in vitro and in silico, antioxidant, and anticholinesterase activities of extracts and constituents of *Ouratea fieldingiana* (DC.) Baill. *Evid Based Complement Alternat Med* 1748487:2018
- Dominguez-Andres J, Ferreira AV, Jansen T, Smithers N, Prinjha RK, Furze RC, Netea MG (2019) Bromodomain inhibitor I-BET151 suppresses immune responses during fungal-immune interaction. *Eur J Immunol* 49(11):2044–2050
- Dong H, Han X, Bai H, He L, Liu L, Liu R, Chai T, Ding C, Liu H, Yu S (2012) Mutation of lambda-dapL/pR-cl857 system for production of bacterial ghost in *Escherichia coli*. *Sheng Wu Gong Cheng Xue Bao* 28(12):1423–1430
- Dotis J, Simitsopoulou M, Dalakiouridou M, Konstantinou T, Panteliadis C, Walsh TJ, Roilides E (2008) Amphotericin B formulations variably enhance antifungal activity of human neutrophils and monocytes against *Fusarium solani*: comparison with *Aspergillus fumigatus*. *J Antimicrob Chemother* 61(4):810–817
- Drummond RA, Brown GD (2011) The role of Dectin-1 in the host defence against fungal infections. *Curr Opin Microbiol* 14(4):392–399
- Drummond RA, Gaffen SL, Hise AG, Brown GD (2014) Innate Defense against Fungal Pathogens. *Cold Spring Harb Perspect Med* 5(6)
- Drummond RA, Saijo S, Iwakura Y, Brown GD (2011) The role of Syk/CARD9 coupled C-type lectins in antifungal immunity. *Eur J Immunol* 41(2):276–281
- Du X, Xiong H, Yang Y, Yan J, Zhu S, Chen F (2020) Dynamic study of oral *Candida* infection and immune status in HIV infected patients during HAART. *Arch Oral Biol* 115:104741
- Duan Y, Chen J, Pang Z, Ye X, Zhang C, Hu H, Xie J (2020) Antifungal mechanism of *Streptomyces* sp. FS-4 on fusarium wilt of banana. *J Appl Microbiol* 130(1):196–207
- Duraipandiyan V, Ignacimuthu S (2009) Antibacterial and antifungal activity of Flindersine isolated from the traditional medicinal plant, *Toddalia asiatica* (L.) Lam. *J Ethnopharmacol* 123(3):494–498
- El-Baky AN, Sharaf MM, Amer E, Kholef HR, Hussain MZ, Amara AA (2018a) Protein and DNA isolation from *Aspergillus niger* as well as ghost cells formation. *SOJ Biochem* 4(1):1–7
- El-Baky NA, Amara AA (2014) Newcastle disease virus (LaSota strain) as a model for virus Ghosts preparation using H2O2 bio-critical concentration. *International Science and Investigation journal* 3(5):38–50
- El-Baky NA, Sharaf MM, Amer E, Kholef HR, Hussain MZ, Abd ELRR, Amara AA (2018b) The minimum inhibition and growth concentration for controlling fungal infection as well as for ghost cells preparation: *aspergillus flavus* as a model. *Biomed J Sci Tech Res* 10(2):1–5
- Ersland K, Wuthrich M, Klein BS (2010) Dynamic interplay among monocyte-derived, dermal, and resident lymph node dendritic cells during the generation of vaccine immunity to fungi. *Cell Host Microbe* 7(6):474–487
- Espino M, Solari M, Fernandez MLA, Boiteux J, Gomez MR, Silva MF (2019) NADES-mediated folk plant extracts as novel antifungal agents against *Candida albicans*. *J Pharm Biomed Anal* 167:15–20
- Fernandez-Ruiz M, Lopez-Medrano F, San Juan R, Allende LM, Paz-Artal E, Aguado JM (2015) Low natural killer cell counts and onset of invasive fungal disease after solid organ transplantation. *J Infect Dis* 213(5):873–874

- Findley K, Oh J, Yang J, Conlan S, Deming C, Meyer JA, Schoenfeld D, Nomicos E, Park M, Kong HH, Segre JA (2013) Topographic diversity of fungal and bacterial communities in human skin. *Nature* 498(7454):367–370
- Garcia-Carnero LC, Martinez-Alvarez JA, Salazar-Garcia LM, Lozoya-Perez NE, Gonzalez-Hernandez SE, Tamez-Castrellon AK (2020) Recognition of fungal components by the host immune system. *Curr Protein Pept Sci* 21(3):245–264
- Graham LM, Brown GD (2009) The Dectin-2 family of C-type lectins in immunity and homeostasis. *Cytokine* 48(1–2):148–155
- Gross O, Gewies A, Finger K, Schafer M, Sparwasser T, Peschel C, Forster I, Ruland J (2006) Card9 controls a non-TLR signalling pathway for innate anti-fungal immunity. *Nature* 442(7103):651–656
- Guo H, Wu X (2009) Innate responses of corneal epithelial cells against *Aspergillus fumigatus* challenge. *FEMS Immunol Med Microbiol* 56(1):88–93
- Haddad A, Sharaf MM, Kenawy AMA, Amara AA (2019) Oyster mushroom spores ghost preparation for medicinal, biotechnological and forensic applications. *Biomed J Sci Tech Res MS.ID* 003994
- Hedayati MT, Pasqualotto AC, Warn PA, Bowyer P, Denning DW (2007) *Aspergillus flavus*: human pathogen, allergen and mycotoxin producer. *Microbiology* 153:1677–1692
- Heinsbroek SE, Brown GD, Gordon S (2005) Dectin-1 escape by fungal dimorphism. *Trends Immunol* 26(7):352–354
- Henri S, Poulin LF, Tamoutounour S, Ardouin L, Guilliams M, de Bovis B, Devillard E, Viret C, Azukizawa H, Kissenpfennig A, Malissen B (2010) CD207+ CD103+ dermal dendritic cells cross-present keratinocyte-derived antigens irrespective of the presence of Langerhans cells. *J Exp Med* 207(1):189–206
- Hensel A, Huter V, Katinger A, Raza P, Strnistschie C, Roesler U, Brand E, Lubitz W (2000) Intramuscular immunization with genetically inactivated (ghosts) *Actinobacillus pleuropneumoniae* serotype 9 protects pigs against homologous aerosol challenge and prevents carrier state. *Vaccine* 18(26):2945–2955
- Hohl TM, Rivera A, Lipuma L, Gallegos A, Shi C, Mack M, Pamer EG (2009) Inflammatory monocytes facilitate adaptive CD4 T cell responses during respiratory fungal infection. *Cell Host Microbe* 6(5):470–481
- Huang G, Huang H (2019) Synthesis, antiasthmatic, and insecticidal/antifungal activities of allosamidins. *J Enzyme Inhib Med Chem* 34(1):1226–1232
- Huang RH, Xiang Y, Liu XZ, Zhang Y, Hu Z, Wang DC (2002) Two novel antifungal peptides distinct with a five-disulfide motif from the bark of *Eucommia ulmoides* Oliv. *FEBS Lett* 52(1):1–3
- Hussain ZM, Amara AA (2006) Case-by-case study using antibiotic-EDTA combination to control *Pseudomonas aeruginosa*. *Pak J Pharm Sci* 19(3):236–243
- Hussain ZM, Amra AA (2016) Case-by-case study using antibiotic-EDTA combination to control *Pseudomonas aeruginosa*. *Pak J Pharm Sci* 19(3):236–243
- Igyarto BZ, Haley K, Ortner D, Bobr A, Gerami-Nejad M, Edelson BT, Zurawski SM, Malissen B, Zurawski G, Berman J, Kaplan DH (2011) Skin-resident murine dendritic cell subsets promote distinct and opposing antigen-specific T helper cell responses. *Immunity* 35(2):260–272
- Ishikawa T, Itoh F, Yoshida S, Saijo S, Matsuzawa T, Gonoi T, Saito T, Okawa Y, Shibata N, Miyamoto T, Yamasaki S (2013) Identification of distinct ligands for the C-type lectin receptors Mincle and Dectin-2 in the pathogenic fungus *Malassezia*. *Cell Host Microbe* 13(4):477–488
- Islam A, Li SS, Oykhman P, Timm-McCann M, Huston SM, Stack D, Xiang RF, Kelly MM, Mody CH (2013) An acidic microenvironment increases NK cell killing of *Cryptococcus neoformans* and *Cryptococcus gattii* by enhancing perforin degranulation. *PLoS Pathog* 9(7):e1003439
- Jaeger M, Plantinga TS, Joosten LA, Kullberg BJ, Netea MG (2013) Genetic basis for recurrent vulvo-vaginal candidiasis. *Curr Infect Dis Rep* 15(2):136–142
- Jawhara S (2020) How fungal glycans modulate platelet activation via toll-like receptors contributing to the escape of *Candida albicans* from the immune response. *Antibiotics (Basel)* 9(7)

- Jirapongsananuruk O, Luangwedchakarn V, Niemela JE, Pacharn P, Visitsunthorn N, Thepthai C, Vichyanond P, Piboonpocanun S, Fleisher TA (2012) Cryptococcal osteomyelitis in a child with a novel compound mutation of the IL12RB1 gene. *Asian Pac J Allergy Immunol* 30(1):79–82
- Junior EFC, Guimaraes C, Franco LL, Alves RJ, Kato KC, Martins HR, de Souza Filho JD, Bemquerer MP, Munhoz VHO, Resende JM, Verly RM (2019) Glycotriazole-peptides derived from the peptide HSP1: synergistic effect of triazole and saccharide rings on the antifungal activity. *Amino Acids* 49(8):1389–1400
- Kelly MN, Zheng M, Ruan S, Kolls J, D'Souza A, Shellito JE (2013) Memory CD4+ T cells are required for optimal NK cell effector functions against the opportunistic fungal pathogen *Pneumocystis murina*. *J Immunol* 190(1):285–295
- Kerscher B, Willment JA, Brown GD (2013) The Dectin-2 family of C-type lectin-like receptors: an update. *Int Immunol* 25(5):271–277
- Kirkland TN, Fierer J (2020) Innate immune receptors and defense against primary pathogenic fungi. *Vaccines (Basel)* 8(2)
- Korting HC, Schollmann C (2009) The significance of itraconazole for treatment of fungal infections of skin, nails and mucous membranes. *J Dtsch Dermatol Ges* 7(1):11–19, 11–20.
- Laemmli UK (1970) Cleavage of structural proteins during the assembly of the head of bacteriophage T4. *Nature* 227:680–685
- Lang S, Duan Y, Liu J, Torralba MG, Kuelbs C, Ventura-Cots M, Abalde JG, Bosques-Padilla F, Verna EC, Brown RS Jr, Vargas V, Altamirano J, Caballeria J, Shawcross D, Lucey MR, Louvet A, Mathurin P, Garcia-Tsao G, Ho SB, Tu XM, Bataller R, Starkel P, Fouts DE, Schnabl B (2019) Intestinal fungal dysbiosis and systemic immune response to fungi in patients with alcoholic hepatitis. *Hepatology* 71(2):522–538
- Lanoue A, Clatworthy MR, Smith P, Green S, Townsend MJ, Jolin HE, Smith KG, Fallon PG, McKenzie AN (2004) SIGN-R1 contributes to protection against lethal pneumococcal infection in mice. *J Exp Med* 200(11):1383–1393
- Laskai G, Sienkiewicz A, Zjawiony JK, Jacob M, Khan S (2018) Antifungal activity of the root extracts of *Pulsatilla Patens* against *Candida Glabrata*. *Acta Pol Pharm* 74(1):179–185
- Latge JP, Calderone R (2002) Host-microbe interactions: fungi invasive human fungal opportunistic infections. *Curr Opin Microbiol* 5(4):355–358
- Lemos ASO, Florencio JR, Pinto NCC, Campos LM, Silva TP, Grazul RM, Pinto PF, Tavares GD, Scio E, Apolonio ACM, Melo RCN, Fabri RL (2020) Antifungal activity of the natural Coumarin Scopoletin against planktonic cells and biofilms from a multidrug-resistant *Candida tropicalis* strain. *Front Microbiol* 11:1525
- Li AR, Zhu Y, Li XN, Tian XJ (2007) Antimicrobial activity of four species of *Berberidaceae*. *Fitoterapia*. *Fitoterapia* 78(5):379–381
- Li HS, Gelbard A, Martinez GJ, Esashi E, Zhang H, Nguyen-Jackson H, Liu YJ, Overwijk WW, Watowich SS (2011) Cell-intrinsic role for IFN-alpha-STAT1 signals in regulating murine Peyer patch plasmacytoid dendritic cells and conditioning an inflammatory response. *Blood* 118(14):3879–3889
- Lin JS, Yang CW, Wang DW, Wu-Hsieh BA (2005) Dendritic cells cross-present exogenous fungal antigens to stimulate a protective CD8 T cell response in infection by *Histoplasma capsulatum*. *J Immunol* 174(10):6282–6291
- Longhi LN, da Silva RM, Fornazim MC, Spago MC, de Oliveira RT, Nowill AE, Blotta MH, Mamoni RL (2012) Phenotypic and functional characterization of NK cells in human immune response against the dimorphic fungus *Paracoccidioides brasiliensis*. *J Immunol* 189(2):935–945
- Loures FV, Pina A, Felonato M, Calich VL (2009) TLR2 is a negative regulator of Th17 cells and tissue pathology in a pulmonary model of fungal infection. *J Immunol* 183(2):1279–1290
- Luber CA, Cox J, Lauterbach H, Fancke B, Selbach M, Tschopp J, Akira S, Wiegand M, Hochrein H, O'Keeffe M, Mann M (2010) Quantitative proteomics reveals subset-specific viral recognition in dendritic cells. *Immunity* 32(2):279–289

- Makino K, Yokoyama K, Kubota Y, Yutsudo CH, Kimura S, Kurokawa K, Ishii K, Hattori M, Tatsuno I, Abe H (1999) Complete nucleotide sequence of the prophage VT2-Sakai carrying the verotoxin 2 genes of the enterohemorrhagic *Escherichia coli* O157: H7 derived from the Sakai outbreak. *Genes Genet Syst* 74(5):227–239
- Marr KA, Datta K, Pirofski LA, Barnes R (2012) *Cryptococcus gattii* infection in healthy hosts: a sentinel for subclinical immunodeficiency? *Clin Infect Dis* 54(1):153–154
- Mendes-Giannini MJ, Taylor ML, Bouchara JB, Burger E, Calich VL, Escalante ED, Hanna SA, Lenzi HL, Machado MP, Miyaji M, Monteiro Da Silva JL, Mota EM, Restrepo A, Restrepo S, Tronchin G, Vincenzi LR, Xidieh CF, Zenteno E (2000) Pathogenesis II: fungal responses to host responses: interaction of host cells with fungi. *Med Mycol* 38(Suppl 1):113–123
- Menisy M, Hussein A, Ghazy AA, Sheweita S, Amara AA (2017a) *Klebsiella pneumoniae* ghosts as vaccine using sponge like reduced protocol. *Cell Mol Med* 3(2):1–8
- Menisy MMHA, Ghazy A, Sheweita S, Amara AA (2017b) *Klebsiella pneumoniae* ghosts as vaccine using sponge like reduced protocol. *Cell Mol Med* 3(2):8
- Mora-Montes HM (2020) Proteins as virulence factors and immune modulators during the host-fungus interaction. *Curr Protein Pept Sci* 21(3):226
- Moran GP, Sullivan DJ, Henman MC, McCreary CE, Harrington BJ, Shanley DB, Coleman DC (1997) Antifungal drug susceptibilities of oral *Candida dubliniensis* isolates from human immunodeficiency virus (HIV)-infected and non-HIV-infected subjects and generation of stable fluconazole-resistant derivatives in vitro. *Antimicrob Agents Chemother* 41(3):617–623
- Mosser DM, Edwards JP (2008) Exploring the full spectrum of macrophage activation. *Nat Rev Immunol* 8(12):958–969
- Netea MG (2013) Training innate immunity: the changing concept of immunological memory in innate host defence. *Eur J Clin Invest* 43(8):881–884
- Netea MG, Gow NA, Munro CA, Bates S, Collins C, Ferwerda G, Hobson RP, Bertram G, Hughes HB, Jansen T, Jacobs L, Buurman ET, Gijzen K, Williams DL, Torensma R, McKinnon A, MacCallum DM, Odds FC, Van der Meer JW, Brown AJ, Kullberg BJ (2006) Immune sensing of *Candida albicans* requires cooperative recognition of mannans and glucans by lectin and toll-like receptors. *J Clin Invest* 116(6):1642–1650
- Netea MG, Quintin J, van der Meer JW (2011) Trained immunity: a memory for innate host defense. *Cell Host Microbe* 9(5):355–361
- Neto R, Guimaraes MC, Moya MJ, Oliveira FR, Louzada PL Jr, Martinez R (2000) Hypogammaglobulinemia as risk factor for *Cryptococcus neoformans* infection: report of 2 cases. *Rev Soc Bras Med Trop* 33(6):603–608
- Nobile CJ, Andes DR, Nett JE, Smith FJ, Yue F, Phan QT, Edwards JE, Filler SG, Mitchell AP (2006a) Critical role of Bcr1-dependent adhesins in *C. albicans* biofilm formation in vitro and in vivo. *PLoS Pathog* 2(7):e63
- Nobile CJ, Mitchell AP (2007) Microbial biofilms: e pluribus unum. *Curr Biol* 17(10):R349–R353
- Nobile CJ, Nett JE, Andes DR, Mitchell AP (2006b) Function of *Candida albicans* adhesin Hwp1 in biofilm formation. *Eukaryot Cell* 5(10):1604–1610
- O'Neill LA, Golenbock D, Bowie AG (2013) The history of toll-like receptors - redefining innate immunity. *Nat Rev Immunol* 13(6):453–460
- Pantheel K, Jechlinger W, Matis A, Rohde M, Szostak M, Lubitz W, Haas R (2003) Generation of helicobacter pylori ghosts by PhiX protein E-mediated inactivation and their evaluation as vaccine candidates. *Infect Immun* 71(1):109–116
- Park HJ, Oh S, Vinod N, Ji S, Noh HB, Koo JM et al (2016) Characterization of chemically-induced Bacterial Ghosts (BGs) using sodium hydroxide-induced *Vibrio parahaemolyticus* Ghosts (VPGs). *Int J Mol Sci* 17(11):1904
- Pathaw N, Gurung AB, Chungoo NK, Bhattacharjee A, Roy SS, Ansari MA, Sharma SK (2020) In silico molecular modelling, structural dynamics simulation and characterization of antifungal nature of beta-glucosidase enzyme from *Sechium edule*. *J Biomol Struct Dyn*:1–9
- Perumal P, Mekala S, Chaffin WL (2007) Role for cell density in antifungal drug resistance in *Candida albicans* biofilms. *Antimicrob Agents Chemother* 51(7):2454–2463

- Pina A, de Araujo EF, Felonato M, Loures FV, Feriotti C, Bernardino S, Barbuto JA, Calich VL (2013) Myeloid dendritic cells (DCs) of mice susceptible to paracoccidioidomycosis suppress T cell responses whereas myeloid and plasmacytoid DCs from resistant mice induce effector and regulatory T cells. *Infect Immun* 81(4):1064–1077
- Ponnusamy K, Petchiammal C, Mohankumar R, Hopper W (2010) In vitro antifungal activity of indirubin isolated from a south Indian ethnomedicinal plant *Wrightia tinctoria* R. *Br J Ethnopharmacol* 132(1):349–354
- Pooja A, Arun N, Maninder K (2013) Screening of plant essential oils for antifungal activity against *Malassezia furfur*. *Int J Pharm Pharm Sci* 5:1–3
- Ramirez-Ortiz ZG, Lee CK, Wang JP, Boon L, Specht CA, Levitz SM (2011) A nonredundant role for plasmacytoid dendritic cells in host defense against the human fungal pathogen *Aspergillus fumigatus*. *Cell Host Microbe* 9(5):415–424
- Ramirez-Ortiz ZG, Specht CA, Wang JP, Lee CK, Bartholomeu DC, Gazzinelli RT, Levitz SM (2008) Toll-like receptor 9-dependent immune activation by unmethylated CpG motifs in *Aspergillus fumigatus* DNA. *Infect Immun* 76(5):2123–2129
- Richardson MD, Smith H (1981) Resistance of virulent and attenuated strains of *Candida albicans* to intracellular killing by human and mouse phagocytes. *J Infect Dis* 144(6):557–564
- Rivera A, Hohl TM, Collins N, Leiner I, Gallegos A, Saijo S, Coward JW, Iwakura Y, Pamer EG (2011) Dectin-1 diversifies *Aspergillus fumigatus*-specific T cell responses by inhibiting T helper type 1 CD4 T cell differentiation. *J Exp Med* 208(2):369–381
- Roilides E, Holmes A, Blake C, Venzon D, Pizzo PA, Walsh TJ (1994) Antifungal activity of elutriated human monocytes against *Aspergillus fumigatus* hyphae: enhancement by granulocyte-macrophage colony-stimulating factor and interferon-gamma. *J Infect Dis* 170(4):894–899
- Roilides E, Tsapariidou S, Kadiltoglou I, Sein T, Walsh TJ (1999) Interleukin-12 enhances antifungal activity of human mononuclear phagocytes against *Aspergillus fumigatus*: implications for a gamma interferon-independent pathway. *Infect Immun* 67(6):3047–3050
- Romani L (2004) Immunity to fungal infections. *Nat Rev Immunol* 11(4):275–288
- Safdar A (2010) Immunomodulation therapy for invasive aspergillosis: discussion on myeloid growth factors, recombinant cytokines, and antifungal drug immune modulation. *Curr Fungal Infect Rep* 4(1):1–7
- Saini P, Prasad T, Gaur NA, Shukla S, Jha S, Komath SS, Khan LA, Haq QM, Prasad R (2005) Alanine scanning of transmembrane helix 11 of Cdr1p ABC antifungal efflux pump of *Candida albicans*: identification of amino acid residues critical for drug efflux. *J Antimicrob Chemother* 56(1):77–86
- Sar B, Boy S, Keo C, Ngeth CC, Prak N, Vann M, Monchy D, Sarthou JL (2006) In vitro antifungal-drug susceptibilities of mycelial and yeast forms of *Penicillium marneffei* isolates in Cambodia. *J Clin Microbiol* 44(11):4208–4210
- Saunders CW, Scheynius A, Heitman J (2012) *Malassezia* fungi are specialized to live on skin and associated with dandruff, eczema, and other skin diseases. *PLoS Pathog* 8(6):e1002701
- Saville SP, Lazzell AL, Chaturvedi AK, Monteagudo C, Lopez-Ribot JL (2008) Use of a genetically engineered strain to evaluate the pathogenic potential of yeast cell and filamentous forms during *Candida albicans* systemic infection in immunodeficient mice. *Infect Immun* 76(1):97–102
- Schmidt S, Zimmermann SY, Tramsen L, Koehl U, Lehrnbecher T (2013) Natural killer cells and antifungal host response. *Clin Vaccine Immunol* 20(4):452–458
- Sheweita SA, Batah AM, Ghazy AA, Hussein A, Amara AA (2019) A new strain of *Acinetobacter baumannii* and characterization of its ghost as a candidate vaccine. *J Infect Public Health* 12(6):831–842
- Shindo K (1990) Treatment of cryptococcal meningitis with five anti-fungal drugs: the role of amphotericin B. *Drugs Exp Clin Res* 16(7):327–332
- Shing B, Singh S, Podust LM, McKerrow JH, Debnath A (2020) The antifungal drug isavuconazole is both amebicidal and cysticidal against *Acanthamoeba castellanii*. *Antimicrob Agents Chemother* 64(5)

- St Georgiev V (2000) Membrane transporters and antifungal drug resistance. *Curr Drug Targets* 1(3):261–284
- Steinman RM, Adams JC, Cohn ZA (1975) Identification of a novel cell type in peripheral lymphoid organs of mice. IV. Identification and distribution in mouse spleen. *J Exp Med* 141(4):804–820
- Steinman RM, Cohn ZA (1973) Identification of a novel cell type in peripheral lymphoid organs of mice. I. Morphology, quantitation, tissue distribution. *J Exp Med* 137(5):1142–1162
- Steinman RM, Cohn ZA (1974) Identification of a novel cell type in peripheral lymphoid organs of mice. II. Functional properties in vitro. *J Exp Med* 139(2):380–397
- Stojkovic D, Dias MI, Drakulic D, Barros L, Stevanovic M, I CFRF MDS (2020) Methanolic extract of the herb *Ononis spinosa* L. is an antifungal agent with no cytotoxicity to primary human cells. *Pharmaceuticals (Basel)* 13(4)
- Szymczak WA, Davis MJ, Lundy SK, Dufaud C, Olszewski M, Pirofski LA (2013) X-linked immunodeficient mice exhibit enhanced susceptibility to *Cryptococcus neoformans* infection. *MBio* 4(4)
- Szymczak WA, Deepe GS Jr (2009) The CCL7-CCL2-CCR2 axis regulates IL-4 production in lungs and fungal immunity. *J Immunol* 183(3):1964–1974
- Tada H, Nemoto E, Shimauchi H, Watanabe T, Mikami T, Matsumoto T, Ohno N, Tamura H, Shibata K, Akashi S, Miyake K, Sugawara S, Takada H (2002) *Saccharomyces cerevisiae*- and *Candida albicans*-derived mannan induced production of tumor necrosis factor alpha by human monocytes in a CD14- and toll-like receptor 4-dependent manner. *Microbiol Immunol* 46(7):503–512
- Takahara K, Tokieda S, Nagaoka K, Takeda T, Kimura Y, Inaba K (2011) C-type lectin SIGNR1 enhances cellular oxidative burst response against *C. albicans* in cooperation with Dectin-1. *Eur J Immunol* 41(5):1435–1444
- Tronchin G, Pihet M, Lopes-Bezerra LM, Bouchara JP (2008) Adherence mechanisms in human pathogenic fungi. *Med Mycol* 46(8):749–772
- van de Veerdonk FL, Marijnissen RJ, Kullberg BJ, Koenen HJ, Cheng SC, Joosten I, van den Berg WB, Williams DL, van der Meer JW, Joosten LA, Netea MG (2009) The macrophage mannose receptor induces IL-17 in response to *Candida albicans*. *Cell Host Microbe* 5(4):329–340
- Verma A, Wuthrich M, Deepe G, Klein B (2014) Adaptive immunity to fungi. *Cold Spring Harb Perspect Med* 5(3):a019612
- Vinod N, Oh S, Park HJ, Koo JM, Choi CW, Kim SC (2015) Generation of a novel *Staphylococcus aureus* ghost vaccine and examination of its immunogenicity against virulent challenge in rats. *Infect Immun* 83(7):2957–2965
- Vinod N, Oh S, Kim S, Choi CW, Kim SC, Jang CH (2014) Chemically induced salmonella enteritidis ghosts as anovel vaccine candidate against virulent challenge in arat model. *Vaccine* 32:3249–3255
- Vlachos C, Schulte BM, Magiatis P, Adema GJ, Gaitanis G (2012) *Malassezia*-derived indoles activate the aryl hydrocarbon receptor and inhibit toll-like receptor-induced maturation in monocyte-derived dendritic cells. *Br J Dermatol* 167(3):496–505
- Voigt J, Hunniger K, Bouzani M, Jacobsen ID, Barz D, Hube B, Loffler J, Kurzai O (2013) Human natural killer cells acting as phagocytes against *Candida albicans* and mounting an inflammatory response that modulates neutrophil antifungal activity. *J Infect Dis* 209(4):616–626
- von Paleske A, Mullerleile U, Gressler V, Garbrecht M, Hossfeld DK (1987) Incidence and treatment of fungal infections in neutropenic patients. *Haematol Blood Transfus* 30:545–546
- Wagener J, Schneider JJ, Baxmann S, Kalbacher H, Borelli C, Nuding S, Kuchler R, Wehkamp J, Kaeser MD, Mailander-Sanchez D, Braunsdorf C, Hube B, Schild L, Forssmann WG, Korting HC, Liepke C, Schaller M (2013) A peptide derived from the highly conserved protein GAPDH is involved in tissue protection by different antifungal strategies and epithelial immunomodulation. *J Invest Dermatol* 133(1):144–153
- Wang HX, Ng TB (2006) Concurrent isolation of a Kunitz-type trypsin inhibitor with antifungal activity and a novel lectin from *Pseudostellaria heterophylla* roots. *Biochem Biophys Res Commun* 342(1):349–353

- Weibull C (1956) The nature of the ghosts obtained by lysozyme lysis of *Bacillus megaterium*. *Exp Cell Res* 10(1):214–221
- Wells CA, Salvage-Jones JA, Li X, Hitchens K, Butcher S, Murray RZ, Beckhouse AG, Lo YL, Manzanero S, Cobbold C, Schroder K, Ma B, Orr S, Stewart L, Lebus D, Sobieszczuk P, Hume DA, Stow J, Blanchard H, Ashman RB (2008) The macrophage-inducible C-type lectin, mincle, is an essential component of the innate immune response to *Candida albicans*. *J Immunol* 180(11):7404–7413
- Wildfeuer A, Laufen H, Haferkamp O (1990) Interaction of fluconazole and human phagocytic cells. Uptake of the antifungal agent and its effects on the survival of ingested fungi in phagocytes. *Arzneimittelforschung* 40(9):1044–1047
- Wildfeuer A, Reisert I, Laufen H (1992) Subcellular distribution and antifungal effects of fluconazole in human phagocytic cells. Demonstration of the antifungal agent in neutrophil polymorphonuclear leucocytes and monocytes by autoradiography and electron micrography. *Arzneimittelforschung* 42(8):1049–1052
- Willment JA, Brown GD (2008) C-type lectin receptors in antifungal immunity. *Trends Microbiol* 16(1):27–32
- Witte A, Wanner G, Sulzner M, Lubitz W (1992) Dynamics of PhiX174 protein E-mediated lysis of *Escherichia coli*. *Arch Microbiol* 157(4):381–388
- Wu X, Ju X, Du L, Yuan J, Wang L, He R, Chen Z (2017) Production of bacterial ghosts from gram-positive pathogen *Listeria monocytogenes*. *Foodborne Pathog Dis* 14(1):1–7
- Wuthrich M, Gern B, Hung CY, Ersland K, Rocco N, Pick-Jacobs J, Galles K, Filutowicz H, Warner T, Evans M, Cole G, Klein B (2011) Vaccine-induced protection against 3 systemic mycoses endemic to North America requires Th17 cells in mice. *J Clin Invest* 126(2):795
- Xie J, Du H, Guan G, Tong Y, Kourkoumpetis TK, Zhang L, Bai FY, Huang G (2012) N-acetylglucosamine induces white-to-opaque switching and mating in *Candida tropicalis*, providing new insights into adaptation and fungal sexual evolution. *Eukaryot Cell* 11(6):773–782
- Zelante T, De Luca A, Bonifazi P, Montagnoli C, Bozza S, Moretti S, Belladonna ML, Vacca C, Conte C, Mosci P, Bistoni F, Puccetti P, Kastelein RA, Kopf M, Romani L (2007) IL-23 and the Th17 pathway promote inflammation and impair antifungal immune resistance. *Eur J Immunol* 37(10):2695–2706
- Zhang J, Cui N, Wang H, Han W, Li Y, Xiao M, Liu D (2018) Invasive fungal disease in critically ill patients at high risk: usefulness of lymphocyte subtyping. *J Intensive Care Med* 35(9):909–918
- Zhou YQ, Fan ZW, Yang JY, Kang AZ, Cao Y (2007) Anti-cancer Chinese medicinal herbs. Chemical industry Press: Biology, Medicine Publication Branch, Beijing
- Zuniga LA, Jain R, Haines C, Cua DJ (2013) Th17 cell development: from the cradle to the grave. *Immunol Rev* 252(1):78–88

Chapter 10

Antifungal Resistance in Animal Medicine: Current State and Future Challenges



Sergio Álvarez-Pérez, Marta E. García, Blanca Anega, and José L. Blanco

10.1 Introduction

Antibiotic resistance is a dominant research area due to the high prevalence of nosocomial infections caused by multidrug-resistant bacterial strains, and the dramatic impact of such infections on the healthcare system and the global economy (Prestinaci et al. 2015). In contrast, resistance to antifungal drugs has received much less attention, even when the occurrence of fungal diseases is far from negligible (Delarze and Sanglard 2015). Actually, surveillance systems to monitor the incidence of fungal diseases and antifungal resistance are still suboptimal and often rely on not-for-profit initiatives, such as the “Global Action Fund for Fungal Infections” (GAFFI, <http://www.gaffi.org/>). Information about the burden of fungal infections and antifungal resistance is even scarcer in veterinary medicine, as fungal diseases of animals have been more neglected than human mycoses (Rochette et al. 2003; Kwon-Chung 2018).

The current limited antifungal armamentarium and the slow pace at which new drugs become available represent major challenges for clinicians (Beardsley et al. 2018). Furthermore, the antifungal drugs currently available have important limitations, including their high cost, remarkable toxicity to animal cells, poor bioavailability, and/or relative inefficacy (Beardsley et al. 2018; Elad 2018). In this context, the emergence and escalation of resistance to antifungal drugs are causing great concern in the scientific community, as exemplified by the inclusion of the

S. Álvarez-Pérez (✉) · M. E. García · J. L. Blanco

Department of Animal Health, Faculty of Veterinary Medicine, Universidad Complutense de Madrid, Madrid, Spain

Veterinary Clinical Hospital, Universidad Complutense de Madrid, Madrid, Spain

e-mail: sergioaperez@ucm.es

B. Anega

Department of Animal Health, Faculty of Veterinary Medicine, Universidad Complutense de Madrid, Madrid, Spain

© Springer Nature Switzerland AG 2021

A. Gupta, N. Pratap Singh (eds.), *Fungal Diseases in Animals*, Fungal Biology, https://doi.org/10.1007/978-3-030-69507-1_10

163

multidrug-resistant species *Candida auris*, other drug-resistant species of genus *Candida*, and azole-resistant *Aspergillus fumigatus* in the updated list of “Antibiotic Resistance Threats in the United States” published by the Centers for Disease Control and Prevention, under the categories of “urgent threats,” “serious threats,” and “watch list,” respectively (CDC 2019). Similarly, reports from different countries suggest that antifungal resistance is also prevalent among fungal isolates of animal origin (e.g., Cafarchia et al. 2012b, c, 2015; Cordeiro et al. 2015; Talbot et al. 2015; Álvarez-Pérez et al. 2016c; Brilhante et al. 2016). However, the actual impact of antifungal resistance on animal health and the farming system is mostly unknown, as animal mycoses have traditionally received much less attention than those affecting humans, and antifungal susceptibility testing of animal isolates is still uncommon (Rochette et al. 2003; Álvarez-Pérez et al. 2016c).

In this chapter, we present an overview of the current knowledge on antifungal resistance of animal pathogenic fungi. However, a detailed account of the information available for the different species of yeasts and filamentous fungi of veterinary importance and different animal groups (e.g., pets, farm animals, and wildlife) is beyond the scope of this chapter. Instead, we focus on some general aspects that may be of greater interest for the non-expert reader. In addition, we discuss some issues that, in our view, should be addressed in the near future to optimize antifungal therapies in the veterinary setting and minimize the impact caused by resistant strains.

10.2 Antifungal Therapy in Animal Medicine

Antifungal therapy is a central component of human and animal protection against fungal infections (Seyedmousavi et al. 2018). However, despite recent advances in antifungal pharmacology, therapeutic options are still limited. In particular, most antifungal drugs currently available belong to a few compound classes, namely the polyenes, the azoles, the echinocandins, the allylamines, and the nucleoside analogs (Table 10.1). Overall, the azoles are the antifungal class most widely used for the treatment and prophylaxis of human and animal mycoses, and these compounds also represent a mainstay for crop protection against fungal infections and material preservation (Fisher et al. 2018; Seyedmousavi et al. 2018). Chemically, the azoles are heterocyclic organic molecules that contain a core azole ring with two or three nitrogen atoms, and this characteristic is used to differentiate two subclasses: the imidazoles and the triazoles, respectively (Table 10.1). Other compounds with antifungal activity, such as griseofulvin, chlorhexidine, ciclopirox, salicylic acid, and tolnaftate, are often used to treat dermatophytosis and other superficial mycoses (Dias et al. 2013; Moriello et al. 2017; Bond et al. 2020). Additionally, several new antifungals that may be more advantageous than the current ones, both in terms of overcoming antifungal resistance and avoiding adverse effects and drug–drug interactions, are currently under preclinical and clinical evaluation (Wiederhold 2017;

Table 10.1 Overview of the main antifungal classes used in human and animal medicine^a

Compound class	Mode of action	Representative compounds
Allylamines	Non-competitive inhibition of the squalene epoxidase, an enzyme that participates in the fungal ergosterol biosynthesis pathway	Terbinafine
Azoles	Inhibition of the synthesis of ergosterol from lanosterol in the fungal cell membrane by binding of the free nitrogen atom of theazole ring to the iron atom of the heme group of the fungal enzyme cytochrome P450 lanosterol 14- α -demethylase (CYP51 or Erg11p). Such inhibition depletes ergosterol, and methylated sterols accumulate in the cell membrane, which inhibits fungal growth or induces cell death	Imidazoles (2 N atoms in theazole ring): clotrimazole, enilconazole (imazalil), ketoconazole, and miconazole Triazoles (3 N atoms in theazole ring): fluconazole, isavuconazole, itraconazole, posaconazole, and voriconazole
Echinocandins	Inhibition of the β -1,3-D-glucan synthase, which catalyzes the biosynthesis of β -1,3-D-glucan, a key component of the fungal cell wall	Anidulafungin, caspofungin, and micafungin
Nucleoside analogs	Incorporation into RNA instead of uracil (after conversion into 5-fluorouracil [5-FU] and subsequent phosphorylation), which leads to miscoding and disruption of protein synthesis by fungal cells. Additionally, phosphorylated 5-FU is converted to its deoxynucleoside and can block DNA synthesis by inhibiting the thymidylate synthase, thus leading to the disruption of DNA replication.	Flucytosine (5-fluorocytosine).
Polynes	Binding to the ergosterol in the fungal cell membrane, which results in the formation of transmembrane pores that disrupt cell membrane integrity and lead to cellular damage and, eventually, to cell death	Amphotericin B, nystatin

^aSource of data: Foy and Trepanier (2010), Mazu et al. (2016), Fisher et al. (2018), Seyedmousavi et al. (2018), and Gintjee et al. (2020)

Gintjee et al. 2020), but the spectrum of action of such compounds and their applicability to the treatment of different animal species remain to be established.

One of the main limitations of antifungal therapy in human and animal medicine is the toxicity and other serious adverse effects of most available compounds, which prevent their prolonged use or dosage escalation (Wiederhold 2017; Antonissen and Martel 2018; Elad 2018). Drug–drug interactions and reduced water solubility are other drawbacks of most currently available antifungals (Gubbins and Amsden 2005; Wiederhold 2017; Antonissen and Martel 2018). In this regard, combination antifungal therapy is gaining popularity as a potential strategy to enhance the efficacy of treatments while reducing some of their side effects (Johnson and Perfect 2010; Belanger et al. 2015).

On the other hand, the difficulties in diagnosing some human and animal mycoses often lead to an advanced stage of the infection when the treatment is prescribed (Rochette et al. 2003; Ostrosky-Zeichner 2012). Early diagnosis of systemic fungal diseases remains challenging because the clinical signs are unspecific and, in most cases, there are no reliable non-invasive diagnostic tests available (Ostrosky-Zeichner 2012; Antonissen and Martel 2018). Consequently, antifungal therapy in human and animal patients is often administered empirically, before a definite diagnosis of fungal infection is made (Klastersky 2004; Antonissen and Martel 2018).

Apart from the aforementioned issues, antifungal therapy in the veterinary setting has some specific limitations. For example, there is still scarce information about the pharmacokinetics and optimal dosage of currently available antifungal drugs in most animal species, and such parameters can display large interspecies and even interindividual variability, which significantly determines drug safety and efficacy (Rochette et al. 2003; Antonissen and Martel 2018). Moreover, veterinary experience with some antifungals is yet too limited to allow a detailed analysis of their possible side effects in most animal species (Elad 2018). Additionally, only a few antifungals are licensed for use in animals, and, consequently, off-label use of drugs approved for human therapy is quite common (Rochette et al. 2003; Antonissen and Martel 2018; Seyedmousavi et al. 2018). Nevertheless, many of the newer drugs used in human medicine are cost-prohibitive in veterinary settings, thus limiting their use in the routine practice (Foy and Trepanier 2010; Elad 2018). Even when some antifungals that have come off patent are currently more accessible, they are still not an option for prolonged therapy. This issue is non-trivial and often results in discontinuation of the antifungal therapy before complete clinical recovery (Nakasu et al. 2020). The stress and/or other difficulties generated by repeated drug administration to some animal species, in particular to wild animals, should also be taken into account (Elad 2018).

Finally, environmental considerations have great importance in the management of animal mycoses, especially of those affecting farm animals. In general, fungal infections of livestock, poultry, and other farm animals should be treated as herd conditions rather than as individual infections. Although the infection source of animal mycoses may vary, this is in most cases the environment (Asfaw and Dawit 2016; Elad 2018; Elad and Segal 2018). Therefore, prevention measures mostly focus on reducing the environmental fungal load in the farm facilities and avoiding the unhygienic management of animals. For example, strategic treatment of conditions such as dermatophytosis should always include measures for environmental decontamination, so as to prevent re-infections and/or the spread of the infection to other animals or human hosts once the antifungal therapy is discontinued (Rochette et al. 2003). Environmental decontamination is also important to prevent outbreaks of avian aspergillosis (Nawrot et al. 2019). Some antifungals such as enilconazole (also known as imazalil), thiabendazole, or natamycin are available for environmental decontamination as emulsifiable concentrates and/or smoke generator formulations (Rochette et al. 2003). Environmental factors may also be important in the prevention and management of the fungal infections of pets, but individualized

antifungal prophylaxis and/or treatment based on the animal's clinical history are often crucial for a successful outcome (Moriello et al. 2017; Barrs and Talbot 2020).

10.3 Antifungal Resistance: General Concepts and Study Methods

The rapid worldwide emergence of resistance to antifungal drugs represents a major threat to human and animal health and food security (Fisher et al. 2018). Antifungal resistance can arise in the clinical setting under prolonged therapy or, alternatively, through resistance selection upon long-term exposure of the microorganism to sub-lethal concentrations of the compounds in the environment due to the widespread use of fungicides in diverse applications (e.g., agriculture, preservation of materials, disinfection of farm facilities, etc.) (Azevedo et al. 2015; Perlin et al. 2017; Beardsley et al. 2018; Seyedmousavi et al. 2018). A detailed analysis of the environmental origin of antifungal resistance is out of the scope of this chapter, but the reader is referred to the magnificent studies and review articles on this issue published in recent years (e.g., Berger et al. 2017; Schoustra et al. 2019). Besides, some fungi display intrinsic resistance to certain antifungals (Delarze and Sanglard 2015; Perlin et al. 2017). Regardless its origin, antifungal resistance can worsen the clinical outcome and even result in clinical failure (Beardsley et al. 2018).

At the molecular level, antifungal resistance occurs through various non-exclusive mechanisms, including the following: (a) non-synonymous point mutations within the gene encoding the target enzyme; (b) increased expression of the target enzyme; (c) decreased concentrations of the drug within fungal cells due to drug efflux; and (d) reduced production of the target of the antifungal drugs due to changes in the biosynthetic pathway (Perlin et al. 2017; Beardsley et al. 2018; Fisher et al. 2018; Seyedmousavi et al. 2018). Biofilm formation, which reduces the drug concentration by trapping it into polysaccharide-rich matrices, is another important resistance mechanism in some fungal species (Perlin et al. 2017). These mechanisms of antifungal resistance can occur either alone or concomitantly in a single isolate, and can produce additive effects or lead to cross-resistance among different drugs (e.g., different azoles) (Perlin et al. 2017).

In vitro susceptibility testing is key for comparing the susceptibility of different fungal species and strains against the different antifungal drugs and determining resistance rates. The most popular methods for in vitro antifungal susceptibility testing of filamentous fungi and yeasts are those based on the guidelines developed by the Clinical and Laboratory Standards Institute (CLSI) (CLSI 2008b, c) and the European Committee on Antifungal Susceptibility Testing (EUCAST) (Arendrup et al. 2020a, b). Despite some technical differences, both the CLSI and EUCAST procedures are broth microdilution methods, where the growth of isolates is evaluated in a series of increasing concentrations of an antifungal agent, prepared by serial dilution with growth medium (Beardsley et al. 2018; Elad and Segal 2018;

Table 10.2 Basic concepts in antifungal susceptibility testing

Concept ^a	Definition
Minimum inhibitory concentration (MIC)	Lowest concentration of an antifungal agent that prevents visible growth of a fungal strain in a susceptibility test. The MIC refers to some defined test conditions (e.g., incubation time and temperature) and end point (e.g., 80% or 50% reduction in growth respective to the growth control).
Minimum effective concentration (MEC)	Lowest concentration of an antifungal drug resulting in morphological changes (growth of small, rounded, compact hyphal balls) compared with the filamentous hyphal growth seen in control wells. MECs are mostly defined for filamentous fungi and fungistatic drugs (e.g., echinocandins).
Minimal fungicidal concentration (MFC)	Lowest concentration of an antifungal drug required to achieve fungicidal killing, generally defined as a 99.9% reduction in the initial inoculum (colony-forming unit (CFU) count).
Clinical break point (CBP)	MIC threshold used to classify fungal isolates as “susceptible” or “resistant” to a given antifungal. CBPs for isolates that cannot be included in the aforementioned categories (e.g., “susceptible-dose dependent” and “intermediate” isolates) have also been defined for some species–antifungal combinations.
Epidemiological cutoff value (ECV/ ECOFF ^b)	MIC threshold used to classify fungal isolates as “wild type” (i.e., without any phenotypically expressed resistance mechanism) or “non-wild type” (i.e., showing phenotypically expressed resistance mechanism). For a given antifungal, the ECV/ECOFF is the upper limit of the wild-type population and usually includes 90–95% of the strains.

^aMICs, MECs, MFCs, CBPs, and ECVs are usually expressed in terms of mg/l or µg/ml (but note that CBPs and ECVs can also refer to inhibition zone diameters)

^bAbbreviations used by the CLSI and EUCAST, respectively

Sanguinetti and Posteraro 2018). The results of these tests are expressed as minimum inhibitory concentration (MIC), minimum effective concentration (MEC), or minimum fungicidal concentration (MFC) values (Table 10.2). There are also diverse commercial systems for antifungal susceptibility testing, including the agar-based Etest and the broth microdilution method Sensititre (Beardsley et al. 2018; Elad and Segal 2018; Sanguinetti and Posteraro 2018) (Fig. 10.1). Additionally, homemade or commercial four-well azole-supplemented screening plates containing itraconazole (4 mg/l), posaconazole (0.5 mg/l), voriconazole (2 mg/l), and no antifungal (growth control) in each of the wells have emerged as an inexpensive, rapid screening method for azole resistance in *A. fumigatus* and other aspergilli (Arendrup et al. 2017; Guinea et al. 2019).

Due to the difficulty of establishing reliable clinical breakpoints (CBPs) to classify fungal isolates as susceptible or resistant to a given drug, the CLSI and EUCAST have proposed the definition of epidemiological cutoff values (ECVs or ECOFFs) for different species–antifungal combinations (CLSI 2020; <https://mic.eucast.org/Eucast2/>). Such ECVs/ECOFFs split the fungal populations into wild-type strains and non-wild-type strains, where the latter are those strains that may present any phenotypically expressed resistance mechanism and are less likely to respond to a given antifungal agent (Beardsley et al. 2018; Sanguinetti and Posteraro 2018)

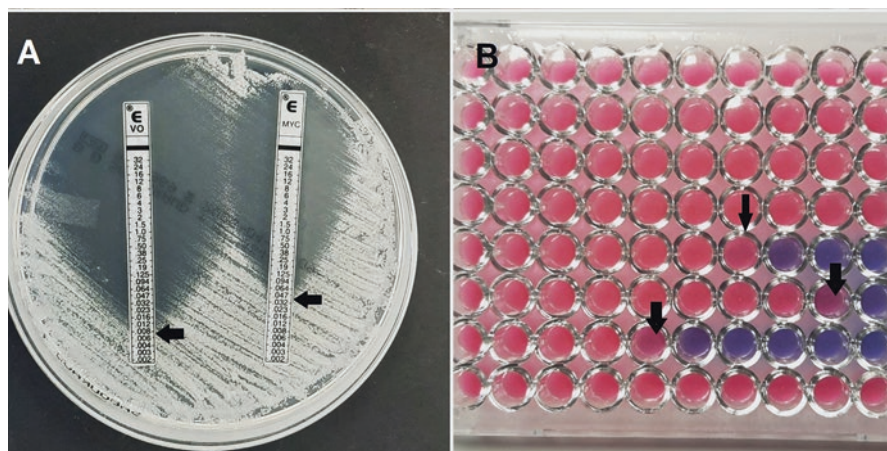


Fig. 10.1 Some examples of commercial methods for in vitro antifungal susceptibility testing. (a) Agar-based Etest, testing the susceptibility of a yeast strain against voriconazole (VO) and micafungin (MYC). Note the growth inhibition ellipses and the black arrows indicating the minimum inhibitory concentration (MIC; i.e., point where the inhibition halo intersects the Etest strip). (b) Sensititre YeastOne plate, testing (by a broth microdilution method) the susceptibility of the same yeast strain as in panel A against nine different antifungals (one per row of the microplate, plus an additional one in the last column). The MIC end points were defined as the lowest concentration of antifungal drug preventing the development of a pink color (i.e., first blue or purple well), and are indicated by black arrows

(Table 10.2). However, classification of a fungal isolate as resistant or non-wild type does not necessarily mean clinical failure, as there are many different factors that contribute to the clinical outcome, including host factors (e.g., animal species, immune state, type of infection, and comorbidities), therapeutic factors (e.g., pharmacokinetics/pharmacodynamics, dosage regime, administration route, toxicity, and compliance with the treatment), and ancillary factors (e.g., environmental decontamination) (Ostrosky-Zeichner and Andes 2017; Beardsley et al. 2018). In any case, the value of in vitro detection and characterization of antifungal resistance should not be overlooked, as these can assist clinicians to select the best drug regimen (Beardsley et al. 2018).

10.4 Antifungal Resistance in the Veterinary Setting

The results of recent studies dealing with the in vitro susceptibility testing of fungal isolates of animal origin suggest that antifungal resistance is relatively common among isolates from diverse host species, and that even healthy individuals can serve as a reservoir of resistant strains (Cordeiro et al. 2015; Cafarchia et al. 2012a, b, c, 2015; Talbot et al. 2015; Álvarez-Pérez et al. 2016c; Brilhante et al. 2016; Rocha et al. 2017). Nevertheless, resistance figures vary widely depending on the

animal species, the geographical location, and the methods used for in vitro susceptibility testing. In general, a major limitation of such studies is their small sample size, especially when compared with similar studies that focus on human isolates. Additionally, until recently, antifungal susceptibility testing of veterinary isolates was in most cases performed by non-standardized methods using different test conditions (antifungal panels, incubation time and temperature, MIC end points, etc.), which further hinders the direct comparison of results across studies. In particular, as not all fungi grow well in the synthetic medium (RPMI 1640) used in the CLSI and EUCAST protocols, some methodological adjustments have to be introduced for testing fungal species with special growth requirements. Such is the case, for example, of the yeast *Malassezia pachydermatis*, for which Sabouraud dextrose broth supplemented with 1% (v/v) of Tween 80 is recommended as test medium for the CLSI-based method (Cafarchia et al. 2012a, b, c, 2015; Álvarez-Pérez et al. 2014a). Additionally, susceptibility testing of slow-growing, scantily sporulating filamentous fungi such as *Microsporum canis*, *Trichophyton mentagrophytes*, and other dermatophyte species remains particularly challenging, as the MIC results depend largely on the type of inoculum used for the assays (conidia, hyphae + conidia, or arthroconidia) and other test conditions (Favre et al. 2003; Aneke et al. 2020).

Another limitation of most in vitro susceptibility studies testing animal isolates is that when antifungal-resistant isolates are detected, these are generally not studied for presence of gene mutations or other characteristics (potentially) responsible of the resistant phenotype. Luckily, this aspect is changing in recent years, and the number of publications reporting mechanisms of antifungal resistance in isolates of animal origin is increasing, as illustrated by the examples below.

One of the most detailed reports of antifungal resistance among fungal isolates of animal origin is that of Rocha et al. (2017), who studied potential mechanisms of azole resistance in *Candida albicans* strains recovered from different mammal and avian species. The authors concluded that azole resistance in this yeast species is a multifactorial process that involves increased efflux pump activity and the overexpression of different genes, including *ERG11*, which encodes the azole target 14 α -sterol demethylase, the multidrug-resistant 1 (*MDR1*) gene of the major facilitator superfamily (MFS), which encodes proton-dependent efflux pumps, and the efflux pump genes for *Candida* drug resistance 1 (*CDR1*) and 2 (*CDR2*) (Rocha et al. 2017). In contrast, the ergosterol content of fungal cell walls showed no significant differences between resistant and susceptible strains (Rocha et al. 2017). The results of Castelo-Branco et al. (2020) further confirmed that efflux-mediated mechanisms are involved in the azole resistance of *Candida* spp. isolates from animals.

Another study dealing with potential mechanisms of antifungal resistance in *Candida* isolates of animal origin is our report of multi-azole resistance acquisition by *Candida tropicalis* in a dog with urinary candidiasis (Álvarez-Pérez et al. 2016b). Multi-azole resistance appeared after prolonged fluconazole therapy followed by a five-day course of bladder irrigation with amphotericin B, both of which were unsuccessful in controlling the yeast infection. Notably, pre- and post-azole

treatment isolates were clonally related and had identical silent mutations in the *ERG11* gene, but post-treatment isolates displayed increased azole MICs. Furthermore, a novel frameshift mutation in the *ERG3* gene, which encodes for sterol $\Delta^{5,6}$ -desaturase, was found in some isolates recovered after resistance development, so it is unlikely that this mutation was responsible for the multi-azole-resistant phenotype (Álvarez-Pérez et al. 2016b).

Mechanisms of antifungal resistance have also been studied in non-*Candida* yeasts of veterinary origin, including *M. pachydermatis* and *Cryptococcus gattii*. For example, Kim et al. (2018) compared the whole genome sequences of a ketoconazole-resistant isolate of *M. pachydermatis* retrieved from the ear canal of a dog with otitis externa and the type strain of the same yeast species and found that a ~ 84-kb region in the chromosome 4 of the clinical isolate was tandemly quadruplicated. Notably, such quadruplicated region contained 52 protein-encoding genes, including homologs of *ERG11* and *ERG4* (which encodes sterol C-24 reductase). Moreover, transcriptome analysis indicated an overexpression of both *ERG11* and *ERG4* (3.68- and 2.81-fold, respectively) in the ketoconazole-resistant isolate (Kim et al. 2018). Soon thereafter, Kano et al. (2019) reported the isolation of a strain of *M. pachydermatis* from a case of canine dermatitis that displayed elevated MICs to itraconazole and ketoconazole. The combination of itraconazole and the calcineurin inhibitor FK506, which can reverse multidrug resistance in different types of eukaryotic cells by blocking ATP-dependent efflux pumps, exerted an additive effect against the azole-resistant strain (Kano et al. 2019). Furthermore, the studied strain had two missense mutations (A412G and C905T) in the sequence of the *ERG11* open reading frame, but the relationship between those mutations and azole tolerance was not further investigated (Kano et al. 2019). More recently, the same research group studied the in vitro susceptibility to ravuconazole of 13 isolates of *M. pachydermatis* retrieved from clinical cases of canine dermatitis and detected one isolate with an MIC >32 mg/l (Kano et al. 2020). The ravuconazole-resistant isolate was also resistant to clotrimazole, miconazole, and voriconazole, and had a G1382A substitution in the *ERG11* gene (Kano et al. 2020). In contrast, Sykes et al. (2017) did not find any mutation in the sequences of *ERG11* and the efflux pump gene *PDR11* of isogenic fluconazole-susceptible and fluconazole-resistant isolates of *C. gattii* retrieved from a case of invasive cryptococcosis in a domestic longhair cat. However, an increase in the number of copies and overexpression of *ERG11* and *PDR11* were detected in the post-treatment-resistant isolate compared to the fluconazole-susceptible isolate collected prior to initiation of antifungal therapy (Sykes et al. 2017). Moreover, reversion to wild-type susceptibility was observed when the resistant isolate was maintained in antifungal-free media, thus confirming the in vivo development of fluconazole resistance (Sykes et al. 2017).

Regarding the filamentous fungi, potential mechanisms of antifungal resistance among animal isolates have been mainly investigated in *A. fumigatus* (but see, for example, Talbot et al. (2019) for a study focusing on the members of the *Aspergillus viridinutans* species complex). For instance, Wang et al. (2014) examined *A. fumigatus* collected in avian farms from France ($n = 57$) and southern China ($n = 51$) where azole chemoprophylaxis was and was not performed, respectively. Although

all tested isolates were susceptible to itraconazole, posaconazole, and voriconazole, sequencing of the *cyp51A* gene, which encodes the cytochrome P450 14- α sterol demethylase in *A. fumigatus*, for a selection of 61 isolates revealed 11 isolates with a total of 20 point mutations (Wang et al. 2014). Eleven of such point mutations were silent, but the other nine yielded amino acid substitutions (Wang et al. 2014). Similarly, Talbot et al. (2015) analyzed the azole resistance in canine and feline isolates ($n = 46$ and 4 , respectively) of *A. fumigatus* collected between 1988 and 2014, and identified an isolate from 1992 showing multi-azole resistance and a F46Y point mutation in the *cyp51A* gene that seems to be associated with azole resistance. Finally, Bunskoek et al. (2017) reported a case of azole-resistant invasive aspergillosis in a female captive bottlenose dolphin (*Tursiops truncatus*). The *A. fumigatus* strain recovered from this case showed in vitro resistance to itraconazole, posaconazole, and voriconazole, and harbored the TR₄₆/Y121F/T289A mutation in the *cyp51A* gene (Bunskoek et al. 2017), which is associated with environmental resistance selection (van der Linden et al. 2013). Fortunately, the animal was successfully treated with high-dose posaconazole that reached plasma levels >3 mg/l (Bunskoek et al. 2017).

The main conclusion extracted from the aforementioned examples is that susceptibility testing and the study of gene mutations and other mechanisms involved in antifungal resistance can provide very useful information for veterinary professionals, including, for instance, data about the epidemiology of antifungal resistance in the studied animal population(s) and about the treatment options to fight infections that are refractory to standard treatments.

10.5 Future Challenges

Despite recent advances in the study of the prevalence and mechanisms of antifungal resistance among fungal pathogens of animals, there are still some issues that, in our view, should be further addressed in order to optimize antifungal therapies in animal medicine and minimize the impact caused by resistant species and strains including, for example: (a) species-level identification of animal pathogenic fungi; (b) establishment of meaningful breakpoints for antifungal resistance of veterinary isolates; and (c) reduction of the environmental impact of antifungal use. These aspects are briefly described below.

10.5.1 Species-Level Identification of Animal Pathogenic Fungi

Many fungal species cannot be reliably identified based on phenotypic features alone, and a polyphasic approach combining morphological, metabolic, ecological, and (phylo)genetic data is often required for better taxonomic resolution (Crous et al. 2015). This is the case, for example, of many members of the genera *Aspergillus* and *Candida* (Howard 2014; Criseo et al. 2015; Paulussen et al. 2017; Barrs and Talbot 2020), including relevant animal pathogens. Furthermore, the term “cryptic species” has been coined to describe recognized morphospecies that represent a suite of (almost) indistinguishable taxa according to macro- and microscopic criteria, but are clearly different based on phylogenetic inference (Crous et al. 2015). Notably, some of these cryptic species also have different ecology (including host range and pathogenicity), geographic distribution, and/or antifungal susceptibility patterns than their sibling species (Cendejas-Bueno et al. 2012; Howard 2014; Crous et al. 2015; Barrs and Talbot 2020). For example, *Aspergillus felis* is an emerging agent of invasive aspergillosis in cats, dogs, and humans which phenotypically resembles its close relatives *A. viridinutans* and *A. fumigatus* but can be differentiated from these by molecular-based methods and often displays itraconazole and voriconazole cross-resistance (Barrs et al. 2013; Álvarez-Pérez et al. 2014b; Barrs and Talbot 2020). Therefore, accurate identification of clinical isolates to the species level may be helpful for effective antifungal treatment. However, some cryptic species do not have predictable susceptibility patterns, so in vitro susceptibility remains as an invaluable tool to aid directed antifungal therapy (Howard 2014). Unfortunately, to date, polyphasic identification and susceptibility testing of fungal isolates recovered from clinical cases are not included in the routine of most veterinary diagnostic laboratories, but are mostly executed during the course of research projects.

10.5.2 Establishment of Meaningful Breakpoints for Antifungal Resistance of Veterinary Isolates

Current efforts for defining CBPs and ECVs for antimicrobial drugs used in veterinary medicine, such as those headed by CLSI's Subcommittee on Veterinary Antimicrobial Susceptibility Testing (VAST) (CLSI 2008a, 2013) and EUCAST's subcommittee for Veterinary Antimicrobial Susceptibility Testing (VetCAST) (Toutain et al. 2017), mostly focus on antibacterial compounds. Furthermore, antifungal susceptibility testing has been standardized mostly using human isolates, and its predictive value for animal isolates remains to be determined (Elad 2018).

In absence of breakpoints for antifungal resistance of fungal isolates of animal origin, published reports on this issue show MIC results without any interpretation of these in terms of susceptibility or resistance (or wild type/non-wild type) (e.g.,

Table 10.3 Comparison of the tentative epidemiological cutoff values (ECVs) for animal isolates of *Candida* spp. with those previously established for human isolates^a

<i>Candida</i> species	Origin of isolates	ECVs (µg/ml)				
		AMB	CAS	FCZ	ITZ	VCZ
<i>C. albicans</i>	Human	2	0.125	0.5	0.125	0.0312
	Animal	1	0.25	≥64	≥16	1
<i>C. parapsilosis</i> ‘sensu lato’	Human	2	1	2	0.5	0.125
	Animal	1	2	4	0.5	NA
<i>C. tropicalis</i>	Human	2	0.125	2	0.5	0.0625
	Animal	1	1	≥64	≥16	1

^aAbbreviations: AMB amphotericin B, CAS caspofungin, ECVs epidemiological cutoff values, FCZ fluconazole, ITZ itraconazole, NA not available, VCZ voriconazole. Source of data: Cordeiro et al. (2017), Castelo-Branco et al. (2020), and references therein

Álvarez-Pérez et al. 2014a; Talbot et al. 2019; Aneke et al. 2020), establish their own in-house breakpoints (e.g., Cafarchia et al. 2012b, c), or use the CBPs/ECVs established for human isolates of the tested fungal species (e.g., Wang et al. 2014; Cordeiro et al. 2015; Talbot et al. 2015; Álvarez-Pérez et al. 2016c; Brilhante et al. 2016) or other different species (e.g., Cafarchia et al. 2012a). Tentative ECVs for animal isolates of some yeast species such as *Candida albicans*, *Candida parapsilosis* ‘sensu lato’ and *Candida tropicalis* (Cordeiro et al. 2017; Castelo-Branco et al. 2020), and *Malassezia pachydermatis* (Cafarchia et al. 2015) have also been proposed. Notably, the fluconazole, itraconazole, and voriconazole ECVs proposed by Castelo-Branco et al. (2020) for *C. albicans* and *C. tropicalis* are remarkably higher than those determined for human isolates (Table 10.3), thus emphasizing the importance of azole resistance among *Candida* isolates from animals. Nevertheless, these tentative ECVs should be further validated by testing larger collections of fungal isolates of animal origin and by determining if non-wild-type isolates actually display any mechanism of antifungal resistance. Furthermore, it would be desirable to establish specific ECVs for different animal groups (e.g., small animals, horses, and ruminants), as the epidemiology of fungal infections and antifungal pressures may be different in each group.

10.5.3 Reduction of the Environmental Impact of Antifungal Use

Residuals of the antifungal compounds used in veterinary medicine can eventually enter the environment, especially when the treatment is applied topically or the compounds are used for fungal decontamination of hatcheries and other farm facilities (Chen and Ying 2015; Bártíková et al. 2016). Such environmental contamination with antifungal residuals may affect non-target fungi and potentially alter key ecosystem functions (Dijksterhuis et al. 2011; Dimitrov et al. 2014; Chen and Ying 2015; Álvarez-Pérez et al. 2016a). Furthermore, the presence of sublethal

concentrations of antifungals in the environment can select for fungal species and strains that are less susceptible to these compounds and, eventually, result in the emergence of resistant phenotypes that may become a threat for human and animal hosts (Faria-Ramos et al. 2014; Buil et al. 2019; Schoustra et al. 2019). Therefore, there is an urgent need to minimize the amount of antifungals released to the environment and reduce their potential side effects.

10.6 Conclusion

Despite recent advances in the study of the prevalence and mechanisms of antifungal resistance among fungal isolates of animal origin, there is still little public awareness about the relevance of antifungal resistance in veterinary medicine, especially when compared with the current focus on the emergence of antibiotic-resistant bacteria. Therefore, in our modest view, veterinarians and other animal health professionals should take action to demand more resources for improving the monitoring of fungal infections and antifungal resistances in veterinary clinics and the farming system worldwide. Additionally, a closer collaboration and improved data sharing between researchers working on animal mycology would also be welcome.

Acknowledgments Sergio Álvarez-Pérez acknowledges a “Ramón y Cajal” contract funded by the Spanish Ministry of Science and Innovation [RYC2018-023847-I]. The funders had no role in the preparation of the manuscript or decision to publish.

References

- Álvarez-Pérez S, Blanco JL, Peláez T, Cutuli M, García ME (2014a) *In vitro* amphotericin B susceptibility of *Malassezia pachydermatis* determined by the CLSI broth microdilution method and Etest using lipid-enriched media. *Antimicrob Agents Chemother* 58(7):4203–4206
- Álvarez-Pérez S, Mellado E, Serrano D, Blanco JL, García ME, Kwon M, Muñoz P, Cuenca-Estrella M, Bouza E, Peláez T (2014b) Polyphasic characterization of fungal isolates from a published case of invasive aspergillosis reveals misidentification of *Aspergillus felis* as *Aspergillus viridinutans*. *J Med Microbiol* 63(4):617–619
- Álvarez-Pérez S, de Vega C, Pozo MI, Lenaerts M, Van Assche A, Herrera CM, Jacquemyn H, Lievens B (2016a) Nectar yeasts of the *Metschnikowia* clade are highly susceptible to azole antifungals widely used in medicine and agriculture. *FEMS Yeast Res* 16(1):fov115. <https://doi.org/10.1093/femsyr/fov115>
- Álvarez-Pérez S, García ME, Cutuli MT, Fermín ML, Daza MA, Peláez T, Blanco JL (2016b) Acquired multi-azole resistance in *Candida tropicalis* during persistent urinary tract infection in a dog. *Med Mycol Case Rep* 11:9–12
- Álvarez-Pérez S, García ME, Peláez T, Martínez-Nevado E, Blanco JL (2016c) Antifungal susceptibility testing of ascomycetous yeasts isolated from animals. *Antimicrob Agents Chemother* 60(8):5026–5028

- Aneke CI, Rhimi W, Pellicoro C, Cantacessi C, Otranto D, Cafarchia C (2020) The best type of inoculum for testing the antifungal drug susceptibility of *Microsporum canis*: in vivo and in vitro results. *Mycoses* 63(7):711–716
- Antonissen G, Martel A (2018) Antifungal therapy in birds: old drugs in a new jacket. *Vet Clin North Am Exot Anim Pract* 21(2):355–377
- Arendrup MC, Verweij PE, Mouton JW, Lagrou K, Meletiadis J (2017) Multicentre validation of 4-well azole agar plates as a screening method for detection of clinically relevant azole-resistant *Aspergillus fumigatus*. *J Antimicrob Chemother* 72(12):3325–3333
- Arendrup MC, Meletiadis J, Mouton JW, Lagrou K, Hamal P, Guinea J, and the Subcommittee on Antifungal Susceptibility Testing (AFST) of the ESCMID European Committee for Antimicrobial Susceptibility Testing (EUCAST) (2020a) EUCAST DEFINITIVE DOCUMENT E.DEF 9.3.2. Method for the determination of broth dilution minimum inhibitory concentrations of antifungal agents for conidia forming moulds. https://www.eucast.org/astoffungi/methodsinantifungalsusceptibilitytesting/ast_of_moulds/. Accessed on 25 Aug 2020
- Arendrup MC, Meletiadis J, Mouton JW, Lagrou K, Hamal P, Guinea J, and the Subcommittee on Antifungal Susceptibility Testing (AFST) of the ESCMID European Committee for Antimicrobial Susceptibility Testing (EUCAST) (2020b) EUCAST DEFINITIVE DOCUMENT E.DEF 7.3.2. Method for the determination of broth dilution minimum inhibitory concentrations of antifungal agents for yeasts. https://www.eucast.org/astoffungi/methodsinantifungalsusceptibilitytesting/susceptibility_testing_of_yeasts/. Accessed on 25 Aug 2020
- Asfaw M, Dawit D (2016) Review on major fungal disease of poultry. *Br J Poult Sci* 6(1):16–25
- Azevedo MM, Faria-Ramos I, Cruz LC, Pina-Vaz C, Rodrigues AG (2015) Genesis of azole antifungal resistance from agriculture to clinical settings. *J Agric Food Chem* 63(34):7463–7468
- Barrs VR, van Doorn TM, Houbraken J, Kidd SE, Martin P, Pinheiro MD, Richardson M, Varga J, Samson RA (2013) *Aspergillus felis* sp. nov., an emerging agent of invasive aspergillosis in humans, cats, and dogs. *PLoS One* 8(6):e64871. <https://doi.org/10.1371/journal.pone.0064871>
- Barrs VR, Talbot JJ (2020) Fungal rhinosinusitis and disseminated invasive aspergillosis in cats. *Vet Clin North Am Small Anim Pract* 50(2):331–357
- Bártíková H, Podlipná R, Skálová L (2016) Veterinary drugs in the environment and their toxicity to plants. *Chemosphere* 144:2290–2301
- Beardsley J, Halliday CL, Chen SC, Sorrell TC (2018) Responding to the emergence of antifungal drug resistance: perspectives from the bench and the bedside. *Future Microbiol* 13(10):1175–1191
- Belanger ES, Yang E, Forrest GN (2015) Combination antifungal therapy: when, where, and why. *Curr Clin Micro Rpt* 2:67–75
- Berger S, El Chazli Y, Babu AF, Coste AT (2017) Azole resistance in *Aspergillus fumigatus*: a consequence of antifungal use in agriculture? *Front Microbiol* 8:1024. <https://doi.org/10.3389/fmicb.2017.01024>
- Bond R, Morris DO, Guillot J, Bensignor EJ, Robson D, Mason KV, Kano R, Hill PB (2020) Biology, diagnosis and treatment of *Malassezia* dermatitis in dogs and cats: Clinical Consensus Guidelines of the World Association for Veterinary Dermatology. *Vet Dermatol* 31(1):75. <https://doi.org/10.1111/vde.12809>
- Brilhante RS, Bittencourt PV, Castelo-Branco Dde S, de Oliveira JS, Alencar LP, Cordeiro RA, Pinheiro M, Nogueira-Filho EF, Pereira-Neto Wde A, Sidrim JJ, Rocha MF (2016) Trends in antifungal susceptibility and virulence of *Candida* spp. from the nasolacrimal duct of horses. *Med Mycol* 54(2):147–154
- Buil JB, Hare RK, Zwaan BJ, Arendrup MC, Melchers WJG, Verweij PE (2019) The fading boundaries between patient and environmental routes of triazole resistance selection in *Aspergillus fumigatus*. *PLoS Pathog* 15(8):e1007858. <https://doi.org/10.1371/journal.ppat.1007858>
- Bunskoek PE, Seyedmousavi S, Gans SJ, van Vierzen PBJ, Melchers WJG, van Elk CE, Mouton JW, Verweij PE (2017) Successful treatment of azole-resistant invasive aspergillosis in a bottle-nose dolphin with high-dose posaconazole. *Med Mycol Case Rep* 16:16–19

- Cafarchia C, Figueredo LA, Favuzzi V, Surico MR, Colao V, Iatta R, Montagna MT, Otranto D (2012a) Assessment of the antifungal susceptibility of *Malassezia pachydermatis* in various media using a CLSI protocol. *Vet Microbiol* 159(3–4):536–540
- Cafarchia C, Figueredo LA, Iatta R, Colao V, Montagna MT, Otranto D (2012b) *In vitro* evaluation of *Malassezia pachydermatis* susceptibility to azole compounds using E-test and CLSI micro-dilution methods. *Med Mycol* 50(8):795–801
- Cafarchia C, Figueredo LA, Iatta R, Montagna MT, Otranto D (2012c) *In vitro* antifungal susceptibility of *Malassezia pachydermatis* from dogs with and without skin lesions. *Vet Microbiol* 155(2–4):395–398
- Cafarchia C, Iatta R, Immediato D, Puttilli MR, Otranto D (2015) Azole susceptibility of *Malassezia pachydermatis* and *Malassezia furfur* and tentative epidemiological cut-off values. *Med Mycol* 53(7):743–748
- Castelo-Branco DSCM, Paiva MAN, Teixeira CEC, Caetano ÉP, Guedes GMM, Cordeiro RA, Brilhante RSN, Rocha MFG, Sidrim JJC (2020, 135) Azole resistance in *Candida* from animals calls for the One Health approach to tackle the emergence of antimicrobial resistance. *Med Mycol Myz*. <https://doi.org/10.1093/mmy/myz135>
- CDC (2019) Antibiotic resistance threats in the United States, 2019. Department of Health and Human Services. Centers for Disease Control and Prevention, Atlanta, GA, USA
- Cendejas-Bueno E, Kolečka A, Alastruey-Izquierdo A, Theelen B, Groenewald M, Kostrzewa M, Cuenca-Estrella M, Gómez-López A, Boekhout T (2012) Reclassification of the *Candida haemulonii* complex as *Candida haemulonii* (*C. haemulonii* group I), *C. duobushaemulonii* sp. nov. (*C. haemulonii* group II), and *C. haemulonii* var. *vulnera* var. nov.: three multiresistant human pathogenic yeasts. *J Clin Microbiol* 50(11):3641–3651
- Chen ZF, Ying GG (2015) Occurrence, fate and ecological risk of five typical azole fungicides as therapeutic and personal care products in the environment: a review. *Environ Int* 84:142–153
- CLSI (2008a) Development of in vitro susceptibility testing criteria and quality control parameters for veterinary antimicrobial agents; approved guideline, 3rd edn. CLSI document VET02-A3. Clinical and Laboratory Standards Institute, Wayne, PA, USA
- CLSI (2008b) Reference method for broth dilution antifungal susceptibility testing of yeasts; approved standard, 3rd edn. CLSI document M27-A3. Clinical and Laboratory Standards Institute, Wayne, PA, USA
- CLSI (2008c) Reference method for broth dilution antifungal susceptibility testing of filamentous fungi; approved standard, 2nd edn. CLSI document M38-A2. Clinical and Laboratory Standards Institute, Wayne, PA, USA
- CLSI (2013) Performance standards for antimicrobial disk and dilution susceptibility tests for bacteria isolated from animals; approved standard, 4th edn. CLSI document VET01-A4, Clinical and Laboratory Standards Institute, Wayne, PA, USA
- CLSI (2020) Epidemiological cutoff values for antifungal susceptibility testing, 3rd edn. CLSI supplement M59. Clinical and Laboratory Standards Institute, Wayne, PA, USA
- Cordeiro RA, de Oliveira JS, Castelo-Branco Dde S, Teixeira CE, Marques FJ, Bittencourt PV, Carvalho VL, Bandeira Tde J, Brilhante RS, Moreira JL, Pereira-Neto Wde A, Sidrim JJ, Rocha MF (2015) *Candida tropicalis* isolates obtained from veterinary sources show resistance to azoles and produce virulence factors. *Med Mycol* 53(2):145–152
- Cordeiro RA, Sales JA, Castelo-Branco DSCM, Brilhante RSN, Ponte YB, Dos Santos Araújo G, Mendes PBL, Pereira VS, Alencar LP, Pinheiro AQ, Sidrim JJC, Rocha MFG (2017) *Candida parapsilosis* complex in veterinary practice: a historical overview, biology, virulence attributes and antifungal susceptibility traits. *Vet Microbiol* 212:22–30
- Crisoe G, Scordino F, Romeo O (2015) Current methods for identifying clinically important cryptic *Candida* species. *J Microbiol Methods* 111:50–56
- Crous PW, Hawksworth DL, Wingfield MJ (2015) Identifying and naming plant-pathogenic fungi: past, present, and future. *Annu Rev Phytopathol* 53:247–267
- Delarze E, Sanglard D (2015) Defining the frontiers between antifungal resistance, tolerance and the concept of persistence. *Drug Resist Updat* 23:12–19

- Dias MF, Quaresma-Santos MV, Bernardes-Filho F, Amorim AG, Schechtman RC, Azulay DR (2013) Update on therapy for superficial mycoses: review article part I. *An Bras Dermatol* 88(5):764–774
- Dijksterhuis J, van Doorn T, Samson R, Postma J (2011) Effects of seven fungicides on non-target aquatic fungi. *Water Air Soil Pollut* 222(1–4):421–425
- Dimitrov MR, Kosol S, Smidt H, Buijse L, Van den Brink PJ, Van Wijngaarden RP, Brock TC, Maltby L (2014) Assessing effects of the fungicide tebuconazole to heterotrophic microbes in aquatic microcosms. *Sci Total Environ* 490:1002–1011
- Elad D (2018) Therapy of non-dermatophytic mycoses in animals. *J Fungi* 4(4):120. <https://doi.org/10.3390/jof4040120>
- Elad D, Segal E (2018) Diagnostic aspects of veterinary and human aspergillosis. *Front Microbiol* 9:1303. <https://doi.org/10.3389/fmicb.2018.01303>
- Faria-Ramos I, Tavares PR, Farinha S, Neves-Maia J, Miranda IM, Silva RM, Estevinho LM, Pina-Vaz C, Rodrigues AG (2014) Environmental azole fungicide, prochloraz, can induce cross-resistance to medical triazoles in *Candida glabrata*. *FEMS Yeast Res* 14(7):1119–1123
- Favre B, Hofbauer B, Hildering KS, Ryder NS (2003) Comparison of in vitro activities of 17 antifungal drugs against a panel of 20 dermatophytes by using a microdilution assay. *J Clin Microbiol* 41(10):4817–4819
- Fisher MC, Hawkins NJ, Sanglard D, Gurr SJ (2018) Worldwide emergence of resistance to antifungal drugs challenges human health and food security. *Science* 360(6390):739–742
- Foy DS, Trepanier LA (2010) Antifungal treatment of small animal veterinary patients. *Vet Clin North Am Small Anim Pract* 40(6):1171–1188
- Gintjee TJ, Donnelley MA, Thompson GR 3rd (2020) Aspiring antifungals: review of current antifungal pipeline developments. *J Fungi* 6(1):28. <https://doi.org/10.3390/jof6010028>
- Gubbins PO, Amsden JR (2005) Drug-drug interactions of antifungal agents and implications for patient care. *Expert Opin Pharmacother* 6(13):2231–2243
- Guinea J, Verweij PE, Meletiadiis J, Mouton JW, Barchiesi F, Arendrup MC, Subcommittee on Antifungal Susceptibility Testing (AFST) of the ESCMID European Committee for Antimicrobial Susceptibility Testing (EUCAST) (2019) How to: EUCAST recommendations on the screening procedure E.Def 10.1 for the detection of azole resistance in *Aspergillus fumigatus* isolates using four-well azole-containing agar plates. *Clin Microbiol Infect* 25(6):681–687
- Howard SJ (2014) Multi-resistant aspergillosis due to cryptic species. *Mycopathologia* 178:435–439
- Johnson MD, Perfect JR (2010) Use of antifungal combination therapy: agents, order, and timing. *Curr Fungal Infect Rep* 4(2):87–95
- Kano R, Yokoi S, Kariya N, Oshimo K, Kamata H (2019) Multi-azole-resistant strain of *Malassezia pachydermatis* isolated from a canine *Malassezia* dermatitis. *Med Mycol* 57(3):346–350
- Kano R, Aramaki C, Murayama N, Mori Y, Yamagishi K, Yokoi S, Kamata H (2020) High multi-azole-resistant *Malassezia pachydermatis* clinical isolates from canine *Malassezia* dermatitis. *Med Mycol* 58(2):197–200
- Kim M, Cho YJ, Park M, Choi Y, Hwang SY, Jung WH (2018) Genomic tandem quadruplication is associated with ketoconazole resistance in *Malassezia pachydermatis*. *J Microbiol Biotechnol* 28(11):1937–1945
- Klastersky J (2004) Empirical antifungal therapy. *Int J Antimicrob Agents* 23(2):105–112
- Kwon-Chung KJ (2018) Foreword. In: Seyedmousavi S, de Hoog GS, Guillot J, Verweij PE (eds) *Emerging and epizoonotic fungal infections in animals*. Springer, Cham, Switzerland, pp v–vi
- Mazu TK, Bricker BA, Flores-Rozas H, Ablordeppay SY (2016) The mechanistic targets of antifungal agents: an overview. *Mini Rev Med Chem* 16(7):555–578
- Moriello KA, Coyner K, Paterson S, Mignon B (2017) Diagnosis and treatment of dermatophytosis in dogs and cats. *Clinical Consensus Guidelines of the World Association for Veterinary Dermatology*. *Vet Dermatol* 28(3):266–e68
- Nakasu CCT, Waller SB, Ripoll MK, Ferreira MRA, Conceição FR, Gomes ADR, Osório LDG, de Faria RO, Cleff MB (2020) Feline sporotrichosis: a case series of itraconazole-resistant

- Sporothrix brasiliensis* infection. Braz J Microbiol. <https://doi.org/10.1007/s42770-020-00290-5>
- Nawrot U, Wieliczko A, Włodarczyk K, Kurzyk E, Brillowska-Dąbrowska A (2019) Low frequency of itraconazole resistance found among *Aspergillus fumigatus* originating from poultry farms in Southwest Poland. J Mycol Med 29(1):24–27
- Ostrosky-Zeichner L (2012) Invasive mycoses: diagnostic challenges. Am J Med 125(1 Suppl):S14–S24
- Ostrosky-Zeichner L, Andes D (2017) The role of in vitro susceptibility testing in the management of *Candida* and *Aspergillus*. J Infect Dis 216(Suppl 3):S452–S457
- Paulussen C, Hallsworth JE, Álvarez-Pérez S, Nierman WC, Hamill PG, Blain D, Rediers H, Lievens B (2017) Ecology of aspergillosis: insights into the pathogenic potency of *Aspergillus fumigatus* and some other *Aspergillus* species. Microb Biotechnol 10(2):296–322
- Perlín DS, Rautemaa-Richardson R, Alastruey-Izquierdo A (2017) The global problem of antifungal resistance: prevalence, mechanisms, and management. Lancet Infect Dis 17(12):e383–e392
- Prestinaci F, Pezzotti P, Pantosti A (2015) Antimicrobial resistance: a global multifaceted phenomenon. Pathog Glob Health 109(7):309–318
- Rocha MFG, Bandeira SP, de Alencar LP, Melo LM, Sales JA, Paiva MAN, Teixeira CEC, Castelo-Branco DSCM, Pereira-Neto WA, Cordeiro RA, Sidrim JJC, Brilhante RSN (2017) Azole resistance in *Candida albicans* from animals: highlights on efflux pump activity and gene overexpression. Mycoses 60(7):462–468
- Rochette F, Engelen M, Vanden Bossche H (2003) Antifungal agents of use in animal health – practical applications. J Vet Pharmacol Ther 26(1):31–53
- Sanguinetti M, Posteraro B (2018) Susceptibility testing of fungi to antifungal drugs. J Fungi 4(3):110. <https://doi.org/10.3390/jof4030110>
- Schoustra SE, Debets AJM, Rijs AJMM, Zhang J, Snelders E, Leendertse PC, Melchers WJG, Rietveld AG, Zwaan BJ, Verweij PE (2019) Environmental hotspots for azole resistance selection of *Aspergillus fumigatus*, the Netherlands. Emerg Infect Dis 25(7):1347–1353
- Seyedmousavi S, Wiederhold NP, Ebel F, Hedayati MT, Rafati H, Verweij PE (2018) Antifungal use in veterinary practice and emergence of resistance. In: Seyedmousavi S, de Hoog GS, Guillot J, Verweij PE (eds) Emerging and epizootic fungal infections in animals. Springer, Cham, Switzerland, pp 359–402
- Sykes JE, Hodge G, Singapurí A, Yang ML, Gelli A, Thompson GR 3rd (2017) *In vivo* development of fluconazole resistance in serial *Cryptococcus gattii* isolates from a cat. Med Mycol 55(4):396–401
- Talbot JJ, Kidd SE, Martin P, Beatty JA, Barrs VR (2015) Azole resistance in canine and feline isolates of *Aspergillus fumigatus*. Comp Immunol Microbiol Infect Dis 42:37–41
- Talbot JJ, Frisvad JC, Meis JF, Hagen F, Verweij PE, Hibbs DE, Lai F, Groundwater PW, Samson RA, Kidd SE, Barrs VR, Houbbraken J (2019) *cyp51A* mutations, extrolite profiles, and antifungal susceptibility in clinical and environmental isolates of the *Aspergillus viridinutans* species complex. Antimicrob Agents Chemother 63(11):e00632–e00619. <https://doi.org/10.1128/AAC.00632-19>
- Toutain PL, Bousquet-Mélou A, Damborg P, Ferran AA, Mevius D, Pelligand L, Veldman KT, Lees P (2017) En route towards European clinical breakpoints for veterinary antimicrobial susceptibility testing: a position paper explaining the VetCAST approach. Front Microbiol 8:2344. <https://doi.org/10.3389/fmicb.2017.02344>
- van der Linden JW, Camps SM, Kampinga GA, Arends JP, Debets-Ossenkopp YJ, Haas PJ, Rijnders BJ, Kuijper EJ, van Tiel FH, Varga J, Karawajczyk A, Zoll J, Melchers WJ, Verweij PE (2013) Aspergillosis due to voriconazole highly resistant *Aspergillus fumigatus* and recovery of genetically related resistant isolates from domiciles. Clin Infect Dis 57(4):513–520
- Wang DY, Gricourt M, Arné P, Thierry S, Seguin D, Chermette R, Huang WY, Dannaoui E, Botterel F, Guillot J (2014) Mutations in the *Cyp51A* gene and susceptibility to itraconazole in *Aspergillus fumigatus* isolated from avian farms in France and China. Poult Sci 93(1):12–15
- Wiederhold NP (2017) Antifungal resistance: current trends and future strategies to combat. Infect Drug Resist 10:249–259

Index

A

- Accidental skin infiltration, 131
- Actidione, 96
- Adaptation mechanisms, 52
- Adaptive immune system
 - CD8+T cells, 149
 - CR3, 147
 - DC-SIGN, 147
 - Dectin-1, 146
 - Dectin-2, 146
 - humoral immunity, 149
 - IL-17 defenses, 147
 - inflammasomes, 149
 - Mincle, 146
 - MR, 147
 - PPRs, 145
 - regulatory T cells, 145
 - T-and B-cell immunity, 149
 - Th1 immunity, 148
 - Th2 immunity, 148
 - Th17 immunity, 148
- Adjuvant therapy, 101, 102
- Affinity probe capillary electrophoresis
 - (APCE) assay, 18
- Aflatoxins (AF), 16, 18, 24, 25, 27, 28, 130
- Aged/immune-compromised individuals, 96
- Agglutinin-like sequence (ALS), 132
- Airborne manner, 7
- Allergic bronchopulmonary aspergillosis
 - (ABPA), 139
- Alleviate symptoms (pruritus), 42
- Allium porrum*, 137
- Allylamines, 94, 100, 164
- Alternative animal model, 88
- Ambient temperature, 131
- Amphibians, 83, 84
- Amphotericin B, 7
- Anal candidiasis, 37
- Animal medicine, 172
- Animal pathogenic fungi, 173
- Annelids, 84
- Antibiotic penicillin, 16
- Antibiotic resistance, 163
- Antibiotic therapy, 5
- Antifungal activity, 43
- Antifungal agents, 85, 87
- Antifungal armamentarium, 163
- Antifungal classes, 165
- Antifungal drug, 3, 4, 6, 9, 86, 94, 102
 - biosynthetic pathway, 167
 - compound classes, 164
 - health and food security, 167
 - in vitro susceptibility testing, 167
 - limitations, 163
 - pharmacokinetics and optimal dosage, 166
 - resistance, 163
- Antifungal medications, 144
- Antifungal resistance
 - animal isolates, 171
 - animal origin, 164, 170
 - animal pathogenic fungi, 164
 - clinical setting, 167
 - environmental origin, 167
 - fungal isolates, 173, 175
 - fungal pathogens, 172
 - gene mutations, 172
 - impact, 164
 - in vitro detection and characterization, 169
 - mechanism, 167, 170, 171
 - non-exclusive mechanisms, 167

- Antifungal resistance (*cont.*)
 non-wild-type isolates, 174
 suboptimal, 163
 veterinary clinics, 169, 175
- Antifungal resistance/tolerance, 93, 94, 101
- Antifungal susceptibility test, 99
 animal isolates, 164, 173
 commercial systems, 168
 filamentous fungi, 170
 fungal isolates, 169
 in vitro antifungal, 167
 polyphasic identification, 173
- Antifungal targets, 86
- Antifungal therapy
 antifungal activity, 164
 azoles, 164
 clinical recovery, 166
 dermatophytosis, 166
 environmental considerations, 166
 environmental factors, 166
 human and animal medicine, 165
 human and animal patients, 166
 human and animal protection, 164
 human therapy, 166
 veterinary setting, 166
- Antifungal treatment*, 85
- APRES, 21
- Aptamer-related techniques, 18
- Arabian horse, 128
- ArrayExpress, 52
- Arthrospores, 99
- Aspergillosis, 4, 5, 79
 antifungal agents, 116
Aspergillus species, 105
 bronchopulmonary aspergillosis, 108
 chemotherapy, 116
 DCA, 107
 direct lytic effect, 116
 drugs, 116
 Posaconazole, 116
 SNA, 105–106
 topical antifungal treatment, 116
 topical clotrimazole, 116
- Aspergillus*, 52
- Aspergillus felis*, 173
- Aspergillus fumigatus*, 52, 53, 79, 80, 132, 172
- Aspergillus* Genome Database (AspGD), 52
- Aspergillus ochraceus*, 18
- Aspergillus pulmonary* infection, 143
- Aspergillus* species, 4
- Aspergillus viridinutans*, 171
- Azole, 86, 100, 130, 164
- Azole-supplemented screening plates, 168
- B**
- Bacteriophage *E* lysis gene, 150
- Basement membranes, 132
- Batrachochytrium dendrobatidis*, 83
- Baxter's medium, 96
- Biochemical and biosynthetic pathways, 86
- Bioconductor (Version 3.11), 51
- Biopsy material, 76
- Biopsy specimens, 109
- Blastomyces dermatitidis*, 7, 109
- Blastomycosis
B. dermatitidis, 109, 110
 blood parameters, 111
 clinical signs, 111
 commonness, 110
 cytological examination, 111
 cytology/histopathology, 111
 EIA, 111
 granulomatous/pyogranulomatous inflammation, 110
 mycelium form, 111
 ocular lesions, 110
 pathogenesis, 111
 prevention methods, 117
 respiratory abnormalities, 110
 respiratory/disseminated infection, 110
 saprophytic mycelial forms, 110
 snowstorm pattern, 110
 systemic fungal infection, 109
- Borelli lactrimel agar, 96
- Bovine alimentary mycosis, 79
- Bovines
 agricultural sector and economy, 1
 aspergillosis, 4, 5
 cutaneous pythiosis, 8, 9
 epizootic lymphangitis, 2, 3
 farm animals, 1
 fungal abortions, 7, 8
 mycotic mastitis, 5, 6
 paracoccidioidomycosis, 7
 pithomycotoxicosis, 9, 10
 ringworm (dermatomycosis), 3, 4
 species and domesticated, 1, 2
 sporotrichosis, 6
 subfamily, 1
 zygomycosis (mucormycosis), 10
- Bronchoalveolar lavage samples, 108
- Bronchopulmonary aspergillosis, 108, 116
- C**
- Calm-tempered animals, 128
- Calotropis procera*, 43
- Candida albicans*, 35, 40, 53, 134, 170

- Candida Genome Database (CGD), 52
- Candida* isolates, 170
- Candida pintolopesii*, 78
- Candida* sp., 5, 6, 79, 131, 132, 170
- Candida tropicalis*, 170
- CandidaDB, 52
- Candidiasis
 - anal, 37
 - chronic candidiasis, 35
 - colony formation, 35
 - diagnosis, 39
 - genital, 36
 - intrauterine, 36, 37
 - nail, 37, 38
 - oral and perioral, 38
 - predisposing factors, 38, 39
 - prevention, 39, 40
 - signals and symptoms, 39
 - treatment, 40
 - yeast, 35
- Candidosis, 66
- Canine sinonasal aspergillosis (SNA)
 - A. fumigatus*, 106
 - Aspergillus* species, 106
 - chronic nasal disease, 106
 - clinical diagnosis, 106
 - clinical signs, 106
 - common form, 105
 - depigmentation, 106
 - diagnostic imaging, 106
 - dogs infection, 106
 - dolichocephalic/mesaticephalic head, 106
 - rhinoscopic examination, 106
- Cardiovascular blastomycosis, 110
- Carnivores, 128
- Catharanthus roseus*, 42
- Cattle
 - aflatoxins, 28
 - deoxynivalenol, 28
 - diagnosis, 29
 - extremes, 27
 - Fumonisin B1, 28, 29
 - fungal growth and production, 27
 - in milk, 27
 - T-2 toxin, 28
 - treatment, 29
- Cattle farming, 3
- Cattles, 78
- CD103+ DCs cross-present antigens, 141
- CD8+T cells, 149
- Cell-mediated host response
 - conventional DCs, 143
 - DC/monocyte subsets characterization, 142, 143
 - inflammatory DCs, 144
 - migratory DCs, 143
 - monocytes, 144
 - pDCs, 143
- Cell-mediated immunity, 40, 108
- Centers for Disease Control and Prevention, 164
- Central Aspergillus Data Repository (CADRE), 52
- Central nervous system (CNS), 119
- Chaetothyriales*, 84
- Chemiluminescent ELISA, 18
- Chemoprophylaxis, 171
- Chloramphenicol, 96
- Cholangiohepatitis, 10
- Chronic aspergillosis, 81
- Chronic candidiasis, 35, 38
- Chronic pulmonary histoplasmosis, 112
- Chytridiomycosis, 83
- Clinical and Laboratory Standards Institute (CLSI), 167
- CLSI-based method, 170
- Colony morphology, 45
- Common fungal infections, lab animals
 - amphibians, 83, 84
 - candidiasis, 73
 - categories, 73
 - cattles, 78–80
 - fungal spores, 73
 - guinea pigs, 78
 - histopathology (*see* Histopathological diagnosis)
 - indirect infections, 73
 - invertebrates, 84, 85
 - laboratory birds, 81–82
 - murine animals and rodents, 78
 - opportunistic fungal pathogens, 74
 - rabbit-derived pathogenic dermatophytes, 78
 - rats, 78
 - reptiles, 82, 83
 - swine, 80
 - systemic, 74
- Common superficial mycosis, 79
- Complement receptor 3 (CR3), 147
- Comprehensive digestive stool analysis (CDSA), 39
- Computational modeling
 - biological network modeling (*see* Network modeling)
 - fungal-human interactome network, 55
 - regulatory biological strategies, 55
 - TransNet analysis, 55
- Conidiobolomycosis, 68, 69

Conventional DCs, 143
 Corticosteroids, 118
 Crustaceans, 84
 Cryptic species, 173
 Cryptococcosis, 66, 67
Cryptococcus, 53
Cryptococcus gattii, 171
Cryptococcus neoformans, 52
 Cutaneous pythiosis, 8, 9
 Cycloheximide, 96
 Cytotoxic T lymphocytes (CTLs), 141

D

Dairy industry, 5
 DC-SIGN, 147
 Dead fungi, 136
 Dectin-1, 146
 Dectin-2, 146
 Dendrimers, 101
 Deoxynivalenol (DON), 24, 28
 Dermatophytes, 3, 79, 131
 Dermatophytosis
 animals and reservoirs, 97–98
 antifungal drug resistance, 94
 biosynthetic pathway, 94
 cell-mediated immunity, 40
 classification, 94
 climate conditions, 108
 colonies, 40
 colonization, 99
 communicability, 44
 conventional techniques, 76
 cultural characteristics, 96
 definitive diagnosis, 109
 dermatophytes, 75
 diagnosis, 44, 45, 75, 109
 epidemiology, 96
 Epidermophyton, 40, 94
 fungal agents, 108
 fungal hyphae, 109
 fungi Microsporum, 75
 fungi Trichophyton, 75
 hair/trichogram, 76
 hot and humid climate, 94
 hunting and training dogs, 108
 hygienic measures, 109
 immunosuppressive diseases, 108
 infection progress, 108
 ketoconazole, 117
 laboratory diagnosis
 accurate, 99
 direct visualization under
 microscope, 100

 isolation and identification, 99
 molecular approaches, 100
 Wood's Lamp, 99
 lesions, 109
 metal oxide nanoparticles, 94
Microsporum, 40, 94, 109
 morphology
 filamentous form, 95
 granular-powdery form, 95–96
 membranous form, 95
 nanoparticle-based remedies, 94
 oral medications, 117
 pathogenesis, 99
 PCR, 109
 prevalence rate, 96
 prevention, 45, 117
 pruritus, 109
 superficial infection, 93
 symptoms, 94
 synthetic drugs, 94
Tinea capitis, 41
Tinea corpora, 41
Tinea cruris, 40
Tinea faciei, 41
Tinea manuum, 41
Tinea pedis, 40
 topical antifungal agents, 117
 transmission, 98
 treatment, 41–44, 100–102
Trichophyton, 40, 41, 94
 types, 40
 Diagnosis
 candidiasis, 39
 cattle, 29
 dermatophytosis, 44, 45
 poultry, 26, 27
 Dimorphic fungus, 109
 Direct visualization, 100
 Disease characterization, 76
 Disease prevention, 6
 Disease transmission, 96
 Disseminated Canine Aspergillosis (DCA)
 abnormalities, 107
 causing factors, 107
 clinical signs, 107
 diagnosis, 107
 German Shepherd Dogs, 107
 granulomatous inflammation, 107
 immunosuppression, 107
 pyogranulomatous inflammation, 107
 Disseminated infections, 6
 Dogs, fungal diseases
 aspergillosis, 105, 116
 blastomycosis, 109–111, 117

- dermatophytosis, 108–109
- diagnosis, 120
- geotrichosis, 114–115, 119
- histoplasmosis, 111–112, 117, 118
- local infections, 119
- phaeohyphomycosis, 115, 119
- rhinosporidiosis, 113, 118
- sporotrichosis, 113–114, 118
- zoonotic, 120
- Drug combination*, 87
- Drug molecules, 86
- Drug resistance, 94, 101, 102
- Drug target protein, 85
- Drynaria quercifolia*, 43
- Dual RNA-seq, 53
- Ductal hyperplasia, 10
- E**
- Echinocandins, 86, 130, 164
- Ecosystem functions, 174
- Egyptian methods, 133, 134, 137
- Eisenia foetida*, 84
- Electrochemical immunosensors, 18
- Elongate hemlock scale (EHS), 84
- Endocarditis, 112
- Endospores, 113
- Enilconazole antifungal, 5
- Entomopathogenic fungal species, 84
- Enzyme immunoassay (EIA), 111
- Enzyme-linked immunosorbent assay (ELISA), 18, 31
- Enzymes, 16
- Epidemiological cutoff values (ECVs/ ECOFFs), 168, 174
- Epidemiology
 - dermatophytosis, 96
- Epidermis-associated LCs, 141
- Epidermophyton*, 40, 93, 94
- Epithelial cells (ECs), 139
- Epizootic lymphangitis, 2, 3
- ERG11* open reading frame, 171
- Ergosterol, 130
- Ergot alkaloids, 24
- Error-prone, 54
- Erythematous nodules, 6
- Eucalyptus rostrata*, 43
- EUCAST protocols, 170
- European Committee on Antifungal
 - Susceptibility Testing (EUCAST), 167
- European Food Safety Authority (EFSA), 16
- Eurotiomycetes*, 4
- Exophiala cancerae*, 84
- Exophiala jeanselmei*, 84
- F**
- Facial dermatitis, 9
- Facial eczema, 9
- Farm animals, 1
- Fatal disease, 136
- Fibrosis, 10
- Fluconazole, 42, 117
- Fluorescein-tagged OTA aptamer (F-Apt-O)-
 - based assays, 18
- Fluorescence microscopy, 53
- Folk remedies, animal immunizations
 - open growing hen, 138
 - young turkeys, 137
- Fonsecaea brasiliensis*, 84
- Food and Drug Administration (USA), 16
- Fumonisin B1, 28, 29
- Fumonisin, 16, 26, 27
- Fungal abortions, 7, 8
- Fungal arthrospores, 98
- Fungal cell wall, 129
- Fungal cultures, 44
- Fungal decontamination, 174
- Fungal diseases
 - bovines (*see* Bovines)
 - ovine (*see* Ovine fungal diseases)
 - transmission, 1, 2
- Fungal ghosts, 150
- Fungal infections
 - animals, 128
 - causative agents, 128
 - causes, 128
 - early warning signs, 128
 - folk medicine, 151–152
 - fungal stains, 88
 - health and environment, 128
 - histopathological diagnosis tools, 77
 - treatment, 85
 - types, 129
- Fungal isolates, 169
- Fungal pathogens, 132
- Fungal therapy, 130
- Fungal toxins and allergic responses, 130
- Fungi, 93
 - attachments, 132
 - cell wall, 129
 - eukaryotes, 128
 - filaments, 129
 - hydrophobic cell surfaces, 131
 - infiltration, 131, 132
 - morphological features, 74
 - obligate aerobes, 131
 - organic matter, 129
 - parasitic/symbiotic relationships, 129
 - secondary metabolite production, 16

Fungi (*cont.*)

- toxins and allergic responses, 130
- types, 128

Fungus

- dimorphic, 109, 113
- isolation and identification, 115
- mycelium, 111
- saprophytic soil, 111
- traumatic wounds, 113

G

- Gastrointestinal (GI), 5, 9, 38
- Gene Expression Omnibus (GEO), 52
- Gene regulatory network (GRN), 55, 56
- Genes encoding, 86
- Genital candidiasis, 36
- Genomics
 - omics-based data, 51, 52
- Gentamicin, 96
- Geophilic species, 98
- Geotrichosis
 - diagnosis, 115
 - G. candidum*, 114
 - granulomas, 114
 - immunocompromised hosts, 114
 - infection symptoms, 114
 - opportunistic pathogen, 115
 - prevention methods, 119
 - radiographic examination, 114
- Geotrichum candidum*, 114
- Global Action Fund for Fungal Infections (GAFFI), 163
- Goats, 63–67, 69
- Granular-powdery form, 95–96
- Granulomatous inflammation, 107
- Granulomatous ulcerative lesions, 8
- Griseofulvin, 42
- Grocott's methenamine-silver nitrate (GMS), 80

H

- Health degeneration, 128
- Healthy poultry, 25
- Hematoxylin-eosin (HE) stain, 77
- High-performance liquid chromatography (HPLC), 18
- High-throughput sequencing, 53
- Histochemical stains, 77
- Histopathological diagnosis
 - dermatophytosis*, 75, 76
 - histochemical stains, 77
 - methods, 74

- microscopic observation, 75
- morphologic interpretation, 75
- P. jiroveci*, 74

systemic mycoses, 76

Histoplasma capsulatum, 111, 143

Histoplasma-containing apoptotic macrophages, 143

Histoplasmosis, 111

- central nervous system symptoms, 112
- disseminated disease, 112
- dog breeds, 111
- endocarditis, 112
- H. capsulatum*, 111, 112
- histoplasma-laden areas, 112
- infection, 112
- mycelial fragments, 112
- noncommunicable systemic infection, 111
- prevention methods, 117, 118
- thoracic abnormalities, 112
- tracheobronchial lymph nodes, 112
- ulcerative lesions, 112

Host defense system, 93

Host interaction, 99

Host-fungal interaction, 49, 55, 58

- in biological system, 50

Host-pathogen interaction, 49, 53–57, 93

Humoral immunity, 149

Humoral mucosal immunity, 108

Hypersensitive responses, 130

Hyphae, 44

I

IL-12 signaling pathway, 148

IL-17 defenses, 147

Image-based data, 53–55

Image-based system biology, 54

Immobilized oligonucleotide probe, 100

Immune system efficacy

- folk practices, 133
- fungal pathogens interactions, 135, 136
- immunity building, 137
- infection/susceptibility/both, 134–137
- traditional medicine, 132

Immunoassays, 18

Immunohistochemical diagnosis, 79

In situ hybridization (ISH), 80

In vitro antifungal susceptibility testing, 169

In vitro susceptibility, 170

In vivo testing, 88

Infections

- candidiasis (*see* Candidiasis)
- dermatophytosis* (*see* Dermatophytosis)
- system biology, 50

- Inflammasomes, 149
 Inflammatory signal, 140
 Innate immunity system
 cell barriers
 DCs, 140
 ECs, 139
 immune cells, 139
 monocytes/macrophages, 140
 neutrophils, 140
 NK cells, 141
 cell-mediated host response, 142–144
 genital-urinary tract, 139
 intestine, 142
 lungs, 141, 142
 respiratory tract, 139
 skin, 138, 141
 Interferon (IFN)- α production, 143
 Internalized conidia, 54
 International Programme on Chemical Safety (IPCS), 16
 Intracellular signaling pathways, 145, 146
 Intrauterine candidiasis, 36, 37
 Invasive pulmonary aspergillosis (IPA), 139
 Invertebrates, 84, 85
 Isogenic fluconazole-susceptible, 171
 Itraconazole, 7
- K**
 Ketoconazole, 7, 117, 171
- L**
 Laboratory birds
 Aspergillosis, 81
 Candida spp., 82
 experimental setup, 81
 fungal disease, 81
 fungal pathogens, 81
 GI stasis, 81
 histopathological diagnosis, 81
 pathogenic species, 81
 respiratory tract infections, 81
 Laboratory rats, 78
 Larynx, 38
 Legal disposition, 31
 Lethargic crab disease (LCD), 84
 Lipid-based nanoparticles, 101
 Liquid chromatography tandem mass spectrometry (LC-MS/MS), 18
 Livestock
 mycotoxins, 23
 Livestock models, 78
 Livestock ruminants, 2, 3, 5
- Long noncoding RNA (lncRNA), 52
 Ly6C+ CCR2+ monocytes, 144
 Lymphangitis, 113
 Lysergic acid diethylamide (LSD), 130
- M**
 Macrophages, 54, 140
 Majocchi's granuloma, 41
 Major facilitator superfamily (MFS), 170
 Major histocompatibility complex (MHC), 141
 Malassezia, 138
 Malasseziosis, 67, 68
 Malt agar, 96
 Mannose receptor (MR), 147
 Manual image data analysis, 54
 Mating tests, 45
 Medicinal plants, 101, 151–152
Mentha piperita, 43
 Mesenteric lymph, 142
 Metabolic network, 57
 Metal nanoparticles, 101
 Metal oxide nanoparticles, 94
 Methenamine silver stain (GMS), 77
 Microarray, 52
 Microflora, 135
 Microorganisms, 5
Microsporum, 40, 93, 94
Microsporum canis, 43, 78
Microsporum genus, 109
 Migratory DCs, 143
 Mincle, 146
 Mineral nutrition, 21
 Minimum effective concentration (MEC), 168
 Minimum fungicidal concentration (MFC), 168
 Minimum inhibitory concentration (MIC), 168
 Mitogen-activated protein kinases (MAPKs), 20
 Moisture, 20
 Molecular approaches, 100
 Mollusks, 84
 Monocyte-derived DCs, 141
 Monocytes, 137, 140
 Monokines, 140
 Mononuclear phagocyte system cells, 7
 mRNA synthesis, 130
 Mucormycosis, 79
 Multidrug-resistant bacterial strains, 163
 Multiphoton microscopy (MPM), 53
 Multiplex RT-PCR (real-time PCR), 100
 Mycelial form, 3
 Mycotic mastitis, 5, 6, 79
 Mycotoxins, 17, 26, 27, 29, 31, 32

Mycotoxicosis, 5, 130
 Mycotoxin-producing fungi, 22
 Mycotoxins, 85
 AFBO, 16
 aflatoxin, 16, 18
 animal rearing, 29
 antibiotic penicillin, 16
 biochemists, 17
 biological factors
 livestock, 23
 plant stress, 21, 22
 transmission, 22, 23
 categorization, 17
 chemical factors
 CO₂, 21
 mineral nutrition, 21
 oxygen, 21
 classifications, 17
 cultivation, 29
 destructive cytotoxicity, 15
 edible animal products, 16
 enzymes, 16
 FB1, 16
 food grains, 17
 fumonisins, 16
 legal disposition, 31
 masked/hidden, 16
 ochratoxins, 16
 OTAs, 18
 physical factors
 moisture, 20
 temperature, 20
 pigs, 23, 24
 primary prevention, 30
 processing, 29
 secondary prevention, 30
 STCs, 16
 temperate and tropical region, 15
 tertiary prevention, 30
 toxic effects, 15
 trichothecenes, 16, 19, 20
 X disease, 15
 ZEAs, 16
 ZEN, 19
Myriangium duriae, 84

N

Nail candidiasis, 37, 38
 Nail scrapings, 44
 Naïve T-cell differentiation, 142
 Nanoemulsions, 101
 Nanoparticle-based remedies, 94
 NanoString, 52

Nanostructured lipid carriers, 101
 Natural antisense transcripts (NAT), 52
 Natural/human-directed selections, 128
 Necrotizing granulomas, 76
 Network modeling
 cellular behavior, 55
 GRN, 55, 56
 metabolic network, 57
 PPI, 56
 signaling network, 56
 Neurological syndrome, 5
 Neutrophils, 140
 NK cells, 141
 NOD-like receptors (NLRPs), 149
 Non-*Candida albicans* *Candida* (NCAC), 35
 Non-homogeneous dispersion, 23
 Non-internalized conidia, 54
 Non-phospholipid vesicles, 101
 Non-photosynthetic microorganisms, 1
 Non-synonymous point mutation, 86
 Numerous yellowish-green, 115

O

Oaiviceps purpura, 130
 Ochratoxin A (OTA), 16, 18, 24–26
 Omics-based data
 Bioconductor (Version 3.11), 51
 genomics, 51, 52
 proteomics, 53
 sequencing techniques, 50
 transcriptomics, 52, 53
 Opportunistic infection, 134
 Opportunistic pathogens, 134
 Oral and perioral candidiasis, 38
 Oral candidiasis, 39
 Oral treatment, 41
 Ovine fungal diseases
 candidosis, 66
 conidiobolomycosis, 68, 69
 cryptococcosis, 66, 67
 malasseziosis, 67, 68
 phaeohyphomycosis, 63, 66
 rhodotorulosis, 68
 ruminant herbivores, 63
 Oxygen, 21
 Oyster mushroom spores, 150

P

Pan-dermatophyte PCR, 78
Paracoccidioides brasiliensis, 7
Paracoccidioides spp., 7, 52
 Paracoccidioidomycosis, 7

- Pathogen-associated molecular patterns (PAMPs), 144
 - Pathogenesis
 - dermatophytosis, 99
 - Pathogenic fungi, 82, 85, 131
 - Pattern recognition receptors (PRRs), 140, 144, 145
 - PCR-based methods, 79
 - PCR–ELISA-based method, 100
 - Penicillium* spp., 107
 - Penicillium viridicatum*, 18
 - Periodic acid Schiff (PAS), 45, 77, 100
 - Peripheral blood mononuclear cells (PBMCs), 147
 - Phaeohyphomycosis, 63, 66
 - canine infections, 115
 - clinical findings, 115
 - common fungus, 115
 - diagnosis, 115
 - etiological agents, 115
 - histopathological examination, 115
 - immunosuppressive therapy, 115
 - mycotic infection, 115
 - prevention methods, 119
 - stress conditions, 115
 - Phagocytosed cells, 54
 - Pharynx, 38
 - Phospholipid vesicles, 101
 - Photodynamic therapy, 101
 - Pigs
 - feed, 23
 - growing and breeding, 23
 - mycotoxin-producing fungi, 23, 24
 - sexual intercourse, 24
 - signs and symptoms, 24
 - transmission, 24
 - young and breeding age, 23
 - Pithomyces chartarum*, 9
 - Pithomycotoxicosis, 9, 10
 - Plant-derived essential oils, 94, 101
 - Plant stress, 21, 22
 - Plants, fungal treatment, 150
 - Plasmacytoid DCs (pDCs), 140, 143
 - Pneumocystis carinii*, 80
 - Pneumocystis* cells, 80
 - Pneumocystis* infection, 80
 - Pneumocystis jiroveci*, 74
 - Pneumocystis* organisms, 80
 - Polycystic ovarian syndrome (PCOS), 78
 - Polyenes, 164
 - Polymerase chain reaction (PCR), 109
 - Polymeric micelles, 101
 - Polymeric nanoparticles, 101
 - Pongamia pinnata*, 43
 - Posaconazole, 116
 - Positron emission tomography-computed tomography (PET/CT), 54
 - Potassium hydroxide (KOH), 44
 - Potato dextrose agar (PDA), 96
 - Poultry
 - aflatoxins, 25
 - birds, 24
 - diagnosis, 26, 27
 - fumonisin, 26
 - healthy, 25
 - meat productivity, 24
 - ochratoxins, 25–26
 - toxicity, 24
 - treatment, 27
 - trichothecenes, 26
 - Pre- and post-azole treatment isolates, 170–171
 - Prevention
 - candidiasis, 39, 40
 - dermatophytosis, 45
 - Primary pulmonary infections, 5
 - Primary systemic mycoses, 74
 - Proinflammatory cytokine production, 138, 140
 - Protein-protein interaction (PPI) networks, 56
 - Proteomics
 - omics-based data, 53
 - PRR deficiencies, 145
 - Pseudallescheria boydii*, 80
 - Pseudomonas aeruginosa*, 136
 - Pyogranulomatous inflammation, 107, 115
- R**
- Random amplified polymorphic DNA (RAPD), 79
 - Ranunculus sceleratus*, 43
 - Rapid histologic assessment, 76
 - Real-time PCR, 100
 - Regulation of Ace2 and Morphogenesis (RAM) network, 56
 - Regulatory T cells, 145
 - Reptiles
 - aldabra tortoise, 82
 - Exophiala* species, 82
 - fungal infections, 82, 83
 - pathogenic fungi, 82
 - skin lesions, 82
 - systemic mycoses, 82
 - Respiratory disease, 80
 - Respiratory tract, 5
 - Rhinosporeidiosis
 - definitive diagnosis, 113
 - general hygienic conditions, 113

- Rhinosporidiosis (*cont.*)
 granulomatous mycotic disease, 113
 infections, 113
 nasal swab samples, 113
 Polyps, 113
 prevention methods, 118
R. seeberi, 113
Rhinosporidium seeberi, 113
Rhizopus spp., 83
 Rhodotorulosis, 68
 Ringworm (dermatomycosis), 3, 4
 RNA sequencing data, 52
- S**
 Sabouraud's dextrose agar (SDA), 96
Saccharomyces cerevisiae, 52
 Salicylic acid, 42
 Sanctification, 127
Saprolegnia/water mold, 83
 Saprophytes, 6
 Saprophytic soil fungus, 111
 Secondary metabolite production in fungi, 16
 Sheep, 63–69
 Signaling motifs, 146, 147
 Signaling network, 56
 Signals, 152
 Skin disease, 3
 Skin scraping, 44, 109
 Small ruminants, 63, 69
 Snowstorm pattern, 110
 SNP identification, 51
 Sodium dodecyl sulfate (SDS), 100
Solanum dulcamara, 43
 Solid lipid nanoparticles, 101
 Sporangia, 113
Sporothrix chilensis, 6
Sporothrix of *Ophiostomataceae* family, 6
Sporothrix schenckii, 6
 Sporotrichosis, 6
 clinical manifestation, 114
 commonness, 113
 cytological examination, 114
 hunting dogs and dogs, 113
 practical measures, 114
 prevention methods, 118
 respiratory symptoms infection, 114
 S. schenckii, 113
 skin wounds, 114
 sporadic inhalation, 113
 Sterigmatocystins (STCs), 16
 Subclinical mastitis, 79
 Sulfonamides, 7
 Superficial dermatophyte infections, 41
 Superficial infection, 93, 96, 98
 Surveillance systems, 163
 Swine, 80
 Syk-CARD9 pathway, 146
 Synthetic drugs, 94, 101
 System biology
 categorization, 50
 computational modeling (*see* Computational modeling)
 ectothermic vertebrates, 49
 host-fungal interaction, 49
 host-pathogen interactions, 49
 image-based data, 53–55
 infection, 49, 50
 insects, 49
 omics-based data (*see* Omics-based data)
 web-based bioinformatics resources, 51
 web-based integrative resource, 49
 Systemic mycoses, 76
 Systemic mycosis, 83
- T**
 Takasio medium, 96
 T-cell polarization functions, 141
 T-cell responses, 139
 Tentative ECVs, 174
 Terbinafine, 118
 Testicular enlargement, 110
 Th1 immunity, 148
 Th17 cells, 148
 Th2 immunity, 148
 Thin-layer chromatography (TLC), 18
 Three Rs concept, 86
 Tinea, 75
Tinea capitis, 41
Tinea corpora, 41
Tinea cruris, 40
Tinea faciei, 41
Tinea manuum, 41
Tinea pedis, 40, 42
 Toll-like receptors (TLRs), 145
 Topical/systemic antifungal drugs, 41
 TR₄₆/Y121F/T289A mutation, 172
 Traditional medicine, 150
 Transcriptionally active regions (TARs), 52
 Transcriptomics
 omics-based data, 52, 53
 Transitional zone, 38
 Transkingdom network (TransNet)
 analysis, 55
 Transmission, 1, 2, 64, 65
 dermatophytosis, 98
 mycotoxins, 22, 23

Treatment, 6–10
 candidiasis, 40
 cattle, 29
 dermatophytosis, 41–44, 100–102
 poultry, 27

Trichocomaceae, 4

Trichophyton, 40, 93, 94

Trichophyton mentagrophytes, 43, 78, 170

Trichophyton rubrum, 41, 43

Trichophyton schoenleinii, 109

Trichophyton verrucosum, 79

Trichothecenes, 16, 19, 20, 26, 27

U

US Food and Drug Administration (FDA), 31

V

Vaccination, 88, 101

Veterinary Antimicrobial Susceptibility
 Testing (VAST), 173

Veterinary isolates, 170

Veterinary medicine, 163, 173–175

Virulent fungal infections, 134

Vulvovaginal candidiasis, 139

Vulvo-vaginal candidiasis (VVC), 36

W

Web-based integrative resource, 49

WHO, 16

Wild and captive frogs, 83

Wood's lamp, 44, 99

Y

Yeasts, 1

Z

Zearalenone (ZEN), 16, 19, 24

Zoophilic dermatophytes, 44, 98

Zygomycetes, 7, 10, 83, 131