

Color Atlas of
THE HORSE'S FOOT

Christopher C Pollitt



M Mosby-Wolfe

Color Atlas of

WWW.ELIB4VET.COM

THE HORSE'S FOOT

Christopher C. Pollitt BVSc, PhD

Senior Lecturer in Equine Medicine

School of Veterinary Science

The University of Queensland

Brisbane, Queensland

Australia

M Mosby-Wolfe

London Baltimore Bogotá Boston Buenos Aires Caracas Carlsbad, CA Chicago Madrid Mexico City Milan Naples, FL New York Philadelphia St. Louis Sydney Tokyo Toronto Wiesbaden

Project Manager:	Dave Burin
Designer and Layout Artist:	Jim Evoy
Cover Design:	Pete Wilder
Illustration:	John McDougall
Production:	Jane Tozer
Index:	Jill Halliday
Publisher:	Jane Hunter

Copyright © 1995 Times Mirror International Publishers Limited

Published in 1995 by Mosby-Wolfe, an imprint of Times Mirror International Publishers Limited

Printed in Spain by Grafos S.A. Arte sobre papel, Barcelona, Spain

ISBN 0 7234 1765 2

All rights reserved. No part of this publication may be reproduced, stored in a retrieval system, copied or transmitted, in any form or by any means, electronic, mechanical, photocopying, recording or otherwise without written permission from the Publisher or in accordance with the provisions of the Copyright Act 1988, or under the terms of any licence permitting limited copying issued by the Copyright Licensing Agency, 33-34 Alfred Place, London, WC1E 7DP.

Any person who does any unauthorised act in relation to this publication may be liable to criminal prosecution and civil claims for damages.

Permission to photocopy or reproduce solely for internal or personal use is permitted for libraries or other users registered with the Copyright Clearance Center, provided that the base fee of \$4.00 per chapter plus \$.10 per page is paid directly to the Copyright Clearance Center, 21 Congress Street, Salem, MA 01970. This consent does not extend to other kinds of copying, such as copying for general distribution, for advertising or promotional purposes, for creating new collected works, or for resale.

For full details of all Times Mirror International Publishers Limited titles, please write to Times Mirror International Publishers Limited, Lynton House, 7-12 Tavistock Square, London WC1H 9LB, England.

A CIP catalogue record for this book is available from the British Library.

Library of Congress Cataloging-in-Publication Data has been applied for.

DEDICATION	4
PREFACE	5
ACKNOWLEDGEMENTS	6
1 STRUCTURE AND FUNCTION	7
2 CLINICAL EXAMINATION	46
3 HORSESHOES AND HORSESHOEING	53
4 PROBLEM FEET	70
5 HOOF WALL RECONSTRUCTION	75
6 CONFORMATION	79
7 INTERFERENCE INJURY	91
8 FAILURE OF DIGITAL BLOOD SUPPLY	94
9 RINGBONE	97
10 DISORDERS OF THE CARTILAGES OF THE DISTAL PHALANX	103
11 TRAUMA TO DISTAL INTERPHALANGEAL JOINT AND DISTAL PHALANX	106
12 DISORDERS AND DISEASES OF THE HOOF WALL	109
13 DISORDERS AND DISEASES OF THE CORONET	119
14 DISORDERS AND DISEASES OF THE SOLE, FROG AND BAR	130
15 INFECTED NAIL HOLE	137
16 QUARTER CRACKS	141
17 INFECTIONS AND TUMOURS OF THE FOOT	148
18 NAVICULAR DISEASE (PODOTROCHLEOSIS)	159
19 LAMINITIS	169
INDEX	206

Dedication

To Sandra, my soulmate and mother of my children Benjamin and Jane, my love and gratitude for running our home while writing this book made me an absentee husband and parent.

When I was 14 my father, Cal, bought me my first camera and from my mother, Mabel, I scrounged the money to buy ever-increasing quantities of film, processing chemicals and printing paper. To them I am grateful for nurturing my love of photography and for being the caring parents who made it possible for me to become a veterinarian.

To Keith Swan, my colleague the farrier, who transformed so many horses' feet with his skill and showed me the meaning of balance. We have learned much from each other.

To the horses I shod and rode. They have given me the insight into what correct horseshoeing really means.

When I bestride ride him, I soar, I am a hawk
He trots the air, the earth sings when he touches it,
The basest horn of his hoof is more musical
than the pipe of Hermes.

William Shakespeare

This colour atlas will provide the student of the horse's foot (whether veterinarian, farrier or the interested horse owner) with the means to more fully appreciate and understand equine foot problems. And understand them they must. There is much folklore and nonsense associated with mankind's association with the horse but nowhere more so than with the foot. Facts have rarely entered into the decision-making process, and some of the entrenched dogma has entered the literature to be passed on unchallenged, citation by citation.

Fortunately, with the increase of the horse population in the latter 20th century, many of the established facts have been subjected to test by the scientific method. Many have been found wanting but, remarkably, some of the oldest have been verified. Xenophon, the ancient Greek war general, knew that horses performed best if the axis of the dorsal hoof wall and the pastern were the same. Perhaps his intuitive conclusions, based as they were on his powers of observation and common sense, were correct because his mind was uncluttered with any pre-existing 'facts'. This spirit of taking a fresh look at the horse's foot and sifting fact from fiction is embodied in the philosophy of this book.

Growing alongside the increasing numbers of horses in recent times is the resurgence of the art of farriery. This has occurred because the horse has made a comeback, mainly as a performance athlete, into an environment requiring the highest standards of workmanship for the farrier and testing the diagnostic skills of the veterinarian. The resolution of horse foot problems will often depend on collaboration between veterinarian, farrier and the horse's owner. This book should provide information for both professions about the activities and principles of the other and thus promote greater mutual understanding and co-operation. This should benefit not only the horse but also its owner. Modern horse owners often invest a considerable amount of time and money into the preparation of a horse and expect the highest standards of foot care. The owners will expect an explanation of what is wrong with their horse's foot and why it has to be shod, or medicated, in a certain way. It is envisaged that the illustrations in this book will be used to communicate information between all concerned. With better communication should come greater understanding and better relations between the professions and their client.

Ways and means to demonstrate particular facets of disease or the anatomy of the horse's foot have tested photo-

graphic creativity and it is author's hope that the photographs presented here will maintain the reader's interest throughout the book. A particular effort has been made to provide case histories so that, instead of relying on the author's assurance that this treatment worked or that injury healed, the reader will see for themselves what actually happened. Brief details of the treatments are supplied to put the case history in its context.

Because the principle of this book was to record what was visible with the camera and hence could be seen with the unaided eye, the use of radiographs has been deliberately kept to a minimum. To record disease and problems of bones and joints, areas traditionally illustrated by radiography, the author has resorted to the old-fashioned technique of bone maceration. This allows a more three-dimensional representation to be recorded on film and thus a better appreciation of the disorder.

The major blood vessels of the foot have been injected with coloured latex or red acrylic and then dissected so that their relationships with other structures can be clearly depicted. The author's research into the microcirculation of the foot dermis using the technique of corrosion casting and scanning electron microscopy is shown here for the first time in colour.

This book has sprung from my compulsion as a lecturer in equine medicine to gather material with which to teach and communicate. As with most photographers the need to record everything over the last 15 years of my teaching career was difficult to justify apart from the aesthetic pleasure that a photograph of quality generates. Fortunately, the invitation to produce a Mosby-Wolfe colour atlas suddenly provided an additional reason for the collection's existence. The success of the Mosby-Wolfe concept and the large number of colour atlases in existence, serving many branches of human and veterinary medicine, are testimonies to their enormous educational value.

Thus from a filing cabinet containing over 4000 transparencies, the following 466 have been selected. Rigorous selection criteria were applied to each colour slide; each had to be sharp, with good contrast, well lit and above all had to have meaning.

Since more diagnoses are missed from not looking rather than from not knowing, it is my sincere hope that looking at this colour atlas of the horse's foot will assist the observer and lead to more correct diagnoses.

Christopher C. Pollitt BVSc, PhD

Acknowledgements

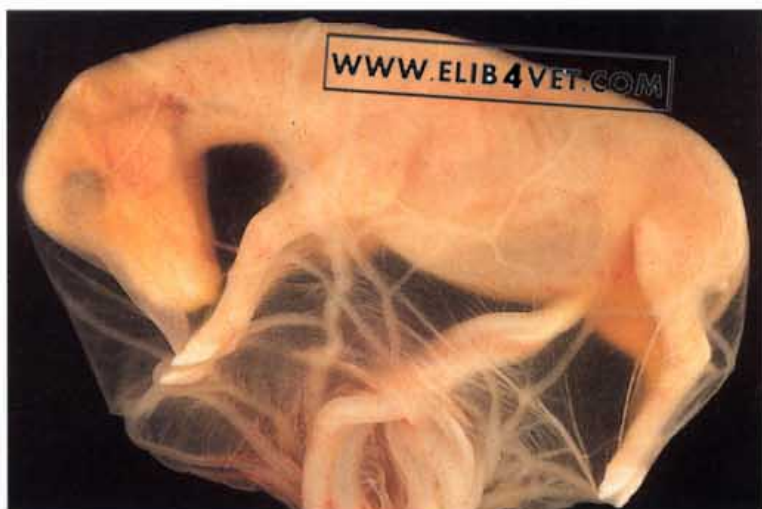Farriers, veterinarians and horse owners who are also capable of taking an in-focus, well-composed photograph are a rare commodity, so I am grateful to the following for allowing me to reproduce their work here: Keith Swan, Bernard Duvernay, Burney Chapman, Mark Caldwell, Denis Leveillard, Ian Wright, Reg Pascoe, Jack Greonendyk, Janice Young, John Walmsley, J Verschooten, Ben Pollitt, Sandra Pollitt, Erika Woodland, Charles Prescott, Sue Crockett, Virginia Osbourne, Chris Colles, Olin Balch, Q.J. Lang, Jim Vasey, Richard Millar, Chris Taylor, Ristan Greer, Robert Eustace and Carl O'Dwyer. Their generosity has made the Atlas close to complete. I would also like to thank John McDougall for the artwork, Allison Arnott for the word processing, and Kira Reynolds and Terry Daley for producing the radiographs of the navicular bones.

WWW.ELIB4VET.COM

1 Structure and Function

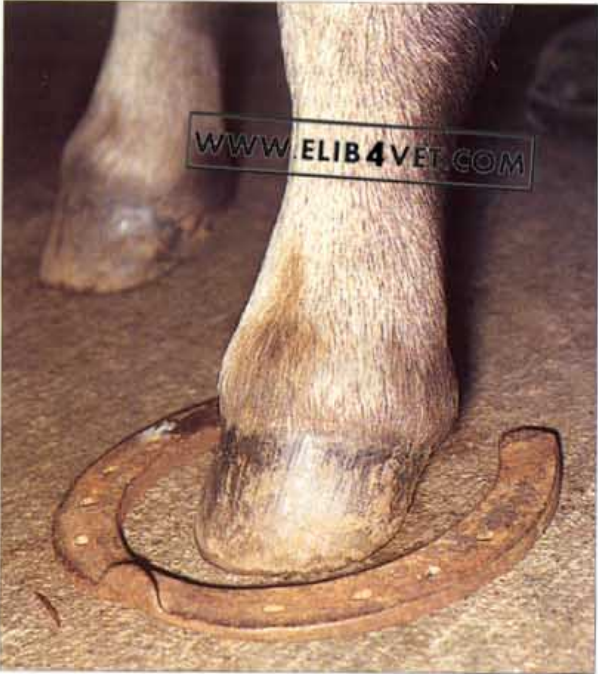Gross Anatomy

1. Horse foetus at 3 months of age. The 12-cm foetus is enveloped in its amniotic sac and is floating hairless and naked in fluid. As if to emphasise the fundamental importance of the feet to the future wellbeing of the horse, the hooves, unpigmented at this stage, are already well formed.

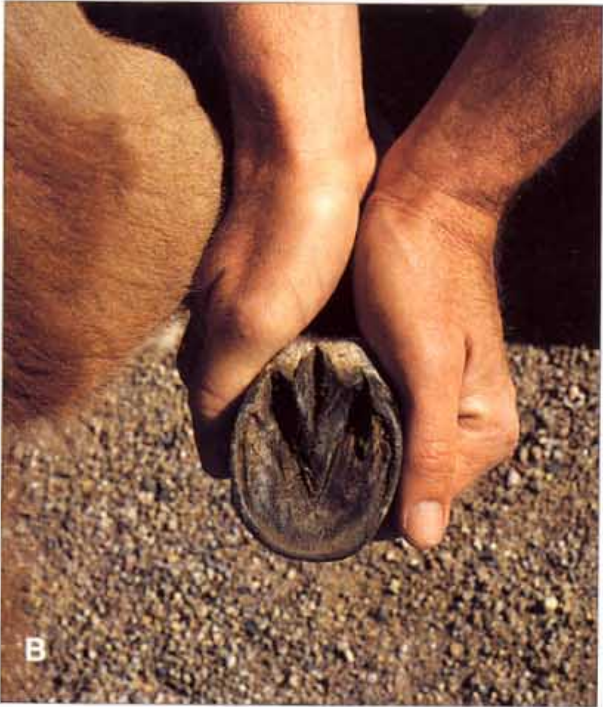
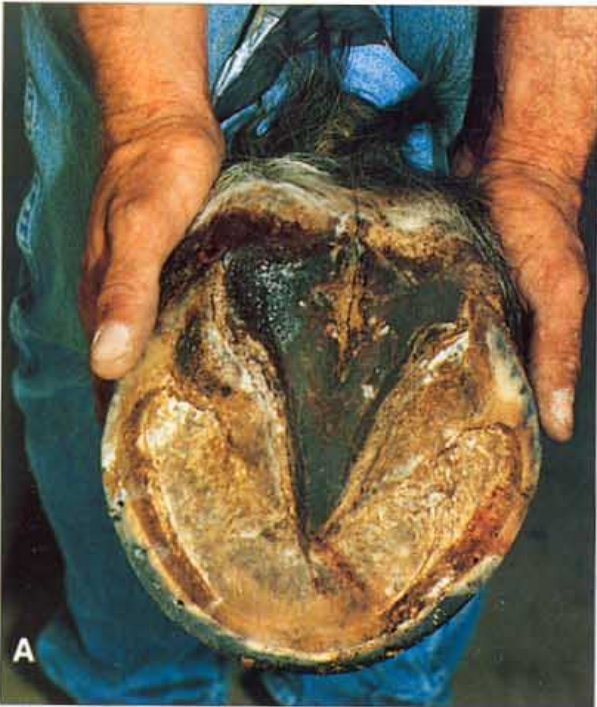

2. Newborn foal's foot. At the time of birth the hard pigmented hoof is capped with soft unpigmented hoof (the perionychium) formed earlier. During the pregnancy, this soft blunt cap lessens the chance of the foal's hooves damaging the mare's uterus. When the foal stands, the cap separates along a preformed break-line, and is soon shredded and lost. Note the obvious tubular structure of the hoof wall.



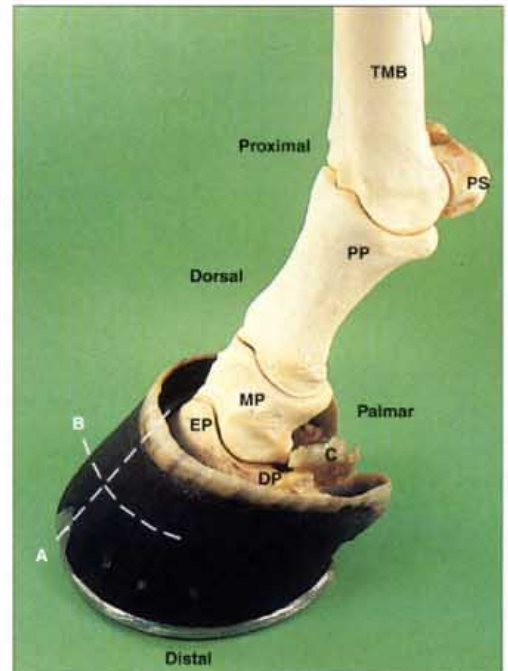


3. The foot of a foal. A 3-week-old foal has been photographed standing with its foot inside the shoe of its mother. The hoof and the structures within, undergo programmed but rapid increases in size and within 18 months the mother's shoe will fit the foot of its offspring.

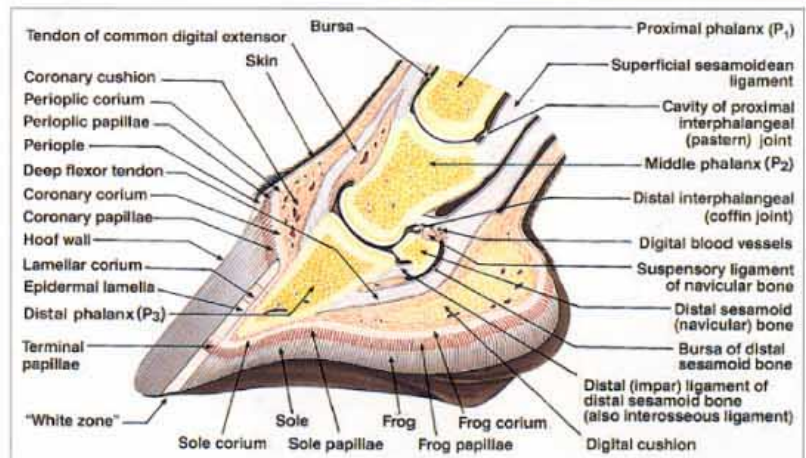


4. The size of horses' feet. The architecture of the horse's foot remains the same whether it is supporting the weight of a 700kg Belgian draft horse (A) or a 170kg miniature horse (B). Photo A: Jan Young.

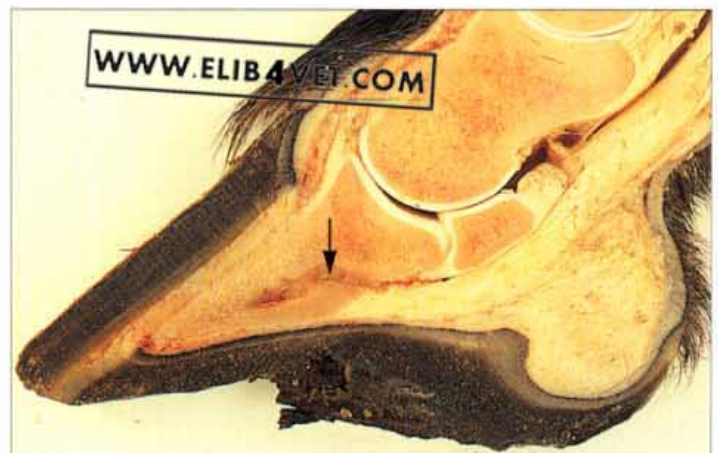5. **Skeleton of the digit.** The three bones of the digit are viewed obliquely from the dorsal surface. The proximal phalanx (long pastern bone) forms two articulations. Above, it articulates with the third metacarpal bone (cannon bone) and the paired proximal sesamoid bones to form the high-motion metacarpo-phalangeal joint (fetlock joint) and below it articulates with the middle phalanx (short pastern bone) to form the low-motion proximal interphalangeal joint (pastern joint). The middle phalanx articulates below with the distal phalanx (coffin bone) and the distal sesamoid (navicular bone) to form the distal interphalangeal or coffin joint. The prominent, pyramid-shaped, extensor process is where the important extensor tendon inserts on the distal phalanx. The cartilages of the distal phalanx (ungual cartilages) originate on the lateral and medial borders of the bone and are palpable above the coronet of the hoof wall. The dotted line through B=plane of transverse sections, the dotted line through A=plane of longitudinal (sagittal) sections, TMB=third metacarpal bone, PS=proximal sesamoid bones, PP=proximal phalanx, MP=middle phalanx, DP=distal phalanx, EP=extensor process, C=cartilage of distal phalanx.

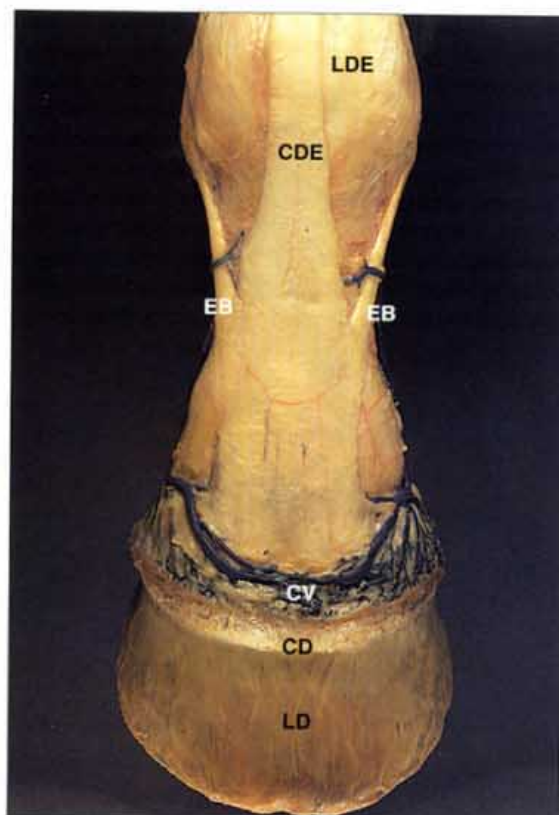


6. **Diagram of the equine foot (sagittal section).** This diagram should be studied in conjunction with the cadaver section in 7 (below). Art: J. McDougall.

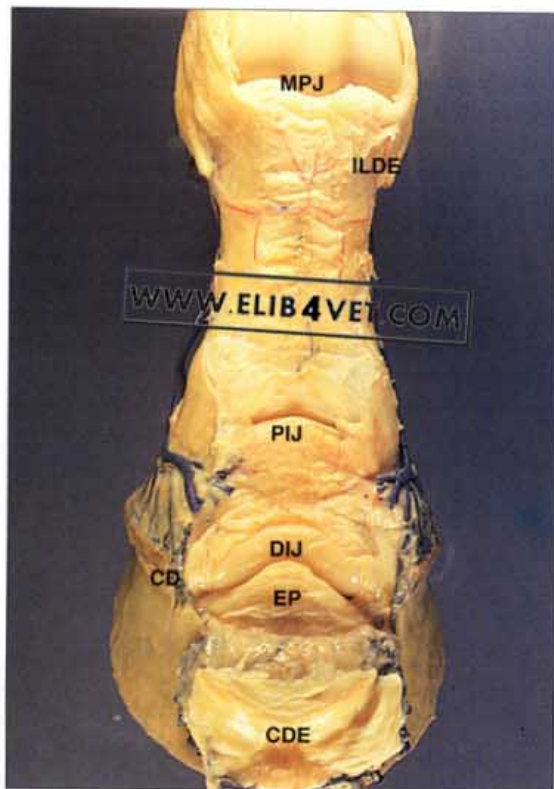

7. **Sagittal section of digit.** The inner surface of the equine hoof is never pigmented and is visible on the ground surface as the white zone (white line). The deep flexor tendon passes down the palmar aspect of the proximal, middle and distal phalangeal bones, is tightly apposed to the distal sesamoid bone and, finally, inserts on the palmar surface of the distal phalanx. In the body of the distal phalanx is a canal for the terminal arch of the paired digital arteries (arrowed).

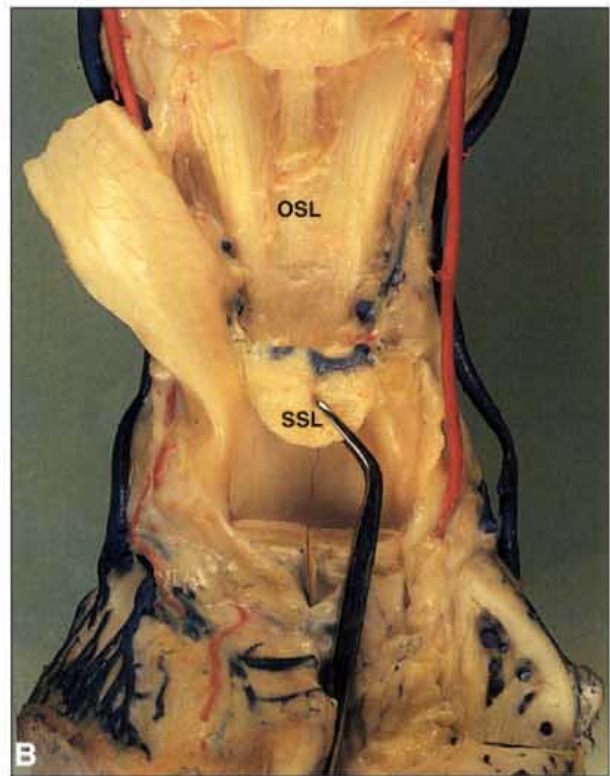
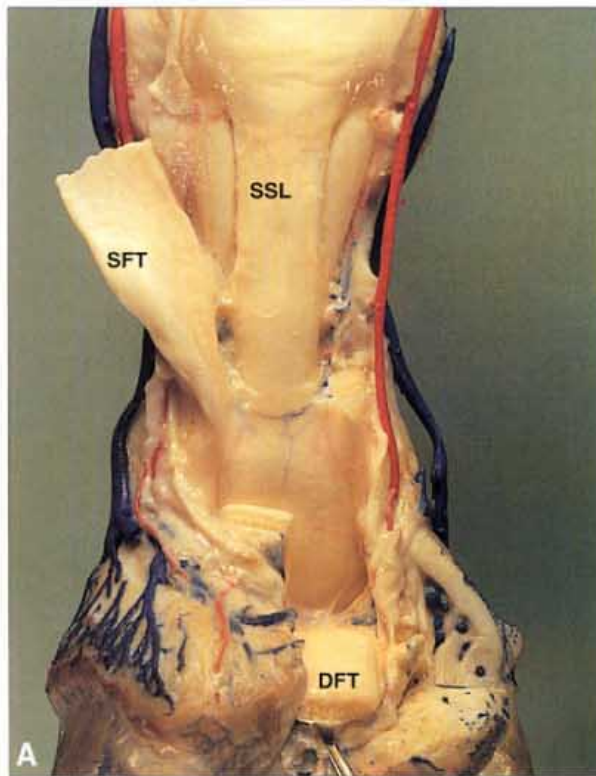




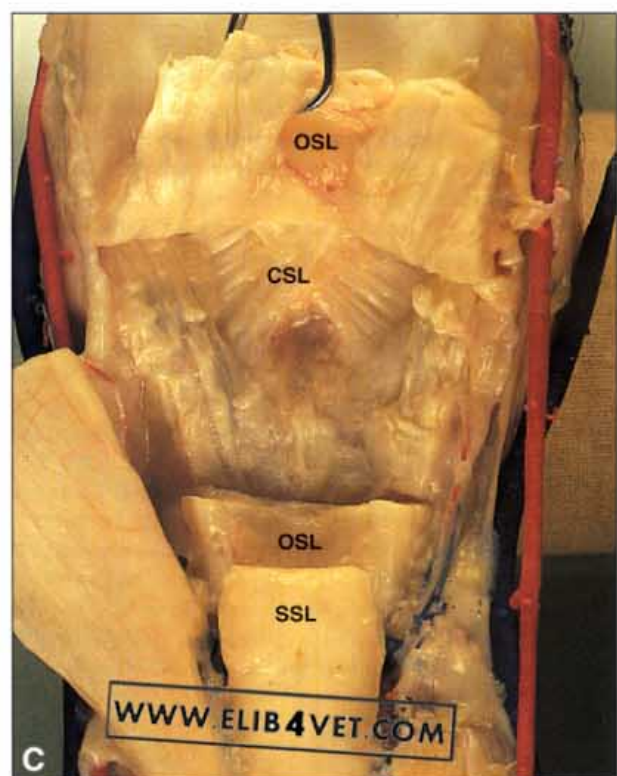
8. The common digital extensor tendon: superficial dissection (A). The common digital extensor tendon inserts weakly on to the proximal and middle phalanges but has its main and most important insertion on the extensor process of the distal phalanx. The lateral digital extensor tendon inserts on the proximal dorsal surface of the proximal phalanx. The extensor branches of the suspensory (interosseus) ligament merge with the common digital extensor tendon and are part of the suspensory apparatus of the forelimb. LDE=lateral digital extensor tendon, CDE=common digital extensor tendon, EB=extensor branches of the suspensory (interosseus) ligament, CV=coronary vein, LD=lamellar dermis, CD=coronary dermis.

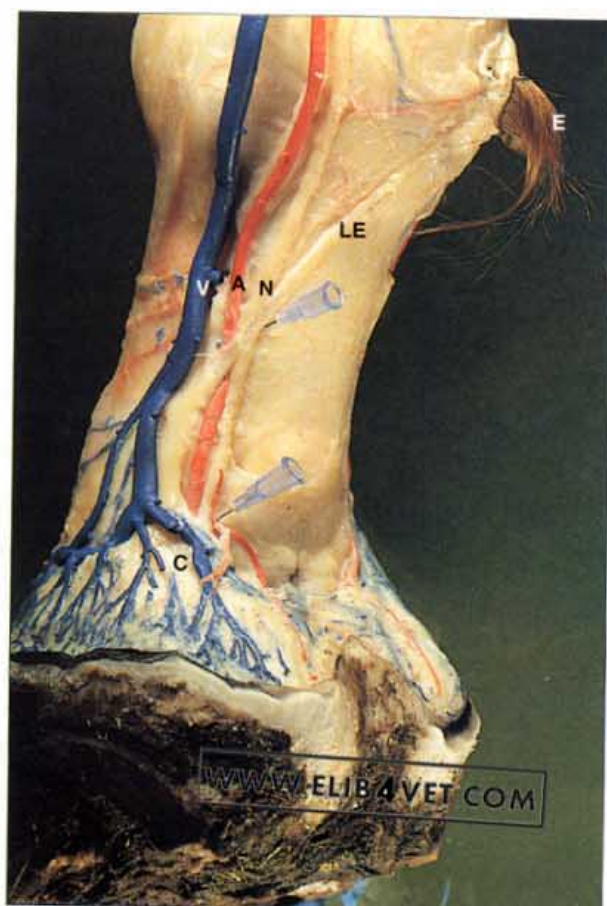

9. The common digital extensor tendon: deep dissection (B). The common digital extensor tendon has been reflected forwards to show the dorsal surfaces of the metacarpophalangeal (fetlock) joint, the proximal interphalangeal (pastern) joint and the distal interphalangeal (coffin) joint. The common digital extensor tendon inserts on the broad extensor process of the distal phalanx and covers the dorsal pouch of the distal interphalangeal (coffin) joint. Although the distal interphalangeal (coffin) joint is below the hoof, its dorsal pouch is well above the level of the coronet. The dorsal pouch can be punctured with a hypodermic needle (arthrocentesis) to obtain samples of joint fluid or to make injections such as local anaesthetic. MPJ=metacarpophalangeal (fetlock) joint, ILDE=lateral digital extensor tendon insertion on proximal phalanx, PIJ=proximal interphalangeal (pastern) joint, DIJ=distal interphalangeal (coffin) joint, EP=extensor process of the distal phalanx, CDE= common digital extensor tendon reflected forwards, CD=coronary dermis.

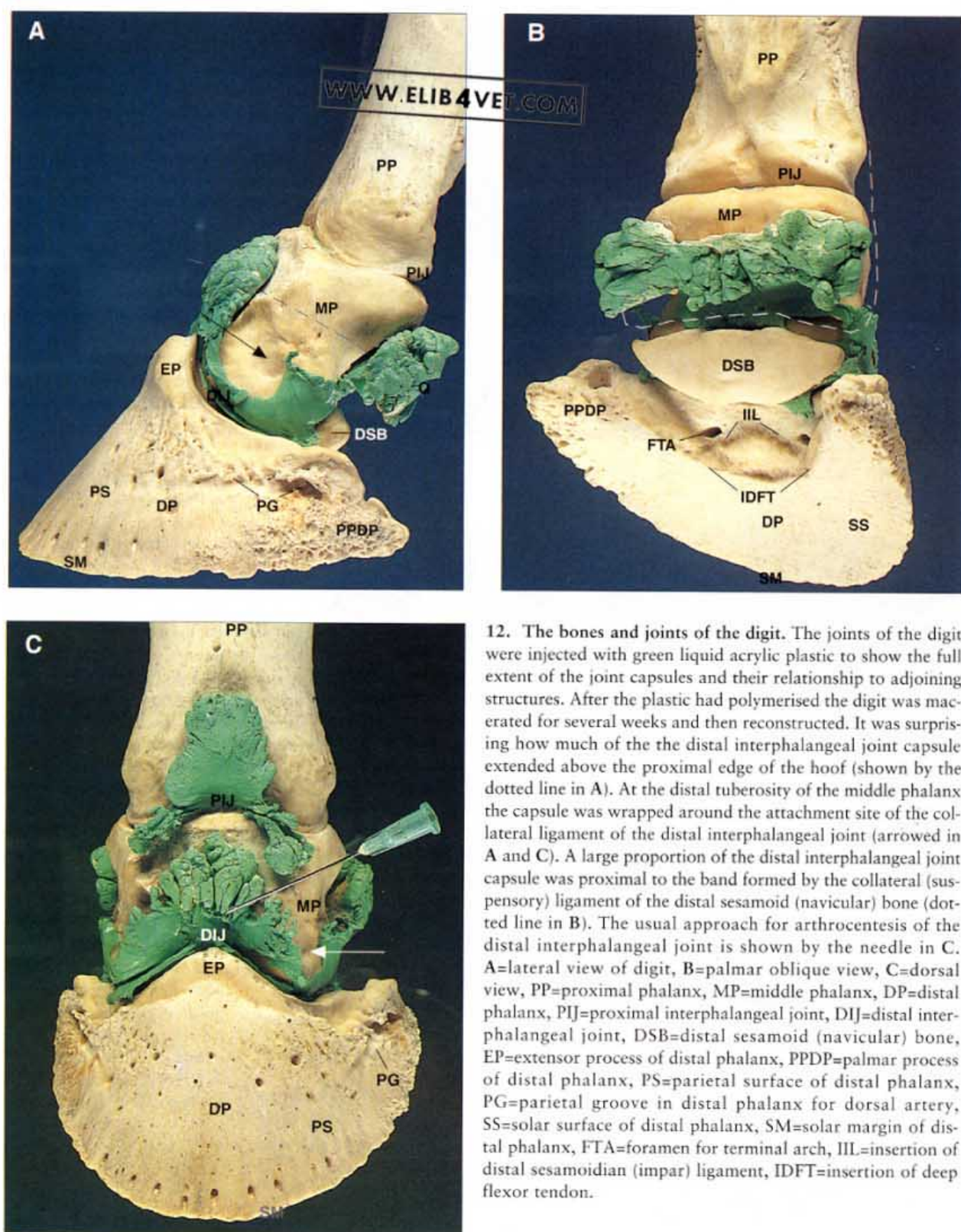


10. The sesamoidean ligaments. The sesamoidean ligaments are really the distal continuation of the suspensory (interosseus) ligament. The proximal sesamoid bones are embedded in the ligament and form the suspensory apparatus of the lower limb. When the fetlock receives its maximum load and is severely over-extended it is the proximal sesamoid bones which receive the thrust of the descending metacarpal (cannon) bone. The sesamoids are held in place by the palmar annular ligament and distally by the three sesamoidean ligaments. In A the deep and superficial flexor tendons have been cut and reflected to show the straight sesamoidean ligament (SSL). B and C are deeper dissections to show the triangular, medial and lateral oblique sesamoidean ligaments (OSL) and the cruciate sesamoidean ligaments (CSL) respectively, on the palmar surface of the proximal phalanx. The straight sesamoidean ligament inserts on to a special fibrocartilagenous extension on the proximal extremity of the palmar surface of the middle phalanx. The medial and lateral oblique sesamoidean ligaments insert on the roughened palmar surface of the proximal phalanx. SFT=superficial flexor tendon, DFT=deep flexor tendon.

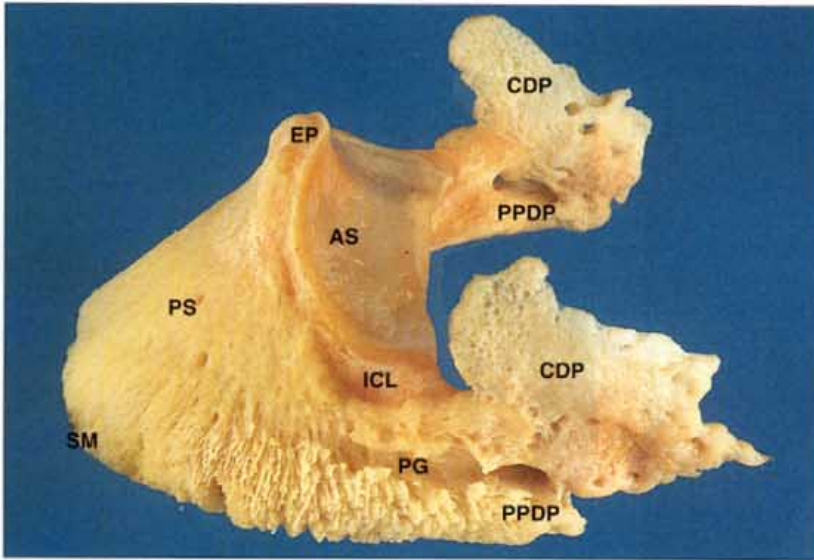




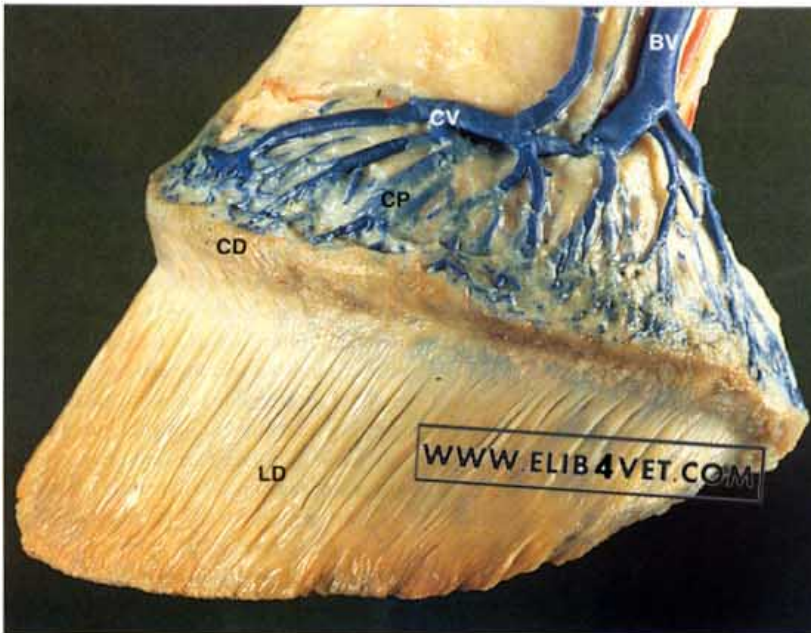
11. The palmar digital nerve. Regional anaesthesia of the palmar digital nerve is frequently used to aid in the diagnosis of lower limb lameness. In the photograph of the dissection, the palmar digital vein has been injected with blue latex and the palmar digital artery with red latex. The palmar digital nerve is palmar to the artery and passes under the ligament of ergot in the mid-pastern region. The needle shows where local anaesthetic can be injected to block the palmar digital nerve at the ligament of ergot site. Distally the nerve can be blocked as it passes under the cartilage of the distal phalanx. The pulse of the artery can be palpated and the injection made just palmar to it. The needle shows the site. A successful palmar digital nerve block will anaesthetize the distal deep flexor tendon, the distal sesamoid bone and its bursa, the palmar half and the palmar processes of the distal phalanx, the digital cushion, the corium of the frog and the palmar half of the sole, wall and coronet. E=ergot, LE=ligament of ergot, V=palmar digital vein, A=palmar digital artery, N=palmar digital nerve, C=cartilage of distal phalanx.



12. The bones and joints of the digit. The joints of the digit were injected with green liquid acrylic plastic to show the full extent of the joint capsules and their relationship to adjoining structures. After the plastic had polymerised the digit was macerated for several weeks and then reconstructed. It was surprising how much of the distal interphalangeal joint capsule extended above the proximal edge of the hoof (shown by the dotted line in A). At the distal tuberosity of the middle phalanx the capsule was wrapped around the attachment site of the collateral ligament of the distal interphalangeal joint (arrowed in A and C). A large proportion of the distal interphalangeal joint capsule was proximal to the band formed by the collateral (suspensory) ligament of the distal sesamoid (navicular) bone (dotted line in B). The usual approach for arthrocentesis of the distal interphalangeal joint is shown by the needle in C. A=lateral view of digit, B=palmar oblique view, C=dorsal view, PP=proximal phalanx, MP=middle phalanx, DP=distal phalanx, PIJ=proximal interphalangeal joint, DIJ=distal interphalangeal joint, DSB=distal sesamoid (navicular) bone, EP=extensor process of distal phalanx, PPDP=palmar process of distal phalanx, PS=parietal surface of distal phalanx, PG=parietal groove in distal phalanx for dorsal artery, SS=solar surface of distal phalanx, SM=solar margin of distal phalanx, FTA=foramen for terminal arch, IIL=insertion of distal sesamoidian (impar) ligament, IDFT=insertion of deep flexor tendon.

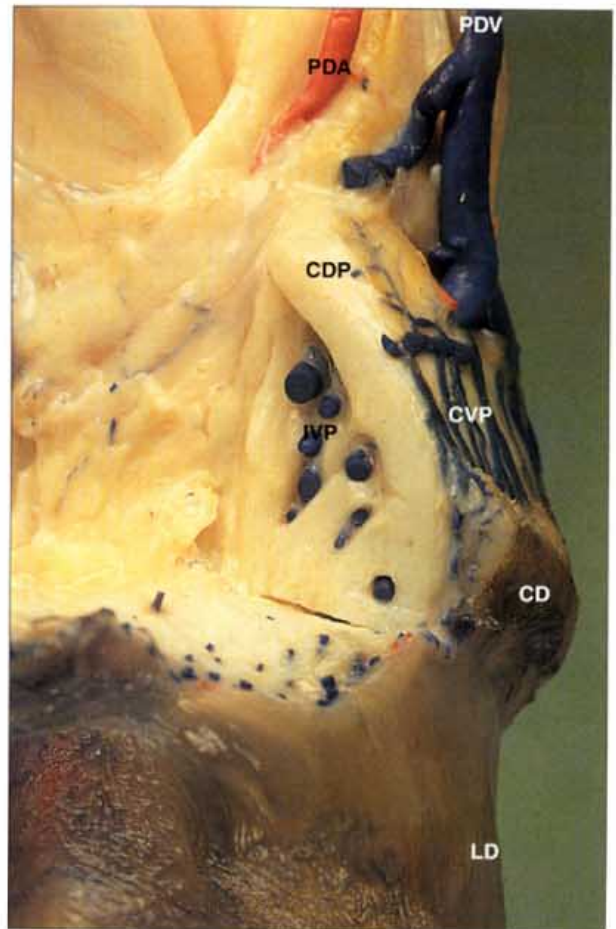


13. The cartilages of the distal phalanx. The medial and lateral cartilages (ungual cartilages) of the distal phalanx are attached to the proximal borders of the distal phalanx. They are large and flexible and can be palpated above the level of the coronet. Between them is the digital cushion and the inner venous plexuses which when compressed aid in the return of venous blood to the heart. Under certain conditions the cartilages may become ossified when they are then known as 'sidebones'. EP=extensor process, CDP=cartilage of distal phalanx, ICL=insertion of collateral ligament, AS=articular surface, PG=parietal groove, PS=parietal surface, PPDP=palmar process of distal phalanx, SM=solar margin.

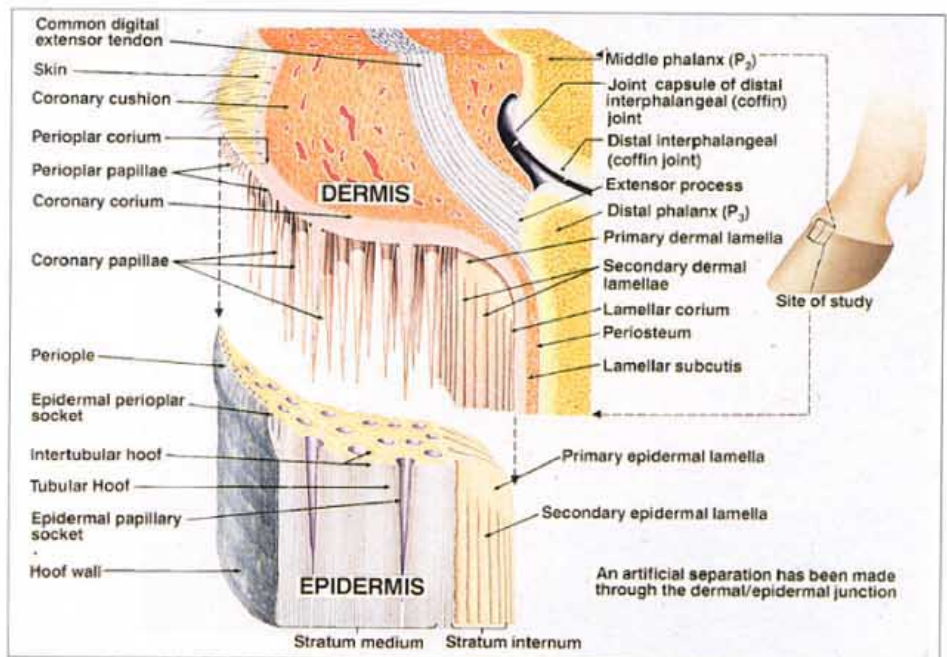


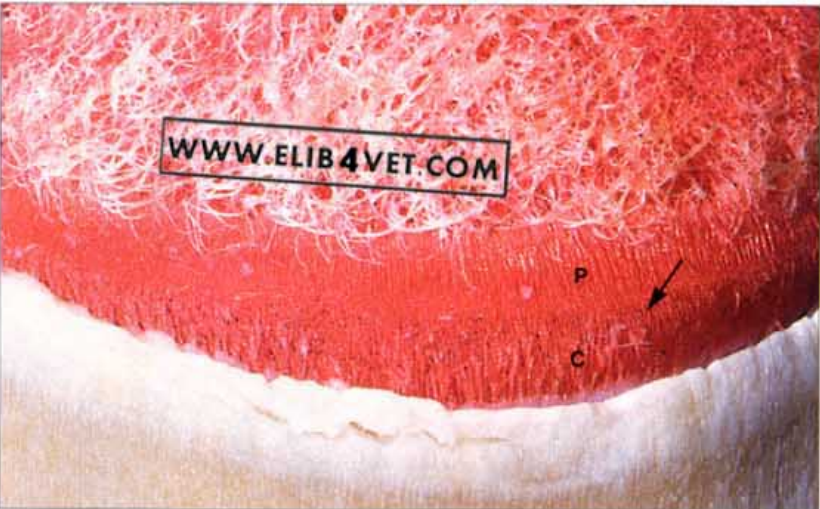14. Venous drainage of the foot. With the hoof removed the coronary and lamellar dermis (corium) is visible. The veins have been injected with blue latex and show the extensive plexus of veins, above the coronet, which drain the deeper veins of the digit. The coronary and bulbar veins rely on soft tissue pressure, developed with each footfall, for the return of venous blood to the heart. LD=lamellar dermis, CD=coronary dermis, CP=coronary venous plexus, CV=coronary vein, BV=bulbar vein.

15. The inner venous plexus. Blood from the veins of the lamellar plexus, the solar plexus and the heels drains to the large inner venous plexus (deep) axial to the cartilage of the distal phalanx. Abaxial to the cartilage is the coronary venous plexus. Expansion of the digital cushion by the descending phalangeal bones during the limb cycle compresses the veins of the inner plexus against the flexible cartilage and 'pumps' venous blood up the leg. Similarly the coronary venous plexus is compressed between the abaxial surface of the cartilage and the taught skin and also aids in the venous return. There are few valves in the veins of the digit and blood can take any of several alternative routes. In the specimen the veins have been injected with blue latex. The cartilage of the distal phalanx has been cut in the longitudinal plane to show the inner venous plexus and the coronary plexus on either side of the cartilage. CDP=cartilage of distal phalanx, IVP=inner venous plexus, CVP=coronary venous plexus, CD=coronary dermis, LD=lamellar dermis, PDA=palmar digital artery, PDV=palmar digital vein.

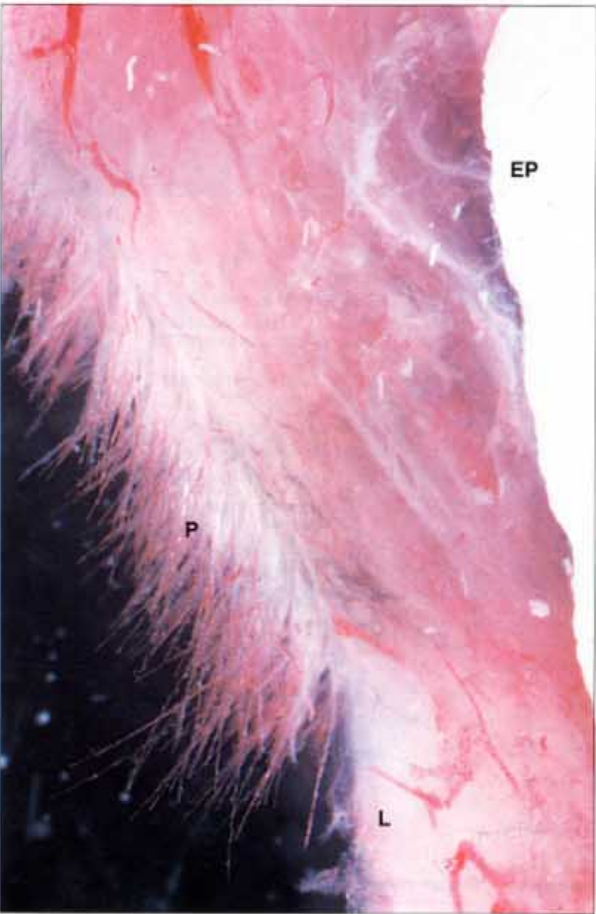


16. Diagram of the coronary region of the hoof. An artificial separation has been made through the dermal/epidermal junction to show the relationship between the two anatomical compartments. Each dermal papilla fits into a socket in the coronary groove and is responsible for the maintenance of a single epidermal hoof wall tubule. A similar relationship exists between the dermal lamellae and their epidermal counterparts, the hoof wall lamellae. Art: J. McDougall.



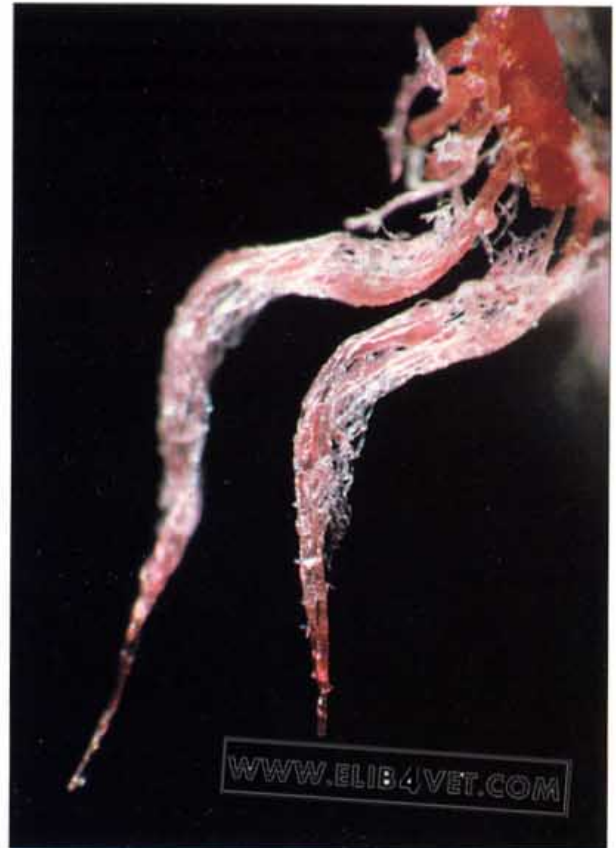

17. The papillae of the coronary band (A). The blood vessels of the coronary band have been injected with red acrylic and maceration in sodium hydroxide (caustic soda) has been underway for two days. The skin and the soft periople have disappeared leaving behind the hard hoof wall and the resistant vascular casts of the blood vessels of the coronary papillae and skin. There is a line of demarcation (arrowed) between the short papillae of the periople (P) and the longer papillae of the coronary groove (C). On the surface of the hoof wall the sodium hydroxide has etched the denser horn tubules in relief against the softer inter-tubular horn. Each papilla is responsible for the growth and maintenance of a single hoof wall tubule.

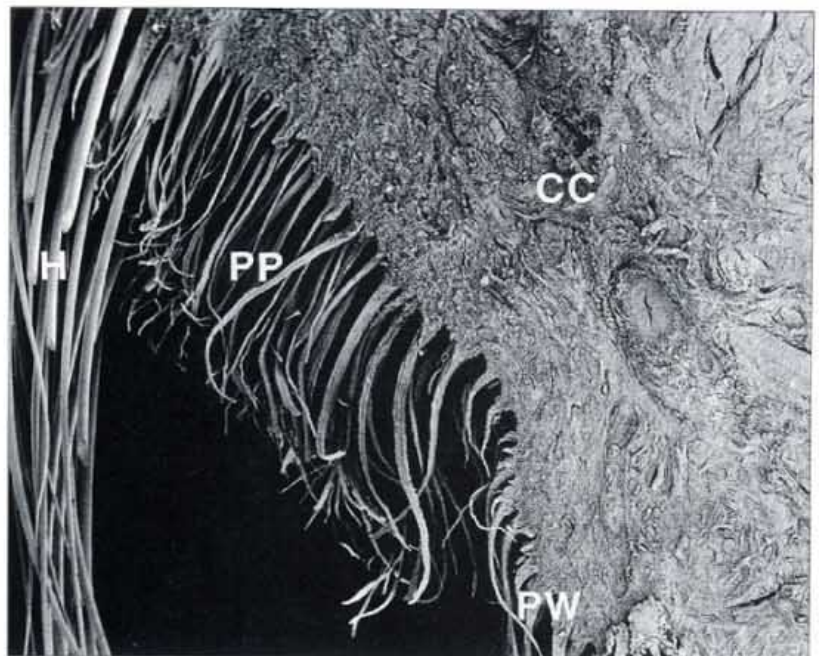


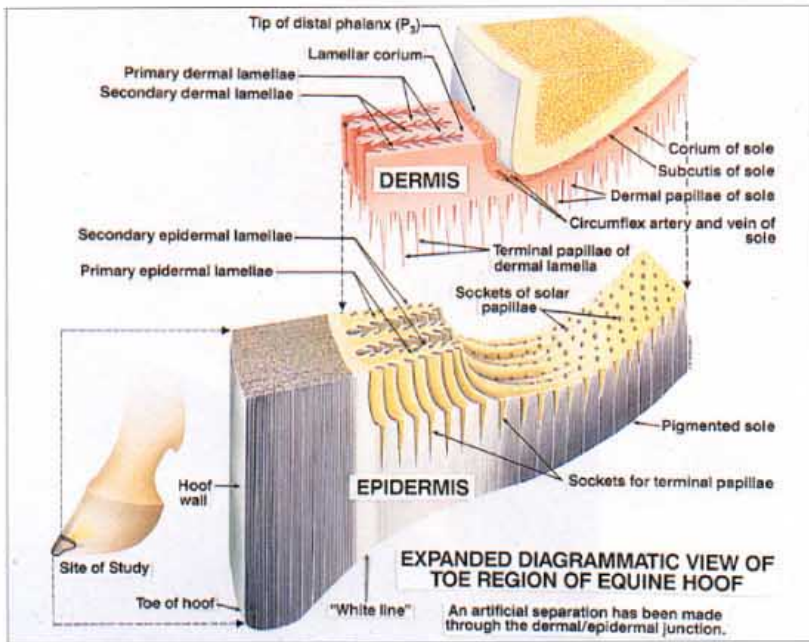
18. The papillae of the coronary band (B). The blood vessels of the coronary band region have been injected with red acrylic and the hoof has been removed by gentle maceration. The extensor process (EP) of the distal phalanx is on the right of the picture and a single dermal lamella (L) is at the bottom right. The numerous fine tapering papillae (P) of the coronary band are clearly shown. In life each papilla fits into a socket in the coronary groove of the epidermal hoof wall and supplies the nutrients and oxygen required for the continual growth and maintenance of a single horn tubule.

19. Vascular cast of the two coronary band papillae. The vascular corrosion cast technique shows that each tapering dermal papilla of the coronary band is made up of a central artery and vein surrounded by a network of fine capillaries.



20. The papillae of the periople. The soft, compliant epidermis of the periople contains keratohyaline and resembles skin. The papillae which produce the periople are shorter and finer than those of the hoof wall proper and form a separate band in the proximal coronet. The picture is a scanning electron micrograph of the macerated coronary band dermis fixed after being teased from the coronary groove of the hoof wall. H=hair, PP=papillae of periople, PW=papillae of hoof wall, CC=coronary cushion.





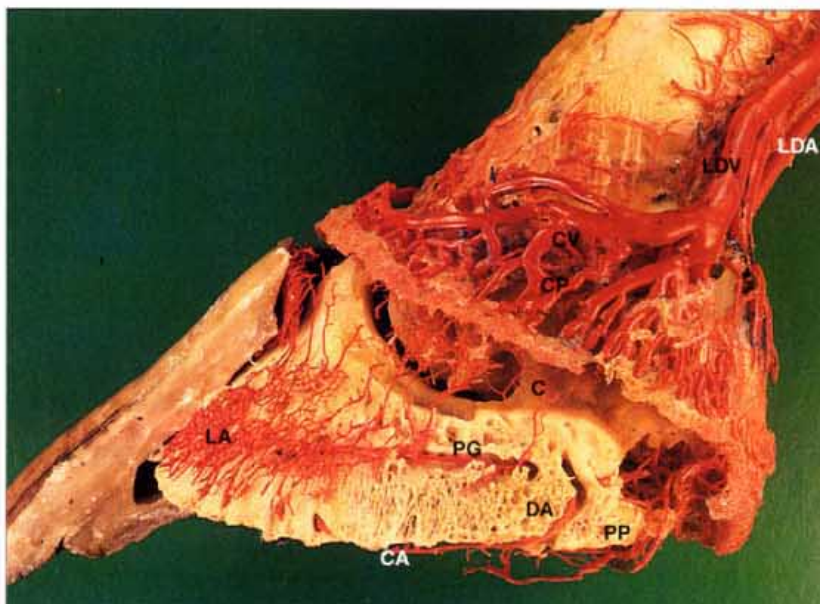
21. Diagram of the toe region of the equine hoof. Again an artificial separation has been made through the dermal/epidermal junction to show the relationship between the two anatomical compartments. As in the coronet each dermal papilla of the sole corium fits into a socket in the epidermal (horn) sole. A similar relationship exists between the dermal lamellae and their epidermal counterparts the hoof wall lamellae. At the distal tip of each dermal lamella is a set of papillae known as the terminal papillae. The epidermis surrounding the terminal papillae is non-pigmented and forms the inner part of the white zone (white line). The white zone is relatively soft and flexible and effectively 'seals' the sole to the hoof wall. It is sometimes subject to degeneration and infection, usually described as 'seedy toe' or 'white line disease'. Art: J. McDougall.



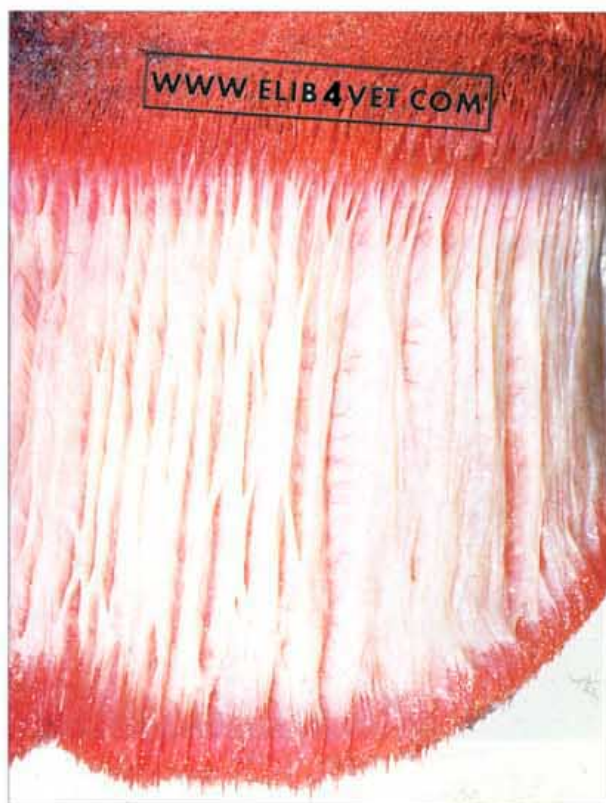
22. Terminal papillae. On the distal end of all dermal lamellae are numerous terminal papillae. Germinal epidermis lining the terminal papillae are responsible for generating keratinised epidermal cells which fill the spaces between the primary epidermal lamellae as they grow toward the ground surface. The epidermis formed is without pigment and forms the inner part of the white zone.

Foot Circulation

23. The blood supply to the digit. The network of arteries which perforate the dorsal surface of the distal phalanx and ramify the lamellar dermis (corium), is in a confined space between the bone and the hoof wall. The veins form a many-branched plexus around the coronet and on either side of the cartilage of the distal phalanx (ungual cartilage). In this dried dissected preparation in which all the blood vessels have been injected with red acrylic, the cartilage can be seen at its origin on the proximal edge of the palmar process of the distal phalanx but is obscured above the coronet by the large plexus of veins. The dorsal artery anastomoses with the circumflex artery of the sole after it crosses or perforates the palmar process of the third phalanx. The parietal groove houses an artery which anastomoses with the arteries of the dorsal lamellar network. LA=lamellar arteries, PG=parietal groove, C=cartilage of distal phalanx, PP=palmar process of distal phalanx, CA=circumflex artery of the sole, DA=dorsal artery, LDV=lateral digital vein, LDA=lateral digital artery, CP=coronary venous plexus, CV=coronary vein.

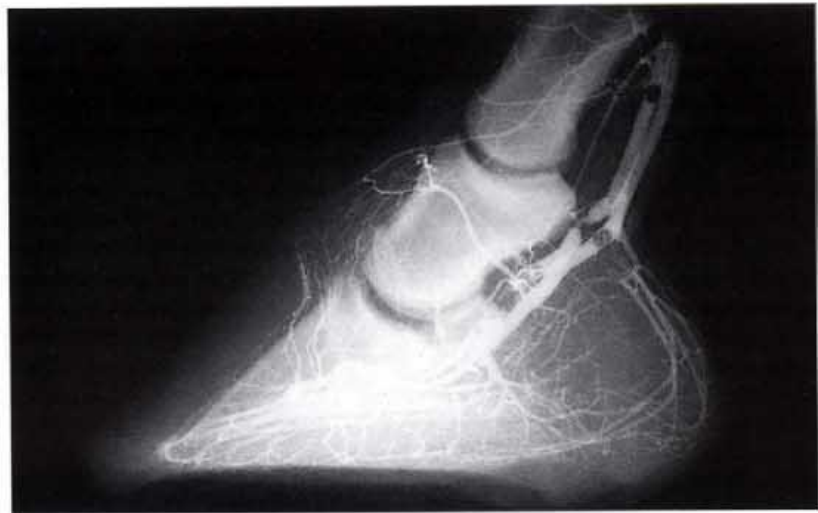

24. The corium of the foot. Liquid red acrylic was injected into the blood vascular system of the amputated foot of a horse. When the acrylic had polymerised and hardened, hoof and skin was gently removed by maceration, thus revealing the dermal structures underneath. At the top of the picture is the convex coronary corium, composed of large numbers of dermal papillae, while at the bottom are the terminal papillae and the papillae of the sole. These regions appear bright red because they are growth areas and are thus highly vascular. On the other hand, the relatively pale dermal lamellae grow but little and are more concerned with maintenance of the hoof distal phalangeal bond.



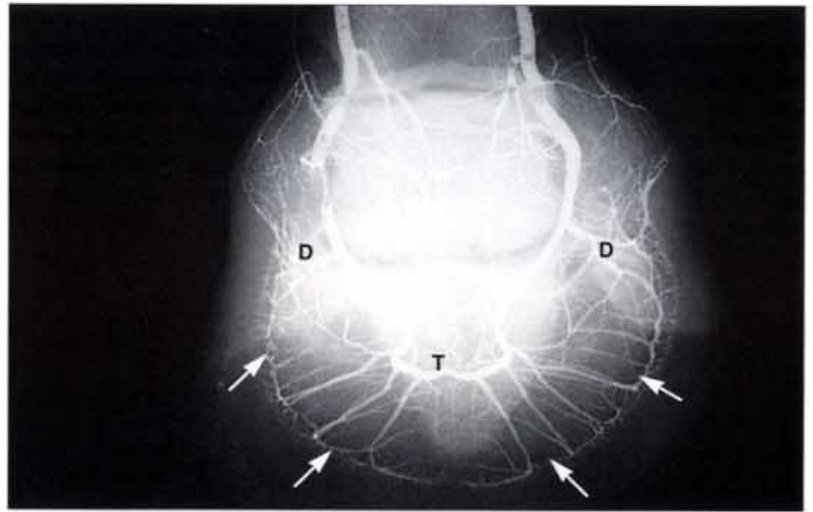


25. Vascular corrosion cast of the horses foot. Liquid red acrylic has been injected into the blood vascular system as in 24, only now all of the tissues have been corroded away by acid. The vascular corrosion cast resembles a horse's foot and the familiar shape of the fetlock, pastern and coronet can be readily identified. Less familiar is the shape of the horse's foot beneath the hoof. The blood vessel casts of the fine papillae of the periople and coronary band have formed a circular band under the proximal border of the hoof. Casts of the terminal papillae and the papillae of the sole form the distal border of the vascular skeleton. The viscosity of the acrylic was too great to form casts of the lamellae so they are not present, except at the distal border, where a few can be seen in parallel rows.

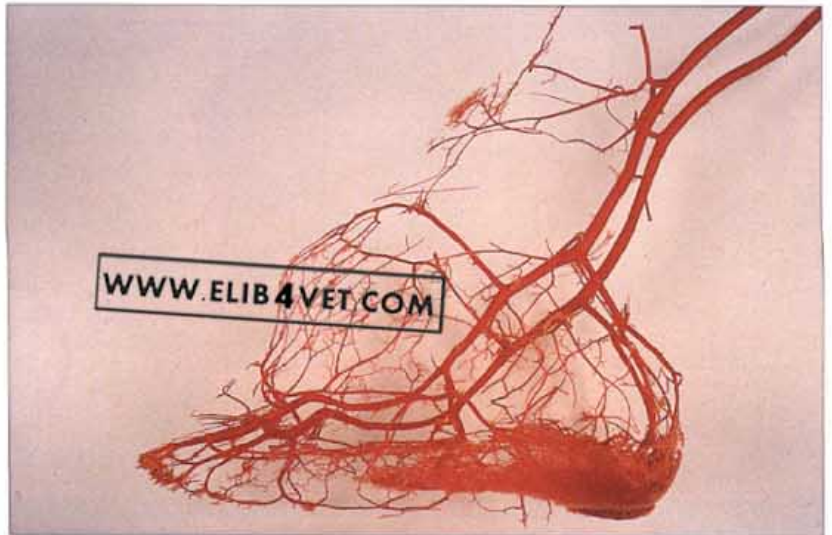

26. Arteriogram of a horse's foot (medial lateral view). An arteriogram of the foot was made by injecting a suspension of barium sulphate into the common digital artery. Eventually back pressure prevented any further injection; presumable because particles of barium sulphate could not enter the capillaries. Radiographs of the foot showed where the radio-opaque barium had filled the arteries. The pattern was similar to that of the vascular cast shown in 28 and was also used as a basis for the diagram in 29.

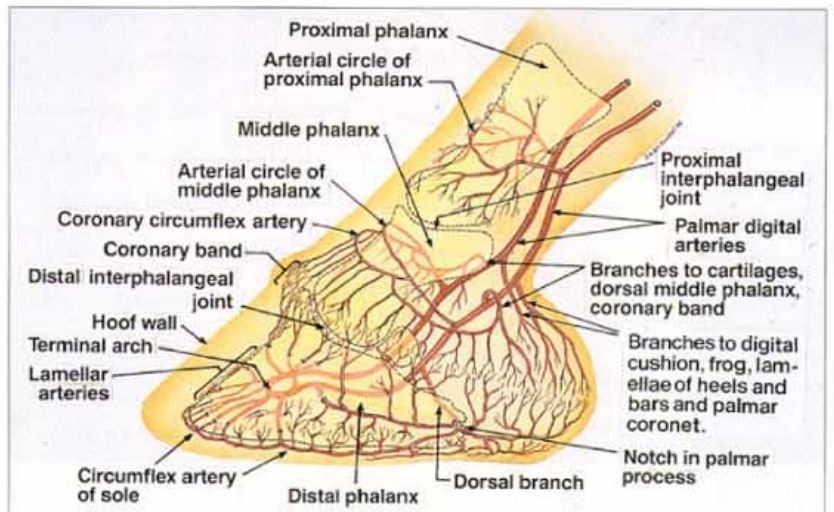
27. Arteriogram of a horse's foot dorso palmar view). Radiograph of the foot with the arterial system injected with barium sulphate; dorso-palmar view. The terminal arch (T) and the circumflex artery (arrowed) of the sole are shown clearly. The paired dorsal arteries (D) contribute to the circumflex artery at the quarters.

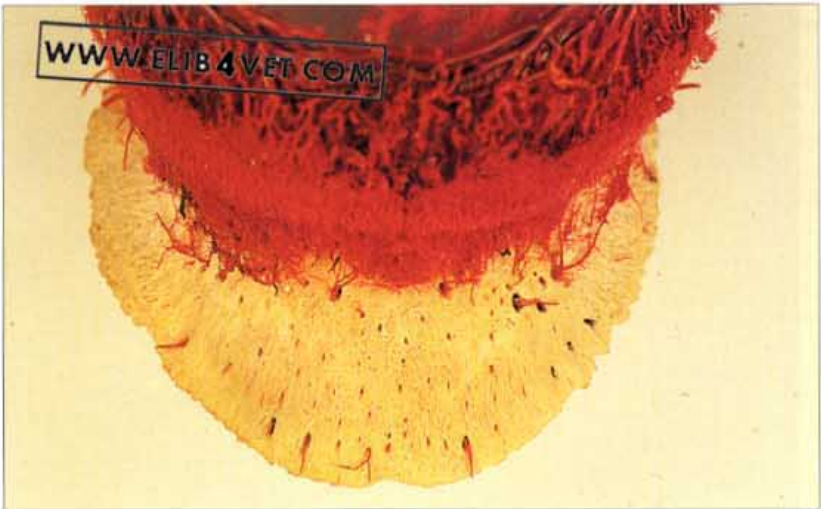


28. The arteries of the horse's foot. A vascular cast of a horse's foot was prepared and the capillaries and veins were removed by careful dissection. Arteries were identified by tracing them to their origin as branches from the easily located lateral and medial digital arteries. Branches of the terminal arch directed proximally supplied the proximal lamellae and the coronet. They anastomosed with distally directed branches of the circumflex artery of the coronet.

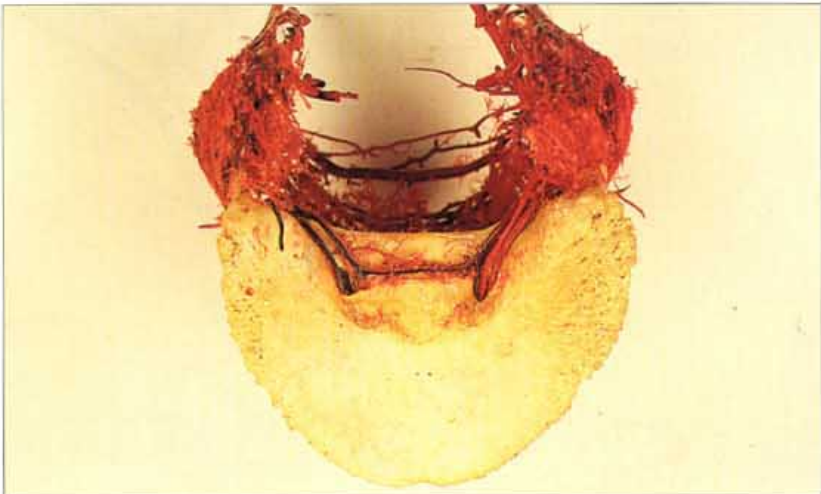

29. Diagram of the main arteries of the foot. To construct this diagram reference was made to the arterial vascular cast in 28 and the arteriograms in 26 and 27. The coronary band receives a dual blood supply from distally directed branches of the coronary circumflex artery and proximally directed branches of the lamellar arteries. All of these branches anastomosed with each other. The dorsal artery passes through a notch (sometimes a foramen) in the palmar process of the distal phalanx. Art: J. McDougall.

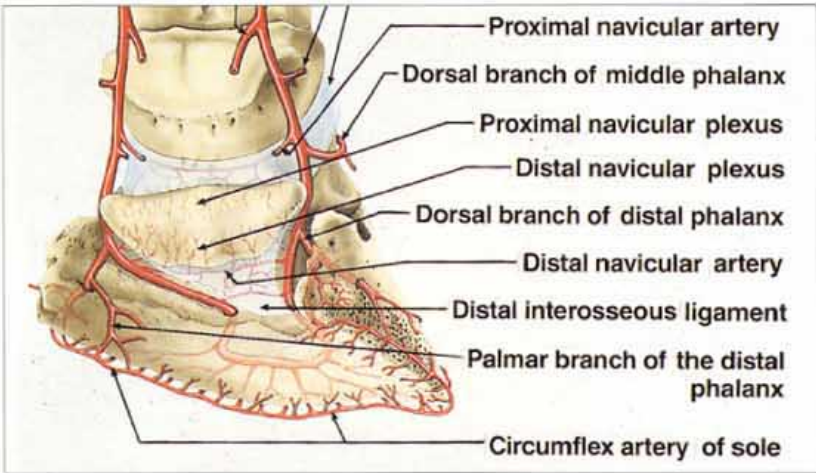




30. Arteries of the dorsal surface of the distal phalanx. A vascular cast was made and the specimen was corroded partially, to preserve the distal phalanx. The cast was dissected and all but the arteries were removed. The arteries which branched from the terminal arch, within the medulla of the bone, passed through the foraminae in the dorsal surface and formed the vascular bed of the lamellar corium.

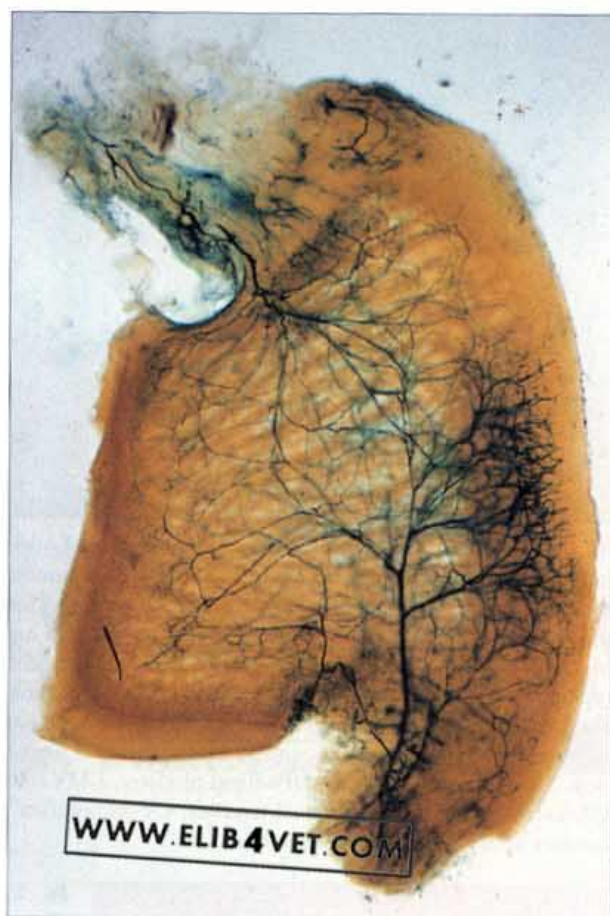

31. Arteries of the palmar surface of the distal phalanx. The palmar surface of the specimen in 30 was devoid of foraminae except at the edge of the palmar processes of the distal phalanx. The solar corium is dependent on axially directed branches of the circumflex artery of the sole. Horseshoes applying sole pressure can compress the circumflex artery and cause severe lameness and necrosis of the sole.

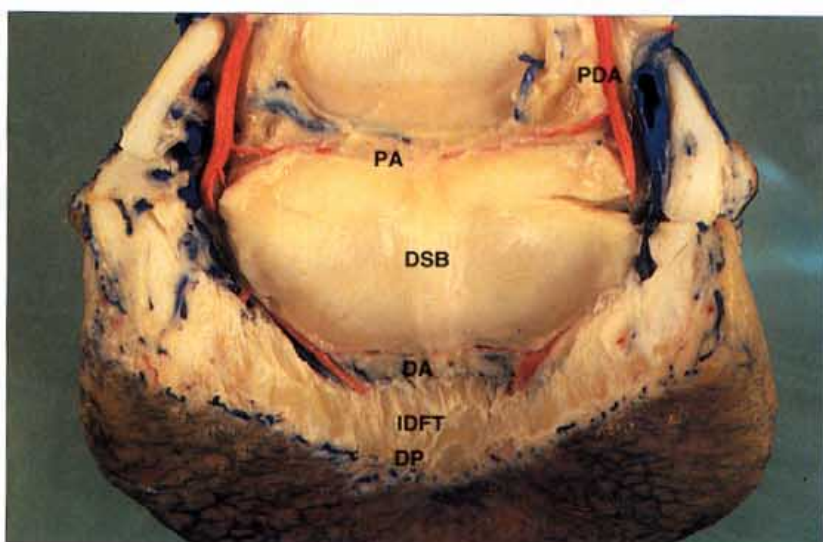


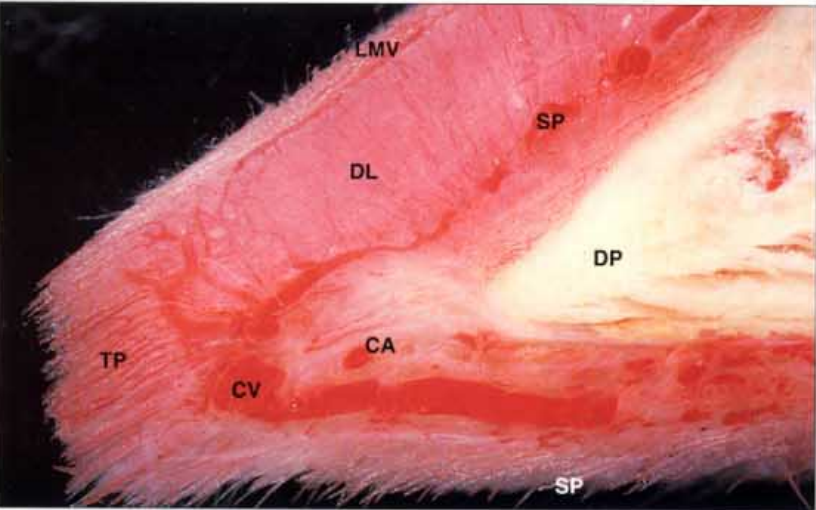
32. The arteries of the navicular bone and the distal phalanx. The paired medial and lateral palmar digital arteries give off branches above and below the distal sesamoid (navicular) bone—the proximal and distal navicular arteries, respectively—before entering the distal phalanx, via the solar foraminae, to form the terminal arch. Branches of the terminal arch perforate the dorsal surface of the distal phalanx to supply the lamellar corium and to anastomose and form the circumflex artery of the sole. The solar corium of the toe is dependent on axially directed branches of the circumflex artery for its blood supply. Art: J. McDougall.

33. Distal sesamoid bone blood supply (A). The arteries in this sagittal section of the distal sesamoid (navicular) bone have been made visible with gelatine and indian ink. Arteries enter the bone along both the proximal and distal borders; the latter is always larger and more branched. As would be expected the highly active bone of the flexor surface receives a rich blood supply. Photo: C. Colles.

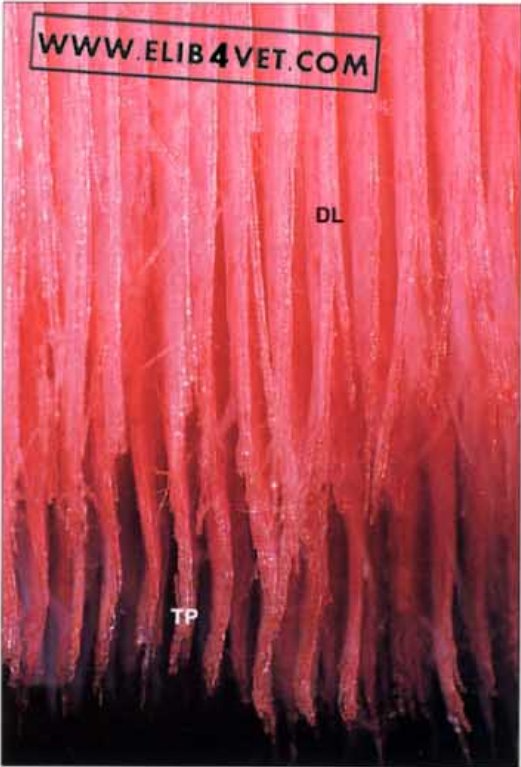


34. Distal sesamoid bone blood supply (B). The arteries of the specimen have been injected with red latex. The deep flexor tendon has been dissected from its broad insertion on the distal phalanx to show the flexor surface of the distal sesamoid bone. The paired medial and lateral digital arteries give off branches which enter the distal sesamoid (navicular) bone on both the proximal and distal borders. Distal to the navicular bone the digital arteries enter the palmar surface of the distal phalanx through paired foraminae to form the terminal arch. PDA=palmar digital artery, PA=proximal artery of distal sesamoid bone, DA=distal artery of distal sesamoid bone, DSB=distal sesamoid bone, DP=distal phalanx, IDFT=insertion of deep flexor tendon.





35. Vascular cast of sagittal section of the toe. The blood vessels of the toe have been injected with red acrylic and the hoof has been removed by gentle maceration; the distal tip of the distal phalanx is on the right. The red acrylic has filled the fine axial arteries and veins of a single dermal lamella and the most peripheral blood vessel is the marginal vein. The lamellar vessels arise from a sublamellar plexus formed from branches of the terminal arch. At the distal border of the lamella is a set of terminal papillae which merge with the papillae of the sole. The casts of the large-diameter circumflex artery and vein have been cut in cross-section. SP=sublamellar plexus, DP=distal phalanx, LMV=lamellar marginal vein, DL=dermal lamella, TP=terminal papillae, CV=circumflex vein of sole, CA=circumflex artery of sole, SP=sole papillae.

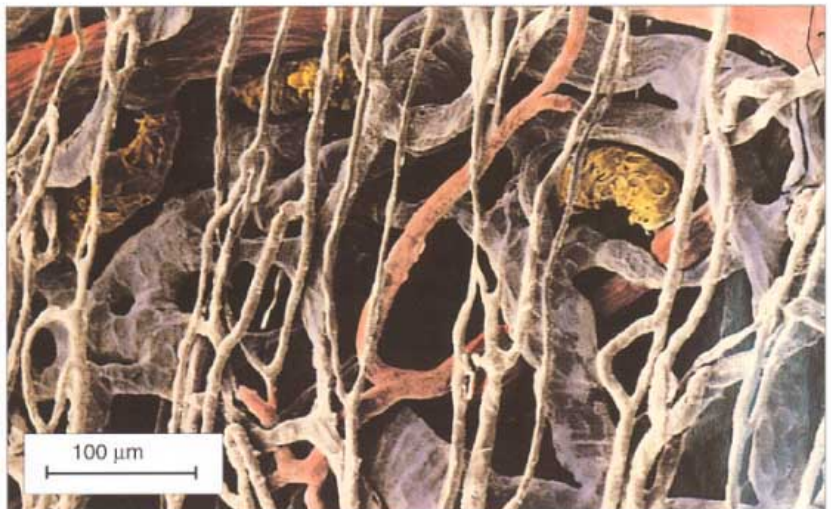

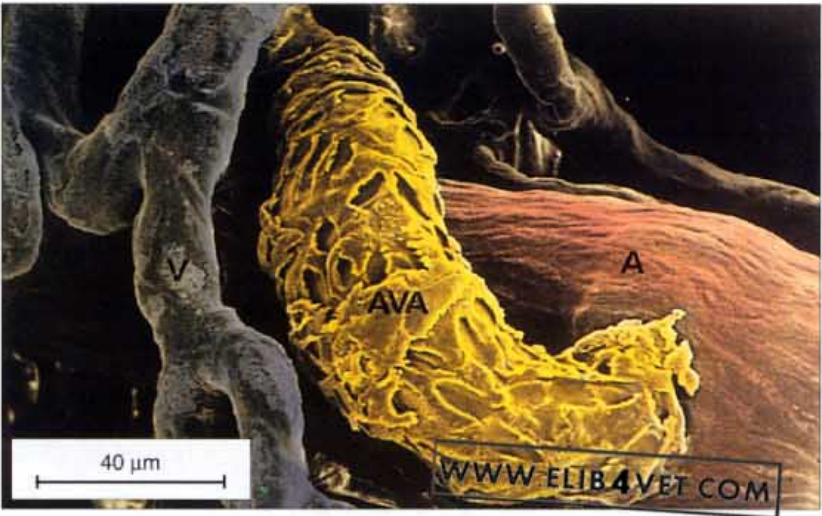36. Vascular cast of the lamellae and terminal papillae. The dorsal view of the corrosion cast of the distal toe shows the vascular casts of the dermal lamellae (DL) arranged in symmetrical parallel rows. In life the spaces between each row would be occupied by the epidermal lamellae of the inner hoof wall. The blood vessel of each lamella closest to the camera is the lamellar marginal vein. At the bottom of the picture receding away from the camera are the terminal papillae (TP) viewed end on.

37. Vascular corrosion cast of a single dermal lamella. A scanning electron micrograph of a corrosion cast of a single dermal lamella greatly magnified shows the marginal vein on the left and the cut ends of the axial arteries (AA) and veins (AV) on the right. The axial arteries branch and anastomose, becoming smaller in diameter and thinner walled, until they subdivide into capillaries. The walls of the capillaries are the thickness of a single endothelial cell and are the smallest vessels of the circulation. In the picture they orientate mainly from top to bottom and form a many-branched network on either side of the axial arteries and veins. The capillaries eventually merge into larger-diameter, thin-walled veins which drain blood from the region. The area boxed, on the right, is an axial artery and it is positioned between a pair of veins. This alternating arrangement between artery and vein is repeated along the length of each lamella. MV=marginal vein.

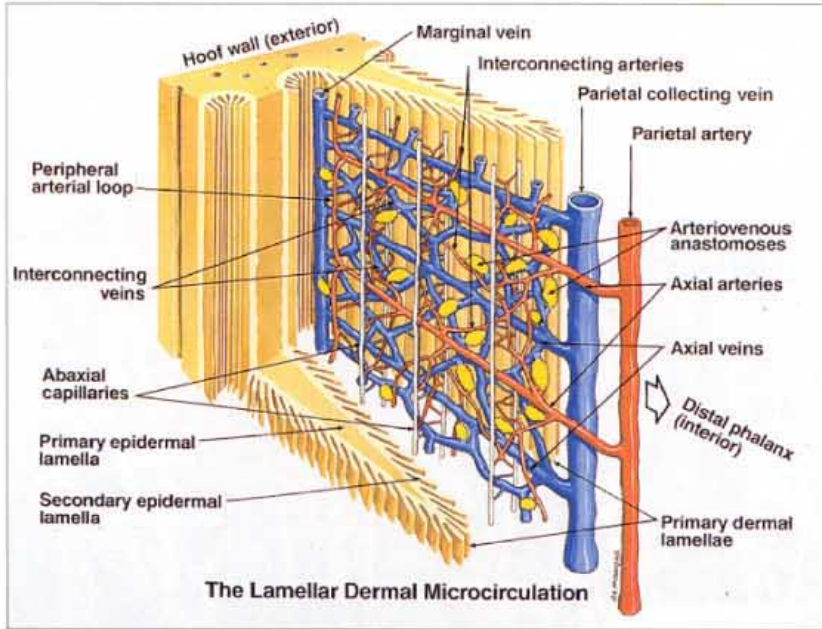


38. Vascular corrosion cast of the dermal lamellar microcirculation. This artificially coloured scanning electron micrograph of a portion of a dermal lamella shows a branch of an axial artery (red) subdividing into small-diameter capillaries. The veins are coloured blue and the fine capillary network can be traced leading back into them. Arteriovenous anastomoses (AVAs) are coloured yellow and connect artery to vein before the capillary level and provide an alternative route for the circulation of blood. The identity of the different vessels was established by the characteristic impressions left by the lining of the vessel wall on the surface of the cast.





39. Vascular corrosion cast of an arteriovenous anastomosis. An arteriovenous anastomosis (yellow) directly connects artery (red) to vein (blue). A network of capillaries, on the left, merges to join the vein. The characteristically tall endothelial cells which line the lumen of the AVA have left their impressions on the surface of the acrylic plastic cast. It is the markings on the surface of the cast that enable the anatomical identity of the different vessels to be established. The inappropriate, prolonged shunting of blood from artery to vein, before it can reach the capillary bed, is theoretically capable of causing laminitis.



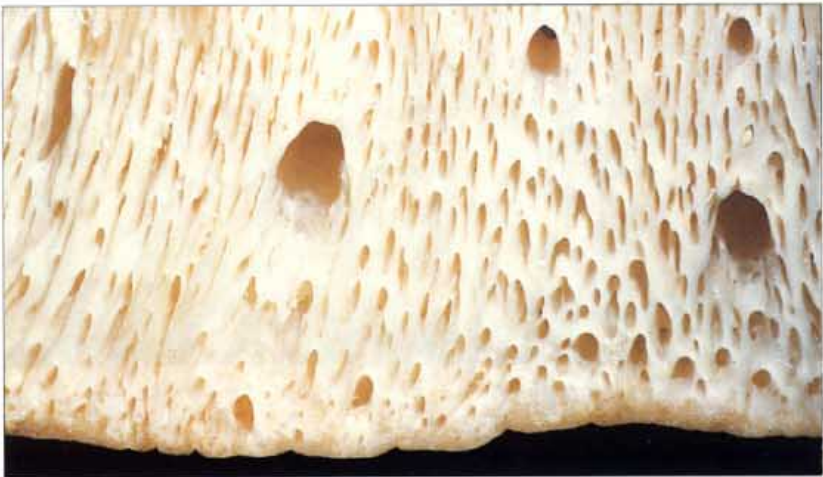40. Diagram of the lamellar dermal microcirculation. This diagram has been constructed from studies of vascular corrosion casts of the lamellar microcirculation. The blood vascular system is a component of the dermis, and each dermal lamella is sandwiched between a pair of epidermal lamellae. Axial arteries and veins branch from the parietal vessels and alternate with each other down the length of the lamella. Arteriovenous anastomoses arise from branches of the axial arteries, never from the axial arteries themselves. The branches of the axial arteries interconnect with each other and form an anastomosing plexus from which, ultimately, the fine capillaries arise. For reasons of clarity the capillaries in the diagram are shown very much reduced in number. The most peripheral vessel of the lamellar circulation is the marginal vein. The lamellar veins follow the same pattern as the arteries and drain into the parietal connecting vein. Art: J. McDougall.

41. **Thermoregulation of the foot.** Horses and ponies are adapted to survive the winter of the Northern Hemisphere without suffering any ill-effects such as frost-bite. There is evidence that their feet are endowed with a specialised, protective circulation similar to that found in the fauna typical of Polar regions. When the foot reaches a critically low temperature, the slow, nutritive circulation of the dermis is rapidly switched to a fast- warming circulation by the reflex opening of the many arteriovenous anastomoses found in the dermal microcirculation of the foot. The feet of horses are said to grow slower in winter than in summer.

Photo: Virginia Osbourne.



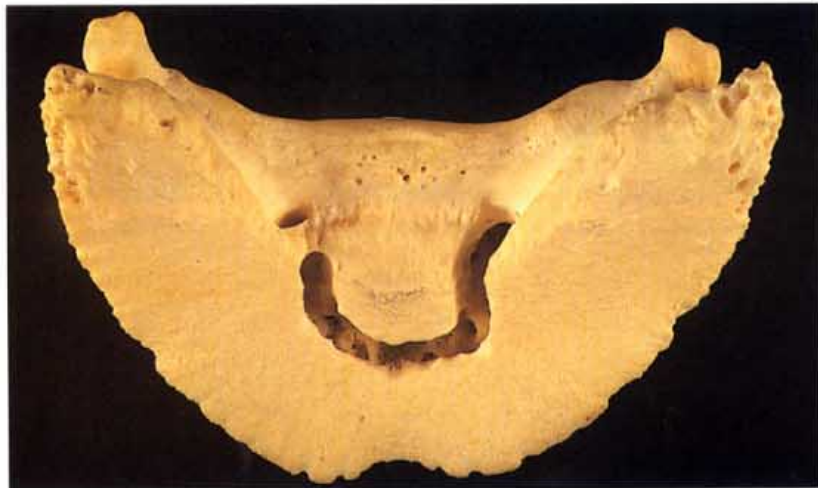Osteology



42. Dorsal surface of distal phalanx (A). Numerous foraminae perforate the dorsal surface of the distal phalanx. The larger foraminae are visible on radiographs and are canals for the larger branches of the terminal arch of the paired digital arteries and veins. Small arteries and veins pass through the lesser foraminae and all form the vascular bed of the lamellar corium.

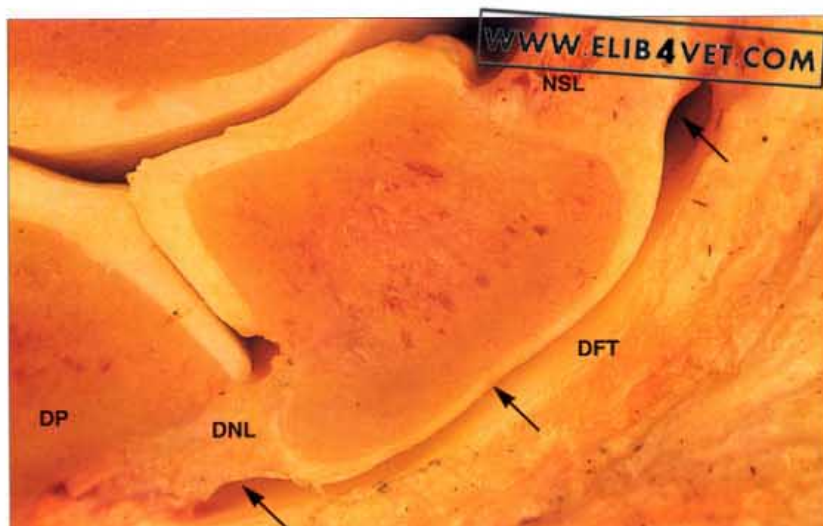


43. Dorsal surface of the distal phalanx (B). Numerous arteries and veins, of small and large diameter, here injected with red acrylic, occupy the foraminae in the dorsal surface of the distal phalanx.

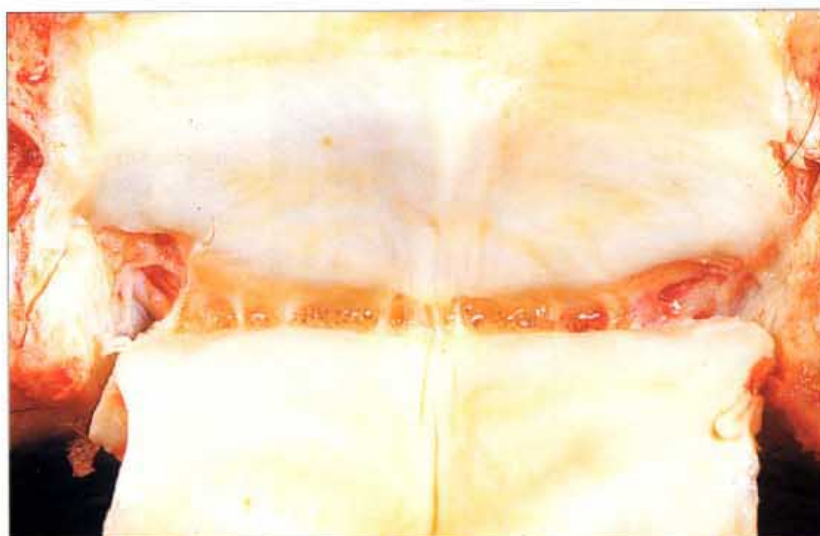

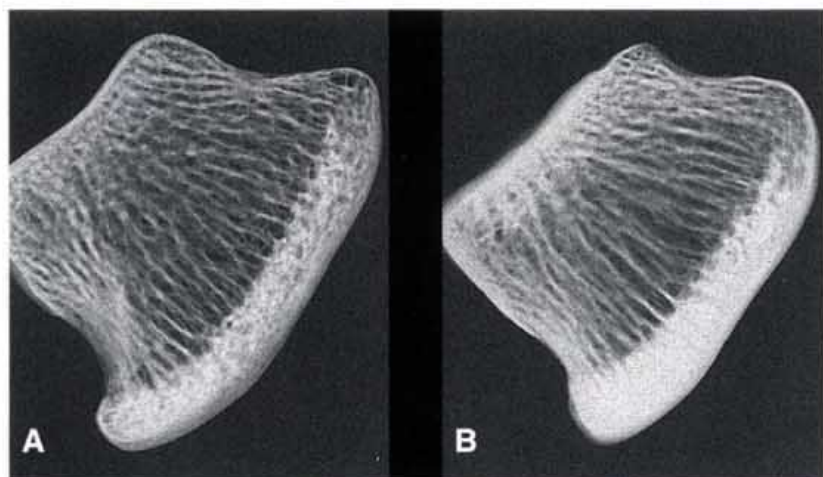
44. The canal in the distal phalanx for the terminal arch. Beneath the tough cortical bone of the palmar distal phalanx is the canal for the terminal arch of the medial and lateral digital artery and vein. In the photo the palmar cortex of the bone has been excavated to show the shape of the canal. The entry foramen on one side has been left unexcavated.

45. The distal sesamoid bone (navicular bone). This navicular bone has been cut in sagittal section and shows the relationship of the bone to the distal interphalangeal joint (coffin joint) on the left and the deep flexor tendon (DFT) on the right. The surfaces of the navicular bone which relate to the coffin joint are lined with hyaline cartilage and are part of a true synovial joint. The surface which apposes the deep flexor tendon is called the flexor surface and is lined with fibrocartilage. It is not a true joint surface and its palmar edge is usually the site where navicular disease develops. The navicular suspensory ligament (NSL) has its origin on the proximal phalanx and inserts along the entire proximal border of the navicular bone. The unpaired distal navicular ligament (DNL), or impar ligament, attaches the distal border of the bone to the palmar edge of the distal phalanx (DP). The space between the flexor surface and the deep flexor tendon is the navicular bursa (arrowed).



46. Distal sesamoid bone: flexor surface. The navicular bursa has been opened and the deep flexor tendon has been reflected downwards to show the smooth, shiny fibrocartilage of the flexor (palmar) surface of a normal distal sesamoid (navicular) bone. Pathological degeneration of the flexor surface is called navicular disease. Bisecting the bone is the sagittal ridge where, often, the first lesions of navicular disease appear.

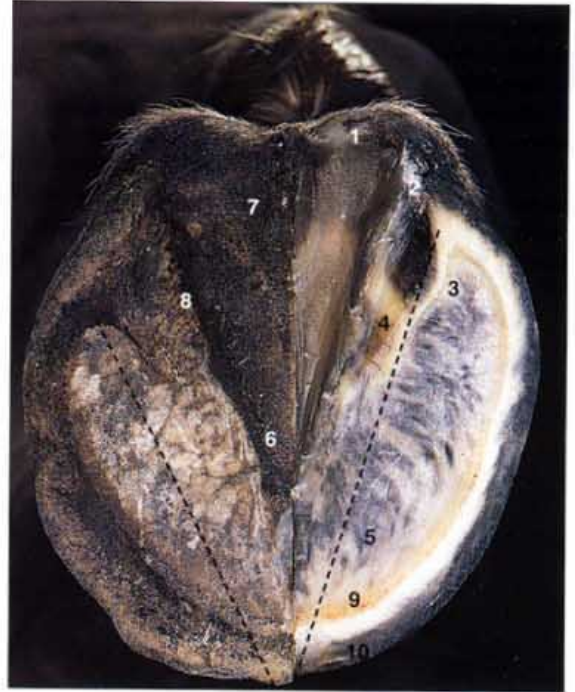



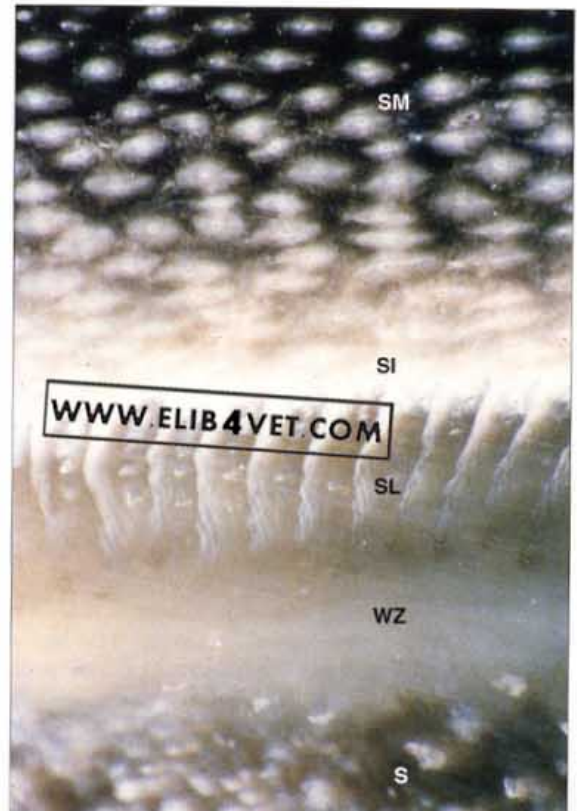
47. Radiographs of distal sesamoid bone sections. Bone is a living tissue and during life is constantly responding to changes in the forces acting upon it. New bone is laid down to reinforce the sites of greatest stress. A navicular bone section from an untrained two-year-old racehorse is shown in A. The flexor surface has to withstand the greatest stress and is thus the densest part of the bone. The calcified trabeculae in the centre of the bone form a loose network of supporting struts. The section B is taken from a mature working Thoroughbred. The distal two-thirds of the flexor surface is densely calcified and is thicker than in the young horse shown in A. The trabeculae have lost their mesh-like appearance and are organised into stronger columns and struts. In addition the two surfaces which relate to the distal interphalangeal joint have been reinforced. These adaptive changes take months to occur and excessive loading of the flexor surface and failure to remodel are important factors in the cause of navicular disease. Radiography: K. Reynolds.

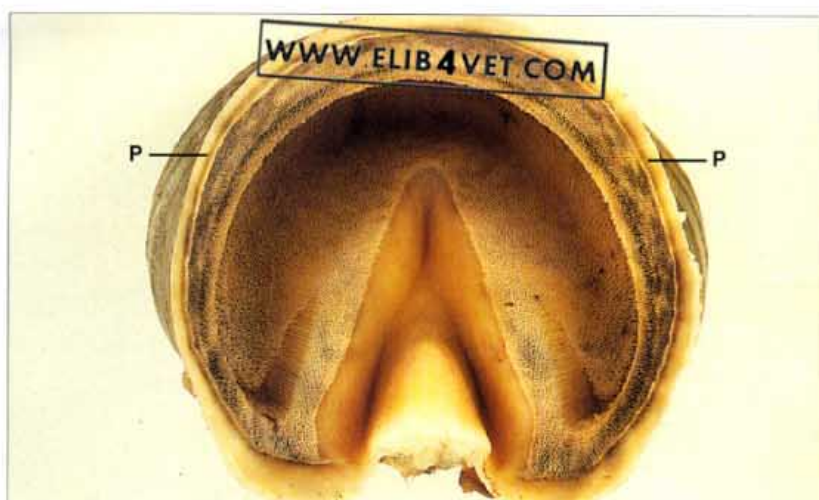Hoof Wall Anatomy

48. Solar surface of the hoof with one half trimmed. Correct foot preparation is one of the hallmarks of a competent farrier. There is a dramatic shift in the position of the heels when an undressed foot is trimmed as if for shoeing. The dressed side would need a shoe a size larger than for the undressed side, as shown by the dotted lines. Shoeing poorly prepared feet with long toes and underrun heels will have disastrous long-term results. 1=bulb of heel, 2=buttress of heel, 3=angle of sole, 4=bar, 5=sole, 6=apex or point of frog, 7=central sulcus(groove) of frog, 8=collateral groove of frog, 9=white zone, 10=stratum medium of distal hoof wall.



49. The ground surface of the wall/sole junction. The hoof wall, darkly pigmented in this case, is at the top of the picture and the similarly pigmented sole is at the bottom. The non-pigmented epidermal lamellae line the inner hoof wall, which is also devoid of pigment. In between each lamella are cross-sections of the tubular horn generated by the terminal papillae. Epidermal lamellae visible on the ground surface of the hoof, arose on the shoulders of the coronary groove 8–9 months previously and have been pushed past the dorsal surface of the distal phalanx by continual growth from above. SM=stratum medium of distal hoof wall, SI=stratum internum, SL=stratum lamellatum, WZ=white zone, S=sole.





50. Hoof with contents removed (A). The inner hoof wall is lined with 600 or so epidermal lamellae that extend inwards at the buttress and line the internal surface of the bars. The surface of the concave coronary groove and the entire sole are dotted with numerous holes into which fit the dermal papillae of the coronary and solar coria, respectively. The soft periople (P), which connects the hoof to the skin, is wider at the heels than at the toe.

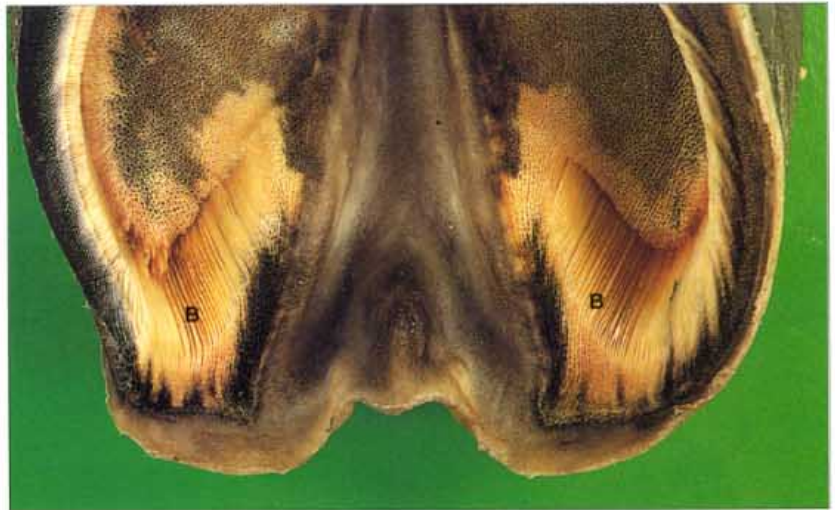

51. Hoof with contents removed (B). This pigmented hoof capsule with the contents removed has a portion of the wall cut away to show some of the inner structures of the hoof capsule. The longitudinal section of the hoof at the toe shows the curve of the coronary groove, the pigmented stratum medium of the hoof wall proper, and the non-pigmented inner hoof wall (stratum internum) which bears the epidermal lamellae. The hoof wall cut in transverse section shows the lamellae lining the non-pigmented inner hoof wall. At the top of the hoof wall, on the outer edge of the coronary groove is the soft, non-pigmented, flexible periople (P) which expands at the heels to form the bulbs of the heel. At the buttress of the heels the lamellae of the inner hoof wall are reflected inwards towards the frog to form the bars (B). Both the concave coronary groove and the surface of the sole and frog are dotted with numerous holes for the dermal papillae. In the centre of the frog is a spine to which is attached the digital cushion. Note how the thickness of the wall is greater at the toe than at the quarter.

52. Hoof with contents removed (C). A close-up of the cut-away section of the hoof capsule shows more clearly the holes in the coronary groove into which the dermal papillae fit. Each papilla is responsible for a single hoof tubule and many tubules are visible in the cut cross-section. The tubules close to the non-pigmented inner hoof wall are much broader in diameter than those close to the outside edge of the hoof wall. The inner hoof wall is lined by numerous lamellae.



53. Hoof with contents removed (D). This close-up view of the buttress and heels shows how the lamellae of the inner hoof wall reflect inwards and line the bars (B). The wall is thickened at the heels to form the supporting buttress. The periople or bulbs of the heel merge with the frog.

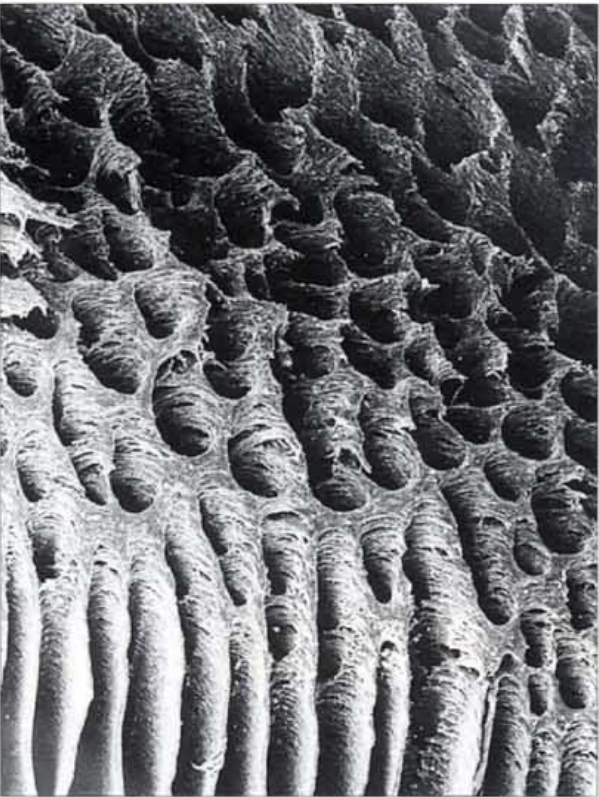


54. Hoof with contents removed (E). A close-up of the transverse section of the hoof wall shows the non-pigmented inner hoof wall and the lamellae. The tubules (cut in cross-section) of the inner hoof wall are relatively large in diameter. The tubules of smallest diameter form the hard outer edge of the hoof wall. The softer inner hoof wall has the highest moisture content (32%), decreasing along a gradient to about 15% in the outer hoof wall.



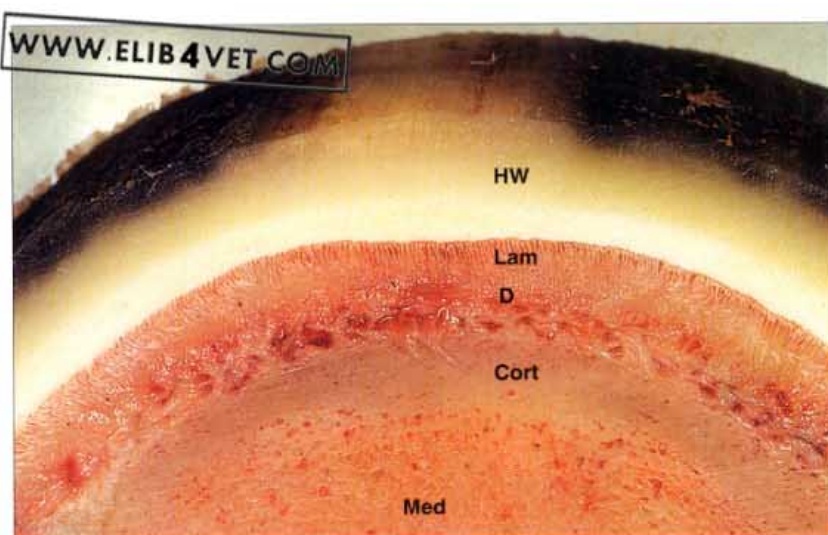


55. The epidermal lamellae of the inner hoof wall. Magnified 7500 times by the scanning electron microscope and separated from the dermis by gentle maceration, the epidermis of the mid-wall region of the hoof wall is shown organised into rows of primary and secondary lamellae. There are three primary epidermal lamellae shown in the picture, to which are attached numerous secondary epidermal lamellae. The parallel secondary epidermal lamellae are all approximately the same length and connect at their bases to the primary lamella at an oblique angle. They orientate towards the dorsal surface of the distal phalanx which is out of picture to the right. In life the spaces between the epidermal lamellae would be occupied by a complementary arrangement of dermal lamellae.

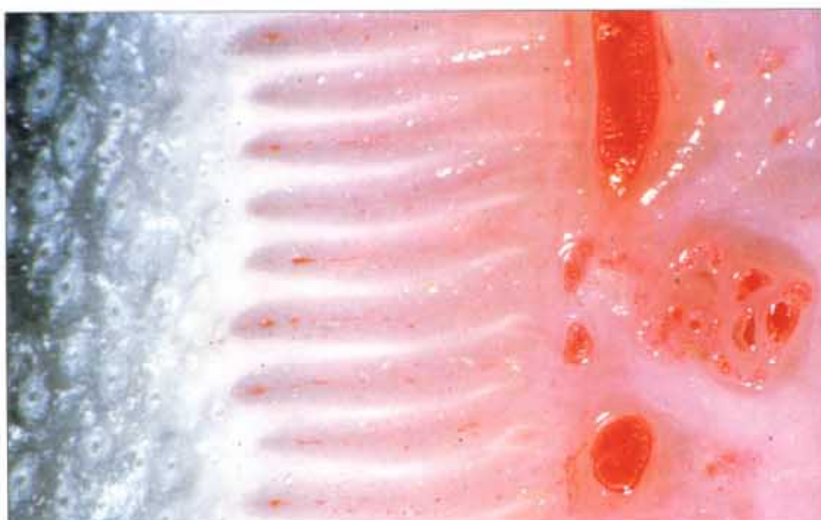

56. The coronary groove of the proximal hoof wall. Magnified 2000 times by the scanning electron microscope, the keratinised cells of the hoof wall coronary groove are shown forming numerous cone shaped holes or sockets. In life the tapering papillae of the coronary dermis fit tightly into the sockets and, being highly vascular, supply nutrients and oxygen to maintain growth of the hoof wall throughout the life of the horse. At the rounded shoulder of the coronary groove the epidermis merges into the inner hoof wall and is arranged in rows of thin parallel leaflets—the epidermal lamellae.

57. Transverse section through the dorsal hoof wall. The foot has been sectioned in the transverse plane through the midpoint of the dorsal hoof wall. The epidermal lamellae occupy about 25% of the distance between the inner hoof wall and the dorsal surface of the distal phalanx. In the sectioned bone there is a well-defined margin between the dense outer cortex and the cancellous bone of the medulla. This photograph should be compared with the chronic laminitis section in 391 which was taken at the same magnification. HW=hoof wall, Lam=epidermal lamellae, D=dermis, Cort=cortex of distal phalanx, Med= medulla of distal phalanx.

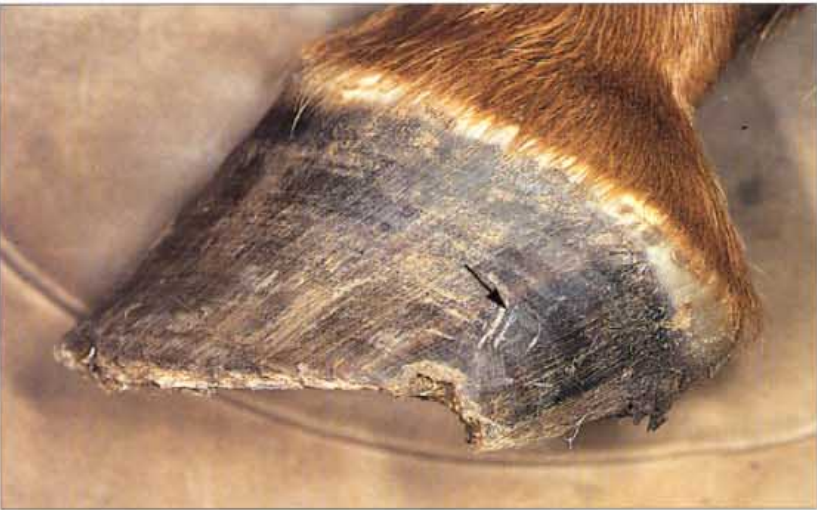

58. Inner hoof wall transverse section. Even in a completely black hoof the inner hoof wall and the epidermal lamellae are never pigmented. In this transverse section the blood vessels have been injected with red acrylic plastic; the largest vessels are the lamellar veins. At this magnification the primary epidermal lamellae are clearly visible and the secondary epidermal lamellae just visible. The white epidermal lamellae interdigitate with the corresponding pink dermal lamellae and small veins cut in cross-section can be seen throughout the length of the latter. In the hoof wall proper many wall tubules have been cut in cross-section; they contain less pigment than the adjacent intertubular horn.





59. The hoof wall tubules (A). The hoof wall is composed of innumerable fine horn tubules welded together by intertubular horn. Ideally, the tubules should all be parallel to each other. In this natural, unshod, feral horse's foot, the tubules at the heel are indeed parallel to the tubules of the dorsal hoof wall. The tubules are aligned along lines of weight-bearing stress and, clearly, the heels are capable of taking their share of the load of weight bearing without distortion or folding under. In the photograph the periople (P) is opaque because it has been moistened with water. The periople is normally flexible and soft and joins the skin to the hard hoof wall. It extends from the hairline down the hoof wall to the point arrowed. The amount of hoof wall covered by the periople depends on the abrasiveness of the horse's environment. In stabled horses it may extend halfway down the hoof wall.

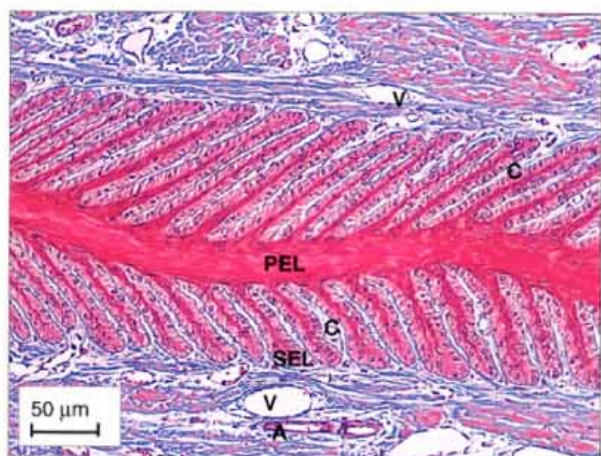


60. The hoof wall tubules (B). In contrast, the hoof tubules of this unshod horse's foot are not parallel; the tubules of the heel are at a much lower angle than those of the toe. The heels are folded under and the heel tubules are not aligned along lines of weight-bearing stress as they are in 59. The unnatural loading of the heels has caused the hoof capsule to distort and flare at precisely the point (arrowed) where quarter cracks develop. It is important to prepare and shoe horses' feet with the heels supported and loaded in as natural a way as possible.

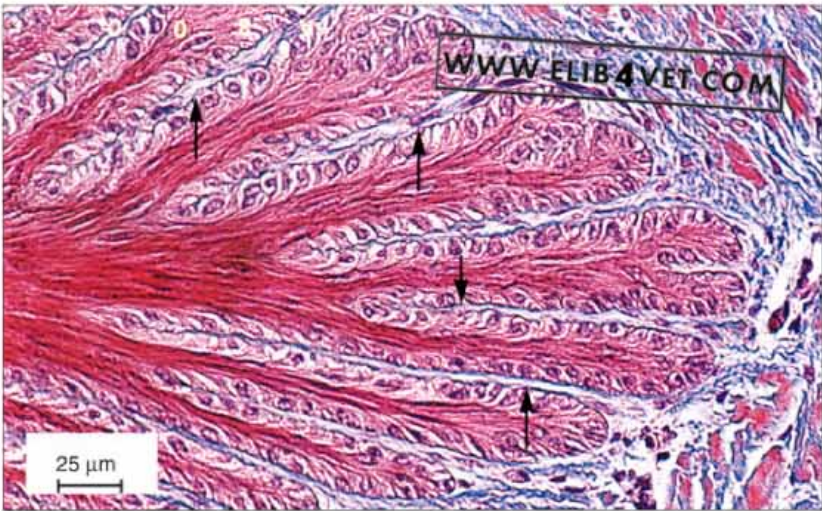Histology



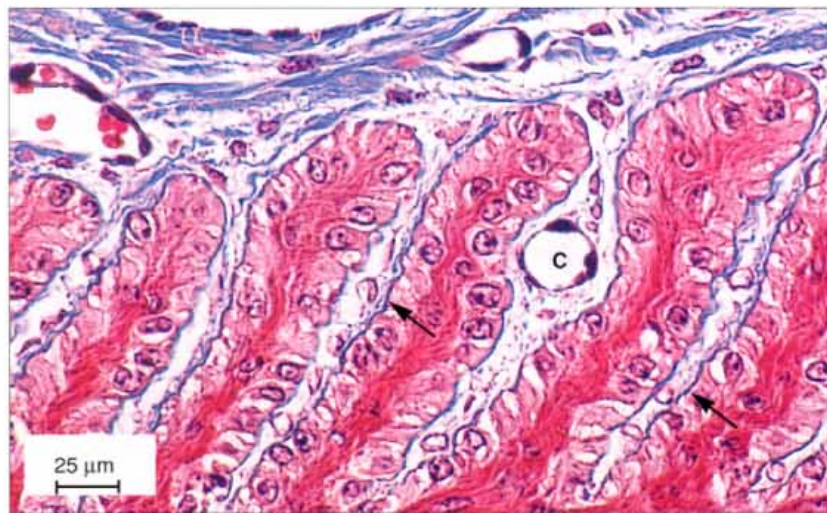
61. Transverse histological section of the inner hoof wall. The section was made in the mid-wall region and has been stained with Masson's trichrome stain. The hoof wall, cut in cross-section, is on the left and the distal phalanx is on the right just out of the picture. All the keratinised epidermal structures have stained red and nine primary epidermal lamellae (leaflets of the inner hoof wall) are shown. The border of each primary epidermal lamella is folded many times over into 100–150 secondary leaflets or secondary epidermal lamellae. The dermal tissue has stained blue and is arranged in a similar, complementary pattern to the epidermal structures: primary dermal lamellae subdivided into smaller secondary dermal lamellae.



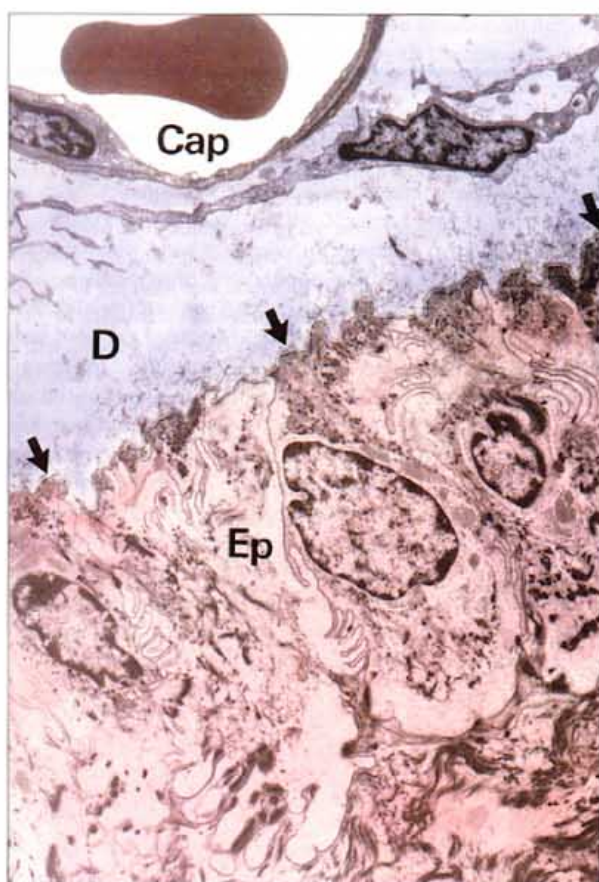
62. Transverse histological section of epidermal lamella. As in 61 the section has been stained with Masson's trichrome so epidermal structures are red and dermal are blue. The distinct fine line between the epidermal compartment (red) and the dermal (blue) is the dark blue basement membrane. The first row of cells on the epidermal side of the basement membrane all contain nuclei and are epidermal basal cells. They continually divide throughout the life of the horse and their daughter cells mature into non-nucleated, keratinised (dark red) cells forming the central axis of each secondary lamella. The continual production of cells from the peripheral basal layer pushes the slender keratinising cells inwards so that they contribute to the thickness and strength of both the secondary and primary epidermal lamellae. On the dermal side of the basement membrane are the blue staining collagen fibers of tough connective tissue. Fine connective tissue fibres anchored firmly to the vast surface area of the basement membrane coalesce between each secondary lamella and form a continuum through to the dorsal surface of the distal phalanx, which forms the basis of the hoof distal phalanx bond. Interspaced throughout the connective tissue of the lamellar dermis are sections of veins, arteries and capillaries. A=arteries, V=veins, C=capillaries, PEL= primary epidermal lamella, SEL=secondary epidermal lamella.



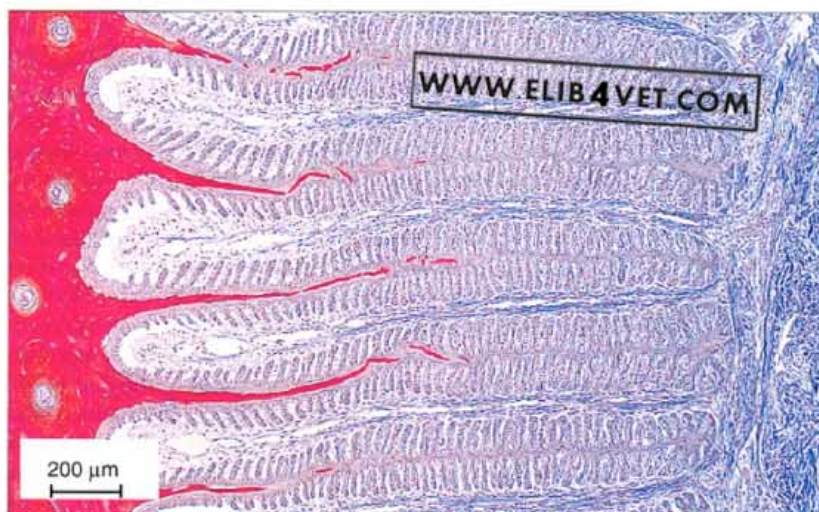
63. Transverse histological section of epidermal lamella tip. As above, in 61, the section has been stained with Masson's trichrome so epidermal structures are red and dermal are blue. Separating the epidermal compartment from the dermal is the dark blue basement membrane (arrowed). The nucleated basal cells of the epidermis are firmly anchored to the basement membrane and throughout the life of the horse continually divide giving rise to cells which mature into the non-nucleated, dark red keratinised cells in the core of each lamella. The tough connective tissue of the dermis (blue) is also anchored to the basement membrane and together the lamellae and the dermal connective tissue bond the inner hoof wall to the dorsal surface of the distal phalanx.



64. Transverse histological section of secondary epidermal lamellae. Stained with Masson's trichrome, epidermal structures are red and dermal structures are blue. Separating the non-vascular (without a blood supply) epidermal compartment from the vascular (with a blood supply) dermal compartment is the dark blue basement membrane. All the nucleated epidermal germinal cells are firmly attached to the basement membrane (arrowed). As the epidermal cells mature they lose their nuclei and secrete a cement substance which bonds the cells together. In the picture these mature non-nucleated cells have stained dark red and make up the tough inner axis of each secondary epidermal lamella. The axis of each secondary epidermal lamella is continuous with the keratinised primary epidermal lamella, which is at the bottom of the picture. Most of the blue staining dermis is made up of tough connective tissue which ultimately penetrates the spaces between the secondary epidermal lamellae and attaches firmly to the dermal side of the basement membrane. The connective tissue in turn attaches firmly to the dorsal surface of the distal phalanx and serves to suspend the bone from the inner surface of the hoof wall. In the dermis are several blood vessels, some still containing red blood cells. The smallest element of the blood vascular system is the capillary (C) and one of these is present between two secondary epidermal lamellae. The dark cells lining the lumen of the blood vessels are endothelial cells.

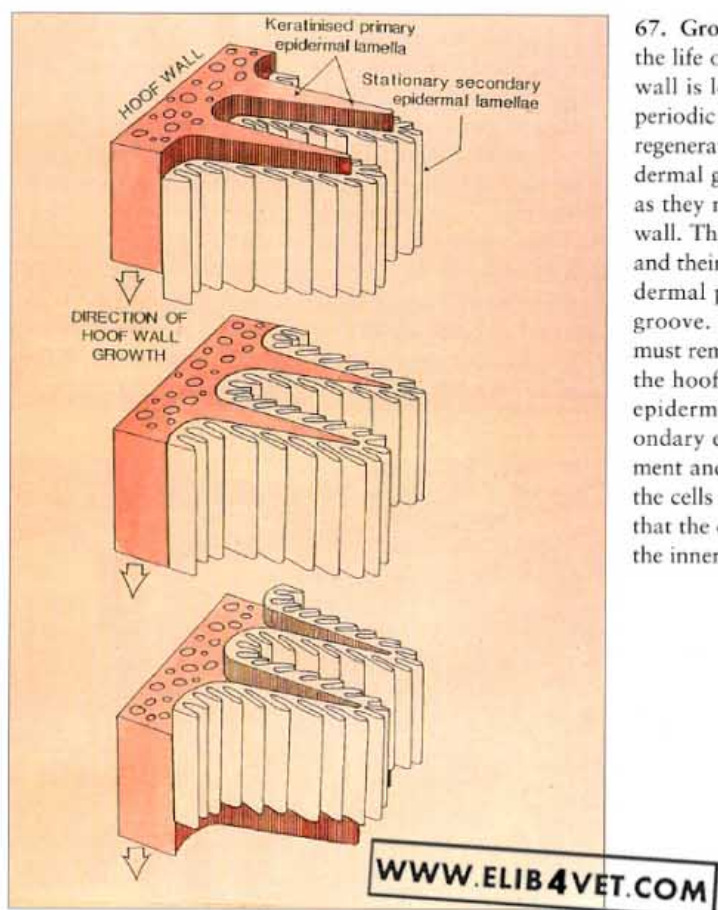


65. Dermal-epidermal junction. In this transmission electron micrograph, the dermis (D) has been tinted blue and the epidermis (Ep) pink. Separating the two layers is the basement membrane (arrowed). Connective tissue from the dorsal surface of the distal phalanx, attaches as fine fibres to the dermal side of the basement membrane. The nucleated epidermal cells anchored to the epidermal side of the basement membrane are the epidermal germinal cells. Daughter cells which bud from the germinal cells lose their nuclei and progressively keratinise to form the hard structures of the hoof. Both the basement membrane and the junctions between the epidermal cells are heavily folded (plicated) so that they can stretch and deform to accommodate the stress of weight-bearing with each footfall. The epidermis is without a blood supply of its own and relies on the adjacent capillaries (Cap) of the dermis for a supply of nutrients and oxygen to diffuse across the basement membrane. Within the capillary is a red blood cell. Magnification $\times 4000$.

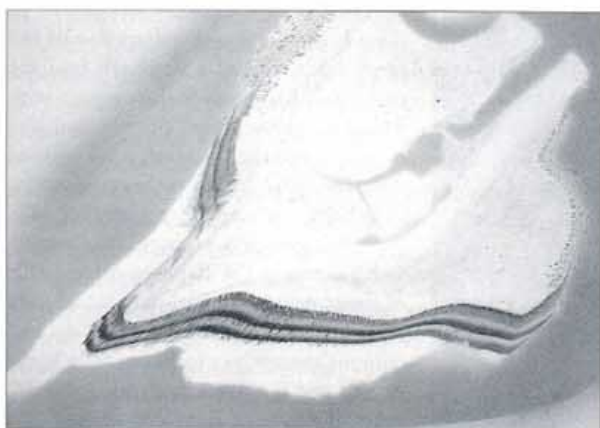


66. Transverse histological section of the inner hoof wall (foal). In contrast to the adult situation, the lamellae of the inner hoof wall of a newborn foal are only partially keratinised (compare with 61). All the hoof wall proper, but less than 50% of the lamellae, have stained the dark red of complete keratinisation. The hoof wall and the lamellae of a rapidly growing foal increase in size as well as length. The basal epidermal cells of the lamellae of a foal have a high rate of proliferation. The lamellae do not commit themselves to being fully keratinised and fixed in length until about 2 years of age.

Hoof Growth



67. Growth of the hoof wall. The hoof wall grows throughout the life of the horse. At the ground surface the distal rim of the wall is lost by wear and abrasion or, if the horse is shod, by periodic removal by a farrier. Continual loss requires continual regeneration and this occurs at the coronary band where the epidermal germinal cells produce populations of new cells which, as they mature and keratinise, are added to the proximal hoof wall. The primary epidermal lamellae are part of the hoof wall and their loss at the ground surface is also accounted for by epidermal proliferation on the inner shoulders of the coronary groove. Because the germinal cells of the epidermal lamellae must remain attached to their basement membrane (to maintain the hoof distal phalanx bond), it is assumed that the primary epidermal lamellae slide past the stationary cells of the secondary epidermal lamellae in a staggered sequence of detachment and reattachment. Presumably only a small percentage of the cells are detached at any one time (rather like a ratchet) so that the distal phalanx never loses its suspensory attachment to the inner hoof wall. The diagram illustrates this principle.




68. Autoradiograph of a sagittal section of the equine foot. An autoradiograph was made by injecting radioactive methionine intravenously into a horse on three separate occasions 2 weeks apart. The horse was euthanased the day after the last injection and a freeze-dried sagittal section was made of the entire foot. The section was mounted on glass and sandwiched against X-ray film for several weeks. When the film was developed the dark exposed areas showed where cell division had incorporated the radioactive methionine into the epidermis of the hoof. The three darkest bands in the hoof wall, white zone, sole and frog, correspond to the three injections of radioactive methionine and clearly show how these regions are constructed of tubules welded together in a matrix of intertubular horn. The radiolabelled tubules are surprisingly long and are parallel to the long axis of the hoof wall. The distances between the major bands, in the proximal hoof wall, were not equal so the conclusion of this study was that the inner hoof wall grew at a faster rate than the more compact outer hoof wall.

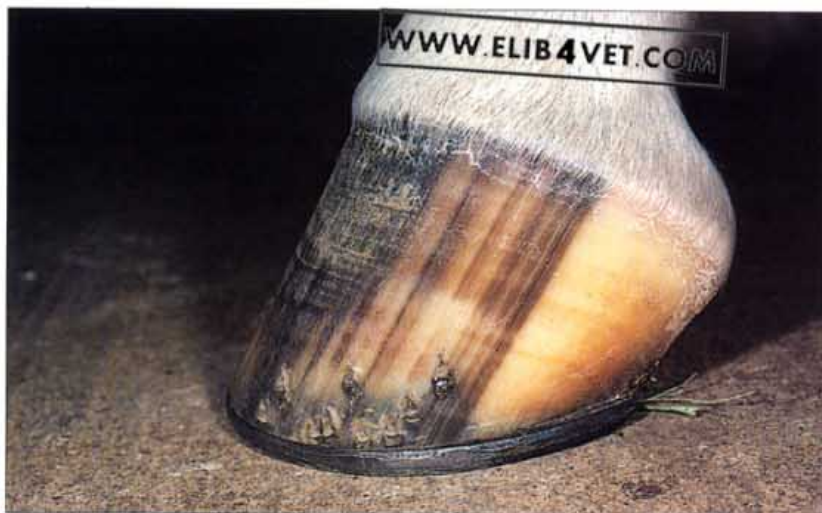69. Autoradiograph of a dorsal hoof wall section. An autoradiograph was made by injecting a horse with a single intravenous dose of radioactive methionine. The horse was euthanased the day after the injection and a thin section was made of the dorsal hoof wall and a single epidermal lamella. This was used to make an autoradiograph, as described in 68. The hoof wall section has been photographed beside its autoradiograph. As before, a dark band in the autoradiograph of the proximal hoof wall, the white zone and the sole, shows where the tubular and intertubular epidermis of the hoof had taken up the radioactive methionine. The epidermal lamella has been labelled, indicating that the lamellae of the inner hoof wall are also undergoing cell division but apparently at a much slower rate.



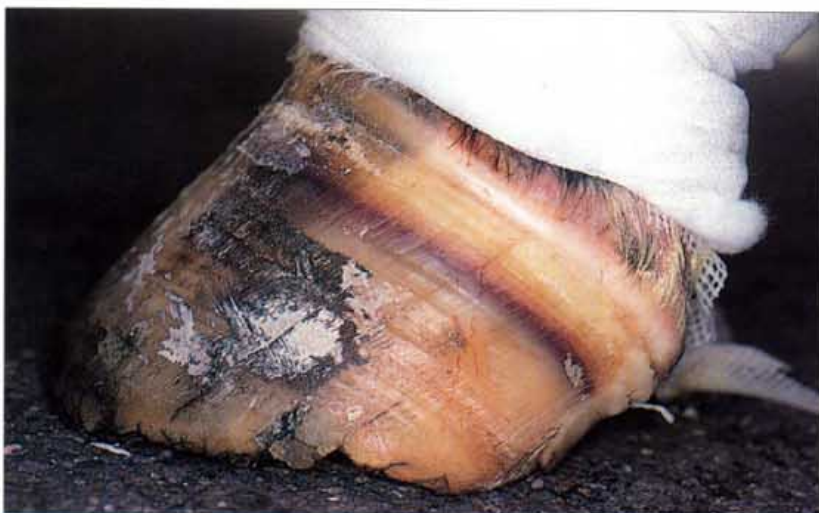70. Polarised light photograph of a section of hoof wall. A thin longitudinal section, photographed with polarised light, shows the tubular nature of the dorsal hoof wall. The hoof wall consists of thousands of tough keratinised tubules all cemented together by intertubular horn. Each tubule is normally continuous from the coronet to the ground surface and grows throughout the life of the horse. To the right of the picture is a single lamella of the inner hoof wall.



Hoof Pigment

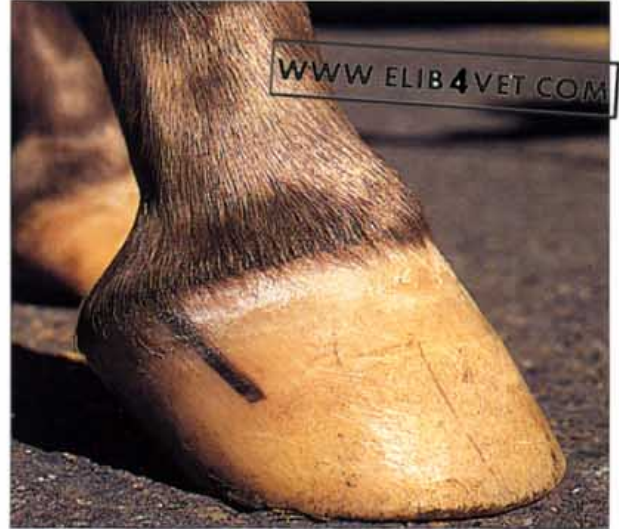

71. Hoof pigmentation. There is a high concentration of melanin in the dorsal hoof wall of this hind foot and very little of the pigment in the heels. In between the heel and the toe the wall is striped because some hoof wall tubules are pigmented and some are not, illustrating clearly, the straight tubular nature of the equine hoof wall. The cells which produce pigment are called melanocytes and are close to the germinal layer of the hoof epidermis at the coronet; they inject granules of pigment (melanin) into maturing epidermal cells and impart varying shades of dark colour to the hoof wall.



72. Haemoglobin staining of the hoof wall. A dark red band parallel to the coronet and extending from the toe to the heel is present in the, otherwise, unpigmented hoof wall of this horse. Eight weeks before this photograph was taken, a severe laceration to the limb occurred above the fetlock. The flexor tendons were severed. Presumably the circulation to the limb below the laceration was not significantly affected; there were no defects in the hoof wall growth. Somehow, at the time of the acute injury, haemoglobin entered the circulation of the papillae of the coronary groove and became incorporated in new hoof wall growth.

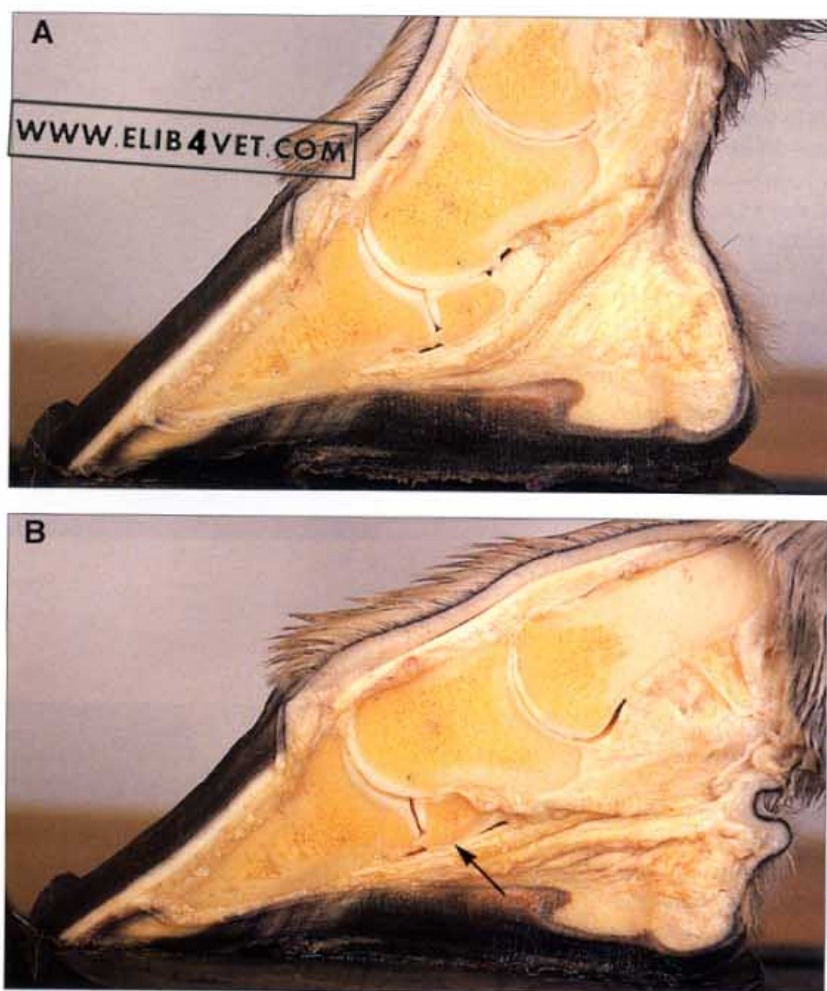
73. **Hoof wall pigmentation (Appaloosa).** The pigmented spots in the skin of Appaloosa horses appear with increasing maturity. This may apply to the hooves as well. In this unshod Appaloosa yearling, pigment production at the coronet was apparently 'switched on' some 3 months before the photograph was taken.



74. **Hoof wall pigmentation.** Normally the hoof wall is pigmented in a proximal distal direction, parallel to the hoof wall tubules, and the permanent stripes in the hoof can be used to identify the horse. The foot of the adult horse in the photograph was once uniformly dark, but is now white with only a narrow band of pigment parallel to the coronet in the hoof wall. This is most unusual and for an unknown reason the production of the pigment melanin had become intermittent. The hoof was otherwise normal and the horse was not suffering from any known medical condition. Photo: R. Pascoe.



Functional Considerations

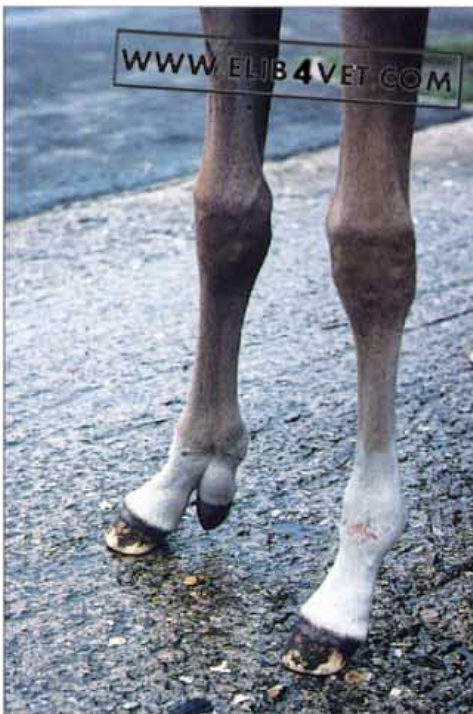
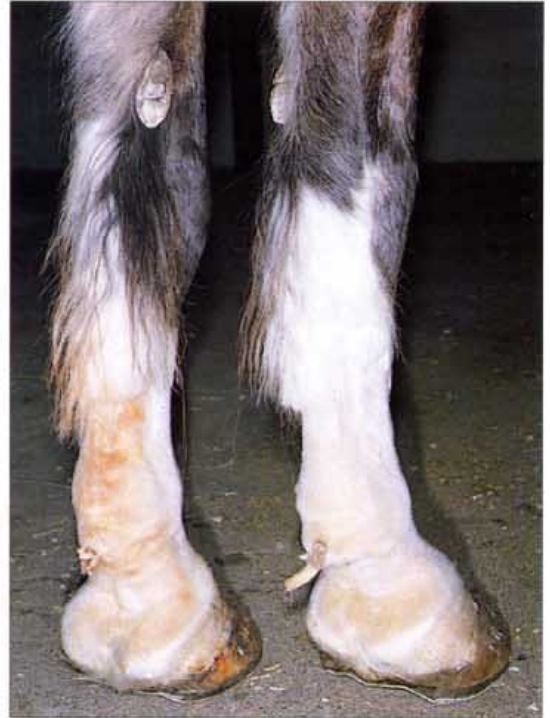
75. The effect on the foot of downward extension of the fetlock. A sagittal section was made of a normal cadaver foot (A) and then a force, approximating the weight of a galloping horse (1000kg), was applied from above (B). When the fetlock was extended the distal interphalangeal joint flexed and the rotating middle phalanx forced the distal sesamoid (navicular) bone down onto to the taught deep flexor tendon which straightened. A space formed in the navicular bursa between the deep flexor tendon and the proximal half of the distal sesamoid flexor surface. In contrast the distal half of the navicular bone was tightly apposed against the deep flexor tendon at precisely the site (arrowed in B) where the pathology of navicular disease develops. Weight bearing curved the dorsal hoof wall and the descent of the middle and distal phalanx into the hoof capsule compressed the solar corium and forced the frog into contact with the ground.

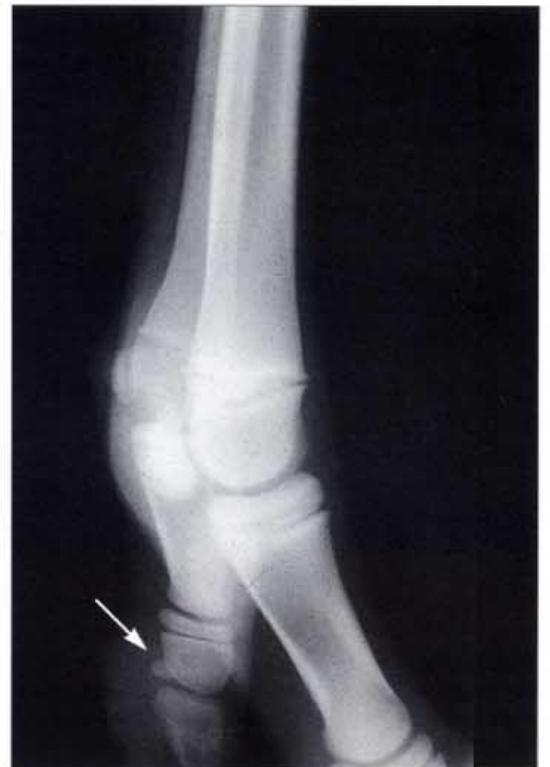Growth Anomalies

76. Ergots and chestnuts. The ergots and chestnuts are all that remain of the hooves that disappeared as the horse's limbs evolved into their present form. In the foreleg the oval chestnuts are located medially just above the carpus and are the vestigial hooves of the first digit (equivalent to the human thumb). The ergots, located on the palmar aspect of the fetlock, are the vestigial hooves of the second and fourth digits. In most Thoroughbreds the ergots are nothing more than a raised patch of thickened skin. However, in the cold-blooded breeds such as this Clydesdale they are often quite prominent. The feathers have been shaved and at the back of each fetlock are a pair of horn-like structures.

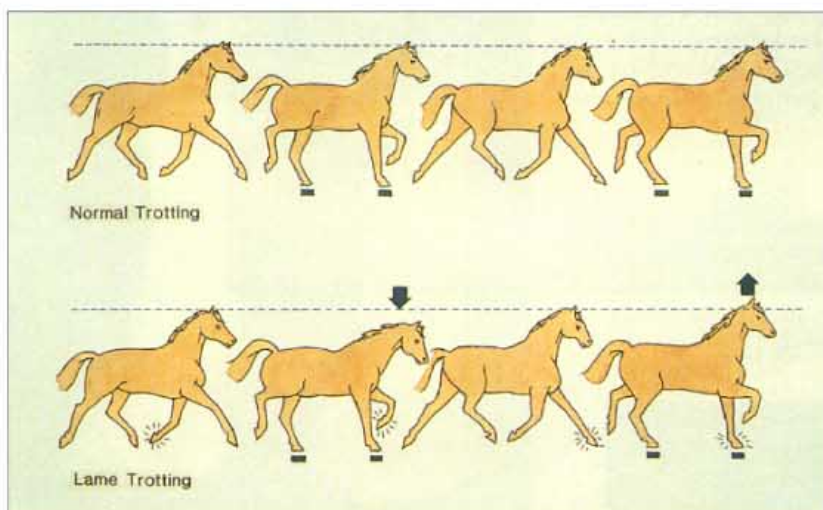
77. Polydactyly (A). Occasionally, as if to remind us what evolution has done to the horse, a foal is born with an extra digit. In this case the second metacarpal bone, instead of being a tapering splint bone, was a fully fledged metacarpus, terminating distally in a fetlock, pastern and hoof. Photo: C. Colles.



78. Polydactyly (B). Radiographs showed that the extra limb had all the bones and joints of a normal limb including a pair of proximal sesamoid bones and a navicular bone (arrowed). Photo: C. Colles.



2 Clinical Examination

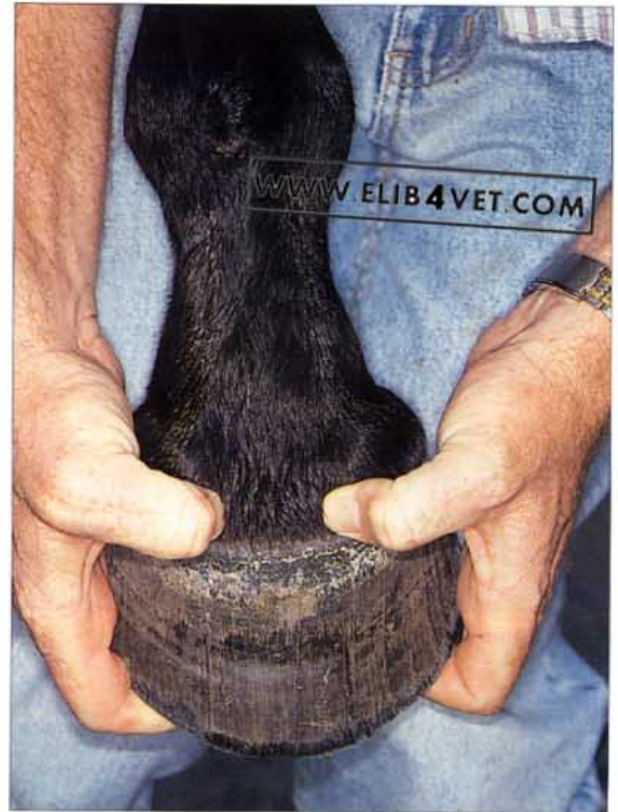

79. **The trot out.** A horse with a suspected forelimb lameness should be trotted out on level ground with the head held loosely. When the lame foot makes ground contact the head is raised. When the sound foot makes ground contact the head is lowered. The head is lowered in preparation for making a counterbalancing upward movement of the head to decrease the loading of the painful foot.

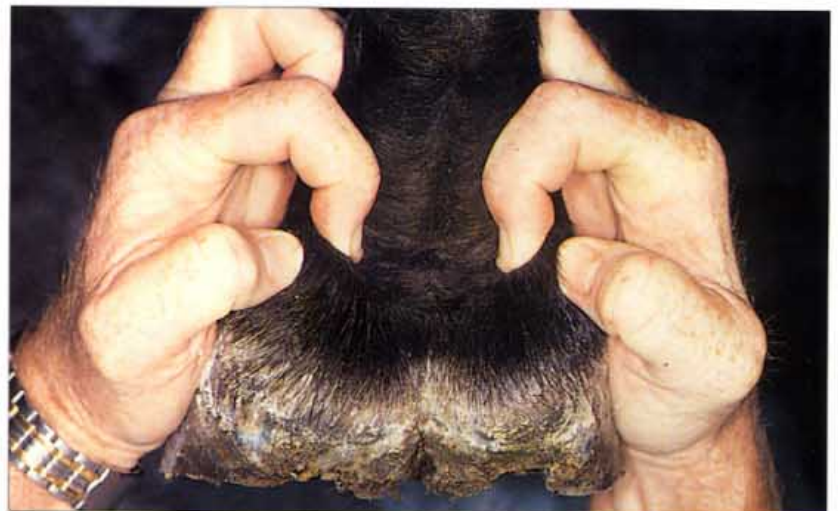

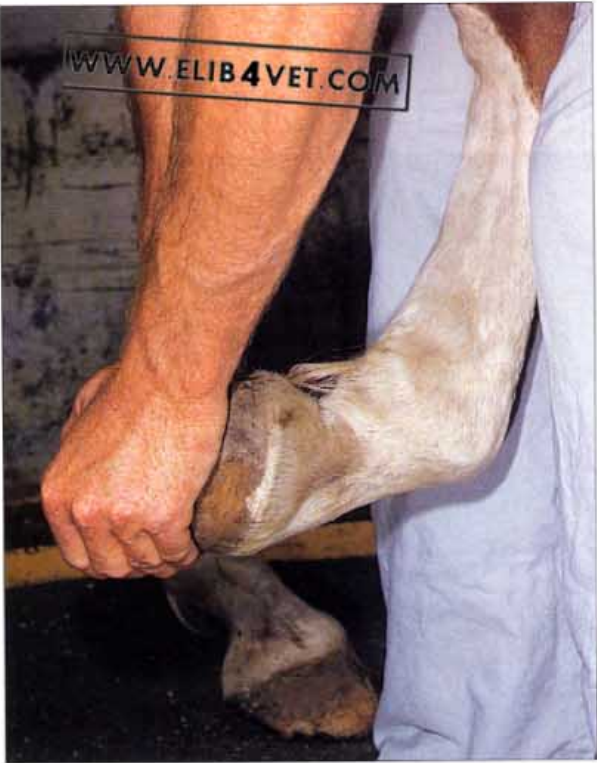
80. **Examination from a distance.** The examination from a distance is important as it can reveal much information about the degree and type of lameness. The horse should be observed while it is standing quietly in its yard or stable before human interference has occurred. The horse pictured is raising its heel and pointing its toe due to chronic heel pain.

81. Palpation of the foot (A). With the horse's limb held forward and flexed, the fingers and thumbs should be used to manipulate and place pressure on all the accessible structures of the foot. This could include the deep flexor tendon, the sesamoidean ligaments, the extensor tendon, the extensor process, the proximal interphalangeal joint, the cartilages of the distal phalanx, the bulbs of the heel, the coronet and the sole and frog. In the picture, the coronet is being palpated to detect the presence of pain. Coronary abscesses and penetrating foreign bodies produce painful lesions in the coronary region.

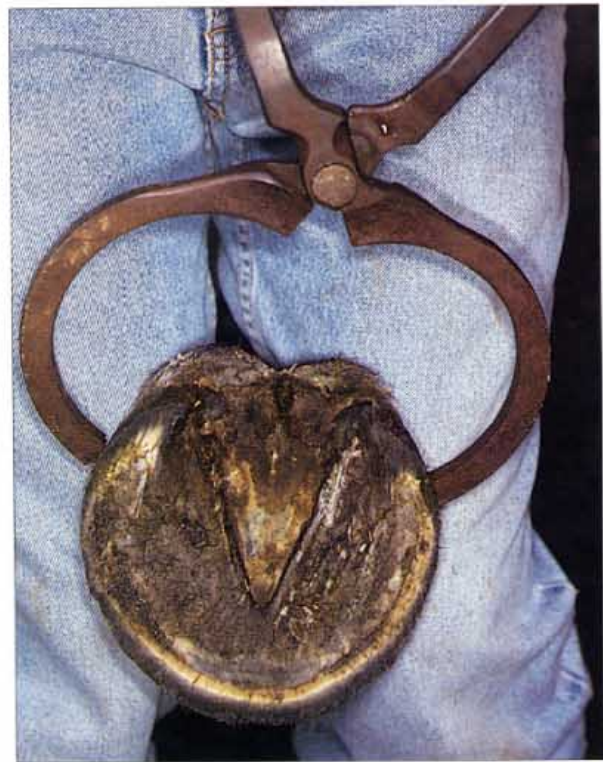

82. Palpation of the foot (B). Particular attention should be paid to the heels. In the picture the fingers and thumbs have grasped the proximal edge of the cartilages of the distal phalanx. Normally, the cartilages are flexible. If they become hard and rigid the horse may have developed calcified cartilages, a condition known as sidebone.





83. The distal interphalangeal joint flexion test. This test is performed to investigate lameness. The distal interphalangeal joint is kept flexed for 60–90 seconds and then the horse is trotted out. It is important not to flex the carpus (knee) and the metacarpophalangeal (fetlock) joint at the same time. Inevitably, there is also flexion of the proximal interphalangeal joint. If the lameness is made worse by the test this is evidence that the cause of lameness may involve the joint. Horses with navicular disease, distal sesamoid bone fractures, articular ringbone and fractures of the distal phalanx react positively to this test. In the diagnosis of navicular disease many veterinarians find this test more reliable than the more logical extension test.

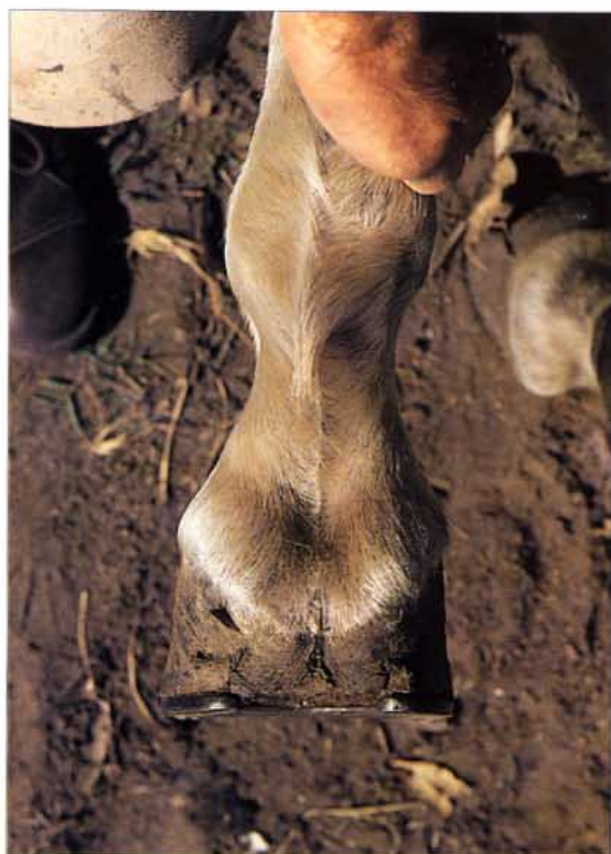

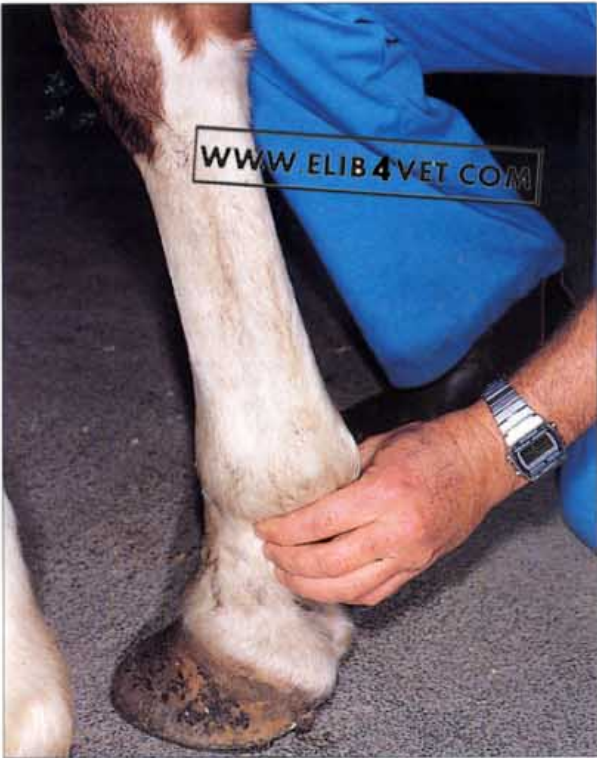84. Examination of the foot with hoof testers. Hoof testers should be used to systematically compress the sole and the frog against the hoof wall. Hoof testers should be of good quality and large enough to accommodate the width of even the largest draft horse. In the picture, pressure is being placed across the heels at the approximate location of the distal sesamoid bone.

85. Examination for medial lateral balance: forefoot (A). Standing beside the forelimb of the horse the limb is lifted from the ground and held lightly at the metacarpus. Support the foot in a natural position and adjust your line of vision to appreciate the medial lateral balance, the height of the heels and walls and the flatness of the foot. Photo: Ben Pollitt.

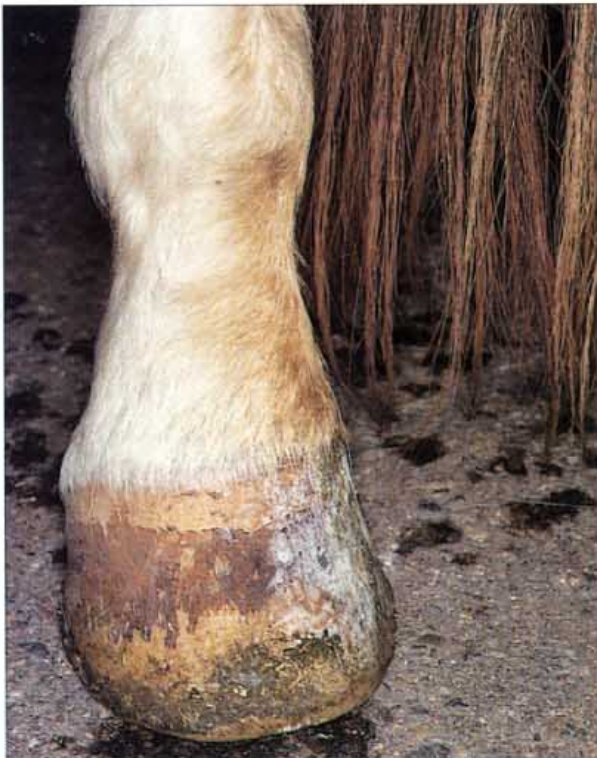

86. Examination for medial lateral balance: forefoot (B). An imaginary line bisecting the fetlock and pastern should bisect the heels. The medial lateral line should be perpendicular to it. The principle for examining the hindfoot is the same.



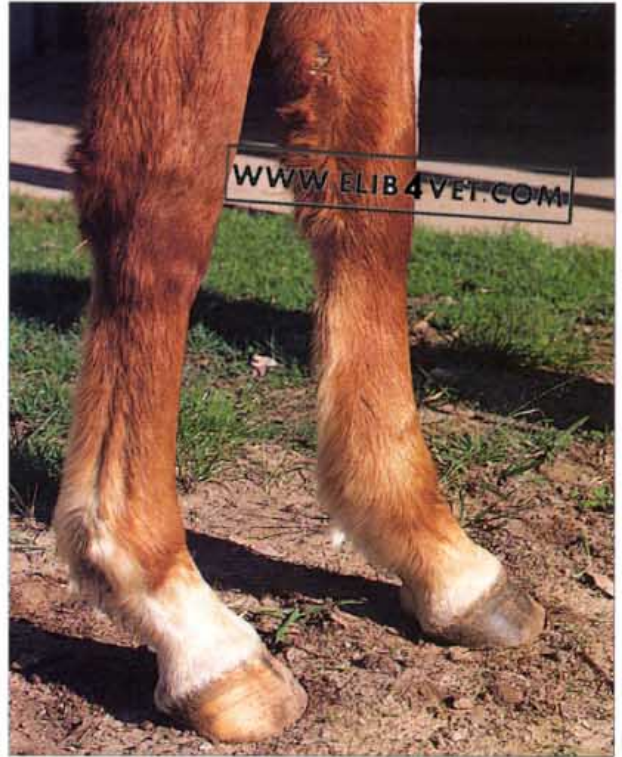

87. Palpation of the digital pulse. The medial and lateral palmar digital arteries should be palpated with the foot in the weight-bearing position. In the normal horse the pulse of the arteries is slight and sometimes barely detectable. The digital pulse will be dramatically increased in amplitude (bounding) in cases of laminitis, distal phalangeal bone fracture, sepsis of the foot and immediately after exercise.

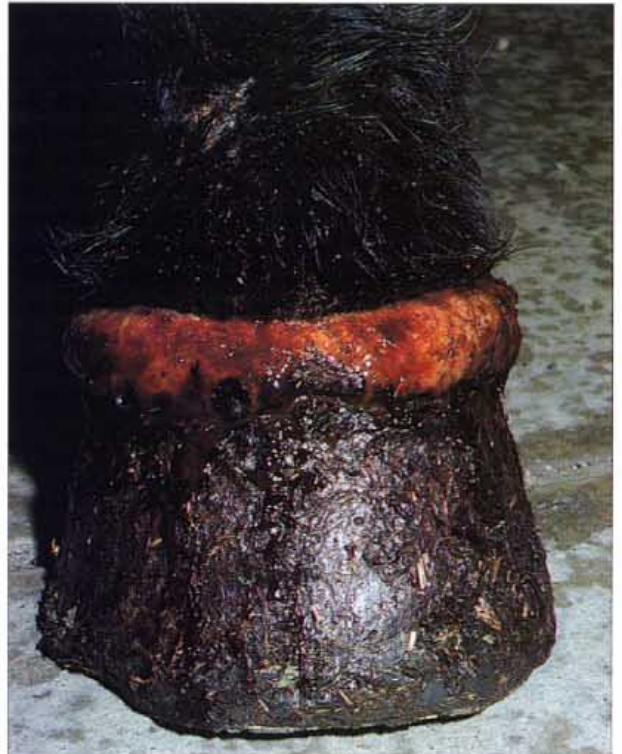

88. Concurrent disease (A). The person examining the foot, whether it be farrier or veterinarian, is often able to detect disease in other parts of the body. The hindfoot illustrated has brown urine stains on the medial pastern and white crystals of dried urine on the medial hoof wall. The horse had lost control of its bladder and was suffering from neuritis of the cauda equina. The horse's farrier was the first to detect the problem and advised that the horse be referred to a veterinarian.

89. **Concurrent disease (B).** The left metacarpus and fetlock of the horse pictured are swollen. The grooves between the flexor tendon, the suspensory ligament and the metacarpal bone are missing because they are distended with oedema. There was no pain or heat in the limb and it eventually transpired that the horse had a rare tumour (teratosarcoma) of the drainage lymph nodes in the left shoulder.



90. **Concurrent disease (C).** The coronet of this horse is severely inflamed and is constantly oozing serum down the hoof wall. The condition is known as granulomatous coronitis and affected all four feet of this 3-year-old Standardbred horse. Despite having a ravenous appetite and consuming large quantities of good-quality food the horse was losing weight rapidly. In fact the coronitis was but one aspect of a severe granulomatous reaction in many organs of the body. Granulomatous ulcers, similar in appearance to the coronitis lesions, covered most of the skin surface. A post-mortem examination showed that the chronic weight loss was occurring because the wall of the entire large intestine was occupied by ulcerating granulomatous lesions. The horse was suffering from a disease known as granulomatous enteritis with skin and coronet manifestations.





91. Concurrent disease (D). This horse has been pawing the ground and has worn away the tip of the toe. It had been suffering severe, unrelenting pain for 3 days. Pawing the ground is a typical clinical sign of colic in the horse.



92. Concurrent disease (E). One hind shoe is severely worn at the tip. The horse had a chronic muscle injury in the hip of the affected side and this was causing it to drag its toe. Photo: K. Swan.

3 Horseshoes and Horseshoeing

93. **Horseshoeing (A).** The distal rim of the hoof wall makes contact with the ground and supports the weight of the horse. A steel horseshoe nailed to the ground surface of the hoof wall will reinforce it so that a horse can work for humans. The unhealthy looking hoof in the picture is overdue for shoeing; the distal hoof wall is long and flared and in danger of developing cracks. The underrun heels are also too long and there is excess sole to be pared away.



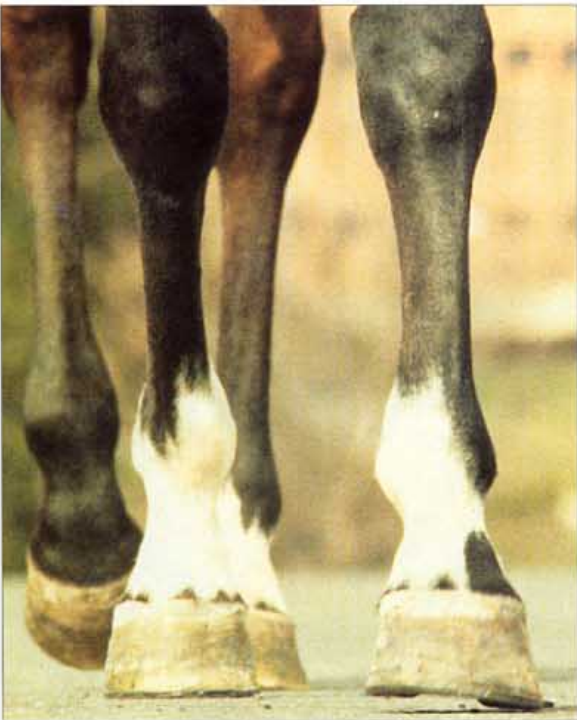94. **Horseshoeing (B).** The same foot shown in (A) but now shod with a hand-forged steel shoe. The sole is well off the ground and protected from damage. The shoe covers the entire bearing surface and looks like a natural extension of the hoof wall. To preclude any further cracking of the wall, the shoe has a pair of side clips.



Medial Lateral Balance

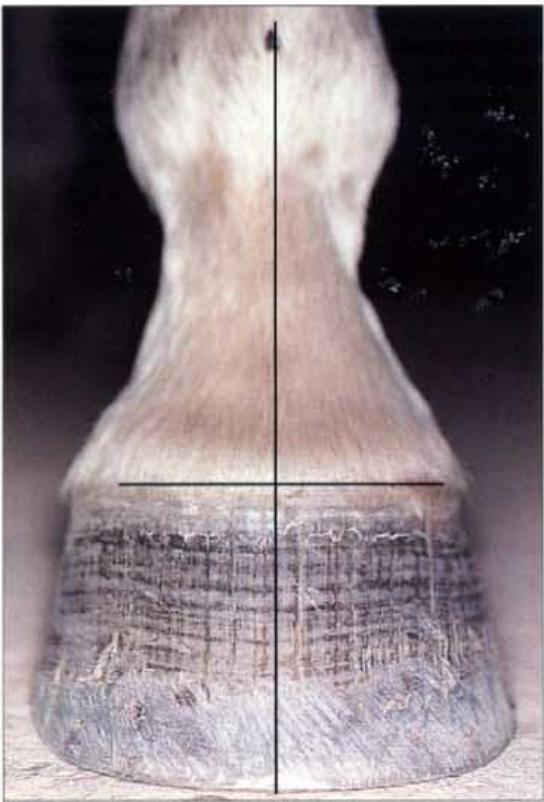


95. **Medial lateral balance (A).** Ideally, when viewed from in front, an imaginary line drawn down the midline of the third metacarpal (cannon) bone, bisecting the metacarpal–phalangeal (fetlock) joint, should also bisect the dorsal hoof wall. The leg pictured is testimony to the soundness of Monivae Warlock, a 15-year-old endurance horse, which has successfully completed 3000 km of competition without ever being lame.



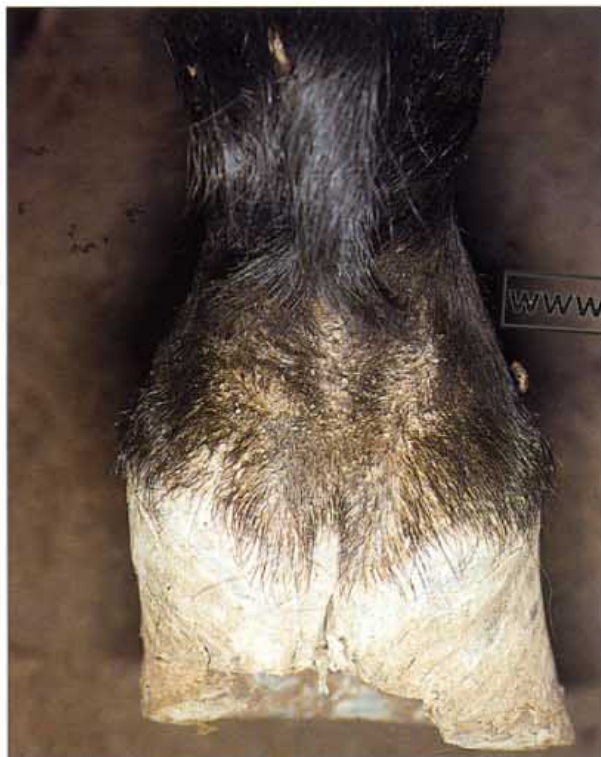
96. **Medial lateral balance (B).** When the feet of horses are out of medial lateral balance one side of the hoof makes contact with the ground before the other. The side that contacts the ground last receives a greater load and thus grows slower than the opposite side. As a consequence, the situation becomes a vicious circle as the imbalance becomes perpetuated with the short, loaded side growing at a lesser rate than the high, less-loaded side. The picture illustrates a horse with straight limb conformation but with unbalanced hooves trotting toward the camera. The lateral wall of the left foot is higher than the medial. The lateral wall has made contact with the ground and the medial wall is about to be loaded. If this situation is allowed to persist for a long period the hoof capsule becomes distorted, symmetry is difficult to restore and the horse becomes prone to lower limb lameness. Photo: O. Balch.

97. Medial lateral balance (C). An imaginary straight line drawn through the hairline of the dorsal coronet should be parallel to the ground and should also bisect the vertical line at right angles. The ground surface of the hoof wall should be rasped to achieve medial lateral balance. In the foot pictured, flared distal hoof wall has been rasped away to make the wall straight.

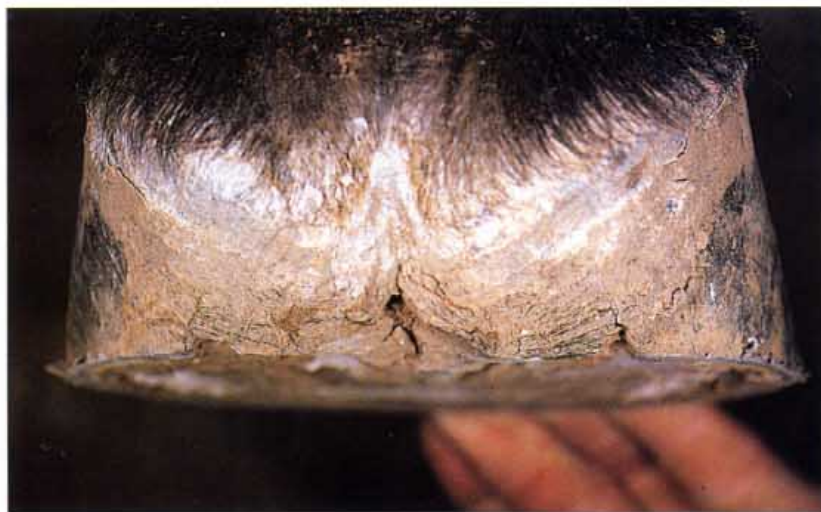

98. Medial lateral balance (D). The line drawn through the midline of the cannon and the fetlock does not bisect the foot in this case. Loading of the foot and the hoof capsule will not be balanced. Perhaps this imbalance has caused the medial hoof wall to crack (arrowed).



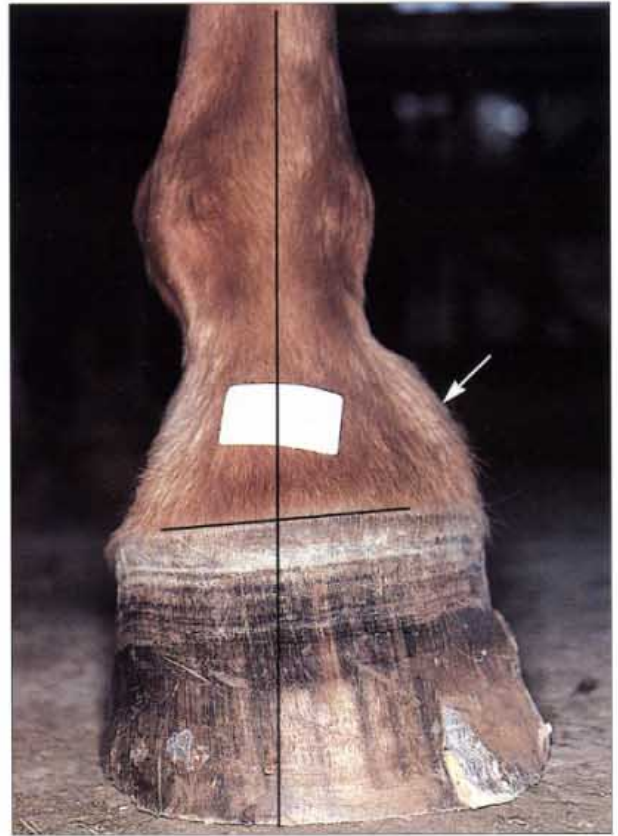

99. Medial lateral balance (E). A hoof held by the pastern and viewed from behind should have heels and quarters of even length and the entire hoof wall or rim should be flat. While working on the heels, care should be taken to ensure the hoof pastern axis is also correct. The forefoot of this Standardbred pacer was grossly out of medial lateral balance resulting in poor race performance.

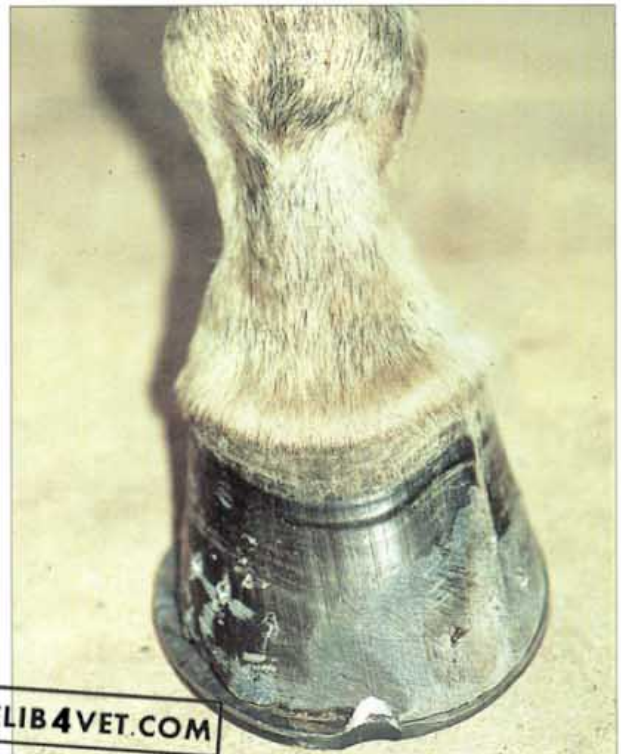

100. Medial lateral balance (F). The foot of this horse has been trimmed flat in preparation for shoeing.

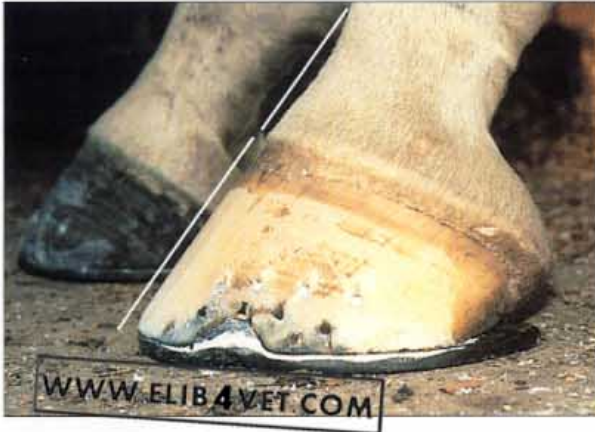101. Medial lateral balance (G). When the line drawn through the coronet is not parallel to the ground the foot is out of medial lateral balance. Careful rasping of the wall at the ground surface and removal of the flare from the medial wall will have to be undertaken to balance this foot. Poor medial lateral balance has already caused high ringbone (arrowed).



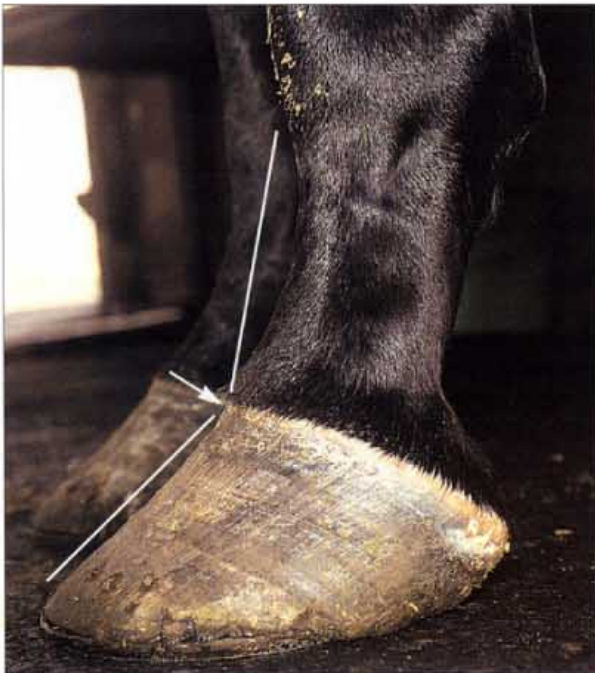102. Restoring correct medial lateral balance. The foot of the adult horse in the photograph had been chronically out of medial lateral balance for a long period. The medial wall was long and flared and the lateral wall was short and upright. This abnormal foot conformation which is largely man made can be gradually returned to normal if corrective measures are undertaken. The medial wall has been shortened and the flares rasped away. To encourage the lateral wall to return to a more natural shape and angle, the lateral branch of the shoe has been placed wide of the hoof wall. In other words, the shoe has been placed where, ideally, the hoof should be. Photo: K. Swan.



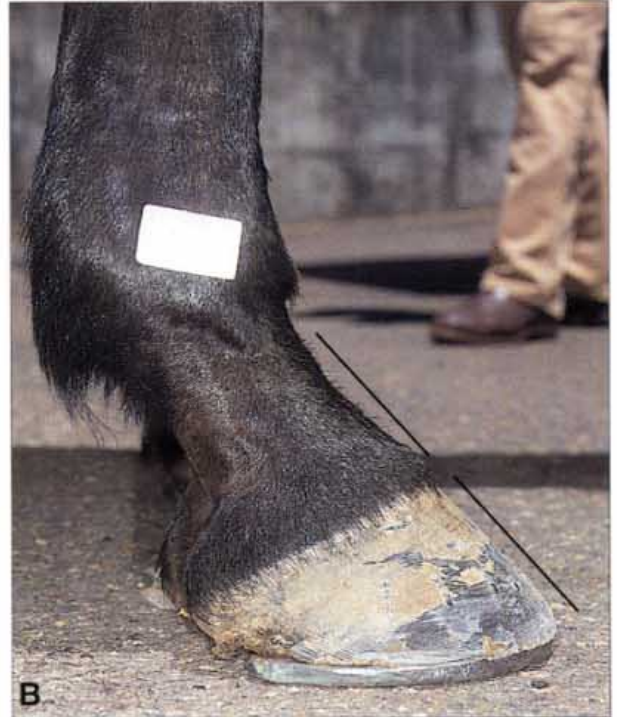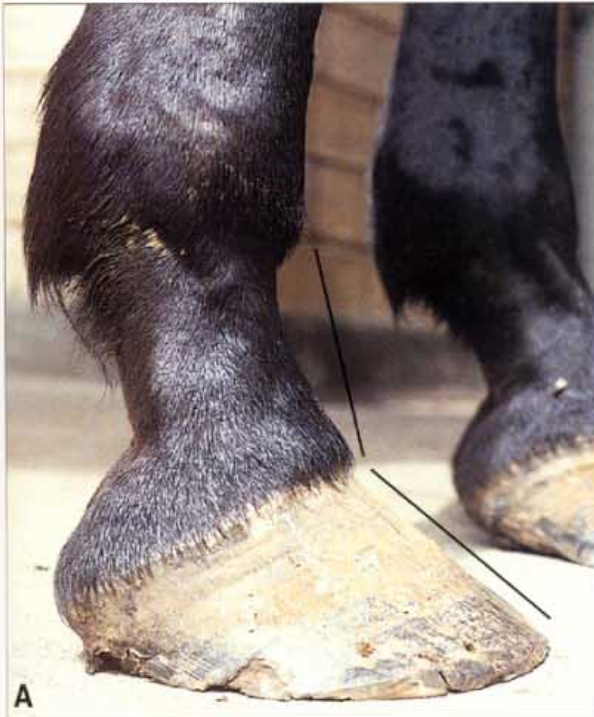Hoof Pastern Axis



103. Correct hoof pastern axis. One of the basic principles of modern horse shoeing is to trim the foot and shape the shoe so that the axes of the pastern and the dorsal hoof wall are in line. Excess distal hoof wall (the rim) is removed with nippers and rasped to establish both medial lateral balance and the correct hoof pastern axis. If the hoof pastern axis is broken forward the rasp is used to lower the heels; if the hoof pastern axis is broken back the toe is lowered. While this process of adjustment is taking place the symmetry of the hoof, with the horse standing square on a level surface, is constantly monitored. When trimming is finished the weight-bearing base of the foot should be flat in preparation for attaching the shoe. If the hoof walls are flared the rasp is used to make them straight and to restore symmetry to the hoof capsule. In the hoof pictured the dorsal hoof wall has been rasped to remove flare and to make the hoof wall straight. This is an acceptable process and if done in moderation does no damage to the health of the hoof wall. It is far more important to the long-term soundness of the horse to restore foot balance than to worry about removing a few millimetres of hoof wall. Compare this picture of a well-shod hindfoot with the hindfoot in 132; the heels are weight bearing and the hoof wall tubules are in line with the hoof pastern axis. The hand-made shoe is providing plenty of heel support and the foot is shod full to provide room for heel expansion. The nail clenchers are placed well above the old nail holes and are evenly spaced. Photo: K. Swan.



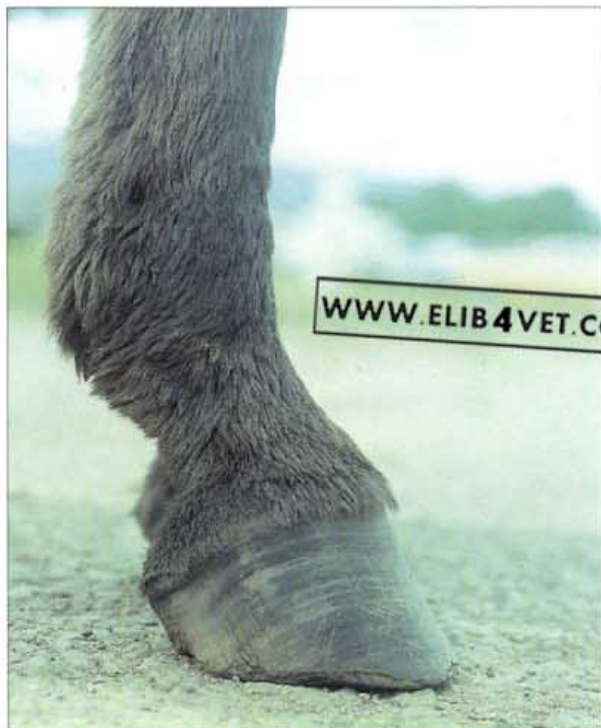104. Broken-back hoof pastern axis. This horse's foot is overdue for re-shoeing. The hoof is shod, you can just see the shoe underneath the overgrown hoof wall. The hoof has continued to grow and has carried the shoe forwards off the walls. The nail clenchers are protruding high above the hoof wall. The excessively long toe and the relatively low heels have caused the hoof pastern axis to be severely broken-back (in the direction of the arrow). The hoof tubules and the dorsal hoof wall should be in line with the axis of the pastern. Many Thoroughbred racehorses perform badly because they are carelessly shod. It is commonly believed that a long toe bestows a race advantage. In fact this causes the hoof pastern axis to be broken-back, distorts the hoof capsule and strains the tendons and ligaments of the palmar limb. Horses shod this way often have sore heels and are predisposed to navicular disease.



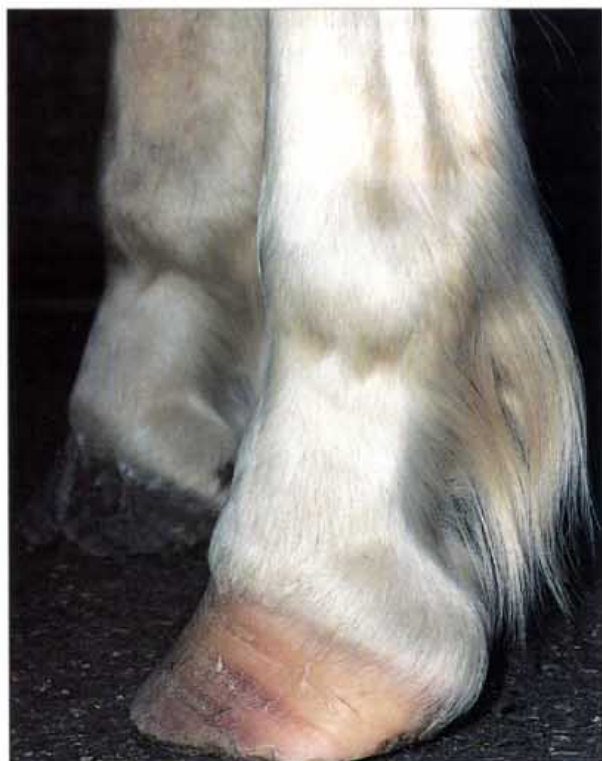105. Restoring correct hoof pastern axis. A competent farrier can transform a badly shod horse's foot. In **A** the foot has a broken-back hoof pastern axis, the toe is excessively long, the heels are low and under-run. The horse had a painful, shuffling gait. In **B** much improvement has occurred. The hoof pastern axis is correct, the toe has been shortened and rasped back. The shoe which has been fitted gives a base of support well back under the heels and this will encourage stronger, more supportive heel growth. The nail clenches are high and the shoe is secure. Shod in this way the horse's gait improved dramatically.

106. Ground contact of the frog. The theory that ground contact of the frog is required for the equine foot to function properly is now considered obsolete. Lowering the heels and quarters to achieve ground contact for the frog at the expense of the correct hoof pastern axis is a practice dangerous to the continued well being of the horse's foot. It is best to ignore the position of the frog and trim the horse's feet to achieve a correct hoof pastern axis as well as medial lateral balance. In the picture the walls have been drastically lowered in an attempt to place the frog on the ground. Photo: K. Swan.





107. **Broken forward hoof pastern axis.** Compared to a foot with a broken back hoof pastern axis, a broken forward hoof pastern axis is the lesser of two evils. Many horses work and compete with their feet 'stood up' and appear to suffer few consequences. Theoretically, a broken forward hoof pastern axis should place excessive strain on the insertions of the extensor tendons and may contribute to ringbone and stress fractures to the extensor process. Only donkeys, like the one in the picture, have a natural broken forward hoof pastern axis.



108. **Conformation: upright pastern, broken-back hoof pastern axis.** Horses with a short upright pastern and a broken-back hoof pastern axis, like this American Quarterhorse, are prone to lameness. The toe cannot be trimmed any lower than it already is and it is virtually impossible to establish a correct (in-line) hoof pastern axis without resorting to the use of artificial wedges and raised heel shoes. Haemorrhagic bands in the white hoof wall are evidence that this conformation fault has been contributing to concussive bruising of the coronet. This breed of horse has a relatively high incidence of navicular disease and many believe that the foot conformation illustrated combined with large body size and immaturity are primary causative factors.

109. Foot care of foals. The managers of many Thoroughbred breeding farms have realised that caring for the feet of foals significantly improves the quality of the feet of yearlings. Yearlings with healthy, strong, symmetrical hooves and feet attract better prices and employing a full-time farrier for the foot care of foals is a wise investment. During the first few months of a foal's life the growth areas of the long bones, digits and hoof capsule are readily influenced by changes in symmetry and it is the farrier's brief to maintain natural hoof balance throughout the sensitive first year. The frequent handling of the limbs of foals produces a more tractable adult, already familiar with the methods of the farrier. The farrier should know when to draw developing angular limb deformities and hoof capsule deformities to the attention of the veterinary surgeon.



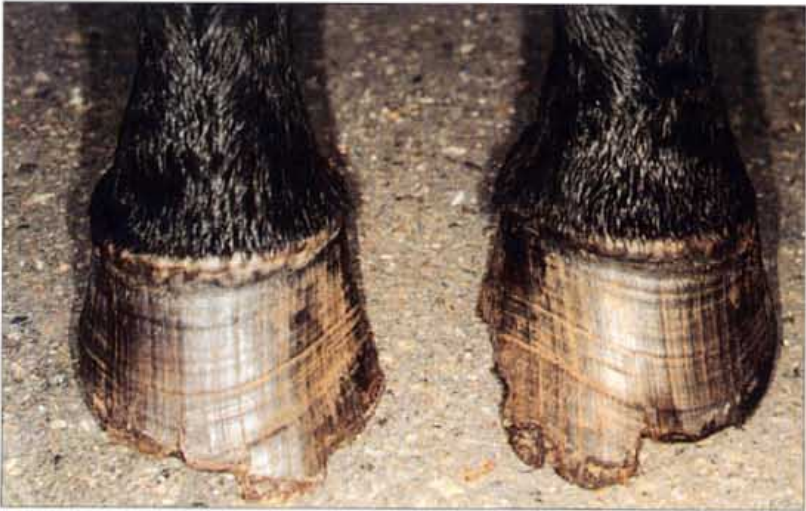110. Uneven feet (A). It is a principle of farriery that the feet of horses should form an even pair; the left should be the mirror image of the right. In the photograph, the left foot is clearly different from the right. The hairline at the coronet of the left foot is not parallel to the ground and the lateral side is higher than the medial. The hoof quality of the right foot is poor; there are many vertical cracks, perhaps because of excessive weight bearing. If the feet are not even there is invariably a reason why. Sometimes the cause is not apparent but as a general rule horses with uneven feet perform poorly and should not be purchased. The reason for the uneven feet of this horse is shown in 111.



111. Uneven feet (B). Two years before the photograph was taken this broodmare was involved in a racetrack accident and subluxated the carpus of the left leg. The resulting lesion healed slowly, changed the angulation of the metacarpal bone and altered the weight-bearing forces acting on the left hoof. The mare lands on the lateral hoof wall and loads the medial, hence the uneven feet.



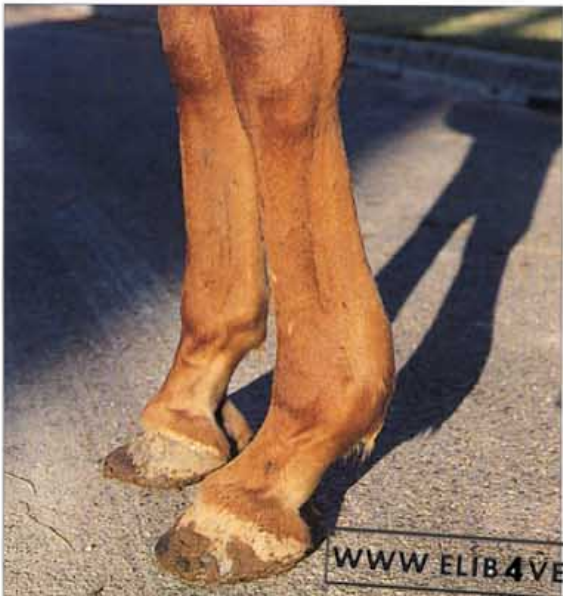WWW.ELIB4VET.COM



112. Shoeing pigeon-toed horses (A). Information regarding the way a horse should be shod can be derived from studying, not only the horse's action, but the wear pattern of its feet. The photograph shows the forefeet of a horse with toe-in conformation. The medial half of the toe is long and flared. In contrast the lateral half of the toe has been chipped away by natural wear and tear and has a normal length and shape. Obviously, it is 'normal' for the feet of this horse to break over to the lateral side of centre. The dilemma for the farrier is whether to trim and shoe the horse according to the textbook pattern or to shoe it to suit its conformation and natural way of going.




113. Shoeing pigeon-toed horses (B). The horse was trained for endurance performance and performed best when shod with rolled-toe, wide-webbed shoes. In recognition of the horse's natural break over action, the toes of the shoes were rolled to the lateral side of centre. The wear pattern of the shoes shows that the foot is close to being balanced. The medial branches are slightly more worn than the lateral branches.



114. The consequences of unbalanced feet. This Thoroughbred racehorse reached maturity with a clubbed right forefoot. Showing initial promise on the track the heels of the club foot were lowered in a misguided attempt to correct its hoof pastern axis. The horse raced several times but broke down with a severe bowed tendon in the left forelimb. It is reasonable to assume that the trauma and pain arising from impact to the toe of the clubbed right foot caused excessive loading of the left, an unbalanced gait and the consequent bowed tendon.

WWW.ELIB4VET.COM

Principles of Farriery



115. Correct nail placement. The modern factory-made horse-shoe nail is designed to be driven obliquely through the hoof wall. The tip of the nail is placed at the inner edge of the white line with the bevel of the nail tip facing inwards (the head of the nail is correspondingly marked). When hammered, the bevel comes into contact with the dense hoof wall and causes the nail to curve outwards, to exit from the wall about 15–25 mm above the level of the shoe. The protruding tip of the nail is then removed and the remainder is trimmed and bent to form the clench which holds the shoe firmly against the hoof. Correct nail placement is important; too far out and the wall is damaged and split, too far in and the nail punctures the corium and causes lameness and infection (with the ever-present possibility of a fatal encounter with tetanus).



116. Horseshoe nails half-way through. The hoof contents have been removed and the wall has been sectioned close to the sole-wall junction. The tips of the nails were placed at the correct location on the outer edge of the white line on the ground surface of the sole and hammered through the wall. The bevel on the tip of the nail has caused the nails to pass obliquely through the wall towards the outside. The photograph illustrates the view from the inside of the hoof when the horseshoe nails are halfway through the wall. They are still in the region where the tubules have wide diameters, are relatively supple and where the wall still has a high moisture content. There is no evidence of splitting.

Shoes and Nails

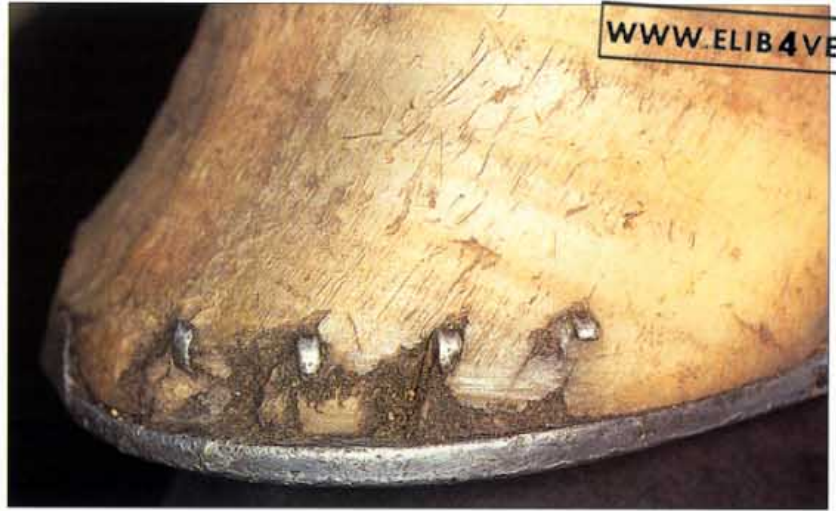

117. Correct placement and pitch of horseshoe nails. A hand-forged shoe is constructed to complement the anatomy of the hoof to which it is to be attached. The pitch of each nail hole should be the same as the angle of the hoof wall which the nail will enter. The toe nails will therefore be more angled than the quarter nails. In addition the hoof wall is thicker at the toe than at the quarter and a correctly made shoe will account for this. The toe hole will be set further from the edge of the shoe (coarser) than the nail hole at the quarter (finer).




118. Incorrect placement and pitch of horseshoe nails (A). Some factory-made shoes display poor nail placement and pitch. The non-angled pitch of the hole will force the nail to exit too low down on the hoof wall. All of the nail holes have been placed the same distance from the edge of the shoe and no attempt has been made to account for the differences in thickness of the hoof wall at the toe and the quarter. If this shoe is set so that its edge is level with the edge of the hoof wall, the front nails will be driven into the brittle outer hoof wall and will cause splitting. Although experienced farriers can pritchel nail holes, to improve their pitch and position the use of a better-quality shoe is preferred.

119. Incorrect placement of horseshoe nails (B). In this picture a hoof has been shod with a factory made horseshoe such as the one illustrated in 118. The nails have been driven into the brittle outer hoof wall and have exited too low down. This incorrect nail placement has seriously damaged the wall around the nails which has chipped and broken away; the shaft of a nail is visible where a portion of hoof has cracked away. Not only is the horseshoe unstable and likely to fall off but the weakening of the hoof wall may cause serious damage to internal structures, loss of performance and even lameness. The dorsal hoof wall already appears flared.



120. Horseshoe nails (A). The modern horseshoe nail is invariably factory made to high standards of quality control. The head shape and thickness of the shaft are produced in a variety of dimensions according to the style and weight of the horseshoes. The tip is always bevelled to ensure that when driven into the hoof wall the nail exits to the outside.

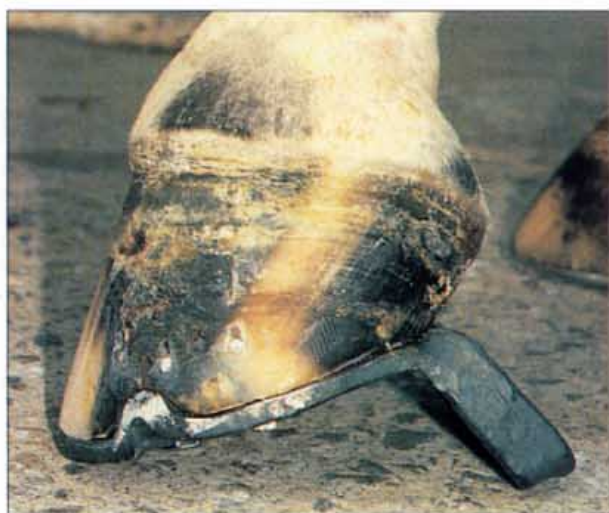

121. Horseshoe nails (B). The head of each nail is marked or branded on one side only—the same side as the bevel. Before driving the nail the farrier either feels for the brand or makes a visual check. The brand and the bevel always face inwards (axially) so that hammering the nail forces it to travel obliquely through the hoof wall to exit on the outside (abaxially).

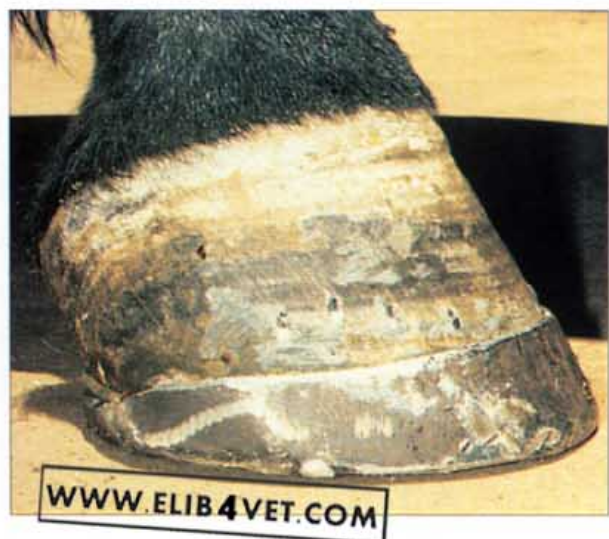



122. Horseshoe wear. Shoes must not normally be nailed further back than the widest part of the hoof. This is to allow for the normal expansion and contraction of the heels with each footfall. Each time the horse bears weight on the foot, at the mid-point of each stride, the heels expand (the faster the gait the greater the effect). The heels retract when the effect of the weight is relieved. The repetition of this inwards and outwards movement of the heels excavates a groove in the heels of a mild-steel horseshoe. The groove in the horseshoe is evidence not only of the normal contraction and expansion of the heel, but of the toughness of the hoof substance itself.

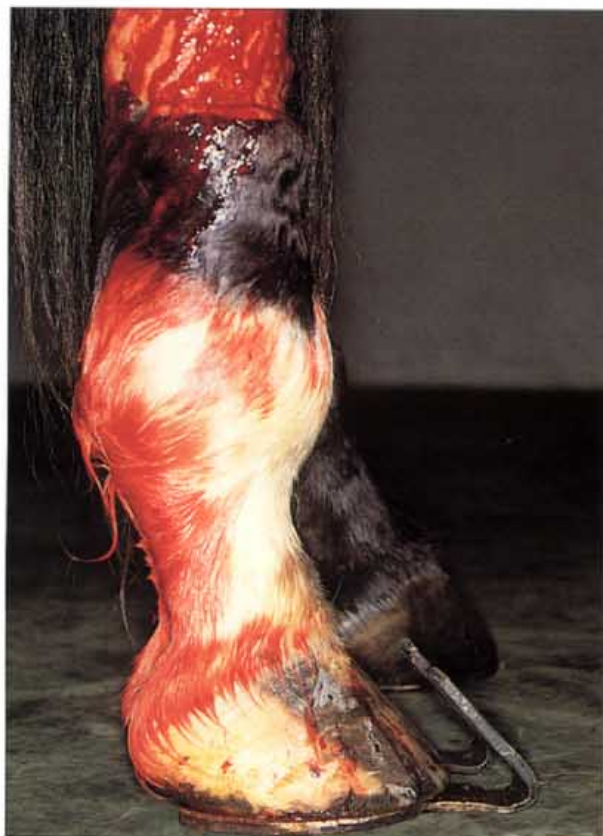

123. The patten shoe. The patten shoe dramatically raises the heels and reduces tension on the flexor tendons. If the flexor tendons are damaged a raised heel shoe will encourage healing. During healing of the damaged flexor tendons the height of the shoe can be adjusted. When the heel lift is no longer required the heel can be cut out of the shoe.

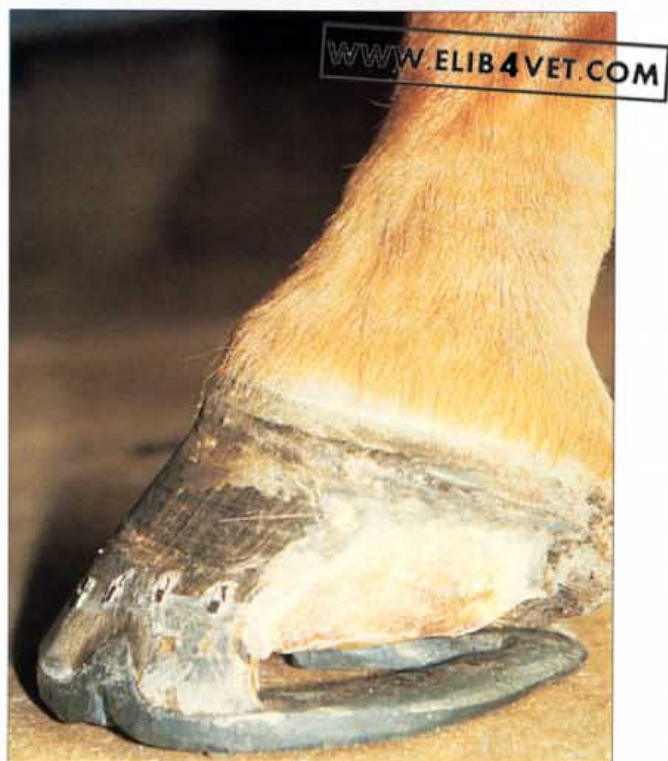

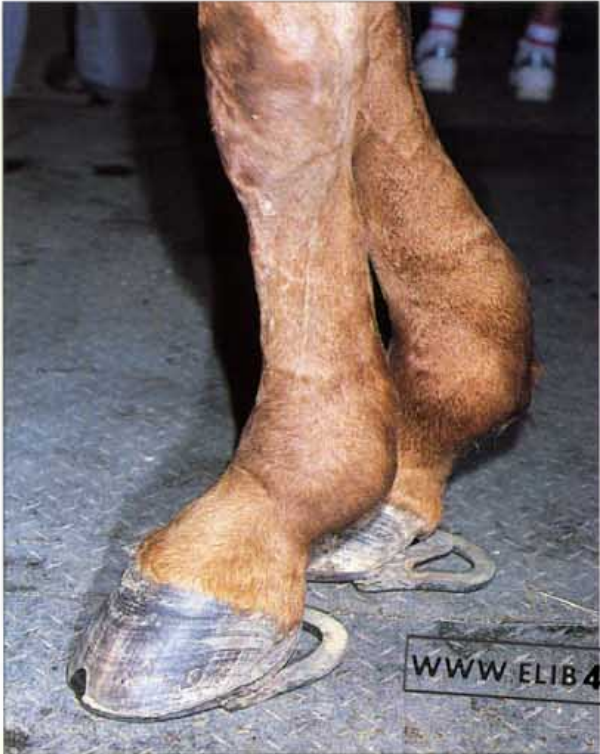124. The rim shoe. The rim shoe totally encloses the distal rim of the hoof wall and eliminates any expansion of the heels. Horses lame with fractures of the distal phalanx will often become sound if shod in a well-fitted rim shoe.

125. Extended-toe shoe. This horse has severed the extensor tendons of one hindlimb. The injured limb has a tendency to knuckle over onto the dorsal surface of the pastern. The extended toe shoe assisted in the correct placement of the foot and encouraged healing of the damaged extensor tendon.

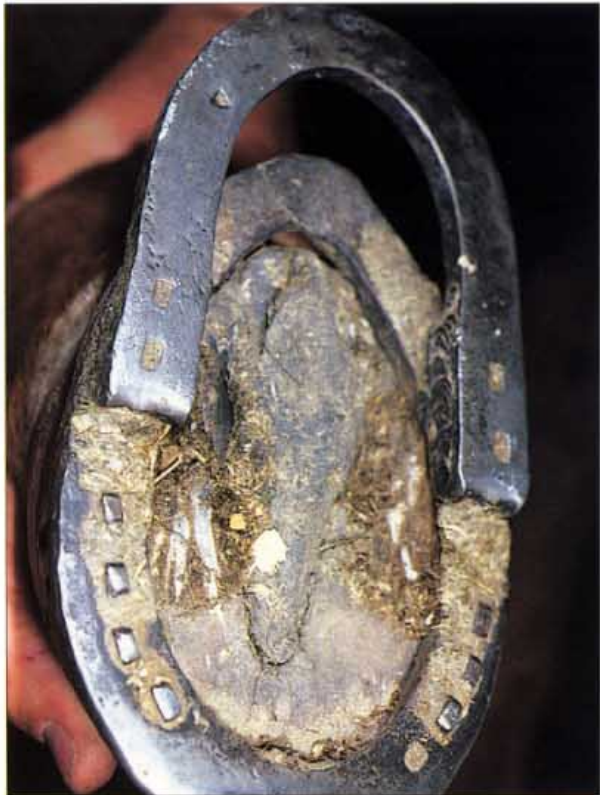

126. Heart-bar shoe for heel injuries. The heart-bar shoe has many uses apart from its well-known application in the treatment of chronic laminitis. It is also a useful shoe for the treatment of chronic quarter injuries. In the foot pictured the entire heel and quarter on one side have been resected and the foot is being supported through the frog plate of the heart-bar shoe and the wall on the opposite side. The injured wall and quarter have been relieved of weight bearing and thus have been given every chance of regenerating. After the photograph was taken and the damage to the hoof had grown out, this champion racehorse resumed its career and won several races. Photo: K. Swan.





127. Shoes for rupture of the suspensory apparatus (A). With the suspensory apparatus ruptured there is a tendency for the toe to rise upwards. Horses appear more comfortable if their heels are wedged and they are shod with extended-heel shoes. The broken down brood mare in the picture reared several foals shod in the extended egg-bar shoes illustrated.

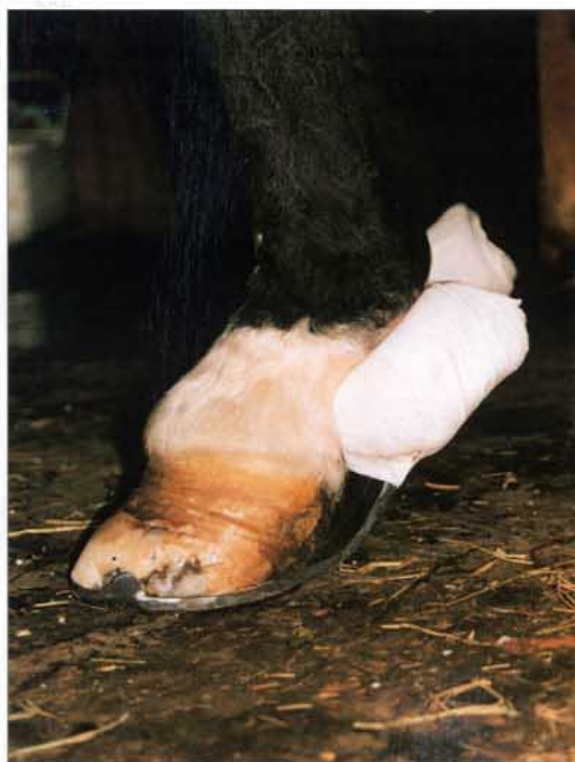

128. Shoes for rupture of the suspensory apparatus (B). The heels of the egg-bar shoe were raised and extended by welding to it a second shoe. As can be seen in the picture this second shoe was facing backwards.

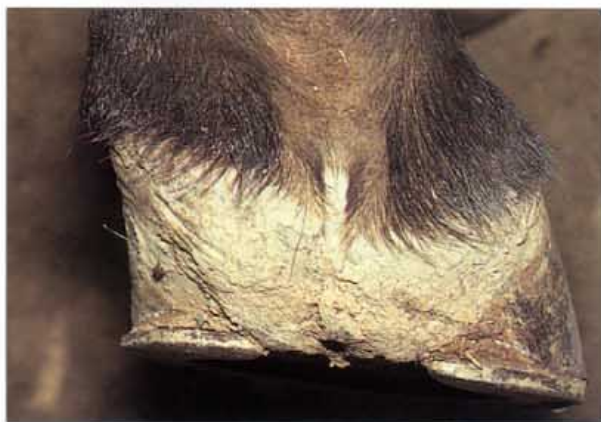129. Fetlock sling shoe for rupture of the suspensory apparatus (A). Each of these two shoes was forged from a single piece of bar stock and are a tribute to the blacksmithing skills of the farrier who created them. They were used to successfully manage a horse with bilateral fractured proximal sesamoid bones and ruptured suspensory ligaments. Photo: D. Leveillard.



130. Fetlock sling shoe for rupture of the suspensory apparatus (B). When adequately padded the shoes provided mechanical support for the collapsed fetlocks. Photo: D. Leveillard.



4 Problem Feet



131. Foot deformity. An imaginary line dropped through the metacarpal bone and bisecting the fetlock joint should also bisect the pastern and the heels when viewed from behind. As a consequence of a severe carpal injury and a gross metacarpal deviation (unilateral acquired varus) this Thoroughbred broodmare now has a foot that is severely out of balance. The picture demonstrates how the foot compensates for changes in the forces of weight bearing.



132. Crushed heels. A sound-footed horse should have all the tubules of the hoof wall, at the heels as well as the toe, in line with the pastern. Horses with crushed heels which are folded under and forward, like the one in the picture, have the tubules of the heels parallel to the ground and suffer from chronic heel pain. Only when shod with wide web, egg-bar shoes, to provide maximum heel support, could this horse perform well in the dressage arena. If the shoeing period exceeded 6 weeks the horse's performance deteriorated; its ability to perform depended entirely on the quality of its shoeing.

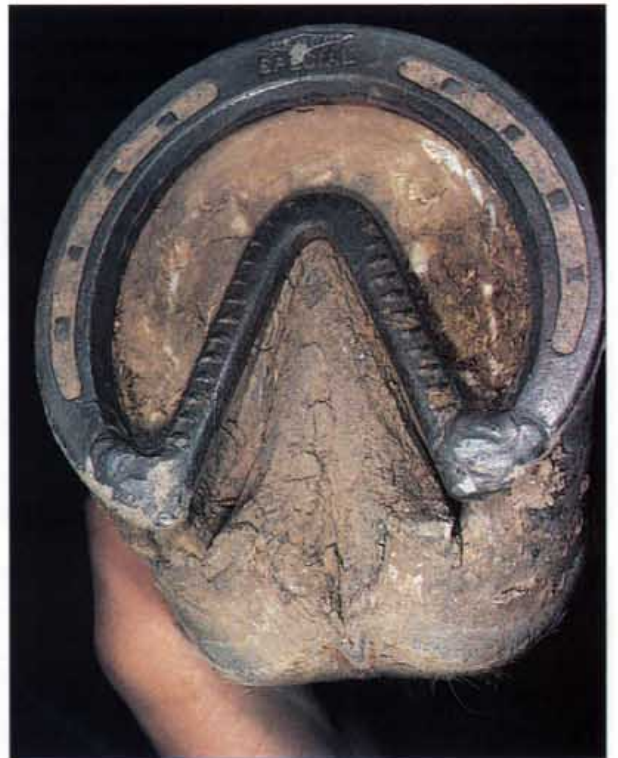

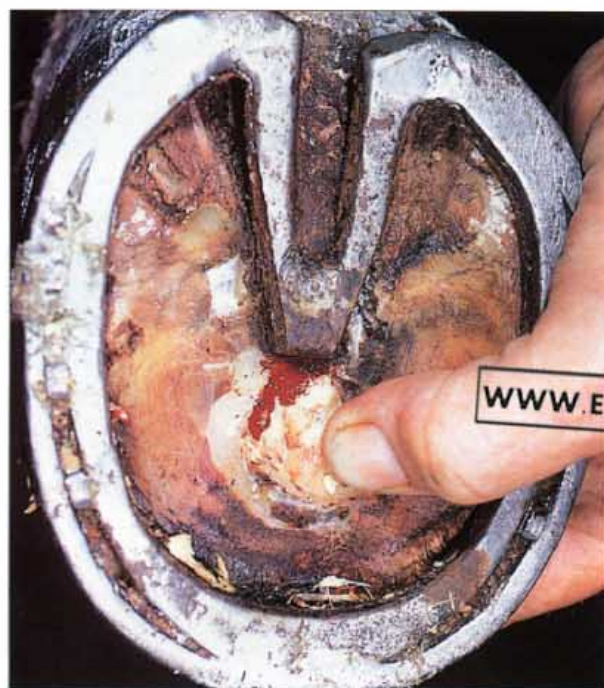133. Shoeing the donkey's foot. Sometimes donkeys require shoeing and special shoes may have to be forged. The foot of a donkey is quite different to that of a horse and has a characteristic long, narrow shape. The frog is relatively large and occupies the entire space between the heels. Because of the near vertical slope of the hoof wall at the toe and the quarters it is very easy to 'quick' a donkey's foot.

134. Shoeing to make chronic laminitis worse. The worst way to shoe a horse with chronic laminitis is to fit a shoe with a welded bar directly beneath the descending distal phalanx. The unyielding steel bar exacerbates the pressure necrosis that develops between the descending distal phalanx, the solar corium and the horny sole. When the shoe was removed, necrosis was extensive in the region of the bar; there was osteomyelitis of the tip of the distal phalanx. 389 shows a sagittal section of the same foot.



135. Incorrectly made heart-bar shoe. The heart-bar shoe should be in the shape of a heart, but not quite like the one in the picture. Instead of 'circumnavigating' the frog, the central bar of the heart-bar shoe should provide a weight-bearing platform for the frog. A painful, corn-like abscess had developed where the tip of the bar was in contact with the sole.

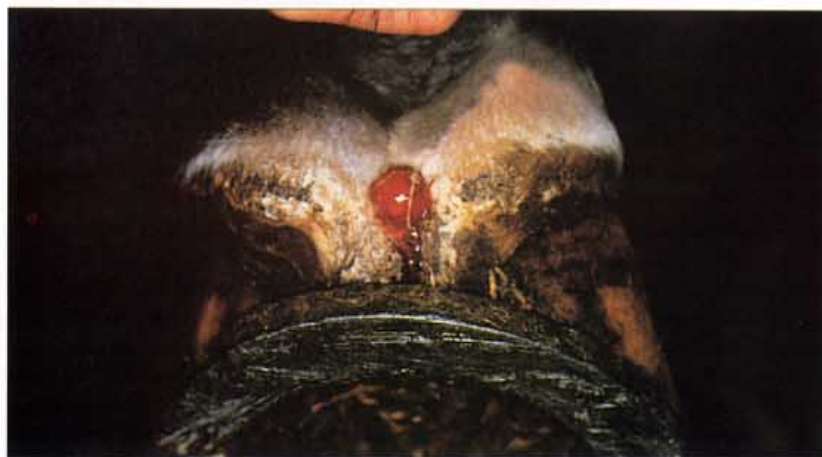



136. Incorrectly fitted heart-bar shoe. A properly applied heart-bar shoe should apply even pressure over the entire surface of the frog. The apex of the frog plate should not be tilted upwards and it should not apply any sole pressure. The heart-bar shoe in the photograph illustrates what happens when a heart-bar shoe is placed too far forward. The tip of the frog plate has caused necrosis and ulceration of the sole.

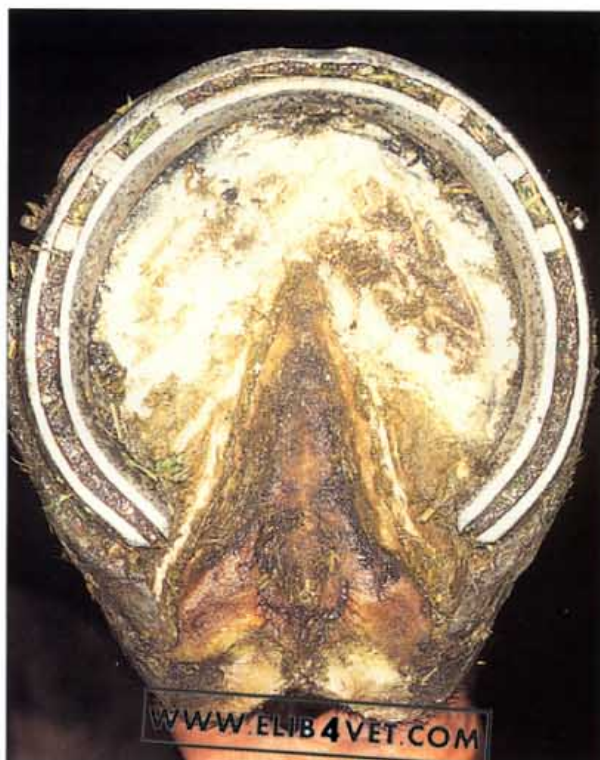

137. Adjustable heart-bar shoe. The adjustable heart-bar shoe is but one of many variations on the standard model. The increased complexity of the adjustable shoe makes it difficult to fit and prone to error. Corrosion and seizing up of the adjustment screw is a common problem. In practice there seems to be little advantage in being able to adjust the pressure of the frog plate. A properly made, standard heart-bar shoe, in the hands of a competent farrier, achieves better results at less cost.

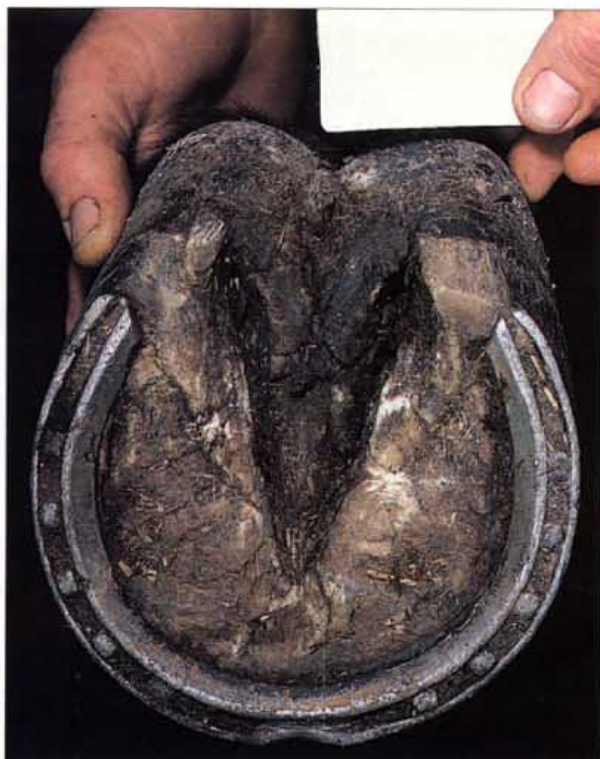

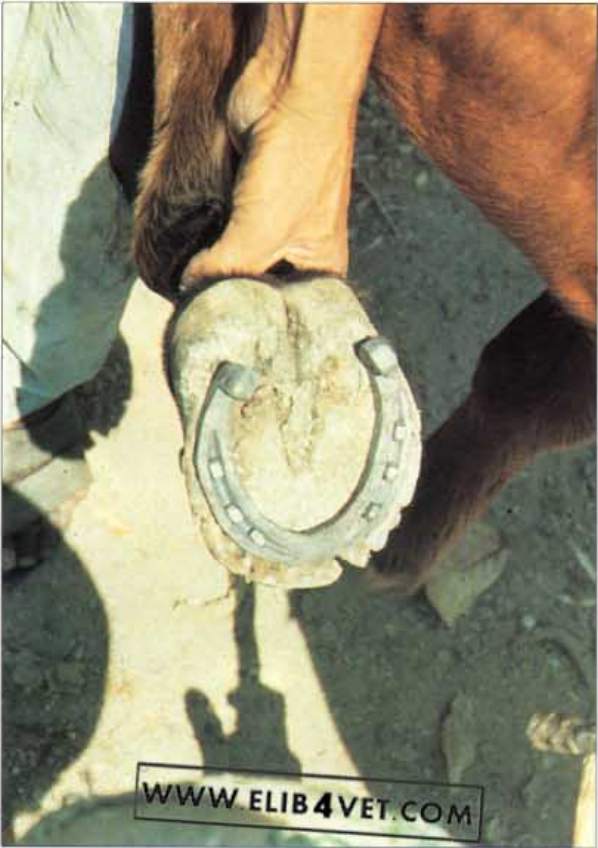138. Sheared heels. When one heel of the foot is left longer than the other, the bulbs of the heel encounter a shearing force which can lead to structural breakdown. Asymmetrical weight bearing on either the medial or lateral heel causes the coronet to be higher on the loaded side. Faulty shoeing and trimming, leaving one side of the foot higher than the other, is the usual cause. In the case illustrated, independent movement between the medial and lateral heels has caused a granuloma to develop. The medial heel is considerably higher than the lateral heel and the horse is lame. Photo: I.M. Wright.

139. Overdue shoeing. When a steel horseshoe is nailed to the ground surface of the hoof wall, the hoof continues to grow. Eventually the shoe will be drawn forward until it no longer supports the quarters and heels. In the photograph the branches of the shoe are exerting pressure on the angles of the sole (the so-called seat of corn). There is a risk that this continued compression will cause necrosis of the sole and ulcers known as 'corns'.



140. Incorrect shoeing. Steel horseshoes were invented to protect the ground surface of the hoof wall from wear and tear. It follows that the shoe should cover the entire surface area of the distal rim of the hoof wall, from the buttress of each heel to the toe. The shoe in the photograph falls about 15 mm short of each heel. The heels are exposed to the risk of trauma.





141. Bad shoeing (A). The shoe has to fit the foot! This example of horseshoeing in the Honduras is a clear demonstration of what not to do. This new shoe has been fitted within the hoof wall and has made the sole weight bearing. The nails have been driven into the sole. Photo: B. Duvernay.



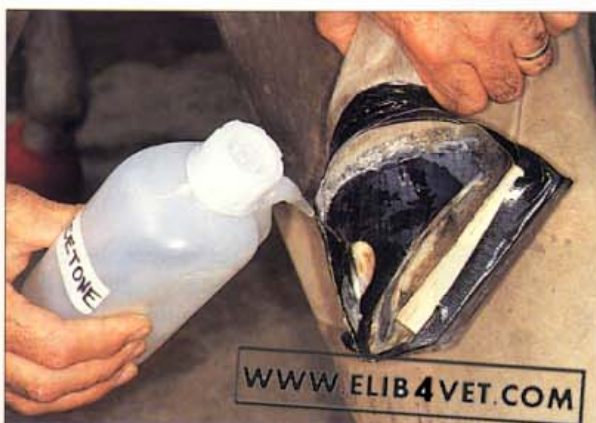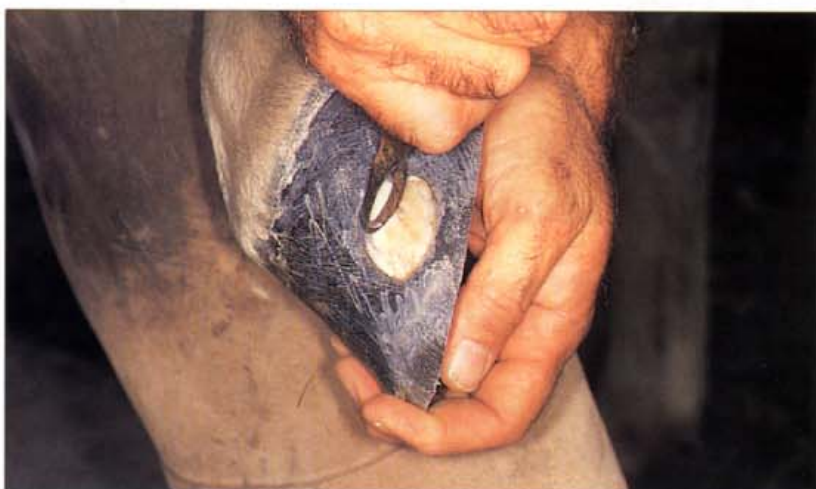142. Bad shoeing (B). The foot shown in A. The hoof wall has been drastically rasped (dumped) in an attempt to make the foot fit the shoe. Photo: B. Duvernay.



143. Unethical shoeing. To 'improve' the high-stepping gait of American Saddle-horses, they are sometimes shod with heavy, high-heeled shoes. This one was so heavy that it was flung off and took a large portion of the distal hoof wall with it.

5 Hoof Wall Reconstruction

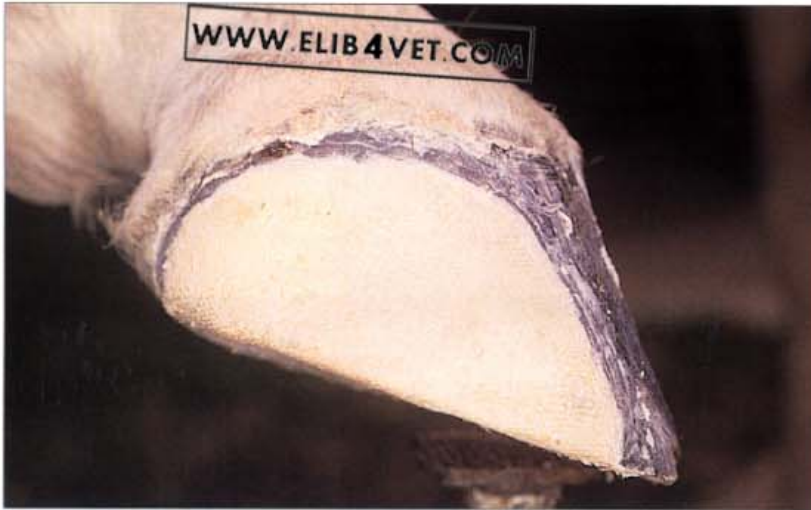144. Hoof wall reconstruction (A). This hoof wall defect is being prepared for reconstruction with a special polymethyl-methacrylate hoof repair compound called Equilox. The original injury was a stake wound to the coronary band which occurred 4 months earlier. The coronary band has now healed and the hoof wall lesion is migrating down the hoof wall. For the hoof capsule to withstand the rigours of training for endurance performance, it was necessary to strengthen the hoof wall around the lesion and to fill in the deficit with Equilox. Photo: E. Woodland.



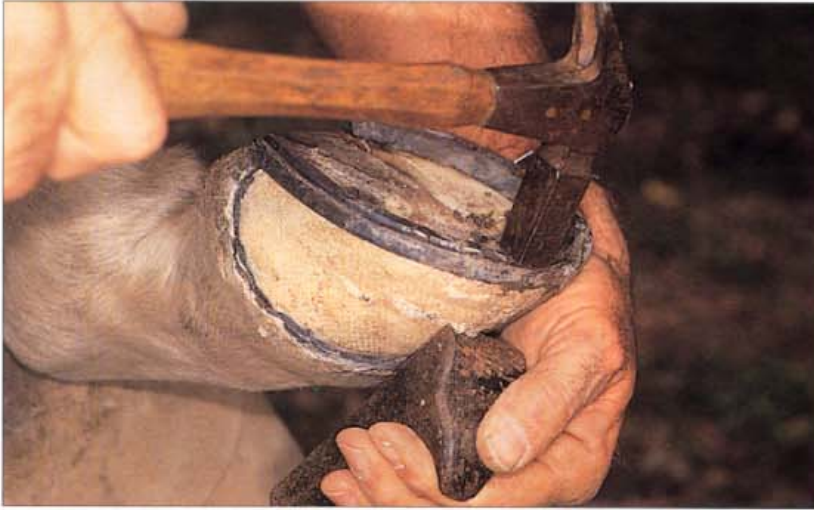145. Hoof wall reconstruction (B). The hoof wall surface and the deficit have been cleaned and sanded. Acetone is applied to the hoof wall to remove grease and any traces of moisture as the final preparation before application of Equilox. To keep the foot off the ground and to allow weight bearing while the Equilox cures a block of wood is taped to the sole of the foot. Photo: E. Woodland.



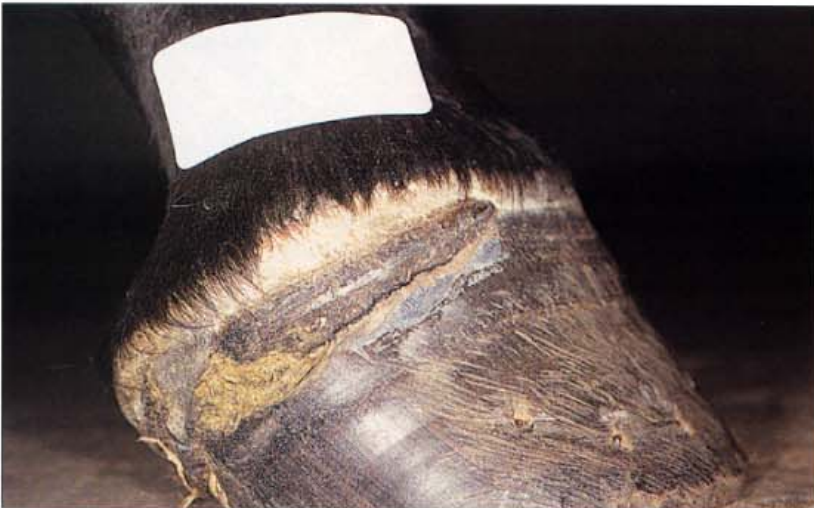146. Hoof wall reconstruction (C). The two components of Equilox have been mixed and are being squeezed from their pack into the deficit and over the surface of the prepared hoof wall. Equilox is also available in small mixing pots and, for large applications, in large multidose syringes. Photo: E. Woodland.



147. Hoof wall reconstruction (D). The second stage of the repair is complete and glass fibre cloth impregnated with Equilox has been applied to the hoof wall covering the lesion. Photo: E. Woodland.

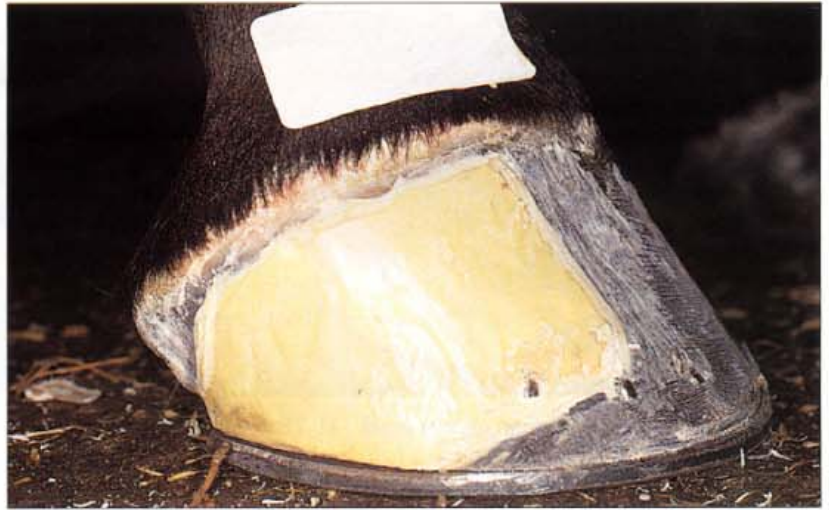

148. Hoof wall reconstruction (E). After hooves have been reconstructed with Equilox a horseshoe can be nailed to the repaired area and the horse can return to normal training and performance. The repaired area matches the flexibility and durability of normal hoof wall. Photo: E. Woodland.

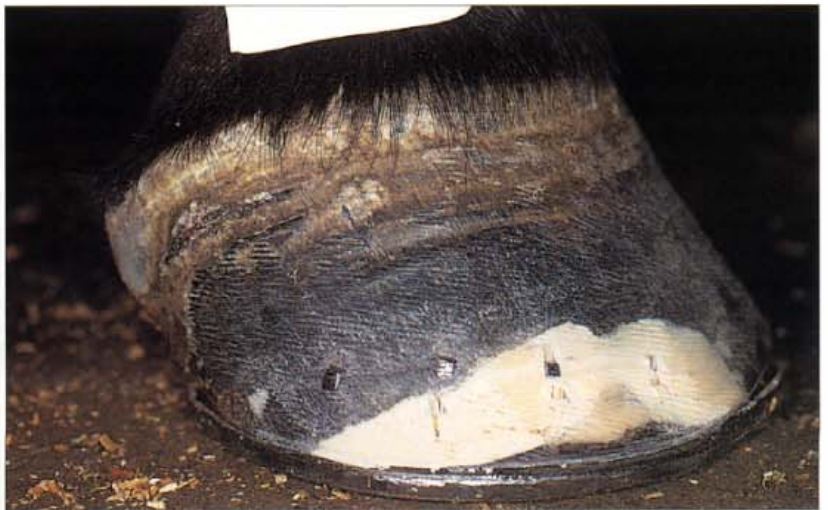

149. Hoof wall reconstruction: coronet injury (A). This Thoroughbred filly trapped her foot under the metal fencing material of her yard and deeply lacerated the coronet. The photograph was taken 8 weeks after the accident and it is already apparent that no serious scarring or permanent damage to the papillae of the coronary groove have occurred; hoof growth above the hoof wall defect is normal. However, to race the filly in this condition would put the hoof wall distal to the extensive defect at risk of collapsing, so the foot was prepared for hoof wall reconstruction.

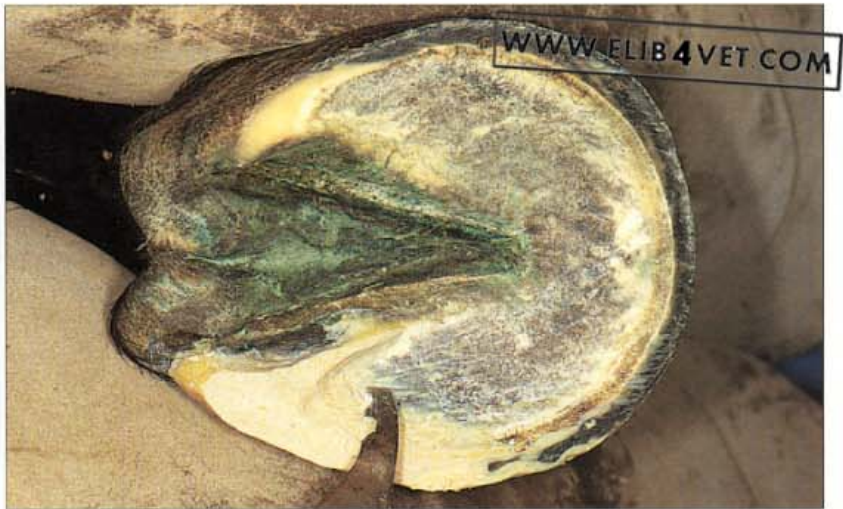150. Hoof wall reconstruction: coronet injury (B). All of the necrotic hoof wall in the region of the defect was resected and the hoof wall thoroughly cleaned, sanded and washed with acetone. To stabilise the hoof, proximal and distal to the defect, the hoof reconstruction compound Equilox was applied using the usual two-layer technique. The hoof was shod with a training shoe and the filly was returned to work.

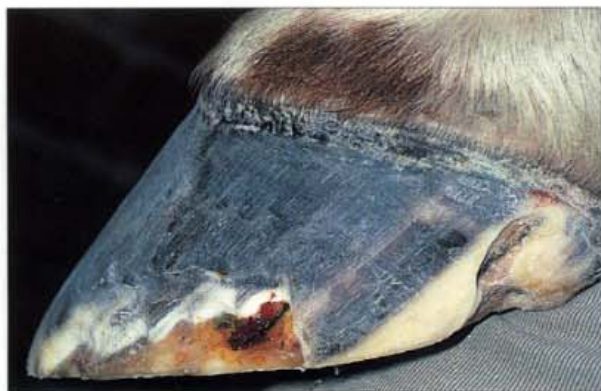

151. Hoof wall reconstruction: coronet injury (C). The Equilox hoof wall reconstruction was treated like normal hoof and as the patch grew down the hoof was trimmed and shod without problems. Photographed 5 1/2 months later, the defect, still filled with the original Equilox, has almost reached the ground surface and the hoof wall above is stable and healthy. Equilox in this case was used to safeguard against further injury and allowed the racehorse to return to training earlier than would otherwise have been the case.

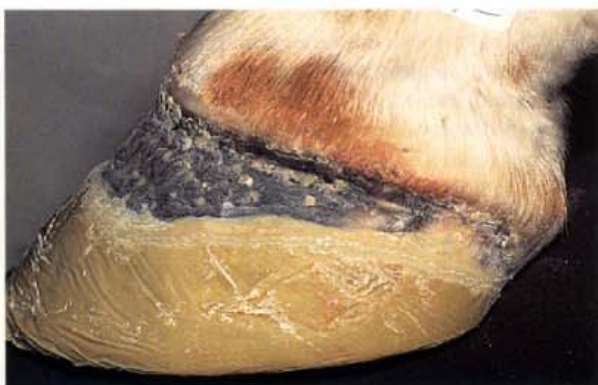

152. Hoof wall reconstruction: heel repair. Equilox can be used to completely reconstruct an injured heel. In the photo the bar and buttress of the heel have been reconstructed with Equilox and are being carved with a hoof knife to resemble the normal weight-bearing structures.

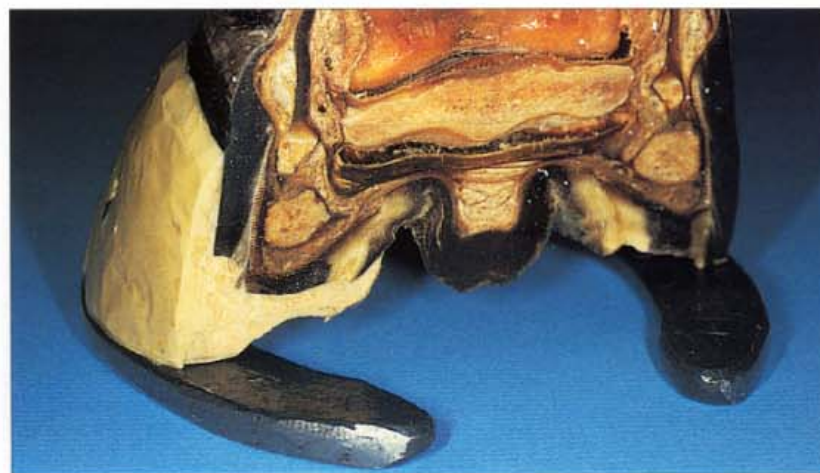



153. Hoof wall reconstruction: quarter crack (A). These photographs shows the forefoot of a champion racehorse mare a few days before a major race. The heel has a half- healed quarter crack, still causing lameness, and the walls on both forefeet have broken away from frequent nailing on of horseshoes. The mare has the small, weak-walled feet of many Thoroughbreds. The heel was reconstructed and the walls reinforced with Equilox. Shod initially with training shoes and then with racing plates, the mare lost no training days and competed honourably on race day.

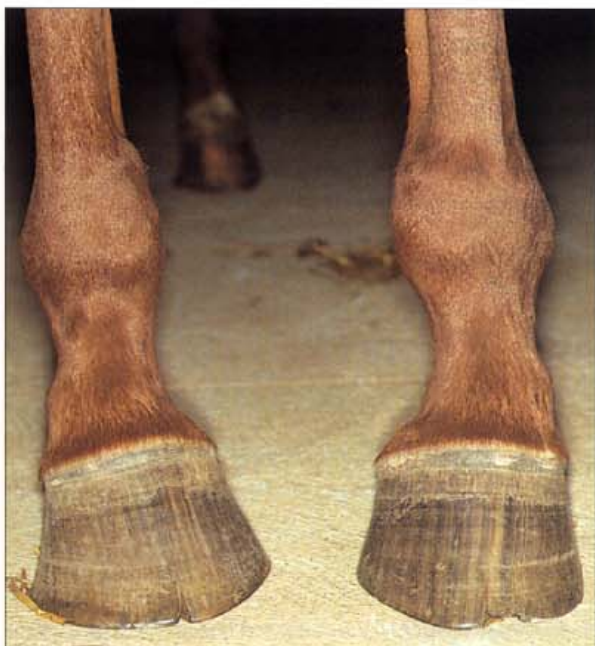

154. Hoof wall reconstruction: quarter crack (B). The racehorse mare in A, leading the field down the straight, several days after the hoof wall reconstruction. Note the Equilox reconstruction on both forefeet (arrowed). Photo: Q.J. Lang.

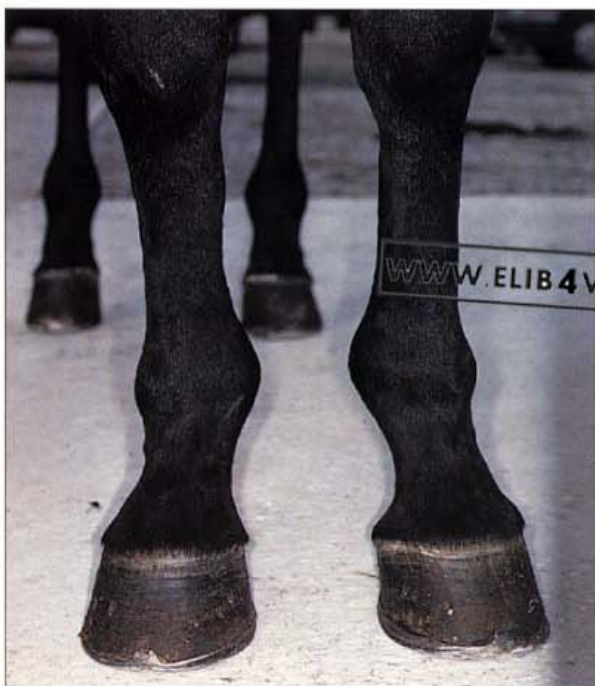


155. Hoof wall reconstruction: freeze-dried section. An Equilox heel reconstruction applied to the freeze-dried foot of a horse, has been sectioned to show the principles of the technique. Equilox must never come into contact with living tissue and can only be safely applied to keratinised, healing, hoof wall. The leading edge of the hoof wall has been recessed to lock the Equilox to the hoof wall and assist in weight bearing. The final layer of Equilox is carefully prepared and shod to ensure that the end result is balanced and as near to a natural shape as possible.

6 Conformation



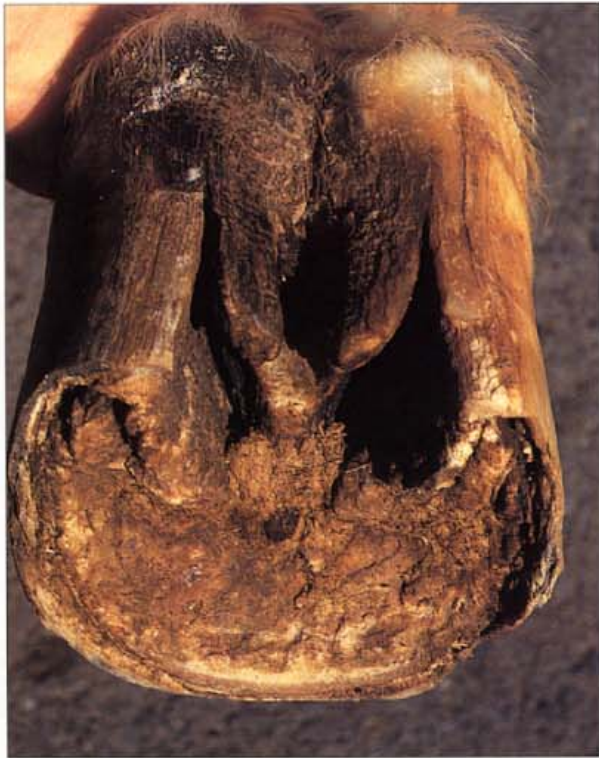156. Toe-in conformation. If the toes point towards one another when viewed from the front, the conformation is described as toe-in or pigeon-toed. Horses trotting with toe-in conformation tend to 'paddle' and there is an outward deviation of the foot in its flight. The break-over point is lateral (outside) to the centre of the foot and the foot will land on the lateral wall and load the medial. The lateral point of break-over and the loading of the medial side will be revealed in the pattern of shoe wear. It will always be difficult, if not impossible, for pigeon-toed horses to land flat. They should be shod to make their way of going as easy as possible; the toe of the shoe should be rolled at the natural point of break-over. Note that the hairline at the coronary bands is not parallel to the ground.



157. Toe-out conformation (A). Horses with toe-out conformation receive great stress on the medial aspect of their limbs and often develop medial sidebone and ringbone. The foot usually breaks over medial (inside) to the centre of the foot, swings inwards and lands on the outside wall. When viewed from the front, horses with a toe-out conformation have a 'plaiting' gait.

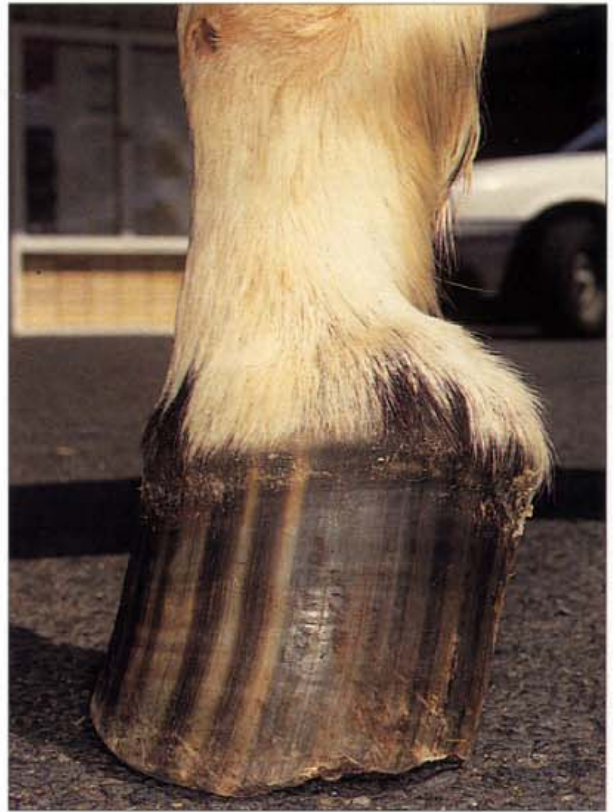

158. **Toe-out conformation (B).** Adult horses with severe turned-out feet (fetlock varus) are prone to injury and lameness and rarely make successful athletes. Uneven weight bearing creates asymmetrical hoof capsules which are difficult to shoe. The best compromise is usually to shoe the horse so that the foot lands and takes off evenly. In the case pictured it is clear that the lateral wall of the right foot will strike the ground first and will result in greater loading of the medial side. Because of this uneven loading the lateral wall will tend to be longer than the medial. When the feet leave the ground the point of break-over will be off-centre towards the medial side, and the left foot shows this in the photograph. It would be considered acceptable to shoe the feet of this horse with uneven wall and heel heights and with the toe of the shoe rolled towards the medial side of centre.

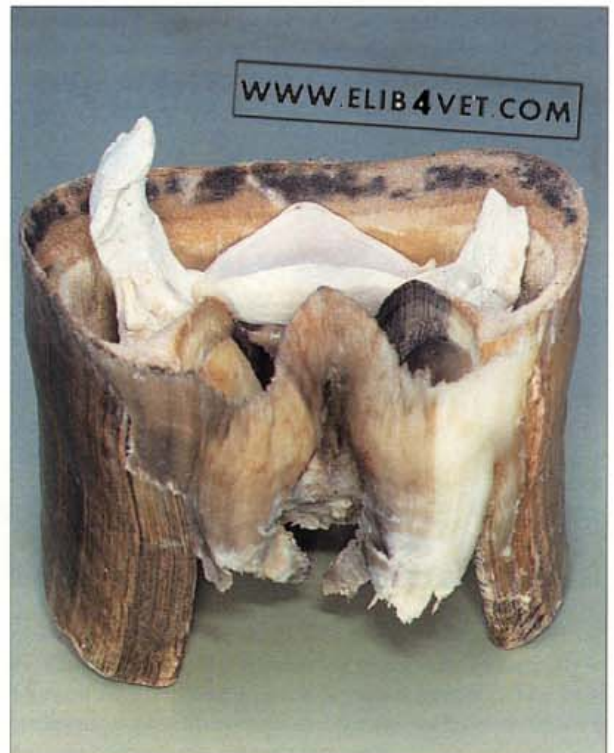


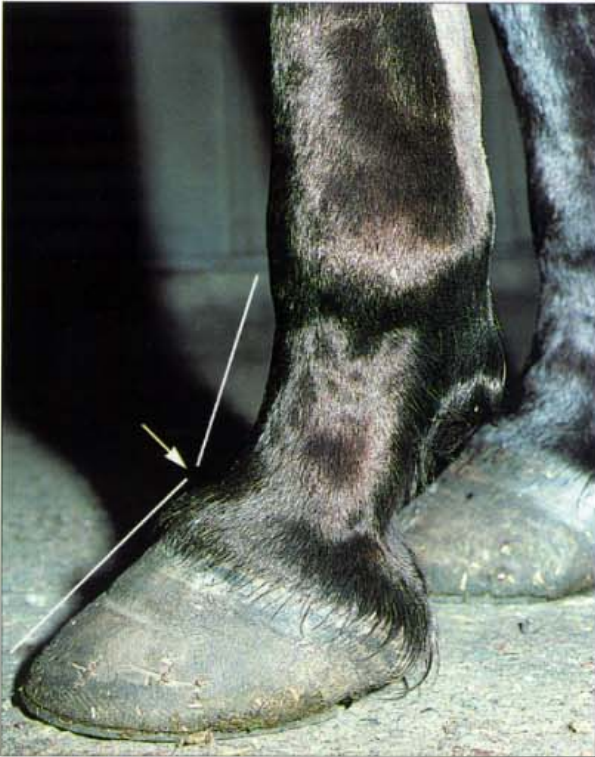159. **Contracted heels (A).** Contracted heels and atrophy of the frog can usually be attributed to a painful lesion causing the palmar half of the hoof to lose function. In this case the frog has been 3cm from the ground surface for years.

160. Contracted heels (B). The lateral view of the foot in A. The pastern is extremely upright and the hoof-pastern axis is near vertical. This abnormal conformation generates concussion and pathological changes within the foot.

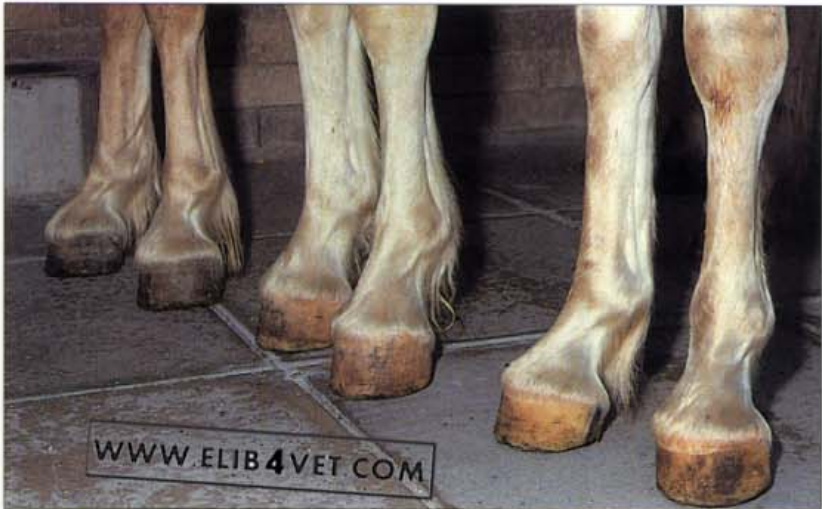

161. Contracted heels (C). Maceration of the specimen revealed the cause of the heel dysfunction and frog atrophy. The collateral cartilages of the distal phalanx were extensively ossified—a condition known as sidebones. The flexor surface of the navicular bone was normal and in this case appeared not to be involved in the cause of the contracted heels. The ossified cartilages were making contact with the inner border of the coronet and were presumably causing pain when locomotion loaded the foot. To minimise pain the horse limited its range of motion and, escaping the influence of loading, the heels grew long and the frog atrophied.

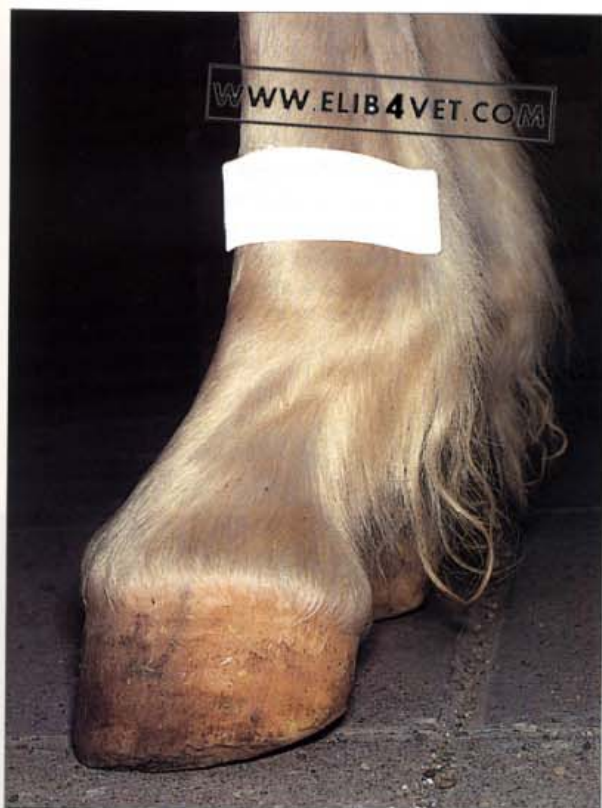



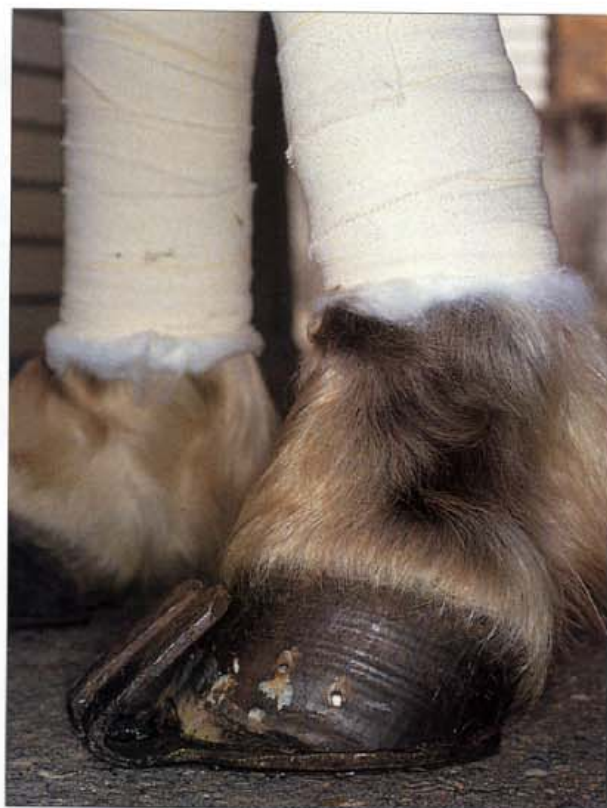162. Conformation: broken-back hoof pastern axis. Many young horses start their racing careers with normal hoof pastern conformation only to have this ruined by careless and misguided farriery. The heels of this Thoroughbred racehorse have been trimmed too low and the small shoe is providing insufficient heel support. As a consequence the hoof pastern axis is broken back (arrow) and the heels are chronically deformed and painful. This induced conformation fault has unbalanced the foot and has probably directly caused the 'bowed tendon' that this horse was presented with.



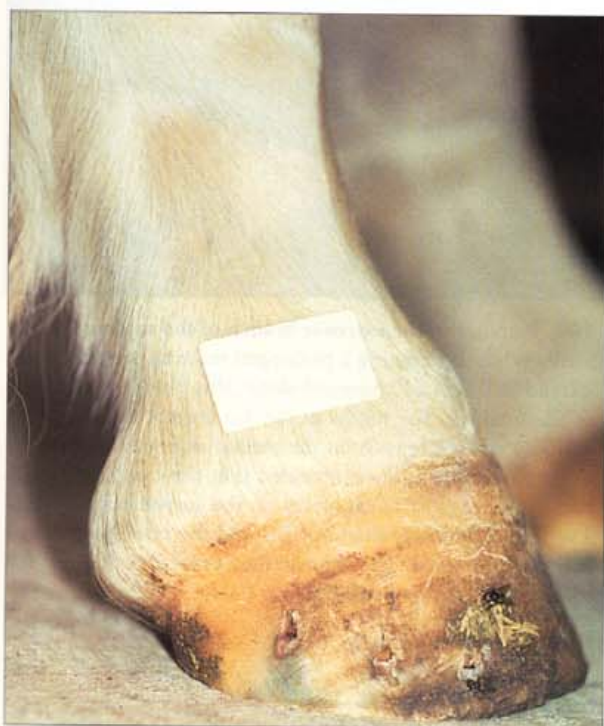163. Club foot (A). When the axis of the dorsal hoof wall exceeds 60° the foot is considered clubbed. Usually, a club foot only affects one of the two front feet. When the condition is bilateral it may have been inherited or may be due to, as yet, unknown nutritional factors. In this case three related Hafflinger ponies of the same age, kept under the same conditions, all developed bilateral clubbed feet when they were between 6 and 12 months of age.



164. Club foot (B). One of the three Haflinger ponies had a dorsal hoof axis close to 90° and was unable to place its heels on the ground.



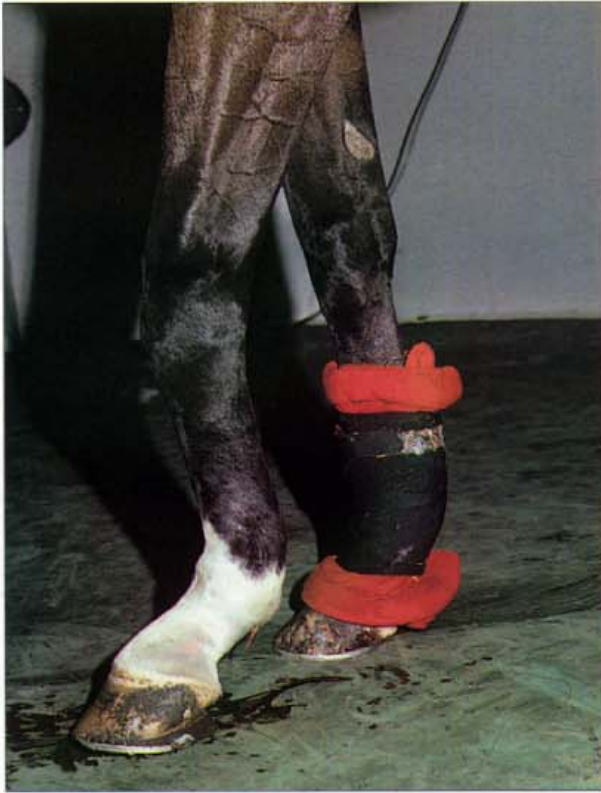165. Club foot (C). All three Haflinger ponies underwent surgery to relieve the tension on the deep flexor tendon. The surgical technique was to transect the distal or inferior check ligament. Immediately after the surgery the heels were lowered to establish the correct hoof pastern axis and a shoe with a forward extension was nailed to the hoof. The ponies were exercised frequently in the days immediately following the surgery to minimise the formation of adhesions at the surgical site.



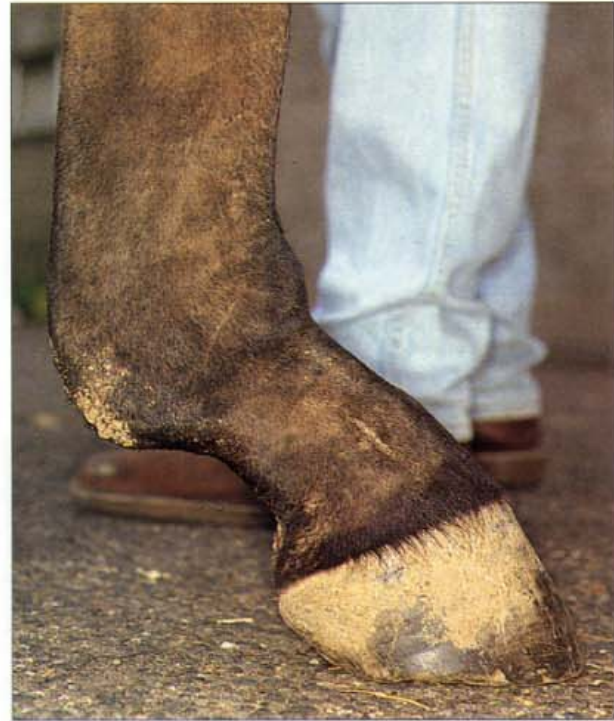166. Club foot (D). The appearance of the foot of the pony in B 18 months after distal check ligament surgery. The hoof pastern axis is now acceptable and the ponies were performing in harness competition without lameness.



167. Severe deep flexor tendon contracture. This severely contracted deep flexor tendon has caused the dorsal hoof wall to become the weight-bearing surface of the foot. Flexure deformities of the distal interphalangeal joint of this degree of severity cannot be treated. Note that the angle of the pastern is near-normal, indicating that the superficial flexor tendon was not involved. Photo: J. Vasey.

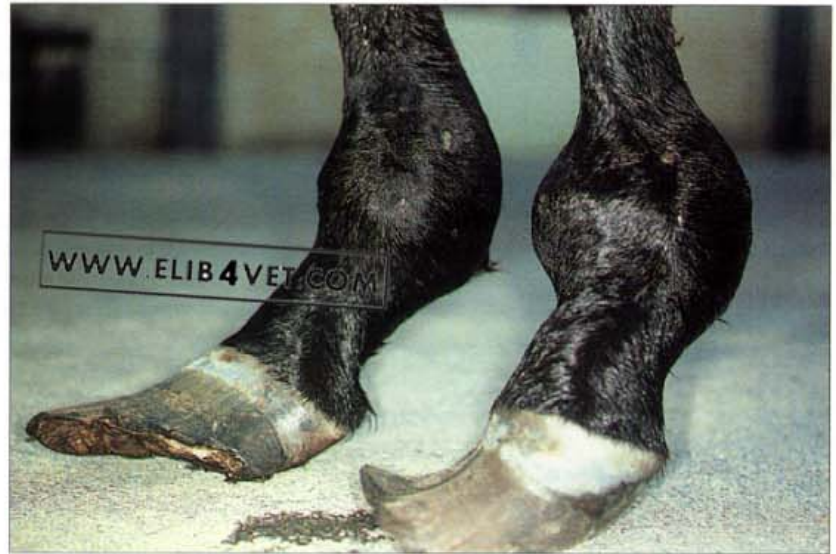

168. Traumatic rupture of the suspensory apparatus. As a result of extreme extension (dorsiflexion) of the fetlock while racing, this horse has ruptured its suspensory ligament and fractured both proximal sesamoid bones of the left foreleg. Typically there is sinking of the fetlock, flexion of the knee and extreme swelling in the region of the suspensory ligament and the flexor tendons. There was little hope that the racehorse could return to an athletic career so it was humanely destroyed. The severe trauma of this syndrome can lead to compromise of the blood supply and ischaemic necrosis of the hoof.

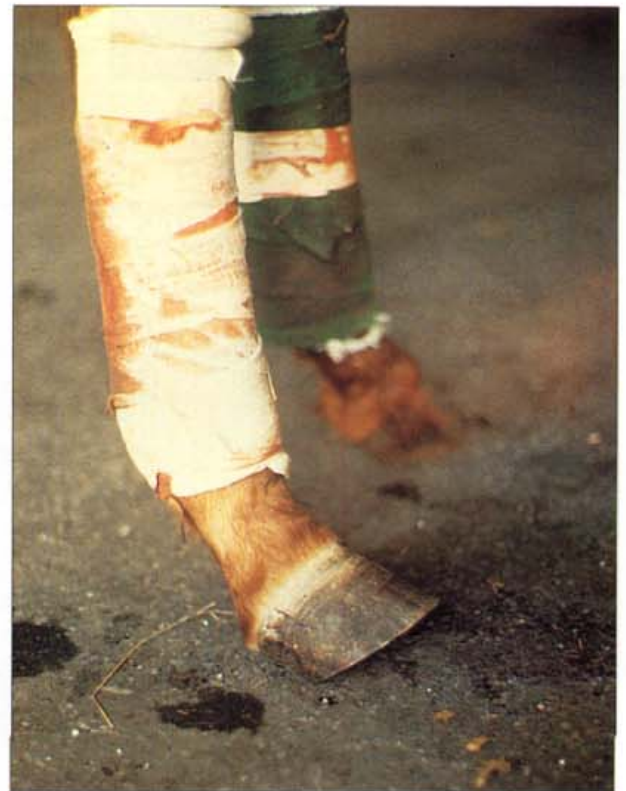

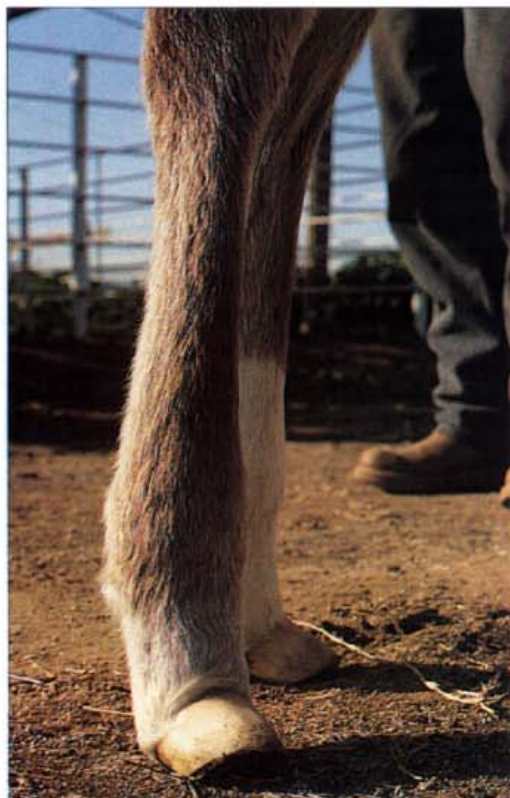169. Rupture of the extensor branch of the suspensory ligament. While undergoing a prolonged training programme on a treadmill with a 7° upward slope, this horse became lame in one hind leg. The region of the distal suspensory ligament and its extensor branch on the medial side was swollen. An ultrasound examination revealed that the extensor branch had ruptured close to its origin on the suspensory ligament. The fetlock is lower than normal and the hoof pastern axis is broken forward. The skin on the dorsal aspect of the fetlock is abnormally wrinkled.

170. Deformed hoof growth. Hooves of normal size and shape will remain that way for the life of the horse as long as weight bearing and function remain normal. If disease or injury in the limb above the foot causes gross changes in balance, the hoof will grow abnormally. Severe crippling osteoarthritis of the metacarpophalangeal joints has altered the way the weight of this horse is bearing on the hooves and has caused them to become deformed.

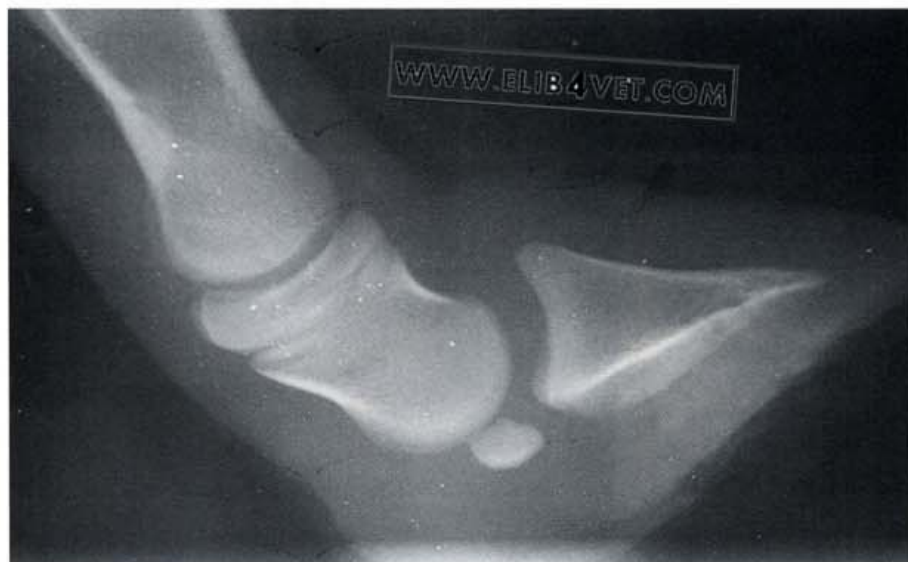

171. Rupture of the deep flexor tendon. When the deep flexor tendon is severed the horse has difficulty placing its foot on the ground and the toe points upwards. Correct placement of the foot can sometimes be achieved with judicious trimming of the hoof. If this is not successful, the hoof should be shod with heel extensions.



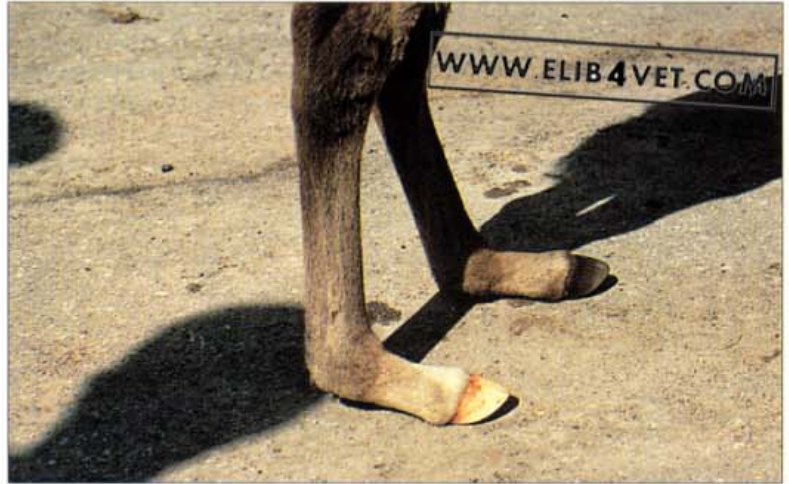

172. Deep flexor tendon flaccidity (A). Newborn foals affected with deep flexor tendon flaccidity (weakness) walk on the plantar/palmar aspect of their heels and do not bear weight on their toes. In other words they bear weight on the bulbs of their heels with the toes pointing upwards. Hindfeet are more frequently involved than the forefeet. The condition usually corrects itself spontaneously but can be a problem if foals are born weak, immature or ill. Severe cases may subluxate the distal interphalangeal joint. Treatment consists of trimming the heels, but not the toe. Glue-on shoes with heel extensions encourage correct weight bearing and protect the bulbs of the heels from trauma. As the foal matures, the tendons and the associated muscles strengthen and most cases resolve within a few days.

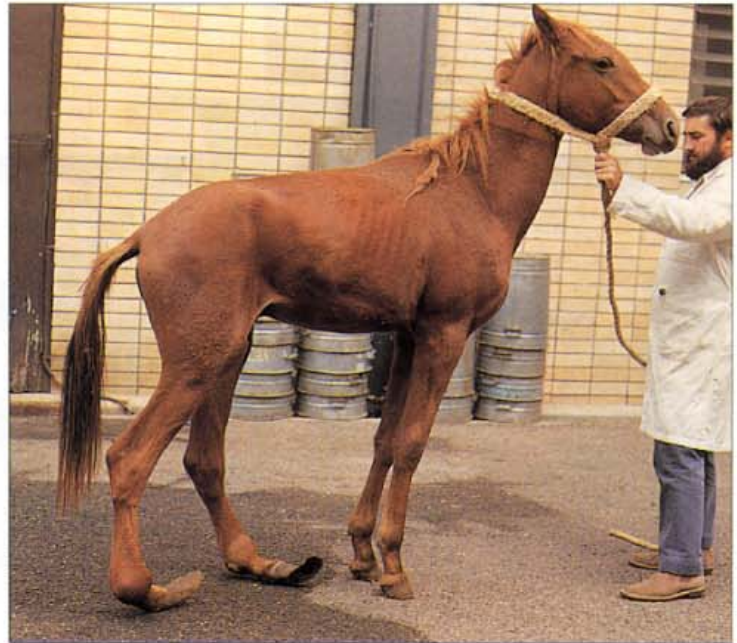

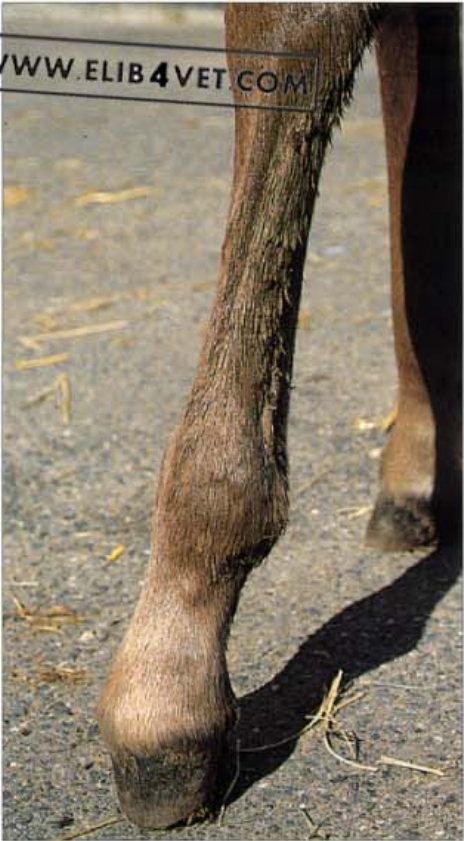173. Deep flexor tendon flaccidity (B). The radiograph of the foot of the foal in A shows that the distal interphalangeal joint is already beginning to subluxate. Photo: Jan Young.

174. Flaccidity of the flexor tendons. This sick orphan foal, affected with flaccidity of the flexor tendons, walked on the plantar aspect of the heels and did not bear weight on the toes. This condition usually affects only the hindlimbs and often resolves spontaneously as the foal matures. Some form of support bandage may be necessary to protect the heels and the plantar aspect of the pastern from trauma. In severe cases surgery to shorten the flexor tendons may offer some hope. Photo: J. Vasey.



175. Hoof growth deformity. This young horse was born with a severe, angular hindlimb deformity. The neonatal history is unknown but it is likely that flaccidity of the plantar flexor tendons was involved from the onset. The ground surface of the hind hoof walls has never made contact with the ground and no losses have occurred to abrasion. The hind hooves are 19cm long at the toe and this represents all the hoof this horse has produced in its short life (about 14 months). There is now severe osteoarthritis of both hind metatarsophalangeal joints (fetlocks) and the phalanges and the hooves are grossly deformed. Photo: J. Groenendyk.



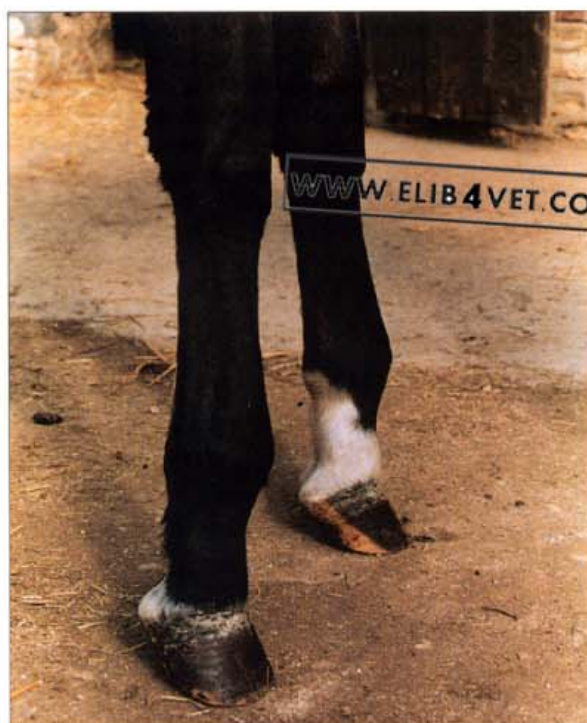

176. Congenital flexure deformity: a mild case. Foals are sometimes born with mild contracture of their flexor tendons. The hoof pastern axis is broken forward and the pastern is upright. Note the tension of the digital extensor tendon on the dorsal surface of the cannon bone. This case resolved spontaneously within 3 days. The foal never stumbled or knuckled forward onto the dorsal surface of its fetlock.

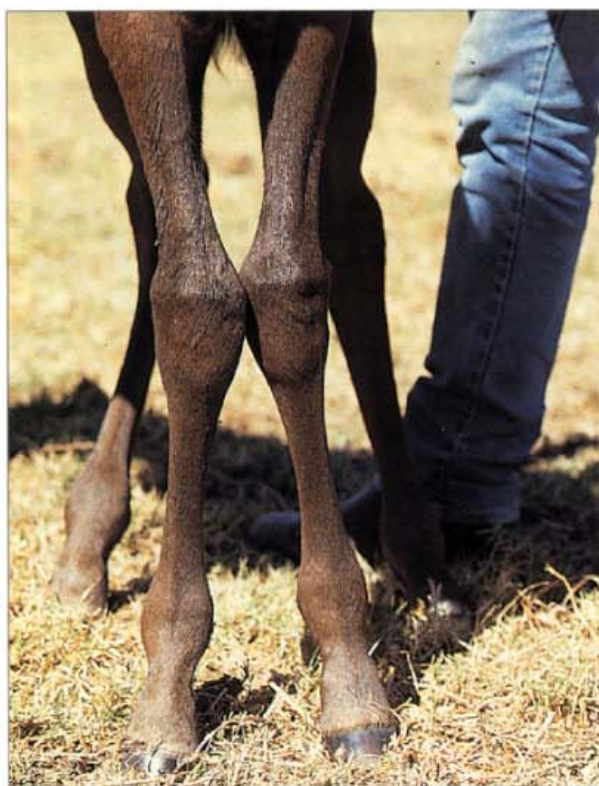

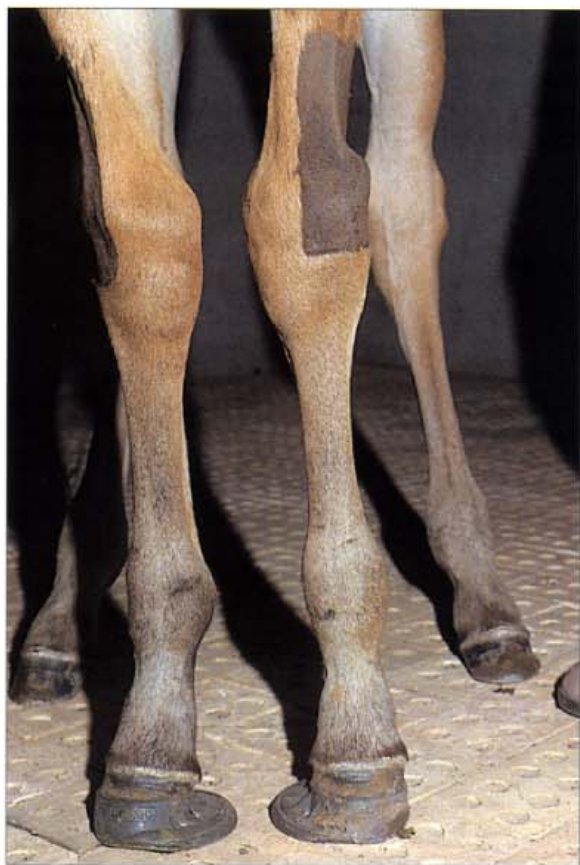177. Congenital flexure deformity of the metacarpo/metatarso phalangeal joints. An unusual case of flexure deformity affecting only the right forelimb and the right hindlimb; the limbs on the left side were not affected. Both the metacarpophalangeal and the metatarso-phalangeal joints are affected, the latter most severely. The contracture involves the superficial flexure tendons and not the deep flexor tendons, as the axis of the dorsal hoof wall is relatively normal. Surgery to correct this type of deformity may require sectioning of the inferior check ligaments, superficial deep flexor tendon and branches of the suspensory ligament to return the joint to a normal position. Photo: J. Vasey.

178. Acquired flexure deformity of the metacarpophalangeal joints. This type of flexure deformity does not involve the deep flexure tendon as the axis of the dorsal hoof wall is normal. However, the axis of the pastern is grossly abnormal and this has come about because the superficial digital flexure tendon, which inserts on the middle phalanx, along with its muscular unit, has undergone contraction. Photo: D. Leveillard.

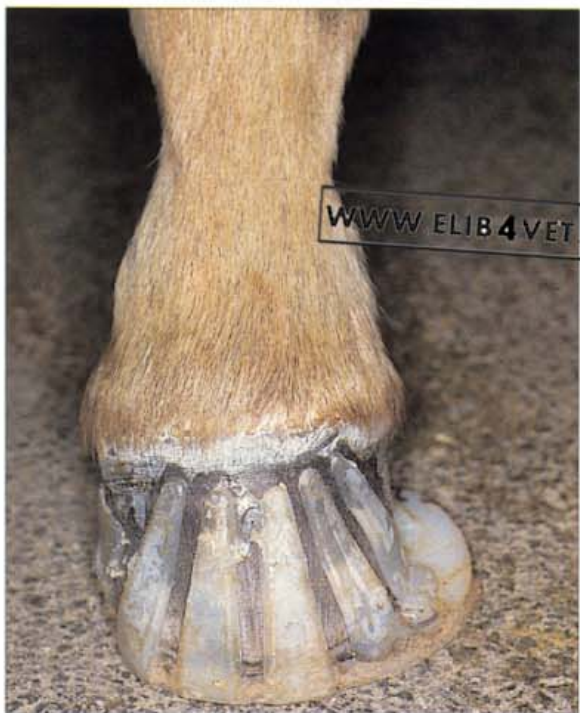

179. Angular limb deformity (A). Many Thoroughbred foals are born with angular limb deformities. One of the most common is outward deviation (varus) of the carpus. The foal pictured at 2 weeks of age is a moderately severe case and when walking its knees brushed together. The growth plate of the distal radius begins to close at about 6 months of age so surgery, to correct the deformity, must be complete before the foal reaches this age. The surgical technique most commonly employed is periosteal elevation. In this case the periosteum over the lateral radial epiphyses would be elevated so that the growth of the radius would be accelerated to straighten the limbs. Although the alignment of the metacarpo phalangeal bones of this foal appear correct at this stage, the non-vertical forces arising from the deviated carpus will soon cause their growth plates to deform resulting in fetlock varus. To prevent this occurring and to assist with alignment of the vertical forces, it is advisable to shoe foals like this with medial extension shoes.





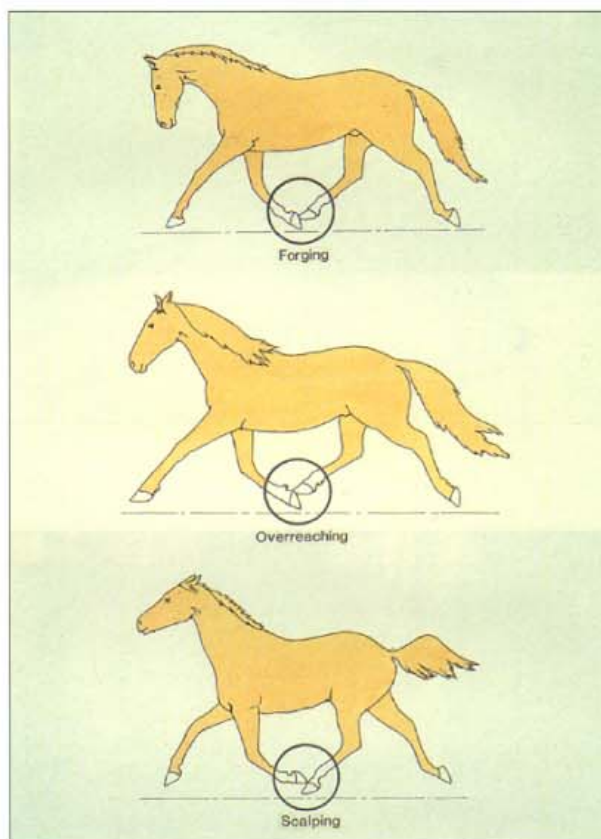
180. Angular limb deformity (B). The same foal a few days after periosteal elevation of the lateral distal epiphyses of each radius. The foal has had medial extension shoes (cuff type) glued to its forefeet to encourage realignment of vertical forces. Already there is considerable improvement.



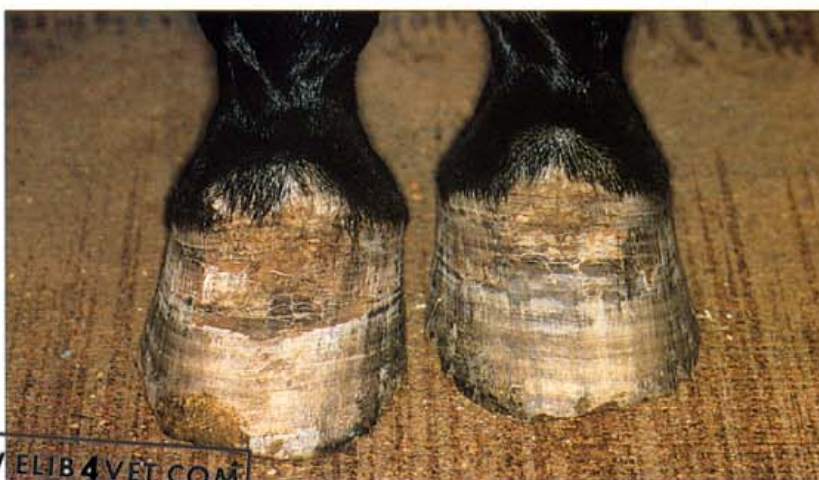181. Medial extension shoe. An alternative to the cuff type medial extension shoe is the glue on tab type shoe. These can be fabricated by heat-welding the tabs to the base plate which can be designed to meet the particular requirements of each case.

7 Interference Injury

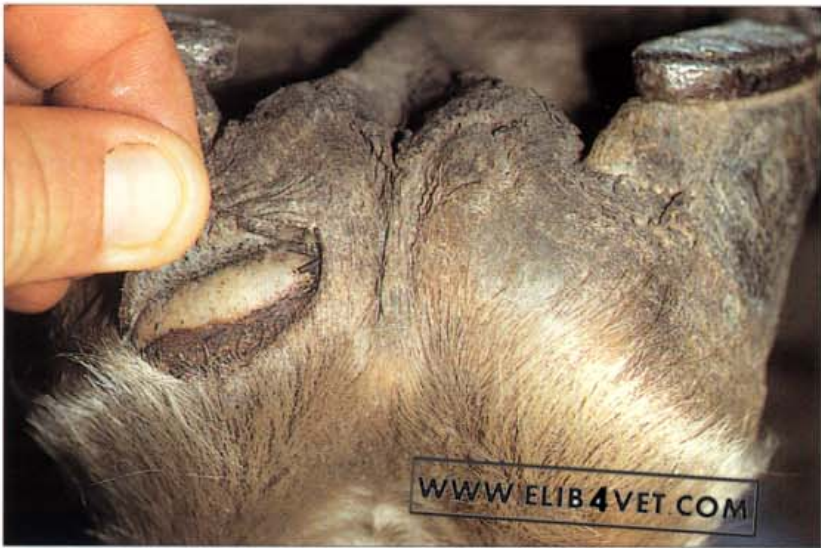182. Diagram showing common types of interference injury.



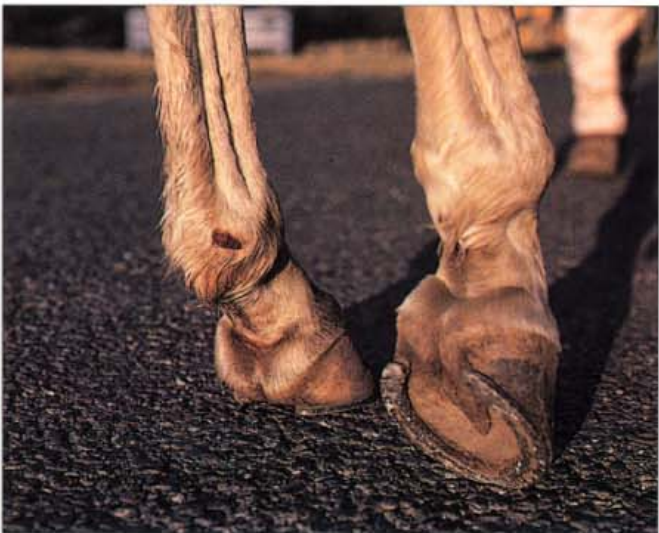183. **Scalping injury.** The hindfeet of a trotting horse with chronic scalping injuries. The toe of the forefoot has been making contact with the coronet of the hindfoot on the same side. Photo: I.M. Wright.



WWW.ELIB4VET.COM

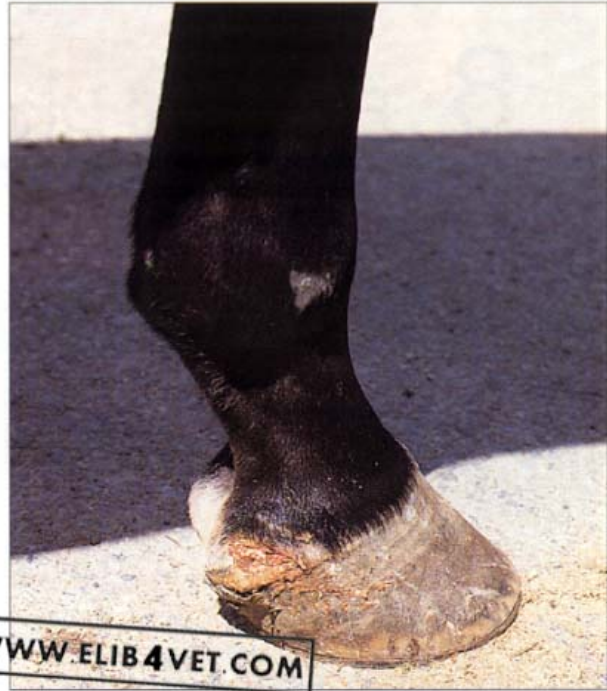


184. Over-reaching injury. This over-reaching injury was caused by the toe of the hindfoot over-reaching and scalping the heel of the forefoot. If a horse stumbles or flounders in deep mud this sort of injury may occur by accident. In the horse illustrated, however, the over-reaching occurred frequently and either injured the bulb of the heel as shown or caused loss of the shoe. The problem was corrected by shoeing the front feet with wider, more protective shoes, with rolled toes. The hindfeet were shod with side-clipped shoes with the toe of the hoof slightly over-hanging the shoe. The subtle changes in the timing of break-over between fore- and hindfeet apparently allowed the forefeet to leave the ground, quicker than before, without interference from the hindfeet.

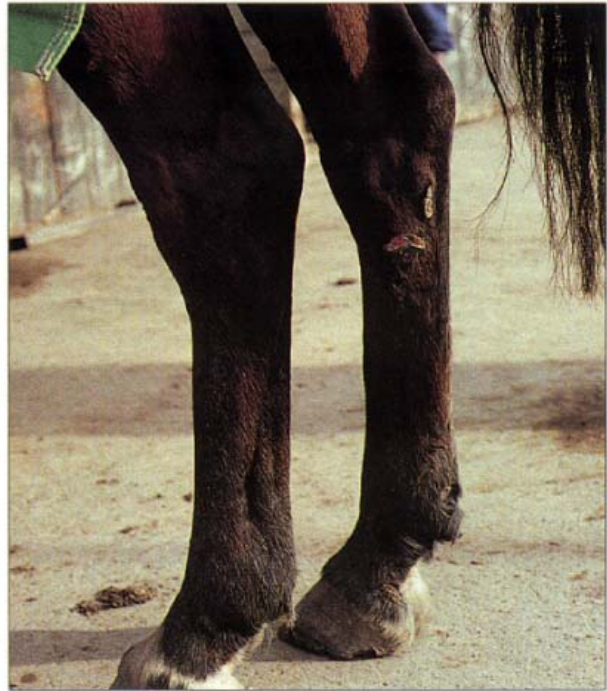

185. Endurance horse brushing injury. Endurance horses cover many hundreds of kilometres both in training and competition. Conformation faults and shoeing problems frequently result in injuries like this brushing wound to the medial fetlock. Fatigue undoubtedly plays a role in the production of these injuries as their occurrence becomes less frequent when endurance horses become well conditioned and experienced. The severity of the trauma can be minimised by ensuring that the medial nail clenchers are recessed into the hoof wall and the medial branches of the hind shoes are fitted tight at the quarters and heels (flush with the hoof wall). Horses shod in this way will have to be reset more frequently than usual because the hoof will soon overgrow the shoe at the heels. Theoretically, lateral trailers on the hind shoes may be expected to prevent brushing injuries like this, but in practice help but little because of the unlevel terrain over which endurance horses have to travel.

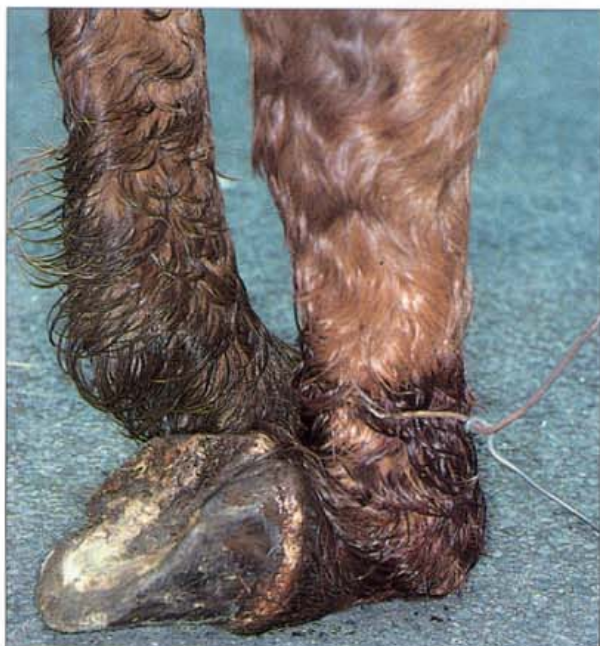186. Interference injury. Some interference injuries can never be corrected. This Standardbred 2-year old, when broken in to harness, repeatedly injured the heels of both front feet by over-reaching with the hind toes. On clinical investigation it was found to be suffering from a disease of the central nervous system called equine degenerative myeloencephalopathy (EDM). The horse was permanently disabled and unable to coordinate its limbs; hence the interference problem. EDM can be prevented by ensuring the diet of pregnant mares and foals contains adequate, active vitamin E.



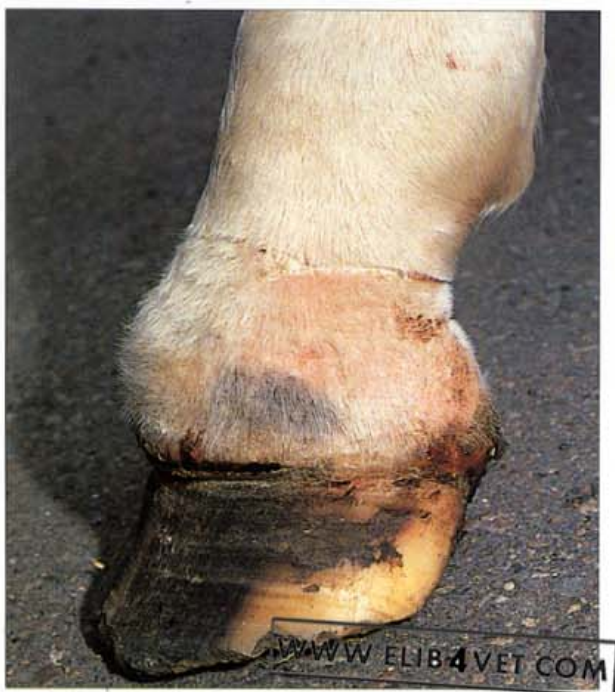187. Interference injury - medial hock. Only horses with perfect conformation are able to achieve race winning performance free of interference injuries. This Standardbred racing trotter regularly lacerated the medial hock in the region of the proximal metatarsus after racing on tracks with tight turns. The lateral edge of the shoe on the right forefoot caused the injury to the medial right hock.



8 Failure of Digital Blood Supply

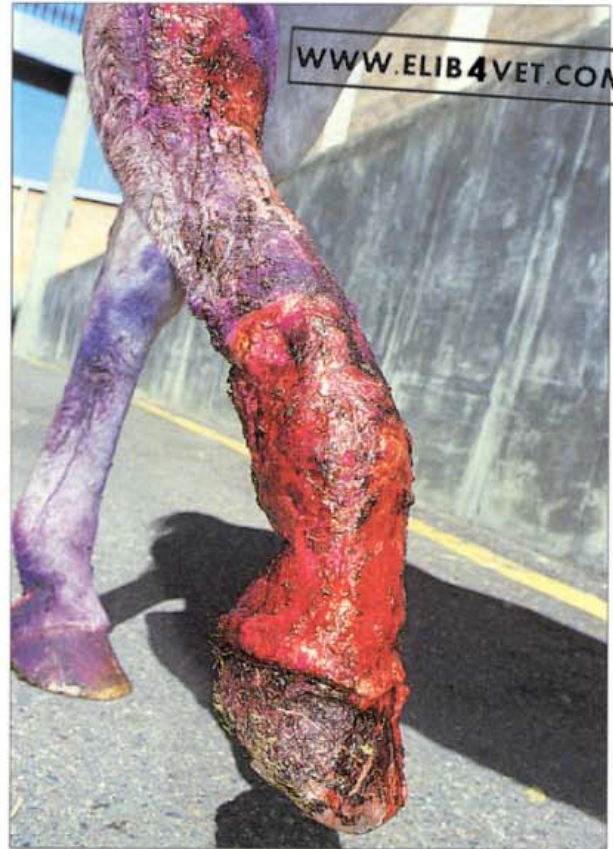

188. Gangrene. A strand of plain, fence wire accidentally formed a tourniquet above the fetlock and caused gangrene of the limb below. The extensor tendon was severed by pressure necrosis and the horse was unable to extend the fetlock. It walked on the dorsal aspect of the joint and the foot was cold and malodorous. The horse was humanely destroyed.

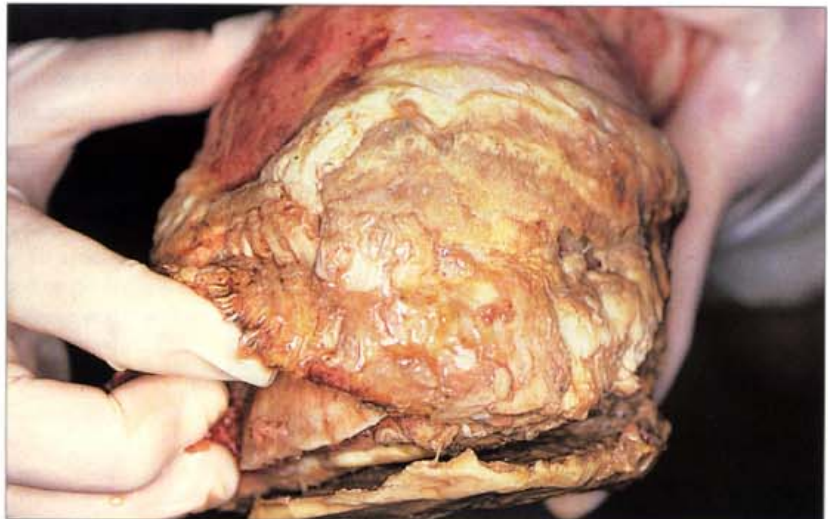

189. Gangrene of the foot. This horse caught its foot in a loop of plain wire which formed a tourniquet around the pastern. When the accident was discovered and the wire removed the injury did not look severe as the skin was barely broken. However, the wire had caused internal bruising and occlusion of the digital arteries. The foot distal to the wound became gangrenous. The skin shows a clear line of demarcation between normal and abnormal in the mid-pastern region. The hoof wall is in the process of sloughing away from the underlying dermis and dark, smelly fluid is discharging from the coronet. The distal phalanx descended into the hoof capsule and perforated the sole.

190. Gangrene of the distal limb (A). This mare was cast in a plain wire fence for 2 days before being discovered. Most of the trauma was confined to the hock and the distal metatarsus and initially the damage seemed insignificant. However within a few days it became apparent that the circulation to the distal limb was severely compromised. When presented for veterinary examination 2 weeks after the initial injury the skin was sloughing from the fetlock and pastern.

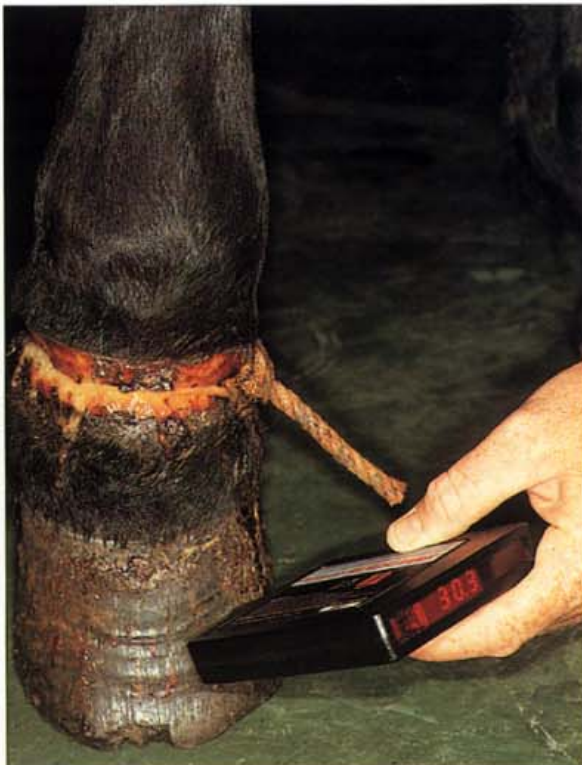

191. Gangrene of the distal limb (B). Despite intensive treatment the mare had to be destroyed when gangrene caused the hoof to slough and the distal interphalangeal joint to disintegrate. In the photograph the solar margin of the distal phalanx can be seen under the oedematous remains of the hoof wall corium.





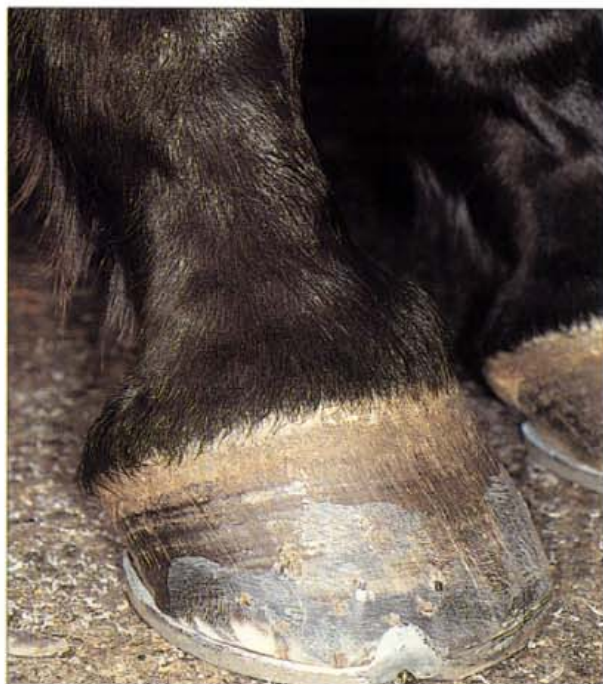192. Pastern trauma (A). A restraining rope hobble was applied to the pasterns of this Standardbred stallion. The horse was turned out in an overgrown paddock and ignored for several weeks. One end of the hobble tightened around the pastern until it cut through the skin and became embedded in suppurating granulation tissue. The horse was extremely lame when reported by concerned neighbours and became the subject of a successful cruelty prosecution against the owner. Because of the lameness there is disuse atrophy of the muscles of the shoulder, and the spine of the shoulder blade (scapula) is unnaturally prominent.



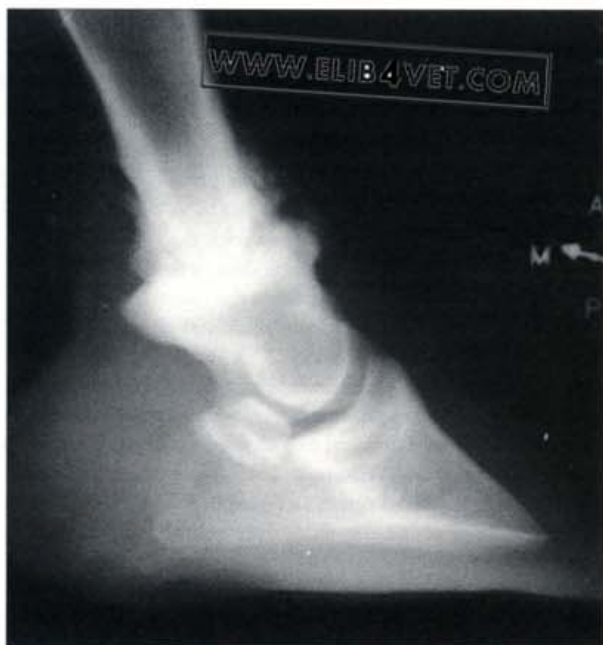
193. Pastern trauma (B). Amazingly the foot distal to the constriction was not seriously compromised. Radiographs showed that no bone or joint damage had occurred and, as the digital infra-red thermometer shows, the temperature of the hoof was in the normal range. There were no clinical signs of laminitis and when the hobble was removed the horse made a complete recovery.

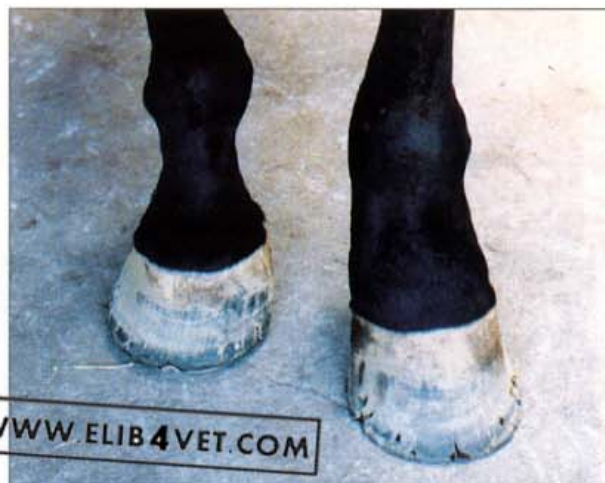9 Ringbone

194. Ringbone (A). On the dorsal aspect of the pastern, just above the coronet, there is a suspicious lump. Palpation revealed that the lump had a hard bony feel to it and was not superficial. This is a classic case of articular ringbone of the proximal interphalangeal (pastern) joint and the horse should not be purchased. Horses with articular ringbone show chronic intermittent lameness. A radiograph would be required to confirm the diagnosis.

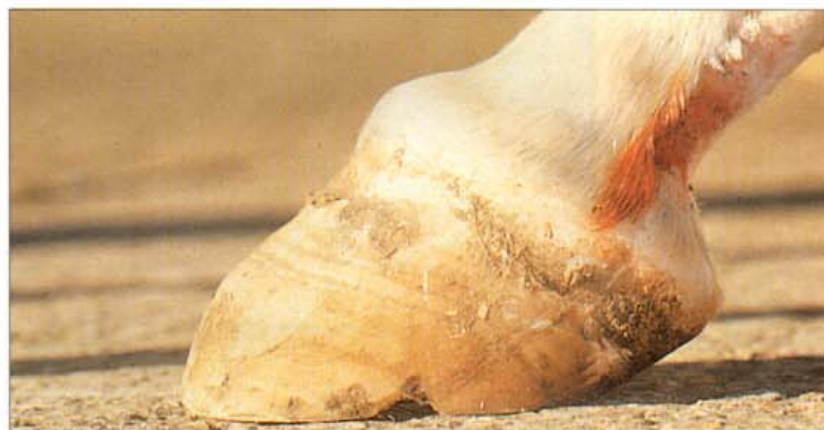

195. Ringbone (B). The radiograph, taken at an oblique angle to highlight the lump, shows that the proximal interphalangeal (pastern) joint is almost totally obliterated by periosteal new bone growth (ringbone). This case would be classified as a high ringbone because it involves the distal end of the first phalanx and the proximal end of the middle phalanx (low ringbone involves the distal end of the middle phalanx and the proximal distal phalanx). It would also be classified as an articular ringbone because it involves the joint (as opposed to periarticular ringbone which does not). Surprisingly, the horse was hardly lame, probably because the joint had fused (ankylosed).



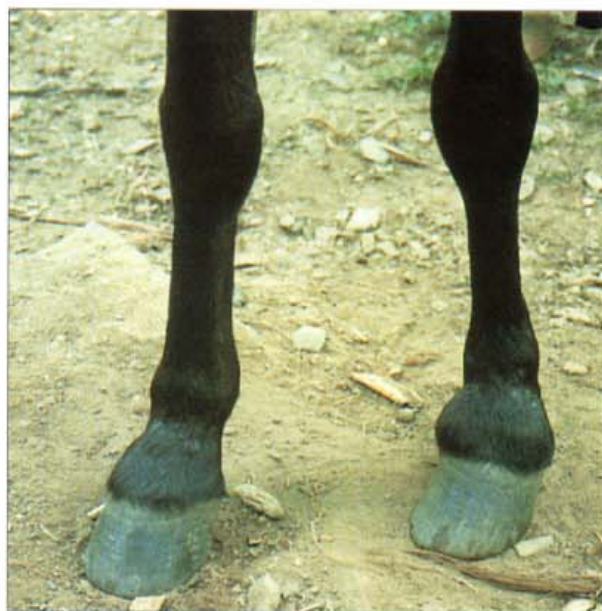

196. Ringbone. When new bone growth (exostosis) occurs on the proximal, middle or distal phalanx the condition is known as ringbone. This horse suffered a traumatic dislocation of the proximal interphalangeal (pastern) joint and subsequently developed severe articular and peri-articular ringbone. The articular ringbone involved the proximal interphalangeal joint and the peri-articular ringbone involved the ligaments of the proximal and middle phalanges. Tearing of the insertions and origins of the ligaments damages the periosteum of the bones and causes new bone growth and the formation of exostoses. The left pastern is clearly swollen and deformed. Photo: B. Duvernay.

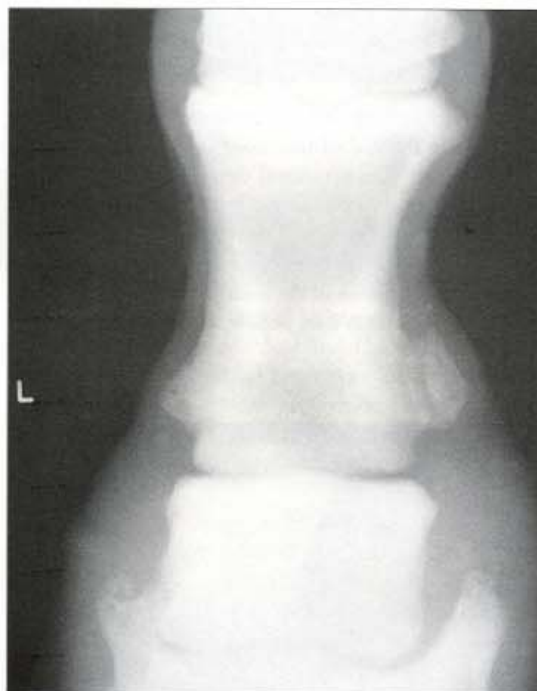

197. Buttress foot (Pyramidal disease). New bone growth associated with chronic fracture or periostitis of the extensor process of the distal phalanx causes the dorsal midline coronary band to enlarge. The horse usually exhibits a pain response if the enlargement is pressed hard with the thumbs. The condition occurs because the attachment of the extensor tendon to the extensor process of the distal phalanx is strained and torn. In some cases the tension is so great that the extensor process fractures and is torn away from the distal phalanx. High-heeled, short-toed horses with a high stepping action such as Hackneys and Paso Finos are reported to be predisposed to this condition. When the condition becomes chronic, radiographs show that new bone growth involves the distal phalanx, the distal interphalangeal (coffin) joint and the distal end of the second phalanx. Over time the foot changes shape and becomes V-shaped. There is no effective treatment for a buttress foot. Shortening the toe as much as possible (like the horse in the photograph) and the application of rolled-toe shoes may help, but the prognosis is grave. Photo: I.M. Wright.

198. Nonarticular low ringbone. Nonarticular ringbone can result when the attachments of the extensor tendon to the proximal, middle or distal phalanx are strained or torn. Periostitis (inflammation of the periosteum) causes new bone growth (an exostosis) to develop at the site of the injury. Working horses that are deliberately shod with high heels and a broken forward hoof-pastern axis (stood up) place a greater than normal strain on their extensor tendons and are prone to this form of ringbone. For a similar reason horses with an exaggerated, high-stepping action, like this Peruvian Paso Fino, are also predisposed to this condition. Photo: B. Duvernay.



199. Nonarticular high ringbone (A). Nonarticular high ringbone, involving the distal end of the proximal phalanx, can occur when the attachments of the collateral ligaments of the proximal interphalangeal joint are torn. Nonarticular ringbone does not usually cause pain. However, lameness may result if the exostosis continues to enlarge and interferes with the action of the tendons. The swelling on the medial side of the pastern of this Australian Stock Horse was hard to the touch. The medial cartilage of the distal phalanx was non-flexible.



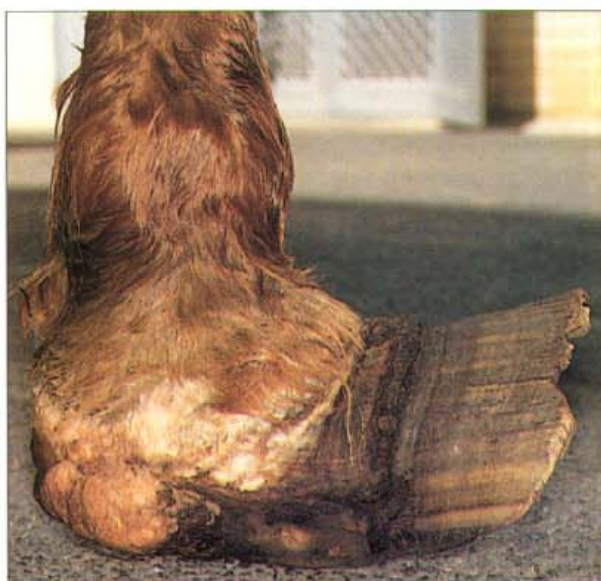200. Nonarticular high ringbone (B). A radiograph confirms the diagnosis of ringbone. There is new bone growth at the distal end of the proximal phalanx on both the medial and lateral sides of the bone and the medial cartilage is extensively calcified (sidebone).



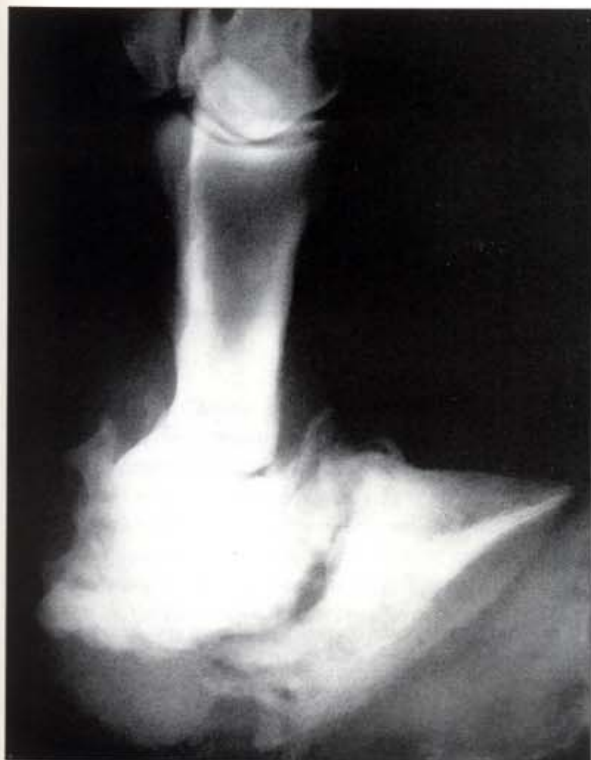201. Low articular ringbone and abnormal hoof wall growth (A). The proximal third of this hoof is several centimetres larger in diameter than the distal two thirds. The dramatic change in hoof growth coincided with the onset of severe lameness 4 months previously. The reason for the increase of hoof diameter remained a mystery until radiographs revealed a severe articular ringbone of the middle interphalangeal joint and the distal phalanx. A case of low articular ringbone.



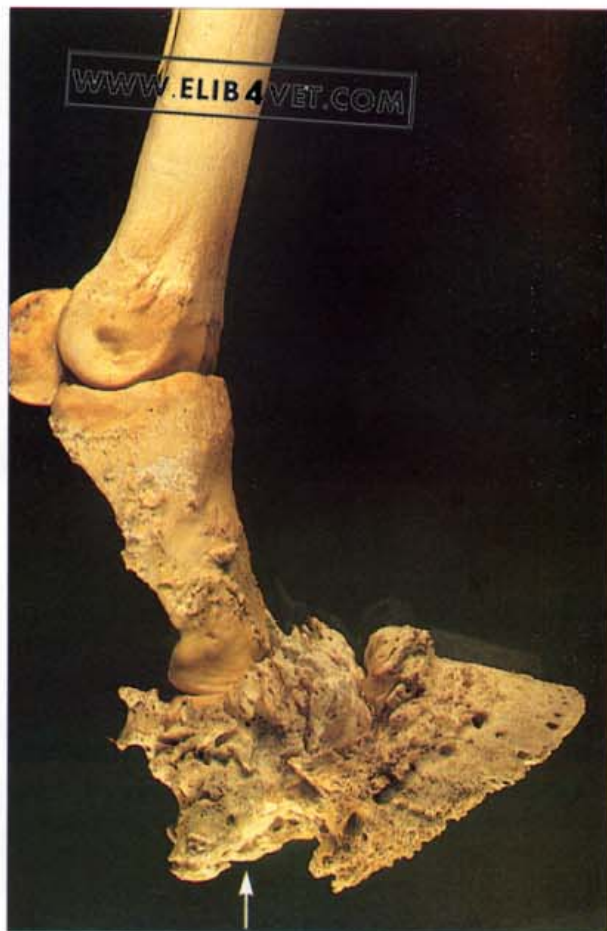202. Low articular ringbone and abnormal hoof wall growth (B). The onset of severe bony proliferation at the site of the ringbone had apparently increased the internal diameter of the coronet. A new larger hoof wall is now being produced to accommodate the larger-sized skeleton.



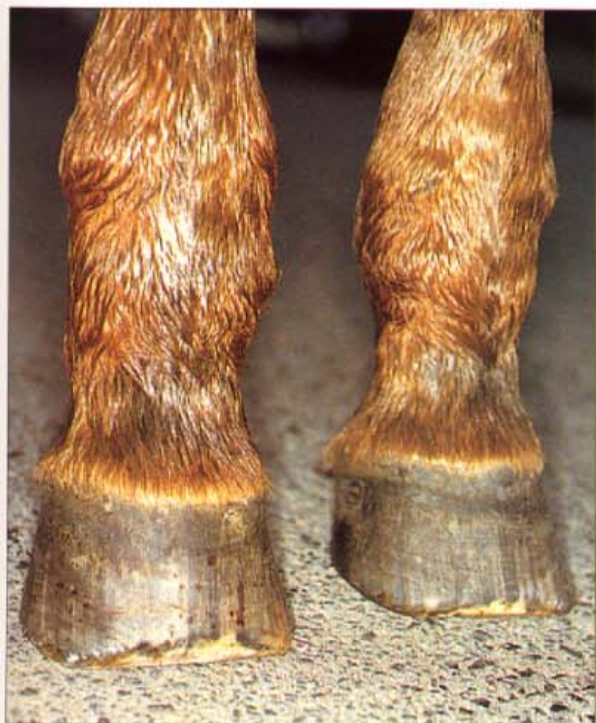203 Low articular ringbone and distal interphalangeal joint subluxation (A). To alleviate the pain of navicular disease a palmar digital neurectomy was performed on this horse. Although navicular pain was abolished, the pathological processes of severe chronic navicular disease continued until eventually the deep flexor tendon ruptured. The distal phalanx subluxated dorsally and without the protection of the pain response the horse continued to walk on the palmar surface of its pastern. By the time the injury was discovered the skin of the pastern was severely ulcerated and the distal interphalangeal joint had developed severe osteoarthritis.



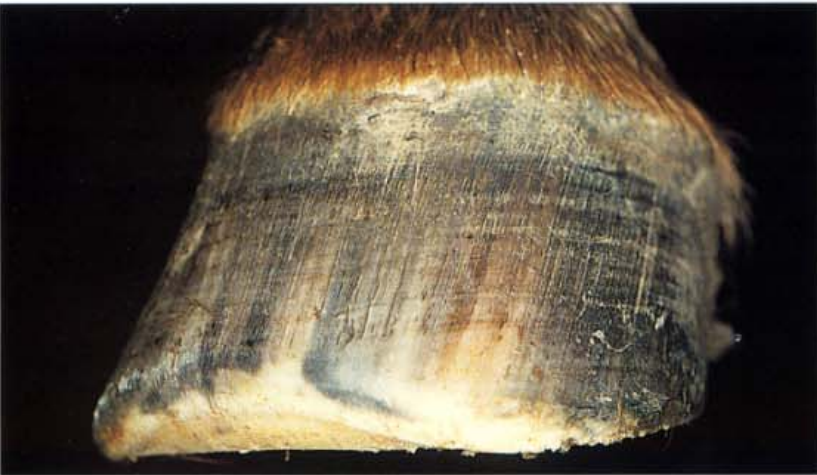204. Distal interphalangeal joint subluxation: radiograph (B). The radiograph of the distal interphalangeal joint shows severe osteoarthritis.



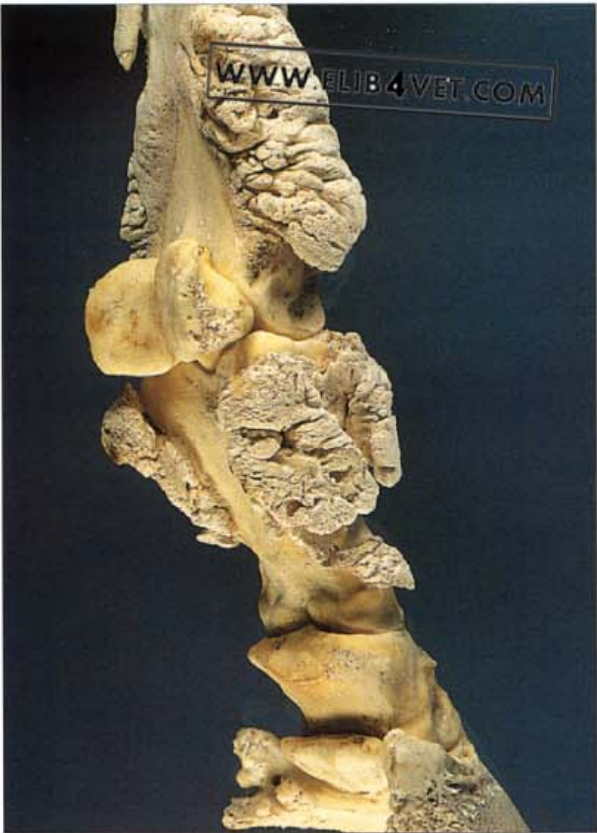205. Distal interphalangeal joint subluxation: macrated specimen (C). The middle and distal phalanges were already ankylosed. The navicular bone was incorporated into the mass of proliferating bone growth on the palmar aspect of the middle phalanx (arrowed).



206. Hypertrophic osteopathy-pulmonary hypertrophic osteoarthropathy-Marie's disease (A). When presented for veterinary examination, this elderly pony mare could only walk with a stiff, shuffling gait and had severe respiratory disease. It was impossible to flex either the carpal or the fetlock joints and the metacarpus and the proximal pastern were grossly enlarged with what appeared to be solid bone. The bony enlargements affected all four limbs and were symmetrical. The limbs had been in this state for over a year but it was the respiratory disease that was causing concern to the owners.



207. Hypertrophic osteopathy-pulmonary hypertrophic osteoarthropathy-Marie's disease (B). To walk with limbs that would not flex, the mare had to drag the limbs forward with an exaggerated shoulder movement. The dragging had caused the tips of the hooves to be worn away.



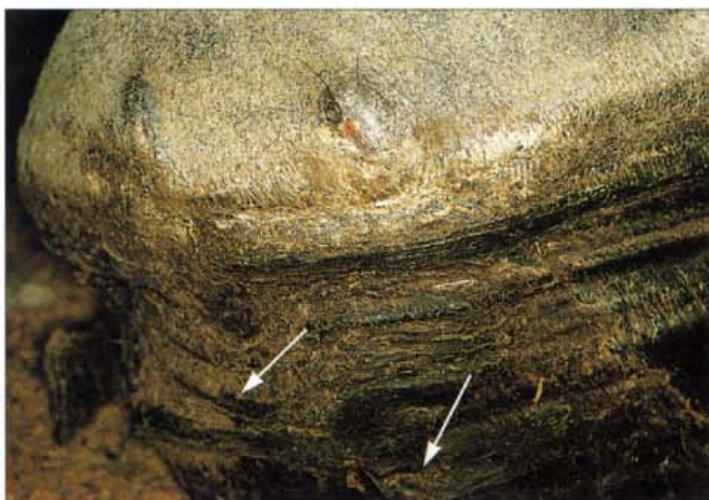
208. Hypertrophic osteopathy-pulmonary hypertrophic osteoarthropathy-Marie's disease (C). The cause of the respiratory disease was diagnosed as a large lung tumour occupying the entire right side of the thorax. The tumour was a primary granular cell neoplasm of probable mesenchymal origin. After euthanasia the forelimbs were macerated to reveal the extent of the bony changes. The distal ends of the metacarpus and the proximal first phalanx were enormously enlarged with cauliflower-like growths of periosteal new bone. The joints were not affected. The disease is rare in horses and, although more common in man and dog, how the presence of lung disease induces proliferation of subperiosteal bone growth has yet to be explained.

10

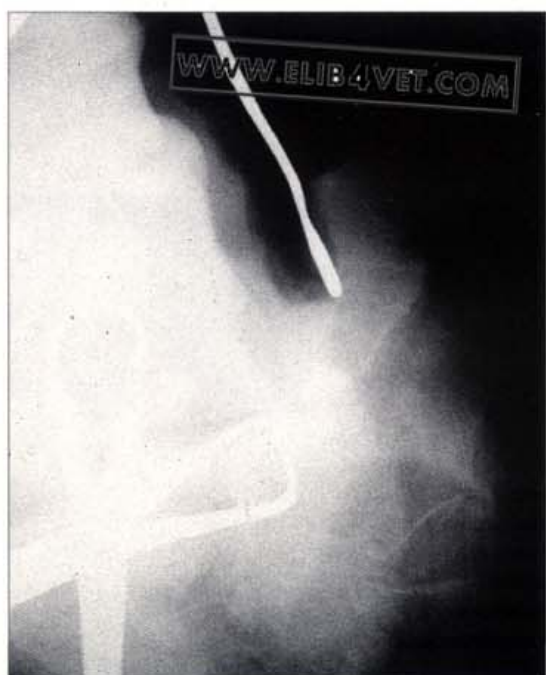Disorders of the Cartilages of the Distal Phalanx

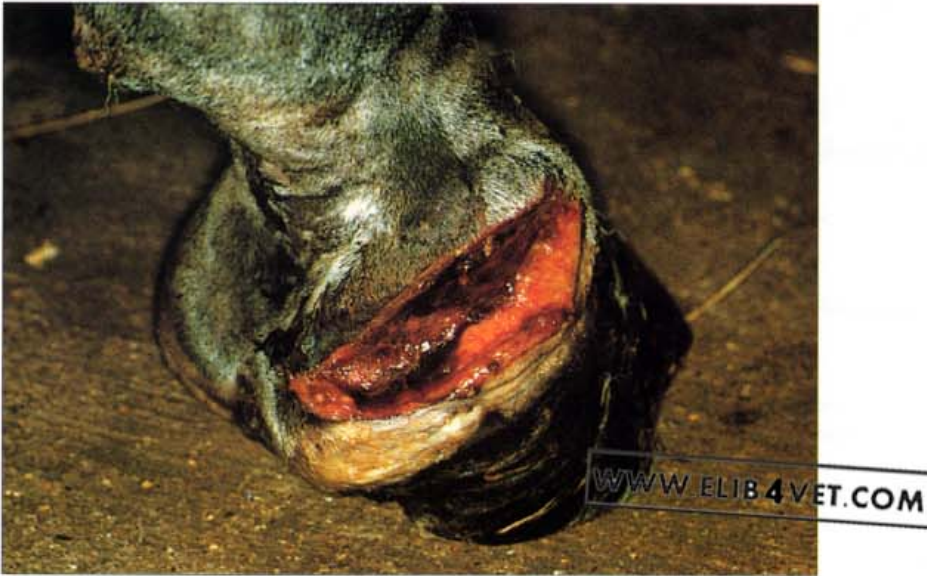Quittor

209. Quittor (A). Chronic infection and necrosis of the cartilage of the distal phalanx is known as quittor. The cartilage is prone to infection and necrosis because of its relatively poor blood supply. Severe interference injuries to the coronet and penetrating wounds to the cartilage, from above or below, can cause quittor. Characteristically there are discharging sinuses, at or proximal to, the hairline of the coronet, over the affected cartilage. The sinus tends to heal for a time and then break open again. Successful treatment requires the surgical excision of necrotic cartilage and care must be taken to avoid damage to the coronary groove. The horse in the photograph was intermittently lame and pus had discharged from the same two points on the coronet several times. There are defects parallel to the coronary band, below the currently discharging sinuses (arrowed), which indicates that the previous episodes of suppuration had occurred 5 months before. In this case of quittor there are two discharging sinus tracts just above the hairline of the coronet. There is a painful, generalised swelling over the region of the cartilage. Photo: I.M. Wright.



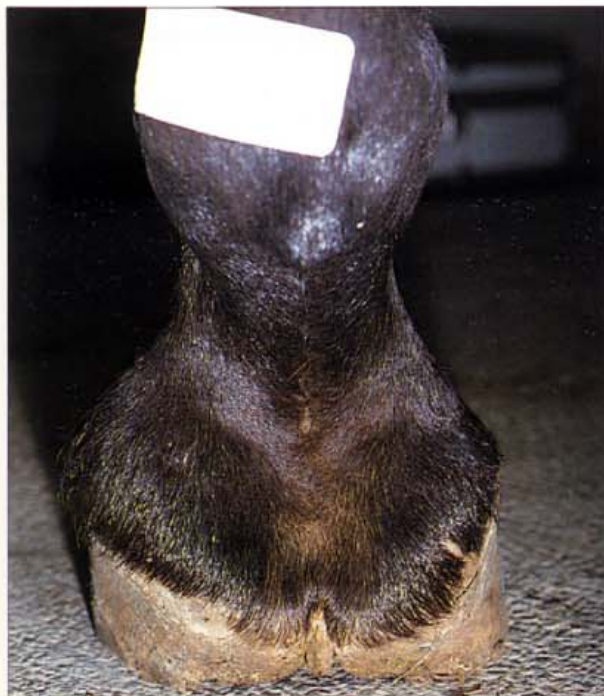210. Quittor (B). The differential diagnosis of quittor includes superficial coronary band abscesses and 'gravel' (puncture wounds to the white line). To properly diagnose quittor it is important to establish that the sinus tract does indeed emanate from the cartilage of the distal phalanx. In the radiograph, the probe has been inserted down the sinus tract and leads to the area of necrotic cartilage close to the proximal border of the distal phalanx. Photo: I.M. Wright.



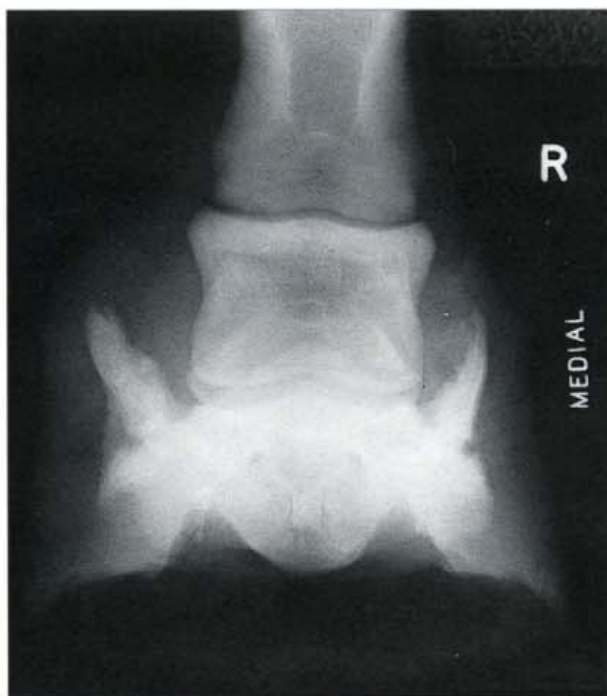


211. Quittor (C). The treatment of choice for quittor is surgical excision of the necrotic cartilage. An elliptical incision is made over the diseased cartilage, proximal to the coronet, and all necrotic tissue and cartilage is excised. Necrotic cartilage is recognised by its dark blue/red appearance. When the infection of the cartilage is deep and close to the proximal border of the distal phalanx it will be necessary to establish drainage to the outside by drilling a hole through the hoof wall. A gauze seton connects the hole to the incision and postoperatively the wound is left open under a dressing and periodically flushed with antiseptic for several days. The photo shows the postoperative appearance of the wound. If all the necrotic, infected cartilage can be successfully removed, the prognosis is generally good. Photo: I. M. Wright.

Sidebones

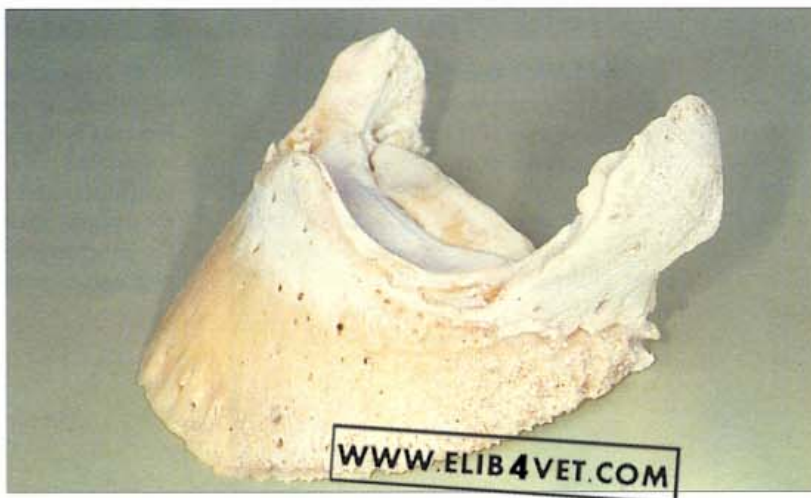

212. Sidebones (A). The foot of this hard-working Australian Stockhorse mare has hard, unyielding bulges over the medial and lateral coronets—a characteristic of the condition known as sidebones. The cartilages of the distal phalanx have ossified and the horse is lame because the medial sidebone has been fractured recently. The mare was put in foal and was able to return to work, free of lameness, when the fracture in the sidebone had re-ossified.



213. Sidebones (B). A radiograph (dorsopalmar projection) of the foot in A showing the extensive ossification of the paired cartilages of the distal phalanx. The medial sidebone is fractured.

214. Sidebones. The replacement of the cartilage with bone (ossification) usually starts along the border of the distal phalanx and is not palpable at this early stage. However, when the ossification becomes extensive the sidebones can be palpated above the coronary border. Generally, sidebones are not a cause of lameness unless trauma causes them to become fractured.



11

Trauma to Distal Interphalangeal Joint and Distal Phalanx

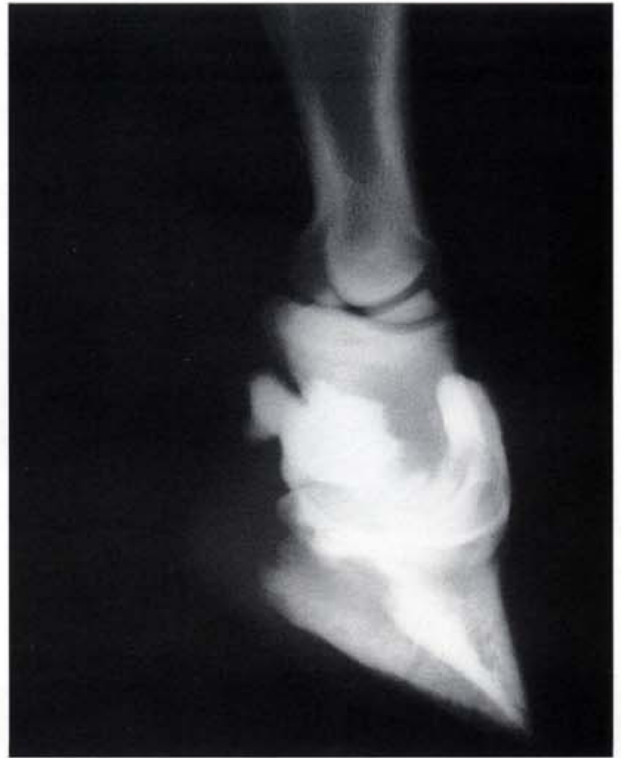

215. Penetrating wound to the distal interphalangeal joint (A). This Thoroughbred yearling was presented with extreme lameness in one forelimb which had been present and untreated for ten days. On the lame limb there was a discharging sinus 2 centimetres above the dorsal coronet and the dorsal hoof wall was separated from the underlying coronary dermis. The fluid discharging from the sinus was clear and yellow and resembled joint fluid. It was important to establish the source of the fluid because chronically infected puncture wounds to the distal interphalangeal joint carry a grave prognosis for racehorses.

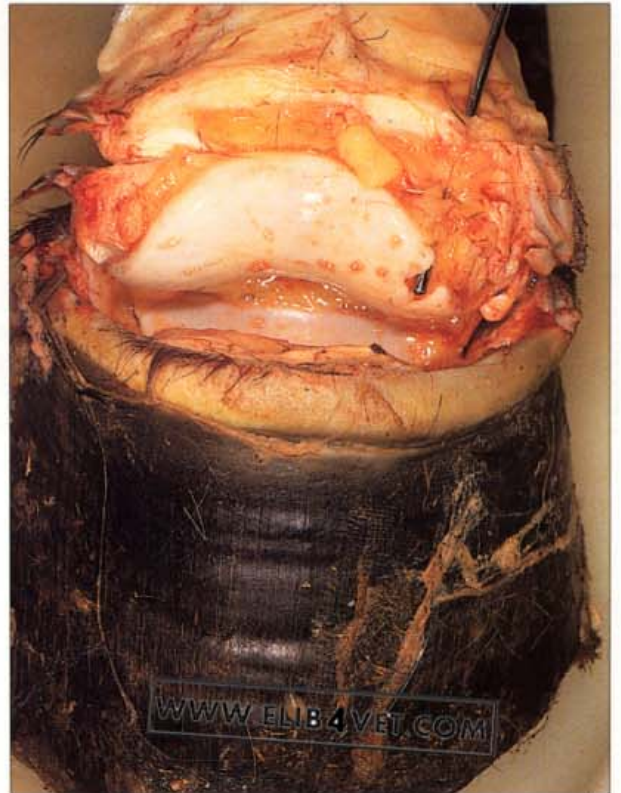

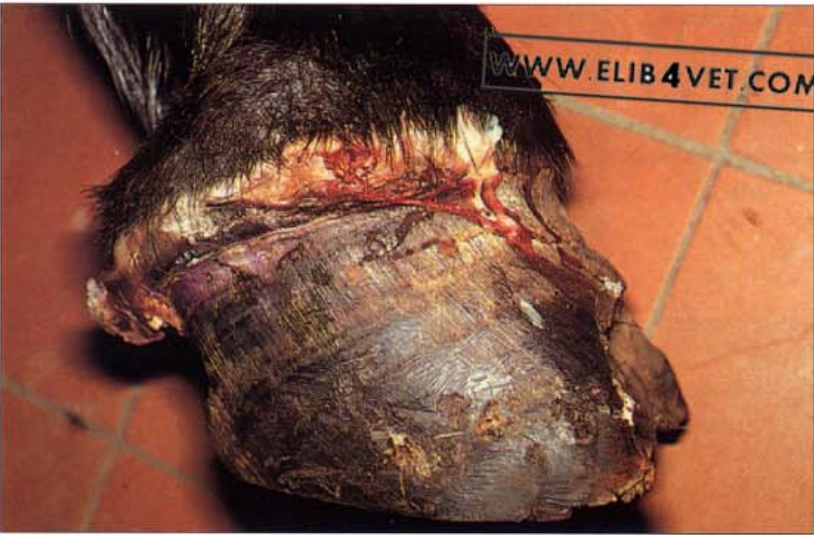216. Penetrating wound to the distal interphalangeal joint (B). Under general anaesthesia, a polythene cannula was inserted into the discharging sinus tract. As the cannula entered the tract it appeared to orientate towards the distal interphalangeal joint. Sterile contrast medium was injected through the cannula in an attempt to identify the extent of the penetrating wound. Oblique dorsopalmar and lateral radiographs were made.

217. Penetrating wound to the distal interphalangeal joint (C). The radiograph showed contrast medium outlining the entire distal interphalangeal joint, thus confirming that the wound had penetrated the joint capsule.

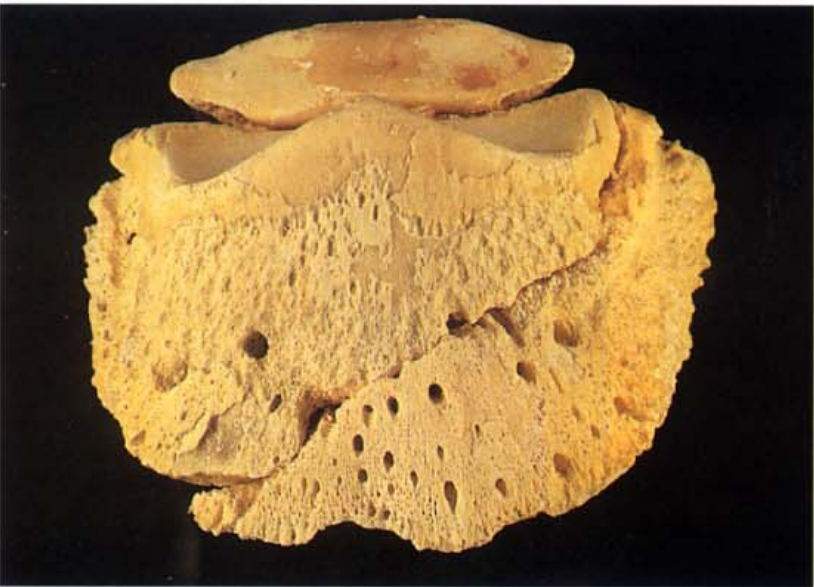


218. Penetrating wound to the distal interphalangeal joint (D). Because chronic infections of the distal interphalangeal joint are notoriously difficult to treat and the chances of the yearling returning to full athletic soundness were limited, the animal was humanely destroyed. This dorsal view of the distal interphalangeal joint at necropsy shows a blunt probe in the sinus tract. The tip of the probe shows where the penetrating foreign body had entered the joint. Apparently the yearling had a habit of pawing at the fencing of its paddock and had driven the sharp end of some wire, into the joint, in a proximodistal direction.





219. Fracture of the distal phalanx (A). The acute lameness in this valuable pony was initially diagnosed as acute, severe laminitis. The hoof was sloughing from the coronet and a lateral radiograph showed that the dorsal hoof wall was rotating from the distal phalanx. However the dorsoproximal–palmarodistal oblique view (D60Pr–PaDiO) showed that the distal phalanx was in fact fractured. Apparently the fracture had caused changes to the circulation of the foot which lead to sloughing of the hoof.



220. Fracture of the distal phalanx (B). After the pony was humanely destroyed the foot was macerated. There was a sagittal non-articular fracture of the distal phalanx.

12

Disorders and Diseases of the Hoof Wall

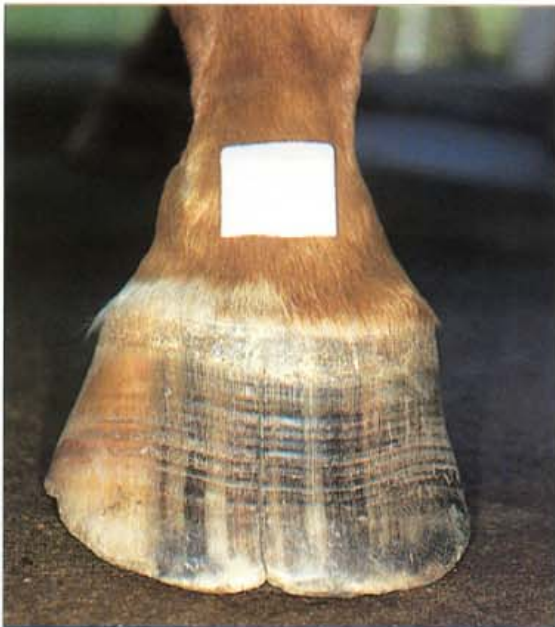Toe Cracks

221. The aetiology of toe cracks (A). This large, rapidly growing Thoroughbred filly developed dorsal hoof wall cracks in both front feet. The bloodline of this horse contained many horses with similar foot problems, suggesting that poor hoof quality and conformation are inherited. The heels were running under and the toe was long and flared. The toe crack was deepest and most severe, 3–4 cm below the coronet and in fact the distal one-third of the toe was virtually unaffected. The central fault line, which develops into a crack, appears to develop from a folding inwards of the proximal and central hoof wall. This principle is illustrated in the photographs A and B. In A, the foot is non-weight bearing and a space separates the two halves of the foot.



222. The aetiology of toe cracks (B). When the foot is weight-bearing, one-half of the foot overlaps the other and causes pain and chronic inflammation at the site of the crack. The overlap is greatest in the proximal half of the foot. While this independent movement of each half of the foot is allowed to occur, there is little chance that the toe crack will heal. Equilox was used to reconstruct and stabilise the two halves of the foot.

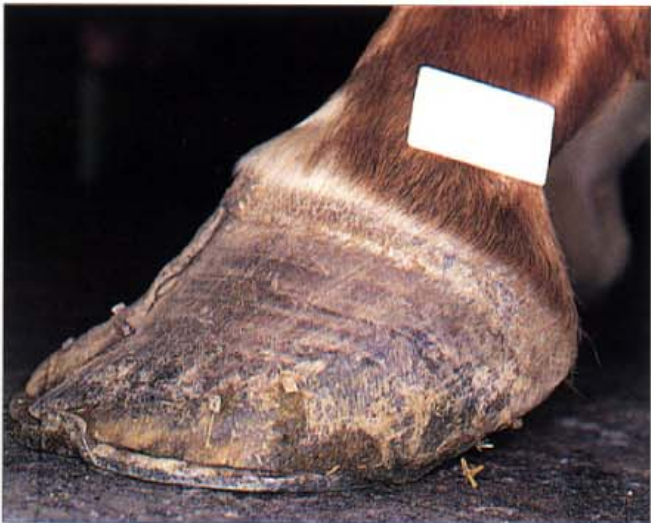



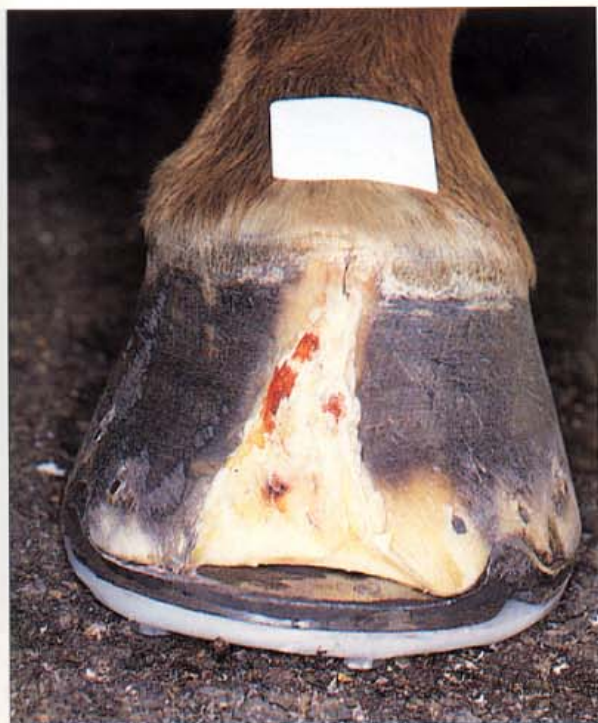223. The aetiology of toe cracks (C). Eight months later the crack and the Equilox have grown out and the mare is sound without shoes. A residual defect remains in the dorsal hoof wall because the original lesion has left scar tissue in the coronary band.



224. Toe crack case history (A). This heavily muscled Quarterhorse stallion had deep cracks in the dorsal hoof walls extending from the hairline to the ground surface of both front feet. In the foot illustrated, the medial and lateral sides of the hoof are moving independantly of one another, causing chronic, painful inflammation to the dermal tissues beneath the crack and preventing any hope of healing. The coronet, above the crack, is chronically inflamed and in danger of losing its ability to generate normal hoof wall. A futile attempt has been made to stabilise the crack with a sideclipped shoe and sutures made of horseshoe nails. However, the fault causing this toecrack lies with the style of horseshoeing which is shown in B.



225. Toe crack case history (B). The lateral view of the foot with the toe crack shown in A. The toe is too long and has become flared close to the ground surface. The long flared toe has caused the proximal hoof wall to fold inwards and develop a central fault line, manifest as the toecrack. The heels are underrun and are growing forward at an acute angle. The shoe is at least a size to small for the foot.



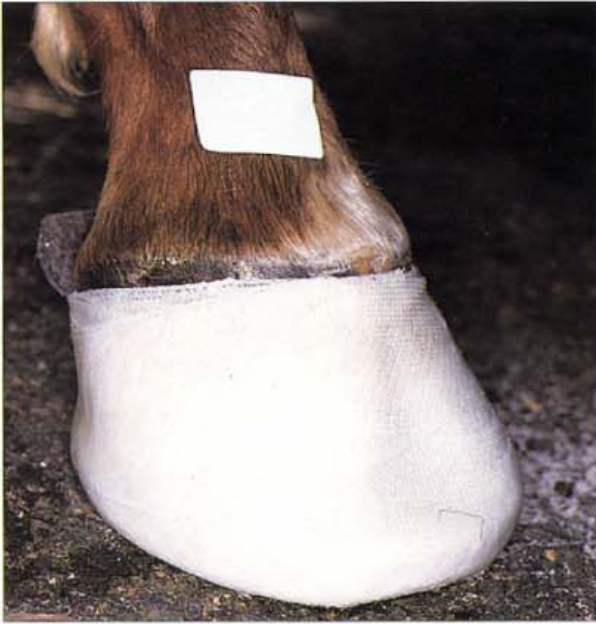226. Toe crack case history (C). The crack in the dorsal hoof wall was entirely resected using half-round nippers, a motorised rotating burr and a loop knife. A wide zone of necrotic and degenerate epidermal material was removed as close to the dermis as possible. Sideclips were drawn on a shoe to support the medial and lateral halves of the foot. A hospital plate has been fitted to the shoe.



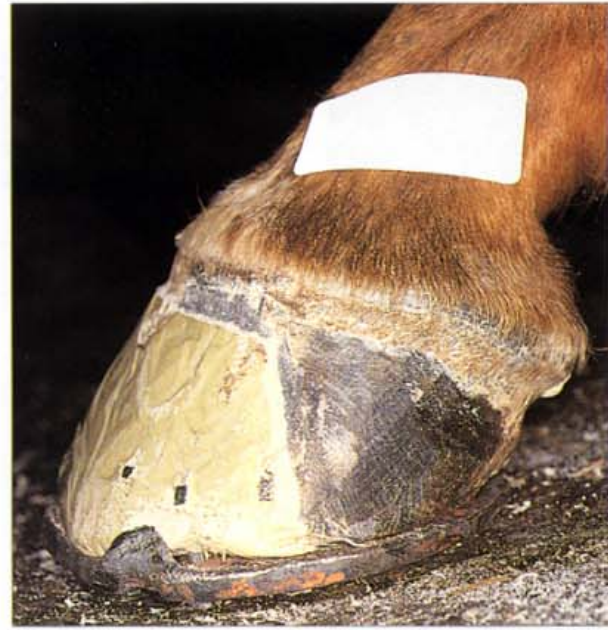227. Toe crack case history (D). Because a large portion of the toe had been removed, thus weakening the hoof distal phalangeal bond, a heart-bar shoe was fitted to the foot to provide additional support. Note the four drilled and tapped holes in the shoe; two at the toe and two at the heels.

228. Toe crack case history (E). The space between the resected toe and the shoe was in danger of becoming filled with dirt, stones and other contaminating material. If this occurred, pressure could develop which could damage the solar corium and the solar margin of the distal phalanx. In addition the distal phalanx was close to the surface because of the resection and was in need of protection. To protect the sole of the foot a dense, plastic hospital plate was bolted to the shoe via the holes previously drilled and tapped (and mentioned in D).

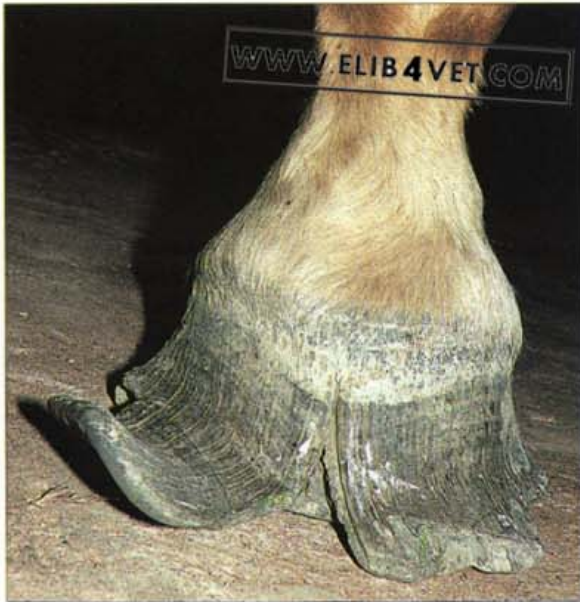



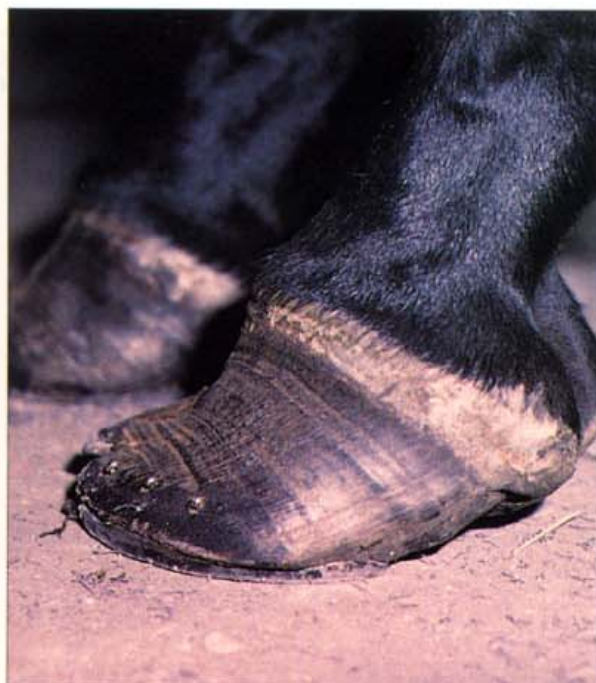229. Toe crack case history (F). For the coronary groove to replace the crack with intact hoof wall, it is essential to stabilise the medial and lateral halves of the foot. This is usually achieved by making a full-rim steel shoe, a time-consuming process requiring considerable skill. A useful, new method is to simply encase the foot and the shoe in a cast made with 3M hoof casting tape. The resin impregnated tape is activated by immersion in water and wrapped around the foot. Within a few minutes the tape sets hard and effectively immobilises the entire hoof. Note the felt padding at the heels. This is essential to prevent the tape from causing pressure necrosis at the bulbs of the heels.



230. Toe crack case history (G). Six weeks later removal of the cast revealed that the hoof was healing well. The coronet appeared normal and was generating a band of new hoof wall, thus replacing the deficit. The resected area of toe was no longer inflamed and cracked and was covered with a thin layer of keratinised epidermis. The owner of the Quarterhorse was eager to commence competition so the toe was reconstructed with Equilox. A lateral view of the Equilox reconstructed toe shows the new, more functional shape of the foot. Compare this view with B. The dorsal hoof wall is now the correct length and shape (not flared) and the heels are growing at an angle parallel to the toe. The shoe is the correct size and is set full at the heels to provide good heel support.



231. Chronic toecrack - unshod horse. Even in what would normally be considered ideal conditions for unshod horses (dry stony ground, abrasive surfaces), some horses may develop severe lameness from central toe cracks. A large group of barefoot stock-horses running in outback Australia all had excellent feet except this one. For some reason the hoof walls were flared and torn away from the sole and the toe had developed a deep, painful crack. The existing hoof wall was of good quality so perhaps a conformation fault or previous neglect had initiated the deformity. Once the flared walls had grown overlong it became impossible for the ground surface to chip and break away the hoof, as would happen normally. Photo: K. Swan.

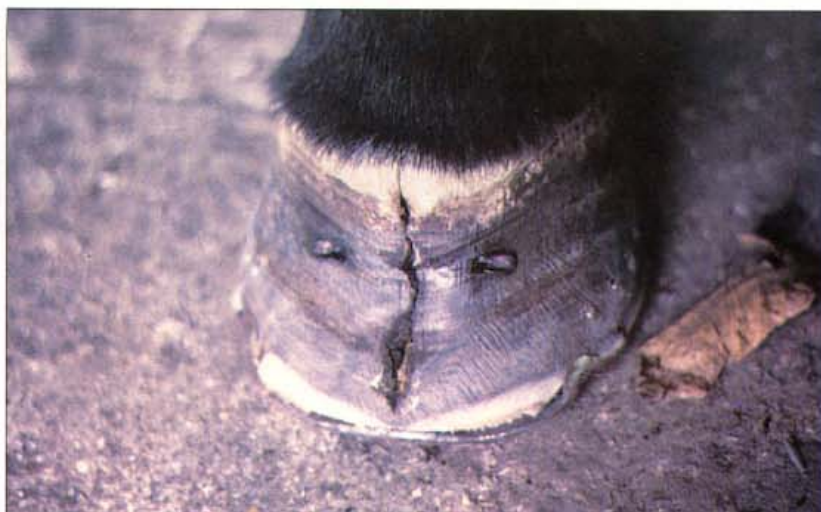

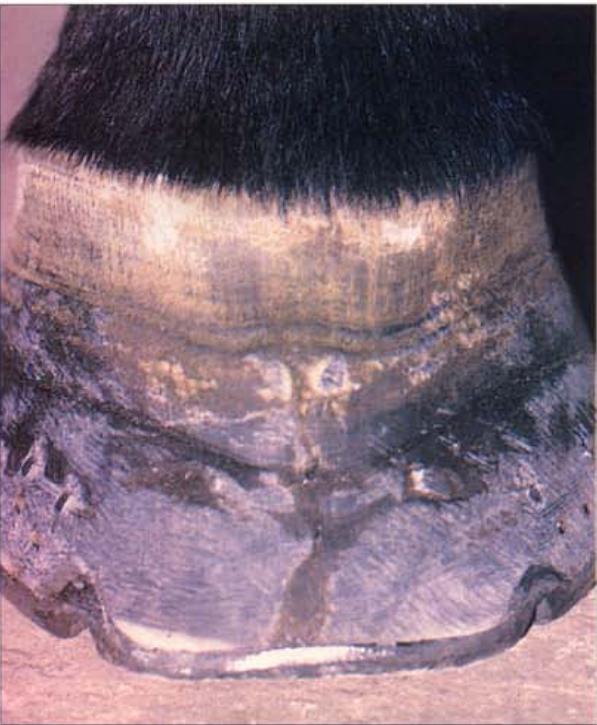232. Toe crack repair (A). A similar case to 221 and 225 showing the pathological effect of placing shoes forward of grossly underrun heels and shoeing to extremely flared and distorted hoof walls. The mechanical effect of this is to cause the dorsal hoof wall to fold inwards and develop the central fault line shown in B. Photo: C. Colles.



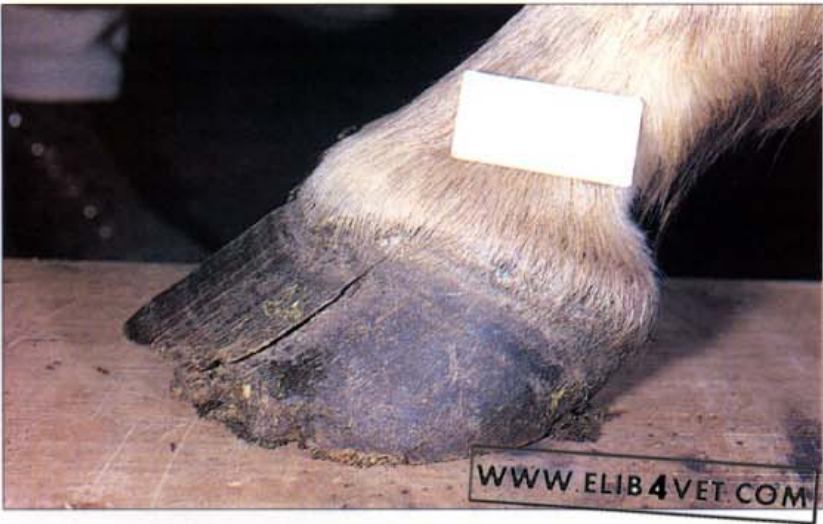233. Toe crack repair (B). The central toe crack extends from the ground surface and into the coronet and is causing severe lameness. It is tempting to blame the toe clip of the shoe for weakening the wall and causing the crack. However, a close examination of these cases usually reveals that the distal hoof wall is the least affected. The most destructive part of the crack is in the proximal third of the hoof wall which is in keeping with the proposed aetiology. Photo: C. Colles.

234. Toe crack repair (C). Attention to the correct principles of farriery in conjunction with stabilisation of the medial and lateral halves of the foot is beginning to effect a cure. The toe has been rasped back and flared hoof wall has been removed. The extent to which the toe has been rasped back is indicated by the presence of non-pigmented inner hoof wall, visible just above the shoe. The toe of the shoe has been rolled (ski-tipped) to minimise stress on the dorsal hoof wall and the shoe has side-clips to prevent movement on either side of the crack. For extra stability the crack has been stapled with a horseshoe nail. Photo: C. Colles.





235. Toe crack repair (D). A few months later and the crack, along with the metal staple, is growing out. The coronet appears not to have been permanently damaged as the new hoof wall appears to be near perfect. Photo: C. Colles.



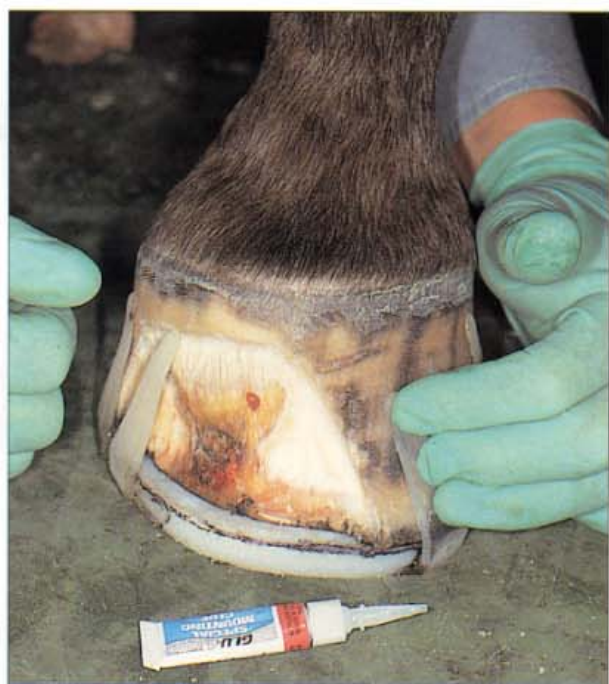236. Dorsal hoof wall avulsion. For an unknown reason the coronary groove of the dorsal hoof wall was growing two separate toes. The upper hoof wall was a crescent-shaped shell and the hoof wall below it was apparently normal. There was no history of coronary band trauma, but it is assumed that the toe of the hoof suffered some sort of impact injury which split the wall on either side of the toe, rather like a dorsal 'quarter-crack'. The avulsed portion has been growing separately ever since. Hoof growth returned to normal after the extra toe was surgically stripped from the coronary corium.

Toe Infections

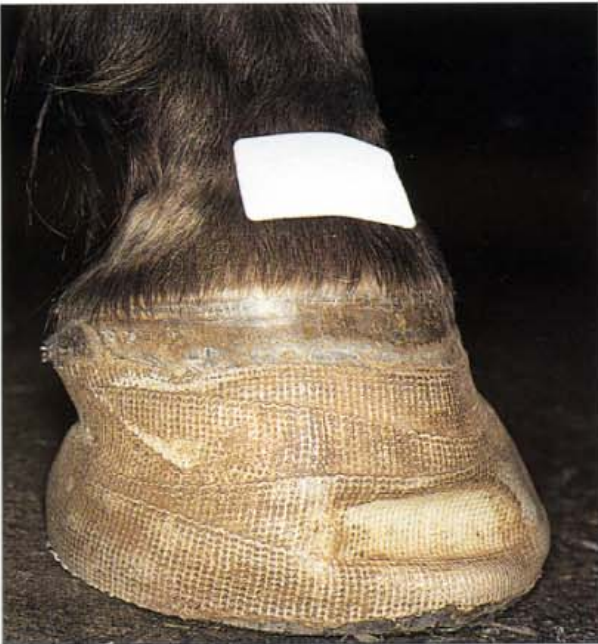237. Toe infection. An active infection at the toe /sole junction frequently causes pus to discharge from the hair line of the coronet at a site directly above the original infection. In the photograph the telltale horizontal crack in the coronet shows where the infection erupted, after tracking up the hoof wall lamellae from the toe. Secreted under the hoof wall or sole, in an environment where they flourish, these infections cause intense lameness and remain refractory to treatment unless thoroughly opened up and debrided. All traces of diseased tissue were removed and the weakened hoof wall was supported by a hand-forged shoe with side-clips on either side of the defect. A hospital plate was fitted to the shoe to protect the wound and prevent contamination. The defect in the coronet grew down as a small horizontal crack in the hoof wall.



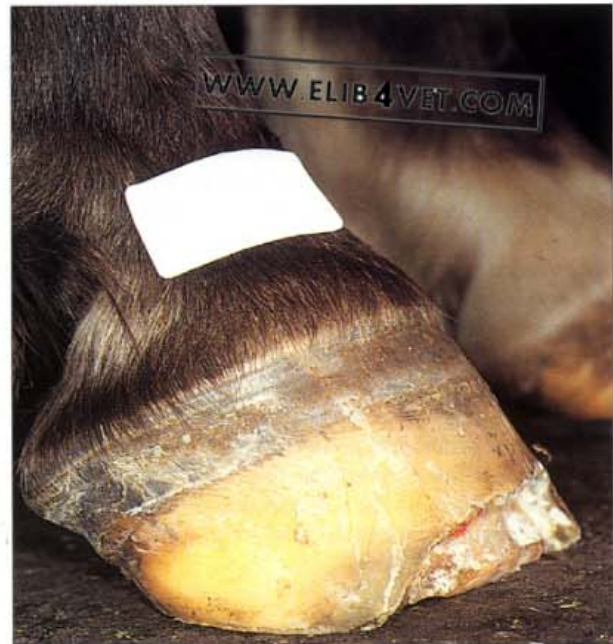
238. Severe chronic toe infection (A). Toe infections sometimes go unnoticed or ignored for long periods of time and when eventually presented for therapy require radical, time-consuming treatment. The horse pictured had been treated previously for an extensive infection under the toe necessitating resection of the overlying wall. A large keratinising wedge had formed under the injured wall and because the unsupported sole was bearing weight at the toe the horse remained lame. Hoof wall growth was distorted and the foot was unbalanced. The treatment plan was to further resect the wall until the wedge was removed and support the foot until a new more functional wall grew. There was little chance that normal wall growth and foot balance could be restored if the large lamellar wedge was left in place.



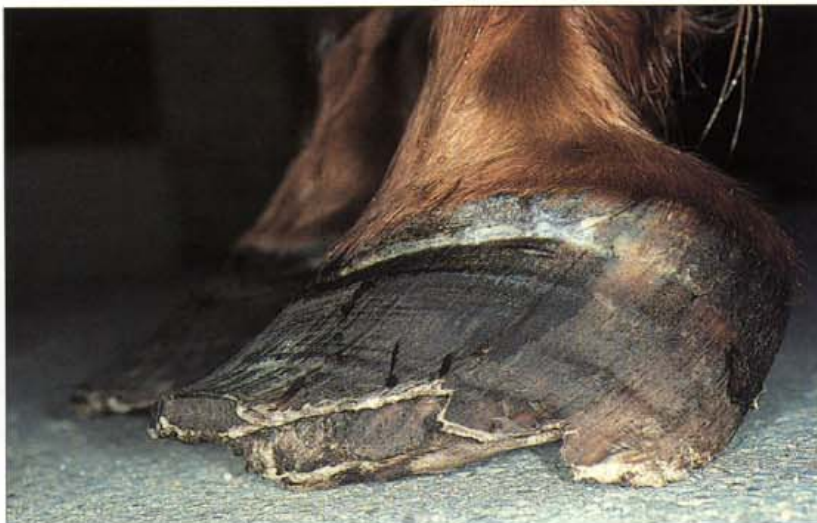239. Severe chronic toe infection (B). The horse was sedated and all diseased tissue and the bulk of the wedge was removed with a loop knife and a motorised rotating burr. Too little wall remained for a shoe to be nailed on so a glue-on, plastic, heart-bar shoe was fashioned and glued to the remaining intact hoof wall. The inner edge of the plastic shoe, under the lesion where the wall was missing, was relieved with the burr to minimise sole pressure.



240. Severe chronic toe infection (C). The entire hoof capsule and the large wall deficit was wrapped with an epoxy resin tape (3M hoof repair tape) to keep the shoe on and to protect the resected area. The resin tape set hard and bridged the gap between the resected wall and the shoe, thus acting as a substitute wall. At 4-weekly intervals the plastic shoe was reset and taped until sufficient wall had grown for a steel heart-bar shoe to be nailed on.

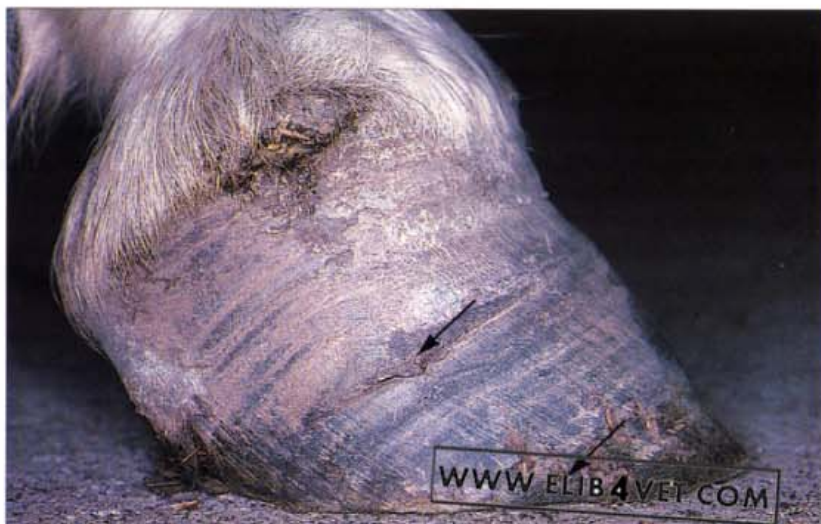

241. Severe chronic toe infection (D). After 3 months' treatment the foot had regained a balanced shape and the horse was no longer lame. Eventually the wall grew to reach the ground surface and could be shod with a normal shoe.



242. Severe chronic wall separation. The equine hoof is designed to bear weight on the distal hoof wall and not on the sole. If the sole does become weight bearing, the circulation to the sole corium is compromised and bruising, necrosis and abscessation of the epidermal sole and damage to the tip of the third phalanx may result. Horses bearing weight on the sole, like the one pictured, are described as having a 'dropped sole' and are invariably lame. The cause of the hoof wall deformity of the horse in the picture was not known. There was no history of laminitis or founder; the hoof wall separation may be an example of severe wall separation or seedy toe.

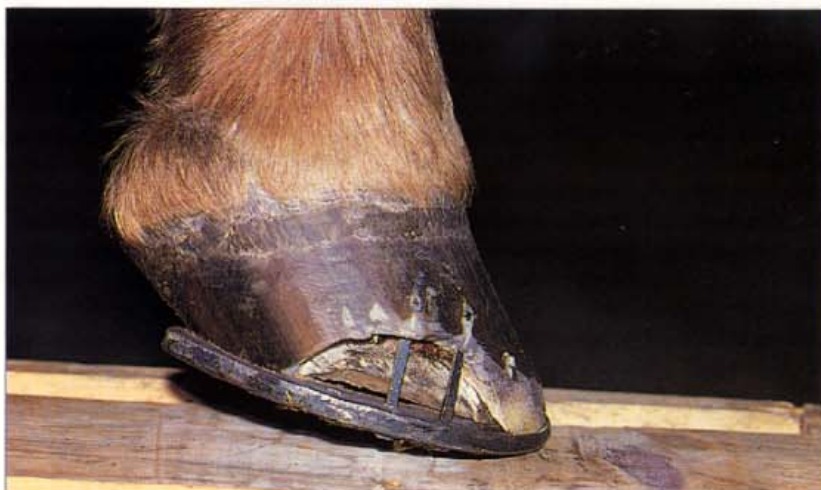243. White line disease discharging at the coronet. If the sole wall junction has been separated for a long time the resultant chronic infection may track up the lamellae of the inner hoof wall and discharge as an abscess in the coronet. This has happened to the pony in the photograph at least three times. The arrows show where coronary abscessation has affected hoof wall growth on two occasions prior to the current episode. The pony's response to hoof tester pressure was used to locate a purulent infection, under the hoof wall, distal to the coronary abscess.

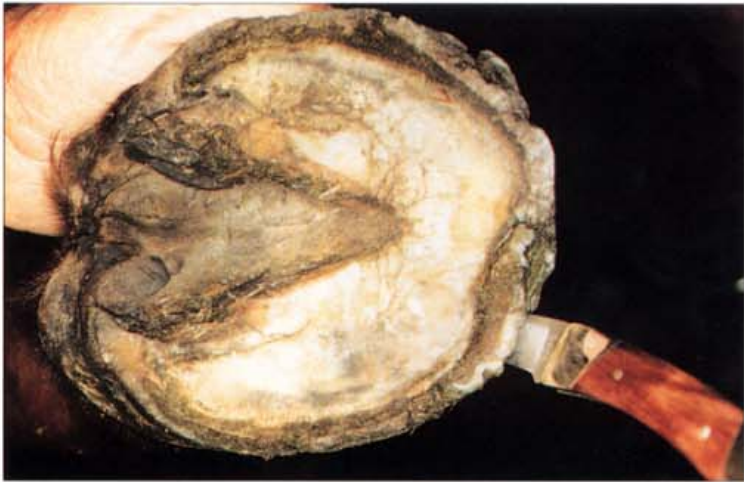

244. White line disease; barefoot pony (A). The zone of epidermis between the sole and the inner hoof wall (white zone or white line) is relatively soft and prone to penetration by foreign matter. The pony in the photograph was kept in swampy conditions and when ridden, went barefoot along dirt roads. Veterinary attention was sought when it became lame in both forefeet. The medial and lateral sole wall junction was packed with black, infected material shown by the arrows in the photograph.

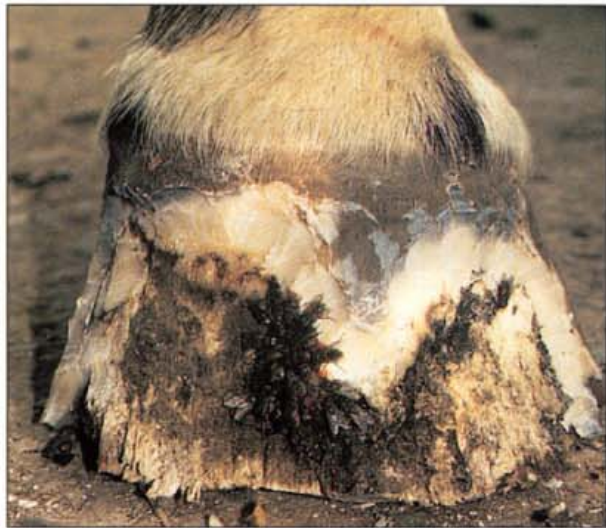

245. White line disease; barefoot pony (B). A probe was inserted at the diseased sole wall junction and this showed there was a cavity under the wall extending proximally for 3–4 cm. The wall over the cavity was resected and all of the black, smelly material was removed. Only the medial and lateral walls were affected, the toes were spared, and sufficient hoof wall remained for the pony to be shod. The lameness disappeared and the pony was shifted to a dry environment where it made an uncomplicated recovery. The hoof wall grew out without further treatment other than regular resetting of the shoes.





246. White line disease; gravel (A). The blade of the pocket knife has disappeared up the hollow, separated hoof wall of the toe of this horse.



247. White line disease; gravel (B). The separated hoof wall has been removed and the photograph shows the extent to which white line disease has destroyed the inner hoof wall. Surprisingly, despite the presence of a large cavity beneath the hoof wall at the toe, horses with white line disease show little lameness. The infection appears to confine its activity to the inner layers of the stratum medium, sparing the innermost layer, the stratum lamellatum. The position of the distal phalanx within the hoof capsule does not change and the horses do not founder. Photo: K. Swan.



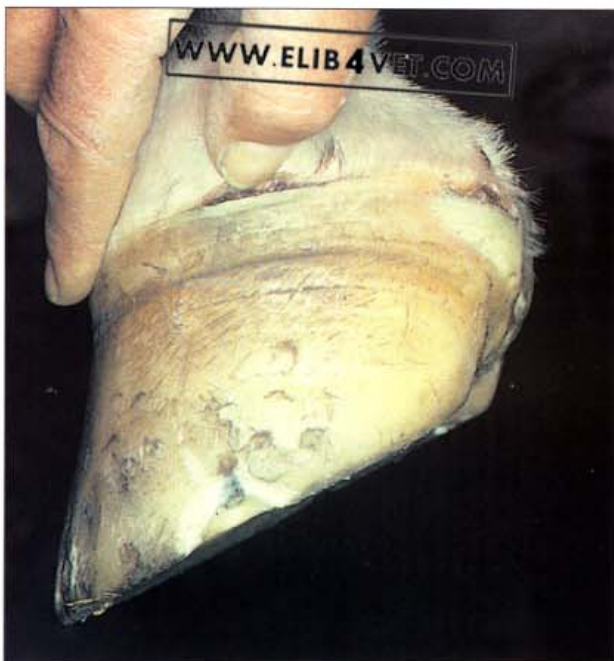248. White line disease; gravel (C). The keratinolytic micro-organisms that cause white line disease appear to be anaerobic. Resecting the hoof wall and exposing the infection to air is all that is required to effect a cure. The horse was shod with a heart-bar shoe and within a few months the hoof wall had recovered its normal size and shape. Diets containing biotin, methionine and zinc encourage the formation of good-quality horn and promote recovery from white line disease. Photo: K. Swan.

WWW.ELIB4VET.COM

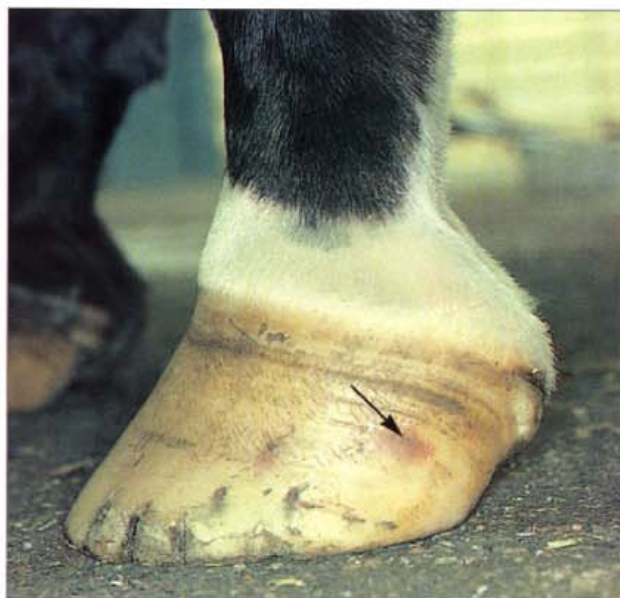13

Disorders and Diseases of the Coronet

249. Coronary band bruising (A). When horses compete in vigorous contact sports, the coronets may be accidentally injured by being trodden on by their own feet or by the feet of other horses. The injuries are worse if shod horses are involved. This case shows two coronet injuries, one at the quarter under the photographer's thumb and another slightly older one at the heel. Focal injuries like these cause temporary cessation of hoof growth at the site of the trauma. When the lesion heals, normal hoof growth will be restored above the lesion and the defect will grow out as a small horizontal gap in the hoof wall. Bellboots protect the coronets from lesions such as these.

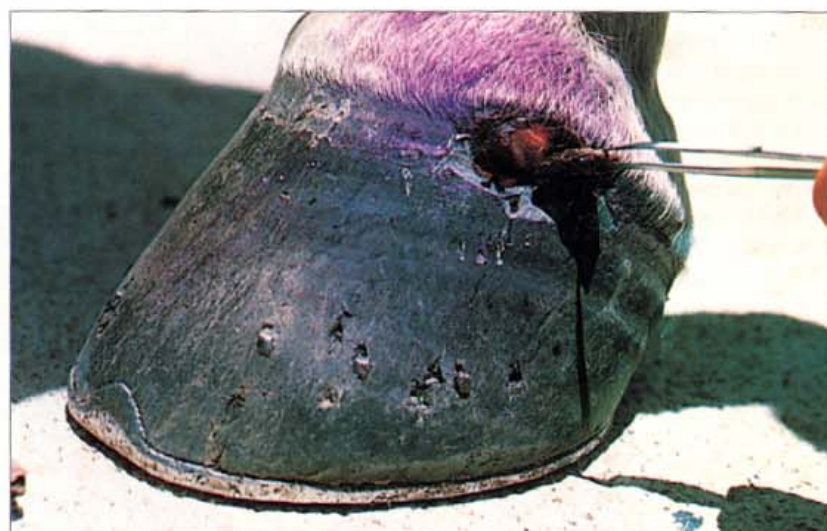

250. Coronary band bruising (B). This non-pigmented hoof of a Standardbred racehorse has suffered coronary band trauma at various times. A minor coronet bruise to the quarter occurred 3 months previously and has grown out as a bright red patch of haemoglobin staining, now half way down the hoof wall (arrowed). More recently the horse has overreached from behind and has scalped the lateral heel.



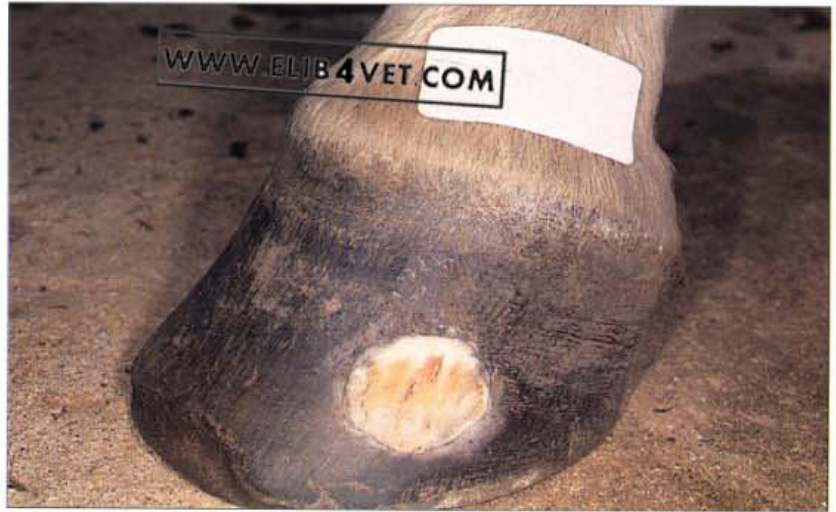

251. Coronary band injury growing out. Five months before the photograph was taken, this Australian stock horse was at work mustering cattle in heavily timbered country. At some stage during the muster a stake of wood pierced the coronet and was driven down, beneath the hoof wall, before breaking off. The stake was promptly removed with a pair of pliers and the horse was only lame for a few days. Despite the apparent severity of the wound the coronet, above the defect, has made a complete recovery and is generating normal hoof wall. The integrity of the horn tubules below the defect is compromised and the hoof wall is beginning to crack.

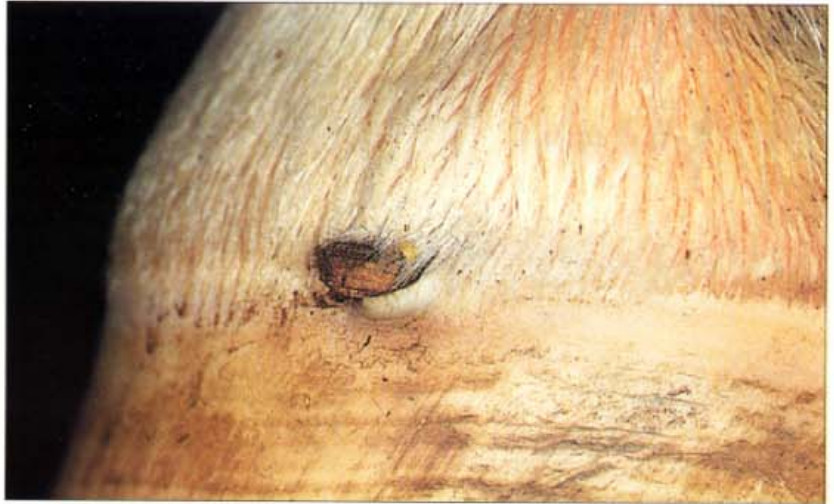

252. Coronary band stake wound (A). During training through wooded country this endurance horse brushed a tree stump and a splinter of wood was driven deep into the coronet of the quarter. The horse did not become lame until after the training ride was completed when the rider removed a piece of wood from the now obvious wound. Unfortunately, some of the wood (a large piece as it turned out) remained lodged deep in the coronary groove and the horse remained lame despite antibiotic therapy and rest. Two weeks after the initial injury the palmar nerve on the side of the injury was infiltrated with local anaesthetic. The corrupt hoof, around the now discharging sinus, was pared away to expose the wooden stake. The photograph shows it being removed from the wound in the coronet with forceps.

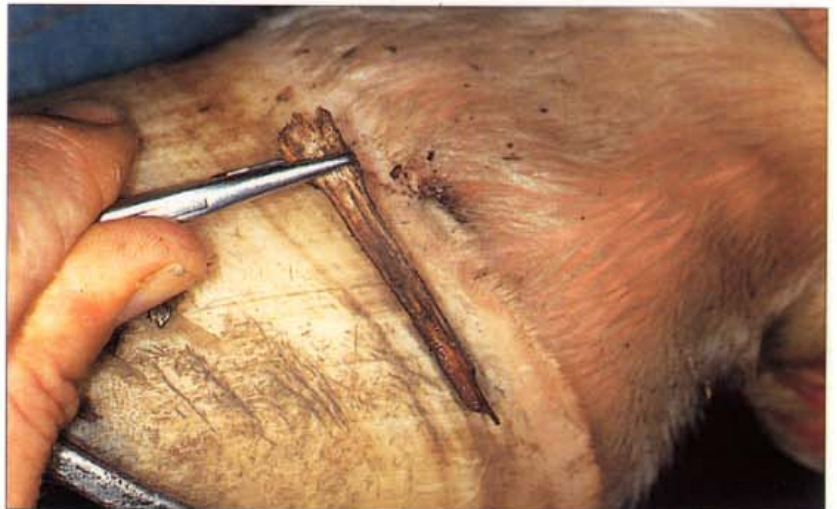
253. Coronary band stake wound (B). The same foot 4 months later; the trauma and infection of the chronic stake wound to the coronet has left a large defect in the hoof wall. The defect is large because of the sepsis and necrosis that developed while the foreign body remained undetected, deep in the tissues of the coronet. Prompt removal of penetrating foreign bodies and effective treatment of the wound is vital if damage to the sensitive papillae of the coronet is to be avoided.

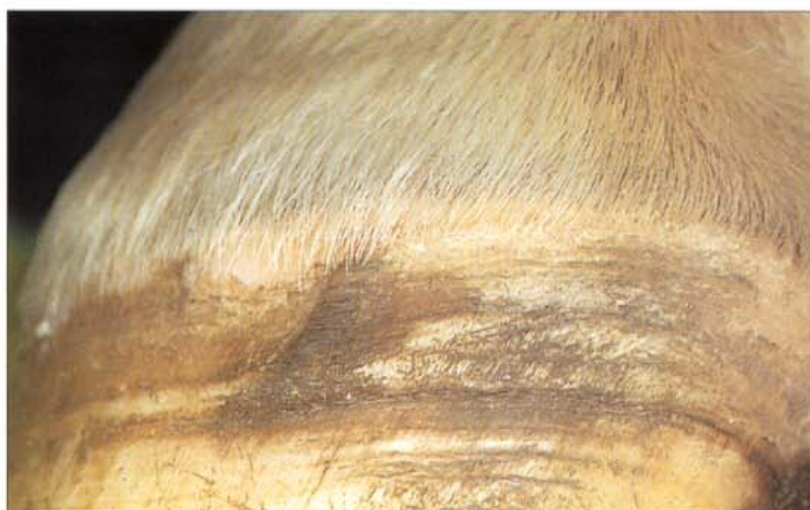

254. Coronary band stake wound (C). A similar stake wound has occurred to this pony club horse during a tail ride in the forest. A piece of wood is visible at the hair line of the coronet; the length of the stake cannot be ascertained at this stage. The horse was quite lame and veterinary attention was sought later the same day.

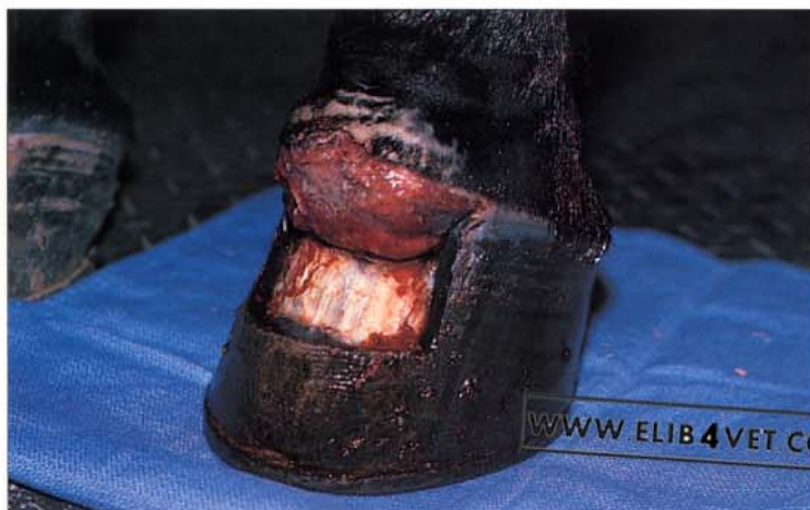

255. Coronary band stake wound (D). The palmar nerve (abaxial sesamoid site) on the side of the wound was infiltrated with local anaesthetic and the stump of the stake was grasped with needle holders. Considerable force was required to extricate the stake which was notable for its length. After-treatment consisted of a topical dressing, tetanus prophylaxis and a 3-day course of procaine penicillin, injected intramuscularly twice a day for 3 days. The lameness disappeared within 2 days. Photo: Sandra Pollitt.

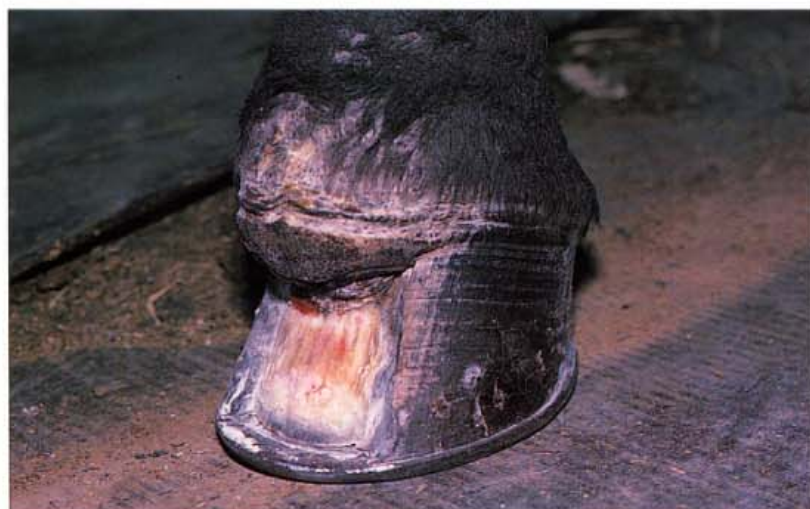



256. Coronary band stake wound (E). Several months later only a small defect is present in the hoof. Prompt, complete, removal of the stake and prevention of infection has produced a far better outcome than the neglected case shown in 252 and 253.



257. Coronary band laceration (A). Lacerations and trauma to the coronary band severely disturb normal hoof growth. This Quarterhorse mare lacerated the dorsal coronet on some exposed sheet metal which also entered the capsule of the distal interphalangeal joint causing septic arthritis. In this photograph of the injury several weeks after it occurred the proximal dorsal hoof wall has been resected to relieve pressure on the granulating coronary band wound. Photo: Jan Young.



258. Coronary band laceration (B). A few months later the damaged coronary band has recovered sufficiently to produce the beginnings of a new hoof wall. The foot is shod with a heart-bar shoe and the dorsal hoof wall beneath the lesion has been resected to encourage parallel alignment of the dorsal hoof wall (when it grows down) with the dorsal surface of the distal phalanx. Photo: Jan Young.

259. Coronary band laceration (C). The same horse 7 months after the initial injury and growth of the dorsal hoof wall is progressing well. Eventually the dorsal hoof wall grew to the ground surface. Regular shoeing with a heart-bar shoe enabled the horse to lead a comfortable life as a broodmare. As a result of the trauma and the joint infection, the distal interphalangeal joint became ankylosed. Photo: Jan Young.

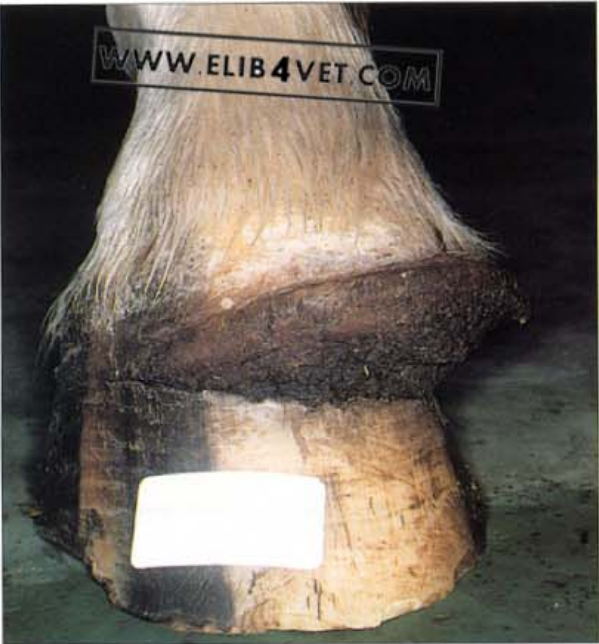

260. Coronary band trauma (A). This horse jammed its foot in the piping of an automatic watering trough and while attempting to free itself deeply lacerated the coronet. Injuries such as this severely disturb future hoof growth. Photo: B. Duvernay.

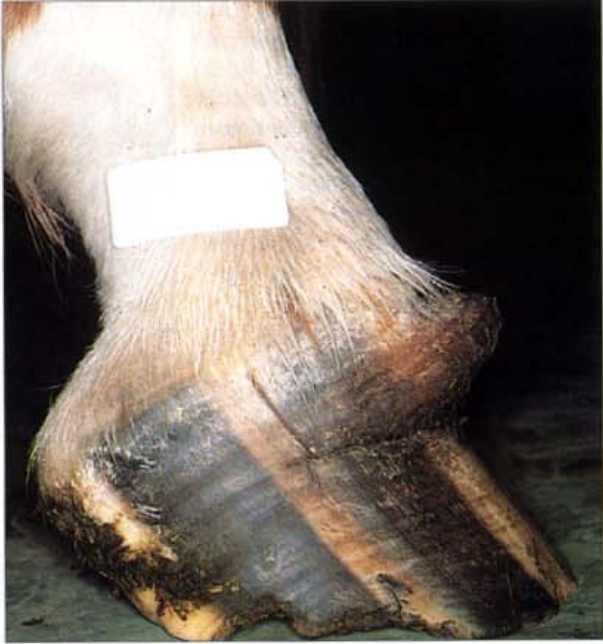

261. Coronary band trauma (B). One month later; the tubules of the proximal hoof wall are growing in a most abnormal direction forming a step-like projection similar to the horse in 262. Photo: B. Duvernay.

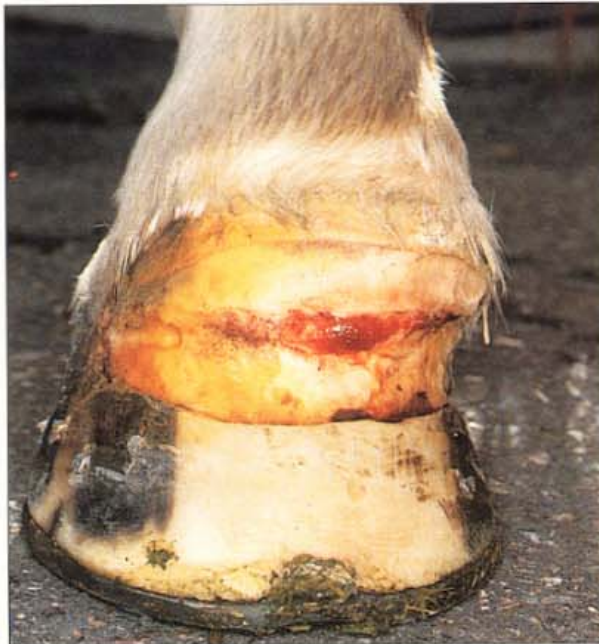



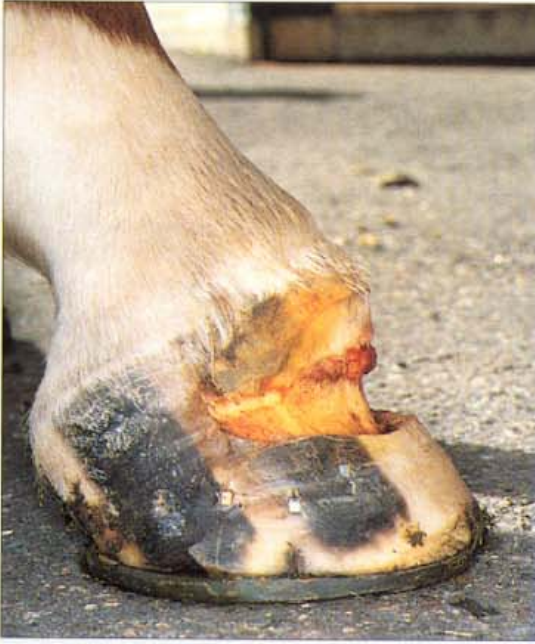262. Hoof growth defect after coronary band trauma (A). Deep laceration of the coronet has caused a severe disturbance to hoof growth. Instead of the hoof wall tubules being oriented in the normal proximal–distal direction, they are, in this case, oriented in an abnormal horizontal direction. The lesion has caused the formation of a step-like ledge of hoof just below the coronet.



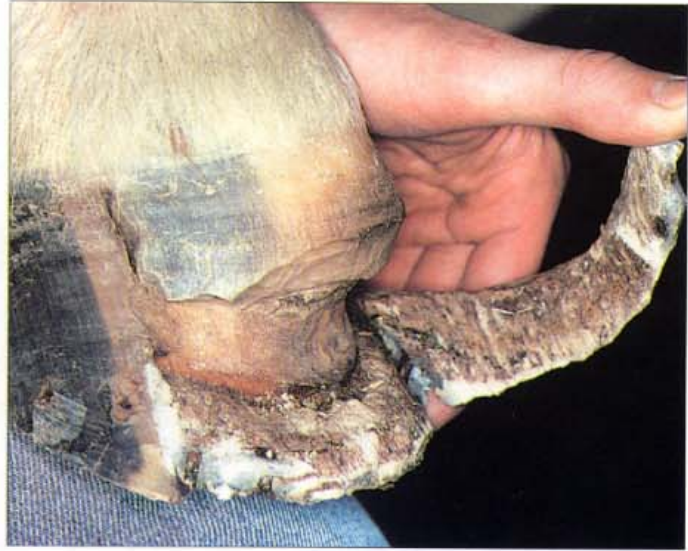263. Hoof growth defect after coronary band trauma (B). Side view of the abnormal horizontal hoof growth. The hoof defect was like a step and was solid enough to bear the weight of a man without causing discomfort to the horse.



264. Hoof growth defect after coronary band trauma (C). The bulk of the abnormal horizontal hoof growth was resected away as close to the underlying dermis as possible. The foot was shod with a heart-bar shoe for support. The long-term treatment plan was to encourage the damaged coronet to grow hoof wall in a more normal direction.

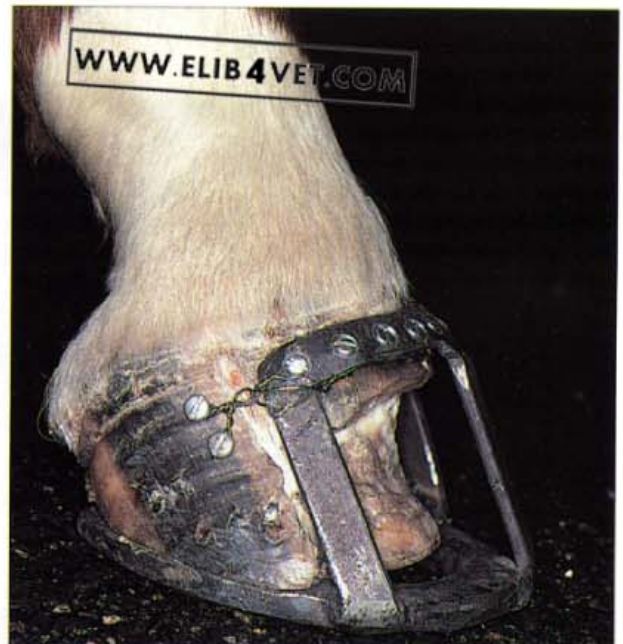


265. Hoof growth defect after coronary band trauma (D). Side view of the foot with the abnormal hoof growth resected. Compare with 263.



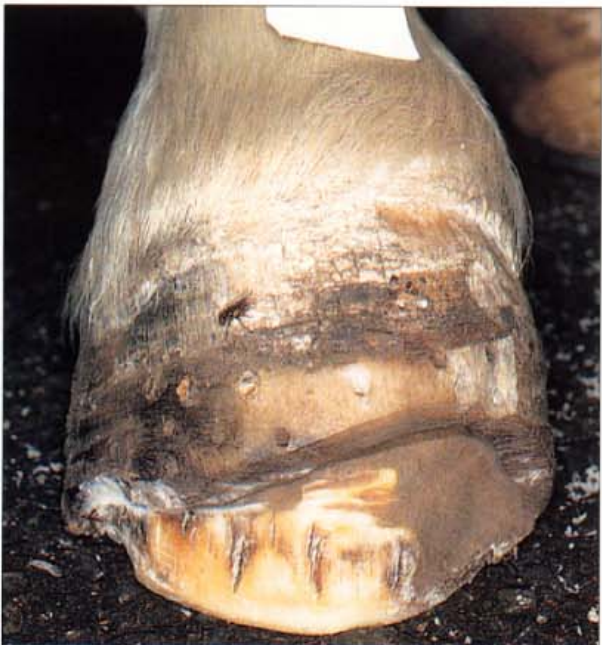266. Hoof growth defect after coronary band trauma (E). Six weeks after the resection, hoof growth from the coronet was relatively normal. However, despite the support from the heart-bar shoe, the remaining toe was collapsing in a proximal direction and was no longer available as a support base for the foot. The remaining toe was resected.

267. Hoof growth defect after coronary band trauma (F). It was essential to protect the exposed toe from ground contact and the potential damage of weight bearing. Fortunately there was now sufficient good-quality hoof wall beneath the coronet onto which a steel bracket could be screwed. Steel supports were welded to the coronet bracket to form a bridge between the coronet and the heart-bar shoe and this effectively kept the toe clear of the ground. To stabilise a quarter-crack that had developed between the lesion and the heel, two extra screws were placed in the quarter and wired to the steel bracket.

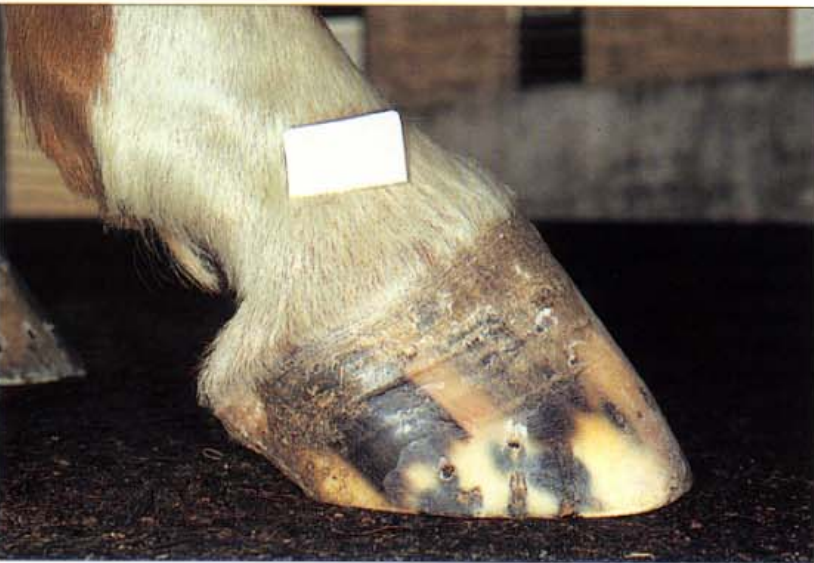



268. Hoof growth defect after coronary band trauma (G). For extra strength and support, the hoof reconstruction compound SUPA was placed between the edge of the proximal hoof wall, the steel coronet bracket and the shoe. The horse found this arrangement satisfactory and was able to move about with only slight lameness.




269. Hoof growth defect after coronary band trauma (H). Seven months after the treatment had begun, the coronet was generating hoof wall of a satisfactory quality and the distal tip of the third phalanx had escaped damage. The steel bracket was removed and the foot was shod with a standard heart-bar shoe.



270. Hoof growth defect after coronary band trauma (I). Almost 1 year later, the injured coronet was generating hoof wall that was near-normal in quality and appearance. However, radiographs showed that the distal phalanx was not parallel with the dorsal hoof wall and that a lamellar epidermal wedge was present. The lamellar wedge remained prone to seedy toe infections and the foot needed constant care and attention. The horse was intermittently lame and had to be shod with a heart-bar shoe.

271. Coronet concussion injury (A). When endurance horses are ridden fast over hard ground, they frequently develop a break in hoof growth (arrowed) at the coronet. The cause of this is not clear and although competing endurance horses encounter considerable stress, classic laminitis appears not to be involved. Affected horses are not lame at the trot, although initially they may be sensitive to palpation of the dorsal coronet. Some endurance horses compete successfully with 2–3 such bands in the dorsal hoof wall. Perhaps repetitive concussion during the endurance ride bruises the dorsal coronet. If oedema develops, this, coupled with the transient severe dehydration of exertion in hot weather, may cause a localised temporary failure of the coronary circulation and, hence, a break in hoof growth.

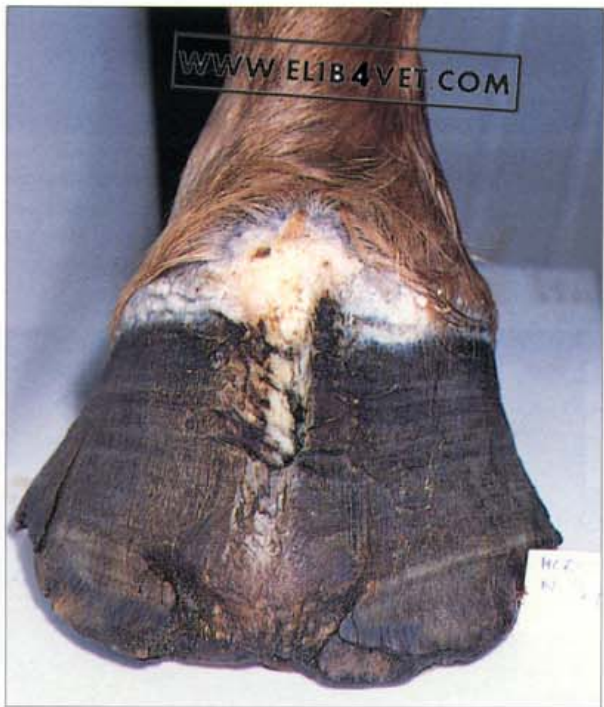

272. Coronet concussion injury (B). The same foot photographed 5 months later. The ring in the hoof wall has been pushed 55mm from the hair line because of continual growth of hoof wall from the coronary groove. The toe distal to the ring is developing a central crack because the hoof has been structurally weakened.

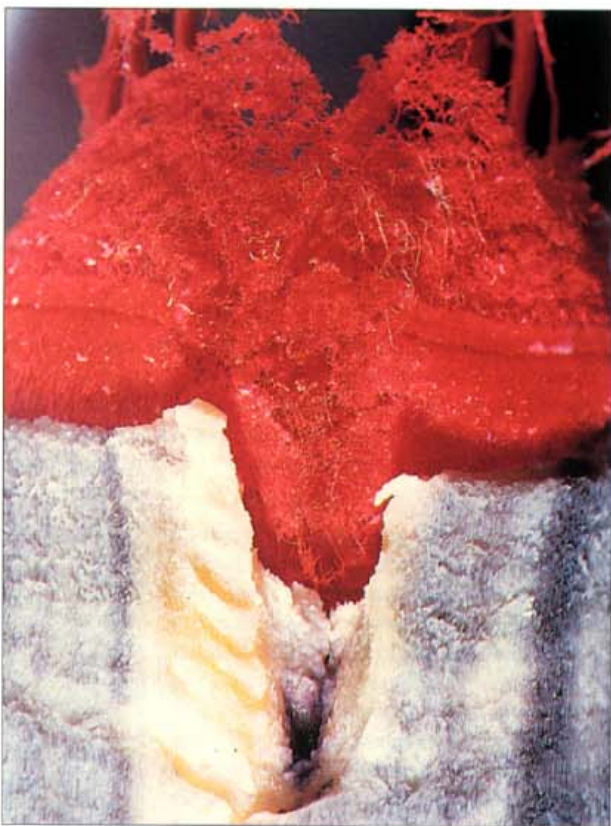




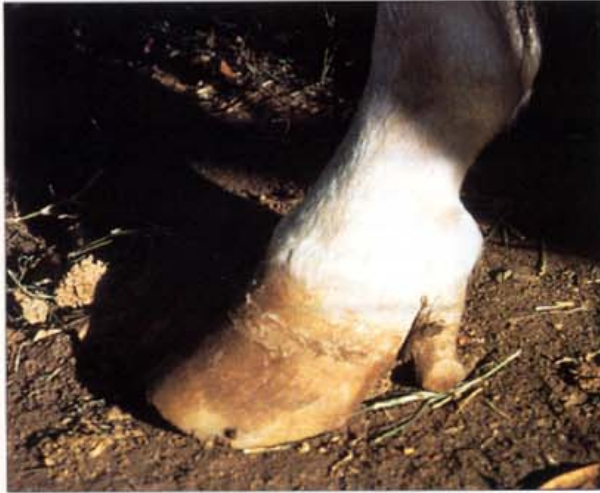273. Selenium toxicity and coronary band changes. Ingestion of excessive amounts of selenium causes hoof damage and loss of hair from the mane and tail. Fragile, non-functional hoof and hair is produced because selenium replaces sulphur in the sulphur-containing amino acids of the structural protein keratin. Affected horses are lame and develop deep rings in the hoof wall from heel to toe. Severe cases may slough the entire hoof. The horse pictured was poisoned over a short period of time when excess selenium was accidentally added to the diet. The photograph was taken 8 weeks after the poisoning and shows a single deep ring around the entire circumference of the hoof wall. Horses ingesting selenium-accumulating plants, such as *Astragalus bisulcatus*, *Morinda reticulata* and *Stanleya pinnata*, will develop similar hoof wall lesions and lameness. Photo: J. Walmsley.



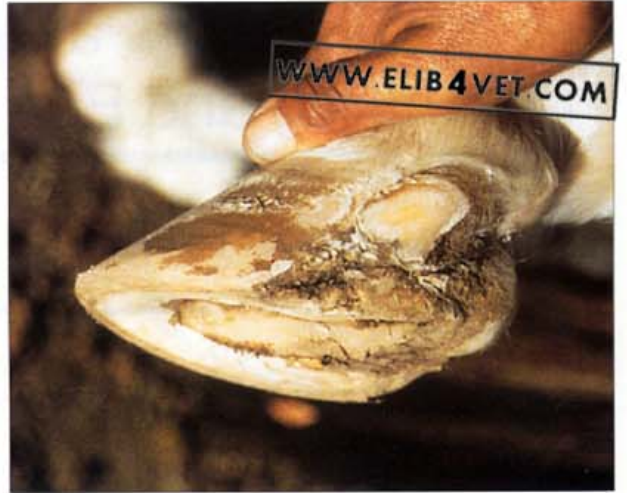274. Chronic coronary band trauma (A). If the architecture of the coronet is severely traumatised and the papillae of the coronary band are replaced with scar tissue, a permanent wall defect will result. The injury illustrated occurred when a wooden stake pierced the dorsal coronet of a stock horse and broke off. The splinter remained undetected, embedded deep beneath the hoof for several weeks. The infection and the intense foreign body reaction destroyed a portion of the coronary band which was replaced with a cicatrix of scar tissue. The horse was chronically lame and the hoof was left with a permanent wall crack.



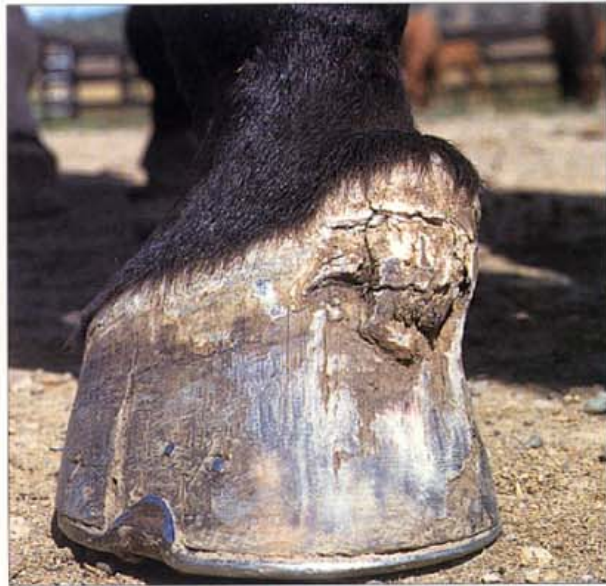275. Chronic coronary band trauma (B). The horse was destroyed and an acrylic plastic vascular cast of the foot was made. The dermal area above the crack was devoid of recognisable papillae, in sharp contrast to the ordered brush border of normal papillae on either side of the crack. The tangled, disorganised appearance of the scar explained why the crack persisted and no normal hoof wall could grow.



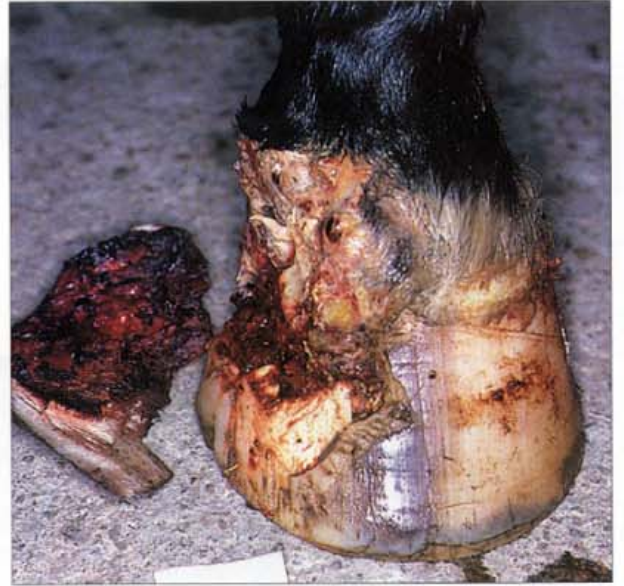276. Chronic heel coronet injury (A). The heel and coronet of this Peruvian horse were accidentally slashed with a machete. When the lesion resolved the heel grew in a deformed fashion and produced a separate claw-like heel. With every step the horse was lame because the claw pressed on an ulcerated crack between the heel and the quarter. Photo: B. Duvernay.



277. Chronic heel coronet injury (B). Resection of the claw and trimming of the hoof resolved the lameness. Photo: B. Duvernay.



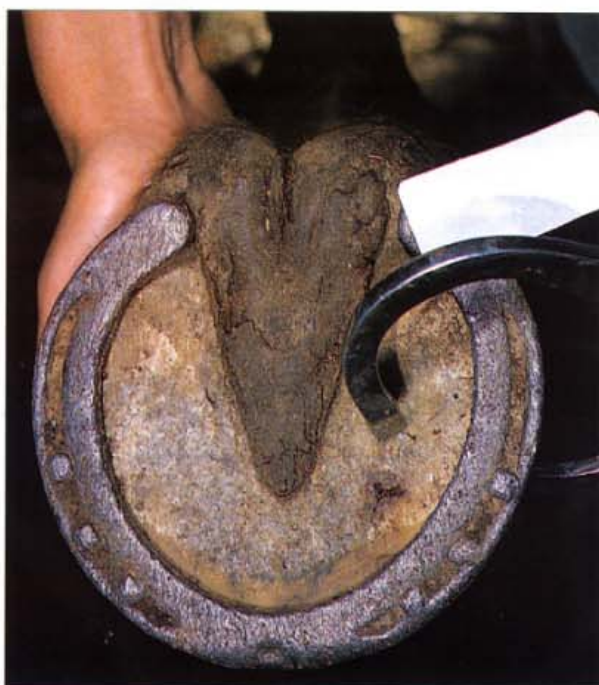278. Deformed coronary band. Severe trauma to the coronary band may result in chronic scarring and permanent disorganisation of the hoof wall papillae. In many cases, during the healing process, the papillae are replaced by scar tissue and the coronary groove is never able to generate normal hoof wall. Horses with deformed coronary bands are often lame, but can be salvaged for breeding purposes if the hoof is kept trimmed and well shod.



279. Hoof wall avulsion. Barbed wire can cause devastating injuries to horses' feet, particularly to those individuals that habitually paw at a fence while waiting to be fed. This gelding pawed at a fence and got the wire caught under the cartilage of the distal phalanx. Pulling back along several metres of fence caused the wire to act like a chain saw until most of one side of the foot was amputated. Despite intensive treatment for several days, the horse was humanely destroyed when it became apparent that the distal interphalangeal joint was septic.

14 Disorders and Diseases of the Sole, Frog and Bar

Sole Injuries

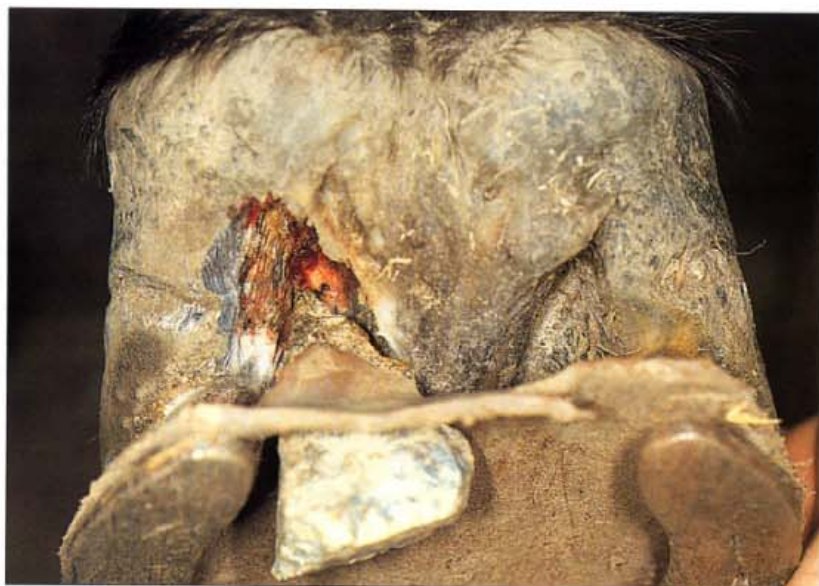

280. Severe stone bruise. Competing in an endurance ride over stony country the sole of this horse was perforated by a sharp stone. The puncture was located using the hoof testers and when pressure was applied blood squirted from the site. The spot of blood is visible in the picture. The horse was treated immediately with antibiotics, anti-inflammatories and tetanus prophylaxis but remained lame for several weeks. The sole can be protected from this sort of injury by shoeing with a plastic pad placed between the sole and the shoe.

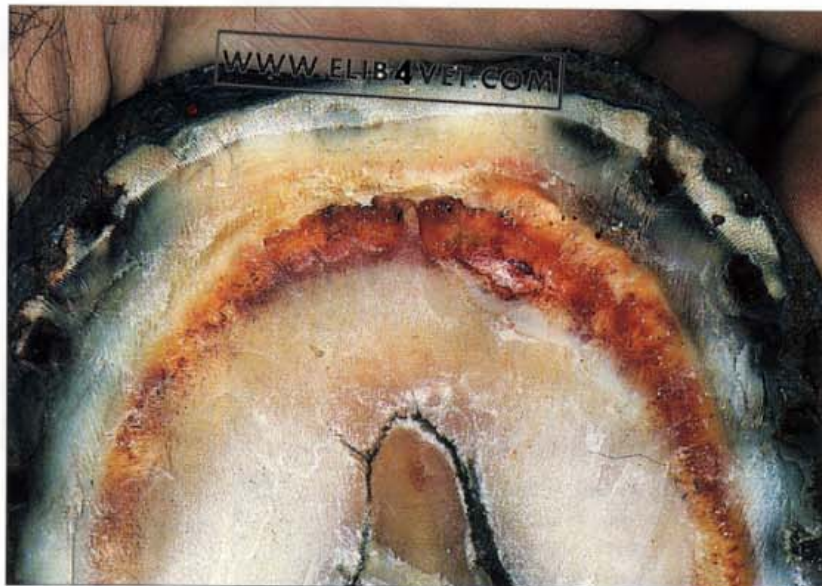

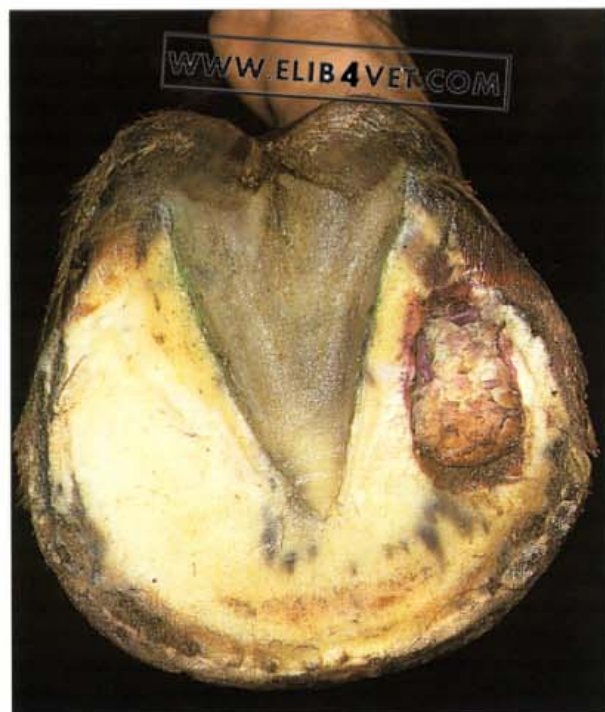281. Puncture wound to the bar (A). Tough plastic pads, placed between the sole and the shoe are used to protect the sole from stone bruises and to act as a shock-absorbing cushion. The quality of the plastic varies and the photograph shows a relatively soft pad which failed to prevent a sharp, pyramid-shaped stone from damaging the foot of an endurance horse.

282. Puncture wound to the bar (B). The sharp tip of the stone pierced the pad and lodged in the collateral groove of the frog. The horse continued to be ridden and by the time it was noticeably lame the stone had been driven deep into the groove and had perforated the bar. The degree of bruising was severe and 10 days later the entire bar, buttress and heel was underlain with infection and was therefore resected. It was 8 weeks before the horse was ridden again.

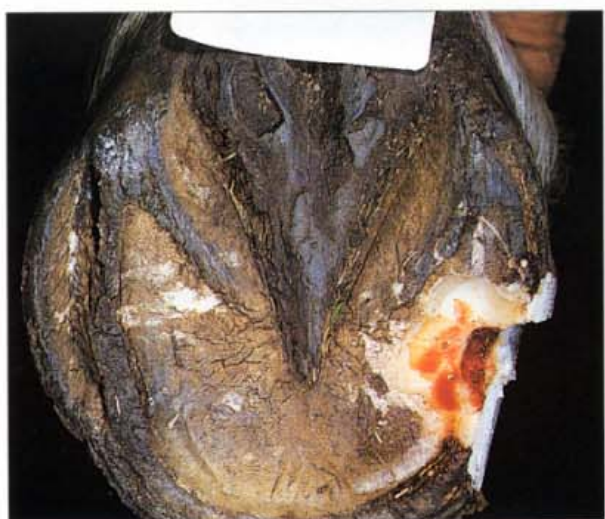

283. Sole pressure. The foot of this endurance horse was shod with wide-web shoes and plastic pads which put excessive pressure on the sole of the foot and caused severe lameness. The dark red bloodstained zone shows where the solar corium was crushed between the solar margin of the distal phalanx and the unyielding pad and shoe. The photograph was taken about a month after the incident when the sole was pared away to reveal the evidence of severe bruising.

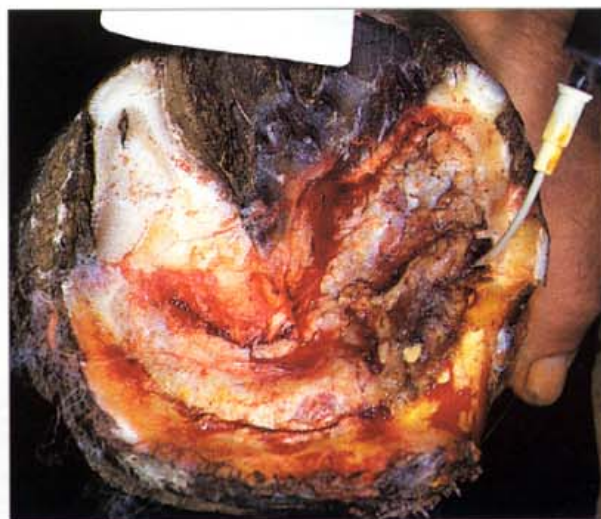



284. Puncture wound to the sole. This horse was standing on a slab of concrete pavement while it was being shod. It stepped on a bent horse nail and somehow the nail became lodged in a crack in the concrete, point uppermost and, in a freak accident, was driven deep into the sole of the hoof. The nail was promptly removed, but despite the usual therapy with antibiotics and tetanus antitoxin, the horse became increasingly lame over the following days. Suspecting a subsolar abscess the attending veterinarian pared away a circular portion of the sole, 10mm in diameter, to encourage drainage. The severity of the lameness increased as a large spherical mass of granulation tissue (proud flesh) protruded through the hole in the sole. The photograph showing the granulation tissue was taken 16 days after the initial injury. Radiographs taken then and a month later showed a large circular (22mm diameter) radiolucent zone over the site of the puncture wound. Apparently the nail had perforated not only the sole and the solar corium but also the palmar surface of the distal phalanx. The radiolucent zone corresponded to an area of bone loss due to osteomyelitis. The granulation tissue responded to surgical excision and a pressure dressing under a hospital plate (see 228) and the infection causing the osteomyelitis responded to a 10-day course of gentamycin and penicillin injections. The horse returned to soundness, but the radiolucent area in the distal phalanx was still present 2 years later.

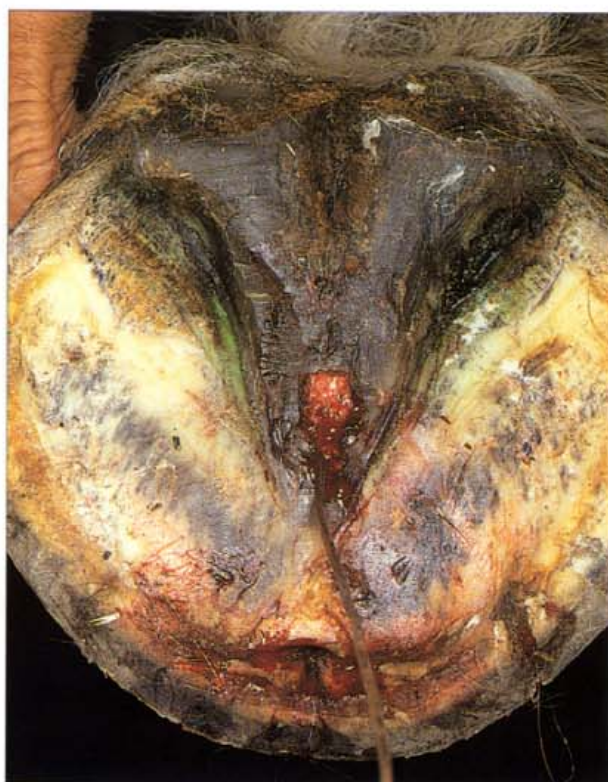

285. Penetrating wound to the sole (A). This unshod pony broodmare was extremely lame and the entire medial sole of the left forefoot was very sensitive to hoof tester pressure. Pus was discharging from a sinus in the medial coronet. Paring the medial sole with a sharp hoof knife revealed a small black hole which, on further exploration with the knife, led to the explosive release of a large volume of blood-tinged pus. Apparently, a penetrating wound to the sole, which had subsequently sealed over, introduced the infection. The sole was underrun and the infection had tracked up the lamellae to discharge at the sinus in the coronet. The extent of the damage was revealed when the underrun sole was resected.

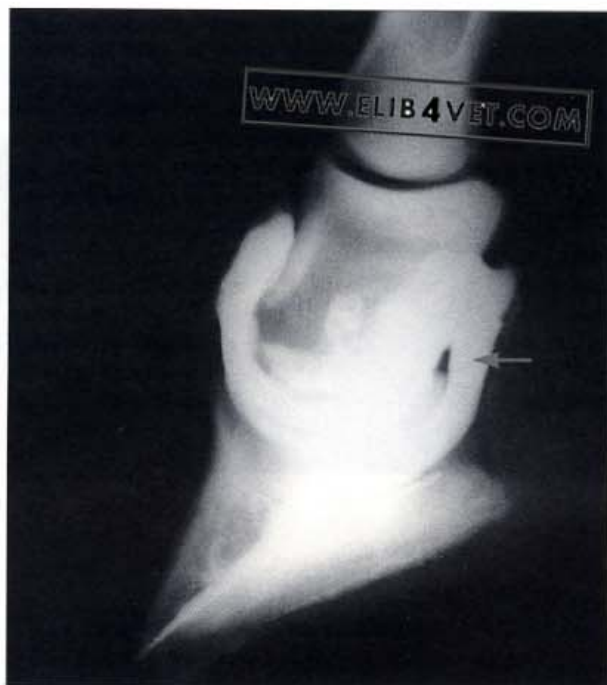


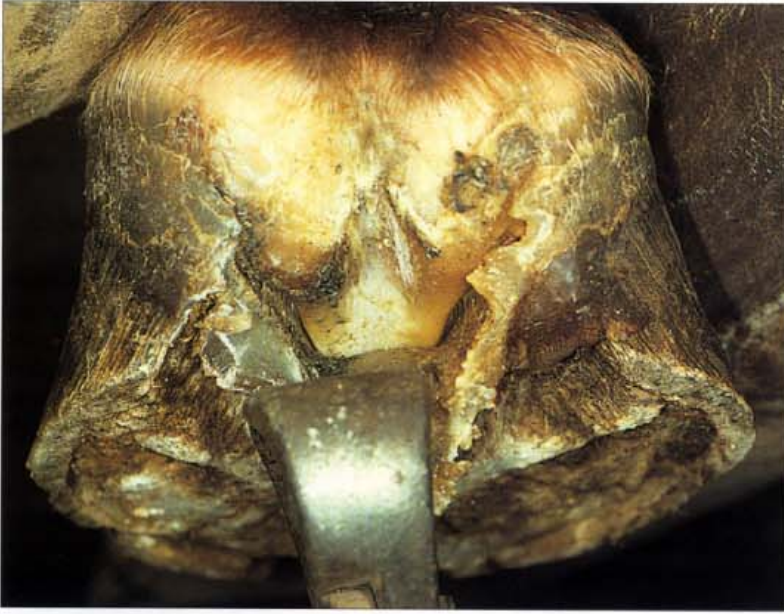286. Penetrating wound to the sole (B). Only necrotic sole, separated from the adjacent corium by the lysing action of bacterial enzymes, was removed. Antiseptic solution, introduced into the primary sole wound via a catheter, flowed from the sinus in the coronet. To protect the exposed corium a hospital plate shoe (see 228) was fitted and intensive topical and parenteral antimicrobial treatment followed. Although the mare was lame for months, the sole gradually responded to treatment and made a satisfactory recovery. Puncture wounds to the sole can be life-threatening and should be treated seriously and promptly.

287. Penetrating wound to the frog (A). The frog is the softest part of the hoof and is prone to penetrating injuries. A sharp foreign body, penetrating the frog, can gain access to the distal sesamoid (navicular) bone, the navicular bursa and the distal interphalangeal joint. It is important to establish if penetration of these structures has occurred as deep-seated infection and severe, chronic lameness is likely to result. The Clydesdale horse pictured, trod on the upward-pointing tine of a harrow and punctured the apex of the frog. The probe could be passed up the discharging sinus tract in the frog for some distance but did not really establish the full extent of the injury.

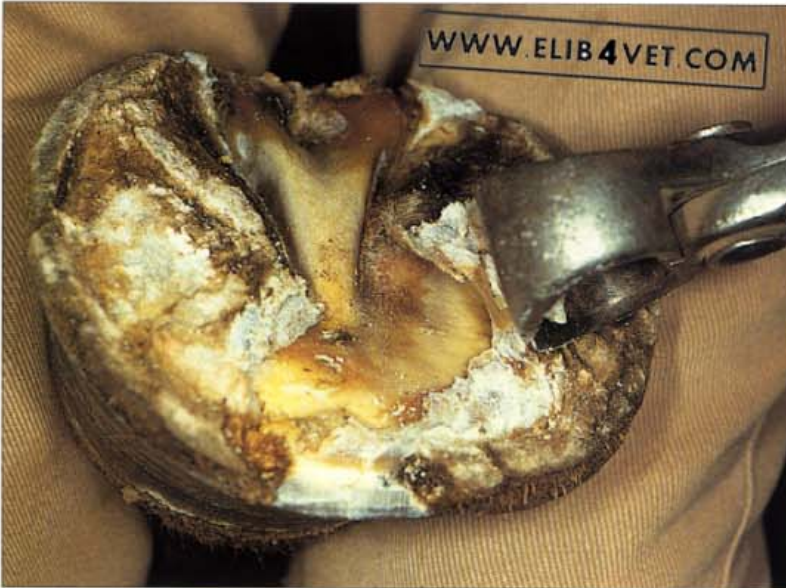

288. Penetrating wound to the frog: contrast study (B). To investigate which structures the foreign body had penetrated, 15ml of radiopaque contrast medium was injected into the distal interphalangeal joint capsule by the dorsal approach. Contrast medium was already flowing from the sinus tract in the frog before the injection was complete. Radiographs showed that the contrast medium had entered the navicular bursa (arrowed) via the distal interphalangeal joint. This is not normally possible, but had occurred in this instance because of penetration of both the distal sesamoid (impar) ligament and the deep flexor tendon at its point of insertion. Radiographic contrast studies of the joint are a useful aid to diagnosis and prognosis when puncture wounds to the frog have occurred. They help reconstruct the way these injuries occur and determine precisely which structures have been penetrated.

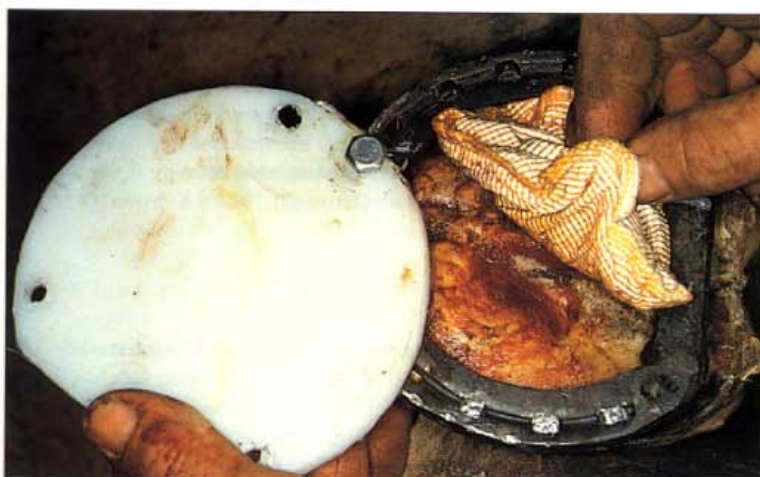




289. Underrun sole and frog (A). Penetrating wounds can infect the sole with mixed populations of bacteria capable of enzymatically lysing or stripping the horny sole (epidermis) from the underlying corium (dermis). When this occurs the sole is termed 'underrun'. Thus a wound to the toe can soon have pus discharging from the heels. When the infection subsides or is brought under control with antibiotic therapy, the germinal layer of the epidermis replaces the old sole with a new generation of keratinised cells and another sole appears. The new sole will be soft and sensitive and needs protection until its normal hardness is regained. In the photograph an infection has underrun both the sole and the frog. The old, separated frog has been grasped with pull-offs and is being peeled away. The new frog underneath is already covered with a layer of yellowish, keratinised epidermal cells.



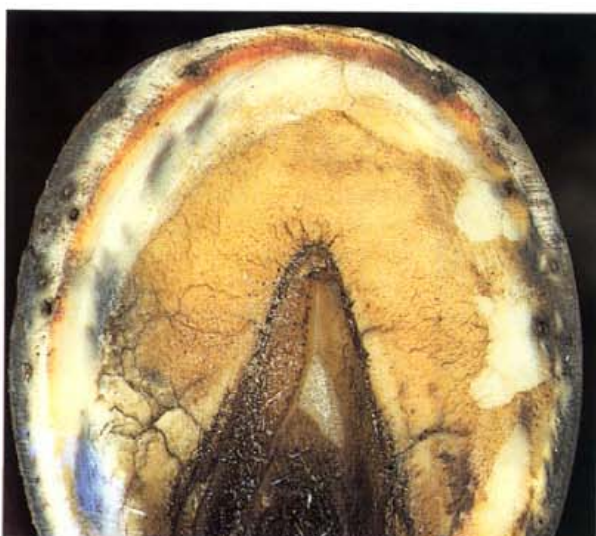290. Underrun sole and frog (B). The old separated frog has been removed and the sole is being peeled back. A thin new sole has formed under the previous separated one. If care is taken not to traumatise the still-sensitive sole and frog, the whole procedure can be done without the need for sedation or anaesthesia.



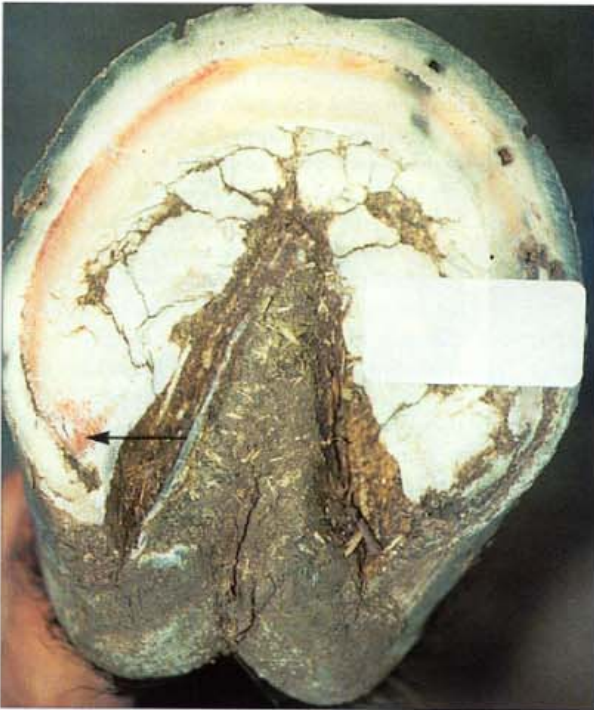291. Underrun sole and frog (C). To protect the sensitive new sole and frog, and to treat the primary infection in the toe, a bar shoe with hospital plate was made and fitted. Four holes were drilled and tapped in the shoe so that a dense plastic plate could be bolted to it. The absorbent pad contains methylcellulose and forms a poultice when medicated with an antiseptic solution, in this case povidone-iodine. Hospital plates like this allow easy access for follow-up medical treatment. It is important that only bland medications be used on healing epidermis. The general use of formalin, phenol and tincture of iodine are contraindicated as they destroy the very cells which will heal the wound and reconstruct the hoof.



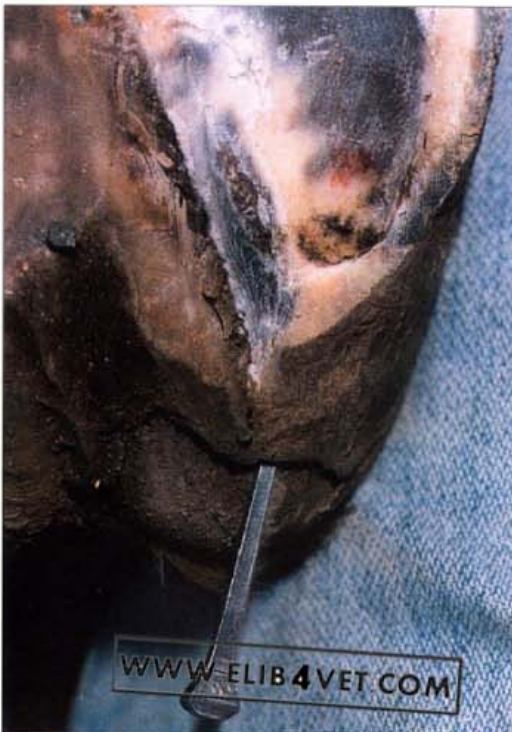292. Sole trauma. When horses, particularly yearlings, are stabled in unfamiliar surroundings they frequently paw the stable floor. If the floor of the stable has an abrasive surface and the horses are not shod, the action of pawing can severely abrade the toe. After a night in a stable this unshod Thoroughbred yearling was extremely lame. The horny sole at the toe has been abraded away and the red-coloured dermis exposed.



293. Haemoglobin staining at the white zone (A). Endurance horses and racehorses competing on hard tracks frequently develop a red haemoglobin stained white zone (not to be confused with the crescent shaped solar bruise of chronic laminitis). Long toe, low heel shoeing (broken-back hoof-pastern axis) increases the likelihood of lamellar tearing near the tip of the distal phalanx. The presence of haemoglobin in the white zone at the ground surface means that trauma to the lamellae had caused haemorrhage about 6–8 weeks previously. The toe of the horse in the picture has been rasped back to correct the hoof-pastern axis problem.



294. Haemoglobin staining at the white zone (B). Haemoglobin staining confined to one side is an indication that the foot is out of medial lateral balance. In the foot illustrated the haemoglobin-stained white zone on the medial side is grossly lower than on the lateral. Distortion of the medial buttress and internal bruising of the medial bar has caused haemoglobin staining in the angle of the sole—a so-called corn (arrowed). Photo: K. Swan.



295. Heel abscess, infected corn. Unlevel shoeing has caused trauma and bruising to the buttress, bar and heel. As a result there is horn degeneration in the angle of the sole (corn) and, in conjunction with wet, unhygienic conditions, an infection has developed. Pus, generated at the site of the infection (in the angle of the sole or 'seat of corn') has underrun the bar and buttress, and discharged at the heel. The point of the horseshoe nail has been placed in the zone of separated horn at the heel; the cavity was connected to the infected corn. The separated heel and buttress were resected and the exposed corium treated with antiseptic dressings. A change to a dry environment and careful attention to balanced horseshoeing has prevented this lesion from recurring.

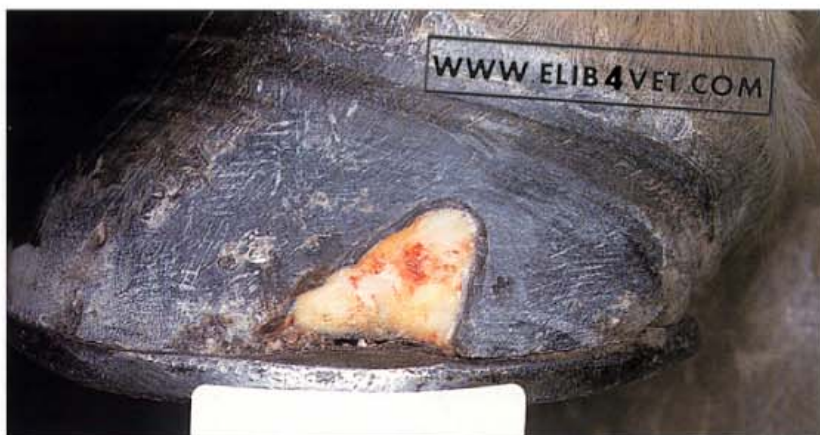15

Infected Nail Hole

296. Infected nail hole (A). When horseshoe nails are driven 'too close' and penetrate the vascular corium, infection is the inevitable result. Lameness may not always be apparent immediately. This horse only became lame 5 days after shoeing when pus, trapped under the hoof wall, began to exert pressure. The shoe was removed; hoof testers were used to localise the source of the pain and a loop knife was used to explore the adjacent nail holes. A large volume of black, malodorous pus squirted from one nail hole when the sole was squeezed with the hoof testers. Black pus is typical of infections of horny tissue such as hoof.

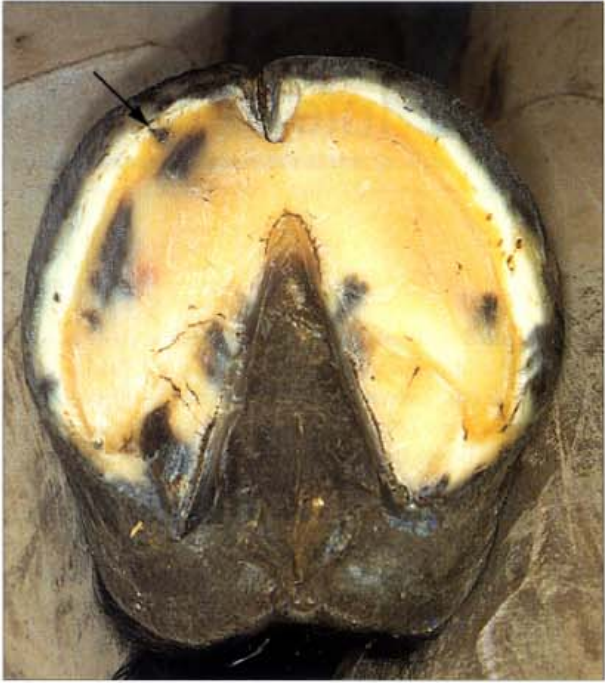

297. Infected nail hole (B). All trace of the infection was resected away with half-round nippers and a sharp loop knife. The picture shows the extent of the damage from one infected nail hole. To ensure that the weakened quarter would not crack or tear a heart-bar shoe was fitted. When the resected area had hardened and was free of pain, the hoof wall was reconstructed with Equilox (see 144).

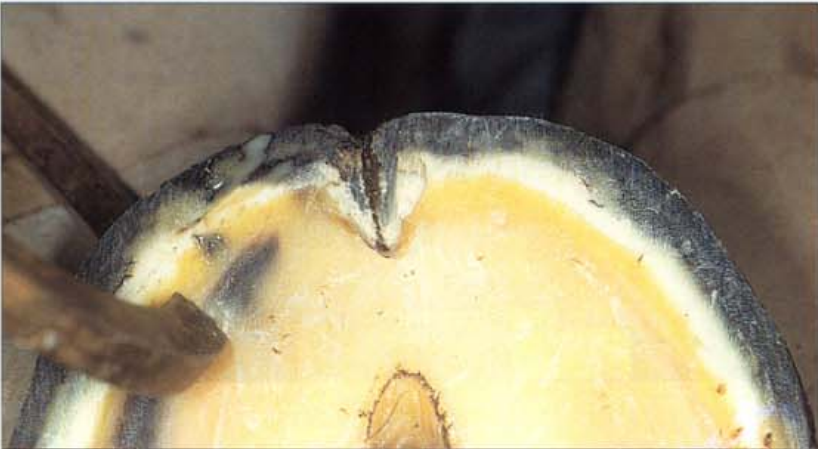



298. Infected nail hole with coronet abscess (A). Five days after shoeing, this endurance horse became acutely lame in the right forefoot. It was treated for a further 3 days with intramuscular injections of procaine-penicillin but the degree of lameness worsened. Examined from a distance the horse was toe pointing and there was a suspicious swelling in the coronet above the lateral toe (arrowed). In the region of the swelling, the hair of the coronet was erect, exposing the proximal border of the hoof. Normally, hair covers the proximal border of the hoof. Palpation of the swelling was resented by the horse.

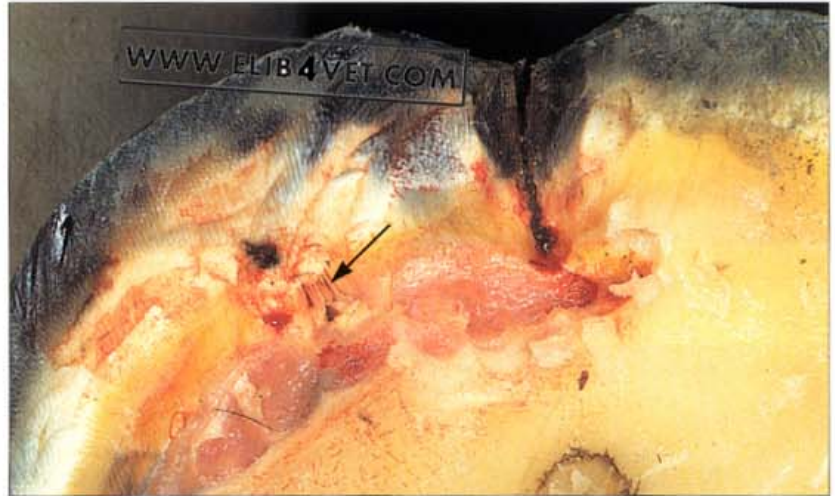
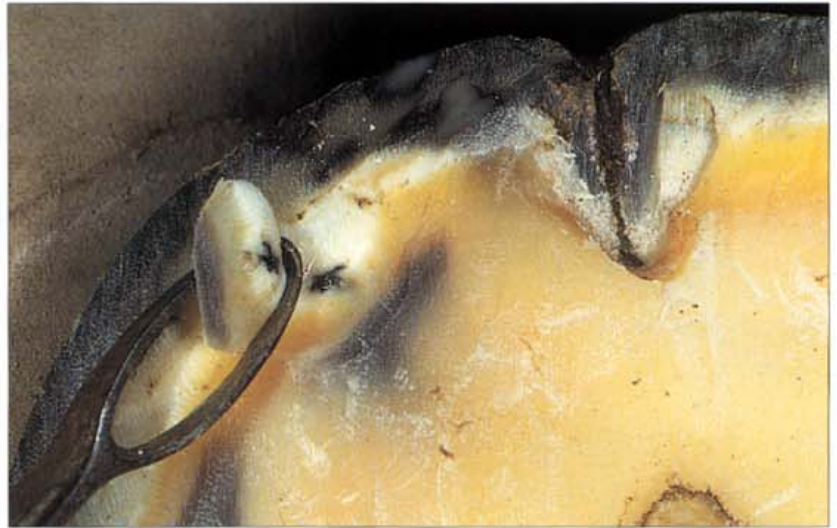

299. Infected nail hole with coronet abscess (B). The shoe was removed and the sole was carefully pared with a sharp hoof knife. Paying particular attention to the nail holes, any suspicious foci of black necrotic sole were explored and removed with a loop knife. Paring of these suspicious spots was discontinued when removal of the necrotic material revealed normal sole. It is important not to be overzealous with this exploratory sole trimming; many a horse with a sound foot (lame perhaps in the fetlock) has been made lame by carelessness at this stage. When paring of the sole was complete, two areas remained that had obvious necrosis of deeper structures. One was the central toe crack and the other was the first nail hole (arrowed) on the lateral side (directly below the coronet swelling).



300. Infected nail hole with coronet abscess (C). Using hoof testers to compress the sole, one region at a time, the entire sole was tested. Only the region of the nail hole caused a pain response from the horse. In fact sole compression beside the nail hole caused a flow of bubbling yellow pus.

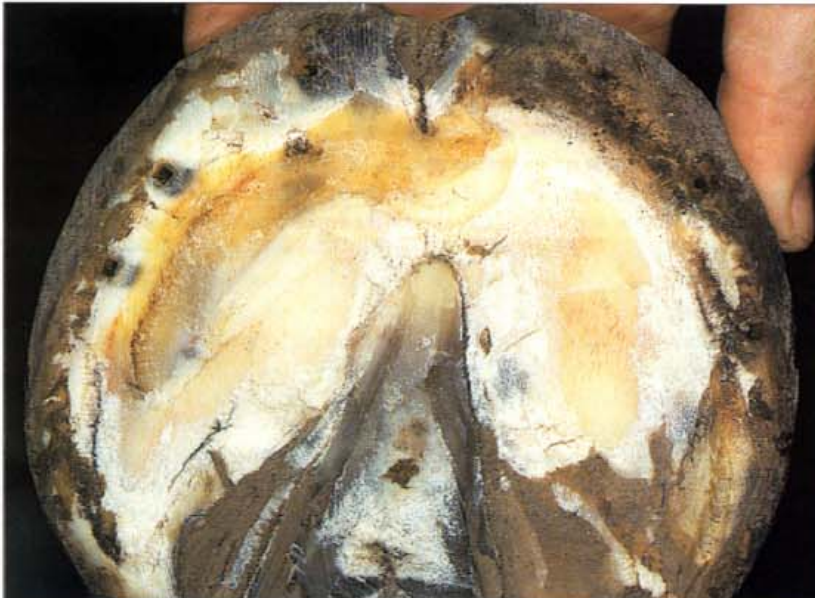301. Infected nail hole with coronet abscess (D). An infected nail hole and a sole abscess was the diagnosis, but more had to be done to ensure a satisfactory recovery. Drainage had been established and the pressure of the sole abscess released. However, leaving a small drainage hole and calling a halt to proceedings at this stage could have led to an unsatisfactory outcome. The keratinolytic bacteria that get established in sole infections have strict growth requirements and exposure to air is not one of them. Bearing in mind the likely commitment to protecting sole with a hospital plate or at least a pad, it is best to continue resection of the abscess until all necrotic under-run sole is removed. A sharp loop knife is ideal for this purpose.



302. Infected nail hole with coronet abscess (E). As is often the case, a suprisingly large area of the sole was destroyed by the infection. From one nail prick a zone of sole 10mm x 70mm was destroyed (almost the entire lateral perimeter of the sole). This is why it is so important to fully resect these sole infections. It is difficult to predict their full extent and any pockets left behind have a tendency to seal off and re-establish themselves. The sole resection in this case was done without sedation or local anaesthesia. As long as the exposed solar corium is not treated roughly most horses will tolerate the procedure well. The arrow points to a zone of hoof wall epidermal lamellae which have been stripped of their dermal attachments by enzymes produced by the infection. These infected lamellae are the clue, revealing the true aetiology (cause) of the painful swelling at the hair line of the coronet. The bacteria introduced by the nail prick are able to lyse keratin and not only have they under-run the sole, but they have used the lamellae as an elevator and gained access to the coronet. It was a safe prediction that the coronary swelling would discharge pus from the hair line within the next few days. The exposed solar corium was dressed with a gauze swab soaked in povidone-iodine and the foot was re-shod with a plastic pad covering the sole. No further antibiotic treatment was advised because the resection had resolved the infection. The horse was not lame the next day.



303. Infected nail hole with coronet abscess (F). As predicted, an abscess (arrowed) had formed at the hair line of the coronet, directly aligned with the hoof wall tubules leading to the infected nail hole. The precise location of discharges from the coronet is an important diagnostic point. Sole infections tracking up the hoof wall lamellae to the coronet always discharge at the hair line (another example is shown in 344). On the other hand, wounds or foreign objects penetrating the coronet may discharge at the hair line or several millimetres from it. The discharge from quitter (see 209) is usually a few millimeters above the hair line.



304. Infected nail hole with coronet abscess (G). When examined 7 days after the sole resection, the horse was no longer lame. The exposed solar dermis was well covered with a layer of yellow keratinised epidermis which was beginning to harden. The horse made an uncomplicated recovery and returned to training 3 weeks after the resection. The abscess in the coronary band left a small horizontal defect in the hoof wall which gradually grew out.

16

Quarter Cracks

305. Quarter crack: unshod horse (A). Broodmares need regular hoofcare particularly if the ground underfoot is soft and loamy. If the heels are left to grow long and flared the entire quarter may fracture and tear away from the underlying structures. Just like a torn human finger nail, the torn quarter will cause pain whenever it is moved.

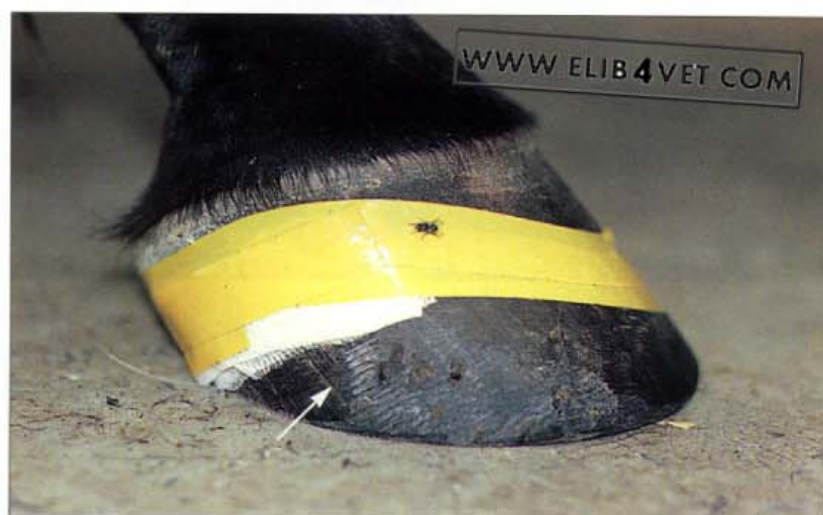

306. Quarter crack: unshod horse (B) There is only one satisfactory treatment for the torn, loose quarter: removal. A quick and easy way to accomplish this is by having one operator hold the affected foot (in this case a hindfoot) while another grips the loose quarter with a pair of pull-offs. When the foot is released the horse will react to the pain by drawing the foot quickly away, leaving the quarter in the grasp of the tongs. A temporary, light dressing to protect the exposed corium was applied and within a few days the mare was walking free of pain. The quarter grew back in completely normal fashion.

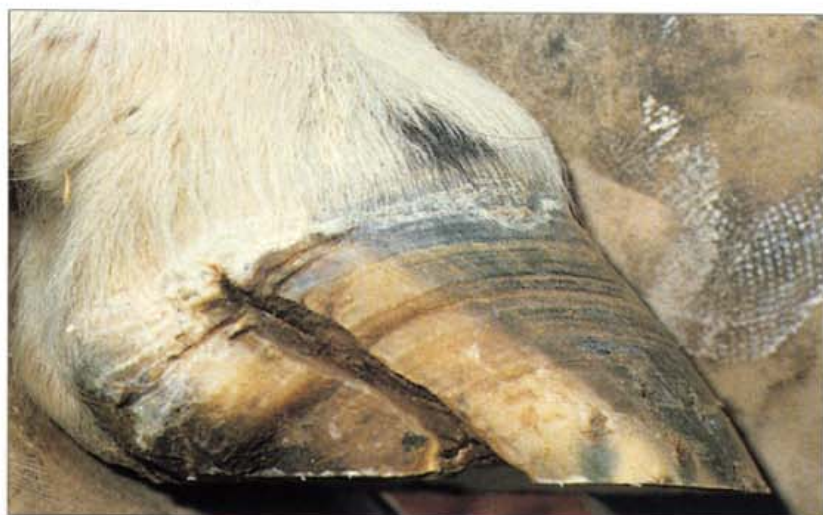



307. Acute blind quarter crack (A). When a quarter crack first occurs there is lameness because the heel palmar (behind) to the crack moves independently of the rest of the foot. The crack may appear insignificant on the outside (hence blind) but pain from the torn and inflamed corium within can cause quite severe lameness. The quarter crack illustrated had occurred during training the day before a race. Blood was oozing from the proximal end of the crack. The crack was sensitive to thumb pressure. The heel was long, running under, and only poorly supported by a narrow, tightly fitted shoe.

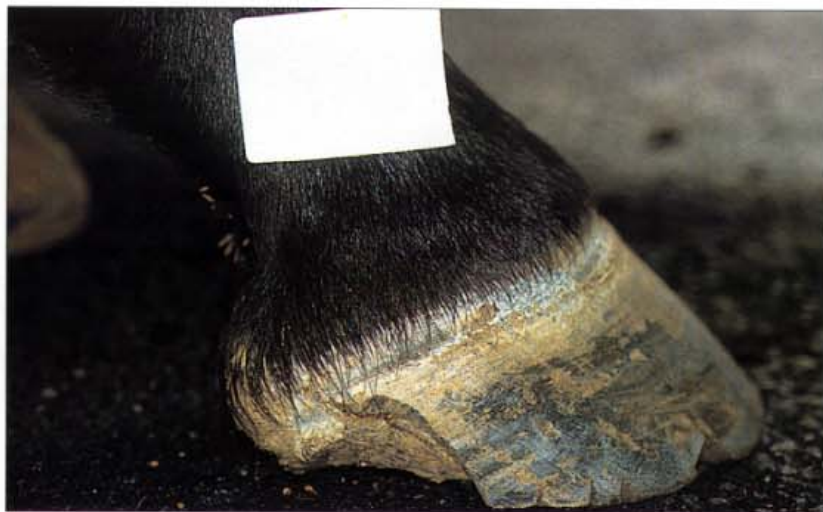

308. Acute blind quarter crack (B). With a dressing to control infection and several tightly applied layers of plastic tape, the Standardbred pacer was able to race to form. The arrow shows the crack below the dressing. The fact that the horse could perform without lameness shows how important it is to stabilise the heel when quarter cracks occur. The photograph was taken before the advent of adhesive quarter crack patches or hoof reconstruction compounds such as Equilox. The use of the latter produces a more permanent and satisfactory stabilisation and has generally superseded the use of tape.

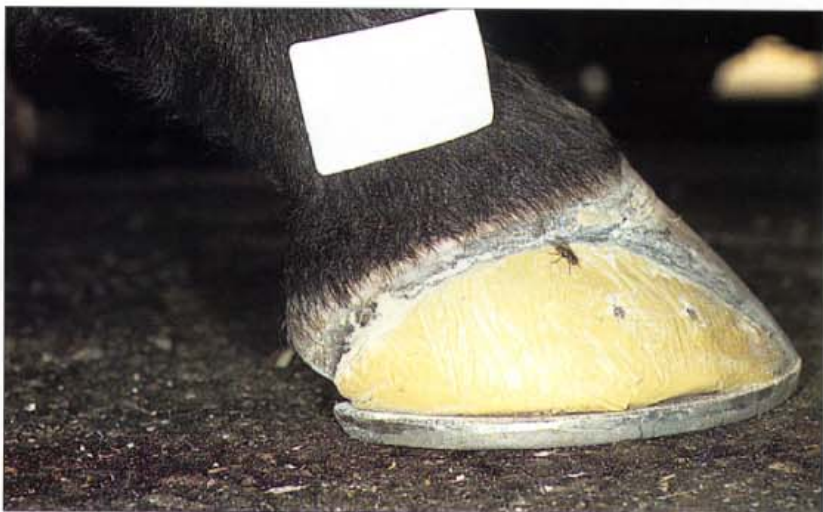

309. Chronic quarter crack. If the coronet above the quarter crack is not permanently damaged and the crack is free of infection, the lesion will usually grow out if the heel palmar (behind) to the crack is relieved of the stress of weight bearing. In this case the wall of the heel has been rasped lower than the rest of the foot so that when shod the heel will not be loaded. To form a bridge from the sound heel on the opposite side, across the frog, to the wall dorsal (in front of) to the crack, the horse was shod with a heart-bar shoe. Utilising the weight-bearing capabilities of the frog, to spare the heels, is but one of the many uses of the heart-bar shoe.

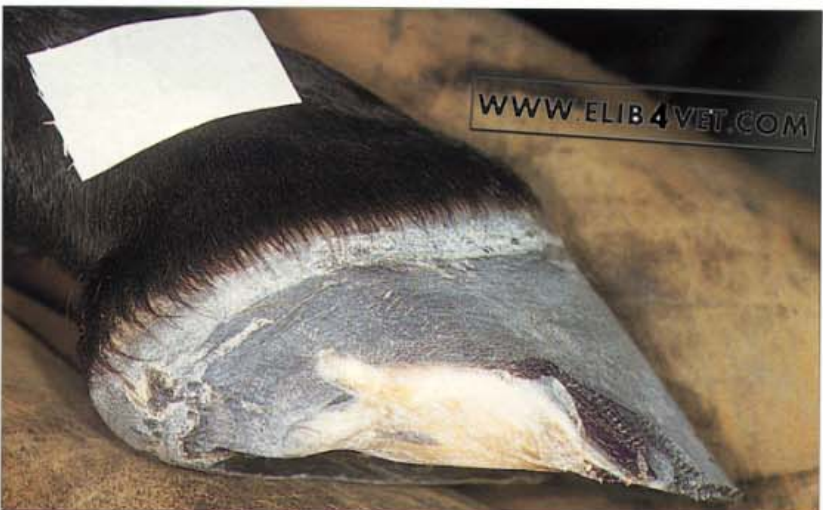310. Quarter crack: racehorse case history (A). This quarter crack was deeply infected and necrotic and much of the heel and quarter had to be resected. The lesion is beginning to resolve and the exposed lamellae are now covered with a solid layer of keratinised epidermal cells. However, the area is still unstable and painful and it was impossible to train the horse without risking further damage to the heel.



311. Quarter crack: racehorse case history (B). The damaged area was debrided and prepared for an Equilox quarter crack patch and heel reconstruction. With the heel and quarter stabilised and protected from trauma the horse was shod and returned to training.

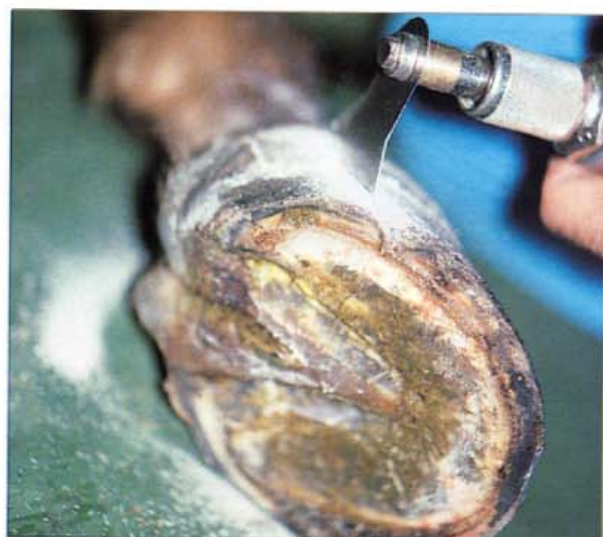

312. Quarter crack: racehorse case history (C). Three months later the horse had been re-shod twice and the crack, complete with its Equilox patch, was growing out. No training days had been lost to lameness.

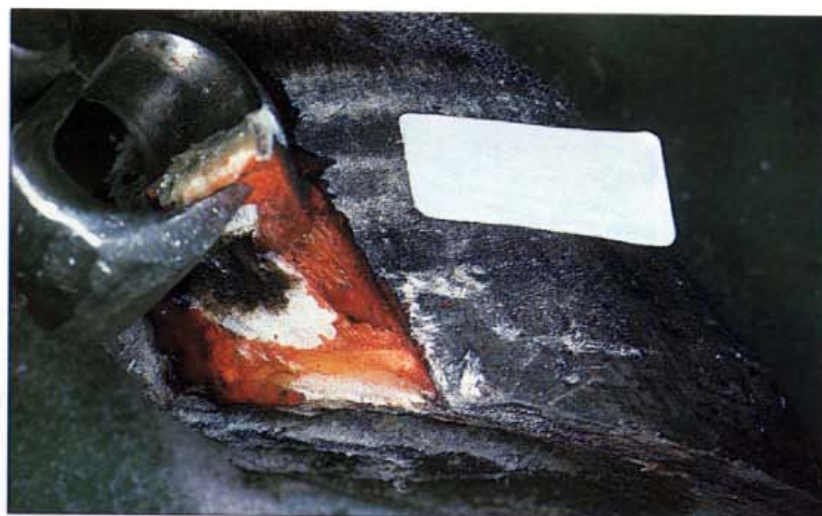



313. Quarter crack: shod horse, wall strip surgery (A). For a quarter crack to develop there is usually an underlying conformation or farriery problem. Whether from racing on hard tracks with insufficient heel support, unlevel foot preparation or accidental trauma, the quarter crack is an insidious cause of lameness. When the crack occurs the heel and buttress tend to move independently of the rest of the wall separated by a band of torn, involuting, often infected hoof wall. Resolution of the problem is unlikely until the underlying cause is corrected and the separated heel and quarter are reunited and stabilised.



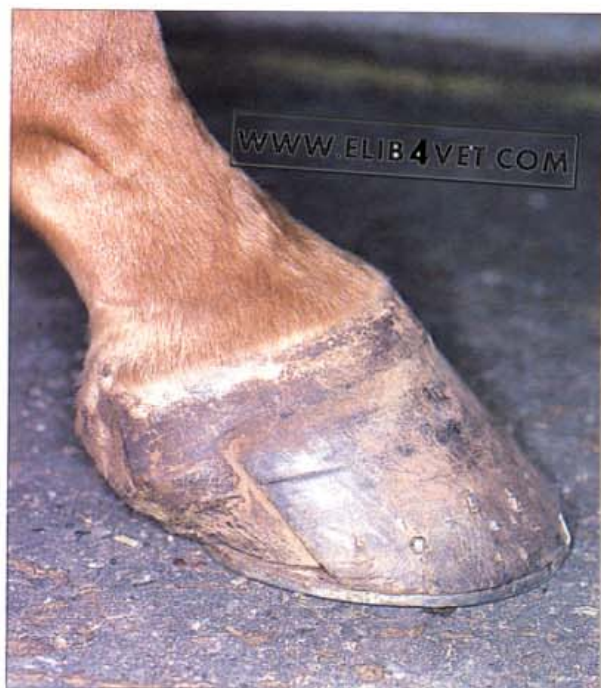314. Quarter crack: shod horse, wall strip surgery (B). When the quarter crack is severe and chronic, one way to resolve the problem is to perform a wall strip operation. In the photograph, the horse is under general anaesthesia and Esmarch's bandage has been applied to the lower limb to control haemorrhage. An oscillating plaster saw was used to make saw cuts, parallel to the direction of the wall tubules, on either side of the crack. The saw cuts must be no deeper than the thickness of the wall so as not to damage the underlying corium.



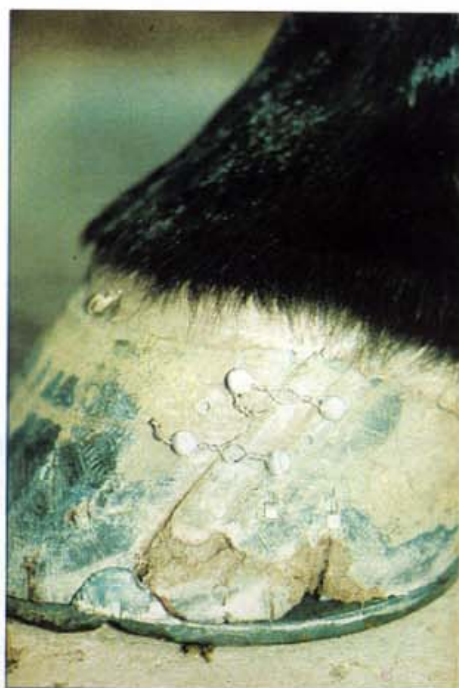315. Quarter crack: shod horse, wall strip surgery (C). The wall between the saw cuts was grasped with blunt horseshoe pull-offs and with a peeling action the wall was stripped up to the coronet. Care must be taken to gently ease the hoof from the papillae of the coronary band. If the coronary band is accidentally excised the hoof may not grow back normally. All diseased and infected hoof that failed to come away with the strip was carefully removed later.



316. Quarter crack: shod horse, wall strip surgery (D). It is important that the stripped quarter is relieved of weight bearing until a new intact quarter has grown in its place. A simple half-bar shoe bridges the gap between the frog and the wall and protects the sensitive area. A heart-bar shoe is equally satisfactory.



317. Quarter crack: shod horse, wall strip surgery (E). Two months later new hoof has grown to fill the deficit left by the resection. The horse has since returned to racing and the quarter crack has not recurred.



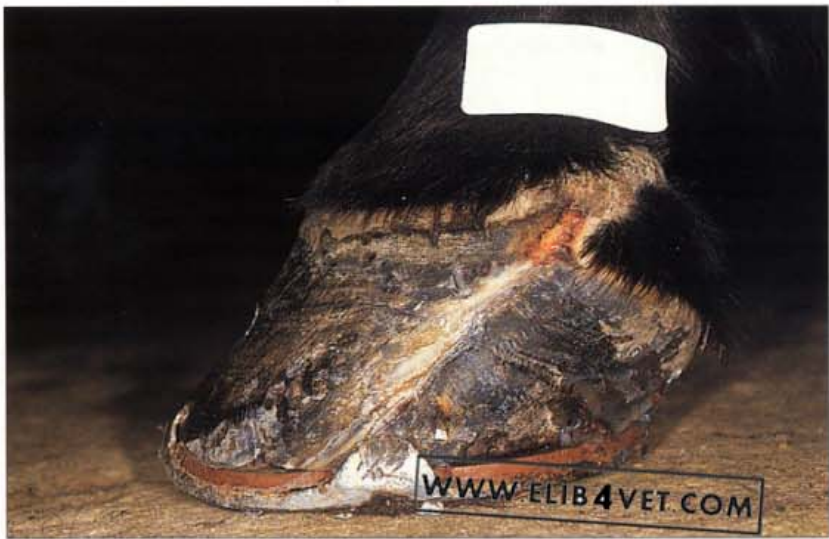318. Quarter crack repair with wire. Stabilising the hoof wall on either side of a quarter crack can be achieved with screws and wire. Holes are drilled on either side of the crack and self-tapping metal screws (5–7mm) are screwed into the holes. Stainless steel wire (surgical cerclage wire is best) is twisted around the screws to draw the two sides of the crack together. Since the advent of patches made of modern composite resins (Equilox) with excellent adhesive properties this method has been superseded.



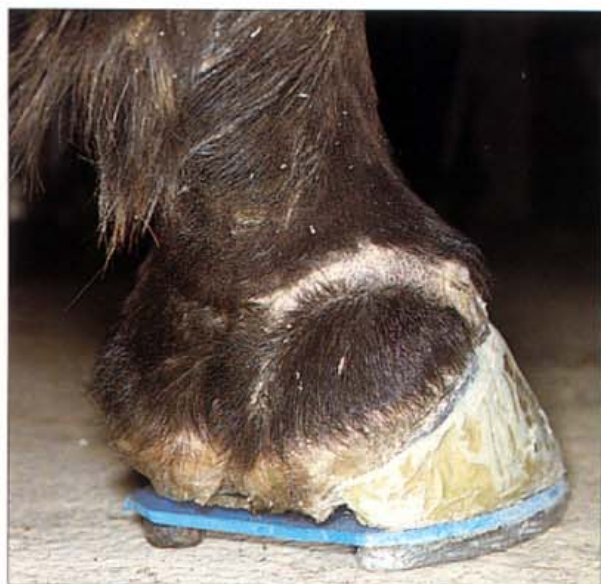319. Quarter crack (A). Not all quarter cracks are man-made and caused by faulty trimming and shoeing. The photograph shows the front foot of a mature feral horse confined to a habitat of sand. Without the influence of abrasion and firm conditions underfoot horses' feet soon become deformed and cracked.



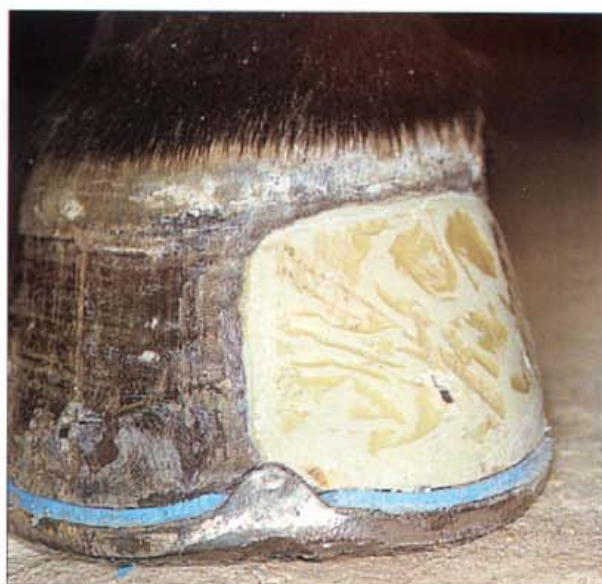320. Quarter crack (B). Another horse from the same environment as the horse shown in A. Most of the horses, particularly the mares, in this band of feral horses had deformed cracked hooves, and many were lame.



321. Chronic quarter injury repair and maintenance (A). A deep barbed wire laceration severely injured the heel and quarter of this endurance horse. When the coronet healed, a wedge of scar tissue in the coronary groove permanently prevented normal hoof wall growth and left the horse with a chronic disunited quarter crack. Endurance competition caused the hoof on either side of the crack to move independently, resulting in chronic lameness problems. In the picture, there is haemorrhage at the proximal end of the crack and there is a new line of separation between hoof and coronary corium. It was impossible to achieve medial lateral balance of this foot because of the presence of this painful lesion.



322. Chronic quarter injury repair and maintenance (B). The medial wall of the foot, from heel to toe, was reconstructed with Equilox. This reunited the heel to the rest of the foot and prevented any further movement between the two portions. The lameness disappeared and the horse was able to train and compete successfully.

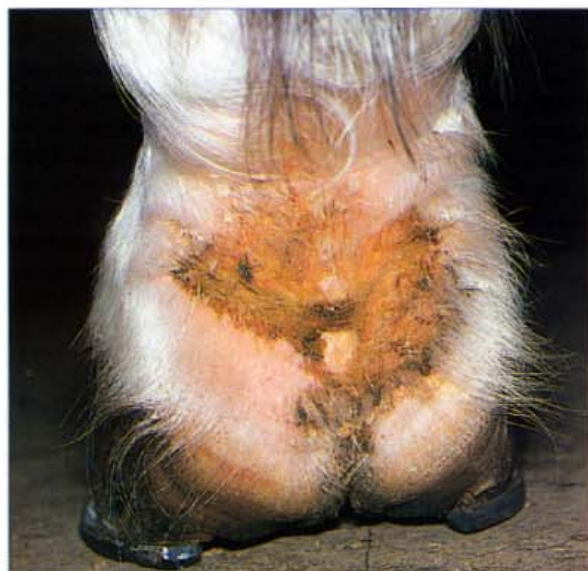

323. Chronic quarter injury repair and maintenance (C). The Equilox reconstruction, of the foot in B, shown from in front. The wide webbed, steel shoe has a rolled toe and is nailed securely to the Equilox. Medial lateral balance has been achieved for the first time.

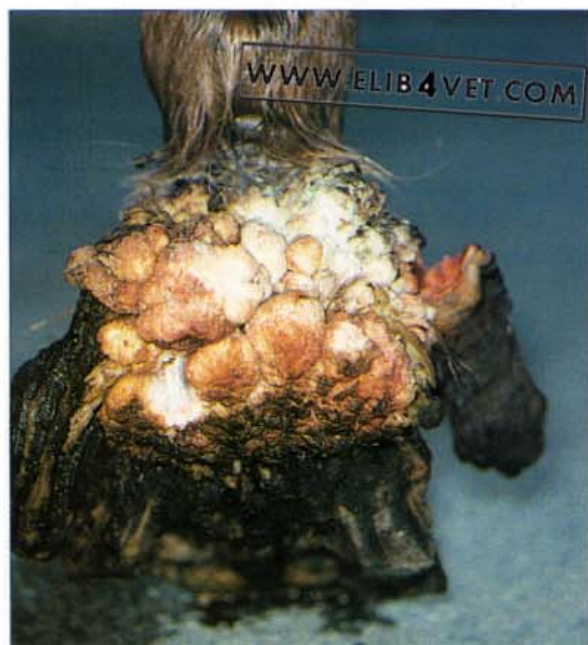324. Chronic quarter injury repair and maintenance (D). The horse has since successfully completed several 50-mile (80-km) and 100-mile (160-km) endurance rides. The composite reconstructed heel has been replaced several times and carrying its heavyweight rider (riding weight 100kg) the horse has remained free of lameness. The photograph shows the reconstructed medial heel (arrowed) from behind. Photo: Sue Crockett.



17 Infections and Tumours of the Foot

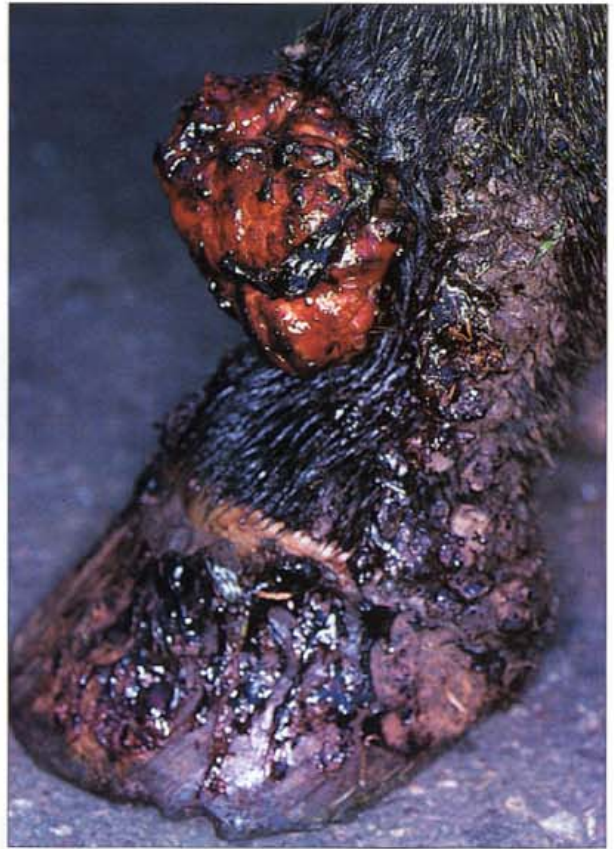

325 Greasy heel (mud rash, mud fever). Greasy heel is a bacterial skin infection of the palmar aspect of the pasterns and heels. It is usually secondary to a primary insult which has damaged the skin and allowed the invasion of bacteria. Predisposing factors include constant moisture and abrasion to the pasterns from mud and gravel. The infection is usually mixed and may be caused initially by *Dermatophilus* with secondary infection by *Staphylococcus* and *Pseudomonas*. Sometimes horses with greasy heel can be severely lame. Treatment requires a change of environment and management, frequent antimicrobial and anti-inflammatory topical dressings and, occasionally, parenteral treatment with antibiotics.

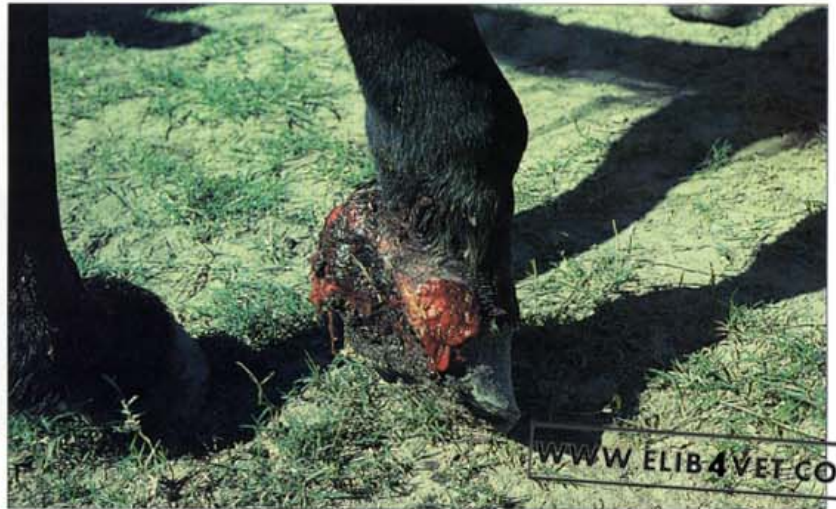

326 Sarcoid (A). Sarcoid is the most common neoplasm of horses and often occurs on the lower limbs. It is locally aggressive, non-malignant, and does not metastasise. It is thought to have a viral aetiology and usually develops at the sites of cuts and abrasions. The usual treatment is either cryosurgery with liquid nitrogen or immunotherapy using BCG (bacille Calmette-Guérin) in conjunction with surgical debulking. Surgical removal alone is rarely successful. A granulomatous form of the disease, on the heels of this horse's foot, has been neglected and has grown too large to treat.

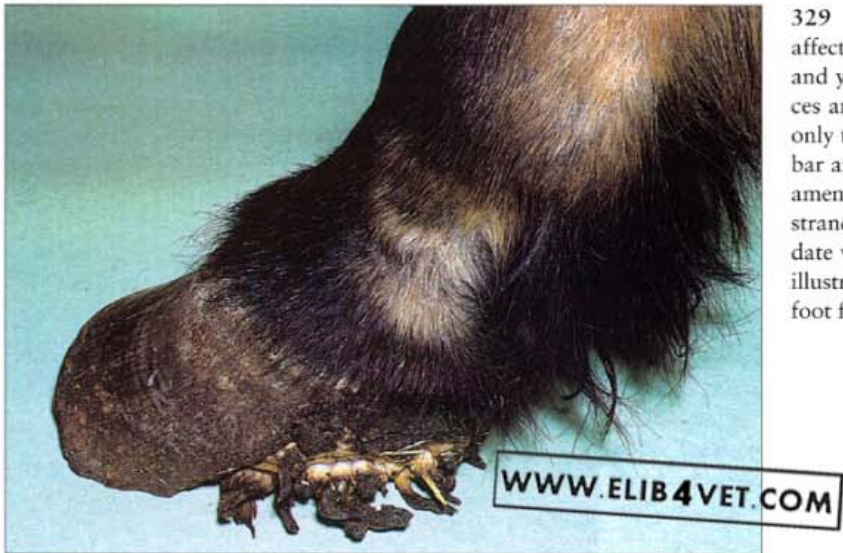327 Sarcoid (B). This small fibroblastic or granulomatous type of sarcoid developed from a wound in the skin of the dorsal pastern. Under general anaesthesia the lesion was surgically removed and the cut surface was subjected to two cycles of freezing and thawing with liquid nitrogen. This cryotherapy was successful; the lesion did not recur.



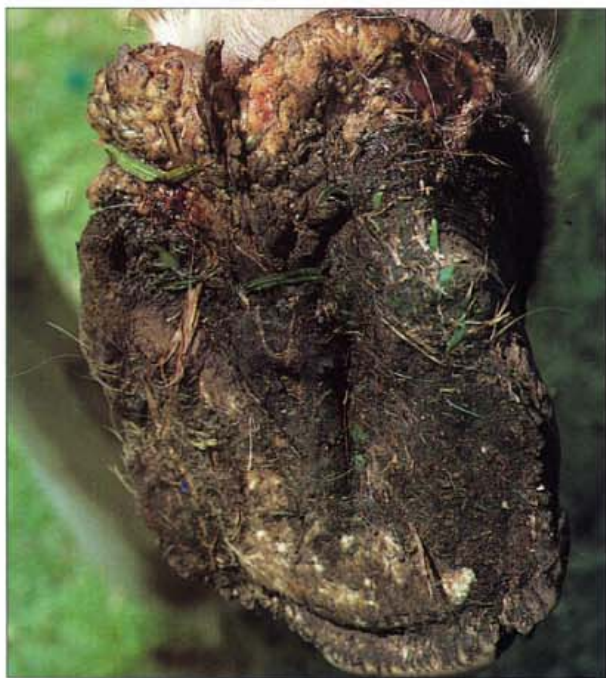328. Phycomycosis (Pythiosis). Wounds to the lower limbs can become infected with fungi of the Pythiosis group if horses in tropical climates have access to swamps and dams. The microorganism is usually a saprophyte of damaged aquatic plants, but can gain access to animal tissue through wounds. Typically the lesions are fast growing granulomas which exude copious quantities of serosanguineous mucoid pus. The horse will often mutilate the lesion with its teeth because it is itchy (pruritus). In the photograph a wire cut to the heels is infected with the *Pythiosis* fungi and is showing the typical stringy serosanguineous discharge. Photo: R. Miller.



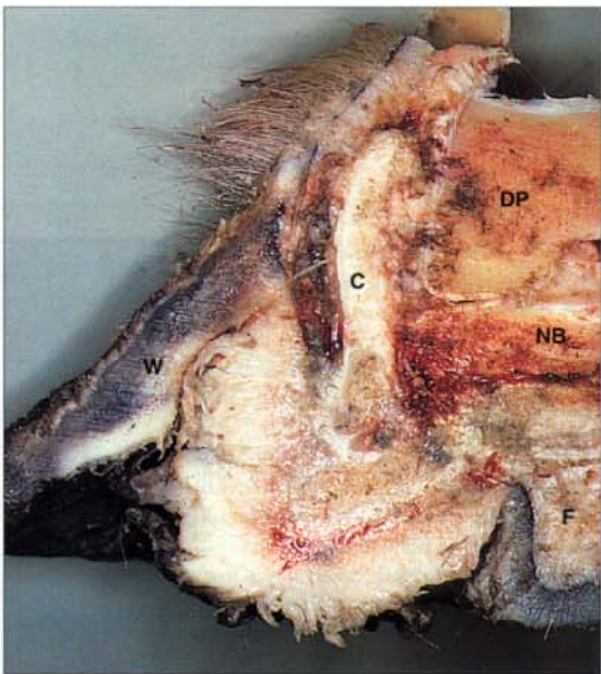
Canker



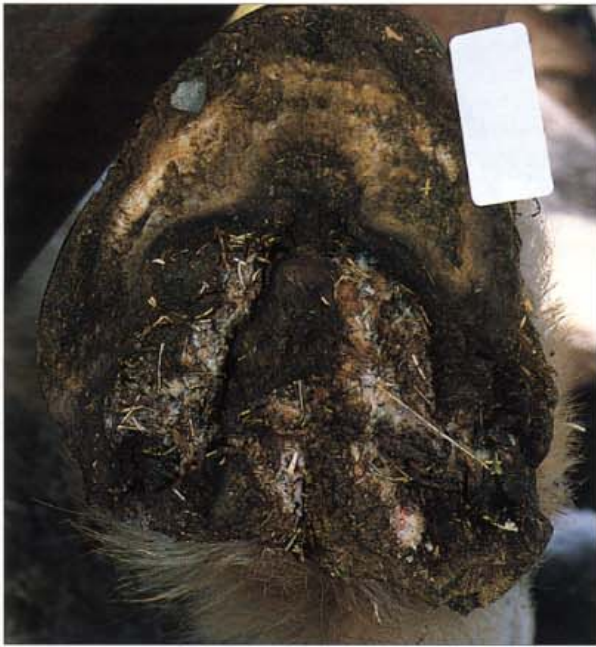329 Canker (A). Canker most commonly affects draft horses kept standing in wet stables and yards heavily contaminated with stale faeces and urine. The disease usually develops in only the hindfeet and causes the heels, buttress, bar and sulci of the frog to disintegrate into filamentous strands of soft, vegetative horn. The strands of horn are caked in cheesy, white exudate with a characteristic foul odour. The foot illustrated was a severe case involving the entire foot from the toe back. Photo: C. W. Prescott.



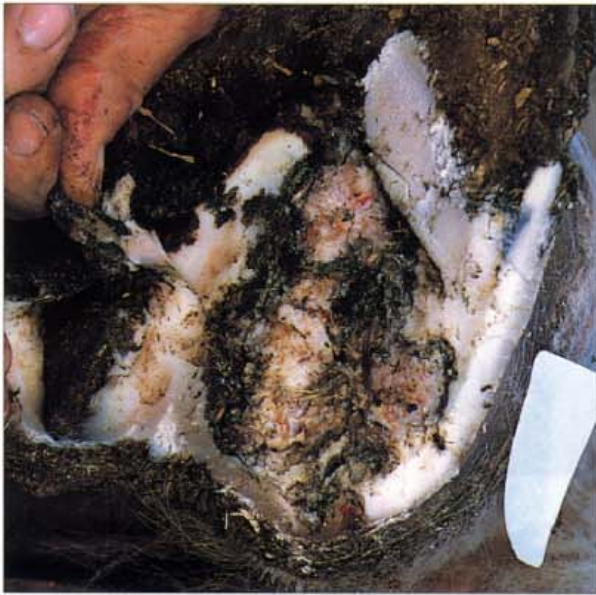330 Canker (B). Canker also occurs in horses kept outdoors in wet conditions in tropical climates. The photograph shows the foot of a horse which was confined to swampy conditions in South-East Queensland. Both hindfeet were affected but the canker had only invaded the bulbs of the heels and the palmar frog.



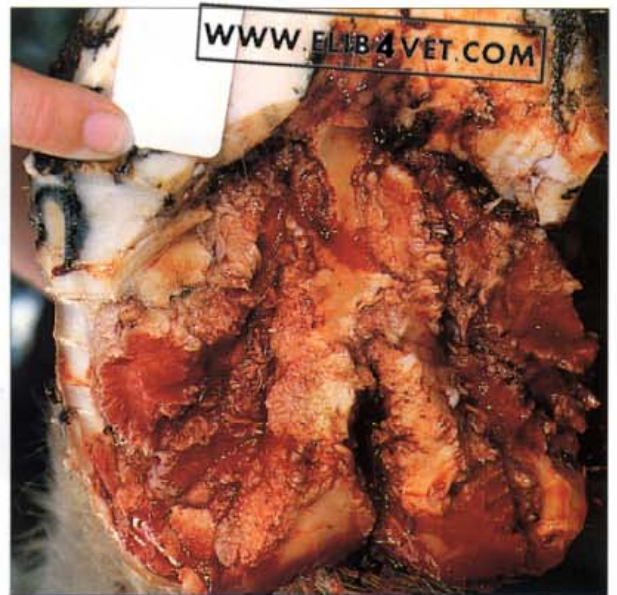331 Canker: cross-section. A longitudinal section, at the level of the navicular bone (NB), shows that canker, in the form of a vegetative mass of white, diseased tissue has replaced the papillae of the sole and the lamellae of the wall. The wall was loose and only attached at the coronet. DP= distal phalanx, C=cartilage of distal phalanx, F=frog, W=wall of hoof at the level of the quarter.



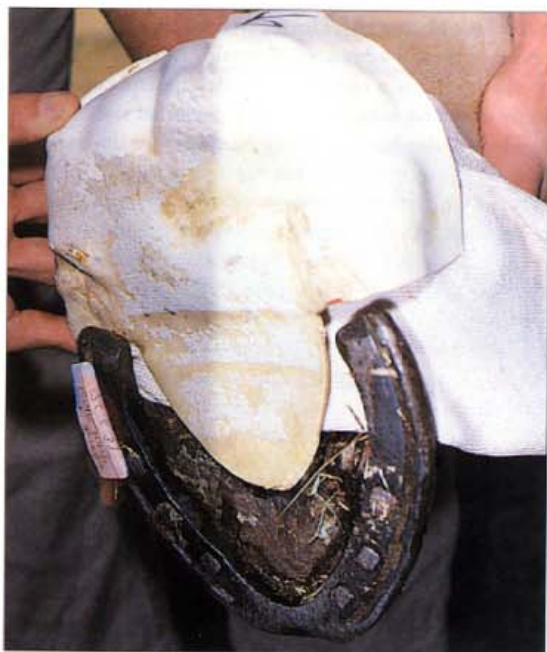332. Canker: case history (A). Horses with canker are not lame until the disease is well advanced. Biopsies of diseased tissue show that the lesion is a chronic pododermatitis caused by Gram-negative bacteria infecting the deep germinal layers of the epidermis. The tubular horn seems to be spared at the expense of the intertubular horn and the net result is a mass of unconnected tubules (dyskeratosis) enveloped in a paste of cheesy, white pus. Because the infection penetrates the deepest layers of the epidermis it is difficult, time-consuming and expensive to treat and the prognosis is always guarded. The picture shows the hindfoot of a Clydesdale, chronically infected with canker. The collateral grooves (sulci), the central groove of the frog and the buttress, heels and sole of the entire palmar hoof are occupied with strands of the white, vegetative tissue typical of canker. The walls of the heels were loose and only attached at the coronet. The horse was lame and frequently stamped his hindfeet to the ground with awesome force, as only an angry Clydesdale can.



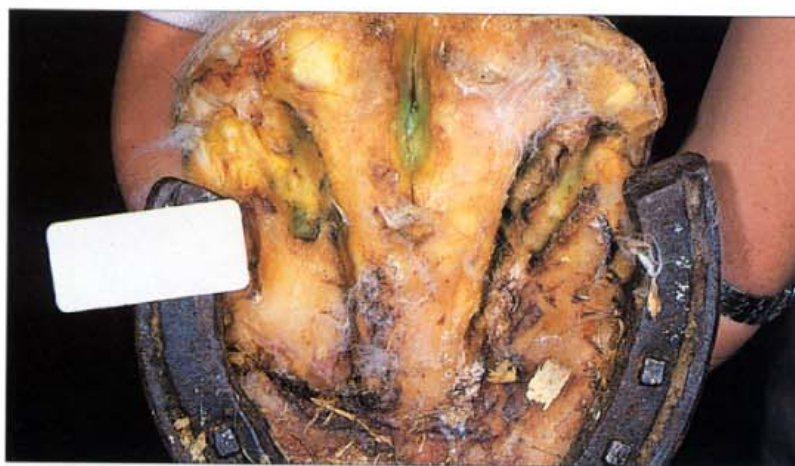333. Canker: case history (B). The initial treatment involved extensive debridement and removal of all diseased tissue under general anaesthesia. The photo shows the first stage of treatment of the Clydesdale. The wall of the quarter, the heel, the bar and the angle of the sole are diseased and underrun and have been resected.



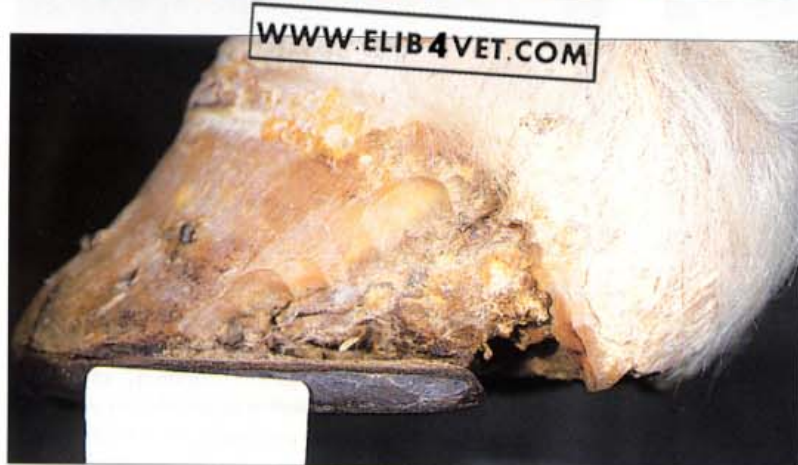334. Canker: case history (C). In the next stage the lesions of canker have been scrubbed and debrided to remove as much of the caseous material as possible. The long strands of filamentous material were cut back, with a scalpel, close to the bed of granulation like tissue. The full extent of the lesion is now revealed. The affected area was painted with a suspension of 2% benzoyl peroxide in acetone. Culture and sensitivity had shown that the lesion was infected with a mixed growth of Gram-negative bacteria, including *Pseudomonas*. The mixed growth was sensitive to penicillin and gentamicin so parenteral treatment, by intramuscular injection of these antibiotics, was commenced.



335. Canker: case history (D). A significant part of the treatment was finding the means to keep the infected area clean and dry. The tip of the intact toe was shod and a gauze dressing was placed under the heels of the shoe. A protective cast conforming to the sole and heel of the foot was moulded from orthoplast and taped in place. The horse was kept stabled on dry wood shavings and fed a balanced maintenance diet. In the literature there are numerous stated cures for canker which usually means that no single remedy will be effective in all circumstances. Since the disease is invariably linked to an environment of filth and moisture it is of paramount importance to relocate the horse to clean, dry conditions. A topical dressing applied to the diseased tissue should be antiseptic, astringent and drying.

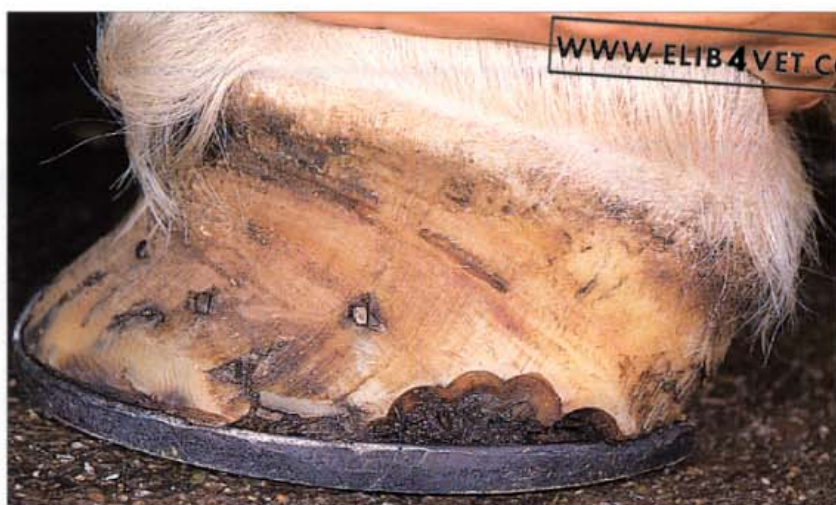

336. Canker: case history (E). Every second day, the heel cast was removed and the diseased regions gently curetted. The collateral and central grooves of the frog were packed with dry gauze swabs and the lesions and swabs were painted with the suspension of benzoyl peroxide in acetone. After 6 weeks of this therapy the affected area began to take on a normal appearance.

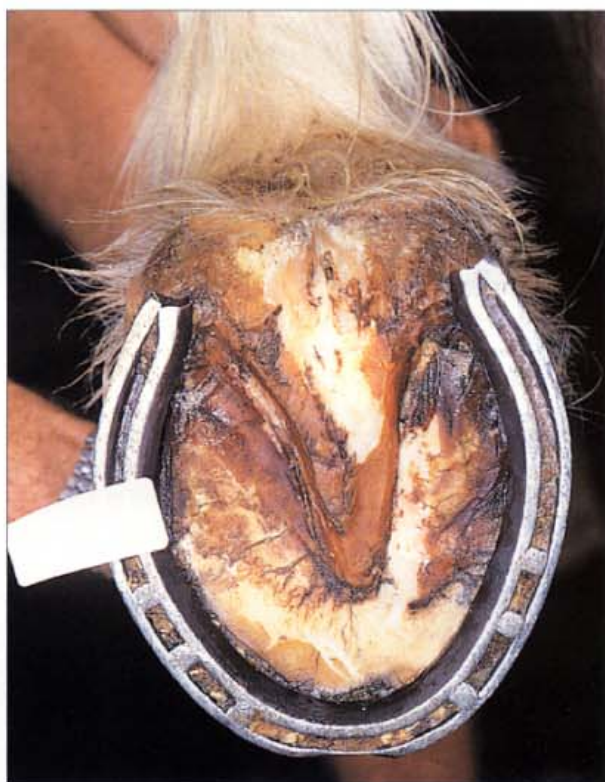

337. Canker: case history (F). The photograph shows the lateral view when the infection had come under control. The diseased quarters and heels are dry and the exposed epidermis is beginning to keratinise.

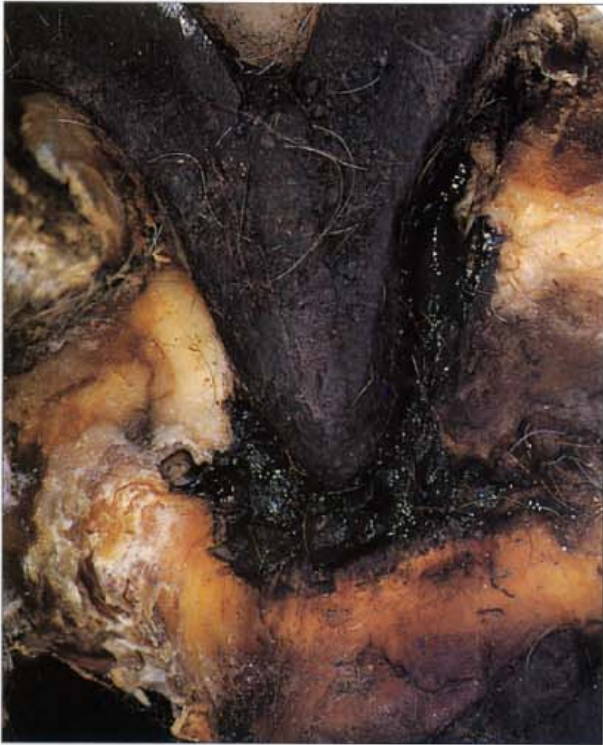338. Canker: case history (G). Three months later the heels have grown and the horse can be shod with a full-sized shoe.



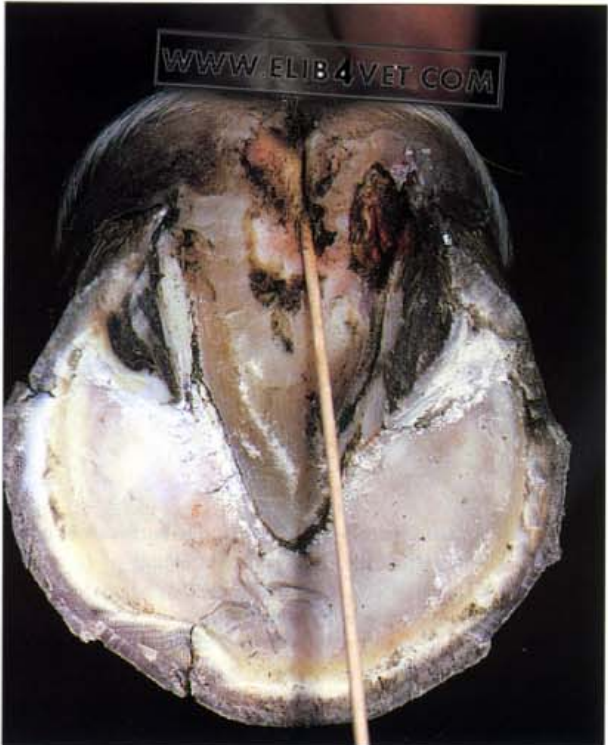
339. Canker: case history (H). The under-surface of the diseased foot 3 months after the commencement of treatment. The bars, heels and quarters have a normal appearance and the horse was shod with a normal shoe.



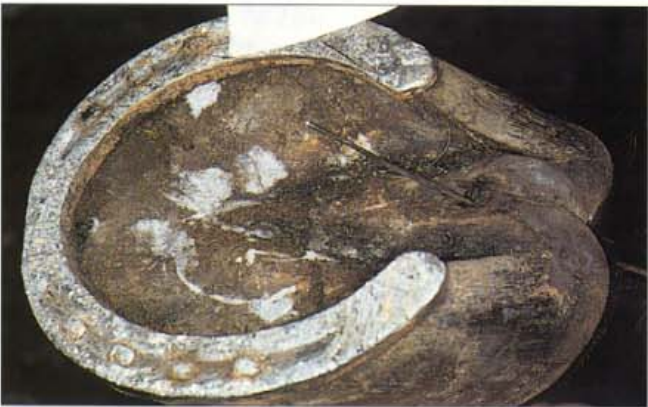Thrush



340. Thrush (A). Thrush is a degenerative condition of the central groove and collateral grooves (sulci) of the frog. It is characterised by a black discharge and an extremely offensive odour. The microorganisms which cause it are keratolytic and usually include the sheep footrot organism *Fusobacterium necrophorum*. Severe infections can under-run the adjacent sole and cause swelling of the legs and lameness. In the case illustrated a badly fitting frog plate of a heart-bar shoe has caused pressure necrosis of the frog. The black shiny discharge is typical of thrush.



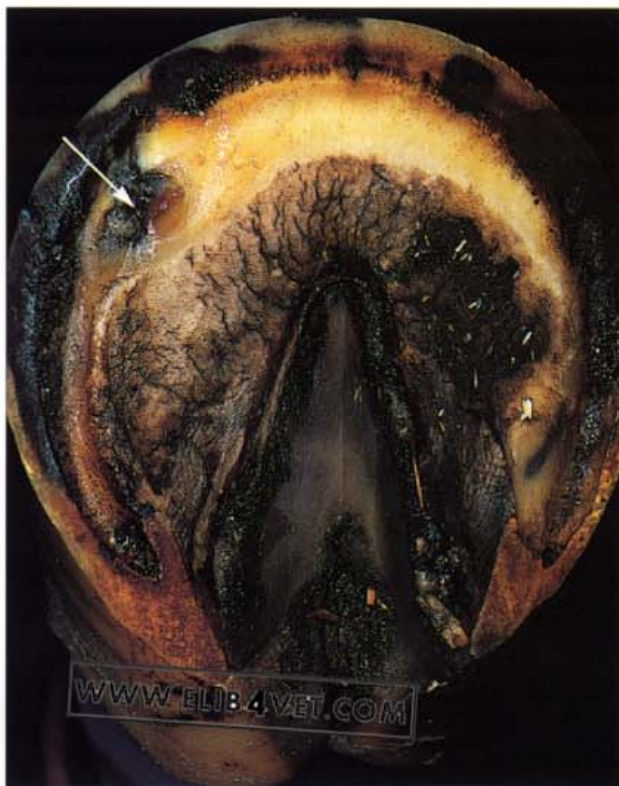341. Thrush (B). Horses stabled for long periods in wet, unhygienic conditions are prone to developing thrush. In the case illustrated the central groove (sulcus) of the frog is involuted and infected with thrush. The probe shows the depth of the infection. The lateral groove (sulcus) of the frog is also infected to the depth of the underlying corium. Treatment required an improvement in stable and paddock conditions, in particular limiting access of the feet to moisture and frequent applications of povidone-iodine to the affected areas.



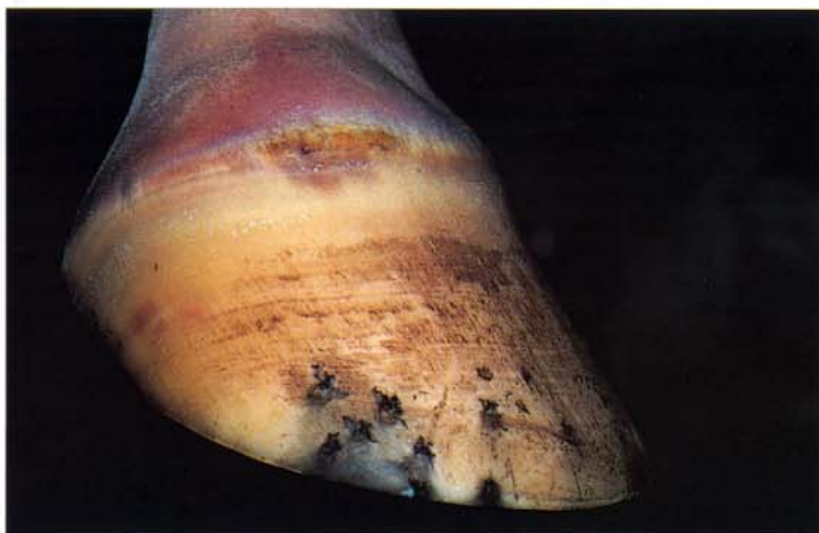342. Thrush (C). The frog of this horse is small and narrow. The central groove (sulcus) has become involuted and is discharging smelly, black material (thrush). The horse was not lame although palpation of the palmar frog and the bulbs of the heel caused a pain response. The probe shows the depth to which the sulcus had involuted. The normal sulcus is little more than a groove on the surface of the frog. A possible cause for the atrophy of this frog and its infection with thrush is that the over-long heels and nailing too far back could be preventing normal expansion and contraction of the heels.

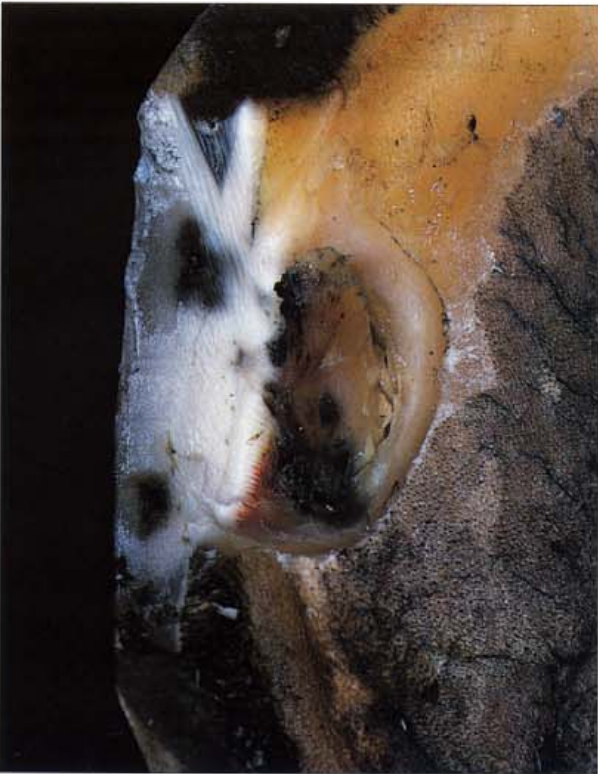Keratoma

343. Cylindrical keratoma (A). Tumours of the epidermis of the inner hoof wall are known as keratomas. They grow slowly and become a cause of lameness when their size exerts pressure on the lamellar dermis and the surface of the distal phalanx. This horse was presented with an acute, severe, lameness and what appeared to be a routine puncture wound to the sole. The photograph shows the focal area of damaged sole (arrowed) at the toe quarter junction.

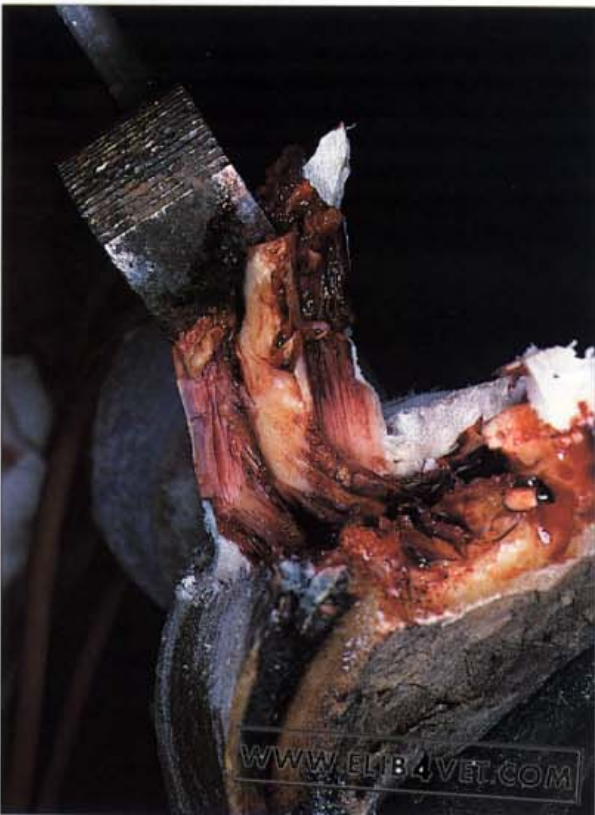

344. Cylindrical keratoma (B). The lateral view of the same foot shows nothing abnormal except a small crack along the hairline of the coronet. Pus was discharging from the crack. The direction of the hoof wall tubules, between the crack and the lesion of the sole, indicated that the two were connected. Pus generated at the sole was apparently tracking up the lamellae to discharge at the hairline of the coronet.

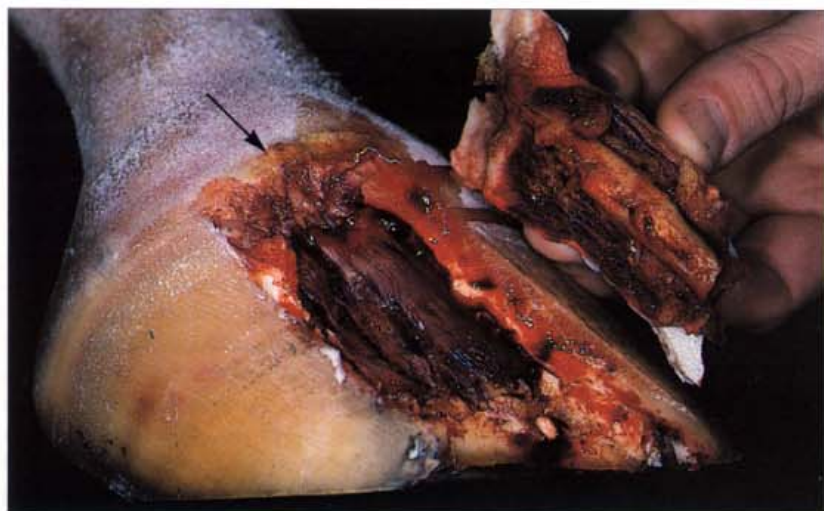



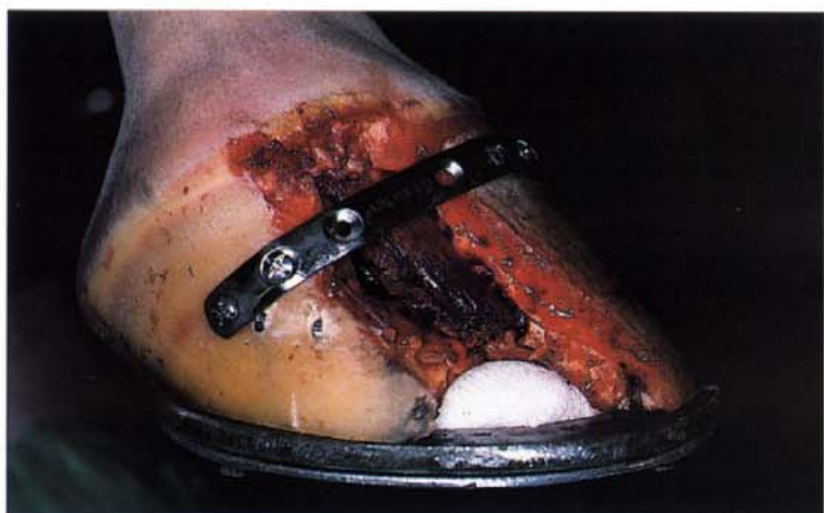345. Cylindrical keratoma (C). The horse was anaesthetized and Esmarch's bandage was applied to the lower limb to control haemorrhage. When the horn surrounding the lesion in the sole was pared away, the cause of the lesion was revealed. A long thin carrot-shaped keratoma was present projecting from the inner hoof wall towards the sole. Considerable necrotic material and pus surrounded the keratoma.



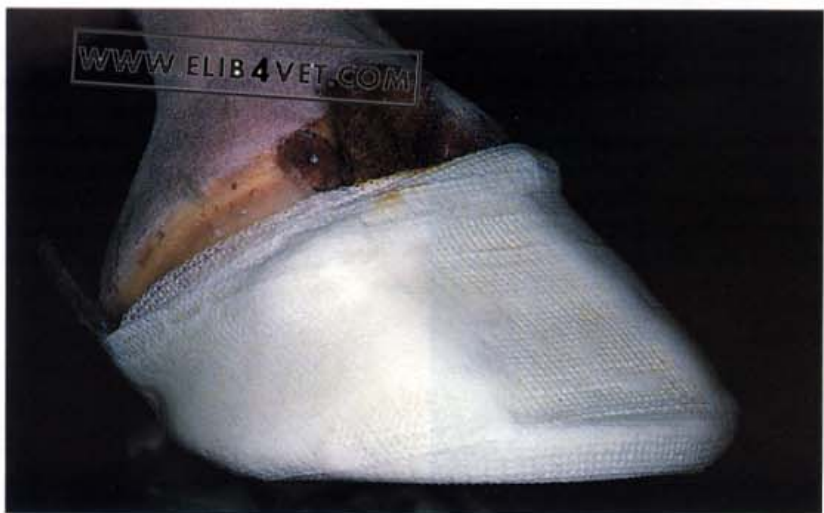346. Cylindrical keratoma (D). To remove the entire keratoma, two parallel cuts were made in the hoof wall on either side of the tumour. The sole was undermined and the wall and the keratoma were grasped with pull-offs and the hoof wall was peeled away from the dermis up to the coronet. Care was taken when the strip of wall was being separated from the coronary papillae to ensure that as little damage as possible occurred.



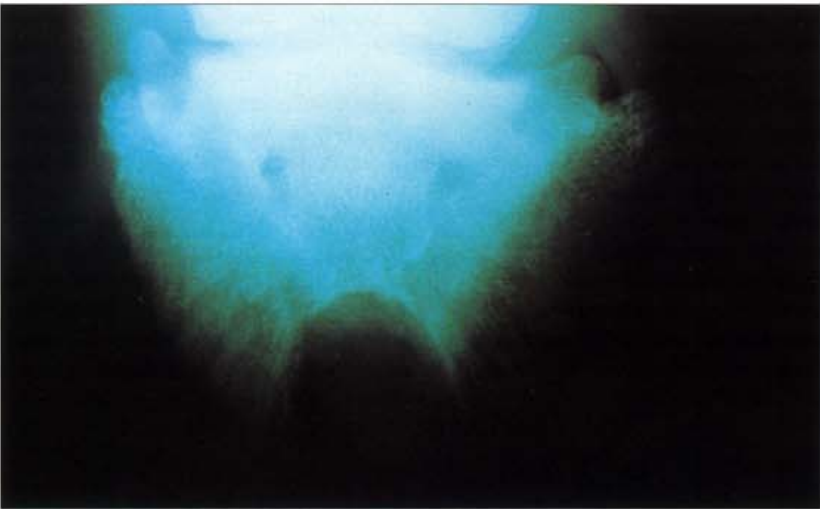
347. Cylindrical keratoma (E). This intra-operative photograph shows the strip of wall that was removed. The cylindrical keratoma can be seen still attached to the inner hoof wall and the point of discharge at the hairline of the coronet can be clearly identified (arrowed).



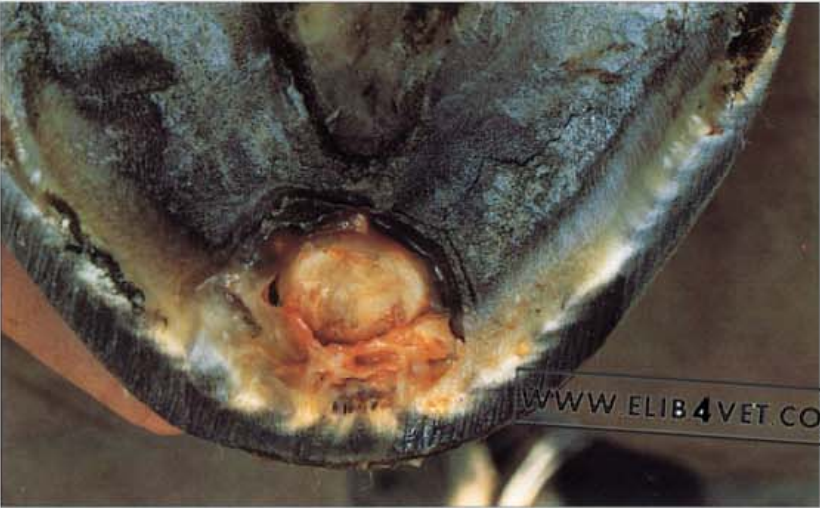348. Cylindrical keratoma (F). Surgery such as this, which removes a large portion of the hoof wall, seriously destabilises the integrity of the hoof capsule. Every effort must be made to maintain normal shape and function. In this case an orthopaedic bone plate was shaped and screwed into the wall to bridge the gap and stabilise the hoof. A hospital shoe was nailed to the foot.



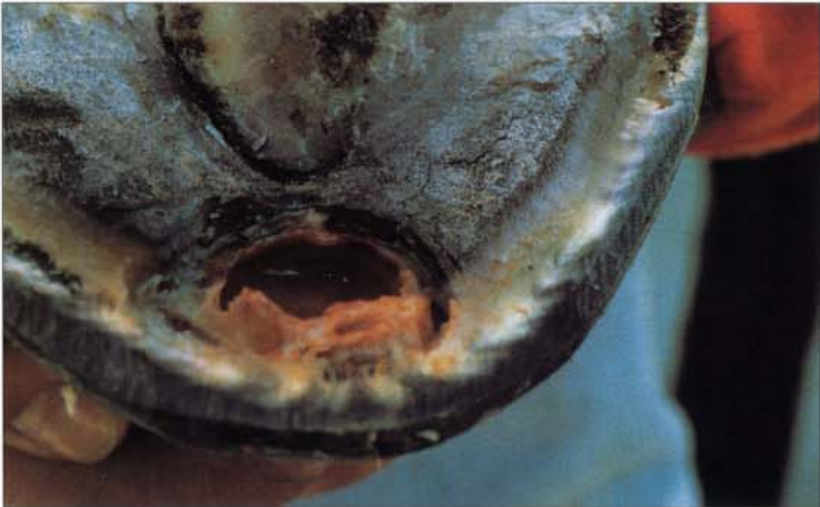349. Cylindrical keratoma (G). To add further stability to the hoof wall the hoof was cast with 3M hoof repair tape. Close to the coronet a swab was placed over the lesion so that the operation site could be dressed with a bland antiseptic such as povidone-iodine. The day after the surgery the horse was remarkably free of lameness and has made an uneventful recovery.



350. Spherical keratoma (A). This horse was presented with lameness to the right hindfoot and was sensitive to hoof tester pressure over the toe. Initially the diagnosis was an abscess and the horse responded to a course of antibiotic injections, although it remained sensitive to hoof testers applied to the toe. A fracture of the distal phalanx was suspected and radiographs were taken. A large walnut-sized cavity was present in the tip of the distal phalanx and the diagnosis was changed to keratoma. Photo: B. Duvernay.



351. Spherical keratoma (B). Resection of the sole at the toe revealed a large, spherical, pale-coloured mass which could be removed easily from its cavity. Photo: B. Duvernay.



352. Spherical keratoma (C). The photograph shows the cavity from which the spherical keratoma was removed. The lesion was dressed and the foot was shod with a wide-webbed shoe with hospital plate and the horse was completely sound 1 week later. Photo: B. Duvernay.

18 Navicular Disease (Podotrochleosis)

353. Navicular disease—*toe pointing*. An illustration from a mildewed page of the classic 1901 textbook *Mayhew's Illustrated Horse Doctor* shows a sorry-looking horse pointing its toe to ease the pain of chronic navicular disease. Nothing much has changed and horses almost a century later will show the same clinical sign if the disease has progressed to its 'end stage' (see 355).



A HORSE, WITH NAVICULAR DISEASE, POINTING IN THE STABLE.

354. Navicular stance. Horses with advanced navicular disease often stand with their forefeet 'in front'—i.e. more forward than normal. This posture apparently eases the pain and fits the hypothesis that the disease is somehow caused by the pressure of the deep flexor tendon on the flexor surface of the distal sesamoid (navicular) bone. Placing the feet forward appears to lessen the tension applied to the bone by the tendon. Photo: I. M. Wright.





355. Fractured navicular bone. The navicular bone in the right forefoot is fractured and the horse has adopted a posture typical when navicular pain is present. The toe is placed forward of the normal stance, with the heel raised, so that pressure from the deep flexor tendon against the flexor surface of the bone is minimised. When trotted, the horse was lame, and avoided the posterior phase of the limb cycle. Photo: Chris Taylor.

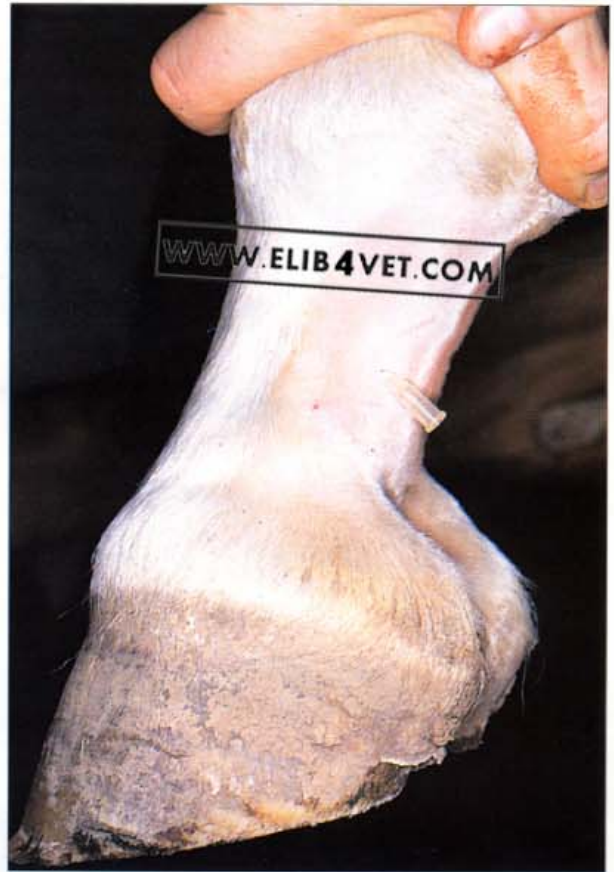

356. Navicular disease: clinical examination (A). A normal horse will show no discomfort if its toe is elevated like the one in the picture. However, a horse with navicular disease resents having its toe raised and will take avoidance action.

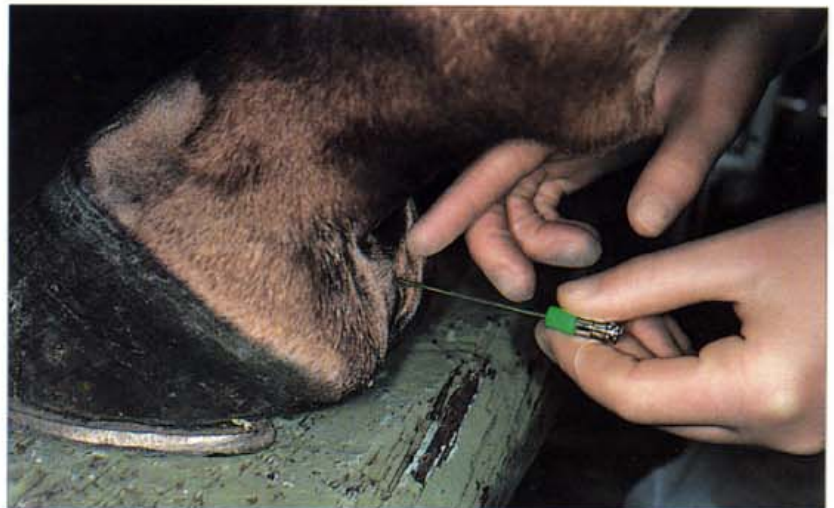

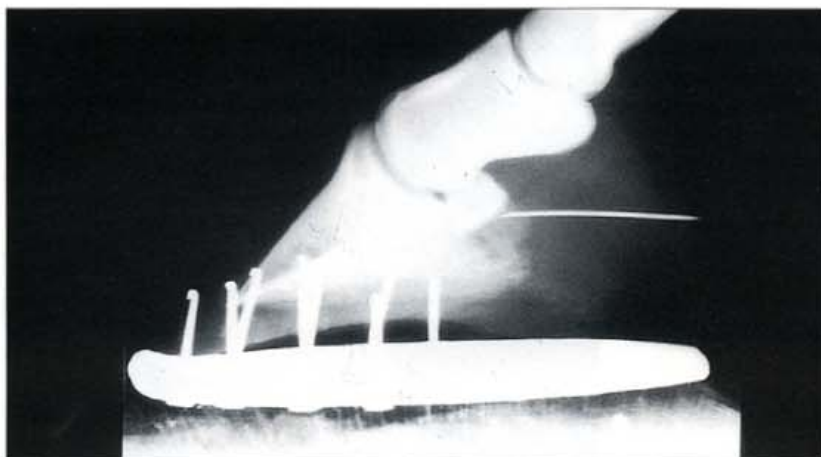
357. Navicular disease: clinical examination (B). The clinical examination of a horse suspected of having navicular disease should include compression of the middle third of the frog with hoof testers. The deep flexor tendon, the navicular bursa and the flexor surface of the distal sesamoid (navicular) bone lie deep to the middle third of the frog. If the horse repeatedly flinches when pressure is applied in this region it usually means that pathology to navicular structures is present. It is important to check that the pain response to the hoof testers is not being caused by injuries to other parts of the foot, for example a quarter crack.

358. Palmar digital nerve block. Local anaesthesia infused over the palmar digital nerves anaesthetises the foot from the quarters back. A successful bilateral palmar digital nerve block abolishes the pain of navicular disease and aids in its diagnosis. The nerve can be located under the skin of the mid ligament of ergot. In the photograph the operator is raising the ligament with thumb tension on the ergot. A 25 gauge hypodermic needle has been pushed through the skin ready for the infusion of local anaesthetic. An alternative site for this nerve block is illustrated in 11.

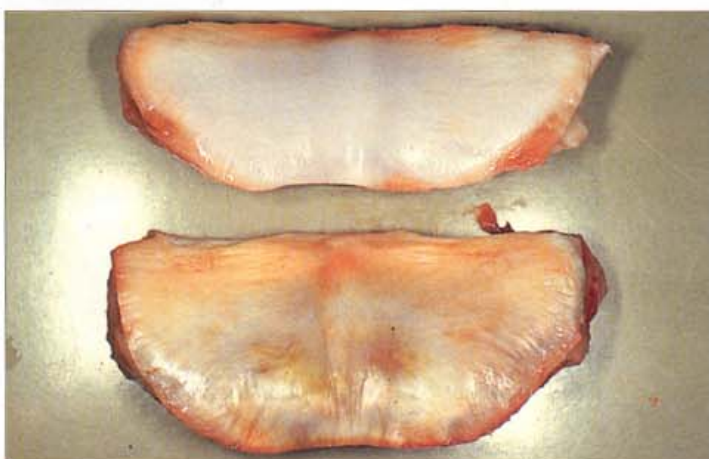

359. Local anaesthesia of the navicular bursa (A). Direct infiltration of the navicular bursa with local anaesthetic may aid in the diagnosis of navicular disease. The technique localises the source of pain to the navicular bursa and the flexor surface of the distal sesamoid (navicular) bone more specifically than does the palmar digital nerve block. It fails or is difficult to perform if extensive adhesions between the deep flexor tendon and the flexor surface have obliterated the bursa. The technique is performed aseptically (hence the gloved hands in the picture) and the long hypodermic needle needs to be guided to the bursa using an X-ray image intensifier or serial radiographs.

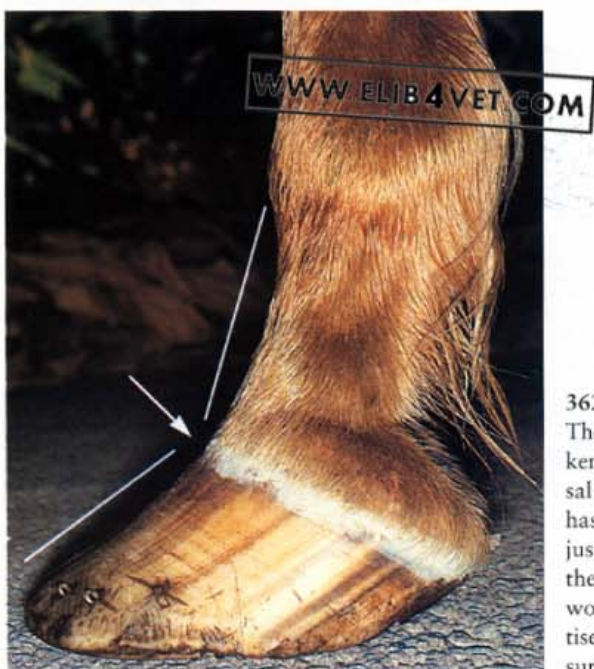



360. Local anaesthesia of the navicular bursa (B). A lateral radiograph taken to check that the hyperdermic needle has been correctly located in the navicular bursa. Photo: I.M. Wright.

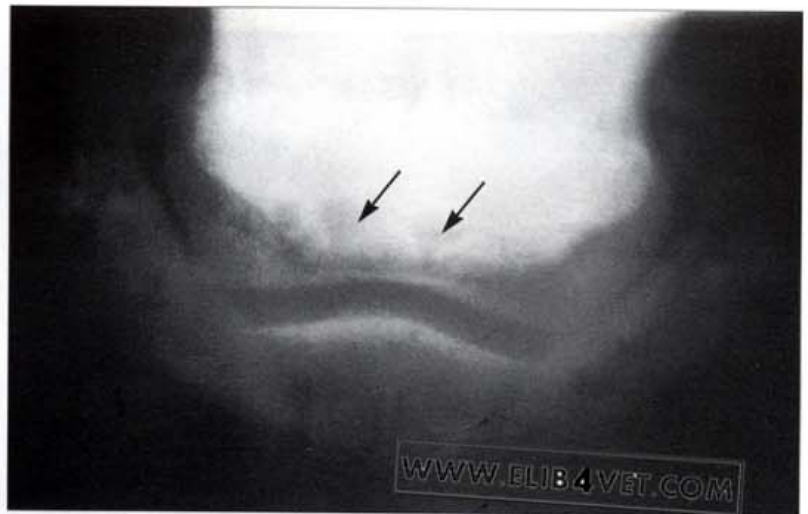
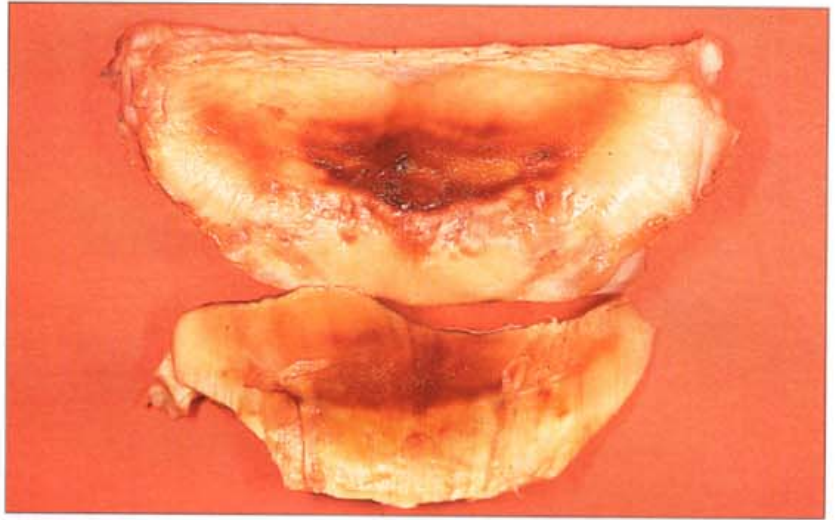


361. Distal sesamoid bone: flexor surface. Many consider navicular disease to be a man-made condition. The stress of competition or work, carrying the weight of riders or pulling heavy loads induces degenerative changes on the flexor surface of the bone. The distal sesamoid in the top of the picture comes from a 7-year-old feral horse which had never been ridden. The flexor surface is smooth, shiny and without blemish. In contrast the flexor surface shown in the bottom of the picture is from a horse which had just completed a 100-mile endurance ride carrying 96 kg. The surface is ridged, roughened and discoloured. These changes are centred at precisely the site where navicular disease develops.

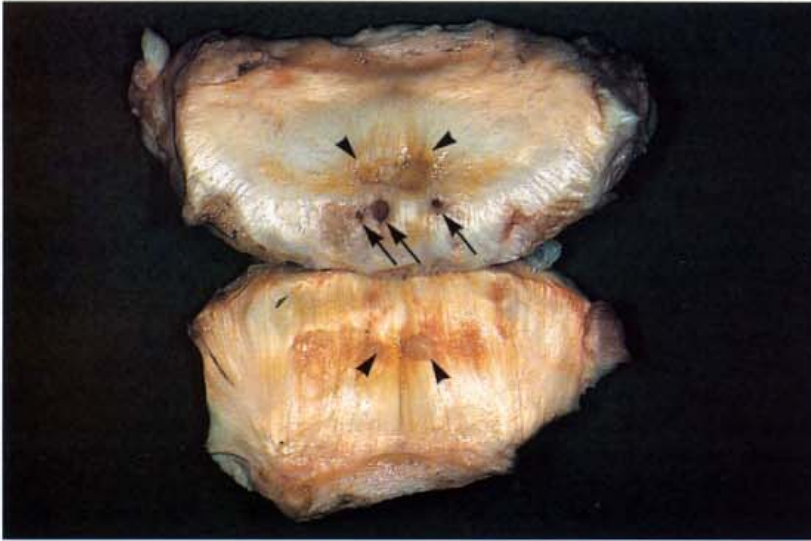


362. Navicular trauma caused by broken-back hoof pastern axis (A). The hoof pastern axis of this Thoroughbred racehorse is severely broken back (in the direction of the arrow). The hoof tubules and the dorsal hoof wall should be in line with the bones of the pastern. The toe has been left long and the heels low. The horse is shod, and you can just see the shoe underneath the overgrown hoof wall at the toe, but the shoe is providing no support for the heels. If a horse is made to work with its feet in this state, excessive and unnatural forces traumatise the flexor surface of the navicular bone and the opposing (kissing) surface of the deep flexor tendon.

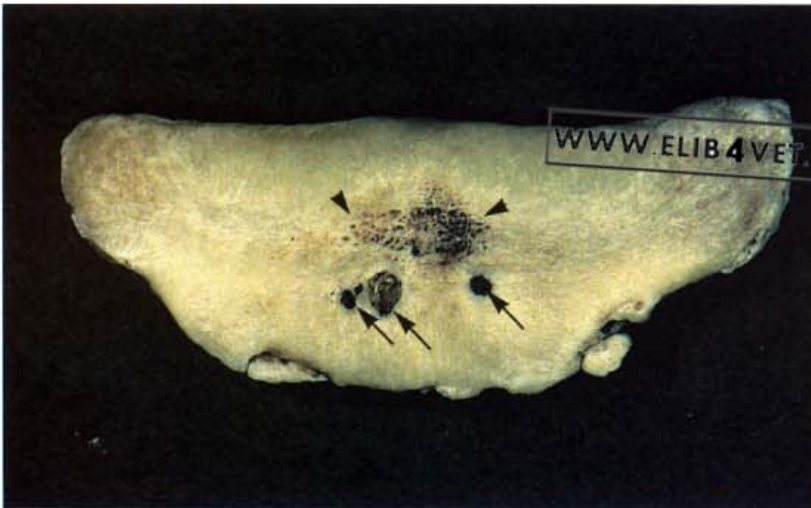
363. Navicular trauma caused by broken-back hoof pastern axis (B). The navicular bones from the horse in 362 were harvested after the horse met with an accident. The severely broken-back hoof pastern axis appears to have caused severe damage to the flexor surface of the navicular bone. The fibrocartilage is pitted and eroded and trauma has caused it to haemorrhage. The portion of the deep flexor tendon, which makes contact with the flexor surface of the distal sesamoid bone, bears mirror image or 'kissing' lesions and is shown in the bottom of the picture. This is a graphic example of the consequences to the navicular bone when a horse with a broken-back hoof pastern axis is galloped.



364. Navicular disease lameness: case history (A). When the flexor surface of the distal sesamoid (navicular) bone degenerates significantly the lesions can be detected with radiographs. Careful positioning of the horse's foot and good radiographic technique are required to obtain diagnostic images. The radiograph illustrated is from a 9-year-old Thoroughbred gelding used initially for eventing and later for dressage. At the time the radiograph was made the horse was chronically lame in the left foreleg. The lameness was abolished when the palmar digital nerves were infiltrated with local anaesthetic. The radiograph shows two large circular, radiolucent areas (arrowed) which were assumed to represent foci of collapsed, lysed bone in the cortex of the flexor surface of the bone. The horse was rested for 18 months but despite medical treatment no improvement in the lameness occurred. After euthanasia the distal sesamoid bones were subjected to detailed examination.

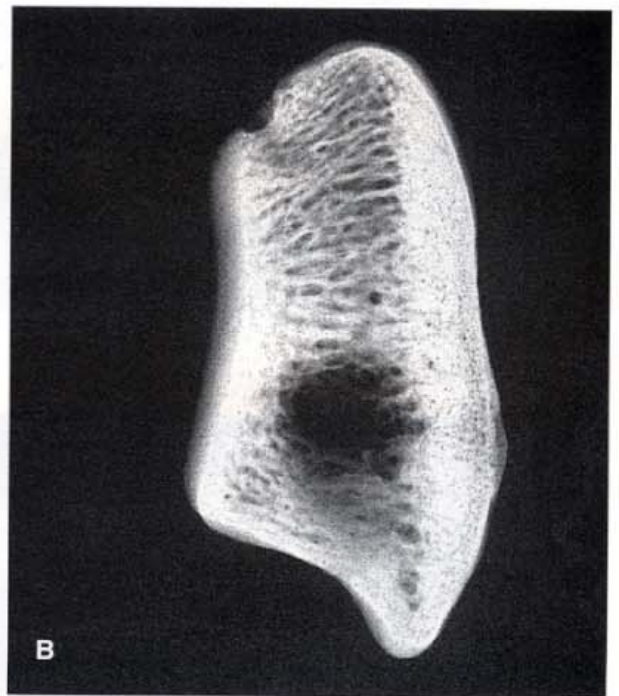
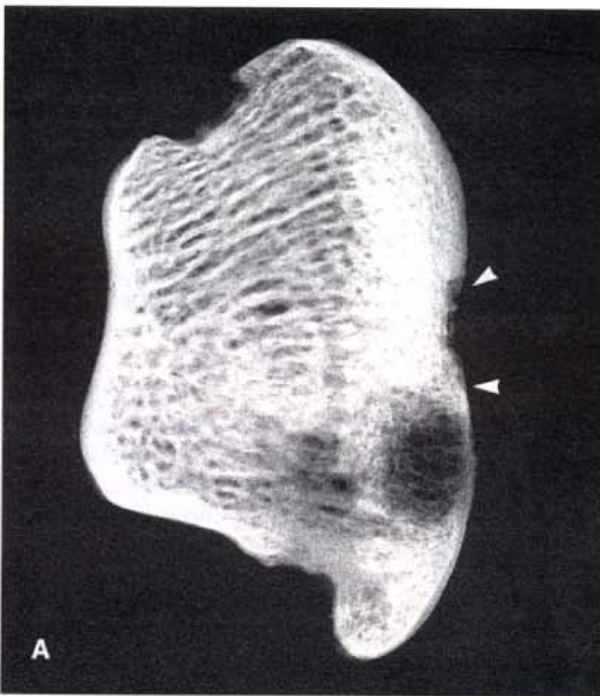
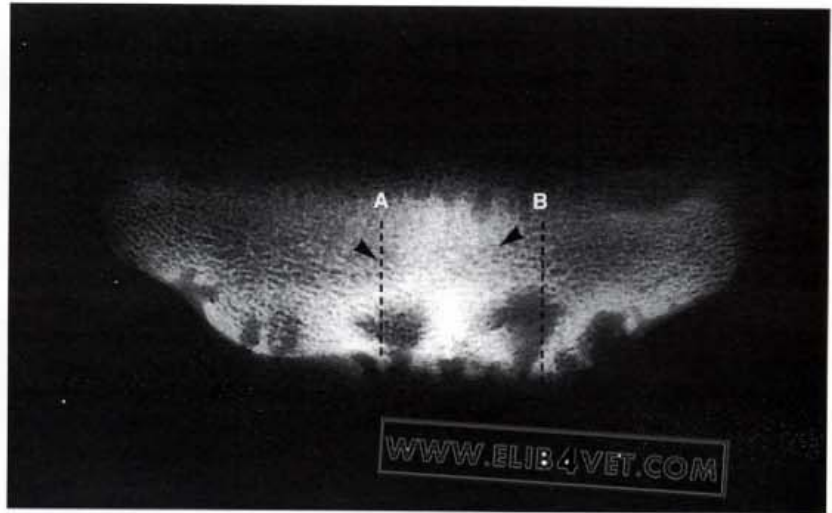


365. Navicular disease lameness: case history (B). Three cavities filled with granulation tissue were present on the flexor surface of the left navicular bone (arrowed), and correlated with the two lucent areas on the radiograph. The cavities on the surface of the fresh bone appeared smaller than the circular lucent areas on the radiograph, suggesting the presence beneath of even larger cavities, in the body of the bone. In the centre of the flexor surface of the bone was a large ulcerating patch of degenerate fibrocartilage (arrowheads); the major adhesions on the opposing surface of the deep flexor tendon (arrowheads) corresponded with this. The clinical radiographs did not detect this central lesion.

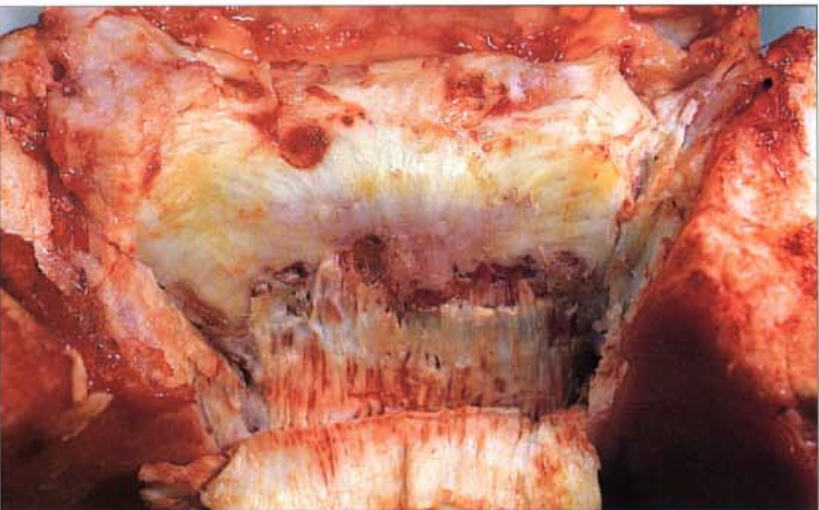

366. Navicular disease lameness: case history (C). The left navicular bone was boiled in water for several hours. This removed cartilage and connective tissue and exposed the surface of the bone to further examination. The three granulating cavities identified on the fresh bone were present in the cortex of the flexor surface of the bone (arrowed). They appeared to connect to hollow cavities beneath. The central lesion (arrowheads) was also clearly visible and appeared to be an area of bone lysis on the point of collapse. A surprising finding was two fractures on the distal border of the bone. Neither the central lesion nor the two fractures were detectable on the radiographs of the living animal. All of the pathology detected, contributed to the horse's lameness. However, only the cause of some of it could be detected with radiographs. This is why navicular disease is never a diagnosis based solely on the results of radiology. It must always be a clinical diagnosis, taking into account the history, clinical signs and results of nerve blocks.

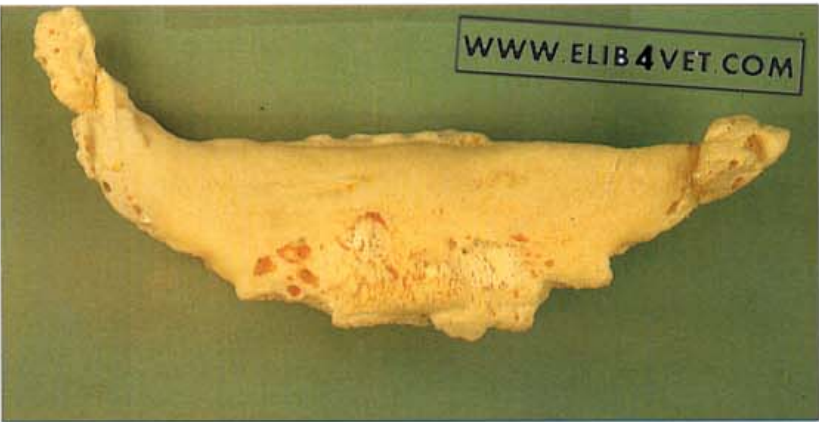367. Navicular disease lameness: case history (D). A fine-detail radiograph of the isolated left navicular bone yields additional information. The two chip fractures of the distal border of the navicular bone, which could not be detected from radiographs made when the horse was alive, are not visible here because they are superimposed on densely calcified bone. The three cavities on the flexor surface, which are arrowed in 365 and 366, are not directly above the radiolucent cavities in the body of the bone. Whether the surface defects connect to the internal cavities cannot be ascertained at this stage. The bone beneath the central lesion (arrowheads in 365 and 366) is densely mineralised and sclerotic and does not appear to be a zone of bone lysis on the point of collapse. Radiography: Kira Reynolds.



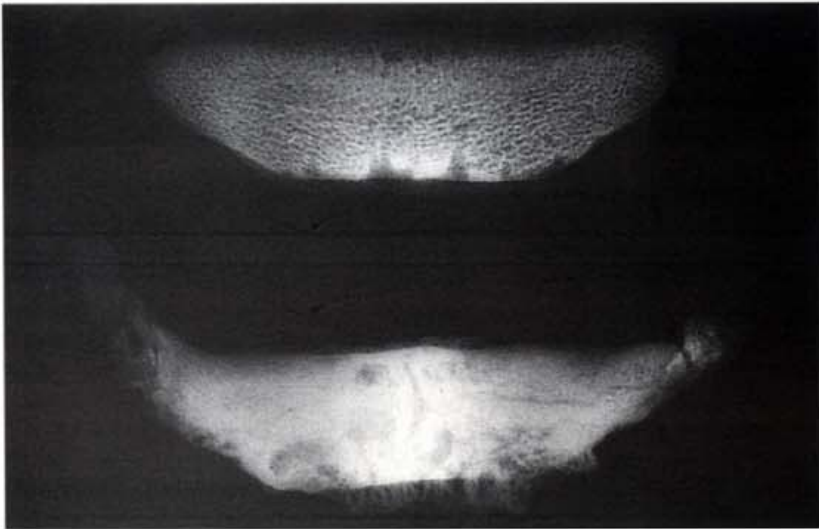
368. Navicular disease lameness: case history (E). The left navicular bone was sectioned along the planes A and B as shown in 367 above. Fine-detail radiographs were made of each section. Section A, taken through the large cavity on the flexor surface, shows that a large portion of the dense cortical bone of flexor surface had been resorbed. Resorption of bone in the region of the central lesion (arrowheads) was also underway. The section at B shows a large resorption cavity in the spongiosa of the bone. In life these cavities in the body of the distal sesamoid bone are filled with fibrotic inflammatory tissue, which perpetuates the destructive resorption of bone, and leads to the build-up of pressure within the bone. This high intramedullary bone pressure is thought to be the cause of most of the chronic, unrelenting pain of navicular disease. The crippling effect of bone-related pain in one small bone, in one foreleg, led to the destruction of this large Thoroughbred horse. Radiography: T.Daley.



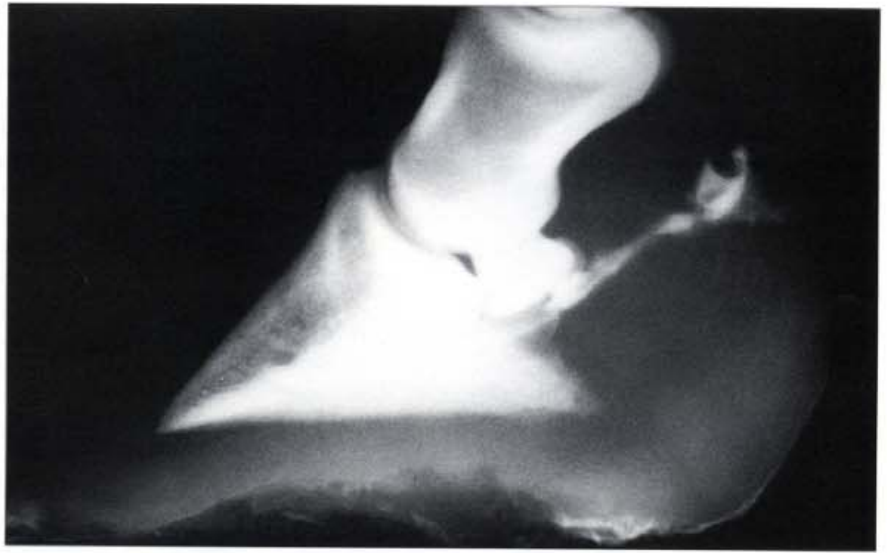
369. End-stage navicular disease (A). The view is the same as 46: the deep flexor tendon has been reflected down to show what remains of the flexor (palmar) surface of the distal sesamoid bone. The normally smooth surface of the bone is ulcerated and roughened and there are many adhesions between the bone and the tendon. The normal range of movement between the tendon and the bone is severely restricted and a source of considerable pain for the horse.



370. End-stage navicular disease (B). The distal sesamoid bone from the specimen in 369 has been removed and cleaned. The flexor surface is eroded and pitted and all the borders of the bone show osteoarthritic changes. The insertions of the distal sesamoidean suspensory ligament have calcified to form enthesiophytes.

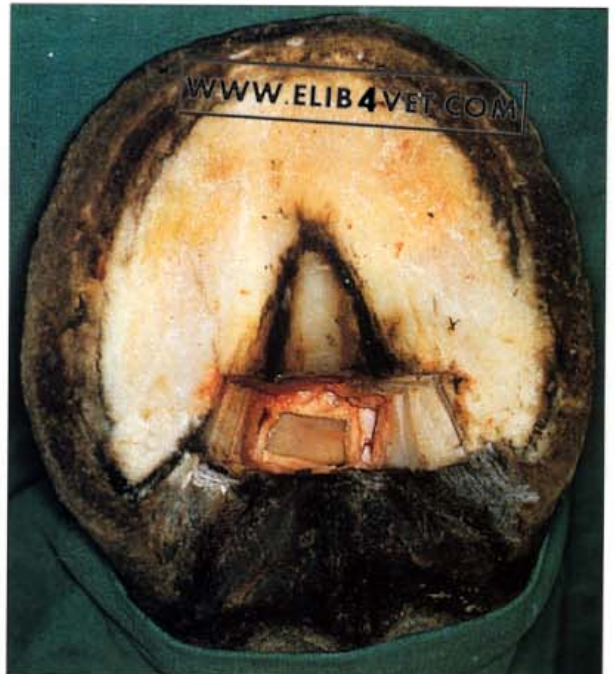

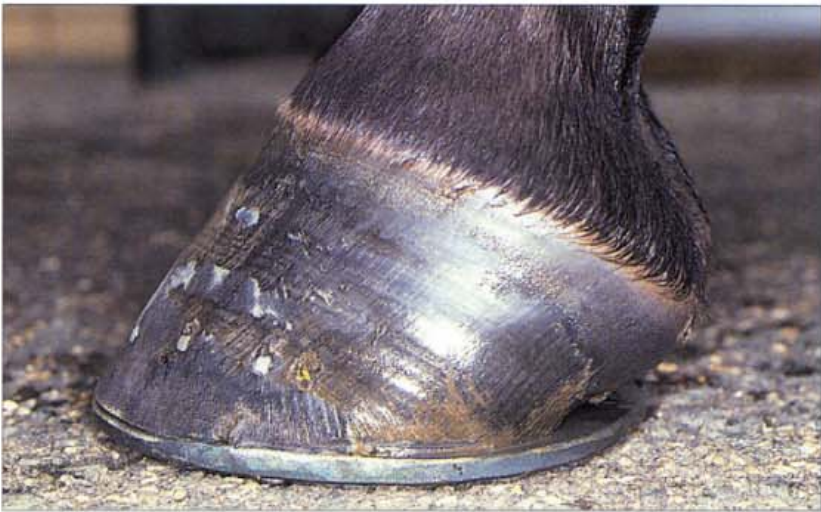371. End-stage navicular disease (C). Radiograph of a normal navicular bone (top) compared to the end-stage navicular bone in 370. Chronic sclerosis has caused dense calcification of the diseased bone.



372. Infection of the navicular bursa (A). Occasionally, deep puncture wounds to the foot penetrate the navicular bursa and set up an infection. A septic navicular bursa carries a grave prognosis for the future athletic capability of a horse and requires the establishment of prompt surgical drainage. The longer this is delayed the worse the likely outcome. Thus, it is important to diagnose with certainty the extent of penetrating wounds to the foot. Injecting radio-opaque contrast medium either into the wound to outline the bursa or into the bursa to outline the wound will usually achieve the desired result. In the case illustrated the horse somehow managed to draw its foot over the sharp end of a wire fence tie to cause a deep wound between the bulbs of the heels. Contrast medium injected into the wound proved that the wound had penetrated the navicular bursa. Radiograph: R. Greer.

373. Infection of the navicular bursa (B). To achieve surgical drainage of an infected navicular bursa an operation, known as the 'street nail operation', is performed. Under sterile surgical conditions, a rectangular window is cut through the frog, digital cushion and deep flexor tendon to open the bursa by exposing the flexor surface of the distal sesamoid (navicular) bone. In the photograph the flexor surface of the navicular bone can be seen at the base of the surgical site. The foot is kept dressed until the wound heals by granulation. Photo: I.M. Wright.

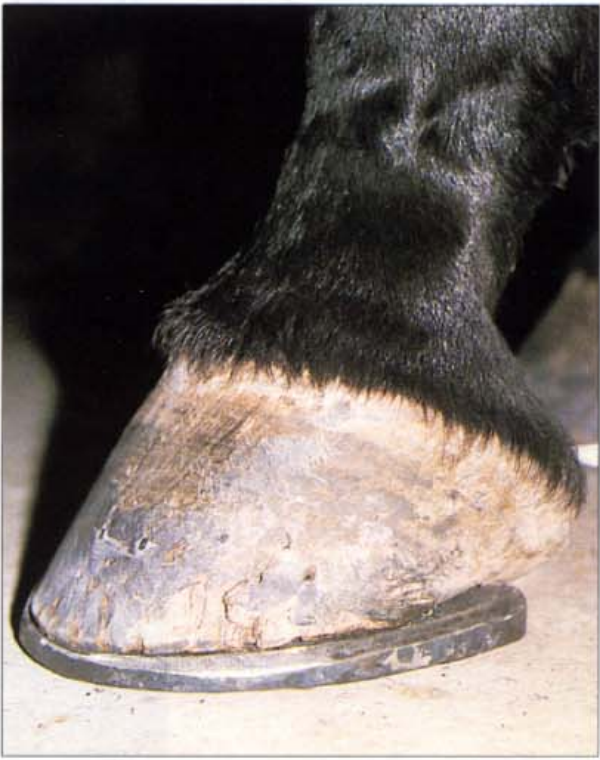



374. Egg-bar shoe (side view). Many horses with the early clinical signs of navicular disease respond favourably to being shod with egg-bar shoes and nothing else. The biomechanical imbalance responsible for early navicular pain appears to be neutralised when the hoof pastern axis is corrected and the shoe provides the heels with support and plenty of room for expansion.



375. Egg-bar shoe (solar view). Egg-bar shoes are quite difficult to make and need to be custom forged by an experienced farrier. The shoes improve the action of the horse, so over-reaching causing loss of the shoe, is rarely a problem. The toe of this shoe has been rolled to improve the speed of break-over. Photo: K. Swan.



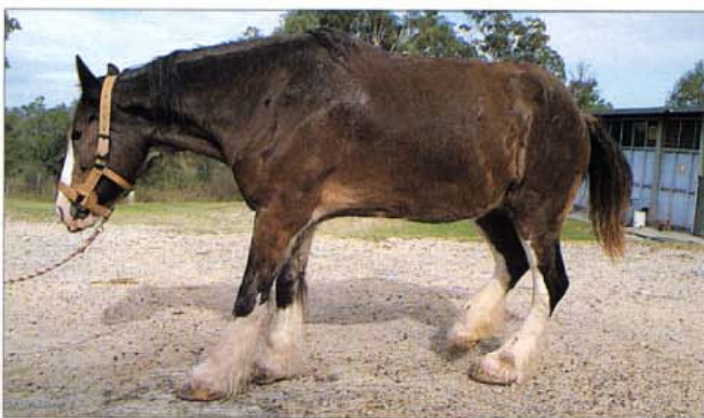376. Wedged egg-bar shoe. Sometimes, to correct the hoof pastern axis it is necessary to raise the heels. Although this can be done with plastic wedges, a better response in terms of heel growth and support is achieved if a wedged, steel, egg-bar shoe can be made and fitted. Photo: K. Swan.

19 Laminitis


377. The gait of a horse with severe laminitis (A). When a horse develops laminitis the front feet are invariably the most severely affected. It becomes extremely painful for the horse to accept weight on its front toes, but if forced to walk it will bring its hind legs well under and half rear before stepping forward in front. The posterior phase of the stride in front is thus very much shortened. Although the relief of pain is ethically important it is nevertheless detrimental to abolish it completely with peripheral nerve blocks and large doses of analgesics, because walking without the warning signal of pain will worsen the mechanical destruction of the already compromised hoof-distal phalanx bone bond.



378. The gait of a horse with severe laminitis (B). Large, heavy horses, such as this Clydesdale mare, are often more severely affected by laminitis than are small ponies. A generous, but misguided baker, caused the mare to founder by dumping a large load of bread into her paddock.

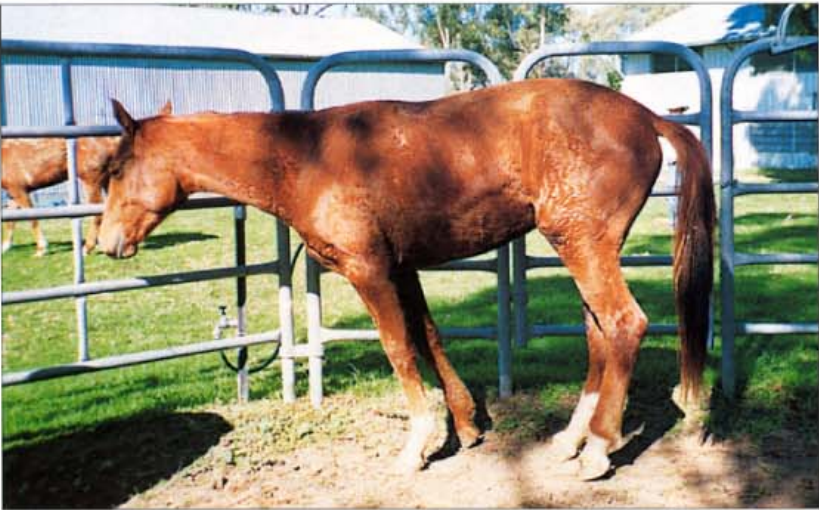

379. The gait of a horse with severe laminitis (C). Horse owners of the last century were quite familiar with the sight of horses suffering from laminitis. This engraving from Dollar's 1898 textbook, *The Handbook of Horseshoeing*, shows a horse with the same painful gait as the horses photographed more recently (377 and 378).



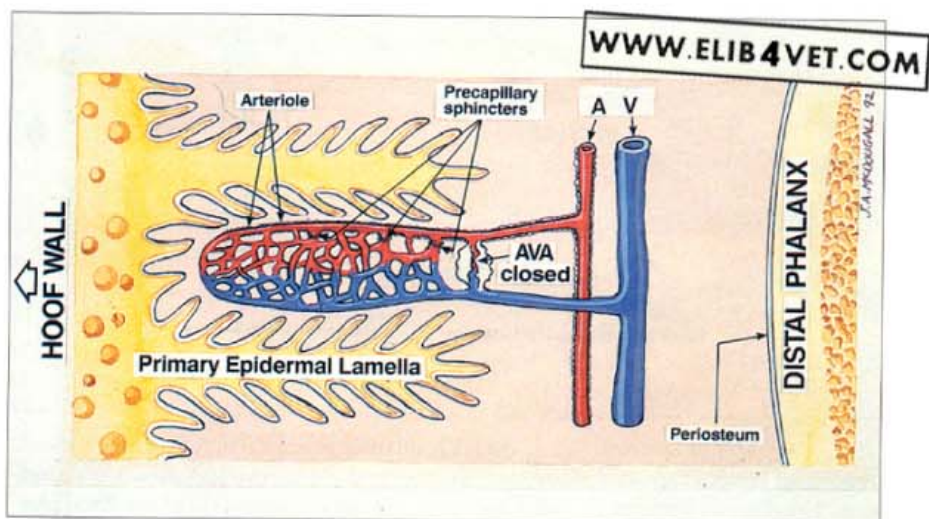


380. Laminitis stance: forefeet. Laminitis usually affects the forefeet more severely than the hind; presumably because the forequarters carry a greater proportion of the horse's weight (about 65%). Often the hind feet appear to be spared completely. In the chronic laminitis case pictured, the mare is shifting weight from one forefoot to the other (the right limb is flexed and off the ground). The weight-bearing foot is placed forward to minimise the pull of the deep flexor tendon on the distal phalanx and to thus relieve the pressure of the descended distal phalanx on the sole. The shifting weight behaviour of horses with laminitis, is undoubtedly performed to relieve pain. The common explanation is that when the pain in one foot becomes unbearable the foot is lifted off the ground. Pain then mounts in the weight-bearing foot until the horse feels compelled to relieve it by shifting weight to the other foot. Horses with chronic laminitis shift weight like this for months, sometimes years.



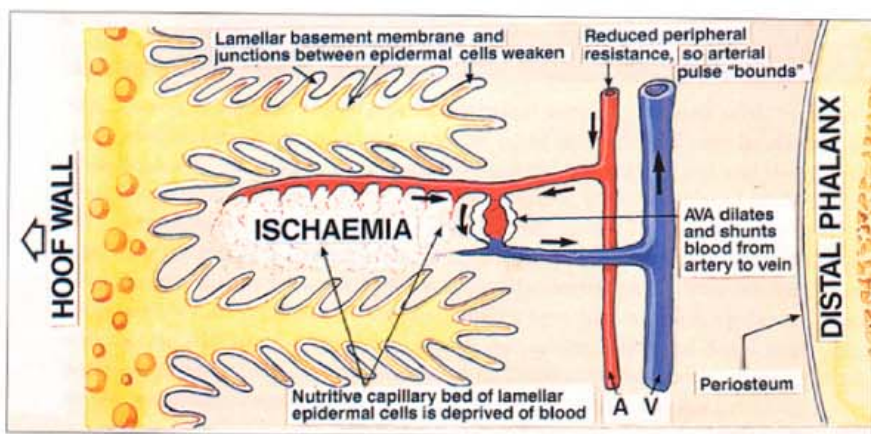
381. Laminitis stance: hind feet. When laminitis occurs in the hind feet instead of the fore the laminitis stance is quite different (compare with 377 and 378). In the picture the horse is shifting weight from one hind foot to the other and the forefeet are placed well back under the belly. The head is lowered to act as a counterbalance and the horse is leaning over its forefeet in an attempt to relieve its hind feet of weight bearing.

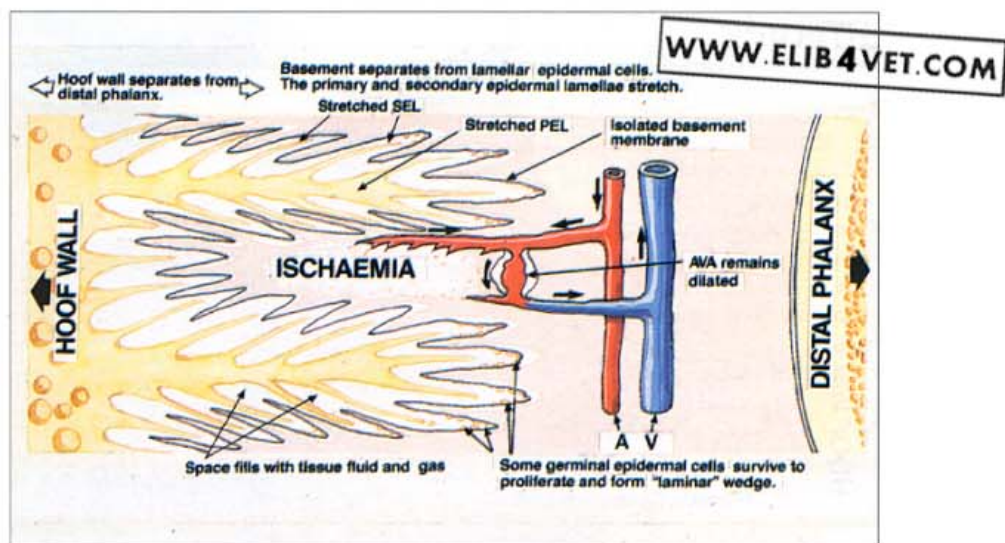
Development of Laminitis



382. The cause of laminitis (A). Prolonged inappropriate dilation of the dermal arteriovenous anastomoses (AVAs) in the microcirculation of the foot has been implicated in the development of laminitis. AVAs are involved in the thermoregulation of the foot and are well endowed with nerves and smooth muscle. In very cold conditions AVA dilation can bring warm arterial blood rapidly to the tissues of the foot to prevent freezing. However, blood is drained from the capillary bed (the 'steal effect') when AVA dilation is at its maximum, so the shunting of blood can only occur on a periodic basis; the avascular epidermal cells of the hoof/distal phalanx bond depend on the capillary circulation for their survival. When AVAs are closed, blood circulates slowly through the capillaries and serves the gaseous exchange and nutrient requirements of the epidermis. When AVAs are open the circulation is in thermoregulation mode. It is yet to be discovered how a perturbation in AVA control of the feet is brought about by disease processes elsewhere in the body.

383. The cause of laminitis (B). During developmental laminitis AVAs remain pathologically dilated for long periods of time (around 18 hours) and shunt blood away from the nutritive capillary bed of the lamellar epidermal cells. Deprived of their blood supply (ischaemia) the epidermal cells lose their attachments to one another and to the basement membrane, and the architecture of the hoof/distal phalanx bond deteriorates. While this initial AVA dilation is occurring there are no clinical signs of foot pain.

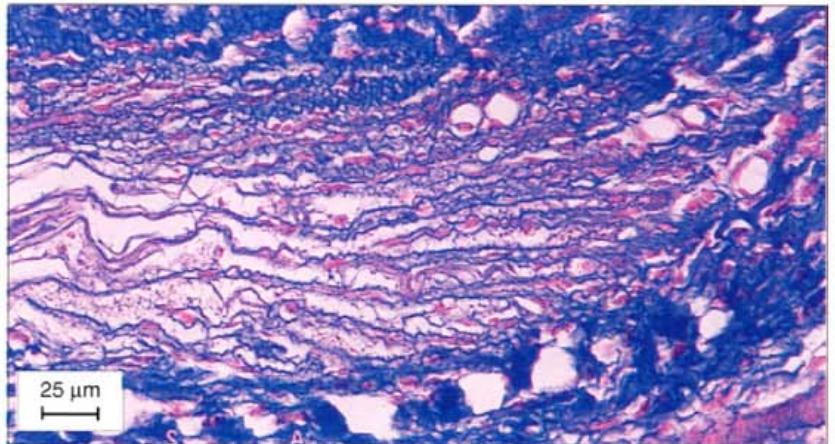
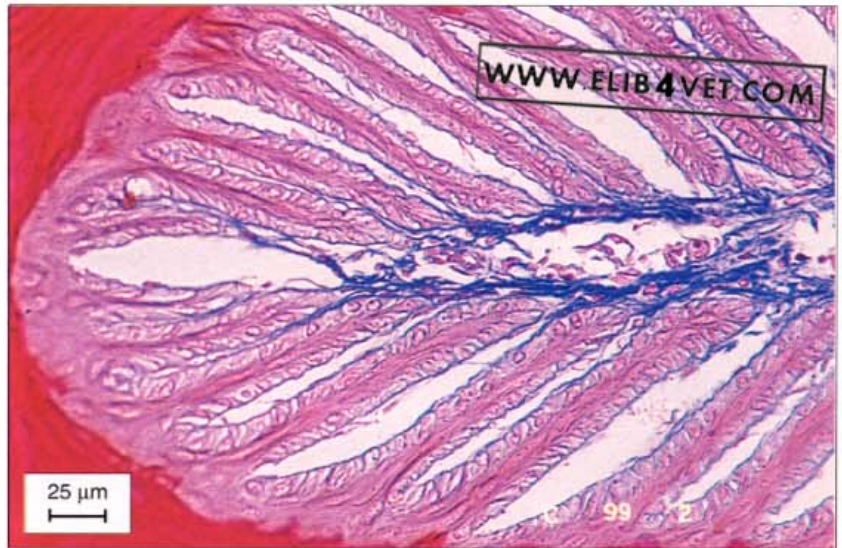




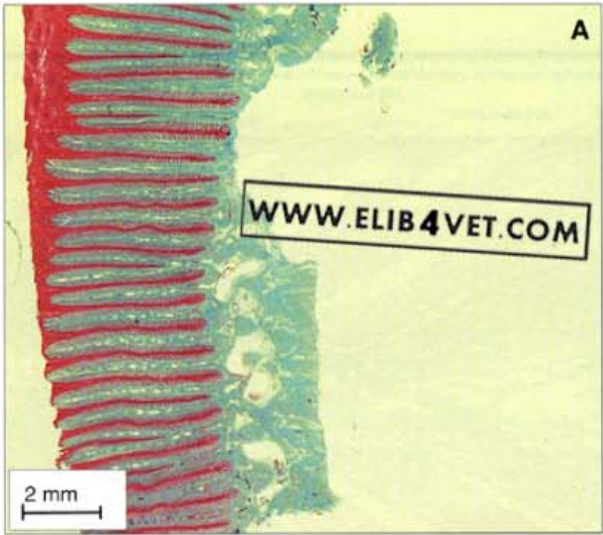384. The cause of laminitis (B). If the AVA dilation persists, the ischaemia worsens. Epidermal lamellae are stripped from their basement membrane and stretch and elongate. The distance between the inner hoof wall and the dorsal surface of the distal phalanx increases as one tears from the other. Clinical signs of pain are evident as the distal phalanx begins to descend down into the hoof capsule and on to the sole. Islands of epidermal cells survive to proliferate and form the lamellar wedge.

Laminitis: Histology

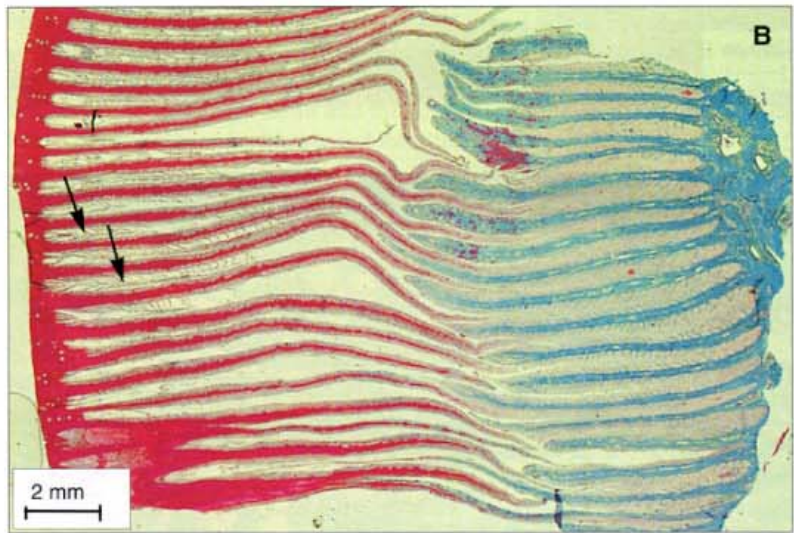
385. Acute laminitis—transverse histological section. Stained with Masson's trichrome, the transverse section is taken from the base between two epidermal lamellae (the tip of a dermal lamella). Already affected by acute laminitis, the blue-staining connective tissue has peeled and stripped away from the epidermal lamellae and is accumulating in the region of the primary dermal lamella. At this stage the pink-staining epidermal cells seem unaffected but without the support of the dermal blood supply they will soon disintegrate. The picture shows the failure at the hoof-distal phalangeal bond at its earliest stages. Refer to 61 for the normal appearance of this region.



386. Acute laminitis: transverse histological section. Stained with Masson's trichrome, this is a transverse section of the tip of an epidermal lamella affected by acute laminitis. As before, the epidermal material has stained red and the dermal blue, but now the striking thing about this section, when compared with normal (63), is the almost total absence of red epidermal tissue. The pathological mechanism of acute laminitis has apparently caused the epidermal basal cells and the dark red keratinised cells to be stripped of their attachment to the blue-staining basement membrane and connective tissue. Only a few, pink-stained, epidermal basal cells remain still attached to the basement membrane. The hoof-distal phalangeal bond has disintegrated and the blue-staining connective tissue now shows a loose, wavy pattern characteristic of structures no longer under tension.

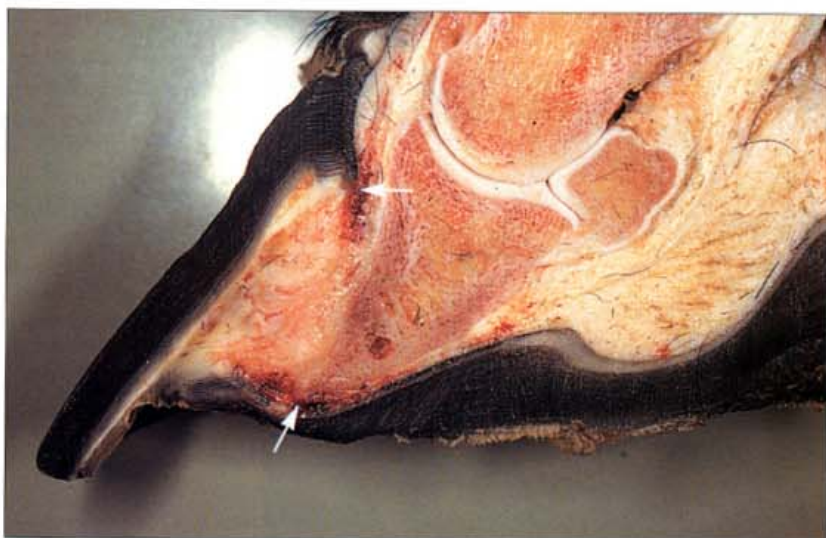

387. Chronic laminitis: histology. When laminitis causes failure of the hoof-distal phalanx bond the epidermal lamellae are stretched well beyond their normal limits. Both these sections have been stained with Masson's trichrome and have been photographed at the same magnification. The upper picture (A) shows the epidermal lamellae of the dorsal hoof wall of a normal Thoroughbred. The bottom picture (B) shows the lamellae of a Thoroughbred horse 14 days after first developing laminitis. Laminitis has caused the red- and pink-staining epidermal lamellae in (B) to stretch and distort almost five times the normal cross-sectional length. There is now a space between the blue- staining dermal tissue and the inner hoof wall. The remnants of a few secondary epidermal lamellae (arrowed) project into the spaces between the primary lamellae. The section is a graphic illustration of how laminitis weakens the important bond between the inner hoof wall and the distal phalanx.

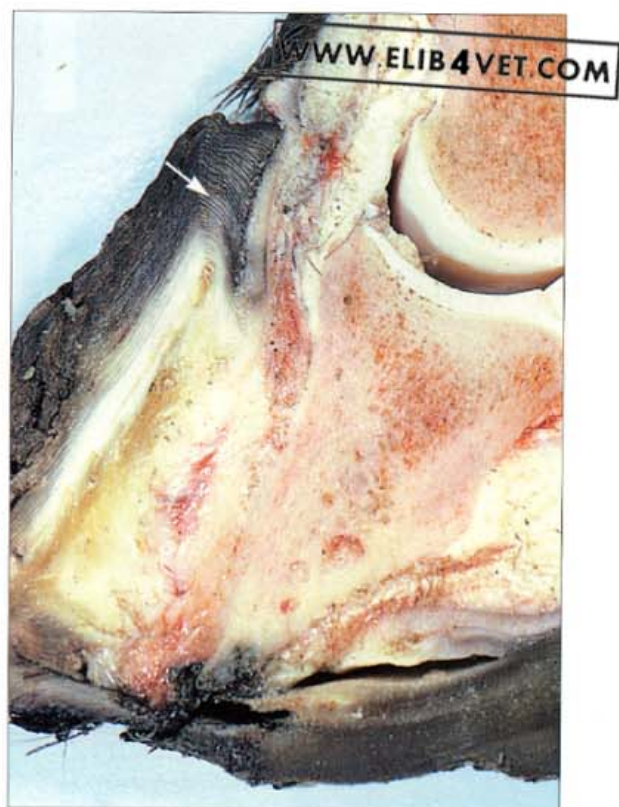


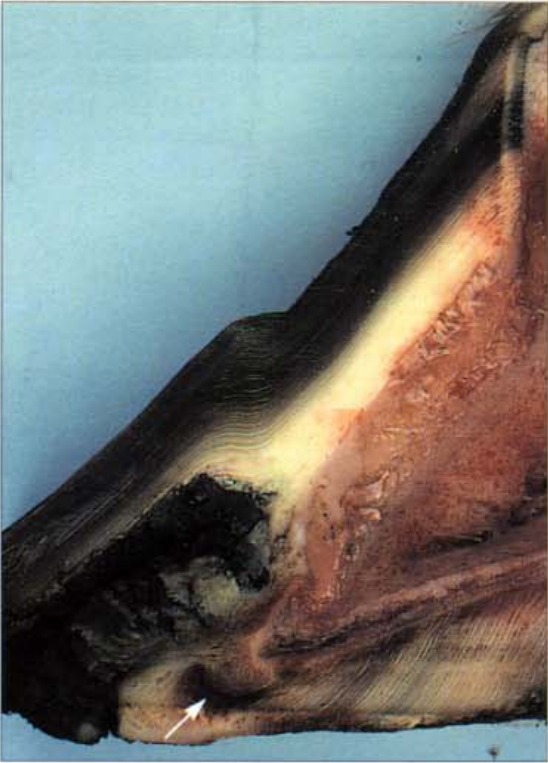Laminitis: Sections

388. Severe chronic laminitis: sagittal section . A feeding mistake caused this 2-year-old Thoroughbred racehorse to founder. The distal phalanx and the dorsal hoof wall have lost their attachment and have become widely separated (compare with 7). The tissue now between the inner hoof wall and the bone is abnormal and consists of epidermal tissue proliferating to form a weak, disorganised mass called the lamellar wedge. The descent of the unattached distal phalanx into the hoof capsule has distorted the growth of the proximal hoof wall tubules and has caused the sole to become convex instead of concave (dropped sole). Two dark haemorrhagic zones (arrowed) show the sites of greatest pressure and trauma.

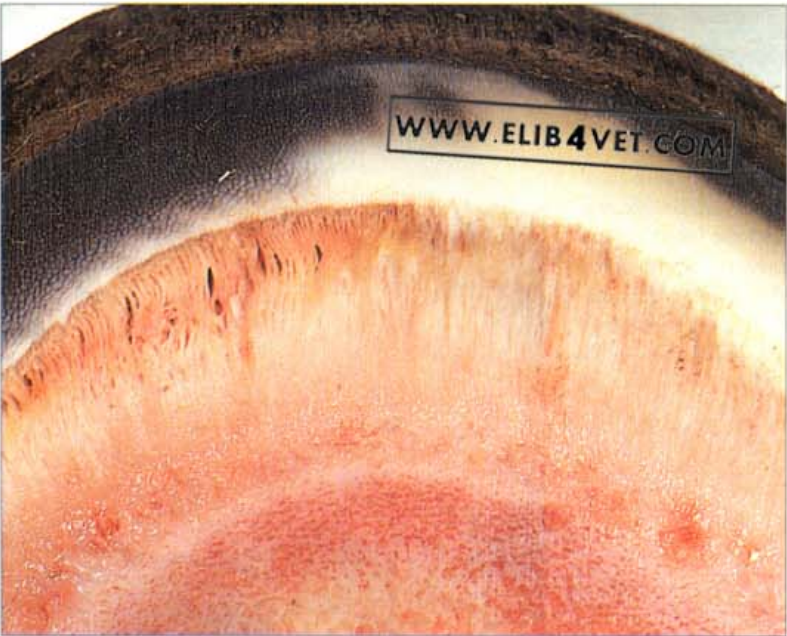

389. Severe chronic laminitis with osteomyelitis. In laminitis, when the distal phalanx is torn from the inner hoof wall, cells of the lamellar epidermis which survive, proliferate to form the weak, flaky lamellar wedge. The wedge fills the space between the bone and the hoof wall but is no longer able to adequately suspend the distal phalanx within the hoof capsule. The bone descends and its distal tip may crush the solar corium and the sole proper unless early mechanical support is applied to the foot. Only certain areas of the foot can be employed for support and the sole is NOT one of them. The illustration shows what happens when a steel bar is fixed directly beneath a descending distal phalanx (see 134). The sole and the solar corium are necrotic and gangrenous and the infection has underrun the sole. Osteomyelitis is present in the tip of the distal phalanx. Note also how the descent of the distal phalanx has distorted the direction of hoof tubule growth at the coronet (arrowed). The distal hoof wall has disintegrated because the circulation to the toe has failed.



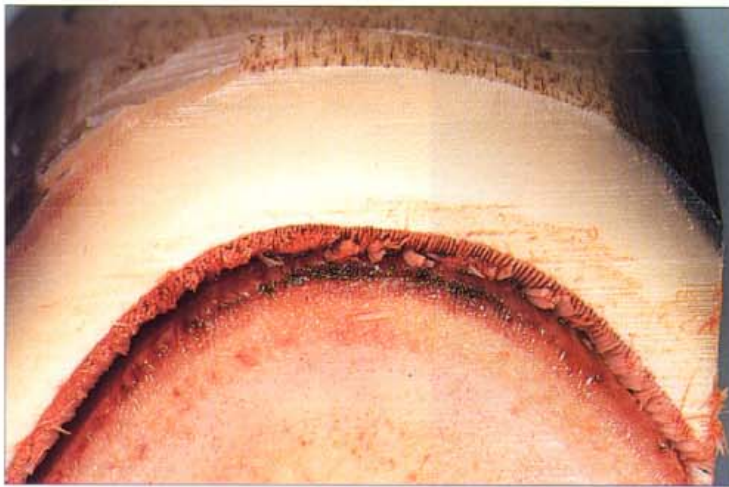
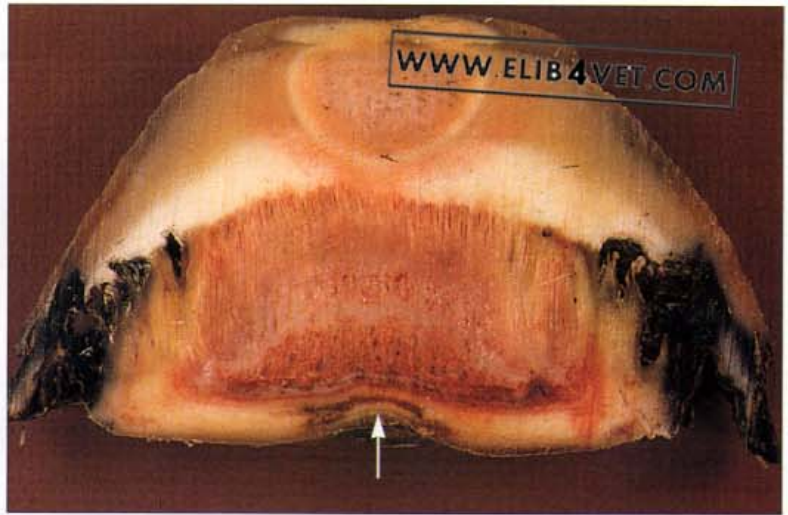


390. Sagittal section of a foot with chronic laminitis. Four and a half months after a moderately severe attack of laminitis this untreated Quarterhorse gelding was humanely destroyed at the owner's request. Sagittal sections revealed the history of the front feet as they coped with the problems associated with failure of the hoof-distal phalanx bond. Half-way down the length of the hoof wall the hoof wall tubules are deformed. This marks the time when laminitis first occurred. Proximal to this mark the lamellae of the inner hoof wall appear to have recovered; distal to the mark the remnants of the lamellae are necrotic and infected (seedy toe). There is a cavity in the sole wall junction (arrowed) where the tip of the distal phalanx caused necrosis of the solar corium during the initial attack. Since then, during the recovery period, the cavity has grown forward and will soon appear on the ground surface of the sole as a crescent-shaped bruise. It would be reasonable to assume that had the owner adopted a modern treatment approach for this horse it would have made a good recovery.

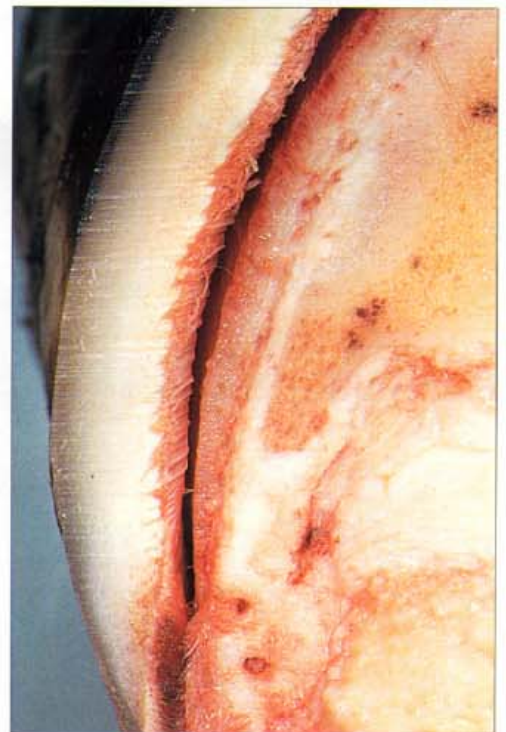


391. Lamellar wedge: transverse section. As the acute phase of laminitis merges into the chronic phase, the surviving lamellar epidermal cells proliferate into a disorganised weak mass of keratinised material known as the lamellar wedge. Here the foot has been sectioned transversely through the middle of the dorsal hoof wall and the lamellar wedge occupies the bulk of the distance between the inner hoof wall and the dorsal surface of the distal phalanx. The epidermal lamellae have stretched many times their normal length as can be seen by comparing this figure with the normal transverse section in 57. Many of the epidermal lamellae will be devoid of any contact with the dermis and there is gas between some of them. This gas appears as a lucent line beneath the dorsal hoof wall in the lateral projection of radiographs of chronically foundered feet (see 419).

392 Severe chronic laminitis: medial lateral section. A medial lateral section has been made of this chronically foundered foot. The tip of the distal phalanx and the tip of the frog can be seen in the bottom of the picture. Dorsal to the bone is an extensive region of lamellar wedge. Both the medial and lateral walls have become separated from the distal phalanx by large zones of septic, black, necrotic lamellar wedge material. When attempting to support a chronically foundered foot with a heart-bar shoe it is difficult to predict the extent of the separation of the hoof walls at the quarters and heels. The condition of this horse worsened after heart-bar shoes were applied because the quarters were unable to suspend the distal phalanx. The dark haemorrhagic zone of sole above the tip of the frog shows where the frog-plate of the heart-bar shoe was causing pressure necrosis (arrowed).

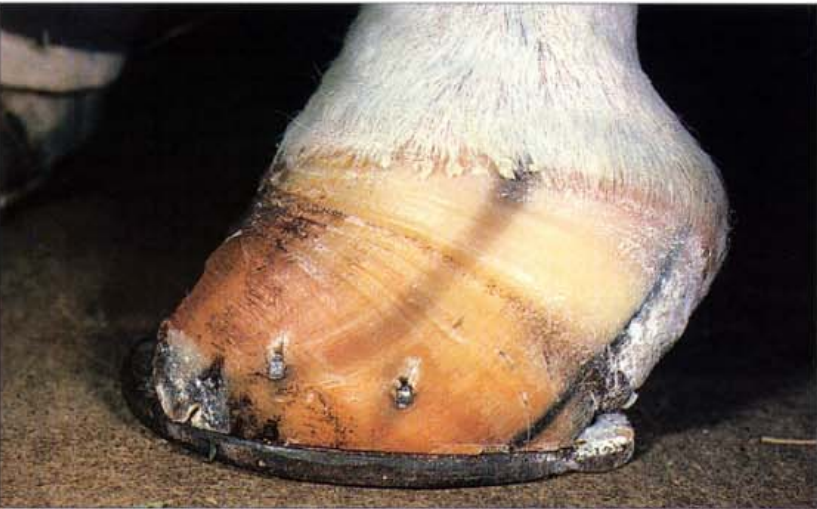

393. Acute severe laminitis: sinker (A). Sometimes, laminitis occurs with such rapid and devastating severity that there is total separation of the epidermal from the dermal lamellae and the distal limb sinks into the hoof capsule (hence the term 'sinker'). When this foot was sectioned, in the transverse plane, the whole of the distal phalanx and the attached dermis was floating unattached within the hoof capsule. The photograph shows the toe region. All four feet were affected, the hind worse than the fore, and the horse was so lame it could not move. The stance of the horse was not typical of laminitis; weight was evenly distributed to each limb and because of muscle trembling, sweating and distress, the clinical signs were initially confused with acute, severe, exertional rhabdomyolysis (tying-up syndrome).



394. Acute severe laminitis: sinker (B). The heel region of the transverse section shown in 393. The zone of total separation between the hoof wall lamellae and the dermis of the distal phalanx extends right back to the heels.

Laminitis: Wall Changes



395 Deformed hoof wall growth (A). Within this foundered foot pathological anatomical changes have occurred which have caused the dorsal toe to virtually cease growing. The heel has been spared and is growing faster than the toe. The pigmented tubules in the centre of the side of the hoof are curved instead of straight and clearly show the direction of the growth deformity. The growth rings in the wall should be parallel to the coronet and evenly shaped but in this case they converge at the toe. Compare with 71, the normal hind hoof from the same horse.



396 Deformed hoof wall growth (B). Nine months of history is recorded on the surface of the horse's hoof. The hooves of horses and ponies being examined prior to purchase should be closely scrutinised. Five months before the photograph was taken this overweight pony mare was allowed unrestricted access to lush spring pasture. She developed laminitis and the impact of the pathological changes which occurred on the growth regions of the hoof remains on view. The onset of laminitis is marked by the groove half-way down the side of the hoof wall (arrowed). Distal to this groove the hoof wall appears normal; the rings in the wall, due to changes in nutrition and workload, are evenly spaced and parallel to each other (concentric). Proximal to the groove the rings are not parallel because pathological changes are limiting hoof growth in the dorsal coronet. The growth rings converge in the dorsal hoof wall, above the arrowed groove, but are virtually normal in the heel. The toe is not making contact with the ground, suggesting that the pony is weight bearing on a dropped sole. See 409 for the solar view of this foot.

397. Severe chronic laminitis, untreated for 18 months. Gorging on wheat grain is a common cause of laminitis in Australia. This pony gained access to a ripe wheat field and after surviving a severe digestive disturbance and endotoxaemia, developed severe laminitis in both fore and hind feet. Unless effectively treated in its early stages the disease causes a chronic growth disturbance to the hooves. The heel grows faster than the toe and the hoof, if given enough time (in this case 18 months), will assume the classic shape of Aladdin's slipper.

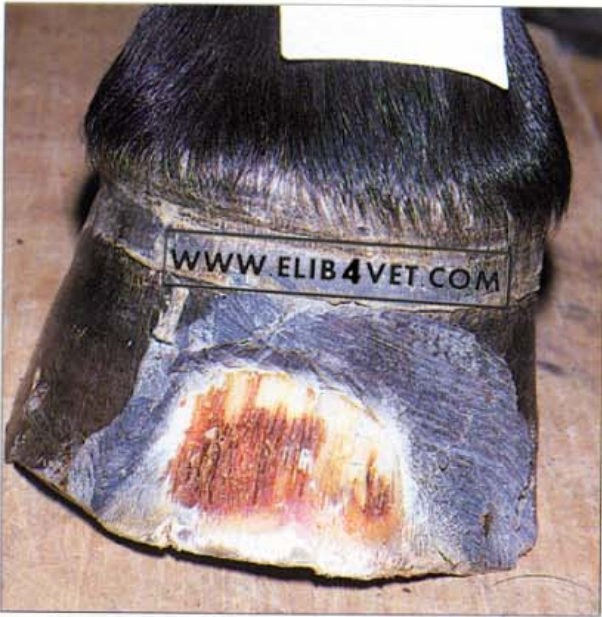

398. Bizarre hoof growth (A). The growth of this foot has been disturbed by chronic laminitis. The heel is growing faster than the toe, so the hoof adopts a curved Aladdin's slipper shape. However, in this case, the hoof was not trimmed for 3 years and a recurve shape, resembling a ram's horn, has developed. Photo: B. Chapman.

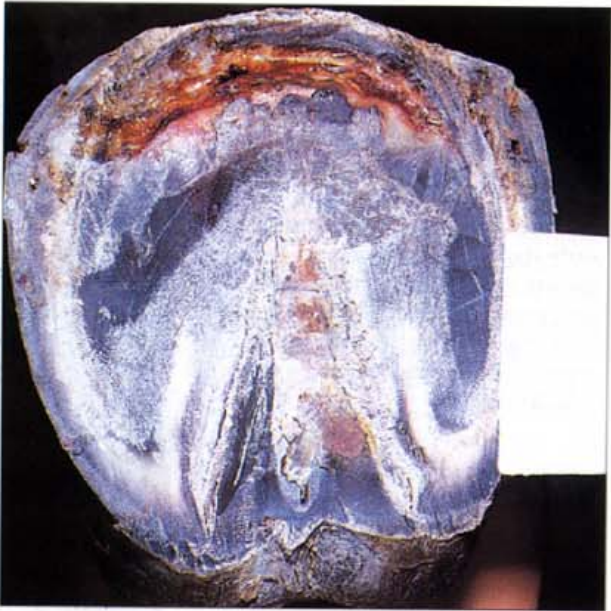

399. Bizarre hoof growth (B). After a family tragedy nobody was allowed to trim the hooves of this child's pony for a number of years. When eventually they were trimmed, the pony had a high-stepping gait and took some time to adjust to the changed weight and shape of its feet. Photo: J. Verschooten.





400. Laminitis induced by corticosteroid therapy: (A) dorsal view. Injecting horses with long-acting, potent corticosteroids may induce laminitis. This class of drugs is contraindicated in laminitis therapy and has even been known to cause laminitis when administered for some other, apparently unrelated, condition. In the case illustrated a pony mare was injected with triamcinalone to alleviate the itch from chronic insect bite skin hypersensitivity (Queensland Itch). Three days later the mare was lame, showing all the clinical signs of acute laminitis. When photographed a few weeks later, the groove in the hoof wall, which coincided with the injection (arrowed), had grown 15mm down from the coronet. The dorsal hoof wall was rasped back until the stretched haemoglobin-stained lamellae of the lamellar wedge were visible.



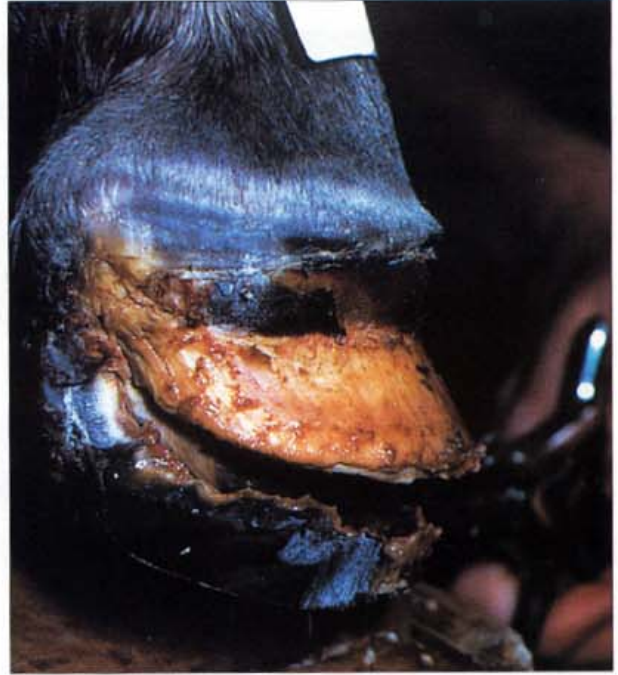401. Laminitis induced by corticosteroid therapy: (B) solar view. The hoof distal phalangeal bond had weakened and the distal phalanx had descended into the hoof capsule. A crescent-shaped zone of necrosis, typical of chronic laminitis, had appeared in the sole. Shod with heart-bar shoes, the pony made a full recovery.



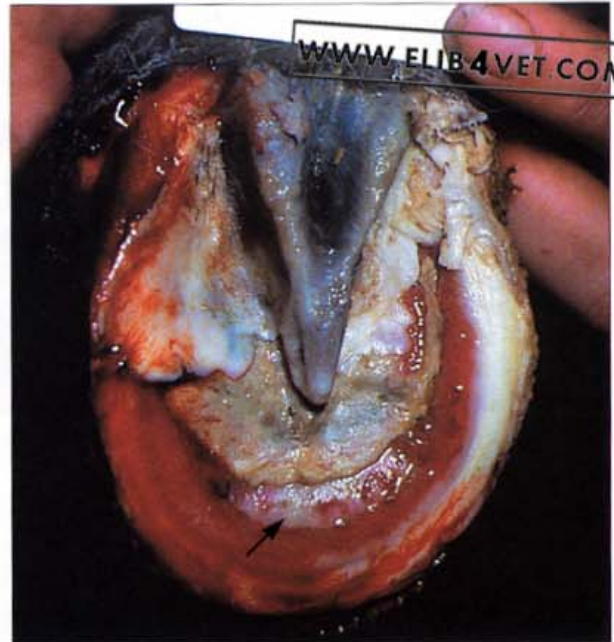402. Supporting limb laminitis. The fractured proximal phalanx of this mare was placed in a plaster cast. The mare was unable to walk on the fractured limb and was thus forced to bear the entire weight of her forequarters on the opposite, unfractured foot. When a horse's foot is weight bearing, blood ceases to circulate to the lamellae. In the normal situation this happens only momentarily with each footfall and the pressure of weight bearing is part of the venous return mechanism. However, if the period of weight bearing is abnormally prolonged, ischaemia of the hoof wall lamellae will cause failure of the hoof-distal phalanx bond. In the picture the hoof of the supporting limb shows the typical altered growth rings of chronic laminitis. Hoof growth at the toe has virtually ceased and the growth rings diverge towards the heel where growth is near normal. The opposite pattern of hoof growth is occurring on the fractured limb. When the picture was taken the fracture had healed and the limb was able to support weight. The extension on the shoe has concentrated weight bearing at the heels, so the growth rings are compressed at the heels and diverge towards the toe. Veterinarians and farriers must learn to read the history stored in the growth patterns of the hooves of their patients.

Laminitis: Hyperlipaemia

403. Hyperlipaemia laminitis (A). Obese ponies suffering the stress of pregnancy, starvation and transport may develop the disease entity known as hyperlipaemia. Apart from the severe depression, loss of appetite and liver damage associated with this disease, affected ponies usually develop severe laminitis. In this case the entire hoof wall and sole separated from the necrotic corium overlying the distal phalanx and associated structures.



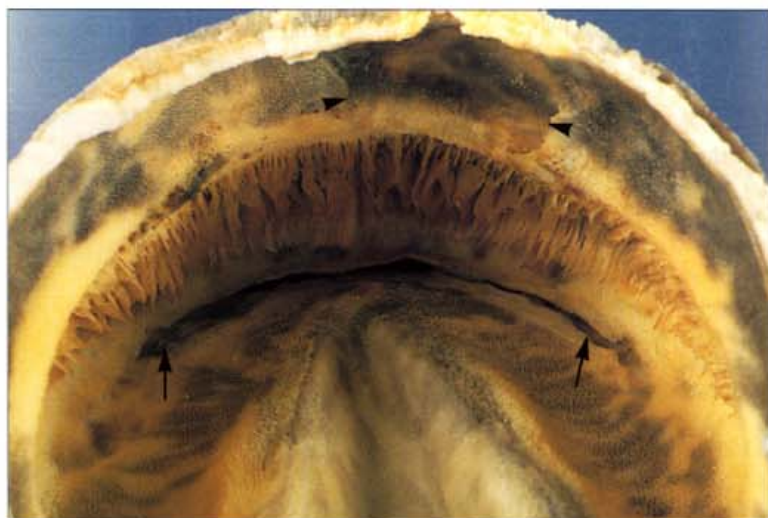404. Hyperlipaemia laminitis (B). When the necrotic sole was peeled from the foot the glistening white surface of the distal phalanx was visible (arrowed). Only the frog and a portion of one heel remained viable. Despite intensive care this valuable pony stallion died 8 days after the disease became apparent.



Laminitis: Sole Changes

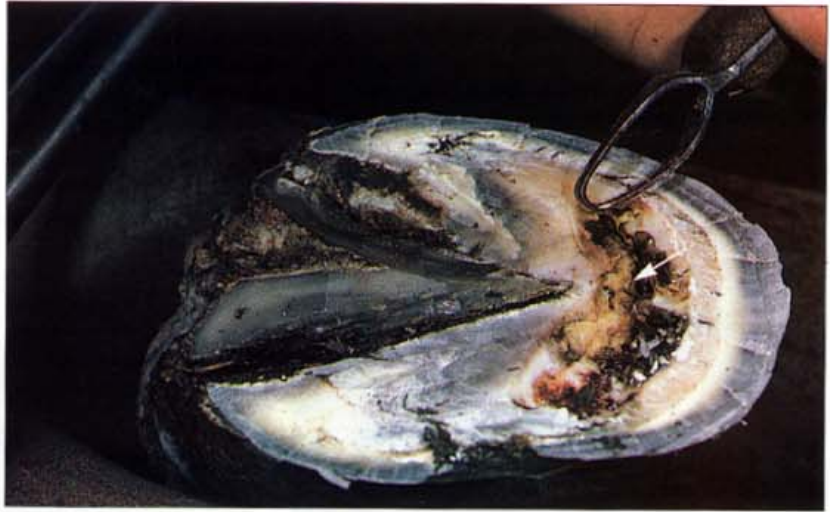

405. Dropped sole (A): viewed from the outside. One of the characteristic features of chronic laminitis is the dropped sole. As the bond between the hoof and distal phalanx fails, the bone descends into the hoof capsule and causes the sole to bulge downwards. The sole appears convex or 'dropped' in appearance. The solar corium, trapped between the tip of the descending third phalanx and the rigid horny sole, is crushed and results in a crescent-shaped area of bruised and sometimes necrotic sole. It is important to shoe foundered horses with dropped soles so that this painful, compromised region is kept clear of the ground. In this case a sole abscess is already erupting from the coronet (the mechanism of this is explained in 447).

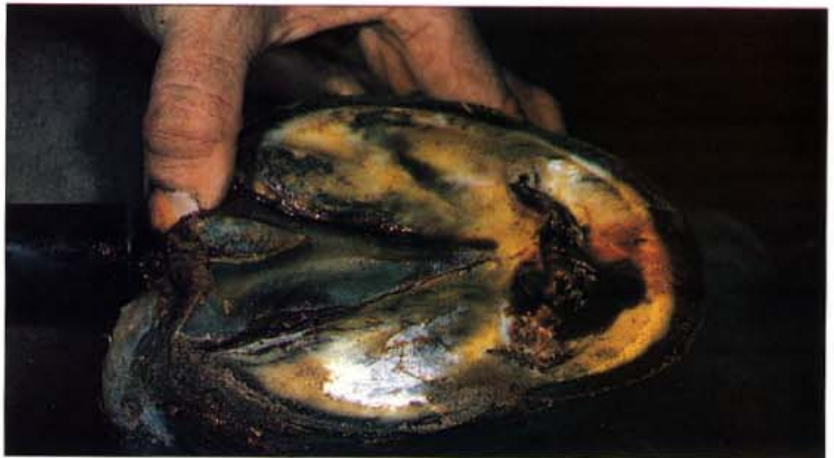

406. Dropped sole (B): viewed from the inside. The epidermal lamellae of the inner hoof wall are distorted and stretched to many times their normal length. Pressure from the sharp edge of the distal margin of the distal phalanx, in its new abnormal rotated position, has caused a crescent-shaped zone of sole necrosis (arrowed). A purulent infection, penetrating the weak compromised sole, has been discharging from the coronet and has caused a zone of necrosis in the coronary groove (arrowheads). The holes in the epidermal coronary groove into which the coronary papillae normally fit are absent in the zone of necrosis.

407. Septic lamellar wedge. In severe cases of laminitis the distal phalanx descends into the hoof capsule and destroys the solar corium. The sole becomes convex instead of concave and a crescent shaped zone of necrotic sole may develop. In the picture the necrotic sole and the lamellar wedge are infected and exuding black, smelly material. The margin of the palmar surface of the distal phalanx is just visible anterior to the tip of the frog (arrowed). Note that its original position would have been close to the margin of the white zone.

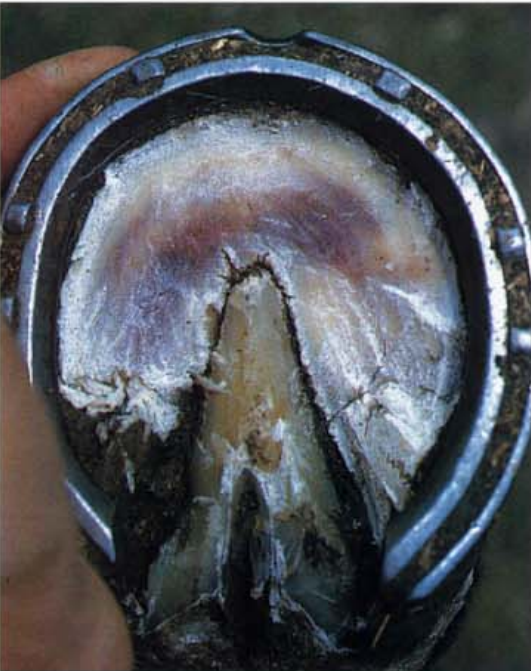

408. Chronic laminitis: underrun sole. The solar corium and the horny epidermal sole are perforated, and infection has underrun the sole and frog. In the picture a syringe containing a brown solution of povidone-iodine has been inserted into the separation line on the caudal aspect of the frog. When the solution was injected from the syringe it flowed freely from the crescent-shaped gap in the sole, thus demonstrating the extent of the damage.

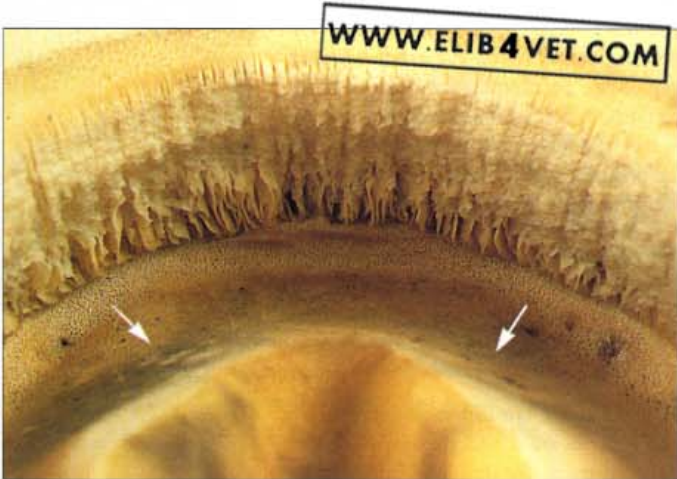

409. Chronic dropped sole. With light-weight horses and ponies, the sole sometimes survives the downward displacement of the distal phalanx, without prolapse of the solar corium. This is the same pony foot illustrated in 396. The white marks on the sole are abrasions which occurred when the pony walked on concrete pavement and indicate that it was the sole, and not the toe, that was weight bearing. The white zone at the toe is stretched and torn and if allowed to become impacted with soil and filth will develop infection (seedy toe).

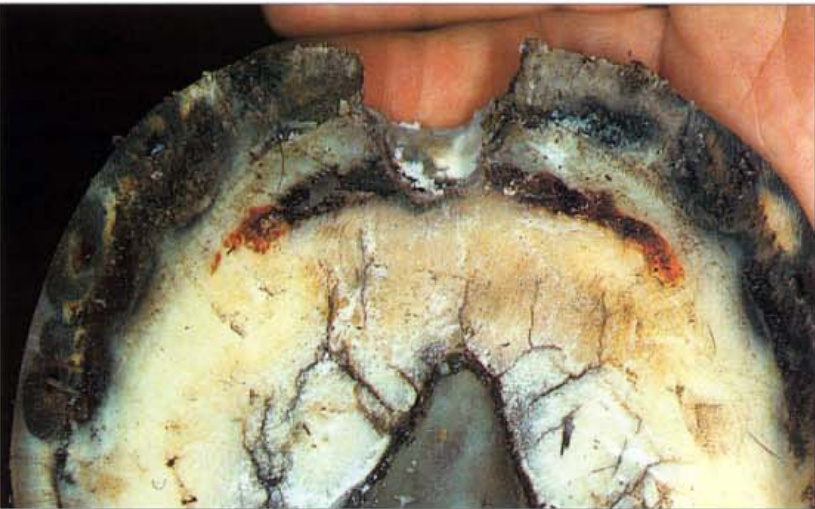




410. The sole of a pony's foot with early chronic laminitis (A). This obese pony mare developed laminitis on spring pasture 6 weeks previously. At the time the photograph was taken the pony would stand for long periods painfully shifting its weight from one front foot to the other and walked with the typical laminitis gait. When the outer layers of the sole were pared away, an ominous dark red bruise was visible. The shape of the bruise and its position is evidence that the distal phalanx had become detached from the inner hoof wall and had crushed the solar corium against the horny sole.

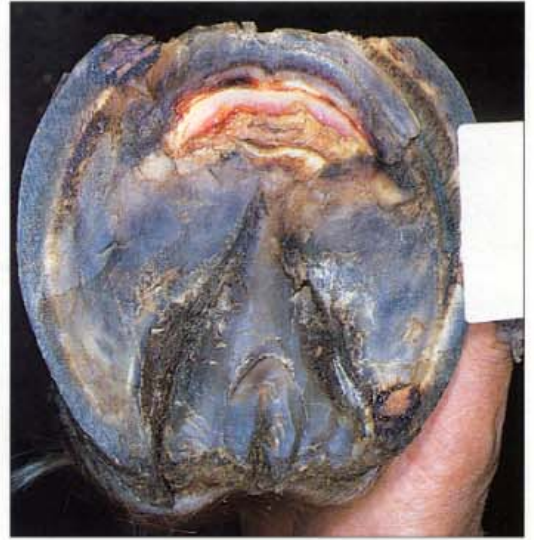

411. The sole of a pony's foot with early chronic laminitis (B). With the foot removed from the hoof the sole can be viewed from the inside. The epidermal lamellae of the inner hoof wall are stretched and distorted. The crushing of the solar corium by the descending third phalanx has left a crescent-shaped zone of smooth, compressed sole (arrowed). This compressed sole is weak and thin and no longer has the structural integrity of normal sole. Compare with the normal appearance in 50.

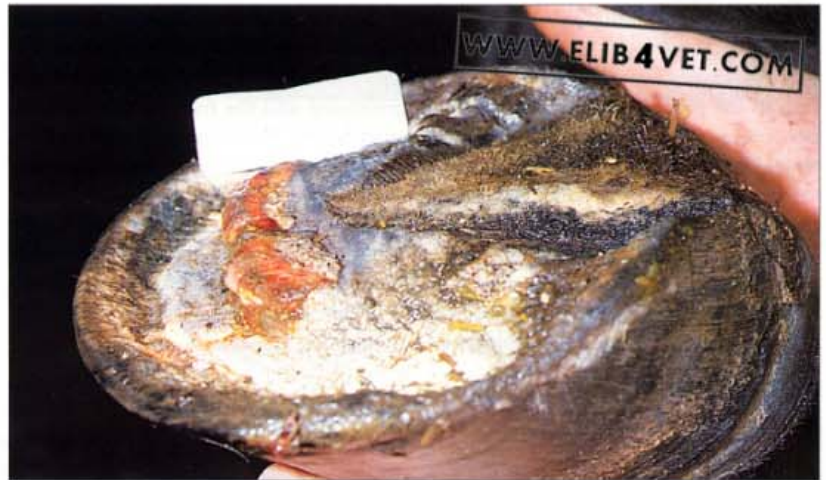

412. The crescent-shaped sole bruise of chronic laminitis. As the distal phalanx descends into the hoof capsule it crushes the solar corium and produces a characteristic crescent shaped bruise in the sole. The size and position of the sole bruise to some extent indicates the severity of the founder. In this case an over-fat pony with a cresty neck foundered on pasture after summer rain. Radiography showed that only mild separation of the hoof wall from the dorsal surface of the distal phalanx had occurred. The sole was not 'dropped' and was still concave in appearance. The pony made a good recovery when shod with heart-bar shoes.

413. Moderately severe chronic laminitis: prolapse of the solar corium. This 3-year-old Arabian mare accidentally gorged on grain and developed moderately severe laminitis. The distal phalanx had descended into the hoof capsule and had destroyed a crescent shaped band of solar corium. The dead sole was resected and the photograph shows the exposed solar corium. The solar margin of the distal phalanx still had a covering of dermal tissue and was not palpable or visible. The front feet were fitted with heart-bar shoes and the exposed tissues were dressed. Eventually the mare recovered to paddock soundness.

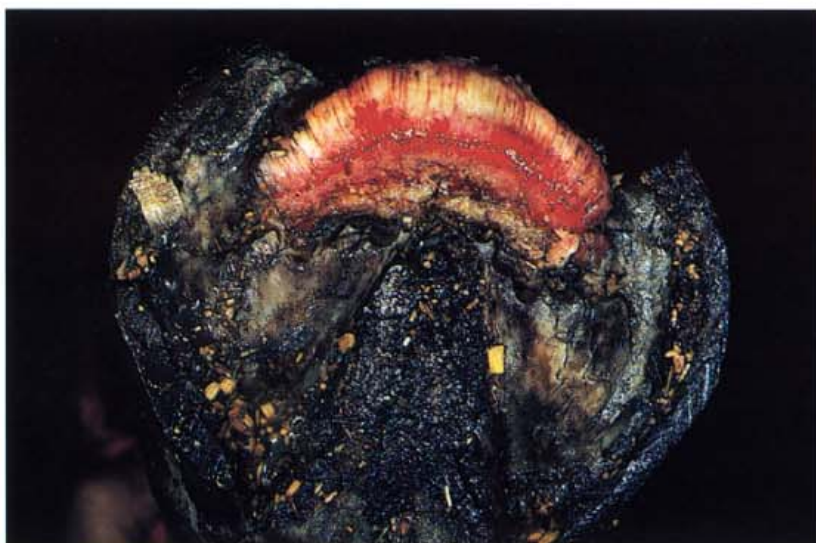

414. Severe chronic laminitis: prolapse of the solar corium (A). After giving birth to her foal this 17-hand Warmblood mare failed to pass the foetal membranes and developed acute severe metritis (infection of the uterus). Two days of septicaemia and fever followed and the mare then began to show the clinical signs of laminitis. Within 20 days the tip of the third phalanx was protruding through the sole of the foot.

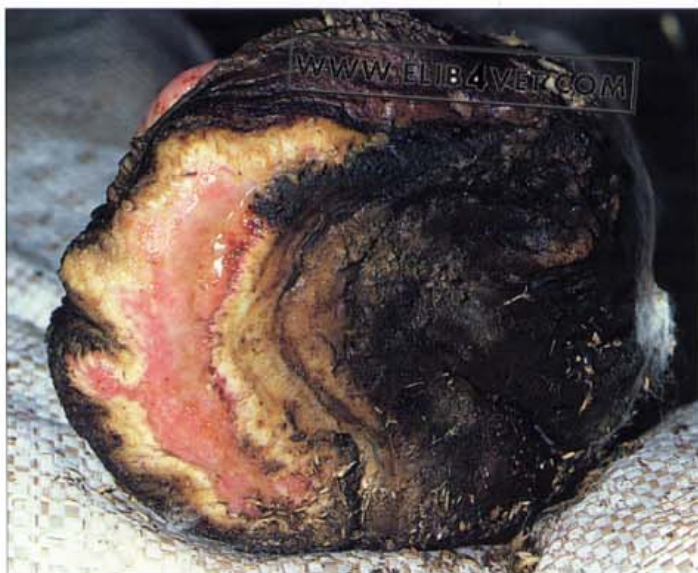

415. Severe chronic laminitis: prolapse of the solar corium (B). Obesity, insufficient exercise and the stress of an artificial lifestyle appear able to trigger laminitis in the occasional Thoroughbred stallion. Without any clinically apparent, concurrent disease, this middle-aged stallion developed severe laminitis in a matter of days. Despite the frog support shoe, the distal phalanx has rapidly descended into the hoof capsule and along with the remains of the solar corium has prolapsed through the sole of the hoof. The avascular, already necrotic tip of the distal phalanx could be palpated through the gap in the sole.





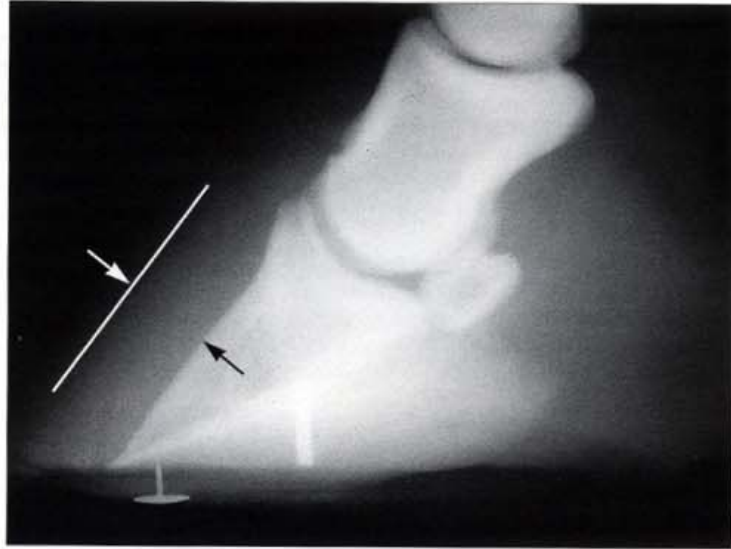416. Severe chronic laminitis: prolapse of the solar corium (C). In severe cases of chronic laminitis the descent of the distal phalanx into the hoof capsule destroys the sole and causes a prolapse of the solar corium. Invariably the solar margin of the distal phalanx makes contact with the ground and results in osteomyelitis. The circulation to the prolapsed solar corium is compromised and the tissues often become oedematous. The condition is extremely painful for the horse and every effort should be made to keep the prolapsed tissues clean and to prevent them from making contact with the ground. Antiseptic dressings and heart-bar shoes help in this respect. In the picture the dark red areas are granulation tissues; the pale yellow areas are epidermal tissues attempting to regenerate the horny sole. It is important that tissue-destroying dressings such as strong tincture of iodine or formalin are NEVER applied to prolapsed solar corium. Healing and regeneration of the sole depend on the survival of the epidermal tissues.



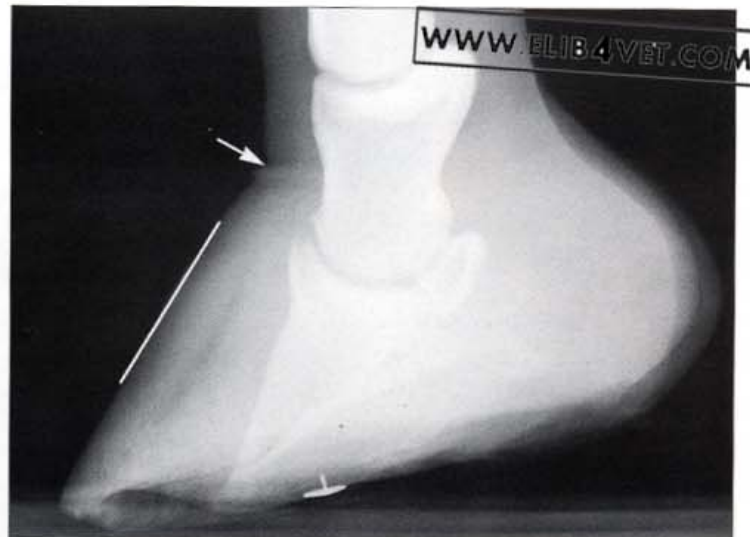417. Severe chronic laminitis: prolapse of the solar corium (D). Sometimes the laminitis episode is so severe that the entire hoof wall separates from the underlying lamellar corium. The sinking of the distal phalanx into the hoof capsule can be so rapid and dramatic that the horses are described as 'sinkers' (see 393 and 394). Without the support of a hoof wall-distal phalanx bond, horses that are 'sinkers' cannot be shod with any sort of support shoe and have to bear weight on the solar corium. The distal phalanx invariably develops osteomyelitis and there is little hope that the prolapsed solar corium will ever return to normal if it has to support the weight of the horse. The picture shows the sole of a sinker with a chronically prolapsed solar corium. The crescent represents the area of the sole that was weight bearing and this constant pressure permanently prevented healing. This situation was extremely painful for the horse which was eventually destroyed.

Laminitis: Radiology

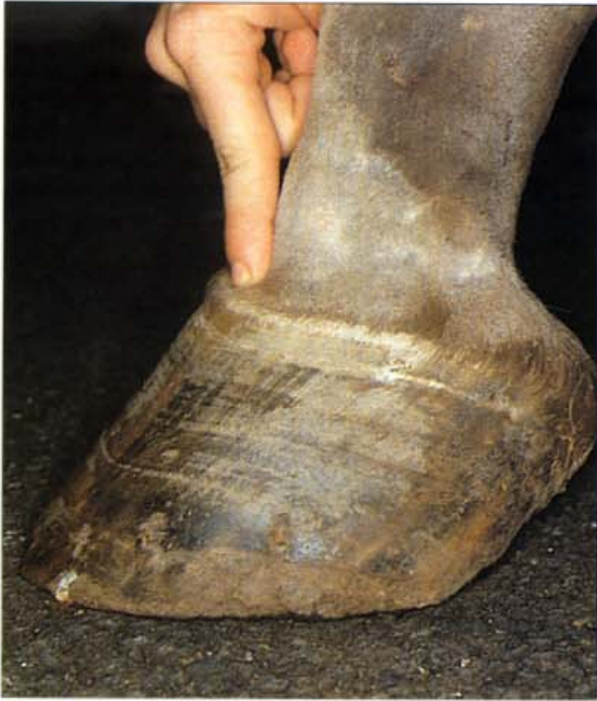418. Severe chronic laminitis: lateromedial radiograph (A). A radiographic examination of the foot is an important part of the clinical work-up of the laminitis case. The position of the distal phalanx relative to the dorsal hoof wall changes as the bone descends into the hoof capsule. If the distance between the marker on the dorsal hoof wall and the dorsal surface of the distal phalanx exceeds 15–17mm this is early, valuable evidence that laminitis has occurred. Remedial medical and mechanical support for the foot should begin immediately. In the laminitis radiograph illustrated the distance between bone and dorsal hoof wall (between arrows) was 23mm. The drawing pin was placed in the tip of the frog to act as a reference point for the accurate placement of a heart-bar shoe. The sole is already convex (dropped sole) but there is no rotation of the distal phalanx from either the dorsal hoof wall or the axis of the phalangeal bones.



419. Severe chronic laminitis: lateromedial radiograph (B). The radiograph of the same foot 10 days later shows the distal phalanx has descended further into the hoof capsule. The torn, stretched lamellae of the inner hoof wall have become demarcated by a radiolucent gas line which outlines the previous, normal, position of the dorsal surface of the distal phalanx. The distance between the distal phalanx and the marker on the dorsal hoof wall has increased (33mm) and is about double the normal distance of 15–17mm. The descent of the distal phalanx into the hoof capsule has made the sole convex instead of concave (dropped sole) and by taking the corium of the coronary band with it, has caused an obvious radiological defect in the coronet (arrowed). The radio-opaque drawing pin marks the tip of the frog. This is the same foot illustrated in 423.



Laminitis: Coronet Changes

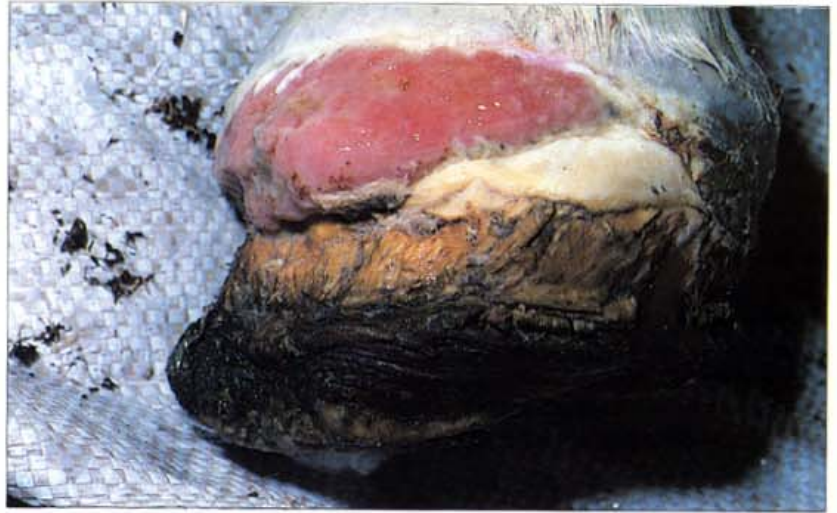

420. Severe early chronic laminitis:coronary band changes. As failure of the hoof–distal phalanx bond develops, the bone and the attached subcutis descend into the hoof capsule. If this occurs it can be palpated with the finger as a distinct deficit at the coronet. It is a grave clinical sign, especially if the deficit extends around to the quarters and heels, because it means that considerable destruction and descent of the distal phalanx has already occurred.



421. Severe chronic laminitis: coronary band changes. Hooves that survive the initial laminitis episode develop a characteristic defect of hoof wall growth known as the laminitis ring. In this case, human fingers have been placed in a deep ring at the toe; the heels are relatively unaffected.

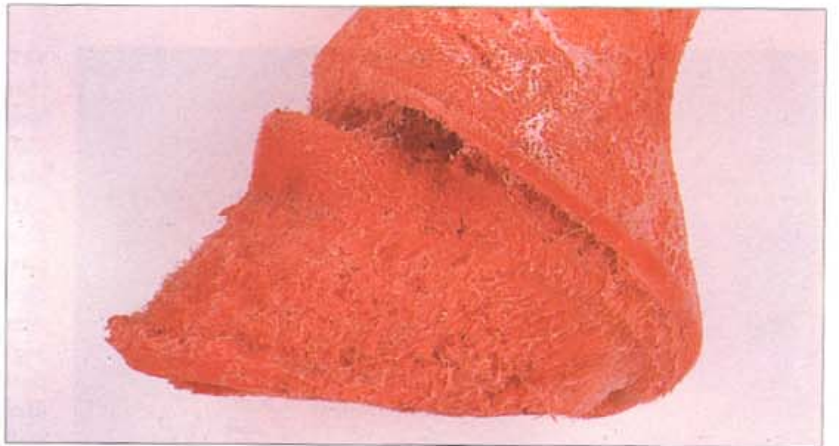422. Severe chronic laminitis (sinker): prolapse of the coronary band. The dressings used to protect the sole of this sinker were applied tightly to the coronet. The pressure has caused necrosis and a mass of granulation tissue has prolapsed through the coronary band. For healing to occur the granulation tissue would have to be removed by surgery or by chemical cautery and this would result in extensive scarring of a large portion of the coronary band. There is little hope this severely damaged coronet could ever generate a weight-bearing hoof wall again. The horse was humanely destroyed soon after the photograph was taken.



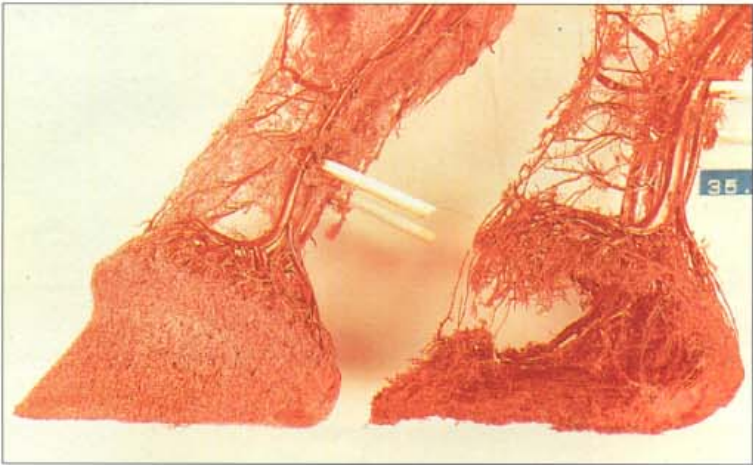
423. Severe early chronic laminitis: colitis case history (A). This champion Standardbred gelding developed severe colitis and consequently foundered. For humane reasons the horse was destroyed 7 days after the first signs of laminitis. The photograph shows a break in the periople of the dorsal hoof wall—a sign that the distal phalanx had descended into the hoof capsule taking the subcutis with it. The convex or dropped sole is visible below the level of the distal hoof wall because the descending distal phalanx had forced it down.



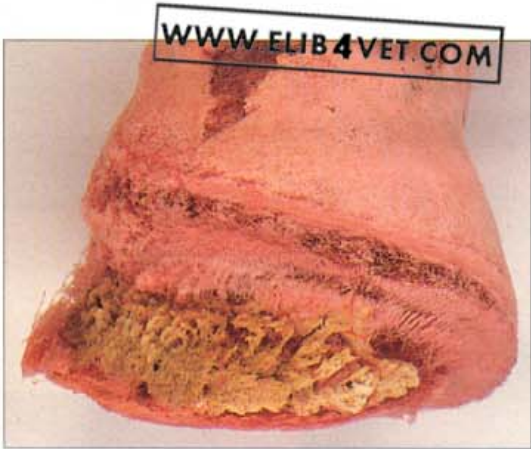424. Severe early chronic laminitis: colitis case history (B). A vascular cast of red acrylic plastic was made to examine the gross changes in the circulation of the foot. The vessels of the dorsal hoof wall, periople and coronary band failed to fill, presumably because the structural collapse of the foot had destroyed them. This explains the break in the periople shown in 423. However, the vascular cast shows the full extent of the destruction. Towards the heel the vessels of a few dermal lamellae are intact but at the quarters and toe there are none. The distal toe is distorted and there is a hole in the sole.



Lamellar Wedge



425. The effect of the lamellar wedge on the circulation (A). In the chronic stage of laminitis the lamellar epidermis continues to proliferate between the hoof wall and the dorsal surface of the distal phalanx. The pressure caused by the ever-growing wedge of disorganised epidermis appears to compromise the lamellar circulation. On the left is the vascular cast of a normal horse's foot after the fine capillaries have been removed; the vessels of the coronary and lamellar venous circulation are intact. In contrast, the vascular cast of a foot with severe chronic laminitis, shows that the lamellar circulation is absent. While the lamellar wedge remains there is little chance that a normal relationship between the distal phalanx and the inner hoof wall can be re-established.

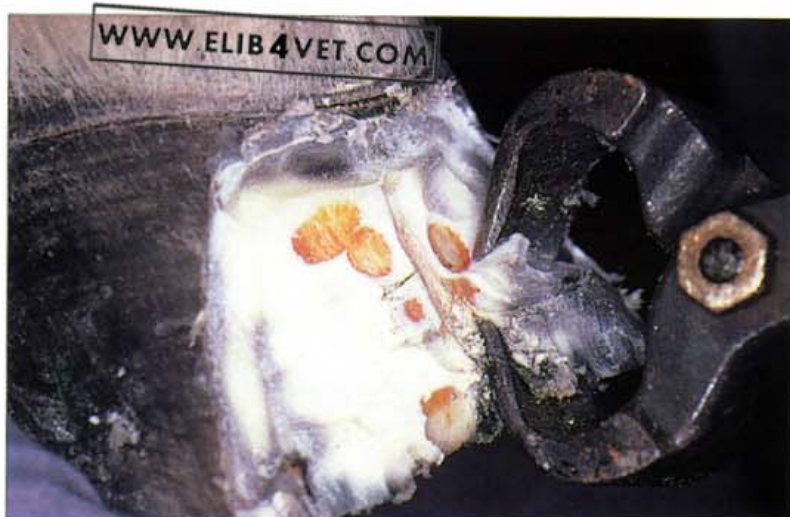

426. The effect of the lamellar wedge on the circulation (B). In this vascular cast of a chronic laminitis foot the corrosion process has removed the hoof, but left the distal phalanx. There are no lamellar vessels and the distal phalanx has become grossly remodelled—a direct effect of the lamellar wedge.

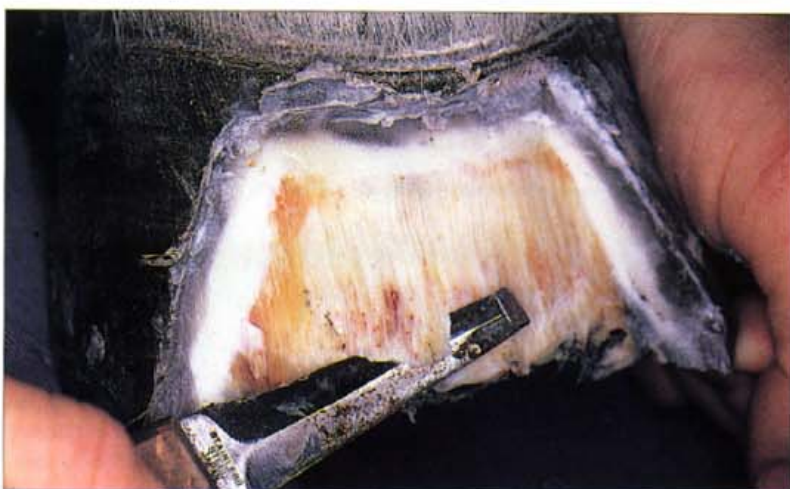

427. Dorsal hoof wall resection. One of the characteristics of chronic laminitis is the development of the lamellar wedge. The lamellar epidermal cells which survive the acute laminitis phase proliferate in a haphazard, disorganised fashion and produce a wedge-shaped mass of weak horn beneath the hoof wall. The lamellar wedge occupies a position between the dorsal hoof wall and the distal phalanx and if not removed will prevent the re-establishment of the normal hoof-pedal bone bond. To initiate the resection of the dorsal hoof wall a motorised, rotating burr is used. Deep grooves are cut in the dorsal hoof wall to a depth of 8–12mm. This allows the hoof between the grooves to be easily removed with half-round nippers or a hoof knife.

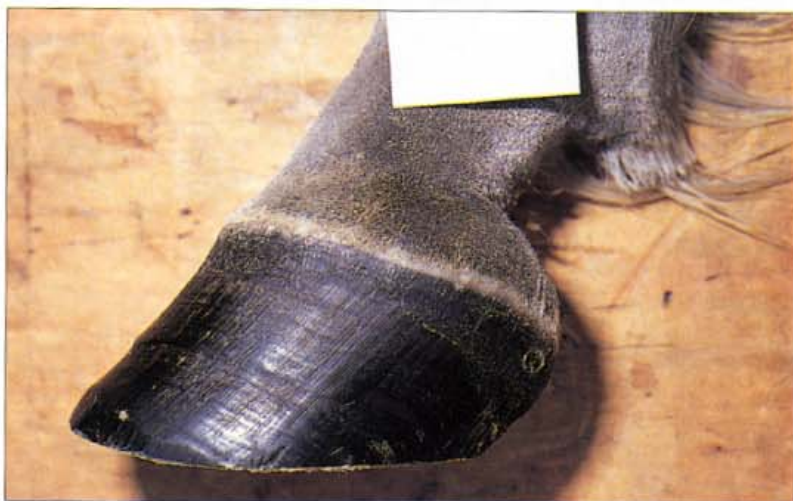428. Resection of the lamellar wedge (A). The dorsal hoof wall has been painlessly resected, without analgesia, to expose the yellow avascular lamellar wedge. In the normal horse, resection of the dorsal hoof wall to this depth would cause pain and copious haemorrhage.



429. Resection of the lamellar wedge (B). The same foot shown in 428 with the resection of the yellow lamellar wedge almost complete. The removal of the wedge can continue until fine haemorrhages begin to appear on the surface of the resected toe. The appearance of blood means that contact with the lamellar dermis has been made and the resection has gone far enough. It is important not to remove too much of the proximal hoof wall as this will destabilise the hoof capsule. It is considered negligent to resect a foundered hoof to this extent and to not shoe it. The heart-bar shoe is a good support shoe after the dorsal hoof wall resection.

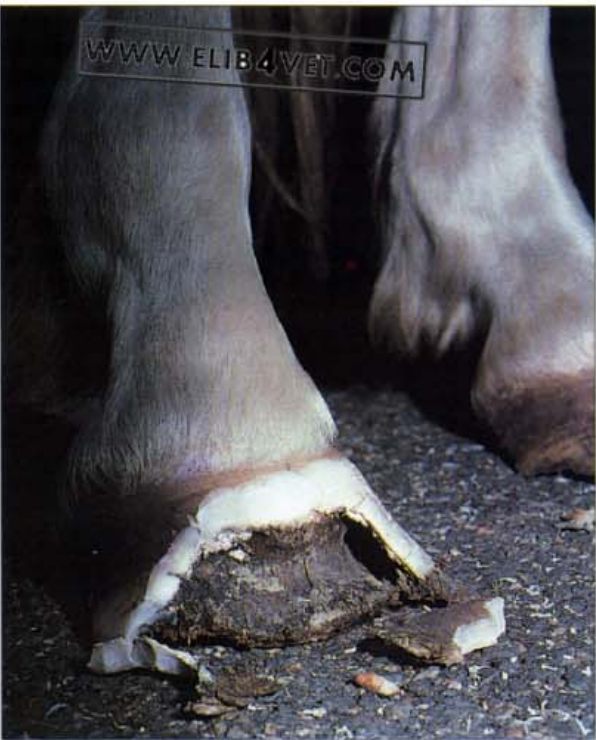

430. Resection of the lamellar wedge (C). Two years later, the pony has made a good recovery. The hoof is a natural shape and the dorsal hoof wall and the hoof tubules are in correct alignment with the pastern. There are no laminitis rings in the hoof wall and hoof growth is parallel to the coronary band. Throughout the 2-year period the pony was kept shod in correctly fitted heart bar shoes which were reset at 4-weekly intervals. Care was taken to remove any regrowth of the lamellar wedge as the new hoof wall grew down from the coronet. A strict diet ensured that the pony remained in light body condition. During periods of rapid pasture growth the pony was kept in a yard from dusk until dawn.



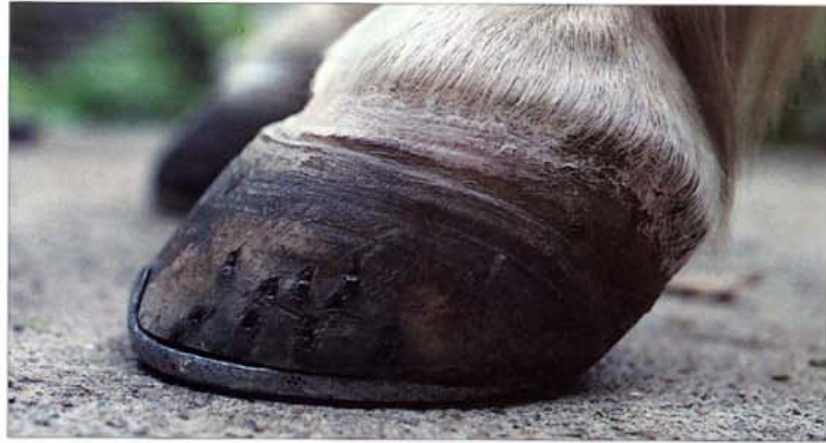

431. Resection of the lamellar wedge (D). The sole was concave and there was no sign of any internal sole bruising from a partially rotated distal phalanx. Radiographs showed that the distal phalanx was in the normal position but the distance between the dorsal hoof wall and the distal phalanx was slightly greater than normal. The pony was slightly tender-footed if asked to walk over rough ground without shoes. Before the use of the heart-bar shoe and the technique of dorsal hoof wall resection became widespread this is the sort of horse or pony which would have remained chronically foundered. Attention to detail and sticking to a strict rehabilitation programme makes a return to near-normal life possible for many horses and ponies.



432. Dorsal hoof wall resection. During severe laminitis the inner hoof wall separates from the dorsal surface of the distal phalanx. In this case, the separation was so complete that there was a 10mm gap between the hoof and the distal phalanx. Treatment consisted of resecting the dorsal hoof walls, shoeing with steel heart-bar shoes and surgically transecting the distal check ligament. The horse was a lightweight Arabian, only 14 hands high, and surprisingly little damage occurred to the palmar surface of the distal phalanx or to the sole. The horse was paddock-sound within a year.

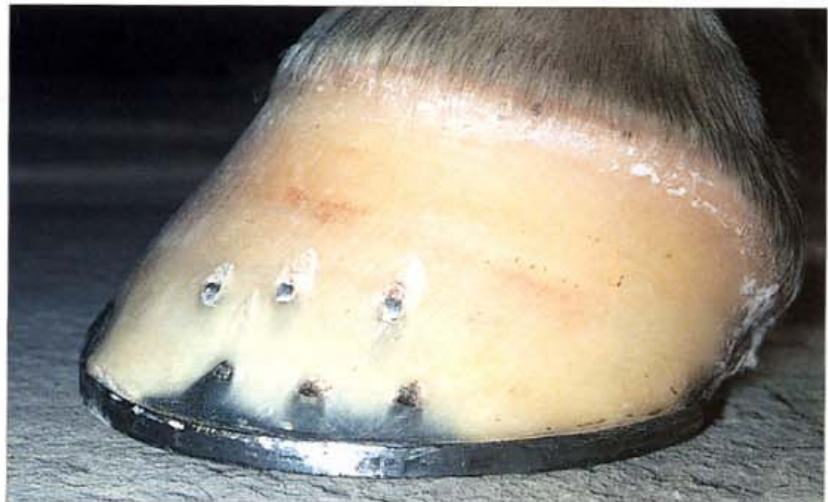433. Chronic laminitis after sole bruising (A). This is the same foot illustrated in 283 photographed 2 months later. Via an unknown mechanism the severe sole bruising has caused classic, chronic laminitis. The growth rings converging at the toe indicate that the distal phalanx has shifted within the hoof capsule. The feet were treated conservatively.



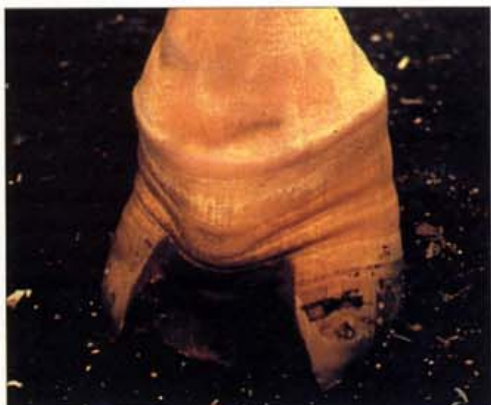434. Chronic laminitis after sole bruising (B). The abnormal dorsal hoof wall was rasped back until it was aligned parallel with the new position of the distal phalanx. In the process of doing this the dry, necrotic lamellae of the old hoof wall have been exposed. Because the hoof was without pigment it was possible to see the transition between normal and abnormal lamellae growing down the dorsal hoof wall. The transition line was stained with haemoglobin (arrowed).



435. Chronic laminitis after sole bruising (C). Twelve months after the sole bruising incident, the hoof wall was growing normally. However, the white zone of the sole was broader than normal and the sole was slightly dropped. Nevertheless the gelding, shod with adequate sole protection, was back in training as an endurance horse.



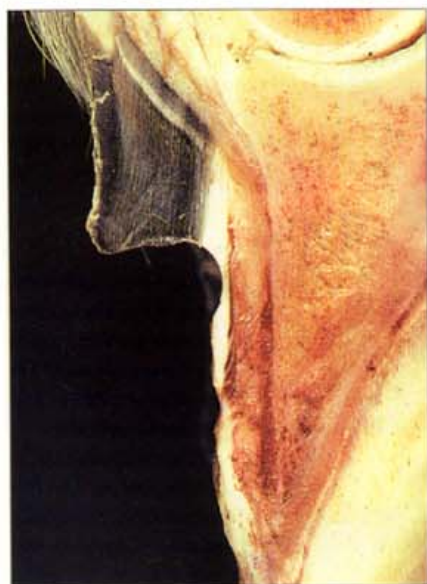Hoof Wall Resection



436. Dorsal hoof wall resection (A). Resection of the dorsal hoof wall, to remove the lamellar wedge, and shoeing with a heart-bar shoe has dramatically improved the growth of the hoof wall of this chronically foundered foot. Constricted growth rings converging at the top of the resection window are evidence that at the time of the resection dorsal hoof wall growth was severely retarded. The act of removing the lamellar wedge and supporting the hoof capsule and its contents with a heart-bar shoe has improved the circulation to the coronary groove and has restored the rate of growth of the dorsal hoof wall to normal. The return of parallel hoof wall growth below the coronary band indicates that the foot is responding to treatment. Photo: B. Chapman.

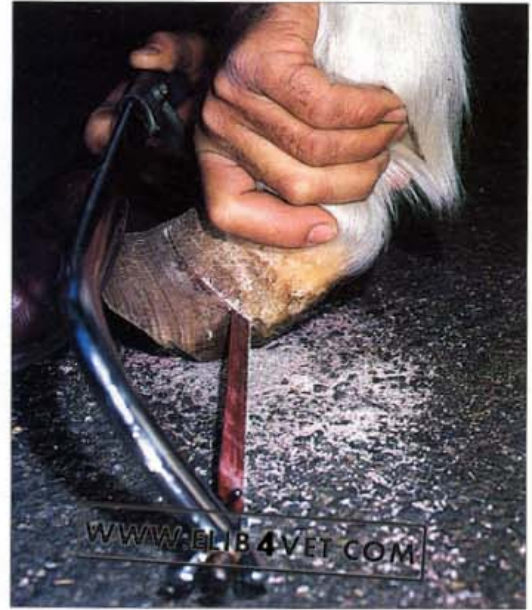

437. Dorsal hoof wall resection (B). Shoeing with heart bar shoes and resecting the lamellar wedge from the dorsal hoof wall has restored parallel hoof growth below the coronary band to the hooves of this Connemara mare. Prior to the resection, growth of the dorsal hoof wall was severely restricted as shown by the converging growth rings. The heart-bar shoes were reset at regular 4-weekly intervals and any regrowth of the lamellar wedge was removed. After 14 months the regrown hoof wall appeared sound and the mare was competing in Pony Club events shod with wide-webbed, well-seated-out shoes.

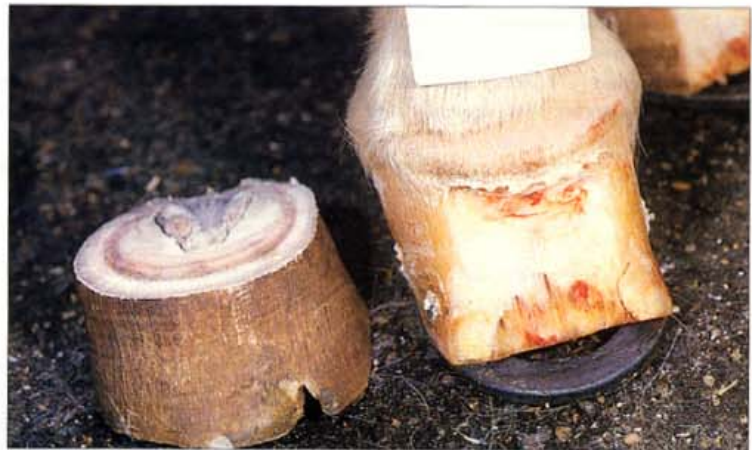

438. Dorsal hoof wall resection (C). The principle behind dorsal hoof wall resection and removal of the lamellar wedge is to encourage the new hoof wall to grow back as close to the dorsal surface of the distal phalanx as possible. After recovery from an episode of laminitis the coronet often generates a near-normal hoof wall. Unfortunately, as it grows down from the coronet, the wall is forced away from the distal phalanx by the lamellar wedge. While the wedge remains, a functional hoof distal phalangeal bond can never be re-established. The photograph shows the sagittal section of a chronically foundered foot after the lamellar wedge has been removed. If the lamellar wedge is kept as thin as possible (it will have to be freshly resected every few weeks) the new hoof wall will grow down close to the distal phalanx, reforming hoof distal phalangeal bond attachments as it goes.

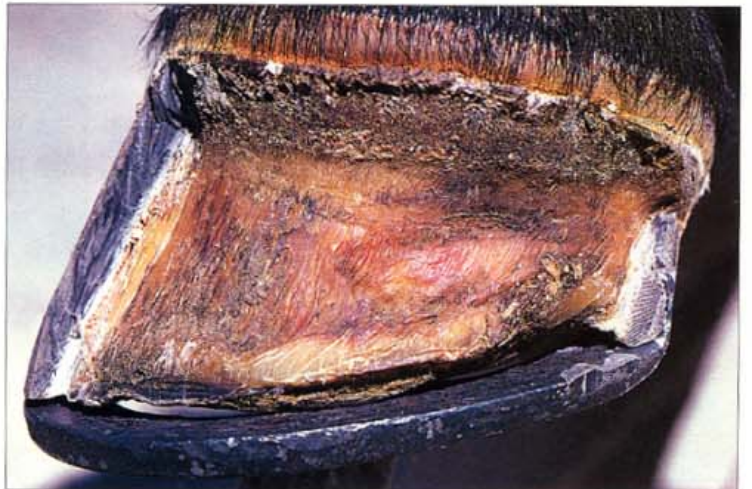439. The overgrown toe of chronic laminitis (A). A knowledge of anatomy and confidence is sometimes required to treat ponies with chronic laminitis. Radiographs were taken of this long-toed case of chronic laminitis to establish the position of the saw cut.



440. The overgrown toe of chronic laminitis (B). The photograph shows the cut-off hoof (representing 7 months of hoof growth) and the remaining foot after dorsal hoof wall resection. The sole was pared with a hoof knife until it was thin enough to just 'give' to thumb pressure; this establishes the correct sole thickness. The pony made a satisfactory recovery when shod with a heart-bar shoe.

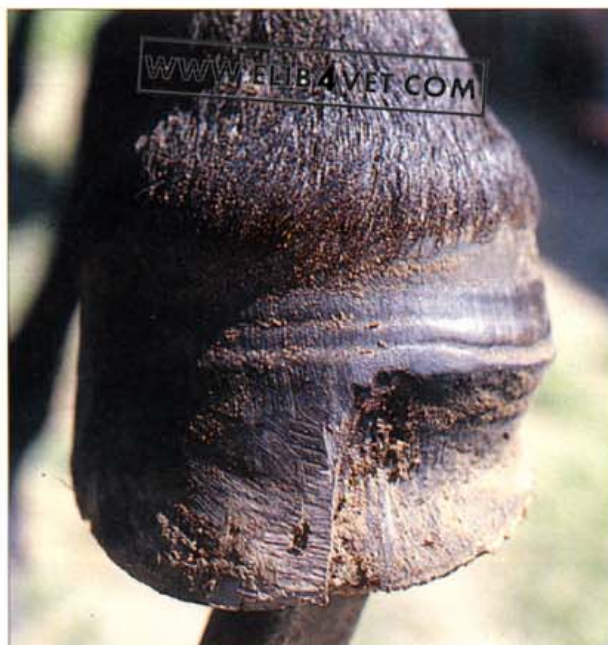

441. Unilateral laminitis (A). For an unknown reason the left forefoot of this Standardbred gelding developed laminitis of the lateral half of the foot. The entire lateral hoof wall, from toe to heel, was completely separate from the structures beneath. Initial treatment was resection of the loose hoof wall and support of the remainder with a heart-bar shoe. Fortunately a nail could be placed in the portion of remaining heel. The photograph shows the foot immediately after the wall was resected. The epidermis of the lamellae and the coronary papillae are already covered with keratinised tissue.



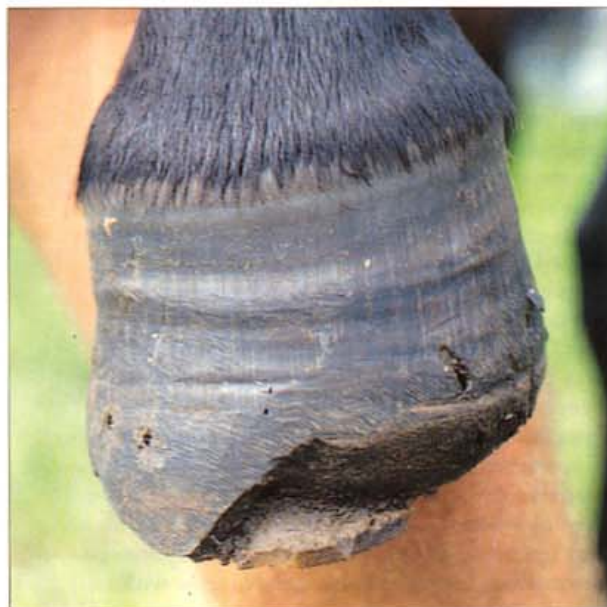

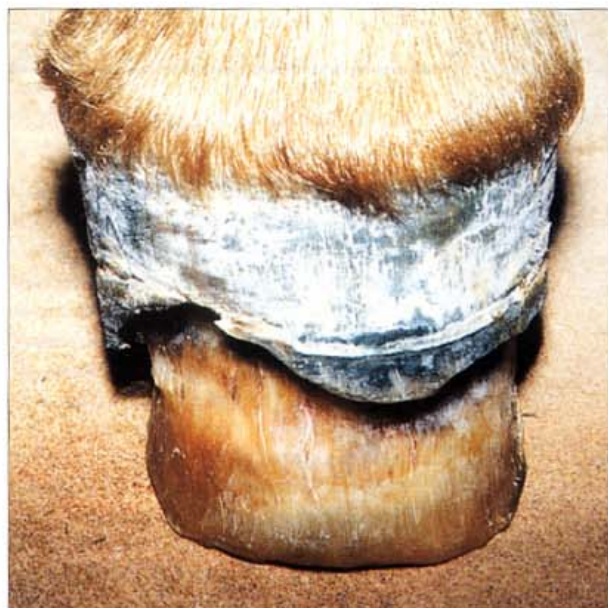442. Unilateral laminitis (B). Front view of the same foot. Pressure from the unattached lateral hoof wall has compressed the lateral coronet and pushed it upwards. The compression has so far prevented any regrowth of the hoof wall.



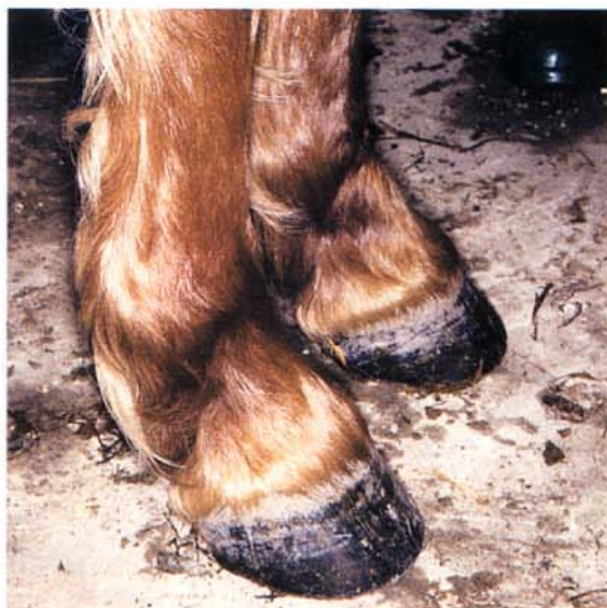443. Unilateral laminitis (C): 3 months later. Released from compression by the resection, a normal-looking, new hoof wall, has been generated by the papillae of the coronet, and is growing down towards the ground surface.

444. Unilateral laminitis (D): 7 months later. Whatever caused this bizarre syndrome left no permanent damage to the coronet or the hoof wall lamellae. Keeping the foot shod with a heart-bar shoe protected the sole and border of the distal phalanx from damage. A normal hoof wall replaced the deficit and the horse returned to racing and performed without lameness. Since the affected side of the foot was non-weight bearing for 7 months it grew faster than the opposite weight-bearing side. This is shown by the difference in the distance of the rings in the hoof wall from the hairline of the coronet.





445. Regrowth after total hoof slough (A). Four months after severe chronic laminitis, during which the hooves of both forefeet sloughed, the coronet of this pony is regenerating a relatively normal hoof wall. The lamellar and solar epidermis covering the exposed distal phalanx is sufficiently hard to allow weight bearing by the pony. The exposed epidermis was regularly trimmed to allow the new hoof wall to grow down in a natural shape. Photo: R. Eustace.

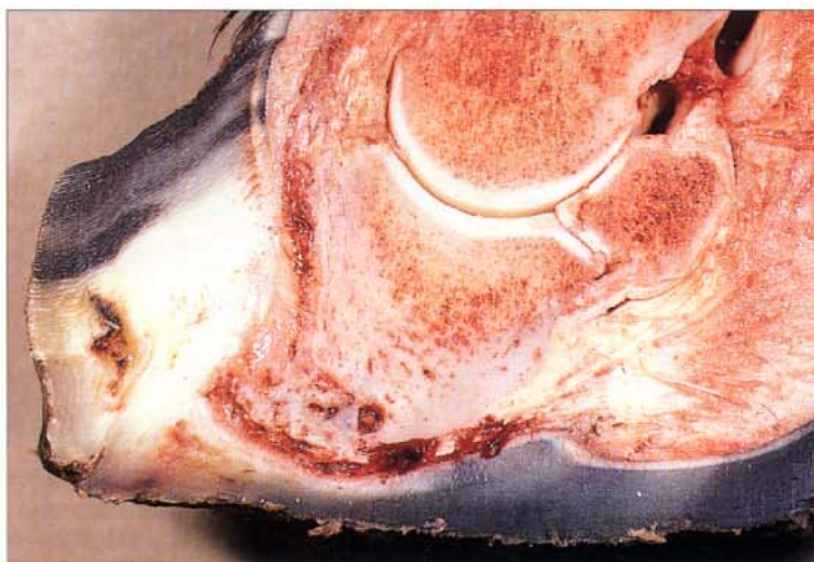

446. Regrowth after total hoof slough (B). Eighteen months after the initial laminitis incident, the hooves had regrown to near-perfect appearance and the pony was able to lead a normal life. Photo: R. Eustace.

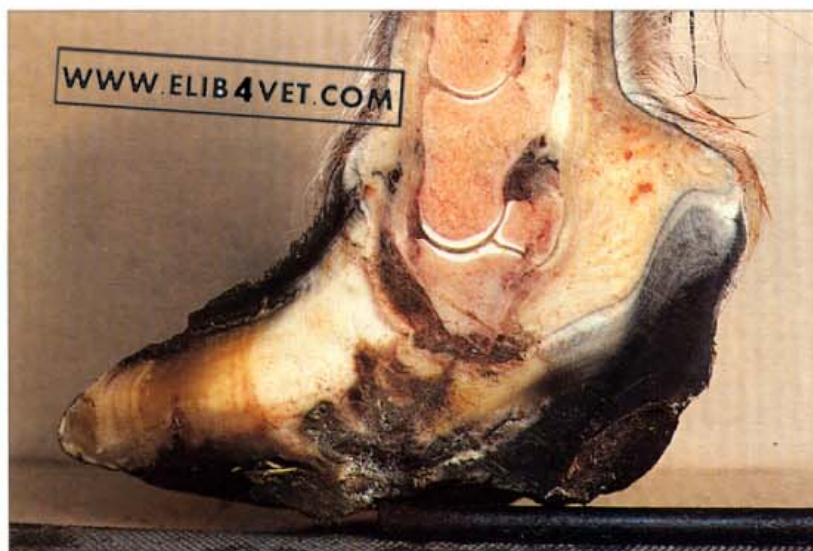447. Chronic laminitis: osteomyelitis. A feature of chronic laminitis is repeated episodes of osteomyelitis. With the distal phalanx abnormally placed within the hoof capsule, its tip bearing down on the sole, portions of the bone become necrotic and initiate a severe inflammatory reaction. The pus generated by the reaction undermines the lamellae and discharges at the coronary band. In this hoof the deep lamellar rings are evidence of previous exacerbations and remissions of laminitis and there is a large separation at the coronet from which pus has been discharging. Other marks on the hoof show where a similar incident had occurred about 6 weeks previously.



Laminitis: Osteomyelitis

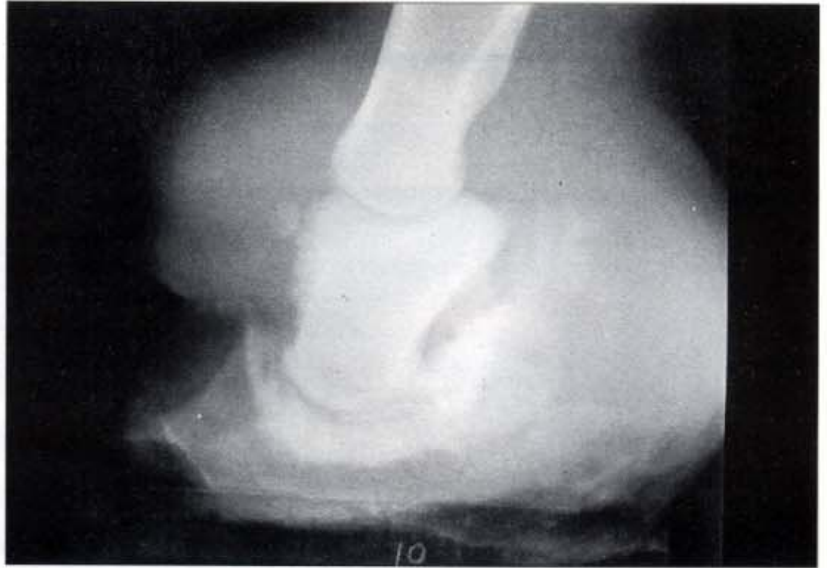

448. Severe chronic laminitis with osteomyelitis: sagittal section (A). This aged broodmare has survived with severe chronic laminitis for 5 years. The sagittal section shows the characteristic dropped concave sole. The tip of the distal phalanx is extensively remodelled and shows areas of osteomyelitis. The distal phalanx has rotated and its dorsal surface is near-vertical. The tip of the distal phalanx has remodelled because of chronic long-term sole pressure. There is bruising in the corium between the distal phalanx and the sole. A broad lamellar wedge has prevented the dorsal hoof wall, which is growing in a near-normal fashion, from making contact with what remains of the dorsal surface of the third phalanx: there is no functional hoof-distal phalanx bond. The horse is taking its weight on its sole and was suffering severe pain.

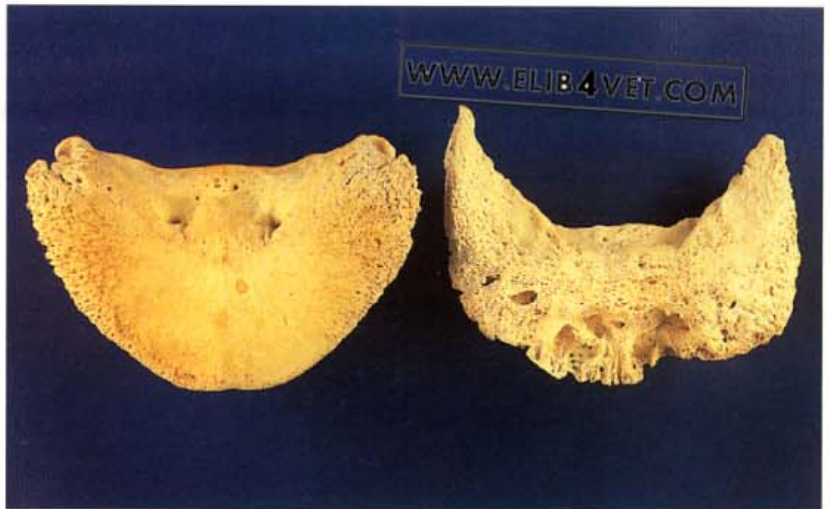


449. Severe chronic laminitis with osteomyelitis: sagittal section (B). Kept alive far too long this chronically foundered pony mare has severe rotation and osteomyelitis of the distal phalanx. The dorsal aspect of the distal phalanx has rotated even past vertical! The tip of the bone is necrotic and the thickened sole shows a series of infected cavities from previous episodes of osteomyelitis. When the pony was eventually destroyed, infection surrounded the entire distal phalanx and there was septic arthritis of the distal interphalangeal (coffin) joint. Note the brown infected material in the joint capsule above the distal sesamoid (navicular) bone. Photo: C. O'Dwyer.

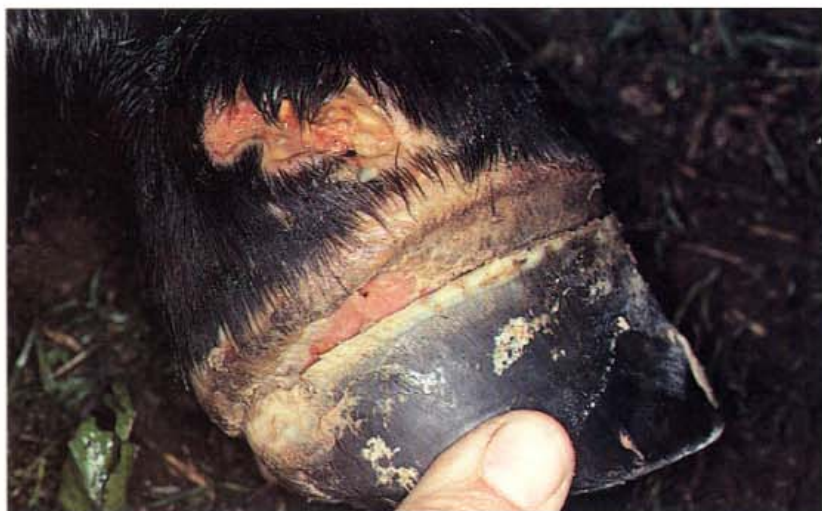450. Severe chronic laminitis: osteomyelitis radiograph. A sequel to severe cases of chronic laminitis is osteomyelitis of the solar margin of the distal phalanx. In this radiograph, of a long-standing case, the osteomyelitis was so severe that the distal phalanx has almost disappeared. There was septic osteoarthritis of the distal interphalangeal joint which involved the distal sesamoid (navicular) bone. The proximal interphalangeal (pastern) joint is level with what remains of the coronet. Photo: B. Chapman.



451. Chronic laminitis: osteomyelitis of the distal phalanx. When laminitis occurs and the distal phalanx separates from the inner hoof wall, the tip of the bone often develops osteomyelitis. On the left is the palmar surface of a normal distal phalanx. The bone on the right comes from a horse which had chronic laminitis for 18 months. The bone is light and porous and much of the tip has disappeared due to lysis.



Road Founder

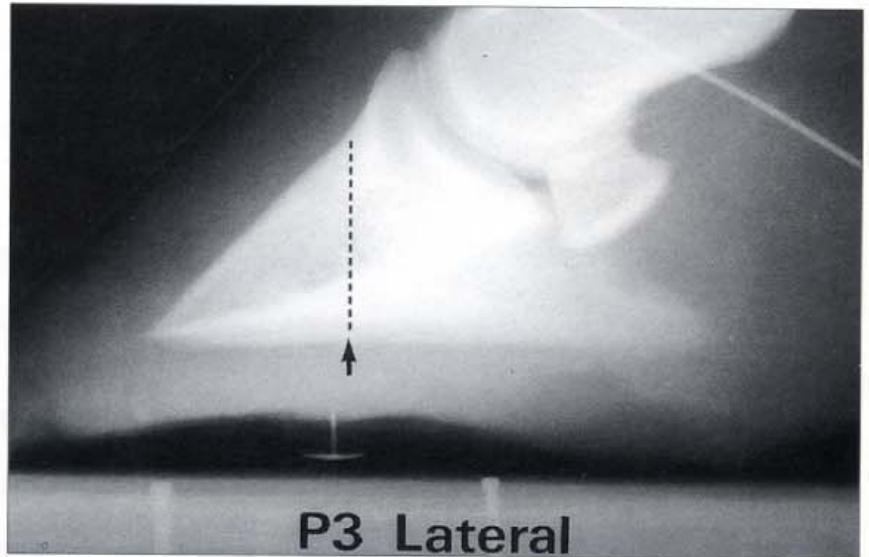


452. Road Founder (A). Road founder occurs when unshod horses gallop over hard surfaces. Severe trauma and concussion occur in the feet and often the toe is so abraded that the distal phalanx is exposed. This young unshod Warmblood horse escaped from an agistment paddock and galloped all night, up and down a paved road. Inexplicably the hindfeet were most severely effected and the entire hoof capsule sloughed from the underlying dermis.



453. Road Founder (B). Solar view of the same horse's foot shows the extent of the damage to the toe. Contact with the road surface has abraded the dorsal hoof wall and sole of the toe and the distal phalanx has been torn from the inner hoof wall. The avascular necrotic tip of the distal phalanx (arrowed) can be seen through the gap in the toe.

Laminitis Treatment and Aftercare



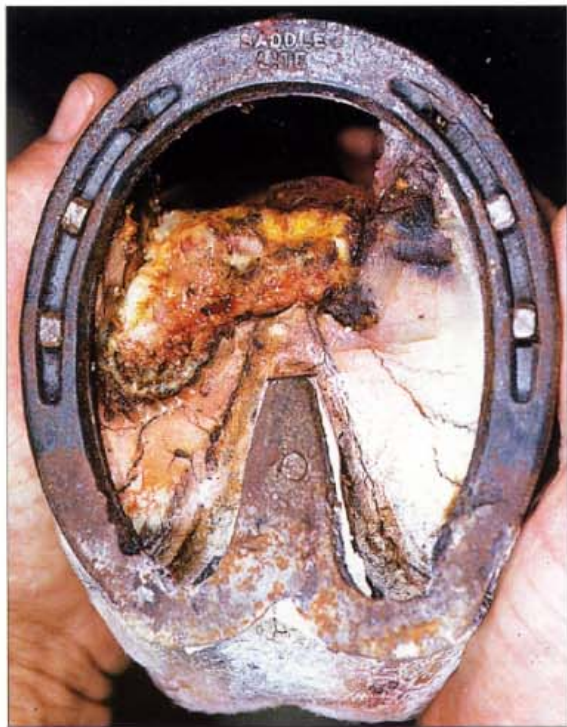454. Fitting the heart-bar shoe (A). It is essential that the heart-bar shoe is made and fitted with reference to the internal structures of the foot. If the frog plate is too far forward a painful sole abscess may result. Too far back, and the shoe will be ineffective. If there is likely to be displacement of the distal phalanx within the hoof capsule as occurs in chronic laminitis, the only sure way to fit a heart-bar shoe correctly is to refer to a lateral radiograph. A drawing pin (thumb tack) is placed at the tip of the frog as a radio-opaque reference point. In the radiograph illustrated the arrow shows where the tip of the frog plate of the heart bar shoe should be. There are two ways of determining the correct position. The first method is to drop a line from the base of the extensor process, perpendicular to the outline of the solar margin (shown by the dotted line in the photograph). A second method is to measure the length of the solar margin of the distal phalanx; the correct point is 37% of the distance back from the tip of the distal phalanx.



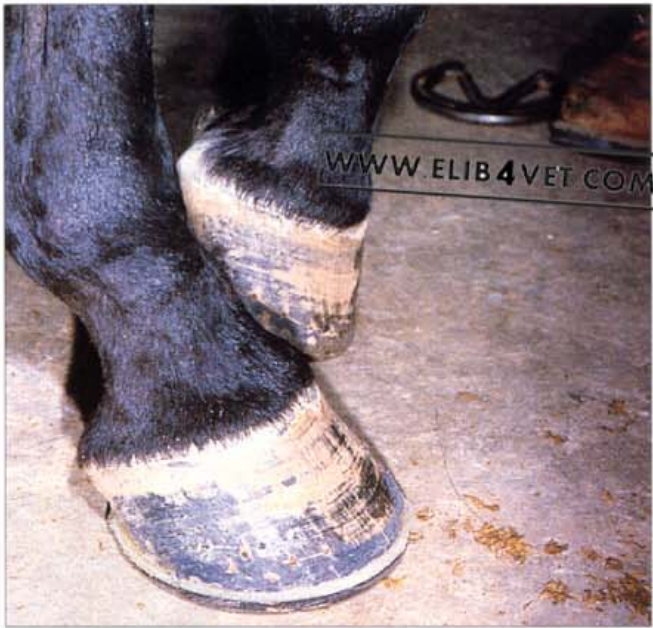455. Fitting the heart-bar shoe (B). Reference to the position of the drawing pin (thumb tack) on the radiograph allows the measurement of the correct position for the tip of the frog plate to be transferred to the under-surface of the hoof.



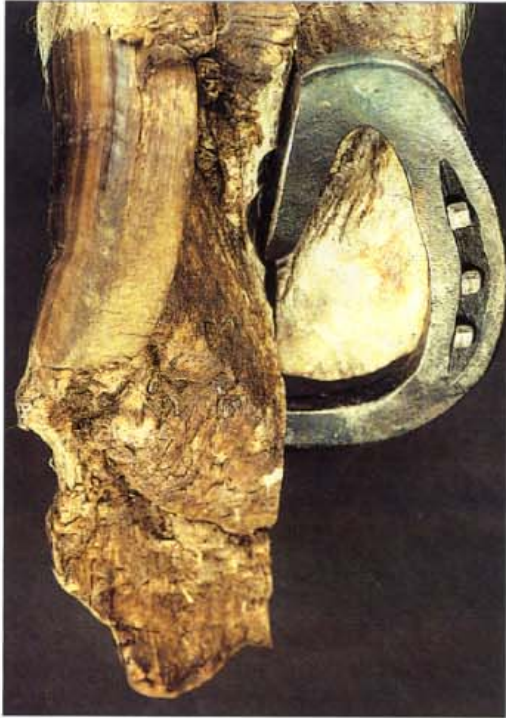456. The steel heart-bar shoe. The heart-bar shoe was originally developed to protect the heels of carriage horses working on cobblestone roads in the nineteenth century. It is currently a popular therapeutic shoe and has a wide range of applications. The frog is not normally a weight-bearing structure, but when a heart-bar shoe is fitted, the frog is recruited to bear a portion of the horse's weight. This relieves the toe and any injured part of the foot from the stress of weight bearing and facilitates healing. The shoe in the picture was made by Mr Burney Chapman of Lubbock, Texas, who pioneered the modern use of the heart-bar shoe in the treatment of chronic laminitis. The frog plate was forged separately and then welded to the heels of the shoe with the tip of the frog plate aligned to the chalk mark. The chalk mark has been transferred from measurements made on the radiograph of the foot and ensures that the tip of the frog plate has been located precisely.



457. The use of the heart-bar shoe. A properly fitted heart-bar shoe transfers some of the weight-bearing capacity of the foot to the frog, thus allowing other parts of the foot to be rehabilitated. In this case of severe laminitis the descent of the distal phalanx into the hoof capsule has caused severe sole necrosis. Fitted with a heart-bar shoe, the injured sole is kept clear of the ground and is beginning to recover.



458. The effect of the heart-bar shoe: pain relief. When a correctly made heart-bar shoe is fitted to the foot of a horse, in the early stages of laminitis, there is often dramatic relief of pain. The frog plate, exerting pressure on the frog and the digital cushion above it, appears able to offer some support to the distal phalanx. This is beneficial if the distal phalanx is descending into the hoof capsule because of weakened epidermal lamellae, damaged during the development of laminitis. The prompt application of a heart-bar shoe is often all that is needed to prevent a mild to moderate case of laminitis developing into a disaster. In the picture, the foot closest to the camera was the most painful of the two foundered front feet. It has been fitted with a heart-bar shoe and the horse has gained such relief that it is now able to stand on this foot and rest the other.

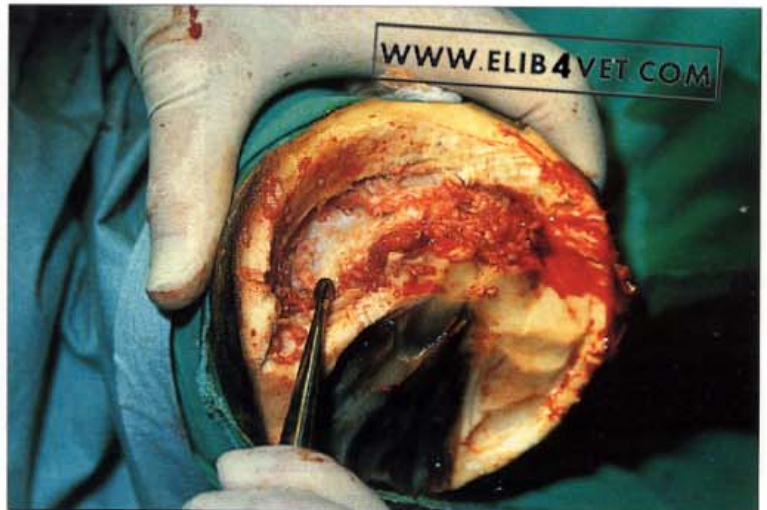

459. Chronic laminitis: foot preparation. This post-mortem specimen demonstrates the art of correct foot preparation and fitting of the steel heart-bar shoe. One half of a chronic laminitis foot was left in its original overgrown state and the other half was trimmed and fitted with half a heart-bar shoe. Therapeutic shoeing with heart-bar shoes is not a job for beginners.



460. Chronic laminitis: care of the patient. It is important that horses recovering from chronic laminitis are provided with soft, hygienic bedding on which to lie down. Being able to get the weight off their feet protects the hoof distal phalangeal bone bond from further damage and provides some measure of pain relief. It is unnatural for horses to lie down for long periods of time and decubitus ulcers will develop on pressure points if the bedding is not deep and soft. In the picture, a recumbent, chronically foundered mare is suckling her foal and eating hay at the same time.

461. Severe chronic laminitis: osteomyelitis surgery. Chronically foundered horses periodically discharge creamy, yellow pus from the coronary band. The source of the pus is the osteomyelitis of the solar margin of the tip of the distal phalanx which often does not respond to antibiotic therapy. In severe cases the necrotic bone can be removed surgically. In the picture the surgeon has removed most of the horny sole and is using a curette to scrape away portions of dead bone from the distal phalanx. The dead bone is recognised by its dry, discoloured, avascular appearance and scraping continues until normal bone is reached. This operation has salvaged some valuable horses for breeding purposes but requires intense, expensive after-care and entails a painful, prolonged convalescence for the horse.





462. Home-made after-care boots(A). The treatment of open wounds to horses' feet often fails because of the unhygienic conditions to which horses return after hospitalisation. Unless the injured area can be kept free of contaminants, like mud, faeces and urine, there is little hope of a successful outcome. Illustrated is a simple, cheap way to protect an injured area and to keep dressings in place. A drawstring, threaded through holes in the circumference of a circular piece of leather, was tightened around the pastern.



463. Home-made after-care boots (B). A version of the same thing made from rubber and baling twine. The dressing is sulphonilamide powder on cotton wool. This cheap, effective after-care boot was used to successfully treat a large number of road-foundered Warmblood yearlings.



464. Custom-made after-care boots (A). A saddler made this leather after-care boot for a horse which could only be kept outdoors. The boot had a rubber sole and successfully kept a foot with a dorsal hoof wall injury clean and dry.



465. Custom-made after-care boots (B). Commercially manufactured after-care boots for horses have a wide range of applications for the treatment of foot infections.

466. **Severe chronic laminitis: flexure deformity.** The severe, unrelenting pain in the digits of horses with chronic laminitis eventually causes acquired flexure deformity. The pain of the descending distal phalanx exerting pressure on the solar corium and the pain of chronic osteomyelitis initiate a withdrawal reflex, contraction of the flexor muscles and an altered position of the digits and the digital joints. This crippled Arabian mare has had chronic laminitis for a number of years and has developed severe flexure deformity. The dorsal surface of the distal phalanx is near-vertical and the pasterns are knuckling forwards. Surgically transecting the deep flexor tendons in the mid-cannon region failed to help this horse in the long term, probably because the superficial flexor tendon was involved as well.



Index

Note—numbers refer to page numbers

- after-care boots 204
- arteries of foot 21
- arteriogram of foot 20–1
- arteriovenous anastomoses (AVAs) 25–6, 27
 - dilation 171
- arthrocentesis 10, 13
- articular ringbone 48
- bar, puncture wound 130, 131
- BCG (bacille Calmette–Guérin) 148
- birth, hoof 7
- bone plate, orthopaedic 157
- broodmares 141
- bulbar vein 14
- buttress foot 98
- canker 150–3
- cannon bone 9, 11
- cartilage
 - calcified 47
 - distal phalanx 14, 15
- cauda equina neuritis 51
- chestnuts 45
- circumflex artery of coronet 21, 22, 24
- circumflex vein 24
- clinical examination 46–52
 - concurrent disease 50–2
- club foot 82–3
 - forefoot 62
- coffin bone 9
- coffin joint 10, 29
- colic 52
- colitis 189
- common digital artery 20
- conformation 79–90
 - club foot 82–3
 - contracted heel 80–1
 - flexor tendons 84, 85, 86, 87, 88
 - toe-in 79
 - toe-out 79, 80
- corium 19, 132, 134
 - bruising 198
 - lamellar 22, 28
 - prolapse 185, 186
- corn 73, 136
 - infected 136
- coronary band 21
 - bruising 119
 - deformed 129
 - injury 120
 - laceration 122–3
 - laminitis 188–9
 - papillae 16, 17
 - prolapse 189
 - selenium toxicity 128
 - stake wound 120–2
- coronary band trauma 123
 - chronic 128
 - hoof growth defect 124–6
- coronary groove 15, 32, 33, 34
 - scar tissue 146
- coronary vein 14
- coronet 21
 - abscess 138–40
 - chronic heel injury 129
 - concussion injury 127
 - disorders/diseases 119–29
 - injury 76–7
 - laminitis changes 188–9
 - palpation 47
 - pigment production 43
- coronitis, granulomatous 51
- cryotherapy 149
- deep flexor tendon 29, 44
 - adhesions 164
 - contracture 84
 - flaccidity 86
 - kissing lesions 162–3
 - navicular disease 159, 160, 162–3, 164
 - rupture 85
- dermal lamellae 15, 16, 18, 19, 24, 37
 - microcirculation 25, 26
- dermal papilla 15, 18, 32, 33
- dermal–epidermal junction 39
- Dermatophilus* 148
- digit
 - bones 13
 - joints 13
 - sagittal section 9
 - skeleton 9
- digital blood supply 19
 - arteries 20, 23
 - failure 94–6
- digital pulse 50
- distal interphalangeal joint 10, 13, 29
 - flexing 44
 - flexion test 48
 - subluxation 100–1
 - trauma 106–8
- distal phalanx 9, 10, 28
 - bond 37
 - cartilage 14, 15, 19
 - cartilage disorders 103–5
 - dorsal surface arteries 22
 - extensor process 16
 - fracture 48, 50, 108
 - hoof capsule 185, 186, 187
 - osteomyelitis 198, 199
 - palmar surface arteries 22
 - partial rotation 192
 - rotation 198
- distal sesamoid (navicular) bone 9, 23, 29, 30, 44
 - arteries 22
 - blood supply 23
 - calcification 166
 - flexor surface 162
 - fracture 48, 160, 164–5
 - navicular disease 159, 160, 162–3
 - resorption 165
- distal sesamoidean suspensory ligament 166
- donkey 60
 - shoeing 70
- dorsal pouch 10
- dyskeratosis 151
- endurance horse 92, 127, 130, 138
 - distal sesamoid (navicular) bone 162
 - quarter crack 146–7
- enteritis, granulomatous 51
- enthesiophytes 166
- epidermal lamellae 31, 32, 34, 35
 - dropped sole 182
- foal 39
 - histology 37, 38, 39
 - hoof growth 41
 - laminitis 173, 174, 176, 177
- Equilox 75, 76, 77, 78, 137
 - quarter cracks 142, 143, 147
- equine degenerative myeloencephalopathy (EDM) 93
- ergots 45
- Esmarch's bandage 144, 156
- extensor process 9
 - stress fractures 60
- extensor tendon 9, 10
 - severed 67
- farriery 63
- feet
 - problem 70–4
 - unbalanced 62
 - uneven 61
- fetlock
 - downward extension 44
 - joint 9, 10, 11
 - varus 80
- flexor tendon
 - damage 66
 - flaccidity 87
- flexure deformity
 - acquired 89, 205
 - congenital 88

- foal 7, 8
 - angular limb deformity 89–90
 - deep flexor tendon flaccidity 86
 - flexor tendon contracture 88
 - foot care 61
 - foot size 8
 - hoof wall histology 39
- foetus 7
- foot
 - circulation 19–27
 - deformity 70
 - diagram 9
 - growth rate 27
 - palpation 47
 - size 8
 - trimming 56, 58
 - venous drainage 14, 15
 - see also* hoof
- founder; *see* laminitis
- frog 31, 32, 33
 - atrophy 80, 81, 154
 - ground contact 59
 - penetrating wound 133
 - underrun 134
- Fusobacterium necrophorum* 154
- gangrene 94–5
- granulomatous enteritis 51
- greasy heel 148
- haemoglobin staining, white zone 135, 136
- heel
 - abscess 136
 - contracted 80, 81
 - crushed 70
 - greasy 148
 - injury 67
 - medial lateral balance 56
 - palpation 47
 - repair 77
 - sheared 72
 - underrun 53
- hoof
 - foetal 7
 - reconstruction compound 126
 - repair tape 157
 - testers 48
 - total slough 197
 - trimming 56, 58
 - unbalanced 55
 - see also* foot
- hoof growth
 - bizarre 179
 - coronary band trauma defect 124–6
 - deformed 85, 87
 - laminitis 179, 180
- hoof pastern axis 58–62
 - broken forward 60
 - broken-back 58, 59, 82, 135, 162–3
 - restoring 59
- hoof wall 32, 33, 34, 35
 - anatomy 31–6
 - avulsion 114, 129
 - cracks 55
 - deformed growth 178
 - disorders/diseases 109–18
 - epidermal tubule 15
 - growth 40
 - histology 37
 - lamellae 15, 18, 139, 140
 - pigmentation 42–3
 - rasping 55, 57
 - reconstruction 75–9
 - resection 190–1, 192, 194–7
 - severe chronic separation 116
 - tubules 36, 37, 40, 41
- horseshoe/horseshoeing; *see* shoe/shoeing
- hospital plate 111, 132, 135, 139, 157, 158
- hyperlipaemia 181
- infections 148, 149–54
- injury
 - brushing 92
 - interference 91–3
 - over-reaching 92, 93
 - scalping 91
- keratoma 155–8
 - cylindrical 155–7
 - spherical 158
- lamellar rings 197
- lamellar vessels 24
- lamellar wedge 176, 177, 180, 190–3
 - resection 190–2, 194
 - septic 183
- lameness 46
- laminitis 50, 71, 169–70
 - acute 177
 - aftercare 201–5
 - bedding 203
 - boots 204
 - cause 171–2
 - chronic 174–6, 177, 179, 182, 183, 184–6
 - colitis 189
 - coronet changes 188–9
 - corticosteroid therapy induced 180
 - development 171–2
 - flexure deformity 205
 - foot preparation 203
 - gait 169
 - histology 173–4
 - hoof wall resection 190–1, 192, 194–7
 - hyperlipaemia 181
 - lamellar wedge 190–3
 - osteomyelitis 175, 197, 198–9, 203
 - overgrown toe 195
 - radiology 187
 - ring 188, 197
 - road founder 200
 - sections 175–7
 - sinker 177
 - sole bruising 193
 - sole changes 182–6
 - stance 170
 - supporting limb 180
- total hoof slough 197
 - treatment 201–5
- underrun sole 183
- unilateral 195–6
- wall changes 178–80
- see also* shoe, heart-bar
- lateral digital arteries 23
- ligament of ergot 12
- limb deformity, angular 89–90
- Marie's disease 101–2
- medial digital arteries 23
- medial lateral balance 54–7
 - foot trimming 56
 - forefoot 49
 - restoration 57
- melanin 42, 43
- melanocytes 42
- metacarpal bone 9, 11
- metacarpo/metatarso phalangeal joints, flexure deformity 88
- metacarpophalangeal joint 9, 10
 - flexure deformity 89
- middle phalanx 9, 10
- mud rash/fever 148
- muscle injury 52
- nail hole, infected 137–40
 - with coronet abscess 138–40
- nails 65
 - pitch 64
 - placement 63, 64, 65
- navicular bone; *see* distal sesamoid (navicular) bone
- navicular bursa 29, 44, 160
 - infection 167
 - local anaesthesia 161–2
- navicular disease 29, 30, 44, 159–68
 - diagnosis 164
 - egg-bar shoe 168
 - end-stage 166
 - flexion test 48
 - lameness 163–5
 - palmar digital nerve block 161
 - stance 159
- navicular suspensory ligament 29
- navicular trauma 162–3
- obesity 181, 184, 185
- orthoplast 152
- osteoarthritis 85, 87
 - septic 199
- osteoarthropathy, pulmonary hypertrophic 101–2
- osteomyelitis 132, 186
 - laminitis 175, 197, 198–9
 - surgery 203
- osteopathy, hypertrophic 101–2
- palmar digital nerve 12
 - block 161
- palmar process 19
- parietal groove 19

- pastern
 - axis 56
 - bone 9
 - joint 9, 10
 - trauma 96
 - see also* proximal interphalangeal (pastern) joint
- perionychium 7
- periople 32, 33, 36
- papillae 17, 20
- phalanx 9, 10
- phycomycosis 149
- pigeon-toes 62
- pigmentation, hoof wall 42–3
- pododermatitis 51
- podotrochleosis; *see* navicular disease
- polydactyly 45
- proximal interphalangeal (pastern) joint
 - 9, 10
 - ringbone 97, 98
- proximal phalanx 9, 10
- proximal sesamoid bones 11
- Pseudomonas* 148, 151
- pus, black 137
- pyramidal disease 98
- Pythiosis* 149
- quarter cracks 78, 141–7
 - acute blind 142
 - adhesive patches 142
 - chronic 142, 146
 - injury repair/maintenance 146–7
 - race horse 144
 - shod horse 144–5
 - underfoot conditions 141, 146
 - unshod horse 141
 - wall strip surgery 144–5
 - wire repair 145
- quittor 103–4, 140
- ringbone 60, 97–102
 - articular 48
 - high 57
 - nonarticular high 99
 - nonarticular low 99, 100
 - road founder 200
 - after-care boots 204
- sarcoid 148–9
- selenium toxicity 128
- sesamoid bones 9, 11
- sesamoidean ligaments 11
- shoe 53
 - egg-bar 68, 70, 168
 - extended heel 68
 - extended toe 67
 - fetlock sling 69
 - frog support 185
 - half-bar 145
 - high-heeled 74
 - hospital plate 111, 132, 135, 139, 157, 158
 - medial extension 90
 - patten 66
 - rim 66
 - rolled toe 147
 - wear 66
- shoe, heart-bar 67, 71, 72, 118, 122, 123
- chronic laminitis 177, 184, 186, 187, 195
- drug-induced laminitis 180
- fitting 201–2
- frog weight bearing 202
- hoof wall resection 194
- lamellar wedge resection 191, 192
- laminitis 191, 192, 194, 201–2
- pain relief 202
- quarter crack 142, 145
- unilateral laminitis 195–6
- shoeing 53, 58
 - bad 74
 - donkey 70
 - foot trimming 56
 - incorrect 73
 - medial lateral balance restoration 57
 - overdue 73
 - pigeon-toed horse 62
 - unethical 74
- short pastern bone 9
- sidebone 14, 47, 105
- sinker 177, 186, 189
- skeleton of digit 9
- sole 31, 32
 - abscess 139, 182
 - bruising 130, 184, 193
 - corium prolapse 185, 186
 - dropped 178, 182, 183
 - horn degeneration 136
 - horny 134
 - laminitis 182–6
 - paring 138
 - penetrating wound 132
 - pressure 131
 - puncture wound 132
 - resection 139, 140
- shoeing 53
- stone bruise 130
- trauma 135
- underrun 134, 183
- Staphylococcus* 148
- street nail operation 167
- SUPA 126
- suspensory apparatus rupture 68–9, 84
- suspensory ligament 10
 - rupture of extensor branch 84
- teratosarcoma 51
- terminal arch 21, 22, 28
- terminal papillae 18, 24
- thermoregulation of foot 27
- thrush 154
- toe
 - abrasion 135
 - infections 115–18
 - region 18
- toe cracks 109–14
 - repair 113–14
- trot out 46
- tumours 148–9, 155–8
- underrunning 134, 183
- ungual cartilage 9, 14, 19
- venous plexus
 - coronary 15
 - inner 15
- wall strip surgery 144–5
- white line disease 117–18
- white zone
 - dropped sole 183
 - haemoglobin staining 135, 136

WWW.ELIB4VET.COM

Color Atlas of the Horse's Foot provides the reader – whether veterinarian, farrier or interested horse owner or trainer – with a valuable guide to the accurate diagnosis of equine foot problems.

Rapid visual recognition and interpretation of signs are vital elements of successful treatment of equine foot disorders. These requirements are aptly met in this unique Atlas. Containing 466 full-color photographs and line illustrations, selected from the author's vast collection, this Atlas covers the entire spectrum of conditions, from laminitis to tumors. The illustrations are accompanied by succinct, accessible, and descriptive text that clarifies differential diagnosis and gives details of actual case histories.

Features

- 466 superb color photographs and line diagrams illustrate every aspect of normal and abnormal structure of the horse's foot
- Clinically focused material presents the reader with a wide range of conditions
- Case histories followed pictorially from initial presentation through diagnosis to treatment and recovery

Equine medicine titles of related interest

Anatomy of the Horse: An Illustrated Text 2e **Budras**

Self-Assessment Picture Tests in Veterinary Medicine:

Equine Practice **Dyson**

Color Atlas of Diseases and Disorders of the Horse **Knottenbelt**

Slide Atlas of Diseases and Disorders of the Horse **Knottenbelt**

A Colour Atlas of Equine Dermatology **Pascoe**

ISBN 0-7234-1765-2



9 780723 417651