SAUNDERS
ELSEVIER

© 2010, Elsevier Limited. All rights reserved.

No part of this publication may be reproduced or transmitted in any form or by any means, electronic or mechanical, including photocopying, recording, or any information storage and retrieval system, without permission in writing from the publisher. Permissions may be sought directly from Elsevier's Rights Department: phone: (+1) 215 239 3804 (US) or (+44) 1865 843830 (UK); fax: (+44) 1865 853333; e-mail: healthpermissions@elsevier.com. You may also complete your request on-line via the Elsevier website at http://www.elsevier.com/permissions.

ISBN: 978-0-7020-2863-2

British Library Cataloguing in Publication Data
A catalogue record for this book is available from the British Library

Library of Congress Cataloging in Publication Data
A catalog record for this book is available from the Library of Congress

Notice
Knowledge and best practice in this field are constantly changing. As new research and experience broaden our knowledge, changes in practice, treatment and drug therapy may become necessary or appropriate. Readers are advised to check the most current information provided (i) on procedures featured or (ii) by the manufacturer of each product to be administered, to verify the recommended dose or formula, the method and duration of administration, and contraindications. It is the responsibility of the practitioner, relying on their own experience and knowledge of the patient, to make diagnoses, to determine dosages and the best treatment for each individual patient, and to take all appropriate safety precautions. To the fullest extent of the law, neither the Publisher nor the Authors assumes any liability for any injury and/or damage to persons or property arising out or related to any use of the material contained in this book.

Neither the Publisher nor the Authors assume any responsibility for any loss or injury and/or damage to persons or property arising out of or related to any use of the material contained in this book. It is the responsibility of the treating practitioner, relying on independent expertise and knowledge of the patient, to determine the best treatment and method of application for the patient. *The Publisher*

ELSEVIER your source for books, journals and multimedia in the health sciences
www.elsevierhealth.com

Working together to grow libraries in developing countries
www.elsevier.com | www.bookaid.org | www.sabre.org
ELSEVIER BOOK AID International Sabre Foundation

The publisher's policy is to use **paper manufactured from sustainable forests**

Printed in China

1 IMAGE FORMATION

All radiographic images reflect a pattern of x-ray photons (particles of energy) that have passed through the subject with a proportion being absorbed, depending on the nature of the tissue (fluid, soft tissue or bone). X-rays are a form of energy, which are emitted from tungsten when the metal is subjected to a stream of electrons. In traditional radiography using non-screen film the x-rays emitted from the x-ray machine pass through the patient, subsequently causing ionisation of silver halide embedded in the emulsion coating the film (exposure). The introduction of fluorescent intensifying screens into radiographic cassettes adds one further step to the process: the x-rays cause light to be emitted from the screens and it is this light that ionises the silver. Because one x-ray photon produces many light photons the x-ray machine exposure settings can be reduced when screens are used. The latent image present on the film is then converted to the familiar radiographic image by processing the film through liquid developing and fixation chemicals.

Regardless of whether the x-ray system is film-based, CR (computed radiography) or DDR (direct digital radiography), the image produced reflects the quantity of x-rays passing through the subject. Starting at the source of the x-ray beam, the machine controls allow variation of the total number of x-rays emitted per exposure (milliamperes and time, mAs) and of their energy (kilovoltage, kV). Insufficient mAs will result in an overall grey appearance to the image (under-exposed). For most equine orthopaedic radiography high-contrast images are desirable and these are achieved by using a 'low-kV technique'. Exposures of less than 70 kV result in x-rays with moderate energy, which are readily absorbed by tissue that is slightly thicker or has a higher atomic number. If the energy is increased (higher kV) more x-rays will pass through the subject to the image, resulting in less contrast. The overall exposure of the film also depends on the distance between the machine and the film (film-focus distance, FFD) and this should be kept constant to ensure image consistency.

Regions of film that are not exposed to x-ray photons (e.g. under metal markers) will be white following processing, while regions exposed to the primary beam without any absorption by the subject will be black. All other regions will be various shades of grey and the combination of the various regions of grey comprises the image of the structure being examined. CR and DDR systems retain this convention, although the images can be manipulated post acquisition. Dense tissue with a high atomic number (e.g. bone) absorbs more x-rays than fluid, muscle or fat. Thicker and denser tissues also absorb more x-rays; therefore, a region of sclerotic bone will appear slightly whiter than adjacent bone.

Downloaded From Vet-eBooks.com

IMAGE FORMATION

Radiography produces a two-dimensional image of a three-dimensional structure and to compensate for this reduction in information at least two views of the region being radiographed are usually required.

Downloaded From Vet-eBooks.com

2 RADIOGRAPHIC EQUIPMENT

X-ray machine

There are three main types of x-ray machine available – portable, mobile and ceiling mounted. Portable machines are ideal for the veterinary surgeon in ambulatory practice as they can be transported to the clients' premises and set up anywhere within reach of a power supply. These machines are capable of a simultaneous mA and kV output which is adequate for radiography of the equine distal limbs, skull and cranial cervical vertebrae. The relatively low mA capacity makes movement blur more likely than with the more powerful machines. Mobile units can be wheeled from room to room within the same premises, but are too large and heavy to be easily transported in a vehicle. They have higher output capabilities than portable units and most are capable of producing diagnostic views of the larger structures in the horse (stifle, elbow, shoulder, caudal cervical vertebrae). Fixed x-ray machines must be ceiling mounted for equine work and they have the greatest output range. They are required if high-quality radiographs of regions such as the pelvis and thoracolumbar vertebrae, are regularly being obtained. Some of these machines incorporate linked cassette holders, which move with the machine while remaining centred, and may have fluoroscopy capability. In the authors' clinic all three x-ray machine types are used, with the mobile machine useful for intra-operative radiography in the surgical theatres.

When considering the purchase of an x-ray machine, be aware that, particularly for the portable machines, the mA and kV values are inversely related and the quoted maximum output values may not actually be obtainable simultaneously. Some of the cheaper machines do not allow the mA and kV to be controlled separately; as one is increased the other is automatically reduced. A stand for the machine is essential; health and safety legislation in most European countries bans the exposure of an x-ray machine while it is being held by the operator and the risk to the humans involved in holding the machine far outweighs any minor gain in convenience. Also consider how close to the ground the tube head can be lowered for foot radiography. Collimation is achieved by a light-beam diaphragm in modern machines, but some older machines may still use a metal cone, which allows no flexibility.

Cassettes and screens

Radiographic cassettes are manufactured for human hospital use and care must be taken when using them for the more robust requirements of equine radiography. The authors use three cassette sizes: 18 × 24 cm, 24 × 30 cm and 36 × 45 cm. The larger

Downloaded From Vet-eBooks.com

cassette/film size is required for the skull, thorax, abdomen (foals) and lateromedial views of the proximal appendicular joints and vertebrae.

Radiographic intensifying screens allow exposure factors to be reduced (see Ch. 1) by emitting light in response to x-rays. Standard cassettes contain a screen on both inner surfaces and are used with double emulsion film. Higher detail images can be obtained by using single emulsion film in cassettes with only one screen, but at the cost of increased exposure values. In general, the film type must match the screen being used. Screens vary in their sensitivity to x-rays; 'fast' screens (usually rare earth) require less exposure, but produce images with less detail than 'slow' screens, which contain calcium tungstate. In equine radiography, the risk of movement blur is high; therefore, a fast film-screen combination is preferred. Screens are easily scratched and accumulate dirt so must be regularly inspected and cleaned.

Grids

A grid is used to reduce the amount of scattered radiation reaching the cassette. Excess scattered radiation produces a fogged appearance on the radiograph. Grids consist of a mesh of thin lead strips embedded in plastic and are placed directly in front of the cassette. The thickness and alignment of the lead strips varies between different grid types. In general, regions over 12 cm in diameter benefit from the use of a grid, although individual clinicians vary in their preference for a grid. Use of a grid requires increased exposure values. In the case of a focussed grid, where the lead strips are angled slightly towards the centre, the primary beam must be centred exactly on the middle of the grid, otherwise the image quality will suffer due to lines appearing on the image ('grid cut-off').

Film labels

Some form of labelling is essential. Ideally, each radiograph should be marked with the patient details, date and projection. In equine radiography the same multiple views of contralateral structures are frequently obtained and inadequate labelling easily causes confusion. For instance, it can be difficult to distinguish the standard oblique views of the fetlock without markers. It should be remembered that radiographs are part of the patient's medical record and there may be legal consequences to incorrect labelling. Labelling can be applied prior to exposure (writing on lead tape, or lead letters) or between exposure and processing (light flash on unexposed corner of film in dark room; computerised labelling of the cassette in CR).

Cassette holders

These should be available for every cassette size. The only view for which holding the cassette by hand is acceptable is the lateromedial view of the stifle, as the cassette has to be pushed upwards, and in this case the largest available cassette should be used to ensure the assistant's hands are not exposed to the primary beam. Cassette holders can be home-made from wood or aluminium and the handle is usually 70–100 cm long (see Fig. 3.3).

Downloaded From Vet-eBooks.com

Foot-positioning aids

Several blocks are required to position the foot for radiography. One block should contain a wedge or large groove to securely hold the toe for the 'upright' views of the foot. It is convenient if the same block has a groove behind the wedge to hold a cassette, obviating the need for an assistant to hold the cassette. For lateromedial views of the distal limb a simple block, usually wooden, is required to raise the foot to the level of the centre of the primary beam; the required height of the block depends on how close the tube head can be lowered to the ground. For the PaPr-PaDi ('skyline') view of the palmar aspect of the foot a flat box (cassette tunnel) is required to protect the cassette from the weight of the horse (see Fig. 2.1).

Fig. 2.1 Cassette tunnel and equine foot in position for a 'skyline' view of the navicular bone

Computerised radiography and direct digital radiography

Computed radiography systems have been available for about 20 years and are rapidly gaining acceptance in equine practice. Cassettes used in CR contain phosphor screens but no film and are available in the same range of sizes as conventional cassettes. The latent image produced by x-rays is held within the screen until scanned by a laser. The images are similar in quality to the best film images, but have the advantages of being digital and, therefore, can be manipulated to adjust factors such as brightness, contrast and magnification. All radiographic images in this book were produced on a CR system. DDR systems produce images immediately without a processing stage and the image quality is superior to that of CR. Other than slight modifications in exposure values the techniques of acquiring radiographic views and the ancillary equipment required are the same regardless of which radiographic system is used.

Downloaded From Vet-eBooks.com

3 RADIATION SAFETY AND PATIENT PREPARATION

It is well established that x-ray radiation increases the risk of cancer and genetic abnormalities and, therefore, taking appropriate safety precautions is of great importance when performing radiography of equine patients.

Radiation laws and regulations may vary from state to state and country to country; however, there are practical principles that should be applied to minimise the radiation exposure received by all personnel involved in equine radiography, regardless of geographic location.

Principles of radiation safety

- There must be a clear clinical indication for performing any procedure involving the use of ionising radiations.
- Exposure of personnel to radiation should be kept as low as reasonably achievable (the 'ALARA' principle).
- Dose limits for individual personnel should not be exceeded.

Radiation sources

The primary x-ray beam is the main source of radiation during equine radiography. Scattered radiation is also produced, particularly when high exposures are used (e.g. for the proximal limb, neck and thorax). The use of a horizontal beam as standard for many radiographic projections in the horse means that staff are at increased risk of being exposed to the primary beam, as compared to small animal radiography, which most commonly utilises a vertically orientated x-ray beam.

Collimation of the x-ray beam using a light beam diaphragm (Fig. 3.1) as a guide should restrict the size of the primary beam. To ensure that the edges of the primary beam do not extend farther than the edge of the cassette, all margins of the primary beam should be visible on the film once processed (Fig. 3.2).

Downloaded From Vet-eBooks.com

Fig. 3.1 The light beam diaphragm should be used to collimate the primary beam to include only the areas of interest and ensure all edges of the primary beam are on the cassette

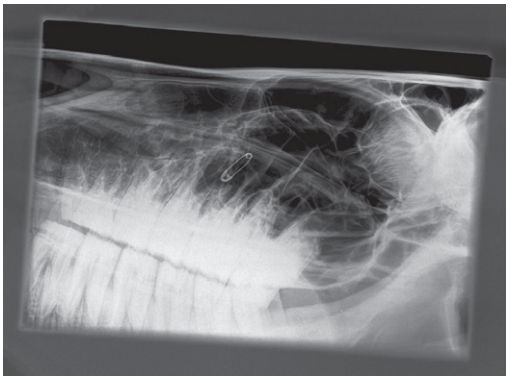

A

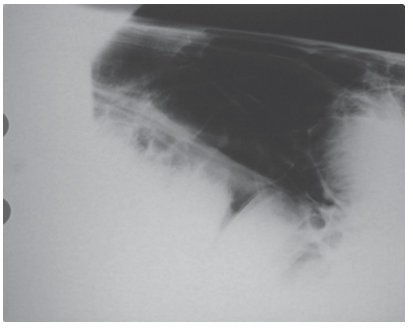

B

Fig. 3.2 (A) Adequately collimated radiograph of the skull – all edges of the primary beam are clearly defined. **(B)** Inadequately collimated radiograph of the skull – the edges of the primary beam are only visible on the left border of this radiograph. The primary beam extends further than the edge of the film on the other three sides

Restricting exposure to radiation

Personnel within an area where radiation exposure is a possible hazard ("controlled area") must wear appropriate protective clothing. This should include lead-lined gowns and gloves (Fig. 3.3). Staff working within the controlled area must also wear a radiation dosemeter (Fig. 3.4), beneath protective clothing, which is checked regularly to ensure that an individual has not been exposed to excessive amounts of radiation. Clients who assist during radiographic procedures should be over 16 years of age and not pregnant, and should be made aware of the risks of radiation.

The distance between people within the controlled area and the primary beam should be maximised as this is paramount in reducing the amount of exposure to x-rays. This may be done using aids such as cassette holders instead of hand-holding cassettes

Downloaded From Vet-eBooks.com

Fig. 3.3 Protective clothing suitable for use during equine radiography – lead gown, gloves and thyroid guard. In the background is a mobile lead screen

Fig. 3.4 Radiation dosemeter

Fig. 3.5 Cassette holders should be held at arms length to increase the distance between personnel and the primary beam

(Fig. 3.5), utilising supports such as wooden blocks to minimise the requirement for manual restraint of the horse, or simply by stepping further away from the area being radiographed.

Compiling an exposure chart for various radiographic views that is specific for the system being used and adjusted for different sizes of horse (see Appendix), will help to reduce the number of repeat radiographs required due to inappropriate exposure.

Downloaded From Vet-eBooks.com

Patient preparation

Preparing the patient adequately for radiographic examination is important both for obtaining good-quality radiographs and for minimising radiation exposure to personnel.

Movement blur, poor positioning of the patient and/or primary beam and inadequate exposure are the most common reasons for having to repeat radiographs, which is undesirable due to the additional radiation exposure to personnel and the patient. Movement blur can often be minimised by sedating horses, for example, using an alpha-2 agonist (e.g. detomidine, romifidine or xylazine) with butorphanol. The choice and dose of sedative used should depend on the temperament of the individual horse and the radiographic procedure being performed. Taking time to ensure correct patient and cassette position, and proper direction and collimation of the primary beam also minimises the requirement for repeat exposures. These are outlined for specific radiographic views in the relevant chapters.

The hair-coat should also be clear of dirt or other debris, as these may cause artefacts on radiographs (Fig. 3.6). Similarly, clumps of wet hair can also create radiographic artefacts, so the hair should be dried and brushed out if at all possible. Preparation of the foot for radiographs of this area is described in more detail in Chapter 5.

Fig. 3.6 Radiograph of the metatarsus of a horse with a muddy, wet coat – note the multiple radio-opaque artefacts present

Downloaded From Vet-eBooks.com

4 RADIOLOGICAL INTERPRETATION AND DIAGNOSIS

Reading radiographs has been compared to performing a clinical examination; both require the collation and processing of information to form a conclusion, or diagnosis. To continue the analogy, just as missing out key parts of a clinical examination such as taking the temperature of a patient will increase the likelihood of an incorrect or missed diagnosis, so an inadequate number of radiographic views or technically poor-quality films can lead to errors in diagnosis. Radiological interpretation requires the synthesis of visual pattern recognition with a sound knowledge of normal anatomy, effect of disease processes and patient details. Experienced and successful radiologists (and clinicians) are able to rapidly identify 'key features' during an examination and formulate a working hypothesis, but are also able to be flexible in dropping that hypothesis when contradictory information is encountered. Inexperienced radiologists are much more likely to over-interpret innocuous findings and make the radiographic changes fit their diagnosis rather than the other way around.

A systematic method of reading films helps to reduce errors. Images should be viewed the same way, with the horse's head to the viewer's left and medial to the viewer's left. All views of the same structure should be grouped together. Taking time to review films often reveals subtle abnormalities, which were not observed on initial examination under perhaps less than ideal conditions. A radiological atlas and bone specimens are essential reference tools, particularly for less common and oblique views.

Common pitfalls in interpretation technique include:

- lack of familiarity with the wide range of normal variations seen on equine limb radiographs; these can be influenced by age, breed and type of activity
- the detection of an obvious abnormality, which then causes the observer to stop looking for other, perhaps more significant lesions
- only looking at the region of interest at the centre of the image, not evaluating the whole film
- reaching a diagnosis based on the resemblance of a finding with cases seen previously (pattern recognition). While this approach is often successful, the lack of a systematic radiological examination will result in errors when an atypical case is encountered.

Radiographs should be evaluated on an adequate number of viewing boxes in a darkened room. Masking the viewing screen around the film can be helpful. The quality

Downloaded From Vet-eBooks.com

of the radiographs should be evaluated first. If they are over-exposed then use of a bright light is essential. No such remedy is available for under-exposed films, which should be repeated if they are non-diagnostic. Assess whether a sufficient number of views have been obtained for the region being investigated. In general, the more complex the structure, the more views are required (see later chapters). The labelling should be checked and, if necessary, amended at the time of initial assessment.

Some subtle lesions (for example, an ill-defined medial condylar subchondral bone cyst on a caudocranial view of the stifle) are more readily seen when the radiograph is viewed from a distance so this is a useful way to begin. Assessment of soft-tissue changes (swelling, tracts) will usually require use of a bright light on radiographs exposed to image bone. The same is true for early periosteal proliferation. Always evaluate the whole radiograph as well as the region of interest, which should be positioned in the centre of the film. Clinically significant lesions, such as a fracture line, may be present at the edge of a film.

When an apparent abnormality is located, it frequently must be differentiated from an artefact. The suspected lesion is more likely to be 'real' if it can be seen on more than one view. Radiographing the contralateral limb is often used to differentiate a normal variation in an individual animal, which is frequently bilateral, from a lesion. Whenever a lesion is found that commonly occurs bilaterally, the contralateral limb should also be examined.

The purpose of most radiographs taken in equine practice is to evaluate the bones of the skeleton; therefore, the responses of bone to insult and disease are of particular relevance to equine clinicians. Bone can become sclerotic (making it appear more radio-opaque on a radiograph) or demineralised (appearing more radiolucent). These changes are frequently subtle or undetectable, because an increase of at least 30% in the bone mineral matrix is required to become apparent radiographically. If a region contains more bone than is thought normal, that new bone should be characterised. Irregular, hazy or spiculated new bone suggests a recent or on-going process. Smooth new bone of homogenous radio-opacity is indicative of an old process that may no longer be clinically relevant (e.g. a healed periosteal reaction on a small metacarpal or metatarsal bone or 'splint'). Diffuse sclerosis may reflect increased bone modelling as an adaptation to altered forces on the affected region, which in many instances will be normal, such as the increased thickness of the metacarpal dorsal cortex when compared to the palmar cortex. Focal new bone formation is frequently seen at attachment sites of ligaments (enthesiophyte), tendons and joint capsules (osteophytes) to bone. The shape and size of the enthesiophytes and osteophytes will give an indication of the severity and chronicity of the underlying disease process.

Bone loss should also be characterised to gain maximum knowledge from that finding. Is the reduction in bone resorbtion or lysis? Bone resorbtion is commonly due to pressure on the bone, such as that seen in the distal phalanx in response to a keratoma on the inner hoof wall. Chronic bone resorbtive processes may result in a sclerotic rim around

Downloaded From Vet-eBooks.com

the more radio-opaque region. Lysis of the bone is usually more irregular in nature and suggests a more aggressive condition, such as osteomyelitis.

The limitations of radiography must also be recognised; it is very poor at imaging soft tissue, such as ligaments, tendons and articular cartilage. Therefore, while we make a diagnosis of osteoarthritis based on a finding of periarticular osteophytes, this is only a minor manifestation of the disease and not the source of the pain itself. The cardinal feature of osteoarthritis is loss of articular cartilage, which cannot be imaged radiographically, and most of the pain originates from the subchondral bone, where radiographic changes (sclerosis, subchondral cyst-like lesions) appear only in the advanced stages of the condition.

Finally, consideration should be given to whether sufficient information has been obtained to make an accurate diagnosis and prognosis, or whether additional imaging techniques (ultrasonography, cross-sectional imaging modalities such as computed tomography or magnetic resonance imaging, scintigraphy) or other diagnostic tests are required.

Downloaded From Vet-eBooks.com

5 RADIOGRAPHY OF THE FOOT

Introduction

As most causes of equine forelimb lameness are located in the foot, this region is the most frequently radiographed. The hoof capsule and the irregular soft-tissue opacity caused by the frog and adjacent clefts, and the need to centre the primary beam close to the ground, present specific problems in obtaining good-quality radiographs of the foot.

Common indications include:

- lameness localised to the foot by clinical examination (pain on pressure from hoof testers; increased digital pulses, etc.) or by diagnostic analgesia
- laminitis
- penetrating wounds
- pre-purchase examination.

A standard radiographic examination of the foot usually requires at least four views, although this may vary depending on clinician preference and case history.

Preparation

For a complete study of the foot, at least one block to raise and hold the foot and a tunnel to protect the cassette will be required (see Ch. 2). Due to the construction of x-ray machines the primary beam cannot be centred less than approximately 10 cm from the ground, which means the foot must be raised to allow the beam to be centred correctly for a lateromedial foot projection. Ideally, the horse should be weight bearing evenly on both feet, which would require raising both fore feet. Usually, however, only the foot being examined is raised, resulting in extension of the distal limb joints.

The foot requires cleaning and trimming to reduce artefacts caused by grit and air pockets. For 'upright' (dorsoproximal-palmarodistal oblique DPr-PaDiO) views of the foot packing the sulci adjacent to and in the centre of the frog with a substance of similar radiographic opacity to horn (e.g. plasticine) will eliminate gas shadows caused by these grooves. Although the shoe can be left in place for a lateromedial view, shoe removal is essential for most other views of the foot.

Downloaded From Vet-eBooks.com

Views

❶ Lateromedial (LM) view of the foot

This view includes all of the distal phalanx, navicular bone, distal interphalangeal joint, part of the second phalanx and all the soft tissues of the foot. It is the optimal view for assessing dorsopalmar foot balance (see Fig. 5.3), hoof-pastern angle (only when horse is standing evenly on both limbs), displacement of the distal phalanx in laminitis, diseases of distal interphalangeal joint and of the distal phalanx. Some navicular bone pathology may be evident in this view.

Positioning

The foot should be raised on a block in order that the radiograph includes the sole and the cassette is placed medial to the foot.

Beam centring and collimation

The beam is directed from lateral, parallel with the bulbs of the heel and centred on the distal interphalangeal joint, 1 cm distal to the coronary band, midway between the heels and the dorsal hoof wall.

This view should include the whole hoof wall, distal phalanx (P3), middle phalanx (P2), distal part of proximal phalanx (P1), navicular bone, distal interphalangeal and proximal interphalangeal joints.

Downloaded From Vet-eBooks.com

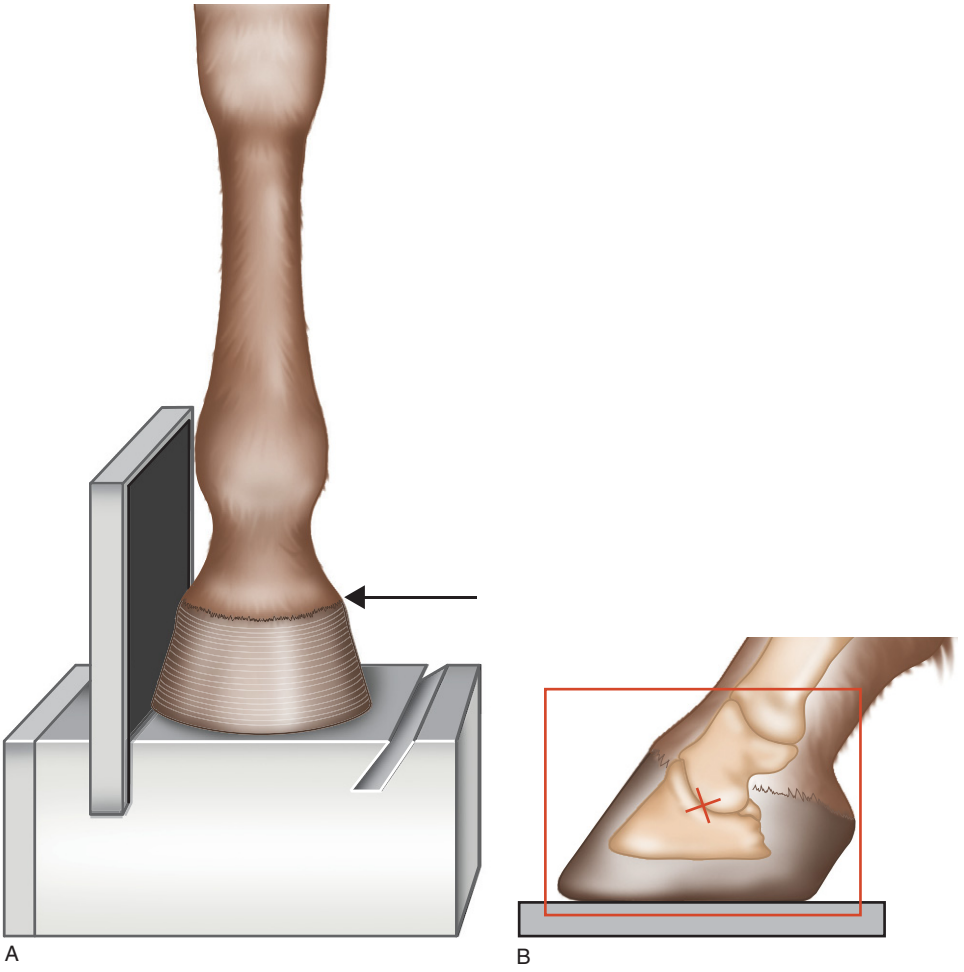

Fig. 5.1 (A & B) Positioning of foot, cassette and x-ray beam to obtain a lateromedial view of the foot

Downloaded From Vet-eBooks.com

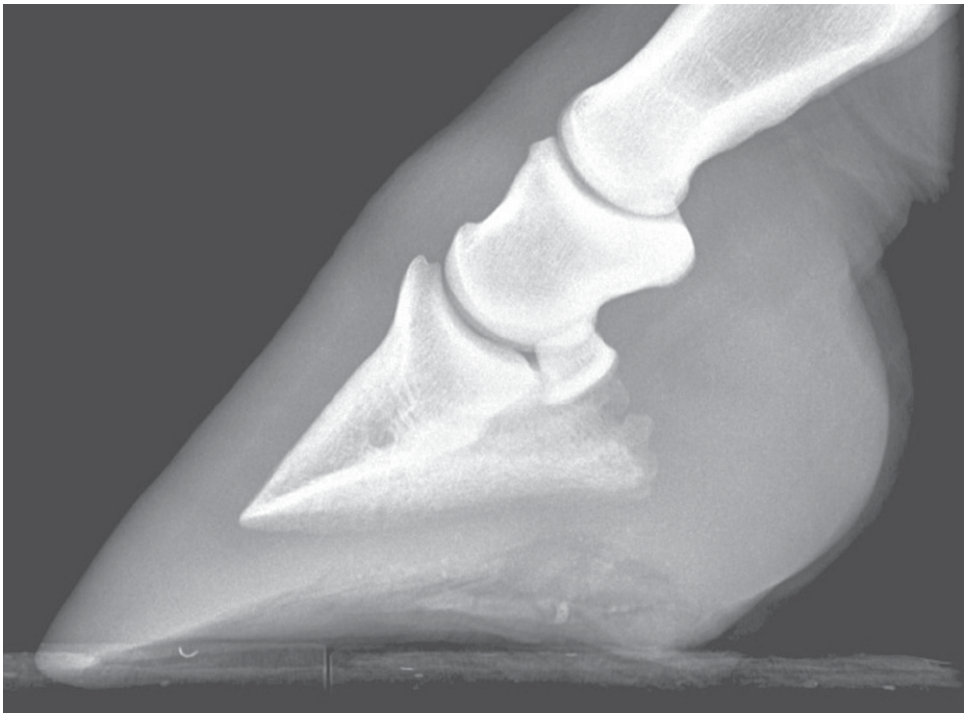

A

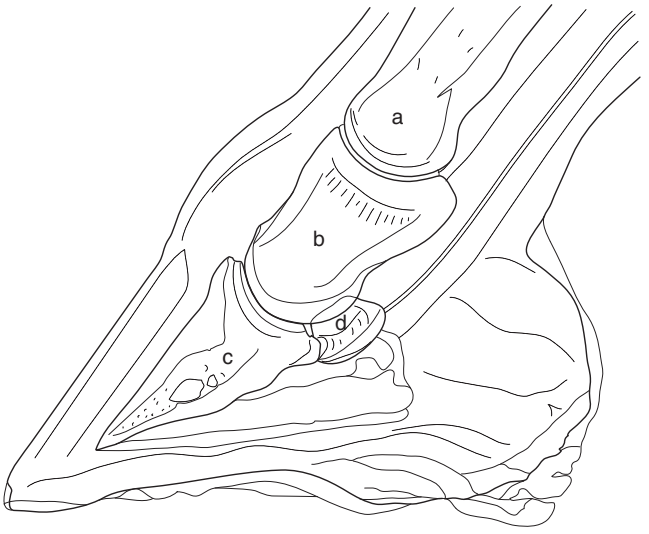

B

Fig. 5.2 (A & B) Lateromedial radiographic view of the foot. a – proximal phalanx (P1), b – middle phalanx (P2), c – distal phalanx (P3), d – navicular bone

Downloaded From Vet-eBooks.com

Tips

- ✔ An ideal LM view will have no superimposition of distal P2 and proximal P3 at the distal interphalangeal joint space.
- ✔ When radiographing a horse with laminitis, place a metal marker along the dorsal hoof wall with its proximal end at the coronary band to facilitate measurement of pedal bone rotation angle and the "founder" distance.
- ✔ An alternative to raising the foot on a block is to stand the horse on a platform with, for example, a slatted floor to allow a cassette to be placed close to the foot and extend below weight-bearing level. This allows a true weight-bearing view to be obtained.

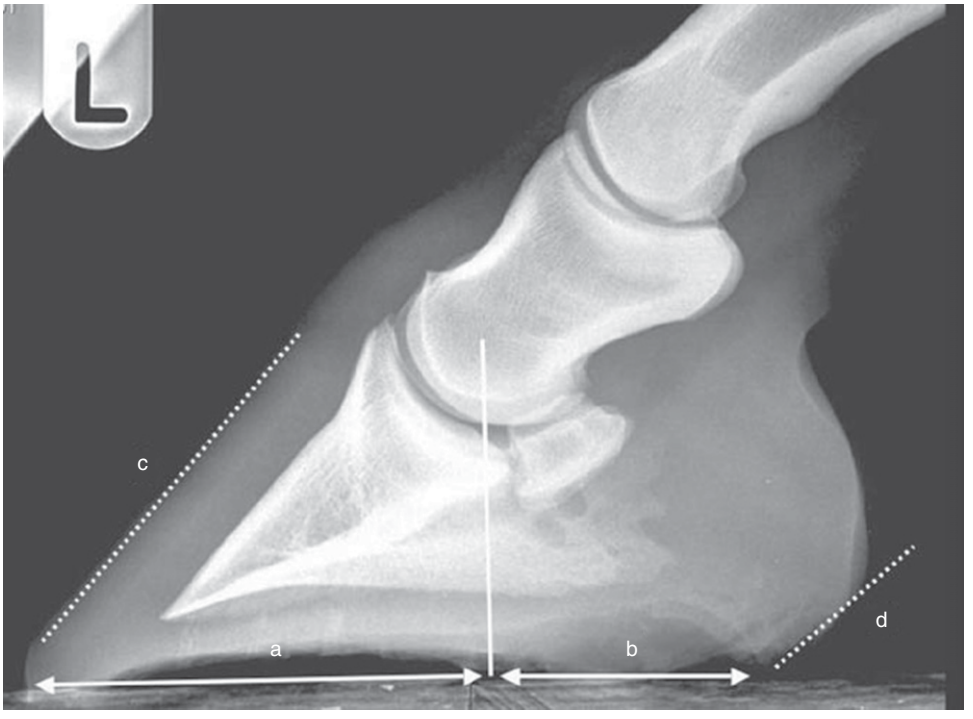

Fig. 5.3 Lateromedial view of a normal foot to show the criteria for assessing foot balance. A perpendicular line through the sole from the centre of an imaginary circle drawn to include the distal articular surface of P2 should bisect the bearing surface of the foot. In many horses, such as the example above, the toe region is longer than the heel region. The dorsal hoof wall should be parallel to the bulbs of the heel (dotted lines c and d). Very few horses have this 'ideal' conformation. The 'long toe low heel' conformation is very common, particularly in Thoroughbreds (TB) and TB-cross horses

Downloaded From Vet-eBooks.com

❷ Dorsopalmar (DPa) view of the foot (weight bearing)

The view is of more limited use than the others described in this chapter, but is good for assessing lateromedial foot imbalances, some distal phalanx fractures and ossification of the collateral cartilages of the pedal bone.

Positioning

The foot should be placed on a flat block to raise it to the level of the x-ray tube, with the cassette positioned vertically behind the foot.

Beam centring and collimation

The horizontal beam is centred on the dorsal hoof wall, midway between the sole and the coronary band. The whole foot should be included within the primary beam.

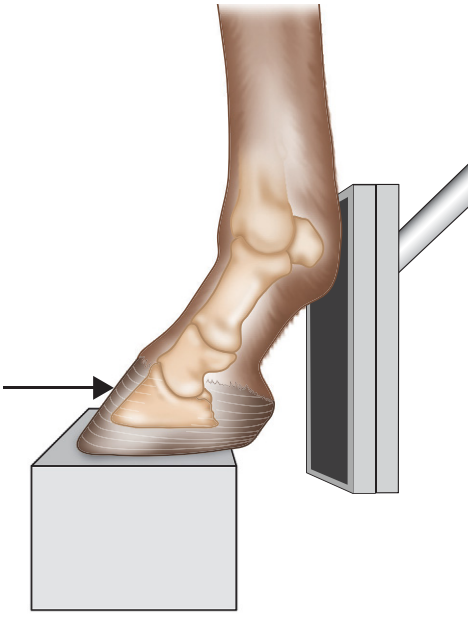

Fig. 5.4 Positioning of foot, cassette and x-ray beam to obtain a (weight bearing) dorsopalmar view of the foot

Tips

✔ The view should include the hoof wall, pedal bone, navicular bone (superimposed), P2 and distal P1.

Downloaded From Vet-eBooks.com

A

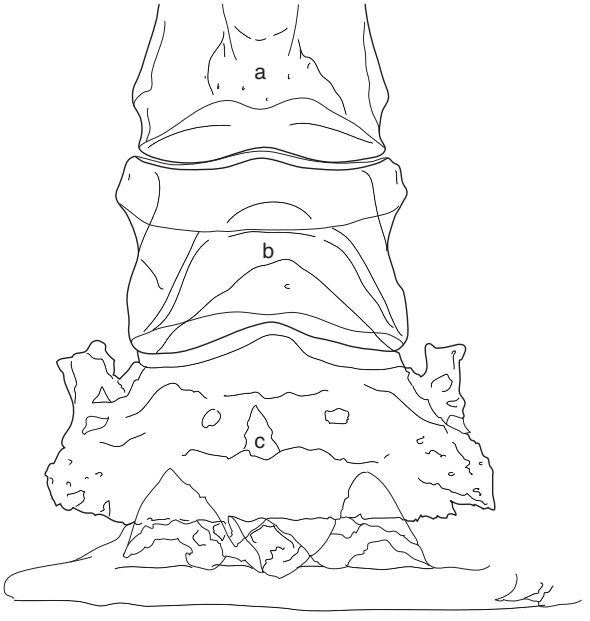

B

Fig. 5.5 (A & B) Dorsopalmar weight-bearing radiographic view of a normal foot. The navicular bone is superimposed on the coffin joint. a – proximal phalanx, b – middle phalanx, c – distal phalanx

Downloaded From Vet-eBooks.com

❸ Dorsoproximal – palmarodistal oblique (DPr-PaDiO) view of the foot

At low exposures, this projection images the pedal bone, including the palmar processes and solar margin. Higher exposures and tighter collimation are used to evaluate the navicular bone. Two projections can be used to achieve this view – the 'upright pedal' and the 'high coronary' projections.

Positioning for the pedal bone

For the 'upright pedal' projection the foot is positioned with the toe pointing downwards, the sole perpendicular to the ground and the dorsal hoof wall at approximately 45° to the horizontal. For the 'high coronary view' the foot is placed flat on a cassette tunnel.

Beam centring and collimation for the pedal bone

When using the 'upright pedal' technique the beam is horizontal; if using the 'high coronary' method the beam is angled downward towards the weight-bearing foot at 65° from the horizontal. In both methods the beam is centred on the midline just distal to coronary band for the pedal bone.

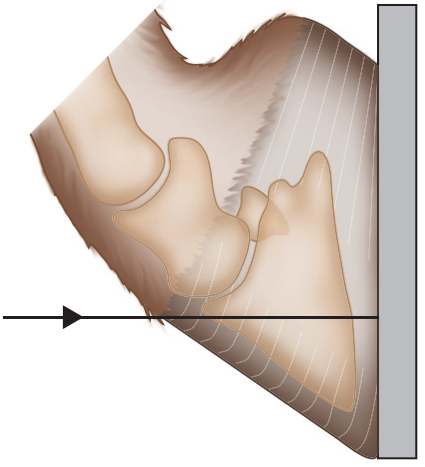

Fig. 5.6 Positioning of foot, cassette and beam for a dorsoproximal – palmarodistal oblique ("upright pedal") view of the pedal bone

Downloaded From Vet-eBooks.com

A

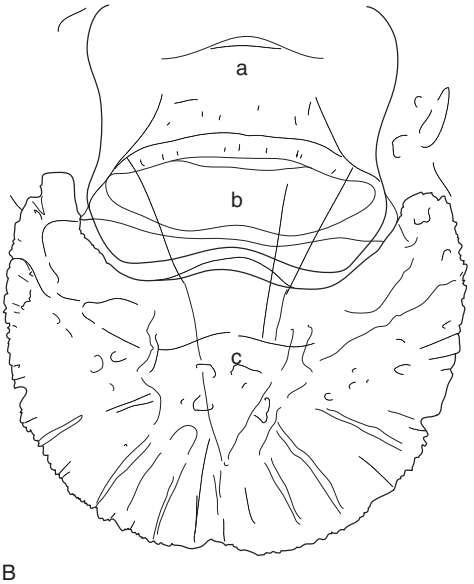

B

Fig. 5.7 (A & B) Dorsoproximal – palmarodistal oblique radiographic view of the foot ('upright pedal'). a – middle phalanx (P2), b – navicular bone, c – distal phalanx (P3)

Downloaded From Vet-eBooks.com

Tips

- ✔ Care should be taken to avoid positioning the foot too far in front of the horse or directly beneath it, as either will result in reduced image quality.
- ✔ Although the 'high coronary' projection has the advantage of requiring less restraint of the horse, it produces an image with more geometric distortion (as the beam is not perpendicular to the cassette).

Positioning for the navicular bone

For this view of the navicular bone, the foot is positioned as for the 'upright pedal', but with the dorsal hoof wall either perpendicular or at approximately 85° to the ground. Positioning the hoof wall upright improves definition of the proximal border of the navicular bone while angling it forward better defines the distal border of the bone.

Beam centring and collimation

The beam is centred on the midline approximately 2 cm proximal to the coronary band. For optimum image quality the primary beam should be tightly collimated to the navicular bone; this means the margins should be just inside the medial and lateral aspect of the foot, and extending 3 cm proximally and distally.

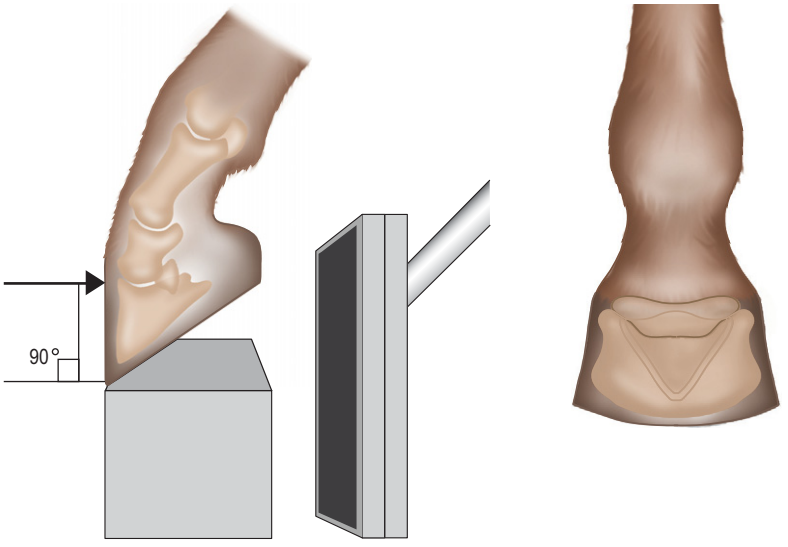

A

Fig. 5.8 (A) Positioning of foot in block to obtain a DPr-PaDiO view of the navicular bone with the dorsal hoof wall at 90° to the ground

Downloaded From Vet-eBooks.com

A

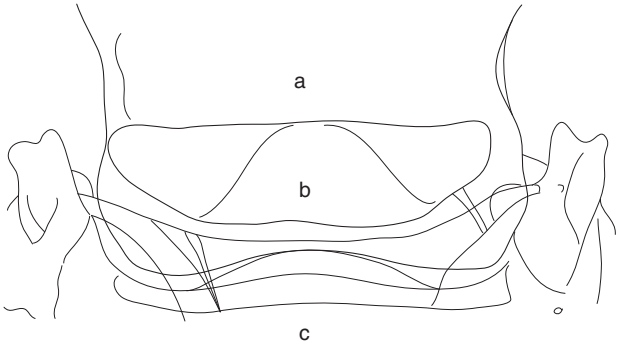

B

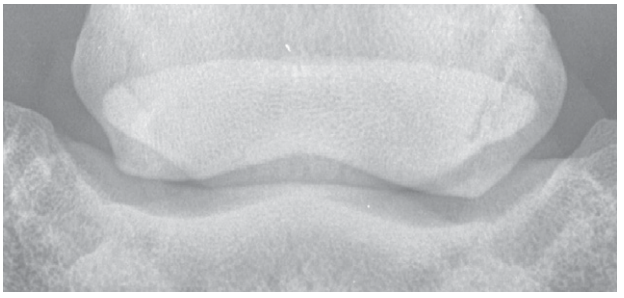

C

Fig. 5.9 (A, B & C) DPr-PaDiO view of a normal navicular bone, obtained with dorsal hoof wall at 85° (A and B) and 90° (C) to the vertical. a – middle phalanx (P2), b – navicular bone, c – distal phalanx (P3)

Downloaded From Vet-eBooks.com

❹ Palmaroproximal-palmarodistal oblique ('flexor') view of the navicular bone

This view defines the flexor surface, palmar cortex and medulla of the navicular bone. Subtle changes can be seen on this view that cannot be seen on the LM or DPr-PaDiO views, so, although it is tricky to obtain, it is required for a complete examination of this bone.

Positioning

The foot being imaged should be positioned further caudally than the contralateral foot (Fig. 5.10A), on the centre of a radiolucent cassette tunnel (see Fig. 2.1).

Beam centring and collimation

With the x-ray tube positioned directly behind the foot the x-ray beam is centred between the heel bulbs at approximately 45°, but without superimposing the palmar aspect of the fetlock on the image.

Collimate as closely to the navicular bone as possible.

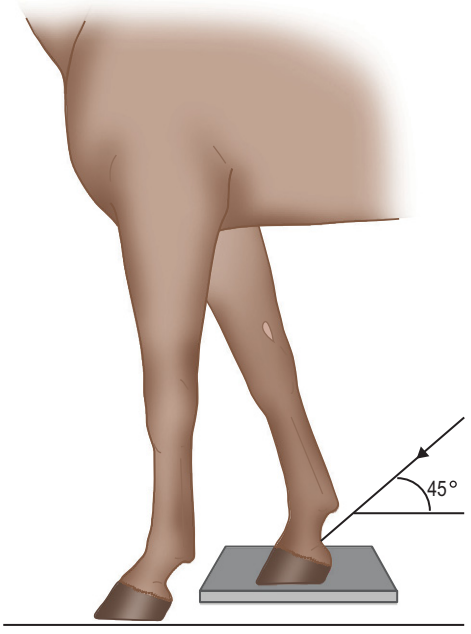

A

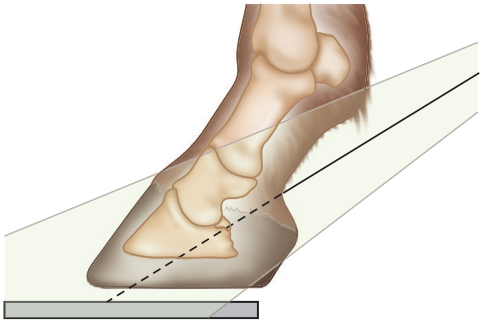

B

Fig. 5.10 (A & B) Positioning of horse, cassette (protected by cassette tunnel) and beam for a 'flexor skyline' view of the navicular bone

Downloaded From Vet-eBooks.com

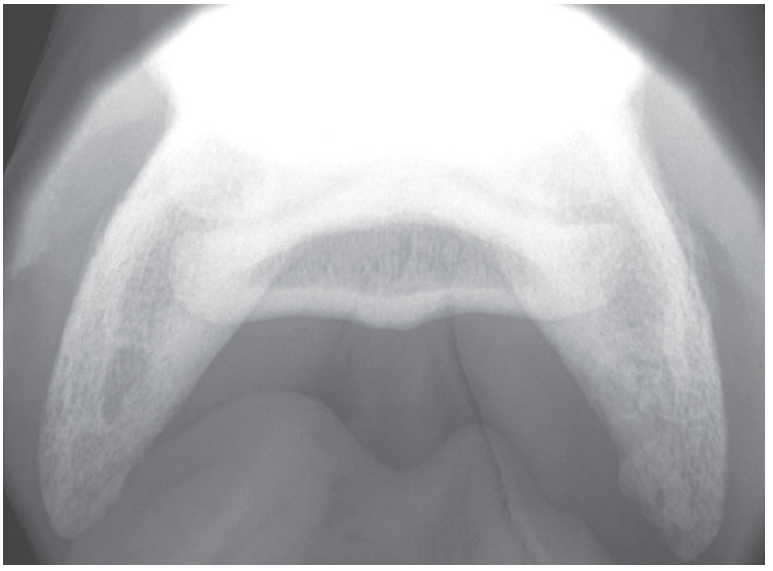

A

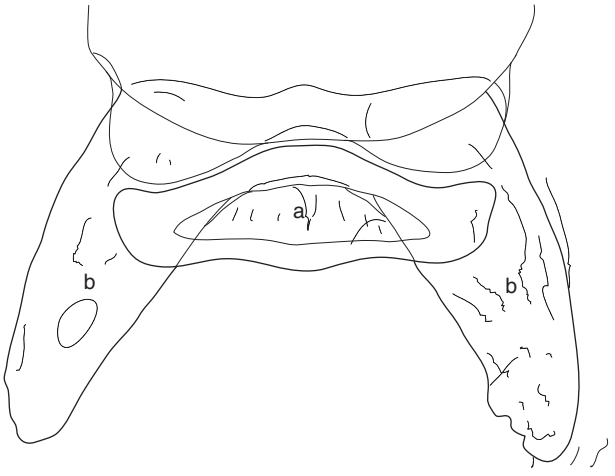

B

Fig. 5.11 (A & B) Palmaroproximal-palmarodistal oblique ('flexor') view of the navicular bone and palmar processes of P3. a – navicular bone, b – palmar processes of distal phalanx (P3)

Tips

- ✔ Inadequate foot preparation readily produces artefacts in this view, such as linear gas shadows mimicking fractures.
- ✔ This view is more difficult to obtain in small horses and ponies due to the difficulty in manoeuvring an x-ray machine partially under the abdomen.
- ✔ A low-heel foot conformation requires a slightly more horizontal x-ray beam angle to avoid superimposition of the palmar fetlock on the area of interest.

Downloaded From Vet-eBooks.com

❺ Dorso 45° lateral-palmaromedial oblique (D45°L-PaMO) and dorso 45° medial-palmarolateral oblique (D45°M-PaLO) views of the foot

These views allow assessment of the lateral (D45°L-PaMO) and medial (D45°M-PaLO) palmar processes of the pedal bone.

Positioning

The foot is positioned as for the DPr-PaDiO view; raised on a block with the toe pointing downwards and the sole perpendicular to the ground.

Beam centring and collimation

For the lateral palmar process, the beam is centred on the lateral hoof wall, midway between dorsal and lateral (D45°L-PaMO). The cassette is placed perpendicular to the beam. To examine the medial palmar process the beam is directed from dorsomedial (D45°M-PaLO).

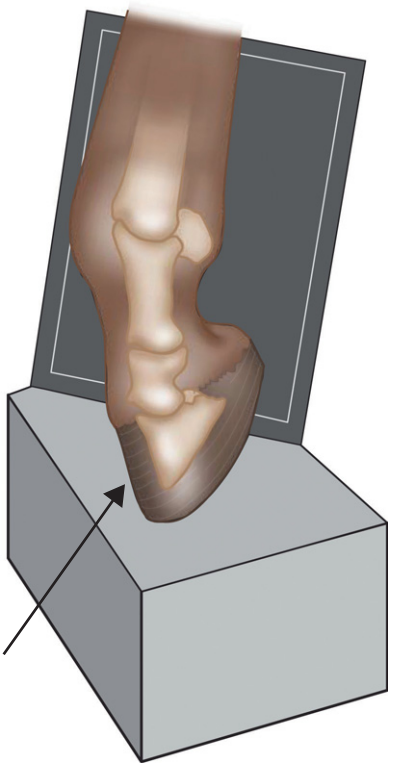

Fig. 5.12 Positioning of foot, cassette and x-ray beam to obtain a view of the palmar process of the pedal bone

Downloaded From Vet-eBooks.com

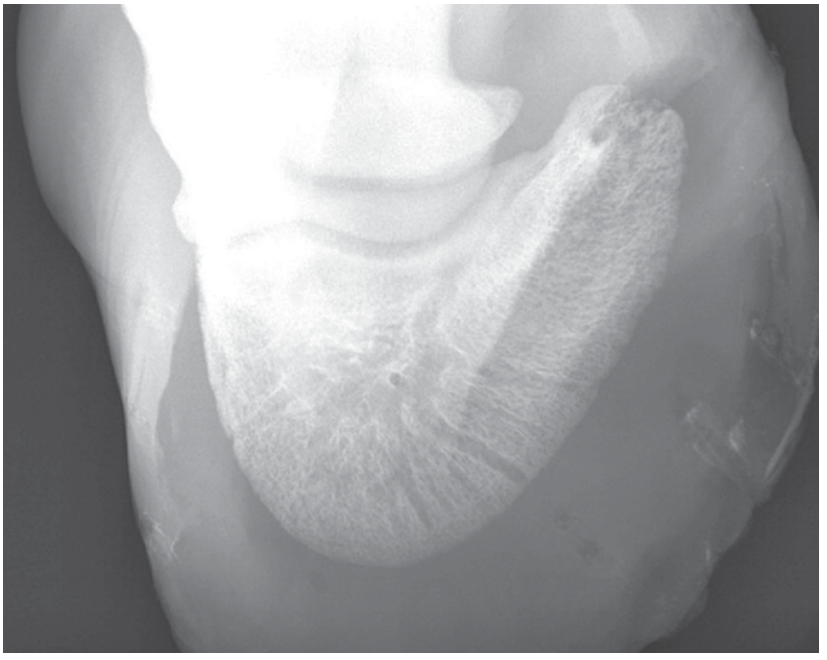

A

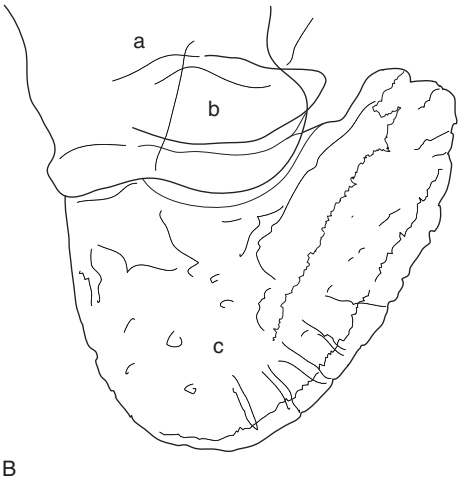

B

Fig. 5.13 (A & B) Dorso 45° lateral-palmaromedial oblique radiographic view of the foot, exposed for the pedal bone. a – middle phalanx (P2), b – navicular bone, c – distal phalanx (P3)

Tips

- ✔ Do not forget to label the views, as the medial and lateral palmar processes are hard to distinguish.
- ✔ In a limited number of cases, this view may be useful for detecting lesions at the lateral and medial margins of the navicular bone.

Downloaded From Vet-eBooks.com

6 RADIOGRAPHY OF THE PASTERN

Introduction

The pastern region includes the middle and proximal phalanges and the proximal interphalangeal (pastern) joint. The main indications for radiography of this region include:

- lameness localised to the pastern region by clinical examination or by diagnostic analgesia
- penetrating wounds.

A standard radiographic examination of the pastern consists of four views: lateromedial, dorsopalmar and two 45° oblique views. As this joint is anatomically relatively simple, specialised views are infrequently required; though a flexed oblique view may give additional information about dorsal periarticular bone formation. Each view should include the distal and proximal interphalangeal joints and the distal half of the proximal phalanx. The views described here for the forelimb are the same for the hindlimb.

Preparation

Any dirt should be brushed and washed off. Heavily feathered horses may require more extensive cleaning or clipping. The horse should be standing square and evenly weight bearing on both front limbs. Foot blocks are not required, as all x-ray machines should be capable of centring to the pastern joint, unless a small pony is being examined. As with other views, routinely sedating the patient reduces the need for repeat exposures due to movement blur.

Standard views

❶ Lateromedial (LM) view of the pastern

Positioning

The cassette is placed against the medial aspect of the joint, resting on the ground or on a small block if required.

Beam centring and collimation

The horizontal beam is centred on the lateral aspect of the pastern, midway between the coronet and the fetlock, and aligned parallel to the heel bulbs.

Downloaded From Vet-eBooks.com

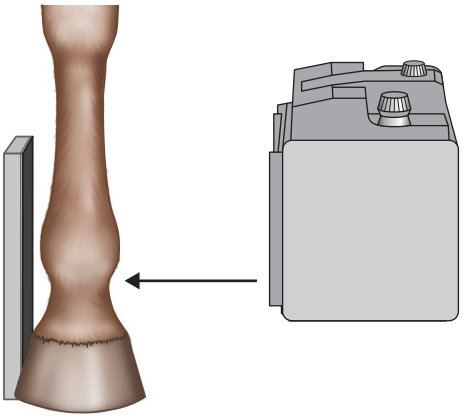

Fig. 6.1 Diagram showing positioning of limb, cassette and primary beam to obtain a lateromedial view of the pastern region

A

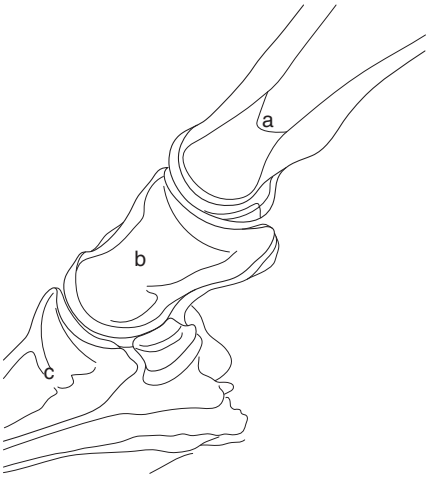

B

Fig. 6.2 (A & B) Lateromedial view of a normal pastern. a – proximal phalanx, b – middle phalanx, c – distal phalanx

Tips

✔ The pastern joint space should be clearly defined with minimal superimposition of the opposing articular surfaces.

Downloaded From Vet-eBooks.com

❷ Dorsoproximal-palmarodistal oblique (DPr=PaDiO) view of the pastern

This oblique view is preferred over a dorsopalmar (DPa) view using an horizontal beam as it results in less distortion.

Positioning

The cassette is positioned on the palmar aspect of the limb, resting on the ground or a small block and angled parallel with the sloping pastern.

Beam centring and collimation

The beam is centred on the dorsal aspect of the pastern region, midway between coronet and the fetlock joint, and angled from proximal until perpendicular with the cassette. The exact angle will depend on the stance and conformation of the pastern.

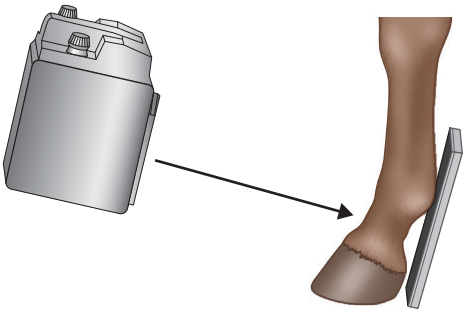

Fig. 6.3 Diagram showing positioning of limb, cassette and primary beam to obtain a dorsopalmar view of the pastern joint

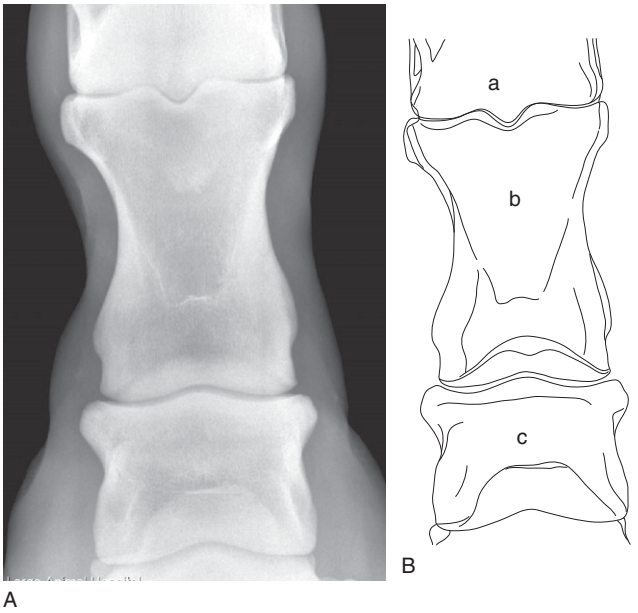

Fig. 6.4 (A & B) Dorsoproximal-palmarodistal oblique view of the pastern region of a normal adult horse. a – third metacarpal, b – proximal phalanx, c – middle phalanx

Tips

✔ If the horse is not standing straight and weight bearing evenly, the joint space will appear narrowed on one side.

Downloaded From Vet-eBooks.com

❸ Dorsolateral-palmaromedial oblique (D45°L-PaMO) and dorsomedial-palmarolateral oblique (D45°M-PaLO) views of the pastern

These views can be virtually indistinguishable; therefore, it is imperative that markers are used on the films accordingly. They highlight the ligament insertion sites on the dorsomedial and dorsolateral as well as palmaromedial and palmarolateral surfaces of the second phalanx. Some small fracture fragments are only apparent on oblique views.

Positioning

As for the DPr-PaDO view, but with the cassette positioned on the palmaromedial or palmarolateral aspect of the pastern, perpendicular to the x-ray beam.

Beam centring and collimation

The horizontal beam is angled mid-way between dorsal and lateral (at 45°) for the dorsolateral oblique view and mid-way between dorsal and medial for the dorsomedial oblique view and centred on the mid-pastern.

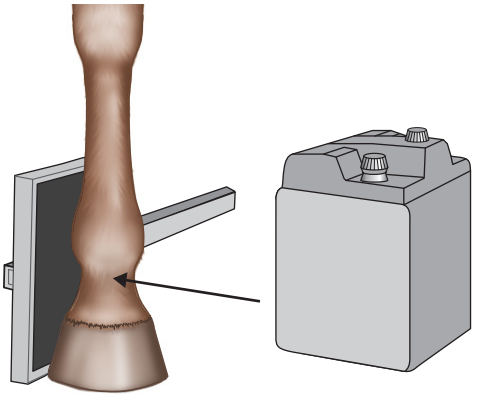

Fig. 6.5 Diagram showing positioning of limb, cassette and primary beam to obtain a dorsolateral-palmaromedial or dorsomedial-palmarolateral oblique view of the pastern joint

Downloaded From Vet-eBooks.com

A

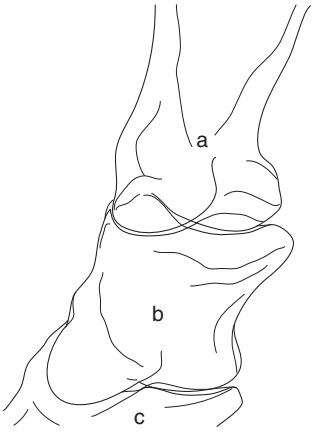

B

Fig. 6.6 (A & B) Dorsolateral-palmaromedial view of the pastern region. This view is usually indistinguishable from the dorsomedial-palmarolateral oblique view. a – proximal phalanx (P1), b – middle phalanx (P2), c – distal phalanx (P3)

Tips

✔ Both oblique views can also be obtained by reversing the beam direction, i.e. from palmar, although the cassette will then be positioned further from the joint, increasing geometric distortion. As the two views are alike, accurate labelling is important.

Downloaded From Vet-eBooks.com

7 RADIOGRAPHY OF THE FETLOCK

Introduction

The fetlock region includes the proximal phalanx, distal metacarpus/metatarsus and paired proximal sesamoid bones. Indications for radiography of this region include:

- lameness localised to the fetlock region by clinical examination or by diagnostic analgesia
- penetrating wounds and other traumatic injuries to the area
- pre-purchase examination (forelimb fetlock studies are often included in routine radiographic surveys).

A standard radiographic examination of the fetlock consists of at least four views: lateromedial, dorsopalmar/plantar and two 45° oblique views. In addition, many clinicians include a flexed lateromedial view as standard. Each view should include the distal third of the metacarpus, the proximal half of the proximal phalanx and the proximal sesamoid bones. Additional oblique views are frequently obtained when confirmation of specific lesions is sought or to better evaluate abnormalities detected on the routine views. The views obtained by individual clinicians vary depending on the conditions common in their caseload; what is a routine view in racehorse practice may be infrequently required in sports horse practice. The special oblique views and the areas they project are summarised in Table 7.1.

Preparation

Any dirt overlying the fetlock should be brushed and washed off. Heavily feathered horses may require more extensive brushing, washing or clipping. The horse should be standing square and evenly weight bearing on both front/hind limbs. Foot blocks are not usually required as all x-ray machines should be capable of centring at the level of the fetlock, although if small cassettes are used in large animals a small block may be useful to raise the cassette to centre the region of interest and keep it stable. As with other views, routinely sedating the patient reduces the need for repeat exposures due to movement blur.

Downloaded From Vet-eBooks.com

Standard views

❶ Lateromedial (LM) view of the fetlock

Positioning

The cassette is placed on the medial aspect of the joint, resting on the ground or on a small block.

Beam centring and collimation

The beam is centred on the lateral epicondyle of the distal metacarpus, horizontal and parallel to the heel bulbs.

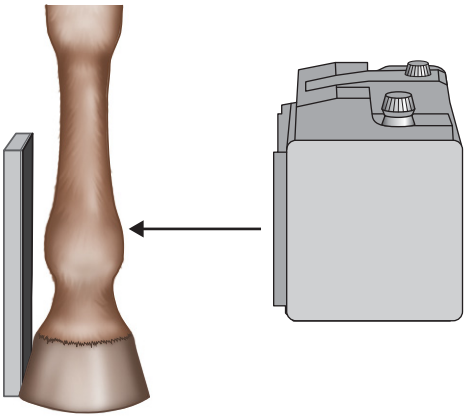

Fig. 7.1 Diagram showing positioning of limb, cassette and primary beam to obtain a lateromedial view of the fetlock joint

Downloaded From Vet-eBooks.com

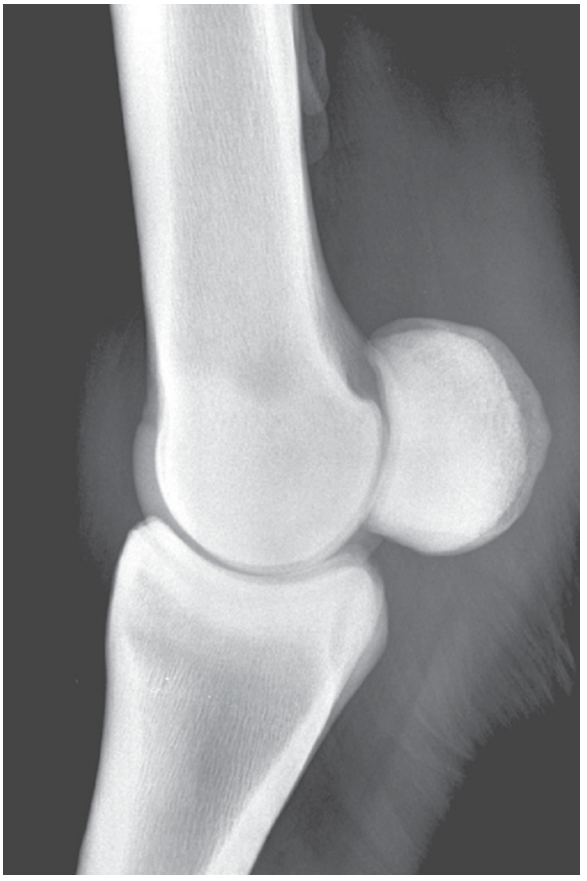

A

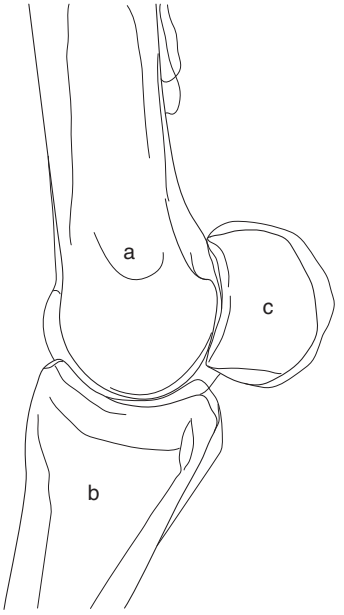

B

Fig. 7.2 (A & B) Lateromedial radiographic view of a normal adult fetlock (forelimb).
a – Metacarpus, b – Proximal phalanx (P1), c – Superimposed medial and lateral sesamoid bones

Tips

✔ In many horses angling the beam from slightly palmar by 3° to 5° gives a more true LM view. This applies especially to the metatarsophalangeal joint as most horses stand with the distal hindlimb rotated outwards. The dorsal sagittal ridge of the distal metacarpus should be visible without superimposition by either condyle.

Downloaded From Vet-eBooks.com

❷ Dorsoproximal-palmarodistal oblique (DP10°-PaDO) view of the fetlock

Positioning

The cassette is positioned on the palmar aspect of the limb, resting on the ground or a small block and aligned parallel to the pastern axis.

Beam centring and collimation

The beam is centred on the dorsal aspect of the joint space, angled from proximal by approximately 10° and collimated to the fetlock joint (Fig. 7.3).

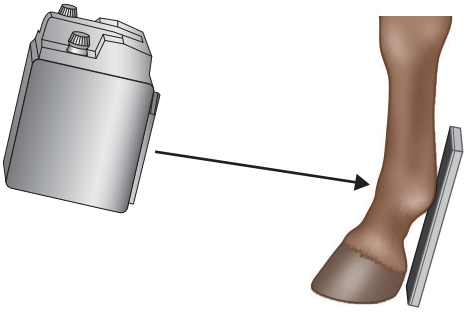

Fig. 7.3 Diagram showing positioning of limb, cassette and primary beam to obtain a dorsopalmar view of the fetlock joint with the beam angled from proximal

Downloaded From Vet-eBooks.com

Tips

✔ This view is an adaptation of the dorsopalmar fetlock view and is often referred to as the DP view. Using a primary beam angled from proximal rather than a horizontal beam avoids superimposition of the sesamoid bones over the joint space. For the hindlimb the beam should be angled from proximal by 15–20°.

A

C

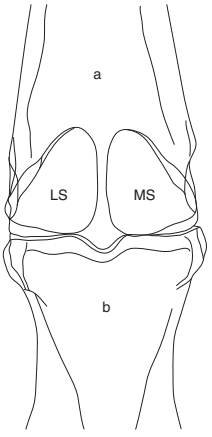

B

Fig. 7.4 (A & B) Dorso10° proximal-palmarodistal oblique view of a normal adult fetlock. **(C)** Dorso15° proximal-palmarodistal oblique view of a fetlock showing the sesamoids projected proximally by increasing the angle of obliquity. This fetlock is not normal; the medial sesamoid shows ill-defined lucency on its abaxial surface. a – Third metacarpal bone, b – Proximal phalanx, LS – Lateral sesamoid bone, MS – Medial sesamoid bone

Downloaded From Vet-eBooks.com

❸ Dorsolateral-palmaromedial oblique (D45°L-PaMO) and dorsomedial-palmarolateral oblique (D45 M-PaLO) views of the fetlock

These two views highlight the lateral sesamoid and dorsomedial aspects of the joint (D45°L-PaMO) or medial sesamoid and dorsolateral aspects (D45°M-PaLO) of the joint respectively.

Positioning

As for the DPa view, but with the cassette positioned on the palmaromedial or palmarolateral aspect of the joint, perpendicular to the x-ray beam.

Beam centring and collimation

The horizontal beam is angled mid-way between dorsal and lateral (45°) for the dorsolateral oblique view and mid-way between dorsal and medial for the dorsomedial oblique view and centred on the fetlock joint.

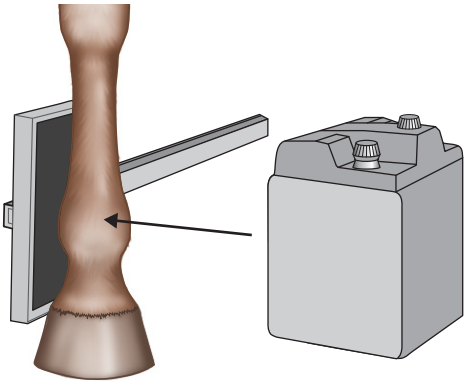

Fig. 7.5 Diagram showing positioning of limb, cassette and primary beam to obtain a dorsolateral-palmaromedial or dorsomedial-palmarolateral oblique view of the fetlock joint

Downloaded From Vet-eBooks.com

A

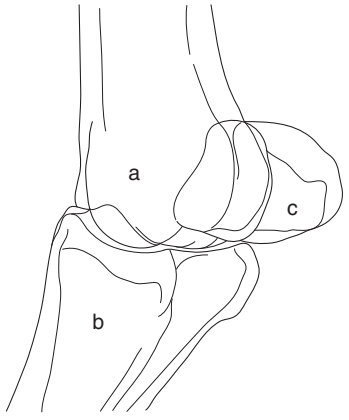

B

Fig. 7.6 (A & B) Dorsomedial-palmarolateral view of a normal adult fetlock. a – Metacarpus, b – Proximal phalanx (P1), c – Medial sesamoid

Tips

- ✔ Angulation of the beam by 60° instead of 45° from dorsal gives a more complete projection of the dorsal articular margins of the proximal phalanx. The 45° oblique views are better for evaluating the regions of insertion of the suspensory ligament branch on the abaxial surface of the proximal sesamoid bone.
- ✔ Both oblique views can also be obtained by reversing the beam direction, although the cassette will then be positioned further from the joint, increasing geometric distortion.

Downloaded From Vet-eBooks.com

Additional views

❹ Flexed lateromedial view of the fetlock

In the flexed position the sesamoid bones move away from the third metacarpal (-tarsal) bone, allowing better evaluation of the sesamoidean articular surfaces and the distal aspect of the sagittal ridge.

Positioning

The limb is held off the ground at the toe, with the fetlock joint in flexion.

Beam centring and collimation

As for the weight-bearing LM view.

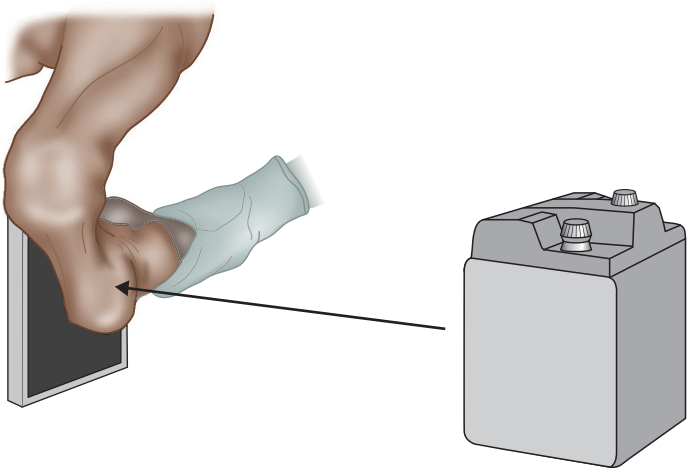

Fig. 7.7 Diagram showing positioning of limb, cassette and primary beam to obtain a flexed lateromedial view of the fetlock joint

Downloaded From Vet-eBooks.com

A

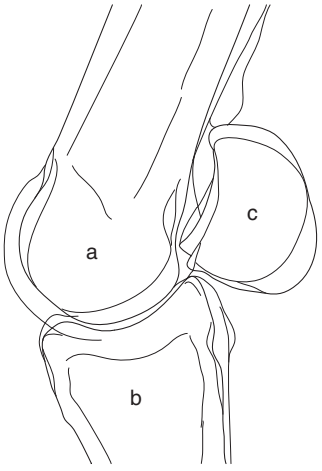

B

Fig. 7.8 (A & B) Lateromedial view of a normal flexed fetlock. a – Metacarpus, b – Proximal phalanx (P1), c – Superimposed medial and lateral sesamoid bones

Tips

✔ Careful collimation is required to avoid inadvertent exposure of the assistant's hands.

Downloaded From Vet-eBooks.com

❺ Lateral 45° proximal-medial distal oblique (L45°Pr-MDiO) and medial 45° proximal-lateral distal oblique (M45°Pr-LDiO) views of the fetlock

These views allows better assessment of the abaxial surface of the medial sesamoid bone (L45°Pr-MDiO) or lateral sesamoid bone (M45°Pr-LDiO), which are predilection sites for insertional desmopathy of the suspensory ligament branches.

Patient positioning

To obtain the L45°Pr-MDiO view the horse is positioned as for the routine lateromedial view. For the M45°Pr-LDiO view the x-ray machine is positioned on the contralateral side of the horse and the limb being radiographed is placed slightly forwards to avoid superimposition of the limbs.

Beam centring and collimation

In both views, the sesamoid bone being profiled is closer to the cassette. The beam is centred on the fetlock joint while being angled downwards at 45° to the horizontal. The cassette is held vertically on the opposite side of the joint. Collimate to the joint.

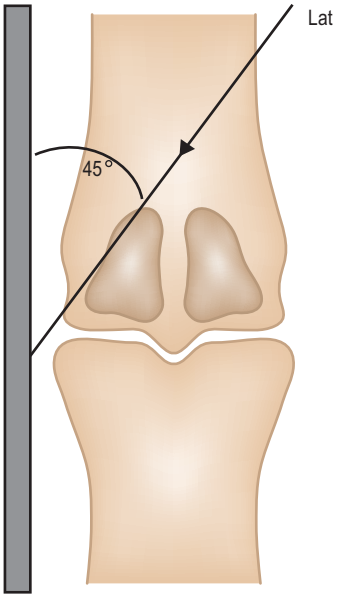

Fig. 7.9 Diagram showing positioning of limb, cassette and primary beam to obtain a lateral 45° proximal-medial distal oblique and a medial 45° proximal-lateral distal oblique view of the fetlock joint

Downloaded From Vet-eBooks.com

A

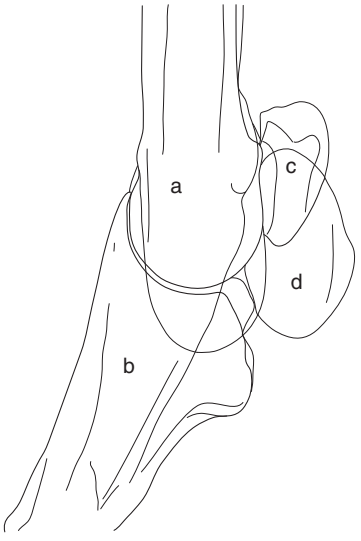

B

Fig. 7.10 (A & B) Lateral 45° proximal-medial distal oblique of a normal adult fetlock. a – Metacarpus, b – Proximal phalanx (P1), c – Medial sesamoid bone, d – lateral sesamoid bone

Downloaded From Vet-eBooks.com

Table 7.1 Summary of additional oblique views of the fetlock to better visualise specific regions of the joint

Radiographic view	Region(s) projected
Dorsal 45° proximal 45° lateral-palmar distal medial oblique (D45°Pr45°L-PaDiMO)	Palmar condyles (medial and lateral) of third metacarpal bone
Dorsoproximal-palmarodistal and dorsodistal-palmaroproximal oblique views of the third metacarpus See Chapter 9, Figures 9.13–9.18	Articular surfaces of condyles and palmar metacarpus. Angling the beam from progressively more distally by flexing the fetlock projects the more palmar regions of the distal metacarpal articular surface. Useful for cases with condylar fractures
Dorsoproximal-dorsodistal oblique view	Dorsal aspect of third metacarpal condyles and sagittal ridge
Dorsal 30° proximal 70° lateral-palmar distal medial oblique (D30°Pr70°L-PaDiMO) or dorsal 30° proximal 70° medial-palmar distal lateral oblique (D30°Pr70°M-PaDiLO) views	Lateral (D30°Pr70°L-PaDiMO) and medial (D30°Pr70°M-PaDiLO) palmar processes of the proximal phalanx
Palmaroproximal-palmarodistal (PaPr-PaDi) view	Axial surface and abaxial recess of proximal sesamoid bones

Downloaded From Vet-eBooks.com

8 RADIOGRAPHY OF THE METACARPUS AND METATARSUS

Introduction

Indications for radiography of the metacarpal and metatarsal regions include:

- lameness localised to the region by perineural anaesthesia
- fractures or suspected fractures of the metacarpal or metatarsal bones (cannon bones)
- periosteal 'splints' on the cannon bone
- desmitis of the suspensory ligament origin ('high suspensory disease')
- other traumatic injuries to the area.

Throughout this chapter, reference will be made to the forelimb (metacarpus, palmar), although the same views are obtained in the hindlimb (metatarsus, plantar).

Weight-bearing lateromedial, dorsopalmar, dorsolateral-palmaromedial (DLPMO) and dorsomedial-palmarolateral (DMPLO) views will provide sufficient diagnostic information for most cases.

If fractures of the cannon bones are suspected, the entire length of the metacarpal/metatarsal bone should be included in the primary beam. Due to the long length of this bone, there may be some obliquity of projection at the most proximal and distal ends of this bone due to divergence of the x-ray beam. If a lesion is suspected at these sites, additional radiographs positioned more proximally or distally can then be taken as required.

Patient preparation

No specific patient preparation is necessary for radiography of the metacarpal or metatarsal regions, however, most horses will be easier to radiograph if they are sedated. Fractious horses may inflict serious injury/damage to personnel and equipment, particularly when the hind limbs are being radiographed.

Ensure the horse is weight bearing and standing square with the metacarpal/metatarsal bones as vertical as possible, and no abduction or adduction present.

Tips

✔ Many horses have a slightly 'toe out' hindlimb conformation: the degree of outward rotation for individual horses should be assessed and all standing radiographic views aligned accordingly.

Downloaded From Vet-eBooks.com

Views

❶ Lateromedial

This view highlights the dorsal cortex of the third metacarpal bone and the palmar aspects of the splint bones (second and fourth metacarpals/metatarsals). The second and fourth metacarpal/metatarsal bones are superimposed in the lateromedial view.

Positioning

The cassette is held in a cassette holder on the medial aspect of the metacarpus/metatarsus, in line with the dorso-palmar axis of these bones. When imaging the metatarsals, it is safer to handle the cassette holder from the dorsal aspect of the hindlimb rather than stand directly behind the horse where possible.

Beam direction, centring and collimation

The primary beam should be horizontal and centred at the mid-point of the cannon bone or, alternatively, at the area of interest (wound, area of bony proliferation, etc.).

Collimation of the primary beam should include the area of interest or the entire third metacarpal/metatarsal bone if fractures of the cannon are suspected.

Downloaded From Vet-eBooks.com

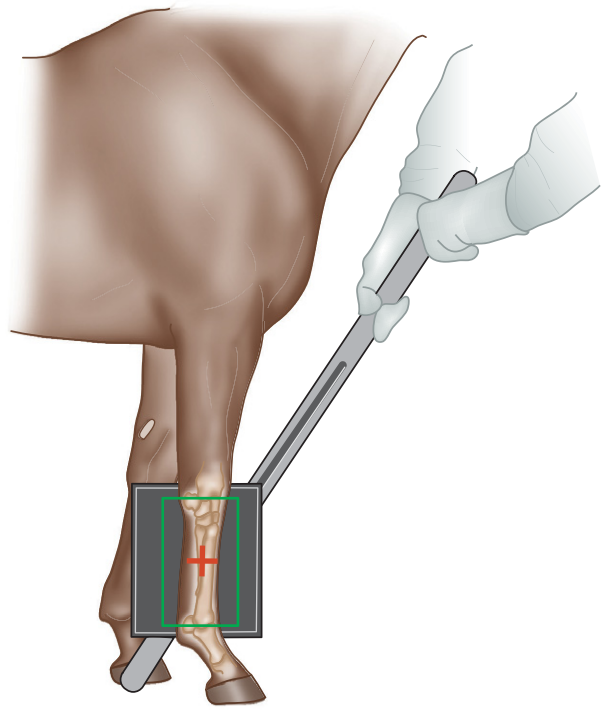

A

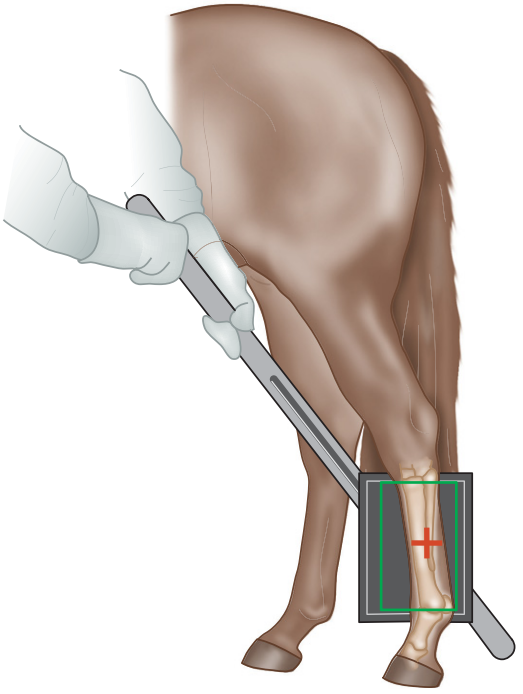

B

Fig. 8.1 (A & B) Position of the patient, cassette, centring point of the x-ray beam (red cross) and collimation of the primary beam (green outline) to obtain a lateromedial view of the metacarpus (A) or metatarsus (B)

Downloaded From Vet-eBooks.com

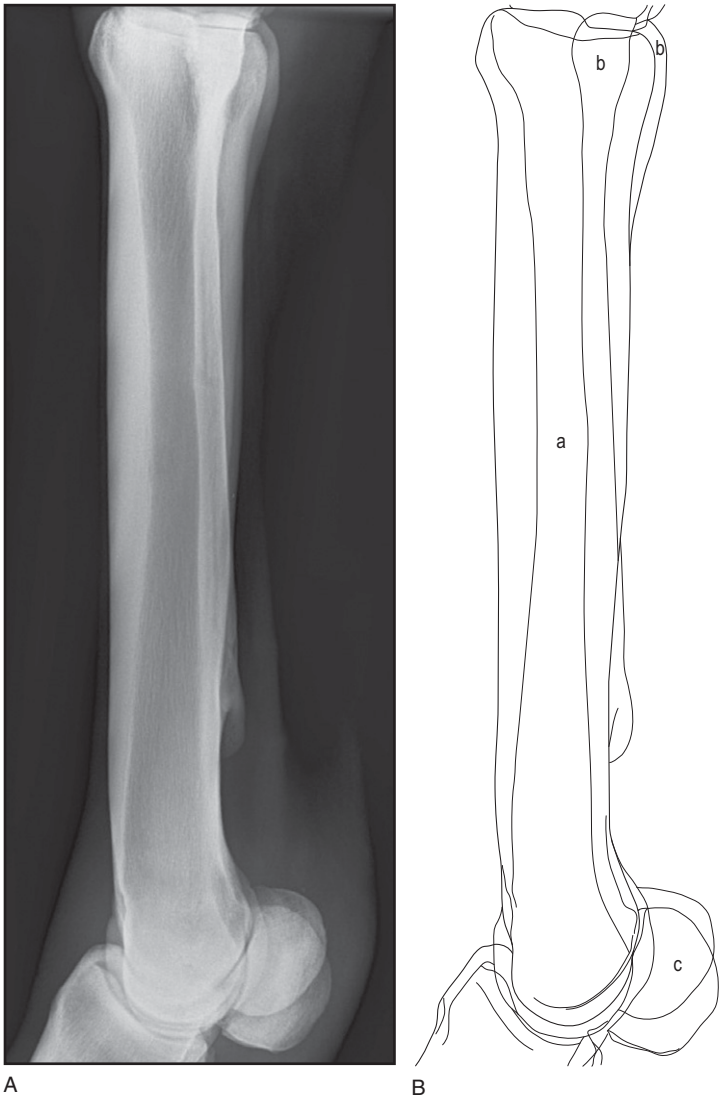

Fig. 8.2 (A & B) Lateromedial radiographic view of the metacarpus. a – Third metacarpal, b – Second and fourth metacarpal, c – Proximal sesamoids

Tips

- ✔ Multiple, slightly oblique views taken at slightly varying angles may be necessary to identify small, nondisplaced stress fractures of the dorsal cortex of the third metacarpal bone.
- ✔ A much lower exposure is required to optimally image the second or fourth metacarpal bones.

Downloaded From Vet-eBooks.com

❷ Dorsopalmar

This view highlights the medial and lateral aspects of the third metacarpal/metatarsal bone and the medial and lateral aspects of the second and fourth metacarpal bones respectively. The dorsopalmar view is also used to image the area of origin of the suspensory ligament.

Positioning

The cassette is held vertically in a cassette holder on the palmar aspect of the metacarpus/metatarsus.

Beam direction, centring and collimation

The primary beam should be horizontal and centred at the mid point of the cannon bone or, alternatively, at the area of interest (wound, area of bony proliferation, etc.).

Collimation of the primary beam should include the area of interest, or the entire third metacarpal/metatarsal bone if fractures of the cannon are suspected.

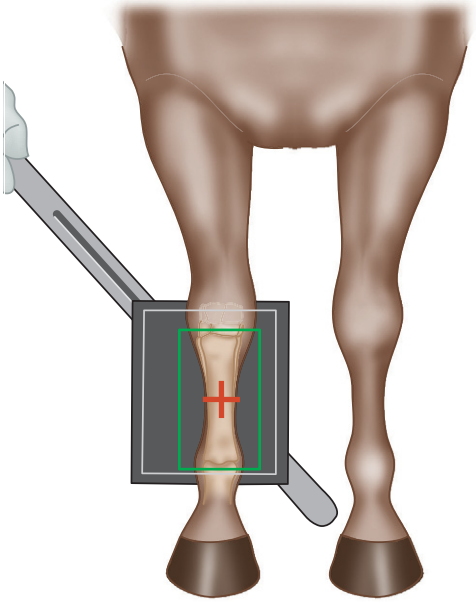

Fig. 8.3 Position of the patient, cassette and centring point of the x-ray beam (red cross) to obtain a dorso-palmar view of the metacarpus

Downloaded From Vet-eBooks.com

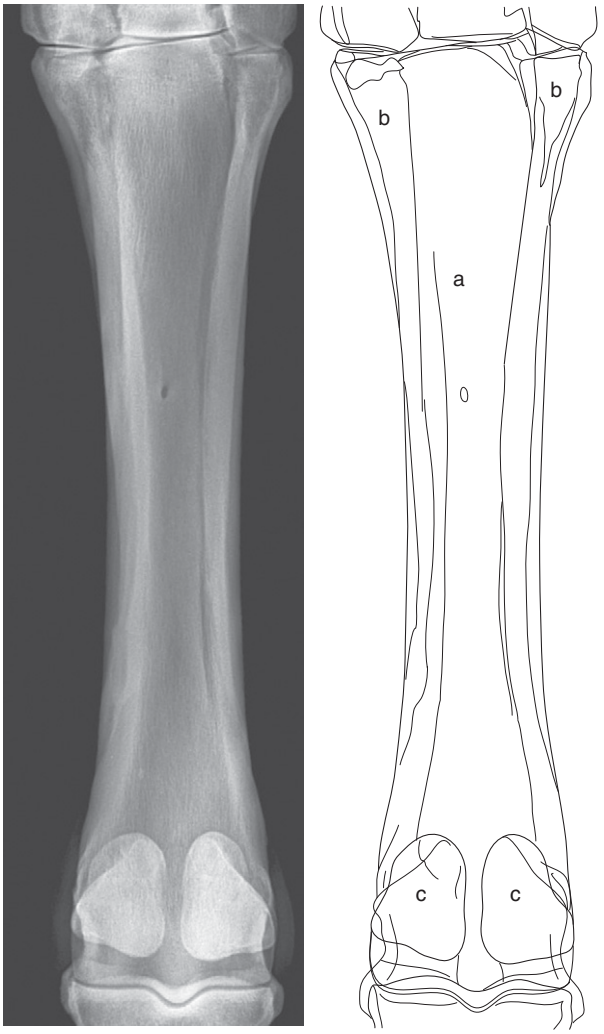

A B

Fig. 8.4 (A & B) Dorso-palmar radiographic view of the metacarpus. a – Third metacarpal, b – Second and fourth metacarpals, c – Proximal sesamoids

Tips

✔ Many horses have a slightly 'toe out' hindlimb conformation which actually makes it easier to obtain good dorsoplantar radiographs of the metatarsus because the x-ray machine does not need to be positioned under the horse's body.

Downloaded From Vet-eBooks.com

❸ Dorsolateral-palmaromedial oblique (D45°L-PaMO) and dorsomedial-palmarolateral oblique (DM-PaLO)

The (DL-PaMO) view highlights the dorsomedial and palmarolateral aspects of the third and fourth metacarpal bones. The (DM-PaLO) highlights the dorsolateral and palmaromedial aspects of the second and third metacarpal bones.

Positioning

The cassette is held vertically in a cassette holder on the palmaromedial (for DL-PaMO) or palmarolateral (for DM-PaLO) aspects of the metacarpus, perpendicular to the direction of the x-ray beam.

Beam direction, centring and collimation

The primary beam should be horizontal and centred at the mid-point of the cannon bone or, alternatively, at the area of interest (wound, area of bony proliferation, etc.).

Collimation of the primary beam should include the area of interest, or the entire third metacarpal/metatarsal bone if fractures of the cannon are suspected.

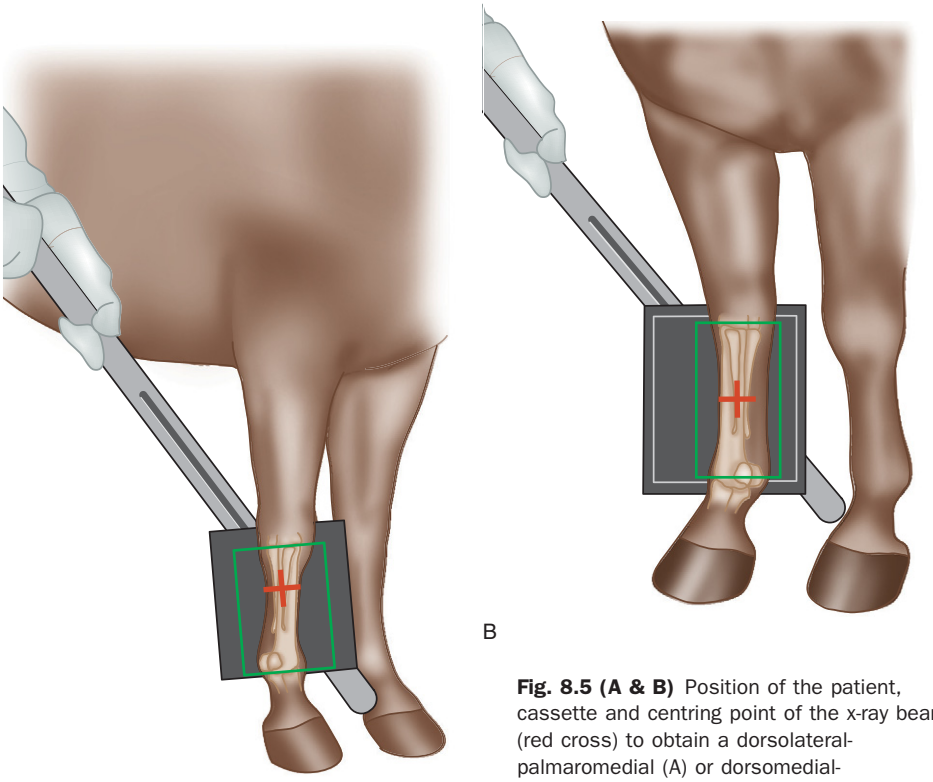

A

B

Fig. 8.5 (A & B) Position of the patient, cassette and centring point of the x-ray beam (red cross) to obtain a dorsolateral-palmaromedial (A) or dorsomedial-palmarolateral (B) view of the metacarpus

Downloaded From Vet-eBooks.com

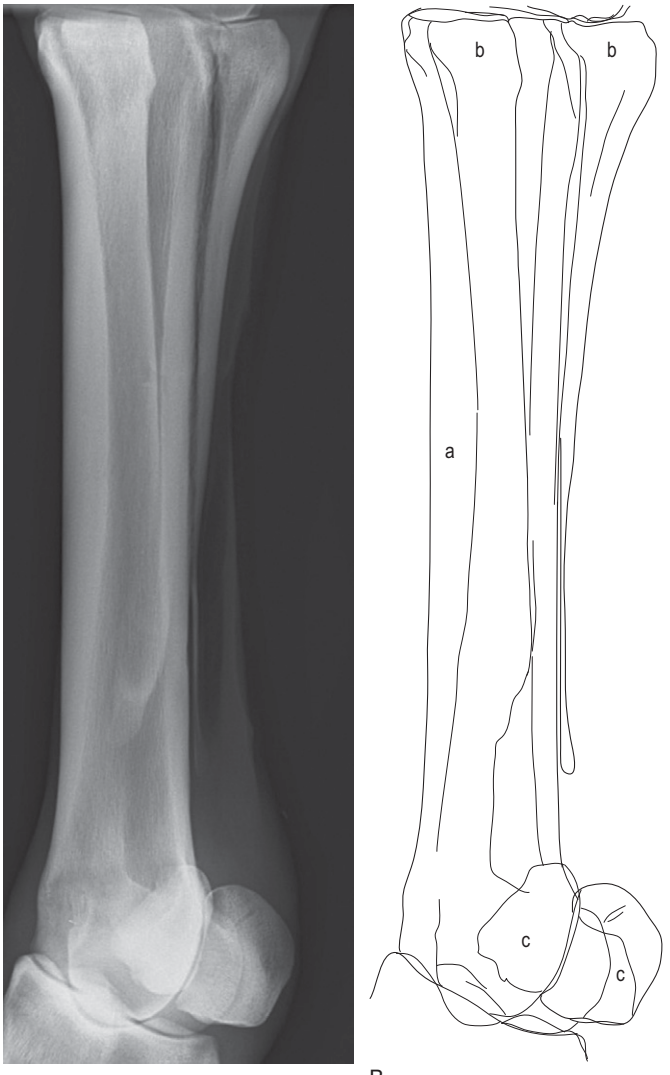

A B

Fig. 8.6 (A & B) Dorsolateral-palmarmedial radiographic view of the metacarpus. a – Third metacarpal, b – Second and fourth metacarpals, c – Proximal sesamoids

Tips

✔ A much lower exposure is required to optimally image the second or fourth metacarpal/metatarsal bones as compared to the third metacarpal/metatarsal bones.

Downloaded From Vet-eBooks.com

❹ Dorsal 10° proximal-palmarodistal oblique view of the distal metacarpus

This view is particularly useful for identification of incomplete articular condylar fractures of the distal metacarpus. The 10° oblique angle of the x-ray beam projects the proximal sesamoids further proximally than a standard dorsopalmar view taken with a horizontal x-ray beam. It therefore gives a clearer image of the distal condyles of the third metacarpal bone by avoiding superimposition.

Positioning

This view can be taken with the horse weight-bearing, but flexing the fetlock by positioning the foot as if taking an 'upright pedal' projection with the dorsal hoof wall orientated vertically (see Ch. 5) is usually easier. This moves the sesamoids more proximally and a larger portion of the distal cannon is free of superimposition from these bones. The cassette is held perpendicular to the x-ray beam, as close to the palmar aspect of the fetlock as possible.

Beam direction, centring and collimation

The primary beam should be horizontal and centred at the level of the fetlock joint. Collimation should include the distal third of the cannon bone.

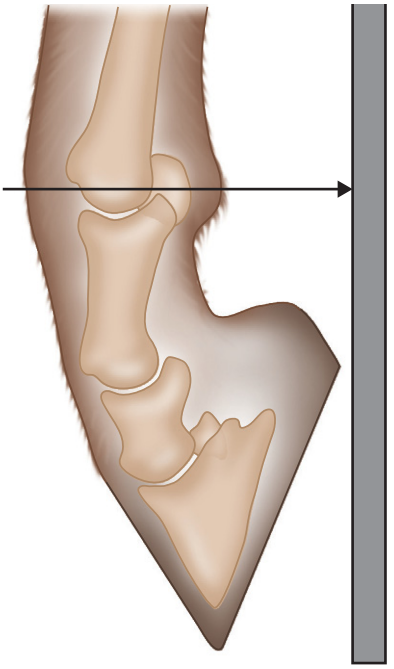

Fig. 8.7 Position of the patient, cassette and direction of the x-ray beam to obtain a dorsal 10° proximal-palmarodistal oblique view of the distal metacarpus

Downloaded From Vet-eBooks.com

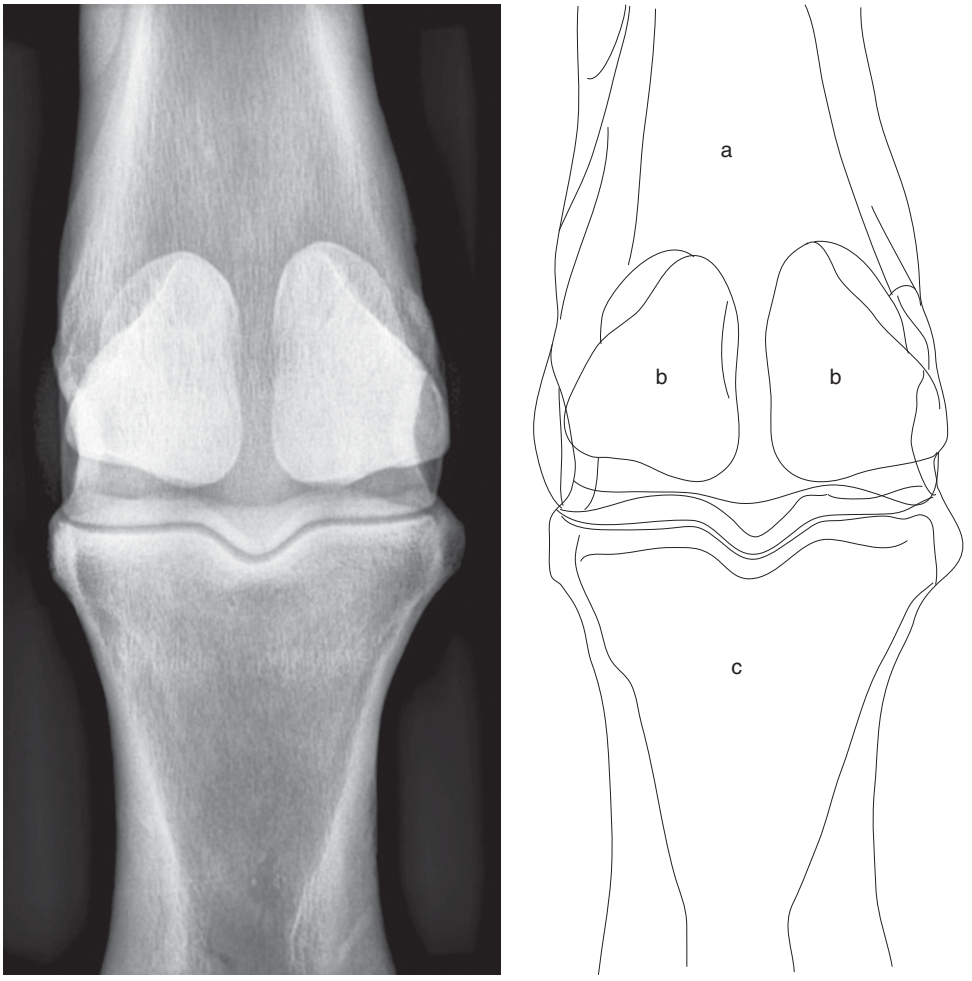

A B

Fig. 8.8 (A & B) Dorsal 10° proximal-palmarodistal oblique radiographic view of the distal metacarpus. a – Third metacarpal, b – Proximal sesamoid, c – Proximal phalanx (P1)

Downloaded From Vet-eBooks.com

❺ Dorsodistal-palmaroproximal view of the distal metacarpus

This view is used to highlight the palmar aspect of the distal metacarpal condyles and is particularly useful to ascertain if palmar fragmentation is present in horses with condylar fractures of the third metacarpal bone.

Positioning

The horse should be positioned with the foot placed in slight extension on a wooden block. The cassette is held parallel with the cannon bone at the palmar aspect of the fetlock.

Beam direction, centring and collimation

The primary beam should be directed 15° disto-proximally (i.e. up from the horizontal) and centred at the level of the fetlock joint. Collimation should include the distal third of the cannon bone and fetlock joint.

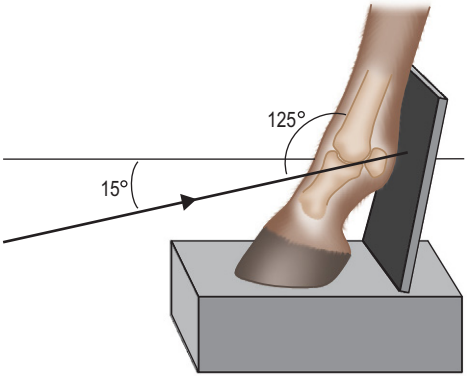

Fig. 8.9 Diagram of patient and cassette position (foot placed on a wooden block) and direction of the x-ray beam for dorsodistal-palmaroproximal view of the distal metacarpus

Downloaded From Vet-eBooks.com

A

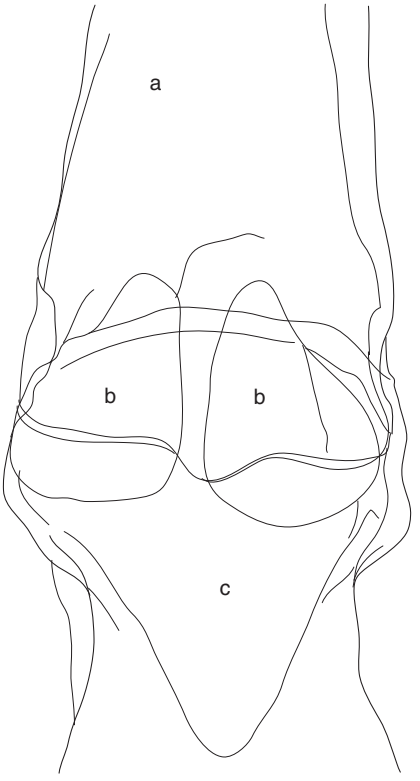

B

Fig. 8.10 (A & B) Dorsodistal-palmaroproximal radiographic view of the distal metacarpus.
a – Thrid metacarpal,
b – Proximal sesamoids,
c – Proximal phalanx (P1)

Downloaded From Vet-eBooks.com

9 RADIOGRAPHY OF THE CARPUS

Introduction

The carpus is a common site of lameness in young equine athletes, but a less significant site of orthopaedic pathology in older pleasure horses. Common conditions involving the carpus include osteoarthritis and fractures. Pathology and radiographic changes are most frequently seen on the dorsomedial aspect of the radiocarpal and middle carpal joints.

Indications for radiography include:

- lameness localised to the carpal region by clinical examination (swelling, pain, reduced range of movement) or by local analgesia (positive intercarpal and/or radiocarpal joint blocks or positive radial/ulnar nerve block).
- carpal wounds and angular limb deformities involving the carpus.

A standard radiographic examination of the carpus consists of at least four views: lateromedial (LM), dorsopalmar (DPa), dorsolateral-palmaromedial oblique (DL-PaMO) and dorsomedial-palmarolateral oblique (DMPaLO). Additional views commonly obtained are: flexed lateromedial and two or three 'skyline' views projecting the dorsal aspects of the distal radius, proximal carpal row and distal carpal row respectively.

Preparation

For the standard views the horse is weight-bearing evenly on both forelimbs with the cannon bones vertical. The flexed views require an additional assistant to lift the limb. All assistants must be protected by protective clothing and careful collimation of the x-ray beam.

Downloaded From Vet-eBooks.com

Views

❶ Lateromedial (LM) view of the carpus

Positioning

The cassette is held vertically against the medial aspect of the carpus perpendicular to the x-ray beam.

Beam centring and collimation

The beam should be horizontal and parallel to the bulbs of the heel to avoid obliquity. Centre the beam on the middle carpal joint, which is level with the distal edge of the accessory carpal bone and collimate to include the distal radius and proximal metacarpus.

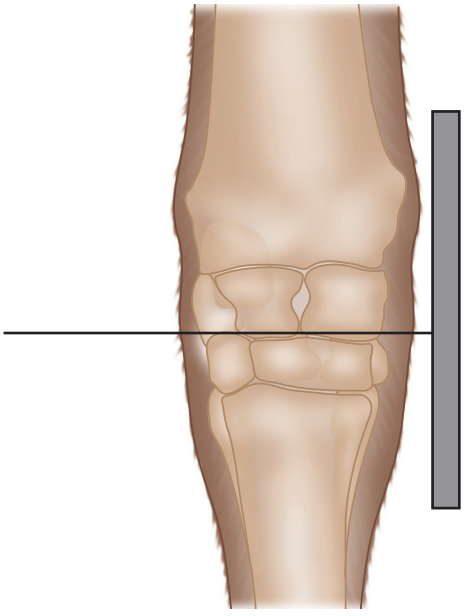

Fig. 9.1 Positioning of the limb and cassette to obtain a lateromedial view of the carpus. The cassette is on the medial side of the joint

Downloaded From Vet-eBooks.com

A

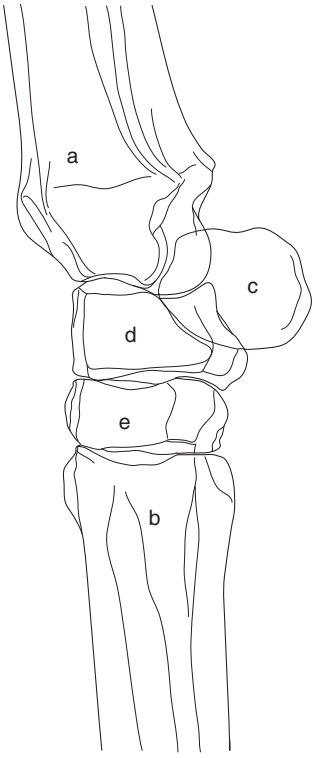

B

Fig. 9.2 (A & B) Lateromedial view of a normal adult carpus. a – Radius, b – Metacarpus, c – Accessory carpal bone, d – Radial, intermediate and ulnar carpal bones, e – Second, third and fourth carpal bones

Tips

✔ The articular surfaces of the carpus undulate so it is not possible to avoid partial superimposition of opposing joint surfaces.

Downloaded From Vet-eBooks.com

❷ Dorsopalmar (DPa) view of the carpus

Positioning

The horse is positioned as for the LM view.

Beam centring and collimation

Centre the beam on the intercarpal joint from dorsal. The cassette is held perpendicular to the horizontal primary beam, palmar to the carpus.

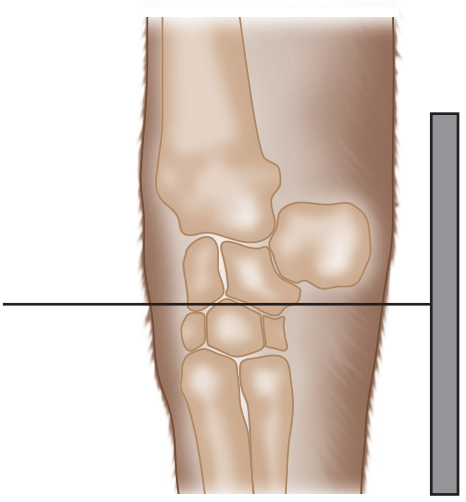

Fig. 9.3 Positioning for a dorsopalmar view of the carpus. The cassette is held against the palmar aspect of the joint using a cassette holder

Downloaded From Vet-eBooks.com

A

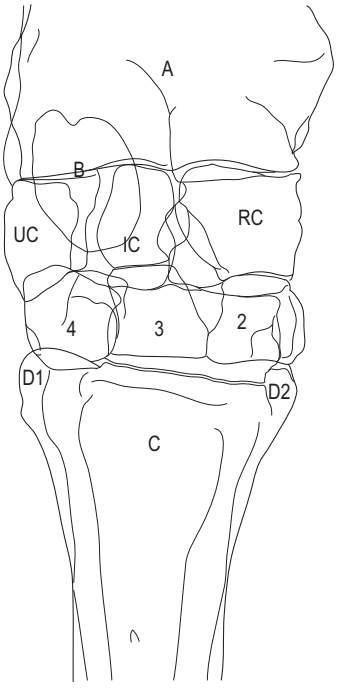

B

Fig. 9.4 (A & B) Dorsopalmer view of a normal adult corpus. A – Radius, B – Accessory carpal bone, C – Third metacarpal bone, D1 + 2 – Fourth (1) and second (2) metacarpal bones, RC – Radiocarpal bone, UC – Ulnar carpal bone, IC – Intermediate carpal bone, 2 – Second carpal bone, 3 – Third carpal bone, 4 – Fourth carpal bone

Tips

✔ A well-aligned DPa view will contain a radiolucent space between the intermediate and radiocarpal bones.

Downloaded From Vet-eBooks.com

❸ Dorsolateral-palmaromedial oblique (DLPaMO) view of the carpus

As the predilection sites for common conditions such as carpal osteoarthritis and fractures are located on the dorsomedial aspect of the joint, this oblique view is more likely to reveal abnormalities than the LM, DPa or DMPaLO views. In particular, the dorsomedial aspects of the radial and third carpal bones are highlighted.

Positioning

With the horse weight-bearing evenly, centre the beam on the intercarpal joint at an angle midway between dorsal and lateral (45° oblique). For the optimal view of the dorsomedial region of the joint most likely to show pathology, use an angle of 75° to dorsal. In both instances, the cassette should be positioned perpendicular to the direction of the primary beam.

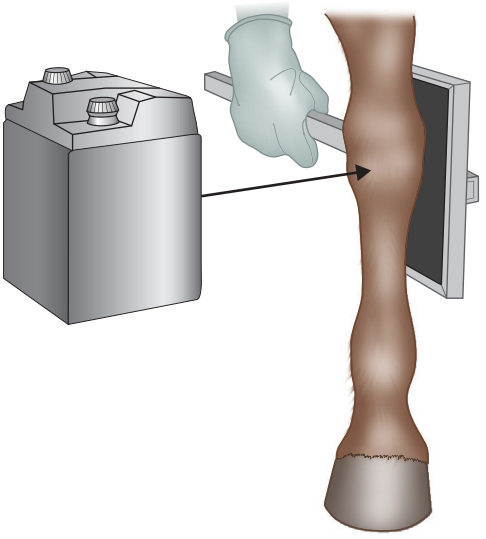

Fig. 9.5 Dorsolateral-palmaromedial oblique (DLPaMO) view of the carpus

Downloaded From Vet-eBooks.com

A

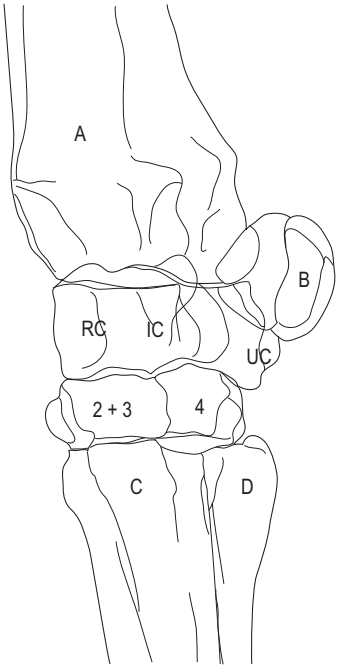

B

Fig. 9.6 (A & B) Positioning and beam angulation required to produce a dorsolateral-palmaromedial oblique view of the carpus. A – Radius, B – Accessory carpal bone, C – Third metacarpal, D – Fourth metacarpal, RC – Radiocarpal, IC – Intermediate carpal, UC – Ulnar carpal, 2 + 3 – Second and third carpal, 4 – Fourth carpal

Downloaded From Vet-eBooks.com

❹ Dorsomedial-palmarolateral oblique (DMPaLO) view of carpus

Positioning

With the horse weight-bearing evenly, centre the beam on the intercarpal joint at an angle midway between dorsal and medial (45° oblique). The cassette should be perpendicular to the direction of the primary beam.

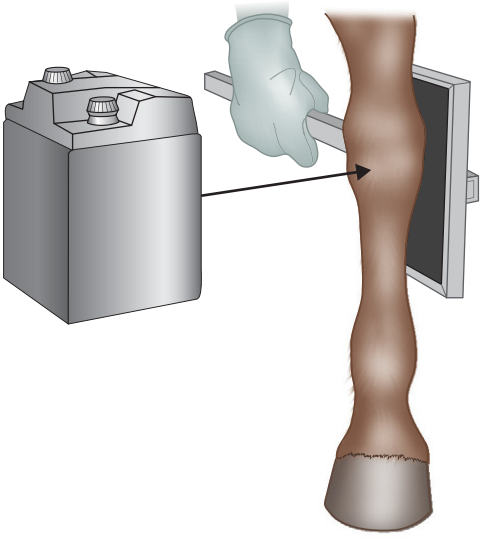

Fig. 9.7 Positions for dorsomedial-palmarolateral oblique (DMPaLO) view of the carpus

Downloaded From Vet-eBooks.com

A

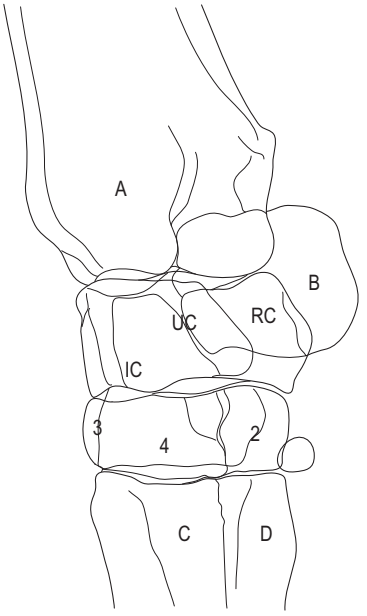

B

Fig. 9.8 Dorsomedial-palmarolateral oblique (DMPaLO) view of the carpus. A – Radius, B – Accessory carpal bone, C – Third metacarpal, D – Second metacarpal, RC – Radiocarpal, IC – Intermediate carpal, UC – Ulnar carpal, 2 – Second carpal, 3 – Third carpal, 4 – Fourth carpal. Note round first carpal bone palmar to the second carpal bone. This bone is not always present

Tips

✔ For convenience and improved operator safety, a similar result can be achieved by obtaining a palmarolateral-dorsomedial oblique view.

Downloaded From Vet-eBooks.com

❺ Flexed lateromedial view of the carpus

This view improves visualisation of the periarticular regions of the radiocarpal and middle carpal joints. Displaced dorsal slab fragments which reduce when the joint is flexed carry a better prognosis following surgical repair than those which remain displaced.

Positioning

The limb being examined is raised with the carpus in approximately ⅔ of maximum flexion and the beam is centred as for the weight-bearing LM view.

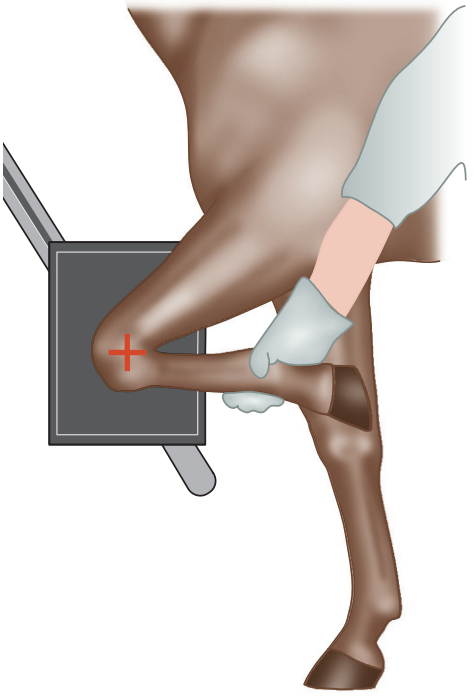

Fig. 9.9 Positions for flexed lateromedial radiograph of the carpus

Downloaded From Vet-eBooks.com

A

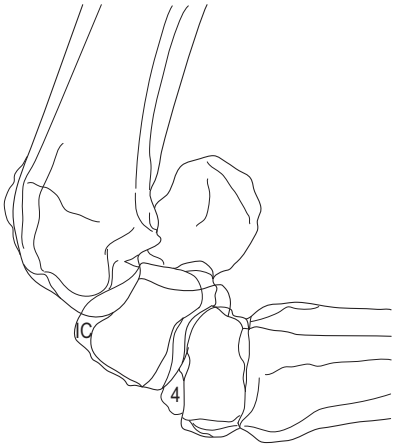

B

Fig. 9.10 Lateromedial radiograph of a normal flexed carpus. IC – intermediate carpal bone; 4 – fourth carpal bone

Tips

✔ Avoid inward or outward rotation of the distal limb, which will create obliquity. This view requires an extra assistant and radiation protection requirements must be adhered to.

Downloaded From Vet-eBooks.com

❻ Dorsoproximal-dorsodistal oblique views of distal radius, proximal row of carpal bones and distal carpal row

These views are essential for complete definition of fractures at the dorsal aspect of the proximal or distal carpal rows or distal radius. Detection of medullary sclerosis of the radiocarpal and third carpal bones, a sign of stress remodelling, is usually only possible in these views.

Positioning

The carpus is held in flexion. With the cassette held parallel to the floor immediately below the carpus the beam is centred from dorsal at the centre of the dorsal aspect of the carpus or distal radius (Fig. 9.11). Increasing the degree of flexion and holding the carpus cranial to the contralateral limb highlights the proximal and distal row of carpal bones:

- Flexed D65° Pr-DDiO. This view skylines the dorsodistal radius (Fig.9.12). The limb is held with the radius vertical and the carpus in slight flexion adjacent to the contralateral carpus.
- Flexed D45° Pr-DDiO. This view skylines the dorsal aspect of the proximal carpal row (radiocarpal and intermediate carpal bones, Fig. 9.13). The limb is held in moderate flexion with the radius forward at approximately 45° to the ground.
- Flexed D30° Pr-DDiO. This view skylines the dorsal aspect of the distal carpal row (mainly the third carpal bone, Fig. 9.14). The limb is held in maximum flexion with the radius held forward at approximately 60° to the ground.

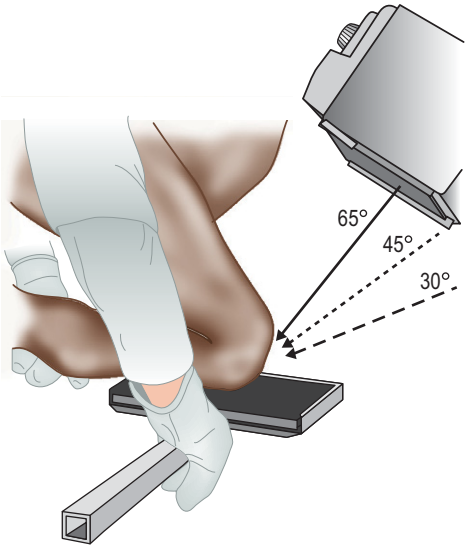

Fig. 9.11 Positioning of the limb and cassette for the three dorsal skyline views of the carpus: distal radius (65°, solid arrow); the proximal carpal row (45°, dotted arrow); and the distal carpal row (30°, dashed arrow)

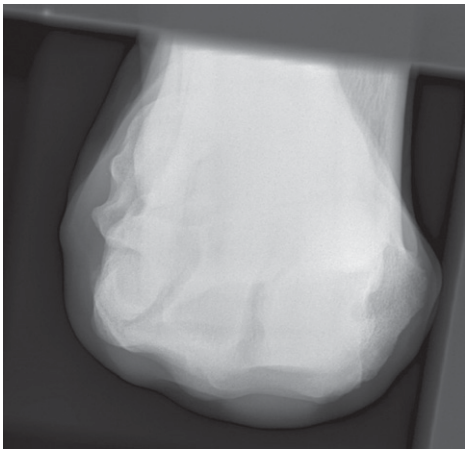

Fig. 9.12 Skyline view of dorsal aspect of a normal distal radius. Note the proximal row of carpal bones are partially superimposed over the distal radius

Downloaded From Vet-eBooks.com

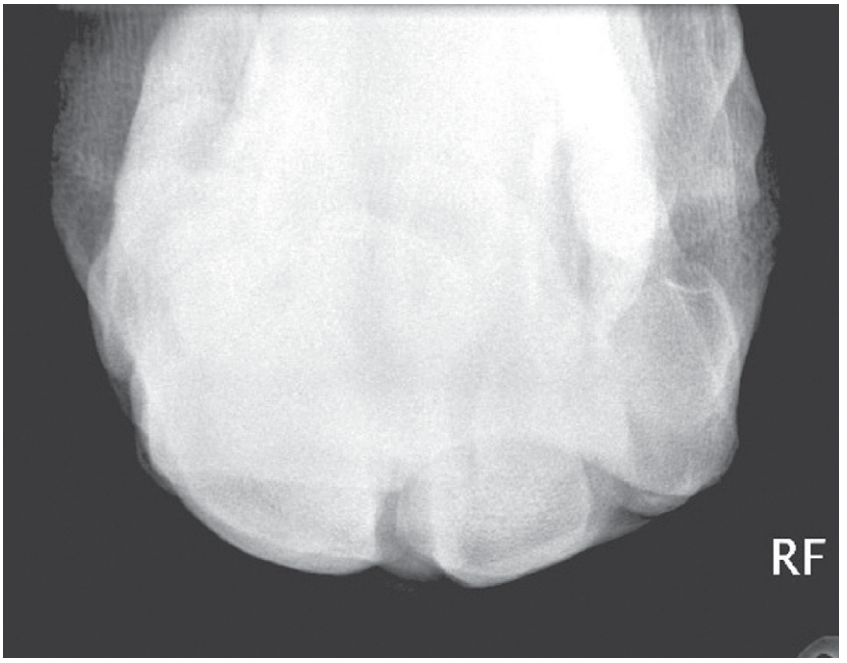

A

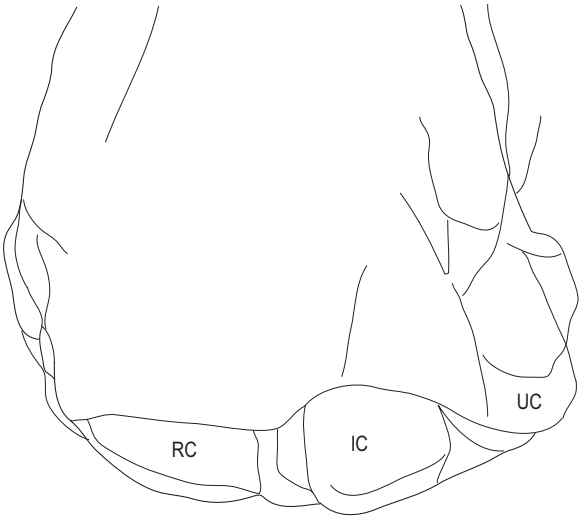

B

Fig. 9.13 (A & B) Skyline view of dorsal aspect of the proximal carpal row (flexed D45°Pr-DDiO). RC – Radiocarpal bone, IC – Intermediate carpal bone, UC – Ulnar carpal bone

Downloaded From Vet-eBooks.com

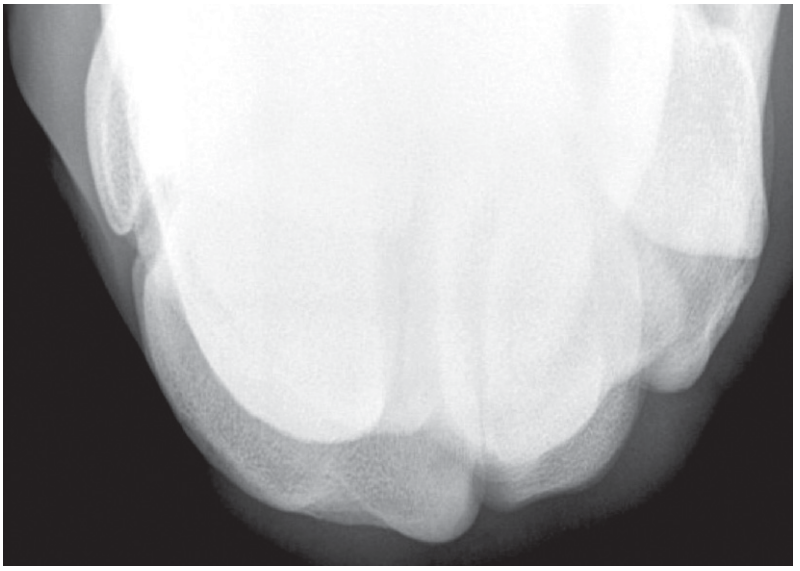

A

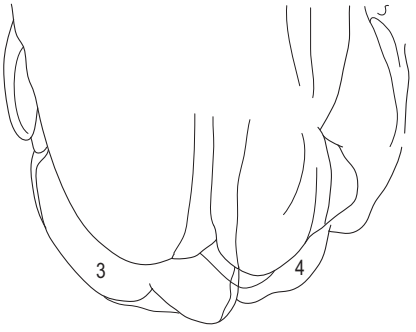

B

Fig. 9.14 (A & B) Skyline view of dorsal aspect of distal carpal row. Lateral is to the right 3 – Third carpal bone, 4 – Fourth carpal bone

Tips

✔ Avoid the tendency to abduct the flexed carpus.

Downloaded From Vet-eBooks.com

10 RADIOGRAPHY OF THE TARSUS

Introduction

Indications for tarsal radiography include:

- effusion of the tarsocrural joint or tarsal sheath
- lameness localised to the tarsal region by intra-articular or perineural anaesthesia
- traumatic injury to the area.

Weight-bearing lateromedial, dorsoplantar, dorsolateral-plantaromedial and dorsomedial-plantarolateral views will provide sufficient diagnostic information for most cases. Occasionally, flexed lateromedial views or the 'skyline' (dorsoplantar) view of the calcaneus will give useful extra information.

Patient preparation

No specific patient preparation is necessary for radiography of the hock; however, most horses will be easier to radiograph if they are sedated. Fractious horses may inflict serious injury/damage to personnel and equipment.

Downloaded From Vet-eBooks.com

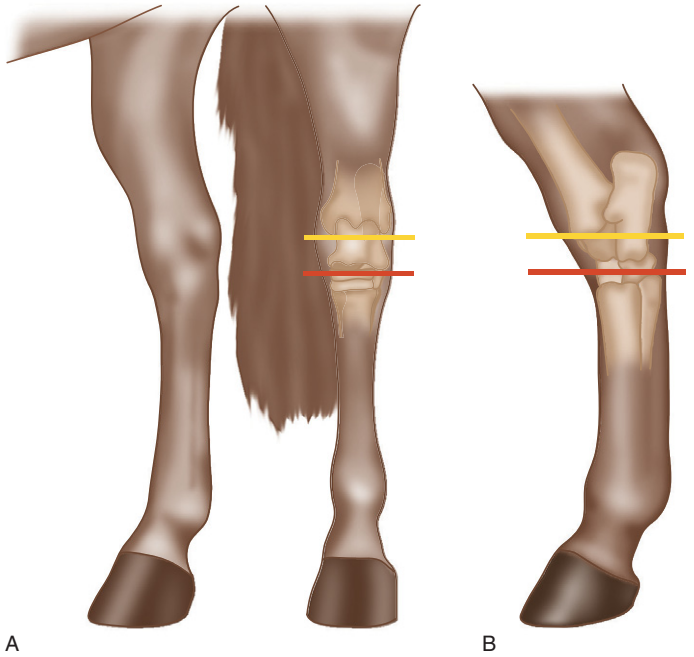

Fig. 10.1 (A & B) Diagrams showing different levels for centring the x-ray beam for the tarso-crural joint (yellow lines) and the distal hock joints (red lines) as viewed from dorsal (A) and lateral (B) aspects of the hock

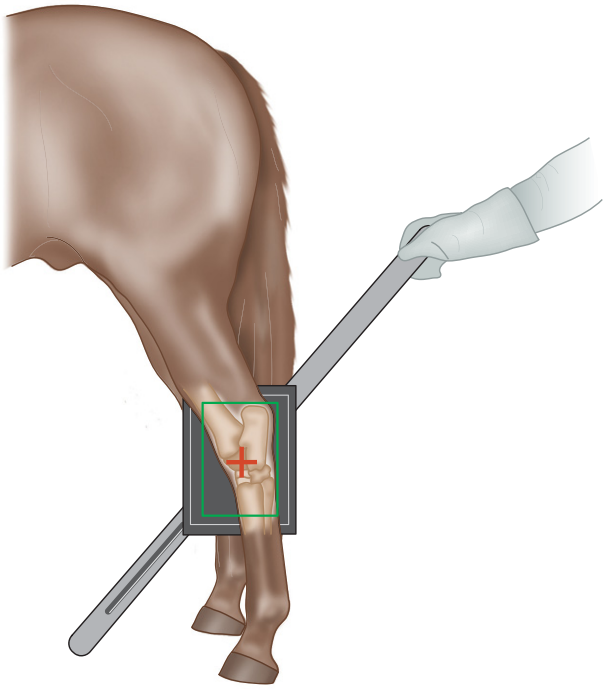

Fig. 10.2 Position of the patient, cassette, centring point of the x-ray beam (red cross) and collimation of the primary beam (green outline) to obtain a lateromedial view of the hock

Downloaded From Vet-eBooks.com

Tips

- ✔ For all views apart from the flexed views (5 and 6), ensure the horse is weight bearing and standing square with its metatarsal bones as vertical as possible, and no abduction or adduction of the limbs present.
- ✔ If the small hock joints (tarsometatarsal, distal and proximal intertarsal) are the area of interest, centre the primary beam slightly more distal than if the area of interest lies within the tarsocrural joint (Fig. 10.1).
- ✔ Many horses have a slightly 'toe out' hindlimb conformation: the degree of outward rotation for individual horses should be assessed and all standing radiographic views aligned accordingly.

Downloaded From Vet-eBooks.com

Views

❶ Lateromedial

This view highlights the calcaneal tuberosity and plantar aspect of the calcaneus, the (superimposed) lateral and medial trochlear ridges of the talus, the dorsal aspects of the central and third tarsal bones, the plantar aspect of the fourth tarsal bone and the dorso-proximal aspect of the third metatarsal bone, and the proximal aspect of the splint bones (second and fourth metatarsals).

Positioning

The cassette is held in a cassette holder on the medial aspect of the hock, in line with the dorso-plantar axis of this joint. It is safer to hold the cassette holder from the dorsal aspect of the hock to avoid standing directly behind the horse; however, in some horses, particularly those with a very straight or toe-in hindlimb conformation, it may be difficult to position the cassette accurately from this position.

Beam direction, centring and collimation

The primary beam should be horizontal for a true lateromedial view. The beam is centered on either the tarsocrural or small hock joints. Alternatively, to avoid/reduce superimposition at the small hock joints, the x-ray beam may be angled slightly (5–10°) downwards (proximodistally). Collimation of the primary beam should include the point of the hock, the cranial aspect of the distal tibia and the proximal metatarsal bones.

Downloaded From Vet-eBooks.com

A

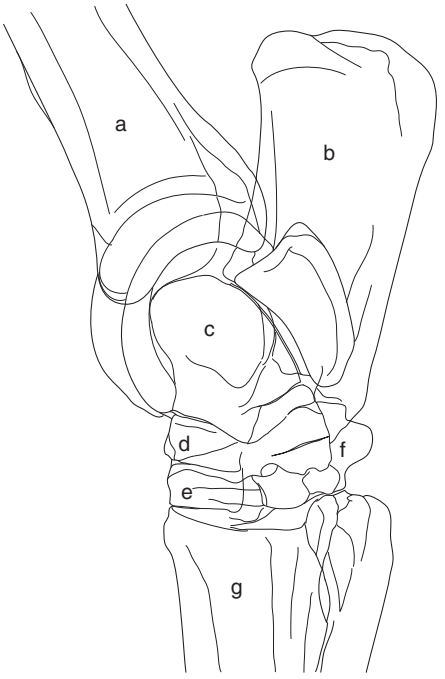

B

Fig. 10.3 (A & B) Lateral radiograph of the hock. a – Tibia, b – Calcaneus, c – Talus, d – Central tobal, e – Third tarsal, f – Fourth tarsal, g – Third metatarsal

Tips

- ✔ The small hock joints in normal horses slope slightly proximo-distally from lateral to medial. Therefore, to angle the x-ray beam directly through these narrow joint spaces, the x-ray beam can be directed 5–10° downwards.
- ✔ If there is marked latero-medial foot imbalance the x-ray beam can be re-directed so that it is parallel to this to allow for the sharpest views through the small hock joints.

Downloaded From Vet-eBooks.com

❷ Dorsoplantar

This view highlights the medial and lateral malleoli of the tibia, the medial aspect of the talus, the medial aspect of the central and third tarsal bones, and the lateral aspect of the fourth tarsal bone and the splint bones (second and fourth metatarsals).

Positioning

The cassette is held vertically in a cassette holder on the plantar aspect of the hock.

Beam direction, centring and collimation

The primary beam is usually directed horizontally, but in some horses, directing the beam 5–10° proximo-distally will assist in imaging the medial aspects of the small hock joints more clearly. The beam should be centred on either the tarsocrural or small hock joints. Collimation of the primary beam should include the point of the hock at the proximal limit, the proximal splint bones distally, and the medial and lateral malleoli of the tibia.

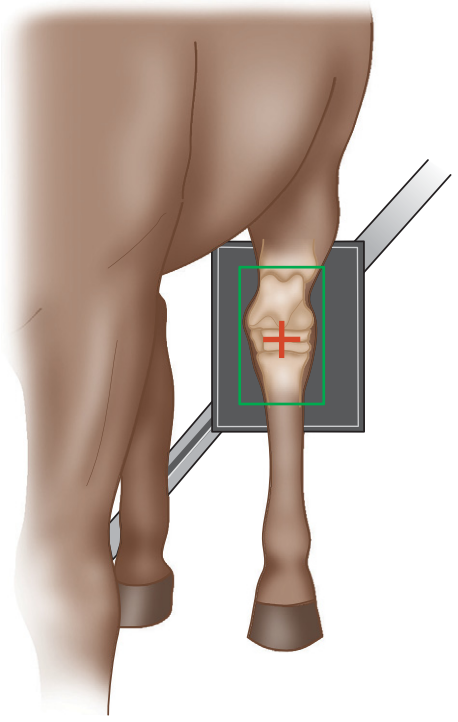

Fig. 10.4 Position of the patient, cassette and centring point of the x-ray beam (red cross) to obtain a dorso-plantar view of the hock

Downloaded From Vet-eBooks.com

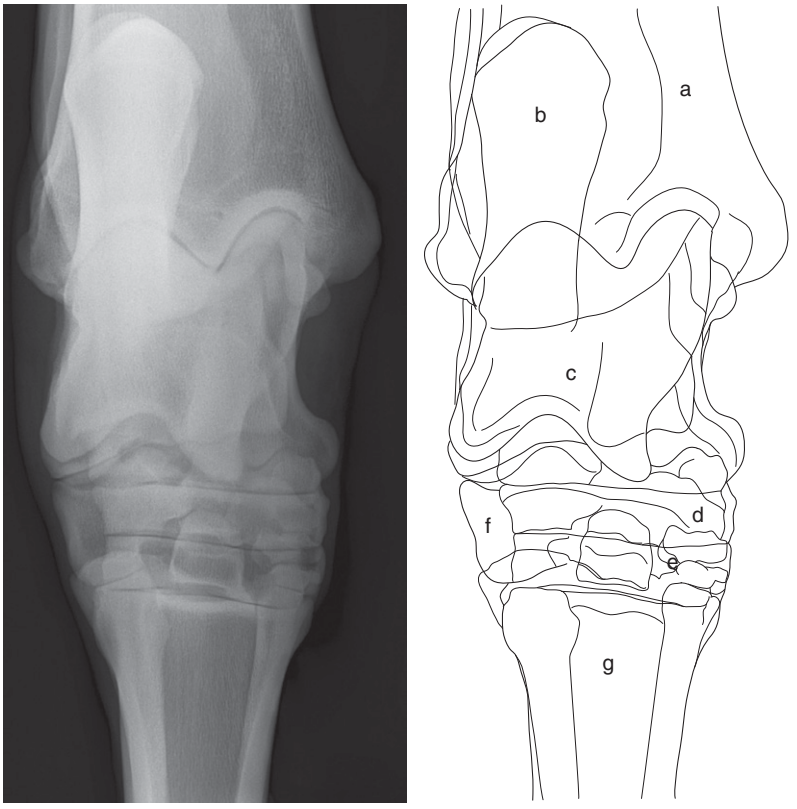

A B

Fig. 10.5 (A & B) Dorsoplantar radiograph of the hock. a – Tibia, b – Calcaneus, c – Talus, d – Central tarsal, e – Third tarsal, f – Fourth tarsal, g – Third metatarsal

Downloaded From Vet-eBooks.com

❸ Dorsolateral-plantaromedial oblique

This view highlights the medial malleolus of the tibia, the medial trochlear ridge of the talus, and the dorsomedial aspects of the central and third tarsal bones and the third metatarsal bone. On the plantar aspect, the plantaro-lateral aspect of the calcaneus, fourth tarsal bone and the fourth metatarsal bone are highlighted.

Tips

✔ Taking a plantarolateral-dorsomedial (PLDMO) projection will give approximately the same radiographic view as a dorsomedial-plantarolateral projection, however, there will be more magnification with the PLDMO because the cassette can not be held as close to the limb due to the angulation of the distal tibia.

Positioning

The cassette is held vertically in a cassette holder on the plantaro-medial aspect of the hock, perpendicular to the direction of the x-ray beam.

Beam direction, centring and collimation

The primary beam is directed horizontally, and centred on either the tarsocrural or small hock joint. Collimation of the primary beam should include the point of the hock at the proximal limit, the proximal splint bones distally, the medial malleolus of the tibia and the plantar aspect of the calcaneus.

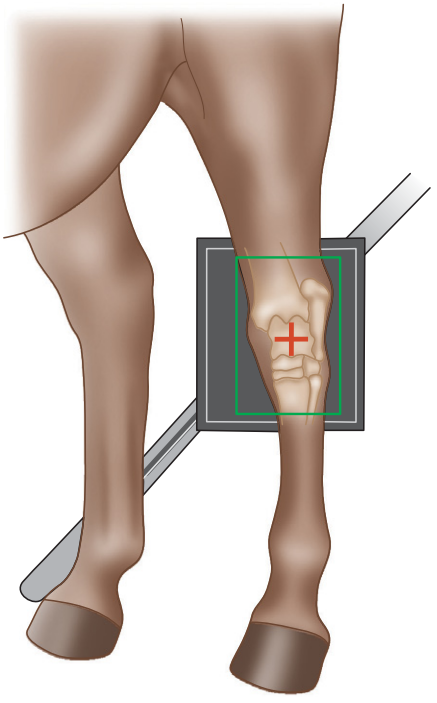

Fig. 10.6 Position of the patient, cassette, centring point of the x-ray beam (red cross) and collimation of the primary beam (green outline) to obtain a dorsolateral-plantarmedial view of the hock

Downloaded From Vet-eBooks.com

A

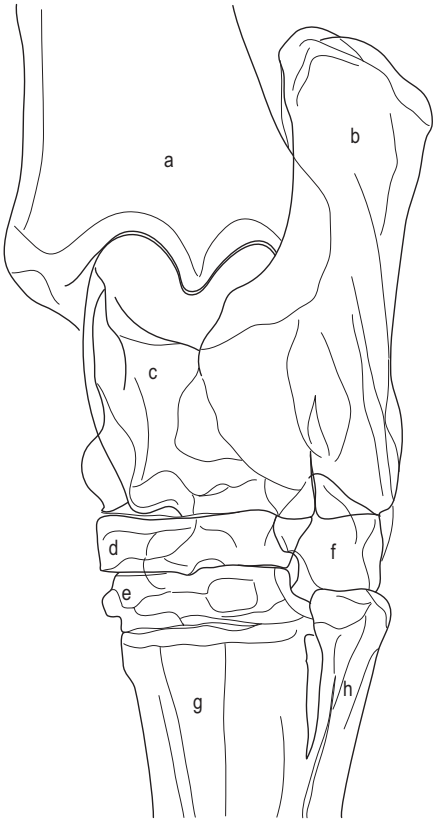

B

Fig. 10.7 (A & B) Dorsolateral-plantaromedial radiograph of the hock. a – Tibia, b – Calcaneus, c – Talus, d – Central tarsal, e – Third tarsal, f – Fourth tarsal, g – Third metatarsal, h – Fourth metatarsal

Downloaded From Vet-eBooks.com

❹ Dorsomedial-plantarolateral oblique

This view highlights the sustentaculum tali, the lateral trochlear ridge of the talus, the dorsolateral aspect of the central and third tarsal bones and the second and third metatarsal bones, and the plantaro-medial aspect of the fourth and fused first and second tarsal bones.

Positioning

The cassette is held vertically in a cassette holder on the plantaro-lateral aspect of the hock, perpendicular to the direction of the x-ray beam.

Beam direction, centring and collimation

The primary beam is directed horizontally, and centred on either the tarsocrural or small hock joints. Collimation of the primary beam should include the point of the hock at the proximal and plantar limits, the proximal splint bones distally, and the dorsal aspect of the distal tibia.

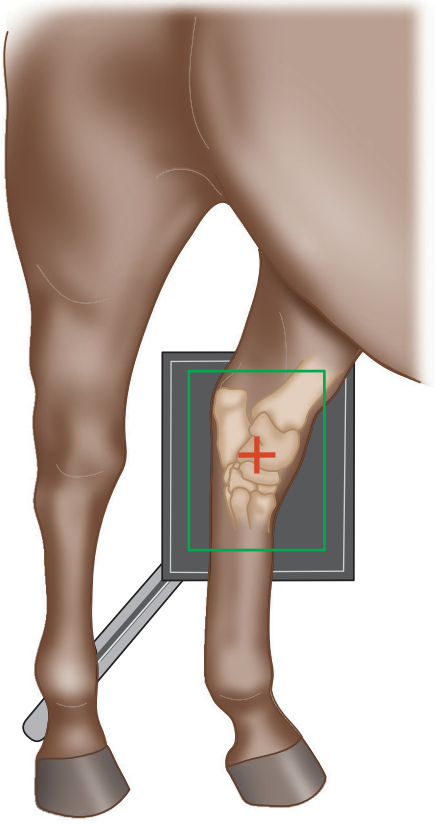

Fig. 10.8 Position of the patient, cassette, centring point of the x-ray beam (red cross) and collimation of the primary beam (green outline) to obtain a dorsomedial-plantarolateral view of the hock

Downloaded From Vet-eBooks.com

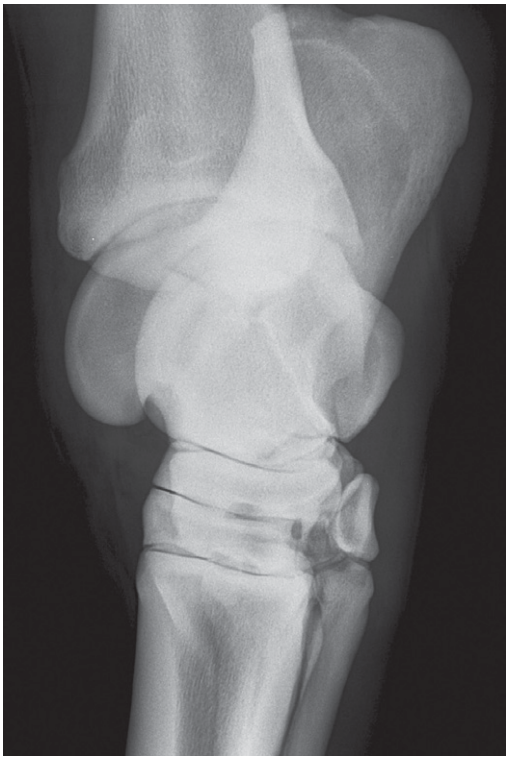

A

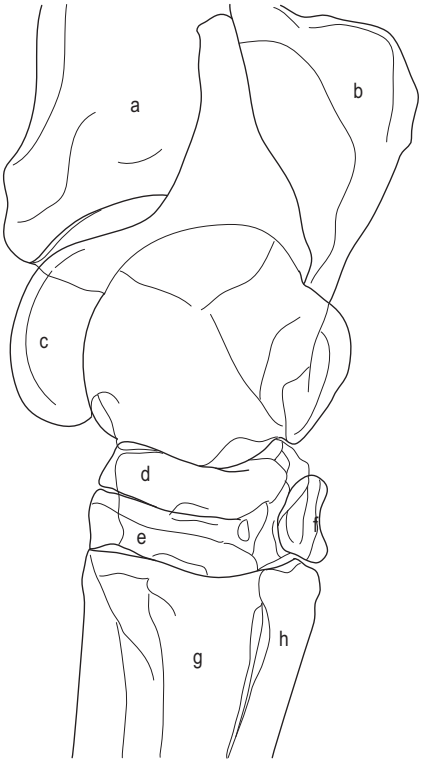

B

Fig. 10.9 (A & B) Dorsomedial-plantarolateral view of the hock. a – Tibia, b – Calcaneus, c – Talus, d – Central tarsal, e – Third tarsal, f – Fused first and second tarsals, g – Third metatarsal, h – Second metatarsal

Downloaded From Vet-eBooks.com

❺ Flexed lateromedial

This view is useful for evaluating the plantarodistal aspect of the tibia, the proximal aspects of the trochlear ridges of the talus and the coracoid process of the calcaneus.

Positioning

With the horse standing, the hind limb should be flexed by an assistant standing by the side of the horse's abdomen. The cassette is positioned on the medial aspect of the hock in a vertical plane.

Beam direction, centring and collimation

The x-ray beam should be horizontal, centred at the talus. Collimation of the primary beam should include the point of the hock, the distal tibia and proximal metatarsal bones.

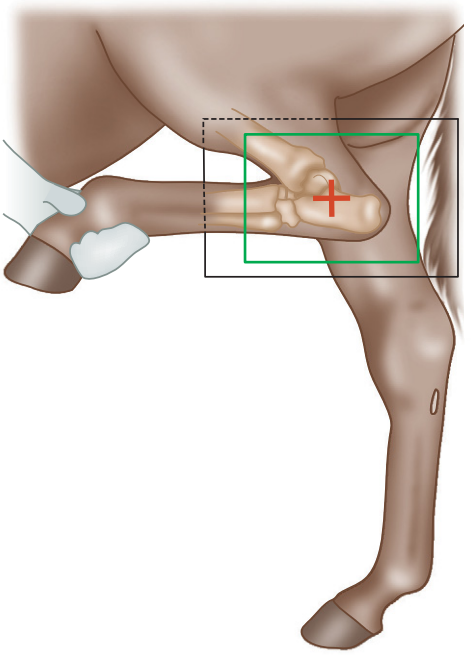

Fig. 10.10 Position of the patient, cassette and centring point of the x-ray beam (red cross) to obtain a flexed lateral view of the hock

Tip

- ✔ It is essential that the people holding the cassette and the horse's limb are wearing lead gloves in addition to a protective lead gown.
- ✔ Care should be taken not to abduct the limb when flexing, as this will cause rotation of the joint.

Downloaded From Vet-eBooks.com

A

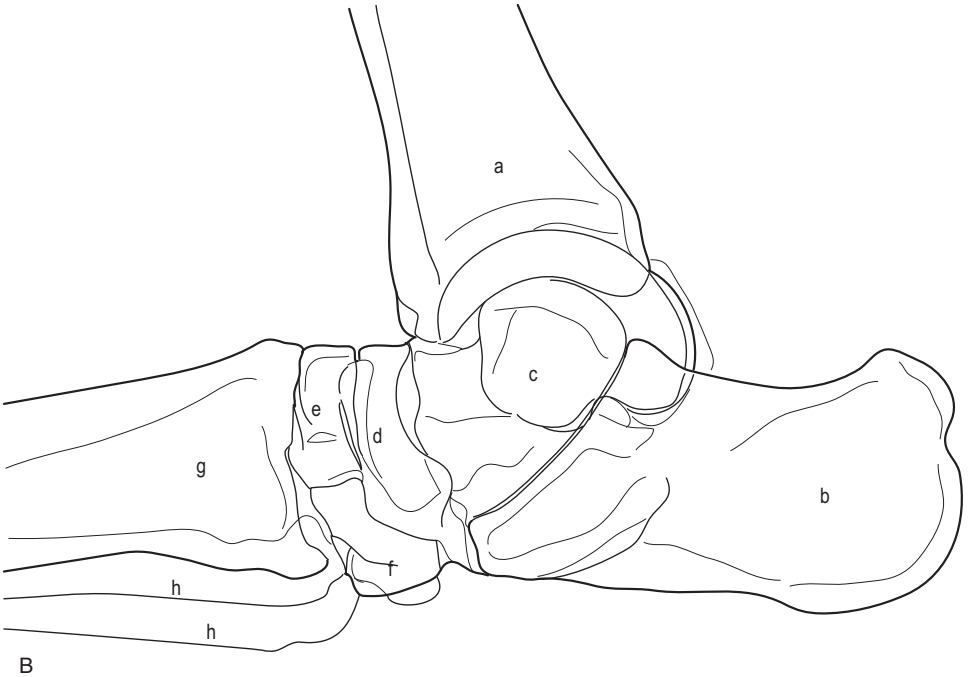

B

Fig. 10.11 (A & B) Flexed lateral radiographic view of the hock. a – Tibia, b – Calcaneus, c – Talus, d – Central tarsal, e – Third tarsal, f – Fused first and second tarsals, g – Third metatarsal, h – Second and fourth metatarsals

Downloaded From Vet-eBooks.com

❻ Flexed plantaroproximal – plantarodistal view of the calcaneus and sustentaculum tali ('skyline')

This view highlights the calcaneal tuberosity and the sustentaculum tali along with the proximal aspect of the medial trochlear ridge of the talus. With higher exposures, the talocalcaneal joint can be identified in some horses.

Positioning

With the horse standing, the hind limb should be flexed and held as caudally as possible by a gloved assistant standing next to the horse's abdomen. The cassette is positioned horizontally, facing upwards with its caudal aspect resting against the plantar aspect of the calcaneus/metatarsus.

Beam direction, centering and collimation

The x-ray beam is directed as close to vertically (down) as possible, whilst avoiding the musculature of the caudal aspect of the thigh. The x-ray beam can be collimated quite tightly to include only the most plantar aspect of the flexed hock, i.e. the calcaneus and sustentaculum tali.

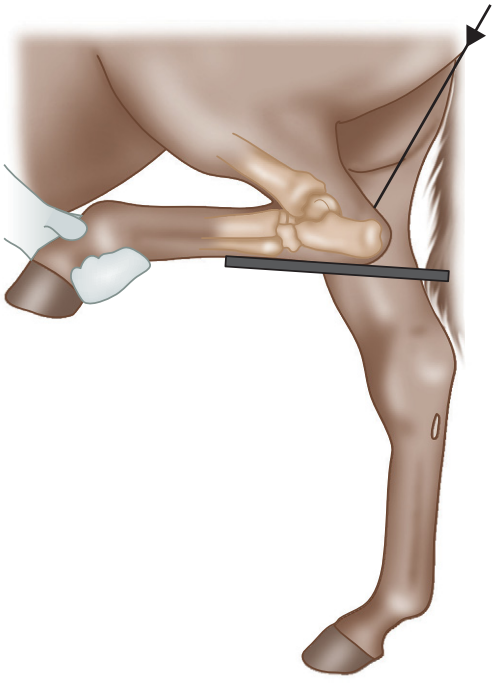

Fig. 10.12 Position of the patient, cassette and orientation of the x-ray beam to obtain a plantaroproximal – plantarodistal view of the calcaneus and sustentaculum tali of the hock

Downloaded From Vet-eBooks.com

A

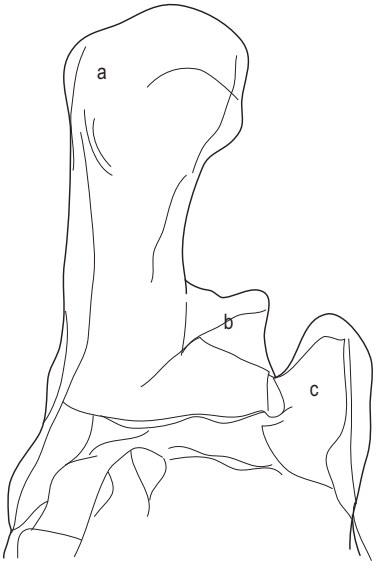

B

Fig. 10.13 (A & B) Plantaroproximal – plantarodistal radiographic view of the calcaneus and sustentaculum tali of the hock. a – Tuber calcaneus, b – Sustentaculum tali, c – Medial trochlear ridge of talus

Tip

✔ It is essential that the people holding the cassette and the horse's limb are wearing lead gloves in addition to a protective lead gown.

Downloaded From Vet-eBooks.com

11 RADIOGRAPHY OF THE ELBOW

Introduction

Indications for radiography of the elbow include:

- lameness localised to the elbow by intra-articular anaesthesia
- abnormal stance ('dropped' elbow)
- traumatic injury to the area.

Mediolateral and craniocaudal views of this joint can be obtained using most x-ray machines. Using a large cassette and cassette holder facilitates imaging the entire area of interest. Fast film-screen combinations give the best results. Occasionally, oblique views may give useful additional information.

Patient preparation

No specific patient preparation is necessary for radiography of the elbow; however, adequate sedation makes patient and cassette positioning easier, particularly in patients with painful traumatic injuries of the elbow that may resent protraction of the limb, which is necessary to obtain the mediolateral view.

Downloaded From Vet-eBooks.com

Views

❶ Mediolateral view

This view highlights the olecranon, trochlear process and aconeal process of the ulna, the proximal articular surface of the radius, the radial tuberosity, and the humeral condyles and epicondyles.

Positioning

The horse is positioned so that the contralateral limb is nearest to the x-ray machine. The distal aspect of the limb to be radiographed is then held by an assistant and pulled cranially as far as possible so that the point of the elbow (olecranon) is cranial to the muscle mass of the brisket and contralateral limb. The cassette is positioned in the vertical plane as close to the lateral aspect of the elbow joint as possible.

Beam direction, centring and collimation

The primary beam should be horizontal, centred at the proximal aspect of the radius. Collimation of the primary beam should include the point of the elbow, the proximal third of the radius and a portion of the distal humerus.

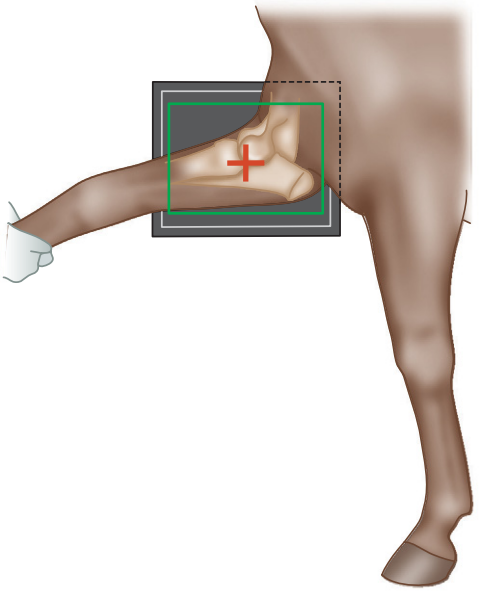

Fig. 11.1 Position of the patient, cassette and centring point of the x-ray beam (red cross) to obtain a medio-lateral view of the elbow joint

Downloaded From Vet-eBooks.com

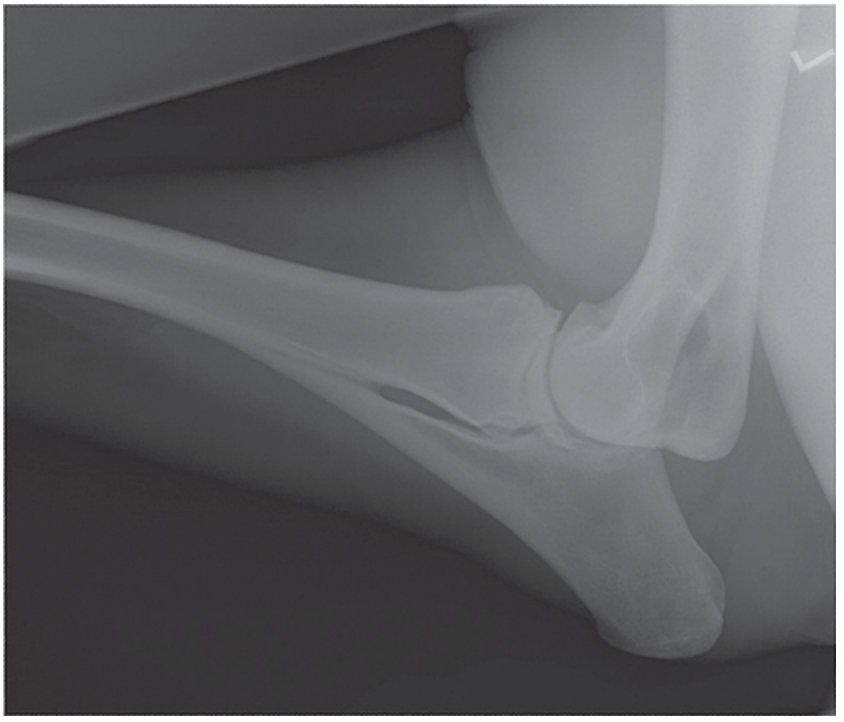

A

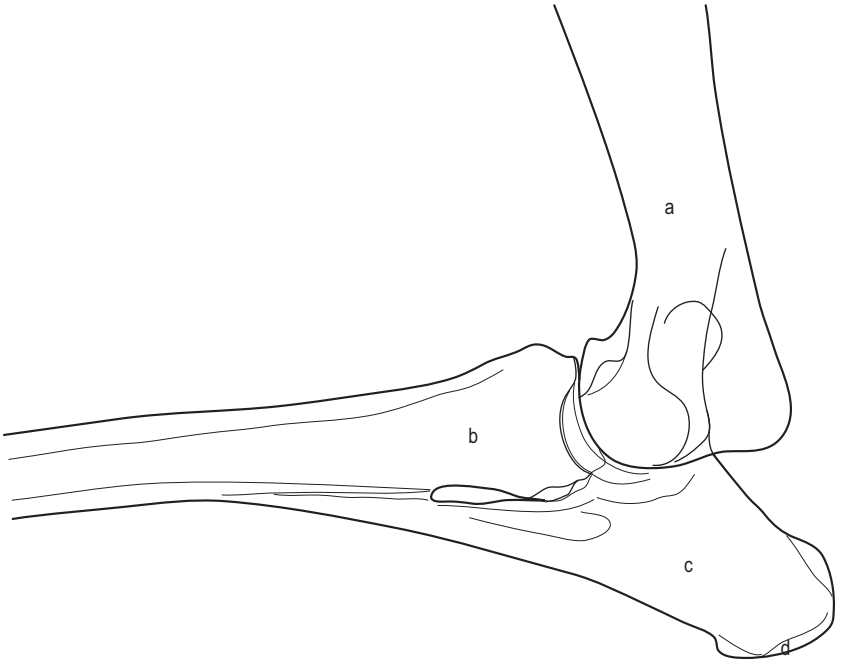

B

Fig. 11.2 (A & B) Mediolateral radiographic view of the elbow. a – Humerus, b – Radius, c – Ulna, d – Olecranon

Tips

✔ As with radiographic examinations of other larger structures, using a radiolucent skin marker to identify the centring point of the primary beam can be helpful if repositioning is necessary subsequently.

Downloaded From Vet-eBooks.com

❷ Craniocaudal view

This view highlights the humero-radial joint space and medial and lateral aspects of the humerus and radius. Some fractures not apparent on mediolateral views can be imaged using this projection.

Positioning

The horse should be weight bearing. The cassette is held at the caudal aspect of the elbow. Positioning the cassette at an angle with the inside edge touching the ventro-lateral aspect of the thorax and its lower inner corner extending below the thorax (Fig. 11.4) will help ensure that the distal humerus is included in the radiograph.

Beam direction, centring and collimation

The x-ray beam is directed horizontally from cranial to caudal, centred on the proximal radius. Collimation of the primary beam should include as much of the distal humerus as possible (usually 3–4 cm of the humerus proximal to the point of the elbow can be radiographed).

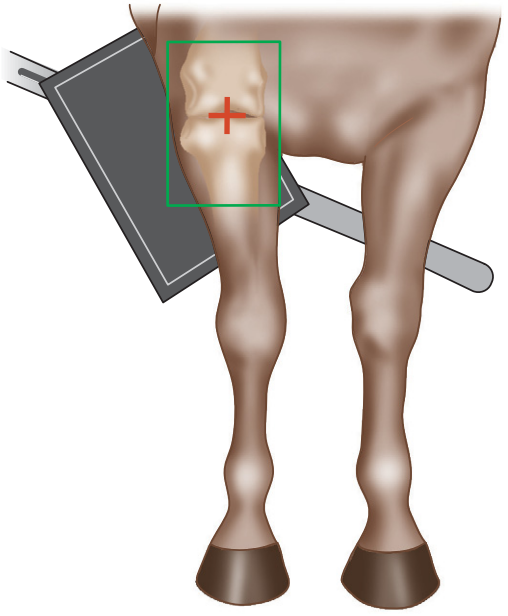

Fig. 11.3 Position of the patient, cassette, centring point of the x-ray beam (red cross) and collimation of the primary beam (green outline) to obtain a craniocaudal view of the elbow joint

Downloaded From Vet-eBooks.com

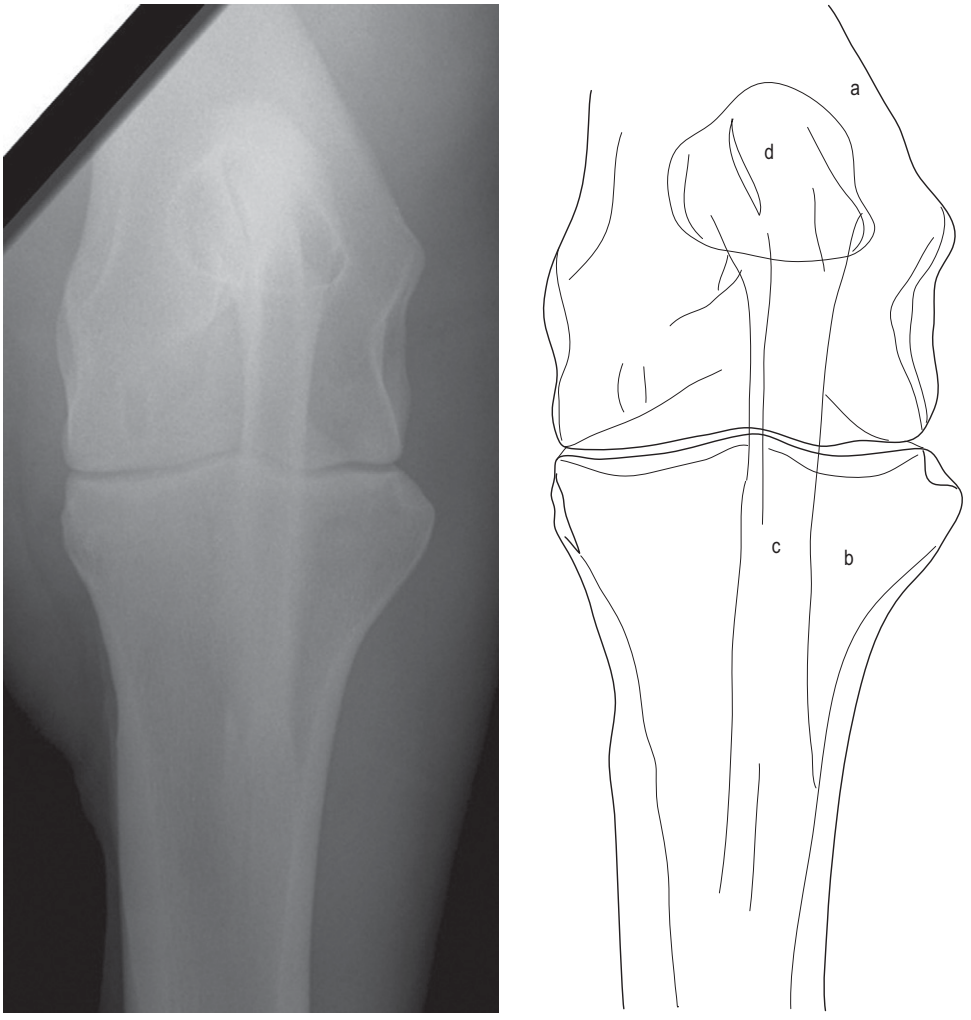

A B

Fig. 11.4 (A & B) Craniocaudal view of the elbow joint. a – Humerus, b – Radius, c – Ulna, d – Olecranon

Tips

✔ If the horse has a low ventral thoracic wall in relation to its elbow joint, the beam may have to be directed 10–15° proximo-distally (downwards) to examine the distal humerus and elbow joint. However, this angulation will distort the image and should be avoided if possible.

Downloaded From Vet-eBooks.com

❸ Craniomedial-caudolateral oblique view

This view is rarely indicated, but may be useful for full evaluation of fractures.

Positioning

The horse should be weight bearing. The cassette is positioned vertically at the caudolateral aspect of the elbow. Positioning the cassette at an angle so that the inside edge touches the ventro-lateral aspect of the thorax and the lower inner corner extends below the chest wall (see Fig. 11.5) will assist in including as much of the distal humerus as possible.

Beam direction, centring and collimation

The x-ray beam should be angled horizontally, centred at the proximal aspect of the radius. Collimation of the primary beam should include the point of the elbow and the distal humerus.

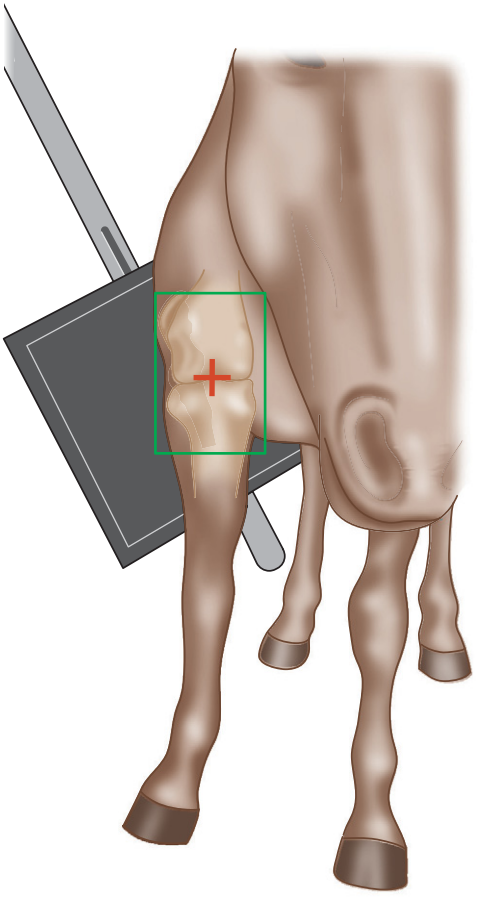

Fig. 11.5 Position of the patient, cassette, centring point of the x-ray beam (red cross) and collimation of the primary beam (green outline) to obtain a craniomedial-caudolateral oblique view of the elbow joint

Downloaded From Vet-eBooks.com

A

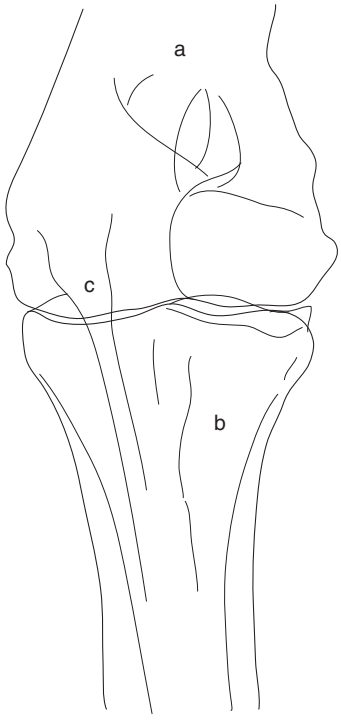

B

Fig. 11.6 (A & B) Craniomedial-caudolateral oblique radiographic view of the elbow joint.
a – Humerus, b – Radius, c – Ulna

Downloaded From Vet-eBooks.com

12 RADIOGRAPHY OF THE SHOULDER

Introduction

Indications for radiography of the shoulder include:

- lameness localised to the shoulder by intra-articular anaesthesia
- atrophy of the muscles overlying the scapula (supra- and infra- spinatus muscles)
- traumatic injury to the area.

A high-output x-ray machine is required to image this joint and a fast film-screen combination should also be used. Using a grid will help to reduce scatter. Mediolateral and oblique views can be obtained in the standing sedated horse. A large cassette facilitates imaging the entire area of interest, and the cassette should be placed in a cassette holder, not hand-held. A lower exposure can be used if the area of interest is the cranioproximal aspect of the humerus (i.e. tubercles or deltoid tuberosity of the humerus), rather than the scapulohumeral joint itself, as there is less soft tissue coverage in this region.

Patient preparation

No specific patient preparation is necessary for radiography of the shoulder; however, adequate sedation makes patient and cassette positioning easier, particularly in patients with painful lesions of the area that may resent protraction of the limb that is necessary to obtain radiographs. It is essential that the person protracting the horse's limb wears lead gloves in addition to a protective lead gown.

Downloaded From Vet-eBooks.com

Views

❶ Medio-lateral view

This is the most commonly obtained view and highlights the tubercles of the humerus, the articular surface of the humeral head, the glenoid cavity of the scapula and the supraglenoid tubercle. Having the trachea positioned over the scapulohumeral joint can aid radiographic interpretation; however, this is not always possible.

Positioning

The horse is positioned so that the contralateral limb closer to the x-ray machine. The distal aspect of the limb to be radiographed is then held by an assistant and protracted (pulled cranially) as far as possible to prevent superimposition of left and right shoulder joints. The cassette is positioned in a cassette holder, in the vertical plane orientated and resting against the lateral aspect of the affected shoulder.

Beam direction, centring and collimation

The primary beam should be horizontal. The radiographer should palpate the distal aspect of the spine of the scapula of the contralateral limb (nearest the x-ray machine), and then centre the primary beam at a point 10 cm cranial and 10 cm proximal to this, in order to centre on the scapulohumeral joint on the opposing side. Collimation of the primary beam should include the proximal humerus and distal spine of the scapula.

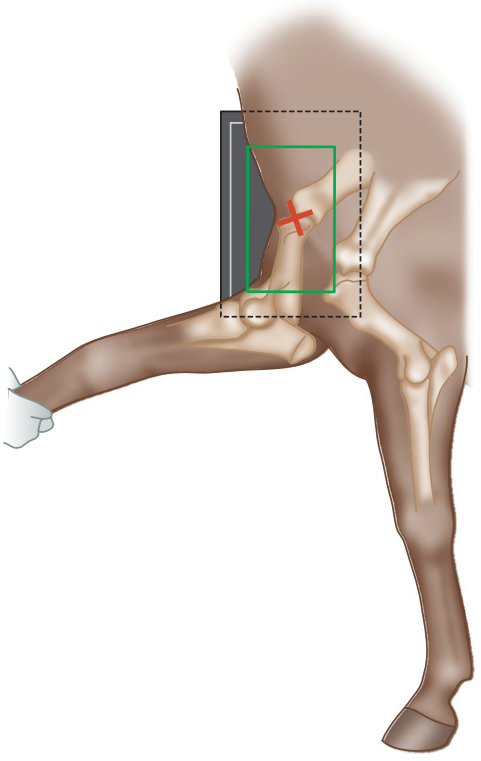

Fig. 12.1 Position of the patient, cassette, centering point of the x-ray beam (red cross) and collimation of the primary beam (green outline) to obtain a mediolateral view of the shoulder joint

Downloaded From Vet-eBooks.com

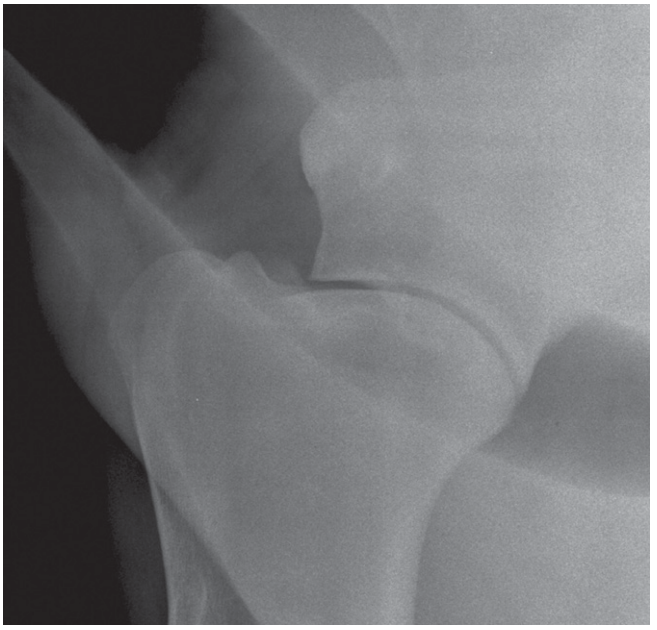

A

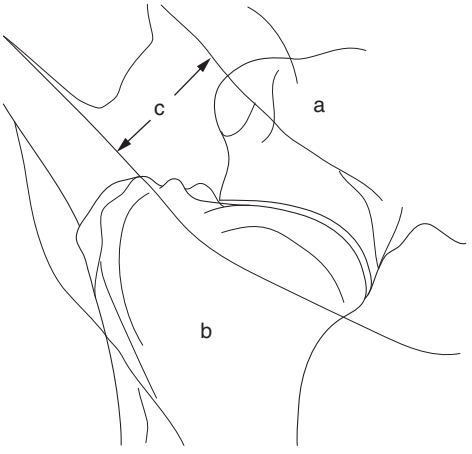

B

Fig. 12.2 (A & B) Lateral radiographic view of shoulder a normal. a – Scaplula, b – Humerus, c – Trachea

Tips

- ✔ When taking the radiographs, the centring point can be marked with a radiolucent marker, e.g. a small piece of tape. This gives a reference point that allows alterations to be made more efficiently if the first radiograph is found to be positioned incorrectly.
- ✔ The distal aspect of the spine of the scapula on the contralateral limb can be palpated and also marked to aid identification of the correct centring point once the affected limb is protracted.

Downloaded From Vet-eBooks.com

❷ Cranial 45° medial-caudolateral oblique view

This view is useful for lesions and fractures that are in the sagittal plane of the shoulder joint, which may be difficult to visualise in a mediolateral view. It highlights the craniodorsal aspect of the greater tubercle, the cranial aspect of the intermediate tubercle, and the deltoid tuberosity of the humerus.

Positioning

The horse is positioned with the contralateral limb to that being radiographed nearest to the machine. The distal aspect of the limb to be radiographed is then held by an assistant and pulled cranially as far as possible. The cassette is held against the caudolateral aspect of the shoulder, close to the body wall.

Beam direction, centring and collimation

The x-ray beam is directed horizontally from craniomedial to caudolateral, and centred on the shoulder joint, which will be at approximately the same level as the distal spine of the scapula on the contralateral weight-bearing limb. Collimation of the primary beam should include the proximal humerus and distal aspect of the scapular spine.

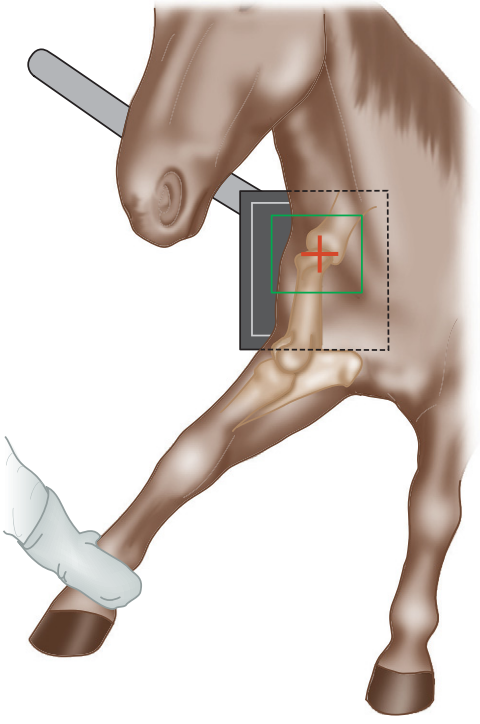

Fig. 12.3 Position of the patient, cassette, centering point of the x-ray beam (red cross) and collimation of the primary beam (green outline) to obtain a cranial 45° medial-caudolateral oblique view of the shoulder joint

Downloaded From Vet-eBooks.com

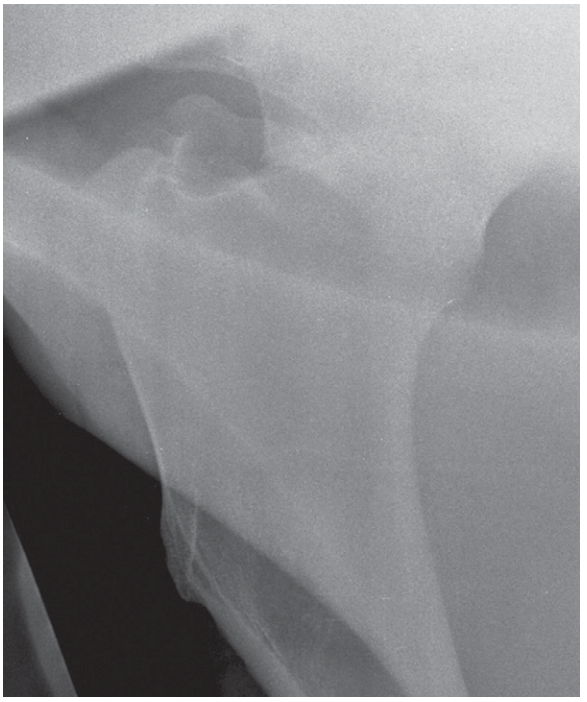

A

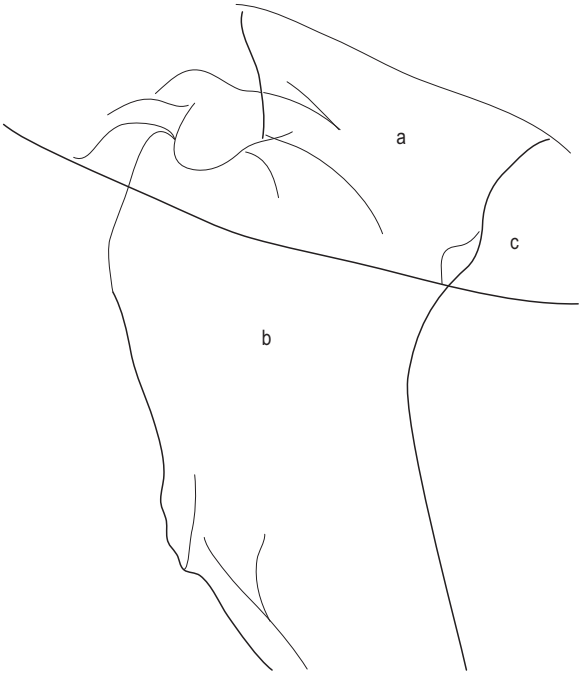

B

Fig. 12.4 (A & B) Craniomedial-caudolateral oblique radiograph of the shoulder joint. a – Scapula, b – Humerus, c – Trachea

Downloaded From Vet-eBooks.com

13 RADIOGRAPHY OF THE STIFLE

Introduction

Indications for stifle radiography include:

- joint effusion with or without lameness
- lameness localised to the stifle by intra-articular anaesthesia or clinical examiuation
- traumatic injury to the area.

Most portable x-ray machines are powerful enough to take lateromedial views of this joint; however, for caudocranial views in adult horses exposure values of at least 90 kV and 20 mAs are required. Using a large cassette facilitates imaging the entire area of interest. Fast film-screen combinations give the best results. Although cassette holders should preferably be used, it is often difficult to get the cassette into the optimum position when it is in a cassette holder and, therefore, cassettes are usually hand held for stifle radiographs. The person holding the cassette should be wearing lead gloves, try to hold the cassette from the edge only and the largest available cassette should be used. Tight collimation of the primary beam will also reduce radiation exposure to the person holding the cassette.

Weight-bearing lateromedial, caudocranial and 60° caudolatero-craniomedial oblique views will provide sufficient diagnostic information for most cases. Occasionally, flexed lateromedial views and the 'skyline' view (cranioproximal-craniodistal) will give useful extra information.

Patient preparation

No specific patient preparation is necessary for radiography of the stifle; however, the horse must be adequately sedated, because for lateral and oblique views, the cassette must be positioned high up on the medial aspect of the stifle, which most unsedated horses will resent. Similarly, for the caudocranial view the x-ray machine and radiographer are positioned immediately behind the hindlimb and are, therefore, at risk of kick injuries. Fractious horses may inflict serious injury/damage to personnel and equipment.

Downloaded From Vet-eBooks.com

Views

❶ Lateromedial

This view highlights the trochlear ridges of the femur, the patella, area of insertion of the cranial cruciate ligament and the tibial crest.

Positioning

Weight-bearing lateromedial views are more easily obtained if the horse is positioned with the leg being radiographed extended slightly caudal to the contralateral limb. The cassette is held as high up in the groin region medial to the stifle as possible.

Beam direction, centring and collimation

The primary beam should be horizontal, but the radiographer should take note of the mediolateral foot balance of the horse and adjust the beam so that it is parallel to this. The beam is centred at the level of the femorotibial joints.

Collimation of the primary beam should be wide proximo-distally to include the distal femur and proximal tibia, but the beam should be collimated tightly in a cranio-caudal direction to maximise the distance between the primary beam and the hands of the person holding the cassette.

Downloaded From Vet-eBooks.com

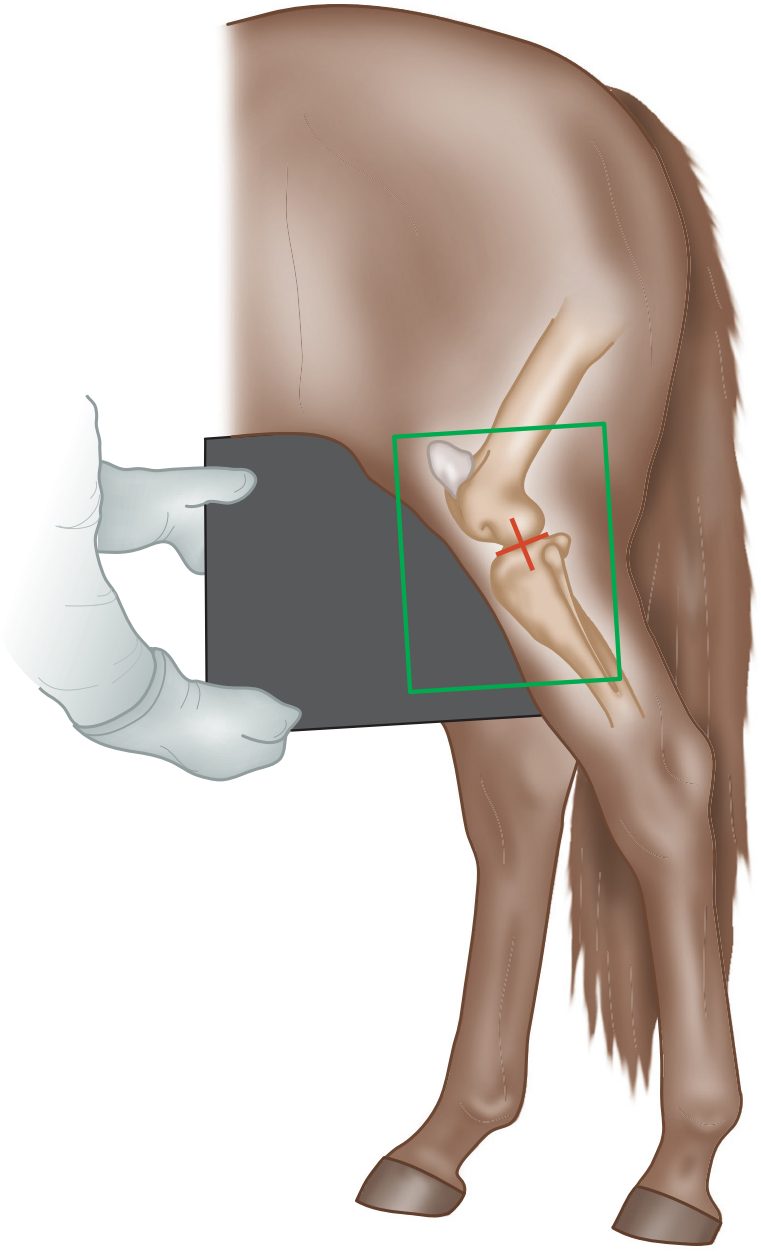

Fig. 13.1 Position of the patient, cassette, centring point of the x-ray beam (red cross) and collimation of the primary beam (green outline) to obtain a lateral view of the stifle joint

Downloaded From Vet-eBooks.com

A

B

Fig. 13.2 (A & B) Lateral radiographic view of the stifle. a – Femur, b – Patella, c – Tibia

Fig. 13.3 Placing a small piece of tape (red arrow) at the proximal end of the tibia can help when centring the primary beam for stifle radiographs

Tips

- ✔ The level of the femorotibial joint may not be visually obvious to inexperienced radiographers and, as a result, radiographs may not be accurately centred proximo-distally. Palpating the stifle joint and placing a radiolucent marker (e.g. a small piece of tape) at the level of the proximal aspect of the tibial crest (Fig. 13.3) often helps when positioning the x-ray machine and centring the primary beam, particularly for caudocranial views.
- ✔ Rubbing or touching the flank and medial aspect of the stifle with a hand prior to putting the cassette in position often improves patient compliance as the horse becomes accustomed to physical contact in this region and is not startled by the sudden presence of the cassette touching its inner thigh!

Downloaded From Vet-eBooks.com

❷ Caudocranial

This view highlights the intercondylar eminences of the tibia, the intercondylar fossa of the femur, the weight-bearing aspects of the medial and lateral femoral condyles and the lateral and medial condyles of the tibia.

Positioning

The horse should be weight bearing. The caudocranial view is more easily obtained if the horse is positioned with the leg being radiographed extended slightly caudal to the contralateral limb. The cassette is held at the cranial aspect of the stifle, taking care when advancing it medially so as not to touch the horse's flank or sheath without warning.

Beam direction, centring and collimation

The x-ray beam is directed 10–15° proximodistally (downwards), centred on a line that divides the caudal aspect of the limb in half, and so that the exit point of the beam is at the level of the proximal cranial tibia (the radiographer can check this from the lateral aspect of the horse).

Collimation of the primary beam should be wide proximo-distally to include the distal femur and proximal tibia, but the beam should be collimated tightly in themdio-lateral direction so that it includes the medial and lateral tibial condyles, but maximises the distance between the primary beam and the hands of the person holding the cassette.

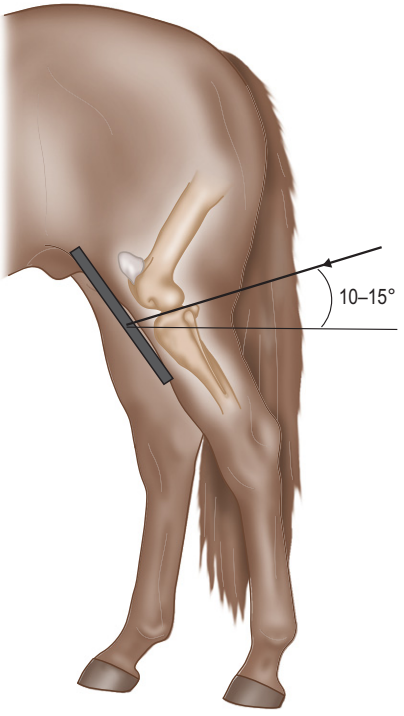

Fig. 13.4 Position of the patient, cassette and direction of the x-ray beam to obtain a caudo-cranial view of the stifle joint

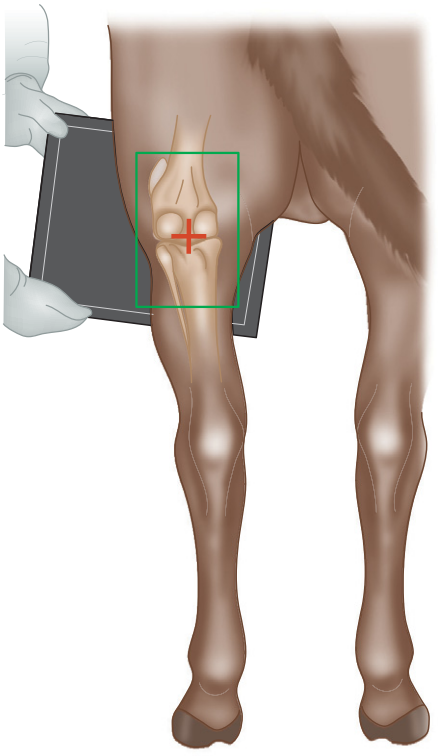

Fig. 13.5 Position of the patient, cassette, centering point of the x-ray beam (red cross) and collimation of the primary beam (green outline) to obtain a caudo-cranial view of the stifle joint

Downloaded From Vet-eBooks.com

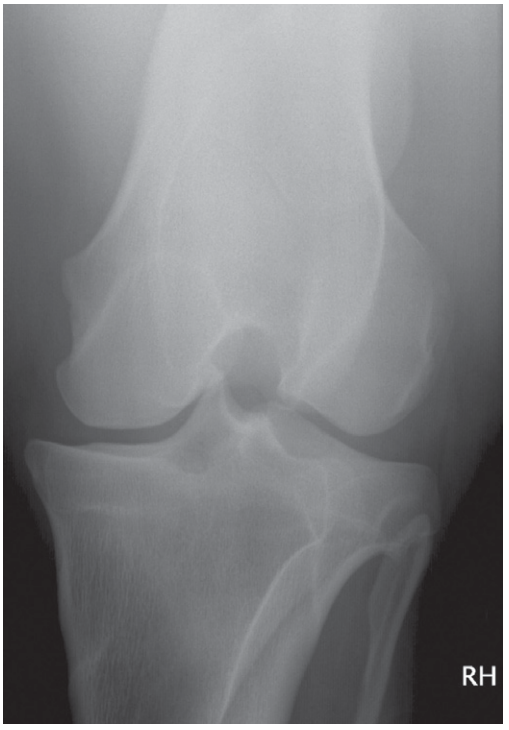

A

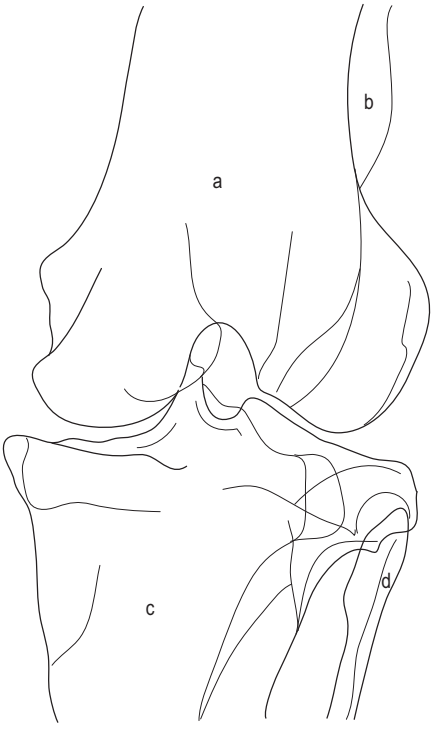

B

Fig. 13.6 (A & B) Caudo-cranial radiographic view of the stifle. a – Femur, b – Patella, c – Tibia, d – Fibula

Tips

✔ Use a marker placed on the caudal aspect of the limb at the level of the femorotibial joint space for accurate centring.

Downloaded From Vet-eBooks.com

❸ Caudal 60° lateral-craniomedial oblique

This view is often easier to obtain than a true lateromedial view, particularly in horses that resent insertion of the cassette into the groin area. It highlights the trochlear ridges of the femur, the tibial crest, the patella and the area of insertion of the cranial cruciate ligament.

Positioning

The horse should be weight bearing. The caudal 60° lateral-craniomedial oblique view is more easily obtained if the horse is positioned with the leg being radiographed extended slightly caudal to the contralateral limb. The cassette is held at the craniomedial aspect of the stifle, as high up as possible.

Beam direction, centring and collimation

The x-ray beam should be angled 10° proximodistally (downwards) and centred at the level of the femorotibial joints, at the junction of the cranial ⅓ and caudal ⅔ of the limb.

Collimation of the primary beam should be wide proximo-distally to include the distal femur and proximal tibia, but the beam should be collimated tightly in a cranio-caudal direction to include the medial and lateral tibial condyles, but to maximise the distance between the primary beam and the (gloved) hands of the person holding the cassette.

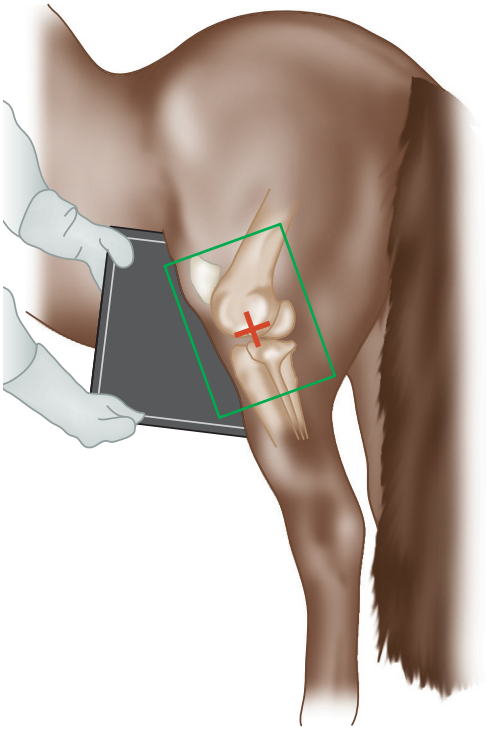

Fig. 13.7 Position of the patient, cassette, centering point of the x-ray beam (red cross) and collimation of the primary beam (green outline) to obtain a Caudal 60° lateral-craniomedial oblique view of the stifle joint

Downloaded From Vet-eBooks.com

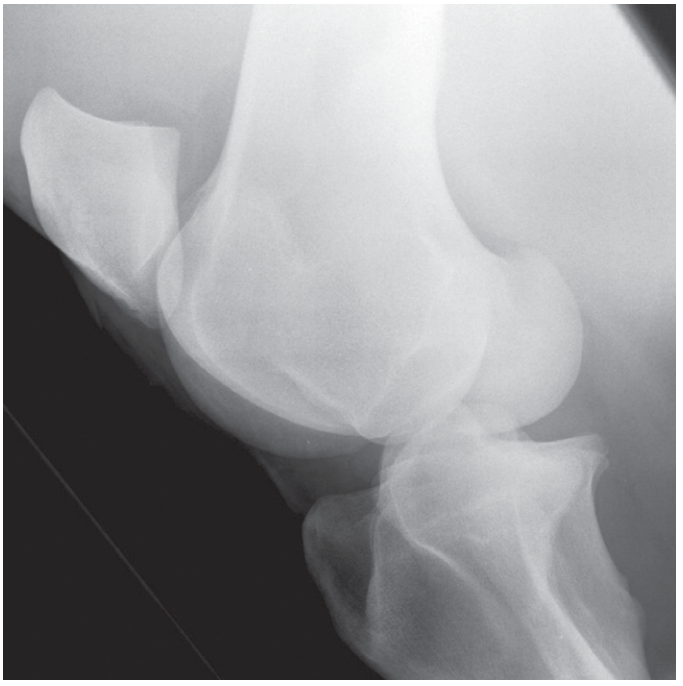

A

B

Fig. 13.8 (A & B) Caudal 60° lateral-craniomedial oblique radiograph of a normal stifle. a – Femur, b – Patella, c – Tibia

Downloaded From Vet-eBooks.com

❹ Flexed lateromedial

In this view the patella is displaced distally with respect to the distal femur as compared to a weight-bearing lateromedial view and, hence, it allows better visualisation of the proximal aspects of the trochlear ridges of the femur, the proximal tibia in the region of the intercondylar eminences and the apex of the patella.

Positioning

The stifle is flexed by a gowned and gloved assistant standing caudal to the horse and holding the distal limb in an elevated position. The degree of flexion can be varied according to the specific area of interest. The cassette is held as high up as possible in the groin region medial to the stifle.

Beam direction, centring and collimation

The primary beam should be horizontal and centred on the femorotibial joints.

Collimation of the primary beam should include the distal femur and proximal tibia.

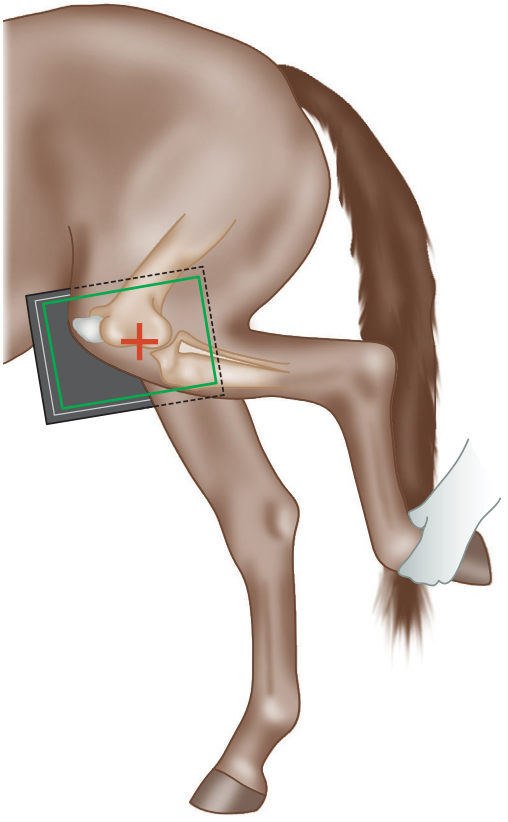

Fig. 13.9 Position of the patient, cassette, centering point of the x-ray beam (red cross) and collimation of the primary beam (green outline) to obtain a lateral view of the stifle joint

Downloaded From Vet-eBooks.com

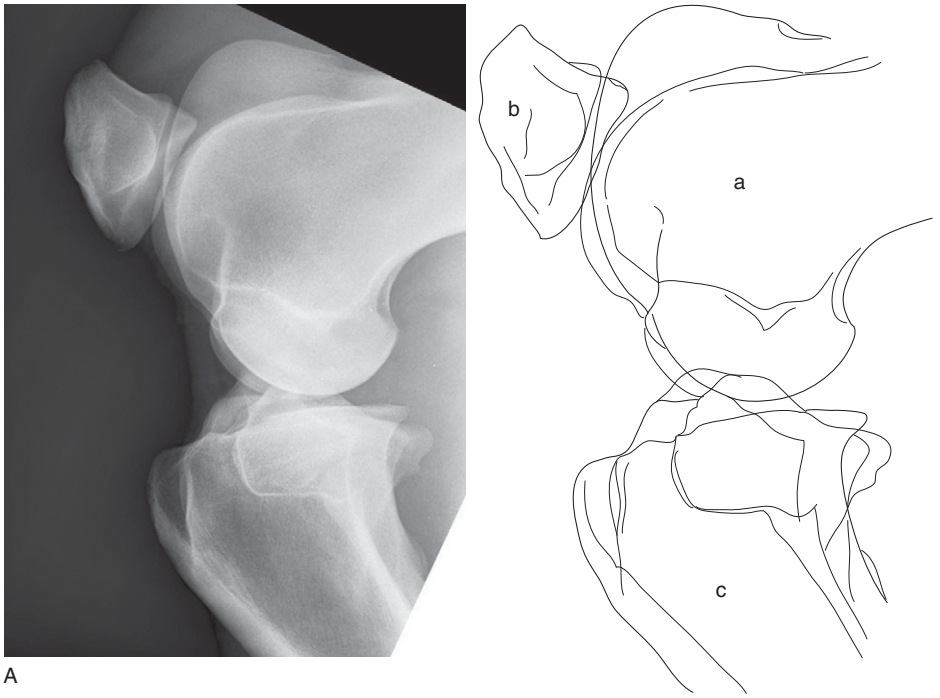

Fig. 13.10 (A & B) Flexed lateral radiographic view of a normal stifle. a – Femur, b – Patella, c – Tibia

Tips

- ✔ Care should be taken not to rotate the stifle when flexing the limb.
- ✔ It is essential that the person holding the cassette or the horse's limb (for flexed, skyline or stressed views) wears lead gloves in addition to a protective lead gown.

Downloaded From Vet-eBooks.com

❺ Cranioproximal-craniodistal oblique ('skyline')

This view is most commonly used to assess the patella when fractures are suspected. It also highlights the medial and lateral trochlear ridges and the intertrochlear groove of the femur.

Positioning

With the horse standing, the hindlimb should be flexed by an assistant and the distal part of the limb held so that the tibia is approximately horizontal (i.e. by lifting and then retracting the distal limb caudally). The cassette is positioned horizontally, facing upwards with its caudal aspect touching the tibial crest. It is possible to use a medium-sized cassette in a cassette holder for this view.

Beam direction, centring and collimation

The x-ray beam is directed distally (downwards), with a 10° lateral to medial angulation. The x-ray beam can be collimated quite tightly to include the most cranial aspect of the flexed stifle, i.e. the cranial patella.

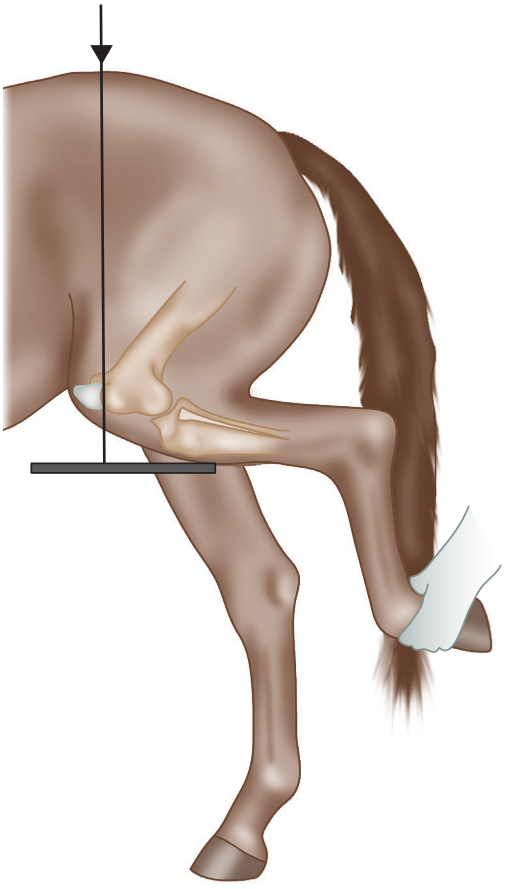

Fig. 13.11 Position of the patient, cassette and direction of the x-ray beam to obtain a cranioproximal-craniodistal oblique ('skyline') view of the stifle joint

Downloaded From Vet-eBooks.com

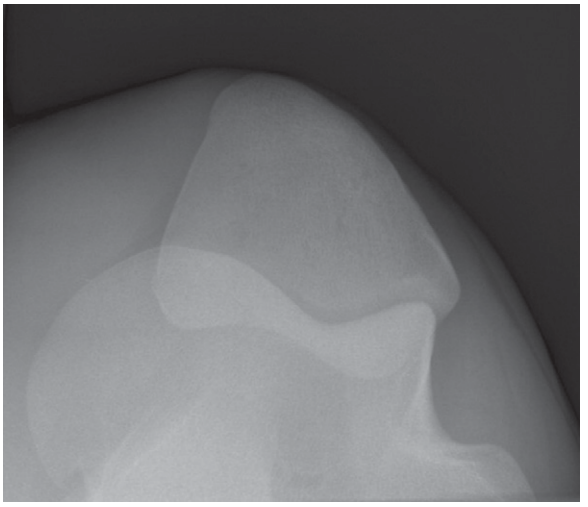

A

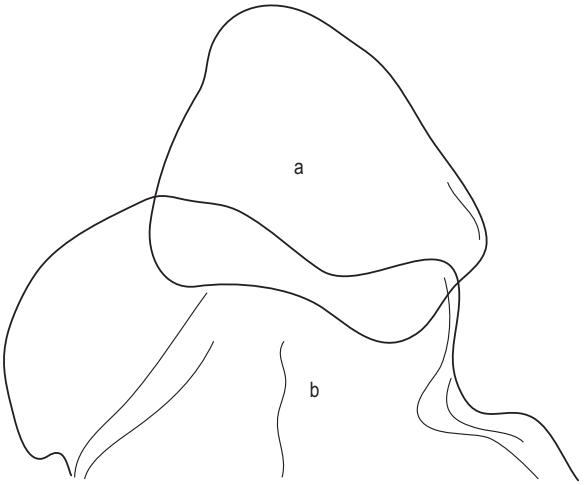

B

Fig. 13.12 (A & B) Cranioproximal-craniodistal oblique ('skyline') radiographic view of the stifle. a – Patella, b – Femur

Tips

✔ The lateral to medial angulation described is necessary because it is very difficult to get an image of the patella with a truly vertical alignment of the x-ray beam as a result of the mass of the lateral quadriceps obstructing the x-rays.

Downloaded From Vet-eBooks.com

14 RADIOGRAPHY OF THE HIP AND PELVIS

Introduction

The coxofemoral joint and pelvis are radiographed only occasionally in the horse. Coxofemoral joint disease is rare in the horse, compared to other species. Severe trauma to the hip can result in osteoarthritis. Fractures of the pelvis are not uncommon, particularly in racehorses, with the ilium being the most frequently affected bone. Due to the size of the structures involved, diagnostic quality radiographs require high exposures and the use of grids. The x-ray machine must be capable of exposures above 200 mAs and 100 kV. In the standing horse ventrodorsal or lateral oblique views of the coxofemoral joint and part of the pelvis can be obtained. Standing ventrodorsal views present problems in collimation and centring the primary beam, particularly with the use of a focussed grid, and the x-ray equipment may be at risk of damage. Lateral views of the pelvis are of little diagnostic value, other than in foals or small ponies.

A complete radiographic examination of the pelvis requires the horse to be anaesthetised and in dorsal recumbency. To avoid the risk of further pelvic fracture displacement during anaesthesia induction or recovery, scintigraphy provides a valuable screening technique for the entire pelvis, and ultrasonography can be used to detect disruption in normal pelvic bone contour.

Indications for radiography of the pelvis and coxofemoral joint include:

- hindlimb lameness where the lower limb(s) has been ruled out as a source of pain
- crepitus in the pelvic region
- better definition of findings on prior scintigraphic or ultrasonographic examination.

Preparation

The anaesthetised horse is in dorsal recumbency with the hindlimbs flexed in a ‘frog-leg’ position. It should be carefully positioned to avoid lateral tilting for views of the pelvis, but tilted slightly towards the side of interest when radiographing the coxofemoral joint. All personnel should leave the room at the point of exposure.

Downloaded From Vet-eBooks.com

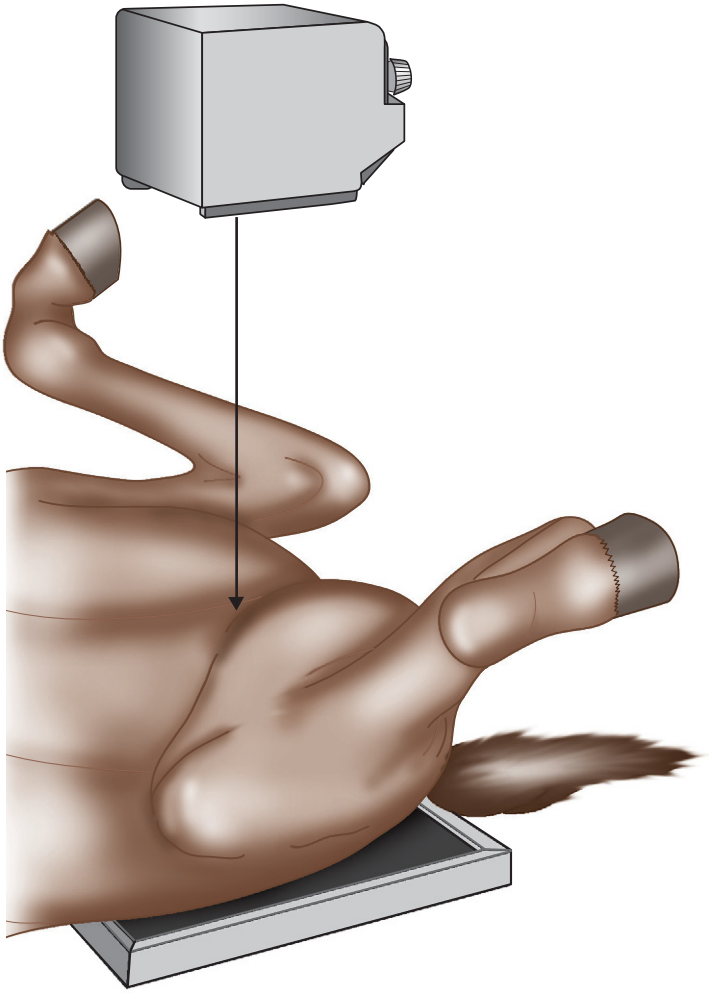

Fig. 14.1 Positioning of the anaesthetised horse, x-ray machine and cassette with grid for a ventrodorsal view of the pelvis at the level of the coxofemoral joints

Views

Using the largest available cassette size, several overlapping ventrodorsal views are required for a complete survey of the pelvis. In the case of an adult 500 kg horse and a 35 cm × 43 cm cassette, this will require five to seven separate views. Beginning caudally, the cassette is centred beneath the caudal pelvis to image the tubera ischii then moved cranially in stages to image the coxofemoral and obturator foramen region,

Downloaded From Vet-eBooks.com

and, finally, the cranial pelvis, including the lumbosacral and sacroiliac joints. For the coxofemoral joint the horse is tilted towards the side being examined after placing the cassette beneath the hip joint. Landmarks are hard to palpate from the ventral aspect. By palpating for the 3rd trochanter of the location of the hip joint can be estimated.

In the standing horse, the cassette is placed over the pelvis at an angle of approximately 20° to the dorsal midline and the x-ray machine is angled upwards, perpendicular to the cassette from beneath the abdomen (see Fig. 14.2).

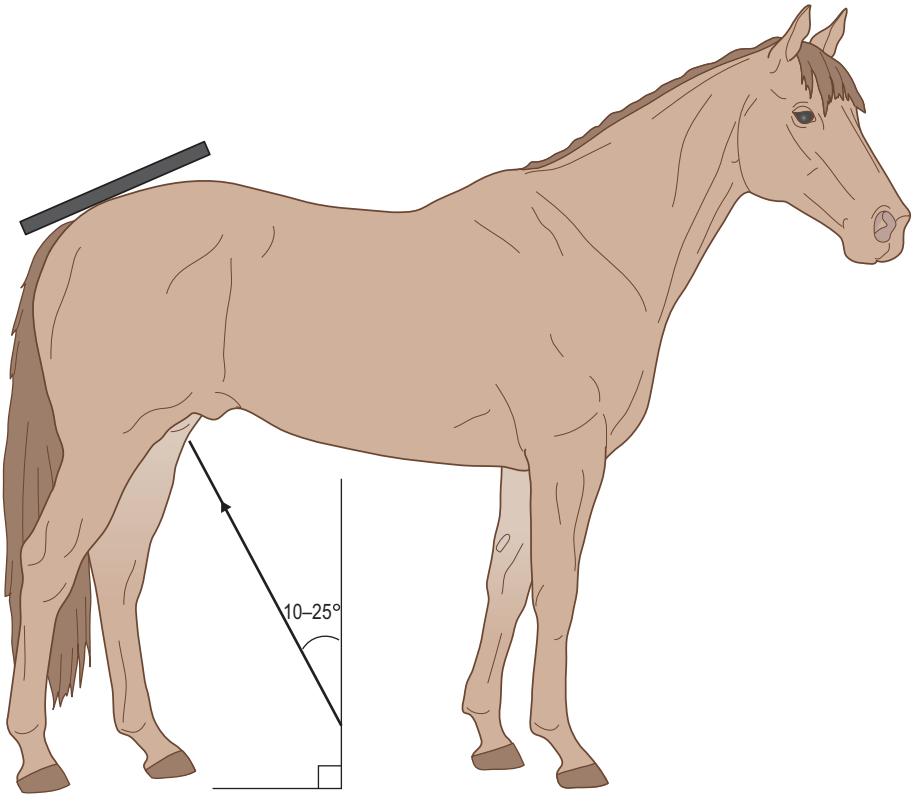

Fig. 14.2 Positioning of the cassette and x-ray beam direction to obtain a ventrodorsal view of the pelvis in the standing horse

Downloaded From Vet-eBooks.com

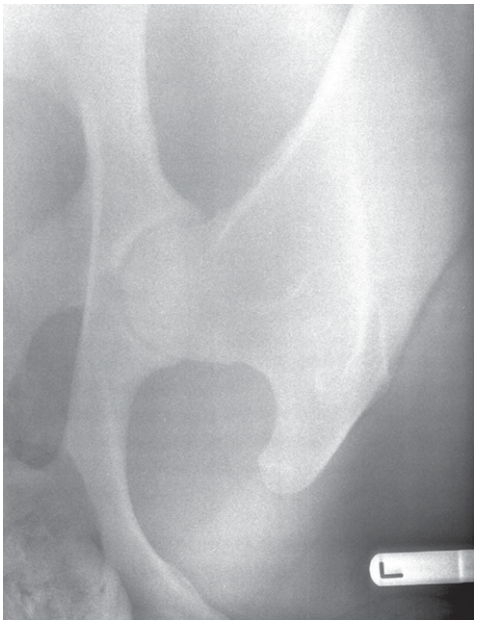

A

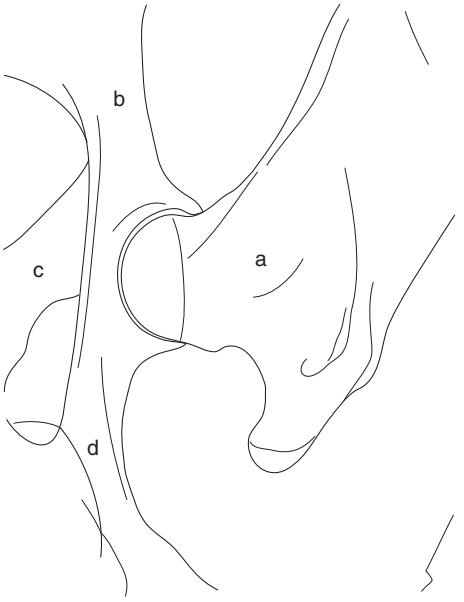

B

Fig. 14.3 (A & B) Ventrodorsal view of a normal coxofemoral joint. This view was obtained with the horse under general anaesthesia. a – Femur, b – Ilium, c – Pubis, d – Ischium

Tips

✔ To reduce scattered radiation reaching the film, a grid should be used. Positioning the cassette accurately under the pelvis of a large horse can be tricky. Care must be taken to ensure the beam is centred on, and perpendicular to, the cassette. Faeces in the rectum may obscure regions of interest; rectal evacuation will assist in reducing this problem.

Downloaded From Vet-eBooks.com

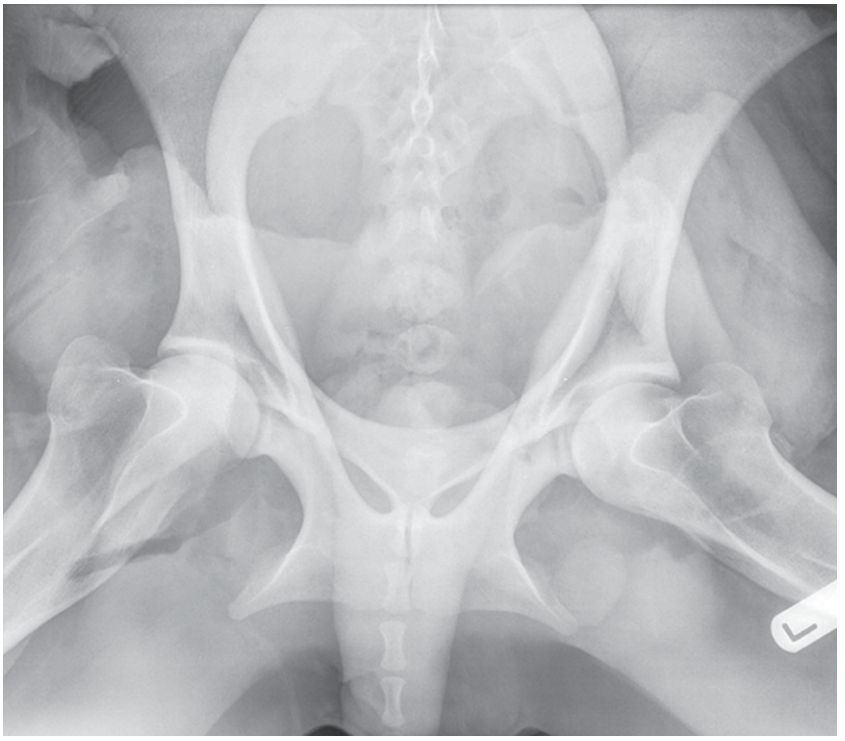

A

B

Fig. 14.4 (A & B) Ventrodorsal view of the pelvis of a normal (cadaver) horse. a – Femur, b – Ilium, c – Ischium

Downloaded From Vet-eBooks.com

15 RADIOGRAPHY OF THE CERVICAL VERTEBRAE

Introduction

Indications for radiography of the cervical vertebral column include:

- ataxia
- neck pain
- swelling or reduced mobility
- recumbency
- (rarely) forelimb lameness.

Good-quality lateral views of the cranial and mid-cervical vertebrae can be obtained using portable x-ray machines in the standing, sedated horse, but images of the caudal cervical and first thoracic vertebrae require higher exposure values than most portable machines are capable of. Ventrodorsal views are occasionally useful, but usually require positioning under general anaesthesia. Myelography is indicated when surgical treatment of a compressive lesion is being considered and also requires general anaesthesia.

Preparation

Heavy sedation will reduce the responses of the horse as the cassette and x-ray machine are manoeuvred into position. Metal markers placed on the neck may be useful to aid in beam centring. If the caudal skull is to be included a rope halter should be used to avoid superimposition of leather straps and metal buckles from a head-collar. A cassette holder, ideally linked to the x-ray machine, is required. For a standard complete study of the cervical vertebrae in an adult horse, four overlapping lateral views using large (35 cm × 43 cm) cassettes are required. All personnel standing in the room must be protected from radiation exposure (lead gowns and gloves).

Positioning

The horse should be weight bearing equally on all limbs. The neck and head must be straight and care should be taken to avoid even slight rotation.

Downloaded From Vet-eBooks.com

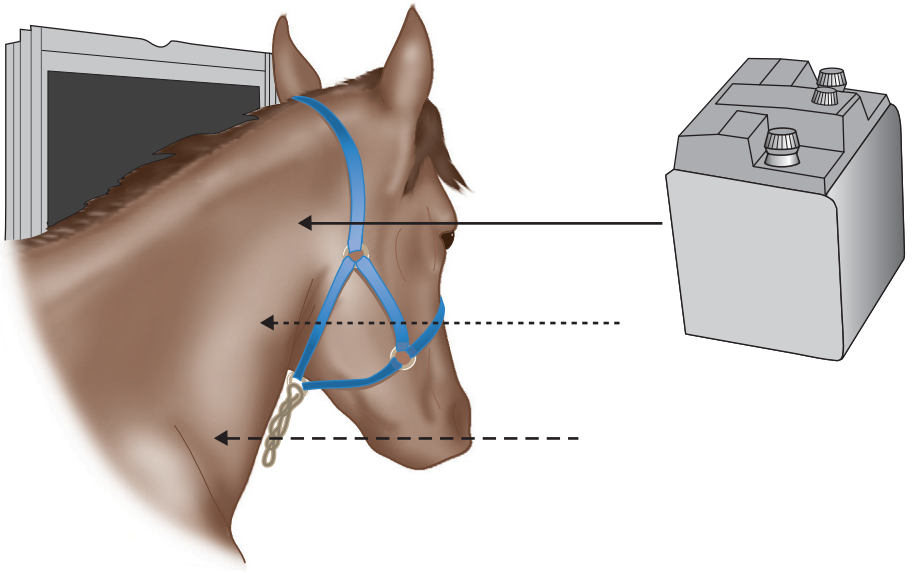

Fig. 15.1 Diagram showing the positioning of horse, cassette and x-ray machine to obtain lateral views of the cranial cervical (solid arrow), mid-cervical (dotted arrow) and caudal cervical (dashed arrow) vertebrae

Beam centring and collimation

The most cranial view is centred on C1 and should include the occipital bone. The subsequent views should include C1–C3, C3–C5 and C5–C7 respectively. In each case, the beam is centred on the body of the middle vertebra and collimated to the bones rather than the soft tissues of the neck. The cervical vertebrae are aligned in a slight S-shaped curve within the neck and the caudal cervical vertebrae are located towards the ventral aspect of the neck. Palpation of the neck will aid in precise localisation of the vertebrae.

Downloaded From Vet-eBooks.com

A

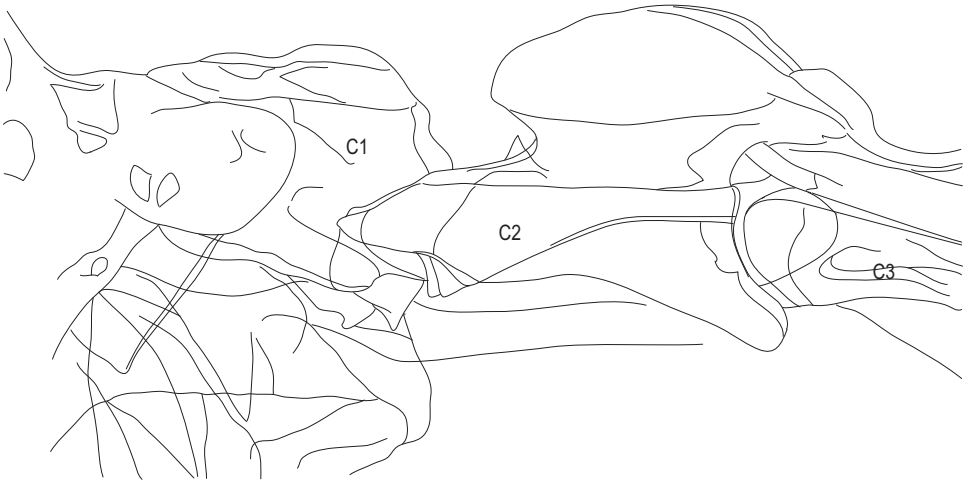

B

Fig. 15.2 (A & B) Lateral view of the atlas, axis and cranial aspect of the third vertebra (C1–C3)

Downloaded From Vet-eBooks.com

A

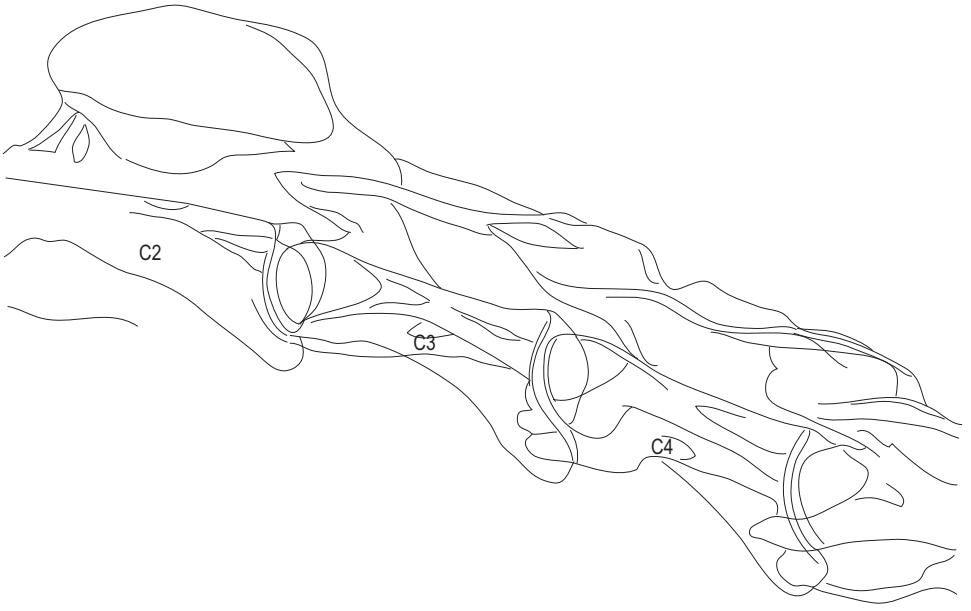

B

Fig. 15.3 (A & B) Lateral view of the second to fifth cervical vertebrae. The radiograph has been labelled to indicate that the right side was positioned next to the cassette

Downloaded From Vet-eBooks.com

A

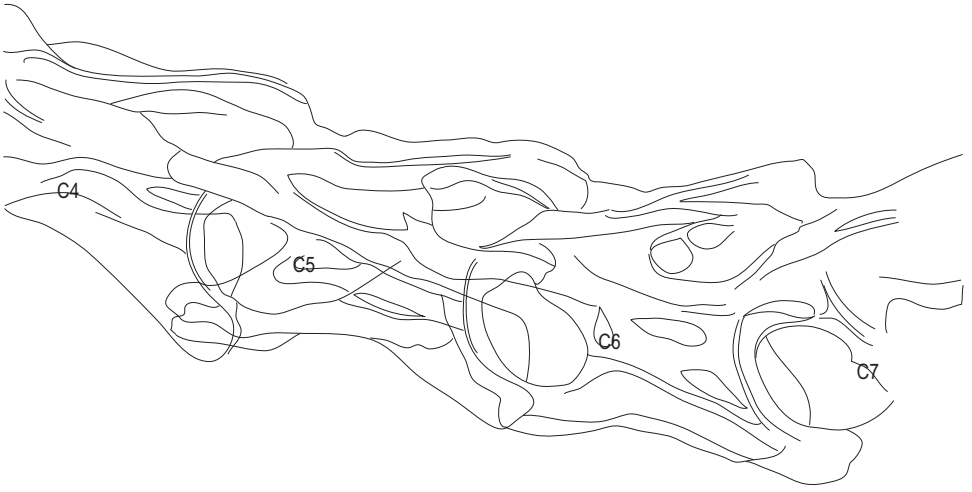

B

Fig. 15.4 (A & B) Lateral view of the fourth (caudal aspect) to the seventh cervical (cranial aspect) vertebrae

Tips

- ✔ Lateral radiographs are usually obtained from one side only, but repeating the view from the other side can help in localising an asymmetric lesion, as the lesion will be magnified when it is further from the cassette.
- ✔ Placing 2 or 3 radio-opaque markers at various positions along the neck dorsal to the vertebrae but still within the primary beam can help with positioning if repeat radiographs are required, and with identification of vertebrae.

Downloaded From Vet-eBooks.com

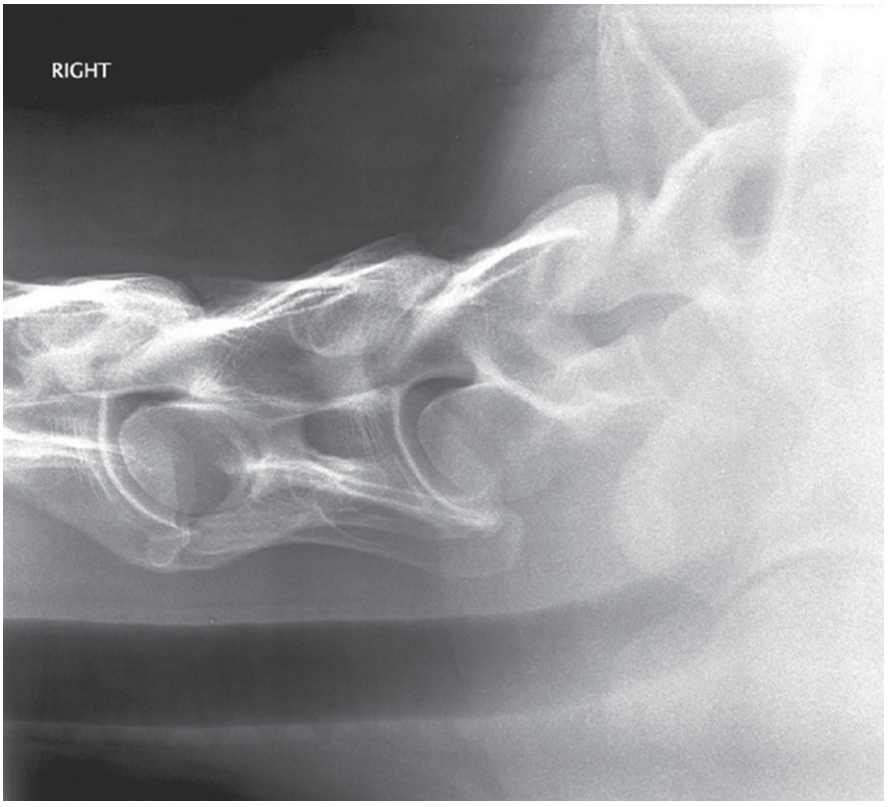

A

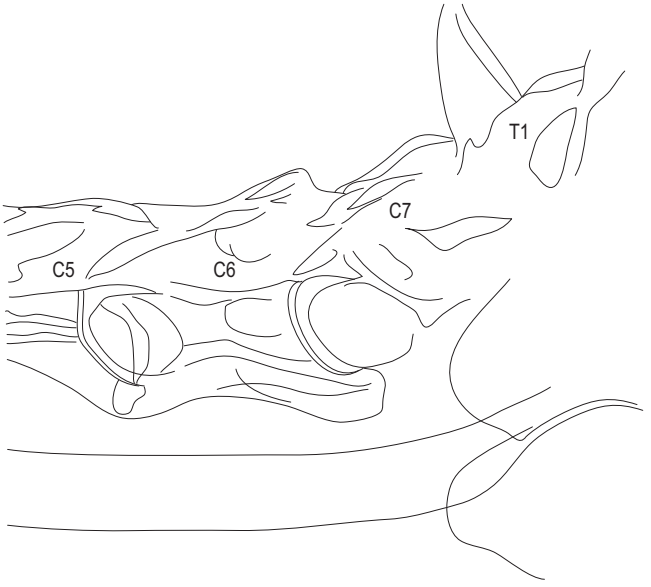

B

Fig. 15.5 Lateral view of the fifth cervical vertebra (caudal aspect) to first thoracic vertebra. The radiograph has been marked to indicate that the right side was positioned next to the cassette. t – Trachea

Downloaded From Vet-eBooks.com

16 RADIOGRAPHY OF THE THORACOLUMBAR AND SACRAL VERTEBRAE

Introduction

An indication for radiography of the vertebrae in the thoracic, lumbar and sacral regions is pain, causing signs such as:

- poor performance
- equitation problems localised to the region by palpation and/or local analgesia.

Conditions that can be diagnosed using radiography include:

- fractures (most commonly at the withers)
- impingement of the dorsal spinous processes (DSPs), usually in the saddle region T12–T16
- osteoarthritis of the dorsal intervertebral joints
- ventral (ossifying) spondylosis
- congenital abnormalities (kyphosis and lordosis).

Adequate views of the thoracolumbar vertebral bodies require a high-powered x-ray machine. Portable machines are capable only of radiographing the tips of the dorsal spinous processes in the cranial and mid-thoracic region. Further caudal, as the soft tissue mass increases, higher exposures are required.

Radiographic positioning

Radiographs are usually obtained with the horse standing and weight bearing evenly; if the horse rests one hind limb, the vertebral column will become moderately rotated. When centring on the vertebral bodies, these are located approximately 15 cm ventral to the dorsal midline. If the tips of the DSPs are being imaged, centre approximately 3 cm ventral to dorsal midline. Several different exposures of the same region are usually required to adequately expose the deeper and more superficial structures separately. A 30° oblique view can result in better definition of the dorsal intervertebral (facet) joints.

Downloaded From Vet-eBooks.com

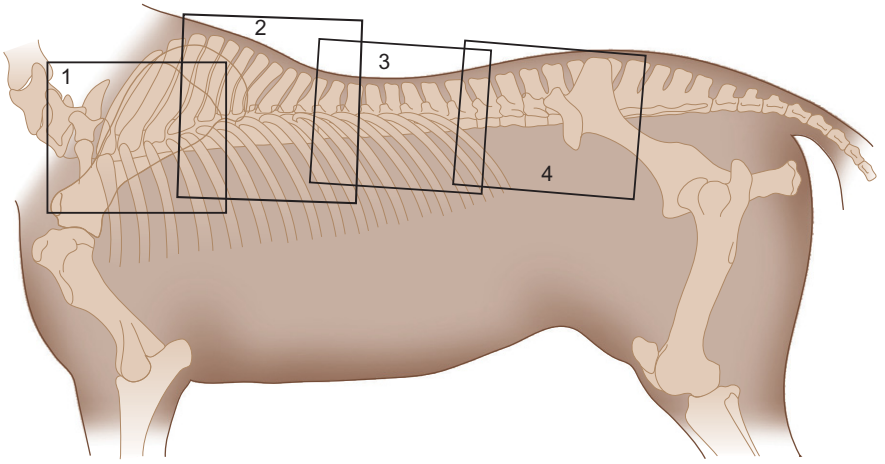

Fig. 16.1 Diagram illustrating the positioning of the cassette for four successive overlapping views for a complete examination of the thoracic and lumbar vertebrae

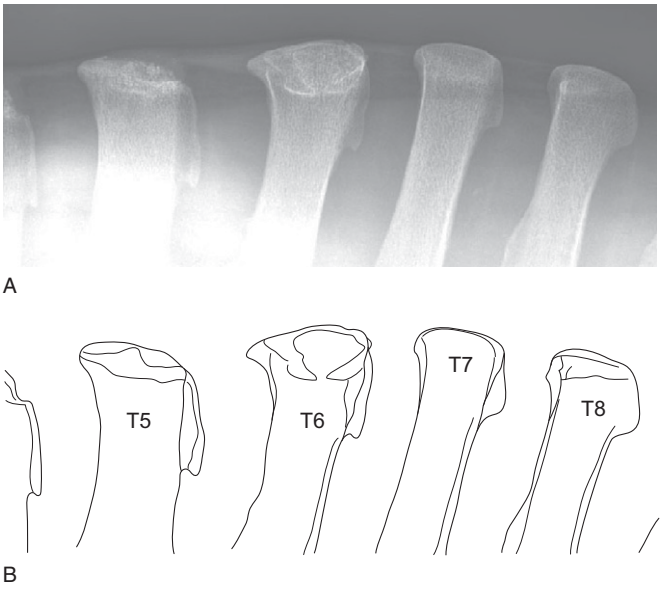

Fig. 16.2 (A & B) Lateral radiograph of the normal dorsal spinous processes of thoracic vertebrae T5–T8

Downloaded From Vet-eBooks.com

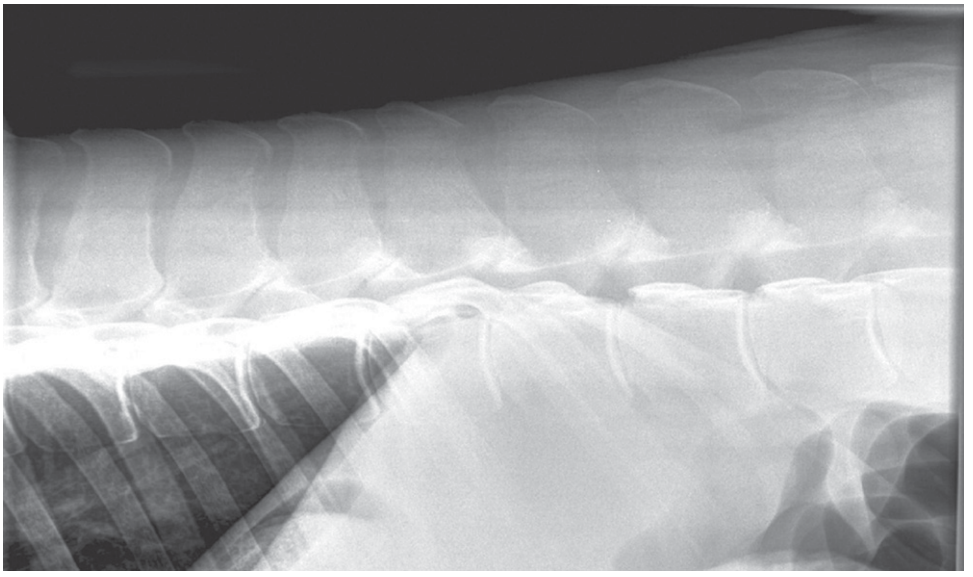

A

B

Fig. 16.3 (A & B) Lateral radiograph of the vertbrae of the caudal thoracic and cranial lumbar region (T14–L3)

Downloaded From Vet-eBooks.com

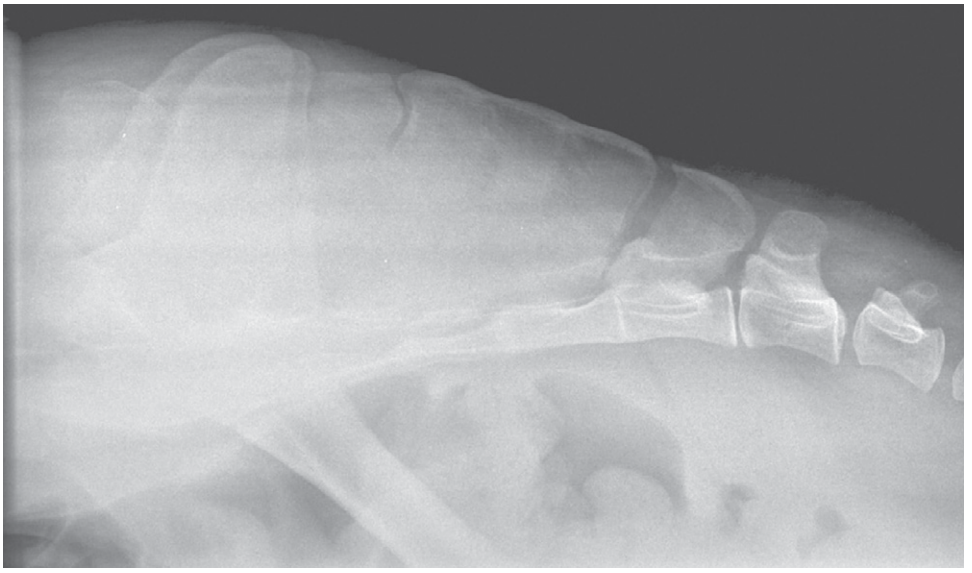

A

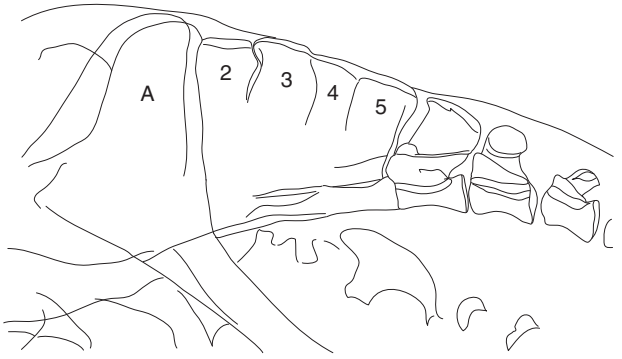

B

Fig. 16.4 (A & B) Lateral radiograph of a normal dorsal pelvis and sacrum. Note that several of the sacral dorsal spinous processes are partially fused. A – ilium; 2–5 – dorsal spinous processes of (fused) sacral vertebrae

Tips

- ✔ Orientation is aided by the use of metallic markers placed at intervals along the area of interest.
- ✔ Several anatomic landmarks are useful in identifying individual vertebrae: the diaphragm attaches to the ventral surface of the 16th thoracic vertebra (see Fig. 16.3); the highest dorsal spinous process is that of T6; the anticlinal vertebra is normally T15.

Downloaded From Vet-eBooks.com

17 RADIOGRAPHY OF THE SKULL

Introduction

Indications for radiography of the equine skull are numerous, but most commonly include:

- clinical signs associated with periapical dental disease
- disorders of the paranasal sinuses or nasal cavities (presenting with unilateral nasal discharge, facial swelling, quidding, discharging sinus tracts).

Occasionally, it may be useful to radiographically examine horses with suspected abnormalities of the guttural pouches, pharynx/larynx and traumatic injuries of the skull.

Any x-ray machine can be used to obtain good-quality radiographs of the skull. Fast film-screen combinations produce the best results. The use of grids is unnecessary and is discouraged because of the associated increased exposure of handlers to radiation. Lateral views of the skull are easy to obtain, but inexperienced radiographers may find it more difficult to obtain consistently good reproducible results for oblique radiographic views.

Patient preparation

The vast majority of equine patients will require sedation to facilitate radiography of the skull. General anaesthesia is not necessary. A rope or woven headcollar should be used to avoid artefacts from the metal buckles on a standard headcollar appearing on the radiograph. However, even rope headcollars can create radiographic artefacts; therefore, the headcollar should be moved out of the area of interest if possible.

Tips

- ✔ Using a large cassette and collimating the primary beam to include a large area, e.g. the entire maxillary dental arcade and sinuses if a maxillary dental disorder is suspected, can make interpretation of skull radiographs easier, as abnormalities can be related to easily identifiable anatomical structures.
- ✔ Resting the nose of a sedated horse on a stool can sometimes help to reduce movements of the head.
- ✔ Attaching the cassette directly to the head using bungee type cords is an alternative way to prevent movement blur and means a second person is not required to hold the cassette holder.
- ✔ Use a lower exposure to view the paranasal sinus contents, incisors or guttural pouch/laryngeal areas as compared to the relatively radio-opaque cheek teeth.

Downloaded From Vet-eBooks.com

- ✔ If a facial swelling is present, placing a small radio-opaque marker (e.g. paperclip) on the area of maximal swelling, and taking an additional lateral or oblique radiograph can help when deciding if radiographic changes are likely to be clinically significant (Fig. 17.1).
- ✔ If a cutaneous draining tract is present, a blunt, malleable, metallic probe can be gently guided into the tract and held in place with tape. This is particularly useful to definitively identify periapical infection in the mandibular or rostral maxillary cheek teeth (Fig. 17.2).
- ✔ There is marked normal age-related variation in the appearance of the cheek teeth apices. Radiographing the contralateral (unaffected) cheek teeth row can be useful when deciding if a suspected abnormality is likely to be significant or not.

A

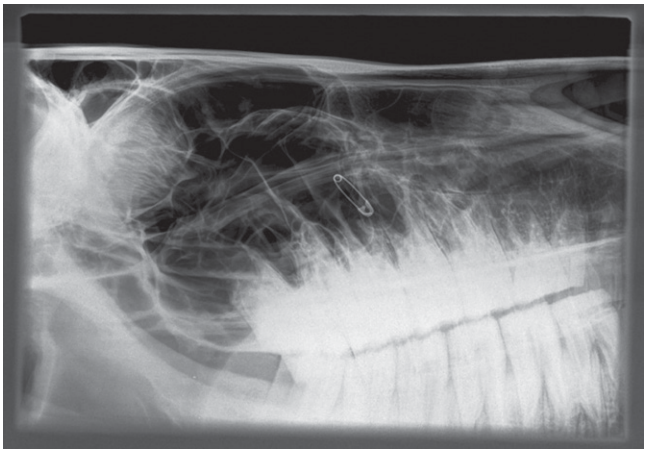

B

Fig. 17.1 (A & B) A radio-opaque marker placed at an area of facial swelling and attached to the skin using tape (a) can be useful for locating the area of interest on the radiograph (b)

Downloaded From Vet-eBooks.com

A

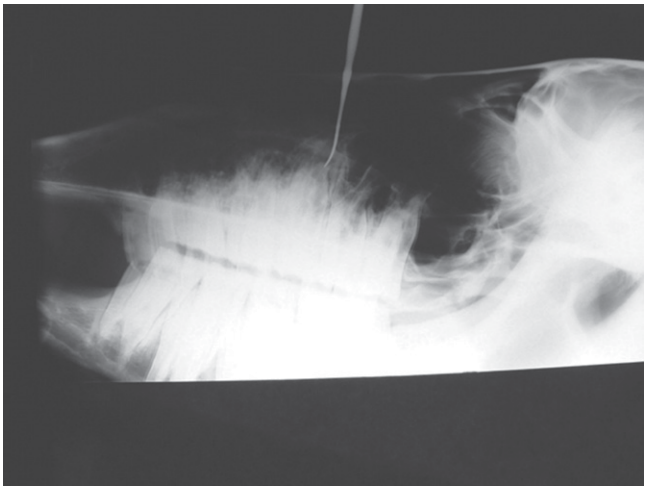

B

Fig. 17.2 (A & B) Using a blunt, malleable metallic probe inserted into a cutaneous draining tract can give useful information regarding which structures are likely to be involved

Downloaded From Vet-eBooks.com

Views

❶ Lateral view

The lateral view is useful to visualise fluid lines and abnormalities within the paranasal sinuses because the anatomy of the sinuses is not distorted by obliquity of the x-ray beam. The major disadvantage of the lateral view is that lesions cannot be localised to the left or right sides, because the two are superimposed. For this reason, individual cheek teeth apices cannot be evaluated using this view.

Positioning

The horse should be positioned with the lesion side furthest from the x-ray machine. The cassette should be held in the cassette holder in the vertical plane, close to the head on the lesion side.

Beam direction, centring and collimation

The primary beam should be horizontal, perpendicular to the long axis of the head and centred just dorsal to the rostral aspect of the facial crest if the cheek teeth and/or paranasal sinuses are being examined. If the area of interest is elsewhere in the skull, the x-ray beam should be centred at the appropriate site (see separate sections for radiography of the guttural pouches, nasopharynx and larynx, pages 156–158).

The primary beam should be collimated to reduce scatter, but should include the entire maxillary cheek teeth row and all the paranasal sinuses.

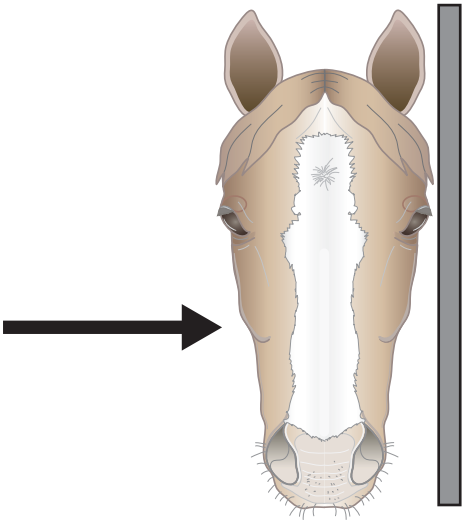

Fig. 17.3 Position of cassette and angle of x-ray beam to obtain lateral views of the skull

Downloaded From Vet-eBooks.com

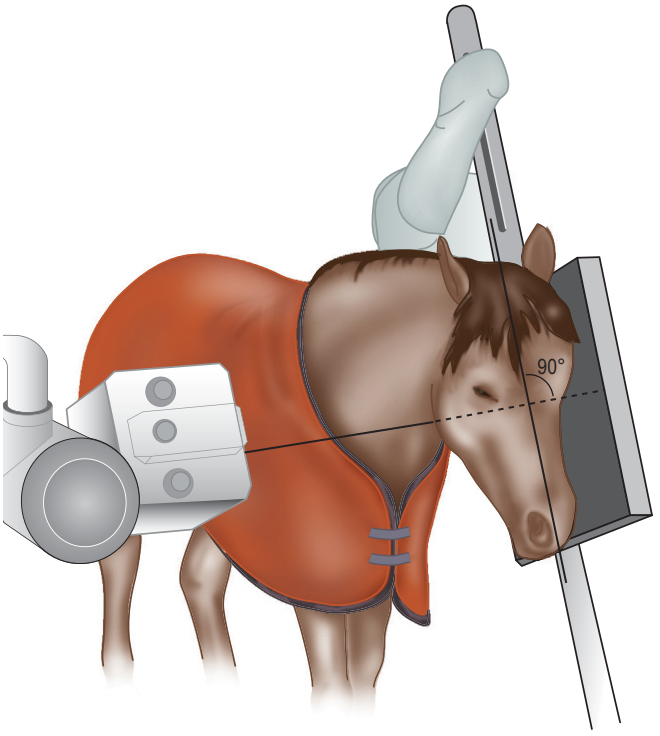

Fig. 17.4 Position of the patient, cassette and x-ray machine to obtain a lateral view of the skull

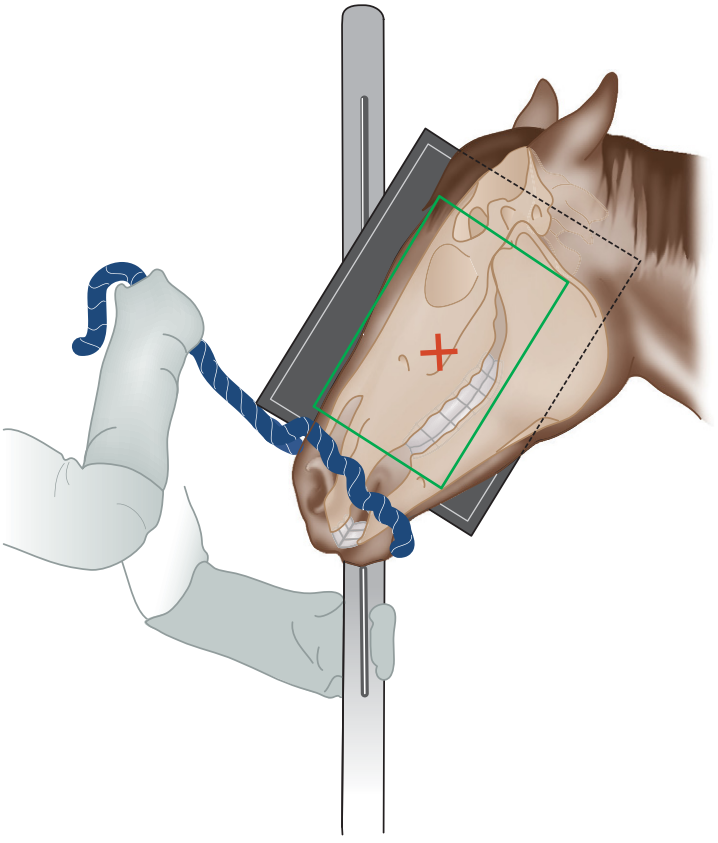

Fig. 17.5 Cassette position, centering (red cross) and collimation (green outline) for lateral or oblique views of the sinuses and/or maxillary cheek teeth

Downloaded From Vet-eBooks.com

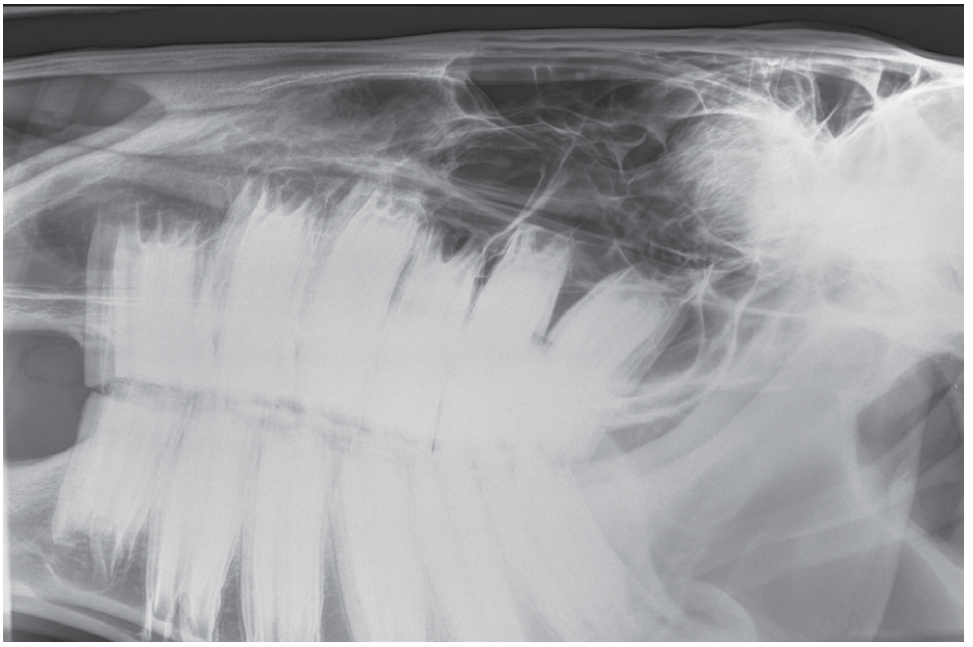

A

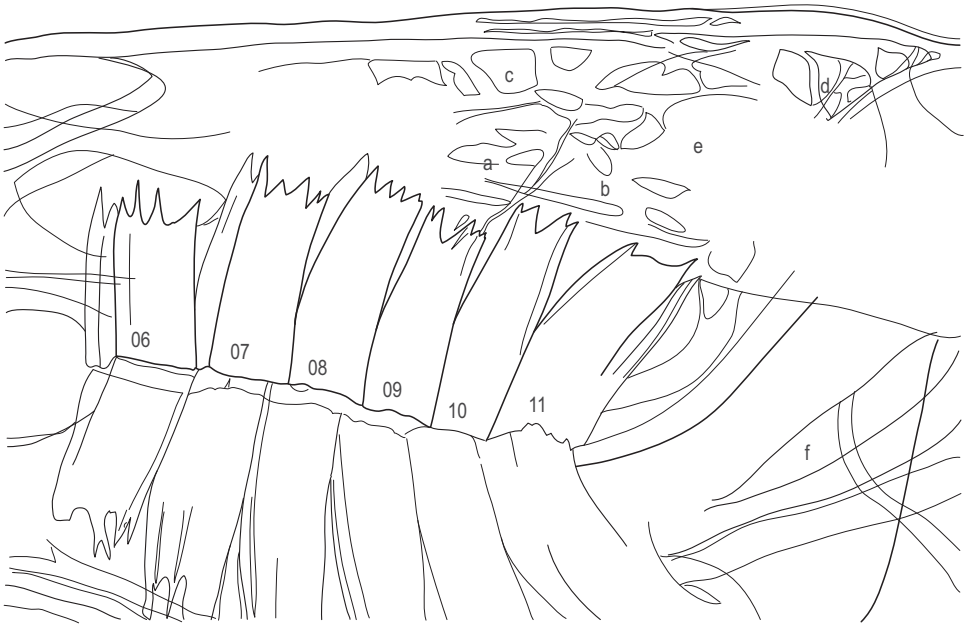

B

Fig. 17.6 (A & B) Lateral radiograph of the normal equine skull, in an adult horse (7 year old) positioned to view the maxillary cheek teeth and paranasal sinuses. 06–11 – maxillary cheek teeth, a – rostral maxillary sinus, b – caudal maxillary sinus, c – dorsal conchal sinus, d – frontal sinus, e – ethmoidal labyrinth, f – vertical ramus of mandible

Downloaded From Vet-eBooks.com

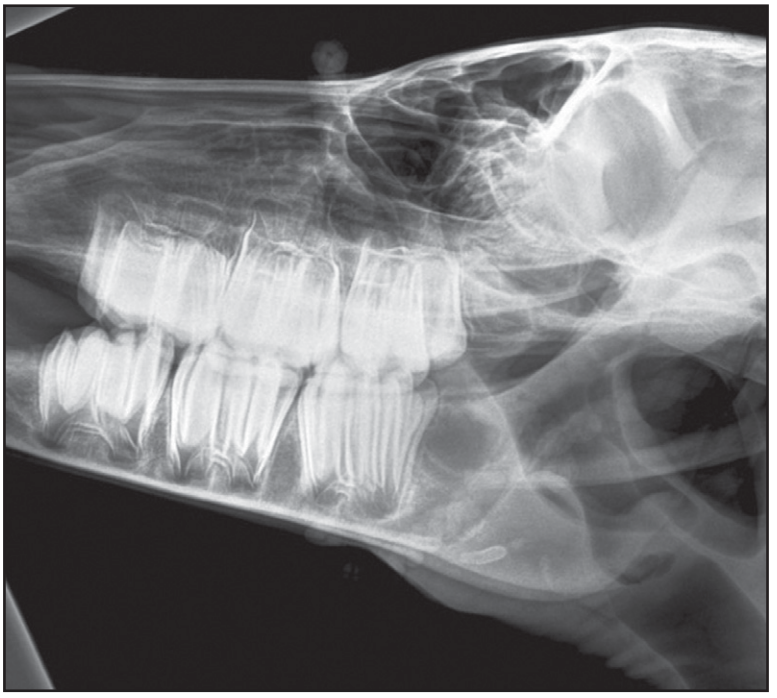

A

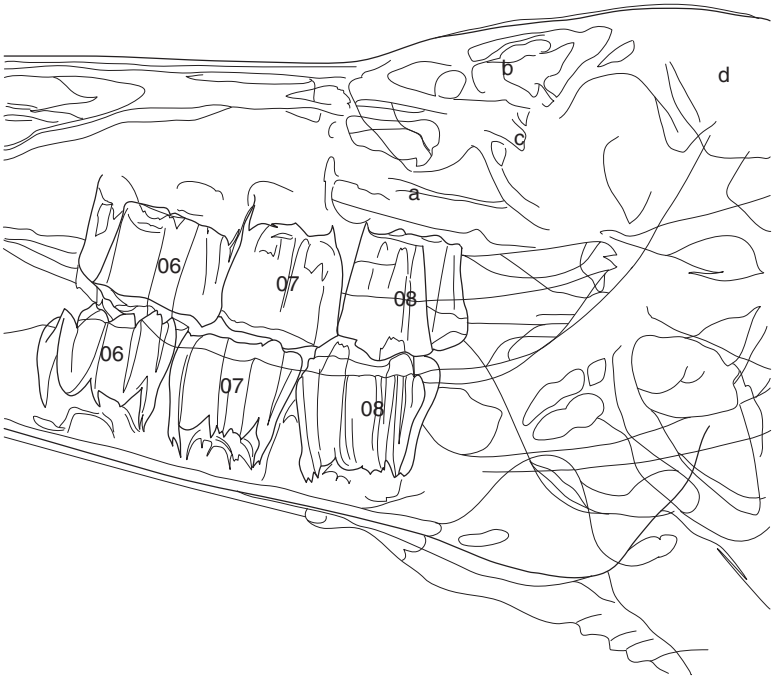

B

Fig. 17.7 (A & B) Lateral radiograph of the normal equine cheek teeth and paranasal sinuses in a 2-week-old foal. There are three deciduous cheek teeth (caps) in each row. The maxillary sinuses are relatively small in size. Dental buds of the permanent teeth are not yet apparent. a – maxillary sinuses, b – frontal sinuses, c – ethmoturbinates, d – cranium, 06, 07, 08 – deciduous cheek teeth

Downloaded From Vet-eBooks.com

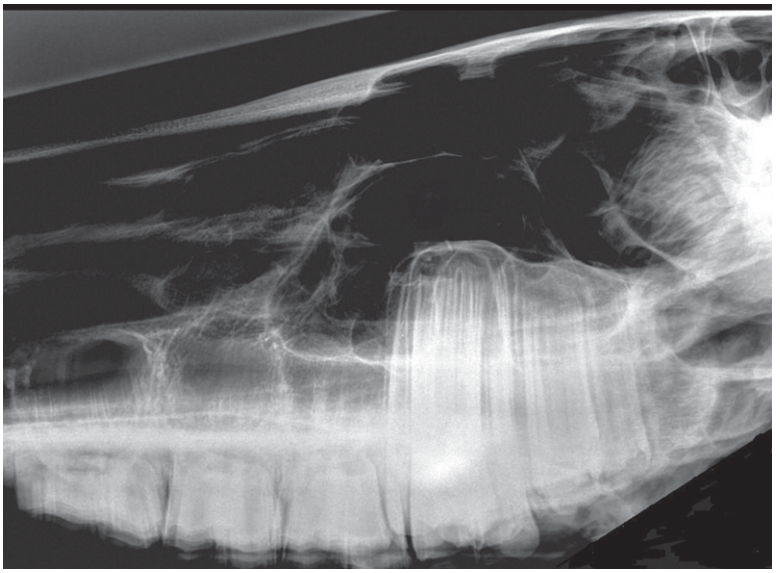

A

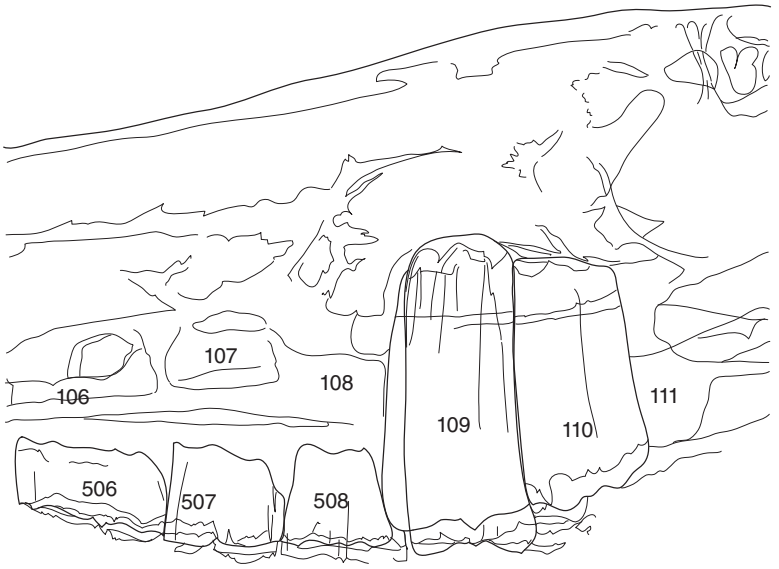

B

Fig. 17.8 (A & B) Lateral radiograph of the normal equine cheek teeth and paranasal sinuses in a 1-year-old horse. There are three deciduous cheek teeth (caps) at the rostral aspect of each row (506, 507, 508) with dental buds of the permanent teeth apparent as radiolucent structures dorsal to them (106, 107, 108). The first permanent tooth (109) has erupted and the 110 and 111 are developing caudal to this, but have not yet erupted

Downloaded From Vet-eBooks.com

❷ Latero 30° dorsal-lateroventral oblique view

This view separates structures on the left and right sides of the skull so that they are not superimposed on each other. It gives the clearest view of the apices of individual maxillary cheek teeth and can help to localise sinus lesions to the left or right sides if this is not clinically obvious. A higher exposure should be used to radiograph the radio-opaque cheek teeth as compared to the relatively radiolucent sinus contents.

Disadvantages of the oblique view are that it can be more difficult to consistently obtain good quality oblique radiographs, and that fluid lines in the sinuses are often not apparent, being replaced with indistinct soft tissue opacity. Additionally, it can be more difficult to localise abnormalities to specific sinuses due to superimposition of some structures, e.g. the dorsal caudal maxillary sinus and the concho-frontal sinuses are often superimposed.

Tip

✔ Inadvertent rostro-caudal angulation of the x-ray beam is a common fault and should be avoided if possible. Excessive angulation distorts anatomical structures, particularly the apices of the cheek teeth, making them difficult to evaluate accurately.

Positioning

The horse should be positioned so that the lesion side is furthest from the x-ray machine. The cassette should be held in the cassette holder a vertical plane, close to horse's head on the lesion side.

Beam direction, centring and collimation

The primary beam should be angled 30° down from the horizontal and centred just dorsal to the rostral aspect of the facial crest if the cheek teeth and/or paranasal sinuses are being examined. If the area of interest is elsewhere in the skull, the x-ray beam should be centred at the appropriate site.

The primary beam should be collimated to reduce scatter, but should include the entire maxillary cheek teeth row and the paranasal sinuses.

Downloaded From Vet-eBooks.com

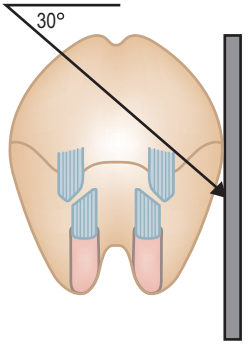

Fig. 17.9 Cassette positioning and angle of incidence of the x-ray beam to obtain a latero 30° dorsal-lateroventral oblique view of the skull

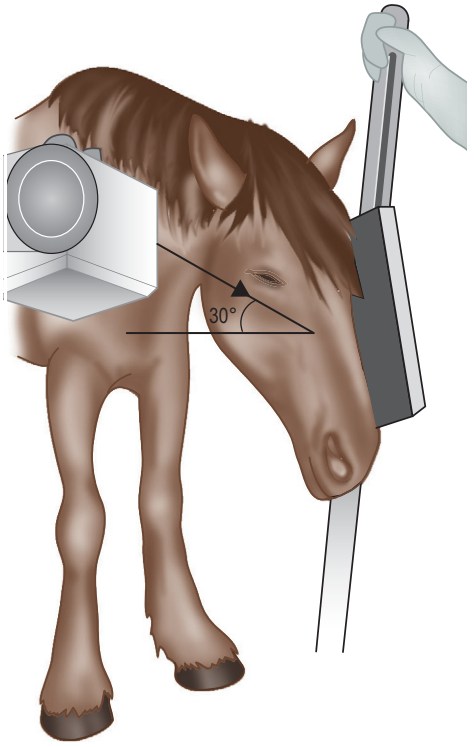

Fig. 17.10 Patient position, cassette position and x-ray machine position for obtaining a latero 30° dorsal-lateroventral oblique view of the skull

Downloaded From Vet-eBooks.com

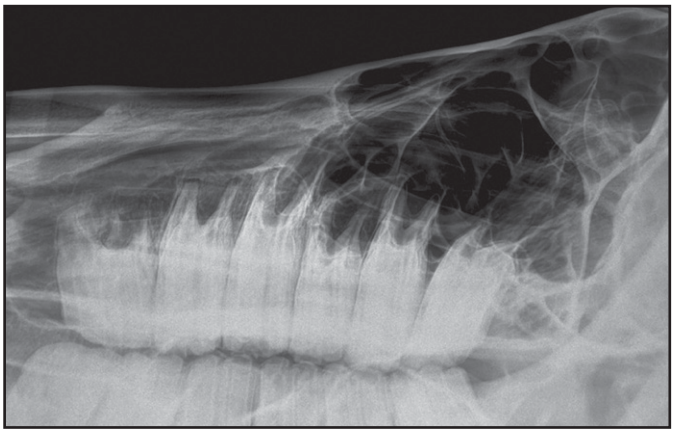

A

B

Fig. 17.11 (A & B) Latero 30° dorsal-lateroventral oblique view of the normal equine cheek teeth and paranasal sinuses in an adult horse (12 year old). 06–11 – maxillary cheek teeth, a – rostral maxillary sinus, b – caudal maxillary sinus, c – dorsal conchal sinus, d – frontal sinus

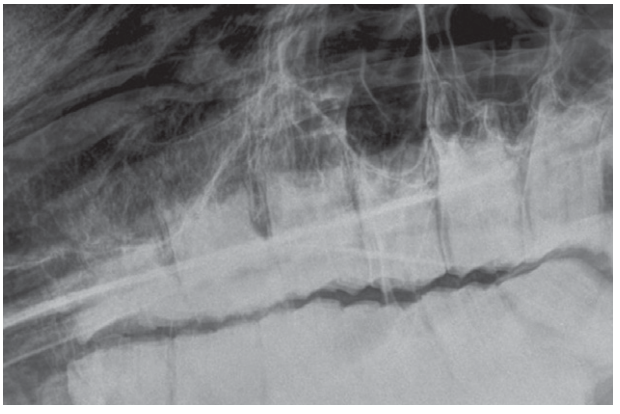

Fig. 17.12 Lateral radiograph of the normal equine skull, in an aged horse (23 years old). Note the short reserve crowns of the teeth and ill-defined roots

Downloaded From Vet-eBooks.com

❸ Latero 35–45° ventral-laterodorsal oblique view

This view is used to separate structures on the left and right sides of the ventral aspect of the skull so that they are not superimposed on each other, i.e. the left and right hemi-mandibles and mandibular cheek teeth apices. A higher exposure is required when imaging the caudal 3 cheek teeth because the thick masseter muscle overlies the apices of these teeth. A larger angle is usually required for radiographing the caudal cheek teeth apices because these are positioned more dorsally within the mandibular bone. For the same reason, a larger angle is also required in older horses with short reserve crowns.

Tips

- ✔ As for the dorsolateral-lateral oblique view, inadvertent rostro-caudal angulation of the x-ray beam is a common fault and should be avoided if possible because excessive rostro-caudal angulation distorts anatomical structures, particularly the apices of the cheek teeth, making them difficult to evaluate accurately.
- ✔ The minimum dorsoventral angle of x-ray beam, which clearly separates the left and right cheek teeth apices, should be used. Using a very large angle gives better separation of the cheek teeth rows and allows visualisation of more of the reserve crown, but also can cause artefactual distortion of the apices.

Positioning

The horse should be positioned so that the lesion side is furthest from the x-ray machine. The cassette should be held in the cassette holder in a vertical plane, close to horse's head on the lesion side.

Beam direction, centring and collimation

The primary beam should be angled 35–45° up from the horizontal and centred at the area of interest.

The primary beam should be collimated to reduce scatter, but should include the ventral mandibular cortex and the entire cheek teeth row if possible.

Downloaded From Vet-eBooks.com

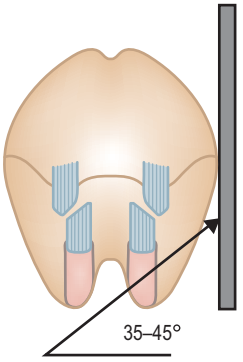

Fig. 17.13 Cassette positioning and angle of incidence of the x-ray beam to obtain a latero 35–45° ventral-laterodorsal oblique view of the skull

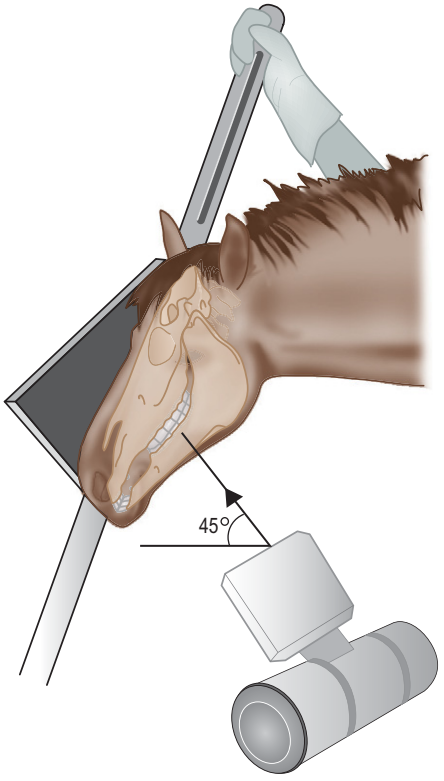

Fig. 17.14 Patient position, cassette position and x-ray machine position for obtaining a latero 35–45° ventral-laterodorsal oblique view of the skull

Downloaded From Vet-eBooks.com

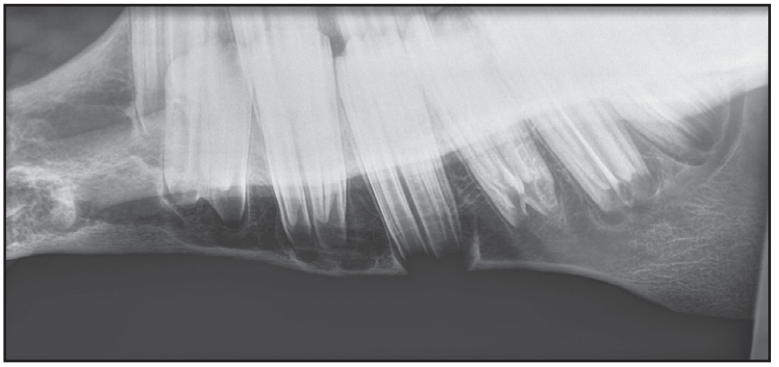

A

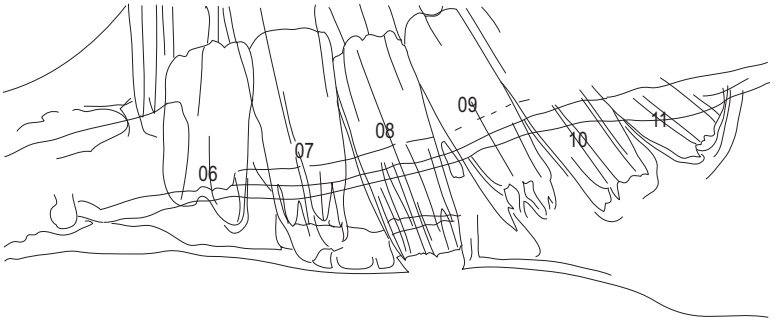

B

Fig. 17.15 (A & B) Latero 45° ventral-laterodorsal oblique view of the normal equine mandible and apices of mandibular cheek teeth (06–11) in a normal 4-year-old horse. Note the varied appearance of the cheek teeth apices at this age. The 08 (youngest tooth) has a wide radiolucent apical region situated very close to the ventral mandibular cortex and has no true root formation, whereas the 09 (the oldest tooth) has already developed roots

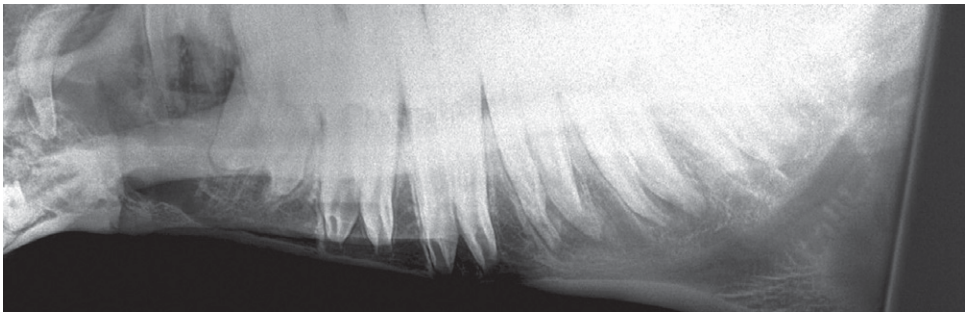

Fig. 17.16 Latero 45° ventral-laterodorsal oblique view of the normal equine mandible and apices of mandibular cheek teeth in a normal 9-year-old horse. Note the presence of true roots in all the cheek teeth at this age, as compared to those in a younger horse (Fig. 17.15)

Downloaded From Vet-eBooks.com

❹ Dorso-ventral view

This view is actually easy to obtain in the sedated horse and is particularly useful for visualising the ventral conchal sinus, nasal cavities and nasal septum. Additionally, it can be used for diagnosis of maxillary/mandibular fractures, evaluating bony distortion of the maxilla associated with periapical infection of rostral cheek teeth or intra-sinus masses. Laterally or medially displaced teeth and fractured teeth (particularly sagittal fractures) can also be visualised with this view; however, these abnormalities should be apparent during a thorough oral examination.

Tips

- ✔ An increased exposure is required compared to that used for lateral or lateral-oblique views of the skull.
- ✔ The radiographer should ensure that the x-ray beam is exactly perpendicular to horizontal ramus of mandible (which rests on the cassette). Even a small degree of obliquity will obscure one nasal cavity, ventral conchal sinus and maxillary cheek teeth row and will render comparison of left and right maxillary sinus opacity inaccurate.

Positioning

The cassette should be held parallel with ventral mandible, positioned as caudally as possible (tucked under the horse's chin).

Beam direction, centring and collimation

The x-ray beam is directed perpendicular to the cassette and centred in midline at level of the rostral aspect of the facial crests. Collimation of the primary beam should include the left and right lateral extents of the skull and the caudal aspects of the bony orbits.

Downloaded From Vet-eBooks.com

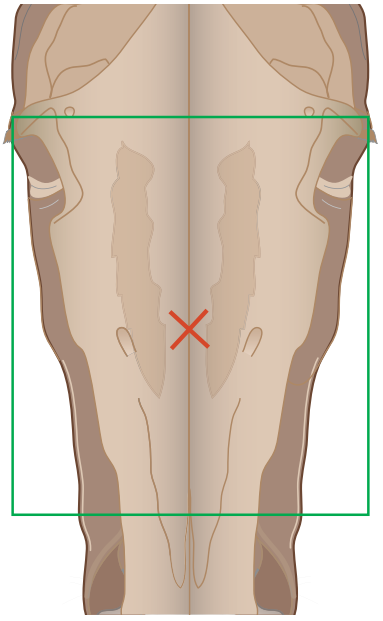

Fig. 17.17 Centering (X) and collimation of primary beam (green outline) for obtaining dorso-ventral view of the skull

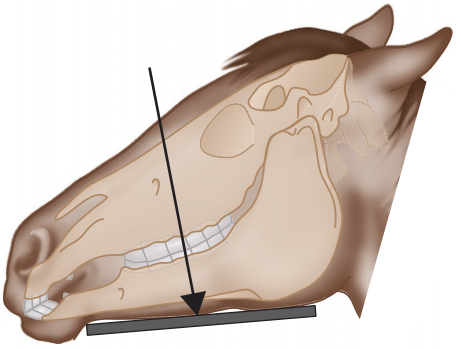

Fig. 17.18 Patient position, cassette position and angle of incidence of x-ray beam for obtaining a dorso-ventral view of the skull

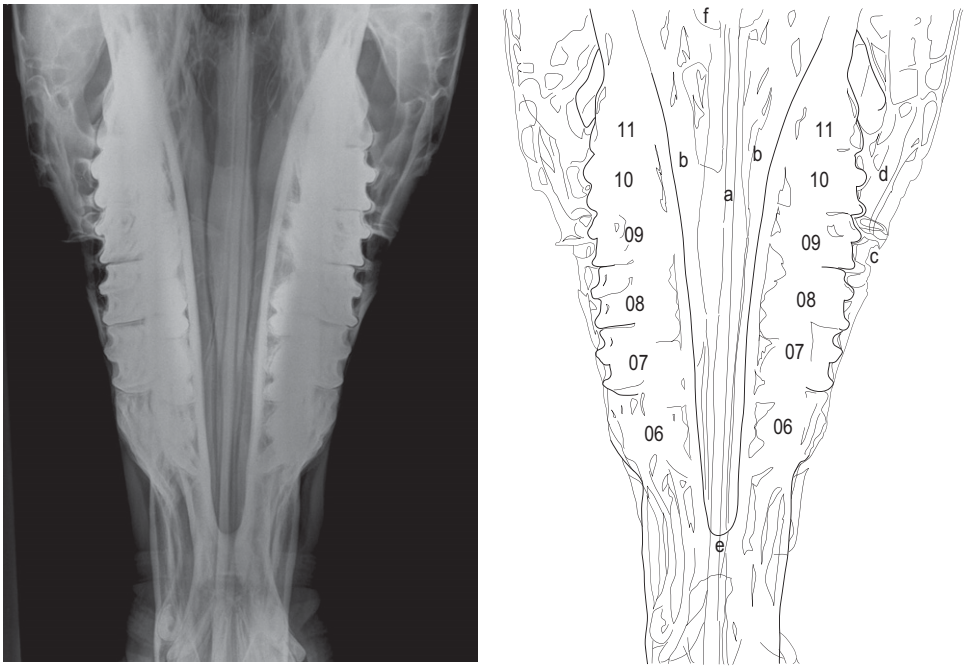

A B

Fig. 17.19 (A & B) Dorso-ventral radiograph of a normal equine skull. a – nasal septum, b – nasal cavity, c – rostral maxillary sinus, d – caudal maxillary sinus, e – mandibular symphysis, f – choana

Downloaded From Vet-eBooks.com

❺ Intra oral views (incisors and canines)

These views are used to radiograph the incisors and canines. The smallest cassette available should be used and the patient must be sedated to prevent damage to the cassette. A low exposure is required compared with that used to image the cheek teeth.

Positioning

The cassette should be placed between the incisors, as far caudally as possible, and held in place by an assistant wearing a lead glove.

Beam direction, centring and collimation

The x-ray beam is directed at 60–80° from vertical, depending on the conformation of the incisors, aiming up to image the mandibular incisors/canines and down to image the maxillary incisors/canines. The beam should be centred on the central incisors and collimation should include the rostral lateral aspects of the lips.

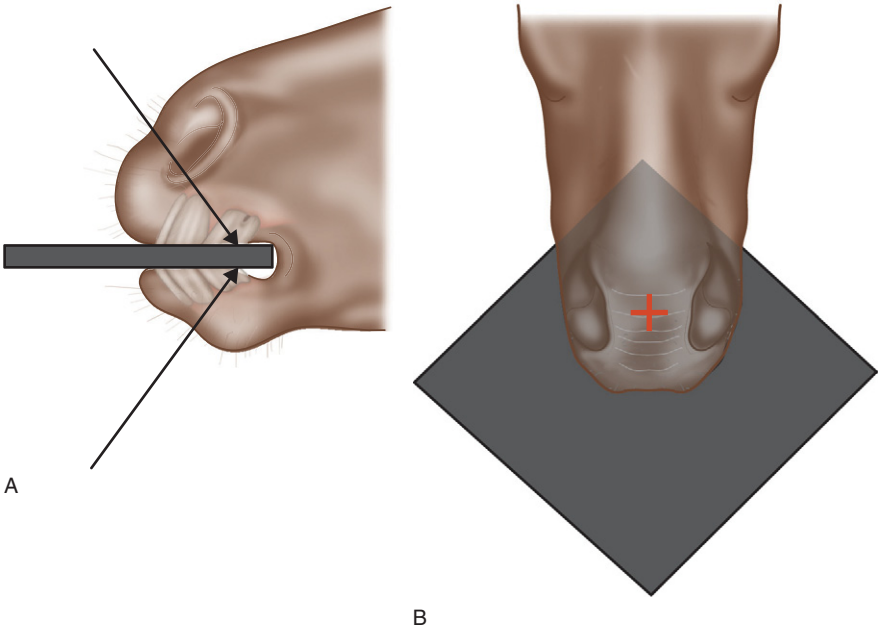

Fig. 17.20 (A & B) Cassette position, centering point (red cross) and angle of incidence (arrows) of the x-ray beam for obtaining intra-oral views of the incisors and canines

Downloaded From Vet-eBooks.com

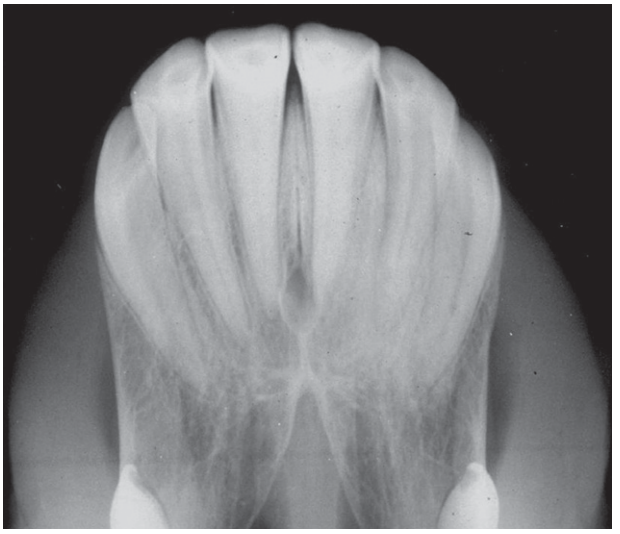

A

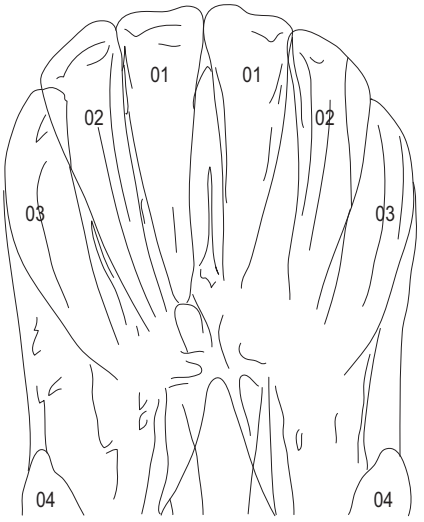

B

Fig. 17.21 (A & B) Intra-oral view of the mandibular incisors of a normal adult horse. 01 – Central incisors, 02 – Middle incisors, 03 – Corner incisors, 04 – Canines

Downloaded From Vet-eBooks.com

❻ Open-mouthed oblique views

This radiographic view is useful for imaging the erupted crowns of equine cheek teeth, e.g. for diastemata, coronal fractures, abnormalities of wear. A gag must be placed between the incisors, or alternatively a short length of hollow PVC tubing or a block of wood can be used to separate the occlusal aspects of the cheek teeth rows.

Positioning

The cassette is positioned vertically on the lesion side, close to horse's head.

Beam direction, centring and collimation

For these views, the x-ray beam is directed in the opposite direction to conventional (closed mouth) oblique views, i.e. dorsolateral-ventrolateral to image the mandibular erupted crowns, ventrolateral-lateral to image the maxillary erupted crowns. The angle of incidence of the x-ray beam is latero 10° dorsal-lateroventral (down) for mandibular cleek teeth, latero 15° ventral-laterodorsal (up) for maxillary cheek teeth.

The primary beam should be centred on the rostral aspect of the facial crest and collimated to include all the erupted crowns in the cheek teeth row.

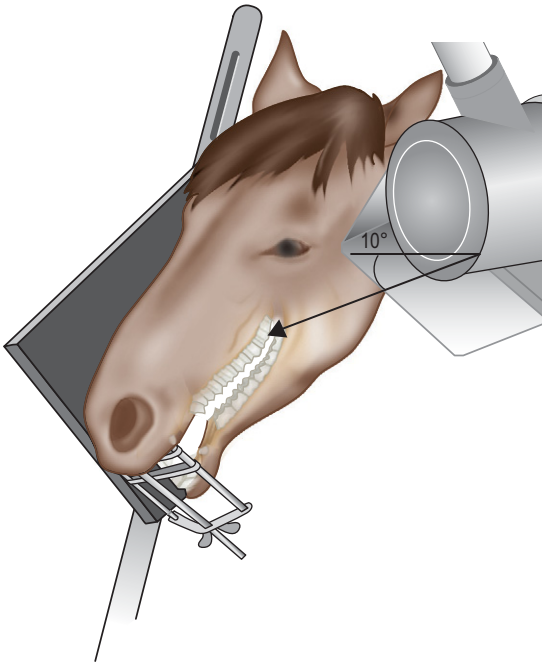

Fig. 17.22 Patient, cassette and x-ray machine position, and angulation of the x-ray beam for latero 10° dosal-lateroventral open mouthed oblique radiographic view, used to image the occlusal surfaces of the right mandibular cheek teeth

Downloaded From Vet-eBooks.com

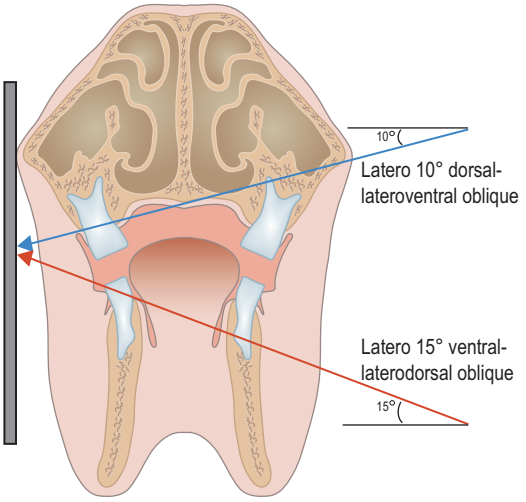

Fig. 17.23 Diagram showing direction of the x-ray beam used to obtain open-mouthed oblique views of the occlusal surface of the maxillary (blue arrow) and mandibular (red arrow) cheek teeth

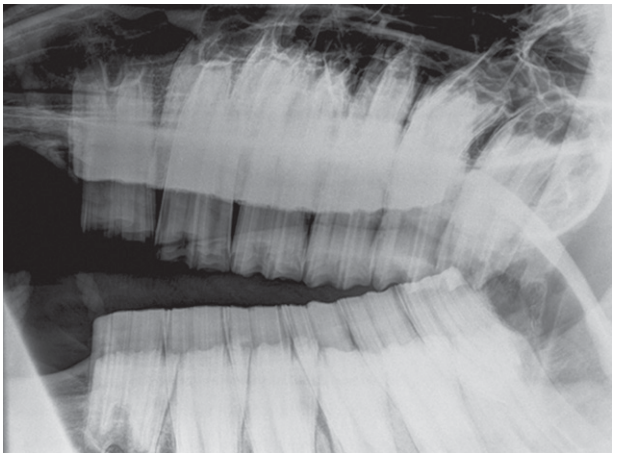

Fig. 17.24 Latero 10° dorsal-lateroventral open mouthed oblique view of the skull, highlighting the occlusal surfaces of the mandibular cheek teeth

Downloaded From Vet-eBooks.com

❼ Guttural pouches – lateral view

Imaging the guttural pouch region and hyoid bones can be useful for horses with suspected lesions of these areas, particularly if endoscopic examination is unavailable or inconclusive. The lateral view is most commonly used, but oblique views can also be beneficial in some cases, as they separate structures on the left and right sides. Oblique views are obtained by setting up for a lateral view and simply adding 10–20° of caudorostral angulation.

Positioning

The cassette is positioned vertically on the lesion side close to horse's head.

Beam direction, centring and collimation

The x-ray beam is horizontal, perpendicular to long axis of head and centred approximately half-way up the caudal border of vertical ramus of the mandible. The primary beam should be collimated to reduce scatter.

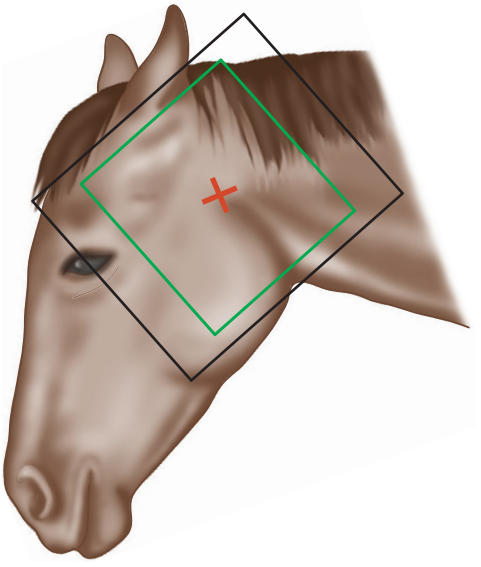

Fig. 17.25 Diagram showing position of patient, cassette, collimation and centering point of x-ray beam to obtain lateral view of the guttural pouches

Downloaded From Vet-eBooks.com

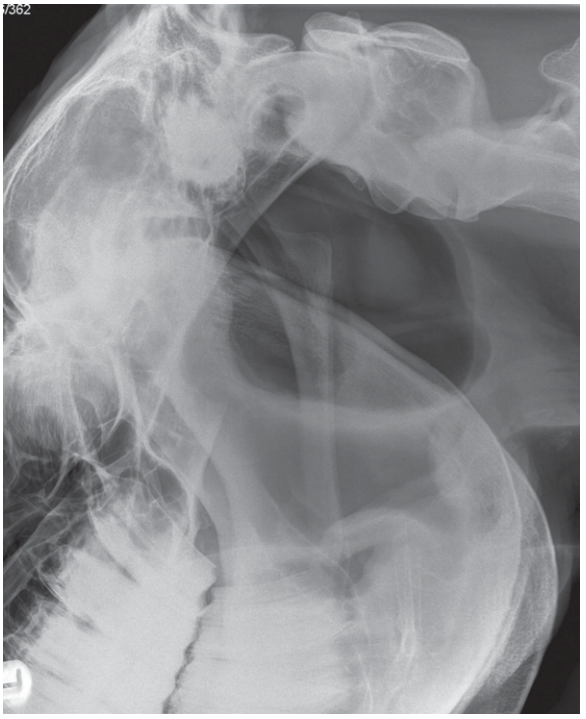

A

B

Fig. 17.26 (A & B) Lateral view of the guttural pouches in a normal horse. a – Guttural pouches, b – stylohyoid bones, c – caudal border of vertical ramii of mandible, d – ventral border of horizontal ramii of mandible, e – nasopharynx, f – epiglottis, g – tympanic bulla, h – tempero-mandibular joint, 09–11 – cheek teeth

Downloaded From Vet-eBooks.com

❽ Nasopharynx, larynx and proximal trachea – lateral view

Examination of the nasopharynx, larynx and proximal trachea is best performed with a flexible endoscope; however, radiography can be useful if endoscopic examination is unavailable or inconclusive. In particular, radiography is useful for diagnosis of some horses with fourth branchial arch defects and sub-epiglottic cysts, which may not be detectable using endoscopy per nasum.

Positioning

The cassette is positioned vertically on the lesion side close to horse's head.

Beam direction, centring and collimation

The x-ray beam is horizontal, perpendicular to long axis of head, and centred at the caudo-ventral angle of the mandible. The primary beam should be collimated to reduce scatter.

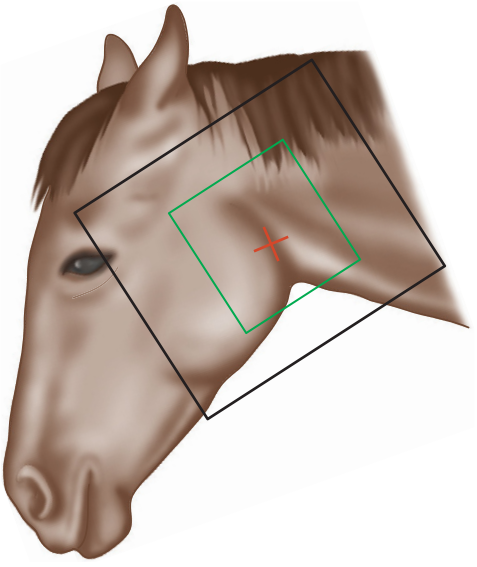

Fig. 17.27 Diagram showing position of patient, cassette, collimation and centering point of x-ray beam to obtain lateral view of the larnyx

Downloaded From Vet-eBooks.com

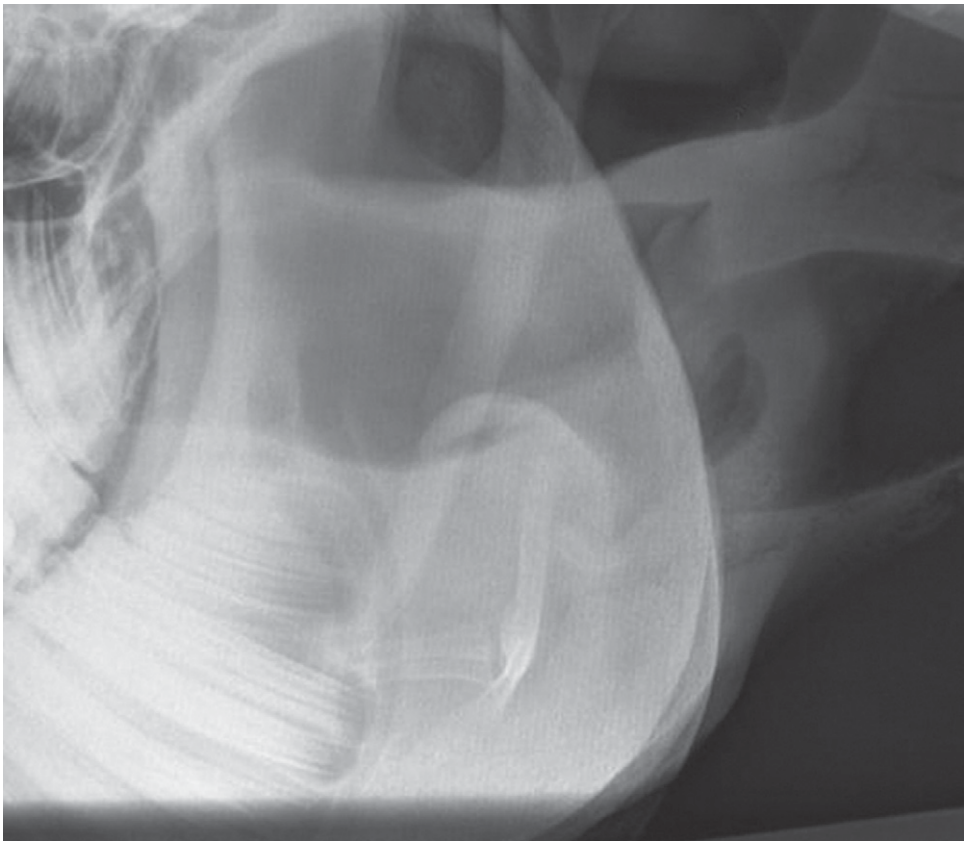

A

B

Fig. 17.28 (A & B) Lateral view of the larynx in a normal horse. 10, 11 – cheek teeth, a – stylohyoid bone, b – epiglottis, c – ary-epiglottic fold, d – corniculate process of arytenoid, e – laryngeal ventricles, f – trachea, g – nasopharynx, h – guttural pouch

Downloaded From Vet-eBooks.com

18 RADIOGRAPHY OF THE THORAX

Introduction

Equine thoracic radiography is indicated in horses with clinical signs of lower respiratory disease such as cough, bilateral nasal discharge, tachypnea and dyspnea. Radiography may also be useful for horses with abnormal noises heard on thoracic auscultation or with abnormalities observed during thoracic ultrasonography. It has been shown, however, that thoracic radiographic findings do not necessarily correlate well with the severity of disease processes in horses and that, in particular, improvement of radiographic lesions often lags behind clinical recovery of the patient.

Ideally, thoracic radiographs should be taken at full inspiration. However, inspiratory films are at higher risk of movement blur. Expiratory films have reduced air/tissue contrast and resultant increased lung opacity. For some cases, e.g. horses with restrictive lung disease or intrathoracic tracheal collapse, it may be beneficial to take both inspiratory and expiratory films.

Patient preparation

Some equine patients will require sedation to facilitate radiography of the thorax, but caution must be exercised when using sedative drugs in horses with severe respiratory compromise. The horse should be standing square, and if a unilateral lesion or disease process is suspected the cassette should be placed on the lesion side. In most cases, both left and right lateral radiographs are obtained because lesions in the hemithorax closest to the cassette will be better defined (and slightly smaller, due to less magnification).

Views of the caudodorsal and caudoventral thorax are most commonly taken and it may be possible to obtain these using a mobile x-ray unit, depending on the size of patient. To obtain the two cranial views in adult horses, more powerful non-portable systems are required.

Tips

- ✔ Large cassettes (42 cm × 35 cm) should be used and placed in a free-standing cassette holder rather than using a hand held cassette holder.
- ✔ Use a film-focal distance of 100–120 cm.
- ✔ To prevent movement blur a short exposure time is necessary, used with a fast film-screen combination.
- ✔ Using a grid may improve the quality of the final image, but requires an increased exposure, with increased risks to radiation safety and risk of movement blur.

Downloaded From Vet-eBooks.com

Views

❶ Caudodorsal thorax

This view is the most commonly taken and depicts the dorso-caudal lung fields, dorsal margin of the diaphragm, aorta and tapering pulmonary versels.

Positioning

The horse should be standing square. The cassette should be held in a cassette holder or gantry in a vertical plane, close to the thorax on the affected side (unless using the air gap technique, see tip, next page).

Beam direction, centring and collimation

The primary beam should be horizontal, centred approximately 20 cm caudal to and 15 cm ventral to the most caudal point of the scapula in an average-sized adult horse. Collimation should be wide enough to include the 14th rib dorso-caudally, but the primary beam should be kept within the margins of the cassette.

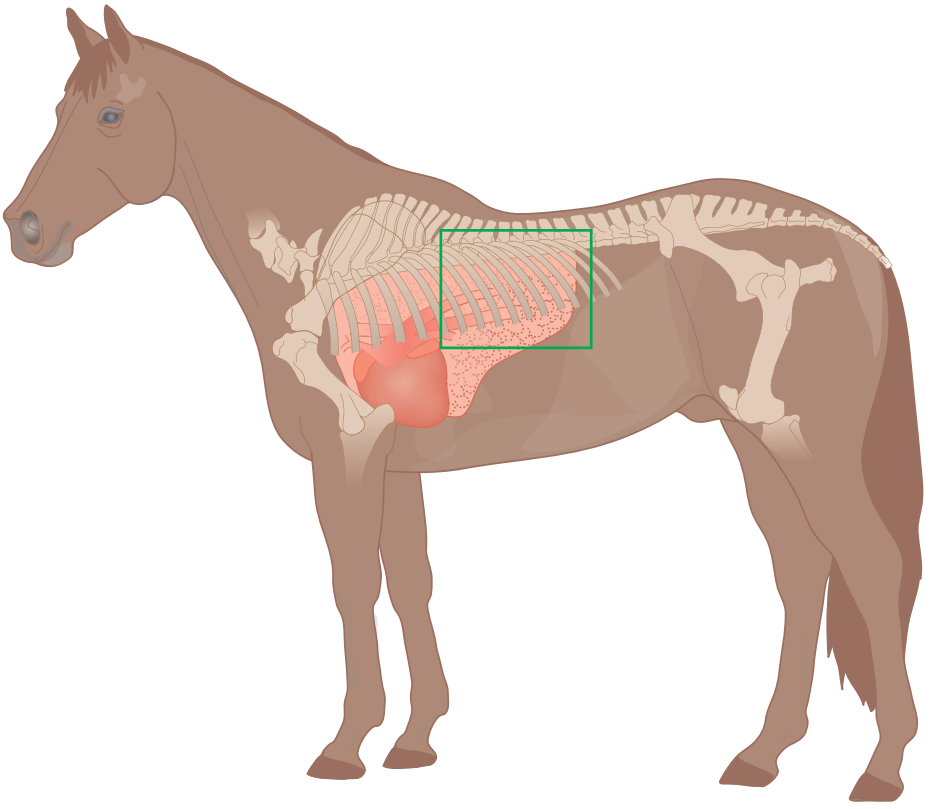

 Fig. 18.1 Position of cassette to obtain radiograph of the dorso-caudal thorax

Downloaded From Vet-eBooks.com

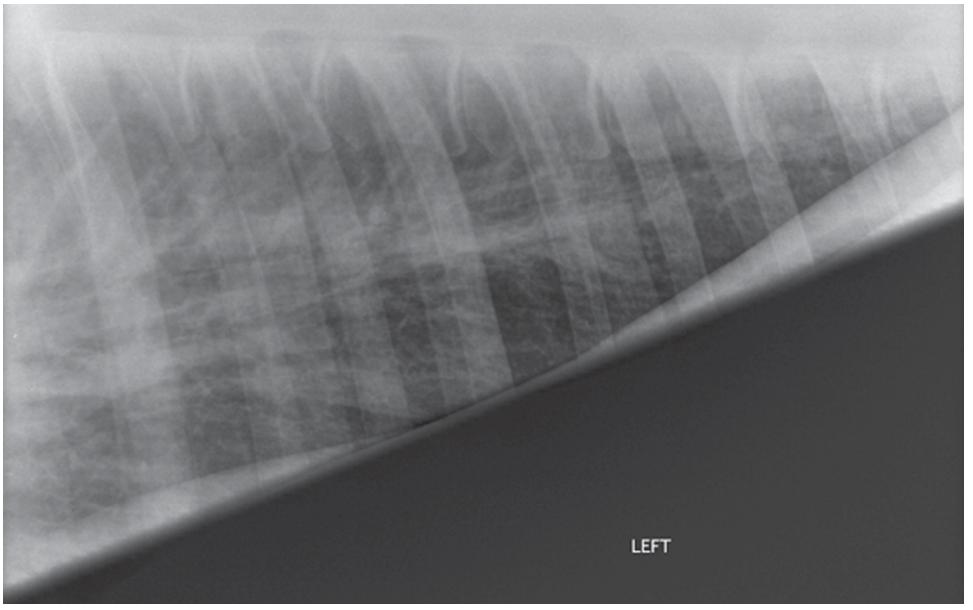

A

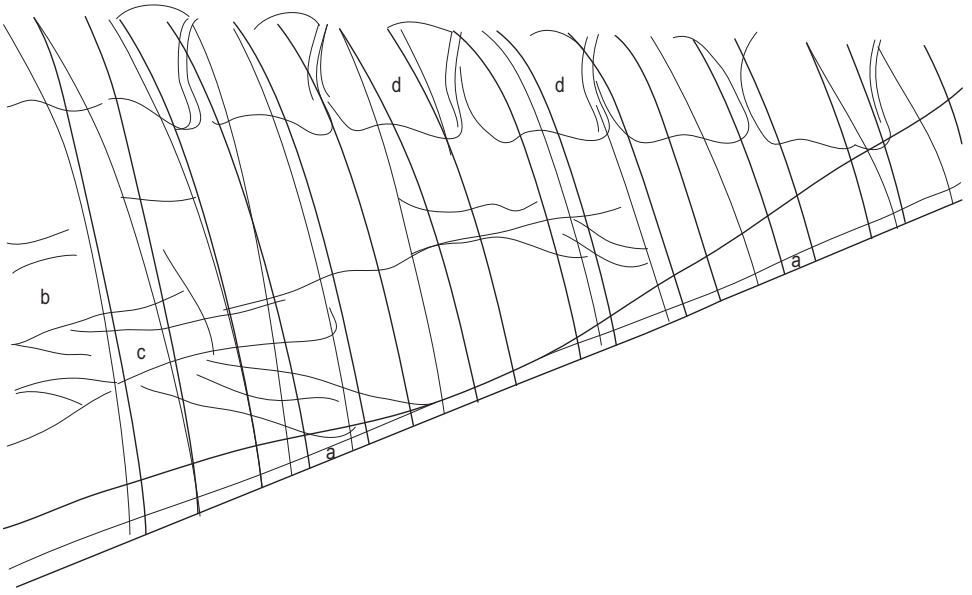

B

Fig. 18.2 (A & B) Radiograph of the dorso-caudal thorax. a – Diaphragm, b – Pulmonary artery, c – Pulmonary vein, d – Vertebral bodies

Tips

✔ If a grid is not used, the amount of scattered radiation can be reduced by leaving an air gap (15–30 cm) between the patient and the cassette. This technique causes magnification of intra thoracic structures.

Downloaded From Vet-eBooks.com

❷ Caudoventral thorax

This view depicts the caudal border of the cardiac silhouethe, the mid-portion of the diapleragm the caudo-ventral lung field, emergeme of pulmonary versels from the luart base and the vena ceva.

Positioning

The horse should be standing square. The cassette should be held in a cassette holder or gantry in a vertical plane, close to the thorax on the affected side (unless using the air gap technique see 'Tips' on previous page).

Beam direction, centring and collimation

The primary beam should be horizontal, centred 20 cm ventral to and 10 cm caudal to the most caudal point of the scapula in an average-sized adult horse. Collimation should be wide, but the primary beam should remain within the margins of the cassette.

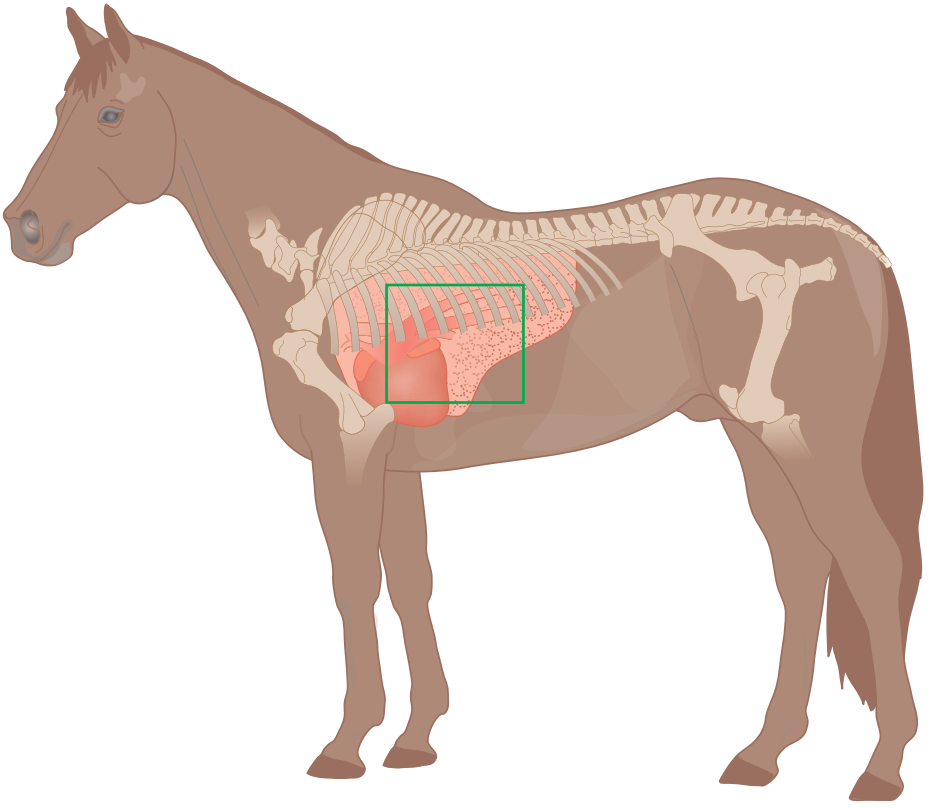

Fig. 18.3 Position of cassette to obtain radiograph of the ventro-caudal thorax (cassette position b in Fig. 18.1)

Downloaded From Vet-eBooks.com

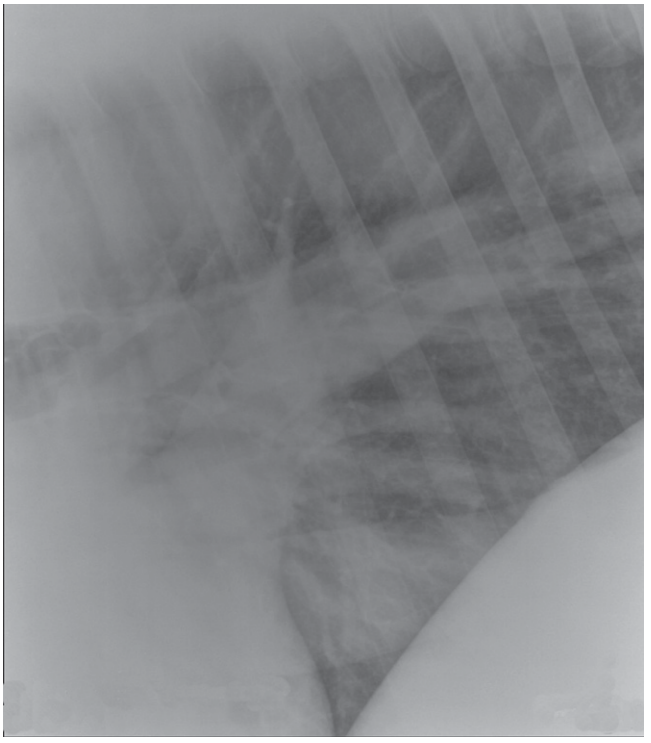

A

B

Fig. 18.4 (A & B) Radiograph of the caudoventral thorax. a – Caudal vena cava, b – Diaphragm, c – Trachea, d – Heart, e – Pulmonary artery, f – Pulmonary vein

Downloaded From Vet-eBooks.com

❸ Craniodorsal thorax

This view depicts the cranio-dorsal aspect of the heart base, aortic arch, trachea and tracheal bifurcation.

Positioning

The horse should be standing square. The cassette should be held in a cassette holder or gantry in a vertical plane, close to horse's chest on the affected side (unless using the air gap technique).

Beam direction, centring and collimation

The primary beam should be horizontal, centred 10–15 cm ventral to the most caudal point of the scapula in an average-sized adult horse. Collimation should be wide, but the primary beam must remain within the margins of the cassette.

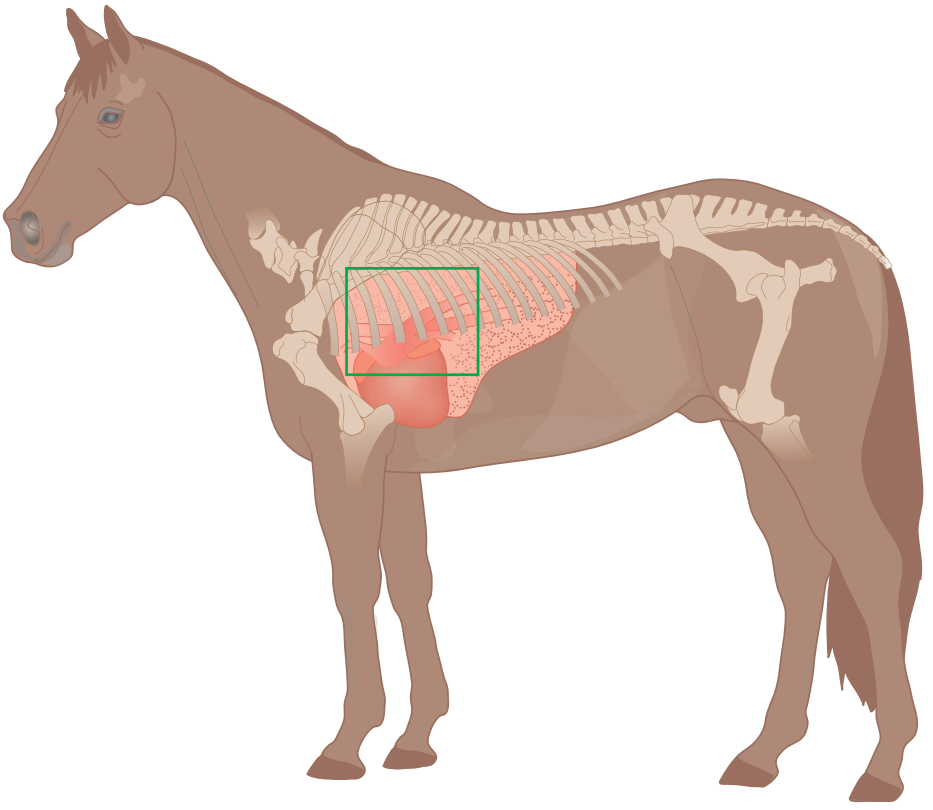

Fig. 18.5 Position of cassette to obtain radiograph of the craniodorsal thorax (cassette position c in Fig. 18.1)

Downloaded From Vet-eBooks.com

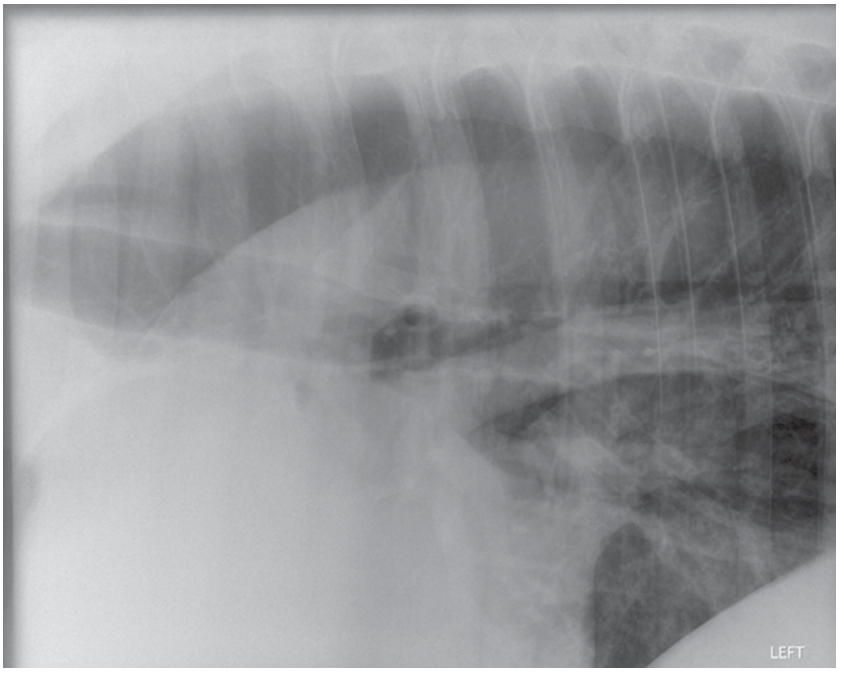

A

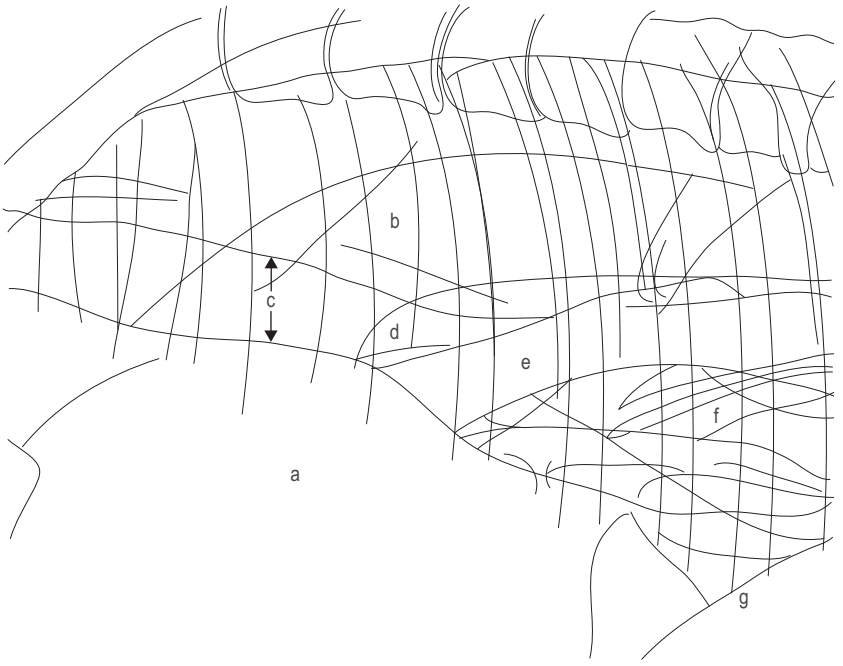

B

Fig. 18.6 (A & B) Radiograph of the craniodorsal thorax. a – Heart, b – Aorta, c – Trachea, d – Tracheal bifurcation (carina), e – Pulmonary artery, f – Pulmonary vein, g – Diaphragm

Downloaded From Vet-eBooks.com

❹ Cranioventral thorax

This view can be extremely difficult to obtain in adult hores and is rarely indicated. The crawo-dorsal aspect of the cardiac silhouetle, cranial intrathoracic trachea and candal aspect of the shoulder joint should be visible.

Positioning

The horse should be standing square. The cassette should be held in a cassette holder or gantry in a vertical plane, close to the thorax on the affected side (unless using the air gap technique).

Beam direction, centring and collimation

The primary beam should be horizontal, centred 15 cm caudal to the shoulder joint in an average-sized adult horse. Collimation should be wide, but the primary beam should remain within the margins of the cassette.

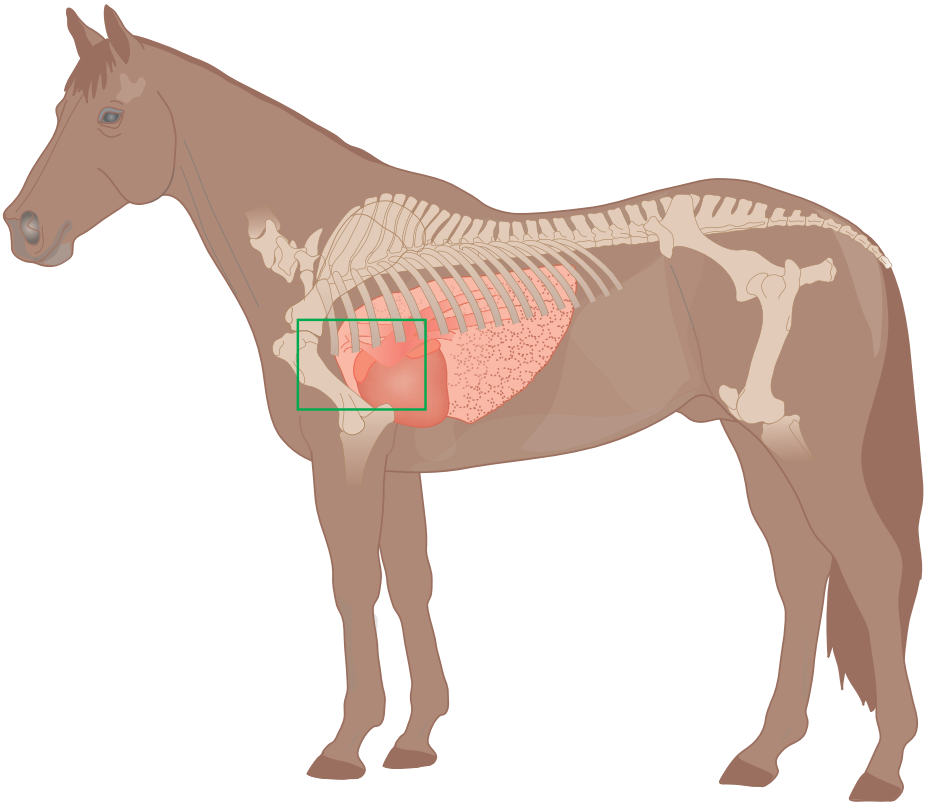

Fig. 18.7 Placement of cassette to obtain radiograph of the cranioventral thorax (cassette position d in Fig. 18.1)

Downloaded From Vet-eBooks.com

19 RADIOGRAPHY OF THE ABDOMEN

Introduction

The abdomen in rarely radiographed in the horse. Indications include:

- investigation of colic
- suspected bladder or ureter rupture or ectopic ureters.

Diagnostic ultrasound has largely superseded the occasional use of this technique. Owing to the size of the equine abdomen, diagnostic radiographs can be reliably obtained only in foals, small ponies and miniature horses. One lateral view using the largest available cassette size is usually sufficient to image most of the abdomen in these animals. If possible, radiographs are obtained with the foal or pony standing and the primary beam is centered on the mid-abdomen.

Downloaded From Vet-eBooks.com

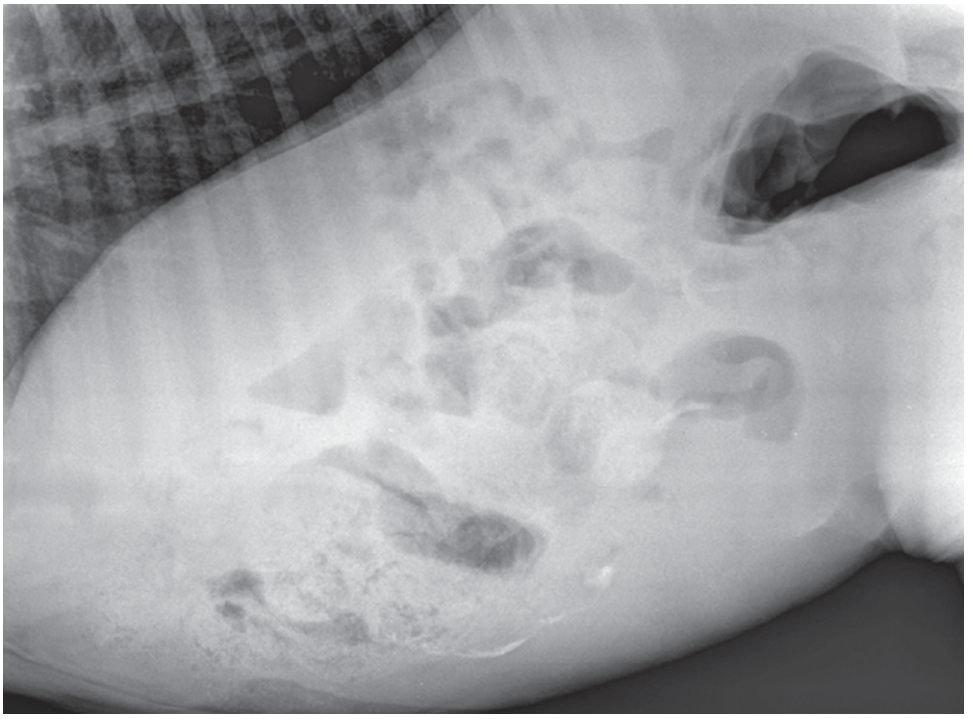

A

B

Fig. 19.1 (A & B) Normal lateral radiograph of a 5-day-old foal obtained in the standing position. Note the gas pocket in the caudal large bowel. There is poor contrast between the abdominal contents due to lack of fat

Downloaded From Vet-eBooks.com

20 ADDITIONAL RADIOGRAPHIC PROCEDURES (CONTRAST RADIOGRAPHY)

The widespread availability of diagnostic ultrasound machines has superseded most uses of radiographic contrast media to delineate soft-tissue structures. In addition, the use of positive contrast injections to detect articular cartilage defects (arthrography) is now rarely performed, as arthroscopy has become the technique of choice for evaluating most joints, sheaths and bursae. Barium given *per os* is occasionally used to demonstrate oesophageal strictures, diverticuli and functional abnormalities. The main remaining indication for the use of contrast agents is imaging the synovial spaces of the foot to investigate possible communication between a wound and the navicular bursa, distal interphalangeal joint and, in some horses, the distal aspect of the palmar (plantar) digital flexor tendon sheath.

Contrast radiography of the foot

This examination is usually performed with the horse standing. Sedation and regional infiltration of local anaesthetic (i.e. an abaxial sesamoid nerve block) will make the procedure considerably easier. The proposed injection sites are aseptically prepared. In the typical case with a wound that has penetrated the sole in the region of the frog (a 'street-nail' injury) the distal interphalangeal joint is injected through the dorsal aspect of the coronary region. The navicular bursa is injected via a needle placed between the bulbs of the heel and the palmar digital tendon sheath is most reliably injected into a small pouch in the palmar midline of the pastern or at the base of one sesamoid. Occasionally the use of other injection sites may be required to avoid passing through potentially contaminated tissue into the synovial space.

❶ Technique

Any sterile iodinated contrast agent that is suitable for intravenous use can be injected into a synovial space to give positive radiographic contrast. A plain lateromedial view of the foot is obtained prior to the use of the contrast agent. A further view with a metallic probe placed gently into the wound tract will give information about the direction of penetration, although it will not rule out synovial involvement. After correct needle placement is confirmed by the appearance of synovial fluid in the hub, some fluid is drawn off for analysis and to permit filling of the space with contrast agent. The contrast agent should be injected slowly until slight resistance is felt, to ensure the joint/bursa/sheath is adequately filled. In a 500 kg horse this will usually require 6–8 ml injected into the distal interphalangeal joint, 1–2 ml into the navicular bursa and 10–12 ml for the digital flexor tendon sheath. After each contrast injection a further lateromedial view of

Downloaded From Vet-eBooks.com

the foot is obtained. If a synovial space has been penetrated, contrast medium will be seen communicating with the wound.

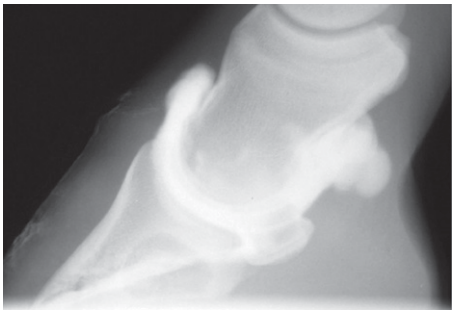

Fig. 20.1 Lateromedial view of the foot, collimated to the distal interphalangeal joint, which has been filled with iodinated contrast medium. The joint is distended without any leakage of contrast, ruling out synovial penetration from a wound

Fig. 20.2 Lateromedial view of the foot of an adult horse. A metal probe is in place to mark the location of a wound penetrating the sole. Contrast medium has been injected into the navicular bursa. The bursa is distended without leakage of contrast and is therefore intact

Fig. 20.3 Lateromedial radiograph of the fetlock with approximately 15 ml contrast medium injected into the palmar digital sheath. The contrast outlines the two flexor tendons proximal to the fetlock joint and the deep digital flexor tendon in the pastern region. Note that the distended digital sheath extends into the hoof

Downloaded From Vet-eBooks.com

Appendix I
SUGGESTED EXPOSURE CHART

Please note exposures will have to be altered for individual X-ray machines, different film-screen combinations and varying size of patient.

		Pony		TB/TBx		
Region	**View**	**kV**	**mAs**	**kV**	**mAs**	**GRID**
Abdomen, foal	Lateral	70	25	70	25	No
Carpus	LM, flexed LM, DP, DLPMO, DMPLO	60	5	63	6.3	No
Carpus	'Skyline'	66	6.3	66	8	No
Elbow	Mediolateral	66	6.3	66	8	No
Elbow	Craniocaudal	70	8	73	8	No
Fetlock	LM, DLPMO, DMPLO	55	6.3	60	6.3	No
Fetlock	DP	63	12.5	66	16	Yes
Humerus (proximal)	Mediolateral	77	16	81	25	Yes
Metacarpus/metatarsus	LM/DP	60	6.3	63	6.3	No
Metacarpus/metatarsus (2nd and 4th metacarpal/tarsal)	DMPLO, DLPMO	55	5	60	5	No
Navicular bone	LM	63	16	66	16	Yes
Navicular bone	Dorsoproximal-palmarodistal oblique	63	16	70	16	Yes
Navicular bone	Palmeroproximal-palmarodistal oblique	63	16	70	16	Yes

Downloaded From Vet-eBooks.com

SUGGESTED EXPOSURE CHART

		Pony		TB/TBx		
Region	**View**	**kV**	**mAs**	**kV**	**mAs**	**GRID**
Pastern	LM, DP, DLPMO, DMPLO	55	6.3	63	6.3	No
Pedal bone	LM	60	6.3	66	6.3	No
Pedal bone	Dorsoproximal-palmarodistal oblique	50	5	55	5	No
Pedal bone	DP (horizontal beam)	55	6.3	63	6.3	No
Pelvis/hip	Ventrodorsal, Oblique	81	32	97	50	Yes
Radius	LM, Craniocaudal, DLPMO, DMPLO	63	6.3	66	8	No
Shoulder	Mediolateral	73	20	90	32	Yes
Skull (sinus)	Lateral	60	6.3	63	6.3	No
Skull (maxillary dental)	Lateral oblique	63	6.3	66	8	No
Skull (mandibular dental)	Lateral oblique	66	6.3	66	8	No
Skull	Dorsoventral	70	8	73	8	No
Sternum	Lateral	81	25	90	32	Yes
Stifle	LM	66	8	70	10	No
Stifle	Caudocranial	77	25	96	40	Yes
Stifle	Caudolateral-craniomedial oblique	66	8	70	10	No
Tarsus	LM, DLPMO, DMPLO	60	5	63	6.3	No
Tarsus	DP	63	6.3	70	6.3	No
Thorax, cranial lungfield	Lateral	77	32	85	32	Yes
Thorax, caudal lungfield	Lateral	73	25	81	32	Yes

Downloaded From Vet-eBooks.com

		Pony		TB/TBx		
Region	**View**	**kV**	**mAs**	**kV**	**mAs**	**GRID**
Thorax, foal	Lateral	66	16	66	16	Yes
Tibia	LM, Obliques	63	8	66	8	No
Tibia	Caudocranial	66	8	70	8	No
Vertebrae: cervical (cranial)	Lateral	66	16	70	20	Yes
Vertebrae: cervical (middle)	Lateral	70	20	73	25	Yes
Vertebrae: cervical (caudal)	Lateral	77	32	90	40	Yes
Vertebrae: dorsal spinous processes (mid-thoracic)	Lateral	60	8	63	10	No
Vertebrae: dorsal spinous processes (lumbar)	Lateral	70	12	77	12	No

LM = lateromedial, DP = dorsopalmar/planter, DLPMO = dorsolateral-palmaro/planteromedial oblique, DMPLO = dorsomedial-palmaro/planterolateral oblique

Downloaded From Vet-eBooks.com

Appendix II

EXPOSURE CHART FOR YOUR PRACTICE

		Pony		TB/TBx	
Region	**View**	**kV**	**mAs**	**kV**	**mAs**
Abdomen, foal	Lateral				
Carpus	LM, flexed LM, DP, DLPMO, DMPLO				
Carpus	'Skyline'				
Elbow	Mediolateral				
Elbow	Craniocaudal				
Fetlock	LM, DLPMO, DMPLO				
Fetlock	DP				
Humerus (proximal)	Mediolateral				
Metacarpus/metatarsus	LM/DP				
Metacarpus/metatarsus	DMPLO, DLPMO				
Metacarpus/metatarsus	LM				
Navicular bone	Dorsoproximal-palmarodistal oblique				
Navicular bone	Palmaroproximal-palmarodistal oblique				
Navicular bone	LM, DP, DLPMO, DMPLO				
Pastern	LM				

Downloaded From Vet-eBooks.com

EXPOSURE CHART FOR YOUR PRACTICE

		Pony		TB/TBx	
Region	**View**	**kV**	**mAs**	**kV**	**mAs**
Pedal bone	Dorsoproximal-palmarodistal oblique				
Pedal bone	DP (horizontal beam)				
Pedal bone	Ventrodorsal, Oblique				
Pedal bone	LM, Craniocaudal, DLPMO, DMPLO				
Pelvis/hip	Mediolateral				
Radius	Lateral				
Radius	Lateral oblique				
Shoulder	Lateral oblique				
Skull (sinus)	Dorsoventral				
Skull (maxillary cheek teeth)	Lateral				
Skull (mandibular cheek teeth)	Lateral				
Skull	Lateral				
Sternum	Lateral				
Stifle	LM				
Stifle	Caudo-cranial				
Stifle	Caudolateral-craniomedial oblique				
Tarsus	LM, DLPMO, DMPLO				
Tarsus	DP				
Thorax, cranial lung field	Lateral				
Thorax, caudal lung field	Lateral				
Thorax, foal	Lateral				

Downloaded From Vet-eBooks.com

		Pony		TB/TBx	
Region	**View**	**kV**	**mAs**	**kV**	**mAs**
Tibia	LM, Obliques				
Tibia	Caudocranial				
Vertebrae: cervical (cranial)	Lateral				
Vertebrae: cervical (middle)	Lateral				
Vertebrae: cervical (caudal)	Lateral				
Vertebrae: dorsal spinous processes (mid-thoracic)	Lateral				
Vertebrae: dorsal spinous processes (lumbar)	Lateral				
LM = lateromedial, DP = dorsopalmar/planter, DLPMO = dorsolateral-palmaro/planteromedial oblique, DMPLO = dorsomedial-palmaro/planterolateral oblique					

Downloaded From Vet-eBooks.com

INDEX

Note: Page numbers in **bold** refer to figures.

Abdomen, 169–70, **170**
ALARA principle, 9
Anconeal process of the ulna, 96
Aorta, 162
Aortic arch, 166

Barium, 171
Bone
  demineralised, 14
  loss, 14
  lysis, 15
  new formation, 14
  resorption, 14–15
  sclerotic, 14

Calcaneal tuberosity, 82
Calcaneus
  coracoid process, 90
  plantar aspect, 82
  plantaro-lateral aspect, 86
  views, plantarodistal, 92–3, **92–3**
Canine teeth, 153–4, **153–4**
Cannon bones
  fractures, 53, 54
  see also Metacarpus; Metatarsus
Carpus, 65–78
  distal row, dorsoproximal-dorsodistal oblique view, 76–8, **76–8**
  indications, 65
  preparation, 65
  proximal row, dorsoproximal-dorsodistal oblique view, 76–8, **76–8**
  views, 66–78
    dorsolateral-palmaromedial oblique (DLPaMO), 70–1, **70–1**
    dorsomedial-palmarolateral oblique (DMPaLO), 72–3, **72–3**
    dorsopalmar (DPa), 68–9, **68–9**
    dorsoproximal-dorsodistal oblique, 76–8, **76–8**
    lateromedial (LM), 66–7, **66–7**
      flexed, 74–5, **74–5**
Cassette holders, 6, **7,** 10, **11**
Cassettes, 5–6, 7
Cassette tunnel, 7, **7**
Ceiling mounted x-ray machines, 5
Cervical vertebrae, 127–32
  indications, 127
  preparation, 127–32, **128–32**
Cheek teeth
  erupted crowns, 155
  mandibular, 148, **150**
  maxillary, 140, **141–4,** 145, **147**
Coat artefacts, 12, **12**
Collimation, 5, 9, **10**
Computed radiography, 3, 7
Contrast radiography, 171–2, **172**
Coxofemoral joint *see* Hip and pelvis
Cranial cruciate ligament, 110, 115

Diagnosis, 13–15
Diaphragm, 162, 164
Direct digital radiography, 3, 7
Dorsopalmar foot balance, 20, **23**
Dosemeter, radiation, 10, **11**

Elbow, 95–101
  indications, 95
  preparation, 95
  views, 96–101
    craniocaudal view, 98–9, **98–9**
    craniomedial-caudolateral oblique, 100–1, **100–1**
    mediolateral view, 96–7, **96–7**
Equipment, 5–7
Exposure
  film, 3, 14
  radiation, 10–11

Fast screens, 6
Femur
  condyles, 113
  intercondylar fossa, 113
  inter-trochlear groove, 119
  trochlear ridges, 110, 115, 117–18, 119
Fetlock, 41–52, 52
  indications, 41
  preparation, 41
  views
    additional
      dorsal 30° proximal 70° lateral-palmar distal medial oblique (D30°Pr70°L-PaDiMO), 52
      dorsal 45° proximal 45° lateral-palmar distal medial oblique (D45°Pr45°L-PaDiMO), 52
      dorsal 30° proximal 70° medial-palmar distal lateral oblique (D30°Pr70°M-PaDiLO), 52
      dorsodistal-palmaroproximal oblique, 52
      dorsoproximal-dorsodistal oblique, 52
      dorsoproximal-palmarodistal oblique, 52
      flexed lateromedial, 48–9, **48–9**
      lateral 45° proximal-medial distal oblique (L45°Pr-MDiO), **50–1,** 50–2
      medial 45° proximal-lateral distal oblique (M45°Pr-LDiO), **50–1,** 50–2
      palmaroproximal-palmarodistal (PaPr-PaDi), 51
    standard, 42–52
      dorsolateral-palmaromedial oblique (D45°L-PaMO), 46–7, **46–7**
      dorsomedial-palmarolateral oblique (D45°M-PaLO), 46–7, **46–7**
      dorsoproximal-palmarodistal oblique (DP10°-PaDO), 44–5, **44–5**
      lateromedial (LM), 42–3, **42–3**

Downloaded From Vet-eBooks.com

Film-based x-rays, 3
Film-focus distance (FFD), 3
Film labels, 6
Fixed x-ray machines, 5
Fluorescent intensifying screens, 3
Foot, 19–34
  balance/imbalance
    dorsopalmar, 20, **23**
    lateromedial, 24
  contrast radiography, 171–2, **172**
  indications, 19
  preparation, 19
  soft-tissues, 20
  views, 20–34
    dorso 45° lateral-palmaromedial oblique (D45°L-PaMO), 32–3, **32–3**
    dorso 45° medial-palmarolateral oblique (D45°M-PaLO), 32–3, **32–3**
    dorsopalmar (DPa) (weightbearing), 24–5, **24–5**
    dorsoproximal-palmarodistal oblique (DPr-PaDiO), 19, 26–30, **26–30**
    lateromedial (LM), 20–3, **21–3**
    palmaroproximal-palmarodistal oblique (flexor), 30–1
    palmaroproximal-palmarodistal (PaPr-PaDi), 7
Foot-positioning aids, 7, **7**
Fur artefacts, 12, **12**

Grids, 6
Guttural pouches, 157–8, **157–8**

Hair/coat artefacts, 12, **12**
Health and safety legislation, 5
  see also Radiation safety
Heart, 164, 166, 168
High suspensory disease, 53
Hip and pelvis, 121–5
  indications, 121
  preparation, 121–2, **122**
  views, 122–5, **122–5**
Hock *see* Tarsus
Hoof-pastern angle, 20
Humero-radial joint space, 98
Humerus
  condyles, 96
  deltoid tuberosity, 106
  epicondyles, 96
  greater tubercle, 106
  head, articular surface, 104
  intermediate tubercle, 106
  lateral aspect, 98
  medial aspect, 98
  tubercles, 104, 106
Hyoid bones, 157

Image formation, 3–4
Incisor teeth, 153–4, **153–4**
Intensifying screens, 3, 5–6
Intercondylar eminence, 117
Interphalangeal joint, distal, 20
Interpretation of radiographs, 13–15

Kilovoltage (kV), 3

Labelling, 6
Laminitis, 20, 23
Larynx, 161, **161**
Light beam diaphragm, 9, **10**
Low-kV technique, 3
Lumbar vertebrae *see* Thoracolumbar vertebrae
Lungs, 162, 164

Mandible, 148, **150**
  cheek teeth, 148, **150**
  fractures, 151
Markers, film, 6
Maxilla
  cheek teeth, 140, **141–4,** 145, **147**
  fracture, 151
Metacarpus, 53–65
  distal, 41, 43
    dorsal 10° proximal-palmarodistal oblique view, 61–2, **61–2**
    dorsodistal-palmaroproximal view, **63–4**
  fractures, 53
  indications, 53
  preparation, 53
  views, 54–65
    dorsal 10° proximal-palmarodistal oblique, 61–2, **61–2**
    dorsodistal-palmaroproximal, 63–4, **63–4**
    dorsolateral-palmaromedial oblique (D45°L-PaMO), 59–60, **59–60**
    dorsomedial-palmarolateral oblique (DM-PaLO), 59–60, **59–60**
    dorsopalmar, 57–8, **57–8**
    lateromedial (LM), 54–6, **55–6**
Metatarsus, 53–65
  distal, 41
    dorsal 10° proximal-palmarodistal oblique view, 61–2, **61–2**
    dorsodistal-palmaroproximal view, **63–4**
  fractures, 53
  indications, 53
  preparation, 53
  views, 54–65
    dorsal 10° proximal-palmarodistal oblique, 61–2, **61–2**
    dorsodistal-palmaroproximal, 63–4, **63–4**
    dorsolateral-palmaromedial oblique (D45°L-PaMO), 59–60, **59–60**
    dorsomedial-palmarolateral oblique (DM-PaLO), 59–60, **59–60**
    dorsopalmar, 57–8, **57–8**
    lateromedial (LM), 54–6, **55–6**
Milliamperes (mAs), 3
Mobile x-ray machines, 5
Movement blur, 12

Nasal cavities, 151
Nasal septum, 151
Nasopharynx, 161
Navicular bone, 20
  dorsoproximal-palmarodistal oblique (DPr-PaDiO) view, 26, 28, **29**
  palmaroproximal-palmarodistal oblique (flexor) view, 30–1, **30–1**

Olecranon, 96
Over-exposed films, 14

Paranasal sinuses, 140, **141–4,** 145, **147**
Pastern, 35–9
  indications, 35
  preparation, 35
  views, 35–9
    dorsolateral-palmaromedial oblique (D45°L-PaMO), 38–9, **38–9**
    dorsomedial-palmarolateral oblique (D45°M-PaLO), 38–9, **38–9**
    dorsoproximal-palmarodistal oblique (DPr-PaDiO), 37, **37**
    lateromedial (LM), 35–6, **36**
Patella, 110, 115, 117, 119
Patient preparation, 12
  see also specific anatomical region
Pedal bone
  collateral cartilages ossification, 24

Downloaded From Vet-eBooks.com

dorsoproximal-palmarodistal oblique (DPr-PaDiO) view, 26
palmar processes
dorso 45° lateral-palmaromedial oblique (D45°L-PaMO), 32
dorso 45° medial-palmarolateral oblique (D45°M-PaLO), 32
Pelvis *see* Hip and pelvis
Phalanx
distal, 20
displacement, 20
fractures, 24
second, 20
Portable x-ray machines, 5
Protective clothing, 10, **11**
Pulmonary vessels, 162, 164

Radiation safety, 9–12
principles, 9
radiation sources, 9–10, **10**
restricting exposure, 10–12
Radiation sources, 9–10, **10**
Radiographs/radiography
equipment, 5–7
interpretation, 13–15
limitations, 15
Radius
distal, dorsoproximal-dorsodistal oblique view, 76–8, **76–8**
lateral aspect, 98
medial aspect, 98
proximal articular surface, 96
tuberosity, 96
Reading radiographs, 13–15

Sacral vertebrae, 133–6
indications, 133
positioning, 133–6, **134–6**
Safety, radiation *see* Radiation safety
Scapula, glenoid cavity, 104
Scattered radiation, 6, 9
Screens, 3, 5–6
Sedation to avoid movement blur, 12
Sesamoid bones
dorsolateral-palmaromedial oblique (D45°L-PaMO), 46
dorsomedial-palmarolateral oblique (D45°M-PaLO), 46
lateral 45° proximal-medial distal oblique (L45°Pr-MDiO), 50
medial 45° proximal-lateral distal oblique (M45°Pr-LDiO), 50
proximal, 41
Shoulder, 103–7
indications, 103
preparation, 103
views, 104–7
cranial 45° medial-caudolateral oblique, 106–7, **106–7**
medio-lateral, 104–5, **104–5**
Skull, 137–58
indications, 137
preparation, 137–9, **138–9**
views, 140–61
30° dorsolateral-lateral oblique, 145–7, **146–7**
dorso-ventral, 151–2, **152**
guttural pouches, 157–8, **157–8**
intra oral (incisors and canines), 153–4, **153–4**
lateral, 140–4, **140–4**
nasopharynx/larynx/proximal trachea, 161, **161–2**
open-mouthed oblique, 155–6, **155–6**
35-45° ventrolateral-lateral oblique view, 148–50, **149–50**
Slow screens, 6
Splint bones, 54
lateral aspect, 84
proximal aspect, 82
see also Metacarpus; Metatarsus
Splints, periosteal, 53
Stands, 5
Stifle, 109–20
indications, 109
preparation, 109
views, 110–20
caudal 60° lateral-craniomedial oblique, 115–16
caudocranial, 113–14, **113–14**
cranioproximal-craniodistal oblique (skyline), 119–20, **119–20**
lateromedial (LM), 110–11, **111–13**
flexed, 117–18, **117–18**
Supraglenoid tubercle, 104
Suspensory ligament desmitis, 53
Sustentaculum tali, 88, 92–3, **92–3**

Talus
lateral trochlear ridge, 82, 88, 90
medial aspect, 84
medial trochlear ridge, 82, 86, 90
Tarsus, 79–93
indications, 79
preparation, 79–80, **80**
views, 82–93
dorsolateral-plantaromedial oblique, 86–7, **86–7**
dorsomedial-plantarolateral oblique, 88–9, **88–9**
dorsoplantar, 84–5, **84–5**
lateromedial (LM), 82, **83**
flexed, 90–1, **90–1**
plantarolateral-dorsomedial (PLDMO), 86
plantaroproximal, flexed, 92–3, **92–3**
Teeth
canines, 153–4, **153–4**
cheek
erupted crowns of, 155
mandibular, 148, **150**
maxillary, 140, **141–4,** 145, **147**
displaced, 151
fractured, 151
incisors, 153–4, **153–4**
Thoracolumbar vertebrae, 133–6
indications, 133
positioning, 133–6, **134–6**
Thorax, 161–9
indications, 161
preparation, 161
views, 162–9
caudodorsal, 162–3, **162–3**
caudoventral, 164–5, **164–5**
craniodorsal view, 166–7, **166–7**
cranioventral, 168, **168**
Tibia
condyles, 113
intercondylar eminences, 113
lateral malleoli, 84
medial malleoli, 84, 86
plantar-distal aspect, 90
proximal, 117
Tibial crest, 110, 115
Trachea, 166, 168
bifurcation, 166
proximal, 161
Trochlear process of the ulna, 96

Ulna, 96
anconeal process, 96
trochlear process, 96
Under-exposed films, 14

Vena cava, 164
Ventral conchal sinus, 151

X-ray beam, 9
X-ray machines, 5

Downloaded From Vet-eBooks.com