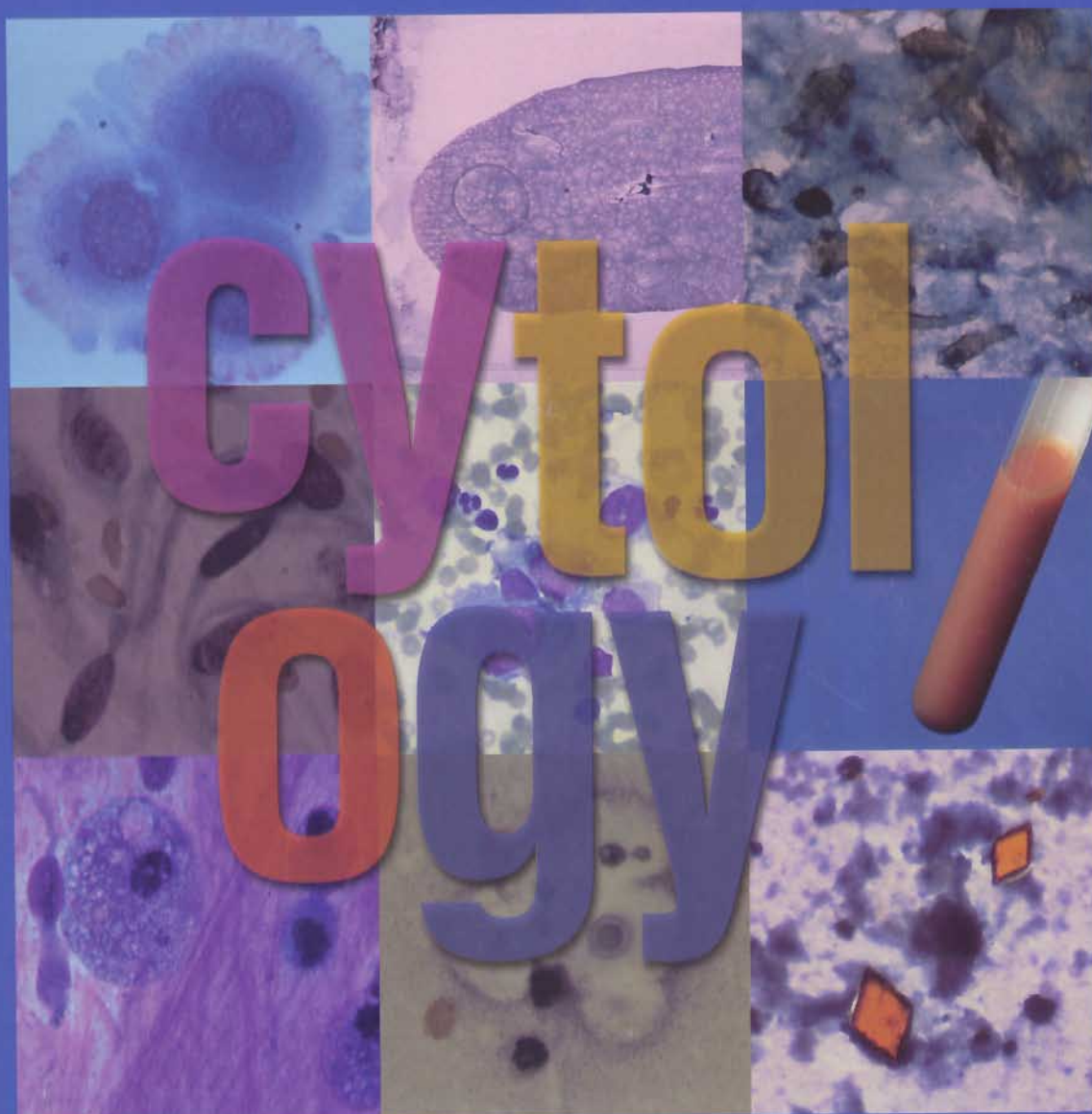


\$50.00

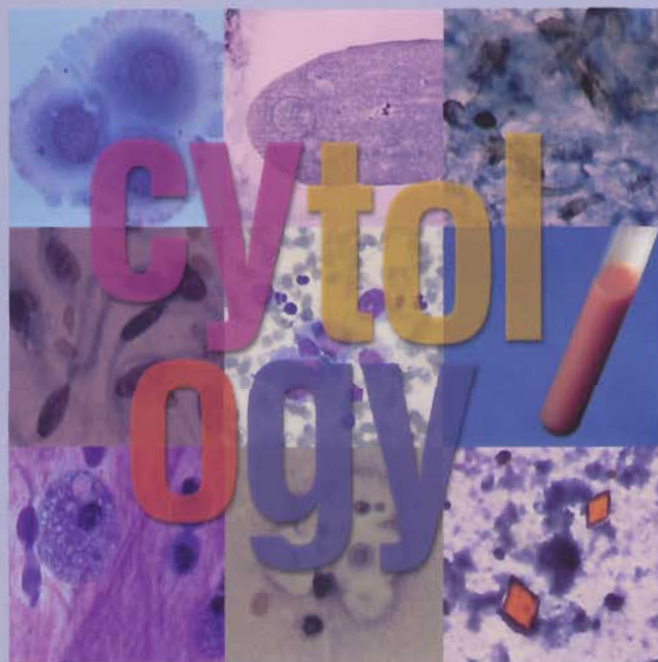
# Interpretation of Canine and Feline Cytology



*M. Judith Radin, DVM, PhD, DACVP*  
*Maxey L. Wellman, DVM, PhD, DACVP*



Ralston Purina Company **Clinical Handbook Series**



## Interpretation of Canine and Feline Cytology

*M. Judith Radin, DVM, PhD, DACVP*  
*Maxey L. Wellman, DVM, PhD, DACVP*



Ralston Purina Company  
**Clinical Handbook Series**

## Table of Contents

Introduction ..... 1

### Part I

#### Chapter 1

*Sample Collection and Specimen  
Preparation* ..... 5

#### Chapter 2

*Approach to a Cytologic Specimen* ..... 9

### Part II

#### Chapter 3

*Interpretation of a Cytologic Specimen* ..... 13

#### Chapter 4

*Cytologic Appearance of Etiologic Agents* ..... 19

### Part III

#### Chapter 5

*Body Cavity Effusions and Synovial Fluid—  
Case Studies* ..... 25

#### Chapter 6

*Skin and Connective Tissue—Case Studies* .. 33

#### Chapter 7

*Lymph Node and Spleen—Case Studies* ..... 51

#### Chapter 8

*Respiratory System and Internal Organs—  
Case Studies* ..... 63

### Part IV

*Guidelines to Distinguishing Transudates  
and Exudates* ..... 78

*Guidelines for Evaluation of Synovial Fluid* .... 78

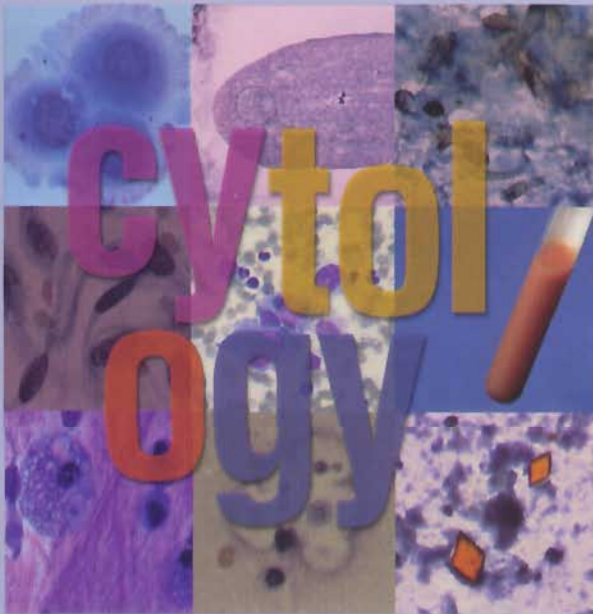
*Index of Figures* ..... 79

*Glossary of Terms* ..... 85

*Suggested Reading* ..... 87

*Subject Index* ..... 89

# Introduction



**Cytology** is the microscopic evaluation of cells. In many cases, cytology can be useful in establishing a provisional diagnosis, determining a prognosis, and formulating a diagnostic or therapeutic plan. Although cytology should be viewed as a screening tool, most reactions can be classified as inflammatory, hyperplastic, or neoplastic. The type of inflammation usually can be determined, and etiologic agents sometimes can be identified. For neoplastic processes, an experienced cytologist can definitively diagnose several specific neoplasms, make a tentative diagnosis of neoplasia for many types of tumors, identify sites of tumor metastasis, and monitor tumor recurrence following anticancer therapy.

There are several advantages to cytology. Most tissues, organs, and fluids can be sampled; sample collection is relatively noninvasive; and most samples can be collected on an outpatient basis. Sample collection and specimen preparation make use of inexpensive equipment that is readily available in most veterinary practices. In-house interpretations can be made the same day, and interpretations from reference laboratories frequently are available within 24 hours.

Complications associated with sample collection are uncommon and usually are limited to minor hemorrhage. Infection, injury to adjacent structures, and dissemination of neoplastic cells are rare. Absence of tissue architecture is the most notable disadvantage of cytology. The arrangement of neoplastic cells within tissues is critical in the diagnosis of many types of tumors, in evaluating surgical margins, and in establishing whether a tumor is benign or malignant. When the cytologic diagnosis of neoplasia is uncertain, the presence of a tumor and the tumor cell type should be confirmed histologically. Some lesions do not shed cells well, and too few cells may be present for the cytologist to evaluate. In those cases, histologic evaluation may be necessary.

**Interpretation of Canine and Feline Cytology** is divided into four parts: **Part I** covers basic information on sample collection, specimen preparation, and microscopic evaluation. **Part II** discusses interpretation of the microscopic evaluation to reach a cytologic diagnosis of inflammation, hyperplasia, or neoplasia and includes a chapter devoted to identification of organisms. **Part III** contains case studies organized by systems. Reference material is located in **Part IV**. This handbook provides an introduction to cytology, presents some of the more common abnormalities in which cytology is useful for establishing a diagnosis, and points out certain situations in which the cytologic interpretation results in a provisional diagnosis that should be confirmed by histologic evaluation.



# Part I

# Chapter 1: Sample Collection and Specimen Preparation

Choosing an area from which to collect a sample for cytology and deciding the method of sample collection depend on what abnormality is detected clinically. Samples for cytologic evaluation are collected by fine needle aspiration, touch impression, or gentle tissue scraping. Ultrasound is useful for guiding fine needle aspiration of internal organs to increase the likelihood of a diagnostic sample and to decrease the risk of complications. Sampling several sites within the lesion may be beneficial to avoid missing the actual lesion, sampling only an area that is not representative of the lesion, sampling only a necrotic area, or obtaining only blood.

## Preparation of the Collection Site

Preparation of the superficial sites to be aspirated is similar to preparing for venipuncture. Surgical preparation of the aspiration site is recommended for collection from internal masses, joint fluid, body cavity fluids, cerebrospinal fluid, and bone marrow. Specific aspiration sampling techniques for a wide variety of tissues are described in numerous references.

## Fine needle aspirates from solid tissues

Tissues easily aspirated include skin and subcutis, deep and superficial lymph nodes, spleen, liver, kidneys, lungs, thyroid, prostate, and intracavitary masses. The mass, tissue, or organ is identified by palpation, radiography, or ultrasonography and manually isolated. Fine needle aspiration is performed using a 21- to 25-gauge needle of the appropriate length for the desired specimen, coupled to a 6- to 20-ml syringe. Some clinicians prefer using an aspiration device (AspirGun—Helmuth Industries, Linden, NJ), which allows one hand to remain free to immobilize a mass while the other hand is used to aspirate the sample. The needle, coupled to a syringe or aspiration device, is introduced through the skin to penetrate the lesion or tissue and negative pressure is applied several times. Negative pressure should be released before removing the needle from the mass to avoid contamination of the sample with blood or cells from surrounding tissue.

For some small skin masses, using only a small gauge needle to “prick and poke” several times seems to work better

than using a syringe to apply negative pressure. After the mass has been sampled, a syringe filled with air is attached to expel the sample onto a glass slide. This method is similar to the nonaspiration technique that has been described for aspiration of internal masses, in which a syringe filled with a few milliliters of air is attached to a needle. The mass is isolated and the needle is introduced into the mass and redirected several times. No negative pressure is applied. The sample is collected only by the cutting action of the needle. The needle is removed, and the air in the syringe is used to expel the sample onto a glass slide.

Frequently only a small volume of aspirated material is present in the needle or hub of the syringe, but this amount usually is adequate to produce several smears. The syringe can be removed from the needle, filled with air, and reattached to the needle to dispel the sample onto a clean glass slide (stationary slide). A second (spreader) slide is used to disperse the sample using a pull (*Figure 1.1*) or push technique (*Figure 1.2*).

Failure to disperse the cells on the slide creates smears that are too thick for interpretation (*Figure 1.3*). Too much pressure during slide preparation results in broken cells. Preparation of high-quality smears is critical for optimal microscopic evaluation and interpretation. Gentle handling of samples and application of minimal pressure during slide preparation usually result in slides of acceptable quality (*Figure 1.4*).

After smear slides are made, they should be air-dried and labeled. They should not be fixed with heat or acetone or exposed to formalin fumes, as subsequent staining may be inadequate. After the slides have been air-dried, they can be sent to a reference laboratory or stained for in-house interpretation.

## Fine needle aspirates of fluid samples

Fluid from body cavities, joints, and fluid-filled masses can be collected using fine needle aspiration. Collected fluid should be placed in a tube containing ethylenediaminetetraacetic acid (EDTA) to prevent clotting. If the sample clots, cell counts will be inaccurate because most of the cells will be retained in the clots. A portion of the fluid can be placed in a sterile tube for culture and sensi-

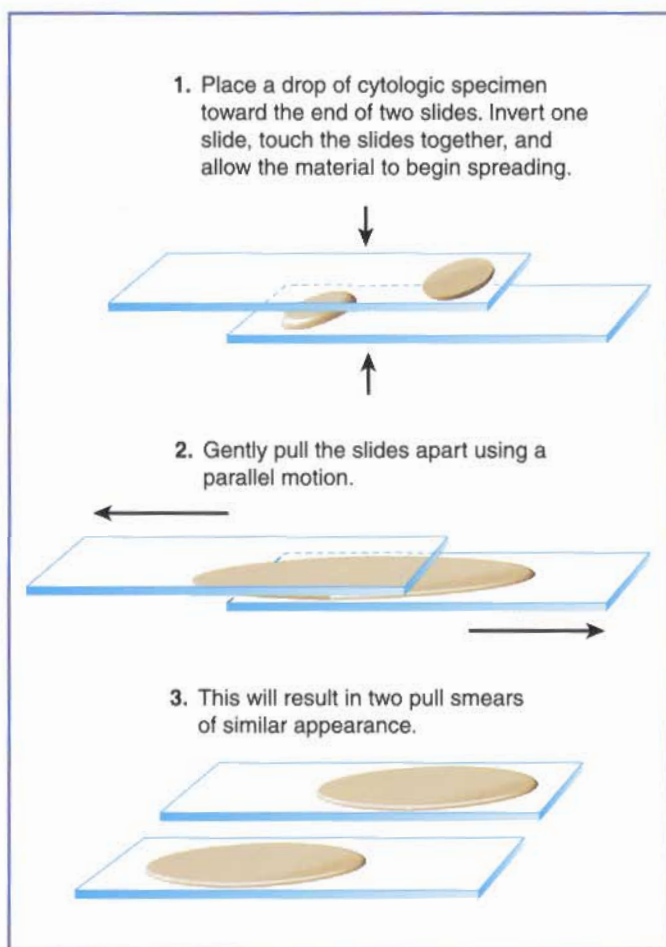


Figure 1.1. The pull technique for making a smear for cytology. (Illustration by Tim Vojt.)

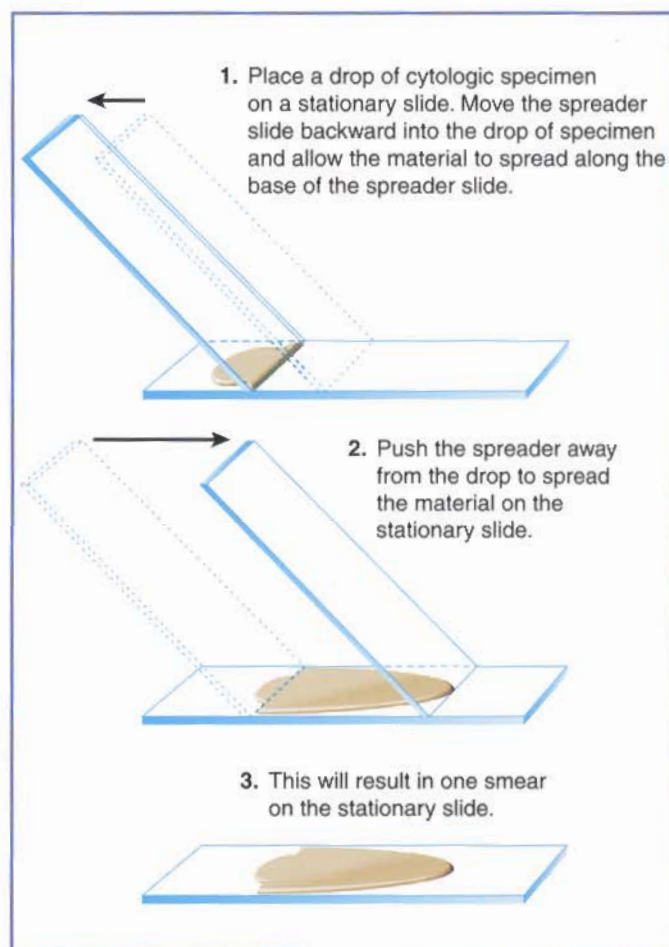


Figure 1.2. The push technique for making a smear for cytology. (Illustration by Tim Vojt.)

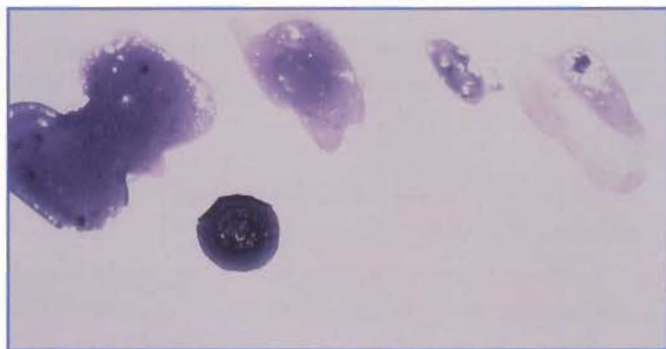


Figure 1.3. This specimen was not dispersed on the slide, resulting in a smear that is too thick for cytologic evaluation.

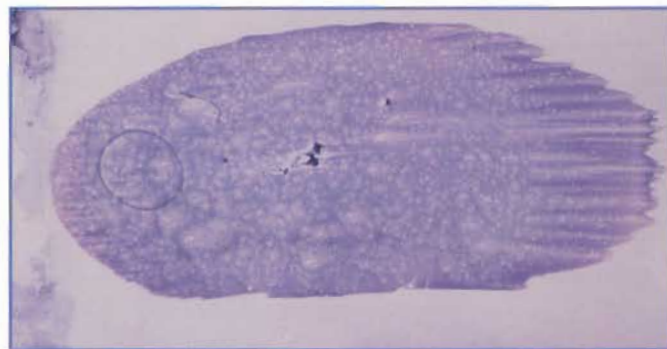
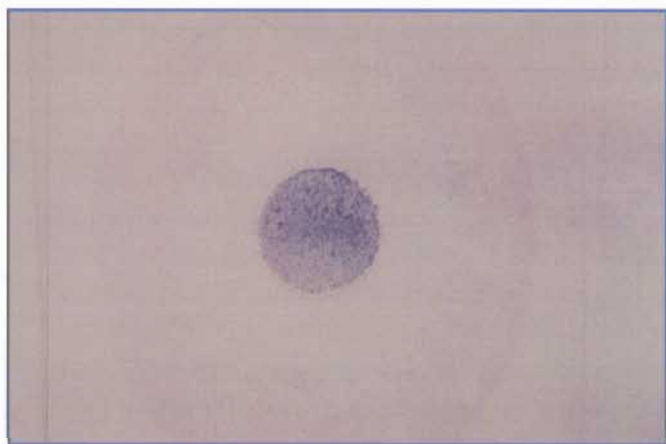


Figure 1.4. This specimen was gently dispersed using the push technique. The smear is a monolayer of intact cells that is adequate for cytologic evaluation.

tivity testing. Analysis of cell count, protein concentration, and specific gravity will determine if the fluid is a transudate, a modified transudate, or an exudate (*see the table "Guidelines to Distinguishing Transudates and Exudates," Part IV*). Cells should be enumerated manually or by electronic particle counters, or should be estimated from a

direct smear. Total protein concentration, specific gravity, or both should be determined by refractometry.

Direct smears should be made if the cell count is  $>10,000/\mu\text{l}$  or if the fluid is turbid or bloody. The pull or push technique can be used. If the fluid is relatively clear, then the cell count will be low, and cytologic interpretation is more



**Figure 1.5.** This fluid specimen was prepared using a cytocentrifuge. The cells are concentrated in a small circular area on the slide.

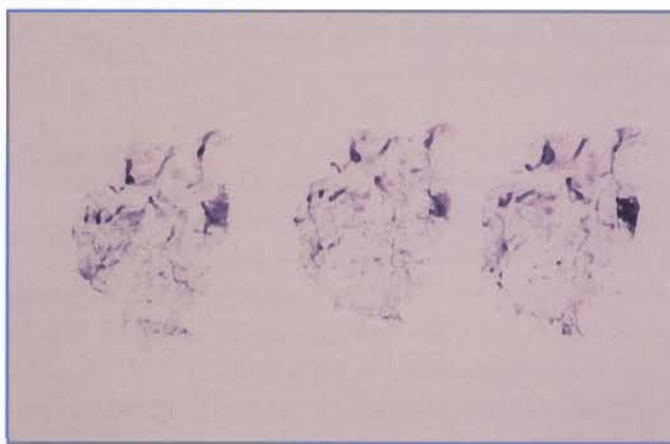readily accomplished if the cells are concentrated. Cells can be concentrated using a cytocentrifuge (*Figure 1.5*) or using techniques similar to preparing urine sediment. The slides are then air-dried and sent to a reference laboratory or stained for in-house interpretation. If a fluid sample is to be sent to a reference laboratory, air-dried direct and sediment smears should be made and submitted with the fluid. Many changes can occur during transport of fluid specimens, including cell degeneration and bacterial overgrowth. Slides made at the time the sample was collected are useful to the clinical pathologist in assessing cell morphology and determining whether clinically significant bacteria are present.

### Impression smears

Impression smears can be made from external masses with an ulcerated surface or from excised tissue. Imprints from ulcerated masses may reveal only secondary inflammation or dysplasia, whereas an aspirate of the underlying tissue might be more diagnostic. Impression smears of ulcerated masses should be made before and after gentle cleansing with 0.9% sterile saline. The ulcerated surface is gently imprinted on a clean glass slide, and the slides are air-dried. For impression smears of tissue biopsies, a scalpel is used to make a freshly cut surface from an area representative of the lesion. The tissue should be gently blotted to remove blood and tissue fluid, then lightly touched to the surface of a clean glass slide. Several impressions can be made from the same tissue on one glass slide (*Figure 1.6*).

### Tissue scrapings

Tissue scrapings can be used for superficial lesions or for excised tissue. Cells are collected by gently scraping the sur-



**Figure 1.6.** Several impression smears were made of an excised piece of tissue. Each impression is adequate for cytologic evaluation.

face of the lesion with the dull side of a scalpel blade or the edge of a microscope slide. The cells are then gently smeared across the surface of a clean microscope slide and allowed to air-dry. This method of sample collection is especially useful for masses with abundant connective tissue or mesenchymal neoplasms, which may not release many cells when fine needle aspirates or impression smears are attempted. Disadvantages of using this method include sampling only superficial areas of the lesion and breakage of many of the cells.

## Mailing Slides to a Reference Laboratory

Slides that are to be sent to a reference laboratory should be air-dried and placed in appropriate slide mailers, which often are provided by the laboratory. The slides should be transported at room temperature to prevent water from condensing on the surface and causing cell lysis. Ideally, cytology samples should be mailed to the reference laboratory separately from formalin-fixed tissues to avoid contact with formalin fumes, which may inhibit optimal staining of air-dried smears.

Cytology specimens should be submitted to the reference laboratory with all of the following information:

- ☐ signalment,
- ☐ a brief history,
- ☐ relevant physical examination findings,
- ☐ previous therapy,
- ☐ a summary of results of pertinent diagnostic tests,
- ☐ the tentative diagnosis, and
- ☐ the site from which the sample was collected.

Often the site can be indicated on a line drawing of the animal included on the submission form from the reference

laboratory. This information is helpful to the pathologist in making an interpretation.

## Stains

Wright's stain, Wright-Giemsa stain, and new methylene blue stain are most commonly used for cytologic preparations. Most commercially available stains, such as Diff-Quik (Harleco, Gibbstown, NJ) and Dip-Stat (Medi Chem Corp, Santa Monica, CA), are modifications of Wright's or Wright-Giemsa stain and are inexpensive and easy to use. Wright's and Wright-Giemsa stains provide good color contrast, cytoplasmic detail is very good, nuclear detail is acceptable, and most infectious agents are stained. These stains also are permanent, which is an advantage to practitioners who interpret cytology in-house and want a second opinion from a clinical pathologist. Wright's and Wright-Giemsa stains will stain mast cell granules purple, whereas some commercially available quick stains do not consistently stain mast cell granules. This is important to remember because cutaneous mast cell tumors occur relatively commonly in dogs. These tumors may be misdiagnosed by cytology if only commercial quick stains are used.

New methylene blue stain results in better nuclear detail than does Wright's stain, but color contrast is poor and it is not a permanent stain. Nucleoli are very prominently stained with new methylene blue, which may lead the novice cytologist to incorrectly interpret a benign lesion as a malignant one. New methylene blue also does not stain

the granules in some mast cell tumors. Because the granules are such a characteristic feature of mast cell tumors, mast cells stained with new methylene blue may be incorrectly interpreted as macrophages.

Special stains may sometimes be used to determine cell lineage or to identify etiologic agents. These stains usually are available at commercial reference laboratories or academic institutions. Identification of intermediate filaments, immunophenotyping, determination of surface antigens, and polymerase chain reaction technology are newer techniques that have been used to increase the sensitivity of cytologic evaluation.

### SAMPLE COLLECTION AND SPECIMEN PREPARATION TIPS

- ☐ Use clean glass slides.
- ☐ Avoid formalin fumes.
- ☐ Disperse cells on the slide.
- ☐ Avoid blood contamination.
- ☐ Be gentle in preparing smears.
- ☐ Sample several representative areas.
- ☐ Evaluate multiple slides from each lesion.
- ☐ Air-dry specimens quickly (do not use heat or hairspray).
- ☐ Work quickly so sample does not clot or dry before smears are prepared.

## Chapter 2: Approach to a Cytologic Specimen

### Microscopic Evaluation

The cytologist should use a high quality microscope equipped with 10× and 100× (oil immersion) objectives and adjusted for optimal Koehler illumination (*Figure 2.1*). Cytologic findings should be correlated with other clinical and laboratory information to avoid misinterpretation. Primary differentials may vary with species, breed, and age

of the patient, and geographic area. Knowledge about tumor incidence, site predilection, and gross morphology is useful in the cytologic diagnosis of neoplasia. The cytologist should recognize that histologic evaluation of excised tissue might be necessary to distinguish hyperplasia from neoplasia and to make the definitive diagnosis for many neoplasms.

A cytologic smear or imprint should be observed grossly

### INSTRUCTIONS FOR KOEHLER ILLUMINATION OF A MICROSCOPE

- ❑ Place a glass slide with a stained smear on the **stage**, turn on the light source, swing the **10× objective** in place, and use the **coarse focus knob** to adjust the image to slightly out of focus.
- ❑ Close the field diaphragm to its smallest size using the field diaphragm control ring. The **field diaphragm control ring** usually is located on the base of the microscope. Visualize closing the field diaphragm as a circle of light that decreases in size (*B*).
- ❑ Move the **condenser** vertically by rotating the **condenser focus knob** until a sharp image of the leaves of the field diaphragm forms on the specimen. The condenser focus knob usually is located on the side of the microscope, just below the stage. As the knob is moved, the leaves or edges of the field diaphragm come into focus. When the edges are in sharp focus, they typically appear slightly green or light orange.
- ❑ Use the **condenser centering screws** to bring the image of the field diaphragm to the center of the field of view. The condenser centering screws are located on the front or sides of the **condenser**, which is the apparatus under the stage of the microscope. When this adjustment is made, a circle of light moves toward the center of the field of view (*B*).
- ❑ Use the field diaphragm control ring to open the field diaphragm so that the diaphragm's image is about the same size

as that of the field of view. The circle of light becomes larger as this adjustment is made.

- ❑ Check frequently to ensure that the condenser is properly positioned for optimal illumination, especially if the microscope has multiple users.

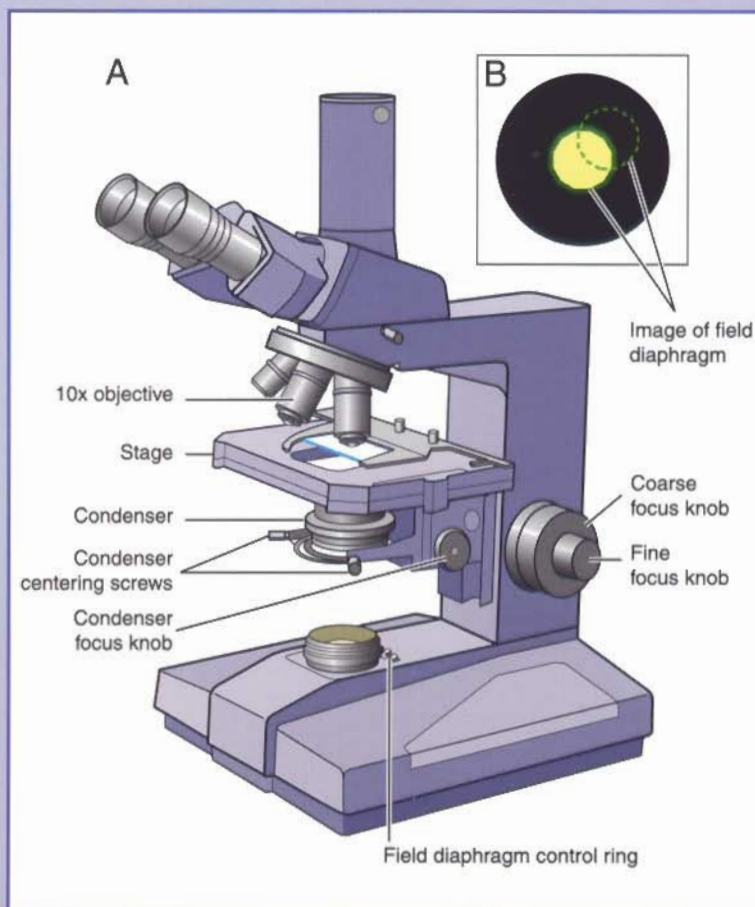


Figure 2.1. A, Microscope equipped with 10X objective. B, Representation of the field diaphragm. (Illustration by Tim Vojt.)

---

to evaluate the quality of the preparation and to locate cellular areas on the slide to examine microscopically. The slide is then scanned with the 10× objective to estimate cellularity of the sample; observe cell-to-cell associations; identify large etiologic agents, such as parasites and fungal hyphae; and locate areas to be examined with higher magnification. Scanning the entire slide with the 10× objective is important because cells may be distributed on only a small part of the slide, or a single etiologic agent may be present that would be missed if only portions of the slide were examined.

The 100× (oil immersion) objective is used to determine what kinds of cells are present, examine cellular detail, and identify etiologic agents. Changes in nuclear and cytoplasmic morphology characteristic of neoplastic cells are best evaluated at this higher magnification. Only intact cells that are adequately dispersed should be examined and interpreted. Disrupted cells reveal artifactually enlarged nuclei, pale-staining diffuse chromatin, and nucleolar prominence, all of which may be misinterpreted as cytologic characteristics of neoplastic cells. Nuclear and cytoplasmic detail cannot be adequately evaluated in cells that are inadequately dispersed.

## Part II

## Chapter 3: Interpretation of a Cytologic Specimen

Interpreting cytologic specimens requires knowledge of normal cellular and tissue morphology, recognition of the limitations of cytology, and experience. Correlation of cytologic findings with clinical and laboratory information as well as knowledge of location, gross appearance, and behavior of the lesion allow maximum useful information to be obtained from a sample and help avoid overinterpretation. It is helpful to try to categorize a cytologic specimen as inflammatory or noninflammatory, to distinguish between hyperplasia and neoplasia, to differentiate between benign and malignant tumors, and to distinguish between hemorrhage and blood contamination.

### USEFUL DISTINCTIONS FOR A CYTOLOGIC SPECIMEN

- ☐ Inflammatory vs noninflammatory
- ☐ Hyperplasia vs neoplasia
- ☐ Benign vs malignant tumor
- ☐ Hemorrhage vs blood contamination

### Inflammation

Inflammation is characterized by a mixed population of cells that may include neutrophils, lymphocytes, plasma cells, monocytes, macrophages, eosinophils, and mast cells. These cells appear in varying proportions, depending on the cause and chronicity of the inflammatory process (Table 1). Inflammation may be present as a response to an infectious agent, foreign material, tissue necrosis, or allergen. In addition, some benign and malignant neoplasms may induce an inflammatory response.

In general, an acute inflammatory response is characterized by a predominance of neutrophils. Neutrophils can be described as nondegenerate (morphologically normal, Figure 3.1) or degenerate (Figure 3.2). Characteristics of degenerate neutrophils include nuclear swelling, karyorrhexis, karyolysis, cytoplasmic basophilia, and cytoplasmic vacuolization. Presence of degener-

ative changes in neutrophils usually is suggestive of a bacterial etiology. The specimen should be carefully examined for bacteria (Figure 3.2) and a culture should be performed.

As an inflammatory response becomes more chronic, increasing numbers of lymphocytes, plasma cells, mono-

**TABLE 1. INFLAMMATORY CELLS AND ASSOCIATED DIFFERENTIAL DIAGNOSIS**

<i>Predominant Cell Type</i>	<i>Differential Diagnosis</i>
<b>Neutrophils</b>	Bacterial infection Fungal infection Protozoal infection Immune-mediated disease Trauma Chemical injury Inflammation secondary to neoplasia
<b>Neutrophils and macrophages</b>	Bacterial infection ( <i>Nocardia</i> spp, <i>Actinomyces</i> spp) Fungal infection Protozoal infection Foreign body or injection site reaction Trauma Chemical injury Inflammation secondary to neoplasia
<b>Macrophages</b>	Fungal infection Protozoal infection Foreign body reaction Lick granuloma Inflammation secondary to neoplasia Neoplasia involving macrophages
<b>Eosinophils</b>	Hypersensitivity Parasitic infection Fungal infection Eosinophilic granuloma Mast cell tumor

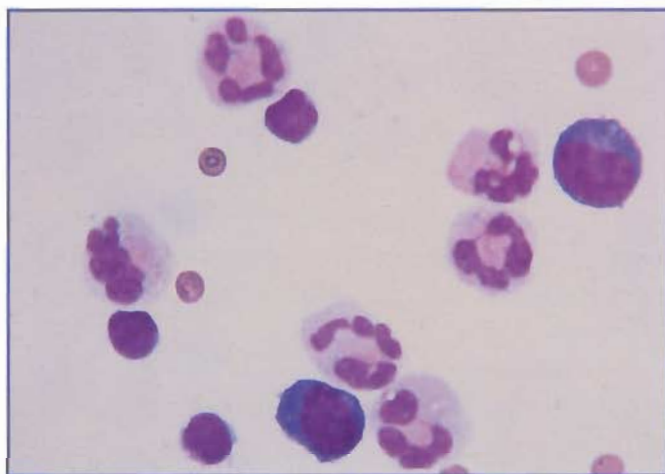


Figure 3.1. Pleural effusion from a cat. The neutrophils have normal morphology (ie, are nondegenerate). (Wright's stain; 1000X)

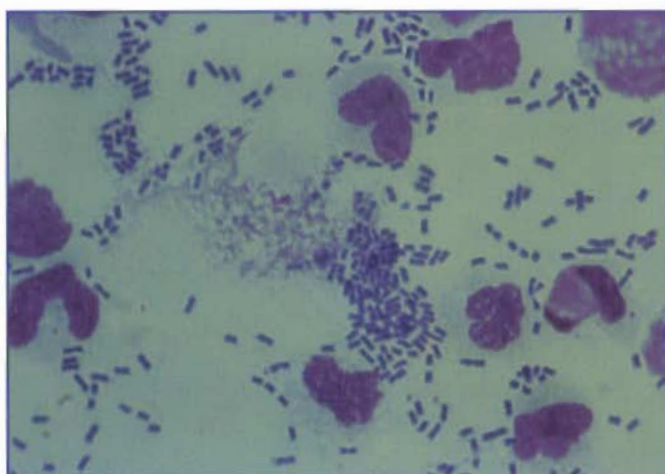


Figure 3.2. Degenerative changes in neutrophils frequently occur as a result of bacterial infection. Note the many rod-shaped bacteria in this effusion. (Wright's stain; 1000X)

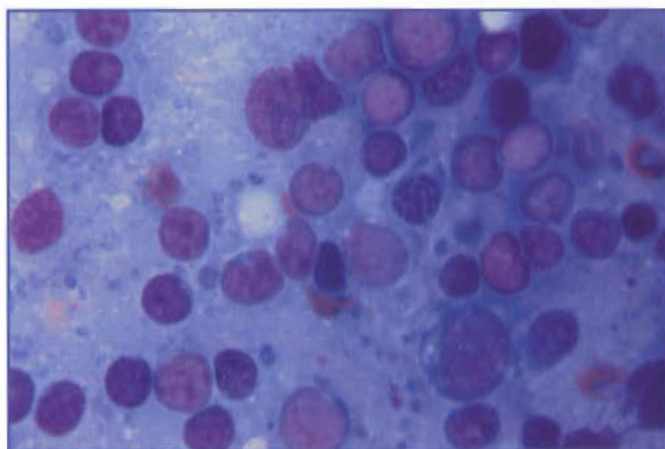


Figure 3.3. Lymphoplasmacytic inflammation is characterized by a mixed population of mature lymphocytes, plasma cells, and a few large lymphocytes. (Wright's stain; 1000X)

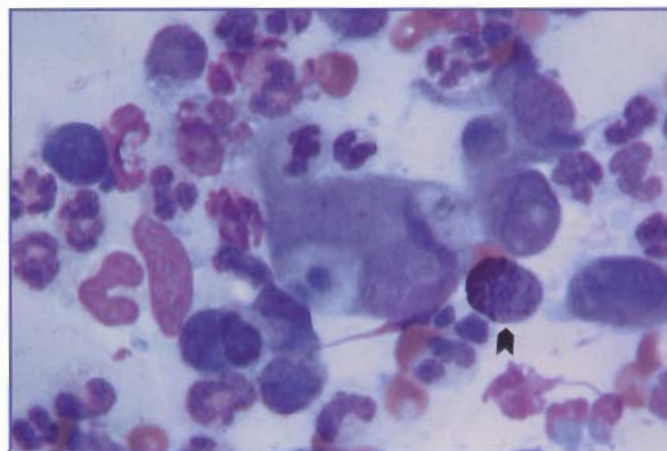


Figure 3.4. Pyogranulomatous inflammation is evident in this aspirate from a skin nodule on the ear of a dog. The large macrophage in the center has phagocytized cellular debris. The arrow indicates a mast cell. (Wright's stain; 1000X)

cytes, and macrophages appear (*Figures 3.3 and 3.4*). Macrophages may be assessed for level of activity, including vacuolization of their cytoplasm and phagocytosis. In chronic responses, epithelioid macrophages or multinucleated giant cells (*Figure 3.5*) may be seen. Mixed or pyogranulomatous inflammation may result from chronic bacterial infections, mycotic infections, protozoal infections, or reactions to foreign material.

Eosinophils and mast cells may be part of an inflammatory response. These cells are more likely to be encountered with chronic inflammation. Allergic reactions, presence of a parasite, and response to foreign material are more likely to have an eosinophilic component in the inflammatory response. High numbers of eosinophils are seen in lesions from cats with indolent ulcers or eosinophilic granulomas. Eosinophils may be associated with some neoplasms, such as mast cell tumors or, occasionally, lymphoma.

### Hyperplasia, Metaplasia, Dysplasia

Hyperplasia, metaplasia, and dysplasia can occur in response to irritation, inflammation, altered cellular signaling (eg, hormone imbalances), or subsequent to tissue destruction and regeneration. Because of the association with inflammation, inflammatory cells are often present in the specimens. Cells from hyperplastic tissues usually appear more immature but otherwise resemble normal cells (*Figure 3.6*). Cytologic characteristics of hyperplastic cells include large nuclei with poorly condensed chromatin and prominent nucleoli. Cytoplasm is often basophilic. Hyperplastic cells have a relatively constant nuclear to cytoplasmic (N:C) ratio (nuclear size compared to amount

of cytoplasm present). This is an important feature in distinguishing hyperplasia from neoplasia.

In metaplasia, cellular characteristics are altered to resemble a different type of tissue and must be distinguished from the presence of neoplastic cells. This change is most commonly seen when glandular epithelium has areas that take on the appearance of squamous epithelium, for example, in squamous metaplasia of the prostate (Figure 3.7). Dysplasia can also occur and is characterized by abnormal development of the cells of the involved tissue. Dysplastic cells may exhibit many of the criteria of malignancy and be misinterpreted as neoplastic cells. Distinguishing between neoplasia and a hyperplastic, metaplastic, or dysplastic tissue response can be difficult. If there is concern that an inflammatory or other process is associated with a neoplasm, biopsy and histologic evaluation may be indicated for a definitive diagnosis.

## Neoplasia

In cytologic preparations, neoplasia may be recognized when there are cells present that do not have normal characteristics expected for the tissue or are clearly out of place (eg, metastatic to a location, such as lymph node, liver, or spleen). Because neoplasms are clonal expansions of a single cell type, cells from a tumor appear similar and are often described as a uniform or monomorphic population, even though they may show marked morphologic atypia. Cytologic features of neoplastic cells vary with the cell of origin. In general, neoplastic cells are larger, more pleomorphic, and have a higher and more variable N:C ratio when compared to normal cells from the same tissue. Some neoplasms may be associated with an inflammatory response, complicating interpretation of the cytologic specimen.

Benign neoplasms tend to yield cells that are uniform in size and appearance, and cells appear to be at the same stage of differentiation. Nuclei have a similar chromatin pattern, and nucleoli usually are small and regular in outline and number. Frequently, the variation in N:C ratio is minimal. It is often necessary to use histology to distinguish between a benign tumor and hyperplasia.

In malignant neoplasms, cells appear more pleomorphic and less well differentiated (Figure 3.8). There is moderate to marked variation in cell size (anisocytosis) and in nuclear size (anisokaryosis). While the N:C ratio tends to increase with malignancy, marked variability in N:C ratio from cell to cell may occur in a given specimen. In some cases malignant cells may appear to be at different stages of

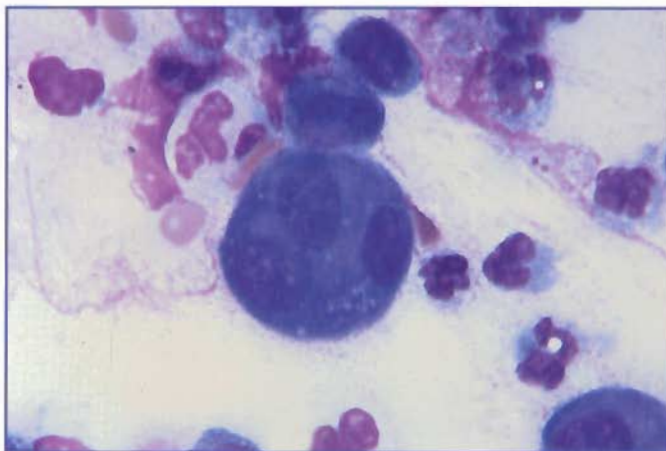


Figure 3.5. Tracheal wash from a dog. The large cell in the center is a multinucleated giant cell. (Wright's stain; 1000X)

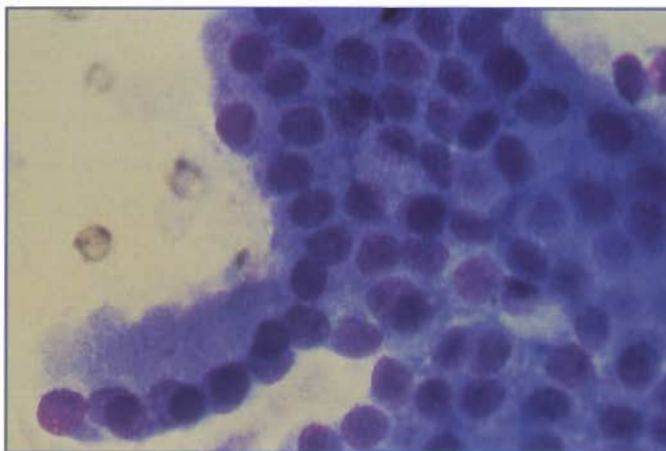


Figure 3.6. Sheet of hyperplastic prostatic epithelial cells from a dog with benign prostatic hyperplasia. The N:C ratio is uniform, albeit somewhat greater than normal. In addition, the hyperplastic cells have more basophilic cytoplasm and finer, reticulated chromatin, but otherwise resemble normal prostatic epithelial cells. Prostatic hyperplasia typically occurs secondary to inflammation or a hormonal imbalance in older dogs. It can be a preneoplastic change. (Wright's stain; 1000X)

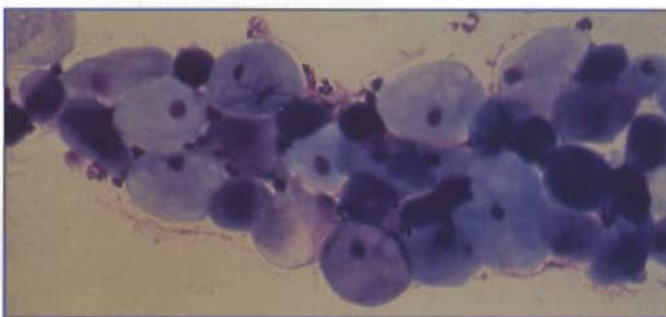
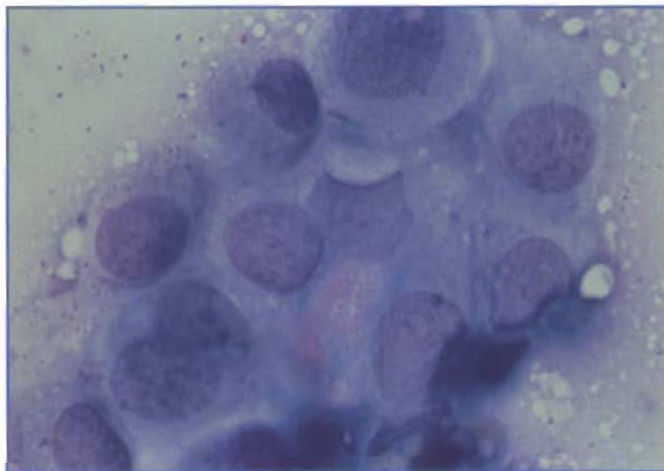


Figure 3.7. Squamous metaplasia of prostatic epithelium from a dog. Cells have an enlarged, flattened appearance instead of the normal tall, cuboidal appearance. This change may occur in response to hormonal stimulation, such as estrogen secretion from a Sertoli cell tumor, or in response to inflammation. (Wright's stain; 400X)



**Figure 3.8.** Prostatic adenocarcinoma from a dog. These cells display many of the nuclear criteria of malignancy, including fine chromatin, nucleoli, and multinucleation. The N:C ratio is variable, and the cells show anisokaryosis and anisocytosis. (Wright's stain; 1000X)

differentiation, and there may be asynchrony in nuclear and cytoplasmic maturation.

Nuclear features are of primary importance in assessing malignancy. Those suggestive of malignancy include anisokaryosis; macronuclei; multinucleation with abnormal nuclei; nuclear molding; finely dispersed or coarsely clumped chromatin; a thickened, angular, or indented nuclear membrane; nucleoli that are large, multiple in number, or irregularly shaped; and abnormal mitotic figures.

Cytoplasmic features suggestive of malignancy include increased basophilia, abnormal vacuoles or granules, and phagocytosis of other cells.

### CRITERIA FOR ASSESSING MALIGNANCY

#### Nuclear features

- ☐ Anisokaryosis
- ☐ Macronuclei
- ☐ Multinucleation
- ☐ Nuclear molding
- ☐ Finely dispersed or coarsely clumped chromatin
- ☐ Thickened, angular, or indented nuclear membrane
- ☐ Large, multiple, or irregularly shaped nucleoli
- ☐ Abnormal mitotic figures

#### Cytoplasmic features

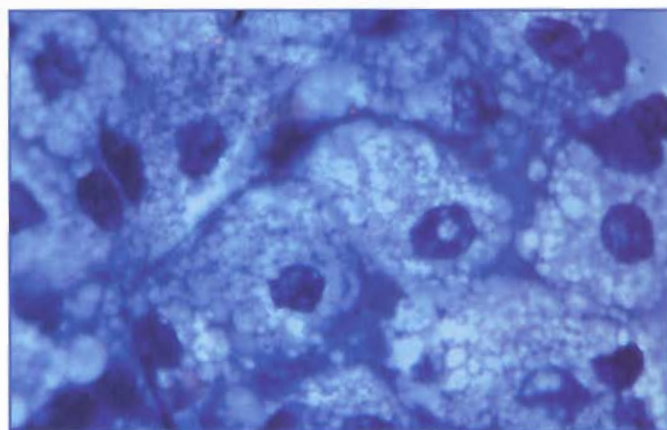
- ☐ Increased basophilia
- ☐ Abnormal vacuoles or granules
- ☐ Cytophagia

## Comparison of Epithelial, Mesenchymal, and Round Cell Neoplasms

### Epithelial neoplasms

Neoplastic epithelial cells tend to exfoliate readily in clusters and sheets of round to polygonal cells. The cell borders usually are well defined, although some types of neoplastic epithelium tend to lose their cytoplasm as an artifact of preparation. This loss results in clusters of bare nuclei stripped of their cytoplasm (eg, basal cell tumors or thyroid tumors). Cells from benign epithelial tumors or adenomas are uniform in appearance and may appear relatively well differentiated (*Figure 3.9*). In contrast, cells from malignant epithelial neoplasms or carcinomas can be markedly pleomorphic.

Adenocarcinomas, originating from glandular epithelial cells, may form patterns reminiscent of acinar or ductular structures. Their cytoplasm often is deeply basophilic and may be vacuolated or distended, suggesting production of a secretory product (*Figure 3.10*). In contrast, cells obtained from a squamous cell carcinoma are more individualized (*see Figure 6.16*), have deeply basophilic cytoplasm, and may show varying degrees of keratinization. Cells derived from carcinomas of the uroendothelium (transitional cell carcinomas) usually are very pleomorphic and may exfoliate as clusters or as individual cells (*Figure 3.11*). Multinucleation and nuclear molding are common. Cytoplasmic basophilia is variable. Often, individual large cells with abundant cytoplasm are interspersed within clusters of cells with higher N:C ratios.



**Figure 3.9.** Sebaceous gland adenoma from a dog. In this benign epithelial neoplasm, the cells have small nuclei with condensed chromatin and abundant, foamy cytoplasm. Cytoplasmic borders are distinct, and the cells form clusters. These cells are well differentiated, and it is not possible cytologically to distinguish sebaceous gland hyperplasia from benign adenoma. (Wright's stain; 1000X)

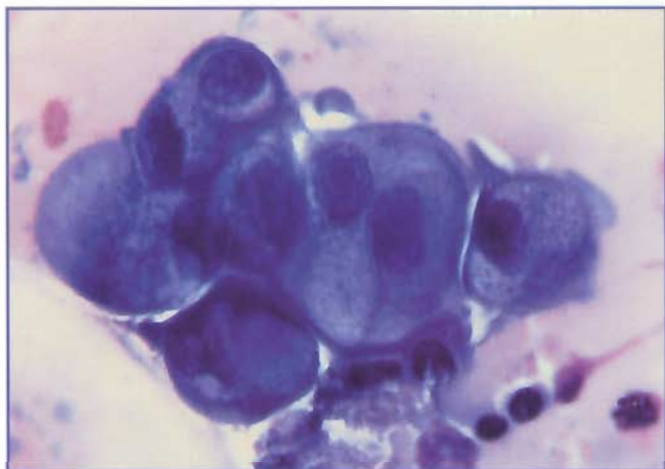

Figure 3.10. Mammary adenocarcinoma from a cat. The majority of mammary tumors in cats are malignant. Cells in this aspirate show typical characteristics of an adenocarcinoma, including exfoliating in clusters, multinucleation, and fine chromatin. These cells have the appearance of secretory cells with eccentrically placed nuclei and distended basophilic cytoplasm. (Wright's stain; 1000X)

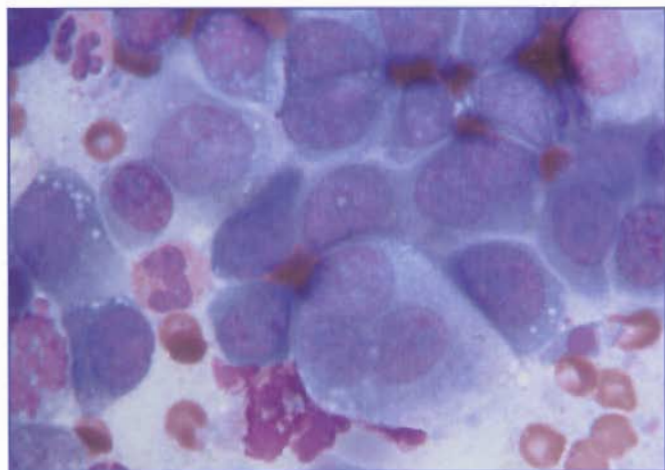


Figure 3.11. Transitional cell carcinoma from the bladder of a dog. These neoplasms of the uroendothelium occur in aged dogs and rarely in cats. Cells may exfoliate as individuals or in clusters, and there is often marked atypia. Large cells with abundant cytoplasm are often interspersed with groups of cells that have higher N:C ratios. Multinucleation is common. (Wright's stain; 1000X)

### Mesenchymal neoplasms

Neoplastic mesenchymal cells generally do not exfoliate well when sampled by aspiration or impression. It may be necessary to scrape the sample to obtain cells for evaluation. Mesenchymal cells usually are individualized and may be elongated to spindle-shaped (Figure 3.12). Nuclei are oval to irregular in shape, and the cytoplasm may vary in degree of basophilia. Depending on cell lineage, extracellular matrix may be observed (eg, osteoid with osteosarcomas). Malignant mesenchymal neoplasms are called sarcomas and can be very pleomorphic in appearance.

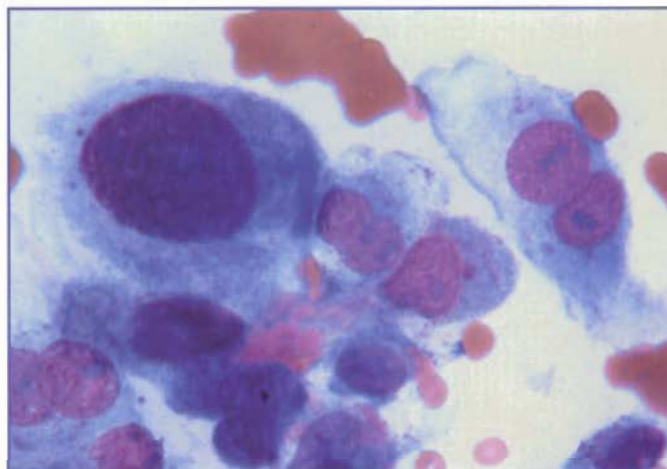


Figure 3.12. Sarcoma in a cat. These cells show typical characteristics of a malignant mesenchymal neoplasm or sarcoma. Nuclear characteristics include multinucleation, marked anisokaryosis, fine chromatin, and prominent nucleoli. The cells are individualized, elongated, and have indistinct cytoplasmic borders. (Wright's stain; 1000X)

### Round cell tumors

Several neoplasms involving skin and subcutaneous tissue can be definitively diagnosed with confidence using cytology. These neoplasms are referred to as round cell tumors or discrete cell tumors because of their characteristic appearance both cytologically and histologically. Round cell tumors include mast cell tumor, lymphoma, plasmacytoma, histiocytoma, and transmissible venereal tumor. Microscopically, cells from these tumors are round and have well defined cytoplasmic margins (Figure 3.13). These cells do not have cell-to-cell attachments and, therefore, appear as separate or discrete cells.

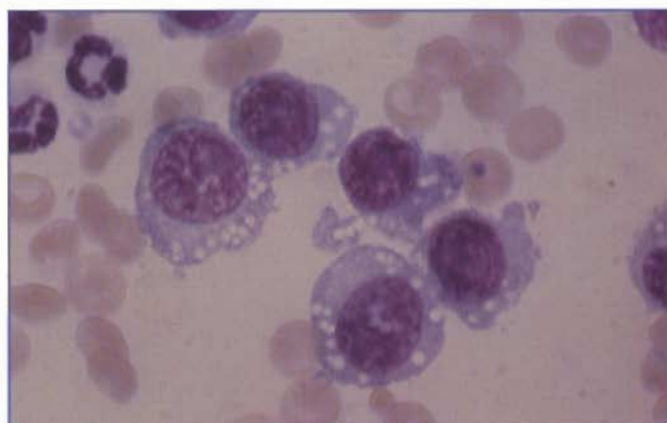


Figure 3.13. Transmissible venereal tumor on the prepuce of a dog. This round cell neoplasm is characterized by individualized cells containing a single, round, often eccentrically placed nucleus. The chromatin is coarsely granular; and there is usually a single, prominent nucleolus. Cytoplasm is moderately abundant, is pale blue to moderately basophilic, and often contains small vacuoles. (Wright's stain; 1000X)

Most round cell tumors exfoliate well when sampled by fine needle aspiration or impression, and many have characteristic cytologic features that are useful in making a definitive diagnosis.

#### ROUND CELL TUMORS

- ☐ Mast cell tumor
- ☐ Lymphoma
- ☐ Plasmacytoma
- ☐ Histiocytoma
- ☐ Transmissible venereal tumor

### Hemorrhage Versus Blood Contamination

It is important to recognize when hemorrhage has occurred into body cavities, joint spaces, or other tissues. Many tissues (eg, liver and spleen), as well as many neoplasms, are highly vascular. As a result, samples from these sites may have significant blood contamination, where blood is introduced during the collection process. In these cases, blood in the sample is an artifact of obtaining the sample and does not reflect a pathologic process. Therefore, it is important to try to distinguish cytologically between hemorrhage and blood contamination.

With fresh blood contamination, platelets can be seen. However, absence of platelets does not rule out blood contamination because platelets may be lost prior to slide preparation as a result of clotting. With blood contamination, the distribution of erythrocytes and leukocytes resembles that observed in peripheral blood.

Phagocytosis of erythrocytes by macrophages along with formation of hemosiderin (Figure 3.14) and/or hematoidin crystals (Figure 3.15) secondary to erythrocyte breakdown, indicates that hemorrhage has occurred within at least the past 24 hours. Fluids may take on an orange to yellow color (xanthochromia) as erythrocytes are metabolized and bilirubin is released. Interpretation of erythrophagocytosis in fluids without evidence of erythrocyte metabolism may be more problematic if slides are not prepared immediately following sampling. Macrophages may remain active within sample tubes and phagocytize erythrocytes *ex vivo*. This is sometimes observed in fluid samples that have been shipped overnight to a reference lab.

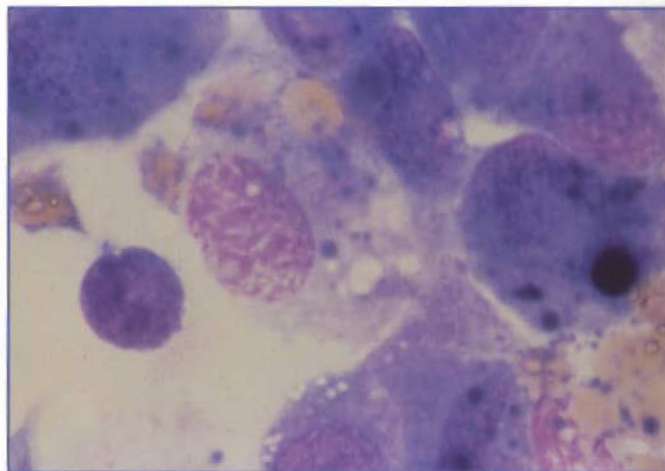


Figure 3.14. Erythrophagocytosis and hemosiderin within macrophages indicate that hemorrhage has occurred. The macrophage on the left contains several erythrocytes. The blue-black pigment in the cytoplasm of the two macrophages is hemosiderin. (Wright's stain; 1000X)

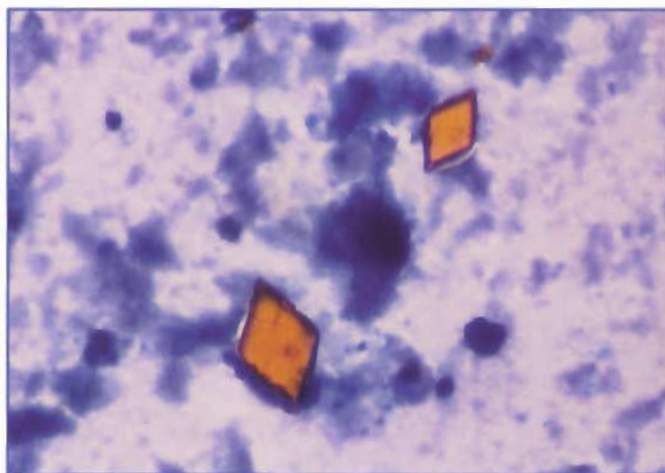


Figure 3.15. Hematoidin crystals are yellow-orange, rhomboid-shaped crystals that result from the breakdown of hemoglobin. They may be seen in aspirates of tissues or fluids in which hemorrhage has occurred. (Wright's stain; 1000X)

It is also necessary to determine whether leukocytes present in a cytology sample are derived from blood contamination or are part of an inflammatory response. The best approach is to compare cytologic observations of leukocyte number and differential with the findings obtained from a complete blood count (CBC).

# Chapter 4: Cytologic Appearance of Etiologic Agents

Infectious agents that can be recognized by cytology include bacterial, fungal, and parasitic organisms.

Selected organisms in these categories are illustrated in the following figures.

BACTERIA ASSOCIATED WITH SKIN LESIONS		
Organism	Cytologic Appearance	Schematic
<i>Actinomyces</i> , <i>Nocardia</i> , <i>Fusobacterium</i> spp	Branching, filamentous "beaded" rods (anaerobic) 0.2-1.0 $\mu\text{m}$ $\times$ 2-5 $\mu\text{m}$ ; filaments 10-50 $\mu\text{m}$ long	
<i>Clostridia</i> spp	Large rods; may form spores (anaerobic) 0.3-2.0 $\mu\text{m}$ $\times$ 1.5-20 $\mu\text{m}$	
<i>Dermatophilus congolensis</i>	Branching filaments of paired rows of cocci Resembles "stacked coins" (aerobic, facultative anaerobe)	
<i>Mycobacterium</i> spp	Clear rods; stain red with acid- fast stains Usually intracellular (aerobic) 0.2-0.7 $\mu\text{m}$ $\times$ 1-10 $\mu\text{m}$	
<i>Simonsiella</i> organisms	Large rods positioned side by side Dark blue or purple Often adhere to squamous epithelial cells 0.6-1.0 $\mu\text{m}$ $\times$ 0.5-3 $\mu\text{m}$ rods, occurring in stack 10-50 $\mu\text{m}$ long	
<i>Staphylococcus</i> spp	Clusters of 4-12 purple cocci (aerobic) 0.5-1.5 $\mu\text{m}$	
<i>Streptococcus</i> spp	Chains of purple cocci (aerobic) 0.5-2.0 $\mu\text{m}$	

Figure 4.1. Selected bacteria that can be associated with skin lesions. (Holt JG, Krieg NR, Sneath PHA, Staley JT, Williams ST. *Bergey's Manual of Determinative Bacteriology*, Ninth Edition. Baltimore, Md: Williams & Wilkins, 1994. Illustration by Tim Vojt.)

### FUNGI ASSOCIATED WITH SKIN LESIONS


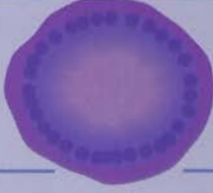





Organism	Cytologic Appearance	Schematic
<i>Blastomycosis dermatitidis</i>	Round, thick-walled, broad-based budding yeasts 8-20 $\mu\text{m}$ in diameter Deeply basophilic	
<i>Coccidioides immitis</i>	Round spherules that may contain endospores 10-100 $\mu\text{m}$ (spherules), 2-5 $\mu\text{m}$ (endospores) Blue or clear, double-contoured spherules	
<i>Cryptococcus neoformans</i>	Round (typical) to fusiform yeasts 4-40 $\mu\text{m}$ in diameter, depending on capsule Pink to bluish-purple with thick nonstaining capsule (occasionally nonencapsulated)	
<i>Histoplasma capsulatum</i>	Round to oval yeasts 2-4 $\mu\text{m}$ in diameter Pale to medium blue with halo around yeast Eccentric pink or purple nucleus	
<i>Malassezia</i> organisms	Oval or club-shaped yeasts 2-4 $\mu\text{m}$ in diameter Deeply basophilic	
<i>Microsporum</i> , <i>Trichophyton</i> spp	Mycelia and arthrospores within hair shafts Medium to dark blue with thin, clear halo	
<i>Sporotrichum schenckii</i>	Round, oval, or fusiform (cigar-shaped) yeasts 3-10 $\mu\text{m}$ long, 1-3 $\mu\text{m}$ wide Pale to medium blue, pink, or purple nucleus	

Figure 4.2. Fungi that can be associated with skin lesions. (Illustration by Tim Vojt.)

### SELECTED PARASITES ASSOCIATED WITH RESPIRATORY DISEASE







Organism	Species	Cytologic Appearance	Schematic
<i>Aelurostrongylus abstrusus</i>	Cats	First-stage larvae S-shaped tail 360 $\mu\text{m}$ long	
<i>Capillaria aerophila</i>	Cats and dogs	Double-operculated, oval eggs Asymmetrical terminal plugs 70 $\mu\text{m}$ long, 35 $\mu\text{m}$ wide	
<i>Crenosoma vulpis</i>	Dogs	Bluntly conical anterior end Finely tapered posterior end with slight bend 246-308 $\mu\text{m}$ long	
<i>Filaroides hirthi</i>	Dogs	Larvae with kinked tail 240-390 $\mu\text{m}$ long Found in lung	
<i>Ostertesia osleri</i> ( <i>Filaroides osleri</i> )	Dogs	Larvae with kinked tail 240-390 $\mu\text{m}$ long Found in trachea	
<i>Paragonimus kellicotti</i>	Cats and dogs	Operculated, ovoid eggs Appear golden 75-120 $\mu\text{m}$ long, 45-65 $\mu\text{m}$ wide	

Figure 4.3. Selected parasites that can be associated with respiratory disease. (Illustration by Tim Vojt.)

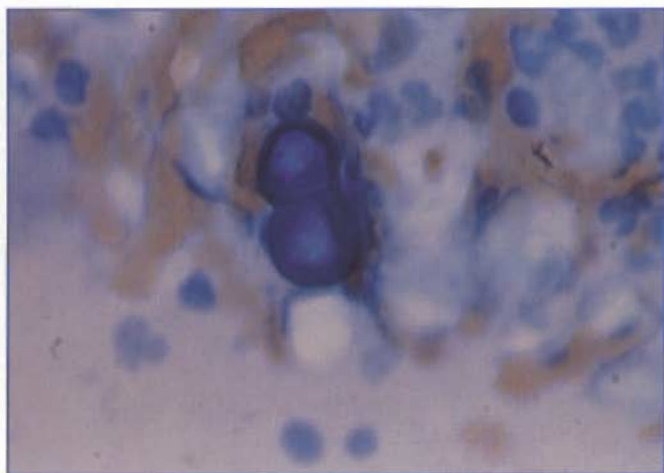


Figure 4.4. Aspirate of a lung mass from a cat. The large, thick-walled, deeply basophilic yeasts in the center are *Blastomyces dermatitidis*. Broad-based budding typical of this organism is evident. The organism has elicited a pyogranulomatous inflammatory response. (Wright's stain; 1000X)

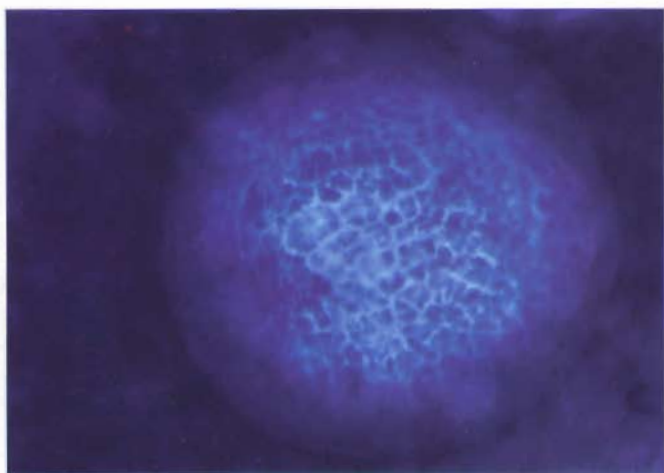


Figure 4.5. The spherule of *Coccidioides immitis* is large and may stain deeply basophilic. It is necessary to focus up and down to observe the detail of the endospores, as illustrated. (Wright's stain; 1000X)

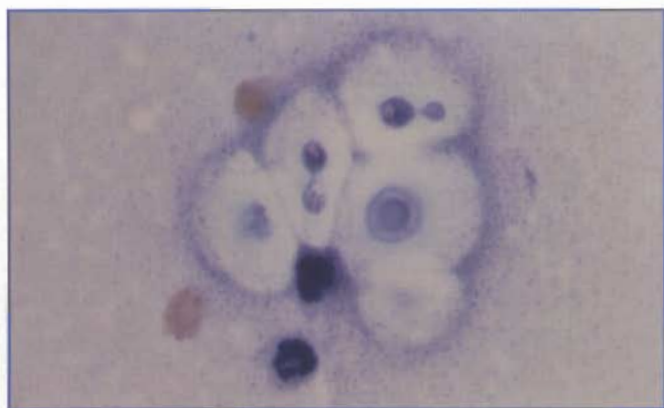


Figure 4.6. Aspirate of a periorbital mass from a dog. The extracellular, round fungal organisms with a large, clear, prominent capsule are *Cryptococcus neoformans*. Variation of the yeast and capsule size results in a pleomorphic appearance. Narrow-based buds are seen on two of the organisms. Although *C. neoformans* elicits a pyogranulomatous inflammatory response, aspirates of the lesions often result in numerous organisms with few inflammatory cells evident. (Wright's stain; 1000X)

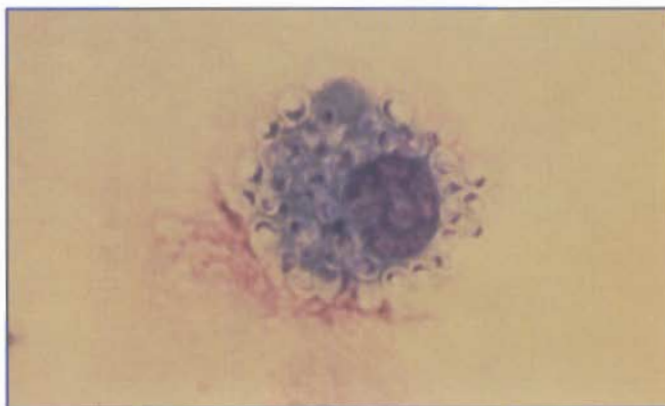


Figure 4.7. Tracheal wash from a cat. Many *Histoplasma capsulatum* organisms are seen within a macrophage. This yeast has a small, round body with a basophilic center and lighter halo. While the organisms usually are within macrophages, it is also common to see them free in the background as a result of breakage of cells during smear preparation. (Wright's stain; 1000X)

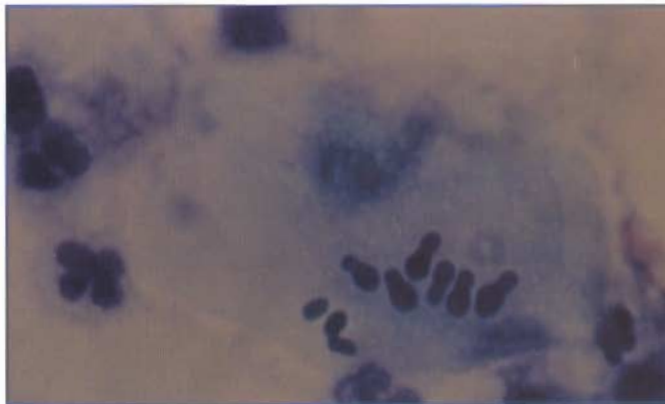

Figure 4.8. Ear swab from a dog. The oval to club-shaped (footprint-shaped) yeasts on the surface of the keratinized epithelial cells are *Malassezia* spp. A neutrophilic inflammatory response is apparent. (Wright's stain; 1000X)

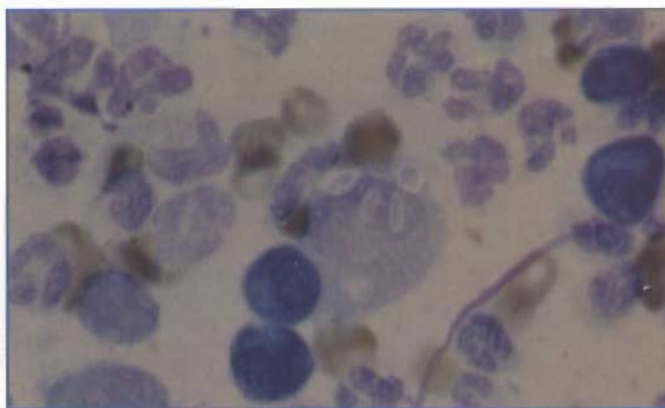


Figure 4.9. Aspirate of a draining skin lesion from a dog. The macrophage in the center contains three oval to cigar-shaped yeasts, compatible with *Sporothrix schenckii*. These organisms induce a pyogranulomatous response; and neutrophils, macrophages, lymphocytes, and plasma cells are seen in this photograph. (Wright's stain; 1000X)

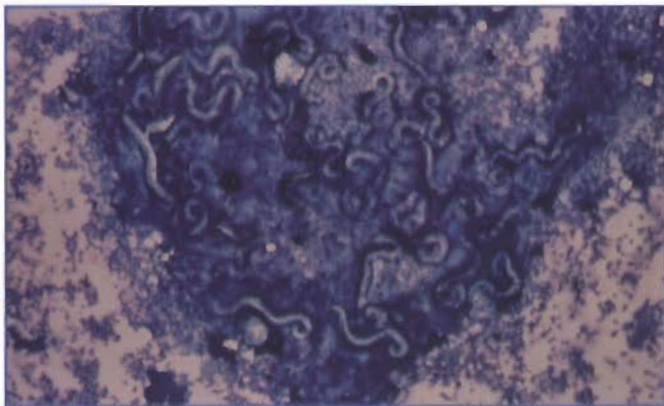


Figure 4.10. Tracheal wash from a cat with many first-stage larvae of *Aleurostrongylus* spp. (Wright's stain; 40X)

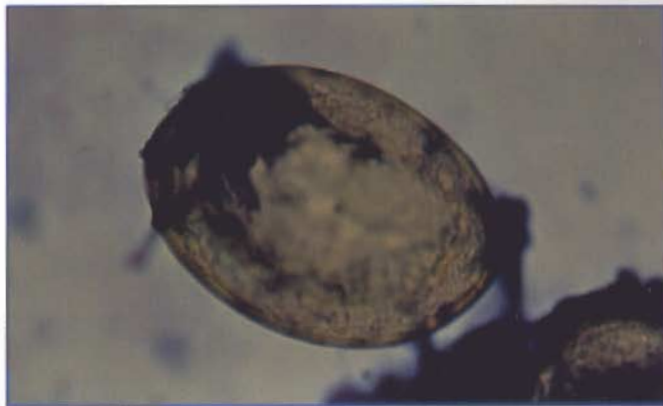

Figure 4.11. The bronchoalveolar lavage from this dog contains a *Paragonimus* spp egg. (Wright's stain; 400X)

## Part III

## Chapter 5: Body Cavity Effusions and Synovial Fluid— Case Studies

### CASE 1

**SIGNALMENT:** Six-year-old male Doberman pinscher dog

**CLINICAL FINDINGS:** Progressive exercise intolerance and dyspnea. A thoracic effusion was found on radiographs.

**CYTOLOGIC DESCRIPTION:** Pleural fluid

Appearance	Light pink, hazy
Specific gravity	1.020
Protein (g/dl)	3.0
Nucleated cells (cells/ $\mu$ l)	4,800

The majority of the cells are large mononuclear cells. There are occasional reactive mesothelial cells (*Figure 5.1*). Occasional nondegenerate neutrophils and small lymphocytes are also present.

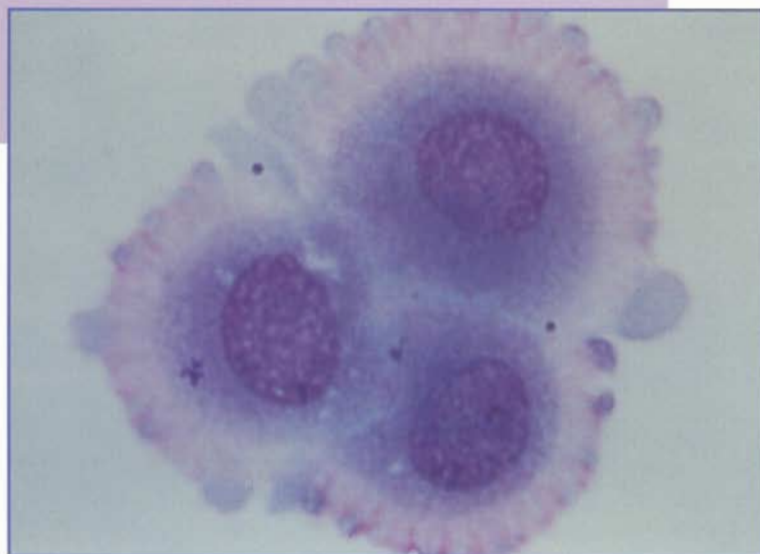


Figure 5.1. Pleural fluid from a dog. There are three reactive mesothelial cells with a characteristic pink cytoplasmic fringe. (Wright's stain; 1000X)

### Interpretation: Modified transudate

Body cavity fluids may be classified as transudates, modified transudates, or exudates, depending on the cellularity and protein content of the fluid (*see the table "Guidelines to Distinguishing Transudates and Exudates," Part IV*). These classifications are useful when trying to understand how the fluids are formed.

**Transudates** are noninflammatory fluids that form when there is decreased fluid reabsorption or increased hydrostatic pressure in capillaries or lymphatics. Transudates are characterized by low protein and low cellularity and may occur with congestive heart failure, liver failure, or any etiology resulting in hypoproteinemia. In contrast, **exudates** are the result of inflammation and have high nucleated cell counts and protein concentrations.

A **modified transudate** is highly variable in cell count and protein concentration. It is a relatively nonspecific type of effusion that may be associated with any condition or event that increases vascular permeability, increases hydrostatic pressure of the vascular or lymphatic systems, or both. Examples include liver disease, heart failure, neoplasia, diaphragmatic hernia, and lung lobe torsion. A modified transudate may be a transition stage in the development of an exudate. In this case, the dog had congestive heart failure.

### CLASSIFICATION OF BODY CAVITY FLUID

- ☐ Transudate
- ☐ Modified transudate
- ☐ Exudate

## CASE 2

**SIGNALMENT:** Two-year-old castrated male domestic longhair cat

**CLINICAL FINDINGS:** Acute onset of dyspnea, lethargy, and fever

**CYTOLOGIC DESCRIPTION:** Pleural fluid

Appearance	Tan, cloudy
Specific gravity	1.030
Protein (g/dl)	4.8
Nucleated cells (cells/ $\mu$ l)	55,000

Cellularity is very high, and the predominant cell type is a degenerate neutrophil. Many intracellular and extracellular bacteria are present. These bacteria consist of a mixed population with an overabundance of filamentous forms (*Figure 5.2*). There are large, extracellular clusters of filamentous bacteria (which grossly appear as "sulfa granules").

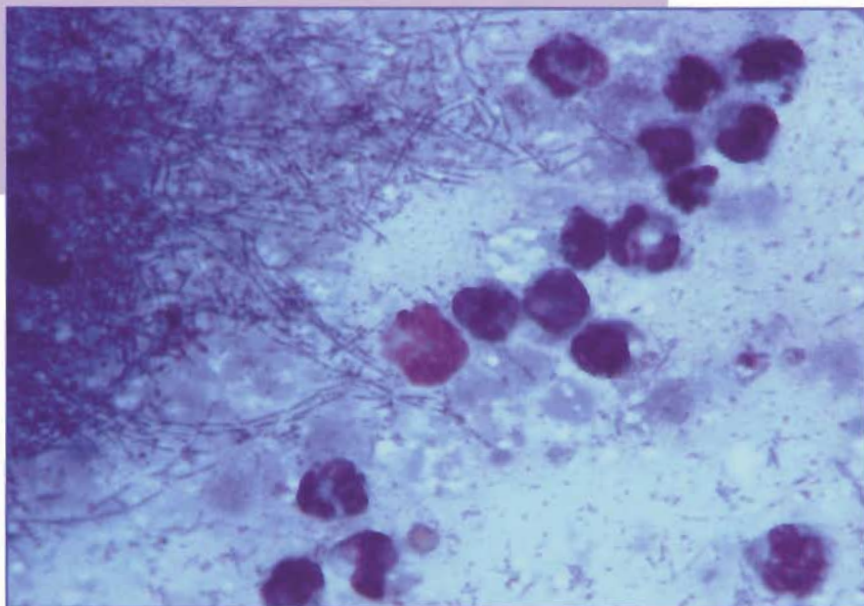


Figure 5.2. Pleural fluid from a cat with pyothorax. The neutrophils appear degenerate and border a large clump of filamentous bacteria. These bacteria are compatible with *Actinomyces*, *Nocardia*, or *Fusobacterium* spp. (Wright's stain; 1000X)

## INTERPRETATION: Septic suppurative exudate

The high cell count and protein concentration are compatible with an exudate. Presence of degenerate neutrophils typically accompanies bacterial infection; however, a culture is warranted for any neutrophilic exudate, even if the neutrophils do not show degenerative changes. The filamentous bacteria observed in this case likely are *Actinomyces* or *Nocardia* species. Both species are gram-positive organisms that require special culture conditions. *Nocardia* tend to be acid-fast. *Fusobacterium* are gram-negative bacteria that may have a similar filamentous appearance. This cat's pyothorax was probably the result of a bite or puncture wound.

**CASE 3**

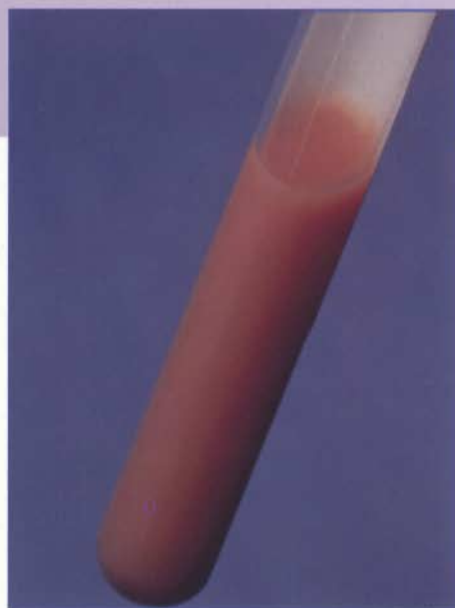**SIGNALMENT:** Ten-year-old spayed female  
Siamese cat

**CLINICAL FINDINGS:** Lethargy and dyspnea

**CYTOLOGIC DESCRIPTION:** Pleural fluid

Appearance	Milky pink, cloudy ( <i>Figure 5.3</i> )
Specific gravity	1.035
Protein (g/dl)	5.5
Nucleated cells (cells/ $\mu$ l)	9,100

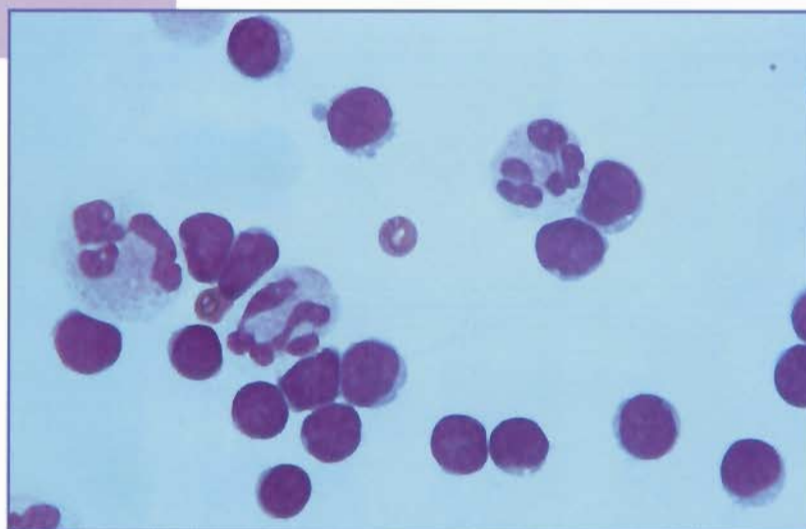
There are 70% lymphocytes, 24% neutrophils, and 6% large mononuclear cells (*Figure 5.4*). Neutrophils appear nondegenerate. Lymphocytes are small and well differentiated. No etiologic agents were seen.



**Figure 5.3.** Pleural fluid from a cat with chylothorax. This fluid has the typical milky pink appearance of a chylous effusion.

**INTERPRETATION: Chylous effusion (chylothorax)**

Chyle accumulates in the thoracic cavity as a result of lymphatic obstruction or, rarely, a rupture of the thoracic duct. This results in a fluid that may be milky white to pink in color. Conditions associated with chylothorax include heart disease, neoplasia, trauma, lung lobe torsion, heartworm disease, diaphragmatic hernia, and fungal granulomas. Because of the high concentration of chylomicrons, the triglyceride content of a chylous effusion is greater than that observed in the serum, and the ratio of cholesterol to triglycerides in the effusion is  $<1$ . Early on, the predominant cell type is the small lymphocyte, as seen in this case. However, with prolonged duration, the cytologic characteristics often become more inflammatory, with increased numbers of neutrophils and macrophages.



**Figure 5.4.** Pleural fluid from a cat with chylothorax. The majority of the cells are small lymphocytes with occasional nondegenerate neutrophils. (Wright's stain; 1000X)

## CASE 4

**SIGNALMENT:** Two-year-old neutered male shorthair cat

**CLINICAL FINDINGS:** Progressive abdominal distention

**CYTOLOGIC DESCRIPTION:** Abdominal fluid

Appearance	Yellow, cloudy
Specific gravity	1.045
Protein (g/dl)	6.8
Nucleated cells (cells/ $\mu$ l)	5,600

There is a mixture of nondegenerate neutrophils and large mononuclear cells (*Figure 5.5*). The mononuclear cells have foamy cytoplasm and appear activated. Cytophagia can be seen. There is a pink granular background, which is compatible with the high protein concentration of the fluid. No etiologic agents were seen. Results of a protein electrophoresis of the abdominal fluid were compatible with increased globulins and a polyclonal gammopathy (*Figure 5.6*).

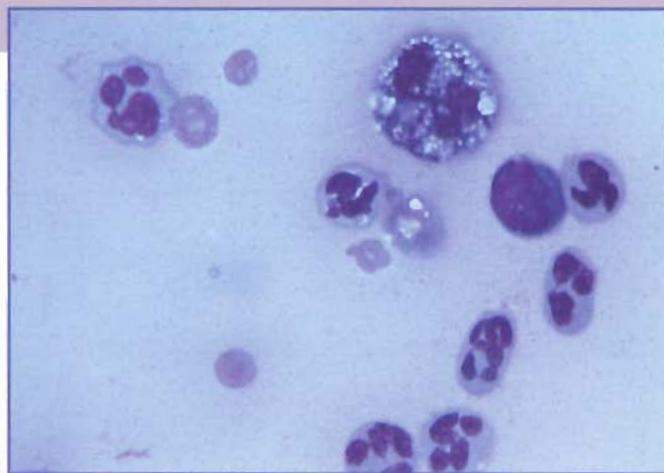


Figure 5.5. Abdominal fluid from a cat with FIP. Neutrophils appear nondegenerate, and there are two large mononuclear cells. The hazy background is caused by the presence of precipitated protein. (Wright's stain; 1000X)

## INTERPRETATION: Proteinaceous effusion, compatible with feline infectious peritonitis (FIP)

FIP is caused by a coronavirus and is often difficult to diagnose. Typically, the fluid from a cat with FIP is yellow and may have fibrin strands. Criteria supporting a diagnosis of FIP include a total protein concentration  $>3.5$  g/dl,  $>50\%$  total globulins, and  $>32\%$  gamma globulin in abdominal or thoracic fluid. The cellular pattern is non-specific and consists of a mixture of nondegenerate neutrophils, large mononuclear cells, and lymphocytes, with occasional plasma cells. Polymerase chain reaction (PCR) tests for the FIP virus can be performed on the effusion to aid in diagnosis.

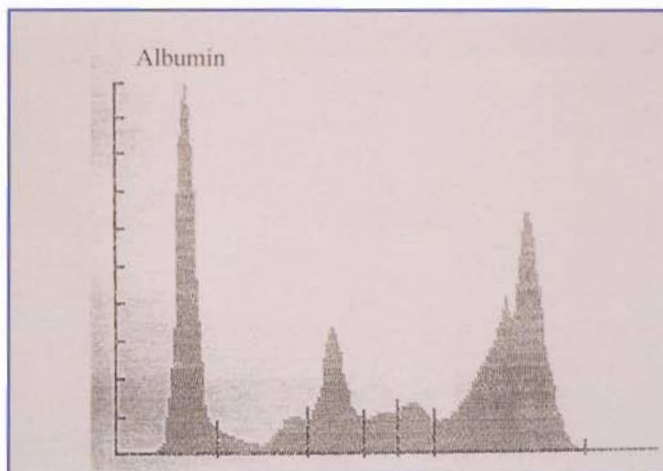


Figure 5.6. Protein electrophoresis of abdominal fluid from the cat with FIP. The fluid contains 28% albumin. Globulins total 72% of the protein and consist of 6%  $\alpha_1$ , 13%  $\alpha_2$ , 4%  $\beta_1$ , 5%  $\beta_2$ , and 44% gamma. The high concentration of globulins ( $>50\%$  of the total) and gamma globulins ( $>32\%$ ) is compatible with a diagnosis of FIP.

## CASE 5

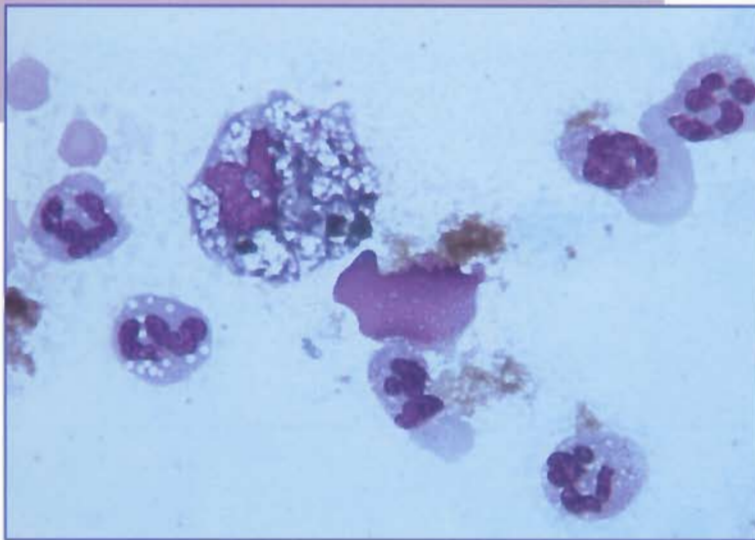
**SIGNALMENT:** Four-year-old spayed female mixed breed dog

**CLINICAL FINDINGS:** Painful and swollen abdomen after being hit by a car

**CYTOLOGIC DESCRIPTION:** Abdominal fluid

Appearance	Brown, cloudy
Specific gravity	1.031
Protein (g/dl)	5.0
Nucleated cells (cells/ $\mu$ l)	34,300

There are 80% nondegenerate neutrophils, 18% large mononuclear cells, 1% lymphocytes, and 1% eosinophils. Macrophages contain variable amounts of golden-yellow to blue-green pigment. Yellow pigment also is free in the background (*Figure 5.7*). There are moderate numbers of red blood cells present.



**Figure 5.7.** Abdominal fluid from a dog with bile peritonitis. The majority of the cells are neutrophils. The large mononuclear cell (upper left) has phagocytized green material, compatible with bile pigment. Yellow bile pigment is also free in the background. (Wright's stain; 1000X)

## INTERPRETATION: Suppurative exudate with bile pigment, compatible with bile peritonitis

A tear in the gallbladder or bile duct results in leakage of bile into the peritoneal cavity. Because bile is irritating, it initiates an inflammatory response that may be neutrophilic acutely, eventually becoming predominantly mononuclear. Bile pigment is typically yellow to green in color and amorphous. Bilirubin crystals may be seen in chronic cases. A chemically determined bilirubin concentration for the abdominal fluid will be high in comparison to serum bilirubin.

## CASE 6

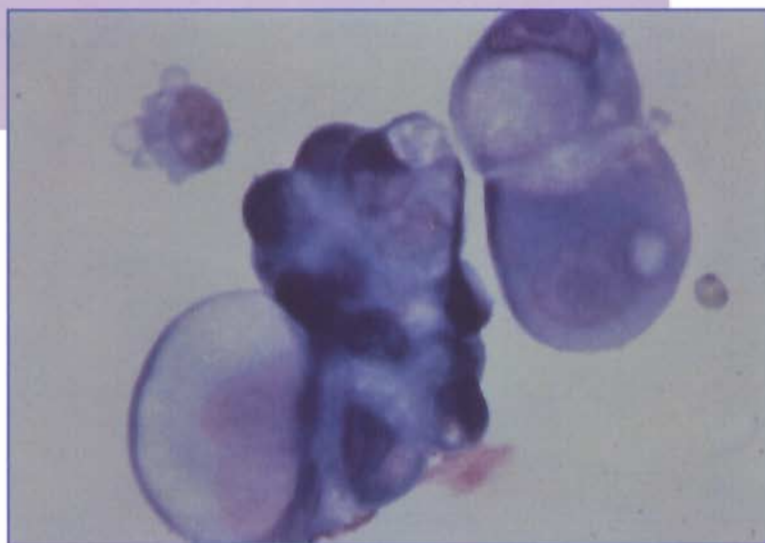
**SIGNALMENT:** Ten-year-old female beagle dog

**CLINICAL FINDINGS:** Progressive weight loss and lethargy. The dog has several mammary tumors.

**CYTOLOGIC DESCRIPTION:** Pleural fluid

Appearance	Orange, hazy
Specific gravity	1.025
Protein (g/dl)	3.5
Nucleated cells (cells/ $\mu$ l)	4,200

The majority of the cells are large mononuclear cells, with moderate numbers of nondegenerate neutrophils. There are large clusters of pleomorphic cells that contain one to several nuclei with fine chromatin and multiple nucleoli (*Figure 5.8*). There is marked anisokaryosis, and nuclear molding is observed. The N:C ratio is variable. Cytoplasm is basophilic and appears distended with secretory product. These cells are compatible with an adenocarcinoma.

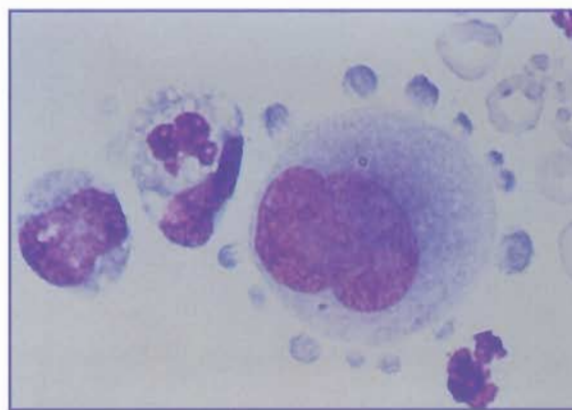


**Figure 5.8.** Pleural fluid from a dog with metastatic mammary adenocarcinoma. The clusters of neoplastic cells are characterized by anisocytosis, anisokaryosis, and a variable N:C ratio. The cytoplasm is deeply basophilic and appears distended with secretory product in several of the cells (signet ring appearance). (Wright's stain; 1000X)

## INTERPRETATION: Neoplastic effusion, compatible with metastatic mammary adenocarcinoma

Identification of neoplastic cells in an effusion depends on recognizing the presence of an abnormal cell type and the criteria for malignancy (*see Chapter 5*). Neoplastic effusions can be highly variable in appearance, ranging from a modified transudate to an exudate with marked inflammation. In general, carcinomas and lymphomas are more likely than sarcomas to exfoliate into cavity fluids. The absence of neoplastic cells in an effusion does not rule out the possibility of a tumor.

It is very important to recognize and not overinterpret reactive mesothelial cells (*Figure 5.9*; *see also Figure 5.1*). Reactive mesothelial cells may show many of the criteria of malignancy, including variation in cell and nuclear size, multinucleation, pronounced cytoplasmic basophilia, and frequent mitoses. In fact, there are no morphologic criteria that clearly distinguish between reactive mesothelial cells and cells derived from a malignant neoplasm. If a malignant neoplasm is suspected following cytology, its presence should be confirmed by histology.



**Figure 5.9.** Pleural fluid from a dog. The large cell in the center is a reactive mesothelial cell. This cell is binucleate, has fine chromatin, shows nuclear molding, and has prominent cytoplasmic blebs. It can be difficult to distinguish reactive mesothelial cells from neoplastic cells. (Wright's stain; 1000X)

## CASE 7

**SIGNALMENT:** Five-year-old spayed female golden retriever dog

**CLINICAL FINDINGS:** Acute onset of polyarthritis

**CYTOLOGIC DESCRIPTION:** Synovial fluid from the left stifle

Appearance	Red-orange, cloudy
Specific gravity	1.032
Protein (g/dl)	5.3
Nucleated cells (cells/ $\mu$ l)	15,200
Viscosity	Watery
Mucin clot test	Poor

There are 90% nondegenerate neutrophils, 9% large mononuclear cells, and 1% lymphocytes (*Figure 5.10*). A rare LE (lupus erythematosus) cell is seen (*Figure 5.11*). The granular background appears decreased. No etiologic agents are apparent. When other joints are sampled, a similar cytologic pattern is observed.

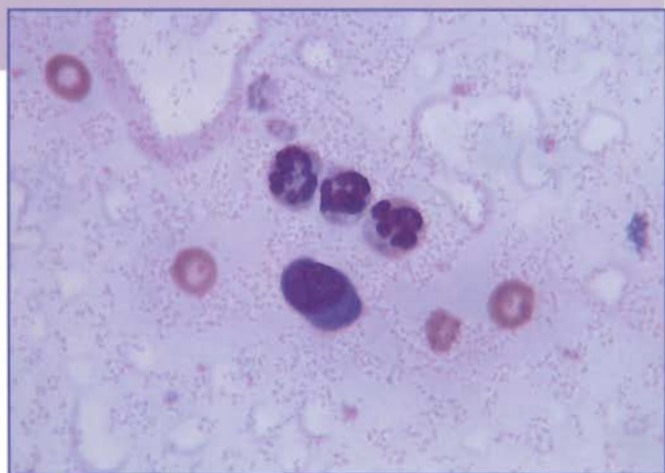


Figure 5.10. Synovial fluid from a dog with immune-mediated polyarthritis. There are three nondegenerate neutrophils, one mononuclear cell, and four erythrocytes. (Wright's stain; 1000X)

## INTERPRETATION: Suppurative inflammation

Normal synovial fluid is clear and colorless, has high viscosity, low cell counts ( $<3,000/\mu$ l), a protein concentration of about 3.0 g/dl, and does not clot (*see the table Guidelines for Evaluation of Synovial Fluid, Part IV*). The majority of cells are mononuclear cells with very few neutrophils. Hyaluronic acid content of the synovial fluid is assessed by the mucin clot test. When synovial fluid from a normal joint is added to 2.5% acetic acid at a ratio of 1:4, a solid clot forms (rated "good"). When inflammation results in degradation of the hyaluronic acid, the clot becomes more friable (rated "fair") or fails to form (rated "poor"). In general, as severity of inflammation in a joint increases, results of the mucin clot test are more likely to be fair to poor.

Neutrophilic inflammation in synovial fluid usually indicates infection or immune-mediated disease. The presence of nondegenerate neutrophils in synovial fluid does not preclude the possibility of bacterial infection, and a culture is recommended any time suppurative inflammation is observed. In this case, the presence of multiple affected joints and rare LE cells is compatible with an immune-mediated arthropathy. Further evaluation of this dog for systemic lupus erythematosus (SLE) is warranted. In contrast to immune-mediated polyarthritides, bacterial arthritis usually involves a single joint. Exceptions are cases of Lyme disease (*Borrelia burgdorferi* infection), ehrlichial infection, or polyarthritis secondary to septicemia.

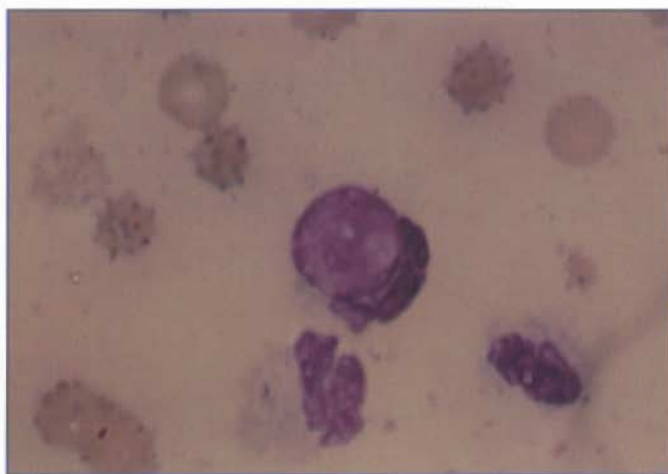


Figure 5.11. Synovial fluid from a dog with SLE-associated polyarthritis. The cell in the center is a neutrophil that has phagocytized the nucleus from another cell. This is an LE (lupus erythematosus) cell and, although an uncommon cytologic finding, supports a diagnosis of immune-mediated disease. (Wright's stain; 1000X)

### CASE 8

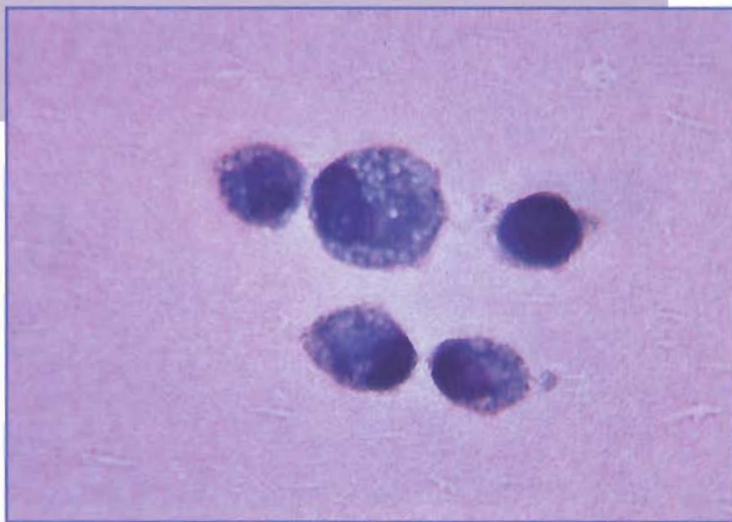**SIGNALMENT:** Ten-year-old male German shepherd dog

**CLINICAL FINDINGS:** Chronic, progressive lameness involving the shoulder joints

**CYTOLOGIC DESCRIPTION:** Synovial fluid from the right shoulder joint

Appearance	Colorless, hazy
Specific gravity	1.029
Protein (g/dl)	4.5
Nucleated cells (cells/ $\mu$ l)	5,700
Viscosity	Stringy
Mucin clot test	Good

Cellularity is moderately increased, and the cells line up in rows (windrowing), suggesting that the fluid has relatively high viscosity. The majority of the cells are large mononuclear cells (*Figure 5.12*). A few lymphocytes and rare nondegenerate neutrophils are seen. There are scattered red blood cells. No etiologic agents were seen. There is a dense granular background.



**Figure 5.12.** Synovial fluid from a dog with degenerative arthropathy, characterized by the presence of predominantly mononuclear cells. Note the dense, granular background typical of synovial fluid. (Wright's stain; 1000X)

### INTERPRETATION: Nonsuppurative inflammation, compatible with degenerative joint disease

Inflammation characterized by predominantly large mononuclear cells may occur with degenerative joint disease or trauma. The cellularity and relative proportion of cell types (neutrophils versus mononuclear cells) depends on the stage of the disease. Recent trauma results in more neutrophils and red blood cells, and erythrophagocytosis may be observed. As the injury resolves, the relative proportion of large mononuclear cells increases and the overall number of cells decreases. With degenerative joint disease, acute flare-ups may be associated with higher cell counts and an increased percentage of neutrophils.

With degenerative arthropathy, the synovial fluid is usually colorless. Viscosity is normal to mildly decreased. The results of the mucin clot test are often normal, but may vary to fair or poor in some cases.

## Chapter 6: Skin and Connective Tissue—Case Studies

### CASE 1

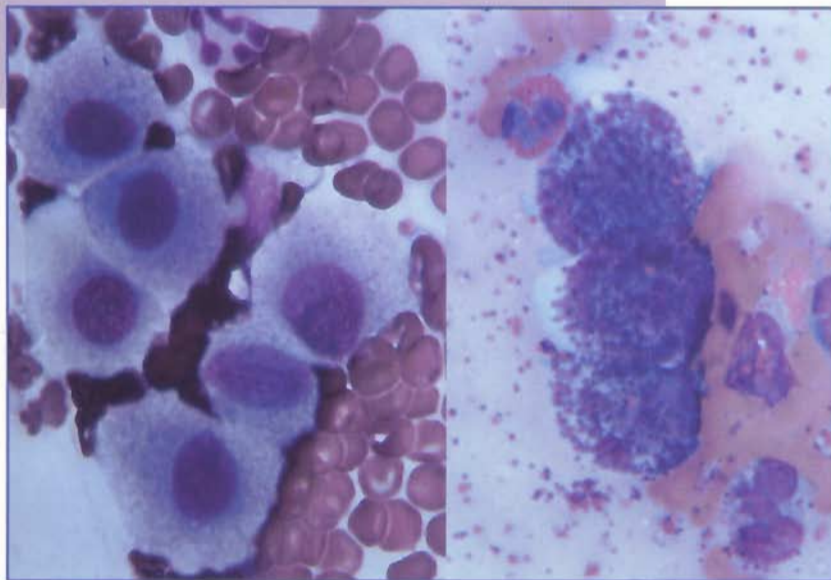
**SIGNALMENT:** Fourteen-year-old male Boston terrier dog

**CLINICAL FINDINGS:** Ulcerated, edematous mass in the right inguinal region

**CYTOLOGIC DESCRIPTION:** Aspirate of inguinal mass

**Diff-Quik stain (Figure 6.1, left).** The sample is very cellular. The majority of the cells are large, round, individual cells. Nuclei are round to oval, have stippled chromatin, and have nucleoli. These cells have abundant cytoplasm that is moderately basophilic and appears to contain numerous small vacuoles. The provisional diagnosis is a round cell tumor.

**Wright's stain (Figure 6.1, right).** The sample is very cellular. The majority of the cells are large, round, individual cells. Nuclei are obscured by numerous purple cytoplasmic granules. There appears to be minimal variation in the number of granules, nuclear size, and cell size. These cells are interpreted as mast cells. Occasional eosinophils also are present.



**Figure 6.1.** Cutaneous mast cell tumor from a dog. Left, The smear was stained with Diff-Quik stain. Cells are large, individual, round to polygonal cells and have round to oval, centrally located nuclei with finely stippled chromatin and nucleoli. Abundant cytoplasm appears grainy, but no granules are apparent. Right, The smear was stained with Wright's stain. Three mast cells with characteristic purple cytoplasmic granules are present. There also are several eosinophils and moderate numbers of erythrocytes. This mast cell tumor appears relatively well differentiated. (1000X)

### INTERPRETATION: Mast cell tumor

Mast cell tumors are common skin cell tumors in dogs. Canine mast cell tumors most commonly occur on the thigh, groin, or scrotum but can occur in any region of the skin. Most dogs have single tumors but multiple tumors can occur. Cutaneous mast cell tumors are often well-circumscribed nodules but also can present as a diffuse edematous swelling. They usually involve the dermis but may extend into the subcutaneous tissues and underlying musculature. In dogs, cutaneous mast cell tumors usually occur in older animals but may be present in dogs less than 1 year of age. Breeds predisposed to development of mast cell tumors include boxer, Boston terrier, bull terrier, Staffordshire terrier, fox terrier, and Labrador retriever.

Cytologic evaluation is an accurate method for the diagnosis of mast cell tumors. In fact, some mast cell tumors are more readily diagnosed cytologically than histologically. Aspirates from mast cell tumors usually are cellular. The predominant cells are mast cells, with variable numbers of eosinophils and fibroblasts. Mast cells are round to polygo-

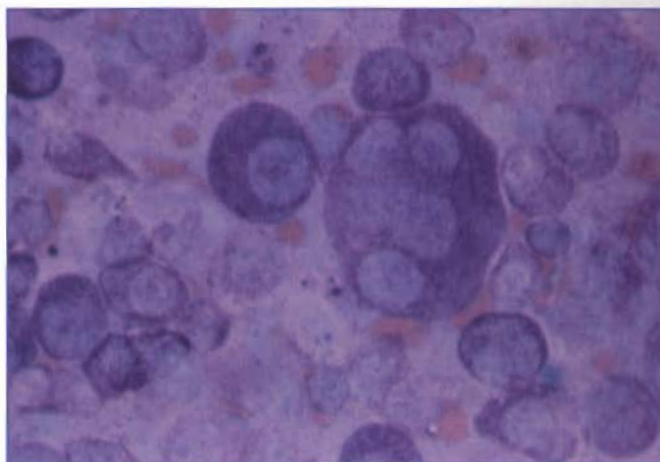
nal and 10 to 35  $\mu\text{m}$  in diameter. The round to oval nucleus is eccentric and has finely stippled or aggregated chromatin. Nuclei frequently stain poorly and may be obscured by the presence of distinct cytoplasmic granules. These round or oval, fine to coarse, variable-sized cytoplasmic granules are the striking feature that allows the specific identification of mast cells. With Wright's stain, the granules are metachromatic (stain blue-black to purple-red). Diff-Quik may stain the granules poorly or not at all, as was true in this case.

Canine mast cell tumors are graded histologically, according to degree of granulation and cellular anaplasia. Dogs with anaplastic mast cell tumors have significantly shorter survival times than those with well-differentiated tumors. The cytologic appearance often resembles the histologic appearance, although the cytologic appearance of mast cells does not always correlate with clinical behavior. Well-differentiated mast cells con-

tain numerous granules and exhibit minimal variation in cell size and nuclear size, whereas poorly differentiated mast cells contain few granules and exhibit marked variation in cell size and nuclear size (*Figure 6.2*). In dogs, all cutaneous mast cell tumors should be considered potentially malignant. Mast cell tumors involving the inguinal, perianal, and scrotal regions may be particularly aggressive.

Mast cell tumors in cats commonly involve internal organs but can also occur as cutaneous masses. In cats, cutaneous mast cell tumors typically develop on the head and neck. Feline cutaneous mast cell tumors are seemingly benign. Recurrence is uncommon and metastases are rare. This is in contrast to mast cell tumors involving hematopoietic or gastrointestinal tissues, which are often clinically aggressive.

Mast cell tumors must be differentiated from inflammatory processes containing mast cells. The presence of other inflammatory cells, such as neutrophils and macrophages, usually makes this distinction relatively



**Figure 6.2.** Cutaneous mast cell tumor from a dog. This mast cell tumor appears anaplastic. There is marked variation in cell size, nuclear size, and N:C ratio. A multinucleated mast cell is in the center. (Wright's stain; 1000X)

easy; but, in some cases, histologic evaluation may be required.

## CASE 2

**SIGNALMENT:** Four-year-old male mixed breed dog

**CLINICAL FINDINGS:** Multiple areas of thickened skin and several cutaneous nodules

**CYTOLOGIC DESCRIPTION:** Aspirate of cutaneous nodule

The sample is very cellular. There is a uniform population of large, round, individualized cells (*Figure 6.3*). These cells have a moderate amount of basophilic cytoplasm. Nuclei are round or indented and contain finely stippled chromatin and prominent nucleoli. The cells have a high N:C ratio. There is moderate variation in cell and nuclear size.

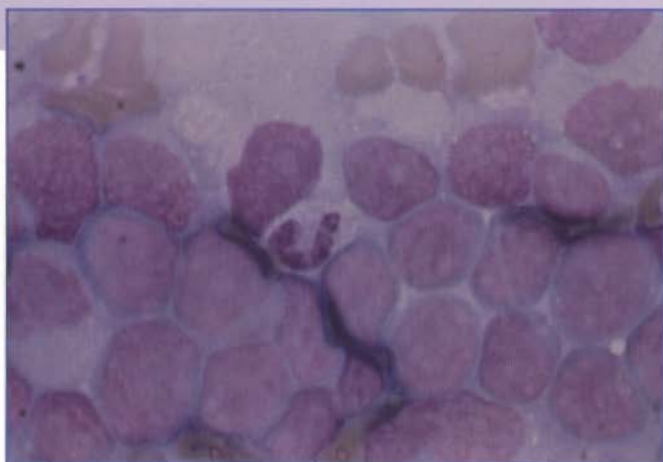


Figure 6.3. Cutaneous lymphoma from a dog. There is a monomorphic population of large lymphocytes with abundant basophilic cytoplasm. Nuclei are round or indented and have finely stippled chromatin and prominent nucleoli. These cells have a high N:C ratio. There is moderate variation in cell size and nuclear size. (Wright's stain; 1000X)

## INTERPRETATION: Lymphoma

Primary cutaneous lymphoma in dogs and cats is rare. Most cutaneous lymphomas typically exfoliate cells well and involve a uniform population of poorly differentiated lymphoid cells. Cytologically, these cells are larger than neutrophils and have a moderate amount of blue-staining cytoplasm. The nucleus typically is round, but very irregularly shaped nuclei may be present (*Figure 6.4*). Nuclei have a finely stippled chromatin pattern and one to several nucleoli. Cutaneous lymphomas may occasionally be composed of small lymphocytes. These lymphocytes are smaller than neutrophils and cannot be distinguished cytologically from hyperplastic lymphoid tissue. Although cytology is useful in tentatively diagnosing cutaneous lymphoma, histologic confirmation is recommended.

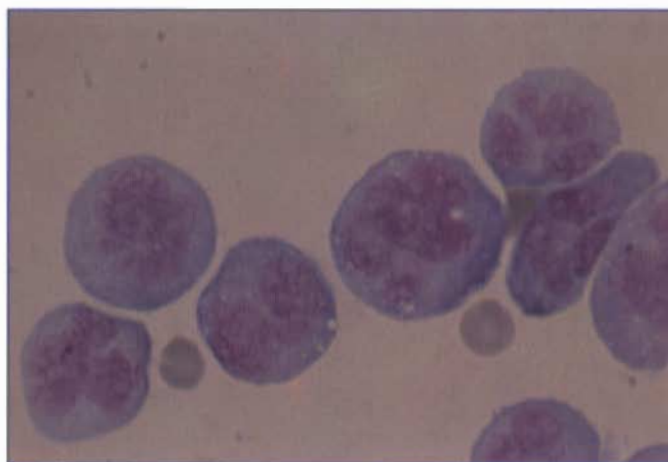


Figure 6.4. Cutaneous lymphoma from a dog. These neoplastic lymphocytes have very irregularly shaped nuclei, which can occur in some cases of lymphoma. It would be difficult to make a definitive diagnosis of lymphoma in this case without immunophenotyping or identification of cell surface antigens to document the lymphoid lineage of the neoplastic cells. (Wright's stain; 1000X)

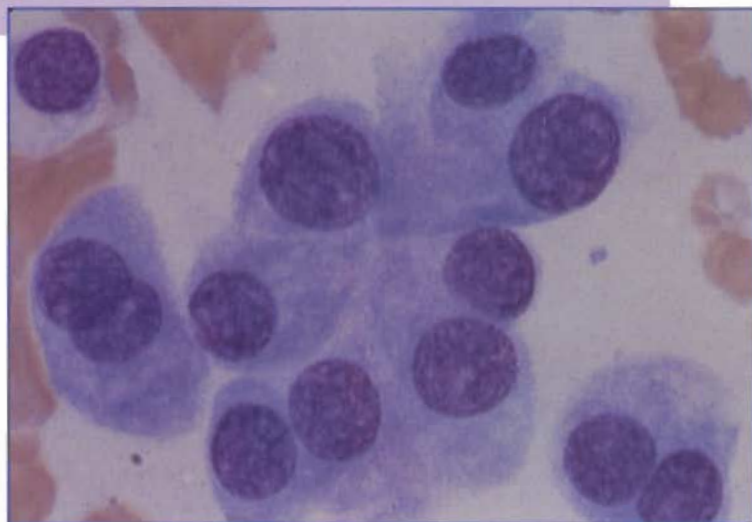
### CASE 3

**SIGNALMENT:** Five-year old spayed female coonhound dog

**CLINICAL FINDINGS:** Mass on upper lip

**CYTOLOGIC DESCRIPTION:** Aspirate of mass on lip

The sample is very cellular. There is a uniform population of large cells with round nuclei (*Figure 6.5*). There are moderate numbers of binucleated and multinucleated cells. Nuclei have finely stippled chromatin and nucleoli. A moderate amount of basophilic cytoplasm is present and, in some cells, there is a perinuclear clear region. These cells are interpreted as neoplastic plasma cells.



**Figure 6.5.** Extramedullary plasma cell tumor from a dog. There is a uniform population of plasma cells that have round nuclei with moderately clumped chromatin. Nuclei are eccentrically located, and nucleoli are present in some cells. These cells have abundant basophilic cytoplasm, and a few cells have a perinuclear clear zone that is typical of plasma cells. There is moderate variation in cell size and nuclear size. There is a binucleated cell on the left. (Wright's stain; 1000X)

### INTERPRETATION: Plasma cell tumor

Extramedullary plasma cell tumors (plasmacytomas) are localized, neoplastic proliferations of plasma cells involving soft tissues and lacking bone marrow involvement. These tumors have been described in both dogs and cats but occur more commonly in dogs. Plasmacytomas usually occur in middle-aged to old dogs. Typically, they are solitary masses involving the skin (most commonly the digits, lips, face, and ears), oral cavity, or gastrointestinal tract. Extramedullary plasma cell tumors involving the gastrointestinal tract have been reported in cats.

Aspirates from plasmacytomas usually are moderately to markedly cellular. The cells occur as individualized cells that may resemble differentiated plasma cells, or may appear minimally differentiated and be difficult to recognize as plasma cells. Typically, the cells are round to oval and 12 to 30  $\mu\text{m}$  in diameter. Nuclei are round or oval and often are eccentrically located. Binucleated and multinucleated cells may be relatively common. Nuclei have finely to moderately clumped chromatin, and nucleoli may be present. There is a variable amount of amphophilic to basophilic cytoplasm. There may be a perinuclear clear zone that represents the Golgi apparatus. In addition, there may be minimal to marked variation in cell size, nuclear size, and N:C ratio.

Plasma cell tumors often can be diagnosed with confidence using cytology. Histologic confirmation may be necessary for a definitive diagnosis of plasma cell tumors in which the cells are very anaplastic and do not resemble plasma cells. Plasma cell tumors involving skin are usually considered benign tumors that are cured by surgical excision. However, recurrence, local invasions, and metastasis have been reported. Plasmacytomas involving the gastrointestinal tract may be more aggressive than cutaneous tumors.

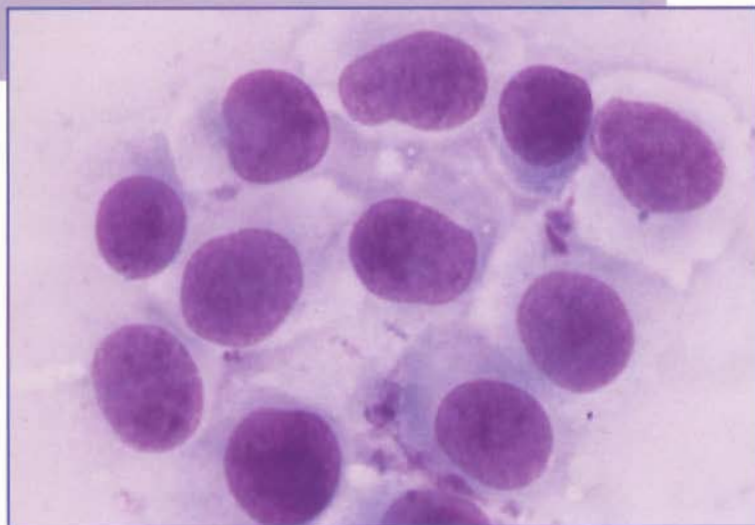
#### CASE 4

**SIGNALMENT:** Seven-month-old male Labrador retriever dog

**CLINICAL FINDINGS:** Solitary mass on the dorsal surface of the right front foot

**CYTOLOGIC DESCRIPTION:** Aspirate of mass on foot

The sample is very cellular. The majority of cells are round cells with a moderate amount of pale blue cytoplasm (*Figure 6.6*). Nuclei are round or indented and have stippled or linear chromatin. Nucleoli are not apparent.



**Figure 6.6.** Histiocytoma from a dog. A uniform population of large, round, individual cells is present. Nuclei are round or indented and have stippled chromatin. There is moderate variation in nuclear size. Nucleoli are not apparent. There is a moderate amount of pale cytoplasm. (Wright's stain; 1000X)

#### INTERPRETATION: Histiocytoma

Histiocytomas are very common tumors of the dermis and subcutis of young dogs. Most occur in dogs less than 2 years of age. Breeds predisposed to development of histiocytomas include boxer, dachshund, and other purebred dogs. Histiocytomas are considered benign tumors of dendritic or Langerhans cells. They usually occur as single masses, most commonly involving skin on the head, ears, scrotum, and distal portions of the limbs. These tumors may rapidly grow but most, if not all, histiocytomas spontaneously regress over a period of weeks to months.

Cytologic samples from histiocytomas contain a uniform population of round, oval, or irregularly shaped cells, morphologically resembling monocytes or epithelioid cells. Histiocytoma cells are 12 to 26  $\mu\text{m}$  in diameter. Nuclei are eccentric and variable in size and shape. Chromatin is lacey or finely stippled, and nucleoli usually are not apparent. There is a moderate amount of pale blue-staining cytoplasm with distinct borders that may appear scalloped. There may be moderate to marked variation in cell size and nuclear size.

Histiocytomas may be infiltrated with lymphocytes and plasma cells or may be ulcerated and secondarily inflamed. In those cases, the cytology resembles chronic inflammation and the definitive diagnosis may require histopathology. Differentiation between histiocytoma and large cell lymphoma, transmissible venereal tumor, basal cell tumor, and anaplastic mast cell tumor also may be difficult without histologic evaluation. Large cell lymphoma usually involves lymph nodes, and the neoplastic lymphocytes have more prominent nucleoli and more basophilic cytoplasm than cells from histiocytomas. Transmissible venereal tumors are rare and most often involve the skin around the external genitalia. Cells from transmissible venereal tumors have prominent nucleoli, which is not a typical feature of histiocytoma cells (*see Figure 3.13*). Basal cell tumors usually exfoliate cells in small clusters or rows, and there is minimal variation in nuclear size and shape. Aspirates from anaplastic mast cell tumors typically have some cells with purple cytoplasmic granules.

## CASE 5

**SIGNALMENT:** Eleven-year-old black male cocker spaniel dog

**CLINICAL FINDINGS:** Ulcerated mass on the second digit of the right front foot

**CYTOLOGIC DESCRIPTION:** Aspirate of digital mass

The sample is moderately cellular. There is a uniform population of individualized cells that are spindle-shaped or polygonal (*Figure 6.7*). These cells have a moderate amount of basophilic cytoplasm, which often contains numerous, small, brown granules. Nuclei are round or oval and have finely stippled chromatin. Nuclei are obscured by cytoplasmic granules. There is moderate to marked variation in cell size, nuclear size, and N:C ratio. These cells are interpreted as malignant melanocytes.

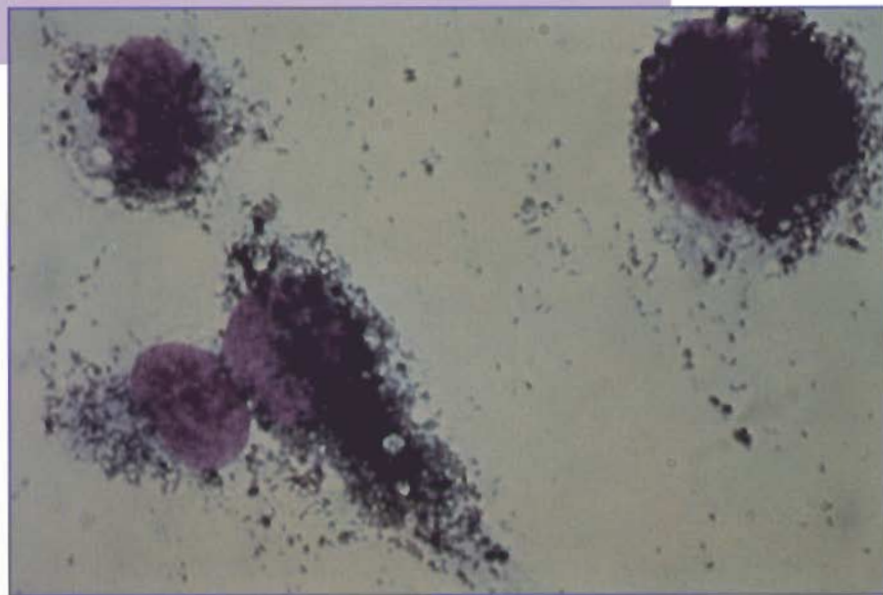


Figure 6.7. Malignant melanoma from the digit of a dog. Melanocytes may be spindle-shaped (elongated cell in the left center) or polyhedral (large cell in the upper right). Melanin granules usually appear brown to greenish-black. They occur in the cytoplasm and in the background from broken cells. (Wright's stain; 1000X)

## INTERPRETATION: Malignant melanoma

Melanomas are of neuroectodermal origin, are relatively common in dogs, and are rare in cats. In dogs, melanomas occur most often in middle-aged to older animals, especially in dogs with heavily pigmented skin. Breeds predisposed to development of melanoma include Scottish terrier, Boston terrier, Airedale, and cocker spaniel.

Cytologically, cells from melanomas usually occur singly; but small aggregates of cells may be present. Round, stellate, and spindle-shaped cells can occur in the same neoplasm (*Figure 6.7*), which may be useful in the cytologic diagnosis, especially when melanin granules are not readily apparent. Melanocyte nuclei are round or oval, and prominent nucleoli may be present (*Figure 6.8*). Malignant melanomas may contain tumor giant cells and cells with giant nuclei.

Melanin pigment cytologically appears as brown to greenish-black cytoplasmic granules that are very fine and of relatively uniform size (*Figure 6.7*).

Melanin granules often are more obvious cytologically than histologically, and their presence is an important criterion used to identify melanocytes. Melanomas may be sparsely or heavily pigmented. If the tumor is highly pigmented, the mass appears dark grossly and is easily recognized cytologically. The sample may appear brown even on unstained slides. Poorly pigmented melanomas (amelanotic melanomas) are more difficult to recognize cytologically. In most cases, careful observation will reveal a few pigmented melanocytes. If no melanin granules are found, melanomas are difficult to distinguish from other mesenchymal tumors.

Melanocytes from a melanoma must be differentiated from macrophages that con-

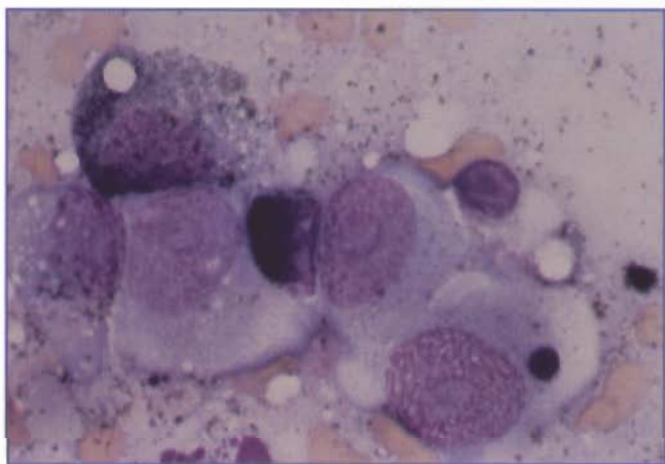


Figure 6.8. Malignant melanoma from the oral cavity of a cat. There is marked variation in cell size, nuclear size, and N:C ratio. Nuclei have fine chromatin and prominent nucleoli. Some cells are poorly pigmented and would be difficult to recognize as melanocytes. (Wright's stain; 1000X)

tain melanin pigment (melanophages, *Figure 6.9*).

Melanophages can accompany melanomas, but they also can occur in inflammatory lesions. Melanophages usually are larger than melanocytes and have vacuolated cytoplasm. Melanin pigment granules in melanophages are coarser and more variable in size than the pigment granules in melanocytes.

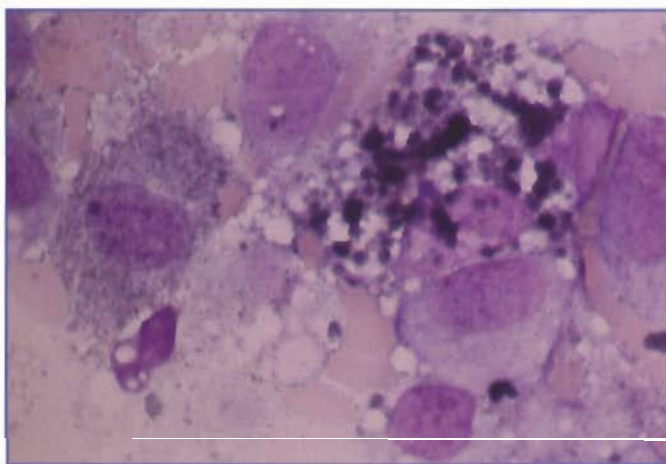


Figure 6.9. Malignant melanoma from the oral cavity of a dog. The cell on the left is a pigmented melanocyte and contains fine melanin granules. The cell in the center is a melanophage and has coarse granules and vacuoles. (Wright's stain; 1000X)

Most cutaneous melanomas are benign, but distal extremity (*Figure 6.7*) and oral cavity (*Figure 6.8*) melanomas are uniformly malignant. Malignant melanomas may appear very anaplastic or well differentiated cytologically, so histologic evaluation is recommended for a definitive diagnosis.

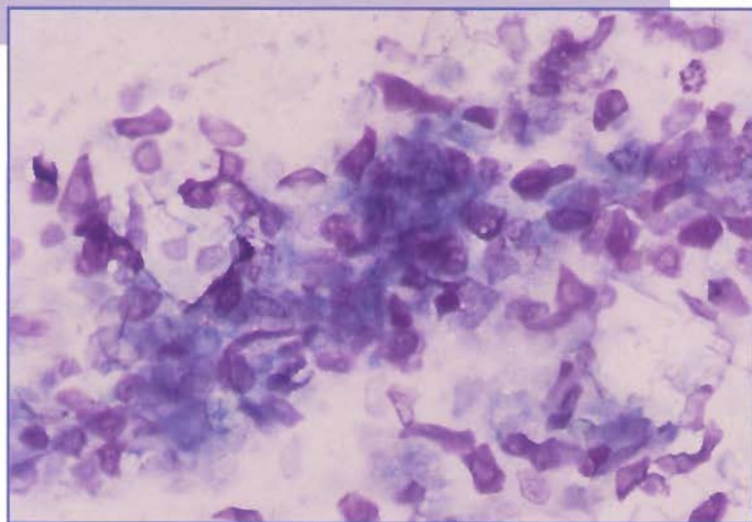
## CASE 6

**SIGNALMENT:** Eight-year-old male mixed breed dog

**CLINICAL FINDINGS:** Small mass on dorsal cervical region

**CYTOLOGIC DESCRIPTION:** Aspirate of cervical mass

The sample is very cellular. There is a uniform population of mature, keratinized, squamous epithelial cells, many of which are anucleate (*Figure 6.10*). Abundant amorphous cellular debris is present.



**Figure 6.10.** Epidermal inclusion cyst from a dog. There are numerous keratin flakes that appear eosinophilic. (Wright's stain; 200X)

## INTERPRETATION: Epidermal inclusion cyst or other similar benign epithelial tumor

Epidermal inclusion cysts are non-neoplastic cystic structures arising from hair follicles. They are relatively common in older dogs. They usually are relatively small and may occur as single or multiple masses.

Aspirates from epidermal inclusion cysts usually are very cellular. There are numerous mature, keratinized, squamous epithelial cells, which often are anucleate. These cells may appear eosinophilic (*Figure 6.10*), basophilic (*Figure 6.11*), or be poorly stained. There may be abundant amorphous cellular debris (*Figure 6.12*) and occasional cholesterol crystals (*Figure 6.13*). Epidermal inclusion cysts may become inflamed, in which case neutrophils, macrophages, and giant cells will be present. Occasionally, bacterial infection occurs.

It is difficult to distinguish between epidermal inclusion cysts and other similar benign epithelial tumors, such as trichoepithelioma and pilomatrixoma, based on cytologic evaluation. Histologic evaluation can be used to make a definitive diagnosis.

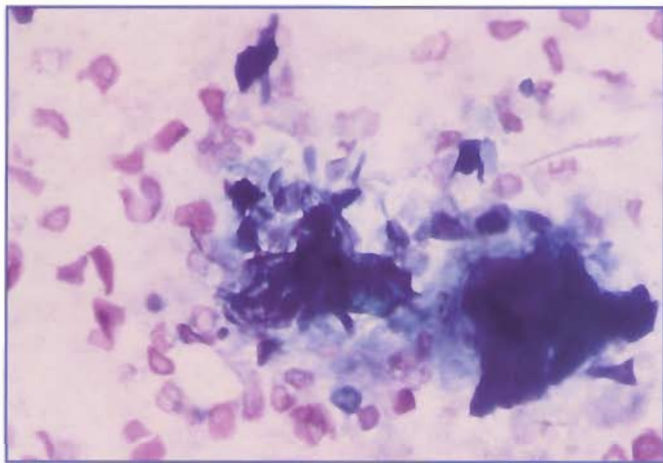


Figure 6.11. Epidermal inclusion cyst from a dog. There are numerous keratin flakes that appear basophilic. (Wright's stain; 200X)

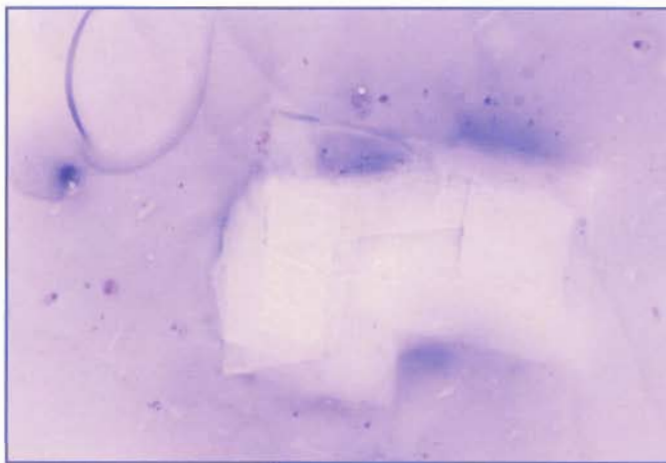


Figure 6.13. Cholesterol crystals from an epidermal inclusion cyst. These usually appear as large, clear, rectangular to rhomboid crystals with very sharp borders that sometimes are notched. (Wright's stain; 200X)

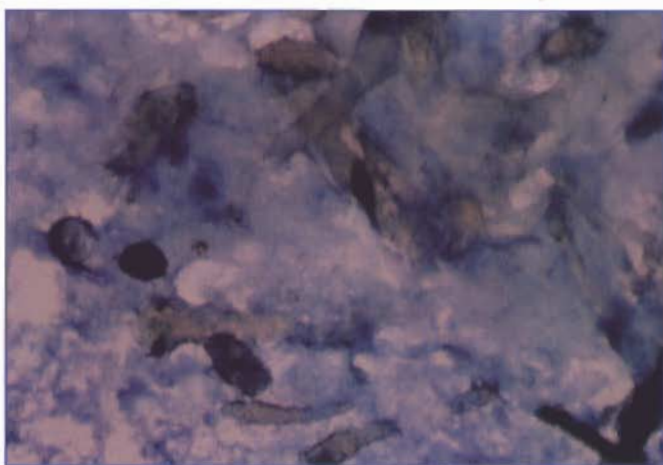


Figure 6.12. Epidermal inclusion cyst from a dog. There is abundant cellular debris. The dark-stained material is melanin pigment. (Wright's stain; 400X)

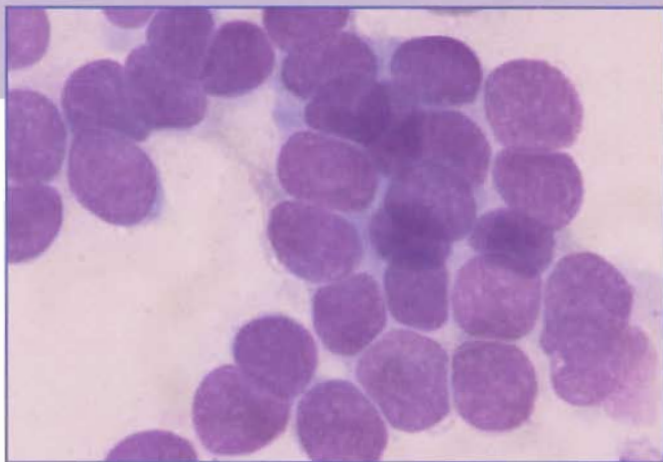
## CASE 7

**SIGNALMENT:** Seven-year-old male cocker spaniel dog

**CLINICAL FINDINGS:** Small, solitary mass on the top of the head

**CYTOLOGIC DESCRIPTION:** Aspirate of mass on head

The sample is minimally cellular. There are small clusters of uniform round cells that appear to be arranged in rows (*Figure 6.14*). These cells have a high N:C ratio. Nuclei are round and have finely stippled chromatin and inconspicuous nucleoli. There is a scant amount of pale cytoplasm. These cells are interpreted as basal epithelial cells.



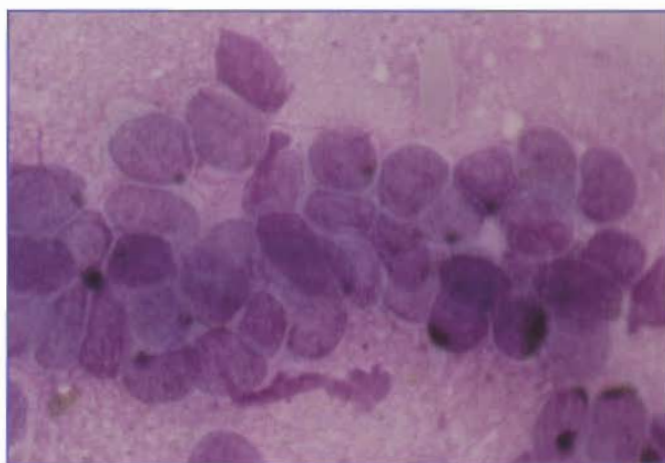
**Figure 6.14.** Basal cell tumor from a dog. There is a cluster of basal epithelial cells in which the nuclei appear to be arranged in several perpendicular rows. These cells have stippled chromatin and a scant amount of cytoplasm. Nucleoli are not apparent. There is minimal variation in cell size, nuclear size, and N:C ratio. (Wright's stain; 1000X)

## INTERPRETATION: Basal cell tumor

Basal cell tumors arise from trichoblastic epithelium of the epidermis or adnexal structures and are common in middle-aged dogs and cats. These tumors occur in the dermis and subcutis, usually as solitary masses on the head, neck, or ears in dogs and on the trunk in cats. Basal cell tumors may be pigmented (*Figure 6.15*), especially in cats, and may contain cystic spaces. Ulceration is relatively common.

Aspirates from basal cell tumors usually are minimally to moderately cellular. Typically, there are small clusters, cords, or ribbons of small (7  $\mu$ m in diameter), uniform epithelial cells. In some samples, there may be only single cells, in which case it may be difficult to distinguish a basal cell tumor from a histiocytoma. The cells have a high N:C ratio (1:1) with scant basophilic cytoplasm. These cells often are broken, and it may be difficult to see cytoplasmic borders. There is minimal variation in cell size, nuclear size, and N:C ratio.

Histologic confirmation of basal cell tumors is recommended because similar-appearing cells can be seen cytologically with other cutaneous tumors, and basal cell carcinomas can occur. Basal cell carcinomas develop relatively commonly on the head in cats and uncommonly on the head, neck, and thorax in dogs. Basal cell tumors and carcinomas can form cysts, become pigmented with melanin, and show adnexal differentiation. Basal cell tumors are benign, slow-growing, and noninvasive whereas basal cell carcinomas are locally invasive but usually do not metastasize.



**Figure 6.15.** Basal cell tumor from a dog. There is a cluster of pigmented basal epithelial cells. These cells are smaller and have round nuclei and a uniform N:C ratio, when compared to melanocytes. (Wright's stain; 1000X)

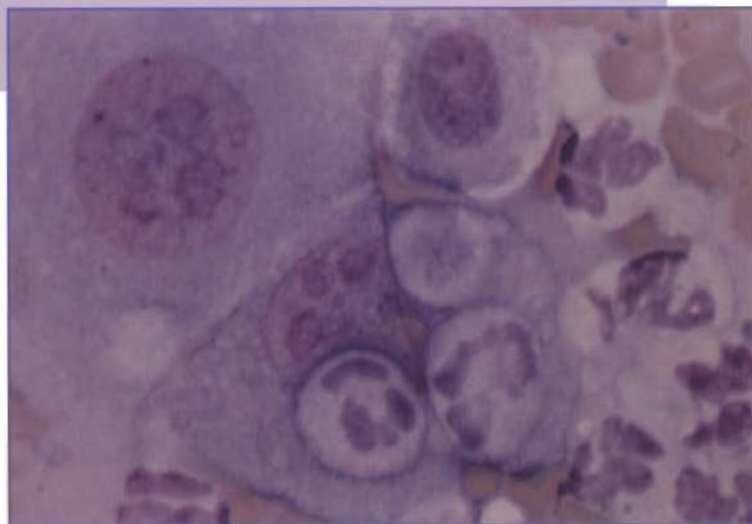
## CASE 8

**SIGNALMENT:** Eight-year-old male Labrador retriever dog

**CLINICAL FINDINGS:** Ulcerated mass on the fourth digit of the left hind foot

**CYTOLOGIC DESCRIPTION:** Aspirate of digital mass

The sample is very cellular. The majority of the cells are very large, anaplastic, squamous epithelial cells (*Figure 6.16*). These cells are characterized by marked variation in cell size, nuclear size, and N:C ratio. There appears to be asynchrony in maturation of the cytoplasm and nucleus. Numerous neutrophils also are present. Rare extracellular bacteria are interpreted as superficial contaminants.



**Figure 6.16.** Squamous cell carcinoma from a dog. There are two very large and one smaller anaplastic squamous epithelial cells. These cells have fine chromatin and prominent nucleoli. Squamous cell carcinomas are often associated with neutrophilic inflammation. The cell in the center has several neutrophils associated with its cytoplasm. (Wright's stain; 1000X)

**INTERPRETATION:** Squamous cell carcinoma with secondary neutrophilic inflammation. Histologic evaluation is recommended for a definitive diagnosis.

Squamous cell carcinomas are malignant tumors of squamous epithelial cells that affect adults or aged animals. Nonpigmented skin is more frequently involved than pigmented skin. Squamous cell carcinomas can involve skin anywhere on the body; but, in dogs, the skin of the ventral abdomen, medial stifles, scrotum, lips, and digital nail beds are most commonly affected. In cats, squamous cell carcinomas occur on the head and usually involve the pinnae, nasal planum, external nares, lips, or eyelids.

Squamous cell carcinomas may be papillary growths or shallow masses, both of which typically are ulcerated.

Secondary bacterial infection and inflammation are sometimes present. Impression smears from the ulcerated surface of squamous cell carcinomas may reveal only bacteria and inflammatory cells.

Squamous cell carcinomas usually exfoliate well. The neoplastic cells may occur as single cells or clusters. Poorly differentiated squamous cell carcinomas are characterized by small, medium, or large round cells with a moderate amount of basophilic cytoplasm. Neoplastic squamous epithelial cells may contain small, clear cytoplasmic vacuoles that often are arranged around the nucleus. Nuclei are large and have finely stippled to moderately clumped chromatin. Multiple nucleoli that vary in size and shape often are present. There may be marked variation in cell size, nuclear size, and N:C ratio. Unless there is evidence of keratinization, it may be difficult to identify these cells as squamous epithelial cells. However, kera-

---

tinized squamous cells and keratin debris usually are present and aid in the diagnosis of squamous cell carcinoma.

In differentiated squamous cell carcinomas, the cells are very large and have abundant, keratinized cytoplasm. These cells may have large nuclei with minimally condensed chromatin and nucleoli. Cytoplasmic borders may appear angular because of keratin production. In normal squamous epithelial cells, the nucleus is small and pyknotic if the cytoplasm is keratinized; whereas asynchronous maturation of the cytoplasm and nucleus is typical of malignant squamous epithelial cells.

Many squamous cell carcinomas are accompanied by neutrophilic inflammation, either from ulceration of the mass or keratin induction of inflammation. This presents a diagnostic challenge to the cytologist because chronic inflammation unassociated with a squamous cell carcinoma is often accompanied by epithelial cell dysplasia, which may be difficult to differentiate cytologically from a well-differentiated squamous cell carcinoma. The definitive diagnosis of squamous cell carcinoma should be made histologically.

## CASE 9

**SIGNALMENT:** Nine-year-old male beagle dog

**CLINICAL FINDINGS:** Mass adjacent to the anus

**CYTOLOGIC DESCRIPTION:** Aspirate of perianal mass

The sample is moderately cellular. There are clusters of round or polygonal cells with abundant, pinkish-gray granular cytoplasm (*Figure 6.17*). These cells have round nuclei with finely stippled chromatin and a single nucleolus. There is minimal variation in cell size, nuclear size, and N:C ratio. There is no evidence of inflammation, and no etiologic agents were seen.

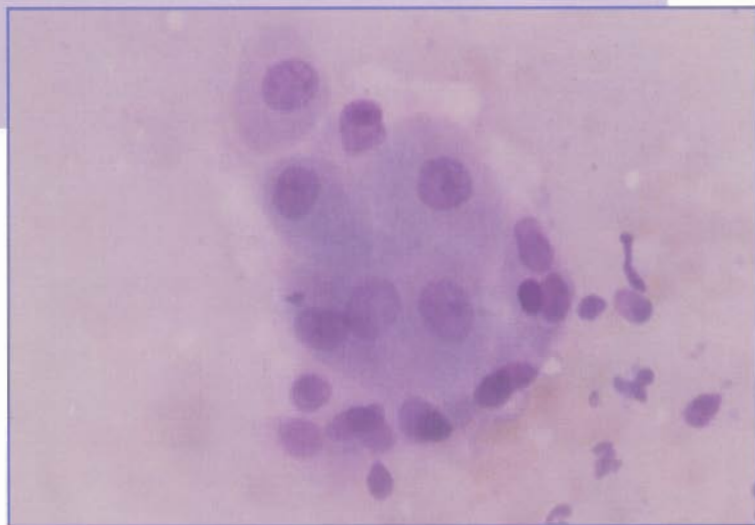


Figure 6.17. Perianal gland adenoma from a dog. There is a cluster of perianal gland epithelial cells in the center. The smaller cells along the bottom of this cluster likely are reserve cells. (Wright's stain; 400X)

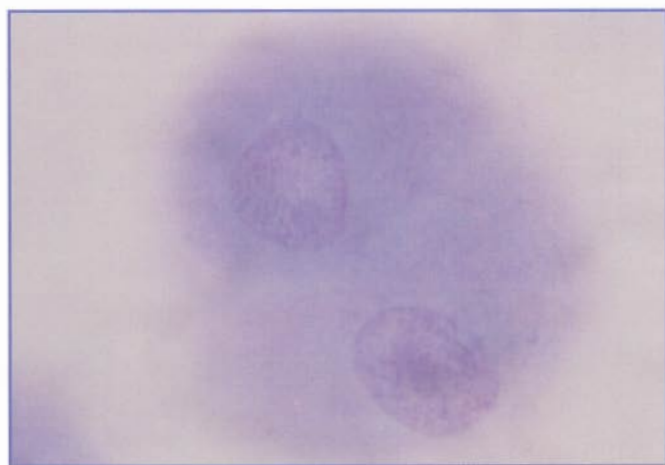


Figure 6.18. Perianal gland adenoma from a dog. These two perianal gland epithelial cells resemble hepatocytes. (Wright's stain; 1000X)

## INTERPRETATION: Perianal gland adenoma

Perianal gland adenomas are benign tumors involving modified sebaceous glands that surround the anus. They occur most commonly in older, intact male dogs as solitary or multiple masses. Most perianal gland adenomas develop adjacent to the anus; but they occasionally are found on the tail, perineum, prepuce, thigh, ventral abdomen, or dorsal sacral and lumbar areas. Large tumors may become multinodular, ulcerated, and infected.

Aspirates from perianal gland adenomas usually are very cellular. There are clusters or individual cells that are round or polygonal. These cells have abundant, pinkish-gray cytoplasm, which may appear somewhat granular. Small, round, centrally located nuclei have finely stippled chromatin and one or two nucleoli. There is minimal variation in cell size or nuclear size. Cells from perianal gland adenomas often are called "hepatoid" cells because their morphology resembles that of hepatocytes (*Figure 6.18*). In some aspirates from perianal gland adenomas, there are smaller reserve cells with cytoplasm that is more basophilic and has a higher N:C ratio than hepatoid cells.

Most perianal gland tumors are adenomas. The differentiation of nodular hyperplasia of the perianal glands from adenoma is difficult cytologically or histologically. Perianal gland adenocarcinomas are rare. Cells from perianal gland adenocarcinomas usually exhibit variation in nuclear size and number and size of nucleoli. Well-differentiated perianal adenocarcinomas are hard to distinguish from adenomas cytologically or histologically.

## CASE 10

**SIGNALMENT:** Six-year-old spayed female mixed breed dog

**CLINICAL FINDINGS:** Small mass next to the anus. She has hypercalcemia of 16.3 g/dl (reference range = 9.4-12.0 g/dl).

**CYTOLOGIC DESCRIPTION:** Aspirate of perianal mass

There are sheets of cuboidal epithelial cells that contain a single round nucleus with granular chromatin and a scant amount of basophilic cytoplasm (*Figure 6.19*). The N:C ratio is high. While the cells tend to be uniform in appearance, occasional cells show mild to moderate anisokaryosis.

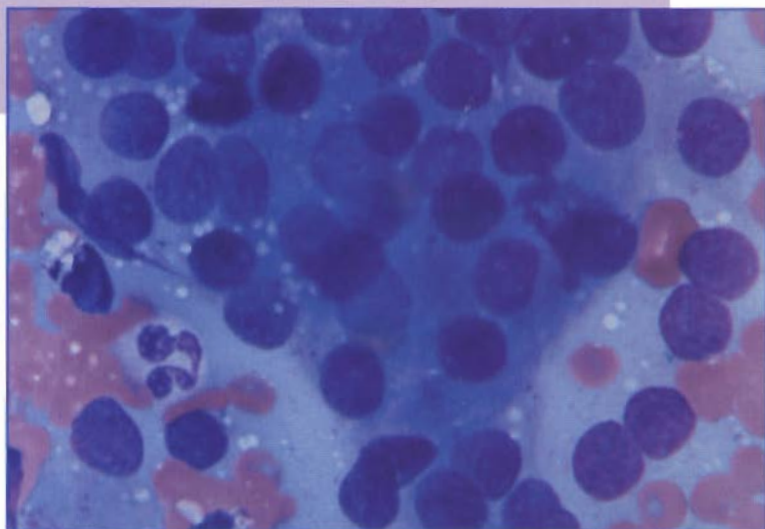


Figure 6.19. Aspirate of an anal-sac apocrine gland adenocarcinoma from a dog. There are sheets of uniform cuboidal epithelial cells that contain a single round nucleus, granular chromatin, and a scant amount of basophilic cytoplasm. (Wright's stain; 1000X)

## INTERPRETATION: Anal-sac apocrine gland adenocarcinoma

Apocrine gland adenocarcinomas of the anal sac occur in aged dogs without an apparent breed predilection. The mass in the perianal region is often small, and the neoplasm frequently metastasizes to the sublumbar lymph nodes. Cytologically, the cells form tubular, ascinar, or solid sheets of cuboidal cells. While relatively uniform in appearance, there is regional anisocytosis with enlarged nuclei. Because these tumors can produce parathyroid hormone-related protein (PTH-RP), presence of this tumor or recurrence following excision is frequently associated with hypercalcemia.

## CASE 11

**SIGNALMENT:** Ten-year-old spayed female mixed breed dog

**CLINICAL FINDINGS:** Obesity and a solitary, soft, freely moveable, subcutaneous mass on the ventral thorax

**CYTOLOGIC DESCRIPTION:** Aspirate of subcutaneous mass

The sample is minimally cellular. There are clusters of very large cells with abundant, clear cytoplasm (*Figure 6.20*). Nuclei appear eccentric and have condensed chromatin. There is minimal variation in cell size and nuclear size. These cells are interpreted as well-differentiated adipocytes. There is no evidence of inflammation, and no anaplastic cells are seen.

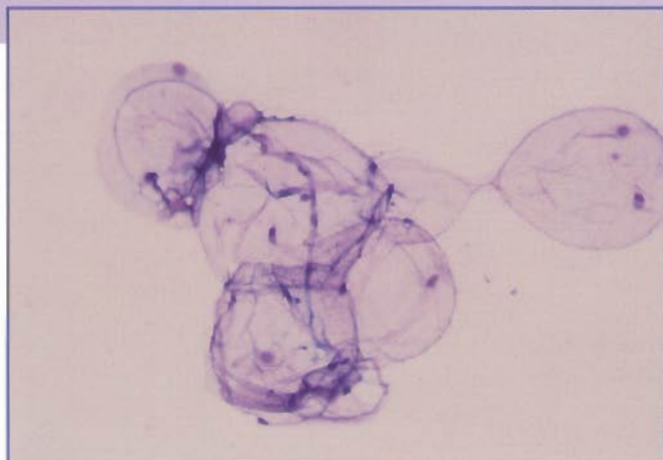


Figure 6.20. Lipoma from a dog. There is a cluster of well-differentiated adipocytes. (Wright's stain; 200X)

## INTERPRETATION: Lipoma

Lipomas are benign tumors of adipocytes that occur in subcutaneous tissue. They are common in dogs and rare in cats. Lipomas occur predominantly in older animals and are more common in overweight females than in male dogs. Lipomas in dogs are found most often on the lateral and ventral thorax, abdomen, and upper hindlimbs and forelimbs. They are usually single masses, but some older animals may have multiple lipomas.

Lipomas typically are soft. The skin is freely moveable over the tumor, and the tumor is not attached to the underlying fascia and muscle. Grossly, aspirates from lipomas appear oily and smears do not dry on microscope slides. The alcohol fixative used in some stains dissolves the lipid so the slide may appear acellular.

Adipocytes are very large, round cells. They may occur as single cells or aggregates of cells that are easily observed with a 10X objective. The lipid-laden cytoplasm appears clear, and the nucleus often is compressed against the outline of the cell. Nuclear chromatin is condensed, and nucleoli are not visible. There is minimal variation in cell size, nuclear size, and N:C ratio.

Clinical findings are useful in the cytologic diagnosis of lipomas because cells from lipomas cannot be distinguished from normal adipocytes cytologically. Subcutaneous fat commonly is aspirated during sampling of other masses or tissues. An aspirate from normal subcutaneous fat could be misinterpreted as a lipoma. Slides from lipomatous tumors always should be examined microscopically because malignant tumors can invade subcutaneous fat. Aspirates from these masses may have adipocytes and neoplastic cells.

Infiltrative lipomas occur much less frequently than lipomas. Cytologically, infiltrative lipomas appear similar to lipomas but clinically and histologically they are different. Infiltrative lipomas are soft, poorly circumscribed masses that infiltrate into and between muscle bundles. These tumors usually grow slowly and often recur following surgical excision. Metastasis is rare.

Liposarcomas are malignant tumors of adipocytes and are rare in all species. In contrast to lipomas, liposarcomas are firm and attached to the underlying tissue. Aspirates from liposarcomas often are more cellular than aspirates from lipomas. Liposarcoma cells usually are spindle-shaped or irregular in shape. The cytoplasm is basophilic and may contain lipid vacuoles. Nuclear chromatin is stippled; nucleoli may be present; and there is variation in cell size, nuclear size, and N:C ratio.

## CASE 12

**SIGNALMENT:** Nine-year-old spayed female German shepherd dog

**CLINICAL FINDINGS:** Large, subcutaneous mass on right lateral thigh

**CYTOLOGIC DESCRIPTION:** Aspirate of mass on thigh

The sample is very cellular. There is a uniform population of large, spindle-shaped cells (*Figure 6.21*). The cells occur singly or in small aggregates. Nuclei are round to oval and have finely stippled to moderately clumped chromatin with one or two nucleoli. The cytoplasm is moderately basophilic and extends in opposite directions from the nucleus. There is minimal to moderate variation in nuclear size and cell size.

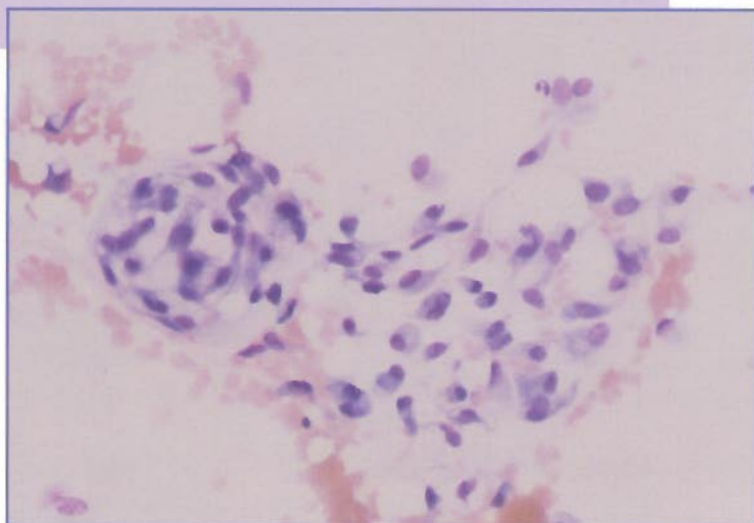


Figure 6.21. Hemangiopericytoma from a dog. There is a uniform population of spindle-shaped cells. The aggregate on the left shows the swirling pattern typical of hemangiopericytomas. (Wright's stain; 200X)

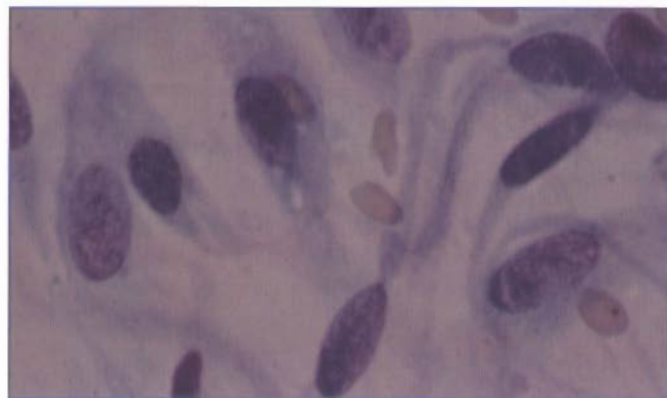


Figure 6.22. Hemangiopericytoma from a dog. The cytoplasm appears to extend from one side of the nucleus. (Wright's stain; 1000X)

**INTERPRETATION: Spindle cell tumor. The primary differential is a hemangiopericytoma, but other similar mesenchymal neoplasms cannot be excluded.**

Hemangiopericytomas have been well documented in dogs. They occur in older dogs, most frequently in the subcutaneous tissues of the lateral surface of the extremities. Breeds predisposed to development of hemangiopericytomas include the boxer, German shepherd, and springer spaniel.

Hemangiopericytomas usually are soft to firm, nodular masses that may become alopecic, ulcerated, or pigmented. Aspirates from hemangiopericytomas usually are moderately cellular, and cells may be arranged in swirled aggregates (*Figure 6.21*). The cells are spindle- to caudate-shaped and

have a moderate amount of blue-gray cytoplasm that often extends from one side or in opposite directions from the nucleus (*Figure 6.22*). Cytoplasmic borders may appear indistinct or wispy. Nuclei are round to oval and have finely stippled to moderately clumped chromatin. Nucleoli may be inconspicuous or prominent. There often is moderate variation in cell size and nuclear size.

Hemangiopericytomas usually are slow-growing. They may recur following surgical excision but rarely metastasize. Using only cytologic evaluation, it may be difficult to differentiate between hemangiopericytomas and other mesenchymal neoplasms, such as fibromas and fibrosarcomas. Histologic evaluation is recommended for a definitive diagnosis.

### CASE 13

**SIGNALMENT:** Four-year-old spayed female domestic shorthair cat

**CLINICAL FINDINGS:** Firm, subcutaneous interscapular mass

**CYTOLOGIC DESCRIPTION:** Aspirate of interscapular mass

The sample is moderately cellular. The majority of the cells are large, individual, spindle-shaped cells with abundant, basophilic cytoplasm (*Figure 6.23*). Large, oval nuclei have finely stippled chromatin and several prominent nucleoli. There is moderate to marked anisocytosis and anisokaryosis. Several multinucleated giant cells are present.

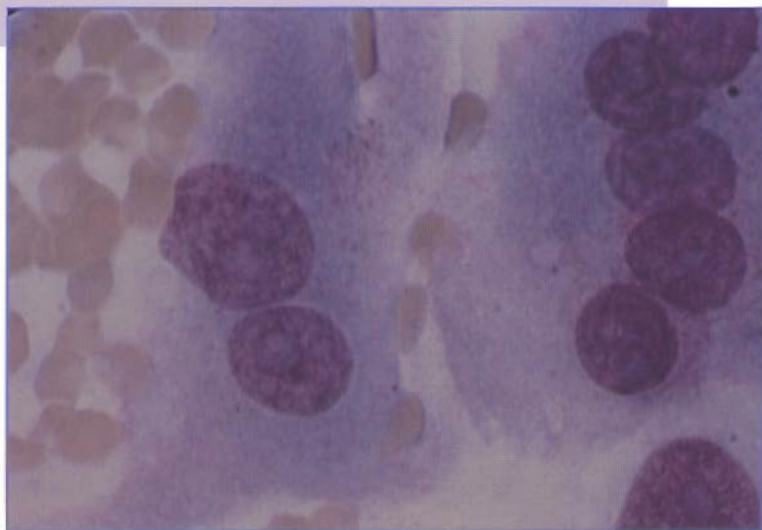


Figure 6.23. Vaccine-induced sarcoma from a cat. There are large, irregularly shaped cells on the left and one multinucleated giant cell on the right. These cells have finely stippled chromatin and prominent nucleoli. (Wright's stain; 1000X)

### INTERPRETATION: Fibrosarcoma

This cat had been vaccinated 6 months ago at the site of the mass and likely had a vaccination-induced sarcoma. Vaccination-induced sarcomas can occur several months to years after vaccination. These tumors usually are well-demarcated masses composed of spindle cells, multinucleated giant cells, and pleomorphic histiocytic cells. There may be lymphocytic inflammation. The spindle cells can be very large and have abundant, basophilic cytoplasm. Nuclei are large, oval, and have finely stippled chromatin and several nucleoli. There often is marked variation in cell size and nuclear size. Most vaccination-induced sarcomas have been diagnosed histologically as fibrosarcomas. They are locally aggressive neoplasms that frequently recur but usually do not metastasize.

Cats may develop a focal area of inflammation at the injection site several days to a few weeks after vaccination. Aspirates from inflammatory nodules are moderately cellular and composed of neutrophils, lymphocytes, macrophages, eosinophils, mast cells, and fibroblasts (*Figure 6.24*). The fibroblasts may appear anaplastic on cytology. If there is concern that the nodule is neoplastic, then histologic evaluation is recommended.

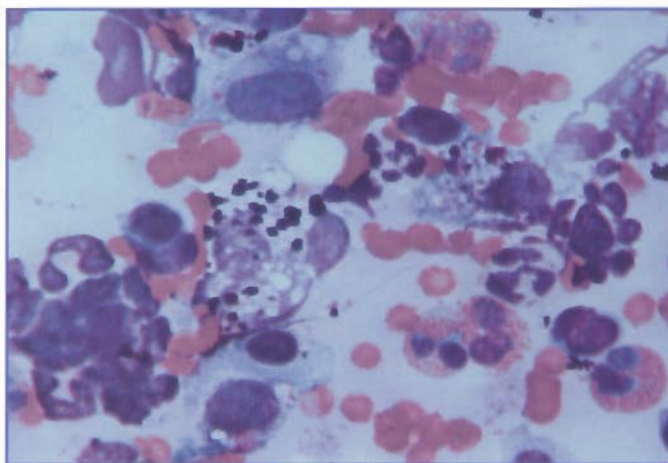


Figure 6.24. Vaccine-induced inflammatory reaction in a cat. There is a mixed population of neutrophils, eosinophils, small lymphocytes, macrophages, mast cells, and fibroblasts. Extracellular purple material may be from the vaccine. (Wright's stain; 1000X)

## Chapter 7: Lymph Node and Spleen—Case Studies

### CASE 1

**SIGNALMENT:** One-year-old male Doberman pinscher dog

**CLINICAL FINDINGS:** Enlarged left submandibular lymph node. Evaluation includes two aspirates.

#### CYTOLOGIC DESCRIPTION

**Aspirate 1.** The red blood cells in the background appear to line up in rows. The sample is moderately cellular. There are clusters of very large cells with abundant vacuolated cytoplasm. These cells resemble normal epithelial cells from the salivary gland (*Figures 7.1 and 7.2*).

**Aspirate 2.** The sample is very cellular. The majority of the cells are small lymphocytes. There are increased numbers of prolymphocytes, lymphoblasts, and plasma cells (*Figure 7.3*). No etiologic agents were seen.

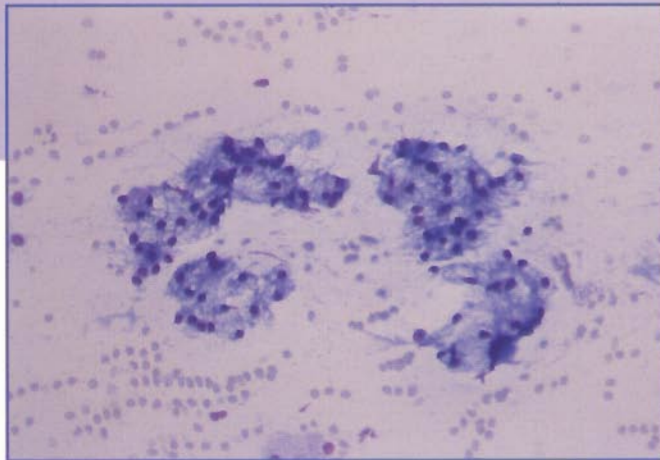


Figure 7.1. Salivary gland aspirate from a dog. The red blood cells appear to line up in rows because of the mucus that is present. There are several clusters of salivary gland epithelial cells. (Wright's stain; 200X)

**INTERPRETATION:** The first aspirate is compatible with normal salivary glandular tissue. The second aspirate is compatible with lymphoid and plasma cell hyperplasia.

Lymphadenopathy may be associated with lymphoid hyperplasia, inflammation, or hematopoietic or metastatic neoplasia. Fine needle aspiration cytology of enlarged lymph nodes often provides a quick diagnosis involving minimum inconvenience and expense. With experience, the cytologic diagnosis of lymphadenopathy can be highly accurate.

When submandibular lymph nodes are aspirated, it is not unusual to aspirate submandibular salivary glandular tissue. If there is blood contamination, the erythrocytes may appear to line up in rows because of the mucus that is present (*Figure 7.1*). Salivary gland epithelial cells are large and have abundant, vacuolated cytoplasm. Nuclei are round and have condensed chromatin (*Figure 7.2*).

Clinical history and physical findings are useful in the cytologic evaluation of lymphoid tissue. For example, immunization might cause diffuse paracortical hyperplasia to the extent that the lymphocytes may appear neoplastic. A dog with multiple enlarged peripheral lymph nodes is more likely to have lymphoma than a dog with a single enlarged lymph node. Young cats with enlarged peripheral

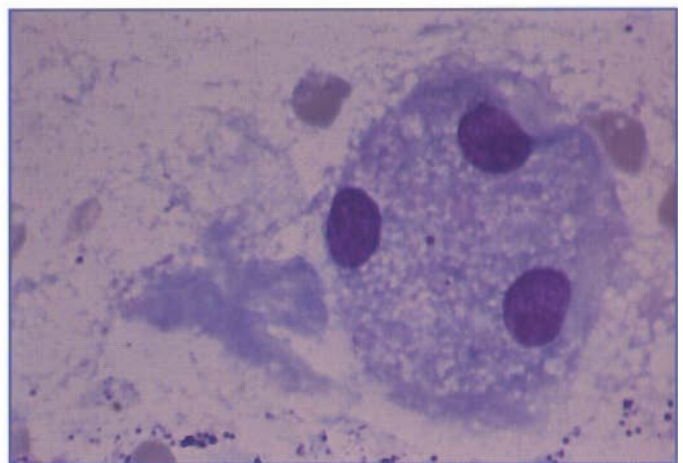


Figure 7.2. Salivary gland aspirate from a dog. Salivary gland epithelial cells have abundant, vacuolated cytoplasm and round nuclei with condensed chromatin. The basophilic material to the left of the epithelial cells is mucus. (Wright's stain; 1000X)

lymph nodes may have non-neoplastic proliferative disease instead of lymphoma.

Knowledge of normal lymph node morphology is also useful in the cytologic evaluation of lymphoid tissue. Normal lymph nodes consist of a heterogeneous cell population that includes 90% to 95% mature lymphocytes and prolymphocytes and 5% to 10% lymphoblasts. Mature lymphocytes are smaller than neutrophils (Figure 7.3) and have a high N:C ratio, coarsely clumped chromatin, and scant cytoplasm. Nucleoli are absent. Prolymphocytes are slightly larger than neutrophils, have moderately clumped chromatin, and have a moderate amount of cytoplasm. Lymphoblasts are large (two to four times the size of mature lymphocytes) and have a relatively high N:C ratio, finely stippled chromatin, one to two nucleoli, and variable amounts of cytoplasm.

Occasional plasma cells may be present in aspirates from normal lymph nodes. Plasma cells have eccentric nuclei, abundant basophilic cytoplasm, and a perinuclear clear area (Figure 7.4). Inflammatory cells, such as neutrophils, macrophages, and mast cells, are rare in most normal lymph nodes. However, the cell population in lymphoid tissue may vary according to location. Lymphoid tissue associated with the gastrointestinal tract contains slightly increased numbers of plasma cells and inflammatory cells because of regular antigenic exposure.

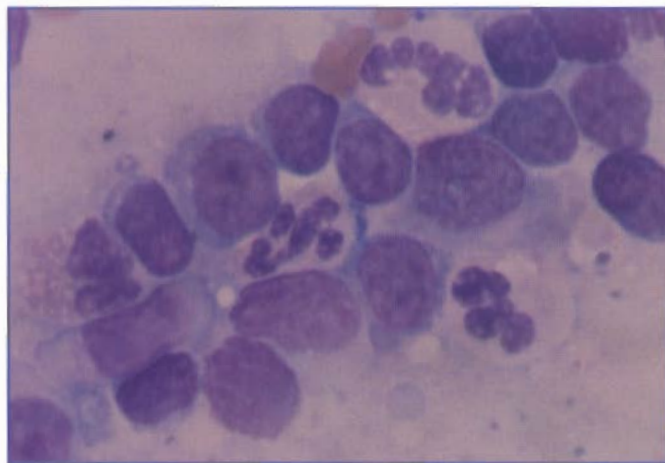


Figure 7.3. Lymph node aspirate from a normal dog. Mature lymphocytes are smaller than neutrophils and have condensed chromatin. Nucleoli are small or not apparent. The neutrophils in this aspirate were from blood contamination. (Wright's stain; 1000X)

Hyperplastic lymph nodes contain lymphoid cells at all stages of differentiation. There are increased numbers of immature lymphoid cells (prolymphocytes and lymphoblasts), but these less mature cells are less than 50% of the lymphoid population. If more than 50% of the lymphoid cells appear immature, there should be concern that the animal has lymphoma. Increased numbers of plasma cells are associated with antigenic stimulation. Although increased numbers of plasma cells often are present in hyperplastic lymph nodes, they rarely are present in lymphoma. Sometimes the term *reactive node* is used when there are increased numbers of plasma cells.

In this case, the dog had an oral abscess. The left submandibular lymph node was moderately enlarged as a result of increased antigenic stimulation. No other lymph nodes were enlarged. This clinical information is helpful in the interpretation of lymph node aspirates. Lymphoid hyperplasia and inflammation usually cause mild to moderate enlargement of a single lymph node. In contrast, lymphoma typically causes moderate to marked enlargement of multiple lymph nodes.

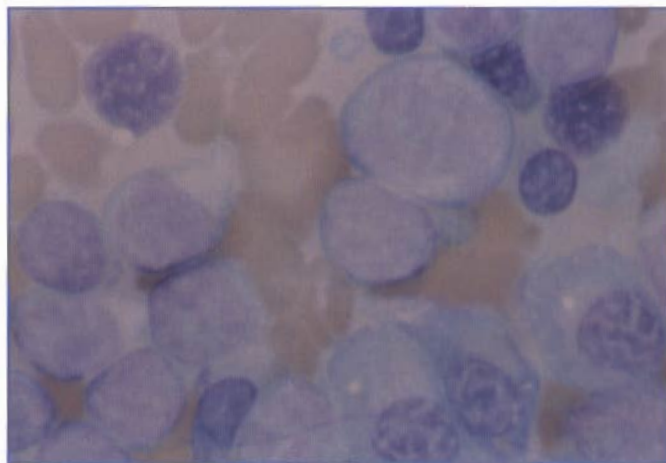


Figure 7.4. Lymph node aspirate from a dog with lymphoid and plasma cell hyperplasia. There are several plasma cells characterized by abundant, intensely basophilic cytoplasm, a perinuclear clear zone, and eccentric nuclei with moderately condensed chromatin. Several small lymphocytes with condensed chromatin and large lymphocytes with fine chromatin and nucleoli are present. (Wright's stain; 1000X)

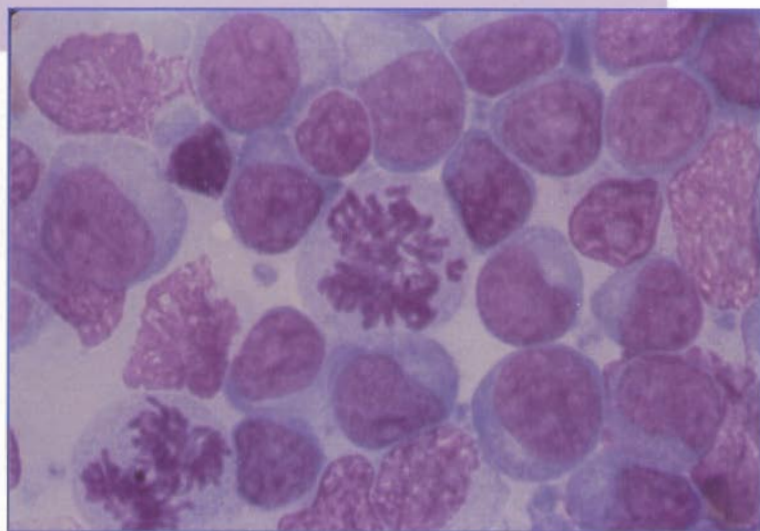
## CASE 2

**SIGNALMENT:** Five-year-old neutered male golden retriever dog

**CLINICAL FINDINGS:** Multiple, markedly enlarged, peripheral lymph nodes

**CYTOLOGIC DESCRIPTION:** Lymph node aspirate

The sample is very cellular. There is a uniform population of large lymphocytes with abundant, basophilic cytoplasm (*Figure 7.5*). Nuclei have finely stippled chromatin and multiple, prominent nucleoli. Numerous mitotic figures are present (*Figure 7.5*).



**Figure 7.5.** Lymph node aspirate from a dog with lymphoma. There is a uniform population of large lymphocytes with abundant, basophilic cytoplasm. Nuclei have finely stippled chromatin and multiple nucleoli. Two mitotic figures are present. (Wright's stain; 1000X)

## INTERPRETATION: Lymphoma

Lymphoid neoplasms are relatively common in adult dogs and cats and may involve multiple tissues, including lymph nodes, intestine, thymus, and hematopoietic organs. The classic clinical presentation in dogs is marked, generalized, peripheral lymphadenomegaly in an otherwise healthy animal. Breeds predisposed to development of lymphoma include golden retriever, boxer, basset hound, Saint Bernard, Scottish terrier, rottweiler, cocker spaniel, and bulldog.

Most dogs have diffuse lymphoma, in which the normal heterogeneous population of mature lymphocytes is replaced by a monomorphic population of immature lymphoid cells. Immature lymphocytes usually are >90% of the lymphoid cells. Plasma cells and inflammatory cells are rare. The morphology of the neoplastic lymphocytes varies with the degree of differentiation and type of lymphocyte. Most lymphoid neoplasms in dogs involve immature lymphoid cells, which are large (larger than neutrophils) and have basophilic cytoplasm, finely stippled chromatin, and multiple prominent nucleoli (*Figure 7.5*).

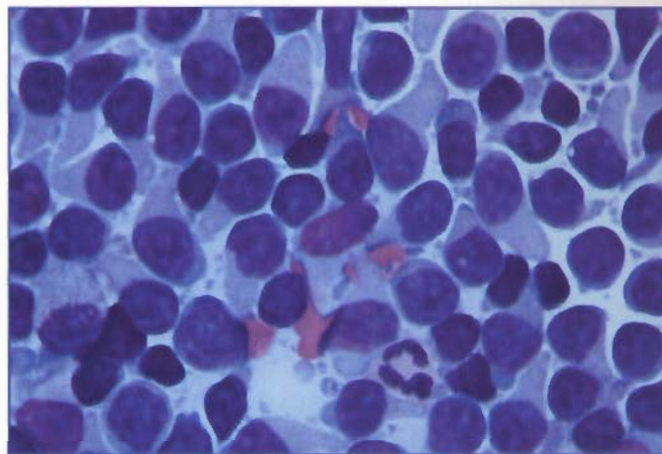
The degree of differentiation and the histologic classification of lymphoma may affect response to treatment and prognosis. A classification system of canine lymphomas based on histologic evaluation of tissue architecture, cell morphology, and mitotic rate has been described. The cytologic classification of lymphoma is based almost entirely on nuclear characteristics, including nuclear size, shape, and chromatin pattern and nucleolar number and size. While cytologic classification is not as reliable as histologic classification, it is sufficient to recognize the common cell types.

The classification system groups tumors into low-grade, intermediate-grade, and high-grade lymphomas based on clinical behavior. Low-grade tumors are the least aggressive and have the best prognosis, whereas high-grade tumors are the

most aggressive and have the worst prognosis. The majority of canine lymphomas are classified as intermediate- or high-grade tumors and usually involve large, immature cells.

Cytologic diagnosis of intermediate- and high-grade lymphomas usually can be made with confidence if the sample is cellular and intact cells are evenly dispersed on the slide. Neoplastic lymphocytes are fragile and rupture easily during specimen preparation. If only broken cells are present, the lymph node should be aspirated again.

The cytologic diagnosis of lymphoid neoplasia is more difficult if there is incomplete tumor involvement of the node, atypical benign hyperplasia, lymphoma involving small lymphocytes (*Figure 7.6*), or concurrent proliferation of a non-neoplastic cell type. In these cases, histologic evaluation may be necessary for a definitive diagnosis.



**Figure 7.6.** Lymph node aspirate from a dog. This dog had lymphoma involving small lymphocytes (smaller than the neutrophil). The cytologic diagnosis of lymphoma was confirmed histologically. (Wright's stain; 1000X)

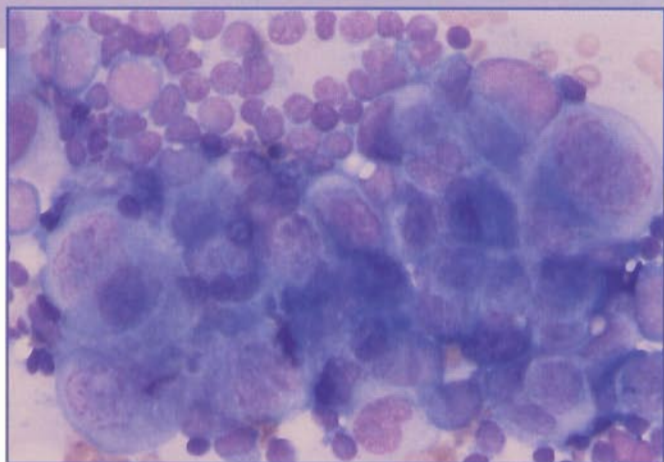
### CASE 3

**SIGNALMENT:** Nine-year-old female Airedale dog

**CLINICAL FINDINGS:** Enlarged left inguinal lymph node

**CYTOLOGIC DESCRIPTION:** Lymph node aspirate

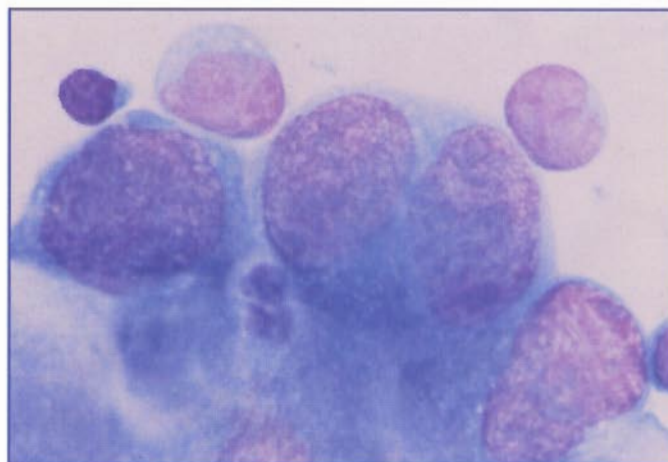
The sample is moderately to markedly cellular. The majority of the cells are small lymphocytes, but there are numerous clusters of large round to polyhedral cells with round to oval nuclei (*Figure 7.7*). Nuclei have finely stippled or irregularly clumped chromatin and multiple nucleoli (*Figure 7.8*). The cytoplasm is intensely basophilic and sometimes vacuolated. There is moderate to marked variation in cell size, nuclear size, and N:C ratio.



**Figure 7.7.** Lymph node aspirate from a dog with a metastatic carcinoma. There is a cluster of anaplastic epithelial cells in a background of small lymphocytes. The carcinoma cells show moderate to marked variation in cell size, nuclear size, and N:C ratio. (Wright's stain; 400X)

### **INTERPRETATION: Metastatic neoplasia. The primary differential is mammary adenocarcinoma.**

The presence of nonlymphoid, neoplastic cells in a lymph node indicates metastatic neoplasia. Carcinomas are more likely than sarcomas to metastasize to lymph nodes and may be identified by the tendency of cells to remain in aggregates or clusters. This dog had a history of mammary adenocarcinoma. With most metastatic neoplasms, the resident lymphoid population is not altered markedly. In advanced metastases, tumor cells may replace the entire node. Absence of neoplastic cells using cytologic evaluation does not exclude the possibility of metastases.



**Figure 7.8.** Lymph node aspirate from a dog with a metastatic carcinoma. These cells are large (there is a small lymphocyte in the upper left for size comparison), round to polyhedral cells with round to oval nuclei, finely stippled chromatin, and multiple nucleoli. The cytoplasm is very basophilic. (Wright's stain; 1000X)

#### CASE 4

**SIGNALMENT:** Four-year-old male coonhound dog

**CLINICAL FINDINGS:** Moderately enlarged right prescapular lymph node.

**CYTOLOGIC DESCRIPTION:** Lymph node aspirate

The sample is very cellular. There is a mixed population of small, medium, and large lymphocytes with increased numbers of plasma cells, neutrophils, and macrophages (Figure 7.9). Numerous large (1  $\mu\text{m}$  wide, 2 to 5  $\mu\text{m}$  long), intracellular, nonstaining rod-shaped structures are present (Figure 7.10).

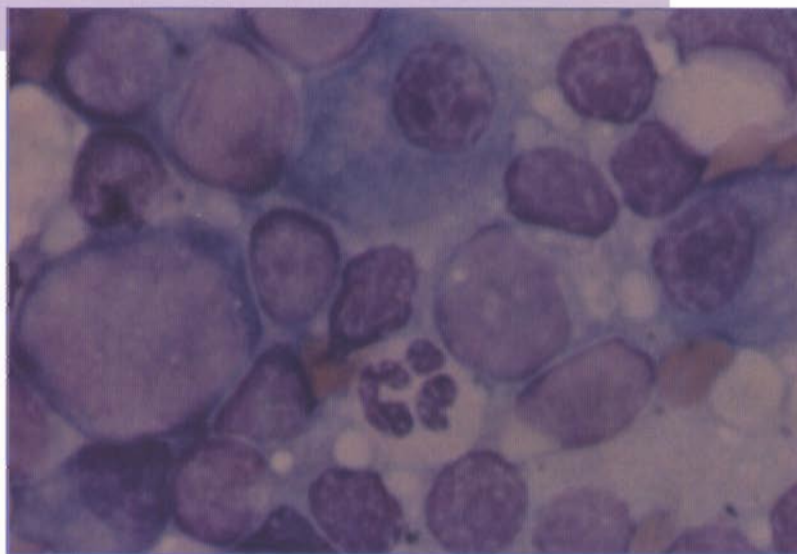


Figure 7.9. Lymph node aspirate from a dog with *Mycobacterium intracellulare* infection. There is a mixed population of small and large lymphocytes. There are two plasma cells and one neutrophil. (Wright's stain; 1000X)

**INTERPRETATION:** Pyogranulomatous lymphadenitis with lymphoid and plasma cell hyperplasia caused by infection with a *Mycobacterium* spp. It was identified by culture as *M intracellulare*.

Increased numbers of inflammatory cells in lymph nodes may include neutrophils, macrophages, eosinophils, and mast cells. The type of inflammatory cell can be helpful in establishing the differential diagnosis. This dog had a *Mycobacterium intracellulare* infection. Some bacteria (eg, *Mycobacterium* spp) and fungi (eg, *Blastomyces dermatitidis* and *Histoplasma capsulatum*) induce an inflammatory reaction in lymph nodes. *B dermatitidis* infections are typically associated with pyogranulomatous (neutrophils and macrophages) inflammation, whereas infection with *Mycobacterium* species or *H capsulatum* usually causes pyogranulomatous or granulomatous (macrophages) inflammation. When lymph node aspirates contain a predominance of neutrophils or macrophages, the slide should be carefully evaluated for infectious agents. Most of these infectious agents have a characteristic cytologic appearance that can be used to make an etiologic diagnosis (see Figure 4.1, Chapter 4).

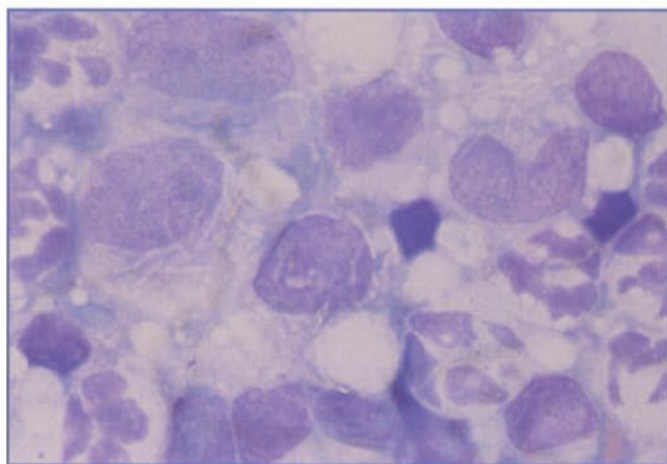


Figure 7.10. Lymph node aspirate from a dog with *Mycobacterium intracellulare* infection. There are several macrophages with large (1  $\mu\text{m}$  wide, 2 to 5  $\mu\text{m}$  long), intracellular, nonstaining, rod-shaped structures. The morphology of these structures is typical of *Mycobacterium* spp. (Wright's stain; 1000X)

**CASE 5**

**SIGNALMENT:** Five-year-old female greyhound dog

**CLINICAL FINDINGS:** Marked hemolytic anemia and thrombocytopenia. Marked, diffuse splenomegaly.

**CYTOLOGIC DESCRIPTION:** Splenic aspirate

The sample is very cellular. There is a mixed population of small, medium, and large lymphocytes (*Figure 7.11*). There is a mild to moderate increase in the number of plasma cells and macrophages. Macrophages often contain phagocytized erythroid precursors (*Figure 7.11*) and hemosiderin pigment. Increased numbers of erythroid and myeloid precursors are present (*Figure 7.12*). Moderate numbers of megakaryocytes also are present (*Figure 7.13*)

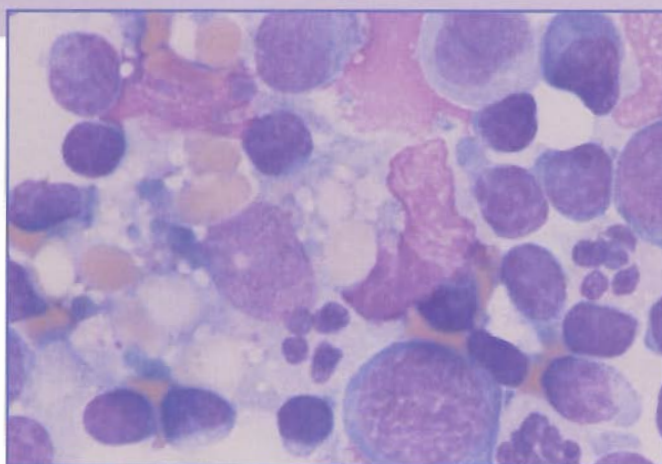


Figure 7.11. Splenic aspirate from a dog with immune-mediated hemolytic anemia. There is a mixed population of small and large lymphocytes. There are several neutrophils. The macrophage has phagocytized erythrocytes. (Wright's stain; 1000X)

**INTERPRETATION: Lymphoid, plasma cell, and macrophage hyperplasia with marked extramedullary hematopoiesis resulting from immune-mediated hemolytic anemia**

Diffuse or nodular splenomegaly is an indication for a splenic aspirate. Diffuse splenomegaly can be caused by splenic hyperplasia, extramedullary hematopoiesis, hemolymphatic neoplasia, or circulatory disturbances, such as portal hypertension. Nodular splenomegaly can be associated with hemolymphatic neoplasia, splenic neoplasia, or hematomas.

Normal splenic tissue is characterized by a mixed population of small, medium, and large lymphocytes. Usually, small lymphocytes are the predominant cell type. Occasional plasma cells, macrophages, and neutrophils as well as rare mast cells also may be present. Macrophages may contain hemosiderin pigment (*Figure 7.14*).

Frequently, aspirates of splenic tissue are bloody and only minimally to moderately cellular. There may be aggregates of cells that resemble macrophages or fibroblasts that likely represent stromal or reticuloendothelial cells.

Splenic hyperplasia may cause mild to moderate diffuse splenomegaly and can be associated with systemic infectious or immunologic diseases. Cytologic findings depend on the infectious agent, mechanism of disease, and host response. Splenic hyperplasia is characterized by increased numbers of immature lymphocytes, plasma cells (*Figure 7.15*), and macrophages; but small lymphocytes usually are the predominant cell. Etiologic agents, such as *Histoplasma*, *Leishmania*, *Haemobartonella*, *Babesia*, *Cytauxzoon*, and *Ehrlichia* spp occa-

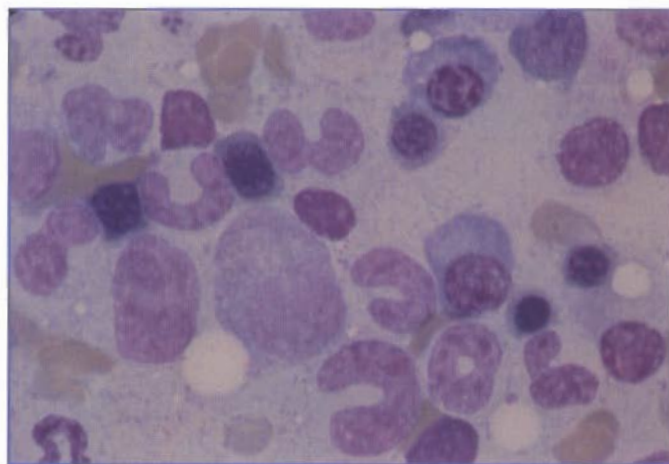


Figure 7.12. Splenic aspirate from a dog with extramedullary hematopoiesis secondary to immune-mediated hemolytic anemia. There are erythroid and myeloid precursors and a plasma cell in the center. (Wright's stain; 1000X)

## Spleen Cases

sionally may be found in splenic aspirates.

As in this case, most dogs with immune-mediated hemolytic anemia have splenomegaly. It is usually unnecessary to aspirate the spleen in these cases. However, if the spleen is aspirated, it is not unusual to find hyperplasia of lymphocytes, plasma cells, and macrophages with prominent erythrophagocytosis and hemosiderin.

The extramedullary hematopoiesis (EMH) in this case was associated with chronic hemolytic anemia. EMH also can occur with myeloproliferative disorders, lymphoproliferative disorders, and hemangiosarcoma in dogs. EMH is characterized by the presence of erythroid and myeloid precursors. If thrombocytopenia also is present, moderate numbers of megakaryocytes may be seen. If EMH is associated with hemolysis, there may be increased numbers of macrophages containing hemosiderin and phagocytized erythroid precursors.

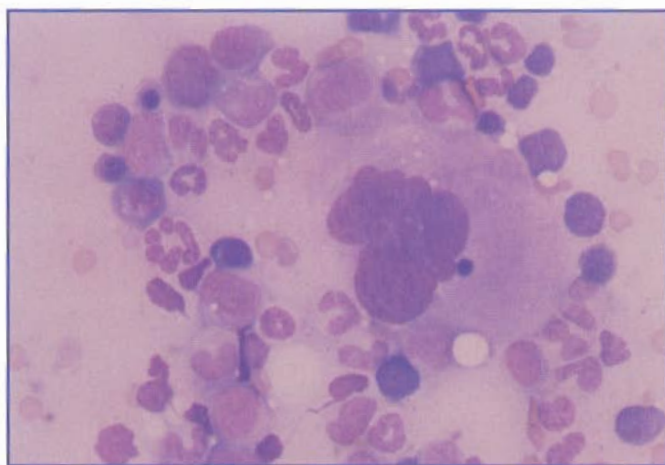


Figure 7.13. Splenic aspirate from a dog with extramedullary hematopoiesis secondary to immune-mediated hemolytic anemia. A megakaryocyte in the center is surrounded by erythroid and myeloid precursors. (Wright's stain; 200X)

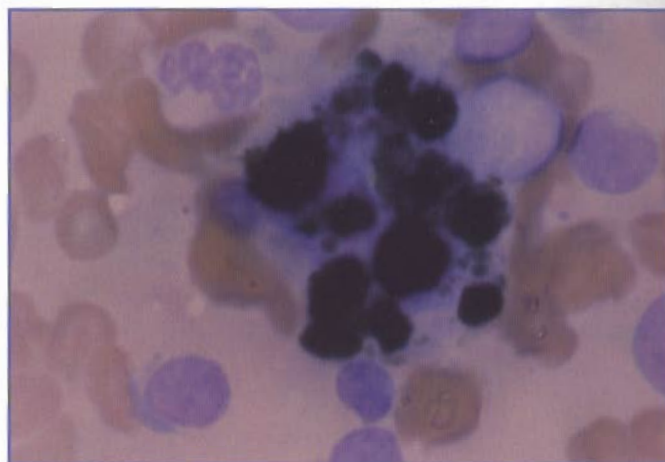


Figure 7.14. Splenic aspirate from a dog with immune-mediated hemolytic anemia. The large cell in the center is a macrophage containing hemosiderin pigment. (Wright's stain; 1000X)

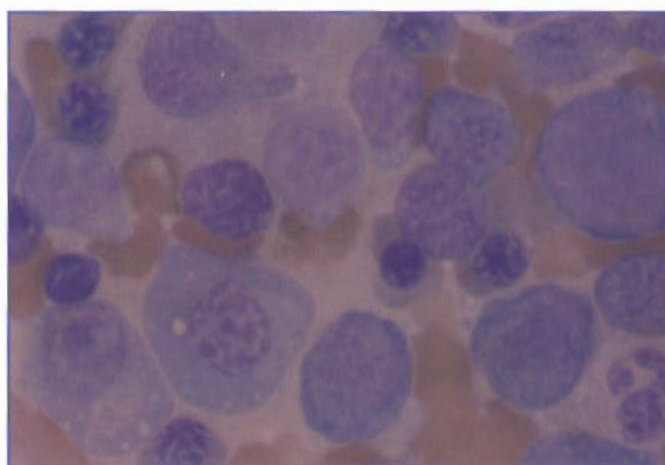


Figure 7.15. Splenic aspirate from a dog with immune-mediated hemolytic anemia. There are increased numbers of erythroid precursors, immature lymphocytes, and plasma cells compatible with EMH and lymphoid hyperplasia. (Wright's stain; 1000X)

## CASE 6

**SIGNALMENT:** Six-year-old castrated male German shepherd dog

**CLINICAL FINDINGS:** Acute collapse. Severe, mildly regenerative anemia with marked fragmentation and normoblastemia. Marked splenomegaly that appears to involve the caudal portion of the spleen.

**CYTOLOGIC DESCRIPTION:** Splenic aspirate

The sample is bloody but otherwise only minimally to moderately cellular (*Figure 7.16*). There are occasional large, spindle-shaped or irregularly shaped cells that have a moderate amount of basophilic cytoplasm. Large, oval nuclei contain finely stippled chromatin and multiple nucleoli (*Figure 7.17*). There appears to be mild to moderate variation in cell size and nuclear size. These cells are interpreted as malignant mesenchymal cells.

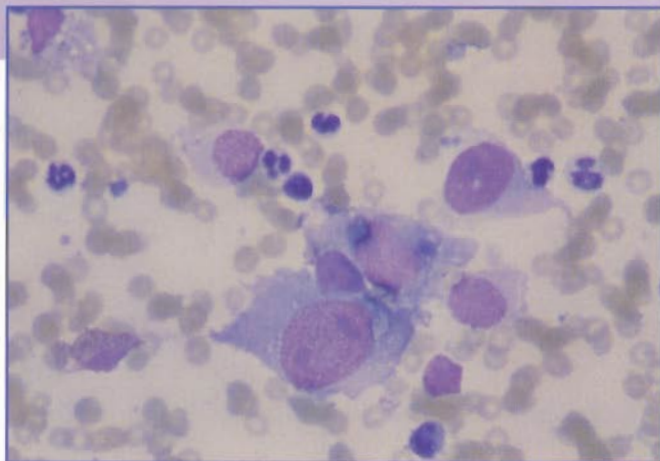


Figure 7.16. Splenic aspirate from a dog with hemangiosarcoma. There is a large, spindle-shaped cell in the lower center compatible with a neoplastic mesenchymal cell. (Wright's stain; 400X)

### INTERPRETATION: Suggestive of malignant mesenchymal neoplasia

Primary splenic neoplasms include hemangiosarcomas, leiomyosarcomas, and fibrosarcomas. The microscopic appearance of these tumors is characterized by anaplastic mesenchymal cells. These cells often exfoliate as single cells or small aggregates, and frequently only small numbers of neoplastic cells are seen. The cytologist may be able to suggest that a primary splenic neoplasm is present, but it is difficult to differentiate these tumors based only on cytologic evaluation. Histologic evaluation is recommended for a definitive diagnosis.

Hemangiosarcoma is the most common malignant mesenchymal neoplasm involving the spleen. It may be associated with rupture and acute intra-abdominal hemorrhage and collapse, as were present in this dog. Splenic hemangiosarcomas can cause red blood cell fragmentation and may be associated with increased numbers of nucleated red blood cells that are out of proportion to the degree of anemia. Some dogs with splenic hemangiosarcoma develop disseminated intravascular coagulation. The cytologic diagnosis of hemangiosarcoma can be difficult because often only small numbers of neoplastic cells are present. Although these cells appear anaplastic, there really are no distinguishing features that differentiate them from other mesenchymal neoplasms.

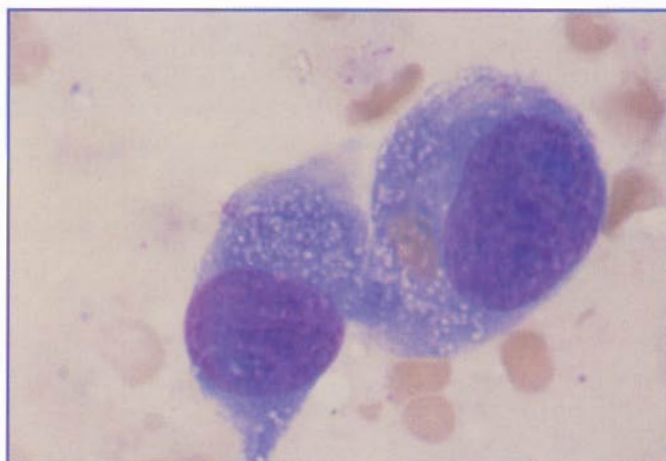


Figure 7.17. Splenic aspirate from a dog with hemangiosarcoma. There are two large neoplastic spindle-shaped cells with basophilic cytoplasm, fine chromatin, and nucleoli. (Wright's stain; 1000X)

## CASE 7

**SIGNALMENT:** Seven-year-old castrated male golden retriever dog

**CLINICAL FINDINGS:** Anorexia, depression. Severe nonregenerative anemia and thrombocytopenia as well as marked, diffuse splenomegaly.

**CYTOLOGIC DESCRIPTION:** Splenic aspirate

The sample is very cellular. There are moderate numbers of small lymphocytes; but the majority of the cells are large, round, individual cells with abundant, moderately basophilic cytoplasm. These latter cells have round, oval, or irregularly shaped nuclei with irregularly clumped chromatin and nucleoli. There is moderate variation in cell size and nuclear size (*Figure 7.18*). Also, there is a moderate amount of cytophagia that appears to include erythroid precursors (*Figure 7.19*).

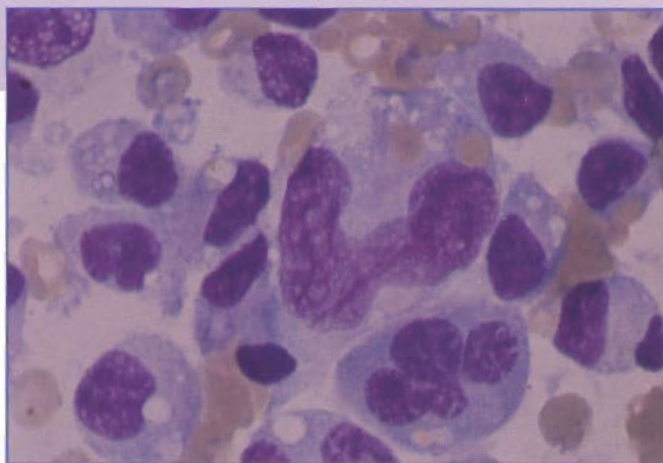


Figure 7.18. Splenic aspirate from a dog with malignant histiocytosis. The malignant histiocytes are large, round, individual cells with abundant, moderately basophilic cytoplasm. These cells have round, oval, or irregularly shaped nuclei with irregularly clumped chromatin and nucleoli. There is moderate to marked variation in cell size and nuclear size. (Wright's stain; 1000X)

## INTERPRETATION: Compatible with malignant histiocytosis

Malignant histiocytosis is a neoplastic proliferation of macrophages that frequently involves the spleen and other hematopoietic tissues, such as bone marrow, liver, and lymph nodes. It typically occurs in large-breed dogs (especially Bernese mountain dogs, golden retrievers, rottweilers, and flat-coated retrievers) and may occur more often in males. Malignant histiocytosis has been reported in cats but appears to be rare. The hemogram often shows nonregenerative anemia. Thrombocytopenia and leukopenia may also be present.

Fine needle aspirates of involved tissue may be helpful in the diagnosis of malignant histiocytosis. The neoplastic macrophages typically display features of anaplasia, such as irregular chromatin, multiple nucleoli, anisokaryosis, and

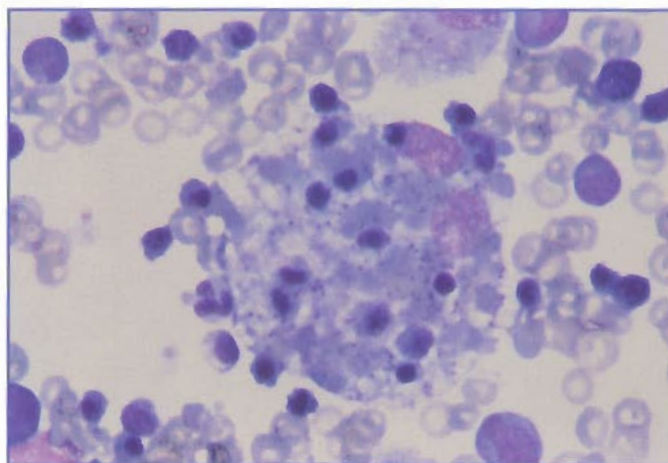


Figure 7.19. Splenic aspirate from a dog with malignant histiocytosis. The macrophage in the center has phagocytized erythroid precursors. (Wright's stain; 400X)

anisocytosis. These characteristics differ from those of macrophages in hemophagocytic syndrome, which is a non-neoplastic proliferation of macrophages that can occur secondary to infectious, metabolic, or neoplastic disease or postvaccination. The macrophages in hemophagocytic syndrome usually appear differentiated. Phagocytosis of erythroid and myeloid precursors can occur in malignant histiocytosis and in hemophagocytic syndrome.

The distinction between malignant histiocytosis and hemophagocytic syndrome is important because one is a malignant neoplastic disease and the other may regress following treatment of the primary disease. Although the macrophages in malignant histiocytosis usually appear

anaplastic and the macrophages in hemophagocytic syndrome usually appear differentiated, there are exceptions. The definitive diagnosis should be based on histologic evaluation of involved tissue and on clinical findings.

Other hemolymphatic neoplasms involving the spleen include acute and chronic myeloid leukemia, acute and chronic lymphoid leukemia, lymphoma, multiple myeloma, and mast cell tumor. Usually, there is diffuse replacement of normal splenic parenchyma. The microscopic appearance depends on the neoplastic cell type. Frequently, splenic aspirates are very helpful in the diagnosis of hematopoietic neoplasia involving the spleen.

## Chapter 8: Respiratory System and Internal Organs— Case Studies

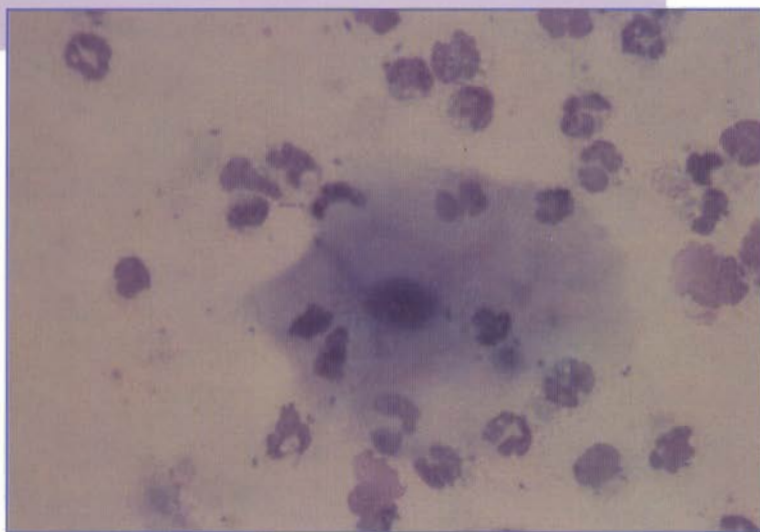
### CASE 1

**SIGNALMENT:** Two-year-old male German shepherd dog

**CLINICAL FINDINGS:** Repeated episodes of vomiting and regurgitation shortly after eating, fever, and coughing. Radiographs are compatible with pneumonia.

**CYTOLOGIC DESCRIPTION:** Tracheal wash

The cellularity of the specimen is high. The predominant cell type is a neutrophil (*Figure 8.1*). There are a few macrophages and occasional squamous epithelial cells. Occasional clusters of ciliated columnar respiratory epithelial cells are present (*Figure 8.2*). There is a mixed population of bacteria, which are found both extracellular (free in the background) and intracellular (phagocytized by neutrophils). Bacteria are associated with the surface of the squamous epithelial cells, which is characteristic of cells and bacterial flora originating from the oropharynx (*Figure 8.3*).



**Figure 8.1.** Tracheal wash from a dog with megaesophagus. There are increased numbers of neutrophils and a mixed bacterial population. The cell in the center is a squamous epithelial cell derived from the oropharynx. (Wright's stain; 400X)

### INTERPRETATION: Septic suppurative inflammation with cells and bacteria derived from the oropharynx

Tracheal washes obtained from normal dogs and cats contain primarily respiratory epithelial cells (*Figure 8.2*) and a few goblet cells. Small numbers of macrophages and lymphocytes typically are seen; however, occasional neutrophils may also be seen. The increased number of neutrophils in this case indicates active, suppurative inflammation. Neutrophil numbers may increase with a variety of etiologies associated with inflammation, including bacterial, viral, fungal, or protozoal infection; neoplasia; tissue trauma; tissue necrosis; or exposure to an irritating substance (such as smoke inhalation).

In this case, an active inflammatory response directed at the bacteria (evident as phagocytosis by the neutrophils) suggests that the bacteria are playing a role in the pneumonia observed in this dog. However, the picture is complicated by the presence of squamous epithelial cells and bacteria that are clearly derived from the oropharynx (*Figure 8.3*). Oropharyngeal contamination may occur if the animal coughs up the

## Respiratory Cases

catheter during the tracheal wash or if an endoscope is contaminated while being placed. When squamous epithelial cells are observed in a tracheal wash, cultures of the tracheal wash fluid must be viewed with caution, as it is not possible to determine if the cultured bacteria are lung-origin pathogens or simply contaminating oropharyngeal flora.

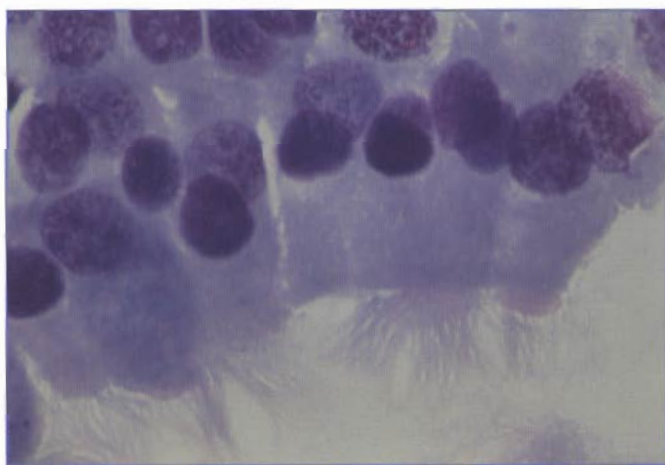


Figure 8.2. Normal-appearing ciliated, respiratory epithelial cells found in a tracheal wash from a dog. Typically, respiratory epithelial cells line up in rows, are columnar, have a basal nucleus, and have a ciliated apical border. (Wright's stain; 1000X)

Additional radiographs showed that this dog had megaesophagus. Pneumonia was the result of aspiration following regurgitation, which accounted for the presence of the mixed bacterial population and the squamous epithelial cells from the oropharynx in this particular case.

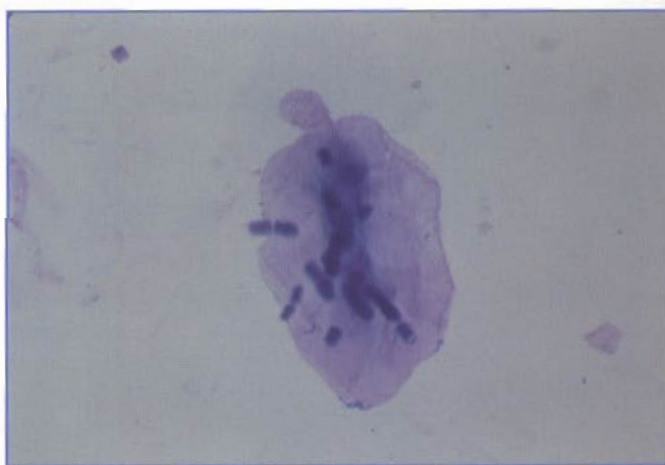


Figure 8.3. Tracheal wash from a dog. The large organisms on the surface of the squamous epithelial cell are *Simonsiella* (or *Karyophanon*) spp. These bacteria are normal oropharyngeal flora and, when found in a tracheal wash, should alert the clinician that there was contamination of the specimen. In this particular case, the presence of these cells and bacteria were the result of aspiration pneumonia rather than contamination of the specimen. (Wright's stain; 400X)

## CASE 2

**SIGNALMENT:** Six-year-old spayed female mixed breed dog

**CLINICAL FINDINGS:** Chronic coughing

**CYTOLOGIC DESCRIPTION:** Tracheal wash

The majority of cells are eosinophils and neutrophils (*Figure 8.4*). In addition, a few lymphocytes and macrophages were seen. No etiologic agents were seen.

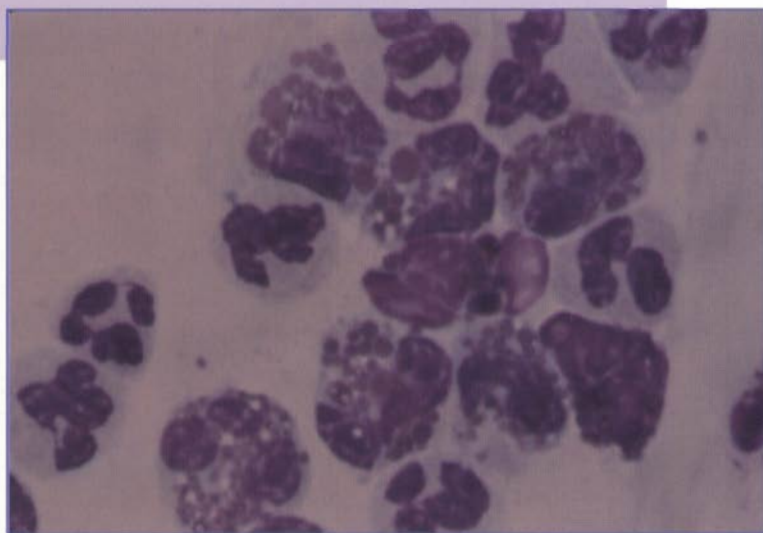


Figure 8.4. Tracheal wash from a dog with heartworm disease. There is a mixture of eosinophils and neutrophils. (Wright's stain; 1000X)

## INTERPRETATION: Eosinophilic inflammation

In tracheal washes, >10% eosinophils in dogs and >25% eosinophils in cats are compatible with an eosinophilic inflammatory response. The presence of an increased number of eosinophils is usually associated with parasitic infestation or a hypersensitivity reaction. Disorders associated with eosinophilic inflammation include allergy, parasites (such as heartworms, lungworms, or larval migration), fungal infection, pulmonary infiltrate with eosinophilia (PIE), feline asthma, and hypereosinophilic syndromes. A heartworm test in this dog was positive.

### CASE 3

**SIGNALMENT:** Four-year-old castrated male rottweiler dog

**CLINICAL FINDINGS:** Chronic coughing and wasting

**CYTOLOGIC DESCRIPTION:** Bronchoalveolar lavage

The cellularity of the sample is high. There are moderate numbers of macrophages (*Figure 8.5*) and occasional multinucleated giant cells. Occasional neutrophils were seen. In addition, there are increased numbers of goblet cells (*Figure 8.6*), and the cells are embedded in thick mucous strands. No etiologic agents were seen.

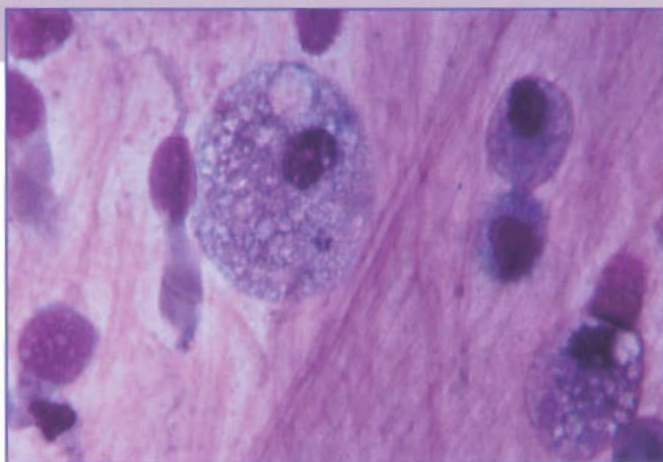


Figure 8.5. Bronchoalveolar lavage from a dog with chronic bronchitis. The majority of the cells are macrophages with foamy cytoplasm. The long thin cell to the left is a ciliated columnar respiratory epithelial cell. All of the cells are embedded in thick mucous strands. (Wright's stain; 1000X)

### INTERPRETATION: Nonsuppurative inflammation with goblet cell hyperplasia

Numbers of macrophages increase with chronic inflammatory conditions, such as chronic bronchitis, persistent bacterial infection, mycotic infection, neoplasia, tissue necrosis, and congestive heart failure. The increased amount of mucus and number of goblet cells is compatible with goblet cell hyperplasia, a change that may occur with chronic inflammation or airway irritation.

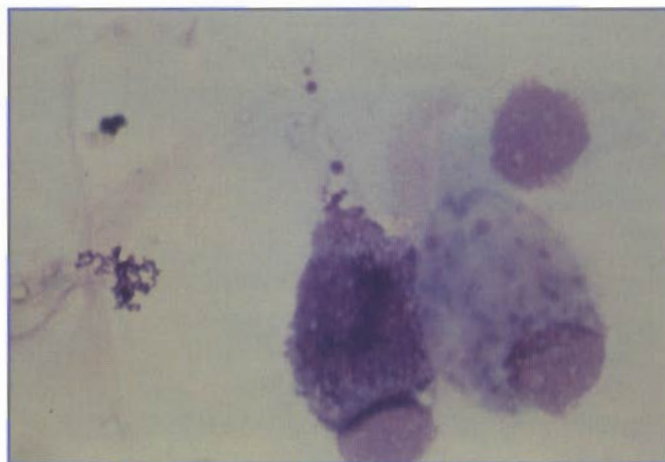


Figure 8.6. Goblet cells in a tracheal wash from a dog. Goblet cells have a basal nucleus and cytoplasm distended with large, pink to purple mucin granules. (Wright's stain; 1000X)

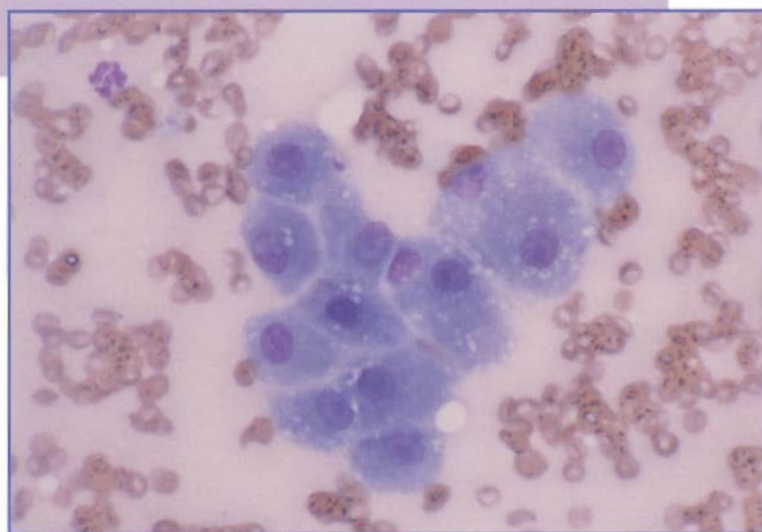
**CASE 4**

**SIGNALMENT:** Nine-year-old spayed female mixed breed dog

**CLINICAL FINDINGS:** Fever, anorexia, depression. Increased liver enzymes. Mild hepatomegaly.

**CYTOLOGIC DESCRIPTION:** Liver aspirate

The sample is moderately cellular. There are clusters of what appear to be well-differentiated hepatocytes (*Figure 8.7*). There are extracellular bile plugs (*Figure 8.8*). There is an increased number of neutrophils, many of which appear degenerate. Intra- and extracellular bacteria are present (*Figure 8.9*).



**Figure 8.7.** Cluster of normal hepatocytes in a liver aspirate from a dog. Normal hepatocytes are large, round or polyhedral cells with abundant amphophilic, grainy cytoplasm. (Wright's stain; 200X)

**INTERPRETATION: Compatible with septic, suppurative inflammation**

Hepatomegaly can occur with inflammatory, metabolic, and neoplastic disorders as well as with extramedullary hematopoiesis. Cytologic evaluation of fine needle aspirates of the liver often provides useful information in the differential diagnosis of hepatomegaly when paired with other clinical findings. Diffuse hepatomegaly is the most common indication for aspiration of the liver, but focal lesions also can be sampled using ultrasound guidance. Fine needle aspiration usually yields a sample adequate for cytologic evaluation. If a biopsy is collected, impression smears can be made before the sample is placed in formalin. Evaluation of hemostasis is recommended before fine needle aspiration or biopsy. Fine needle aspiration may be preferable to biopsy if bleeding problems are present.

Complications from fine needle aspiration occur in <1% of cases in which liver aspirates are collected. Nonclinical hemorrhage may occur (visible on ultrasound but no clinical findings), but fatal hemorrhage very rarely occurs.

Aspirates from normal liver tissue are minimally to moderately cellular. The majority of the cells are hepatocytes, which occur in small clusters or as single cells (*Figure 8.7*). Normal hepatocytes are large, round, or polyhedral cells with abundant amphophilic, grainy cytoplasm. Bile pigment, which appears as greenish granules, may be present in the cytoplasm of normal

hepatocytes (*Figure 8.10*). Small casts of bile pigment also may be seen between hepatocytes in some animals and may indicate cholestasis (*Figure 8.8*). Nuclei of normal hepatocytes are round and centrally located. Nuclei have coarsely stippled chromatin and usually one nucleolus. Occasional binucleated cells may be present.

Nodular hyperplasia of the liver is common in older dogs. Cytologically, hepatocytes appear normal except for mild variation in cell size and nuclear size and mildly increased numbers of binucleated cells (*Figure 8.11*). There may be increased cytoplasmic basophilia.

Small clusters of bile duct epithelial cells also may be seen. These are round cells with round nuclei, condensed chromatin, inconspicuous nucleoli, and a high N:C ratio.

Occasional macrophages may occur in aspirates from nor-

mal hepatic tissue. Macrophages often are increased in animals with hemolytic disease and in some inflammatory diseases. With hemolysis, hemosiderin may be present in the cytoplasm of some macrophages. Hemosiderin usually appears golden brown, but it may be difficult to distinguish hemosiderin from bile pigment with routine cytologic stains.

The presence of neutrophils, lymphocytes, plasma cells, and macrophages can be used to categorize the type of inflammatory disease in hepatic aspirates. With adequate sampling, cytology can be used to diagnose the type of inflammation present. However, the cytologic diagnosis of inflammation of the liver is not as sensitive as histologic evaluation of a liver biopsy, especially if there is only mild inflammation.

In suppurative inflammation, neutrophils are the primary inflammatory cell present, as in this case. There may be

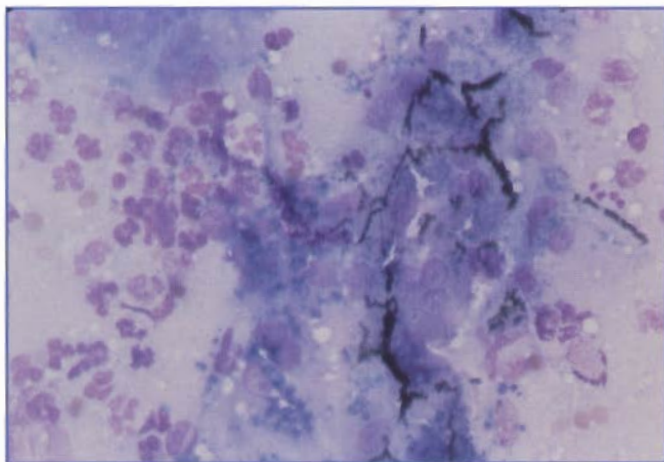


Figure 8.8. Liver aspirate from a dog with septic suppurative hepatitis. There are extracellular bile plugs that are compatible with cholestasis. (Wright's stain; 20X)

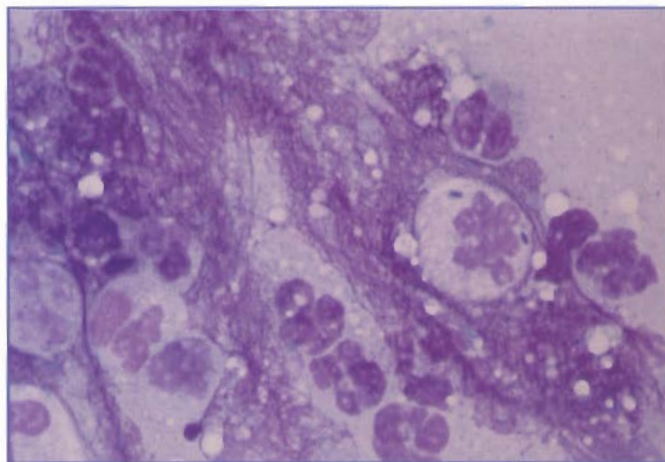


Figure 8.9. Liver aspirate from a dog with septic suppurative hepatitis. There are increased numbers of neutrophils, many of which appear degenerate. Intracellular bacteria are present. (Wright's stain; 1000X)

occasional lymphocytes and macrophages. It may be difficult to distinguish between suppurative inflammation and the increased number of neutrophils associated with blood contamination, especially if the animal has peripheral leukocytosis. In suppurative inflammation, there may be more neutrophils associated with clusters of hepatocytes than in the background of the smear. Suppurative hepatitis usually is associated with bacterial infection. Bacteria were present in this case, but it is unusual to identify the bacteria by cytology in cases of suppurative hepatitis.

Lymphocytic/plasmacytic hepatitis and cholangiohepatitis are characterized by a predominance of lymphocytes and plasma cells. Inflammation of this kind is more common in cats than in dogs. It may be difficult to distinguish lymphocytic/plasmacytic inflammation from chronic lymphocytic

leukemia and lymphoma, both of which occur in dogs and cats. Chronic lymphoid leukemia typically is associated with persistent lymphocytosis of small lymphocytes and splenomegaly. Lymphoma usually involves a cell that appears immature cytologically. In these cases, the cytologic diagnosis can be made with confidence. However, if there is lymphoma involving a small cell type, histologic evaluation is recommended for a definitive diagnosis.

Mixed or pyogranulomatous inflammatory reactions are characterized by neutrophils and macrophages. This type of inflammation occurs with feline infectious peritonitis, fungal infections, mycobacterial infections, protozoal infections, and in some cases of immune-mediated hemolysis.

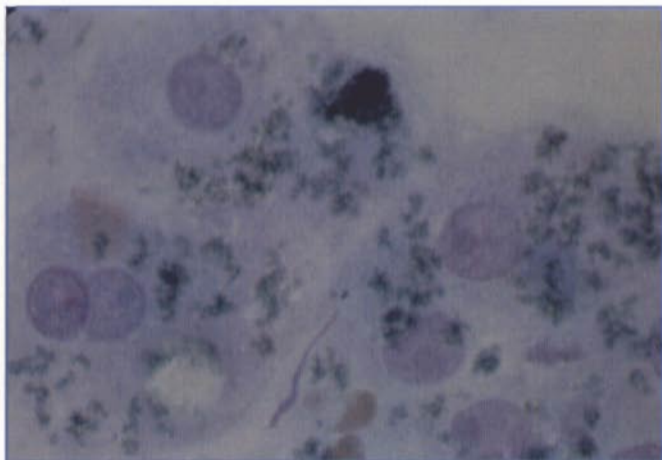


Figure 8.10. Liver aspirate from a dog. Abundant intracellular bile pigment, as seen in these hepatocytes, may be normal. (Wright's stain; 1000X)

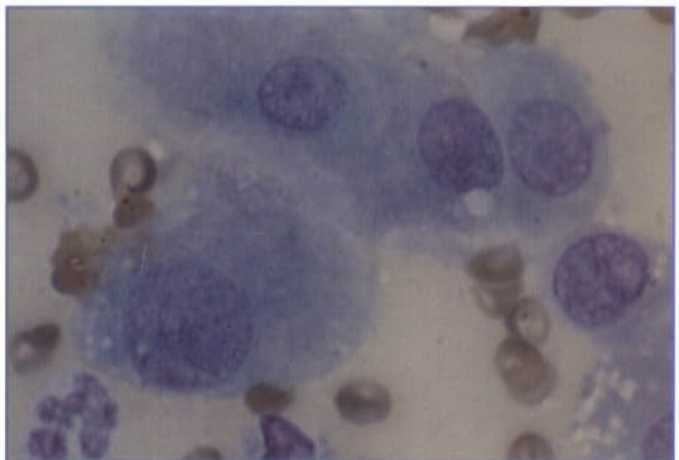


Figure 8.11. Liver aspirate from a dog with a regenerative nodule. The hepatocyte on the lower left is large and has a large nucleus, compared with the more normal hepatocytes at the top. (Wright's stain; 1000X)

## CASE 5

**SIGNALMENT:** Nine-year-old obese spayed female domestic shorthair cat

**CLINICAL FINDINGS:** Depressed, anorexic, and icteric. Diffuse hepatomegaly and increased serum alkaline phosphatase and alanine aminotransferase activities, increased bilirubin concentration, and normal  $\gamma$ -glutamyltransferase activity.

**CYTOLOGIC DESCRIPTION:** Liver aspirate

The sample is very cellular. There are clusters of hepatocytes, most of which have distinct, clear cytoplasmic vacuoles (*Figures 8.12 and 8.13*). There is no evidence of inflammation, and no etiologic agents or anaplastic cells are present.

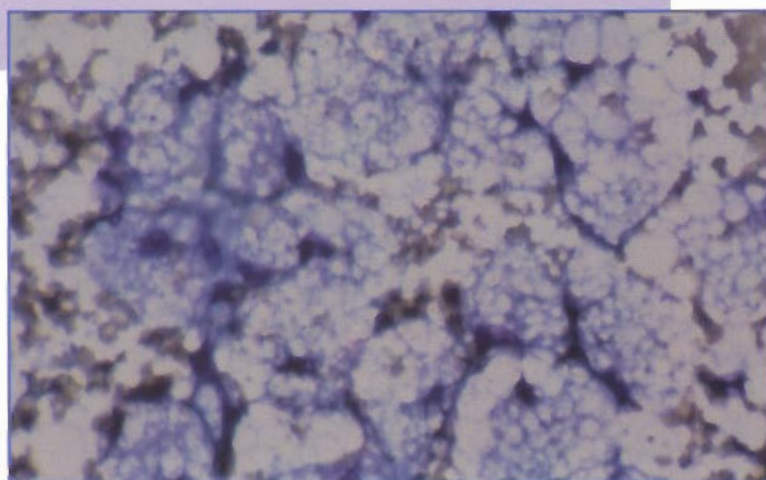


Figure 8.12. Liver aspirate from a cat with lipidosi. There are numerous hepatocytes with vacuolated cytoplasm because of increased lipid. Similar lipid vacuoles are present in the background. (Wright's stain; 200X)

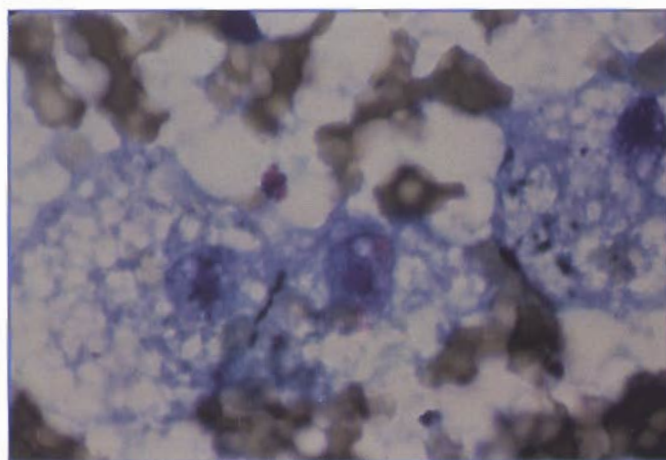


Figure 8.13. Liver aspirate from a cat with lipidosi. The hepatocyte cytoplasm is markedly distended with large lipid vacuoles. (Wright's stain; 1000X)

## INTERPRETATION: Vacuolar degeneration compatible with hepatic lipidosi

Lipidosi is a common cause of icterus and hepatomegaly in cats. Cytologically, lipidosi is identified by the presence of distinct, round, clear vacuoles that occur in the cytoplasm of most hepatocytes and in the background of the slide. These vacuoles can vary in size and number. There may be a single large vacuole or multiple smaller vacuoles. The vacuoles often distend the cytoplasm of the hepatocyte and displace the nucleus to the periphery of the cell. In severe cases, it may be difficult to recognize the cells as hepatocytes (*Figure 8.13*). Clinical findings and cytologic evaluation are useful in the diagnosis of hepatic lipidosi, but definitive diagnosis of vacuole content requires special stains.

It is important to recognize that lipidosi in cats may be a primary disease or may occur secondary to inflammation or neoplasia. The slide should be carefully evaluated for evidence of inflammatory or neoplastic cells (*Figure 8.14*).

Lipid accumulation in hepatocytes is uncommon in dogs, but may occur secondary to diabetes mellitus or other metabolic disorders.

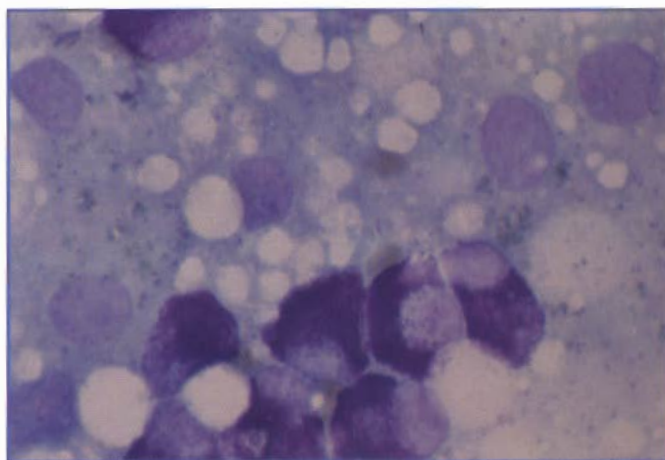


Figure 8.14. Liver aspirate from a cat with lipidosi and a mast cell tumor. There are both vacuolated hepatocytes and neoplastic mast cells. (Wright's stain; 1000X)

## CASE 6

**SIGNALMENT:** Five-year-old spayed female toy poodle

**CLINICAL FINDINGS:** Polydipsia, polyuria, and pendulous abdomen. Moderately increased serum glucose concentration and markedly increased alkaline phosphatase activity.

**CYTOLOGIC DESCRIPTION:** Liver aspirate

The sample is very cellular. There are clusters of well-differentiated hepatocytes, most of which have numerous small cytoplasmic vacuoles (*Figure 8.15*).

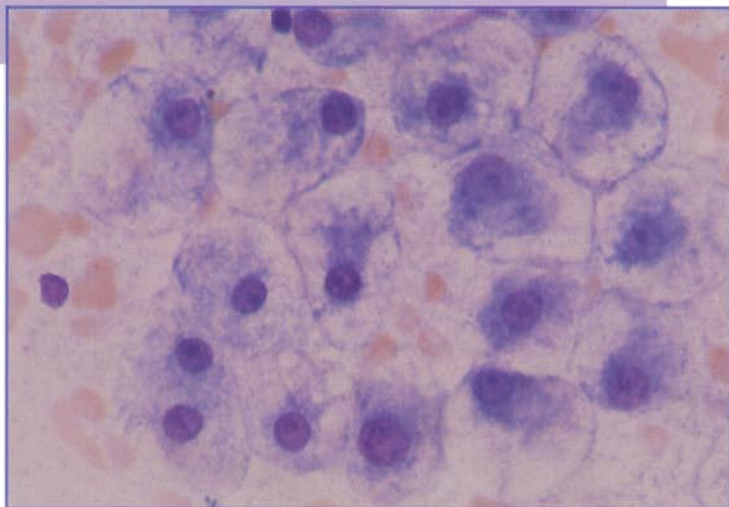


Figure 8.15. Liver aspirate from a dog with steroid hepatopathy. The hepatocytes are markedly distended, and the cytoplasm appears vacuolated. These vacuoles have a feathery appearance, compared to the more discrete vacuoles in feline lipidosis. (See case 5.) (Wright's stain; 400X)

## INTERPRETATION: Compatible with glucocorticoid-induced hepatopathy

Increased endogenous glucocorticoids (Cushing's disease) or the exogenous administration of glucocorticoids is associated with hepatomegaly from glycogen deposition in dogs. Cytologically, hepatocytes are markedly distended and the cytoplasm appears vacuolated. The vacuoles may have a feathery appearance, compared with the more discrete vacuoles in feline lipidosis. Clinical findings and cytologic evaluation are useful in the diagnosis of glucocorticoid-induced hepatopathy, but definitive diagnosis of vacuole content requires special stains.

## CASE 7

**SIGNALMENT:** Nine-year-old male Irish setter

**CLINICAL FINDINGS:** Anorexia, vomiting, lethargy. Liver enzymes are increased. A large mass is present in the left lateral lobe of the liver. An ultrasound-guided, fine needle aspirate of the hepatic mass was submitted for cytologic evaluation.

**CYTOLOGIC DESCRIPTION:** Liver mass aspirate

This sample is very cellular. There is a uniform population of large cells that occur singly and in clusters (Figure 8.16). The cells have a moderate amount of basophilic cytoplasm. Nuclei are large, round, and contain finely stippled chromatin and multiple nucleoli. There is moderate variation in cell size and nuclear size.

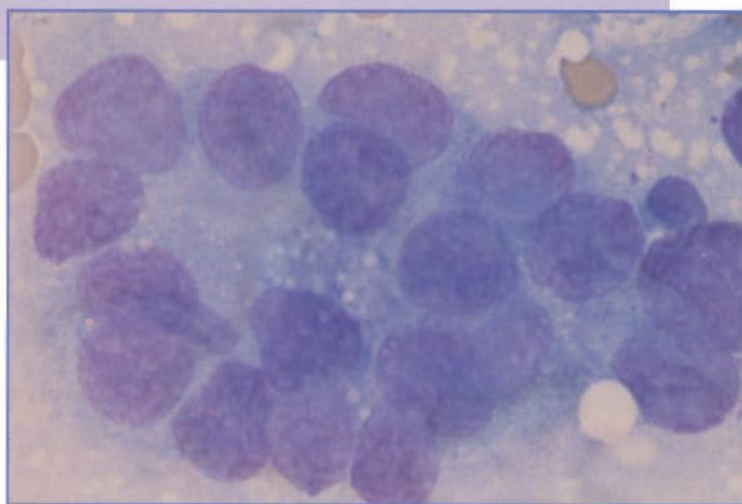


Figure 8.16. Liver aspirate from a dog with a metastatic carcinoma. There is a cluster of anaplastic epithelial cells. These cells are large and have a moderate amount of basophilic cytoplasm. Nuclei are large and round with finely stippled chromatin and multiple nucleoli. There is moderate variation in cell size and nuclear size. (Wright's stain; 1000X)

**INTERPRETATION:** Suggestive of malignant epithelial neoplasia. The primary differential is a metastatic carcinoma.

This dog had a metastatic pancreatic carcinoma. Neoplasia involving the liver may be primary (hepatocyte or bile duct origin) or metastatic. Cells from a hepatocellular carcinoma may appear relatively well differentiated or very anaplastic. It may be difficult to distinguish well-differentiated hepatic carcinomas from hepatic adenomas or nodular hyperplasia. Most hepatocellular carcinomas have neoplastic cells that appear anaplastic (Figure 8.17). These cells have marked variation in cell size, nuclear size, and N:C ratio. Prominent nucleoli are present, and nucleoli vary in size and shape. Bile pigment may be present. A cytologic diagnosis of hepatocellular carcinoma should be confirmed histologically.

Cells from cholangiocarcinomas usually are smaller than cells from hepatocellular carcinomas. These cells have features of malignancy but otherwise do not have distinguishing cytologic characteristics. It may be difficult to differentiate hepatocellular carcinomas from cholangiocarcinomas and metastatic endocrine, pancreatic, and gastrointestinal tumors. Recognition of the primary tumor may be useful in the diagnosis of metastatic endocrine and gastrointestinal tumors. Primary sarcomas of the liver are uncommon. Metastatic sarcomas can occur, and hemangiosarcoma is the most common. A cytologic diagnosis of primary or metastatic neoplasia involving the liver should be confirmed histologically, preferably by evaluation of the primary tumor.

Lymphoma, acute myeloid leukemia, mast cell tumors, and malignant histiocytosis can also involve hepatic tissue. Lymphoma is the most common hematopoietic neoplasm that involves the liver. In acute myelogenous leukemia, neoplastic myeloblasts can infiltrate the liver. These cells resemble immature hematopoietic cells, but their myeloid lineage may be difficult to recognize without cytochemical stains. Information from the hemogram or a bone marrow aspirate may be helpful in the diagnosis. Although small numbers of mast cells may be present in normal liver aspirates, numerous mast cells are suggestive of systemic mastocytosis (Figure 8.14). Examination of a peripheral-blood buffy coat smear and a bone marrow aspirate may be helpful in the diagnosis of mast cell neoplasia involving the liver. Malignant histiocytosis is characterized by macrophages that cytologically appear immature or atypical.

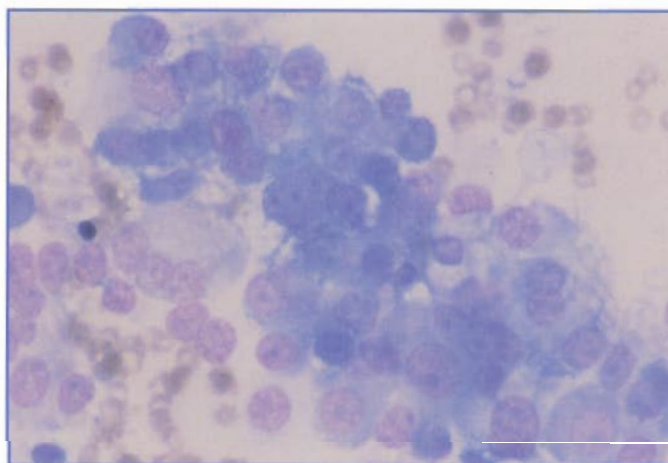


Figure 8.17. Liver aspirate from a cat with hepatocellular carcinoma. There is a cluster of anaplastic cells with marked variation in cell size, nuclear size, and N:C ratio. Prominent nucleoli are present. Bile pigment was present in some cells. (Wright's stain; 400X)

## CASE 8

**SIGNALMENT:** Twelve-year-old spayed female domestic shorthair cat

**CLINICAL FINDINGS:** Vomiting, weight loss, lethargy. Feline leukemia virus (FeLV) test was negative. A mass was palpable in the abdomen.

**CYTOLOGIC DESCRIPTION:** Ultrasound-guided aspirate of the abdominal mass

Cellularity of the sample is high and consists of lymphocytes that are 12 to 18  $\mu\text{m}$  in diameter (*Figure 8.18*). Nuclei are round to slightly indented, with moderately clumped chromatin. These cells contain multiple, 0.2- to 3.0- $\mu\text{m}$  azurophilic cytoplasmic granules, which tend to cluster in the cytoplasm.

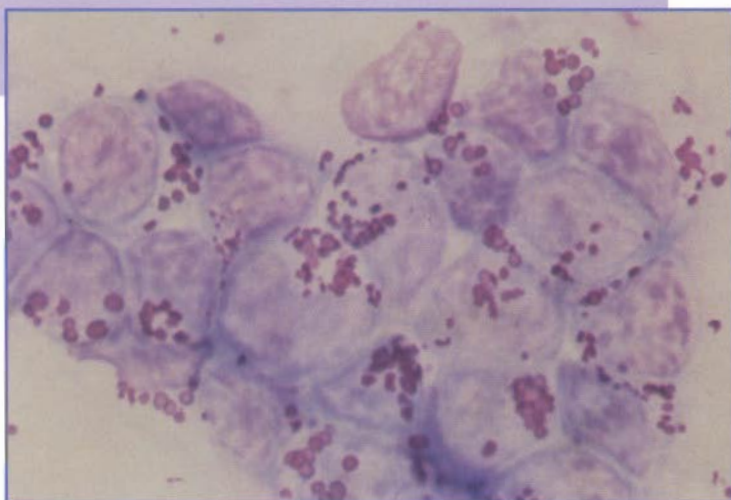


Figure 8.18. Aspirate of an abdominal mass from a cat with lymphoma of large granular lymphocytes (LGL). The neoplastic lymphocytes contain characteristic clusters of azurophilic, cytoplasmic granules. (Wright's stain; 1000X)

## INTERPRETATION: Lymphoma of large granular lymphocytes (LGL)

LGL are a distinctive population of lymphocytes that are characterized by the presence of azurophilic cytoplasmic granules. Normally, LGL function as natural killer cells and cytotoxic T cells.

Lymphoma of LGL occurs in aged cats and may be associated with tumors of the abdominal viscera (especially the jejunum) and involvement of abdominal lymph nodes. However, lesions may be more widespread and include cutaneous masses and/or infiltration of the liver, spleen, pancreas, heart, lung, or spinal cord. Immature LGL may be observed in the peripheral blood. Cats with LGL lymphoma are usually FeLV negative.

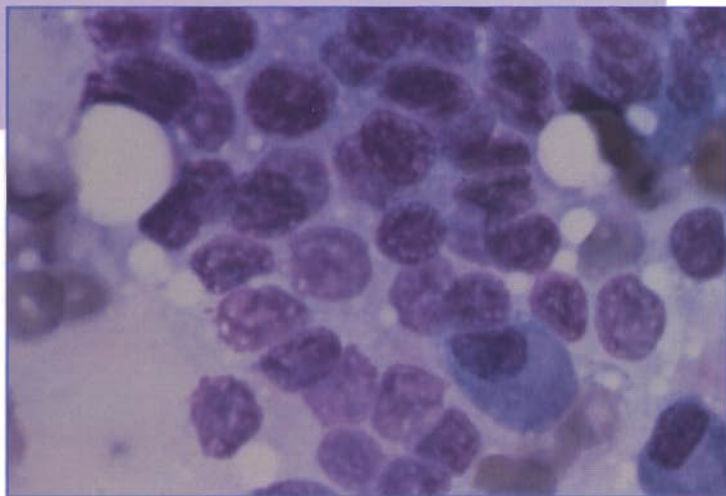
**CASE 9**

**SIGNALMENT:** Ten-year-old spayed female boxer dog

**CLINICAL FINDINGS:** Difficulty swallowing. A mass is palpable dorsal to the larynx.

**CYTOLOGIC DESCRIPTION:** Aspirate of the mass

The cellularity of this specimen is high. The cells consist of sheets of cuboidal epithelial cells that contain a single, round nucleus (*Figure 8.19*). Chromatin is coarsely granular and small nucleoli are often apparent. The cytoplasm of the cells is scant and basophilic.



**Figure 8.19.** Aspirate of a thyroid adenocarcinoma in a dog. The sample consists of sheets of cuboidal epithelial cells that are often stripped of their cytoplasm. Two plasma cells are seen in the lower right corner. (Wright's stain; 1000X)

**INTERPRETATION: Thyroid adenocarcinoma**

Thyroid tumors occur in aged dogs and cats. Approximately two thirds of thyroid masses in dogs are adenocarcinomas, with a breed predilection in golden retrievers, beagles, and boxers. In contrast, thyroid masses in cats are usually adenomas. Aspiration of these tumors usually yields sheets of epithelial cells with round nuclei and scant amounts of basophilic cytoplasm. Often, the cytoplasm appears to have been stripped away and bare nuclei are present. Occasionally, green/blue, linear granules may be found in the cytoplasm. Colloid may also be aspirated and appear as pink, amorphous, extracellular material. Because a thyroid tumor may be highly vascular, samples often have marked blood contamination.

Thyroid adenocarcinomas may vary from uniform and well differentiated to moderately pleomorphic. Often, it is not possible to distinguish an adenoma from a carcinoma cytologically. If necrosis of the tumor occurs, then inflammation may be apparent.

## Part IV

### GUIDELINES TO DISTINGUISHING TRANSUDATES AND EXUDATES

	<i>Transudate</i>	<i>Modified Transudate</i>	<i>Exudate</i>
Appearance	Clear, colorless	Variable	Usually cloudy
Specific gravity	<1.018	Variable	>1.018
Protein concentration (g/dl)	<2.5	Variable	>3.0
Nucleated cell count (cells/ $\mu$ l)	<1,000	1,000-10,000	>10,000
Cell type	Mostly mononuclear	Variable	Mostly neutrophils
Bacteria	Absent	Absent	+/-

### GUIDELINES FOR EVALUATION OF SYNOVIAL FLUID

	<i>Normal</i>	<i>Degenerative Arthropathy</i>	<i>Neutrophilic Inflammation: Nonseptic</i>	<i>Neutrophilic Inflammation: Septic</i>	<i>Hemarthrosis</i>
Color	Colorless	Colorless to yellow	Yellow to red	Yellow to gray/green	Red
Clarity	Clear	Clear	Turbid	Turbid	Turbid
Protein	1.8-4.8 g/dl (usually <3.0)	Normal to mild increase	Increased	Increased	Increased
Viscosity	High	Normal to decreased	Decreased	Decreased	Decreased
Nucleated cell count (cells/ $\mu$ l)	<3,000	Normal to mild increase	Mild to marked increase (2,000->100,000)	Marked increase (20,000->100,000)	Variable
Differential cell count					
Neutrophils	Usually <12%	Normal to mild increase	Marked increase (often 80%-100%)	Marked increase (>90%)	Variable
Mononuclear cells	60%-90%	Normal to mild increase	Variable	Variable	Variable
Mucin clot test	Good	Good to fair (occasionally poor)	Fair to poor	Poor	Fair to poor
Causes	—	Degenerative joint disease, trauma	Immune-mediated diseases, such as rheumatoid arthritis, systemic lupus erythematosus	Infectious agents (culture recommended)	Coagulopathies, trauma
Number of joints involved	—	Single or multiple	Multiple; usually polyarthritis	Usually single, but involve multiple (eg, septicemia, Lyme disease, <i>Ehrlichia</i> infection)	Single (trauma) or multiple (coagulopathy)

Modified from Fernandez FR, Grindem CB, Lipowitz AJ, Perman V. Synovial fluid analysis: preparation of smears for cytologic examination of canine synovial fluid. *J Am Anim Hosp Assoc.* 1983;19:727.

# Index of Figures

## Chapter 1

- Fig. 1.1..... The pull technique for making a smear for cytology. (Illustration by Tim Vojt.)
- Fig. 1.2..... The push technique for making a smear for cytology. (Illustration by Tim Vojt.)
- Fig. 1.3..... This specimen was not dispersed on the slide, resulting in a smear that is too thick for cytologic evaluation.
- Fig. 1.4..... This specimen was gently dispersed using the push technique. The smear is a monolayer of intact cells that is adequate for cytologic evaluation.
- Fig. 1.5..... This fluid specimen was prepared using a cytocentrifuge. The cells are concentrated in a small circular area on the slide.
- Fig. 1.6..... Several impression smears were made of an excised piece of tissue. Each impression is adequate for cytologic evaluation.

## Chapter 2

- Fig. 2.1..... A, Microscope equipped with 10× objective.  
B, Representation of the field diaphragm. (Illustration by Tim Vojt.)

## Chapter 3

- Fig. 3.1..... Pleural effusion from a cat. The neutrophils have normal morphology (ie, are nondegenerate). (Wright's stain; 1000×)
- Fig. 3.2..... Degenerative changes in neutrophils frequently occur as a result of bacterial infection. Note the many rod-shaped bacteria in this effusion. (Wright's stain; 1000×)
- Fig. 3.3..... Lymphoplasmacytic inflammation is characterized by a mixed population of mature lymphocytes, plasma cells, and a few large lymphocytes. (Wright's stain; 1000×)
- Fig. 3.4..... Pyogranulomatous inflammation is evident in this aspirate from a skin nodule on the ear of a dog. The large macrophage in the center has phagocytized cellular debris. The arrow indicates a mast cell. (Wright's stain; 1000×)

- Fig. 3.5..... Tracheal wash from a dog. The large cell in the center is a multinucleated giant cell. (Wright's stain; 1000×)
- Fig. 3.6..... Sheet of hyperplastic prostatic epithelial cells from a dog with benign prostatic hyperplasia. The N:C ratio is uniform, albeit somewhat greater than normal. In addition, the hyperplastic cells have more basophilic cytoplasm and finer, reticulated chromatin, but otherwise resemble normal prostatic epithelial cells. Prostatic hyperplasia typically occurs secondary to inflammation or a hormonal imbalance in older dogs. It can be a preneoplastic change. (Wright's stain; 1000×)
- Fig. 3.7..... Squamous metaplasia of prostatic epithelium from a dog. Cells have an enlarged, flattened appearance instead of the normal tall, cuboidal appearance. This change may occur in response to hormonal stimulation, such as estrogen secretion from a Sertoli cell tumor, or in response to inflammation. (Wright's stain; 400×)
- Fig. 3.8..... Prostatic adenocarcinoma from a dog. These cells display many of the nuclear criteria of malignancy, including fine chromatin, nucleoli, and multinucleation. The N:C ratio is variable, and the cells show anisokaryosis and anisocytosis. (Wright's stain; 1000×)
- Fig. 3.9..... Sebaceous gland adenoma from a dog. In this benign epithelial neoplasm, the cells have small nuclei with condensed chromatin and abundant, foamy cytoplasm. Cytoplasmic borders are distinct, and the cells form clusters. These cells are well differentiated, and it is not possible cytologically to distinguish sebaceous gland hyperplasia from benign adenoma. (Wright's stain; 1000×)
- Fig. 3.10..... Mammary adenocarcinoma from a cat. The majority of mammary tumors in cats are malignant. Cells in this aspirate show typical characteristics of an adenocarcinoma, including exfoliating in clusters, multinucleation, and fine chromatin. These cells have the appearance of secretory cells with eccentrically placed nuclei and distended basophilic cytoplasm. (Wright's stain; 1000×)
- Fig. 3.11..... Transitional cell carcinoma from the bladder of a dog. These neoplasms of the uroendothelium occur in aged dogs and rarely in cats. Cells may exfoliate as individuals or in clusters, and there is often marked atypia. Large cells with abundant cytoplasm are often interspersed with groups of cells that have higher N:C ratios. Multinucleation is common. (Wright's stain; 1000×)

Fig. 3.12.....Sarcoma in a cat. These cells show typical characteristics of a malignant mesenchymal neoplasm or sarcoma. Nuclear characteristics include multinucleation, marked anisokaryosis, fine chromatin, and prominent nucleoli. The cells are individualized, elongated, and have indistinct cytoplasmic borders. (Wright's stain; 1000X)

Fig. 3.13....Transmissible venereal tumor on the prepuce of a dog. This round cell neoplasm is characterized by individualized cells containing a single, round, often eccentrically placed nucleus. The chromatin is coarsely granular; and there is usually a single, prominent nucleolus. Cytoplasm is moderately abundant, is pale blue to moderately basophilic, and often contains small vacuoles. (Wright's stain; 1000X)

Fig. 3.14....Erythrophagocytosis and hemosiderin within macrophages indicate that hemorrhage has occurred. The macrophage on the left contains several erythrocytes. The blue-black pigment in the cytoplasm of the two macrophages is hemosiderin. (Wright's stain; 1000X)

Fig. 3.15....Hematoidin crystals are yellow-orange, rhomboid-shaped crystals that result from the breakdown of hemoglobin. They may be seen in aspirates of tissues or fluids in which hemorrhage has occurred. (Wright's stain; 1000X)

## Chapter 4

Fig. 4.1.....Selected bacteria that can be associated with skin lesions. (Illustration by Tim Vojt.)

Fig. 4.2.....Fungi that can be associated with skin lesions. (Illustration by Tim Vojt.)

Fig. 4.3.....Selected parasites that can be associated with respiratory disease. (Illustration by Tim Vojt.)

Fig. 4.4.....Aspirate of a lung mass from a cat. The large, thick-walled, deeply basophilic yeasts in the center are *Blastomyces dermatitidis*. Broad-based budding typical of this organism is evident. The organism has elicited a pyogranulomatous inflammatory response. (Wright's stain; 1000X)

Fig. 4.5.....The spherule of *Coccidioides immitis* is large and may stain deeply basophilic. It is necessary to focus up and down to observe the detail of the endospores, as illustrated. (Wright's stain; 1000X)

Fig. 4.6.....Aspirate of a periorbital mass from a dog. The extracellular, round fungal organisms with a large, clear, prominent capsule are *Cryptococcus neoformans*. Variation of the yeast and capsule size results in a pleomorphic appearance. Narrow-based buds are seen

on two of the organisms. Although *C. neoformans* elicits a pyogranulomatous inflammatory response, aspirates of the lesions often result in numerous organisms with few inflammatory cells evident. (Wright's stain; 1000X)

Fig. 4.7.....Tracheal wash from a cat. Many *Histoplasma capsulatum* organisms are seen within a macrophage. This yeast has a small, round body with a basophilic center and lighter halo. While the organisms usually are within macrophages, it is also common to see them free in the background as a result of breakage of cells during smear preparation. (Wright's stain; 1000X)

Fig. 4.8.....Ear swab from a dog. The oval to club-shaped (footprint-shaped) yeasts on the surface of the keratinized epithelial cells are *Malassezia* spp. A neutrophilic inflammatory response is apparent. (Wright's stain; 1000X)

Fig. 4.9.....Aspirate of a draining skin lesion from a dog. The macrophage in the center contains three oval to cigar-shaped yeasts, compatible with *Sporothrix schenckii*. These organisms induce a pyogranulomatous response; and neutrophils, macrophages, lymphocytes, and plasma cells are seen in this photograph. (Wright's stain; 1000X)

Fig. 4.10.....Tracheal wash from a cat with many first-stage larvae of *Aleurostrongylus* spp. (Wright's stain; 40X)

Fig. 4.11.....The bronchoalveolar lavage from this dog contains a *Paragonimus* spp egg. (Wright's stain; 400X)

## Chapter 5

Fig. 5.1.....Pleural fluid from a dog. There are three reactive mesothelial cells with a characteristic pink cytoplasmic fringe. (Wright's stain; 1000X)

Fig. 5.2.....Pleural fluid from a cat with pyothorax. The neutrophils appear degenerate and border a large clump of filamentous bacteria. These bacteria are compatible with *Actinomyces*, *Nocardia*, or *Fusobacterium* spp. (Wright's stain; 1000X)

Fig. 5.3.....Pleural fluid from a cat with chylothorax. This fluid has the typical milky pink appearance of a chylous effusion.

Fig. 5.4.....Pleural fluid from a cat with chylothorax. The majority of the cells are small lymphocytes with occasional non-degenerate neutrophils. (Wright's stain; 1000X)

Fig. 5.5.....Abdominal fluid from a cat with FIP. Neutrophils appear nondegenerate, and there are two large mononuclear cells. The hazy background is caused by the presence of precipitated protein. (Wright's stain; 1000X)

Fig. 5.6.....Protein electrophoresis of abdominal fluid from the cat with FIP. The fluid contains 28% albumin. Globulins total 72% of the protein and consist of 6% alpha<sub>1</sub>, 13% alpha<sub>2</sub>, 4% beta<sub>1</sub>, 5% beta<sub>2</sub>, and 44% gamma. The high concentration of globulins (>50% of the total) and gamma globulins (>32%) is compatible with a diagnosis of FIP.

Fig. 5.7.....Abdominal fluid from a dog with bile peritonitis. The majority of the cells are neutrophils. The large mononuclear cell (upper left) has phagocytized green material, compatible with bile pigment. Yellow bile pigment is also free in the background. (Wright's stain; 1000X)

Fig. 5.8.....Pleural fluid from a dog with metastatic mammary adenocarcinoma. The clusters of neoplastic cells are characterized by anisocytosis, anisokaryosis, and a variable N:C ratio. The cytoplasm is deeply basophilic and appears distended with secretory product in several of the cells (signet ring appearance). (Wright's stain; 1000X)

Fig. 5.9.....Pleural fluid from a dog. The large cell in the center is a reactive mesothelial cell. This cell is binucleate, has fine chromatin, shows nuclear molding, and has prominent cytoplasmic blebs. It can be difficult to distinguish reactive mesothelial cells from neoplastic cells. (Wright's stain; 1000X)

Fig. 5.10.....Synovial fluid from a dog with immune-mediated polyarthritis. There are three nondegenerate neutrophils, one mononuclear cell, and four erythrocytes. (Wright's stain; 1000X)

Fig. 5.11.....Synovial fluid from a dog with SLE-associated polyarthritis. The cell in the center is a neutrophil that has phagocytized the nucleus from another cell. This is an LE (lupus erythematosus) cell and, although an uncommon cytologic finding, supports a diagnosis of immune-mediated disease. (Wright's stain; 1000X)

Fig. 5.12.....Synovial fluid from a dog with degenerative arthropathy, characterized by the presence of predominantly mononuclear cells. Note the dense, granular background typical of synovial fluid. (Wright's stain; 1000X)

## Chapter 6

Fig. 6.1.....Cutaneous mast cell tumor from a dog. Left, The smear was stained with Diff-Quik stain. Cells are large, individual, round to polygonal cells and have round to oval, centrally located nuclei with finely stippled chromatin and nucleoli. Abundant cytoplasm appears grainy, but no granules are apparent. Right, The smear was stained with Wright's stain. Three mast cells with characteristic purple cytoplasmic granules

are present. There also are several eosinophils and moderate numbers of erythrocytes. This mast cell tumor appears relatively well differentiated. (1000X)

Fig. 6.2.....Cutaneous mast cell tumor from a dog. This mast cell tumor appears anaplastic. There is marked variation in cell size, nuclear size, and N:C ratio. A multinucleated mast cell is in the center. (Wright's stain; 1000X)

Fig. 6.3.....Cutaneous lymphoma from a dog. There is a monomorphic population of large lymphocytes with abundant basophilic cytoplasm. Nuclei are round or indented and have finely stippled chromatin and prominent nucleoli. These cells have a high N:C ratio. There is moderate variation in cell size and nuclear size. (Wright's stain; 1000X)

Fig. 6.4.....Cutaneous lymphoma from a dog. These neoplastic lymphocytes have very irregularly shaped nuclei, which can occur in some cases of lymphoma. It would be difficult to make a definitive diagnosis of lymphoma in this case without immunophenotyping or identification of cell surface antigens to document the lymphoid lineage of the neoplastic cells. (Wright's stain; 1000X)

Fig. 6.5.....Extramedullary plasma cell tumor from a dog. There is a uniform population of plasma cells that have round nuclei with moderately clumped chromatin. Nuclei are eccentrically located, and nucleoli are present in some cells. There is a binucleated cell on the left. These cells have abundant basophilic cytoplasm, and a few cells have a perinuclear clear zone that is typical of plasma cells. There is moderate variation in cell size and nuclear size. (Wright's stain; 1000X)

Fig. 6.6.....Histiocytoma from a dog. A uniform population of large, round, individual cells is present. Nuclei are round or indented and have stippled chromatin. There is moderate variation in nuclear size. Nucleoli are not apparent. There is a moderate amount of pale cytoplasm. (Wright's stain; 1000X)

Fig. 6.7.....Malignant melanoma from the digit of a dog. Melanocytes may be spindle-shaped (elongated cell in the left center) or polyhedral (large cell in the upper right). Melanin granules usually appear brown to greenish-black. They occur in the cytoplasm and in the background from broken cells. (Wright's stain; 1000X)

Fig. 6.8.....Malignant melanoma from the oral cavity of a cat. There is marked variation in cell size, nuclear size, and N:C ratio. Nuclei have fine chromatin and prominent nucleoli. Some cells are poorly pigmented and would be difficult to recognize as melanocytes. (Wright's stain; 1000X)

Fig. 6.9.....Malignant melanoma from the oral cavity of a dog. The cell on the left is a pigmented melanocyte and contains fine melanin granules. The cell in the center is a melanophage and has coarse granules and vacuoles. (Wright's stain; 1000X)

Fig. 6.10....Epidermal inclusion cyst from a dog. There are numerous keratin flakes that appear eosinophilic. (Wright's stain; 200X)

Fig. 6.11....Epidermal inclusion cyst from a dog. There are numerous keratin flakes that appear basophilic. (Wright's stain; 200X)

Fig. 6.12....Epidermal inclusion cyst from a dog. There is abundant cellular debris. The dark-stained material is melanin pigment. (Wright's stain; 400X)

Fig. 6.13....Cholesterol crystals from an epidermal inclusion cyst. These usually appear as large, clear, rectangular to rhomboid crystals with very sharp borders that sometimes are notched. (Wright's stain; 200X)

Fig. 6.14....Basal cell tumor from a dog. There is a cluster of basal epithelial cells in which the nuclei appear to be arranged in several perpendicular rows. These cells have stippled chromatin and a scant amount of cytoplasm. Nucleoli are not apparent. There is minimal variation in cell size, nuclear size, and N:C ratio. (Wright's stain; 1000X)

Fig. 6.15....Basal cell tumor from a dog. There is a cluster of pigmented basal epithelial cells. These cells are smaller and have round nuclei and a uniform N:C ratio, when compared to melanocytes. (Wright's stain; 1000X)

Fig. 6.16....Squamous cell carcinoma from a dog. There are two very large and one smaller anaplastic squamous epithelial cells. These cells have fine chromatin and prominent nucleoli. Squamous cell carcinomas are often associated with neutrophilic inflammation. The cell in the center has several neutrophils associated with its cytoplasm. (Wright's stain; 1000X)

Fig. 6.17....Perianal gland adenoma from a dog. There is a cluster of perianal gland epithelial cells in the center. The smaller cells along the bottom of this cluster likely are reserve cells. (Wright's stain; 400X)

Fig. 6.18....Perianal gland adenoma from a dog. These two perianal gland epithelial cells resemble hepatocytes. (Wright's stain; 1000X)

Fig. 6.19....Aspirate of an anal-sac apocrine gland adenocarcinoma from a dog. There are sheets of uniform cuboidal epithelial cells that contain a single round nucleus, granular chromatin, and a scant amount of basophilic cytoplasm. (Wright's stain; 1000X)

Fig. 6.20....Lipoma from a dog. There is a cluster of well-differentiated adipocytes. (Wright's stain; 200X)

Fig. 6.21....Hemangiopericytoma from a dog. There is a uniform population of spindle-shaped cells. The aggregate on the left shows the swirling pattern typical of hemangiopericytomas. (Wright's stain; 200X)

Fig. 6.22....Hemangiopericytoma from a dog. The cytoplasm appears to extend from one side of the nucleus. (Wright's stain; 1000X)

Fig. 6.23....Vaccine-induced sarcoma from a cat. There are large, irregularly shaped cells on the left and one multinucleated giant cell on the right. These cells have finely stippled chromatin and prominent nucleoli. (Wright's stain; 1000X)

Fig. 6.24....Vaccine-induced inflammatory reaction in a cat. There is a mixed population of neutrophils, eosinophils, small lymphocytes, macrophages, mast cells, and fibroblasts. Extracellular purple material may be from the vaccine. (Wright's stain; 1000X)

## Chapter 7

Fig. 7.1.....Salivary gland aspirate from a dog. The red blood cells appear to line up in rows because of the mucus that is present. There are several clusters of salivary gland epithelial cells. (Wright's stain; 200X)

Fig. 7.2.....Salivary gland aspirate from a dog. Salivary gland epithelial cells have abundant, vacuolated cytoplasm and round nuclei with condensed chromatin. The basophilic material to the left of the epithelial cells is mucus. (Wright's stain; 1000X)

Fig. 7.3.....Lymph node aspirate from a normal dog. Mature lymphocytes are smaller than neutrophils and have condensed chromatin. Nucleoli are small or not apparent. The neutrophils in this aspirate were from blood contamination. (Wright's stain; 1000X)

Fig. 7.4.....Lymph node aspirate from a dog with lymphoid and plasma cell hyperplasia. There are several plasma cells characterized by abundant, intensely basophilic cytoplasm, a perinuclear clear zone, and eccentric nuclei with moderately condensed chromatin. Several small lymphocytes with condensed chromatin and large lymphocytes with fine chromatin and nucleoli are present. (Wright's stain; 1000X)

Fig. 7.5.....Lymph node aspirate from a dog with lymphoma. There is a uniform population of large lymphocytes with abundant, basophilic cytoplasm. Nuclei have finely stippled chromatin and multiple nucleoli. Two mitotic figures are present. (Wright's stain; 1000X)

Fig. 7.6.....Lymph node aspirate from a dog. This dog had lymphoma involving small lymphocytes (smaller than the neutrophil). The cytologic diagnosis of lymphoma was confirmed histologically. (Wright's stain; 1000X)

Fig. 7.7.....Lymph node aspirate from a dog with a metastatic carcinoma. There is a cluster of anaplastic epithelial cells in a background of small lymphocytes. The carcinoma cells show moderate to marked variation in cell size, nuclear size, and N:C ratio. (Wright's stain; 400X)

Fig. 7.8.....Lymph node aspirate from a dog with a metastatic carcinoma. These cells are large (there is a small lymphocyte in the upper left for size comparison), round to polyhedral cells with round to oval nuclei, finely stippled chromatin, and multiple nucleoli. The cytoplasm is very basophilic. (Wright's stain; 1000X)

Fig. 7.9.....Lymph node aspirate from a dog with *Mycobacterium intracellulare* infection. There is a mixed population of small and large lymphocytes. There are two plasma cells and one neutrophil. (Wright's stain; 1000X)

Fig. 7.10.....Lymph node aspirate from a dog with *Mycobacterium intracellulare* infection. There are several macrophages with large (1  $\mu$ m wide, 2 to 5  $\mu$ m long), intracellular, nonstaining, rod-shaped structures. The morphology of these structures is typical of *Mycobacterium* spp. (Wright's stain; 1000X)

Fig. 7.11.....Splenic aspirate from a dog with immune-mediated hemolytic anemia. There is a mixed population of small and large lymphocytes. There are several neutrophils. The macrophage has phagocytized erythrocytes. (Wright's stain; 1000X)

Fig. 7.12.....Splenic aspirate from a dog with extramedullary hematopoiesis secondary to immune-mediated hemolytic anemia. There are erythroid and myeloid precursors and a plasma cell in the center. (Wright's stain; 1000X)

Fig. 7.13.....Splenic aspirate from a dog with extramedullary hematopoiesis secondary to immune-mediated hemolytic anemia. A megakaryocyte in the center is surrounded by erythroid and myeloid precursors. (Wright's stain; 200X)

Fig. 7.14.....Splenic aspirate from a dog with immune-mediated hemolytic anemia. The large cell in the center is a macrophage containing hemosiderin pigment. (Wright's stain; 1000X)

Fig. 7.15.....Splenic aspirate from a dog with immune-mediated hemolytic anemia. There are increased numbers of erythroid precursors, immature lymphocytes, and plasma cells compatible with EMH and lymphoid hyperplasia. (Wright's stain; 1000X)

Fig. 7.16.....Splenic aspirate from a dog with hemangiosarcoma. There is a large, spindle-shaped cell in the lower center compatible with a neoplastic mesenchymal cell. (Wright's stain; 400X)

Fig. 7.17.....Splenic aspirate from a dog with hemangiosarcoma. There are two large neoplastic spindle-shaped cells with basophilic cytoplasm, fine chromatin, and nucleoli. (Wright's stain; 1000X)

Fig. 7.18.....Splenic aspirate from a dog with malignant histiocytosis. The malignant histiocytes are large, round, individual cells with abundant, moderately basophilic cytoplasm. These cells have round, oval, or irregularly shaped nuclei with irregularly clumped chromatin and nucleoli. There is moderate to marked variation in cell size and nuclear size. (Wright's stain; 1000X)

Fig. 7.19.....Splenic aspirate from a dog with malignant histiocytosis. The macrophage in the center has phagocytized erythroid precursors. (Wright's stain; 400X)

## Chapter 8

Fig. 8.1.....Tracheal wash from a dog with megaesophagus. There are increased numbers of neutrophils and a mixed bacterial population. The cell in the center is a squamous epithelial cell derived from the oropharynx. (Wright's stain; 400X)

Fig. 8.2.....Normal-appearing ciliated, respiratory epithelial cells found in a tracheal wash from a dog. Typically, respiratory epithelial cells line up in rows, are columnar, have a basal nucleus, and have a ciliated apical border. (Wright's stain; 1000X)

Fig. 8.3.....Tracheal wash from a dog. The large organisms on the surface of the squamous epithelial cell are *Simonsiella* (or *Karyophanon*) spp. These bacteria are normal oropharyngeal flora and, when found in a tracheal wash, should alert the clinician that there was contamination of the specimen. In this particular case, the presence of these cells and bacteria were the result of aspiration pneumonia rather than contamination of the specimen. (Wright's stain; 400X)

Fig. 8.4.....Tracheal wash from a dog with heartworm disease. There is a mixture of eosinophils and neutrophils. (Wright's stain; 1000X)

Fig. 8.5.....Bronchoalveolar lavage from a dog with chronic bronchitis. The majority of the cells are macrophages with foamy cytoplasm. The long thin cell to the left is a ciliated columnar respiratory epithelial cell. All of the cells are embedded in thick mucous strands. (Wright's stain; 1000X)

Fig. 8.6.....Goblet cells in a tracheal wash from a dog. Goblet cells have a basal nucleus and cytoplasm distended with large, pink to purple mucin granules. (Wright's stain; 1000X)

Fig. 8.7.....Cluster of normal hepatocytes in a liver aspirate from a dog. Normal hepatocytes are large, round or polyhedral cells with abundant amphophilic, grainy cytoplasm. (Wright's stain; 200X)

Fig. 8.8.....Liver aspirate from a dog with septic suppurative hepatitis. There are extracellular bile plugs that are compatible with cholestasis. (Wright's stain; 20X)

Fig. 8.9.....Liver aspirate from a dog with septic suppurative hepatitis. There are increased numbers of neutrophils, many of which appear degenerate. Intracellular bacteria are present. (Wright's stain; 1000X)

Fig. 8.10.....Liver aspirate from a dog. Abundant intracellular bile pigment, as seen in these hepatocytes, may be normal. (Wright's stain; 1000X)

Fig. 8.11....Liver aspirate from a dog with a regenerative nodule. The hepatocyte on the lower left is large and has a large nucleus, compared with the more normal hepatocytes at the top. (Wright's stain; 1000X)

Fig. 8.12....Liver aspirate from a cat with lipidosis. There are numerous hepatocytes with vacuolated cytoplasm because of increased lipid. Similar lipid vacuoles are present in the background. (Wright's stain; 200X)

Fig. 8.13....Liver aspirate from a cat with lipidosis. The hepatocyte cytoplasm is markedly distended with large lipid vacuoles. (Wright's stain; 1000X)

Fig. 8.14....Liver aspirate from a cat with lipidosis and a mast cell tumor. There are both vacuolated hepatocytes and neoplastic mast cells. (Wright's stain; 1000X)

Fig. 8.15....Liver aspirate from a dog with steroid hepatopathy. The hepatocytes are markedly distended, and the cytoplasm appears vacuolated. These vacuoles have a feathery appearance, compared to the more discrete vacuoles in feline lipidosis. (*See case 5.*) (Wright's stain; 400X)

Fig. 8.16....Liver aspirate from a dog with a metastatic carcinoma. There is a cluster of anaplastic epithelial cells. These cells are large and have a moderate amount of basophilic cytoplasm. Nuclei are large and round with finely stippled chromatin and multiple nucleoli. There is moderate variation in cell size and nuclear size. (Wright's stain; 1000X)

Fig. 8.17....Liver aspirate from a cat with hepatocellular carcinoma. There is a cluster of anaplastic cells with marked variation in cell size, nuclear size, and N:C ratio. Prominent nucleoli are present. Bile pigment was present in some cells. (Wright's stain; 400X)

Fig. 8.18....Aspirate of an abdominal mass from a cat with lymphoma of large granular lymphocytes (LGL). The neoplastic lymphocytes contain characteristic clusters of azurophilic, cytoplasmic granules. (Wright's stain; 1000X)

Fig. 8.19....Aspirate of a thyroid adenocarcinoma in a dog. The sample consists of sheets of cuboidal epithelial cells that are often stripped of their cytoplasm. Two plasma cells are seen in the lower right corner. (Wright's stain; 1000X)

# Glossary of Terms

## -A-

**Adenocarcinoma:** malignant neoplasm derived from glandular epithelium.

**Amphophilic:** having affinity for basic and acidic dyes. Amphophilic cytoplasm appears basophilic and eosinophilic.

**Anaplastic:** loss of normal differentiation. Cytologically, anaplastic cells appear immature. They usually are large cells with large nuclei, finely stippled chromatin, prominent nucleoli, and moderate to marked variation in cell size, nuclear size, and nuclear-to-cytoplasmic ratio.

**Anisocytosis:** variation in cell size.

**Anisokaryosis:** variation in nuclear size.

## -B-

**Basophilic:** preferential staining with the basic or blue dyes of the stain.

**Benign:** not malignant. Less likely to recur if completely excised. In general, benign cells appear less mature than their normal counterpart, but they have relatively uniform cell size, nuclear size, and nuclear-to-cytoplasmic ratio compared to malignant cells. It is often difficult to distinguish benign neoplasia from hyperplasia based only on cytologic evaluation.

**Blood contamination:** blood introduced during collection. The distribution of erythrocytes and leukocytes resembles peripheral blood. Platelets may be present.

## -C-

**Carcinoma:** malignant neoplasm of epithelial cells.

**Chromatin:** the stainable portion of the DNA-protein complex in the nucleus of a cell. Chromatin patterns differ among different types of cells. Chromatin may appear minimally to markedly condensed and irregularly or evenly dispersed. Markedly condensed chromatin appears darkly stained and minimally condensed chromatin appears lightly stained. Changes in chromatin patterns are important in recognizing hyperplastic and neoplastic cells. Typically, mature, differentiated cells have condensed, evenly dispersed chromatin, whereas malignant cells have minimally condensed, irregularly dispersed chromatin.

## -D-

**Dysplasia:** abnormal, but non-neoplastic, development of cells. Dysplastic cells may resemble malignant cells, and this distinction may be very difficult based only on cytologic evaluation.

## -E-

**Eosinophilic:** preferential staining with the acidic or pink dyes of a stain.

**Epithelial:** pertaining to epithelial tissue.

**Erythrophagocytosis:** phagocytosis of erythrocytes. Usually occurs by macrophages as a result of hemorrhage or hemolysis but also occurs rarely by neoplastic mast cells and T lymphocytes.

## -G-

**Goblet cell:** mucus-producing epithelial cell in the respiratory tract.

## **-H-**

**Hemorrhage:** loss of blood from the vessel.

**Hyperplasia:** increased cell proliferation in response to irritation, inflammation, altered cellular signaling, or subsequent to tissue destruction and regeneration. Hyperplastic cells usually are larger and have less condensed chromatin and more prominent nucleoli than their normal counterpart, but their nuclear-to-cytoplasmic ratio remains relatively constant compared to malignant cells from the same tissue.

## **-K-**

**Karyolysis:** nuclear swelling and loss of chromatin staining.

**Karyorrhexis:** breaking apart of the nucleus into fragments.

**Koehler illumination:** adjustment of the condenser height and iris diaphragm on a microscope for optimal illumination.

## **-M-**

**Macronuclei:** nuclei that are larger than normal for the particular cell type.

**Malignant:** refers to neoplastic cells that resist treatment, tend to metastasize, and result in death of the patient. Malignant cells commonly appear highly pleomorphic. They usually are large and have finely stippled chromatin, prominent nucleoli, and moderate to marked variation in cell size, nuclear size, and nuclear-to-cytoplasmic ratio.

**Metachromatic:** condition in which staining results in different colors or hues of the same dye, eg, the purple staining of mast cell granules by Wright's or Wright-Giemsa stains.

**Mesenchymal:** pertaining to connective tissue.

**Metaplasia:** condition in which cellular characteristics are altered to resemble a different type of tissue; ie, glandular epithelial cells may transform to resemble squamous epithelial cells. Metaplastic cells must be distinguished from neoplastic cells.

**Mitotic figure:** the morphologic appearance of cells in the metaphase stage of division. The chromosomes are arranged on the equator of the spindle. Increased numbers of mitotic figures may be present in hyperplastic or neoplastic tissue.

## **-N-**

**Normoblastemia:** increased numbers of nucleated red blood cells in the peripheral blood.

**Nuclear molding:** the shape of one nucleus conforms around the shape of an adjacent nucleus; characteristic of malignant cells.

**Nuclear-to-cytoplasmic (N:C) ratio:** nuclear size compared to amount of cytoplasm; eg, normal lymphocytes have a high N:C ratio, while normal keratinized squamous epithelial cells have a low N:C ratio.

## **-P-**

**Pleomorphic:** variation in morphologic appearance. Cytologically, pleomorphism is recognized by variation in cell size, nuclear size, and nuclear-to-cytoplasmic ratio.

## **-R-**

**Round cell tumor:** discrete cell tumors that include mast cell tumors, lymphoma, plasma cell tumors, histiocytomas, and transmissible venereal tumors.

## **-S-**

**Sarcoma:** malignant neoplasm derived from mesenchymal tissue.

## Suggested Reading

Baker R, Lumsden JH. *Color Atlas of Cytology of the Dog and Cat*. St Louis, Mo: Mosby-Year Book; 1999.

Boon GD. Synovial fluid analysis: a guide for small animal practitioners. *Vet Med*. 1997;92:443-451.

Brown DE, Thrall MA, Getzy DM, Weiser MG, Ogilvie GK. Cytology of canine malignant histiocytosis. *Vet Clin Pathol*. 1994;23:118.

Cowell RL, Tyler RD, Meinkoth JH. *Diagnostic Cytology and Hematology of the Dog and Cat*. 2<sup>nd</sup> ed. St Louis, Mo: Mosby; 1999.

Darbes J, Majoub M, Breuer W, Hermanns W. Large granular lymphocyte leukemia/lymphoma in six cats. *Vet Pathol*. 1998;35:370.

Dellman HD, Eurell JA. *Textbook of Veterinary Histology*. 5<sup>th</sup> ed. Baltimore, Md: Williams & Wilkins; 1998.

Duncan JR, Prasse KW, Mahaffey EA. *Veterinary Laboratory Medicine: Clinical Pathology*. Ames, Ia: Iowa State University Press; 1994.

Fernandez FR, Grindem CB, Lipowitz AJ, Perman V. Synovial fluid analysis: preparation of smears for cytologic examination of canine synovial fluid. *J Am Anim Hosp Assoc*. 1983;19:727.

Greene CE. *Infectious Diseases of the Dog and Cat*. 2<sup>nd</sup> ed. Philadelphia, Pa: WB Saunders Co; 1998.

Hawkins EC, DeNicola DB, Plier ML. Cytological analysis of bronchoalveolar lavage fluid in the diagnosis of spontaneous respiratory tract disease in dogs: a retrospective study. *J Vet Intern Med*. 1995;9:386-392.

Hawkins EC, Kennedy-Stoskopf S, Levy J, et al. Cytologic characterization of bronchoalveolar lavage fluid collected through an endotracheal tube in cats. *Am J Vet Res*. 1994;5:795-802.

Jergens AE, Andreasen CB, Hagemoser WA, Ridgway J, Campbell KL. Cytologic examination of exfoliative specimens obtained during endoscopy for diagnosis in dogs and cats. *J Am Vet Med Assoc*. 1998;213:1755.

Meadows RL, MacWilliams PS. Chylous effusions revisited. *Vet Clin Pathol*. 1994;23:54.

Mouton JE. *Tumors in Domestic Animals*. 3<sup>rd</sup> ed. Berkeley Ca: University of California Press; 1990.

Rebar AH, Hawkins EC, DeNicola DB. Cytologic evaluation of the respiratory tract. *Vet Clin North Am Small Anim Pract*. 1992;22:1065-1085.

Sparkes AH, Gruffydd-Jones TJ, Harbour DA. An appraisal of the value of laboratory tests in the diagnosis of feline infectious peritonitis. *J Am Anim Hosp Assoc*. 1994;30:345.

Wellman ML. Cytology and the diagnosis of neoplasia. *Proceedings of the 20th Annual Waltham/OSU Symposium, Hematology & Cytology, Columbus, Ohio, September 1996*. Vernon, Ca: Waltham USA, Inc; 1996.

Wellman ML, Couto CG, Starkey RJ, Rojko JL. Lymphocytosis of large granular lymphocytes in three dogs. *Vet Pathol*. 1989;26:158.

Wellman ML, Davenport DJ, Morton D, Jacobs RM. Malignant histiocytosis in four dogs. *J Am Vet Med Assoc*. 1985;187:919.

# Subject Index

- A-**
- Actinomyces* spp .....19, 26
  - Adenocarcinoma .....16-17, 30, 46, 55, 75
  - Adenoma .....16, 45
  - Adipocytes .....47
  - Aleurostrongylus* spp .....20, 22
  - Anal-sac apocrine gland adenocarcinoma .....46
  - Anemia, immune-mediated hemolytic .....57
  - Anisocytosis .....16, 30, 46, 61
  - Anisokaryosis .....16, 30
- B-**
- Babesia* spp .....57
  - Bacteria
    - Associated with skin lesions .....19
    - Extracellular .....14, 43, 63, 67
    - Intracellular .....14, 63, 67-68
  - Basal cell tumor .....37, 42
  - Basophilia .....16, 30
  - Bile peritonitis .....29
  - Bile pigment .....29, 67-69
  - Bilirubin .....29
  - Biopsy .....67
  - Blastomyces dermatitidis* .....20-21, 56
  - Blood contamination .....18
  - Bronchoalveolar lavage .....66
- C-**
- Carcinomas .....30, 42-43, 72
  - Cell types
    - Basal cell .....42
    - Dendritic cell .....37
    - Epithelial cell .....42, 45, 51, 68
    - Goblet cell .....66
    - Langerhans cell .....39
    - LE cell .....See *Lupus erythematosus*
    - Mast cell .....14, 33, 56
    - Mesothelial cell .....25, 30
    - Mononuclear cell .....28
    - Squamous epithelial cell .....44, 63-64
  - Cholesterol (crystals) .....40-41
  - Chylous effusion (chylothorax) .....27
  - Clostridia* spp .....19
  - Coccidioides immitis* .....20-21
  - Collection, sample
    - Aspiration .....5
    - Pull technique .....5-6
    - Push technique .....5-6
    - Site preparation .....5-6
    - Slide preparation .....5
  - Cryptococcus neoformans* .....20-21
  - Cyst, epidermal inclusion .....40-41
  - Cytauxzoon* spp .....57
  - Cytologic specimen
    - Interpretation .....13
    - Preparation for reference laboratory .....7-8
- D-**
- Degenerative joint disease .....32, 78
  - Dermatophilus congolensis* .....19
  - Diff-Quik stain .....8, 33
  - Direct smears .....6-7
  - Discrete cell tumor .....See *Round cell tumor*
  - Disseminated intravascular coagulation .....59
  - Dysplasia .....15
- E-**
- EDTA .....5
  - Effusion
    - Chylous (chylothorax) .....27
    - Classification .....25-30, 78
    - Inflammatory .....14, 26, 28-29
    - Neoplastic .....30
    - Proteinaceous .....28
  - Ehrlichia* spp .....57, 58
  - Eosinophilic inflammation .....65
  - Eosinophils .....13-14, 56, 65
  - Epidermal inclusion cyst .....40-41
  - Erythrophagocytosis .....18, 32
  - Extramedullary hematopoiesis (EMH) .....57-58, 67
  - Exudates
    - Septic suppurative .....25-26, 78
    - Suppurative .....29, 78
- F-**
- Feline infectious peritonitis (FIP) .....28, 69
  - Fibroblasts .....49
  - Fibrosarcoma .....49, 59
  - Fine needle aspirates
    - From solid tissues .....5, 67-75
    - Of fluid samples .....5, 7, 78
    - Pull technique .....5-6

Push technique .....	5-6
FIP .....	<i>See Feline infectious peritonitis</i>
Fluid	
Abdominal .....	28-29
Body cavity .....	25
Classification .....	25
Pleural .....	25-27, 30
Samples, aspirates from .....	5-7
Synovial .....	31-32, 78
Fungi associated with skin lesions .....	20
<i>Fusobacterium</i> spp .....	19, 26

## **-G-**

Goblet cell hyperplasia .....	66
Goblet cells .....	66
Glucocorticoid-induced hepatopathy .....	71
Guidelines for evaluation of synovial fluid (table) .....	78
Guidelines to distinguishing transudates and exudates (table) .....	78

## **-H-**

<i>Haemobartonella</i> spp .....	57
Hemangiopericytoma .....	48
Hemangiosarcoma .....	59, 72
Hemarthrosis .....	78
Hematoidin crystals .....	18
Hemolysis .....	69
Hemophagocytic syndrome .....	61
Hemorrhage .....	18, 67, 78
Hemosiderin .....	18, 58, 68
Hepatitis .....	69
Hepatocellular carcinoma .....	73
Hepatocytes .....	67-71
Hepatomegaly .....	67, 70-71
Histiocytoma .....	17, 37
Histiocytosis .....	60, 73
<i>Histoplasma capsulatum</i> .....	21, 56-57
Hypercalcemia .....	46
Hyperplasia .....	14-16, 51-52, 57, 66

## **-I-**

Immune-mediated hemolytic anemia .....	57-58
Immunophenotyping .....	35
Impression smears .....	7
Inflammation .....	13-14, 31-32, 63, 65, 69
Inflammatory response .....	13, 63

## **-K-**

<i>Karyophanon</i> spp .....	<i>See Simonsiella</i> spp
Koehler illumination .....	9

## **-L-**

Leiomyosarcomas .....	59
<i>Leishmania</i> spp .....	57
Leukemia .....	61, 73
Lipidosis .....	70
Lipomas .....	47
Liver .....	67-68, 70-73
Lupus erythematosus .....	31
Lymphadenomegaly .....	53
Lymph node .....	52-56
Lymphocytes, large granular .....	74
Lymphoid hyperplasia .....	52, 57
Lymphocytes .....	27, 29, 51-56
Lymphoma .....	17, 35, 37, 51-54, 69, 73-74
Lymphoplasmacytic inflammation .....	14

## **-M-**

Macrophages .....	13-15, 29, 34, 36, 66, 68
<i>Malassezia</i> spp .....	20-21
Malignancy, criteria for assessing .....	16
Malignant histiocytosis .....	60-61, 73
Mammary adenocarcinoma .....	17, 30, 55
Mast cell tumor .....	17-18, 33-34, 70
Mast cells .....	33
Megaesophagus .....	64
Melanin pigment .....	38-39
Melanocytes .....	38-39
Melanoma .....	38-39
Melanophages .....	39
Metaplasia .....	14-15
Metastatic neoplasia .....	55, 72
Microscopic evaluation (technique) .....	9-10
Modified transudate .....	25, 78
Mucin clot test .....	31-32, 78
Mucus .....	66
<i>Mycobacterium</i> spp .....	19, 56
<i>Mycosporum</i> spp .....	20

## **-N-**

N:C ratio .....	<i>See Nuclear-to-cytoplasmic ratio</i>
Neoplasia .....	15-18
Neoplasms	
Benign .....	15
Epithelial .....	16
Malignant .....	15
Mesenchymal .....	17, 49, 59
Round cell .....	17-18
Neutrophils .....	13-14, 32, 34, 56, 63, 67-69
New methylene blue stain .....	8
<i>Nocardia</i> spp .....	19, 26

Nuclear-to-cytoplasmic (N:C) ratio .....14

## **-O-**

Oil immersion objective .....10

### **Organisms**

*Actinomyces* spp .....19, 26  
*Babesia* spp .....57  
*Blastomyces dermatitidis* .....20-21, 56  
*Clostridia* spp .....19  
*Coccidioides immitis* .....20-21  
*Cryptococcus neoformans* .....20-21  
*Cytauxzoon* spp .....57  
*Dermatophilus congolensis* .....19  
*Ehrlichia* spp .....57, 78  
*Fusobacterium* spp .....19, 26  
*Haemobartonella* spp .....57  
*Histoplasma capsulatum* .....20-21, 56  
*Karyophanon* spp .....See *Simonsiella* spp  
*Leishmania* spp .....57  
*Malassezia* spp .....20-21  
*Mycobacterium* spp .....19, 56  
*Mycosporum* spp .....20  
*Nocardia* spp .....19, 26  
*Simonsiella* spp .....19, 64  
*Sporothrix schenckii* .....20-21  
*Staphylococcus* spp .....19  
*Streptococcus* spp .....19  
*Trichophyton* spp .....20  
Oropharyngeal contamination .....63

## **-P-**

*Paragonimus* spp .....20, 22

### **Parasites associated with respiratory disease**

*Aleurostrongylus* spp .....20, 22  
*Capillaria* spp .....20  
*Crenosoma* spp .....20  
*Filaroides* spp .....20  
*Ostertesia* spp .....20  
*Paragonimus* spp .....20, 22

Parathyroid hormone-related protein (PTH-RP) .....46

PCR .....See *Polymerase chain reaction*

Perianal gland adenoma .....45

Peritonitis, bile .....29

Phagocytosis .....18, 61

Plasma cells .....14, 36, 52-53, 57-58, 68-69

Plasma cell tumor .....36

Plasmacytoma .....17, 36

Pleural fluid .....25-27, 30

Polymerase chain reaction .....28

### **Prostate**

Adenocarcinoma .....16  
Hyperplasia .....15  
Squamous metaplasia .....15  
Pull technique for slide preparation .....5-6  
Push technique for slide preparation .....5-6  
Pyogranulomatous inflammation .....14, 56  
Pyogranulomatous lymphadenitis .....56  
Pyothorax .....26

## **-R-**

Reference laboratory, use of .....7-8

Respiratory epithelial cell .....64

Round cell tumor .....17

## **-S-**

Salivary gland .....51

Sarcoma .....17, 30, 49, 59

Sarcoma, vaccination-induced .....49

Sebaceous gland adenoma .....16

Sertoli cell tumor .....15

*Simonsiella* spp .....19, 64

### **Smears**

Direct .....6

Impression .....7

Specimen, cytologic interpretation of .....13-18

Spindle cell tumor .....48-49

Spleen .....57-59, 61

Splenomegaly .....57-58

*Sporothrix schenckii* .....20-21

Squamous cell carcinoma .....43

### **Stains**

Diff-Quik .....8, 33

Characteristics of .....8

New methylene blue .....8

Wright-Giemsa .....8

Wright's .....8, 33

*Staphylococcus* spp .....19

*Streptococcus* spp .....19

Suppurative inflammation .....25-26, 29, 63, 67-69, 78

Synovial fluid .....31-32, 78

## **-T-**

Thyroid adenocarcinoma .....75

Tissue scrapings .....7

Transitional cell carcinoma .....17

Transudate .....25, 78

*Trichophyton* spp .....20

Tracheal wash .....15, 63-65

Transmissible venereal tumor .....17, 37

---

**-W-**

Windrowing .....	32
Wright-Giemsa stain .....	8
Wright's stain .....	8, 33

**-X-**

Xanthochromia .....	18
---------------------	----